https://t.me/MedicalEbooksLibrary

Fischer's Mastery of Surgery

Seventh Edition

Editor
Josef E. Fischer

Associate Editors
E. Christopher Ellison
Gilbert R. Upchurch Jr.
Susan Galandiuk
Jon C. Gould
V. Suzanne Klimberg

Assistant Editors
Peter K. Henke
Steven N. Hochwald
Gregory M. Tiao

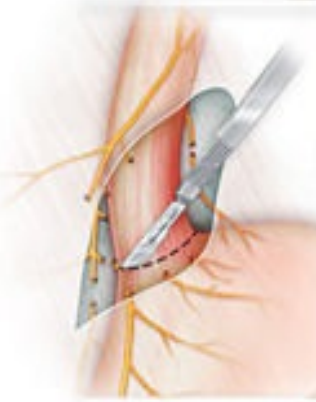



Volume 1

Wolters Kluwer

https://t.me/MedicalEbooksLibrary

Editor

Josef E. Fischer, MD, FACS, DM(Hon) Lund, FRCS(E)(Hon)
William V. McDermott Distinguished Professor of Surgery
Harvard Medical School
Christian R. Holmes Professor of Surgery and Chair Department of Surgery
University of Cincinnati College of Medicine, Emeritus
Chair, Department of Surgery
Beth Israel Deaconess Medical Center, Emeritus
Boston, Massachusetts

Associate Editors

E. Christopher Ellison, MD
The Robert M. Zollinger Professor of Surgery
The Ohio State University
Columbus, Ohio

Gilbert R. Upchurch Jr., MD
Chief of Vascular and Endovascular Surgery
William H. Muller, Jr. Professor of Surgery
University of Virginia
Charlottesville, Virginia

Susan Galandiuk, MD
Professor of Surgery
Program Director, Section of Colon & Rectal Surgery
Hiram C. Polk, Jr. MD Department of Surgery
Director, Price Institute of Surgical Research
University of Louisville
Louisville, Kentucky

Jon C. Gould, MD
Chief of General Surgery
Walker Chair in General Surgery
Professor of Surgery
Medical College of Wisconsin
Milwaukee, Wisconsin

V. Suzanne Klimberg, MD, PhD

Courtney M. Townsend, Jr., MD Distinguished Chair in Surgical Oncology
Vice Chair of the Department of Surgery
Chief of Surgical Oncology
Medical Director for the University of Texas Medical Branch Cancer Institute
Galveston, Texas

Assistant Editors

Peter Henke, MD
Leland Ira Doan Professor of Surgery
Section of Vascular Surgery
Department of Surgery
University of Michigan
Ann Arbor, Michigan

Steven N. Hochwald, MD, MBA
Professor of Oncology
Vice Chair and Chief of GI Surgery
Roswell Park Cancer Institute
Professor of Surgery
University at Buffalo
Buffalo, New York

Gregory M. Tiao, MD
Ryckman Chair of Pediatric Surgery
Division Chief of Pediatric Surgery
Director of Pediatric Liver Transplantation
Cincinnati Children's Hospital and Medical Center
Professor of Surgery
University of Cincinnati
Cincinnati, Ohio

Manuscript Editor

Erica N. Slavin

https://t.me/MedicalEbooksLibrary

FISCHER'S MASTERY OF SURGERY

SEVENTH EDITION

Volume 1-2



Philadelphia • Baltimore • New York • London
Buenos Aires • Hong Kong • Sydney • Tokyo

https://t.me/MedicalEbooksLibrary

Acquisitions Editor: Keith Donnellan
Development Editors: Brendan Huffman and Kristina Oberle
Editorial Coordinators: Emily Buccieri and Tim Rinehart
Strategic Marketing Manager: Dan Dressler
Senior Production Project Manager: Alicia Jackson
Senior Designer: Joan Wendt
Senior Manufacturing Coordinator: Beth Welsh
Prepress Vendor: Aptara, Inc.

7th edition

Copyright © 2019 Wolters Kluwer.

Copyright © 2012 by LIPPINCOTT WILLIAMS & WILKINS, a WOLTERS KLUWER business

All rights reserved. This book is protected by copyright. No part of this book may be reproduced or transmitted in any form or by any means, including as photocopies or scanned-in or other electronic copies, or utilized by any information storage and retrieval system without written permission from the copyright owner, except for brief quotations embodied in critical articles and reviews. Materials appearing in this book prepared by individuals as part of their official duties as U.S. government employees are not covered by the above-mentioned copyright. To request permission, please contact Wolters Kluwer at Two Commerce Square, 2001 Market Street, Philadelphia, PA 19103, via email at permissions@lww.com, or via our website at lww.com (products and services).

9 8 7 6 5 4 3 2 1

Printed in China

Library of Congress Cataloging-in-Publication Data

Names: Fischer, Josef E., 1937- editor.
Title: Fischer's mastery of surgery / editor, Josef E. Fischer ; associate editors, E. Christopher Ellison, Gilbert R. Upchurch Jr., Susan Galandiuk, Hiram C. Polk Jr., Jon C. Gould, V. Suzanne Klimberg ; assistant editors, Peter K. Henke, Steven N. Hochwald, Gregory M. Tiao.

Other titles: Mastery of surgery
Description: Seventh edition. | Philadelphia : Wolters Kluwer, [2019] | Includes bibliographical references and index.
Identifiers: LCCN 2017041639 | ISBN 9781469897189
Subjects: | MESH: Surgical Procedures, Operative
Classification: LCC RD11 | NLM WO 500 | DDC 617–dc23
LC record available at https://lccn.loc.gov/2017041639

This work is provided “as is,” and the publisher disclaims any and all warranties, express or implied, including any warranties as to accuracy, comprehensiveness, or currency of the content of this work.

This work is no substitute for individual patient assessment based upon healthcare professionals’ examination of each patient and consideration of, among other things, age, weight, gender, current or prior medical conditions, medication history, laboratory data and other factors unique to the patient. The publisher does not provide medical advice or guidance and this work is merely a reference tool. Healthcare professionals, and not the publisher, are solely responsible for the use of this work including all medical judgments and for any resulting diagnosis and treatments.

Given continuous, rapid advances in medical science and health information, independent professional verification of medical diagnoses, indications, appropriate pharmaceutical selections and dosages, and treatment options should be made and healthcare professionals should consult a variety of sources. When prescribing medication, healthcare professionals are advised to consult the product information sheet (the manufacturer’s package insert) accompanying each drug to verify, among other things, conditions of use, warnings and side effects and identify any changes in dosage schedule or contraindications, particularly if the medication to be administered is new, infrequently used or has a narrow therapeutic range. To the maximum extent permitted under applicable law, no responsibility is assumed by the publisher for any injury and/or damage to persons or property, as a matter of products liability, negligence law or otherwise, or from any reference to or use by any person of this work.

LWW.com

To Karen
Erich and Hallie
Alexandra and Peter
and
The late Dr. Howard I. Down

https://t.me/MedicalEbooksLibrary

COMMENTARY EDITORS

Kirby I. Bland, MD, FACS
Professor of Surgery and Chair *Emeritus*
Distinguished Faculty Scholar, UAB School of Medicine
Advisor to Director, UAB Comprehensive Cancer Center
UAB Department of Surgery
UAB University Hospital and The Kirklin Clinic
Birmingham, Alabama

Charles H. Cook, MD
Associate Professor of Surgery
Harvard Medical School
Division Chief, Acute Care Surgery, Trauma, Surgical Critical Care
Beth Israel Deaconess Medical Center
Boston, Massachusetts

A. Roshni Dasgupta, MD, MPH
Pediatric Surgeon
Division of Pediatric General and Thoracic Surgery
Cincinnati Children's
Cincinnati, Ohio

Katherine J. Deans, MD, MHSc
Associate Professor of Surgery
The Ohio State University
Columbus, Ohio

Karen Deveney, MD, FACS
Professor of Surgery Emerita
Vice-Chair of Surgical Education
Department of Surgery
Oregon Health and Science University
Portland, Oregon

Mary Dillhoff, MD, MS, FACS
Assistant Professor of Surgery
Division of Surgical Oncology

James Cancer Center
The Ohio State University
Columbus, Ohio

R. Bruce Donoff, DMD, MD
Dean and Walter C. Guralnick Distinguished Professor of Oral and Maxillofacial Surgery
Harvard School of Dental Medicine
Boston, Massachusetts

E. Christopher Ellison, MD
The Robert M. Zollinger Professor of Surgery
The Ohio State University
Columbus, Ohio

Douglas B. Evans, MD
Donald C. Ausman Family Foundation
Professor in Surgery and Chair
Department of Surgery
Medical College of Wisconsin
Milwaukee, Wisconsin

Josef E. Fischer, MD, FACS, DM(Hon) Lund, FRCS(E)(Hon)
William V. McDermott Distinguished Professor of Surgery
Harvard Medical School
Christian R. Holmes Professor of Surgery and Chair Department of Surgery
University of Cincinnati College of Medicine, Emeritus
Chair, Department of Surgery
Beth Israel Deaconess Medical Center, Emeritus
Boston, Massachusetts

Susan Galandiuk, MD
Professor of Surgery
Program Director, Section of Colon & Rectal Surgery
Hiram C. Polk, Jr. MD Department of Surgery
Director, Price Institute of Surgical Research
University of Louisville
Louisville, Kentucky

Ryan Gobble, MD
Assistant Professor of Plastic Surgery
University of Cincinnati College of Medicine

University of Cincinnati
Cincinnati, Ohio

Leonard G. Gomella, MD, FACS
The Bernard W. Godwin Professor of Prostate Cancer
Chairman, Department of Urology
Senior Director for Clinical Affairs
Sidney Kimmel Cancer Center
Thomas Jefferson University/Thomas Jefferson University Hospital
Philadelphia, Pennsylvania

Gayle M. Gordillo, MD, FACS
Associate Professor of Plastic Surgery
Medical Director of Wound Services
The Ohio State University
Columbus, Ohio

Jon C. Gould, MD
Chief of General Surgery
Walker Chair in General Surgery
Professor of Surgery
Medical College of Wisconsin
Milwaukee, Wisconsin

Vishal Gupta, MD
Assistant Professor
Staff Physician
Department of Head and Neck/ Plastic Reconstructive Surgery
Roswell Park Cancer Institute
Buffalo, New York

Douglas W. Hanto, MD, PhD
Deputy Chief of Surgery
VA St. Louis Health Care System
St. Louis, Missouri
Lewis Thomas Professor of Surgery Emeritus
Harvard Medical School
Boston, Massachusetts

Peter Henke, MD
Leland Ira Doan Professor of Surgery
Section of Vascular Surgery
Department of Surgery

University of Michigan
Ann Arbor, Michigan

Steven N. Hochwald, MD, MBA
Professor of Oncology
Vice Chair and Chief of GI Surgery
Roswell Park Cancer Institute
Professor of Surgery
University at Buffalo
Buffalo, New York

Eric S. Hungness, MD, FACS
Associate Professor of Surgery
S. David Stulberg Research Professor
Northwestern University
Chicago, Illinois

Syed G. Husain, MD, FACS, FACRS
Assistant Professor of Surgery-Clinical
The Ohio State University Wexner Medical Center
Columbus, Ohio

Daniel B. Jones, MD, MS, FACS
Professor of Surgery
Harvard Medical School
Vice Chair of Surgery
Director of the Bariatric Program
Beth Israel Deaconess Medical Center
Boston, Massachusetts

V. Suzanne Klimberg, MD, PhD
Courtney M. Townsend, Jr., MD Distinguished Chair in Surgical Oncology
Vice Chair of the Department of Surgery
Chief of Surgical Oncology
Medical Director for the University of Texas Medical Branch Cancer Institute
Galveston, Texas

Bodo Knudsen, MD, FRCSC
Henry A. Wise II Endowed Chair in Urology
Associate Professor, Department of Urology
The Ohio State University Wexner Medical Center

Columbus, Ohio

Moshim Kukar, MD, FACS
Assistant Professor of Oncology
Department of Surgical Oncology
Roswell Park Cancer Institute
Buffalo, New York

Russell R. Lonser, MD
Professor and Chair
Dardinger Family Chair in Oncological Neurosurgery
Department of Neurological Surgery
The Ohio State University Wexner Medical Center
Columbus, Ohio

Robert E. Merritt, MD, FACS
Associate Professor of Surgery
Director, Division of Thoracic Surgery
Associate Program Director, Cardiothoracic Surgery
The Ohio State University Wexner Medical Center
Columbus, Ohio

R. Lawrence Moss, MD
Surgeon-in-Chief
Nationwide Children's Hospital
E. Thomas Boles, Jr., Professor of Surgery
The Ohio State University College of Medicine
Columbus, Ohio

John T. Mullen, MD, FACS
Associate Professor of Surgery
Harvard Medical School
Program Director, General Surgery Residency
Massachusetts General Hospital
Boston, Massachusetts

Richard J. Mullins, MD, FACS
Professor of Surgery
Oregon Health & Science University
Portland, Oregon

Khalid Mumtaz, MBBS, MSc
Assistant Professor, Director Research, Section of Hepatology

The Ohio State University Wexner Medical Center
Columbus, Ohio

Theodore N. Pappas, MD
Distinguished Professor of Surgical Innovation
Chief, Advanced Oncologic & GI Surgery
Department of Surgery
Duke University Medical Center
Vice Dean for Medical Affairs, School of Medicine
Duke University School of Medicine
Durham, North Carolina

Kamal S. Pohar, MD, FRCSC
Julius and Diana Skestos Endowed Chair
Associate Professor of Urology
The Ohio State University
Columbus, Ohio

Vanessa Teaberry Schroder, MD
Assistant Professor
Department of Surgery
Duke University Medical Center
Durham, North Carolina

John H. Stewart, IV, MD, MBA
Chief of Surgery
Durham Veterans Administration Health System
Associate Professor of Surgery
Duke University School of Medicine
Durham, North Carolina

Gregory M. Tiao, MD
Ryckman Chair of Pediatric Surgery
Division Chief of Pediatric Surgery
Director of Pediatric Liver Transplantation
Cincinnati Children's Hospital and Medical Center
Professor of Surgery
University of Cincinnati
Cincinnati, Ohio

Gilbert R. Upchurch Jr., MD
Chief of Vascular and Endovascular Surgery
William H. Muller, Jr. Professor of Surgery

University of Virginia
Charlottesville, Virginia

Hunter Wessells, MD, FACS
Professor and Nelson Chair of Urology
University of Washington
Seattle, Washington

CONTRIBUTORS

Naji N. Abumrad, MD, FACS
Professor of Surgery
Section of Surgical Sciences
Vanderbilt University School of Medicine
Chairman Emeritus
Department of Surgery
Vanderbilt University Medical Center
Nashville, Tennessee

Steven Agle, MD, MPH
Assistant Professor
Department of Surgery
Division of Surgical Oncology
University of Texas Medical Branch
Galveston, Texas

Bestoun H. Ahmed, MD, FACS, FASMBS
Associate Professor
Department of Surgery
University of Pittsburgh School of Medicine
Attending Surgeon and Associate Director MIS/Bariatrics Fellowship Program
Department of Surgery
Magee-Women's Hospital of UPMC
Pittsburgh, Pennsylvania

Vance L. Albaugh, MD, PhD
Fellow in Surgical Metabolism and Metabolic Surgery
Section of Surgical Sciences
Vanderbilt University School of Medicine
Instructor
Department of Surgery
Vanderbilt University Medical Center
Nashville, Tennessee

Mohamad Allaf, MD
Professor of Urology, Oncology, and Biomedical Engineering
Vice-Chairman

Department of Urology
James Buchanan Brady Urological Institute
Johns Hopkins Hospital
Baltimore, Maryland

Robert J. Allen, SR, MD, FACS
Clinical Professor of LSUHSC
Ochsner Baptist Medical Center
New Orleans, Louisiana

Fernando Andrés Alvarez, MD
Staff Surgeon
General Surgery Service
Clínica Universitaria Reina Fabiola
Córdoba, Argentina

Parviz K. Amid, MD
Clinical Professor
Department of Surgery
University of California
Attending Staff
Department of Surgery
Ronald Reagan UCLA Medical Center
Los Angeles, California

Benjamin O. Anderson, MD
Director, Breast Health Clinic
Seattle Cancer Care Alliance
Professor of Surgery and Global Health Medicine
University of Washington
Seattle, Washington

Shalini Arora, MD, FACS
Assistant Professor
Department of General Surgery
Icahn School of Medicine at Mount Sinai
Director of Endocrine Surgery
Department of General Surgery
Kings County Hospital
New York, New York

Stanley W. Ashley, MD
Chief Medical Officer
Senior Vice President for Clinical Affairs
Brigham and Women’s Hospital

Boston, Massachusetts

Salman Ashruf, MD
Plastic Surgeon
Cosmetic Plastic Surgery of Maryland
Hanover, Maryland

Sam B. Atallah, MD, FACS, FASCRS
Associate Professor
Department of Surgery
University of Central Florida College of Medicine
Chairman
Department of Colorectal Surgery
Florida Hospital
Orlando, Florida

Toms Augustin, MD, MPH, FACS
Staff, Department of General Surgery
Digestive Disease Institute
Cleveland Clinic
Cleveland, Ohio

Bernadette Aulivola, MD, MS, RVT, RPVI, FACS
Director, Division of Vascular Surgery and Endovascular Therapy
Professor, Department of Surgery
Medical Director, Vascular Non-Invasive Lab
Loyola University Chicago Stritch School of Medicine
Maywood, Illinois

Dr. Kirk K. S. Austin, BSc, MBBS, BAO, AFRCSI, FRACS
Research Affiliate
The Surgical Outcomes Research Centre
Colorectal Surgeon
Department of Colorectal Surgery
Royal Prince Alfred Hospital
Camperdown, Australia

Edward D. Auyang, MD, FACS
Assistant Professor of Surgery
University of New Mexico
Staff Surgeon
University of New Mexico Hospital
Albuquerque, New Mexico

Faisal Aziz, MD

Vascular Surgery
Assistant Professor, Surgery
Penn State College of Medicine
Hershey, Pennsylvania

Brian D. Badgwell, MD, MS
Associate Professor
Department of Surgical Oncology
MD Anderson Cancer Center
Houston, Texas

Charles E. Bagwell, MD, FACS, FAAP
Arnold M Salzberg Professor of Surgery
Chair, Division of Pediatric Surgery
Virginia Commonwealth University/Medical College of Virginia
Richmond, Virginia

Michael Bahr, MD
Assistant Professor
Department of Surgery
University of Louisville
Louisville, Kentucky

Chad G. Ball, MD, MSC, FRCSC, FACS
Associate Professor of Surgery
Departments of Surgery and Oncology
University of Calgary
Foothills Medical Center
Calgary, Alberta

Hans G. Beger, MD, MD hon., FACS hon., JSS hon., CSS hon.-Prof.em. of Surgery
Chairman em.
Department of General- and Visceralsurgery University of Ulm
Ulm, Federal Republic of Germany

Robert Bendavid, MD
Advisory Council Member
American Hernia Society
Haifa, Israel

Parag Bhanot, MD, FACS
Associate Professor
Department of Surgery
Georgetown University School of Medicine

Vice-Chairman
Department of Surgery
MedStar Georgetown University Hospital
Washington, DC

Elisa H. Birnbaum, MD
Professor
Department of Surgery
University of Colorado
Division of GI
Trauma and Endocrine Surgery
Denver, Colorado

Kirby I. Bland, MD, FACS
Professor of Surgery and Chair *Emeritus*
Distinguished Faculty Scholar, UAB School of Medicine
Advisor to Director, UAB Comprehensive Cancer Center
UAB Department of Surgery
UAB University Hospital and The Kirklin Clinic
Birmingham, Alabama

Joseph-Vincent V. Blas, MD
Assistant Program Director of Vascular Surgery
Division of Vascular Surgery
Department of Surgery
Greenville Health System & University of South Carolina School of Medicine
Greenville, South Carolina

David A. Bloom, MD
Division of Pediatric Urology
Department of Urology
University of Michigan Health System
Ann Arbor, Michigan

Jonathan M. Bock, MD, FACS
Associate Professor
Division of Laryngology and Professional Voice Department of Otolaryngology & Communication Sciences
Medical College of Wisconsin
Milwaukee, Wisconsin

Branko Bojovic, MD
Assistant in Surgery
Massachusetts General Hospital

Chief of Plastic, Reconstructive and Laser Surgery
Shriners Hospitals for Children—Boston
Boston, Massachusetts

Cristiano Boneti, MD, FACS
Assistant Professor
DeWitt Daughtry Department of Surgery
Leonard M. Miller School of Medicine
Miami, Florida

Jonathan Boone, MD
Department of Obstetrics and Gynecology
University of Alabama at Birmingham
School of Medicine
Birmingham, Alabama

Daniel Borja-Cacho, MD
Assistant Professor of Transplant Surgery
Department of Surgery
University of Arkansas for Medical Sciences
Little Rock, Arkansas

Thomas C. Bower, MD
Chair, Division of Vascular and Endovascular Surgery
Professor of Surgery
Mayo Clinic College of Medicine
Rochester, Minnesota

Richard Branson, MSc, RRT, FCCM, FAARC
Professor of Surgery
Division of Trauma & Critical Care
University of Cincinnati
Cincinnati, Ohio

Karen J. Brasel, MD, MPH
Professor and Program Director, General Surgery
Department of Surgery
Division of Trauma/Critical Care
Oregon Health and Science University
Portland, Oregon

Igal Breitman, MD
Assistant Professor
Department of Surgery
University of Illinios

Director
Bariatric and Metabolic Surgery
Department of Surgery
Rockford Memorial Hospital
Rockford, Illinois

David C. Brewster, MD
Clinical Professor of Surgery
Harvard Medical School
Senior Attending Surgeon
Division of Vascular Surgery
Massachusetts General Hospital
Boston, Massachusetts

L. Michael Brunt, MD
Professor of Surgery
Section Chief, Minimally Invasive Surgery
Washington University School of Medicine
Attending Surgeon
Barnes-Jewish Hospital
St. Louis, Missouri

Henry Buchwald, MD, PhD
Professor
Department of Surgery
University of Minnesota
Minneapolis, Minnesota

Rudolf Bumm, MD
Professor of Surgery
Chief, Department of Surgery
Klinik Weilheim
Germany

Richard A. Burkhart, MD
Assistant Professor
Department of Surgery
John Hopkins Hospital
Baltimore, Maryland

Bryan M. Burt, MD
Associate Professor of Surgery
Associate Chief, Division of Thoracic Surgery
Director of Thoracic Surgery Research
Department of Surgery

Baylor College of Medicine
Attending Surgeon
Department of Surgery
Baylor St. Luke's Medical Center
Houston, Texas

Ronald W. Busuttil, MD, PhD, FACS
The Dumont-UCLA Liver Transplant Center
University of California Los Angeles
Los Angeles, California

Aileen Caceres, MD, MPH
Clerkship Director
Assistant Professor
University of Central Florida College of Medicine
Director
Minimally Invasive Gynecologic Surgery
Florida Hospital Celebration Health
Celebration, Florida

Kristine E. Calhoun, MD, FACS
Associate Professor
Department of Surgery, Division of Surgical Oncology
University of Washington
Seattle, Washington

Richard P. Cambria, MD
Professor of Surgery
Harvard Medical School
Chief, Division of Vascular and Endovascular Surgery
Massachusetts General Hospital
Boston, Massachusetts

Jeremy W. Cannon, MD, SM, FACS
Associate Professor
Division of Trauma, Surgical Critical Care & Emergency Surgery
Perelman School of Medicine at the University of Pennsylvania
Philadelphia, Pennsylvania

Tobias Carling, MD, PhD
Associate Professor of Surgery (Endocrine Surgery)
Director
Yale Endocrine Neoplasia Laboratory
New Haven, Connecticut

Azadeh A. Carr, MD
Department of Surgery
Division of Surgical Oncology
Medical College of Wisconsin
Milwaukee, Wisconsin

William R. Carroll, MD
George W Barber, Jr., Professor and Chair
Department of Otolaryngology
University of Alabama at Birmingham
Department of Otolaryngology
UAB Hospitals
Birmingham, Alabama

Jane V. Carter, MB ChB, MRCS, PGCE
Price Institute of Surgical Research
Department of Surgery
University of Louisville School of Medicine
511 South Floyd Street
Medical Dental Research Building
Louisville, Kentucky

Robert J. Cerfolio, MD, MBA, FACS, FCCP
Professor of Cardiothoracic Surgery
NYU Langone Medical Center
Chair of Clinical Division Thoracic Surgery NYU
Inaugural Director of the Lung Cancer Service Line
Senior Advisor Robotic Committee
New York, New York

William C. Chapman, MD, FACS
Eugene M. Bricker Chair of Surgery
Professor and Chief, Section of Transplantation
Chief, Division of General Surgery
Surgical Director, Transplant Center
Washington University School of Medicine
Attending Physician
General Surgery
Barnes Jewish Hospital
St. Louis, Missouri

Eric J. Charles, MD
Department of Surgery
University of Virginia
Charlottesville, Virginia

Clark C. Chen, MD, PhD
Professor of Neurosurgery
University of Minnesota
Minneapolis, Minessota

David C. Chen, MD
Assistant Clinical Professor
Department of Surgery
University of California at Los Angeles
Los Angeles, California

Margaret Chen, MD, FACS
New York-Presbyterian/Columbia University Medical Center
Herbert Irving Pavilion
New York, New York

Dennis S. Chi, MD
Professor
Department of OB/GYN
Weill Cornell Medical College
Attending
Gynecology Service
Department of Surgery
Memorial Sloan Kettering Cancer Center
New York, New York

Kathleen K. Christians, MD
Professor
Division of Surgical Oncology
Department of Surgery
Medical College of Wisconsin
Milwaukee, Wisconsin

Kristin Chrouser, MD, MPH
Assistant Professor
Department of Urology
University of Minnesota
Section of Urology
Minneapolis VA Health Care System
Minneapolis, Minnesota

Ronald H. Clements, MD
Professor of Surgery
Vice-Chairman of Business Development
Vanderbilt University Medical Center

Nashville, Tennessee

G. Travis Clifton, MD, FACS
Department of Surgical Oncology
University of Texas MD Anderson Cancer Center
Houston, Texas

W. Darrin Clouse, MD, FACS
Professor of Surgery
Uniformed Services University of the Health Sciences
Bethesda, Maryland
Associate Professor of Surgery
Harvard Medical School
Division of Vascular and Endovascular Surgery
Massachusetts General Hospital
Boston, Massachusetts

Dawn M. Coleman, MD
Associate Professor
Department of Surgery
University of Michigan
Ann Arbor, Michigan

Kelly M. Collins, MD
Attending Physician
General Surgery
Henry Ford Hospital
Detroit, Michigan

Anthony J. Comerota, MD, FACS, RVT
Director, Jobst Vascular Center
The Toledo Hospital
Toledo, Ohio

Robert E. Condon, MD†
Department of Surgery
Medical College of Wisconsin
Milwaukee, Wisconsin

Mark F. Conrad, MD, MMSc
Associate Professor of Surgery
Harvard Medical School
Director of Clinic Research and Program Director
Division of Vascular and Endovascular Surgery
Massachusetts General Hospital

Boston, Massachusetts

Willy Coosemans, MD, PhD
Professor
Department of Clinical and Experimental Medicine: Thoracic Surgery
KU Leuven University
Clinical Head
Thoracic Surgery
University Hospital Gasthuisberg
Leuven, Belgium

Alain Corcos, MD, FACS
Clinical Assistant Professor of Surgery
Division Chief & Trauma Medical Director
Chief, Surgical Critical Care
Academic Chief, Surgical Residency
UPMC Mercy
Faculty
McGowan Institute for Regenerative Medicine (MIRM)
Pittsburgh, Pennsylvania

Michael S. Cowher, MD
Breast Surgeon
Quality Assurance Director
Breast Surgical Oncology Co-Director
Breast Surgical Fellowship
Department of Surgery
Allegheny Health Network
Pittsburgh, Pennsylvania

Gregory Dakin, MD, FACS
Associate Professor
Department of Surgery
Weill Cornell Medicine
Division of GI, Metabolic, & Bariatric Surgery
Associate Attending Surgeon
New York Presbyterian Hospital
New York, New York

Mani A. Daneshmand, MD
Associate Professor
Department of Surgery
Duke University Medical Center
Durham, North Carolina

Siamak Daneshmand, MD
Associate Professor of Urology (Clinical Scholar)
Director of Clinical Research
Keck School of Medicine of USC
Los Angeles, California

Brian R. Davis, MD
Department of Surgery
Texas Tech University School of Medicine
El Paso, Texas

Herbert Decaluwe, MD
Joint Clinical Head
Department of Thoracic Surgery
University Hospital Gasthuisberg
Leuven, Belgium

Malcolm M. DeCamp, MD, FACS
Fowler McCormick Professor of Surgery
Chief, Division of Thoracic Surgery
Department of Surgery
Northwestern University Feinberg School of Medicine
Chicago, Illinois

Georges Decker, MD
Thoracic Surgeon
Groupe Chirurgical Zithaklinik
Zithaklinik-Hôpitaux Robert Schuman
Luxembourg, Luxembourg

Amy C. Degnim, MD
Joe M. & Ruth Roberts Professor of Surgery
Consultant, Department of Surgery
Division of Breast, Endocrine, Metabolic, and GI Surgery
Mayo Clinic
Rochester, Minnesota

Jorge I. de la Torre, MD, MSHA
Professor
University of Alabama at Birmingham
Director, Division of Plastic Surgery
Birmingham, Alabama

Paul De Leyn, MD, PhD
Professor

Department of Clinical and Experimental Medicine: Thoracic Surgery
KU Leuven University
Chief of Surgery
Chairman, Department of Thoracic Surgery
University Hospital Gasthuisberg
Leuven, Belgium

Eric J. DeMaria, MD, FACS, FASMBS
Bariatric Surgeon
Bon Secours General Surgery at St Mary's Hospital
Richmond, Virginia

Tom R. DeMeester, MD
Emeritus Professor
Department of Surgery
University of Southern California
Los Angeles, California

Daniel T. Dempsey, MD
Professor of Surgery at the Hospital of the University of Pennsylvania
Chief, Gastrointestinal Surgery
Surgeon
Assistant Director, Peri-Operative Services
Hospital of the University of Pennsylvania
Philadelphia, Pennsylvania

Lieven De Pypere, MD
Joint Clinical Head
Thoracic Surgery
University Hospital Gasthuisberg
Leuven, Belgium

Sapan S. Desai, MD, PhD, MBA
Assistant Professor of Vascular Surgery and Vice Chair of Research
Southern Illinois University School of Medicine
Springfield, Illinois

Eduardo de Santibañes, MD, PhD
Professor and Chairman
Liver Transplant Unit
Hospital Italiano de Buenos Aires
Buenos Aires, Argentina

Sarah M. DeSnyder, MD, FACS
Assistant Professor

Department of Breast Surgical Oncology
The University of Texas MD Anderson Cancer Center
Houston, Texas

J. Michael Dixon, MD, MB ChB, FRCS, FRCP Hon
Professor of Surgery
Institute of Genetics and Molecular Medicine
University of Edinburgh
Consultant Surgeon
Edinburgh Breast Unit
Western General Hospital
Edinburgh, Scotland

R. Bruce Donoff, DMD, MD
Dean and Walter C. Guralnick
Distinguished Professor of Oral and Maxillofacial Surgery
Harvard School of Dental Medicine
Boston, Massachusetts

Eric J. Dozois, MD
Program Director
Department of Colon and Rectal Surgery
Mayo Medical School
Rochester, Minnesota

Roger R. Dozois, MD
Department of Colon and Rectal Surgery
Mayo Clinic
Rochester, Minnesota

Richard L. Drake, PhD, FAAA
Director of Anatomy
Professor of Surgery
Cleveland Clinic Lerner College of Medicine
Cleveland, Ohio

David J. Dries, MSE, MD
Professor of Surgery
John F. Perry, Jr., Chair of Trauma Surgery Clinical Adjunct Professor of Emergency Medicine
Surgery and Emergency Medicine
University of Minnesota
Minneapolis, Minnesota
Division Medical Director
Department of Surgery

Regions Hospital/HealthPartners Medical Group
St. Paul, Minnesota

Matthew Edwards, MD, MS, RVT, FACS
Professor and the Richard H. Dean, MD Chair in Vascular Surgery
Vascular and Endovascular Surgery
Winston-Salem, North Carolina

John F. Eidt, MD
Professor
Department of Surgery
Texas A&M College of Medicine
Bryan, Texas
Vice-Chairman
Vascular Surgical Services
Baylor Scott & White Health
Baylor Jack and Jane Hamilton Heart and Vascular Hospital
Dallas, Texas

Brian H. Eisner, MD
Assistant Professor of Surgery
Co-Director, Kidney Stone Program
Harvard Medical School
Department of Urology
Massachusetts General Hospital
Boston, Massachusetts

Kevin El-Hayek, MD, FACS
Assistant Professor of Surgery
Cleveland Clinic Lerner College of Medicine
Staff Physician
Digestive Disease Institute
Cleveland Clinic
Cleveland, Ohio
Cleveland Clinic Abu Dhabi
Abu Dhabi, UAE

Jonathan L. Eliason, MD
Associate Professor
Section of Vascular Surgery
Department of Surgery
University of Michigan
Ann Arbor, Michigan

Mustapha El-Lakis, MD

Department of Surgery
Virginia Mason Medical Center
Seattle, Washington

E. Christopher Ellison, MD, AFCS
Robert M Zollinger Professor of Surgery and Vice-Dean of Clinical Affairs
Department of Surgery
The Ohio State University College of Medicine
Columbus, Ohio

Guillermo A. Escobar, MD, FACS
Assistant Professor of Surgery
University of Arkansas for Medical Sciences
Little Rock, Arkansas

Mohammad H. Eslami, MPH, MD
Visiting Professor of Surgery
Division of Vascular Surgery
Department of Surgery
University of Pittsburgh School of Medicine
Chief of Vascular Surgery
UPMC Mercy Hospital
Pittsburgh, Pennsylvania

Douglas B. Evans, MD
Donald C. Ausman Family Foundation Professor of Surgery and Chair
Department of Surgery
Medical College of Wisconsin
Milwaukee, Wisconsin

Stephen R.T. Evans, MD
Professor
Department of Surgery
Georgetown University Medical Center
Washington, DC
Executive Vice-President/Chief Medical Officer
MedStar Health
Columbia, Maryland

Amy R. Evenson, MD
Instructor
Department of Surgery
Beth Israel Deaconess Medical Center
Harvard Medical School
Boston, Massachusetts

Russell W. Farmer, MD, FACS, FASCRS
Assistant Professor of Surgery/Colon and Rectal Surgery
Hiram C. Polk, Jr., MD Department of Surgery
University of Louisville School of Medicine
Louisville, Kentucky

Oluwadamilola (Lola) Fayanju, MD, MA, MPHS
Assistant Professor of Surgery
Duke University School of Medicine
Durham, North Carolina

Robert J. Feezor, MD, FACS, RPVI
Associate Professor of Surgery
University of Florida
UF Health Heart and Vascular Surgery—Halifax Health
Daytona Beach, Florida

Sheldon Feldman, MD, FACS
New York-Presbyterian/Columbia University Medical Center
Herbert Irving Pavilion
New York, New York

David V. Feliciano, MD
Clinical Professor
Department of Surgery
University of Maryland
Attending Surgeon
Department of Surgery
Shock Trauma Center at University of Maryland Medical Center
Baltimore, Maryland

Linda Ferrari, MD
Department of Surgery
University of Washington
University of Washington Medical Center
Seattle, Washington

Alessandro Fichera, MD
Professor
Department of Surgery
University of Washington
Section Chief Gastrointestinal Surgery
University of Washington Medical Center
Seattle, Washington

Josef E. Fischer, MD, FACS, DM(Hon) Lund, FRCS(E)(Hon)
William V. McDermott Distinguished Professor of Surgery
Harvard Medical School
Christian R. Holmes Professor of Surgery and Chair Department of Surgery
University of Cincinnati College of Medicine, Emeritus
Chair, Department of Surgery
Beth Israel Deaconess Medical Center, Emeritus
Boston, Massachusetts

Laura E. Fischer, MD, MS
Department of Surgery
Oregon Health and Science University
Portland, Oregon

Robert J. Fitzgibbons, Jr., MD, FACS
Harry E. Stuckenhoff Professor and Chairman
Department of Surgery
Creighton University School of Medicine
Omaha, Nebraska

R. Jobe Fix, MD, FACS
Professor
Division of Plastic Surgery
University of Alabama at Birmingham
Birmingham, Alabama

Spiros G. Frangos, MD, MPH
Professor, Department of Surgery
Professor, Department of Anesthesiology, Perioperative Care, and Pain Medicine
Chief of Surgery
Director of Trauma/Critical Care
Bellevue Hospital Center
Director, Division of Acute Care Surgery
NYU Langone Medical Center
New York, New York

Herbert R. Freund, MD
Hadassah University Medical Center
Jerusalem, Israel

Michael R. Freund, MD
Department of General Surgery, Shaare Zedek Medical Center
The Hebrew University School of Medicine
Jerusalem, Israel

Arlan F. Fuller, Jr., MD
Irene and Telemachus Demoulas Chair in Women's Health
Chief of Gynecologic Oncology
Associate Professor of OB/GYN
Tufts University School of Medicine
Winchester, Massachusetts

Wolfgang B. Gaertner, MD, MSc
Assistant Professor
Colon & Rectal Surgery
University of Minnesota
Staff Surgeon
Colon & Rectal Surgery
University of Minnesota Medical Center
Minneapolis, Minnesota

Susan Galandiuk, MD
Professor of Surgery
Program Director, Section of Colon & Rectal Surgery
Hiram C. Polk, Jr. MD Department of Surgery
Director, Price Institute of Surgical Research
University of Louisville
Louisville, Kentucky

Norman J. Galbraith, BSc, MBChB, MRCS
Price Institute of Surgical Research
Department of Surgery
University of Louisville School of Medicine
Medical Dental Research Building
Louisville, Kentucky

Ian Ganly, MD, PhD, MS, FRCS, FRCS-ORL
Associate Professor
Department of Otolaryngology—Head and Neck Surgery
Weill Cornell Medical College
Cornell University
Associate Attending Surgeon
Surgery, Head, and Neck Service
Memorial Sloan Kettering Cancer Center
New York, New York

Julio Garcia-Aguilar, MD, PhD
Surgeon
Chief, Colorectal Service
Benno C. Schmidt Chair in Surgical Oncology

Department of Surgery
Memorial Sloan Kettering Cancer Center
New York, New York

Manuel Garcia-Toca, MD, FACS
Clinical Associate Professor of Surgery
Stanford University
Stanford, California

O. James Garden, CBE, MD, FRCSEd, FRCPEd, FRCScan(Hon), FRACS(Hon), FACS(Hon), FRSE
Regius Professor of Clinical Surgery
University of Edinburgh
Honorary Consultant Hepatobiliary Surgeon
Royal Infirmary of Edinburgh
Edinburgh, Scotland

Keith S. Gersin, MD, FACS, FASMBS
Clinical Professor of Surgery
UNC—Chapel Hill
Chapel Hill, North Carolina
Chief, Bariatric Surgery
Specialty Medical Director of Bariatrics & Metabolic Surgery
Carolinas HealthCare System Medical Group
Carolinas Medical Center
Charlotte, North Carolina

Karthik Ghosh, MD
Associate Professor of Medicine
Consultant, General Internal Medicine
Breast Diagnostic Clinic
Mayo Clinic
Rochester, Minnesota

Arthur I. Gilbert, MD, FACS
Voluntary Associate Professor
DeWitt Daughtry Family Department of Surgery
Leonard M. Miller School of Medicine
Miami, Florida

Ana Luiza Mandelli Gleisner, MD
Assistant Professor
Department of Surgery
University of Colorado Anschutz Medical Campus
Aurora, Colorado

Peter Gloviczki, MD, FACS
Roberts Professor of Surgery and Chair, Emeritus
Division of Vascular and Endovascular Surgery
Mayo Clinic
Rochester, Minnesota

Philip H. Gordon, MD, FRCS(C), FACS, FASCRS, FCSCRS, FRSM(Hon), FACPGBI(Hon)
Professor of Surgery and Oncology
Director, Colon & Rectal Surgery
McGill University
Montreal, Quebec

Jon C. Gould, MD
Chief of General Surgery
Walker Chair in General Surgery
Professor of Surgery
Medical College of Wisconsin
Milwaukee, Wisconsin

Clive S. Grant, MD
Professor, Emeritus
Department of Surgery
Mayo Clinic
Rochester, Minnesota

Arin K. Greene, MD, MMSc
Associate Professor
Department of Plastic and Oral Surgery
Boston Children's Hospital
Harvard Medical School
Boston, Massachusetts

Gwen M. Grimsby, MD
Assistant Professor
Department of Urology
Mayo Clinic Hospital
Pediatric Urologist
Division of Urology
Department of Surgery
Phoenix Children's Hospital
Phoenix, Arizona

Lukasz Filip Grochola, MD, PhD
Department of Visceral and Transplantation Surgery

Swiss HPB and Transplant Center
University Hospital of Zurich
Zurich, Switzerland

Shawn S. Groth, MD
Assistant Professor of Surgery
Division of General Thoracic Surgery
Assistant Professor of Surgery
Division of Surgical Research
Director of Esophageal Surgical Services
Division of General Thoracic Surgery
Baylor College of Medicine
Attending Surgeon
Surgery
Baylor St. Luke's Medical Center
Houston, Texas

Jose G. Guillem, MD, MPH
Professor of Surgery
Weill Cornell Medical College
Attending
Department of Surgery
Memorial Sloan Kettering Cancer Center
New York, New York

Juan P. Gurria, MD
Department of Surgery
University of Cincinnati
Division of Pediatric General and Thoracic Surgery
Cincinnati Children's Hospital Medical Center
Cincinnati, Ohio

Khurshid A. Guru, MD
Professor of Oncology
Director of Robotic Surgery
Department of Urology
Roswell Park Cancer Institute
Buffalo, New York

Ellen Hagopian, MD, FACS
Associate Professor
Department of Surgery
Seton Hall-Hackensack Meridian School of Medicine
South Orange, New Jersey
Hepato-Pancreato-Biliary Surgery

Department of Surgery
Hackensack University Medical Center
Hackensack, New Jersey

Michael E. Halkos, MD
Assistant Professor of Surgery
Division of Cardiothoracic Surgery
Department of Surgery
Emory University School of Medicine
Atlanta, Georgia

Karem C. Harth, MD
Clinical Assistant Professor, Surgery
Department of Vascular Surgery
Case Western Reserve University School of Medicine
Cleveland, Ohio

Per-Olof Hasselgren, MD, PhD
George H.A. Clowes, Jr.,
Professor of Surgery
Harvard Medical School
Vice Chairman—Research
Director of Endocrine Surgery
Department of Surgery
Beth Israel Deaconess Medical Center
Boston, Massachusetts

Bruce H. Haughey, MD
Otolaryngology-Head and Neck Surgery
Washington University School of Medicine
St. Louis, Missouri

Robert J. Havlik, MD
Chairman and George Korkos Professor
Department of Plastic Surgery
Medical College of Wisconsin
Milwaukee, Wisconsin

Jeffrey W. Hazey, MD, FACS
Memorial Health
Columbus, Ohio

R.J. Heald, CBE
Surgical Director
Pelican Cancer Foundation

United Kingdom

Peter Henke, MD
Leland Ira Doan Professor of Surgery
Section of Vascular Surgery
Department of Surgery
University of Michigan
Ann Arbor, Michigan

Patrick C. Hettinger, MD
Assistant Professor
Plastic Surgery
Medical College of Wisconsin
Milwaukee, Wisconsin

Frank Hinman, Jr., MD†
Clinical Professor
Department of Urology
University of California
San Francisco, California

Steven N. Hochwald, MD, MBA
Professor of Oncology
Vice Chair and Chief of GI Surgery
Roswell Park Cancer Institute
Professor of Surgery
University at Buffalo
Buffalo, New York

Mitchel S. Hoffman, MD
Senior Member
Moffitt Cancer Center
Professor
USF Morsani College of Medicine
Tampa, Florida

George W. Holcomb III, MD, MBA
Katharine Berry Richardson Professor of Pediatric Surgery
University of Missouri—Kansas City School of Medicine
Senior Vice-President
Director, Center for Minimally Invasive Surgery
Chief, Section of General Surgery
Children's Mercy Hospital
Kansas City, Missouri

James Jason Hoth, MD, PhD, FACS
Professor
Department of Surgery
Trauma Medical Director
Wake Forest Baptist Medical Center
Winston-Salem, North Carolina

Jeffrey D. Howard, Jr., MD
Department of Surgery
University of Louisville
Louisville, Kentucky

Thomas S. Huber, MD, PhD
Division of Vascular Surgery and Endovascular Therapy
Department of Surgery
University of Florida College of Medicine
Gainesville, Florida

Franziska Huettner, MD, PhD
Assistant Professor
Institute for Plastic Surgery
Southern Illinois University School of Medicine
Springfield, Illinois

Warner Huh, MD
Professor and Division Director of Gynecologic Oncology
University of Alabama at Birmingham
Birmingham, Alabama

Eric S. Hungness, MD, FACS
Associate Professor of Surgery
Northwestern University
Evanston, Illinois
Staff Surgeon
Northwestern Memorial Hospital
Chicago, Illinois

John G. Hunter, MD, FACS, FRCS(Edin)(hon)
Chief Clinical Officer
Mackenzie Professor
Department of Surgery
OHSU School of Medicine
Portland, Oregon

Ahmed A. Hussein, MD

Assistant Lecturer
Department of Urology
Cairo University
Cairo, Egypt

Elias S. Hyams, MD
Assistant Professor of Urology
Columbia University Medical Center
New York, New York

Neil H. Hyman, MD, FACS
Professor
Chief, Section of Colon and Rectal Surgery
Department of Surgery
University of Chicago Pritzker School of Medicine
Chicago, Illinois

Corey W. Iqbal, MD, FAAP, FACS
Medical Director of Pediatric and Fetal Surgery
Overland Park Women and Children's Specialty Services
Overland Park Regional Medical Center
Overland Park, Kansas

Arjun Jayaraj, MBBS, MPH, RPVI
Vascular Surgeon
RANE Center for Venous and Lymphatic Disease
St. Dominic's Hospital
Jackson, Mississippi

Jeffrey Jim, MD, MS
Associate Professor
Vascular Surgery
Washington University School of Medicine
St. Louis, Missouri

Jay A. Johannigman, MD, FACS, FCCM
Professor of Surgery
Director, Division of Trauma, Critical Care, & Acute Care Surgery
University of Cincinnati
Cincinnati, Ohio
Attending Surgeon
University Hospital Inc
Cincinnati, Ohio
Col, US Army (R)

Daniel B. Jones, MD, MS, FACS
Professor of Surgery
Harvard Medical School
Vice-Chair of Surgery
Chief, Minimally Invasive Surgical Services
Director of the Bariatric Program
Beth Israel Deaconess Medical Center
Boston, Massachusetts

Edward L. Jones, MD, FACS
Assistant Professor of Surgery
Section Chief, General Surgery
Denver Veterans Affairs Medical Center
Anschutz Medical Campus
University of Colorado
Denver, Colorado

Jeffrey R. Jorden, MD
Director of Robotic & Minimally Invasive Surgery
Hiram C. Polk, Jr., MD Department of Surgery
University of Louisville School of Medicine
Louisville, Kentucky

Thomas B. Julian, MD
Allegheny Health Network Cancer Institute
Allegheny General Hospital
National Surgical Adjuvant Breast and Bowel Project (NSABP)
Pittsburgh, Pennsylvania

Enjae Jung, MD
Assistant Professor
Vascular Surgery
OHSU Knight Cardiovascular Institute
Oregon Health & Science University
Portland, Oregon

Vikram S. Kashyap, MD
Professor, Surgery, Case Western Reserve University School of Medicine
Division Chief, Vascular Surgery, University Hospitals Cleveland Medical Center
Co-Director, Harrington Heart and Vascular Institute, University Hospitals Cleveland Medical Center
Cleveland, Ohio

Burkhard S. Kasper, MD

Privadozent, Neurologische Klinik
Stellvertretender Sektionsleiter Epilepsie
Universitaet Erlangen Germany

Ekkehard M. Kasper, MD, PhD
Associate Professor in Neurosurgery
Harvard Medical School
Director, Neurosurgical Oncology
Beth Israel Deaconess Medical Center
Boston, Massachusetts

Louis R. Kavoussi, MD, MBA
Waldbaum Gardiner Professor and Chairman of Urology
Hofstra-Northwell School of Medicine
Hempstead, New York

Ahmed Kayssi, MD
Limb Preservation Fellow
Inova Health System, IFMC
Falls Church, Virginia

Michael R. B. Keighley, MBBS, FRCS (Edin), FRCS (Eng), MS
Emeritus Professor
University of Birmingham
President of the MASIC Foundation
Trustee, Bowel Disease Research Foundation
London, United Kingdom

Scott R. Kelley, MD, FACS, FASCRS
Assistant Professor of Surgery
Division of Colon and Rectal Surgery
Mayo Clinic
Rochester, Minnesota

Edward Kelly, MD
Assistant Professor
Department of Surgery
Harvard Medical School
Attending Surgeon
Department of Surgery
Brigham and Women's Hospital
Boston, Massachusetts

Michael P. Kim, MD
Assistant Professor

Department of Surgical Oncology
MD Anderson Cancer Center
Houston, Texas

Dennis Y. Kim, MD
Associate Professor of Clinical Surgery
David Geffen School of Medicine at UCLA
Division of Trauma/Acute Care Surgery/Surgical Critical Care
Department of Surgery
Harbor-UCLA Medical Center
Torrance, California

Cindy Kin, MD
Colorectal Surgeon
Surgical Oncologist
Assistant Professor of Surgery (General Surgery)
Department of Surgery
Stanford University School of Medicine
Stanford, California

Allan D. Kirk, MD, PhD
David C. Sabiston, Jr., Professor and Chairman
Department of Surgery
Duke University Medical Center
Surgeon-in-Chief
Duke University Health System
Durham, North Carolina

V. Suzanne Klimberg, MD, PhD
Courtney M. Townsend, Jr., MD Distinguished Chair in Surgical Oncology
Vice Chair of the Department of Surgery
Chief of Surgical Oncology
Medical Director for the University of Texas Medical Branch Cancer Institute
Galveston, Texas

Badrinath R. Konety, MD, FACS, MBA
Professor and Chair
Department of Urology
Dougherty Family Chair in Uro-Oncology
Associate Director for Clinical Affairs
Masonic Cancer Center
University of Minnesota
Minneapolis, Minnesota

Matthew C. Koopmann, MD
Assistant Professor of Surgery
Division of Vascular Surgery
Oregon Health and Science University
Staff Vascular Surgeon
VA Portland Health Care System
Portland, Oregon

Kate H. Kraft, MD
Division of Pediatric Urology
Department of Urology
University of Michigan Health System
Ann Arbor, Michigan

Mukta Krane, MD
Associate Professor
Department of Surgery
University of Washington
Outpatient Medical Director—Surgical Specialties
University of Washington Medical Center
Seattle, Washington

Jake E. J. Krige, MBChB, MSc, FACS, FRCS, FCS (SA)
Professor
Department of Surgery
University of Cape Town Health Sciences Faculty
Cape Town, South Africa

Matthew Kroh, MD, FACS
Institute Chief, Associate Professor of Surgery
Digestive Disease Institute
Cleveland Clinic Abu Dhabi
Cleveland Clinic Lerner College of Medicine
Abu Dhabi, United Arab Emirates

Irving L. Kron, MD
Professor and Chair
Department of Surgery
University of Virginia
Charlottesville, Virginia

Helen Krontiras, MD
Professor of Surgery
UAB School of Medicine
Birmingham, Alabama

Robert D. Kugel, MD
Surgeon, Inventor
Hernia Treatment Center Northwest
Olympia, Washington

Moshim Kukar, MD
Assistant Professor
Department of Surgical Oncology
Roswell Park Cancer Institute
Buffalo, New York

Michael E. Kupferman, MD, MBA
Senior Vice-President, Clinical and Academic Network Development
Professor, Department of Head & Neck Surgery
The University of Texas MD Anderson Cancer Center
Houston, Texas

Moon O. Kwoun, MD, RVT, RPVI
Instructor in Surgery
Harvard Medical School
Cambridge Health Alliance
Cambridge, Massachusetts

Gregory J. Landry, MD
Professor
Vascular Surgery
Oregon Health & Science University
OHSU Knight Cardiovascular Institute
Portland, Oregon

Erin O. Lange, MD
Department of Surgery
University of Washington Medical Center
Seattle, Washington

Jacob C. Langer, MD
Professor
Department of Surgery
University of Toronto
Attending Pediatric Surgeon
Hospital for Sick Children
Toronto, Ontario

David W. Larson, MD, MBA, FACS, FASCRS
Chair of Colorectal Surgery

Director of Enterprise Cancer Quality
Mayo Clinic
Rochester, Minnesota

Michael Latzko, MD
Assistant Professor
Department of Surgery
University of Florida College of Medicine—Jacksonville
Jacksonville, Florida

Yosef Laviv, MD
Attending Neurosurgeon
Department of Neurosurgery
Rabin Medical Center
Tel Aviv, Israel

Simon Law, MBBChir, MS (HK), MA (Cantab), FRCSEd, FCSHK, FHKAM, FACS
Cheung Kung-Hai Professor in Gastrointestinal Surgery
Chief, Division of Esophageal and Upper Gastrointestinal Surgery
Department of Surgery
The University of Hong Kong
Queen Mary Hospital
Hong Kong

Anna M. Ledgerwood, MD
Professor
Department of Surgery
Wayne State University School of Medicine
Staff
Department of Surgery
Detroit Receiving Hospital & Harper University Hospital
Detroit, Michigan

Cheong J. Lee, MD, FACS
Division of Vascular Surgery
Medical College of Wisconsin
Milwaukee, Wisconsin

Dr Peter J. Lee, MBBS, MSc (Med), MS, FRACS
Research Affiliate
The Institute of Academic Surgery at RPA & The Surgical Outcomes Research Centre
Colorectal Surgeon
Department of Colorectal Surgery

Royal Prince Alfred Hospital
Camperdown, Australia

Ken Lee, MD
Department of Surgery
George Washington University
Washington, DC

Toni Lerut, MD, PhD
Emeritus Professor
Department of Clinical and Experimental Medicine: Thoracic Surgery
KU Leuven University
Emeritus Chairman
Thoracic Surgery
University Hospital Gasthuisberg
Leuven, Belgium

Mark Levin, MD, MS
Fellow in Vascular Surgery
Section of Vascular & Endovascular Surgery
Department of Surgery
University of Texas Southwestern Medical Center
Dallas, Texas

Edward A. Levine, MD
Professor of Surgery
Chief, Surgical Oncology
Wake Forest University
Winston-Salem, North Carolina

Carol M. Lewis, MD, MPH, FACS
Associate Professor
Department of Head and Neck Surgery
University of Texas MD Anderson Cancer Center
Houston, Texas

Kui-Hin Liau, MBBS, MMed(Surgery), FRCS(Edin), FAMS (Surgery)
Medical Director & Senior Consultant Surgeon
Department of Surgery & Surgical Oncology
Nexus Surgical Associates Pte Ltd
Singapore

Keith D. Lillemoe, MD
W. Gerald Austen Professor
Harvard Medical School

Chief of Surgery
Surgeon in Chief
Massachusetts General Hospital
Boston, Massachusetts

Foong-Yen Lim, MD
Associate Professor
Department of Surgery
Cincinnati Children's Hospital and Medical Center
Surgical Director
Cincinnati Fetal Center
Cincinnati, Ohio

Ryan Little, MD
Department of Otolaryngology & Communication Sciences
Medical College of Wisconsin
Milwaukee, Wisconsin

Chung Mau Lo, MS, FRCS (Edin), FRACS, FACS
Department of Surgery
The University of Hong Kong
Queen Mary Hospital
Hong Kong, China

James N. Long, MD
Magnolia Regional Health Center
Corinth, Mississippi

Marios Loukas, MD, PhD
Chair and Professor
Department of Anatomical Sciences
School of Medicine at St George's University
Grenada, West Indies

Donald E. Low, MD, FACS, FRCS(C)
Head, Thoracic Oncology and Thoracic Surgery, Department of Surgery
Virginia Mason Medical Center
Clinical Assistant
Professor of Surgery
University of Washington School of Medicine
Seattle, Washington

Ann C. Lowry, MD
Clinical Professor
Division of Colon and Rectal Surgery

Department of Surgery
University of Minnesota
Minneapolis, Minnesota

Layla C. Lucas, MD
Arizona Vascular Specialists
Tucson, Arizona

Charles E. Lucas, MD
Professor
Department of Surgery
Wayne State University School of Medicine
Staff
Department of Surgery
Detroit Receiving Hospital & Harper University Hospital
Detroit, Michigan

Anthony Lucci, MD, FACS
Professor of Surgery
Departments of Breast Surgical Oncology and Surgical Oncology
The University of Texas MD Anderson Cancer Center
Houston, Texas

Natalie Lui, MD, MAS
Assistant Professor
Department of Cardiothoracic Surgery
Stanford University
Stanford, California

James D. Luketich, MD, FACS
Henry T. Bahnson Professor of Cardiothoracic Surgery
Chair, Department of Cardiothoracic Surgery
Chief, Division of Thoracic & Foregut Surgery
University of Pittsburgh Medical Center
Pittsburgh, Pennsylvania

Junji Machi, MD, PhD
Professor
Department of Surgery
Assistant Director, Office of Global Health and Medicine
John A. Burns School of Medicine
University of Hawaii
Honolulu, Hawaii

Robyn A. Macsata, MD

Chief, Vascular Surgery
Associate Professor of Surgery
The George Washington University
Washington, DC

Robert D. Madoff, MD
Professor and Stanley M. Goldberg Chair in Colon & Rectal Surgery
University of Minnesota
Staff Surgeon and Chief of the Division of Colon & Rectal Surgery
Colon & Rectal Surgery
University of Minnesota Medical Center
Minneapolis, Minnesota

James W. Maher, MD
Professor
Department of Surgery
Division of Bariatric and Gastrointestinal Surgery
Virginia Commonwealth University
Richmond Veterans Administration Medical Center
Richmond, Virginia

Brian A. Mailey, MD
Assistant Professor
Department of Surgery
Southern Illinois University School of Medicine
Springfield, Illinois

Mohan K. Mallipeddi, MD
Clinical Instructor
Department of Surgery
Cedars-Sinai Medical Center
Los Angeles, California

Eleftherios P. Mamounas, MD
National Surgical Adjuvant Breast and Bowel Project (NSABP)
Pittsburgh, Pennsylvania
UF Health Cancer Center at Orlando Health
Orlando, Florida

Paul Mansfield, MD, FACS
Professor
Department of Surgical Oncology
University of Texas MD Anderson Cancer Center
Houston, Texas

Christopher R. Mantyh, MD, FACS, FASCRS
Professor
Department of Surgery
Duke University School of Medicine
Chief
Section of Colon and Rectal Surgery
Duke University Medical Center
Durham, North Carolina

Jeffrey M. Marks, MD, FACS, FASGE
Professor of Surgery
Director, Surgical Endoscopy
Program Director
Jeffrey L. Ponsky Professorship in Surgical Education
Case Western Reserve University School of Medicine/University Hospitals Cleveland Medical Center
Cleveland, Ohio

David J. Maron, MD, MBA
Vice Chair, Department of Colorectal Surgery
Director, Colorectal Surgery Residency Program
Cleveland Clinic Florida
Weston, Florida

Robert G. Martindale, MD, PhD
Professor of Surgery
Department of Surgery
Oregon Health & Science University
Chief and Director of Hospital Nutrition Services
Division of General and Gastrointestinal Surgery
Oregon Health & Science University
Portland, Oregon

Viraj Master, MD, PhD, FACS
Professor of Urology
Emory University School of Medicine
Atlanta, Georgia

Douglas J. Mathisen, MD
Hermes C. Grillo Professor of Surgery
Harvard Medical School Chief of Thoracic Surgery
Massachusetts General Hospital
Boston, Massachusetts

James L. Mayo, MD

Aesthetic and Reconstructive Surgery Institute
Orlando Health
University of Florida Health Cancer Center
Orlando, Florida

Jack W. McAninch, MD, FACS (Eng)(Hon)
Professor of Urology
University of California, San Francisco
San Francisco, California

Jennifer M. McBride, PhD
Director of Virtual Anatomy Education
Director of Histology
Associate Professor of Surgery
Cleveland Clinic Lerner College of Medicine
Cleveland, Ohio

Daniel P. McCarthy, MD, MBA, MEM
Assistant Professor
Division of Cardiothoracic Surgery
Department of Surgery
University of Wisconsin School of Medicine and Public Health
Madison, Wisconsin

John B. McCraw, MD
Crossgates River Oaks Hospital
University of Mississippi Medical Center
Jackson, Mississippi

Sarah A. McLaughlin, MD
Associate Professor
Department of Surgery
Medical Director, Robert and Monica Jacoby Center for Breast Health
Mayo Clinic
Jacksonville, Florida

James T. McPhee, MD
Assistant Professor
Department of Surgery
Boston University School of Medicine
Staff Surgeon
Vascular and Endovascular Surgery
VA Boston Healthcare System
Boston, Massachusetts

David S. Medich, MD, FACS, FASCRS
Division of Colon and Rectal Surgery
University of Pittsburg Medical Center
Pittsburgh, Pennsylvania

Manish Mehta, MD, MPH
Professor of Surgery
Albany Medical College
Albany Medical Center, Vascular Surgery
Albany, New York

W. Scott Melvin, MD
Department of Surgery
Montefiore Medical Center
Bronx, New York

Matthew T. Menard, MD
Assistant Professor of Surgery
Brigham and Women's Hospital
Boston, Massachusetts

Emanuele Lo Menzo, MD, PhD
Associate Professor of Surgery
Florida International University
Miami, Florida
Florida Atlantic University
Boca Raton, Florida
Director, Research Department
Staff Surgeon
The Bariatric and Metabolic Institute
Weston, Florida

Miguel A. Mercado, MD
Professor of Surgery
Post-Graduate School of Medicine
Universidad Nacional Autónoma de México
Professor and Chairman
Department of Surgery
Instituto Nacional de Ciencias Médicas y Nutrición Salvador Zubirán
Mexico City, Mexico

J. Wayne Meredith, MD
Professor
Department of Surgery
Wake Forest University Health Sciences

Winston-Salem, North Carolina

Fabrizio Michelassi, MD
Professor
Department of Surgery
Weill Cornell Medicine
Chairman and Surgeon-in-Chief
NewYork-Presbyterian Weill Cornell Medical Center
New York, New York

Dean J. Mikami, MD, FACS
Associate Professor of Surgery
Division Chief, General Surgery
John A. Burns School of Medicine
University of Hawaii
Honolulu, Hawaii

Miroslav N. Milicevic, MD, PhD
Professor of Surgery
The First Surgical Clinic, Clinical Center of Serbia
University of Belgrade
Belgrade, Serbia

Keith R. Miller, MD, FACS
Assistant Professor
Hiram C. Polk, Jr., MD Department of Surgery
University of Louisville
Director of Surgical Nutrition
Department of Surgery
University of Louisville Hospital
Louisville, Kentucky

Joseph L. Mills, Sr., MD
Reid Professor of Surgery
Chief Division of Vascular Surgery and Endovascular Therapy
Baylor College of Medicine
Chief, Vascular Surgery
CHI St. Luke's Medical Center
Houston, Texas

Petros Mirilas
Clinical Professor of Surgical Anatomy and Technique
Centers for Surgical Anatomy and Technique
Emory University School of Medicine
Atlanta, Georgia

Attending Pediatric Surgeon
Agia Sophia Children's Hospital
Athens, Greece

Gregory L. Moneta, MD
Professor of Surgery
Oregon Health & Science University
Chief, Vascular Surgery
OHSU Knight Cardiovascular Institute
Portland, Oregon

John R.T. Monson, MD, FRCS (Ire, Eng, Ed (Hon) Glas (Hon)), FASCRS, FACS
Professor of Surgery
University of Central Florida College of Medicine
Executive Director, Colorectal Surgery
Centre for Colon and Rectal Surgery
Florida Hospital
Orlando, Florida

Stephen G. Moon, MS
Instructor, Pathophysiology and Medical Illustration (former)
The School of Health and Rehabilitation Sciences
The Ohio State University College of Medicine
Columbus, Ohio

Harvey G. Moore, MD, FACS, FASCRS
Assistant Professor
Department of Surgery
Duke University School of Medicine
Durham, North Carolina
Attending Surgeon
Department of Surgery
Duke University Medical Center
Durham, North Carolina

Thomas R. Moore, MD
Professor of Maternal Fetal Medicine
Dean for Clinical Affairs
CEO of Faculty Practice
UC San Diego Health
San Diego, California

Wesley S. Moore, MD
Professor and Chief

Emeritus
Division of Vascular and Endovascular Surgery
David Geffen School of Medicine at UCLA
Professor and Chief
Emeritus
Division of Vascular and Endovascular Surgery
Ronald Reagen UCLA Medical Center
Los Angeles, California

John T. Moore, MD, FACS
Program Director, Surgery Residency Program
Chair
Department of Surgery
Exempla Saint Joseph Hospital
Denver, Colorado

Christopher R. Morse, MD
Assistant Professor
Harvard Medical School
Associate Visiting Surgeon
Massachusetts General Hospital
Boston, Massachusetts

John T. Mullen, MD, FACS
Associate Professor of Surgery
Harvard Medical School
Program Director, General Surgery Residency
Department of Surgery
Massachusetts General Hospital
Boston, Massachusetts

John B. Mulliken, MD
Professor of Surgery
Harvard Medical School
Director, Craniofacial Center
Co-Director, Vascular Anomalies Center
Department of Plastic and Oral Surgery
Boston Children's Hospital
Boston, Massachusetts

Noriko Murase, MD
Adjunct Associate Professor of Surgery
University of Pittsburgh
Pittsburgh, Pennsylvania

Zuri Murrell, MD
Medical Director, Colon and Rectal Cancer Program
Samuel Oschin Comprehensive Cancer Institute
Department of Surgery
Cedars-Sinai Medical Center
Los Angeles, California

Peter Muscarella, MD
Director of Pancreatic Surgery
Department of Surgery
Montefiore Medical Center
Bronx, New York

Philippe Nafteux, MD, PhD
Assistant Professor
Department of Clinical and Experimental Medicine: Thoracic Surgery
KU Leuven University
Clinical Head
Thoracic Surgery
University Hospital Gasthuisberg
Leuven, Belgium

Jaimie D. Nathan, MD
Associate Professor
Department of Surgery
University of Cincinnati
Surgical Director, Kidney and Intestinal Transplant Programs
Surgical Director, Pancreas Care Center, Division of Pediatric General and Thoracic Surgery
Cincinnati Children's Hospital Medical Center
Cincinnati, Ohio

William H. Nealon, MD
Executive Director Perioperative Services
Clinical Chief
Yale New Haven Health System
Yale School of Medicine
New Haven, Connecticut

Mark R. Nehler, MD
Professor of Surgery
University of Colorado
Denver, Colorado

Uri Netz, MD

Department of Surgery
Price Institute of Surgical Research
Hiram C. Polk, Jr., MD Department of Surgery
University of Louisville School of Medicine
Louisville, Kentucky
Faculty of Health Sciences
Ben-Gurion University of the Negev
Department of Surgery
Soroka University Medical Center
Beersheba, Israel

Michael W. Neumeister, MD, FRCSC, FACS
Chair and Professor, Department of Surgery
Chairman of the Division of Plastic Surgery
Southern Illinois University School of Medicine
Springfield, Illinois

Richard F. Neville, MD
Associate Director
Inova Heart and Vascular Institute
Director, Vascular Services
Vice-Chairman, Department of Surgery
Inova Health System
Inova Fairfax Medical Center
Falls Church, Virginia

Kelvin K. Ng, MS, PhD, FRCS (Edin)
Department of Surgery
The University of Hong Kong
Queen Mary Hospital
Hong Kong, China

Heather R. Nolan, MD
Fetal Surgery Fellow
Division of Pediatric General and Thoracic Surgery
Cincinnati Children's Hospital Medical Center
Cincinnati, Ohio

Steven Nurkin, MD, MS, FACS
Assistant Professor
Department of Surgical Oncology
Roswell Park Cancer Institute
Buffalo, New York

Michael S. Nussbaum, MD, FACS

Professor and Chair
Department of Surgery
Virginia Tech Carilion School of Medicine
Senior Vice-President and Chair
Department of Surgery
Carilion Clinic
Roanoke, Virginia

Lloyd M. Nyhus, MD†
Department of Surgery
University of Illinois College of Medicine
Peoria, Illinois

Paul E. O'Brien, BBS(Hons), FRACS, MD
Emeritus Professor of Surgery
Emeritus Director
Centre for Obesity Research and Education
Monash University
Melbourne, Australia

Gustavo S. Oderich, MD
Associate Program Director and Director of Endovascular Therapy
Division of Vascular and Endovascular Surgery
Professor of Surgery
Mayo Clinic College of Medicine
Rochester, Minnesota

Kelly Olino, MD
Assistant Professor
Department of Surgery
Division of Surgical Oncology
University of Texas Medical Branch
Galveston, Texas

Marshall J. Orloff, MD
Distinguished Professor of Surgery, Emeritus
Founder of School of Medicine
Founder of Department of Surgery
University of California, San Diego
San Diego, California

Mark B. Orringer, MD
Cameron Haight Distinguished University Professor
Active Professor Emeritus of Surgery
University of Michigan

Ann Arbor, Michigan

Marc C. Osborne, MD
Clinical Associate Professor
Department of Surgery
University of Minnesota
Minneapolis, Minnesota
Staff Surgeon
Fairview Southdale Hospital
Edina, Minnesota

Harald C. Ott, MD
Associate Professor in Surgery
Harvard Medical School
Assistant Surgeon
Massachusetts General Hospital
Boston, Massachusetts

C. Keith Ozaki, MD
John A. Mannick Professor of Surgery
Department of Surgery
Harvard Medical School
Associate Surgeon
Department of Surgery
Brigham and Women's Hospital
Boston, Massachusetts

H. Leon Pachter, MD, FACS
The George David Stewart Professor
Chairman of the Department of Surgery
NYU Langone Medical Center
New York, New York

Theodore N. Pappas, MD
Professor
Department of Surgery
Duke University School of Medicine
Chief, Division of Advanced Oncologic & GI Surgery
Department of Surgery
Duke University Medical Center
Durham, North Carolina

Catherine Caldwell Parker, MD
Assistant Professor
Division of Surgical Oncology

Department of Surgery
UAB School of Medicine
Birmingham, Alabama

Himanshu J. Patel, MD
Joe D. Morris Collegiate Professor
Section Head, Adult Cardiac Surgery
Department of Cardiac Surgery
University of Michigan Medical School
Ann Arbor, Michigan

Philip S. K. Paty, MD
Professor of Surgery
Albany Medical College
Albany Medical Center, Vascular Surgery
Albany, New York

Eric M. Pauli, MD, FACS, FASGE
Associate Professor of Surgery
Director of Endoscopic Surgery
Department of Surgery
Division of Minimally Invasive and Bariatric Surgery
Penn State Milton S. Hershey Medical Center
Hershey, Pennsylvania

Timothy M. Pawlik, MD, MPH, PhD
Professor and Chair, Department of Surgery
The Urban Meyer III and Shelley Meyer Chair for Cancer Research
The Ohio State University Wexner Medical Center
Columbus, Ohio

Jonathan P. Pearl, MD
Associate Professor
Department of General Surgery
University of Maryland
Baltimore, Maryland

Andrew B. Peitzman, MD
Distinguished Professor of Surgery
Mark M. Ravitch Chair in Surgery
Executive Vice-Chair, Department of Surgery
Vice-Chair, General/Community Surgery, Department of Surgery
Chief, Division of General Surgery
Vice-President for Trauma and Surgical Services University of Pittsburgh Medical Center

Pittsburgh, Pennsylvania

Kyle A. Perry, MD, FACS
Associate Professor of Surgery
Division of General & Gastrointestinal Surgery
The Ohio State University
Columbus, Ohio

Laura A. Peterson, MD, MPH
Professor
Health Services Research
Baylor College of Medicine
Associate Chief of Staff for Research
Michael E. DeBakey VA Medical Center
Houston, Texas

Carrie Y. Peterson, MD, MS
Assistant Professor
Division of Colorectal Surgery
Medical College of Wisconsin
Milwaukee, Wisconsin

Henrik Petrowsky, MD, FACS
Department of Visceral and Transplantation Surgery
Swiss HPB and Transplant Center
University Hospital of Zurich
Zurich, Switzerland

Henry A. Pitt, MD
Associate Vice-Dean for Clinical Affairs
Professor of Surgery
Lewis Katz School of Medicine at Temple University
Chief Quality Officer
Temple University Health System
Philadelphia, Pennsylvania

Bertram Poch, MD
Priv.Doz.-Zentrum of Oncologic, Endocrine and Minimal-invasive Surgery, Donau
Klinikum, Neu-Ulm/Germany-Surgeon-in Chief of the Department
Neu-Ulm, Germany

Javier Salgado Pogacnik, MD
Assistant Professor of Surgery
Division of Colon and Rectal Surgery

University of Pittsburg Medical Center
Pittsburgh, Pennsylvania

Hiram C. Polk, Jr., MD
Ben A. Reid, Sr. Professor of Surgery, Emeritus
Department of Surgery
University of Louisville
Louisville, Kentucky

Alfons Pomp, MD, FACS, FRCSC
Leon C. Hirsch Professor of Surgery
Vice-Chairman, Department of Surgery
Chief, GI, Metabolic, and Bariatric Surgery
Weill Cornell Medicine
Division of GI, Metabolic, & Bariatric Surgery
New York Presbyterian Hospital
New York, New York

Frank B. Pomposelli, MD
Professor of Surgery
Tufts School of Medicine
Chair
Department of Surgery
St. Elizabeth's Medical Center
Director of Surgery
Steward Health Care Network
Boston, Massachusetts

Jeffrey L. Ponsky, MD, MBA, FACS
Professor of Surgery
Lynda and Marlin Younker Chair in Endoscopy
Cleveland Clinic Lerner College of Medicine
Director of Development Endoscopy
Digestive Disease & Surgery Institute
Cleveland Clinic
Cleveland, Ohio

Benjamin K. Poulose, MD, MPH, FACS
Associate Professor of Surgery
Vanderbilt University Medical Center
Nashville, Tennessee

Richard Powell, MD
Professor of Surgery
Section Chief of Vascular Surgery

Heart and Vascular Center
Dartmouth–Hitchcock Medical Center
Geisel School of Medicine
Lebanon, New Hampshire

Richard A. Prinz, MD, FACS
Clinical Professor
Department of Surgery
The University of Chicago Pritzker School of Medicine
Chicago, Illinois
Vice-Chairman
Department of Surgery
NorthShore University HealthSystem
Evanston, Illinois

Timothy L. Pruett, MD
John S. Najarian Surgical Chair in Clinical Transplantation
Chief, Division of Transplantation
Department of Surgery
University of Minnesota
Minneapolis, Minnesota

Bettina M. Rau, MD
Prof. of Surgery
Klinikum Neumark, Germany
Surgeon-in-Chief Department of Surgery
Neumark/Oberpfalz, Germany

John E. Rectenwald, MD, MS
Associate Professor
Chief, Division of Vascular & Endovascular Surgery
Department of Surgery
University of Texas Southwestern Medical Center
Dallas, Texas

KMarie Reid, MD, MS, FACS
Department of Surgery
Mayo Clinic
Rochester, Minnesota

Richard R. Ricketts, MD
Emory University
Children's Healthcare of Atlanta
Atlanta, Georgia

Michael L. Ritchey, MD
Professor
Department of Urology
Mayo Clinic Hospital
Phoenix, Arizona

Patricia L. Roberts, MD
Professor of Surgery
Tufts University School of Medicine
Medford, Massachusetts
Chair, Department of Surgery
Lahey Hospital and Medical Center
Burlington, Massachusetts

Kara Long Roche, MD
Assistant Professor
Department of OB/GYN
Weill Cornell Medical College
Assistant Attending
Gynecology Service
Department of Surgery
Memorial Sloan Kettering Cancer Center
New York, New York

John Rodriguez, MD
Assistant Professor
Section of Surgical Endoscopy
Department of General Surgery
Cleveland Clinic Lerner College of Medicine
Cleveland, Ohio

Sanziana Roman, MD, FACS
Professor of Surgery
Associate Chief, Division of Advanced Oncologic and GI Surgery
Director
Endocrine Surgery Fellowship Program
Duke University Medical Center
Durham, North Carolina

Alexander S. Rosemurgy, MD
Director, Surgical Digestive Disorders and GERD Center
Director, HPB Surgery and Fellowship Program
The Southeastern Center for Digestive Disorders & Pancreatic Cancer,
Advanced Minimally Invasive & Robotic Surgery
Florida Hospital Tampa

Tampa, Florida

Raul J. Rosenthal, MD, FACS, FASMBS
Chairman, Department of General Surgery
Director, The Bariatric and Metabolic Institute
Cleveland Clinic Florida
Weston, Florida
Professor of Surgery
Herbert Wertheim School of Medicine
Florida International University
Miami, Florida

Ornob P. Roy, MD, MBA
Assistant Professor of Urology
Levine Cancer Institute
Carolinas Medical Center
Charlotte, North Carolina

Michael Ruebhausen, MD
Institute for Plastic Surgery
Southern Illinois University School of Medicine
Springfield, Illinois

Aaron Ruhalter, MD, FACS[†]
Professor of Anatomy
University of Cincinnati College of Medicine
Executive Director of Medical Education
Johnson & Johnson Endo-Surgery Institute
Cincinnati, Ohio

Michael S. Sabel, MD
William W. Coon Collegiate Professor of Surgical Oncology
Chief, Division of Surgical Oncology
University of Michigan
Ann Arbor, Michigan

Jacqueline M. Saito, MD
Assistant Professor of Surgery
Division of Pediatric Surgery
Washington University School of Medicine
Attending Surgeon
Department of Pediatric Surgery
St. Louis Children's Hospital
St. Louis, Missouri

Atef A. Salam, MD
Professor
Division of Vascular Surgery
Department of Surgery
Emory University School of Medicine
Chief of Vascular Service
Atlanta VA Medical Center
Atlanta, Georgia

Arghavan Salles, MD, PhD
Assistant Professor of Surgery
Washington University School of Medicine
Attending Surgeon
Barnes-Jewish Hospital
St. Louis, Missouri

Dawn Sander, MSN, ANP-BC
Nurse Practitioner
Nursing Administrator
Department of Surgery, Section of Vascular Surgery
Washington University in St. Louis
St. Louis, Missouri

Michael G. Sarr, MD
Department of Surgery
Mayo Clinic
Rochester, Minnesota

Aaron Saunders, MD
Clinical Fellow
Department of Surgical Oncology
Roswell Park Cancer Institute
Buffalo, New York

Lara W. Schaheen, MD
Department of Cardiothoracic Surgery
University of Pittsburgh Medical Center
Pittsburgh, Pennsylvania

Randall Scheri, MD
Associate Professor
Section of Endocrine Surgery
Department of Surgery
Duke University Medical Center
Durham, North Carolina

Richard Schulick, MD, MBA
The Aragón/Gonzalez-Gíustí Chair Professor & Chair of the Department of Surgery
University of Colorado
Aurora, Colorado

Jatin P. Shah, MD, PhD
Professor
Department of Otolaryngology—Head and Neck Surgery
Weill Cornell Medical College
Cornell University
Attending Surgeon
Surgery, Head, and Neck Service
Memorial Sloan Kettering Cancer Center
New York, New York

Rupen Shah, MD
Clinical Fellow
Surgical Oncology
Roswell Park Cancer Institute
Buffalo, New York

Courtney Shepard, MD
Division of Pediatric Urology
Department of Urology
University of Michigan Health System
Ann Arbor, Michigan

Gregorio A. Sicard, MD
Emeritus Professor
Vascular Surgery
Washington University School of Medicine
St. Louis, Missouri

Anton N. Sidawy, MD, FACS
Professor and Lewis B. Saltz Chair
Vascular Surgery
Department of Surgery
George Washington University School of Medicine & Health Sciences
Washington, DC

J. Rüdiger Siewert
Univ.-Prof. Dr. Dr. h.c. mult. J. R. Siewert
Chief Medical Director and CEO
Medical Center University of Freiburg

Freiburg, Germany

Celso Silva, MD, MS
Associate Professor
University of Central Florida College of Medicine
Orlando, Florida

Parul Sinha, MD
Otolaryngology Head & Neck Surgery
St. Louis, Missouri

LaShondria Simpson-Camp, MD
Allegheny Health Network Cancer Institute
Allegheny General Hospital
Pittsburgh, Pennsylvania

Lee J. Skandalakis, MD, FACS
Clinical Professor of Surgical Anatomy and Technique
Centers for Surgical Anatomy and Technique
Emory University School of Medicine
Attending Surgeon
Piedmont Hospital
Atlanta, Georgia

Eila C. Skinner, MD
Thomas A. Stamey Research Professor in Urology
Stanford University School of Medicine
Stanford, California

Alexis D. Smith, MD
Children's Healthcare of Atlanta
Emory University
Scottish Rite Hospital
Atlanta, Georgia

J. Joshua Smith, MD, PhD
Assistant Member
Attending Surgeon
Colorectal Service Department of Surgery
Memorial Sloan Kettering Cancer Center
Assistant Professor of Surgery
Weill Cornell Medical College
New York, New York

J.S. Solomkin, MD, FACS, FIDSA

Professor of Surgery (Emeritus)
University of Cincinnati College of Medicine
Cincinnati, Ohio

Professor Michael Solomon, MB Bch BAO (Hons), MSc, DMedSc, LRCPI, FRACS, FRCSI (Hons)
Professor of Surgical Research
Sydney Medical School
University of Sydney
Chairman, Institute of Academic Surgery at RPA
Director & Head, Surgical Outcomes Research Centre
Sydney Local Health District & University of Sydney
Academic Head
Department of Colorectal Surgery
Royal Prince Alfred Hospital
Camperdown, Australia

Nathaniel J. Soper, MD, FACS
Loyal and Edith Davis Professor and Chair of Surgery
Northwestern University
Evanston, Illinois
Chief of Surgery
Northwestern Memorial Hospital
Chicago, Ilinois

Julie Ann Sosa, MD, FACS
Professor of Surgery and Medicine
Chief, Section of Endocrine Surgery
Leader, Endocrine Neoplasia Diseases Group and Solid Tumor Therapeutics Program
Duke Cancer Institute and Duke Clinical Research Institute
Duke University Medical Center
Durham, North Carolina

Matthew D. Spann, MD
Assistant Professor
Department of Surgery
Vanderbilt University Medical Center
Nashville, Tennessee

Michael J. Stamos, MD, FACS, FASCRS
Professor of Surgery and the John E. Connolly Chair
Department of Surgery
University of California, Irvine
Irvine, California

Thomas E. Starzl, MD, PhD
Distinguished Service Professor of Surgery
Thomas E. Starzl Transplantation Institute
University of Pittsburgh School of Medicine
Pittsburgh, Pennsylvania

David J. Sugarbaker, MD
The Olga Keith Wiess Chair of Surgery
Department of Surgery
Baylor College of Medicine
Chief, Division of Thoracic Surgery
Director, The Lung Institute
Baylor St. Luke's Medical Center
Houston, Texas

Ryan M. Svoboda, MD
Division of Vascular Surgery
Department of Surgery
Dartmouth-Hitchcock Medical Center
Lebanon, New Hampshire

John D. Symbas, MD
Plastic Surgeon
Department of Surgery
WellStar Kennestone Hospital
Marietta, Georgia

Panagiotis N. Symbas, MD
Emory University School of Medicine
Atlanta, Georgia

Samuel Szomstein, MD, FACS, FASMBS
Associate Professor of Surgery
Florida International University
Miami, Florida
Associate Director
The Bariatric and Metabolic Institute
Director Fellowship Advance MIS
General and Vascular Surgery
Cleveland Clinic Florida
Weston, Florida

Kenneth K. Tanabe, MD
Professor of Surgery
Harvard Medical School

Chief, Surgical Oncology and Deputy Clinical Director
Massachusetts General Hospital Cancer Center
Boston, Massachusetts

Giorgio Tarchini, MD, FIDSA
Chairman
Department of Infectious Diseases
Cleveland Clinic Florida
Weston, Florida

Mehdi J. Teymouri, BS
Center for Vascular Awareness
Syracuse University
Albany, New York

Robert Thompson, MD
Departments of Surgery (Section of Vascular Surgery), Radiology, and Cell Biology and Physiology
Washington University School of Medicine
Barnes-Jewish Hospital
St. Louis, Missouri

Sandie R. Thomson, ChM, FRCS (Eng&Ed), FRCP (Ed)
Professor & Chair of Gastroenterology
Department of Medicine
University of Cape Town
Division Head Gastroenterology
Gastrointestinal Unit
Groote Schuur
Cape Town, South Africa

Gregory M. Tiao, MD
Professor of Surgery
University Of Cincinnati
Ryckman Chair of Pediatric Surgery
Division Chief of Pediatric Surgery
Director of Liver Transplantation
Cincinnati Children's Hospital and Medical Center
Cincinnati, Ohio

Joshua S. Tierney, MD
Interventional Endoscopy and Pancreaticobiliary Surgery Fellow
Department of Surgery
University of Louisville
Louisville, Kentucky

Parag P. Tolat, MD
Assistant Professor of Radiology
Chief, Section of Abdominal/Body Imaging
Division of Diagnostic Radiology
Medical Director
Imaging IT Strategy
Section of Informatics
Division of Imaging Sciences
Department of Radiology
Medical College of Wisconsin
Milwaukee, Wisconsin

Gonzalo Torres-Villalobos, MD, PhD
Associate Professor
Department of Surgery
Instituto Nacional de Ciencias Médicas y Nutrición Salvador Zubirán
Mexico City, Mexico

Megan Tracci, MD, JD
Assistant Professor of Surgery
Division of Vascular and Endovascular Surgery
University of Virginia
Charlottesville, Virginia

Thomas F. Tracy, MD, MBA
Professor of Surgery and Pediatrics
Penn State College of Medicine
Senior Vice President
Chief Medical Officer
Penn State Milton S. Hershey Medical Center
Hershey, Pennsylvania

Nam T. Tran, MD
Associate Professor of Surgery
Program Committee
University of Washington
Seattle, Washington

Donald D. Trunkey, MD
Professor Emeritus
Department of Surgery
Oregon Health and Science University
Portland, Oregon

Kiran K. Turaga, MD, MPH, FACS

Vice Chief, Surgery and Surgical Oncology (Strategy and Finance)
Director, Complex General Surgical Oncology Program
Associate Professor of Surgery, Department of Surgery
University of Chicago
Chicago, Illinois

Douglas Tyler, MD
John Woods Harris Distinguished Professor
Chairman
Department of Surgery
University of Texas Medical Branch
Galveston, Texas

Robert Udelsman, MD, MBA
William H. Carmalt Professor
Department of Surgery
Yale University School of Medicine
New Haven, Connecticut

Konstantin Umanskiy, MD, FACS, FASCRS
Associate Professor
Section of Colon and Rectal Surgery
Department of Surgery
University of Chicago Pritzker School of Medicine
Chicago, Illinois

Heidi Umphrey, MD
Associate Professor
UAB Department of Radiology
Birmingham, Alabama

Gilbert R. Upchurch Jr., MD
Chief of Vascular and Endovascular Surgery
William H. Muller, Jr. Professor of Surgery
University of Virginia
Charlottesville, Virginia

Dirk Van Raemdonck, MD, PhD
Professor
Department of Clinical and Experimental Medicine: Thoracic Surgery
KU Leuven University
Clinical Head
Thoracic Surgery
University Hospital Gasthuisberg
Leuven, Belgium

Hans Van Veer, MD
Assistant
Department of Clinical and Experimental Medicine: Thoracic Surgery
KU Leuven University
Joint Clinical Head
Thoracic Surgery
University Hospital Gasthuisberg
Leuven, Belgium

Luis O. Vásconez, MD
Clinical Professor
Mountain Brook Plastic Surgery
University of Alabama at Birmingham
Birmingham, Alabama

Vic Velanovich, MD
Division of General Surgery
University of South Florida
Tampa, Florida

Dionysios K. Veronikis, MD
Female Pelvic Medicine & Reconstructive Surgery
Mercy Hospital St. Louis
Saint Louis, Missouri

Gary C. Vitale, MD
Department of Surgery
University of Louisville School of Medicine
Louisville, Kentucky

Daniel von Allmen, MD
Surgeon-in-Chief
Lester W. Martin Chair of Pediatric Surgery
Senior Vice President, Surgical Services
Cincinnati Children's Hospital and Medical Center
Cincinnati, Ohio

Michel Wagner, MD, FACS
Assistant Professor
Division of Trauma
Department of Surgery
Creighton University School of Medicine
Omaha, Nebraska

John C. Wain, MD

St. Elizabeth's Medical Center
Brighton, Massachusetts

Jessica Wallaert, MD, MS
Division of Vascular Surgery
Department of Surgery
Dartmouth-Hitchcock Medical Center
Lebanon, New Hampshire

R. Matthew Walsh, MD, FACS
Professor of Surgery
Rich Family Distinguished Chair of Digestive Diseases
Chairman, Department of General Surgery
Digestive Disease Institute
Chairman, Academic Department of Surgery
Education Institute
Cleveland Clinic
Cleveland, Ohio

Tracy S. Wang, MD, MPH
Department of Surgery
Division of Surgical Oncology
Medical College of Wisconsin
Milwaukee, Wisconsin

Brad W. Warner, MD
Jessie L. Ternberg, MD, PhD,
Distinguished Professor of Pediatric Surgery
Surgeon-in-Chief
St. Louis Children's Hospital
St. Louis, Missouri

David I. Watson, MBBS, MD, PhD, FRACS, FAHMS
Professor and Head of Department
Department of Surgery
Flinders University
Senior Consultant Surgeon
Oesophago-Gastric Surgery Unit
Flinders Medical Centre
Adelaide, Australia

Kaare J. Weber, MD
Member of Montefiore Health System
White Plains Hospital
New York, New York

Director of Surgery
Associate Medical Director, Surgical Services
Department of Surgery
White Plains Hospital
White Plains, New York

Martin R. Weiser, MD
Surgical Oncologist
Vice Chair for Education and Faculty Development
Department of Surgery
Stuart H.Q. Quan Chair in Colorectal Surgery
Memorial Sloan Kettering Cancer Center
New York, New York

Mark Welton, MD
Chief of Colorectal Surgery
Department of Surgery
Stanford University School of Medicine
Stanford, California

Hadley Katharine Wesson, MD, MPH
Assistant Professor
Department of Surgery
Johns Hopkins University
Baltimore, Maryland

Steven Wexner, MD, PhD (Hons), FACS, FRCS, FRCS(Ed)
Director, Digestive Disease Center
Chair, Department of Colorectal Surgery Cleveland Clinic Florida
Affiliate Professor
Florida Atlantic University College of Medicine
Clinical Professor
Florida International University College of Medicine
Weston, Florida

Julia White, MD
Department of Radiation Oncology
The Ohio State University Comprehensive Cancer Center
Columbus, Ohio

T. Jeffrey Wieman, MD
Formerly Professor of Surgery
Department of Surgery
University of Louisville
Louisville, Kentucky

Hale E. Wills, MD, MS
Trauma Medical Director
Director of Pediatric Surgical Critical Care
Hasbro Children's Hospital
Assistant Professor of Surgery and Pediatrics
Division of Pediatric Surgery
Alpert Medical School
Brown University
Providence, Rhode Island

Chad T. Wilson, MD, MPH, FACS
Associate Professor
Department of Surgery
Baylor College of Medicine
Houston, Texas

Alan C. Wittgrove, MD, FACS, FASMBS
Department of Surgery
Scripps Memorial Hospital La Jolla
San Diego, California

Bo Yang, MD, PhD
Assistant Professor of Cardiac Surgery
Department of Cardiac Surgery
University of Michigan Medical School
Ann Arbor, Michigan

Jerrold Young, MD, FACS
Voluntary Associate Professor
DeWitt Daughtry Family Department of Surgery
Leonard M. Miller School of Medicine
Miami, Florida

Jonathan S. Zager, MD, FACS
Chair of Graduate Medical Education
Director of Regional Therapies
Senior Member, Moffitt Cancer Center
Departments of Cutaneous Oncology and Sarcoma
Professor of Surgery, University of South Florida School of Medicine
Moffitt Cancer Center
Tampa, Florida

Steven M. Zeitels, MD
Chief
Center for Laryngeal Surgery & Voice Rehabilitation

Massachusetts General Hospital
Boston, Massachusetts

Nicholas J. Zyromski, MD
Associate Professor
Department of Surgery
Indiana University School of Medicine
Indianapolis, Indiana

[†]Deceased.

PREFACE

I am writing from my favorite place in the world—Nantucket Island. I have only a few instruments with me—an ink pen, a pencil, and a pad of paper. An American flag is flying over the water, and a few boats are making their way through the harbor.

The scene is special to me. Our house, discovered by our son Erich after my wife Karen and I returned from Cincinnati to Boston after 23 years, is blessed by a 40-foot Osprey pole where the female is right now standing guard after feeding two rapidly growing chicks. And I am fortunate having some of my family here with me; Alexandra, who is resting a broken foot, and her husband Peter.

I recently turned 80 years old as did Karen. I have been blessed both professionally and personally. As one who slept on the couch when 8 to 10 years old living on the lower east side of New York City in the 1930s and 1940s in my grandparents' apartment, I have been privileged to have been able to work my way to a position where I hope that I have contributed at least somewhat to expanding the knowledge of surgical science and practice. It has indeed been a privilege to have taken a part in educating and mentoring some 105 Fellows from the United States and abroad and to know that today 22 of those Fellows have their own departments. It is also a privilege to have been part of great institutions during the course of my career—from the Massachusetts General Hospital to 23 years as Chairman of Surgery at the University of Cincinnati, then 8 years as Chairman of Surgery at Harvard at the Beth Israel Deaconess in Boston.

I also have been blessed personally. None of my professional accomplishments would have been possible without my wife Karen, a beautiful and very bright and articulate social worker whom I met on my first Saturday as an intern at the Massachusetts General Hospital in 1961. Karen and I have been together for 56 years and married for 52. She has been a source of advice, has played a central role in building my departments, and has raised two wonderful children—Erich and

Alexandra.

Erich, 50, is a successful business consultant who, with his wife Hallie, has given us two grandchildren—Asher and Aleksei. Asher, 4, is a very bright and articulate little boy who shows early signs of fascination with the medical profession (we can only hope!). When not swimming he is exploring the outside and playing with my vintage Lionel train set that has 32 engines, many cars and a huge number of accessories. He is also somewhat of a conman and very good at it. On the second day of camp this summer he ran down for breakfast exclaiming, "No camp today." At 7:30 AM of the same day Erich came down to the kitchen asking Asher if he was ready to leave for camp. Asher left without an apology. He is also a caring and vigilant older brother to Aleksei. At 2 months old, Aleksei is the newest member of the family, a relaxed baby (except when hungry!), he has started to smile—and we have all the best hopes for him. Our daughter-in-law Hallie recently "retired" from the financial world and is a graphic designer. She is very beautiful, very bright, and is an extremely attentive mother. She is currently progressing with her own graphic design business.

Alexandra, 47, did not fall far from the tree medically and chose to care for animals. She has been named one of the top veterinarians in Washington, DC and is married to Peter, an award-winning anesthesiologist who pilots his own plane and recently joined the Naval Reserves. They have no human children by choice but foster several dogs and cats—many of whom may outlive us all thanks to her.

The good Lord has been kind to us indeed. It has been a pleasure to contribute as editor to the third and fourth editions as well as produce the fifth, sixth and now seventh edition. I am pleased for how relevant the *Mastery of Surgery* remains despite radical changes in learning and media influence on our own society.

Principal mentors in my career, although there are many luminaries who have helped and supervised my development of my career, there are three who stand out:

Professor Claude Welch

As a surgeon and human being Claude Welch was my idol. He was a

quick, very accurate surgeon and very knowledgeable. He was especially quick in removing cancer. When I undertook cancer of the rectum I tried to allow patients to retain their rectum. He said I was wrong. But when I did not have recurrence he stopped criticizing but never adopted this approach himself.

Professor Julias Axelrod

He was a role model for me at the National Institutes of Health. He started as a technician and became the head of the Laboratory section. He never forgot his past. He was a great teacher and only had one technician who ground up the tissues and washed the glassware. Helen was African American, rare at that time.

Reuven Katz, Esquire

Mr. Katz was a wonderful attorney and head of a major Cincinnati law firm. He was a brilliant teacher and was a major influence on my success, for the 23 years I was chair of the Department of Surgery, and as how to relate to various people. He became a major influence in the 23 years I was chair of the Department of Surgery at the University of Cincinnati.

Josef E. Fischer
August 2017
Nantucket, Massachusetts

CONTENTS

 *Chapters with icon are web-only*

VOLUME I

SECTION I

PERIOPERATIVE CARE OF THE SURGICAL PATIENT

CHAPTER 1: Metabolic and Inflammatory Responses to Trauma and Infection
Vance L. Albaugh • Igal Breitman Naji N. Abumrad

CHAPTER 2: Perioperative Management: Practical Principles, Molecular Basis of Risk, and Future Directions
Per-Olof Hasselgren • Jeremy W. Cannon Josef E. Fischer

CHAPTER 3: Enteral Nutrition Support
Keith R. Miller • Robert G. Martindale

CHAPTER 4: Cardiovascular Monitoring and Support
Eric J. Charles • Irving L. Kron

CHAPTER 5: Pulmonary Risk and Ventilatory Support
Jay A. Johannigman • Richard Branson

CHAPTER 6: Hemorrhagic Risk and Blood Components
Karen J. Brasel

CHAPTER 7: Perioperative Antimicrobial Prophylaxis and Treatment of Surgical Infection
Kui-Hin Liau • Giorgio Tarchini J.S. Solomkin

CHAPTER 8: Multiple Organ Dysfunction Syndrome: Prevention and Clinical Management
David J. Dries

CHAPTER 9: Immunosuppression in Organ Transplantation
Mani A. Daneshmand • Allan D. Kirk

 **CHAPTER 10: Surgeons and the Opioid Epidemic**

Jeffrey D. Howard, Jr. • *Hiram C. Polk, Jr.*

SECTION II
BASIC SURGICAL SKILLS: NEW AND EMERGING TECHNOLOGY

CHAPTER 11: Ventral Abdominal Hernia: Open and Minimally Invasive and Component Separation Release
Stephen R.T. Evans • *Parag Bhanot*

CHAPTER 12: Laparoscopic Suturing and Stapling
Jon C. Gould

CHAPTER 13: Ultrasonography by Surgeons
Ellen Hagopian • *Junji Machi*

CHAPTER 14: Tumor Ablation: Technologies and Clinical Applications
Michael S. Sabel

CHAPTER 15: Upper and Lower Gastrointestinal Endoscopy
Jeffrey L. Ponsky • *Jonathan P. Pearl*

CHAPTER 16: Soft Tissue Reconstruction With Flap Techniques
Luis O. Vásconez • *Salman Ashruf Franziska Huettner* • *Michael Ruebhausen*

CHAPTER 17: Hand Surgery: Traumatic and Infectious Emergencies
Brian A. Mailey • *Michael W. Neumeister*

CHAPTER 18: Robotic Surgery
Michael S. Nussbaum • *Michael Latzko*

CHAPTER 19: Surgical Energy
Edward L. Jones • *Dean J. Mikami*

SECTION III
THE HEAD AND NECK

CHAPTER 20: Anatomy of the Head and Neck
Aaron Ruhalter

CHAPTER 21: Surgery of the Major Salivary Glands
Carol M. Lewis • *Michael E. Kupferman*

CHAPTER 22: Anatomy of the Parotid Gland, Submandibular Triangle, and Floor of the Mouth
Aaron Ruhalter

CHAPTER 23: Lip Reconstruction
Patrick C. Hettinger • *Robert J. Havlik*

CHAPTER 24: Surgery for Cancer of the Oral Cavity
William R. Carroll

CHAPTER 25: Neck Dissection
Ian Ganly •Jatin P. Shah

CHAPTER 26: Congenital Lesions: Thyroglossal Duct Cysts, Branchial Cleft Anomalies, and Cystic Hygromas
Juan P. Gurria • Jaimie D. Nathan

CHAPTER 27: Vascular Anomalies of Infancy and Childhood
Arin K. Greene • John B. Mulliken

CHAPTER 28: Surgical Treatment of Laryngeal Cancer: A Legacy of Minimally Invasive Innovation and the Preservation of Airway, Swallowing, and Vocal Function
Steven M. Zeitels • John C. Wain

CHAPTER 29: Surgical Treatment of Pharyngeal Cancer
Bruce H. Haughey • Parul Sinha

CHAPTER 30: Malignant Melanoma and Skin Cancer
Hiram C. Polk, Jr. • Jane V. Carter • Uri Netz

CHAPTER 31: Melanoma
Douglas Tyler • Kelly Olino

CHAPTER 32: Inguinal Lymph Node Dissection: Indications and Surgical Technique
Steven Agle • Douglas Tyler

CHAPTER 33: Evaluation and Repair of Common Facial Injuries
Branko Bojovic

CHAPTER 34: Resection and Reconstruction of the Trachea
Natalie Lui • Harald C. Ott • Douglas J. Mathisen

CHAPTER 35: Penetrating Neck Injuries
Alain Corcos • Andrew B. Peitzman

CHAPTER 36: Neurosurgical and Neurologic Emergencies for Surgeons
Ekkehard M. Kasper • Yosef Laviv • Clark C. Chen • Burkhard S. Kasper

CHAPTER 37: Tracheotomy
Ryan Little • Jonathan M. Bock

SECTION IV
ENDOCRINE SURGERY

CHAPTER 38: Surgical Anatomy of the Thyroid, Parathyroid, and Adrenal Glands
Clive S. Grant

CHAPTER 39: Biopsy, Lobectomy, Total Thyroidectomy, and Lymph Node Dissection for Thyroid Cancer
Randall Scheri • Sanziana Roman • Julie Ann Sosa

CHAPTER 40: Comprehensive Parathyroidectomy for the Treatment of PHPT, Including Intraoperative Parathyroid Hormone Assay–Guided Parathyroidectomy
Azadeh A. Carr • Tracy S. Wang

CHAPTER 41: Minimally Invasive Parathyroidectomy
Robert Udelsman • Tobias Carling

CHAPTER 42: Secondary and Tertiary Hyperparathyroidism
Richard A. Prinz • Kaare J. Weber • Shalini Arora

CHAPTER 43: Transsternal, Transcervical, and Minimally Invasive Thymectomy for Benign and Malignant Disease
Daniel P. McCarthy • Malcolm M. DeCamp

CHAPTER 44: Adrenalectomy—Minimally Invasive and Open
L. Michael Brunt • Arghavan Salles

CHAPTER 45: Pancreatic Neuroendocrine Tumors
Michael P. Kim • Brian D. Badgwell

SECTION V
THE BREAST, CHEST, AND MEDIASTINUM

CHAPTER 46: Embryology and Anatomy of the Breast
Kirby I. Bland

CHAPTER 47: Benign Disease and Breast Pain
Amy C. Degnim • Karthik Ghosh

CHAPTER 48: Diagnostic Approach to Breast Abnormalities
Catherine Caldwell Parker • Heidi Umphrey Helen Krontiras • Kirby I. Bland

CHAPTER 49: Breast-Conserving Surgery
J. Michael Dixon

CHAPTER 50: Radiation Treatment, Whole and Partial Breast and Intraoperative Irradiation
Julia White

CHAPTER 51: Ablative Techniques for Benign and Malignant Breast

Tumors
Sheldon Feldman • Margaret Chen

CHAPTER 52: Sentinel Lymph Node Biopsy in Breast Cancer
Anthony Lucci • Sarah M. DeSnyder • Oluwadamilola (Lola) Fayanju

CHAPTER 53: Lymphedema—Pathophysiology, Prevention, and Treatment
Sarah A. McLaughlin

CHAPTER 54: Modified Radical Mastectomy and Radical Mastectomy
Kirby I. Bland

CHAPTER 55: Oncoplastic Techniques for Breast Conservation Surgery
Kristine E. Calhoun • Benjamin O. Anderson

CHAPTER 56: Breast Reconstruction Following Mastectomy
James N. Long • John B. McCraw • Jorge I. de la Torre • Luis O. Vásconez

CHAPTER 57: Chest Wall Resection and Reconstruction for Advanced/Recurrent Carcinoma of the Breast
Kirby I. Bland • Cristiano Boneti • R. Jobe Fix • Robert J. Cerfolio

CHAPTER 58: Clinical Trials and Follow-Up for Breast Cancer
Michael S. Cowher LaShondria Simpson-Camp Eleftherios P. Mamounas • Thomas B. Julian

CHAPTER 59: The Deep Inferior Epigastric Perforator Flap for Breast Reconstruction
Robert J. Allen • James L. Mayo

CHAPTER 60: Applied Anatomy of the Chest Wall and Mediastinum
Petros Mirilas • Michael E. Halkos • John D. Symbas • Panagiotis N. Symbas • Lee J. Skandalakis

CHAPTER 61: Thoracic Trauma
J. Wayne Meredith • James Jason Hoth

CHAPTER 62: Pulmonary Resection
Bryan M. Burt • Shawn S. Groth • David J. Sugarbaker

SECTION VI
THE DIAPHRAGM

CHAPTER 63: Surgical Anatomy of the Diaphragm
Petros Mirilas • Lee J. Skandalakis • Richard R. Ricketts • Marios Loukas

CHAPTER 64: Congenital Diaphragmatic Hernia
Corey W. Iqbal

CHAPTER 65: Eventration of the Diaphragm
Heather R. Nolan • Daniel von Allmen • Foong-Yen Lim

CHAPTER 66: Traumatic Injury to the Diaphragm
H. Leon Pachter • Chad T. Wilson • Spiros G. Frangos

CHAPTER 67: Paraesophageal Hernia—Open Repair
W. Scott Melvin • Kyle A. Perry

CHAPTER 68: Gastroesophageal Reflux Disease in Infants and Children
George W. Holcomb III • Brad W. Warner

SECTION VII
THE GASTROINTESTINAL TRACT
Part A: The Esophagus

CHAPTER 69: The Anatomy of the Esophagus
Toni Lerut • Willy Coosemans • Herbert Decaluwe • Georges Decker • Paul De Leyn • Lieven De Pypere • Philippe Nafteux • Dirk Van Raemdonck • Hans Van Veer

CHAPTER 70: Transthoracic Antireflux Procedures
Tom R. DeMeester

CHAPTER 71: Laparoscopic Esophagectomy
James D. Luketich • Lara W. Schaheen

CHAPTER 72: Nissen–Rossetti Antireflux Fundoplication (Open Procedure)
David I. Watson

CHAPTER 73: Modified Hill Repair for Gastroesophageal Reflux
Donald E. Low • Mustapha El-Lakis

CHAPTER 74: Laparoscopic Antireflux Surgery
Nathaniel J. Soper • Eric S. Hungness

CHAPTER 75: Peroral Endoscopic Myotomy for Achalasia and Endoluminal Approaches for GERD
Edward D. Auyang • Eric S. Hungness

CHAPTER 76: Minimally Invasive Treatment of Achalasia and Other Esophageal Dysmotility
Michael S. Nussbaum • Bestoun H. Ahmed • Jeffrey L. Ponsky

CHAPTER 77: Esophagogastrectomy for Carcinoma of the Esophagus
Simon Law

CHAPTER 78: Transhiatal Esophagectomy Without Thoracotomy

Mark B. Orringer

CHAPTER 79: Esophageal Perforation
Eric M. Pauli • Jeffrey M. Marks

CHAPTER 80: Repair of Esophageal Atresia and Tracheoesophageal Fistula
George W. Holcomb III

CHAPTER 81: Pathology and Treatment of Zenker Diverticulum
Christopher R. Morse

Part B: The Stomach and Duodenum

CHAPTER 82: Anatomic Considerations in Gastroduodenal Surgery
Petros Mirilas • Marios Loukas • Lee J. Skandalakis

CHAPTER 83: Percutaneous Endoscopic Gastrostomy
Jeffrey L. Ponsky • Benjamin K. Poulose

CHAPTER 84: Distal Gastrectomy With Billroth I or Billroth II Reconstruction
Rudolf Bumm • J. Rüdiger Siewert

 **CHAPTER 85: Selective Vagotomy, Antrectomy, and Gastroduodenostomy for the Treatment of Duodenal Ulcer**
Lloyd M. Nyhus

CHAPTER 86: Selective and Nonselective Vagotomies
Theodore N. Pappas • Mohan K. Mallipeddi

CHAPTER 87: Duodenal Ulcer Disease: Pathogenesis and Management of Complications
James W. Maher • Daniel T. Dempsey • E. Christopher Ellison

CHAPTER 88: Gastric Cancer
John T. Mullen

CHAPTER 89: Distal Gastrectomy With Roux-en-Y Reconstruction and Laparoscopic Gastrectomy
Miguel A. Mercado Gonzalo Torres-Villalobos

CHAPTER 90: Postgastrectomy Syndromes in the Current Era
KMarie Reid • Michael G. Sarr

CHAPTER 91: Congenital Pyloric Stenosis and Duodenal Obstruction
Hale E. Wills • Alexis D. Smith • Thomas F. Tracy

CHAPTER 92: Diabetes and Other Metabolic Diseases

Kevin El-Hayek • R. Matthew Walsh

CHAPTER 93: Vascular Compression of the Duodenum
Stanley W. Ashley • Matthew T. Menard

Part C: Bariatric and Metabolic Diseases

CHAPTER 94: Gastrointestinal Stromal Tumors
G. Travis Clifton • Paul Mansfield

CHAPTER 95: The Laparoscopic Gastric Band Technique of Placement
Paul E. O'Brien

CHAPTER 96: Revision and Conversion of Vertical Banded Gastroplasty
Eric J. DeMaria • Daniel B. Jones

CHAPTER 97: Laparoscopic Gastric Bypass
Alan C. Wittgrove

CHAPTER 98: Laparoscopic Gastric Sleeve
Emanuele Lo Menzo • Samuel Szomstein • Raul J. Rosenthal

CHAPTER 99: Laparoscopic Biliopancreatic Diversion With Duodenal Switch
Gregory Dakin • Alfons Pomp

CHAPTER 100: EndoBarrier for the Treatment of Morbid Obesity and Type II Diabetes
Keith S. Gersin

CHAPTER 101: Revisional Bariatric Surgery
John Rodriguez • Matthew Kroh

CHAPTER 102: Management of Complications of Gastric Bypass and Repair
Ronald H. Clements • Matthew D. Spann

VOLUME II

Part D: The Liver and Biliary Tract

CHAPTER 103: Surgical Anatomy of the Liver and Bile Ducts
Chung Mau Lo • Kelvin K. Ng

CHAPTER 104: Diagnostic Considerations in Biliary and Liver Disease
Kelly M. Collins • William C. Chapman

CHAPTER 105: Approaches to Drainage of Hepatic, Perihepatic, and Subhepatic Abscesses
Timothy L. Pruett • Daniel Borja-Cacho

CHAPTER 106: Echinococcal Cyst—Open and Laparoscopic Approach
Miroslav N. Milicevic

CHAPTER 107: Hepatic Resection for Primary and Metastatic Tumors
Richard Schulick • Ana Luiza Mandelli Gleisner

CHAPTER 108: Treatment of Major Hepatic Trauma
Donald D. Trunkey

CHAPTER 109: Cholecystostomy, Cholecystectomy, and Intraoperative Evaluation of the Biliary Tree
O. James Garden

CHAPTER 110: Laparoscopic Cholecystectomy, Intraoperative Cholangiography, and Common Bile Duct Exploration
John G. Hunter • Laura E. Fischer

CHAPTER 111: Reconstruction of the Bile Duct: Anatomic Principles and Surgical Techniques
Toms Augustin • R. Matthew Walsh

CHAPTER 112: Current Application of Endoscopic Sphincterotomy, Lateral Choledochoduodenostomy, and Transduodenal Sphincteroplasty
E. Christopher Ellison • Jeffrey W. Hazey • W. Scott Melvin • Stephen G. Moon

CHAPTER 113: Primary Sclerosing Cholangitis
Nicholas J. Zyromski • Henry A. Pitt

CHAPTER 114: High Malignant Biliary Tract Obstruction
Richard A. Burkhart • Timothy M. Pawlik

CHAPTER 115: Cholecystojejunostomy and Choledocho/Hepaticojejunostomy
Herbert R. Freund • Michael R. Freund

CHAPTER 116: Operative Treatment for Choledochal Cysts
Charles E. Bagwell Hadley Katharine Wesson

CHAPTER 117: Biliary Atresia—Portoenterostomy
Gregory M. Tiao

CHAPTER 118: Liver Transplantation
Henrik Petrowsky • Lukasz Filip Grochola • Ronald W. Busuttil

CHAPTER 119: Special Comment: The Unfinished Legacy of Liver Transplantation
Thomas E. Starzl • Noriko Murase

CHAPTER 120: The Associating Liver Partition and Portal Vein Ligation for Staged Hepatectomy (ALPPS) Approach

Kenneth K. Tanabe Fernando Andrés Alvarez Eduardo de Santibañes

Part E: The Pancreas

CHAPTER 121: Surgical Anatomy of the Pancreas
Petros Mirilas • Marios Loukas • Lee J. Skandalakis

CHAPTER 122: Selection of Surgical Therapy for Chronic Pancreatitis
Peter Muscarella • William H. Nealon

CHAPTER 123: Operative Interventions for Chronic Pancreatitis
Keith D. Lillemoe • Chad G. Ball

CHAPTER 124: Parenchyma-Sparing, Limited Partial and Total Pancreatic Head Resection for Inflammatory Tumor, Cystic Neoplasia, Neuroendocrine Adenoma, and Low-Risk Periampullary Malignant Tumor
Hans G. Beger • Bettina M. Rau • Bertram Poch

CHAPTER 125: Necrosectomy for Acute Necrotizing Pancreatitis
Peter Muscarella • E. Christopher Ellison

CHAPTER 126: Management of Complications of Acute and Chronic Pancreatitis: Endoscopic, Laparoscopic, and Open Approaches to Pancreatic Pseudocysts and Pancreatic Necrosis
Gary C. Vitale • Brian R. Davis • Michael Bahr

CHAPTER 127: Pancreaticoduodenectomy and Total Pancreatectomy for Cancer
Douglas B. Evans • Parag P. Tolat • Kathleen K. Christians

CHAPTER 128: Operative Management of Pancreatic Trauma
David V. Feliciano

CHAPTER 129: Splanchnic Denervation of the Pancreas for Intractable Pain
Joshua S. Tierney • Gary C. Vitale • Keith D. Lillemoe

Part F: Introduction to Portal Hypertension

Josef E. Fischer

CHAPTER 130: Anatomy of the Portal System and Experience With Portacaval Shunt
Marshall J. Orloff

CHAPTER 131: Small-Diameter Prosthetic Interposition Shunt
Alexander S. Rosemurgy


CHAPTER 132: Distal Splenorenal Shunts: Hemodynamics of Total Versus Selective Shunting

Atef A. Salam

 **CHAPTER 133: Central Splenorenal Shunts**
Josef E. Fischer

CHAPTER 134: Endoscopic Therapy in the Management of Esophageal Varices
Jake E. J. Krige • Sandie R. Thomson

Part G: Surgery of the Small Intestine

CHAPTER 135: Small Bowel Obstruction
Susan Galandiuk

 **CHAPTER 136: Metabolic Surgery and Intestinal Bypass for Hypercholesterolemia**
Henry Buchwald

 **CHAPTER 137: The Continent Ileostomy**
Eric J. Dozois • Roger R. Dozois

CHAPTER 138: Technique of Ileostomy Construction and Closure
Harvey G. Moore • Christopher R. Mantyh

CHAPTER 139: Gastrointestinal-Cutaneous Fistulas
Josef E. Fischer • Amy R. Evenson

CHAPTER 140: Surgical Treatment of Small Bowel Crohn Disease
Erin O. Lange • Linda Ferrari • Mukta Krane • Fabrizio Michelassi • Alessandro Fichera

Part H: Surgery of the Colon

CHAPTER 141: Clinical Anatomy for Procedures Involving the Small Bowel, Colon, Rectum, and Anus
Uri Netz • Susan Galandiuk

CHAPTER 142: The Appendix
Vic Velanovich

CHAPTER 143: Large Bowel Obstruction
Neil H. Hyman • Konstantin Umanskiy

CHAPTER 144: Surgical Treatment of Colonic and Perianal Crohn Disease
Linda Ferrari • Erin O. Lange • Mukta Krane • Fabrizio Michelassi • Alessandro Fichera

CHAPTER 145: Surgery for Toxic Megacolon

Scott R. Kelley • David W. Larson

CHAPTER 146: Total Proctocolectomy and Inter-Sphincteric Proctectomy for Benign Disease
Javier Salgado Pogacnik David S. Medich

CHAPTER 147: Ileoanal Pouch Procedure for Ulcerative Colitis and Familial Adenomatous Polyposis
Susan Galandiuk • Jeffrey R. Jorden • Russell W. Farmer • Josef E. Fischer

CHAPTER 148: Total Colectomy and Ileorectal Anastomosis
David J. Maron • Steven Wexner

CHAPTER 149: Surgery for Diverticulitis
Patricia L. Roberts

CHAPTER 150: Technique of Colostomy Construction and Closure
Aaron Saunders • Moshim Kukar

CHAPTER 151: Care of Stomas
Marc C. Osborne • Ann C. Lowry

CHAPTER 152: Open and Minimally Invasive Right Hemicolectomy for Cancer
Martin R. Weiser

CHAPTER 153: Open and Minimally Invasive Left Hemicolectomy for Neoplasms of the Descending Colon, Sigmoid, and Upper Rectum
Zuri Murrell • Michael J. Stamos

CHAPTER 154: Historical Perspectives on Total Mesorectal Excision
R.J. Heald

CHAPTER 154A: Advances in Total Mesorectal Excision
Steven Nurkin • Rupen Shah Aaron Saunders • Steven N. Hochwald

CHAPTER 155: Open and Minimally Invasive Sphincter-Preserving Radical Resection for Malignant Disease of the Middle and Lower Thirds of the Rectum
Wolfgang B. Gaertner • Robert D. Madoff

CHAPTER 156: Abdominoperineal Resection for Rectal Cancer
Carrie Y. Peterson • Julio Garcia-Aguilar

CHAPTER 157: Abdominoperineal Resection for Rectal Cancer
Steven Nurkin • Aaron Saunders • Rupen Shah • Steven N. Hochwald

CHAPTER 158: The Approach to Reoperative Pelvic Surgery in Rectal Cancer
J. Joshua Smith • Jose G. Guillem

CHAPTER 159: Sacral Resection for Recurrent Rectal Cancers
Peter J. Lee • Michael Solomon • Kirk K. S. Austin

CHAPTER 160: Cytoreductive Surgery and Hyperthermic Intraperitoneal Chemotherapy for Cancers of the Appendix and Colon
Edward A. Levine

CHAPTER 161: Management of Retrorectal Tumors
Cindy Kin • Mark Welton

CHAPTER 162: Rectal Prolapse: The Open Abdominal Approach
Philip H. Gordon

CHAPTER 163: Rectal Prolapse
Elisa H. Birnbaum

CHAPTER 164: Anorectal Disorders
Michael R. B. Keighley

CHAPTER 165: Transanal Excision of Rectal Neoplasms
Sam B. Atallah • John R.T. Monson

CHAPTER 166: Functional Bowel Disorders
Michael R. B. Keighley

CHAPTER 167: Groin Dissection
Kiran K. Turaga • Jonathan S. Zager

CHAPTER 168: Transanal Pull-Through for Hirschsprung Disease
Jacob C. Langer

CHAPTER 169: Neonatal Enterocolitis and Short Bowel Syndrome
Brad W. Warner • Jacqueline M. Saito

SECTION VIII
NONGASTROINTESTINAL TRANSABDOMINAL SURGERY

Part A: The Spleen

CHAPTER 170: Laparoscopic Splenectomy
Charles E. Lucas • Anna M. Ledgerwood

Part B: The Urinary Tract and Bladder

CHAPTER 171: Anatomy of the Kidneys, Ureter, and Bladder
Jennifer M. McBride • Richard L. Drake

CHAPTER 172: Surgical Management of Nephrolithiasis
Brian H. Eisner

 **CHAPTER 173: Operations on the Ureteropelvic Junction**
Frank Hinman, Jr.

CHAPTER 174: Radical Nephrectomy for Renal Cell Cancer
Elias S. Hyams • Mohamad Allaf

CHAPTER 175: Radical Cystectomy and Orthotopic Urinary Diversion for Bladder Cancer
Eila C. Skinner • Siamak Daneshmand

CHAPTER 176: Laparoscopic Pelvic and Retroperitoneal Lymph Node Dissection
Ornob P. Roy • Louis R. Kavoussi

CHAPTER 177: Robot-Assisted Radical Prostatectomy
Ahmed A. Hussein • Khurshid A. Guru

CHAPTER 178: The Undescended Testis
Courtney Shepard • Kate H. Kraft • David A. Bloom

CHAPTER 179: Surgical Management of Wilms Tumor
Gwen M. Grimsby • Michael L. Ritchey

CHAPTER 180: Genitourinary Tract Trauma
Jack W. McAninch • Viraj Master

CHAPTER 181: Supravesical Urinary Diversion
Kristin Chrouser • Badrinath R. Konety

Part C: Gynecologic Surgery

CHAPTER 182: Cesarean Delivery
Thomas R. Moore

CHAPTER 183: Abdominal Hysterectomy
Mitchel S. Hoffman • Celso Silva • Aileen Caceres

CHAPTER 184: Radical Hysterectomy
Jonathan Boone • Warner Huh

CHAPTER 185: Surgical Management of Ovarian Carcinoma
Kara Long Roche • Arlan F. Fuller, Jr. • Dennis S. Chi

CHAPTER 186: Anterior and Posterior Colporrhaphy
Dionysios K. Veronikis

Part D: Surgery of the Hernia

CHAPTER 187: Surgical Anatomy of the Hernial Rings
Petros Mirilas • Lee J. Skandalakis

CHAPTER 188: Overview of Inguinal and Femoral Hernia Repairs
Robert J. Fitzgibbons, Jr. • Michel Wagner

 **CHAPTER 189: The Shouldice Method of Inguinal Herniorrhaphy**
Robert Bendavid

 **CHAPTER 190: Iliopubic Tract Repair of Inguinal Hernia: The Anterior (Inguinal Canal) Approach**
Robert E. Condon

 **CHAPTER 191: Iliopubic Tract Repair of Inguinal and Femoral Hernia: The Posterior (Preperitoneal) Approach**
Lloyd M. Nyhus

 **CHAPTER 192: Kugel Technique of Groin Hernia Repair**
Robert D. Kugel • John T. Moore

CHAPTER 193: Generations of the Plug-and-Patch Repair: Its Development and Lessons From History
Jerrold Young • Arthur I. Gilbert

CHAPTER 194: Postherniorrhaphy Inguinodynia: Causes, Prevention, and Surgical Treatment: Triple Neurectomy
Parviz K. Amid • David C. Chen

SECTION IX
VASCULAR SURGERY

Part A: Cerebrovascular Disease

CHAPTER 195: Carotid Bifurcation Disease: Carotid Endarterectomy and Stenting
Sapan S. Desai

CHAPTER 196: Brachiocephalic Reconstruction: Open and Endovascular
Joseph-Vincent V. Blas • John F. Eidt

CHAPTER 197: Carotid Body Tumors
Wesley S. Moore

Part B: Aneurysmal Disease

CHAPTER 198: Open Thoracoabdominal Aortic Aneurysm Repair
Mark F. Conrad • Richard P. Cambria

CHAPTER 199: Open Infrarenal and Pararenal Aortic Aneurysm Repair

Gregorio A. Sicard • Jeffrey Jim

CHAPTER 200: Endovascular Repair of Abdominal Aortic Aneurysms
Gregorio A. Sicard • Dawn Sander

CHAPTER 201: Ruptured Abdominal Aortic Aneurysms
Manish Mehta • Philip S. K. Paty • Mehdi J. Teymouri

CHAPTER 202: Femoral and Popliteal Artery Aneurysms
Mohammad H. Eslami

CHAPTER 203: Treatment of Splenic Artery Aneurysms: Open and Endovascular
Dawn M. Coleman • Gilbert R. Upchurch, Jr.

Part C: Chronic Lower Extremity Occlusive Disease

CHAPTER 204: Aortofemoral Bypass
David C. Brewster

CHAPTER 205: Aortoiliac Occlusive Disease: Extraanatomic Bypass
Enjae Jung • Gregory J. Landry • Gregory L. Moneta

CHAPTER 206: Endovascular Procedures for Aortoiliac Occlusive Disease
Vikram S. Kashyap • Karem C. Harth

CHAPTER 207: Reversed Vein Bypass Grafts to Popliteal, Tibial, and Peroneal Arteries
Joseph L. Mills • Layla C. Lucas

CHAPTER 208: Peripheral Arterial Disease: Prosthetic Bypass
Ahmed Kayssi • Ken Lee • Richard F. Neville

CHAPTER 209: Dorsalis Pedis, Tarsal, and Plantar Artery Bypass
Bernadette Aulivola • Frank B. Pomposelli

CHAPTER 210: Peripheral Vascular Occlusive Disease: Endovascular
Richard Powell • Ryan Svoboda • Jessica Wallert

CHAPTER 211: Minor Amputations
Peter Henke

CHAPTER 212: Major Lower Extremity Amputation
Mark R. Nehler

CHAPTER 213: The Prevention and Treatment of Problems With the Diabetic Foot
Norman J. Galbraith • T. Jeffrey Wieman Hiram C. Polk, Jr.

Part D: Acute Lower Extremity Ischemia

CHAPTER 214: Embolectomy
Peter Henke

CHAPTER 215: Fasciotomy
Jonathan L. Eliason

Part E: Mesenteric and Renal Artery Disease

CHAPTER 216: Renal Artery Occlusive Disease: Open and Endovascular Management
Laura A. Peterson • Matthew Edwards

CHAPTER 217: Acute Mesenteric Artery Ischemia: Open and Endovascular
James T. McPhee • Edward Kelly • C. Keith Ozaki

CHAPTER 218: Techniques of Open and Endovascular Revascularization to Treat Chronic Mesenteric Ischemia
Thomas C. Bower • Gustavo S. Oderich

Part F: Vascular Infection

CHAPTER 219: Mycotic Aneurysms
Cheong J. Lee

CHAPTER 220: Surgical Management of Aortic Graft Infections
Manuel Garcia-Toca • Guillermo A. Escobar

Part G: Venous Disorders

CHAPTER 221: Contemporary Operative Venous Thrombectomy
Anthony J. Comerota • Faisal Aziz

CHAPTER 222: Acute Deep Venous Thrombosis: Endovascular
Moon O. Kwoun

CHAPTER 223: Chronic Deep Vein Thrombosis/Postthrombotic Syndrome: Open and Endovascular Treatment
Peter Gloviczki • Arjun Jayaraj

CHAPTER 224: Vena Cava Filter Placement
Mark Levin • John E. Rectenwald

CHAPTER 225: Venous Insufficiency
Megan Tracci

Part H: Dialysis Access

CHAPTER 226: Autogenous Arteriovenous Hemodialysis Access
Robert J. Feezor • Thomas S. Huber

CHAPTER 227: Hemodialysis Access-Prosthetic Arteriovenous Access

Robyn A. Macsata • Anton N. Sidawy

Part I: Thoracic

CHAPTER 228: Thoracic Outlet Syndrome
Robert Thompson

CHAPTER 229: Thoracic Aortic Transection
Himanshu J. Patel • Bo Yang

Part J: Trauma

CHAPTER 230: Vascular Injuries to the Neck, Including the Subclavian Vessels
Nam T. Tran

CHAPTER 231: Injury to the Abdomen: Open and Endovascular
Dennis Y. Kim • Matthew C. Koopmann

CHAPTER 232: Injury to the Extremities: Open and Endovascular Management
W. Darrin Clouse

Index

SECTION

PERIOPERATIVE CARE OF THE SURGICAL PATIENT

1 Metabolic and Inflammatory Responses to Trauma and Infection

Vance L. Albaugh, Igal Breitman, and Naji N. Abumrad

INTRODUCTION

Surgery has its roots in providing care for those patients coping with injury or infection. The last several decades, especially with the advancements in molecular biology, have seen an enormous amount of progress describing the wide spectrum of illnesses that result following trauma or infection—from minor, local reactions to surgery, to systemic stress responses, to sepsis, to systemic inflammatory response syndrome (SIRS), and, finally, to multisystem organ failure (MSOF). The scientific tools and methods that have evolved over this time period have led to elaborate understandings of the cellular and molecular physiologic underpinnings of the response to trauma and infection. Regardless of the amount of progress, our knowledge continues to be refined as we are continually reminded of the intricacy of the body's response to trauma and infection. A thorough understanding of the mechanisms at work following trauma and infection is crucial for any practicing surgeon, as this understanding is the hallmark of transferring knowledge gained in research to innovative surgical care at the bedside.

OVERVIEW

Following extensive tissue damage or systemic insult (e.g., infection, hypoperfusion, hypothermia, acid–base disturbance, pain), a number of local and systemic physiologic and biochemical alternations can present and are referred to collectively as "the stress response." This systemic response is mediated by complex signaling systems, including afferent and efferent nervous signals, immunologic and hormonal adaptations, and systemic washout of locally produced substances (e.g., cytokines). Sir David Cuthbertson first referenced the stress response in the 1930s from his keen observations of a biphasic immune, inflammatory, and metabolic response to injury, which was further modified by Francis Moore in the

1970s. The early (<24 hours) hypometabolic phase (termed “ebb” by Cuthbertson) represents a coordinated response directed toward immediate survival of the overall organism. It starts with the activation of local coagulation and innate immune factors. At that time, while evidence of a systemic response may be minimal in subjects with mild injury, an insult of sufficient magnitude will trigger local activation of the stress response that is followed by systemic inflammatory and endocrine responses. These responses present as surges in plasma catecholamine, cortisol, and aldosterone concentrations that result in tachycardia, tachypnea, vasoconstriction, decreased cardiac output and oxygen consumption, lower basal metabolic rate, increased sodium and water retention, shunting of blood from the periphery to the vital organs, and acute-phase protein (APP) production. If the organs survive, there is transition from the initial “ebb” phase to the “flow” phase. The flow phase of the stress response is characterized by explosive metabolic and immune activity, enhanced enzymatic function, as well as tissue repair. Massive neuroendocrine flux involving the production and secretion of catecholamines, antidiuretic hormone (ADH), cortisol, insulin, glucagon, and growth hormone (GH) characterize the flow phase. Moreover, the increased adrenergic stimulation increases the glucagon to insulin ratio and, combined with the increased serum cortisol and cytokine concentrations, induces a state of enhanced proteolysis and lipolysis to mobilize carbon sources for hepatic gluconeogenesis.

This fuel mobilization typically comes from amino acid release from increased catabolism of skeletal muscle and visceral proteins. Some of these amino acids are then released into the plasma and are available to be taken up by the liver to be used as gluconeogenic substrates and hepatic protein synthesis, while others are used for enzyme synthesis and collagen deposition at the site of injury. During this time the energy needs of most other tissues are met by the increased availability of free fatty acids (FFAs) and ketone bodies that result from increased adipocyte lipolysis. This increased lipolytic flux is marked by adipocyte glycerol release that is used as a glucose precursor by the liver, while the FFAs are available for hepatic oxidation and energy production for these gluconeogenic processes.

Clearly this massive catabolic process requires augmented blood flow to the muscle, liver, and areas of tissue injury. As one might expect, individuals present with tachycardia and tachypnea, peripheral edema,

fever, hyperglycemia, leukocytosis, increased O_2 consumption, increased CO_2 production, increased minute ventilation, elevated resting energy expenditure (REE), and negative nitrogen balance. Consequently, the liver provides substrates through gluconeogenesis and synthesis of ketone bodies, detoxifies nitrogenous waste via the synthesis of urea, and elaborates a series of APPs that bind metabolic by-products or limit the activity of proteolytic enzymes secreted by activated leukocytes. Renal blood flow and glomerular filtration increase and aid excretion of nitrogenous by-products. Cytokines and adipokines released from macrophages and adipose tissue, respectively, result in disrupted capillary tight junctions, leading to vascular leak allowing fluid and substrates to flow toward the avascular area of injury, as well as to the interstitium in other body parts.

Manifestations of this hypermetabolic phase can be seen clinically in every postoperative patient. Patients retain fluid and sodium through urine concentration and redistribution of blood flow to vital organs, as well as compensate for the intravascular depletion secondary to capillary leak and possible external fluid losses (e.g., blood loss, insensible operative losses). If allowed to go unchecked, this catabolic response would deplete endogenous resources and become maladaptive. Systemic inflammatory response, severe metabolic depletion, and possible secondary infection can all cause damage to vital organs that were not initially compromised by the injury. Acute respiratory distress syndrome (ARDS), renal insufficiency, hepatic dysfunction, loss of gut epithelial barrier function, immunoparalysis, and sepsis may develop and the multiorgan dysfunction can be fatal. Fortunately, with appropriate support measures, the stress response nearly always resolves itself without complications.

The intensity and duration of the flow phase roughly correlate to the extent and type of injury, with the catabolic process usually peaking at approximately 48 to 72 hours postinjury. If the insult resolves, the body transitions to an anabolic state, marked by surges in insulin, GH, and insulin-like growth factor I (IGF-I) concentrations within 5 to 10 days of injury. These hormonal changes are associated with a flux of protein, fluid, and electrolytes returning to the depleted intracellular space, particularly the skeletal muscle. Interstitial edema fluid is reabsorbed and the excess fluid is eliminated with a brisk diuresis. As the cellular space re-expands, the need for electrochemical equilibrium mandates the movement of ions (K^+, Mg^{2+}, and PO_4^{3-}) from the blood into the cells, and subsequently

serum levels of these ions decrease which requires sufficient replacement. Anorexia and fatigue gradually resolve, and heart rate, respirations, and plasma glucose normalize. As the entire process nears resolution, nitrogen balance becomes positive and homeostasis is restored.

INFLAMMATORY RESPONSE

The inflammatory response to injury involves interplay between several hormones (catecholamines and cortisol) and a large number of mediators (cytokines and chemokines). The immune and inflammatory responses to injury are predictable and well-orchestrated, and adaptive series of events evolve leading to maximize healing potential. The inflammatory response is a normal and vital part of healing and recovery from either traumatic injury or elective surgery. A normal, balanced, and well-controlled inflammatory response in previously healthy patients almost always results in an uneventful recovery.

Innate Immune System

The immune response can be divided into early innate and later adaptive responses. The innate immune system is the first line of defense and its principal components are the epithelial barriers and the immune cells that reside within them. These cellular components of the innate immune system include phagocytes such as neutrophils, macrophages and dendritic cells, and natural killer (NK) cells. It is noteworthy that these antigen-presenting cells (e.g., macrophages, dendritic cells) also play important roles in the adaptive immune response as well as innate immunity. Tissue damage, or microorganisms invading one or more of the epithelial barriers, is immediately recognized by the multiple components of the innate response. This rapid response is due to an elaborate system of receptors expressed on innate immune cells that recognize nonself antigens and pathogen-associated molecular patterns (PAMPs) (also known as microorganism-associated molecular patterns [MAMPs]). The best known examples of PAMPs are lipopolysaccharides (LPS) in gram-negative bacteria, lipoteichoic acids in gram-positive bacteria, mannose-rich oligosaccharides in microbial glycoproteins, mannans, unmethylated CpG sequences in bacteria DNA, double-stranded RNA in replicating viruses, glucans, and N-formylmethionine (a bacterial eukaryotic protein).

The receptors that have evolved to recognize these PAMPs are called pattern-recognition receptors, and these can functionally be divided into

endocytic receptors, which internalize microorganisms for phagocytosis, and signaling receptors, which activate cellular signaling pathways that induce the expression of a variety of immune-response genes. The most important receptors that mediate endocytosis are the mannose receptors of the calcium-dependent lectin family, which recognize terminal mannose and fucose residues of glucoproteins and glycolipids that are characteristic of microorganisms, as well as the scavenger receptors that bind to bacterial cell walls. Among these signaling receptors, the two main groups of receptors are the Toll-like receptors (TLRs) and the G-protein–coupled receptors, of which the TLRs are the most prominent in the induction of immune and inflammatory responses.

Toll-like Receptors

The Toll signaling pathway was initially described in Drosophila in 1985, with the human homologue identified in 1997. TLRs are single, transmembrane spanning receptors that consist of an external ligand binding domain and an internal activation domain that transmits an intracellular signal. Binding of extracellular ligand (e.g., LPS, peptidoglycan) induces dimerization of receptors that appear to be necessary for a robust activation of the signaling pathway. At least 10 human TLRs have been described and are specific for different PAMP molecules. TLR1, 2, 4, 5, and 6 recognize bacterial products, of which TLR2 has been implicated in detection of gram-positive bacteria. The well-studied TLR4 binds LPS, while TLR3, TLR7, and TLR8 are specific for viral detection. TLR9 appears to be involved in both microbial and viral recognition.

TLRs are involved in crosstalk between the innate and the adaptive immune systems. They are expressed by dendritic cells and T-lymphocytes, as well as on a variety of parenchymal cells (e.g., adrenals, liver, and spleen). The adrenal-expressed TLRs influence the systemic inflammatory response by their effect on cortisol secretion. Upon “sensing” danger by binding their specific ligands, TLRs activate immune and endothelial cells resulting in the upregulation of nuclear factor (NF)-κB signaling. Prior to activation NF-κB is sequestered in the cytosol by inhibitor of κB (IκB). With activation of the TLR-coupled signaling cascade IκB is targeted for proteasomal degradation by ubiquitin, which allows NF-κB to translocate to the nucleus and transcriptionally activate a number of inflammatory mediators (e.g., chemokines, adhesion molecules, growth factors) and proinflammatory cytokines (e.g., tumor necrosis

factor-α [TNF-α] and interleukin-1 [IL-1]). With ligand binding the IL-1 and TNF-α receptors further activate the same signaling pathways amplifying the immune response (Fig. 1.1). TLRs are also involved in the recognition of endogenous ligands, which are released from damaged or dying cells, or come from a depredated extracellular matrix. These molecules include lipids, carbohydrates, proteins, and nucleic acids.

Extensive research has been conducted on whether genetic variations can be used to identify patients at high risk of developing sepsis and organ dysfunction during severe infection. There is evidence suggesting that genetic polymorphisms in TLRs may influence a patient's outcome in sepsis. For example, a single nucleotide polymorphism (SNP) of TLR1 (TLR1–7202A/G) is associated with higher organ dysfunction, increased gram-positive infections, and death by sepsis. Patients with a TLR4 gene mutation, especially those involving TLR4, $Asp^{299}Gly$ allele have a higher incidence of gram-negative infections; this polymorphism is also attributed to the severity of SIRS. Similar to other investigations of SNPs, however, further research is needed to validate and quantify the degree of clinical impact and whether or not any significant therapeutic potential might be leveraged.

G-Protein–Coupled Receptors

These receptors initiate intracellular responses transmitted by guanine nucleotide-binding G protein. These receptors are activated by chemokines, proteolytic products of complement proteins (e.g., C5a), and lipid mediators of inflammation (platelet-activating factor, prostaglandin E, and leukotriene B4).

Complement

The complement system consists of more than 30 proteins that initiate a cascade of events that ultimately results in destruction of foreign organisms. Complement is a nonspecific system that can be rapidly activated by one of three pathways: classic, alternative, and mannan-binding lectin. In the classical pathway an IgM or IgG antibody–antigen complex activates the complement cascade. The alternative pathway does not rely on an antibody–antigen complex, but is rather activated directly by bacterial cell wall components. The mannan-binding lectin pathway is homologous to the classical pathway, except that the cascade is initiated by a mannan-binding lectin protein produced by the liver. Each of these three pathways results in construction of the membrane attack complex, which

effectively creates pores within the membrane of the targeted cell (i.e., the invader/bacterium) that cause cell destruction. Aside from this microbial lysis, activation of the complement cascade results in platelet activation, histamine release, neutrophil recruitment through chemotactic factors, and stimulation of neutrophil degranulation.

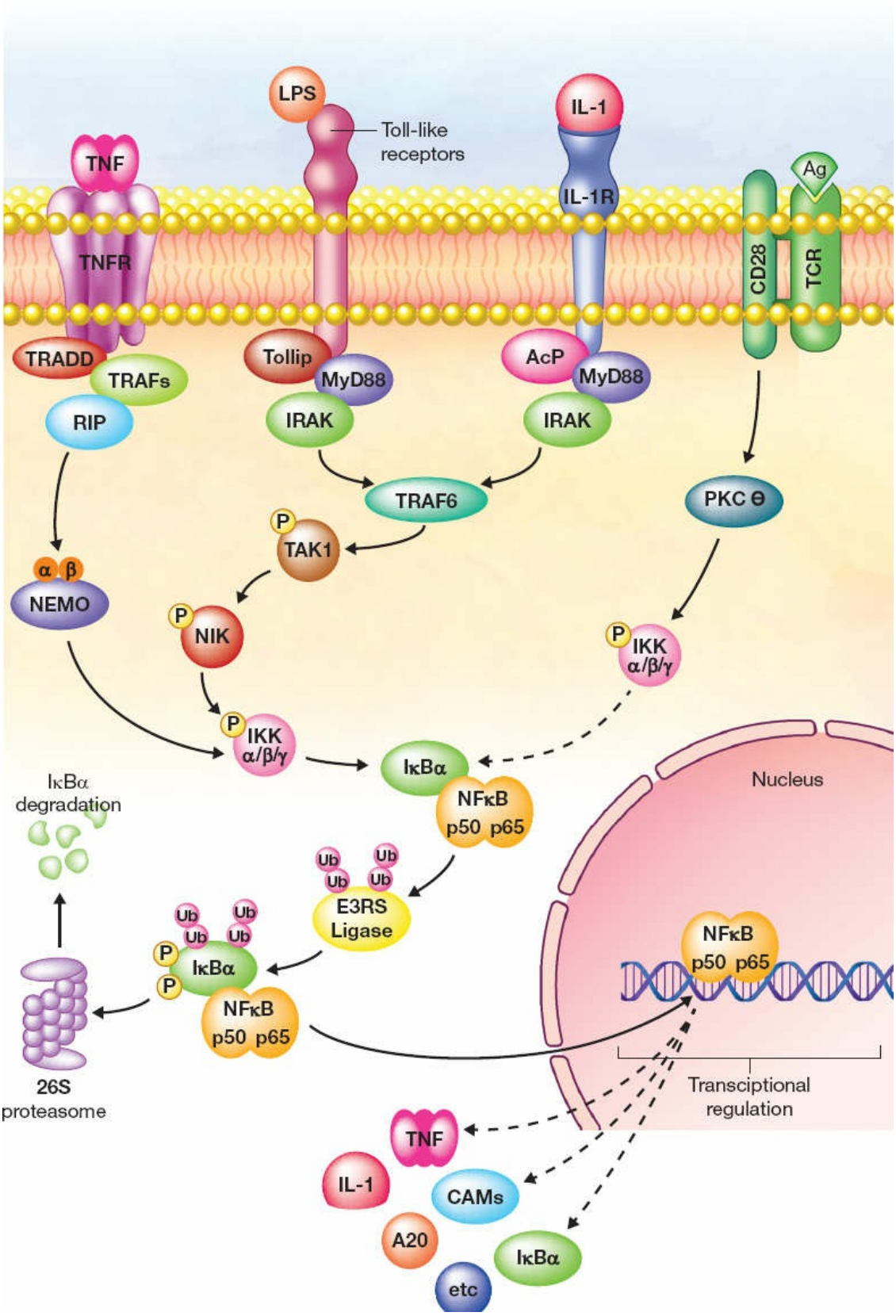

Figure 1.1. Brief overview of proinflammatory signal transduction pathways. ACP, accessory membrane-spanning protein; IKKα, inhibitory protein IκB kinase α; IKKβ, IκB kinase β IL-1, interleukin-1; IL-1R, IL-1 receptor; IRAK, IL-1R-activated kinase;

NIK, NF-κB-inducing kinase; NEMO, NF-κB essential modulator; RIP, receptor-interacting protein; TCR, T-cell receptor; TNFR, tumor necrosis factor receptor; TRADD, TNFR and associated death-domain protein; TRAF2, TNFR-associated factor 2. (Adapted from Baeuerle PA. Pro-inflammatory signaling last pieces in the NF-kappaB puzzle. *Curr Biol* 1998;8:R19, with permission.)

Complement activation pathways are regulated by a large number of regulatory complement-control proteins, preventing overactivation of the whole system; systemic overwhelming activation of the system can result in changes in hemodynamic parameters, leading to shock. Persistent elevation of the complement-derived chemotaxins C3a, C4a, and C5a have been correlated with increased remote organ damage and mortality following sepsis. Neutralization of C5a, using a monoclonal antibody, resulted in improved survival and decreased organ damage in animal models.

Alarmins

Activation of the immune system can also be triggered by injury or trauma without evidence of a bacterial focus, which is mediated by alarmins or damage-associated molecular patterns (DAMPs). Alarmins are released either after a nonprogrammed cell death (i.e., necrosis) or by cells of the immune system. Within this family of endogenous triggers are high mobility group box 1 (HMGB1), heat shock proteins (HSPs), beta-defensins, cathelicidin, eosinophil-derived neurotoxins (EDN), as well as others. These structurally diverse proteins serve as endogenous mediators of innate immunity as chemoattractants and activators of antigen-presenting cells.

HMGB1 was originally identified as a chromatin-binding protein that exists ubiquitously in the nucleus of all eukaryotic cells. HMGB1 plays a critical role in stabilizing nucleosome formation and in regulating transcription; it also plays an important role in signaling following tissue damage. When present in an extracellular location, HMGB1 can activate the innate immune system and promote inflammation. HMGB1 is passively released by necrotic cell death, but not during cells undergoing apoptosis cells as well as actively secreted by immune cells, macrophages, and NK cells upon activation with TNF. HMBG1 acts as a chemokine and is a chemoattractant for macrophages, neutrophils, and dendritic cells and

causes the secretion of several proinflammatory cytokines (e.g., TNF, IL-1a, IL-1b, IL-1RA, IL-6, IL-8, MIP-1a, and MIP2b) (Fig. 1.2).

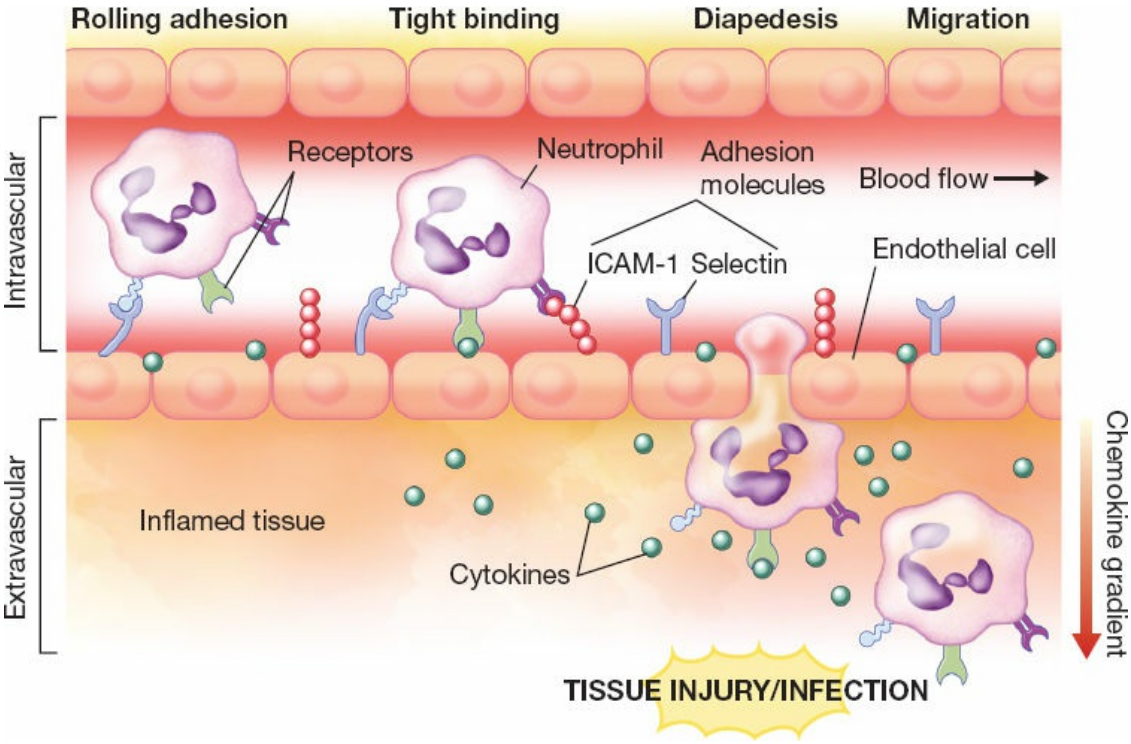

Figure 1.2. Schematic of the chemokine-mediated process of neutrophil recruitment and infiltration. Chemokines emanating from a source of injury and/or infection induce expression of cellular adhesion molecules on the endothelial surfaces. Adhesion molecules (e.g., selectins and integrins) allow for tumbling and adherence, respectively, of PMNs to the endothelial lumen wall. The adherent PMNs then move through the wall by diapedesis and migrate along the chemokine gradient, eventually infiltrating in and around the focus of injury. ROS, reactive oxygen species. (Adapted from Guyton and Hall Textbook of Medical Physiology, 13th edition, with permission.)

Adaptive Immune System

Adaptive immunity constitutes the second, but more specific response to pathogenic organisms and damaged tissues. It is subdivided into cellular and humoral immunity.

Cellular Immunity

Surgical insult leads to the activation of local host responses necessary for protection against invading microorganisms, as well as the initiation of tissue repair following injury. The sequence of events begins at the time of

injury, with activation of the coagulation cascade and the initiation of local inflammation. Local inflammatory mediators, such as cytokines, histamine, kinins, and arachidonic acid metabolites increase capillary permeability, which allows leukocyte infiltration (primarily neutrophils, followed by monocyte/macrophages). Immune cell migration is a complex process involving attachment to the endothelial cells and extravasation regulated by many substances, the most important of which are the chemokines and adhesion molecules. Most of these mediators act in a paracrine fashion and they are short-lived because of rapid metabolism. Therefore, serum measurements of these mediators may not reflect their activity in local tissues.

TLR activation increases cytokine (TNF-α and IL-1) and chemokine secretion, especially by local macrophages. Chemokines are produced and secreted into the extracellular matrix by activated leukocytes and various other cells (epithelial cells, fibroblasts, and endothelial cells) to mediate cell motility toward the site of injury/infection. The local microcirculatory inflammatory response is reflected by a pronounced leukocyte accumulation and adherence to the endothelial lining of postcapillary and collecting venules. This response is associated with an increase in microvascular permeability, indicating the disruption of endothelial integrity. In addition to the increased capillary permeability and leukocyte accumulation, cytokines act on endothelial cells, leukocytes, and cells within the extracellular matrix to induce expression of adhesion molecules (e.g., selectins, cadherins, integrins). These molecules allow low-affinity interactions between the endothelium, and leukocytes begin to roll along the endothelial surface in the direction of blood flow. Subsequently, the increased expression of adhesion molecules promotes the extravasation of leukocytes from the circulation toward the damaged or infected tissue along a chemotactic gradient.

Finally, at the time of injury, the production of proinflammatory cytokines and the expression of adhesion molecules and chemokines mediate the selective recruitment of cutaneous lymphocyte antigen (CLA)-positive T-cells into the wound. The local macrophages present antigens and express costimulatory molecules that are necessary for T-cell activation. After antigen binding and activation, T-cells differentiate preferentially into Th1 subsets, and secrete interferon-gamma (IFN-γ), the major macrophage-activating cytokine. Activated macrophages remove debris from dead cells to facilitate repair after the infection is controlled,

which promotes resolution of the inflammatory phase. The process of tissue repair ensues, with formation of granulation, re-epithelialization, and neovascularization.

In the normal host response, these processes are mostly limited to the site of trauma; however, every substantial traumatic injury also leads to a degree of systemic inflammation. Depending on the magnitude of tissue damage, the local inflammatory process will cause washout of proinflammatory mediators into the systemic circulation and inflicts a systemic inflammatory process. The systemic leak of cytokines leads to further activation of immune cells, mostly neutrophil priming, more cytokine secretion, activation of complement and the coagulation cascade, and secretion of APPs and neuroendocrine mediators. This systemic inflammation is followed by a compensatory anti-inflammatory response, creating a balance, which will have significant impact on the clinical outcome. Hence, the “right tuning” of systemic inflammation is crucial for restoration of homeostasis. Severe inflammation may lead to tissue destruction in organs not originally affected by the initial trauma by a process commonly referred to as the multiple-organ dysfunction syndrome (MODS). A lesser inflammatory response (or too much anti-inflammatory regulation) will induce a state of immunosuppression during the vulnerable time of recovery, which can result in deleterious sepsis for the host.

Cytokines

Cytokines are small protein hormones, secreted by systemic immune cells, macrophages, monocytes, or lymphocytes (T-cells and B-cells) and by diverse cell types at the site of injury. Cytokines are crucial mediators in cell immunity and inflammatory response. In healthy humans, they are produced at low constitutive levels, reaching just picograms per milliliter in plasma, and function in an endocrine, paracrine, or autocrine manner. Cytokine receptors are expressed on the surface of the majority of human cells, and some soluble cytokine receptors are detectable in plasma at low levels. Cytokines activate intracellular signaling pathways that regulate gene transcription. Examples include NF-κB, activating protein 1 (AP-1), signal transduction- and transcription-activating factor 3 (STAT-3), and members of the CCAAT/enhancer-binding protein (C/EBP) family of transcription factors, in particular C/EBP-β and δ.

The NF-κB family of transcription factors is well studied because of its central role in the inflammatory process, which targets expression of a number of cytokines that influence immune cell activity, differentiation,

proliferation, and survival. These mediators also regulate the production and activity of other cytokines in a watershed manner. There is a significant overlap in bioactivity among different cytokines.

Cytokines are not antigen-specific and their effect can be stimulatory or inhibitory. TNF, IL-1b, IL-6, IL-8, IL-12, and IFN-γ are the dominant stimulatory (or proinflammatory) cytokines and IL-4, IL-10, and IL-13 are considered inhibitory (or anti-inflammatory). Those compounds acting in between cells of the immune system are called ILs, and those inducing chemotaxis of leukocytes are referred to as chemokines. Including about 50 chemokines and 30 ILs, the number of characterized cytokines is now well in excess of 100.

During acute localized inflammation, connective tissue, endothelial cells, and local immune cells are first to secrete proinflammatory cytokines, mostly IL-1 and TNF. Excess cytokines may leak to the circulation and exceed the levels of soluble receptors, resulting in systemic inflammatory responses and possible development of SIRS and MODS. The monocyte/macrophage also produces the only natural and well-characterized competitive cytokine antagonist, IL-1 receptor antagonist (IL-1ra), as well as liberates soluble forms of TNF and IL-1 receptors (IL-1RI) that are able to bind and neutralize TNF and IL-1, respectively.

Interleukins

One of the best-described proinflammatory cytokines, TNF (originally known as cachectin) is produced by macrophages/monocytes and by T-cells, endothelial cells, fibroblasts, and adipose tissue. TNF is among the early cytokines secreted after trauma and acts through its receptors TNF-receptor 1 and TNF-receptor 2 (i.e., TNFR1 and TNFR2). TNF-R1 activates the caspase cascade and induces cellular apoptosis, as well as induction of transcription factors (e.g., NF-κB) and activation of the mitogen-activated protein kinase (MAPK) pathways, which are both involved in cell proliferation, transcription of inflammatory genes, and antiapoptosis. Binding of TNF to TNFR2 leads to activation and proliferation of immune cells. TNF induces secretion of a variety of pro- and anti-inflammatory cytokines (e.g., IL-6, IL-8, IFN-γ, and IL-10), increases synthesis of nitric oxide and arachidonic acid metabolites to induce activation of cyclooxygenase and lipoxygenase enzymes. This activation leads to the production of thromboxane A2 and prostaglandins E2, which have multiple physiologic effects, including increased permeability of endothelial cells. It also induces the production of

adhesion molecules (e.g., selectins), platelet-activating factors, and intracellular adhesion molecules (ICAM). In addition, TNF increases the procoagulated activity of endothelial cells. The local effects of TNF can be physiologic, but the systemic effects often lead to adverse outcomes. TNF has been identified as a principal mediator in septic shock. In the central nervous system (CNS), TNF stimulates the release of corticotropin-releasing hormone (CRH), induces fever, and reduces appetite. In the liver, it stimulates production and secretion of APPs, and also causes insulin resistance. Inhibition of TNF by either anti-TNF antibodies or soluble receptors for TNF has become a strategy in the treatment of patients with chronic inflammatory diseases, but this strategy does not work in septic patients.

IL-1 is another IL that was first described as endogenous pyrogen over a half century ago, because it caused fever when injected into rabbits. After being secreted by monocytes, macrophages, or endothelial cells, IL-1 has a half-life of only 6 minutes. IL-1 has two forms, IL-1α and IL-1β, which are regulated by different antigens, but bind to the same IL-1RI. IL-1 is a potent pyrogen, which influences the hypothalamus to reset the temperature of the body and induces fever. It is associated with local hyperalgesia. IL-1 has similar effects to TNF on the immune system following trauma. In fact, TNF and IL-1 are often described as synergistically acting mediators.

Similar to other cytokines, IL-6 is produced by a variety of cell types and is induced by TNF and IL-1. It is detectable within an hour of trauma, and peaks at 4 to 48 hours following surgery. IL-6 induces a proliferation and differentiation of B- and T-lymphocytes, activates NK cells and neutrophils, and inhibits its apoptosis. IL-6 also regulates hepatic synthesis of APP, such as C-reactive protein (CRP), fibrinogen, complement factors, α-2 macroglobulin, α1-antitrypsin, and others. IL-6 also induces the release of soluble TNF-R and IL-I receptor antagonist, and therefore plays a dual role in the inflammatory response by acting as both a proinflammatory and an anti-inflammatory mediator. IL-6 has a longer half-life than TNF or IL-1, which makes it easier to monitor, and seem to correlate with the magnitude of trauma. For example, despite similar procedure times, there is a greater degree of IL-6 elevation after abdominal aortic and colorectal surgery than after hip replacement; there are lower IL-6 levels after laparoscopy than after open procedures, including cholecystectomy and small-bowel and colon resection. Furthermore, IL-6

is regarded as a prognostic marker of trauma patients with SIRS, sepsis, or MODS and has been used in the intensive care unit (ICU) setting as an indicator for the severity of the inflammatory responses that is relatively independent of bacterial infections.

Chemokines

Overall, >18 chemokine receptors and >43 chemokines have been described, demonstrating a sharing of receptors. The name “chemokine” is a shortened version of “chemotactic cytokines,” which is the major function of these molecules—that is, they act as chemical attractants to almost all cell types of the innate and adaptive immune responses. In lower doses, chemokines act mostly as chemoattractants, while in increased concentrations they can lead to cell activation, including cytotoxicity and even respiratory burst. Their receptors have also been detected in endothelial cells, keratinocytes, and fibroblasts, suggesting that some chemokines also contribute to the regulation of epithelialization, angiogenesis, and tissue remodeling. The chemokine receptors belong to the family of G-protein–coupled receptors, and binding to these receptors leads to effects, including both chemotaxis and activation. IL-8 is a typical chemotactic cytokine and its secretion is induced by IL-1, TNF-α, C5a, microbes and their products, hypoxia, hyperoxia, and reperfusion. Interferons attenuate the expression of IL-8. It can be produced in an early state of inflammation following trauma and can persist over a long period of time, even weeks. It has the ability to act as potent angiogenic factor, as a potent chemoattractant, and as an activator of immune cells.

Cytokines Postelective Surgery

Elective surgery followed by an uneventful clinical course may induce only minor systemic inflammatory changes. As one could expect, the acute-phase response, post-elective surgery, is proportional to the surgery-related tissue trauma or to the severity of the procedures. Virtually, all inflammatory mediators (cellular, cytokines, and APPs) peak postinjury at about day 1 to 2 and then return to baseline levels by postinjury days 6 to 7. Persistent postoperative pain, stress, or a second insult will change that pattern.

THE NEURO-IMMUNE AXIS

The systemic and even local inflammatory responses posttrauma are

regulated by the nervous system. Evidence continues to identify that the autonomic nervous system is an important regulator of the inflammatory response, with both afferent sensory and efferent effector pathways having important roles. Considerable attention has been given to the effectiveness of parasympathetic nerve stimulation in suppressing the magnitude of the proinflammatory response, leading to coining of the term “inflammatory reflex”; however, like our understanding of the autonomic nervous system in classical physiologic responses, the inflammatory reflex comprises both afferent and efferent arms.

Afferent/Sensory Input to the Brain

During stress, afferent signals from the injury site can reach the CNS through two main routes: the neural route, mostly by afferent vagal or other autonomic nerve fibers throughout the body, and through blood-borne inflammatory mediators.

Neural Route

The neural afferents offer rapid means to activate the CNS in response to trauma, and the molecular mechanisms leading to their activation remains an important area of investigation. Various investigators have demonstrated the effects of complement (C5a) fragments, PGE_2, coagulation factors (Factor XII), kinins (bradykinin), and cytokines (TNF, IL-1, and IL-6) as afferent signals to the CNS. For example, intraperitoneal administration of LPS or IL-1 (typically resulting in fever, increased secretion of adrenocorticotrophic hormone [ACTH]) can be blocked or attenuated by subdiaphragmatic vagotomy. This vagal-dependent sensory arm can be also be activated by the presence of IL-1 in peripheral tissues.

Humoral Route

Cytokines are lipophobic molecules without direct access to the CNS, as the blood–brain barrier (BBB) excludes entry of such proteins. An exception is in regions where the BBB is less selective, such as around the circumventricular organs (CVOs), the meninges, and the choroid plexus or areas in which active transport of circulating cytokines by the vascular endothelium may exist. Alternatively, cytokines may damage and increase BBB permeability and enter the brain to stimulate central neural circuits through that route as well. Several factors have been implicated, most notably IL-1 and IL-6. Prostaglandins, mostly PGE_2, locally produced in

the hypothalamus in reaction to cytokines, play a crucial role in inducing pyrexic reaction, as known for many years from the ability of cyclooxygenase inhibitors to prevent fever.

Efferent Regulation

Following integration of afferent signals, the CNS has two major effector arms that regulate physiologic responses. The first is the activation of the hypothalamus–pituitary–adrenal (HPA) axis, and the second is the direct activation of the sympathetic and parasympathetic branches of the autonomic nervous system. Efferent CNS regulation of the inflammatory response suppresses the immune system through at least two main routes: (1) by increasing corticosteroid hormone levels (activation of the HPA axis) and (2) by activation of the cholinergic anti-inflammatory pathway. For example, TNF-α, IL-1, and IL-6 stimulate the HPA axis resulting in the release of ACTH and glucocorticoids (Fig. 1.3), which downregulates cytokine release from macrophages and other inflammatory cells. These negative feedback processes between glucocorticoids and cytokines is a major mechanism leading to prevention of overactivation of the inflammatory response.

Immunosuppression Following Trauma

Increasing evidence has demonstrated that the neurologic system plays a major role in the coordination of inflammatory and anti-inflammatory immune response. While minor surgery is suggested to stimulate components of the immune system, it is generally agreed that after the acute-phase response, major surgery, and to a higher extent, major trauma cause immunosuppression that may render the host anergic to opportunistic infections. The initial response to surgical trauma is characterized by activation of the specific and nonspecific immune system's release of proinflammatory cytokines (e.g., TNF, IL-1β, IL-6, IL-18, HMGB1), neutrophil activation, microvascular adherence, as well as PMN and macrophage oxidative burst, but this rapidly gives way to a state of depressed immune function.

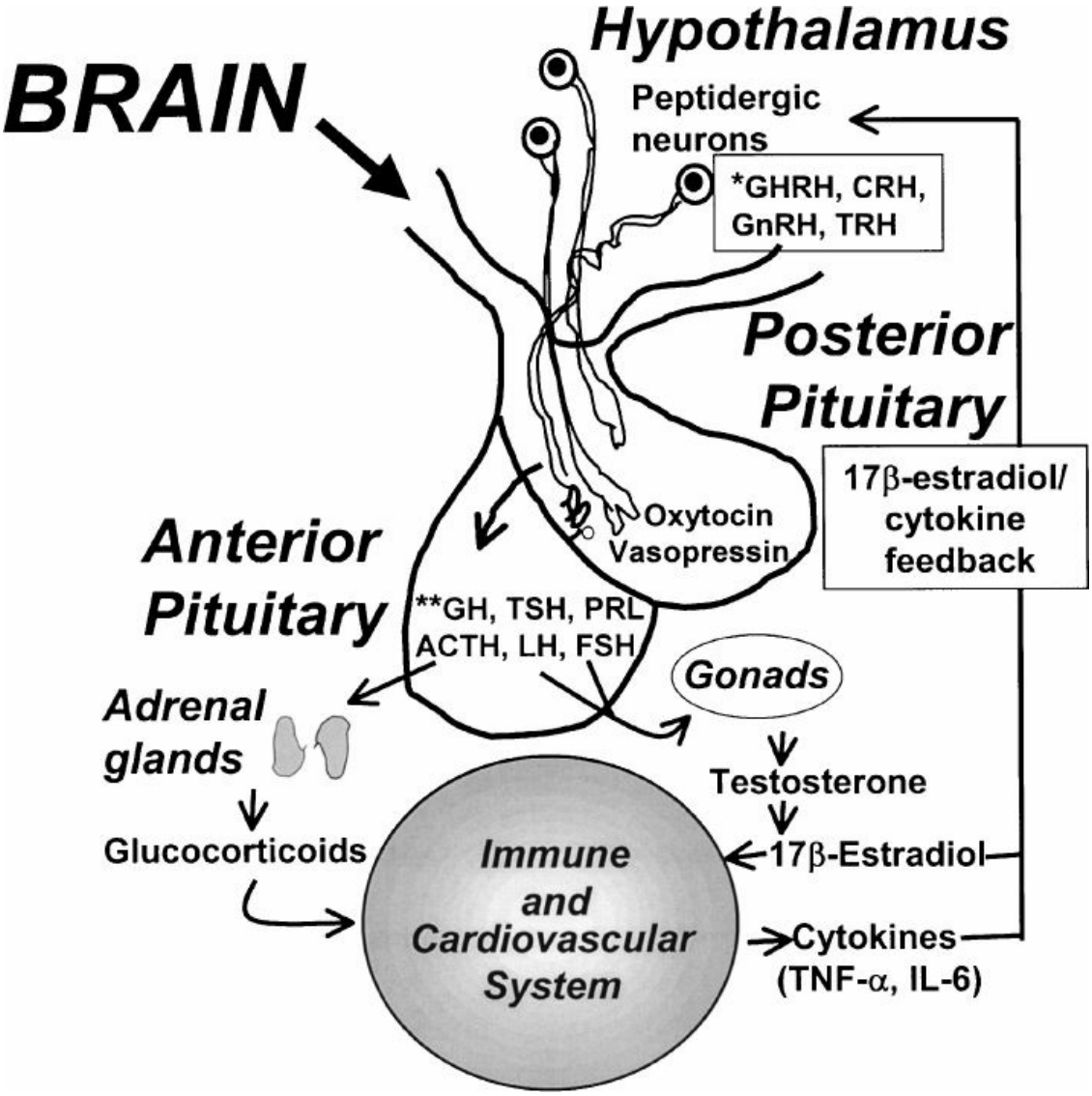

Figure 1.3. Relationship between the hypothalamus–pituitary–gonad-adrenal (HPA) axis and the immune system in physiologic responses to injury. The HPA is a neuroendocrine system that also has bidirectional communication with the immune system in homeostasis and in times of injury, giving the brain a major role in regulating endocrine and immune functions. The hormonal responses are apparent at three levels: the hypothalamus, the pituitary, and the adrenals. It can be seen that organs are coupled with one another (functioning as a biologic oscillators), with the coupling being mediated by neural, hormonal, and cytokine networks. Notably, cytokines and sex hormones are closely coupled in a counterregulatory fashion, which sheds light on the beneficial effects of sex hormones, especially β-estradiol, in responses to injury.

The production of immunoglobulins fall and many patients become

anergic as assessed by delayed hypersensitivity skin testing. Defects in neutrophil chemotaxis, phagocytosis, and lysosomal enzyme content and respiratory burst have all been reported. This condition is referred to as a compensatory anti-inflammatory response syndrome; it is induced by multiple mediators and affects all subtypes of immunity. The counter anti-inflammatory mechanism is as complex and multi-factorial as the proinflammatory one. It includes cytokines such as IL-10, TGF-β, TNF-binding protein, and hormones such as corticosteroids, adrenaline, and α-melanocyte stimulating hormone (α-MSH). These act in concert with local effectors, such as PGE_2, HSPs, and APPs. These factors interact to inhibit macrophage activation and downregulate the synthesis of proinflammatory cytokines.

The Cholinergic Anti-Inflammatory Pathway

In recent years the activation of the cholinergic pathway leading to acetylcholine release in the reticuloendothelial system (which includes the spleen, liver, lymphoid tissue, and GI tract) has been linked to anti-inflammatory pathways that quell the inflammatory response. Acetylcholine binds to acetylcholine receptors expressed on tissue macrophages, which inhibits the release of proinflammatory (e.g., TNF, IL-1β, IL-6, and IL-18), but not the anti-inflammatory cytokines (e.g., IL-10). In addition, direct electrical stimulation of the peripheral branches of the vagus in vivo during lethal endotoxemia in rats inhibits TNF synthesis in liver, attenuated peak serum TNF amounts, and prevents the development of shock. Several reports have confirmed that the activation of this pathway, is effective in ameliorating inflammation and improving survival in a number of experimental models, such as sepsis, hemorrhagic shock, pancreatitis, and postoperative ileus.

Cell-Mediated Immune Dysfunction

Cellular immuno-incompetence (also called “immune paralysis”) is induced by elevated PGE_2, IL-10, soluble cytokine receptors, and other anti-inflammatory mediators, mainly caused by the deactivation of monocytes. The central role of IL-10 and TGF-β in inducing monocyte “immune paralysis” is demonstrated by the upregulation of HLA-DR expression on monocytes following the application of an IL-10 neutralizing antibody and the restoration of macrophage antigen presentation by using TGF-β neutralizing antibodies.

Lymphocyte Dysfunction

Major surgical interventions are also associated with a significant decrease in total systemic lymphocyte counts, including $CD4^+$ and $CD8^+$ T-cells. This lymphocyte depression correlates with the duration of the surgical procedure and the volume of blood loss; however, this is not associated with the extent of the trauma, the age of the patient, or the type of intensive care intervention. These events are accompanied (within 24 hours) with elevated IL-10 and increased frequency of apoptosis of $CD4^+$ and $CD8^+$ cells accompanied by marked downregulation of antiapoptotic factors such as Bcl-2. Furthermore, the $CD4^+$ T cells can be subdivided into functionally distinct subsets, with Th1cells supporting proinflammatory responses by producing IL-2, IL-12, and IFN-γ and Th2 cells acting promoting anti-inflammatory responses by secreting IL-4, IL-5, IL-6, IL-10, and IL-13. Major trauma is associated with a shift of the Th1/Th2 balance toward a Th2 response.

The Second Hit Phenomenon

The so-called two-hit model of inflammatory insult has become a commonly accepted paradigm in the care of critically ill patients. It takes place in many common scenarios in which the patient has to undergo a surgical procedure following initial trauma or suffers further insults due to a complication. The second hit may be sterile- (operation after trauma) or a pathogen-induced infection postsurgery. Although influenced by many factors, the inflammatory and metabolic response is relatively predictable. The immune reaction to further insults is not as consistent or predictable. Variations in the competence of innate and adaptive immune defenses become evident; there is an innate immune tolerance and diminished adaptive immune capacity of response to a new antigen. On the other hand, recurrent immunologic activation causes a persistent systemic proinflammatory activity that may lead to SIRS and MOF. Depending on the patient the recurrent inflammation could trigger some aspects of immunity and not in others. An example of this is the continuation of coagulation system activation, even as other proinflammatory activity is waning. Not infrequently, a prolonged stress state manifests diminishing amplitude, frequency, and efficiency of autonomic and neuroendocrine signaling. Disturbances in circadian rhythmicity of neuroendocrine hormone secretion are also observed during prolonged inflammatory illness. The attenuated hormone rhythmicity and signal amplitude may

contribute to disordered metabolic and immune functions.

Systemic Inflammatory Response Syndrome and Multiple Organ Dysfunction Syndrome

Cytokine-mediated inflammation is usually short-lived and is resolved. In some cases, however, cytokine production can become excessive, and rather than resolving, inflammation persists or even spreads, causing damage in adjacent tissues. This hypermetabolic response, often called the SIRS, encompasses excessive whole body inflammation and is considered a major determinant in the development of MODs, often with a lethal result. The pathophysiology of SIRS and MODS is explored in subsequent chapters in this text.

Endocrine Response

Role of the Central Nervous System

The CNS response consists primarily of three parallel, coordinated effects: fever, HPA axis activation, and sickness behavior (such as anorexia or somnolence). Following integration of afferent signals, the hypothalamus has two major effector arms that are used to regulate physiologic responses —the activation of the HPA axis and the autonomic nervous system. At rest, the hypothalamus secretes, in a pulsing manner, CRH, thyrotropin-releasing hormone (TRH), gonadotropin-releasing hormone (GnRH), growth hormone-releasing hormone (GHRH), and dopamine. During stress, the afferent signals from the injury site reach the hypothalamus through the neural route mostly by afferent vagal fibers or through blood-borne inflammatory mediators. Humoral mediators reach the hypothalamic-hypophyseal portal capillaries in the median eminence through the anterior hypophyseal arteries. The cytokines can diffuse into the portal capillaries, areas that are free from the BBB.

Endogenous Opioids (Endorphins)

Many of the mediators released during inflammation of peripheral tissue are known to elicit pain by activation of specialized primary afferent neurons called “nociceptors” (defined as “neurons preferentially sensitive to a noxious stimulus or to a stimulus which would become noxious if prolonged”). Nociceptor stimuli propagate through the dorsal horn of the spinal cord to the supraspinal sites where a sensation of pain is eventually elicited. Various opioid peptides, such as β-endorphin, met-enkephalin, dynorphin, and endomorphins are produced and secreted by the

hypophysis, hypothalamus, and, as demonstrated most recently, locally by leukocytes. Opioid peptides can bind to opioid receptors. The most studied opioid receptor groups are μ, κ, and δ. These receptors are part of the G-protein–coupled receptors, which are synthesized in dorsal root ganglia and are transported intra-axonally. The opioid receptors are represented in the brain, spinal cord, sensory peripheral nerve endings, and in the intestinal tract. Agonist binding elicits potent analgesia, a quality often used to treat pain, with induction of external opioids.

Immune cells carry all three opioid receptors. Opioids have been shown to modulate a number of aspects of the immune response, including antibody responses in vitro and in vivo, phagocytic cell function, NK-cell activity, chemokine-induced chemotaxis, the development and function of T-cells in the thymus, and cytokine and cytokine receptor expression. Opiate-mediated immune effects have been postulated to result from either direct interaction with opioid receptors on cells of the immune system or indirectly through the activation of opioid receptors within the CNS, and the resulting modulation of HPA axis (cortisol) and the sympathetic nerve system activities. Although alternations in various aspects of immune function in patients exposed to opioid treatment were demonstrated in clinical practice (postelective abdominal surgery, orthopedic surgery, and in healthy volunteers), there are no actual prospective clinical studies exploring the possible interaction between exposure to opiates and rates of infection.

Hormonal Changes During Acute and Chronic Surgical Illness

There is a biphasic neuroendocrine response to critical illness. The acute phase is characterized by an actively secreting pituitary; whereas, in prolonged critical illness, there is a hypothalamic suppression of the neuroendocrine axes.

Glucocorticosteroids

In a stress-free healthy human, cortisol is secreted from the zona fasciculata of the adrenal cortex in a diurnal fashion. Cortisol release is controlled by ACTH produced by the pituitary, in turn under the influence of the hypothalamic CRH. Cortisol itself exerts negative-feedback control on CRH and ACTH. Approximately 10% cortisol is found free in the plasma. Of the remainder, 20% is bound to albumin, and 70% is bound to cortisol-binding globulin. Only the free hormone, however, is biologically active. Glucocorticoids exert their effects by binding to and activating an

intracellular receptor protein that acts as a transcriptional activator or repressor, and the cortisol–glucocorticoid receptor complex can modulating inflammatory transcriptional activity (e.g., NF-κB).

Cortisol Secretion During Stress

Cortisol levels usually rise in the early phase of critical illness. The excited neurons in the hypothalamus release CRH and arginine vasopressin (AVP) from their terminals into the capillaries of the hypothalamo-hypophyseal portal venous plexus. CRH and AVP act on CRH-1 and vasopressin-1β receptors on the anterior pituitary to stimulate ACTH secretion. Plasma ACTH levels rise directly due to increased secretion and due to resistance to or inhibition of the negative-feedback mechanism exerted by cortisol. Several of the elevated cytokines have been shown to modulate cortisol production, either by directly affecting the hypothalamus/pituitary (IL-1α, IL-1β, IL-6, and TNF-α) or by direct stimulation of the adrenal cortex (IL-1α, IL-1β, and IL-6). Cytokines can also influence glucocorticoid receptor numbers and affinity. During severe illness, corticosteroid-binding globulin levels are decreased, resulting in proportionate increases in the free hormone. The diurnal variation in cortisol secretion is lost in response to any type of acute illness or trauma. An appropriate activation of the HPA axis and cortisol in response to critical illness is essential for survival. The adrenal gland does not store cortisol; therefore, increased secretion arises due to increased synthesis of cortisol from its principal precursor, cholesterol.

Cortisol Influence on Posttrauma Physiology

The stress-induced hypercortisolism fosters the acute provision of energy. Glucocorticoids increase blood glucose concentrations by increasing the rate of hepatic gluconeogenesis and inhibiting adipose tissue glucose uptake. Hepatic gluconeogenesis is stimulated by increasing the expression of phosphoenolpyruvate carboxykinase and glucose-6-phosphatase as a result of binding of glucocorticoids to the glucocorticoid response elements of the genes for these enzymes. Glucocorticoids stimulate FFA release from adipose tissue and amino acid release from body proteins, which supplies energy sources and amino acid substrates for the response to stress and repair of injured tissues.

The rise in glucocorticoids also protects against excessive inflammation, acting as a negative feedback on the inflammatory response. The rise in glucocorticoids during acute illness plays a crucial role in

preventing hazardous overstimulation of the immune system, including lymphocytes, NK cells, monocytes, macrophages, eosinophils, neutrophils, mast cells, and basophils. Glucocorticoids decrease the accumulation and function of most of these cells at inflammatory sites. Most of the suppressive effects of glucocorticoids on immune and inflammatory reactions appear to be a consequence of the modulation of production or activity of cytokines, chemokines, eicosanoids, complement activation, and other inflammatory mediators.

A rise in glucocorticoid concentrations plays an important role in improving hemodynamic levels, by inducing fluid and sodium kidney retention. Glucocorticoids are also required for the needed increased sensitivity of the cardiovascular system to vasoconstrictors. The reactivity to angiotensin II, epinephrine (Epi), and norepinephrine (NE) contributes to the maintenance of cardiac contractility, vascular tone, and blood pressure. These effects are mediated partly by the increased transcription and expression of the receptors for these hormones. Glucocorticoids are required for the synthesis of Na^+, K^+-ATPase, and catecholamines. The effects of glucocorticoids on synthesis of catecholamines and catecholamine receptors are partially responsible for the positive inotropic effects of these hormones. Glucocorticoids also decrease the production of nitric oxide, a major vasorelaxant and modulator of vascular permeability.

During surgical procedures such as laparotomy, serum corticotropin and cortisol rise rapidly, peaking in the immediate postoperative period. The magnitude of the postoperative increase in serum cortisol concentration is correlated with the extent of the surgery. From a normal secretion rate of 10 mg/day, cortisol production rate increases to 75 to 150 mg/day following major surgery and can reach to 250 to 300 mg/day in severe stress. Unless there is a repeated insult, such as sepsis, the glucocorticoid concentrations decline to baseline levels over the next 72 hours. This decline can often be noticed clinically as increased diuresis, improved glucose control, and, occasionally, increased pain. In critical illness, the kinetics of the response differ from those mentioned above: pain, fever, hypovolemia, hypotension, and tissue damage all result in a sustained increase in corticotropin and cortisol secretion and a loss of the normal diurnal variation in these hormones. During severe illness, serum cortisol concentrations tend to be higher than even in patients undergoing major surgery (～30 μg/dL vs. 40 to 50 μg/dL).

Adrenal Insufficiency

Critical illness is associated with activation of the HPA axis; however, many factors can impair the integrity of the HPA axis, such as blunt normal response leading to either transient or, rarely, permanent adrenal insufficiency. This scenario can lead to a potentially lethal condition. Refractory hypotension is the most common aspect of acute adrenal insufficiency. Adrenal insufficiency should be suspected in any critically ill patient who has persistent hypotension and hemodynamic instability that persists despite adequate fluid resuscitation and/or requires vasopressor support. Other nonspecific signs can include MOD, otherwise unexplained hypoglycemia, hyponatremia, hyperkalemia metabolic acidosis, eosinophilia, hyperdynamic circulation, and other pituitary deficiencies (gonadotropin, thyroid, and diabetes insipidus). Much attention was previously focused on the so-called relative or functional adrenal insufficiency of critical illness, a condition defined as subnormal adrenal corticosteroid production in the absence of any structural defects of the HPA axis. The explanation for the development of this condition is hypothetical exhaustion of the secretory adrenocortical reserve as a result of ongoing near-maximal stimulation. Other contributing factors may include the suppression of cortisol and ACTH production by circulating cytokines and other inflammatory mediators, as well as the development of target tissue resistance to glucocorticoids and/or adrenal cortex resistance to ACTH action. A number of trials and other studies have attempted to identify a role for glucocorticoids in patients with critical illness, though none of them has been able to come to a consensus for diagnosis and treatment indications for adrenal insufficiency. These studies have examined the roles of provocative testing (i.e., ACTH stimulation tests) as well as other plasma markers such as the random cortisol concentration. These tests and laboratory values can be highly variable and skewed in critically ill patients and potentially misleading. As such, the Surviving Sepsis guidelines currently suggest that hydrocortisone therapy is warranted in resuscitated patients with pressor requirements who are suspected of having adrenocortical insufficiency. No provocative testing or other laboratory tests are warranted to confirm diagnosis.

Vasopressin

Vasopressin, also known as ADH, is synthesized as a large prohormone in the hypothalamus. The prohormone complex is transported to the posterior pituitary where it is stored in granules. Vasopressin is released mainly in response to hyperosmolality, hypotension, and hypovolemia, and has

vasopressor and antidiuretic effects. Vasopressin levels increase rapidly in the early phase of certain stressful situations, such as hemorrhagic and septic shock. With persistence of the septic shock state, however, vasopressin stores are depleted and plasma concentration falls to low levels.

Thyroid

TRH secreted by the hypothalamus stimulates the pituitary to produce thyrotropin (TSH), which, in turn, regulates the synthesis and secretion of thyroid hormones in the thyroid gland. The thyroid hormones, in turn, exert feedback control on both TRH and TSH secretions. The early response of the thyroid axis to a severe physical stress consists of a rapid decline in the circulating levels of T3 and a rise in rT3 levels, predominantly as a consequence of altered peripheral conversion of T4 to T3, a reaction that is catalyzed by 5′ monodeiodinase (or type 1 deiodinase) located in the kidney, the liver, and the muscle. TSH and T4 levels are elevated very briefly and subsequently return to "normal," although in more severe illness, T4 levels can be decreased. The low T3 levels persist beyond TSH normalization, a condition referred to as "the low T3 syndrome." The severity of illness is reflected in the degree of the fall in serum T3 during the first 24 hours after the insult. Furthermore, an inverse correlation between T3 levels and mortality has been demonstrated. Other factors involved in the low-T3 syndrome at the tissue level include low concentrations of thyroid hormone-binding proteins, and inhibition of hormone binding, transport, and metabolism by elevated levels of glucocorticoids, FFA, and some commonly used medications (amiodarone, iodine contrast). It remains controversial whether development of the aforementioned changes in thyroid metabolism reflects a protective mechanism (attempt to reduce the elevated energy expenditure) or a maladaptive process during illness.

In prolonged critical illness, a state of euthyroid sick syndrome is usually present, in which the pulsatile TSH secretion is dramatically reduced and serum levels of both T4 and T3 are low. Reduced *TRH* gene expression in the hypothalamus has been observed in chronically ill patients who died, which is in line with the predominantly central origin of the suppressed thyroid axis. Since the presence of euthyroid sick syndrome is associated with an increased mortality among critically ill patients, it could indicate an aberration that may delay recovery from acute illness and, therefore, would require intervention. To date, however, a routine

thyroid hormone therapy has not been demonstrated to improve clinical outcomes in critically ill patients with normal previous thyroid function. If hypothyroidism is suspected clinically (hypothermia, bradycardia, respiratory acidosis, pleural effusions, and failure to wean), thyroid function should be measured and corrected. In a critically ill patient with hypothyroidism, central hypothyroidism should be ruled out.

Growth Hormone

The regulation of the physiologic pulsatile release of GH by the somatotrope cells in the anterior pituitary is highly complex. Hypothalamic GHRH stimulates, while somatostatin inhibits the secretion of GH. But many other stimulating (ghrelin, androgens, estrogen, hypoglycemia, sleep, fasting, and exercise) and inhibiting (circulating GH and IGF-I, hyperglycemia, and glucocorticoids) factors have been identified. GH exerts both direct and indirect effects. It directly promotes muscle mass increase through sarcomere hyperplasia, lipolysis, protein synthesis, and liver gluconeogenesis. The indirect effects are mediated by increases in IGF-I, whose bioactivity is regulated by several IGF-binding proteins and it has growth stimulation effects on a wide variety of tissues. The pulsatile nature of GH secretion consists of peak serum GH levels alternating with virtually undetectable troughs. During the first hours to days after an acute insult, the GH profile changes dramatically. The amount of circulating GH rises, with increased pulsatile peak secretion and frequency. Concomitantly, a state of peripheral GH resistance develops, in part, triggered by cytokines such as TNFα and IL-6. These events are preceded by a drop in circulating GH-binding protein, which presumably reflects the functional GH receptor status. Theoretically, these effects could enhance the direct lipolytic and insulin antagonizing effects of GH, resulting in elevated fatty acid and glucose levels in the circulation, whereas the indirect, IGF-I-mediated somatotropic effects of GH are attenuated. As a result, costly anabolism, largely mediated by IGF-I and considered less vital at this time, could be postponed. Hence, from a teleologic point of view, this response to acute injury within the GH axis seems appropriate in the struggle for survival.

The role of GH in critical illness has been previously examined in a number of randomized studies and clinical scenarios. In contrast with the observations during the acute phase of critical illness, the pulsatile release of GH is suppressed in patients who are critically ill for a prolonged time. The loss of pulsatile GH release contributes to the low levels of IGF-I in

prolonged critical illness and a relative hyposomatotropism, which has been thought to contribute to the pathogenesis of the “wasting syndrome” commonly seen in critically ill patients. This “wasting syndrome” is believed to increase the rate of organ dysfunction, muscle weakness, prolonged mechanical ventilation, and length of stay in the ICU. Thus, recombinant GH supplementation in surgical trauma and burn injury patients was previously examined and adopted in critically ill patients; however, two large randomized trials demonstrated its increased morbidity and mortality. Thus, currently GH/IGF-1 replacement is not advocated in critical illness.

The Gonadal Axis

GnRH, secreted in a pulsatile pattern by the hypothalamus, stimulates the release of luteinizing hormone (LH) and follicle-stimulating hormone (FSH) from the gonadotropes in the pituitary. In men, LH stimulates the production of androgens (testosterone and androstenedione) by the Leydig cells in the testes, whereas the combined action of FSH and testosterone on Sertoli cells supports spermatogenesis. In women, LH also mediates androgen production by the ovary, whereas FSH drives the aromatization of androgens to estrogens in the ovary. Sex steroids exert a negative feedback on GnRH and gonadotropin secretion.

Acute stress brings along an immediate fall in the serum levels of testosterone, even though LH levels are elevated. The enhanced release of CRH and β-endorphin suppresses GnRH release directly and indirectly through the release of glucocorticoids, which in turn also produce gonadotropin resistance at the gonads. Clinical data on the changes within the gonadal axis are scarce in critically ill women, as most patients are older and thus in the menopausal state. It seems that in the days directly following surgery, the FSH, LH, and estradiol levels decline, while the progesterone and prolactin levels do not change significantly. The state of relative hypogonadism is often expressed in premenopausal women by an unexpected menorrhagia shortly after trauma.

With prolongation of the disease, a more substantial hypogonadotropism in both men and women ensues. The circulating levels of testosterone become extremely low and are often even undetectable; yet the mean LH concentrations and pulsatile LH release are suppressed. Total estradiol levels in women are relatively low. Since exogenous GnRH is only partially and transiently effective in correcting these abnormalities, the profound hypoandrogenism must result from combined central and

peripheral defects.

Prolactin

Prolactin is synthesized and secreted by lactotrophs in the anterior pituitary. Prolactin levels are higher in females than in males, and the role of prolactin in male physiology is not completely understood. Like other pituitary hormones, secretion is pulsatile and diurnal; predominately under control of tonic inhibition from projecting hypothalamic dopaminergic neurons. Prolactin release is affected by a large variety of stimuli, the most important being suckling, increased levels of estrogen, and stress. Several neuropeptides have been identified as prolactin-releasing factors. These include TRH, oxytocin, vasoactive intestinal peptide (VIP), and neurotensin.

Prolactin is a well-known stress hormone and is presumed to have immune-enhancing properties. It increases the synthesis of IFN-γ and IL-2 by Th1 lymphocytes, and induces proinflammatory responses and antibody production. While the main physiologic functions of prolactin are related to the mammary glands and the ovaries, it has been shown to also have an important role in the innate and adaptive immune response. Prolactin receptors can be found throughout the immune system cells. Binding of prolactin to its receptor activates several signaling pathways, which include the Janus kinase-signal transducer and activator of transcription (Jak-Stat), the MAPK, and the phosphoinositide 3 kinase (PI3K). Activation of these cascades results in endpoints such as differentiation, proliferation, survival, and secretion.

Sympathetic Stress Response

Physiology of Sympathetic Activation

The sympathetic reaction is activated by a vast range of stressful stimuli, including both psychological and physical stressors. Afferent neurons of the sympathetic system are multiple in quantity and quality (chemoreceptors, baroreceptors, and visceral receptors). The activity of autonomic nerves is dependent on descending excitatory and inhibitory inputs from several brain regions, including the cortex and the hypothalamus. A major source of excitatory drive to sympathetic preganglionic neurons comes from the rostral ventrolateral medulla in the medulla oblongata. This region of the brain stem contains the cardiac, respiratory, and vasomotor autonomic centers, and connects the upper

brain area to the spinal cord. Medullary neurons project to the spinal cord to inhibit or excite sympathetic activity. In addition, many brain stem nuclei that feed directly into these pathways can modulate these activities. In contrast to the parasympathetic nervous system with its predominantly selective innervation of single effector organs, the sympathetic system often reacts with a "massive none organ specific discharge." Increased traffic down the spinal cord via the lateral funiculi causes an increased activity in the sympathetic preganglionic nerve fibers, which results in burst-pattern release of NE from the sympathetic postganglionic nerve terminals, as well as Epi (about 80% of the secretion), NE, and dopamine from the adrenal gland. The secretion of NE from nerve terminals is immediate following the trigger (some of it originating from a spinal reflex arc). After secretion into the synaptic gap, NE is cleared by reuptake into the nerve endings, degradation by the catechol-*o*-methyltransferase or diffusion into the extrasynaptic space and blood. During stress, the latter mechanism is the main source of circulating NE. In view of its richness in sympathetic nerve endings, the intestinal tract is the main producer of NE (40% of total body NE) and dopamine (>50% of total body dopamine). Circulating Epi and NE are degraded 5 to 10 times more slowly than when secreted into the synaptic gap (20 to 30 seconds). Mechanisms of degradation of circulating catecholamine are nonenzymatic (extraneural uptake in the lung, kidney, and intestines, and neural uptake into postsynaptic sympathetic nerve endings), and enzymatic (cytoplasmic monoamine-oxidase in sympathetic nerve endings, the liver, kidney, stomach, and jejunum).

Adrenal catecholamine secretion is rapid, taking place within seconds of stimulation because NE and Epi are stored in preformed granules within the adrenal medulla. Their exocytosis is initiated by preganglionic sympathetic fibers that innervate the adrenal medulla. The normal resting rate of secretion by the adrenal medulla is about 0.2 μg/kg/min of Epi and ~0.05 μg/kg/min NE. These quantities give rise to circulating levels of catecholamines that in basal conditions are enough to maintain the blood pressure near normal, even if all direct sympathetic pathways to the cardiovascular system are removed. During severe physical stress or sepsis, both plasma Epi and NE rise significantly.

Medullary Epi secretion is dependent not just on neural acetylcholine stimulation, but also on the hormonal HPA axis. The activity of phenylethanolamine *N*-methyltransferase (the rate-limiting enzyme in the

conversion of NE to Epi) is enhanced by high doses of glucocorticoids. The medulla is exposed to uniquely high doses of glucocorticosteroids directly through a cortical–medullary, intra-adrenal portal vascular system.

The sympathetic system plays a crucial role in the maintenance of homeostasis during the stress response, and the changes to this system affect almost every possible body system. The cardiac output increases by β-receptor enhancement of heart rate and myocardial contractility. Blood pressure increases by α-receptor-mediated vasoconstriction, and blood flow is redistributed in favor of the more vital functions. Bronchodilatation, through the β2 influence, eases the need for increased minute ventilation. Thermoregulation is reset. The kidneys retain water and sodium, and secrete renin. Bowel motility decreases. Based on these effects, Walter Cannon called the emergency-induced discharge of the noradrenergic system the “preparation for flight or fight.”

Adrenergic tone also plays a significant role in regulating intermediary metabolism in the body. Epi’s capacity to influence metabolism is 5 to 10 times greater than NE. Catecholamine-related hyperglycemia is induced by increased liver glucose secretion, on one side, and by decreased peripheral intake of glucose, due to insulin resistance and inhibition of insulin secretion, on the other. Catecholamines induce catabolism, leading to extensive lipolysis and protein breakdown, which are needed to supply energy for vital functions and substrates for synthesis of various enzymes, antibodies, and glucose.

Autonomic Dysfunction

The sophisticated sympathetic–parasympathetic balance of the autonomic nervous system is maintained by several reflex arcs: arterial baroreflex, peripheral arterial chemoreflex, central arterial chemoreflex, and pulmonary stretch reflex. These reflexes represent the major components of blood pressure control and breathing regulation. Aside from massive stimulation during critical illness, defects in the afferent and central pathways of the autonomic nervous system may develop, referred to as “autonomic dysfunction.” This is seen mostly in ICU patients suffering from MODS, sepsis, severe head and brain injuries, as well as Guillain–Barré syndrome or myocardial infarction. Clinically, the heart rate, which is strongly influenced by the impact of sympathetic and parasympathetic tones, is usually the most sensitive measure of autonomic dysfunction. Autonomic dysfunction is usually expressed as restricted heart rate variability. It is not clear whether this phenomenon is an integral part of

MODS or secondary to sedation, neuromuscular blocking agents, catecholamines, and mechanical ventilation, all frequently used in ICU setup. The reduction in physiologic heart rate variability is one of the strongest predictors of death in critically ill patients.

Adverse Effects of Adrenergic Stress

The adrenergic reaction is crucial to survive the insult of major trauma or injury; however, an overshooting influence of the sympathetic nervous system can become hazardous. This hazardous influence is exacerbated in commonly seen ICU requiring high-dose sympathetic support. Several organ systems may be affected. The heart seems to be most susceptible to sympathetic overstimulation: detrimental effects include impaired diastolic function, tachycardia and tachyarrhythmia, myocardial ischemia, apoptosis, and necrosis. Adverse catecholamine effects have also been observed in other organ functions, such as the lungs (pulmonary edema and elevated pulmonary arterial pressures), coagulation (hypercoagulability and thrombus formation), GI (hypoperfusion and inhibition of peristalsis), endocrinologic (decreased prolactin, thyroid, and GH secretion) immune systems (immunomodulation and stimulation of bacterial growth), metabolism (increase energy expenditure, hyperglycemia, catabolism, lipolysis, hyperlactatemia, and electrolyte changes), bone marrow (anemia), and skeletal muscles (enhanced protein degradation and apoptosis). Apart from their metabolic effects, catecholamines are known to have effects on the transcellular shift of electrolytes. Epi causes, at first, a transient increase in potassium (mediated by α1 and α2 receptor stimulation of hepatic calcium-dependent potassium channels), but shortly thereafter, β2 and β3 receptor stimulation of membrane-bound Na/K-ATPase in skeletal muscle and other tissues, as well as activation of the renin–angiotensin–aldosterone system, causes a decrease in serum potassium and magnesium concentrations. The electrolyte disturbances that increase the risk of cardiac arrhythmias can contribute to or induce neuromuscular weakness and result in difficulty weaning from mechanical ventilation. Other effects may include changes in renal (polyuria), gastrointestinal (intestinal paralysis), and metabolic (alkalosis) functions. Finally, it seems that prolonged sympathetic stimulation carries a myotoxic and apoptotic effect on skeletal and cardiac muscles, which contributes to myopathy, muscle wasting, and difficulty in ventilatory weaning.

METABOLIC ALTERATIONS

Injury and infection induce substantial changes in carbohydrate, lipid, and protein metabolism in most organs and tissues. The short initial ebb response is characterized by an enhanced gluconeogenesis, glycogenolysis, and lipolysis to mobilize potential energy sources. As the "stress response" continues, the energy needs, lack of dietary intake, and the body's limited available energy sources (i.e., glycogen) mandate the hypercatabolic state, which is the focus of this section. An integrative overview (Fig. 1.7) at the end of this chapter diagrams this complex fuel redistribution in trauma and/or infection injury.

Hypercatabolic Syndrome

Hypercatabolic syndrome is a biochemical state induced by increased circulating catabolic hormones (cortisol and catecholamines) and cytokines (TNF, IL-1β), as well as decreased anabolic insulin effects. The most important metabolic consequence of the hypercatabolic syndrome is the skeletal and cardiac muscle protein breakdown that releases amino acids, which, in turn, supports indispensable body energy requirements but also reduces skeletal and cardiac physiologic and metabolic functions (Fig. 1.4).

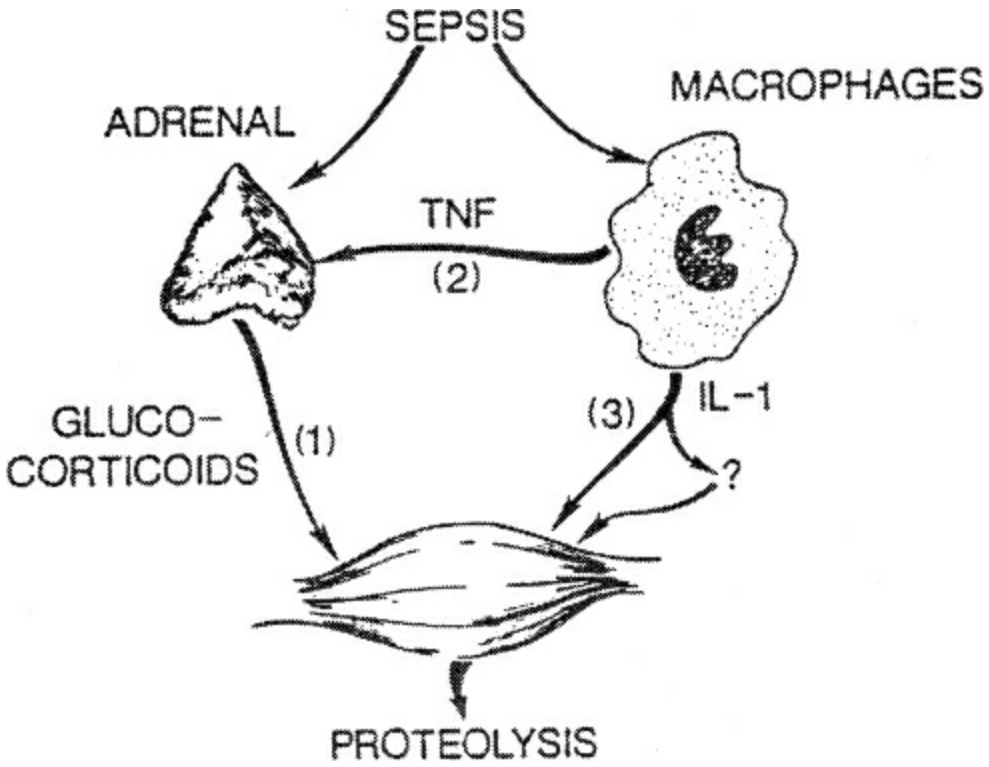

Figure 1.4. Interactions among (1) glucocorticoids, (2) tumor

necrosis factor (TNF), and (3) interleukin-1 (IL-1) in the regulation of sepsis-induced muscle proteolysis. The effect of TNF on muscle proteolysis is mediated primarily by glucocorticoids, whereas IL-1 regulates muscle proteolysis by glucocorticoid-independent pathway(s). (From Hasselgren PO. *Protein metabolism in sepsis*. Austin, TX: RG Landes; 1993, with permission from the author.)

An abundance of substrate is provided to ensure the function of essential visceral organs, supply building blocks for tissue repair, and support an upregulated and expanding immunologic system, postinjury or during infection. The total body energy requirements during the hypermetabolic period are not necessarily substantially higher than in a normal state. Although the REE is higher, the bed rest and diminished physical activity compensates for that change. Due to lack of dietary intake in the immediate posttrauma period, the metabolic energy requirements of the body must be provided by endogenous sources (i.e., glucose, FFAs). Glucose is the main source of energy in normal physiologic circumstances. The liver supplies the majority of endogenous glucose during this time mostly by using hepatic glycogen stores. The kidney has a role as well, but only becomes a significant contributor during prolonged fasting (>48 to 72 hours). The quantity of glucose stored as liver glycogen is about 65 g/kg of liver mass, which is about 100 g of glycogen for a normal 1,500 g adult liver. This amount of liver glycogen is limited to approximately 1 to 1.5 days of systemic glucose supply. Thus, at about 24 hours postinjury, hepatic glucose production changes from hepatic glycogenolysis to gluconeogenesis. An average human of 75 kg has roughly 15 kg of fat stored in 16 kg of adipose tissue (the rest is water) and 10 to 12 kg of protein suspended in 60 kg of lean body mass, mostly muscle. Nearly all of the body fat is expendable without serious adverse effects. Unfortunately, glucose synthesis by the liver to supply the glucose-dependent metabolism is primarily from protein, as the human body does not have the ability to convert lipid to glucose. Unlike lipids and glucose that can be stored as triglyceride (TG) and glycogen, respectively, there is no storage form of protein. The body protein component consists of muscle and visceral protein stores, which include structural protein, visceral organ proteins, as well as enzymes. Under normal circumstances, there is a continuous protein turnover, mostly of skeletal and cardiac muscles. In healthy humans under physiologic conditions, approximately

250 to 350 g of proteins are degraded each day. Most of the amino acids produced are reused to synthesize new proteins, but some are lost (energetic purposes, secreted in urine or feces). These protein losses are normally replaced by dietary protein.

In the postinjury period, the balance between muscle degradation and synthesis is altered because of the increase in catabolic hormones and cytokines produced as part of the inflammatory response, which is further exacerbated by the limitations imposed by bed rest and lack of dietary intake. The muscle is not merely an organ restricted to movement or contraction; it also plays an important role in maintaining the general metabolism of the human body. Muscle mass is ~45% of the dry weight of a healthy person, and most receptors for insulin, cortisol, and glucagon are located in the muscle.

With mild to moderate injury, this catabolic response causes minimal debility. In the more extensive injuries and/or infections, one can see a urinary loss of up to 30 g nitrogen/day, which represents degradation of about 180 g protein or 900 g muscle a day. Utilization of body protein may prolong convalescence and even contribute to mortality.

In contrast to fat, less than one half of the body's protein can be mobilized before death occurs, which means that only about 4 to 5 kg of protein (or 500 to 800 g of nitrogen) can be degraded. This suggests that only 1,500 to 2,400 g of glucose could be synthesized without an external source of glucose and/or proteins (1 g of nitrogen can be equated to hepatic synthesis of about 3 g of glucose). If the brain continued to oxidize 100 to 145 g of glucose each day during starvation, survival would be limited to 10 to 20 days. During "simple" fasting, the patient's body gradually adapts to use FFAs and ketone bodies as the main energy source, which decreases the daily glucose consumption to about 30 to 40 g. This enables the gradual decrease of the protein degradation rate to about 10 g/day of nitrogen after a week and about 5 g/day of nitrogen loss after 3 weeks of starvation, allowing a much longer survival period. (There are reports of up to 2 months of starvation with drinking.) Unlike in starvation, posttrauma patients are exposed to the persistent influence of catecholamines, glucocorticoids, and glucagon. These catabolic hormones preclude similar reduction in protein degradation and the hypercatabolism of muscle and organ protein continues as part of the systemic inflammatory process.

Mitochondria: The Center of Metabolism

Although metabolic dysfunction posttrauma or infection affects critical organs in a variety of ways, its genesis is generally linked to a single organelle, the mitochondrion (Fig. 1.5). The mitochondria are the sites of aerobic, oxidative metabolism that generates the overwhelming majority of ATP, the cellular energy currency. The energy is harnessed (~7 kcal per mole of ATP) in the terminal phosphate bond, whose hydrolysis can be coupled to energetically unfavorable reactions to drive them forward. ATP is a safe and stable fuel, which contains a large amount of energy that may be used to facilitate a wide variety of biologic processes. The oxidation of substrates (e.g., glucose, ketones, fatty acids, lactate) to generate ATP is accomplished via a highly efficient process that uses oxygen. Although it is extremely efficient, the process is not absolutely perfect as it has the capacity to "leak" electrons. As a consequence, these free electrons can generate oxygen-free radicals. Mitochondria can increase the output of ATP in response to a variety of triggering events. These include accumulation of ADP or the greater availability of "fuel" and oxygen. Cell-stimulatory signals, such as the presence of increased Ca^{2+} in the cytoplasm, also stimulate the mitochondria to generate more ATP. These stimuli are tied to an increased demand for work from the body, be it muscular (heart or skeletal muscle contraction), biosynthesis (production of proteins by the liver), cell division (immune responses or tissue repair), or the generation of heat (response to hypothermia). Clearly, all of these functions can be tied to the demands of dealing with infection and injury.

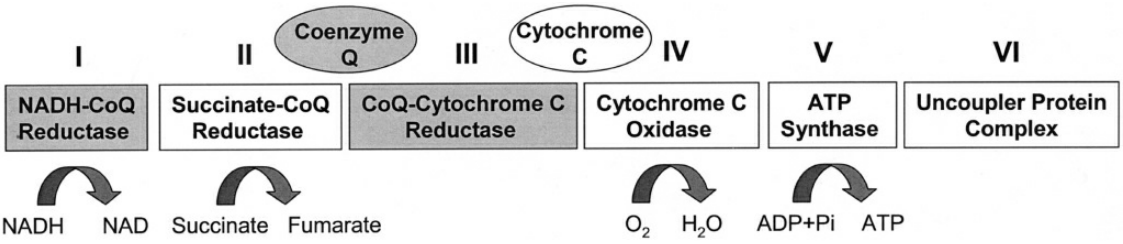

Figure 1.5. Oxidative phosphorylation in mitochondria. The diagram depicts the enzymes and cofactors involved in oxidative phosphorylation employed within the mitochondrion to produce ATP from a variety of substrates. Electrons are transferred via a sequence of redox acceptors, ultimately being accepted by oxygen. The molecules that shuttle electrons are coenzyme Q and cytochrome c. Gray shading denotes the points at which reactive oxygen species (ROS) may be liberated. ROS are prominent in injury, and have the potential to do damage to

biologic molecules, compromising cells and organs.

Mitochondrial Dysfunction

The failure of mitochondrial energy production lies not with the organelle itself, but with its various "supplies." Unlike sugars or fats, which are stored as glycogen or adipose tissue, respectively, there are no depot stores of ATP. Thus, with a failure to deliver any of the essential components (cardiac output and/or blood flow, lung oxygenation, glucose transport, etc.), there is a rapid onset of metabolic dysfunction of the mitochondrion. An immediate biochemical consequence of this dysfunction is the production of reactive oxygen species (ROS) that are toxic and can damage cells. These products take numerous forms, such as superoxide, peroxides, nitric oxide, and peroxynitrite. ROS are constitutively produced by mitochondria, and thus neutralizing compounds (antioxidants) such as glutathione normally buffer against the damage of ROS (Fig. 1.6). An additional consequence of mitochondrial dysfunction is leakage of the mitochondrial contents into the cytoplasm, which occurs at these times of stress by "permeability transition pores" open in response to stress, enabling molecules <1,500 Da to move between the inner mitochondrial membranes. Mitochondrial transition pore opening can subsequently lead to swelling and mitochondrial rupture. This rupture ultimately will allow larger molecules, such as cytochrome C, to enter the cytosol and trigger programmed cell death (apoptosis). Thus, besides failing to produce urgently needed ATP in times of crisis, the mitochondrion generates compounds that potentially cause considerable, often irreparable, damage and cell death. This is the stage in which insults of injury and infection can wreak havoc on metabolism.

Under conditions of severe injury and especially shock, there will very likely be severe morphologic damage to the mitochondria. This damage leads to decreasing mitochondrial ATP levels and increased ROS burden, exhausting the reserve of antioxidants that leads not only to the mitochondrion itself, but also other cellular organelles and molecules, including DNA. Serious impairment of vital (renal, hepatic, lung, and cardiac) and nonvital (skeletal muscle) organ functions can ensue. These failures are exacerbated by persistent hypotension, even in the face of more than adequate volume resuscitation. In most cases, these tissues exhibit a loss of mitochondrial function. Cellular tissue ATP levels will also fall, matched by a rise in ADP and adenosine monophosphate (AMP).

Although injuries vary greatly, serious injuries have common characteristics that can unfavorably affect mitochondrial metabolism. Hemorrhage effectively produces hypoxia, which initiates a cascade of responses that are directed toward adaptation to lowered oxygen, which, at the same time, can be damaging to an already injured body. Hypoxia and ischemia–reperfusion, with their lowered oxygen availability to the tissues, drive cells to depend on anaerobic glycolysis for ATP production. This can initiate a feedback situation, wherein lactic acid increases, effectively shutting down anaerobic glycolysis as an energy source. In this setting, FFA can also increase systemically, probably from peripheral adrenergic stimulation of lipolysis. However, limited oxygen availability also compromises β-oxidation, the principal means of converting fats to energy. This, in turn, causes a similar "stacking up" of FFA, acyl coenzyme A (acyl CoA), acylcarnitines, and so on, which compromises the heart. Under these conditions, the heart and other tissues are already at a disadvantage because, despite the high energy stored in fat, β-oxidation cannot match the efficiency of carbohydrate metabolism. Thus, reoxygenation, if it occurs, may take place in a setting in which aerobic metabolism is not possible, because of large-scale diversion of metabolism into the less efficient "backup" modes of β-oxidation and anaerobic glycolysis. There is one additional consequence of elevated lactic acid worth noting. As mentioned previously, an intracellular flux of calcium will cause a demand for increased ATP synthesis. The presence of increased lactic acid in the cell will cause calcium influx, providing a spurious signal for increased workload at a time when the metabolic machinery is incapable of reacting appropriately. This has the untoward effect of further depleting already low supplies of ATP.

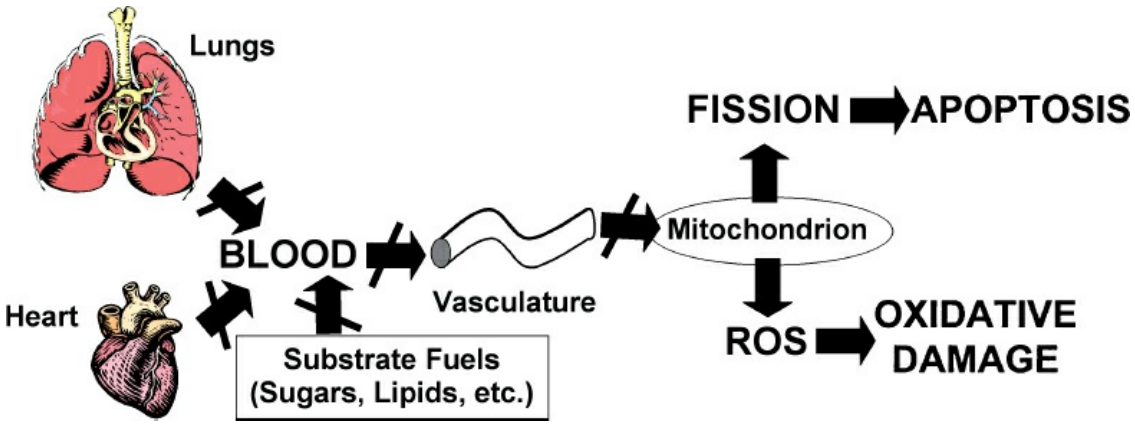

Figure 1.6. Consequences of mitochondrial dysfunction in injury. Mitochondrial dysfunction has several forms, the most important

of which are the generation of reactive oxygen species (ROS) and the opening of permeability transition pores. The transition pores release mitochondrial contents, which can cause severe damage to the cell, such as induction of apoptosis as mediated by mitochondrial cytochrome c. The combination of lung, heart, and vascular pathophysiology in injury can lead to mitochondrial dysfunction by virtue of inadequate respiration, poor blood flow, and vascular transport and delivery, which in turn adversely affects these same organs.

Carbohydrate Metabolism

Plasma glucose concentration in healthy subjects is strictly controlled. During the fed state, digested carbohydrates are delivered to the liver, with galactose and fructose rapidly converted into glucose. The glucose is either secreted to the circulation or used for storage in the form of glycogen or fat. An increased postprandial glucose level is followed by pancreatic β-cell insulin secretion, which enhances peripheral glucose utilization, as well as glycogen and fat synthesis. In the fasted state, the plasma glucose originates mostly from hepatic output. Liver glucose production arises from glycogen breakdown, synthesis from recycled carbons (lactate and glycerol), and (to a much lesser extent) de novo synthesis from amino acids such as alanine. Under normal conditions, the rates of liver glucose production and peripheral incorporation of glucose is matched exactly, keeping the plasma concentration of glucose set within a very strict limit.

After being actively taken up by peripheral tissues, the glucose is metabolized by glycolysis. The glycolytic pathway yields three products: ATP, pyruvate, and intermediates for amino acid production. Pyruvate can be further metabolized via the irreversible reaction of pyruvate dehydrogenase to yield acetyl-CoA, which can then enter the citric acid cycle to be completely metabolized to water and carbon dioxide to produce more ATP, or pyruvate be secreted into the blood stream as lactate.

Pathophysiology of Hyperglycemia in Critical Illness

Early in the course of the stress response, plasma glucose levels rise. Glucose availability is needed to supply the immediate energy demand during the posttrauma hypermetabolism, especially for the explosive immune activity. Glucose utilization is increased in multiple tissues, including liver, spleen, small intestine, skin, and some muscles. A common feature of some of these tissues is a high content of macrophages.

Studies have shown that in the liver, the high glucose uptake reflects increased utilization of glucose by Kupffer cells. However, because the overall rate of glucose secretion into the plasma exceeds the rate of glucose disposal, serum glucose levels are elevated.

Hyperglycemia as a sequela of critical illness commonly appears even in patients who do not have diabetes mellitus. There are many pre-existing conditions (diabetes mellitus, pancreatitis, cirrhosis, advancing age, and obesity) or possible iatrogenic causes (administration of corticosteroids, sympathomimetics, total parenteral nutrition, or excess dextrose) of hyperglycemia in the posttraumatic patient, but usually hyperglycemia is due to alterations in glucose metabolism secondary to the adaptive metabolic response. The synergistic activities of the HPA axis (catecholamines and glucocorticoids), pancreatic endocrine hormones (glucagon and insulin), and proinflammatory cytokines are central to those changes in glucose metabolism (Fig. 1.7).

Increased Sympathetic Tone and Hyperglycemia

Elevated catecholamine levels postinjury have well-established effects on glucose metabolism through a number of mechanisms. Epi directly promotes hepatic and skeletal muscle glycogenolysis, and hepatic gluconeogenesis independent of insulin or glucagon concentrations. Dufour et al. demonstrated that under constant insulin concentration, an increase of Epi plasma concentration from 100 to 2,000 pmol/L (which is equivalent to the levels observed during exercise at 60% to 80% of VO_{2max}) was followed by a 3-fold increase in glucose plasma concentration and a 2.5-fold increase in liver glucose production. During the first hour of Epi infusion, glycogenolysis was the source of 60% of glucose production and later gluconeogenesis accounted for about 80%.

Gluconeogenesis is further increased by catecholamines through the peripheral induction of lipolysis, which supplies the liver with glycerol. In addition, Epi stimulates pancreatic release of glucagon and inhibits release of insulin, further contributing to hyperglycemia. The catecholamines also affect glucose disposal through increased peripheral insulin resistance.

Hypercortisolism

Diabetes mellitus is very common (>50%) in patients with Cushing syndrome and hypercortisolism also occurs posttrauma. Elevated cortisol concentrations promotes hyperglycemia through a number of mechanisms. In the liver, cortisol stimulates phosphoenolpyruvate carboxykinase, the

enzyme that catalyzes the rate-controlling step of gluconeogenesis. Cortisol also stimulates the activity of the enzyme glucose-6-phosphatase, which catalyzes the completion of the final step in gluconeogenesis and glycogenolysis. Hepatic glucose production is further enhanced by the excessive flow of substrates to the liver, secondary to peripheral lipolysis and proteolysis. As with catecholamines, glucocorticosteroids not only increase the amount of glucose secreted to the blood stream, but also induce increased insulin resistance. In this manner, it contributes even more to hyperglycemia.

Insulin

Insulin levels vary depending on the phase of injury. During the ebb phase, insulin levels are reduced despite hyperglycemia. The combined effects of catecholamines, somatostatin, glucocorticoids, and reduced pancreatic blood flow may reduce pancreatic β-cell sensitivity to glucose. During the flow phase, β-cells regain their sensitivity, and insulin concentrations rise. Despite increased insulin concentrations, however, hyperglycemia may persist due to peripheral insulin resistance.

Insulin resistance is the inability of insulin to adequately stimulate glucose uptake, mainly into skeletal muscle, or to inhibit gluconeogenesis in the liver. Unlike in the case of chronic insulin resistance, such as in type 2 diabetes, which takes years and even decades to develop, insulin resistance postinjury develops within hours or minutes of insult. This form of insulin resistance is called “acute insulin resistance” and sometimes “stress diabetes” or “critical illness diabetes.” There are numerous studies on the development of chronic insulin resistance, but little is known regarding the pathophysiology of acute insulin resistance. Studies suggest that acute insulin resistance is complex and might differ in a tissue-specific manner, involving multiple causative factors and intracellular signaling pathways.

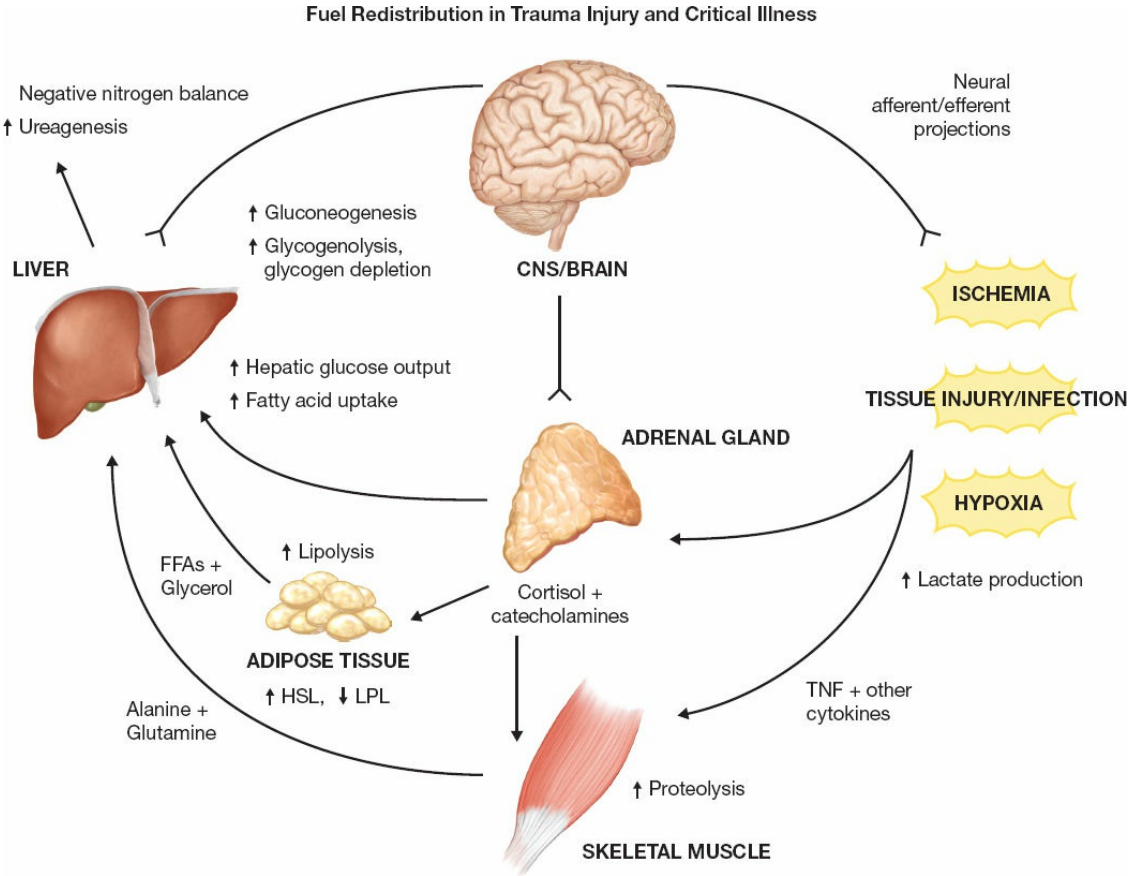

Figure 1.7. Metabolic fuels redistribute in response to severe trauma and/or infection. A number of pathways of fuel mobilization and usage are affected by critical illness and the accompanying inflammatory response. In general, the catabolic hormones (i.e., catecholamines and glucocorticoids) induce a state of increased proteolysis and lipolysis from muscle and adipose tissues, respectively. This increase in fuel release allows them to circulate in the blood and be used by the liver for gluconeogenesis as well as other energy-demanding processes like acute phase protein responses. The cytokines released as part of the inflammatory response at the site of injury, as well as afferent neural projections also add to the complex regulation and redistribution of metabolic fuel to aid in the body's response.

Insulin signaling is initiated by binding of insulin to its receptor, followed by activation of two main intracellular insulin-signaling pathways: the IRS/PI3K/Akt pathway and the MEK/ERK pathway. Several tissue-specific mechanisms are involved in the development of insulin resistance including alterations related to insulin receptors, such as impairment of receptor expression, or binding or inhibition of intermediaries involved in the insulin-signaling pathway for glucose

uptake. Studies investigating potential mechanisms of skeletal muscle insulin resistance in experimental animal models demonstrated decreased insulin signaling via the metabolic pathway following burn injury and reduced GLUT4 mRNA and protein levels in rat adipose tissue during sepsis. Epi has been reported to enhance insulin resistance through inhibition of insulin binding, GLUT-4 translocation, and IRS-1 (metabolic pathway). Moreover, different tissues have been shown to develop various degrees of insulin resistance and to be affected by different mechanisms. Some proinflammatory cytokines, including TNF, decrease insulin signaling via the metabolic pathway. Administration of a TNF-α neutralizing antibody following trauma and hemorrhage in rodents reverses the acute insulin-resistant state in the liver, but not in skeletal muscle. Overall, a number of tissue-specific mechanisms are involved in the development of insulin resistance.

Glucagon

Another counterregulatory hormone of interest during stress of the critically ill is glucagon. Glucagon, like Epi, is responsible for increased glucose production through both gluconeogenesis and glycogenolysis. The action of glucagon alone is not maintained over time; however, its action on gluconeogenesis is sustained in an additive manner with the presence of Epi, cortisol, and GH. Likewise, Epi and glucagon have an additive effect on glycogenolysis. The important role of hyperglucagonemia, present during sepsis, was demonstrated in experiments in which the hormone was blocked by infusion of somatostatin in septic rats, and the elevated rate of glucose production was reduced to control levels.

Cytokines

Proinflammatory cytokines promote hyperglycemia through stimulation of release of counterregulatory hormones, including cortisol, Epi, NE, and glucagon. The most extensively studied cytokine with regard to carbohydrate metabolism is TNF. Changes in glucose metabolism during endotoxemia and sepsis can be reproduced by administration of TNF, which increases hepatic glucose production, hyperglycemia, and stimulated glucose utilization by macrophage-rich tissues and the diaphragm. The hepatic increase in glucose production secondary to TNF can be blocked by an infusion of phentolamine and propranolol, suggesting that the TNF effect on the liver is secondary to adrenergic activation. In addition to the effect on the counterregulatory hormones,

TNF may have a direct effect on cellular glucose kinetics in muscle and adipose tissue.

Similar to TNF, IL-1 also can influence carbohydrate metabolism. According to animal models, it seems that the IL-1β main effect is in inducing hypoglycemia by binding the hypothalamic receptors. Other factors also play a role in the regulation of metabolism during infection and injury, including nitric oxide and prostaglandins.

Glucose Control in ICU

Persistent hyperglycemia is hazardous and has been shown to impair wound healing, increase susceptibility to infections, and even increase mortality. Not surprisingly, previous studies have asked the question of whether or not tighter control of blood glucose concentrations is associated with clinical benefits in critically ill patients. A single-center trial in Leuven, Belgium, published in the *N Engl J Med*, emphasized the importance of tight glucose and changed the approach to glucose control in the ICU. In this study that involved 1,548 patients, most of whom had undergone cardiac surgery, patient hyperglycemia was aggressively treated with insulin, and glucose levels were kept in between 80 and 110 mg/dL (4.4 and 6.1 mM) as compared with conventional insulin therapy, which had a target blood glucose level of 180 to 200 mg/dL (10.0 to 11.1 mM). This approach significantly reduced mortality from 8% in the controls to 4.6% in the experimental group. However, the study was criticized because of serious hypoglycemia that occurred in 5% of the patients. These improvements in mortality were unable to be reproduced in a subsequent study and were associated with an even greater increase in serious hypoglycemic episodes (18.7%). Moreover, several other studies including the Normoglycemia in Intensive Care Evaluation–Survival Using Glucose Algorithm Regulation (NICE–SUGAR) have failed to demonstrate a benefit in mortality. These studies have culminated in current guidelines that emphasize less intensive insulin therapy to maintain blood glucose in the 140 to 180 mg/dL range, while minimizing the risk of hypoglycemia.

Lipid Metabolism

Lipids, as a class of biologic molecules, are the most efficient molecules for energy storage. The energy yield from 1 g of fatty acid is ~9 kcal, compared to ~4 kcal from 1 g of carbohydrates. Moreover, since lipids

are hydrophobic in nature, these molecules can be stored in a relatively water-free environment. Carbohydrates, on the other hand, are hydrophilic. This fact increases the total mass of glycogen storage; for example, 1 g of glycogen binds ~2 g of water, which translates to an actual 1.33 kcal/g stored. This means that fat can actually hold more than six times the amount of energy per weight unit than glycogen. As such, lipids, in the form of TGs, are the main source of stored energy. Lipids also play an important role in many other cellular functions, such as synthesis of cell membranes, and production of steroid hormones, intracellular signal mediators as prostaglandins, fat-soluble hormones, and others. Fatty acids are either derived from diet or synthesized in the liver from carbohydrates. Dietary lipids absorbed as fatty acids form into TG and are transported as chylomicrons. These newly synthesized FFAs as well as those derived from diet are converted to TG in the liver, a process called esterification. The insoluble esterified, hepatic TG are packaged into the soluble very low–density lipoproteins (VLDL) and secreted into the blood. TGs are mainly stored in adipocytes in distinct anatomic locations, such as fat tissue or within other tissue types, including muscle or liver. The endothelial enzyme lipoprotein lipase hydrolyzes circulating TGs to fatty acids, enabling their diffusion and transport into the cells of peripheral tissues.

Hydrolysis of TGs within adipocytes into FFA and glycerol is known as lipolysis, which is stimulated by various hormones. Some examples are glucagon during fasting/hypoglycemia; Epi, NE, and possibly cortisol during stress; and GH during anabolism. These hormones bind to cell-surface receptors that are coupled to the activation of adenylate cyclase upon ligand binding. The result is activation of cAMP-dependent protein kinase (also known as protein kinase A), which, in turn, activates hormone-sensitive lipase (HSL). The net result of the action of these enzymes is hydrolysis of TG to release FFA and glycerol. The FFAs diffuse from adipose cells, combine with albumin in the blood, and are transported to other tissues where they are transported into cells. Fatty acids are the most efficient source of energy for most cell types. For example, catabolism of 1 mole of a six-carbon fatty acid through the citric acid cycle to CO_2 and H_2O generates 44 moles of ATP, compared with the 38 moles generated by catabolism of 1 mole of the six-carbon carbohydrate glucose.

In the normal state, glucose is the dominant contributor of energy

production. Active glucose metabolism downregulates FFA oxidation, thereby shuttling those FFAs into TG stores in the muscle, liver, and adipose tissue. In the fasted state, however, FFA is the dominant contributor of energy production. The major site of fatty acid oxidation occurs within the mitochondria by β-oxidation, as this process occurs by recurrent oxidation of the fatty acid chain at the β-carbon position. The rate of FFA oxidation is determined by the rate of transfer into the mitochondria. Medium- and short-chain fatty acids can enter the mitochondria without difficulty, but long-chain fatty acids (the majority of FFAs) must be actively transferred through the mitochondrial outer membrane. This process transports fatty acids into the mitochondria by first conjugating them to carnitine. The fatty acyl-carnitine is then transferred to the mitochondria via the carnitine palmitoyltransferase enzyme system (CPT-I, CPT-II), which is the crucial point in the regulation of the FFA oxidation. Glucose availability and metabolism control the oxidation of fatty acyl-CoA by regulating CPT-I activity via changes in malonyl-CoA concentration. Malonyl-CoA inhibits fatty acyl-carnitine transport into the mitochondrion and favors lipid synthesis/storage.

Lipid Metabolism During Critical Illness

The increased influence of catabolic hormones (e.g., Epi, glucagon) and proinflammatory cytokines of critical illness promotes excessive peripheral lipolysis and mobilization of FFAs. Likewise, a concomitant increase in the de novo synthesis of FFAs takes place in the liver. The FFAs are used as an alternative, available energy source for the peripheral tissue in a time of need, which spares much needed glucose reserves for use by the nervous system and erythrocytes. TNF was found to play a major role in enhancing peripheral lipolysis and hepatic synthesis of FFAs. TNF has an inhibitory effect on peripheral lipoprotein lipase, which causes a peripheral resistance to TG resulting in increased lipemia. Other cytokines, including IL-1, IFN-α, β, and γ, may also influence lipid metabolism.

At the same time, while the organism recruits its energy sources, there is a paradoxical increase in liver esterification of FFAs to TG. A number of contributing factors play a part in this paradox:

1. FFA flux is elevated to a higher level than the oxidation rate of the body, which exposes the liver to an excess of FFAs.

2. Both glucose and FFA levels simultaneously increase in blood plasma. This hyperglycemia leads to increased hepatic glucose uptake and metabolism, which leads to inhibition of CPT-I and fatty acid oxidation, leading to more accumulation of hepatic pool FFAs.
3. The increased β-adrenergic stimulation causes increased peripheral glycolysis with concomitant production of pyruvate, which exceeds its capacity for metabolism and utilization by the mitochondria. The pyruvate–lactate equilibrium results in excessive secretion of lactate to the blood even without any hypoxia or hypoperfusion. This lactate is metabolized by the hepatocytes, increasing either gluconeogenesis or the citrate production through the Krebs cycle, and possibly the de novo fatty acid synthesis, thereby also contributing to the inhibition of FFA oxidation or TG synthesis in the liver.

The result of this process is an enhanced liver TG synthesis causing hypertriglyceridemia and often accumulation of hepatic TG that leads to a fatty liver. The reduced activity of the enzyme lipoprotein lipase in the muscle and the adipose tissue decreases the clearance of lipoproteins, leading to worsened hypertriglyceridemia. The clinical significance of this hyperlipidemia, hypertriglyceridemia, and the tendency for fatty liver during critical illness is not completely clear. However, these findings have important implications to the management of nutrition support in these patients. It has been observed with regularity that overfeeding, especially by parenteral access, causes enhanced steatohepatitis and a deteriorating prognosis for ICU patients.

Protein Metabolism

Proteins contribute to both structure (skeletal muscle) and the function (enzymes) of the body. The absolute amount of protein depends on the age, weight, disease state, and nutritional status of the patient. Skeletal muscle mass represents 30% to 50% of total body protein, is greater in men than women, and declines with age. Between the ages 20 and 80, total muscle cross-sectional area declines about 40%. Following injury, the increased urinary excretion of nitrogen from the body is roughly related to the extent of the injury. Nitrogen is primarily lost in the form of urea, which represents about 85% of the urinary nitrogen loss, although this proportion varies widely. Creatinine, ammonia, uric acid, and amino acids are also found in the urine in larger quantities than normal following injury. The nitrogen molecule is used as a surrogate marker of protein

because of the fixed relation between the two substances (6.25 g protein to 1 g of nitrogen). Thus, the net loss or gain of body protein is determined by nitrogen balance, and this is a general measure of the catabolic state.

Maintenance of protein within an individual tissue is a balance between rates of protein synthesis and breakdown. Synthesis and breakdown are often mismatched during catabolic states, resulting in organ protein loss or gain. The catabolic response occurs by a relative increase of breakdown over synthesis. Protein turnover responds to injury and infection in a manner that redistributes body protein to satisfy its needs. The synthesis rate is decreased in "nonessential" tissues (e.g., limb skeletal muscle or gut) and is maintained or enhanced in tissues where work is increased (respiratory and cardiac muscle, lung, liver, and spleen). These events result in translocation of protein from skeletal muscle to the visceral organs (primarily liver, spleen, and heart), which are vital for survival.

Two amino acids, alanine and glutamine, account for approximately 50% to 75% of the amino acid nitrogen released from skeletal muscle. Alanine is used as a building block for various proteins and it is an important glucose precursor. Glutamine plays a very important role during the stress response. Similar to alanine, glutamine is also a gluconeogenic substrate, but it mainly serves as a primary substrate for immune cells and enterocytes as both rely on glutamine for optimal function and energy production. Glutamine also participates in acid–base homeostasis, and serves as a precursor for glutathione, an important intracellular antioxidant. In critically ill patients, the intramuscular concentration of glutamine may fall by as much as 80% to 90%. Part of this drop is due to accelerated outward transport and partly due to a decrease in glutamine de novo synthesis. Glutamate serves as the precursor for both glutamine and alanine. Under a variety of circumstances, the formation of alanine from glutamate is the preferred pathway, leading to depletion of glutamate availability for glutamine synthesis. It has been hypothesized that the tissue requirements for glutamine may outstrip the body's ability to produce this amino acid. Hence, a relative deficiency state exists characterized by a fall in glutamine concentrations in both plasma and tissue compartments. Thus, glutamine is considered a conditional essential amino acid.

Muscle Catabolism

The story of muscle in the stress response is the story of protein degradation and wasting. Accelerated catabolism of muscle protein is a

universal problem in critically ill patients; loss of muscle mass and strength is secondary to protein breakdown due to the metabolic needs. The typical prolonged bed rest and inactivity play a large role in muscle wasting. Muscle wasting may impair recovery if severe enough and certainly limits the return of patients to normal function after recovery. Plank et al. demonstrated the changes in total body protein over a 21-day period, following onset of sepsis or major trauma. They noted that losses were greatest during the first 10 days, amounting to approximately 1.0% of total body protein per day during both sepsis and trauma. Total protein lost over the study period averaged 1.21 ± 0.13 kg in sepsis patients and 1.47 ± 0.20 kg in trauma patients. Approximately 70% of the total protein loss came from skeletal muscle. This loss occurred in sepsis patients during the first 10 days and in trauma patients in the first 5 days. After these intervals, more of the protein loss was derived from the nonmuscle tissues.

Liver

The liver plays a major role in a number of critical aspects of the stress response. It is the central metabolic organ coordinating the cardinal changes in glucose, protein, and lipid metabolism. The hepatic cell types that are involved in liver response to sepsis and SIRS include Kupffer cells, hepatocytes, and sinusoidal endothelial cells. These cell types communicate in a paracrine fashion and with bidirectional signaling via different mediators. These mediators modify the metabolic pathway of hepatocytes to support amino acid uptake, ureagenesis, increased synthesis of coagulant factors, complement factors, APPs, and antiproteolytic enzymes.

Immunologic Function

The liver contains the largest mass of macrophages (Kupffer cells) in the body and plays a crucial role in the inflammatory response, both as a source of inflammatory mediators and as a target organ for the effects of inflammatory mediators. The interaction between hepatocytes and Kupffer cells plays a key role in the regulation of the acute-phase response. Kupffer cells are pivotal in the hepatic response to sepsis. Once activated, Kupffer cells are a major source of soluble mediators of sepsis, including proinflammatory cytokines, chemokines, nitric oxide, reactive oxygen products, and eicosanoid mediators. Kupffer cells are also important in preventing the dissemination of bacteria and endotoxins from the portal

circulation to the systemic circulation. In animal models, within 5 minutes of intravenous injection, 50% of radiolabeled endotoxin is localized in the Kupffer cells. Hepatocytes play not only a crucial metabolic role, but also an immune role. Hepatocytes exhibit receptors for most of the soluble mediators of sepsis, including endotoxin, cytokines, inflammatory mediators, and vasoactive substances. Studies in rats showed that treatment with gadolinium chloride, which blocks Kupffer cell function, resulted in clearance of circulating endotoxin with endotoxin secreted in bile, where it was inactivated and secreted in the feces. The liver is also a major site for removal of bacteria from the systemic circulation. About 70% of radiolabeled *Escherichia coli* and 96% of *Pseudomonas aeruginosa* are localized within the liver only 10 minutes after intravenous injection.

Hepatic endothelial cells are in contact and interact with Kupffer cells and hepatocytes. The endothelial cells participate in the inflammatory reaction by secreting proinflammatory cytokines (IL-1 and IL-6). They also play an important role in the regulation of the hepatic, and to some extent, systemic circulation. The liver sinusoids, which are analogous to tissue capillaries, lack smooth muscle cells and, therefore, hepatic sinusoidal flow is instead regulated by NO and CO, which are released by the sinusoidal endothelium.

APP are plasma proteins primarily of hepatic origin; their plasma levels increased by at least 25% following sepsis, injury, or inflammation. The APPs consist of coagulation and anticoagulation (α2-macroglobulin), complement system components, and inflammatory (CRP, serum amyloid A), anti-inflammatory (α1-antitrypsin and α1-antichemotrypsin), and various other proteins (e.g., haptoglobin and ceruloplasmin). The concentration of other liver-derived proteins, particularly albumin, is reduced in sepsis (negative APP). In a rat model of chronic sepsis, studies showed that albumin synthesis was actually increased within 4 days of initiation of sepsis. It seems that the decreased circulating levels of albumin reflect increased leak of albumin to the extravascular compartment and possibly an increased rate of degradation, but not a reduced synthesis. The enhanced synthesis of all these APPs is regulated by the Kupffer cell–derived cytokines and is a part of the complex systemic and local changes needed to defend the host. Additional hepatic APP scavengers include ceruloplasmin and α2-macroglobulin, which inactivate reactive oxygen radicals. One of the key factors of APP is the

CRP, which functions as part of the innate immune system. Its main role is in binding to a phosphocholine present on the surface of dying cells and some bacteria, causing activation of the complement (classical pathway) and promotion of macrophage phagocytosis. The CRP level is elevated within hours of insult and peaks at about 48 hours postinjury. The measurement of CRP plasma level has become a common and reliable tool for the evaluation of the extent of a patient's inflammatory process.

Hypercoagulation

During the stress response, the liver promotes a hypercoagulable state by the enhanced synthesis of coagulation factors, such as fibrinogen, prothrombin, factor VIII, von Willebrand, and, at the same time, decreased synthesis of protein C and antithrombin III. The increased CRP plasma level also promotes the expression of tissue factor, the initial activator of the extrinsic clotting system, by mononuclear cells and neutrophils. Promotion of coagulation capacity by the liver is needed in case of tissue injury and possible excess consumption of coagulation factors, but it is also responsible for many fatal thrombotic and thromboembolic complications.

Liver Dysfunction During Critical Illness

The unusually high metabolic and inflammatory needs associated with severe illness must be met by a liver that may already be compromised due to stress (shock and sepsis), a situation that may lead to liver dysfunction. Liver dysfunction can be divided into primary and secondary dysfunction. In normal physiologic conditions, postprandial splanchnic blood flow accounts for up to 30% of total cardiac output. During the stress response period after a severe tissue trauma or sepsis, the portal flow, which arises from the splanchno-mesenteric vascular bed, is subject to disproportionate vasoconstriction (under the influences of α-adrenergic and renin–angiotensin stimulus). A physiologic compensatory process (referred to as hepatic arterial buffer response) of inverse changes in hepatic blood flow in response to changes in portal flow takes place, but this response of the hepatic artery is often altered during severe sepsis or shock, compromising hepatic blood flow. Primary hepatic dysfunction that occurs in the hours after the insult or onset of sepsis is most likely linked to hypoperfusion. The outcome of such acute liver dysfunction can be catastrophic with disseminated intravascular coagulation, reduced hepatic lactate and amino acid clearance with metabolic acidosis, decreased gluconeogenesis, and

glycogenolysis with subsequent hypoglycemia—all of which are potentially fatal.

Secondary hepatic dysfunction is thought to be a result of "spillover" of bacteria or endotoxin and the subsequent activation of inflammatory cytokines and mediators in the absence of circulatory changes. Mild cholestasis is a common sign of secondary liver dysfunction during critical illness. It is often an isolated finding secondary to intrahepatic cholestasis caused by rapid downregulation of transporter proteins, such as NTCP (a basolateral sodium-dependent bile salt transporter) and multidrug-resistant protein 2 (MRP2), which is a canalicular anionic conjugate transporter, and a bile salt pump.

Heat Shock Proteins

One of the hepatic mechanisms to deal with the stress and avoid a secondary liver dysfunction is dramatic upregulation of liver synthesis of HSPs. The HSPs are a group of proteins discovered during the 1960s in Drosophila cells that were exposed to sublethal temperature. Although named heat shock proteins after their discovery, HSPs actually serve as general survival proteins by increasing cellular resistance against a vast range of stressors and not just elevated temperatures. In normal physiologic conditions, HSPs act as regulatory intracellular proteins, stabilizing other proteins in proper formation by chaperoning proteins across cell membranes. HSPs have the capacity to repair denatured/injured proteins and serve as part of the cells' own repair system. HSPs serve as one of the most highly conserved mechanisms of cellular protection, are found in virtually all living organisms, and are a key part of cellular response to stress. Enhanced HSP expression, using transgenic mice or by a mild stress before the insult, has been shown to be cytoprotective in experimental models of sepsis and other types of stress. Increased expression of HSPs has been detected in a variety of clinical settings. In patients with severe trauma the ability to mount a higher HSP response is predictive of survival.

Glutathione

Cellular glutathione plays an important role in the cellular ability to detoxify free radicals and limit cellular damage in times of high oxidative stress that accompany severe illness. In an animal model of sepsis, a six-fold increase in de novo synthesis of glutathione by hepatocytes was demonstrated in the first 2 days of sepsis. In contrast to APPs, persistence

of stress response throughout the course of sepsis in rats (4 days after infection) led to depletion of liver glutathione. The mechanism of late glutathione depletion is not clear; one hypothesis is that it is secondary to selenium depletion. Selenium is an essential cofactor for glutathione peroxidase activity and it has been shown that depletion of that micronutrient in sepsis is associated with increased morbidity and mortality. The selenium requirement in sepsis increases in parallel with increased glutathione peroxidase activity and glutathione turnover. Randomized and placebo-controlled trials have indicated that high-dose selenium supplementation can improve outcomes in sepsis and septic shock.

Steatohepatitis

Another important factor related to liver dysfunction in critically ill patients is steatohepatitis. As mentioned previously, the liver in critically ill patients faces an increased flux of FFA, amino acids, and carbon-3 compounds, such as lactate and glycerol, together with conditions of hyperglycemia and hyperinsulinemia. The hepatic capacity of FFA oxidation and secretion seems to be inhibited, and TGs accumulate in hepatocytes leading to steatosis. Steatohepatitis in critically ill patients has been reported mostly in relation to artificial nutrition, especially total parenteral nutrition. Previous studies have confirmed that critical illness and liver dysfunction are associated with liver damage not only biochemically but pathologically as well.

Intestine and Gut Barrier

Our understanding of intestinal barrier function biology, its potential clinical importance, as well as the pathophysiology and consequences of gut barrier failure has changed considerably over the course of time. Now, it is clear that the intestinal mucosa functions physiologically as a local defense barrier to prevent bacteria and endotoxin, which normally are present within the intestinal lumen, from escaping and reaching extraintestinal tissues and organs. Moreover, it has become apparent that the gut can become proinflammatory and gut-derived factors, especially those liberated after periods of splanchnic hypoperfusion, can lead to acute distant organ dysfunction.

Initial interest in gut barrier failure and bacterial translocation was based on clinical observations that trauma, burn, and critically ill patients,

especially those developing MODs, frequently had life-threatening bacteremia with enteric organisms in the absence of an identifiable focus of infection. These clinical observations resulted in a large body of work investigating the relationships among gut barrier function, intestinal bacterial flora, systemic host defenses, and injury in an attempt to delineate the mechanisms by which bacteria contained within the GI tract can translocate to cause systemic infections. From these and subsequent studies, the current role of the gut and gut barrier function in the prevention and potentiation of systemic infections and MODS have evolved.

Gut Barrier and Bacterial Translocation

The tremendous importance of intestinal barrier function is obvious when one considers that the distal small bowel and colon contain enormous concentrations of bacteria and endotoxin ($\sim 10^{11}$ bacteria per gram of feces). Under certain clinical circumstances, intestinal barrier function becomes impaired, resulting in the uninhibited movement of bacteria and/or endotoxin to the systemic tissues. The underlying mechanisms of this bacterial translocation have been studied extensively. Although both an intact epithelial barrier and a normal functioning immune system are important for adequate gut barrier function, even an intact mucosa will prevent bacterial translocation in rats with selectively impaired cell-mediated immunity. Reduced splanchnic blood flow, leading to an ischemia–reperfusion-mediated gut injury has been shown to be a key factor in the loss of mucosal barrier function and bacterial translocation in models of thermal injury, hemorrhagic shock, and endotoxemia. In these models, mucosal injury appears secondary to a gut ischemia–reperfusion injury, which is mediated, in part, by xanthine oxidase–generated oxidants.

Nutrition and Gut Barrier

The area of nutrition continues to receive increasing clinical and experimental attention. The optimal functional and structural integrity of the GI tract depends on whether or not the gut is fed enterally. Enteral feeding supports intestinal structural integrity by maintaining mucosal mass, stimulating epithelial cell proliferation, maintaining villus height, and promoting the production of brush border enzymes. Functional integrity of the mucosa is also supported by enteral feeding through maintenance of epithelial tight junctions, stimulation of gut blood flow, and the production and release of a variety of endogenous agents that exert

trophic effect on the intestinal epithelium (e.g., bile acids, cholecystokinin, gastrin, and bombesin). Enteral feeding preserves intestinal barrier function better than parenteral feeding, with enterally fed animals better tolerating those fed an identical diet parenterally. These findings have been verified in several prospective randomized clinical studies involving burn and trauma patients and have influenced the current practices of nutritional support in critical illness. Although bacterial translocation has been demonstrated consistently in experimental animal models, results of clinical human trials failed to find bacteria or endotoxin in the portal blood of severely injured patients and its relevance to humans is uncertain. One possible explanation to resolve these discordant results, however, is that gut-derived factors contributing to systemic inflammation and organ injury reach the systemic circulation via the mesenteric lymphatics rather than the portal venous system. One important conceptual consequence of the gut–lymph hypothesis is that the lung rather than the liver would be the first major vascular bed to be exposed to gut-originated mesenteric lymphatic factors (mesenteric lymph bypasses the liver and follows the thoracic duct that empties into the subclavian vein and directly proximal to the pulmonary circulation). There is extensive clinical and experimental evidence showing that after hemorrhagic shock, trauma, or a major burn injury, the gut releases proinflammatory and tissue injurious factors that lead to acute lung injury.

Suggested Readings

Andersson U, Wang H, Palmblad K, et al. High mobility group 1 protein (HMG-1) stimulates proinflammatory cytokine synthesis in human monocytes. *J Exp Med* 2000;192:565–70.

Beutler B, Milsark IW, Cerami AC. Passive immunization against cachectin/tumor necrosis factor protects mice from lethal effect of endotoxin. *Science* 1985;229(4716):869–71.

Cuthbertson D, Tinstone WT. Metabolism during the postinjury period. *Adv Clin Chem* 1969;12:1–55.

Friedrich O, Reid MB, Van den Berghe G, et al. The sick and the weak: neuropathies/myopathies in the critically ill. *Physiol Rev* 2015;95(3)1025–109.

Gupta RG, Hartigan SM, Kashiouris MG, et al. Early goal-directed resuscitation of patients with septic shock: current evidence and future directions. *Critical Care* 2015;19:286.

Hendrik S, Dirk H, Joachim W, et al. The alteration of autonomic function in

multiple organ dysfunction syndrome. *Crit Care Clin* 2008;24:149–63.

Hoebe K, Janssen E, Beutler B. The interface between innate and adaptive immunity. *Nat Immunol* 2004;5(10):971–4.

Huston JM, Gallowitsch-Puerta M, Ochani M, et al. Transcutaneous vagus nerve stimulation reduces serum high mobility group box 1 levels and improves survival in murine sepsis. *Crit Care Med* 2007;35(12):2762–8.

Mantovani A, Bonecchi R, Locati M. Tuning inflammation and immunity by chemokine sequestration: decoys and more. *Nat Rev Immunol* 2006;6:907–18.

Pavlov VA, Tracey KJ. The vagus nerve and the inflammatory reflex – linking immunity and metabolism. *Nat Rev Endo* 2012;8(12)743–54.

Rittner HL, Brack A, Stein C. Pain and the immune system. *Br J Anaesth* 2008;101:40–4.

Schmidt H, Müller-Werdan U, Hoffmann T, et al. Autonomic dysfunction predicts mortality in patients with multiple organ dysfunction syndrome of different age groups. *Crit Care Med* 2005;33(9):1994–2002.

Sims GP, Rowe DC, Rietdijk ST, et al. HMGB1 and RAGE in inflammation and cancer. *Ann Rev Immunol* 2010;28:367–88.

Stein C, Schafer M, Machelska H. Attacking pain at its source: new perspectives on opioids. *Nat Med* 2003; 9:1003–8.

Tracey KJ. Reflex control of immunity. *Nat Rev Immunol* 2009;9(6):418–28.

EDITOR'S COMMENT

Nothing about surgery makes sense until one understands the metabolic and inflammatory responses to trauma and infection, and these are beautifully described in the current edition of Chapter 1. The commentator from the previous edition (J.E.F.) described this chapter as "encyclopedic," which in my opinion is not always a flattering descriptor, but in this case it is apt. The authors have diligently reviewed and outlined the cytokine, endocrine, and neurohormonal responses to surgical trauma and infection. To the uninitiated this material may be considered to be dry, but understanding these hormonal, cytokine, and neurologic responses of the body to surgical stress is paramount to understanding why our patients respond the way that they do after surgery and trauma. For any aspiring student of surgical physiology the importance of this chapter cannot be overemphasized.

From innumerable studies done in this field, we now have a scientific foundation for and have in some ways redefined the "ebb and flow" concept first described by Cuthbertson in the early 1930s. The concept has been broadened not only to include metabolism but also to explain another surgical

fascination—perioperative fluid avidity. This chapter clearly explains why our patients become sodium (and thereby water) avid in the immediate postoperative period, and likewise why fluid "mobilization" should be expected within 2 to 3 days after surgical/trauma encounters. The advent of laparoscopic surgery has allowed further insights, corroborating the importance of the magnitude of the insult relative to the subsequent inflammatory/hormonal response and resultant sodium avidity. It is worth noting that understanding this ebb and flow might tempt one to hasten postoperative recovery by use of diuretics. This implies a condition I term "lasixpenia," which I have yet to see in the index of any surgical text. A more patient practice is to wait for fluid mobilization to begin on its own. For those patients not mobilizing their fluids as expected, concern for ongoing stress (i.e., infection, ischemia, etc.) should be raised, thereby prompting early thoughtful investigations for possible complications.

Despite all of our progress, this chapter also shows that there is much more to be done. For example, we have just begun to scratch the surface of the neuroimmune axis. While it has been known for many years that the CNS influences hormonal responses to stress, the direct influence of the CNS on immune function has been a relatively new addition to the literature. There are compelling animal data now suggesting that vagotomy enhances inflammation during shock, and that vagal nerve stimulation might temper these immune responses. To my eye, the question of whether vagotomy enhances septic shock in people remains to be answered. I also find it a bit humbling to consider that for decades Western medicine has focused mostly on the bodily response to surgery, while the influence of the mind and spirit on surgical outcomes remains a relative mystery. Study in this area could contribute greatly to outcomes for our surgical patients.

Likewise, there is much more to learn about the impact that opiates have on immune function during surgical convalescence. It has been known for years that our immune cells express the three main opioid receptors, and there are growing data suggesting the immune suppressive influences that opiates have on their function. Nevertheless, poorly treated pain will also stimulate unwanted neural afferent and efferent activities enhancing the inflammatory response and perhaps neurologic attenuation of immune function. This latter concern and the assignment of pain as the "fifth vital sign" have led to a lean toward overuse of narcotics in postoperative patients. It is becoming increasingly evident that overprescribing is contributing to our national opiate dependence epidemic, but the earlier influences of such practice on patient immunity and infectious complications remain grossly understudied.

Another area that remains understudied is the differential response of individual patients to surgical stress. Despite the thoughtful catalog of physiologic responses to surgery presented here, the simple fact remains that not all patients respond the same way to comparable stress. We have been quick to assume that these differences must be due to genetics, and the authors rightly

point out that there are described polymorphisms of Toll-like receptors. Likewise, there are polymorphisms of other cytokines and receptors that might influence immune and inflammatory responses. Nevertheless, as studies of the influence of genetics on other diseases progress, it seems safer to conclude that genetics are likely only part of this puzzle, and not the entire puzzle.

To add to this puzzle, we must also consider the influence of pre-existing immunity on responses to surgery and trauma. We have learned from recent examples such as respiratory syncytial virus and H1N1 that viral infections can predispose hosts to dramatic and often fatal bacterial pneumonia. The potential detrimental influence of chronic viral infections, such as herpesviruses, on surgical outcomes is also receiving increasing attention. Likewise, it has become clear that critical illness has significant impact on epigenetic regulation, which might also influence surgical outcomes. Altogether these data suggest that immunologically, what has come before might indeed influence what happens next after surgery or trauma, and this area of research remains mostly unexplored.

Finally, once all of these holes in our knowledge have been filled (and yet others recognized), we will still be left with a somewhat bewildering pile of observations that need to be integrated and understood as a system. As intimated by the authors, there is significant overlap and interaction between the myriad cytokine and hormonal responses to surgical stress, and this complexity does not even consider genetics or immune memory. Lifelong practice and careful study certainly have allowed surgeons glimpses of the “big picture,” but as our dataset has continued to grow we have mostly surpassed this possibility as individuals. Future understanding will require rule engines and advanced statistical techniques, combining methods such as Ingenuity’s Pathway Analysis and Gene Wide Association Study (GWAS). By using such approaches, we will hopefully come to understand how individuals respond to surgical stress, allowing us to tailor our expectations and therapy for each of them.

In conclusion, after studying this chapter and perhaps this commentary, it is my sincere hope that some of you are inspired to continue the great work outlined here. Most of us spend our entire career at some level trying to understand why patients respond to our treatments the way that they do. Even if you choose not to pursue this subject academically, if you give this chapter the full attention that it deserves, your patients will be richly rewarded by your better understanding of their response to your ministrations.

Charles H. Cook

2 Perioperative Management: Practical Principles, Molecular Basis of Risk, and Future Directions

Per-Olof Hasselgren, Jeremy W. Cannon, and Josef E. Fischer

INTRODUCTION

Preparing patients for surgery has grown increasingly complex as the severity of chronic illness within our patients has worsened even as the options for managing these conditions in the perioperative period have expanded. In addition, over the past decade, the process of surgical care in the operating room (OR) and afterward has been refined in a number of respects aimed at improving patient safety and quality of care. Throughout this perioperative time, the patient's physiology is taxed to tolerate the surgical insult and then to heal the operative site. This chapter has three sections. First, practical and clinical aspects of the perioperative management of surgical patients are discussed, including preoperative evaluation, intraoperative considerations, and immediate postoperative management. The second part of the chapter provides a discussion of metabolic alterations and molecular mechanisms involved in muscle wasting, a prevalent and dreaded condition seen in many critically ill patients and that may have significant impact on the perioperative management and influence the outcome of surgical procedures. Finally, in the third section of the chapter, the perioperative assessment of the surgical patient from a nutritional standpoint, in particular the need for nutritional support in the malnourished patient and in patients with cancer or sepsis is highlighted. This section also provides a historical perspective dating back to the 1970s of the development of nutritional support in surgical patients.

Perioperative Evaluation and Management

The perioperative period is defined as the time from preoperative workup through the first 30 days of postoperative care. From the patient's perspective, a surgical procedure and the perioperative period are often a

momentous occasion, which involves significant loss of personal control. As such, the surgeon's responsibility is to engender trust that the decision to operate is sound and that every measure to ensure the patient's safety throughout the perioperative course is taken.

A careful preoperative history, review of systems, and physical examination will reveal pre-existing medical conditions and risk factors known to worsen surgical outcomes. This process can be facilitated by a screening questionnaire structured to trigger the patient's memory about significant medical illnesses or previous perioperative experiences (Table 2.1). Findings during this evaluation then guide the array of laboratory studies and additional tests needed to more specifically assess the patient's risk of an adverse perioperative event. Once all of this information is gathered, a perioperative management plan can be fashioned by the surgeon often with input from the patient's primary care physician and possibly other specialty consultants in fields such as cardiology, geriatrics, and anesthesiology. The following sections review many of the issues that arise during the perioperative period and provide a recommended approach based on current evidence.

TABLE 2.1 Preoperative Screening Questionnaire

1. Do you usually get chest pain or breathlessness when you climb up two flights of stairs at normal speed?
2. Do you have kidney disease?
3. Has anyone in your family (blood relatives) had a problem following an anesthetic?
4. Have you ever had a heart attack?
5. Have you ever been diagnosed with an irregular heartbeat?
6. Have you ever had a stroke?
7. If you have been put to sleep for an operation, were there any anesthetic problems?
8. Do you suffer from epilepsy or seizures?
9. Do you have any problems with pain, stiffness, or arthritis in your neck or jaw?
10. Do you have thyroid disease?
11. Do you suffer from angina?
12. Do you have liver disease?
13. Have you ever been diagnosed with heart failure?
14. Do you suffer from asthma?
15. Do you have diabetes that requires insulin?
16. Do you have diabetes that requires tablets only?
17. Do you suffer from bronchitis?

Adapted from Hilditch WG, Asbury AJ, Crawford JM. Pre-operative screening: criteria for referring to anaesthetists. *Anaesthesia* 2003;58(2):117–24.

SCREENING TESTS IN GENERALLY HEALTHY PATIENTS

For patients with no or few comorbidities, a selective preoperative testing approach is advised (Table 2.2). Laboratory testing options include a complete blood count (CBC), electrolyte and renal function tests, serum glucose, liver function tests (LFTs), coagulation studies, urinalysis, and pregnancy test. With the exception of pregnancy test, these studies can be obtained within several months of the planned procedure. Patient's age has been identified as a minor predictor of morbidity and mortality although this seems to be related more to the associated comorbidities that develop with advancing age. Consequently, age alone should not be used in determining the types of preoperative tests to obtain with the exception of a baseline hemoglobin (Hb) for those over 65 years undergoing major surgery and any patient in whom significant blood loss is anticipated. The cost of an added white blood cell and platelet count is often minimal; so these are often obtained as part of the baseline Hb. Because renal insufficiency strongly correlates with poor perioperative outcomes, identifying patients with occult renal disease is essential. No consensus exists on the indications for such testing, but it has been suggested that a BUN and Cr should be obtained in patients over 50 years of age scheduled for intermediate- or high-risk surgery or when perioperative hypotension is considered likely or when nephrotoxic medications are planned. Routine electrolyte, serum glucose, and LFT are not recommended in healthy patients. Patients with a history of a bleeding disorder or an associated illness, which can result in abnormal coagulation function should have coagulation studies performed. Otherwise, routine testing of the partial thromboplastin time, prothrombin time, and international normalized ratio (INR) is not recommended. Routine urinalysis testing is a matter of ongoing debate. On the one hand, patients scheduled to have a surgical prosthesis implanted may be at an increased risk for wound or implant infections from a pre-existing urinary tract infection (UTI). However, even with treatment, patients with an asymptomatic preoperative UTI develop more postoperative infections, and the cost–benefit ratio of prosthetic infection prevention with routine urinalysis screening does not clearly favor testing the asymptomatic patient. Patients of childbearing age should have a urine or serum pregnancy test, which many institutions require as a matter of policy.

TABLE 2.2 Preoperative Laboratory Testing Indications

Laboratory Test	Indication
CBC	Age ≥65 + major surgery; anticipated significant blood loss
Renal function	Age ≥50 + major surgery; suspected renal disease; anticipated hypotension; planned nephrotoxic agents; poorly controlled hypertension
Serum electrolytes	Routine testing not recommended
Serum glucose	Routine testing not recommended
Liver function	Routine testing not recommended
Nutrition laboratory values	History of unintentional weight loss; chronic GI illness
Coagulation studies	Routine testing not recommended
Urinalysis	Routine testing not recommended
Pregnancy test	Women of childbearing age
Additional Basic Tests	**Indication**
EKG	Vascular surgery planned; history of cardiovascular disease; poorly controlled hypertension
CXR	Age ≥50 + AAA or upper abdominal/thoracic surgery; history of cardiopulmonary disease
PFT	Unexplained dyspnea

CBC, complete blood count; GI, gastrointestinal; EKG, electrocardiogram; CXR, chest x-ray; PFT, pulmonary function tests.

Additional basic testing options include a 12-lead electrocardiogram (EKG), PA and lateral chest x-ray (CXR), and pulmonary function test (PFT). We reserve these tests almost exclusively for patients with prior history of cardiovascular or cardiopulmonary disease. With regard to PFT, these are only obtained in patients with dyspnea in whom a thorough history and physical examination fails to reveal the source of this complaint. Our approach to obtaining these additional tests is also summarized in Table 2.2.

RISK ASSESSMENT AND MANAGEMENT IN PATIENTS WITH CHRONIC MEDICAL ILLNESS

The most common pre-existing medical condition requiring perioperative risk assessment and management is either known or suspected cardiovascular disease. Other common pre-existing conditions that are amenable to risk modification include pulmonary diseases, renal insufficiency, liver failure, diabetes mellitus, immunosuppression, and hematologic conditions. The surgeon's goal should be to minimize the impact of these conditions on the surgical outcome while using a surgical and anesthetic approach, which avoids any further deterioration of the

involved organ system and the patient. In each case, communication between the surgeon and the primary care physician or medical specialists involved in the patient's care is essential while preparing such patients for surgery.

Cardiovascular

Cardiovascular events are responsible for one third to one half of perioperative deaths, and of the patients who present for noncardiac surgery, nearly one third have a known diagnosis of cardiovascular disease. Consequently, cardiovascular risk stratification and modification are fundamental to the perioperative care of many patients.

Patients with a good functional status have a low risk of perioperative cardiovascular complications. This can be assessed by determining the types of daily routines the patient can perform, which translate into multiples of the amount of oxygen consumed while seated at rest (1 MET). Patients who are unable to walk up two flights of steps or four blocks (>4 METs) have an increased risk of postoperative cardiovascular events. In addition to functional status, cardiovascular risk scoring systems are useful in quantifying the risk of a major perioperative cardiovascular event. The Revised Cardiac Risk Index (RCRI) is the tool we prefer given its simplicity and validation in multiple clinical studies (Table 2.3).

In addition to basic laboratory studies, patients with cardiovascular disease should have a baseline EKG. Additional testing options include transthoracic echocardiography, exercise or chemical stress testing with or without supplemental echocardiography or radionuclide myocardial perfusion imaging, and coronary angiography. The 2014 American College of Cardiology/American Heart Association (ACC/AHA) guidelines reflect the most current recommended approach to the use of these additional studies (Fig. 2.1). Alternative algorithms have been proposed by the American College of Physicians (ACP) and by Fleisher and Eagle. In general, if the patient's cardiovascular disease warrants immediate intervention (i.e., the cardiovascular symptoms are more pressing than those that prompted surgical consultation), additional studies are warranted. Although these algorithms serve to identify and further evaluate patients deemed to be at either intermediate or high risk for adverse perioperative cardiovascular events, their use has, to date, not been shown to improve patient outcomes.

Based on the coronary artery revascularization prophylaxis (CARP)

trial and the DECREASE-V pilot study, prophylactic coronary revascularization by percutaneous coronary intervention (PCI) or coronary artery bypass grafting does not appear to alter postoperative outcomes. Accordingly, the current ACC/AHA guidelines recommend preoperative PCI only in patients with an acute coronary syndrome for whom PCI is independently indicated. Patients who undergo coronary revascularization with a bare metal stent should have surgery delayed for 4 to 6 weeks but no more than 12 weeks when the incidence of stent restenosis begins to rise. Conversely, patients who have a drug-eluting stent (DES) placed should have surgery delayed for a year if possible while the patient is on dual antiplatelet therapy. Aspirin should be continued in the perioperative period if at all possible, and thienopyridine therapy (e.g., clopidogrel) should be resumed as soon as possible after surgery to minimize the risk of stent thrombosis.

TABLE 2.3 Revised Cardiac Risk Index and Associated Rates of Significant Perioperative Cardiovascular Events

Risk Factor	Comment
High-risk surgery	Intraperitoneal, intrathoracic, or suprainguinal vascular procedures
Ischemic heart disease	History of myocardial infarction, history of a positive exercise test, current complaint of chest pain considered to be secondary to myocardial ischemia, use of nitrate therapy, or ECG with pathologic Q waves
History of heart failure	History of congestive heart failure, pulmonary edema, or paroxysmal nocturnal dyspnea; physical examination showing bilateral rales or S3 gallop; or chest radiograph showing pulmonary vascular redistribution
History of cerebrovascular disease	History of transient ischemic attack or stroke
Insulin therapy for diabetes	
Preoperative serum Cr >2 mg/dL	
Risk of perioperative cardiac complications including cardiac death, nonfatal MI, and nonfatal cardiac arrest based on the number of risk factors (% [95% CI])	
0	0.4 [0.1–0.8]
1	1.0 [0.5–1.4]
2	2.4 [1.3–3.5]
3	5.4 [2.8–7.9]

Adapted from Lee TH, Marcantonio ER, Mangione CM, et al. Derivation and prospective validation of a simple index for prediction of cardiac risk of major noncardiac surgery. *Circulation* 1999;100(10):1043–9 and Devereaux PJ, Goldman L, Cook DJ, et al. Perioperative cardiac events in patients undergoing noncardiac surgery: a review of the magnitude of the problem, the pathophysiology of the events and methods to estimate and communicate risk. *CMAJ* 2005;173(6):627–34.
MI, myocardial infarction; CI, confidence interval.

Patients with unstable angina or a recent MI bear special consideration. Historic studies suggested that a significant and persistent risk of reinfarction or death existed for up to 6 months after an acute MI. However, with improved perioperative monitoring and management, the rates of such complications after subsequent noncardiac surgery have dropped significantly. A stress test after MI or an episode of unstable angina reliably identifies patients who will benefit from revascularization. Those who have no evidence for at-risk myocardium have a low likelihood of reinfarction with noncardiac surgery and can likely be taken for surgery within 4 to 6 weeks.

Pre-existing essential hypertension is a common medical problem among patients facing surgery. Good blood pressure control (<140/90 mm Hg in most patients or <130/80 mm Hg in patients with DM or CKD) is ideal. However, national guidelines do not recommend delaying surgery unless the patient's blood pressure is over 180/110 mm Hg. Patients with

poorly controlled hypertension have an increased risk of perioperative blood pressure lability, arrhythmias, and myocardial ischemia. Such patients should have an EKG and renal function testing and should be evaluated for secondary hypertension prior to elective surgery if this workup has not been previously performed. Then, improved blood pressure control should be pursued for 6 to 8 weeks prior to surgery if the urgency of the indicated procedure permits.

Pulmonary

Patients with a known diagnosis of chronic obstructive pulmonary disease (COPD), asthma, upper respiratory tract infections, pneumonia, or other pulmonary conditions warrant special attention. In addition to an assessment of the patient's smoking status, pulmonary functional baseline, need for supplemental oxygen, and current pulmonary medications, use of a pulmonary risk index can aid in the quantification of the perioperative risk of respiratory failure (Table 2.4). Patients with pulmonary risk factors should have a preoperative CXR supplemented by PFTs in those with unexplained dyspnea. There is no role for routine preoperative arterial blood gas testing. The benefits of perioperative smoking cessation are discussed below. If the patient has had a recent deterioration in pulmonary function in the recent past due to a reversible cause, elective surgery should be deferred until the patient returns to their prior baseline. Patients with COPD should be managed with an inhaled anticholinergic (e.g., ipratropium) and as needed inhaled beta agonists. Patients with asthma should be maintained on their home medication regimen unless their current symptom control is poor. In these cases, a step-up in therapy in the perioperative period is warranted. Prophylactic administration of glucocorticoids to asthmatics is not required unless they are maintained on systemic or high-dose inhaled steroids. In patients at high risk for perioperative pulmonary complications, consideration should be given to use of spinal or epidural anesthesia over general anesthesia. Long-acting neuromuscular blockade (e.g., pancuronium) should be avoided. If a laparoscopic surgical option is available, this should be used over open surgery if possible. For postoperative risk mitigation, an epidural catheter for analgesia should be planned in these patients, and preoperative incentive spirometry teaching should be conducted so that the patient is prepared to participate in early and aggressive postoperative lung expansion.

Renal

Chronic renal insufficiency with a serum Cr of ≥2 mg/dL is an independent predictor of postoperative cardiac complications. In addition, the surgical team must take special care to avoid further kidney injury in these patients by maintaining euvolemia, taking appropriate precautions to avoid contrast-induced nephropathy, and by appropriately dosing all medications while minimizing the use of those with potential nephrotoxic effects. In addition, in the perioperative period, intravascular volume status can be more difficult to gauge in this patient population; so we are aggressive with employing all available monitors to assure adequate intravascular volume to include use of a pulmonary artery catheter in some cases.

Patients with end-stage renal disease (ESRD) require coordination of perioperative care between the surgical team, the anesthesia team, and nephrology. Preoperative electrolytes should be obtained in close proximity to the procedure to ensure that serum potassium is within normal limits and that there are no significant derangements in the other values. If the patient is on hemodialysis or peritoneal dialysis, the timing of pre- and postoperative dialysis should be decided upon in advance. Patients who are on the cusp of requiring renal replacement therapy (RRT) require similar surveillance and coordination in the event that transient RRT is required for postoperative electrolyte management, volume overload, or azotemia.

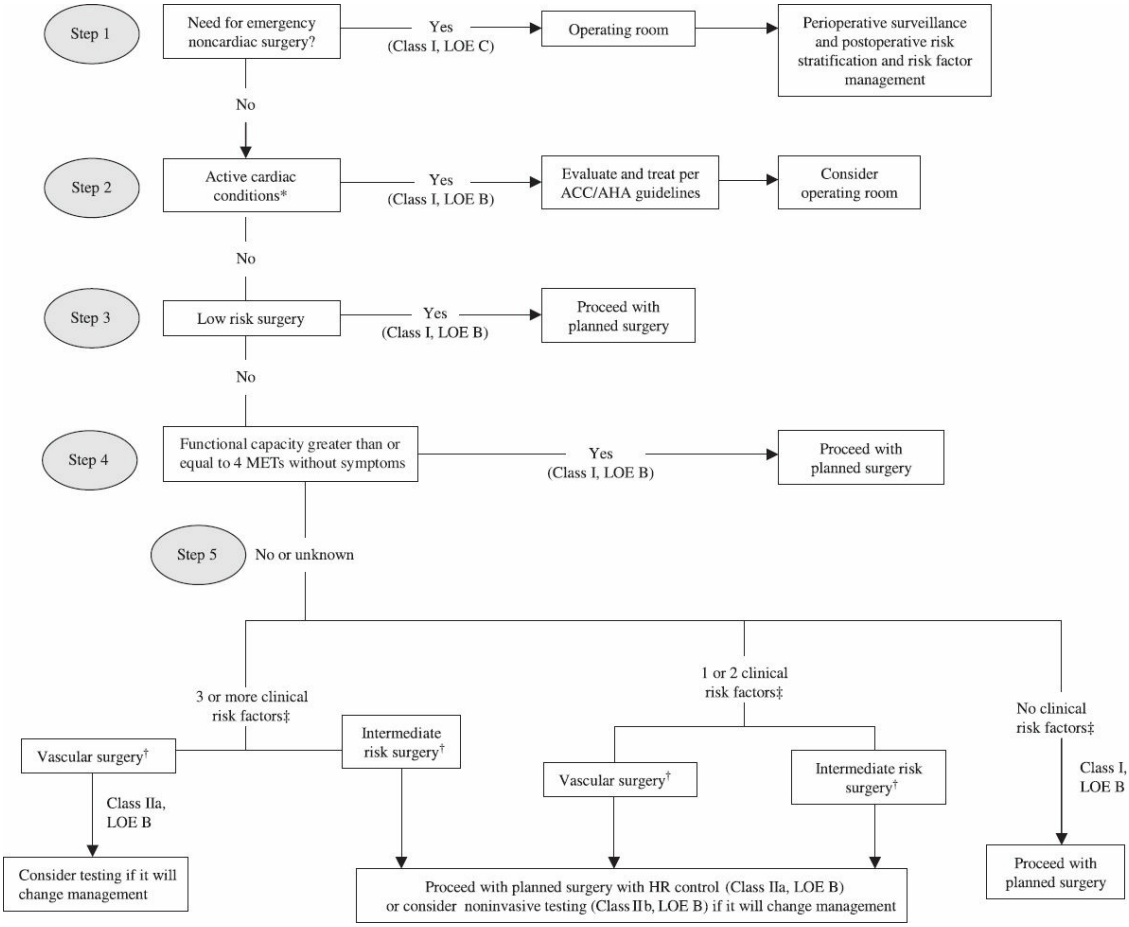

Figure 2.1. 2007 ACC/AHA algorithm for the perioperative cardiovascular management of patients aged 50 and above undergoing noncardiac surgery. (Adapted from Fleisher AJ, Bjork BJ, Bui TQ, et al. Mid-infrared time resolved frequency comb spectroscopy of transient free radicals. *J Phys Chem Lett* 2014;5(13):241–6). *Active cardiac conditions include unstable or severe angina, MI between 7 and 30 days prior, decompensated heart failure, significant arrhythmia, severe aortic stenosis, or symptomatic mitral stenosis. †Low risk surgery includes endoscopic procedures, superficial procedures, cataract surgery, breast surgery, and ambulatory surgery; intermediate risk surgery includes intraperitoneal/intrathoracic surgery, carotid endarterectomy, head and neck surgery, orthopedic surgery, and prostate surgery; vascular surgery includes aortic and other major vascular surgeries (except carotid endarterectomy) and peripheral vascular surgery. ‡Clinical risk factors are similar to the revised Cardiac Risk Index factors in Table 2.3 and include history of ischemic heart disease, cerebrovascular disease, compensated or prior heart failure, diabetes mellitus, and renal insufficiency.

Liver

Patients with pre-existing hepatic failure are at increased risk for complications and death after surgery. The Child–Turcotte and Child–Pugh classification schemes were originally developed to estimate the risk of death after portal-caval shunting and have since been validated as a good estimate for death following a range of other surgeries. More recently, the model for end-stage liver disease (MELD) score has also been used to assess perioperative risk in these patients (Table 2.5). An online calculator, which uses the patient's age, ASA class, and MELD score to calculate 7-day, 3-day, 90-day, 1-year, and 5-year predicted mortality is also available at http://www.mayoclinic.org/meld/mayomodel9.html.

In general, patients with mild cirrhosis (Child's A or MELD <10) tolerate surgery well while patients with fulminant hepatic failure, severe hepatitis, extrahepatic complications, and advanced cirrhosis (Child's C or MELD >15) are likely to have a poor postoperative outcome and should have surgery delayed until their liver function can be optimized or they undergo a liver transplantation if possible. Patients with moderate cirrhosis (Child's B or MELD 10 to 15) can be considered for surgery after careful preoperative evaluation. Reports of herniorrhaphy outcomes in these patients (both umbilical and inguinal) suggest that these operations can be performed safely. Similarly, cholecystectomy has been reported in patients with cirrhosis for a range of indications, and recent reports indicate that the laparoscopic approach is safe and appears to have improved outcomes when compared with open cholecystectomy. The preoperative preparation of these patients should focus on minimizing ascites, correcting vitamin deficiencies (especially vitamin K), and assessing for and correcting malnutrition.

TABLE 2.4 Arozullah Respiratory Failure Index and the Associated Risk of Respiratory Failure[a]

Preoperative Predictor	Points
Type of Surgery	
Abdominal aortic aneurysm	27
Thoracic	21
Neurosurgery, upper abdominal, peripheral vascular	14
Neck	11
Emergency surgery	11
Albumin <3 g/dL	9
BUN >30 mg/dL	8
Partially or fully dependent functional status	7
History of COPD	6
Age	
>70 years	6
60 to 69 years	4

Class	Points	Risk of Respiratory Failure (%)
1	≤10	0.5
2	11–19	1.8–2.1
3	20–27	4.2–5.3
4	28–40	10.1–11.9
5	>40	26.6–30.9

Adapted from Arozullah AM, Daley J, Henderson WG, et al. Multifactorial risk index for predicting postoperative respiratory failure in men after major noncardiac surgery. The national veterans administration surgical quality improvement program. *Ann Surg* 2001;232(2):242–53.
[a]Respiratory failure is defined as either mechanical ventilation for >48 hours after surgery or reintubation and mechanical ventilation after initial postoperative extubation.

TABLE 2.5 Use of the MELD Score for Preoperative Risk Assessment in Patients With Cirrhosis

MELD Score	Mortality (%)		
	7-day	30-day	90-day
0–7	1.9	5.7	9.7
8–11	3.3	10.3	17.7
12–15	7.7	25.4	32.3
16–20	14.6	44.0	55.8
21–25	23.0	53.8	66.7
≥26	30.0	90.0	90.0

Adapted from Teh SH, Nagorney DM, et al. Risk factors for mortality after surgery in patients with cirrhosis. *Gastroenterology* 2007;132(4): 1261–9; with permission from Elsevier.
MELD, model for end-stage liver disease.

Endocrinopathies and Obesity

Diabetes mellitus is a common medical condition present in up to 20% of surgical patients. As shown in Table 2.3, insulin-requiring diabetes is a marker for increased postoperative cardiac morbidity in the RCRI. Historic glycemic control is a known marker for postoperative infections (pneumonia, wound infection, UTI, and sepsis), and poor perioperative glycemic control has been shown to correlate with surgical complications and death. Thus, careful attention must be paid by the surgical team to cardiac risk modification in diabetic patients and to glucose management throughout the entire perioperative period to assure optimal outcomes.

A reliable measure of historic glycemic control over the previous 3 months is the hemoglobin A_{1C} (Hb A_{1C}). If the Hb A_{1C} is >7%, postoperative infections are increased while a preoperative glucose level of >200 mg/dL is associated with an increased rate of postoperative deep wound infections. Perioperative management of oral hypoglycemics and insulin is discussed below (see section on “Medication Management”).

Patients with hypothyroidism should continue on their baseline medication regimen throughout the postoperative period. Those who are nil per os (NPO) can have these medications safely held or converted to IV supplementation if a prolonged period of fasting is anticipated. Those with hyperthyroidism undergoing surgery should achieve a euthyroid state before surgical intervention and their antithyroid medications should be

continued up until the time of surgery. If urgent surgery is required in a thyrotoxic patient, consultation with an endocrinologist is warranted.

Obesity (BMI ≥30 kg/m^2) has been extensively evaluated as a risk factor for poor perioperative outcomes. Recent evidence suggests that, in fact, there may be a so-called “obesity paradox” in that such patients have fewer complications than controls. The exceptions to this paradox are wound and thromboembolic complications including deep venous thrombosis (DVT) and pulmonary embolism (PE). Furthermore, superobese patients (BMI >50 kg/m^2) are still considered to be at increased perioperative risk for a range of complications including death.

Important aspects in the preoperative evaluation of obese patients include calculating the BMI and eliciting a history of obstructive sleep apnea (OSA), hypertension, coronary artery disease, renal disease, diabetes mellitus, thromboembolic events, or any adverse outcome from prior to surgery. Obese patients who do not carry a diagnosis of OSA can be quickly screened with a questionnaire such as the STOP-BANG screening tool. Those at high risk for OSA should be referred to a sleep specialist for further testing prior to elective surgery. Many centers have special monitoring protocols for patients with OSA, and those who use CPAP at home should be continued on this therapy in the postoperative period.

In selecting the operative approach, a recent systematic review found that obese patients have significantly decreased wound infection rates following laparoscopic versus open surgery.

Malnutrition

Preoperative malnutrition has been recognized as an important risk factor for postoperative morbidity and mortality for over 70 years. Quantification of the degree of malnutrition and the correction of severe malnutrition preoperatively remain an important part of surgical management. Assessment of nutritional status begins with a thorough history and physical examination paying careful attention to dietary changes, evidence of malabsorption, and evidence for loss of lean body mass. The Subjective Global Assessment has been used to facilitate this evaluation. Laboratory testing should include albumin, transferrin, and prealbumin to assess the long-term, intermediate-term, and short-term nutritional state of the patient, respectively. If the patient is found to be severely malnourished, surgery should be delayed so that supplemental nutrition can be administered. Enteral supplementation is preferred if the patient can

tolerate this route; otherwise, parenteral nutrition (PN) should be initiated. In this population, improvements in nutritional status are assessed at regular intervals until surgery is deemed safe (after 7 to 15 days in some studies). Supplemental nutrition is then continued postoperatively until the patient can meet their caloric needs independently.

Coagulopathy

Patients with inherited coagulopathies and those who are maintained on therapeutic anticoagulation present special challenges with regard to achieving and maintaining postoperative hemostasis. Perioperative management of anticoagulant and antiplatelet medications is discussed below (see section on “Medication Management”). The most common intrinsic coagulopathies in surgical patients are von Willebrand disease and the hemophilias. Patients with chronic renal insufficiency also have some baseline degree of platelet dysfunction. The surgical review of systems should specifically focus on a predilection for prolonged epistaxis, easy bruising, and any bleeding complications during previous surgeries. If this evaluation is negative for a bleeding history and the physical examination does not reveal any petechiae or stigmata of chronic renal or liver disease, routine testing of coagulation studies is not indicated. If these studies are obtained and are abnormal, a mixing study is required to determine whether the abnormality is the result of a factor deficiency or an inhibitor (e.g., lupus anticoagulant). If the patient’s personal family history is strongly suggestive of an undiagnosed coagulopathy, consideration should be given to testing for von Willebrand disease using the triad of plasma von Willebrand factor (VWF) antigen, plasma VWF activity, and factor VIII activity. Patients who carry a diagnosis of von Willebrand disease should be pretreated in consultation with a hematologist with either desmopressin (DDAVP) for minor surgery if the patient has previously responded or with VWF concentrate for major surgery. Patients with mild hemophilia A or B can similarly be pretreated with DDAVP while those with severe hemophilia can be treated with specific factor concentrates (Factor VIII or IX) or activated Factor VII in the presence of inhibitors. Patients with thrombocytopenia (e.g., those with inherited thrombocytopenic purpura) should have a preoperative platelet transfusion targeting a minimum of 50,000/μL.

Malignancy and Immunocompromise

Patients with malignancy and those on immunosuppressive medications or with an inherited or acquired immunocompromised state frequently undergo surgery. The preoperative evaluation should proceed as described above guided by the patient's other medical conditions and nutritional status. For patients on chemotherapy, the timing of the last dose of chemotherapy, the projected cell count nadirs, and planned future therapy should be discussed with the patients and their oncologist. For patients with HIV, a history of an AIDS-defining illness and their current medication regimen should be elicited. Laboratory testing should include a CBC with differential, chemistries, renal function, and liver function studies. If malnutrition is suspected by history and physical examination, nutrition laboratory values should be obtained. Patients with HIV should have a CD4 and a viral load obtained as the former is a surrogate for immunocompetence while the latter has been specifically correlated with increased perioperative complications at a level of 30,000 copies/mL or greater. Patients with neutropenia should have surgery delayed if at all possible. For those with neutropenia in the postoperative state, development of fever should prompt treatment with broad-spectrum antibiotics and, in some cases, an antifungal agent as well. The role of colony stimulating factors in neutropenic patients is limited to those with additional indicators that prolonged neutropenia will be poorly tolerated such as poor functional status, poor nutrition, an open wound, or active infection. It has been shown that although these stimulating factors reverse the neutropenia, they do not reliably reduce hospital length of stay or culture-positive infections.

Rheumatologic

Patients with rheumatologic diseases have a high incidence of associated cardiovascular disease as well as unique pathology, which increases the risk of perioperative complications. Patients with rheumatologic conditions are often maintained on immune-modulating medications such as glucocorticoids, methotrexate, and so-called biologic agents that interfere with the action of TNF and IL-1. The perioperative management of these medications is discussed in section on "Medication Management." In patients with rheumatoid arthritis, lateral cervical spine films with flexion and extension should be obtained within a year of surgery to assess for atlanto-axial subluxation. Patients with ankylosing spondylitis with severe kyphotic deformities may be difficult to intubate, and thoracic cavity

restriction may require postoperative ventilator support. Thus, preoperative anesthesia and critical care consultations should be considered. Likewise, patients with scleroderma can present special anesthetic challenges, including a small oral aperture, difficult intravenous access, a propensity for vasospasm, prolonged response to local anesthetics, and a significant risk of aspiration due to esophageal dysmotility. In addition, preoperative detection of pulmonary or myocardial involvement is essential; so consideration should be given to obtaining PFTs, an arterial blood gas, and echocardiography in addition to a CXR and EKG. Patients with psoriatic arthritis should be advised of the risk for a psoriatic flare at both the surgical and the remote sites. In addition, these patients may be at increased risk for postoperative infection. Patients with systemic lupus erythematosus (SLE) are at increased risk for postoperative wound infection, renal insufficiency, and thrombotic complications, including PE. SLE patients with active disease and imminent vital organ failure can be treated with intravenous immunoglobulin in the perioperative period.

PREOPERATIVE BEHAVIORAL MODIFICATION

In addition to risk modification interventions discussed above, a number of preoperative behavioral modification strategies have been investigated in an attempt to improve surgical outcomes. The most widely published interventions include smoking cessation, preoperative weight loss, and various preoperative exercise regimens (so-called prehabilitation). Historic evidence suggested that smoking cessation within 8 weeks of surgery actually results in increased pulmonary complications, presumably from bronchorrhea. On the other hand, several smaller studies indicate that some complications such as wound infections and seromas are reduced if smoking cessation occurs as early as 4 weeks prior to surgery although these studies have been inadequately powered to detect differences in pulmonary complications.

Although obesity is associated with an overall increase in cardiovascular disease as well as perioperative wound and thromboembolic complications, the effect of preoperative weight loss on these risks has not been well studied. In patients preparing for bariatric surgery, preoperative weight loss has been correlated with more durable postoperative weight loss. However, improved perioperative surgical outcomes in terms of fewer surgical complications, cardiovascular events, or pulmonary complications have yet to be documented for either bariatric

surgery or other surgical procedures in the obese population.

Because functional status correlates strongly with cardiovascular and pulmonary complication rates, several groups have investigated the benefits of specifically targeting improved functionality in the preoperative period. Recent evidence suggests that a simple regimen of daily walking and deep breathing exercises improves exercise capacity in patients awaiting abdominal surgery, an effect that is preserved postoperatively. Similarly, preoperative inspiratory muscle training appears to result in fewer pulmonary complications and a shorter hospital stay.

MEDICATION MANAGEMENT

Adult patients facing surgery are often taking a number of medications for management of their chronic medical conditions. Prior to surgery, a complete list of all medications and herbal supplements must be obtained from the patient and reconciled with the most recent list of medications in their medical record. The most common outpatient medications and their recommended perioperative management are summarized in Table 2.6. In general, essential medications are continued through surgery with any doses due at the time of surgery taken with a sip of water. Essential medications and those with a significant risk of rebound effects (e.g., beta blockers and clonidine) are continued in an enteral, parenteral, transdermal, or inhaled form during the early postoperative period. As soon as feasible, the patient's outpatient medication regimen should be resumed or revised in consultation with their primary care physician or medical specialist.

Because of the risk of hemorrhage with surgical intervention, the management of outpatient therapeutic anticoagulation in the perioperative period bears special mention. Patients are maintained on anticoagulation for a range of indications from the management of thromboembolic events to anticoagulation for prosthetic heart valves. The indication for anticoagulation dictates the need for therapeutic "bridge" therapy with a short-acting agent while both the surgical procedure and the indication for anticoagulation are used to develop a postoperative anticoagulation plan. For patients with mechanical heart valves, the 2014 ACC/AHA guidelines are the most straightforward to apply. In a patient with a bi-leaflet mechanical aortic valve and no additional risk factors for hypercoagulability (e.g., atrial fibrillation or previous thromboembolism among others), warfarin can be held 48 to 72 hours prior to surgery with

an INR checked on the day of surgery targeting less than 1.5. All other patients (e.g., those with mechanical mitral valves and those with additional risk factors for thromboembolism or hypercoagulability) should be managed with bridge therapy. These guidelines recommend the use of therapeutic heparin during this time although therapeutic low-molecular-weight heparin is included in other guidelines. Postoperatively, in patients who do not require bridge therapy, warfarin is resumed 24 hours after surgery. Those on bridge therapy have their anticoagulation resumed as soon as the bleeding risk permits, usually at 24 hours after surgery.

In all other conditions for which patients are on therapeutic anticoagulation, the perioperative management of this regimen requires an estimate of the bleeding risk from surgery and the risk of a perioperative thromboembolic complication. There are no guidelines to inform practice, but some general practice recommendations can be made from the current literature on this topic. Patients with a recent episode of venous or arterial thromboembolism should have surgery delayed for at least 1 month if at all possible. Minor surgery (e.g., outpatient herniorrhaphy or cataract surgery) can be done safely in patients on warfarin so long as the INR is at the low end of the therapeutic range. Those undergoing major surgery should have warfarin therapy withheld approximately 5 days prior to surgery with an INR checked on the day of surgery. Those on the orally available direct thrombin inhibitor dabigatran (Pradaxa) should have this withheld 1 to 2 days before surgery if renal function is normal or 3 to 4 days with a Cr clearance <50 mL/min. Bridging anticoagulation with either intravenous heparin or therapeutic low-molecular-weight heparin should be used in patients at high or intermediate risk for a thromboembolic event. For many indications including atrial fibrillation, individual patient risk stratification should be conducted to determine the need for bridge therapy. Bridge therapy with heparin should be held 4 to 5 hours prior to surgery while low-molecular-weight heparin should be held 24 hours prior. As mentioned above, postoperative resumption of bridge therapy or oral anticoagulants depends on the risk of postoperative bleeding but generally can be considered after 24 hours.

Patients on antiplatelet therapy also commonly face noncardiac surgery. The availability of thienopyridines (e.g., clopidogrel) and the significant increase in DES implantation have also made the scenario of dual antiplatelet therapy in the surgical patient increasingly common. Patients on antiplatelet therapy should have a careful history taken to determine

their indication for treatment—primary prevention versus prophylaxis against stent thrombosis. As described above, in patients with coronary stents, the timing of surgery should take into consideration the type of stent and the age of the stent. Similarly, the risk of hemorrhage from the surgery should be considered. Cataract surgery is often performed in the patient on aspirin as is coronary artery bypass grafting. If aspirin is held, this should be 7 to 10 days prior to surgery and then resumed when surgical hemostasis is assured, typically within or at 24 hours of the operation. The use of clopidogrel or another thienopyridine either alone or in combination with aspirin should be elicited as well. Some limited data in the vascular surgery literature suggests that with careful attention to hemostasis, even major vascular operations can be done on dual antiplatelet therapy if necessary with no significant increase in perioperative bleeding complications. For patients on dual antiplatelet therapy, the Dual Anti-Platelet Therapy (DAPT) Score can be used to evaluate the specific risks associated with transitioning to monotherapy.

Patients with rheumatologic diseases as well as many other conditions ranging from reactive airway disease to inflammatory bowel disease are maintained on systemic glucocorticoids. Although historically, these patients were given additional steroid doses in the perioperative period, so-called stress dose steroids; recent evidence has called this routine practice into question. Patients who have been on prednisone doses of 20 mg/day (or the equivalent of another agent) for 3 weeks or more or who have a Cushingoid appearance should be presumed to have hypothalamic–pituitary–adrenal (HPA) suppression, which will require supplemental steroid dosing. For patients on lower doses, our usual approach is to resume their home dose or the equivalent in the postoperative period and observe for hemodynamic instability or significant malaise as a trigger for supplemental steroid dosing. An alternative strategy is to perform specific testing for HPA suppression using either high- or low-dose ACTH stimulation testing. Those who respond normally will likely not need supplemental steroid dosing postoperatively.

TABLE 2.6 Perioperative Management of Outpatient Medications and Herbal Supplements

Medication Class	Comment
Cardiovascular Medications	
Beta blockers and nondihydropyridine calcium channel blockers	Acute withdrawal of beta blockers can increase morbidity and mortality. Continue perioperatively. Consider substituting a beta blocker in patients taking nondihydropyridine calcium channel blockers.
Alpha-2 agonists	Acute withdrawal can precipitate rebound hypertension although this is usually at higher oral doses. Continue perioperatively.
ACE inhibitors, ARBs	Generally continue perioperatively when blood pressure is stabilized and renal function is at baseline. Consider holding one preoperative dose in patients with a low baseline blood pressure.
Dihydropyridine calcium channel blockers	Resume when blood pressure has stabilized.
Diuretics	Resume when blood pressure has stabilized and renal function is at baseline.
Statins	Withdrawal may increase perioperative cardiovascular events. Continue perioperatively.
Other lipid lowering agents	Increased risk of myopathy perioperatively with some (e.g., niacin); others interfere with GI absorption (e.g., colestipol). Hold perioperatively.
Agents Affecting Hemostasis	
Aspirin	Balance individual patient risk of cardiovascular event versus the consequences of a bleeding complication. Hold for 7 to 10 days preoperatively if bleeding would cause significant morbidity. Resume when hemostasis is adequate (e.g., within 12–24 hours of surgery).
Thienopyridines (e.g., clopidogrel and ticlopidine)	If given for a DES placed within the past year, consider delaying surgery. Hold for 5–10 days preoperatively if bleeding would cause significant morbidity. Resume when hemostasis is adequate (e.g., within 12 to 24 hours of surgery).
Dipyridamole	Hold for 2 days preoperatively if bleeding would cause significant morbidity.
NSAIDs/COX-2 Inhibitors	Hold NSAIDs for 24–72 hours preoperatively. COX-2 inhibitors have minimal effect on platelet function but have potential for renal toxicity and can lead to cardiovascular events.
Heparin/LMWH	Management depends on the indication and dose. Administer prophylactic doses preoperatively if indicated according to the patient's risk profile for a VTE complication; therapeutic doses are generally held for 6–12 hours preoperatively and are resumed when hemostasis is assured postoperatively (usually within 12–24 hours).
Warfarin	See discussion in the body of the chapter for recommendations on holding and resuming warfarin.
Dabigatran	See discussion in the body of the chapter for recommendations on holding and resuming dabigatran (Pradaxa).
Pulmonary Medications	
Inhaled bronchodilators	Continue perioperatively
Leukotriene inhibitors (e.g., montelukast [Singulair])	Resume when tolerating oral medication
Theophylline	May cause arrhythmias and neurotoxicity. Hold perioperatively.
Diabetic Medications	
Insulin	See discussion in the body of the chapter. Determine the sensitivity factor for patients using an insulin pump.
Oral hypoglycemics	Hold on the morning of surgery. Resume when tolerating a regular diet and risk of returning to NPO status is minimal. Ensure normal renal function prior to resuming metformin.
Other Endocrine/Hormonal Agents	
Thyroxine (T4)	Can be safely held for 5–7 days postoperatively; resume when tolerating oral medications. Parenteral dose is approximately 80% of the oral dose.
Oral contraceptives, HRT, and selective estrogen receptor modulators (e.g., tamoxifen)	In patients at increased risk for VTE, discontinue 6 weeks preoperatively. Resume when the risk of VTE has resolved.
Glucocorticoids	See discussion in the body of the chapter.
Rheumatologic Agents	
Antirheumatic agents	There is no definitive increased risk of wound complications with these agents. Methotrexate can be continued preoperatively in patients with normal renal function; sulfasalazine and azathioprine should be held for 7 days preoperatively; hydroxychloroquine can be continued perioperatively; biologic agents (e.g., etanercept [Humira] and rituximab [Rituxan]) should be held for 7 or more days preoperatively.
Gout agents	Hold on the morning of surgery. Resume when tolerating oral medications.

Neurologic Agents and Chronic Opioids	
Antiepileptic agents	Continue perioperatively. In patients at low risk of a generalized seizure, resume when tolerating oral medications. In patients at increased risk, administer a parenteral antiepileptic agent.
Anti-Parkinson agents	Anti-Parkinson agents increase the risk of perioperative hemodynamic lability and arrhythmias while abrupt withdrawal may result in neuroleptic malignant syndrome and worsening of Parkinsonian symptoms. Dopaminergic agents should be tapered to the lowest possible dose 2 weeks preoperatively and restarted at this dose postoperatively.
Chronic opioids	Patients on methadone should have their maintenance dose continued perioperatively. Methadone can be given subcutaneously or intramuscularly (at 1/2 to 2/3 of the usual dose divided into two to four equal doses) for patients who cannot tolerate oral medications.
Psychotropic Medications	
SSRI	May interfere with platelet aggregation; so balance the risk of bleeding against the risk of exacerbating the underlying disorder.
MAOI	Management of an MAOI perioperatively should involve consultation with an anesthesiologist and the patient's psychiatrist.
Lithium	Consider checking thyroid function tests preoperatively. Continue perioperatively; monitor for nephrogenic DI and serum lithium levels.
Antipsychotics	Continue with caution in patients at risk for exacerbation of psychosis; monitor QT interval; be aware of drug–drug interactions.
Anxiolytics	Continue perioperatively if used on a chronic, routine basis.
Psychostimulants (e.g., methylphenidate [Ritalin])	Hold on the day of surgery. Resume when the patient is stable.
Other	
Herbal medications	Some are associated with an increased risk of MI and stroke (ma huang), bleeding (ginko, ginseng, and garlic), hypoglycemia (ginseng), or altered drug effects. Hold for 7 days preoperatively.

ACE, angiotensin-converting enzyme; ARB, angiotensin receptor blocker; NSAID, nonsteroidal anti-inflammatory drug; LMWH, low-molecular-weight heparin; HRT, hormone replacement therapy; VTE, venous thromboembolism; SSRI, selective serotonin reuptake inhibitor; MAOI, monoamine oxidase inhibitor; DI, diabetes insipidus; MI, myocardial infarction.

There has been some recent interest in perioperative risk reduction through initiating new medications around the time of surgery. Examples include starting a beta blocker or statin in patients with cardiovascular risk factors in the immediate preoperative period. Enthusiasm for initiation of beta blockers around the time of surgery has been recently tempered by the results of the POISE trial and a subsequent meta-analysis, which indicated that although this practice reduces the incidence of perioperative MI, the incidence of perioperative stroke is increased and all-cause mortality is either increased or, at best, unchanged (although the dose of beta blockade in the POISE trial was moderately aggressive at 200 mg of extended release metoprolol daily). In light of these results, the ACC/AHA released a focused update to their perioperative guidelines in 2009, which recommend against the initiation of high-dose beta blockade without dose titration in beta blocker–naïve patients undergoing surgery. Similarly, the indications for perioperative statin initiation in those without classic indications for lipid lowering therapy have been clarified by recent studies. These indicate that vascular surgery patients likely benefit from this intervention with fewer episodes of myocardial ischemia and a lower perioperative cardiac death rate.

PREOPERATIVE SPECIALTY CONSULTATION

Patients with complex or refractory medical problems may benefit from preoperative consultation by a general medical internist, geriatrician, or other medical specialists. Studies evaluating patient outcomes and utilization of medical resources with this practice have generated mixed results. However, provided the consultant's role is clearly delineated in the initial request and the consultant makes evidence-based recommendations, surgeon satisfaction is high and the surgical patient's care is likely to improve. It should be evident from the discussion above that asking a medical consultant to "clear" a patient for surgery is a nonsequitur. Instead, the surgeon should ask specific questions relating to risk stratification and perioperative management of particular disease processes or medications. With this approach, the consultant's input is more likely to be useful to the surgeon and the surgical team in making decisions on surgical timing and perioperative management strategies. Postoperatively, continued involvement of these consultants or a medical hospitalist can, in some cases, improve the care of the patient and should be considered by the surgeon.

RISK REDUCTION IN THE IMMEDIATE PERIOPERATIVE PERIOD

Multiple interventions and quality improvement measures have been advanced in recent years to reduce the risk of adverse events in the OR ranging from wound infections to wrong-site surgery. This section reviews some of the processes that now routinely occur as a result of these initiatives and the management decisions that are most often made from the time the patient enters the preoperative area until the surgical intervention commences. In our view, surgeons should continue to take a leading role in directing the surgical team during this time in the patient's care as it sets the stage for the entire postoperative course.

SURGICAL CHECKLIST AND PREOPERATIVE TIMEOUT

Increased awareness of wrong-site surgery led to a summit to address this problem in 2003 and 2007. Attended by leaders from multiple surgical organizations and the Joint Commission on Accreditation of Healthcare Organizations (JCAHO), the 2003 summit resulted in the introduction of the Universal Protocol for Preventing Wrong Site, Wrong Procedure,

Wrong Person Surgery in 2004. This protocol consists of three components: preoperative verification of patient information, surgical site marking to prevent ambiguity with unilateral procedures, and conducting a presurgical timeout to review the planned procedure and resolve any concerns. Many hospitals promote use of the final presurgical time out as an opportunity for the entire OR team to review the surgical plan and to confirm that all necessary medications have been given. Despite (or perhaps because of) this increased emphasis on patient safety, the number of reported wrong-site procedures has steadily increased since the introduction of the Universal Protocol. The anticipation by proponents of this culture of safety is that as the number of reports rise and the freedom to raise safety concerns in the OR disseminates, the frequency of major errors will decrease significantly.

The Safe Surgery Saves Lives Study Group has recently evaluated an intraoperative checklist developed from the World Health Organization (WHO) guidelines for improving perioperative surgical safety. The 19-item checklist used by this group (Fig. 2.2) emphasizes communication between the patient and all the various surgical team members in the immediate preoperative period and then focuses the team on critical decisions and communication points in the OR and at the conclusion of the procedure. Use of this checklist in eight different hospitals in eight countries resulted in fewer postoperative complications, including death. This report and others highlight the importance of communication between the surgeon, anesthesiologist, OR nurse, surgical technician, and the patient to ensure that the planned surgical procedure is conducted safely and unplanned intraoperative contingencies are readily identified and well managed.

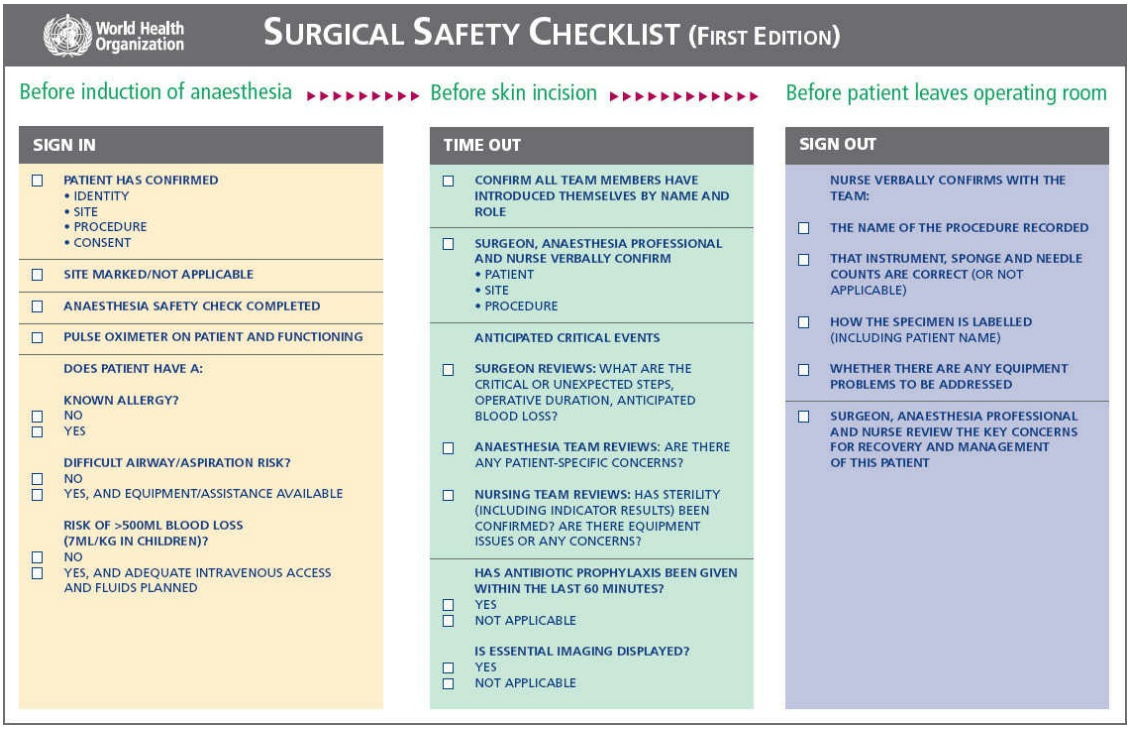

Figure 2.2. Perioperative checklist. (Reproduced with permission of the World Health Organization whqlibdoc.who.int/publications/2009/9789241598590_eng_Checklist.p 'Based on the WHO Surgical Safety Checklist, URL http://www.who.int/patientsafety/safesurgery/en © World Health Organization 2009 All rights reserved.)

PREVENTION OF DEEP VENOUS THROMBOSIS

Venous thromboembolic (VTE) complications are an all too common perioperative complication. Over half of surgical patients are at moderate risk or greater for VTE events in the postoperative period, and PE is still the most common preventable cause of hospital death. In a recent study of surgical inpatients in 358 hospitals in 32 different countries, although 64.4% of patients were found to be at-risk for VTE, only 58.5% of patients received appropriate VTE prophylaxis. The American College of Chest Physicians Evidence-based Clinical Practice Guidelines (8th edition) on the Prevention of Venous Thromboembolism have been used to establish local policies in many hospitals and serve as a benchmark for best practice in this area (Table 2.7). These guidelines stratify patients into low-, moderate-, and high-risk categories based principally on the nature of the surgical procedure—an approach that relies on overall group risk assessment as opposed to individual risk assessment. Although some investigators have attempted to develop individual patient risk assessment

models, to date, none of these models have been validated. In fact, it appears with few exceptions that the principal predictor of risk is the primary reason for the patient's hospitalization.

Mechanical thromboprophylaxis includes intermittent pneumatic compression devices, venous foot pumps, or graduated compression stockings. These modalities have been shown to reduce the risk of DVT in numerous patient populations. However, they have not been demonstrated to reduce the rate of PE or death, and compliance with their use is often poor in the postoperative period. Nonetheless, they are at low risk preventive measure that can be initiated prior to induction of anesthesia in most surgical patients. Those patients at moderate to high risk of VTE should be considered for pharmacologic prophylaxis starting preoperatively within 2 hours of surgery. If the patient is to receive an epidural catheter, local policies should be developed weighing the risk of VTE versus an epidural hematoma as detailed in the American Society of Regional Anesthesia and Pain Medicine (ASRA) evidence-based guideline on regional anesthesia in the patient receiving antithrombotic or thrombolytic therapy. In patients at moderate and greater risk of VTE perioperatively, pharmacologic prophylaxis should be started or resumed as soon as bleeding risk is acceptably low, often shortly postoperatively. This therapy should be continued through the inpatient course in most cases. High-risk general surgical patients, who have undergone major oncologic surgery should also be considered for extended pharmacologic prophylaxis for up to 28 days, even as an outpatient.

TABLE 2.7 Summary of the Level of Thromboembolism Risk and Recommended VTE Prophylaxis in Hospitalized Patients from the American College of Chest Physicians' Evidence-Based Clinical Practice Guideline on the Prevention of Venous Thromboembolism (8th Edition)

Risk Group	Group Characteristics	DVT Risk Without Prophylaxis	Suggested Prophylaxis
Low	Minor surgery in mobile patients	<10%	No specific prophylaxis; early, "aggressive" ambulation
Moderate	Most general surgery patients	10–40%	LMWH, LDUH BID or TID, fondaparinux
	Moderate VTE risk and high bleeding risk		Mechanical prophylaxis
High	Major trauma, SCI	40–80%	LMWH, fondaparinux, warfarin (INR 2–3)
High	High VTE risk and bleeding risk		Mechanical prophylaxis

Reprinted from Geerts WH, Bergqvist D, et al. Prevention of venous thromboembolism: American college of chest physicians evidence-based clinical practice guidelines (8th Ed.). *Chest* 2008; 133(6 Suppl):381S–453S; with permission from Elsevier.
LMWH, low-molecular-weight heparin; LDUH, low-dose unfractionated subcutaneous heparin; VTE, venous thromboembolism; SCI, spinal cord injury; INR, international normalized ratio.

POSTOPERATIVE ILEUS PREVENTION

Patients undergoing bowel resection are at risk for development of a postoperative ileus. The recent availability of peripherally acting mu-opioid receptor antagonists (PAM-OR) such as alvimopan (Entereg) allows surgeons to preemptively treat patients at risk for postoperative ileus. The first dose is given orally from 30 minutes to 5 hours prior to surgery and is then continued during the inpatient course. Use of this preventive strategy appears to result in earlier return of bowel function by multiple measures and shorter inpatient hospital length of stay. Use of chronic narcotics is a contraindication to use of this medication, and hospitals that wish to offer this medication must participate in the ENTEREG Access Support and Education (E.A.S.E.) Program.

WOUND INFECTION

The Surgical Care Improvement Project (SCIP) sought to reduce postoperative complications (primarily SSI and VTE) by 25% from 2006 to 2010. This broad-based initiative supported by numerous national organizations used a number of quality measures to achieve this goal by promoting evidence-based practice. SCIP quality measures specific to perioperative infectious complications include timely administration of prophylactic antibiotics (within 1 hour prior to the incision), use of appropriate antibiotics for SSI prophylaxis, timely discontinuation of

prophylactic antibiotics (within 24 hours of the end of the operation for noncardiac surgery or 48 hours for cardiac surgery), and appropriate hair removal (no hair removal or use of clippers). Additional SCIP measures relating to infectious complications include use of intraoperative temperature management, early removal of indwelling urinary catheters, and glycemic control on the morning after surgery in cardiac patients. Evidence of the impact of compliance with these measures is just now emerging—initial reports suggest that while global compliance may result in a small reduction in SSI, compliance on individual measures results in little or no improvement in SSI rates.

Recommended perioperative antimicrobial prophylaxis regimens are periodically updated in several publications including Treatment Guidelines from the Medical Letter (2016). In addition to timely antibiotic dosing described above, for long surgical procedures (>2 half-lives, e.g., 4 hours for cefazolin) and those with major blood loss (>1,500 mL), prophylactic antibiotics should be redosed intraoperatively. The role of several additional SSI reduction strategies have been clarified in the recent literature, including topical antisepsis, the role of mechanical bowel preparation for colorectal surgery, fascial closure techniques, and perioperative oxygen supplementation. A recent study comparing skin antisepsis with a chlorhexidine–alcohol preparation versus betadine in a range of clean contaminated surgical cases demonstrated significantly reduced SSI rates with the use of chlorhexidine–alcohol. However, there was no description of whether the betadine was allowed to dry, and a betadine–alcohol preparation was not included in the study. In addition, alcohol-containing solutions can increase the risk of OR fires if not allowed to dry completely and use of chlorhexidine-containing solutions is not recommended for preparation of exposed mucosal surfaces. Nonetheless, chlorhexidine–alcohol preparation appears to be a good choice for a range of surgical procedures.

Mechanical bowel preparation has been a mainstay of perioperative surgical practice aimed at reducing anastomotic and wound complications for decades. However, systematic study by multiple investigators and subsequent meta-analyses have not convincingly demonstrated any benefit to this practice with respect to either of these complications. In fact, there may be a slight reduction in anastomotic leakage when preoperative mechanical bowel preparation is not performed, although, as of 2003, mechanical bowel preparation was still widely practiced by colorectal

surgeons. Current guidelines leave the use of mechanical bowel preparation to the discretion of the surgeon for open low anterior resection and all laparoscopic colonic procedures where the site of the tumor may not be immediately obvious and where intraoperative colonoscopy may be required. In the 6th edition of mastery it was recommended that for all other colonic resections, preoperative mechanical bowel preparation can be safely eliminated. This has changed. Most authorities today use of oral antibiotics and mechanical bowel prep in elective colon and rectal surgery. The use of mechanical bowel prep **alone** before elective colorectal resection to prevent SSI is ineffective and should be abandoned. In contrast, oral antibiotics and mechanical bowel prep are associated with decreased risks of SSI and are not associated with increased risks of other adverse outcomes compared with no preparation. Prospective studies to determine the efficacy of oral antibiotics are warranted; in the interim, mechanical bowel prep and oral antibiotics should be used routinely before elective colorectal resection to prevent SSI. As a part of the first Perioperative Quality Initiative (POQI-1) workgroup meeting the American Society for Enhanced Recovery (ASER) and POQI recommends to reduce SSI there should be routine use of a combined isosmotic mechanical bowel preparation with oral antibiotics before elective colorectal surgery and that infection prevention strategies (also called bundles) be routinely implemented as part of colorectal early recovery programs. Fascial closure techniques for abdominal operations have also been evaluated over many years searching for the optimal method, which re-establishes abdominal domain while minimizing the risk of postoperative wound complications ranging from superficial wound infections to complete dehiscence with evisceration. Most studies evaluating fascial closure methods use incisional hernia as the primary endpoint, and until recently, SSI was thought to not be affected by the technique of fascial closure. However, a recent study suggests that when using a running absorbable suture technique, relatively small (5 to 8 mm), closely spaced fascial bites resulting in a suture to wound length ratio of ≥4:1 may reduce the incidence of SSI. Likewise, there is growing interest in using antibiotic-coated suture material that may also reduce the rate of wound infections.

Oxygen supplementation in the immediate postoperative period has also been evaluated by several randomized controlled trials, including the recently published Perioperative Oxygen Fraction (PROXI) study.

Although the original US-based study demonstrated increased infections in the oxygen-treated group and the PROXI study showed no benefit to 80% O_2 supplementation for 2 hours postoperatively, three other studies have shown a benefit to various types of O_2 supplementation. Consequently, pooled analysis of these results still falls in favor of perioperative hyperoxia although the likely benefit is relatively small.

INTRAOPERATIVE RESUSCITATION, VENTILATION, AND TEMPERATURE MANAGEMENT

Inappropriate management of intravenous fluid volumes during surgery can result in a number of postoperative complications ranging from pulmonary and renal dysfunction to anastomotic failure and sepsis. However, achieving the appropriate balance of adequate intravascular volume and oxygen delivery during the surgical procedure has proven difficult. This difficulty arises for many reasons, mostly because direct measures of intravascular volume and end-organ perfusion are not readily available while estimates of intraoperative bleeding and insensible losses are notoriously inaccurate. Furthermore, a standard nomenclature for the various fluid administration strategies is lacking, leading to imprecise and variable definitions from study to study. Recognizing these limitations, it has become clear that either too much or too little intravenous fluid administration of any type is harmful. In major abdominal operations where additional monitoring is justified, a “goal-directed” approach based on surrogates for intravascular volume measurement (e.g., esophageal Doppler measurement of changes in peak aortic stroke velocity or arterial waveform variability) while monitoring indicators of oxygen consumption such as $ScvO_2$ is appealing. Combining this approach with a relatively restrictive (but not too restrictive) background of intravenous fluid administration (e.g., 8 to 12 mL/kg/h) appears to balance the various risks of respiratory failure, renal insufficiency, wound infections, congestive heart failure, and postoperative arrhythmia.

Recent evidence suggests that intraoperative ventilator management significantly affects the postoperative course in patients undergoing major abdominal surgery. In one study, patients were randomized to lung-protective ventilation (defined as 6 to 8 mL/kg predicted body weight, PEEP of 6 to 10 cm H_2O, and intermittent recruitment maneuvers) or conventional ventilation (10 to 12 mL/kg predicted body weight, no PEEP,

and no recruitment maneuvers) intraoperatively. Those managed with lung protective ventilation had significantly fewer postoperative respiratory complications and a significantly shorter length of hospital stay. Surgeons should thus be in communication with the anesthesia team about ventilator management during major abdominal procedures. This approach likely has little downside in other long cases as well.

Finally, maintaining normothermia during anesthesia is critical to minimizing a number of intraoperative and postoperative complications. Coagulopathy and subsequent increased blood loss are the most widely reported complications related to mild intraoperative hypothermia (35° to 36°C). Other potential complications include increased surgical site infection, myocardial ischemia, prolonged anesthetic effect, and shivering. Using active surface warming measures (e.g., Bair Hugger, 3M Health Care, St. Paul, MN) effectively maintain normothermia and can significantly reduce these complications.

POSTOPERATIVE RISK MINIMIZATION

Relative to preoperative office visits and OR time, the postoperative course typically represents the time in which the patient has the most direct contact with the healthcare system. This poses both advantages and disadvantages—the patient is immediately at hand so that care can be directly monitored, although as the complexity of the system and the duration of contact increases, so too does the possibility of error. The overall goals of this phase of care should be to restore the patient to their preoperative functional level or to an even higher functional level as quickly as possible while minimizing iatrogenic events and nosocomial infections. Recent advances in postoperative care include the introduction of clinical care pathways, development of a systematic approach to care provider handoffs, recognition of the importance of early mobilization even in an intensive care unit (ICU) setting, refinement of our use of postoperative organ support devices and monitors, and clarifying the management goals for chronic illnesses (e.g., diabetes mellitus) in the postoperative time period.

CLINICAL PATHWAYS AND HANDOFFS

Clinical pathways are tools which incorporate evidence-based practice guidelines into a timeline, which is then tracked so that deviations can be monitored. Hospitals and clinical services may develop these pathways to

communicate expected postoperative events to patients and support staff while ensuring the consistent use of evidence-based practice for a given disease process. They are best applied to common surgical procedures within moderate- to high-volume centers. Examples include coronary artery bypass graft surgery, laparoscopic Roux-en-Y gastric bypass, and laparoscopic cholecystectomy. Use of these pathways has been shown to standardize patient care while reducing length of hospital stay and use of resources with improved patient satisfaction.

Multiple forces within healthcare from resident work hour restrictions to changing practice models have increased the frequency of patient handoffs between providers. This represents both a time when critical information can be reviewed and summarized and a time where lapses in communication can ultimately lead to poor patient care. Approaches to minimizing the latter include use of a standardized approach to handoffs such as the Situation–Background–Assessment–Recommendation model, specific training on how to perform a comprehensive patient handoff, and proctored simulation training on performing handoffs. There is emerging evidence that such efforts do indeed avoid lapses in patient care.

POSTOPERATIVE MONITORING AND MANAGEMENT OF CHRONIC MEDICAL ILLNESSES

Postoperatively, patients with chronic medical illnesses require monitoring of these illnesses and a plan for resuming their home medication regimen. Our general approach to postoperative medication management in patients with chronic medical conditions is included in Table 2.6. Regarding postoperative monitoring, selecting the appropriate level of monitoring usually depends on local hospital policies and unit expertise. In some cases, the type of surgery will dictate the level of care required such as craniotomy patients who need frequent neurologic examinations or vascular surgery patients who require frequent pulse checks in a specialized unit. Patients on a mechanical ventilator universally undergo postoperative care in an ICU for some period of time. For patients who do not require specialized checks or a ventilator, the patient's chronic illnesses and the extent of surgery will guide the need for postoperative monitoring. In recent years, enthusiasm for the use of pulmonary artery catheter for routine postoperative monitoring in certain patient populations has waned in the absence of any demonstrable benefit and significant risks of complications, including pulmonary artery embolism and rupture in

addition to incorrect management decisions made due to misinterpretation of available data. Other monitoring decisions are discussed below individually in the context of each specific organ system.

Patients with known cardiovascular disease should be considered for telemetry monitoring. Some recommend a postoperative 12-lead EKG and a single set of cardiac enzymes in these patients as well although this practice is not universal. These patients should have beta blockers and statins resumed as soon as feasible in the postoperative period. For patients with essential hypertension, target blood pressures are relaxed to avoid hypoperfusion with intervention warranted if systolic pressures trend around 180 mm Hg or diastolic pressures rise to 100 to 110 mm Hg. These patients should have pain and other causes of elevated blood pressure, such as urinary retention ruled out as well. Patients chronically on clonidine should have this resumed early in the postoperative course. Angiotensin-converting enzyme (ACE) inhibitors and angiotensin receptor blockers (ARBs) are generally resumed when intravascular volume shifts have subsided and renal function is shown to either remain at baseline or returns to baseline. Similarly, after major surgery, diuretics are resumed when the patient is ready to mobilize fluid or the patient is determined to have little risk for becoming excessively dehydrated.

Patients with chronic pulmonary conditions should be resumed on their home regimen of inhaled beta agonists and anticholinergics via metered dose inhaler or nebulizer either orally or in-line with the ventilator. Inhaled and systemic glucocorticoids for control of reactive airway disease should similarly be continued postoperatively. Leukotriene inhibitors (e.g., montelukast [Singulair]) can be resumed when the patient is taking oral medications. Theophylline should be discontinued perioperatively given its narrow therapeutic window.

Surgical intervention can result in poor glycemic control in diabetic patients or can unmask insulin resistance in patients not previously known to be diabetic. Much attention has been given to glycemic control in the perioperative period over the past decade. Initial enthusiasm for tight glycemic control has been tempered by the recognition of the significant deleterious effects of hypoglycemic events which, in some cases, negate the benefits of tight control. Current recommendations aim for “reasonable” control over normoglycemia in the postoperative period generally defined as most readings below 180 to 200 mg/dL. One benefit of this movement is that surgeons and surgical units are now much more

familiar with the management options for patients with hyperglycemia in both the fasted and the partially fasted state ranging from insulin infusions to resumption of subcutaneous insulin regimens. Patients on oral hypoglycemics can generally be managed with a short-acting insulin administered on a sliding scale until oral intake has reliably returned when most of these agents can be restarted. One exception is metformin, which should not be resumed until renal function is proven to be normal and there is little risk of significant intravascular volume shifts, which is generally proximate to the time of discharge.

Postoperative nutritional support is sometimes required if patients were severely malnourished preoperatively or if bowel function does not return within a week of surgery. Options include enteral and PN. If the patient is unable to take adequate calories due to critical illness but the gastrointestinal system is functional, enteral support is preferred. In cases where enteral support is not possible or only partial enteral support can be achieved, PN is used. When this strategy is chosen, care must be taken to meticulously care for the central venous catheter (CVC) to avoid bloodstream infections, glycemic control should be maintained in a "reasonable" range as described above often with insulin added to the PN mix, protein doses are initially estimated based on the patient's diagnosis and other chronic conditions and then adjusted to avoid azotemia, and fat is used sparingly in balancing the avoidance of fatty acid deficiency against the immunosuppressive effects of long-chain fatty acids and the concern that cholestasis and PN-associated hepatic injury may result from intravenous fat formulations currently available in the United States.

Patients with rheumatologic conditions should generally have their medications resumed with the initiation of a postoperative diet. Patients taking methotrexate should have normal renal function confirmed before this agent is restarted. Patients with a history of gouty arthropathy should have colchicine or any hypouricemic agents resumed when they can tolerate oral medications. If a gout flare occurs postoperatively in a patient who is an NPO, management options include intravenous ketorolac (Toradol), intra-articular steroid injections, or systemic steroids.

EARLY MOBILIZATION

Although bed rest was historically routinely prescribed after surgical interventions, the negative side effects of this practice ranging from pressure sores to osteopenia have been recognized for decades. As

discussed in the next section, loss of lean body mass is associated with a range of adverse outcomes in the postoperative period, and enforced bed rest has been shown to reduce lean body mass and total body strength in healthy adults. In fact, prolonged weakness is now recognized as one of the most durable and troublesome side effects of critical illness. Efforts to minimize this complication by increasing postoperative mobility have been advanced in a number of patient populations, including cardiac surgical patients, patients undergoing elective colon resection, and in those with respiratory failure on ventilator support. These interventions range from passive range of motion exercises performed by family members and bedside nurses to lengthy training sessions with physical therapists depending on the patient's clinical condition and tolerance. These interventions have been shown to reduce loss of lean body mass while accelerating postoperative recovery and reducing ventilator and ICU days.

Muscle Wasting in Surgical Disease

INTRODUCTION

Many surgical patients suffer from metabolic alterations related to both the disease state and the surgical trauma. Frequently, changes in lipid, carbohydrate, and protein metabolism occur in patients with surgical disease and all of these changes can significantly influence the perioperative care of the patients.

One of the most dramatic metabolic changes seen in surgical patients is altered protein metabolism in skeletal muscle, resulting in loss of muscle mass and strength. Proteins in skeletal muscle undergo constant synthesis and degradation (protein turnover). Under normal conditions, protein homeostasis is maintained by equal rates of synthesis and degradation. When this balance is perturbed, loss of muscle mass may occur. Muscle wasting can be caused by reduced protein synthesis, increased protein degradation, or a combination of these changes; the relative role of these changes probably differs between different catabolic conditions. Different proteins have different rates of turnover (short- and long-lived proteins) and may be regulated individually. In order for increased protein degradation to result in muscle wasting, the degradation needs to affect a large pool of cellular proteins. Contractile proteins (the myofibrillar proteins actin and myosin) make up a large portion of muscle proteins and in various muscle wasting conditions, the degradation of myofibrillar

proteins is increased, at least in part explaining why these conditions result in loss of muscle mass and strength.

MUSCLE WASTING IN SURGICAL PATIENTS

Muscle wasting occurs in a number of different disease states commonly cared for by surgeons, including cancer, severe injury (in particular head injury and severe burn injury), and sepsis. Other conditions in which loss of muscle mass occurs include uremia, diabetes, heart failure, and AIDS. Muscle atrophy in elderly patients (sarcopenia) may affect quality of life by reducing the capacity to perform daily physical activities and by increasing the risk of falls and fractures. Sarcopenia may also increase the risk of postoperative complications in elderly patients undergoing surgery.

Although some of the conditions associated with loss of muscle mass (such as sepsis) are involved in muscle wasting and weakness seen in patients in the ICU, critically ill patients cared for in the ICU have their own set of characteristics with regard to muscle atrophy. Thus, in addition to the primary disease, a number of ICU-associated conditions promote muscle wasting and weakness. Such conditions include reduced physical activity, prolonged bed rest, side effects of treatment with various drugs (in particular glucocorticoids and neuromuscular blocking agents), sedation, mechanical ventilation, and altered nutritional status. The term “intensive care unit-acquired weakness” (ICUAW) has been used to illustrate the fact that certain aspects of muscle weakness are unique for patients in the ICU. Recent aspects of muscle wasting in critical care have been published recently. Because sepsis is a common condition necessitating care in the ICU and is an important cause of muscle wasting, a substantial amount of recent information with regard to cellular and molecular mechanisms is related to sepsis-induced muscle wasting. Although different mechanisms may be involved in the loss of muscle mass in different disease states, there is evidence that muscle wasting shares many (albeit not all) mechanisms regardless of underlying cause.

CLINICAL CONSEQUENCES OF MUSCLE WASTING

At least three different aspects of muscle wasting are important in the surgical care. First, patients may present with evidence of muscle wasting having already occurred, including patients with advanced cancer (Fig. 2.3) or elderly patients with sarcopenia. Second, patients may present with a condition that typically results in loss of muscle mass, such as sepsis and

severe injury, in particular, head and burn injury. Third, patients may need care in the ICU, a situation that in itself commonly aggravates muscle wasting (Fig. 2.4).

Weight loss in cancer patients reflects not only loss of muscle mass, but also depletion of adipose tissue. The loss of body weight in these patients, however, closely reflects the loss of muscle tissue and strength. The pronounced loss of muscle in cancer patients is an important factor why these patients have reduced mobility and quality of life. In addition, impaired response to chemo- and radiotherapy has been reported in cancer patients with pronounced muscle cachexia. Studies suggest that in patients with nonresectable pancreatic cancer, death occurs with 25% to 30% loss of body weight. Pneumonia and other pulmonary complications, at least in part reflecting wasting of respiratory muscles, are common causes of death in patients with advanced cancer.



Figure 2.3. Patients with advanced cancer frequently develop severe muscle wasting and weakness. The patient shown in this figure was a 59-year-old man with metastasizing gastric cancer who had lost approximately 35% of his normal body weight during his illness. (Picture kindly provided by Dr. Maurizio Muscaritoli, Department of Clinical Medicine, Sapienza-University

of Rome, Rome, Italy.)

The most significant consequences of muscle wasting and weakness during critical illness cared for in the ICU include difficulty to wean the patient from ventilatory support, recurrence of respiratory failure after extubation, and inability to ambulate due to profound weakness (even quadriplegia). These manifestations reflect the fact that the wasting can affect both respiratory (diaphragm and intercostal muscles) and extremity muscles. Although loss of muscle mass is probably the most important cause of muscle weakness in the ICU, the weakness can also be caused by peripheral neuropathy, initially described in the setting of sepsis and multiorgan failure. Indeed, critical illness myopathy (CIM) and critical illness polyneuropathy (CIP) are commonly described as two separate entities although the muscle weakness can also be caused by a combination of CIM and CIP, so-called critical illness neuromyopathy.



Figure 2.4. Patients with critical illness cared for in an intensive care unit (ICU) are at risk of developing muscle wasting and weakness. Mechanical ventilatory support adds to the risk of muscle wasting. Because muscle wasting and weakness increase the need for ventilatory support, a vicious circle is created.

Importantly, mechanical ventilatory support in itself results in wasting and weakness of the diaphragm and other respiratory muscles. Studies suggest that muscle weakness occurs early during mechanical ventilation with >50% of ICU patients showing evidence of neuromuscular abnormalities after 5 to 7 days of mechanical ventilation. Septic shock was a predictor of respiratory muscle weakness in some reports. One consequence of respiratory muscle weakness is difficulty to wean the patient from ventilatory support resulting in prolonged need for mechanical ventilation thus creating a vicious circle. Another vicious circle is created by weakness of extremity muscles. Thus, weakness of peripheral muscles prevents ambulation resulting in prolonged bed rest. Bed rest in itself promotes loss of muscle mass and there is evidence that this effect of inactivity is potentiated by underlying disease. Bed rest is a potent mechanism of muscle wasting and a rapid and profound loss of muscle mass has been documented even in healthy volunteers during bed rest with the loss of 1% to 1.5% of quadriceps strength per day.

Muscle weakness in patients cared for in the ICU is commonly long-lasting with weakness significant enough to cause problems walking being present up to 5 years after the stay in the ICU. The persistent weakness clearly reduce the quality of life in these patients, sometimes manifesting itself as difficulty to walk and inability to perform other seemingly trivial tasks. In some studies, long-term weakness and important restrictions in daily functioning were reported in >50% of survivors of critical illness with restricted ability to walk being the most commonly impaired physical quality of life. It is obvious that loss of muscle mass and weakness acquired during critical illness have long-lasting effects in patients surviving ICU care with important personal and socioeconomic consequences.

ACUTE QUADRIPLEGIC MYOPATHY

A special condition sometimes seen in patients in the ICU is acute quadriplegic myopathy. This condition is caused by a specific decrease, or even an almost complete loss, of thick filament muscle proteins (myosin) and is characterized by a sometimes dramatic clinical picture of complete paralysis. The quadriplegia is typically symmetric and affects both proximal and distal muscle groups, whereas muscles innervated by the cranial nerves are not affected. The prognosis is usually good if the patients survive the underlying disease but recovery of muscle strength

may require several months. Although the mechanisms of acute quadriplegic myopathy are not fully understood at present, there is evidence that the synthesis of myosin is blocked at the transcriptional level concomitant with stimulated degradation of the protein. A number of risk factors for development of acute quadriplegic myopathy have been identified and include treatment with corticosteroids and neuromuscular blocking agents (perhaps the most important risk factors), mechanical ventilation, immobilization, and probably sepsis as well.

DIAGNOSIS OF MUSCLE WASTING

The diagnosis of muscle wasting and weakness is commonly obvious from bedside clinical observations. Patients will also experience and complain of weakness when trying to ambulate or use upper extremity muscles. Respiratory muscle weakness typically manifests itself as difficulty weaning the patient from the ventilator or respiratory failure after extubation. Objective measures of muscle atrophy can be obtained from various imaging tests such as CT, MRI, or ultrasound. More sophisticated methods are also available and can be used if more objective assessment is needed, such as in the research setting. Such methods include objective measurements of muscle strength, electrophysiologic tests, and muscle biopsy. Various methods to assess respiratory muscle strength and function have been described, including magnetic phrenic nerve stimulation.

When muscle biopsy is performed, the histopathologic picture is typically characterized by reduced fiber size (atrophy) and changes in fiber type. Electron microscopy may reveal sarcolemmal changes, disruption of the sarcomere, disintegration of Z-disks, and morphologic changes of mitochondria (including swelling and loss of membrane structures) and loss of mitochondria. Of note, reduced muscle-specific force generation may exist in the absence of atrophy although in most cases of muscle weakness, the loss of muscle strength is probably associated with morphologic abnormalities in skeletal muscle.

MECHANISMS OF MUSCLE WASTING

Loss of muscle mass during various catabolic conditions is regulated at multiple levels as illustrated in Figure 2.5. Circulating factors (including proinflammatory cytokines and glucocorticoids) as well as regulators that act in an autocrine or a paracrine fashion (e.g., myostatin) participate in the regulation of muscle mass in different conditions characterized by muscle

wasting. When the balance between anabolic factors, for example, insulin and insulin-like growth factor 1 (IGF-1), and catabolic factors, for example, TNFα, corticosteroids, and possibly myostatin, is perturbed, muscle mass may be lost. Although both reduced protein synthesis and increased protein degradation may contribute to muscle wasting, there is evidence that in sepsis, severe injury, and cancer, the loss of muscle mass mainly reflects stimulated protein breakdown.

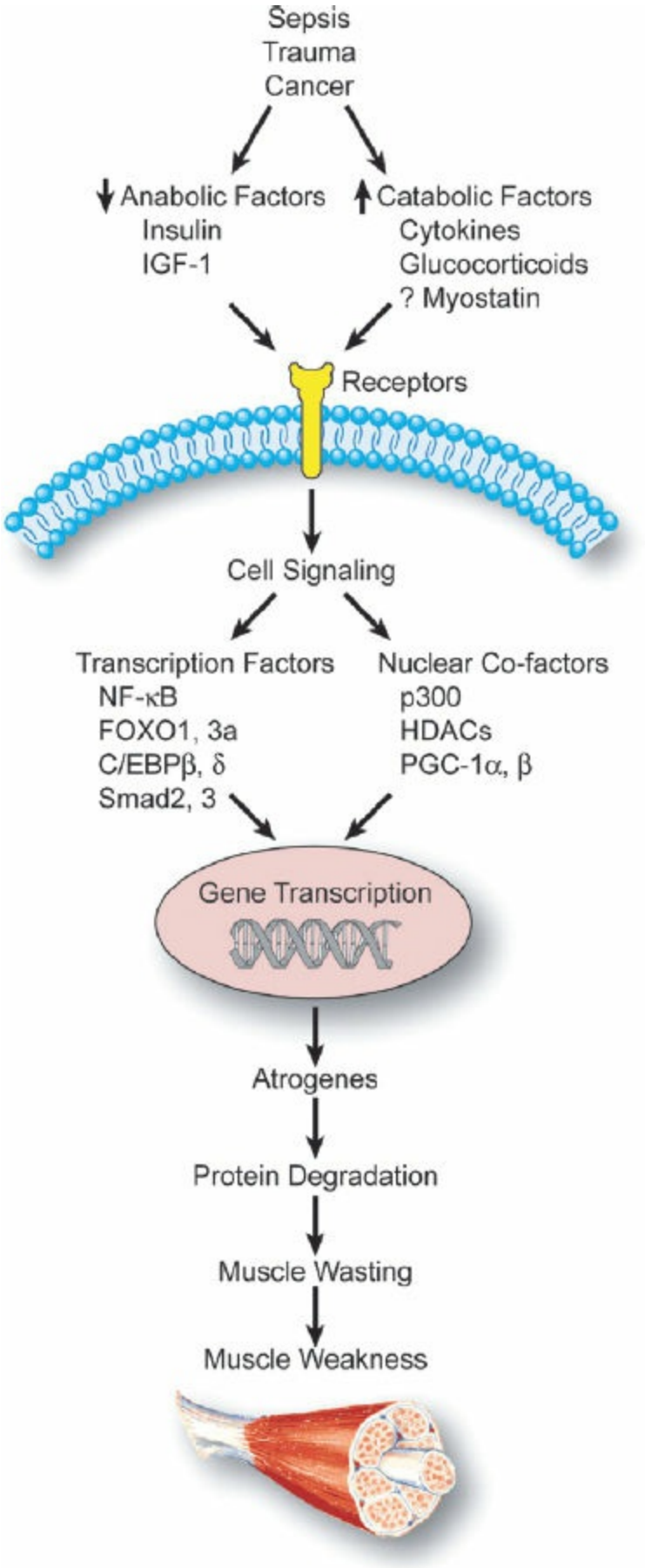

Figure 2.5. Muscle wasting in various catabolic conditions,

including cancer, sepsis, and severe injury, is regulated at multiple levels. Anabolic factors including insulin and IGF-I are reduced, and catabolic factors including cytokines and glucocorticoids are increased. These changes result in altered cell signaling and expression and activity of transcription factors and nuclear cofactors that regulated genes involved in muscle proteolysis. Loss of muscle mass, muscle weakness, and fatigue are the ultimate results of the molecular events set in motion by the catabolic conditions. (Reproduced by permission from Aversa et al., Critical Reviews in Laboratory and Clinical Investigations.)

Although initial reports of pronounced muscle hypertrophy in myostatin-deficient cattle are strong indicators that myostatin is a potent-negative regulator of muscle mass, the role of myostatin in muscle wasting during various catabolic conditions is somewhat controversial. Several reports in the literature, including a recent study in septic rats, suggest that myostatin expression and activity are not universally upregulated during muscle wasting conditions (but may actually even be downregulated). This is important to keep in mind when interpreting results from studies in which inhibition of myostatin was tested in the prevention and treatment of muscle wasting.

PROTEOLYTIC MECHANISMS INVOLVED IN MUSCLE BREAKDOWN

Intracellular proteins are degraded by multiple proteolytic mechanisms. It is beyond the scope of this chapter to give a detailed description of the different proteolytic pathways participating in the breakdown of intracellular proteins and they will be discussed only briefly here. More extensive reviews of muscle proteolysis during muscle wasting conditions have been provided elsewhere. Typically, three major proteolytic pathways account for the degradation of cellular proteins: lysosomal, calcium-dependent, and ubiquitin-proteasome-dependent pathways. Lysosomal degradation of proteins is regulated by intralysosomal enzymes (cathepsins) in an acidic environment. Early studies performed mainly in hepatocytes provided evidence that components of the cytoplasm can be taken up in so-called autophagosomes that are subsequently taken up and degraded by lysosomes. Importantly, recent reports suggest that autophagic/lysosomal degradation plays an essential role in the degradation of muscle proteins during various conditions characterized by

muscle wasting.

Among calcium-dependent mechanisms, calpain-regulated protein degradation plays an important role. Previous studies suggest that calpain-dependent mechanisms may be involved in the initial step of myofibrillar protein disassembly and cleavage, at least in muscle wasting caused by sepsis. In other studies, evidence was found that increased calpain activity in catabolic muscle is mainly caused by decreased activity of the endogenous calpain inhibitor calpastatin. It should be noted that the role of calpains in muscle wasting is somewhat controversial. Other studies suggest that caspase-3 participates in the early release of myofilaments from the sarcomere during muscle wasting caused by uremia. It is possible that the roles of calpains and caspases vary in different muscle wasting conditions.

Ubiquitin-proteasome-dependent degradation is probably the proteolytic mechanism that has attracted most interest in the field of muscle wasting during the last 15 to 20 years. In this mechanism, proteins are degraded inside the multicatalytic 26S proteasome after having been targeted for the proteasome by conjugation of multiple ubiquitin molecules. The ubiquitination of protein substrates is regulated by multiple enzymes, including the ubiquitin activating enzyme (E1), ubiquitin-conjugating enzymes (E2s), and ubiquitin ligases (E3s). The length of the ubiquitin chain conjugated to the protein destined for the proteasome can be edited by deconjugating enzymes that also play an important role for the proteasome-dependent proteolysis. Among the factors regulating the ubiquitination of proteins and subsequent degradation by the proteasome, ubiquitin ligases are particularly important because they account for substrate specificity, thereby deciding which protein(s) will be degraded. The muscle-specific ubiquitin ligases atrogin-1 (also called MAFbx) and MuRF1 play important roles in muscle wasting caused by a number of different catabolic conditions, including sepsis, severe injury, and cancer. Increased expression of atrogin-1 and MuRF1 is commonly used as a “molecular marker” of muscle wasting (although this is probably an oversimplification because there are multiple examples of conditions where there is not a close correlation between changes in the expression of atrogin-1 and MuRF1 and changes in protein breakdown rates).

Another recently described ubiquitin ligase, TRIM32, plays an important role in muscle wasting by targeting the Z-bands of the sarcomere and other proteins in the cytoskeletal network contributing to

the release and breakdown of myofibrillar proteins (Fig. 2.6).

Although most early information regarding the role of the ubiquitin–proteasome pathway in muscle wasting was generated in experimental animals with different models of sepsis, burn injury, cancer, and uremia, there is evidence that similar mechanisms are involved in patients. For example, it is almost 15 years ago that the gene expression of ubiquitin was reported to be upregulated in skeletal muscle from patients with sepsis and several subsequent reports have confirmed that the ubiquitin–proteasome pathway is activated in patients with sepsis and other catabolic conditions as well, including cancer and burn injury.

TRANSCRIPTION FACTORS AND MUSCLE WASTING

Because the expression of atrogin-1 and MuRF1 as well as other molecules involved in the regulation of muscle mass, such as molecules regulating the expression and activity of the autophagosome and the lysosomal enzyme cathepsin L, is upregulated at the transcriptional level in atrophying muscle, it is not surprising that a great deal of attention has been paid to the potential role of transcription factors and nuclear cofactors involved in the regulation of gene transcription. Genes that are upregulated in muscle wasting conditions are commonly referred to as “atrogenes.” Among transcription factors that are involved in the regulation of muscle mass, early studies provided evidence that NF-κB may play an important role, at least in muscle wasting associated with sepsis. In more recent studies, muscle-specific genetic manipulation of the expression and activity of NF-κB-regulated muscle mass at least in part by influencing the expression of MuRF1 (but not atrogin-1) and the rate of proteasome-dependent protein degradation. Other reports have also provided support for a role of NF-κB in muscle wasting.

Forkhead Box O 1 (FOXO1) and FOXO3a are additional transcription factors that participate in the expression of muscle wasting-related genes, including atrogin-1 and MuRF1, and were found in recent studies to play an important role in the development of muscle atrophy. In recent experiments, evidence was found that FOXO1 may be particularly important for muscle wasting in sepsis and other critical illness. Interestingly, recent studies suggest that FOXO transcription factors regulate the transcription of autophagy-related genes providing further support for the important role of FOXOs in muscle wasting.

An additional group of transcription factors that are involved in muscle

wasting are members of the family of C/EBP transcription factors, in particular C/EBPβ and δ. In recent experiments, the expression as well as DNA binding activity and transcriptional activity of these transcription factors were increased in skeletal muscle during sepsis and after treatment with glucocorticoids. In addition, genetic evidence suggests that C/EBPβ is involved in glucocorticoid-induced atrophy of skeletal muscle cells.

Of note, the activity of transcription factors can be regulated at different levels. First, the abundance of the transcription factors may be increased in catabolic muscle as found for FOXO transcription factors and C/EBPβ and δ. Second, the transcription factors may form complexes with other transcription factors or with nuclear cofactors. Finally, and perhaps most important, the activity of transcription factors can be regulated by posttranslational modifications, including phosphorylation, ubiquitination, and acetylation.

Additional transcription factors involved in the regulation of muscle mass include SMAD2 and SMAD3 mediating myostatin- and activinA-induced wasting.

Taken together, multiple studies suggest that several transcription factors may be involved in the regulation of muscle mass during various muscle wasting conditions. Most of these observations have been made in animal models of muscle atrophy and in cultured muscle cells and it will be important in future studies to determine whether these transcription factors are involved in muscle wasting in critically ill patients as well.

NUCLEAR COFACTORS AND MUSCLE WASTING

In addition to being regulated by transcription factors, gene transcription is also influenced by various nuclear cofactors (coactivator or repressor proteins) and proteins in the transcriptional machinery. Although transcription factors bind to DNA in a sequence-specific fashion, they typically lack enzymatic activities required for modification of chromatin, unwinding of DNA, and recruitment of RNA polymerase. In contrast, several nuclear cofactors exert enzymatic activities and influence gene transcription by modifying chromatin or by changing the structure and function of transcription factors or other nuclear cofactors. The function of some of the nuclear cofactors is also to serve as docking sites for other proteins that are recruited to transcription factors thereby influencing gene transcription.

In recent studies, the nuclear cofactor p300 was found to regulate

glucocorticoid-induced atrophy of cultured muscle cells and the role of p300 may at least in part reflect its interaction with muscle wasting-related transcription factors. Because an important function of p300 is to exert histone acetyl transferase (HAT) activity, the observations suggest that hyperacetylation may be involved in muscle wasting. This hypothesis was supported by the observation that the expression and activity of the histone deacetylases SIRT1, HDAC3, and HDAC6 are reduced in skeletal muscle during glucocorticoid- and sepsis-induced muscle wasting. In other experiments, treatment of cultured muscle cells or experimental animals with the HDAC inhibitor trichostatin A (TSA) resulted in increased expression of the ubiquitin ligase atrogin-1 and stimulated protein breakdown. Taken together, the observations discussed here suggest that hyperacetylation of transcription factors and probably other cellular proteins as well may be involved in muscle wasting. Indeed, acetylation is evolving as an important posttranslational modification that may even rival other posttranslational modifications, such as phosphorylation, in the regulation of many cellular metabolic events.

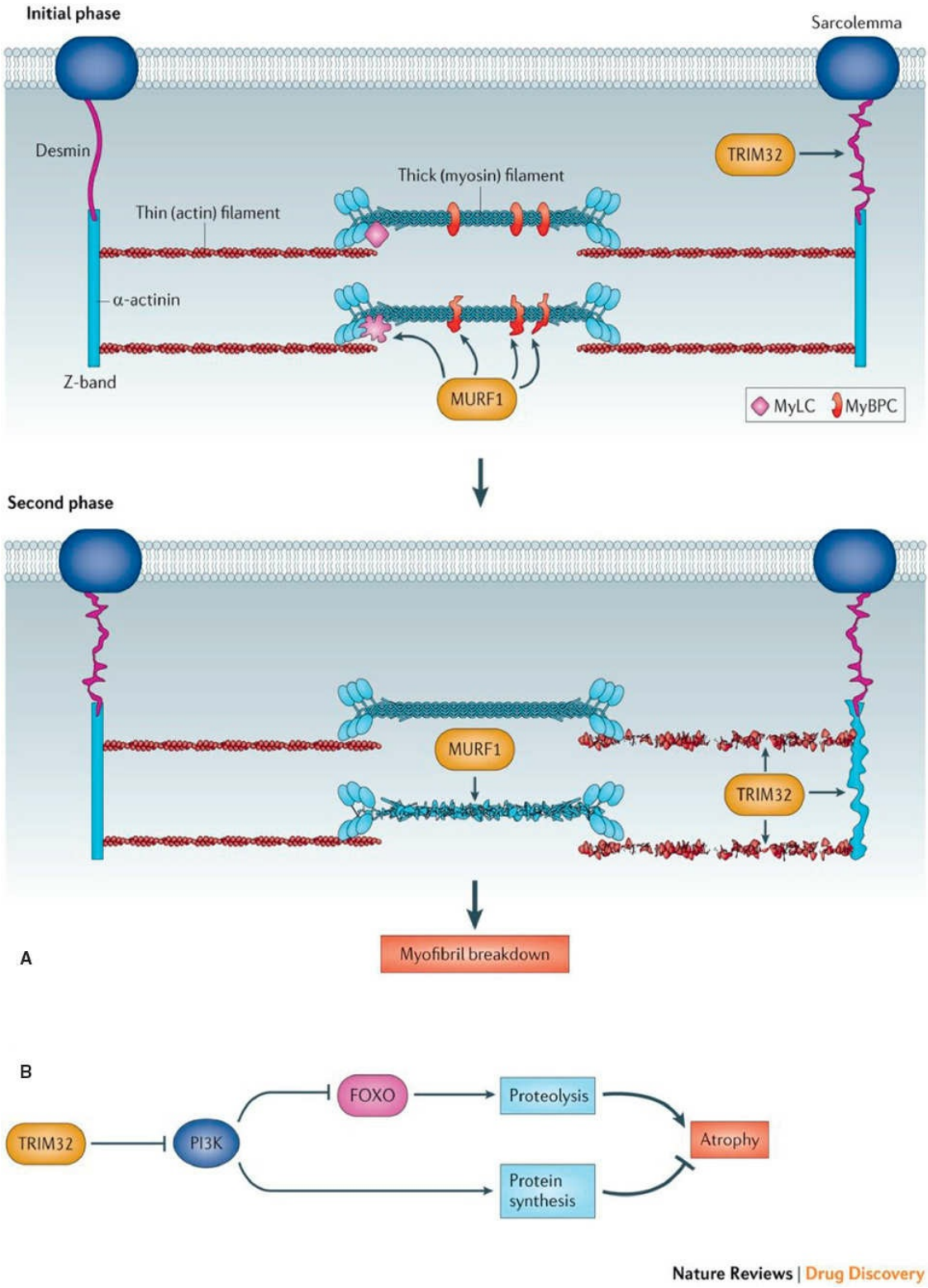

Figure 2.6. Mechanisms of myofibril breakdown and wasting. **A:** Loss of myofibrils during atrophy is primarily mediated by two ubiquitin ligases: MURF1 and TRIM32. MURF1 catalyzes the loss of thick filament stabilizing-proteins and then of myosin itself. Loss of the thin myofilament requires TRIM32, which also catalyzes the destruction of the Z-band and the desmin cytoskeleton. **B:** In addition to its role in degradation of myofibrils

and the cytoskeleton, TRIM32 also reduces PI3K-AKT signaling, which results in decreased protein synthesis and increased proteolysis. (Reprinted by permission from MacMillan Publishers Ltd: from Cohen S, Nathan JA, Goldberg AL, et al. Muscle wasting in disease: molecular mechanisms and promising therapies. *Nat Rev Drug Discov* 2015;14(1):58–74.)

Another group of nuclear cofactors that has been implicated in muscle wasting recently are members of the PPARγ co-activator-1 (PGC-1) family. There is evidence that PGC-1α and β are repressors of genes involved in muscle wasting, including some of the genes in the ubiquitin–proteasome pathway. Studies suggest that reduced expression and activity of both PGC-1α and β may induce muscle atrophy, at least in part secondary to increased expression of the ubiquitin-ligases atrogin-1 and MuRF1. In recent experiments, the expression of PGC-1α and β was substantially downregulated in skeletal muscle during sepsis in rats concomitant with increased expression of atrogin-1 and MuRF1. In the same study, overexpressing PGC-1β in cultured muscle cells reduced the expression of atrogin-1 and MuRF1, providing further support to the concept that PGC-1 cofactor may regulate muscle mass at least in part by regulating the expression of atrogin-1 and MuRF1.

Similar to transcription factors, most of the evidence suggesting a role of p300, HDACs, and PGC-1 cofactors has been generated in animal models of muscle wasting or in cultured muscle cells and it remains to be determined whether similar mechanisms are involved in patients with muscle wasting. The observations are important, however, because they suggest that it may be possible in the future to prevent or treat muscle wasting by targeting small molecules based on an increased understanding of the molecular regulation of processes involved in muscle wasting.

PREVENTION AND TREATMENT OF MUSCLE WASTING

In some patients with muscle wasting, correcting the underlying cause of the catabolic response will ameliorate the metabolic changes in skeletal muscle. There are situations, however, when the cause of muscle cachexia cannot always be corrected or is difficult to treat. For example, patients with advanced cancer cannot always be cured from their disease and in those patients, the accompanying muscle wasting may become a

significant factor reducing quality of life and may even contribute to death. Patients with severe and protracted sepsis who develop multiple organ failure and require long stay in the ICU, frequently on the ventilator, are another group that may benefit from more specific treatment of the catabolic response in skeletal muscle. Patients with burn injury develop severe muscle wasting even when the burn is managed by experts. AIDS is an additional example of a condition that cannot always be treated successfully and where effective treatment of muscle wasting would greatly benefit the patients. Finally, the growing population of elderly people makes the prevention and treatment of sarcopenia increasingly important.

Different strategies employed to prevent or treat muscle wasting are summarized in Table 2.8. Some of these strategies have been tested in patients, whereas other modalities are still experimental (or even speculative). Although mechanisms underlying loss of muscle mass may differ between various muscle wasting conditions, there are also multiple similarities that make strategies to prevent and treat muscle weakness applicable in several conditions.

TABLE 2.8 Strategies for Prevention and Treatment of Muscle Wasting and Weakness

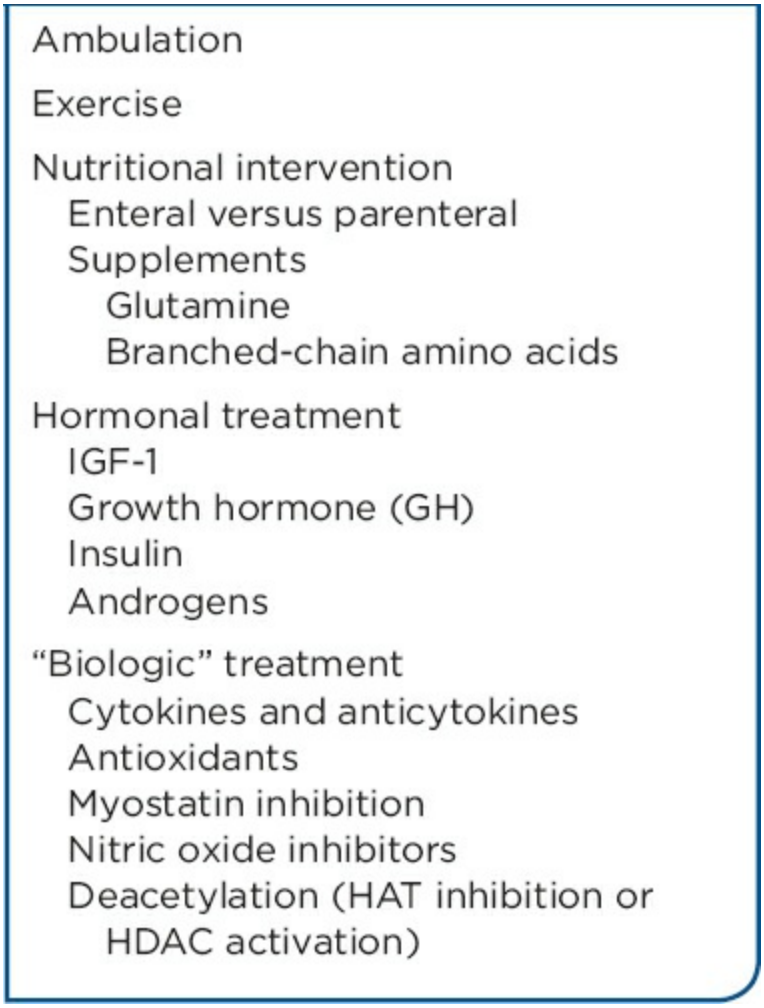

AMBULATION AND EXERCISE

Because bed rest and inactivity are potent mechanisms of muscle atrophy, it is not surprising that attempts have been made to prevent muscle wasting by early ambulation and exercise. By nature, of course, patients in the ICU, frequently sedated and on a mechanical ventilator, cannot always ambulate or exercise. Even in patients without significant contraindications for ambulation, however, that aspect of the care is not always prioritized. One reason for this may be lack of resources (it requires the involvement of physical therapists and nursing personnel to ambulate the patients) but probably also concerns for safety to mobilize critically ill patients with complex surgical wounds, intravenous and intra-arterial lines, feeding tubes, and still on mechanical ventilator. Interestingly, several recent studies, including randomized controlled trials, have documented the safety and feasibility of early ambulation and mobility in the ICU, even in patients requiring mechanical ventilatory support, and have shown improved neuromuscular and physical function

by early mobilization of patients in the ICU. Studies suggest that early mobilization results in decreased ICU and total hospital length of stay and decreased duration of ventilatory support.

The involvement of physical therapists and active and passive exercises are additional important strategies that should be employed to prevent and treat muscle wasting and weakness. In general, resistance (strength) training is considered the most effective exercise for slowing the rate of loss of muscle mass and to improve muscle strength (as opposed to aerobic exercise training, which may be more beneficial from a cardiovascular standpoint). Even passive exercise of extremity muscles bedside in patients who are sedated may be beneficial and slow the process of muscle atrophy.

NUTRITIONAL INTERVENTION

The role of nutritional support in the prevention and treatment of muscle wasting is less clear. Although it is well documented that starvation and malnutrition will result in loss of muscle mass, the effects of nutritional intervention in critically ill patients with regard to muscle wasting have been disappointing, at least in patients with sepsis. Several previous reports suggested beneficial effects of early nutritional support, in particular enteral nutritional support, as they relate to overall clinical outcome, length of stay in the ICU, survival rates and infectious complications, but there is little evidence that nutritional intervention prevents of reverses muscle wasting.

Based on early studies in experimental animals, there has been a great deal of interest in the field of nutritional supplements to prevent the loss of muscle mass. In particular, supplementation with glutamine and branched-chain amino acids (especially leucine) has been used in this context. Recent studies suggest that the leucine metabolite β-hydroxy-β-methylbutyrate may be able to inhibit loss of muscle mass in various catabolic conditions, including cancer, but its role in the treatment of critically ill patients in the ICU remains to be defined. Other nutritional supplements that have been used in critical care include arginine, ω-3 polyunsaturated fatty acids, and RNA. Overall, however, the role of nutritional intervention, including supplementation with glutamine, branched-chain amino acids, and other substances, in the prevention and treatment of muscle wasting in critical illness, remains unclear.

HORMONAL TREATMENT

Hormones that have been used to reduce the catabolic response in skeletal muscle include growth hormone (GH) and IGF-1. These hormones exert an anabolic effect by stimulating protein synthesis and inhibiting protein breakdown in skeletal muscle. Although there was an early enthusiasm for treatment of critically ill patients with GH, some of that enthusiasm was stifled by reports of increased mortality in ICU patients treated with GH (possibly caused by suboptimal control of hyperglycemia). Subsequent studies in burn patients suggest, however, that treatment with GH is safe (provided blood glucose levels are monitored carefully) and may reduce the catabolic response in skeletal muscle.

In addition to GH, there is evidence that IGF-1 may exert muscle-sparing effects in critical illness. For example, there is evidence that treatment of burn victims with IGF-1 preserves muscle mass and improves clinical outcome. In animal experiments, protein synthesis in muscle from septic rats was stimulated by IGF-1, whereas protein breakdown was not influenced by the hormone, even at high concentrations, suggesting that muscle proteolysis becomes resistant to the effects of IGF-1 during sepsis. Because, at the same time, the regulation of protein synthesis by IGF-1 was unaffected by sepsis, it is likely that the sepsis-induced resistance of protein breakdown to IGF-1 reflects a postreceptor event. Interestingly, in other studies, treatment of burned rats with IGF-1 stimulated protein synthesis and inhibited protein breakdown without evidence of resistance to the hormone. Thus, muscle wasting in different catabolic conditions may respond differently to IGF-1, probably at least in part reflecting different mechanisms involved in muscle wasting in different disease states.

The anabolic effects of IGF-1 at least in part reflect stimulated PI3K/Akt signaling with downstream phosphorylation and activation of mTOR-regulated protein synthesis. It is possible that PI3K/Akt signaling is involved in the inhibition of muscle proteolysis as well. For example, PI3K/Akt-regulated phosphorylation of FOXO transcription factors results in inactivation of FOXOs and downregulated expression of atrogin-1 and MuRF1. The enzyme glycogen synthase-3β (GSK-3β) is an additional downstream target of the PI3K/Akt signaling pathway; increased phosphorylation of GSK-3β results in its inactivation, an important effect considering that activation of GSK-3β is probably involved in burn- and sepsis-induced muscle wasting.

The influence of insulin on muscle protein synthesis and degradation is

similar to that caused by IGF-1. In fact, some of the signaling of IGF-1 and insulin may be caused by a nonselective binding to and activation of the insulin and IGF-1 receptors, which in part explains why the metabolic effects of the hormones are similar. Interestingly, we reported previously that septic muscle becomes resistant to insulin with regard to regulation of protein degradation but retains its sensitivity to insulin's regulatory effects on protein synthesis (identical to the response to IGF-1 in septic muscle). Although the mechanisms of sepsis-induced resistance to IGF-1 and insulin in skeletal muscle are not fully understood, cytokine- and glucocorticoid-induced alterations of receptor-associated docking proteins may be involved. Interestingly, studies suggest that ghrelin may have muscle-sparing effects, possibly secondary to stimulation of the GH/IGF-1 axis.

Recent studies suggest that tight glucose control by the administration of insulin improves survival of patients in the ICU. In addition to improved survival, other effects, including reduced infectious complications and length of stay in the ICU have also been ascribed to tight glucose control protocols. It has also been suggested that tight glucose control may inhibit ICU-acquired muscle weakness. It should be noted that although the initial reports on the beneficial effects of tight glucose control were received with great enthusiasm and resulted in changes in the care of critically ill patients, recent studies have challenged the initial reports finding no evidence of beneficial effects of this protocol. Some studies have even reported increased mortality in ICU patients on a tight glucose control protocol, at least in some cases reflecting the development of significant hypoglycemia. The potential benefits of tight glucose control in the ICU with regard to prevention of muscle wasting and weakness need to be tested in randomized controlled trials.

There is solid evidence in the literature that androgens, such as testosterone, regulate muscle mass in humans. Although the use of testosterone by athletes has attracted a great deal of attention (and controversy), testosterone has also been used in certain patient groups to improve muscle mass and function, such as older men with normal or low testosterone levels and HIV-infected men with low serum testosterone. The best and most extensive support for a beneficial effect of testosterone, as well as the anabolic steroid oxandrolone, with regard to muscle wasting in critical illness has been generated in patients with severe burn injury. In several of those studies both short- and long-term beneficial effects were

reported with regard to muscle mass, strength, and function.

Selective androgen receptor modulators (SARMs) are a relatively new class of compounds that have been suggested to be beneficial for the treatment and prevention of muscle wasting without the potential cardiovascular and prostate cancer risks often associated with androgen therapy. Although experiments in rats suggest that some of the SARMs exhibit anabolic effects in skeletal muscle, the effects of these drugs on muscle wasting in ICU patients are not known.

BIOLOGIC TREATMENT

Most “biologic” treatments are experimental and await clinical trials. Some of the potential treatments discussed here can even be considered speculative. In general, though, the evolving understanding of the molecular mechanisms involved in muscle wasting over the last several decades has identified potential drug targets for specific interventions aimed at blocking or activating certain molecules depending on their roles in the loss of muscle mass.

The biologic treatment that has probably attracted most interest and that may be closest to definitive clinical trials is the one aimed at inhibiting myostatin, for example, with myostatin antibodies. The rationale for this treatment is previous observations that myostatin is a strong negative regulator of muscle growth and development. Myostatin is a member of the transforming growth factor β family that is produced in skeletal muscle and probably exerts most of its effects in muscle by autocrine and paracrine mechanisms. The potential role of myostatin in muscle wasting has been supported by studies in which the expression of myostatin was increased in skeletal muscle during various catabolic conditions. It should be noted, however, that the role of myostatin may vary in different catabolic conditions since its expression is not universally upregulated in all muscle wasting conditions. For example, in recent experiments, myostatin expression was not increased but was actually significantly decreased in skeletal muscle during sepsis in rats. Unchanged or even decreased expression of myostatin has been reported in other catabolic conditions as well. Thus, antimyostatin treatment may not be beneficial in all conditions characterized by loss of muscle mass.

Other biologic treatments that have been reported in animal experiments to have beneficial effects on muscle mass and function include treatment with interleukin-15, anti-TNFα antibodies, antioxidants,

and nitric oxide inhibitors. The effects of these treatments in patients with muscle wasting conditions are not known.

Recently, sepsis-induced muscle wasting in experimental animals was associated with increased expression and HAT activity of the nuclear cofactor p300 and reduced expression and activity of HDACs. Taken together, these changes set the stage for increased acetylation of cellular proteins. The potential role of hyperacetylation in muscle wasting was supported by upregulated expression of atrogin-1 and increased muscle proteolysis after treatment of rats with the HDAC inhibitor TSA. Based on these observations, it may be speculated that inhibition of acetylation may reduce loss of muscle mass in catabolic conditions, at least catabolic conditions in which there is evidence of hyperacetylation. Interestingly, the recent development of small molecules that can stimulate HDAC activity (resulting in reduced acetylation of cellular proteins) may provide an opportunity to test whether muscle wasting can be treated or prevented by reducing the level of acetylation. It may also be speculated that treatment with resveratrol, a compound that has both antioxidant and HDAC stimulatory effects, may be an additional avenue worth trying to prevent muscle wasting in critical illness. Importantly, the recent development of small molecules specifically targeting and inhibiting p300/HAT activity may offer an additional way to reduce hyperacetylation (and protein breakdown) in catabolic muscle.

Although many of the potential drug targets discussed in this section are still far from clinical application, a number of clinical trials are in progress to evaluate treatments of muscle wasting (Table 2.9). Presently, treatments aimed at blocking myostatin seems to be attracting the greater interest and perhaps promise.

Nutritional Assessment and the Need for Nutritional Support

Historical Perspective

It would have been fun to write this section in the early 1970s, as nutrition and nutritional support was wonderfully exciting. Dr. Stanley Dudrick had just wowed the world in the late 1960s by showing beagle puppies that had never eaten keeping up with puppies that were fed normal chow and were eating. A seminal observation was the baby who had not been fed and yet seemed to have fairly normal development. The senior editor of this book

was fortunate to be involved in the evolution of total parenteral nutrition (TPN) and to set, with Dudrick and others, some of the parameters by which nutritional support was carried out. Ron Abel, who was an intern on the pediatric surgical service when JEF was the chief pediatric resident, told about a young surgeon named Stanley Dudrick who was doing experiments with dogs and finally with babies to support them without eating at all. The residents were somewhat incredulous but Ron Abel suggested inviting him up to speak. He spoke to the residents and staff in the Bigelow Amphitheatre, who were astonished. In about 1968, they put together a nutritional support group to start supporting patients by hyperalimentation. The team included a pharmacist who was interested and who had heard about what was going on at the University of Pennsylvania at that time and agreed to make up the solutions in his spare time after hours. In the early years the team did not have the knowledge we have today and did just about everything wrong. The solutions had too many calories, a fat substitute was not available and the initial team gave too much volume and too much glucose. Despite this the hyperalimentation allowed some fistulas to close and supported patients who could not eat.

It was known that central venous access was needed and that the subclavian insertion site of the catheter needed a sterile dressing. (Dr. Robert Linton, who was consulted on this, said to leave it open with nothing on it—maybe that should have been done, although it seemed unlikely that with the bedclothes scraping on it that the catheter site would remain sterile.) The floor nurses were stretched much too thin and were terribly disinterested in doing this, hence a TPN nurse was added to the team. Regular dressing changes and insertion site care, kept the sepsis rate at a reasonably low level. The TPN service took off and grew to as many 70 patients. International fellows came from all parts of the world to learn about TPN. TPN has now evolved into a hospital service at many institutions and is a mainstay of nutritional support although it is only recommended is enteral feedings are not possible. We know so much more about the physiology of malnutrition today than we did in the early years of TPN based on the evolution of this technique.

There were many missed opportunities. Research money was very plentiful. Although the companies were competitive, they were pretty good about giving young, aggressive, mostly surgical investigators money for doing research in TPN. Unfortunately, the research was not of high quality

and most of it could never be funded by the NIH, although some of it was. Instead of competing, we should have gotten together and in fact we might have—there was an organization known as the Society of Parenteral Alimentation (SPIA), which was a 30-member organization by invitation only that had an annual meeting and a different format: only five papers, 2 hours each, material which had never been published, and if you used any of it, you were thrown out, never to be invited again. One person did and was never invited back. There were other opportunities lost. We failed to get CPT codes for initial assessment, nutritional support, daily visits and ordering of the bottles, and judging the electrolytes. We could have done a lot to maintain the field and to reproduce ourselves. But we were too busy competing with each other because we were all young and, to a certain extent, we were all male rhinoceroses competing for Lord knows what. It did not happen, and we did not reproduce ourselves. The problem now as this author sees it is that TPN has become something that you use until you can get rid of the catheter. The reason for this is because catheter infection has become a bugaboo on all services and, in addition to causing death and metastatic infection elsewhere, costs at least $63,000 per line infection. The TPN nurse, who metastasized to an IV nurse, no longer exists. The TPN nurse has been a casualty of hospital efficiency. It only takes the prevention of two line infections a year to actually pay for the salary and benefits of a TPN nurse, whose job it is to go endlessly around all the units and teach people aseptic technique and how to avoid line infection. As noted earlier, TPN is something that you put in when you are desperate and you try to prevent line infection if you can without adequate help, especially in the ICU, and then you get the line out as quickly as possible and go to enteral nutrition. Not that there is anything wrong with enteral nutrition, but this author would venture to say that with the inappropriate use of excessive osmolar nutritional aspects, there are probably more deaths with enteral nutrition and pneumatosis and bowel necrosis than there are in patients who get TPN. What has happened to TPN is that it is no longer a surgical discipline. If it is staffed at all, it is some reluctant gastroenterologist who takes this on. Surgeons are basically excluded or have excluded themselves from the management of the patient. The goal is to put people on TPN for as little time as possible and then to transition to enteral nutrition. This is not a bad idea but it is an idea that may never happen because patients may not be able to accept sufficient support by enteral nutrition.

TABLE 2.9 Summary of Clinical Trials Evaluating Treatments for Muscle Wasting

Drug/Target	Disease Process	Trial Details	Outcomes	Ref. or ClinicalTrials.gov Identifier
TNFα				
Etanercept (TNFα Ligand bound to Fc-IgG1)	Cancer	■ IV administration ■ RCT	No inhibition of muscle wasting	100
Infliximab (TNFα-specific mAb)	Non-small-cell lung cancer	■ IV administration ■ RCT	Trial stopped early because of decreased quality of life in infliximab-treated group	101
IL-6				
ALD518 (BMS-945429; IL-6-specific mAb)	Lung cancer	■ IV administration ■ Phase I/II	No inhibition of muscle wasting	108
Myostatin/activin				
BYM338 (bimagrumab; ActRIIB-specific mAb)	Sarcopenia	■ IV administration ■ RCT	In progress	NCT01669174
	COPD	■ IV administration ■ RCT	In progress	NCT01601600
	Cancer	■ IV administration ■ RCT	In progress	NCT01868685
	Mechanical ventilation	■ IV administration ■ RCT	In progress	NCT01433263
	Sporadic inclusion body myositis	■ IV administration ■ RCT	In progress	NCT01925209 (RESILIENT trial)
LY2495655 (myostatin-specific mAb)	Pancreatic cancer	■ IV administration ■ Phase II	In progress	NCT01505530
Ghrelin receptor				
Ghrelin	COPD	■ IV administration ■ RCT	Improvement in quality-of-life score but not physical activity	246
Anamorelin (growth hormone secretagogue receptor agonist)	Cancer	■ Oral administration ■ RCT	Improvement in symptoms score	247
	Non-small-cell lung cancer	■ Oral administration ■ RCT	In progress	NCT01387282
SUN11031 (ghrelin agonist)	COPD	■ SC administration ■ Phase II	Increased muscle mass but not function	NCT00698828
Androgen receptor				
Enobosarm	Ageing	■ Oral administration Phase II	Increased muscle mass and function	248
	Cancer	■ Oral administration ■ RCT	Increase muscle mass but not function	NCT01355484 and NCT01355497 (POWER trials); NCT00467844 (REF. 249)
MT-102 (SARM)	Non-small-cell lung cancer	■ Oral administration ■ RCT	In progress	ACT-ONE trial[250]
GSK2849466 (SARM)	Healthy volunteers	■ Oral administration ■ Phase 1	No serious adverse events	NCT01696604
LGD-4033 (SARM)	Healthy volunteers	■ Oral administration ■ Phase 1	No serious adverse events	251

ActRIIB, activin A receptor, type IIB; COPD, chronic obstructive pulmonary disease; IgG1, immunoglobulin G1; IV, intravenous; IL-6, interleukin-6; mAb, monoclonal antibody; RCT, randomized controlled trial; SARM, selective androgen receptor modulator; SC, subcutaneous; TNFα, tumor necrosis factor-α.

Reprinted by permission from MacMillan Publishers Ltd: from Cohen S, Nathan JA, Goldberg AL. Muscle wasting in disease: molecular mechanisms and promising therapies. *Nat Rev Drug Disc* 2015;14:58–74.

THE ROLE OF ALBUMIN MEASUREMENT IN NUTRITIONAL SUPPORT

For the past three editions, the approach to nutritional support and nutritional assessment has been in particular a European approach. In the third and fourth editions, Graham Hill, from the UK and working in Australia as Chair of a Department of Surgery, did wonderful things introducing enteral and PN in Australia. His approach is particularly

European. In the fifth edition, Peter Soeters, who spent several years with me in the laboratory and wrote the classic review of gastrointestinal cutaneous fistulas, wrote about the risk assessment and nutritional support, again with a strictly European cast. Unfortunately, it is not that way in this country, and the concepts, which are well regarded, that Graham Hill and Peter Soeters and his coworkers put forth in previous editions are all true and are all brought to bear. However, they are not the approach that we use in this country and so it is time to take a strictly American approach.

How do these approaches differ? The cardinal difference between the American point of view and the European approach is the role of albumin. Most of us can pick out a malnourished patient prior to operation. This was well proven in the study as carried out by the University of Pennsylvania team, and showing that patients who had lost between 10% and 15% of their body weight over 3 or 4 months were at risk of serious postoperative complications and failure to heal. Hence, the essence of operative risk as determined in the United States is a loss of lean body mass. It is lean body mass that we are trying to salvage with TPN and to stop from being broken down for energy. And yet it is more than that. Serum albumin and transferrin, which are used as indicators of nutritional adequacy, albumin being a rapid turnover protein with a half-life of approximately 20 days, allegedly tell us about the health of lean body mass. The European point of view is that albumin is not so much a characteristic of malnutrition but of inflammation. Although we do not think about this that way in the United States, albumin level in the serum is largely determined by the percentage of extravascular albumin since it is the rate of degradation rather than the rate of synthesis which is the biggest determinant of serum albumin. This was shown by Rothschild at his laboratory at the New York, VA in the late 1950s and early 1960s in which he showed that patients with cirrhotics who often presented with low serum albumins did so not because they were not making it but because the percentage of extravascular albumin to which the rate of catabolism related was more important in determining the level of serum albumin. The European point of view is that a low albumin, again brought about by increased catabolism rather than decreased synthesis, is usually the result of longstanding, chronic infection or, if not an infection, inflammation, and this is the signature of a low serum albumin, not so much starvation, not so much decreased synthesis, but increased degradation because of the percentage of extravascular albumin and its rate of degradation. The Europeans may be correct and it

may all be about inflammation. And it may be that inflammation poorly characterized, which is the sine qua non of patients who are in poor metabolic shape and even poorer metabolic shape to survive operation. These patients are most at risk because of the mechanism which a low serum albumin then brings forward.

Thus, we have come full circle. In 1936 at the University of Pennsylvania and independently in the University of Edinburgh, it was shown that a high level of serum albumin equaled survival following gastrectomy. It was thought that this represented increased synthesis, and perhaps it does. However, one must keep an eye over one's shoulder to think about albumin as being degraded and hence the depressed serum albumin level is a marker on ongoing inflammation.

Operative risk is best related to the status of lean body mass. Lean body mass is that operant amount of protein, which carries out the various functions that we characterize as being important in patients. To have a low serum albumin means that the lean body mass is deficient and hence lack certain enzyme systems and other systems of defense, which make the difference between survival and death. Let us now consider what we can do about a patient whom we believe to be at risk and has deficiencies not only in lean body mass, but also in those proteins, which we associate with the synthesis of lean body mass and thus perhaps survival. Included in these proteins that may be deficient with weight loss are the immunologic armamentarium of the body, various enzymatic and defense mechanisms and the inability to synthesize phagocytes and immunologic cells. Remember that there are 10 billion neutrophils released each day and programmed to die within a few hours by apoptosis. Some of the products of dying neutrophils may contribute to the resynthesis of valuable protein and defense mechanisms. Not to have these important recycling and immunologic functions puts the organism at risk.

RISK OF CATHETER-RELATED BLOOD STREAM INFECTION

The major risk of TPN is line sepsis. This is termed catheter-related blood stream infection (CLABSI) today. CLABSIs are associated with substantial morbidity and mortality. Although according to the CDC a 46% decrease in CLABSIs had occurred in hospitals across the United States from 2008 to 2013, an estimated 30,100 central line-associated bloodstream infections (CLABSI) still occur in ICUs and wards of US

acute care facilities each year. CLABSIs are preventable and are considered serious infections typically causing a prolongation of hospital stay and increased cost and risk of mortality. The infection rates vary in a wide range. Hospitals monitor such rates and compare to a risk adjusted incidence where a rate less than 1 is the goal…the lower the better. This data is readily available for providers and patients so the rates between hospitals. The national standardized infection ratio is 0.50. Employing CVC bundles and other strategies US hospitals reported a significant decrease in CLABSI. Among 2,442 hospitals in the United States with sufficient data to calculate the SIR 10% had an SIR significantly worse than 0.50 (2014 data published in 2016). CVC Bundles include: optimal site selection (avoid the femoral site), hand hygiene, alcohol-based chlorhexidine skin preparation, maximum barrier precautions, and catheter care guidelines.

The mean attributable cost and LOS between matched CLABSI cases (1,339) and non-CLABSI controls (2,678) was $55,646 (**2011 dollars**) and 19 days, respectively, in a study reported in March of 2014. The cost relates to blood cultures, perhaps time in the ICU, various diagnostic aspects, and nearly 3 weeks of hospitalization to get the line sepsis under control. CLABSI may be caused by bacteria or *Candida*. The mortality is greater with a yeast infection. Thus ideally TPN is something to be avoided, not surprisingly, because of the high infection rate. Line sepsis can be avoided by excellent nursing care but it needs to be continuous. In the past, TPN nurses needed to make their way from unit to unit, emphasizing the care of lines to which it is directly related. This was not rocket science. This has been known since a paper in the *New England Journal of Medicine* that our team published in 1973 (Abel RM, Beck Ch Jr, Abbott WM, et al. Improved survival from acute renal failure after treatment with intravenous essential L-amino acids and glucose. Results of a prospective, double-blind study. *N Engl J Med* 1973; 288(14):695–9). The introduction of TPN nurses in Cincinnati decreased the sepsis rate from 27% to 0.78%, which I think is about the lowest it can be. Today institutional practice guidelines exist and TPN and CVC care is highly regulated and monitored. Standard practice reduces errors and complications as well as infection. In general, either a port or a subclavian line has the lowest rate of sepsis. Internal jugular lines in the ICU, particularly in patients with a tracheostomy, will experience high rates of sepsis because it is almost impossible to keep a dressing on, especially

with trach ties and everything else. Line sepsis in the ICU, in addition to all the other disasters, is often a fatal coup de grace. In a well-run unit, it should be possible to have a line sepsis rate of less than 1%.

WHAT IS NEEDED FOR TOTAL ENERGY REQUIREMENT

It is highly unlikely that many patients will be in hospitals that have research functions to determine the total energy requirements. Thus, it is better to estimate this by calculating the resting metabolic expenditure. According to the Harris Benedict equation, basal metabolic rate and essentially what patients need can be computed using the following equations:

$$\begin{aligned}\text{Males} = {} & 66.5 + (13.8 \times \text{weight in kg}) \\ & + (5 \times \text{height in cm}) \\ & - (6.8 \times \text{age in years}) \\ \text{Females} = {} & 66.5 + (9.6 \times \text{weight in kg}) \\ & + (1.9 \times \text{height in cm}) \\ & - (4.7 \times \text{age in years})\end{aligned}$$

Thus, one can get a reasonably accurate estimate of not only the caloric requirements, but also how it might be administered and, utilizing 6.25× the number of calories, some idea of what the constituents of TPN might be.

What kind of energy requirements do we need? In general in the ill patient most of the calories should be supplied as glucose. Yes, one does need a modicum of fat, and this is thought by some to be in the range of 25 to 40 mL of a fat emulsion three times per week to provide essential fatty acids. Some authorities believe that large doses of fatty acids may be harmful, and it would be difficult for patients and their immunologic functions to tolerate it.

CALORIC REQUIREMENTS AND THE CALORIE TO NITROGEN RATIO

The main consideration when administering fat and carbohydrates in PN is not to overfeed the patient. The commonly used formula of 25 kcal/kg ideal body weight furnishes an approximate estimate of daily energy

expenditure and requirements. Under conditions of severe stress requirements may approach 30 kcal/kg ideal body weights.

Calorie to nitrogen ratio is normally 6.25 cal/g of nitrogen. The amount of protein that we need is 1.5 g protein/kg/day, which some have suggested to be the upper limit of normal. It may be, but certainly in certain protein-losing enteropathies, the loss is increased so what we would say in respect to nitrogen is that there is a range of 0.25 to 2.0 g nitrogen/kg/day. Some patients have protein needs much higher than those with normal metabolic processes. For example, patients with inflammatory bowel disease may lose 0.5 to 1.0 g protein/kg/day in the stool. I agree with the recommendations made by Professor Hill in the previous edition:

1. For maintenance, prescribe 1.0 to 1.5 g protein/kg/day.
2. For a hypercatabolic patient, prescribe 1.5 to 2.0 g protein/kg/day.
3. For those with excessive losses, prescribe up to 2.5 g protein/kg/day.

PATIENT SELECTION FOR TPN

Operative risk is the sum of various risk factors, which, in combination determine the type of complication that may occur in a surgical patient. One of these risk factors is malnutrition. Some of the key elements in determining operative risk and correcting it are:

1. Patients who have lost 10% to 15% of their body weight over the previous 4 months are at risk.
2. The period of time necessary to reconstitute the patient's nutritional status is probably between 5 to 7 days.
3. Serum albumin should be 3.0 g/dL (a value of 3.5 g/dL is better according to some).

Early experience on the Surgical Services at Mass General, demonstrated that with administration of TPN for 3 days before the patient was taken to the OR, there was a trend toward improvement, although that it was not statistically significant. From that study it was determined that we could (a) identify the patient at risk and (b) probably do something about the operative risk by supplementing TPN for probably 5 days prior to operation. Furthermore, 5 days was the point at which serum transferrin began to improve and most importantly, the patient began to feel better. Thus 5 days was determined as the time that the patient needed to restore lean body mass and the protein functions thereof. Since the early experience, the European Society for Enteral and Parenteral Nutrition

reviewed several studies that have “demonstrated that 7 to 10 days of preoperative PN improves postoperative outcome in patients with severe undernutrition who cannot be adequately orally or enterally fed.” Conversely, its use in well nourished or mildly undernourished patients is associated with either no benefit or with increased morbidity. Postoperative PN is recommended in patients who cannot meet their caloric requirements within 7 to 10 days orally or enterally. In patients who require postoperative artificial nutrition, enteral feeding or a combination of enteral and supplementary parenteral feeding is the first choice. The report of the Veterans Affairs Total Parenteral Nutrition Cooperative Study Group “confirmed the lack of benefit of TPN in borderline malnourished patients, provided strong evidence against clinically important efficacy in mildly or moderately malnourished patients, and suggested but did not confirm efficacy in severely malnourished patients. In this report, the incidence of severely malnourished population was small, representing less than 5 percent of the surgical candidates.” They concluded that “in the absence of severe malnutrition or other specific indications for preoperative TPN, most patients are probably best served by prompt surgery.”

GENERAL INDICATIONS FOR TPN

1. TPN is useful either in patients who cannot or will not eat, or in patients who cannot eat adequate amounts. It is also used in patients who are ill or who are about to undergo elective surgery. This has been previously discussed and the author believes that the amount and duration of this TPN should be approximately 5 or 6 days, at which time we should see the patient feeling better and serum transferrin increasing.
2. When the alimentary tract is obstructed or with prolonged ileus postoperatively and nutrition is not possible in the postoperative period.
3. Caution is advised in the use of TPN in obstructive GI malignancy. The duration of the TPN should be short and that the patient should have the possibility of an operation without increasing the rate of the growth of the tumor. Malignancy with obstruction without any hope of removing the tumor is not an indication for TPN. In addition, TPN to foster chemotherapy is not appropriate unless the patient has a markedly responsive tumor, such as a lymphoma or a lymphosarcoma.

4. Short bowel syndrome. The limits of short bowel syndrome have been reasonably defined, and when patients have had a massive small bowel volvulus and only have less than 36 cm of small bowel with an ileocecal valve, there is an indication for TPN. One must try very hard to save the ileocecal valve, which one usually can do, with the ileocolic vessel branch so that 2 cm is sufficient. In addition, if the ileocecal valve's blood supply is problematic, it is worthwhile if there is any omentum left, to wrap the anastomosis in omentum and suture it around the ileocecal valve to heal. In general if the patient has 64 in or 2m of small bowel, even without the ileocecal valve, anastomosis of distal transverse colon or the sigmoid colon, it should be possible to ultimately wean from TPN.
5. Enterocutaneous fistula. Enterocutaneous fistula from the large bowel, can often be managed with enteral nutrition, but a high output small bowel fistula is an excellent indication for TPN. One can generally expect that between 33% and 38% of those patients whose anatomy is favorable (not obstructed, no stricture, reasonable small bowel) will ultimately heal without the need for operation.
6. Inflammatory bowel disease. Particularly in Crohn disease, TPN itself may prove to be healing and will quiet down the inflammation. When a fistula complicates Crohn disease, and is treated with infliximab, the fistula may close but it will reopen. The optimal approach is to allow the fistula to close, let the abdominal wall calm down, treat infection, and then operate and resect the area of the fistula.
7. Patients with major intra-abdominal sepsis or inflammatory processes such as pancreatitis, and in general when the gut is not usable, are excellent candidates.

PLACING A CENTRAL VENOUS CATHETER

A catheter may be placed by an internal jugular route, an external jugular route, or a subclavian route. Some prefer a peripherally inserted central catheter (PICC) line. The current literature supports that this is a safe alternative to a CVC provided that unnecessary catheters are discontinued promptly. For PICCs central line associated blood stream infection (CLABSI) rate has been reported at 2 to 2.3 for 1,000 catheter days. The longevity and complications of PICCs in burn patients differs little from CVCs. CVCs may have a higher rate of CR-BSI in burn patients than PICCs. Although PICCs are not adequate for the fluid volumes typically required during burn shock resuscitation, they can provide a safe and

effective alternative for central access in the ongoing care of the burn patient. There are many techniques for placement of a CVC. The following technique that is employed by the senior editor (JEF).

1. The patient should be supine in bed and three chucks or a small roll should be placed longitudinally between the patient's shoulder blades.
2. The patient's shoulders should be allowed to droop downward and back and relaxed. A small IV injection of valium for patients who are agitated or nervous is often helpful.
3. The arms are at the side and the neck is turned slightly to the opposite side.
4. After being prepped and draped, the patient should be placed at a 30-degree Trendelenburg. If the external jugular veins cannot be visualized, then a crystalloid or plasma (depending on the patient's need) should be utilized to make certain that the veins are of a proper diameter.
5. A careful prep of both sides, usually with povidone iodine followed by chlorhexidine after the povidone iodine is washed off with alcohol, is carried out. The operator should be totally gowned and draped, as should everyone else in the room, with a mask and a hat.
6. The subclavian vein is identified with a number 22 needle, which is placed just at one third of the clavicle. The periosteum of the clavicle is anesthetized the periosteum of the clavicle and aim for one finger breadth above the sternal notch. With practice, one injects the xylocaine and/or Marcaine and one feels the pop as the needle enters the subclavian vein. It is important that the needle not be any more than 10 degrees to the horizontal. If one keeps less than 10 degrees to the horizontal, one will not get a pneumothorax. After the needle enters the subclavian vein, one immediately takes a larger needle by the Seldinger technique, which is prepared, looks at how far in the number 22 needle is, and passes the Seldinger needle into the vein. A wire is then introduced through this needle and the catheter is then placed over the wire. The suture, which is absorbable but of sufficient dimensions such as a 3-0 pds, is then used to sew the catheter in place. The IV is then hooked up; I generally at that point ask the nurse to dress the catheter.
7. Infusion is done with 5% dextrose in saline and a CXR is obtained, making certain the catheter is in the right place. The operator should examine the x-ray themselves. The tip of the catheter should be at the junction of the superior vena cava and the right atrium. If the catheter

is in place and there is no pneumothorax and the bottle is lowered and the blood comes back into the catheter, the TPN can be hung and usually starts at 40 cc/hr. Care we have previously dealt with.

SUSPECTED CLABSI

The fever curve of CLABSI is usually a very low grade fever of several days before, followed by a fever spike and rigors. It may or may not be associated with a high white count and there is not another source of sepsis. One takes blood cultures from the catheter and also from a remote spot so to make certain that, if there is a positive blood culture, it is not a contaminant around the catheter. If this is correct, then after the starting of a peripheral IV, the catheter is withdrawn and the tip is cultured. If a fungus is suspected, an ophthalmologic examination for candida in the eye fundus is also necessary. If the sepsis occurs without prior prodrome when the new bottle is hung, the bottle is removed, the catheter is left in place, and the TPN is cultured; it is very rarely the source of sepsis.

If the catheter is a source of sepsis, 24 to 48 hours must elapse with adequate antibiotic coverage before another catheter is attempted. If a fungemia is present, then one must look for other sources of nutrition not including glucose and one must try especially hard to use enteral nutrition. One can only be certain that sepsis is no longer existent when one has 2 weeks of adequate therapy. If the therapy is not adequate, it may take 6 weeks for sepsis to subside.

TPN SOLUTIONS

Most hospitals have TPN solutions, which are made up and ordered by a system of prepared solutions. The average physician whose patient needs it only check the box and, based on electrolyte values, the additives to the patient's TPN. In this way, errors in TPN are omitted. The most likely errors occur in the lack of monitoring of solutions and the failure to make up, for example, for GI losses including the loss of chloride in nasogastric tube drainage and/or the loss of enteral contents in patients with gastrointestinal cutaneous fistulas. A particular area of loss that most do not pay much attention to is both the energy and the sodium loss of a hepatobiliary fistula. The sodium content as well as some other electrolytes of both a biliary and a pancreatic juice loss is particularly energy-dependent because it is hypertonic to the plasma. This means that patients who lose large amounts of bile and pancreatic juice may lose

fluids with a sodium content of up to 180 as compared to a plasma, which contains a sodium of 140. Potassium loss to excess is uncommon but may occur. Sending the drainage fluid to the laboratory for determination of electrolytes may be helpful in managing such patients. Calcium and phosphorus need to be carefully adjusted. Hypophosphatemia is manifest usually by a somewhat bizarre symptomatology beginning with numbness in the lower jaw and in the skin around the mouth and may, if untreated, end with hypophosphatemic coma. This usually occurs when the serum phosphorus reaches the level of 0.5 mEq/L. Other deficiencies may occur in multivitamins and bizarre amino acid patterns in the plasma. When, for example, multivitamin infusions were unavailable because of an FDA action, patients presented with a metabolic acidosis, which resembled the metabolic acidosis of dead bowel, and more than one patient was explored looking for dead bowel until amino acid patterns were obtained and were bizarre, with large amounts of hydroxyproline and proline and it became obvious that we were not dealing with dead bowel but with a shortage of various B vitamins.

Some of the trace metals need to be added and one must be aware of chromium, which has an additive effect to insulin. Absence of chromium may lead to uncontrolled blood sugars and chromium is part of the multivitamin and trace element solution, which is usually added to the TPN. Other rare occurrences include selenium, which has been rarely reported as it is so ubiquitous that deficiency almost never occurs. Zinc, however, particularly in patients with liver disease and in patients with diarrhea and inflammatory bowel disease, may be a real problem and one must be aware of the tendency of patients with large amounts of diarrhea to be zinc deficient. The symptomatology here is a pustular rash, which is usually perioral and a rash around the skin. Zinc levels are difficult to measure and take a long time, and if one sees a pustular rash around the mouth (this is usually where it first appears), it is better to add zinc to the solution particularly in patients who have profound diarrhea with inflammatory bowel disease.

MANAGEMENT OF TPN DURING OPERATION

For some reason, most surgeons who have patients on TPN stop the infusion before the operation and give patients 10% dextrose. This is not necessary. Patients can tolerate TPN during operation quite well, but because of the stress related to surgery and potential volume shifts the rate

needs to be decreased. The rate should be slowed on the day before operation and by midnight previous to the operation; the rate should be slowed again to 40 cc/hr, at which time there will be no hypoglycemia, which one chances when one decreases TPN at a time when the patient is physiologically secreting large amounts of insulin. After the operation is completed, one can then increase TPN to 60 cc/hr on the first night and carefully monitor glucose with patients who may require insulin prior to resuming the previous rate. Hyperglycemia in the postoperative period may very well mean infection in some place, anastomotic leak, or a latent wound infection and one must be completely vigilant to this particular aspect.

RELATIONSHIP BETWEEN TPN AND ENTERAL NUTRITION

The good Lord intended patients to take food orally, and indeed one of the characteristics important to the way food is administered is that calories and protein must be cleared by the gut and must pass through the liver. The liver will clear at least 75% of the glucose presented to it in the portal vein. It is controversial as to whether the liver should do this or in fact requires the passage of most of the calories and amino acids into it to maintain its function. The liver is dependent on first pass clearance of 75% of glucose and many other nutrients, and failure to do so will contribute to hepatic dysfunction. So a case can be made for enteral nutrition, not the least of which is hepatic health. On the other hand, the adage that enteral nutrition has far fewer complications than TPN is simply not true. In TPN, line sepsis and some incidences of electrolyte abnormalities are the principal complications. Patients certainly do die from line sepsis; they should not, but they do. However, the complications of enteral nutrition as currently given in various hospitals may have an equivocal or even a higher incidence of mortality than in TPN. The reason is the failure to understand the concept of the challenged bowel. To begin with, much of enteral nutrition is given into the stomach, especially in the elderly. The elderly patients' stomach may not take or tolerate hyperosmolar feeds as easily as younger patients. In addition, loss of motility, especially on the evening and night shift when patients are unattended, often leads to aspiration, pneumonia, and death. A well-run enteral nutrition unit will stop feedings at 9 PM (or earlier) and the patient should remain elevated at 45 degrees, which is difficult.

Another problem with enteral nutrition from my standpoint is the failure to understand hyperosmolality and its effect on the bowel. The manufacturers' guidelines for starting enteral nutrition take very little account of the hyperosmolality of many tube feedings and will start tube feedings on a hyperosmolality of 400 or 500. In patients in the ICU or in elderly patients, this requires an increase in cardiac output and increase in blood flow to the bowel to dilute the hyperosmolar material by secreting free water. The elderly bowel may not be able to do this and if one starts hyperosmolar tube feedings without being certain that the bowel can tolerate it, it leads to pneumatosis, bowel necrosis, and death. Starting hypo-osmolar tube feedings with a strength of 150 mOsm/L and gradually increasing it so that it never exceeds 280 mOsm/L will prevent any pneumatosis or hyperosmolar-related deaths from bowel necrosis. At times one cannot give as much bowel or enteral feeds as is necessary to maintain the patient totally, and in this case, one should opt for a combined enteral and parenteral nutritional support.

HEPATIC FAILURE

The administration of conventional amino acid mixtures to patients with hepatic encephalopathy and an impaired liver will almost certainly lead to worsening of hepatic encephalopathy. The reason is that hepatic encephalopathy is thought by many to lead to high levels of phenylalanine and other aromatic amino acids and tryptophan, while not total tryptophan but free tryptophan, across the blood/brain barrier, and results in derangement of the central nervous system neurotransmitters. Since the aromatic amino acids gain entry into the brain by competing with the branched-chain amino acids, a different solution has been proposed and has been in use since the 1970s. Randomized prospective trials have clearly shown an improvement in outcome, including close to improved survival in patients receiving a high branched-chain, low aromatic amino acid ratio in TPN. In addition, the studies have clearly shown that, when one gets to upper levels of amino acid infusion, between 80 and 120 g/24 hours, the results are better. Fat should not be used as an energy source in patients with liver disease because they do not metabolize it. Glucose is the preferred fuel and one needs to watch glucose intolerance. In other countries, the use of high branched-chain, low aromatic amino acids mixtures is very common and is part of the armamentarium, but in the United States, for the most part, this is not routine therapy. In patients with

impaired hepatic function, a high branched-chain, low aromatic amino acid ratio may result in improvement in liver function and survival in patients who otherwise might die. Such solutions have been tested both parenterally and orally, and except for the two studies that relied on fat as a major caloric source the results have all been positive. Use of oral branched-chain amino acids, notably in Europe, has shown improvement in long-term encephalopathy in patients with chronic liver disease as well.

RENAL FAILURE

Renal failure especially in surgical patients is an unfortunate concomitant of critically ill patients. To say that it complicates their management is an understatement. Approximately 40 years ago, there was a Giordano Giovanetti diet, which was intended for oral patients with chronic renal failure. The purpose was to avoid dialysis. In these studies, high biologic value protein such as egg yolk and other types of protein, which had little waste nitrogen, were part of a diet, which was very rigid, but in fact it was shown in chronic renal failure patients to decrease the frequency of dialysis. The essential amino acids are the amino acids, which could not be synthesized by the body. There were some additional essential amino acids from the standpoint of the inability to synthesize it such as arginine, and some have advocated using a more complete formula. The problem is that most situations in which one is using an essential amino acid regimen involved surgical patients in acute renal failure. The addition of any other amino acid other than the eight that have become the standard decreases the efficacy as far as the lowering of BUN, which is an essential part of the regimen. In surgical patients, the use of essential amino acids is so important. The glucose regimen is usually about 35%. The essential amino acid load is quite small, about 16 g/L, much lower than the 40 g/L that is usually given in TPN solutions. There is evidence that decreasing the protein load may aid more rapid recovery from acute renal failure, and in fact the addition of the eight essential amino acids only, which keep down the BUN, should help the recovery from renal failure. In fact, in a 1973 publication in the *New England Journal of Medicine*, the late Dr. Ron Abel and the rest of the team with the addition of the renal consulting unit at the Mass General Hospital carried out a randomized prospective trial of the essential amino acids and hypertonic dextrose versus isocaloric hypertonic dextrose alone. The use of essential amino acids and hypertonic dextrose versus caloric equivalent dextrose resulted in increased survival in the

group of patients receiving essential amino acids. In addition the outcomes with pneumonia and gastrointestinal hemorrhage were substantially better. Subsequently, Dr. Herbert Freund, later the Chair of the Hebrew University Department of Surgery at Mount Scopus, tried to conduct a study in which a diluted solution of standard amino acids was compared with the essential amino acids. Although there was some indication that the outcome might be better, the study was insufficiently powered to provide a definitive answer. Thus, our recommendation for patients in acute renal failure is that a solution consisting of 35% dextrose and 16 g essential amino acids/L does seem to confer some type of survival advantage in these critically ill patients.

RESPIRATORY FAILURE

There has been an attempt to have a respiratory solution in patients with acute respiratory failure who need nutritional support. Because of some data that John Kinney brought to our attention, the focus seemed to center on the amount of glucose that was given, which appeared to increase arterial CO_2 and thus perhaps delay the weaning of these patients from the ventilator.

In fact, this was a very good example of how a specific event with a few patients treated in a certain way was generalized to the entire group of patients with respiratory failure. The patients, who got a high dose of glucose early on acutely, without a gradual ramp up, did increase their CO_2 and actually by the numbers it made their respiratory failure worse. However, this was a very small group of patients who were put on TPN acutely. They were septic and their CO_2 went up markedly so that they got a larger dose of glucose than they should have. After reviewing the data, there is no reason to utilize a solution for respiratory failure unless the routine management of patients who are septic and in respiratory failure is to give them large doses of glucose. As currently use of high glucose solutions is avoided in respiratory failure, there is no need for a respiratory solution.

CARDIAC FAILURE

Earlier studies in nutrition carried out by Starling in 1912 suggested that the heart was spared the ravages of starvation. A careful look at these experiments revealed that Starling utilized two cats, one of which was

starved and the other was not. The unfortunate cat that was starved was sacrificed at a later date and it was found that its heart did not change remarkably during this period of starvation. Since then these experiments have been repeated and it does appear that after a prolonged period of time starvation does effect the heart in similar fashion to the way it effects other protein and other lean body mass, only much more slowly. In an initial attempt to devise a solution for cardiac failure, a concentrated solution of amino acids and glucose was administered to patients in congestive failure who could not eat. The results showed no change in cardiac parameters after 4 weeks, but we did see some changes in cardiac parameters after 6 weeks. Hence any beneficial effect in cardiac failure in giving nutritional support was bound to be delayed and probably was not going to be particularly useful. This does not mean that patients who are in cardiac failure and who require parenteral nutritional supplementation should get the standard solution. One should make an attempt to make certain that the solution is concentrated.

GLUTAMINE

For a while the research field went through a period in which glutamine was thought to be the best thing since sliced bread. There were large contracts written and there was an attempt to include glutamine in various amino acid solutions. Nussbaum utilizing 2% oral glutamine and 2% parenteral glutamine clearly indicated that in rats oral glutamine was quite efficacious in preserving GI fitness but no effect was seen with parenteral glutamine. Since that time, glutamine has been regularly utilized in enteral formulations.

IMMUNOLOGICALLY ACTIVE SOLUTIONS

Unfortunately, despite the fact that one of the holy grails in TPN is the desire to develop a solution, which is beneficial to patients who are infected or who have lower ability to respond to infection, there has been no success thus far. There have been solutions, mostly enteral, including various components such as glutamine, nucleic acids, and other such solutions which seem to have some efficacy, but there is no commercial solution which is currently available. The trial of glutamine-enriched solution by Bower and colleagues in patients who underwent large operations when they were malnourished and treated with enteral nutrition resulted in shorter length of stay, reduced incidence of infection, and an

enhanced recovery. There does seem to be a valid criticism of the study as the experimental and control solution were not given in an isonitrogenous fashion and there was a difference of about 20 g of amino acids/day.

COMPLICATIONS

I have mentioned many of the complications of nutritional support. Tables 2.10 and 2.11 show most of the complications that exist, most of which have been dealt with. However, there will always be complications that one has never seen before, such as the first observation of chromium deficiency in patients with diabetes and the inability to actually control blood glucose.

TABLE 2.10 Daily Vitamin Requirements for Enteral Feeding[a]

Vitamin	Daily Requirement
Thiamin	1.2 mg
Riboflavin	1.3 mg
Niacin	16 mg
Folic acid	400 µg
Pantothenic acid	5 mg
Vitamin B_6	1.7 mg
Vitamin B_{12}	2.4 µg
Biotin	30 µg
Choline	550 mg
Ascorbic acid	90 mg
Vitamin A	900 µg
Vitamin D	15 µg
Vitamin E	15 mg
Vitamin K	120 µg

[a]Prescriptions must be individualized per patient needs.

TABLE 2.11 Daily Trace Elements[a]

Trace Element	Daily Requirement
Chromium	30 µg
Copper	0.9 mg
Fluoride	4 mg
Iodine	150 µg
Iron	18 mg
Manganese	2.3 mg
Molybdenum	45 µg
Selenium	55 µg
Zinc	11 mg

[a]Prescriptions must be individualized per patient needs.

Our Inability to Support Patients Nutritionally With Sepsis and Cancer: A Hypothesis

In the last two chapters the influence of metabolism on the outcome in extremely ill surgical patients was discussed. One group of patients that still need effective metabolic and nutritional support are those with advanced cancer and cachexia and the patient with sepsis. Nonetheless, despite all efforts, these two classes of patients, stand as exceptions to an otherwise reasonably successful programs of nutritional and metabolic support. The two sources of calories in all patients are carbohydrate (glucose, generally) and fat. Carbohydrate as it is administered to patients is bimodal—it either increases ATP production by glycolysis or under certain hormonal circumstances ends up in glycogen for energy storage. Glycolysis is universal. The brain requires glucose as do red cells exclusively, but under certain circumstances the brain can switch over from glucose to ketone bodies to support it. The kidney can do this as well. Also, it is a sensitive negative feedback system, so that, when intracellular ATP is high, glycolysis is down, and, when it is low, glycolysis proceeds. The synthesis of ATP results from a base of phosphoenolpyruvate plus ADP to form pyruvate and ATP. Under normal circumstances, when we give sources of fuel, such as long-chain fatty acids, they are metabolized, and in the presence of acetyl coenzyme A, these are also important fuels for ATP production and can decrease glycolysis but not by themselves, and only when ATP levels are sufficiently high.

The hormonal environments which exist in distressed patients with either sepsis or cancer are well known (Fig. 2.7). The cytokines and mediators and hormones have also been elucidated and possibly also myostatin in sepsis, although Dr. Hasselgren has already stated that in experiments in his laboratory myostatin levels in sepsis are probably low. The counter regulatory hormones, mediated cytokines, and so forth, have been dealt with in great detail. They also break down in sepsis and probably in cancer, namely involving MuRF-1 and sometimes atrogin-1, have also been elucidated. There is one aspect, however, of nutritional support which has not been involved, and that is the cytoskeleton and the proximity of various enzymatic systems and sources of fuel for these enzymatic systems and not the three-dimensional space relationship and its effect on certain critical enzymatic and hormonal interactions. A hypothesis for why we cannot provide effective nutritional support and decrease the proteolysis in cancer and sepsis may involve the following observations and reasoning:

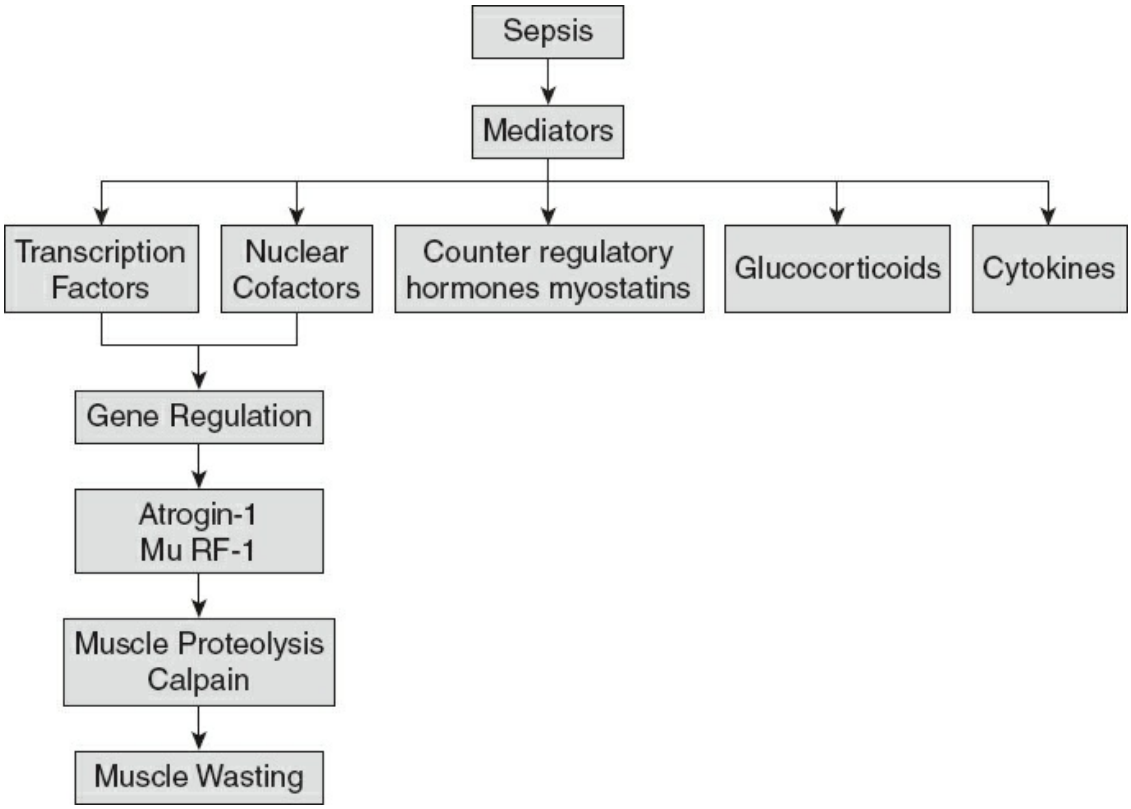

Figure 2.7. The factors involved in muscle breakdown and muscle wasting.

1. There is ineffective glycolysis, which results in an insufficient generation of ATP.

2. Under normal circumstances, fat administration for nutritional support decreases glycolysis in sepsis and cancer—but the “switch” that shuts off glycolysis in this case does not seem to work.
3. There appears to be a continued need for gluconeogenesis from protein —the inability to get glucose into certain cells may well be a membrane problem, in which there may be:
   a. Disordered submembrane space
   b. Insufficient transport mechanisms
   c. A pathologic increase in processes that depend on the cytoskeleton structure
4. The cell has an internal structure, and the internal structure is surrounded by a cell membrane. There are excrescences from the cell membrane, which break it into subcompartments arising from the membrane, which provide order into the interior of the cell, which we call a cytoskeletal structure. It may be, and this unfortunately is a teleologic argument, that there are various biochemical reactions that organize the cell, so that the reactions that are necessary may proceed better if there is a special relationship between two enzymatic or metabolic processes because they are adherent to the cell membrane. Thus, if there is a deviant pathophysiologic mechanism and two other mechanisms that are attached to the cells are adjacent to each other in the cytoskeletal structure, these pathologic processes may be increased by the proximity of these enzymatic processes and by the ready availability of fuel to run the enzymatic processes.
5. One may then ask the following question: in sepsis and cancer are there any cytoskeletally related processes that might explain some of the aberrant phenomena seen in these two diseases?
6. What is the role of aerobic glycolysis in these diseases? Aerobic glycolysis is a process involving sodium–potassium ATPase, which takes place in an area adjacent to the cell membrane and produces lactate. Lactate is usually an end product, and we are accustomed to viewing lactate as being an indicator of dead or dying cells or an incomplete end product of metabolism of glucose. The failure to process lactate further via the classic Kreb cycle means that the process of aerobic glycolysis results in only eight ATPase produced per molecule of glucose rather than the normal 32–36, if the process continued through a Cori cycle. Aerobic glycolysis is stimulated by epinephrine and produces lactate. Every intern and resident, at least on the surgical service, knows that, when blood lactate is higher, there is something dead, because lactate is usually the result of an anaerobic

end product. This is not necessarily the case, and the production of lactate by aerobic glycolysis is because of the proximity of stored glycogen, which fuels sodium potassium ATPase, which is spatially related to or close to the cell membrane. When aerobic glycolysis is stimulated by epinephrine (Fig. 2.8), which then releases glycogen, it is close to the enzymatic system of sodium potassium ATPase and yields a final end product of eight ATPs per molecule of glucose.

Not surprisingly, the absence of 32 ATP per molecule of glucose likely produces an energy shortage. Because of the shortage of ATP, increased gluconeogenesis results, and, when this happens, the glucose produced is transported to certain sites within the cell, avoiding the cell membrane block in glucose uptake, and when it is synthesized to glycogen, those sites probably are different from the sites normally circulating glucose, if it gets into cell and it gets into the liver. There is a membrane transport block for circulating glucose in the first place, which in sepsis is certainly well known. In the second place, it suggests that perhaps the mechanism by which glycogen is kept at a high level is somewhat deficient either because of spatial problems, which is unlikely, or more likely because of a transport block at the cell membrane. Thus, it may be that the only glucose that can get easily into the cell is when amino acids or other substrates get into the cell and are metabolized to glucose and then to glycogen. If this hypothesis is correct, the difference between the glucose, which is blocked at the cell membrane, and the relatively free availability of intracellular amino acids, which are broken down by proteolysis and then to glucose by intracellular gluconeogenesis, makes the source of the glycogen dependent on muscle-protein breakdown.

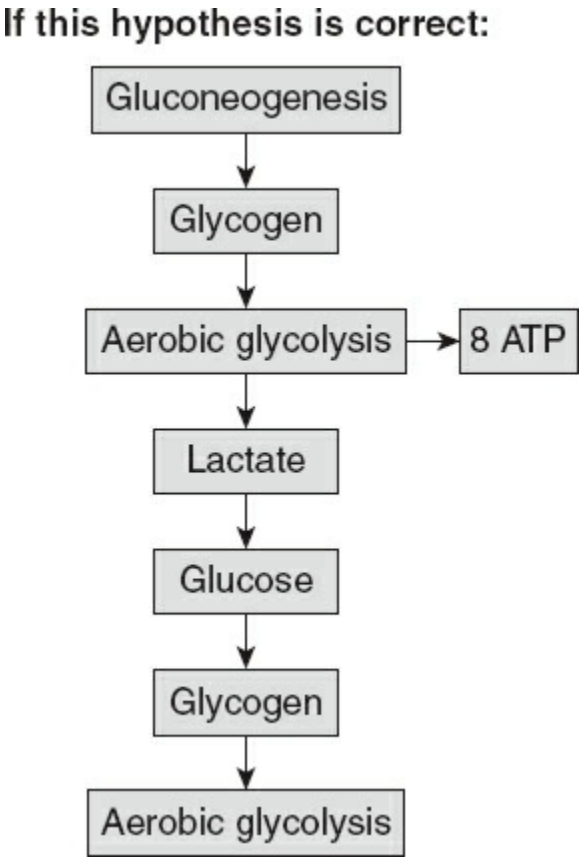

Figure 2.8. Brief outline of a futile cycle which may be involved in the metabolic derangements of sepsis and cancer.

Does lactate always mean dead bowel, hypoperfusion, or inadequate oxygenation? It is pretty clear that, whereas traditionally high blood lactate has been associated with hypotension, hypoperfusion and hypoxia, under certain circumstances blood lactate elevation does not mean these things. In the burn patient, 2 weeks after the burn, if one were to look at lactate as an indication that resuscitation is not completed, it would be dangerous because continued resuscitation with high volume of fluids may be injurious and in fact blood pressure, pulse, urine output, and PO_2 are normal at that time. The question has been raised, how does this happen? The answer is, if this theory is correct, resuscitation in the face of normal blood pressure, pulse, urine output, and PO_2 may be harmful, with which most people would agree but is due to still high circulating epinephrine. One way in which this might be explained is by some experiments done by Sir Miles Irving (1967 to 1969) that, after alpha and beta blockade in hemorrhaged dogs, as published in the Hunterian lectures, combination of phenoxybenzamine, an alpha blocker, and propranolol, a beta blocker, in hemorrhaged dogs, both plasma catecholamines and hyperlactatemia were

reduced. More recently, the senior editor's laboratory has shown that the production of lactate in vitro from extensor digitorum longus muscle in shocked, burned, or septic rats was decreased when ouabain was used to block the activity of sodium potassium ATPase. Although this was known somewhat previously, and indicated that the sodium potassium ATPase was essential for the production of lactate, these studies showed that the regulatory cascade controlling glycogen breakdown was often dependent on adenyl cyclase stimulated by epinephrine and mediated by the activation phosphorylase B Kinase to phosphorylase B to glycogen plus an organic phosphate and finally to glucose-6-phosphate. Furthermore, the stimulation of lactate production and extensor digitorum longus either by epinephrine or by amylin could be inhibited by ouabain. Thus James and colleagues proposed the following hypothesis:

1. Within cells, oxidative and glycolytic energy production can proceed in separate compartments intracellularly.
2. Most lactate production occurs in muscle and the source of the calories and fuel is glycogen.
3. Most lactate production is linked to aerobic glycolysis, which in turn is linked to sodium potassium ATPase.
4. Epinephrine and, to a lesser extent, insulin stimulate sodium potassium ATPase to maintain membrane polarity and muscle contraction. This then supposed that the sodium potassium pump function on glycolysis is likely associated with a degree of compartmentalization. This had been previously suggested by Paul and his coworkers, who suggested an association of glycolytic enzymes and calcium ATPase, or sodium–potassium ATPase at the plasma membrane, the segment of which is shown in the figure. This was supported by the effects of glycogen and the production of lactate—when ouabain is added, glycogen remains intact, and for the most part lactate production is diminished (Fig. 2.9). This indicates that sodium potassium ATPase stimulated by epinephrine is at least partially responsible for lactate production. In fact, as in the figure, when glycogen remaining versus lactate production is expressed as glucose equivalence after incubation in the presence or absence or either epinephrine or ouabain, an increase in lactate resulted in the decrease in glycogen, and, when epinephrine and ouabain were both added to the bath, the lactate production was largely blocked, whereas glycogen concentrations were maintained. It may be possible to explain these effects by some differential blockage of the actions of insulin—for example, if the glucose used by glycolysis is

not blocked in other areas such as glycogen storage. In that sense, the differential effects of insulin might conceivably participate in a disordered glucose metabolism, which we know exists in sepsis and cancer (Fig. 2.10).

5. Also, this hypothesis unifies the effects of epinephrine on these cells, which was traditionally viewed as stimulating two entirely different processes—increasing sodium potassium ATPase and separately increasing glycogen phosphorylase, which indirectly increased lactate production, thus increasing pumping-membrane hyperforce correlation. What our laboratory suggested was that these two processes are linked because of the cytoskeleton and because of proximity of both to the cell membrane, in the same area (Fig. 2.11).

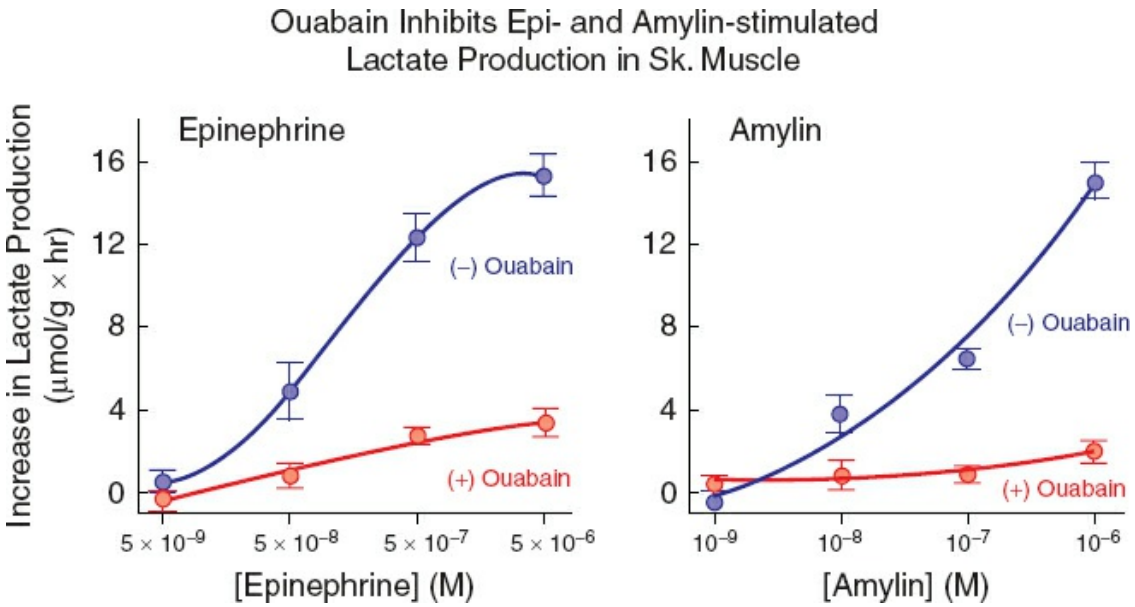

Figure 2.9. Epinephrine and amylin separately stimulate lactate production, but they are blocked by ouabain demonstrating that sodium/potassium ATPase must be active.

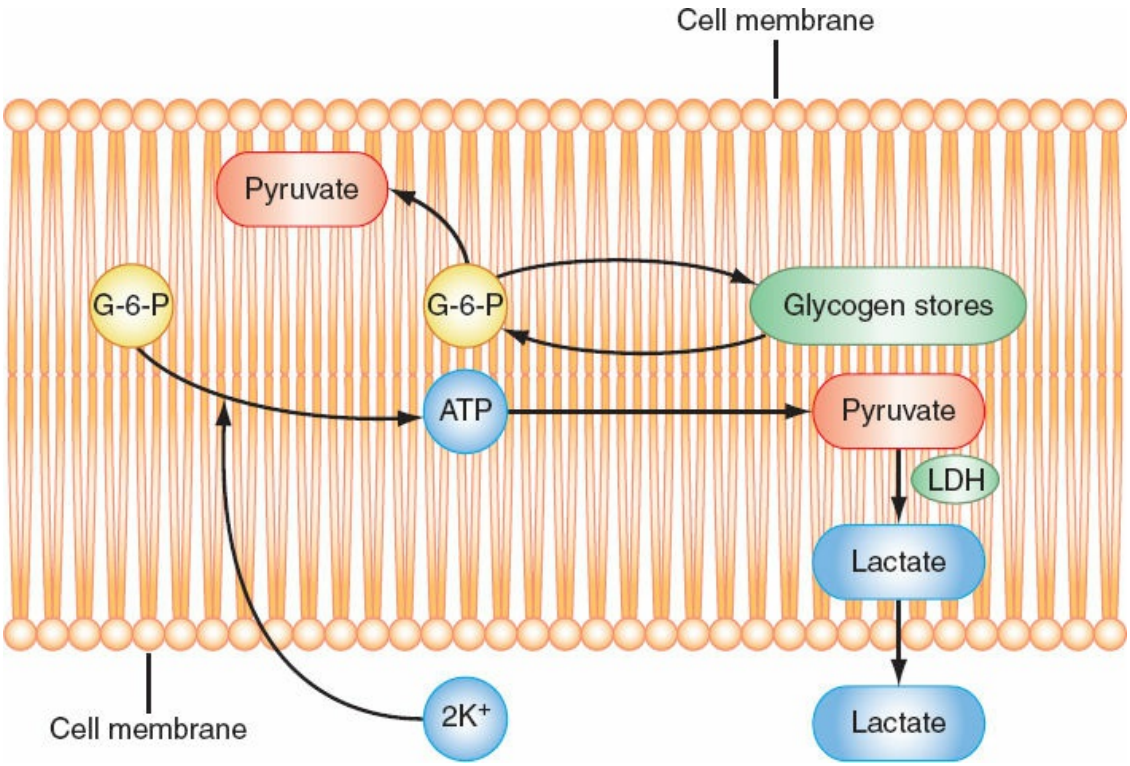

Figure 2.10. This figure attempts to show the two mechanisms, which are closely linked because of the cytoskeletal structure of the cell. It also attempts to show that the glucose derived from glycogen is preferentially from gluconeogenesis derived from amino acids.

Proteolysis and Sepsis in Cancer

In a normal organism, protein synthesis and degradation and in this case muscle synthesis and degradation are matched, and no net breakdown of protein takes place, and no synthesis takes place unless in the presence of exercise and increased caloric and protein intake. However, in cachexia brought on by a variety of stimuli, not the least of which are sepsis and cancer, muscle breakdown far exceeds muscle protein synthesis. The reasons for this have been previously detailed, in which it appears that the normal mechanisms of protein breakdown were seen as bad, but perhaps not always, in the initial phases of injury and sepsis, for example, increased production of acute-phase protein by amino acids derived from muscle breakdown might mean the difference between death and survival. It is only with the coming of the ICU, in which prolonged muscle breakdown takes place, under which terms in the past the patient would have been dead, that this becomes something which is not beneficial. Nutritional support our patients in the ICU in such a way that would derive

the benefits of both muscle breakdown and minimizing the breakdown, if by manipulating various fuels, so that it would not be necessary to have proteolysis to maintain these essential functions, muscle breakdown might be decreased.

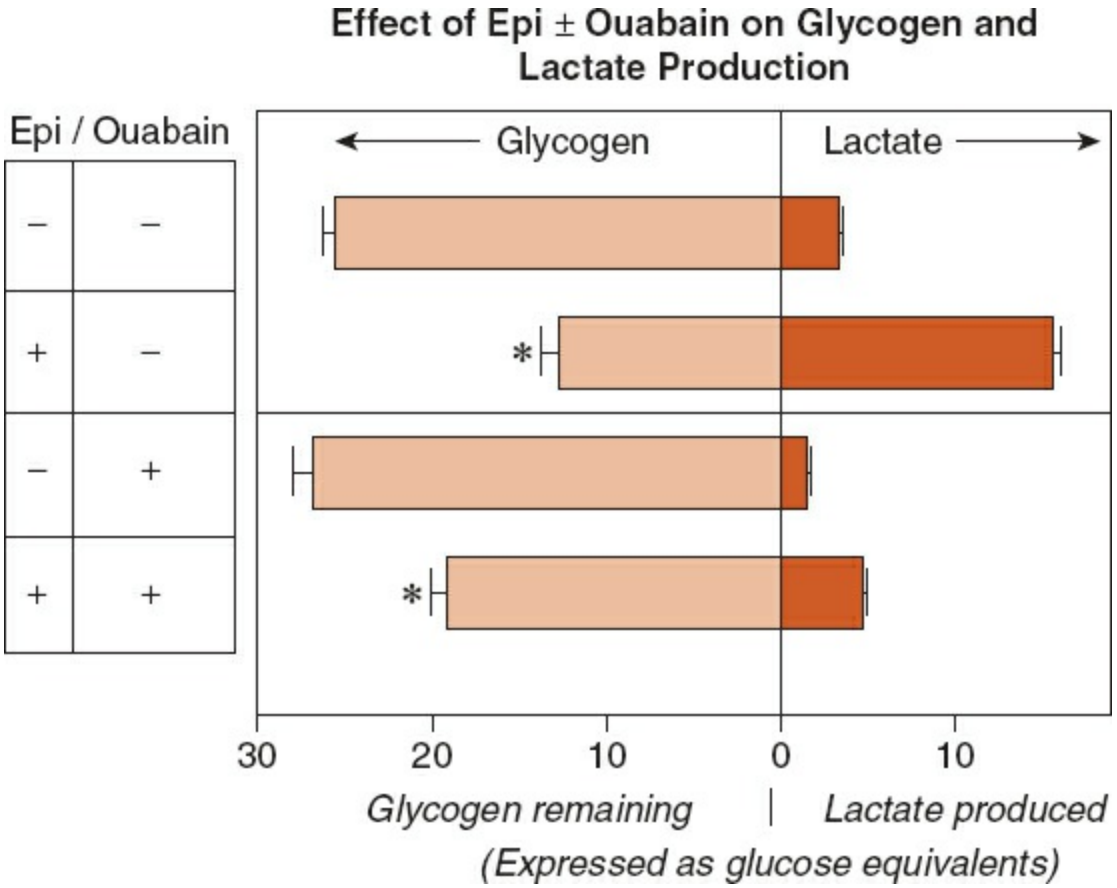

Figure 2.11. Note that when glycogen is broken down by epinephrine, the final product is lactate, despite the fact that hypoxia is not present. When sodium/potassium ATPase is blocked by ouabain, glycogen remains intact.

Myostatin

Myostatin has achieved some notoriety, and the most exciting thing about myostatin research is that, if one uses the myostatin antibody in certain catabolic situations, the catabolism and protein breakdown decreases. This has not gotten from the animal to the human type of experiment, and as stated earlier it would be nice if in sepsis and in cancer myostatin were increased. There has been more positive data from animal experiments in cancer, especially in the use of the antimyostatin antibody. It is too early to tell whether or not myostatin can be a summative aspect of support of patients in the ICU.

Possible Avenues of Support of Patients With Sepsis and Cancer

If the hypothesis concerning cytoskeletal proximity and different types of glucose and different destinations of glucose is true, then the appropriate way in which we might decrease muscle proteolysis is to provide substrate for gluconeogenesis, which openly goes to glycogen, and which is not derived from muscle-protein breakdown. Initially what seems most likely is, if you could overcome the metabolic block to glucose getting into a cell in the presence of sepsis and perhaps in cancer, in cancer it might be that it is not glucose not getting into the cell but the fact that the presence of the cancer "sops up," as it were, all of the glucose available, so there is nothing really to get into the cell in the form of glucose and nothing that goes to glycogen, allowing sodium potassium ATPase to have its first priority, which is keeping membrane integrity and the cell membrane functioning properly. In sepsis, the answer might be to provide a fuel, either protein or some other type of substrate which might get to glucose in the proper place to keep the glycogen stores fueled. Amino acids get past the cell membrane, and there is no such block as there is to glucose. Internal gluconeogenesis from protein might explain the accelerated decrease in proteolysis in an effort for the cell to keep its first priority, and that is cellular integrity. Alternatively, there might be other fuels, which get into the cell, and which do not have the block to their entry, and they can also keep glycogen full and sodium potassium ATPase functioning. Some have proposed that beta-hydroxybutyrate might be one such substrate, which might be utilized. In fact, this might be a key, because one of the problems that we have in sepsis is the fat/glucose switch.

The Fat/Glucose Switch

Traditionally, if fat is given, glucogenesis and proteolysis do not cease to occur in sepsis. A new type of hormone, if you will, was recently described by Cao and coworkers, which he identified as C16:1N7 palmito oleate that strongly stimulated insulin action in muscle and the liver as well. They called this molecule a cytokine and proposed a mechanism of action, which involves specific fatty acid-binding protein that then binds intracellular fatty acids and conveys them, as it were, to their ultimate cellular destination. Publication in *Cell* by Cao in 2008 excited enough that Olefsky, a well-known metabolic investigator, wrote a very favorable editorial as to the possibility that a lipokine might increase sensitivity in muscle and liver to insulin despite insulin resistance.

However, the sad part is that no one has been able to repeat what Cao published, and the status of lipokines is very much in doubt.

In summary, with respect to sepsis and cancer it will only be through our increased understanding of metabolism and what happens in these two diseases, to intracellular metabolism and to the interaction of different substrates and nutrients can we solve the problem of cancer cachexia and sepsis cachexia and maintain patients who are so afflicted.

CONCLUSION

There is little question that TPN and its introduction by Dudrick, followed by the unit at the Mass General Hospital, was a startling and remarkable advance in perisurgical care in patients who could not eat with some beneficial results. The enthusiasm of young surgeons, their involvement in TPN and the research they were doing, was really a wonderful thing to watch and be part of. Money was plentiful. TPN and nutrition and immunology were the hot topics. There is much work to be done in this field today particularly in cancer and sepsis and other proteolytic syndromes.

Suggested Readings

Antimicrobial prophylaxis for surgery. *Treat Guidel Med Lett* 2009;7(82):47–52.

Arozullah AM, Daley J, Henderson WG, et al. Multifactorial risk index for predicting postoperative respiratory failure in men after major noncardiac surgery. The national veterans administration surgical quality improvement program. *Ann Surg* 2000;232(2):242–53.

Aversa Z, Alamdari N, Hasselgren PO. Molecules modulating gene transcription during muscle wasting in cancer, sepsis, and other critical illness. *Crit Rev Clin Lab Sci* 2011;48:71–86.

Braga, M, Ljungqvist O, Soeters P, et al. ESPEN guidelines on parenteral nutrition: Surgery. *Clin Nutr* 2009; 28:378–86.

Cohen S, Nathan JA, Goldberg AL. Muscle wasting in disease: molecular mechanisms and promising therapies. *Nat Rev Drug Disc* 2015;14:58–74.

DAPT Score Calculator. http://www.daptstudy.org/for-clinicians/score_calculator.htm

Devereaux PJ, Goldman L, Cook DJ, et al. Perioperative cardiac events in patients undergoing noncardiac surgery: a review of the magnitude of the problem, the pathophysiology of the events and methods to estimate and communicate risk. *CMAJ* 2005;173(6):627–34.

Fleischmann KE, Beckman JA, Buller CE, et al.; American College of Cardiology Foundation/American Heart Association Task Force on Practice Guidelines. 2009 ACCF/AHA focused update on perioperative beta blockade. *J Am Coll Cardiol* 2009;54(22):2102–28.

Fleisher LA, Fleischmann KE, Auerbach AD, et al. 2014 ACC/AHA guideline on perioperative cardiovascular evaluation and management of patients undergoing noncardiac surgery: executive summary: a report of the American College of Cardiology/American Heart Association Task Force on Practice Guidelines. *Circulation* 2014;130(24):2215–45.

Futier E, Constantin JM, Paugam-Burtz C, et al. IMPROVE Study Group. A trial of intraoperative low-tidal-volume ventilation in abdominal surgery. *N Engl J Med* 2013;369(5):428–37.

Geerts WH, Bergqvist D, Pineo GF, et al. Prevention of venous thromboembolism: American college of chest physicians evidence-based clinical practice guidelines (8th Ed.). *Chest* 2008;133(6 Suppl):381S–453S.

Hasselgren PO. Ubiquitination, phosphorylation, and acetylation—triple threat in muscle wasting. *J Cell Physiol* 2007;213:679–89.

Hilditch WG, Asbury AJ, Jack E, et al. Validation of a pre-anaesthetic screening questionnaire. *Anaesthesia* 2003;58(9):874–7.

Holubar SD, Hedrick T, Gupta R, et al.; Perioperative Quality Initiative (POQI) I Workgroup. American Society for Enhanced Recovery (ASER) and Perioperative Quality Initiative (POQI) joint consensus statement on prevention of postoperative infection within an enhanced recovery pathway for elective colorectal surgery. *Perioper Med (Lond)* 2017;6:4.

Joshi GP, Amhad S, Riad W, et al. Selection of obese patients undergoing ambulatory surgery: a systematic review of the literature. *Anesth Analg* 2013;117(5):1082–91.

Koller SE, Bauer KW, Egleston BL, et al. Comparative effectiveness and risks of bowel preparation before elective colorectal surgery. *Ann Surg* 2017. doi: 10.1097/SLA.0000000000002159. [Epub ahead of print].

Lee TH, Marcantonio ER, Mangione CM, et al. Derivation and prospective validation of a simple index for prediction of cardiac risk of major noncardiac surgery. *Circulation* 1999;100(10):1043–9.

Nishimura RA, Otto CM, Bonow RO, et al.; American College of Cardiology/American Heart Association Task Force on Practice Guidelines. 2014 AHA/ACC guideline for the management of patients with valvular heart disease: executive summary: a report of the American College of Cardiology/American Heart Association Task Force on Practice Guidelines. *J Am Coll Cardiol* 2014;63(22):2438–88.

Shabanzadeh DM, Sørensen LT. Laparoscopic surgery compared with open surgery decreases surgical site infection in obese patients: a systematic review and meta-analysis. *Ann Surg* 2012;256(6):934–45.

Smetana GW, Macpherson DS. The case against routine preoperative laboratory testing. *Med Clin North Am* 2003;87(1):7–40.

Teh SH, Nagorney DM, Stevens SR, et al. Risk factors for mortality after surgery in patients with cirrhosis. *Gastroenterology* 2007;132(4):1261–9.

The Veterans Affairs Total Parenteral Nutrition Cooperative Study Group. Perioperative total parenteral nutrition in surgical patients *N Engl J Med* 1991;325:525–32.

von Haehling S, Anker SD. Treatment of cachexia: an overview of recent developments. *JAMDA* 2014;15:866–72.

EDITOR'S COMMENT

The authors of this chapter are international authorities in perioperative care, metabolism, and nutrition. We all know that high-quality perioperative management is essential. My commentary will focus on some of the practical aspects of this chapter including Checklists, Enhanced Recovery After Surgery Protocols, and mechanical bowel prep.

The concept of using a checklist in surgical and anesthetic practice was energized by publication of the WHO Surgical Safety Checklist in 2008. The checklist movement began with the recognition that adverse events in health care are estimated to result in more deaths in the United States annually than car crashes. In Great Britain, adverse events accounted for an additional 3 million days in the hospital on an annual basis. The magnitude of improvement demonstrated by the WHO pilot studies has been surprising. Haynes et al. (A surgical safety checklist to reduce morbidity and mortality in a global population. *N Engl J Med* 2009:360:491–9) reported the effect of the WHO checklist in eight hospitals worldwide. The data prospectively collected was in-hospital complications which occurred within the first 30 days after noncardiac surgery. There were 3,733 before the checklist was implemented and 3,955 patients after the checklist was being used. There were four hospitals with high-income settings and four with low-income settings. The mortality rate was reduced from 1.5% to 0.8% ($p < 0.003$) and complications were reduced from 11.0% to 7% ($p < 0.001$). These findings have been verified in other studies and it is generally accepted that checklists enhance patient safety. Checklists are currently employed in more than 4,000 hospitals in 122 countries.

One of the valuable and perhaps unexpected outcomes of using checklists has the positive impact on institutional culture. When successfully used a checklist brings the focus of health care on the patient and engenders teamwork. Also we have learned that implementing checklists is not that easy. It requires a

cultural change. Successful implementation requires ownership of the checklist by the entire health care team. The next generation of checklists is focused on emergency care and treatment.

I think the natural evolution of checklists has been the development of practice guidelines and most recently Enhanced Recovery After Surgery (ERAS) protocols. A recent Medline search conducted on May 29, 2017 on this subject generated over 3,500 publication in the last 10 years. There are ERAS protocols for almost all surgical procedures. These are put together by multidisciplinary teams including surgeons, anesthesiologist, internal medicine physicians, nursing, physical therapy, respiratory therapy, and patients. This in essence is a proactive and evidence-based postoperative care plan rather than a reactive plan based on personal preference and anecdote. Essential elements include preoperative glucose loading, a pain management plan, IV fluid volume reduction methods, prophylaxis for thromboembolism and postoperative infection, early ambulation, early enteric nutrition post op, and planning for postacute care (Mosquera C, Koutlas NJ, Edwards KC, et al. Impact of malnutrition on gastrointestinal surgical patients. *J Surg Res* 2016;205:95–101). ERAS protocols have resulted in reduction of hospital stays by 30% to 50% and similar decreases on postoperative complications.

When preparing for a marathon athletes “carbohydrate load” to reduce “breakdown of muscle.” Pogatschnik and Steiger (Review of preoperative carbohydrate loading. *Nutr Clin Pract.* 2015;30:660–4) reviewed carbohydrate hydrate loading. The current recommendation from the ERAS Society is to include preoperative carbohydrate–containing liquids (generally 12% carbohydrate in a maltodextrin form) prior to surgery. The rationale for this is that carbohydrate metabolism is greatly impacted by the fed state achieved by giving preoperative carbohydrate fluids prior to surgery in contrast to the traditional midnight preoperative fast. Carbohydrate-rich fluids enhance patient comfort prior to surgery. In addition they may reduce insulin resistance, reducing catabolism, resulting in improved perioperative glucose control and reduced muscle breakdown. However, the benefits of preoperative carbohydrate fluid loading are difficult to prove. Outcome is often more related to the type of surgery and other factors. The use of carbohydrate-loading protocols is appealing as it is simple and engages in patients. There is evidence from animal studies that carbohydrate loading increases spontaneous postoperative food intake, maintains the intestinal barrier function and muscle catabolism. No doubt further study is required. Preoperative carbohydrate loading is just one of the myriad of interventions linked to the success of ERAS protocols.

Pain management is a critical aspect of postoperative management. Pain management does not mean more narcotics. With the raging opioid epidemic in the United States, more emphasis has been placed on techniques to reduce perioperative narcotics. This includes liberal use of epidural techniques, neuroaxial opiates (intrathecal morphine), alternative to opiates such as anti-inflammatory medication to reduce inflammation and use of gamma-

aminobutyric analogs to reduce treat nerve pain, and nerve blocks. Transversus abdominal pain (TAP) block has been shown to be an effective method of postoperative pain control. Brogi et al. reported a systemic review and meta-analysis of this technique. (Brogi E, Kazan R, Cyr S, et al. Transversus abdominal plane block for postoperative analgesia: a systematic review and meta-analysis of randomized-controlled trials. *Can J Anaesth* 2016;63(10):1184–96.) They identified 51 trials and reported that compared with placebo, TAP block reduced the pain scores and morphine consumption. TAP block proved beneficial in gynecologic surgery, appendectomy, inguinal surgery, bariatric surgery, and urologic surgery. However, in separate studies comparing intrathecal morphine with TAP block revealed that the former seemed to have a greater analgesic efficacy. Reducing opiates at discharge is considered an essential element in fighting the opioid epidemic. Current guidelines suggest that at discharge patients should receive less than 200 mg oral morphine equivalents. A study by Thiel and colleagues, from the Mayo Clinic, reported at the annual meeting of the American Surgical Association in April 2017 is instructive in this regard. This study, based on the National Surgical Quality Improvement Program data, showed that 75.2% of 5,756 opiate naïve received greater than 200 OME at discharge. This indicates that we have a long way to go to achieve this goal. ERAS pain management programs may lead to more prescribing practices aligned with current opiate guidelines.

There has been much debate about the use of mechanical bowel preparation in colon and rectal operations. Do they reduce skin and soft tissue infection and anastomotic leak or do they create more problems with dehydration and associated complications. Indeed in the 6th edition of this text there was a statement that such a preparation was no longer necessary. We have come full circle in the last 5 years. There are increasing reports about the efficacy of mechanical bowel preparation and oral antibiotics in reducing anastomotic leak and wound infection. Rencuzogullari et al. (Predictors of anastomotic leak in elderly patients after colectomy: nomogram-based assessment from the American College of Surgeons National Surgical Quality Program Procedure-Targeted Cohort. *Dis Colon Rectum* 2017;60:527–36) assessed data from the National Surgery Quality Program to determine predictors of anastomotic leak in patients greater than 65 years. A total of 10,392 patients were analyzed, and anastomotic leak occurred in 332 (3.2%). Factors associated with an increased risk of anastomotic leak were “ASA score III and IV ($p < 0.001$), chronic obstructive pulmonary disease ($p = 0.004$), diabetes mellitus ($p = 0.003$), smoking history ($p = 0.014$), weight loss ($p = 0.013$), previously infected wound ($p = 0.005$), omitting mechanical bowel preparation ($p = 0.005$) and/or preoperative oral antibiotic use ($p < 0.001$), and wounds classified as contaminated or dirty/infected ($p = 0.008$).” Increasing evidence is accumulating that ERAS for colon and rectal surgery should include bowel prep and oral antibiotics.

As for the future, I predict that when the 8th edition of Mastery is published

that many more ERAS protocols based on the metabolic response to surgery and disease and the molecular basis of risk will be developed with widespread implementation.

E. Christopher Ellison

3 Enteral Nutrition Support

Keith R. Miller and Robert G. Martindale

INTRODUCTION

Clearly, pre-existing nutritional and metabolic deficiencies predispose patients to significant morbidity and mortality following major surgical insult and critical illness. Despite overwhelming acceptance of this principle, meticulous strategies regarding peri-operative nutrition support have not been widely adopted. The practicing surgeon must be able to consistently identify patients at increased nutrition risk and initiate appropriate nutrition support measures in order to optimize outcomes.

Enteral Nutrition

Dating to ancient Egypt and Greece, the importance of nutrition support during periods of illness has been appreciated. Early attempts to facilitate substrate provision in patients unable to tolerate volitional intake involved the colonic delivery of wine, eggs, and other foods via enemas. This practice continued into the late 19th century as nutrient enemas were given to President James Garfield following his assassination attempt from which he eventually succumbed 80 days after sustaining his injuries. These practices provided the foundation for the evolution of more proximal enteral access options to optimize absorption. Eel skin was utilized for the first reported “feeding tube” in 1598, followed by gastric feeding reports by John Hunter in 1790, and naso/orojejunal feeding tubes described by Ravdin and Stengal in 1939. Throughout this history, surgeons have been instrumental in the development of current enteral formulations as well as techniques utilized to obtain enteral access throughout the proximal gastrointestinal (GI) tract through increasingly less invasive means.

The enteral route remains optimal for the delivery of energy substrates. Oxygenation, perfusion, and substrate provision are fundamental requirements at the cellular, organ, and system levels. Macro and micronutrient absorption and incorporation are required for continual remodeling, tissue repair, and maintenance of structure and function.

Metabolic demand increases following surgery, burns, critical illness, and trauma to address increased requirements for tissue repair and to mount an appropriate inflammatory and reparative response to the insult. In addition to expertise in technical aspects of enteral access allowing for the delivery of nutrition support, surgeons have been instrumental contributors to our evolving understanding of the metabolic response to physiologic stress. Despite these contributions, nutrition support has remained an underemphasized and underutilized adjunctive measure in the care of the surgical patient. The last decade has seen resurgence in interest in critically examining the evidence supporting our nutrition support strategies. This increased scrutiny has culminated in significant recent contributions to the evidence available to assist with clinical decision making.

In the surgical, trauma, and critical care setting, increasing caloric deficits have consistently been demonstrated to be associated with poor outcomes, likely at least in part by serving as a marker for disease severity. Traditional objectives in nutrition support have involved emphasis on adequate provision of protein and calories in order to preserve lean body mass and to prevent metabolic complications associated with prolonged macro- and micronutrient depletion. There has been a recent paradigm shift as the focus has now become a multimodality approach composed of appropriate nutrition therapy, adjuncts to modulate the immune and metabolic response, and the prevention and treatment of oxidative cellular injury. The acknowledgment that nutrition support strategies can result in improved outcomes should also remind the clinician that inappropriate strategies can result in significant harm.

NUTRITION ASSESSMENT

The concept of nutrition risk has emerged over the last decade, replacing older categorizations of malnutrition. Malnutrition has proven to be exceedingly difficult to define in a meaningful way, and current definitions encompass distinctions for acute and chronic illness. The primary objective of nutrition assessment is to allow for identification and stratification of patients at risk for poor outcomes as a result of pre-existing nutritional status. Nutrition risk takes into account both pre-existing nutritional status in addition to disease severity. As will be discussed, there are significant limitations inherent in the available nutrition assessment tools and none are considered perfect. The ability to appropriately identify patients at nutrition risk is more important for the

practicing surgeon than the ability to assign an overall severity of malnutrition. The rate limiting step in the identification of nutrition risk is most commonly the surgeon's willingness to utilize any of the available tools in clinical practice.

Anthropometric and Body Composition Assessment

Although methods for the assessment of body composition have been developed, they are generally expensive, invasive, and inconvenient with limited applicability in the hospital setting. Anthropometrics involve the attempted quantification of body composition through multiple pre-determined measurements. Body weight and height are the most commonly obtained parameters and allow for determination of body mass index (BMI) expressed in kg/m^2. Increased morbidity and mortality are associated with both ends of the BMI spectrum, particularly <20 and >40. Dry weight, or usual weight, should be used in the setting of organ insufficiency to improve overall validity.

Skin fold thickness assessment (with the use of calipers) and mid-arm circumference (MAC) measurements have been used as surrogates for determining body fat composition. Bioelectric impedance (BIA) estimates fat-free mass by determining differences in electrical conductivity (as muscle has far greater conductivity than fat) as a current is transmitted through various tissues. The two predominant drawbacks in using either BIA or anthropometrics in the clinical setting include significant inter-observer variability and the fluid shifts and peripheral edema associated with resuscitation, capillary leak, and organ failure. Although useful in study populations, these tools are of little to no value in the hospital setting.

There has been recent enthusiasm surrounding the utilization of information derived from computed tomography (CT) and ultrasound as tools to assess body composition. With CT, quantification of lean body mass in a standardized fashion at the level of the third lumbar vertebrae (psoas) can now be relatively accurately determined through the utilization of varying tissue densities associated with adipose and muscle tissue. Diminished lean body mass, as calculated using these methods, has been demonstrated to be associated with poor outcomes in critically ill and cancer patients irrespective of BMI and other traditional measures. The lean body tissue using axial CT at L3 has been shown to be the best predictor of outcome for the majority of visceral malignancies. Ultrasound

has become readily accessible in the majority of intensive care units (ICUs), and attempts have been made to standardize techniques for evaluating muscle content in the thigh. Because of the relative commonality of CT imaging in surgical practice and availability of ultrasound, this will likely become increasingly more important as a component of nutrition assessment.

Functional Tests

Poor global functionality prior to insult will clearly yield poor outcomes. Much of the information relevant to functionality can be elicited during the history component with simple questions regarding ability to walk up a flight of stairs and involvement in activities of daily life. Muscle strength should be subjectively assessed at the bedside. Additional traditional adjuncts including hand dynamometry and immune competence testing have significant limitations and are not widely incorporated. Hand dynamometry correlates with functional recovery following critical illness but requires patient cooperation for assessment. Immune competence, as measured by delayed-hypersensitivity skin tests and lymphocyte counts, is subject to multiple confounding issues in the surgical and ICU populations and is of limited utility. Elements relevant to functional status should be noted acknowledging the patients baseline status (from history) in conjunction with bedside assessment of muscle strength and there is little gained from additional testing.

BIOCHEMICAL ASSESSMENT

Serum Creatinine and Nitrogen Balance Studies

Serum creatinine can provide some insight into the overall lean body mass as lower values can be attributed to lower muscle mass. Collection of urinary creatinine over 24-hour periods can be used to calculate creatinine-height index (CHI) based on the assumption that 20 kg of muscle is required to produce 1 g of creatinine. Given the multiple confounders associated with serum creatinine (dietary intake and renal insufficiency) and difficulties in accurate 24-hour collection, these variables provide limited information in the surgical population and values must be considered individually within the clinical context to have any value.

Amino acid metabolism and protein catabolism result in the production of nitrogen that is subsequently eliminated in the urine (urea). Urinary urea

nitrogen can then be collected over a 24-hour period and compared to intake in order to estimate nitrogen balance. A positive balance (2 to 4 g/day) would suggest whole body anabolism, and negative balances would be indicative of ongoing catabolism. Nitrogen balance g/day = (protein or amino acid intake/6.25) - (UUN + 4).

Additional estimates for insensible losses are included in the equation and are prone to inaccuracy in the setting of increased nitrogen losses (large wounds, high output fistulas/ostomies, and diuresis). Due primarily to these issues regarding accuracy of nitrogen intake and losses, nitrogen balance studies have significant limitations in clinical practice.

Serum Proteins

Because of the relative ease of obtaining visceral protein levels such as serum albumin, pre-albumin, transferrin, and retinol-binding protein, these parameters have unfortunately become synonymous with the biochemical assessment of nutritional status. In fact, they are merely surrogate markers for nutritional status and may better be surrogate markers indicative of ongoing inflammation. However, in the preoperative state, these values remain powerful prognostic indicators of surgical outcomes as demonstrated in the large VA Cooperative trial. Accurate biochemical markers for the sole assessment of nutrition risk have proven elusive. The evaluation of serum protein concentrations must consider synthesis, degradation, and distribution all of which can be impacted by the clinical context in which they are measured. Albumin serves several key physiologic functions including maintenance of colloid oncotic pressure, transportation of fatty acids, bile acids, cholesterol and metal ions, and has antioxidant potential. The half-life of albumin is 20 days, whereas pre-albumin has a half-life of 48 hours. This shorter half-life has led to pre-albumin becoming the more commonly assayed parameter in the settings of preoperative nutrition support and in the ICU.

The relevance of serum proteins to nutritional status must be viewed skeptically. Distribution is impacted by volume shifts from the intravascular to extravascular spaces, and hepatic reprioritization markedly alters synthesis. Hepatic reprioritization describes increased synthesis of acute phase proteins (such as C-reactive protein, fibrinogen, and alpha 1-antitripsyn), while the synthesis of constitutive proteins such as albumin (so called negative acute phase reactants) is decreased. Protein synthesis generally returns to baseline over several days following the insult unless

additional insults are incurred. In fact, serial monitoring of CRP: prealbumin ratios can often allow clinicians to anticipate the onset of secondary infectious complications in the hospital setting prior to overt symptomatology.

Nutrition Assessment Tools

Given the limitations discussed above, the history and physical examination remain the cornerstones of nutritional assessment. Multiple bedside tools have incorporated within their framework nutrition-specific variables in order to organize relevant parameters. Included in nearly every nutrition screening set are questions concerning unintentional weight loss and dietary tolerance. Unintentional weight loss, regardless of BMI, >5% (over the preceding month) or >10% (preceding 6 months) is the single most important factor in the assessment of nutrition risk.

In an attempt to organize these components, a multitude of nutritional assessment tools (SGA, MUST, NRS, etc.) have been developed and are composed of history and physical elements specific to nutrition risk. Unfortunately, many of these existing tools are complex, exhaustive, and unusable in clinical practice. However, the NRS-2002 is relatively easily applied and is composed of a nutritional impairment section (score 0–3) in addition to severity of disease section (score 0–3) resulting in a total score between 0 and 6 (Fig. 3.1). The NRS-2002 has been validated both in the perioperative setting and in critical illness as a predictor of morbidity and mortality. In the elective surgery setting, the magnitude of the surgical insult is considered a surrogate for disease severity as longer, more invasive procedures result in more dramatic metabolic alterations. By applying the NRS-2002 in both the hospital and outpatient settings, resources and time wasted on historical nutrition assessment maneuvers (body composition analysis, nitrogen balance studies, etc.) can better be dedicated to the development of individualized nutrition support strategies commiserate with nutrition risk.

Summary: Nutritional Assessment of the Surgical Patient

A thorough nutrition assessment in the surgical ICU includes one of the earlier described tools, composed primarily of physical examination and dietary history in conjunction with injury severity assessment. In the outpatient and elective surgery setting, a serum albumin should be obtained as well. Despite the problems associated with using albumin

following physiologic insult, albumin remains an excellent and inexpensive marker and has been demonstrated to share a nearly direct linear correlation with risk of major complication and death following surgery.

METABOLIC ALTERATIONS FOLLOWING INSULT

Severe illness is characterized by hypermetabolism, catabolism, and immune dysregulation, and metabolism during these periods differs markedly from times of health. Multiple factors contribute to this individualized response, including age, gender, genetic influences, body habitus, functional status, and pre-existing nutritional status. Seemingly similar insults can result in markedly different magnitudes of response in different individuals. In order to mount and sustain this response, readily available fuels are rapidly exhausted and there is reliance upon mobilization of endogenous fuel sources composed of protein, glycogen, and adipose. In addition, micronutrients are utilized quickly serving as co-factors in multiple biochemical processes and decreased serum levels are observed during critical illness. Readily available calories are minute (113 calories), as Cahill described 40 years ago. The largest caloric reservoir resides in visceral and peripheral adipose, but access to these stores varies markedly depending upon the presence (critical illness) or absence (starvation) of underlying inflammatory processes.

Fuel Utilization: Starvation Versus Hyperdynamic States

In the absence of exogenous fuel source, glycogenolysis (primarily from the liver) occurs in the first 2 to 4 hours in order to sustain obligate glucose dependent tissues. Additional energy is provided from mobilization of lean body mass that yields gluconeogenic substrates. Proteolysis, characterized by increasing urinary urea nitrogen, peaks during days 2 to 10 in the setting of starvation and replaces glycogen as the source of glucose, via gluconeogenesis. There are concomitant increases in lipolysis and ketogenesis that serve as the predominant energy sources due, in part, to alterations in insulin–glucagon ratios. Proteolysis subsequently decreases during the prolonged protein conservation stage of starvation. The central nervous system transitions to the use of fatty acids and ketones derived from adipose stores. The rate of weight loss is greatest during the first several days of starvation and stabilizes over the following days and weeks as resting energy expenditure (REE) decreases. The objective of these

underlying mechanisms is the avoidance of lean body mass mobilization and reliance upon endogenous fat stores for the provision of energy during prolonged starvation.

Following stress, there are significant changes in metabolism when compared to the state of unstressed starvation. This classically described response is characterized by increased circulation of mediators, including cortisol, ACTH, epinephrine, glucagon, growth hormone, and inflammatory cytokines. Liver synthetic activity increases as acute phase reactants are upregulated. REE increases substantially, peaks at 10 to 12 days following severe insult, and can remain persistently elevated for weeks following the insult before returning to baseline. The hypermetabolic response is characterized by fevers, increased oxygen and glucose consumption, accelerated proteolysis, insulin resistance, hyperglycemia, and increased oxidative stress.

Glycogen, during periods of stress, is rapidly mobilized and utilized within the first 4 to 6 hours. Gluconeogenesis continues at an accelerated pace, primarily from protein conversion to carbohydrate resulting in rapid and prolonged loss of lean body mass in the setting of persistent insult. Increased levels of glutamine and alanine are released from the muscle diverting glutamine to the GI tract and alanine to the liver for gluconeogenesis. Hyperglycemia results from accelerated gluconeogenesis and relative peripheral insulin resistance resulting in decreased peripheral glucose uptake. Increasing insulin resistance has been demonstrated relative to the severity or magnitude of surgical insult (laparoscopic vs. open interventions) as well. Additional protein is sacrificed in order to provide amino acids for the production of acute phase reactants (CRP, transferrin, cytokines, etc.), and visceral protein synthesis is downregulated resulting in rapid reductions in serum albumin. Due largely to advances allowing for rescue of patients in the setting of acute illness, prolonged critical illness has become increasingly common as patients continue to utilize protein at the expense of lean body mass. This prolonged state of catabolism has resulted in patients seemingly recovering from their initial injuries only to eventually succumb in long-term acute care facilities long after their initial injuries. Unfortunately, the triggers that induce the shift toward adipose utilization during periods of unstressed starvation have yet to be fully elucidated. This explains the inadequacy and futility of simple caloric provision in the setting of prolonged critical illness and suggests that a multimodality approach consisting of physical

therapy (resistance exercise), glycemic control, and substrate provision to be a more beneficial approach.

Nutrition Assessment - Nutrition Risk Screening (NRS 2002 System)*

Initial Screening

BMI <20.5?	Yes	No
Weight loss in last three months?	Yes	No
Reduced dietary intake in past week?	Yes	No
Severe illness?	Yes	No

Final Screening (Complete if "yes" to any of above questions)

Part I Impaired Nutritional Status

Absent	Score 0: Normal nutritional status
Mild	Score 1: Wt loss >5% in three months or food Intake <50–75% normal in last week
Moderate	Score 2: Wt loss >5% in last two months or BMI 18.5–20.5 Or food intake <25–50% normal in last week
Severe	Score 3: Wt loss >5% in last month (>15% in last 3 mos) Or BMI < 18.5 + impaired general condition Or food intake 0–25% normal in last week

Part II Severity of Disease

Absent	Score 0: Normal nutritional requirements
Mild	Score 1: Hip fracture, chronic patients (hemodialysis, diabetes, cancer, cirrhosis, COPD) with acute complication
Moderate	Score 2: Major abdominal surgery, stroke, severe pneumonia, hematologic malignancy
Severe	Score 3: Head injury, bone marrow transplantation, APACHE II score >10

Total Nutritional Risk Score

Part 1 Impaired NS score____ + Part II Severity of Disease Score____ + 1 (if age >70)____ = _____Total
[If total of 3 or more, nutritional support is indicated]

Consider Disease Severity and Comorbidities

Severity of Illness: Calculate score, as indicated by patient ICU admitting diagnosis
APACHE II, SOFA, Ranson, ISS,

Pre-existing conditions:

Diabetes mellitus?	Yes	No	If yes, carefully target glucose control
Liver Dysfunction?	Yes	No	If yes, carefully monitor protein tolerance
Renal Dysfunction?	Yes	No	If yes, carefully monitor protein tolerance
Alcohol abuse and related malnutrition?	Yes	No	If yes, carefully monitor for refeeding syndrome
Drug abuse and related malnutrition?	Yes	No	If yes, carefully monitor for refeeding syndrome

Determining Energy Requirements

Indirect Calorimetry if available:

Calories:

BMI <30:	**Use 25–30 kcal/kg ABW/day _____ kcal**	**ABW = Actual Body Weight**
BMI 30–50:	**Use 11–14 kcal/kg ABW/day _____ kcal**	**IBW = Ideal Body Weight**
BMI >50:	**Use 22–25 kcal/kg IBW/day _____ kcal**	

Protein:

BMI <30:	**Use 1.5–2.0 gm protein/kg ABW/day _____ gms protein**
BMI 30-40:	**Use 2.0 gm protein/kg IBW/day _____ gms protein**
BMI >40:	**Use 2.5 gm protein/kg IBW/day _____ gms protein**

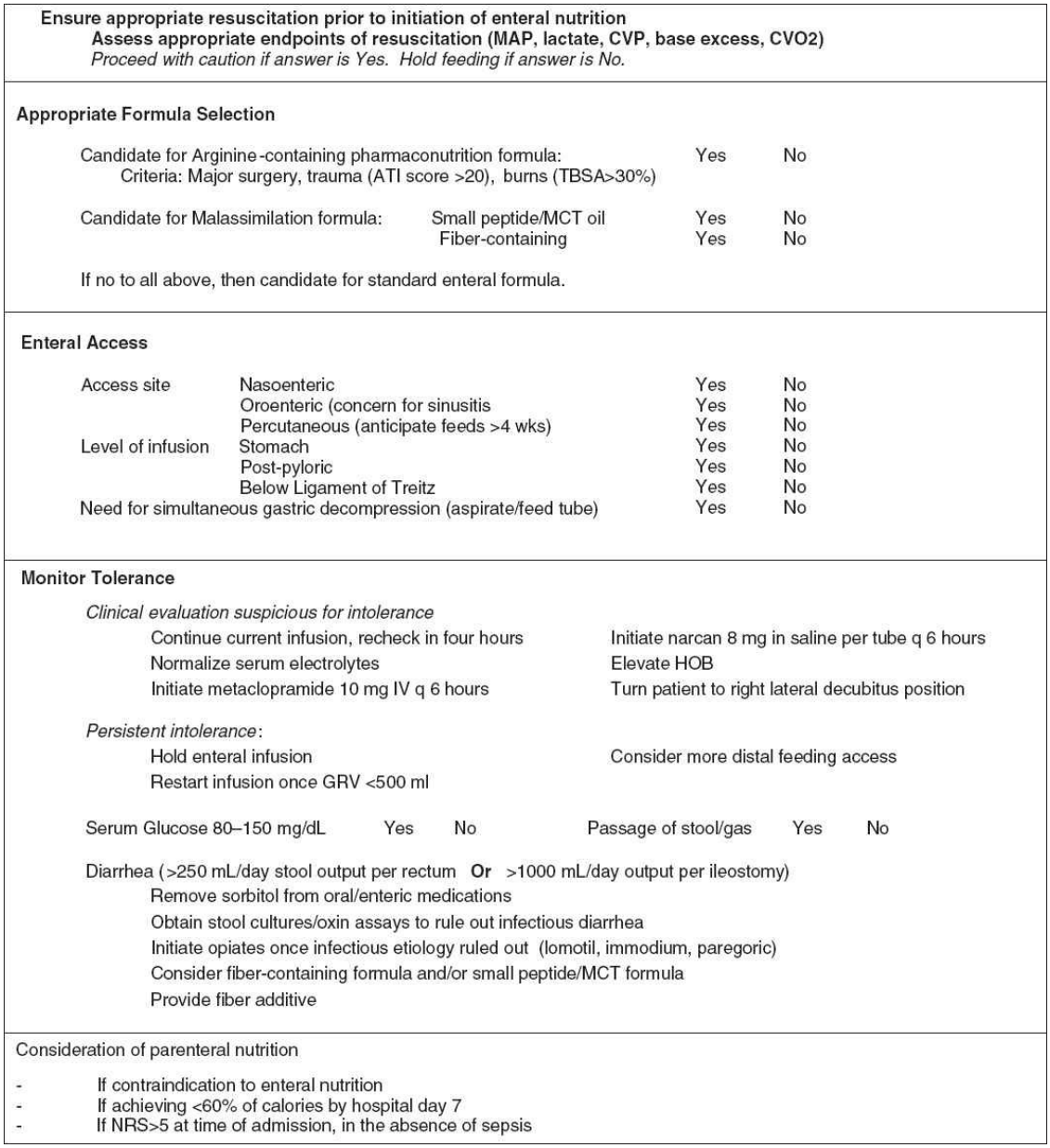

Figure 3.1. Synopsis of nutrition support algorithm. (Adapted from Miller KR et al. "Can we feed. "CAN WE FEED?" A Mnemonic to Merge Nutrition and Intensive Care Assessment of the Critically Ill Patient *JPEN J Parenter Enteral Nutr* 2011;35(5):643–59; copyright © 2011 by SAGE Publications, Inc; reprinted by Permission of SAGE Publications, Inc.)

ENERGY AND PROTEIN REQUIREMENTS

The determination of energy requirements has traditionally involved provision of substrate in quantities that meet resting energy requirements (REE) in addition to supplemental calories to address hypermetabolic alterations associated with illness. The traditional objective of substrate provision is to avoid the relentless assault upon lean body mass for energy

utilization. Unfortunately, the metabolic alterations discussed above limit the efficacy of simple exogenous substrate provision with regard to fuel utilization. Although appropriate caloric and protein dosing remain controversial, recent observational studies have suggested that 80% of goal calories is optimal with protein delivery up to 2.0 or 2.5 g/kg/day in the setting of major surgery and surgical critical illness.

Caloric Requirements

REE refers to the amount of energy (in kcal) required for ongoing function over a 24-hour period during the resting state. The gold standard for the determination of REE is indirect calorimetry (IC). IC involves the determination of REE through measurement of carbon dioxide production and oxygen consumption during steady-state conditions. Experienced personnel, cost, and patient confounders (high FiO_2 requirements, chest tubes, inability to achieve steady state) somewhat limit the applicability of IC. For these reasons, multiple predictive equations based predominately on body weight have been developed to assist in the determination of energy requirements. Predictive equations, although easily applied, have limitations including the tendency to overestimate caloric requirements. In the absence of these equations, estimates can generally be determined for short-term therapy simply by multiplying 25 to 30 kcal by ideal body weight in kilograms to determine caloric needs. Because of the inaccuracy of predictive equations when compared to IC in the setting of obesity, hypocaloric feeding strategies (60% to 70% of goal) are generally preferred. Current American Society of Parenteral and Enteral Nutrition (ASPEN) guidelines suggest, in the absence of IC, 11 to 14 kcal/kg/day of actual body weight (ABW) in patients with a BMI 30 to 50, and 22 to 25 kcal/kg/day of ideal body weight (IBW) in patients with BMI >50.

Protein Requirements

The recommendation for healthy unstressed adults is as least 0.8 g/kg per day but surgery or metabolic stress can result in substantial increases in protein requirements. The minimum amount of protein provided would ideally achieve nitrogen balance, although this is exceedingly difficult in critical illness and difficult to measure accurately. According to the recent ASPEN/SCCM guidelines, 1.5 to 2 g/kg of protein is recommended in the setting of critical illness and following major surgery. Recent data since the Guideline publications have shown fairly conclusive evidence to

support increasing the protein intake in severely stressed to up to 2.5 g/kg/day. In obese patients, targets should be 2 (BMI 30 to 40) to 2.5 mg/kg/day (BMI >40). Protein should rarely be withheld in the setting of organ failure or to prevent the need for dialysis in critically ill patients and, in fact, increased protein replacement (2.5 g/kg/day) is recommended in the setting of continuous renal replacement therapy due to substantial amino acid losses.

MACRONUTRIENTS: ABSORPTION AND UTILIZATION

The body is composed of 55% to 60% fluids with the majority of this being intracellular fluid. The solid component, consisting of roughly 30 kg in the 70-kg man with minimal body fat, is composed of 15-kg protein, 10-kg lipids, 3 kg of minerals, and 2 kg of carbohydrates. Each of these macronutrients is utilized in the maintenance of structure and ongoing function and has unique properties that determine the complexity by which they are absorbed and incorporated.

Carbohydrate

Carbohydrates yield 4 kcal/g of energy and are available for rapid utilization. Carbohydrate provision should be optimized to result in sparing of protein without resultant hyperglycemia. In addition to energy provision, carbohydrates are important in membranes as glycoproteins and glycolipids, as well as in the carbon backbone of lipid and nonessential amino acids. Carbohydrate is stored as glycogen that is housed in the liver, skeletal muscle, and cardiac muscle. Glycogen stored within the liver is most readily accessible and is the only systemically available free glucose source. Because of the absence of the enzyme glucose 6-phosphatase (the final step of glycogenolysis), muscle glycogen is used primarily by the muscle itself and is not readily available to other tissues.

Dietary carbohydrates consist of mono- and disaccharides, in addition to large molecular weight polysaccharides such as starch and glycogen. Fibers are large, indigestible sugars. Enteral formulas contain both simple sugars and starches, and these contribute to osmolality, sweetness, and digestibility. In general, the larger molecular weight carbohydrate molecules (e.g., starch) exert less osmotic pressure and require more digestion prior to absorption than simple sugars.

Enterocytes absorb carbohydrate exclusively as monosaccharides. The predominant three carbon sugars are glucose, galactose, and fructose, and

absorption occurs via multiple glucose transporters. Larger sugars require complete digestion in the intestinal lumen before absorption can occur. Starch and glycogen are substrates for the endosaccharidase α-amylase, which is secreted from the pancreas (and less so in the saliva) in response to a large intake of starch. The di- and oligosaccharides arising from α-amylase digestion are further broken down to monosaccharides by enterocyte surface saccharidases. Fiber in the diet is available as soluble and insoluble, but both are indigestible carbohydrate that occur naturally in food and cannot be broken down by the above enzymes in the small bowel. These soluble oligosaccharides remain unaltered through the proximal GI tract until fermented by colonic flora (e.g., bifidobacteria) producing lactate, acetate, butyrate, and other short chain fatty acids (SCFAs). SCFAs not only serve as the primary fuel source of the colonocyte but have recently been shown to have major regulatory influence on the maintenance of not only mucosal integrity but immune function. The additional byproducts of fermentation (lactate, acetate) assist in the maintenance of a suitable local environment within the GI lumen promoting proliferation of microbiome, which deters proliferation of pathogenic bacteria (*Clostridium difficile*) or the conversion to a "pathobiome."

Protein

Protein provides 3.5 kcal/g when utilized as an energy source, but no storage form of protein exists and all protein should be considered functional. Total body protein accounts for only 15% to 18% of body weight in a healthy man. Proteins and amino acids serve as enzymes, hormones, neurotransmitters, immunoglobulins, transporters, and are components of essential cell function including receptor binding, transport systems, and contractile elements. Obligate protein turnover rates of 2.5% of total body protein occur daily in adulthood, and these rates decrease with aging.

Protein intake is composed largely of intact protein, some free amino acids and peptides, and endogenous proteins. Protein digestion within the GI lumen is "incomplete" resulting in a mixture of free amino acids and oligopeptides with much of the subsequent conversion to free amino acids occurring within the luminal epithelial cell. Di/tripeptides, primarily in the proximal small bowel, are transported via the peptide transporter PEPT1 into the enterocyte accounting for the majority of protein uptake from a

meal, with individual amino acid transporters accounting for a lesser role. In addition to intake, significant protein recycling occurs arising from saliva, gastric, biliary, pancreatic, intestinal secretions as well as desquamated epithelial cells of the GI tract and can account for reabsorption of 50 to 60 g of protein per day.

Lipids

Complete oxidation of lipids results in 9 kcal/g, and adipose is the major metabolic energy reserve with an estimated 140,000 calories in a 70-kg male. In addition to serving as a storable energy source, lipids are integral in cell membrane structure due to their nonpolar and hydrophobic properties and are required for absorption of fat soluble vitamins (D, E, A, K). Lipids serve as lubricants for body surfaces, joints, and mucous membrane and are precursors for prostaglandin synthesis, thereby playing key roles in cell signaling, gene expression, and inflammation.

Following absorption, lipids are eventually stored (lipogenesis) or utilized for energy via ketogenesis or lipolysis. Beta-oxidation results in the production of fatty acyl-CoA in the outer mitochondrial membrane, which is then transported via a carnitine carrier to the inner membrane. Ketogenesis is generally triggered in the absence of available glucose to serve as an alternative fuel source and occurs primarily in the liver. Finally, lipogenesis is triggered by increasing mitochondrial concentrations of acyl-CoA derivatives (malonyl-CoA), thereby shunting acetyl-CoA to fatty acid and triglyceride synthesis and secretion from the liver as very low density lipoproteins (VLDLs) for storage.

In contrast to carbohydrates and proteins, lipids are poorly soluble in aqueous solutions and require several steps in order to transition from the GI tract to the blood for utilization. Because of these complexities, lipid absorption is particularly vulnerable during periods of altered physiology and illness. Dietary lipids are characterized by the relative length of the fatty acid chains linked to the glycerol backbone. Although long chain triacylglycerols (LCTs) have received recent scrutiny for poor utilization during periods of hypermetabolism and pro-inflammatory potential when given through the parenteral route, they are required for the provision of the essential fatty acids, linoleic and linolenic acid. Medium chain triglycerides (MCT), derived from tropical oils, have increased solubility relative to LCTs, are rapidly hydrolyzed, and require minimal pancreatic lipase or bile salts for absorption. MCTs can be transported via the

lymphatics or directly transported into the portal vein and do not require acyl-carnitine to cross mitochondrial membranes to be available for beta-oxidation.

Lipids encounter gastric lipase in the stomach and enter the proximal small intestine as small droplets. Pancreatic and biliary enzymes including lipase and co-lipase work at the oil–water interface in order to liberate free fatty acids and mono-acylglycerol. Phospholipase (phospholipids) and cholesterol esterase (cholesterol) activity forms mixed micelles that are then transitioned into the enterocyte via both passive uptake and carrier-mediated transport. Re-esterification occurs rapidly within the enterocyte forming triacylglycerol, phospholipids, and cholesterol esters in order to maintain low intracellular concentrations of free fatty acids to promote continued diffusion of fatty acids into the cell from the GI lumen. Re-esterified lipids are then transitioned into the endoplasmic reticulum and leave as VLDL or chylomicrons.

Vitamins and Minerals

Vitamins and minerals (trace elements) are essential substances that are not metabolized to carbon dioxide and water, unlike macronutrients, but instead facilitate and serve as cofactors in chemical reactions. Vitamins E, C, and β-carotene serve as nonenzymatic antioxidants and selenium, zinc, manganese, and iron facilitate enzymatic scavenger systems including superoxide dismutase, catalase, and glutathione peroxidase. The 13 essential vitamins include 8 B vitamins, ascorbic acid (C), and the fat soluble vitamins (ADEK). Vitamins and minerals are absorbed at various locations within the GI tract and predominately excreted in the kidneys. Deficiencies are often difficult to identify but can have catastrophic consequences when not recognized. Patients who have had major upper tract surgery, undergone bariatric surgery, or have significant loss of absorptive capacity (short gut) are the most common surgical patients in which vitamin deficiency is noted and must be monitored for.

ENTERAL NUTRITION

Benefits of Enteral Nutrition

Despite significant advances in parenteral support, enteral nutrition support remains the preferred nutrition support option in the hospitalized patient. Historically, when compared to parenteral nutrition, enteral

nutrition has resulted in improved patient outcomes with regard to morbidity, mortality, and cost and remains the route of choice in hospitalized patients. The objectives inherent in enteral support have transitioned from simple caloric and protein provision (nutrition support) to include the "nonnutritional" benefits (nutrition therapy) (Fig. 3.2). The GI tract serves as an internal integumentary system providing separation from the external environment (intraluminal toxins/bacteria) and this barrier function is essential to maintenance of homeostasis. In the absence of substrate within the GI lumen, villous atrophy and thinning of visceral mucous layers occur, which can be reversed with the provision of enteral nutrition. Physiologic stress can result in relative or absolute gut ischemia contributing to barrier function porosity, uncoupling of tight junctions, and increased permeability. Disruption in this barrier can result in translocation of bacterial cell wall fragments, free bacterial DNA, and cellular debris resulting in downstream activation of inflammatory cascades. The GI tract is a massive immunologic organ and contains approximately 60% of the body's immunoglobulin-producing cells with 80% of manufactured immunoglobulin secreted across the GI tract. The GI tract houses a significant proportion of our microbiome, and the GI ecosystem can be substantially disrupted during periods of illness resulting in increased virulence and pathogenicity of organisms. In addition to the underlying illness, many common medications including antibiotics, "GI prophylaxis" medications (H2 antagonists, PPIs), and opiates can contribute to bacterial overgrowth and alterations of the microbiome. Provision of enteral nutrition has been demonstrated to reduce permeability and membrane disruption, increase respiratory and GI IgA levels, attenuate the inflammatory cascade, and reduce bacterial virulence. Many of these nonnutritional benefits are likely achieved even in the absence of traditional "full caloric" support.

Contraindications

Contraindications to enteral nutrition support are few but must be recognized to prevent potentially catastrophic consequences. Bowel obstruction, loss of bowel wall integrity, persistent profound shock, acute peritonitis, GI ischemia, and inability to obtain enteral access are among accepted contraindications. Relative contraindications include high output fistula and paralytic ileus. GI intolerance, although often difficult to characterize, should not be considered an absolute contraindication to

enteral nutrition and can usually be addressed in a multimodal fashion to facilitate successful enteral support.

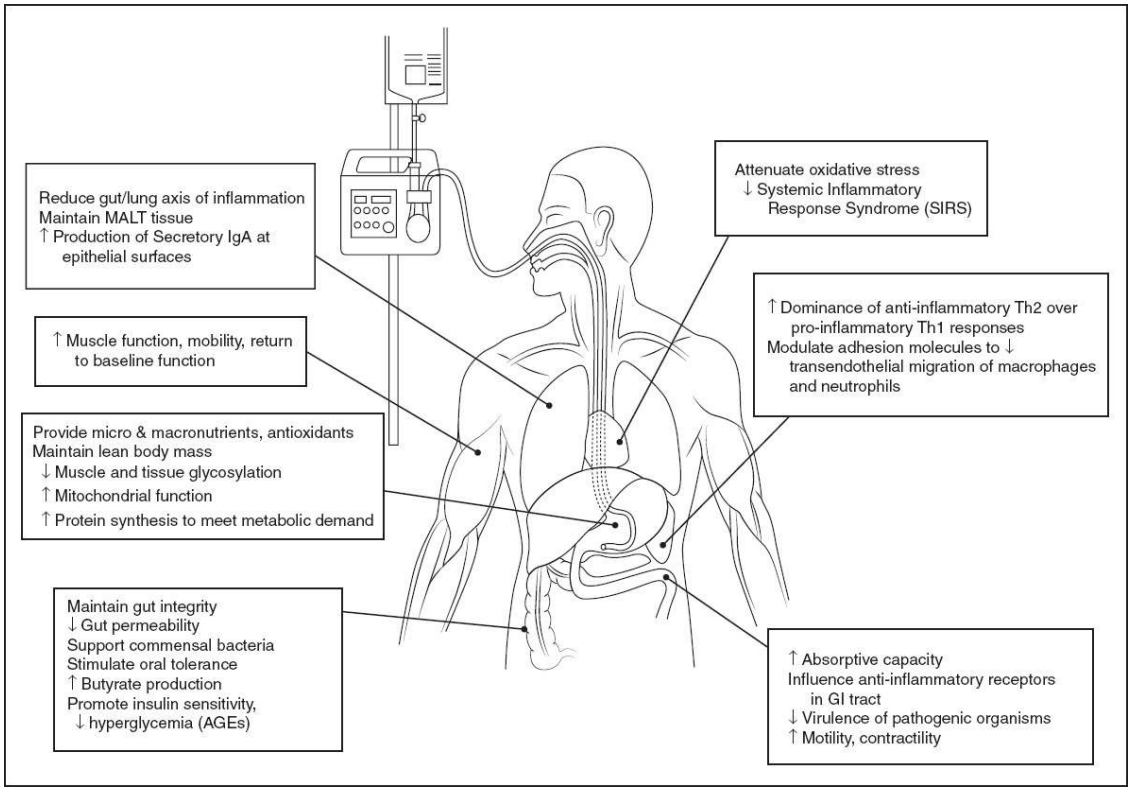

Figure 3.2. Benefits of enteral nutrition support. (From McClave SA, Martindale RG, Rice T, et al. Feeding the critically ill patient. *Crit Care Med* 2014;42(12):2600–10; with permission from Wolters Kluwer Health, Inc.)

Enteral Access

Enteral access is essential to successful nutrition support strategies and has become a multidisciplinary endeavor. A stepwise approach is appropriate in the hospital setting and is initiated with less invasive techniques such as naso/oroenteric access options. These large-bore tubes can also be utilized for decompression in the acute setting and later transitioned to feeding conduits. Various techniques are available for advancement of these tubes in a post-pyloric fashion and can be performed at the bedside with good success. In the event that longer access is required (typically >4 weeks), percutaneous access should be considered and is attainable in the stomach and jejunum via endoscopic and radiographic approaches. Surgical access remains exclusively within the domain of the surgeon and is now reserved only for the most complex patients where less invasive measures are prohibitive. When laparotomy is performed in the setting of critical illness,

the operating surgeon should always at least consider concomitant placement of enteral access via the appropriate route. As will be discussed later, careful risk–benefit analysis is imperative prior to surgical access procedures as they are not without complication (Table 3.1).

Administrative Methods of Enteral Nutrition

The administration of enteral nutrition support involves determining timing, level of infusion, dose and duration, and assessment of tolerance. Dosing has previously been discussed. The establishment of enteral nutrition support protocols has consistently demonstrated benefit with regard to caloric provision and should be adopted in order to address commonly encountered issues.

Timing of Initiation

It is generally accepted that the earlier enteral nutrition support is initiated, the better the outcomes with regard to the length of hospitalization and infectious complications. Much of this outcome has been attributed to the "nonnutritional" benefit of enteral nutrition discussed earlier including maintenance of barrier function and attenuation of the downstream inflammatory response. Early initiation has been recognized as within the first 24 to 48 hours following admission. This is most difficult in critically ill patients, and this may very well be the population where the impact is greatest. Initiation of enteral nutrition support should follow appropriate resuscitation and is generally avoided during periods of central hemodynamic instability or suspicion for splanchnic hypoperfusion. Permissive underfeeding strategies are easily implementable in the ICU and generally well-tolerated.

TABLE 3.1 Access Options in the Hospitalized Patient

Tube Type	Absolute Contraindications	Advantages	Disadvantages	Complications
Large bore Nasogastric/ Orogastric	Certain facial fractures/trauma	Avoid sedation Allows decompression	Blind placement Patient discomfort	Nasal septum necrosis, Tube malposition/ occlusion, Vocal cord paralysis Sinusitis, Tracheobronchial intubation, pneumothorax
Blind Nasojejunal Feeding Tubes	Certain facial fractures/trauma	Avoid sedation Cost Reduced aspiration	Blind placement Patient discomfort	Nasal septum necrosis, Malposition, Tube occlusion, Vocal cord paralysis Sinusitis, Tracheobronchial intubation, pneumothorax
Endoscopic Nasoenteric Tubes	Inability to pass the endoscope	Visual confirmation	Endoscopy Conscious sedation	Nasal septum necrosis, Tube occlusion Vocal paralysis, Sinusitis Scope trauma (perforation)
Percutaneous Endoscopic Gastronomy	Inability to pass the endoscope Relative: ascites, severe neutropenia	Long-term access	Endoscopy Conscious sedation	Bleeding, leakage, ulceration, inadvertent organ injury (colon, liver), peristomal wound infection, tube dislodgement, gastrocolic fistula, scope trauma (perforation)
Percutaneous Endoscopic Jejunostomy	Inability to pass the endoscope Relative: ascites, severe neutropenia	Long-term access Distal feeding	Endoscopy Conscious sedation	Bleeding, leakage, ulceration, inadvertent organ injury (colon, liver, small bowel), peristomal wound infection, tube dislodgement, scope trauma (perforation)
Radiologic Gastronomy	None	No endoscopic access required	Limited availability Conscious sedation	Bleeding, leakage, ulceration, inadvertent organ injury (colon, liver, small bowel), peristomal wound infection, tube dislodgement
Surgical Gastronomy/ Jejunostomy	None	Direct visualization	General anesthesia Laporatomy/ Laproscopy	Wound infection, inadvertent enterotomy/ organ injury, tube occlusion, wound dishiscence/hernia, complications of general anesthesia

Adapted from Miller KR et al. A Tutorial on Enteral Access in Adult Patients in the Hospitalized Setting *JPEN* 2014;38(3):282–95; copyright © 2011 by SAGE Publications, Inc; reprinted by Permission of SAGE Publications, Inc.

Dosing and Permissive Underfeeding Strategies

Appropriate caloric revision in the critically ill patient remains in evolution. A teleologic argument can be made that a relative "anorexia of illness" develops after insult as a mechanism to avoid continued exposure of the host to substrate during a period where it simply cannot be utilized. Autophagy, or the degradation and recycling of nonfunctional intracellular debris, is essential to the maintenance of homeostasis and is suppressed in the setting of exogenous substrate. This has been a proposed mechanism as to how substrate provision during times of critical illness could be disadvantageous. Rather convincingly, recent evidence has suggested that permissive underfeeding can provide much of the benefit of "full" nutrition support in critically ill patients during initial phases of management (first 7 days) while at the same time minimizing the risk of overfeeding. Recent trials in heterogeneous ICU patient populations, perioperative patients in the ICU, and in acute lung injury have demonstrated "trophic" feeding rates to have equivalent outcomes when compared to traditional feeding strategies with regard to mortality, infectious complications, and hospital duration. Protein provision was similar between the groups, and the differences in caloric provision were predominately from carbohydrates. This has led to increased emphasis

upon the nonnutritional benefits of enteral support and protein provision in the ICU.

Level of Infusion

The level of infusion is characterized as gastric, duodenal (post-pyloric), or jejunal (distal to ligament of Treitz). In most surgical and critical care settings, it is common practice to attempt gastric feeding and only when unsuccessful more distal access is obtained. Tubes initially placed in the stomach can often migrate to more distal locations. Fortunately, gastric feeding is tolerated by the vast majority of patients. However, there are clinical scenarios where altering the level of infusion is desirable and can impact tolerance. In the setting of foregut reconstruction, jejunal access may be warranted in order to bypass tenuous anastomoses and prevent exacerbation of anastomotic complications. More distal tubes typically result in fewer aspiration events and are appropriate in patients with gastroparesis and those demonstrating intolerance to gastric feeding. Ongoing reassessment is necessary to achieve appropriate tolerance, and attempts should be made to advance tubes to more distal locations when intolerance is encountered.

Bolus, Intermittent, and Continuous Feeding Strategies

Bolus feedings, consisting of 200 to 500 mL (large amounts over a short time) of formula pushed via syringe several times per day, are the most physiologic and easiest method of administration. This method should only be utilized through the gastric route. They allow for limited access intervals, but patients should demonstrate adequate gastric emptying and the ability to protect their airway prior to initiation of this method.

Intermittent feeding refers to formula being infused over 20 to 30 minutes and is generally tolerated well. This method can be used with gastric and small bowel feeding tubes depending on the overall volume delivered.

Finally, continuous feeding is the most commonly applied strategy in the ICU. Infusion pumps administer smaller volumes over a 12- to 24-hour period and can be delivered through any available enteral access tube. GI intolerance is less common with this method than bolus or intermittent feeding strategies. Rates range from 10 to 50 mL/hr and are typically increased over several hours following initial administration. Feedings may be adjusted to nocturnal or cycled in order to increase appetite as the

patient transitions to oral intake. The obvious disadvantage to continuous feeding is the constant need for the tube to be accessed and connected to the infusion pump.

Monitoring Tolerance

GI intolerance has historically been defined by increased gastric residual volumes (GRVs) and clinical factors such as increasing distension, nausea, vomiting, and diarrhea. GRVs have come under increased scrutiny due to irreproducibility, highly variable methodology, and failure in recent randomized controlled trials to be of any utility. Clearly more important than GRVs, clinical examination remains the key component in assessment of tolerance. Abdominal distension, vomiting, and increasing pain suggest intolerance and demand attention. Diarrhea, defined as >250 g of liquid stool per day per rectum or >1,000 mL/day per ileostomy, is often attributed to tube feeds but is more commonly associated with sorbitol-based medications and other osmotic agents with enteral formulations being the causative agent in <20% of cases.

When intolerance is encountered, efforts should be continued to prevent aspiration. Measures to improve tolerance include the establishment of more distal feeding access and the use of prokinetic agents including metoclopramide and erythromycin. Institutional protocols designed to address intolerance clearly improve the overall efficacy of enteral nutrition support, particularly in the ICU setting, and should be incorporated (Fig. 3.1).

Enteral Formulations

Given the ubiquity of enteral nutrition support in the hospitalized patient, hundreds of enteral formulations have been developed and vary depending upon osmolality, renal solute load, caloric density, source of macro/micronutrients, soluble and insoluble fiber content, and various additives. Enteral products are classified as medical foods and do not require Food and Drug Administration (FDA) approval.

Osmolality, the preferred term in reference to enteral formulations, is essential to maintaining balances between extra- and intracellular fluids and ranges from 270 to 700 mOsm/kg in available formulas. Caloric density, ranging from 1 to 2 kcal/mL of formula, will impact osmolality as increasing densities are associated with increased osmolality and reduced amounts of free water composition. When calculating free water

supplementation, the concentration of water within the formula (generally approximately 80%) should be considered and additional free water is often appropriate with the use of high caloric density formulas. The renal solute load, composed predominately of protein, sodium, potassium, and chloride, can also impact free water requirements as renal excretion requires obligate water loss. The osmolality impacts GI tolerance and gastric emptying as gastric contents must generally reach iso-osmolarity prior to leaving the stomach. Concurrently administered medications (ranging from 450 to 11,000 mOsm/kg) can impact osmolality substantially and contribute to poor tolerance. In general, the more "broken down" the macronutrients (amino acids and simple sugars vs. proteins and starch) are within the formula, the higher the osmolality. Following attempts by NASA to develop chemically engineered diets to minimize fecal output during space travel, a multitude of disease-specific diets have become increasingly available in an attempt to simplify and individualize formula selection.

DISEASE-SPECIFIC FORMULATIONS AND ADDITIVES

Because of the ability to manipulate the various physical properties discussed above, attempts have been undertaken to develop disease-specific formulations in the setting of organ dysfunction. There is little evidence to support these formulations be used on a routine basis and standard high protein enteral formulations are appropriate in the vast majority of hospitalized surgical patients. The use of specific nutrients in surgical practice should be considered as part of an overall nutrition approach to the surgical patient, including treating undernutrition, optimizing lean body tissue when possible, and encouraging resistance exercise.

Pulmonary/Diabetic Formulas

Pulmonary formulas have been designed to provide higher fat to carbohydrate ratios in order minimize CO_2 production and manipulate the respiratory quotient (RQ). The RQ (CO_2 produced per O_2 utilized) is 1.0 for carbohydrate and 0.7 for fat. This lower RQ (CO_2 production) has been the basis for the development of relatively high fat (~45% to 55% of calories) and high caloric density enteral formulas. Ultimately, the goal is to minimize hypercapnia, reduce inflammation, and facilitate ventilator

weaning. Data regarding anti-inflammatory formulas and altered fat to carbohydrate ratios are lacking, and standard high protein formulas are recommended in these patients. The caloric density of enteral formulations is occasionally relevant in the setting of respiratory failure, and the use of higher density, fluid restrictive formulas can assist with minimizing overall volume repletion. High fat to carbohydrate ratio formulas utilizing fructose as a source of carbohydrates and additive fiber have been designed to assist with glycemic control in diabetic patients as well, but there are no supportive outcome data in the ICU or perioperative period.

Malabsorptive Formulas

Small peptide and MCT formulas, also referred to as semi-elemental formulas, have been developed for patients with reduced absorptive capacity or impaired digestion. Pancreatic insufficiency and malabsorptive disorders (inflammatory bowel disease) are common examples. MCTs, although lacking in essential fatty acids, can be absorbed directly into the portal vein across the small bowel interface dispensing with many of the complexities of lipid absorption. Soluble fibers are often utilized in this setting as well due to SCFA contributions and trophic effects on the GI mucosa. The high osmolarity and associated GI intolerance with these formulas is the major limitation for use in the clinical setting.

Renal Formulas

Historically, renal formulas consisted of reduced protein, potassium, magnesium, calcium, and phosphorus content, with the majority of available protein consisting of essential amino acids. Through the provision of essential amino acids, it was theorized that nitrogen recycling would allow for provision of nonessential amino acids, but unfortunately this does not appear to occur in the critically ill patients. Although renal formulas likely do have some benefit in patients with severe electrolyte abnormalities, protein requirements are substantially increased (due to increased protein loss) in the setting of renal replacement therapy and protein should not be withheld in the ICU.

Hepatic Formulations

The goal with formulas designed for use in patients with pre-existing liver disease is to manipulate the amino acid profile in order to minimize

increases in aromatic amino acids (AAA). Catabolism associated with liver disease results in increased utilization of branched-chain amino acids (BCAA) resulting in reduced BCAA:AAA ratios. This, in conjunction with hyperammonemia, is thought to contribute to encephalopathy as BCAAs move across the blood brain barrier and act as false neurotransmitters. Recent data would support the use of standard formulae in most settings of hepatic compromise and only resort to the high BCAA formulations in a very limited population Although some studies suggest reduced hospitalizations for encephalopathy in the outpatient setting, high protein standard formulas are preferred in the hospitalized and critical care setting.

Immune and Metabolic Modulation With Nutrition (Immunonutrition)

The concept that specific nutrients could modulate the metabolic response to surgery has been studied since the early 1980s. There are numerous nutrients that can alter or attenuate the immune and inflammatory components associated with surgery and trauma. Examples of metabolic modulating nutrients, or pharmaconutrition, include fish oils containing the omega-3 fatty acids (FA), eicosapentaenoic acid (EPA), and docosahexaenoic acid (DHA); amino acids such as glutamine, leucine, and arginine; antioxidants such as vitamin C and selenium; and probiotics and prebiotics. Current literature appears to support the benefit in the use of pharmaconutrition in the trauma and surgical ICUs, but data to support the routine use in medical ICU patients have not shown consistent benefit.

Recent animal and clinical research has led to the incorporation of omega-3 fatty acids into several enteral formulas. Omega-3 fatty acids found in fish EPA and DHA) have multiple beneficial effects in the perioperative period, including modulation of leukocyte function and regulation of cytokine release through nuclear signaling and gene expression. In addition, DHA and EPA are metabolized to a group of bioactive compounds called specialized pro-resolving molecules (SPMs), which play a role in accelerating the resolution of the inflammatory state. These SPMs stimulate the cardinal signs of resolution of inflammation, which include the cessation of leukocytic infiltration, a countering of the effects of pro-inflammatory mediators, stimulation of the uptake of apoptotic neutrophils, promotion of the clearance of necrotic cellular debris, and enhancement of the host’s ability to eliminate microbial

invasion. In contrast to EPA and DHA, omega-6 fatty acids are associated with higher inflammatory response and are precursors to leukotrienes, thromboxane, and prostaglandins, which are vasoconstrictive, and induce platelet aggregation. Data suggest that fish oil containing enteral formulations can lower total complications, anastomotic dehiscence, and potentially decrease mortality. Numerous reports using various in-vivo and in-vitro models suggest that the slight structural difference between omega-3 and omega-6 fatty acids supports the anti-inflammatory, antithrombotic, antiarrhythmic, hypolipidemic, and antiatherosclerotic effects of the omega-3 compounds.

Glutamine has been supplemented in the surgical and surgical critical care setting for the past three decades and until recently was a mainstay in surgical nutrition practice. Glutamine is a nonessential amino acid, which in times of trauma and severe catabolic illness is believed to become essential. Since the first descriptions of the benefits of glutamine in surgery and critical illness, multiple early studies reported benefit. Recently several multicenter trials have shown no clinical benefit of glutamine in the ICU and two large trials, REDOX and MetaPlus, suggested potential harm and increased mortality in the glutamine groups. Based on these trials, ASPEN/SCCM guidelines recommend against the use of supplemental parenteral glutamine to critically ill patients and should only be considered in specific situations.

In health, arginine is a nonessential amino acid. However, like glutamine, arginine is considered a conditionally essential amino acid due to endogenous supply falling short of demand during periods of physiologic stress. Over the past four decades, arginine has been used in the clinical setting for a wide variety of conditions from wound healing to pulmonary hypertension. Arginine is available to the host from the diet with the majority of arginine coming from endogenous production. Numerous studies, using differing doses of arginine from 5 to 30 g/day in the normal host, have shown generally beneficial results in the surgical population. It is estimated that, on average, a postop or SICU patient receiving an arginine-supplemented enteral feeding at goal delivery rates would receive between 15 and 30 g/day of arginine. The authors are unaware of any reports of toxicity when using immune modulation with arginine-containing formulations. Arginine acts via numerous mechanisms with immune function of key focus in the surgical population. Numerous reports have shown inadequate T-cell function with depleted arginine

availability and recent data show the importance of arginine in regulation and conversion of the M1 to M2 macrophage classes, which has been shown to enhance resolution of inflammation.

Lastly, since most studies in surgical patients have supplied arginine with other immune modifying agents (e.g., fish oils, arginine, glutamine and/or nucleic acids), the exact contribution of each agent has been difficult to discern. Potential metabolic interactions between arginine and other delivered nutrients must be considered. To date, the vast majority of clinical trials and meta-analysis using the arginine fish oil formulations have proven beneficial in surgical populations. These have been delivered and shown benefit as a pre-op formulation in order to modulate the metabolic response to the upcoming surgical insult or in both the pre-op and postop setting.

Antioxidant Additives/Supplementation

Numerous trials have reported a benefit from the provision of antioxidant cocktails to trauma and ICU patients. The most effective cocktails appear to contain selenium at higher doses, but the optimal combination and method of administration (bolus versus continuous infusion) are not clear. In the most recent large randomized control trial, combination therapy did not report any positive effects on outcome.

Probiotics and Prebiotics

Probiotics are defined as viable organisms that exert a beneficial health effect on the host when ingested in adequate amounts. Most probiotics are composed of anaerobic Lactobacillus and Bifidobacterium strains. Prebiotics are indigestible foods, such as oligosaccharides, that are ultimately fermented by colonic bacteria. Synbiotics are a combination of both prebiotics and probiotics. Given improved understanding regarding the importance of the microbiome in immunomodulation, colonization resistance, enhancement of the epithelial barrier, production of antimicroorganism substances, inhibition of pathogen adhesion, mucosal barrier support, and nutritional contributions, exogenous enteral administration of bacteria is now considered potential adjunctive therapy in the setting of acute and chronic illness.

The human microbiome has only recently been recognized as a key contributor to health and disease. The intestinal microbiome is diverse with over 1,000 species inhabiting the GI tract, and influences immune

function, host metabolism and physiology, nutritional status, and global well-being. Bacteria colonize the alimentary tract soon after birth, are altered throughout early growth and development, and later become relatively stable during healthy states in adulthood. However, periods of antibiotic exposure, surgery, illness, or even exposure to a new household pet can dramatically alter an individual's microbiome. The inhospitable environment created by gastric acid, bile, and constant peristalsis results in the proximal GI tract (stomach and small bowel) hosting reduced numbers and diversity of bacteria. The colonic microbiome is predominately composed of anaerobic bacteria (Bacteroides, Bifidobacterium, Clostridium, and Lactobacillus) with ratios of anaerobes to aerobes 100 to 1,000:1 and is essential to maintaining homeostasis within the colonic ecosystem. In addition to the inhibition of pathogen adhesion and enhancement of epithelial barrier function, colonic bacteria ferment insoluble fibers producing SCFAs that serve as fuel for the colonocyte, enhance macrophage function, and decrease microvascular thrombosis.

Following acute alterations in the microbiome as a result of physiologic insult, the concept of replenishing the "normal" microbiome has obvious theoretical advantages. Trials are highly variable with regard to dosing strategies, timing, and species administered. However, it is now well-established that prebiotics and probiotics can attenuate the inflammatory response, support the mucosal barrier, and improve immune function. Several meta-analyses have now shown benefits of probiotics in colorectal surgery, other visceral surgery, prevention of antibiotic associated diarrhea and *Clostridium difficile* diarrhea, and it has recently been shown to decrease sepsis in high-risk surgical cases.

ENTERAL FEEDING COMPLICATIONS

Enteral feeding, as with any other adjunctive therapeutic endeavor, is not without risk, and surgeons should be familiar with the recognition and management of these issues. The most common complications can be categorized as mechanical, metabolic, or GI.

GI complications include the clinical manifestations of GI intolerance. Nausea and vomiting occur in 10% to 20% of patients receiving enteral nutrition and is most commonly attributed to delayed gastric emptying. Abdominal distension and diarrhea are also commonly encountered issues and should warrant investigation. Aspiration is often cited as a reason for delaying the initiation of enteral nutrition and is a common occurrence

among critically ill patients. Interestingly, aspiration of GI contents does not appear to directly correlate with the development of pneumonia as this appears more closely linked to aspiration of oropharyngeal secretions. However, aspiration of significant amounts of tube feeding formulations or GI secretions can be catastrophic with resultant pneumonitis, adult respiratory distress syndrome (ARDS), and rapid respiratory decompensation. Avoidance of aspiration includes routine elevation of the head of bed to 45 degrees, utilization of continuous feeding strategies, reassessment of sedation and analgesia requirements, oropharyngeal decontamination, and distal feeding and use of prokinetic agents when appropriate. Patients deemed at high risk for aspiration or who have demonstrated prior intolerance to gastric feeds should undergo more distal access.

Not unlike parenteral nutrition support, much of the risk associated with enteral nutrition is related to the establishment and maintenance of access, and these are referred to as mechanical complications. Risk varies dependent on the access route undertaken as well as the skill and expertise of clinicians establishing access. Risk associated with the naso/oroenteric route includes sinusitis, tube dislodgement/occlusion (40% to 60%), and malpositioning (2%) with potential for pneumothorax and inadvertent administration of feeding into the tracheobronchial tree. Percutaneous gastrostomy and jejunostomy are infrequently associated with GI perforation, inadvertent organ injury (particularly the colon/stomach), and GI bleeding with a major complication rate of 1% to 3%. However, minor complications such as persistent leakage, erosion, and tube malfunction/dislodgment are likely underreported and as high as 30%. Open gastrostomy and jejunostomy are associated with complications inherent in laparoscopy and laparotomy that are discussed extensively throughout this text. Early recognition and correction of access issues is paramount to the provision of enteral support.

The metabolic complications of enteral nutrition include refeeding syndrome and nonocclusive mesenteric ischemia (NOMI) and, although rare, are associated with significant mortality. Refeeding syndrome can be seen with both enteral nutrition and parenteral nutrition support. Refeeding syndrome was first described following the surrender of thousands of French troops to Spanish forces following the Battle of Bailen of the Peninsula War where delayed shipments of food on Cabrera Island resulted in prolonged starvation. Following the arrival of food shipments,

hundreds of prisoners of war succumbed following their initial meals. Similar patterns were described following the liberation of Bergen-Belsen concentration camp in 1945. In addition to overt cachexia, alcoholism, anorexia nervosa, marasmus, rapid refeeding, and excessive dextrose infusion are identified as risk factors for the development of this syndrome. The hallmarks of refeeding syndrome are hypophosphatemia, hypokalemia, and hypomagnesemia following initiation of nutrition support in patients with severe pre-existing chronic malnutrition. Rapid fluid shifts and intracellular migration of potassium and phosphorus result in hemodynamic lability and death. Refeeding syndrome likely represents the severe end of a spectrum of clinical manifestations resulting from caloric and protein provision in the ICU. Recent data suggest that elements of refeeding occur in the majority of critically ill patients, and these alterations are only recognized when severe. The prevention of refeeding syndrome involves recognition of at-risk patients, hypocaloric support over the first several days (10 kcal/kg, advancing 5 kcal/kg day over days 2 to 4), interval electrolyte monitoring, and deliberate electrolyte replacement prior to advancement of nutrition support.

NOMI is associated with inadequate splanchnic perfusion to meet the increased metabolic demands in the setting of enteral nutrition support. enteral nutrition can increase splanchnic perfusion 40% to 60% (post-prandial hyperemia), and when demand is not met NOMI can ensue. Although extremely rare and difficult to predict, this is a devastating complication with mortality rates as high as 80%. Interestingly, NOMI has been more commonly associated with both surgical and nasoenteric jejunal feeding strategies. Current recommendations suggest withholding enteral nutrition until patients are fully resuscitated to avoid this catastrophic complication.

Appropriate patient assessment for needs and risks, proper feeding route, and formula selection, in addition to appropriate monitoring of the enteral nutrition feeding regimen, can increase the success of enteral feeding and reduce the incidence of enteral nutrition-associated complications.

SPECIAL CONSIDERATIONS IN THE ELECTIVE PERIOPERATIVE SETTING

In contrast to the post-injury or surgical emergency setting, elective surgery affords the luxury of knowing when the physiologic insult is to

occur and thereby allows for nutritional optimization prior to the insult. Just as weight loss, smoking, and cardiac optimization are routinely performed prior to elective surgery, so too should assessment and optimization of nutritional status. This requires nutrition assessment to be performed, risk to be recognized, and actions to be taken prior to the day of the operation. The NRS-2002 discussed earlier is a simple and easily applicable tool to identify nutrition risk and intervene. In addition to perioperative nutrition support, multiple components of the enhanced recovery pathways have incorporated carbohydrate loading and early initiation of enteral support into existing protocols with good success.

Perioperative Nutrition

In the setting of major elective surgery, perioperative administration of supplemental protein and calories in a regimented fashion for 5 days prior to and at least 5 days following the intervention has been demonstrated to improve outcomes and reduce postoperative infections. Two factors contribute to the overall efficacy of preoperative nutrition supplementation, including pre-existing nutritional status and the magnitude of the planned operation. For example, operations with a low complication rate would be expected to demonstrate minimal improvements. In contrast, patients with pre-existing nutrition risk (severe malnutrition) undergoing a lengthy operation with a high complication rate would benefit most from perioperative nutrition. Perioperative (both prior to and following) support strategies have been demonstrated to have more significant outcome benefits than either pre- or postoperative strategies alone. Immunonutrition formulas have demonstrated some efficacy over standard therapy with regard to infectious complications and length of stay. Perioperative nutrition support is a relatively inexpensive adjunctive therapy to improve outcomes but remains underutilized. The importance of compliance with nutrition support strategies should be highlighted as contributions patients can make to improve their own outcomes and should be emphasized by the surgeon.

Early Initiation of Enteral Support

As in critically ill populations, reduced infectious complications and length of stay have been demonstrated with early enteral nutrition support in the perioperative setting. Surgical dogma including delaying initiation of oral intake until the onset of bowel function has never been demonstrated to

improve outcomes, even in the setting of GI anastomosis, and yet is still widely practiced. Early discontinuation of decompressive nasogastric tubes following surgery is an integral component of most fast-track strategies. On-demand feeding strategies, whereby patients are provided oral intake when they feel ready, have demonstrated efficacy in the setting of acute pancreatitis and are likely applicable in the majority of postoperative patients.

In the event that operative intervention is deemed necessary, patients are determined to be at high nutrition risk, and sufficient enteral nutrition cannot be delivered, parenteral nutrition should be considered. Although the duration required to result in meaningful outcome improvements is controversial, most would suggest that 7 to 14 days of parenteral nutrition delivered preoperatively is appropriate.

Preoperative Carbohydrate Loading

Traditionally, the "NPO after midnight" order has been synonymous with surgical preparation. However, this notion has recently been challenged as preoperative carbohydrate loading has become more widely practiced as a component of "fast-track" surgical strategies. Emerging and relatively conclusive evidence suggests that the provision of clear liquids and carbohydrate up until 2 hours prior to the procedure results in no increased risk of aspiration as well as potential benefit. Complex carbohydrate (maltodextrin) drinks are given as 300 mL (12.6 g/100 mL) volumes the pre-op at least 3 hours before induction. This strategy is compliant with recent American Society of Anesthesiologist recommendations that suggest that solids are discontinued 6 hours prior and clear liquids 2 hours prior to induction. Perioperative fasting may not only be unnecessary, but also harmful as a contributor to postoperative insulin resistance, increased immunosuppression, and patient discomfort. Preoperative "carbohydrate loading" involves giving a carbohydrate-rich drink the night before and 3 hours prior to the scheduled procedure and has been demonstrated to reduce insulin resistance, attenuate resultant immunosuppression, and improve patient comfort.

SUMMARY

Surgeons have been instrumental in characterizing the metabolic response to stress and should have expertise in the establishment of enteral nutrition. Enteral nutrition therapy is an important and underemphasized adjunctive

therapy in the surgical patient. Strategies have shifted importance from caloric and protein provision to the additional “nonnutritional” benefits of enteral support including preservation of structure and function of the GI barrier and gut-associated lymphoid tissue and efficient nutrient utilization. There has been a recent shift in the goals of nutrition support from that of support (caloric and protein provision) to therapy (maintenance of GI structure and function, attenuation of the immune response). A multimodality approach consisting of nutrition support, appropriate supplementation, and resistance exercise should be initiated to combat the metabolic alterations associated with physiologic insult. Surgeons must be capable of recognizing patients with increased risk for morbidity and mortality as a result of pre-existing nutritional risk and in the implementation of an individualized nutrition support strategy. When appropriate, enteral nutrition should be the route of choice and efforts should be made to assess and troubleshoot GI intolerance. In the event that enteral nutrition is inappropriate, surgeons should understand the role of parenteral nutrition support and utilize it when necessary. Finally, as with any therapy, there are significant risks associated with the inappropriate administration and implementation of nutrition support strategies, and surgeons must be familiar with the recognition and management of these issues in order to optimize patient outcomes.

Suggested Readings

Casaer MP, Mesotten D, Hermans G, et al. Early versus late parenteral nutrition in critically ill adults. *N Engl J Med* 2011;365:506–17.

Gabay C, Kushner I. Acute-phase proteins and other systemic responses to inflammation. *N Engl J Med* 1999;340:448–54.

Harvey SE, Parrott F, Harrison DA, et al.; CALORIES Trial Investigators. Trial of the route of early nutritional support in critically ill adults. *N Engl J Med* 2014;371(18):1673–84.

Kondrup J, Allison SP, Elia M, et al. ESPEN guidelines for nutrition screening 2002. *Clin Nutr* 2003;22:415–21.

McClave SA, Martindale RG. Feeding the critically ill patient. *Crit Care Med* 2014;42(12):2600–10.

McClave SA, Taylor BE, Martindale RG, et al. Guidelines for the provision and assessment of nutrition support therapy in the adult critically ill patient: Society of Critical Care Medicine (SCCM) and American Society for Parenteral and Enteral Nutrition (A.S.P.E.N.). *JPEN J Parenter Enteral Nutr* 2016;40:159–211.

O'Leary PO, Tabuenca A. The physiologic basis of surgery. In: Martindale RG, Zhou M, eds. *Nutrition and Metabolism.* 4th ed. Philadelphia, PA: Lippincott Williams & Wilkins; a Wolters Kluwer business; 2007:112–49.

Plank LD, Hill GL. Sequential metabolic changes following induction of systemic inflammatory response in patients with severe sepsis or major blunt trauma. *World J Surg* 2000;24:630–8.

Serhan CN. Pro-resolving lipid mediators are leads for resolution physiology. *Nature* 2014;510(7503):92–101.

Tawa NE, Maykel JA, Fischer JE. *Metabolism in surgical patients.* In: Townsend CM, Beauchamp RD, Evers BM, eds. *Sabiston Textbook of Surgery.* 17th ed. Philadelphia, PA: WB Saunders; 2004:137–82.

EDITOR'S COMMENT

As Dr. Mardindale and colleague so aptly put it, nutritional support has been an underemphasized and underutilized adjunctive to surgical care. I would even more strongly emphasize, nutritional repletion is integral to surgical success. One can do a technically successful and even perfectly carried out surgery only to have the wound fall apart days later because the patient cannot heal. The concept of nutritional risk takes into account pre-existing nutritional status as well as disease severity. Stratifying by risk and developing strategies and proactively implementing them prior to surgery are just as important as having a patient in good glucose control or to have them stop smoking prior to reconstruction.

There are many tools to assess nutritional status, but none are more valuable, as in all things, than a simple history and physical examination–what are their dietary habits, how much protein do they eat, what supplements do they take, if and how much weight have they lost, and how much exercise do they get? On physical examination, a quick look at hypothenar or malar muscle wasting can quickly identify the severely "at-risk" patient. Along with our authors, I would like to emphasize to not let the obese patient fool you. I would say that obesity by its very nature is considered malnutrition. The ever dieting or poorly dieting youth are likewise at risk. Again, a good history can help identify these patients before a complication occurs.

The authors have very nicely summarized biochemical assessment. I would emphasize that if the admitting albumin and phosphate are low on admission, then surgery should be delayed if possible and if not nutritional supplementation started immediately. If labs are normal on admission and nutrition is suspected or in a patient with advance cancer, repeat labs after the start of intravenous fluid as often the patients are dehydrated and labs are surreptitiously high. In addition, with the introduction of glucose and the occurrence of refeeding syndrome, phosphate will drop 1 or 2 days later or after surgery. In this day of

overzealous dieting, refeeding syndrome can be seen in seemingly fit and young patients. Poor dietary habits should always be suspected in the elderly patients especially if they live alone. One postop patient was diagnosed with Alzheimer's until her phosphate was found to be low and replenished. She made a complete recovery. In my practice, a postoperative ileus especially if accompanied by dysphoria is due to phosphate nearly every time. Hypophosphatemia itself is associated with risk or infectious complications. When severe enough patients can go into respiratory arrest, heart and/or liver failure.

The geriatric population is at special risk. In a study of 111 elderly patients (≥65 years of age) undergoing colorectal, heptopancreatobiliary or gastric/duodenal surgery undersent comprehensive baseline and geriatric assessment including functional status, nutritional status, comorbidity index, mental status, depression scale score, fatigue inventory scale, and polypharmacy scale. Variables associated with discharge to a nursing facility on multivariate analysis included weight loss ≥10% (OR 6.52, $p = 0.02$), ASA score ≥2 (OR 5.08, $p = 0.03$), and ECOG score ≥2 (OR 4.51, $p = 0.03$). Variables independently associated with prolonged hospital stay included ≥10% weight loss (OR 4.03, $p = 0.03$) and the presence of polypharmacy (OR 2.45, $p = 0.03$). Again a good history and physical examination are at the heart of a complete surgeon.

The release of alanine from the muscle during stress associated with catabolism after trauma, surgery, with advanced cancer, or during sepsis is well-known. Numerous strategies have been initiated to replenish muscle. What isn't clear is how early-stage cancer affects the protein metabolic response to major surgery. We looked a group of patients undergoing bilateral mastectomy and reconstruction, half for noncachectic breast cancer and half for genetic risk reduction. Whole body protein synthesis and breakdown rates were assessed after overnight fasting and after meal intake by stable isotope methodology in order to calculate net protein catabolism in the postabsorptive state and net protein anabolic response to a meal. As expected, the net anabolic response to a defined amino acid meal was reduced but was independent of early-stage breast cancer after major surgery. However, in the presence of severe malnutrition preoperative intravenous or enteral nutrition can significantly decrease infection and complications after surgery. How much and for how long to give nutritional repletion before surgery are not certain and are usually guided by albumin and acute phase reactants but vary with the underlying disease, the supplement and, to me, depend on good clinical judgment. Home infusion capability, nutrition at home with oral supplements when possible, and parenteral nutrition when not are easy and really required in today's cost saving environment. In the emergency setting or when a prolonged recovery period is expected, one should ask at the end of every case—do I need parenteral and/or enteral access? Enteral feeds are ideal, but early initiation of enteral nutrition in the setting of a tenuous blood supply is not always safe and parenteral nutrition can act as a bridge and

should not be frowned on.

V. Suzanne Klimberg

Suggested Readings

Badgwell B, Stanley J, Chang GJ, et al. Comprehensive geriatric assessment of risk factors associated with adverse outcomes and resource utilization in cancer patients undergoing abdominal surgery. *J Surg Oncol* 2013;108(3):182–6.

Burden ST, Gibson DJ, Lal S, et al. Pre-operative oral nutritional supplementation with dietary advice versus dietary advice alone in weight-losing patients with colorectal cancer: single-blind randomized controlled trial. *J Cachexia Sarcopenia Muscle* 2017. doi: 10.1002/jcsm.12170.

Engelen MP, Klimberg VS, Allasia A, et al. Presence of early stage cancer does not impair the early protein metabolic response to major surgery. *J Cachexia Sarcopenia Muscle* 2017. doi: 10.1002/jcsm.12173.

Longchamp A, Harputlugil E, Corpataux JM, et al. Is overnight fasting before surgery too much or not enough? How basic aging research can guide preoperative nutritional recommendations to improve surgical outcomes: a mini-review. *Gerontology* 2017. doi: 10.1159/000453109.

Wang L, Tian Z, Liu Y. Nasoenteric tube versus jejunostomy for enteral nutrition feeding following major upper gastrointestinal operations: a meta-analysis. *Asia Pac J Clin Nutr* 2017;26(1):20–6.

4 Cardiovascular Monitoring and Support

Eric J. Charles and Irving L. Kron

Cardiovascular monitoring and support are essential to the care of surgical patients. The goals of cardiovascular monitoring are to ensure adequate tissue oxygenation and perfusion intraoperatively and postoperatively. Monitoring of the cardiovascular system involves an assessment of four major components:

1. Cardiac function
2. Peripheral and pulmonary vascular tone
3. Intravascular volume status
4. Oxygen metabolism

Accurate and thorough evaluation of all four components is a prerequisite to the proper management of cardiovascular support. It must be noted that measurement of these parameters is accompanied with an increase in the cost of care, complexity of management, and risks of harm to the patient. Therefore, the decision to utilize these technologies must take into account the usefulness and necessity of the data compared to the added risks and increased cost.

PHYSICAL FINDINGS

Cardiovascular monitoring involves a clinical assessment of organ-specific and systemic perfusion (Table 4.1). Physical signs are notoriously unreliable in estimating the adequacy of tissue perfusion, particularly in anesthetized or critically ill patients. Therefore, physical findings should be interpreted in the context of the patient and adjunct information obtained from more sophisticated monitoring techniques.

TABLE 4.1 Physical Signs of Organ-Specific and Systemic Perfusion

Physical Sign	Implication
Obtundation	Impaired cerebral perfusion
Oliguria	Impaired renal perfusion
Flat jugular veins	Intravascular volume depletion, impaired systemic perfusion
Weak or absent pulse(s)	Impaired regional or systemic perfusion
Cool, pale, or mottled skin	Impaired systemic perfusion

Electrocardiography

Continuous monitoring of the electrocardiogram (ECG) is the most sensitive, rapid, and cost-effective modality for detecting disturbances of cardiac rate, rhythm, and conduction and should therefore be routinely employed. Such disturbances are common during general anesthesia, in critical illness, and especially in patients with a history of arrhythmias or coronary artery disease.

One of the most useful features of continuous ECG monitoring is ST-segment monitoring, which is quite reliable for the early detection of myocardial ischemia and infarction. Leads II and V_5 are most commonly monitored, as these two leads together can detect >90% of intraoperative ischemic events in high-risk patients. Intraoperative ST-segment monitoring has become a standard practice in patients at high risk for cardiac events. Any electrical disturbances of the heart detected on continuous ECG monitoring (ST-segment changes, T-wave abnormalities, arrhythmias, etc.) should prompt a 12-lead ECG to confirm and further characterize the abnormality.

Blood Pressure Measurement

Blood pressure is the most commonly monitored cardiovascular parameter in current surgical practice. Blood pressure is prone to abrupt changes as a result of anesthesia, surgical procedures, changes in volume status and cardiac function, and underlying surgical illnesses. As arterial blood pressure is an indirect marker of systemic perfusion and a direct marker of

hemodynamic status, diligent monitoring of this parameter is essential to early detection and treatment of cardiovascular instability.

Noninvasive Methods

Together with continuous ECG, noninvasive blood pressure measurement is considered standard intraoperative cardiovascular monitor for the majority of patients undergoing routine surgery. Noninvasive blood pressure monitoring is considered indirect because no measurements are made with a device *within* the arterial lumen itself. Instead, such measurements are made with an inflatable cuff (sphygmomanometer) around the arm or leg and inflated to a pressure sufficient to compress the underlying artery. With the *auscultatory method*, gradual cuff deflation permits the artery to reopen and turbulent blood flow to produce Korotkoff sounds, which are heard with a stethoscope placed over the compressed artery. The pressures at which these sounds appear and then disappear during cuff deflation determine the systolic and diastolic blood pressures, respectively. Alternatively, the *oscillometric method* relies on the principle of plethysmography, in which the inflated cuff senses the pulsatile pressure changes in the underlying artery. On most devices available for clinical use, the systolic, diastolic, and mean arterial pressures and pulse are displayed on a digital screen for clinician review.

Although practical and noninvasive, these indirect techniques are limited by the time required to obtain each measurement and the likelihood of inaccurate results. For example, the use of an inappropriately small cuff in relation to the size of the limb will yield a spuriously elevated blood pressure reading. The American Heart Association (AHA) recommends the cuff bladder length should be 80% of the patient's limb circumference, and its width a minimum of 40%. Unfortunately both auscultatory and oscillatory methods are limited in the setting of hypotension. Therefore, in cases of sustained or expected hemodynamic instability, noninvasive blood pressure monitoring techniques should be abandoned in favor of more accurate and reliable invasive methods.

Invasive Methods

Invasive blood pressure monitoring provides a direct and accurate assessment of arterial pressure. The advantage of this approach is the rapid detection of fluctuations in blood pressure and immediate feedback on interventions that affect hemodynamics. Furthermore, these methods provide a convenient source for frequent arterial blood sampling, both in

the operating room and in mechanically ventilated patients in the intensive care unit (ICU). For these reasons, invasive blood pressure monitoring is recommended in patients that are or expected to become hemodynamically unstable, including those undergoing major abdominal, vascular, or cardiothoracic procedures. In addition, any major surgical operation in patients with a history of coronary artery disease, congestive heart failure, aortic stenosis, or poorly controlled hypertension should be accompanied by invasive blood pressure monitoring.

Direct blood pressure measurement is performed with an indwelling intra-arterial catheter connected to fluid-filled high-pressure tubing and a transducer. The zero reference point for the transducer is at the level of the right atrium, which corresponds to the midaxillary line at the fourth intercostal space. If the transducer is positioned below the level of the right atrium, the resultant pressure will be spuriously elevated. Conversely, if the transducer is situated above the right atrium, the displayed blood pressure will be falsely low. Specialized transducers exist, such as the FloTrac Sensor (Edwards Lifesciences, Irvine, California), that can be attached to the arterial catheter and provide additional data such as cardiac index (CI) and stroke volume variation.

The contour of the arterial pressure waveform in the aorta differs from that in the peripheral arteries (Fig. 4.1). As the propagating pressure wave migrates from the aortic root to the periphery, the systolic pressure gradually increases such that the peak systolic pressure in the radial artery can be 20 mm Hg higher than that in the proximal aorta. Thus, the mean arterial pressure, not the systolic pressure, determines the perfusion of blood into peripheral tissues. This increased systolic pressure in the distal arterial tree is due to less vascular elastic tissue and greater impedance, which is transmitted in a retrograde direction from vascular bifurcations and the artery–arteriolar junction. Such systolic amplification is especially prominent in more diseased, less compliant peripheral arteries, which is the physiologic basis for isolated systolic hypertension in the elderly. Amplification of peak systolic pressure in peripheral arteries is counterbalanced by a narrowing of the systolic waveform; the net result is that *mean* arterial pressure is unchanged. As a result, when peripherally placed intra-arterial catheters are employed, mean arterial pressure is the most accurate estimate of central arterial (aortic) pressure.

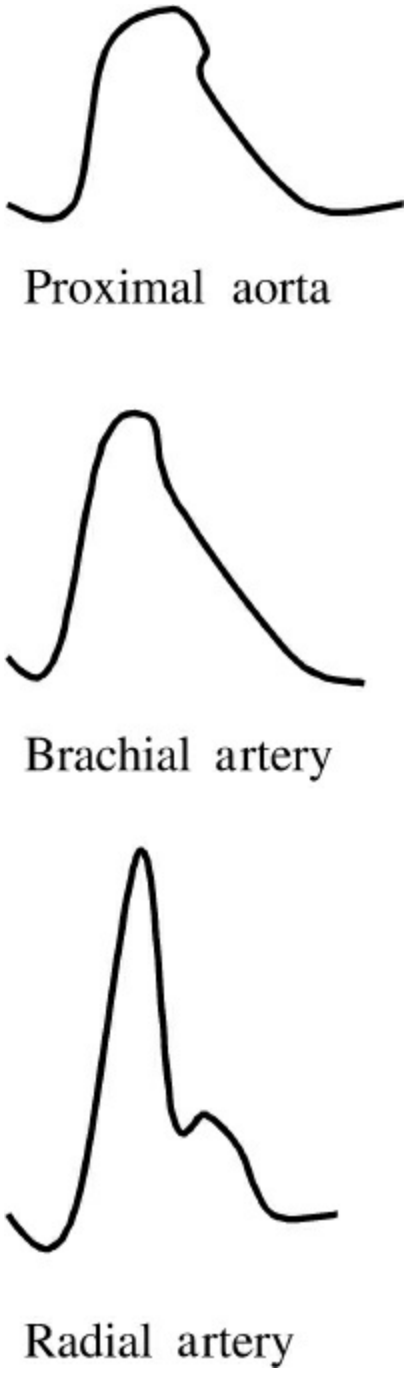

Figure 4.1. The appearance of the arterial pressure waveform at various sites in the circulation.

Radial Artery Cannulation

The radial artery at the wrist is the most common site for insertion of an intra-arterial catheter. The advantages of this site are that the vessel is fairly superficial and easily palpable, it is of adequate diameter to accept a standard-size catheter (18- or 20-gauge), and the area is easy to keep clean. To facilitate cannulation of the radial artery, the wrist should be gently hyperextended to bring the vessel to a more superficial location and allow

for cannulation without interference from the thenar eminence. The entry site is determined by digital palpation of the arterial pulse or with the use of ultrasound. Vessel entry is performed with a percutaneous Seldinger technique utilizing either an integrated catheter-over-needle device or a separate needle, guidewire, and catheter. Successful vessel entry is heralded by a flash of arterial blood in the catheter hub. At this point, it is important to advance the needle another 0.5 to 1 mm to ensure that its beveled tip is entirely within the vessel lumen and not partially within its wall. The catheter or guidewire may then be safely advanced into the vessel. Historically, the Allen test has been used prior to radial arterial cannulation to evaluate ulnar artery supply to the hand; however, it is now generally believed that this test does not always predict ischemic complications from radial artery cannulation. Other potential sites for arterial cannulation include the femoral and axillary arteries, both of which have the advantages of central arterial access and a low thrombotic rate. The pedal arteries are less often utilized as a result of their small diameter and lower successful cannulation rates. The brachial artery should be avoided since this vessel has no collateral blood supply and thrombosis of it could yield severe forearm and hand ischemia.

Complications of Arterial Cannulation. The most common complication associated with all sites of arterial cannulation is thrombosis. The risk of this complication increases with the duration of cannulation; the risk of radial artery thrombosis may be as high as 29% in vessels cannulated for >4 days. However, the risk of clinically significant distal ischemia is <1%, as most thrombosed vessels tend to recanalize. Arterial catheter insertion sites should be routinely inspected for signs of ischemia, the presence of which mandates immediate catheter removal. Signs of arterial insufficiency distal to the site of catheter removal may persist for several hours as a result of vasospasm. However, ischemia persisting beyond 6 hours after catheter removal is an indication for surgical exploration with an eye toward thrombectomy and vessel repair. In addition to the duration of cannulation, other risk factors for catheter-induced arterial thrombosis include use of a larger catheter, insertion during shock, multiple needle passes and/or careless insertion technique, infusion of vasoconstricting agents, and a small recipient vessel. Other clinically important complications of arterial catheterization are infection, bleeding, and cerebral embolism. The incidence of local wound infection is 10% to 15% for radial artery catheters, but systemic infectious

complications of such catheters are rare. Efforts to reduce the infection rate of radial artery catheterization include avoidance of a cutdown technique, replacement of the connector tubing every 48 hours, routine sterile dressing changes to the insertion site, and prompt removal of obviously infected catheters. However, in the absence of local or systemic infection, scheduled catheter changes are not necessary. Significant bleeding complications are most commonly associated with femoral and axillary artery lines, particularly in coagulopathic patients. For this reason, the radial artery is the preferred site of arterial catheterization in the presence of a bleeding diathesis. Although exceedingly rare, improper flushing of arterial lines has resulted in embolization of air and thrombi to the cerebral circulation. Employing small-volume, low-pressure flushes and evacuating all air from the tubing and transducer assembly can avoid this complication.

Pitfalls in Invasive Blood Pressure Monitoring

There are potential sources of error in the interpretation of data provided by invasive arterial pressure monitoring systems. In addition to improper positioning of the transducer, the monitoring system is vulnerable to artifacts that distort the contour of the arterial waveform and display false blood pressure readings. An *overdamped* system results in attenuation of the peak systolic pressure and an overestimation of diastolic pressure, yielding an incorrectly reduced pulse pressure. This is caused by a partial thrombus within the catheter, air bubbles within the tubing or transducer, or kinking of the catheter or tubing. Conversely, *underdamping* or *ringing* occurs with extraordinarily long lengths of tubing and is characterized by augmentation of the peak systolic pressure and a blunting of the diastolic pressure, producing a falsely elevated pulse pressure. It is important to note that with either an overdamped or underdamped system, the *mean arterial pressure is unaffected.* Hence, if there is ever any doubt as to the fidelity of an invasive arterial pressure monitoring system, only the mean pressure readings should be considered reliable. Finally, it should be mentioned that in intensely vasoconstricted patients, such as those undergoing treatment with α_1-agonists such as phenylephrine, invasive blood pressure readings via the radial artery may be significantly lower than central aortic pressure.

CENTRAL VENOUS CATHETERS

Cannulation of the central venous circulation facilitates both monitoring and support of the cardiovascular system, allowing for fluid resuscitation, drug administration, infusion of parenteral nutrition, passage of pacing electrodes into the right heart, hemodialysis, and monitoring of central venous pressure (CVP). CVP, or right atrial pressure, is an estimate of right ventricular preload. Although commonly monitored in the ICU setting, studies have shown that CVP is an inaccurate indication of a patient's responsiveness to fluid resuscitation. Other options for assessing changes in fluid status include measurement of inferior vena cava diameter and passive leg-raise maneuver. Nevertheless, a decreased CVP may indicate hypovolemia, while an elevated CVP may indicate hypervolemia, increased intrathoracic pressure, positive-pressure ventilation, pulmonary hypertension, or heart dysfunction. Normal CVP values range from 0 to 8 mm Hg and should be measured at end-expiration in both the mechanically ventilated and spontaneously breathing patient. The normal CVP tracing has three positive waves (*a*, *c*, and *v* waves) and two negative descents (*x* and *y*, Fig. 4.2). These waveforms reflect tricuspid valvular function as well as right atrial and ventricular size, compliance, and contraction. Characteristic abnormalities of the central venous waveforms may be seen in a variety of conditions, including tricuspid stenosis and regurgitation, dysrhythmias, and atrial septal defect. Similar to the setup for intra-arterial blood pressure monitoring, the central venous catheter is connected to a transducer that must be zeroed at the level of the right atrium. Considering that many decisions regarding implementation of cardiovascular support will be made based on both the blood pressure and CVP monitoring, proper zeroing of the transducers is absolutely essential and should not be overlooked.

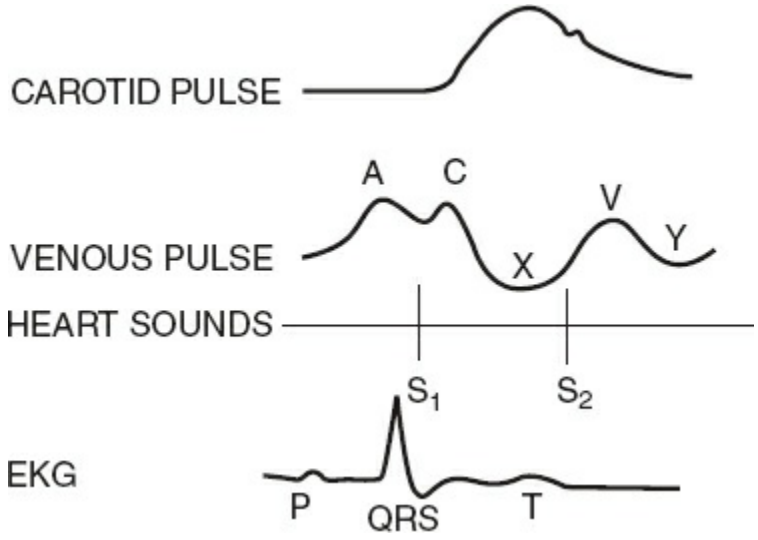

Figure 4.2. Central venous waves and descents. *a, c, v, x, y.*

Subclavian Vein Cannulation

All central venous cannulas should be placed under strict sterile technique, which includes sterile preparation of the skin and wide sterile draping of the entire patient and bed. Operators are required to wear sterile gown and gloves and all personnel in the patient room must wear hat and mask. The infraclavicular approach to the subclavian vein is fairly consistent with regard to anatomic landmarks, the exit site is more comfortable to the patient, and indwelling catheters at this site have a lower infection rate than the internal jugular (IJ) approach. The subclavian vein originates lateral to the first rib (Fig. 4.3). During its course, it passes anterior to the first rib and directly posterior to the clavicle. The external landmarks for the site where the vein passes between the first rib and the clavicle are: (a) the junction between the medial and middle thirds of the clavicle and (b) the lateral edge of the sternocleidomastoid muscle where it inserts into the clavicle. The skin, subcutaneous tissues, and periosteum of this area just below the clavicle should be infiltrated with 1% lidocaine. The classic method for accessing the subclavian vein is the Seldinger technique. With the patient in the Trendelenburg position, the needle should be advanced just beneath the clavicle and directed toward the suprasternal notch. To avoid causing a pneumothorax, it is very important to maintain a needle trajectory that is parallel to the floor. Return of free-flowing venous blood indicates entry into the lumen of the subclavian vein. At this point, the needle should be advanced a few millimeters to ensure that its beveled tip is completely within the vessel lumen. A J-tip guidewire is then carefully passed through the needle. If undue resistance is encountered upon passage

of the wire, both the needle and the wire should be removed and the process repeated. If vessel puncture is unsuccessful with the technique described above, a more cephalad direction of the needle may prove successful; occasionally, the subclavian vein is displaced superiorly by the apex of the lung, particularly in emphysematous patients. Ensuring puncture of the subclavian vein and not the artery is crucial and should be confirmed prior to dilating the tract leading into the blood vessel. A single-lumen 18-gauge angiocatheter can be inserted over the wire to facilitate this step. The options for accomplishing this step include (a) performing a blood gas analysis and comparing it to an arterial blood gas analysis from another location on the body, (b) transducing a pressure waveform, or (c) most commonly, by using extension tubing to set up a pressure column. After filling the extension tubing with blood and raising the distal end up in the air, a column of venous blood will fall while a column of arterial blood will continue to rise. Color of the blood or pulsatility after syringe removal are not acceptable methods for confirming venous puncture especially in critically ill patients who may be hypoxic or hypotensive. After confirmation of venous puncture, the wire is advanced back into the central venous circulation, the angiocatheter is removed, the skin exit site is enlarged with a scalpel blade, and a vascular dilator is passed slowly and progressively over the wire. It is critical to maintain control of the guidewire especially during maneuvers to advance the dilator and the catheter and ensure that it moves freely at all times. Once the subcutaneous tract and the hole into the vessel are dilated, the catheter is threaded over the guidewire; the latter can then be removed. For most types of indwelling central venous catheters, the catheter tip should be situated at the junction of the superior vena cava and right atrium. Table 4.2 is a useful guide for estimating the distance to this junction from the skin exit site for each of the subclavian and IJ venous approaches.

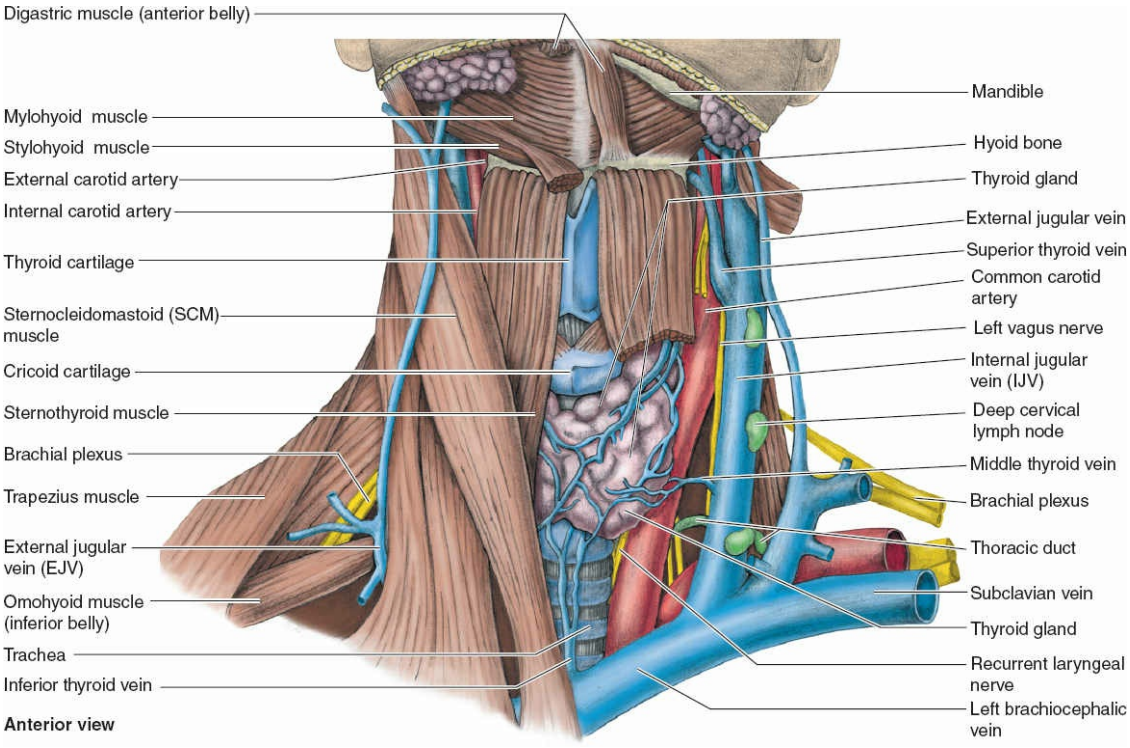

Figure 4.3. Anatomy of the neck. Note the relationship of the subclavian and internal jugular (IJ) veins. (From Moore KL, Dalley AF. Clinically Oriented Anatomy, 5th ed. Philadelphia, PA: Lippincott Williams & Wilkins; 2005, with permission.)

Internal Jugular Vein Cannulation

The IJ vein is an alternative to the subclavian vein for central venous cannulation. The advantages of this site over the subclavian approach are a lower risk of pneumothorax and a straighter course to the right atrium, especially on the right side. Shortcomings of the IJ approach are that it is occasionally more uncomfortable for the patient, carries a higher risk of arterial puncture, and has a higher reported infection rate. It is important to note that in approximately 70% of individuals, the IJ lies anterolateral to the carotid pulse at the base of the neck (see Fig. 4.3). However, one should be aware that not infrequently this vein may lie directly anterior or even deep to the carotid artery, thus increasing the risk of inadvertent arterial puncture. Use of ultrasound guidance for proper placement of the central venous catheter into the IJ vein is highly recommended as it reduces the risk of mechanical complications and increases the speed at which the procedure can be completed. The ubiquitous nature of ultrasound machines in today's healthcare environment make improper IJ catheter placement or pneumothorax after "blind" insertion indefensible unless performed in an emergent situation, during which the subclavian or

femoral veins should be accessed instead. With the patient in the Trendelenburg position and his/her head rotated to the contralateral side, the triangle formed by the two heads of the sternocleidomastoid muscle is identified. Using ultrasound to visualize the IJ vein, a needle is inserted at the apex of this triangle, keeping the carotid pulse medial to the course of the needle. The needle is slowly advanced toward the vein at a 45-degree angle to the skin. Once the operator is certain of needle entry into the lumen of the IJ and confirms venous puncture by one of the methods mentioned above, Seldinger technique is used to insert the catheter. After both IJ and subclavian central line placement, a chest radiograph must be ordered and visualized by the operator of the procedure to ensure proper placement and absence of pneumothorax.

TABLE 4.2 Approximate Distance From Skin Exit Site to Junction of Superior Vena Cava and Right Atrium (to Facilitate Correct Positioning of Central Venous Catheters)

Vessel	Distance (cm)
Right subclavian vein	(H/10) – 2
Right internal jugular vein	(H/10)
Left subclavian vein	(H/10) + 2
Left internal jugular vein	(H/10) + 4

H, patient height in cm.

Femoral Vein Cannulation

The femoral vein can be cannulated rather easily and expediently, and in select circumstances is the preferred route for central venous access. Examples include victims of burns to both sides of the neck and upper chest, trauma patients in extremis, and certain patients with acquired obstruction or congenital anatomic anomalies of the superior vena cava. The disadvantages of the femoral approach are a 10% risk of venous thrombosis, the need for the patient to remain supine and immobile, and a higher risk of catheter infection. The femoral vein is the most medial structure in the femoral sheath, lying just medial to the femoral artery. Puncture of the femoral vein is performed by first palpating the arterial pulse 2 cm below the inguinal ligament. At a point 1 to 2 cm medial to the

femoral pulse, the needle is advanced at a 45-degree angle through the skin until venous blood is encountered. If the femoral pulse is nonpalpable, the femoral vein can be located at a point 1 to 2 cm medial to the junction of the medial and middle thirds of the inguinal ligament. Ultrasound guidance can be used to facilitate proper catheter placement if preferred but is usually not necessary.

Complications of Central Venous Cannulation

Complications of central venous cannulation can be mechanical, infectious, or thrombotic. The most common mechanical complications are pneumothorax, hematoma formation, or inadvertent arterial puncture. Comparing IJ to subclavian, arterial puncture is more likely to occur with IJ cannulation, but the risk of pneumothorax is higher with subclavian cannulation. Considering that the risk of any mechanical complication is highest overall at the femoral location, IJ or subclavian central venous cannulation is recommended unless otherwise contraindicated. The following can help reduce the likelihood of mechanical complications: use ultrasound-guidance for IJ line placement, avoid routine central line changes, confirm venous puncture prior to introduction of the dilator, and involve an experienced operator whenever possible as performance of more than 50 central line placements has been shown to decrease the likelihood of mechanical complications by 50%. In addition, after three unsuccessful insertion attempts, the risk of mechanical complication increases six-fold. In the case of arterial puncture, unless the patient is coagulopathic, immediate withdrawal of the needle and 10 minutes of digital pressure is usually sufficient treatment. If it is apparent that the carotid, subclavian, or femoral artery has been cannulated with the dilator or catheter, these devices should not be removed blindly, particularly in an anticoagulated patient as this may produce serious life-threatening hemorrhage. It is safer to remove the dilator or catheter via direct surgical exposure, followed by suture repair of the artery. In addition, it is important to recognize that central venous cannulation of the subclavian vein increases the risk of subclavian vein stenosis which may be problematic in patients needing future dialysis catheter placement.

Risk factors for catheter infections include immunosuppression, insertion under emergent conditions or cutdown technique, and ineffective use of sterile barriers during insertion. Microorganisms at the skin insertion site are the most common cause of infections for nontunneled catheters left in place for less than 10 days. Organisms migrate from the

skin insertion site along the external surface of the catheter and form a biofilm, which prevents eradication with antibiotic treatment. Introduction of contamination via the catheter hub is another possible cause of infection. Subclavian vein cannulation has the lowest rate of infectious complications. Additional recommendations to avoid infection include (a) prompt removal of catheters when no longer clinically necessary, (b) avoidance of routine central line changes, (c) proper disinfection of catheter hubs prior to access, (d) use of antimicrobial-impregnated catheters (chlorhexidine, silver sulfadiazine, minocycline, or rifampin), (e) strict adherence to full sterile precautions at time of insertion, (f) use of central line care bundles (antimicrobial hubs and dressings), and (g) daily inspection of central line dressings, with sterile replacement if wet, soiled, or loose, or every 7 days otherwise.

Venous thrombosis is estimated to occur in approximately 15% of patients with indwelling central venous catheters but is often undiagnosed and not clinically significant. Nevertheless, thrombus formation carries the associated risk of embolization. Therefore, it is important to consider that subclavian central line placement has the lowest risk of thrombus formation.

Other less common complications include venous air embolism, central vein perforation, and embolization of catheter fragments or guidewire. During spontaneous inspiration, negative intrathoracic pressure may facilitate air entry into the central venous system through defects in the catheter, the uncapped hubs of the catheter, and the uncovered end of the needle during vessel puncture. This is a potentially fatal complication and may present initially as acute dyspnea and hypoxia. If suspected, place the patient in Trendelenburg position and rotate the patient into the left lateral decubitus position in an effort to minimize the likelihood of air migrating into the right ventricular outflow tract. An attempt can be made to withdraw air through the catheter. To avoid central vein perforation, ensure that the guidewire moves freely within the dilator and is not being bent against the wall of the vein. The dilator is quite stiff and can easily perforate a central vein if forcefully advanced. If embolization of catheter fragments or the guidewire occurs, it can usually be retrieved through a second catheter under fluoroscopic visualization.

Catheter-Related Bloodstream Infections

The topic of indwelling central venous catheter infections deserves special mention, as this is the number one cause of healthcare-associated

bloodstream infections. Such infections contribute significantly to morbidity, mortality, and increased healthcare costs. A catheter-related infection is diagnosed by semiquantitative culture when 15 or more colonies of the same pathogen grow from the catheter tip. There may or may not be accompanying signs of local infection (e.g., erythema, purulence, tenderness, or warmth at skin insertion site) or systemic inflammation (e.g., fever or leukocytosis). Catheter-related infection is a prelude to catheter-related bloodstream infection, which is defined as growth of the same organism from a peripheral blood culture and the catheter tip. Replacing central venous catheters at regularly scheduled intervals has not been shown to decrease the risk of catheter-related infections. However, the following guidelines are recommended: (a) If there are clear signs of infection at the skin exit site, the catheter should be promptly removed and, if clinically indicated, a new catheter should be inserted at a fresh site; (b) when a catheter-related infection is suspected (with or without signs of local exit site infection), the catheter should be exchanged over a guidewire; (c) if the tip of any catheter replaced via guidewire exchange grows >15 colonies of a pathogen in semiquantitative culture, the existing catheter should be removed and replaced at a new site; and (d) any catheter placed emergently and without strict sterile technique should undergo guidewire exchange. It is important to note that central line–associated bloodstream infections (CLABSIs) differ in that they are diagnosed with a laboratory-confirmed bloodstream infection in a patient who has, or had within the previous 48 hours, a central line and no other cause for the infection. CLABSI rates are an important hospital quality indicator. It is imperative to balance the patient's need for a central line with the potential for infection.

PULMONARY ARTERY CATHETERS

In 1970, Swan and colleagues introduced the concept of bedside right heart catheterization via manipulation of a flexible balloon-tipped catheter into the pulmonary artery (PA). Although many studies have shown no clinical benefit from use of PA catheters in both critically-ill medical or surgical patients, certain practitioners comfortable and familiar with their use continue to find the information they provide valuable. General indications for use of the PA catheter include characterization and management of shock states, assessment and management of pulmonary hypertension, and perioperative monitoring of patients at high risk for hemodynamic

instability. With specific regard to the latter, examples of such patients include those with significant cardiovascular disease, advanced age, and significant burns or trauma, as well as those undergoing a surgical procedure associated with increased risk of hemodynamic disturbances. Clearly, in such patients clinical evaluation alone is inaccurate. Furthermore, as cardiac function can be impaired for a variety of reasons in critically ill surgical patients, a central venous catheter is an unreliable surrogate for estimating left-sided filling pressures in such individuals.

Pulmonary Artery Catheter Features

The PA catheter is 100 to 110 cm in length and usually has three lumens: a distal lumen, which opens at the catheter tip into the PA for measurement of PA pressures, PA wedge pressure (PAWP), and cardiac output (CO); a proximal lumen 30 cm from the tip, which communicates with the right atrium and is used for measurement of CVP; and a third lumen approximately 15 cm from the tip, which can be used for infusion. In addition, the basic catheter is equipped with a temperature-sensing thermistor a few centimeters proximal to the catheter tip, as well as a 1.5-mL balloon surrounding the tip. Newer PA catheters are able to provide continuous monitoring of CO, measurement of right ventricular ejection fraction (RVEF), and continuous assessment of mixed venous oxygen saturation (SvO_2).

Pulmonary Artery Catheter Insertion

Prior to insertion, the balloon should be tested for defects by inflating it with 1.5 mL of air, all lumens should be flushed with sterile saline, and the distal port connected to a pressure transducer and an oscilloscope monitor. As described for invasive blood pressure monitoring, the pressure transducer must be zeroed at the level of the right atrium. The PA catheter is first placed through a sterile sheath to facilitate future manipulations, and is then inserted through a large-bore (7 or 8 French) introducer or multiaccess catheter in the subclavian or IJ vein. If necessary, a femoral vein approach may also be used. During insertion, pressure waveforms are monitored continuously via the *distal port* to identify the intravascular location of the catheter tip (Fig. 4.4). With the balloon fully deflated, the catheter should be inserted to a distance of 15 cm, where the CVP tracing of the superior vena cava or right atrium appears. At this point, the balloon is slowly inflated with 1.5 mL of air and the catheter is advanced into the

right ventricle. The characteristic right ventricular waveform is normally one of a pulsatile systolic pressure of 15 to 30 mm Hg and a diastolic pressure equal to CVP. With further advancement, the catheter should reach the PA, as identified by an abrupt increase in diastolic pressure while systolic pressure remains unchanged. As the catheter is manipulated farther into the pulmonary arterial system, the systolic waveform disappears and gives way to the characteristic pulmonary artery wedge (PAW) tracing. Under normal circumstances, the PAWP is similar to the PA diastolic pressure (6 to 12 mm Hg). With the appearance of the PAW tracing, the balloon is deflated, whereupon the pulsatile PA waveform should reappear. If not, the catheter may be advanced too far into a PA branch (colloquially termed "overwedged") and should be withdrawn slightly with the balloon deflated. When the tip of the catheter is in the proper position, the inflated balloon obstructs antegrade flow through the PA branch in which it is lodged. This creates a continuous stationary blood column from the catheter tip to the left atrium, such that the pressure measured through the distal port should be equivalent to left atrial pressure. Since under normal circumstances left atrial pressure is equivalent to left ventricular end-diastolic pressure (LVEDP), PAWP is used as an estimate of LVEDP or left ventricular (LV) preload. After PA catheter insertion, as with any cannulation of the central venous system, a chest radiograph must be obtained to confirm proper placement and lack of any complications.

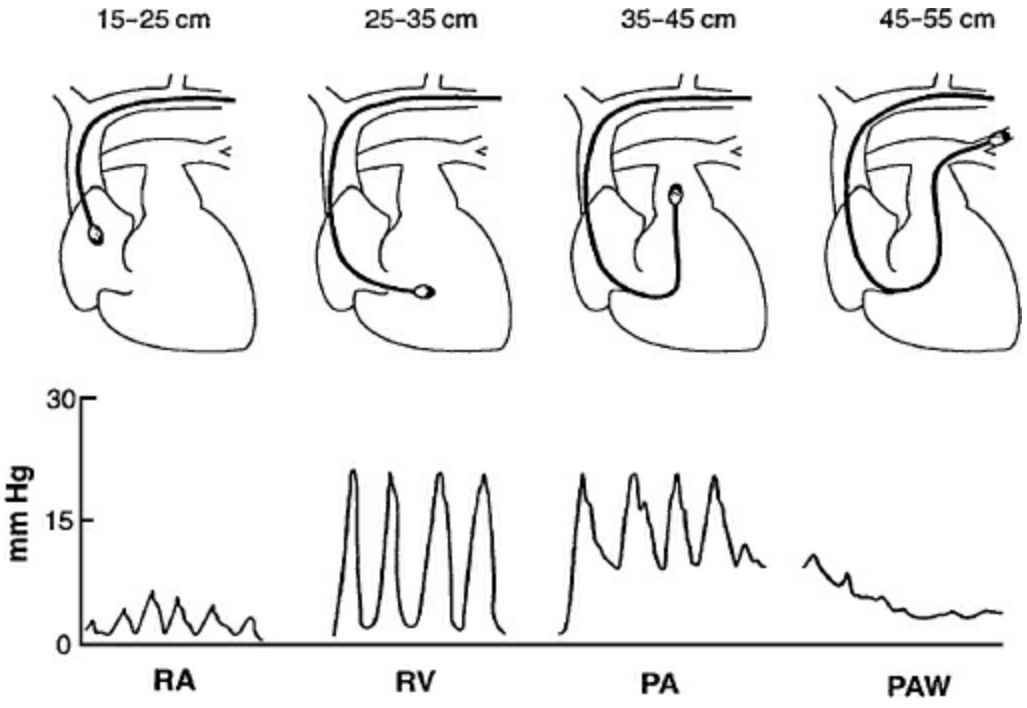

Figure 4.4. Pressure waveforms recorded during advancement of a pulmonary artery (PA) catheter through the right atrium (RA), right ventricle (RV), and PA, and ultimately into the pulmonary artery wedge (PAW) position. In this case, the catheter is inserted via the left subclavian vein. Approximate distances shown are from catheter tip to insertion site.

Pitfalls in Pulmonary Artery Catheter Insertion

A potential difficulty encountered during PA catheter insertion is failure of the catheter to advance into the PA. This is caused by coiling of the catheter in the right ventricle, and is most often a result of the catheter being advanced too rapidly and forcefully. A simple and often successful solution to this problem is to advance the catheter more slowly and continuously, avoiding thrusting. This technique takes full advantage of the balloon-flotation characteristics of the PA catheter, allowing it to float gently with the stream of blood across the pulmonary valve.

Another common problem of PA catheterization is failure to obtain a PAW tracing. Although, in most cases, the reason for this is uncertain, it may be due to a faulty balloon or eccentric inflation. After several unsuccessful attempts to obtain a PAW waveform, the catheter should be removed and the balloon retested. If the balloon is not the source of the problem, there are two options. First, if the patient does not have known pulmonary hypertension, the PA diastolic pressure can be monitored as an estimate of PAWP. However, in cases in which the presence of pulmonary hypertension confounds the use of PA diastolic pressure as a surrogate of PAWP and it is essential to patient management that PAWP be determined, the authors have had success utilizing portable fluoroscopic guidance to manipulate the catheter into the wedge position.

Pitfalls in Interpretation of Pulmonary Artery Wedge Pressure

There are several sources of potential error in interpreting PAWP (and CVP). As mentioned in the section on invasive arterial pressure monitoring, the transducer must remain at the level of the right atrium for pressure measurements to be valid. This is especially important in measuring right heart pressures, as the magnitude of the resultant error in the pressure reading due to transducer malposition is greatest in low-pressure systems.

A source of error in correlating PAWP with LV preload involves changes in intrathoracic pressure. Pressures measured by the PA catheter

are intravascular pressures, whereas the most accurate estimate of actual LV filling pressure is *transmural* pressure. Transmural pressure is equal to the difference between intravascular pressure and intrathoracic pressure. At end-expiration, intrathoracic pressure is normally equivalent to atmospheric pressure and thus considered negligible. For this reason, PAWP should only be determined at end expiration for both spontaneously breathing and mechanically ventilated patients (Fig. 4.5). However, in certain pathologic states (e.g., adult respiratory distress syndrome, high positive-pressure ventilatory settings, and tension pneumothorax), intrathoracic pressure may be significantly increased and produce a false elevation in intravascular pressure (i.e., PAWP). In this setting, the increased PAWP does not reflect a true increase in LV preload, since the physiologically more accurate transmural pressure remains unchanged.

Another situation in which PAWP does not accurately reflect LV preload occurs when the tip of the PA catheter is improperly positioned within the lung. Three physiologic lung zones have been described based on pulmonary arterial, alveolar, and venous pressures. Alveolar pressure exceeds both arterial and venous pressures in zone 1, and exceeds venous pressure in zone 2. As a result, in zones 1 and 2 PAWP is actually more a reflection of airway pressure than left atrial pressure. Only in zone 3 PAWP is accurately reflective of left atrial pressure and not subject to the confounding effects of alveolar pressure. In the supine patient, zone 3 represents the region of the lung posterior to the left atrium, which is the most dependent area of the lung. Since zone 3 has the greatest blood flow, the air-filled balloon tip of the PA catheter will most often float into this zone. However, clues that the PA catheter tip is not positioned within zone 3 are: (a) the presence of marked respiratory variation on the PAW tracing; (b) if the positive end-expiratory pressure (PEEP) is increased and the PAWP increases by 50% or more of the increased PEEP; and (c) if the PAWP is greater than the pulmonary artery diastolic pressure (PADP). The presence of any of these criteria should prompt repositioning of the catheter. It is important to note that any condition that decreases pulmonary vascular pressure (e.g., hypovolemia) or increases alveolar pressure (e.g., high PEEP) can reduce the total area of physiologic zone 3 in the lung, even if the catheter tip is positioned posterior to the plane of the left atrium.

Mitral stenosis creates another pitfall in correlating PAWP with LV preload. In this condition, there is a pressure gradient between the left

atrium and ventricle, such that left atrial pressure is higher than LV end-diastolic pressure. Therefore, although PAWP does reflect left atrial pressure in mitral stenosis, it cannot be used as an accurate predictor of LV preload in this condition.

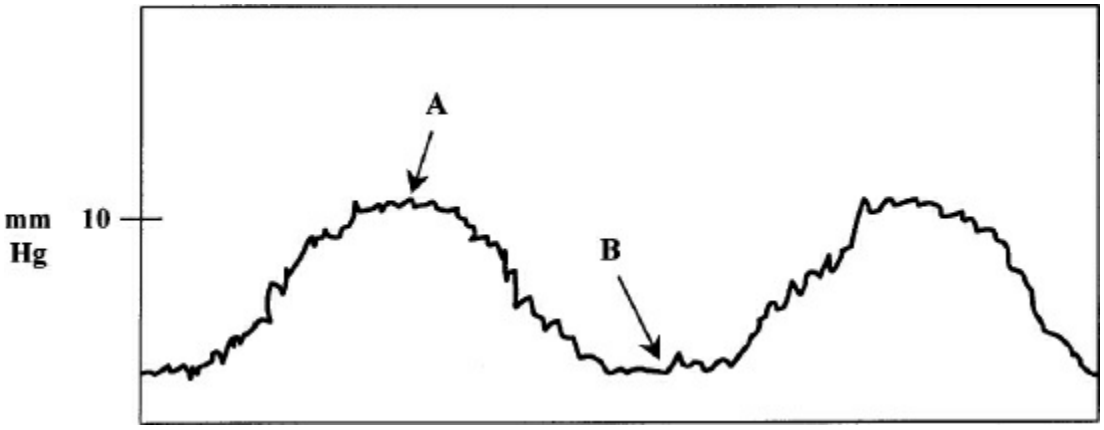

Figure 4.5. Pulmonary artery wedge (PAW) tracing with the usual cyclical respiratory variations. PAW pressure should be measured at end-expiration. This corresponds to the peak of the wedge tracing for spontaneously breathing patients (*point A*) and the valley of the tracing for patients undergoing positive-pressure ventilation (*point B*).

In the presence of normal LV compliance, PAWP provides an accurate estimation of LV end-diastolic volume and thus preload. However, in conditions associated with decreased LV compliance (e.g., ventricular hypertrophy and myocardial ischemia), PAWP may be high even in the face of a normal or even decreased preload. Hence, PAWP is not a reliable index of LV preload in the setting of a poorly compliant ventricle.

The physician who uses a PA catheter to assist in the management of critical illness should bear in mind the above-mentioned shortcomings of PAWP in estimating LV preload. In situations in which PAWP is an unreliable index of left heart filling pressures, there are other modalities currently available to estimate LV preload. These alternative modalities, such as transesophageal echocardiography (TEE) or RVEF obtained from the newer fast-response PA catheters, are discussed in detail below. Due to the increased risk of injury to the PA during wedging of the balloon and the uncertainty of how accurate the data may be, many intensivists follow the PADP in critically ill patients and avoid routine wedging.

Hemodynamic Variables

When used appropriately and knowledgeably, the PA catheter is capable of generating a great deal of information on cardiovascular status. The more commonly utilized hemodynamic variables obtained by the PA catheter are listed in Table 4.3. While many of these variables are measured directly, others must be derived by a calculation. A few parameters, such as CO and systemic vascular resistance (SVR), can be normalized for differences in body size by dividing by the patient's body surface area in square meters, thus yielding CI and systemic vascular resistance index (SVRI), respectively. It is important to mention that in assessing response to treatment interventions, trends in each of the hemodynamic indices listed in Table 4.3 are of more clinical importance than a single reading.

Right Ventricular Ejection Fraction

In 1986, a modified PA catheter was developed for bedside evaluation of right heart function. The device consists of a fast-response thermistor, which permits thermodilution measurement of RVEF and right ventricular end-diastolic volume (RVEDV). This technology provides a direct measurement of preload based on volume rather than estimating preload by pressure criteria (e.g., CVP and PAWP). This concept is particularly important in the setting of positive-pressure ventilation, in which pressure-derived estimates of preload can be inaccurate. The RVEF thermodilution catheter has been especially useful in resuscitation of multiply injured trauma victims. In such individuals, many of whom have significant fluid requirements in the face of high positive-pressure ventilatory requirements, evaluation of preload by conventional parameters (e.g., PAWP) is particularly unreliable.

TABLE 4.3 Hemodynamic Variables Obtained by the Pulmonary Artery Catheter

Variable	Derivation	Range of Normal Values
Central venous pressure (CVP)	N/A	0–8 mm Hg
Pulmonary artery systolic pressure (PASP)	N/A	15–30 mm Hg
Pulmonary artery diastolic pressure (PADP)	N/A	6–12 mm Hg
Mean pulmonary artery pressure (MPAP)	N/A	10–16 mm Hg
Pulmonary artery wedge pressure (PAWP)	N/A	6–12 mm Hg
Cardiac output (CO)	N/A	4.0–8.0 L/min
Cardiac index (CI)	N/A	2.5–4.5 L/min/m^2
Right ventricular ejection fraction (RVEF)	N/A	45–50%
Mixed venous oxygen saturation (SvO_2)	N/A	70–80%
Systemic vascular resistance (SVR)	$80 \times [(MAP - CVP)/CO]$	900–1,400 dynes·s·cm^{-5}
Systemic vascular resistance index (SVRI)	$80 \times [(MAP - CVP)/CI]$	1,600–2,400 dynes·s·cm^{-5}·m^2
Pulmonary vascular resistance (PVR)	$80 \times [(MPAP - PAWP)/CO]$	150–250 dynes·s·cm^{-5}
Pulmonary vascular resistance index (PVRI)	$80 \times [(MPAP - PAWP)/CI]$	200–400 dynes·s·cm^{-5}·m^2
Oxygen delivery (DO_2)	$CI \times 13.4 \times Hgb \times SaO_2$	520–570 mL/min·m^2
Oxygen consumption (VO_2)	$CI \times 13.4 \times Hgb \times (SaO_2 - SvO_2)$	110–150 mL/min·m^2

Hgb, hemoglobin; N/A, not applicable; SaO_2, arterial oxygen saturation.

Cardiac Output

CO, an index of cardiac performance, is defined as the product of heart rate and stroke volume. Stroke volume, in turn, is determined by preload (PAWP), afterload (SVR), and the contractile state of the heart. As a result, all of these factors must be considered when interpreting changes in CO and in making therapeutic decisions to optimize this parameter (see section “Cardiovascular Support”).

The thermodilution method for determining CO was introduced into clinical practice by Ganz and colleagues in 1971. This method is based on the indicator-dilution principle, in which an indicator is injected into the circulation and the CO is determined by the rate of change of the concentration of indicator in the bloodstream. The indicator may either be a dye (dye-dilution method) or a fluid at a temperature above or below that of the blood (thermodilution method). With regard to the latter, 10 mL of an iced or room temperature crystalloid solution (e.g., normal saline) is rapidly injected into the right atrium via the proximal port of the PA catheter. The cold solution then cools the blood with which it mixes in the right heart. As the cool blood flows into the PA, the thermistor near the tip of the catheter senses the change in blood temperature over time. From this data, a computer generates a thermodilution curve; the area under this curve is inversely proportional to the CO. Explained differently, with faster blood transit times through the right heart, the less the blood will be cooled by the cold solution. As a result, the thermistor will detect a lower magnitude of temperature change over time, and the computer will translate this information into a higher displayed CO.

There are a number of pitfalls in the thermodilution method of CO measurement. For example, the injection must be completed within 4 seconds to yield an accurate CO measurement. To reduce variability and

improve accuracy, it is recommended that the CO be determined from the average of three different injections, all of which should be initiated at the same point in the respiratory cycle. In tricuspid regurgitation, the cold solution is transported both antegrade and retrograde across the valve, producing a spuriously low CO. Tricuspid regurgitation can be a common source of error in CO determination in critically ill patients, as many such individuals will have high right-sided heart pressures from acute lung disease and high positive-pressure ventilatory settings. Accuracy of the thermodilution method for measuring CO is also limited in states of severely impaired cardiac performance. In such states, the system experiences difficulty in accurately measuring very low COs (below 2.0 mL/min), especially with the use of room temperature injectates. The use of iced injectates in patients with poor cardiac function can improve the likelihood of an accurate measurement. Finally, the presence of intracardiac shunts confounds interpretation of CO obtained by thermodilution. In both right-to-left and left-to-right shunts, the recorded CO is erroneously high.

Recent technologic advances have made possible the continuous measurement of CO, which obviates the labor-intensive task of manually injecting fluid. Some of the newer models of PA catheters are equipped with an accessory thermal filament approximately 20 cm from the catheter tip. This filament emits heat, which warms the surrounding blood. The thermistor located at the catheter tip detects changes in blood temperature over time in the same manner as described above for the cold fluid injectate method. A computer measures the average CO over a 3-minute interval and displays new values every 30 to 60 seconds. The ideal clinical scenario for use of continuous CO monitoring is the patient with extreme hemodynamic instability who requires frequent adjustments in cardiovascular support.

Indices of Oxygen Metabolism

Since the ultimate goal of cardiovascular monitoring is to ensure adequate tissue oxygenation, it is imperative that critically ill patients, particularly those suffering from shock, be monitored for disturbances in oxygen metabolism. Indeed, it has been demonstrated that in such patients this approach translates into improved survival. There are a variety of parameters reflecting the status of systemic oxygen metabolism, all of which can be measured with the PA catheter. SvO_2 represents the oxygen

saturation of “mixed” blood from three central veins: the superior vena cava, inferior vena cava, and coronary sinus. Normal SvO_2 values range from 60% to 80%. This parameter may be determined *in vitro* with use of a blood gas machine by measuring the oxygen saturation of a pulmonary arterial blood sample drawn through the distal port of the PA catheter. Alternatively, continuous *in vivo* SvO_2 monitoring via reflectance spectrophotometry is possible. This in-line oximetric technique, which is facilitated by a specialized PA catheter equipped with an accessory fiberoptic system, eliminates the cumbersome task of drawing serial PA blood samples and provides new data points at 5-second intervals. The indications for use of this device are similar to those described for continuous CO monitoring.

SvO_2 reflects the discrepancy between total body oxygen delivery (DO_2) and oxygen consumption (VO_2). Alternatively, this relationship is expressed as $SvO_2 = DO_2/VO_2$. Since DO_2 = CO × hemoglobin (Hgb) × arterial oxygen saturation (SaO_2), changes in SvO_2 must reflect a change in CO, Hgb, SaO_2, and/or VO_2. Hence, a low SvO_2 (<60%) indicates a systemic DO_2/VO_2 imbalance caused by one or more of the following: depressed cardiac function, anemia, arterial hypoxemia, or hypermetabolism. A critically ill patient with a decreasing SvO_2 should prompt investigation of the four parameters mentioned above, with an aim toward a specific therapeutic intervention. SvO_2 monitoring is an effective method for early detection and subsequent correction of derangements of these four parameters.

As Table 4.3 indicates, the normal range for DO_2 is 520 to 570 mL/min·m², while for VO_2 it is 110 to 150 mL/min·m². Thus, under normal physiologic conditions, DO_2 exceeds VO_2 by a 5:1 ratio and VO_2 is independent of DO_2 (i.e., supply independent). In a normal, healthy individual VO_2 remains independent over a wide range of DO_2 values. VO_2 can remain in the normal range even at lower DO_2 ranges, because as DO_2 falls the tissues respond by increasing the amount of oxygen they extract. However, increased oxygen extraction compensates only up to a point. If DO_2 continues to fall below a critically low level, as in cardiogenic shock, VO_2 will begin to decrease and become dependent on DO_2 (i.e., supply dependent). In this scenario, CO, Hgb, and SaO_2 should be examined and optimized to restore the supply-independent relationship

between DO_2 and VO_2. In septic shock, metabolic demands are dramatically increased and VO_2 must therefore rise concomitantly to meet these demands. However, if DO_2 does not rise proportionately, VO_2 will become limited by DO_2 and supply dependency will ensue. In general, a sudden decrease in SvO_2 heralds a developing supply-dependent situation. The goal of monitoring parameters of oxygen metabolism is to maintain an adequate DO_2, so that VO_2 remains supply independent and adequate tissue oxygenation is ensured. However, attempts to achieve supranormal DO_2, while once believed to improve outcomes in critically ill patients, have not proven beneficial.

Blood Lactate Levels

The use of blood lactate levels is a valuable adjunct to guide therapy and gauge illness severity in the management of both medical and surgical patients. As a practical matter, the ready availability of blood gas analyzers with immediate lactate turnaround increases the utility of lactate measurement to the clinician.

When tissue demands for oxygen exceed supply, anaerobic metabolism begins and metabolic acidosis results. Pyruvate is unable to enter the Krebs cycle and undergo oxidative phosphorylation secondary to inadequate oxygen supply. In states in which lactate production exceeds the capacity for clearance by the liver, kidneys, and skeletal muscle, elevated blood lactate levels result. Hyperlactatemia may occur in the setting of adequate tissue perfusion such as with catecholamine administration, alkalosis, or states of increased metabolic activity (i.e., sepsis and burns). In these cases, the body's buffering mechanisms may compensate for any fall in pH. In states of poor tissue perfusion, the body's buffering capacity is overwhelmed and metabolic acidosis results.

Substantial data exist for the use of serial lactate measurement as an endpoint for resuscitation in surgical patients. In addition, initial lactate levels and lactate clearance rates have been used to predict mortality rates in the ICU setting. Failure to normalize lactate levels within 96 hours uniformly predicted mortality. Although conflicting data on the utility of lactate monitoring exists, a recent multicenter randomized controlled trial found a reduction in hospital mortality with lactate-guided treatment and a meta-analysis found that lactate clearance in critically ill patients is predictive of lower mortality.

Complications of Pulmonary Artery Catheters

Although extremely useful, the PA catheter is an invasive monitoring device with a number of potential complications. Thus, the PA catheter should only be used when the benefit of the information provided by it outweighs the risks associated to the patient. Similarly, when the data obtained from a PA catheter are no longer clinically useful, it should be promptly removed.

In addition to adverse effects of central venous cannulation, the PA catheter insertion process can cause cardiac dysrhythmias. Premature ventricular contractions are quite common as the catheter tip traverses the right ventricle, and usually resolve spontaneously after the catheter is advanced into the PA. Rarely, ventricular tachycardia and fibrillation can occur, but usually resolve with electrical cardioversion. New right bundle branch block may occur in up to 3% of patients undergoing PA catheterization. This conduction disturbance is normally of a benign and transient nature, but in patients with preexisting left bundle branch block, complete heart block may result. Therefore, a transthoracic pacemaker should be immediately available when advancing a PA catheter in a patient with known left bundle branch block.

PA catheters can also cause thromboembolism of the central veins, right heart chambers and valves, and PA. Various degrees of venous thrombosis may occur in over half of individuals with a PA catheter in place, and when identified, mandates catheter removal and anticoagulation. Autopsy studies of patients who died with indwelling PA catheters have identified right-sided valvular injury as well as endocarditis.

Another infrequent complication is catheter knotting within the right ventricle. Risk factors for this include a dilated right ventricle and advancing long lengths of catheter too forcefully and quickly. A clue to the presence of a knotted intraventricular catheter is difficulty encountered during its removal. Most knotted catheters can be successfully removed with the assistance of fluoroscopy and angiographic techniques.

The most serious and potentially life-threatening complication of PA catheterization is PA rupture. The reported frequency of this unfortunate complication is approximately 1 in 800 catheterizations, with an attendant mortality of >50%. Risk factors for PA perforation include pulmonary hypertension, anticoagulation, and hypothermia. In addition, advancement of the catheter with the balloon fully deflated, as well as overinflation of the balloon, particularly in the “overwedged” position, predispose to this

complication. Massive hemoptysis usually heralds the onset of this devastating complication. Treatment consists of isolation of the contralateral lung with selective endobronchial intubation, initiation of PEEP, and maintenance of the catheter in its existing position. If these measures fail, emergent pulmonary resection is indicated. Should a pseudoaneurysm develop following clinical resolution of a ruptured PA, this can most often be managed with endovascular coil embolization.

TABLE 4.4 Hemodynamic Profile for Each Type of Shock

Type of Shock	PAWP	CI	SVRI	SvO_2
Hypovolemic	↓	↓	↑	↓
Cardiogenic	↑	↓	↑	↓
Early septic	↓	↑	↓	↑
Late septic	↑	↓	↓ or ↑	↓
Neurogenic	↓	↓ or ↔	↓	↓

CI, cardiac index; PAWP, pulmonary artery wedge pressure; SvO_2, mixed venous oxygen saturation; SVRI, systemic vascular resistance index.

Hemodynamic Profiles of Shock

Although the hallmark of all shock states is a deficit in tissue oxygenation, each type of shock has its characteristic hemodynamic profile (Table 4.4). The PA catheter is a useful instrument for generating these hemodynamic data to assist in differentiating between the various shock states. In hypovolemic shock, the primary problem is reduced intravascular volume, as reflected by a decreased PAWP. As a result of the decreased preload, CI is likewise decreased. The peripheral vascular tone increases in response to increased endogenous catecholamines, yielding an increased SVRI. In this case, DO_2 is markedly less than tissue oxygen extraction resulting in a fall in SvO_2. The hallmark of cardiogenic shock is a reduced CI, yielding a high PAWP and SVRI. The net result is a decrease in SvO_2. Conversely, early septic shock is characterized by a hyperdynamic state and extreme loss of vascular tone, producing a profound decrease in SVRI and an increase in CI. Early in sepsis, SvO_2 rises as a result of the hyperdynamic state, peripheral vascular shunting, and impaired tissue oxygen uptake. Late septic shock is complicated by cardiac failure, as indicated by a decreased CI. As the heart fails in the face of ongoing septic shock, the PAWP rises and the SVRI may increase or decrease, depending upon

which condition predominates. A falling SvO_2 in prolonged septic shock is an ominous sign that heralds an extreme deficit in tissue oxygenation. Finally, neurogenic shock is characterized by a primary deficit of vascular tone (i.e., low SVRI). As a result of peripheral blood pooling, PAWP decreases and consequently a decreased CI often results. SvO_2 is reduced by the same mechanism as in hypovolemic shock.

TRANSESOPHAGEAL ECHOCARDIOGRAPHY

TEE plays a vital role in the hemodynamic evaluation of surgical patients as an integral diagnostic device for evaluation of the heart, aorta, and pericardial space. As a result of its portability, TEE is readily available for use in the ICU, emergency department, or operating room.

TEE is favored over transthoracic echocardiography (TTE) for the cardiovascular assessment of surgical patients for a variety of reasons: (a) Logistically, TEE is more practical for intraoperative use; (b) TEE offers better visualization of the left atrium and descending aorta; (c) critically ill trauma and postoperative surgical patients often have interfering dressings, central venous catheters, thoracostomy tubes, and chest wall abnormalities rendering TTE difficult or impossible; and (d) a mechanically ventilated patient who is difficult to properly position for optimal acoustic windows precludes an adequate TTE examination.

TEE provides excellent anatomic detail of the cardiac chambers and valves. It can be used to evaluate global and regional cardiac wall motion abnormalities, valvular structure and function, vegetations, cardioembolic sources, and intravascular volume status. In addition, TEE permits clear visualization of the pericardial space, and is therefore beneficial in evaluating pericardial effusions. Furthermore, since the esophagus lies directly adjacent to the descending aorta, the latter structure is particularly amenable to visualization with TEE.

TEE has proven itself as an essential tool in the critical care unit, especially in the setting of unexplained hypotension. Detection of cardiac contractile dysfunction and wall motion abnormalities suggestive of myocardial ischemia are important findings that prompt specific treatment. The diagnosis of new intraoperative segmental wall motion abnormalities was found to be a more sensitive indicator of myocardial ischemia than ECG monitoring. In addition, LV end-diastolic volume can be closely approximated with TEE, and is more reliable than PAWP in evaluating preload. The limitations of PAWP for assessing preload are discussed in

the section on PA catheters. A final application of TEE to critical illness is in patients with both unexplained hypotension and hypoxia, in whom a bedside TEE examination is an accurate and rapid technique for detecting pulmonary emboli.

The most common indication for TEE in trauma patients is the assessment of blunt cardiac injury. Disruption of the cardiac chambers, valvular injury, coronary artery thrombosis, and the echocardiographic stigmata of myocardial contusion may be visualized with TEE. Also, since severe myocardial contusion and cardiac tamponade from blunt cardiac trauma may present with identical clinical features, TEE is a valuable imaging modality for differentiating between these two. Finally, in experienced hands TEE has been shown to have high sensitivity and specificity to diagnose blunt aortic injury and can be performed rapidly in an unstable patient in the emergency room or operating room.

CARDIOVASCULAR SUPPORT

The goals of cardiovascular support of surgical patients are to maintain adequate tissue oxygenation and organ perfusion. The achievement of these goals requires effective clinical management and technical support. As mentioned in detail earlier in this chapter, a variety of cardiovascular monitors are available to facilitate interpretation of hemodynamic status. Once monitoring is properly established, cardiovascular support can be initiated in a safe and effective manner. Volume resuscitation warrants special consideration as traditional methods of liberal crystalloid infusion to improve fluid status have fallen out of favor. Current recommendations support early initiation of blood product administration in a 1:1:1 or 1:1:2 ratio of red blood cells to plasma to platelets when loss of blood volume is contributing to critical illness. Also important to the care of septic patients is the concept of goal-directed resuscitation which uses monitoring targets to help drive cardiovascular support. To date however, trials have not demonstrated a survival benefit with goal-directed resuscitation. Pharmacologic agents, the cornerstone of cardiovascular support, fall into three general categories, with some medications falling into more than one category: (a) inotropic agents, which strengthen the cardiac contraction and thereby increase CO and DO_2; (b) vasodilators, which decrease vascular resistance; and (c) vasopressors, which may be used to elevate blood pressure in acute situations of profound hypotension. All of these groups of drugs have the distinct advantages of a rapid onset and short

duration of action, while having anticipated and manageable adverse effects.

INOTROPIC AGENTS

Inotropic agents are usually administered in an attempt to improve cardiac performance and thus preserve vital organ perfusion. Inotropic support is frequently used in the surgical ICU to treat patients in the septic or posttraumatic state. Suboptimal CO in these settings leads to inadequate tissue perfusion, manifested by elevated lactate levels, decreased SvO_2, and multiorgan failure. In addition, short-term inotropic therapy is frequently needed during major surgical procedures (cardiac and noncardiac) for patients with chronic heart failure. Short-term cardiac support may also be needed for patients with acute heart failure, such as after acute myocardial infarction. Furthermore, inotropic support may be indicated as a "pharmacologic bridge" for patients who are awaiting more definitive treatment, such as coronary artery bypass surgery, valve repair/replacement, ventricular assist device placement, or cardiac transplantation. Finally, inotropic support is commonly used in the early period after cardiac surgery, in an attempt to optimize postoperative cardiac function until the heart fully recovers from cardiopulmonary bypass.

β-Adrenergic Receptor Agonists

To varying degrees, β-agonists enhance both myocardial contractility (inotropy) and diastolic relaxation (lusitropy) and increase heart rate (chronotropy). They function by binding cell surface β-receptors and activating guanine nucleotide-bound protein. This in turn activates adenylate cyclase, which catalyzes the synthesis of cyclic adenosine 3′, 5′ monophosphate (cAMP). cAMP-dependent protein kinases phosphorylate intracellular proteins, resulting in intracellular calcium influx and enhanced myocardial contraction.

Dobutamine

Dobutamine is a synthetic catecholamine existing as a racemic mixture of two stereoisomers and providing both α-adrenergic activity (levo-isomer) and β-adrenergic activity (dextro-isomer). Dobutamine is very effective in augmenting cardiac contractility, stroke volume, CO, and pulse pressure. In addition, it reduces right and LVEDPs, as well as systemic and

pulmonary vascular resistances, all with minimal change in heart rate. Dobutamine may also exert favorable metabolic effects on compromised or ischemic myocardium. Coronary perfusion pressure is augmented, coronary artery vasodilation occurs, and diastolic perfusion time is lengthened. The increased oxygen requirements of positive inotropy are countered by the favorable effects of ventricular unloading in both systole and diastole. As a result, coronary blood flow and myocardial perfusion are increased in proportion to or exceeding any increases in myocardial VO_2.

Traditionally, dobutamine has been primarily considered a myocardial β_1-agonist, while having minimal effects on peripheral vascular α_1- and β_2-receptors. However, this mechanism has been debated as more recent studies have demonstrated an increase in CO in the absence of enhanced ventricular contractility after racemic dobutamine infusions. Instead, peripheral β_2 stimulation augmented CO by reducing SVR. At the same time, stimulation of the α-receptors potentiated an increase in CO by reducing venous capacitance and thus increasing venous return. The combined properties of β_1-mediated inotropy and β_2-induced afterload reduction make dobutamine an ideal agent for treating the failing heart.

The typical dose of dobutamine ranges from 2 to 20 μg/kg/min. Infusion rates between 5 and 15 μg/kg/min predominantly cause an increase in cardiac contractility, peripheral vasodilation, and a dose-dependent increase in heart rate. This dose range is commonly used in patients with advanced heart failure, cardiac failure complicating septic or traumatic shock, cardiogenic shock after an acute myocardial infarction, or for hemodynamic support following cardiac surgery.

There are a few limitations of dobutamine. Higher doses may cause tachycardia, leading to an imbalance of myocardial oxygen supply and demand. At higher heart rates diastolic myocardial perfusion time shortens, while myocardial VO_2 increases. Although uncommon, atrial and ventricular arrhythmias may occur, particularly at higher doses.

Dopamine

As a biochemical precursor of epinephrine, dopamine activates α- and β-receptors in addition to dopamine 1 and 2 (DA_1 and DA_2) receptors. DA_1-receptor activation leads to renal, mesenteric, coronary, and cerebral arterial vasodilation, while DA_2-receptor activation inhibits endogenous norepinephrine release. Dopamine works in a dose-dependent fashion. At

low doses (1 to 3 μg/kg/min), it predominantly stimulates DA_1 receptors, producing renal artery vasodilation. This so-called renal dose of dopamine is touted to improve renal blood flow and urine output in patients at higher risk for acute renal failure, such as those in septic shock or those undergoing major surgical procedures who have preexisting renal artery stenosis or chronic renal insufficiency. Because of the splanchnic vasodilatory properties associated with DA_1 activation, low-dose dopamine infusion may improve intestinal perfusion during mesenteric ischemia.

At moderate doses (3 to 6 μg/kg/min), cardiac β_1-receptors are stimulated, leading to enhanced ventricular contractility with minimal effect on heart rate and blood pressure. However, at higher doses (>6 μg/kg/min), peripheral α_1-receptor stimulation occurs, causing vasoconstriction and elevation of blood pressure. With escalating doses, dopamine produces tachycardia and should be used cautiously in patients with coronary artery disease. Additionally, higher doses of dopamine cause increased ventricular wall stress, which can further disrupt the balance of myocardial oxygen supply and demand. This drug also has a dose-related arrhythmogenic effect. Since its effect is based on the release of endogenous catecholamines, dopamine is not as effective in patients who are catecholamine depleted. It is important to note that at least two randomized trials comparing dopamine to norepinephrine for treatment of sepsis do not demonstrate any greater renal protective effect with dopamine. In fact, there has been some suggestion of greater renal injury in those patients treated with dopamine.

Epinephrine

Epinephrine is an endogenous catecholamine secreted by the adrenal medulla. Pharmacologically, epinephrine stimulates β_1, β_2, and α-receptors in a dose-dependent manner. At lower doses of infusion (0.01 to 0.1 μg/kg/min), β-receptors are primarily stimulated, leading to increased cardiac contractility and heart rate (myocardial β_1), as well as peripheral vasodilation (peripheral β_2). At higher infusion rates (>1 μg/kg/min), peripheral α-adrenergic stimulation produces increased SVR (peripheral vasoconstriction) and a subsequent rise in arterial blood pressure (vasopressor activity). In addition, there is a dose-dependent rise in heart rate and an increased risk of arrhythmias and myocardial ischemia.

Norepinephrine

Norepinephrine is a potent catecholamine exerting both α- and β-adrenergic activity. It typically results in a significant increase in mean arterial pressure due to its vasoconstrictive effects, while causing minimal change in heart rate. It has some inotropic effects and will slightly increase CO. It is typically used in patients with profound hypotension in a setting of adequate volume resuscitation. Norepinephrine is traditionally used in patients with septic shock or following severe neurologic events with hypotension from decreased SVR (with preserved CO). There were historical concerns that further vasoconstriction may worsen the shock syndrome and perfusion, thus leading to end-organ ischemia (especially renal hypoperfusion resulting in oliguria and renal failure). However, several recent studies investigating norepinephrine in septic shock suggest that it can successfully increase blood pressure without causing the feared deterioration in organ function and in fact, may be the preferred agent for sepsis. It has been shown that when CO is maintained, treatment with norepinephrine alone has no negative effects on splanchnic tissue oxygenation. Norepinephrine effects on serum lactate levels in patients with septic shock have been studied. Tissue oxygenation, as assessed in several studies by serum lactate levels in patients with septic shock, does not worsen, and may even improve with norepinephrine. Clearly, there has been concern regarding the effects of norepinephrine on the kidney. In the setting of hypotension and hypovolemia during hemorrhagic shock, many vasoconstrictors, including norepinephrine, may have several harmful effects on renal function. However, in hyperdynamic septic shock, norepinephrine has been shown to cause a significant decrease in serum creatinine, blood urea nitrogen, free water clearance, and fractional excretion of sodium, while causing an increase in urine output, creatinine clearance, and osmolar clearance.

In summary, clinical experience with norepinephrine in patients with septic shock suggests that it can effectively increase blood pressure without causing deterioration in CI or end-organ function. Norepinephrine doses of 0.01 to 3 μg/kg/min have consistently been shown to improve hemodynamic variables in the large majority of patients with septic shock.

Isoproterenol

A synthetic catecholamine, isoproterenol, possesses potent β-agonist properties. Significant increases in CO, myocardial contractility, and

chronotropy all result from myocardial β_1-stimulation. Peripheral β_2-activation causes peripheral vasodilation, which decreases afterload and thereby facilitates an increase in CO and pulse pressure. Usual indications for isoproterenol infusions are limited to situations in which enhancement of both heart rate and contractility are desired, such as for early postoperative support of the denervated, bradycardic transplanted heart. A major advantage of isoproterenol is that it directly decreases pulmonary vascular resistance. Thus, this agent is also beneficial in right ventricular failure and chronic pulmonary hypertension. However, because of its potent β-adrenergic activity, myocardial oxygen demand is increased and tachycardia-induced diastolic coronary filling is decreased. Therefore, isoproterenol is contraindicated in patients with ongoing coronary ischemia.

Phosphodiesterase Inhibitors

Phosphodiesterase III inhibitors (PDIs) are a unique category of inotropic drugs. These agents inhibit myocardial cAMP phosphodiesterase activity, thus increasing cellular concentrations of cAMP and improving the myocardial contractile mechanism. In addition to enhancing ventricular performance, the increased cAMP in vascular smooth muscle causes peripheral vasodilation and reduced resistance.

Amrinone

Amrinone is the prototypical PDI. This agent concomitantly improves cardiac performance and decreases SVR. However, due to the absence of catecholamine effects, there are minimal associated increases in heart rate. As a result, amrinone does not affect myocardial oxygen demand. An additional advantage of amrinone is that it reduces pulmonary vascular resistance. As a result, this agent can be particularly effective in patients with left heart failure complicated by pulmonary hypertension as well as in right ventricular failure. Amrinone is frequently used in combination with other inotropic agents. Although these combined agents act through different mechanisms, they exert potentiative effects in enhancing myocardial contractility.

Amrinone is typically initiated as a 0.75 mg/kg loading dose over several minutes, followed by an infusion that is started at 5 μg/kg/min and can be titrated to 20 μg/kg/min. Although lower rates of infusion usually do not have much effect on blood pressure, higher infusion rates may lead

to profound vasodilation. Other drawbacks of this agent are its long half-life (3.5 hours), its potential for causing arrhythmias (particularly supraventricular), and the risk of thrombocytopenia with prolonged infusions.

Milrinone

Milrinone is the preferred PDI for clinical use. The drug's mechanisms of action and hemodynamic effects closely parallel those of amrinone. However, the potency of milrinone is 10 to 30 times higher than amrinone, which translates into smaller doses used and fewer side effects. Thrombocytopenia is unusual, arrhythmias are less frequent, and the half-life is much shorter (1.5 to 2 hours). The usual loading dose of milrinone is 50 μg/kg infused over 10 minutes, followed by a continuous infusion rate of 0.375 to 0.75 μg/kg/min. It is useful in patients who are unresponsive to β-agonists, and does not significantly increase myocardial O_2 demand.

Ionized Calcium

Calcium is a major regulatory cation that plays a central role in muscular contraction and relaxation by regulating the actomyosin contractile apparatus. In addition to being critical to optimal myocardial contraction, calcium is important for mediating contraction of vascular smooth muscle and maintenance of vascular tone. Ionized calcium is the physiologically active fraction that circulates in blood. Ionized calcium levels generally range from 4.0 to 5.0 mg/dL (1.0 to 1.25 mmol/L). As a result of altered protein binding, acid–base status, and other circulating factors, ionized calcium levels are frequently diminished during shock. Other causes of reduced ionized calcium include chronic renal failure, blood transfusions (containing calcium binding citrate), and cardiopulmonary bypass. While patients with mildly or moderately reduced ionized calcium levels may maintain a normal CO and blood pressure, those with severely reduced levels frequently have significant hypotension and cardiac contractile dysfunction. Therefore, patients with decreased ionized calcium levels usually manifest an immediate cardiovascular improvement from parenteral calcium administration.

Levosimendan

Levosimendan is a new inotrope currently being evaluated in a Phase III clinical trial (Levosimendan in Patients With Left Ventricular Systolic

Dysfunction Undergoing Cardiac Surgery on Cardiopulmonary Bypass [LEVO-CTS]) in the United States. It works as a calcium-sensitizing agent as it enhances the cardiac myocyte function by binding to cardiac troponin C, improving its response to calcium. The net effect on the heart is inotropy and lusitropy (cardiac relaxation). It also acts by opening ATP-dependent potassium channels on vascular smooth muscle cells and cardiac myocytes, leading to coronary and peripheral vasodilation and a resultant decrease in cardiac preload and afterload. A recently published meta-analysis of 25 trials that compared levosimendan to dobutamine or placebo in the treatment of decompensated heart failure found a reduction in total mortality with levosimendan but an increased risk of hypotension.

VASODILATORS

Parenteral vasodilators are useful in treatment of the failing ventricle. These agents reduce both preload and afterload, thus reducing metabolic demands of the myocardium. Arterial vasodilation decreases afterload, which decreases the systolic workload of the heart and allows it to eject more effectively. By causing venodilation, these drugs also reduce preload and thus myocardial wall tension. By the mechanisms just mentioned, a reduction in afterload or preload independently enhances the myocardial oxygen supply/demand ratio. Vasodilators are also useful in the setting of poorly controlled hypertension in the early postoperative period. In such cases, a reduction in blood pressure is desirable to reduce the risk of bleeding from operative sites.

Nitroprusside

Nitroprusside is an effective vasodilator acting on venous and arterial vascular smooth muscle in both the systemic and the pulmonary vascular beds. Systemic venodilation reduces blood pressure by decreasing venous return and thus CVP. Arterial vasodilation reduces afterload, thereby decreasing blood pressure and at the same time enhancing CO. Nitroprusside has the advantage of an extremely rapid onset of action, effectively lowering blood pressure within seconds to minutes. Similarly, its effects rapidly dissipate after decreasing or terminating the infusion, permitting precise titration of the desired blood pressure.

Infusion rates of nitroprusside typically begin at 0.5 μg/kg/min and can be titrated upward until the desired blood pressure is achieved. Hypotension may develop, particularly in patients with inadequate filling

pressures, thus stressing the need for continuous arterial blood pressure monitoring during nitroprusside therapy. Because nitroprusside is degraded by light exposure, the infusion bag must be wrapped in aluminum foil or other opaque materials.

A very rare but potentially serious side effect of nitroprusside is cyanide toxicity. This complication usually accompanies excessive dosages (>3 µg/kg/min) used over a prolonged period of time (>72 hours). Nitroprusside is metabolized by red blood cells and the liver to cyanide and thiocyanate, both of which inhibit aerobic metabolism. Toxicity is manifested by lactic acidosis from anaerobic tissue metabolism, as well as elevated SvO_2 as the result of a disturbance in oxidative phosphorylation. Clinically, toxicity is manifested as tremors, hypoxia, nausea, and disorientation. The diagnosis is confirmed with serum cyanide or thiocyanate levels. The treatment is immediate cessation of nitroprusside and administration of hydroxocobalamin, which converts cyanide to cyanocobalamin (a form of vitamin B_{12}).

Nitroglycerine

By acting directly on vascular smooth muscle, nitroglycerine predominately causes venodilation, while possessing some arterial vasodilatory properties as well. An important attribute of nitroglycerine is that it dilates coronary arteries; hence, this agent is preferable to nitroprusside in patients with coronary artery disease. Both large and small coronary arteries are dilated, which results in enhanced blood flow to vulnerable subendocardial myocardium. Postoperatively, nitroglycerine is also effective in preventing coronary artery vasospasm.

Nitroglycerine is available in intravenous, oral, sublingual, and topical forms, all of which are commonly used in the perioperative setting in patients at risk for myocardial ischemia. Intravenous infusion of nitroglycerine is typically started at a rate of 5 to 20 µg/min. The dose may be increased every few minutes in 10 µg increments until the desired blood pressure or improvement in angina is achieved. Nitroglycerine has a low risk of serious toxicity. Headache, nausea, dizziness, tachyphylaxis, and hypotension are adverse effects associated with this drug.

Inhaled Pulmonary Vasodilators

Inhaled Nitric Oxide

Pulmonary hypertension can be characterized by an increase in pulmonary vascular resistance, pulmonary arterial wall thickening, and right ventricular dysfunction, which results in impaired oxygen exchange. The goal of patients with clinically significant pulmonary hypertension is to improve right ventricular function without increasing myocardial oxygen demand or compromising the hemodynamic function of the systemic circulation. Experimental models have shown that inhaled nitric oxide (NO) reverses hypoxic pulmonary vasoconstriction without affecting systemic hemodynamic function.

NO is a naturally occurring local vasodilator synthesized by the vascular endothelium. Its synthesis is mediated by the activity of NO synthase on the amino acid L-arginine. NO activates guanylate cyclase, which generates cyclic guanosine 3, 5′-monophosphate (cGMP). The latter causes relaxation of adjacent vascular smooth muscle. Upon entering the bloodstream, NO binds hemoglobin with a high affinity and is quickly inactivated. Therefore, the molecule is essentially devoid of any systemic effects. Inhaled NO reaches pulmonary vascular smooth muscle by diffusion through ventilated alveoli, causing relaxation of adjacent PAs. This concept is important in patients with intrapulmonary shunts, because inhaled NO increases arterial oxygenation by redistributing blood flow to well-ventilated regions and thereby improving ventilation/perfusion mismatch. This is in contrast to intravenous vasodilators (e.g., nitroprusside), which may exacerbate the ventilation/perfusion mismatch by nonselectively dilating the entire pulmonary vasculature bed.

One of the most important clinical uses of inhaled NO is in the treatment of acute respiratory distress syndrome (ARDS). Patients with ARDS characteristically suffer from pulmonary arterial hypertension, intrapulmonary shunting, and reduced arterial oxygenation. Inhaled NO in patients with ARDS reduces pulmonary arterial pressure and increases arterial oxygenation by decreasing intrapulmonary shunting, all in the absence of systemic vasodilation.

Inhaled NO is also extremely effective in neonates with persistent pulmonary hypertension of the newborn. By reducing pulmonary arterial pressure and improving arterial oxygenation, inhaled NO often circumvents the need for extracorporeal membrane oxygenation. Another major clinical application of inhaled NO is in patients with severe pulmonary hypertension, right ventricular failure, and hypoxemia following certain cardiothoracic surgical procedures. Examples include

valvular surgery, coronary artery bypass, implantation of ventricular assist devices, heart transplantation, and lung transplantation.

The toxic effects of inhaled NO remain to be completely defined. Concentrations of >20 ppm in patients for several weeks have been used without any apparent untoward effects. However, there are concerns that methemoglobinemia and tachyphylaxis may complicate prolonged NO therapy.

Inhaled Epoprostenol

Inhaled epoprostenol (prostacyclin, PGI_2) has been used increasingly in patients with pulmonary hypertension. It acts by countering the effects of Thromboxane A_2, which stimulates platelet activation and aggregation. In addition to its function as a platelet inhibitor, epoprostenol is a potent vasodilator with a very short half-life (25 minutes), similar to NO. However, because it is less costly than NO, many centers utilized inhaled epoprostenol as a first-line agent for reversible pulmonary hypertension. While there is data to suggest that inhaled NO has greater beneficial effects in neonates and children, there is little data to support any superiority over inhaled epoprostenol in adults. It is increasingly being used after cardiothoracic surgery in select patients including those undergoing lung transplantation and postcardiopulmonary bypass. Specifically, patients with pulmonary hypertension undergoing cardiac surgery respond from inhaled epoprostenol with reduced pulmonary pressure and improved right ventricular function. With inhaled administration, there is no evidence of platelet dysfunction or increased risk of bleeding. The toxicity profile is quite low, although it does cause mild systemic vasodilation and resultant hypotension.

VASOPRESSORS

Vasopressor therapy is usually reserved for patients in septic or neurogenic shock whose blood pressure fails to respond to volume resuscitation. In these settings, peripheral vasoconstriction may increase SVR and blood pressure, thus improving coronary and cerebral blood flow. Another common setting in which these agents are used is in the perioperative maintenance of blood pressure that has been artificially lowered by general or regional anesthetics.

Vasopressin

Vasopressin, also termed antidiuretic hormone, is a peptide hormone produced in the hypothalamus and stored in the posterior lobe of the pituitary gland. Vasopressin affects numerous organ systems. In the brain, vasopressin acts as a neurotransmitter mediating thermoregulation, nociception, and release of adrenocorticotropic hormone. Moderate doses of vasopressin cause vasodilation in the pulmonary vasculature, whereas higher doses stimulate pulmonary vasoconstriction. Hematologically, vasopressin has several effects on thrombosis and hemostasis, including promotion of platelet aggregation and release of both factor VIIIa and von Willebrand factor from the vascular endothelium. In the distal tubule and collecting duct of the kidney, vasopressin stimulates water reabsorption, producing concentrated urine. High vasopressin levels stimulate smooth muscle contraction in both the uterus and the gastrointestinal tract and promote hepatic glycolysis. Finally, elevated concentrations of vasopressin produce vasoconstriction in vascular smooth muscle cells.

Vasopressin plays a critical role in the regulation of fluid balance. It is released in response to a decrease in blood volume and an increase in osmolarity. Two distinct receptor subtypes mediate the principal end-organ effects. The V_1 receptor is present on vascular smooth muscle cells throughout the body, particularly in the skin, skeletal muscle, and thyroid gland vasculature. The majority of end-organ effects are mediated by the V_1 receptor. The direct vasopressor effects are a result of V_1-mediated intracellular signal transduction. G protein-coupled activation of phospholipase C results in the release of calcium from the sarcoplasmic reticulum and a subsequent increase in peripheral resistance. The V_2 receptor is present in the distal and collecting tubules of the glomeruli and promotes water reabsorption. These effects are mediated by an increase in intracellular levels of cAMP and by activation of protein kinase A. A third receptor, V_3, is located in the posterior lobe of the pituitary gland.

Under normal physiologic conditions, endogenous vasopressin levels are below the vasoactive range. Septic shock-associated exhaustion of neurohypophyseal stores secondary to intense and prolonged stimulation, as well as impairment of baroreflex-mediated stimulation of vasopressin release, often lead to inappropriately low levels of endogenous vasopressin. Low doses of exogenous vasopressin stimulate the vascular V_1 receptors and have been shown to produce a significant rise in mean arterial pressure in septic shock, often leading to the discontinuation of traditional vasopressors. Clinical evidence suggests that vasopressin

therapy may be an available alternative or adjunct for patients in septic shock as well as refractory vasodilatory shock after cardiopulmonary bypass. As such, vasopressin is often a first-line agent for patients with sepsis or vasodilation after cardiopulmonary bypass. Vasopressin has been used clinically to treat a variety of disorders, both as an antidiuretic and as a vasoconstrictor. Other uses of vasopressin include diabetes insipidus and gastrointestinal bleeding. Desmopressin, a synthetic, longer-acting analog of vasopressin with minimal vasopressor activity, has been used to treat nocturnal enuresis, hemophilia A, and von Willebrand disease.

Vasopressin is distributed throughout the extracellular space. With a half-life of 10 to 35 minutes, the vasopressor effects after a single dose last about 30 to 60 minutes. When the goal is to maintain continuous hemodynamic support, vasopressin must be given by continuous intravenous infusion. The dosing range of 0.01 up to 0.1 U/min is most effective with vasodilatory shock without causing significant adverse effects. Vasopressin is inactivated and metabolized by the kidney and liver; 5% to 15% is excreted in the urine. Possible adverse effects of therapeutic vasopressin include decreased CO, angina, myocardial ischemia, ventricular dysrhythmia, bronchial constriction, and splanchnic ischemia.

Phenylephrine

Phenylephrine is a pure α_1-agonist. It is a potent pulmonary and systemic vasoconstrictor without significant direct cardiac effects. This drug has a rapid onset and short duration of action. Because of its pure α-adrenergic effects, phenylephrine can increase SVR and blood pressure without causing arrhythmias. Thus, this is a useful vasopressor if arrhythmias are complicating the therapy of inotropic agents such as dopamine or norepinephrine, and is the drug of choice when pure vasoconstriction is desired. Phenylephrine is often the drug of choice administered intraoperatively during general or regional anesthesia and can be extremely useful in maintaining blood pressure in patients with epidural anesthesia postoperatively, as these patients often develop profound vasodilation secondary to the local anesthetics used in the pump. The dose for infusion ranges from 20 to 200 μg/min.

Metaraminol

Metaraminol (Aramine) is an older indirect-acting sympathomimetic

amine with hemodynamic actions similar to norepinephrine. Systolic and diastolic blood pressures are increased predominately by vasoconstriction. Metaraminol will also cause venoconstriction and pulmonary vasoconstriction. Unlike norepinephrine and phenylephrine, it is a long-acting agent, with effects lasting from 20 to 60 minutes. Clinical indications for metaraminol parallel those of phenylephrine. However, the use of metaraminol has decreased because of the immediate and short-acting effects of phenylephrine. Metaraminol may cause cardiac arrhythmias, particularly in patients with myocardial infarctions and in patients receiving volatile anesthetics, such as halothane, which sensitize the heart to catecholamines.

INTRA-AORTIC BALLOON COUNTERPULSATION

Despite the recent availability of LV assist devices and other new devices to support the failing heart, the intra-aortic balloon pump (IABP) remains the mainstay of mechanical ventricular support. The basic physiologic principle behind the IABP, counterpulsation, was first described in 1958 by Harken. In 1962, Moulopoulos et al. proposed the use of a single-chambered IABP in the descending thoracic aorta to achieve counterpulsation. Counterpulsation is based on the premise that reducing LVEDP improves ventricular function. The mechanism of action of the IABP involves rapid balloon inflation with helium during diastole (concurrent with aortic valve closure). The balloon remains inflated until onset of systole, at which time the balloon rapidly deflates. Balloon inflation raises diastolic pressure within the proximal aorta, causing improved coronary and cerebral perfusion during diastole. With the rapid balloon deflation during systole, there is a sudden volume loss (equivalent to the volume of the balloon) in the aorta resulting in decreased afterload against which the heart must work (Fig. 4.6). Direct effects on the heart include improving coronary artery blood flow, and decreasing afterload resulting in improved CO and less myocardial oxygen demand. Early IABP insertion can decrease the size of the potential infarct area following coronary occlusion.

The clinical indications for the IABP have expanded over the past several years. There are many situations in the critical care setting in which temporary ventricular support of the failing heart is needed. It has been shown that early application of the IABP in patients who have experienced acute myocardial infarctions reduces the severity of

cardiogenic shock and improves patient survival. The IABP is often employed preoperatively in high-risk patients with acute cardiogenic shock and/or unstable angina prior to cardiac surgery. In this setting, IABP decreases perioperative morbidity and mortality. Although it is assumed that patients requiring IABP use in the cardiac surgical setting are a higher-risk group of patients, the overall survival rates for patients undergoing myocardial revascularization procedures who required the use of the IABP are similar to patients who did not require this device.

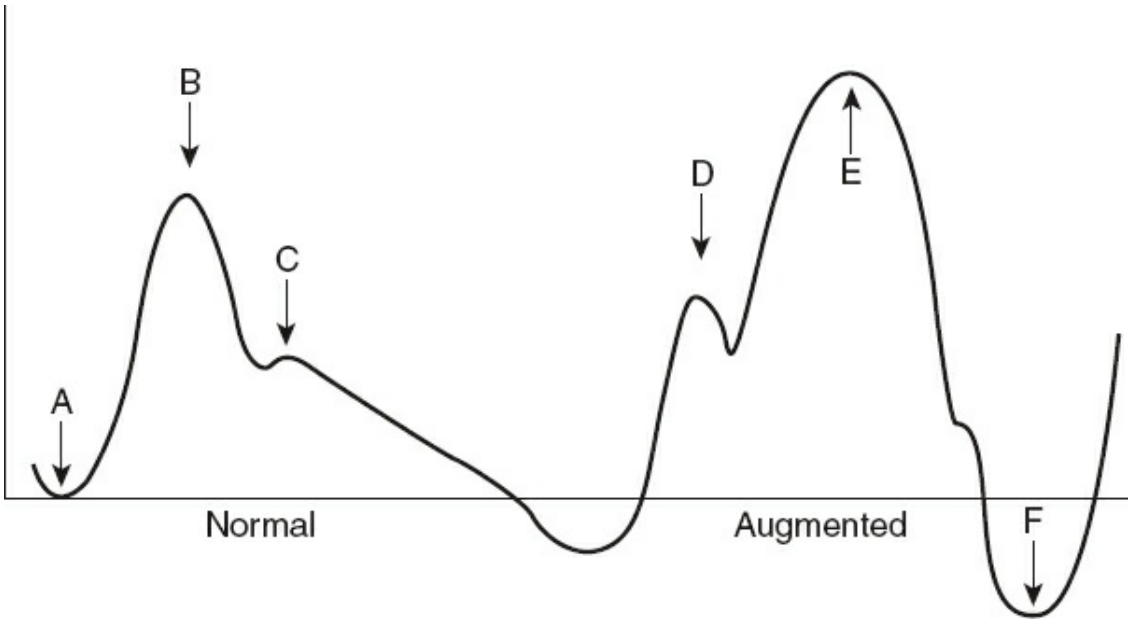

Figure 4.6. Intra-aortic balloon pump (IABP) counterpulsation results in diastolic augmentation and afterload reduction. (**A**) End-diastolic pressure. (**B**) Peak systolic pressure. (**C**) Dicrotic wave. (**D**) Reduced peak systolic pressure. (**E**) Diastolic augmentation. (**F**) Reduced end-diastolic pressure.

The IABP has also been used more recently in patients with septic shock. As a result of myocardial depressants that circulate in advanced septic states, CO can diminish significantly. Berger et al. examined the use of the IABP in septic patients with decreased ventricular function. Adequate CO was maintained in such patients and permitted application of more traditional treatment modalities for septic shock, such as fluid resuscitation. Another potential use of the IABP has been reported in experimental models of blunt chest trauma. Saunders and Doty produced blunt chest injury in dogs and demonstrated that early application of the IABP improves ventricular function following myocardial contusion. The clinical application of the IABP to blunt chest injuries, particularly in the

multitrauma patient, may also prove beneficial in select patients.

Absolute contraindications to use of the IABP include severe aortic insufficiency and acute aortic dissection. Aortic aneurysms, atherosclerotic aortas, aortoiliac occlusive disease, or mild aortic insufficiency are relative contraindications. Known complications of the IABP include bleeding, infection, and balloon leak or malfunction. Arterial injury can occur especially during guidewire and/or balloon advancement. Embolization to the visceral and renal vessels can occur from thrombus on the balloon or from atherosclerosis in the thoracic aorta and can lead to intestinal ischemia and/or renal failure. Careful and accurate placement of the IABP is necessary to prevent occlusion of the visceral vessels with each cardiac cycle. A rare and dreaded complication of the IABP is aortic dissection. As such, the IABP should be placed under fluoroscopic or echocardiographic (TEE) guidance. In addition, the balloon can produce lower limb ischemia as it is placed through the femoral vessels and can occlude iliac blood flow, which is usually relieved by balloon removal. Removal of the balloon must be carefully performed to eliminate the risk of distal embolization from a dislodged thrombus. Finally, thrombocytopenia and hemolysis can occur as a result of hematologic trauma produced by the IABP.

Percutaneous mechanical circulatory support systems, such as the TandemHeart (CardiacAssist, Inc, Pittsburgh, PA), are an additional option for support of the failing heart. The TandemHeart system is left atrial-to-femoral artery bypass system that can be rapidly implemented and provides up to 5.0 L/min of CO when used with a 17-French arterial return cannula. Via access through the femoral vein, a transseptal puncture is made allowing for placement of an inflow cannula directly into the left atrium. The integrated pump and motor then delivers the oxygenated blood back to the patient via the femoral artery return cannula. This device can be used to allow for cardiac recovery in patients with postcardiotomy cardiac failure, as a bridge to transplantation, or during high-risk coronary catheterization procedures. Compared to cardiogenic shock patients treated with IABP, a meta-analysis found that patients treated with percutaneous mechanical circulatory support systems such as the TandemHeart had improved hemodynamics (including CI and mean arterial pressure) but no improvement in 30-day mortality.

CARDIOVASCULAR RISK

An often difficult issue for surgeons is whether to pursue an aggressive cardiac evaluation for patients before considering noncardiac operations. With an aging population, more patients with unrecognized coronary artery disease are referred for these types of surgical procedures. It remains true that operative morbidity and mortality are most often direct results of cardiac complications, and the proper recognition of the “at-risk” patient is important in limiting these postoperative cardiac problems.

Quite often, elderly patients referred for surgical intervention have not had adequate health care evaluation and the challenge for the surgeon is to accurately assess the cardiac risk in a timely manner before performing an operative procedure. The surgeon should take a thoughtful approach to preoperative cardiac screening rather than simply referring the patient to a cardiologist. A thorough history and physical examination should be performed to uncover any signs or symptoms of underlying cardiac disease. Symptoms such as chest pain or shortness of breath should be thoroughly interrogated with specific attention to frequency, character, precipitating causes, and duration. Family and social histories are very important and should be noted, along with the findings of the physical examination. Chest radiographs and ECGs should be reviewed closely. Beyond the routine office evaluation, there are a myriad of noninvasive, invasive, functional, and anatomic imaging modalities to further quantify cardiac function. These tests may help identify patients with underlying silent cardiac disease who may be in need of further treatment. As with any decision in health care, the risk to benefit ratio of a diagnostic study or therapeutic intervention deserves thoughtful consideration before its implementation.

Clinical predictors of increased risk are stratified into major, intermediate, or minor. Major predictors include unstable coronary syndromes, decompensated heart failure, significant arrhythmias, or severe valve disease. Intermediate predictors include mild stable angina, previous myocardial infarction with stable compensated heart function on appropriate medical therapy, compensated heart failure, and diabetes mellitus. Minor predictors include advanced age, minor electrocardiographic changes, low functional capacity with no other intermediate or major risk factors, history of stroke, or uncontrolled hypertension. Procedural risk can also be classified as high, intermediate, or low. High-risk procedures include emergent operations in elderly patients, aortic or major vascular procedures, and prolonged operations

with large fluid shifts. Intermediate-risk procedures would include carotid endarterectomy; head and neck procedures; intraperitoneal, intrathoracic, and orthopedic procedures; and prostate surgery. Low-risk procedures include endoscopy, superficial procedures, cataract surgery, and breast and soft tissue operations. Based on this evaluation of clinical and procedural risk, many patients require no further testing if the overall risk is judged to be low or may need further noninvasive assessment if the overall risk is intermediate. There may also be some patients who are easily identified as being best served by coronary angiography. However, this group is the minority and consideration should be given with respect to the urgency of the intended operation. A diagnosis of significant coronary artery disease that may require percutaneous intervention or surgical coronary revascularization will delay the initial planned procedure.

Risk assessment strategies for preoperative evaluation of patients before noncardiac operations were reviewed comprehensively by the American College of Cardiology (ACC)/AHA Task Force on Practice Guidelines. The published guidelines were evidence-based and recommended the use of a combination of an initial clinical evaluation and functional testing in certain patient subsets. High-risk clinical variables include recent MI, history of diabetes mellitus, poor functional status, decompensated heart failure, significant arrhythmias, and severe valvular disease. Noninvasive testing is most useful in patients who have more than one clinical risk factor and are scheduled to undergo intermediate- or high-risk operations. Noninvasive testing includes resting ECG, echocardiography, treadmill exercise stress testing, stress perfusion imaging, and dobutamine stress echocardiography. These tests help further quantify cardiac function and help identify patients with underlying silent cardiac disease who may be in need of further work-up or treatment.

When assessing cardiovascular risk in the noncardiac surgical setting, the Goldman Cardiac Risk factors should be discussed. This multifactorial index was developed for preoperative identification of patients at risk for major perioperative cardiovascular complications. The data was obtained retrospectively from 1,001 patients over 40 years of age undergoing noncardiac surgery. By multivariate discriminant analysis, nine independent significant correlates of life-threatening and fatal cardiac complications were identified. These were preoperative third heart sound or jugular venous distention; myocardial infarction in the preceding 6 months; more than five premature ventricular contractions per minute

documented at any time before operation; rhythm other than sinus or presence of premature atrial contractions on preoperative ECG; age over 70 years; intraperitoneal, intrathoracic, or aortic operation; emergency operation; important valvular aortic stenosis; and poor medical condition. Patients in the highest-risk group (based on a point scale given to the risk factors) had a 56% incidence of death, with a 22% incidence of severe cardiovascular complications. Patients in the intermediate-risk group had a 4% incidence of death, with a 17% incidence of severe cardiovascular complications. Patients in the lowest-risk group had a 0.2% incidence of death and a 0.7% incidence of severe cardiovascular complications. With the advances made in anesthesia and medical care, this data is mentioned more for a historical perspective. However, these studies still provide a basis for presurgical evaluation today.

Several important factors should be considered when patients are screened. One obvious consideration is the urgency of the operation. Patients who undergo urgent/emergent surgery have a two- to fivefold increased rate of experiencing a cardiovascular complication than patients who undergo comparable surgery on an elective basis. There may also be times when the results of screening will not affect the decision to operate but may assist in alerting the anesthesia and surgical teams about the degree of risk. Currently, high-risk procedures carry a risk of nonfatal MI or cardiac death of 5% or more. Intermediate-risk procedures carry a combined risk of 1% to 4% and low-risk procedures carry a combined risk of <1%.

Suggested Readings

Ganz W, Donoso R, Marcus HS, et al. A new technique for measurement of cardiac output by thermodilution in man. *Am J Cardiol* 1971;27:392–6.

Gupta RG, Hartigan SM, Kashiouris MG, et al. Early goal-directed resuscitation of patients with septic shock: current evidence and future directions. *Crit Care* 2015;19:286.

Jansen TC, van Bommel J, Schoonderbeek FJ; LACTATE Study Group. Early lactate-guided therapy in intensive care unit patients: a multicenter, open-label, randomized controlled trial. *Am J Respir Crit Care Med* 2010;182:752–61.

Lehman LW, Saeed M, Talmor D, et al. Methods of blood pressure measurement in the ICU. *Crit Care Med* 2013;41:34–40.

Marino PL. *The ICU Book.* 4th ed. Philadelphia, PA: Wolters Kluwer Health/Lippincott Williams & Wilkins; 2014.

McGee DC, Gould MK. Preventing complications of central venous catheterization. *N Engl J Med* 2003; 348:1123–33.

Rajaram SS, Desai NK, Kalra A, et al. Pulmonary artery catheters for adult patients in intensive care. *Cochrane Database Syst Rev* 2013;2:CD003408.

Swan HJ, Ganz W, Forrester J, et al. Catheterization of the heart in man with use of a flow-directed balloon-tipped catheter. *N Engl J Med* 1970;283:447–51.

The Joint Commission. *Preventing Central Line-Associated Bloodstream Infections: A Global Challenge, a Global Perspective*. Oak Brook, IL: Joint Commission Resources; 2012. http://www.preventingCLABSI.pdf.

Zhang Z, Xu X. Lactate clearance is a useful biomarker for the prediction of all-cause mortality in critically ill patients: a systematic review and meta-analysis. *Crit Care Med* 2014;24:2118–25.

EDITOR'S COMMENT

Drs. Charles and Kron have written an exceptional and detailed chapter on cardiovascular monitoring. It is amazing how much progress has been made in this area in the past 20 years. Not only have new technologies been developed to more accurately assess cardiovascular function, but also our understanding of fluid resuscitation and other physiologic variables that matter in determining a patient's cardiovascular status has evolved as well.

Much has been learned about the pros and cons of different central venous access sites, proper line insertion techniques, and central line care as well as maintenance. I was a surgical resident in the late 1990s in the era before peripherally inserted central venous catheters caught on. Surgical residents, most often unsupervised interns, placed the majority of the central lines in our hospital. I learned how to place a central line by watching a second-year surgical resident place one. Sterile technique was fairly casual and nearly every line was placed in the subclavian vein. We got to be exceedingly good at placing these lines—even in the most challenging circumstances. Central line–associated blood stream infections were fairly commonplace. Occasional central line–associated complications including subclavian artery cannulation and pneumothorax were much more frequent than today when these have really become "never events." Much has changed in the past 20 years. We have simulator-based training, central line insertion bundles, and care protocols, and much more that have rendered the days of unsupervised and poorly trained residents throwing lines in patients all over the hospital a thing of the past.

The three most common insertion sites for central venous catheters are the internal jugular, the subclavian, and the femoral vein. A recently published Cochrane Review on central venous access sites for the prevention of venous thrombosis, stenosis, and infection included four studies with data from more than 1,500 subjects. Subclavian and internal jugular central venous access

routes were determined to have similar risks for catheter-related complications in long-term catheterization in cancer patients. Subclavian access was found to be preferable to femoral access in short-term catheterization because of lower risks of catheter colonization and thrombotic complications. In short-term hemodialysis catheterization, femoral and internal jugular routes have similar risks for catheter-related complications although internal jugular routes were associated with higher risks of mechanical complications. The 3SITES central venous catheter trial results were recently published in *the New England Journal of Medicine.* In this multicenter trial, adult patients in the ICU were randomly assigned to nontunneled central lines in the subclavian, jugular, or femoral vein. The primary outcome measure was a composite of catheter-related bloodstream infection and symptomatic deep-vein thrombosis. There were 3,471 catheters placed. In pairwise comparisons, the risk of the primary outcome was significantly higher in the femoral group than in the subclavian group (hazard ratio, 3.5; 95% confidence interval [CI], 1.5 to 7.8; $p = 0.003$) and in the jugular group than in the subclavian group (hazard ratio, 2.1; 95% CI, 1.0 to 4.3; $p = 0.04$). The risk in the femoral group was similar to that in the jugular group (hazard ratio, 1.3; 95% CI, 0.8 to 2.1; $p = 0.30$). Pneumothorax requiring chest tube insertion occurred in association with 1.5% of the subclavian vein insertions and 0.5% of the jugular vein insertions. The authors concluded that subclavian vein catheterization was associated with a lower risk of bloodstream infection and symptomatic thrombosis and a higher risk of pneumothorax than jugular vein or femoral vein catheterization.

Patients with acute kidney injury and chronic kidney disease frequently require nontunneled central venous catheterization for the treatment of acute illness. Temporary catheters are also widely used for emergent inpatient hemodialysis access. In addition to minimizing catheter-related complications, preserving veins for hemodialysis vascular access is an important goal for these patients. Central venous stenosis is a major barrier to arteriovenous access creation for hemodialysis. Central venous stenosis has been demonstrated to be associated with the number of catheter insertions, duration of catheter exposure, and use of the subclavian site. Catheter contact with the vessel wall is postulated to cause endothelial damage and turbulent flow, which may initiate release of prothrombotic cytokines leading to thrombosis, fibrosis, and stenosis. The catheter site with the least vessel wall contact is the right internal jugular vein. Clinical practice guidelines and position papers have recommended vein preservation for patients with estimated glomerular filtration rates of less than 30 mL/min per 1.73 m^2 (Kidney Disease Outcomes Quality Initiative). The complication rate of a central venous access site must be balanced against the potential need for dialysis access in the future in patients with chronic renal insufficiency.

Central line–associated blood stream infections (CLABSIs) result in thousands of deaths each year and billions of dollars to the US health care system. The Centers for Medicare and Medicaid Services (CMS) Hospital

Acquired Condition (HAC) Reduction Program is designed to encourage hospitals to improve patient safety and reduce the number of hospital-acquired conditions. Each year, Medicare withholds approximately $350 million in payments for care rendered for the hospitals that perform the worst on 6 HAC conditions—one of which is CLABSI. These data are reported publicly on the Hospital Compare website. CLABSIs are largely preventable. The Agency for Healthcare Research and Quality partnered with the American Hospital Association, the Johns Hopkins Medicine Armstrong Institute for Patient Safety and Quality, and the Michigan Health and Hospital Association's Keystone Center for Patient Safety and Quality on the project "Eliminating CLABSI: A National Patient Safety Imperative." Participating States reduced their CLABSI rate from a baseline of 1.915 infections per 1,000 line days to 1.133—a 41% relative reduction. The percentage of ICUs with zero CLABSIs for at least one quarter increased from 30% at baseline to 68% at quarter 6 of the study. The five steps included in the reducing CLABSI initiative were: (1) educate staff, (2) create a central line cart, (3) implement a central line checklist, (4) empower staff to stop the procedure, and (5) remove unnecessary lines. These policies and procedures have been adopted across the country saving many lives and significant expense. The Centers for Disease Control (CDC) estimates that the rate of mortality in CLABSI is 12% to 25% and the cost is approximately $16,550 per event.

Goal-directed resuscitation is discussed in this chapter—especially as it relates to sepsis and septic shock. There is a massive body of literature on this subject that is difficult to digest. The general consensus is that goal-directed therapy has not been definitively demonstrated to reduce mortality in sepsis. Two recent large multicenter randomized controlled trials, the Australasian Resuscitation in Sepsis Evaluation (ARISE) and Protocolized Care for Early Septic Shock (ProCESS) studies, examined goal-directed therapy in early septic shock. The ARISE study found no reduction in all-cause mortality at 90 days, and the ProCESS study showed no improvement in outcomes including 1-year mortality or the need for organ support. In studies evaluating goal-directed therapy, there is variability in the type of fluid administered, whether an inotrope is used, and the algorithms applied. The hemodynamic goal also varies with some studies using cardiac output or stroke volume while others utilize mixed venous oxygen saturation or another parameter. No single hemodynamic goal or monitoring method has been universally accepted in the literature. This makes it quite difficult to draw definitive conclusions about the value or lack thereof for goal-directed therapy.

As a surgeon at a large teaching institution, I have observed a lot of variability in fluid and vasopressor use, and the parameters that are used to guide these choices on a case-by-case basis by my anesthesia colleagues during the surgeries I perform. The concept of perioperative goal-directed therapy in some of my higher-risk gastrointestinal surgery patients is of interest to me. I stumbled upon an interesting study while doing research for this commentary.

The OPTIMISE trial (Optimization of Cardiovascular Management to Improve Surgical Outcome) was a multicenter randomized, observer-blinded trial of 734 high-risk patients (aged 50 and older) undergoing major gastrointestinal surgery. A systematic review and meta-analysis of similar randomized clinical trials were also included in the article. Patients were randomly assigned to a cardiac output–guided hemodynamic therapy algorithm for intravenous fluids and inotrope infusion during and 6 hours following surgery or to usual care. The primary outcome was a composite of predefined 30-day moderate or major complications and mortality. The primary outcome occurred in 36.6% of intervention and 43.4% of usual care participants (relative risk 0.84, absolute risk reduction, 6.8%). Findings of the meta-analysis of 38 trials, including data from this study, suggested that goal-directed perioperative therapy is associated with fewer complications versus control patients. Outside of a clinical trial, if nothing else goal-directed perioperative therapy gives the anesthesiologist a predefined target and forces him/her to pay close attention to exactly what is going on with my patient in a way that I find reassuring. I would rather resuscitate a patient in real time than spend the evening following an operation playing "catch up" and resuscitating a patient in the ICU.

This is a great chapter that includes information that is relevant to all surgeons. It is interesting to me how far we have come in the past few years, and how far we have to go still. This chapter on cardiovascular monitoring and support provides an excellent overview of past, present, and future.

Jon C. Gould

As the (very junior) faculty of the hyperalimentation unit at the Massachusetts General Hospital Professor Gould is absolutely correct that "central line–associated blood stream infections were fairly commonplace."

J.E.F.

Suggested Readings

Ge X, Cavallazzi R, Li C, et al. Central venous access sites for the prevention of venous thrombosis, stenosis and infection. *Cochrane Database Syst Rev* 2012; (3):CD004084.

https://www.ahrq.gov/professionals/quality-patient-safety/cusp/clabsi-final/index.html. Accessed May 2, 2017.

National Kidney Foundation. KDOQI clinical practice guidelines and clinical practice recommendations for 2006 Updates: hemodialysis adequacy, peritoneal dialysis adequacy and vascular access. *Am J Kidney Dis.* 2006;48(suppl 1):S1–S322.

Parienti JJ, Mongardon N, Mégarbane B, et al. Intravascular complications of central venous catheterization by insertion site. *N Engl J Med*

2015;373(13):1220–9.

Pearse RM, Harrison DA, MacDonald N, et al. Effect of a perioperative, cardiac output-guided hemodynamic therapy algorithm on outcomes following major gastrointestinal surgery: a randomized clinical trial and systematic review. *JAMA* 2014;311(21):2181–90.

The ARISE, Investigators ANZICS, Clinical Trials Group. Goal-directed resuscitation for patients with early septic shock. *N Engl J Med* 2014;371:1496–506.

Vats HS. Complications of catheters: tunneled and non-tunneled. *Adv Chronic Kidney Dis* 2012;19:188–94.

Yealy DM, Kellum JA, Huang DT, et al. A randomized trial of protocol-based care for early septic shock. *N Engl J Med* 2014;370(18):1683–93.

5 Pulmonary Risk and Ventilatory Support

Jay A. Johannigman and Richard Branson

INTRODUCTION

The pulmonary system includes a complex milieu consisting of the conducting airways, pulmonary parenchyma, the alveolar capillary interface, an intricate mechanism for control of breathing, a complex muscular interplay, and an elaborate defense mechanism. Yet despite the sophistication of the respiratory system, pulmonary complications are the single most common source of morbidity in the critically ill surgical patient. Postoperative pulmonary complications (PPCs) include atelectasis, bronchospasm, bronchitis, pneumonia, exacerbation of chronic lung disease, and pulmonary embolism (PE) (Table 5.1). Uniformly, these complications result in a predictable set of symptoms including tachypnea, hypoxemia and hypercapnia followed by respiratory failure each of which are associated with increased morbidity and mortality. Arozullah and colleagues found the need for reintubation and/or mechanical ventilation occurred in only 3% of patients in the VA database of almost 100,000 postoperative patients. Importantly, mortality in this group increased from 1% in those without respiratory failure to 27% in those with respiratory failure. Development of postoperative respiratory failure requiring mechanical ventilation results in an increased length of stay from 4.5 to 28 days. The definition of a PPC is often elusive. Radiographic atelectasis following cardiothoracic surgery is common, but rarely results in pulmonary symptoms or morbidity. This results in both overreporting and underreporting of pulmonary complications. The literature reveals an incidence of pulmonary complications from 2% to 19% after general surgical procedures and 8% to 39% following cardiothoracic surgery.

PPCs occur most commonly in those undergoing major abdominal and/or thoracic procedures. Other risk factors include advanced age, history of chronic obstructive pulmonary disease (COPD), and history of obstructive sleep apnea (OSA), use of nasogastric tubes, malnutrition,

renal failure, and duration of anesthesia. Diaphragmatic dysfunction, ventilation–perfusion (V/Q) mismatching, and a reduction in functional residual capacity (FRC) routinely occur after general anesthesia and surgery. Anesthetic-induced muscular paralysis during surgery results in a cephalic movement of the diaphragm into the domain of the dorsal lung compartment because of the displacement affected by the weight of the abdominal contents. Positive pressure ventilation results in preferential ventilation of nondependent (ventral) lung units while pulmonary blood flow is gravity dependent. This derangement created by mechanical positive pressure ventilation inherently accentuates the degree of ventilation to perfusion mismatching in the supine and sedated patient. General anesthesia has also been shown to inhibit intrinsic pulmonary defense mechanisms including altered alveolar macrophage function, disruption of the mucociliary escalator, and diminished surfactant release. Severe chronic lung disease is often thought to preclude the consideration of complex open thoracoabdominal procedures. The progressive evolution of minimally invasive surgery has facilitated postoperative pulmonary function and recovery in such patients. Advances in pain control (including epidural catheter analgesics) have also reduced morbidity in patients undergoing major surgery or with thoracic injuries. Comparisons of laparoscopic to open procedures demonstrate that in some cases (cholecystectomy, esophageal cancer) pulmonary complications are reduced, while in other procedures pulmonary complications are unchanged. This chapter will include sections on pulmonary anatomy and physiology, risk assessment, and management of acute lung injury (ALI) including mechanical ventilation, prevention and treatment of ventilator-associated pneumonia (VAP), and adjunctive surgical measures to treat complex intrathoracic infections.

TABLE 5.1 Common Perioperative Pulmonary Complications and Risk Factors

Common Complications Following General Surgery
Pulmonary embolus
Obstructive sleep apnea
ARDS
Ventilatory failure ($PaCO_2$ >60 mm Hg, pH <7.20)
Atelectasis
Infection—Pneumonia—Bronchitis
Bronchospasm
Aspiration of gastric contents
Exacerbation of chronic pulmonary disease

Intraoperative Risk Factors
Thoracic or upper abdominal incision

Common Complications Following Cardiothoracic Surgery
Bronchpleural fistula
General anesthesia
Duration of anesthesia/surgery
Pleural effusion
Emergent procedures
Phrenic nerve injury
Sternal wound infection and dehiscence
Empyema
Arrhythmias

Preoperative Risk Factors
COPD
Advanced age
Smoker
Pulmonary hypertension
Obstructive sleep apnea
Malnutrition
Obesity

ANATOMY AND PHYSIOLOGY

The lungs lie lateral to the mediastinum in the thoracic cavity. The lung surface is covered by a single cell layer of pleura, which also lines the parietal surface. A minute amount of pleural fluid is present to lubricate the lung/thorax interface reducing friction. The pleural space under normal circumstances is not a space at all, but can markedly increase in disease states. The right lung has three lobes and the left two, including the lingula, and each lobe contains two to five segments with tertiary order bronchi, which can be visualized on bronchoscopy. The basic functioning unit is the alveolus. The terminal alveolar unit is a grape-like cluster of individual air sacs often sharing a common wall surrounded by a web of capillaries, giving the lung its elastic nature. Ventilation–perfusion in the lungs based on an upright model divides the lung into three zones. In zone I (the upper lung fields), alveolar pressure is greater than both arterial and venous blood pressure resulting in an excess of ventilation to perfusion (high V/Q ratio). Regions of the lung in which ventilation exceeds perfusion are referred to as dead space. In zone II (mid-lung zones) arterial pressure is greater than alveolar pressure which is greater than venous pressure and V/Q is well matched. In zone III (lower lung fields), the

vascular pressures exceed alveolar pressure and V/Q is low. When perfusion exceeds ventilation, shunt results. The ICU patient is typically cared for in the supine position. This reorients the zones of the lung into a horizontally based consideration rather than a vertically based system (when a patient is standing). In the supine position the nondependent lung is shifted to the ventral aspect of the lung and the dependent lung is now in the dorsal position. Improvement in ventilation–perfusion matching during ALI helps explain the effects of positive end-expiratory pressure (PEEP) and changes in position (prone) on arterial oxygenation. Lymph drainage from the lungs occurs through the hilar and mediastinal lymph nodes to the thoracic duct via the mediastinal lymphatics.

The critical function of the lung is gas exchange, specifically oxygen extraction from the atmosphere and transfer to the intravascular space, and elimination of carbon dioxide. The latter is virtually dependent on minute ventilation (respiratory rate), while oxygen transport is dependent on the fractional inspired oxygen concentration (FIO_2), transport across the alveolar-capillary membrane, and V/Q matching. Blood oxygen content is determined primarily by hemoglobin concentration and percent oxygen saturation, while oxygen dissolved in plasma contributes minutely. Oxygen tension in the alveolus is described by the following alveolar air equation:

$$PAO_2 = [(P_B - P_{H_2O} \times FIO_2) - PACO_2/RER]$$

where P_B is the barometric pressure, P_{H2O} is the partial pressure of water vapor which is constant under alveolar conditions at 47 mm Hg, PCO_2 is the alveolar CO_2 concentration, and RER is the respiratory exchange ratio (normally = 0.8).

The arterial partial pressure of CO_2 ($PaCO_2$), readily available on routine blood gas measurement, can be substituted for $PACO_2$. Normal PAO_2 on room air is 95 to 100 mm Hg and PaO_2 is 85 to 95 mm Hg. The degree of V/Q mismatching will determine the shunt fraction of unsaturated blood. Shunt fraction is normally 2% to 5%, but can be significantly increased in the face of atelectasis, pneumonia, ALI, and acute respiratory distress syndrome (ARDS). The shunt fraction can be estimated by measurement of the alveolar–arterial (A-a) O_2 gradient. This is defined as:

$$\text{A-a}O_2 \text{ gradient} = (P_B - P_{H_2O}) \times FIO_2 - PaCO_2 - PaO_2$$

This is normally 10 mm Hg, but markedly increases in disease which limits gas exchange across the alveolar capillary membrane. The ratio of PaO_2/FIO_2 is commonly used to assess the severity of pulmonary dysfunction in disease states such as ALI, ARDS, and pneumonia in the mechanically ventilated patient. The normal value is over 500. A value <300 indicates ALI and <200 indicates ARDS, when observed concurrently with bilateral infiltrates on chest x-ray and a pulmonary capillary wedge pressure <18 mm Hg. The calculation of intrapulmonary shunt requires a pulmonary artery catheter, mixed venous blood from the pulmonary artery, and the measurement of cardiac output.

The $PaCO_2$ normally is responsible for central respiratory drive by CO_2 diffusion across the blood–brain barrier, producing a decrease in cerebrospinal fluid pH and an increase in minute ventilation. Normal $PaCO_2$ is 35 to 45 mm Hg, but can be elevated by disorders in the control of breathing and in ALI and ARDS by dead space. Physiologic dead space is defined as the dead space to tidal volume ratio (V_D/V_T) which is normally 0.3 owing to the anatomical dead space. V_D/V_T is calculated as

$$V_D/V_T = PaCO_2 - PECO_2/PaCO_2$$

where $PaCO_2$ is used as an approximate for alveolar CO_2 and $PECO_2$ is the mixed expired CO_2. In ARDS V_D/V_T predicts mortality, as values >0.7 are associated with >80% mortality.

PULMONARY MECHANICS AND LUNG VOLUMES

There are several lung volumes and capacities used to describe mechanical function of the lung, respiratory muscles, and chest wall (Fig. 5.1). Most of these are measured during pulmonary function testing. Tidal volume (V_T) is the amount of air exchanged per breath during normal breathing. Vital capacity (V_C) is the amount of air exchanged from peak inspiration to maximal expiration. FRC is the amount of residual air in the lung after maximal expiration. Compliance of the lung is a measure of elasticity and is defined as change in volume/change in pressure. During mechanical ventilation dynamic compliance is measured as the difference between peak inspiratory pressure (PIP) and $PEEP/V_T$. Static compliance is measured as the difference in plateau pressure and (Pplat) and $PEEP/V_T$.

Dynamic compliance includes the effects of airway resistance and lung compliance while static compliance estimates alveolar pressure and lung elasticity alone. Plateau pressure is important in both lung expansion and lung injury in ARDS. Data suggest that for every increase in plateau pressure of 6 cm H_2O, the development of ARDS (in patients initially without ARDS) increases by 50%. Pressure/volume curves can be produced which demonstrate the beginning of alveolar recruitment (lower inflection point) and the beginning of alveolar overdistention (upper inflection point) and can be used to guide the choice of V_T and PEEP. The pressure–volume curve is not a standard of care and should be used cautiously.

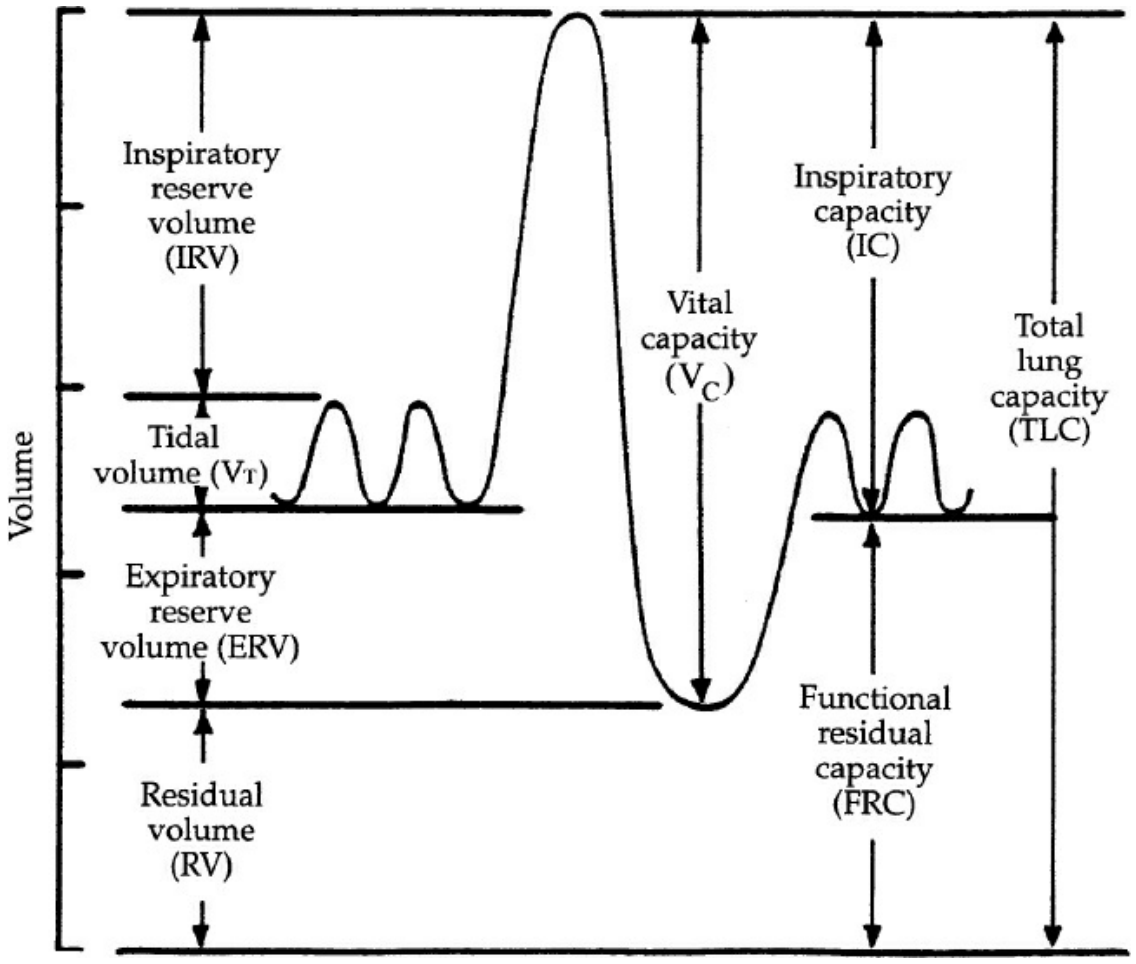

Figure 5.1. Standard measurements of lung volumes.

PREOPERATIVE ASSESSMENT

The ability of preoperative pulmonary function assessment to predict the incidence of pulmonary complications is relatively strong when individualized to a specific patient and clinical parameters. Despite this

observation, preoperative pulmonary function evaluations are not commonly performed. The reason for the relative paucity of standard preoperative pulmonary function testing remains unclear but may be related to an inadequate understanding of what testing can predict, the absence of guidelines detailing which test should be performed and in what populations and the utility of preventative postoperative care in all patients or just high-risk patients.

In emergency or urgent procedures the opportunity for preoperative assessment is not afforded and the surgical procedure must be undertaken regardless of the risk. Complete pulmonary function tests include lung volumes, spirometry, maximal respiratory pressures, diffusing capacities, and oximetry (Table 5.2). However, office-based observations such as ease of breathing, use of accessory muscles, ability to blow out a match with a wide-open mouth, and stair climbing are helpful indicators of pulmonary reserve (Table 5.3). Hypoxia or CO_2 retention on arterial blood gas measurements is also useful in patients with known chronic pulmonary disease. Development of office-based spirometry has afforded those physicians with an interest in treating such disorders with immediate access to results. Therapy and interventional treatment strategies may be initiated early based on such testing. The objectives of PFTs are to quantitate dysfunction and severity, and to assess long-term prognosis as endorsed by the American Thoracic Society. The National Lung Health Program has recommended routine use of spirometry by primary care physicians.

TABLE 5.2 Pulmonary Function Tests

Lung Volumes
- Total lung capacity (TLC)
- Vital capacity (VC)
- Reserve volume (RV)
- RV/TLC

Spirometry
- Forced vital capacity (FVC)
- Forced expiratory volume over the first second (FEV_1)
- FEV_1/FVC,
- Maximum voluntary ventilation (MVV)

Maximal Respiratory Pressures
- Maximal inspiratory pressure ($P_I$max)
- Maximal expiratory pressure ($P_E$max)

Diffusing Capacity
- Diffusing capacity of lung for carbon monoxide (D_{LCO})
- Alveolar volume (V_A)

Oximetry
- O_2 saturation

TABLE 5.3 Preoperative Assessment of Pulmonary Risk

History: Shortness of breath, dyspnea on exertion, fever, yellow or discolored sputum, smoking (current or past), COPD history

Physical Examination: Comfort of breathing, respiratory rate, thoracic excursion, temperature, use of accessory muscles to breathe, skin color, digital clubbing, wheezing, rales, rhonchi on auscultation

Chest X-ray: Hyperaeration, flattening of diaphragm, increase in width of lung fields, parenchymal changes

Arterial Blood Gas: Hypoxemia, hypercarbia

Pulmonary Function Testing: Elevated FRC, reduced FVC and FEV_1, reduced FEF 25–75%

The primary result of interest reported by preoperative spirometry is the forced vital capacity (FVC). FVC testing is accomplished by allowing the patient to inhale to total lung capacity and then exhale as fast and for as long as possible. FVC is the difference between total lung capacity and reserve volume. The forced expiratory volume over the first second is referred to as the FEV_1 and reflects the severity of obstruction to outflow (usually as a consequence of smoking). The ratio of FEV_1/FVC is also reported in addition to the maximal voluntary ventilation (MVV). The MVV is the maximal amount of ventilation over a 10- to 12-second period, and may vary widely based upon the fitness and effort expended by the patient. Predicted values for these parameters are calculated based on height, weight, and body mass index. Based on the observed values, a percent of predicted value is obtained, and is readily interpreted. These tests are performed before and after pharmacologic intervention such as bronchodilators, to determine the degree of reversibility of the airway disease. A significant response has been defined as a change of either a 12% or 0.2 L or more from baseline. Tests for lung volume and diffusing capacity are more complex and not routinely done for most patients. An

FEV_1 less than 50% of predictive value, resting hypoxemia, and hypercarbia have all been associated with increased postoperative pulmonary morbidity. The American Society of Anesthesiologists (ASA) has developed the ASA Class system which can be useful in predicting intraoperative and postoperative morbidity and mortality (Table 5.4). This system relies more on the overall physical condition of the patient, not the results in individual measurements.

TABLE 5.4 ASA Physical Status Classification and Rate of Postoperative Complications

ASA Class	Definition	Rate of Pulmonary Complications
I	A normally healthy patient	1.2%
II	A patient with mild systemic disease	5.4%
III	A patient with severe systemic disease but it is not incapacitating	11.4%
IV	A patient with incapacitating systemic disease that is a constant threat to life	10.9%
V	A patient not expected to survive 24 hours without surgery	NA
VI	A brain dead patient donating organs	NA

PREOPERATIVE ASSESSMENT OF PULMONARY RISK

The National Surgical Quality Improvement Program represents the most significant effort in identifying preoperative risk (Table 5.5). Factors associated with increased pulmonary morbidity, include age over 60, low serum albumin, renal failure, smoking, history of COPD, high ASA score, anesthetic time of 180 minutes or more, and type of operation. In the VA study, over 180,000 patients were studied. Postoperative respiratory failure was defined as the requirement for mechanical ventilation for more than 48 hours postoperatively, or reintubation and mechanical ventilation after postoperative extubation. This study more appropriately predicts postoperative respiratory failure, not PPCs. The study did not consider other findings such as atelectasis, pneumonia, or PE in the absence of mechanical ventilation. The study included noncardiac procedures done under general or regional anesthesia. The rate of postoperative respiratory failure was just less than 3%. Point values were assigned to these various factors and five classes of patients were then developed based on their scores. Class IV and V patients had predicted risks of 11% and 30%,

respectively, for development of postoperative respiratory failure, which closely matched the incidence from both phases of the study. Class I patients, which comprised almost half of the study population, had only a 0.5% risk of respiratory failure.

TABLE 5.5 Veterans Affairs Pulmonary Risk Index

Type of surgery (abdominal aortic aneurism > thoracic > neurosurgery, upper abdominal, or peripheral vascular > head and neck)
Emergency surgery
Serum albumin <3.0 g/L
Blood urea nitrogen >30 mg/dL
Partially or fully dependent functional status
History of chronic obstructive pulmonary disease
Age (>60)

Preoperative pulmonary risk has been studied thoroughly in patients who undergo thoracotomy and lung resection. Of major importance is the estimate of residual lung function to minimize the risk of permanent pulmonary dysfunction resulting in ventilator dependence. Lung cancer often occurs concurrently with COPD. Even when other risk factors are accounted for, the presence of COPD is the predominant risk factor for PPCs following thoracotomy. Lung volume is actually reduced by thoracotomy alone, and typically FEV_1 is reduced by 10% after lobectomy and by 30% after pneumonectomy. Methods for determining postoperative function after lung resection include PFTs, CT, and lung scanning. Split perfusion lung scanning has been found to be most accurate, as other methods consistently underestimate postoperative residual lung function. A predicted FEV_1 of at least 700 mL has been used as a cutoff for resectability. With regard to prediction of postoperative morbidity and mortality, the inability to climb two flights of stairs and a percentage of predicted DL_{CO} (derived from lung scan) less than 40% have consistently been shown to be associated with adverse clinical outcome.

Patients at Risk for Postoperative Pulmonary Complications

Several chronic disease states are associated with greater risk of pulmonary complications. These include chronic respiratory disease, cardiac comorbidities, and select surgical procedures. The most significant will be reviewed here.

The COPD Patient

COPD is an independent risk factor for the development of PPCs following both thoracic and nonthoracic surgery. COPD is characterized by airflow limitation and has been classified into five stages according to the Global Initiative for Chronic Obstructive Lung Disease (GOLD). The small airways from resected lung tissue of COPD patients demonstrate inflammatory leukocytes in both the lumen and walls. The severity of infiltration correlates with the GOLD stage, indicating the chronic inflammatory status of the lungs, which is often steroid resistant. Physiologically, COPD is characterized by decreased FEV_1, alveolar hypoventilation, reduction in alveolar capillary diffusing capacity, hypoxemia, and/or hypercarbia. The GOLD guidelines state that COPD is present when the FEV_1 is less than 80% of predicted and FEV_1/FVC is less than 0.7.

Pulmonary Hypertension

Pulmonary hypertension (defined as a right ventricular systolic pressure of >35 mm Hg) is a significant and often overlooked preoperative risk. In patients undergoing noncardiac surgery, a New York Heart Association functional class >2, a history of pulmonary embolus, or OSA postoperative pulmonary and cardiac complications are substantially increased. Postoperative congestive heart failure, cardiac ischemic events, arrhythmias, strokes, respiratory failure, hepatic dysfunction, renal dysfunction, and the need for postoperative inotropic or vasopressor support are known postoperative complications in this group. Postoperative respiratory failure is the most common complication.

Preoperative risk factors in patients with pulmonary hypertension include right-axis deviation on ECG, right ventricular hypertrophy, or a history of pulmonary embolus. In the absence of inhaled nitric oxide (iNO), the use of intraoperative epinephrine, or a right ventricular systolic pressure/systolic BP ratio of ≥0.66 is associated with increased perioperative morbidity and mortality.

Pulmonary hypertension patients unable to walk >332m during a 6-minute walk test have a higher mortality rate than those who can. The presence of a pericardial effusion, the presence of septal shift, or an enlarged right atrium on echocardiogram also predicts worse outcomes. If a patient has known pulmonary hypertension, determining their preoperative response to vasodilator therapy may be useful in managing postoperative complications.

Asthma

Although some evidence suggests that patients with asthma are at greater risk for PPCs, more recent studies have failed to corroborate this impression. Preoperatively patients should continue to use their inhaled medications to optimize peak expiratory flow. Intraoperatively, tracheal intubation and dry anesthetic gases may trigger bronchospasm in these patients. Short-acting β_2-agonists typically control this problem.

Smoking

A history of smoking increases the risk of pulmonary complications for patients undergoing any type of surgery. Patients who are smoking at the time of surgical intervention have an even greater risk.

Age

Patients >65 years of age undergoing nonthoracic surgery are at increased risk of PPCs.

Obstructive Sleep Apnea

Patients undergoing surgery should be screened for OSA. Preoperative evaluation for OSA can be a simple list of questions for the patient and their bed partner with regards to snoring, periods of apnea, and disrupted sleep pattern. Preoperative polysomnography has not been shown to assist in preventing postoperative complications. A study of 170 patients undergoing bariatric surgery found that only 15% of patients were diagnosed with OSA; however, the actual incidence was 77%, as documented by polysomnography. In the general surgical population the incidence of OSA has been estimated to be as low as 1% and as high as 9%. A plethora of studies have demonstrated that the presence of OSA correlates closely with increased postoperative morbidity and mortality. Sleep disturbances are exaggerated after surgery and general anesthesia. Appropriate preoperative treatment of OSA with continuous positive

airway pressure (CPAP) may reduce these risks.

TABLE 5.6 Preoperative Preparation of the High-Risk Patient

Identification that patient is at high risk
Reduce or stop smoking
Treat associated infection with antibiotics
Maximize lung function with medication and exercise
Regional anesthetic and appropriate sedation
Postoperative epidural analgesia

Perioperative Therapies to Prevent Postoperative Complications

Many interventions for reducing PPC have been explored (Table 5.6). These interventions should begin preoperatively, and continue through the intraoperative, perioperative, and postoperative periods. These interventions should be carried out regardless of the risk of the development of PPCs.

Smoking Cessation

Patients enrolling in a smoking cessation program 6 to 8 weeks prior to elective orthopedic surgery required less frequent postoperative mechanical ventilation. A number of other studies with varying durations of smoking cessation and operative interventions have demonstrated mixed results (http://chestjournal.chestpubs.org/content/132/5/1637). It long appears that to reduce PPCs, smoking cessation must begin a minimum of 6 weeks prior to the operation.

Preoperative Corticosteroids and Bronchodilators

Preoperative treatment with a β-agonist and methylprednisolone for 5 days, may reduce the incidence of bronchospasm during intubation in patients with asthma and bronchial hyperactivity. This is more effective in patient's naïve to routine β-agonists than those on long-term therapy.

Anesthesia and Analgesia

Anesthetic agents may contribute to the development of PPCs by

decreasing respiratory muscle tone and augmenting airway closure promoting atelectasis. Comprehensive reviews comparing the effect of general anesthesia, and spinal anesthesia on postoperative complications in patients undergoing nonthoracic surgical procedures have found no difference in the rate of postoperative pneumonia. A meta-analysis evaluating the incidence of postoperative pneumonia in patients undergoing hip surgery found no differences based on anesthetic technique. Despite conventional wisdom, regional anesthesia has not been clearly established as an approach for reducing PPCs. Patients receiving pancuronium and those with residual blockade have an increased incidence of postoperative pneumonia.

Surgical Techniques

Studies examining the incidence of PPCs using laparoscopic techniques compared to open techniques have generated variable outcomes and failed to favor one surgical approach over the other. However, common sense and clinical experience seems to favor laparoscopic techniques.

Lung-Expansion Maneuvers

Lung expansion maneuvers have been advocated to decrease the risk of complications by counteracting the adverse effects of surgery on pulmonary mechanics which predispose patients to atelectasis and retained secretions. Deep-breathing exercises, incentive spirometry, intermittent CPAP, and noninvasive ventilation have all been advanced as methods for lung expansion. Studies have failed to demonstrate the advantage of one technique over another and interestingly, several studies have shown that incentive spirometry has no advantage over deep breathing exercises alone. In summary, the techniques used for lung expansion appear to be equally effective in preventing PPCs. CPAP may be helpful in patient unable to perform deep-breathing exercises and in patients with OSA and/or obesity.

Use of Regional Anesthesia

Anesthesia is often classified into two main techniques: general anesthesia and regional anesthesia. General anesthesia refers to techniques that depress the central nervous system by a gaseous and/or intravenous delivery. Regional anesthesia refers to the delivery of pharmaceuticals directly to the spinal cord or nerves to locally anesthetize afferent and efferent neuronal pathways. Effective regional anesthesia for major

thoracic, abdominal, and limb surgery often requires the injection of these drugs into the subarachnoid space (spinal anesthesia) or into the epidural space (epidural anesthesia) to create a neuraxial blockade.

The use of neuraxial blockade for major general surgical procedures is well established though the additional benefit it may confer is controversial. These benefits are thought to originate through the attenuation of the neuroendocrine stress response that is reported during surgical interventions. When compared to patients undergoing systemic analgesia, the use of regional techniques is associated with a decrease in plasma levels of cortisol, catecholamines, and pro-inflammatory cytokines. The reduction of spinal sympathetic stimulation in the perioperative setting has presumed advantages for coagulation, pain relief, cardiovascular, pulmonary, gastrointestinal, and immunologic functions. Such techniques are appealing in that a blunted stress response during this period may translate into a reduction in morbidity and mortality especially in patients that have additional risk due to inherent co-morbidities.

When clinical outcomes are critically evaluated, the benefits of regional techniques become less clear. In a meta-analysis of 141 smaller randomized trials that included 9,559 patients, Rodgers et al. demonstrated a significant reduction in postoperative mortality for those patients that underwent neuraxial blockade. Furthermore, significant reductions in the odds of obtaining a deep vein thrombosis (DVT), PE, blood product transfusion, pneumonia, and respiratory depression were found in the blockade group. Rigg et al. examined the impact of epidural use during the operative and postoperative period in high-risk patients undergoing major abdominal or thoracic procedures when compared to a cohort receiving only systemic analgesia. This prospective, randomized trial of 915 patients demonstrated no difference in 30-day mortality. Of multiple morbid conditions that were examined postoperatively, only the rate of respiratory failure was significantly reduced in those with epidural use. In this group, there was a reduction in pain scores during the first 3 days of infusion though there was also a significant decrease in systolic blood pressure and maximal heart rate.

The implementation of such techniques in an elective surgical setting needs to be first discussed preoperatively with both the patient and in consultation with the anesthesiology team. Strong contraindications for placement include clotting defects and local sepsis at the insertion site. Clotting disorders, whether acquired or inherent, increase the risk of

epidural hematoma formation. Infection at the site of placement or in the locality of insertion could lead to spinal seeding and abscess formation. Patients with poor cardiac function should be evaluated closely in light of the heighted risk of cardiac dysfunction that may occur due to the spinal sympathetic block of neuraxial local anesthetics. Such patients may benefit from narcotic-only infusions or the removal of local anesthetics at the first signs of hypotension or bradycardia.

PROPHYLAXIS FOR VENOUS THROMBOEMBOLISM AND PULMONARY EMBOLISM

Venous thromboembolism (VTE), the formation of clot in the larger extremity or central veins, and PE, emboli from a large vein thrombus that occludes the pulmonary artery tree, continue to be the major health issues in the United States. These clots affect 350,000 to 600,000 Americans annually and are directly or indirectly related to 100,000 deaths over such a period. This crisis has grown to such a magnitude that a “Call to Action” was issued by the Surgeon General of the United States in 2008. The rationale for the prevention of VTE and PE is based on the premise that almost all hospitalized patients have at least one risk factor for formation and that approximately 40% have three or more (Table 5.7).

Without thromboprophylaxis, the rate of VTE is 10% to 40% in medical and surgical populations (moderate risk) with a rate as high as 40% to 60% following major orthopedic surgical interventions or major traumatic injury (high risk). Vast amounts of irrefutable evidence exist stating that VTE and PE are preventable entities. Based on these works, timely evidence-based clinical practice guidelines exist for the prevention of VTE and are the basis for this brief review.

The prevention of VTE begins with the institutional-wide identification of moderate to high-risk surgical patients. A formal, written policy for thromboprophylaxis and strategy for adherence has clear benefit. Low-risk surgical patients, those undergoing outpatient type procedures, have no additional thromboembolic risk and likely need nothing more than early and frequent ambulation. Most general surgical procedures incur a moderate risk of VTE though a high risk is often assigned to hip or knee operations, major trauma patients, and moderate risk patients with multiple individual risk factors. Risk factors for VTE in general surgical patients accrue based on the presence of obesity, cancer, increasing age, use of general anesthesia, duration of surgery, presence of postoperative

infection, and mobilization. The pathophysiologic basis of these risks is Virchow triad of vascular endothelial damage, venous stasis, and blood hypercoagulability. The use of mechanical methods for prophylaxis specifically graduated compression stockings, intermittent pneumatic compressions devices and venous foot pumps, have been appealing due to the lack of bleeding risk associated with such devices. Though the rate of DVT is lower with the use of these devices, no mechanical thromboprophylaxis option has been studied in such rigorous detail to impact PE or death rate and the quality of such trials is often debated.

TABLE 5.7 Risk Factors for Development of Venous Thromboembolism

Disease-Specific Risks	■ Surgery ■ Trauma (major trauma or injury to a lower extremity) ■ Cancer (active or occult) ■ Venous compression by tumor or hematoma ■ Inflammatory bowel disease ■ Nephrotic syndrome ■ Myeloproliferative disorders ■ Paroxysmal nocturnal hemoglobinuria ■ Inherited or acquired thrombophilia
Comorbid Risks	■ Immobility, lower-extremity paresis ■ Previous VTE ■ Increased age ■ Pregnancy and the postpartum period ■ Acute medical illness ■ Obesity
Drug and Treatment Risks	■ Cancer treatment (hormonal, chemotherapy, angiogenesis inhibitors, radiation) ■ Estrogen-containing oral contraceptives or hormone replacement therapy ■ Selective estrogen receptor modulators ■ Erythropoiesis-stimulating agents ■ Central venous catheterization

Current recommendations for those receiving major general surgical procedures focus on the early use of low-dose unfractionated heparin (LDUH), low-molecular-weight heparin (LMWH), or fondaparinux. Both LDUH and LMWH have been demonstrated to reduce the rate of symptomatic and asymptomatic VTE by 60%. In higher-risk patients undergoing oncologic surgical procedures, three times a day dosing of LDUH, LMWH or manufacture recommended dosing of fondaparinux is

recommended. The use of mechanical methods along with chemoprophylaxis is encouraged in any high-risk patient. The use of these agents, both mechanical and pharmaceutical, is to be used until discharge from the hospital. In patients with high risks or previous VTE, evidence exist that chemoprophylaxis with LMWH be considered after discharge for up to 28 days.

Recommendations for prophylaxis for surgical subspecialty patients do exist. The foundation of these recommendations is commonly based on the risk factors accumulated by the patient and not the type of surgical procedure to be performed. For high-risk patients undergoing vascular, laparoscopic, and thoracic surgery, the routine use of LMWH, LDUH, or fondaparinux is recommended. Those undergoing inpatient bariatric procedures often required higher doses of LMWH or LDUH than those given to nonobese patients. For surgical patients that require critical care who are at a moderate risk of VTE, the recommendation is for routine prophylaxis with LMWH or LDUH. Higher risk surgical critical care patients (often major trauma or orthopedic surgery) will require LMWH.

A great deal of evidence has accumulated for the prophylaxis of the traumatically injured patient. By the nature of a major trauma, these patients are considered high risk for the development of VTE. As such, routine thromboprophylaxis with LMWH is currently recommended. In those patients in whom the bleeding risk of chemoprophylaxis is too great, mechanical prophylaxis is to be started until LMWH can be initiated. For many, the risk of PE in this patient population is too high to rely solely on stocking and/or pneumatic compression devices. The insertion of inferior vena cava filters is growing in popularity to direct a method of mechanical prophylaxis above the common anatomical area of DVT formation. This attractiveness has spilled over to many patient subsets that have failed or cannot undergo the risk of chemoprophylaxis and/or full anticoagulation for known DVT or PE. However, these filters predispose patients to an increase risk of DVT in the lower extremities by reducing venous flow. Even more alarming is the incredibly low retrieval rate of these filters from patients with reversal factors for the formation of DVT. Many await large, prospective, multicenter studies to delineate the indication for filter use in those patient subsets that require chemoprophylaxis that is otherwise contraindicated.

DIAGNOSIS AND MANAGEMENT OF VENTILATOR-

ASSOCIATED PNEUMONIA

VAP is the most common infectious complication in critically ill surgical patients. Between 30% and 60% of mechanically ventilated patients will develop VAP varying between surgical population and diagnostic strategy. Critically ill trauma patients are at the highest risk of developing VAP followed by general surgical, cardiothoracic, burn, and neurosurgical patients. Although the attributable mortality in surgical patients is debated, VAP is independently associated with prolonged mechanical ventilation, and intensive care unit (ICU) and hospital lengths of stay. In addition, the excess cost of each episode of VAP exceeds $40,000. Risk factors for the development of VAP include patient comorbidities such as diabetes mellitus, malnutrition, alcoholism, immunosuppression, and COPD. Concomitant surgical risks include immunosuppressive effects of injury; breakdown of natural epithelial barriers by incision or instrumentation; manipulation of the alimentary tract; and prophylactic antibiotic therapy. Although lack of association between pneumonia and antacids or histamine-2 antagonists has been settled by meta-analysis, independent associations between proton pump inhibitor use and community- and hospital-acquired pneumonia have revived a debate surrounding gastric alkalinization for stress-related mucosal injury (SRMI) prophylaxis. Nevertheless, the Institute for Healthcare Improvement (IHI) recommends SRMI prophylaxis along with VTE prophylaxis, daily wake-up from sedation, head of bed elevation, and daily assessment for extubation as a bundle of interventions to diminish the risk and sequelae of VAP. Prevention of VAP using these and other evidence-based interventions (e.g., hand hygiene; oral care; infection control) should be routine in the management of critically ill patients.

The diagnosis and management of VAP in critically ill surgical patients include (1) a combination of clinical suspicion and quantitative, lower respiratory tract culture; (2) timely initiation of adequate (i.e., active against identified pathogen) empiric antibiotic therapy; (3) antibiotic de-escalation or discontinuation based on quantitative culture; and (4) appropriate duration of definitive antibiotic therapy. Interdisciplinary, evidence-based, institution-specific protocol implementation improves diagnostic accuracy, increases the frequency of adequate empiric antibiotic therapy, and decreases unnecessary antibiotic use.

In 2013, The Centers of Disease Control and Prevention (CDC) proposed a new method of monitoring VAP using a quality metric known

as ventilator-associated events (VAE). These definitions were developed to overcome shortcomings of traditional VAP definitions, including the subjectivity and low attributable mortality. However, these definitions include clinician response to changes in physiologic conditions, for instance an increase in PEEP to combat hypoxemia, which may be unrelated to any infectious process. A description of VAEs is provided in Figure 5.2.

The VAE definitions are fraught with difficulties, but the need to consistently diagnose pneumonia in an era of payers creating financial penalties for infections, inappropriately termed "never events" dictates compliance.

Despite the new CDC definitions, there remain two common strategies for the diagnosis of VAP: clinical and bacteriologic. Because traditional clinical criteria for VAP (e.g., new or changing infiltrate on chest radiograph [CXR]; macroscopically purulent sputum production; elevated white blood cell count; and elevated temperature) are overly sensitive and nonspecific, a bacteriologic diagnostic strategy using quantitative lower respiratory tract culture for definitive diagnosis can effectively differentiate VAP from noninfectious systemic inflammatory response syndrome (SIRS) or ARDS. Quantitative respiratory tract cultures, if possible, should be done before initiation of empiric antibiotic therapy and can be obtained using noninvasive endotracheal aspirate (EA), bronchoscopic protected specimen brush (PSB), or bronchoscopic/nonbronchoscopic bronchoalveolar lavage (BAL). Meta-analyses and large studies comparing EA and BAL are limited by clinical diagnostic defaults and relevant exclusion criteria, specifically patients at risk of more pathogenic organisms (e.g., *Pseudomonas aeruginosa*; methicillin-resistant *Staphylococcus aureus* [MRSA]). One of the more objective investigations was a large, randomized study in Spain that demonstrated an invasive strategy using bronchoscopic BAL (invasive) to obtain quantitative lower respiratory tract culture is associated with decreased unnecessary antibiotic use and decreased mortality compared to a strategy using quantitative EA (noninvasive). Consequently, concern exists surrounding potential upper respiratory tract contamination during noninvasive sampling and resultant false-positive culture.

The concept of quantitative culture for the diagnosis of VAP is not novel. In 1975, Polk performed serial quantitative cultures in EA in 97 surgical patients. He reported low false-positive and false-negative rates

when 100,000 colony forming units (cfu)/mL were used as the diagnostic threshold. Although debate persists around the appropriate diagnostic threshold for BAL, it has been repeatedly demonstrated that the threshold magnitude is inversely proportional to sensitivity and proportional to specificity, that is, a lower threshold has fewer false-negative, but higher false-positive results, whereas a higher threshold has fewer false-positive, but higher false-negative results. In a prospective study in critically ill trauma patients, Croce et al. noted that there is a poor predictability between clinical evidence of pneumonia and quantitative BAL culture. All enrolled patients received empiric antibiotic therapy based on clinical suspicion; however, patients with final quantitative BAL culture growth less than 100,000 cfu/mL were considered to have noninfectious SIRS and had their empiric antibiotic therapy discontinued. Based on subsequent investigation for VAP, the false-negative rate for quantitative BAL in this subset of patients was 7%. There was no difference in mortality between patients with false-negative and true-positive BAL. Overall, quantitative BAL and associated diagnostic threshold in this study had a sensitivity of 89% and specificity of 100%. Most data in critically ill surgical patients, primarily trauma, support a diagnostic threshold of 100,000 cfu/mL with consideration for using a threshold of 10,000 cfu/mL for *P. aeruginosa* in more severely injured or ill patients. As the progression of antibiotic resistance continues to challenge the fight against infectious complications, it may be reasonable to consider a more specific diagnostic strategy to avoid unnecessary antibiotic use. Nevertheless, contemporary guideline consensus and expert opinion stress the imperative of using a diagnostic threshold (e.g., 10,000 cfu/mL or 100,000 cfu/mL for BAL) rather than the specific threshold used.

Empiric antibiotic therapy for VAP should be guided by ICU-specific ecology, antibiogram data, and the presence of risk factors for multidrug-resistant (MDR) organisms. Commonly defined MDR risk factors include previous hospitalization or antibiotic use within 30 days; chronic hemodialysis; admission from long-term care facility; or immunosuppression. The most objective MDR risk factor influencing VAP pathogen prevalence is the duration of index hospitalization before developing VAP. Using a day cutoff, usually between 5 and 7 days, allows categorization of early- versus late-onset VAP.

Empiric antibiotic therapy should differ between early-onset VAP without other MDR risk factors compared to late-onset or early-onset VAP

with MDR risk factors (Table 5.8). Generally, patients without MDR risk factors who develop early-onset VAP are at risk for community-associated pathogens such as *Haemophilus influenzae;* methicillin-sensitive *S. aureus* (MSSA), α- or β-hemolytic *Streptococcus* spp., and limited-resistance enteric Gram-negative bacilli (e.g., *Escherichia coli; Klebsiella* spp.). Therefore, less broad-spectrum empiric antibiotic therapy is recommended. Institutions with high rates of community-acquired MRSA may need to consider anti-MRSA in these patients. In contrast, patients with late-onset VAP or those with MDR risk factors are at risk for *P. aeruginosa,* MRSA, *Enterobacter* spp., resistant *E. coli* or *Klebsiella* spp., and *Acinetobacter* spp. Because of the breadth of resistance mechanisms and bacterial classifications (i.e., Gram staining) encountered in these VAP episodes, a combination of anti-MRSA and anti-pseudomonal therapy is recommended. Reasonable options for MRSA include vancomycin (weight-based dosing) or linezolid, particularly for isolates wherein vancomycin minimum inhibitory concentration (MIC) exceeds 1 μg/L or if the patient experiences vancomycin intolerance. Empiric antibiotic therapy for Gram-negative bacilli should include an antipseudomonal β-lactam antibiotic and maximize the probability of initially covering *P. aeruginosa* based on local antibiogram. In institutions with low empiric resistance (e.g., less than 10%), it is reasonable to consider monotherapy antipseudomonal therapy, whereas institutions with unacceptable resistance rates should employ a combination of antipseudomonal β-lactam plus aminoglycoside or antipseudomonal fluoroquinolone. Subsequent to final culture result, empiric antibiotic therapy should be promptly de-escalated to the narrowest, organism-appropriate definitive regimen. This includes appropriate β-lactam (rather than vancomycin) for MSSA; monotherapy β-lactam for susceptible *P. aeruginosa;* monotherapy carbapenem for extended-spectrum β-lactamase (ESBL)-producing Gram-negative bacilli; and vancomycin for most MRSA strains. Unless obligated by MDR pathogens, monotherapy intravenous aminoglycoside therapy should be discouraged because of decreased clinical response and increased mortality. A key consideration to empiric and definitive antibiotic therapy regimens is the use of appropriate dosages to achieve acceptable pulmonary tissue concentrations. Strategies such as prolonged or continuous β-lactam infusions; aerosolized β-lactam or aminoglycoside therapy; and monitoring of real-time pulmonary antibiotic concentrations may be advantageous and are under broader investigation. Aerosolized

antibiotics may prove useful as adjunct to intravenous therapy. The use of aerosolized aminoglycosides allows maximum concentrations at the site of infection while limiting nephrotoxicity by minimizing blood concentrations. Current clinical trials are near completion to determine the utility of this therapy. The use of aerosolized antibiotics as monotherapy in uncomplicated, early pneumonia in trauma patients is attractive, but no evidence supports this regimen. Historical concerns related to aerosolized antibiotics, including development of resistance, appear to have been mitigated by improvements in aerosol delivery technology and management of the expired gas with filtration.

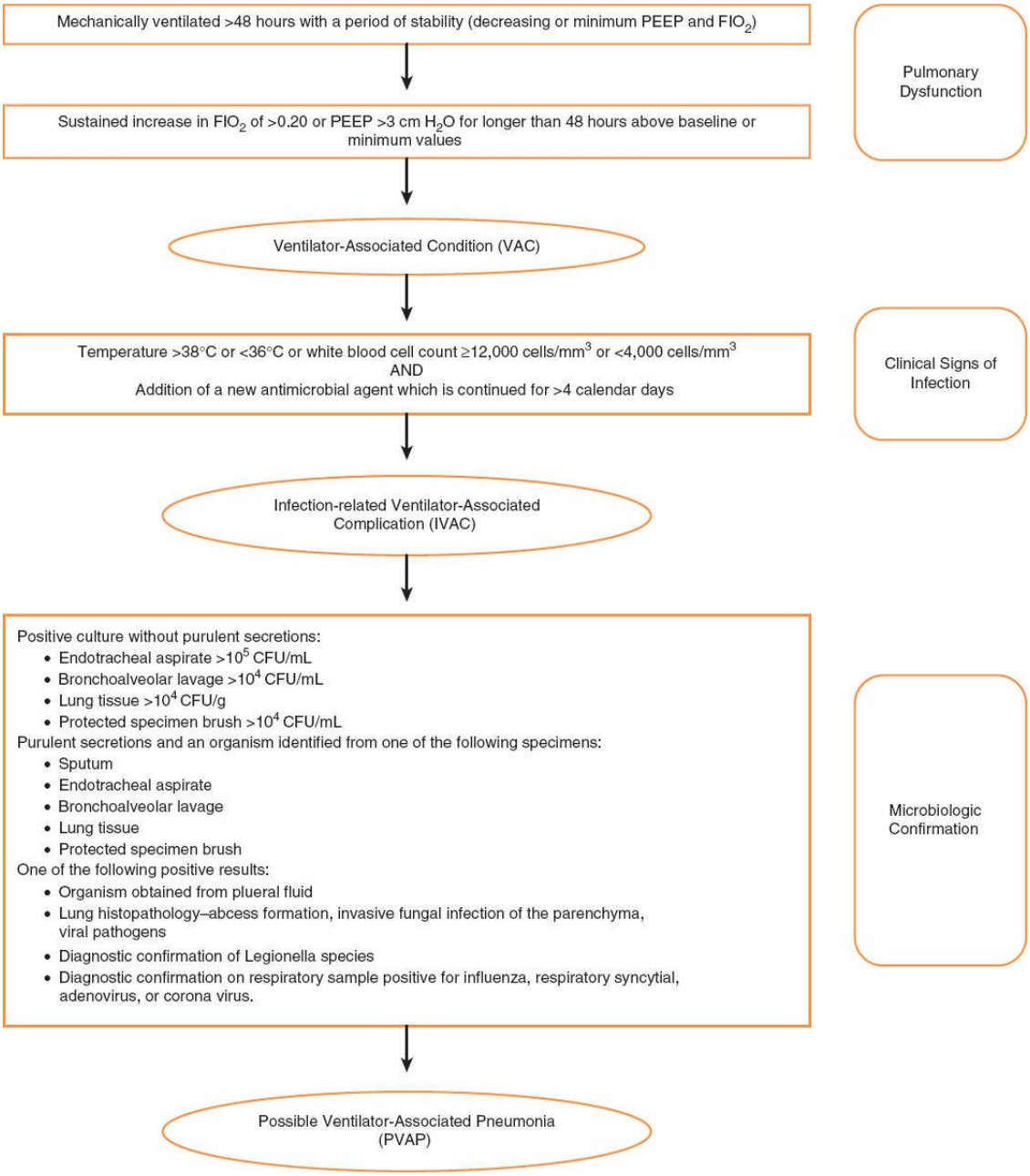

Figure 5.2. Ventilator-associated events surveillance algorithm.

TABLE 5.8 Empiric Antibiotic Regimens for Ventilator-Associated Pneumonia

VAP Classification	Antibiotic	Dosage, Intravenous[a]
Early-onset without MDR Risk Factors (choose one)	Ceftriaxone	2 g every 12–24 h
	Ampicillin/ Sulbactam	3 g every 6 h
	Moxifloxacin	400 mg every 24 h
	Levofloxacin	500–750 mg every 12–24 h
	Ertapenem	1 g every 24 h
Late-onset or early-onset with MDR risk factors (one primary agent, one combination agent, if necessary, and one anti-MRSA agent)	**Primary Agent**	
	Cefepime	2 g every 8–12 h (consider infusion over 4–6 h if suspect higher MIC *P. aeruginosa*)
	Piperacillin–Tazobactam[b]	3.375–4.5 g every 6 h (consider every 8 h infused over 4 h if suspect higher MIC *P. aeruginosa*)
	Imipenem	500 mg every 6 h
	Meropenem	1 g every 8 h
	Combination Agent	
	Tobramycin	7 mg/kg every 24 h
	Amikacin	25 mg/kg every 24 h
	Ciprofloxacin	400 mg every 8 h
	Anti-MRSA	
	Vancomycin	15–20 mg/kg every 8–12 h (consider goal serum trough concentration 15–20 μg/L)
	Linezolid	600 mg every 12 h

[a]Dosage for patients with creatinine clearance above 60 mL/min.
[b]Consider de-escalating to piperacillin (i.e., without tazobactam) 4 g every 4–6 h for piperacillin-sensitive *P. aeruginosa* based on final susceptibility results.
VAP, ventilator-associated pneumonia; MDR, multidrug resistance; MIC, minimum-inhibitory concentration; MRSA, methicillin-resistant *S. aureus*.

The optimal duration of antibiotic therapy for VAP is unknown, particularly in patients with nonlactose-fermenting Gram-negative bacilli (e.g., *P. aeruginosa*). Historically, antibiotic durations between 14 and 28 days were recommended for all patients with VAP. As with most typical bacterial infections, contemporary evidence demonstrates that shorter antibiotic durations result in similar patient outcomes, decrease antibiotic use, and may limit the progression of MDR. Moreover, low specificity of clinical response parameters (e.g., white blood cell count; temperature; sputum production) injects unacceptable subjectivity into the assessment of antibiotic duration. A landmark trial in France randomized 400 mostly critically ill medical patients with bronchoscopically diagnosed VAP (BAL greater than 10,000 cfu/mL) to 8 or 15 days of adequate antibiotic therapy regardless of clinical response. Overall, there was a significant

decrease in antibiotic-free days with no difference in VAP recurrence or 28-day mortality between the groups. On sub-group analysis, VAP relapse and mortality remained equivalent between groups for VAP caused by MRSA and lactose-fermenting Gram-negative bacilli. Conversely, patients with nonlactose-fermenting Gram-negative VAP, primarily *P. aeruginosa*, who received 8 days of therapy had significantly higher rates of VAP relapse (32.8% vs. 19.0%). However, of the patients who had a VAP relapse, those who received 15 days of therapy were 1.5 times more likely to have a MDR pathogen as the cause of the subsequent VAP.

In a concurrently conducted before-and-after, case-matched, single-center pilot study, antibiotic duration was compared in two groups of critically ill trauma patients with bronchoscopically diagnosed VAP (BAL greater than 100,000 cfu/mL): a control group whose antibiotic duration was at the discretion of the ICU service and a study group who underwent repeat BAL after 3 days of adequate antibiotic therapy. If pathogen growth on repeat BAL culture was less than 10,000 cfu/mL, then definitive antibiotic therapy was discontinued. Compared to control patients, study group patients received significantly shorter durations of definitive antibiotic therapy (9.8 days ± 3.8 days vs. 16.7 days ± 7.4 days; $p < 0.001$) with no difference in VAP recurrence or in-hospital mortality. Corroborating the results of the French trial, study patients with nonlactose-fermenting Gram-negative bacilli more often received longer durations of therapy because of persistence of significant growth on repeat BAL, whereas greater than 95% of all other pathogens had less than 10,000 cfu/mL on repeat BAL and were treated for 8.8 ± 3.3 days. Results of these studies support contemporary guideline recommendations for antibiotic duration in patients with VAP: most patients who receive adequate empiric antibiotic therapy and demonstrate reasonable clinical or microbiologic response should receive 7 to 8 days of antibiotic therapy, whereas patients with nonlactose-fermenting Gram-negative bacilli may require 14 days of antibiotic therapy.

PATHOPHYSIOLOGY AND TREATMENT OF ACUTE RESPIRATORY DISTRESS SYNDROME

ARDS is an acute inflammatory lung injury that was first described by Ashbaugh and colleagues in 1967. This syndrome is characterized by hypoxia, diffuse “ground-glass” pulmonary infiltrates on chest x-ray, and decreased lung compliance in the absence of ongoing heart failure (Fig.

5.3). The reported incidence of ARDS ranges between 1.5 and 13.5 per 100,000 population, with a mortality rate of 27% to 60%. Forty years after the initial description, the mortality as associated with ARDS remains high and is often part of the sequence of multiple organ failure (MOF). Recent investigations have suggested that the mortality associated solely to ARDS is declining to a range of 30%. Assuming that the finding of reduced mortality in ARDS is genuine, the cause is undoubtedly multifactorial. Over the past decades, improvements in understanding the pathogenesis of sepsis and multiorgan dysfunction, development of improved surveillance and treatments for infection, appreciation of the role of appropriate nutrition, and changing concepts in ventilatory support have likely all contributed. In addition, the development of consistent protocol-based approaches to the management of ARDS, as shown by the Acute Respiratory Distress Syndrome Network (ARDSNet) trial, appear to improve outcome. Finally, advances in ventilator technology, including airway graphics packages and improved dynamic monitoring capability have provided the practitioner with a more precise understanding of the dynamic interplay between patient and machine.

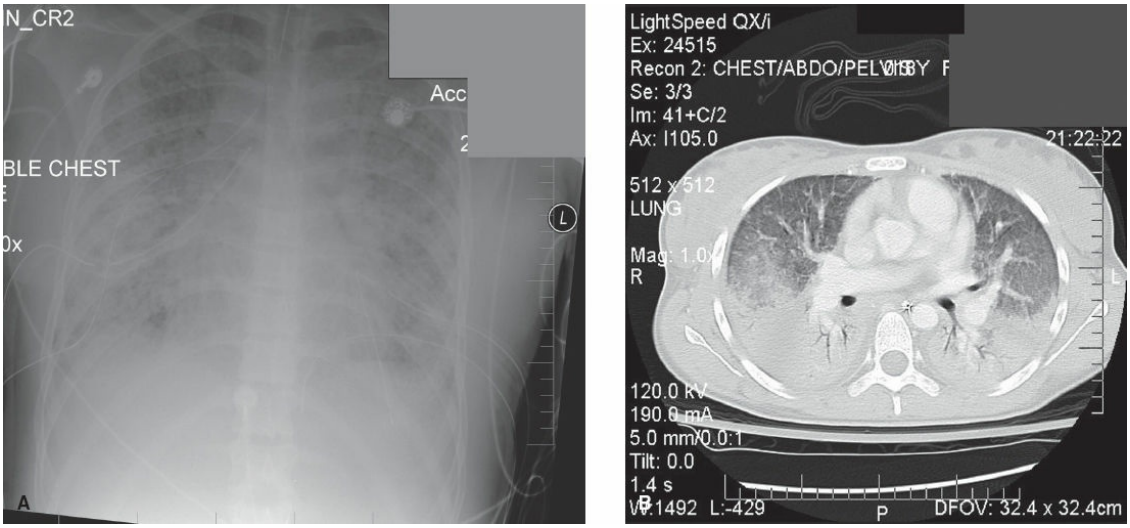

Figure 5.3. Characteristic chest radiograph (**A**) and CT scan (**B**) in a patient with severe ARDS following multiple trauma.

The hallmark clinical symptom of ARDS is hypoxemia refractory to oxygen therapy. The defining characteristics of ARDS have remained constant but a new one, the Berlin definition, was introduced in 2011. This system eliminates the definition of ALI and classifies ARDS into mild, moderate, and severe forms as detailed in Table 5.9.

The major difference in the new definition is the requirement for a minimum of 5 cm H_2O PEEP at the time of the oxygenation measurement. Categorizing ARDS based on oxygenation allows determination of the interval at which rescue therapies can be applied and aids in the determination of mortality. The observed clinical sequelae of ARDS results from ventilation–perfusion (V/Q) inequalities, specifically intrapulmonary shunt (perfusion in the absence of ventilation). Gravitational forces acting on the edematous lung induce consolidation in dependent lung regions altering distribution of ventilation and worsening V/Q matching. The preponderance of disease in dependent lung regions complicates mechanical ventilation, leads to maldistribution of tidal volume, and promotes ventilator-induced lung injury (VILI).

TABLE 5.9 Definition of Berlin Acute Respiratory Distress Syndrome

Timing	Acute onset within 1 wk of insult or new/worsening respiratory symptoms.		
Origin of lung edema	Known risk factors for lung edema not explained by cardiac failure or fluid overload. In the absence of known risk, objective assessment of cardiac failure or fluid overload must be undertaken.		
Radiographic findings	Bilateral opacities not explained by pleural effusion, lobar collapse or nodules.		
	Mild	**Moderate**	**Severe**
Oxygenation, Pao_2:Fio_2	201–300 PEEP/CPAP ≥5 cm H_2O	<200 PEEP ≥5 cm H_2O	<100 PEEP ≥5 cm H_2O

CPAP, continuous positive airway pressure; PEEP, positive end-expiratory pressure.

A more detailed and sophisticated approach to the various “types” of ARDS is obtained by understanding additional definitions that further refine the etiology and pathophysiology of ARDS. More importantly these discriminators highlight important differences in the very broad category that is ARDS. By understanding the evolution and key derangements present in the various “forms” of ARDS the clinician may more appropriately tailor the clinical response to the specific patient needs. An understanding of the various “forms” also allows one to understand that surgical patients with ARDS are often quite different from medical patients with ARDS. Understanding these distinctions both explains traditional differences in management strategies between the MICU and

the SICU as well as aids in the appropriate bedside management concepts. The key components to understanding the various "forms" of ARDS include the following:

Primary versus secondary ARDS
Early versus late ARDS
The role of extrapulmonary changes in compliance

The ensuing sections will attempt to distinguish these differences with specific attention to the surgical patient with ARDS.

Primary Versus Secondary ARDS

The distinguishing characteristic between primary and secondary ARDS is related to the locus of injury in the lung. In direct (primary) ARDS the injury occurs at the alveolar interface whereas with indirect (secondary) ARDS the injury occurs at the capillary side of the alveolus (as the result of substances/toxins transmitted via blood). The most common cause of direct lung injury is pulmonary infection and the presumed toxins/toxic effect exerted by bacteria in the alveoli (pneumonia). Other primary insults leading to ARDS include aspiration, barotrauma, atelectrauma, near-drowning, and inhalation injury. Most of these etiologies are managed within the MICU. Surgical sources of direct ARDS include pulmonary contusion, lung laceration, blast injury, and bronchial injury. In all cases, direct lung injury is characterized by an insult which impacts on the alveolar (as opposed to the capillary) side of the alveolar/capillary interface.

Indirect lung injury may be related to sepsis, shock, massive transfusion/resuscitation, fat/PE, pancreatitis, peritonitis, and the SIRS. In this instance the defining injury is on the capillary side of the alveolar/capillary interface and the majority of these patients reside within a SICU. The pathophysiology of ARDS is an area of significant continuing research as patients with these multiple risk factors demonstrate heterogeneity with respect to the expression of the disease state of ARDS. The "trigger" for the sequence of ALI to SIRS to ARDS to MOF is an unsolved scientific question and demonstrates variable expression among patients. Most investigators believe that increased lung capillary permeability with subsequent alveolar capillary leak occurs from a complex inflammatory response to a primary event and remains the cornerstone pathologic disturbance of this process. The diagnosis of ARDS

remains a clinical determination and the treatment primarily supportive.

Early Versus Late ARDS

A second key characteristic that aids in distinguishing the "forms" of ARDS is the distinction of early versus late ARDS. Early ARDS is a dynamic disease entity and the manifestation of lung edema may be quite variable. In early ARDS the lung remains malleable and is often recruitable with compliance approaching normal values. Late ARDS is a form of the disease which is more static in nature, less responsive to therapeutic recruitment maneuvers (PEEP, prone positioning, etc.), and more likely to be chronic and slowly changing. The transition point from early to late ARDS is variable but the may occur around the time of 5 to 7 days of clinically established ARDS. This subtle, and often overlooked distinction between early and late ARDS must be accounted for by the clinician as it may significantly impact on the success (or failure) of the therapeutic option(s) pursued in the management of the patient with ARDS.

Numerous clinical trials with various treatment protocols have been performed with the goal of supportive therapy to decrease VILI, improve oxygenation, and decrease the number of ventilator days. Similarly there have been additional trials of pharmacologic agents (including surfactants) which reduce the inflammatory response without increasing infectious complications and therefore potentially attenuate the severity of the clinical course. There have been a variety of ventilator protocols and surrogates to respiratory support studied as well. The outcome of most of these trials demonstrates a degree of improvement in oxygenation and limitation in VILI but with little impact on mortality of established ARDS or prevention of ALI. Pharmacologic studies have been even less promising with no approved agent currently for treatment of this disease. Otherwise, no major difference has been achieved with a series of failed or terminated clinical trials primarily focused on the inflammatory phase. Table 5.10 summarizes many of the supportive and pharmacologic modalities with their results.

The ARDSNet was established to facilitate the development of effective therapeutic protocols for the treatment of ARDS. The National Heart, Lung, and Blood Institute of the National Institutes of Health (NIH), initiated a clinical network in 1994 to carry out multicenter clinical trials of novel therapeutic agents for ARDS. More recently, NIH has established

the Prevention and Early Treatment of Acute Lung Injury (PETAL) network with the aim of preventing ARDS through early intervention. Current treatment of ARDS is primarily supportive, with the goal of minimizing further lung injury and allowing spontaneous resolution of the process. There remains some controversy as to what constitutes the best supportive measures and there is yet no current effective treatment for the pathophysiologic derangement of ARDS. The first ARDSNet trials that received widespread interest included ventilator management trials investigating lower tidal volume ventilation and higher PEEP. In the low tidal volume trial, an improved survival rate was observed when limiting ventilator tidal volumes to 6 mL/kg of idealized body weight. Success was attributed to decreasing volutrauma related to traditional higher tidal volumes. This trial was halted early with 861 subjects noting a decrease in mortality from 39.8% to 31% when comparing high to low tidal volume ventilation. It is important for the practitioner to remember that the tidal volume utilized in this trial is the *idealized* body weight (determined solely by gender and patient height). The second ventilator management trial examined the role of low and high PEEP with lower tidal volumes in patients with ARDS. No survival benefit was noted with the addition of higher PEEP than achieved by lower tidal volumes alone.

More recent data from the ARDSNet group suggests that fluid restriction based on pressure data from a central venous catheter is superior to more aggressive fluid strategies. This trial also noted no advantage to use of a pulmonary artery catheter in the management of fluids in ARDS. The role of steroids in late ARDS remains controversial. However, recent studies have demonstrated that steroids in late ARDS can be associated with an increased incidence of infection and mortality.

Early use of paralysis was associated with improved outcomes in a single center European trial. Cisatracurium for the first 3 days compared to analgesia and sedation demonstrated a decrease in mortality and duration of ventilation. This finding may relate to eliminating the need for patient–ventilator interaction and achieving absolute control of driving pressure and tidal volume. The PETAL network is currently re-exploring this treatment in a US multicenter trial.

In trauma patients, experience from the conflict in Iraq and Afghanistan has demonstrated that initial hypotensive resuscitation followed by a 1:1:1 ratio of blood to plasma and platelets results in a reduced incidence of ARDS. This observed benefit is clearly complex and multifactorial but

appears clearly supported by a growing body of published data. Robinson and the Prospective Observational Multicenter Massive Transfusion Trial (PROMMTT) study group evaluated the application of the Berlin definition in PROMMTT patients with respect to the impact of resuscitation on the incidence of hypoxemia. The PROMMTT study enrolled 1,245 patients undergoing massive transfusion following traumatic injuries. The authors concluded that severe chest injury, increasing age, and crystalloid-based resuscitation, but not blood transfusions, were associated with increased risk of developing moderate-to-severe hypoxemia following injury. At our own institution, we examined the impact of a change in our transfusion practice following the military clinical practice guidelines of damage control resuscitation (DCR) which emphasizes balanced blood component administration with limited crystalloid use. This study demonstrated that a military-derived DCR strategy can be implemented in the civilian setting. DCR led to significant increases in FFP transfusion, decreases in crystalloid use, and a statistically significant decrease in acute hypoxia.

TABLE 5.10 Supportive and Pharmacologic Interventions for ARDS

Respiratory Supportive Measures		Pharmacologic Interventions	
Intervention	Result	Intervention	Result
Prone ventilation	Improved oxygenation Improved outcomes in severe ARDS (PaO_2/FIO_2 <100)	Corticosteroids	No early benefit? Late benefit in fibroproliferative phase. May increase mortality in select groups.
Permissive hypercapnia	Decreased barotrauma? Survival benefit	Surfactant	No benefit
Pressure control ± inverse ratio ventilation and airway pressure release ventilation (APRV)	Commonly used for "rescue" when conventional ventilator modes fail Improved oxygenation using high mean airway pressures Requires additional fluid loading secondary to reduced cardiac output	Pentoxifylline/ Lisofylline	No benefit
High-frequency modes of ventilation	Recent trials demonstrate either no benefit or worse outcomes with high frequency owing to high mean airway pressure, excess sedation, and increased fluid requirements	Ketoconazole	No benefit
Extracorporeal cardiopulmonary bypass (ECMO)	Mixed results in adults, institution dependent	Antioxidants	No benefit
Inhaled nitric oxide	Improved oxygenation, no survival benefit	Paralysis (Cisatracurium)	Improved outcomes during paralysis for first 3 days of ventilator support
Recruitment maneuvers and increased PEEP	Recruitment maneuvers have been shown to increase PaO_2 and improve lung compliance but have not decreased mortality. Higher PEEP is associated with a shorter duration of ventilation, less frequent use of rescue therapy, and a mortality benefit in severe ARDS. Higher PEEP should be limited to severe ARDS	Prostaglandin	Improved oxygenation, no survival benefit

A Practical Approach to ARDS

Ventilatory management of the surgical patient with ARDS should follow the principles of lung protection. The approach to ventilation should begin with a determination of the mechanism of injury and the pattern of pulmonary involvement (direct versus indirect ARDS). The patient with direct ARDS resulting from postoperative pneumonia commonly has patchy infiltrates on CXR and moderate hypoxemia. The patient with indirect ARDS following multiple trauma, hypotension, and massive blood transfusion will demonstrate a pattern of diffuse alveolar infiltrates on CXR and profound hypoxemia. In each instance, the goals of ventilation should prioritize limiting plateau pressures, tidal volumes based on ideal body weight of 6 mL/kg, and PEEP sufficient to reduce FIO_2 <0.60.

Despite the success of the ARDSNet trial, the adjustment of ventilatory parameters based solely on rules for tidal volume and PEEP belies the complexity of ventilator management and the disease process. In patients with direct ARDS, PEEP should be adjusted to maintain oxygenation and tidal volume adjusted between 4 and 8 mL/kg of ideal body weight to maintain a plateau pressure <30 cm H_2O. Ideal body weight should be determined through the measurement of height (height is the major determinant of lung volume not weight) using the following equations.

$$\text{Men} - \text{IBW} = 50 + 2.3\ (\text{Height in inches} - 60)$$

$$\text{Women} - \text{IBW} = 45.5 + 2.3\ (\text{Height in inches} - 60)$$

Direct ARDS rarely requires PEEP >12 cm H_2O as higher pressures result in overdistension, increased shunt fraction, and a paradoxical decrement in oxygenation. This observation reflects the patchy/isolated nature of early direct ARDS. Indirect ARDS commonly requires PEEP up to 20 cm H_2O (diffuse widespread changes in pulmonary compliance) and similar adjustment of tidal volume based on IBW. This may also reflect global changes in thoracic and abdominal compliance due to third spacing and capillary leak which occurs at extrapulmonic locations; but is a result of the same inflammatory insult which generated the secondary ARDS. Measurement of the pressure–volume curve of the respiratory system can be useful in determining the lower and upper inflection points corresponding to the initiation and end of alveolar recruitment (Fig. 5.4). During the last decade a number of newer ventilators have incorporated

the ability to conduct an automated pressure/volume curve at the bedside. This relatively simple procedure requires the establishment of (temporary) muscular paralysis but in return may provide significant clinical information regarding the lower and upper inflection points of the lung. It is our practice to measure the P/V curve in most patients with moderate or severe ARDS and to repeat this maneuver as needed (daily) over the early phase of management.

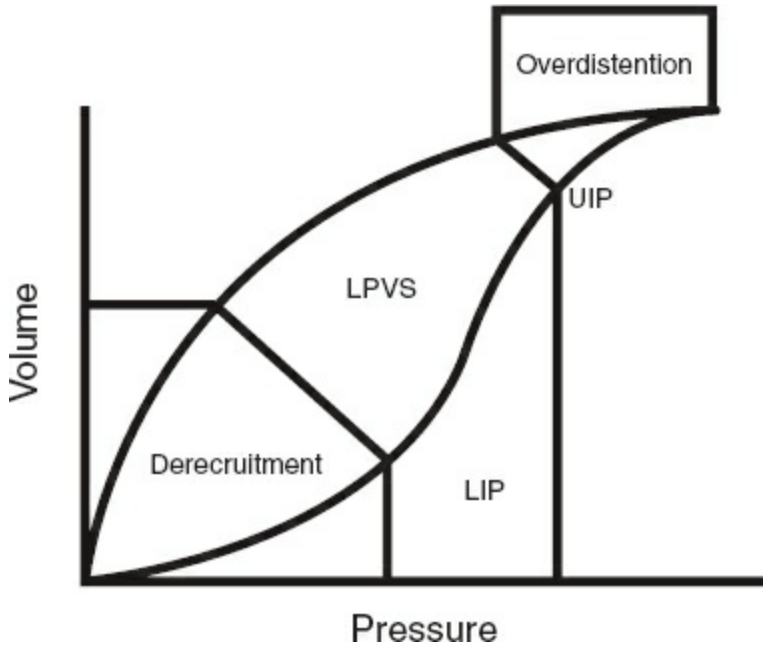

Figure 5.4. Pressure–volume curve of the respiratory system demonstrating the lower inflection point (LIP) representing the start of alveolar recruitment and the upper inflection point (UIP) representing the end of alveolar recruitment. Identification of these landmarks allows rapid adjustment of PEEP and tidal volume to maximize gas exchange and limit ventilator-induced lung injury.

Plateau pressure as measured during an inspiratory pause has been employed as a surrogate of alveolar pressure. This assumption is simplistic and may often be misleading in the surgical patient. More appropriately, the main determinant of lung inflation should be considered as related to the transalveolar distending pressure (alveolar pressure minus chest wall pressure). This observation remains one of the critical distinctions that must be understood by the surgical intensivist. The surgical patient often differs from their medical counterpart due to significant changes in chest and abdominal compliance prompted by surgical interventions and large

volume fluid resuscitation. These striking changes also often accompany the patient who has suffered an indirect (secondary) insult as the etiologic agent for ARDS. The surgical patient with reduced chest wall compliance as a consequence of fluid resuscitation, abdominal distension, or obesity frequently requires a plateau pressure higher than 35 cm H_2O in order to sustain an appropriate transalveolar distending pressure. Transalveolar distending pressure can be estimated by measurement of airway plateau pressure minus the esophageal or intra-abdominal pressure. Recent studies by Talmor and associates have demonstrated that this measurement algorithm may significantly impact on the management strategy of surgical patients with ARDS. Talmor's group examined surgical patients meeting the consensus criterion definition of ARDS the management of PEEP was randomly distributed between an algorithm utilizing the ARDSNet standard of care recommendations versus an algorithm that adjusted PEEP per measurements of esophageal pressure. This study was halted early after the enrollment of 61 patients secondary to the demonstration of a significant improvement in the ratio of partial pressure of arterial oxygen to the fraction of inspired oxygen (PaO_2/FiO_2 ratio) at 72 hours in the esophageal pressure–guided group. This effect was persistent over the entire follow-up time (24, 48, and 72 hours). This study lends support to the contention that surgical patients with elevated intra-abdominal pressures (fluid resuscitation, bowel distension, surgical changes, etc.) and/or noncompliant chest walls may respond in a fundamentally different fashion to increases in PEEP as compared to the patient with direct ARDS and pre-existing chronic lung disease. Further investigations of this modality must be conducted but it appears to be straightforward and to offer significant opportunity for improvement in ventilator management techniques.

Considerable controversy remains (and continues) regarding the ideal mode of ventilation and type of ventilator breaths delivered for the surgical patient. Volume control breaths provide constant flow and assure a constant minute ventilation (but varying peak pressure). Pressure control breaths may improve oxygenation by virtue of increased mean airway pressure, but this modality cannot guarantee tidal volume consistency. Either of these techniques can be used to provide lung protection but neither is lung protective per se. The volume and pressure delivered to the patient should follow the guidelines presented above. If these considerations are understood then there is no specific advantage of one

ventilator modality breath type over the other. Choices for modes of ventilation multiply with each passing year (and with increasing sophistication of mechanical ventilators), but the seminal issue remains the clinical decision to provide either full ventilatory support or allow spontaneous breathing. In the critically ill patient requiring heavy sedation and/or paralysis, full ventilatory support with continuous mandatory ventilation (often called assist control) is usually required. In the previously healthy patient with moderate hypoxemia, spontaneous breathing may be promoted by either synchronized intermittent mandatory ventilation (SIMV) or airway pressure release ventilation (APRV). Maintenance of spontaneous breathing improves V/Q matching, enhances venous return, and improves cardiac output. To date there is no compelling evidence which demonstrates an advantage of one technique over the other.

Following the establishment of initial ventilator settings an assessment of intravascular volume status should be accomplished, and fluid replacement and inotropic support implemented as required to promote effective ventilator management. Recruitment maneuvers to assess the degree of potential alveolar recruitment and improve gas exchange are warranted if gas exchange does not improve immediately. This can be accomplished by increasing PEEP to 30 cm H_2O for 40 seconds. Recruitment maneuvers are generally more effective in indirect than direct ARDS. An improvement in oxygenation and reduction in the minute ventilation to maintain the current CO_2 elimination are seen when the maneuver is successful. If the beneficial effects of recruitment maneuvers are short lived, increasing levels of PEEP following the maneuver are recommended to maintain recruitment. The normal ratio of inspiration to expiration (I:E) allows for a 2 to 3 times longer expiratory phase during gas exchange. Failure of increased PEEP to improve oxygenation can often be overcome by a reversal of the I:E ratio. Increasing the inspiratory phase allows a greater period of time for oxygen exchange at the alveolar level. Given that the normal diffusion process favors CO_2 elimination by a 20-fold difference, a shortened expiratory phase is usually not problematic. Reverse I:E ratios vary from 1:1 to 4:1 based on the severity of hypoxia. Caution should be exercised when increasing the I:E ratio. Often the increase in PaO_2 is offset by the decrease in cardiac output with a resulting fall in oxygen delivery.

Recent advances in ventilator mechanics and sophistication have

created the opportunity for the clinician to conduct bedside pressure/volume curve analysis to establish the optimum PEEP level. Establishing a pressure/volume curve requires a short period of chemical paralysis in order to eliminate the variability imposed by spontaneous respiratory effort. Once this is established the ventilator will complete a constant flow maneuver while simultaneously evaluating circuit pressure and volume delivered. This pressure/volume curve represents the global compliance of the respiratory system as well as allowing for the detection of the upper and lower inflection points. In an ideal situation PEEP is set at (or slightly above) the lower inflection point. This establishes an end-expiratory pressure which prevents repetitive alveolar collapse at the end of each ventilatory cycle. The upper inflection point establishes the upper plateau pressure limit which will aid in the elimination of alveolar overdistension. This technique allows the clinician to establish ventilator parameters which allow for "ventilating between the points." To date the utility of setting PEEP and plateau pressures via the utilization of modern ventilator pressure/volume curves has yet to be established despite the intuitive nature of this practice. If hypoxemia persists, a trial of prone positioning is warranted. Prone positioning improves the distribution of inspired volumes via alteration(s) in pleural pressure gradients. In addition, prone positioning changes the physical relationship of recruited versus collapsed lung segments as well as the physical location of displacing entities such as the heart. These combined effects result in more efficacious pressure gradients that favor recruitment. The duration of prone position should be based on patient tolerance as judged by edema formation and need to perform assessments or care procedures in the supine position. Ideally a period of 9 to 12 hours prone should be interspersed with 4 to 6 hours supine. In severe ARDS both aggressive PEEP and prone position provide a mortality benefit and shorter duration of ICU stay. Care must be exercised to avoid pressure points at the contact points between the patient's face and ventilator circuit. The authors also advocate for a trial of proning using simple pillows and pads to demonstrate potential efficacy before committing to the more expensive commercial bed devices. An objective demonstration of the benefit of proning would be the improvement of PaO_2/FiO_2 ratio of >20%.

When proning can be accomplished safely, the improvements are worth the risk in the patient with severe ARDS (PaO_2/FIO_2 <100). Prone positioning has shown to be effective in improving the PaO_2/FiO_2 ratio for

up to 10 days and can be discontinued when gas exchange benefits are no longer seen.

iNO may improve oxygenation by selective pulmonary vasodilation and subsequent improvement in V/Q. Several trials of iNO have demonstrated an improvement in the PaO_2/FiO_2 ratio but all have failed to demonstrate any survival benefit.

All of the above maneuvers (pressure–volume curves, prone positioning, recruitment maneuvers, and iNO) are correctly understood as adjuncts in the management of ARDS. Individually each of these maneuvers have been demonstrated to improve some aspect of the pulmonary dysfunction associated with ARDS (V/Q mismatch, hypoxemia, atelectasis, alveolar overdistension, etc.), but none have been associated with an improvement in mortality. It is up to the clinician to ascertain when, which, and for how long all of these maneuvers may be combined in the individual patient with ARDS. Managing ARDS is a dynamic process which requires vigilance and understanding of the pathophysiology of the disease. Protocol-driven treatment can be useful as a starting point, but modification of protocols to meet the needs of the critically ill surgical patient must be employed to maximize success.

INTRAOPERATIVE VENTILATORY SUPPORT

Previous editions of this chapter have focused on the preoperative, postoperative, and ICU aspects of pulmonary risk and ventilator support. Recent work by multiple investigators has focused on the potential impact of ventilator strategies and management techniques during surgery. This body of evidence suggests that this is an important additional consideration and is now included for consideration.

The observation (discussed above) by the ARDSNet study group and others that a limited tidal volume strategy improves outcomes in patients with ARDS stimulated investigations of a similar approach during operative intervention and anesthesia. Yang and colleagues completed a meta-analysis of intraoperative ventilation techniques and the impact on subsequent PPCs. Their work produced two separate analyses. The first was an examination of the impact of low tidal volume ventilation versus conventional tidal volume ventilation during surgery. The group demonstrated a decreased incidence of postoperative infection but no impact on the occurrence of ALI or atelectasis. The second analysis examined a protective lung strategy (limited tidal volume, PEEP 5 to 10

cm H_2O, and intermittent recruitment maneuvers during the procedure) versus conventional tidal volume use. This second analysis demonstrated a statistically significant reduction in ALI, pulmonary infection, and postoperative atelectasis.

In contrast, the PROtective VEntilation (PROVE) network evaluated the use of high level PEEP (12 cm) along with intermittent recruitment maneuvers and found no difference in the rate of PPC. In addition, the study group demonstrated an increased incidence of intraoperative hypotension and required more vasoactive drugs during surgery. This contrary finding may relate to this study's intentional enrollment criterion which selected patients at increased risk for the development of PPC as well as the relatively elevated (12 cm) level of PEEP utilized.

Finally, a recently published Cochrane analysis examined the intraoperative use of limited tidal volume ventilation and its impact on PPC. Their conclusions with a moderate quality of level of evidence included a lower incidence of pneumonia, a lower need for postoperative invasive as well as noninvasive ventilator support, and no difference in ICU or hospital length of stay. The finding of no difference in the primary endpoint of hospital mortality was judged to be low quality secondary to inadequate sample size.

POSTOPERATIVE VENTILATORY SUPPORT

Postoperatively the surgical patient may require mechanical ventilation for respiratory muscle weakness, pneumonia, prolonged effects of anesthesia, or chronic lung disease (COPD). The principles of ventilation for ARDS apply for the most part in these patients. In the patient without chronic lung disease, ventilation at a tidal volume of 6 to 8 mL/kg of IBW which maintains plateau pressure <30 cm H_2O should be used. Recent evidence suggests that patients requiring mechanical ventilation for reasons other than ALI are more likely to develop ALI if plateau pressures are excessive. The odds ratio of developing ALI is 1.5 for every 6 cm H_2O increase in plateau pressure. Spontaneous breathing should be encouraged and a PEEP of 5 cm H_2O should be considered the minimum value. PEEP should be adjusted to maintain adequate arterial oxygen saturation (>92%).

The patient with COPD represents a particular challenge. Noninvasive ventilation (ventilation via a face mask) can prevent the need for intubation, reduce hospital stay, and mortality in this patient population.

Much of this work is in the nonsurgical patient, but a trial of noninvasive ventilation may be warranted in the absence of abdominal distension in the cooperative surgical patient. Keys to the success of noninvasive ventilation include use of a full face mask, choice of a motivated, cooperative patient, use of pressure support or CMV, and a time period for respiratory therapist and nurse to acclimate the patient to the system. Success with noninvasive ventilation can be judged by monitoring pulse oximetry and evaluating patient comfort and rate of breathing. Failure to alleviate air hunger generally indicates failure and endotracheal intubation should be undertaken prior to respiratory collapse. PEEP at low levels (5 to 8 cm H_2O) should be used in the patient with COPD to overcome terminal airway collapse, promote more complete alveolar emptying, and improve the ability of the patient to trigger the ventilator. Set PEEP helps overcome intrinsic PEEP and reduces the effort required to initiate inspiration.

The use of nasogastric tubes in the postoperative period remains a surgical tradition; albeit one without evidence-based support. The incidence of PPCs appears to increase with the use of nasogastric decompression while the incidence of anastomotic leak, incisional hernia, gastric upset/vomiting is equivalent regardless of their placement.

LIBERATION FROM MECHANICAL VENTILATION

Discontinuing mechanical ventilation includes the processes commonly known as weaning and extubation. These terms are often confused, but are quite different events. One implies a progressive decrement in ventilatory support while the other describes the removal of the artificial airway (usually an endotracheal or tracheostomy tube). Consequently, a patient can be ready for discontinuing ventilatory support without being ready for extubation (i.e., a deeply comatose patient who is unable to clear secretions or maintain an adequate airway). Numerous reports now clearly demonstrate that the timing of discontinuation of mechanical ventilation is best determined through the use of a screening technique and daily spontaneous breathing trials (SBTs).

Evaluating Weaning Readiness

The most recent literature suggests that a protocol of daily screening for weaning readiness and an SBT are the best modalities for determining weaning readiness. The daily screen consists of evaluating the overall condition of the patient through the use of five criteria.

1. Patient coughs when suctioned suggesting intact gag reflex.
2. No continuous infusions of sedatives or vasopressors (hemodynamic stability).
3. PaO_2/FIO_2 >200 (FIO_2 <0.50)
4. PEEP ≤8 cm H_2O.
5. f/V_T ≤105 (measured while breathing spontaneously with respiratory rate off and pressure support off, for 1 minute).

If the patient passes the first 1-minute trial, then an SBT of 30 to 120 minutes is performed. The trial is successful if the patient tolerates 30 to 120 minutes of spontaneous breathing. The trial may be terminated if any of the following adverse events occur:

1. Respiratory rate is >35 for >5 minutes.
2. SpO_2 <90% for >30 seconds.
3. Heart rate increases >20% for >5 minutes.
4. Systolic blood pressure >180 mm Hg or <90 mm Hg for >1 minute.
5. Agitation, anxiety, or diaphoresis (compared to baseline) lasting >5 minutes.

Patients who tolerate an SBT without adverse events have a 90% chance of successfully remaining off the ventilator for 48 hours.

Determining the ability of the patient to protect the upper airway following extubation remains a subjective observation. Clearly patients who are awake and oriented are likely to remain extubated longer than those who are obtunded. The decision to extubate a patient who has successfully completed an SBT, but has an altered mental status remains an exercise in physician judgment. The use of tracheostomy in these selected cases may prove beneficial. Generally speaking, in the head-injured patient if the Glasgow Coma Score (GCS) is ≤8 (postinjury day >3) tracheostomy may facilitate discontinuation of ventilation and decrease the rate of ventilator-associated complications. If GCS is >8, patients can frequently be successfully extubated. Tracheostomy can also facilitate ventilator discontinuation in the elderly trauma patient or patient with COPD by reducing work of breathing, enhancing secretion removal, and improving patient comfort.

Weaning Failure

The most common cause of weaning failure is likely an underestimation of the ability of patients to adequately support their own oxygenation and

ventilation. Prior to weaning attempts, the underlying cause, which resulted in institution of mechanical ventilation, must be alleviated. Ely and others have developed a pneumonic to describe the difficulty to wean patient, "WHEANS NOT." This allows the clinician to evaluate the many potential causes of weaning failure:

Wheezes
Heart disease, **H**ypertension
Electrolyte imbalance
Anxiety, **A**irway abnormalities, (metabolic) **A**lkalosis
Neuromuscular disease, use of **N**euromuscular blockers
Sepsis, **S**edation
Nutrition (under and over feeding)
Opiates, **O**besity
Thyroid disease

Weaning failure typically results as a consequence of an imbalance between respiratory neuromuscular capacity and respiratory load. This imbalance leads to respiratory muscle failure. Common causes of respiratory muscle failure include dynamic hyperinflation, respiratory acidosis, decreased oxygen delivery, malnutrition, excessive CO_2 production, increased dead space ventilation, increased respiratory system impedance, and intrinsic PEEP.

Other causes of weaning failure include a decreased output of the respiratory control center caused by oversedation, neurologic dysfunction, or use of narcotic drugs. Cardiovascular dysfunction may also impede weaning and left heart failure has been demonstrated to be a cause of weaning failure in COPD. Myocardial ischemia may occur during weaning due to increased oxygen consumption of the respiratory muscles and stress.

Electrolyte abnormalities, acid–base disturbances, and unrecognized infection are also occasionally seen. Acidosis is commonly seen as a cause of weaning failure, but metabolic alkalosis can also depress respiratory drive. After fluid resuscitation with Lactated Ringer's, metabolic alkalosis is a common finding. Critical illness polyneuropathy is increasingly recognized as a potential cause of weaning failure. This syndrome has been reported in up to 20% of ventilator-dependent patients. Critical illness polyneuropathy is more common in patients with sepsis and the use of corticosteroids and neuromuscular blocking agents increase the incidence dramatically. This combination, which is common in the

asthmatic patient who requires mechanical ventilation, places that population at significant risk for polyneuropathy.

Improper ventilator settings may also interfere with weaning. Proper setting of sensitivity and matching of ventilator flow output to patient demand is necessary to eliminate patient/ventilator asynchrony. Asynchrony, leading to tachypnea in the patient with COPD can result in worsening hyperinflation, increased triggering effort, and impede weaning.

Nutritional state may also affect weaning readiness. Malnourished patients may have reduced respiratory muscle strength, blunted responses to hypoxemia and hypercarbia, and electrolyte abnormalities. Adequate nutrition should be provided early with an emphasis on isocaloric feeding. Overfeeding with carbohydrate calories has been implicated in weaning failure and generally includes not only excessive carbohydrate calories, but a total caloric intake in excess of patient requirements.

AIRWAY MANAGEMENT

Establishing a patent airway via intubation or surgical access is an essential skill of the surgical intensive care team. Airway management facilitates mechanical ventilation, allows for improved removal of secretions and can aid in the discontinuation of ventilation. Airway management should be undertaken under the supervision of the most skilled person available and the method of access dictated by patient condition. General indications for intubation including hypoxemia, hypercarbia, altered mental status, and respiratory muscle weakness are not always clinically practical. Generally speaking, the astute clinician can determine who needs to be intubated by clinical observation.

Endotracheal intubation with the largest internal diameter (ID) tube (7.0 to 7.5 mm for women and 8.0 to 8.5 for men) is the preferred method of airway control. Larger tubes allow bronchoscopy, facilitate secretion removal, and reduce the work of breathing. Nasotracheal intubation should be avoided unless there is a contraindication to endotracheal intubation. This is due to frequent traumatic insertion through the turbinates, increased incidence of sinusitis, need for a smaller ID tube, tortuous path that effectively reduces in vivo resistance, and patient discomfort. Nasotracheal intubation is often performed in the field, and conversion to an endotracheal tube is advocated in those patients thought to require prolonged mechanical ventilation. Elective endotracheal intubation should be accomplished in a controlled environment with adequate patient

sedation and paralysis if necessary, and rapid sequence intubation can be used if appropriately trained personnel are immediately available. Following tube placement appropriate position should be verified by the presence of carbon dioxide in expired gas. This can be accomplished by capnography or by CO_2 detector, a device that changes color in the presence of CO_2. Auscultation of bilateral breath sounds can be helpful, but misleading. Verification by CXR should eventually be performed.

Tracheostomy has been traditionally advocated for those patients who fail weaning over the first 2 weeks of illness. Rodriguez has shown that early tracheostomy reduced the risk of pneumonia, allowed earlier weaning, and was associated with fewer days in the ICU. Tracheostomy was initially performed at the bedside when first described, but because of occasional disastrous cases of lost airway and significant bleeding, was then advocated to be performed in the operating room. This is still the safest place in a patient who is stable enough for transport. However, bedside percutaneous tracheostomy has become a safe and standard procedure. This procedure allows for earlier tracheostomy and in some cases facilitates discontinuation of mechanical ventilation. After removal from the ventilator, the cuffed tracheostomy can be downsized over a few weeks followed by decannulation.

MANAGEMENT STRATEGIES FOR RETAINED HEMOTHORAX AND EMPYEMA

Hemothorax is frequent occurrence following blunt and penetrating trauma. The standard management of a hemothorax is drainage via a closed tube thoracostomy. Most patients are managed successfully with this strategy. In a small percentage (5% to 10%) of patients, the chest tube fails to completely evacuate the entire hemothorax. A retained collection can then lead to a fibrotic collection with entrapped lung and/or an empyema. Treatment options include placement of additional chest tubes, enzymatic debridement, video-assisted thoracoscopy (VATS), or thoracotomy with decortication. CXRs are of limited utility in the diagnosis of retained hemothorax. Pulmonary contusion, atelectasis with lobar collapse, or infiltrates can appear as persistent opacities on CXR making the diagnosis of retained hemothorax difficult with this study alone. Computed tomography (CT) of the chest is the preferred method for confirming the diagnosis. CT has been shown to be very accurate in the prediction of the amount of retained fluid and assisting with operative

decision making.

There remains some controversy in the choice of management following failure of initial chest tube drainage for hemothorax. Placement of a second CT is a reasonable option if positioning of the primary CT was not deemed adequate. Typically a second CT has the highest rate of success when placed early (<72 hours) following injury. A few small series have demonstrated a benefit to enzymatic treatment with urokinase or streptokinase. Both enzymes work by clot lysis and required serial treatments. This type of treatment strategy offers the advantage of continued nonoperative management in patients in whom operative intervention represents a high risk. The theoretic concern of increased bleeding has been suggested as a relative contraindication. The preferred method of treatment for retained hemothorax by the authors is VATS, as it has been found to be a safe and effective alternative to open thoracotomy for the management of retained hemothorax. The highest rate of success was obtained in patients who underwent VATS within 3 to 5 days post injury. VATS has also been useful in the treatment of persistent posttraumatic pneumothorax by mechanical pleurodesis. The rate of conversion to an open procedure increases daily for each day beyond 5 days postinjury. Once a fibrotic peel has been established or evidence of empyema is seen on CT, most patients will require open thoracotomy for decortication of the entrapped lung segment. Patients who have required mechanical ventilation in these scenarios will often wean quickly after re-expansion of the involved lung. Microorganisms cultured from empyemas are often *S. aureus* and differ from concomitant intrabronchial cultures, implying that these collections are seeded from skin through the chest tube itself. Chest tubes should therefore be placed with a sterile technique whenever possible.

Suggested Readings

Adhikari N, Burns K, Meade M. Pharmacologic therapies for adults with acute lung injury and acute respiratory distress syndrome. *Cochrane Database Syst Rev* 2004;18(4):CD004477.

ARDS Definition Task Force; Ranieri VM, Rubenfeld GD, Thompson BT, et al. Acute respiratory distress syndrome: the Berlin definition. *JAMA* 2012;307:2526–33.

Barnes PJ, Hansel TT. Prospects for new drugs for chronic obstructive pulmonary disease. *Lancet* 2004; 364(9438):985–96.

Brower RG, Lanken PN, MacIntyre N, et al.; National Heart, Lung, and Blood Institute ARDS Clinical Trials Network. Higher versus lower positive end-expiratory pressures in patients with the acute respiratory distress syndrome. *N Engl J Med* 2004;351(4):327–36.

Croce MA, Fabian TC, Mueller EW, et al. The appropriate diagnostic threshold for ventilator-associated pneumonia using quantitative cultures. *J Trauma* 2004;56(5):931–4.

Evans SE, Scanlon PD. Current practice in pulmonary function testing. *Mayo Clin Proc* 2003;78(6):758–63.

Guay J, Ochroch EA. Intraoperative use of low volume ventilation to decrease postoperative mortality, mechanical ventilation, lengths of stay and lung injury in patients without acute lung injury. *Cochrane Database Syst Rev* 2015; (12):CD011151. doi: 10.1002/14651858.CD011151.pub2.

Guérin C, Reignier J, Richard JC, et al.; PROSEVA Study Group. Prone positioning in severe acute respiratory distress syndrome. *N Engl J Med* 2013;368:2159–68.

Hemmes SN, Gama de Abreu M, Pelosi P, et al. High versus low positive end-expiratory pressure during general anaesthesia for open abdominal surgery (PROVHILO trial): A multicentre randomised controlled trial. PROVE Network Investigators for the Clinical Trial Network of the European Society of Anaesthesiology. *Lancet* 2014;384(9942):495–503.

Hoth JJ, Burch PT, Bullock TK, et al. Pathogenesis of posttraumatic empyema: the impact of pneumonia on pleural space infections. *Surg Infect (Larchmt)* 2003;4(1):29–35.

Hoth JJ, Franklin GA, Stassen NA, et al. Prophylactic antibiotics adversely affect nosocomial pneumonia in trauma patients. *J Trauma* 2003;55:249.

Knudson MM, Ikossi DG, Khaw L, et al. Thromboembolism after trauma: an analysis of 1602 episodes from the American college of surgeons national trauma data bank. *Ann Surg* 2004;240:490–6.

Kollef MH. Inadequate antimicrobial treatment: an important determinant of outcome for hospitalized patients. *Clin Infect Dis* 2000;31(suppl 4):S131–8.

McAlister FA, Bertsch K, Man J, et al. Incidence of and risk factors for pulmonary complications after non-thoracic surgery. *Am J Respir Crit Care Med* 2004;171(5):514–7.

Richardson JD, Cocanour CS, Kern JA, et al. Perioperative risk assessment in elderly and high-risk patients. *J Am Coll Surg* 2004;199(1):133–46.

Robinson BR, Cotton BA, Pritts TA, et al.; PROMMTT study group. Application of the Berlin definition in PROMMTT patients: the impact of resuscitation on the incidence of hypoxemia. *J Trauma Acute Care Surg* 2013;75(1 suppl 1):S61–7.

Rodgers A, Walker N, Schug S, et al. Reduction of postoperative mortality and morbidity with epidural or spinal anaesthesia: results from overview of randomized trials. *BMJ* 2000;321:1493.

Yang D, Grant MC, Stone A, et al. A meta-analysis of intraoperative ventilation strategies to prevent pulmonary complications: Is low tidal volume alone sufficient to protect healthy lungs? *Ann Surg* 2016;263(5):881–7.

EDITOR'S COMMENT

You may wonder why a colorectal surgeon is writing a commentary on a chapter on ventilatory risk assessment! Please realize; however, that I have for more than 25 years lived in a state that has the nation's highest rate of lung cancer and, depending on the year, ranks either first or second in the United States for having the highest number of adult cigarette smokers. For me, this is even more challenging since one of the main conditions that I see is Crohn disease, a disease whose severity is substantially worsened by cigarette smoking. A significant part of my time is spent in efforts aimed at behavioral modification, that is, trying to get patients to stop smoking one at a time. Due to the widespread extent of COPD, in my day-to-day clinical practice, much time is spent in preoperative risk assessment.

Several years ago, when we were trying to gauge the effect of cigarette smoking on the course of Crohn disease, we used the Behavioral Risk Factor Surveillance Survey (Remington PL, Smith MY, Williamson DF, et al. Design, characteristics, and usefulness of state-based behavioral risk factor surveillance: 1981–1987. *Public Health Rep* 1988;103:366–75) and modified it slightly to obtain data regarding pediatric smoke exposure. The data we obtained were astounding! Comparison of smoking data for Crohn patients with controls showed that greater number of Crohn patients were regular smokers by age 10 (OR, 3.65 [95% CI, 1.44–11.2]; $P = 0.005$) and by age 15 (OR, 3.06 [95% CI, 1.79–5.38]; $P < 0.001$) (Mahid SS, Minor KS, Stromberg A, et al. Active and passive smoking in childhood is related to the development of inflammatory bowel disease. *Inflamm Bowel Dis* 2007;13(4):431–8). It is therefore, not surprising that I have many patients who are two-to-three pack per day smokers and have been doing so for over 50 years!

Johannigman and Branson provide excellent information in this chapter, for example, the fact that postoperative respiratory failure increases mortality from 1% to 27% based on study of the VA database. In addition, postoperative respiratory failure results in a nearly sevenfold increase in the length of stay. This highlights the need for preventative action, based on an accurate preoperative assessment.

It may be that the increasing focus on enhanced recovery pathways may lead to a decrease in the frequency of pulmonary complications, not only because of the early patient mobilization but because of the decreased tendency for fluid

overload due to goal-directed intravenous fluid administration, and early postoperative discontinuation of intravenous fluids. Today, it seems that there is a constant lack of adequate nurse staffing, or that they are there, but busy entering data into the burdensome electronic health record. What that means practically is that there is no one to help the patient ambulate. Minimally invasive surgery does not always correlate with minimal pain. The significant torqueing of the abdominal wall that is associated in particular with robotic surgery can lead to significant abdominal wall pain. In these patients adequate pain control is as important as for patients with open procedures. Without adequate pain control following abdominal procedures, no matter the route of access; respiratory complications are likely to follow.

It seems that an increasing number of patients are diagnosed with sleep apnea; however, this may be due to the large amount of very significantly overweight (≥40 BMI) patients that we all encounter. Johannigman's description of preoperative smoke cessation and assessment of pulmonary hypertension is invaluable, accentuating the whole idea of pulmonary risk assessment. In the emergent setting, one has to play the cards one is given. However, in the elective setting, the entire idea of "pre-habilitation" is becoming more and more popular. The idea that if one has an operation that is not required immediately, one can precondition or improve, so to speak, the patient's physical condition, and specifically, in the context which we are discussing, improve their pulmonary condition. This was the case, for example, recently with a patient who was a 56-year-old, very thin white male who had two synchronous colon cancers who required a subtotal colectomy. He had a 60 pack-year history of smoking and at first assessment was unable to climb a flight of stairs. In fact, he was only able to step up three steps before he had to stop to catch his breath. Through the use of varenicline (Chantix®) preoperatively and through the intervention of a very loving wife who helped him with a preoperative exercise program, we were able to improve his condition preoperatively to such an extent that, with the aid of perioperative epidural analgesia, he was able to undergo an operation without any adverse pulmonary sequelae. While this is, of course, not the typical scenario, it illustrates that much can be gained from preoperative patient preparation with optimization of pulmonary function. In addition to pulmonary problems, smokers also have an increased incidence of all kinds of postoperative complications. The incidence of these will also hopefully be reduced following such intervention. Tønnesen et al. undertook an exploratory prospective trial to establish a preoperative smoking and alcohol cessation clinic for patient referral by general practitioners at the time of referral for surgery (Tønnesen H, Faurschou P, Ralov H, et al. Risk reduction before surgery. The role of the primary care provider in preoperative smoking and alcohol cessation. *BMC Health Serv Res* 2010;10:121). This showed that only 10% of patients were referred during the course of the study. Sadly, it is likely that such initiatives will have to be surgeon-led, as we have more at stake.

Recently there have been interesting efforts aimed at rehabilitation of frail patients, in other words those with decreased physiologic reserve using wearable fitness tracking devices (Rumer KK, Saraswathula A, Melcher ML. Prehabilitation in our most frail surgical patients: are wearable fitness devices the next frontier? *Curr Opin Organ Transplant* 2016;21(2):188–93). Such devices monitor and record the user's physical activity and can collect a variety of data points from steps taken to heart rate, sleep duration, and others. They include many different types of devices (Fitbit, Jawbone Up, Apple watch among others). These have been used on professional athletes, even on racehorses, why not on our patients to improve our postoperative outcomes with physician tracking? If you examine patient variables that affect postoperative outcome that can be changed in the preoperative period, these include nutritional status, optimal hemoglobin level, physical inactivity, excessive alcohol use, smoking, and anxiety (Levett DZ, Edwards M, Grocott M, et al. Preparing the patient for surgery to improve outcomes. *Best Pract Res Clin Anaesthesiol* 2016;30(2):145–57). Readers should see the excellent review "Preparing the patient for surgery to improve outcomes" (Levett DZ, Edwards M, Grocott M, et al. Preparing the patient for surgery to improve outcomes. *Best Pract Res Clin Anaesthesiol* 2016;30(2):145–57).

In elderly patients and in those with congestive heart failure, great care must be paid to avoiding fluid overload, as the same factors that prolong postoperative ileus, that is, increased fluids at the time of surgery, also adversely pulmonary function. In fact, these both work synergistically to worsen pulmonary function, for example, with the ileus; there is increased abdominal distension, increased upward pressure on the diaphragms, and decreased room for normal downward pulmonary excursion. As mentioned previously, it may be that with the increased use of early enhanced recovery after surgery pathways, which focus on goal-directed fluid administration intraoperatively, early resumption of diet, early discontinuation of postoperative intravenous fluids, avoidance of postoperative narcotics, early postoperative mobilization, and minimization of postoperative ileus, we may actually be doing much to improve postoperative ventilatory function.

The increased use of minimally invasive techniques should be associated with decreased ventilatory events. Even though there has been an increase in minimally invasive procedures, in our population we have seen a parallel increase in opioid medication for other uses. This means that, although we are inflicting less pain on our patients, that pain is more difficult to control, that is, requiring a greater amount of medication. This in itself is associated with respiratory depression. The large amount of narcotic further contributes to ileus, which promotes abdominal distention, difficulty breathing, and respiratory compromise. Hopefully, in the future, more effective prokinetic drugs, without many of the adverse cardiac effects of prior effective drugs, will allow rapid resumption of gastrointestinal function without any of the adverse cardiac effects and help diminish postoperative ileus and related subsequent undesirable

postoperative pulmonary complications.

Susan Galandiuk

6 Hemorrhagic Risk and Blood Components

Karen J. Brasel

INTRODUCTION

Surgeons are trained to control hemorrhage. However, the vast majority of that training relates to control of bleeding from visible vessels. There is less training on the management of so-called medical bleeding or bleeding due to inherited or acquired coagulopathy. The increasing use of oral anticoagulants and antiplatelet agents, along with the increasing medical complexity of surgical patients, demands that surgeons become knowledgeable about evaluation of bleeding risk prior to elective intervention along with evaluation and management of patients with massive hemorrhage. Familiarity with newer screening tools can help identify when additional help from consultants may be necessary. However, in the vast majority of these patients the management of identified abnormalities and the guidelines for blood product administration are relatively straightforward.

DISSEMINATED INTRAVASCULAR COAGULATION

Disseminated intravascular coagulation (DIC) is the systemic activation of blood coagulation, leading to generation and deposition of fibrin and systemic microvascular thrombi. Depending on the degree and location of these clots, end-organ dysfunction may occur. If unchecked, it may proceed to consumption and subsequent exhaustion of coagulation proteins and platelets, resulting in accelerated fibrinolysis and severe bleeding. DIC is due to an underlying condition, such as trauma, sepsis, or amniotic fluid embolus, and can only be effectively treated by treating the underlying condition. Supportive care may involve blood product administration or anticoagulation to treat resultant thrombosis or coagulopathy.

Patients with DIC have variable laboratory parameters. Prothrombin time (PT) and partial thromboplastin time (PTT) may be normal or elevated, reflecting the depletion of clotting factors. Platelet count may be

normal, although the majority of patients with DIC have some degree of thrombocytopenia that can reach levels <50,000 μL. A steadily decreasing platelet count or a grossly reduced absolute platelet count is a sensitive but not specific indicator of DIC. Due to the microvascular thrombosis, platelet transfusion based on platelet count is not recommended. Fibrinogen levels are variable; although consumed through massive fibrin deposition, the increased production as an acute phase reactant results in this variability. Hypofibrinogenemia is seen in only 25% of cases, and only in those that are most severe.

The hallmark of DIC is fibrinolysis, so regardless of other laboratory parameters, there will be evidence of breakdown products of fibrinogen. Testing for D-dimer or fibrinogen degradation products (FDPs) may therefore be helpful for differentiating DIC from other conditions that are associated with a low platelet count and prolonged clotting times (CTs), such as chronic liver disease. The specificity of high levels of D-dimer and FDPs in isolation is limited; however, as many other conditions (thromboembolism, recent surgery, chronic inflammation) may be associated with elevated FDP levels.

ACUTE TRAUMATIC COAGULOPATHY

Acute traumatic coagulopathy (ATC) is present in approximately 25% of severely injured patients admitted to trauma centers, and is associated with a significantly higher mortality than similarly injured patients without ATC. It is an impairment of hemostasis with fibrinolytic activation that is independent of hypothermia, acidosis, and hemodilution. It is mediated by elevated levels of activated protein C, causing activation of the thrombomodulin-protein C system and irreversibly inactivating factor Va and VIIa. Generation of thrombin is inhibited, clot formation impaired, and fibrinolysis is enhanced. It is only seen in the setting of tissue damage and systemic hypoperfusion, and therefore early balanced resuscitation is the best treatment strategy, without waiting for results of coagulation parameters to use in a targeted resuscitation strategy.

DILUTIONAL COAGULOPATHY

Dilutional coagulopathy occurs in the setting of massive transfusion that is devoid of clotting factors, such as aggressive transfusion of crystalloid and/or packed red blood cells (pRBCs). This results in factor V and VIII deficiency, with both quantitative and qualitative platelet defects. It is

treated with administration of platelets and fresh frozen plasma (FFP), although a much better strategy is to use balanced resuscitation from the start in patients requiring massive transfusion, thus preventing dilutional coagulopathy.

INHERITED COAGULOPATHIES

Von Willebrand Disease

Von Willebrand disease (vWD) is a hereditary deficiency of von Willebrand factor (vWF). These patients have mild bleeding tendencies, which can become significant in the setting of major surgery or trauma. They may therefore be unknown by the patient, particularly if previous bleeding episodes have been negligible. Platelet count is normal, but the platelets do not function normally. PTT may be slightly elevated. The diagnosis is made by establishing low levels of vWF antigen and abnormal ristocetin cofactor activity. Treatment involves control of bleeding with replacement therapy (virally inactivated, intermediate-purity factor VIII concentrate) or desmopressin.

Hemophilia A and B

Hemophilias are hereditary bleeding disorders caused by deficiencies of either factor VIII (hemophilia A) or IX (hemophilia B). The severity of bleeding is determined by the amount of normal circulating factor. Most patients with hemophilia have levels <5%; some have extremely low levels (<1%). Similar to vWD, the diagnosis is suspected in a patient with an elevated PTT and normal PT and platelet count; it is confirmed by specific factor assays. Treatment includes replacement of the deficient factor. Normal hemostasis requires >30% of normal factor levels. Carriers usually have levels of about 50% and therefore do not require replacement prior to elective surgery.

COAGULOPATHY OF LIVER DISEASE

Patients with liver disease often have a prolonged PT. Previously thought to reflect a bleeding tendency, it is now clear that both a bleeding and a clotting tendency exist. The hypercoagulability is due to increases in factors produced in the endothelium of the blood vessels, such as factor VIII and vWF.

Bleeding events are more common than clotting events among

hospitalized patients with cirrhosis. The risk of postprocedure bleeding is about 20%. Assessment of bleeding risk in these patients is complex, as neither bleeding nor thrombosis risk is adequately assessed by standard laboratory evaluation. The PT test and international normalized ratio (INR) only measure the procoagulant pathway and do not detect the defects in the anticoagulant pathway, and targeting the INR or the PT alone leads to unnecessary volume expansion and overuse of plasma. Use of thromboelastography (TEG) can be valuable in determining whether the bleeding or clotting tendency predominates, and which factors may be necessary to correct it.

A platelet count >50,000 μL is associated with improved thrombin production. Adequate fibrinogen is also important in minimizing bleeding risk, as fibrinogen is the main target of thrombin and a final step in clot formation. If a patient is producing enough thrombin and has enough fibrinogen, then he or she should be able to form an adequate clot.

DRUG-INDUCED COAGULOPATHY AND REVERSAL

Current drugs in widespread use that commonly affect coagulation status and bleeding risk include warfarin, low–molecular-weight heparins, direct thrombin inhibitors, factor Xa inhibitors, aspirin, and clopidogrel. When intervention is required on patients taking anticoagulants or antiplatelet agents, interruption and/or reversal of their anticoagulation increases their thromboembolic risk. The decision on whether and how aggressively to correct their anticoagulants is an exercise in risk–benefit analysis.

Warfarin

Warfarin blocks vitamin-K–dependent protein synthesis (factors II, VII, IX, and X). Determination of resolution of warfarin effect is measured by the PT/INR. Timing of discontinuation of warfarin prior to elective surgery is dependent on the degree of INR elevation, patient age, and renal function. After warfarin is restarted postintervention, it takes approximately 5 to 10 days to achieve full anticoagulant effect (INR >2.0).

For those patients at excessive risk of thromboembolism, bridging therapy with heparin or low–molecular-weight heparin may be necessary. History of a prior thromboembolic event with discontinuation of warfarin therapy, systemic embolism or thromboembolic event within the previous 3 months, atrial fibrillation with a CHADS2 score of 5 or 6, mechanical mitral valve, or a mechanical aortic valve with an additional

thromboembolic risk factor are all situations in which periprocedural bridging is recommended.

Unfractionated and Low–Molecular-Weight Heparins

Management of bleeding in patients receiving heparin or low–molecular-weight heparin is based on the severity of bleeding, heparin level or aPTT (heparin) or anti-factor Xa activity, and the time since last dose. The half-life of intravenous heparin is 30 to 60 minutes, and so discontinuation results in normalization of coagulation status without intervention in a few hours. If reversal is needed more quickly, full neutralization can be achieved with the administration of protamine sulfate, 1 mg/100 units of heparin.

Protamine sulfate does not completely reverse low–molecular-weight heparins, but may help neutralize the higher–molecular-weight fractions that are thought to be more responsible for bleeding. For enoxaparin administered within the previous 8 hours, a dose of 1 mg protamine per 1 mg of enoxaparin is recommended. For enoxaparin administered >8 hours ago, 0.5 mg of protamine per 1 mg of enoxaparin is recommended. For dalteparin or tinzaparin, 1 mg of protamine per 100 anti-factor Xa units is recommended.

Direct Thrombin Inhibitor

The oral direct thrombin inhibitor dabigatran is now widely available as an alternative to warfarin for many patients. Although it must be taken twice daily, it does not require monitoring. Activated charcoal and hemodialysis have been used with some effect for dabigatran reversal, but it now has a specific reversal agent (idarucizumab) that is the recommended therapy. Idarucizumab consists of humanized dabigatran-specific antibody fragments and has no activity against oral factor Xa inhibitors or warfarin.

Factor Xa Inhibitors

Rivaroxaban, edoxaban, and apixaban are the currently available oral factor Xa inhibitors. Like dabigatran, they are approved for treating thromboembolic complications and the prevention of thromboembolism in patients with nonvalvular atrial fibrillation. Unlike dabigatran, there is no specific reversal agent for any of the oral factor Xa inhibitors, although trials of both specific and nonspecific agents are underway.

Antiplatelet Agents

Establishing that a patient has been taking an antiplatelet agent does not necessarily mean that these drugs are currently affecting platelet function. Resistance to both aspirin and clopidogrel has been described, although clopidogrel resistance is much more common. Resistance to an antiplatelet drug is a pharmacodynamic phenomenon where there is no clinically important change in platelet function after treatment as compared to the baseline. Aspirin resistance is defined as the inability of aspirin to inhibit platelet thromboxane A2 production or to inhibit tests of platelet function that are dependent on platelet thromboxane production. Using this method, aspirin resistance has been generally defined as ≥20% platelet aggregation when using 0.5 to 1.6 mg/mL arachidonic acid as the agonist.

Clopidogrel response variability was initially demonstrated by measuring adenosine diphosphate (ADP)-induced platelet aggregation, as well as p-selectin and activated GPIIb/IIIa expression. When the absolute difference between pre- and posttreatment platelet aggregation is ≤10%, patients are regarded as "resistant." The prevalence of resistant patients is time dependent; in one study it was 31% at day 5 and it fell to 15% at day 30.

The majority of guidelines suggest that patients should discontinue clopidogrel 5 to 10 days prior to elective operation and continue aspirin through the operation if at all possible. The outlier is the 2012 update to the Society of Thoracic Surgeons guideline on use of antiplatelet drugs in patients having noncardiac operations. These guidelines suggest that preoperative point-of-care testing to assess bleeding risk may be useful in identifying patients with high residual platelet reactivity after usual doses of antiplatelet drugs, and who can undergo operation without elevated bleeding risk.

EVALUATION OF BLEEDING RISK

In patients undergoing elective operations or other invasive procedures, evaluation of bleeding risk begins with a careful history and physical. Standard laboratory evaluation that includes platelet count, PTT, and INR is the appropriate next step if areas of concern are identified during the history and physical. The vast majority of inherited coagulopathies will be uncovered with this approach and can be addressed in collaboration with a hematologist. Thrombocytopenia can be associated with both bleeding and thrombotic risk, with thrombosis primarily seen in the setting of heparin-

induced thrombocytopenia (HIT) and DIC.

In patients undergoing massive transfusion, those taking medication affecting the coagulation system, and those with liver disease or other acquired coagulopathies, standard laboratory evaluation is often not adequate. In addition to measurement of fibrinogen, D-dimer, and FDPs, specific investigations may be appropriate.

Platelet Function

Several studies can be used to determine the degree to which both aspirin and clopidogrel affect platelet function. They should be used to determine whether administration of platelets or potentially DDAVP is warranted in the setting of normal platelet number. Most often, this is in the setting of patients known or suspected of taking antiplatelet agents, although it also may be indicated in patients with unexplained bleeding and otherwise normal coagulation parameters.

1. Aggregometry measures the degree to which ADP induces aggregation using platelet-rich plasma. It is not available as a point-of-care testing.
2. Flow cytometry is used to determine P2Y12 receptor reactivity.
3. VerifyNow is a point-of-care P2Y12 assay.
4. TEG with platelet mapping assay and the platelet function assay-100 are near point-of-care assays. Platelet mapping assays report percent inhibition and net platelet function; this is available as a point-of-care testing.

TEG and ROTEM

TEG was first described in 1948. Rotational thromboelastometry (ROTEM) is newer, but provides the same information. Unlike static tests, both provide dynamic information about in vivo clot development, stabilization, and dissolution. For both TEG and ROTEM, whole blood is used to measure global hemostasis reflecting both platelet function and coagulation. Initially, ROTEM was developed as a point-of-care testing with results available more quickly, although that advantage has disappeared with the advent of rapid TEG. ROTEM avoids some of the traditional limitations to TEG technology, including susceptibility to vibrations and mechanical shocks. They are available as a point-of-care testing, in the case of TEG both as standard and rapid TEG. It is common to use an activator for both standardization and to minimize the time required to obtain results.

TEG has been used to measure coagulation parameters and bleeding risk in liver transplantation, cardiac surgery, obstetrics, and trauma. Values obtained from TEG analysis include *r* time, *k* time, alpha angle, and mA. The *r* time is the time until first evidence of clot formation. *k* value is the speed of clot formation. The alpha angle also represents speed of clot formation. mA is maximum amplitude, a reflection of clot strength. Corresponding values from ROTEM include CT, EXTEM, INTEM, MCF (maximum clot firmness), and FIBTEM. The CT is the latency time from adding the start reagent to blood until the clot starts to form. INTEM tests the contact phase of hemostasis. EXTEM is a screening test for the extrinsic hemostasis system. FIBTEM eliminates the platelet contribution of clot formation by irreversibly inhibiting platelets. MCF reflects the absolute strength of the fibrin and platelet clot. ML, or maximum lysis, is the reduction in clot firmness after MCF. Increased ML is indicative of fibrinolysis, as is the finding of better clot formation with APTEM compared to EXTEM. APTEM is a method in which a fibrinolysis inhibitor is used together with an activator. In addition to numeric interpretation of the values, both TEG and ROTEM can be interpreted qualitatively by appearance (Fig. 6.1).

PACKED RED BLOOD CELLS

Most RBC products are derived by collection of 450 to 500 (±10%) mL of whole blood from volunteer donors and removal of the plasma by centrifugation. After removal of the plasma, the resulting product is red blood cells (pRBCs). The most commonly available RBC product in the United States has a 42-day blood bank shelf life and a hematocrit of 55% to 65%.

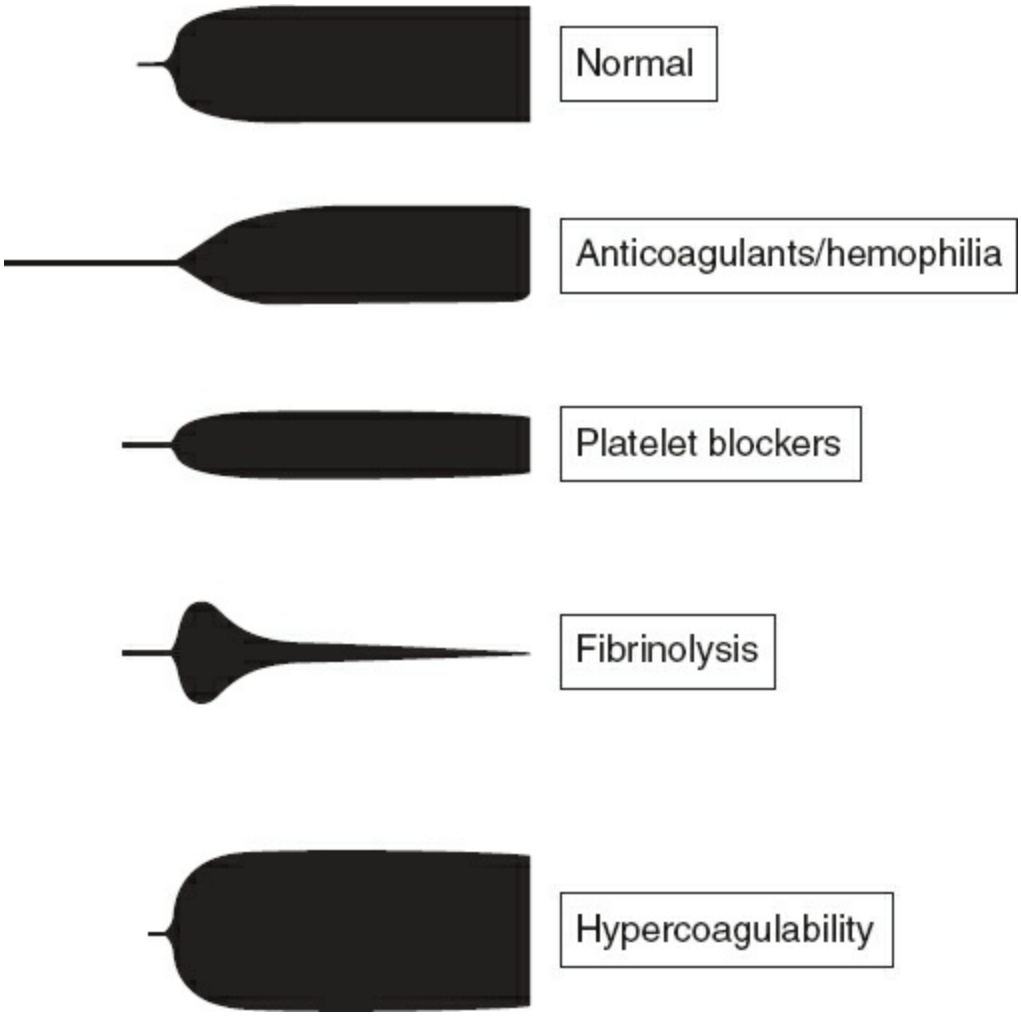

Figure 6.1. Representative thromboelastograms.

Leukoreduction, which is performed in approximately 85% of blood transfused in the United States, leaves residual leukocyte counts below 5×10^6, and generally below 1×10^6. This decreases the risk of recurrent febrile nonhemolytic transfusion reactions, decreases the risk of cytomegalovirus (CMV) transmission and decreases the risk of human leukocyte antigen (HLA) alloimmunization. Current risk of these complications is noted in Table 6.1. It also may decrease the risk of all late immunologically mediated complications.

Red cell transfusion is indicated in the treatment of symptomatic anemia, in patients with ongoing blood loss including massive hemorrhage, for exchange transfusion in patients with sickle cell disease and severe parasitic infection, patients with severe methemoglobinemia, and newborns with severe hyperbilirubinemia.

In general, guidelines recommend that transfusion is not indicated for a hemoglobin >10 g/dL, but the lower threshold varies from 6 to 8 g/dL. A

recent Cochrane review identified 19 randomized clinical trials comparing higher versus lower transfusion thresholds in a total of 6,264 medical and surgical patients (adults and children). Trials were included if transfusion was administered on the basis of a transfusion trigger, defined as a hemoglobin or hematocrit level below which a blood transfusion was to be given. Most trials compared outcomes in patients transfused at hemoglobin thresholds between 7 and 10 g/dL; specific thresholds differed for each trial. This review included the Transfusion Requirements in Critical Care (TRICC) trial of adult intensive care unit (ICU) patients. Compared with liberal transfusion strategies (higher thresholds), restrictive strategies (lower thresholds) resulted in fewer units of pRBCs transfused, no difference in the risk of myocardial infarction, and no difference in functional recovery, hospital or ICU stay.

A second meta-analysis that included eight trials, with 6,033 hospitalized patients, demonstrated a lower risk with restrictive versus liberal transfusion strategy (RR 0.84; 95% CI 0.73–0.96). Also, in a subset analysis of seven trials in which all RBC units were leukoreduced, infections were less frequent with a restrictive than with a liberal transfusion strategy (RR 0.83; 95% CI 0.69–0.99).

FRESH FROZEN PLASMA

FFP is the fluid portion of one unit of human blood that has been centrifuged, separated, and frozen solid at ≤–18.5°C within 6 to 8 hours of collection. It contains the labile and stable components of the coagulation, fibrinolytic, and complement systems, as well as other plasma proteins, fats, carbohydrates, and minerals. Once thawed, if not used it can be stored and used for up to 5 days. The factor with the greatest decrease in activity during extended thawed storage is factor VII, with 60% to 70% of activity remaining at day 5. There is a 20% to 30% decrease in levels of factor V, with <10% loss of remaining factors and little change in levels of fibrinogen, antithrombin, and protein C. Levels of protein S are much more variable.

Practice surrounding the transfusion of FFP is extremely variable. There is fairly good agreement on transfusion as apheretic treatment of thrombotic microangiopathies (thrombotic thrombocytopenic purpura, hemolytic uremic syndrome, hemolytic anemia elevated liver enzymes, and low platelet count [HELLP] syndrome (grade of recommendation: 1A). The recommendation for use to reconstitute whole blood for

exchange transfusion is not as strong (grade of recommendation: 2C).

TABLE 6.1 TEG and ROTEM Values and Corresponding Suggested Treatment in the Bleeding Patient

	ROTEM			
TEG (standard and rapid)	CT EXTEM >100 s and/or CT INTEM >230 s	MCT FIBTEM <8 mm	MCF EXTEM <45 mm and MCF FIBTEM >10 mm	ML EXTEM >15%, better clot formation APTEM than EXTEM
r >9 min (standard) or Activated clotting time >128 s (rapid)	PLASMA			
k time >4 min (standard) or >2.5 min (rapid)		PLASMA and/or CRYO		
Alpha angle <60 degrees		CRYO		
mA <55 mm			PLATELETS	
LY30 >7.5% (standard) or LY30 >3% (rapid)				Antifibrinolytics

There is now fairly good agreement around the use of FFP in the setting of massive hemorrhage, where in the traumatic setting ratio-based resuscitation improves outcome. Currently accepted ratios are 1:1:1 to 1:1:2, or 1 to 2 units of FFP for every unit of pRBCs administered. As a component of massive transfusion protocols in busy clinical centers, thawed plasma is both useful and necessary for early resuscitation to achieve these ratios. The volume of massive transfusions required to allow storage of thawed plasma to be cost-effective is unknown.

Perhaps the most common reason for administration of FFP is vitamin K antagonist reversal. Although appropriate for those who have clinical bleeding in the setting of warfarin-induced coagulopathy, administration of an elevated INR in the absence of clinical bleeding is not recommended. This may be true even in the setting of proposed invasive procedures, as there is no correlation between bleeding risk and a mildly elevated INR (<2.0). In fact, many patients with a mildly elevated INR actually have a greater risk of thrombosis, such as those with liver disease. This suggests that additional measures to evaluate bleeding risk are necessary in these patients. FFP has optimal value when transfused at the appropriate dose. The recommended adult therapeutic dose of FFP is 12 to 15 mL/kg, and should always be at least 10 mL/kg.

Lyophilized plasma was developed by the US Army for the resuscitation of combat casualties during World War II. It is compatible with all blood types, can be stored at room temperature for up to 2 years, and reconstitution takes <5 minutes. It was first produced for use in France in 1949, although production stopped in 1987 due to the elevated risk of

HIV. Production began again after product received updated approval in 1994 and subsequently began undergoing even more rigorous safety processing in 2010 using a photochemical pathogen inactivation process. It contains approximately 75% of factor V and 80% of factor VIII, with unchanged activity in fibrinogen, antithrombin, proteins C and S, and factors XI and XIII. PT and activated PTTs were slightly increased compared to FFP, but in vitro hemostatic properties of plasma were not different after lyophilization using TEG. This product has been shown effective in a swine model of polytrauma and hemorrhage and has been used by the French Military in Afghanistan. It is not currently approved for human use in the United States.

Liquid plasma is plasma that has been separated from whole blood at any time from collection to 5 days after the whole blood unit expires. It is stored between 1°C and 6°C and has never been frozen. Depending on when it has been separated from the donor unit of whole blood, it has a shelf life of 1 to 26 days. Clotting factors, particularly factors V and VIII, decline during storage, but the majority of both clotting factors and inhibitors retain up to 90% of initial activities at day 26. When compared to thawed standard FFP, the hemostatic profile is at least similar, and early during storage significantly improved. It is indicated for the initial treatment of patients undergoing massive transfusion.

PROTHROMBIN COMPLEX CONCENTRATE

Prothrombin complex concentrates (PCCs) are inactivated concentrates of pooled plasma. They contain the vitamin K–dependent factors II, IX, and X with variable amounts of factor VII and are standardized according to factor IX content. It is the variability in the amount of factor VII that results in the classification of PCC as 3- or 4-factor.

PCCs have been available for some time, but their use has recently become more widespread with the availability of a 4-factor PCC that is FDA approved for warfarin reversal in patients with clinical bleeding. They are lyophilized and can therefore be reconstituted quickly in a small volume and rapidly administered. This, and their increased potency compared to FFP (approximately 25 times greater factor concentration), gives them a significant advantage over FFP for quick reversal of warfarin-induced coagulopathy. The use of PCC is currently recommended in the most recent clinical practice guideline by the American College of Chest Physicians for urgent vitamin K antagonist reversal in patients with

active bleeding or urgent procedures, although the recommendation is not strong (grade 2C). This recommendation is based on rapidity of INR correction to <1.5, which can occur in as little as 10 minutes, and the potential benefits of less volume administration. Despite these potential benefits, there are no randomized trial data demonstrating improved patient outcomes when compared to FFP. PCC dosing is based on INR and weight, with a range of 25 to 50 units of factor IX/kg body weight. Maximum dose in patients with an INR >6 should not exceed 5,000 units/kg of factor IX.

PCC has been suggested as a nonspecific reversal agent for bleeding associated with oral coagulants other than warfarin, including direct thrombin and factor Xa inhibitors. The majority of evidence supporting this practice comes from animal studies, and the clinical results are variable. Although it may be appropriate with massive anticoagulant-related bleeding, the increasing availability of specific reversal agents for these newer oral anticoagulants will hopefully make this strategy obsolete in the future.

Thromboembolic complications are the most concerning adverse event with PCC administration. To help prevent these complications, PCCs contain small amounts of heparin as well as the thromboinhibitor proteins C and S. Another disadvantage of PCC compared to FFP is cost.

PLATELETS

Platelets are prepared as single unit pooled from multiple donors, or apheresis platelets prepared from a single donor. Six units of pooled platelets or one apheresis unit both provide approximately 5×10^{11} platelets.

Apheresis platelets have the advantages of limiting the recipient exposure to a single donor, which potentially reduces the possibility of infection and alloimmunization; some centers use apheresis platelets exclusively. The platelet count increment and hemostatic effects of pooled and apheresis platelets are comparable.

Transfusion of platelets can be divided into two broad areas: prophylactic, to prevent spontaneous hemorrhage, and therapeutic, to treat active bleeding. There is a significantly increased risk of spontaneous hemorrhage when the platelet count is <5,000/μL, and the risk of bleeding does not seem to change between 10,000 and 100,000/μL. Approximately 7,500 μL are required for platelet–endothelial interaction; these

observations together form the basis for the recommendation of prophylactic transfusion to prevent bleeding at a threshold level of 10,000/μL.

Prophylactic transfusion is also recommended for patients with a platelet count <50,000/μL undergoing major surgery or invasive procedures. For patients undergoing surgical interventions in critical sites, such as ocular surgery and neurosurgery, a transfusion threshold of 100,000 platelets/μL is suggested. A standard dose of platelets for prophylactic therapy in adults is approximately one random donor unit per 10 kg of body weight, which translates to four to six units of pooled platelets or one apheresis unit, both providing approximately 3 to 4×10^{11} platelets.

Therapeutic platelet transfusion is suggested for patients with active bleeding and a platelet count of <50,000/μL. As a part of massive transfusion in patients with active hemorrhage, one unit of platelets should be given for every unit of pRBCs. As most platelets are now packaged as a pool of six individual units, this functionally ends up as one pooled unit for every six units of pRBCs.

Following a platelet transfusion, the platelet count should rise, with a peak at 10 minutes to 1 hour and a gradual decline over 72 hours. A general rule of thumb is that transfusion of six units of pooled platelets or one apheresis unit should increase the platelet count by approximately 30,000/μL in an adult of average size.

One of the more controversial areas of platelet administration is their use in patients taking the antiplatelet agents aspirin and clopidogrel. Current recommendations suggest that administration of platelets is warranted in patients with hemorrhage who are on antiplatelet agents; however, administration of platelets may not result in any improvement in platelet function as measured by platelet function assays and may in fact be harmful.

A recent randomized trial compared platelet transfusions with standard care in 190 individuals with intracerebral hemorrhage (ICH) in the setting of aspiring or other antiplatelet agents (the PATCH [Platelet Transfusion in Cerebral Hemorrhage] trial). Compared with those assigned to standard care, individuals who received platelet transfusions had a higher rate of a composite end point of death or lower score on the modified Rankin Scale for functional independence. When analyzed separately, the increase in mortality did not reach statistical significance. Serious adverse events were

more frequent in the platelet transfusion arm, and ICH enlargement was similar in both arms at approximately 15%.

CRYOPRECIPITATE

Cryoprecipitate is the insoluble material that comes out of solution after plasma is frozen and thawed at 4°C. The resulting precipitate is then frozen and can be used for up to 1 year. Cryoprecipitate contains virtually all of the fibrinogen (factor I), factor VIII, fibronectin, factor XIII, and vWF from one unit of FFP. Cryoprecipitate cannot be used to reverse the anticoagulant effect of warfarin or other vitamin K antagonists, because it does not contain the vitamin K–dependent factors. It is also ineffective in reversing other anticoagulants.

Cryoprecipitate can be provided as single units or as “pools” containing five or more units. In the average patient, each unit raises the plasma fibrinogen concentration by approximately 7 to 10 mg/dL; thus, 10 units will raise the fibrinogen by approximately 70 to 100 mg/dL in a 70-kg recipient.

Cryoprecipitate remains an effective therapy for bleeding in patients with fibrinogen disorders, liver disease, DIC, or uremia after desmopressin and transfusions are found to be ineffective.

TRANEXAMIC ACID

Tranexamic acid, or aminocaproic acid, is a synthetic derivative of the amino acid lysine that exerts its antifibrinolytic effect through the reversible blockade of lysine-binding sites on plasminogen molecules. It inhibits plasminogen activation and plasmin activity stabilizing clot formation. Similar to other approaches, tranexamic acid can be used empirically or when increased fibrinolytic activity is found on point-of-care testing. The dose of tranexamic acid is 1 g intravenously over 10 minutes followed by an infusion of 1 g over 8 hours.

Empiric use has been studied in the trauma population, with the CRASH-2 trial suggesting benefit in patients with massive hemorrhage when tranexamic acid was administered within 3 hours of injury. Due to its time-sensitive nature, it is now carried by many prehospital systems. It is currently undergoing investigation in prehospital trials of patients with severe traumatic brain injury. The primary adverse effect of tranexamic acid is an increase in the rate of thromboembolic events.

RECOMBINANT FACTOR VIIa

Recombinant factor VIIa was developed for the treatment of hemophilia and continues to be used for this purpose. Its use in the setting of warfarin-induced and traumatic coagulopathy is less clear, as it may reduce the number of red cell transfusions required but has no impact on overall mortality.

DESMOPRESSIN

Desmopressin is a synthetic vasopressin analog that has been used for the treatment of mild hemophilia A, vWD, and uremia. Use of desmopressin rather than blood component therapy eliminates the immunologic and infectious risk of factor transfusion and is therefore preferable in mild disease. It is effective in improving the bleeding time or in vitro tests of platelet dysfunction and appears to act by increasing the release of large factor VIII: vWF multimers from endothelial cells. Other factors may include increases in platelet membrane glycoprotein expression. It is most effective in patients with quantitative deficiencies, as the result in those with qualitative deficiency of vWF is to release large amounts of defective protein. An increase of two to six times the concentration of FVIII:C is seen in most patients that return to baseline within 8 hours. Whether desmopressin actually reduces active bleeding or the risk of clinically important bleeding associated with invasive procedures in patients with uremic platelet dysfunction has not been conclusively demonstrated.

COMPLICATIONS OF TRANSFUSION

The most clinically important adverse effects of transfusion in medical patients are infectious or immunologic phenomena. The most significant infectious risks are addressed during the donor screening process, and most blood centers employ bacteriologic surveillance measures on certain blood products (Table 6.2).

Other complications include those from excessive volume administration (transfusion-associated circulatory overload [TACO]) and immunologically mediated complications sometimes referred to as transfusion-related immunomodulation (TRIM). When any of these are suspected, the transfusion should be stopped immediately and reported to the blood bank. Blood should be drawn from the patient and sent for tests including complete blood count, bilirubin, haptoglobin, direct antiglobulin

test, and HLA typing (Table 6.2). Further blood bank investigation in the case of transfusion-related acute lung injury (TRALI) involves efforts to identify donors and test for HLA and human neutrophil antigen (HNA) antibodies.

Transfusion-Associated Circulatory Overload

TACO is volume overload in the setting of underlying congestive heart failure that occurs within 6 hours of administration of blood products. It is related to the volume transfused, and is therefore uncommon after infusion of cryoprecipitate and much more common when multiple units of pRBCs and FFP are transfused. Brain natriuretic peptide (BNP) and N-terminal pro-BNP are elevated in TACO, although this is not required for diagnosis.

Transfusion-Related Acute Lung Injury

TRALI is the rapid onset of hypoxemia within minutes to 6 hours of transfusion of blood products. In addition to hypoxemia, noncardiogenic pulmonary edema is a hallmark manifestation, along with fever and hypotension. Bilateral pulmonary infiltrates on chest x-ray are required for the diagnosis. The pathogenesis involves a two-hit phenomenon, first requiring neutrophils that have been sequestered and primed in the lung microvasculature which are then activated by a factor in the blood product.

TABLE 6.2 Transfusion-Related Complications, Presentation, and Treatment

	Incidence	Presentation	Action
HIV	1:1,467,000		
Hepatitis B	1:282,000		
Bacterial infection	1:2–3,000		
Acute hemolytic reaction	1:76,000		Stop transfusion, notify blood bank
ABO incompatibility	1:40,000 fatal 1:8,000,000	Fever, chills, hypotension, back pain, renal failure	Stop transfusion, administer fluids; pressors as needed, notify blood bank
Delayed hemolytic reaction		Fever, jaundice, anemia, newly positive antibody screen	
Febrile nonhemolytic reaction	1:100–1,000	≥1°C (2°F) rise in temperature within 2 h of start of transfusion with no other explanation for fever. Acetaminophen premedication if reactions are recurrent	
Allergic (urticarial reaction)	1:33–100	Pruritus, flushing, mild wheezing	Pause transfusion, administer antihistamines; may resume transfusion if reaction resolves, but still report reaction to blood bank
Anaphylaxis/anaphylactoid	1:20,000–50,000	Hypotension, urticaria, bronchospasm, angioedema, anxiety	Epinephrine 1:1,000 0.2–0.5 mL SC, antihistamines, corticosteroids, notify blood bank
TACO	1:100	Hypoxemia, hypertension, tachycardia, pulmonary edema, positive fluid balance	Stop transfusion, diuresis, oxygen, assist ventilation as needed
TRALI	1:10,000	Hypoxemia, hypotension, bilateral pulmonary edema, transient leucopenia, and fever within 6 hours of transfusion	Supportive care, notify blood bank, defer implicated donors

More remote complications are also likely immunologically mediated. These include an increased risk of postoperative infection, an increased incidence of tumor recurrence and metastasis, and an increase in renal allograft survival. The data on these complications, and their relationship to the use of leukoreduced blood, are inconsistent and somewhat conflicting.

SUMMARY

The increasing number and widespread use of anticoagulants, along with the general increase in complexity of surgical patients, have increased the depth and breadth of knowledge that surgeons should know relative to the assessment of coagulation status and hemorrhagic risk in both the elective and emergent setting. Traditional tests of coagulation do not adequately reflect patients' clinical bleeding or thromboembolic risk. For example, patients with liver disease and an elevated INR and thrombocytopenia may in fact be hypercoagulable; patients with normal platelet count may actually be at increased bleeding risk due to a qualitative platelet defect. Using point-of-care testing, either TEG or ROTEM, allows assessment of global hemostasis along with an indication of which aspect of the coagulation system should be treated. This is particularly important as the risks and adverse events, including increased mortality, associated with administration of platelets, pRBCs, and plasma become known.

In addition, the approach to resuscitation in patients with active

bleeding, along with better understanding of the risks of transfusion, mandates that surgeons guide ongoing resuscitation as well as administration of blood products administered in a less urgent manner. In the setting of massive hemorrhage, whether in the operating room, as a result of traumatic injury, or gastrointestinal (GI) bleeding, prevention of coagulopathy is paramount. This is accomplished with use of minimal crystalloid and a ratio of pRBCs to platelets and plasma of 1:1:1 to 1:1:2.

Suggested Readings

Baharoglu MI, Cordonnier C, Al-Shahi Salman R, et al. Platelet transfusion versus standard care after acute stroke due to spontaneous cerebral haemorrhage associated with antiplatelet therapy (PATCH): a randomised, open-label, phase 3 trial. *Lancet* 2016; 387:2605.

Carson JL, Carless PA, Hebert PC. Transfusion thresholds and other strategies for guiding allogeneic red blood cell transfusion. *Cochrane Database Syst Rev* 2012:CD002042.

Carson JL, Grossman BJ, Kleinman S, et al. Red blood cell transfusion: a clinical practice guideline from the AABB. *Ann Intern Med* 2012;157:49–58.

CRASH-2 Trial Collaborators, Shakur H, Roberts I, Bautista R, et al. Effects of tranexamic acid on death, vascular occlusive events, and blood transfusion in trauma patients with significant haemorrhage (CRASH-2): a randomized, placebo-controlled trial. *Lancet* 2010; 376(9734):23–32.

Hébert PC, Wells G, Blajchman MA, et al. A multicenter, randomized, controlled clinical trial of transfusion requirements in critical care. Transfusion Requirements in Critical Care Investigators, Canadian Critical Care Trials Group. *N Engl J Med* 1999;340:409.

Holbrook A, Schulman S, Witt DM, et al. Evidence-based management of anticoagulant therapy: antithrombotic therapy and prevention of thrombosis, 9th ed: American College of Chest Physicians evidence-based clinical practice guidelines. *Chest* 141(2 Suppl):e152S–e1584S.

Liumbruno G, Bennardello F, Lattanzio A, et al. Recommendations for the transfusion of plasma and platelets. *Blood Transfusion* 2009;7:132–50.

Marinaud C, Ausset S, Deshayes AV, et al. Use of freeze-dried plasma in French intensive care unit in Afghanistan. *J Trauma* 2011;71:1761–5.

Rohde JM, Dimcheff DE, Blumberg N, et al. Health care-associated infection after red blood cell transfusion: a systematic review and meta-analysis. *JAMA* 2014; 311:1317.

EDITOR'S COMMENT

The management of surgical hemostasis has changed significantly over the last decade. The reasons for this are multiple, but represent a shift from the constant and very real threat of hemorrhagic shock associated with even minor trauma of the liver, spleen, or vasculature to the management of patients who are on novel and strong anticoagulants and antithrombotic agents who must undergo emergent/urgent operations. A clear understanding of the reversible nature of many of these drugs is required even in the elective setting, especially when patients call to ask "when am I supposed to stop drug X before my surgery?"

In this chapter by Dr. Brasel focused on hemorrhage, but also importantly addressing clotting and thrombosis, we are once again reminded of the complexity of these systems and thus the tenuous nature of hemostasis. Having just taken my general and vascular surgery boards for the third time, I can assure you that all of this material is tested. The section of this chapter on "drug-induced coagulopathy" is especially important as an increasing number of patients are being placed on direct thrombin inhibitors (Pinho-Gomes AC, Hague A, Ghosh J. Management of novel oral anticoagulants in emergency and trauma surgery. *Surgeon* 2016;14(4):234–9). Originally, there was no antidote for these drugs and I suspect multiple patients suffered from this. Presently, there is a specific reversal agent idarucizumab, which is a humanized antibody, that has no activity against factor Xa inhibitors or warfarin. Factor Xa inhibitors are also discussed in detail in this chapter, of which there are at least three. These drugs are used for atrial fibrillation and to prevent thromboembolic complications. Unfortunately, there are no direct reversal agents for these drugs, and thus time is required to allow them to wear off.

The use of strong antiplatelet agents, such as Plavix, has become common especially in the setting of coronary and peripheral stenting. It has been shown specifically following drug eluting coronary stents that patients need to stay on these drugs for a year at best to prevent stent thrombosis. I so remember performing a carotid endarterectomy with a patch as a chief resident in 1997 in a patient on a strong antiplatelet agent in which I had to stand there with my hand on the neck holding pressure for about an hour while the patient received platelet transfusions. There is a fair amount of literature now suggesting that performing vascular surgery on patients on Plavix is safe (Saadeh C, Sfeir J. Discontinuation of preoperative clopidogrel is unnecessary in peripheral arterial surgery. *J Vasc Surg* 2013;58(6):1586–92) and may decrease stroke rates following carotid endarterectomy (Jones DW, Goodney PP, Conrad MF, et al. Dual antiplatelet therapy reduces stroke but increases bleeding at the time of carotid endarterectomy. *J Vasc Surg* 2016;63(5):1262–70). Other literature suggests there are more neck hematoma's on Plavix (Moon K, Nanaszko M, Levitt MR, et al. Carotid endarterectomy on antiplatelet agents in the era of point-of-care testing. *World Neurosurg* 2016;93:215–20). I will go on record as

saying I still will not perform an elective open abdominal aortic aneurysm (AAA) repair on a patient who needs to remain on Plavix.

Finally, the blood components and drugs to stop bleeding are described. I want to emphasize that similar to what Dr. Brasel suggests, I believe a 1:1:1 red cells to platelets to plasma seems to work. The use of whole blood transfusions also may be making a comeback! (Auten JD, Lunceford NL, Horton JL, et al. The safety of early fresh, whole blood transfusion among severely battle injured at US Marine Corps forward surgical care facilities in Afghanistan. *J Trauma Acute Care Surg* 2015;79(5):790–6) Most hospital systems have Blood Alerts or Massive Transfusion Protocols, which have helped to speed the resuscitation process along. I think that we have learned a lot about transfusion medicine from the war theater (Haider AH, Piper LC, Zogg CK, et al. Military-to-civilian translation of battlefield innovations in operative trauma care. *Surgery* 2015;158(6):1686–95). The use of thromboelastograms (see Fig. 6.1 in chapter) has allowed us to tailor our approach to intraoperative bleeding, rather than just transfusing based on a clinical hunch (Camazine MN, Hemmila MR, Leonard JC, et al. Massive transfusion policies at trauma centers participating in the American College of Surgeons Trauma Quality Improvement Program. *J Trauma Acute Care Surg* 2015;78(6 Suppl 1):S48–53). My guess is that we will continue to make significant and advanced scientific strides in this area over the next decade.

Gilbert R Upchurch Jr.

7 Perioperative Antimicrobial Prophylaxis and Treatment of Surgical Infection

Kui-Hin Liau, Giorgio Tarchini, and J.S. Solomkin

INTRODUCTION

The discovery of antimicrobial agents in the mid-20th century has revolutionized the practice of surgery. Antimicrobial agents are central to the practice of surgery in two different settings: the prophylaxis of surgical site infection (SSI) and the management of established infections. This effective solution creates other problems following prolonged use of the antimicrobial agents. A dramatic increase in antimicrobial resistance, by enzymatic mechanisms including extended spectrum β-lactamases (ESBLs) and carbapenem-resistant *Enterobacteriaceae* (CREs), and other nonenzymatic mechanisms, has created new sets of clinical problems. Antimicrobial stewardship programs have gained prominence in most medical centers as part of the immediate and longer-term solutions to the control of multidrug resistant microorganisms.

PRINCIPLES OF PREVENTION OF SURGICAL SITE INFECTION

SSIs remain an important problem for both patients and the health care system. Among an estimated 27 million surgical procedures performed each year in the United States, SSIs occur at a rate of 2 per 100 procedures, or approximately 500,000 per year. These infections may lead to increased duration of hospitalization, costs, morbidity, and risk of death.

The impact of an SSI on both the patient and health care system varies by infection type. Superficial incisional SSIs often do not require hospitalization and are inconsistently diagnosed by postdischarge surveillance. Collectively, deep incisional and organ/space infections are considered “complex” SSIs. In most series, complex SSIs represent about one third to one half of SSIs, although this varies according to procedure.

Complex SSIs typically require rehospitalization, drainage or debridement, and systemic antimicrobial therapy. These infections generate considerable morbidity, cost, and even mortality. Unfortunately, many surveys examining incidence, cost, morbidity, or mortality do not make a distinction between complex and superficial SSIs.

Definition and Classification

The definition and criteria for the diagnosis of SSI were standardized by the Centers for Disease Control and Prevention (CDC) and the National Nosocomial Infections Surveillance System (NNIS). The infection must fall within the timeline of 30 days after the primary operation or up to 1 year if an implant is present. Upon diagnosis, SSIs are classified into superficial incisional SSI, deep incisional SSI when deeper tissue layers are involved, and organ/space SSI as shown in Figure 7.1. The criteria for the classification are spelt out in Table 7.1.

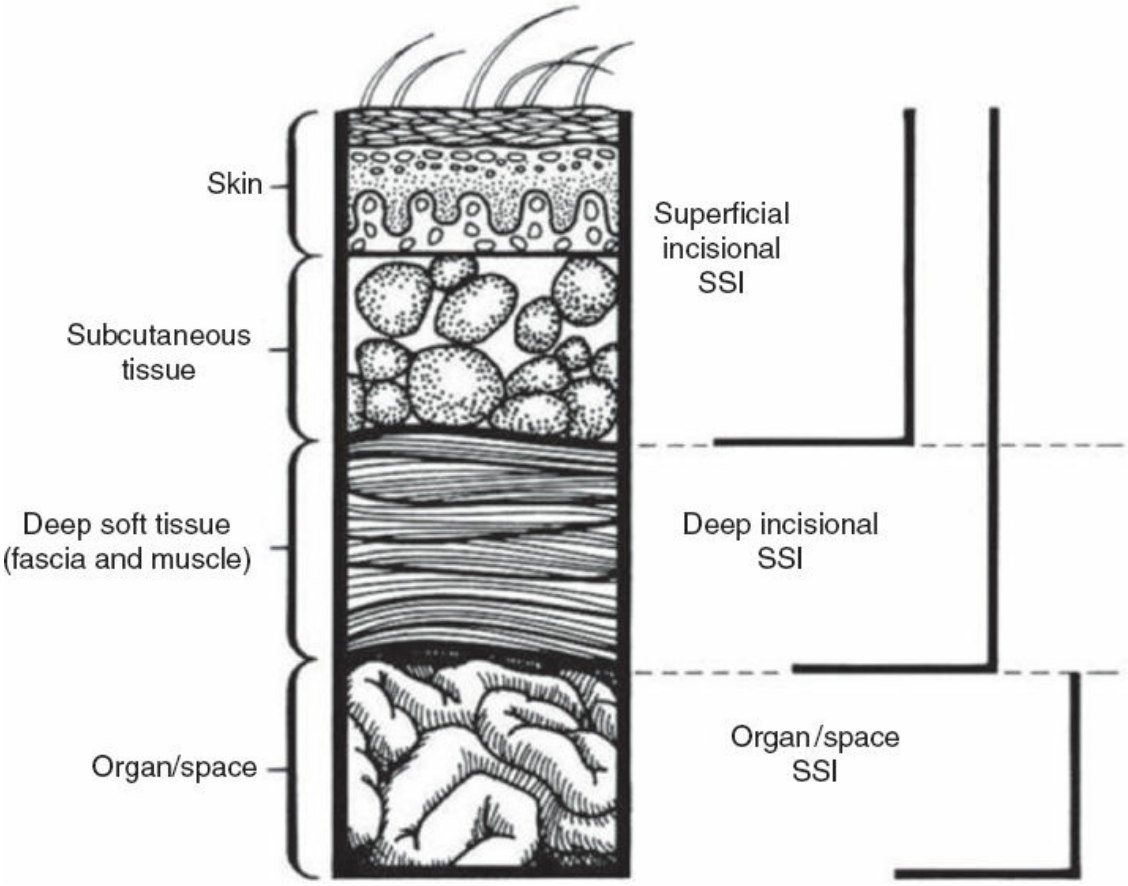

Figure 7.1. Infographic of the classification of surgical site infection.

TABLE 7.1 National Healthcare Safety Network Criteria for Defining a Surgical Site Infection

Superficial Incisional SSI

Occurs within 30 days postoperatively and involves skin or subcutaneous tissue of the incision and at least one of the following:

1. purulent drainage from the superficial incision,
2. organisms isolated from an aseptically obtained culture of fluid or tissue from the superficial incision,
3. at least one of the following signs or symptoms of infection: pain or tenderness, localized swelling, redness, or heat, and superficial incision is deliberately opened by surgeon and is culture-positive or not cultured (a culture-negative finding does not meet this criterion), and
4. diagnosis of superficial incisional SSI by the surgeon or attending physician.

Deep Incisional SSI

Occurs within 30 days after the operative procedure if no implant is left in place or within 1 year if implant is in place and the infection appears to be related to the operative procedure, involves deep soft tissues (e.g., fascial and muscle layers) of the incision, and the patient has at least one of the following:

1. purulent drainage from the deep incision but not from the organ/space component of the surgical site,
2. a deep incision spontaneously dehisces or is deliberately opened by a surgeon and is culture-positive or not cultured and the patient has at least one of the following signs or symptoms: fever (>38°C) or localized pain or tenderness (a culture-negative finding does not meet this criterion),
3. an abscess or other evidence of infection involving the deep incision is found on direct examination, during reoperation, or by histopathologic or radiologic examination, and
4. diagnosis of a deep incisional SSI by a surgeon or attending physician.

Organ/Space SSI

Involves any part of the body, excluding the skin incision, fascia, or muscle layers, that is opened or manipulated during the operative procedure. Specific sites are assigned to organ/space SSI to further identify the location of the infection (e.g., endocarditis, endometritis, mediastinitis, vaginal cuff, and osteomyelitis).

Organ/space SSI must meet the following criteria:

1. infection occurs within 30 days after the operative procedure if no implant is in place or within 1 year if implant is in place and the infection appears to be related to the operative procedure,
2. infection involves any part of the body, excluding the skin incision, fascia, or muscle layers, that is opened or manipulated during the operative procedure, and
3. the patient has at least one of the following:
   (a) purulent drainage from a drain that is placed through a stab wound into the organ/space,
   (b) organisms isolated from an aseptically obtained culture of fluid or tissue in the organ/space,
   (c) an abscess or other evidence of infection involving the organ/space that is found on direct examination, during reoperation, or by histopathologic or radiologic examination, and
   (d) diagnosis of an organ/space SSI by a surgeon or attending physician.

Data from Mangram AJ, Horan TC, Pearson ML, et al. Guideline for prevention of surgical site infection. *Infect Control Hosp Epidemiol* 1999;20:250–78; Horan TC, Andrus M, Dudeck MA. CDC/NHSN surveillance definition of health care-associated infection and criteria for specific types of infections in the acute care setting. *Am J Infect Control* 2008;36:309–32.

TABLE 7.2 Established Risk Factors for Surgical Site Infections

Patient-Related Factors
Age
Obesity or malnutrition
Diabetes or hyperglycemia
Smoking
Colonization
Remote infection
Preoperative hospital stay

Procedure-Related Factors
Instrument cleaning, decontamination, and sterilization
Operating room ventilation
Preoperative shaving
Surgical skin preparation
Surgical scrub
Surgical technique
Surgical drains
Tourniquet time
Revision arthroplasty
Procedure duration

Risk Factors and Risk Scores

Risk factors for the development of SSI are typically divided into patient-related (preoperative), procedure-related (perioperative), and postoperative categories (Table 7.2). In general, patient-related risk factors for SSI can be categorized as either modifiable (e.g., poorly controlled diabetes mellitus, obesity, tobacco use, length of preoperative hospitalization, and colonization) or nonmodifiable (e.g., age). Procedure-related risk factors include, but are not limited to, wound class, organ site, and length of surgery. Postoperative risk factors can include wound care, postoperative blood transfusions, and hyperglycemia in both diabetic and nondiabetic patients.

TABLE 7.3 Wound Class by NNIS Class

Wound Class	All	NNIS 0	NNIS 1	NNIS 2	NNIS 3
Clean	2.1%	1.0%	2.3%	5.4%	N/A
Clean Contaminated	3.3%	2.1%	4.0%	9.5%	N/A
Contaminated	6.4%	N/A	3.4%	6.8%	13.2%
Dirty Infected	7.1%	N/A	3.1%	8.1%	12.8%
All	2.8%	1.5%	2.9%	6.8%	13.0%

National Nosocomial Infections Surveillance (NNIS) System report, data summary from January 1992–June 2001, issued August 2001. *Am J Infect Control* 2001;29:404–21.

In 1991, the CDC developed National Nosocomial Infections Surveillance System (NNIS) risk index. This is a composite index that predicts the risk of SSI after operation. It is defined by three independent and equally weighted variables, namely, American Society of Anesthesiology (ASA) score, information on risk factors for SSI such as wound class and duration of operation. NNIS SSI Risk Index is one of the common tools to predict SSI risk in a broad range of operations (Table 7.3). The clinical utilities of quantitative SSI risk scores are to predict the likelihood of SSI in a patient and guide decision on preventive strategies such as prophylactic antibiotics. In addition, it allows accurate and meaningful comparison of SSI rates between medical centers and health care providers.

Pathogenesis and Microbiology

The microorganisms causing SSIs are well known. Staphylococcal species are the predominant pathogens in all but gastrointestinal procedures (Table 7.4). In those procedures, particularly those involving the small and large intestines, *Escherichia coli, Pseudomonas aeruginosa, Klebsiella* spp., and other facultative and obligate aerobes predominate.

TABLE 7.4 Percentage of Surgical Site Infections With Select Pathogen, by Procedure Category, Deep Incision and Organ/Space Infections, Detected Upon Admission or Readmission, National Healthcare Safety Network, 2011[a,b]

	Procedure Category											
	All		Orthopedic		Abdominal		Cardiac		Ob/gyn		Neurologic	
Pathogen	N	%	N	%	N	%	N	%	N	%	N	%
Staphylococcus aureus												
MSSA[c]	1,656	14.2	1,112	24.9	131	3.1	272	20.3	35	4.1	61	19.6
MRSA[c]	1,199	10.3	779	17.4	141	3.3	193	14.4	34	4.0	21	6.7
Escherichia coli	1,184	10.2	203	4.5	773	18.1	55	4.1	123	14.4	8	2.6
Coagulase-negative staphylococci	1,084	9.3	601	13.5	128	3.0	194	14.5	45	5.3	78	25.0
Enterococcus faecalis	691	5.9	174	3.9	383	9.0	38	2.8	76	8.9	4	1.3
Pseudomonas aeruginosa	561	4.8	169	3.8	210	4.9	104	7.8	29	3.4	14	4.5
Klebsiella pneumoniae (and *K. oxytoca*)	491	4.2	92	2.1	285	6.7	54	4.0	29	3.4	11	3.5
Enterobacter spp.	483	4.1	168	3.8	185	4.3	76	5.7	20	2.3	13	4.2
Enterococcus spp.	410	3.5	73	1.6	256	6.0	18	1.3	35	4.1	2	0.6
Enterococcus faecium	290	2.5	39	0.9	201	4.7	15	1.1	7	0.8	2	0.6
Candida albicans	218	1.9	12	0.3	157	3.7	19	1.4	14	1.6	5	1.6
Other *Candida* spp. or NOS	124	1.1	17	0.4	82	1.9	13	1.0	2	0.2	2	0.6
Acinetobacter baumanii	40	0.3	21	0.5	6	0.1	6	0.4	2	0.2	2	0.6
Other	3,122	26.8	941	21.1	1,320	31.0	267	19.9	397	46.6	87	27.9
TOTAL	11,650	100	4,468	100	4,264	100	1,341	100	852	100	312	100

[a]Preliminary analysis based on data available at 9/2012.
[b]The types of surgery included in each category are as follows: orthopedic: open reduction of fracture, hip prosthesis, knee prosthesis, limb amputation, spinal fusion, refusion of spine, and laminectomy; abdominal: appendectomy, bile duct, liver, or pancreatic surgery, gallbladder surgery, colon surgery, gastric surgery, herniorrhaphy, small-bowel surgery, spleen surgery, abdominal surgery, and rectal surgery; cardiac: cardiac surgery, coronary artery bypass graft with chest incision with or without donor incision, pacemaker surgery, and thoracic surgery; obstetric/gynecologic (Ob/gyn): cesarean section, abdominal hysterectomy, ovarian surgery, and vaginal hysterectomy; neurologic: craniotomy and ventricular shunt.
[c]MRSA denotes methicillin-resistant *S. aureus*, defined as resistant to methicillin, oxacillin, or cefoxitin; MSSA denotes not resistant to these antibiotics.

Staphylococcus aureus is an extraordinarily versatile pathogen that can survive in hostile environmental conditions; colonize mucous membranes and skin; and cause severe, nonpurulent, toxin-mediated disease or invasive pyogenic infection. There has been rapid appearance and spread of a particular genotype of *S. aureus*, which in the United States is predominately the USA300 strain. A variety of surface protein adhesins, excreted toxins, and complex translational and transcriptional regulatory systems allow this strain to be a highly virulent and common pathogen in skin and soft tissue infections (SSTIs), SSIs, pneumonia, bacteremia, and osteomyelitis. The incidence of soft tissue and pulmonary infections due to community-associated methicillin-resistant *Staphylococcus aureus* (MRSA) has increased dramatically, particularly in children and young, immunocompetent adults. Although initially described as community-associated or community-onset MRSA, this strain is now quite common in the health care settings, and has other strains of MRSA as a cause of health care–associated infections (HAIs). USA300 strain has also become a common pathogen for SSIs; it is the most common form of *S. aureus* found in SSIs in hospitalized patients. Methods to reduce the risk of infection due to this organism are an important focus for clinical research.

As part of ongoing efforts to reduce the incidence and burden of SSIs, the CDC and the Healthcare Infection Control Practices Advisory Committee (HICPAC) have updated recommendations for the prevention

of these infections made in 1999. Furthermore, the World Health Organization (WHO) has generated an even more recent guideline for prevention of SSIs.

While many elements of the 1999 guideline remain current, others warrant updating to incorporate new knowledge as well as changes in patient populations, operative techniques, emerging pathogens, and guideline development methodology. The background health of the US population has clearly changed, with increasing incidences of obesity, diabetes, and other metabolic diseases. The dramatic increase in the use of minimally invasive surgical techniques and implants may require a different approach to SSI prevention. The emergence of MRSA and other antimicrobial resistant pathogens may impact the rate and severity of SSI as well as potential prevention strategies.

Rationale and Concepts of Antibiotics Prophylaxis

SSIs are preventable HAIs, particularly in clean and clean/contaminated surgery. The primary goals of antibiotics prophylaxis in surgical patients are to prevent SSI and SSI-related morbidity and mortality. To meet these goals, the parenteral antibiotics used must be effective and active against the pathogens that are likely to contaminate the surgical site. To optimize the effectiveness of the antibiotics, appropriate dosage is administered at a time to ensure adequate tissue concentration during the period of potential contamination with redosing to maintain sufficient antibiotics concentration.

PREOPERATIVE ANTIMICROBIAL PROPHYLAXIS

There is a wide consensus on specific procedures that warrant antimicrobial prophylaxis. These are identified in clean surgery (with implants, cardiac, breast surgery, extensive soft tissue procedures, hernia) and clean-contaminated (gastrointestinal/colorectal and appendicitis) (Table 7.5). There is good evidence that extending surgical antimicrobial prophylaxis into the postoperative stage is of no value in reducing SSIs. Cardiothoracic surgery may be an exception to this rule. In such cases, there seem to be potential benefits in continuing antibiotic prophylaxis for up to 24 hours.

Another important aspect of surgical prophylaxis is antibiotic choice. In particular, there has been some degree of controversy about the optimal use of vancomycin in this setting. A recent review concluded that there is

not enough evidence to determine in what scenarios vancomycin is a critical component of perioperative prophylaxis. In addition, the authors pointed out that there are concerns about under dosing of vancomycin, particularly in obese patients, which would present a possible bias against the efficacy of this drug.

Preoperative antibiotics recommendation will follow the SHEA/IDSA reference. The recommendations for surgical antimicrobial prophylaxis are summarized in Table 7.6. Details on the strength of recommendations can be obtained from the reference.

ANTIMICROBIAL STEWARDSHIP

The release of the New Antimicrobial Stewardship Standard by the Joint Commission has sparked renewed interest in this topic in the United States by requiring more hospital leadership commitment and enterprise-wide accountability. Antibiotic stewardship programs are of particular importance to surgical specialties due to their prominent role in prophylactic antibiotic usage. The goal of such programs is not only to reduce the development of resistant organisms, but also to ensure that misguided overuse of prophylactic antibiotics does not result in direct deleterious effects to patients.

TABLE 7.5 National Healthcare Safety Network Criteria for Classifying Wounds

Clean

An uninfected operative wound in which no inflammation is encountered and the respiratory, alimentary, genital, or uninfected urinary tracts are not entered. In addition, clean wounds are primarily closed and, if necessary, drained with closed drainage. Operative incisional wounds that follow nonpenetrating (blunt) trauma should be included in this category if they meet the criteria.

Clean-Contaminated

Operative wounds in which the respiratory, alimentary, genital, or urinary tracts are entered under controlled conditions and without unusual contamination. Specifically, operations involving the biliary tract, appendix, vagina, and oropharynx are included in this category, provided no evidence of infection or major break in technique is encountered.

Contaminated

Open, fresh, accidental wounds. In addition, operations with major breaks in sterile technique (e.g., open cardiac massage) or gross spillage from the gastrointestinal tract and incisions in which acute, nonpurulent inflammation is encountered are included in this category.

Dirty or Infected

Includes old traumatic wounds with retained devitalized tissue and those that involve existing clinical infection or perforated viscera. This definition suggests that the organisms causing postoperative infection were present in the operative field before the operation.

National Healthcare Safety Network. Patient safety component manual: key terms. www.cdc.gov/nhsn/PDFs/pscManual/16pscKeyTerms_current.pdf

TABLE 7.6 Summary of Clinical Practice Guidelines for Antimicrobial Prophylaxis in Surgery

Type of Procedure	Recommended Agent	Alternative Agents in Patients With B-Lactam Allergy
Cardiac Surgery (e.g., coronary artery bypass)	Cefazolin, cefuroxime	Clindamycin, vancomycin
Thoracic Surgery (e.g., video-assisted thorascopic surgery)	Cefazolin, ampicillin-sulbactam	Clindamycin, vancomycin
Gastrointestinal Surgery (e.g., bariatric and Whipple's)	Cefazolin	Clindamycin or vancomycin+aminoglycoside or aztreonam or fluoroquinolone
Biliary Surgery (e.g., open procedure)	Cefazolin, cefoxitin, cefotetan, ceftriaxone, ampicillin-sulbactam	Clindamycin or vancomycin+aminoglycoside or aztreonam or fluoroquinolone; Metronidazole+aminoglycoside or fluoroquinolone
Small Bowel Surgery—Nonobstructed	Cefazolin	Clindamycin+aminoglycoside or aztreonam or fluoroquinolone
Small Bowel Surgery—Obstructed	Cefazolin+metronidazole, cefoxitin, cefotetan	Metronidazole+aminoglycoside or fluoroquinolone
Hernia Repair	Cefazolin	Clindamycin, vancomycin
Colorectal Surgery	Cefazolin+metronidazole, cefoxitin, cefotetan, ampicillin-sulbactam, ceftriaxone+metronidazole, ertapenem	Clindamycin+aminoglycoside or aztreonam or fluoroquinolone, metronidazole+aminoglycoside or fluroquinolone
Cesarean Delivery	Cefazolin	Clindamycin+aminoglycoside
Vascular	Cefazolin	Clindamycin, vancomycin
Liver Transplantation	Piperacillin-tazobactam, cefotaxime+ampicillin	Clindamycin or vancomycin+aminoglycoside or aztreonam or fluoroquinolone
Orthopedics (e.g., hip fracture repair and total knee replacement)	Cefazolin	Clindamycin, vancomycin
Urologic Surgery—clean contaminated	Cefazolin+metronidazole, cefoxitin	Fluoroquinolone, aminoglycoside+metronidazole or clinidamycin
Head and Neck—clean contaminated cancer surgery	Cefazolin+metronidazole, cefuroxime+metronidazole, ampicillin-sulbactam,	Clindamycin

(Originally published in Bratzler DW, Dellinger EP, Olsen KM, et al. Clinical practice guidelines for antimicrobial prophylaxis in surgery. *Am J Health Syst Pharm* 2013;70(3):195–283. doi:10.2146/ajhp120568. ©2013, American Society of Health-System Pharmacists, Inc. All rights reserved. Adapted with permission.)

The intersection of stewardship and prophylaxis has become even more important because of the increase in methicillin-resistant *Staphylococci* and resistant gram-negatives encountered in bowel procedures. There is a growing consensus that patients scheduled for orthopedic implant, cardiac, and vascular surgery should undergo nasal swabs to detect *S. aureus* colonization. Aggressive treatment with intranasal mupirocin and chlorhexidine body washes greatly reduce the incidence of subsequent infection. These patients additionally are commonly treated with vancomycin.

In many areas of the world, intestinal colonization with gram-negatives possessing ESBLs is common. There have been no studies examining the benefits of anti-ESBL prophylaxis (carbapenems, particularly ertapenem) in these settings. Indirect evidence has accumulated from studies on patients undergoing transrectal prostate biopsy. As expected, individuals with fluoroquinolone-resistant *E. coli* rectal colonization were at a much higher risk of developing a post-biopsy infection, particularly if preoperative prophylaxis consisted only of a fluoroquinolone. As a proof of concept, it paves the way for further studies, such as one quality improvement study that compared targeted to empirical antibiotic prophylaxis in the same subset of patients. The authors concluded that the

targeted prophylaxis approach avoided the use of more than one empirical antibiotic without an increase in post-biopsy infections. Such models could be applied to other surgical specialties, where identifying carriage rates of multidrug resistant organisms with fecal cultures in target populations could also improve antibiotic selection. This approach is likely to provide more meaningful and actionable data than the current one that relies mainly on regional reported resistance rates.

A national action plan to prevent HAIs has been developed. The updated SSI guideline addresses concerns raised in the Health and Human Services plan. Beginning in 2012, hospitals participating in the Centers for Medicare & Medicaid Services (CMS) Inpatient Prospective Payment System were required to report SSI data related to two procedures, total abdominal hysterectomy and colon surgeries, through CDC's National Healthcare Safety Network (NHSN) surveillance system. These data are included in the Inpatient Quality Reporting data publicly reported by CMS through the Hospital Compare Web site.

The Elements of Antimicrobial Stewardship

The release of the New Antimicrobial Stewardship Standard by the Joint Commission has sparked renewed interest in this topic in the United States by requiring more hospital leadership commitment and enterprise-wide accountability. Antibiotic stewardship programs are of particular importance to surgical specialties due to their prominent role in prophylactic antibiotic usage and management of surgical infections. The goal of such programs is not only to reduce the development of resistant organisms, but also to ensure that misguided overuse or inappropriate use of prophylactic and therapeutic antibiotics does not result in direct deleterious effects to patients.

Currently, certain initiatives make implementation of specific care bundles mandatory or nearly so. Payers, such as CMS, are increasingly monitoring compliance with care bundles, such as process measures from the Surgical Care Improvement Project, both as a publicly reportable quality measure and as a tool to determine remuneration for certain medical services.

Care bundles include elements that cover across the preoperative phase, intraoperative and postoperative phase. Practices advocated in the preoperative phases are avoid routine hair removal and use electric clippers with a single-use head on the day of surgery if necessary.

Administer antibiotic prophylaxis to patients before clean surgery especially those involving the placement of a prosthesis or implant, clean-contaminated surgery, and contaminated surgery. Routine antibiotic prophylaxis for clean nonprosthetic uncomplicated surgery is not advocated. A single dose of antibiotic prophylaxis should be given intravenously within 60 minutes of incision.

GUIDELINES ON PREVENTION OF SURGICAL SITE INFECTION

Centers for Disease Control and Prevention Guidelines

HICPAC, a federal advisory committee to CDC, published the CDC/SSI guideline in 2016. The guideline covers six core topics applied to all surgical procedures, namely, parenteral antimicrobial prophylaxis, nonparenteral antimicrobial prophylaxis, glycemic control, normothermia, oxygenation, and antiseptic prophylaxis (Table 7.7). The other seven topics are related specifically to prosthetic joint arthroplasty procedures. The seven topics are blood transfusions, systemic immunosuppressive therapy, intra-articular corticosteroid injections, anticoagulation, orthopedic surgical space suit, postoperative antimicrobial prophylaxis, and biofilm.

World Health Organization Global Guidelines

In recognition of SSI as one of the major HAI affecting patient safety worldwide, the WHO published international guidelines for the prevention of surgical infection in 2016. These guidelines provide consistency in the interpretation of scientific evidence and strength of recommendations. The evidence-based recommendations for interventions cover pre-, intra-, and postoperative periods for prevention of SSI. Table 7.8 is the summary of the core topics and recommendations for the prevention of surgical sites infections.

WHO emphasizes the importance in the translation of these recommendations into practices in surgical services and operation rooms. The key step in developing these guidelines is to ensure its implementation, with the ultimate goal to achieve a reduction of harm due to SSI through the continuum of patient's surgical journey. A surgical champion can implement these guidelines successfully in an enabling environment supportive of patient safety culture. A well-chosen strategy

such as Surgical Unit-based Safety Program (SUSP), which has a package of more than 20 implementation tools, is crucial for the successful uptake and adoption of these recommendations.

TREATMENT OF SURGICAL INFECTION

Principles of Management of Surgical Infection

The principles in the management of surgical infection are based on two aspects, precise diagnosis and the three pillars of treatment. Prompt clinical assessment and microbiologic sampling are the key to a precise diagnosis of surgical infection. The three pillars, which should be treated as parallel priorities, consist of source control or focus elimination, appropriate use of antimicrobial agents, and organ supports through intensive care medicine. Source control refers to the therapeutic interventions that eliminate a focus of infection, control ongoing contamination, and restore premorbid anatomy and physiologic function. It involves managing the source of leakage of microbial pathogens from the gut, such as by resection or drainage. Conceptually, the principles embody the 3Ps: the **p**atient's complexity; the **p**athogen's virulence and its susceptibility; and the **p**hysician's knowledge, skills, and medicine.

TABLE 7.7 CDC and WHO Guideline Comparisons

Area of Recommendation	CDC Guideline	WHO Guideline
I. Parenteral Antimicrobial Prophylaxis	Administer preoperative antimicrobial agent(s) only when indicated, based on published clinical practice guidelines and timed such that a bactericidal concentration of the agent(s) is established in the serum and tissues when the incision is made. **(Category IB)** No further refinement of timing can be made for preoperative antimicrobial agent based on clinical outcomes. (**No recommendation/unresolved issue**) 1A.2 No further refinement of timing can be made for preoperative antimicrobial agent based No evidence for weight based or intra-op dosing. In clean and clean-contaminated procedures, do not administer additional prophylactic antimicrobial agent doses after the surgical incision is closed in the operating room, even in the presence of a drain. (**Category IA**)	The panel recommends that SAP should be administered prior to the surgical incision when indicated (depending on the type of operation). The panel recommends the administration of SAP within 120 minutes before incision, while considering the half-life of the antibiotic.
S. aureus nasal carriage		The panel recommends that patients undergoing cardiothoracic and orthopedic surgery with known nasal carriage of *S. aureus* should receive perioperative intranasal applications of mupirocin 2% ointment with or without a combination of CHG body wash.

II. Nonparenteral Antimicrobial Prophylaxis	2A.1. RCT evidence suggests uncertain trade-offs between benefits and harms regarding intraoperative antimicrobial irrigation (e.g., intra-abdominal, deep or subcutaneous tissues) for the prevention of SSI. Other organizations have made recommendations based on the existing evidence and a summary of these recommendations can be found in the Other guidelines section of the narrative summary for this question. (**No recommendation/unresolved issue**) 2B.1. Do not apply antimicrobial agents (i.e., ointments, solutions, powders) to the surgical incision for the prevention of SSI. (**Category IB**) 2B.2. Application of autologous platelet-rich plasma (APRP) is not necessary for the prevention of SSI. (**Category II**) 2C. Consider the use of triclosan-coated sutures for the prevention of SSI. (**Category II**) 2D. RCT evidence suggests uncertain trade-offs between benefits and harms regarding antimicrobial dressings applied to surgical incisions following primary closure in the operating room for the prevention of SSI. (**No recommendation/unresolved issue**)	
III. Glycemic Control	3A.1. Implement perioperative glycemic control and use blood glucose target levels <200 mg/dL in diabetic and nondiabetic patients. (**Category IA**)	
IV. Normothermia	4. Maintain perioperative normothermia. (**Category IA**)	
V. Oxygenation	6A. RCT evidence suggests uncertain trade-offs between benefits and harms regarding the administration of increased FiO_2 via endotracheal intubation during only the intraoperative period in patients with normal pulmonary function undergoing general anesthesia for the prevention of SSI. (**No recommendation/unresolved issue**) 6B. For patients with normal pulmonary function undergoing general anesthesia with endotracheal intubation administer increased fraction of inspired oxygen (FiO_2) both intraoperatively and post-extubation in the immediate postoperative period. To optimize tissue oxygen delivery, maintain perioperative normothermia and adequate volume replacement. (**Category IA**)	
VI. Antiseptic Prophylaxis	8A.1. Advise patients to shower or bathe (full body) with either soap (antimicrobial or nonantimicrobial) or an antiseptic agent on at least the night before the operative day. (**Category IB**) 8B. Perform intraoperative skin preparation with an alcohol-based antiseptic agent, unless contraindicated. (**Category IA**) 8C. Application of a microbial sealant immediately following intraoperative skin preparation is not necessary for the prevention of SSI. (**Category II**) 8D. Use of plastic adhesive drapes with or without antimicrobial properties is not necessary for the prevention of SSI. (**Category II**) 9A. Consider intraoperative irrigation of deep or subcutaneous tissues with aqueous iodophor solution for the prevention of SSI. Intraperitoneal lavage with aqueous iodophor solution in contaminated or dirty abdominal procedures is not necessary. (**Category II**) 9B. The search did not identify RCTs that evaluated soaking prosthetic devices in antiseptic solutions prior to implantation for the prevention of SSI. (**No recommendation/unresolved issue**) 10. RCT evidence is insufficient to evaluate the trade-offs between the benefits and harms of repeat application of antiseptic agents to the patient's skin immediately prior to closing the surgical incision for the prevention of SSI. (**No recommendation/unresolved issue**)	It is good clinical practice for patients to bathe or shower prior to surgery. The panel suggests that either plain soap or an antimicrobial soap may be used for this purpose.

TABLE 7.8 Summary of Core Topics and Recommendations for Prevention of Surgical Infection (WHO Global Guidelines for Prevention of Surgical Site Infection)

Topic	Research Questions	Recommendations	Strength	Quality of Evidence
Preoperative measures				
Preoperative bathing	1. Is preoperative bathing using an antimicrobial soap more effective in reducing the incidence of SSI in surgical patients compared to bathing with plain soap?	It is good clinical practice for patients to bathe or shower prior to surgery. The panel suggests that either plain soap or an antimicrobial soap may be used for this purpose.	Conditional	Moderate
	2. Is preoperative bathing with CHG-impregnated cloths more effective in reducing the incidence of SSI in surgical patients compared to bathing with antimicrobial soap?	The panel decided not to formulate a recommendation on the use of CHG-impregnated cloths for the purpose of reducing SSI due to the very low quality of evidence		
Decolonization with mupirocin ointment with or without CHG body wash for the prevention of *S. aureus* infection in nasal carriers	Is mupirocin nasal ointment in combination with or without CHG body wash effective in reducing the number of *S. aureus* infections in nasal carriers undergoing surgery?	The panel recommends that patients undergoing cardiothoracic and orthopedic surgery with known nasal carriage of *S. aureus* should receive perioperative intranasal applications of mupirocin 2% ointment with or without a combination of CHG body wash.	Strong	Moderate
		The panel suggests considering to treat also patients with known nasal carriage of *S. aureus* undergoing other types of surgery with perioperative intranasal applications of mupirocin 2% ointment with or without a combination of CHG body wash.	Conditional	Moderate
Screening of ESBL colonization and the impact on antibiotic prophylaxis	1. Should SAP be modified in high (>10%) ESBL prevalence areas? 2. Should SAP be modified in patients who are colonized with or a carrier of ESBL? 3. Should patients be screened for ESBL prior to surgery?	The panel decided not to formulate a recommendation due to the lack of evidence.	NA	NA
Optimal timing for preoperative SAP	How does the timing of SAP administration impact on the risk of SSI, and what is the precise optimal timing?	The panel recommends that SAP should be administered prior to the surgical incision when indicated (depending on the type of operation).	Strong	Low
		The panel recommends the administration of SAP within 120 minutes before incision, while considering the half-life of the antibiotic.	Strong	Moderate
Mechanical bowel preparation and the use of oral antibiotics	Is mechanical bowel preparation combined with or without oral antibiotics effective for the prevention of SSI in colorectal surgery?	The panel suggests that preoperative oral antibiotics combined with mechanical bowel preparation should be used to reduce the risk of SSI in adult patients undergoing elective colorectal surgery.	Conditional	Moderate
		The panel recommends that mechanical bowel preparation alone (without administration of oral antibiotics) should not be used for the purpose of reducing SSI in adult patients undergoing elective colorectal surgery.	Strong	Moderate

Hair removal	1. Does hair removal affect the incidence of SSI? 2. What method and timing of hair removal are associated with the reduction of SSI?	The panel recommends that in patients undergoing any surgical procedure, either hair should not be removed or, if absolutely necessary, it should be removed only with a clipper. Shaving is strongly discouraged at all times, whether preoperatively or in the OR.	Strong	Moderate
Surgical site preparation	Should alcohol-based antiseptic solutions or aqueous solutions be used for skin preparation in surgical patients and, more specifically, should CHG or PVP-I solutions be used?	The panel recommends alcohol-based antiseptic solutions based on CHG for surgical site skin preparation in patients undergoing surgical procedures.	Strong	Low to moderate
Antimicrobial skin sealants	Should antimicrobial sealants (in addition to standard surgical site skin preparation) be used in surgical patients for the prevention of SSI compared to standard surgical site skin preparation only?	The panel suggests that antimicrobial sealants should not be used after surgical site skin preparation for the purpose of reducing SSI.	Conditional	Very Low
Surgical hand preparation	1. What is the most effective type of product for surgical hand preparation to prevent SSI? 2. What is the most effective technique and ideal duration for surgical hand preparation?	The panel recommends that surgical hand preparation should be performed by scrubbing with either a suitable antimicrobial soap and water or usng a suitable alcohol-based handrub before donning sterile gloves.	Strong	Moderate
Preoperative and/or intraoperative measures				
Enhanced nutritional support	In surgical patients, should enhanced nutritional support be used for the prevention of SSI?	The panel suggests considering the administration of oral or enteral multiple nutrient-enhanced nutritional formulas for the purpose of preventing SSI in underweight patients who undergo major surgical operations.	Conditional	Very Low
Perioperative discontinuation of immunosuppressive agents	Should immunosuppressive agents be discontinued Perioperatively, and does this affect the incidence of SSI?	The panel suggests not to discontinue immunosuppressive medication prior to surgery for the purpose of preventing SSI.	Conditional	Very Low
Perioperative oxygenation	How safe and effective is the perioperative use of an increased fraction of inspired oxygen in reducing the risk of SSI?	The panel recommends that adult patients undergoing general anesthesia with endotracheal intubation for surgical procedures should receive an 80% fraction of inspired oxygen intraoperatively and, if feasible, in the immediate postoperative period for 2–6 hours to reduce the risk of SSI.	Strong	Moderate
Maintaining normal body temperature (normothermia)	Should systemic body warming vs. no warming be used for the prevention of SSI in surgical patients?	The panel suggests the use of warming devices in the OR and during the surgical procedure for patient body warming with the purpose of reducing SSI.	Conditional	Moderate

Use of protocols for intensive perioperative blood glucose control	1. Do protocols aiming to maintain optimal perioperative blood glucose levels reduce the risk of SSI?	The panel suggests the use of protocols for intensive perioperative blood glucose control for both diabetic and nondiabetic adult patients undergoing surgical procedures to reduce the risk of SSI.	Conditional	Low
	2. What are the optimal perioperative glucose target levels in diabetic and nondiabetic patients?	The panel decided not to formulate a recommendation on this topic due to the lack of evidence to answer question 2.		
Maintenance of adequate circulating volume control/ normovolemia	Does the use of specific fluid management strategies during surgery affect the incidence of SSI?	The panel suggests the use of goal-directed fluid therapy intraoperatively to reduce the risk of SSI.	Conditional	Low
Drapes and gowns	1. Is there a difference in SSI rates depending on the use of disposable nonwoven drapes and gowns or reusable woven drapes and gowns? 1.1. Is there a difference in SSI rates depending on the use of disposable nonwoven or reusable woven drapes? 1.2. Is there a difference in SSI rates depending on the use of disposable nonwoven or reusable woven gowns?	The panel suggests that either sterile, disposable nonwoven or sterile, reusable woven drapes and gowns can be used during surgical operations for the purpose of preventing SSI. No specific evidence was retrieved to answer to Questions 1.1 and 1.2.	Conditional	Moderate to very low
	2. Does the use of disposable, adhesive, incise drapes reduce the risk of SSI?	The panel suggests not to use plastic adhesive incise drapes with or without antimicrobial properties for the purpose of preventing SSI.	Conditional	Low to very low
Wound protector devices	Does the use of wound protector devices reduce the rate of SSI in open abdominal surgery?	The panel suggests considering the use of wound protector devices in clean-contaminated, contaminated and dirty abdominal surgical procedures for the purpose of reducing the rate of SSI.	Conditional	Very low
Incisional wound irrigation	Does intraoperative wound irrigation reduce the risk of SSI?	The panel considered that there is insufficient evidence to recommend for or against saline irrigation of incisional wounds before closure for the purpose of preventing SSI.	NA	NA
		The panel suggests considering the use of irrigation of the incisional wound with an aqueous PVP-I solution before closure for the purpose of preventing SSI, particularly in clean and clean-contaminated wounds. The panel suggests that antibiotic incisional wound irrigation should not be used for the purpose of preventing SSI.	Conditional	Low
Prophylactic negative pressure wound therapy	Does prophylactic negative pressure wound therapy reduce the rate of SSI compared to the use of conventional dressings?	The panel suggests the use of prophylactic negative pressure wound therapy in adult patients on primarily closed surgical incisions in high-risk wounds for the purpose of the prevention of SSI, while taking resources into account.	Conditional	Low

Use of surgical gloves	1. When is double-gloving recommended? 2. What are the criteria for changing gloves during an operation? 3. What type of gloves should be used?	The panel decided not to formulate a recommendation due to the lack of evidence to assess whether double-gloving or a change of gloves during the operation or the use of specific types of gloves is more effective in reducing the risk of SSI.	NA	NA
Changing of surgical instruments	At the time of wound closure, is there a difference in SSI when instruments are changed for fascial, subcutaneous, and skin closure using a new set of sterile instruments?	The panel decided not to formulate a recommendation on this topic due to the lack of evidence.	NA	NA
Antimicrobial-coated sutures	Are antimicrobial-coated sutures effective to prevent SSI? If yes, when and how should they be used?	The panel suggests the use of triclosan-coated sutures for the purpose of reducing the risk of SSI, independent of the type of surgery.	Conditional	Moderate
Laminar flow ventilation systems in the context of OR ventilation	1. Is the use of laminar air flow in the OR associated with the reduction of overall or deep SSI?	The panel suggests that laminar airflow ventilation systems should not be used to reduce the risk of SSI for patients undergoing total arthroplasty surgery.	Conditional	Low to very low
	2. Does the use of fans or cooling devices increase SSIs? 3. Is natural ventilation an acceptable alternative to mechanical ventilation?	The panel decided not to formulate a recommendation on these topics due to the lack of evidence to answer Questions 2 and 3.	NA	NA
Postoperative measures				
SAP prolongation	Does continued postoperative SAP reduce the risk of SSI compared with preoperative and (if necessary) intraoperative prophylaxis only?	The panel recommends against the prolongation of SAP after completion of the operation for the purpose of preventing SSI.	Strong	Moderate
Advanced dressings	In surgical patients, should advanced dressings vs. standard sterile wound dressings be used for the prevention of SSI?	The panel suggests not using any type of advanced dressing over a standard dressing on primarily closed surgical wounds for the purpose of preventing SSI.	Conditional	Low
Antimicrobial prophylaxis in the presence of a drain and optimal timing for wound drain removal	1. In the presence of drains, does prolonged antibiotic prophylaxis prevent SSI?	The panel suggests that preoperative antibiotic prophylaxis should not be continued in the presence of a wound drain for the purpose of preventing SSI.	Conditional	Low
	2. When using drains, how long should they be kept in place to minimize SSI as a complication?	The panel suggests removing the wound drain when clinically indicated. No evidence was found to allow making a recommendation on the optimal timing of wound drain removal for the purpose of preventing SSI.	Conditional	Very low

From Solomkin JS, Mazuski JE, Bradley JS, et al. Diagnosis and management of complicated intra-abdominal infection in adults and children: guidelines by the Surgical Infection Society and the Infectious Diseases Society of America. *Clin Infect Dis* 2010;50(2):133–64, by permission of Oxford University Press.

Complicated Intra-Abdominal Sepsis

More often than not, patients with intra-abdominal sepsis are managed under the leadership of a surgeon. The main reason is because the chances for surgical intervention in this group of patients are high. Intra-abdominal sepsis could be primary from infections arising from digestive system or secondary following an elective abdominal operation. In complicated intra-abdominal infections, the infectious process proceeds beyond the organ where infection originates. The infection may be complicated by localized peritonitis, abdominal abscess, or diffuse peritonitis, depending on the host immune response to contain the infection within the abdominal cavity. Intra-abdominal infections are often polymicrobial (aerobic, anaerobic, gram-negative and positive) in etiology. Mixed aerobic–

anaerobic bacteria act in synergy. Abscess forming obligate anaerobe such as *Bacteroides fragilis* increases the lethality of a nonlethal inoculum of the endotoxin generating facultative anaerobes such as *E. coli.*

Early clinical diagnosis, adequate source control, and prompt initiation of appropriate empirical therapy to arrest the infectious process and restore anatomical structures and physiologic function are the cornerstones in securing good clinical outcome in complicated intra-abdominal sepsis. Surgical interventions are required to achieve adequate source control in majority of these cases.

Diagnostic Workup

Initial diagnosis of complicated intra-abdominal infection can be made following clinical history, physical examination, and routine laboratory studies. Further evaluation is warranted to identify the source of infection, severity, and the nature of pathogen. In the presence of obvious diffuse peritonitis, no further radiologic studies are necessary so that emergent surgical intervention is not delayed. Noninvasive diagnostic imaging, including helical computed tomography (CT) scan and in some cases magnetic resonance imaging (MRI) scan, has greatly added to the accuracy of preoperative diagnosis and allowed patient-specific intervention plans to be developed. In patients whose physical signs are assessed to be unreliable such as an altered mental status from head injury, or spinal cord injury or immunocompromised patients, high index of suspicion for the diagnosis of intra-abdominal infection is needed especially when there is clinical evidence of infection from an undetermined source.

Timing and Nature of Empiric Antimicrobial Management

Most guidelines for antimicrobial management in complicated intra-abdominal infections are standardized accordingly to community-associated infections and HAIs, with recommendation of either monotherapy or combination therapy. Patients at high risk of having multidrugs resistant pathogens should be vigilantly identified. Consider antimicrobial coverage against enterococci in selected clinical situations, such as in patients with septic shock in previous prolonged cephalosporins treatment, immunosuppressed patients at risk for bacteraemia, patients with prosthetic heart valves and recurrent intra-abdominal infection complicated by severe sepsis. Administer antifungal therapy especially for patients at risk for invasive candidiasis, in particular, patients with

extended duration of antimicrobial therapy and immunosuppressed patients. Discipline in antimicrobial usage to balance between optimizing antibiotics therapy and avoiding unnecessary antimicrobial use should be exercised so as to combat and control the emergence of multidrug resistant pathogens.

Microbiology in Patients With Community-Associated Infections

In the era of organism-based rather than severity-based concept, what is the utility of microbiology to guide antimicrobial usage for community-associated infections? There are no data indicating that Gram stain, culture, and susceptibility results alter outcome in patients with a community-associated complicated intra-abdominal infection. This is in large part a consequence of the fact that most studies primarily include patients with acute appendicitis. However, there is increasing resistance of community-associated strains of gram-negative organisms to selected antibiotics in many locales.

If resistance for a given antibiotic is greater than 10% to 20% for a common intra-abdominal pathogen in the community, use of that agent should be avoided. Because of widespread resistance of *E. coli* to ampicillin/sulbactam, that antibiotic is no longer recommended for routine empiric therapy of complicated intra-abdominal infections. There is high penetration of fluoroquinolone-resistant *E. coli* in Latin America and East Asia, and locations with a high prevalence of ESBL-producing strains of *Klebsiella* sp. and *E. coli.* Quinolone-resistant *E. coli* are similarly becoming a problem in some areas, and this mandates review of hospital susceptibility data. In some populations and communities, a relatively high prevalence of more resistant nonenteric gram-negative organisms, such as *Pseudomonas aeruginosa,* will impact the selection of appropriate empiric antibiotic therapy.

Routine cultures of patients with community-associated intra-abdominal infections may facilitate recognition of local changes in resistance, and thereby optimal selection of antimicrobial agents for both definitive treatment and oral step-down therapy. There are marked differences in susceptibility patterns within and between different groups of patients.

Microbiology in Patients With Health Care-Associated Infections

For patients with HAIs, antimicrobial therapy that fails to cover eventual

pathogens has been associated with higher rates of treatment failure and mortality. Thus, Gram stains may be of value in detecting gram-positive cocci or yeast that would lead to additional empiric antimicrobial therapy before definitive culture results are available. Local susceptibility patterns for *S. aureus* and for enterococci might warrant addition of an MRSA-active agent until results of cultures and susceptibility testing are available. For enterococci, local susceptibilities should be monitored for penicillin and vancomycin resistance.

Risk factors for vancomycin resistant *Enterococcus faecium* (VRE) colonization include previous antibiotic therapy, the duration and multiplicity of antimicrobial therapy, extended hospital stay, intensive care unit (ICU) long stayer, and serious comorbidity. Therefore, in patients with postoperative or nosocomial infections, recent exposure to broad-spectrum antimicrobial agents especially cephalosporins, in immunocompromised patients and in patients with valvular heart disease or prosthetic intravascular materials, Enterococcal infection should be suspected.

The emergence of multidrug-resistant gram-negative bacteria in the recent years has presented a new dimension of challenges for both surgeons and physicians. This is partly contributed by the selective pressure from an intensive use of antimicrobial therapy and partly due to the increasing number of invasive procedures performed in more multimorbid patient populations. Other factors include higher patient volume in huge medical institutions with greater movement of patients and health care workers. *Pseudomonas aeruginosa, Acinetobacter baumannii, Stenotrophomonas maltophilia,* ESBL-producing *Enterobacteriaceae* and *Carbapenem-resistant Enterococci and Pseudomonas aeruginosa,* identified by the Antimicrobial Availability Task Force of the Infectious Diseases Society of America (IDSA), have become a universal clinical problem in the management of complicated intra-abdominal infection. Most recently, *Klebsiella pneumoniae* carbapenemase-producing bacteria and extended drug-resistant bacteria are major concerns.

TABLE 7.9 Initial Empirical Antimicrobials for Extra-Biliary Complicated Intra-Abdominal Infection

Regimen	Community-Acquired Infection in Pediatric Patients	Community-Acquired Infection in Adults: Mild-to-Moderate Severity: Perforated or Abscessed Appendicitis and Other Infections of Mild-to-Moderate Severity	Community-Acquired Infection in Adults: High Risk or Severity: Severe Physiologic Disturbance, Advanced Age, or Immunocompromised State
Single agent	Ertapenem, meropenem, imipenem-cilastatin, ticarcillin-clavulanate, and piperacillin-tazobactam	Cefoxitin, ertapenem, moxifloxacin, tigecycline, and ticarcillin-clavulanic acid	Imipenem-cilastatin, meropenem, doripenem, and piperacillin-tazobactam
Combination	Ceftriaxone, cefotaxime, cefepime, or ceftazidime, each in combination with metronidazole; gentamicin or tobramycin, each in combination with metronidazole or clindamycin, and with or without ampicillin	Cefazolin, cefuroxime, ceftriaxone, cefotaxime, ciprofloxacin, or levofloxacin, each in combination with metronidazole[a]	Cefepime, ceftazidime, ciprofloxacin, or levofloxacin, each in combination with metronidazole[a]

[a]Because of increasing resistance of *E. coli* to fluoroquinolones, local population susceptibility profiles and, if available, isolate susceptibility should be reviewed.

From Solomkin JS, Mazuski JE, Bradley JS, et al. Diagnosis and management of complicated intra-abdominal infection in adults and children: guidelines by the Surgical Infection Society and the Infectious Diseases Society of America. *Clin Infect Dis* 2010;50(2):133–64, by permission of Oxford University Press.

If yeasts are identified on a Gram stain, additional therapy for *Candida* sp. may be considered. The failure to provide adequate antimicrobial therapy in such patients has been repeatedly associated with an increased incidence of therapeutic failure, and in some cases increased mortality. Numerous prospective, blinded, and randomized trials have compared regimens active against routine isolates of *Enterococcus* for community-associated infections. In at least six of these studies, the comparator regimen did not have similar coverage. None of these trials demonstrated an advantage to treatment for enterococci. There is no evidence that routine use of agents effective against enterococci improves outcome from community-associated infections, but the presence of this organism appears to increase failure rates in selected patient groups, primarily those with high severity infections. Isolation of staphylococci and yeast are quite uncommon in patients with community-associated intra-abdominal infections, and use of agents with effective methicillin resistant staphylococci and yeast is not indicated in the absence of evidence that such organisms are involved in the infection.

Broad-Spectrum Antimicrobial Therapy for Severe Community-Associated Infection

Recommended empiric regimens for patients with biliary and nonbiliary community-associated intra-abdominal infections are summarized in Tables 7.9 and 7.10. Several attempts have been made to identify clinical features in patients with complicated intra-abdominal infections that increase the risk of adverse outcomes. These analyses have identified parameters predictive of mortality rather than the risk of recurrent infection. These risk factors include higher APACHE II scores, poor

nutritional status, significant cardiovascular disease, and an inability to achieve adequate source control. Similarly, patients who are immunosuppressed by medical therapy for transplantation, cancer, or inflammatory disease are at higher risk of an adverse outcome. Prolonged prehospital length of stay (>5 days) and prolonged (>2 days) preoperative antimicrobial therapy are significant predictors of failure from recurrent infection. Patients with other acute and chronic diseases may also be immunosuppressed, although this is difficult to define. Intraoperative cultures, including cultures from percutaneous drainage procedures, are therefore central to the prescribing of definitive therapeutic regimens for these patients, and may allow de-escalation to less broad-spectrum therapy.

TABLE 7.10 Initial Empirical Antimicrobials for Biliary Complicated Intra-Abdominal Infection

Infection	Regimen
Community-acquired acute cholecystitis of mild-to-moderate severity	Cefazolin, cefuroxime, or ceftriaxone
Community-acquired acute cholecystitis of severe physiologic disturbance, advanced age, or immunocompromised state	Imipenem-cilastatin, meropenem, doripenem, piperacillin-tazobactam, ciprofloxacin, levofloxacin, or cefepime, each in combination with metronidazole[a]
Acute cholangitis following bilioenteric anastamosis of any severity	Imipenem-cilastatin, meropenem, doripenem, piperacillin-tazobactam, ciprofloxacin, levofloxacin, or cefepime, each in combination with metronidazole[a]
Health care–associated biliary infection of any severity	Imipenem-cilastatin, meropenem, doripenem, piperacillin-tazobactam, ciprofloxacin, levofloxacin, or cefepime, each in combination with metronidazole, vancomycin added to each regimen[a]

[a]Because of increasing resistance of *E. coli* to fluoroquinolones, local population susceptibility profiles and, if available, isolate susceptibility should be reviewed.
From Solomkin JS, Mazuski JE, Bradley JS, et al. Diagnosis and management of complicated intra-abdominal infection in adults and children: guidelines by the Surgical Infection Society and the Infectious Diseases Society of America. *Clin Infect Dis* 2010;50(2):133–64, by permission of Oxford University Press.

In patients with such higher severity infections, the consequences of treatment failure may be more significant than in those patients with mild-to-moderate infections. The use of initial empiric antimicrobial regimens that are subsequently identified as lacking in in vitro activity against the

organisms actually isolated from the intra-abdominal infection has been associated with an increased need for additional source-control procedures and more aggressive antimicrobial therapy, increased hospital lengths of stay and costs, and increased mortality. As such, use of broader-spectrum agents providing activity and some gram-negative facultative and aerobic organisms occasionally isolated from such patients have the potential to improve outcome, although this hypothesis has not been rigorously examined in clinical trials.

In these cases, cultures and susceptibility tests are particularly important. The rationale for the widening of coverage to less common organisms is that the risk of treatment failure in such patients is higher and the consequences potentially greater. Increasing antimicrobial resistance with *B. fragilis* is similarly of concern, and there are data indicating higher failure rates if these organisms are treated with an inactive agent, particularly cefotetan and cefoxitin. No randomized clinical trials have been performed with this agent since resistance was first reported. Similarly, moxifloxacin use for the treatment of patients likely to have *B. fragilis* should be avoided if patients have recently received quinolone therapy, as organisms from such patients are likely to have quinolone-resistant isolates.

Local microbiology laboratories show great variation in reliably performing in vitro susceptibility tests. Sentinel studies of *B. fragilis*, the major pathogen, show uniform susceptibility to metronidazole, carbapenems, and β-lactam/β-lactamase inhibitors. Susceptibility testing of individual anaerobic isolates should be considered when there is persistent isolation of the organism, bacteremia, or when prolonged therapy is needed because of immunosuppression or prosthetic infection. Laboratories can purify and hold isolates for additional testing if requested by the clinician.

Antimicrobials in Patients With Health Care–Associated Intra-Abdominal Infections

Recommended empiric regimens for patients with health care–associated intra-abdominal infections include meropenem, imipenem/cilastatin, doripenem, piperacillin/tazobactam, ciprofloxacin plus metronidazole, ceftazidime or cefepime plus metronidazole, and aztreonam plus metronidazole plus vancomycin (Table 7.11). Empiric antibiotic therapy for hospital-acquired intra-abdominal infections should be guided by

knowledge of the flora seen at the particular hospital and their antimicrobial susceptibilities. In general, this will necessitate use of multidrug regimens with expanded spectra of activity against gram-negative aerobic and facultative bacilli, which may include aminoglycosides or colistin. Such broad-spectrum antimicrobial therapy should be tailored when culture and susceptibility reports become available to reduce the number and spectra of administered agents.

HAIs are commonly caused by a more resistant flora, which may include the nonfermenting gram-negatives *Psuedomonas aeruginosa* and *Acinetobacter* sp., extended spectrum β-lactamase-producing *Klebsiella* and *E. coli*, *Enterobacter* sp., *Proteus* sp., MRSA, *enterococci*, and *Candida* sp. For these infections, complex multidrug regimens are recommended because adequate empiric therapy appears important in determining postoperative complications and mortality. Failure to adequately treat resistant organisms has, in similar HAIs, been associated with increased death. Local resistance patterns of nosocomial isolates seen in the specific hospital should dictate empiric treatment, and treatment should be altered based upon a thorough microbiologic workup of infected fluid.

In infections occurring after elective or emergent operation, a more resistant flora is routinely encountered. The organisms seen are similar to those seen in other nosocomial infections, and anaerobes are not frequently important sources of resistant organisms. The selection of antibiotics would be tailored according to the known nosocomial flora present at the institution where the patient developed the infection.

TABLE 7.11 Recommendations for Empirical Antimicrobial Therapy for Health Care–Associated Complicated Intraabdominal Infection

Organisms Seen in Health Care–Associated Infection at the Local Institution	Regimen				
	Carbapenem[a]	Piperacillin-Tazobactam	Ceftazidime or Cefepime, Each With Metronidazole	Aminoglycoside	Vancomycin
<20% Resistant *Pseudomonas aeruginosa,* ESBL-producing Enterobacteriaceae, *Acinetobacter,* or other MDR GNB	Recommended	Recommended	Recommended	Not recommended	Not recommended
ESBL-producing Enterobacteriaceae	Recommended	Recommended	Not recommended	Recommended	Not recommended
P. aeruginosa >20% resistant to ceftazidime	Recommended	Recommended	Not recommended	Recommended	Not recommended
MRSA	Not recommended	Not recommended	Not recommended	Not recommended	Recommended

"Recommended" indicates that the listed agent or class is recommended for empiric use, before culture and susceptibility data are available, at institutions that encounter these isolates from other health care–associated infections. These may be unit- or hospital-specific.
[a]Imipenem-cilastatin, meropenem, or doripenem.
ESBL, extended-spectrum β-lactamase; GNB, gram-negative bacilli; MDR, multidrug resistant; MRSA, methicillin-resistant *Staphylococcus aureus.*
From Solomkin JS, Mazuski JE, Bradley JS, et al. Diagnosis and management of complicated intra-abdominal infection in adults and children: guidelines by the Surgical Infection Society and the Infectious Diseases Society of America. *Clin Infect Dis* 2010;50(2):133–64, by permission of Oxford University Press.

Fungal infection has been the subject of recent guidelines from the Infectious Diseases Society of America. *Candida albicans* or other fungi are cultured from about 20% of patients with acute perforations of the gastrointestinal tract. Even when fungi are recovered, antifungal agents are unnecessary in adults unless the patient has recently received immunosuppressive therapy for neoplasm or has a perforation of a gastric ulcer on acid suppression or malignancy, transplantation, or inflammatory disease, or has postoperative or recurrent intra-abdominal infection. In neonates with necrotizing enterocolitis, Candida is not uncommon, and is more likely to represent a true pathogen than in previously healthy adults. Nonetheless, in the listed settings Candida is associated with increased mortality. Patients with health care–associated intra-abdominal infections are at higher risk for Candida peritonitis, particularly those with recurrent gastrointestinal perforations and surgically treated pancreatic infections.

Preemptive antifungal therapy with fluconazole may decrease the incidence of Candida peritonitis in such high-risk patients. There has been an evolution of the species of Candida seen in candidemia and candida peritonitis. Because of its high susceptibility to fluconazole, *C. albicans* has decreased in frequency and *C. glabrata* and other species have become somewhat more common. This observation, coupled with the common use of fluconazole prophylaxis in the ICU, suggests empiric use of echinocandins (caspofungin, anidulafungin, micafungin).

Certain patient groups are at particularly high risk for a poor outcome because of enterococcal infection, and include (i) immunocompromised patients, (ii) patients with health care–associated postoperative peritonitis,

(iii) patients with severe sepsis of abdominal origin who have previously received cephalosporins and other broad spectrum antibiotics selecting for *Enterococcus* spp., and (iv) patients with peritonitis and valvular heart disease or prosthetic intravascular material, which place them at high risk of endocarditis.

Isolation of *Enterococcus* is more common in patients with nosocomial intra-abdominal infections, particularly those with postoperative infections, and its isolation is a risk factor for treatment failure and death. Thus, in patients with health care associated intra-abdominal infections, including those with postoperative infections, a reasonable option would be to include coverage of Enterococcus in the empiric regimen, until definitive culture results are available. Ampicillin and vancomycin are agents that have activity against this organism, and could be added to a regimen lacking anti-enterococcal activity. Specific risk factors for vancomycin-resistant enterococci have been detailed, which center upon transmission from other colonized or infected patients in an epidemic manner.

MRSA isolates are recovered from patients with postoperative infections, pancreatic infections, and tertiary peritonitis. MRSA is not commonly isolated from patients with community-acquired intra-abdominal infections. There are no specific data with regard to antibiotic preferences in treatment of intra-abdominal infections because of MRSA. In general, vancomycin has been used to treat infections caused by this organism. Other antibiotics including quinupristin/dalfopristin, linezolid, daptomycin, and tigecycline have in vitro activity against methicillin-resistant staphylococci, but there are little published data regarding their efficacy in the treatment of patients with intra-abdominal infections. Thus, vancomycin should probably remain the first-line agent, with use of the others restricted to situations in which vancomycin cannot be used because of severe adverse reactions or when initial therapy with vancomycin is thought to have failed.

Pharmacokinetic and Pharmacodynamic Considerations in Intra-Abdominal Sepsis

Pharmacokinetic–pharmacodynamic properties of specific antibiotics should be considered in selecting an adequate dosing regimen. Antimicrobial dosing considerations are needed in critically ill patients. Physiologic changes can occur in both of these patient populations, which

may alter the apparent volume of distribution or clearance of commonly used antibiotics. In addition, if the estimate of a dosage regimen is dependent on renal function, an accurate estimate of creatinine clearance (CLCR) based on serum creatinine values and body weight may be difficult with commonly used equations and direct measurement of CLCR may be required. For β-lactams and aminoglycosides, the critically ill patient with the early stages of sepsis may have shifts in body fluid and be in hypermetabolic state, resulting in an increase in both, volume of distribution and clearance and lower serum antibiotic concentrations. These studies suggest that higher doses and more frequent administration of β-lactams may be needed in selected patients who are critically ill, with altered distribution and increased clearance of renally excreted antibiotics. Initial dosing regimens for aminoglycosides and vancomycin should be based on adjusted body weight and total body weight, respectively. Serum drug concentration monitoring is recommended for dosage individualization of aminoglycosides and vancomycin in these patient populations. There is considerable evidence that less frequent dosing of metronidazole, in particular, is effective. The metronidazoles are bactericidal through toxic metabolites, which cause DNA strand breakage. Resistance, both clinical and microbiologic, has been described only rarely. Liver disease leads to a decreased clearance of metronidazole and dosage reduction is recommended.

A duration of therapy no greater than 1 week was appropriate for most patients with intra-abdominal infections, with the exception of those who had inadequate source control. Within this window, resolution of clinical signs of infection provides the termination point for antimicrobial therapy. The risk of subsequent treatment failure appears to be quite low in patients who have no clinical evidence of infection at the time of cessation of antimicrobial therapy. This usually implies that the patients are afebrile, have normal white blood cell counts, and are tolerating an oral diet. These conditions are unlikely to occur in a critically ill patient in the ICU who is suffering from a postoperative infection with multisystem organ failure. These patients display persistent or recurrent signs of peritoneal irritation, failure of bowel function to return, or continued fever or leukocytosis, and are at high risk for an intra-abdominal or other infection that may require additional intervention to achieve source control. CT of the abdomen is usually the most accurate method by which to diagnose an ongoing or recurrent intra-abdominal infection. The possibility of an extra-abdominal

infection, such as nosocomial pneumonia or urinary tract infection, or a noninfectious cause of fever or leukocytosis, such as venous thrombosis or a pulmonary embolism, should also be considered. For complex patients in the ICU, with multiple organ failures, CT scans may be the only means to determine if conditions for cessation of therapy (no defined collections) are met.

Antimicrobial regimens should be adjusted according to the results of the diagnostic investigations. For patients with a confirmed intra-abdominal infection, this may require broadening the regimen to include agents with activity against health care–associated organisms typically isolated with these infections. Appropriate antimicrobial therapy, based upon cultures of the infected site, should be continued while the investigation proceeds, particularly if the patient manifests signs of sepsis, such as organ dysfunction. The current state of the art would be to terminate antimicrobial therapy and observe for worsening of the overall clinical condition of the patient. If the patient continues to be relatively stable, therapy should not be resumed unless a documented source is identified.

De-Escalation Approach for Polymicrobial Infections

It has been recommended that the two-stage approach of using initial broad spectrum therapy followed by de-escalation allows serious infection to be treated promptly, at the same time effectively avoiding antibiotic overuse and averting potential resistance. The concept in the likelihood of colonization with resistant microorganisms could be minimized by reducing antimicrobial exposure in patients is attractive. However, when clinicians treating critically ill patients with polymicrobial infection, decision to de-escalate is not so straightforward and often it is a tricky decision. Simply because the margin of error in ill patients is not wide, patients may deteriorate rapidly and fastidious organisms are often difficult to culture and identified. Anaerobic microorganism may not grow if sample collection, transport medium, and culture techniques are incorrect.

As it stands, surgeons managing intensive care patients are facing tremendous challenges in combating sepsis in critically ill patients. Moreover, current evidence on the safety and effectiveness of antimicrobial de-escalation in severe sepsis and septic shock patients is feeble and inadequate. Consensus on de-escalation in this group of patients

has yet to be reached. Existing data and literature have varied definition and elements on de-escalation strategy. More studies with consistency in definition and defined elements of de-escalation must be aligned to polymicrobial infection to answer the question. Elements such as when to switch from combination therapy to monotherapy, cessation of vancomycin, cessation of antimicrobial therapy, and using consistent and reliable end-points measures are equally helpful for studies comparison.

Data are available on bio-marker guiding antimicrobial therapy for pneumonia but not for polymicrobial infection in sick surgical patients. The search for bio-markers to guide de-escalation in surgical patients with polymicrobial infections should be one of our investigators agenda. Given the current situation, surgeons have to exercise their complex clinical judgment by weighing all the relevant information ranging from the possible pathogenic microorganisms with the likelihood of bacteria that are not reported in the culture as well, the antibiogram of the local institutions, dosage and frequency adjustment according to patients' physiology and pathology, the risks and benefits of combination therapy versus monotherapy and short versus extended duration therapy. Whether pathogen-based approach is more superior to severity-based approach and risk factors based approach in de-escalation is still every clinician conundrum. More randomized controlled trials are needed to address many of these unanswered questions before surgeons will know whether they are truly treating the patients rather than merely treating themselves.

Although the concept of de-escalation of antimicrobials in medical practice has gained strong support with current data and clinical evidence, the actual recipes as to when to de-escalate, how best to do it, mono or double therapy, duration of therapy remain elusive. This is even more so for polymicrobial infection in surgical patients. In the context of downsizing to fewer targeted and adequate antimicrobials, the pivotal elements in antimicrobial de-escalation are use of targeted antimicrobials in adequate dosage, reducing the duration of therapy, and stop as soon as bacterial eradication is evidenced. Even in the mid of its limitation and unresolved issues, surgeons are mindful that timely, appropriate, and adequate use of antimicrobials has significant impact on the morbidity and mortality of their surgical patients at hands, and de-escalation strategy assures excellent surgical outcomes in the future through the preservation of the antimicrobial effectiveness and retardation of bacterial resistance by limiting the antimicrobial exposure. The recommendation for de-escalation

of antimicrobial therapy remains compelling even though good-quality randomized control trials on this issue are lacking.

Newer Antimicrobial Agents

Ceftolozane/tazobactamis a novel second-generation cephalosporin β-lactam/β-lactamase combination antibiotic that retains activity against ESBL-producing *Enterobacteriaceae*. Ceftazidime/avibactam is another recently approved second-generation β-lactam/β-lactamase combination antibiotic with the added advantage of having activity against multidrug resistant *Pseudomonas aeruginosa*. Ceftazidime/avibactam plus metronidazole was also noninferior to meropenem in the treatment of complicated intra-abdominal infections. Efficacy was similar against infections caused by ceftazidime-susceptible and ceftazidime-resistant pathogens. The safety profile of ceftazidime-avibactam plus metronidazole was consistent with that previously observed with ceftazidime alone.

Both ceftolozane/tazobactam and ceftazidime/avibactam have suboptimal activity against *Bacteroides* species and, therefore, should be prescribed together with metronidazole for complicated intraabdominal infections. Baseline resistance to these novel antibiotics is present, and testing for sensitivity is therefore recommended. These antibiotics should be reserved for infections caused by known or strongly suspected gram-negative multidrug resistant organisms as widespread use will likely lead quickly to the development of further resistance.

Surgical Interventions and Nonoperative Procedures

Source control can be achieved either by radiologic-guided percutaneous drainage, endoscopic procedures, laparoscopic operations, or surgical intervention. With the availability of interventional radiology expertise, percutaneous drainage in selected patients is effective with cure rates of 62% to 91%. It also has acceptable morbidity and mortality rates. The technique in percutaneous drainage is dictated by the site and size of the abscess. In general, extraperitoneal approach is preferred to transperitoneal approach in accessing the abscess cavity for drainage because it minimizes the risk of peritoneum contamination and peritonitis. While localized intra-abdominal and liver abscess are indications for percutaneous drainage, the source of the infection must be identified. Acute cholangitis is no longer a surgical emergency as the biliary tract could be successfully decompressed and drained by endoscopic or radiology-guided percutaneous techniques.

Despite advances in nonoperative procedures, surgery remains an indispensable therapeutic armamentarium in the management of intra-abdominal source of infections.

With the availability of high-resolution imaging, the source of infection is rarely misdiagnosed. In situation, when the diagnosis on the source of infection is dubious, diagnostic laparoscopy may assist in determining the etiology of peritonitis, for instance, the uncertainty of right-lower-quadrant pathology in female patients. At the present day, exploratory laparotomy can rarely be justified in the management of complicated intra-abdominal infection.

Decision on the choice of procedure is influenced by a multitude of factors, ranging from anatomical source of infection, extent of peritoneal contamination and inflammation, metabolic response to sepsis to patient's comorbidity and general conditions. Surgical interventions to control the source of infection vary from debridement of necrotic tissue and simple repair of perforated viscus to resection of infected organ, bowel resection of ischemic gut or traumatic perforations. In general, the three fundamental principles are (1) drainage of abscesses; (2) debridement of nonviable or infected tissues; and (3) restoring physiologic function and anatomy, managing anatomic abnormality that causes the ongoing microbial contamination. Common conditions encountered in clinical practice that may require surgical interventions are colonic diverticular perforation, gastroduodenal perforation, acute appendicitis, acute emphysematous cholecystitis, acute perforated diverticulitis, peritonitis following blunt and penetrating abdominal injury.

Timing of Source of Control

To optimize clinical outcome, the source of infection must be addressed timely. Timing is issue. Delayed intervention is as unsatisfactory as inadequate drainage of the source of infection. The surgical maxim of "doing too little too early and doing too much too late" should be borne in mind. Timing and adequacy of source control are important prognostic factors in the management of intra-abdominal infections. Therefore, adequate and timely intervention has a positive impact on the outcome and conversely delayed in source control correlates with poor outcomes.

Adequacy of Source Control

The definition of adequacy of source control is based on the degree of

certainty of source control or the temporal relationship between the presumed acquisition of source control and the subsequent therapeutic intervention. For abdominal infections, adequate source control means drainage, lavage, repair of perforation, resection, restoring bowel continuity, exteriorization and closure of abdomen. Therapeutic antimicrobial therapy works best when the source of infection is adequately controlled by these interventions.

Adequacy of source control is an independent predictor of good clinical outcome. If clinical improvement is not witnessed within 24 to 72 hours following source control, inadequacy of drainage should be suspected. Search for extra-abdominal and intra-abdominal infection is warranted when patients have persistent signs of infection or fail to improve clinically. The principal reason for inadequate source control is misdiagnosis of the magnitude, extent, complexity, location of the abscess, or source of infection. Patients initially have percutaneous drainage and do not improve clinically should be reimaged to reevaluate the adequacy of source control. CT scan of the abdomen and tube sinogram to delineate the size of the residual source of infection may be indicated. Laparoscopy or laparotomy may be indicated to look for a surgically correctable intra-abdominal disorder.

In stable patients, second attempt with percutaneous drainage may be appropriate unless it is judged to be ineffective and where surgical intervention is mandated. For those patients who deteriorate after the initial percutaneous drainage, operative intervention should be considered and carried out promptly if indicated. Any delay in making the decision to intervene early will result increase the morbidity and mortality.

Prognosis and Clinical Outcome

Early prognostic evaluation of complicated intra-abdominal infections is important to assess the severity and the prognosis of the disease. Prognostic factors in patients with complicated intra-abdominal sepsis include advanced age, poor nutrition, comorbidities, immune-suppression, generalized peritonitis, septicemic shock, inadequate source control, multiorgan failures, prolonged ICU and hospital stays, and nosocomial infection.

Scoring systems have been used to predict the clinical outcome more precisely. These scoring systems generally do not guide clinical decision in managing the patients; however, they provide useful data for quality and

audit reviews as well as standardized score for inter-hospitals comparison.

Currently, there are broadly two groups of scoring systems—the disease-independent scores and peritonitis-specific scores for evaluation of critically ill patients requiring intensive medical care.

An example of disease-independent score is APACHE II. Mannheim peritonitis index (MPI) and Simplified Acute Physiology Score (SAPS II) are examples of peritonitis-specific score. The limitation of APACHE II in peritonitis evaluation is that it does not take into consideration the interventions that might significantly alter many of the physiologic variables and consequently the final score. The MPI, on the other hand, is specific for peritonitis evaluation. Moreover, its calculation is straightforward and the reliability in risk evaluation and classification for patients with peritonitis has been validated by Billing et al.

Skin and Soft Tissue Infection (SSTI)

SSTIs are among the most common bacterial infections in humans. They represent one of the most common indications for antibiotic treatment. SSTIs have a broad range of etiology, clinical manifestation, and severity. At one end of the spectrum, the outcome may be spontaneous resolution without antibiotics, but at the other end, it may present with sepsis with lethal outcome.

SSTI is one of the frequent focus for severe sepsis or septic shock, after pneumonia and abdominal infections. US Food and Drug Administration's (FDA) classification differentiates between uncomplicated and complicated SSTI according to the extent of infection. Classes 2, 3, and 4 are classified as complicated SSTI (Table 7.12). The complicated group is characterized by either deep soft tissue involvement with signs of systemic sepsis, severe immunosuppression in patients, or the necessity for major surgical intervention.

Useful classifications are those that differentiate SSTI according to urgency of surgical intervention. Three categories can be differentiated: infections treated conservatively (e.g., erysipelas), infections with the need for surgical intervention (e.g., infective diabetic foot), and severe SSTIs that require urgent surgery (e.g., necrotizing fasciitis).

TABLE 7.12 Classification of Skin and Soft-Tissue Infections

Class	Clinical Presentation of Patient With Skin Infection
Class 1	Localized infection, no signs or symptoms of systemic toxicity; afebrile and healthy, other than cellulitis
Class 2	Febrile and ill-appearing
Class 3	Toxic appearance or at least one unstable comorbidity
Class 4	Sepsis syndrome or life-threatening infection

Complicated Skin and Soft Tissue Infections (cSSTI)

The FDA defines the term "complicated skin and skin structure infections" according to the following three criteria. First, advanced infection that requires an extensive surgical intervention such as debridement on devitalized tissue, abscess drainage, removal of foreign bodies that facilitate infection, and operative fascia incision. Second, the infection process shows evidence of deeper soft tissue, fascia or muscle involvement. Third, severe concomitant systemic and/or localized disease is present that prevents an adequate response to therapy. These diseases are, among others, diabetes mellitus, bacteremia, cellulitis with more than 3% of the body surface area involvement, steroid therapy more than 7.5 mg per day prednisolone equivalent, neutropenia (granulocytes $<500/mm^3$), Child-Pugh classification B or C liver cirrhosis, burns more than 10% body surface area, local or systemic radiation therapy, history of alcoholism more than 6 months, orthotopic organ transplant recipients, malnutrition, and immunosuppressive therapy.

Common cSSTIs are listed in Table 7.13. Many of the deep-seated subcutaneous tissue infections are classified as complicated SSTIs, such as suppurative hidradenitis, deep or extensive subcutaneous abscesses, furuncle or carbuncle, acne inversa, anal abscess, iatrogenic injection abscesses, inguinal injection abscesses in intravenous drug abusers, SSIs, self-inflicted injury, diabetic foot syndrome, necrotizing fasciitis types I and II, clostridial myonecrosis, scalp phlegmon, pressure or decubitus ulcer, and radiation damage.

TABLE 7.13 Common Complicated Skin and Soft-Tissue Infections

Secondary infections of diseased skin
Acute wound infections (traumatic, bite-related, postoperative)
Chronic wound infections (diabetic foot infections, venous stasis ulcers, pressure sores)
Perianal cellulitis with or without abscess
Deeper soft tissue infections, or those that require surgical intervention
Infected ulcers, burns, major abscesses, and superficial infections or abscesses with a high risk of an anaerobic or gram-negative pathogen

Microbiology in cSSTIs

The two most pathogenic agents in SSTI are *S. aureus* and Group A *Streptococci.* Besides these gram-positive bacteria, SSTI can be caused by a multitude of other bacterial agents, including gram-negative enterococci and anaerobic bacteria with necrotizing, gangrenous infections, and those close to the trunk as well as bite injuries. More than half of all SSTIs were caused by staphylococcal or streptococcal species.

The bacteriology ranges from garden variety bacteria to resistant bacteria, which primarily are MRSA, VRE, ESBL-producing bacteria, and carbapenem-resistant strains. Similar to complicated intra-abdominal infection, in the recent decades, an increase trend in infections caused by multidrug resistant pathogens has been observed in both hospital- and community-acquired complicated skin and soft-tissue infections.

The causative pathogens associated with SSIs in US hospitals have changed over the past two decades. Importantly, community-acquired MRSA (CA-MRSA) is frequently isolated in cSSTI and necrotizing STI. Such epidemiologic shift toward drug-resistant pathogens in the context of limited number of currently available effective antimicrobial agents poses significant problems in managing seriously ill patients inflicted with complicated SSTI.

Antimicrobial Therapy

The therapeutic recommendations for cSSTIs are summarized in Table 7.14. We will now briefly discuss recently approved antibiotics useful in the treatment of such infections. Oritavancin is a long-acting antibiotic with activity against MRSA. It lends itself to the treatment of cSSTIs in the outpatient setting as only one single infusion is necessary for treatment. Telavancin is a semisynthetic, lipoglycopeptide antibiotic with similar efficacy to vancomycin. It also has a similar side effect profile with a comparable to possibly higher risk of nephrotoxicity. Its advantage lies in the once-daily dosing, which may simplify outpatient therapy in selected patients. Lastly, tedizolid is an oxazolidinone antibiotic similar to linezolid in its activity and efficacy. Advantages are provided by its once-daily dosing and by being a much weaker inhibitor of monoamine oxidase compared to linezolid. This probably confers a substantially lower risk of serotonin syndrome in patients using selective serotonin reuptake inhibitors (SSRIs).

TABLE 7.14 Recommendation for Antimicrobial Therapy for cSSTI

	Nonpurulent	Purulent
	Necrotizing Infection/ Cellulitis/Erisepelas	Furuncle/Carbuncle/Abscess
MILD	Oral Penicillin VK Oral Cephalosporin Oral Docloxacillin Oral Clindamycin	Surgical Drainage ■ Culture and sensitivity of CA-MRSA suspected
MODERATE	IV Penicillin IV Ceftriaxone IV Cefazolin IV Clindamycin	Surgical Drainage + Culture & Sensitivity *Empirical Therapy* ■ TMP/SMX ■ Doxycycline *Definitive Therapy* 1. MRSA ■ TMP/SMX ■ Tedizolid 2. MSSA ■ Doxycycline
SEVERE	Emergent Surgical Debridement Nonnecrotizing Infection *Empirical Therapy* ■ Vancomycin ■ Pip/Tazo *Definitive Therapy* **1. Monomicrobial** ■ *S. pyogenes* & *Clostridial*spp – Penicillin + Clindamycin ■ Vibrio vulnificus – Doxycycline + Ceftazidime ■ Aeromonas – Doxycycline + Ciprofloxacin **2. Polymicrobial** ■ Pip/Tao + Vancomycin	Surgical Drainage + Culture & Sensitivity *Empirical Therapy* ■ Vancomycin ■ Daptomycin ■ Linezolid ■ Tedizolid ■ Telavancin ■ Ceftaroline *Definitive Therapy* **1. MRSA** ■ Vancomycin ■ Daptomycin ■ Linezolid ■ Tedizolid ■ Telavancin ■ Oritavancin ■ Ceftaroline **2. MSSA** ■ Nafcillin ■ Clindamycin ■ Cefazolin

Principles of Surgical Intervention

Surgical debridement is the gold standard in managing cSSTI because it can reduce the risk of wound complications and facilitate the natural healing process. It is one of the central strategies in the management of cSSTIs. Aggressive surgical debridement is crucial to prevent progressive tissue destruction while repetitive surgical debridement may be indicated

to minimize the risk of mortality or limb amputation. The rationale for debridement is that by removing the dead tissue, which acts as a nidus of infection and also a rich culture medium for colonized bacteria to multiply, particularly anaerobic *Bacteroides* species, the source of infection is controlled, conditions for wound healing are optimized, and the risk of sepsis is minimized. Furthermore, most cSSTI wounds are difficult to assess unless all the devitalized tissue is removed to reveal the healthy underneath anatomy.

The surgical principle in debridement is that all gangrenous, necrotic, ischemic and devitalized tissues must be debrided. Care should be exercised to handle the tissue gently without causing unnecessary tissue devascularization and injury to the noninfected vital tissues or anatomical structures. Debride till healthy and well-vascularized tissue is witnessed. In situation of uncertainly of the extent of debridement, iterative surgical debridement to allow the tissue to demarcate itself is commonly practiced.

Necrotizing Soft Tissue Infection (STI)

Necrotizing STI is a life-threatening and rapidly progressive soft tissue infection caused by usually gas-forming bacteria. It carries a high mortality about 25%. The infection involves the superficial or deep fascia and extends rapidly along subcutaneous tissue planes. Necrosis of the subcutaneous tissues is common in necrotizing fasciitis, due to thrombosis of dermal vessels following inflammation of the deep fascia. The skin and underlying muscles are relatively spared. Those patients with myonecrosis, the prognosis is significantly worse.

Clinical presentation may be nonspecific. Pain may be out of proportion to the clinical findings. Clinical signs, if present, are diffuse erythema, marked edema, and livid geographical lesions with central necrosis. Cutaneous findings may be lacking. For this reason, misdiagnosis and delayed diagnosis resulting in spreading infection with subsequent septic complications are not uncommon. To the unwary, the extent of infection and severity may be initially unrecognized. High index of suspicion and clinical vigilance are needed to avoid misdiagnosing this challenging clinical entity late. Ecchymosis and blistering of the skin with and without tense and tender soft tissues may be the only early signs. Clear clinical anatomical boundaries or limit of infection in necrotizing fasciitis is often absence. Although radiology using CT or MRI may expedite making the diagnosis, frequently, the diagnosis is only confirmed following surgical

debridement. Whenever the diagnosis is dubious and clinical suspicion is high, surgical exploration or an incision over the suspected site in the operation theatre is indicated.

Early diagnosis followed by prompt surgical debridement, appropriate intravenous antibiotics, intensive care medical support, and analgesia are the cornerstones of effective therapy. Necrotizing fasciitis is a surgical emergency. Reiterative surgical debridement at 24 hourly or shorter interval is usually indicated to achieve the source control. Occasionally, amputation may be necessary to save life. In some cases, useful adjunctive therapies such as hyperbaric oxygen therapy, negative pressure dressing, and intravenous immunoglobulins may be considered.

Microbiologically, polymicrobial organisms involving *Staphylococcus* sp., *Streptococcus* sp., and anaerobes are the commonest. MRSA should be suspected in patients with HAI. a-hemolytic *Streptococcus pyogenes* is cultured in some patients with necrotizing STI. Other microorganisms responsible for necrotizing STI are clostridium, vibrio, and fungus.

Fournier Gangrene

Fournier gangrene is a form of necrotizing fasciitis. It was first described by the French Jean Alfred Fournier in 1883. It occurs in the fascial compartments of the pelvis, Colles', Dartos', and Buck's fascia, by polymicrobial organisms from the urogenital tract and perineal infections. It may spread to the penis and scrotum via Buck's and Dartos' fascii, or to the anterior abdominal wall via Scarpa fascia, or vice versa. The spread and progress of the infection are limited by the anatomy of Colles' fascia that is attached to the perineal body and urogenital diaphragm posteriorly and to the pubic rami laterally. Testicular involvement is rare because of the independent blood supply directly from the aorta. The common causative microorganisms are *Streptococcal* species, *Staphylococcal* species, *Enterobacteriaceae*, anaerobic organisms, and fungi.

cSSTI in Immunosuppressed Patients

Managing SSTIs in patients with immunosuppression called for special attention. Unusual and diverse pathogens, including fungi such as cryptococcosis or histoplasmosis, have to be considered. Infections often progress rapidly to become life-threatening. Establishing a diagnosis and performing susceptibility testing are crucial because empiric treatment regime may be ineffective due to drug resistance among gram-positive and

gram-negative bacteria in these patients.

Acute Bacterial Skin and Skin Structure Infection (ABSSSI)

An ABSSSI is defined as bacterial infection of the skin with a lesion size area of at least 75 $cm^{2.}$ It is measured by area of redness, edema, or induration. The minimum area of involvement is 75 cm^2. The quantitative size is chosen to select patients with acute bacterial skin infections for which a reliable control drug treatment effect can be estimated. ABSSSIs are common and encompass a variety of disease presentations and severity. It may be complicated or uncomplicated. With this definition, minor cutaneous abscess (<75 cm^2) can be distinguished from major cutaneous abscess (>75 cm^2), which is defined as an infection characterized by collection of pus within the dermis or deeper that is accompanied by redness, edema and /or induration.

The FDA classifies the uncomplicated category to include simple abscesses, impetiginous lesions, furuncles, and cellulitis. These are mainly caused by *S. aureus* and *S. pyogenes.* The complicated category includes infections either involving deeper soft tissue or requiring significant surgical intervention, such as infected ulcers, burns, and major abscesses or a significant underlying disease state that complicates the response to treatment. Superficial infections or abscesses in an anatomical site, such as the rectal area, where the risk of anaerobic or gram-negative pathogen involvement is higher, also should be considered complicated infections.

The mainstays of treatment continue to be appropriate antimicrobial therapy combined with prompt surgical intervention.

CONCLUSION

There have been important changes in the epidemiology of SSI in the United States and elsewhere in the world since the publication of the previous SSI prevention guideline in 1999. These include changes in risk factors for SSI, particularly the increased resistance and virulence of infecting organisms and the increasing use of surgical procedures in vulnerable patients at risk for infections due to underlying diseases such as obesity and diabetes. There have also been new insights into microbial mechanisms of infection as well as the mechanisms by which some disease processes lead to increased rates of infection. These developments warrant review and revision of previous recommendations for the prevention of SSI.

Antibiotics Stewardship Program has transformed the entire health care landscape, changing once opinion-based practice to evidence-based practice with the primary goal of delivery outcome-based health care end points. Improving the use of antibiotics and managing the microorganism ecology through antibiotics stewardship program are a common goal shared by both the surgical and medical disciplines. We all have the same mission.

In treating surgical infection, the fundamental principles revolve around timely and correct diagnosis, timely administration of appropriate and adequate antimicrobial therapy, and adequate and timely source control of the infection in conjunction with physiologic support. Sound knowledge, skills and experience in critical care medicine, diagnostic and interventional radiology, endoscopy, surgery, infectology medicine, antimicrobial pharmacology, and therapy are needed to deliver excellent outcomes to each patient with surgical infection.

Suggested Readings

Allegranzi B, Bischoff P, de Jonge S, et al. New WHO recommendations on pre-operative measures for surgical site infection prevention: an evidence-based global perspective. *Lancet Infect Dis* 2016;16(12):276–87.

Allegranzi B, Zayed B, Bischoff P, et al. New WHO recommendations on intraoperative and postoperative measures for surgical site infection prevention: an evidence-based global perspective. *Lancet Infect Dis* 2016;16(12):288–303.

Assink-de Jong E, de Lange DW, van Oers JA, et al. Stop Antibiotics on guidance of Procalcitonin Study (SAPS): a randomised prospective multicenter investigator-initiated trial to analyse whether daily measurements of procalcitonin versus a standard-of-care approach can safely shorten antibiotic duration in intensive care unit patients - calculated sample size: 1816 patients. *BMC Infect Dis* 2013;13:178.

Bratzler DW, Dellinger EP, Olsen KM, et al. Clinical practice guidelines for antimicrobial prophylaxis in surgery. *Surg Infect* 2013;14(1):73–156.

Bratzler DW, Dellinger EP, Olsen KM, et al. Clinical practice guidelines for antimicrobial prophylaxis in surgery. *Am J Health Syst Pharm* 2013;70(3):195–283.

Crawford T, Rodvold KA, Solomkin JS. Vancomycin for surgical prophylaxis? *Clin Infect Dis* 2012;54(10):1474–9.

Dellit TH, Owens RC, McGowan JE Jr, et al. Infectious Diseases Society of America and the Society for Healthcare Epidemiology of America guidelines for developing an institutional program to enhance antimicrobial stewardship. *Clin*

Infect Dis 2007;44(2):159–77.

Jakobsen L, Kuhn KG, Hansen F, et al. Fecal carriage of extended-spectrum and AmpC β-lactamase-producing Enterobacteriaceae in surgical patients before and after antibiotic prophylaxis. *Diagn Microbiol Infect Dis* 2016;86(3):316–21.

Mangram AJ, Horan TC, Pearson ML, et al. Hospital Infection Control Practices Advisory Committee. Guideline for prevention of surgical site infection, 1999. *Infect Control Hosp Epidemiol* 1999;20(4):250–78.

Montravers P, Augustin P, Grall N, et al. Characteristics and outcomes of anti-infective de-escalation during health care-associated intra-abdominal infections. *Critical Care* 2016;20:83.

Sartelli M, Weber DG, Ruppe E, et al. Antimicrobials: a global alliance for optimizing their rational use in intra-abdominal infection (AGORA). *World J Emerg Surg* 2016;11:33.

Sievert DM, Ricks P, Edwards JR, et al.; National Healthcare Safety Network (NHSN) Team and Participating NHSN Facilities. Antimicrobial-resistant pathogens associated with healthcare-associated infections: summary of data reported to the National Healthcare Safety Network at the Centers for Disease Control and Prevention, 2009–2010. *Infect Control Hosp Epidemiol* 2013;34:1–14.

The Joint Commission on Hospital Accreditation. New antimicrobial stewardship standard. *Jt Comm Perspect* 2016;36(7):1,3–4,8.

Umscheid CA, Agarwal RK, Brennan PJ. Updating the guideline development methodology of the Healthcare Infection Control Practices Advisory Committee (HICPAC). *Am J Infect Control* 2010;38:264–73.

Xue DQ, Qian C, Yang L, Wang XF. Risk factors for surgical site infections after breast surgery: a systematic review and meta-analysis. *Eur J Surg Oncol* 2012;38:375–81.

EDITOR'S COMMENT

The authors present an excellent overview of contemporary antibiotic prophylaxis and treatment of surgical infection. I think the most important points are:

1. Methods of prevention of SSI
2. The importance of an effective antibiotic stewardship program.
3. Antibiotic selection
4. Intra-abdominal infection and source control
5. Complicated skin and soft tissue infection

Methods of SSI Prevention

Multiple recommendations exist for the prevention of SSI. These are of various evidential strength. Table 7.7 comparing CDC and WHO guidelines is very helpful. First there is conditional evidence of moderate quality that preoperative bathing can reduce SSI. Either a plain soap or an antimicrobial soap can be used for this purpose. Although some centers use CHG-impregnated cloths for the purpose of reducing SSI, it is supported by only low-quality evidence. In addition, there is strong evidence that supports patients undergoing cardiothoracic procedures and orthopedic surgery with known nasal carriage of *S. aureus* should receive perioperative intranasal applications of mupirocin 2% ointment with or without a combination of CHG body wash. In our institution we recommend preoperative nasal screening cultures for *S. aureus* (MRSA and MSSA) be collected on patients undergoing the following high-risk surgeries:

- All Cardiothoracic surgeries (CABG, valves, VADs, heart/lung transplants, etc.)
- Craniotomy, Laminectomy, Spinal Fusion, VP Shunt Placement (not for angiograms)
- Total Hip, Total Knee, and Total Shoulder Replacements, Geriatric Fractures

These cultures should be obtained not less than 3 days or more than 4 weeks prior to the operation. If MSSA or MRSA positive, we recommend starting mupirocin 2% nasal ointment to both nares BID × 5 days (total 10 doses). Treatment should be started at least 2 days before surgery or as soon as possible if surgery is imminent and continued in the postoperative period until treatment is complete. In addition, if MRSA is positive then contact isolation should be ordered. If MSSA is identified on nasal screening then Cefazolin 2 g is recommended preoperatively and if MRSA is identified then we recommend adding vancomycin to the prophylactic regimen.

An area of debate is whether there should be changes in your standard protocols if your hospital has a high prevalence (>10%) of extended spectrum beta lactamase producing bacteria. There is a lack of strong evidence to currently support any medication in prophylactic regimens and hence this is not recommended at this point in time.

The timing of administration of antibiotics prior to the surgical incision has strong supporting evidence. The antibiotic should be administered within 120 minutes of the incision. In our institution we recommend starting prophylactic antibiotics such as cefazolin within 60 minutes prior to incision and vancomycin, Cipro, and fluconazole 60 to 120 minutes prior to incision.

There is no strong evidence to support antibiotic irrigation, application of antimicrobial agents to incisions, application of autologous platelet-rich plasma, the use of antibiotic coated sutures or antimicrobial dressings.

There is evidence to support glycemic control, normothermia in prevention of infection. The data for increased oxygenation administration is less clear.

Antibiotic Stewardship

The loss of effective antibiotics profoundly impacts the practice of surgery. The days of being able to count on antibiotic prophylaxis to prevent postoperative infections are quickly disappearing due to the emergence of multidrug-resistant organisms. Antibiotic resistance limits the efficacy of antibiotic prophylaxis thereby leading to worse outcomes in surgical patients. A 30% reduction in the efficacy of antibiotic prophylaxis would result in 120,000 additional infections per year in the United States and 6,300 infection-related deaths. This in part has led to the development of antimicrobial stewardship programs.

Antimicrobial stewardship is a coordinated multidisciplinary program that promotes the appropriate use of antimicrobials (including antibiotics), improves patient outcomes, reduces microbial resistance, and decreases the spread of infections caused by multidrug-resistant organisms. The multidisciplinary team consisting of infectious diseases (ID) physicians, pharmacists, microbiologists, epidemiologists, and frequently a data manager.

Initially, antibiotic stewardship was more focused on cost savings. Physicians and surgeons responded negatively to that, because they often felt it was best to give patients the newest medication. While these programs do save hospitals' money, their most important benefit is that they improve patient outcomes and reduce the emergence of antibiotic resistance. More and more hospitals have developed these programs. The goal is to ensure the selection of the right antibiotic, at the right dose, for the right duration in order to cure infection while minimizing toxicity and emergence of resistance.

Antibiotic Selection

Appropriate antibiotic selection is critical to the treatment of infection. Hospital antibiograms are commonly used to help guide empiric antimicrobial treatment and are an important component of detecting and monitoring trends in antimicrobial resistance. Every surgeon should be familiar with the antibiogram for their unit and hospital. The hospital antibiogram is a periodic summary of antimicrobial susceptibilities of local bacterial isolates submitted to the hospital's clinical microbiology laboratory. Antibiograms are often used to assess local susceptibility rates, as an aid in selecting empiric antibiotic therapy, and in monitoring resistance trends over time within an institution. These can also be used to compare susceptibility rates across institutions and track resistance trends. Institutions may have developed antibiograms for specific units such as the intensive care unit or surgical services. To be effective antibiograms must be constructed using standardized methods that allow inter- and intrahospital comparisons. Antibiograms have several limitations, such as their inability to track emergence of resistance during therapy. The antibiogram can serve as a valuable tool in guiding antimicrobial therapy, but other patient factors, such as previous infection history and antibiotic use, also need to be considered.

In the initial selection of antibiotics it is helpful for the surgeon to use an antibiogram. Once cultures and sensitivities are determined the antibiotics can

be changed to a more specific and potentially more effective treatment.

Intra-Abdominal Infection and Source Control

The cornerstones of successful treatment of intra-abdominal infection are controlling the source of the infection and antibiotic therapy. In the treatment of complicated intra-abdominal infections, assessment of adequacy of the initial surgical approach to the management of the infection is of primary importance in determining outcome. Antibiotic therapy is not expected to adequately treat the infection if the surgical procedure was inadequate with respect to controlling the source of the infection. Both the timing and adequacy of source control are important. The most common source of infection in community-acquired intra-abdominal infections is the appendix, followed by the colon, and then the stomach. Anastomotic breakdown is a key cause in the postoperative patient.

Ultrasound and CT-guided percutaneous drainage of abdominal and extraperitoneal abscesses in selected patients are safe and effective. Numerous studies in the surgery and radiology literature have documented the effectiveness of percutaneous drainage in selected patients, with cure rates of 62% to 91% and with morbidity and mortality rates equivalent to those of surgical drainage. The principal cause for failure of percutaneous drainage however is misdiagnosis of the magnitude, extent, complexity, and location of the abscess. In these situations surgical exploration may be warranted. Surgical source control entails resection or suture of a diseased or perforated viscus (e.g., perorated duodenal ulcer), removal of the infected organ (e.g., appendix, gall bladder, sigmoid colon), debridement of necrotic tissue, resection of ischemic bowel and repair/resection of traumatic perforations. A laparotomy is best performed through a midline incision.

Complicated Skin and Soft Tissue Infections

The key to successful treatment is early diagnosis, debridement, and appropriate antibiotic therapy. Cellulitis can be deceptive and want appear as a superficial soft tissue infection may in fact be a deep infection and an early sign of necrotizing fasciitis. A high index of suspicion and early axial imaging with CT and in some cases MRI may be helpful. Source control is critical and may require multiple procedures for successful debridement. Antibiotic coverage should be broad spectrum and include aerobic and anaerobic coverage. As streptococcal species play a major role in necrotizing fasciitis penicillin or similar medications are important to consider. Clearly therapy should be guided by cultures.

Biomarkers to Monitor Antibiotic Therapy

It is important to continue antibiotic treatment for an appropriate duration. Making this decision is not easy. Clinical response with resolution of fever, tachycardia, and local signs of pain and redness are good indicators of

successful treatment as well as normalization of the white blood cell count. These indicators often lag behind other biomarkers or be less accurate than other biomarkers in determining treatment duration.

Over the last decade, the biomarkers and C-reactive protein (CRP) and procalcitonin (PCL) have gained interest in sepsis research to enhance diagnosis as well as monitoring and guiding antibiotic therapy. In particular both of these biomarkers may help determine when it is appropriate to discontinue antibiotic. Whether these markers are better predictors of successful treatment than the white blood cell count or clinical to monitor antibiotic therapy has not been determined with certainty. However, several randomized controlled trials (RCTs) have shown the safety and efficacy of measuring CRP and procalcitonin levels to guide discontinuation of antibiotic therapy in patients with severe sepsis or septic shock.

CRP is a general acute-phase reactant protein that rises in concentration up to 1,000-fold in the blood in response to inflammation and infection. Studies have shown CRP to be highly sensitive and also highly specific for infection. However, it is unclear if CRP can be used to distinguish gram-positive from gram-negative bacterial infections. CRP has also been studied as a diagnostic marker for other illnesses. A recent study on community-acquired pneumonia showed CRP as a prognostic marker in determining the severity of community-acquired pneumonia and the need for hospitalization when using a value of 110 mg/L. In some studies there is evidence that antibiotics may be monitored with CRP levels. However, the levels and decision points are highly variable in the literature. There is some evidence that a CRP level less than 60 mg/L when combined with other clinical indicators can be used as a point to determine when antibiotics can be discontinued or switched to an oral route.

Procalcitonin (PCT), a precursor to the hormone calcitonin, is another candidate biomarker for bacterial infection. It is reported to be present at very low concentrations of 0.033 ng/mL in the serum of healthy individuals and is known to increase by up to 1,000-fold under inflammatory conditions. It is reported to rise within 2 to 4 hours of infection and peak at 6 to 8 hours. Persistent elevated levels are indicative of persistent infection or sepsis. Procalcitonin has been shown to have high diagnostic accuracy for bacterial infection. Similar to the studies on CRP, there is variation in sensitivity and specificity. However, as a biomarker for bacterial infection, most studies find PCT to be a useful and accurate biomarker and more useful than other common inflammatory markers. Indeed it is an accurate biomarker for anastomotic leak in colon surgery. Several studies have reported significantly elevated levels of PCT in patients with sepsis compared with those without sepsis. Studies have also reported PCT being used as a prognostic marker indicating that levels of PCT are a good indicator of response to treatment severity of sepsis and mortality from sepsis. PCT has demonstrated utility in the risk stratification of patients with potential life-threatening bacterial infections. In addition, PCT has been documented as having a role in reducing the rate of unnecessary antibiotics

while positively impacting antibiotic resistance rates and cost savings. With greater emphasis on antimicrobial stewardship and cost it behooves surgeons to seek improved methods of monitoring response to antibiotic therapy that is likely to include biomarkers.

E. Christopher Ellison

8 Multiple Organ Dysfunction Syndrome: Prevention and Clinical Management

David J. Dries

ETIOLOGY AND PATHOPHYSIOLOGY

Evolution of a Concept

Multiple organ failure (MOF) emerged in the 1970s as a result of advances in resuscitation and intensive care unit (ICU) technology resulting in survival of single organ failure. The epidemiology of multiple organ failure continues to change as management strategies evolve. In the late 1970s, reports by a variety of surgical investigators promoted the belief that multiple organ failure resulted from uncontrolled infection and research was focused on infection-driven multiple organ failure. Throughout the 1980s, infection became less common due to advances in surgery and intensive care management, including initial care for abdominal trauma, better use of perioperative antibiotics, and earlier diagnosis of postoperative intra-abdominal infection with drainage via computerized tomography.

At the same time, reports from Europe demonstrated that multiple organ failure could occur after blunt trauma without infection. Initially, this phenomenon was termed sepsis syndrome because patients appeared to be septic but had no obvious source of infection. Etiology of this sepsis syndrome remained unclear. As shock was a frequent early event in these patients, ischemia with reperfusion was an attractive mechanistic explanation. Other studies implicated the gut as the source of bacteria or bacterial products that produced the sepsis syndrome. Trials testing selective gut decontamination and early enteral nutrition found decreased rates of nosocomial infection with gut-directed therapy. This clinical work was supported by experimental data favoring bacterial translocation as a unifying mechanism characterizing noninfection-induced multiple organ failure.

By the mid-1990s, sepsis syndrome had evolved into the systemic inflammatory response syndrome (SIRS). SIRS was presumed to be inherently beneficial; however, if exaggerated, SIRS could progress to multiple organ failure independent of infection. More recent research suggests that SIRS in the absence of obvious microbial infection represents host response to a noninfectious insult and tissue injury with the release of endogenous mediators that serve as “danger signals.” Tissue damage, per se, releases molecules that can stimulate innate immunity through sensing systems including toll-like receptors. Noninfectious insults can elicit exaggerated inflammation through the same pathways used by microbial pathogens and produce similar SIRS.

Additional work in the 1990s revealed that multiple organ failure occurred early or late in the course of patients in the surgical intensive care unit (SICU). Two different patterns of SIRS induced early multiple organ failure. In one model, a massive initial insult culminated in fulminant SIRS and multiple organ failure, while in a “two-hit” setting, resuscitating severe injury with SIRS followed by an early second inflammatory insult (blood transfusion, infection, aspiration, orthopedic intervention) amplified SIRS to induce multiple organ failure. This was believed to be due to priming and activation of the innate immune response (neutrophil-medicated). In this two-hit model, SIRS was followed by delayed immunosuppression associated with late infection that appeared to precipitate later multiple organ failure (7 to 10 days).

Research after the turn of the millennium revealed that many interventions in the critical care unit (high tidal volume ventilation, large volume crystalloid resuscitation, liberal use of blood products, early parenteral nutrition, intermittent hemodialysis) were actually promoting nosocomial infection and late multiple organ failure. Over the last decade, with more consistent delivery of ICU care designed to minimize deleterious practices, abdominal compartment syndrome has become less frequent, death from traumatic shock-induced multiple organ failure has decreased substantially, and late multiple organ failure following trauma is much less common. Management strategies often require implementation of evidence-based operating procedures such as those demonstrated by the recent “Glue Grant” cohort, the Surviving Sepsis Campaign, and the ARDSNet. Despite the release of multicenter trials and generation of treatment strategies consistent with the weight of recent experimental work, low compliance with accepted treatment approaches is often noted

and outcomes are enhanced by strategies that improve compliance. Glue Grant participants found modest compliance with consensus protocols to be associated with a dramatic reduction in overall mortality from 22% before to 11% after protocol implementation.

A continuing problem is a large number of patients who linger in the critical care unit with manageable organ dysfunction but do not meet established criteria for late multiple organ failure. Clinical course of these patients is characterized by ongoing catabolism with poor nutrition status, inadequate wound healing, immunosuppression, and recurrent infection. These patients may be discharged to long-term care facilities but often develop secondary complications and are less likely to rehabilitate and return to functional life. Clinical management of patients with persistent inflammation and immunosuppression as they progress toward indolent death is one of the important contemporary challenges in surgical critical care.

With identification of proinflammatory cytokines and tumor necrosis factor in the 1980s, death, particularly from sepsis, was presumed to be caused by early, overabundant inflammatory response. Overproduction of proinflammatory mediators with neutrophil activation, endothelial injury, and tissue damage caused early multiple organ failure and led to death. There have been over 100 clinical trials of agents designed to block early proinflammatory response. The only Food and Drug Administration (FDA)-approved agent for severe sepsis and septic shock (activated Protein C) was voluntarily withdrawn from the market in late 2011 after failure of postmarketing clinical trials to confirm earlier outcome benefit. Anti-inflammatory approaches to sepsis may have failed because of treatments initiated hours after the onset of symptoms missed the early inflammatory mediator release and initiation of inflammatory cascades. This has been demonstrated in studies of early coagulopathy after trauma where a failing organ system is demonstrated in the field after injury and before standard interventions and diagnostic testing are feasible. In addition, redundancy of early inflammation made success of monotherapies unlikely.

The importance of immunosuppression was identified by Bone and other workers and initially termed compensatory anti-inflammatory response syndrome (CARS). CARS was described as an anti-inflammatory response characterized by increased appearance of anti-inflammatory cytokines and cytokine antagonists. Appearance of anti-inflammatory

cytokines was thought to be delayed when compared with early proinflammatory mediators. In patients with critical illness, concentrations of anti-inflammatory mediators were found to be increased for days and weeks, whereas proinflammatory cytokines seemed to disappear. In the 1990s, it was recognized that patients with sepsis and injury exhibited not only ongoing inflammation but also multiple defects in adaptive immunity. Many workers demonstrated that critical illness victims could not mount delayed type hypersensitivity response to common antigens and that T-cell proliferation was suppressed. CARS came to describe all shared defects in adaptive immunity that followed trauma and sepsis, including decreased antigen presentation, macrophage paralysis, depressed T-cell proliferation, increased lymphocyte and dendritic cell apoptosis, and shifts in T-cell phenotypes.

New data have led to the revision of the early proinflammatory to later anti-inflammatory SIRS to CARS sequence (Fig. 8.1). More recent reports suggest that production of anti- and proinflammatory cytokines actually occurs simultaneously. These findings and other work from the Glue Grant have generated a model to replace the classic SIRS–CARS construct. Persistent inflammation is characterized by persistent acute phase response, neutrophilia, increased immature granulocyte count, anemia, lymphopenia, and tachycardia. Although these patients are immunosuppressed, inflammation is also ongoing. The inflammation–immunosuppression process consumes energy derived from fat and protein catabolism, which has long been recognized as a consequence of critical illness. Despite aggressive nutritional intervention, ongoing catabolism frequently results in the loss of lean body mass and decrease in functional status.

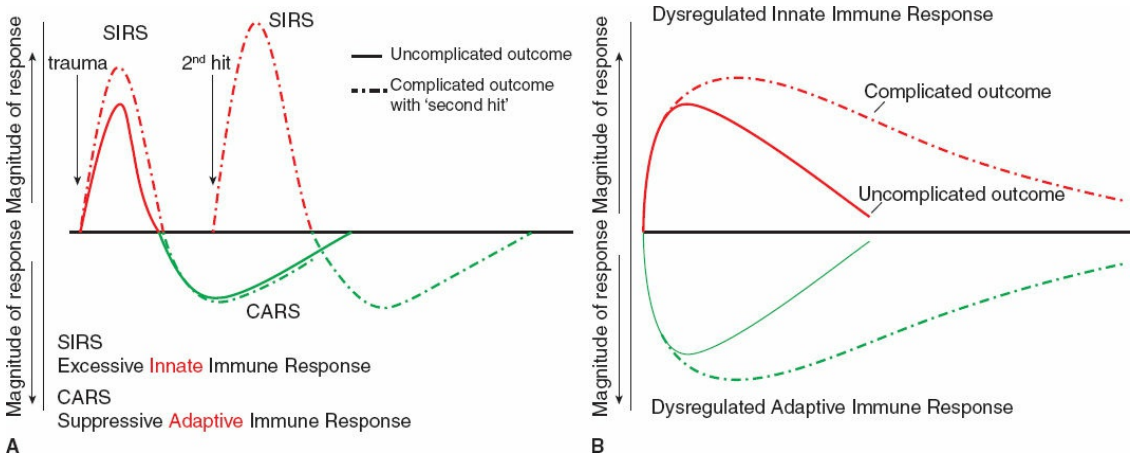

Figure 8.1. The genomic storm: refining the immune,

inflammatory paradigm in trauma. **A.** The current paradigm explains complications of severe injury as a result of excessive proinflammatory response (SIRS) followed temporally by CARS and suppression of adaptive immunity. A second hit phenomenon results from sequential insults, which lead to more severe recurrent SIRS and organ dysfunction. **B.** The proposed new paradigm involves simultaneous and rapid induction of innate (both proinflammatory and anti-inflammatory genes) and suppression of adaptive immunity genes. Complicated recoveries are delayed resulting in a prolonged dysregulated immune inflammatory state. (From Xiao W, Mindrinos MN, Seok J. et al. A genomic storm in critically injured humans. *J Exper Med* 2011;208(13):2581–90.)

The modern critical care unit effectively recognizes and manages the initial presentation of SIRS. Many patients survive their initial infection or emergency surgical insult only to encounter prolonged, complicated critical care stays. Contemporary emphasis has shifted beyond addressing exaggerated inflammation but identifying mechanisms of simultaneous immunosuppression, restoration of immune function, and, perhaps most important, prevention.

The Insult

Most clinicians know the innate immune response as inflammation. It is the first line of defence against pathogens that breech tissue barriers. Inflammation is nonspecific in that the response is the same for tissue injury and for the broad array of organisms that cause infection. Inflammation is distinct from adaptive immunity, but it is the first step in identification and processing of antigens that are critical for programming cellular and humoral responses.

The activation stimulus begins the inflammatory process (Fig. 8.2). Tissue injury, ischemia/reperfusion, and invasive infection result in disruption of both cells and the extracellular matrix. Micro- and macrocirculatory units are disrupted or thrombosed from injury or infection. Cellular contents are released, ischemic cells lose polarity and leak cytoplasmic proteins, collagen is exposed, and blood extravasates from the vascular compartment. The activation stimulus leads to important signals that initiate components of the inflammatory response. Tissue Factor, a protein residing on the surface of adventitial and perivascular

cells binds with coagulation system proteins to launch the intrinsic coagulation pathway. Exposed collagen and released adenosine diphosphate (ADP) serve to activate and aggregate platelets. Factor XII of the coagulation cascade is activated by contact with exposed tissue surfaces and by activated platelets to initiate the contact coagulation system.

The most important stimuli to activate inflammation are the Danger-Associated Molecular Patterns (DAMPs). DAMPs can be considered in two separate groups that are derived either intrinsically from host cells or extrinsically from pathogens. Alarmins are the DAMPs from the host, and they are typified by Human Mobility Box Group-1, which is an alarmin that is a normal nuclear protein released extracellularly with cell disruption or excreted by cells under stress. Other alarmins may be normal cellular constituents that are released with cellular necrosis or disruption or from cells in distress. A second group of exogenous DAMPs are the Pathogen-Associated Molecular Patterns (PAMPs). Representative PAMPs are structural or secreted products from pathogens found in injured or infected tissues. Alarmins and PAMPs bind to surface and intracellular receptors of myeloid cells and their derivatives to initiate the secretion of proinflammatory cytokine signals.

From the perspective of mediator production, the pathologic process of multiple organ dysfunction is composed of two phases. In the early phase, overproduction of numerous inflammatory mediators results in leukocyte and endothelial activation, increased endothelial permeability, and polymorphonuclear neutrophil adhesion and migration. Inflammatory cells in the spleen, liver, and bloodstream produce the first *"cytokine storm"* (Fig. 8.3).

In the second or later phase of multiple organ injury, intrinsic inflammatory cells in the interstitial compartment play an important role in the development of parenchymal injury. After adhesion to endothelium, activated leukocytes migrate to the interstitial space from postcapillary venules. Leukocytes, extravasated cytokines, and intrinsic inflammatory cells initiate and amplify inflammation in the interstitial space. As there are studies supporting organ dysfunction in the setting of leukopenia, high concentrations of selected cytokines in the interstitial space may prove directly toxic to vulnerable parenchyma (heart, skeletal muscle, etc.) and cytokines leaking into the bloodstream may induce remote organ injury by activating intrinsic inflammatory cells at those locations.

Within injured or infected tissue, a vasoactive response facilitates mobilization and infiltration of phagocytic cells. Vasodilation occurs as a consequence of bradykinin, histamine, and other local effects. Local vasodilatation increases blood flow to the area but slows flow velocity to accommodate margination of leukocytes. Increased permeability provides exit routes for marginated leukocytes to leave the intravascular compartment and enter injured or infected tissues. Edema is seen with this process. Chemokines contribute to leukocyte trafficking at this stage.

As the vasoactive phase progresses, the phagocytic phase begins. Neutrophils become adherent to the endothelial cells in the evolving site of inflammation. Upregulation of adhesion molecules on the surface of endothelial cells occurs in response to chemoattractants. Neutrophil-endothelial adherence results in margination of the phagocyte, and chemoattractant gradients provide direction for migration of neutrophils to the site of inflammation. Monocytes similarly migrate into the area, and proinflammatory cytokines are produced by monocytes and other cell populations. Among proinflammatory cytokines, Tumor Necrosis Factor, Interleukin-1, Interleukin-6, and others orchestrate the vigor of phagocytosis of pathogens or foreign bodies and the degradation or removal of dead host cells.

Unfortunately, containment of proinflammatory insults is not always achieved. The effects of necrotic cells, ischemia and reperfusion injury, and pathogenic bacteria causing infection may exceed the efficiency of the inflammatory response to achieve containment. Necrotic cellular elements, bacteria, bacterial products, bacterial toxins, alarmins, PAMPs, and other defined and undefined elements of local response gain systemic access in sufficient quantity to cause generalized inflammation. Failure of containment may reflect inadequate host response or quantity and virulence of the pathogen.

Lessons From Genetics

Data from the ongoing Glue Grant Trial demonstrate a consistent pattern of genome response after injury. Affected genes can be clustered into temporal patterns. First are genes that are shown to be upregulated as early as 12 hours after injury. This cluster of genes contains interleukin-1β and tumor necrosis factor-α. These genes recover to preinjury levels of expression within 24 hours of injury. Other genes recover to preinjury expression levels days to weeks after injury. IL-10 is an example of this

gene group. Some genes remain highly expressed even 28 days after injury. Compared to studies in normal volunteers, many genes that are highly expressed in healthy individuals are significantly downregulated after injury. In fact, more genes are downregulated relative to normal than are upregulated. The vast majority of gene expression changes occur within the first 24 hours after injury with the exception of a small proportion of genes with delayed maximum change in expression occurring days after injury.

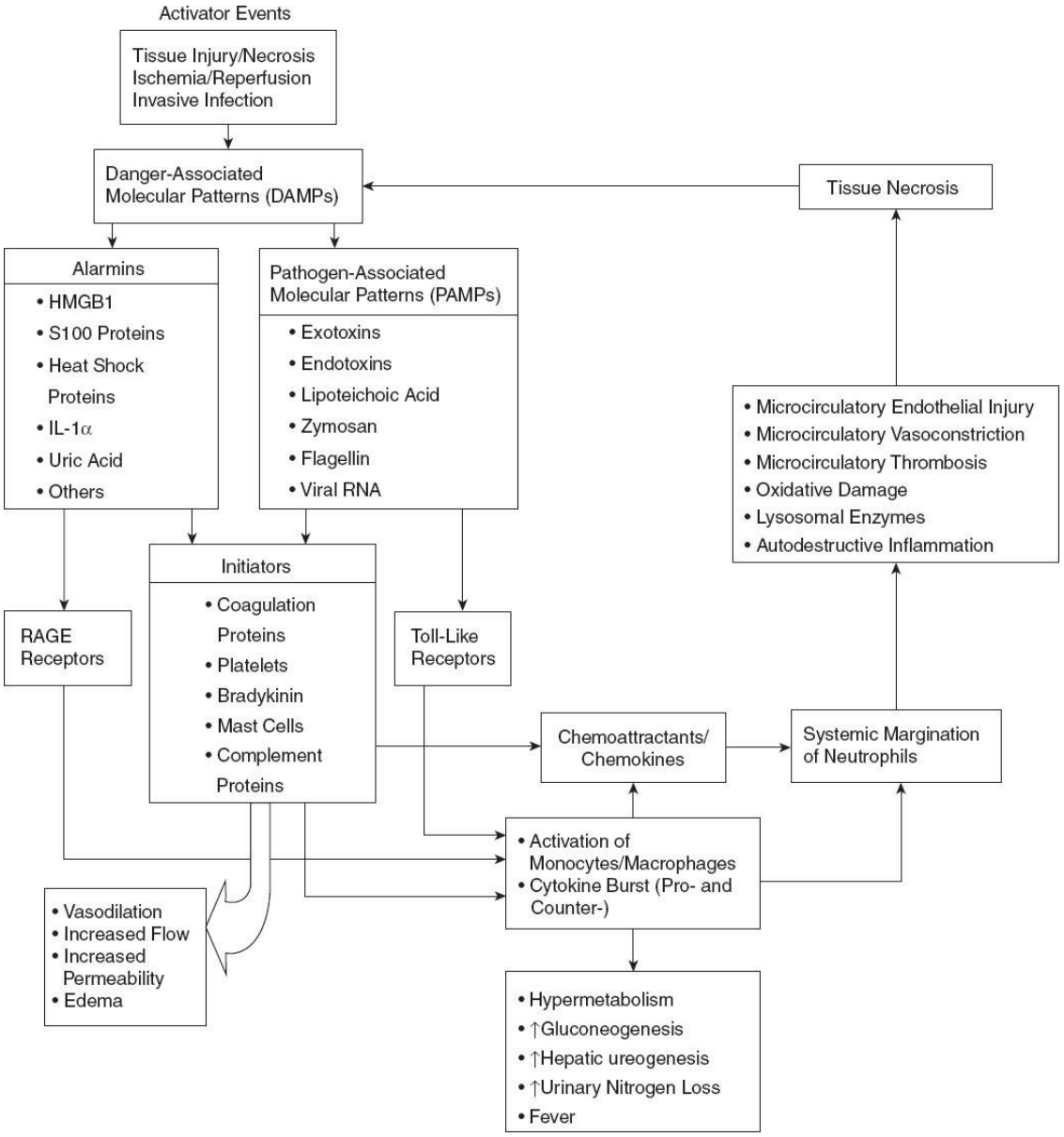

Figure 8.2. There are numerous components of the innate host response leading to SIRS and MODS. Release of danger-associated molecular patterns from damaged cells or bacteria results in binding to toll-like receptors, RAGE receptors, and activation of initiators of inflammation. Initiators lead to vasoactive changes in tissue and phase I of the inflammatory response. With systemic distribution of DAMPs, cytokines, and chemoattractants, the inflammatory cascade is activated on a systemic basis. Activation of leukocyte populations results in margination and activation at the site of injury and remote organs, which then leads to tissue damage from cellular products of leukocytes and consequences of damage to the microcirculation. Tissue ischemia and necrosis result in the release of additional DAMPs that perpetuate the process. A point may be reached where there has been resolution of the inciting event but the results of tissue

level inflammation provide the stimulus to repeat the entire cascade. (Republished with permission of Southeastern Surgical Congress from Fry DE. Sepsis, systemic inflammatory response, and multiple organ dysfunction: the mystery continues. *Am Surg* 2012;78:1–8; permission conveyed through Copyright Clearance Center, Inc.)

The Glue Grant examined two patient cohorts: uncomplicated patients simply responding to severe injury versus complicated patients responding not only to injury but also experiencing complications such as nosocomial infections and organ failure. Remarkably, the complicated and uncomplicated cohorts were not readily distinguishable by cytokine or white blood cell panels. Dozens of cytokine plasma concentrations were compared between complicated and uncomplicated patients. Only IL-6, IL-1 receptor antagonist, IL-8, and MCP-1 were different between the groups. No differences in white blood cell parameters were found between the complicated and uncomplicated cohorts. From over 1,000 genes that were significantly different by twofold for at least one time point, less than 100 genes were different between the complicated and uncomplicated cohorts at the twofold level at all time points studied. More than two thirds of these genes were directly related to protective immunity. Adaptive immunity studies showed suppression of genes involved in antigen presentation (e.g., HLA-DR), interferon and interferon-inducible genes. These HLA and interferon responsive genes downstream of the interferons were greatly suppressed in complicated patients relative to those genes in the uncomplicated patients. Thus, there are two distinct genomic patterns or signatures associated with different patient outcomes.

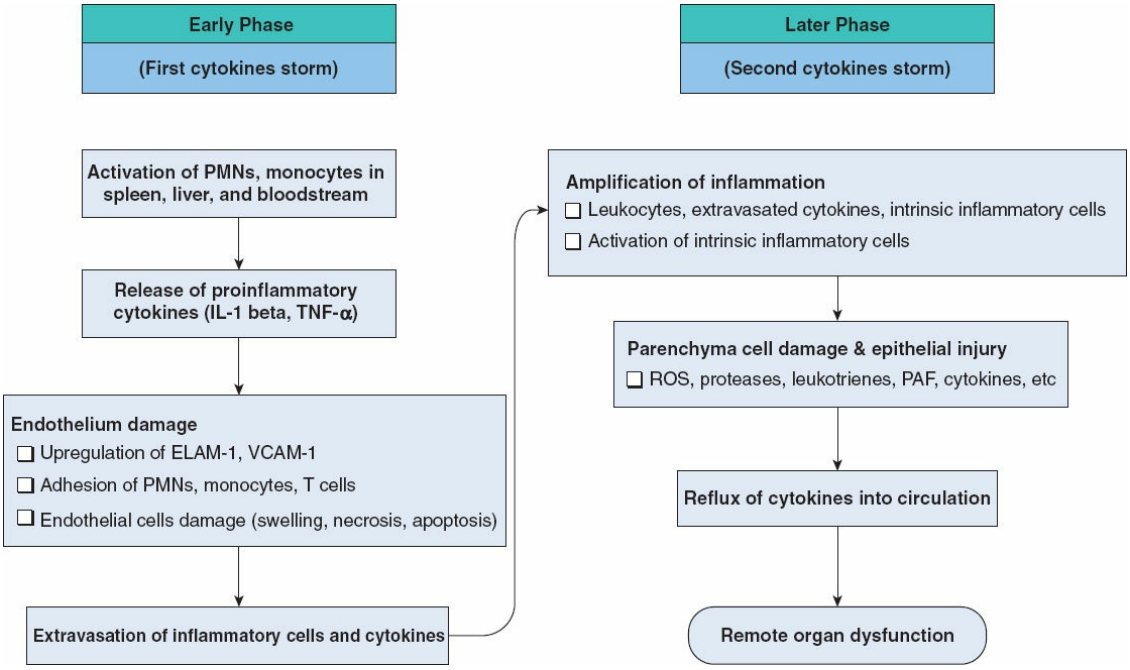

Figure 8.3. Main pathologic mechanisms in early and later phases of multiple organ dysfunction. ELAM-1, endothelial leukocyte adhesion molecule 1; PAF, platelet activating factor; TNF-α, tumor necrosis factor-α; VCAM-1, vascular cell adhesion molecule 1. (Reprinted from Wang H, Ma S. The cytokine storm and factors determining the sequence and severity of organ dysfunction in multiple organ dysfunction syndrome. *Am J Emerg Med* 2008;26(6):711–5. Copyright © 2008, with permission from Elsevier.)

When transcription is examined, there is an immediate genomic response causing upregulation of innate immune response and a downregulation of adaptive immune response. Transcription responses are triggered in the early hours after injury. These transcriptional changes are more dramatic and longer lasting in the complicated than in the uncomplicated patients. It is likely that these genomic changes translate into the phenotypic changes described as SIRS and CARS in critical care patients. The transcriptional responses leading to SIRS and CARS are simultaneous. The CARS response is not a compensatory response, and the transcriptional responses are continuous in nature and do not wax and wane. If an intervention to alter components of the innate immune or adaptive immune response is contemplated, it must be initiated very early after injury. At present, our management strategies cannot utilize the insight gleaned from molecular and genetic studies.

MANAGEMENT STRATEGIES

Fluids

The ideal resuscitation fluid should produce predictable sustained increase in intravascular volume and have chemical composition close to that of extracellular fluid. The ideal resuscitation fluid should also be metabolized and completely excreted without accumulation in tissue and not produce adverse metabolic or systemic effects. Finally, such a fluid should be cost-effective. Resuscitation fluids are broadly categorized into colloid and crystalloid solutions. Colloid solutions, of which the most popular is albumin, are suspensions of molecules that are relatively incapable of crossing healthy, semipermeable capillary membranes. Crystalloids are solutions of ions that are freely permeable but contain concentrations of sodium and chloride that determine the tonicity of the fluid.

A recent comparison of crystalloids and colloids is the Saline versus Albumin Fluid Evaluation (SAFE) study. No significant difference between albumin and saline was identified with respect to the rate of death or the development of new organ failure. Resuscitation with albumin was associated with a significant increase in the rate of death at 2 years among patients with traumatic brain injury. While a mechanism has not been demonstrated, this outcome has been referred to increased intracranial pressure, particularly during the first week after injury. Resuscitation with albumin was associated with a decrease in the adjusted risk of death at 28 days in patients with severe sepsis suggesting a potential, but unsubstantiated, benefit. No significant difference in hemodynamic resuscitation endpoints, such as mean arterial pressure or heart rate, was observed between albumin and saline groups, although the use of albumin was associated with a statistically significant but clinically small increase in central venous pressure (CVP). The ratio of volumes of albumin to saline administered to achieve comparable hemodynamic endpoints was 1:1.4. In acute illness, it appears that the hemodynamic reflects and effects on patient resuscitation outcomes for albumin are largely equivalent to those of saline.

The relative expense of human albumin has prompted development and increasing use of semisynthetic colloid solutions, particularly starches and gelatins. The use of high molecular weight starches may be associated with alterations in coagulation, specifically changes in viscoelastic measurements and fibrinolysis, although the clinical consequences of these effects in surgical patients are unclear. A recent Scandinavian study

reported that the use of 6% hydroxyethyl starch (HES) compared with Ringer's acetate was associated with a significant increase in the rate of death at 90 days and a significant relative increase in the rate of renal replacement therapy. Another large trial found that the use of 6% HES as compared to saline was not associated with a significant difference in the rate of death at 90 days but again, was associated with a significant relative increase in the need for renal replacement therapy. Whether these results are generalizable to the use of other semisynthetic colloids is unknown. In light of recent evidence of the lack of improved outcomes and potential nephrotoxicity, the use of semisynthetic colloids for fluid resuscitation in critically ill patients is not justified.

Among crystalloid solutions, sodium chloride is the most commonly used product on a global basis, particularly in the United States. Normal saline contains sodium and chloride in equal concentrations, which makes it isotonic as compared with extracellular fluid. Administration of large volumes of normal saline results in a hyperchloremic metabolic acidosis with adverse effects, including immune and renal dysfunction. Concern about sodium and water overload with saline resuscitation has resulted in the concept of small volume crystalloid administration with the use of hypertonic saline solutions. The early use of hypertonic saline for resuscitation has not improved short-term or longer-term outcomes. Given the concern regarding an excess of sodium chloride associated with normal saline administration, balanced salt solutions are increasingly recommended as first-line resuscitation fluids in patients undergoing surgery, victims of trauma, and patients with diabetic ketoacidosis. A recent comparison trial noted a significant decrease in the rate of major complications with the use of a calcium-free balanced salt solution (plasma-lyte) for replacement of fluid losses on the day of surgery in comparison to normal saline.

A number of observations can be made regarding fluids for resuscitation in critically ill patients. First, and most important, fluid should be considered with the same caution that is used with any intravenous drug. To avoid excessive administration of resuscitation fluid, catecholamine administration should be considered as concomitant treatment of shock. Fluid requirements change over time in the setting of critical illness. Excessive or prolonged fluid resuscitation is associated with pathologic edema and end organ dysfunction.

Blood Products

Hemorrhagic shock results in a significant rate of fatality in patients arriving at hospital with acute injury. Recognition of the morbidity associated with bleeding and coagulation changes can be traced to the 1960s. At that time, standard tests including prothrombin time and partial thromboplastin time correlated poorly with response of coagulation to acute resuscitation efforts. The American trauma community was drawn to coagulopathy after trauma with the description of the "*bloody vicious cycle*" by the Denver Health team over 20 years ago. These investigators noted the contribution of hypothermia, acidosis, and hemodilution associated with inadequate resuscitation and excessive use of crystalloids building on work of Lucas, Ledgerwood, and others. Subsequent work extended these observations describing early coagulopathy that could be independent of clotting factor deficiency.

Brohi and workers in the United Kingdom have reinvigorated this discussion after their observations regarding coagulopathy after injury by adding new laboratory techniques to earlier clinical observations (Fig. 8.4). These investigators emphasized the observation that acute coagulopathy could occur before significant fluid administration, which was attributable to injury itself and proportional to the volume of injured tissue. Development of coagulopathy was an independent predictor of poor outcome. Mediators associated with tissue trauma including humoral and cellular immune system activation with coagulation, fibrinolysis, complement and kallikrein cascades have since been associated with changes in hemostatic mechanisms similar to those identified in the setting of sepsis. A number of important cofactors must be present to stimulate coagulopathy in the setting of trauma. Shock is a dose-dependent cause of tissue hypoperfusion, and elevated base deficit has been associated with coagulopathy in as many as 25% of patients. Immediate postinjury coagulopathy is likely a combination of effects caused by large volume tissue trauma and hypoperfusion. Studies carefully examining the timing of blood component administration revealed that improved outcomes came with rapid administration of blood products in patients with clinical indications of significant bleeding featuring equivalent amounts of plasma, platelets, and red blood cells. Early administration of products is emphasized to minimize progression of coagulopathy and metabolic derangement associated with tissue hypoperfusion. One simple criterion for blood product administration is Class III shock as defined by the

American College of Surgeons and the *Advanced Trauma Life Support (ATLS) Program.*

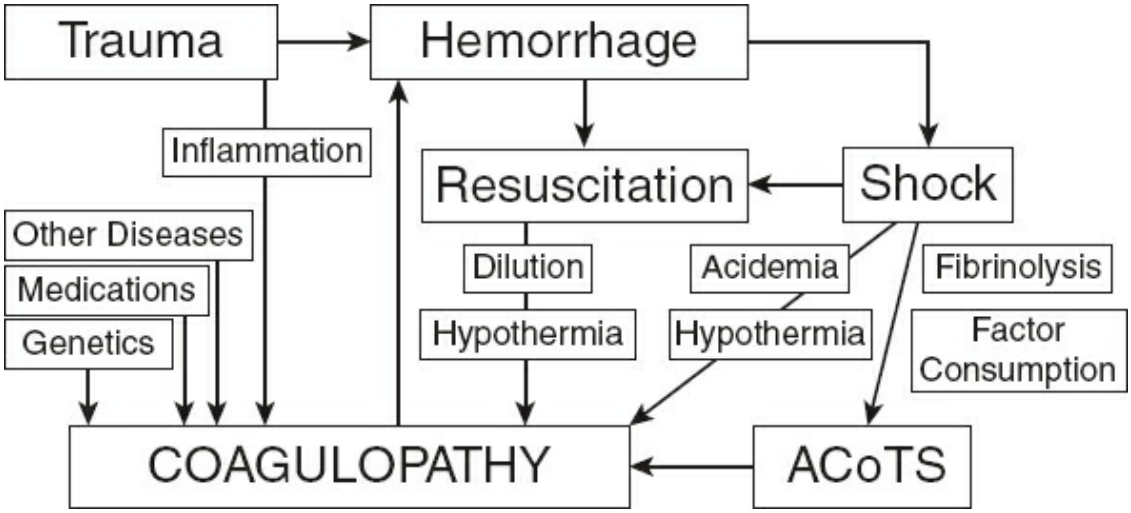

Figure 8.4. Mechanisms leading to coagulopathy in the injured. Trauma contributes to hemorrhage that requires resuscitation leading to dilution and hypothermia contributing to coagulopathy and further hemorrhage. Hemorrhage can also cause shock leading to acidosis and hypothermia with coagulopathy. Trauma and shock along with tissue injury contribute to the acute coagulopathy of trauma shock (ACoTS) with factor consumption and fibrinolysis. Coagulopathy is further associated with inflammation and modified by genetics, medications, and acquired disease. (From Hess JR, Brohi K, Dutton RP, et al. The coagulopathy of trauma: a review of mechanisms. *J Trauma* 2008;65:748–54.)

Endpoints of Resuscitation

Identification of normal hemodynamics is difficult in critically ill patients. Hemodynamic response is likely to be adequate when oxygen delivery to tissues is sufficient to maintain aerobic metabolism. This may occur in critical illness at values greater than or less than hemodynamic values considered normal in healthy subjects. In the setting of hypermetabolism, for example, cardiac output will be greater than normal to provide adequate oxygen delivery. On the contrary, when metabolic requirements are reduced such as with sleep or administration of neuromuscular blockade, aerobic metabolism may be realized with hemodynamic parameters lower than those considered normal in healthy subjects. Thus, hemodynamic response should be considered in the context of appropriate response of the patient.

Hemodynamic response becomes inadequate when signs of anaerobic metabolism appear despite activation of compensatory mechanisms normally maintaining homeostasis. Central venous oxygen saturation depends on oxygen delivery, appropriate match between oxygen consumption and metabolic requirements, and on cardiac output with the oxygen carrier (hemoglobin). Thus, all determinants of oxygen transport, as well as metabolic demand may influence central venous oxygen saturation making it a sensitive, though not specific, indicator of changes in respiratory, metabolic, cardiac, and hemoglobin status.

In normal conditions, the amount of oxygen extracted from the oxygen delivered is about 25%. Thus, central venous oxygen saturation is approximately 75%. The arbitrary recommended threshold of $ScvO_2$ used in multiple studies and in guidelines for sepsis management is 70%. $ScvO_2$ lower than the typical threshold is not necessarily associated with anaerobic metabolism. The most frequent reason for a low $ScvO_2$ in the critical care unit is cardiac failure. In the setting of cirrhosis or some phases of sepsis, $ScvO_2$ may be greater than 70% to 75%. Normal or higher than normal central venous oxygen saturation may be associated with abnormal hemodynamics caused by activation of compensatory mechanisms including the angiotensin–aldosterone system and vasopressin release. Failure of compensation is reflected by metabolic acidosis with increased plasma lactate concentration. Appearance of acidosis indicates the failure of tissues, which in the absence of correction may result in cellular and tissue death. The ultimate goal of hemodynamic support is maintenance of aerobic metabolism.

Clinical signs including thirst, skin turgor, blood pressure, and urine output are unreliable indices of intravascular volume status. Cardiac filling pressures including central venous pressure and pulmonary artery occlusion pressure are also poor predictors, although these tools and others, such as ultrasound, can be used to optimize pump performance. Heart–lung interaction during mechanical ventilation has more recently been used to evaluate variations in stroke volume, systolic pressure, and pulse pressure. Pulse pressure variation has been found to be predictive of a positive response to a fluid challenge. When hemodynamic changes are evaluated in the setting of cyclic increase or decrease of intrathoracic pressure during mechanical ventilation, change in left ventricular stroke volume of 12% to 13% has been reported predictive of volume responsiveness. These methods, however, are limited by the requirement

of specific tidal volume relationships to body weight and absence of vascular bed changes, spontaneous respiratory activity, and abnormality of cardiac rhythm.

SURGICAL TECHNIQUE

Damage Control Surgery

The major premise of damage control surgery is that the metabolic derangements associated with infection or ongoing bleeding supersede the need for definitive operation. Thus, the main thrust of damage control surgery is rapid surgical control of bleeding, the spillage of succus, and other sources of infection. Classic damage control begins with hemostasis and control of spillage of succus followed by transport to the critical care unit to address conditions of hypothermia, acidosis, and coagulopathy with subsequent return to the operating room for definitive repair of temporized injuries or body cavity closure.

In the case of laparotomy, a rapid midline incision is made with hemoperitoneum and clot removal, suture of bleeding points, packing as necessary, and other measures to control hemorrhage and contamination. Splenic and renal injuries are typically treated with rapid resection, nonbleeding pancreatic injuries are simply drained, and liver injuries typically are packed. Large vessel venous injuries including the inferior vena cava may be treated with ligation. Arterial injuries may be temporized with the placement of shunts with definitive repair to follow as the metabolic condition permits. Hollow viscus injury is managed with simple suture closure or rapid resection of the involved segment. No anastomoses are performed and ostomies are not matured. After control of surgical bleeding, fascia is left open. A variety of temporary dressings, including vacuum techniques, have been developed. These devices keep the skin dry, decrease the workload of the ICU nursing staff, and allow quantification of ongoing fluid or blood loss.

Techniques are also available for rapid control of bleeding or infection in other body regions. For example, damage control thoracotomy for pulmonary injury typically involves rapid tractotomy with suture ligation of bleeding vessels and rarely includes formal pulmonary resection. Injury to the hilum will usually require pneumonectomy for rapid control of hemorrhage. Extremity trauma in patients with multiple injuries usually involves ligation of venous injury and shunting of major arterial injury with external fixation for orthopedic stabilization. Improved outcomes

with damage control surgery have been accompanied by improved rates of recognition and earlier initiation of damage control measures, carefully targeted resuscitation, appropriate maintenance of body temperature, anticipation of blood loss, and avoidance of overresuscitation.

POSTOPERATIVE CARE

Key Interventions: Management of Analgesia and Sedation

One of the key recent developments in critical care management is consistent and coordinated management of pain, agitation/sedation, and delirium in an integrated and interdisciplinary fashion. Pain, agitation, and delirium (PAD) guidelines include tools for detection of over- and undersedation and delirium in the critically ill patients. PAD treatment strategies focus on approaches to management such as treatment of pain before administration of sedatives and maintaining a light level of sedation that allows patients to interact in a meaningful way with the critical care environment. Pain is assessed using standardized tools that, if possible, allow patients to self-report discomfort.

Agitation and anxiety also occur frequently in critically ill patients. Common causes of agitation and anxiety include untreated pain, delirium, hypoxemia, hypoglycemia, hypotension, or withdrawal from alcohol and other drugs. Sedation scoring systems have been developed to assess the degree of sedation and agitation. These scoring systems provide a basis for the use of sedatives in critically ill patients. Administration of sedatives without titration to specific scales generally results in oversedation. It is important to recognize that in the critically ill patients, even those who are mechanically ventilated, the need for sedative medications may be limited if pain is adequately managed. Patients managed with analgesia first have significant reductions in duration of mechanical ventilation and ICU length of stay. Opioids remain the primary analgesic of choice in critically ill patients with nonneuropathic pain. All intravenous opioids are equally effective at equipotent doses. Oral opioids may be variably absorbed with reduced bioavailability in the critically ill patients. Nonopioids, including nonsteroidal medications and ketamine, can provide adjunctive pain relief and reduce opioid requirements. First-line agents for neuropathic pain are gabapentin and carbamazepine.

Optimal sedation management includes use of sedatives only as needed while maintaining a light level of sedation. A level of consciousness allowing ICU patients to be responsive and aware is desirable. Sedative

choice in the critical care unit should be based upon recent data demonstrating reduced side effects and improved outcomes. For example, benzodiazepines, especially midazolam, are commonly employed in adult critical care patients followed by propofol and dexmedetomidine. Barbiturates, diazepam, and ketamine are rarely used for sedation in adults. Over the past decade, a growing body of evidence suggests that the use of intravenous benzodiazepines for sedation of critical care patients, particularly midazolam and lorazepam, is associated with a high risk of delirium relative to sedation with agents such as propofol and dexmedetomidine. Mechanical ventilation remains the major indication for administration of sedation. Ventilator weaning protocols including spontaneous breathing trials may significantly reduce the duration of mechanical ventilation and sedative use.

Delirium is characterized by acute onset of cerebral dysfunction with fluctuation in mental status, inattention, and either disorganized thinking or altered level of consciousness. Patients with delirium may be either agitated (hyperactive delirium), calm or lethargic (hypoactive delirium), or may fluctuate between the two subtypes. Hyperactive delirium is often associated with hallucinations and delusions, whereas hypoactive delirium is often characterized by confusion or somnolence and may be undetected. Delirium is common in critically ill patients. Up to 80% of critically ill patients exhibit delirium at some time during their ICU stay. The presence of delirium is associated with significant negative outcomes including prolonged mechanical ventilation and hospital length of stay. Delirium also increases postdischarge institutionalization, long-term cognitive dysfunction, and risk of death. Hypoactive delirium occurs more commonly than hyperactive delirium and is associated with longer duration of mechanical ventilation and ICU length of stay along with higher mortality risk than hyperactive delirium. Given the prevalence of this problem, all patients in the critical care unit should be screened for delirium.

The first step in managing delirium is to identify and eliminate contributing factors such as sepsis, shock states, glycemic dysregulation, electrolyte disorders, and hypoxia. Other factors contributing to delirium are inadequate pain management, drug withdrawal, discontinuation of psychiatric medications, exposure to deliriogenic medications, or adverse drug effects. Environmental factors including sleep deprivation, disorientation, and prolonged immobilization also contribute to delirium.

Delirium treatment should include nonpharmacologic and pharmacologic strategies with an emphasis on using nonpharmacologic interventions first. Proven nonpharamcologic delirium treatment strategies include frequent reorientation of patients, maintaining sleep–wake cycles, and advancing mobility during the day as tolerated. Pharmacologic management of delirium includes adequate analgesia, discontinuation of benzodiazepines except in patients with specific need for these medications, and resumption of any prior psychiatric medications. Drug withdrawal symptoms should be treated if suspected, and antipsychotics may be considered if needed. Haloperidol is the drug of choice to treat acute delirium. A management role for atypical antipsychotics is also being studied.

Prevention of PAD complications begins with awareness that any critical care procedure may be associated with a significant degree of pain. Procedural pain may trigger a significant stress response leading to hemodynamic instability, metabolic disorders, impaired wound healing, and increased risk of infection. Pain has significant short- and long-term psychological consequences, including sleep deprivation, persistent recollection (see posttraumatic stress disorder [PTSD]), and a higher likelihood of development of chronic pain.

Key Intervention: Mechanical Ventilation

With infrequent use of the pulmonary artery catheter (PAC), mechanical ventilation has become the defining modality of critical care practice. Low tidal volume ventilation and use of noninvasive ventilation after extubation and to manage chronic obstructive pulmonary disease (COPD) have strong evidence to support improved outcomes. Several precautions are needed to avoid iatrogenic complications related to mechanical ventilation. Among the first lessons of invasive mechanical ventilation was the deleterious effect of the endotracheal tube. This device not only increases airway resistance but also provides a pathway for infection and damages delicate tissues of the larynx and trachea. Accumulation of airway debris increases work of breathing, impairs gas exchange, and predisposes to bronchopulmonary infections. Better materials, lower cuff pressures, and improved nursing practices have addressed some of these problems. Noninvasive ventilation was born from the need to address complications related to invasive mechanical ventilation. With improving interfaces, noninvasive ventilation allows intubation avoidance, improved sleep quality, and safer treatment for patients with diverse cardiopulmonary

problems.

Few rules governing mechanical ventilation management apply across all phases and severities of illness. Choices must be conditioned by stage of illness and patient response. For example, high levels of PEEP are relatively helpful in the early stage of ARDS management when the lung is relatively wet and recruitable and benefit of PEEP application outweighs the hazard. Later in the course of ARDS, PEEP may simply increase peak and mean airway pressures increasing stress and tissue strain associated with a given tidal volume and creating dead space. Advisability of prone positioning may also be dependent on time and disease severity. Prone positioning appears to reduce mortality in those patients who are both severely affected by hypoxemic respiratory failure and in the early stage of illness.

It is also important to strike a balance between of benefits of spontaneous breathing and the dangers of oversedation and neuromuscular blockade. Ventilator-induced diaphragm dysfunction should be of concern when controlled ventilation is imposed for extended periods. Unlabored spontaneous patterns of breathing appear to be more mechanically efficient than are breaths administered to a passive patient. However, taking control of ventilation during the earliest phase of life-threatening sepsis and ARDS may enable reduction of potentially damaging mechanical forces arising from high cardiac output and minute ventilation. Brief use of muscle relaxants during the most vulnerable early period of illness is not associated with delayed neuromuscular recovery or with ventilator-associated diaphragmatic injury. On the other hand, sustained suppression of awareness by large doses of sedatives without periodic "*holidays*" increases the likelihood of prolonged mechanical ventilation, delirium, inability to wean, and adverse clinical outcomes.

Clinical trials offer guidance for mechanical ventilation prescriptions, which must be considered in context. For example, the simple rule of 6 mL/kg tidal volume based on predicted body weight, which is now seen frequently in daily practice, is not sufficient for all situations relating to body stature and ventilation demand. The guideline may need to be adjusted upward when patients are small and ventilation demands are high. This 6 mL/kg is also unsafe if tidal volume enters only a small aerated compartment. A tidal volume of 6 mL/kg, depending on aerated compartment capacity, may generate high local tidal volume and excessive transalveolar pressures with injury to the lung during passive inflation.

Physiologic need must also be considered in the prescription for mechanical ventilation. Employing a guideline-approved small tidal volume without addressing high minute ventilation (demand) may result in dyspnea and high breathing frequencies. Ventilation intensity should be reduced as possible along with patient demand for support. Controlling pain, agitation, body temperature, and metabolic acidosis are means to this end.

OUTCOMES

Disability After Critical Care

Critical illness is frequently a disabling process. In one popular model, diseases or injuries (*pathology*) result in dysfunction of body systems (*impairments*) leading to inability to perform basic physical and cognitive functions (*functional limitations*) altering the individual's capacity to meet demands of his or her environment (*disability*). Disability for activities of daily living is common after critical illness and has been noted in 33% to 58% of patients when follow-up occurred less than 3 months after index illness and 12% to 97% of patients for follow-up time points occurring more than 6 months after index illness. Multiple studies have reported newly developed dementia in 12% to 18% of patients assessed between 1 and 8 years after critical illness. Prevalent dementia was reported in 15% of patients at hospital discharge and in 10% of ICU survivors at 1-year follow-up. Mild to moderate cognitive impairment may be present in over 50% of patients.

Postcritical illness disability results from the interaction of baseline health status and vulnerability to the acute stress of critical illness with the effects of the acute illness itself and treatment practices during and after ICU admission. The focus on preventing disability lies with identification of critically ill patients who are at risk for developing or exacerbating disabilities and avoiding iatrogenic contributions to this postcritical illness insult.

Two of the most common and modifiable risk factors for subsequent functional and cognitive decline are immobility and delirium. Immobility is epidemic among hospitalized older adults with deleterious effects on subsequent physical and cognitive function. Delirium is among the strongest predictors of subsequent cognitive impairment. Both immobility and delirium magnify underlying age-related physiologic changes; thus, efforts to manage these insults may have substantial impact on postcritical

illness outcome.

ICU practitioners should assess functional and cognitive status of patients soon after admission with daily monitoring for potential changes. The ABCDE bundle has been recommended to reduce the harms associated with sedation, mechanical ventilation, delirium, and immobility in critically ill patients of all ages. Briefly, the ABCDE bundle includes daily spontaneous awakening and spontaneous breathing trial coordination (ABC), choosing to sedate patients only when necessary and to lighter levels (C), screening for delirium (D), and early mobilization with physical and occupational therapy (E). Implementation of the ABCDE bundle is independently associated with doubling the odds of a patient being mobilized and a 45% decrease in the odds of developing delirium. Individual components of ABCDE are associated with improved functional status at hospital discharge and decreased mortality following critical illness. It should be noted that older adults face additional risk factors for poor functional and cognitive outcomes, including social isolation, forced dependence with ADLs, restraints, poor nutrition, polypharmacy, and unnecessary medical tests and procedures. Thus, additional care models focused on the needs of the elderly patient are essential.

As mortality from critical illness decreases, there is a growing population of survivors who experience long-lasting physical, cognitive, and mental health impairments. PTSD is one important mental health outcome related to life-threatening ICU experiences. PTSD can be diagnosed if an individual is exposed to actual or threatened serious injury or death (typical in critical illness) and subsequently develops symptoms that cause significant distress or changes in functionality such as persistently reexperiencing an event and attempting to avoid trauma-related stimuli. Other manifestations are negative alterations in mood or cognition and new or increased arousal and reactivity. PTSD symptoms are reported in 5% to 63% of critical illness survivors and have a strong association with reduced health-related quality of life. Risk factors for PTSD include younger age, sedation with a benzodiazepine, and recall of frightening ICU experiences.

Pre-existing psychopathology is the only pre-ICU factor consistently associated with PTSD symptoms. PTSD symptoms are not associated with severity of illness, admission diagnosis, length of stay in the critical care unit, and mechanical ventilation. Two ICU-related variables have been

associated with PTSD: sedation and early memories of frightening ICU experiences. Two general management strategies advocated include changes in ICU practice associated with development of PTSD and cognitive therapy to reduce PTSD symptoms.

Suggested Readings

Barr J, Pandharipande PP. The pain, agitation, and delirium care bundle: synergistic benefits of implementing the 2013 Pain, Agitation, and Delirium Guidelines in an integrated and interdisciplinary fashion. *Crit Care Med* 2013;41(Suppl):S99–S115.

Barr J, Fraser GL, Puntillo K, et al. Clinical practice guidelines for the management of pain, agitation, and delirium in adult patients in the intensive care unit. *Crit Care Med* 2013;41:263–306.

Dellinger RP, Levy MM, Rhodes A, et al. Surviving sepsis campaign: international guidelines for management of severe sepsis and septic shock: 2012. *Crit Care Med* 2013;41:580–637.

Dries DJ. The contemporary role of blood products and components used in trauma resuscitation. *Scand J Trauma Resusc Emerg Med* 2010;18:63.

Duchesne JC, McSwain NE Jr, Cotton BA, et al. Damage control resuscitation: the new face of damage control. *J Trauma* 2010;69:976–90.

Fry DE. Sepsis, systemic inflammatory response, and multiple organ dysfunction: the mystery continues. *Am Surg* 2012;78:1–8.

Gattinoni L, Carlesso E. Supporting hemodynamics: what should we target? What treatments should we use? *Crit Care* 2013;17(Suppl 1):S4.

Gentile LF, Cuenca AG, Efron PA, et al. Persistent inflammation and immunosuppression: a common syndrome and new horizon for surgical intensive care. *J Trauma Acute Care Surg* 2012;72:1491–501.

Hess JR, Brohi K, Dutton RP, et al. The coagulopathy of trauma: a review of mechanisms. *J Trauma* 2008;65:748–54.

Marini JJ. Mechanical ventilation: past lessons and the near future. *Crit Care* 2013;17(Suppl 1):S1.

Tompkins RG. Genomics of injury: the Glue Grant experience. *J Trauma Acute Care Surg* 2015;78:671–86.

EDITOR'S COMMENT

Dr. Dries has written an exceptional chapter on multiple organ dysfunction syndrome (MODS). MODS is defined as a clinical syndrome with altered organ

function in an acutely ill patient requiring medical intervention to achieve homeostasis. It usually involves two or more organ systems. MODS is a hypometabolic, immunodepressed condition that develops following an acute injury or illness. MODS contributes to about 50% of intensive care unit (ICU) deaths. It remains unclear what triggers MODS and why it only seems to occur in certain patients. Almost any disease or event that results in significant tissue injury can result in MODS including sepsis, major trauma, burns, pancreatitis, poisoning, or ischemia–reperfusion injury. The mechanism likely involves a complex interplay of interdependent factors including genetics, comorbidities, medications and therapies, macro- and microcirculatory changes, inflammation, and mitochondrial dysfunction. As I performed my research for this commentary, I came across several interesting articles discussing the potential role of mitochondria in MODS. Sepsis damages the structure and function of the mitochondria, and conversely mitochondrial dysfunction aggravates sepsis. Reduced ATP production and mitochondrial dysfunction contribute to a compromise in normal metabolic function and organ dysfunction. Mitochondrial modification may be a potentially important therapeutic target in MODS.

There is an interesting discussion and good information on fluid resuscitation in this chapter. The colloid versus crystalloid discussion is relevant. This is a debate that has carried on for years, and it appears that a consensus has finally been reached that these are equivalent for resuscitation in critical illness. A Cochrane Systematic Review and meta-analysis evaluated randomized, controlled trials of colloids compared to crystalloids in critically ill patients. There were 78 eligible trials. The pooled relative risk (RR) of mortality of crystalloid compared to albumin or plasma protein fraction was 1.00 (0.92 to 1.09). The authors of this review conclude, "*There is no evidence from randomized controlled trials that resuscitation with colloids reduces the risk of death, compared to resuscitation with crystalloids, in patients with trauma, burns, or following surgery.*"

Damage control surgery is discussed in this chapter and is an important concept that represents a major advance in care of the critically injured patient. The concept is also applied to the critically septic patient undergoing surgery for a perforated viscus. Pringle described this technique in patients with substantial hepatic trauma in the early 20th century. Hepatic packing rather than definitive repair in the setting of massive hemorrhage evolved to a concept of "damage control" or temporization and prioritizing physiologic recovery over anatomic repair in patients who are coagulopathic, hypothermic, and acidotic. The damage control surgery concept has dramatically increased survival in the most seriously injured patients. Patients who are injured or sick enough to require a damage control approach may ultimately develop MODS. When initiated early and accompanied by damage control resuscitation, these critically ill patients who survive are probably less likely to develop MODS than if a more prolonged and definitive operation is performed when a temporizing procedure is more

appropriate.

Pain, agitation, and delirium are common issues that critically ill patients in the ICU may face. Assessing whether a patient in the ICU is in pain is difficult. Poorly controlled pain can contribute to agitation, which may lead to accidental removal of endotracheal tubes or lines and catheters. Restraints, sedatives, and analgesics have traditionally been employed to manage these patients. Studies confirm that the majority of patients who are treated in ICUs have pain. The short-term consequences of untreated pain include higher energy expenditure and immunomodulation. Longer-term, untreated pain increases the risk of posttraumatic stress disorder (PTSD). Only a minority of ICU patients has a clinical indication for continuous deep sedation (e.g., intracranial hypertension, status epilepticus, prevention of awareness in those who must be treated with neuromuscular blockade). Most ICU patients, including the majority of those on mechanical ventilation can be administered sedatives and analgesics with the goal of helping them to be calm, with minimal pain, lucid, interactive, and cooperative with their care. The American College of Critical Care Medicine published a revised and updated “Clinical Practice Guidelines for the Sustained Use of Sedatives and Analgesics in the Critically Ill Adult” in 2013. Pain management recommendations include things like routine pain assessments (self-reported in those who can communicate), preemptive analgesia prior to painful procedures like chest tube removal, opioids as first-line therapy, multimodal pain management to minimize opioids, and thoracic epidural in appropriate patients. Agitation recommendations include measures such as routine assessment of depth and quality of sedation, lightest possible sedation and/or daily sedation breaks, the use of analgesia-first sedation, and nonbenzodiazepines such as propofol or dexmedetomidine in mechanically ventilated ICU patients. Recommendations pertaining to delirium include routine assessment with validated tools, early mobilization, and promoting sleep (controlling light and noise, clustering patient care activities, and decreasing stimuli at night).

Care Bundles have been implemented successfully in many areas to address things like surgical site infections after colorectal resection. The ABCDEF bundle builds upon the Pain, Agitation, and Delirium Guidelines. The bundle represents an evidence-based guide for clinicians to approach the organizational changes needed for optimizing ICU patient recovery and outcomes. It stands for the Awakening and Breathing Coordination, Choice of drugs, Delirium monitoring and management, Early mobility, and Family engagement bundle. A recently published study examined the association between ABCDEF bundle compliance and outcomes including hospital survival and delirium-free and coma-free days in seven community hospitals. Of 6,064 patients, 9.7% died before hospital discharge. For every 10% increase in total bundle compliance, patients had 7% higher odds of hospital survival. Likewise, for every 10% increase in partial bundle compliance, patients had a 15% higher hospital survival. Patients experienced more days alive and free of delirium and coma

with both total bundle compliance and partial bundle compliance.

I am quite interested in the long-term effects of critical and prolonged illness, especially with regard to cognitive decline and PTSD. A systematic review and meta-analysis determined that substantial post-ICU PTSD symptoms occur in 25% to 44% of patients from 1 to 6 months post-ICIU and 17% to 34% at 7 to 12 months post-ICU. Significant risk factors for post-ICU PTSD included memories of in-ICU frightening or psychotic experiences, pre-ICU psychopathology, and the use of benzodiazepines. Health-related quality of life is substantially worse in patients with post-ICU PTSD. Treatment and prevention strategies have been investigated and are still being developed. Several studies have demonstrated that survivors of critical illness can suffer from a prolonged and disabling form of cognitive impairment. The Bringing to Light the Risk Factors and Incidence of Neuropsychological Dysfunction in ICU Survivors Study (BRAIN-ICU) was recently published in the New England Journal of Medicine and followed 821 patients with respiratory failure or shock in medical or surgical ICUs at multiple study centers. Of the 821 patients enrolled, 6% had cognitive impairment at baseline, and delirium developed in 74% during the hospital stay. At 3 months, 40% of the patients had global cognition scores that were 1.5 standard deviations below the population means and similar to scores for patients with moderate traumatic brain injury. Another 26% had scores 2 standard deviations below the population means (similar to scores for patients with mild Alzheimer disease). A longer duration of delirium was independently associated with worse global cognition and executive function at 3 and 12 months.

As mortality from single organ dysfunction has decreased, we have observed an increase in critically ill patients with multiple organ dysfunction. As mortality from critical illness decreases, the long-term sequelae for survivors are becoming more and more apparent. There is much work to be done to prevent and optimally treat these survivors. I find this to be a very interesting chapter that highlights these issues and challenges in a very logical and informative manner.

Jon Gould

Suggested Readings

Barnes-Daly MA, Phillips G, Ely EW. Improving hospital survival and reducing brain dysfunction at seven Californian community hospitals: implementing PAD Guidelines via the ABCDEF bundle in 6,064 patients. *Crit Care Med* 2017;45(2):171–8.

Barr J, Fraser GL, Puntillo K, et al. Clinical practice guidelines for the management of pain, agitation, and delirium in adult patients in the intensive care unit. *Crit Care Med* 2013;41(1):263–306.

Dare AJ, Phillips AR, Hickey AJ, et al. A systematic review of experimental treatments for mitochondrial dysfunction in sepsis and multiple organ dysfunction syndrome. *Free Radic Biol Med* 2009;47(11):1517–25.

El-Menyar A, Thani H, Zakaria E, et al. Multiple organ dysfunction syndrome (MODS): is it preventable or inevitable? *Int J Clin Med* 2012;3:722–30.

Lamb CM, MacGoey P, Navarro AP, et al. Damage control surgery in the era of damage control resuscitation. *Br J Anaesth* 2014;113(2):242–9.

Pandharipande PP, Girard TD, Jackson JC, et al. Long-term cognitive impairment after critical illness. *N Engl J Med* 2013;369:1306–16.

Parker AM, Sricharoenchai T, Raparla S, et al. Posttraumatic stress disorder in critical illness survivors: a meta-analysis. *Crit Care Med* 2015;43(5):1121–9.

Perel P, Roberts I, Ker K. Colloids versus crystalloids for fluid resuscitation in critically ill patients. *Cochrane Database Syst Rev* 2013;(2):CD000567.

Rotondo MF, Schwab CW, McGonigal MD, et al. 'Damage control': an approach for improved survival in exsanguinating penetrating abdominal injury. *J Trauma* 1993;35:375–83.

9 Immunosuppression in Organ Transplantation

Mani A. Daneshmand and Allan D. Kirk

Organ transplantation has been a longstanding human dream. Records of transplantation and grafting experiments date back to almost 3,000 years. Although these accounts typically represent myth, legend, and folklore, they demonstrate humanity's desire to heal the wounded with "spare parts" from other individuals. Modern day solid organ transplantation, however, was not technically possible before the advances in surgical anastomoses was developed and described by Alexis Carrel in the 19th century. Although Carrel's techniques won him the Nobel Prize in 1912, they represented only a small victory for transplantation. While the technical surgical hurdles were easily overcome by Carrel's techniques, the biologic barriers posed by the immune system have been more challenging.

Sir Peter Medawar, inspired in part by the clinical challenges of skin grafting for burn victims during World War II, first defined the role of the immune system in allograft rejection. More importantly, he first demonstrated the concept of "acquired immunologic tolerance," originally postulated by Sir F. Macfarlane Burnet, paving the conceptual path toward immune manipulation to facilitate allotransplantation, and establishing the underpinnings of the concepts of rejection, memory, and tolerance. These findings earned both Medawar and Burnet the Nobel Prize in 1960 and impelled the first successful isogenic transplant on December 23, 1954 by Joseph E Murray. At the same time, Gertrude Elion and George Hitchings introduced 6-mercaptopurine (6-MP), demonstrating that it impaired lymphocyte proliferation. The utility of this drug in countering the processes described by Medawar were recognized by a British surgical trainee, Roy Calne, who brought Elion and Hitching's agents to Murray's laboratory to perform the first allogenic transplants using preemptive immunosuppressive medications. These experiments launched initial clinical allograft studies in 1963, and established the fundamental concept of immunosuppressive medication as a means of facilitating organ engraftment. Subsequently, as more potent and specific

immunosuppressive agents have been discovered, organ transplantation has become a successful mainstream therapy for end-stage organ failure. In this chapter, we briefly examine the elements of the immune system that relate to organ transplantation and are targeted by immunosuppressive agents. We then describe established and emerging techniques of immunosuppression for the prevention and treatment of rejection of transplanted organs.

IMMUNE RECOGNITION AND REJECTION

The immune response is generally divided into two subsets: innate immunity and acquired, or adaptive, immunity. Generally, the innate immune system responds to generic molecular motifs associated with tissue injury or pathogenic microbes, and stimulates an initial, nonspecific protective response. The acquired immune system, in contrast, responses specifically to proteins or carbohydrate epitopes, and engenders a lasting, anamnestic, highly specific protective response. Acquired immunity is generally divided into humoral and cellular arms, as will be described below. The innate and acquired systems work in tandem, with the innate system typically activating the acquired system, and the acquired system typically quelling the innate response. Together they defend against infection, clear injured or transformed cells, and avoid autoimmunity.

Innate Immunity

The innate immune system is generally activated by conserved protein and carbohydrate motifs that are typically expressed during infection or tissue damage. The receptors that interact with these motifs exist on macrophages, neutrophils, natural killer cells, and free in the circulation (as in the complement system). These receptors bind common components of pathogenic organisms (like cell wall lipopolysaccharides) and injured tissue (such as mitochondrial DNA). The receptors of the innate immunity are identical within a species and do not contribute to rejection of a specific transplanted organ. However, numerous features associated with organ transplantation in general, such as ischemia, reperfusion injury, and procurement-associated trauma provide signals that foster innate immune system activation. As such, transplantation modulates the acquired system, particularly immediately after a transplant, recruiting cells of the acquired immune system to the region, and processing alloantigen for presentation to elements of the acquired system. For this reason, augmented, fairly

nonspecific immune suppression is required at the time of transplantation. This forms much of the biologic basis for induction immunosuppression, described below.

The main functions of the innate immune system are to facilitate containment of invading organisms and areas of cell death, chemotaxis of other immune elements to the site of injury, and antigen presentation to initiate an acquired response. Physiologically, the complement cascade is primarily activated through binding to mannose residues in microbial cell walls, and thereafter liberates molecules that covalently bind to neighboring cells, opsonizing them for phagocytosis. In the context of transplantation, complement is more typically activated by allospecific antibody (described below). Regardless, complement-mediated opsonization can initiate many initial steps in antigen presentation. Macrophages and dendritic cells engulf both pathogens/cells that are opsonized by complement and those that are recognized by foreign cell surface carbohydrate patterns. In addition, toll-like receptors (TLRs) play an important role in the activation of innate antigen-presenting cells (APCs). These TLRs bind pathogen-associated molecular patterns (PAMPs) such as LPS, flagellin, viral RNA, viral DNA, and heat shock proteins and subsequently promote downstream activation of the innate immune response. Cell injury caused by the transplant procedure itself is thought to liberate PAMPs, providing another means of innate immune system activation early after transplantation.

Antigen Recognition

A key component of the acquired immune system is antigen recognition. Specifically, the evolution of the acquired immune system has, (1) promoted increased specificity in the distinction of foreign, “invading,” tissue from normal tissue, and (2) permitted the development of immunologic “memory.” This recognition occurs through the binding of an antigen (any structural substance that can be bound by the receptors of the acquired immune system). The acquired immune response is mediated by T (cellular immunity) and B (humoral immunity) cells and their respective receptors: the T cell receptor (TCR) and the B cell receptor (or antibody). Each individual T and B cell expresses receptors that optimally bind one specific epitope, although it is now recognized that considerable cross-reactivity can occur. Cross-reactivity between environmental antigens and alloantigens is known as heterologous immunity and likely

plays an important role in the nature of transplant rejection responses and their control by certain types of immunosuppressants. In addition to effecting a highly specific immunologic response, the binding of TCRs or B cell receptors with antigenic epitopes results in a fundamental change in the immune system such that the future response to the same epitope (or heterologously related epitopes) is significantly faster and of higher potency. B cells, through their receptors and antibodies, can independently identify antigenic epitopes and elicit a response. On the other hand, the T cell requires antigens to be processed and presented to the TCR by transmembrane proteins called the major histocompatibility complex (MHC).

The MHC is a group of highly conserved transmembrane proteins. Their primary role within the immune system is the presentation of antigens to the TCR for recognition and response. There are essentially two classes of MHC. MHC class I bind primarily to T cells expressing CD8 (cytotoxic T cells) while MHC class II bind primarily T cells expressing CD4 (helper T cells). All nucleated cells express MHC class I, while only designated APC express MHC class II. APCs include innate immune cells including dendritic cells and mononuclear phagocytes, such that innate immune responses facilitate antigen presentation to CD4 T cells. Class II molecules can also be induced T cells, epithelial cells, and endothelial cells during states of inflammation, such that areas of inflammation develop APC-like capabilities until the inflammatory condition is quelled.

MHC molecules, whose gross structure is conserved across the species, vary in the fine details of their protein substructure, specifically in the area bound by the TCR. This variability, or polymorphism, allows cells expressing donor MHC to be recognized as foreign alloantigens by the recipient’s immune system. As such, rejection in solid organ transplantation is mediated by recognition of both MHC molecule polymorphisms and blood group antigens (A, B, and O). The genes encoding MHC molecules are found on the human leukocyte antigen (HLA) locus of chromosome 6. MHC class I is encoded primarily by HLA-A, B, and C genes, while class II molecules are encoded by HLA-DR, DP, and DQ genes. All adult transplant recipients have preformed antibodies to the blood group antigens; therefore, ABO incompatible transplantation is often complicated by an immediate antibody response, which, when antibodies are present in high concentration can lead to a

syndrome of immediate graft thrombosis known as hyperacute rejection. ABO-incompatible transplantation requires tailored depletion therapy in adults and children based on isohemagglutinin titers. In contrast, most recipients do not have antibodies against HLA antigens prior to transplantation unless they have been previously exposed to those antigens through prior transfusion, pregnancy, or transplantation. It is now generally accepted that T cell memory, established through heterologous immunity, can exist in patients even when there is no antibody response or prior exposure to the specific donor MHC antigens.

T Cell Maturation

Precursor T cells are formed in the fetal liver and bone marrow. These early cells lack TCRs and the associated structural proteins. After migration to the thymus, significant changes in DNA transcription and rearrangement within the precursor T cell lead to the production of the α, β, γ, and δ chains of the TCR as well as other T cell–specific cell surface proteins. TCRs are formed as either αβ or γδ paired chains. The T cell will initially code for a γδ TCR. If this fails to form properly, the more common αβ chain TCR is created. T cells with the more primitive γδ TCR typically recognize conserved moieties (such as heat shock proteins and MHC) and function similar to natural killer cells, while those with αβ TCR are limited to recognizing MHC bound to processed peptides. Each chain of the TCR has a constant domain and a variable domain. It is the combination of the αβ or γδ variable domains that result in the specific binding affinity of the TCR. Recombination yields over 10^9 unique TCR affinity possibilities, providing binding diversity that covers nearly all possible peptide–MHC combinations.

After undergoing DNA rearrangement, these naïve T cells express a TCR as well as both CD4 and CD8. CD4 and CD8 are accessory cell surface molecules that stabilize the interface of the TCR with MHC class II and class I, respectively. Thus early in development, the naïve T cell could potentially be activated by self-MHC expressing self-peptides. Therefore, developing T cells undergo a process of positive and negative thymic selection. Cortical thymic epithelial cells that express MHC and produce thymopoietin, thymosin, interleukin-7, and other cytokines perform “positive selection” of T cells that can recognize self-MHC. Those that do not properly recognize self-MHC, undergo apoptosis. The remaining cells travel to the thymic medulla and mature by losing either

CD4 or CD8. Within the thymic medulla, those cells that bind self-MHC with too high an affinity will also undergo programmed cell death. The remaining cells are either CD4 or CD8 positive cells that can recognize self-MHC without activation.

While the process of T cell maturation very efficiently generates cells that recognize self-MHC without activation, the process does not consider foreign antigens. By sheer chance, there will be TCRs that cross-react with non–self-MHCs. When exposed to these MHC–peptide complexes (as is the case with transplantation), the T cell will bind with sufficient affinity to lead to activation. Since they were not defined as self during the maturation of the T cell, the cell becomes activated and the process of cellular rejection may ensue. Although the frequency of naïve T cells available to react with any given MHC–peptide complex is as scarce as 1 in 500,000, because of the relative similarity between self- and non–self-MHC varieties, the prevalence of "alloreactive" T cells is 1% to 10% of T cells. Thus, T cells can be activated, (1) directly by allo-MHC as a result of a failure of thymic selection to anticipate foreign MHC; (2) indirectly, by allo-MHC being processed and presented by APCs; or (3) heterologously, by cross-reactivity between a self-MHC–foreign peptide complex and an allo-MHC molecule. Regardless, T cell activation is a seminal event in the recognition of allo-MHC and as such, most immunosuppression has been focused on thwarting physiologic T cell function.

T cells can be modified in the periphery leading to accentuated activation, or regulation. These mechanisms primarily exist to downregulate an immune response and activated T cell clones as a pathogen is controlled, and limit the potential for autoimmunity. The peripheral population of activated T cells is generally regulated by either programmed cell death or by being rendered inactive (or anergic). The primary mediator of apoptosis is CD95, or Fas. Fas, a tumor necrosis factor (TNF) receptor, is expressed on activated T cells. Activated T cells whose TCR is bound to MHC-peptide complex will undergo programmed cell death if their CD95 concomitantly binds CD178, also known as Fas ligand (FasL). Not unexpectedly, FasL is expressed in the periphery during inflammatory states to prevent T cells from damaging self tissue adjacent to sites of inflammation.

Alternatively, activated T cells can be controlled by inducing anergy. T cells require both TCR binding and an additional costimulatory signal (see

section on Costimulation) to activate. This costimulatory signal is typically provided by the APC. Without a costimulatory signal, TCR binding does not result in T cell activation. In some instances, TCR binding without costimulation will result in permanent anergy, even if the cell is later exposed to the appropriate signals.

The TCR only recognizes antigen bound to MHC—it will not recognize free antigen. This permits the T cell to destroy only cells expressing viral or mutated peptide sequences. To prevent inappropriate T cell activation by self-antigens that may be quite similar to foreign antigens, isolated TCR binding is insufficient to result in T cell activation. In fact, approximately 8,000 TCR interactions with the same antigen need to occur before T cell activation is achieved. Each TCR binding results in internalization of the TCR complex. This finding, combined with low cell surface TCR density, suggests that T cell activation requires several hours of antigen exposure. This threshold is modulated by costimulation signals.

Given its critical role in T cell activation, many immunosuppressive agents have been developed specifically to interfere with TCR binding and signaling. The TCR complex is comprised of the TCR heterodimer (αβ or γδ) plus several other transmembrane proteins. These include CD3 and the requisite accessory molecules (either CD8 or CD4). The accessory molecules allow for the TCR complex to only interact with either MHC class 1 or class 2, respectively. Binding of the TCR complex to MHC activates protein tyrosine kinases within the cytoplasm of the cell. Multiple binding signals combined with appropriate costimulation results in the ultimate release of inositol triphosphate (IP3) and diacyl glycerol (DAG). IP3 results in Ca^{2+} release, calmodulin binding, and activation of calcineurin. Calcineurin activates transcription factors NF-AT and NF-κB and thereby promotes subsequent production of cytokines, including IL-2 and its receptor (CD25). IL-2 functions in both an autocrine and paracrine manner to potentiate DAG activation of protein kinase C (PKC). Increased PKC activity ultimately results in cell division and proliferation of T cells. Only activated T cells express CD25; therefore, only those T cells activated in response to a presented antigen will proliferate as activated clone lineages. As antigen exposure decreases, the CD25 receptor is reabsorbed and the TCR returns to the cell surface resulting in quiescence.

T Cell Function and Immune Regulation

The accessory molecules (CD4 and CD8) stabilize the TCR interaction

with MHC. CD8 stabilizes interactions between the TCR and MHC class I, while CD4 stabilizes interactions between the TCR and MHC class II. Nearly all nucleated cells express MHC class I receptors that present intracellular peptide fragments for monitoring. $CD8^+$ T cells survey all nucleated cells and induce destruction of all altered cells. Accordingly, these lymphocytes are thus referred to as cytotoxic T cells. Alternatively, MHC class II is expressed primarily by APCs. MHC class II molecules express peptide samples from the phagocytosis of extracellular material and debris. Therefore, by virtue of their interaction with APCs, $CD4^+$ T cells have access to antigens as they invade the body and are engulfed by APCs. The $CD4^+$ cells then regulate the immune response, augmenting responses (helper T cells) or quelling specific responses (regulatory T cells).

Activated $CD8^+$ T cells eliminate infected or defective cells by way of either cytolytic agents or the induction of apoptosis. In the activated cytotoxic T cell, increasing intracellular Ca^{2+} releases granules containing a lytic protein (perforin) and serine proteases (granzymes). The perforin molecules then polymerize and create defects in the target cell's membrane, thus allowing the granzymes to lyse the cell. Alternatively, activated T cells upregulate CD178 (FasL) on their cell surface. This FasL binds CD95 (Fas) on the cell surface of the target cell, thereby initiating the apoptosis sequence.

Meanwhile, activated $CD4^+$ T cells promote APC release of cytokines and express costimulatory molecules that promote $CD8^+$ T cell activation. These $CD4^+$ helper T (T_H) cells in actuality belong to one of two cell types based upon their cytokine profile. T_{H1} cells express interferon-γ (IFN-γ) and TNF. These cytokines promote macrophage activity, cell-mediated immunity, and antibody production by the acquired immune system. T_{H2} cells produce IL-4 and IL-5. These cytokines inhibit macrophage activity while activating eosinophils and IgE production. T_H cells also impact and regulate each other's function. This results in a dynamic immune response whose character varies greatly with the milieu.

In addition to T_H cells, regulatory T cells (T_{REG}) have significant control over the immunologic response. This cell line modulates costimulatory signals, adhesion molecules, integrins, and cytokines, thereby controlling both effector cells and APCs. The subset of T_{REG} cells expressing CD25 has been extensively studied; this cell line has been the target of several attempts at immune response modification.

Costimulation

Costimulation refers to the pathways that modulate the outcome of antigen binding to the TCR. In general, recognition of the peptide/MHC complex via TCR binding is not sufficient in isolation to generate a response in a naïve T cell. Furthermore, TCR complex binding (signal 1) in the absence of costimulation (signal 2) may promote a state of anergy in which a T cell becomes unable to activate despite being provided appropriate stimulation. This anergic state permits tolerance of self-antigens as a means of preventing autoimmunity. It has been actively pursued as a therapeutic for its potential in achieving tolerance of an allograft.

Agents that influence the costimulatory pathway may facilitate or inhibit the efficacy of antigen presentation or recognition, or may alter the threshold for activation of naïve T lymphocytes. Targeting of the costimulatory pathway aims to permit a specific antigen-specific immune manipulation (as only cells undergoing antigen recognition are targets of costimulatory modulation), thereby limiting the extent of nonspecific side effects common to traditional immunosuppression.

CD28 is constitutively expressed on most naïve T cells. When bound by one of its two ligands, CD80 and CD86 (both expressed on APCs), the complex reduces the threshold required for TCR activation. This yields downstream cytokine (IL-4 and IL-8) and chemokine (RANTES) activation, in addition to the upregulation of antiapoptotic factors. In contrast, CD152 (cytotoxic T lymphocyte-associated antigen 4 [CTLA4]) is a molecule structurally similar to CD28 that competitively binds CD80 and CD86, yielding an inhibitory signal that terminates the immune response. CD152 is generally absent on naïve T cells, and is upregulated after antigen engagement. CD152 exhibits significantly (10 to 20 times) greater affinity for CD80/86 compared to CD28, and when upregulated, outcompetes CD28 for costimulatory dominance. In this elegant, reciprocal fashion CD28 and CD152 balance the immune response following stimulation by CD80 or CD86, as CD28 binding facilitates the immune response and CD152 binding quells the immune response.

The costimulatory pathway has been targeted with the development of monoclonal antibodies (MAb) and fusion proteins designed to inhibit T cell activation. The fundamental goal of costimulatory blockade remains induction of tolerance as a means to eliminate the need for maintenance of immunosuppression, though clinically to date these agents have been employed as a part of maintenance minimization strategies, in particular,

in calcineurin-sparing approaches.

B Cell Maturation and Function

Similar to T cells, B cells originate in the bone marrow. Unlike T cells, B cells also mature there. Derived from pluripotent bone marrow stem cells, the growth of pre-B cells is stimulated by IL-7 (produced by bone marrow stromal cells). Subsequently, these cells mature and proliferate as primed B cells following exposure to IL-4, 5, and 6. Similar to the T cell, the B cell has a cell surface bound receptor to recognize antigens. This immunoglobulin molecule is composed of two identical heavy chains and two identical light chains and can be secreted as an antibody to function in the extracellular environment. Similar to the T cell, each B cell is specific for a single antigen. The DNA sequences coding for the heavy chain are located on chromosome 14 in five different loci, and those for the light chains are located on chromosome 2 in two different loci. Each chain, like the TCR, has a variable region and a constant region. The antigen-binding site of the antibody is composed of the variable regions of both the heavy and light chains. DNA rearrangements and mutations in the variable regions of the heavy and light chains allow for an incredibly robust and diverse antigen-binding site. The constant regions of the heavy chains come together to form the fragment crystallizable (Fc) region of the antibody. This interacts with Fc receptors on phagocytes facilitating opsonization and antigen peptide processing. The Fc portion of some immunoglobulin isotypes (see below) also functions to activate the complement system.

There are nine different isotypes of immunoglobulins: IgM, IgD, IgG1, IgG2, IgG3, IgG4, IgA1, IgA2, and IgE. The subtype of the antibody is defined by heavy chain usage. Each isotype has a unique immune function. IgM and IgG function as intravascular immune effectors, while IgA provides mucosal immunity in the gastrointestinal and respiratory tracts. Naïve B cells express IgD and IgM on their cell surface. After exposure to and binding of an antigen, naïve B cells produce an IgM response. This isotype is highly effective at binding of a complement, resulting in cell lysis and phagocytosis. Typically, B cell activation requires the binding of two cell surface antibodies by antigen. These antibodies are then physically approximated by way of a process referred to as cross-linking. This stimulates B cell activation, proliferation, and conversion to an antibody-producing plasma cell. The threshold for B cell activation is quite

high, but this can be modulated by the costimulation signals mediated by CD19 to CD21. B cells and T cells interact through both antigen presentation and costimulation signals thus controlling the immune response.

As the immune response expands, $CD4^+$ T cells induce isotype switching in the activated B cell, resulting in a decrease in IgM production and an increase in IgG production. Interestingly, during the immune response, the antibodies undergo further "somatic hypermutation" within the variable regions resulting in increased affinity of the immunoglobulin for its antigen. After activation, memory B cells remain to provide a more vigorous response to future exposure to the antigen. A portion of the secreted antibodies also remains circulating in the plasma in anticipation of exposure to antigen. In addition to these circulating high-affinity IgG, there are naturally occurring IgM antibodies with low affinity. These natural antibodies respond to a wide combination of carbohydrate epitopes found on bacterial pathogens. These natural antibodies are also responsible for ABO blood group and discordant xenotransplantation rejection.

REJECTION

Rejection is broadly classified into three definitions: (1) Hyperacute rejection, which occurs within minutes to days; (2) Acute rejection, which typically occurs in the first few months but can occur at any time; and (3) Chronic rejection, a fibrotic process that is the most common mode of allograft failure in the long term. More recently, classification has been restructured based on the mechanism of cell injury to include antibody-mediated rejection (ABMR) and T cell-mediated rejection (TCMR). Hyperacute rejection is generally an aggressive form of ABMR, whereas acute rejection can be pure ABMR, pure TCMR, or a hybrid of both. Chronic rejection can be induced by indolent or repetitive ABMR or TCMR, or can be the result of nonimmune insults such as is seen following hypoxia, viral injury, or drug toxicity. The mechanistic classification is much more important when considering immunosuppression, as it suggests the types of immunosuppressants required to mitigate the clinical injury.

Hyperacute Rejection

Primarily mediated by preformed antibodies, hyperacute rejection is a severe, untreatable thrombotic reaction. This reaction occurs within

minutes to hours of reperfusion. Antibodies bind the donor organ and subsequent complement-mediated cell lysis ensues. This proinflammatory milieu results in a procoagulable state and the graft immediately thromboses. The preformed antibodies that result in hyperacute rejection can be "natural antibodies," like those against blood group antigens, or as a result of prior exposure (as is the case with transfusion, prior transplant, or pregnancy). Regardless, hyperacute rejection is entirely preventable with proper tissue typing, antibody screening, and prospective cross-match.

A lymphocytotoxic cross-match is performed by mixing cells from the donor with complement and serum from the recipient. A positive cross-match occurs when preformed donor-specific antibodies (DSA) in the recipient serum result in donor cell lysis. A negative cross-match and correct ABO tissue type matching will prevent hyperacute rejection in nearly all transplants. Unfortunately, it is not possible to perform a prospective cross-match on all potential transplants. Therefore, a more common technique is to screen a patient's serum against a panel of random donor cells that represent the regional donor pool. This panel of reactive antibody assay (PRA) will provide an understanding of a patient's degree of sensitization. Typically expressed as a percentage of the panel showing a reaction, a nonsensitized patient will have a PRA of 0% while a highly sensitized patient may have a PRA of up to 100%. In the current era, the PRA test is performed using polystyrene beads coated with HLA antigens. The assay detects all anti-HLA antibodies and yields a PRA percentage based on the frequency of HLA types in the regional donor pool. Highly sensitized patients may be candidates for desensitization therapy using plasmapheresis, intravenous immunoglobulin (IVIg), or certain myelodepleting chemotherapeutic agents. The success with these therapies has been quite variable.

Acute Rejection

Most immunosuppressive therapies are designed to target cellular acute rejection, either pure TCMR or mixed TCMR and ABMR. Pure ABMR, like hyperacute rejection, is best avoided through preventive typing, as the agents available for its treatment are less well developed. Regardless, most treatments for acute rejection target the T cells driving the effector response (TCMR) or impelling the antibody response (ABMR). Fortunately, with improved T cell–specific immunosuppression, the rate of graft loss due to acute rejection has been significantly minimized. As

previously described, recipient T cells encounter their antigen, either through donor peptide presented by self MHC or by direct recognition of donor MHC. While the former is infrequent (occurring at a rate of less than 1 in 200,000 T cells), the latter occurs as frequently as 1 in 10 T cells. Once activated, these alloreactive T cells initiate the process of acute rejection. Quick and extensive influx of T cells and monocytes results in cytolysis and a general inflammatory milieu that leads to parenchymal dysfunction, small vessel thrombosis, and organ injury. To prevent and/or treat this, the bulk of immunosuppressive therapies are directed at T cells and the pathways that result in T cell activation. To prevent acute cellular rejection, most authors advocate for "induction therapy" early in the transplant phase. These agents (see below) globally deplete or inactivate T cells immediately posttransplant when the physiologic stress of surgery combined with the injuries associated with ischemia and reperfusion are most likely to promote immune recognition of the donor organ. Given the sensitive milieu immediately posttransplant, most immunosuppressive regiments focus on intensive immune suppression initially and then taper to lower levels over time.

In addition to TCMR, ABMR can occur in the early stages after a transplant. In the setting of ABMR, either preformed antibodies (at undetectable titers) or memory B cell clones capable of producing DSA attack the offending donor organ. In the setting of ABMR, there is rapid graft dysfunction after a "honeymoon" period of graft function. Rapid recognition and response are critical to ensure graft survival. ABMR can be treated with aggressive immunosuppression, antibody depletion with plasmapheresis, and IVIg. Unfortunately, graft damage is usually permanent and proportional to the magnitude of rejection.

Chronic Rejection

Chronic rejection is a poorly understood hybrid of both immune-mediated rejection and nonimmune-mediated graft fibrosis. Given that this clinical entity is not entirely due to repeated or indolent TCMR or ABMR, more appropriate organ-specific terms are used. Specifically, interstitial fibrosis and tubular atrophy (IF/TA) or chronic allograft nephropathy for kidneys, chronic allograft vasculopathy (CAV) for hearts, vanishing bile duct syndrome for livers, and bronchiolitis obliterans syndrome (BOS) for lungs are histologic findings used to characterize and stratify the degree of chronic rejection observed. Chronic rejection occurs over years and results

in fibrosis without significant lymphocyte infiltration. Chronic rejection is mediated by both long-term response to alloantigen as well as ischemia/reperfusion injury. Although chronic rejection is untreatable, several factors have been identified that contribute to its progression, most importantly, recurrent acute rejection. Therefore, better prevention of acute rejection is likely to decrease and postpone graft failure from chronic rejection.

IMMUNOSUPPRESSION

Contemporary immunosuppression consists primarily of multiagent strategies designed to prevent rejection of the allograft. Overall, these strategies yield excellent outcomes with respect to allograft survival. However, all agents presently in use target the global immune response, and do not target the recipient's specific response to the allograft. As such, the multidrug approach in common use today employs multiple agents to address the redundant nature of the immune system and thereby modulate the normal global immune response. While successful at the prevention of rejection, this strategy leaves the recipient at increased risk of bacterial and viral infections, and at a higher risk for virally driven malignancies. Immunosuppressive therapy is thus a dynamic process in which the risk of rejection must be weighed against risk of both immune and nonimmune side effects that pose a threat to the recipient.

The optimal degree of immunosuppression varies in the posttransplant period. Unfortunately, there is no method for measuring the individual's need for immunosuppression, either in type or magnitude. As such, general assumptions are made that are reasonable approximations of a person's needs based on the organ system involved. Immediately posttransplant, a high degree of immunosuppression is required given an increased risk of rejection. Graft injury due to the mandatory periods of ischemia and reperfusion at the time of transplant and initial antigen presentation contribute to an increased inflammatory state that drives innate immune activation, accentuates initiation of acquired immune responses, and thus mandates a higher degree of immunosuppression immediately posttransplant in order to establish a stable state of immunologic unresponsiveness. The amount of immunosuppression required in this period is typically unsustainable, and must be tapered fairly rapidly. Unfortunately, it is impossible to measure the degree of immunosuppression afforded by current medications, and the rate of taper

is based on broad generalizations, with drugs dosed to control side effects. Regardless, following an induction phase, patients are chronically treated with maintenance drugs. Maintenance immunosuppression is designed to be chronically tolerable. Current multidrug maintenance regimens are designed to suppress multiple pathways at subtoxic doses of medications. In some patients, this dosing may represent "over immunosuppression" while others may be "under immunosuppressed." Unfortunately, we cannot "measure" the degree of immunosuppression directly and therefore it is impossible to dose immunosuppression to "effect." Rescue therapies are designed to treat existing rejection, and like induction therapies, are chronically intolerable.

The agents below are reviewed both in mechanism as well as by their role in the multiagent drug therapy to achieve immunosuppression. Their relationships to the major pathways of T cell activation are shown in Figure 9.1. There are over 50 different combinations reported in the literature for kidney transplant immunosuppression alone, and many of the drugs used are approved only for very specific indications, but used for other indications (e.g., approved for adults and used in children, or approved for use with steroids, but used in steroid free regiments). It is fair to say that over half of the prescriptions written for transplant immunosuppressants are written for "off-label" indications. It is beyond the scope of this chapter to advocate any particular regimen, and the reader should recognize that immunosuppressive drug use requires considerable experience, and cannot be prescribed based on a "cookbook" format.

Corticosteroids

Steroids are commonly employed in induction, maintenance, and rescue immunosuppressive strategies. Prednisone is the most commonly employed oral glucocorticoid, while methylprednisolone is available as an intravenous equivalent, and is generally used when high-dose induction therapy is involved. While exhibiting potent immunosuppressive properties, steroids produce a particularly broad and nonspecific effect. Glucocorticoids bind an intracellular receptor that in complex enters the nucleus to act as a transcription factor. Inhibition of NF-κB is of particular importance, preventing activation of proinflammatory cytokines and decreasing T cell activation. Downstream, this results in diminished IL-1 and TNF-α production. In addition, the arachidonic acid cascade and vasodilation are inhibited. The broad effects of steroids make them

appropriate for use to control initial innate immune activation immediately after transplantation, to control immune activation as a maintenance drug, or for immunosuppressive augmentation to reverse acute rejection. These potent and diverse immunosuppressive properties must be weighed against their well-documented contributions to poor wound healing, the development of diabetes mellitus, hypertension, and osteoporosis.

Purine Analogs

Azathioprine (Imuran)

Azathioprine is a purine analog used to limit clonal expansion of T and B cells by means of inhibition of DNA synthesis. In this manner azathioprine nonselectively targets cells undergoing rapid division and nucleotide synthesis. Following hepatic conversion to 6-mercaptopurine (6-MP) and 6-thio-inosine monophosphage (6-tIMP), alkylation of DNA precursors results in the net drug effect. The drug is particularly active in rapidly dividing cells (like activated lymphocytes) and tissues with high cell turnover (like the skin, and gut). As such, azathioprine has toxicity seen as lymphopenia, GI distress, hepatic toxicity, and hypertrophic and malignant skin lesions.

Mycophenolate Mofetil (Cellcept)

Mycophenolate mofetil (or MMF, a derivative of the *Penicillium stoloniferum* fungus) acts in an antiproliferative manner similar to azathioprine. Hepatic metabolism yields the activated mycophenolic acid, which proceeds to inhibit inosine monophosphate dehydrogenase, the rate-limiting enzyme in the synthesis of guanine monophosphate (GMP) in the de novo purine synthesis pathway. While global inhibition of purine synthesis would potentially be catastrophic for the recipient, the majority of body tissues can generate adequate purine stores by way of a salvage pathway for GMP synthesis. Of great importance is the finding that lymphocytes lack the ability to utilize the GMP salvage pathway, yielding a relatively lymphocyte-specific mechanism of action for MMF. This results in a blockade of the proliferative response and expansion of both T and B cells in addition to the inhibition of antibody formation. MMF has succeeded AZA in many protocols as it has been shown to decrease the rate of biopsy-proven rejection in most organ systems. Its toxicity profile is better than that of azathioprine, given its more targeted intracellular mechanism. It still induces lymphopenia and gut irritation, but its impact

on skin and hepatic damage is substantially less than that seen with azathioprine. Economically, it is more expensive than azathioprine, and its therapeutic effect is largely equivalent as evidenced by modern comparative trials.

Calcineurin Inhibitors

Calcineurin inhibitors remain the mainstay of most multimodal immunosuppressive regimens regardless of the organ system transplanted. They are used in over 95% of patients, typically in combination with MMF or azathioprine with or without prednisone. They block signal transduction downstream of the TCR, and as such, inhibit T cell activation. Given the critical role of T cells in TCMR, and in providing B cell help for ABMR, calcineurin inhibitors target one of the most critical elements of the alloimmune response.

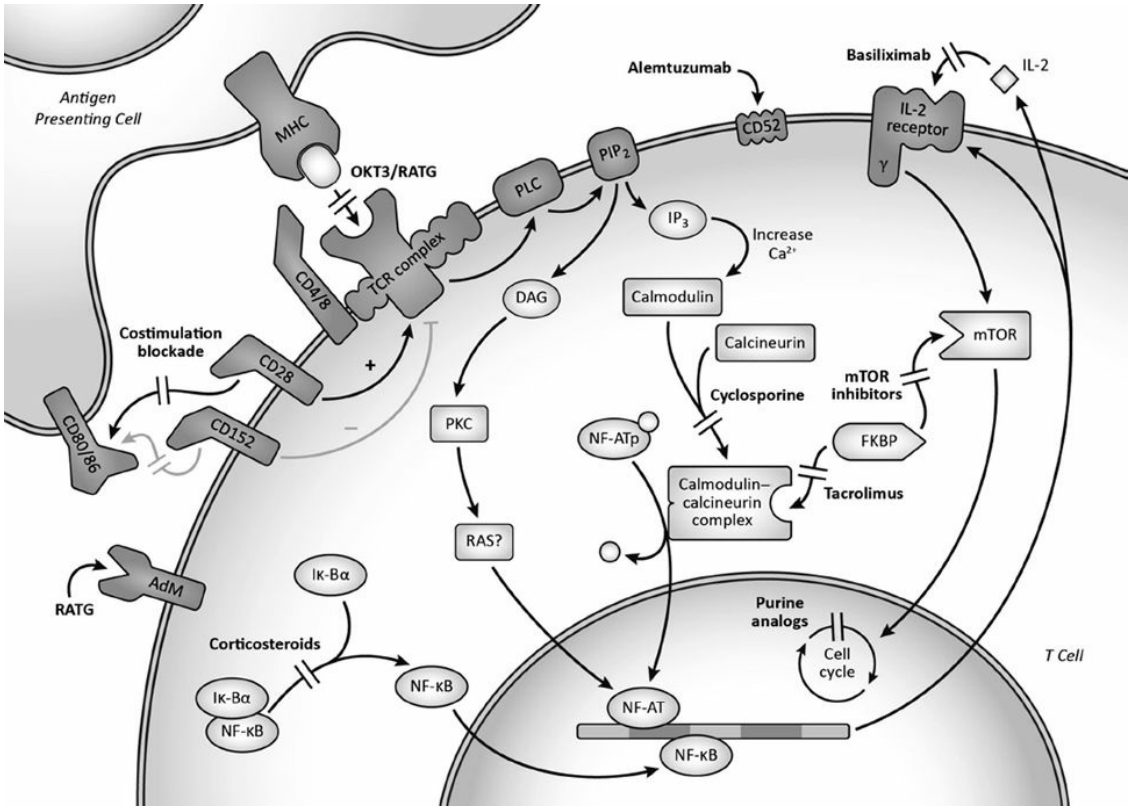

Figure 9.1. Sites of action of immunosuppressive drugs currently in use. Shown are stylized representations of the major pathways of T cell activation during association with an antigen presenting cell. Rabbit antithymocyte globulin (RATG) likely works at many sites, including blocking function of the T cell receptor (TCR) and numerous types of adhesion molecules (AdM). Note that costimulation blockade, such as that evoked with the fusion

protein belatacept, targets the activating interaction between CD28 and the CD80/86, but also has the potential to impede the mollifying effects of CD152, which also binds to CD80/86. Alemtuzumab facilitates T cell depletion after binding to CD52; the function of CD52 remains incompletely defined. Note also that the calcineurin pathway can be blocked by either CsA or tacrolimus such that there is no mechanistic rationale for using both of these agents concurrently. Although mTOR inhibitors bind to the same molecule as tacrolimus (FKBP), their effect is on a different pathway downstream of the common gamma chain of many cytokine receptors, including the IL-2 receptor.

Cyclosporine

Cyclosporine (CsA) was first approved in clinical medicine in 1983 and has played an important role in the advancement of the field of transplantation. Its approval dramatically improved the success of all transplanted organs and is generally considered as the drug that facilitated modern clinical transplantation. CsA is an 11-amino acid peptide from the fungus *Tolypocladium inflatum gams.* CsA blocks the calcineurin–calmodulin complex downstream of the TCR, and thus prevents all specific T cell functions (both activating and inhibitory). CsA is metabolized by the hepatic cytochrome P450 system, and as such serum levels are susceptible to agents that modulate the P450 pathway. Renal toxicity is an important side effect of CsA therapy due to vasoconstrictor effect on the proximal renal arterioles, resulting in significant decrease in renal blood flow. It also has substantial impact on systemic hypertension, worsens hyperlipidemia, and induces hirsutism and gingival hyperplasia. To control the numerous side effects and navigate its interaction with many P450-associated drugs, CsA is dosed based on 12-hour trough levels. CsA requires bile for enteral uptake, and as such its effect is limited in circumstances of hepatic dysfunction. Newer microemulsion preparations are less dependent on enterohepatic circulation and have become the dominant form of CsA prescribed for transplantation.

Tacrolimus

Tacrolimus (Prograf) is a macrolide derived from the fungus *Streptomyces tsukubaensis.* It arrests T cell activation through blockade of calcineurin pathway by binding to a component known as FK-binding protein. Though the side effect profile is similar to that of CsA with regard to renal toxicity and hypertension, its cosmetic side effects are markedly reduced. As such,

tacrolimus-based immunosuppression regimens are favored in many centers, particularly in North America. Tacrolimus has greater potential to induce neurotoxicity, particularly dose related tremors. Tacrolimus is not influenced by bile production and for this reason, tacrolimus is highly favored in liver transplant regimens. Comparator trials versus CsA seem to indicate better efficacy in liver transplantation, but its performance in other organ systems is comparable. Like CsA, tacrolimus is dosed based on 12-hour trough levels.

mTOR Inhibitors

Rapamycin, or sirolimus, is a macrolide derived from the bacterium *Streptomyces hygroscopicus.* Everolimus is an analogue with similarly potent immunosuppressive properties. Both bind to the FK-binding protein, but sterically hinder a site distinct from that bound by tacrolimus and thus block a pathway unrelated to the calcineurin pathway. As such, they do not inhibit TCR signaling. Rather, they block a protein called the mechanistic target of Rapamycin (mTOR). This molecule is downstream of the common gamma chain used by numerous cytokine receptors (those for IL-2, -4, -7, -15, and -21), and thus blocks the amplification signal of many T cells. Resultant inhibition of p70 S6 kinase activity arrests cell cycle progression, and has been shown to be effective in the prevention of rejection. In multidrug therapies, mTOR inhibition can be used as an alternative to calcineurin inhibition, though the efficacy in preventing rejection is typically lower than with calcineurin inhibitors. Side effects of hypercholesterolemia and thrombocytopenia may require discontinuation of therapy, limiting more widespread adoption of mTOR inhibition-based regimens. As T cell amplification is critically important to normal wound maturation, mTOR inhibitors are known to worsen early phases of wound healing and foster hernia formation. Their use in lung transplantation has been hampered by concerns over bronchial wound healing. They also impair mucosal healing and can promote nonhealing oral and gut ulceration. Regardless, the fact that they do not have the nephrotoxicity seen with calcineurin inhibitors has made them an attractive alternative for long-term maintenance therapy, particularly in patients with marginal renal function. mTOR inhibitors are dosed based on trough levels (24 hours for sirolimus and 12 hours for everolimus). Apart from a difference in half life, there are no demonstrated differences between everolimus and sirolimus.

Lymphocyte-Depleting Agents

Lymphocyte depletion is frequently employed as induction therapy in the peritransplant period, inducing profound immunosuppression and acceptance of the allograft, but this degree of immunosuppression is tolerated only for limited periods of time on account of increased risk of opportunistic infection. It can also be used for rescue therapy when faced with ongoing acute rejection.

Antilymphocyte Globulin

Antilymphocyte globulin is a polyclonal antibody preparation comprised of antibodies against multiple antigens on lymphocytes or thymocytes. This is prepared by the purification of gamma globulin fraction of sera of animals immunized with an inoculum of human lymphocytes. Most commonly employed preparations include rabbit antithymocyte globulin (RATG) and horse antithymocyte globulin (ATGAM). Each utilizes human thymocytes as the immunogen. Following administration, complement-mediated lysis and opsonization deplete recipient T cells, and sterically hinder numerous surface receptors for up to 3 months after administration. RATG is approved for the treatment of established acute rejection, but often used as an induction agent at the time of graft introduction as a means to achieve profound immunosuppression while minimizing the need for steroids and calcineurin inhibitors. While depletional therapy is well tolerated, side effects are related to polyclonal composition and can include thrombocytopenia, leukopenia, and anemia. Recipients are also at risk of viral reactivation and primary infection. Meta-analyses of induction depletion show that these agents clearly reduce the rate of acute rejection, but have failed to show convincing improvement in long-term graft or patient survival. Since RATG and ATGAM are made in other species, repeated use can be limited by neutralizing antibodies against rabbit or horse immunoglobulin, respectively. Both preparations can result in serum sickness with prolonged usage.

OKT3

Muromonab-CD3 (OKT3) is a monoclonal antibody against human CD3. This murine antibody was the first commercially used monoclonal antibody in any human indication. OKT3 binding of CD3 results in both internalization of the TCR complex (preventing antigen recognition) and

opsonization of the T cell for elimination by phagocytosis. OKT3 leads to elimination of peripheral $CD3^+$ T cells immediately after administration. Although $CD4^+$ and $CD8^+$ cells return to the periphery several days after administration, these cells lack a TCR and cannot bind antigen. OKT3 has been effective as both an induction agent and as a therapy for acute rejection, but its direct binding to the CD3 complex leads to pan-T cell activation and a resulting cytokine storm (fever, hypotension, and general malaise). For this reason, its use has been curtailed and it is now mentioned largely for historical context in interpreting older transplant literature. It results in depletion of both naïve and activated T cells. Unfortunately, most recipients will develop antimurine antibodies limiting the effect of OKT3, preventing subsequent dosing, and potentially resulting in a vigorous serum sickness.

Anti-IL-2 Receptor Antibodies

Daclizumab and basiliximab are (respectively) humanized and mouse–human chimeric antibodies directed against CD25. These agents are used in induction therapy to block the high-affinity conformation of the IL-2 receptor (specifically CD25). The disruption of the binding of IL-2 prevents T cell clonal expansion of naïve T cells encountering antigen for the first time. In induction therapy regimens, these anti-IL-2 receptor antibodies marginally reduce the rate of acute rejection, but have not shown substantial differences in graft or patient survival. Some authors suggest that they reduce the need for calcineurin inhibition or glucocorticoids early after transplantation. Daclizumab was the first humanized antibody approved for use in humans, and is currently off the market.

Costimulation Blockade

Costimulation blockade has been of great interest in transplantation as a potentially ideal target to permit immunosuppression. Belatacept is a second-generation fusion protein consisting of the extracellular component of CTLA-4 (CD152) and the heavy chain of the human IgG1. As described earlier, CD28 signaling (by way of CD80/CD86 interaction) provides permissive activation signals to allow for TCR signaling and T cell activation. CTLA-4 (CD152) outcompetes CD28 for binding positions at CD80 and CD86. During the immune response, activated T cells express CD152 to block CD28 binding and ensure that the immune response is

appropriately downregulated after the initial activation. Belatacept makes use of this pre-existing feedback by blocking the interaction of CD28 and CD80/CD86 and consequently impairing both costimulation and T cell activation. Of note, this pathway is only relevant when the TCR is activated, as such, use of costimulation with calcineurin inhibition limits the mechanistic rationale of this approach. Also, at high doses, belatacept can block both the stimulatory CD28 and the inhibitory CD152 signaling. As such, approved dosing regimens specifically limit the dose to avoid over dosing and producing a paradoxical activating effect similar to that seen in oncologic checkpoint inhibition. Belatacept is currently approved for use with MMF and prednisone in kidney transplant alone. Its optimal usage has not been defined. Importantly, it seems to be most efficacious for primary immune responses, and it appears to be less effective in sensitized patients, or patients with heterologous T cell alloimmunity.

Additional Monoclonal Antibody Therapies

Rituximab is a murine anti-human CD20 chimeric antibody used in the treatment of posttransplant lymphoproliferative disorder (PTLD). CD20 binding facilitates antibody-dependent cellular cytotoxicity of B cells. Indications for rituximab have broadened to treat disorders of autoimmunity. It is now being explored as a treatment for ABMR, and for use in alloantibody desensitization trials. As CD20 is not expressed on antibody producing plasma cells, the rational for its use in ABMR remains challengeable.

Alemtuzumab is a humanized antibody against CD52, a protein expressed on the surface of mature lymphocytes, and monocytes. Alemtuzumab has demonstrated efficacy in the depletion of T and B cells in both peripheral blood and in secondary lymphoid organs, providing a therapy for lymphoma in addition to use as an induction therapy in immunosuppressive regimens. Although it has not been approved for any transplant indication, it is now used off-label for approximately 10% of all kidney transplants in North America. It has recently been introduced as a therapy for multiple sclerosis and its availability for transplant usage is dependent on a specific compassionate use program from its maker.

CONCLUSIONS

Over 100 years after Alexis Carrel’s development of ground-breaking surgical techniques, clinical solid organ transplantation is a standard

therapy for end-stage organ failure. Given all of the advances of the last decade, transplantation is now stymied most by lack of donor organ availability. However, its practice is dominated by attempts to control immune rejection. As our understanding of the immune system has improved, so too has our ability to control rejection. Nevertheless, immune management remains a life-long imperative for transplant recipients, and as such, a long-term concern for all transplant surgeons.

Suggested Readings

Adams AB, Kirk AD, Larsen CP. Transplantation immunobiology and immunosuppression. In: Townsend CM, Beauchamo RD, Evers BM, Mattox KL, eds. *Sabiston Textbook of Surgery. The Biological Basis of Modern Surgical Practice*. 18th ed. WB Saunders; 2012:617–54.

Halloran PF. Immunosuppressive drugs for kidney transplantation. *N Engl J Med* 2004;351:2715–29.

Kirk AD. Overview: induction immunosuppression. *Transplantation* 2006;82:503–602.

OPTN/SRTR 2013 annual data report. *Am J Transplant* 2015;15(2):4–7.

Vincenti F, Luggen M. T cell costimulation: a rational target in the therapeutic armamentarium for autoimmune diseases and transplantation. *Annu Rev Med* 2007;58:347–58.

EDITOR'S COMMENT

When I think of transplantation I think of complicated immunology and intricate pathways but transplantation really began with a surgeon, Alexis Carrel, developing techniques for something we think of as quite simple today, vascular anastomoses. After that it was all about immune manipulation to decrease rejection and invoke tolerance to facilitate allotransplantion. The innate immune system is taken care of by general immune suppression at the time of organ transplantation targeting activation caused by ischemia, reperfusion injury, and the trauma of procurement. However, the mainstay of transplantation modulates the acquired system, humoral (B-cell) and cellular (T-cell [helper and regulatory]) immunity. T cells require the presentation of antigens by the major histocompatibility complex (MHC). Rejection is mediated by recognition of both MHC molecule polymorphisms as well as blood group antigens (A, B, and O). Mismatch of blood group or prior exposure to antigens is the cause of hyperacute rejection (within minutes) and can be avoided by proper tissue typing, antibody screening, and prospective crossmatch. As such most immunosuppression is focused on preventing or quelling T-cell activation.

Acute rejection (first few months) can be mediated by B- or T-cell activation or a mix of both. Chronic rejection (over years) can be caused by repetitive acute rejection or by nonimmune insults such as hypoxia, viral or drug toxicity and is not treatable and best prevented by avoiding acute rejection. If activated, T cells can be controlled by programmed cell death or by inducing anergy and thus tolerance via preventing necessary coactivation with monoclonal antibodies. The latter has been employed as part of a maintenance minimization strategy.

T-cell manipulation, especially with induction therapy in the early posttransplant period to deplete or inactivate T cells, is responsible in large part for the significant diminution of acute rejection. If antibody-mediated rejection is at play as well then in addition to aggressive immunosuppression, antibody depletion with plasmapheresis and immunoglobulin are employed. Immune suppression strategies consist of a combination of corticosteroids, purine analogs (azathioprine, mycophenolate), calcineurin inhibitors (cyclosporine, tacrolimus), mTor inhibitors (everolimus, sirolimus), lymphocyte-depleting agents (antilymphocyte globulin, OKT3, anti–IL-2 receptor antibodies (daclizimab, basiliximab), costimulation blockade (belatacept), and other monoclonal antibody therapies (rituximab, alemtuzumab). There are over 50 different combinations of immunosuppressive regimens reported in the literature just for kidney transplant and that many more for other organs. Unfortunately, the degree of immunosuppression cannot be measured directly such that patients may be over or under immune suppressed and rescue therapies are designed to treat rejection. Complications of immunosuppression by the various treatments include poor wound healing; opportunistic infection; diabetes; hypertension; hyperlipidemia; osteoporosis; lymphopenia; gastroenteritis; hepatic, renal, and neurotoxicity, graft versus host disease; hypertrophic and malignant skin lesions.

More than 30,000 organ transplants were performed in 2015 in the United States, 20% of which were living donations. Half a million transplants have occurred since 1987 according to UNOS (United Network for Organ Sharing). The vast of number of organs transplanted are kidneys (58%), followed by liver (23%), heart (9%), lung or heart/lung (6%), pancreas or kidney/pancreas (3%), and intestine (0.5%). There have also been a handful of vascularized composite allotransplantations (VCA). These include transplantation of multiple tissues such as muscle, bone, nerve, and skin as a function unit (e.g., limbs and face). According to the Organ Procurement and Transplantation Network, failure of kidney transplantation is 4% at 1 year and 21% at 5 years. Failure for liver transplants is 30% at 1 year and 59% at 5 years (Jain A, Reyes J, Kashyap R, et al. Long-term survival after liver transplantation in 4,000 consecutive patients at a single center. *Ann Surg* 2000;232(4):490–500). The 1-year survival rate for heart transplants is 85% to 90% with an annual death rate of about 4% thereafter. The one-year survival rate for lung is 90% to 94% which drops to 55% at 5 years. For pancreas transplant, 65% of patients are insulin independent at 10 years. The rate of intestinal transplantation has dropped by 25% in the first

part of the decade but still is a viable option. Historically, the best 1-year intestinal graft survival of an isolated intestine transplant is 65%. For patients without complications, a survival of 86% to 93% (Sudan D. The current state of intestine transplantation: indications, techniques, outcomes and challenges. *Am J Transplant* 2014;14:1976–84.). Rates are better for females than males and young versus old and Caucasians versus minorities.

As lack of donors are a major deterrent to transplantation, a noteworthy law was fully enacted in 2015 called the HOPE act (HIV Organ Policy Equity Act). This act allows the recovery of transplantable organs from HIV-positive donors that will be used for HIV-positive recipients in an ongoing feasibility study.

In summary, tolerance as well as minimal multiple repressive agents from a variety of types thus decreasing long-term toxicity and improving survival with long-term suppression albeit with smaller doses of multiple agents give a hope of tolerance which is the Holy Grail of transplant biology.

V. Suzanne Klimberg

10 Surgeons and the Opioid Epidemic

Jeffrey D. Howard, Jr. and Hiram C. Polk, Jr.



This Chapter can be accessed in the accompanying eBook edition (see inside front cover for access instructions).

INTRODUCTION

In the short course of 30 years, the United States has dramatically lapsed into an opioid abuse epidemic. Since the late 1990s, overdose deaths have risen at unprecedented rates. During the same period, the number of dispensed opioid prescriptions has risen at an equally unprecedented rate. According to the Centers for Disease Control and Prevention (CDC), there were more than 50,000 overdose deaths in the United States in 2015. More than 30,000 of these deaths involved opioids.

Surgeons can play a vital role in combating this epidemic. More than 100 million surgical procedures are performed annually in the United States, and nearly all patients receive postoperative opioids to manage surgical pain. Some have even suggested that surgeons over-prescribe these drugs, which may contribute to this epidemic.

The etiology of this pervasive disease is bewilderingly complicated and involves, at least, the following: rise of pharmaceutical marketing, poorly performed and interpreted scientific studies, a paradigm change in physician and patient perspectives regarding the treatment of pain and usage of opiates, transition to consumer-based medicine, and a rapidly expanding cheap heroin market. Key historical events leading to the opioid epidemic are reviewed in this chapter (Table 10.1). Strategies for prevention and treatment as well as future aims are analyzed. The role of the surgeon is delineated throughout.

BRIEF HISTORY OF OPIOIDS

Opium is a liquid extracted from the seed pods of the opium poppy *Papaver somniferum.* In the early 1800s, German pharmacist's apprentice Friedrich Sertürner was the first to isolate morphine from opium. He

named this plant alkaloid “morphium” after the Greek god of dreams, Morpheus. More than 300 wars occurred during the 19th century, which was associated with explosive cultivation of opium as treatment for pain in soldiers. Opium itself was the primary basis for two wars between the British and Chinese during this period.

In 1853, Scottish physician Alexander Wood invented the hypodermic needle by modeling his design after a bee’s stinger. His primary intention for this instrument was the injection of opium preparations. By this time, the addictive power of opioids was appreciated by some.

In 1874, Charles Wright synthesized diacetylmorphine while attempting to create a nonaddictive opioid. Wright’s work was one of innumerable failed attempts to discover the “holy grail,” a nonaddictive opioid. Heinrich Dreser, a chemist who worked for Bayer Pharmaceutical, further developed diacetylmorphine, which was subsequently marketed as heroin. The term “heroin” was derived from the German for “heroische” meaning “heroic.”

At this time in history, heroin was generally believed to be nonaddictive. It was prescribed for a multitude of medicinal conditions, including respiratory ailments, diarrhea, and for the treatment of pain. Heroin was widely prescribed by physicians because of its effectiveness and the relative paucity of other therapeutic options. The increase in prescribing heroin occurred in direct proportion with the increase in the number of opioid addicts. This soaring increase in addicts prompted the Harrison Narcotics Act of 1914. Thereafter, the medicinal use of opiates decreased rapidly until the 1980s, when several events converged, thereby leading to the current opioid epidemic in America.

A REVOLUTION IN PHARMACEUTICAL ADVERTISING

In 1951, a psychiatrist working for an advertising entity landed the contract to market a new antibiotic for Pfizer. A grassroots advertising campaign was organized, which focused on outreach to individual physicians, a novel concept at the time. Terramycin (oxytetracycline) and its marketing campaign became a monumental success. A similar campaign was employed by the same ad company in 1963 for Hoffman La Roche’s drug Valium (diazepam). This campaign was also very successful. Valium became the pharmaceutical industry’s first $100 million drug and later the first $1 billion drug.

TABLE 10.1 Key Events Leading to the Opioid Epidemic

Early 1800s	Morphine is isolated from opium.
1898	Heroin marketed by Bayer for a variety of medical ailments.
1914	Because of rising addiction rates, the Harrison Narcotics Act is passed, which regulated the importation, production, and distribution of opium and coca products.
Early 1900s	Opiates are rarely used for medicinal purposes due to risk of addiction.
1951	Terramycin marketing campaign is a success leading to a revolution in pharmaceutical advertising.
1960	Valium becomes the first $100 million drug (later becomes first $1 billion drug).
1980	*NEJM* publishes a 101-word letter to the editor that suggests addiction is rare.
	Stjernsward named WHO cancer program chief and proclaims that it is a patient's "right" to be pain-free.
1986	Pain publishes a review of 38 cancer patients chronically using opioids, which opens the debate regarding expanded usage of opioids.
1990–1999	"Opioids are nonaddictive if used to treat pain" becomes accepted dogma.
	Cheap and accessible heroin spreads across the United States.
1996	Purdue Pharma release OxyContin.
	First "pill mill" established (South Shore, KY).
	"Pain as the Fifth Vital Sign" is introduced.
1998	JCAHO and VA adopt pain as the Fifth Vital Sign.
1999–2015	Overdose deaths increase fourfold.

These advertising campaigns are the basis of modern medical and pharmaceutical advertising. Direct-to-consumer and physician-directed advertising both originated in these campaigns. Thereafter, representatives and letters poured into hospitals and physician offices to promote a product. An infiltration of medicinal advertisements appeared in public entertainment venues. Pharmaceutical agencies even began to overtly target continuing medical education (CME) as an opportunity for advertising. By 2015, pharmaceutical advertising costs exceeded $5 billion. Arthur Sackler, the physician advertiser who engineered this revolution, along with his brothers, went on to purchase a small drug company, Purdue Pharma (formerly Purdue Frederick). This company eventually developed OxyContin—a drug that is essential to America's opioid epidemic.

MISCONSTRUED SCIENCE

In 1979, the *New England Journal of Medicine* (*NEJM*) published a Letter to the Editor framing the conversation regarding the addiction potential of opioids for years to come. This single paragraph, 101-word correspondence, retrospective review of hospitalized patients treated with an unknown quantity of narcotics, for an unknown time frame, while inpatient only, and in an era when physicians were notoriously stingy with opiates, became the cornerstone for the pro-opioid movement. In this published letter, the authors claimed that the "development of addiction was rare." Conversely, we know today that the development of addiction is anything but rare. Despite the total absence of data, this letter became widely and incorrectly cited. A 1990 *Scientific American* publication

referred to it erroneously as an “extensive study.” A 2001, *Time* article referred to it as “a landmark study” and went further to call the fear of addiction to be “exaggerated.” Moreover, the author’s “findings” were quoted in lecture after lecture as a staple of the pro-opioid movement, especially those supplied by opioid advertisers.

In 1986, the journal *Pain* published a review of 38 cancer patients with chronic pain who used opioid medications. Despite the limited cohort, this published article began to be fervently debated across the country. For pro-opioid individuals, the “Pain paper,” as it came to be known, in combination with the 101-word *NEJM* Letter to the Editor, served as clear evidence that opioids, even chronically prescribed, were safe.

Consideration must be given to the fact that these publications occurred during a time long before complete databases were archived online. As such, to review these articles, an interested party either had access to the original publication or had to travel to a medical school library, retrieve the journal, and then copy the article. As a result, much of science was spread by word of mouth. This promoted the propagation of incorrect analyses of these publications, which was not of themselves incorrect but rather grossly misinterpreted and systematically exaggerated. An analysis of the interpretation and dissemination of these publications demonstrates the great burden on journal editors to consider the impact that any paper may produce when published. The issue of overt and concealed conflicts of interests is currently being debated and certainly was present in the interpretation and dissemination of these publications.

PARADIGM CHANGE

During the same time frame that these publications were fallaciously guiding the scientific discussion regarding the use of opiates and their addiction potential, the culture of both patients and physicians alike began to shift dramatically. Prior to this time, physicians had been educated to avoid opiates at all costs. All too soon this changed!

In 1980, the year that the infamous *NEJM* letter to the editor was published, Stjernsward was named chief of the World Health Organization’s (WHO) cancer program. Prior to being appointed to this position, Stjernsward had worked at Kenyan hospitals, where he witnessed many patients suffering from debilitating pain related to cancer. With this background, he proclaimed it a patient’s “right” to be pain-free and developed the “WHO pain ladder,” which included the use of opioids.

Despite the lack of any supporting evidence, the idea that opiates would not, or at least were unlikely to, cause addiction if administered to a patient with pain began to gain a foothold. In fact, this idea became dogma for much of the 1990s and early 2000s. The American Pain Society even supported this claim on its website. Furthermore, it argued that if used to treat pain, opioids would not depress the respiratory system. Both claims are now known to be incorrect.

In 1996, the president of the American Pain Society altered the national conversation on pain, stating that physicians needed "to treat pain as a vital sign." Thereafter, the movement "Pain: The Fifth Vital Sign" was adopted and infiltrated much of medicine in very short order. Almost too quickly, the Joint Commission for Accreditation of Healthcare Organizations (JCAHO) and the Veterans Health Administration adopted this mantra. Hospitals were thereafter evaluated, at least in part, based on how they treated a patient's pain.

Pain is largely a subjective matter. Actual vital signs (temperature, heart rate, blood pressure, and respiratory rate) are objective measures. Pain depends upon a multitude of factors and varies tremendously from one patient to the next and thus does not lend itself to objectivity. The lack of precise objectivity makes interpretation of pain data and a pain response very difficult.

Nonetheless, a public disenchanted with physicians and what they perceived as inadequate pain management demanded medicinal—opioid—treatment for their pain. Hospital administrators, mostly business managers who were focused on consumer satisfaction, pressured physicians to treat pain more agressively. Over a period of no more than 10 years, the culture regarding the use of opioids changed dramatically.

A RAPID INCREASE IN PRESCRIPTION OPIOIDS

Yielding to public and administrative pressures, physicians began to prescribe opiates at staggering rates. Americans demonstrated an equally robust affinity for consuming these addictive drugs. In 2014, the United States consumed 69% of the world's opioid supply despite constituting only 4.6% of the world's population. This consumption included 99.7% of the hydrocodone, 73.1% of the oxycodone, and 51.2% of the morphine. By 2013, more than 250 million opiate prescriptions were dispensed annually in the United States, and pharmaceutical companies earned billions of dollars on these medications.

Physicians were not complete bystanders to this epidemic, however. By the mid-1990s, “pill mills” began to dot the map. Pill mills are cash-only clinics staffed by physicians willing to prescribe very large quantities of opioids and benzodiazepines. The typical cost per visit to one of these clinics was on the order of $200 cash if the patient was in-state. The first of these clinics is believed to have been established in South Shore, KY, which is just across the Ohio River from Portsmouth, Ohio, and is geographically located in the heart of this epidemic.

Often, the physicians staffing these clinics were not specifically trained in the practice of pain medicine. They would see 100 patients or more daily, often spending 3 minutes or less per patient. They would prescribe opioids with little or no medical reasoning and even less documentation. Throughout mid-America, long lines of patients and automobiles could be seen outside these offices. Rumors of these clinics spread rapidly among addict circles, and addicts would drive 10 or more hours to visit them. Prior to the tracking of narcotic prescriptions, addicts and drug dealers would visit multiple clinics, sometimes across state lines, to acquire huge quantities of these potentially lethal medications. Eventually, most of these clinics would be shut down, and in many cases, the physicians’ licenses restricted or revoked and they were prosecuted.

The number of opioid-related overdose deaths soared in direct correlation with the rising number of opioid prescriptions dispensed (Fig. 10.1). According to the CDC, from 1999 to 2015, the number of overdose deaths in the United States has increased fourfold. In 2015, drug overdose deaths (52,404) were greater than the HIV/AIDS epidemic at its peak in 1995 (43,115), motor vehicle accidents (38,022), and gun deaths (36,252) (Fig. 10.2).

In 1996, Purdue Pharma released OxyContin. This drug was marketed as a less addictive (and potentially nonaddictive) opioid. It contained oxycodone in a timed-release tablet. Theoretically, the time-release properties would prevent the euphoric highs and abrupt depressions, which make opioids addictive. The same year as its introduction, in a historic decision, the Food and Drug Administration (FDA) allowed Purdue to write on the warning label that the drug had a lower potential for abuse. The drug was available in tablet form containing up to 160 mg of oxycodone.

Ironically, the drug’s warning label explained to addicts how to subvert the time-released properties and thus immediately access the tablet’s large

concentration of oxycodone. The label read, "…swallowing broken, chewed, or crushed OxyContin tablets could lead to the rapid release and absorption of a potentially toxic dose of oxycodone." Addicts began crushing the tablet to immediately access its very large doses of oxycodone. In short order, it was discovered that the tablet could be dissolved and injected intravenously. OxyContin, because of its high concentration of oxycodone, became an addict's favorite. The drug's street value was $1 for every milligram. Thus, an 80-mg tablet was worth $80. Some patients were prescribed 90 pills per month.

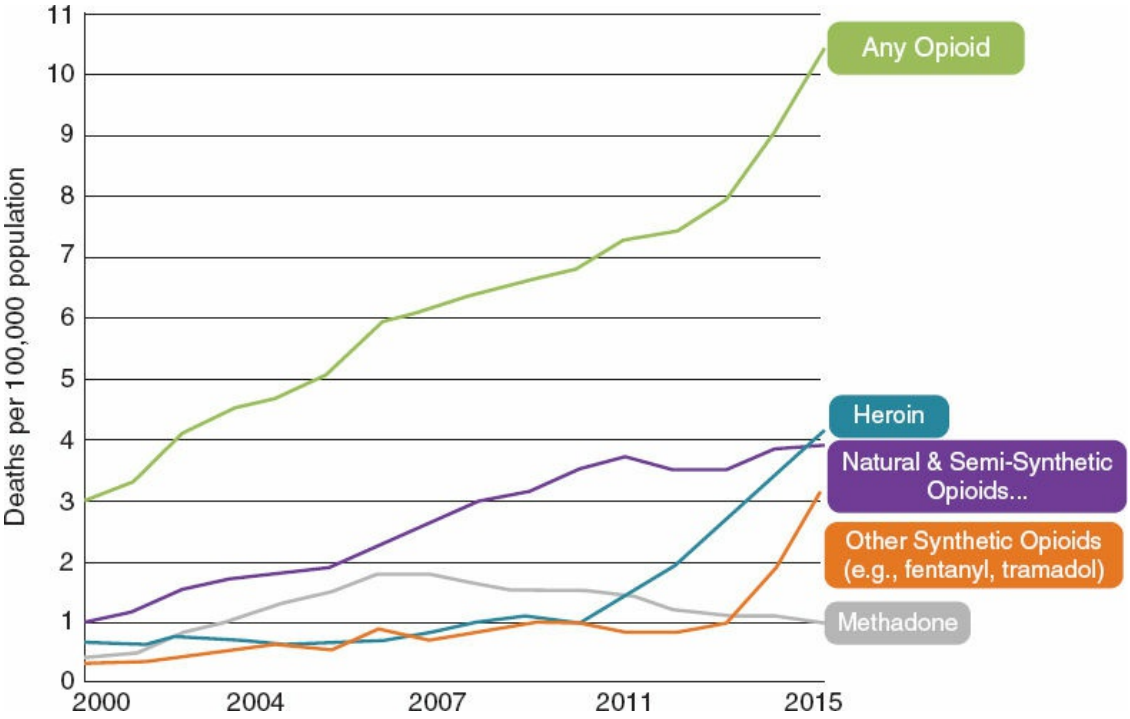

Figure 10.1. Overdose deaths involving opioids—United States, 2000–2015. According to the CDC, by 2015, greater than three fifths of overdose deaths involved opioids. (Modified from CDC/NHCS, National Vital Statistics System, Mortality. CDC WONDER, Atlanta, GA: US Department of Health and Human Services, CVC; 2016. https://wonder.cdc.gov/)

A MIDDLE-AMERICA PROBLEM

The opioid epidemic has witnessed the greatest growth in middle-American states such as Pennsylvania, Ohio, Indiana, Kentucky, Tennessee, and West Virginia. Also, it predominantly affects middle-class Whites. The reasons for these pattern are not completely understood.

Prior the dramatic change in opioid-prescribing habits of physicians, the primary means of obtaining these opioids was through unscrupulous drug

dealers and participants in organized crime. It has been postulated that the safe and relative easy access to opioids through physicians willing to prescribe these medications led to their increased use by middle-class Whites. Data from the CDC have shown that the greatest concentration of dispensed opioid prescriptions were in these mid-American states shown in Figure 10.3A. Correspondingly, the greatest number of overdose deaths was observed in the same geographic regions (Fig. 10.3B).

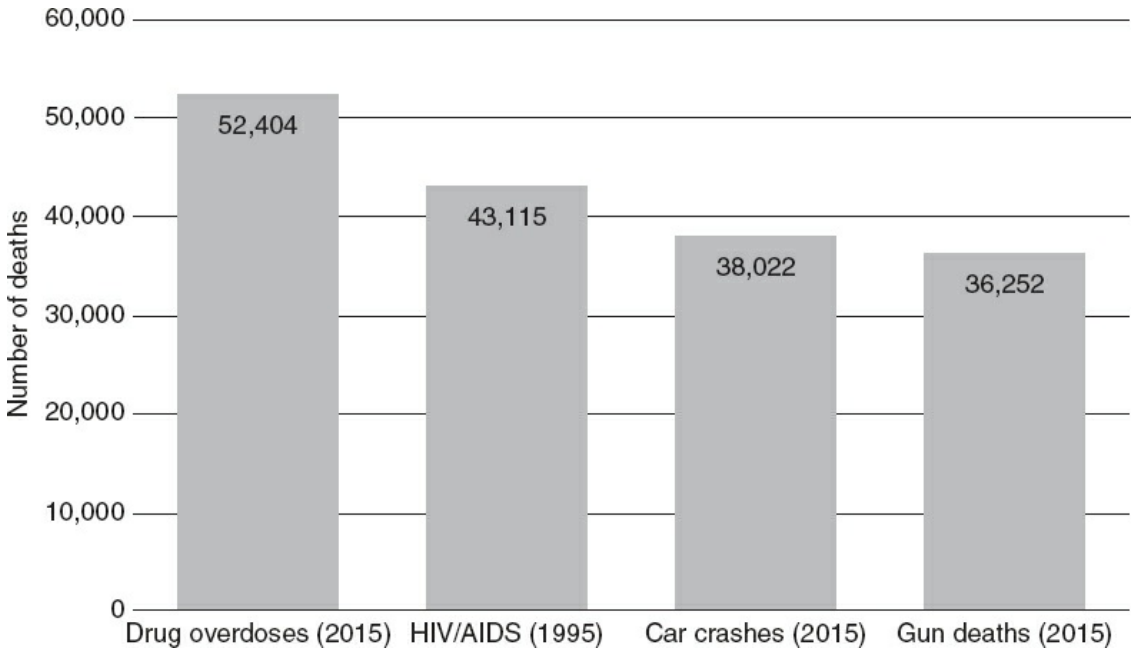

Figure 10.2. Number of annual deaths in the United States. In 2015, drug overdose deaths were greater than car crash and gun deaths. Also, drug overdose deaths were greater than deaths related to HIV/AIDS at the peak of its epidemic.

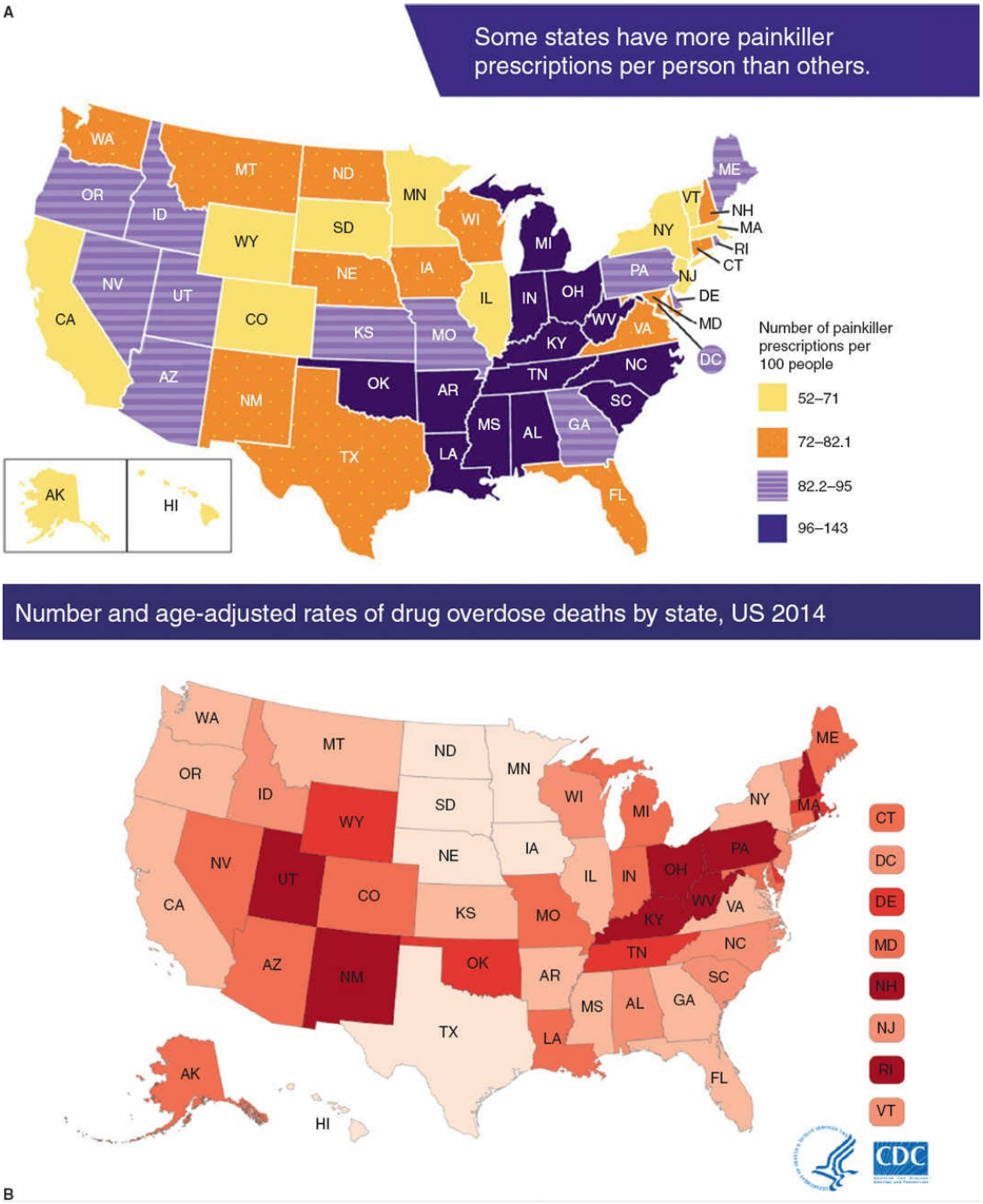

Figure 10.3. **A.** Map demonstrating the per capita number of opiate prescriptions. **B.** Map demonstrating geographic density of overdose deaths. Both overdose deaths and opioid prescriptions are concentrated in middle-America. (Modified from CDC/NHCS, Drug Overdose. CDC WONDER, Atlanta, GA: US Department of Health and Human Services, CVC; 2016. https://wonder.cdc.gov/)

Similar to a plague, the opioid epidemic spread across America from one small town to the next. Predictably, illegal opioid dealers migrated to

meet the needs of each new market of addicts. Opioid abusers became fixated on obtaining the next high no matter the costs. Most were unable to maintain a job, care for children, or perform other tasks expected of contributing members of society. Without a reliable workforce, businesses collapsed and moved from these areas. Addicts turned to thievery to fund their opioid needs. Families eventually lost faith in their addicted love ones after innumerable disappointments. Without the prospect of reasonable employment opportunities, promising young people moved away. In a period of a few short years, the social fabric of these towns collapsed. This story of socioeconomic demise occurred over and over throughout middle-America.

OPIOIDS AND THE SURGEON

During the course of providing surgical care, surgeons inflict pain and have a responsibility to treat this pain. As the early opioid history unveiled, a common scenario for prescribing opioid medications is to treat pain. For the surgeon, it is to treat perioperative pain. Unfortunately, there are no comprehensive guidelines to direct the surgeon in treating operation-related pain. The treatment of acute pain and the properties of common opioids are a minor inclusion in training curricula. The treatment of chronic pain as well as its associated sequelae is conspicuously absent from surgical training curricula, in-training examinations, and licensing examinations. Nonetheless, surgeons must now be knowledgeable regarding the negative potential of opioids, versed in the intricacies of chronic opioid use (COU), and vigilantly strive to prevent harm while adequately treating perioperative pain.

Preoperative Chronic Opioid Use

In the United States, 1 out of every 25 patients regularly uses prescription opioid medications. Some studies suggest that this underestimates the prevalence of COU in surgical populations. As such, surgeons are very likely to encounter patients chronically using opioids, both prescribed and not prescribed. Unfortunately, surgeons are incompletely prepared to treat chronic pain and manage the sequelae that are associated with COU.

COU has been associated with structural and central nervous system changes that mediate affect, impulse, reward, and motivation. These changes may result in a host of postoperative alterations, including increased sensitivity to pain, which may alter the typical postoperative

course. Chronic opioid users suffer increased morbidity and mortality of many kinds, owing to overdose, misuse, and conversion to heroin. COU is also associated with increased utilization of medical resources. A recent study demonstrated that preoperative COU is an independent risk factor for longer length of stay, higher 30-day readmission rates, lower probability of being discharged home, and greater overall expenditures. Moreover, the authors of this study noted a dose-dependent correlation with readmission rates, discharge destination, late health care expenditures, recovery of activities of daily living, and rehabilitation. Surgeons must evaluate previous history of opioid use in the preoperative setting and include appropriate considerations in operative risk assessment.

Surgeons Are Overprescribing Opioids for Postoperative Pain

Opioids remain the standard therapy utilized for the treatment of acute postoperative pain. Annually, more than 100 million surgical procedures are performed and 98.6% of patients receive an opioid to treat the acute pain caused by surgery. Some guidelines exist for the inpatient management of perioperative pain, which includes the use of regional anesthesia and patient-controlled analgesia techniques. However, we were unable to find any comprehensive evidenced-based guidelines for the management of postoperative pain in the outpatient setting.

The management of postoperative pain is complex and deserves serious consideration. Surgeons wish to treat pain adequately but must strive not to overprescribe nor cause addiction. Recent studies suggest that as much as 70% to 80% of opioid tablets prescribed postoperatively are not taken by the patient to whom they were prescribed. This suggests that surgeons are over- prescribing opioids for postoperative pain, and thus may be unintentionally contributing to the opioid epidemic by dispensing a larger than necessary number of opioids. This indirect act may thereby bolster the supply available for abuse. These circumstances beg the question, why are surgeons prescribing opioids in excessive amounts? One reason may be the altruistic desire to reduce the amount of pain experienced by patients. Another reason may be to prevent inconvenience for both the patient and physician. The conspicuous lack of data to guide prescribing practices certainly contributes. No matter the cause, the great burden of addiction requires the physician to become cognizant of the number of opioids that are dispensed. This is further discussed vide infra.

APPROACHES TO PREVENTION

Primary Prevention

Primary prevention is the most important means available to surgeons for gaining control of the opioid epidemic. As noted, recent studies have shown that surgeons are prescribing excess quantities of opioid medications. It has been shown that the majority of prescribed opioids used for abuse are obtained through diversion, mostly from family members with excess, but legally acquired, tablets. As such, reducing the quantity of circulating opioids is enormously important. To accomplish this, education of both patients and physicians is crucial.

Patient Education

Patients, being accustomed to current surgeon practices and conditioned by medical advertising, have come to expect opioid medications in very large quantities postoperatively. Many expect to be pain-free and return to normal activities immediately following an operation. These are unrealistic expectations. It is incumbent that surgeons, in the preoperative and immediate postoperative setting, have frank discussions with patients regarding expectations and risks associated with opioid use. The negative side-effects of opioids are shown in Tables 10.2 and 10.3. Rather than expecting complete absence of pain, patients should be conditioned to expect a manageable and functional level of pain. Furthermore, the patient should be assured that their surgeon will diligently work with them to establish an appropriate pain level. Patients seek surgical care to rid themselves of an existing problem, not to gain new problems. As such, when educated on the risks of opioid use, many patients will find themselves empowered to forego, or at least minimize, opioid usage.

Prescriber Education

Clinical education regarding appropriate opioid prescribing must be initiated at all clinical levels and must proceed with an urgency equal to the present situation. The effects of opioid use, both acute and chronic, must be instilled into the educational process and in medical examinations at all levels of surgical training. A socially conscious approach to opioid prescribing must be emphasized.

TABLE 10.2 Negative Side Effects of Opioids

Nausea
Constipation
Fatigue
Weight loss or gain
Dry mouth
Sweating
Somnolence
Respiratory depression
Pruritis
Hyperalgesia
Cognitive impairment
Addiction
Overdose
Conversion to heroin and other illegal drugs
Acquisition of diseases associated with drug use, including HIV and hepatitis

Abbreviations: HIV, human immunodeficiency virus.

Prescribers must avoid clinical inertia in prescribing of opioids. For example, consider the following patient scenario.

A patient visits the emergency department for a sprained ankle and is prescribed hydrocodone. Two weeks later, the patient visits his/her primary care physician, and the drug is added to their medication list. The patient is still experiencing pain, so the prescription is refilled. One month later, the patient develops constipation secondary to their opioids and revisits the emergency department complaining of abdominal pain. Imaging studies show cholelithiaisis. The patient is given a follow-up appointment with a surgeon one month later and their prescription is refilled again. By the time the patient visits the surgeon, he or she is physically and biochemically addicted to opioids. The surgeon performs cholecystectomy and provides the patient with a higher opioid dose because they have become sensitized to their current dosage. If this patient attempts to stop taking the opioid, they experience withdrawal.

TABLE 10.3 The Effect of Opioids on Surgical Outcomes

Increased morbidity and mortality Increased healthcare costs Increased readmission rates Increased probability of discharge destination other than home Slower return of ADLs Prolonged length of stay Delayed return of bowel function
Abbreviations: ADL, activities of daily living.

This is only one example of how a single prescription for acute pain can easily lead to addiction.

Research

Currently, there is a paucity of data demonstrating the appropriate medication, dosage, and quantity necessary to adequately manage postoperative pain. A recent study defined appropriate narcotic quantities for five outpatient procedures (partial mastectomy ± with sentinel lymph node biopsy, laparoscopic cholecystectomy, laparoscopic inguinal hernia repair, and open inguinal hernia repair). In this study, the authors found that only 28% of prescribed opioids were actively used. Further studies defining normative prescribing practices for common procedures and even trauma are needed to guide surgeons and diminish the number of circulating opioids available for abuse.

Secondary Prevention

Prescription Drug Monitoring

Nearly all states now implement prescription drug monitoring programs (PDMPs). These programs electronically store data regarding the prescribing and dispensing of opioid medications. Prescriber adherence to these programs is important to identify anomalies in prescription receipt, including “doctor shopping,” and thus preventing dispensation of opioids that may be used in diversion. Also, these programs may help identify at-risk populations for targeted intervention. Several states have demonstrated decreased overdose deaths after implementation of PDMPs, but direct causation has not been universally demonstrated. Many PDMPs are state-specific. As such, patients may receive prescriptions across state

lines to circumvent the effectiveness of PDMPs.

Opioid Disposal

Equally important is education regarding the appropriate disposal of dispensed opioids. Several recent studies have demonstrated that only a small percentage of patients understand how to appropriately dispose of excess opioids, and even fewer patients perform this task. This is currently an underutilized opportunity to reduce the number of circulating opioids. A host of disposal options are available to patients.

Many states have Drug Enforcement Agency (DEA)—authorized collectors that accept excess tablets for disposal.
Many pharmacies accept tablets for disposal and some even have mail back options for convenient disposal.
Specific information on prescription medication disposal can be found on the FDA website (https://www.fda.gov/drugs/resourcesforyou/consumers/buyingusingmedi

Deterrents

Several abuse deterrent (AD) mechanisms have been proposed and utilized in hopes of curbing the opioid epidemic and avoid adverse consequences secondary to opioids. Most of these deterrents serve to prevent or discourage crushing or dissolving tablets, which is done to enhance delivery in abuse behaviors. These ADs include physical barriers, combination of opioids with antagonist, formulations less amenable to injection, and combination with aversive agents such as niacin. The most commonly utilized AD is tablets containing an opioid and naloxone. If these pills are crushed, the naloxone is released, thereby rendering the opioid ineffective. Ten drugs have obtained the AD label credential from the FDA. Interestingly, OxyContin is one of the 10 drugs to obtain this label.

Overdose Prevention

Recently, naloxone distribution programs have become widely publicized. First responders, including police personnel, in many states now have been trained in the administration of intranasal naloxone. Further expansion of these programs is currently being pursued by some communities. Currently, anecdotal evidence suggests that widespread implementation of overdose awareness and naloxone education may reduce the number of fatal overdoses. The wide use of this dose in combination with the

expanding use of the powerful opioid, fentanyl, has led to a naloxone shortage.

APPROACHES TO ADDICTION TREATMENT

Addiction is a multifaceted problem that extends beyond physical and biochemical dependence on an opioid, with very complex social and psychiatric factors that involve the addicts, their family, and the community. Accordingly, the approach to treatment is multifaceted and involves physicians, psychologist, social workers, group therapy, medications, and the patient's friends, family, and community. All involved parties must understand that addiction is a chronic and relapsing disease. A full review of opioid abuse treatment is beyond the scope of this chapter; however, the key pharmacologic approaches that the surgeon may encounter are reviewed.

Methadone

Methadone is a long-acting synthetic opioid, which was developed in the late 1930s by German chemists. It is currently the major form of medical therapy utilized for treating opioid dependence. It prevents and reverses the symptoms of opioid withdrawal. It also decreases the euphoric effects of other opioids, thereby decreasing the use of illicit opioids. The resulting effects last for >24 hours, but requires a single daily dose. Thereby, methadone allows opioid addicts to return to normative activities. It can, however, be administered in fatal doses. This is problematic due to its long and variable half-life, which may result in toxic levels.

Methadone maintenance therapy (MMT) is the only opioid dependence therapy that has been clearly shown to decrease illicit opioid use and has been shown to decrease overall mortality in addicts. MMT involves the long-term usage of methadone typically via methadone clinics. Patients in MMT are still physically and biochemically addicted to opioids; however, their addiction is controlled. In a meta-analysis, MMT was shown to be superior to placebo and nonmedication treatment for opioid abuse disorder in terms of continued treatment and reduction of opioid use.

In the past two decades, methadone-related overdose deaths in the United States have increased in direct proportion to the increasing availability of the drug. Unfortunately, many methadone clinics have become for-profit organizations and many have abandoned their goal of eventually transitioning patients off all opioids including methadone. For-

profit methadone clinics are overt conflicts of interest, and these clinics are prime targets for dealers.

Buprenorphine

Buprenorphine is a partial mu-receptor agonist. It is combined with naloxone (Suboxone) for use as an addiction treatment drug. The purpose of combining buprenorphine with naloxone is to deter abuse via intravenous injection. Buprenorphine has less overdose potential than methadone because it has only partial mu-receptor activity. Unlike methadone, buprenorphine can be prescribed from a physician's office for addiction treatment. With a very high affinity for mu-receptors, this can cause withdrawal by displacing full mu-agonists. As such, the initiation of this drug must be undertaken with care. In a meta-analysis, buprenorphine decreased opioid use compared to placebo. It is now considered first-line treatment for opioid abuse by many authors. Unfortunately, this drug is abused by some addicts and has resale value as a street drug.

Naltrexone

Naltrexone is an opioid antagonist that may be used to prevent relapse of the opioid abuse disorder. It is available in a long-acting injectable formulation marketed as Vivitrol. In a meta-analysis comparing oral naltrexone to placebo, no difference was found in sustained abstinence and most other outcomes. The long-acting injectable formulation has been shown more effective than placebo in clinical trials but carries a retail price of approximately $1,700 per dose and duration of treatment of at least of 12 months.

HARM REDUCTIONS STRATEGIES

Needle Exchange Programs

A significant portion of new HIV, hepatitis B, and hepatitis C infections are associated with intravenous drug use (IVDU). Many states and localities have implemented needle exchange programs to allow intravenous drug users the opportunity to exchange old needles for new ones. The hypothesis supporting these programs is that, by eliminating old and contaminated needles, there will be an associated decrease in IVDU-associated disease prevalence and eventually diminished costs to the health care system. The CDC and U.S. Department of Health and Human

Services support needle exchange programs as effective means of decreasing IVDU-associated transmissible illnesses including HIV and hepatitis.

It is currently unclear if a causal relationship between decreasing rates of HIV and hepatitis infections related to needle exchange programs exists; however, anecdotal data indicate that a correlation does exist. The authors support needle exchange programs as a potential method of reductions of IVDU-related transmissible disease and thereby reduced overall health expenditures.

Supervised Injection Facilities

Currently, nine countries contain supervised injection facilities (SIFs). The facilities contain sterile equipment, medical staff, and often addiction treatment specialists. IVDUs can utilize these facilities, and the medical staff may intravenously inject opioids. Following the same logic as needle exchange programs, SIFs are hoped to diminish transmissible disease and injection complications. It is unclear if SIFs accomplish these goals in a cost-effective manner. Some international literature suggests that addicts utilizing SIFs are able to return to a somewhat normal life.

MULTIMODALITY ADDICTION STRATEGIES

Opioid addiction extends beyond physical and biochemical dependence on mu-receptor activation. Rather, there is a host of associated social and psychiatric derangements that accompany this illness. The patient's family, friends, and local community are all affected. As such, the treatment must not only involve correcting biochemical addiction, but also target the psychosocial aspects associated with addiction, including counseling, community involvement, family therapy, and transition to normative activities such as working and maintaining a household.

Recovering addict communities are vital to sustaining abstinence. Much like the Alcoholics Anonymous model, abstinence from opioids after suffering from opioid abuse disorder is a lifelong effort. The best results thus far are found in those who dedicate themselves to becoming recovery coaches and helping others achieve or maintain abstinence. Some communities have established addict hotlines, which allow current addicts, their families, and those in remission to call for assistance as needed. Expansion of such programs may help combat this epidemic.

MAINTAINING ABSTINENCE

The relapse rate for opioid abusers is very high. The overall “cure” rate is unclear secondary to lack of long-term follow-up and high attrition, but it is estimated to be 30% or less. Among patients who maintain abstinence for an extended period, they face the daunting task of piecing their lives back together. Often addicts are isolated from their family, friends, and community due to a history of lying, stealing, and other abuses. They are no longer trusted and, in many cases, no longer welcomed. The uphill psychosocial battle facing a recovering opioid addict is nearly unsurmountable and contributes to the relapse of many patients. Efforts to repair relationships and transition back to normative functions must be facilitated. For many, their life will never be as they hope. Family and friends may never invite them back into their lives, their community may never accept them, and they will forever remember the unfathomable acts they committed.

FINAL DISCUSSION

The rise of the opioid epidemic has occurred at an unprecedented rate. Over a mere 10 years, we transitioned from a medical culture known to be tight-fisted with opioid medications to the opposite. Changes in pharmaceutical advertising techniques and misinterpretation and fallacious dissemination of a few publications combined with shifting medical and public sentiments about the usage and addiction potential of opioids powered this transition. A pharmaceutical industry ready to capitalize stood waiting, and capitalize they did!

As a result, in the last 20 to 30 years, we have seen prescription dispensation, addiction, and overdose rise at shocking and unprecedented rates. Most physicians, secondary to an altruistic nature, prescribed opioids to treat patient pain. A very small number, the “pill-mill” doctors, did so to bolster their personal wealth. Nonetheless, the public and media that once lamented our grudging opioid prescribing habits now blame surgeons for their addiction.

As prescription opioid addiction spread preferentially across mid-America and infiltrated middle-class families, eager heroin dealers migrated to meet their needs. Cheap and powerful black-tar heroin became an addict favorite when OxyContin was not available. It is no surprise that the same mid-American towns became home to the nation’s highest overdose rates.

Surgeons hold an important role in this fight. The surgical patient population has a high rate of COU, which has been shown to result in negative surgical outcomes. Preoperative consideration of COU and inclusion in the risk assessment are necessary. Evidence shows that surgeons, similar to their colleagues, have been prescribing opioids in excessive quantities. Moreover, it has been shown that prescribed opioids are often used for abuse and may serve as a gateway to abuse of illicit opioids. Surgical education must expand to include COU and a more robust inclusion of optimized acute pain management.

Currently, treatment of opioid abuse includes several therapeutic modalities. The long-term cure rates are not very good, and the relapse rate is nearly 100%. Patients who can maintain abstinence face an uphill battle in re-establishing their lives. Vital to their success are transition programs that help the patient re-integrate into society as well as provide a scaffold of support.

Recently, the severity of the opioid epidemic has received national attention in the lay media and the medical community. In April of 2017, *Annals of Surgery* published a special supplement discussing the opioid epidemic. Publications about responsible opioid abuse and prescribing habits are frequent in surgical literature. However, there still exists a noticeable lack of comprehensive data and guidelines to aid surgeons in the management of postoperative pain. Future research aims should be to define normative medications, dosages, and quantities necessary to manage postoperative pain.

Despite the relative short period that was required for the emergence of this epidemic, the expectation of postoperatively prescribed opioids is engrained in our society. Patients often expect to be pain-free immediately after surgery. The arena for changing this perception is the preoperative setting. Surgeons, along with their patient, must develop a postoperative pain management plan. This discussion must condition the patient to expect manageable level of pain rather than be “pain-free.” If opioids are needed, the patient should understand the considerable risks that are associated with these medications.

The search for the “holy grail” continues. Utilization of abuse-deterrent technologies is promising, but currently is isolated to expensive name-brand drugs. Harm reduction programs have shown some promise but are highly politicized.

CONCLUSION

An end to America's opioid epidemic is obtainable. However, the difficult task of shifting both medical and societal norms and expectations is before us. This shift will not happen quickly. Medical and surgical literature alike has begun to reflect the rising awareness of these problems. As such, physicians appear to be upon the precipice of change. Our role as surgeons will be to decrease the number of prescribed opioids and help alter the societal norms surrounding opioids. This can be accomplished by careful and intentional patient education and community involvement. Surgeons are uniquely positioned to lead this fight.

ACKNOWLEDGMENTS

The authors acknowledge the overall influence and concepts developed by Sam Quinones in *Dreamland* and recommend it for further study.

Suggested Readings

Annual reports, 2010–2014. 2015; http://www.incb.org/documents/Narcotic-Drugs/Technical-Publications/2015/part_4_tables_EFS.pdf. Accessed May 1, 2017.

Bates C, Laciak R, Southwick A, et al. Overprescription of postoperative narcotics: a look at postoperative pain medication delivery, consumption and disposal in urological practice. *J Urol* 2011;185(2):551–5.

CDC. Multiple causes of death, 1999–2015 results. https://wonder.cdc.gov/controller/datarequest/D77;jsessionid=F60367C4EB3D5681 Accessed May 7, 2017.

Cron DC, Englesbe MJ, Bolton CJ, et al. Preoperative opioid use is independently associated with increased costs and worse outcomes after major abdominal surgery. *Ann Surg* 2017;265(4):695–701.

Entire issue on conflicts of interest. *JAMA* 2017; 317(17):1707–1812.

Hill MV, McMahon ML, Stucke RS, et al. Wide variation and excessive dosage of opioid prescriptions for common general surgical procedures. *Ann Surg* 2017;265(4):709–14.

Jones CM, Paulozzi LJ, Mack KA. Sources of prescription opioid pain relievers by frequency of past-year nonmedical use United States, 2008–2011. *JAMA Intern Med* 2014;174(5):802–3.

Kenan K, Mack K, Paulozzi L. Trends in prescriptions for oxycodone and other commonly used opioids in the United States, 2000–2010. *Open Med*

2012;6(2):e41–7.

Kessler ER, Shah M, Gruschkus SK, et al. Cost and quality implications of opioid-based postsurgical pain control using administrative claims data from a large health system: opioid-related adverse events and their impact on clinical and economic outcomes. *Pharmacotherapy* 2013;33(4):383–91.

Mattick RP, Breen C, Kimber J, et al. Methadone maintenance therapy versus no opioid replacement therapy for opioid dependence. *Cochrane Database Syst Rev* 2009(3):CD002209.

Minozzi S, Amato L, Vecchi S, et al. Oral naltrexone maintenance treatment for opioid dependence. *Cochrane Database Syst Rev* 2011(4):CD001333.

Parsells Kelly J, Cook SF, Kaufman DW, et al. Prevalence and characteristics of opioid use in the US adult population. *Pain* 2008;138(3):507–13.

Porter J, Jick H. Addiction rare in patients treated with narcotics. *N Engl J Med* 1980;302(2):123.

Portenoy RK, Foley KM. Chronic use of opioid analgesics in non-malignant pain: report of 38 cases. *Pain* 1986;25(2):171–86.

Waljee JF, Cron DC, Steiger RM, et al. Effect of preoperative opioid exposure on healthcare utilization and expenditures following elective abdominal surgery. *Ann Surg* 2017;265(4):715–21.

Younger JW, Chu LF, D'Arcy NT, et al. Prescription opioid analgesics rapidly change the human brain. *Pain* 2011;152(8):1803–10.

SECTION II

BASIC SURGICAL SKILLS: NEW AND EMERGING TECHNOLOGY

11 Ventral Abdominal Hernia: Open and Minimally Invasive and Component Separation Release

Stephen R.T. Evans and Parag Bhanot

ABDOMINAL WALL INCISIONS

The success of any open abdominal operation requires adequate exposure via the appropriate selection of the incision as well as proper closure of the abdominal wall to limit unnecessary morbidity. In the current era of laparo-endoscopic surgery, the general surgeon must still be well versed with the anatomic principles of the abdominal wall. In the past several decades, there has been a broadening of the options available in selecting an incision for an abdominal operation. The primary factors that should be considered are the diagnosed intra-abdominal disease and the organ(s) that must be modified or removed to treat that disease process. Nevertheless, even among experienced surgeons, there are frequently differences of opinion about the best incision for treating a given disease in a particular patient.

There are three primary requirements for an incision to be used for any given operation. The incision must provide optimal exposure, be flexible, and allow for a reliable closure.

1. *Exposure must be optimal.* The incision must provide direct access to the peritoneal cavity without significant limitations if additional exposure is needed at a later point. There must be adequate visualization of the diseased organ or injured area, and provide sufficient working space so that the procedure can be performed directly and rapidly without limiting the intra-abdominal manipulation or excision; especially important in the trauma setting. Appropriate positioning of the patient (e.g., lithotomy for pelvic surgery) and application of abdominal wall retractors are ancillary measures. Inadequate lighting can make even a simple procedure very difficult; thus, headlights and lighted retractors should be readily available.
2. *Flexibility is a requirement of any operative incision.* The popularity of

the vertical midline incision is partly based on its ability to be extended if the scope of the operation dictates a larger incision. The limitations of the vertical incision are the xiphoid process and the pubis symphysis. To some extent, transverse incisions are also amenable to a curvilinear extension. Of concern is the innervation of the abdominal musculature should be minimally interfered with to preserve its functionality. This is a limitation with oblique and transverse incisions. Ideally, it is best to sacrifice less than one segmental nerve trunk ipsilaterally, regardless of the length of the incision. An incision should be so placed that it does not interfere with future stages of planned surgery.

3. *A reliable closure must be obtained, unless postoperative intra-abdominal hypertension is a concern.* The integrity of the abdominal wall must be maintained with adequate fascial closure. In cases involving contamination, such as a perforated viscus, we advocate delayed closure of the skin to minimize postoperative soft tissue infections.

The morbidity from abdominal incisions is poorly reported and probably underestimated. Any error such as a poorly placed incision and/or unsatisfactory method of closure can lead to complications, including hematoma, stitch abscess, infection, wound dehiscence or evisceration, incisional hernia, or an unsightly scar. Rarely, a misdiagnosis may necessitate making a different incision altogether.

TYPES OF INCISIONS

Figure 11.1 illustrates some common types of abdominal incisions.

1. *Vertical.* These incisions may be midline, paramedian, or even pararectus. They can be supraumbilical or infraumbilical and, if necessary (e.g., for extensive intra-abdominal trauma) can be extended in the midline upward to the xiphoid process and/or downward to the symphysis pubis.
2. *Transverse or oblique.* The best examples of these incisions are Kocher's subcostal incision for cholecystectomy, a supraumbilical or infraumbilical transverse incision for intestinal surgery, McBurney's or the Rockey-Davis incision for appendectomy, Pfannenstiel incision for gynecologic surgery, and a transverse or oblique central and lateral incision for exposure of the colon.
3. *Retroperitoneal and extraperitoneal approaches.* These incisions are

ideal for surgery of the kidney or adrenal gland, renal transplantation, and aortoiliac surgery.

4. *Thoracoabdominal.* This incision gives excellent exposure of the upper abdominal organs by connecting the mediastinum, pleural, and peritoneal cavities into a single operative field.
5. *Separate thoracic and abdominal incisions.* These incisions spare the costal margin and cause less postoperative pain and disability than does the thoracoabdominal incision, as in an Ivor-Lewis esophagectomy.

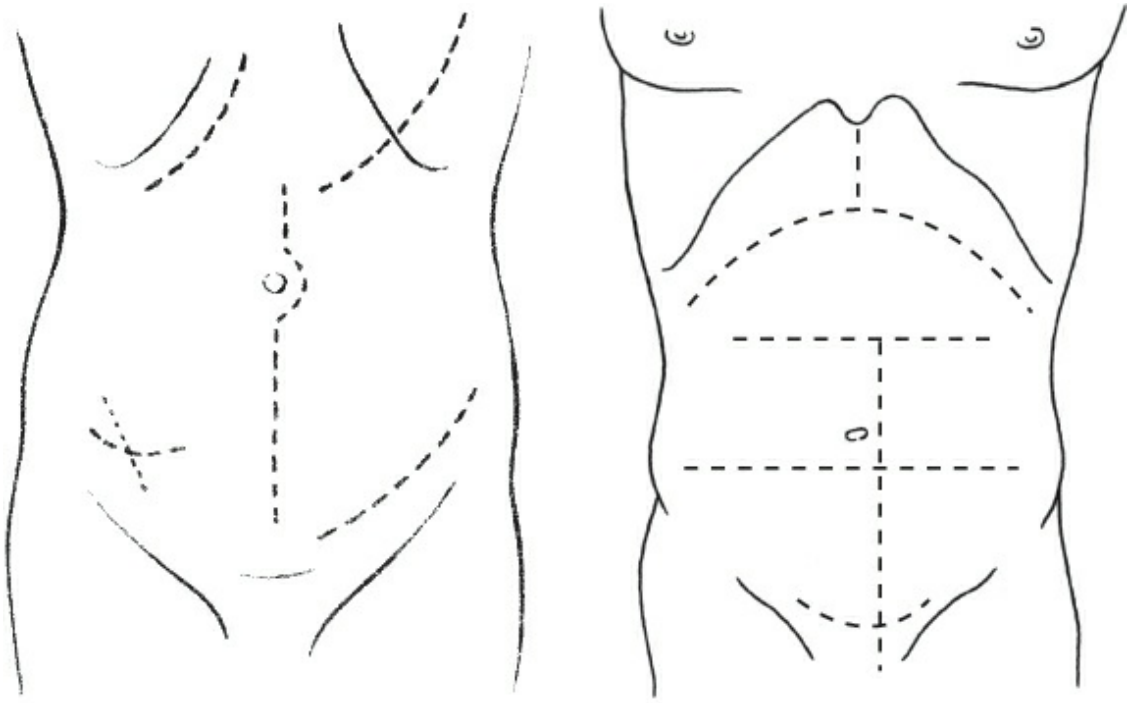

Figure 11.1. Common types of incisions. **A.** Clockwise from the upper right quadrant are subcostal (Kocher), thoracoabdominal, left lower quadrant (extraperitoneal), vertical midline, and Rockey-Davis (transverse)/McBurney (oblique). **B.** From superior to inferior are bilateral subcostal with vertical T extension, supraumbilical transverse, infraumbilical transverse, left paramedian, and Pfannenstiel incision.

SELECTION OF THE INCISION

The choice of incision varies with the surgeon's experience and preferences. Integral to the decision is the organ(s) or site that needs to be exposed, whether rapid access is needed as for severe hemorrhage or trauma, the certainty of the diagnosis, body habitus, the presence of

previous abdominal incisions, and cosmesis.

Many surgeons prefer oblique or transverse incisions when adequate exposure can be obtained because the direction of pull of the lateral abdominal muscles is parallel to the incision, and much less distracting tension occurs on the wound edges than with vertical incisions. The wounds are stronger and less liable to dehiscence or herniation; in general, they seldom dehisce unless infection is present. However, these are somewhat more time-consuming to make than a midline incision. Also noteworthy is that they cause somewhat less postoperative pain than does an upper midline incision.

In emergency operations for major intra-abdominal hemorrhage, the midline approach gives the most rapid access and, if necessary, can be quickly extended from the xiphoid to the symphysis pubis. In general, an upper midline incision may be preferable in a thin patient with a very narrow costal angle, but in a patient with a wide costal angle, a unilateral or bilateral subcostal or transverse incision gives excellent exposure of upper abdominal viscera, especially the pancreas, liver, biliary tract, or spleen.

The McBurney or Rockey-Davis muscle-splitting incision for appendectomy is ideal and can be easily extended medially or obliquely laterally (Weir extension) if greater exposure is required. If an ileostomy or colostomy is to be part of an operative procedure, the main incision should be kept as far from the stoma as possible, with use of either a midline incision or even a paramedian approach on the opposite side from the planned stoma. Transverse incisions above the umbilicus provide ample room for an infraumbilical stoma, or vice versa.

When reoperating on the abdomen, the surgeon should, if possible, enter through the previous incision, particularly if the surgery entails excision of a disfiguring scar or repair of an incisional hernia. When operating through a previous scar, one must be wary of adhesions from bowel or omentum. The surgeon should *never* make a new incision closely parallel to a previous one because it may cause ischemia of the tissue between the incisions and lead to necrosis of the intervening skin and fascia.

CLOSURE OF THE INCISION

Abdominal wall closure, irrespective of the incision, has changed significantly in the past two decades with regard to the type of suture

(absorbable or nonabsorbable) and technique (interrupted or continuous) utilized. For several reasons, most importantly the time consideration, continuous sutures have gradually become far more common closures than interrupted sutures in initial wound closure. In addition, slowly absorbable continuous suture (polydioxanone) has gradually begun to replace all permanent sutures, primarily because the polypropylene knots frequently the cause of draining suture sinuses. For most elective operations, therefore, slowly absorbable continuous sutures (PDS) are more commonly used than other types of suture. On the other hand, when repairing a dehisced incision, closure is done with interrupted permanent suture with consideration of retention sutures.

Regardless of the type of suture used, at least 1-cm bites must be taken from the wound edge, and must be placed at approximately 1-cm intervals, incorporating all layers of the abdominal wall, except for skin and subcutaneous fat. In the morbidly obese patient, it is preferable to clear the fascial edges for 2 cm to avoid loosening of the suture with incorporation of the fat. Some surgeons prefer to close a midline incision with two No. 1 continuous sutures, starting at either end (Fig. 11.2). Because of the bulky knot that occurs, an effort should be made to bury it. A reasonable alternative is to use simple interrupted sutures placed at least 1 cm from the cut fascial edges. The skin is then closed based on individual preferences with staples or sutures. The peritoneum need not be closed as numerous studies have shown that laparotomy wounds heal just as well whether or not the peritoneum is closed. Reperitonealization of the pelvis is worthwhile, however, when that peritoneum has been opened for dissection.

One should never bring drains or ostomies out through the main abdominal incision as they tend to weaken it, predispose to infection, and may precipitate wound sepsis and/or wound dehiscence.

Retention sutures through all the layers of the abdominal wall are seldom used for routine closure because they are painful and may leave unsightly scars. Furthermore, little evidence supports their use to prevent dehiscence or hernia. For difficult abdominal closures, one can use several widely spaced, buried, interrupted full-thickness sutures to reinforce the closure; the closure can be made with a continuous suture, but interrupted sutures may be better. In cases of abdominal dehiscence, some surgeons close the abdomen with deep bites of buried figure-of-eight sutures, but the Gambee suture (Fig. 11.3) is far better. The skin and subcutaneous tissues

are left open in all cases in which sepsis is encountered and a VAC dressing may be employed.

We prefer a two-layer closure of the abdominal wall muscles in a Kocher or transverse incision, closing the posterior rectus sheath and peritoneum with a continuous absorbable suture (Fig. 11.4) and the anterior rectus sheath with a separate, slowly absorbable or nonabsorbable suture. Rockey-Davis or McBurney's incisions are closed in layers, with the peritoneum and transversalis fascia included in one layer using long-acting absorbable sutures and subsequent fascial layers closed separately, as previously described.

INTRA-ABDOMINAL HYPERTENSION AND ABDOMINAL COMPARTMENT SYNDROME

In recent years, the importance of increased intra-abdominal pressure (IAP) leading to intra-abdominal hypertension (IAH) and the ensuing abdominal compartment syndrome (ACS) has been emphasized in patients with severe abdominal trauma and various surgical emergencies such as peritonitis, necrotizing pancreatitis, and intestinal obstruction. IAH is defined as sustained IAP ≥12 mm Hg and be caused by intestinal edema or congestion, accumulation of intraperitoneal or retroperitoneal blood and clot, and extensive retroperitoneal inflammation in acutely ill patients. ACS is a separate clinical entity and is defined as a sustained IAP >20 mm Hg with new organ dysfunction.

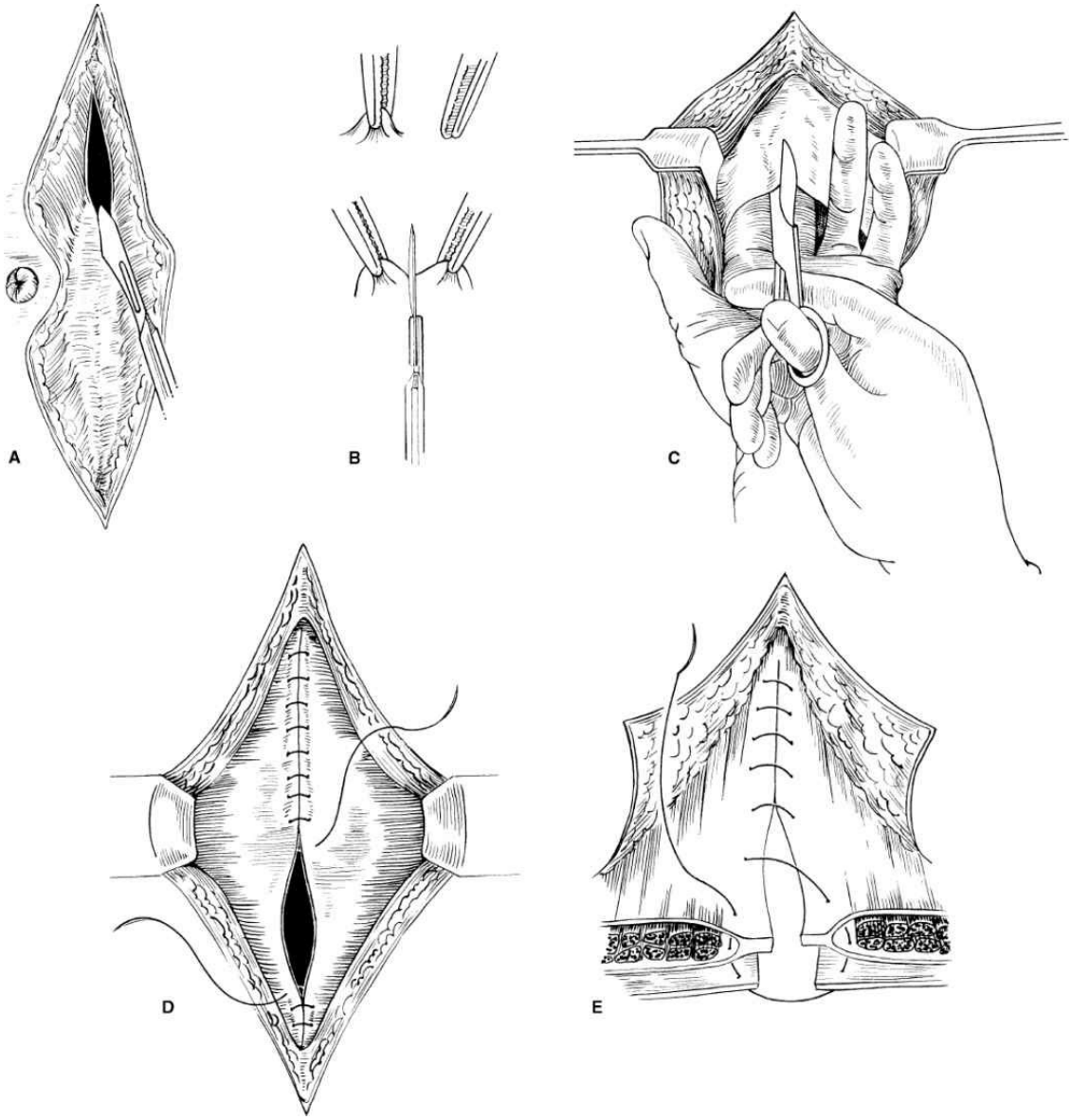

Figure 11.2. Vertical midline incision with gentle curve around the umbilicus, which is preferred over the keyhole. **A.** The peritoneum is opened with a knife, which requires that the surgeon's fingers or a malleable retractor protect the underlying intestine and omentum. **B.** The peritoneum and posterior fascia are grasped with two forceps so as not to crush the intestinal wall if it should happen to be trapped in the jaws of an instrument. The incision should not be made at the apex of the tented-up peritoneum, but 1 cm or so below the instruments, again to avoid cutting into a trapped loop of intestine. When air enters the small opening made with a scalpel, the intestine and omentum will fall away from the peritoneum, unless held there by adhesions. **C.** The peritoneum while the underlying structures are protected with two fingers of the other hand. **D.** The midline fascia and peritoneum can be closed with one layer of continuous suture, with either nonabsorbable or absorbable suture. **E.** Closure of

fascia in one layer with the peritoneum is the technique most surgeons use. For the average abdominal wall, the bites should be at least 1 cm from the cut edge.

Indirect IAP measurement has become an important study in patients following major abdominal trauma or in patients in the intensive care unit with progressive abdominal distention and allows for the definite diagnosis of ACS. IAP is most commonly measured indirectly using bladder pressures and can be done intermittently or continuously if the Foley catheter is connected to a pressure transducer with a recording device. The technique is simple, and the first step is to instill up to 70 mL of sterile saline into the bladder through the Foley catheter, which is then clamped. An 18-gauge needle is inserted into the aspiration port and attached to a pressure transducer. It is critical in order to obtain accurate measurements that the pressure is obtained at end-expiration and the transducer is zeroed at the midaxillary line. Bladder pressures may not provide an accurate measurement in patients with morbid obesity, massive ascites, pelvic hematomas, adhesions, or in a neurogenic bladder. In these situations, IAP can be measured using intragastric, intracolonic, or inferior vena cava catheters.

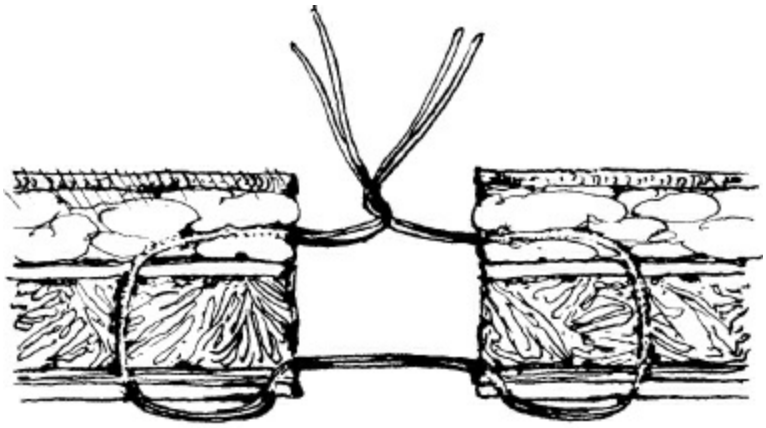



Figure 11.3. When a single full-thickness closure of the abdominal wall is desired, either including peritoneum and fascia or encompassing all layers, including skin as with retention suture closure, excellent closure can be obtained with a modified Gambee stitch. The suture is first introduced at an adequate distance from the wound edge, usually 2.5 to 3.0 cm with retention sutures and slightly less if the skin is not included, as shown. The needle is then passed through the peritoneum–posterior fascia from the inside up; the needle is reversed, and the other side is sewn in the same way. Finally, the needle is passed from peritoneal cavity to above fascia or through skin. The purpose of this suture technique is to prevent the "cheese cutter" effect of simple full-thickness sutures that may injure the underlying bowel. (From Baker RJ. Incisional hernia. In: Nyhus LM, Condon RE, eds. *Hernia*. 3rd ed. Philadelphia, PA: JB Lippincott, 1989, with permission.)

There are several factors involved in the development of ACS in patients regardless of the IAP such as abdominal wall compliance, systemic blood pressure, and body mass index. Thus, in a clinical setting, ACS can be defined as new organ dysfunction with IAH without strict IAP criteria. In general, patients with IAP <10 mm Hg do not have ACS, while a value >25 mm Hg predicts ACS. The incidence of ACS is highest in the most critically ill patients and includes trauma, severe burns, liver transplantation, and medical illnesses that require massive fluid resuscitation.

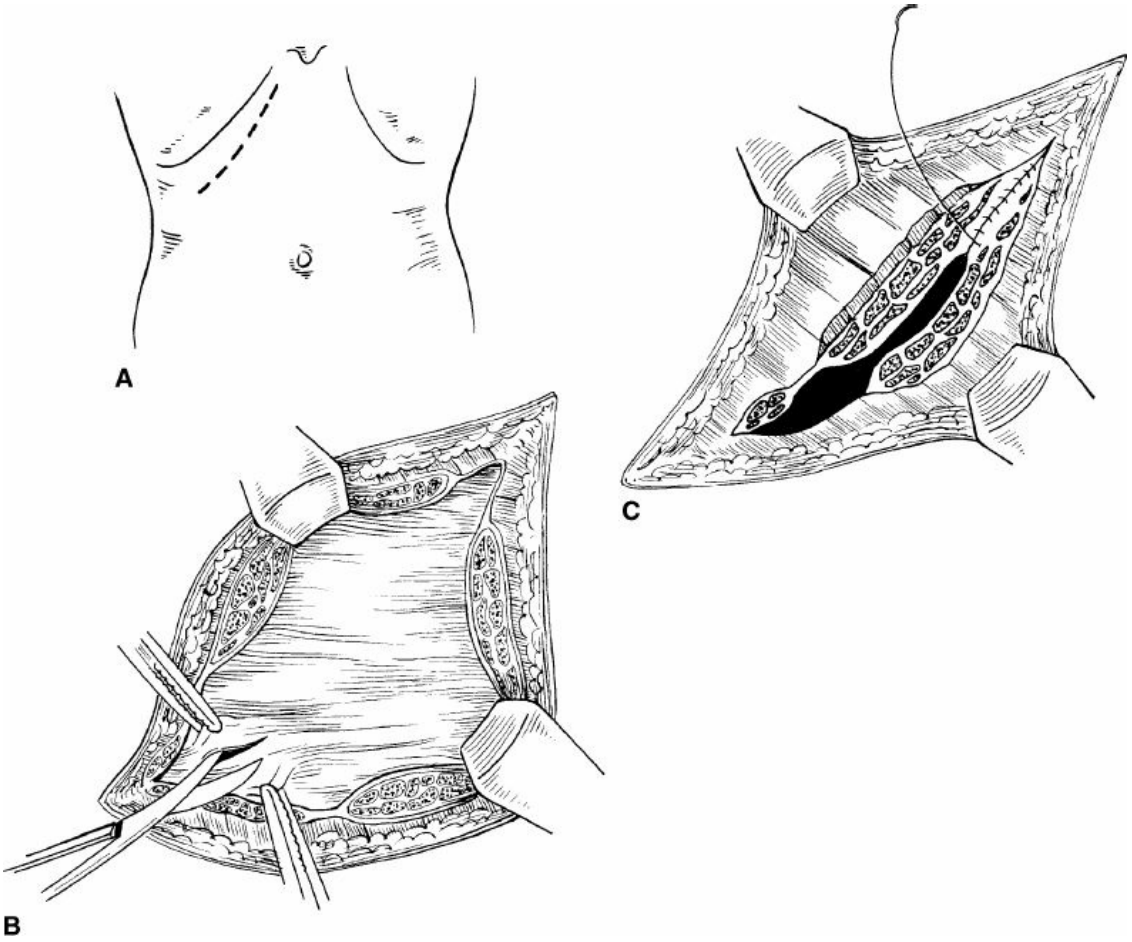

Figure 11.4. Kocher incision. **A.** The subcostal incision should be placed at least two fingerbreadths below the costal margin, which assures that ample fascia is available on the superior side below the costal margin to afford a secure closure. **B.** The rectus muscle is cut transversely or slightly obliquely, usually with monopolar cautery; other muscles can be split laterally as far as necessary to achieve the desired incision length. **C.** The incision is repaired in two layers; posterior fascia and peritoneum, as shown, are the deep layer, and the second layer is the anterior fascia and the aponeurosis of the external oblique. The subcutaneous tissue is irrigated copiously, and the skin is re-approximated with either staples or a continuous absorbable subdermal closure.

The clinical presentation of patients with ACS makes confirming the diagnosis difficult given that they are critically ill and may already have multi-organ dysfunction. Furthermore, imaging studies are not helpful. ACS can be exhibited in every organ system with a multitude of physiologic consequences (Table 11.1).

The management of ACS consists of ventilator and hemodynamic

support along with surgical decompression through the original incision in most cases. Burn patients may respond to escharotomy alone. High airway pressures may require a switch to a pressure limited mode, allowing for permissive hypercapnia. The administration of volume may temporarily improve hemodynamics, but if too much crystalloid is given, IAP will be adversely affected. It is critical that before the decision for surgery is finalized, perioperative morbidity and mortality are considered versus potential benefit for each patient.

TABLE 11.1 Physiologic and Clinical Consequences of IAH

CNS	Cardiac	Pulmonary	GI	Renal
↑ ICP	↑ CVP	↑ Peak pressures	↓ Blood flow	↑ Venous resistance
↓CCP	↑ PCWP	↓ Compliance	↓ Portal flow	Vasoconstriction
	↓ Cardiac output	↓ PaO2	↓ Lactate clearance	↓ GFR
	↓ Venous return	↑ PaCO2		
Cerebral ischemia	Impaired cardiac function	Barotrauma	Bowel edema	Oliguria
	DVT	Pulmonary edema	Bowel ischemia	Anuria
	Peripheral edema	Infection		

After decompression is performed, we advocate maintaining an open abdomen using temporary abdominal wall closure. One technique is to suture a 3-L intravenous fluid bag to the edges of the fascia loosely to allow for additional intra-abdominal expansion. The open wound is then covered with a towel, closed suction drains, and an adhesive drape (Fig. 11.5A). An alternative is the utilization of the vacuum-assisted wound closure (VAWC) dressing that has become increasingly recognized as an effective adjunctive technique in managing the open wound associated with acute abdominal wall defects (Fig. 11.5B). The application of a dressing that covers the open wound under subatmospheric pressure accelerates the healing process and time for complete wound closure. In the immediate postoperative period, it simplifies the wound management of these patients. The contra-indications to its use are a wound without complete debridement, without hemostasis, or the presence of a fistula.

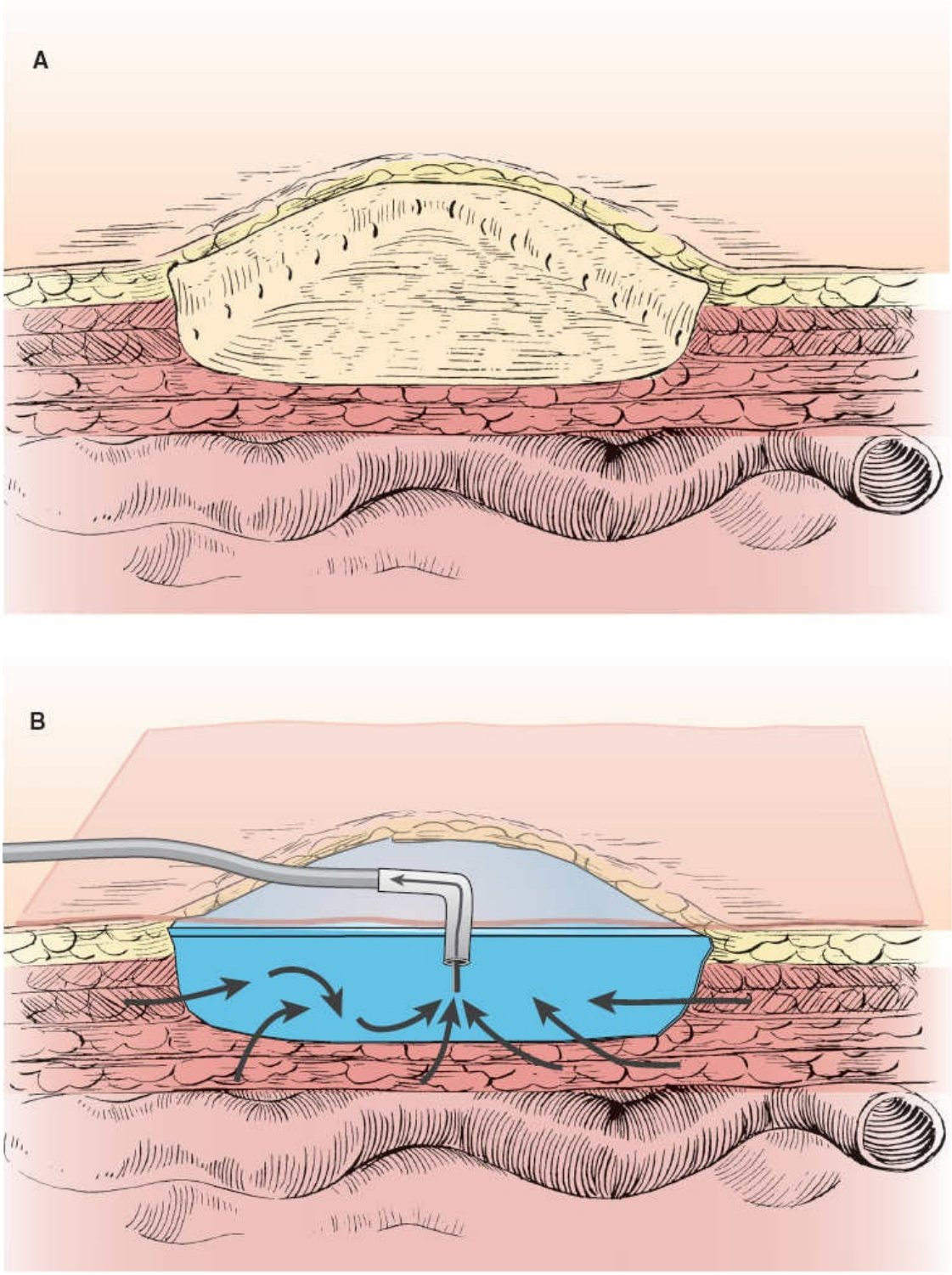

Figure 11.5. A. A temporary closure of the abdomen allows for expansion if necessary from ongoing resuscitation and bowel edema and is particularly useful in patients who require repeat explorations. Any sterile plastic sheet can be used and is sewn to the edges of the fascia with continuous sutures. This prevents excessive fluid loss from an open abdomen and also prevents retraction of the fascia. Suction drains are placed and covered with an adhesive sheet to keep the wound from being saturated

with peritoneal fluid. **B.** An alternative method is the application of a vacuum-assisted wound closure using subatmospheric pressure.

We do not advocate the use of absorbable or permanent mesh for several reasons. In some cases, re-exploration may be necessary wasting the previously placed mesh. The mesh also does not allow for expansion if needed. Absorbable mesh such as polygalactic acid (Vicryl) will require additional surgery at some point after the patient has recovered to repair the resultant hernia or for placement of a split-thickness skin graft. Synthetic mesh is prone to additional risks such as infection, fistulization, and adhesion formation. There are several biologic mesh products available that are ideally suited for this situation in which abdominal wall reconstruction (AWR) can be performed safely in high-risk patients avoiding all of the previously mentioned problems. If a temporary closure was performed, we advocate closure of the fascial defect when the intestinal edema and distension have subsided and as soon as the patient's general status permits. The surgeon should be prepared to schedule the patient for serial attempts at closure if necessary.

OPEN VENTRAL HERNIA REPAIR INCLUDING COMPONENT RELEASE

Introduction

Ventral hernias represent an incredibly varied clinical entity with a wide spectrum of disease. This contributes to the high recurrence rates that exist even with small to moderate defects. The Netherlands group published the long-term results of their randomized, prospective trial looking at suture repair versus mesh repair for incisional hernias with a maximal defect of 6 cm. The 11-year recurrence rate was 32% with mesh and 63% for suture repair.

It is important for the surgeon to be comfortable with several techniques as specific interventions may prove more or less favorable for a given hernia. Consequently, the reconstructive options for hernia repair are diverse and must be tailored to a given clinical situation. Patient comorbidities, hernia characteristics, and skin/soft tissue factors will each impact the technique chosen for the repair. In addition, intra-operative findings should guide the reconstructive approach to optimize outcomes. It is critical to perform the first hernia repair with the proper approach,

technique, and mesh selection to avoid even higher failure rates with subsequent repairs.

PATIENT SELECTION

Results following AWR are variable. Differences in surgical outcomes are partially attributed to differences in patient demographic. Age, gender, obesity, smoking, and medical comorbidities each independently impacts outcomes following ventral hernia repair (VHR). Postoperative morbidity following VHR is increased for each decade after 50 (OR 1.63), preoperative (partial or total) functional dependence (2.34), presence of ascites (9.71), pulmonary compromise (2.47), acute renal failure (11.45), and hyponatremia (3.34).

The risk of hernia recurrence increases proportionately with the number of prior failed repairs; patients presenting for an initial hernia repair are much less likely to develop a postoperative complication. The success of surgical repair is inversely related to the number of prior surgical attempts at VHR. Functional status is another critical element to consider as patients who are not functionally independent are significantly more likely to develop complications following hernia repair. Inactive and sedentary patients may not require surgical repair if there is no involvement of bowel within the hernia sac. It is critical to optimize the medical management of patient's comorbid conditions prior to surgery through a multidisciplinary approach for preoperative risk reduction, select patients for hernia repair with a baseline functional capacity warranting surgery, and determine the safest surgical procedure to ensure a successful repair.

APPROACH (OPEN OR LAPAROSCOPIC)

In addition to patient demographics, hernia morphology affects outcomes and should also dictate treatment. It is critical that the surgeon personally review the imaging study, if available, to determine the extent of the structural involvement to formulate the surgical plan. However, the authors do not advocate the routine use of imaging for small noncomplicated hernias. The factors that need to be considered include: (1) defect size, (2) number of defects, and (3) location of the defect(s).

In general, repairs can be classified as static or functional. Open repairs that do not re-approximate muscle and fascia and most laparoscopic repairs are considered static repairs because they do not restore the inherit anatomy of the abdominal wall. Small defects may be amenable to closure

with a laparoscopic approach as well and possibly offer additional advantage over traditional repair.

The following represents the authors' algorithm based on personal clinical experience and a review of the literature. A primary, single defect <3 cm in a nonobese patient may be repaired with suture repair alone (Fig. 11.6). This situation represents a compromise between a slightly higher recurrence rate and the avoidance of mesh-related complications. It is critical to assess the quality of the fascia if mesh is excluded from the repair. The approximation of poor quality tissue, regardless of the fascia defect size, will lead to an unacceptable recurrence rate. In addition, a rectus diasthesis should be addressed as well.

All other patients, in the optimal setting, should have a mesh reinforcement of the repair. The decision to proceed with a laparoscopic versus open approach is dependent not only on the size of the defect, but also on the quality of the skin and soft tissue coverage.

Adequate Skin/Soft Tissue Coverage

In these patients, the decision to proceed with a laparoscopic or open approach is dependent on the size of the defect. Recurrent hernias, single defects between 3 and 10 cm, several midline defects ("swiss cheese type"), or primary defects <3 cm in a morbidly obese individual are ideal for a laparoscopic approach with synthetic mesh. The presence of a significant rectus diastasis should prompt an open approach

Inadequate Skin/Soft Tissue Coverage

Regardless of the size of the defect, if there is a potential for exposure of the synthetic mesh or the repair is performed in the setting of contamination, we would favor the open approach with the use of a biologic mesh. There are currently no data to support the use of a biologic product via a laparoscopic approach.

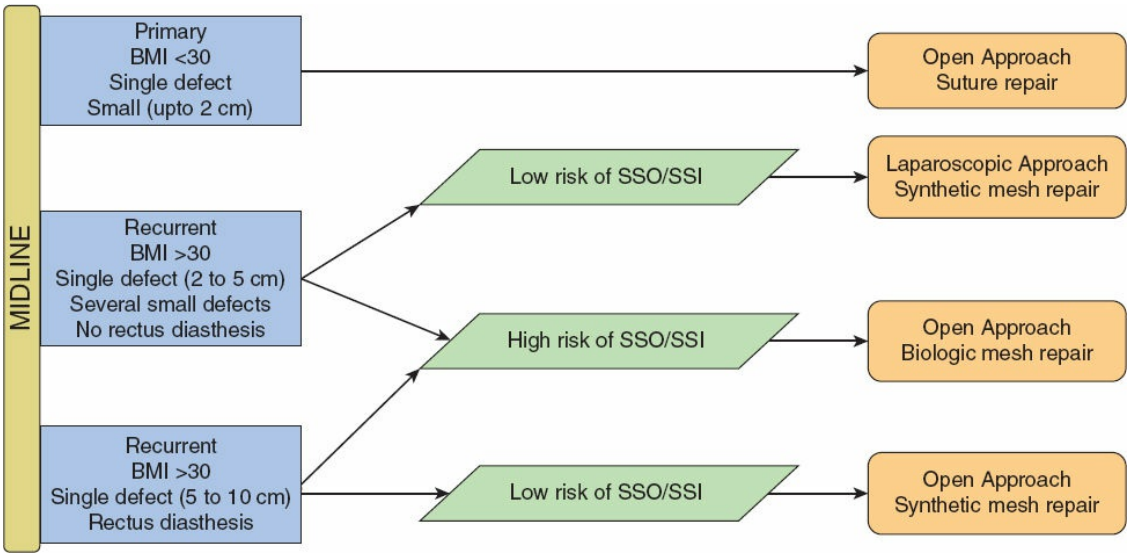

Figure 11.6. Algorithm for abdominal wall reconstruction involving midline defects. The type of repair is based upon both characteristics of the hernia and patient factors that may influence the development of a surgical site occurrence (SSO) or infection (SSI).

CHOICE OF MESH MATERIAL

Reinforcement of a hernia repair with implantable mesh has revolutionized AWR by significantly reducing rates of recurrence compared to suture only repair. However, there is little consensus on which type of reinforcement is best. Primary repair without mesh reinforcement is only appropriate in the setting of defects <2 cm, while all other defect repairs have been shown to reduce rates of recurrence with mesh reinforcement. There is growing evidence to support the use of synthetic mesh for the majority of repairs; however, biologic mesh may prove superior in the setting of high risk or contaminated surgical fields. Despite this, selecting the appropriate mesh for a given clinical scenario remains a matter of debate. Synthetic or biologic mesh may be chosen based upon a number of overlapping criteria including hernia and patient characteristics. It is important to consider the specific advantages and limitations of any mesh selected to reinforce the hernia repair.

The three main meshes available are polypropylene (PPM), polyester, and polytetrafluoroethylene (ePTFE) and various combinations of these materials with a myriad of anti-barrier coatings. It is beyond the scope of this chapter to discuss each product available to the surgeon. Nonetheless, it is the surgeon's responsibility to fully understand the prosthetic that is utilized as part of the repair. There should be comment however on the

recent support of light-weight PPM for reinforcement. Much of the support comes from the hypothesis that these meshes can be employed in the setting of contamination without having to resort to expensive biological mesh with little compromise in recurrence or mesh explantation. However, recent data do not support this rationale. Conze published his prospective randomized study in 2005, which showed a 17% recurrence rate in the light-weight group compared to 7% in the standard group. In the setting of contamination, Carbonell's study of 100 patients with <1 year follow-up showed 4 patients required explantation.

Biologic mesh is a potentially viable alternative to synthetic mesh in the properly selected clinically setting. They are essentially an acellular dermal matrix (ADM) from a variety of animal sources with different processing, which confers their different clinical properties. Much has been published since the last edition of *Mastery of Surgery* to allow surgeons a better insight into their appropriate use. Biologic meshes certainly have an advantage over synthetic mesh in contaminated wounds in allowing single-stage repairs, but their use is not cost-effective in all patient populations. It is also evident that their use in a bridged setting results in either a recurrence or eventration almost 100% with long-term follow-up. Those with and/or at high risk for wound complications should undergo repair with biologic mesh. Ultimately, more large-scale and long-term studies need to be performed to adequately assess the efficacy of biologic mesh products in AWR.

LOCATION OF MESH PLACEMENT

After selecting the ideal mesh product to reinforce a given VHR, the material may be placed in a number of different locations within the abdominal wall for reinforcement. Mesh may be sutured superficial to the primarily closed fascia (onlay), directly to the fascial edges as a bridged repair (interposition), posterior to the rectus abdominis muscle (retrorectus), or deep to the peritoneum (underlay). Each of these has distinct advantages given a particular clinical situation. In general, underlay or retrorectus mesh placement results in the lowest complication rates including less infection, seroma, and hernia recurrence as compared to onlay or interposition mesh placement. Within the context of biologic mesh, interposition mesh placement when primary fascial approximation is not feasible will result in the highest rate of hernia recurrence, approaching 100%.

SPECIFIC HERNIAS

Umbilical and Epigastric Hernias

Hernias involving the umbilicus can be congenital or occur spontaneously. Many congenital umbilical hernias will spontaneously close by 2 to 3 years of age. The repair of the pediatric hernia is not the focus of the following discussion. In adults, multiparity, obesity, ascites, and any pathology that elevates IAP increase the risk of a fascial defect. Although umbilical hernias are common, the differential diagnosis should include soft tissue tumors and urachal cysts. The contents of an umbilical hernia may include preperitoneal fat, mesenteric fat, and/or bowel. For this reason, the hernia should be repaired unless there is a strong contraindication.

Epigastric hernias are another common fascial defect encountered by general surgeons and may be present in up to 2% of the population. They mostly occur spontaneously as a function of the anatomy of the linea alba that becomes thinner and wider cephalad from the umbilicus. These hernias have a male prevalence and can have multiple defects in up to 20% of patients. Given the small defect size that often has a small piece of incarcerated preperitoneal fat, the level of discomfort can be more than expected. The diagnosis is usually made with the clinical examination confirming a palpable bulge. Imaging is not necessary, but can be obtained if the examination is equivocal.

As discussed, the size of the defect, comorbidities, and the skin factors all should be considered in the choice of surgical technique. With our established algorithm, most of the umbilical hernias repaired in our practice in the nonobese population are a primary suture repair without mesh reinforcement. This does represent a compromise between recurrence rates and mesh-related complications. A randomized study by Arroyo et al. showed that umbilical hernia repair with prosthetic mesh had a recurrence rate of 1% at 64 months compared to 11% with direct suture repair alone. Complications in both groups were similar.

Given the same small defect size in an obese individual, mesh reinforcement is necessary. The protocol for synthetic versus biologic mesh has been previously discussed. In the setting of appropriate skin coverage, a laparoscopic approach is recommended with synthetic mesh. Typically, these cases are short and can be performed as a same-day operation. With less than ideal skin coverage, absent or attenuated, a laparoscopic approach is not recommended. An open repair with synthetic

mesh is usually appropriate.

Technique for Open Repair With/Without Mesh Reinforcement

1. An incision is made over the fascial defect to provide proper exposure in either a vertical or a horizontal fashion. For umbilical hernias, the umbilical stalk is dissected free from the hernia sac. It is important not to button-hole the skin.
2. The hernia sac/contents are dissected away from the edges of the fascia. Without the involvement of omentum or bowel, violation of the peritoneal cavity should be avoided. Especially important is individuals with the presence of ascites.
3. (a) The fascial edges are clearly delineated. With a <2-cm defect, a primary repair is carried out using absorbable suture such as 0-PDS figure-of-eight sutures transversely. We typically place our corner sutures beyond the defect (Fig. 11.7). (b) With a defect >2 cm and/or accounting for patient risk factors, mesh can be utilized at this time. The authors recommend underlay mesh (intraperitoneal or sublay) rather than an onlay technique. The size of the mesh should allow for at least 3- to 4-cm support circumferential. The mesh is secured with at least 0-PDS sutures transfascial. The fascia is then re-approximated over the mesh (Fig. 11.8).
4. Closure of the incision. For umbilical hernias, the umbilicus is tacked back down to the linea alba with absorbable suture.

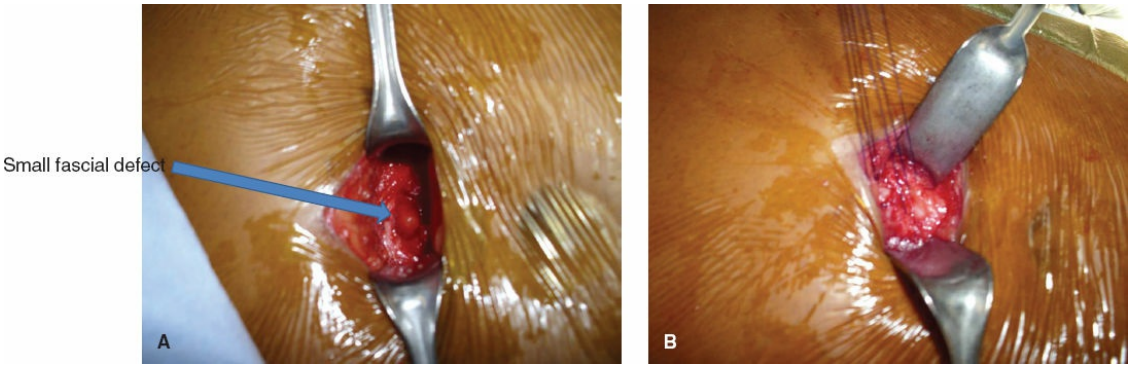

Figure 11.7. A. The small hernia defect size is delineated with healthy fascial edges. **B.** A primary suture repair is performed in a transverse fashion with figure-of-eight sutures extending beyond the corners of the defect.

Technique for Repair in Setting of Rectus Diastasis

1. The incision is a vertical midline incision to provide the proper

exposure from the xiphoid process infra-umbilical. The small fascial defect is repaired as described above with or without mesh reinforcement. The extent of the diastasis is delineated to allow for maximal plication.

2. Either a single or a double row of sutures can be utilized depending upon surgeon preference. The authors prefer either a single row of figure-of-eight No. 1-PDS sutures or a double row consisting of figure-of-eight 0-PDS sutures followed by running No. 1-PDS. Additional onlay mesh reinforcement is not necessary.

INCISIONAL HERNIAS

Incisional hernias develop in up to 20% of patients, which means that annually at least 150,000 patients will develop this issue from an abdominal surgery. As noted earlier, the best practice for abdominal wall closure has yet to be determined. The associated pathology is quite variable and thus so is the technique utilized for repair. A recent Cochrane database review of open surgical techniques for incisional hernias has shown that even in small defects, the use of suture repair was associated with less surgical site infection and seroma but an increased rate of recurrence. Therefore, mesh reinforcement is advocated for in all incisional hernias, regardless of defect size.

There are multiple randomized controlled trials evaluating laparoscopic versus open repair of abdominal wall hernias. The laparoscopic approach provides for lower overall complication rates, decreased wound complications, decreased length of stay, and decreased recurrence rates. However, there is a higher rate of bowel injury with inexperienced surgeons. Also, unless the fascial defect can be closed, the functionality of the abdominal wall remains compromised. This is especially an issue for moderate to large defects.

Preoperative preparation is critical in the patient with an incisional hernia as recurrence rates can be high leading to a much more difficult hernia repair with worsening results. Weight loss should always be considered in the obese patient. Although the authors do not have a strict cutoff, the literature has shown that a BMI >30 kg/m^2 is associated with higher recurrence rate. Not only does the weight loss make the operation technically more feasible, perhaps avoiding a bridge repair, but also it allows the patient an easier recovery. For those patients who are morbidly obese and are unsuccessful in their weight loss attempt, a consultation with

a bariatric program is advised. Smoking cessation is an absolute requirement as well given its negative impact on wound healing and higher incidence of surgical site infection. In the elective setting, the repair is not scheduled unless the patient can be verified to have at least 4 weeks successful with cessation. Lastly, in the diabetic patient, proper blood glucose control needs to be assessed with HgAlc level. A level >7.2 is associated with complications. Methicillin-resistant Staphylococcus aureus clearance and nutritional assessments are also important.

There are many different techniques that have been developed for the repair of the incisional hernia. The central theme of each repair has become midline re-approximation of the autologous tissue (usually rectus muscles) with physiologic tension and proper mesh reinforcement. Suture repair alone is associated with unacceptable recurrence rate and should not be the primary objective. The authors advocate for either intraperitoneal or retrorectus placement of the prosthetic mesh. Most of the literature is consistent with higher recurrence rates with an onlay positioning of the mesh.

TYPES OF REPAIRS

Rives–Stoppa Repair (Retro-Rectus)

Rives described this technique as early as 1973 in which the prosthetic material was placed above the posterior sheath in the retro-rectus location to isolate it from the viscera. This is quite different than the intraperitoneal placement of mesh. Flament reported a recurrence rate of 6.3% at 10-year follow-up on 693 patients. The advantage of the repair is that it allows uncoated inexpensive mesh to be utilized and may provide a more vascular space for the placement of biologic mesh if indicated.

The technique that follows reduction of the hernia contents and lysis of adhesions is the incision of the posterior sheath from the rectus muscle starting just lateral to the edge (Fig. 11.9). It is an avascular plane that can be carried out to the semilunaris line. The dissection can be further carried out if a transversus abdominis release (TAR) is performed. The same dissection is performed on the contralateral side. The posterior sheath is then approximated that isolates the prosthetic mesh from the viscera (Fig. 11.10). Any tearing of the posterior sheath can be primarily repaired or buttressed with omentum. The mesh is then sized accordingly and secured with several slowly absorbable sutures, such as No. 1 PDS, in a circumferential manner (Fig. 11.11). The rectus muscles are then re-

approximated restoring the functionality of the abdominal wall (Fig. 11.12).

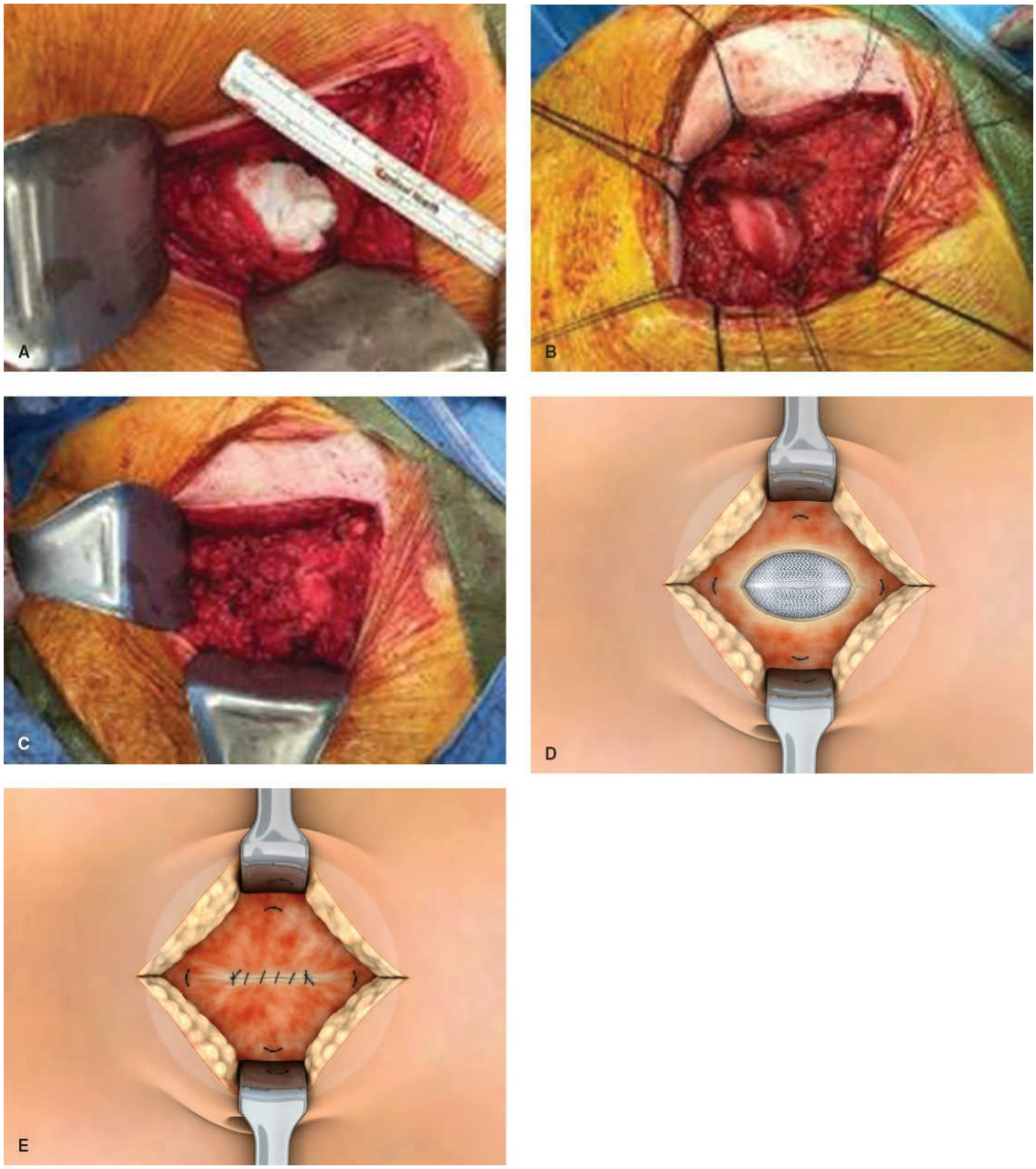

Figure 11.8. **A.** A moderate defect is exposed with fascial edges delineated. **B.** Mesh reinforcement in the intraperitoneal location is utilized given the defect size. The mesh is parachuted in after placement of transfascial sutures. **C.** After the mesh is secured, the fascia is then re-approximated with additional sutures, providing autologous tissue coverage. **D.** Illustration of mesh secured underneath the fascia. **E.** Illustration of the fascia closed over the mesh.

Intraperitoneal

This method remains the popular repair although rapidly losing ground to the retro-rectus repair. The laparoscopic approach to hernia repair is

largely responsible for its popularity as well as the advent of coated meshes. Unlike the retro-rectus repair, there is no limitation to the width of the mesh that can be placed intraperitoneal as the former is limited by the distance between semilunaris lines. Other advantages include it is quicker to do and requires less dissection. Also useful in the abdomen that has been repaired several times in which the posterior sheath is nonexistent or cannot be properly dissected. One disadvantage is the large number of sutures needed to secure the mesh to prevent migration of bowel above the mesh.

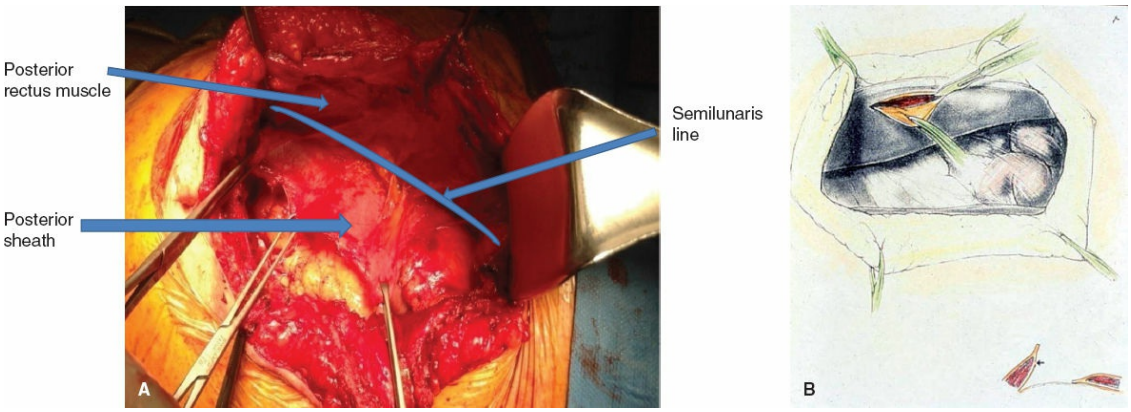

Figure 11.9. **A.** The unilateral dissection of the posterior sheath away from the posterior rectus muscle within an avascular plane to the semilunaris line. **B.** Illustration of the posterior sheath dissection.

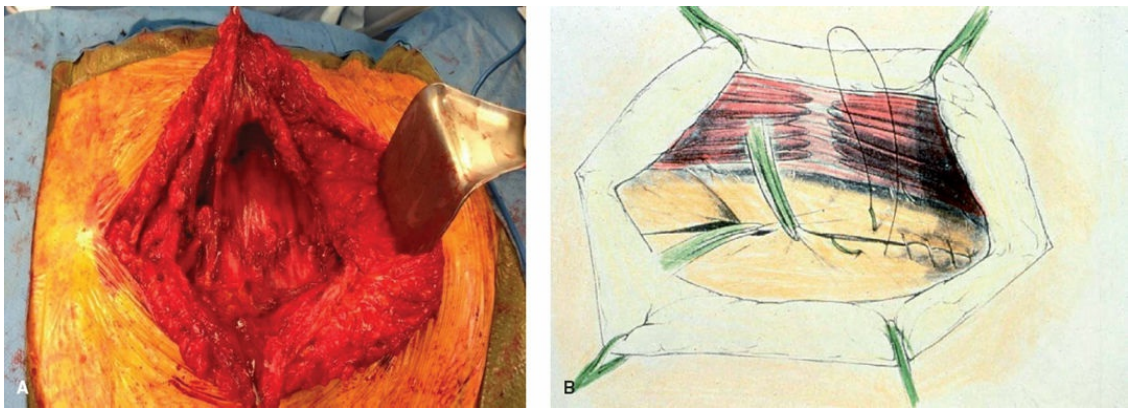

Figure 11.10. **A.** After bilateral dissection of the posterior sheaths from the rectus muscle, both sides are re-approximated with a running suture. **B.** Illustration of posterior sheath closure.

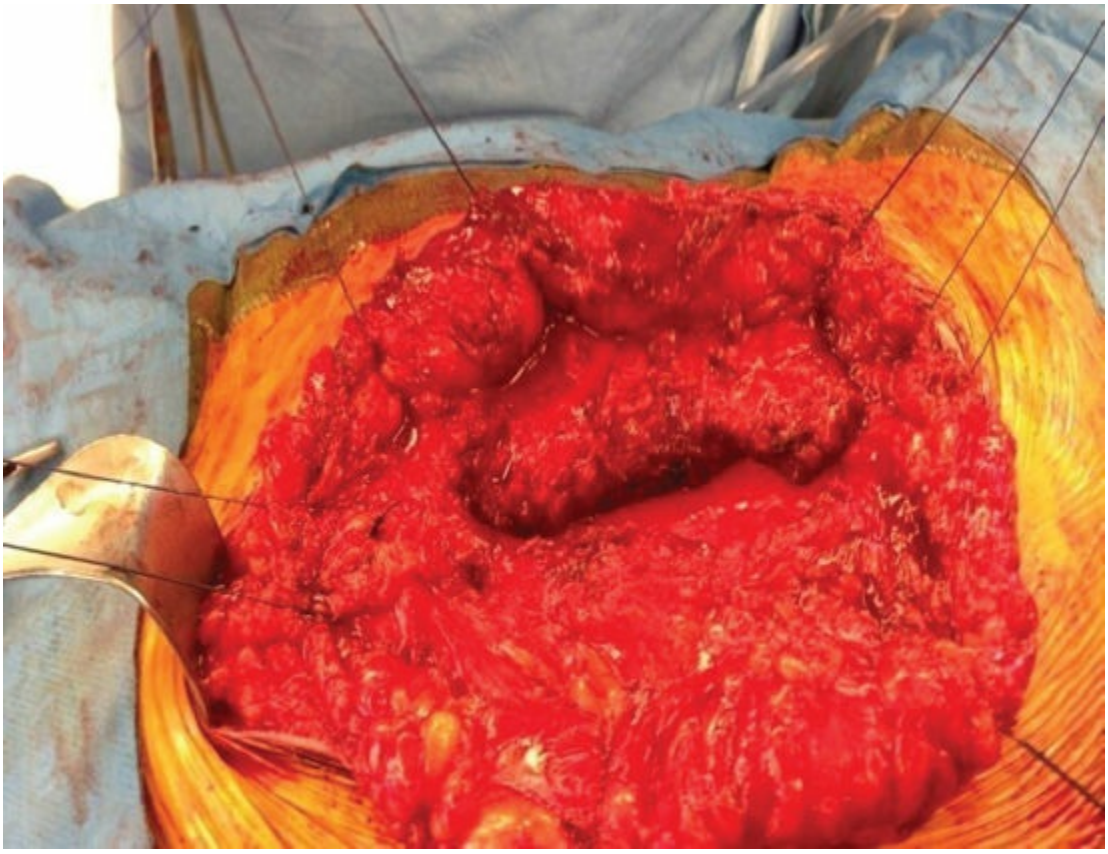

Figure 11.11. The mesh is then secured circumferentially underneath the fascia with tranfascial sutures.

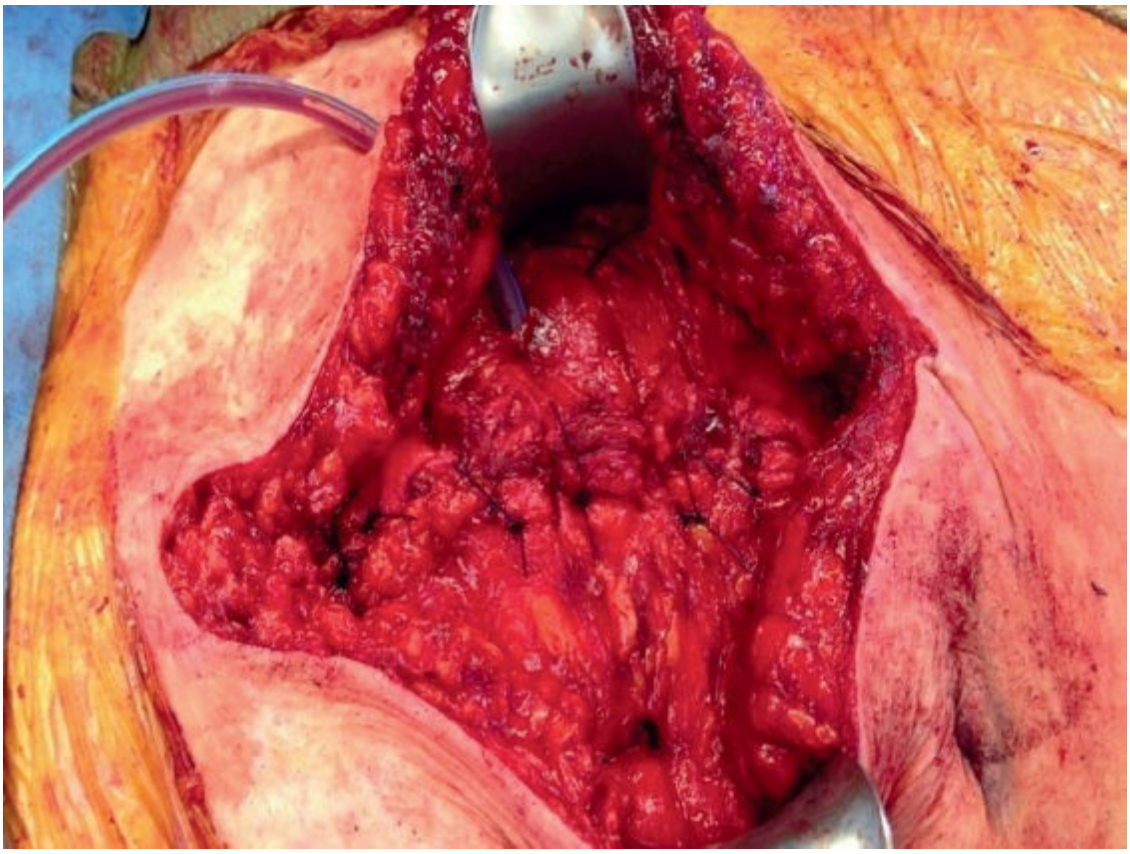

Figure 11.12. The rectus muscles are re-approximated with excessive tension.

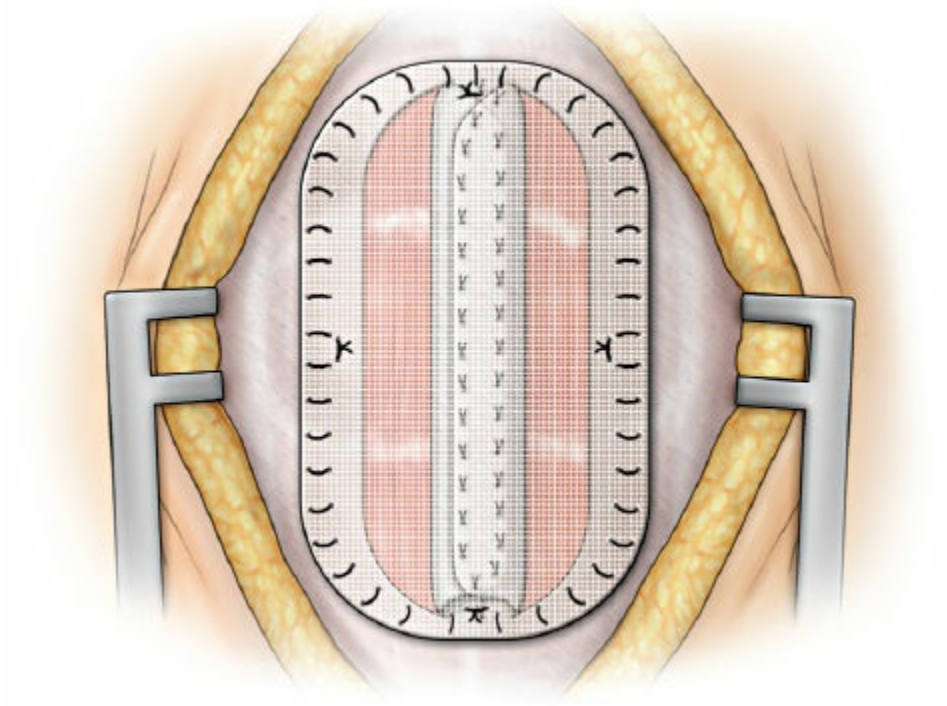

Figure 11.13. Chevrel onlay prosthesis.

The literature has shown essentially similar rates of recurrence with the Rives repair. Voeller reported a series of 115 patients in which there was <1% recurrence rate. This could be attributed to surgeon experience, advanced technical skills, and/or a repair performed well in good patient selection.

Onlay Technique (Chevrel)

This repair accounts for the minority of repairs performed, but should still be part of the surgeon's armenterium in certain cases such as a hostile abdomen with dense adhesions. The technique involves closure of the muscle followed by mesh placement. Relaxing incisions of anterior component separation procedure can be added if there is excessive tension on the closure. The onlay mesh was secured circumferentially as well as fixated centrally with either additional sutures or as described by Chevrel, fibrin glue (Fig. 11.13). Voeller has described and reported excellent results with complete glue fixation of the mesh.

The advantage to the repair is that the defect can be non-midline, unlike the Rives repair. As mentioned, aside from the reduction of the hernia, an

extensive lysis of adhesions is not necessary. The major drawback is the high potential for mesh infection and explantation with any surgical site infection as the mesh is positioned directly below the skin and soft tissue.

COMPONENT SEPARATION

In certain situations that involve large fascial defects in which the surgeon cannot achieve midline approximation of the rectus muscles, a components separation technique is extremely effective and should be in any general surgeon's armamentarium (Fig. 11.14). The neurovascular anatomy of the abdominal wall allows for a bilateral myofascial advancement of the rectus muscles while maintaining the dynamic functionality of the abdominal wall.

The most commonly employed technique involves an anterior or external oblique release described by Ramirez in 1990. The procedure is begun with the elevation of subcutaneous flaps from the underlying abdominal musculature to expose the linea semilunaris. It is critical to preserve the large peri-umbilical perforators to prevent ischemia of the skin flaps. The external oblique fascia is then incised 1 cm lateral to its insertion into the rectus sheath from above the costal margin to the inguinal ligament. This allows for the development of an avascular plane between the external oblique aponeurosis and internal oblique muscle as far as the posterior axillary line (Fig. 11.15). The developed myofascial complex allows for an 8- to 10-cm advancement at the waist; 3- to 5-cm advancement in the upper and lower abdomen. An additional 2-cm advancement can be achieved if the rectus muscle is elevated off of the posterior sheath.

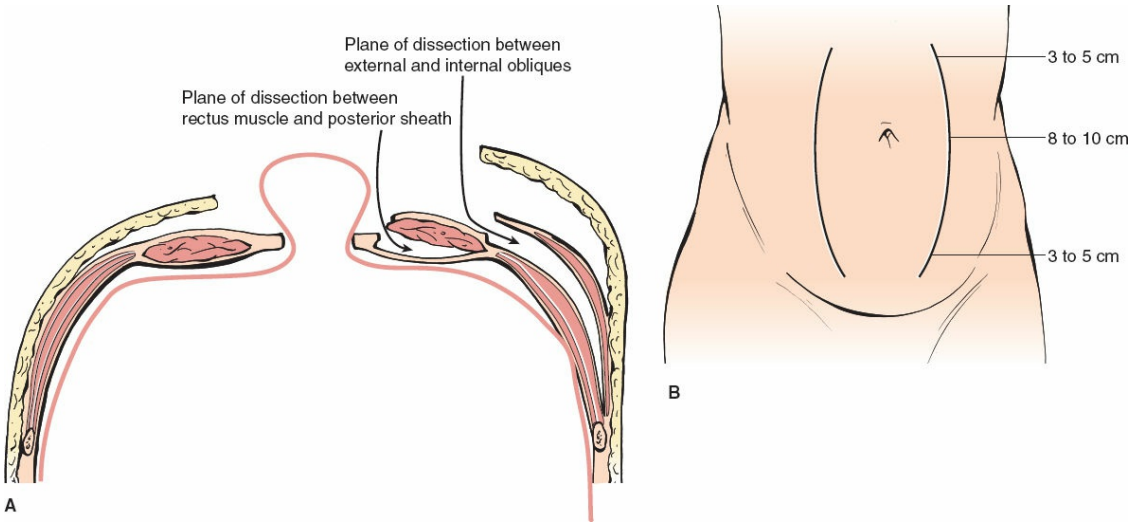

Figure 11.14. A. When a midline abdominal wall defect cannot be closed primarily, a components separation procedure can be utilized. The dissection begins with the elevation of subcutaneous flaps to the anterior axillary line to expose the underlying abdominal musculature. The linea semilunaris line is palpated and the external oblique fascia is then incised lateral to its insertion into the rectus sheath. An avascular plane is developed between the external oblique aponeurosis and internal oblique muscle to allow the rectus muscle to be advanced to the midline. The posterior sheath can also be incised and elevated off of the rectus muscle to achieve additional 2-cm advancement. **B.** There is a variable degree of advancement dependent upon location. The developed myofascial complex allows for an 8- to 10-cm advancement at the waist; 3- to 5-cm advancement in the upper and lower abdomen.

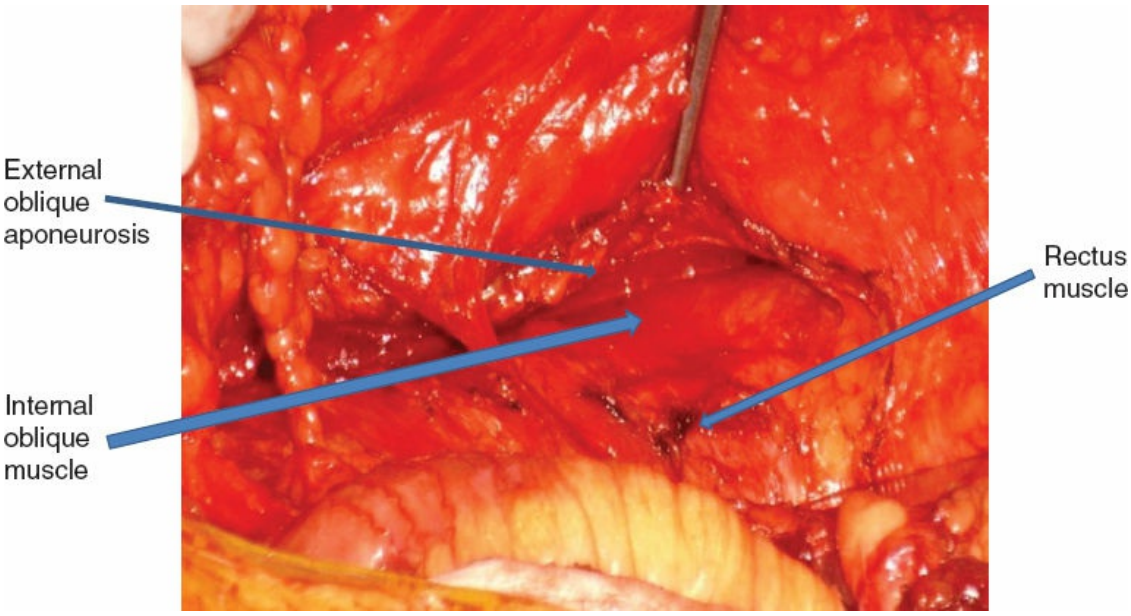

Figure 11.15. The external oblique aponeurosis has been separated from the underlying internal oblique musculature in an avascular plane. This results in a myofascial flap consisting of the internal oblique and transverses abdominis muscles.

Multiple variations have been described, but the one gaining immense popularity over the last few years is the TAR, described by Novistsky in 2012. It has a few advantages over the traditional anterior release. The most significant of which is the avoidance of large subcutaneous skin flaps potentially leading to a reduction in wound morbidity. The second advantage is the necessity of creating the retro-rectus space for mesh

placement, which isolates the prosthetic from the viscera. The dissection of the plane between the transverses abdominis and transversalsis fascia allows for a wide piece of mesh to be utilized. The disadvantage is the decreased advancement of the rectus muscles compared to the anterior release, which can be problematic in large defects. It is important to emphasize that the surgeon cannot perform an anterior release in this situation as the abdominal wall would be severely compromised.

The technique of the TAR as stated involves the separation of the posterior sheath from the rectus muscle to allow exposure of the transverses abdominis muscle. The next step is to incise the medial border of the muscle without injuring the underlying fascia or exposed nerves. Blunt dissection is used to retract the muscle laterally away from the posterior rectus sheath and up from the transversalis fascia (Fig. 11.16). The resultant plane is continuous with the retroperitoneum and can be developed further posterior to the costal margins to the space of Retzius, and laterally to the psoas muscles.

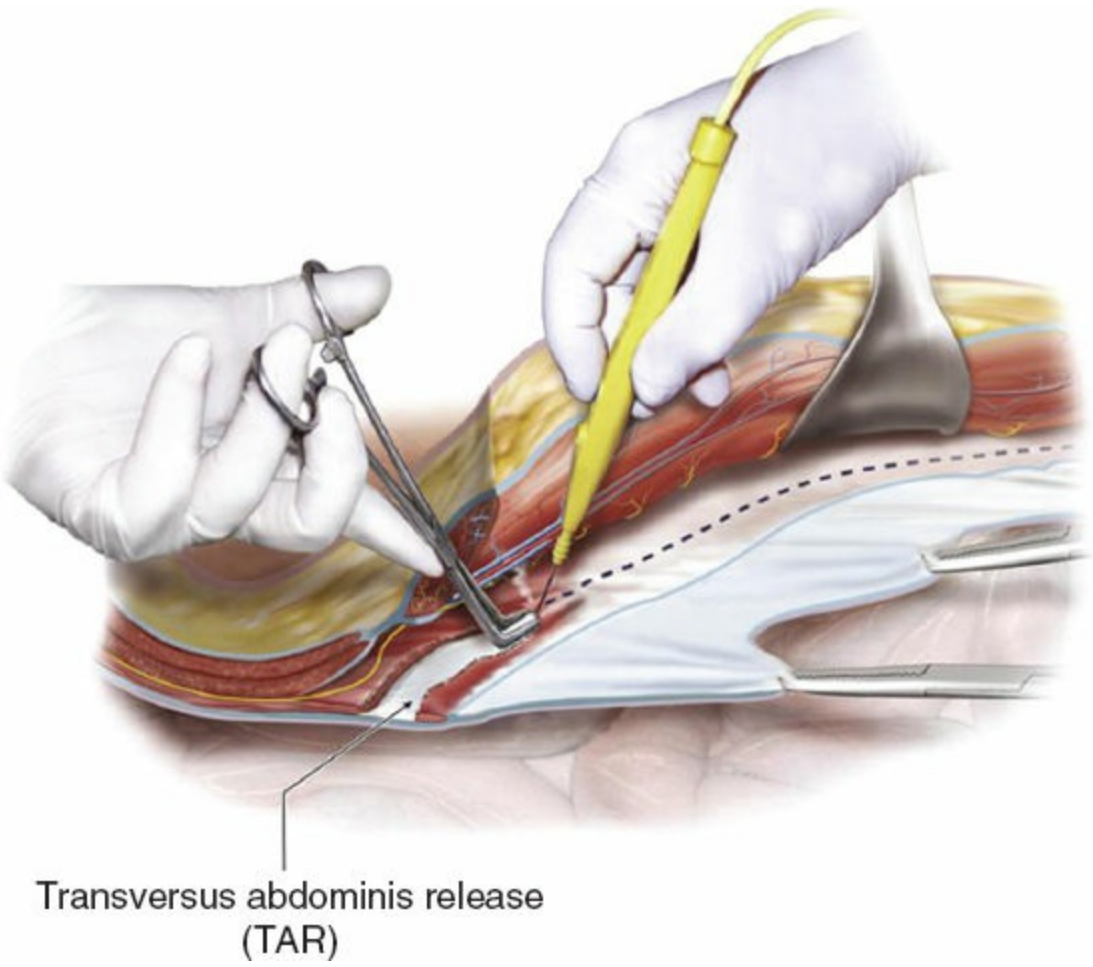

Figure 11.16. The transverses abdominis muscle is divided

above the peritoneum. The preperitoneal plane is then matured laterally between the transverses abdominis muscle and peritoneum/transversalis fascia to the psoas muscle. (From Petro CC, Como JJ, Yee S, et al. Posterior component separation and transversus abdominis muscle release for complex incisional hernia repair in patients with a history of an open abdomen. *J Trauma Acute Care Surg* 2015;78(2):422–9; with permission from Wolters Kluwer Health, Inc.)

LAPAROSCOPIC VENTRAL HERNIA REPAIR

Abdominal wall hernia repairs did not escape the laparoscopic proliferation of general surgery procedures in the 1990s. LeBlanc first described a laparoscopic ventral hernia repair (LVHR) in 1993. The popularity of the procedure coincided with the development of barrier-coated meshes that could be placed in the peritoneal cavity, which allowed tissue ingrowth against the posterior abdominal wall and ability to decrease adhesions with the viscera. As stated above, LVHR is tremendously successful dependent upon proper patient selection. Its distinct advantage is that the laparoscope allows for clear visualization of the abdominal wall to address all fascial defects, wide mesh coverage of the defect(s) without a large open incision, decreased surgical site occurrence/infection, and low recurrence rate.

Indications

The indications for an LVHR are similar to those for an open procedure. The presence of symptoms associated with the hernia such as pain and discomfort, bulging from the defect, and obstructive symptoms such as nausea and emesis. However, not all patients are candidates for the procedure. There are two major disadvantages to LVHR. The first is that it requires almost complete lysis of adhesions for trocar placement and wide mesh overlap. In patients with known history of dense adhesions or history of bowel injury from a hernia repair, there is a higher incidence of enterotomy compared to an open approach. The authors also prefer to avoid LVHR in patients with densely incarcerated viscera to prevent iatrogenic bowel injury. The second major disadvantage is the inability to close the defect in larger hernias. Although there is increasing number of surgeons who are attempting to do so with a myriad of techniques, the data do not reflect a lower recurrence rate. Closure of large defects is not

possible, which will leave the patient with a nonfunctional abdominal wall.

Equipment and Materials

The list of equipment for LVHR is not extensive. The authors prefer a 5-mm 30-degree angled scope that can then be placed through each trocar, which aids in the visualization of the repair. Our previously described technique involves placement of three 5-mm trocars and one 12-mm trocar. Most of the lysis of adhesions can be performed with laparoscopic shears, but ultrasonic shears can be employed for omentum and taking down the falciform ligament. Nontraumatic graspers to prevent serosal injury are important. A small gauze spinal needle is utilized for defect measurement. A suture passer device allows for transfascial suture fixation. The remainder of the mesh is secured with an absorbable tacker.

Perhaps, the most important is the selection of the proper mesh. With intraperitoneal placement, a barrier-coated mesh must be chosen and is based usually upon the facility the operation is performed in. The surgeon should be familiar with the mesh product including individual properties and sizes available. For example, a light-weight mesh would not be appropriate for large fascial defects without fascial closure.

Operative Technique

The following is our standard technique previously described and published (Fig. 11.17). Our method results in securing prolene-based barrier-coated mesh in intraperitoneal location with transabdominal suture fixation and absorbable tacks ensuring at least 3 cm of overlap. Conversion to open technique was performed if the laparoscopic repair was unable to be completed due to either technical issues or patient safety.

All patients receive prophylactic antibiotic prior to first incision based on individual drug allergy information. The patient is positioned supine on the operating table. Compression boots are employed for DVT prevention. A Foley catheter is frequently inserted depending on hernia location and size. Gastric decompression is accomplished with oral gastric tube in all patients.

A Veress needle is used to access the peritoneal cavity, with the location dependent upon the location of the hernia and prior surgical history. A Hasson technique is an alternative, but can be difficult in the morbidly obese patient. Pneumoperitoneum is established to 15 mm Hg. After placement of the first 5-mm trocar, two additional 5-mm and one 12-

mm nonbladed trocars are inserted under direct visualization. All trocars should be placed as lateral as possible to allow appropriate mesh overlap. A 5-mm 30-degree laparoscope is used to fully explore the abdomen and to perform the adhesiolysis. This is performed mainly using laparoscopic shears without energy source to prevent possible thermal injury to bowel. For an incisional hernia, a complete lysis of adhesions is performed to evaluate the entire length of the incision. The hernia sac contents are reduced, leaving the sac in situ. The defect is sized using a spinal needle, and the margins are marked on the abdominal wall.

Mesh is tailored to overlap the fascial defect by at least 3 cm. A minimum of four monofilament sutures are placed on the mesh. The mesh is then introduced through the 12-mm trocar. After proper positioning of the mesh, a suture passer is used to pull the transfascial sutures through separate incisions and tied down. Additional sutures are placed for larger mesh sizes. The circumference of the mesh is then tacked to the posterior fascia at 1- to 2-cm intervals. The absorbable tacker allows for placement of additional tacks in the center of mesh for better apposition to the posterior sheath.

At the completion of mesh placement, the bowel is examined for possible iatrogenic injury. The omentum is observed for hemostasis if involved in the hernia sac. Then the pneumoperitonuem is released. None of the trocar fascial defects are closed. The skin incisions are closed with absorbable sutures. No drains are placed.

Postoperative Care

Postoperative care is centered around return of bowel function and pain control. Thus, patients with smaller hernia repairs without extensive lysis of adhesions can be discharged the day of surgery. Otherwise, the average length of stay in our series is <2 days. An abdominal binder is recommended for comfort purposes.

SPECIAL CONSIDERATIONS

Enterotomy

As mentioned, the LVHR is associated with a higher enterotomy rate compared to open approach. If an injury occurs, it must be repaired either via laparoscopic approach dependent upon surgeon experience or conversion to open approach. A bowel resection may be necessary

dependent upon extent of injury. The lysis of adhesions is then completed. There are two options at this time. The first is to complete the hernia repair with biologic mesh as synthetic mesh is now contraindicated in a clean-contaminated case. The advantage of this option is a second operation does not have to be performed later in the admission. The second option would be to close the abdomen without mesh and admit the patient for antibiotics. The patient would then be brought back to the operating room if no signs of sepsis were evident for delayed placement of synthetic mesh.

Xiphoid Hernia

Subxiphoid hernias will require adjustment in trocar placement for proper triangulation of the defect. Usually, the falciform must be taken down using an energy source. This allows full visualization of the defect and proper mesh overlap. The authors do not advocate placement of sutures through the lower ribs or above the costal margin. There are risks of bleeding and chronic pain. We prefer to place the sutures just below the costal margin and then fixate the mesh superiorly with fibrin glue. Tacking is avoided to prevent injury to the pericardium or pleura.

Suprapubic Hernia

Again, trocar placement must be adjusted for suprapubic hernias. For proper fixation of the mesh, the space of Retzius must be dissected to expose the pubic symphysis and Cooper's ligaments (Fig. 11.18). This avoids injury to the bladder, iliac vessels, and nerves. The mesh is tacked to Cooper's ligament bilaterally similar to inguinal hernia repair. Transfascial sutures are then employed for the remainder of the mesh. We advocate for the placement of a three-way Foley to allow easy manipulation of the urinary bladder.

Flank Hernia

Defined as abdominal wall defects that occur between the costal margin and the iliac crest and between the anterior axillary line and the spine, these hernias can be challenging. The patient must be positioned in lateral decubitus position with the hernia side up (Fig. 11.19). Delineation of the fascial defect is not difficult, but the creation of space to allow mesh overlap can present a challenge. As the defect involves the retroperitoneum, the corresponding structures may have to be mobilized

such as the colon. Significantly more dissection is needed than an inexperienced surgeon may initially have planned such as mobilization inferiorly to expose Cooper's ligament and superiorly to the diaphragm. We prefer to fixate the mesh on three sides only, allowing the posterior mesh to be tucked into the retroperitoneum to prevent nerve injury.

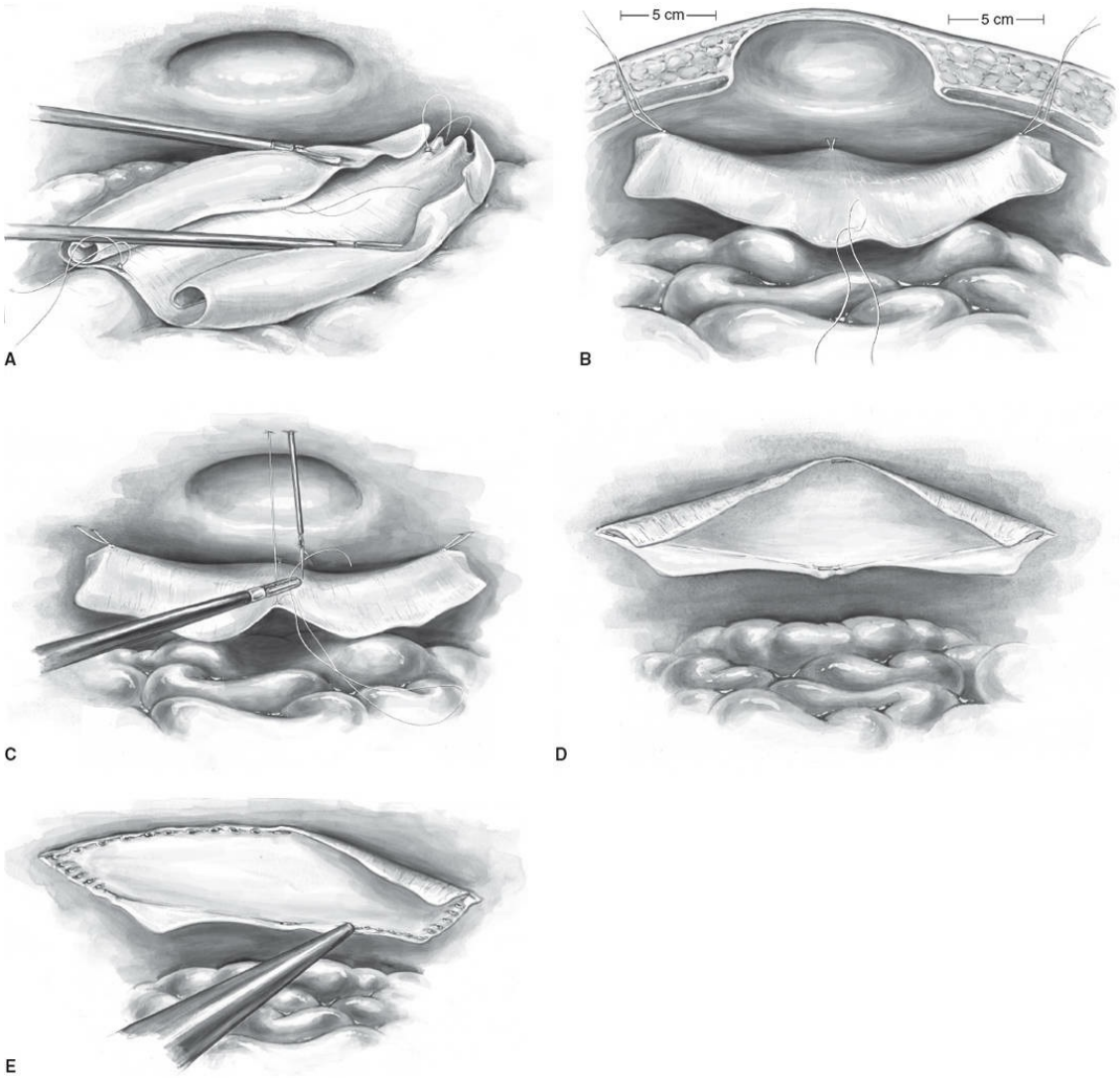

Figure 11.17. **A.** Mesh is oriented in the peritoneal cavity and then unrolled. Stabilizing the center of the mesh with one grasper and unfurling one side at a time works well. **B.** Sutures are preplaced 1 cm in from the mesh edge. The mesh is seen extending at least 5 cm beyond the edges of the hernia defect. The two legs of the suture are brought out of the same skin incision but enter at two different sites intra-abdominally, with at least 1 cm of fascia between the legs. **C.** Sutures are clamped but not tied until all four cardinal sutures have been externalized, allowing for adjustments in the placement of the transfascial sutures if necessary. Alternating between pulling the sutures tight and allowing slack help allow for precise suture placement. **D.** All four cardinal fixation sutures have been gently tied, and the mesh has the appropriate diamond shape, demonstrating tautness. **E.** The point-fixation device should be introduced from ports on the side of the abdomen opposite the area to be fixed. Ideally, the camera is on the same side as the device. Fixing one quadrant at a time and alternating between opposite quadrants help prevent

inadvertent shifting of the mesh across the abdomen. (From Soper NJ, Swanström LL, Eubanks WS, eds. *Mastery of Endoscopic and Laparoscopic Surgery*. 3rd ed. Philadelphia, PA: Lippincott Williams & Wilkins, 2009.)

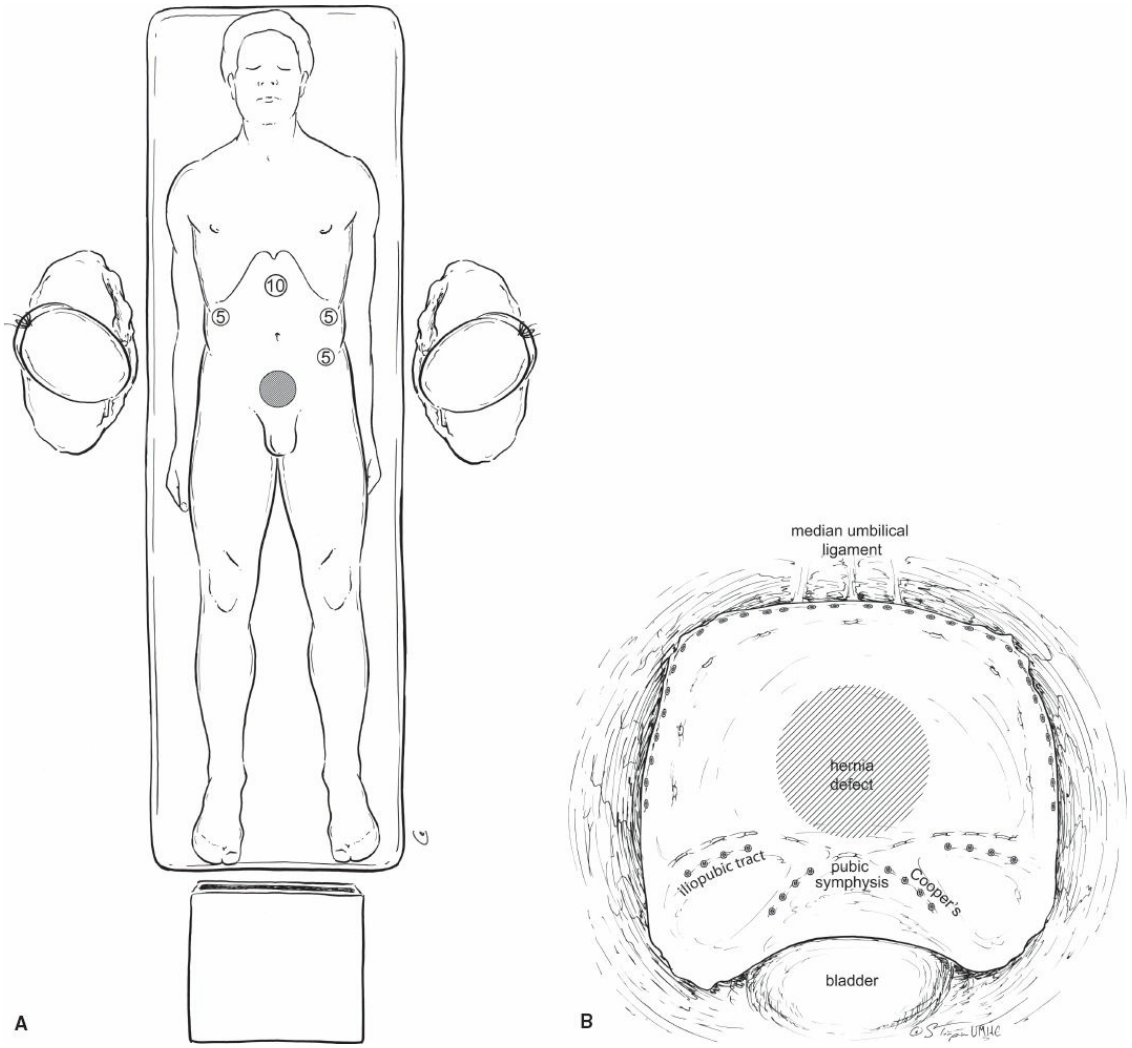

Figure 11.18. **A.** Trocar and operating room positioning for hernias below the umbilicus. **B.** Example of a completed suprapubic hernia repair. Note the extension of mesh below the pubic symphysis and Cooper ligament and the extra fixation along the iliopubic tract. (From Soper NJ, Swanström LL, Eubanks WS, eds. *Mastery of Endoscopic and Laparoscopic Surgery*. 3rd ed. Philadelphia, PA: Lippincott Williams & Wilkins, 2009.)

OUTCOMES

The laparoscopic approach for abdominal wall hernias is safe and effective. The largest meta-analysis of more than 5,300 patients found a lower rate of complications (22.7% vs. 41.7%), shorter length of stay (2.4 days vs. 4.3 days), and less recurrences (4.3% vs. 12.1%) compared to open approach. However, there was a higher rate of enterotomy. Heniford's series of 850 patients demonstrated a 1.7% incidence of intestinal or bladder injury. The success of LVHR is largely dependent

upon two factors: patient selection and surgeon experience.

SUMMARY

The success of an open abdominal operation requires adequate exposure and flexibility via the appropriate selection of the incision. This entails the surgeon having a fundamental knowledge of the anatomic principles of the abdominal wall. Equally as important is the proper closure of the abdominal wall to limit unnecessary morbidity. Immediate consequences result in surgical site occurrences (SSO), which may then develop into long-term morbidity of a hernia requiring another operation.

Reconstructive options for AWR are vast and should start with optimizing patient selection. The surgeon should have within his or her armamentarium a myriad of options to perform the optimal surgery. An algorithm should be incorporated into clinical practice based on high-level data that will allow the surgeon to define which approach, technique, and mesh reinforcement should be utilized for each individual patient. The ultimate goals of ventral hernia repair are to prevent complications from the hernia, restore functional abdominal wall, and minimize future complications including recurrence.

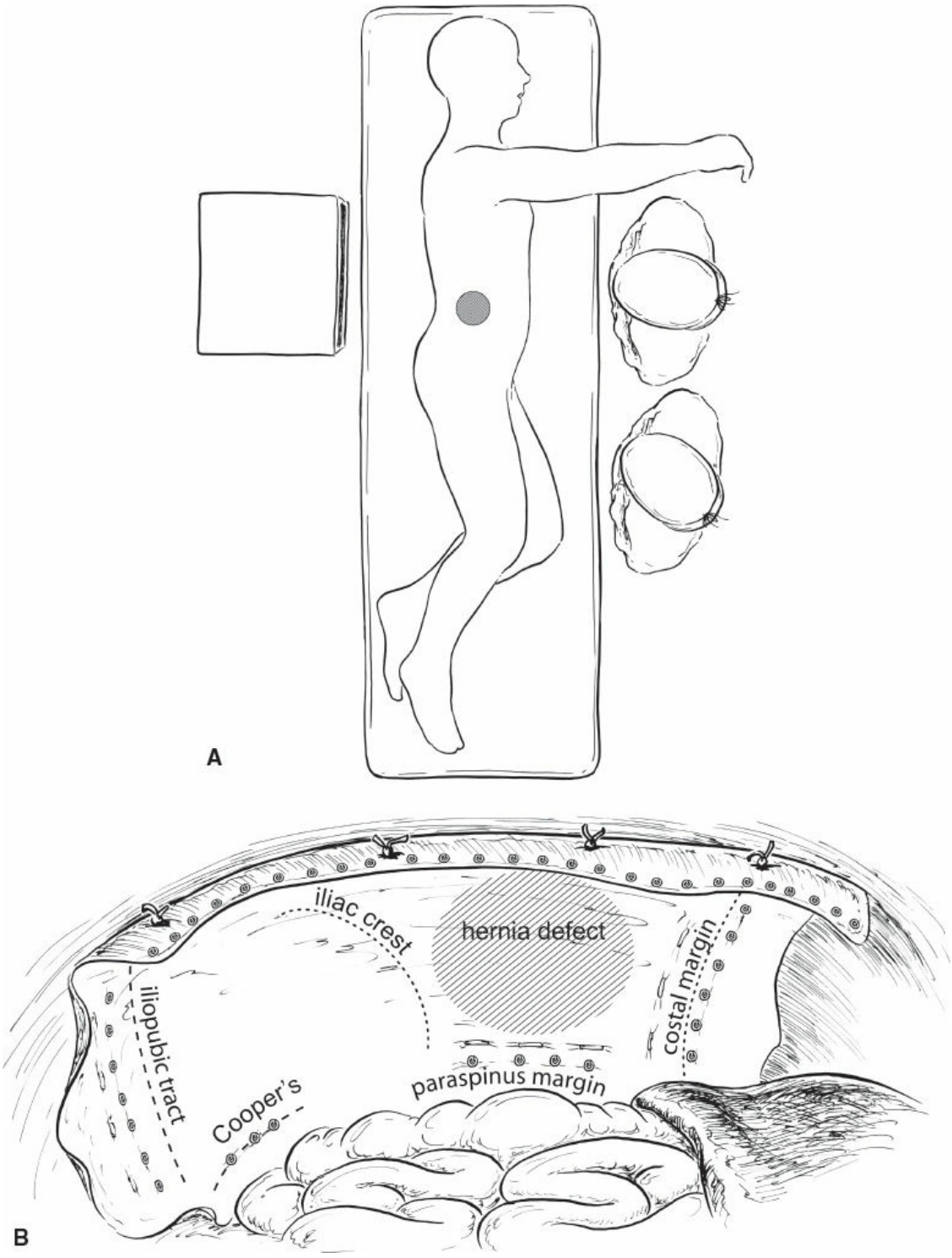

Figure 11.19. **A.** Patient positioning and operating room setup for repair of flank hernias. **B.** Retaining orientation to bony structures can be difficult during repair of flank hernias. This schematic demonstrates these relationships when the patient is in the lateral position, as well as the sites of point and suture fixation. (From Soper NJ, Swanström LL, Eubanks WS, eds. *Mastery of Endoscopic and Laparoscopic Surgery*. 3rd ed. Philadelphia, PA: Lippincott Williams & Wilkins, 2009.)

Suggested Readings

Burger JW, Luijendiji RW, Hop WC, et al. Long-term follow-up of a randomized controlled trial of suture versus mesh repair of incisional hernia. *Ann Surg* 2004;240:578–85.

Conze J, Kingsnorth AN, Flament JB, et al. Randomized clinical trial comparing lightweight composite mesh with polyester or polypropylene mesh for incisional hernia repair. *Br J Surg* 2005;92:1488–93.

Flum DR, Horvath K, Koepsell T. Have outcomes of incisional hernia improved with time? A population-based analysis. *Ann Surg* 2003;237(1):129–35.

Miller PR, Meredith JW, Johnson JC, et al. Prospective evaluation of vacuum-assisted fascial closure after open abdomen: planned ventral hernia rate is substantially reduced. *Ann Surg* 2004;239:608.

Novitsky YW, Elliot HL, Orenstein SB, et al. Transversus abdominis muscle release: a novel approach to posterior component separation during complex abdominal wall reconstruction. *Am J Surg* 2012;204(5):709–16.

Patel KM, Nahabedian MY, Gatti M, et al. Indications and outcomes following complex abdominal wall reconstruction with component separation combined with porcine acellular dermal matrix reinforcement. *Ann Plast Surg* 2012;69(4):394–8.

Pierce RA, Spitler JA, Frisella MM, et al. Pooled data analysis of laparoscopic vs. open ventral hernia repair: 14 years of patient data accrual. *Surg Endosc* 2007;21(3):378–86.

Ramirez OM, Ruas E, Dellon AL. "Component Separation" method closure of abdominal-wall defects: an anatomic and clinical study. *Plast Reconstr Surg* 1990;86:519–26.

Smart P, Mann GB. Meta-analysis of techniques for closure of midline abdominal incisions. *Br J Surg* 2003;90:370.

Williams RF, Martin DF, Voeller GR. Intraperitoneal modification of the Rives-Stoppa repair for large incisional hernias. *Hernia* 2008;12:141–5.

EDITOR'S COMMENT

This is an important chapter. Clearly obtaining excellent exposure is an essential requirement of most abdominal incisions, and hence surgeons must be familiar with a variety of approaches. In addition, incisional hernia is a common problem after surgery. Surgeons should be aware of techniques that may reduce the incidence of postoperative ventral hernia as well as the variety of techniques for repair.

The choice of the incision is best left to the discretion of the surgeon. The basic rule in surgery is to make an incision big enough and adequately placed to

allow comfortable access to the area of operation. With today's focus on smaller incisions, it is important to emphasize that the incision should be such that the operating surgeon is comfortable with the exposure and access. One of my mentors advised me that incisions "heal from side to side and not end to end." In other words, do not hesitate to lengthen an incision if you are having difficulty exposing the area of pathology. The ideal incision allows:

- Easy access to the desired structures
- Easy extension
- Avoids cutting muscle heals quickly with minimal scarring
- Healing with minimal scarring

Plastic surgeons have long taught that in order to enhance the aesthetic appearance, incisions may be placed in the direction of lines of cleavage of the skin (Langer's lines). These lines correspond to the direction of collagen fibers in the dermis and epidermis. Another important point is that incisions should also be placed as far as possible from stoma sites in so as to avoid compromising the stoma site and causing complications such as stoma retraction and prolapse.

The midline incision is frequently employed in abdominal surgery as it provides adequate exposure of most if not all abdominal viscera, is associated with minimal bleeding of made through the linea alba, has minimal associated nerve and muscle injury, and can be made and closed quickly. A potential disadvantage is a midline scar and possibly a higher incidence of incisional hernia. Helm and colleagues reported on 150 female patients who were randomly allocated to cholecystectomy through midline or transverse incision. After a minimum of 12 months follow-up, they observed that 1.6% (1/60) of patients who had undergone the procedure through a transverse incision presented with an incisional hernia as opposed to 14% (9/63) of patients from the midline incision group (P = 0.017) (Halm JA, Lip H, Schmitz PI, et al. Incisional hernia after upper abdominal surgery: a randomised controlled trial of midline versus transverse incision. *Hernia* 2009;13(3):275–80).

The paramedian incision is probably of historic interest only. The incision is made about 2 to 5 cm to the left or right of the midline. It provides access to lateral organs. The surgeon incises the skin, fascia (camper's and scarpa's), and the anterior rectus sheath. The anterior rectus muscle is freed from the anterior sheath and retracted laterally. To gain access to the abdomen, the incision is carried through the posterior rectus sheath (if above the arcuate line) or transversalis fascia (if below the arcuate line) and peritoneum. The incision has few advantages over a midline or transverse incision. Disadvantages include the time it takes to open and close difficulty in extending proximally along the costal margin and that the incision tends to disrupt the lateral blood and nerve supply of the rectus muscle that can lead to atrophy of the muscle medial to the incision. If you are doing a laparotomy on a patient who has had a paramedian incision, I would advise against a midline incision as this may compromise the

blood supply to the tissue between the incisions. The best option is to use the preexisting paramedian incision.

I have already alluded to one advantage of a transverse incision. Interestingly some institutions make greater use of transverse incisions than midline incisions. A transverse incision has an advantage in children and in obesity as there is greater exposure. There is speculation that wound infections are more common; however, I have not observed this in my experience nor did Helm in his aforementioned prospective comparison.

The subcostal incision has excellent exposure to the upper abdomen and may be extended to a Chevron modification or a Mercedes providing excellent exposure to the stomach, liver, biliary tree, pancreas, and spleen. It takes more time to close; however, there is a dividend in the quality of the exposure, particularly in the obese patient and a trend to a lower rate of incisional hernia.

The authors review closure techniques. In choosing a suture material, one takes into consideration strength and qualities of the suture material. Absorbable and nonabsorbable sutures each have characteristics that make them appropriate in a variety of situations. Sutures are classified according to their degradation properties. Sutures that undergo rapid degradation in tissues, losing their tensile strength within 60 days, are considered absorbable sutures. Sutures that generally maintain their tensile strength for longer than 60 days are nonabsorbable sutures. Synthetic absorbable suture made from polyglycylic acid or other related polymers may degrade within 2 weeks. However, delayed absorbable sutures may retain strength for up to 2 months. (http://www.uphs.upenn.edu/surgery/Education/facilities/measey/Wound_Closure Accessed on February 25, 2016.)

The surgeon should be familiar with updates to the half-life and tensile strength of absorbable suture products from manufacturers. Absorbable sutures have many advantages, but they have some limitations. First in the patient with a fever or sepsis and in particular a wound infection, they may dissolve more rapidly. In addition, they may not be the best choice for patients with impaired healing. Nonabsorbable sutures may remain in the wound for up to 300 days and silk may remain permanently and have increased and prolonged tensile strength. As such it might then be predicted that nonabsorbable sutures should decrease the risk of wound dehiscence and hernia, as compared with absorbable sutures. However, the superiority of nonabsorbable sutures has not been consistently found in meta-analyses of randomized trials for midline closure. However, it has been observed that nonabsorbable sutures are associated with an increased risk of suture sinus and prolonged wound pain compared with synthetic absorbable suture (Hodgson NC, Malthaner RA, Ostbye T. The search for an ideal method of abdominal fascial closure: a meta-analysis. *Ann Surg* 2000;231:436).

The authors cite the 1-cm rule for width and depth of the sutures. The European Hernia Society guidelines based recommend a shorter width of 5 to 8 mm. This is based on two randomized trials showing fewer hernias in the

shorter width groups (18% vs. 5.6% in Milbourne D, Cengiz Y, Israelsson LA. Effect of stitch length on wound complications after closure of midline incisions: a randomized controlled trial. *Arch Surg* 2009;144:1056 and 21% vs. 13% in Deerenberg EB, Harlaar JJ, Steyerberg EW, et al. Small bites versus large bites for closure of abdominal midline incisions (STITCH): a double-blind, multicentre, randomised controlled trial. *Lancet* 2015;386:1254–60).

The incidence of incisional hernia following laparotomy is reported between 10% and 15%. The occurrence depends on many factors, including the type of suture, closure techniques, and patient-related factors such as nutritional status, obesity, and infection. As such there has been increased interest in using prophylactic mesh placement at the time of closure of the abdominal wound to reduce the incidence. A systematic review by Nachiappan (Nachiappan S, Markar S, Karthikesalingam A, et al. Prophylactic mesh placement in high-risk patients undergoing elective laparotomy: a systematic review. *World J Surg* 2013;37:1861–71) of five randomized controlled trials and four comparative studies suggested a benefit to prophylactic mesh placement during laparotomy closure in high-risk patients with a significantly reduced incidence of incisional hernia without any significant differences in seroma formation and wound infection rates. However, the studies did not examine the incidence of mesh-specific complications such as foreign body sensation and chronic pain, and the authors concluded that such analyses must be done prior to making definitive recommendations. In similar studies, the incidence of incisional hernia has been reduced from 18% to 4.7% (Timmermans L, Eker HH, Steyerberg EW, et al. Short-term results of a randomized controlled trial comparing primary suture with primary glued mesh augmentation to prevent incisional hernia. *Ann Surg* 2015;261:276) and 31% to 11.3% (Garcia-Urena MA, Lopez-Monclus J, Blazquez Hernando LA, et al. Randomized controlled trial of the use of a large-pore polypropylene mesh to prevent incisional hernia in colorectal surgery. *Ann Surg* 2015;261:876–81). Prior to a definitive recommendation, additional validation with nonindustry sponsored trials will be needed with follow-up to include the incidence of specific mesh-related complications.

The reported incidence of wound dehiscence in patients who have undergone major abdominal operations ranges from 1% to 3%. Theoretically retention sutures designed to reduce tension on the wound edges can reduce the incidence of this complication. Retention sutures were first described by Reid in 1933. He employed silver wire sutures placed with wide tissue bites through all layers of the abdominal wall and tied just tightly enough to allow approximation of tissue. Retention sutures available for use today are usually made of heavy, nonabsorbable synthetic material and often include an added buttress device for skin protection.

Despite the widespread utilization of retention sutures, their use is controversial. Khorgami Z et al. (Khorgami Z, Shoar S, Laghaie B, et al. Prophylactic retention sutures in midline laparotomy in high-risk patients for wound dehiscence: a randomized controlled trial. *J Surg Res* 2013

Apr;180(2):238–43) reported a study in which 300 high-risk patients undergoing a midline laparotomy with at least two risk factors between 2008 and 2010. They were randomly divided into two groups. In the control group, the fascia was continuously repaired using a running looped No. 1 nylon suture. For the intervention group, closure included the addition of retention sutures that included the skin, subcutaneous tissue, rectus muscle, and abdominal fascia. The end points were the rates of wound dehiscence, evisceration, wound infection, postoperative pain, post-dehiscence mortality, and late incisional hernia for these two groups. After excluding early mortalities, 147 patients were followed in the intervention group and 148 patients in the control group. Wound dehiscence occurred in 6 patients (4%) in the intervention group and 20 control patients (13.3%) (P = 0.007). Abdominal evisceration after surgery occurred in 1 patient (0.7%) with retention sutures and 4 control patients (2.7%) (P = 0.371). There was no significant difference in wound infection and incisional hernia between the two groups. From this study, prophylactic retention sutures reduce the occurrence of wound dehiscence following midline laparotomy in high-risk patients with multiple risk factors for impaired wound healing without imposing significant postoperative complications. That is not to say that they are appropriate in all situations. In the case of difficult abdominal closure under tension, retention sutures will not likely help. Rather they will erode through the tissues setting up a nidus for infection. In these cases, staged closure with a wound vac or temporary mesh closure is preferable. The problem that I have observed most frequently with retention sutures is that they are tied too tightly. As swelling occurs after surgery, the buttresses designed to protect the skin erode into the skin along with the sutures causing inflammation and pain. They should be tied loosely. The surgeon should be able to pick the loosely tied suture up and slide her or his finger under the suture.

The authors give an excellent overview of techniques for incisional hernia repair. Indeed repair of ventral hernias constitutes one of the most common surgical procedures. It is also one of the most common topics in the surgical literature with 1,134 publications on this topic in the last 5 years and 1,935 in the last 10 years (PubMed search Ventral Hernia Repair 2-26-17). Despite the publications, most deal with technique and which mesh to use. It is difficult to gather information on indications and contraindications for repair of ventral hernia. Evans KK et al. (Evans KK, Chim H, Patel KM, et al. Survey on ventral hernias: surgeon indications, contraindications, and management of large ventral hernias. *Am Surg* 2012;78(4):388–97) reported the results of two questionnaire sent to a population of general and plastic surgeons active in hernia surgery. The first explored indications and contraindications, and the second examined subjective outcomes. In total, 568 surgeons responded to the first survey and 336 responded to the second survey. They reported that the most common indications for elective repair of abdominal wall hernias were generalized pain (68.7%) and cosmesis (54.6%), whereas the most common contraindications were morbid obesity (43.3%), American Society of

Anesthesiologists Class III or IV (35.4%), and enterocutaneous fistula (33.1%). Interestingly, over two thirds of surgeons did not routinely repair large abdominal wall hernias in asymptomatic patients. Most surgeons reported that the majority of patients had resolution of pain and subjective impression of improved cosmesis after surgery.

The use of prosthetic material, synthetic or biologic, is extremely common in the repair of incisional hernias. These products can be very expensive. In order to reduce costs, it may be prudent for surgeons working in a single hospital to decide on which mesh to stock and employ routinely. This is an effective strategy in reducing the cost to the institution and hence the cost to the patient.

Component separation techniques are gaining popularity particularly if mesh avoidance is desirable. There is increasing evidence that the laparoscopic or endoscopic component separation may enhance outcomes and reduce infection rates. More studies are needed so stay tuned (Fox M, Cannon RM, Egger M, et al. Laparoscopic component separation reduces postoperative wound complications but does not alter recurrence rates in complex hernia repairs. *Am J Surg* 2013;206(6):869–74).

In summary, much progress has been made in repair of ventral hernias since the sixth edition. Evans and colleagues outline the various techniques of repair. It behooves the surgeon should know many different techniques and be able to apply them as indicated in individual patient situations.

E. Christopher Ellison

12 Laparoscopic Suturing and Stapling

Jon C. Gould

BACKGROUND

Procedures popularized in the early days of laparoscopy included appendectomy and cholecystectomy. These were the first laparoscopic procedures, at least in part, because suturing was not required. Laparoscopic suturing is a complex task. The skill set required to perform this task is not derivative from open suturing skills. In the 25 or more years since the first laparoscopic cholecystectomy was performed, laparoscopic surgery has become pervasive. An entire generation of residents has completed their training since the American Board of Surgery first required surgeons to pass the Fundamentals of Laparoscopic Surgery (FLS) curriculum to become board certified. Two of the five tasks in the FLS curriculum at the current time are intracorporeal and extracorporeal knot tying. More advanced laparoscopic procedures requiring extensive and advanced suturing skills have become commonplace. Many new devices have been developed to facilitate suturing. In addition, surgical staplers have undergone a significant evolution and are now more reliable and enable a variety of complex procedures and maneuvers. As the field of minimally invasive surgery has evolved, so has the technology and teaching with regard to laparoscopic suturing and stapling.

LOOP LIGATURE

Ready-to-use and pre-tied loop ligatures are commercially available. These can be used for a variety of purposes including hemostasis and vessel ligation. These “endoloops” can also be used to secure a tissue pedicle in procedures such as appendectomy and cholecystectomy. Placement of a loop ligature is one of the five FLS tasks. A reusable ligating loop for practice on the FLS tasks is also commercially available, but is not intended for clinical use. Ligating loops consist of a prettied slipknot and a pushing rod through which a length of suture extends and is attached to a

breakaway tip of the rod.

Optimal Technique

The surgeon may choose to break the end of the rod and decrease the size of the loop before the device is passed into the abdominal cavity.

1. The loop is passed through a trocar with an appropriate angle and in proximity of the structure to be ligated (Fig. 12.1).
2. The loop is swept or manually placed over the target with a grasper.
3. The grasper is inserted through the loop and the tissue to be ligated is grasped and retracted anteriorly (Fig. 12.2).
4. Sliding the pushing rod down tightens the loop. Traction on the tissue to be ligated should be avoided to prevent avulsing the target tissue (Fig. 12.3).
5. The suture is cut



Figure 12.1. Endoloop.

In the FLS task, users are scored by accuracy in knot placement, security of the knot, and time to successfully place the knot.

SUTURING INSTRUMENTATION

Laparoscopic needle drivers come in a variety different handles, tip configurations, and lengths. The handles may be “pistol grip” or in-line.

In-line handles (Fig. 12.4) allow full rotation without compromising the position of the hand. Needle driver tips can be straight or curved. Curved tips can facilitate a line of site to the actual tip and can accentuate angles than can make intracorporeal knot tying easier. The problem with curved tip needle drivers is that in certain circumstances the tip may be pointed away from where the surgeon would like it to be requiring the surgeon to accommodate to this circumstance or to flip the needle driver over and hold it upside down. “Self-righting” tips are also available. These may facilitate needle control for suturing, although the lack of a fine tip can be an impediment to intracorporeal knot tying. Knot pushers are also necessary with some mechanical suturing devices. Knot pushers may be either closed or open ended. Closed ended knot pushers are easier to use and do not allow the knot to slip off the pusher. After the suture is threaded through the hole in the distal end of the pusher, it cannot be dislodged and sutures can be thrown quicker. To square a knot with a closed knot pusher, the suture tails would need to be switched with each throw. Practically speaking, many surgeons will overcome this potential issue by throwing three granny knots and then switching the knot pusher to the other suture tail for additional knots to prevent the original knot from slipping. With an open knot pusher, there is an open groove rather than a closed loop. The throws of the knot can be alternated and squared without rethreading the eye of the closed loop as for a closed knot pusher. The disadvantage to an open knot pusher is that the knot can easily slip off the pusher. If this happens while the knot is in the trocar, it can be difficult to recover. Should this happen, the knot should be pulled into the abdominal cavity until the knot can be visualized. The open knot pusher can then be placed on the knot under direct visualization, although this requires some practice and is especially difficult under less optimal ergonomic conditions sometimes encountered in the operating room.



Figure 12.2. Retracting the target and using gravity for counter traction.

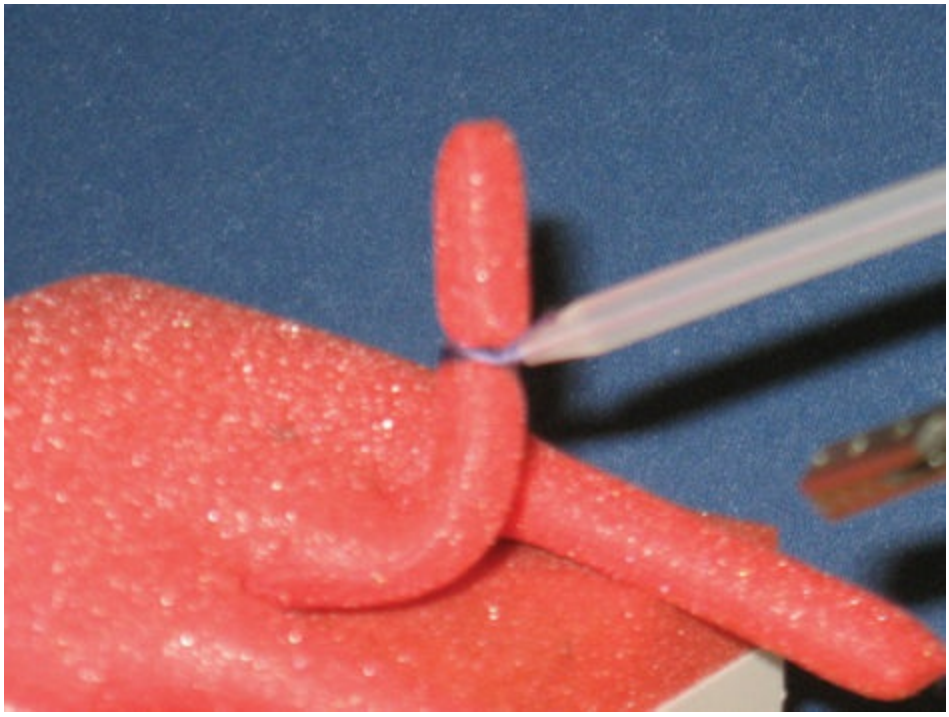

Figure 12.3. Tightening the slipknot completely.



Figure 12.4. Needle driver handles.

EXTRACORPOREAL KNOT

The extracorporeal knot is useful for tying intra-abdominal knots when there is some tension on the target tissue—such as closing a large hiatal defect in a paraesophageal hernia repair. When tying an extracorporeal knot, some degree of tension must be maintained on each suture to prevent the knot from slipping/loosening. This makes an extracorporeal technique less desirable for suturing delicate tissue, such as a mucosal perforation that occurs during the course of a laparoscopic Heller myotomy. It is easier to learn how to successfully and safely tie an extracorporeal knot when compared to an intracorporeal knot. To tie an extracorporeal knot requires a full-length suture as both arms of the suture eventually need to reach from the tissue, out of the same cannula, and still be of sufficient length to hand tie a knot that can be pushed down onto the tissue.

Optimal Technique

1. Most curved needles do not fit through a 5-mm cannula. Since the extracorporeal technique requires surgeons to pass both suture arms and a needle though the same port, most surgeons who use this knot tying technique place their ports in a configuration that calls for a 10-mm port to be placed in a strategic location for suturing and knot pushing. Some “ski” or “canoe” needles will fit through a 5-mm port. Alternatively, a standard curved (SH) needle can be canoed manually by straightening the curve at the midpoint with a couple of handheld needle drivers. The suture should be at least 30-cm long for the ease of extracorporeal knot tying.
2. The needle and suture are passed into the abdominal cavity, most often with the nondominant hand. There are a variety of techniques that can be used to get the needle into the dominant hand in the optimal

position for suturing. One technique is to carefully drag the needle into the correct orientation on intra-abdominal tissue. As the needle is grasped with the dominant hand about two thirds from the tip, the suture still in the nondominant hand can be manipulated to help the needle rotate into the appropriate orientation as it is grasped.

3. The target tissue is sutured. One should make an effort to "follow the curve" of the needle as it passes through the tissue rather than lifting the shaft of the needle driver up or to the side when suturing.
4. Once the needle has been passed through the tissue, the suture near the needle is grasped with the same instrument that was used to pass the needle into the abdominal cavity. The opposite instrument is used as a pulley to protect the suture from sawing into the tissue. The needle and suture are removed through the same port through which the suture tail is hanging.
5. The needle is removed from the suture. It is often helpful to tag the tail of the suture with a clamp to prevent this from falling into the port as the needle is removed.
6. Knots are tied by hand extracorporeally. Either a closed or open-ended knot pusher may be used. Once the suture is secured, the tails are cut.

Extracorporeal knot tying is one of the five FLS tasks. Task performance is scored based on the accuracy of needle placement through the target, security of the knot, and efficiency (time) to successfully complete the task.

INTRACORPOREAL KNOT

To tie a secure surgical knot with laparoscopic instruments using intracorporeal knot tying techniques requires an advanced laparoscopic skill set. The fixed position of the trocars as well as the long instruments and fine maneuvers required under sometimes ergonomically challenging conditions combine to make this a difficult but critical task in advanced laparoscopic surgery. Many different techniques are described and can be effectively employed. Some surgeons choose to grasp the needle in the same hand and rotate clockwise and counterclockwise around the suture swage. The *swage* is the point where the suture material joins the needle. In the FLS intracorporeal knot-tying task, the technique has been standardized. This is the technique we will describe in the following section.

Optimal Technique

1. The suture length in the standardized FLS intracorporeal knot task is 15 cm. In very small spaces in the operating room, a suture of less than 15 cm may be ideal as this shorter length will allow the surgeon to tighten the throw without releasing and regrasping the suture or needle. Too long of a suture may also be an issue, as the surgeon may need to release and regrasp the suture multiple times to tighten each throw.
2. Grasp the suture about 1 to 2 cm behind the swage with the nondominant hand. Pass the needle through a trocar and into the abdominal cavity. The needle can be rested on an intra-abdominal structure and then grasped with the dominant hand needle driver approximately two third from the tip and at the appropriate angle. Avoid fully clamping the dominant hand needle driver or letting go over the suture with the nondominant hand until the angle of the needle is as desired.
3. Pass the needle through the target tissue. A common mistake of novice knot tiers is to lift or move the needle from side to side rather than rotating the needle through the tissue. In the FLS task, these maneuvers may dislodge the Penrose drain and result in a failed attempt. In the operating room, these maneuvers may avulse the tissue being sutured with undesirable consequences.
4. Pull the suture through until there is an approximately 1 to 2 cm tail. Pass the suture near the swage back to the hand that passed the needle (dominant hand).
5. For a surgeons knot, wrap the suture in the dominant hand around the tip of the empty nondominant hand needle driver twice. Grasp the tail of the suture with the nondominant hand. Pull the tail through the loop created around the tip of the nondominant hand needle driver without tightening the loop. Do not pull on or lengthen the tail of the suture, as this will compromise subsequent throws of the knot. Once the suture tail has been pulled out of the loop by the nondominant hand, tighten the loop almost entirely with the dominant hand. Be careful with the needle as it is pulled toward the periphery of your field of view.
6. Pass the suture to the other hand. Grasp the suture about 1 to 2 cm from the swage with the nondominant hand. Wrap the suture around the tip of the dominant hand needle driver once, grab the suture tail with the dominant hand and tighten the loop as in the previous step.
7. Pass the suture back to the dominant hand. Once again, grab the suture about 1 to 2 cm from the swage. Wrap the suture around the tip of the

nondominant hand needle driver once, grab the suture tail with the nondominant hand, and tighten the loop a final time.

8. Pass both tails of the suture to a single instrument. Through the opposite hand trocar, pass a scissors and cut both tails.

In the FLS task, three throws are all that is required. In the operating room, depending on the suture material, what is being sutured, and surgeon preference, additional throws may be placed by continuing the sequence as described. In the FLS task, performance is scored based on the accuracy of needle placement through the target, security of the knot, and efficiency (time) to successfully complete the task. More time (3 additional minutes) is allotted to complete an intracorporeal knot when compared to the extracorporeal knot before the task "times out."

MECHANICAL SUTURING DEIVCES

There are a number of mechanical devices designed to facilitate knot tying. These devices can help to enable the creation of secure knots laparoscopically—often with a shorter learning curve, less intraoperative time, and better ergonomics when compared to standard intracorporeal or extracorporeal techniques. These devices are useful for surgeons just learning to tie knots laparoscopically and for cases where extensive laparoscopic suturing may be necessary. The appropriateness of the various devices for different suturing applications is dependent on the tissue to be sutured, the tension on the tissue itself, and often the cost of the mechanical devices.

Examples of mechanical suturing assist devices include the Endo Stitch device (Covidien and Medtronic, Minneapolis, MN), the Suture Assist device (Ethicon, Somerville, NJ), and the TK-Knot device (LSI Solutions, Victor, NY). For some of these devices (Suture Assist and TK-Knot), standard laparoscopic needle drivers are used.

Endo Stitch Device Technique

The Endo Stitch is a reloadable, disposable laparoscopic mechanical suturing device. Currently, this device must be passed through a 10-mm or larger trocar. This device allows for the needle to be toggled between each arm of the device with a toggle switch located on the handle of the device. Both intracorporeal and extracorporeal knot tying techniques can be employed with this device. A traditional needle driver is not necessary.

Either running or interrupted sutures can be placed. A variety of suture materials are available. The surgeon places the Endo Stitch device in his/her dominant hand and controls the suture with a grasper (Maryland or other) in the other hand.

Optimal Technique—Intracorporeal Knot With Endo Stitch Device

1. Open jaws of Endo Stitch device.
2. Place jaws around tissue to be sutured and squeeze handles to close jaws on the tissue.
3. Toggle switch to move needle to other jaw and open jaws to gently pull needle through tissue and the suture follows through.
4. Lay the suture that extends directly from the needle over the top of the empty jaw.
5. Grasp the suture tail with another instrument, bring the suture tail in between the jaws of the instrument, close the jaws and pass the needle.
6. Pull the jaw through the needle back through the loop of the suture.
7. Clinch the knot with the jaws in the closed position.
8. Return the toggle lever back into the forward position. The needle should be in the same jaw as in step 6.
9. Lay the suture that extends directly from the needle over the top of the empty jaw.
10. Bring the suture in between the jaws of the instrument. Close the jaws and pass the needle.
11. Pull the jaw with the needle back through the loop of the suture.
12. Cinch the knot with the jaws closed. Repeat steps to place additional throws.

Optimal Technique—Extracorporeal Knot With Endo Stitch Device

1. Open jaws of Endo Stitch device.
2. Place jaws around tissue to be sutured and squeeze handles to close jaws on the tissue.
3. Toggle switch to move needle to other jaw and open jaws to gently pull needle through tissue and the suture follows through.
4. Pull device and suture out of port through originally passed. Be careful to avoid tearing through the tissue by shearing and creating friction at the suture. Another grasper can be placed inside the 2 sutures and the suture arm attached to the Endo Stitch device can be

angulated/displaced to minimize friction and tension on tissue as suture and device is removed.
5. Cut suture off device. Preserve maximum length of suture.
6. Hand tie the first throw of your knot. A surgeon's knot will not slide as easily.
7. Pass the knot from extracorporeally to the tissue to be sutured with a knot pusher device, closed or open depending on surgeon preference.

Other Mechanical Suturing Devices

The Suture Assist device (Ethicon) is a reloadable, disposable mechanical suturing device. The suture and pre-tied knot are loaded into the device prior to throwing each interrupted suture. Needles come in standard curved and "canoe" configuration. The canoe needle can be passed through a 5-mm trocar. The device is used in the nondominant hand, with a standard laparoscopic needle driver in the dominant hand. The back handle of the device can be opened and closed and controls the jaws of the device. The jaws can be used to grab the needle as it passes through tissue or to grab tissue itself. Once the needle and suture have been passed though the tissue to be sutured, the needle is dropped through a loop on the knot at the tip of the device. The suture arm with the needle is then pulled at a 90-degree angle to the tip of the suturing device. The trigger on the top of the device is then slowly deployed to tighten and secure the knot.

The TK Ti-Knot device is used to deploy a titanium "knot" to secure a suture. The device is reloadable and disposable. It can be deployed through a 5-mm cannula. After the suture is passed through the target tissue, each tail of the suture is pulled extracorporeally. The TK Ti-Knot device is used to pass and secure the titanium "knot" while concurrently cutting the sutures.

Unidirectional or barbed suture is available in a variety of materials and sizes. Circumferential barbs around the suture material anchor the tissue at numerous points, distributing tension. A major advantage of these sutures in laparoscopy is that the need for tying a knot is eliminated. In addition, when running a barbed suture, the need to maintain tension is eliminated. A third instrument to maintain tension on the suture in order to prevent the running closure from loosening is no longer necessary. This can save considerable time. Several studies have been published in hernia and gastrointestinal surgery demonstrating equivalent clinical outcomes and decreased cost and operative time for barbed compared to standard sutures.

Another technology that can eliminate the need to tie knots in laparoscopy is shape memory polymers such as nitinol clips. These biomaterials can change their shape, configuration, or dimension under appropriate stimuli such as heat, water, light, pH value, electricity, or magnetic field. The use of these materials in laparoscopic suturing is evolving.

LAPAROSCOPIC SUTURING SIMULATION AND TRAINING

As mentioned previously, laparoscopic suturing is a complex task requiring great dexterity. The skills needed to tie a knot laparoscopically are not derivative from those needed in open surgery. The FLS curriculum has been extensively validated and is now a core component of surgical residency programs and becoming FLS certified is required in order to become certified by the American Board of Surgery. Placement of a ligating loop, extracorporeal knot tying, and intracorporeal knot tying are three of the five tasks in the curriculum. Research has demonstrated that trainees can become proficient at laparoscopic suturing in the skills lab in a video trainer box. Unlike the early days of laparoscopic surgery, the learning curve to develop the skills necessary to efficiently perform these tasks has been moved out of the operating room and into the skills lab.

The FLS curriculum is based in a low fidelity video trainer box. Learners use real laparoscopic instruments and suture, but they suture Penrose drains and place loops around foam appendages. High fidelity, computer-based virtual reality simulators have been developed. Many of these commercially available virtual reality simulators have preprogrammed knot tying tasks. These computer-based simulators for the most part lack haptic feedback. They can also cost well over $100,000 in some cases.

STAPLING IN LAPAROSCOPY

The modern era of surgical stapling was launched in the 1800s when American surgeon Mark Ravitch observed a Russian surgeon in Kiev operating with a stapler on the lung. Surgical staplers are pervasive in the modern operating room. Without the use of stapling technology, many procedures that were commonly performed only via laparotomy 20 or more years ago would not have been amenable to a laparoscopic approach. Many kinds of staplers have been modified for laparoscopic use.

Commonly used laparoscopic staplers are of the linear and circular configuration.

Surgical staplers are expected to provide tissue approximation and hemostasis without causing ischemia or tearing of the tissue. Adequate performance of these devices relies on achieving optimal compression force that allows for hemostatic approximation while minimizing shearing and injury. When the stapler is fired, individual titanium staples travel through the target tissue until they hit a hard anvil on the opposite side that bends the staples into a “B” configuration.

Optimal performance of staplers is dependent on picking the right stapler and staple type for the job. Linear staplers may articulate at the end to allow for stapling structures at an angle that would otherwise be difficult given the fixed position of the trocars. Linear staplers also come in various lengths (45-mm and 60-mm are the two most common stapler cartridge lengths). Modern staplers place six parallel rows of staples across the target tissue and a knife blade from within either the stapler cartridge or in the stapler deploys to divide the tissue in the middle.

It is important that surgeons familiarize themselves with the instructions for use (IFU) package insert on each device. The two largest endomechanical surgical stapling device manufacturers at the time of this writing are Ethicon and Covidien. Each of these company’s staplers are slightly different in terms of cartridges (color codes, final fired staple height may be of varied heights in subsequent rows) and methods for optimal use. When the knife blade is contained within the stapler itself and is reused from fire to fire, there is typically a maximum number of uses recommended before the stapler must be replaced. When the knife blade is in the cartridge, it is replaced with each new cartridge and more fires per stapler are usually safe and appropriate. Modern versions of each major manufacturer’s endomechanical linear staplers are internally powered. This allows for consistent firing on a steadier platform. It also facilitates the firing of these devices by surgeons with smaller hands.

Circular staplers differ from linear staplers in that they create round staple lines. They come in different sizes—usually a 21- and 25-mm anvil. A 25-mm anvil creates a stapled gastrointestinal anastomosis with a much smaller diameter—about 15 mm for one manufacturer. Two concentric stapled lines are placed and a circular knife blade on the inside of both is deployed to create a circular stapled anastomosis (Fig. 12.5). Like the linear stapler, staples come in different heights for different applications.

There is a version of this device in which the anvil of the circular device comes preattached to an orogastric tube to facilitate transoral passage for esophageal and high gastric anastomosis.

Choosing the appropriate staple height is important. A staple cartridge with staples that are 2.0 to 2.5 mm in height provides excellent hemostasis of larger arteries provided the vessels can comfortably compress to 0.75 to 1.0 mm. The final fired staple height is a function of the stapler, the selected stapler cartridge, and the tissue itself. Newer staplers employ a technique known as tissue gap control where the final fired staple height is consistent across the length of the staple line. Each individual manufacturer can provide surgeons with this information for the commercially available staple cartridges. In general:

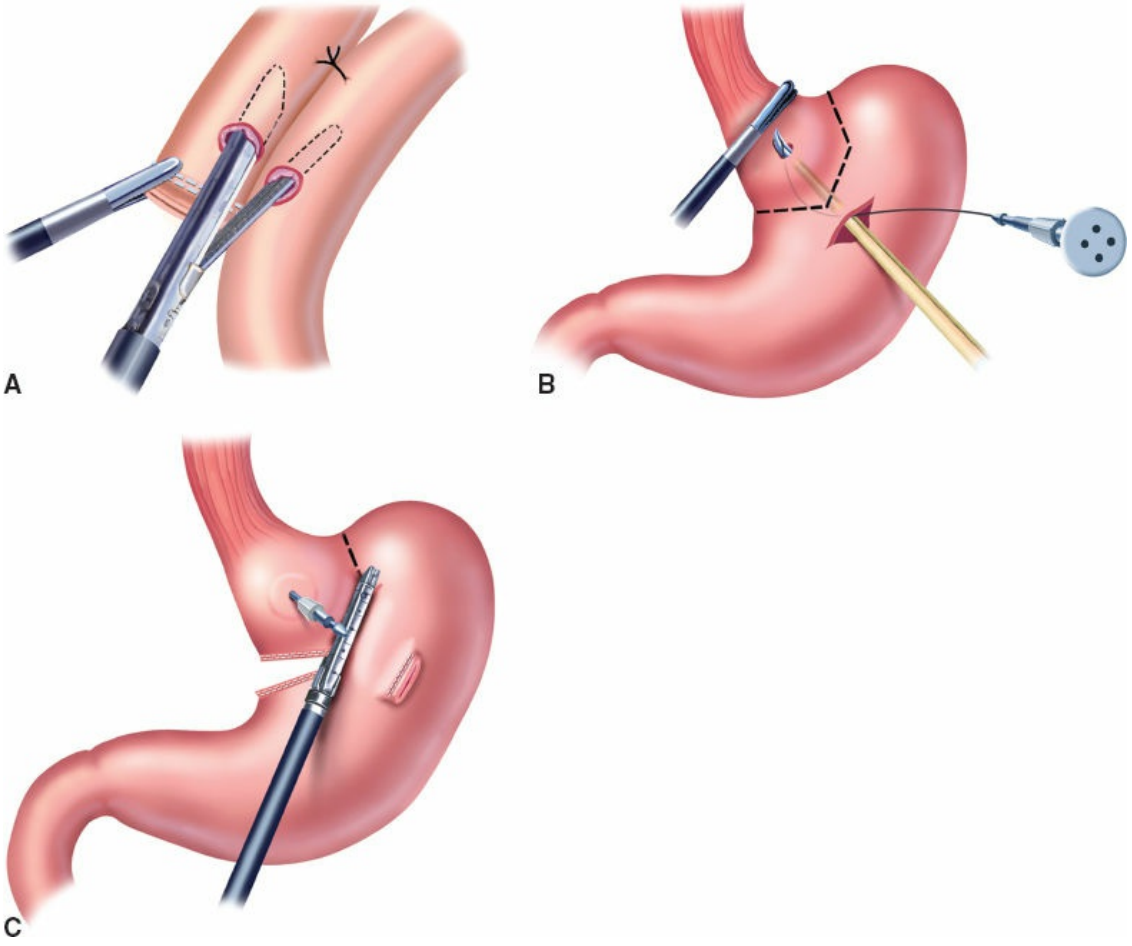

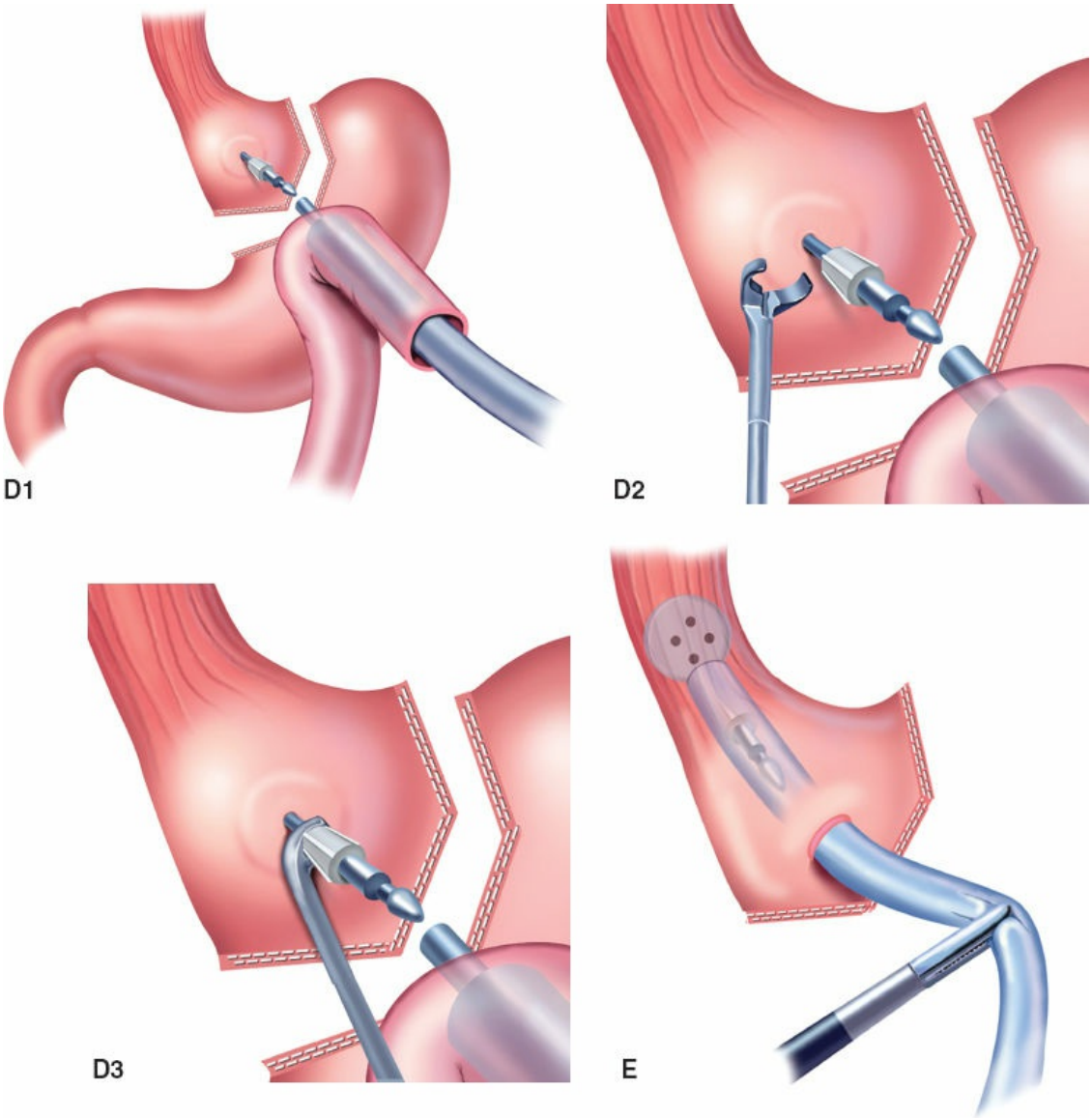

Figure 12.5. **A:** Stapler: linear. **B:** EEA anvil insertion. **C:** EEA pouch preparation. **D:** EEA anvil stapler mating. **E:** EEA anvil transoral placement.

For a 2.0 mm cartridge final tissue compression should be 0.75 to 1.0 mm. This “vascular” load is commonly used to divide arteries such as the splenic artery during laparoscopic splenectomy.
For a 2.5 mm cartridge final tissue compression should be 1.0 to 1.5 mm. This load is often used on small intestine.
For a 3.5 mm cartridge final tissue compression should be 1.5 to 2.0 mm. This load is commonly applied to medium thickness tissue such as the fundus of the stomach or nondiseased colon.
For a 4.8 mm cartridge final tissue compression should be 2.0 mm. This load is often used on thick tissue such as the antrum of the stomach or the lung.

Using too long or too a short staple will lead to bleeding after the stapler is fired. A short staple fired through thick tissue that cannot be compressed to the final staple height will not interlock properly, or will rip through the tissue. Conversely, too long a staple will not adequately compress the vessel or tissue and bleeding will occur through the staple line.

In an effort to increase the security of surgical staple lines and to improve hemostasis, buttressing material can be added to the jaws of laparoscopic stapling devices (Fig. 12.6). Buttressing material is derived from different sources such as bovine pericardium (Peri-Strips, Baxter Healthcare, Deerfield, IL) or synthetic polymer (glycolide copolymer as in Seamguard®, W L Gore, Flagstaff, AZ).

Linear staplers are more versatile and can be used for both resection (appendectomy, colectomy, small bowel resection) and anastomosis (colorectal anastomosis, small bowel anastomosis, gastrojejunostomy in gastric bypass). A linear stapled anastomosis requires an enterotomy in both structures to be anastomosed that must subsequently be closed. For example, in a gastric bypass a gastrotomy in the gastric pouch and an enterotomy in the jejunum must be created to allow the linear stapler to be placed in each lumen and fired. The common enterotomy that results must then be closed. This can be done either with sutures or with another load of the stapler (double stapled anastomosis). The caliber and size of the anastomosis are difficult to consistently control when linear stapled techniques are used when compared to a circular stapler. When a circular stapler is fired to create the anastomosis, the anastomosis itself is completely closed and of a consistent caliber.

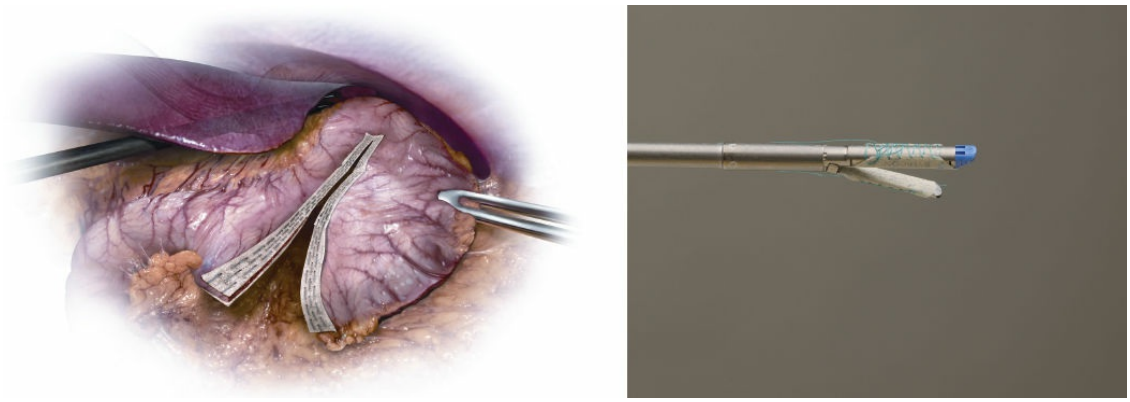

Figure 12.6. Buttress material seam guard.

A disadvantage to the circular stapler in gastrointestinal surgery is that

the stapler is large and often slightly curved at the end making this impossible to pass through a laparoscopic trocar. In gastric bypass surgery, the circular stapler is often passed through a dilated trocar site. Since the stapler is placed in the bowel lumen to create the circular stapled anastomosis, there has been a higher rate of wound infections observed in these cases when compared to linear stapled techniques.

Complications of Stapling

Bleeding from staple lines and gastrointestinal leaks from stapled anastomosis are the two most commonly observed complications related in part to surgical staplers. A brief search of the Food and Drug Administration (FDA) Manufacturer and User Facility Device Experience (MAUDE) database reveals 232 events of "surgical stapler" related adverse events in a recent 12-month period (9/1/15–8/31/15). There were no deaths reported in the database, 81 injuries, and 149 malfunctions included. Malfunctions generally include misfires and incomplete fires of the stapler, difficult opening of the stapler and releasing from tissue after fired, and tearing of the tissue. Many of the injuries involve torn tissue, extended operative time, and in some cases conversion from a laparoscopic to an open procedure.

While stapling technology has advanced dramatically since Ravitch brought that first device back from Russia, the MAUDE database is a testament to the fact that failures still occur. It is critical for surgeons performing laparoscopic stapling cases to understand the IFU on the different stapling platforms and how to select the right stapler and staple load for the application and tissue on which it is to be used. In depth knowledge when it comes to the proper preparation, reloading, and troubleshooting of the device in case of problems is also useful. Finally, the ability to suture laparoscopically as described in the preceding section of this chapter can help avoid the need to convert to an open procedure in the case of a stapler mishap.

CONCLUSIONS

Laparoscopic suturing is necessary in many common advanced laparoscopic surgical procedures. While a variety of devices exist to facilitate the creation of knots in laparoscopic surgery, surgeons should be encouraged to learn intra- and extracorporeal knot tying techniques as well. Given that these skills are now part of the FLS curriculum, a

mandatory requirement to become board certified, the modern laparoscopic surgeon is likely to be comfortable with these techniques. Surgical staplers continue to evolve. The technology readily available today greatly facilitates complex laparoscopic surgery. Surgeons need to be familiar with the proper techniques for using the different stapling devices to ensure the best chance of an optimal clinical outcome.

Suggested Readings

Baker RS, Foote J, Kemmeter P, et al. The science of stapling and leaks. *Obes Surg* 2004;14:1290–8.

Fraser SA, Klassen DR, Feldman LS, et al. Evaluating laparoscopic skills: setting the pass fail score for the MISTELS system. *Surg Endosc* 2003;17(6):964–7.

Giordano S, Salminen P, Biancari F, et al. Linear stapler technique may be safer than circular in gastrojejunal anastomosis for laparoscopic Roux-en-Y gastric bypass: a meta-analysis of comparative studies. *Obes Surg* 2011;21:1958–64.

http://www.accessdata.fda.gov/scripts/cdrh/cfdocs/cfMAUDE/Search.cfm. Accessed September, 2015.

http://www.covidien.com/content/dam/covidien/library/global/english/product/hand instruments-and-ligation/endoscopic-suturing-devices/endo-stitch-knot-tying-manual.pdf. Accessed September, 2015.

http://www.flsprogram.org/wp-content/uploads/2014/03/Revised-Manual-Skills-Guidelines-February-2014.pdf. Accessed September, 2015.

Orzech N, Palter VN, Reznick RK, et al. A comparison of 2 ex vivo training curricula for advanced laparoscopic skills: a randomized controlled trial. *Ann Surg* 2012;255(5):833–9.

Tyner RP, Clifton GT, Fenton SJ. Hand-sewn gastrojejunostomy using knotless unidirectional barbed absorbable suture during laparoscopic gastric bypass. *Surg Endosc* 2013;27(4):1360–6.

Yo LS, Consten EC, Quarles van Ufford HM, et al. Buttressing of the staple line in gastrointestinal anastomoses: overview of new technology designed to reduce perioperative complications. *Dig Surg* 2006;23(5–6):283–91.

EDITOR'S COMMENT

The adage, "You can teach a monkey to operate," is not so readily repeated in the era of laparoscopy. With minimally invasive surgery, the surgeon views the operative field via a laparoscope on a 2D or 3D HD monitor. Thirty-centimeter long laparoscopic instruments lack haptic feedback. The range of motion is

restricted by using fixed ports through the abdominal wall. Laparoscopic suturing is just not that easy and requires deliberate practice to get good at it. In this chapter, Dr Gould reviews a few of the basic minimally invasive surgery (MIS) techniques to suture and staple.

In the early 1990s as laparoscopy became popular, surgeons realized that to do more than a laparoscopic cholecystectomy, surgeons either needed technology to obviate suturing or they needed to develop new skills. Technology advanced clips appliers, staplers, glues, and endosuturing devices. Courses were offered to teach laparoscopic suturing, and competitions such as Top Gun were developed to promote skill acquisition. Video trainers and simulators become commonplace in training programs to practice and eventually the American Board of Surgery required the fundamentals of laparoscopic surgery (FLS) to assure all residents had basic suturing and knot tying skills prior to sitting for their board exams in surgery.

Staplers made dividing and reconstructing tissues quick and easy. Staplers can be linear or circular and come in several sizes. Newer staplers even articulate. And as a general rule, stapled anastomoses do not need to be over sewn. One drawback is that staplers can be somewhat costly.

Over the last 20 years, surgeons have learned they can staple through just about any visceral tissue. The antrum, small bowel, and mesentery require thick, medium, and small staple height staplers respectfully. Failure to gauge the appropriate staple height results in staple line disruptions and leaks. Alternatively, too big of a staple may cause bleeding. Choosing the correct stapler is the most crucial decision to avoiding problems.

In 1995, I went to Gore and other companies with bioabsorbable materials and I proposed that we use buttress materials like the thoracic surgeons were doing for the lung to create a better seal with the staplers for the alimentary tract. Soon, many companies had buttress materials, often bioabsorbable, to reinforce the staple line. Surgeons were all too quick to pay whatever it cost for any product that might decrease the chance of a leak. It’s important to note, that if you choose to use buttress material, then you should consider a higher staple height. Be aware, the package insert on many stapler devices explicitly cautions that buttress material may adversely affect the stapler from closing properly.

It takes about 40 to 60 hours of deliberate practice to get good at laparoscopic suturing. A novice may take more than 5 minutes to lay down a suture in foam and place one surgeons knot and two half hitches. A master surgeon may take 20 seconds. The best way to progress from novice to expert is to practice regularly in a simulation center.

As you hone your skills, you also develop preferences. I rarely use the endoloop unless I am trying to close the peritoneum after a rent is made during a laparoscopic TEPP hernia repair. Through one 5 mm port I can pass the loop ligature and the other 5 mm port allows me to use a grasper to lift up the peritoneum. This prettied knot works fine but is a little more costly. In just about any other setting, I have more working space to intracorporeal suture

instead.

Extracorporeal suturing is best for closure of the paraesophageal hernia where I might be closing tissue against a little tension. I like to introduce no less than 10 cm of extra suture material into the abdominal cavity before I suture, so it's easier to pull back suture after throwing a bite of tissue. It takes less force to pull back suture material that has already been introduced than to pull it in and back through the tissue in one motion. I also like to place a grasper instrument as a pulley so that the tension is pulling back is on my instrument rather than the tissue itself. Once the suture is outside the abdomen, I have a few tricks to extracorporeal knot tying. First, I will place a clamp on the suture strand in my nondominant hand. This way I can keep track of the direction of my knots. Also, when creating my knot I ask my assistant to place a finger of the top of my port to exclude air leak and maintain suture tension. Lastly, I tend to throw a series of knots then advance them with my knot pusher instrument after my first two throws are laid. This is much quicker than doing one half hitch at a time.

In general, I prefer an intracorporeal technique to laparoscopic suturing. The suture length is about 12 to 15 cm long (approximately the length of an open scissors). Silk suture with less memory is easiest to use, especially if dampened with a little saline. The needle should be introduced through the port in your nondominant hand by grabbing the suture 1 cm behind the needle swage. The needle is then presented to your dominant hand. I avoid the self-righting needle holder as it limits the angle of needle presentation to 90 degrees and I usually prefer to have the needle oriented somewhat forward. I also use a curved needle rather than a ski needle. A gentle arch through tissue with a curved needle provides the best bite and precision. To tie a knot, I pull the suture through the tissue to have a short tail. I grab the tip to the needle and position the needle "smiley face up" between the grasper and needle holder instrument. The needle holder goes "in and out" above and below the needle to loop the suture around the needle. Then the tail is grasped by the needle holder and knot is laid. The direction of the loop alternates the half hitch to create a square knot.

I also like the Endo Stitch device. This is particularly nice when you have a lot of suturing to do and less than ideal port placement. (Ideal is laparoscope in the middle, port on left and right side, and target ahead.) The technique is well described and can be easily mastered with practice. With experience, the device can be toggled quicker using the third and pinky fingers. If too generous of a bite of tissue is attempted, the needle will fall off the device. Since it's a straight needle, the needle needs to go through the tissue linearly or it will get snagged. But with these few pearls in mind, the device is great.

All surgeons doing advanced laparoscopic surgery today should be skilled at laparoscopic suturing and not be relying on clips and staplers. This expertise is best learned using a box trainer and not on the job. Dr Gould describes basic steps to get you started. With deliberate practice your lap suturing will be less than 30 seconds and your Endo Stitch less than 15 seconds. And if this is not obtainable in your hands, you may decide that MIS surgery is not for you.

Daniel B. Jones

13 Ultrasonography by Surgeons

Ellen Hagopian and Junji Machi

Surgical ultrasound has become a vital tool of the surgeon. It is often referred to as the “stethoscope” of the surgeon as it allows the unseen to be seen and has naturally been used as an extension of the physical examination in multiple settings. In the operating room, ultrasound provides real-time imaging during a real-time operation. Once effectively performed by surgeons, ultrasound provides valuable intraoperative information to allow execution of the operation. Furthermore, ultrasound can be repeated throughout the operation to provide new information, confirm previous findings, and to potentially change the operative plan. In spite of advances in various preoperative imaging modalities, surgeons often make final decisions during surgery based on intraoperative findings. Meticulous exploration by inspection and palpation may not always be accurate or possible; this is particularly true in the evaluation of solid organs or deep structures. Intraoperative imaging methods can provide useful and, at times, critical information. The use of ultrasound during open or laparoscopic procedures is a valuable and widely applicable modality because it provides high-resolution images of the operative field in real-time, which cannot be obtained by other intraoperative studies.

The value of ultrasound has been demonstrated in a variety of surgical fields including general surgery, neurosurgery, cardiovascular surgery, urology, and gynecology and is recognized as an integral part of many operations. This chapter will provide an overview of the use of ultrasound in the operating room, with a particular focus on hepato-pancreato-biliary surgery. General principles including basic physics, instrumentation, and scanning techniques will be reviewed followed by the application of ultrasound in the operating room. We will end with a perspective on ultrasound training. We hope that the reader will gain an appreciation of the versatility and value of ultrasound in his/her practice of surgery.

INDICATIONS FOR INTRAOPERATIVE ULTRASOUND

Ultrasound procedures performed in the operating room are referred

collectively to as intraoperative ultrasound. Intraoperative ultrasound includes both open intraoperative ultrasound (IOUS) and laparoscopic ultrasound (LUS) procedures. The indications for the use of either IOUS or LUS are similar and can be divided into two general categories: *diagnosis* of disease and *guidance* of procedures. *Diagnostic* IOUS is the acquisition of information including the localization or exclusion of previously suspected lesion(s), the detection of occult lesion(s), and the definition of important anatomic information. IOUS is highly accurate compared to preoperative imaging studies or even to surgical exploration of deeper lesions or structures. Hepatic, endocrine, and other small tumors are often accurately detected and vascular invasion (e.g., portal vein invasion by pancreatic cancer) is precisely assessed. Because of its accuracy, IOUS can assess the extent of disease and detection occult tumor, not otherwise known from preoperative imaging. When used as a screening procedure, IOUS detects occult liver metastases from colorectal carcinoma in 5% to 10% of operations. Precise localization of nonpalpable lesions is possible, such as hepatic or pancreatic tumors or cysts. IOUS is an excellent means to localize pancreatic islet cell tumors. Furthermore, intrahepatic calculi and dilated pancreatic ducts are precisely localized and targeted. By providing important information early during the course of an operation, IOUS facilitates intraoperative decision making and procedure planning.

IOUS is an ideal modality to *guide* surgical procedures. Information obtained during the diagnostic ultrasound assists the surgeon in confirming the planned operation or altering to a different operation. For example, the discovery of extensive occult metastatic disease in the liver may lead to abandoning a planned hepatectomy. Without the use of ultrasound, resection might be undertaken, leaving the patient with residual disease. Detection of portal vein involvement, not seen on preoperative imaging, would prepare the surgeon for portal vein resection during pancreaticoduodenectomy. The real-time advantage of ultrasound allows real-time monitoring of the resection margin during hepatectomy and following specimen removal, and can be used to confirm clear resection margins. Furthermore, IOUS can be used to not only detect but then to confirm biliary stone clearance during laparoscopic cholecystectomy. We believe that intraoperative (laparoscopic) ultrasound can replace traditional operative cholangiography as a routine screening test. Table 13.1 lists some of the many uses of IOUS during liver, pancreatic, and biliary procedures.

TABLE 13.1 Indications for Open Intraoperative/Laparoscopic Ultrasound

LIVER
Evaluation of the extent of known liver lesions
Detection of unknown liver lesions
Staging of malignancies (i.e., colorectal, liver, and gastric)
Guidance of hepatic procedures (resection, targeting—biopsy, ablation)
- Needle/probe placement
- (biopsy/ablation)
- Procedure planning
- Guidance of liver resection
- Confirmation of completeness of resection

PANCREAS
Evaluation of known pancreatic tumor
Determination of vascular involvement of pancreas lesions
Staging of malignancy
Guidance of pancreatic procedures
- Localization and drainage of cysts
- Enucleation of islet tumors
- Cannulation of the pancreatic duct

BILIARY
Evaluation of extrahepatic bile duct (laparoscopic cholecystectomy)
Evaluation of intrahepatic bile ducts
Evaluation of the extent of bile duct/gallbladder tumors
Guidance of biliary procedures
- Confirmation of biliary stone extraction
- Guidance of biliary tumor resection

Ultrasound has been shown to be particularly advantageous during laparoscopic procedures. LUS can compensate for the lack of tactile feedback during minimally invasive procedures and allow examination of deeply located lesions or structures. With advances in laparoscopic instrumentation and technique, many operations are performed with a minimally invasive approach, thereby increasing the need for intraoperative imaging and imaging guidance. However, there are limitations of IOUS, whether performed during an open or laparoscopic procedure. Proper interpretation of ultrasound images and execution of the ultrasound exam requires skill in ultrasound. Overcoming the learning curve for the use and interpretation of ultrasound is resolved by training and practice. There is a learning curve for IOUS, and there is a steeper learning curve for LUS. Mastering the skill for IOUS prior to attempting LUS helps to flatten the LUS learning curve.

BASIC PHYSICS: THE PIEZOELECTRIC EFFECT

The ultrasound image that we are accustomed to viewing is a complex image created by sound waves. Ultrasound technology converts this sound energy into an electrical energy in order to display an image for interpretation. This process of energy conversion between electrical and acoustic energy is known as the piezoelectric effect.

Sound is an oscillation of mechanical waves of compression and decompression through a medium (i.e., tissue). Frequency is the number of times per second the sound wave is repeated, and is measured in cycles/second, or Hz. We can hear frequencies ranging from 20 to 20,000 Hz. Medical ultrasound imaging utilizes frequencies much higher than what the human ear can hear, between 2 and 20 million cycles per second (MHz).

As a sound wave moves through a medium, some of the energy is lost or transformed into other forms of energy. This is referred to as attenuation. As the wave moves through a medium, attenuation of energy occurs by either absorption, reflection, scatter, or refraction. Sound waves move through tissues at different velocities depending on the tissue's density and compressibility. Attenuation is dependent on tissue density, whereas fluid, such as water or saline, will have nearly no attenuation. What is important to understand is that reflection is the redirection of the sound wave back to its source caused by the incident wave striking an interface.

The ultrasound transducer (probe) converts between electrical and acoustic energies by the use of specialized "piezoelectric" crystals. The transducer converts electrical energy into acoustic energy for transmission through a medium, such as saline or gel. The transducer then "listens" for returning ("reflected") sound waves and captures the reflected echoes and converts them back into electrical energy.

Once the acoustic energy is captured and converted into electrical energy by the transducer, electrical voltages are then transmitted to the ultrasound monitor where images are formed (pulse-echo technique). Depending on the imaging mode utilized, the generated image can be depicted differently. The basic modes available include:

1. *A mode* (amplitude modulation): Depicts the amplitude of the acoustic waveform.
2. *B mode* (brightness modulation): Depicts varying shades of gray based on the amplitude of the reflected waves. This is the most common

image that we see in medical ultrasound.
3. *M mode* (time-motion mode): Depicts motion over time. This imaging modality is most often used in echocardiography.
4. *Doppler:* Enables quantification of flow velocity.
5. *Duplex:* Enables a combination of Doppler and B-mode imaging.

INSTRUMENTATION

Transducers (Probes)

The equipment of choice for IOUS and LUS is a so-called "small parts scanner," which is a high-frequency, high-resolution, real-time ultrasound system, which consists of three components: transducer, central processing unit, and display. The transducer (probe), as discussed above, utilizes frequencies ranging from 5 to 10 MHz for IOUS and LUS. Higher frequency probes offer better image resolution, but at the expense of less tissue penetration, due to greater attenuation of acoustic energy. Lower frequency probes provide better penetration of deeper structures, however, at the expense of image resolution. Higher frequency probes are preferable in IOUS and LUS where the greatest image resolution is obtained at the expense of less penetration. With a 7.5-MHz transducer, the sound penetration depth is about 8 to 10 cm, and small lesions such as 1 mm calculi and 3 to 5 mm tumors can be delineated. To meet special requirements of IOUS and LUS applications, several manufacturers have developed high-frequency probes specifically designed for use within the operative field.

IOUS Probes

Two basic shapes of IOUS probes are flat and cylindrical. Flat probes consist of linear-array or curvilinear-array (convex) transducers and are usually configured into "T" or "I" shape (Fig. 13.1). T-shaped probes are either side- or end- (front) viewing. Cylindrical probes consist of a curvilinear-array (convex) or phased-array transducers. They are pencil-like, often with flattened sides to achieve greater slimness. Flat probes are suitable for examination of relatively large, flat organs such as the liver, pancreas, and kidney. Flat side-viewing probes are particularly important for the scanning of the liver because the probe must be placed between the anterior surface of the liver and the diaphragm. However, cylindrical probes are useful for the examination of small target organs such as the extrahepatic biliary duct, especially when areas of interest are situated

deeply in the operative field where manipulation of the probe is limited. It is ideal to have both types of probes; however, a side-viewing flat T-shaped probe can be used for the examination of abdominal organs in almost all abdominal operations.



Figure 13.1. Upper picture: curvilinear array (convex) flat, T- or I-shaped, side-viewing or front-viewing IOUS probes. **Lower picture:** (top two probes) LUS side-viewing flexible and rigid probes, and (bottom two probes) IOUS side-viewing I- and T-shaped probes.

LUS Probes

LUS probes consist of transducers mounted on or near the tip of a slender shaft (Fig. 13.1). The shaft is usually 10 mm in diameter and 50 to 70 cm in length. Several types of LUS probes are presently available, providing linear-array, convex, or sector transducers. A probe can be either side-viewing (i.e., the scanning plane is at a right angle with the probe shaft) or front-viewing (i.e., the scanning plane parallel to the shaft). A side-viewing linear-array or convex probe can be used for LUS scanning of almost all organs of the abdomen and is essential for scanning of the liver. A front-viewing probe is suitable for scanning the extrahepatic bile duct. A rigid-shaft probe and a flexible-tip probe are available. A flexible tip is mobile in two or four directions (bi- or quad-directional). A flexible tip facilitates scanning of areas that are difficult to delineate with a rigid probe (e.g., behind the dome of the liver) and may reduce the number of trocar insertion sites.

Knobology

The ultrasound console can appear quite complex, given the multiple knobs and buttons that exist. As surgeons, we are typically interested in understanding in depth the complexity of each new venture. However, on the ultrasound console there are only a few key buttons to understand and be able to control with ease. These include frequency, gain, depth, focus, freeze, and measurements.

Frequency should be thought as the “resolution” of the image and sound penetration. As discussed above, higher frequency probes are unable to penetrate into deeper tissues, but provide better image resolution. Inversely, lower frequency probes penetrate into deeper tissues, however, with decreased image resolution.

Gain should be thought of as “volume” amplification of the reflected sound. Increasing the gain will amplify all the returning echoes from all depths and tissues. Think of it as increasing the volume in the radio, such that the ultrasound probe will increase its “listening” of the returning echos. Time gain compensation (TGC) selectively allows modifying the amplification of returning echos at different depths.

Depth is the “distance” the sound travels (and back). The depth of the target (area of interest from the transducer) changes the distance that the ultrasound wave travels. As the depth is increased (deeper target), the ultrasound wave travels to and is reflected back over a greater distance.

This can result in a decreased quality of image (lower resolution). The depth of images (use of magnification) should be adjusted to no more than what is required, together with appropriate focusing, for the best image resolution.

Focus is the “point of interest.” The probe can be focused at any depth to improve the image. The focus narrows the ultrasound beam to the point of interest to enhance resolution.

The ability to measure a lesion requires understanding where the *freeze* button and the *measurement* controls are located. As many ultrasound systems are different, it is necessary to familiarize yourself with these areas of the ultrasound console prior to starting an ultrasound exam.

Ultrasound Terminology

Before moving to a description of the various scanning techniques, it is necessary to understand some of the key terms in ultrasound jargon. Ultrasound characteristics of tissue are described in terms of “echogenicity.” Echogenicity refers to the brightness of the tumor, organ, or tissue that is being described. Aechoic describes tissue that is devoid of acoustic wave reflection and appears black on the ultrasound display. Whereas hyperechoic describes tissue that is brighter, hypoechoic is less bright, and isoechoic is the same brightness as compared to the reference tissue (e.g., liver or spleen). Echogenicity is determined by the character of the tissue (i.e., medium) where the velocity of the acoustic waves are determined (Fig. 13.2).

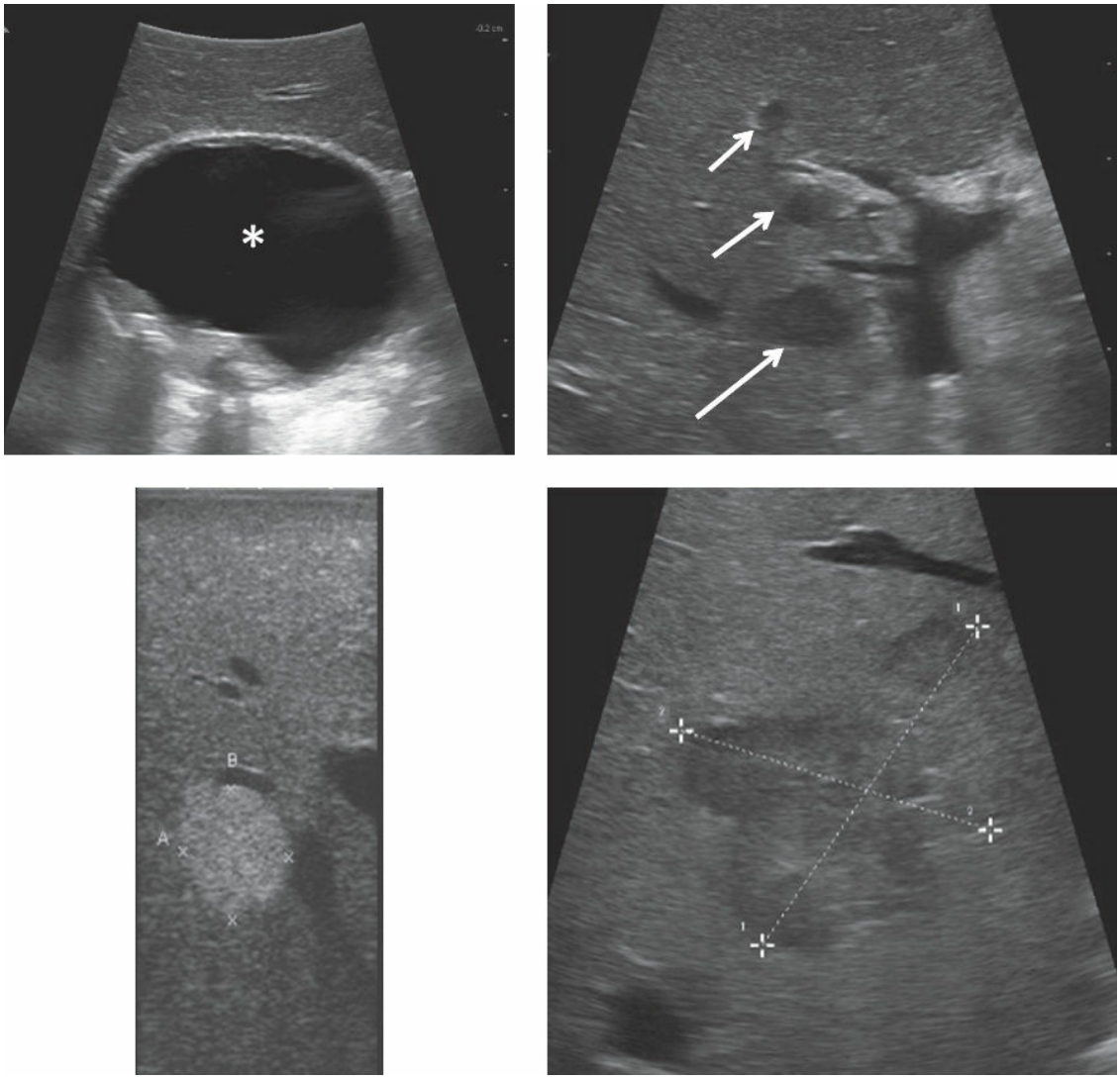

Figure 13.2. Upper left image: gallbladder filled with fluid appears "black" and is referred to as anechoic (*). **Upper right image:** hypoechoic liver masses (*arrows*). **Lower left image:** hyperechoic liver mass (marked by measurements). **Lower right image:** liver mass of mixed echocity—note the varying hypo-, iso-, and hyperechoic characteristics of this lesion (marked by measurements).

SCANNING TECHNIQUES

General Considerations

In the operating room, the person performing the scan should be in the surgeon's position. The monitor should be placed to permit easy viewing of the screen and the operative field with minimal change-of-gaze movement. Typically, the ultrasound system is placed on the opposite side of the table from the surgeon. Probe sterility for intraoperative use is achieved by cold gas sterilization or use of a sterile cover. A newer

sterilization method such as a low-temperature chemical sterilization, which can sterilize instruments in 30 to 60 minutes, is available, and some probes are amenable to this method. Because IOUS/LUS can be performed and repeated at any point during the operation, all ultrasound equipment should be kept available and the probe sterile for the duration of the operation.

There are two primary imaging planes in ultrasound, longitudinal and transverse. In terms of IOUS or LUS, the longitudinal view is parallel to the long axis of the structure or organ being examined, whereas a transverse view is at the right angle to the long axis. Oblique views are intermediate in position between longitudinal and transverse views (Fig. 13.3).

Coupling

A path for transmission of the sound waves between the probe and the target tissue must be established. Because air is an ineffective medium for sound wave transmission, it is necessary to displace air (called *coupling*) in the path (called the *acoustic interface*) between the probe and the target tissue. For transabdominal ultrasound, a gel is used most commonly. For IOUS and LUS, saline on the surface of the organ is all that is needed. The thickness of the acoustic interface can be manipulated and thereby altering the underlying image.

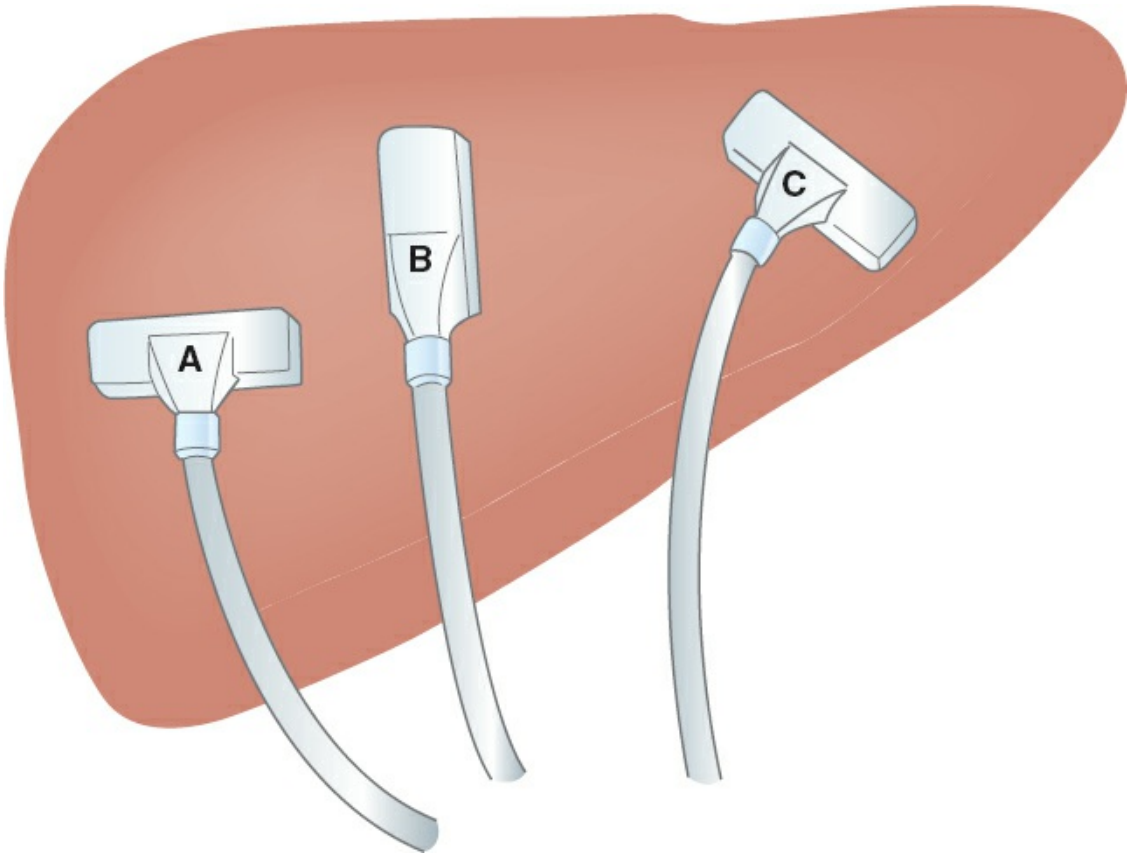

Figure 13.3. Transverse (**A**), longitudinal (**B**), and oblique (**C**) imaging of the liver. Note that the imaging plane is changed by "rotating" the probe.

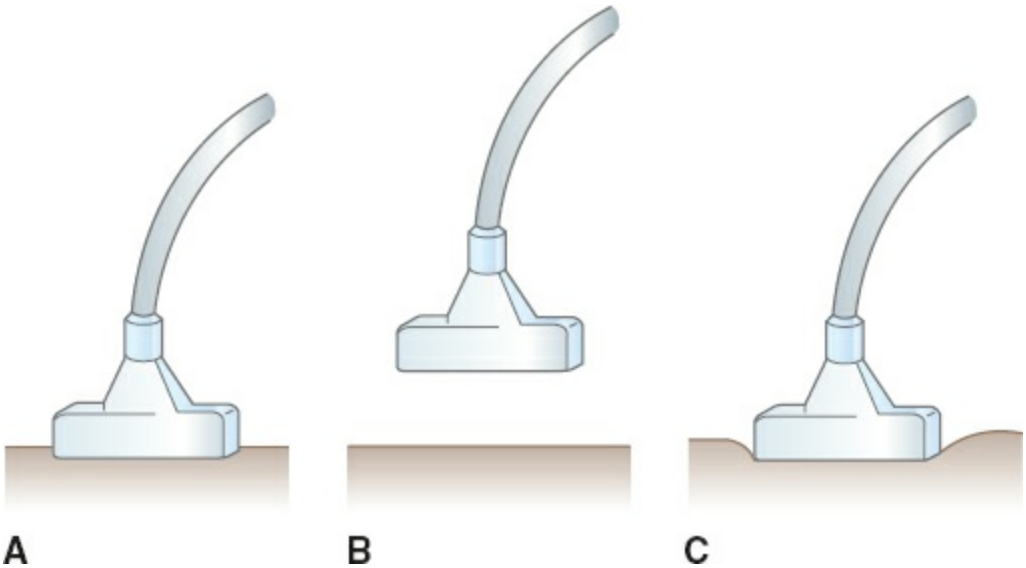

Figure 13.4. Open intraoperative ultrasound probe placement, including contact scanning (**A**), probe standoff scanning (**B**), and compression scanning (**C**).

Probe Placement

Ultrasound scanning is a two-step process: probe placement and probe movement. Various techniques can be performed to facilitate IOUS/LUS scanning and to obtain the best imaging information. Two basic transducer placement techniques of IOUS/LUS are contact scanning and probe standoff scanning. In contact scanning, the probe is placed in direct contact with the tissue or organ, whereas in probe standoff scanning the probe is positioned 1 to 2 cm away from the surface of structure (Fig. 13.4).

The size of the target organ and the distance from the probe to the area of interest in the organ determines which scanning technique should be used. Contact scanning is used for examination of the interior of the liver, kidney, or pancreas. However, when the surface of the superficial tissue needs to be examined, probe standoff scanning should be employed. Probe standoff is very important when the area of interest is within 0.5 to 1 cm from the surface of the tissue and is particularly helpful in the examination of relatively small superficial structures such as the extrahepatic bile ducts (Fig. 13.5). In probe standoff scanning, an acoustic interface is created between the target tissue and probe by filling the operative field with saline or by placing a saline-filled glove on the target tissue and scanning through the fluid-filled acoustic interface (Fig. 13.6). The probe standoff with saline immersion technique is a unique IOUS/LUS method that is not commonly used in transabdominal ultrasound. This permits placement of the target at the appropriate focal distance and also prevents inadvertent compression of structures by the probe. One additional useful technique is compression scanning, in which the tissue is compressed intentionally by the probe (Fig. 13.4). This technique helps to displace air between the transducer and the target tissue. Air in the gastrointestinal tract lumen that overlies a region of interest can be displaced by compression. This is especially effective when air in the duodenum obscures the distal common bile duct or air in the stomach obscures the underlying pancreas. Compression is also used to distinguish arteries from veins, which are more compressible.

Probe Movement/Manipulation

The second step in ultrasound scanning is probe movement. A target or suspected lesion should be scanned from various positions and directions and an organ should be scanned in a systematic fashion for a thorough IOUS/LUS examination. Although the scanning method varies depending on the organ examined, it is usually important to obtain longitudinal,

transverse, and at times oblique views of a lesion or organ (Fig. 13.3). Probe movements are the ways by which the probe is manipulated. There are four basic movements of the probe: sliding, rotating, rocking, and tilting. In “sliding,” the probe is moved across the target tissue without lifting the probe from the scanning surface. In “rotating,” the probe is rotated around its center axis, either clockwise or counter-clockwise, while switching between the longitudinal and transverse planes. With this technique, a lesion or structure is delineated continually through the longitudinal, oblique, and transverse views, providing a three-dimensional (3D) mental picture for the surgeon. During “rocking,” the probe is moved forward and backward along its long axis. This moves the ultrasound image *along* the same plane and therefore is referred to as “in-plane” motion. During “tilting,” the probe is moved side-to-side along its long axis. This moves the ultrasound image *across* different planes and therefore is referred to as “cross-plane” motion. In both rocking and tilting, the probe’s head (transducer surface side) remains in a relatively stationary place, while the shaft of the probe is moved or swung to different angles (Fig. 13.7). This technique is especially useful in a deep and restricted operative field where “sliding” of the probe is limited or impossible. These basic probe movements can be used individually or can be combined to obtain optimal ultrasound imaging.

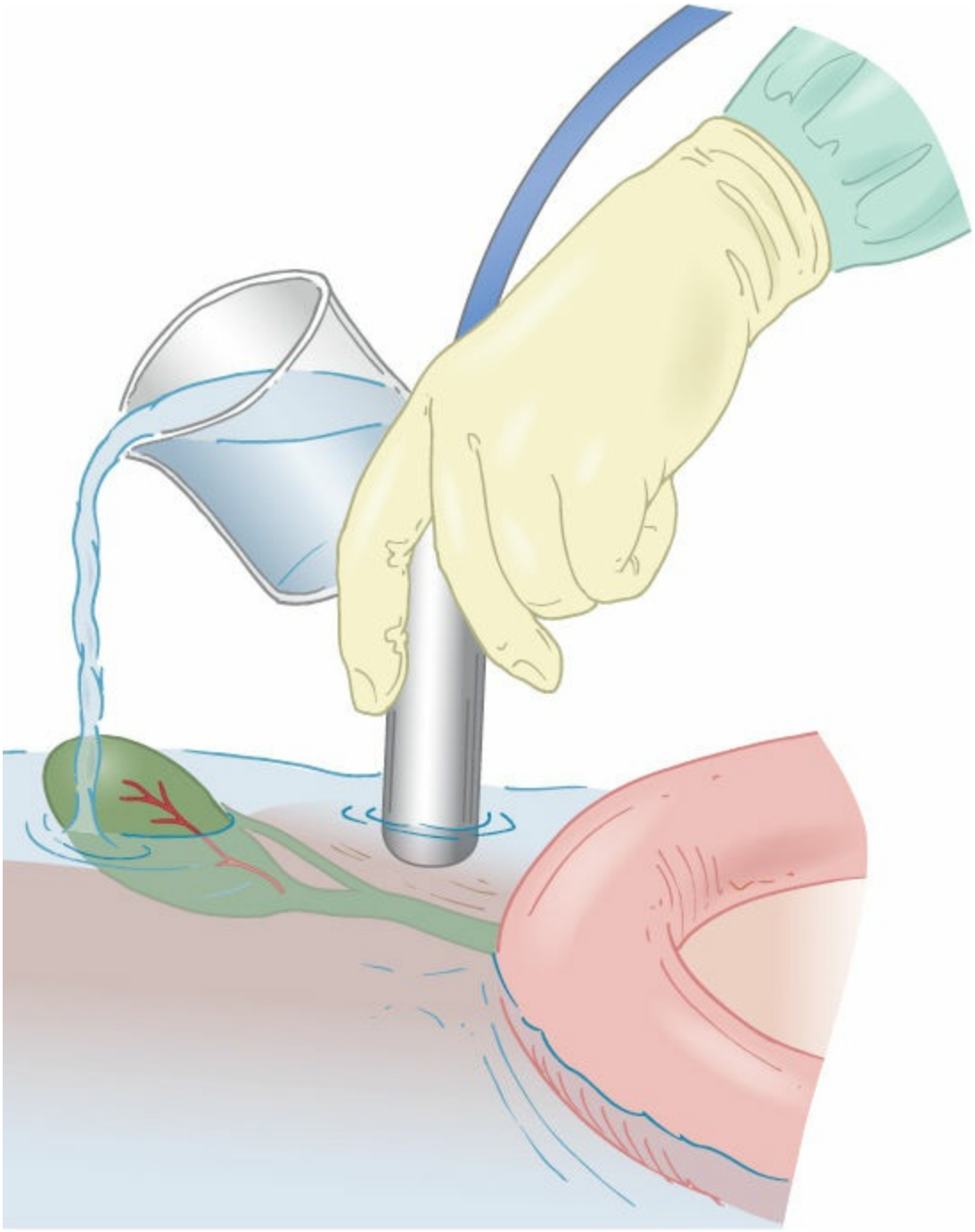

Figure 13.5. Open intraoperative ultrasound scanning of the extrahepatic bile duct using a probe standoff technique. The probe standoff is particularly important when the bile duct is exposed or located superficially in the hepatoduodenal ligament.

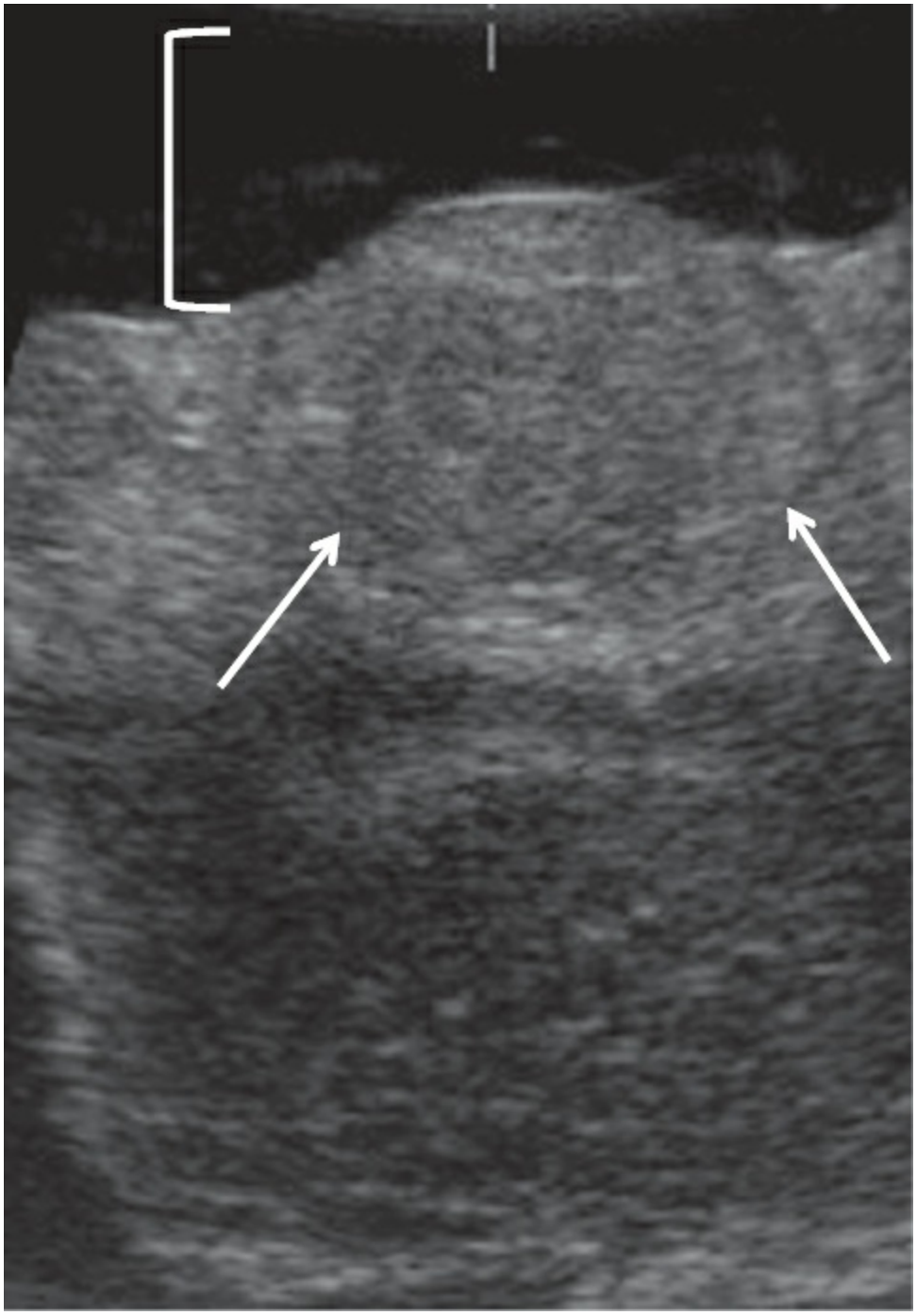

Figure 13.6. Probe standoff: saline is used as an acoustic window (*bracket*) in order to image the superficial surface of the liver. Notice the use of saline helps to define an isoechoic lesion (*arrows*) on the surface of the liver.

OPEN INTRAOPERATIVE ULTRASOUND

Open IOUS is a critical tool to evaluate and manage multiple abdominal diseases, in particular hepatic, biliary, and pancreatic diseases. It is a real-time view and can be used repeatedly throughout a procedure to re-

evaluate and guide the operation. It is important to develop a systematic scanning approach for each type of scan and for each organ.

Liver Scanning Method

The liver is best scanned with the side-viewing flat T-shaped probe. Many current probes are multifrequency, ranging from 5 to 10 MHz in frequency. Using a 7.5-MHz frequency is the most useful for liver ultrasound as this allows adequate penetration to view the entire organ while showing the detail of the intrahepatic structures. For a larger, steatotic or cirrhotic liver, a lower frequency, such as 5 MHz, is sometimes necessary to allow deeper penetration. The probe is passed over the liver surface under the abdominal wall or the diaphragm. Modern probes have a small profile which allows placement in narrow and limited working spaces.

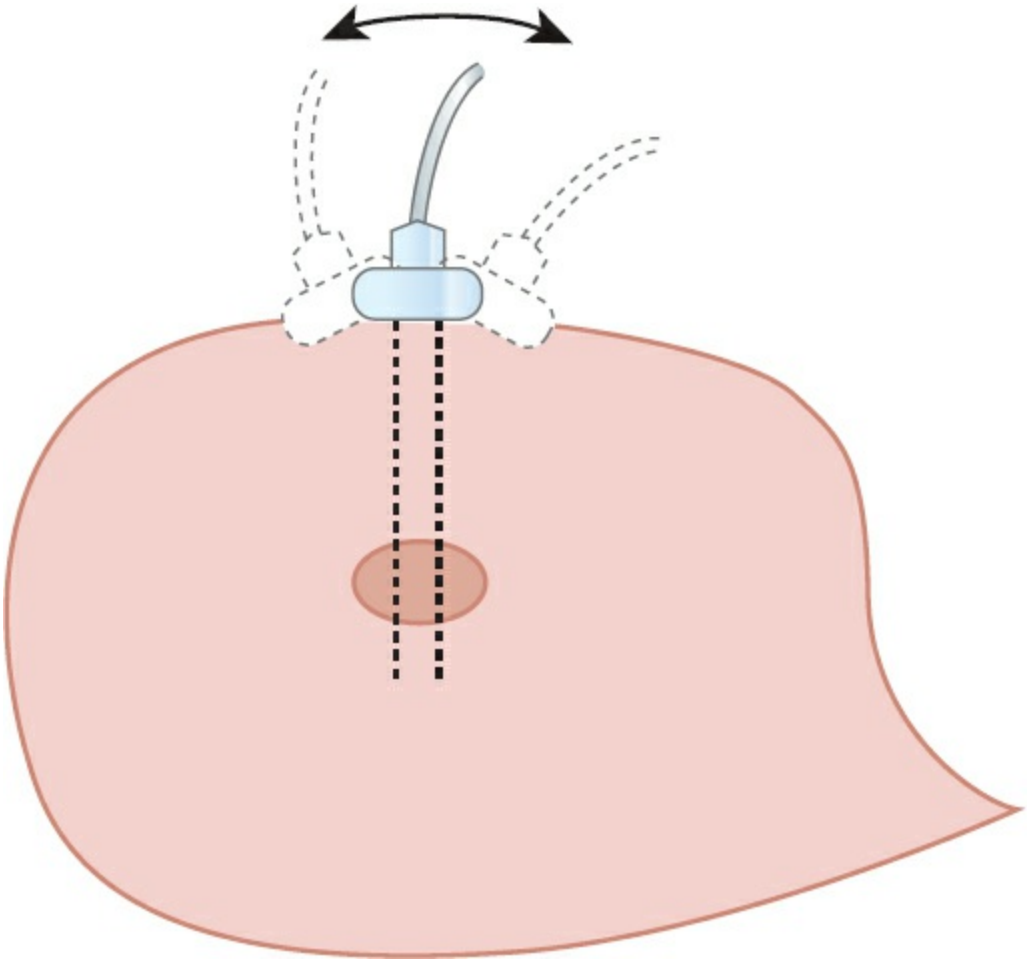

Figure 13.7. Tilting of the probe facilitates visualization of a target in the liver from one location, in different directions. Notice that the head of the transducer stays in one relative position as

the probe is “tilted” along its long axis, moving the image across different imaging planes.

Ultrasound examination of the liver begins with the placement of the probe in direct contact with the liver (contact scanning), typically on the anterior and diaphragmatic surfaces. Scanning from the inferior surface may also be needed. Contact scanning is very useful for most of the liver; however, it has limited visualization just beneath the probe (see above, *Probe Placement*). When a mass or structure is just beneath the probe or if an irregular surface exists (e.g., cirrhosis) whereby contact scanning is not possible, the probe standoff technique becomes very useful. Saline is an excellent interface to establish an acoustic window to enhance visualization of this limited area just beneath the probe (Fig. 13.6).

Table 13.2 outlines a systematic approach to liver ultrasound scanning for either an open or laparoscopic approach. For the open approach, the initial scan is done prior to any mobilization of the liver. Scanning before liver mobilization avoids creating artifact, such as the introduction of air into tissue planes that may have obscured the field of vision. If mobilization is then necessary, such as in a proposed resection, the scan is then repeated after such mobilization. Liver ultrasound scanning is performed with the goal of defining the segmental liver anatomy, its vasculature, and evaluating the liver parenchyma in a systematic fashion.

The liver is a large organ without many landmarks. Segmental anatomy of the liver is based on the hepatic veins and intrahepatic branches of the portal system, which is nicely defined by ultrasound. Several terminologies exist for hepatic anatomy, including Healy and Schroy, Couinaud, and Bismuth. Some refer to “lobes,” whereby others refer to “livers.” In order to standardize terminology, the International Hepato-Pancreato-Biliary Association has adopted the Brisbane 2000 Terminology as the accepted terminology for liver anatomy and resection so that all are “speaking the same language.” When discussing liver anatomy, we will use this accepted terminology in this chapter.

The liver ultrasound examination begins with transverse scanning followed by longitudinal and if needed, oblique views. Using probe movements including sliding, rotating, tilting, and rocking, the surgeon defines the intrahepatic vasculature, segmental anatomy, and any underlying tumor. Rotating the probe over an area of interest allows one to confirm the presence of a lesion and that it is indeed not an artifact.

Liver ultrasound scanning includes (1) identification of the hepatic veins, (2) identification of the portal veins and their branches, and (3) systematic scanning of the parenchyma (see Table 13.2). Begin in the transverse plane by placing a flat side-viewing ("T") probe in the center of liver, just to the right of the suspensory ligament (segment 4). By *tilting* the probe *upward*, the junction of the hepatic veins at the suprahepatic vena cava is demonstrated (Fig. 13.8). Once this image is obtained, each hepatic vein is followed peripherally to its terminus. Sliding the probe back to the junction of the hepatic veins, and rotating the probe in the longitudinal/oblique view, each hepatic vein is then re-examined to its terminus.

Next, the portal vein and its branches are identified. By sliding the probe back to the center of segment 4 and *tilting* the probe *downward* (or sliding the probe to the inferior aspect of segment 4), the bifurcation of the portal vein is seen just distal to the termination of the main portal vein (Fig. 13.9). Sliding the probe inferiorly along segment 4 allows visualization of the main portal vein in the transverse view. Sliding the probe back to the bifurcation and then toward the right, identifies the right portal vein (Fig. 13.10). The right portal vein is then followed peripherally into its division into the anterior (segments 5 and 8) and posterior (segments 6 and 7) branches, defining the segmental anatomy of the right liver (Fig. 13.11). Sliding the probe back to the portal bifurcation is continuing to slide to the left, identifies the horizontal portion of the left portal vein in its longitudinal view (Fig. 13.12). At the base of the umbilical fissure, the left portal vein turns and travels anteriorly and inferiorly in the umbilical fissure and is seen in a transverse view (Fig. 13.12). Continuing to follow the left portal vein identifies segmental branches to segments 2, 3, and 4 (Fig. 13.13). During examination of the left portal vein, segment 1 (caudate lobe) is clearly defined (Fig. 13.14).

TABLE 13.2 Systematic Approach to Liver Ultrasound Scanning

1. Identify hepatic veins (right, middle, and left)
   Identify junction with the vena cava ("trifurcation")
   Define relationship of the middle and left hepatic veins (common trunk)
   Follow each hepatic vein to its terminus
   Identify any anomalous tributaries
2. Identify portal branches
   Identify the main portal vein trunk and its bifurcation
   Identify the right portal vein, its anterior and posterior branches, and follow to their segmental branches
   Identify the left portal vein and follow to its segmental branches
   Identify any anomalous branches
3. Perform a systematic parenchymal scan
   Sweep scan of each individual section/sector
   Identify any lesion, its size, location, and echo characteristics
   Define any vascular or biliary involvement

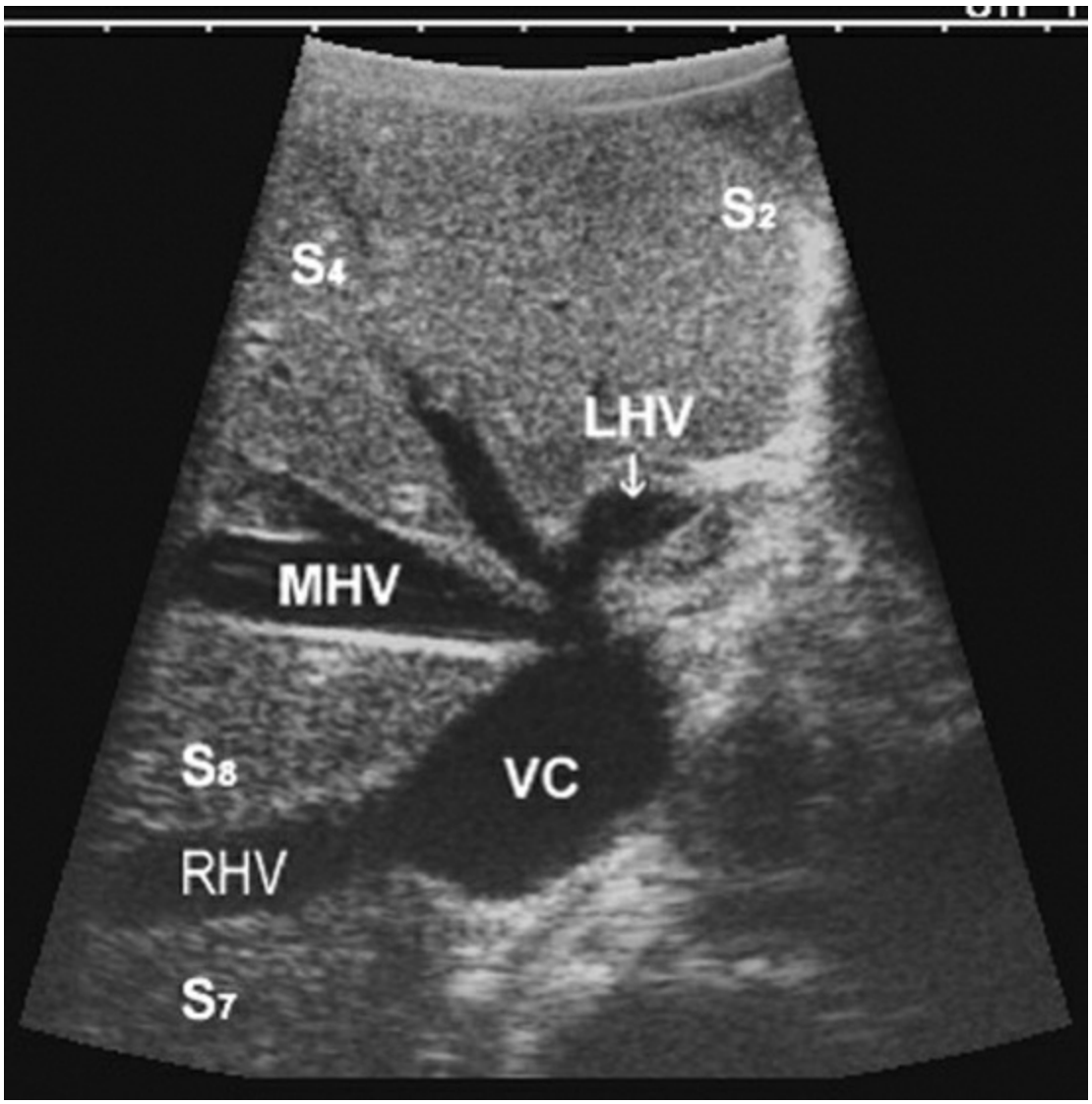

Figure 13.8. Intraoperative ultrasound of three hepatic veins. The right (RHV), middle (MHV), and left (LHV) veins are entering the vena cava (VC) separately, although it is common for the MHV

and the LHV to form a common channel. The relationship of the hepatic veins to the superior liver segments (S2, S4, S8, S7) is shown.

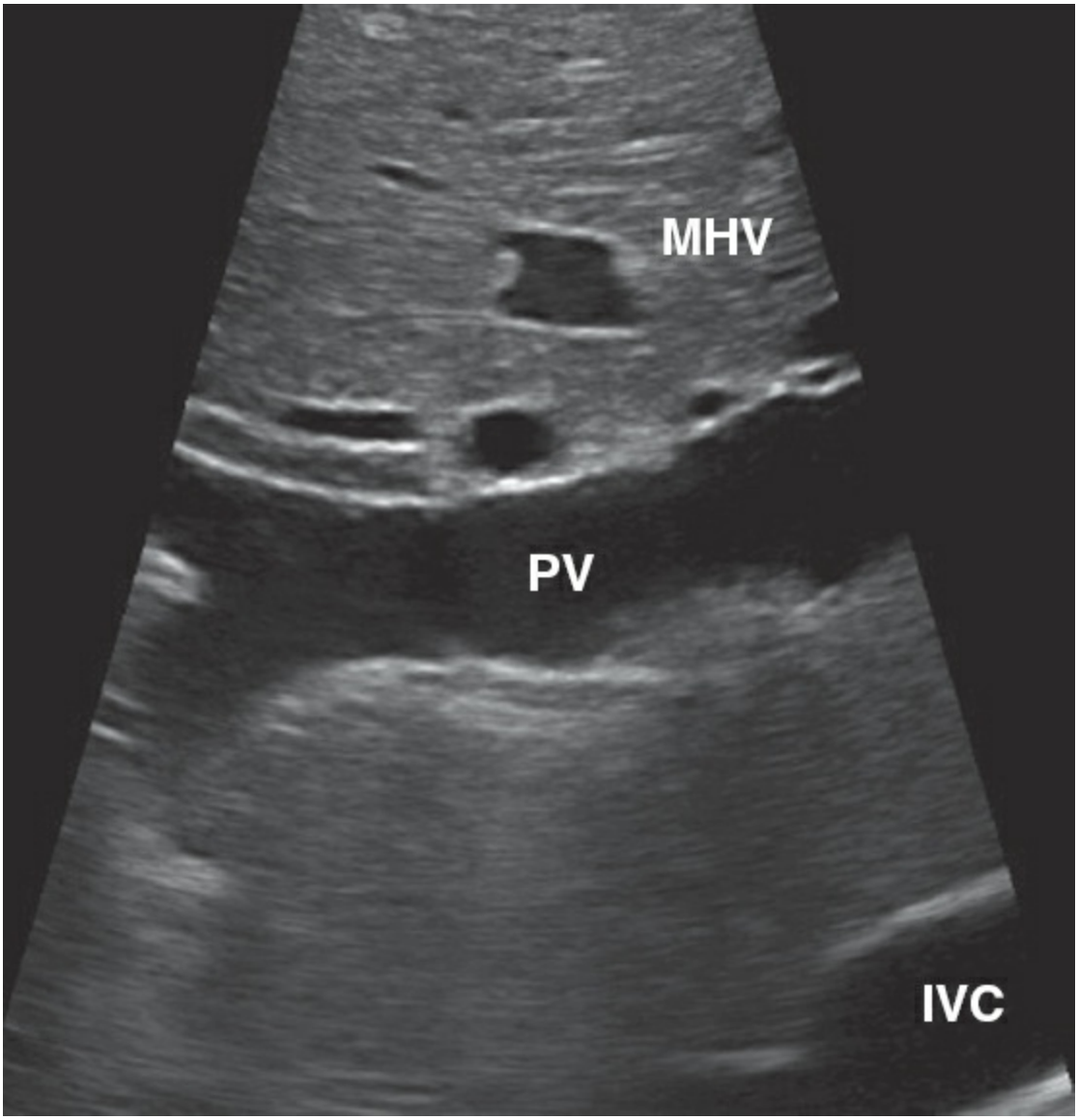

Figure 13.9. The portal bifurcation is seen by tilting the probe downward on segment 4 after visualizing the hepatic veins. Note that the middle hepatic vein (MHV) is located at the center of the bifurcation, indicating the division of the right and left livers.

The final component of the ultrasound examination of the liver includes a systematic survey of the liver parenchyma. Rotating the probe in the longitudinal/oblique view, or maintaining the probe in the transverse view, each section of the liver, as defined by the hepatic venous anatomy, is examined while sliding the probe across the liver parenchyma from right to left and left to right. This is done in a stepwise fashion while continuing

to move from the superior to the inferior aspect of each section. Alternatively, the probe is kept in the transverse view and each section is examined while sliding the probe from superior to inferior and inferior to superior (Fig. 13.15). This systematic survey is referred to as the *sweep-scan* or *lawnmower* method and ensures a complete examination of the liver parenchyma. During this portion of the examination, lesion location, size, and sonographic features are noted in addition to proximity to any vasculature or intrahepatic ducts. For any proposed resection, at this point, a decision can be made regarding resectability and extent of resection (Fig. 13.16).

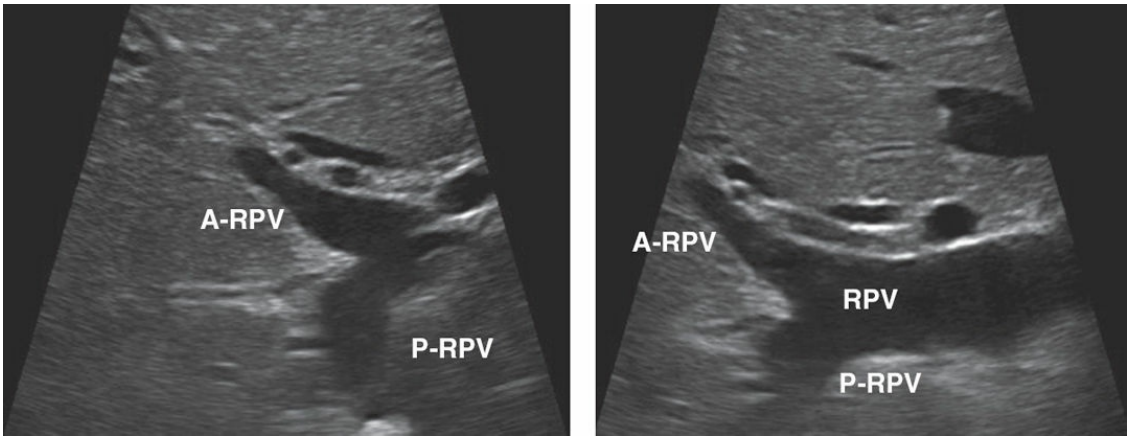

Figure 13.10. Left: Sliding the probe toward the right from the portal bifurcation identifies the right portal vein (RPV) and the beginning of its anterior (A-RPV) and posterior (P-RPV) branches. **Right:** Continuing to slide the probe to the right clearly defines the anterior (A-RPV) and posterior (P-RPV) branches of the right portal vein.

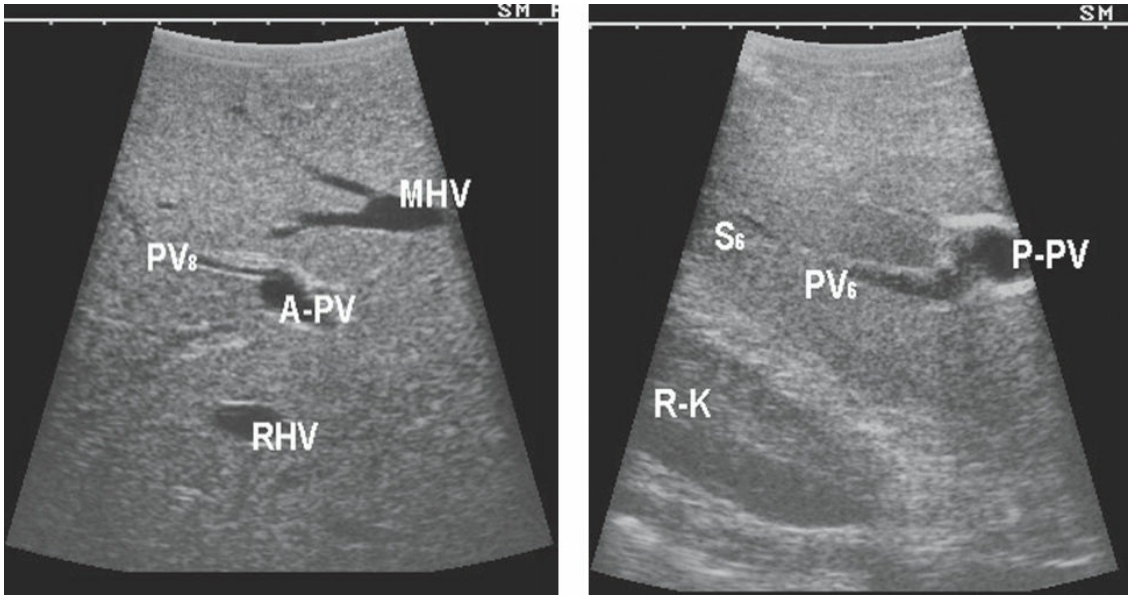

Figure 13.11. Segmental branches of the right anterior and posterior portal veins. The segment 8 branch (PV8) is from the anterior branch of right portal vein (A-PV), and the segment 6 branch is from the posterior branch of right portal vein (P-PV). Note that the A-PV is located between the middle hepatic vein (MHV) and right hepatic vein (RHV). The segment 6 (S6) is adjacent to the right kidney (R-K).

Biliary Scanning Method

Biliary scanning (gallbladder and extrahepatic bile ducts) is optimally performed using two different probes. A flat, side-viewing, linear transducer is very useful for contact scanning of the gallbladder, the intrahepatic bile ducts, or the extrahepatic bile ducts using the liver as an acoustic window. The gallbladder can also be scanned directly with the probe standoff technique using saline as an acoustic window. The extrahepatic bile ducts are best scanned with the end-viewing cylindrical probe, at a frequency higher than 7.5 MHz. Probe standoff scanning is critical for the exposed or superficially situated bile ducts (Fig. 13.5). Initial scanning should always occur prior to any dissection of the gallbladder or hepatoduodenal ligament. As was seen in liver mobilization, tissue dissection can introduce artifacts through entry of air in tissue planes and can limit visualization.

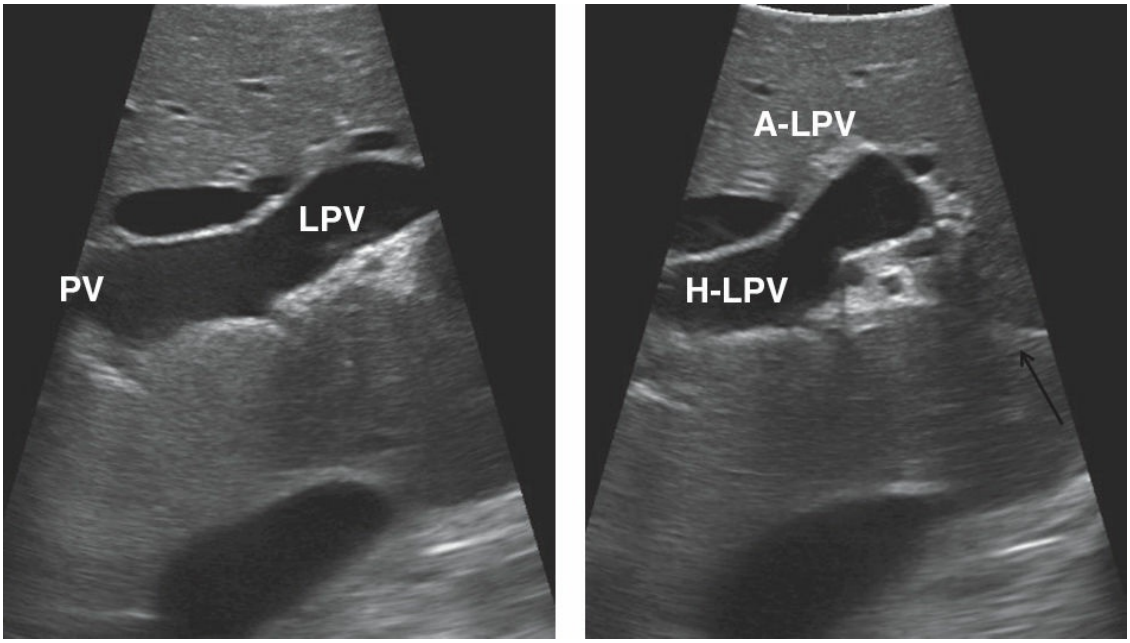

Figure 13.12. Left: Beginning at the portal bifurcation (PV) and sliding the probe to the left identifies the left portal vein (LPV). **Right:** Continuing to slide the probe to the left identifies the horizontal portion of the left portal vein (H-LPV) leading to the ascending portion of the left portal vein (A-LPV). These images were obtained with a T-probe and scanning in the transverse plane.

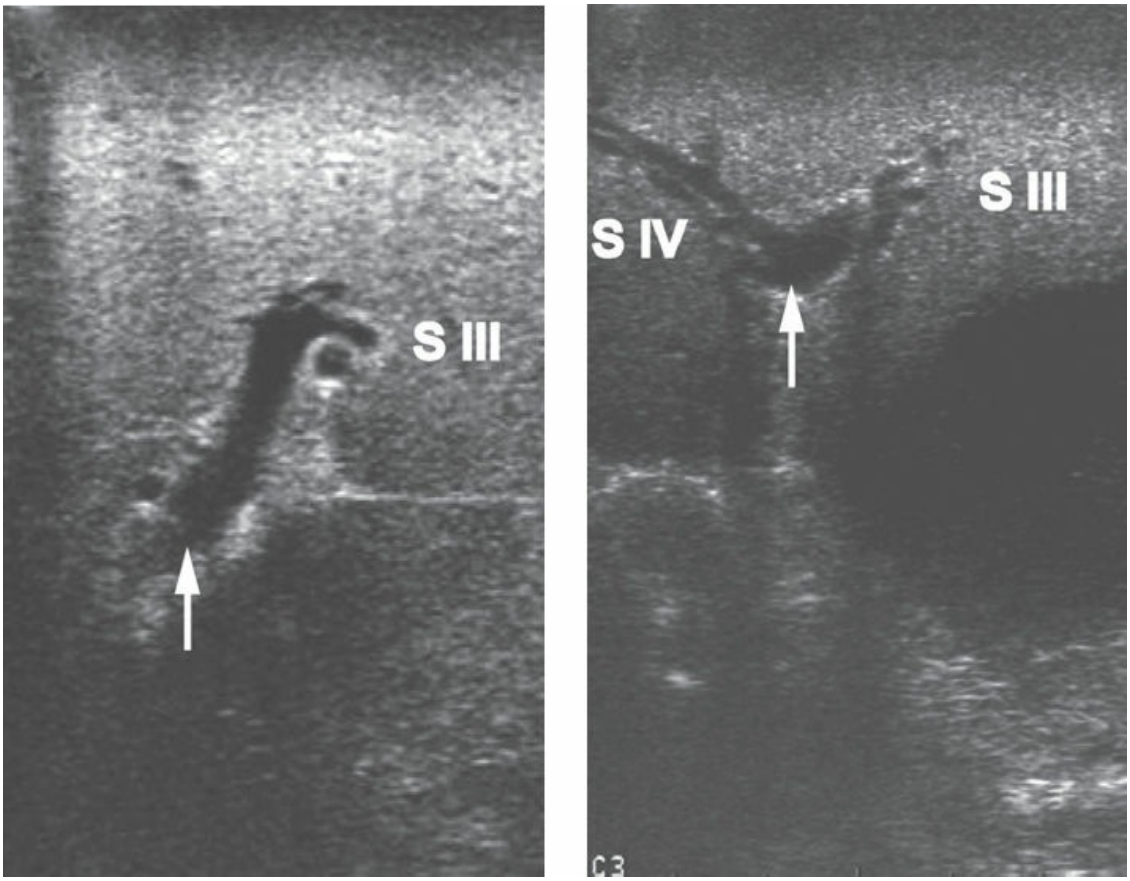

Figure 13.13. Continuing to slide the probe to the left identifies the left portal vein segmental branches. **Left:** Sliding the probe along the ascending portion of the left portal vein (*arrow*) leads to the segment 3 (S III) branch. Not depicted here is the segment 2 branch, the first branch of the ascending left portal vein. **Right:** Continuing to follow the left portal vein (*arrow*) leads to its termination at the segment 3 (S III) and segment 4 (S IV) branches.

A systematic approach to scanning the biliary tree and gallbladder is imperative to ensure a complete exam (Table 13.3). Begin the biliary ultrasound examination by contact scanning with use of the side-viewing transducer. Placing the probe at the anterior inferior aspect of the liver at the gallbladder, visualizes the gallbladder using the liver as an acoustic window (Fig. 13.17). Continuing to rotate the transducer and sliding it toward the lower aspect of segment 4, the main portal vein/portal bifurcation is visualized, as described above in liver scanning method. Anterior to the main portal vein is the confluence of the right and left hepatic ducts (Fig. 13.9). Next, contact scanning is used to image the gallbladder in transverse and then longitudinal planes and is followed down to the cystic duct/common hepatic duct junction (Fig. 13.18). Sliding

the transducer inferiorly visualizes the extrahepatic bile duct in its longitudinal plane. Once contact scanning is complete, probe standoff technique utilizing saline immersion is then performed. The gallbladder is initially scanned from the inferior aspect of the liver and this followed down to the cystic duct and extrahepatic bile duct.

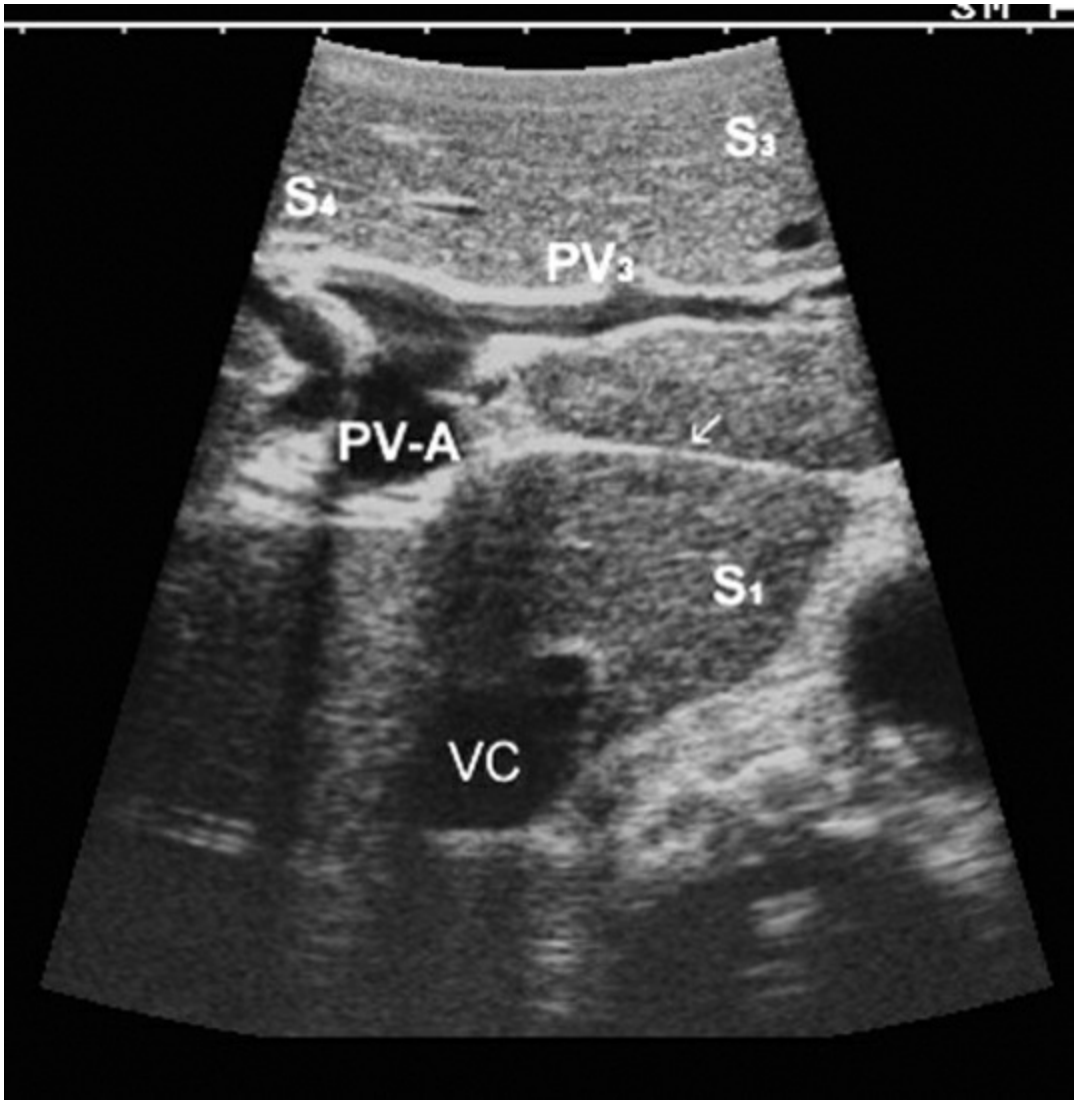

Figure 13.14. Caudate lobe (segment 1). Note the location of segment 1 (S1) to be posterior to the portal vein (in this image, posterior to the ascending left portal vein, PV-A) and the ligament venosum (*arrow*) and anterior and lateral to the vena cava (VC). PV3 = segment 3 portal vein branch, S3 = segment 3, S4 = segment 4.

Switching to the end-viewing transducer is optimal at this point to complete the exam (if available). The gallbladder, cystic duct, and extrahepatic bile duct are examined utilizing probe standoff technique

(Fig. 13.5). The supraduodenal portion of the bile duct is visualized longitudinally, as the probe is moved from the hepatic hilum to the duodenum. The retroduodenal and intrapancreatic bile ducts are then scanned through the duodenum, typically with gentle compression to expel any gas from the duodenum or by contact scanning on the pancreas (Fig. 13.19). The extrahepatic bile duct is also examined transversely, which also displays the portal vein and hepatic artery in transverse sections. Fig. 13.20 shows an extrahepatic cholangiocarcinoma, which was evaluated and determined to be resectable by IOUS.

Pancreas Scanning Method

Pancreatic ultrasound can be done with the use of either a side- (flat) or end-viewing probe. It is helpful to scan the pancreas using an indirect method prior to any dissection using the duodenum, stomach, gastrohepatic–gastrocolic ligaments, or the transverse mesocolon as an acoustic window. Once the anterior surface of the pancreas is exposed by entry into the lesser sac, a direct method is utilized, such as contact scanning. Because the pancreas is a thin organ, it is very helpful to also use probe standoff with saline immersion in order to visualize the surface and superficial areas of the pancreas. The entire pancreas is imaged using longitudinal and transverse planes, remembering that the axis of the plane is in relationship to the long axis of the pancreas. The pancreatic head and the uncinate process can be scanned together with the examination of the extrahepatic bile duct (intrapancreatic portion of the bile duct). The main pancreatic duct, even when normal-size, can be visualized by scanning from the head to the tail of the pancreas.

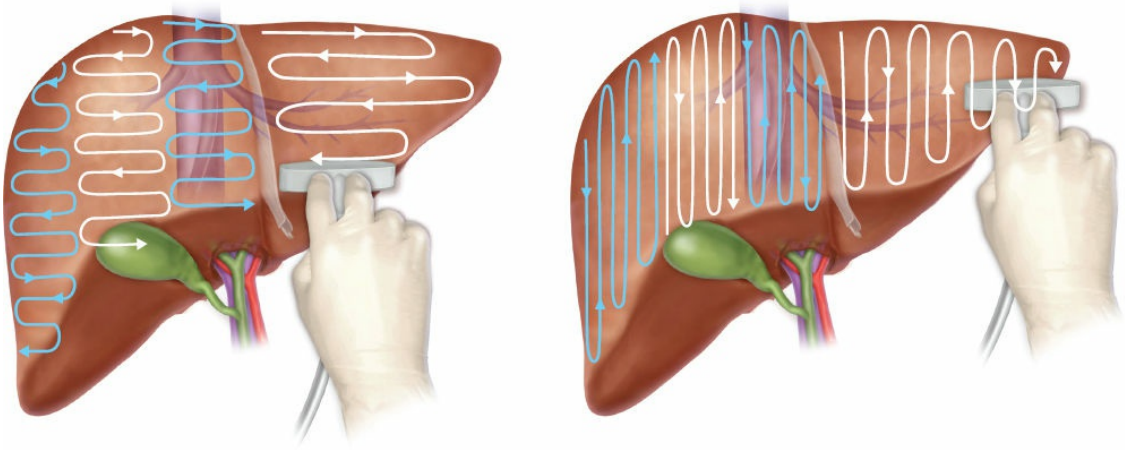

Figure 13.15. Sweep-scan of the liver parenchyma. The parenchymal scan is performed by sliding the probe across each

section of the liver from right to left across (**left image**) or up and down (**right image**) each section of the liver. Note that the probe is slid through each section, one section at a time without lifting the probe from the liver surface. To begin the next section, the probe is repositioned on the next section to be examined.

As noted in liver and biliary scanning, a systematic approach to pancreas scanning is imperative to ensure a complete and thorough scan of the organ (Table 13.4). The pancreas is imaged using indirect followed by direct (contact) scanning, and then by probe standoff in order to ensure a complete examination of the organ. It is helpful to identify the surrounding vessels in order to identify the pancreatic tissue (Fig. 13.21). Start the examination in the longitudinal plane by identifying the superior mesenteric vein or portal vein as it passes posteriorly to the pancreatic neck. Sliding the probe distally (toward the patient's left), the neck, body, and tail of the pancreas are scanned. The splenic vein, which is located just posterior to the pancreatic tissue, is seen in its long axis during this portion of the exam (Fig. 13.21). Also, locate the superior mesenteric artery, to the left of the portal vein/superior mesenteric vein. Identify the pancreatic duct location and size in addition to any lesion in the pancreas (Fig. 13.22). Note the proximity/involvement of any lesion to the vasculature. Once the neck, body, and tail are imaged, slide the probe back to the superior mesenteric vein/portal vein and then slide the probe proximally (toward the patient's right) in order to scan the head and uncinate process. Identify any lesion, its size, and characteristics in addition to vascular involvement/proximity. By turning the probe 90 degrees, repeat these steps in the transverse plane. Finally, when using the direct method (i.e., contact scanning), repeat the entire exam of the pancreas using a probe standoff technique in order to appreciate the superficial pancreas parenchyma.

TABLE 13.3 Systematic Approach to Biliary Ultrasound Scanning

1. Side-viewing probe
   a. Contact scanning (transhepatic)
      Gallbladder (transverse and longitudinal views)
      Intrahepatic bile ducts (transverse view)
      Extrahepatic bile ducts (transverse)
   b. Probe standoff technique (saline)
      Gallbladder, inferior aspect
      Extrahepatic/supraduodenal bile duct (transverse and longitudinal)
2. End-viewing probe
   a. Probe standoff technique (saline immersion)
      Gallbladder/cystic duct
      Extrahepatic/supraduodenal bile duct (transverse and longitudinal)
   b. Compression (transduodenal)/ Contact scanning (transpancreatic)
      Retroduodenal bile duct
      Intrapancreatic bile duct

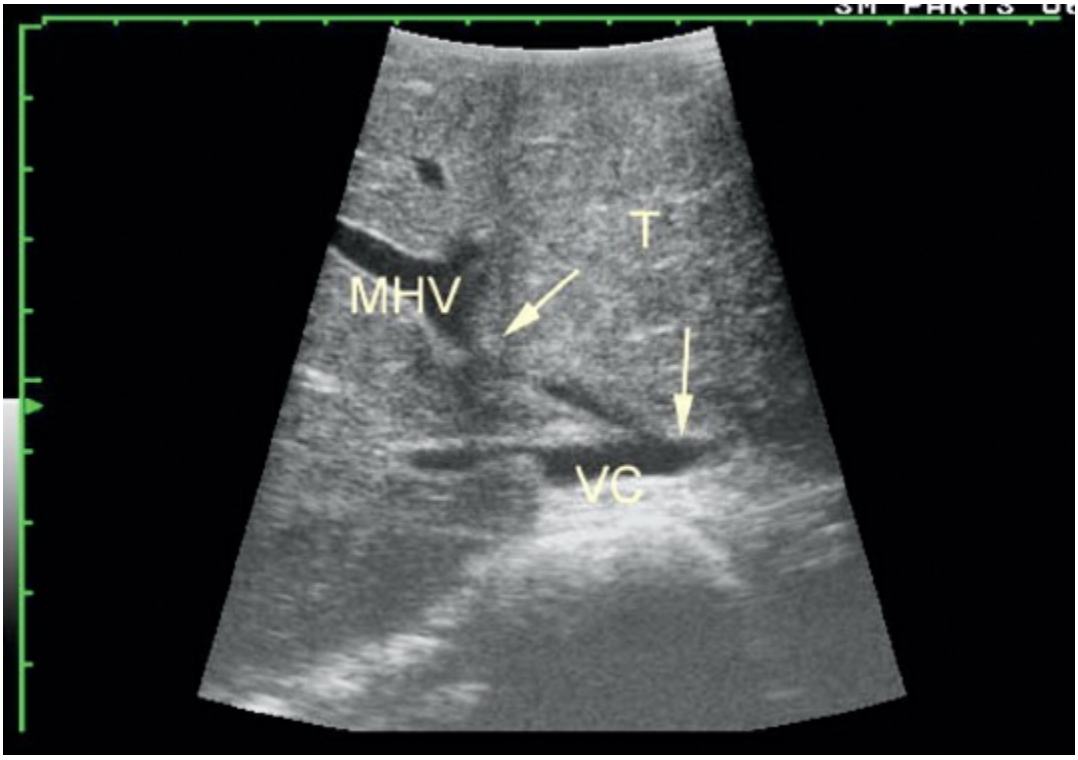

Figure 13.16. Intraoperative ultrasound is particularly important to determine the resectability of liver tumors. This was a metastatic liver tumor from a left colon cancer. The tumor (T) was located in segment 4 into segment 8, and it was invading the middle hepatic vein (MHV) and the vena cava (VC), as indicated by white arrows.

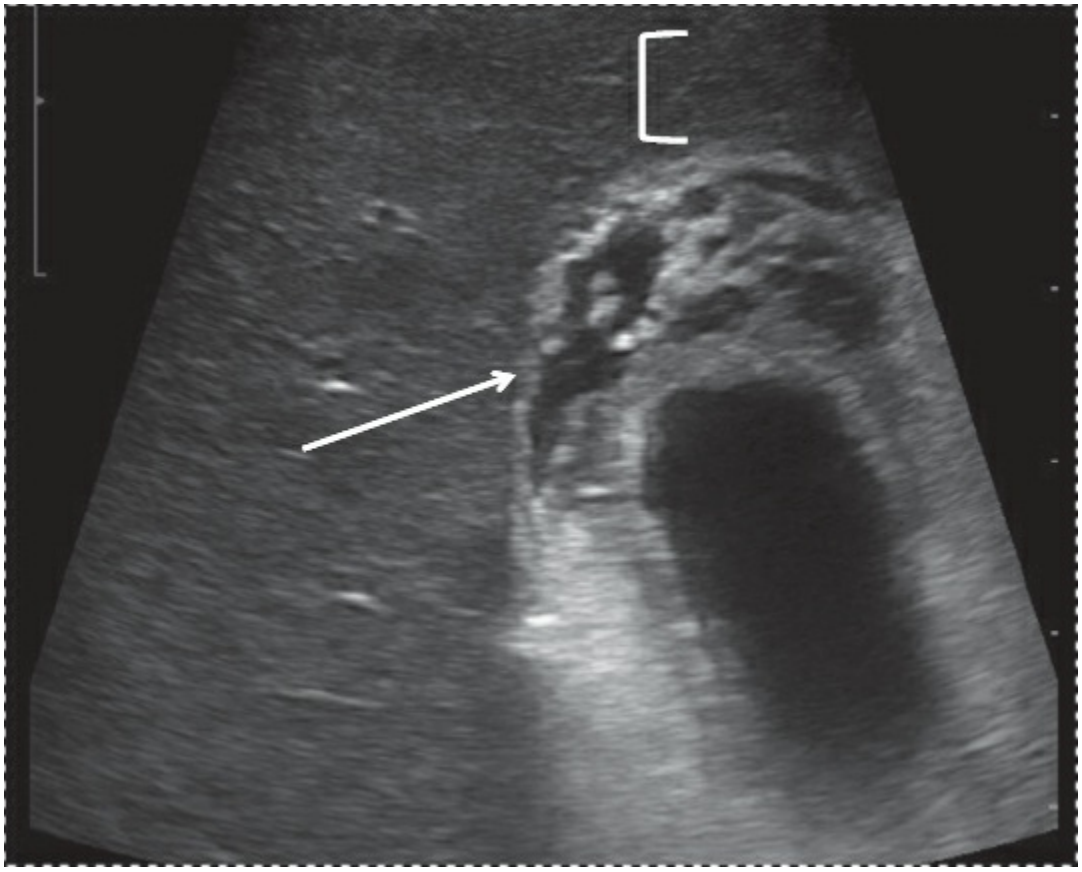

Figure 13.17. Using the liver as an acoustic window (*bracket*) is an excellent means to image the gallbladder and any underlying pathology. Demonstrated here is thickening and edema of the gallbladder wall (*arrow*) as seen in acute cholecystitis.

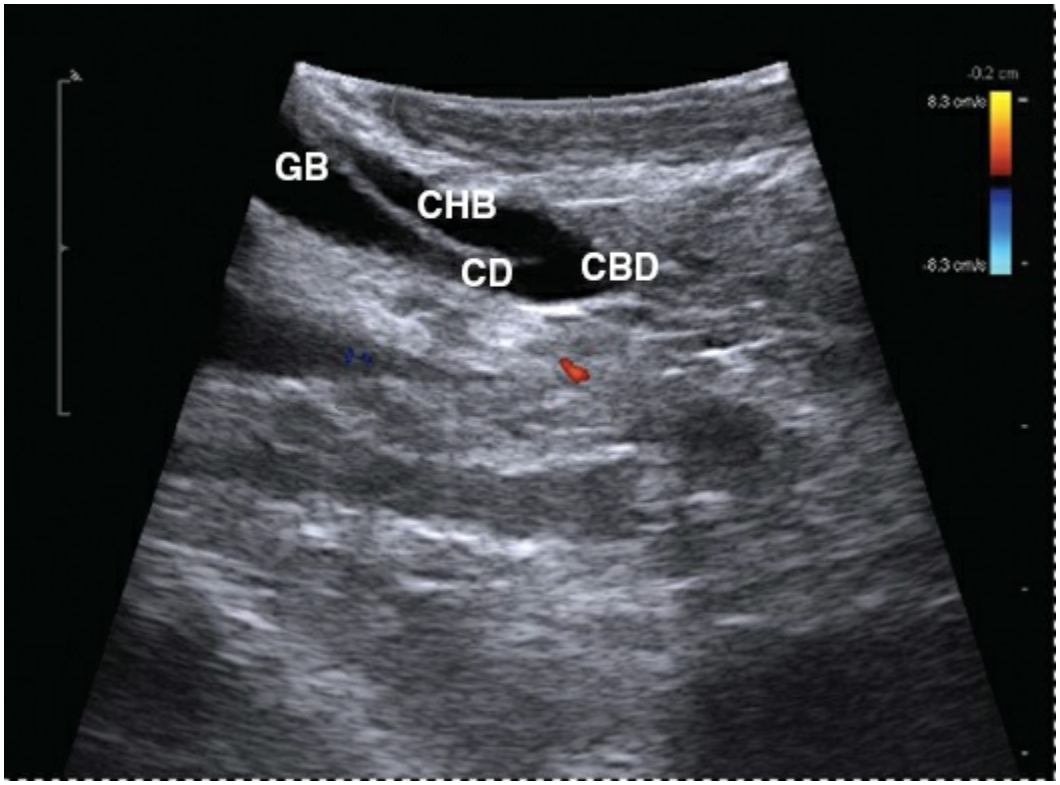

Figure 13.18. Scanning the gallbladder (GB) in the longitudinal plane toward the infundibulum leads to image the cystic duct (CD) and its junction with the common hepatic duct (CHB) to form the common bile duct (CBD).

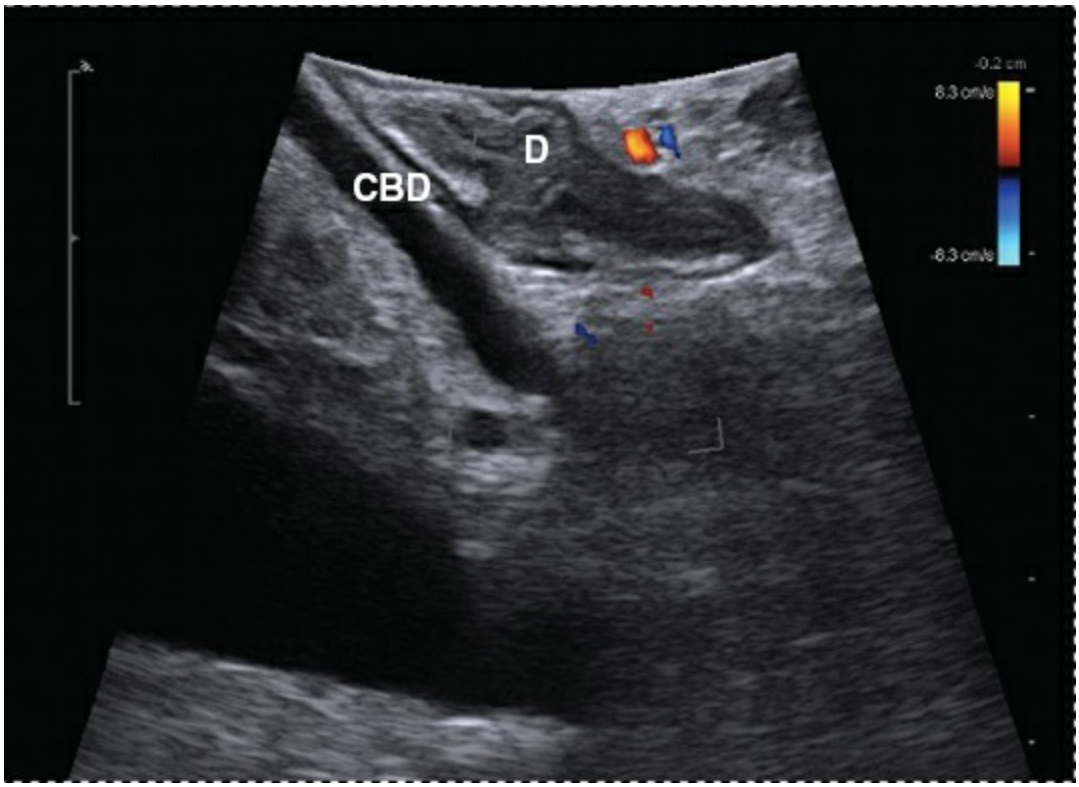

Figure 13.19. Laparoscopic scanning of the common bile duct is

an excellent means to screen for bile duct stones. Here the laparoscopic ultrasound is viewing the retroduodenal common bile duct (CBD) in its longitudinal axis, using the duodenum (D) as an acoustic window. The use of duplex is helpful to confirm the common bile duct.

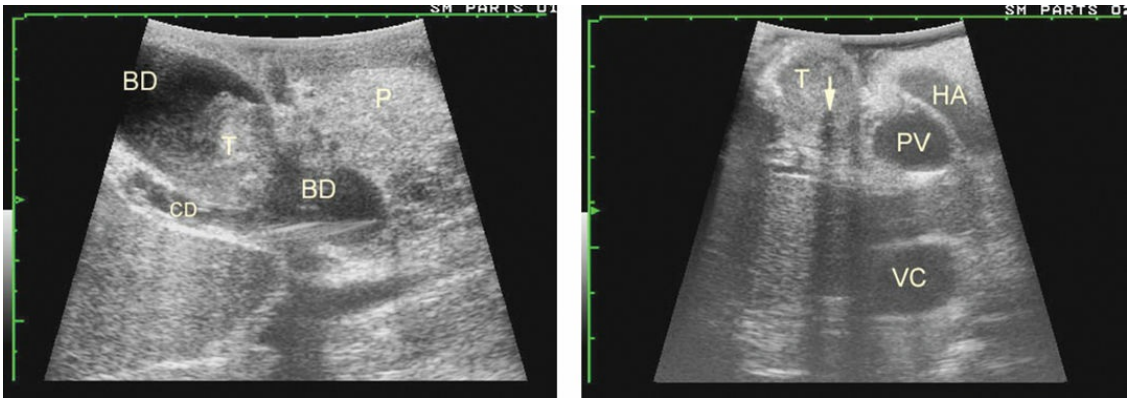

Figure 13.20. Intraoperative ultrasound showing a resectable bile duct cancer (cholangiocarcinoma). **Left:** a longitudinal view of the bile duct (BD) at the level of the junction with the cystic duct (CD). The proximal bile duct is dilated. The tumor (T) (bile duct cancer) was located at that area. It appeared to be a localized tumor. P, head of the pancreas. **Right:** in a transverse view of this cancer, there was no invasion of the tumor (T) to the portal vein (PV) and hepatic artery (HA). An arrow indicates a biliary catheter (associated with shadowing). VC, inferior vena cava.

TABLE 13.4 Systematic Approach to Pancreas Ultrasound Scanning

1. Scan the neck, body and tail (direct/contact, indirect, probe standoff)
   - Locate the portal vein/superior mesenteric vein/splenic vein
   - Scan to the right: neck, body and tail (longitudinal and transverse)
   - Identify the superior mesenteric artery
   - Scan pancreatic duct and note is size and appearance
   - Identify any lesion, its size, location, and echo characteristics
   - Define any vascular or duct involvement
2. Scan the head (direct/contact, indirect, probe standoff)
   - Locate the portal vein/superior mesenteric vein and extrahepatic bile duct
   - Scan to the left: head and uncinate process (longitudinal and transverse)
   - Identify the superior mesenteric artery
   - Identify any lesion, its size, location, and echo characteristics
   - Define any vascular involvement

LAPAROSCOPIC ULTRASOUND

LUS has become important as many of procedures are now performed by a minimally invasive approach. Because of the lack of tactile feedback, LUS is indispensable in staging laparoscopy, and in guiding laparoscopic liver resection or ablation procedures. LUS can identify critical structures during dissection and is extremely important to ensure a proper margin of resection. Screening for biliary stones and clarification of biliary tract anatomy during laparoscopic cholecystectomy has also grown in importance.

The methodology of LUS and IOUS is similar; however, there are important differences to consider in the setup and technique of LUS. The first consideration is the positioning of the ultrasound system. It is extremely important that the ultrasound machine with its display is placed on the same side as the laparoscopic monitor screen to facilitate ease of image visualization and interpretation and probe movement. If feasible, a picture-in-picture setup on the laparoscopic monitor is extremely helpful. The second difference is probe orientation. Because the laparoscopic probe is configured on a long shaft, it is difficult to replicate the transverse plane as seen during IOUS. Especially when imaging the liver, many of the images are seen in the longitudinal/oblique axis and therefore LUS may have a steeper learning curve. It is helpful to learn IOUS prior to LUS to facilitate ease of image interpretation. Probe movements during LUS are very similar as compared to IOUS, although sliding and tilting are the commonly used movements. Also similar to IOUS, contact (both indirect and direct methods) and probe standoff scanning techniques are used during LUS. Finally, the location of the trocar insertion sites depends strongly on the type of exam, the target organ of interest, and type of LUS probe (i.e., side-viewing versus front-viewing, rigid versus flexible probes) chosen. The most common trocar placement for LUS of upper abdominal organs includes periumbilical, right subcostal, and epigastric/subxiphoid positions.

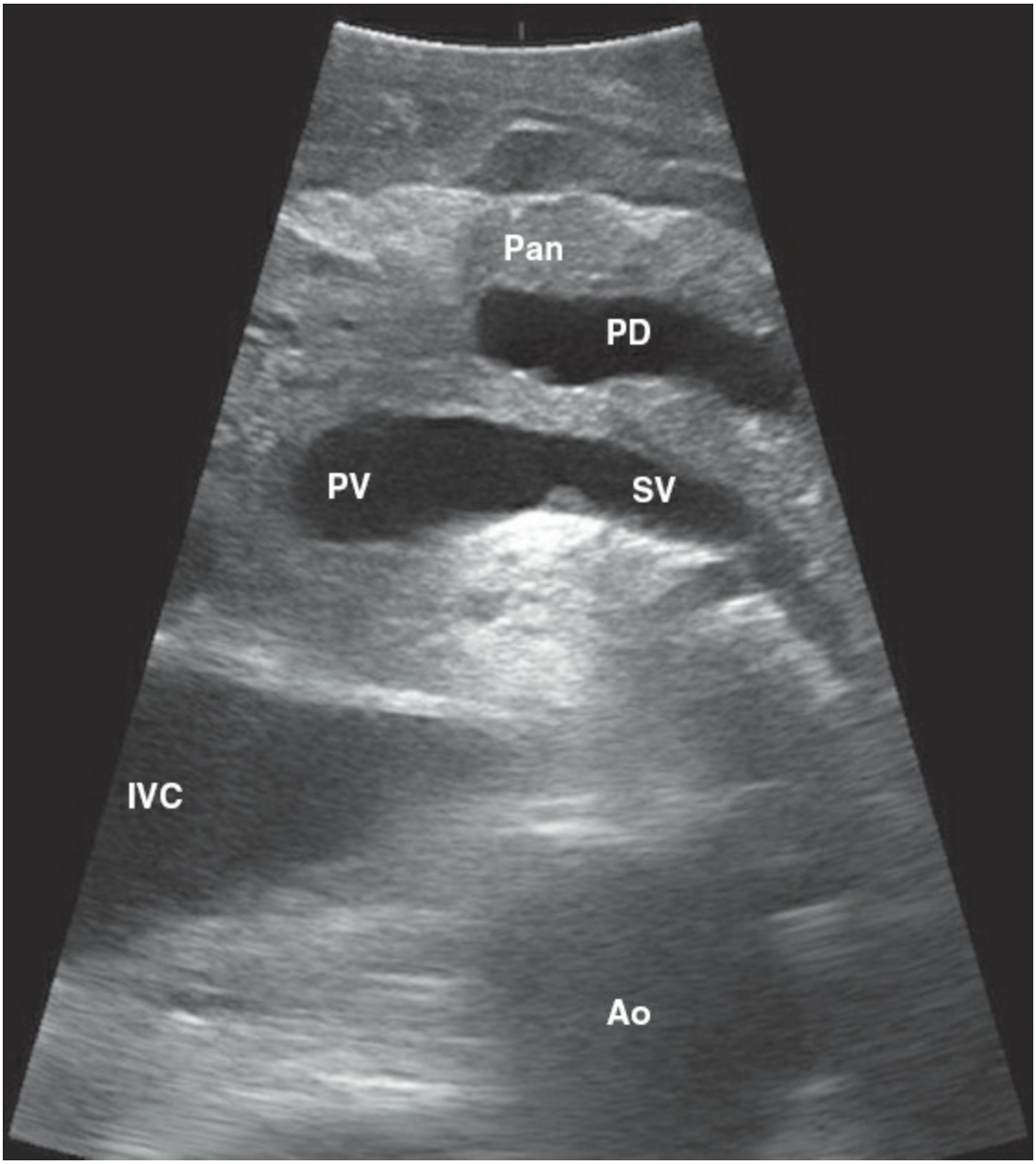

Figure 13.21. Intraoperative ultrasound of the pancreas. Using the stomach as an acoustic window (indirect scanning) is an excellent means to begin the examination of the longitudinal view of the pancreas (Pan). Identifying surrounding vasculature, such as the splenic vein (SV), portal vein (PV), and inferior vena cava (IVC), helps to clearly define the pancreatic parenchyma (Pan). Note the dilated pancreatic duct (PD) anterior to the SV and the aorta (Ao) posteriorly.

Liver Scanning Method

When performing LUS, it is very helpful to use a flexible laparoscopic probe through the right subcostal and epigastric ports. The systematic

approach for laparoscopic is similar to open intraoperative liver ultrasound as previously described (Table 13.2). It is best to begin by scanning from the right subcostal position as this offers the closest approximation to a transverse view. Scanning is begun at the superior aspect of the liver while identifying each hepatic vein and mapping its course. Next, the portal vein bifurcation is identified and each branch is followed to the segmental branches, as previously described. When scanning the portal bifurcation, it is best to move the LUS probe to the epigastric trocar to fully delineate the right portal vein and its branches. The left portal vein is easier to identify and delineate from the right subcostal port. A left subcostal trocar is rarely required for LUS. The vasculature is mapped out using a combination of sliding and tilting probe movements. Parenchymal scanning is then accomplished in the longitudinal/oblique plane beginning at the superior border of the liver and sliding the probe side to side within each section of the liver while sliding the probe toward the inferior edge of the liver. As previously described, these overlapping movements (the *sweep-scan*) allow complete scanning of the liver parenchyma. The *sweep-scan* is repeated within each section of the liver to allow a complete examination. Note the presence of any lesion, its characteristics, and proximity or involvement of vasculature. Lastly, a probe standoff technique (saline immersion) may be required, especially at the superior aspect of the liver and when evaluating superficial lesions. Alternatively, an end-viewing probe can be used for a more focused evaluation of liver lesions (rather than screening) and for subsequent ultrasound-guided liver aspiration, biopsy or ablation.

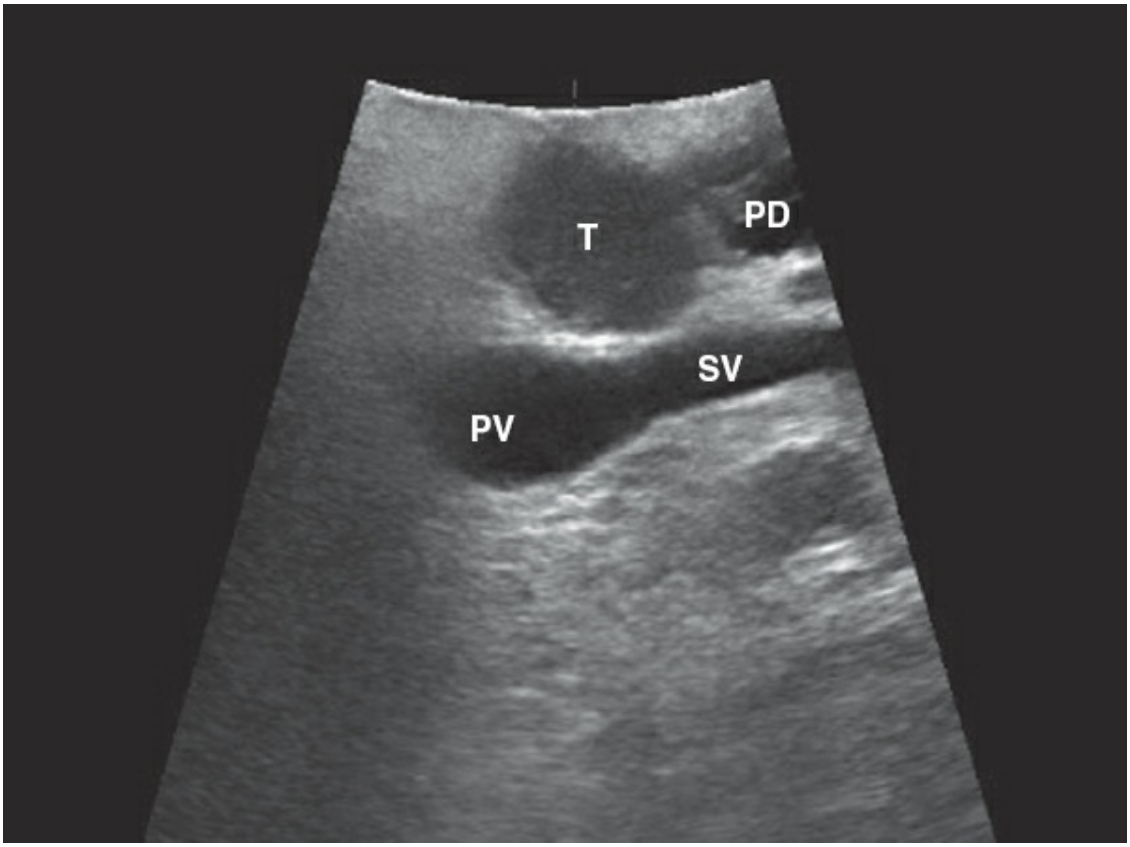

Figure 13.22. Neuroendocrine tumor of pancreas. Here seen is a hypoechoic tumor (T) of the pancreas causing compression and dilation of the pancreatic duct (PD) with the splenic vein (SV) and portal vein (PV) posteriorly. The well-defined, hypoechoic character of this lesion is a typical appearance of a neuroendocrine tumor in the pancreas.

Biliary Scanning Method

Laparoscopic biliary scanning can be achieved utilizing the flexible side-viewing probe or end-viewing probe. The choice of the probe depends on the target location of interest in addition to the surgeon's preference. As noted with IOUS, LUS of the biliary system should be undertaken prior to dissection in order to avoid introducing air into tissue planes and producing artifacts. Contact (direct and indirect) in addition to compression and probe standoff techniques is utilized. In order to ensure a complete exam, a systematic approach is imperative, as previously described (Table 13.3).

Using the flexible side-viewing probe, scanning is performed through the epigastric/subxiphoid and umbilical trocars. Begin the exam with the ultrasound probe through the epigastric/subxiphoid trocar. While retracting the fundus of the gallbladder cephalad, scan the gallbladder and slide the

probe along the gallbladder to the hepatoduodenal ligament to visualize the gallbladder and bile duct (Fig. 13.23). While the probe is positioned perpendicular and lateral to the hepatoduodenal ligament, slide (and tilt, if needed) the probe toward the liver hilum to visualize the common hepatic bile duct in the transverse plane. Sliding the ultrasound probe along the hepatoduodenal ligament produces the "Mickey Mouse" silhouette with the bile duct and hepatic artery anterior to the portal vein. The use of duplex or color Doppler ultrasound is very helpful to delineate these structures. Sliding the probe over the duodenum (compression scanning may be necessary) and the head of the pancreas visualizes the distal and intrapancreatic bile duct (Fig. 13.19). To examine the biliary system in the longitudinal plane, flex the probe tip upward (Fig. 13.23) or switch the ultrasound probe to the umbilical trocar. Place the probe on the hepatoduodenal ligament and slide it along the length of the ligament from superior to inferior. Moving the ultrasound probe down on the duodenum allows visualization of the distal bile duct (Fig. 13.24). During laparoscopic cholecystectomy, laparoscopic evaluation of the bile ducts can be accomplished for the screening of biliary stones and ensuring safety of the bile duct following cystic duct ligation (Fig. 13.25).

Pancreas Scanning Method

The basic steps of laparoscopic pancreas ultrasound are similar to those of IOUS. Scanning is best done from the right subcostal and periumbilical trocars. The pancreas is imaged in the longitudinal and transverse planes using the duodenum, stomach, or gastrohepatic/gastrocolic ligaments as an acoustic window. Because the pancreas is visualized through organs or tissues, exposure of the anterior surface of the pancreas is not required for a screening examination.

As seen in the liver and biliary scanning, a systematic approach to examination should be undertaken (Table 13.4). Scanning should begin from the right subcostal port to view the pancreas in the longitudinal view of the neck, body, and tail. Sliding the probe toward the patient's right allows examination of the pancreatic head and uncinate process. Switching the probe to the umbilical port allows examination of the pancreas in the transverse plane. Saline immersion may also be necessary. The head of pancreas is also examined from the subxiphoid port together with scanning of distal or intrapancreatic bile duct.

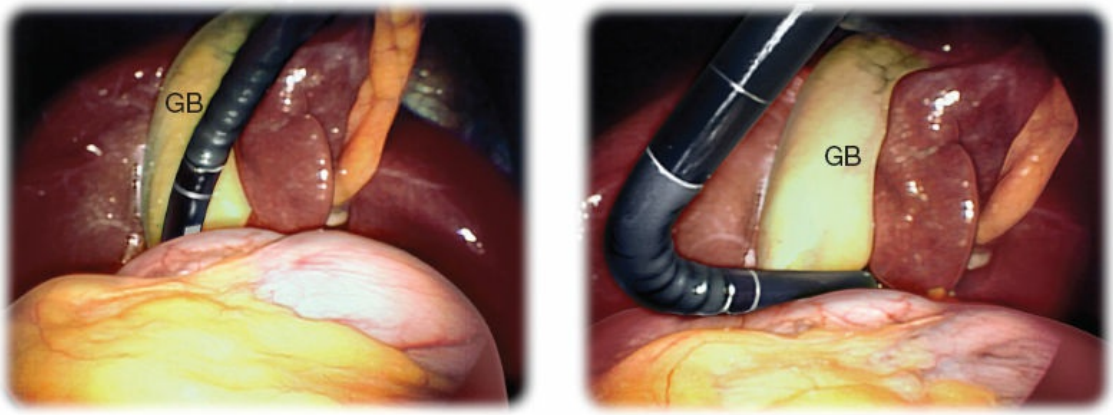

Figure 13.23. Laparoscopic ultrasound scanning of the gallbladder and bile duct using a flexible-tip probe via the subxiphoid port. The gallbladder (GB) is retracted superiorly over the liver. Sliding the probe along the gallbladder toward the bile duct demonstrates the bile duct in the transverse view (**left picture**). After upward flexion of the probe tip, the longitudinal view of the bile duct is then demonstrated (**right picture**).

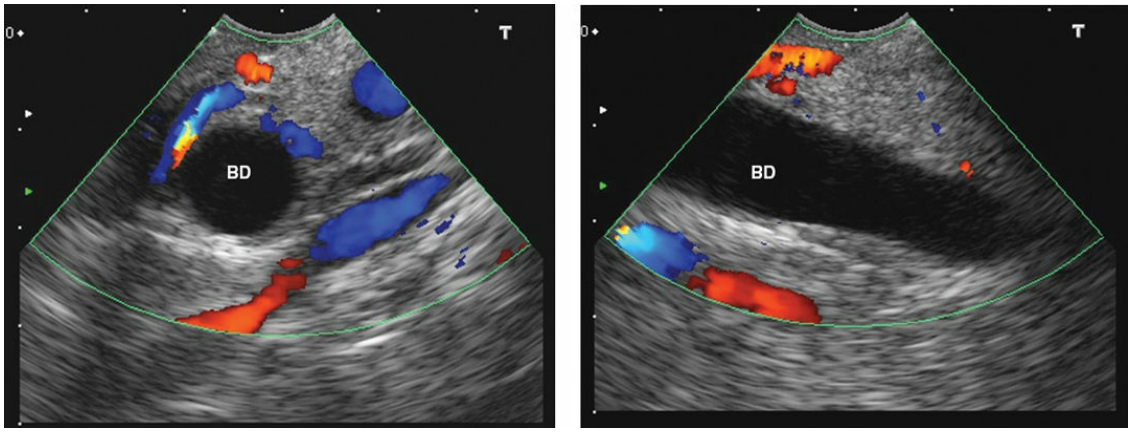

Figure 13.24. Laparoscopic scanning of the extrahepatic bile duct using an end-viewing LUS probe. The initial scan is performed in the transverse view (**left image**) and by rotating the probe demonstrates the longitudinal view (**right image**) of the extrahepatic hepatic bile duct. Note the use of duplex or color Doppler ultrasound helps to differentiate the extrahepatic bile duct from surrounding vasculature.

ULTRASOUND-GUIDED PROCEDURES

Ultrasound can be used to guide procedures in the operating room. These procedures can be divided into (1) ultrasound-guided targeting (biopsy, ablation, or duct cannulation), (2) ultrasound-guided procedure planning, and (3) ultrasound-guided tissue dissection.

Targeting

Technique

Targeting of a lesion for either biopsy or ablation can be performed under ultrasound guidance. It is necessary that the ultrasound probe be positioned *over* the lesion of interest and *flat* (not tilted) against the tissue to provide a clear image along the length of the probe. When targeting a lesion, it is preferable to perform "in-plane" targeting, which refers to passing the needle through the tissue parallel to and directly beneath the ultrasound probe. This allows visualization of the entire length of the needle during targeting. When performing IOUS-targeting, there is greater ease of motion with exposure of the organ of interest. However, during LUS-targeting, there is less flexibility of motion given the interference of the abdominal wall, and laparoscopic targeting becomes more challenging. Planning a proper needle trajectory ideally in line with the LUS probe is extremely important. If an "in-plane" approach is not feasible, then an "out-of-plane" approach becomes necessary. When a needle is inserted out of plane, it is passed perpendicular to the ultrasound probe and is visible only briefly as it passes the plane of the visualized tissue. This technique of targeting is technically difficult with limited experience. Some LUS devices have built-in biopsy channels or needle guidance systems. This is a useful adjunct when available.

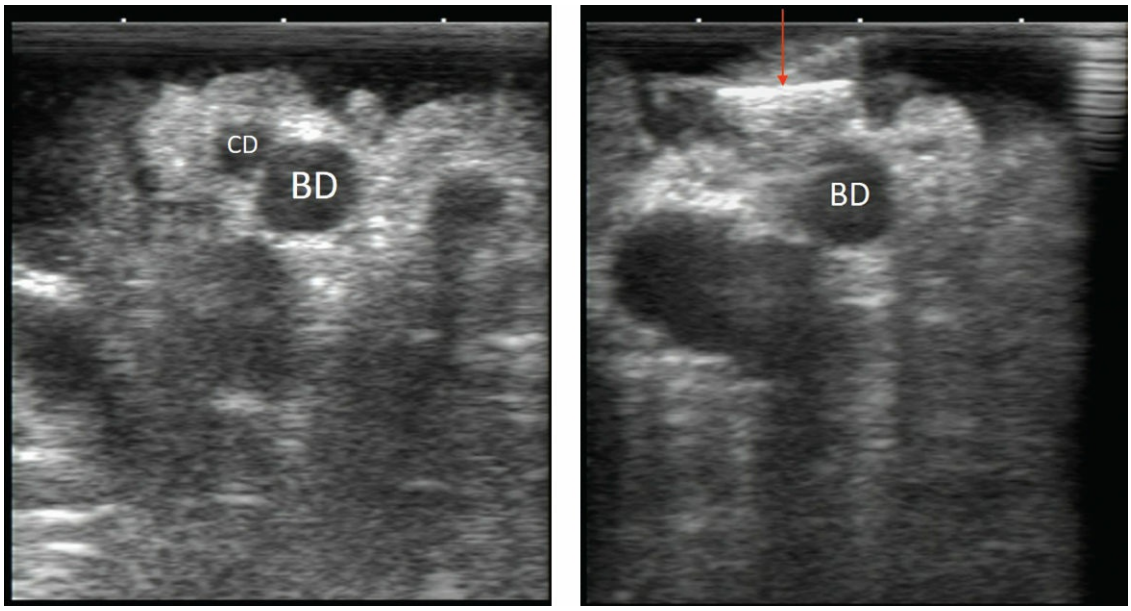

Figure 13.25. Biliary scanning during laparoscopic cholecystectomy. The bile duct (BD) and cystic duct (CD) are identified before tissue dissection and application of clips during cholecystectomy (**left image**). After clipping of the cystic duct, a

clip is visualized (*red arrow*) away from the bile duct (BD), which is intact (**right image**).

Procedures

Ultrasound-guided needle placement aids biopsy of tumors (especially nonpalpable tumors), aspiration of cystic lesions, injection of contrast or other agents, cannulation of bile or pancreatic duct, and ablation of tumors. Following needle placement under ultrasound guidance, biopsy of liver, pancreatic, or other abdominal tumors or suspicious lymph nodes can be performed. Ultrasound-guided needle biopsy is particularly indispensable for deeply located, invisible, nonpalpable tumors or lymph nodes. Ultrasound-guided fluid aspiration can be carried out for fluid-filled lesions, such as liver and pancreatic cysts, and intra-abdominal abscesses. Ultrasound-guided aspiration is also used to confirm the location of the bile duct or pancreatic duct. Agent injection, such as alcohol injection of small hepatocellular carcinomas or celiac ganglion block, can be guided by ultrasound. Ultrasound can also assist in bile duct cannulation and injection of contrast material for intraoperative radiographic examination (e.g., intraoperative cholangiography). Similar to ultrasound-guided needle placement for biopsy, an ablation cannula or probe can be passed into a tumor for thermal ablation, such as microwave or radiofrequency. Furthermore, the ablation process can be precisely planned and monitored with ultrasound (Fig. 13.26).

Ultrasound-Guided Procedure Planning

Ultrasound in the operating room can be used to stage malignancy, determine resectability, determine the extent of operation, and finally to plan the procedure. Certain malignancies are typically staged with diagnostic laparoscopy, and the use of ultrasound may determine, for example, occult metastatic disease in the liver and lead to a change in the plan of the procedure.

Use of ultrasound in the operating room for a planned oncologic resection can assist the surgeon to determine the extent of the operation and tumor resectability (Fig. 13.16). For example, use of ultrasound while operating for a pancreatic adenocarcinoma can assist in defining the limits of the tumor and potential vascular involvement. Similarly, ultrasound can determine involvement of the portal or arterial vasculature during resection of an extrahepatic biliary cancer (Fig. 13.20). Use of ultrasound during a

planned liver resection may find occult disease and the original planned extent of liver resection may be altered. A change in the operative plan with the use of ultrasound occurs between 10% and 15% of cases even with preoperative modern cross-sectional imaging.

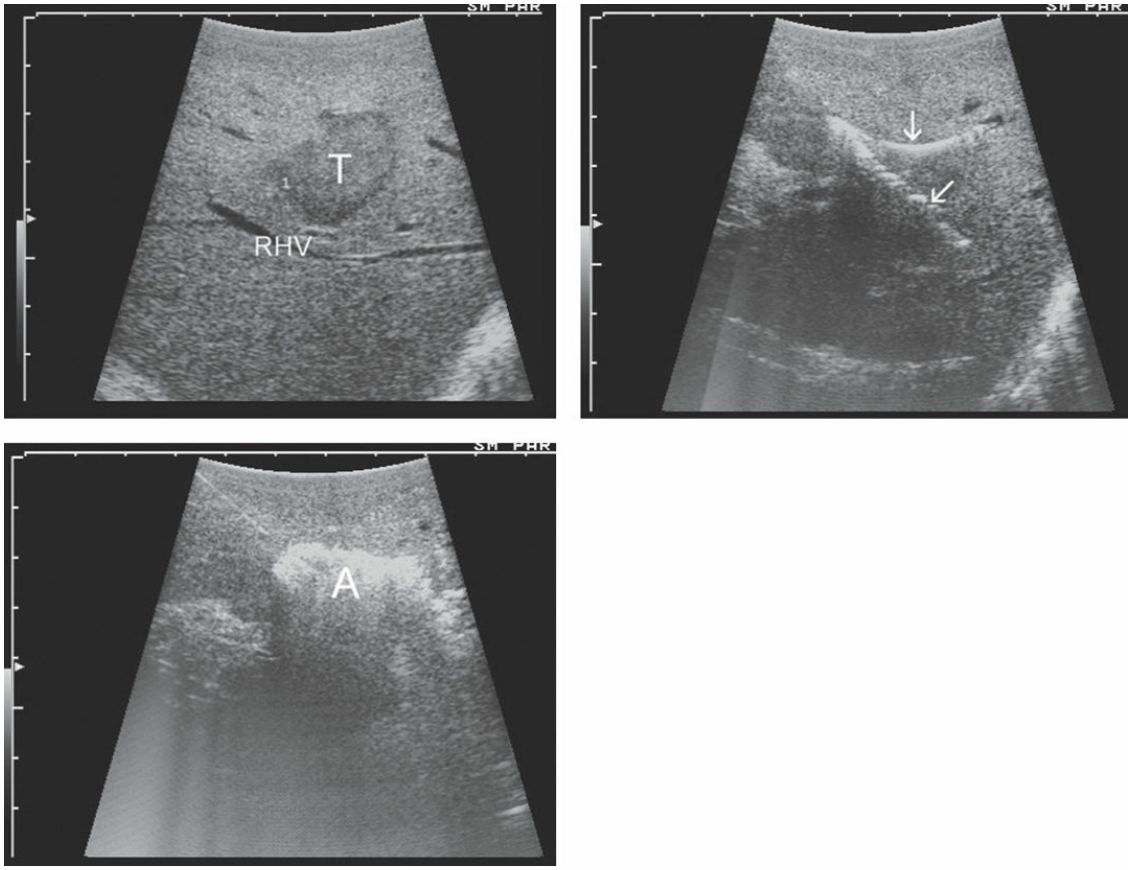

Figure 13.26. Ultrasound-guided radio frequency ablation process. A metastatic tumor (T) was found in segment 8 (**left upper image**). RFA needles (*arrows*) were deployed (**right upper image**), and ablation was undertaken. Ablated areas (A) became hyperechoic due to outgassing (**right lower image**). RHV, right hepatic vein.

The use of ultrasound during hepatic resection is imperative to define the vasculature. Recognizing the variations in portovenous and hepatic venous anatomy is critical in hepatic surgery. Ultrasound can identify the presence of clinically significant abnormalities, which can guide or alter the operation. For example, a significant percentage of patients have variations in both the number and organization of the hepatic veins. An inferior right hepatic vein is found 10% to 15% of patients which drains directly into the inferior vena cava caudal to the right hepatic vein. The presence of this accessory hepatic vein allows resection of segment 7 with

the right hepatic vein while allowing for the preservation of segment 6. Segmental anatomy, as defined by its portal supply, can be delineated easily with ultrasound, either IOUS or LUS, and a limited resection can be undertaken in a patient, for example, with cirrhosis. Knowledge of the particular patient's anatomy and the extent of disease are paramount in planning hepatobiliary and pancreatic resections and guiding surgery once it has begun.

Ultrasound-Guided Tissue Dissection

Ultrasound-guided tissue dissection can assist in guiding resection or incision of solid organs such as the liver or pancreas. During operations for chronic pancreatitis, dilated pancreatic ducts and small pancreatic pseudocysts are often not palpable. In such instances, incision of the pancreatic parenchyma (pancreatotomy) or incision of the cyst wall can be guided by ultrasound for internal drainage (e.g., Puestow operation or cystogastrostomy). For enucleation of islet cell tumors of the pancreas, especially those which are nonpalpable, ultrasound-guided pancreatotomy can be utilized in addition to initial accurate localization of the tumor.

Ultrasound-guided tissue dissection for resection is performed in various organs; however, it is used most frequently during hepatic resection, such as major hepatectomy, partial hepatectomy, segmentectomy, and other nonanatomical resections. During hepatic resection, the transecting plane of the liver is clearly delineated on ultrasound images, and therefore ultrasound can direct resection to ensure an adequate tumor margin and completeness of resection. Segmental liver resection is possible only by identifying the portal and hepatic veins under ultrasound to define the limits of resection. Tumors of the pancreas or biliary system can be also resected with the assistance of ultrasound guidance. When laparoscopic surgery is performed for these operations (e.g., hepatectomy, pancreatectomy, and cystogastrostomy), ultrasound guidance can be used laparoscopically in a manner similar to open surgery for incision or resection. As laparoscopic liver resection techniques continue to diffuse the surgical community, the use of ultrasound becomes imperative to identify tumors and to guide liver resection to ensure a proper margin in the absence of tactile feedback.

TRAINING IN SURGICAL ULTRASOUND

Realizing the value of surgical ultrasound is fundamental to motivating the

surgeon to train for proficiency in performing, interpreting, and utilizing ultrasound in practice. Interpretation of a 2D real-time ultrasound image requires familiarity with how the position of probe (transducer) relates to the image on the monitor screen. This probe-image orientation requires hand–eye coordination by the operator in order to understand where a particular anatomic region is represented on the screen. To acquire this type of orientation, the surgeon who is not familiar with the ultrasound probe and scan display on the monitor is well advised to practice with the probe in a small basin of water; for example, scanning a freshly excised surgical specimen such as a gallbladder. With such practice, image orientation of a target in relation to the position of the probe will be observed and interpretation of images will be facilitated. Although an ultrasound learning curve may appear steep, a surgeon's knowledge of 3D anatomy enables a faster understanding of ultrasound images.

The main obstacle to utilizing ultrasound in the operating room is the difficulty in obtaining sufficient training. Currently, ultrasound is incorporated into many, but not all, surgical residency and fellowship programs. For those surgical residencies without a formal curriculum, the American College of Surgeons offers *Ultrasound for Residents* exported course. A standardized ultrasound training platform for hepato-pancreato-biliary fellows is offered through Americas Hepato-Pancreato-Biliary Association annually. However, for surgeons in practice a formalized curriculum and consistent practice is extremely important. Formalized training in surgical ultrasound including hands-on sessions can be obtained through the American College of Surgeons (*Ultrasound for Surgeons* (basic course)*; Advanced HPB Ultrasound*) and through the Americas Hepato-Pancreato-Biliary Association (*HPB Ultrasound and Advanced Technology*). Taking such courses followed by practical application is helpful for surgeons, especially for the ultrasound neophyte, who is interested in getting started in ultrasound. For general surgeons, particularly hepatobiliary, pancreatic, surgical oncologists, and laparoscopic surgeons, it is critically important to master ultrasound skill.

CONCLUSIONS

Intraoperative ultrasound, both IOUS and LUS, can provide various diagnostic information which is otherwise not available and can guide or assist various surgical procedures in real-time. IOUS is commonly performed during hepatobiliary, pancreatic, endocrine, cardiovascular, and

neurologic surgery; however, its applications are expanding to other surgical fields. Advantages of IOUS, including safety, speed, high accuracy, comprehensive anatomical information and real-time guidance capability, outweigh its disadvantages such as specific equipment requirement and slow learning curve. The use of IOUS by surgeons is expected to increase along with more formal training and experience in ultrasound for surgeons. New ultrasound technologies such as ultrasound contrast enhancement, 3D and 4D ultrasound, elastography, and high-intensity focused ultrasound will be utilized more during future IOUS, and may potentially improve surgical outcome. Being safe, quick, accurate, and versatile intraoperatively, ultrasound is a valuable technique which is recommended to master for surgeons in various fields to improve intraoperative decision making and surgical procedures.

Suggested Readings

Belgihiti J, Clavien PA, Gadzijev E, et al. The Brisbane terminology for liver anatomy and resections. *HPB* 2000;2:333–9.

Garden OJ. *Intraoperative/Laparoscopic Ultrasound.* Cambridge: Blackwell Science; 1995.

Hagopian EJ, Machi J. (eds.) *Abdominal Ultrasound for Surgeons.* New York: Springer Science+Business Media; 2014.

Harness JK, Wisher DB. *Ultrasound in Surgical Practice.* New York: Wiley; 2001.

Jakimowicz JJ. Intraoperative ultrasonography in open and laparoscopic abdominal surgery: an overview. *Surg Endosc* 2006;20:S425–S435.

Machi J, Staren ED. *Ultrasound for Surgeons.* 2nd ed. Philadelphia, PA: Lippincott Williams & Wilkins; 2005.

EDITOR'S COMMENT

The utility of IOUS has increased over the last three decades. An appreciation for the growth of this imaging modality must be firmly rooted in an understanding of the three remarkable periods in the history of IOUS. The first period was marked by the use of A-mode or non-real-time B-mode ultrasound in 1960s. The second period, which encompassed the late 1970s and the 1980s, included the expansion of IOUS with real-time B-mode ultrasound, while the current era includes the utility of laparoscopic ultrasound and color Doppler imaging.

Wild and Reid's diagnosis of a malignant cerebral tumor marked the first successful use of intraoperative A-mode ultrasound (White DN. Historical

survey. In: White DN, ed. *Ultrasound in Medical Diagnosis*. Kingston, Ontario: Ultramedison; 1976:1–36). Thereafter, several investigators utilized ultrasound for the intraoperative detection and localization of renal calculi, biliary calculi, and cerebral mass lesions (Takayasu H, Aso Y. Intraoperative diagnosis of retained renal calculi by ultrasound. *Jpn Soc Ultrason Med Proc* 1967;11:117–8; Yamakawa K, Naito S, Azuma K, et al. Laparoscopic diagnosis of intraabdominal organs: ultrasound diagnosis through laparoscopy. *Jpn J Gastroenterol* 1958;55:741; Hayashi S, Wagai T, Miyazawa R, et al. Ultrasonic diagnosis of breast tumor and cholelithiasis. *West J Surg Obstet Gynecol* 1962;70:34–40). The end of the first period was also significant for epicardial M-mode IOUS for the preoperative and postoperative evaluation of cardiac function in patients undergoing valve surgery (Johnson MC, Holmes JH, Spangler RD, et al. Usefulness of echocardiography in patients undergoing mitral valve surgery. *J Thorac Cardiovasc Surg* 1972;64:922–34; Spotnitz HM, Malm JR, King DL, et al. Outflow tract obstruction in tetralogy of Fallot. Intraoperative analysis by echocardiography. *NY State J Med* 1978;78:1100–3).

Real-time 2D B-mode imaging systems ushered in the second period of the IOUS era. Cook and Lytton in the United States and Makuuchi et al. in Japan were the first to describe the use of IOUS with B-mode real-time imaging (Cook JH III, Lytton B. Intraoperative localization of renal calculi during nephrolithotomy by ultrasound scanning. *J Urol* 1977;117:54; Makuuchi M, Kamiya K, Sugiura M, et al. Ultrasonic examination by electronic scanning during operation. Proceedings of the 32nd Meeting of the Japan Society of Ultrasonics in Medicine, 1977:129–130. 3–546). Cook and Lytton employed IOUS for precise localization of renal calculi to facilitate their removal while Makuuchi et al. applied IOUS for the examination of the liver and pancreas. The expansion of ultrasound technology quickly spread to endocrine (Sigel B, Kraft AR, Nyhus LM, et al. Identification of a parathyroid adenoma by operative ultrasonography. *Arch Surg* 1981;116:234–5; Lane RJ, Coupland GA. Operative ultrasonic features of insulinomas. *Am J Surg* 1982;144:585–7), neurologic (Dohrmann GJ, Rubin JM. Use of ultrasound in neurosurgical operations: a preliminary report. *Surg Neurol* 1981;16:362–6; Shkolink A, McLane DG. Intraoperative real-time ultrasonic guidance of ventricular shunt placement in infant. *Radiology* 1981;141:515–7) and cardiovascular indications (Wong CY, Spotnitz HM. Systolic and diastolic properties of the human left ventricle during valve replacement for chronic mitral regurgitation. *Am J Cardiol* 1981;47:40–9; Spotnitz HM, Malm JR. Two-dimensional ultrasound and cardiac operations. *J Thorac Cardiovasc Surg* 1982;83:43–51). IOUS use gradually increased through the 1980s, with refinement of real-time B-mode ultrasound. Four major benefits of IOUS refinement included the acquisition of new information useful for intraoperative decision making, its use as a complement to or replacement for intraoperative radiography, its utilization as guidance for various surgical procedures, and its role in the confirmation of completion of an operation.

The current era of ultrasound has been marked by the utility of laparoscopic ultrasound and color Doppler imaging. IOUS with color Doppler imaging was first performed during cardiovascular surgery to evaluate cardiac diseases and adequacy of valvular repair. This modality was also found to be useful for the detection of postreconstruction vascular defects and for supplemental hemodynamic information in renal, carotid, and peripheral arterial reconstructions (Bandyk DF, Govostis DM. Intraoperative color flow imaging of difficult arterial reconstructions. *Video J Color Flow Imaging* 1991;1:13–20; Machi J, Sigel B, Roberts AB, et al. Operative color Doppler imaging for vascular surgery. *J Ultrasound Med* 1992;11:65–71). As this chapter's authors have described, the addition of color Doppler to B mode ultrasound revolutionized hepatobiliary surgery by allowing for better delineation of small vessels and biliary ducts.

The use of laparoscopic ultrasound has grown in parallel with the widespread performance of laparoscopic cholecystectomy. Many applications of IOUS were developed to compensate for the loss of tactile feedback that occurs during laparoscopy, including the delineation of the biliary anatomy and evaluation of the common bile duct for calculi (Barteau JA, Castro D, Arregui ME, et al. A comparison of intraoperative ultrasound versus cholangiography in the evaluation of the common bile duct during laparoscopic cholecystectomy. *Surg Endosc* 1995;9:490–6; Goletti O, Buccianti P, Ferrari M, et al. Laparoscopic ultrasonography: a real alternative to cholangiography during laparoscopic cholecystectomy? *Hepato-Gastroenterol* 1995;42:612–8). The application of minimally invasive ultrasonography has also facilitated the accurate staging of esophageal, gastric, pancreatic, and thoracic malignancies (John TG, Greig JD, Garden OJ. Carcinoma of the pancreatic head and periampullary region: tumor staging with laparoscopy and laparoscopic ultrasonography. *Ann Surg* 1995;221:156–64; Murugiah M, Paterson-Brown S, Windsor JA, et al. Early experience of laparoscopic ultrasonography in the management of pancreatic carcinoma. *Surg Endosc* 1993;7:177–181; Pietrabissa A, Di Candio G, Giulianotti PG, et al. Laparoscopic exposure of the pancreas and staging of pancreatic cancer. *Semin Laparosc Surg* 1996;3:3–9). It is clear that the emergence of 3D technology, ultrasonographic contrast media, ultrasmall endoluminal probes, color Doppler, and power Doppler technologies will further support the growth of this field.

Given the history of ultrasonography, I believe it important to consider additional indications for this technology. Chief among these uses are trauma and breast surgery.

The use of ultrasound in the evaluation of abdominal trauma was first described in 1971 by Kristensen and colleagues (Kristensen JK, Buemann B, Kühl E. Ultrasonic scanning in the diagnosis of splenic haematomas. *Acta Chir Scand* 1971;137:653–7). Rozycki and colleagues coined the term FAST (focused assessment with sonography for trauma) in 1996 to describe an emergency room assessment of ultrasound evaluation of patients who suffered

truncal trauma (Rozycki GS, Ochsner MG, Schmidt JA, et al. A prospective study of surgeon-performed ultrasound as the primary adjuvant modality for injured patient assessment. *J Trauma* 1995;39:492–8). The continued growth of this modality has transformed it from a method of detection of free intra-abdominal fluid to that of specific injury identification and from an adjunct for other screening/diagnostic modalities to an exclusive diagnostic modality in an effort to decrease cost and invasiveness. Many reports have demonstrated sensitivities between 67% and 80% due to multiple confounding variables. In contrast, specificity and accuracy have been reported to range from 98% to 100% and 98% to 99%, respectively (Rozycki GS, Ochsner MG, Schmidt JA, et al. A prospective study of surgeon-performed ultrasound as the primary adjuvant modality for injured patient assessment. *J Trauma* 1995;39:492–8; Miller MT, Pasquale MD, Bromberg WJ, et al. Not so FAST. *J Trauma* 2003;54:52–9; Rose JS, Levitt MA, Porter J, et al. Does the presence of ultrasound really affect computed tomographic scan use? A prospective randomized trial of ultrasound in trauma. *J Trauma* 2001;51:545–50; Ma OJ, Mateer JR, Ogata M, et al. Prospective analysis of a rapid trauma ultrasound examination performed by emergency physicians. *J Trauma* 1995;38:879–85; Luks FI, Lemire A, St-Vil D, et al. Blunt abdominal trauma in children: the practical value of ultrasonography. *J Trauma* 1993;34:607–10; McKenney M, Lentz K, Nunez D, et al. Can ultrasound replace diagnostic peritoneal lavage in the assessment of blunt trauma? *J Trauma* 1994;37:439–41; Tso P, Rodriguez A, Cooper C, et al. Sonography in blunt abdominal trauma: a preliminary progress report. *J Trauma* 1992;33:39–43; Jehle D, Guarino J, Karamanoukian H. Emergency department ultrasound in the evaluation of blunt abdominal trauma. *Am J Emerg Med* 1993;11:342–6).

The application of ultrasound technology to breast conservation therapy (BCT) for breast cancer has undergone significant expansion over the past decade. Although the primary goal of BCT is to obtain tumor-free resection margins, positive margins, and re-excisions after lumpectomy are still reported in up to 40% of patients (Sanchez C, Brem RF, McSwain AP, et al. Factors associated with re-excision in patients with early-stage breast cancer treated with breast conservation therapy. *Am Surg* 2010;76:331–4; Coopey S, Smith BL, Hanson S, et al. The safety of multiple re-excisions after lumpectomy for breast cancer. *Ann Surg Oncol* 2011;18:3797–801; Krekel N, Zonderhuis B, Muller S, et al. Excessive resections in breast-conserving surgery: a retrospective multicentre study. *Breast J* 2011;17:602–9; Singletary SE. Surgical margins in patients with early-stage breast cancer treated with breast conservation therapy. *Am J Surg* 2002;184:383–93; Krekel NM, Zonderhuis BM, Stockmann HB, et al. A comparison of three methods for nonpalpable breast cancer excision. *Eur J Surg Oncol* 2011;37:109–15). The secondary goal of BCT is the cosmetic outcome; however, up to 30% of patients report being unsatisfied with the cosmetic outcome (Vrieling C, Collette L, Fourquet A, et al. The influence of patient, tumor and treatment factors on the cosmetic results

after breast-conserving therapy in the EORTC “boost vs. no boost” trial. EORTC Radiotherapy and Breast Cancer Cooperative Groups. *Radiother Oncol* 2000;55:219–32; Wang HT, Barone CM, Steigelman MB, et al. Aesthetic outcomes in breast conservation therapy. *Aesthet Surg J* 2008;28:165–70; Parvez E, Cornacchi SD, Hodgson N, et al. A cosmesis outcome substudy in a prospective, randomized trial comparing radioguided seed localization with standard wire localization for nonpalpable, invasive, and in situ breast carcinomas. *Am J Surg* 2014;208:711–17). Taken together, these findings suggest that additional approaches to the acquisition of appropriate margins and cosmesis are much needed. Current data suggests that breast IOUS provides for a significantly improved acquisition of negative margins relative to other localization techniques for palpable and nonpalpable breast tumors. A 2013 meta-analysis of patients with nonpalpable breast cancer treated with IOUS versus wire-guided localization was performed on one randomized controlled trial (RCT) and nine cohort studies containing 739 patients. A statistically significant difference was found between IOUS and WGL in terms of tumor-free margins favoring IOUS (OR = 0.52; 95% CI: 0.38–0.71) (Ahmed M, Douek M. Intra-operative ultrasound versus wire-guided localization in the surgical management of non-palpable breast cancers: systematic review and meta-analysis. *Breast Cancer Res Treat* 2013;140:435–46). The COBALT trial was the first multicenter RCT for palpable cancer comparing IOUS with palpation alone to evaluate both oncologic and cosmetic outcomes. This trial demonstrated a 3% rate of tumor-involved margin rate for the invasive component in the IOUS group compared to 17% in the palpation-only group (Krekel NM, Haloua MH, Lopes Cardozo AM, et al. Intraoperative ultrasound guidance for palpable breast cancer excision (COBALT trial): a multicentre, randomised controlled trial. *Lancet Oncol* 2013;14:48–54). Current training in ultrasound techniques and emerging technology has extended the utility breast IOUS to achieve adequate margins with acceptable cosmesis.

The continued growth of IOUS has improved the management of patients with a variety of diseases; however, recent developments can extend the usefulness of IOUS. Ultrasonic elastography is a noninvasive method of estimating the elasticity of tissues and thereby identifying and characterizing breast and liver tumors (Itoh A, Ueno E, Tohno E, et al. Breast disease: clinical application of US elastography for diagnosis. *Radiology* 2006;239:341–50; Omichi K, Inoue Y, Hasegawa K, et al. Differential diagnosis of liver tumours using intraoperative real-time tissue elastography. *Br J Surg* 2015;102:246–53). In addition, IOUS elastography can provide real-time visualization of changes in tissue properties after local ablation techniques (Mariani A, Kwiecinski W, Pernot M, et al. Real time shear waves elastography monitoring of thermal ablation: in vivo evaluation in pig livers. *J Surg Res* 2014;188:37–43). Finally, the combination of preoperative planar imaging and IOUS guidance can provide updated information during surgery, thereby improving the precision of surgery.

John H. Stewart, IV

14 Tumor Ablation: Technologies and Clinical Applications

Michael S. Sabel

INTRODUCTION

The principal components of multimodality cancer therapy remain the systemic therapies (cytotoxic chemotherapies, biologic therapies, and targeted therapies), radiation therapy, and surgery. There have been tremendous advances in all three modalities. While surgery has become less invasive, with fewer complications, it still involves the extirpation of a tumor. An alternative to surgery is tumor ablation.

Tumor ablation is defined as the direct application of a chemical or energy-based (thermal and nonthermal) therapy to eradicate or substantially destroy focal tumors. This is in contrast to indirect ablation, which involves the use of oral, intravenous, intra-arterial, or intracavitary agents. Ablation techniques are used for both benign tumors (such as fibroadenomas or angiomyolipomas), metastatic lesions, and increasingly for primary tumors. In the case of cancer, the goal of ablation is 100% eradication of all viable malignant cells, and this often involves ablating the visible tumor along with an adequate margin of normal tissue surrounding it.

Ablative modalities can be divided into two categories. The first are the chemical ablations, or nonenergy based. The second are the energy-based ablations, which can be further divided into thermal and nonthermal. The terminology can often be confusing and misleading. Often these technologies are described as “minimally invasive”; however, this can refer to any approach that is less invasive than conventional surgery, and is more commonly used to describe endoscopic surgery. Another commonly used term is “percutaneous,” but this can also be misleading. While many of these modalities involve the percutaneous placement of an applicator or probe, several do not.

Ablative technologies are highly dependent upon *image guidance*, and optimal outcomes hinge on the ability to visualize the entire tumor mass

for appropriate pretreatment planning as well as through the treatment cycle. Several imaging modalities are used for tumor ablation, including ultrasonography (US), computed tomography (CT), magnetic resonance imaging (MRI), and positron emission tomography (PET). In many cases, more than one imaging modality can be used for any available ablation technique, and one may be preferable over another depending on the site, size, and shape of the tumor mass to be ablated.

This chapter will review the present technologies available for tumor ablation, review the principles of ablation, and describe their present clinical uses and future potential.

POTENTIAL BENEFITS OF TUMOR ABLATION

One of the most significant potential advantages to tumor ablation is the ability to eliminate the malignant cells while minimizing damage and preserving as much normal tissue as possible. In some cases, this is critical such as the preservation of functional hepatic reserve in the cirrhotic patient, nephron-sparing approaches to the treatment of renal cell carcinoma (RCC), or maintaining lung function in the face of emphysema. Another significant advantage of tumor ablation is the decreased morbidity and cost as compared to surgical approaches. While the morbidity and mortality associated with surgery have improved significantly over the past several decades, surgery still carries risks. Complications of surgery can potentially delay the initiation of other modalities, such as systemic therapy or radiation. The cost of surgery is also substantial, and ablative technologies may be particularly cost-effective in comparison, potentially allowing greater access to treatment across the world.

Despite the tremendous potential for ablative technologies, their clinical use in cancer treatment is still limited. There are several reasons for this. While the theoretical potential is great, there are still several hurdles to overcome, particularly when compared to surgery—the gold-standard. Surgery permits pathologic confirmation of complete excision, allowing for evaluation of the margin status, which ablation does not. Tumor ablation is wholly dependent upon imaging studies to assure complete ablation, and therefore success is tied to the ability of the imaging modality to visualize the entire tumor. As tumor-imaging modalities improve, so too will the applicability of tumor ablation. While imaging is critical, it is important to keep in mind that the success or failure of ablative technologies is not solely related to the ability to visualize and

target the tumor tissue. Several of the ablative technologies take advantage of the unusual properties of the tumor microenvironment compared to the surrounding normal tissues. There are several characteristics of the primary organ as well as the tumor tissue (density, fibrosis, water content, vascularity) that can influence the extent of injury. These characteristics impact thermal conductivity, electrical conductivity or tissue elasticity, and for some modalities may be advantageous, while for others they may be prohibitive.

Combination Therapy

For many tumors, such as breast cancer or sarcoma, surgery and radiation are complementary as the former removes large tumor masses but can leave micrometastatic foci while radiation can eradicate small foci but is much less effective against larger deposits. This combination is what allows breast conservation for breast cancer or limb-salvage surgery for soft tissue sarcoma. There are likely similar synergistic effects between tumor ablation and other nonablative modalities.

Compared with surgery, tumor ablation is particularly well-suited toward combination therapy. Ablation is relatively quick, well-tolerated, and rarely associated with complications or wound healing issues that may delay the initiation of additional therapies. Combination therapy has several potential advantages: (1) treatment of residual microscopic disease that may be left behind outside of the ablation zone—similar to the combination of surgery with radiation or systemic therapy, (2) increasing the size of the ablation zone or the efficacy of ablation, and (3) increasing the downstream benefits of tumor ablation, such as the effects on the tumor vasculature or the immunologic response.

One example of synergy is the combination of ablation with radiation therapy. Radiation may help remove residual microscopic disease after ablation, but there may also be greater tumor necrosis with the combination of radiofrequency ablation (RFA) and radiation secondary to effects on the blood flow into the target lesion. Another example of synergy is the addition of regional therapies that may decrease blood flow near tumors. As with radiation, this may not only expand killing beyond the ablation zone, but be synergistic by overcoming the heat-sink effect. For example, regional chemotherapy to the liver using transarterial chemoembolization (TACE) has been combined with RFA. A recent meta-analysis reported that the combination of RFA and TACE improves the

overall survival rate for patients with intermediate and large-sized hepatocellular carcinomas (HCC) compared to RFA alone.

The heat-sink effect may also be overcome by combining ablation with pharmacologic agents that slow blood flow or are antiangiogenic. Agents such as arsenic trioxide or halothane, which decreases blood flow, appear to increase RFA-induced coagulative necrosis in animal models, but are limited clinically by their toxicities. RFA combined with the vascular endothelial growth factor (VEGF) inhibitor sorafenib appears to produce a therapeutic effect superior to RFA alone for small HCCs, although the STORM trial (NCT00692770) failed to show a clinical advantage of using sorafenib after either local ablation or surgical resection.

Other systemic therapies may also be used in combination with ablation. Combining chemotherapy with ablation may increase the overall volume of tumor necrosis by increasing the effects in the peripheral zone of hyperemia surrounding the central zone of ablation. The effects of ablation on blood flow may improve drug accumulation, and the ablation-induced reduction in cellular reparative mechanisms may allow for increased apoptosis or other cytotoxic mechanisms. As an example, in a phase II study of RFA for nonresectable colorectal liver metastases, the combination of RFA with systemic therapy improved progression-free survival over systemic therapy alone. The vascular effects of ablation may also make the combination of ablation with liposomal chemotherapy particularly attractive. Liposomes are artificial phospholipid vesicles that can be loaded with a variety of water-soluble drugs, including chemotherapeutic agents. Liposomal chemotherapy can result in increases in drug concentrations in solid tumors based on the increased permeability of the tumor microvasculature. At the periphery of an ablated tumor, failure may be secondary to the inability to heat tumor cells to lethal temperatures. However, the impact of hyperthermia on the microvasculature around the ablated tissue may increase the uptake of liposomal chemotherapy. This may be even further enhanced through the use of heat-sensitive liposomes, where the drug is released at higher temperatures.

Immunologic Benefit

One of the most interesting and unique aspects of ablation is its potential to stimulate an antitumor immune response. Leaving a tumor to die in situ may generate an antitumor immune response that may then lead to an

abscopal effect, where treatment of one tumor has an impact on distant, untreated tumors. The key to the antitumor immune response appears to be related to the mechanism of cell death induced by tumor ablation.

The two primary mechanisms of cell death are apoptosis and necrosis. Necrosis is characterized by the release of intracellular contents. Many of these intracellular contents can be immune-stimulatory, especially heat shock proteins (HSP), DNA, and RNA that are recognized by Toll-like receptors, or “danger signals” such as uric acid or the chromosomal protein HMGB1 (high mobility group box chromosomal protein 1), which can further activate the innate immune response. The immune system may also be alerted to massive cell death by disruption of tissue architecture and release of fibrinogen, oligosaccharides of hyaluronan, extra domain A (EDA)-containing fibronectin, and heparin sulfate proteoglycan. In this way, the necrosis caused by tumor ablation not only makes tumor-specific antigens available for uptake, but attracts and activates the necessary components of the immune system to generate a tumor-specific response. In contrast, apoptotic cells do not release their contents as do necrotic cells, but rather are taken up by macrophages and dendritic cells. This not only fails to stimulate an immune response, but may lead to immunosuppression. The continual transport of apoptotic cells and presentation of self-antigen may be one mechanism by which we induce tolerance of ‘self’ and prevent autoimmune diseases. While the immunologic response associated with in situ cell death is not completely clear and likely more complex than simply apoptosis versus necrosis, there is significant evidence that tumor ablation can lead to immune recognition and eradication of distant disease.

Development of an antitumor immune response has been associated with RFA and high-intensity focused ultrasound (HIFU), but the most significant correlation between ablation and immunity has been with cryoablation. The potential antitumor immune response triggered by cryoablation was initially reported clinically, when the regression of distant disease was observed after cryoablation of prostate, breast cancer. or lung metastases. These observations led to multiple preclinical and clinical studies examining the mechanisms behind the cryoimmunologic response.

While animal studies clearly demonstrate an antitumor immune response associated with tumor ablation, clinical observations suggest this occurs in a minority of patients, and in some cases, ablation has been

associated with immunosuppression. As stated above, one advantage of tumor ablation is the relative ease of combining ablation with systemic therapies, and this may be particularly valuable in augmenting the clinical benefit of ablation-associated immunity. While several agents have been used over the years, the strongest potential appears to be the combination of in-situ tumor ablation with check-point inhibitors, including anti-CTLA4 and anti-PD1 antibodies.

TECHNOLOGIES USED FOR TUMOR ABLATION

Chemical Ablation (Nonenergy)

Nonenergy-based ablation is typically chemical based; the injection of cytotoxic substances directly into the tumor. The most common use of chemical ablation has been in the liver, where unresectable hepatic tumors can be destroyed by injecting a variety of substances such as absolute ethanol, acetic acid, or heated hypertonic saline. One of the most common human solid malignancies in the world, only a minority of patients are suitable candidates for resection because of either the location of the tumor or the presence of chronic liver dysfunction, particularly cirrhosis. Resection of HCC in cirrhotic patients has an unacceptably high risk of liver failure.

Biologically, HCC are particularly well suited for chemical ablation. The lesions are often softer than the surrounding cirrhotic parenchyma and have a rich vascular network, so chemical agents easily diffuse throughout the lesion. There is often a capsule, so that the agent is trapped within the lesion. The liver is also one of the most common sites of metastases, and while a proportion of patients with hepatic metastases will benefit from surgical resection, many patients are poor candidates for resection due to the number and location of the tumors. However, metastatic lesions don’t have the same difference in tissue density between the malignant tissue and the primary hepatic parenchyma (which is less commonly cirrhotic) and they don’t have capsules. Thus, chemical ablation is less effective.

The most common modality used for chemical ablation is percutaneous ethanol injection (PEI). Using ultrasound or CT, a needle is inserted into the center of a tumor and 100% ethanol is injected into the tumor mass where it diffuses into the tumor cells (Fig. 14.1). Ethanol causes dehydration and protein denaturation, resulting in coagulative necrosis. As with several forms of ablation, this also leads to microvascular thrombosis and tumor ischemia.

Compared with other forms of tumor ablation, PEI is extremely simple and low-tech, as no special equipment is needed. It is very cost-efficient, which is important given the incidence of HCC in developing countries. There are disadvantages to PEI, however. It is limited to smaller lesions (typically <3 cm) and those with well-defined margins. Multiple sessions (5 or 6) are usually needed to completely destroy a tumor, secondary to the presence of intratumoral septations. These occur in approximately 50% of tumors between 1.5 and 2 cm, and in 70% of tumors between 2 and 3 cm in size. Ethanol has a reduced diffusion capacity across intratumoral septations, limiting its efficacy. Newer devices, using multipronged needles with multiple side holes, may help overcome this and allow for single-session PEI.

Another approach to overcoming the septations may be the use of 50% acetic acid instead of EtOH. Percutaneous acetic acid injection (PAI) uses about one third the volume as ethanol injection, but is otherwise similar. Acetic acid has stronger necrotizing power than ethanol because of its ability to dissolve lipids and extract collagen. Acetic acid injected in one nodule will penetrate through septa because of its low pH. This induces swelling of the fibers and promotes dissociation of intermolecular cross-links containing aldimine bonds of collagen within the septa. A meta-analysis found no differences between PEI and PAI regarding local recurrence or survival, but PAI may require fewer sessions.

Energy-Based Ablation

Energy-based ablation can be either thermal or nonthermal, although the majority of modalities are not only thermal, but hyperthermic, using elevated temperatures to kill cancer cells. Exceptions include cryoablation, which uses freezing temperatures, and both irreversible electroporation and histotripsy, which use nonthermal mechanical forces to ablate tumors.

Principles of Hyperthermic Ablation

There are several modalities that elevate tumor temperature, including RFA, microwave ablation (MWA), laser ablation, and HIFU. While they differ in the type of energy used to generate heat, they all depend on the interactions of heat with tissue to induce cell death. While cellular homeostasis is maintained with mild temperature elevations (40°C), when the temperature rises to 42°C to 45°C, the cells become more susceptible to damage from other sources. This includes chemotherapy and radiation,

and in fact this was the initial use of hyperthermia, as an adjuvant to improve the efficacy of these treatments. However, even if this temperature is prolonged, in the absence of other damage, mild hyperthermia will not kill all the cells within the targeted tissue.

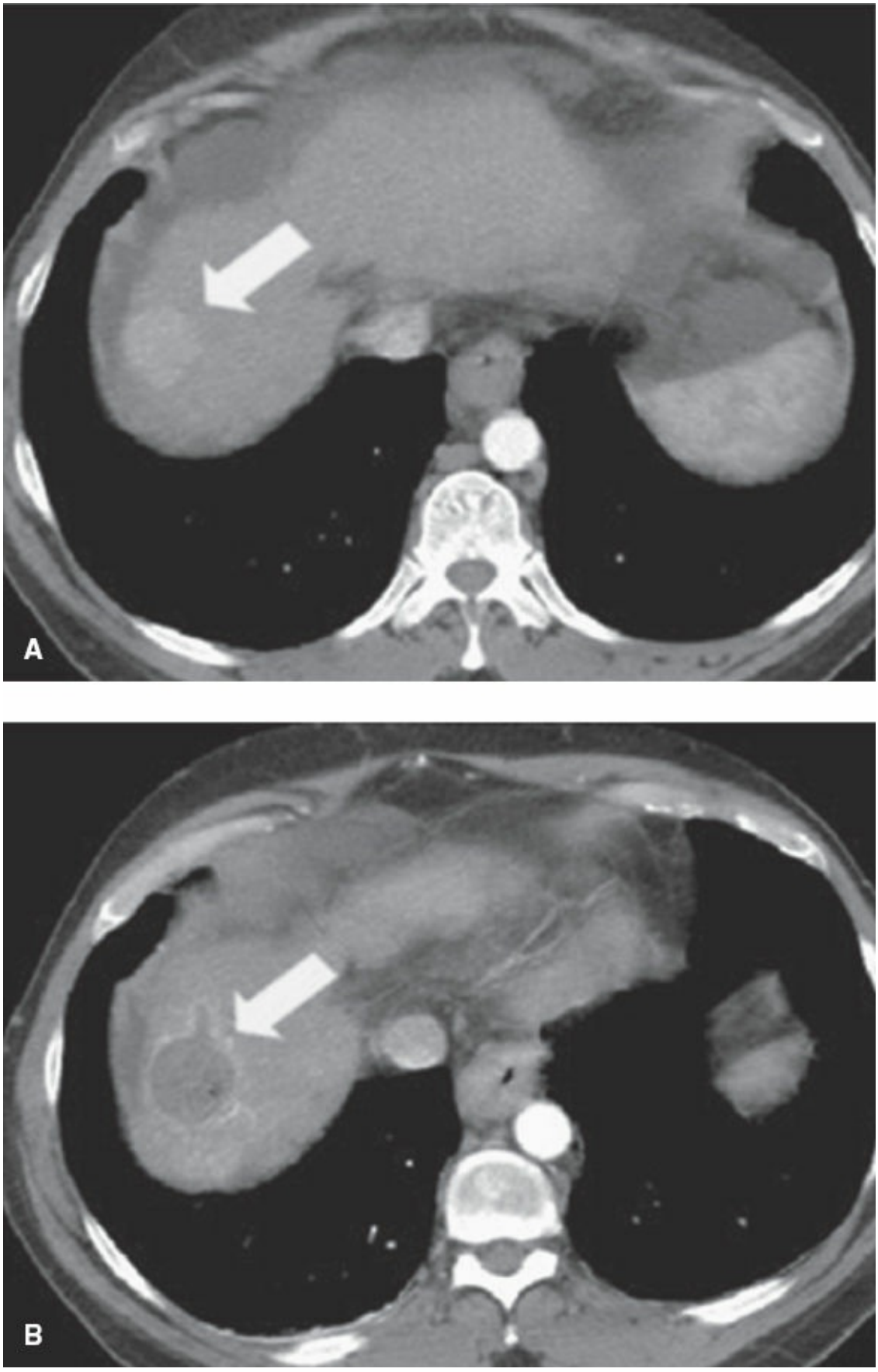

Figure 14.1. Pretreatment contrast-enhanced axial CT image demonstrates a focal hepatocellular carcinoma within the right

lobe of the liver (**A**). Follow-up imaging 3 months after ethanol instillation demonstrates focal tumor necrosis with minimal peripheral enhancement (**B**).

When the temperature is raised above 45°C, cell death is induced, but this is dependent on the time the tissue is maintained at that temperature. Tissue maintained at 46°C for 1 hour will result in irreversible cellular damage. This time is shortened to just minutes for temperatures of 50°C to 52°C. Almost instant coagulation of tissue is induced at temperatures between 60°C and 100°C, with irreversible damage to mitochondrial and cytosolic enzymes of the cells and to DNA. At more than 100°C to 110°C, tissue will vaporize and carbonize. However, this has a negative effect, as these changes decrease further energy transmission, limiting optimal ablation. Therefore, the goal of hyperthermic ablation is to maintain a temperature between 50°C and 100°C throughout the entire target volume.

While this sounds simple enough, the success and/or failure of hyperthermic ablation is dependent upon many factors that can interfere with the ability to heat an entire pre-determined volume to a uniform temperature. Some of these are technical, related to both the applicator and the imaging guidance, while some are related to tissue-specific properties.

Most (but not all) of the hyperthemic technologies are percutaneous, placing a probe into the center of a tumor with the heat propagating outward from the probe. Thus, the heat deposition is greatest surrounding the probe, with that heat falling off as the distance from the probe increases. Cytotoxic temperatures may be achieved at the center, but not at the periphery of the tumor. Increasing the energy deposition at the probe so that higher peripheral temperatures might be obtained won't always work, because if the temperature near the probe gets too high (>100°C), boiling and vaporization occur. The resultant gas formation serves as an insulator that prevents heat spread.

There are several strategies to overcome this. The most obvious would be to repeatedly remove and replace the probe in different positions, or use multiple probes simultaneously, but these approaches take more time and the precise positioning of multiple probes can be technically challenging. Alternatively, energy can be pulsed, alternating high-energy and low-energy deposition, so that time is allowed for the tissue nearest the probe to cool. This allows greater energy to be applied without vaporization and thus deeper heat penetration. The probe can also be internally cooled, for the same effect.

Differences in tissue can also either enhance or inhibit hyperthermic ablation. One example where ablation may be enhanced is the oven effect. In HCC within cirrhotic livers in particular, capsulation around the tumor can “trap” the heat within the lesion, leading to treatment volumes larger than expected. On the other hand, a factor that can inhibit achieving a uniform temperature across the tumor volume is the heat sink effect. Perfusion-mediated tissue cooling counters the thermal energy and leads to incomplete ablation by preventing high temperatures near large vessels or highly vascular regions of a tumor (such as the peripheral tumor–parenchyma interface). In some cases, obstructing blood flow temporarily during ablation may be beneficial, but may also be challenging clinically, requiring more invasive approaches (surgery, balloon occlusion, embolization) and again increasing the overall complexity of the procedure.

Radiofrequency Ablation

RFA is a percutaneous hyperthermic ablation modality. Image guidance for RFA can be via ultrasound, CT, or MRI. The term *radiofrequency* alludes to the alternating electric current oscillating in a high-frequency range between two electrodes (either an active and a reference electrode, or two active electrodes). RFA creates a closed loop circuit consisting of an RF generator, cabling, electrodes, grounding pads, and the patient (Fig. 14.2). As tissues are imperfect conductors of electricity, the current flow leads to agitation of ions within the tissue (known as the Joule effect). The ionic oscillatory agitation leads to frictional heat, which ultimately leads to coagulative necrosis if enough energy is deployed. This effect occurs in the immediate vicinity of the electrode (antenna), and is directly and proportionally dependent on the energy delivered. The heat then needs to disperse as a result of conductivity and convection effects, and the total thermal damage will be dependent on both the tissue temperature achieved and the duration of the heating, both of which can be impacted by several tissue- and technology-related factors. To assure tumor destruction, the tumor and an adequate margin surrounding it need to be treated to temperatures over 50°C for approximately 4 to 5 minutes.

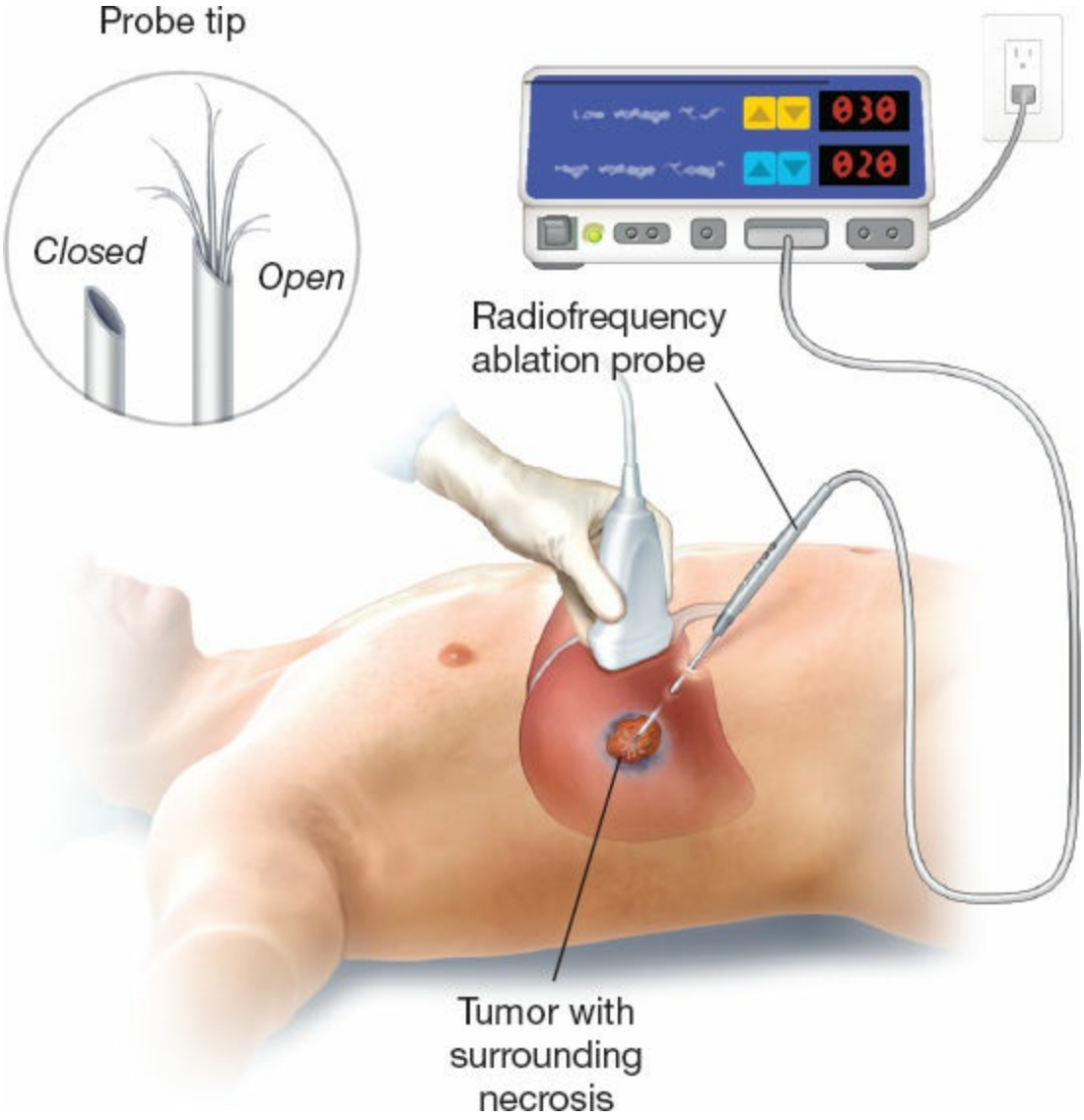

Figure 14.2. Radiofrequency ablation utilizes a closed loop circuit between the RF generator and the patient via electrodes and a grounding pad. Most commonly, an electrode with multiple tines emanating from a single sheath is placed at the site of the tumor and the tines deployed. This allows for greater energy deposition and a larger zone of ablation.

RFA has been the most commonly used thermal ablative technology, with considerable clinical and experimental data. It has been shown to be effective for tumor control, as discussed below. Disadvantages can include the technical complexity, the impact of the heat-sink effect, and the risk of skin burns at the site of the grounding pads. As RFA is increasingly explored as an alternative to resection even among surgical candidates, there is concern that RFA could promote tumorigenesis in nontarget tissues. In the liver, for example, RFA and other forms of ablation can lead

to a mechanism of liver regeneration in the presence of elevated cytokines and growth factors (such as IL-6 and hepatocyte growth factor). As these factors are active in tumorigenesis, the potential of RFA in promoting cancer has been raised in preclinical models.

Laser Ablation

Lasers have been used for some time to treat superficial processes, such as skin or ocular disorders. Newer technologies have made it possible to use lasers for deeper tissues as well. Interstitial laser therapy (ILT) involves the placement of a laser fiber with a diffusing tip through a trocar into a tumor. Laser light is then delivered directly to the target lesion. Absorption of the light leads to an interaction between the photons and the molecules of the tissue, resulting in a transformation of laser energy to heat, which like other modalities, increases the tissue temperature and creates a zone of thermal ablation.

Laser light is a very efficient and precise method of generating heat. Although ILT has several advantages, including the ability to use MR-guidance (the optical fibers are inherently MRI-compatible), early experience has presented challenges. As light is scattered and absorbed by tissue, penetration is less, limiting its use to smaller tumors (1 to 2 cm). In breast cancer, there is an ongoing, multicenter “ablate and resect” trial of ILT for patients with tumors <2 cm that is currently recruiting participants (ClinicalTrials.gov:NCT01478438).

Microwave Ablation

Another hyperthermic ablation uses microwaves (MWA), which has become much more feasible with the development of new antennae and new software tools. A “microwave” is electromagnetic energy in the range of 300 MHz to 300 GHz. When applied to tissue, this energy induces a rapid and continuous realignment of polar molecules (primarily water molecules) within the defined lesion. This molecular rotation results in kinetic energy and subsequently hyperthermia.

Initially, there was interest in focused microwave phased array thermotherapy. This system used transcutaneous opposing microwave waveguide applicators to produce a microwave field in a truly noninvasive manner. Results, however, were limited, and attention turned toward percutaneous MWA, where the microwave energy radiates into the tissue through an interstitial antenna that functions to couple energy from the generator power source to the tissue. The design of the antenna will impact

efficiency as well as the size and the pattern of the ablation zone. Thus, there are many forms of antennas, and multiple antennae can be used to create larger zones of coagulation necrosis. However, smaller-diameter antennas can have trouble handling higher power levels without unwanted thermal damage to tissues around the antenna shaft, requiring the use of cooling jackets and systems to reduce the incidence of skin burns and allow for increased power in smaller diameter antennas.

As the heat originates primarily from water agitation, tissues with a larger concentration of water are particularly susceptible to microwave heating. As cancer cells often have a larger concentration of water than surrounding noncancerous cells, MWA seems particularly well suited to tumor ablation. MWA has several potential advantages compared with other ablative technologies. Microwaves readily penetrate tissues where other forms of ablation are more limited. Whereas other modalities have inherent difficulties in tissue with low electrical conductivity (lung, bone, charred or dehydrated tissue), microwaves could potentially be used in these settings. MWA is presently being studied in the treatment of both lung cancer and lung metastases, and bone tumors. Microwaves also heat tissue more efficiently, and can be continually applied in order to obtain larger ablation zones and more uniform heating throughout the zone. Thus, larger zones of ablation can be created in less time. There may also be less impact by the “heat-sink effect” and thus MWA is being studied as an alternative to RFA in the liver.

Ultrasound Ablation

There are two methods for using ultrasound energy to ablate tumors: direct (or interstitial) and extracorporeal (or transcutaneous). The former involves either the percutaneous or intracavitary placement of a needle-like applicator into a tumor, which is referred to as interstitial ultrasound ablation. The latter is a truly noninvasive procedure, utilizing transcutaneous ultrasound to ablate the target tissue. This is most commonly referred to as high-intensity focused ultrasound, or HIFU.

Ultrasound is a form of vibrational energy. It propagates as a mechanical wave by the motion of particles in the medium. This wave propagation leads to compressions and rarefactions of the particles, so that a pressure wave is transmitted along with the mechanical movement of the particles. As the ultrasound beam propagates through the body, it loses energy due to attenuation in tissue, which is caused by both scattering and absorption. The absorption of this energy causes a local temperature rise in

the tissue if the rate of heating exceeds the rate of cooling.

While ultrasound beams transmit harmlessly through living tissue, they can be focused into a small volume with concentrated high-energy distribution within the body. This makes it possible to use an external source of focused ultrasound for therapeutic purposes. If ultrasound energy is sufficiently concentrated in the focal volume, it can directly kill cells by raising the temperature to destructive levels, similar to a magnifying glass focusing the sun's rays onto a point to set fire to a dry leaf (Fig. 14.3). It provides a noninvasive method of selective tissue ablation at depth without any damage to the surrounding or overlying tissues.

HIFU actually destroys tissues by two mechanisms. The first are the hyperthermic effects from the conversion of mechanical energy into heat. HIFU can raise the temperature to 80°C. Because there is a sharp temperature gradient between the focal volume and the nonfocal surrounding tissue, there is a sharp demarcation between treated and untreated tissue when examined histologically. But HIFU also kills cells through acoustic cavitation. This is defined as the interaction of a sound field with the microscopic gas bodies in a sonicated medium. In this case, the small gaseous nuclei within subcellular organelles and fluid in tissue provide the source of the cavitation. Under the influence of the acoustic pressure, these expand and contract. For some time, efforts were made to avoid cavitation, as the shape and position of the targeted tissue were less predictable than heating. However, recent studies have been investigating the idea of promoting cavitation for enhancing the level of ablation and reducing required exposure time.

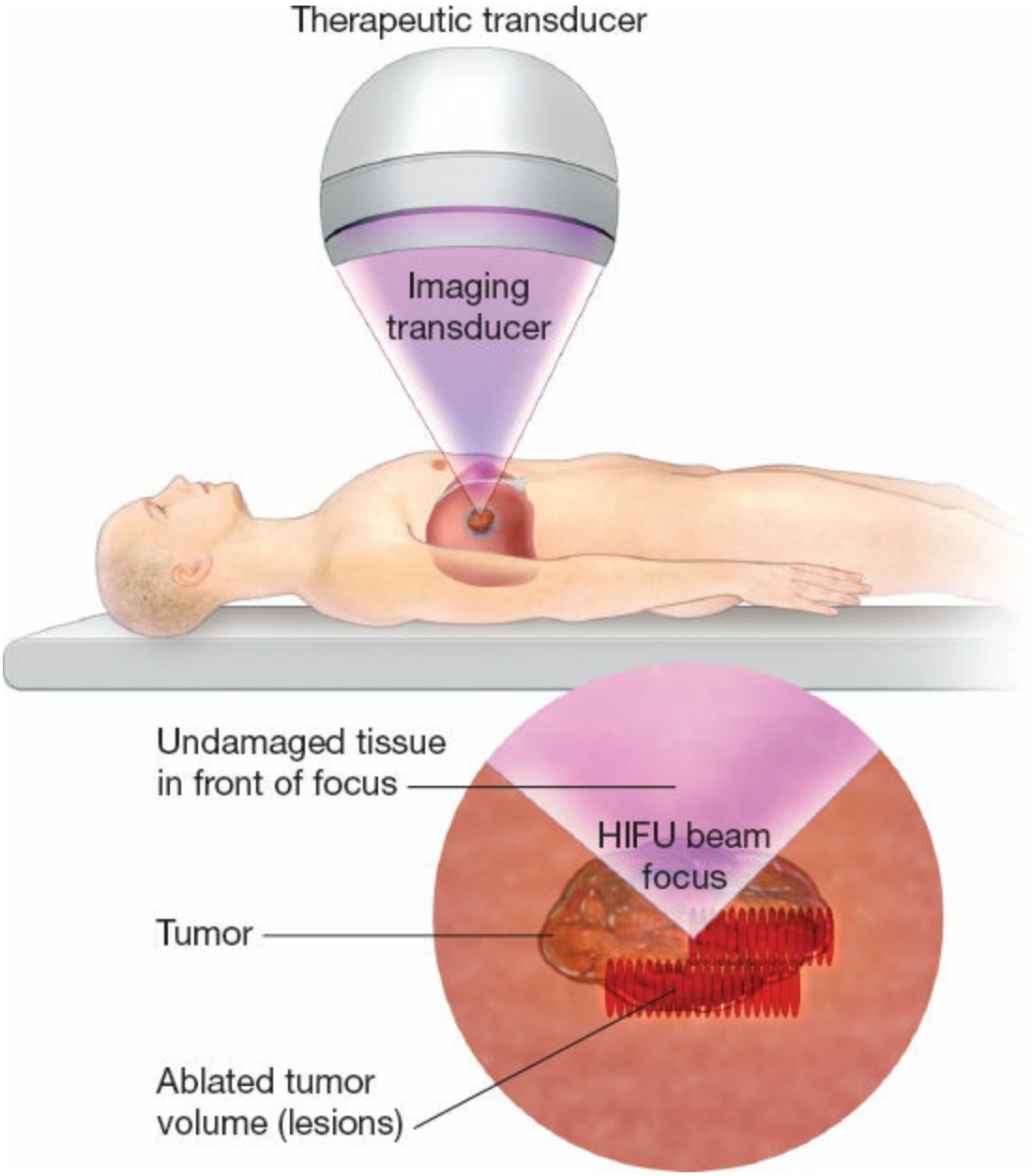

Figure 14.3. High-intensity focused ultrasound uses a therapeutic transducer to concentrate ultrasound energy in the focal volume. Tissue in front of the focus is undamaged.

Histotripsy

As stated above, HIFU is a hyperthermic ablation, primarily destroying cells through heat, although some cells may be destroyed through acoustic cavitation. While the development of HIFU centered on minimizing cavitation to improve the predictability of heating, an alternate approach uses only acoustic cavitation to destroy tumors in a nonhyperthermic form of ablation. In this manner, histotripsy is less like HIFU and more like shockwave lithotripsy.

Acoustic energy is delivered in the form of short (<50 microseconds) very high-intensity pulses to induce cavitation. Cavitation is a process that occurs when a sufficiently negative pressure is applied to a fluid to cause microbubble formation from fluid vaporization and release of dissolved gas. In the case of ablation, this negative pressure is applied to tissue, where the microbubbles exhibit highly dynamic patterns of oscillation and inertial collapse, producing cellular disruption and leading to mechanical homogenization of the target tissue. The tissue bioeffects can be delivered with relatively high accuracy within the targeted tissue, allowing for a very precise tissue ablation. The microbubble clouds reflect sound and appear as hyperechoic (bright) zones with ultrasound imaging, which is used to both guide and monitor the ablation.

The tissue effects of histotripsy are quite different from hyperthermia. With hyperthermic ablation, histologically the treated tissue ranges from coagulative necrosis to carbonization, depending on the highest temperature achieved and the time the tissue remains at that temperature. With histotripsy, the histologic results depend on whether the tissue is also heated or not. Histotripsy parameters can be set so that the cavitational mechanical effects are isolated, and the thermal elevation is minimized. Lesions were desiccated when histotripsy was performed with sonications where tissue temperature was elevated, while lesions were liquefied when sonications when the temperature was not significantly elevated. The in vivo response to the liquefied tissue is also different from other forms of ablation. The homogenized debris is resorbed within 45 to 60 days with little deposition of fibrotic tissue scar formation.

Irreversible Electrocorporation

Irreversible electrocorporation (IRE or IRE ablation) refers to those devices that cause cell death through the repeated application of short-duration high-voltage electrical pulses that create irreversible injuries to cellular membranes. This is considered a nonthermal form of ablation, although there may be some hyperthermic changes seen. Although there are still some questions regarding the exact molecular events that take place at the membrane level, the efficacy of electroporation is related to the creation of structural defects, or “pores” in the plasma membrane. These pores lead to a reversible permeability of the cell membrane, which was initially seen as a method of introducing foreign material into the cells (DNA, protein, chemotherapeutic agents). This is known as reversible

electroporation and has been used for decades for molecular and gene transfer in vivo. Eventually, electroporation shifted from being a delivery agent for other therapeutics to an ablative therapy. There were several potential advantages over other forms of ablation. As IRE is nonthermal, it avoids some of the collateral thermal effects and minimizes the impact of heat sinks (the impact of local perfusion on outcome).

There are four major types of IRE electrodes: plate, needle, clamp, and catheter, with the needle electrodes being the most popular for tissue destruction. The effects of electroporation are related to the behavior of the lipid plasma membrane under the stimulation of an external electric field. Pore formation is dependent upon both membrane properties and the applied external electric field. While there is general agreement about how the electrical field forms pores, there is less information about how the membrane recovers. Pore formation alone will not necessarily lead to cell death. The cellular injury comes from direct membrane destruction (an irreversible pore or cellular rupture) or from an osmolarity imbalance, loss of critical organelles, or influx of cytotoxic molecules.

Although electroporation has been used clinically for over 15 years, this has primarily been in combination with chemotherapy. IRE, as a stand-alone treatment, has only started to emerge over the last 5 years, with studies being performed in liver, kidney, and lung. There have also been some smaller studies of IRE in prostate and pancreatic cancer, with several studies presently accruing patients in the United States. However, IRE has not gained acceptance at the same rate as other ablative technologies do, in part due to the need for multiple electrodes or re-positioning the electrodes to destroy lesions >1 cm. While larger lesions can be destroyed with multiple electrodes or repeat treatments with repositioned electrodes, this greatly increases the complexity, and makes the treatment more invasive. Another drawback to IRE is the heterogeneity of cell death within the treatment zone. This may not be apparent on imaging studies and could lead to cancer recurrence. While hyperthermia and cryoablation may leave tumor cells at the periphery, which can be overcome with better imaging or combination therapy, incomplete ablation within the treatment zone is more unique to IRE and a key challenge for the use of this technology in cancer.

Cryoablation

Cryoablation is performed by placing a cryoprobe at the center of a tumor.

A cryoprobe is a high-pressure, closed loop gas expansion system, where the metal probe is insulated except for the tip. The cryoprobe is rapidly cooled by means of the Joule–Thopmson effect (rapid expansion of a gas results in a change in the temperature of the gas), removing heat from the tissue contacting the probe. For ablation of smaller tumors, a single probe is typically placed under ultrasound guidance through the center of a tumor. For larger tumors, multiple probes can be placed in order to generate cytotoxic isotherms.

Although cryoablation refers to the freezing of tissues, cell damage is induced by a variety of mechanisms during both the freezing and thawing process, as well as indirect damage to the microcirculation (Fig. 14.4). The method by which the cells die is related to the lowest temperature reached, the amount of time at subzero temperatures, and the number of freeze-thaw cycles (allowing the frozen tissue to thaw before freezing again). Close to the cryoprobe, the freezing rates are high enough to induce freezing of the intracellular fluid, or intracellular ice formation (IIF). This is a lethal event associated with irreversible membrane damage. Further from the probe, freezing rates are slower. Here, the extracellular fluid will freeze but the intracellular fluid has better protection by the lipid membrane. This leads to osmotic forces that shift pure water out of the cell, or cellular dehydration. When the tissue is thawed, the intracellular compartment is now hypertonic, and as the ice melts, fluid rushes into the damaged membranes and the cells burst. In addition to this, large ice crystals may form during re-crystallization in the warming period, and these create direct shearing forces that further disrupt the tissues. When the freezing is repeated, the damaged tissue conducts the cold much more efficiently, increasing the area of necrosis beyond the first cycle. Dells not killed by direct cryo-injury may also suffer apoptotic dell death secondary to cryo-induced destruction of the microvasculature and post-thaw platelet aggregation and vascular stasis.

Cryoablation has several advantages that have led to its emergence as a primary choice for ablation across several tumor types. As freezing is inherently anesthetic, it can often be performed without general anesthesia. The iceball that forms around the tumor can be visualized on US, CT, or MRI, allowing for real-time monitoring. That clear visualization also allows for greater safety when treating tumors near critical structures. Cryoablation also has less impact on collagen fibres, so it can be safer around critical structures. This also allows for improved re-modeling and

cosmesis for more superficial tumors. Smaller tumors can be ablated with a single probe placed centrally within the tumor, reducing the complexity of the procedure. Larger lesions can be treated with multiple probes, although this can be more complex and expensive. This can also be more time-consuming than other modalities.

TUMOR ABLATION IN CLINICAL PRACTICE

Liver

The liver is a common location of both primary and secondary malignancies. Worldwide, HCC is one of the most common cancers and the incidence may be rising. Surgical options include partial hepatectomy and liver transplantations, but only a minority (10% to 20%) of patients are candidates for these curative options. The liver is also one of the most common sites of secondary malignancies, particularly colorectal cancer. For patients with metastatic colorectal cancer limited to the liver, resection is the treatment of choice, but only an option in 20% to 30% of patients. This number may be rising with the increased efficacy of systemic agents and the use of novel approaches (radiochemotherapy, embolization), but as with HCC, this leaves a large number of patients with disease confined to the liver who are not candidates for surgery, because of either multifocal disease, inadequate residual size or function after surgery, or comorbid conditions. It is for this reason that interest in ablative therapies for the liver has grown.

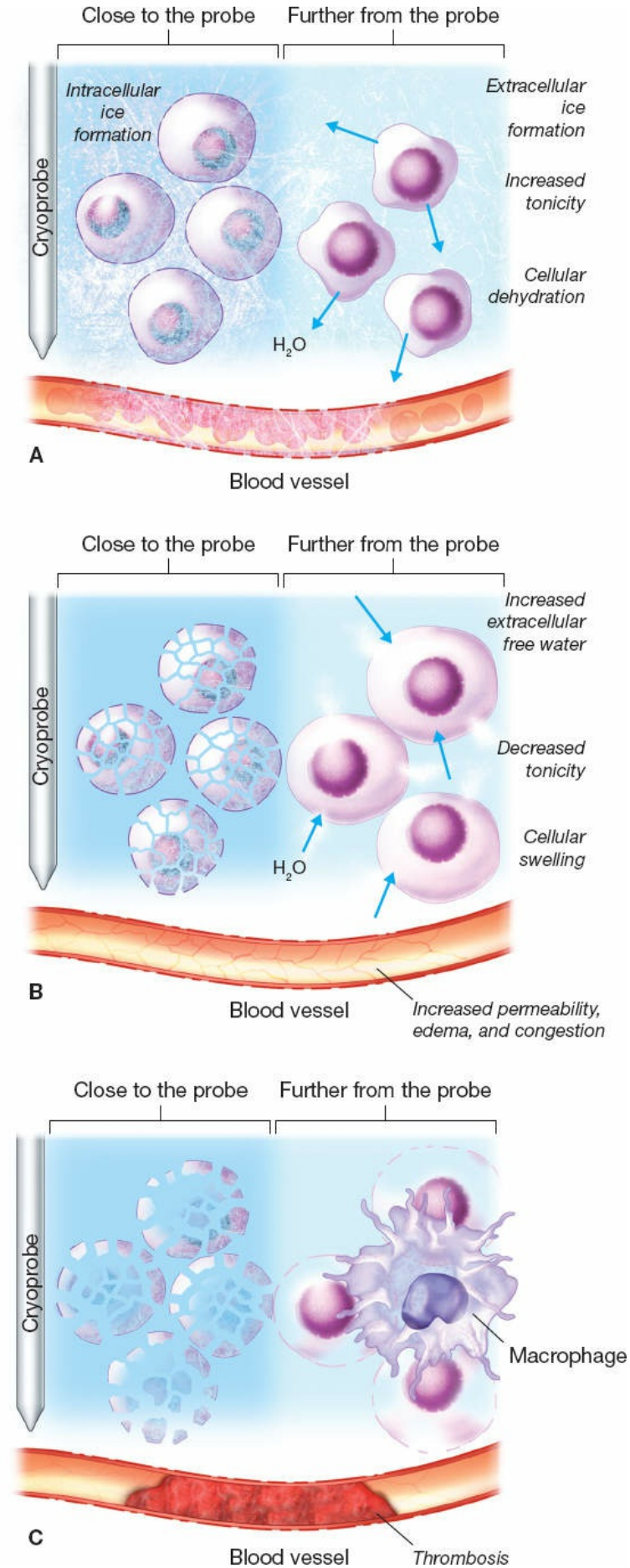
Close to the probe
Further from the probe
Cryoprobe
Intracellular ice formation
Extracellular ice formation
Increased tonicity
Cellular dehydration
H_2O
A
Blood vessel
Close to the probe
Further from the probe
Cryoprobe
Increased extracellular free water
Decreased tonicity
Cellular swelling
H_2O
B
Blood vessel
Increased permeability, edema, and congestion
Close to the probe
Further from the probe
Cryoprobe
Macrophage
C
Blood vessel
Thrombosis

Figure 14.4. **A.** During freezing, close to the probe, free water is trapped in the cells and intracellular ice forms, which shred the cells. Freezing is slower further from the probe, so ice forms in the extracellular fluid, increasing tonicity and drawing water from the cells. Blood vessels are also damaged by the ice. **B.** During the thaw, cells close to the probe undergo necrosis, while cells further from the probe burst due to the flow of water into the cells. Damage to the endothelial cell junctions leads to increased capillary permeability. **C.** Reperfusion brings platelets that cause thrombosis when they come in contact with the damaged endothelial cells, causing ischemia.

For the treatment of HCC, most of the ablative technologies described above have been used, including ethanol or acetic acid injection, RFA, MWA, cryoablation, and HIFU (Figs. 14.5 and 14.6). While there was initial excitement for cryoablation in HCC, the technique had limited application. The complication rate was significant, including the risk of "cryo-shock," secondary to the release of multiple inflammatory cytokines. HIFU (both ultrasound and MRI guided) and MWA are also being investigated for HCC ablation, but today the most common ablative techniques for the liver have been chemical ablation with ethanol and RFA. There have been five randomized trials comparing RFA to PEI for the treatment of early-stage HCC, three from Asia and two from Europe. While there is a consistent advantage to RFA regarding cancer ablation and local control, the impact on survival was less clear. The studies from Asia showed a statistically significant improvement in overall survival associated with RFA, while the European studies failed to achieve statistical significance. However, three meta-analyses including all RCTs have confirmed that RFA offers a survival benefit over PEI, establishing RFA as the standard percutaneous approach.

Beyond the applicability to nonresectable patients, RFA has several potential advantages to surgery, including shorter hospital stays and reduced costs, decreased morbidity, and increased preservation of hepatic parenchyma. Therefore, one might question why RFA shouldn't be considered as first-line therapy, even among resectable patients. Two systematic reviews compared RFA and resection and found no significant differences in survival among patients who meet the Milan criteria (one lesion <5 cm or up to three lesions <3 cm, no extrahepatic manifestations, no vascular invasion). However, RFA was associated with higher

recurrence rates. For patients outside the Milan criteria, resection provided better disease-free and overall survival rates. A meta-analysis of one randomized controlled trial and nine controlled studies also found that RFA was associated with a higher local recurrence and decreased disease-free and overall survival. Finally, a randomized controlled trial by Huang et al. of 230 patients fulfilling the Milan criteria also confirmed the superiority of surgical resection. Surgical resection is associated with not only improved outcomes, but also improved quality of life-adjusted survival in cirrhotic patients. Therefore, liver resection still remains the gold standard for the treatment of HCC, although ablation can be used as a first-line treatment for tumors ≤3 cm when the expected operative mortality rate is above 3%. Both RFA and PEI can be considered for patients with tumors <2 cm who are not surgical candidates, while RFA appears to be superior in patients with tumors >2 cm.

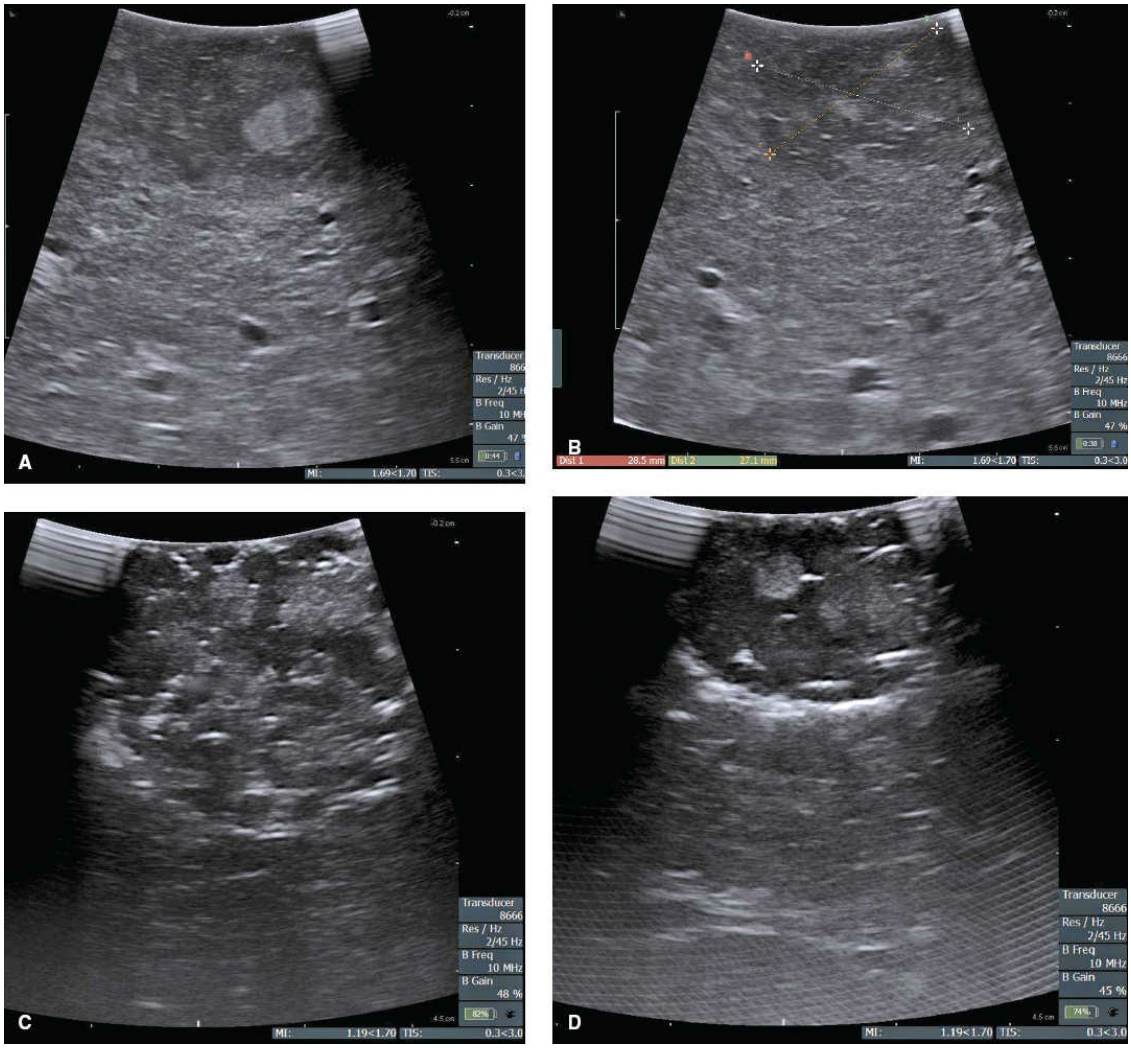

Figure 14.5. Laparoscopic ultrasound-guided RFA of a peripheral HCC. **A.** Before ablation. **B.** Lesion measurments. **C.** During ablation. **D.** Immediate postablation. (From Mulholland MW, Albo D, Dalman RL, et al. *Operative Techniques in Surgery*. Philadelphia, PA: Wolters Kluwer Health; 2015.)

For metastases to the liver, PEI appears to be less effective than RFA in controlling disease, and RFA is the preferred method of ablation. Again, given the potential advantages of RFA over surgery, should ablation be considered as first-line therapy in patients with metastatic colorectal cancer? A meta-analysis by Wu et al. compared RFA and liver resection for solitary metastases, and found surgery to be superior to RFA for both local control and 5-year overall survival. There were no statistically significant differences in adverse events, and quality-adjusted life years also favored resection.

Prostate

Current treatment options for prostate cancer range from radical prostatectomy or radiation therapy to active surveillance. While prostate cancer is quite common, the majority of cases represent low-risk, organ-confined disease, which may be overtreated with conventional surgery or whole-gland external beam radiation. Focal ablative therapies have emerged as a potential middle ground—a treatment for patients with low-risk prostate cancer who either choose not to undergo active surveillance, have progressed and are now seeking treatment, or seek to avoid the undesired side effects associated with more radical therapies. Focal therapies seek to treat only localized tumors while focusing on tissue preservation, particularly near the urethral sphincter and the neurovascular bundles. Patient selection is the key, particularly with regard to tumor location and size; thus, consideration of ablative therapies is dependent upon highly accurate imaging and biopsies to assure focal versus multifocal disease. This can be accomplished through transperineal 3D-prostate mapping biopsies (3D-PMB) or more commonly, MRI-targeted biopsies.

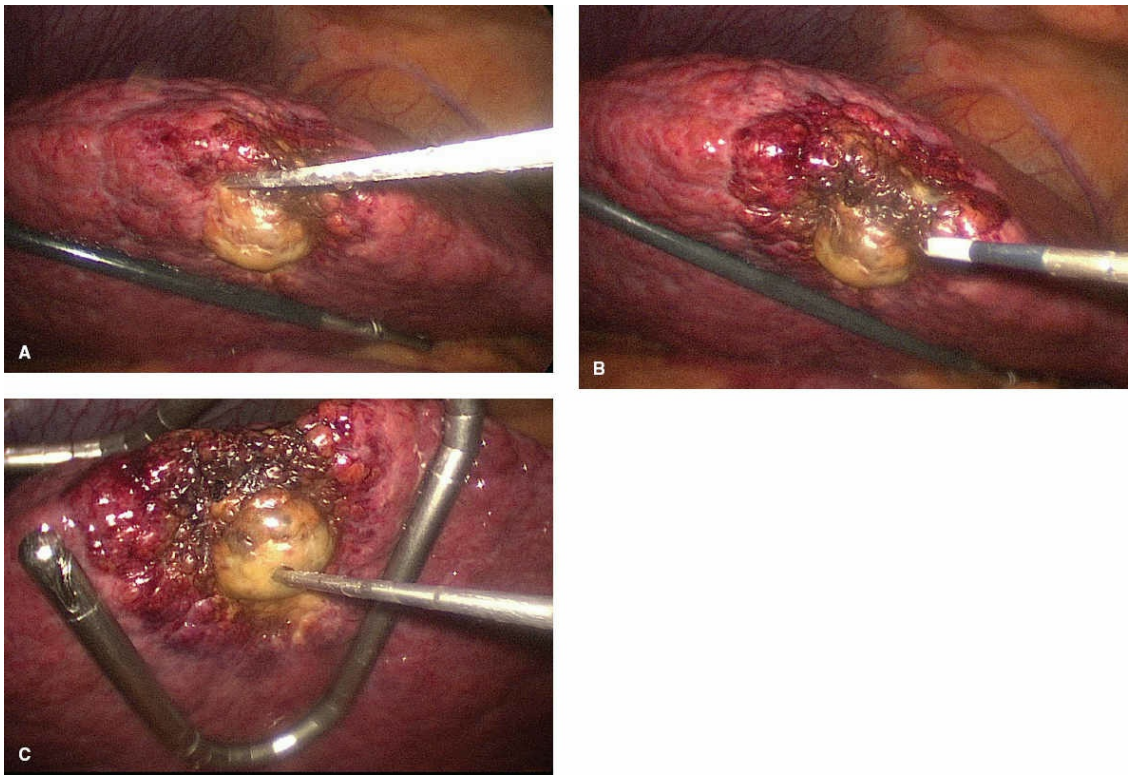

Figure 14.6. Laparoscopic ablation of an HCC using multiple deployments of a microwave probe. (From Mulholland MW, Albo D, Dalman RL, et al. *Operative Techniques in Surgery*. Philadelphia, PA: Wolters Kluwer Health; 2015.)

Several modalities have been studied for ablation of prostate cancer. Both ILT and IRE have several potential benefits for prostate ablation, including precision, real-time monitoring, MRI compatibility, and low cost; however, there are limited studies of efficacy and these are still considered experimental. HIFU has been clinically utilized in the treatment of prostate cancer, with single institution series demonstrating promising results; however, this has not been compared to standard treatment approaches and thus is not considered a standard option for prostate cancer treatment.

There are more clinical data surrounding the use of cryotherapy for prostate cancer. Prostate cryotherapy is typically performed by placing multiple cryoprobes via a percutaneous transperineal approach, using high-precision transrectal ultrasound (TRUS) imaging. TRUS is also used to monitor in real time the prostate and surrounding structures and precisely control the tissue destruction. Cryotherapy can be considered as an alternative to standard therapies in three clinical settings: (1) primary therapy in patients with T1 or T2 tumors, (2) salvage therapy for men with locally recurrent disease, or (3) palliation for men with lower urinary tract symptoms in the face of metastatic disease. In two small randomized trials and in registry data, primary tumor cryoablation appears to be similar to radiation for disease-specific and overall survival; however, follow-up times are relatively short, and there is variability in tumor staging and grading, RT doses used, and the definition of a “biochemical treatment failure.”

Alternatively, there has been interest in focal cryotherapy, which attempts to ablate just the tumor and not the majority of the prostate tissue. The safety profile is greatly improved. Whole gland cryoablation takes longer and has higher rates of urinary morbidity and erectile dysfunction. These are reduced with more focal cryoablation, as the neurovascular bundles are preserved, but there are concerns regarding our ability to truly define the area of involvement and absence of disease in other parts of the gland. Therefore, careful patient selection based on estimated life expectancy and a thorough pretreatment imaging and biopsy evaluation is critical.

Kidney

With the increased use of modern cross-sectional imaging, the incidental diagnosis of renal masses and RCC is rising, resulting in not only an

increased incidence, but a substantially higher number of smaller tumors (<4 cm). Many of these have more indolent behavior, and are diagnosed in older individuals, with either overt or subtle decreases in renal function. Therefore, the preservation of renal function in patients with smaller RCC is increasingly important. While radical nephrectomy had been the standard of care for RCC, there has been a gradual shift toward partial nephrectomy, and ultimately to tumor ablation.

While there are no randomized trials comparing ablation to surgery, there are multiple series demonstrating excellent short-term disease control for both RFA and cryoablation. Most clinical experience has been with RFA, with several series showing excellent short-term outcomes and only a limited effect on renal function. In retrospective comparison of the oncologic outcomes of RFA with partial nephrectomy, there was nearly identical disease-free survival with a median follow-up of 6.5 years.

Cryoablation is also extremely well-tolerated with excellent tumor control. There is some suggestion that it may be more effective than RFA. A retrospective meta-analysis by Kunkle and Uzzo showed that RFA was more often associated with re-ablation than cryo (8.5% vs. 1.3%, $p < 0.0001$) as well as higher rates of local recurrence (12.9% vs. 5.2%, $p < .0001$) and distant metastases (2.5% vs. 1%, $p = 0.06$). However, the retrospective nature of this analysis opens it to criticism. Cryoablation may be more effective for tumors >4 cm when compared with RFA.

The American Urological Association (AUA) and the European Association of Urology are now recommending thermal ablation techniques as a potential treatment of localized renal tumors, particularly as an alternative to surgery for patients who may not be optimal surgical candidates. More long-term follow-up data are needed before RFA or cryoablation can be considered as an alternative to surgery in patients who are otherwise good candidates for definitive surgical resection.

Breast

Given the relative accessibility to tumors of the breast, the trend toward less invasive therapies in breast cancer, and the multiple breast-imaging modalities, the ablation of breast cancer seems the next logical step. As such, most of the modalities discussed in this chapter have been examined as a potential treatment for breast cancer, with the majority of studies involving ablation followed by surgical excision and pathologic confirmation of 100% ablation.

Some modalities did not pan out. Studies of ILT and MWA (using the transcutaneous microwave approach) had disappointing rates of women achieving complete ablation of the tumor, even among smaller size tumors. Percutaneous MWA of breast cancer had slightly better results, and further research is ongoing. Initial studies of HIFU were also disappointing; however, Wu et al., using a wide target that included 1.5 to 2 cm margin of normal tissue around the tumor, reported 100% ablation in 23 patients. This led to a trial of HIFU alone, followed by systemic therapy and radiation therapy. Among 22 patients treated in this manner, the 5-year recurrence-free survival rate was 89%, with the cosmetic result judged to be good to excellent by 94% of patients. Furisawa et al. also reported a local recurrence rate of 1 of 21 patients who underwent HIFU without surgical resection, with a mean follow-up of 14 months.

Several “ablate and resect” studies of RFA demonstrate rates of complete ablation from 76% to 100%. These led to several series of RFA as an alternative to lumpectomy, using MRI and biopsies to assure no residual disease. While results were promising, RFA has several drawbacks in the treatment of breast cancer. As with many hyperthermic approaches, it requires a general anesthesia, minimizing the benefits as compared with surgery. Complications can include burns of the skin, thermal damage to the chest muscle, and pneumothorax. And the procedure itself is relatively complex, requiring real-time sonographic monitoring to verify that the prongs are deployed in a symmetric fashion around the lesion.

Cryoablation has emerged as perhaps the most promising modality for ablation of breast cancer (Fig. 14.7). Compared with RFA, it is technically simpler (the probe is placed under ultrasound guidance within the center of the tumor) and, given the anesthetic effects of freezing, well-tolerated under local anesthesia. Several small “ablate and resect” studies demonstrated high success rates when the procedure was limited to tumors ≤1.5 cm, and certain tumor types were excluded (lobular carcinoma or patients with an extensive intraductal component [EIC]). There have been two studies looking at cryoablation alone. Using both ultrasound and CT guidance to place multiple cryoprobes, Littrup et al. treated 22 lesions in 11 patients who refused surgery. With a mean follow-up of 18 months, there have been no local recurrences. Fukuma et al. have presented results of two clinical trials of cryoablation alone for small breast cancer. More 50 patients with either luminal A invasive ductal carcinoma or DCIS <10 mm

in size were treated and with a median follow-up of 43 months, there have been no local recurrences. These results led to the American College of Surgeons Oncology Z1072 trial—a single arm, phase II trial of ablation followed by surgical resection with pre- and post-MRI to evaluate the ability of MRI to predict complete ablation. This demonstrated complete ablation of the targeted lesion in 80 of 87 patients (92%), although microscopic foci of invasive or in situ disease were found outside of the treatment zone in some patients. The success of this trial led to two ongoing studies of cryoablation as an alternative to lumpectomy for low-risk breast cancers (NCT02200705, NCT01992250).

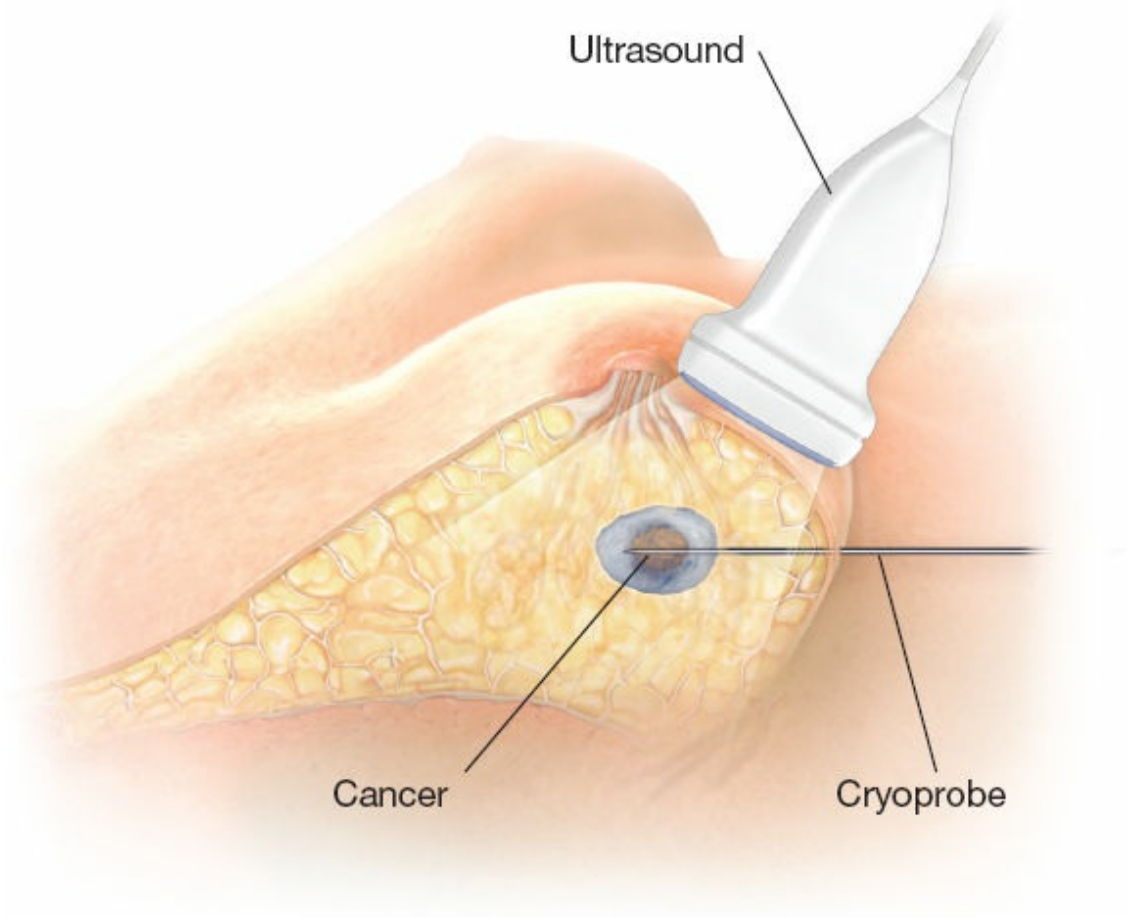

Figure 14.7. Cryoablation of breast tumors, both benign (fibroadenomas) and malignant, is accomplished using ultrasound guidance to place a cryoprobe directly into the center of the tumor. As the temperature at the tip of the probe drops, ultrasound is then used to monitor the development of the iceball around the tumor.

CONCLUSIONS

Tumor ablation is emerging as an alternative to surgery in the treatment of several malignancies, particularly for patients who are not ideal candidates for surgery, require maximum preservation of parenchyma, or with small localized primary tumors. Given the potential advantages of ablation as compared with surgery, particularly in terms of morbidity and cost, in the near future ablation may emerge as a primary modality in the treatment of several tumor types. However, this will require continued advancements in ablative technology (devices, probes) and imaging modalities, along with a better understanding of the mechanisms of tissue destruction induced by thermal or nonthermal energy. This will also be further enhanced through the combination of ablation with adjuvant therapies that can augment tissue destruction, eradicate remaining micrometastatic disease, and potentially increase some of the side benefits, such as the immunostimulatory properties of in situ cell death. Dedicated and rigorous translational research and clinical trials will be necessary to continue to ensure the continued advancement of tumor ablation.

Suggested Readings

Ahmed M, Solbiati, L, Brace CL, et al. Image-guided tumor ablation: standardization of terminology and reporting criteria—a 10 year update. *J Vasc Interv Radiol* 2014;25:1691–705.

Breen DJ, Lencioni R. Image-guided ablation of primary liver and renal tumors. *Nat Rev Clin Oncol* 2015; 12:175–86.

Germani G, Plequezuelo M, Gurusamy K, et al. Clinical outcomes of radiofrequency ablation, percutaneous alcohol and acetic acid injection for hepatocellular carcinoma: a meta-analysis. *J Hepatol* 2010;52(3):380–8.

Jiang C, Davalos RV, Bischof JC. A review of basic to clinical studies of irreversible electroporation therapy. *IEEE Transact Biomed Eng* 2015;62(1):4–20

Kunkle DA, Uzzo RG. Cryoablation or radiofrequency ablation of the small renal mass: A meta-analysis. *Cancer* 2008;113(10):2671–80.

Ruers T, Punt C, Van Coevorden F, et al. Radiofrequency ablation combined with systemic treatment versus systemic treatment alone in patients with non-resectable colorectal liver metastases: a randomized EORTC Intergroup phase II study (EORTC 40004). *Ann Oncol* 2012;23:2619–26.

Sabel MS. Cryo-immunology: a review of the literature and proposed mechanisms for stimulatory versus suppressive immune responses. *Cryobiology* 2009; 58:1–11.

Simmons R, Cox CE, Carp N, et al. A phase II trial exploring the success of cryoablation therapy in the treatment of invasive breast carcinoma: Results from

ACOSOG Z1072. *Ann Surg Oncol* 2016;23(8):2438–45.

Thompson RH, Atwell T, Schmit G, et al. Comparisonof partial nephrectomy and percutaneous ablation for cT1 renal masses. *Euro Urol* 2015;67:252–9.

Tracy CR, Raman JD, Donnally C, et al. Durable oncologic outcomes after radiofrequency ablation: experience from treating 243 small renal masses over 7.5 years. *Cancer* 2010;116:3135–42.

EDITOR'S COMMENT

Dr. Sabel has presented a fairly comprehensive and well-written chapter on ablative technology and its applications. As described, the main problem with ablative techniques, in general, is the lack of sensitivity in presently available imaging techniques for not only imaging the full extent of the tumor but of the ablation zone and the margin for any one particular methodology. Further adding to this is the lack of precise image-guidance of the ablation probes. There is also the utter lack of information preoperatively that details the variability in the properties of any given tumor or for that matter of the surrounding normal native tissue. As has been used most widely in the past, ablation of intact tumors allowed only sampling of tumors and negates the known heterogeneity of tumors for tissue markers, chemosensitivity assays, and research. We know, for example, tumor and naïve tissue ablate at different speeds as do fatty versus dense breast tissue due to variabilities in impedance of those tissues. This potential leads to under- as well as over-ablation and the possibility of poor results or complications.

Dr. Sabel nicely details advances in combination therapies involving radiation and chemotherapy and ablation. What he neglects is the contrasting idea that is the studies of resection followed by ablation. This concept makes a lot of sense in light of the standard of resection followed by irradiation, for example, in treating residual occult breast cancer. Intraoperative trials of radiation of breast cancer followed by resection demonstrated much less efficacy than those of the standard of resection followed by radiation. Such trials have shown similar efficacy to those of whole breast postoperative irradiation. Resection followed by pericavitary radiofrequency ablation has been tried with liver as well as breast. After resection, the ablation can be applied uniformly to the margin of normal tissue of the tumor bed that could potentially harbor micrometastatic foci—mimicking the reasoning behind postoperative radiation therapy for breast, sarcomas, and other tumors.

Intraoperative pericavitary ablation, in a single institution prospective trial as well as an ongoing multi-institutional trial, demonstrated that lumpectomy followed by intraoperative pericavitary ablation is effective in sterilizing the margin and prevention of recurrence without radiation in favorable breast cancer tumors. This methodology lends itself to full tumor availability for

markers, sensitivity assays, and research. More importantly, such simple and relatively inexpensive technology can be easily accomplished by the general surgeon as well as in rural areas. This approach also lends itself to worldwide dissemination to countries where mastectomy is the standard because of the inavailability and cost of radiation. In a pilot study of percutaneous excision of breast tumors followed by ablation demonstrated complete 100% ablation of residual tumor. Residual tumor was detected in 50% of follow-up excisional removals of the ablated zone. This concept of excision followed by ablation primarily lends itself to radiofrequency ablation (RFA) as technologies like cryoablation and laser require direct contact with the tissue. In our studies, we found laser to be highly variable in producing a reproducible percutaneous ablation zone and the catheters too fragile for routine use.

Sensitive and accurate imaging of the tumor is the major downfall of all ablative techniques whether it is accomplished by surgery, chemical, thermal, and nonthermal extirpation. In the past, one of the reasons RFA has not become more widely utilized was the lack of accurate imaging of the ablation zone. However, using a resection followed by ablation approach, a simple Doppler US can demonstrate the off-gassing of nitrogen, i.e., bubbles that accompany complete ablation of tumor and tissue. In a laboratory model, the zone of Doppler imaging of this phenomenon correlated accurately with the zone of ablation. This technique is now used in intraoperatively breast cancer treatment to document the ablation zone as well as progression of the ablation and visualizing the proximity of skin and thus the avoidance of skin burns. In this way, variability in ablation progression due to the variability in tissue impedence can be determined.

Dr. Sabel also raises the issue of ablation causing increased risk of tumorigenesis in nontarget tissues due to the possibility of elevated cytokines and growth factors. In contrast, in a study of the zones around the radiofrequency ablation sites in a percutaneous excision-ablation-open excision human breast cancer protocol antitumor heat shock proteins were elevated. In an animal model of hepatic microwave ablation, low-energy ablation resulted in distant metastatic spread while high-energy ablation did not. Others have advanced the theory of killing tumor in situ would actually immunize the host. More work needs to be evaluated to exclude this concern.

Interest in the development of various ablation techniques holds promise in their ability to treat cancers without the need for costly interventions in an outpatient setting and for the most part without the need for radiation in favorable tumors. As health care costs soar, it makes little sense to develop expensive technologies that require MRI-guidance or other costly imaging modalities. In the United States, most surgeries are done by the general surgeon for all tumor types. To be utilitized on a wider scale, ablative procedures need to be safe, simple, and easy to use as well as effective. To this aim, McKay and colleagues have developed 13 recommendations for the implementation of tumor ablation services. Worldwide implementation requires the development

of low-cost uncomplicated procedures.

V. Suzanne Klimberg

Suggested Readings

Fleming MM, Holbrook AI, Newell MS. Update on image-guided percutaneous ablation of breast cancer. *AJR Am J Roentgenol* 2017;208(2):267–74.

Klimberg VS, Boneti C, Adkins LL, et al. Feasibility of percutaneous excision followed by ablation for local control in breast cancer. *Ann Surg Oncol* 2011;18(11):3079–87.

Klimberg VS, Ochoa D, Henry-Tillman R, et al. Long-term results of phase II ablation after breast lumpectomy added to extend intraoperative margins (ABLATE l) trial. *J Am Coll Surg* 2014;218(4):741–9.

McKay C, Wang J, Baldassarre F et al. Recommendations for the delivery of focal tumor ablation services. *J Clin Oncol* 2016;34(suppl 7):106.

Peek MC, Ahmed M, Napoli A, et al. Minimally invasive ablative techniques in the treatment of breast cancer: a systematic review and meta-analysis. *Int J Hyperthermia* 2017;33(2):191–202.

Todorova VK, Klimberg VS, Hennings L, et al. Immunomodulatory effects of radiofrequency ablation in a breast cancer model. *Immunol Invest* 2010;39(1):74–92.

Velez E, Goldberg SN, Kumar G. Hepatic thermal ablation: effect of device and heating parameters on local tissue reactions and distant tumor growth. *Radiology* 2016;281(3):782–92.

15 Upper and Lower Gastrointestinal Endoscopy

Jeffrey L. Ponsky and Jonathan P. Pearl

INTRODUCTION

Flexible endoscopy is the mainstay of diagnosis and treatment of many gastrointestinal (GI) disorders. Surgeons across the world practice flexible endoscopy and have been the innovators of many of today's advanced endoscopic techniques. As such, surgical training programs and practices have a newfound emphasis on flexible GI endoscopy.

Upper and lower endoscopy procedures are the most common operations performed by general surgeons in many parts of the United States. Surgical residency training now includes more endoscopy didactic and practical training than in years past. The modern GI and general surgeons are expected to offer comprehensive care for their patients, which includes the practice of flexible endoscopy.

INDICATIONS AND CONTRAINDICATIONS FOR DIGESTIVE ENDOSCOPY

Upper endoscopy may be prompted by complaints of dysphagia, odynophagia, or pyrosis. Suspected foreign body impaction, an abnormal barium radiograph, and GI bleeding will also indicate a need for endoscopic examination. Additional indications for esophagogastroduodenoscopy include the need for tube gastrostomy for feeding or drainage, persistent vomiting, unremitting epigastric pain, gastric polyposis, and surveillance for neoplasia in patients with conditions predisposing to malignancy such as Barrett's esophagus, gastric ulcer, pernicious anemia, and previous gastrectomy. In most cases, the endoscopist is prepared to deliver therapy at the time of diagnosis. Therapy may include removal of foreign bodies, dilation of strictures, ablation or stenting of tumors, sclerotherapy or ligation of varices, control of hemorrhage, placement of feeding tubes, and polypectomy.

Colonoscopy is most commonly performed as a screening tool for

colorectal cancer. Screening colonoscopy should begin at age 50 in average-risk patients. The recommended age for screening is lowered in patients with a family history of colorectal cancer, conditions that predispose to colorectal cancer, and high-risk ethnic groups. Patients with a family history of colon cancer require colonoscopy by age 40 or 10 years prior to the age at which their relative developed cancer. Other high-risk conditions, such as familial adenomatous polyposis, mandate colonoscopy in the teenage years.

Other common indications for colonoscopy include diagnosis of infectious or inflammatory colitis, surveillance for dysplasia or carcinoma in patients with ulcerative colitis, and lower GI bleeding. Colonoscopy may be used to decompress dilated bowel in colonic pseudo-obstruction and untwist the sigmoid colon in volvulus.

Endoscopy can be used to treat many conditions that previously required surgery. Barrett's esophagus with high-grade dysplasia can be managed with endoscopic ablation. Early stage, localized gastric cancers can be safely resected endoscopically. Endoscopic esophagomyotomy is effective for relieving the symptoms of achalasia.

There are few absolute contraindications for endoscopy. Severe comorbidities and inability to tolerate conscious sedation preclude safe endoscopy, although general anesthesia can be used in select cases. Endoscopic examinations should be performed with caution in patients with recent GI anastomoses or inflammation of the GI tract, such as diverticulitis. Endoscopy is not without complications and each case should be carefully considered prior to performance of the examination.

INSTRUMENTATION

A large variety of endoscopes are available for diagnostic and specialized therapeutic purposes in adults and children. These include small caliber (9 mm) gastroscopes and pediatric colonoscopes, large caliber (13 mm) and large working channel (6 mm) scopes for complex interventions, mother–daughter scope combinations for biliary and pancreatic ductoscopy, and long slender enteroscopes for small bowel examination. A balloon-assisted endoscope, which includes an overtube and a scope with a balloon at its tip, enables a large proportion of small bowel to be examined.

There has been a recent expansion of the tools available for therapeutic endoscopy. Biopsy forceps, cytology brushes, and snares are most commonly used for tissue sampling. Rotatable snares and snares of various

shapes facilitate difficult polypectomies. Nets may be passed through the working channel for retrieval of large specimens. Specialized electrosurgical devices, in the shape of a hook or triangle, may be used for dissection and tissue division. Powered endoscopic staplers and endoscopic suturing devices are used for resections and closure of enterotomies.

Injection of bleeding sources with epinephrine using a sclerotherapy needle is commonly used for hemostasis. Bipolar energy can be applied using a coapting probe. Nonthermal hemostasis can be achieved with hemostatic clips, loops, or bands. Large over-the-scope clips can be used on large vessels or in attempts to close fistulas or enterotomies.

ADVANCED IMAGING IN ENDOSCOPY

Visible light is the most common imaging modality for flexible endoscopy. High-definition imaging with visible light is becoming more common. While visually appealing, high-definition imaging has not been shown to increase colon polyp detection rate for experienced endoscopists. Wide-angle-view colonoscopies and mother–daughter retrospectoscopes are new imaging techniques that attempt to reduce the rate of missed polyps. Their clinical efficacy requires further investigation in clinical trials.

In another alternative technique, chromoendoscopy, a liquid dye such as methylene blue or Lugol's solution is applied to the GI mucosa using an endoscopic catheter. Barrett's esophagus and squamous cell carcinoma demonstrate differential staining from normal cells. Chromoendoscopy may be useful in patients with long-standing inflammatory bowel disease to detect occult malignancy.

Narrow band imaging (NBI) is available on most contemporary endoscopes. By changing the bandwidth of projected light from the endoscope, metaplasia and flat adenomas can be differentiated from normal mucosa. Large-scale studies have not shown a significant increase in polyp detection comparing NBI with white light imaging.

Optical coherence tomography (OCT) uses reflection of near-infrared light to produce real-time two-dimensional cross-sectional images of the GI tract. A small probe, similar to an endoscopic ultrasound probe, is passed through the scope. OCT produces a high-resolution image of the layers of the GI tract and might be used for early detection of dysplasia or metaplasia.

Technique of Esophagogastroduodenoscopy

Patients are prepared for upper endoscopy by assuring that their stomach is empty. This usually involves a 4- to 6-hour fast. The patient is positioned with the left side down and sedation is administered intravenously while vital signs and oxygen saturation are monitored. Topical posterior pharyngeal anesthesia may also be used. The endoscope handle is held in the left hand regardless of the surgeon's hand dominance. The up and down deflection knob is controlled by the left thumb, while the air, water, and suction buttons are manipulated by the left index and middle fingers. The smaller left–right deflection knob is usually managed by the right hand. The surgeon's right hand controls the shaft of the endoscope for advancing and rotating the instrument.

The safest method of introducing the endoscope into the esophagus is under direct vision (Fig. 15.1). The endoscope is slowly advanced over the tongue until the epiglottis and vocal cords are visualized. The tip is then angled posteriorly between the arytenoids, while the patient is asked to swallow. Gentle pressure is then applied to advance the scope into the esophageal introitus. If the tip of the scope slips into the piriform sinus, it is withdrawn and positioned in the midline above the esophageal introitus, and the patient is asked to swallow again.

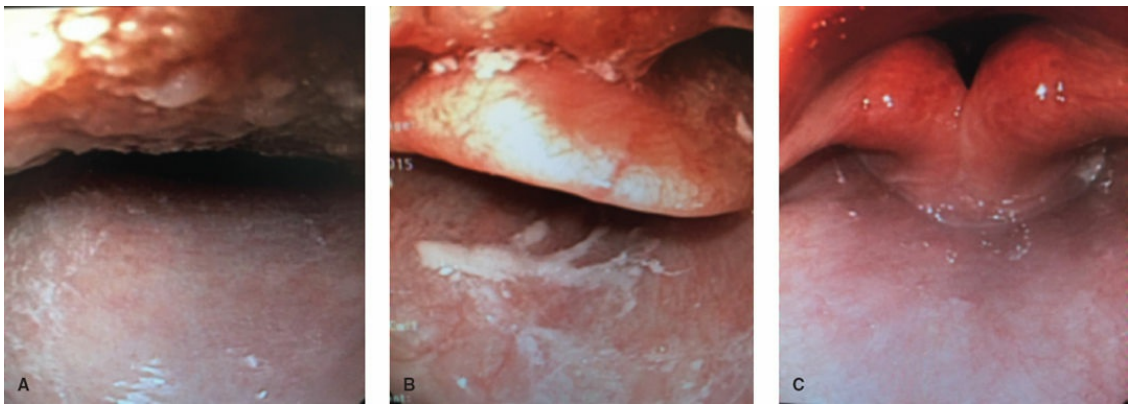

Figure 15.1. A. The scope is introduced under direct vision between the tongue (above) and the hard palate (below). The hard palate becomes continuous with the esophagus. **B.** As the scope is advanced, the epiglottis is visualized. The scope is directed posteriorly to the epiglottis. **C.** Just beyond the epiglottis, the vocal cords and arytenoid cartilages are seen. The scope is advanced in the midline and posteriorly into the esophagus.

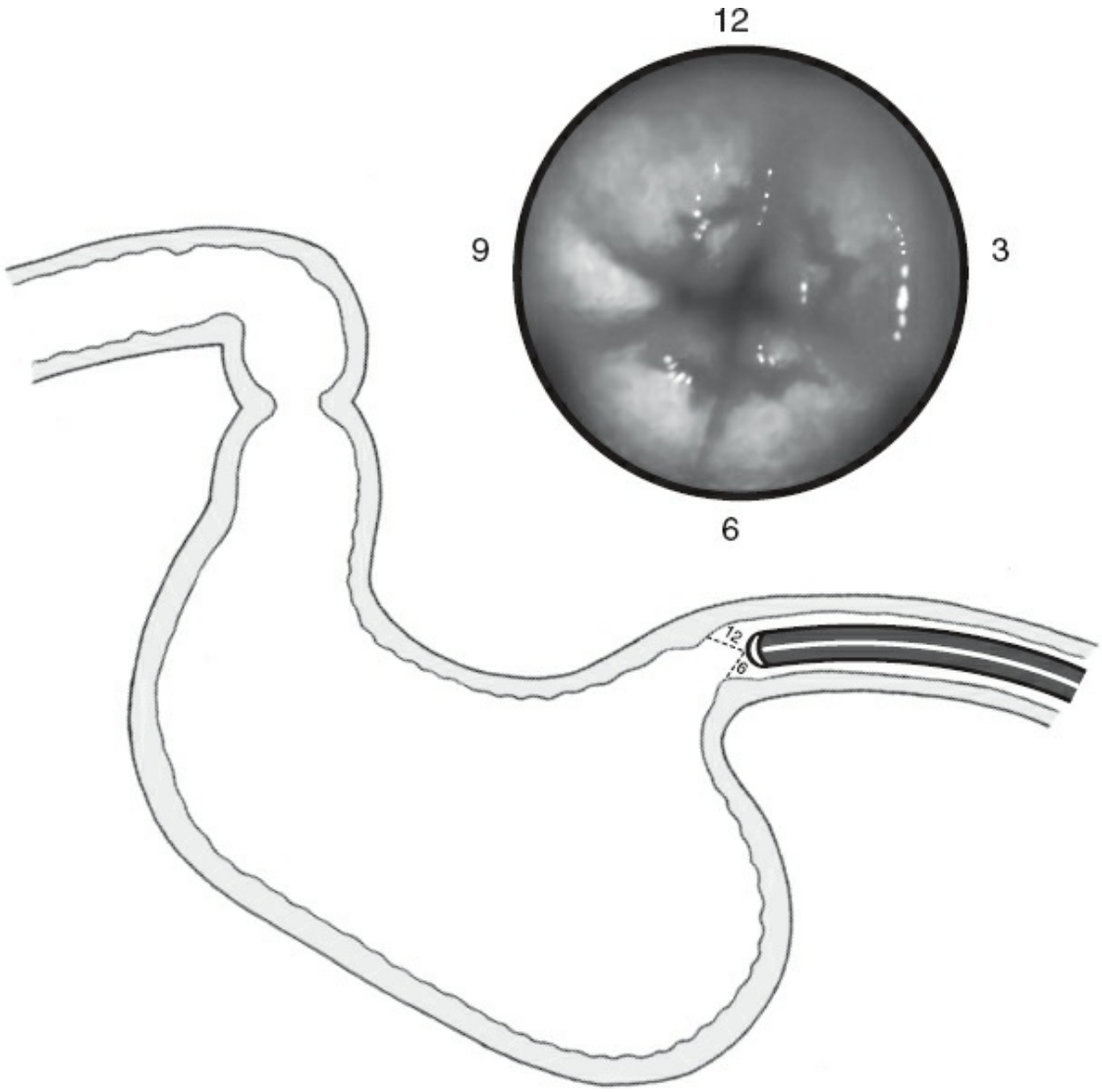

Figure 15.2. The “z” line appears at the esophagogastric junction. It represents the change from the squamous esophageal mucosa to the columnar epithelium of the stomach.

The esophageal lumen appears as a long, straight tube. Once it is entered, air is insufflated. A long view of the esophagus should be obtained and its mucosa inspected. Peristalsis should be noted, and evidence of inflammation or Barrett’s epithelium sought. The endoscope is advanced carefully and only while visualizing the lumen rather than sliding along the mucosa. Interruptions in the normal mucosa by inflammation or suspected neoplasm should be assessed by cytologic brushing and biopsy. A hiatal hernia will appear as a saccular portion of gastric mucosa above the pinching action of the diaphragm. Normally, the esophagus turns slightly to the left as it traverses the diaphragm and enters the abdomen. The esophagogastric junction is noted by the “z” line, an

irregular junction of the orange columnar gastric mucosa with the pale pink squamous mucosa of the esophagus (Fig. 15.2).

The stomach should be fully inflated with air. Any redundancy in the scope should be reduced and the mucosa carefully observed. The scope should be oriented in the gastric body so that the stomach's posterior wall is at the 3 o'clock position, the lesser curvature at the 12 o'clock position, the anterior wall at the 9 o'clock position, and the greater curvature at the 6 o'clock position (Fig. 15.3). Small movements of the control knobs will direct the tip of the scope in any desired direction. Abnormalities noted may include ulcerations, gastritis, vascular lesions, neoplasia, or extrinsic impressions upon the gastric wall. The location of such extrinsic impression may indicate the probable source. For example, a large impression on the posterior wall of the stomach, noted at the 3 o'clock position, may indicate a pancreatic mass such as a pseudocyst or tumor.

The endoscope is advanced toward the gastric antrum by following the lesser curvature, and the incisura angularis will be observed at the 12 o'clock position. It is a smooth curved arch dividing the gastric body from the antrum. Marked elevation of the instrument's tip and a small turn to the left while the scope is positioned at the gastric angle will usually permit a retroflexed view of the gastric cardia and fundus (Fig. 15.4). The shaft of the scope is then withdrawn to bring the tip of the scope toward the gastric cardia. The shaft of the retroflexed scope is rotated to allow careful assessment of the cardia, fundus, and the lesser curvature.

The large rugal folds noted on the greater curvature of the stomach's body disappear as the antrum is entered. The tip of the scope is elevated to permit its advancement toward the pylorus. Small circular motions of the scope's tip will permit visualization of the entire antrum. The pylorus is normally round and may be observed to open and close (Fig. 15.5). Irregularities of the pyloric shape may suggest past or present ulceration. While keeping the pyloric orifice directly in the center of view, the scope is advanced with gentle pressure and slight insufflation of air, into the duodenal bulb. The bulb has no folds and is a frequent site of inflammation and ulceration. Small motions of the instrument's tip will help reveal the more obscure corners of the bulb where ulcers may hide (Fig. 15.6). Once inspection of the anterior and posterior bulb is complete, the scope is advanced into the descending duodenum. This usually requires a maneuver, which is not under direct vision. The scope's tip is turned to the right as the shaft of the instrument is also rotated to the right. The tip is

first moved upward and then down. This turns the instrument posteriorly and then downward into the second portion of the duodenum. Once the lumen of the descending duodenum is in view, slight pressure may be applied to the shaft of the scope to introduce it farther. If resistance is encountered, the scope should be pulled back and straightened. This will usually result in the endoscope advancing further in the duodenum as the redundant gastric loop is straightened. The scope is then withdrawn while close attention is paid to the mucosal detail. The small bowel is noted by the semicircular folds, which are the hallmark of its architecture. The ampulla of Vater may be seen in profile at the 9 o'clock position in the descending duodenum (Fig. 15.7). Its orifice is usually difficult to observe with the end-viewing endoscope used for standard upper endoscopy. The accessory papilla, orifice of the duct of Santorini, may sometimes be observed slightly proximal to the ampulla of Vater in the 1 o'clock position. The instrument is pulled back, with the endoscopist slowly manipulating the controls to again survey the walls of the duodenum, stomach, and esophagus.

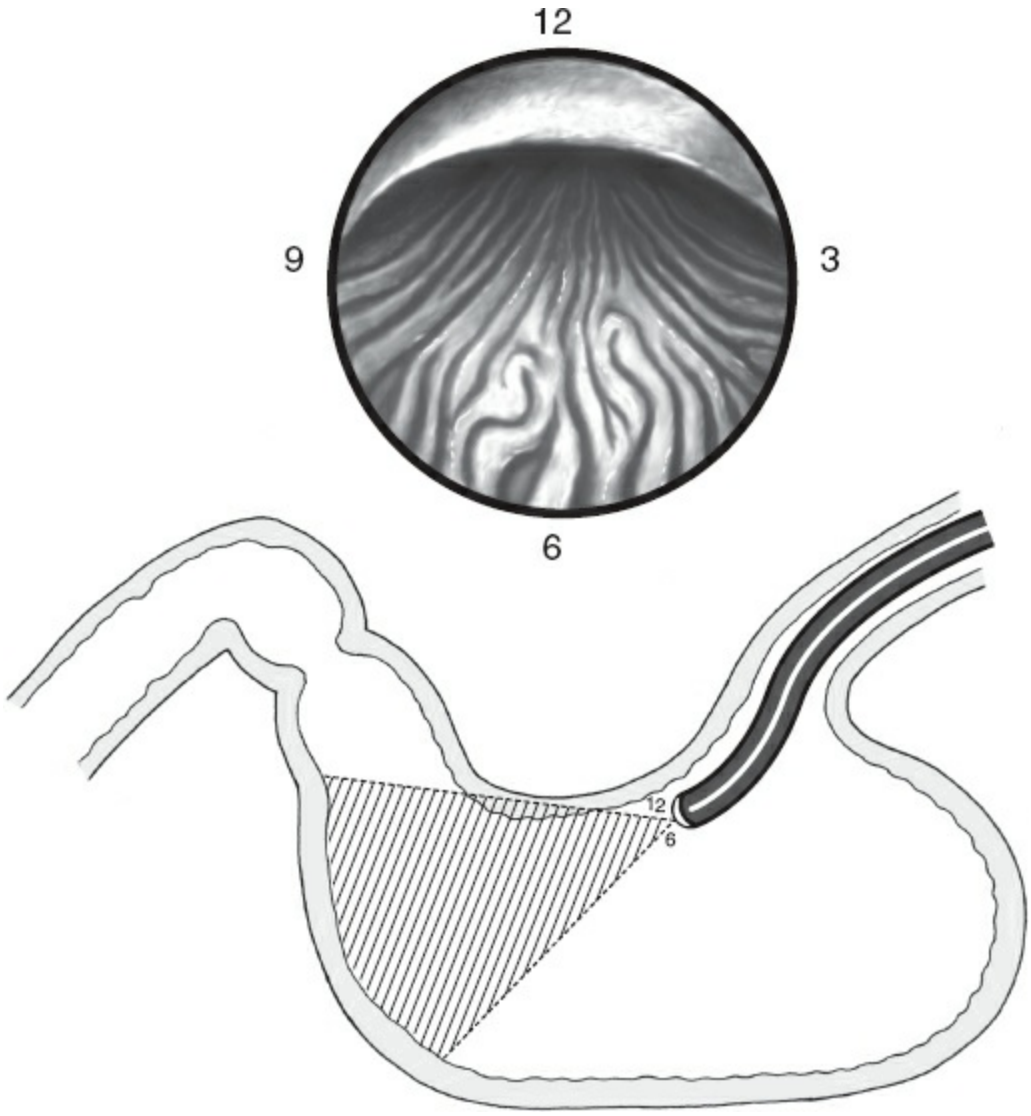

Figure 15.3. In the body of the stomach, with the patient in the left lateral decubitus position, the lesser curvature is at the 12 o'clock position, the posterior gastric wall at 3 o'clock, the anterior wall at 9 o'clock, and the greater curvature at the 6 o'clock position. The gastric angle, separating the gastric body from the antrum, is seen as a smooth arch along the lesser curvature.

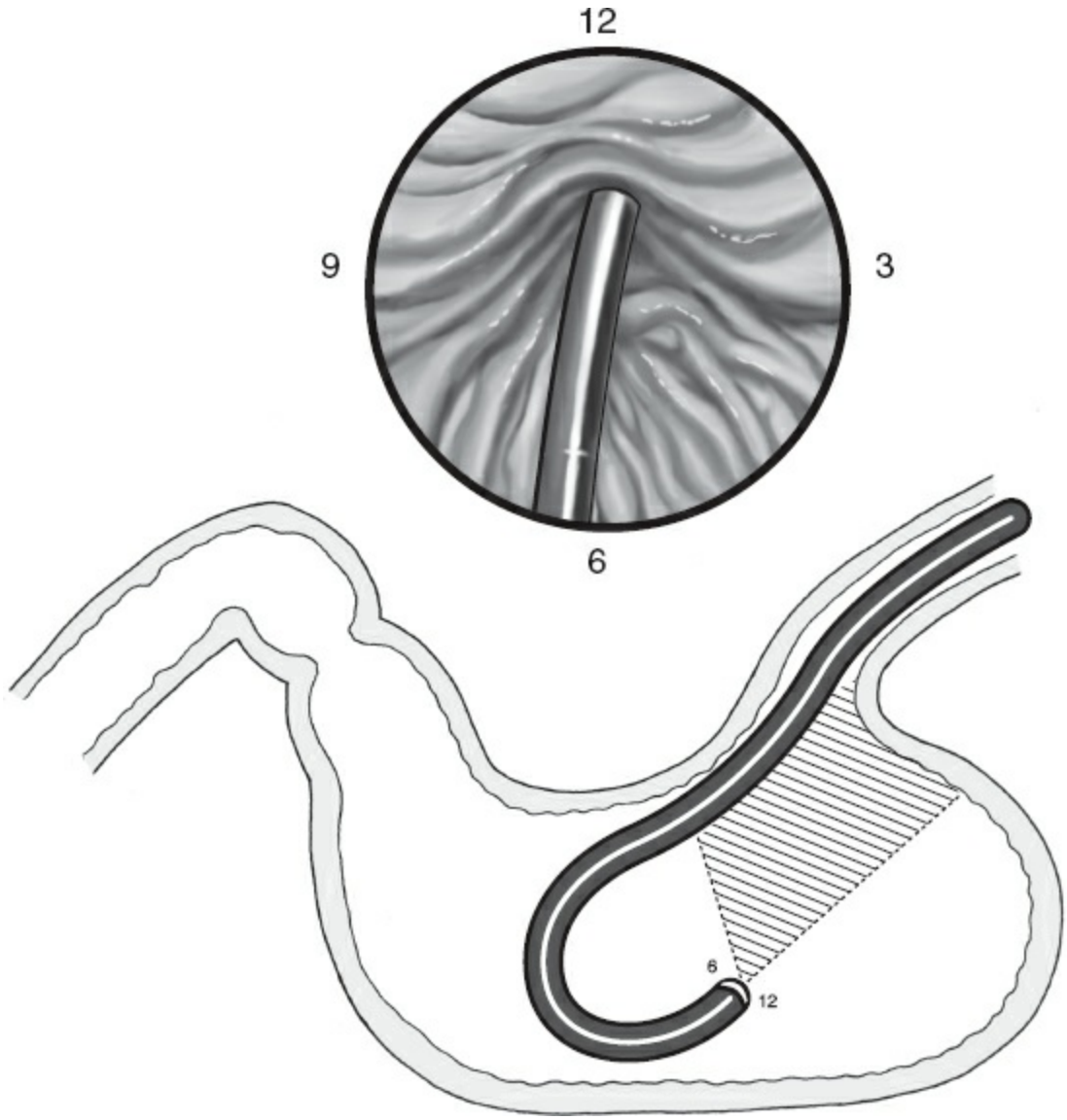

Figure 15.4. A retroflexed view can be easily accomplished and permits inspection of the cardia and fundus.

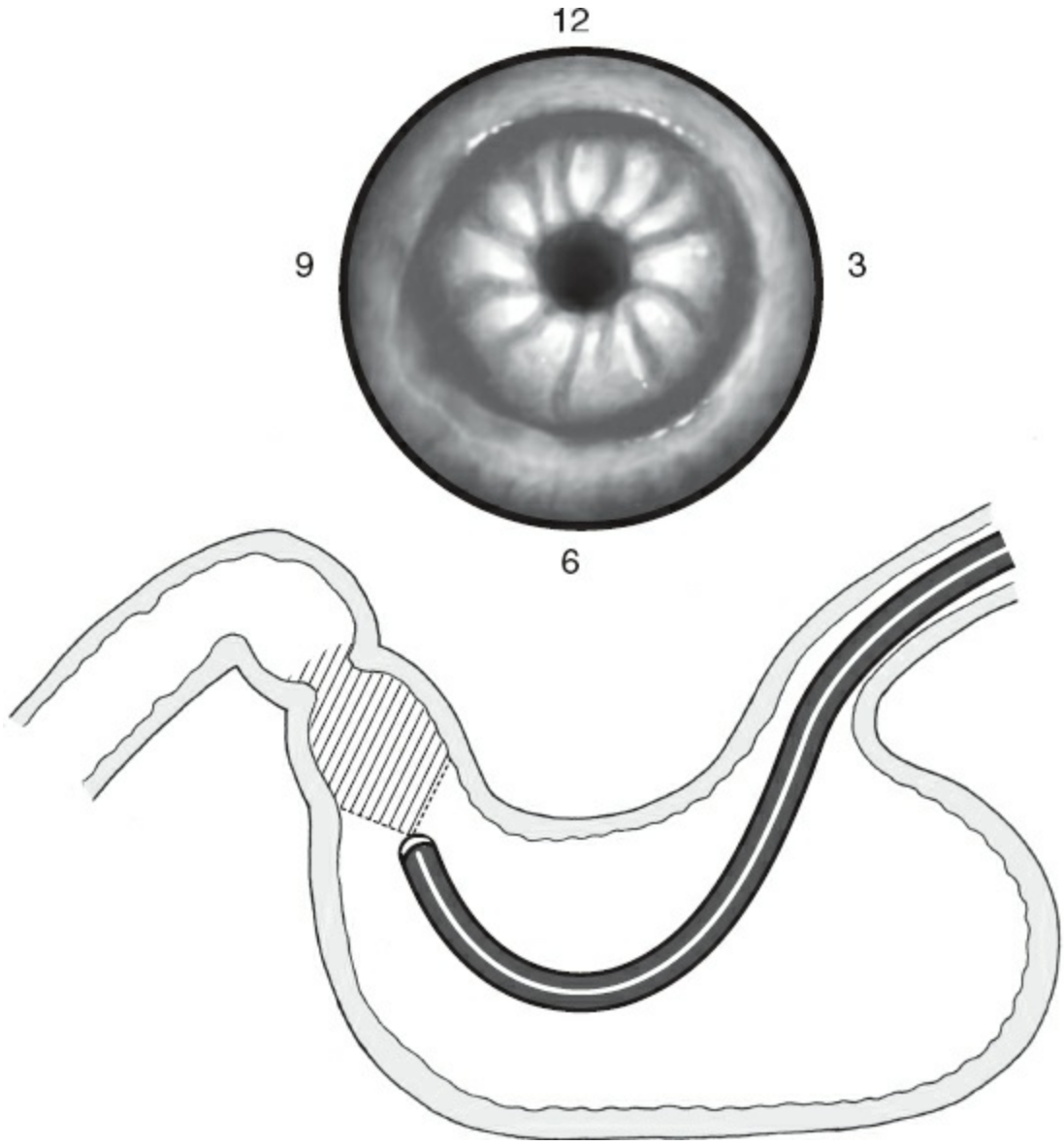

Figure 15.5. The antrum has few rugal folds. The pylorus is typically round and may be observed to open and close.

Therapeutic Interventions During Upper Endoscopy

The ability to deliver endoscopic therapy has increased greatly in recent years as technologies have been developed to permit treatment through the working channel of the endoscope. These applications have included the ability to coagulate bleeding lesions with monopolar or bipolar probes, or to inject them with long needle injection catheters. Esophageal varices can be treated with injection sclerotherapy or rubber band ligation, controlling hemorrhage and eventually obliterating the large venous trunks. Hydrostatic balloons can be introduced through the working channel to dilate esophageal, anastomotic, and pyloric strictures, and laser energy can

be directed through the scope to debulk obstructing esophageal tumors or to treat vascular lesions of the stomach.

Endoscopic mucosal resection (EMR) may be used to remove esophageal and gastric lesions including Barrett's esophagus, dysplasia, and early carcinoma. The most common resection technique uses saline injected beneath the lesion to elevate the mucosal lesion off the underlying submucosa. The area is then resected with a snare. Other EMR techniques include the suck-and-cut and suck-and-ligate techniques. Both of these use specially designed systems to resect lesions in the submucosal plane.

Endoscopic submucosal dissection (ESD) may be used to resect early esophageal neoplasms, localized gastric cancers, and, in rare cases, small duodenal cancers. There are a variety of techniques used to achieve an *en bloc* resection of localized lesions with clear margins. A liquid is first injected into the submucosal plane. The mucosa is then divided and the submucosal plane is entered. A combination of needle cautery and blunt endoscope cap dissection is used to complete the resection. The mucosal defect is typically closed with clips or by using a suturing device. In many parts of the world, ESD has become the standard method for resection of early upper GI malignancies.

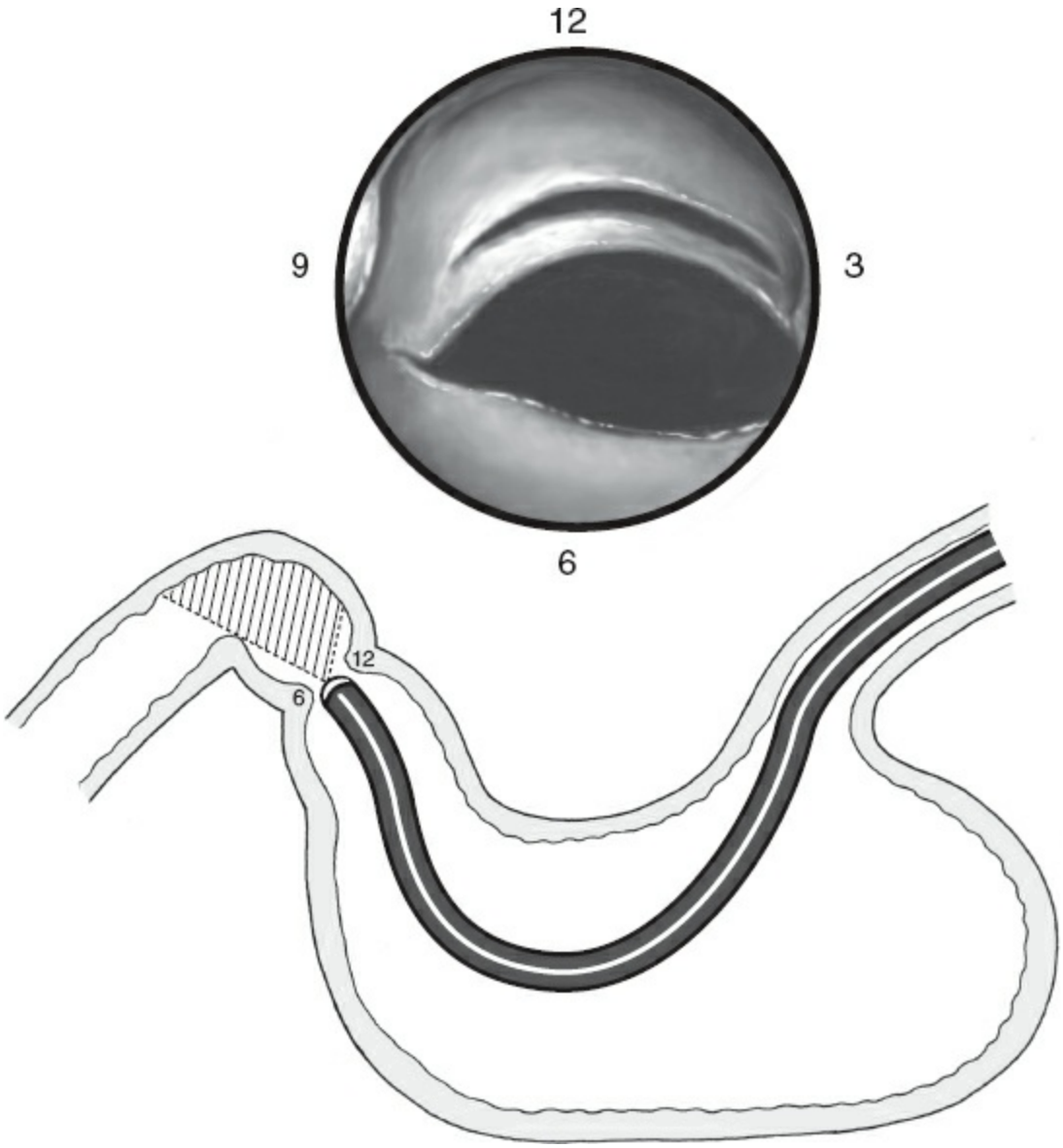

Figure 15.6. Inspection of the duodenal bulb is often best accomplished through the pylorus or with the scope's tip in the pyloric channel. The superior duodenal fold marks the downward turn of the second portion of the duodenum.

Barrett's esophagus with or without dysplasia may be treated with radio frequency ablation. Specially designed balloons deliver controlled doses of energy to the entire circumference of the distal esophagus in long-segment Barrett's. A cap can be affixed to the tip of the endoscope to deliver radio frequency energy to isolated areas of intestinal metaplasia. Radio frequency ablation with or without EMR or ESD has become the standard treatment for Barrett's esophagus with dysplasia. The same techniques are being studies in patients with Barrett's esophagus and intramucosal carcinoma and other early stage esophageal cancers.

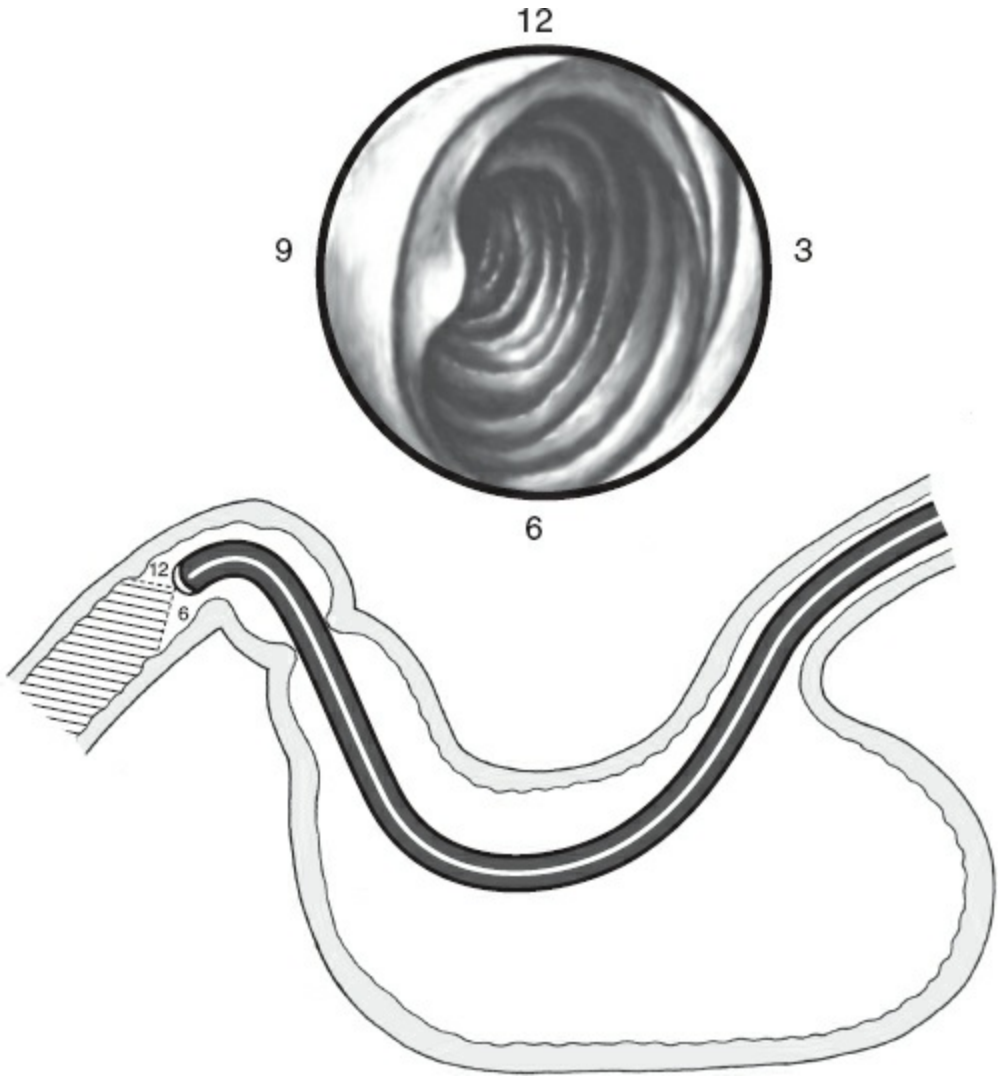

Figure 15.7. Once in the descending duodenum, the scope is pulled back and straightened. The ampulla of Vater may be seen in profile at the 9 o'clock position on the medical duodenal wall.

Upper GI stenting is useful in the management of postoperative stricture, anastomotic leak, or malignant stricture. Covered, self-expanding metal stents are frequently used in the management of staple line leaks after gastric bypass or sleeve gastrectomy. Many patients receive definitive management of the leak from the stents. In others, stenting may permit control of sepsis and nutritional repletion prior to definitive surgical management.

Transgastric natural orifice transluminal endoscopic surgery (NOTES) requires a gastrotomy to access the peritoneum. There are case series of NOTES cholecystectomy, appendectomy, oophorectomy, peritoneoscopy, and other procedures. Specialized instrument platforms have been developed to facilitate these operations. Concerns about reliable closure of

the gastrotomy, effective methods of retraction, and overall patient safety have led to limited adoption of pure NOTES procedures. Many of the techniques initially developed for NOTES have translated into other advanced endoscopic procedures such as ESD and endoscopic myotomy.

Per oral endoscopic myotomy (POEM) is an endoscopic therapy for patients with achalasia. Similar to ESD, the submucosal space of the midesophagus is entered by creating a submucosal bleb and incising the mucosa. A cap is affixed to the tip of the endoscope to facilitate submucosal dissection distally on the esophagus and onto the proximal stomach. The inner circular muscle fibers are then divided with an electrosurgical device, using care to carry the myotomy several centimeters onto the stomach. The mucosal defect is then closed using clips.

POEM is most commonly done under general anesthesia. Patients stay overnight in the hospital and commonly receive an upper GI fluoroscopic examination the following day. The short- and medium-term results of POEM have been favorable. There is good relief of symptoms without severe reflux symptoms. POEM may be used as a primary therapy for achalasia or in patients who have persistent symptoms after surgical esophagomyotomy. Severe complications, such as perforation and tension pneumothorax, have been low.

Technique of Colonoscopy

Mechanical bowel preparation is critical for proper colonoscopic examination. Large volume polyethylene glycol solutions effectively lavage the colon and are safe for most individuals. The dose may be given completely on the day prior to colonoscopy or split to include a portion on the day of the procedure. Sodium phosphate solutions require a lower volume to cleanse the colon but may induce hyperphosphatemia in patients with renal insufficiency.

The left lateral decubitus position is used to begin the procedure, although it is common to turn the patient occasionally during the course of the procedure to facilitate passage of the instrument through tortuous areas. A careful digital rectal examination should precede introduction of the scope, in order to dilate the rectum as well as to assure that no low-lying lesions are overlooked.

The colonoscope is positioned in the rectal vault and inserted proximally by a combination of maneuvers, which include manipulation of

the endoscope tip with the control knobs, advancement and torsion of the instrument shaft, repeated hooking of the scope's tip around colonic folds and withdrawal to remove redundant coils in the shaft, and repeated suctioning (Fig. 15.8).

The colonoscope should be advanced only when the lumen ahead is clearly visible. Blind insertion of the scope in hopes that it will "slide by" may cause perforation. While the latter method may occasionally be employed by experts in difficult circumstances, it remains risky and should be used sparingly. When the lumen is visible ahead, the scope may be inserted further. Should the lumen disappear, it is most effective to pull the shaft back slightly, inflate a bit, and reassess the position of the lumen. These repeated pullbacks and advancements can be accomplished quite rapidly and serve to telescope the colon on the endoscope (Fig. 15.9).

The optimal colonoscopy is performed without any looping of the scope. This can be gauged by the length of scope inserted. A straight scope usually reaches the splenic flexure in 50 to 55 cm, and the cecum can normally be reached in 100 cm or less. During negotiation of the sigmoid colon, a loop often forms. This should be reduced in the descending colon prior to traversing the sigmoid flexure. At times, in spite of the endoscopist's best efforts, insertion of the scope's shaft does not result in the advancement of the tip because of looping. Further introduction of the scope will usually exacerbate the looping, cause the patient discomfort, and risk of perforation. In such situations, it may be useful to have an assistant apply some pressure to, or lift, the left side of the abdomen. This will act to stiffen the sigmoid loop and allow advancement of the scope. Alternatively, the patient's position may be changed to alter the position of the colonic loops. Placing the patient in the supine position, while trying to proceed through a difficult sigmoid colonic segment, is often effective.

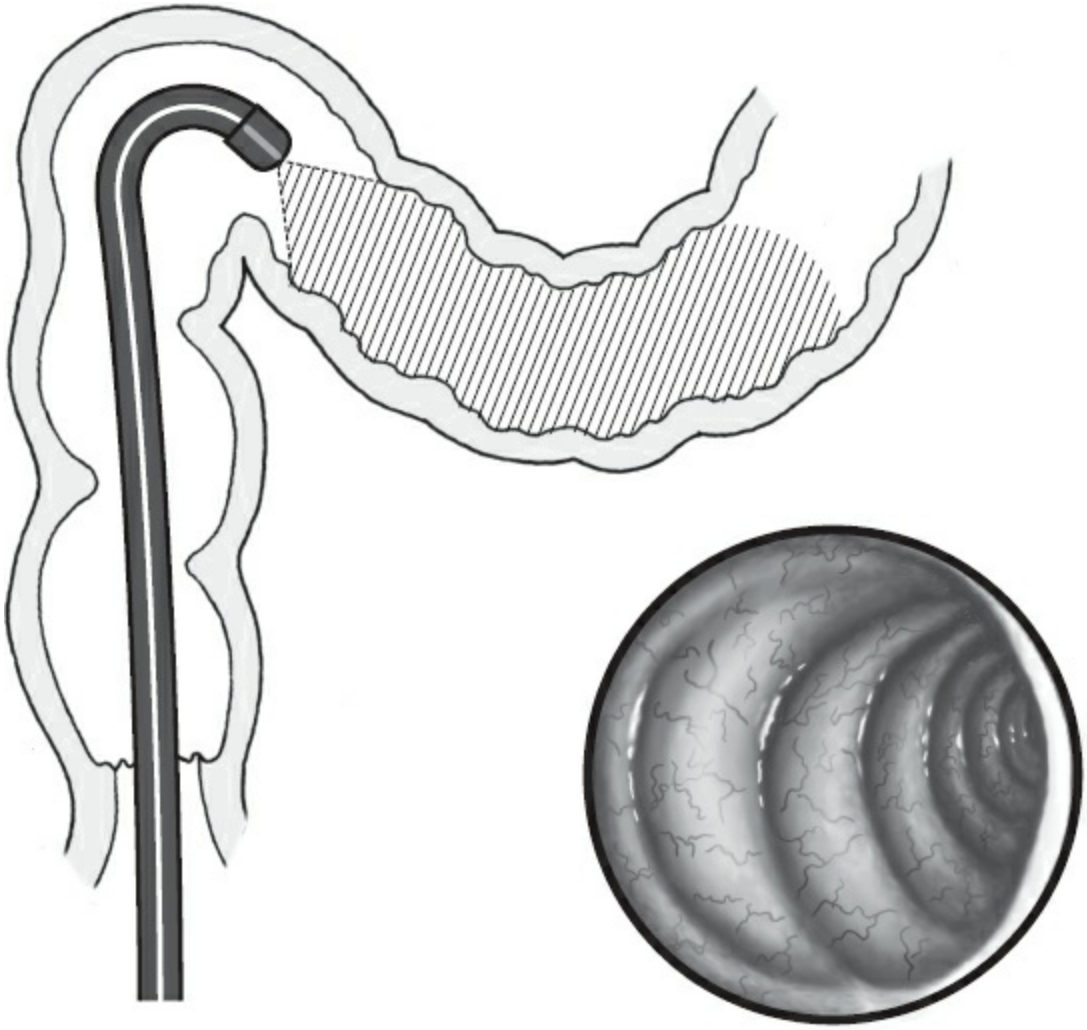

Figure 15.8. After insertion into the rectal vault, the colonoscope is inserted under direct vision.

Even when direct pressure continues to result in the advancement of the scope's tip, it is useful to remove redundant loops by stopping, hooking the tip, and pulling back, in an effort to telescope the colon onto the scope's shaft (Fig. 15.10). This is easily accomplished after entering the transverse colon, and after turning downward into the right colon. In fact, pulling back on the shaft may actually produce significant paradoxical advancement of the scope's tip. Finally, the application of suction, while the instrument is positioned in the center of the colonic lumen, will often draw colon up onto the scope and shorten the colon. The latter technique may be particularly useful in intubating the final several centimeters of the cecum.

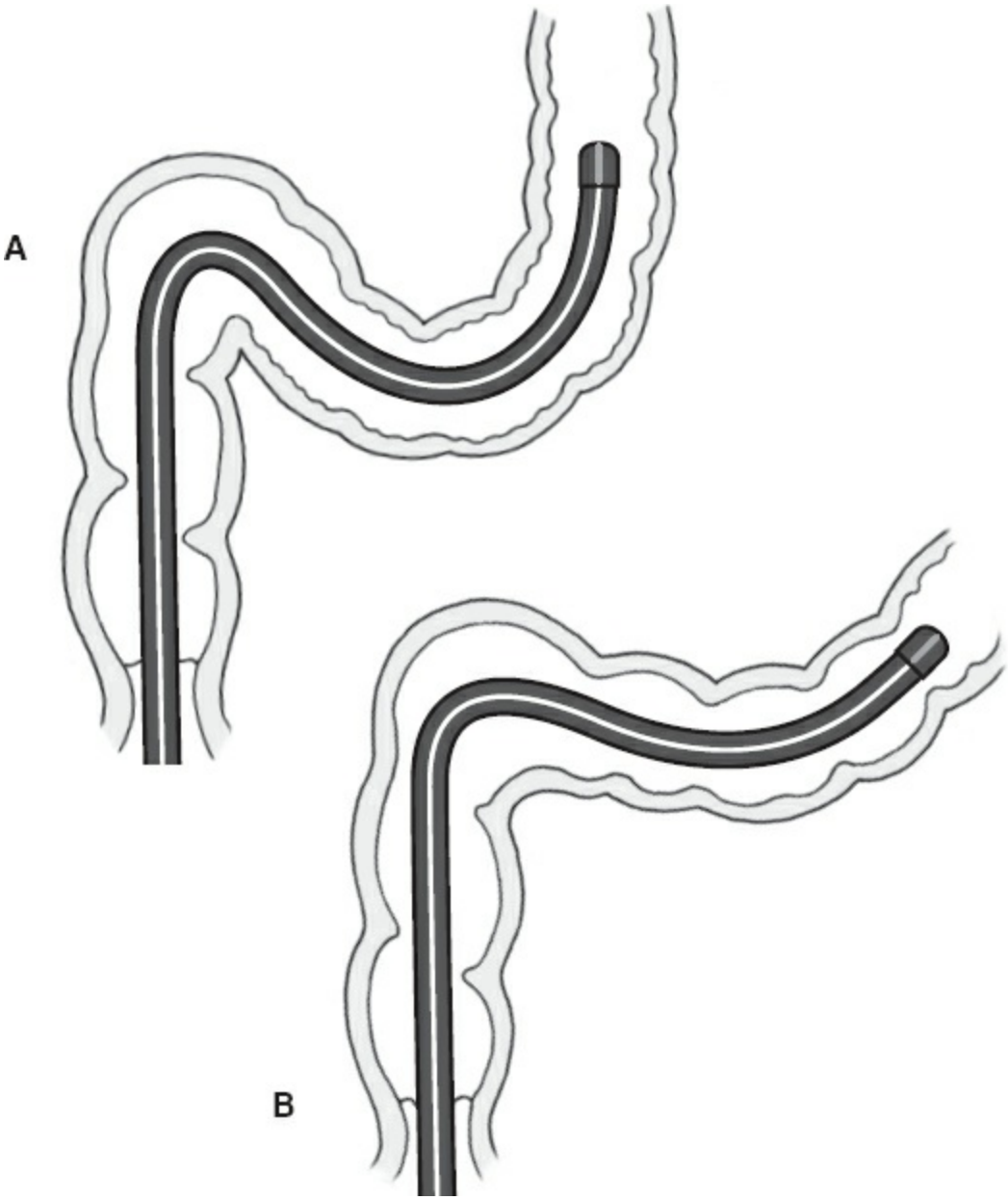

Figure 15.9. Hooking the tip of the scope around folds and pulling back often permits advancement through tortuous colonic turns.

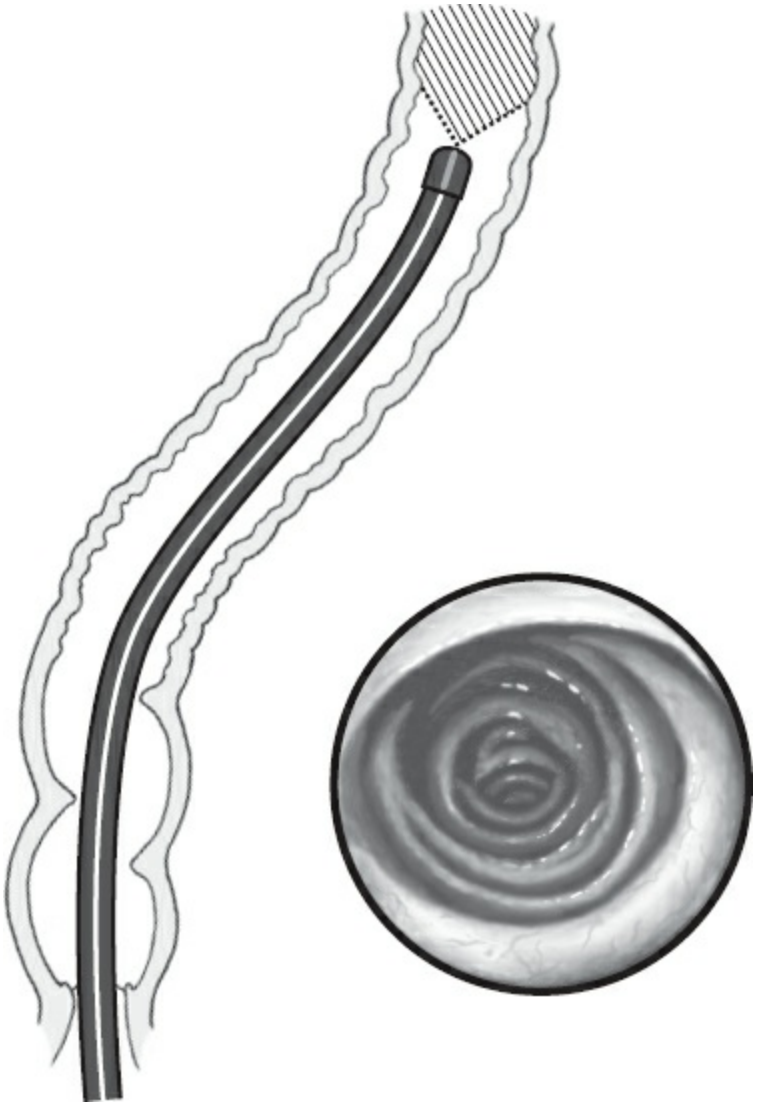

Figure 15.10. Multiple sequences of hooking and pulling back should result of straightening of the colonic loops and telescoping of the colonic segments onto the scope.

After insertion to the cecum, the instrument is slowly withdrawn while slight adjustments to the tip position are made to ensure complete visualization to the colonic mucosa. The varying appearance of the interior colon helps the endoscopist to define the location of the endoscope's tip and the location of any pathology encountered. The cecum demonstrates an arching convergence of the colonic tenia, often described as the "Mercedes sign," and the appendiceal orifice can usually be identified as a slit in the mucosa of the cecum. Just slightly above (distal) to this area is the ileocecal valve, appearing as a slightly thickened fold, occasionally yellow in hue due to some lipomatous infiltration (Fig. 15.11). The hepatic flexure transmits the bluish cast of the liver adjacent to it. Triangular folds

are the distinguishing anatomic feature of the transverse colon, and long segments of the lumen may be viewed at one time. Care should be taken to look behind large folds for lesions, such as small neoplasms, which may be hidden behind them.

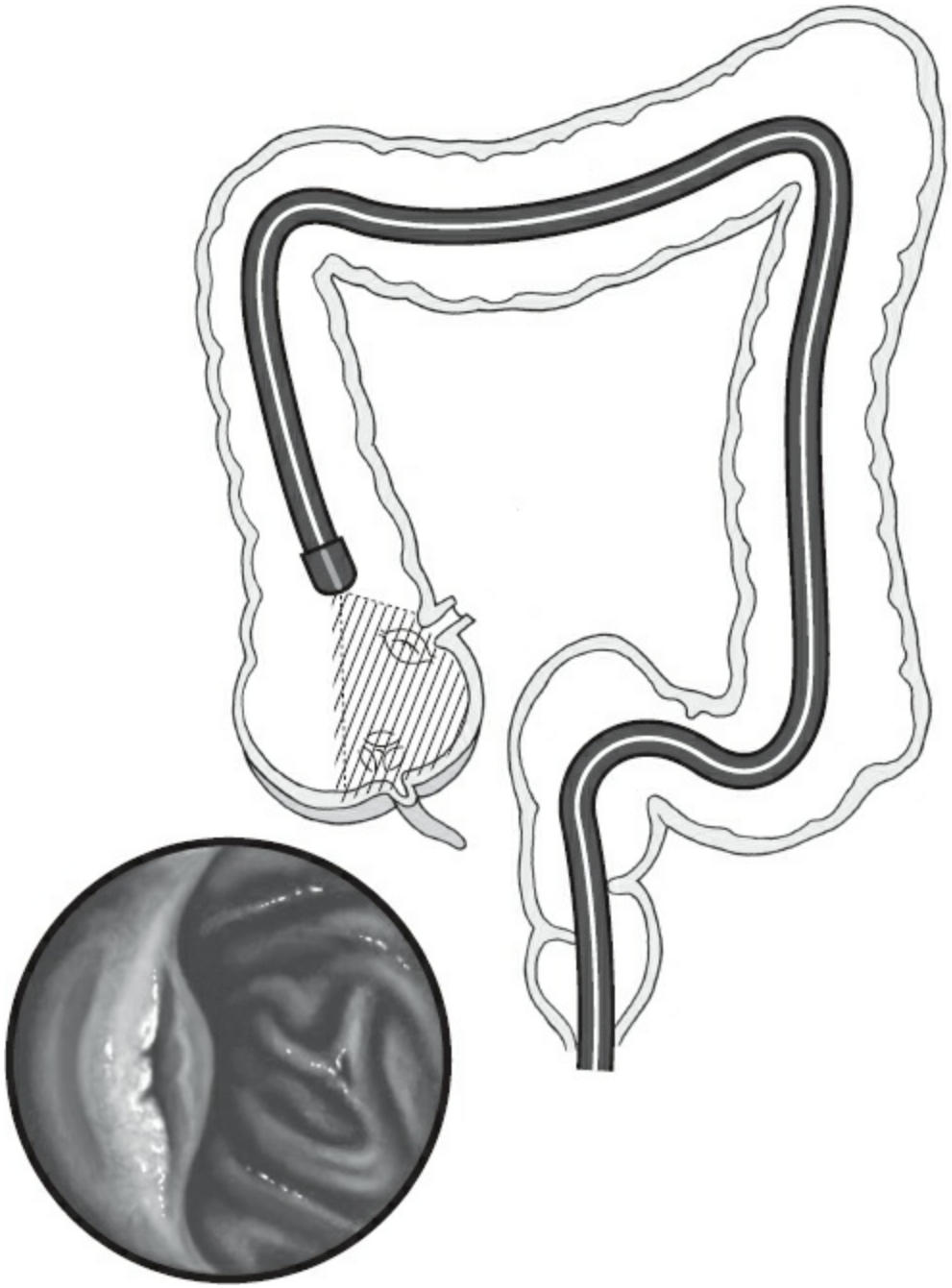

Figure 15.11. The cecum can be recognized by the confluence of the colonic tenia, the “Mercedes sign,” and the profile of the ileocecal valve.

As the scope is withdrawn from the transverse colon past the splenic

flexure, the sharp turns may hinder complete examination of the lumen, and reinsertion past this point several times may be necessary to accomplish satisfactory examination of the area. The descending colon usually appears as a long straight tube with little haustration, and the endoscopist will recognize entry into the sigmoid colon when the lumen turns frequently and folds become eccentric. Finally, the rectum will be noted to display prominent vasculature and a widened lumen. Once the colonoscope has been withdrawn to the level of the rectal columns, a retroflexed view of the rectal vault is usually performed to assure that lesions just adjacent to the anal opening are not overlooked. The retroflexion is accomplished by directing the tip of the instrument severely upward while rotating the shaft of the scope to the left and inserting it further. Should the patient experience pain with the maneuver, the scope should be withdrawn and the procedure started again. Satisfactory retroflexion will be recognized by visualization of the scope entering the rectum, and the dentate line will be clearly visible. In this position, the scope is brought closer to the dentate line by withdrawing the shaft. Rotation of the shaft permits full examination of the rectal vault. Finally, the scope is straightened, air suctioned from the colonic lumen, and removed.

There are several quality measures that all endoscopists should follow. Cecal intubation rate, adenoma detection rate, and rates of complications such as bleeding and perforation are routinely tracked. The cecum should be reached in over 90% of cases. The expected overall adenoma detection rate is over 25%. Perforations have been shown to occur in one of every 10,000 cases. High-quality colonoscopy is possible with a good bowel preparation, careful technique, and appropriate training in flexible endoscopy.

Therapy During Colonoscopy

The most frequent interventions performed at colonoscopy are biopsy and polypectomy. Biopsy forceps may be passed through the working channel of the colonoscope to sample tissue. Areas of suspected neoplasia, dysplasia, or inflammation are sampled. Insulated forceps with large jaws permit simultaneous biopsy and thermal destruction of small lesions (Fig. 15.12). Biopsy without electrocautery is commonly practiced today due to concerns about transmural injury to the colon wall.

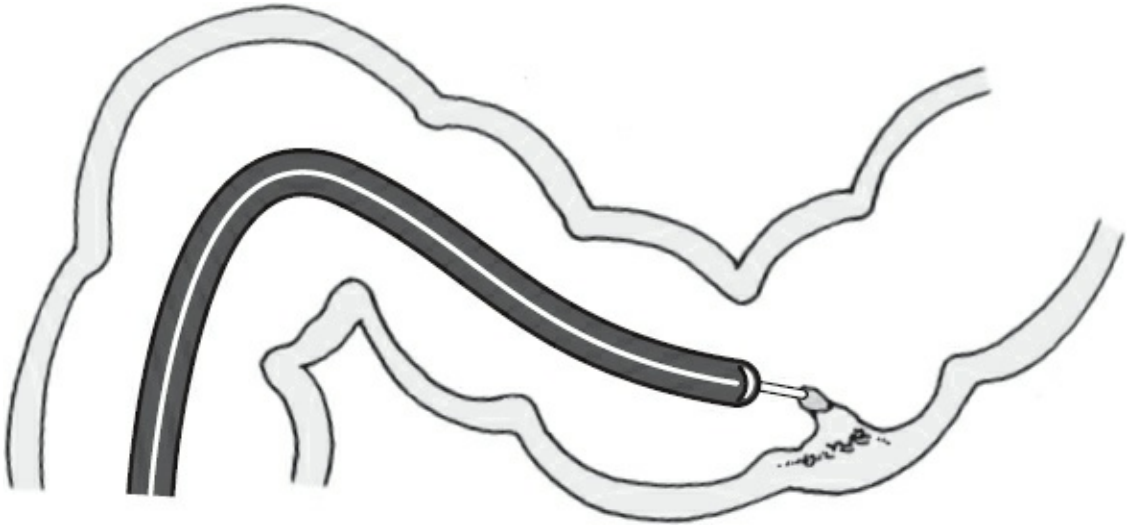

Figure 15.12. A hot biopsy forceps permits sampling of small lesions with their simultaneous destruction. Care must be taken to avoid excessive application of current with subsequent transmural injury.

Polypectomy is the most common therapeutic application of colonoscopy. These techniques have been well described, and involve the encirclement of polypoid tissue with a wire loop, subsequent tightening of the loop, and application of coagulation current to effect separation of the tissue (Fig. 15.13). Small or pedunculated polyps are removed with one application of the snare loop, while larger or sessile lesions usually require piecemeal excision. Cold snare polypectomy, without the application of energy, is being employed with regularity to limit the risk of thermal injury. Once again, with large or sessile lesions, EMR may be accomplished by first injecting saline to elevate the lesion, and then using the snare and cautery for resection. Samples are retrieved with suction, snare, or baskets and sent for pathologic examination (Fig. 15.14). ESD is occasionally used for the resection of large colon polyps. The colon wall is quite thin, especially in the cecum, and care must be taken to avoid full-thickness resections when using these advanced resection techniques.

Recent literature has shown that colonoscopy is less effective at polyp detection in the proximal colon compared to the distal colon. The rate of missed adenomas using a single forward view of the cecum and ascending colon is as high as 10%. To improve the detection rate, retroflexion in the cecum or a second forward-view of the right colon has been recommended. There is a small risk of perforation of the right colon with retroflexion, although large studies with expert endoscopists have shown no adverse events with retroflexion.

The traditional adenoma to carcinoma sequence of colorectal cancer is well known and provides the rationale for polypectomy. In recent years, an alternative serrated adenoma pathways was been elucidated. Serrated adenomas are the precursors for 10% to 40% of colorectal cancer, more commonly in the proximal colon. Serrated polyps arise in hyperplastic lesions and are more difficult to detect since they are flatter with less mucosal distortion than adenomas. While hyperplastic polyps were traditionally considered benign lesions, recent data have identified the risk of malignancy with hyperplasia and serrated polyps. The current recommendation is for resection of all hyperplastic lesions proximal to the sigmoid colon and any hyperplastic lesion greater than 5 mm located in the rectosigmoid region.

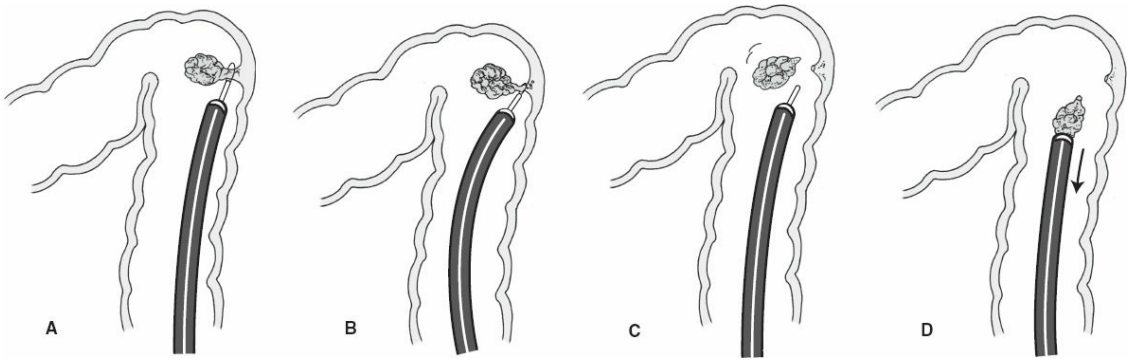

Figure 15.13. **A:** Pedunculated polyps are surrounded by a polypectomy snare. **B:** The snare is tightened at the junction of the stalk and the polyp head. **C:** Coagulation current is then used to transect the stalk. **D:** The head is then retrieved for pathologic examination.

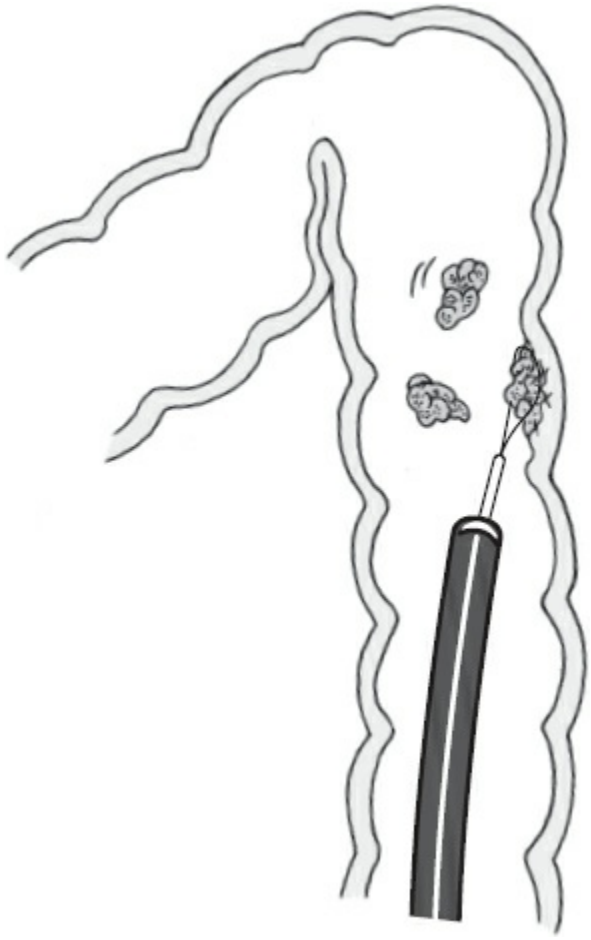

Figure 15.14. Sessile or large pedunculated polyps may require piecemeal excision. All fragments should then be retrieved for pathologic examination.

Stenting of near-obstructing colon neoplasms has been shown to be an effective bridge to definitive surgery and may avoid a colostomy in many cases. Descending and sigmoid colon lesions are most amenable to stenting. The endoscope is advanced to the near-obstructing lesion. A wire is advanced through the residual lumen and the stent is placed over the wire across the lesion. Its proper placement is confirmed endoscopically. Additional therapeutic interventions through the colonoscope include thermal ablation of tumors and vascular malformations, colonic decompression, and detorsion of volvulus.

New and Evolving Endoscopic Techniques

The goal of many evolving endoscopic techniques is to mimic a surgical procedure while limiting the discomfort and scarring which accompanies operation. Procedures which do not require organ resection are most suitable to endoscopic therapies.

POEM has been shown to produce similar outcomes compared to laparoscopic Heller myotomy. More than 90% of patients experience relief of their symptoms with POEM. The rates of clinically significant esophageal reflux are similar to standard myotomy and the complication rate is low.

Endoscopic restrictive and malabsorptive procedures have been developed to induce weight loss. An intragastric balloon may be inserted endoscopically and inflated. This space-occupying prosthesis limits the capacity of the stomach to accept food. A plastic gastroduodenal sleeve may be inserted using an endoscope. The food is transmitted from the stomach to midjejunum without contact with the duodenal and proximal jejunal mucosa. This limits absorption and promotes weight loss. Both techniques are investigational and have not yet been shown to yield significant and sustainable weight loss.

Transgastric endoscopy has been used to perform pancreatic necrosectomy in patients with complicated pancreatitis. This technique is evolved from transgastric drainage of pancreatic fluid collections. Endoscopic ultrasound is used to localize areas of pancreatic necrosis. The wall of the stomach abutting the necrosis is punctured. A self-expanding metal stent may be placed to maintain the tract. The endoscope is then passed through the tract and endoscopic baskets and forceps debride the necrotic tissue. Specialized centers have shown the technique to be safe and effective.

Endoscopic treatment of gastroesophageal reflux disease (GERD) has been attempted using injected polymers, suturing devices, and radio frequency energy. More recent endoscopic therapies for reflux try to mimic a surgical fundoplication. A device using a specialized retractor and T-fasteners can create a 270-degree posterior-to-anterior fundoplication. While appealing, the durability of symptom relief is not optimal.

Although pure NOTES procedures are not commonly performed today, the research and ingenuity devoted to NOTES have spawned many advances in endoscopy. Endoscopists have recognized the utility in accessing the submucosal space, which has led to the development of ESD and POEM. Advanced endoscopic tools meant for NOTES, such as suturing devices and clip appliers, have been used clinically to repair perforations, thus sparing conventional surgery.

CONCLUSION

Flexible endoscopy is a mainstay in surgery practices throughout the world. Emphasis on high-quality endoscopy has led to better endoscopic examinations and improved patient outcomes. Advanced techniques now permit endoscopic resection of localized neoplasms and performance of complex maneuvers, such as myotomy. It is incumbent upon surgeons to take the lead in these advanced techniques. Surgeons have the knowledge of the disease processes, the experience with surgical and endoscopic procedures, and the ability to manage any complications which might arise. The future of flexible endoscopy is certain to include continued advances with more complex techniques. Surgeons should not be left behind.

Suggested Readings

Barclay RL, Vicari JJ, Doughty AS, et al. Colonoscopic withdrawal times and adenoma detection during screening colonoscopy. *N Engl J Med* 2006;355(24):2533–41.

Chandran S, Parer F, Vaughan R, et al. Right-sided adenoma detection with retroflexion versus forward-view colonoscopy. *Gastrointest Endoscopy* 2015;81(3):8–13.

Inoue H, Minami H, Kobayashi Y, et al. Peroral endoscopic myotomy (POEM) for esophageal achalasia. *Endoscopy* 2010;42(4):265–71.

Ponsky JL. *Atlas of Surgical Endoscopy.* St. Louis, MO: Mosby Year Book; 1992.

Rex DK, Ahnen DJ, Baron JA, et al. Serrated lesions of the colorectum: review and recommendations from an expert panel. *Am J Gastroenterol* 2012;107(9):1315–29.

Shaheen NJ, Sharma P, Overholt BF, et al. Radiofrequency ablation in Barrett's esophagus with dysplasia. *N Engl J Med* 2009;360(22):2277–88.

EDITOR'S COMMENT

At its inception, endoscopy was used strictly for diagnosis. In today's world, endoscopic procedures are performed in lieu of what had previously been completed via laparotomy and the discipline of GI endoscopic surgery is rapidly evolving. Novel endoscopic techniques and technologies are being developed to manage complications and treat disease in a manner not considered possible as recently as a decade ago.

Surgical endoscopy has a rich tradition, as many pioneers in interventional endoscopy were surgeons. In 1968, McCune reported the first cannulation of the ampulla of Vater in a precursor to what would become endoscopic retrograde cholangiopancreatography (ERCP). Shinya and Wolff introduced colonoscopic

polypectomy in 1975, essentially abolishing the then common practice of barium enema leading to laparotomy, colotomy, and polypectomy. Dr. Ponsky performed the first percutaneous endoscopic gastrostomy tube in 1979.

A brief discussion about training and credentialing in endoscopy is relevant and not covered in the current chapter in detail. Surgeons around the world provide essential endoscopy services. In the United States, gastroenterologists are rarely available in rural and underserved areas; in such areas surgeons may be the only providers of indispensable endoscopic services. Managing the continuity of disease, including complications of procedures, is important to good quality care. Given that many of the diseases identified at endoscopy are ultimately treated surgically, a surgeon's involvement in the early diagnosis and management is often optimal, to assure continuity of care. Surgical expertise is frequently required to evaluate and manage complications of endoscopy, especially those that are catastrophic or life threatening. There has been some controversy about competency as well as training and credentialing requirements in endoscopy. In recent years, GI and surgical societies have worked closely to define competency in endoscopy and to develop quality indicators and training guidelines (Rizk MK, Sawhney MS, Cohen J, et al. Quality indicators common to all GI endoscopic procedures. *Gastrointest Endosc* 2015;81(1):3–16). This effort is critical, because as the population ages and lives longer, the demand for high quality endoscopic services is increasing rapidly. In 2009, an estimated 6.9 million upper endoscopy procedures were performed in the United States (Peery AF, Dellon ES, Lund J, et al. Burden of gastrointestinal disease in the United States: 2012 update. *Gastroenterology* 2012;143:1179–87; e1–3). From 2000 to 2010, there was an estimated 50% increase in upper endoscopy for Medicare beneficiaries. Based on 2010 data, over 3.3 million outpatient colonoscopies are performed annually in the United States, with screening and polyp surveillance accounting for about half of the indications.

The American Board of Surgery will require all ABS-certified general surgeons to have completed a standard curriculum in the use of endoscopic techniques. This new requirement will apply to certification applicants who complete their residency training in the 2017 to 2018 academic year or thereafter. During their general surgery residency, applicants will be required to have completed the ABS Flexible Endoscopy Curriculum. In addition, one of the final steps in the curriculum is successful completion of the Fundamentals of Endoscopic Surgery (FES) program offered by SAGES. Evidence of FES certification will be required when applying for ABS certification. The FES program includes didactic materials, a multiple-choice examination, and a hands-on skills test (Hazey JW, Marks JM, Mellinger JD, et al. Why fundamentals of endoscopic surgery (FES)? *Surg Endosc* 2014;28(3):701–3).

In their chapter, Ponsky and Pearl discuss a variety of new endoscopic endoluminal and transluminal procedures. The ability to perform surgery through a natural orifice and without incisions has been an area of intense

interest since the early 2000s. More than 1,000 reports have been published describing various applications of NOTES in both animals and humans (Zhang F, Kalloo AN. NOTES: What is currently possible? In: Cameron JL, Cameron AM, eds. *Current Surgical Therapy*. 11th ed. Philadelphia, PA: Elsevier Saunders Publishing; 2014:1443–6). Many novels endoscopic interventions have been described over the past decade, but none has become commonly performed in humans or a standard of care. There are many preliminary data that suggest NOTES is feasible and safe, but true transluminal surgery remains in the preclinical and investigatory stage. There are a variety of reasons to explain the slow adoption of NOTES including a lack of instrumentation specifically designed for these procedures, technical difficulty and poor ergonomics related to the commonly used natural orifice access sites, the potential morbidity of access site incisions, poor insurance coverage, and a plethora of minimally invasive alternatives with already low morbidity rates (NOTES vs. laparoscopic cholecystectomy for example). The interest in NOTES has led to some progress in related areas such as single incision surgery (now even more feasible with the robotic single site platform), true endoluminal procedures (EMR, endoluminal GERD, and obesity procedures), and submucosal procedures (such as POEM). GERD and obesity are two particularly prevalent diseases for which surgery is underutilized (less than 1% of surgical candidates undergo surgery for each disease condition for a variety of reasons) (Funk LM, Kanji A, Scott Melvin W, et al. Elective antireflux surgery in the US: an analysis of national trends in utilization and inpatient outcomes from 2005 to 2010. *Surg Endosc* 2014;28(5):1712–9; Livingston EH. The incidence of bariatric surgery has plateaued in the U.S. *Am J Surg* 2010;200(3):378–85; Poulose BK, Holzman MD, Zhu Y, et al. National variations in morbid obesity and bariatric surgery use. *J Am Coll Surg* 2005;201(1):77–84). New devices offering incisionless approaches to treat these conditions appear on the market on a frequent basis. It will be important for GI and surgical societies to help organize surgeons and gastroenterologists applying these treatments to patients to understand the ideal patient for the different evolving treatment options and the long-term outcomes. It will be important as well for insurance companies to be willing to provide benefits for procedures determined to be both safe and effective, even when the return on investment and health care cost savings is realized in less than 1 year’s time.

As the line between what is in the professional and technical domain of GI surgeons (trained as surgeons) and GI endoscopists (gastroenterologists) has become increasingly blurred, it will be important for surgeons to remain at the forefront and lead these efforts.

Jon C. Gould

16 Soft Tissue Reconstruction With Flap Techniques

Luis O. Vásconez, Salman Ashruf, Franziska Huettner, and Michael Ruebhausen

INTRODUCTION

Sound understanding of reconstructive surgery is imperative to all practicing general surgeons. The integumentary system is the largest organ system of the body. It is subject to systemic disease as well as the extremes of the environment. The ability to surgically manipulate and reconstruct acquired defects in an efficacious fashion is the learning objective of this chapter.

The most common approach to reconstruction begins with the so-called reconstructive ladder. The logical progression of the reconstructive ladder begins, as one does on a ladder, moving from the bottom to the top: primary closure, secondary closure, split- and full-thickness skin graft, local tissue rearrangement, local flaps, regional flaps, and free tissue transfer. There are varying degrees of each type of flap, with each involving more or less tissue, commensurate with the defect to be reconstructed. For reconstructive surgeons, the ladder is inherently more frequently explored from top to bottom; however, every surgeon will use some component of reconstruction with every case.

Skin grafts can include the entire epidermis and dermis, or the epidermis with a portion of the dermis. The former, known as a full-thickness graft, resists contraction, needs a well-vascularized recipient bed, maintains the adnexal structures, and has pigmentation similar to normal skin. Split-thickness skin grafts are more likely to contract or shrink, hyperpigment, and survive under less favorable conditions, and they leave less donor site morbidity. Factors that lead to skin grafts not “taking” include shear, hematoma, seroma, infection, and an avascular bed, such as that in an inadequately debrided wound. For a skin graft to take requires a vascularized bed. These recipient sites can be muscle, fascia, paratenon, or periosteum. When such a bed is absent, a well-vascularized flap is

necessary to provide reliable, durable coverage.

A flap is a unit of moveable tissue that remains attached to its original blood supply. Flaps can contain skin, muscle, bone, fascia, or any combination of these. When the flap contains a named septocutaneous or musculocutaneous blood vessel, it is known as an axial flap and can therefore be transferred reliably to different sites to reconstruct soft tissue defects. Vascular anatomy of any particular flap is well known at this time and makes it reliable as long as one includes the vascular pedicle within the flap. The so-called random flaps (except for the face), where the distinct vascular anatomy is unclear, should be avoided or at a minimum used with caution, because of the uncertainty of success. These flaps are perfused exclusively through the subdermal, or more accurately, the subcutaneous plexus and have no named blood vessel that supplies them. To improve viability of these flaps, length to width ratio traditionally should not exceed 3:1, though this has been challenged in recent years.

Exceptions to this include local tissue rearrangement and advancement flaps, such as rhomboid flaps and V-Y advancement flaps, which can be reliable used to close slightly larger wounds than can be closed by primary or secondary intention. Similarly, so-called delayed procedures, which have the objective to improve the vascularity of a flap, are rarely if ever indicated because there is no assurance that the safety of the flap will be increased. The “delay” procedure also has the disadvantage of an additional operation and the concomitant swelling and edema that ensue, making it more difficult to transfer such a flap. A microvascular free tissue transfer, or “free flap,” first reported in 1973, allows the transfer of tissues to distant sites with the reestablishment of blood flow to the flap by anastomosis of the artery and the vein to appropriate recipient vessels in the vicinity of the defect. The free flaps are most effective in providing coverage of areas with insufficient local or regional soft tissue options. Performed by experienced microsurgeons with an appropriate team, the free flap is one of the safest of all flaps, with a success rate exceeding 98%.

In today’s medical environment, however, the reconstructive ladder is no longer practical. Reconstructive surgeons must have a solid understanding of the surgical options available and those procedures that provide the best outcome, even though it may be the most complex solution.

In the management of large wounds created by extirpation of benign or

malignant tumors, postradiation ulcerations, or posttraumatic defects, the cooperative efforts between the general surgeon and the plastic surgeon will most likely result in satisfactory coverage of the wound and a shorter recovery and hospitalization for the patient. In the occasions when the wound cannot be closed primarily or in cases where a skin graft will not suffice, the use of flaps is the most appropriate option. Different approaches are required in different clinical settings, such as congenital defects, infected wounds, postradiation ulcers, and tumor excision. The coverage needed may be skin alone; skin and fat, such as for reconstruction of the breast; muscle or omentum for the coverage of postradiation wounds; composite tissue such as skin and muscle; and, often, muscle and bone of any combination. In this way, the native tissue and the resulting wound informs the type of reconstruction required.

During the initial evaluation, it is essential to recognize the type of soft tissue defect with which one is dealing. For example, if it is a loss of the skin such as a large excision of a melanoma of the face, the defect can be covered by an adjacent skin flap or skin graft. If one is dealing with a surgical loss of the breast, one needs to reconstruct by replacing the skin and the breast mound with either adipose tissue or, occasionally, the use of an implant. If, on the other hand, one is dealing with a postradiation persistent or recurrent tumor that requires a large extirpation, the defect needs to be covered with muscle, a musculocutaneous, or fasciocutaneous flap. In the case of postradiation wounds, although adjacent musculocutaneous flaps are given first priority, the use of free tissue transfer should be considered, as local or regional flap options or sufficient size and type may be limited.

The essential principle for reconstruction of soft tissue wounds is the application of the most effective flap that will succeed in covering the defect, regardless of the complexity of the procedure. Sufficient experience has determined what is more likely to succeed. One should forego the trial and error of using a simpler procedure that may not work and eventually end up with the appropriate albeit more complex flap reconstruction.

GENERAL PRINCIPLES FOR COVERAGE OF SOFT TISSUE WOUNDS

Difficult wounds usually fall into three categories: (a) superficially infected wounds, (b) wounds over exposed vital structures—such as bone

without periosteum, tendon without paratenon, or large blood vessels or nerves, and (c) postradiation wounds. We describe principles for their management individually.

Superficially Infected Wounds

Chronic wounds in which granulation tissue has been allowed to develop and to persist for a prolonged time are often difficult to treat. Pathophysiologically, one should note that granulation tissue is a combination of capillaries, fibroblasts, and bacteria. Of these three elements, only one is helpful to the surgeon: the capillaries. Consequently, if a wound is filled with granulation tissue, it is essential that one resect surgically in a tangential way until clean viable tissue is visible. Following that a simple meshed split-thickness skin graft may suffice. But in cases in which the wound cannot be completely cleansed or excised because that would entail the removal of essential structures, or in such patients with pressure sores, those infected wounds demand coverage with an adjacent muscle. Muscle has an antibacterial effect on the coverage of infected wounds, most likely because it brings in additional blood supply, which helps in the amelioration of the infection. The use of an adjacent fasciocutaneous flap is a second choice, although this is not as effective as muscle, owing to a diminished blood supply in comparison. Such flaps, however, have the added benefit of increased pliability, and thus better contour.

Wounds With Exposed Vital Structures

In these types of wounds, it is essential that one try to maintain the moisture of the exposed structures with frequent dressing changes. Perhaps the most common traumatic example of this is bone without periosteum. In a recently traumatized extremity with exposed tibia, one could use an adjacent fasciocutaneous flap. However, when dealing with cases in which there is active or chronic infection, such as in chronic osteomyelitis, the treatment is much different. Following an adequate debridement of the wound, it is essential that one cover that defect ideally immediately with an adjacent muscle to fill in the cavity and to cover the exposed bone. If the skull is exposed, as may occur following an electrical burn, it is not essential to remove the exposed skull but to cleanse it and to cover it with a free muscle flap, such as the latissimus dorsi. One has often rejoiced to see what appears to be dead bone revascularized or replenished once it is

covered with well-vascularized muscle (Fig. 16.1).



Figure 16.1. A, B. Knowledge of septocutaneous flaps allow us to move the fasciocutaneous flap in the leg for coverage of defects even in the lower third of the leg. The lowest septocutaneous perforator is located 5 to 6 cm above the medial malleolus.

Postradiation Wounds

The sophistication in the delivery of radiotherapy for the management of malignant tumors has resulted in the markedly decreased injury to the soft tissues, specifically the skin. We see much less ulceration or deformity following radiation. However, we often see postradiation-persistent and/or recurrent malignant tumors that must be salvaged with surgical excision. If one is dealing with a persistent or recurrent tumor, the amount of excision should be left to the oncology surgeon. On the other hand, if one is dealing with a postradiation ulceration, a previous biopsy is not essential because the treatment is going to be the same, and the pathologist is likely to report: “Chronic ulceration with postradiation effects but tumor cannot be ruled out.” In either case, the surgical treatment of these postradiation problems consists of the extirpation not only of the tumor or the ulceration, but also of the entire portal of radiation. One determines the entire portal of radiation by noticing the slight hyperpigmentation of the skin, the lack of the skin appendages, as well as the leathery appearance and feeling of the skin.

Following wide excision of the entire field that has been irradiated, one should immediately cover the defect with muscle, a musculocutaneous flap, or a fasciocutaneous flap, and if that is not available, with omentum.

A skin graft for postradiation wounds is not effective and is very likely to fail. Adjacent skin flaps similarly may not adhere to the underlying postradiation bed or to the skin edges. Muscle or omentum is successful because of the increase in blood supply they bring to the wound. Over the muscle or the omentum, one can immediately place a meshed split-thickness skin graft. A transverse rectus abdominis muscle (TRAM) flap, either pedicled or microvascular, is often successful if the skin edges to be approximated are beyond the field of radiation (Fig. 16.2).

SOFT TISSUE FLAP TECHNIQUES

We will describe specific soft tissue reconstruction with flap techniques throughout the body that are likely to be encountered in a busy general surgical practice.

Facial Defects

Facial defects often result from excision of malignant tumors such as basal cell carcinoma, squamous cell lesions, and melanoma, which is increasingly seen today. One must bear in mind, as with any oncologic resection, that immediate reconstruction will always carry the risk of re-excision should permanent pathology demonstrate persistent disease. The use of intraoperative margin assessment or a staged approach with permanent pathology is recommended (NCCN guidelines). We will describe reconstruction specifically of defects on the ear, nose, and cheek.

Defects of the Ear

Removal of large basal or squamous cell carcinomas of the ear requires immediate reconstruction. If a wedge resection of the upper one third of the ear is so large that it may result in deformity of the ear, a local technique described by Antia is the more desirable method of reconstruction (Fig. 16.3). Following the excision of the large defect along the helix of the ear, the lower portion of the ear is incised along the helix through the skin and underlying cartilage to the ear lobe. If necessary, the upper portion similarly below the helix is also incised through the skin and the cartilage. This leaves the two ends of the helix able to be moved toward each other and to be approximated, thus restoring the normal helical contour of the ear. The inferior cartilage and overlying skin are also approximated.

This method of reconstruction has the advantage of restoring the normal

shape of the ear and is relatively straightforward and effective. One does end up with a slightly smaller ear in comparison with the contralateral normal one, but this is not really a problem because we are seldom able to see both ears at the same time. A smaller, well-contoured ear is accepted by most casual observers.

Segmental helical rim defects can similarly be treated with local flap options. Specifically a posterior auricular interpolation flap (Fig. 16.4) is an example of a delayed flap that gives excellent contour and a well-hidden donor site wound which can almost always be closed with local tissue rearrangement, such as a rhomboid flap.

Defects of the Nose

Basal cell carcinomas that occur along the dorsum or the tip of the nose often require flap coverage for a satisfactory result. The flap coverage should be from adjacent nasal skin because it provides the same color and texture as well as thickness, and in elderly patients, the scar is almost imperceptible. On the other hand, skin grafts may leave a visible concavity and a patch appearance because of the different color of the surrounding skin. We do not favor the routine use of the nasolabial flap for defects of the nose because it is a different skin from the nose, and often leaves a “biscuit” type of appearance. For smaller defects, we advocate the use of the V-Y advancement flap, the banner flap, or the dorsal nasal flap. For total reconstruction of the nose, the midline or the paramedian forehead flap are safe and appropriate.

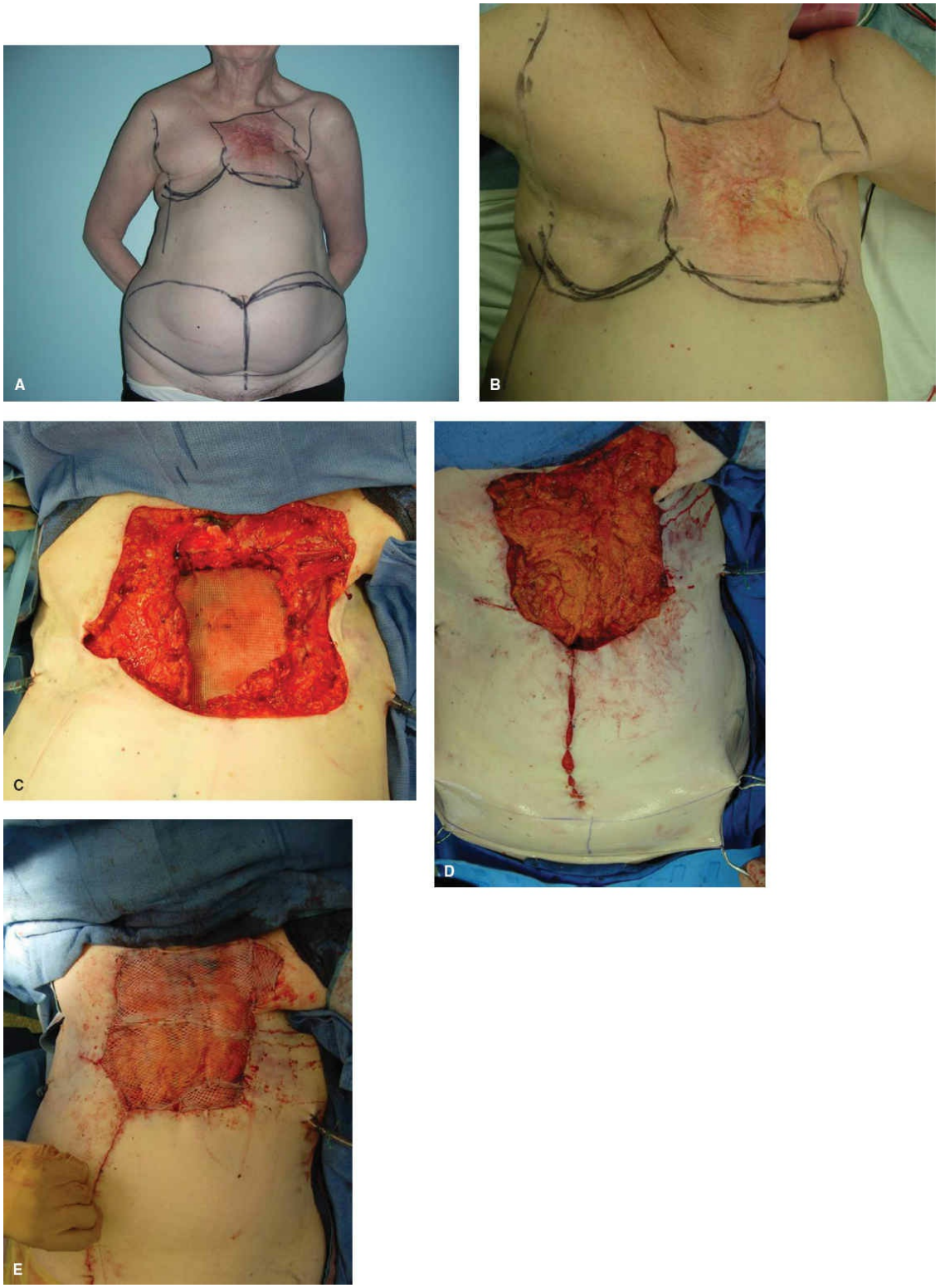

Figure 16.2. A–E. Patient who underwent bilateral mastectomies with radiation 24 years ago presented with large area of radiation necrosis over the sternum. TRAM flap reconstruction was not an option because radiation usually obliterates the arterial walls and in this particular patient, the resection entailed removal of both internal mammary arteries. The chest wall was stabilized with a polypropylene mesh. The omentum was transposed over the

mesh, with immediate application of a mesh split thickness skin graft. The omentum is passed through an opening in the upper abdominal incision at the subcutaneous tissue level. This is preferable to passage of the omentum through the diaphragm.

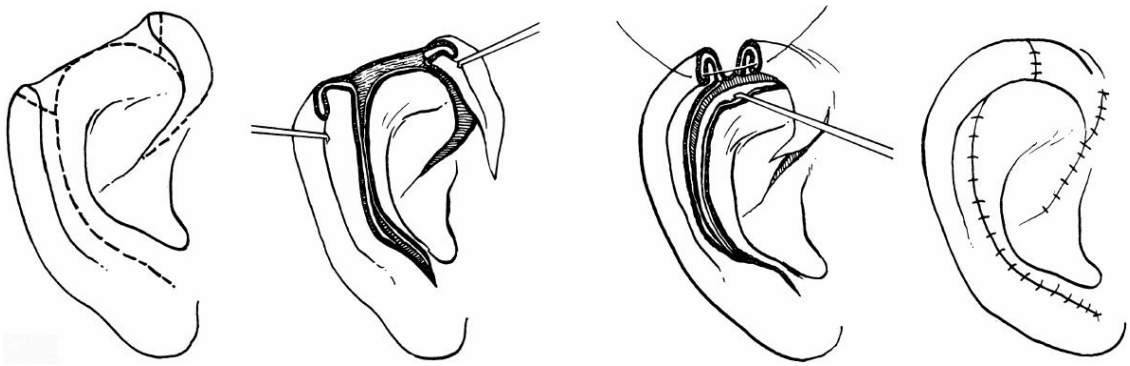

Figure 16.3. Diagrammatic representation of double chondrocutaneous advancement flaps for reconstruction of a large (3 to 4 cm) helical defect. (From Antia NH, Buch VI. Chondrocutaneous advancement flap for the marginal defect of the ear. *Plast Reconstr Surg* 1967;39:472, with permission.)

V-Y Advancement Flap

The V-Y advancement flap relies on the mobility of the subcutaneous layer (Fig. 16.5). For smaller defects on the dorsum or the lateral aspect of the nose one could design an adjacent V-Y flap that is incised and advanced to cover the defect. It is a simple and effective method for coverage of smaller defects. However, one should bear in mind that a true V-Y flap is based on a random blood supply, and extensive undermining of the skin disrupts the primary blood supply of the dermal and subdermal plexi.

Banner Flap

For smaller defects, usually along the tip of the nose, a banner flap is indicated (Fig. 16.6). Again, the created defect is noted, and one outlines a transposition flap, which is elevated and transposed to cover the primary defect while the secondary defect is covered in the form of an Z plasty from the adjacent tissue along the ala. There may be a slight elevation of the involved ala, but this is usually minimally noticeable.



Figure 16.4. **A.** The typical helical rim defect, which can be reconstructed by means of a posterior ear interpolation flap. **B.** The flap is elevated and inset at the time of initial cancer resection, after negative margins are assured. **C:** The flap is divided at 3 to 4 weeks, inset, and the donor site is closed with either a skin graft, or in this case, with local tissue rearrangement (a rhomboid flap).

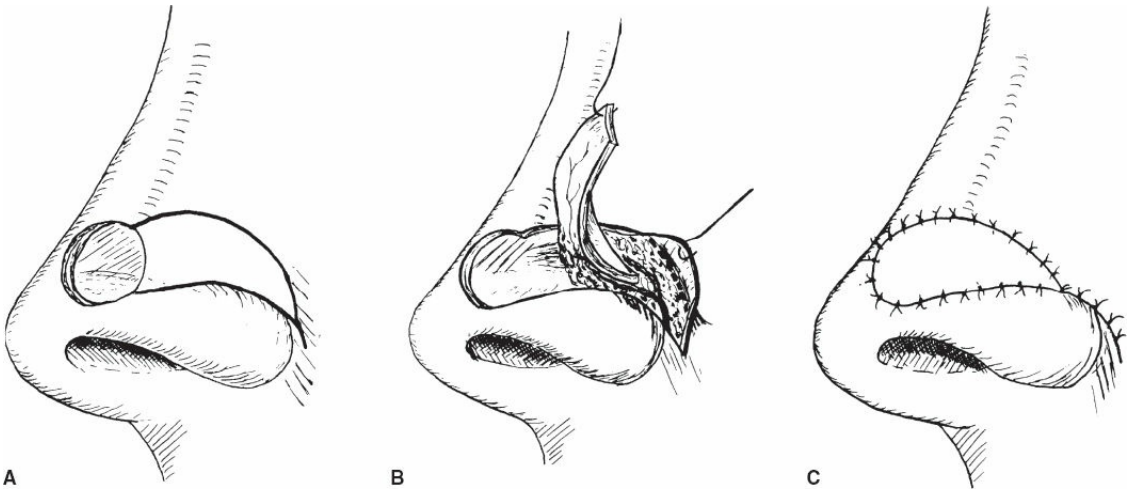

Figure 16.5. **A.** The typical defect is in a paramedian position on the nasal tip. The nasalis musculocutaneous flap is designed with its caudal line right at the alar groove and the cephalad line determined by the width of the defect. **B.** The flap is elevated down to the muscular attachments at the base of the piriform fossa. **C:** The flap is advanced. Any small dog ears resulting from the concave flap merging against a convex recipient area can by excised. (From Rybka FJ. Reconstruction of the nasal tip using nasalis myocutaneous sliding flaps. *Plast Reconstr Surg* 1983;71:40, with permission.)

For larger defects along the tip of the nose where the banner flap will not suffice, it is advisable to use the entire remaining skin on the dorsum of the nose by outlining a dorsal nasal flap that extends beyond the defect and along the lateral aspect of the nose to the glabella. By cutting it toward the opposite side, the angular vessel is maintained, and a skin flap is developed to cover the entire defect and the secondary defect along the glabella; this is closed in a VY type of fashion (Figs. 16.7 and 16.8). The dog-ear that occurs can be handled at the same time by resection, thus making it a single-stage procedure.

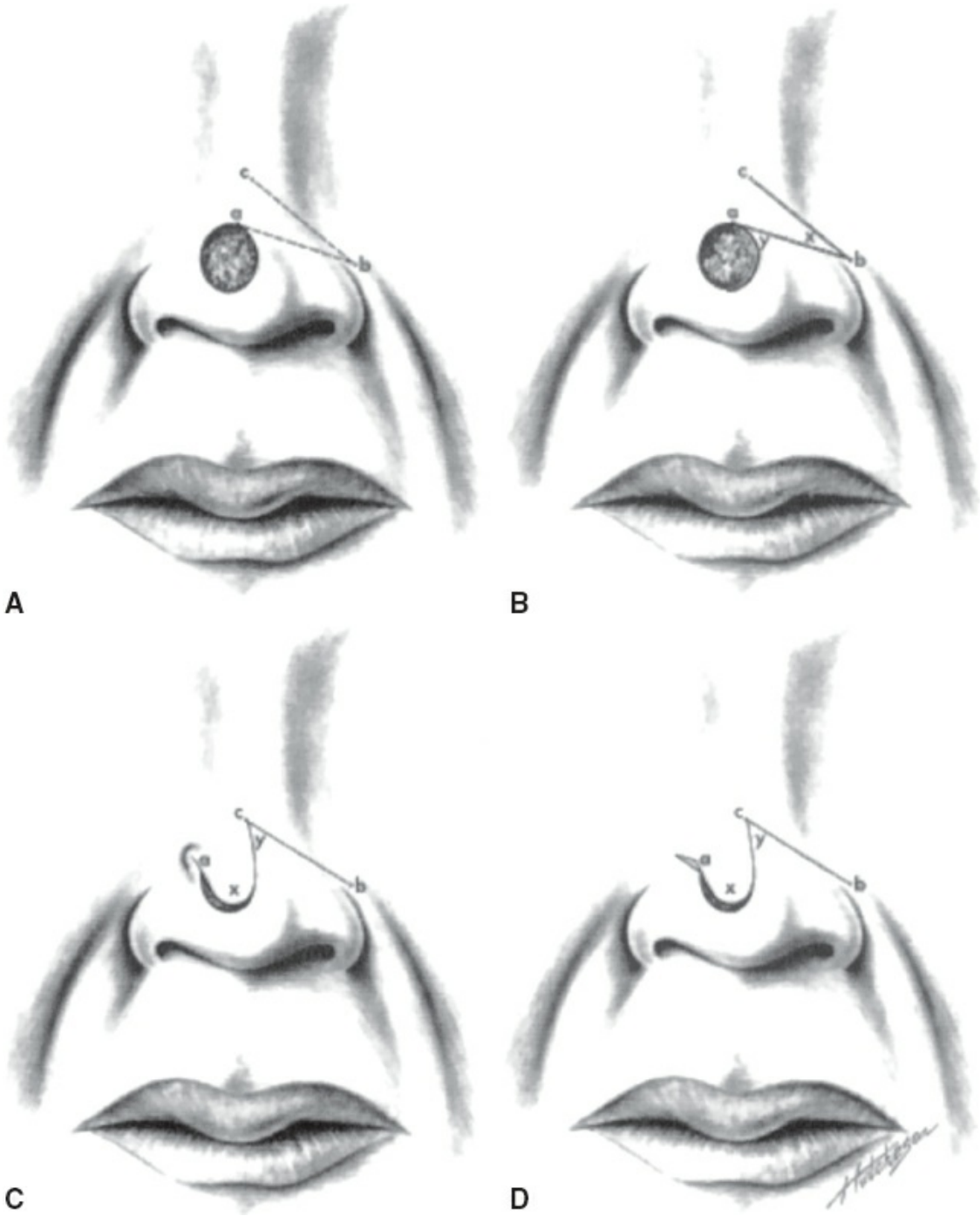

Figure 16.6. Principles of the banner flap procedure. **A.** Triangular flap is outlined by points *a, b,* and *c.* **B.** Larger flap *x* and smaller flap *y.* Each may be transposed as a modified Z-plasty. **C.** Flap *y* is inset, and the tip of flap *x* is trimmed to fit the residual defect. **D.** The resultant dog ear at point *a,* if excessive, may be reduced by a triangular excision (leaving the base untouched). (Reprinted from Masson JK, Mendelson BC. The banner flap. *Am J Surg* 1977;134(3):419–23. Copyright © 1977, with permission from Elsevier.)



Figure 16.7. The axial flap is based on vessels emerging at the level of the inner canthus. This allows increased mobility and precise adjustment. (From Marchac D, Toth B. The axial frontonasal flap revisited. *Plast Reconstr Surg* 1985;76:686, with permission.)

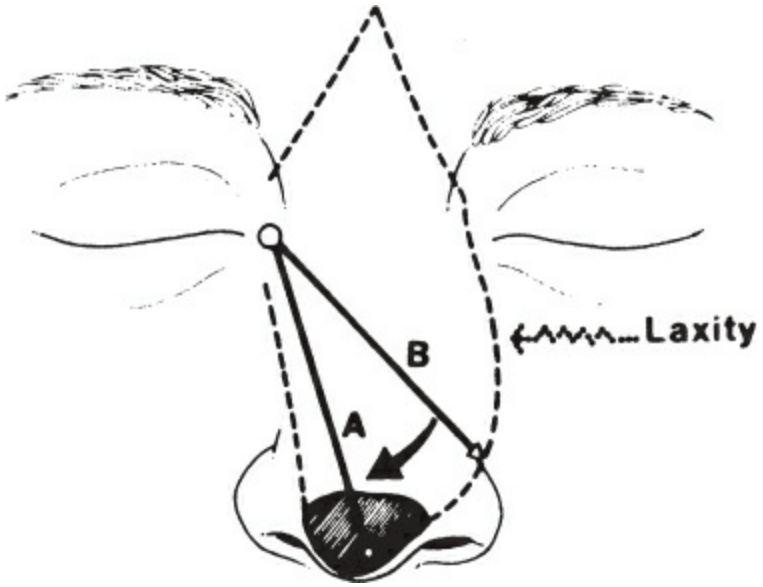

Figure 16.8. The axis of rotation should be considered and the incision taken rather low on the lateral side of the nose. (From Marchac D, Toth B. The axial frontonasal flap revisited. *Plast*

Reconstr Surg 1985;76:686, with permission.)

Total Reconstruction of the Nose With a Midline or Paramedian Forehead Flap

For patients with large basal or squamous cell carcinoma of the nose or postradiation persistent tumors, total excision of the overlying skin is indicated, and reconstruction, after appropriate margins have been obtained, is best done with a midline or paramedian forehead flap (Fig. 16.9).

The technique of the procedure is straightforward. A pattern is obtained of the acquired nasal defect and is transferred to the midline or paramedian area (centering on the supratrochlear vessel) of the forehead. One has to ensure adequate length of the flap to reach the distal part of the nose, which may require extending the flap into the hairline. The forehead flap is then incised and elevated at the subcutaneous tissue level to approximately 2 cm above the glabella. At this point, the flap is deepened to include the galea for the midline forehead flap, and the periosteum for the paramedian flap to ensure that the blood supply, which comes from the angular vessel and the supratrochlear vessel, respectively, is included. The flap is then turned on either the left or the right axis, whichever is easiest to reach the distal portion of the defect. Although it is advisable to save at least one of the supratrochlear and supraorbital vessels in the case of the midline forehead flap, it is not essential because the flap is supplied from the angular vessels of the nose that are located along the lower border of the nasal bones as it meets with the maxilla. In the case of the paramedian compared to the midline forehead flap the arc of rotation is decreased which can minimize the kinking of the pedicle, but the donor site leaves an inevitably asymmetric donor site scar, a disadvantage as compared with the midline forehead flap. Both flaps require a second stage, which is the division and insetting of the pedicle.



Figure 16.9. Forehead flap, based on supratrochlear vessels. It easily reaches the entire notes. The forehead defect is closed primarily as much as possible and the remaining is left open to heal. (Modified from Mathes S, Nahai F. *Reconstructive Surgery: Principles, Anatomy, and Technique*, Page 262, Copyright 1997 Elsevier.)

Additional refinements in nasal reconstruction include a three-stage approach that focuses on nasal subunits, pioneered by Menick in the 1980s. Additional investigation of cosmesis in these reconstructions has been undertaken. One recent study by Stahl et al. showed no difference in cosmetic outcome in two-stage versus three-stage reconstruction.

Breast Reconstruction

What was initially an imperfect product consisting only of the creation of a mound with an implant has now developed into a most satisfactory and acceptable method in which, following the extirpation of a breast, one is able to restore the removed structure and obtain symmetry with the opposite side.

This was made possible initially with of the introduction of the latissimus dorsi myocutaneous flap in 1977, as well as the more sophisticated TRAM flap in the early 1980s. Both methods have undergone considerable development and refinement to increase their safety and versatility. The addition of the muscle sparing TRAM, the DIEP, and other perforator flaps, like the PAP and TUG flaps, used as free tissue transfer, have added to the reconstructive breast surgeon's arsenal, providing additional options for patients with less donor site morbidity.

Most breast centers at the present time offer the patient different alternatives for treatment of breast cancer, and if the patient chooses mastectomy, some form of immediate reconstruction is often suggested.

Objectives and Principles of Breast Reconstruction

The objective of breast reconstruction is to perform a safe operative procedure that will obtain symmetry of both breasts. In the case of unilateral breast reconstruction, this often requires modifying the contralateral normal breast by either reduction mammaplasty or a mastopexy. Ideally this should be done at the same as the breast reconstruction. But in the event of a tissue expander placement, sometimes followed by radiation, it behooves the reconstructive surgeon to await subsequent expansion to perform a symmetry procedure, as expansion outcomes will vary greatly due to a number of factors. Conveniently, a second procedure is necessary in these individuals, as the expander will be replaced by an implant, and/or myocutaneous, or perforator flap, at a later time, which presents an ideal time for a symmetry procedure.

The principles of breast reconstruction, which apply to any method used, include: (a) the preservation or restoration of the inframammary fold, (b) obtaining satisfactory projection, (c) obtaining satisfactory and matching ptosis with the contralateral breast, and (d) closing the axillary defect in immediate reconstructions (Fig. 16.10).

The Inframammary Fold

The inframammary fold is nothing more than the end of the lower pole of the breast. Consequently, the oncology surgeon does not need to extend the dissection any further than the inframammary fold in completing the mastectomy. It is not unusual for some plastic surgeons to preoperatively place some percutaneous sutures or skin staples along the fold prior to the mastectomy to secure this landmark. In a reconstructed breast with a TRAM flap, the inframammary fold is the lower end of the flap. However,

if one has reconstructed the breast with the use of an implant or an expander, the inframammary fold represents the lower edge of the capsule around the implant. Because implants are likely to develop capsular contractures that raise the inframammary fold, most reconstructive surgeons place the expanders or the implants 2 to 3 cm below the inframammary fold so that the folds will be matched with the ensuing capsular contracture.

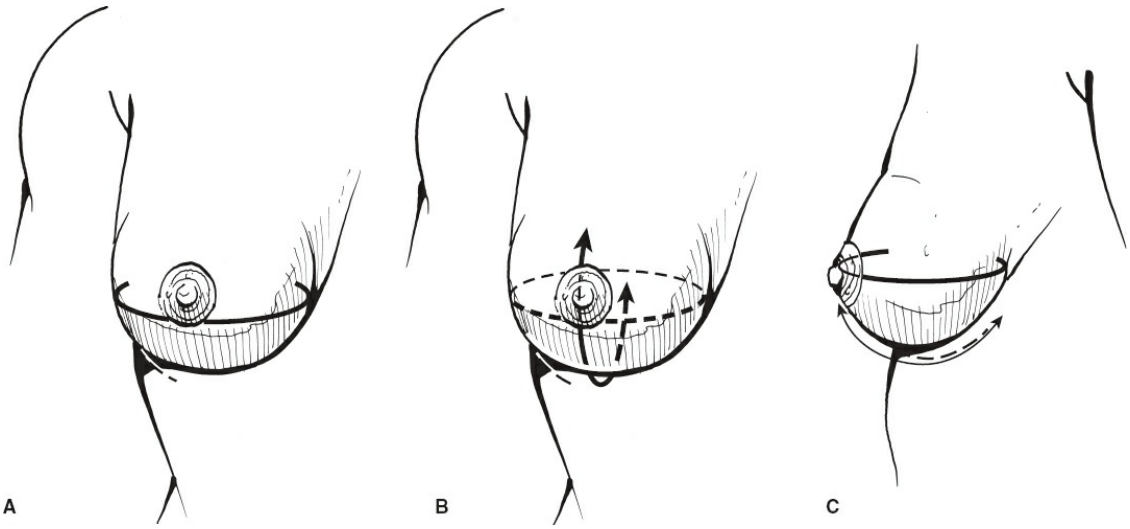

Figure 16.10. Diagrammatic demonstration of projection or ptosis of the breast. **A.** Projection is determined by the transverse diameter over the convex surface of the breast from the sternum to the anterior axillary line. **B.** Ptosis is determined by the vertical distance over the breast to the inframammary fold. **C.** Inframammary line is determined by the lower edge of the breast, or in the case of a reconstructed breast, by the lower edge of the TRAM flap. (Modified from Vasconez LO, Lejeur M, Gamboa-Bobadilla M. *Atlas of Breast Reconstruction.* Philadelphia, PA: JB Lippincott, 1991:12, with permission.)

Projection

Projection is defined as the maximal dimension of distance from the chest wall along the transverse diameter from the sternum to the anterior axillary line. If one is to obtain more projection when a transverse incision has been used for the mastectomy, the upper end of the incision needs to be zigzagged so that the transverse diameter will be larger. This is avoided with the use of the skin-sparing mastectomy because the entire envelope of skin is present except for the nipple and areola, and one need to fill only the skin envelope with tissue, a pedicle or free flap, like the TRAM or

DIEP flap, to obtain satisfactory projection. Alternatively, coning of the flap and proper inset can reproduce an aesthetically pleasing breast mound with appropriate width and projection, regardless of the size, type, and location of mastectomy incision. While an intact breast envelope is ideal to work with, the oncologic burden, vis-à-vis location and size of tumor, informs the general surgeon's ability to leave such an envelope safely for reconstruction with minimal risk of recurrence.

Ptosis

Ptosis refers to a vertical dimension measured over a curved surface from the clavicle over the breast and down to the inframammary fold. It categorizes the relationship of the nipple areolar complex in relation to the breast tissue and the inframammary fold. If one has fixed the inframammary fold, either with sutures or preservation, one can place the flap in such a way that it will hang down below the inframammary fold to obtain ptosis. Usually this is done for a minimal amount of ptosis because it is preferable to modify the contralateral breast with a mastopexy or reduction mammoplasty. Ptosis is rarely possible with the use of an implant or an expander, except in the experienced hands of plastic surgeons who use anatomic type of implants. Ultimately, nipple–areolar complex position will determine ptosis. The ideal aesthetic breast will have a point of maximal projection that coincides with the NAC. If the tissue below the NAC falls below the inframammary fold, this is referred to as pseudoptosis, and is considered acceptable, especially in larger breasted patients. The descent of the NAC below the IMF, while possibly necessary for symmetry and natural appearance, should be minimized to maximize cosmesis, restoring a youthful appearance of the breast.

Closing the Axillary Defect

The fourth principle of breast reconstruction that should be addressed is closing the acquired axillary defect. The breast extends only to the anterior axillary line. The oncology surgeon, even with a skin-sparing mastectomy, dissects the skin flaps to the anterior border of the latissimus dorsi muscle, which is in the posterior axillary line; the surgeon also will perform a sentinel node biopsy of the axilla. Consequently, it is essential that the reconstructive surgeon closes and obliterates the axillary defect by approximating the lateral skin flap to the anterior axillary line with sutures and places a drain along the axilla, particularly in immediate breast reconstructions. In delayed breast reconstructions, the dissection of the

mastectomy flaps is done only to the anterior axillary line.

Bilateral Mastectomies

Presently, patients are electing to undergo bilateral mastectomies and immediate reconstruction. This usually entails doing the mastectomy and sentinel node biopsy on the side of the cancer, and a prophylactic skin-sparing mastectomy on the contralateral side.

Patients who request bilateral mastectomies include not only those done for prophylaxis due to BRCA 1–2 gene but also young patients who do not want to live with the burden of frequent checkups for recurrence of the cancer or the possibility of developing cancer in the opposite breast. Other groups who ask for bilateral mastectomies are those who have undergone previous lumpectomy, irradiation, and chemotherapy, and are fearful of suffering through possible radiation or chemotherapy in the future for cancer in the opposite breast (Fig. 16.11). A study by Boughey et al. indicates that contralateral prophylactic mastectomy (CPM) in high-risk women with a personal history of breast cancer is associated with a survival advantage, reflecting an improved overall and disease-free survival. In subsequent years, this has been challenged, as metachronous contralateral breast cancer is found to provide merely a coincidental improved survival rate, which may disappear if FGR levels are accounted for. Currently, the absolute number of CPMs has increased dramatically over the last decade, however the suggestion that a selection bias exists merits additional prospective, randomized, controlled trials before CPM should continue to be recommended.

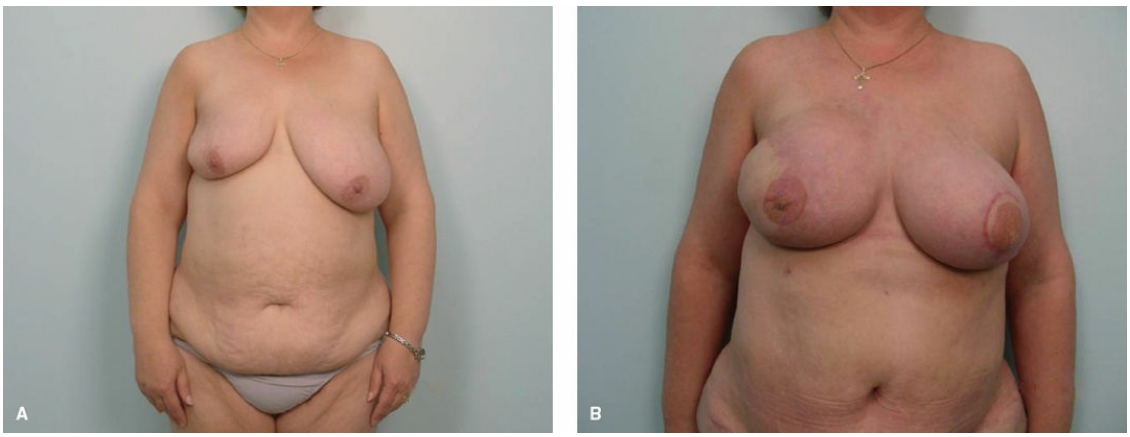

Figure 16.11. A, B. Patient status postlumpectomy and radiation. Above patient presented with postlumpectomy radiation with persistent and or recurrent carcinoma of the breast. Note the shrinking of the irradiated breast. Patient elected to have bilateral

mastectomies with immediate reconstruction. Skin sparing mastectomy was chosen on the left side, which left a larger skin envelope and thus the slight discrepancy in size.

Immediate Versus Delayed Breast Reconstruction

It is our experience that patients who are offered immediate reconstruction following skin-sparing mastectomy accept it and are pleased with the eventual results. A considerable amount of literature has been published indicating the positive and favorable psychologic effects of immediate breast reconstruction, particularly when it is done with relative simplicity, safety, and obtains symmetry with the opposite side. Questions that oncologists as well as patients ask and have been answered include: “Will reconstruction hide or delay the detection of recurrent cancer?” The answer is “No” because most of the recurrent cancers occur at the subcutaneous tissue level and alongside the mastectomy scar. This is easily detectable by palpation. Concerning the development of fat necrosis if a TRAM or perforator flap has been used, and which presents as a hardened mass, one can determine its exact nature by the rapidity of its appearance following the reconstruction (within weeks) and confirmation by fine-needle aspiration, which is read as fat necrosis. Will adjuvant therapy be delayed? No. Adjuvant chemotherapy is usually started 6 weeks following the mastectomy and reconstruction. In most cases, this is an appropriate schedule. In fact, studies have demonstrated that if there is no immediate breast reconstruction, the possibility of flap necrosis or seroma formation along the axilla often delays the initiation of chemotherapy beyond the 6-week interval.

Finally, patients ask whether they need blood transfusions. The answer is, most likely, no. Blood transfusions, although not proven deleterious for carcinoma of the breast as has been shown for carcinoma of the colon, are often not routinely necessary even when one performs unilateral or bilateral TRAM or perforator flaps. A study from 2013 cites the rate of transfusion at 9.1% in DIEP flap reconstruction, a rate much lower than previously described in the literature. Careful analysis of preoperative risk factors will help guide surgeons in proper flap selection to limit the risk of anemia and subsequent transfusion.

Patients in whom immediate reconstruction would not be indicated include those with systemic diseases, which may make reconstruction more hazardous, such as patients on steroids or with uncontrolled diabetes.

Similarly, if one knows preoperatively that the oncology surgeon plans to irradiate postoperatively, one would not perform an immediate definitive reconstruction because, even if one uses a TRAM or a perforator flap, it is likely to shrink and to become fibrotic.

If one were to use an implant, failure—as indicated by the exposure of the implant or infection—is a very likely possibility, and delayed definitive reconstruction is warranted. These risks also account for the use of expanders with planned radiation, but often preradiation expansion can maintain the skin envelope until delayed definitive reconstruction takes place. In patients with large tumors who receive preoperative chemotherapy to shrink the tumor, immediate reconstruction is appropriate, although it is done with caution and with the expectation of problems with delayed healing, not only of the flap used for reconstruction, but also for the secondary defect, most likely in the abdominal wall, if the TRAM flap was used. The reason for this is that the deleterious effect of chemotherapy on wound healing persists for 6 to 12 weeks following the cessation of chemotherapy. Despite this, more recent literature suggests that neoadjuvant chemotherapy does not portend a statistically different complication rate for all autologous breast reconstructions. A 2015 study in Gland Surgery indicated that pedicled TRAMs were more likely than free TRAMs or DIEP flaps to undergo fat necrosis, though no difference in donor site morbidity or wound complications were noted.

In patients with persistent or recurrent tumors, following lumpectomy and radiation requiring completion mastectomy, immediate reconstruction is essential, either with a latissimus dorsi muscle, TRAM, or perforator flap, because delayed wound healing or wound breakdown of the postradiation wound is likely to occur.

Nonetheless, a decreasing number of patients present months or even years later for delayed reconstruction. The aesthetic result is as satisfactory as with immediate reconstruction, although it has the disadvantage of requiring a second operative procedure and a second hospitalization.

Options for Breast Reconstruction

There are several methods for breast reconstruction, and each one must be discussed with the patient, addressing the advantages and disadvantages of each. The methods include the use of implants or expanders, the use of pedicled flaps such as the latissimus myocutaneous flap or the TRAM flap, and free flaps, such as the MS-TRAM, DIEP, TUG, and PAP flaps. These

techniques vary considerably in their complexity.

Implants and Expanders

Immediate breast reconstruction with implant placement represents only 29.4% of breast reconstructions. Patients need to have good skin tone, be nonsmokers, have small breasts, and will not be receiving radiotherapy postoperatively are good candidates.

Most patients undergo immediate placement of tissue expanders for two reasons: as a time and a placeholder. Often patients are unsure what type of reconstructions they definitively want and are often overwhelmed by the cancer diagnosis initially. Also, even if the patient is a candidate for immediate implant placement, one often does not want to add an additional insult, with underlying pressure, to the relatively thin overlying mastectomy skin flaps. In addition, with many mastectomies (except complete skin-sparing mastectomies), skin is removed and skin expansion is required over time.

The tissue expander or implant can be used for immediate or delayed reconstruction (Figs. 16.12 and 16.13). The expander is placed submuscularly beneath the pectoralis major muscle and the serratus fascia laterally, if possible, to provide an extra layer of tissue in the event of a skin breakdown.

If complete muscle coverage cannot be achieved, the use of acellular dermal matrix for inferior pole support can be added. The pectoralis muscle is release to the medial sternal border and the acellular dermal matrix is sewn to the IMF as well as the inferior aspect of the pectoralis muscle in order to achieve complete expander coverage. This does add additional cost and leads to higher seroma rate, but has been shown to be of benefit with lesser rate of expander loss in case of skin breakdown and better aesthetic result.

The majority of expanders used have a built-in port that is located anteriorly and can be identified with a magnet. The hospitalization is short—1 or 2 days—and the expansion is usually begun on the second week and proceeds at weekly or biweekly intervals for a period of 4 to 6 weeks, depending on the amount of expansion required and how much the patient can tolerate each time. After the expansion is complete, the expander is left in place for ~3 months in an effort to avoid the “recall phenomena,” thus allowing the expander capsule to mature so that contraction of the pocket does not occur once the expander is removed. In case of postoperative radiation the expander if left in place often a minimum of 6 months after

completion of radiation in order to allow for radiation changes of the skin to be completed. There is promising new data, that autologous fat grafting immediately after radiation could potentially stop the progression of radiation changes to the skin.

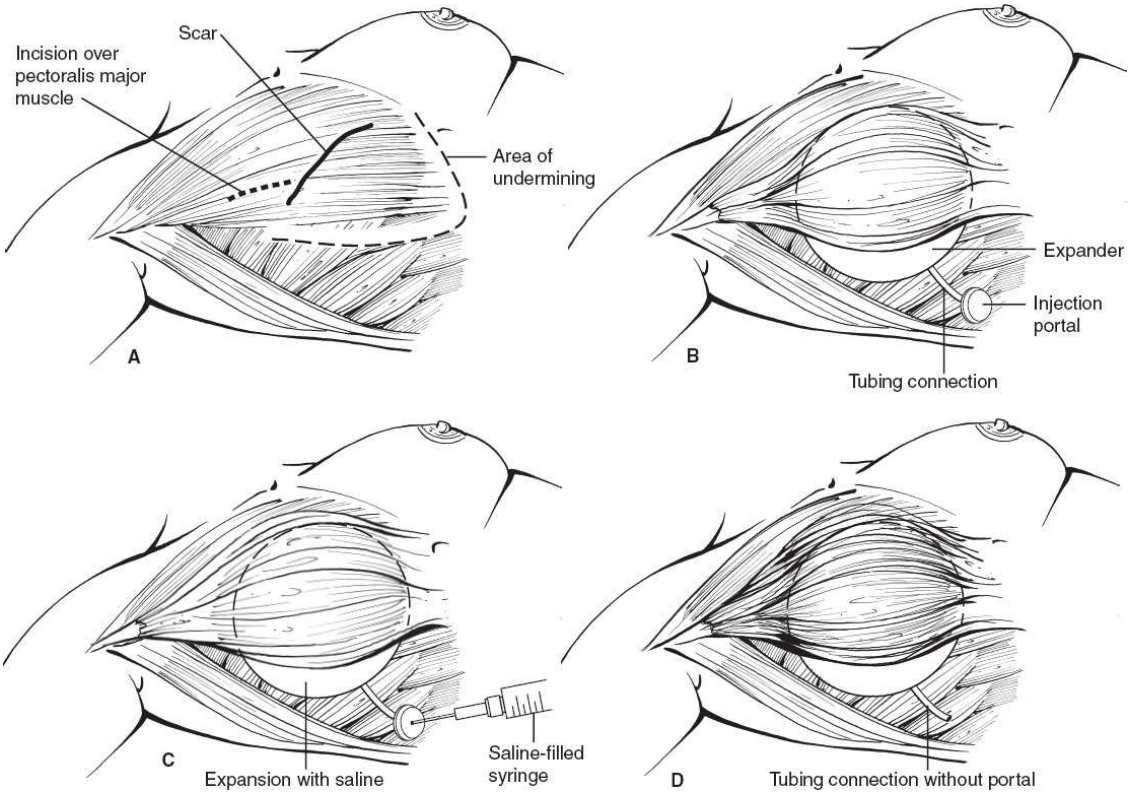

Figure 16.12. A–D. As seen in the diagrams, it is easy to place the expander too high because the pectoralis major does not extend to the inframammary fold. For proper and a lower positioning, the expander does not have muscle coverage in the distal third. (Modified from Vasconez LO, Lejeur M, Gamboa-Bobadilla M. *Atlas of Breast Reconstruction.* Philadelphia, PA: JB Lippincott, 1991:22, with permission.)

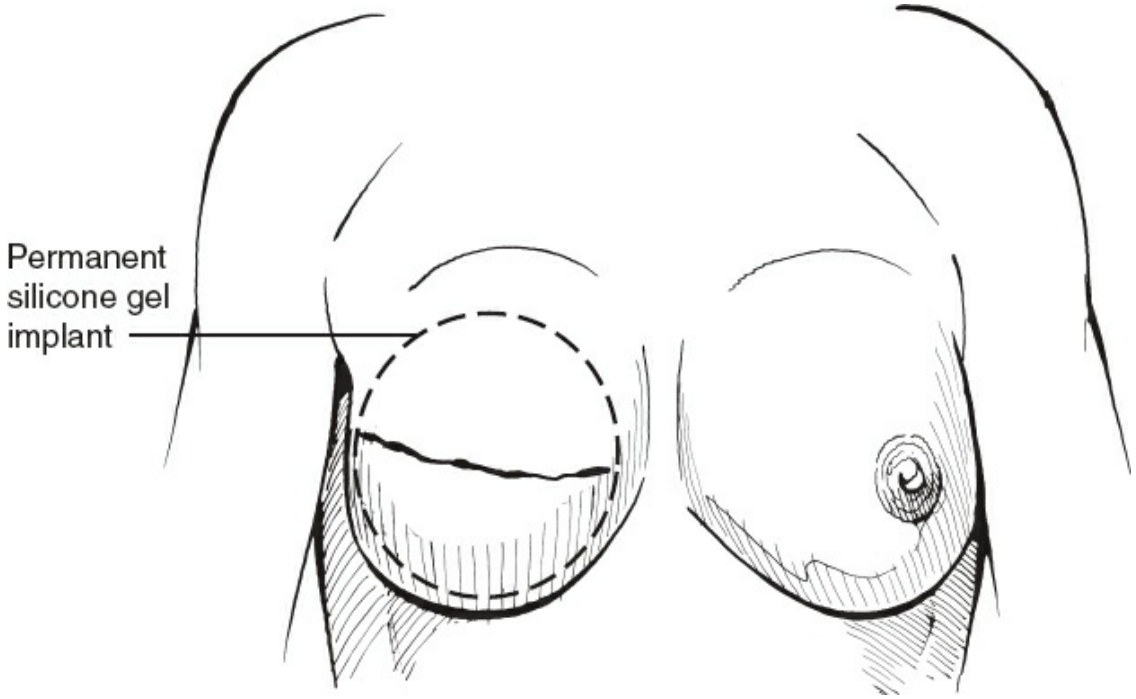

Figure 16.13. The permanent implant is placed 2 to 3 cm below the inframammary fold to allow for the capsular contracture which will invariably ensue. (Modified from Vasconez LO, Lejeur M, Gamboa-Bobadilla M. *Atlas of Breast Reconstruction.* Philadelphia, PA: JB Lippincott, 1991:22, with permission.)

The expander is replaced with either a permanent prosthesis or autologous tissue.

Advantages Expander/Implant Reconstruction

1. Short operating time
2. Short recovery time
3. Lack of donor site scars
4. Lack of donor site morbidity

Disadvantages Expander/Implant Reconstruction

1. The breast is only partly reconstructed and requires an expansion.
2. The use of round implants in the reconstructed breast creates an unnatural upper pole fullness; to obtain symmetry, it is not unusual that one needs to perform a symmetry procedure on the contralateral side and put a smaller implant on the contralateral normal breast. The use of anatomic shaped implants can help create a more natural looking breast shape, with less step-off in the upper pole while providing a fuller lower pole.
3. The reconstructed breast has an unnatural feel, compared to the native

breast.

4. Potential complications are infection, capsular contracture, deflation, and extrusion. Capsular contracture may cause variable amounts of pain and an unnatural appearance of the breast. The incidence of capsular contracture has been reduced with submuscular placement of the implant. Capsulotomy or capsulectomy may be required for capsular contracture. Removal of the implant and autologous reconstruction with vascularized tissue may ultimately be required.

Additional Considerations

Although the use of expanders indicate a two-stage procedure, large multicenter studies have found that there is, in fact, an average of 3.07 operations per patient (vs. 2.32 in DIEP reconstruction) because of the problems with exposure of the implant, capsular contracture, elevation of the inframammary fold, as well as inadequate symmetry.

A second and most important consideration is the increasing use of skin-sparing mastectomy by oncology surgeons. This procedure develops thin skin flaps. Previous reports suggest flap necrosis rates as high as 15%, but more recent, large, multicenter studies suggest flap loss between 5.6% and 8%. Were one to put an implant or an expander under this relatively thin skin, exposure of the implant would be unavoidable. To avoid exposure, total muscle coverage of the implant is essential. Although the serratus muscle fascia does provide a certain amount of coverage to the lower pole of the implant, if one depends only on the serratus muscle fascia for such coverage, one is likely to place the implant higher than without, thus elevating the inframammary fold. Because of this consideration, in our practice when a skin-sparing mastectomy has been performed and an implant reconstruction is planned, we prefer to transpose the latissimus dorsi myocutaneous flap. This provides excellent muscle coverage for the lower portion of the implant and restores the skin island at the site of the nipple and areola. If this is done, as demonstrated in our practice, one does not need to put an expander; instead, a permanent implant is used, thus reducing the number of operative procedures. Even if the overlying skin flap were to necrose in a small portion, the implant is covered with muscle and is salvaged.

Use of Acellular Dermis and Biologic Mesh

If is not possible to cover the lower portion of an implant following a skin-sparing mastectomy, different options exist. We advocate lower coverage

of the implant with the latissimus dorsi muscle, although this entails a bigger operation and turning of the patient. To avoid that, one has the option of using acellular dermis. These materials come in two general classes: human collagen and pig collagen (AlloDerm, FlexHD, AlloMax vs. Strattice).

The materials, although helpful to provide coverage of the implant or reinforce the thin skin flaps, are fraught with deleterious effects. These effects may include the following: there is nearly always a low level of inflammation of the wound, which may be mistaken for an infection. This is due to the fact that collagen has a low level of antigenicity (perhaps more with the xenographic mesh—pig). In severe cases, this can result in a so-called "red-breast syndrome" requiring explantation of the ADM; there is invariable fluid collection or seroma, which requires the use of drains for a prolonged period of time; lastly, one has to be sure that the native skin flaps are well vascularized to avoid exposure of the mesh. Perhaps one of the greatest drawbacks is that the materials are quite costly. This has improved as the market has broadened, but variance in tissue thickness, type and quality makes the added cost difficult to justify at times. Much like any surgical technique, however, the use of ADMs in breast reconstruction varies greatly. Some surgeons will use it almost universally for implant coverage. Others, leery of the potential downfalls, choose autologous, vacularized tissue for coverage instead.

Latissimus Dorsi Myocutaneous Flap and Implant

This procedure is one of the safest methods of breast reconstruction; it is relatively straightforward and very well tolerated by the patient. This technique is particularly applicable to immediate reconstruction following skin-sparing mastectomy. The latissimus provides additional muscle coverage to the implant, particularly on the inferior pole.

The latissimus dorsi is a rhomboid-shaped muscle that originates along the paravertebral fascia in the back and inserts in the upper portion of the humerus. The upper border of the muscle is just above the tip of the scapula, extending obliquely posteriorly, and inferiorly it then reaches the iliac crest (Fig. 16.14). It is a "tree-climbing" muscle, but its function can be taken over by other adjacent muscles. The blood supply is from the thoracodorsal artery, which is a branch of the subscapular artery (third portion of the axillary artery). The pivot point should be as high as possible, limited only by the thoracodorsal pedicle. The insertion does not need to be transected, but the muscle should be freed up as high as

possible to make it transpose as a pendulum rather than rotating it to avoid the bulge along the axilla. The flap is usually harvested as a musculocutaneous flap with a skin island taken transversely across the back so that the scar will be covered with a brassiere. A skin island should usually be limited to no more than 6 to 8 cm to allow primary closure of the donor site.

Technique

The patient is marked in the standing position preoperatively. The anterior border of the latissimus dorsi muscle should be marked on the ipsilateral side, and the inframammary fold should also be marked. The skin paddle is oriented transversely to correspond with the brassiere line. If necessary, an extension along the anterior border of the latissimus dorsi muscle is done to gain access to the upper portion of the muscle.

Working in concert with the oncology surgeon, the flap can be elevated before the mastectomy or following it. If it is elevated before the mastectomy, the patient is placed on a bean bag in the lateral recumbent position. The flap, which is elevated and ready to be transposed, is placed on a sterile plastic bag, and the wound is closed with the insertion of drains. If the mastectomy is done first, the patient is then placed in the lateral decubitus position with the shoulder and arm resting at 90 degrees over a Mayo stand. The skin island is incised perpendicular to the skin through subcutaneous tissue and fascia down to the muscle. The skin flap is elevated superiorly above the tip of the scapula and inferiorly for at least 10 to 15 cm. The dissection of the muscle is begun superiorly, where the upper border of the latissimus dorsi is easily identified, and extends posteriorly along the paravertebral fascia down the inferior border of the dissection while dividing the muscular attachments with the cautery. The anterior border of the latissimus dorsi is identified, the muscle edge is grasped with an Allis clamp, and the elevation is continued by dividing the posterior intercostal attachments.

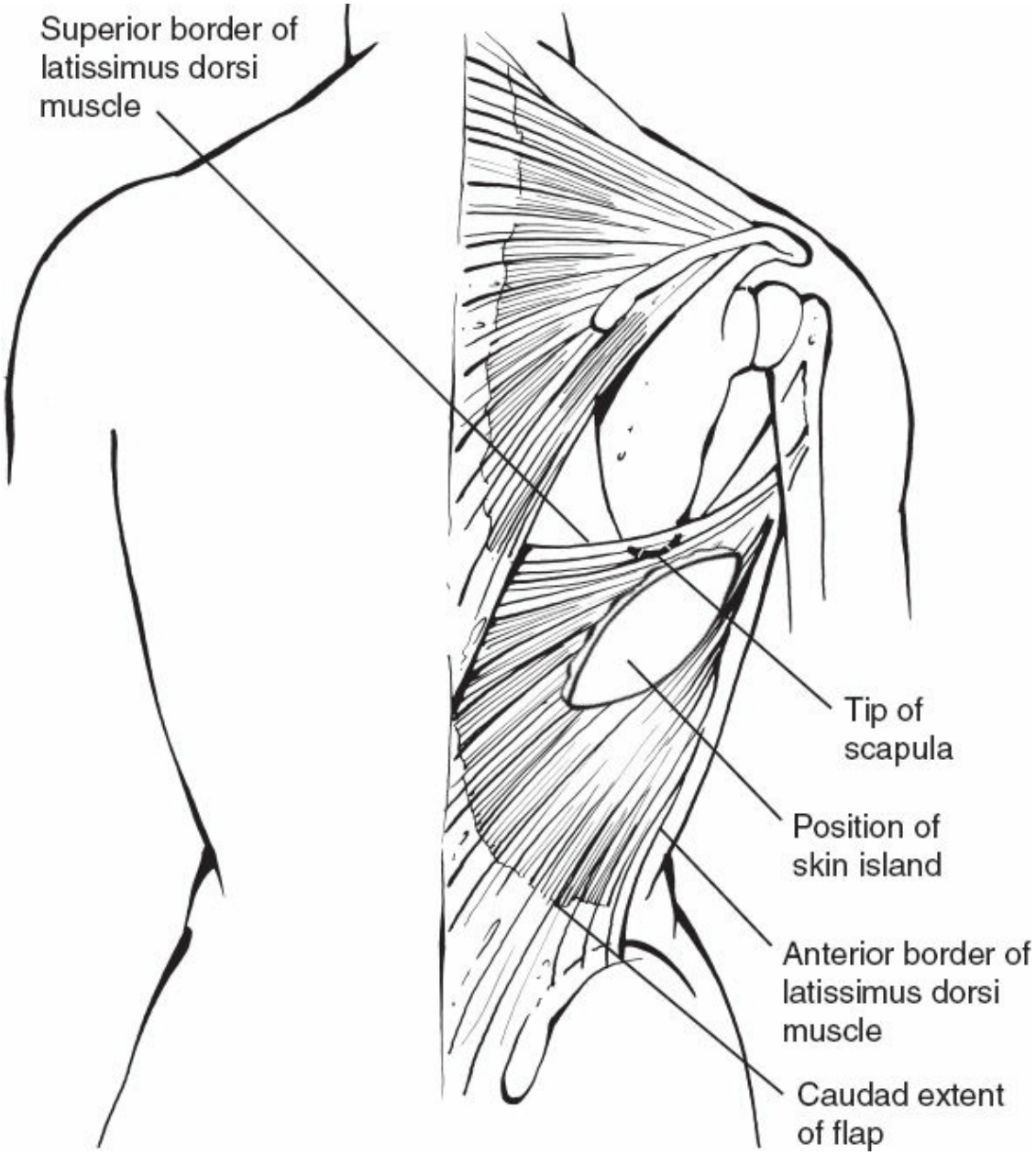

Figure 16.14. External landmarks of the latissimus dorsi muscle. The skin island is preferentially outlined transversely so that the scar will be covered by the brassiere. (Modified from Vasconez LO, Lejeur M, Gamboa-Bobadilla M. *Atlas of Breast Reconstruction.* Philadelphia, PA: JB Lippincott, 1991:39, with permission.)

Care must be exercised to avoid elevating the serratus muscle. This is avoided by beginning the dissection superiorly where one finds the appropriate plane within the planned dissection. The muscle with the overlying skin island is freed up all the way around. The thoracodorsal vessel is easily identified in the axilla. Rarely, the serratus branch needs to be divided to improve the arc of rotation, but this is not routinely done.

The thoracodorsal vessel does not need to be skeletonized, but the muscle should be freed up posteriorly, almost all the way to the humerus. The latissimus myocutaneous flap is then tunneled to the anterior chest by making a very high tunnel through the skin-sparing mastectomy dissection or by using the axillary incision that may have been made for the sentinel node biopsy. Variations of the flap may be used instead (Fig. 16.15).

Once the myocutaneous unit is transposed anteriorly, one elevates the pectoralis major muscle, partially divides its origin along the sternum, and the latissimus dorsi muscle is sutured to the undersurface of the pectoralis major muscle and to the subcutaneous tissue of the skin in the inferior flap, in preference of suturing to the chest wall. An immediate implant is inserted and inflated to the proper volume, but it is advisable that the implant be placed at least 2 to 3 cm below the contralateral inframammary fold (Fig. 16.16). The reason for suturing the lower portion of the latissimus dorsi muscle to the subcutaneous tissue is to avoid restricting the implant pocket. A suction catheter is placed along the axilla.

The patient is then returned to the recumbent position, is sat up on the operating table, and appropriate adjustments are made if necessary by putting another smaller implant on the contralateral side or performing a mastopexy or potentially both.

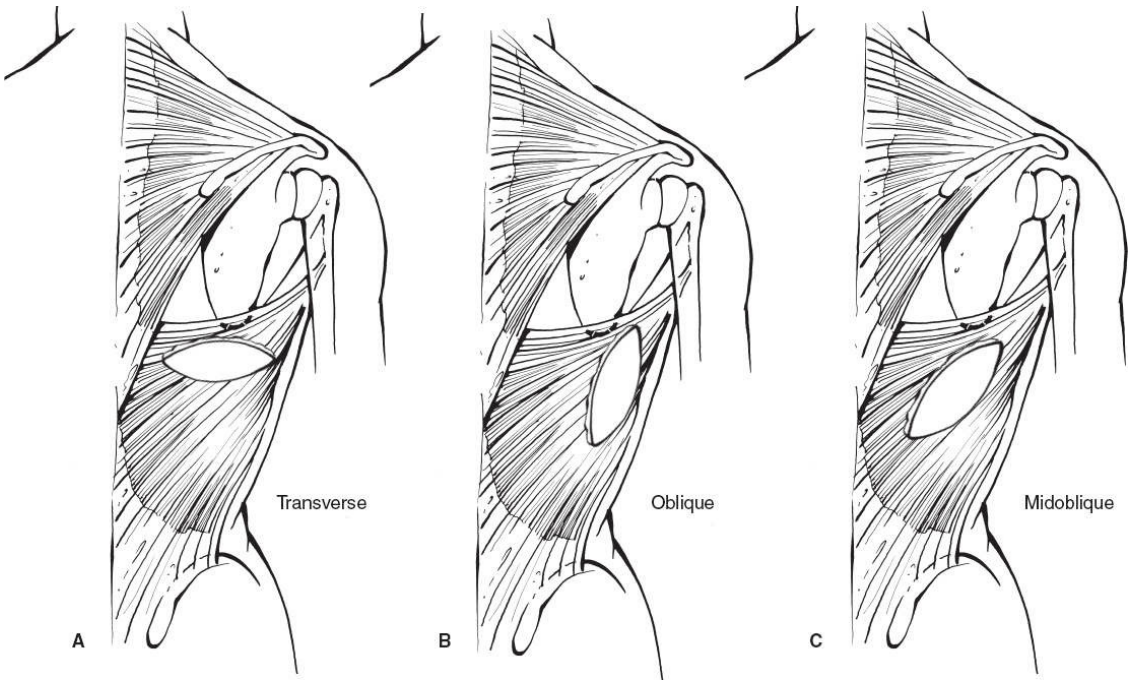

Figure 16.15. A–C. Outline the skin island to fit the different scars from the mastectomy. Transverse outline (**A**) is the most used. (Modified from Vasconez LO, Lejeur M, Gamboa-Bobadilla M. *Atlas of Breast Reconstruction.* Philadelphia, PA: JB

Lippincott, 1991:3.9, with permission.)

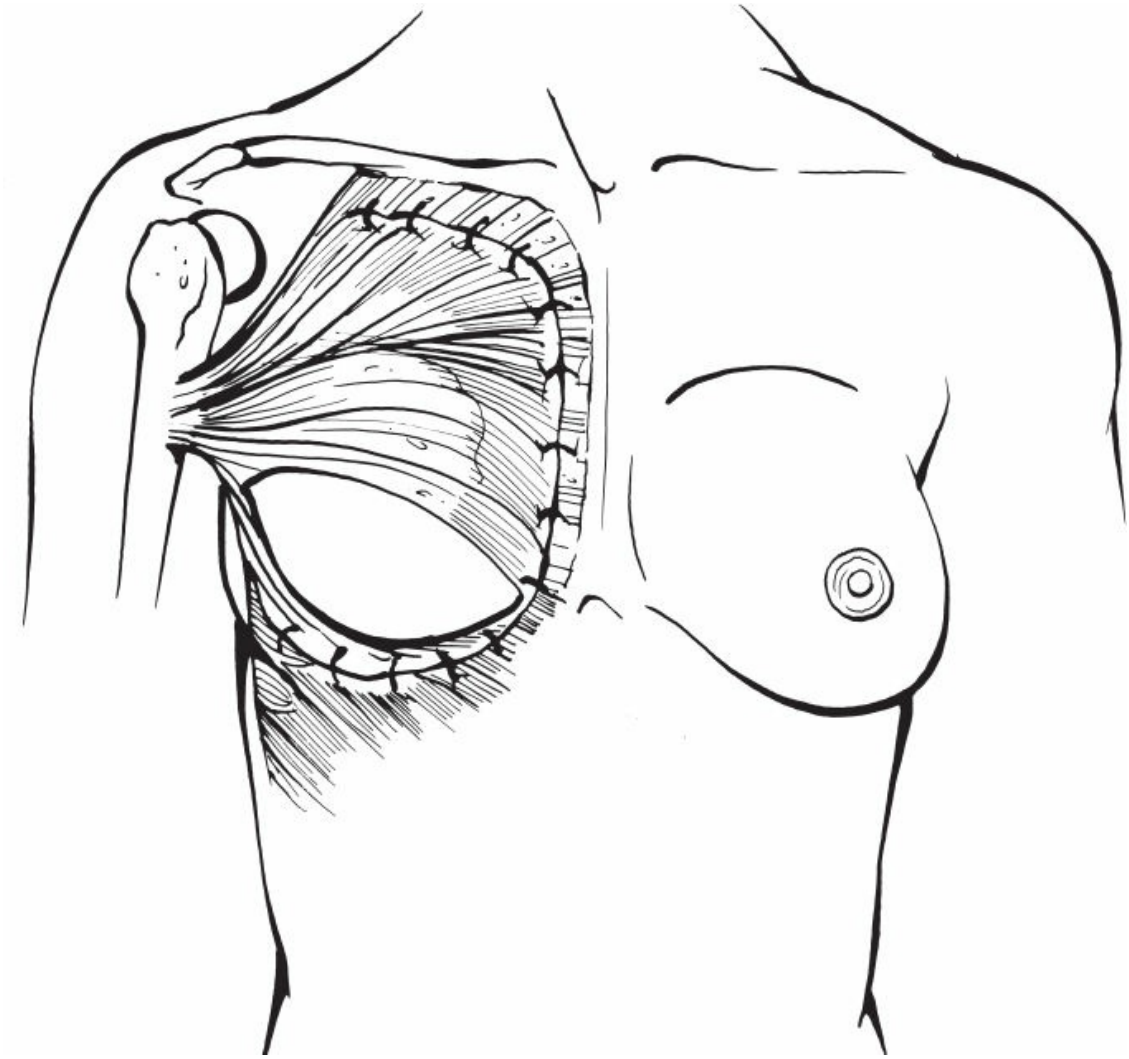

Figure 16.16. Most often the distal third of the implant is not covered by muscle, although occasionally the serratus muscle does help achieve lower coverage of the implant. (Modified from Vasconez LO, Lejeur M, Gamboa-Bobadilla M. *Atlas of Breast Reconstruction.* Philadelphia, PA: JB Lippincott, 1991:3.9, with permission.)

Advantages

1. The implant is totally covered by muscle, and thus protected of the overlying soft tissue.
2. Although it requires repositioning of the patient, thus increasing the operating time, the recovery time and hospitalization are shorter, compared to TRAM or perforator flap reconstruction.

Disadvantages

1. Because an implant is used, capsular contracture remains a possibility even though there is total muscle coverage. Deflation of a saline implant, if used, is also possible, although extrusion is rare.
2. There is a donor site scar on the back, which usually is covered by the brassiere.
3. Seroma is very common at the donor site and is usually treated by a secondary stab wound percutaneous needle aspiration in the most dependent portion of the seroma.

Transverse Rectus Abdominis Myocutaneous Flap

The TRAM flap is the most commonly used method of autogenous reconstruction of the breast, though a paradigm shift toward free flap reconstruction, especially in the CPM group, has been noted in recent years. Nonetheless, it is one of the most natural methods of breast reconstruction, obtaining symmetry with the contralateral breast in the majority of cases. It supplies an abundant amount of soft tissue; however, the recovery time is longer and the hospitalization may be 4 to 6 days. The blood supply is the deep inferior epigastric artery, from the external iliac artery and the superior epigastric artery from the internal thoracic artery (Fig. 16.17). They communicate through a series of vascular interconnections just above the umbilicus, thus forming the epigastric arcade. In addition, the segmental and intercostal vessels join the arcade at the deep portion of the muscle.

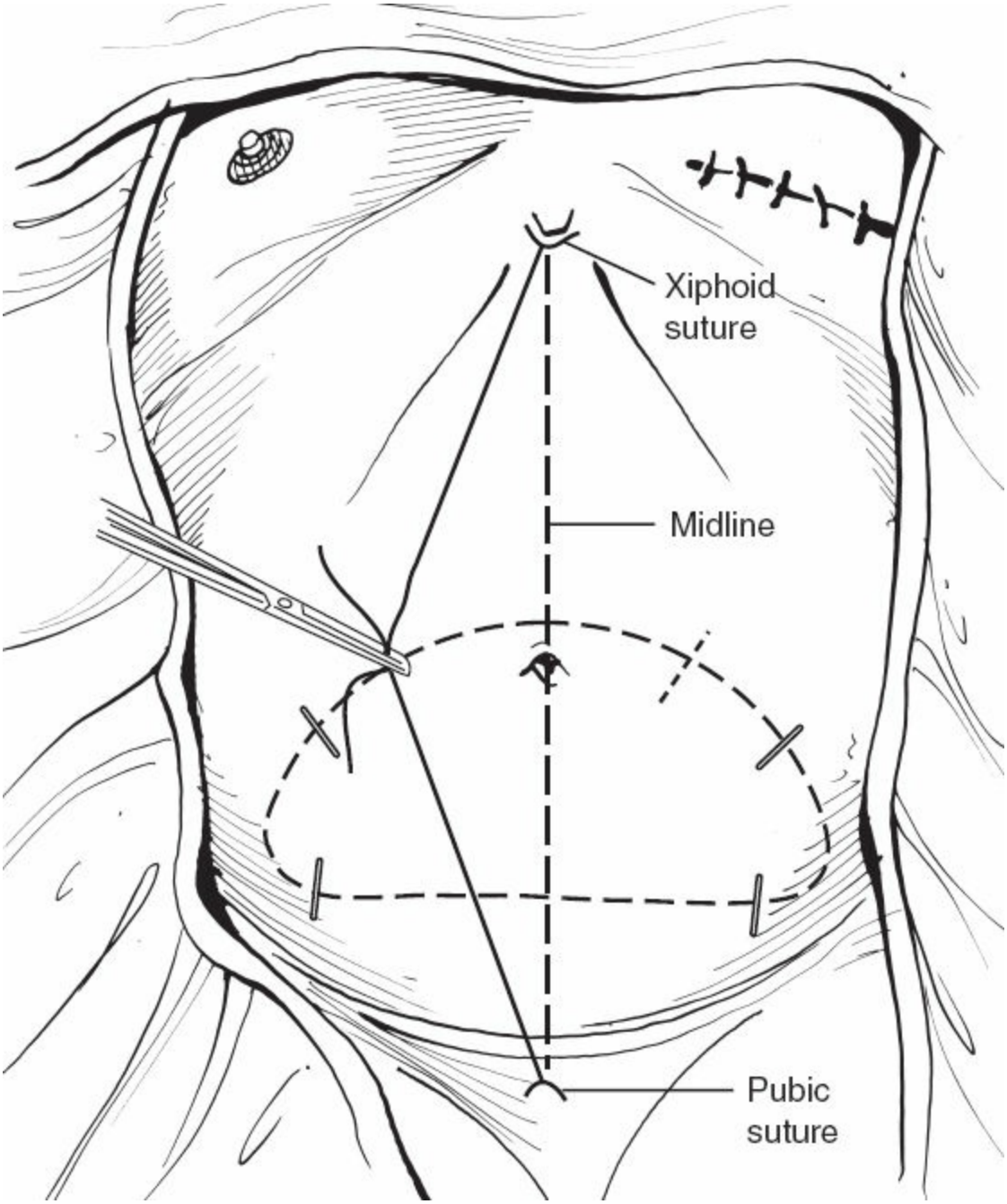

Figure 16.17. Two sutures: one placed on the xiphoid and the second on the mid-pubis allow us to obtain bilateral symmetry by triangulation. (Modified from Vasconez LO, Lejeur M, Gamboa-Bobadilla M. *Atlas of Breast Reconstruction.* Philadelphia, PA: JB Lippincott, 1991:4.31, with permission.)

The inferior epigastric artery is the dominant blood supply and enters the muscle laterally at the semilunar line. The pedicle length is 8 to 10 cm. The blood supply to the overlying skin is through musculocutaneous perforators thought to be arranged in a medial row and a lateral row. The perforators are primarily periumbilical, with few, if any, perforators below

this semicircular line. As determined by the so-called perforator flap, the entire flap is probably nourished by a large periumbilical perforator. This is important to know because the flap should never be outlined with the upper incision below the umbilicus to ensure the inclusion of this perforator. Four zones are designed on a transverse elliptical skin island to describe the availability of the blood supply based on the superior epigastric vessels. The hemiflap is totally reliable, and lateral extension into the flank is also reliable. Interestingly, the only independent risk factor for complications in these patients is smoking history.

The standard design for breast reconstruction is an elliptical lower abdominal transverse skin island at the level of the umbilicus to above the pubis to allow for the direct closure with acceptable tension. Depending on the volume of tissue necessary for the reconstruction, the flap is harvested as a unipedicle, bipedicle, free TRAM flap, or perforator flap. The entire skin paddle can be transferred with a bipedicle flap, and 75% can be transferred as a free tissue transfer. We do not favor bipedicle TRAM flaps for unilateral breast reconstructions except in postradiation cases in which a large amount of skin has been resected from the chest wall.

Unipedicle Transverse Rectus Abdominis Flap

The unipedicle TRAM flap is based on the superior epigastric artery and vein (Figs. 16.18 and 16.19). We advise the use of the ipsilateral TRAM flap because of the shorter arc of rotation and the avoidance of the epigastric fullness. However, when the ipsilateral flap is used, the tunnel must be in the midline and, preferably, extends to the contralateral side so as to preserve at least the lateral half of the inframammary fold. The contralateral rectus may also be used, depending on previous abdominal incisions.

Delayed Unipedicle TRAM

The addition of a delay procedure can improve the viability and performance of the superior epigastric arterial system, especially in zone III. This is performed by dividing the inferior epigastric vessels in a first phase 2 weeks prior to the proposed mastectomy and reconstructive TRAM flap.

Technique

The procedure is begun by circumscribing the umbilicus and leaving it in place. The upper abdominal incision is then made to the anterior rectus

sheath, and the superior abdominal flap is undermined to the costal margin bilaterally and then to the xiphoid in the midline. At this point, working from the chest by either the mastectomy defect or reopening the mastectomy scar in a delayed reconstruction, a midline tunnel is created of sufficient size to allow the passage of the flap. Again, the tunnel must be midline and extend to the contralateral side to preserve the inframammary fold. Having elevated the upper abdominal flap, the anterior rectus sheath is exposed and one can see the location of the perforating vessels, which have either been controlled with hemoclips or electrocautery. A 5-cm wide anterior rectus sheath is preserved with the perforating vessels in the midline, and this anterior rectus sheath is incised on each side, preserving the midline fascia as well as the lateral fascia and freeing up the entire muscle from the posterior rectus sheath.

The lower incision is then made as far down toward the pubis to allow for direct closure. The contralateral side is first elevated rapidly, just past the midline to correspond to the medial incision of the anterior rectus sheath superiorly, and then the fascia along the midline is also divided toward the pubis, preserving the linea alba. The lateral flap is then elevated rapidly, again to the lateral edge of the muscle, and using the incision along the anterior rectus sheath superiorly as a guide, the dissection extends to that level where the fascia is divided again toward the pubis, communicating through a transverse incision with the midline dissection.

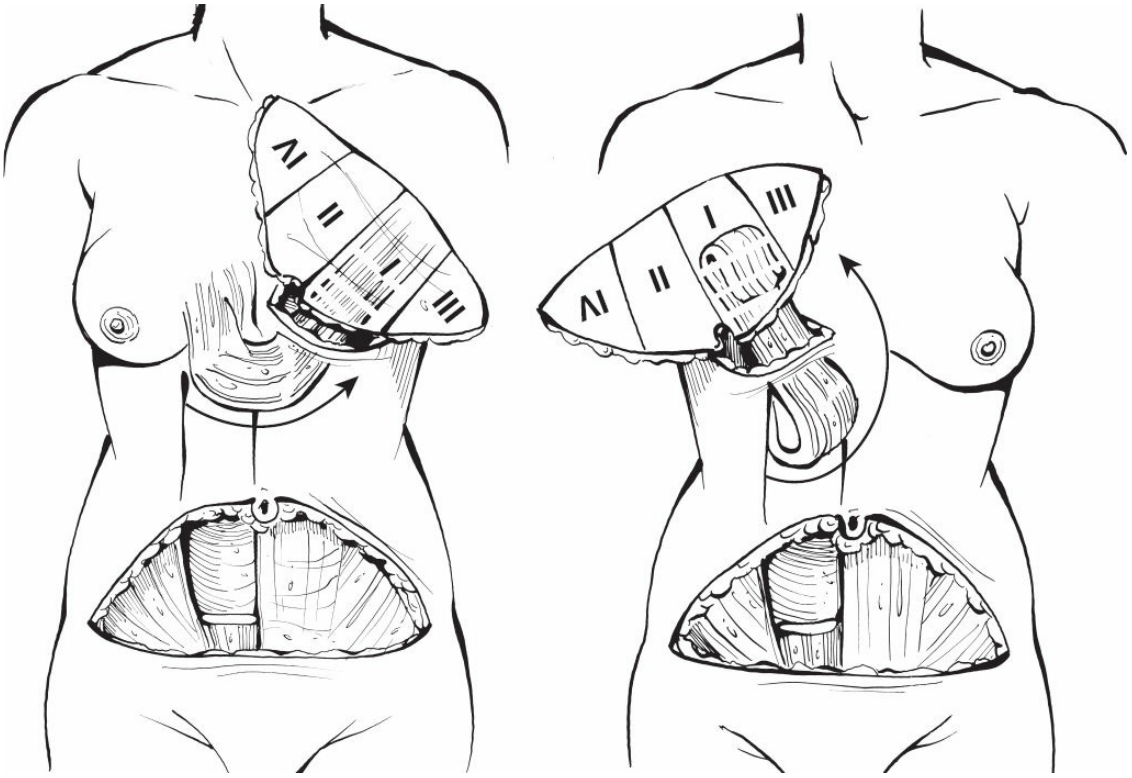

Figure 16.18. Presently, the ipsilateral flap is the first choice. In either case, the tunnel is on the midline of the abdomen and chest. (Modified from Vasconez LO, Lejeur M, Gamboa-Bobadilla M. *Atlas of Breast Reconstruction.* Philadelphia, PA: JB Lippincott, 1991:4.10, with permission.)

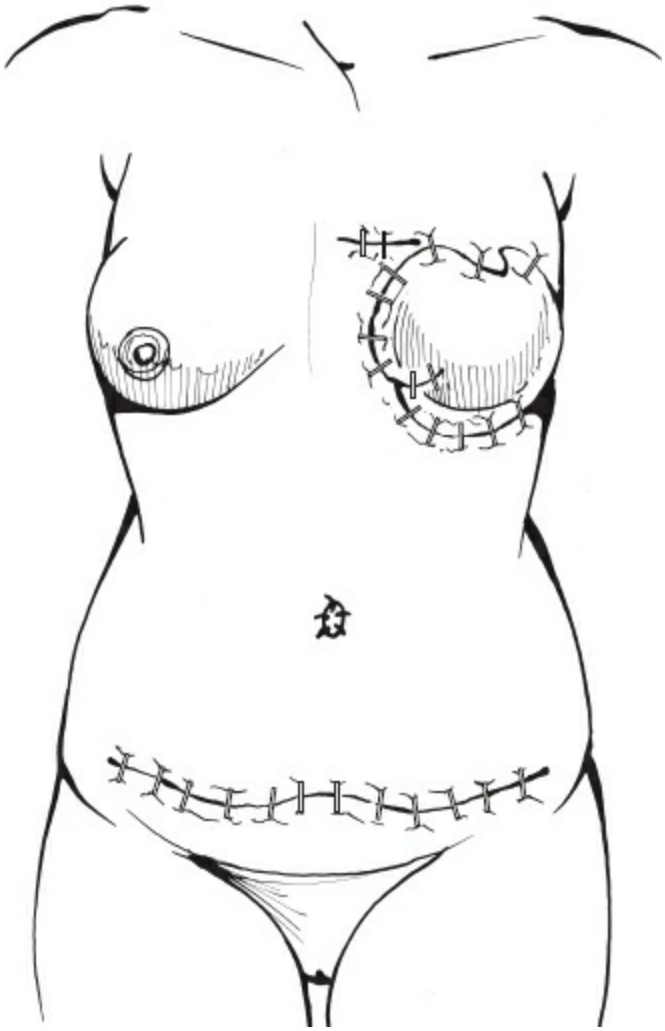

Figure 16.19. In molding the breast, attention is paid to projection, ptosis, and the equal placement of the inframammary fold bilaterally. It is essential to be able to sit the patient intraoperatively, to determine symmetry. (Modified from Vasconez LO, Lejeur M, Gamboa-Bobadilla M. *Atlas of Breast Reconstruction.* Philadelphia, PA: JB Lippincott, 1991:4.10, with permission.)

The rectus muscle is then freed up from the lateral aspect as well as from the medial aspect; the deep inferior epigastric vessels, which are located below the semicircular line, and surrounded by fat, are identified and then divided between hemoclips. The rectus abdominis muscle is then also divided just below this semicircular line, preserving the divided inferior epigastric pedicle. The flap unit is elevated by dividing the segmental intercostal vessels and freed up from the posterior rectus sheath. Once appropriate hemostasis has been obtained, the flap is passed through the midline tunnel toward the chest. The flap is turned with the skin side

out and the distal portion of the contralateral side (zone 4) is discarded, as are additional portions of so-called zone 2. The best way to evaluate the viability of the flap is by observing bright red bleeding from the skin edges. This is observed even if one has used lidocaine with epinephrine for the vasoconstricting effect. The presence of dark blood is indicative of inadequate blood supply and further resection should be performed.

An additional way of checking perfusion is the use of Indocyanine green using the Spy Elite machine. Following injection of ICG into the flap, perforators can be checked individually for flap perfusion. In doing so, perforasomes may be more clearly defined, increasing flap viability when using fasciocutaneous or free-style perforator flaps.

The orientation of the flap is relatively simple as the tip of the flap is placed to simulate the axillary tail of the breast. The remaining flap is allowed to hang down obliquely or vertically, or very simply to fill the envelope of skin-sparing mastectomy (Fig. 16.20). In a case of a delayed reconstruction in which the mastectomy has been done with a transverse incision, the upper edge of the skin flap may be zigzagged to obtain more projection and the lower skin may actually be resected close to the inframammary fold to allow for satisfactory projection and ptosis of the flap. The closure of the abdominal defect is essential, and the most important admonition is to close either separately or together the external and the internal oblique fascias below the umbilicus (Figs. 16.21 and 16.22). One should remember that the anterior rectus sheath splits into the external and internal oblique fascia approximately halfway between the umbilicus and the pubis. The internal oblique fascia has a tendency to retract, and if one does not identify this internal layer and approximate it to the midline, either together or separately with the external oblique, a lower abdominal bulge or pseudohernia will appear.

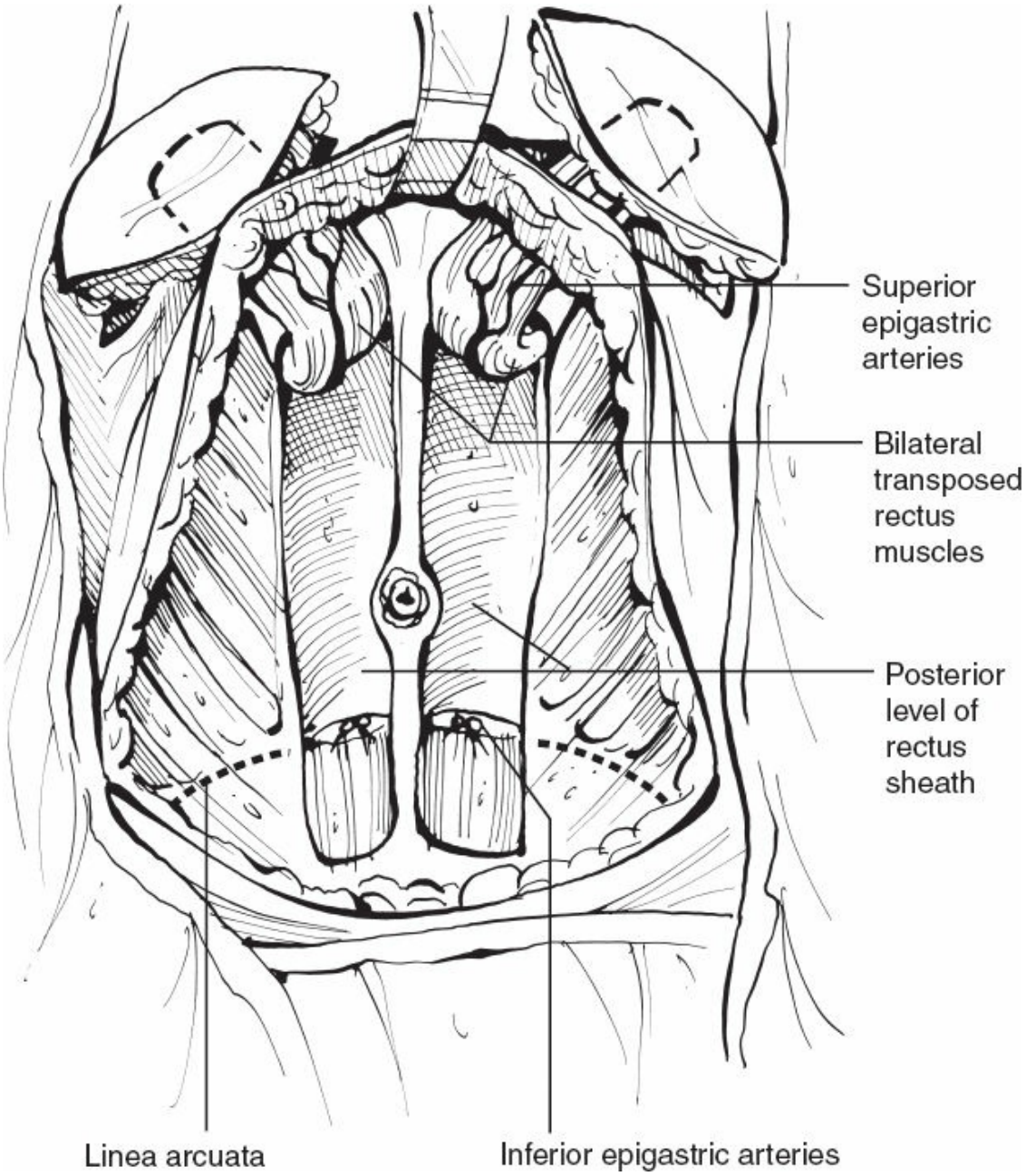

Figure 16.20. For bilateral reconstruction, it is important to design ipsilateral flaps. Rotation of the flap either in clockwise or in anticlockwise direction is safe. (Modified from Vasconez LO, Lejeur M, Gamboa-Bobadilla M. *Atlas of Breast Reconstruction.* Philadelphia, PA: JB Lippincott, 1991:4.10, with permission.)

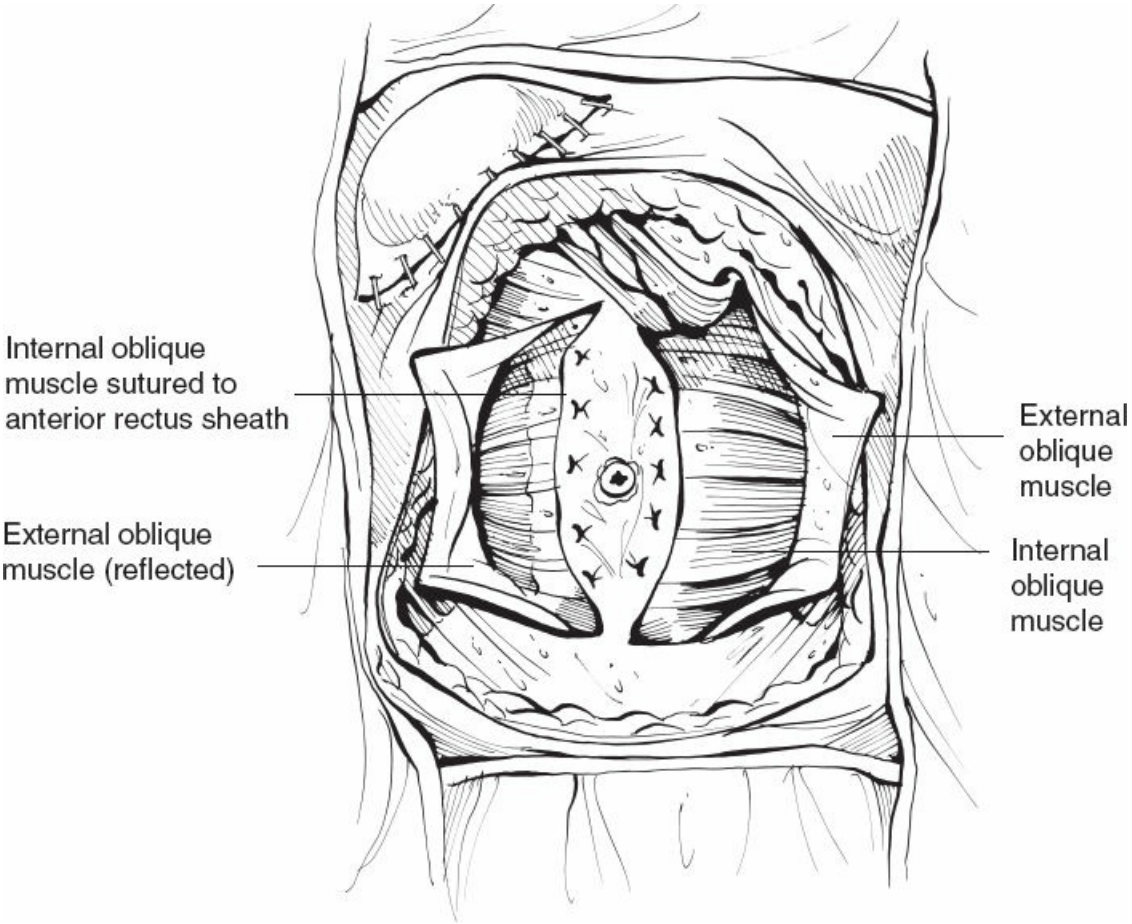

Figure 16.21. The external oblique muscles are freed up to the flanks. The internal oblique muscles are approximated as close to the midline as possible. It is not possible to make them reach the midline. (Modified from Vasconez LO, Lejeur M, Gamboa-Bobadilla M. *Atlas of Breast Reconstruction.* Philadelphia, PA: JB Lippincott, 1991:4.22, with permission.)

In unilateral breast reconstructions, direct closure is almost always possible. To accomplish this, we place three retention sutures of 0 Prolene, one at the level of the umbilicus and one above and one below the umbilicus. Once these sutures are approximated to the midline, we run a loop suture from just below the turn of the muscle in the epigastrium down to the pubis. To centralize the umbilicus, which has been moved to the side of the flap, the contralateral intact anterior rectus sheath is also plicated with interrupted or continuous sutures of Prolene for ~4 cm. If the umbilicus is on a large stalk, additional centralization can be obtained by suturing the umbilicus with interrupted nylon sutures to the anterior rectus sheath as it is pulled toward the center.

The abdominal wound is then closed, and the umbilicus is re-exteriorized at the appropriate level and sutured with fine nylon. Suction

catheters are placed. It should be noted that seromas in a TRAM flap procedure are relatively rare. This is in contrast to the almost universal seromas that are seen in abdominoplasties. The reason for this is not clear, but a possible explanation may be that fluid is suctioned intra-abdominally through small openings in the abdominal sheaths, particularly below the semicircular line.

Advantages

1. Large volume of tissue sufficient to provide excellent shape and symmetry with the contralateral breast.
2. Abdominoplasty results with donor site closure.

Disadvantages

1. Fat necrosis and partial flap loss in 5% to 15% of patients.
2. Pseudohernia is 4%.
3. Possibility of total loss of the flap, particularly in smokers and very obese patients, though not as high as in free tissue transfer.

Bipedicle Transverse Rectus Abdominis Myocutaneous Flap

In cases in which a bilateral mastectomy is performed, bilateral TRAM flaps are performed, again on the ipsilateral side but always with the midline tunnel preserving the inframammary fold in each side. Rarely, a bipedicle TRAM flap is needed for postradiation defects in which large amounts of skin are resected. In such cases, the skin paddle is reliably from the ipsilateral anterior axillary line fold to the contralateral anterior axillary line fold. The flap is harvested in the same manner as the pedicle flap except that both rectus abdominis muscles are harvested along with the transverse skin paddle, preserving both superior epigastric vessels. Although one preserves the linea alba or midline fascia for at least 2 cm as well as the lateral portion of the anterior rectus sheath bilaterally, and primary closure can be done in a good number of patients, mesh is sometimes necessary as an inlay to approximate the remaining fascias. Again, we emphasize that attention must be paid to approximate the internal oblique fascia. If mesh is used, we prefer the use of folded polypropylene mesh, usually four thicknesses, and approximate it with Prolene suture on each side. The use of an onlay mesh is less satisfactory.

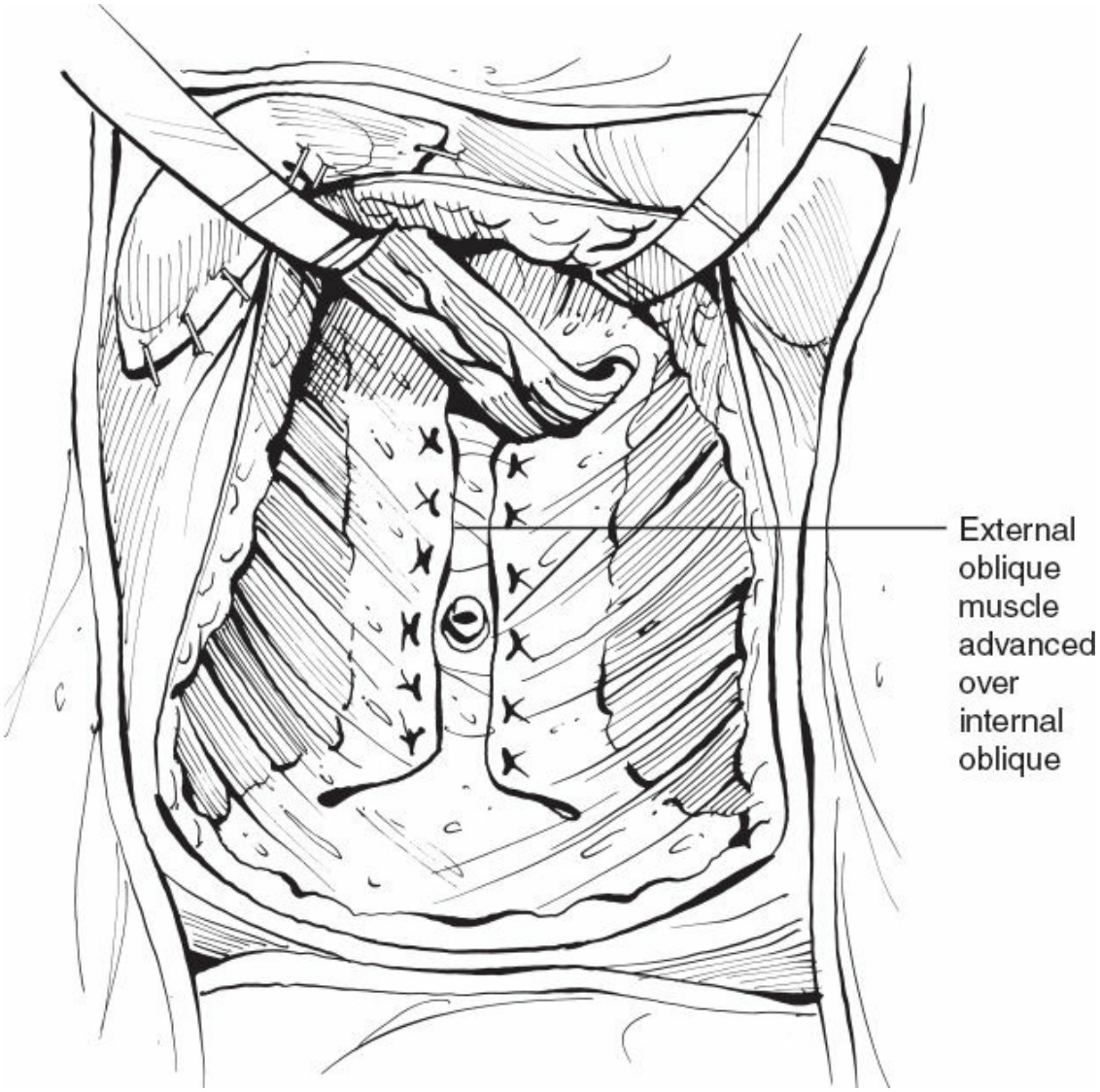

Figure 16.22. Once the internal oblique muscles are plicated, the leaves of the external obliques easily reach the midline. It is imperative that the closure be performed simultaneously on both sides. Otherwise, closure of the second side is nearly impossible due to fascial tears. (Modified from Vasconez LO, Lejeur M, Gamboa-Bobadilla M. *Atlas of Breast Reconstruction.* Philadelphia, PA: JB Lippincott, 1991:4.22, with permission.)

Advantages

1. Larger volume of tissue.
2. Makes for bilateral symmetric reconstructions of the breasts. Preferred also in patients who are markedly obese and have had previous chest wall radiation (patients who have had previous mediastinal irradiation such as for Hodgkin disease, in which internal mammary damage is possible) are best treated with a free TRAM flap anastomosed to the thoracodorsal or other appropriate vessel.

Disadvantages

1. Often requires the placement of mesh.
2. Longer operating time.
3. Greater risk of abdominal wall complications.

Free Transverse Rectus Abdominis Myocutaneous Flap

The dominant blood supply of the free TRAM flap is the deep inferior epigastric vessels. The flap is harvested in the same way as the previously described flaps except that the deep inferior epigastric vessel is preserved along with a small segment of rectus abdominis muscle (Fig. 16.23). It is not necessary to take the entire width of the muscle. The vessel is identified entering the rectus muscle near the semicircular line, traced down to its origin at the external iliac vessels, and ligated at this point. The recipient vessel often used for the anastomosis is the internal mammary artery and its accompanying vein. The thoracodorsal vessel is a second choice at present. The reason for this change is the popularity of the sentinel node dissection. By using the sentinel node, the thoracodorsal vessel is not skeletonized as it was with an axillary dissection, and there is the rare possibility that an initial negative sentinel node may turn out to be positive in the permanent sections, requiring the return to the axilla, where the anastomosis may be compromised. In addition, the internal mammary artery provides a very satisfactory way of molding the breast to match the opposite side.

Advantages

1. Preferred in smokers, obese patients, and patients with mediastinal irradiation for lymphomas
2. Larger volume of tissue
3. Greater freedom of rotation
4. Less incidence of fat necrosis

Disadvantages

1. Longer operating time
2. Requires microsurgical expertise and well-trained team for small artery anastomosis

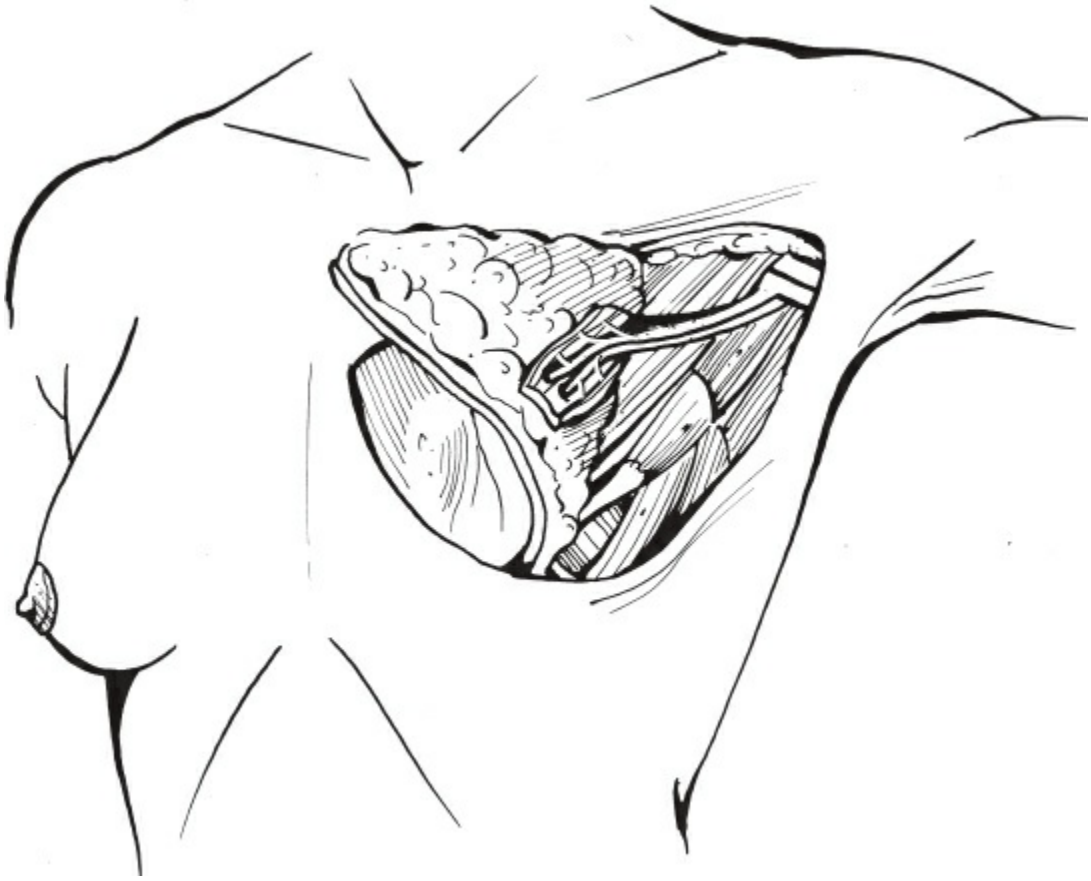

Figure 16.23. For a free TRAM flap, the anastomosis is made to the thoracodorsal vessels as shown above. Presently, most microsurgeons prefer to do the anastomosis to the internal thoracic artery and vein or veins. (Modified from Vasconez LO, Lejeur M, Gamboa-Bobadilla M. *Atlas of Breast Reconstruction.* Philadelphia, PA: JB Lippincott, 1991:13.6, with permission.)

Perforator Flap ("DIEP" Flap)

A modification of the free TRAM flap is the free perforator flap. This entails the preservation of the periumbilical perforator with its accompanying veins dissected along with the deep inferior epigastric vessel, but preserving almost the entire integrity of the rectus abdominis muscle (Figs. 16.24 and 16.25). The proponents of this flap indicate the advantages, such as increasing integrity of the abdominal wall, but it does take a more meticulous and lengthier dissection, at least in less-experienced hands.

One can usually predetermine if a perforator flap type of reconstruction is possible, by performing a CT angiogram. It accurately indicates if the perforators are appropriate for the anastomosis, avoiding the need to visually dissect those vessels. The perforator flap is gaining popularity

because it preserves the integrity of the rectus muscle and of the abdominal wall.

Superficial Inferior Epigastric Breast Reconstruction

This option is a possibility in a minority of the patients who elect microvascular breast reconstruction.

The CT angiogram visualizes the superficial inferior epigastric vessels and one can determine if those vessels are large and long enough to perform the breast reconstruction. It does require additional expertise and does not offer the safety of the deep inferior epigastric vessels. Reconstruction with the superficial inferior epigastric vessels is a superior option taken by well-qualified teams. The vessels can nourish the same amount of abdominal tissue.

A Note on Perforator-Based Flaps

An increasing preference has been noted for perforator flaps due to the decreased rate of morbidity associated with these flaps. Unfortunately, in the less-experienced surgeon—or at least in the case of the surgeon less familiar with these procedures—the so-called perforasome is a somewhat nebulous idea as compared with the angiosome of the more well-characterized musculocutaneous flaps. Fortunately, technology has afforded newer techniques in designing flaps that will be successful. Prior to division, perfusion of an individual perforator can be assessed using intraoperative laser angiography in combination with indocyanine green. This “SPY” system allows the surgeon to confidently assess the viability of the flap on a single (or multiple) perforators prior to committing to flap division. As explained by Gurtner et al. (2013), consensus recommendation regarding intraoperative assessment of flaps suggests this is a safe and potentially beneficial practice.

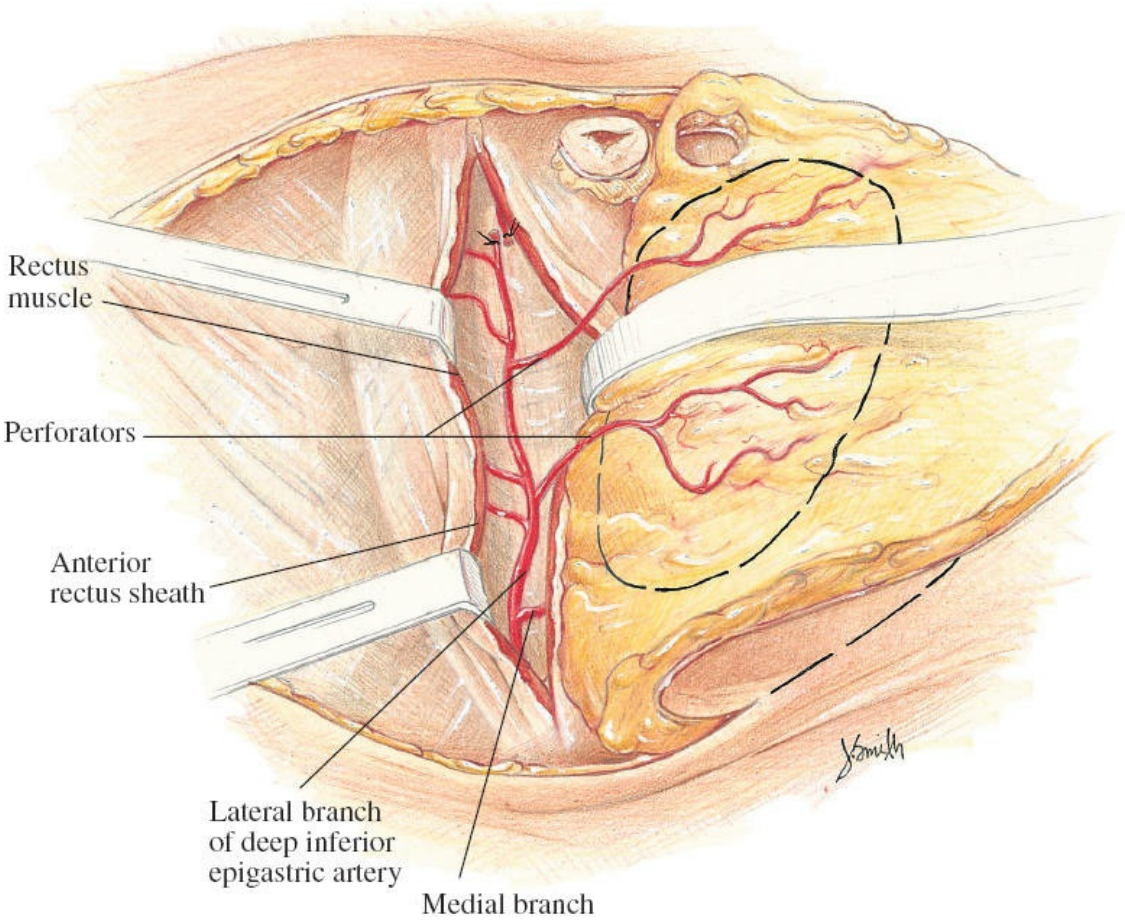

Figure 16.24. Diagrammatic demonstration of the perforators from the deep inferior epigastric vessels. The main perforator is near the umbilicus. (From Spear SL, Little JW, Wood WC, eds. *Surgery of the Breast: Principles and Art,* 2nd ed. Philadelphia, PA: Lippincott Williams & Wilkins, 2006:814.)

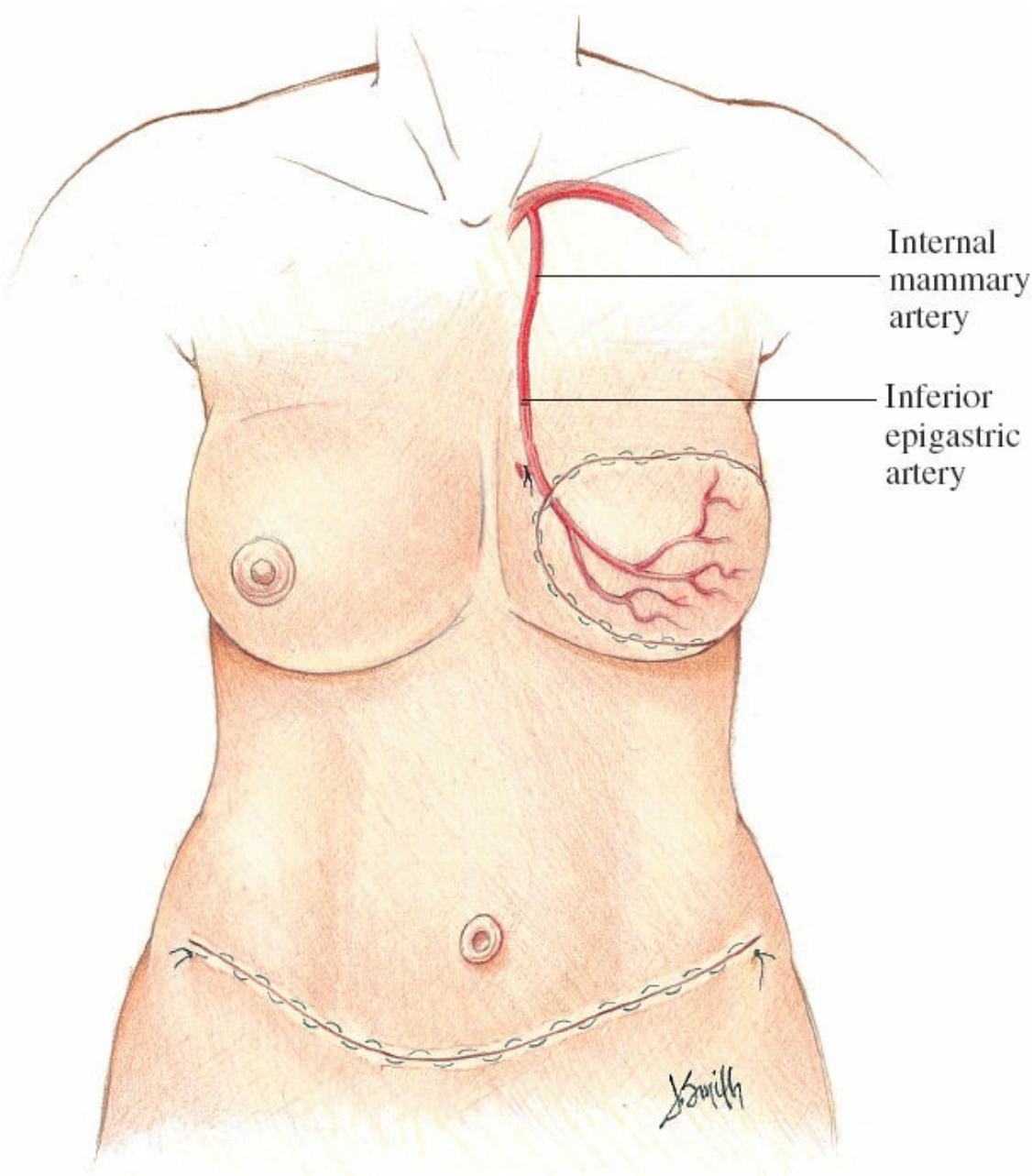

Figure 16.25. The preferred method of anastomosis. It has the advantage of leaving the axillary region free for a possible additional axillary dissection. (From Spear SL, Little JW, Wood WC, eds. *Surgery of the Breast: Principles and Art,* 2nd ed. Philadelphia, PA: Lippincott Williams & Wilkins, 2006:815.)

Other Autologous Options

The TRAM flap may not be indicated in patients who have had previous abdominal operations that have transected the rectus muscle, patients who have had previous abdominoplasty, or in patients in whom there is inadequate abdominal fat to make a breast mound. These following additional free flaps can be offered. (a) The gluteal free flap, based on

either the inferior or more recently the superior gluteal artery, which provides an abundant amount of tissue to be transferred. The pedicle is of good length, 8 to 10 cm, but the patient must be prone during the harvest of the flap and needs to be turned over for the reconstruction. (b) The "Rubens flap," which uses the fat in the flank over the iliac crest region. It is based on the deep circumflex iliac artery and offers adequate volume for breast reconstruction. The vessels offer good caliber and length, 6 to 7 cm, and the donor site scar is hidden underneath pants. During surgery, the patient is supine with the hip lifted by a bean bag during the harvest. (c) The trochanteric free flap, which is applicable to patients who have trochanteric lipodystrophy with a relatively narrow torso. In such patients, the fat from the trochanter can be harvested based on the vessel of the tensor fascia lata, leaving an acceptable defect with a linear incision on the lateral aspect of the leg. If a unilateral reconstruction is performed, a subsequent procedure, such as liposuction, will be needed to match the opposite side. Presently, it is rarely used, although its proper application is clear.

The gracilis free flap is a potential option for thin patients who have small breasts. It is harvested with a transverse orientation, leaving a most acceptable scar, the aptly names TUG flap (Transverse Upper Gracilis). The limiting factor is the relatively small volume of tissue.

Nipple and Areola Reconstruction

With the sophistication and increasing excellence of breast reconstruction, most patients want completion of the reconstruction by having the nipple and areola reconstructed. This is usually performed 3 to 6 months after breast reconstruction, or later if the patient has undergone chemotherapy or radiotherapy. One should wait for the breast to be stable and symmetry has been achieved. In reconstructions using the TRAM flap in which the contralateral flap is modified at the same time, usually by a reduction mammoplasty, the nipple reconstruction is performed on the second operative procedure along with whatever modifications are needed on the reconstructed or the contralateral breast to obtain symmetry, as well as liposuction of the bulging of the epigastrium and the persistent dog ears along the flanks.

The position of the nipple is determined preoperatively with the patient sitting up. No measurements are performed because the nipple sits in relation to the breast itself. The most accurate and effective way to determine the location of the nipple is by visual marking and confirming it

with a digital photograph. Slight asymmetries are easily seen in the picture.

The nipple itself is reconstructed in a TRAM flap by using the adjacent tissue in the form of a flap, the so-called skate flap, which entails elevating a portion of the underlying fat on a superiorly based flap and using the wings from the lateral aspects to wrap the base of the flap (Figs. 16.26 and 16.27). For the areola, tattooing is the method of choice. Occasionally, we tattoo the contralateral areola to obtain satisfactory skin color match. The reconstructed nipple must be planned and made larger than the desired final size because it contracts in the first few months postoperatively. Rarely, if the patient has a very large contralateral nipple, part of the nipple can be used as a free graft to provide adequate size and projection. The use of skin grafts from the medial thigh or any other area of the body to reconstruct the areola has been supplanted with tattooing. The advance in tattooing technology is immense and 3D tattooing has become increasingly common, giving the perception of projection in a 2D image.

Management of Postlumpectomy; Postradiation-Persistent or Recurrent Breast Cancer

Presently, the Multi Center Fischer Study has surpassed 25 years of follow-up. Patients who elected to be treated by lumpectomy and irradiation are now seeking help because of an increasing number of breast cancer recurrences. Though more aggressive local treatment has been found to be associated with lower risk of recurrence, the implementation of conservative breast surgery has inevitably led to an increase in locoregional recurrence as refinements in technique have been undertaken. The treatment for those patients is completion mastectomy. Often those patients elect bilateral mastectomies and immediate reconstruction with autologous tissue. Less often, the reconstruction is done with the latissimus dorsi musculocutaneous flap and an implant. The use of expanders or implants, even with the added attribute of acellular dermis is fraught with complications and is not recommended.

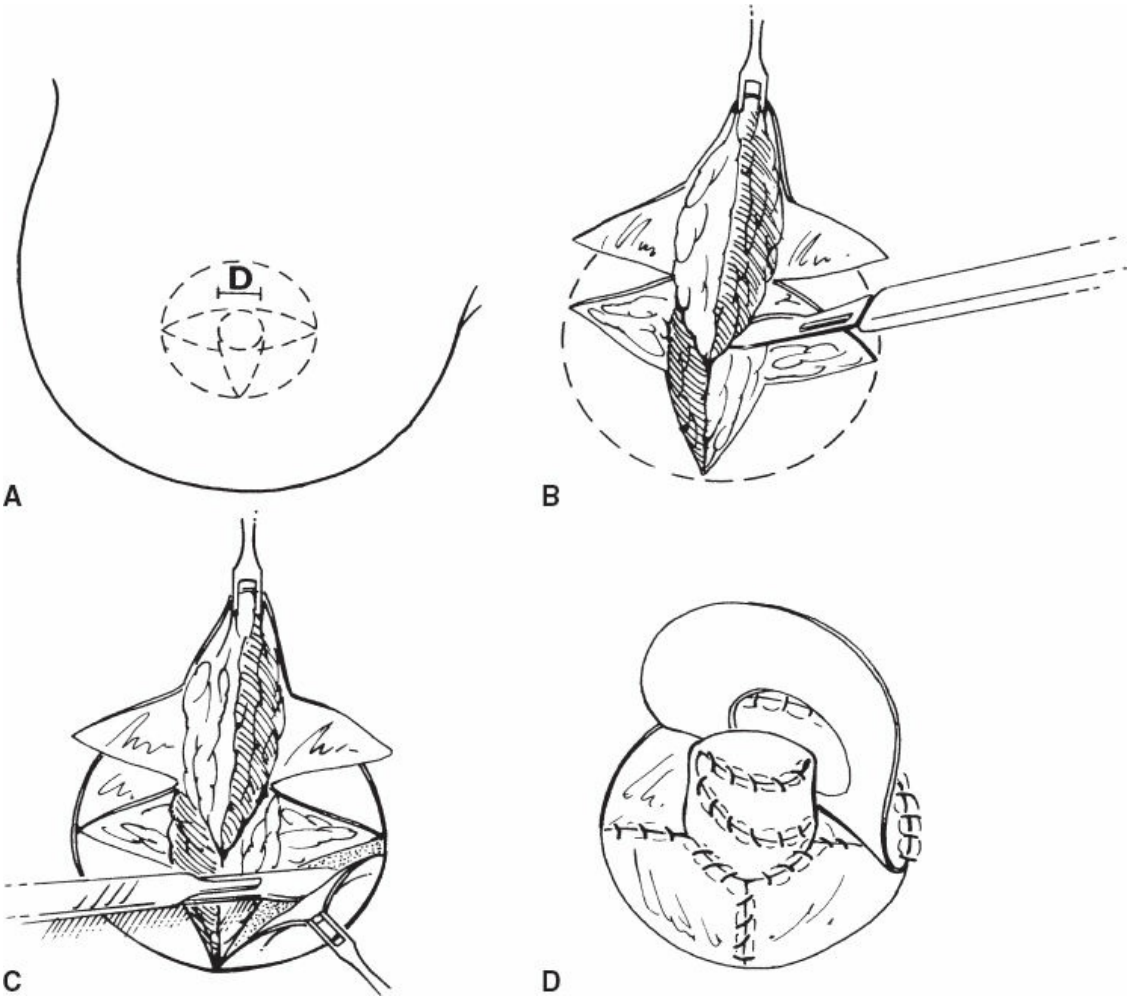

Figure 16.26. **A.** Diagram of modified skate flap on the breast. Flaps extend to the neoareola margin. **B.** Flap elevation is complete, with care taken near the flap base to avoid vascular compromise. **C.** Neoareola is de-epithelialized and grafted. Donor sites may be closed primarily. **D.** Tip of the dermal-fat flap may be de-epithelialized and buried if needed. Closure is complete. Optional areolar grafting is shown. (From Strauch B, Vasconez LO, Hall-Findlay E. *Grabb's Encyclopedia of Flaps.* Philadelphia, PA: JB Lippincott, 1998:1365.)

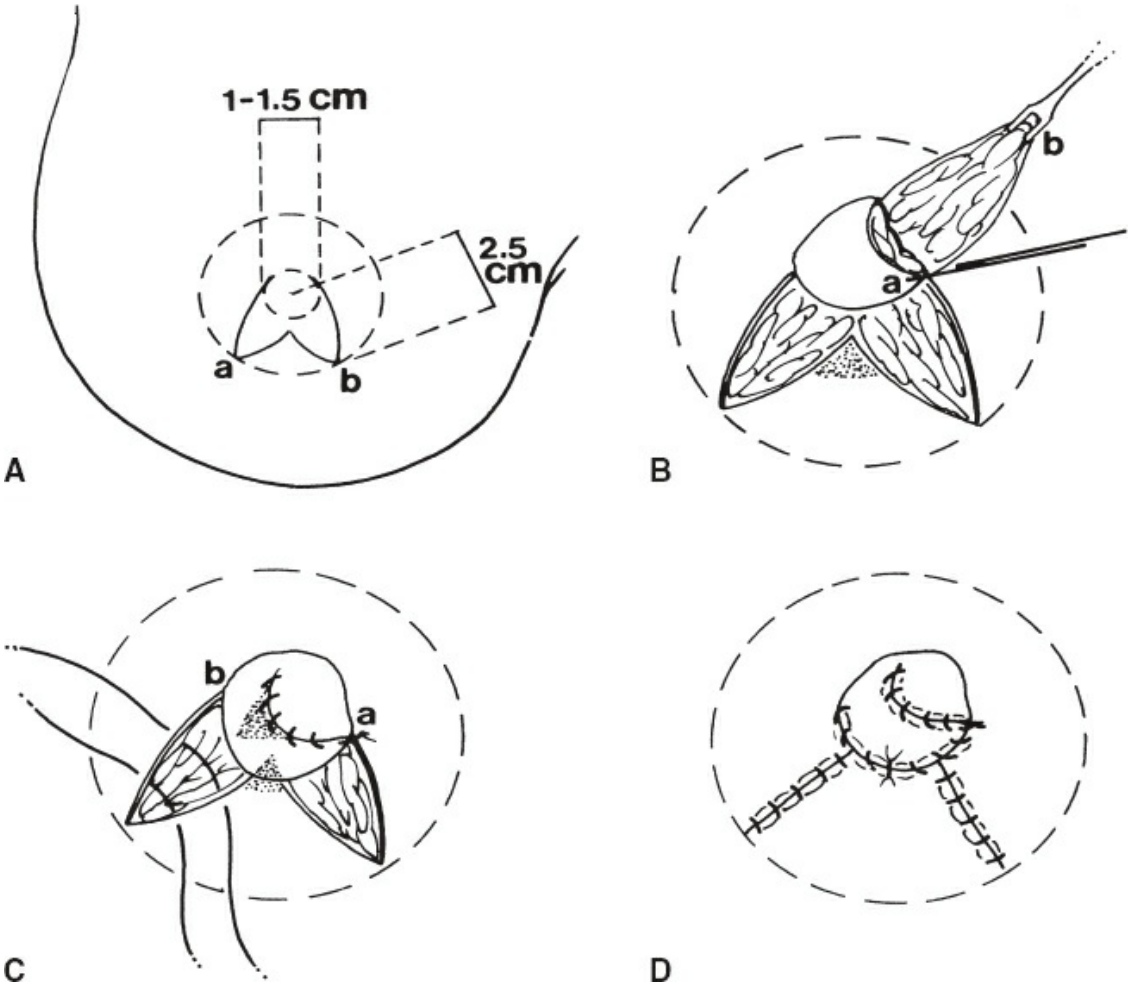

Figure 16.27. A. Diagram of modified fish-tail flap on the breast. The angle between flaps *a* and *b* may vary according to local conditions. **B.** Flaps are elevated, with care taken at the flap base to avoid vascular compromise. Flap *a* is rotated into position and secured. **C.** Flap *b* is de-epithelialized and passed beneath flap *a.* Flap *b* is secured and donor defects are closed. **D.** Completed nipple construct. (From Strauch B, Vasconez LO, Hall-Findlay E. *Grabb's Encyclopedia of Flaps.* Philadelphia, PA: JB Lippincott, 1998:1365.)

Oncoplastic Surgery

The popularity of lumpectomy and irradiation even in the case of larger tumors (over 4 cm) often leaves a significant and unattractive defect in the breast. The so-called oncoplastic techniques have been developed to correct the depression and the asymmetry left by the large removal of breast tissue with the tumor. These maneuvers entail rearrangement of the remaining breast tissue, similar to a breast reduction procedure. It requires considerable knowledge of the anatomy and particularly the blood supply to the breast, to avoid creating worse defects. It is usually accompanied by

a reduction of the opposite breast.

Although such surgical manipulations are possible, and symmetry may be obtained, it does not replace the skin sparing mastectomy and immediate reconstruction in the quality of the appearance of the new breasts, and particularly in diminishing the fear of the patient for a possible cancer recurrence. It should be noted that the recurrence rate following skin sparing mastectomy is between 1.4% and 4%. One drawback of the oncoplastic procedure is the potential need for completion mastectomy in case of positive permanent margins.

While this is of concern, a study published by Losken et al. in 2014 showed that oncoplastic reduction actually decreased the rate of completion mastectomy. The argument with this approach is that more tissue is resected at the time of initial breast cancer treatment, resulting in a more complete margin excision, more frequently, as compares with tumor excision alone. Not only were completion mastectomy rates lower, but re-excision rates were lower as well, suggesting that oncoplastic approaches may convey therapeutic benefits outside of the already superior cosmetic benefits.

Chest Wall Reconstruction

The reconstructive surgeon is presented with thoracic wounds that result from trauma, tumor resection, infection, radiation, and congenital defects. The following principles must be considered: (a) Complete surgical resection and/or debridement. The tumor is completely excised with tumor-free frozen section margins. If dealing with a radiation ulcer, the ulceration as well as the entire surrounding portal of irradiation should be excised, including the underlying ribs if they are affected, leaving only essential or nonirradiated tissue. Infected tissue, whether from empyema, mediastinitis, or necrotic tissue, requires debridement above all, drainage, and appropriate intravenous antibiotics. (b) Obliteration of the intrathoracic dead space. The reconstruction should be performed from the inside to outside. The pleural cavity should first be filled and the intrathoracic organs must be protected. (c) Skeletal stabilization. Paradoxical respiratory motion of the inflated chest must be prevented. Skeletal stabilization is usually required for rib resections of more than four ribs or a defect larger than 5 cm. (d) Soft tissue coverage that is well vascularized, tension-free, and leak-free must be provided.

Bronchopleural Fistulas

Bronchopleural fistulas usually occur following empyema and occasionally following treatment for malignant tumors with irradiation. In most patients with these fistulas, a thoracotomy has been performed; consequently, the use of available muscle flaps such as the latissimus is limited.

Proper treatment requires removal of the fistulous tract, approaching the leaking bronchus in as safe a fashion as possible. The bronchus should be plugged with the use of adjacent muscle. The latissimus dorsi muscle was often divided during the thoracotomy, but there may be portions of the serratus or even the upper portion of the latissimus muscle that can be used to plug the fistula. This still leaves a large cavity or tract. This cavity can be obliterated with the use of the omentum transposed by passing it through the subcostal region based on the right gastroepiploic vessels. The omentum is used to fill in the cavity, the skin edges can be approximated directly (Figs. 16.28 and 16.29). The use of the omentum alone is usually unsatisfactory because it can be blown away with the persistent fistula. It is better to plug it with muscle first, and then additional omentum will provide a second line of defense. Methods for omental transposition will be described later.

Postradiation Ulcerations in the Anterior Chest

Commonly seen in the past with the methods of external irradiation, postradiation ulcerations are much rarer now. Nonetheless, when they occur, the approach follows the principles previously outlined for postradiation ulcers. One should resect not only the ulceration but also all the surrounding tissues that have been irradiated; that is, the entire portal of irradiation. Most often, this also requires the resection of the underlying ribs, which will appear chalky, friable, and devascularized. A formidable defect is thus produced.

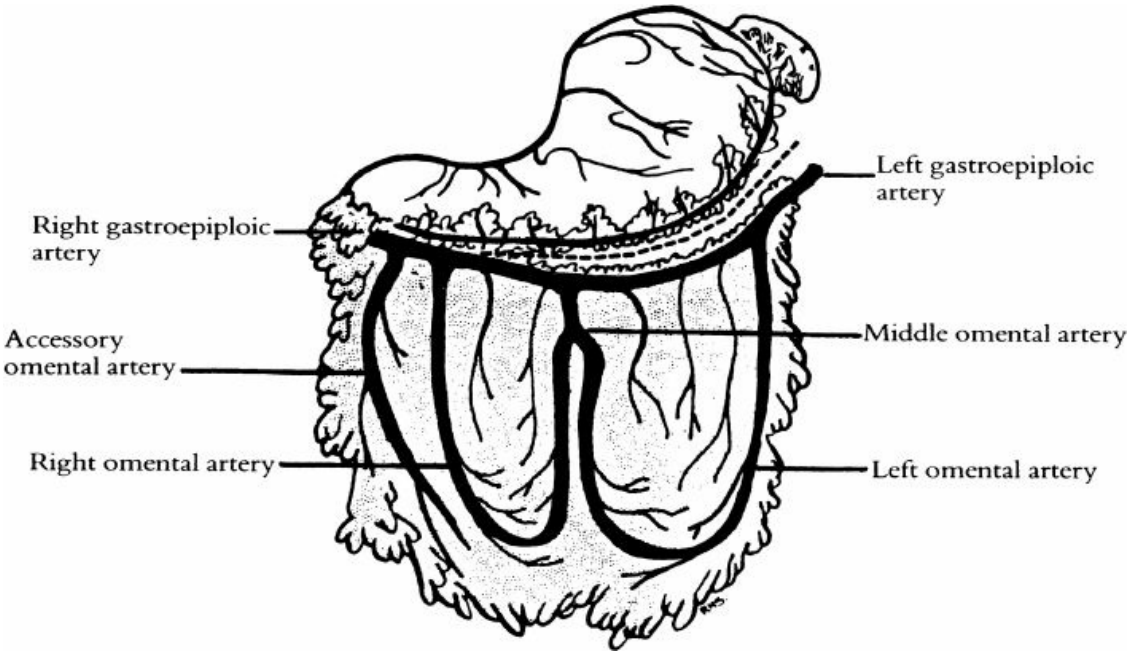

Figure 16.28. Division of the left gastroepiploic artery and detachment of the gastroepiploic arch from the curvature of the stomach. The right gastroepiploic artery is preserved. (From Strauch B, Vasconez LO, Hall-Findlay E. *Grabb's Encyclopedia of Flaps.* Philadelphia, PA: JB Lippincott, 1998:1427.)

For the reconstruction, one must first stabilize the chest wall. To do this, we prefer the use of polypropylene mesh sutured to the ribs, or whatever firm and healthy tissue is found all the way around. We have not found any significant advantage of the newer composite meshes to advocate its use. This mesh is sufficient to provide stabilization of the chest wall and allow for extubation at an early time. Following the placement of the mesh, the omentum is transposed through a midline upper epigastric incision, through the subcutaneous tissue, and over the chest wall. It is preferable not to tunnel the omentum, and to make an incision on the remaining bridge of skin to avoid any undue pressure. The omentum is then spread over the entire wound defect, particularly over the mesh, and stabilized with sutures all the way around; immediately, the meshed split-thickness skin graft is placed over the omentum. By bringing out the omentum in the epigastrium, one would think that a possible hernia site is produced, but this has not occurred because the omentum fills in the defect nicely. We prefer this method to bring the omentum through an opening across the diaphragm and the chest wall.

The advantages of the use of the omentum include the following: (a) A large amount of well-vascularized tissue is available, (b) dissection is

straightforward and reliable, (c) early extubation is possible with the mesh stabilization of the chest wall, and (d) often minimal invasive laparoscopic harvest possible with avoidance of laparotomy. The disadvantages are: (a) the need for laparotomy, if laparoscopy is not an option, (b) improper handling may result in hematomas of the omentum, and (c) herniation of intra-abdominal organs is possible, although unlikely.

Skeletal Stabilization

Skeletal stabilization is required in chest wall resections of more than four ribs and on an area of resection larger than 5 cm to prevent paradoxical motion and inflated chest (flail chest). Location of the skeletal defect also determines whether skeletal stabilization is necessary. Posterior and superior defects near the scapula do not require skeletal stabilization because of the shielding effect of the scapula. Prosthetic and autogenous materials can be used to replace the rigid chest wall.

Prosthetic Options

Prosthetic materials can be used in uninfected and clearly cleansed wounds. (a) Prolene mesh: polypropylene is a fine-grade mesh that is rigid in two directions and allows fibrovascular ingrowth. This mesh is easily handled, cheap, and readily available. (b) Marlex mesh is presently also being made of polypropylene, and is similar to Prolene. (c) GoreTex is a polytetrafluoroethylene mesh, which does not adhere to the underlying lung. It is moldable and flexible, and adapts well to the chest wall movements. It has superior durability and strength, but unfortunately it is easily infected, in which case it has to be removed. We do not favor the use of GoreTex for most chest wall reconstructions.

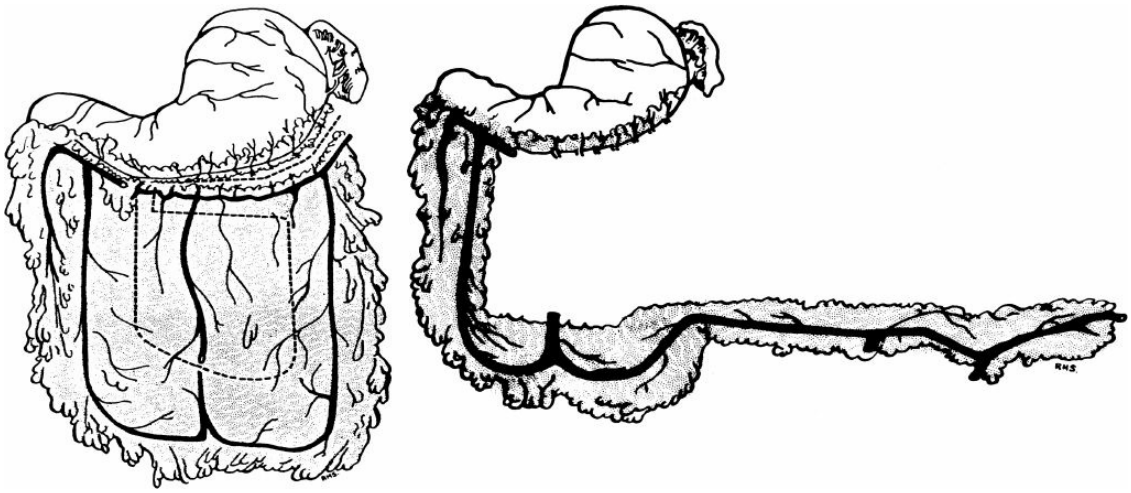

Figure 16.29. Division of the omental arcade along the *dotted*

line converts the omentum into a long vascularized pedicle. (From Strauch B, Vasconez LO, Hall-Findlay E. *Grabb's Encyclopedia of Flaps.* Philadelphia, PA: JB Lippincott, 1998:1427.)

Increasingly, titanium mesh fixation systems are being implemented in place of prosthetic mesh with methyl methacrylate. A recent review by Ng states, "Titanium STRATOS bars and MatrixRIB plates, which have different systems for securing to the chest wall. In general, these new approaches are user friendly, are more ergonomic, and may avoid certain complications associated with the more conventional methods of reconstruction."

Autogenous Options

Split-rib grafts can be used to bridge skeletal defects, but it is not necessary to perform this involved and difficult procedure when simpler procedures are available that are just as effective. If they are used, ribs may resorb with time. They leave a fibrous capsule and are subject to fractures.

It should also be noted that if a latissimus dorsi flap is used occasionally for chest wall coverage and the chest wall defect is relatively small, the muscle itself will be satisfactory to provide skeletal stabilization in a relatively short time, requiring no additional chest wall stabilization.

Fascia Lata Graft

The tensor fascia lata muscle has a long fascial extension that can be harvested in the supine position. An axial incision is made in the lateral thigh beginning approximately 12 to 14 cm below the anterior superior iliac spine. The length of the incision varies, depending on the size of the graft needed. The dissection is carried down to the fascia lata, and skin flaps are elevated medially and laterally. The fascia lata graft can be taken up to 25 to 28 cm in length and 14 to 16 cm in width. The posterior part of the fascia lata is preserved to prevent lateral instability. The graft can be used to cover chest wall defects for skeletal stability. The donor site is then closed with drains.

Advantages

1. Large portion of the fascia lata can be used.
2. Ease of dissection.

3. Minimal functional morbidity.

Disadvantages

1. Graft stretches and becomes flaccid with time.
2. Prosthetic materials are just as effective.

Sternal Wound Reconstruction

Sternal wounds complicating cardiac procedures most often occur in patients who have diabetes, pulmonary disease, and who use steroids. Mediastinitis occurs in 1% to 2.5% of patients who undergo median sternotomy. This represents pooled data, however and is likely representative of overall sternal wound dehiscence, whether sterile or infectious. Fu et al. points out that the rate of sternal wound infection is actually closer to 0.5%, with sterile sternal dehiscence occurring at a rate of 0.9%, for a combined rate of 1.4%, similar to that previously reported in the literature. Regardless, dehiscence is a surgical problem necessitating consultation with a reconstructive surgeon. Risk factors during cardiac surgery include the duration of surgery; excessive bleeding, necessitating reentry; the use of internal mammary arteries, particularly bilaterally; and, most importantly, the length of postoperative intubation. A sudden, otherwise unexplained rise in the blood glucose levels of the patient can be the only sign of a developing septic picture due to sternal wound infection and impending mediastinitis. Sternal wound infections must be treated with adequate debridement of the necrotic tissue, foreign material, blood clots, granulation tissue, and devascularized bone, and exposed cartilage must be removed. Judicious use of antibiotics for infected organisms is necessary. Sometimes, if one is not certain of the debridement or there is a considerable amount of purulence, the wound must be left open, with dressing changes and topical antibacterials prior to a second debridement and definitive coverage.

Temporary coverage utilizing a negative pressure vacuum device system (“wound vac”) between debridements and until final coverage can be considered. Once the wound is clean, coverage is usually possible with the use of the pectoralis advancement musculocutaneous flaps, omental flap, or both. The rectus abdominis muscle is used less often, particularly if the internal mammary artery has been used for revascularization of the heart.

It should be noted that we used to believe that obliteration of the dead

space with larger swaths of tissue was essential for the management of mediastinal wounds, but this is no longer true; the potential dead space is rapidly obliterated with pectoralis myocutaneous flaps and the use of suction.

Flap Options

Pectoralis Major Muscle Flap

When using a pectoralis major muscle flap the mediastinal wound is debrided, resecting the remnants of the sternum on both sides. If the costal cartilages are exposed, they must be removed, particularly if they are devoid of perichondrium; otherwise, they are likely to result in draining fistulous tracts. Following debridement, a myocutaneous flap of pectoralis major muscle is elevated (Fig. 16.30). One divides the origin of the pectoralis major muscle from the lateral aspect of the sternum on both sides and bluntly undermines toward the anterior axillary line and the clavicle. It is not necessary to divide the insertion of the pectoralis major muscle from the clavicle or acromion. Once this mobilization has been obtained, the muscles are sutured with permanent sutures in the midline and over drains, and the overlying subcutaneous tissue and skin are also closed. If the mediastinal wound extends inferiorly, where the pectoralis major muscle cannot cover it, it is possible to free up the origin of the rectus abdominis muscle from the costal cartilages bilaterally and advance it superiorly and suture it to each other. This is preferable to making the formal transposition of the rectus abdominis muscle based superiorly. We do not favor the use of turnover pectoralis major flaps based on the perforating vessels of the internal mammary artery.

The blood supply to the pectoralis myocutaneous flap is from the thoracoacromial blood vessels. The pectoral or the thoracoacromial branch follows a path marked from the tip of the acromion to the xiphoid and is left undisturbed as one frees it from the chest wall. The pectoralis minor muscle is left in place and undisturbed.

The advantage is the ease of dissection and effectiveness, particularly for the upper two thirds of the mediastinal wounds. The disadvantages are that it will not cover the lower-third of the mediastinum, and hematoma is possible, particularly in patients who have been anticoagulated.

Omentum

In patients who have large mediastinal defects in which both internal mammary arteries have been used and the sternum is chalky and necrotic,

and particularly in patients with heart transplants, the omentum is an ideal and most satisfactory method for reconstruction.

The omentum is a large flap, providing 25 × 35 cm of vascularized tissue. It can be used as a pedicle or even as a free flap to fill pleural defects, chest wall wounds, and sternal wounds. It is usually folded as an apron based on the right gastroepiploic vessels, but occasionally, if additional length is needed, it can be based on either one of the gastroepiploic vessels. Selective omental division can be performed to lengthen the omentum. The right gastroepiploic vessel is usually the dominant blood supply. Omentum can be harvested as a pedicle flap by tunneling through the upper end of the midline incision, which is used to dissect the omentum.

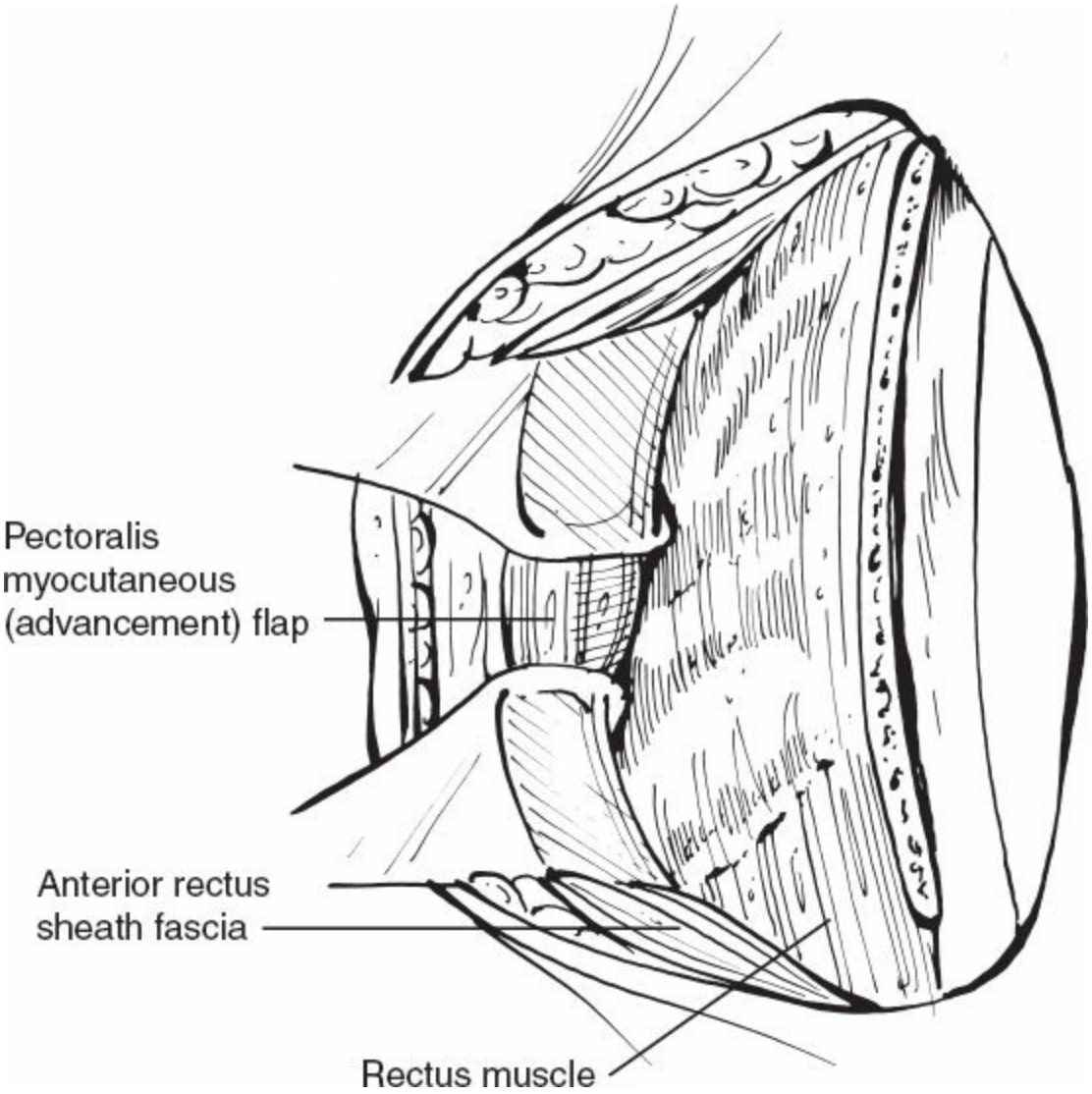

Figure 16.30. The pectoralis muscle and the overlying skin are elevated as a unit. Often, the insertion of the pectoralis muscle

over the humerus is left intact. (Modified from Ascherman JA, Patel SM, Malhotra SM, et al. Management of sternal wounds with bilateral pectoralis major myocutaneous advancement flaps in 114 consecutively treated patients: refinements in technique and outcomes analysis. *Plast Reconstr Surg* 2004;114:678, with permission.)

Technique

The omentum is exposed through a midline laparotomy incision or visualized via minimal invasive laparoscopic approach. It is placed on traction, and separated from its vascular attachments to the transverse colon. The short vessels between the gastroepiploic system and the stomach may be individually clamped and ligated as far as the antrum and duodenum. The right and left gastroepiploic vessels are alternately uprooted to determine the competency of the blood supply. The right gastroepiploic vessel is usually the more pulsatile and larger of the two, and thus the left gastroepiploic vessels may be sacrificed. Depending on the location of the defect, the omental flap can be lengthened by selective omental division. A tunnel is created in the subcutaneous space for passage of the omental flap through the upper midline laparotomy incision. In case of a minimal invasive laparoscopic approach a small opening in the epigastric area is created for the pull through. Care should be taken not to twist the pedicle. Tacking sutures can be placed from the omentum to the exit wound to help secure the flap, although this is usually unnecessary. We prefer exiting the omentum through the upper laparotomy midline incision in case of an open approach, rather than through the diaphragm or a separate incision, which may create more problems. The advantage is that a large flap is created. The disadvantage is that it requires an intra-abdominal operation with subsequent abdominal pain, which may compromise respiratory function.

Postradiation Posterior Neck and Upper Dorsal Wound Reconstruction

Neurosurgical wounds in the lower cervical or upper dorsal spinal cord may have been treated by surgery followed by irradiation. The wounds do not heal because of the radiation, and present a challenging problem to the reconstructive surgeon. For wounds in the occiput, down to the level of the midscapula, the trapezius myocutaneous flap is useful and effective.

Flap Options—Trapezius

The trapezius myocutaneous flap is nourished from the transverse cervical artery, and its minor blood supply comes from branches of the occipital vessels, dorsal scapular vessels, and posterior intercostal vessels (Fig. 16.31). The muscle measures 34 × 18 cm in most patients. A myocutaneous paddle-like flap is outlined at the border of the defect and extends beyond it. It is elevated with the underlying muscle and extends it superiorly by dividing the muscle at the posterior neck, but preserving the transverse cervical artery. The flap is then transposed to cover the defect or rotated to cover the occiput and the upper cervical spine. Care must be used to elevate the skin and/or muscle flap, preserving the underlying latissimus dorsi and rhomboid muscles but dividing the fibers of insertion to the scapula as needed.

Abdomen Reconstruction

The abdominal wall plays multiple functional roles. Its various muscles are arranged in a complex fashion. The muscle fibers are arranged vertically, obliquely, and transversely. These muscles are important in maintaining posture, standing, ambulation, bending, and lifting objects. The abdominal wall also protects the internal organs and regulates the intra-abdominal pressure to assist in defecation, urination, coughing, and vomiting.

There are multiple layers of the abdominal wall; these include skin, Camper and Scarpa fascia, oblique and transverses muscles and their aponeuroses, two recti muscles, preperitoneal fat, and peritoneum. The muscles of the anterior abdomen are the external oblique, internal oblique, transversus abdominis, rectus abdominis, and pyramidalis.

Abdominal wall defects may involve a deficiency of skin, fascia, or both. The most frequent causes of defects include trauma, tumor resection, infection, incisional hernia, congenital anomalies, and radiation therapy. Acute traumatic wounds require multiple stages for abdominal wound closure. These injuries require extensive debridement as abdominal organs are frequently injured. It is best to avoid closure of acute injuries by elevation of local soft tissue flaps. This will open new tissue planes that may spread infection; it also increases operative times. Therefore, in the acute setting of loss of abdominal wall the best operative choice is to apply a trauma dressing a split-thickness skin graft.

Infectious processes involving the abdomen are of special note. Necrotizing fasciitis requires wide surgical debridement of all involved

fascia and overlying skin and subcutaneous tissue. Clostridial myonecrosis involves all layers of the abdominal wall, and therefore requires full-thickness resection. This is a mixed anaerobic and aerobic infection involving at least one *Clostridium* species. These organisms produce a number of exotoxins including lecithinase, collagenase, and hyaluronidase, which allow the infective process to penetrate all layers of the abdominal wall. These infections require prompt diagnosis, intravenous antibiotics, and wide surgical debridement.

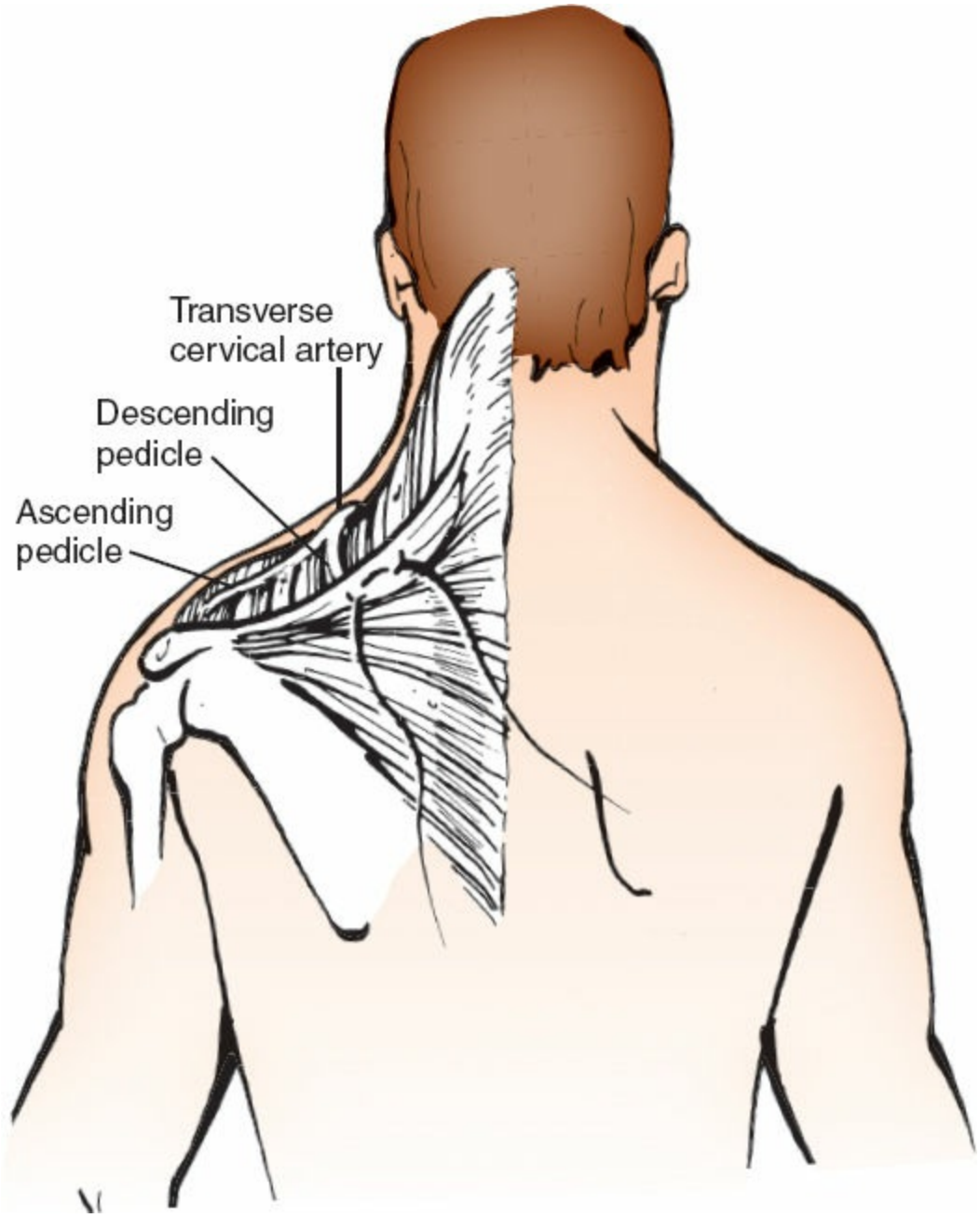

Figure 16.31. Diagrammatic demonstration of the trapezius muscle and its vascular supply from the transverse cervical

artery.

The reconstructive options for abdominal wall reconstruction are varied. Prosthetic materials are used for abdominal wall support. When massive abdominal trauma is present, skin grafts may be required. These are then removed when the wound is stable and the hernia is to be reconstructed. Local flaps such as the external oblique and rectus abdominis muscle may be used with care to avoid creating a larger defect. Regional flaps such as the tensor fascia lata and rectus femoris are also options. Distant flaps include the omentum, latissimus dorsi, and free flaps.

Direct approximation of fascial defects is possible in a good number of cases. In 1990, Ramirez described the components separation technique to allow for closure of large defects (Fig. 16.32). This technique separates the rectus abdominis from the posterior sheath and the external oblique muscle from the internal oblique muscle. Therefore, a composite flap of rectus muscle, anterior sheath, and attached internal oblique and transversus abdominis muscle is advanced toward the midline. Closure of epigastric defects of 6 cm, midabdominal defects of 12 cm and lower abdominal wall defects of 10 cm can be achieved, especially if implemented with a posterior rectus approach, which allows for additional onlay mesh graft. This posterior rectus component separation with rectus abdominis release affords recurrence rates around 5% at 2 year follow-up and allows for durable reconstruction of complex ventral hernias. A simpler technique would be to perform an external oblique flap. To accomplish this, the external oblique fascia is incised along its lateral aspect. The linea alba is then approximated.

Flap Options—Rectus Femoris Fasciocutaneous and Musculocutaneous Flap

Although the tensor fascia lata flap was advocated for autologous reconstruction of abdominal wall defects because of its versatility and distal fascial extension, it now has been supplanted by the rectus femoris fasciocutaneous or musculocutaneous flap (Figs. 16.33 and 16.34). This is because of the latter flap's shorter arc of rotation, higher reach, and the increasing versatility in that one can move the fasciocutaneous unit separately from the rectus femoris muscle. The tensor fascia lata, on the other hand, has to pivot on a wider arc of rotation to reach the abdomen. In addition, the distal third of the tensor lata flap is somewhat unreliable,

making it impossible to reach defects past the midline (Fig. 16.35).

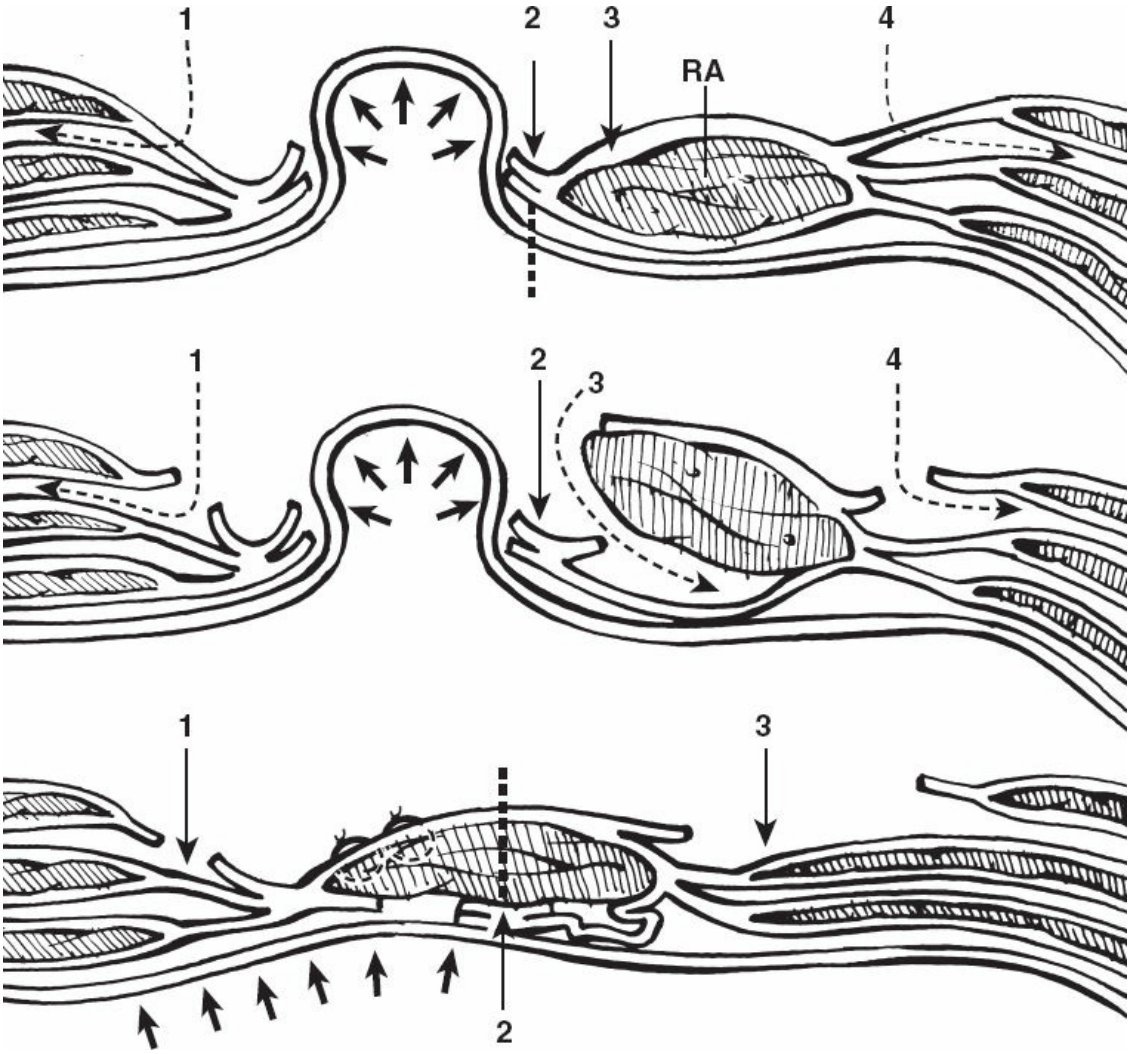

Figure 16.32. Components separation for closure of abdominal wall defects. RA, rectus abdominus (Modified from Ramirez OM, Ruas E, Dellon AL. "Components separation" method for closure of abdominal wall defects: an anatomic and clinical study. *Plast Reconstr Surg* 1990;86:519, with permission.)

The rectus femoris muscle originates from the anterior iliac spine and inserts into the complex of the quadriceps extensor tendon. Dividing its insertion does not interfere with full extension of the knee if the remaining quadriceps tendon is reapproximated with sutures. Its blood supply is from the lateral circumflex femoral artery that enters at its proximal third and has a perforator branch that emerges through the muscle at approximately the same level to supply the overlying skin and fascial unit. As long as one preserves this vascular supply, it is possible to use the two components separately for reconstructive purposes. The rectus femoris muscle can be

harvested alone for lower abdominal defects or for coverage for defects along the groin. If additional skin and fascial coverage is needed, the overlying fasciocutaneous unit can also be elevated, sometimes with a wider extension at the fascial level. The fasciocutaneous unit can also be used to cover defects in the groin, whether because of trauma or following large excisions of carcinomas of the vulva or for postradiation ulcerations in the groin following groin dissections. The use of both rectus femoris musculocutaneous flaps as four separate units allows reconstruction of the entire abdominal wall, and although results are arguably satisfactory, these units have been used to reconstruct the prune belly type of defect of the abdomen. There is an increasing popularity in the use of acellular or biologic meshes for reconstruction of the abdominal wall or in the repair of large incisional herniae. The mesh is used either as an inlay or an overlay type of coverage. No clear advantages have been demonstrated, and the disadvantages include fluid collection, low antigenicity, stretching of the mesh, as well as the possibility for the biologic mesh to serve as culture medium. This fact, however, remains controversial. A recent study of the retrorectus approach to incisional hernia repair compared demonstrated no statistical significance in complication or recurrence rates between synthetic and biologic mesh reconstructions.

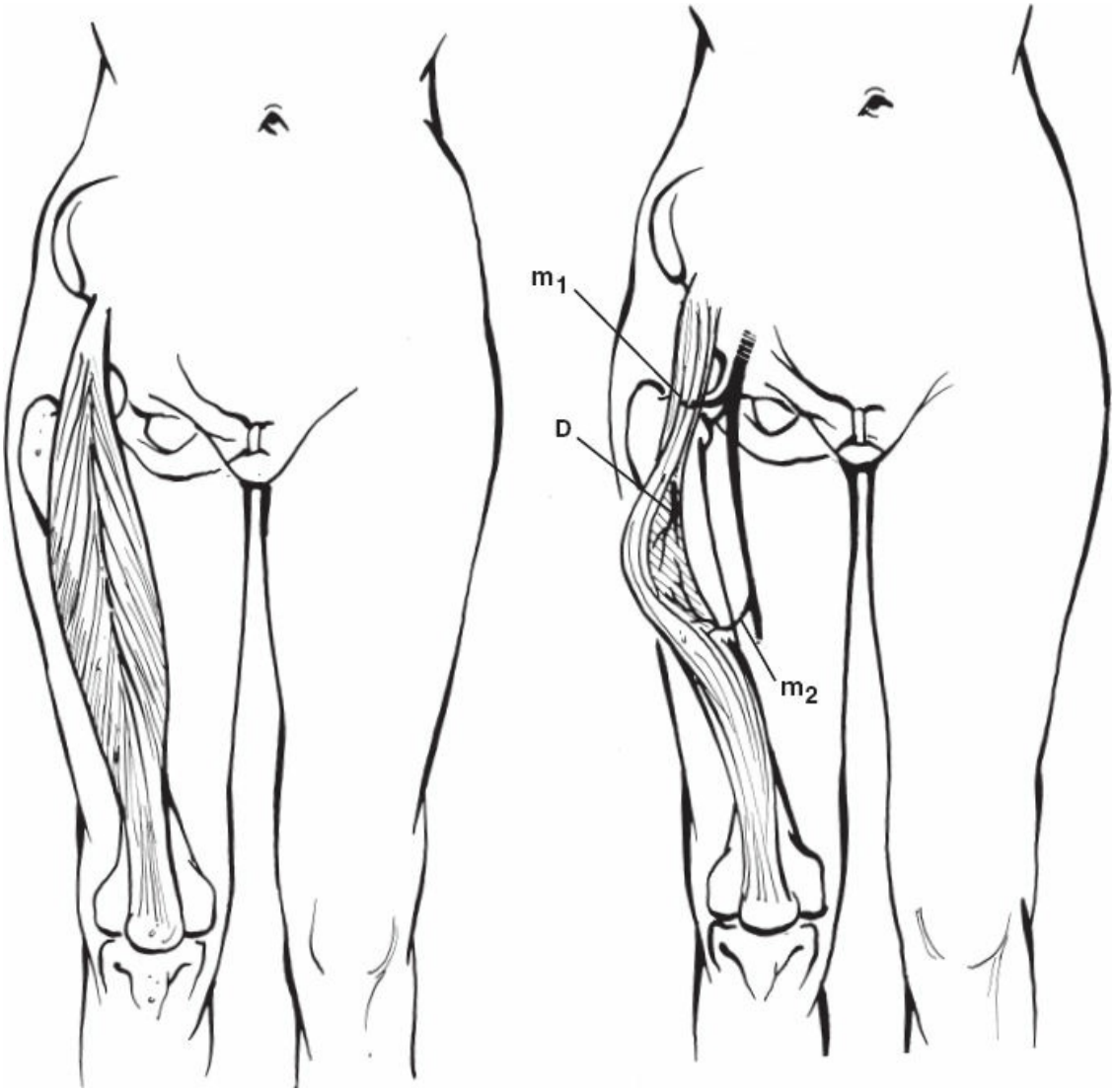

Figure 16.33. The rectus femoris fasciocutaneous and musculocutaneous flaps for abdominal reconstruction. M1 is a secondary pedicle from the trunk of the transverse and ascending lateral circumflex femoral artery. M2 is a distal secondary pedicle from the superficial femoral artery. D is the main pedicle for the rectus femoris muscle, the descending branch of the lateral circumflex femoral artery. (Modified from Mathes S, Nahai F. *Reconstructive Surgery: Principles, Anatomy, and Technique.* New York: Churchill Livingstone, 1997:1234. Copyright © 1997 Elsevier.)

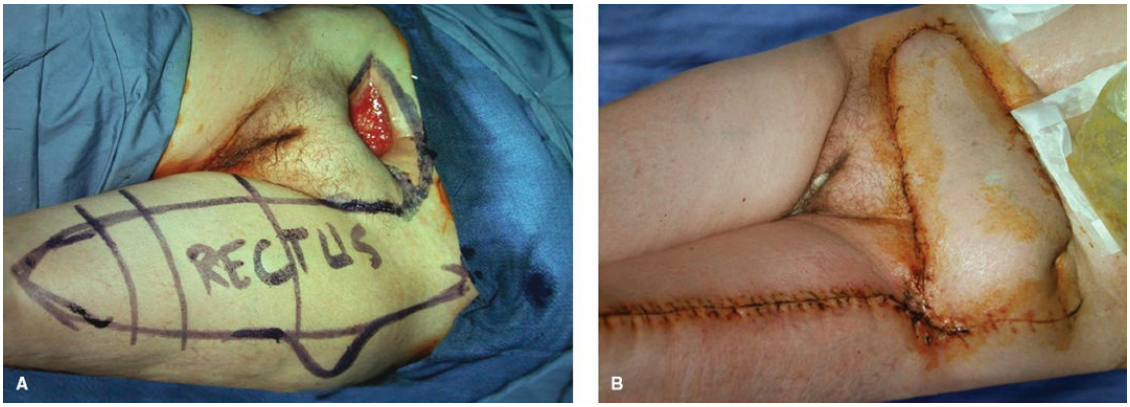

Figure 16.34. A, B. Postradiation defect in the suprapubic region. It is best covered with the rectus femoris myocutaneous flap.

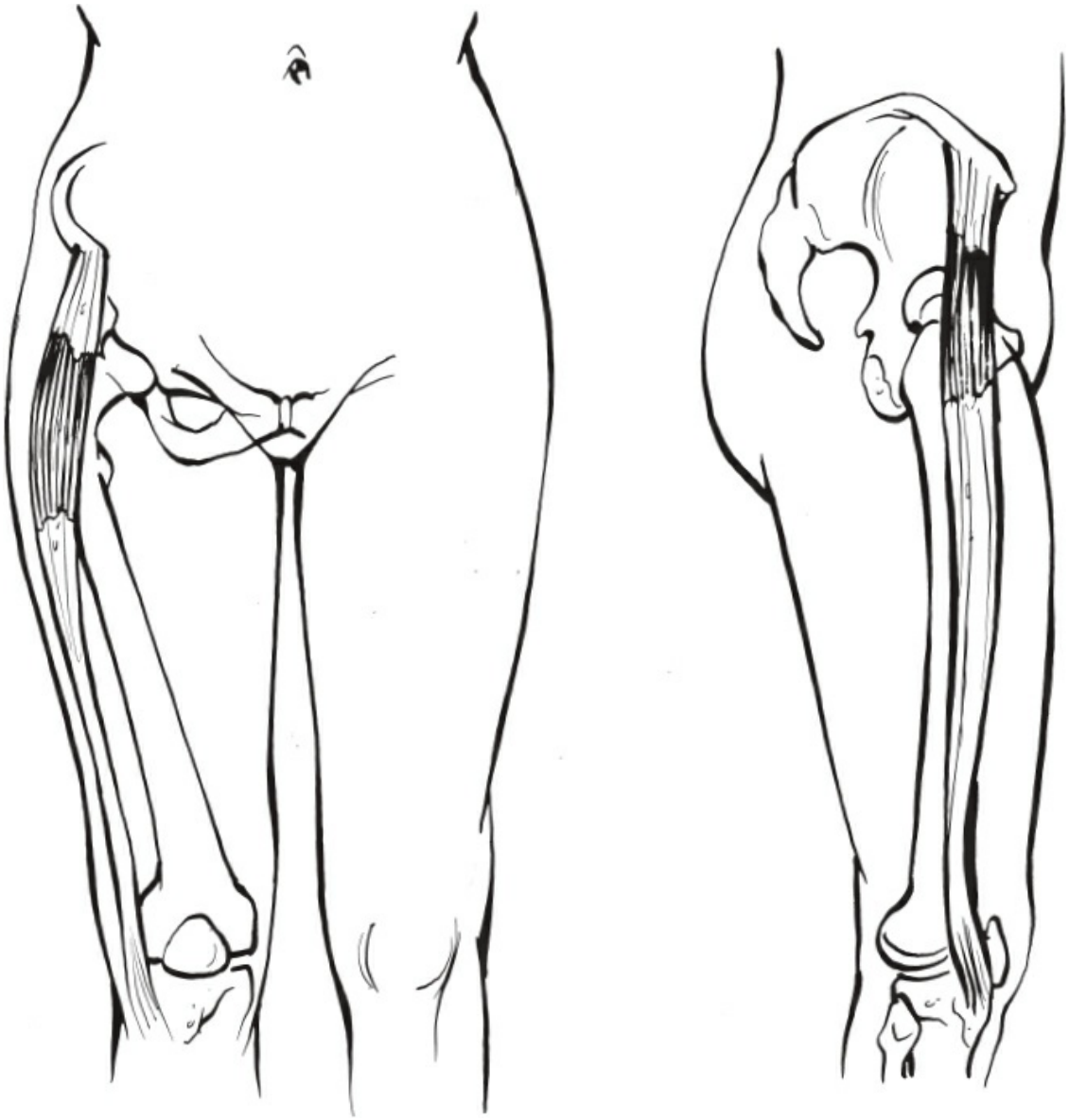

Figure 16.35. The tensor fascia lata flap. (Modified from Mathes S, Nahai F. *Reconstructive Surgery: Principles, Anatomy, and*

Technique. New York: Churchill Livingstone, 1997:1272. Copyright © 1997 Elsevier.)

Advantages

1. Predictable vascular pedicle.
2. A large cutaneous component can be elevated separately from the underlying muscle.
3. Wide arc of rotation, shorter to cover the groin and the abdominal wall.
4. May be used for full-thickness abdominal wall defects in the lower abdomen.

Disadvantages

1. Potential for functional weakness during knee extension and hip flexion
2. Visible and unsightly donor site when a large cutaneous component is required
3. Generally limited to lower abdominal wall reconstruction

Perineal Wound Reconstruction

Abdominal perineal resections for rectal carcinoma or inflammatory bowel disease were initially treated openly, producing large defects requiring open packing and long-term dressing changes. Fortunately, they have been supplanted by the reintroduction of primary closure with closed suction drainage, resulting in an improved quality of life, shorter hospital stay, and decreased perineal pain.

Nonetheless, the present treatment of persistent and/or recurrent carcinoma of the anus, which requires chemotherapy and radiation, does present challenging problems for reconstruction following excision of these perineal cancers.

The treatment of choice for these large perineal wounds is the use of the bilateral gluteus maximus myocutaneous flaps. Previous experience with the use of gracilis flaps was only partly successful. The use of the rectus abdominis muscle is effective in reaching the perineum and closing those wounds, but requires that the muscle be introduced intra-abdominally through an opening in the intra-abdominal cavity.

Flap Options

Bilateral Gluteus Maximus Musculocutaneous Flap

The lithotomy position is often used for the resection of postradiation persistent and/or recurrent carcinoma of the anus and the rectum. The large defect that is thus created necessitates the advancement of the musculocutaneous units from the gluteus maximus region to obliterate the dead space approximating the muscles and the skin in the midline (Figs. 16.36 to 16.38).

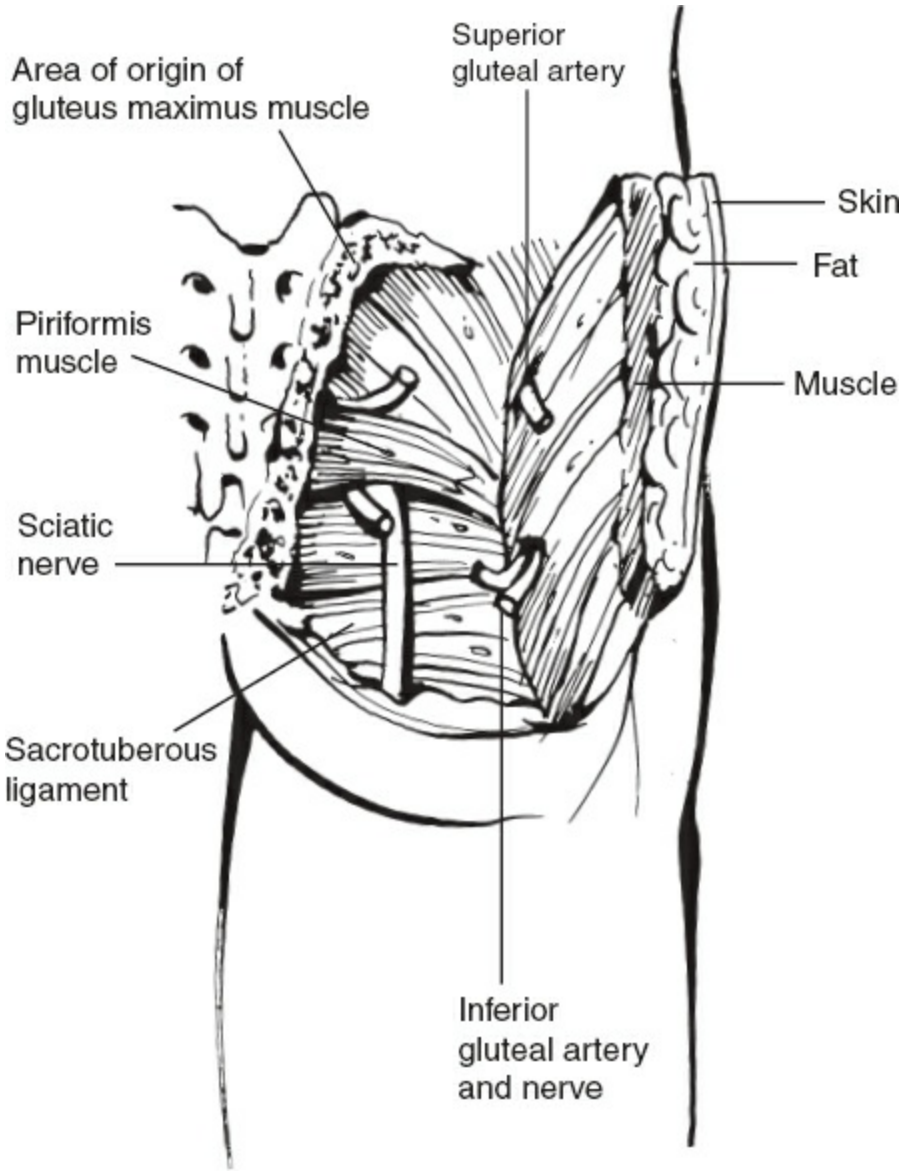

Figure 16.36. The dissection is difficult and bloody, as one needs to disinsert (divide) the origin of the muscle from the sacrum. Once it is disinserted on both sides, it can be approximated to each other to cover defects over the perineum. (Modified from Ramirez OM, Orlando JC, Hurwitz DJ. The sliding gluteus maximus myocutaneous flap: its relevance in ambulatory patients. *Plast Reconstr Surg* 1984;74:68, with permission.)

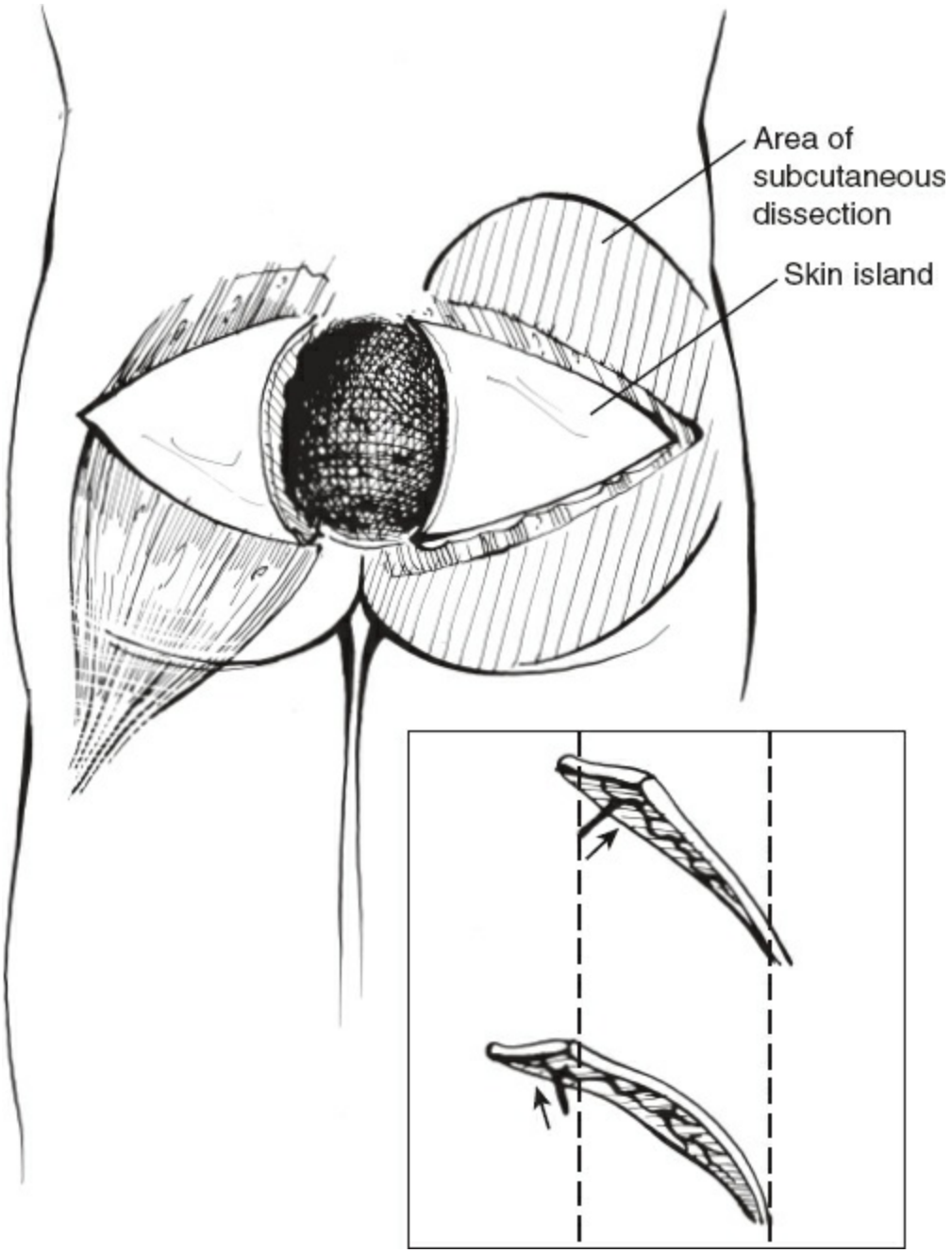

Figure 16.37. Ambulatory patients are also good candidates for the procedure. They will need help, temporarily, in ambulation and particularly climbing stairs. (Modified from Ramirez OM, Orlando JC, Hurwitz DJ. The sliding gluteus maximus myocutaneous flap: its relevance in ambulatory patients. *Plast Reconstr Surg* 1984;74:68, with permission.)

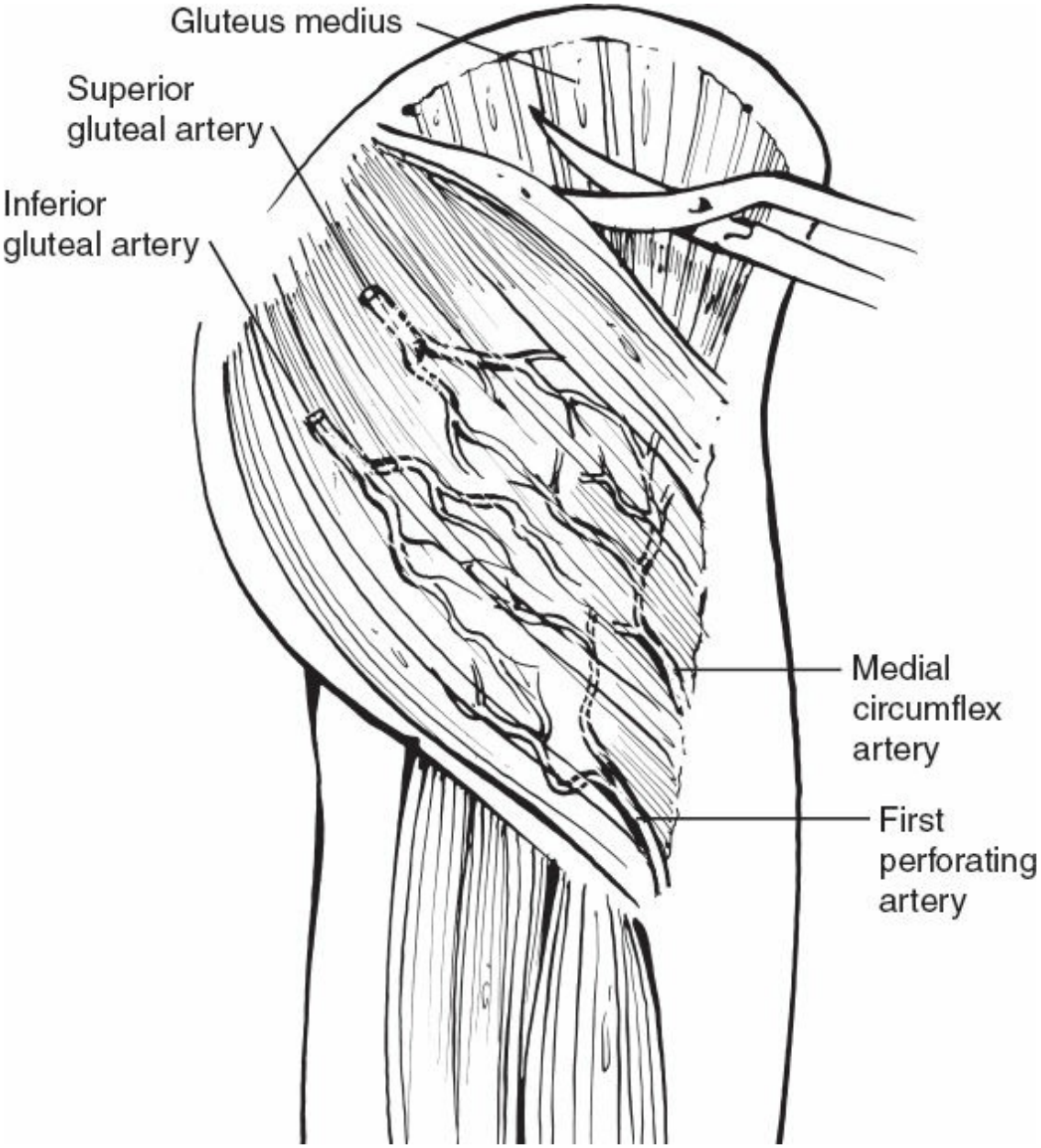

Figure 16.38. Diagrammatic demonstration of the vascular supply to the gluteus maximus. (Modified from Ramirez OM, Orlando JC, Hurwitz DJ. The sliding gluteus maximus myocutaneous flap: its relevance in ambulatory patients. *Plast Reconstr Surg* 1984;4:68, with permission.)

The patient must be changed to the prone position with the legs abducted. The posterior iliac spine as well as the greater trochanters is noted. Bilateral skin islands in the form of triangles are outlined below the iliac crest and with the apex toward the trochanter and the base, along the medial defect on each side of the perineum. The skin island is incised and skin flaps are elevated superiorly and inferiorly to expose the upper and lower portion of the gluteus maximus on each side. The gluteus maximus

is then freed up by careful dissection from the sacrum. This is a bloody dissection because one has to divide a number of the sacral vessels, but once this is accomplished, a blunt dissection is continued with the finger to identify the superior and the inferior gluteal arteries. The inferior gluteal artery is a key, in that the sciatic nerve is inferior and lateral to it and should be protected. With the gluteus maximus freed up medially, one can then incise the upper portion of the gluteus maximus down to the medius superiorly and inferiorly, as much as is necessary to advance it to the midline. This is done bilaterally. Once the mobilization has been accomplished, the muscles are sutured in the midline to each other over drains (Fig. 16.39). The overlying skin is also approximated by a VY maneuver, which is straightforward and easy.

Advantages

1. Healthy muscle and overlying skin is sufficient to obliterate the perineal defect.
2. Different from what was previously believed, the procedure can be done in ambulatory patients without any dysfunction.

Disadvantages

1. The patient needs to be repositioned on the operating table.
2. The dissection is bloody and somewhat difficult, particularly as the gluteus maximus is freed up from the sacrum.
3. There is a possibility of injury to the bladder as well as to the sciatic nerve, although both are rare.

Gluteus Maximus to Reconstruct Anal Sphincter

Particularly in children with Hirschsprung disease, who have weak or absent anal sphincters, a local procedure using portions of the gluteus maximus are effective and synergistic (Fig. 16.40). The anus is circumscribed and a linear incision is extended over the gluteus maximus on each side. A segment of the gluteus maximus, ~2 cm wide and 10 cm long, is removed and freed from the gluteus medius. Each segment of muscle is then turned around and extends circles ~270 degrees, with the anus on each side forming a figure-of-eight type of arrangement. Each end is sutured with sufficient tension so that when the muscle contracts, the anus is obliterated. The secondary defects are closed directly. This is the most effective and synergistic muscle for anal sphincter control.

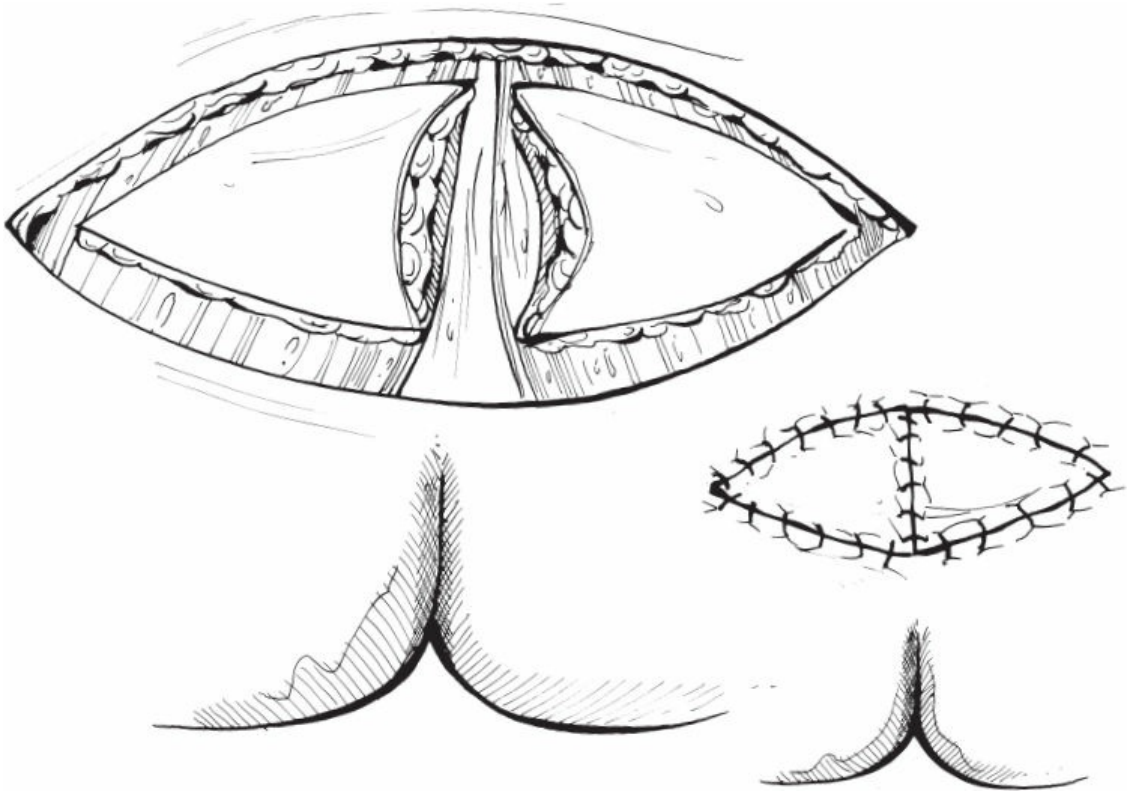

Figure 16.39. Freed up bilaterally, the muscle units can be approximated in the midline, and the skin islands can be moved in a V-Y manner. (Modified from Ramirez OM, Orlando JC, Hurwitz DJ. The sliding gluteus maximus myocutaneous flap: its relevance in ambulatory patients. *Plast Reconstr Surg* 1984;4:68, with permission.)

Advantages

1. The gluteus maximus is synergistic, and the patient can learn a voluntary control of the anal sphincter.
2. The muscle is located in the same operative field.

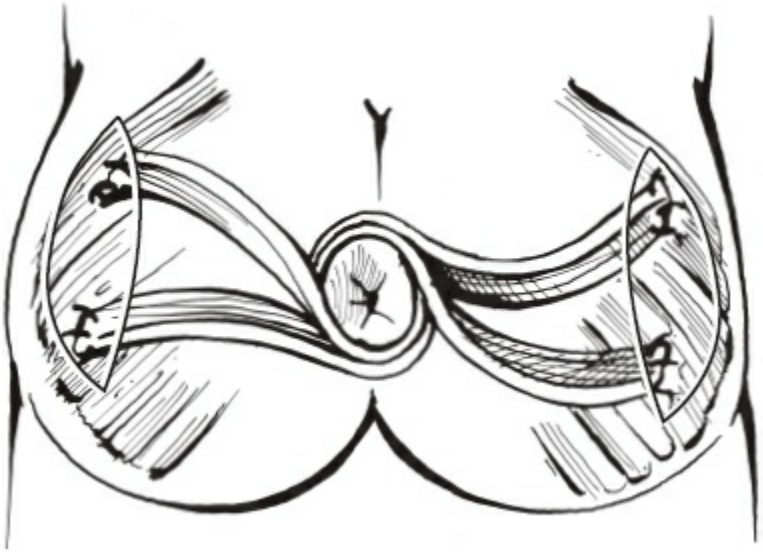

Figure 16.40. Portions of the gluteus maximus are taken from both sides. They are crossed in a figure-eight fashion to allow them to simulate a sphincter as they contract.

Disadvantages

1. Proper tension must be obtained for an effective sphincter control.
2. The dissection is bloody at times.

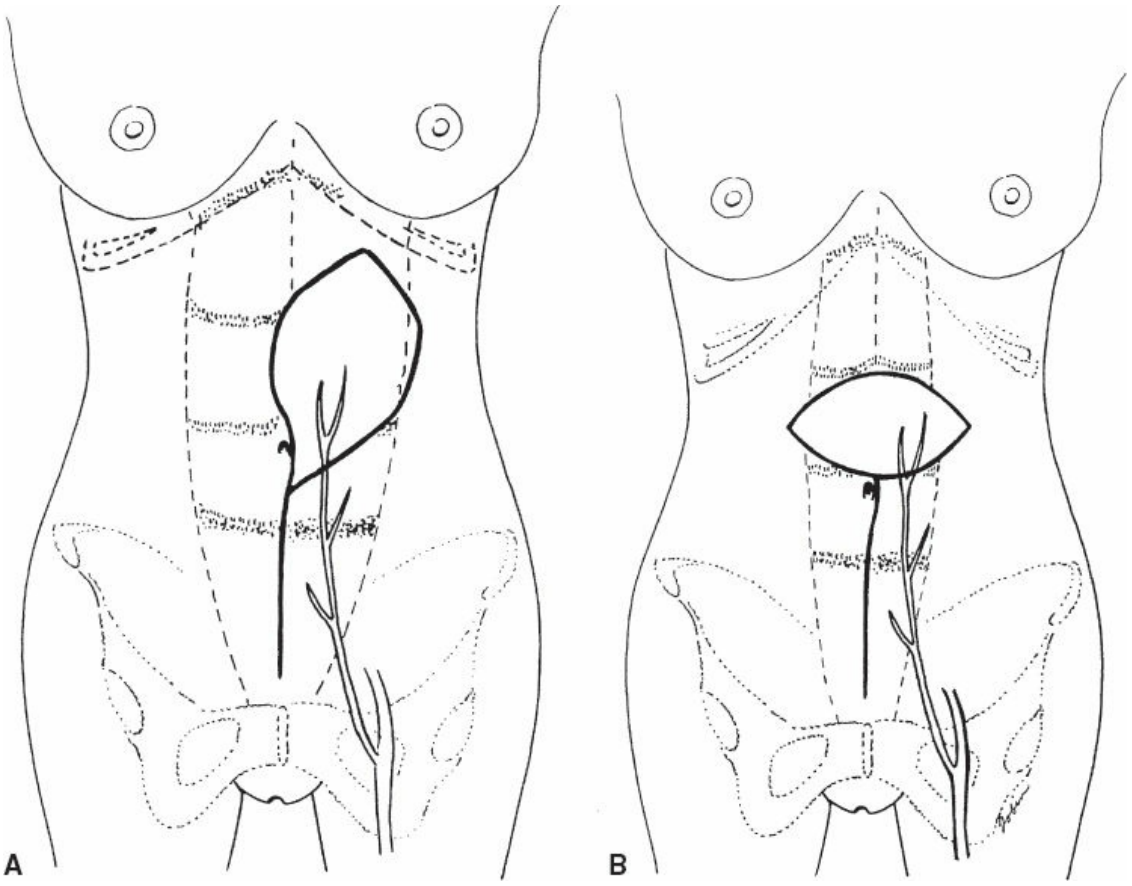

Figure 16.41. Cutaneous paddle design of rectus abdominis flaps for reconstruction showing the relationship of the paddle to the muscle, vascular pedicle, laparotomy incision, and surface landmarks. **A.** Diagram of the most frequently used design, with a vertical paddle axis aligned with the muscle. **B.** Diagram of the transverse paddle, which can be used to lessen tissue bulk in the deep pelvis. (Published in Tobin GR, Persell SH, Day TG. Refinements in vaginal reconstruction using rectus abdominis flaps. *Clin Plast Surg* 1990;17(4):705–12. Copyright © 1990 Elsevier.)

Rectus Abdominis Musculocutaneous Flap

If skin and soft tissue are required for perineal coverage to supplement the filling of dead space by the rectus muscle, the rectus muscle with the overlying skin and soft tissues can be mobilized as a unit. A large skin paddle can be used when designed to include multiple musculocutaneous perforators (Fig. 16.41). The greatest density of perforators exists in the periumbilical region and, therefore, it is often included during the flap design. The skin paddle can be oriented on the vertical, oblique, or transverse fashion, depending on the reconstructive necessity. The skin paddle, whether vertically (known as the VRAM flap) or transversely oriented (known as the TRAM flap), is incised right down to the anterior rectus sheath. The musculocutaneous perforators should be maintained intact to supply the overlying skin. A portion of anterior rectus sheath is included with the flap for ~4 cm, which will facilitate the removal of the entire rectus muscle with its superior and inferior extensions. The medial and lateral borders of the rectus muscles are freed up, and then the muscle is also freed up from the posterior rectus sheath. The superior end of the muscle toward the insertion in the costal margin is divided, and the whole unit is introduced intra-abdominally, usually just above the semicircular line. The unit is then grasped through the perineum, and the skin or muscle is used to obliterate the perineal cavity. The secondary defect is closed by approximating the remaining anterior rectus sheath, making sure that one does not leave too large a defect at the point of entrance of the muscle intra-abdominally (Figs. 16.42 and 16.43).

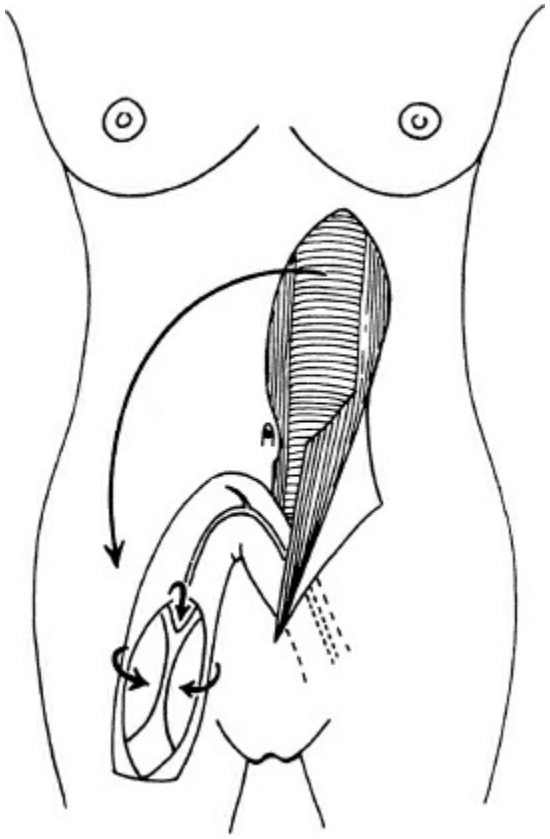

Figure 16.42. Demonstrating steps of the operative procedure. Schema of a vertical flap transposition from the abdominal field to the groin region for formation of the vaginal pouch, which allows simultaneous construction of the urinary conduit and colostomy. (Published in Tobin GR, Persell SH, Day TG. Refinements in vaginal reconstruction using rectus abdominis flaps. *Clin Plast Surg* 1990;17(4):705–12. Copyright © 1990 Elsevier.)

Advantages

1. No change in position of the patient is needed if the abdominal perineal resection was done in the lithotomy position.
2. Large amounts of muscle and skin are easily obtained.

Disadvantages

1. A site of intra-abdominal entrance is necessary for the musculocutaneous unit.
2. A bulge remains in the suprapubic region.

Gracilis Muscle and Musculocutaneous Flaps

The gracilis muscle and musculocutaneous flaps are presently used for reconstruction of the vagina following the rare pelvic exenterations and also for coverage of defects along the ischium. Its use is disappointing in

obliterating defects following abdominal perineal resections or following large excisions for Crohn disease.

The gracilis is the most superficial muscle of the adductor group of the medial side of the thigh. It is a long strap-like muscle with motor innervation arising from the anterior branch of the obturator nerve. It serves to adduct the thigh and to flex and medially rotate the leg. It has an aponeurotic origin from the body and inferior ramus of the pubis, and inserts into the medial surface of the tibia between the sartorius and the semitendinosus muscles. It lies posterior to the adductor longus and anterior to the semimembranosus muscles and superficial to the adductor magnus muscle. Its superficial surface is covered by the deep fascia of the thigh.

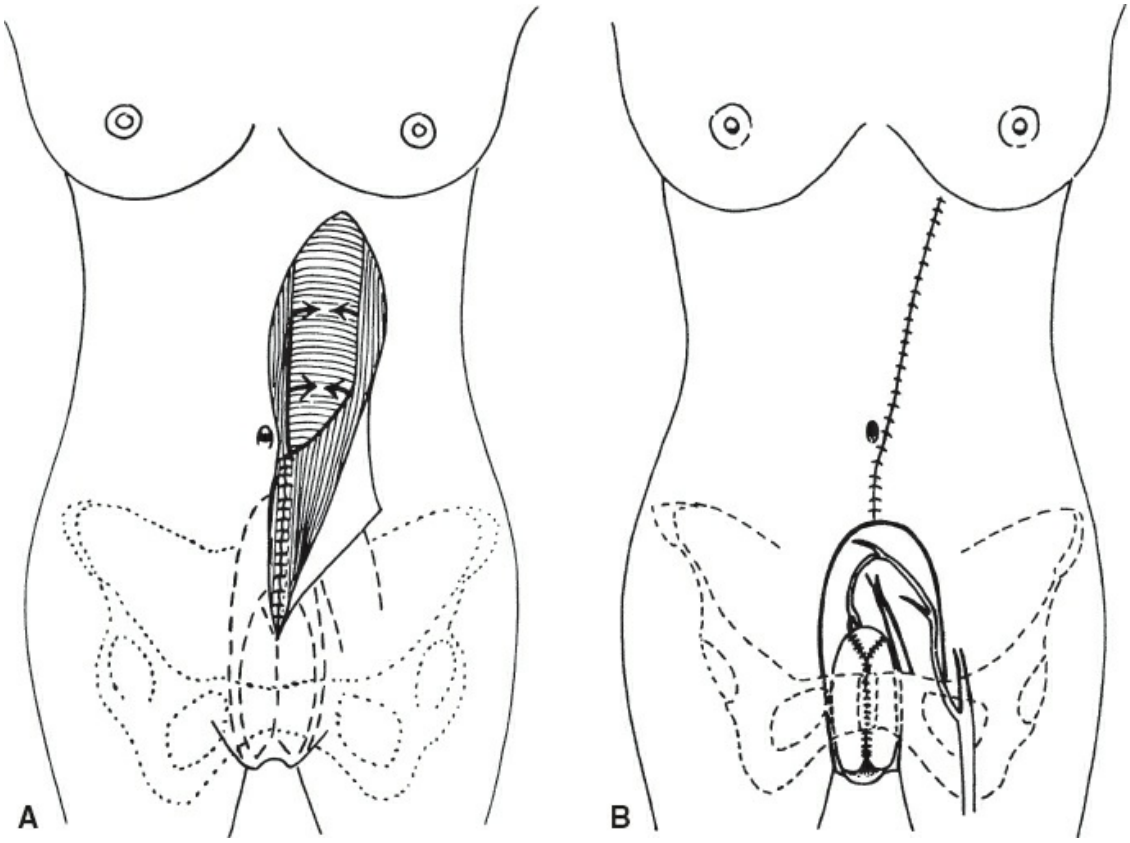

Figure 16.43. Closure of the donor defect after inset of neovagina and stomas. **A.** Diagram illustrating direct closure of the anterior rectus fascia donor site above the umbilicus (*arrows*) and abdominal wall closure below the umbilicus by suture of the anterior rectus fascia to the linea alba. **B.** Direct closure of the cutaneous donor site in continuity with the laparotomy. (Published in Tobin GR, Persell SH, Day TG. Refinements in vaginal reconstruction using rectus abdominis flaps. *Clin Plast Surg* 1990;17(4):705–12. Copyright © 1990 Elsevier.)

Advantages

1. Relative proximity to the perineum
2. An expendable muscle providing a minimal donor deformity with minimal functional loss
3. Relative inconspicuous incision on the inner thigh

Disadvantages

1. Unreliable distal cutaneous territory
2. Most limited arc of rotation of the pedicle, which does not reach the depth of a perineal wound
3. Relatively narrow muscle belly

Puborectalis Fasciocutaneous Flap for Vaginal Reconstruction (Wei Flap)

For vaginal reconstruction in patients who have not undergone radiation, a simple and effective method has been described by Wei. Two fasciocutaneous flaps inferiorly based on the pudendal arteries are elevated on each side of the labia majora. The flaps are made into an island, if necessary, as long as one maintains its proximal blood supply. They are sutured to each other to form a tube and introduced into the vagina in a relatively straightforward fashion. The secondary defect is closed primarily (Fig. 16.44).

Advantages

1. Adjacent, well-vascularized flaps that allow an easy dissection
2. Allows for a one-stage procedure

Disadvantages

Not applicable to patients who have undergone radiation to the vulva or perineum.

Shortly after the repair, the patient is free of pain except for the incisional surgical pain. The rehabilitation is done during a period of 3 months, and most patients are able to return to their athletic endeavors.

Singapore Flap

If defects are small or minimal donor site morbidity is desired, a perforator-based flap can be used. The so-called Singapore flap is based on one of the many perforators arising from the pudendal artery in the line just posterior to the medial groin crease. Additionally, this captures

innervation to this area, making this an excellent sensate reconstructive option. The flap can measure approximately 15 × 6 cm and can be paired with the contralateral side. The flap is raised in an anterior to posterior fashion, incising down through the skin and subcutaneous tissue, but remaining suprafascial. This is elevated until an island is developed about the perforator. One should take care in this posterior elevation, as large veins are sometimes encountered and should be preserved whenever possible. This island can then be elevated, rotated 90 degrees, and tunneled for posterior defects or transposed anteriorly, as in the Wei flap, for anterior introitus defects. The defect is closed primarily behind the flap.

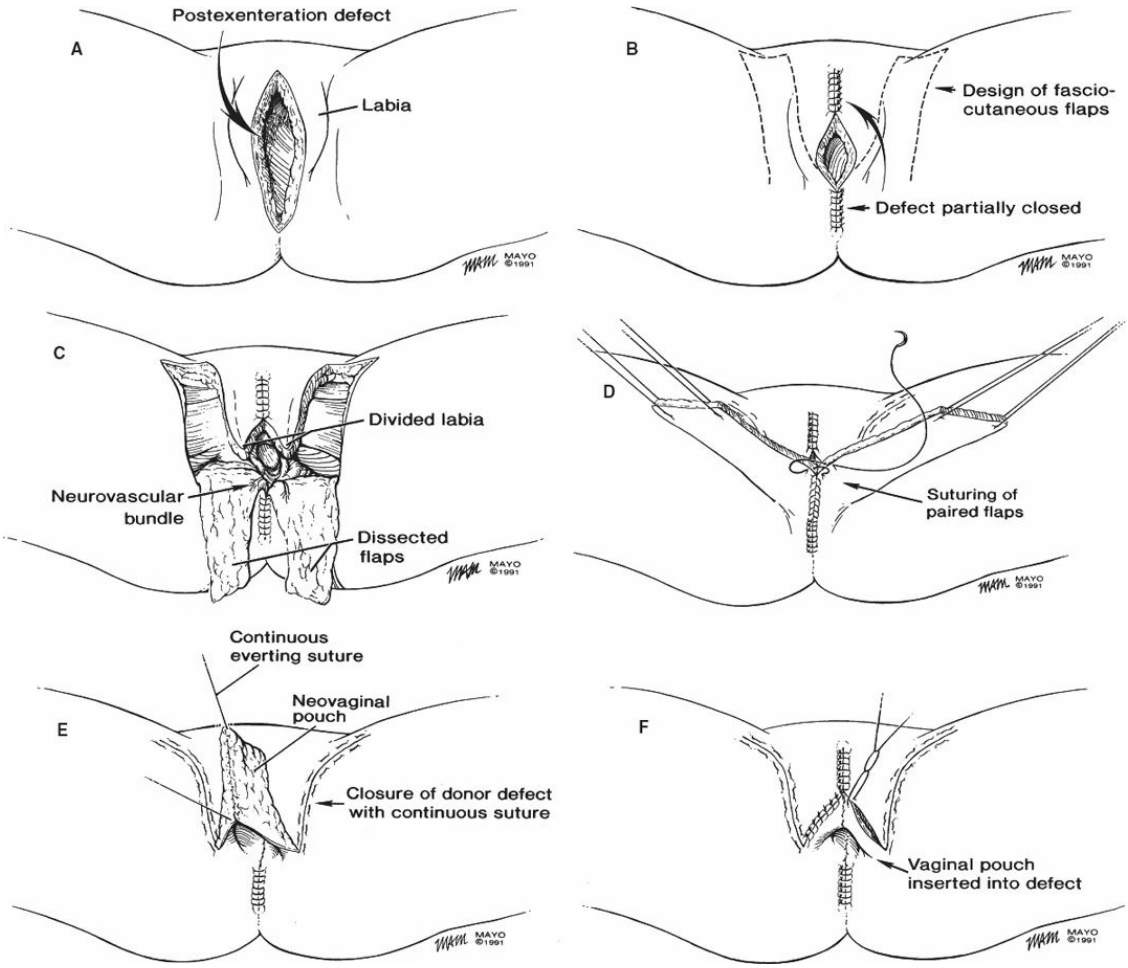

Figure 16.44. Diagrammatic representation of vaginal reconstruction using the modified Singapore flap. **A.** Exenteration defect prior to reconstruction. **B.** Partial suturing of defect with 6 × 15 cm flaps straddling the inguinal crease. **C.** Flaps elevated at the subfascial level, with division of the labia posteriorly, to allow easy insetting of the neovagina without incision of the skin at the base of the flaps. **D.** Initial suturing of the flaps is carried out to even the flap edges into the neovagina, avoiding burial of the

dermis. **E.** The completed pouch prior to insetting. Note preliminary closure of the donor defects. **F.** Nearly completed suturing of neovagina after insetting. (From Woods JE, Alter G, Meland B, et al. Experience with vaginal reconstruction utilizing the modified Singapore flap. *Plast Reconstr Surg* 1992;90:280, with permission. Modified from Strauch B, Vasconez LO, Hall-Findlay E. *Grabb's Encyclopedia of Flaps.* Philadelphia, PA: JB Lippincott, 1998:1477.)

Advantages

1. Minimal donor site morbidity
2. Reliable vasculature that is "perforator-rich."
3. Sensate flap

Disadvantages

1. No muscle coverage, which some may prefer for coverage of irradiated fields
2. Comparatively small
3. Nonaxial blood supply which may become kinked or pinched when tunneled

Internal Oblique Muscle Flap for Athletic Pubalgia

A clinical entity that is probably more common than previously diagnosed is the so-called athletic pubalgia, more commonly known as "sports hernia." Although the pathophysiology is not clear, it appears that this represents a partial rupture of portions of the rectus abdominis muscle as they insert into the pubic tubercle. The patient presents with pain over the pubis and this is exacerbated by forced abduction of the involved thigh. More often than not, radiographs and magnetic resonance images are interpreted as normal, and are not diagnostic.

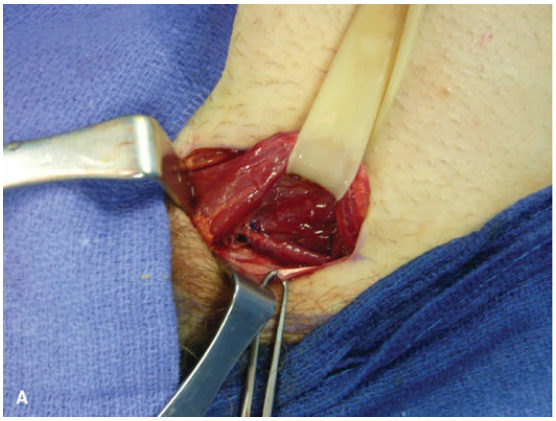

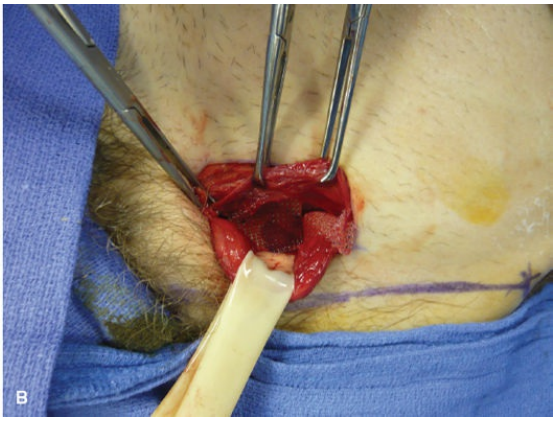

Figure 16.45. **A.** The internal oblique muscle is exposed and then retracted to visualize the origin of the rectus abdominis muscle from the pubis. The Penrose drain is retracting the cord structures. **B.** The mesh is placed in the properitoneal space and deep to the origin of the rectus muscle, prior to advancing the internal oblique to cover the mesh.

Its treatment is straightforward once the proper diagnosis has been made. General surgeons often see patients with this entity because they are referred for the possibility of an inguinal hernia, but when none is found, they are rejected for surgery, even though the patient continues with incapacitating pain, particularly if the patient is an athlete.

The approach for its correction is simple and effective. Access is gained through an incision similar to that used in an inguinal hernia repair. In a male patient, the spermatic cord is isolated and efforts are made to check for an indirect inguinal hernia even if it was not present clinically. As one dissects the floor of the inguinal region, one notices a weakness in that area but no direct hernia. The repair consists in placing a piece of mesh to strengthen the pelvic floor and, over the polypropylene mesh, the conjoined tendon, which is a junction of the internal and transverse abdominis muscle, is approximated to the inguinal ligament. The wound is then closed similar to a hernia repair (Fig. 16.45).

Suggested Readings

Burget GC, Menick FJ. The subunit principle in nasal reconstruction. *Plast Reconstr Surg* 1985;76(2):239–47.

De La Cruz L, Moody AM, Tappy EE, et al. Overall survival, disease-free survival, local recurrence, and nipple-areolar recurrence in the setting of nipple-sparing mastectomy: A meta-analysis and systematic review. *Ann Surg Oncol* 2015;22(10):3241–9.

Fayanju OM, Stoll CR, Fowler S, et al. Contralateral prophylactic mastectomy after unilateral breast cancer: a systematic review and meta-analysis. *Ann Surg* 2014;260(6):1000–10.

Fischer JP, Fox JP, Nelson JA, et al. A Longitudinal assessment of outcomes and healthcare resource utilization after immediate breast reconstruction-comparing implant- and autologous-based breast reconstruction. *Ann Surg* 2015;262(4):692–9.

Fu RH, Weinstein AL, Chang MM, et al. Risk factors of infected sternal wounds versus sterile wound dehiscence. *J Surg Res* 2016;200(1):400–7.

Garza RM, Paik KJ, Chung MT, et al. Studies in fat grafting: Part III. Fat grafting

irradiated tissue–improved skin quality and decreased fat graft retention. *Plast Reconstr Surg* 2014;134(2):249–57.

Gurtner GC, Jones GE, Neligan PC, et al. Intraoperative laser angiography using the SPY system: review of the literature and recommendations for use. *Ann Surg Innov Res* 2013;7:1.

Jones CM, Winder JS, Potochny JD, et al. Posterior component separation with transversus abdominis release: Technique, utility, and outcomes in complex abdominal wall reconstruction. *Plast Reconstr Surg* 2016;137(2):636–46.

Kim JT, Ho SY, Hwang JH, et al. Perineal perforator-based island flaps: the next frontier in perineal reconstruction. *Plast Reconstr Surg* 2014;133(5):683e–7e. doi: 10.1097/PRS.0000000000000146. Erratum in: *Plast Reconstr Surg* 2014;134(1):168. PubMed PMID: 24776571.

Lee KT, Mun GH. Updated evidence of acellular dermal matrix use for implant-based breast reconstruction: a meta-analysis. *Ann Surg Oncol* 2016;23(2):600–10.

Losken A, Pinell-White X, Hart AM, et al. The oncoplastic reduction approach to breast conservation therapy: benefits for margin control. *Aesthet Surg J* 2014;34(8):1185–91.

Medina MA 3rd, Salinas HM, Eberlin KR, et al. Modified free radial forearm fascia flap reconstruction of lower extremity and foot wounds: optimal contour and minimal donor-site morbidity. *J Reconstr Microsurg* 2014;30(8):515–22.

Mirzabeigi MN, Wang T, Kovach SJ, et al. Free flap take-back following postoperative microvascular compromise: predicting salvage versus failure. *Plast Reconstr Surg* 2012;130(3):579–89.

Ng CS. Recent and future developments in chest wall reconstruction. *Semin Thorac Cardiovasc Surg* 2015;27(2):234–9.

Stuart KE, Houssami N, Taylor R, et al. Long-term outcomes of ductal carcinoma in situ of the breast: a systematic review, meta-analysis and meta-regression analysis. *BMC Cancer* 2015;15:890.

Warwick AM, Smart NJ, Daniels IR. Retro-rectus repair of complex incisional hernia leads to low recurrence rate. *ANZ J Surg* 2016. doi: 10.1111/ans.13402. [Epub ahead of print] PubMed PMID: 26749153.

EDITOR'S COMMENT

Plastic surgery and its ability to restore individuals not only to function, but also to psychologically function is one of the marvels of surgery over the past 30 or 40 years. We are indeed privileged to have Dr. Luis Vasconez as the senior author of this important chapter. This chapter demonstrates how far reconstruction has continued to come with the essence of being the restoration

of function, both psychologically and physically and functionally. The main advance over the last decade has been the increasing indications for flap reconstruction and the wider applicability to our patient population.

Professor Vasconez points out the types of difficult wounds that need coverage because of the destruction of tissues around the wounds. These difficult wounds include the following:

- Superficially infected wounds regarding the obvious coverage and the inability to cut out the infection.
- Wounds over bone that do not have periosteum, thereby inhibiting the ability of bone to heal.
- Postradiation wounds, in which all the tissues around the wounds are dead and need transplantation as these were swinging over a flap in order to provide blood supply, muscle, and skin which will survive.

In reconstruction of the face, especially the nose and lips there are four main techniques: skin grafting, tissue rearrangement, nasolabial and forehead flaps and one not really discussed is allowing the defect to heal by secondary intention followed by secondary flap reconstruction. Most such excisions are done for skin cancer and therefore have a clean base and reconstruction can be done immediately. However, in trauma, the main watchword is irrigating and cleaning the wound copiously and if necessary coming back at another time with anything except simple closure at the initial setting. However, one can get away with quite a lot because of the infinite vascularity of the face.

A second difficult area where flaps are needed and perhaps most difficult to perform is when periosteum is denuded from bone in association with crush injuries, most commonly in vehicular collisions. The main goals of treatment after establishing or reestablishing blood are debridement of devitalized tissue and swinging in vascularized tissue. Hyperbaric oxygen can be useful to counteract tissue hypoxia and stimulate wound healing (Chiang IH, Tzeng YS, Chang SC. Is hyperbaric oxygen therapy indispensable for saving mutilated hand injuries? *Int Wound J* 2017. doi: 10.1111/iwj.12730. [Epub ahead of print]) Soft tissue coverage can be obtained with an iliac flap, the adipofascial lateral arm flap, and the gracilis flap as well as corticoperiosteal flaps for the bone defects (Del Piñal F, Urrutia E, Klich M. Severe crush injury to the forearm and hand: The role of microsurgery. *Clin Plast Surg* 2017;44(2):233–55). Restoring functionality to the hand, in particular, may also require digit transfer from foot to hand. Such flaps are also necessary when treating decubitus ulcers where the same principles apply. In addition, diversion of the fecal stream is often necessary to get the wound clean and ready for coverage with a flap.

The third area where flaps can be critical is in prior irradiated fields. This is largely seen in patients who have had a mastectomy and subsequent radiation to the chest wall. Reconstructive options rely on flap reconstruction from a variety of sources most commonly today from deep inferior epigastric perforator

(DIEP) flaps. Healthy vascularized tissue under an irradiated skin can actually revitalize tough leathery skin. Reconstruction with tissue expanders and implants post irradiation never do well or appear normal. Often they can be painful as well. The same cannot be said for tissue expander placed on the chest wall and expanded prior to radiation. This saves the space and skin and then improved reconstruction can be completed with tissue or implant with good cosmetic results (Tanos G, Prousskaia E, Chow W, et al. Locally advanced breast cancer: autologuous versus implant-based reconstruction. *Plast Reconstr Surg Glob Open* 2016;4(2):e622.).

Finally, where flaps are perhaps used the most is in breast reconstruction. Much of the advances with flaps have been made for this purpose. Indications for offering breast reconstruction are broadening. Not offering or delaying reconstruction produces the greatest scar emotionally. Once reconstruction was only be limited to those with stage 0 to IIa but recent studies have shown skin-sparing mastectomy to be safe even with locally advanced breast cancer (Burdge EC, Yuen J, Hardee M, et al. Nipple skin-sparing mastectomy is feasible for advanced disease. *Ann Surg Oncol* 2013;20(10):3294–30; Boneti C, Yuen J, Santiago C, et al. Oncologic safety of nipple skin-sparing or total skin-sparing mastectomies with immediate reconstruction. *J Am Coll Surg* 2011;212(4):686–93; discussion 693–5). Systemic presurgical chemotherapy can be offered to the patients with more aggressive disease who will need radiation, or to those patients who need time to stop smoking. Patients with a recurrence after conservative breast surgery and radiation can also have good results using newer flap dissection techniques. Complication rates are higher in the obese, but some are more than willing to accept this for a chance to look and feel normal. Tissue reconstruction in these patients and the use of their own dermis can lower such complications. In addition, there is no doubt that contralateral prophylactic mastectomy (CPM) is on the rise, increasing from 0.4% in 1998 to 4.7% in 2007 to approximately one third in 2016. Why and whether CPM carries a survival benefit is controversial. Patients often elect CPM out of fear of recurrence or to lessen surveillance. The majority of average-risk women will obtain no oncologic benefit from a CPM with the risk of finding occult disease in a CPM of about 1.8%. Bilateral flap reconstruction can be accomplished with DIEP flaps sparing the abdominal wall musculature or in the slim patient with a combination of flaps and/or implants. An individualized approach is necessary with thorough discussion of the risks and benefits but ultimately is decided by the patient.

There has been amazing progress in reconstructive techniques improving the lives of so many that would be otherwise disfigured or crippled.

V. Suzanne Klimberg

17 Hand Surgery: Traumatic and Infectious Emergencies

Brian A. Mailey and Michael W. Neumeister

INTRODUCTION

Hand injuries and infections represent 20% of all exhibiting visits to emergency departments. The fingers, hand, wrist, and forearm contain a dense amount of anatomic structures that can be challenging to recall for practitioners who infrequently treat this area of the body. This chapter will present a description of high-yield anatomy and the initial management of the most common hand surgery emergencies.

Traumatic injuries often occur from lacerations, avulsions, axial loading, or crush injuries affecting multiple structures. Understanding the anatomy and biomechanics assists in rendering a treatment plan based on a sequential and structured physical examination. The anatomical cutoff for what is covered by the hand surgeon varies by institution; we consider everything distal to the elbow and any nerve injury along the course of the brachial plexus to be included.

HIGH-YIELD HAND, WRIST AND FOREARM ANATOMY

Hand and forearm function is under the control of three peripheral nerves. The radial nerve is primarily responsible for extensor function, while the median and ulnar nerves power wrist and finger flexion and innervate the intrinsic muscles. The median and radial nerves give off an anterior and posterior interosseous nerve branch in the proximal forearm, respectively. These interosseous nerves supply extrinsic motor function proximally and sensation and proprioception to the wrist joint distally. The median nerve and its branches innervate the radial aspect of the volar hand and forearm, which is the part of the hand primarily responsible for fine pincer movements and key pinch. The ulnar nerve innervates the ulnar one and a half digits of the hand and is the part of the hand primarily functioning in heavy lift and carry. This distinction becomes important when evaluating a patient with a mutilating hand injury. Defining the occupation of the

patient can guide the hand surgeon on priorities of salvage. The dorsal aspect of the hand receives its sensory innervation from the superficial branch of the radial nerve and dorsal cutaneous branch of the ulnar nerve on the radial and ulnar aspects, respectively (Fig. 17.1). These nerves supply sensation reliably up to and over the dorsal aspect of the proximal phalanx, but little sensation distal to that, which is received from vertical perforating branches of the respective volar digital nerves. The median and ulnar nerves each have a motor branch distal to the wrist that innervates the intrinsic musculature. The remainder of nerve fascicles supplies the digital sensory nerves for tactile feedback. Each digit has a proper digital nerve located along the midlateral line of the digit approximately the junction between the glabrous and nonglabrous skin.

The muscles of the hand/forearm unit can be classified as extrinsic muscles, which control wrist flexion and power grip and intrinsic muscles, which allow fine motor movement and a chuck grip of large objects (*e.g.*, throwing a baseball and opening a door knob). These unique complex motor tasks are accomplished by the interossei and lumbrical muscles, which permit metacarpophalangeal (MP) flexion with concomitant proximal interphalangeal (PIP) joint extension. Along with the thenar and hypothenar muscle groups (Fig. 17.2), these muscles distinguish many human behaviors from other animals and primates.

The bony skeleton consists of two forearm bones. The ulna is anchored to the humerus and can be thought of as the flagpole with which the radius, carpus, and hand representing the flag are able to rotate around this ulnar axis (Fig. 17.3). Pronation and supination are accomplished by the proximal and distal radioulnar joints (PRUJ and DRUJ, respectively). Flexion and extension of the wrist occur through motion at both the radiocarpal and midcarpal joints; however, their contribution is not equal (sun js, 2000).[1–3] Compensatory motion can occur in one of these joints during conditions limiting motion at the other (*e.g.*, increased midcarpal motion can occur in conditions limiting radiocarpal motion). Radioulnar deviation is thought to occur mostly at the midcarpal joint; however, depending on the lunate articulations (type I: capitate only *vs.* type II: capitate and hamate), the relative motion at each joint can vary.[2] The functional motion of the wrist at which most activities are performed is termed to be the dart-throwers motion (dorsoradial to volar–ulnar deviation).[3] During this motion, there ARE limited radiocarpal or scapholunate movement and it is an important early hand rehabilitation

activity to prevent stiffness.

The wrist comprises eight carpal bones (Fig. 17.4) separated into two rows, termed the proximal and distal carpal rows. The proximal row (scaphoid, lunate, triquetrum, and pisiform) is known as the intercalated segment due its lack of tendinous or muscle insertions. The scaphoid bone, *aka* the navicular bone, has the largest amount of overall motion of all carpal bones. Therefore, it is not surprising that fractures occur in this bone more commonly than all of the others combined (70% of carpal bone fractures). The scaphoid is 80% articular with vascular pedicles entering at the distal tubercle (supplying distal 20%) and along the dorsal ridge (supplying 80% of the scaphoid).[4,5] The proximal pole relies on a retrograde vascular supply and predisposes this bone to nonunion and delayed union.[5] Scaphoid fractures and scapholunate ligament injuries comprise the great majority of carpal bone attention from acute trauma.

In hand injuries, the thumb takes priority in salvage and reconstruction. This digit is considered to possess 40% of overall hand function and resources should be allocated to saving thumb function. Similar to the other digits, thumb movements consist of flexion and extension. However, unlike the other fingers, the thumb can pronate and supinate outside the plane of the hand and abduct in both a radial and palmar direction. During this movement of palmar abduction, the thumb also supinates to meet the other fingers in a pad-to-pad fashion; this motion is known as opposition.

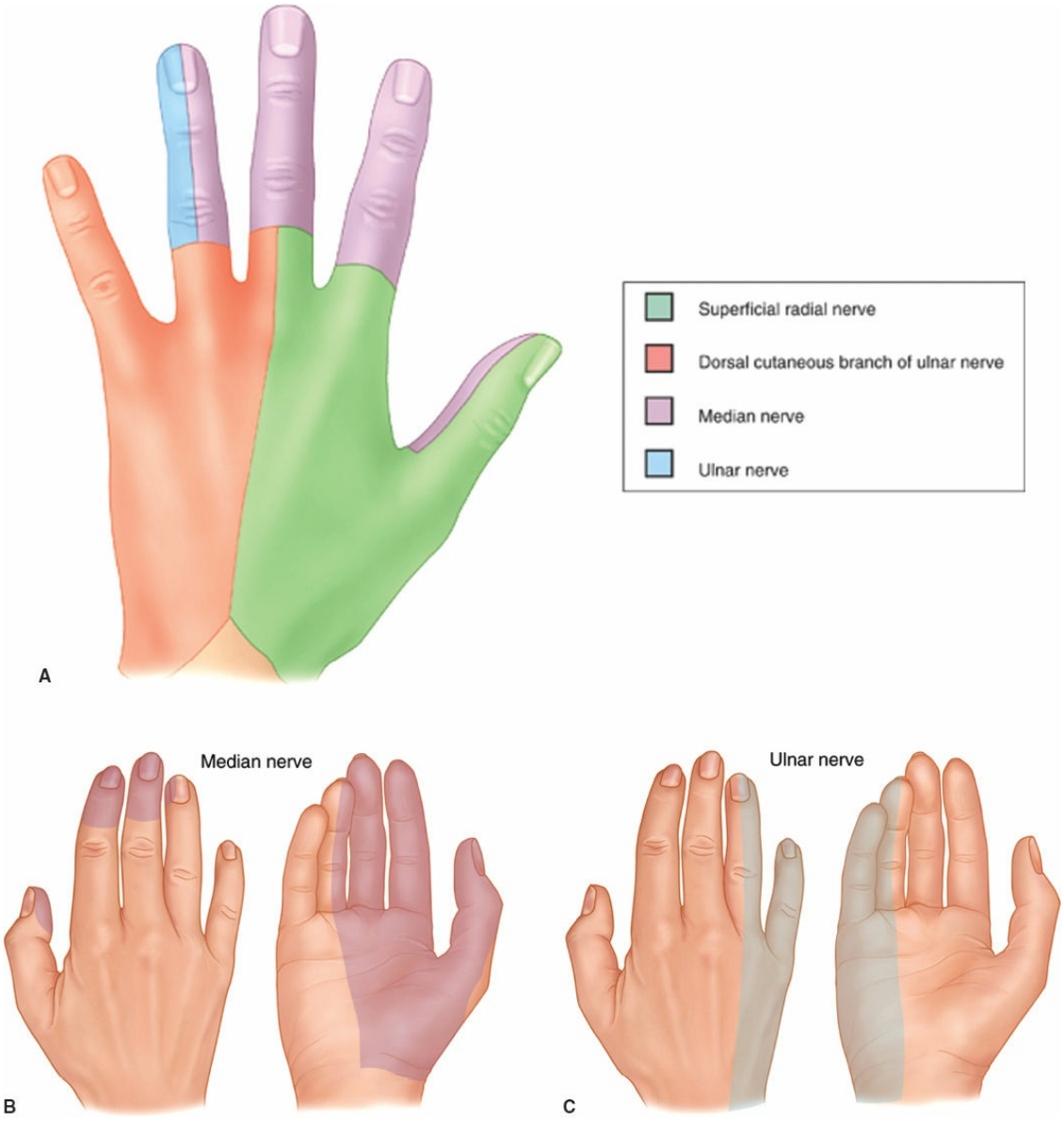

Figure 17.1. Anatomical nerve territory of the hand. (**A**) The dorsal aspect of the hand receives its sensory innervation from the superficial branch of the radial nerve and dorsal cutaneous branch of the ulnar nerve on the radial and ulnar aspects, respectively, up to and over the dorsal aspect of the proximal phalanx, but little sensation distal to that point. Vertical perforating branches of the respective volar digital nerves supply the dorsal aspect of the remainder of the fingers. (**B** and **C**) Volar common and proper digital nerves supply sensation to the volar aspect of the hand and fingers, respectively.

The metacarpal bones link the fingers to the wrist (Fig. 17.5) and create the skeletal structure separating the interossei muscles. When fractured, the metacarpal bones can tolerate a fair amount of dorsovolar angulation

and shortening, with the small finger metacarpal being able to tolerate the most displacement (>40 degrees). Radioulnar angulation, however, can lead to a rotational scissoring deformity and should be reduced or repaired. Each finger, except the thumb, contains three phalanges progressively decreasing in size. The proximal phalanx does not have any direct tendinous insertions from extrinsic musculature, but is primarily under the control of intrinsics and a lasso effect of the extensor tendon. Therefore, the proximal phalanx can both flex and extend, even if the remainder of the finger distal to the PIP joint is lost. The middle phalanx contains the insertions from the flexor digitorum superficialis (FDS) and the central slip from the extensor tendon. The FDS tendon is responsible for independent finger flexion. The flexor digitorum profundus (FDP) tendon and terminal tendon insert on the distal phalanx. Tuft fractures of the distal phalanx with a subungual hematoma were classically thought of as “open fractures” which required removal of the nail plate and repair of the nail bed. It is now acceptable to trephinate the hematoma for pain and manage these injuries closed.

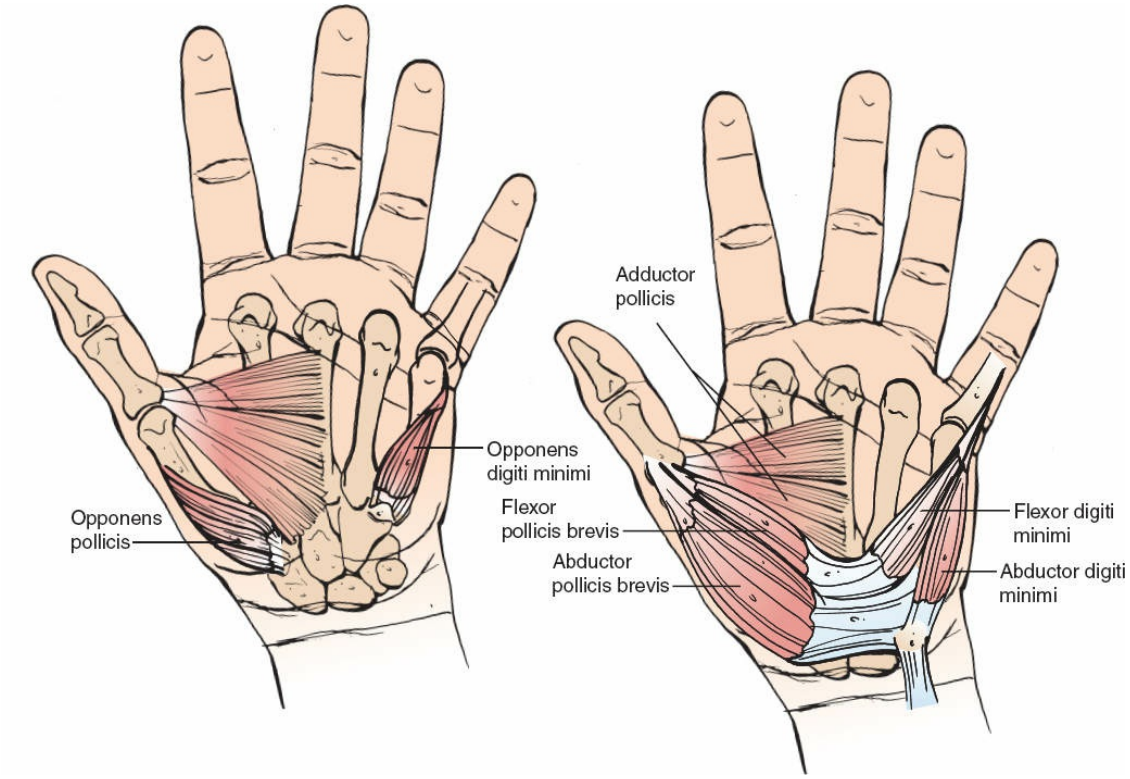

Figure 17.2. Thenar and hypothenar intrinsic muscles of the hand. Complex and fine motor movements of the hand are accomplished by the intrinsic musculature. They allow metacarpal phalangeal flexion with concomitant proximal interphalangeal joint extension. These muscles distinguish many

human behaviors from other animals and primates.



Figure 17.3. The bony skeleton consists of two forearm bones. The ulna is anchored to the humerus and can be thought of as a flagpole or doorframe with which the radius, carpus, and hand representing the flag (or door) are able to rotate around this ulnar axis. Pronation and supination are accomplished by the proximal and distal radioulnar joints, which can be thought of as the hinges of the door or attachments of the flap to the pole.

CLINICAL PRESENTATION AND HAND EXAMINATION

A complete hand examination does not need to be tedious, lengthy, or esoteric. The contralateral hand can be used for comparison in evaluating strength, sensation, and range of motion. The examination commences with inspection. The normal hand is held with natural “C” curvatures, with a “C” curvature made between the thumb and fingers, another one on the

palmar aspect between the thenar and hypothenar areas and a dorsal curvature over the metacarpal heads. Loss or flattening of one of these is indicative of a nerve injury (Fig. 17.6). After inspection, a sensory test can be accomplished by instructing the patient to rate their sensation on a scale of 0 to 10, with 10 being normal sensation. Start by assessing an uninjured area and then move to the injured areas. Generally, even in areas with a complete nerve transection, patients will relay some element of sensation; however, quantifying their sensation less than 5 is indicative of a nerve injury. Finally motor function is assessed. The patient's ability to flex, extend, pronate, and supinate the wrist is evaluated. Various muscle tendon units perform redundant functions; therefore, an injury is suspected when a particular motion is either weaker or produces pain—not necessarily completely incapable of performing.

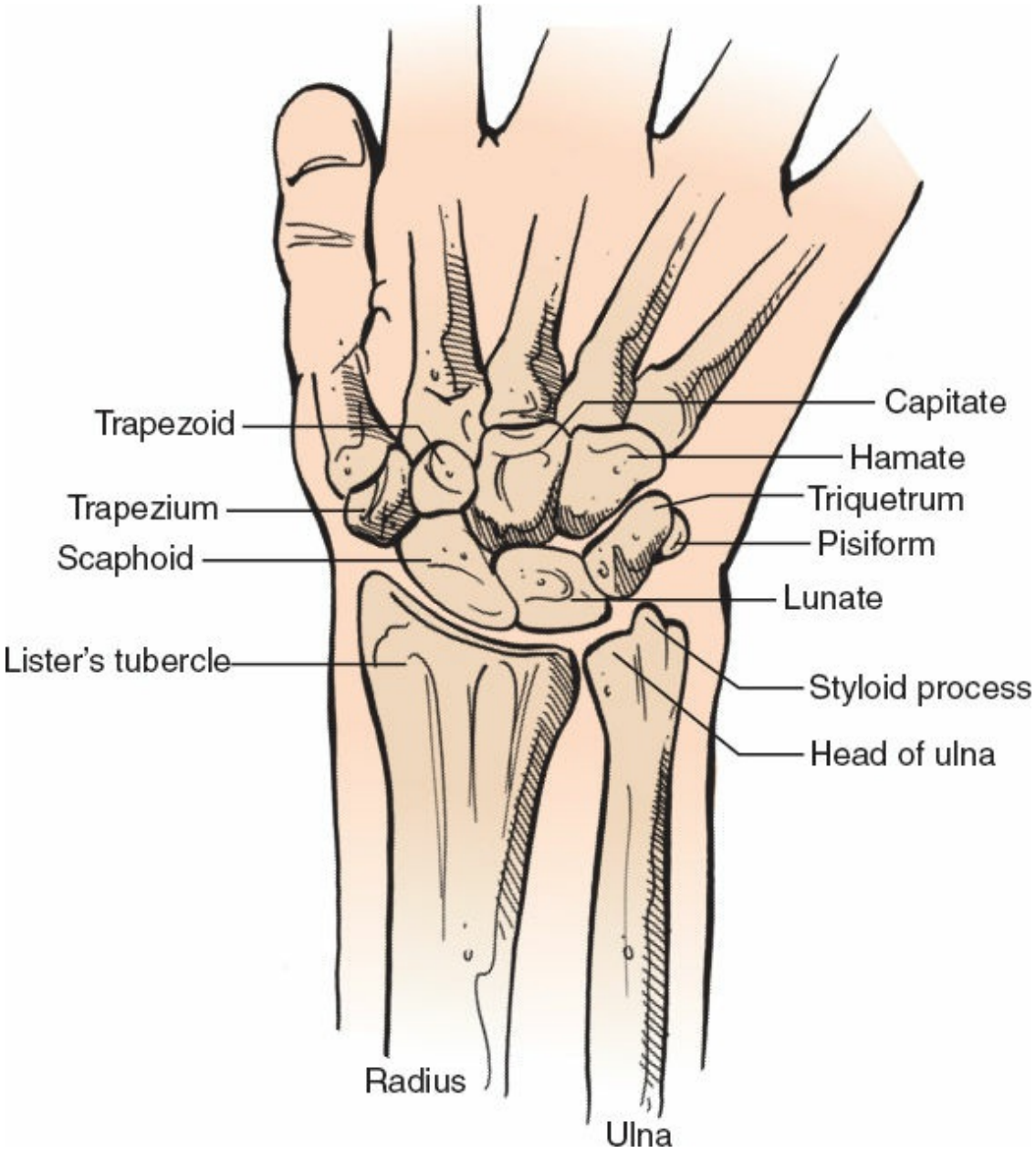

Figure 17.4. The wrist consists of eight carpal bones separated into a proximal and a distal carpal row. The proximal row—scaphoid, lunate, triquetrum, and pisiform—is known as the intercalated segment due its lack of tendinous or muscle insertions.

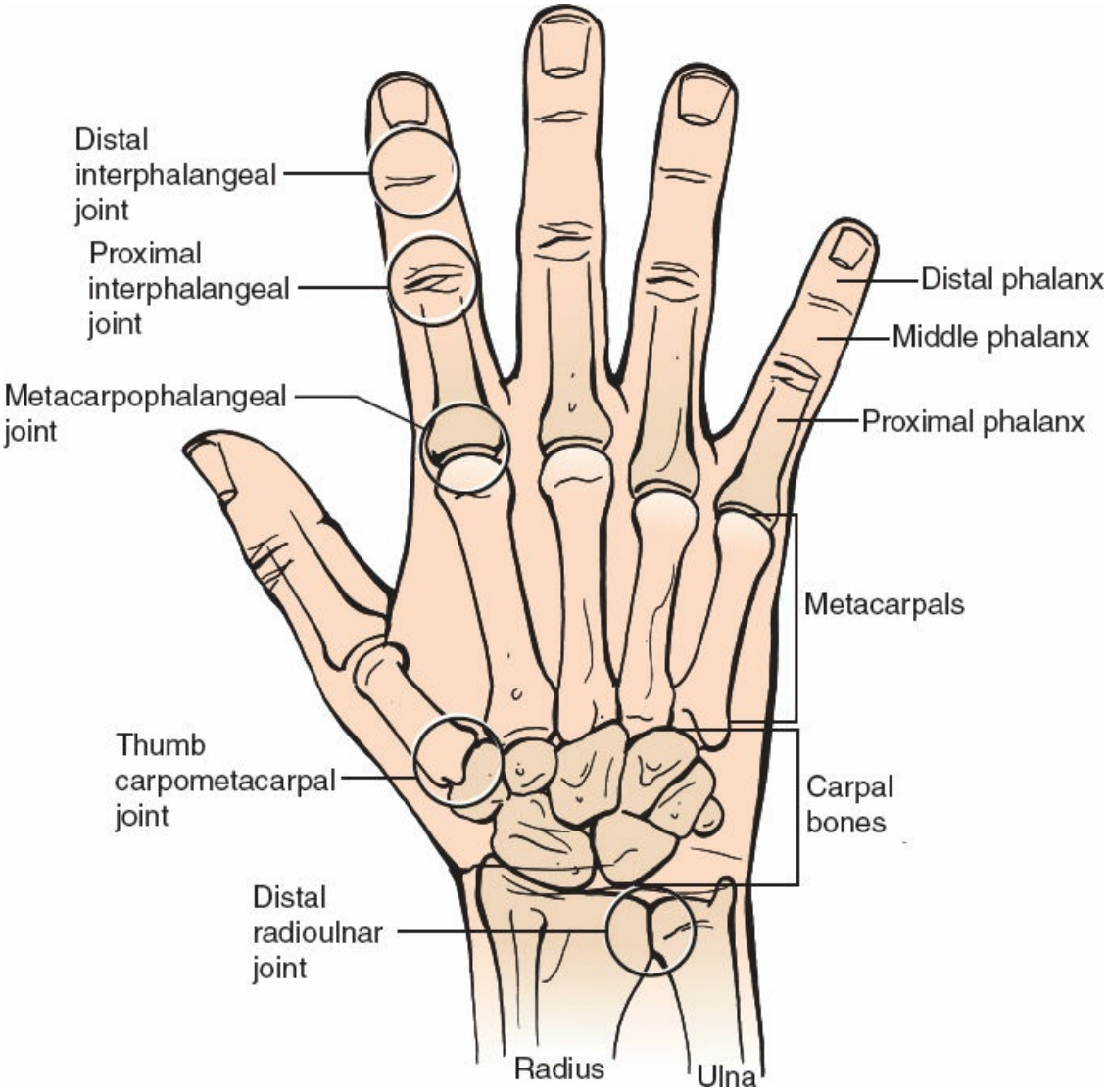

Figure 17.5. The metacarpal bones link the fingers to the wrist and create the skeletal structure separating the interossei muscles. When fractured, the metacarpal bones can tolerate a fair amount of dorsovolar angulation and shortening, with the small finger metacarpal being able to tolerate the most displacement. Indications for repair of metacarpal fractures include extensor lag or rotational deformity.

Assessing finger extension can be misleading, as the juncturae tendineae collate the extensor digitorum communis tendons (Fig. 17.7) over the hand causing the examiner to miss an injury proximal to these structures. An extensor tendon injury is suspected when an extensor lag is present or independent finger extension is weaker or elicits pain. If the patient is too uncomfortable to be examined, a local anesthesia digital block can be performed to elicit pain-free finger motion. Finger flexion is assessed for the FDP and FDS tendons independently. Each FDP tendon

can be examined by having the patient flex at the distal interphalangeal (DIP) joint. The FDS tendons are examined by having the patient independently flex the digit at the PIP joint level while extending the other digits; this prevents FDP finger flexion. Intrinsic function is evaluated by having the patient cross the index finger under the long finger (Fig. 17.8). Alternatively, the patient can radially abduct the index finger to resistance. This assesses the ulnar innervated first dorsal interosseous muscle. Confirming thumb opposition provides information regarding the integrity of the motor branch of the median nerve distal to the wrist (Fig. 17.9). Confirming hypothenar muscle function can be assessed by having the patient hold all fingers together in extension. Loss of hypothenar muscle balance will allow the radial nerve innervated extensor tendons to pull the small finger in an abducted position from the other fingers; this is known as Wartenberg's sign.

The perfusion of the hand and digits is evaluated by assessing the radial and ulnar arteries at the wrist (Fig. 17.10), the presence of a Doppler signal in the superficial palmar arch, and at the lateral aspect of each digit. A dorsal blood supply does exist; however, it is primarily reliably for the thumb but becomes decreasingly present in a radial to ulnar direction. Color, temperature, and turgor remain the most reliable indicators of digital tissue perfusion. Subungual capillary refill is not a reliable indicator of distal tissue perfusion, as this can remain positive even in the immediate postmortem state.

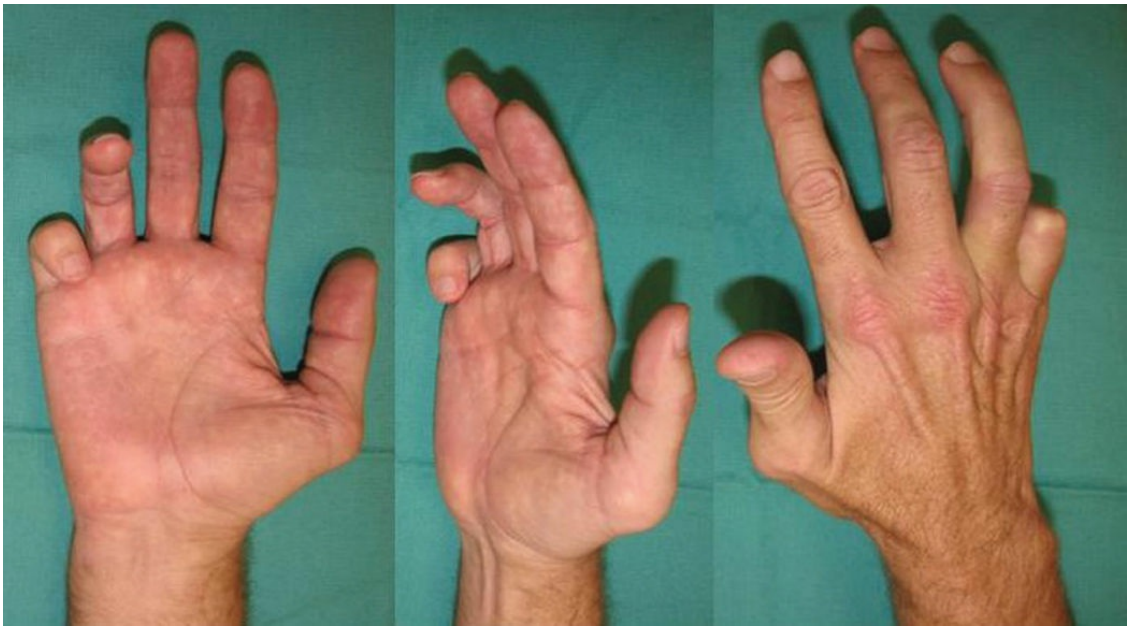

Figure 17.6. The normal hand is held with natural "C" curvatures,

with a “C” curvature made between the thumb and fingers, another one on the palmar aspect between the thenar and hypothenar areas and a dorsal curvature over the metacarpal heads. Loss or flattening of one of these is indicative of a nerve injury. This patient has a claw hand from an ulnar nerve injury. The position of the index and long fingers is still somewhat maintained; this is accomplished by the median nerve innervated lumbricals.

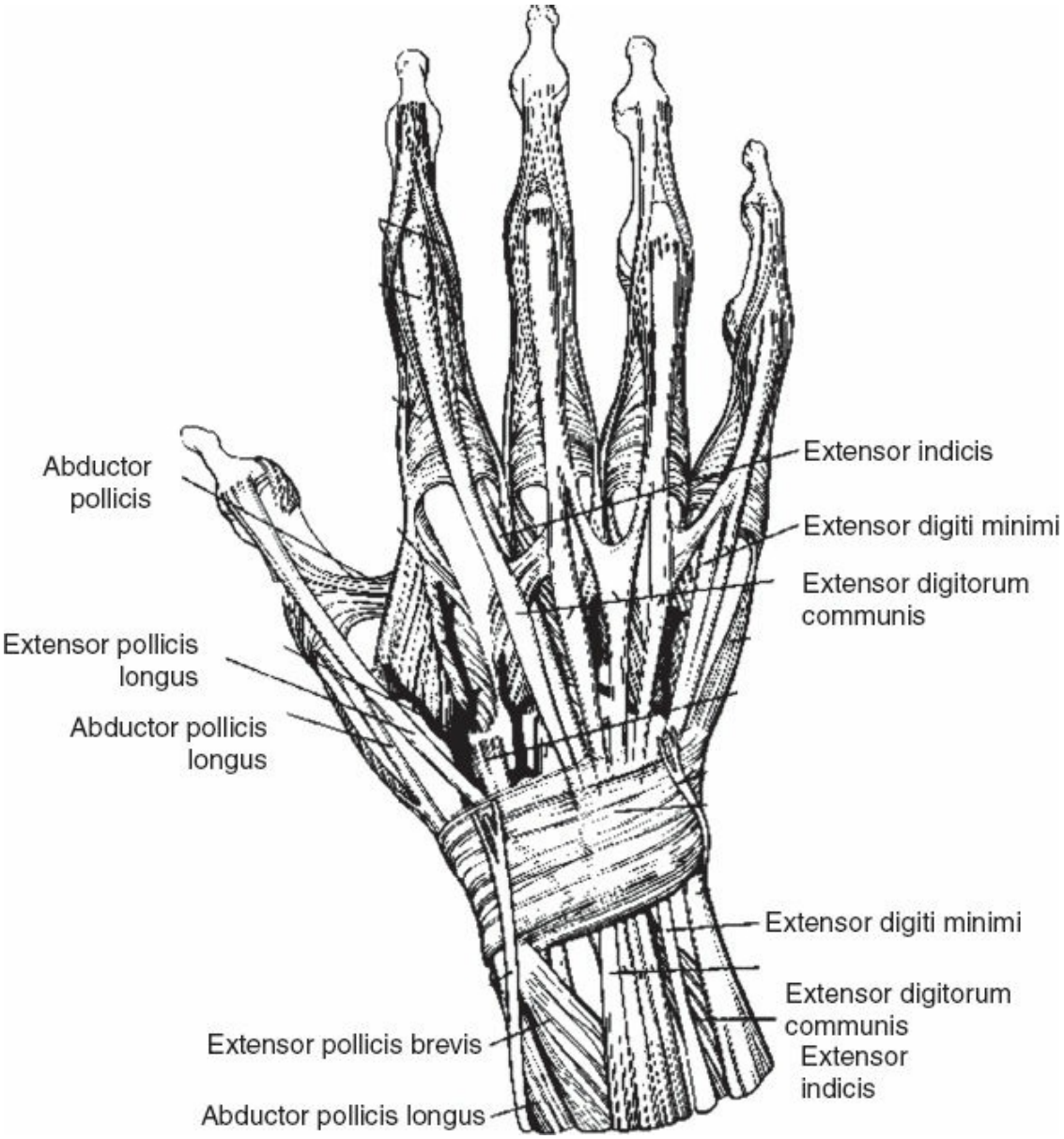

Figure 17.7. Assessing finger extension after a dorsal land laceration can be misleading. The juncturae tendineae collate the extensor digitorum communis tendons over the hand causing the examiner to miss an injury proximal to these structures. An extensor tendon injury is suspected when an extensor lag is present or independent finger extension is weaker or elicits pain.

PREOPERATIVE PLANNING AND MANAGEMENT OF HAND TRAUMA PATIENTS

Hand and wrist radiographs are essential in all hand trauma patients. X-rays are important even in patients with sharp lacerations or injuries, as foreign bodies can frequently be seen and lead to infections if not addressed.

The constellation of hand injuries can be separated into three categories of urgency. A professor of mine, Dr. James Chao, termed these categories as “run, walk, roll-over” divided by the urgency needed to take these patients to the operating room. The most emergent cases include high-pressure injections, compartment syndromes, amputations, and deep space infections, including flexor tenosynovitis and septic arthritis.

Less emergent injuries that require attention of some element on the day of injury but may not require care in the operating room include open fractures, joint and carpal bone dislocations, open wounds, lacerations, nail bed injuries, and lesser infections like paronychias, felons, dorsal subcutaneous abscesses.

Injuries that require elective attention and can usually be treated initially with a referral to clinic include closed fractures (most common is the 5th metacarpal or boxer’s fracture) and tendon, muscle, and nerve injuries.

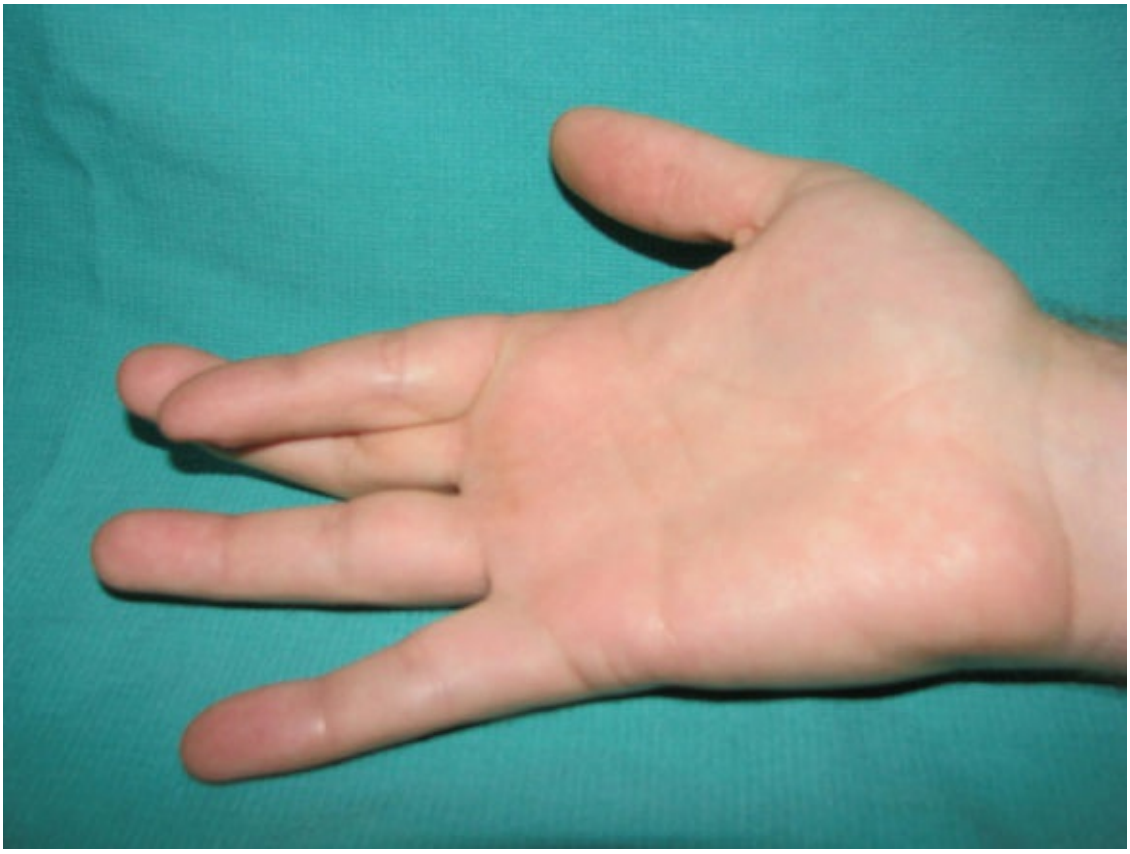

Figure 17.8. Assessing intrinsic function is evaluated by having the patient cross the index finger under the long finger. Alternatively, the patient can radially abduct the index finger to resistance. This maneuver assesses the ulnar innervated first dorsal interosseous muscle.

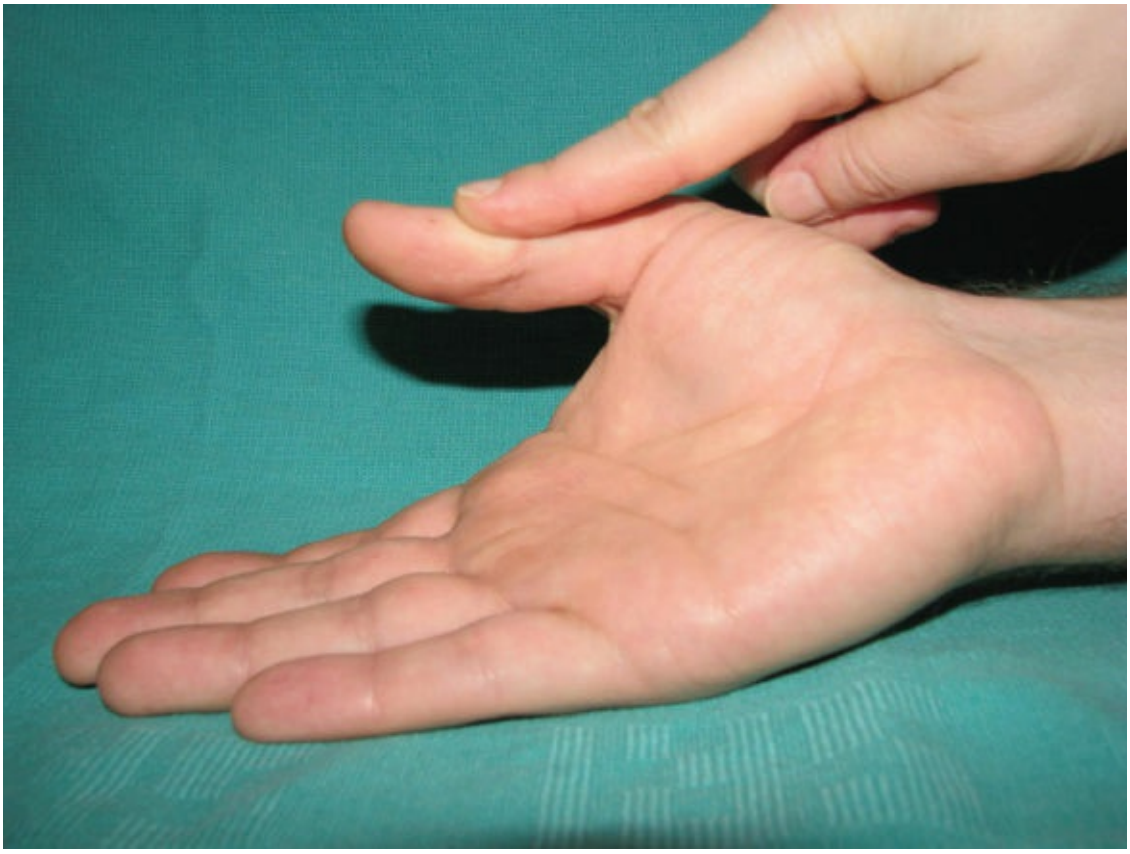

Figure 17.9. Confirming thumb opposition provides information regarding the integrity of the motor branch of the median nerve distal to the wrist. Confirming hypothenar muscle function can be assessed by having the patient hold all fingers together in extension. Abduction of the small finger occurs from the unopposed pull of the extensor tendons.

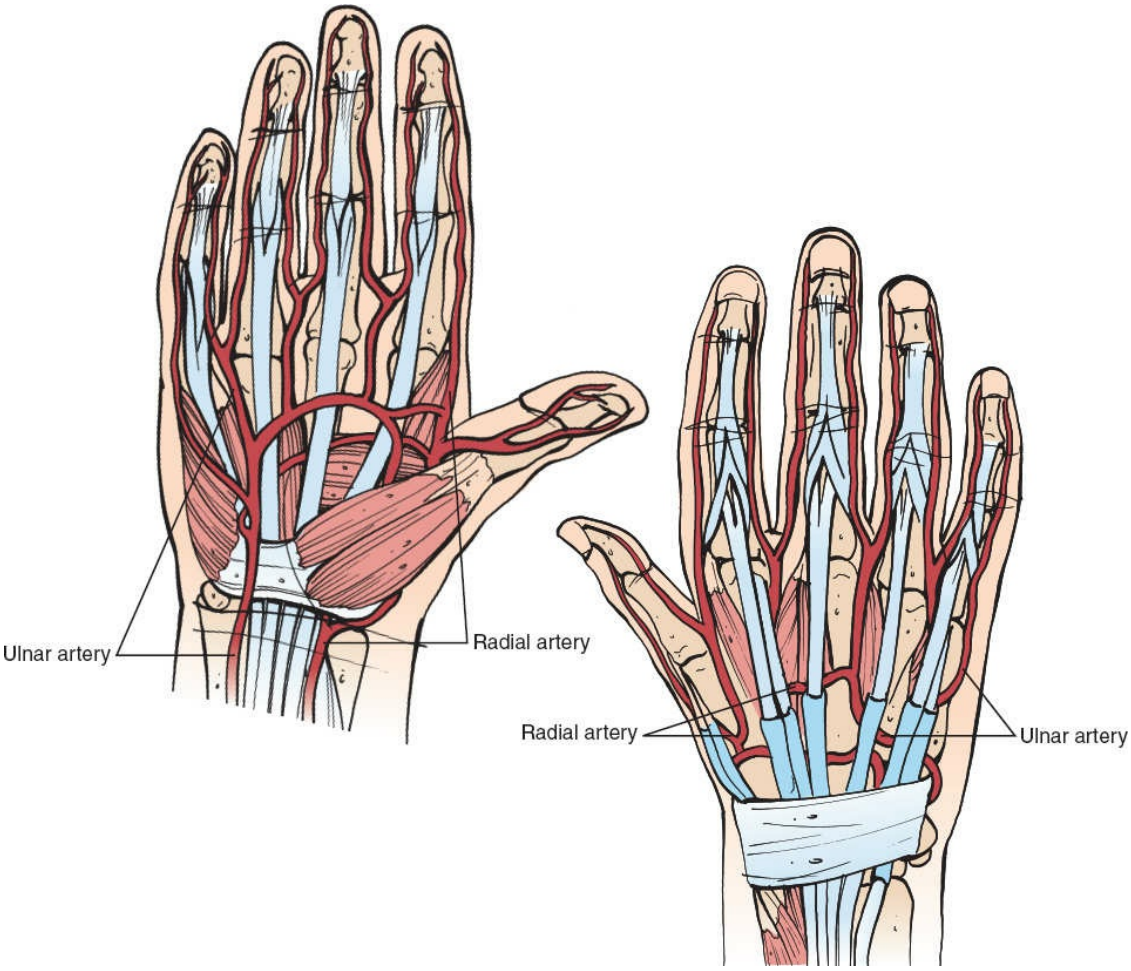

Figure 17.10. Perfusion of the hand and digits is evaluated by assessing the radial and ulnar arteries at the wrist. The presence of a Doppler signal in the superficial palmar arch and at the lateral aspect of each digit. A dorsal blood supply does exist; however, it is only reliable for the thumb and becomes decreasingly present in a radial to ulnar direction.

Describing the management for all injuries would require devotion of an entire separate text. The primary resource referenced by hand surgery fellows and trainees is *Green's Operative Hand Surgery* (Elsevier, Philadelphia, PA). The remainder of this text will describe the initial management of hand emergencies.

VASCULAR COMPROMISE: AMPUTATION, REPLANTATION, AND REVASCULARIZATION

The critical time period for an amputated digit, hand, or extremity to be replanted can be extended by wrapping the specimen in clean, damp gauze, and then placing it into a plastic bag on top of ice with an open lid.

Submerging the piece in ice can cause frostbite rendering it unusable. The maximum amount of time elapsed from injury until reattachment varies in the literature. Reports of extended time period for multiple days have been documented.[6] The usual acceptable time periods are approximately 12 hours of warm ischemia time and 24 hours of cold ischemia time for digits; times are halved for segments with greater amounts of muscle mass. In the United States with modern communication technology and air flight capabilities, it is uncommon for a patient with an amputated digit to be 24 hours away from a replant center; however, occasionally this may occur in a rock or mountain climber or if transportation is hindered by inclement weather. A more common scenario would occur in a patient with multisystem injuries who may not be amenable to replantation on initial presentation. In this scenario, the amputated segment can be placed on ice for 24 hours and reattached when the patient is stabilized. Reports in the Asian literature have successful replantation 94 hours after injury.[6] Certain replant centers even advocate scheduling this procedure for the morning if it comes in during the late hours of night.

The order for repairing structures varies slightly, but the mnemonic BEFANV ("Beef and V") can be remembered. The skeletal fixation is performed first (*i.e.*, bone) (Fig. 17.11), followed by the extensor and flexor tendons. This is followed by repairing the volar digital artery and nerve and finally a dorsal vein. Vein grafts are frequently necessary. When this is necessary, we advocate the use of vein couplers to speed anastamoses. If the replant is successful, the plastic coupler may be palpable or exposed; after 2 weeks, it can be removed without consequence.

Sharp amputations portend a better prognosis than avulsion or crush injuries.[7] The zone of injury is much greater when the amputated segment is avulsed by a blunt or avulsive force. These situations almost universally necessitate a vein graft.

The informed consent process should always include the likelihood of revision amputation, the need for blood transfusions, and a prolonged hospital stay. Patients have a longer time period to return of work if replantation is undertaken and will universally deal with issues of joint stiffness and numbness that will last many months or be permanent.[8,9] The success rate in the best of conditions can be upward of 80%; however, most patients are not "ideal" candidates or have an "ideal" mechanism for replantation.[8]

In the United States, the most common etiology for digit amputations are table and skill saws (Fig. 17.12).[9] This type of machinery causes a ripping and tearing of the tissues extending the zone of injury on the vessels by a number of centimeters. Avulsion injuries occur from water sports, roping injuries, ring avulsions, folding chairs, animal leashes, etc.

Intraoperatively, a thorough debridement is performed first removing all nonviable tissue, foreign material, and blood clot obscuring visualization. We generally perform this step prior to insufflating the tourniquet. Once the tourniquet is up, the surgical team has to work quickly to perform skeletal fixation, tendon repair, and selection of vessels and nerves to anastamose within 2 hours. By the time the patient requires a tourniquet break, it is important to be at a place that diffuses bleeding will not interrupt the flow of work or obscure dissected structures. Tagging structures that still require repair with hemaclips or sutures attached to a labeled hemostat help prevent redundant work. Skin edges are also frequently tacked open; it is important to remember to release these at the tourniquet break to prevent additional tissue ischemia and open wounds. Intraoperatively, concentrated plain lidocaine or papaverine is used to prevent vasospasm. We have also begun instituting the use of botulinum toxin as a long-acting agent for preventing sympathetic restriction of blood flow.[10–12]

Postoperative care varies greatly by surgeon. The decision on admission bed status relies on the surgeon's willingness for a postoperative take back. Many will give a valiant attempt at salvage, but will not attempt a secondary salvage for vascular compromise. After surgery, if the venous anastomoses were tenuous or small or inadequate, we will begin leech therapy immediately. This will constitute one leech every 4 hours. The patient will need to be on *Aeromonas* bacterial coverage with ciprofloxacin, bactrim, or another agent.[13] We will also start systemic amlodipine to promote systemic vasodilation, keep an indwelling brachial plexus catheter in place for 72 hours and immediate hyperbaric oxygen therapy for 5 to 10 days. Full-strength aspirin and prophylactic low-molecular weight prophylactic heparin dosing are also given. Admittedly, the evidence behind many of the adjunctive measures is lacking or inconclusive; however, we have had success with these measures, and given the amount of time and resource investment put forth, we believe it is worth the added adjunctive measures.

Vascular compromise can also result from prolonged ischemia due to a

ring that is too tight in the face of massive edema or a tourniquet from any cause. Figure 17.13 demonstrates an infant with a piece of his mother's hair wrapped around a toe causing a so-called *hair tourniquet.*

EMERGENT INFECTIONS: FLEXOR TENOSYNOVITIS, SEPTIC ARTHRITIS, DEEP SPACE INFECTIONS

Purulent infections within a tendon sheath can destroy and scar synovial lining preventing tendon gliding. These infections can also spread quickly into adjacent areas permanently damaging hand function (Fig. 17.14).

Bacterial infections within a joint can destroy articular surfaces and corrode joint surfaces. The most common infectious organisms are staphylococcus and streptococcus.[14] Mycobacterial or fungi can present as atypical or chronic infections. Cultures should be obtained as soon as possible so that antibiotics can be begun; however, institution of antibiotics should not be delayed out of fear of altering the microbiology specimen. The primary treatment of purulent infections is surgical irrigation and drainage. The most common community-acquired organism in many parts of the United States is methicillin-resistant *Staphylococcus aureus* (MRSA) (60%).[14] The patient should presumptively be treated for MRSA until cultures are identified. Many strains of MRSA are susceptible to trimethoprim/sulfamethoxazole, clindamycin, doxycycline, rifampin, tetracycline, and/or erythromycin.[14]

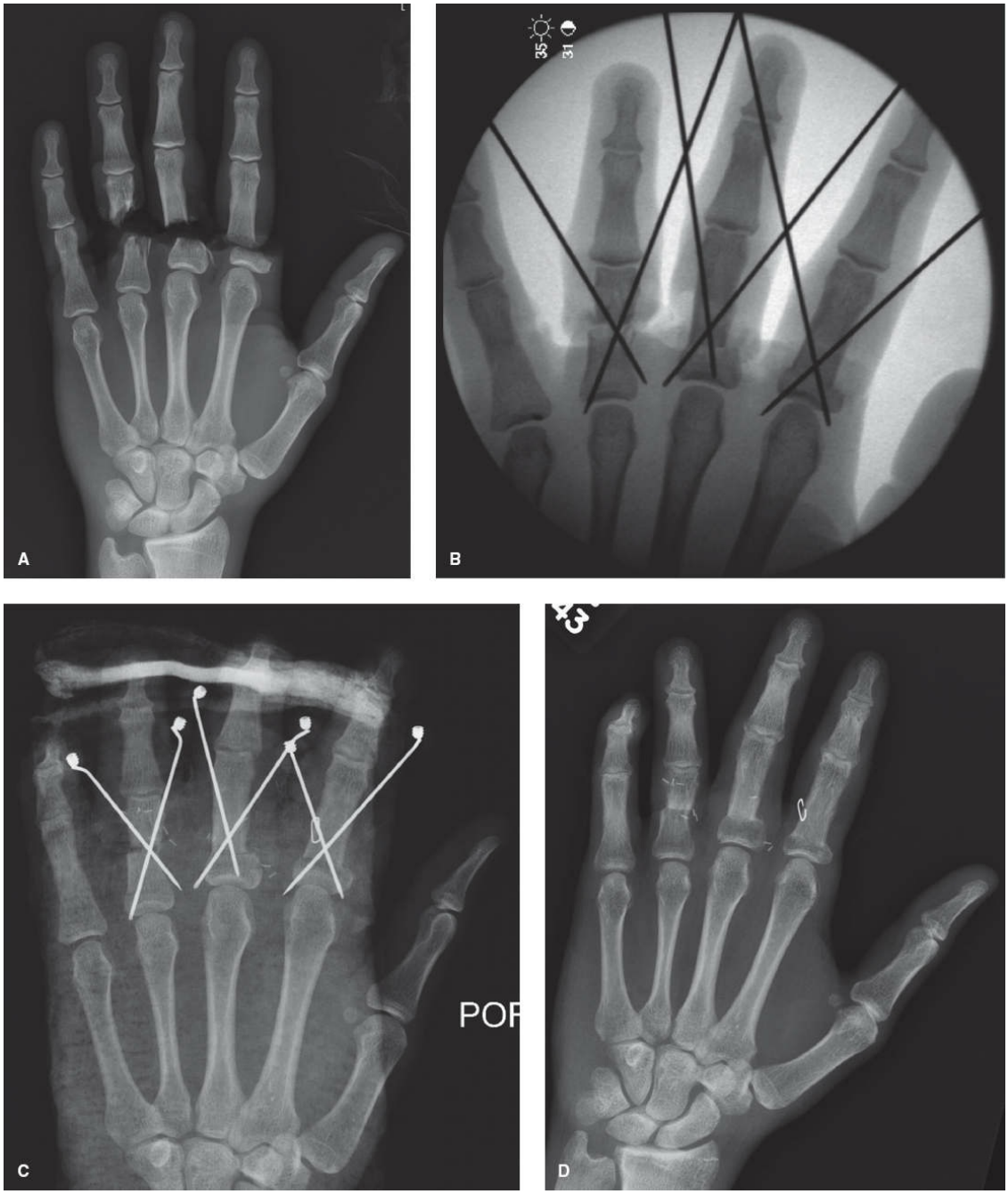

Figure 17.11. **A.** A 23-year-old man suffered a multidigit injury from a table saw accident. **B.** In performing a replantation, the skeletal fixation is performed first (i.e., bone). In this case, it is achieved with crossing k-wires. **C.** The patient is seen at 2 weeks postoperative. **D.** X-ray of the replanted digits at 4 weeks postoperative when the k-wires were removed.



Figure 17.12. A. Clinical picture of the same patient in Figure 17.11. The long and ring fingers were completely detached. The index finger had a small dorsal skin bridge. The volar structures were transected in the small finger, but the bone and dorsal structures were intact. **B.** Early postoperative image of the hand

with k-wires in place. (**C**) At 2-month postoperative, the patient was already regaining a significant amount of function including opposition, (**D**) finger extension, and (**E**) metacarpal phalangeal flexion.



Figure 17.13. Vascular compromise of a digit due to a hair tourniquet. This infant had a piece of his mother's hair wrapped around a toe causing vascular compromise in an infant.

The patients history almost usually includes at least a minor trauma, such as a splinter, spider bite, small penetrating injury, or animal bite, although new onset diabetes mellitus has been reported as the only presenting condition associated with an extremity infection.[15] The tetanus history should be obtained. Patients particularly susceptible to infection include immunosuppressed patients, including diabetics, AIDS, transplant patient, autoimmune disorders, malnutrition, renal failure, or those with

occupation or behavioral factors that increase risk: dental workers—herpetic whitlow; dishwashers—chronic paronychia; nail biting—paronychia.

Flexor Tenosynovitis

The classic signs of flexor sheath infection are known as the four Kanavel signs: fusiform swelling, redness along the finger, tenderness with palpation over the flexor tendons, and pain with passive extension of the finger (Fig. 17.14). These signs point to an infection of the flexor tendon sheath that may propagate along the tendon sheath into the wrist.[16] The most common infectious organisms are gram-positive bacteria being streptococcus and staphylococcus. Flexor tenosynovitis (FTS) should be distinguished from other etiologies like herpes simplex virus (HSV), which is classically seen in the hands of dental workers.

Management of FTS is surgical. There are a number of techniques available and can all be used depending on the clinical scenario. The least invasive method of treating this pathology is using closed catheter irrigation. A small opening is made at the A1 pulley through a V incision and sheathotomy. A separate midlateral incision over the noncontact ulnar surface of the DIP joint in the flexor tendon sheath distal on the finger to provide egress of fluid that is irrigated into the flexor tendon sheath proximally. An 18-gauge catheter is carefully threaded into the sheath and gently irrigated the tendon sheath to evacuate all purulence. The incisions are left open to contract and heal secondarily. If there is concern for residual infection, a 5-french feeding tube can also be placed into the tendon sheath by suturing it to the skin and allowing continuous irrigation after the procedure every 8 hours for 48 hours to evacuate any additional infectious material. The patient is initially placed on broad-spectrum antibiotics until the culture sensitivities return and then the coverage is narrowed. The patient is managed in-house initially in a resting splint and elevated in a sling connected to an intravenous pole.

The more aggressive open approach in which the entire flexor tendon sheath is exposed is used for severe aggressive infections that cannot be adequately treated with the closed catheter system. This is performed by elevating a skin flap over the flexor tendon sheath (Fig. 17.14). The tendon sheath is entered but making sure to preserve the A2 and A4 pulleys. The infection is irrigated and the skin flap loosely tacked back into position.

Deep Space Infections

There are five other potential deep spaces in the hand and wrist susceptible to abscesses.[17] Infections in these areas are suspected by erythema, tenderness, and loss of the normal concavities on the hand (Fig. 17.14). As the infection progresses, these areas become very tender, warm, erythematous, and convex in appearance. The thenar space is bounded by the midpalmar septum on the ulnar side and the dorsal and radial sides by the adductor pollicis fascia and adductor insertion, respectively.[17] This can be approached by an incision in the web space or over the adductor muscle. The choice of incision is generally made over the area of greatest fluctuance.

A midpalmar space abscess occurs deep to the flexor tendons between the thenar and hypothenar areas. It is characterized by loss of volar concavity in the midpalm. This space is bounded by the second and third interossei fascia dorsally and the tendon sheaths of the long, ring and small fingers volarly. Great care must be taken to avoid injury to the superficial palmar arch and the common digital nerves. The common digital nerve to the third web space is the most superficial and most commonly injured.[18]

Infections in the hypothenar space are the least frequently encountered. This infection occurs in the area between the hypothenar septum and hypothenar muscles. The dorsal boundary is the periosteum of the fifth metacarpal and fascia of deep hypothenar muscles.

Parona's space is located in the distal forearm between the pronator quadratus and the FDP tendon sheaths. Infections in this area should be suspected when there is an infection in the thumb flexor tendon sheath or small finger flexor tendon sheath, as they may propagate proximally to the radial and ulnar bursas, respectively. These bursas communicate via parona's space and can lead to a horseshoe abscess.

A collar button abscess occurs in the interdigital web space that is restricted by the deep intermetacarpal ligament. Treatment requires both dorsal and volar incisions.

Fight-Bite and Animal Bite Infections

These infections occur from inoculation by oral flora contamination. The causative organisms are frequently *Staphylococcus, Streptococcus, Bacteroides Eikenella corrodens,* and *Pasturella.* The external skin wound may be unimpressive. Probing this wound with the fingers extended may not reveal injured deeper structures; however, the examiner can be fooled

if the hand is not also examined with the fingers in the position it was in when the injury occurred. This frequently reveals extensor tendon injuries and rents in the joint capsule with inoculation into the metacarpal phalangeal joint. An adequate surgical exploration requires the skin laceration to be opened significantly.



Figure 17.14. **A.** Flexor tenosynovitis of the right ring finger. These infections can spread quickly into adjacent areas permanently damaging hand function. The four signs of flexor sheath infection are known as the four Kanavel signs and include fusiform swelling, redness along the finger, tenderness with palpation over the flexor tendons, and pain with passive extension of the finger. **B.** This finger was not amenable to a minimally invasive approach and required filleting open the finger and the flexor tendon sheath. The A2 and A4 pulleys were preserved. **C.** Thenar space infection in a middle-aged woman.

Septic Wrist Arthritis

Septic arthritis presents as an infection within a joint space and can degrade the articular surface quickly leading to irreversible arthritic changes and progress to osteomyelitis.[19] The diagnosis is made by aspirating the joint and sending the synovial fluid for analysis (Fig. 17.15). A white blood cell count greater than 50,000 per mm^3 is consistent with

joint sepsis.[19] The fluid should also be analyzed for Gram stain, aerobic, anaerobic, afb, and fungal cultures. Crystalline arthropathies (Fig. 17.16) in the wrist can present similar to an infection and therefore the fluid should also be sent for cell count and crystals.[20] Chondrocalcinosis of the triangular fibrocartilage complex is pathognomonic for pseudogout of the wrist.[20]

A septic joint is typically secondary to a penetrating trauma with *Staphylococcus aureus* being the most common pathogen. The infection may also occur from hematogenous seeding. In children, an infectious source somewhere else in the body should be suspected and worked up. For otherwise healthy adults with a single joint arthritis, the clinician should suspect *Gonoccoccus.* On physical examination, the joint is warm, erythematous, tender, and has pain with passive range of motion.



Figure 17.15. A. Right wrist of a middle-aged man with septic arthritis. This infection is within the joint space and can degrade the articular surface quickly leading to irreversible arthritic changes and progress to osteomyelitis. **B.** The diagnosis is made by aspirating the joint and sending the synovial fluid for analysis. A white blood cell count greater than 50,000 per mm^3 is consistent with joint sepsis. The fluid should also be analyzed for Gram stain, aerobic, anaerobic, afb, and fungal cultures. **C.** This septic joint was explored via an arthroscopic approach. The joint space was copiously irrigated, debrided, and the status of the articular surfaces documented.

All septic joints must be explored via an arthroscopic or open procedure

(Fig. 17.15). The joint space is copiously irrigated, debrided, and the status of the articular surfaces documented. The wounds are generally packed open with daily dressing changes until closure by secondary intention or delayed primary closure. A closed irrigation catheter system can also be placed intraoperatively to irrigate the joint for 48 to 72 hours after surgery. It is important to empirically cover for MRSA and until cultures are returned. *Gonococcus* should also be covered in the suspected patient with ceftriaxone or its equivalent. Silver sulfadiazine cream is an excellent local antibiotic and may help prevent tendon dessication for exposed wounds.

HIGH-PRESSURE INJECTIONS

High-pressure injections can lead to extensive internal soft tissue damage (Fig. 17.17).[21] The entry wound and skin may be benign in appearance, but will not be a good representative of the internal tissue. The material is injected through the skin at pressures up to 7,000 psi. The nondominant index finger is the most common site for these injuries. It is important to inquire the specific agent injected; oil-based solvents cause more damage than water-based ones.[21] Amputation rates are reported as high as 50% with oil-based paints.[22] Emergent surgical decompression and debridement are required. The removal of all foreign material may not be possible and the patient may require an additional washout.

COMPARTMENT SYNDROMES

Acute compartment syndrome (ACS) is a limb-threatening condition caused by increased pressure within the confined spaces of a fascial compartment (Fig. 17.18).[23] The condition occurs when tissue pressure (TP) exceeds perfusion pressure. TP is determined by subtracting the interstitial fluid pressure from the capillary perfusion pressure (CPP). Normal cellular metabolism easily maintains an oxygen tension in the tissues of 5 to 7 mm Hg when the CPP is at a physiologic vale of 25 mm Hg with an interstitial pressure of 4 to 6 mm Hg. In ACS, rising interstitial pressure overwhelms perfusion pressure and when venous pressure is higher than CPP, capillaries collapse. The pressure at which this collapse occurs is debated; however, an intracompartmental (*i.e.*, interstitial) pressure greater than 30 requires intervention. At this value, blood flow through the capillaries stops. If the pressure is left unrelieved, tissue necrosis and permanent functional impairment occur as nerve, muscle, and other tissues are deprived of adequate blood flow exchange.[23] ACS can

occur in the hand, forearm, upper arm, buttock, abdomen, and lower extremity.

The conditions leading to ACS can be divided into increased compartment volume (*e.g.*, vascular injury leading to ischemia–reperfusion, crush injury, hemorrhage, envenomation, and fractures) and reduced compartment volumes (*e.g.*, burns, tight dressings or casts or prolonged limb positioning—like Saturday night palsy or prolonged surgery). The most common affected compartment in the body is the anterior one of the leg followed by the deep posterior compartment in the leg.

In the forearm, ACS most commonly affects the deepest compartment muscles first, consisting of the flexor pollicis longus and FDP. Clinically, these can be examined by having the patient flex their thumb at the interphalangeal joint or the other digits at the DIP joints. The classic 6 P's describe the physical exam findings of ACS, consisting of pain, pallor, poikilothermia, pressure, paresthesias/paralysis, and pulselessness. Paraesthesias and paralysis relay to nervous function; sensory nerves are affected before motor nerves, which are observed as the numbness of paresthesias occurs prior to muscle paralysis. The diagnosis of compartment syndrome is further verified with measuring the intercompartmental pressure (ICP). The normal ICP is less than 10 mm Hg and decompression is recommended for pressure greater than 30 mm Hg. When measuring compartment pressure, it is recommended to obtain a pressure within 5 cm of the fracture site.

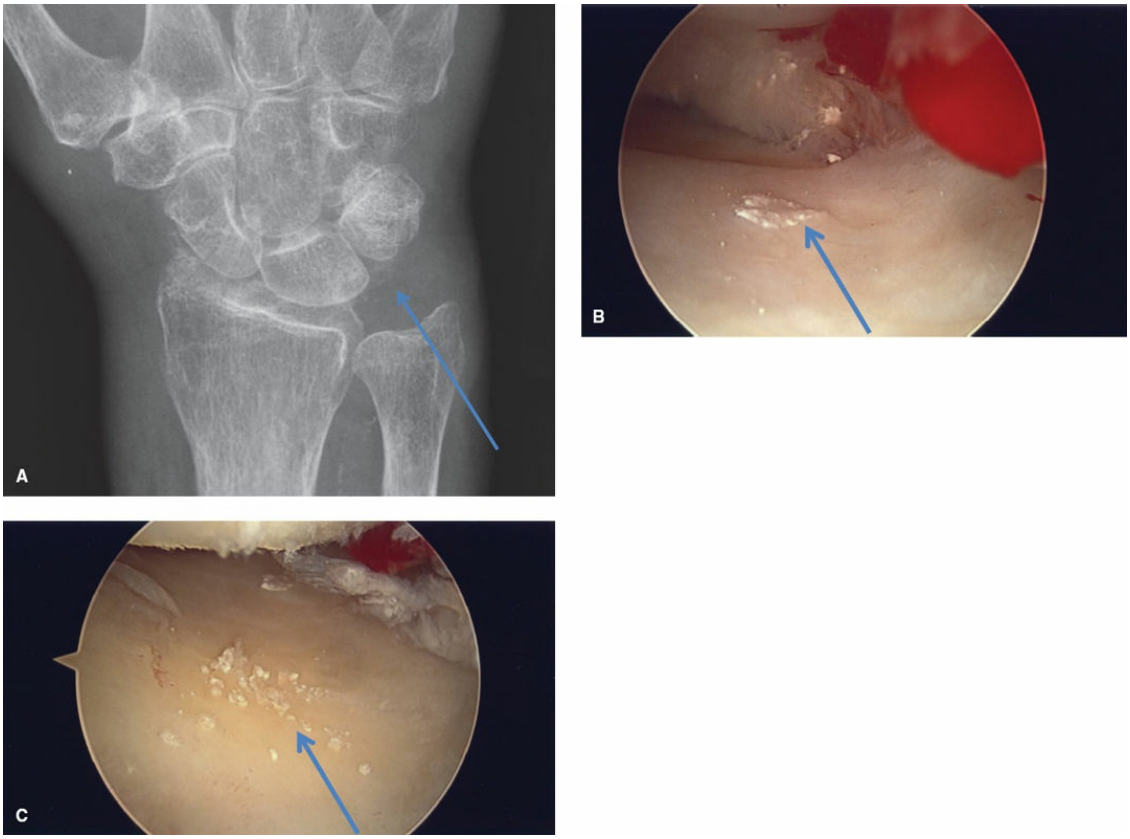

Figure 17.16. **A.** Wrist radiograph from an elderly woman with the crystalline arthropathy pseudogout. This presents similar to an infection and therefore aspirated fluid should be sent for cell count and crystals. The arrow points to chondrocalcinosis of the triangular fibrocartilage complex. This finding is pathognomonic for pseudogout of the wrist. **B** and **C.** Arthroscopic images demonstrating the crystalline deposits on the triangular fibrocartilage complex.



Figure 17.17. High-pressure paint injection into the hand. These injuries can lead to extensive internal soft tissue damage. The entry wound and skin may be benign in appearance, but will not be a good representative of the internal tissue. The material is injected through the skin at pressures up to 7,000 psi. The nondominant index finger is the most common site for these injuries.

Early intervention is critical in the treatment of ACS. Surgical decompression consists of fasciotomy of all involved compartments. In the arm, an incision can be made directly over the biceps muscle. In the forearm, a volar curvilinear incision is made extending from the biceps to the carpal tunnel. The incision is carried down to relieve the pressure on the deep muscles consisting of the flexor pollicis longus, FDP, and pronator quadratus. Dorsally, a straight incision is made over the mobile wad and extensor muscles. In the hand, the interossei muscles are relieved from a dorsal incision and the thenar and hypothenar muscles are relieved volarly.



Figure 17.18. **A.** Intracompartmental needle pressure demonstrating 53 mm Hg. **B** and **C.** Images of a patient with acute compartment syndrome (ACS) after an elbow fracture with dashed lines demonstrating incisions that could be used to decompress the arm. **D.** The kit with the intracompartmental pressure needle is usually stored in the operating room or emergency department at most hospitals. ACS is a limb-threatening condition caused by increased pressure within the confined spaces of a fascial compartment. The condition occurs when tissue pressure (TP) exceeds perfusion pressure. Most agree a value greater than 30 mm Hg can lead to tissue loss.

References

1. Kaufmann R, Pfaeffle J, Blankenhorn B, et al. Kinematics of the midcarpal and radiocarpal joints in radioulnar deviation: an in vitro study. *J Hand Surg* 2005;30(5):937–42.
2. Sun JS, Shih TT, Ko CM, et al. In vivo kinematic study of normal wrist motion: an ultrafast computed tomographic study. *Clin Biomech* 2000;15(3):212–16.
3. Moritomo H, Apergis EP, Herzberg G, et al. 2007 IFSSH committee report of wrist biomechanics committee: biomechanics of the so-called

dart-throwing motion of the wrist. *J Hand Surg* 2007; 32(9):1447–53.
4. Gelberman RH, Panagis JS, Taleisnik J, et al. The arterial anatomy of the human carpus. Part I: the extraosseous vascularity. *J Hand Surg* 1983;8(4):367–75.
5. Panagis JS, Gelberman RH, Taleisnik J, et al. The arterial anatomy of the human carpus. Part II: the intraosseous vascularity. *J Hand Surg* 1983;8(4):375–82.
6. Wei FC, Chang YL, Chen HC, et al. Three successful digital replantations in a patient after 84, 86, and 94 hours of cold ischemia time. *Plast Reconstr Surg* 1988;82(2):346–50.
7. Breahna A, Siddiqui A, Fitzgerald O'Connor E, et al. Replantation of digits: a review of predictive factors for survival. *J Hand Surg Euro Vol* 2016; 41(7):753–7.
8. Sebastin SJ, Chung KC. Challenges in measuring outcomes following digital replantation. *Semin Plast Surg* 2013;27(4):174–81.
9. Matsuzaki H, Narisawa H, Miwa H, et al. Predicting functional recovery and return to work after mutilating hand injuries: usefulness of Campbell's Hand Injury Severity Score. *J Hand Surg* 2009; 34(5):880–5.
10. Neumeister MW. Botulinum toxin type A in the treatment of Raynaud's phenomenon. *J Hand Surg* 2010;35(12):2085–92.
11. Neumeister MW. The role of botulinum toxin in vasospastic disorders of the hand. *Hand Clin* 2015; 31(1):23–37.
12. Neumeister MW, Chambers CB, Herron MS, et al. Botox therapy for ischemic digits. *Plast Reconstr Surg* 2009;124(1):191–201.
13. van Alphen NA, Gonzalez A, McKenna MC, et al. Ciprofloxacin-resistant Aeromonas infection following leech therapy for digit replantation: report of 2 cases. *J Hand Surg* 2014;39(3):499–502.
14. Crum NF, Lee RU, Thornton SA, et al. Fifteen-year study of the changing epidemiology of methicillin-resistant Staphylococcus aureus. *Am J Med* 2006;119(11):943–51.
15. Cohen GD, Schnall SB, Holtom P. New onset diabetes mellitus in patients presenting with extremity infections. *Clin Orthop Relat Res* 2002;(403):45–8.
16. Pang HN, Teoh LC, Yam AK, et al. Factors affecting the prognosis of pyogenic flexor tenosynovitis. *J Bone Joint Surg Am* 2007;89(8):1742–8.
17. Crosswell S, Vanat Q, Jose R. The anatomy of deep hand space infections: the deep thenar space. *J Hand Surg* 2014;39(12):2550.
18. Osterman M, Draeger R, Stern P. Acute hand infections. *J Hand Surg*

2014;39(8):1628–35; quiz 1635.
19. Yap RT, Tay SC. Wrist Septic Arthritis: An 11 Year Review. *Hand Surg* 2015;20(3):391–5.
20. Saffar P. Chondrocalcinosis of the wrist. *J Hand Surg* 2004;29(5):486–93.
21. Cannon TA. High-pressure Injection Injuries of the Hand. *Orthop Clin North Ama* 2016;47(3):617–24.
22. Zamkowski M, Ropel J, Baczkowski B, et al. High Pressure Injection Injury of the Thumb. Case Study. *Ortop Traumatol Rehabil* 2015;17(5):543–52.
23. Vaillancourt C, Shrier I, Vandal A, et al. Acute compartment syndrome: how long before muscle necrosis occurs? *CJEM* 2004;6(3):147–54.

EDITOR'S COMMENT

Traumatic injuries of the hand are common in the emergency department. If you are on call, you are likely to encounter such injuries. As a result of the complexity of hand anatomy, treating hand injuries can be challenging and treatment by the inexperienced physician may lead to unsatisfactory outcomes. In many instances, a specialist in hand surgery is consulted. However, in many regions of the United States and in other countries, a specialist may not be available. In these circumstances, the initial evaluation by the general surgeon is in actuality a triage function in which less consequential injuries may be taken care of by the general surgeon and the more consequential and complicated injuries are referred to a local or regional hand surgeon after initial triage and perhaps emergency management. It behooves the general surgeon to be familiar with the basics of hand anatomy and the principles of a hand examination. Drs. Mailey and Neumeister present a systematic approach to the evaluation of the injured hand founded on the anatomy of the structures, the knowledge of how to do a relevant and focused examination, and an understanding of the principles of treatment.

Traumatic injuries of the hand may occur from laceration or crush accidents. A full understanding of the anatomy of the hand is essential to developing a treatment plan based on a sequential and structured physical examination, rather than haphazard probing of the injured limb. The hand has six distinct structure including the bone, tendon, nerve, blood vessel, joint, and skin. Complex injuries of the hand involving any combination of these structures can be challenging largely owing to the uncertainty of what structures should be treated first.

The first principle is that "Life over Limb" the second above all else do no harm! Chang in the 6th edition described the Do's and Don'ts of the initial

evaluation and management of the patient with an injured hand. I think they are well worth repeating (Table 17.1).

The purpose of the hand examination is to understand the extent of injury. As noted by the authors, the complete examination of the hand does not need to be time intensive, but rather a rapid, sequential examination of the hand and upper limb. The examination in the conscious and alert patient can yield important information about nerve and vascular damage. The injury should not be probed. Clearly, the physician must have a basic understanding of hand anatomy. The authors conceptual "high yield anatomy" is helpful. The key points to me are: compare to the opposite hand if it is uninjured, the three nerves, extrinsic and intrinsic muscles, the ulna as the flagpole and the radius, carpus and hand are the flag, eight carpal bones if the wrist, the thumb takes priority as it possesses 40% of overall hand function!

As the authors point out, after an initial hand examination "hand and wrist radiographs are essential in all hand trauma patients. X-rays are important even in patients with sharp lacerations or injuries, as foreign bodies can frequently be seen and lead to infections if not addressed."

When should a hand surgeon be involved in the emergency care of a hand injury patient? There are two situations in which such consultations are absolutely essential: (1) vascular problems that compromise the viability of the digits or the hand and (2) infection. If blood flow is compromised to the hand or fingers regardless of the mechanism of injury (crush or laceration), then immediate revascularization by an experienced microsurgeon is in order. Infections of the finger or hand that need to be drained, such as bacterial tenosynovitis, should be considered surgical emergencies. It is important that abscesses be properly drained, particularly for patients who are immunocompromised. The majority of other hand injuries can be referred to a hand surgeon for elective treatment including digital nerve injuries that can be repaired within 2 to 3 weeks, tendon injuries that can be repaired within 10 days, and displaced fractures that may be reduced in the emergency setting with definitive fixation within 1 or 2 weeks.

Traumatic hand or digit amputations can be catastrophic injuries and often occur in young productive patients. Figures from the US national database have shown that amputation injuries represent 1% of all trauma occurrences. Finger and thumb amputations were most common (69%). Patients with amputations involving the fingers or thumb are assessed according to the Advanced Trauma Life Support (ATLS) protocol and resuscitated. A detailed history should include the time of injury to establish the duration of ischemia, the mechanism of injury, any coexisting injuries, age, handedness, occupation and hobbies, general medical status (especially in relation to diabetes, vascular diseases, and smoking), and patient's expectations. These are considered important when deciding whether replantation is technically possible and result in a functional outcome. If the amputation results from a severe crush injury, then replantation is less likely to be successful.

TABLE 17.1 Do's and Don'ts of Assessing a Patient with Hand Injury

Do's	Don'ts
1. Put the patient in a quiet room for hand examination. 2. Examine the patient expediently. 3. Give pain medicine and local anesthesia after full sensory examination. 4. Irrigate the wound copiously with saline and suture close the wound, for nonurgent injuries. 5. Get x-rays to evaluate potential bone injuries. 6. Consult a hand surgeon expediently if an operation is required immediately, such as a devascularized limb or severe infection that requires urgent drainage.	1. Probe the wound. 2. Give pain medicine until after a full examination. 3. Give local anesthesia until after the sensory examination is done. 4. Close a contaminated traumatic wound.

Key to successful replantation is the management of the amputated part. This is particularly true if the patient will require transport. There should be minimal handling of the part. The amputated part should be placed on a sterile towel, photographed and radiographed. An effort should be made to preserve any and all amputated fragments as these may be used for skin, bone, or nerve grafting. In order to detect any unexpected bony injuries that may preclude replantation, radiologic imaging of the stump and the amputated part in two planes is essential before a decision to attempt replantation.

Preservation of the amputated part is critical. It should be wrapped in sterile saline soaked gauze, placed in a sealed plastic bag, and either refrigerated at 4°C or placed in iced water solution without placing it directly on ice because this can cause frostbite. Muscle has the highest metabolic demand of any tissue, and deteriorates rapidly during warm ischemia. At 20°C to 25°C, irreversible muscle damage may occur after 6 hours. Replantation is not recommended when warm ischemia time has exceeded 10 to 12 hours for a digit. The technique of preservation described above can extend the ischemia time. Amazingly, successful digital replantation of a preserved finger has been reported after a delay of up to 94 hours.

Fingertip injuries can occur in accidents at home, work, or play. An injury can involve a sharp cut, a crushing injury, a tearing injury, or a combination. If the fingertip is completely amputated, it should be managed as outlined above. After gently cleaning with sterile saline solution, it should be covered in a moistened gauze wrap and placed it in a watertight bag and placed in ice in a sealed container or another watertight bag. Again the amputated part should not be in direct contact with ice as it could be damaged further.

If there is a small fingertip wound which is not deep enough to expose bone, it may heal on its own. A protective dressing is placed over the wound and you may recommend a splint to protect the area while it heals. After about 24 to 48

hours, it is recommended to soak the finger daily in a solution of warm, soapy water or saline solution with peroxide or Betadine. After 48 hours, range-of-motion finger exercises may be started to avoid stiffness. Complete healing usually takes from 2 to 4 weeks, although stiffness and hypersensitivity may remain longer, depending on the severity of the injury.

If the fingertip wound is large and open, there may be insufficient remaining skin to heal and cover the open area. In some cases, the wound may be left open to heal by secondary intention. If it is deemed that simple closure or healing by secondary intention is not appropriate, then referral to hand surgeon should be considered for skin grafting or reconstructive surgery.

E. Christopher Ellison

18 Robotic Surgery

Michael S. Nussbaum and Michael Latzko

INTRODUCTION

The human nature of the surgeon has been to gain the maximal access to the surgical area of interest while inflicting as minimal trauma to the patient as possible. As operative techniques and technologies have evolved, the ability to achieve that goal has advanced tremendously. Surgeons have gained the ability and technical expertise first to make smaller, more strategically located incisions for open surgical access, then to perform the same operation utilizing surgical telescopes and minimal access tools. Finally, through the use of computer-aided technologies and robotics, surgeons are now able to further gain full access to what otherwise would have been difficult-to-approach surgical areas of interest while achieving nearly negligible secondary surgical trauma to the patient.

The minimally invasive surgical revolution began three decades ago with the advent of videochip technology. Since that time, the laparoscopic approach to a wide variety of surgical procedures has become the preferred choice. This allows surgeons to perform a wide variety of operations using small incisions, videoscopes, and long instruments. The benefits of minimally invasive procedures are many including decreased length of hospital stay, less pain and scarring with smaller less obvious incision(s), less risk of infection, less blood loss and fewer transfusions, an accelerated return to normal activities, decreased need for postoperative narcotics, and an overall faster recovery. However, laparoscopic surgery requires a unique set of skills, which may be difficult for some surgeons to acquire. There are also a number of technical limitations to a laparoscopic approach, including a lack of three-dimensional (3D) visualization, limited range of motion due to rigid instrumentation, poor ergonomics, counterintuitive motion, amplification of physiologic tremor, decreased sense of touch, and the fulcrum effect. Robotic integration allows a surgeon to perform more complex minimally invasive procedures utilizing enhanced 3D visualization, improved dexterity, increased range of motion, improved ergonomics, and superior access to difficult to reach areas of the

body. This translates to more minimally invasive procedures with increased technical precision. The next generation of robots are being built smaller, smarter, and at a decreased cost. As these technologies continue to demonstrate their utility and value in improving the surgeon's ability to safely and superiorly treat disease, their use will ultimately become ubiquitous in the operating room much as the surgical telescopic devices have infiltrated surgical practice in recent years.

For the patient, a robotic-assisted procedure offers all of the potential benefits of a minimally invasive operation and clinical studies suggest that robotics may help surgeons provide better clinical outcomes than conventional technologies allow in certain specific clinical settings. Robotics also provides a unique possibility of separating the surgeon from the patient. This separation can be measured in feet or in thousands of miles. Telesurgery along with telementoring has now been tested in several environments and shown to be feasible and beneficial. The removal of a gallbladder across the Atlantic Ocean and the mentoring of surgeons in Canada are examples of how technology is rapidly approaching the day when any surgeon can be connected to a number of colleagues who may be able to consult and in some cases assist during complex surgical procedures. Other robotic technology allows the surgeon to make rounds while sitting in a remote location allowing "telepresence." This enables the physician to be remotely present by controlling robot movements via the Internet. Patients surveyed felt that such encounters are positive and were able to completely believe that they were communicating with their physician in person even if the physician was far removed from the bedside.

Hurdles to overcome include developing and improving the technology and its limitations, improving physician training and expertise to maximize their abilities to safely and effectively use these tools, incorporating the latest available technology into the surgical education of various disciplines, and of course managing the increased cost in a manner that will ultimately allow patients' increased access to the best care available.

ROBOTIC PLATFORMS AND EVOLUTION

The early 2000s brought the convergent digital technology revolution, leading to significant enhancements in information, simulation, telecommunication, and robotic technologies. Historically, current commercial robotic systems for medical use originated from two major

research efforts. The National Aeronautics and Space Administration (NASA) developed robotics initially for space operations, but under a NASA Small Business Innovation Research Contract from the Jet Propulsion Laboratory, Computer Motion Inc., Santa Barbara, CA, developed the Automated Endoscopic System for Optimal Positioning (AESOP)—a robotic arm system whose applications entered the operating room allowing the surgeon to control the surgical camera first with a foot–pedal interface, then later by voice commands. Computer Motion Inc. subsequently developed the Zeus Robotic Surgical System, which was a master-slave robotic system that allowed the surgeon to control up to three surgical arms in addition to the camera system from a separate control console. In parallel, the Defense Advanced Research Projects Agency (DARPA) was developing robotics for battlefield needs including providing remote surgical care in the field.

The Stanford Research Institute (SRI) developed a robotic surgical system with research funded from the National Institutes of Health and with interest from DARPA. Ultimately, becoming the da Vinci Robotic Surgical System by Intuitive Surgical of Mountain View, CA, the *da Vinci*® robot is a master-slave robotic system with some very distinct advantages over its progenitors and conventional laparoscopic surgery. The system has 3D stereoscopic visualization of the operating field, a 7-degree range of motion, tremor elimination, and comfortable seated operating posture. The target anatomy appears at high magnification, in brilliant color and with natural depth of field. The *EndoWrist*® instruments exceed the natural range of motion of the human hand, thus allowing wristed and finger movements that standard laparoscopic instruments do not have; sophisticated motion scaling and tremor reduction further interpret and refine the surgeon’s hand movements. These advantages provide surgeons with hand-like dexterity and enhanced precision through minimally invasive techniques that more closely mimics open surgery. Other robotic systems being developed today include *RoboDoc*® (Curexo Technology Corp., Fremont, CA), *Acrobot*® (London, England), and *SPORT*® (Single Port Orifice Robotic Technology) (Titan Medical Inc., Toronto, Canada).

The *da Vinci* surgical robotic platform has gone through four major system overhauls since its development and release in 1999. Although the core design of the system has remained unchanged, several significant modifications and additions have been introduced since its inception. The

system has a surgeon console where the operator receives a binocular image from the surgical field and operates the robotic arms through a computerized system using master controls. The image is acquired and delivered simultaneously to the console's two monitors and is observed in a parallel binocular fashion by the surgeon's eyes, allowing a magnified 3D stereoscopic view with depth perception. The position of the camera is controlled by the operator at the console. The instrument tips have seven degrees of freedom and wrist action controlled by the surgeon hand controls at the console allowing more complex and delicate tasks than the standard laparoscopic instrumentation at the tissue level. A clutching system allows readjustment of the surgeon hand positions at the console to maintain ergonomic control of the instruments within the surgical field of interest.

The *da Vinci* robot was first introduced to the market in 1999 and upgraded in 2003. The upgrade added a fourth arm to the initial three arm configuration allowing the console surgeon to have greater control of retraction and dissection without reliance on a skilled assistant. The *da Vinci* Surgical System, released in 2006, added high-definition (HD) vision and multi-image display, and is still in use at many institutions across the world today. The *da Vinci* Si was released in 2009 and added several notable adjuncts. Integrated fluorescence imagining capability was incorporated which provides real-time image-guided identification of key anatomical structures using near-infrared technology. It increased the capabilities of the robot immensely by allowing surgeons to perform real-time intraoperative angiography, cholangiography, and other tasks without any additional equipment needs or setup. Dual console capability was also later added to this model, which revolutionized the robotic training regimen, and enabled the fourth arm to be used at the same time as the other three. The second console allows two surgeons to visualize the 3D field simultaneously, as well as swap control of one or more arms between surgeons. Stapling and vessel sealing devices were later also added to the *da Vinci* Si armamentarium of instruments.



Figure 18.1. *da Vinci* Xi robotic surgical arm cart featuring extendable rotating boom. (© 2018 Intuitive Surgical, Inc., Sunnyvale, CA, USA. Used with permission.)

The most current generation of the da Vinci robot at the publication of this chapter is the Xi that was released in 2014 and stands to make this generation of robots the most accessible and user-friendly yet. The upgrades to this platform corrected many of the limitations of the earlier systems that restricted many surgeons' enthusiasm to incorporate robotic technology into their skill set. Two of the most significant limitations of the first three generations of robots were the time involved in docking the robot as well as a very narrow surgical field. The previous generations of robots had a mobile patient cart on which fixed robotic arms were mounted, which is driven to the side of the patient's bed to allow docking of the robot arms and severely limited the working space of the robotic arms in the surgical field based on the location of the cart. For example,

surgery in more than one quadrant of the abdomen was nearly impossible without undocking and maneuvering the patient cart; a time- and labor-intensive process. The Xi, however, utilizes a completely redesigned surgical cart that combines extendable, articulating, boom-mounted robotic arms with the flexibility of a mobile cart (Fig. 18.1). This new cart works with newly tooled software and targeting algorithms to standardize and automate a large percentage of the docking process after the user simply chooses the operation to be performed and the desired location of the patient cart. New port, robotic arm, and camera designs allow the camera to be placed in any working port. These and several other small changes enable robotic surgery in a much wider surgical field, more similar to conventional laparoscopy and thoracoscopy.

The U.S. Food and Drug Administration (FDA) has cleared the da Vinci Surgical System for use in urologic surgical procedures, general surgical procedures, gynecologic surgical procedures, transoral otolaryngology surgical procedures restricted to benign and malignant tumors classified as T1 and T2, general thoracic surgical procedures, and thoracoscopically assisted cardiotomy procedures. The system can also be employed with adjunctive mediastinotomy to perform coronary anastomosis during cardiac revascularization. The system is indicated for adult and pediatric use and was recently approved for transoral otolaryngology surgical procedures. It is intended for use by trained physicians in an operating room environment in accordance with representative, specific procedures set forth in the Professional Instructions for Use.

Representative Uses: According to Intuitive Surgical, Inc., the da Vinci Surgical System has been successfully used in the following procedures, among others:

1. Urology
   - Radical prostatectomy, pyeloplasty, cystectomy, nephrectomy, ureteral reimplantation.
2. Gynecology
   - Hysterectomy, myomectomy, and sacrocolpopexy.
3. General Surgery
   - Cholecystectomy, hernia repair, Nissen fundoplication, Heller myotomy, gastric bypass, gastrectomy, donor nephrectomy, adrenalectomy, splenectomy, and bowel resection.
4. Cardiac Surgery

- Internal mammary artery mobilization, cardiac tissue ablation, mitral valve repair, endoscopic atrial septal defect closure, and mammary to left anterior descending (LAD) coronary artery anastomosis for cardiac revascularization with adjunctive mediastinotomy.

5. Otolaryngology
   - Oropharyngeal, laryngeal, and hypopharyngeal resections; floor of mouth and oral cavity resections.
6. Endocrine Surgery
   - Thyroidectomy, parathyroidectomy, adrenalectomy, partial and total pancreatectomy.

EQUIPMENT AND SETUP FUNDAMENTALS

Principles of triangulation are generally employed with robotic system setup, although with the release of the *da Vanci® Xi*, the stringency of the setup requirements have decreased significantly. Most commonly, the patient cart, camera arm, and camera port are aligned in a straight line with the field of interest. The two working ports are placed on either side of the camera, allowing triangulation to the target field, with the fourth port being ideally placed on the side to be controlled by the surgeon's dominant hand. In situations where abdominal access is gained from a small area at the skin level, as in single incision surgery, curved cannulas are used and the working ports are reversed to allow a wide degree of freedom within the cavity, maintaining triangulation and minimizing equipment conflict.

Cannulas are marked with a fulcrum point such that when the ports are inserted into the cavity of interest to the depth noted on the cannula, the full range of motion is optimized by the premeasured fulcrum point into this remote center of focus as designed in the translational software of the robotic system to minimize torque applied to the patient at the port entry site. Standard robotic cannulas are 8 mm currently and can accommodate most 5 to 8mm robotic instruments, with the exception of the robotic stapling device which requires a 12 mm cannula. Finally the camera and instrument arms are docked while utilizing arm clutches to maximize the space between the instrument arms (Fig. 18.2).

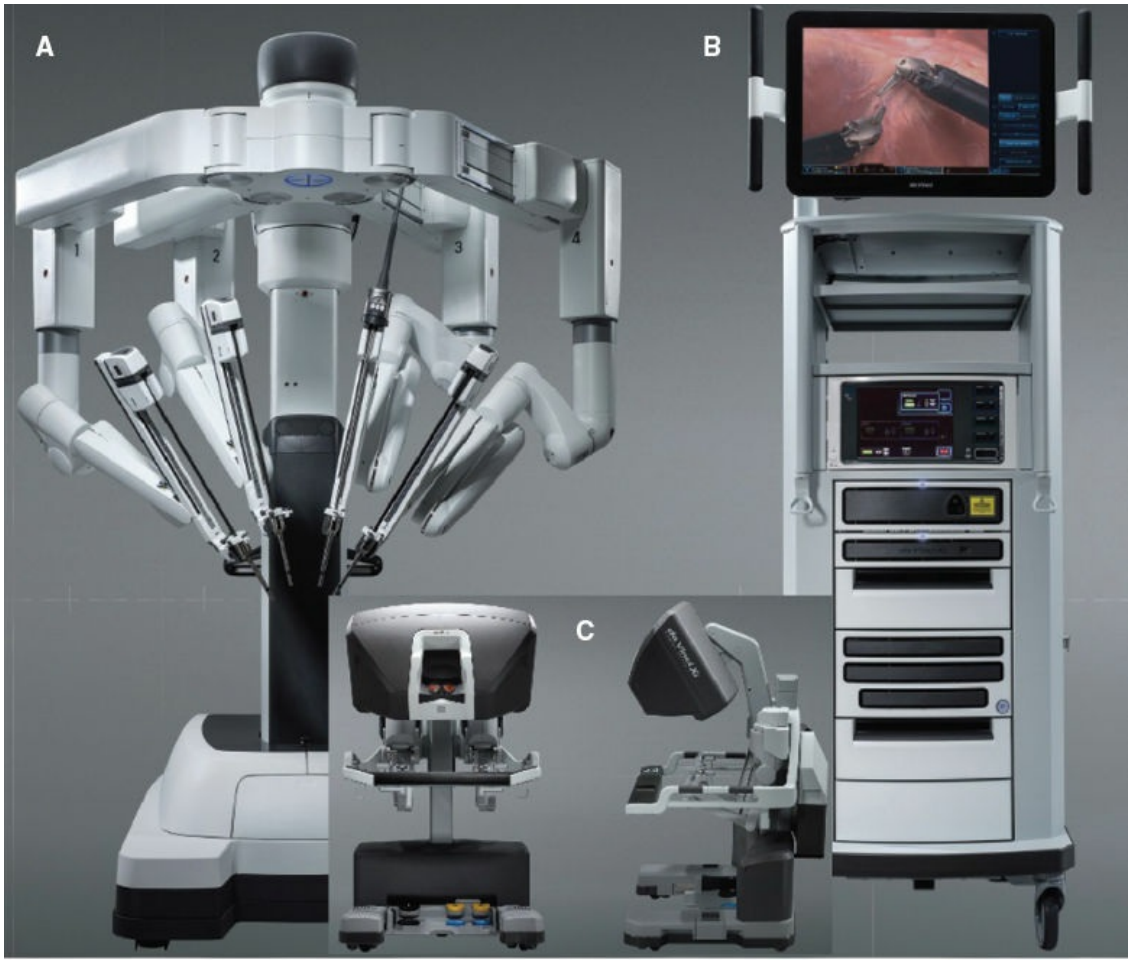

Figure 18.2. (**A**) Surgical arm cart in stowed position, (**B**) control tower, and (**C**) dual surgeon console. (© 2018 Intuitive Surgical, Inc., Sunnyvale, CA, USA. Used with permission.)

ROBOTIC SYSTEM SUMMARY

1. Surgeon console: The surgeon operates while seated at a console using four pedals, a set of console switches, and two hand controls. The movements of the surgeon's fingers are transmitted by the hand controls to the instrument located inside the patient. A 3D image of the surgical field is obtained using a telescope, which contains two cameras that integrate images.
2. Control tower: This component contains a monitor, light sources, and cord attachments for the cameras.
3. Surgical arm cart: This component provides four robotic arms, three instrument arms, and one endoscope arm, which execute the surgeon's commands.
4. Detachable instruments

GENERAL SURGERY

Robotic Foregut Surgery

Gastric Fundoplication and Paraesophageal Hernia Repair

One of the earliest applications of the robot in general surgery was performed in the area of antireflux surgery. The first two cases of robot-assisted Nissen fundoplication were performed by Cadiere et al. in Brussels utilizing the first-generation three-arm Mona *da Vinci*® robot. Comparisons of laparoscopic versus robotic Nissen fundoplication in multiple subsequent trials have demonstrated relatively equivalent results with low morbidity and similar outcomes but with longer operative times at a much greater cost. Increased cost for the robot-assisted cases was attributed to many causes, ranging from the initial investment and maintenance of the technology, to costs for the specialized robotic instrumentation with a limited number of uses, to the increased staff and hospital costs for longer cases. In a retrospective review by Ceccarelli in 2009 comparing robotic fundoplication to conventional laparoscopic fundoplication he noted that subjectively, surgeons felt as though the robot's maneuverability and image magnification facilitated hiatal dissection and made the procedure easier. However, these subjective improvements did not correlate with a measurable improvement in patient outcomes.

Discordance between the surgeon's impressions and the objective results of the procedure is a common finding in studies dealing with robot-assisted surgery. It is conceivable that the exclusive use of robotics in the more difficult procedures could impart a real advantage with regard to improved precision, ergonomics, and tissue handling. Such advantages might be beneficial in the more complex cases involving large paraesophageal hiatal hernias requiring more intricate dissection and manipulation or in the setting of reoperation as improved visualization of the anatomy with the magnified 3D, HD stereoscopic camera facilitates fine dissection with stable, articulating tools, thus allowing the surgeon to successfully and safely identify vital anatomy such as the vagus nerves, aorta, vena cava, pleura, and pericardium in the often difficult reoperative field. Although it is true that no randomized controlled data exists to demonstrate the superiority of robotic antireflux procedures or hiatal hernia repair when compared with conventional laparoscopy, it is fair to note that all relevant existing data on this subject was gathered utilizing already outdated generations of robots by surgeons who were still

experimenting with the optimum setup and application of robotics for this procedure. As operative times and costs decrease, and available instrumentation and mechanical assistance continue to improve, surgeons will be hard-pressed not to choose the approach that provides better visualization and dissection capability.

Heller Myotomy

Achalasia is a rare condition of the esophagus, with an estimated annual incidence in the United States of about 1 in 100,000 individuals. Laparoscopic lower esophageal sphincter myotomy, or Heller myotomy, has become the gold-standard surgical treatment option of achalasia. The minimally invasive approach has proved effective at relieving symptoms in >90% of patients. Mucosal perforation is the most significant complication specific to this procedure with a reported incidence of 1 to 15%. Although a recognized mucosal perforation which is adequately repaired at the time of myotomy has not been demonstrated to adversely affect clinical outcomes, it does take time and skill to repair such a perforation and an undetected or inadequately repaired perforation can be catastrophic. Melvin et al., in a series of 104 patients who underwent robotic Heller myotomy, reported no esophageal mucosa perforations and suggested that the robotic approach may provide superior outcomes. Horgan and colleagues later performed a prospective multi-institutional study comparing 121 patients (62 laparoscopic patients vs. 59 robotically assisted) and demonstrated a 0% perforation rate in the robotic-assisted myotomy group compared to 16% in the laparoscopic group. The authors believe that the magnified 3D visualization of individual muscular fibers and transition to mucosa afforded by the robotic-assisted approach along with superior freedom of movement and instrument control were paramount to ensuring an adequate and safe myotomy. Furthermore, although operative times were initially substantially longer in the robotic-assisted group, in the last 30 cases there was no difference in operative times between the two groups. These observations have been duplicated in subsequent studies by our group and others.

The operative technique for the robotic-assisted procedure is essentially the same as the laparoscopic approach described later in our chapter on the minimally invasive treatment of achalasia with a few small caveats. Because of the increased working length of the robotic endoscope and instruments, the ports should be placed at least 2 cm further caudad and about 4 finger-breadths apart to maximize the strengths of the robot while

allowing full range of motion of the robotic arms without external arm clashing. Additionally, the ports should be placed in a straight line across the abdomen because the working distance of the ports from the operative field is less of a concern in robotic surgery than conventional laparoscopic surgery. However, optimal port placement sites and spacing will likely change with subsequent generations of robots, and general principles of robotic port placement should be followed as opposed to a procedure-specific selection. The right lateral subcostal port is still used for the static placement of a 5 mm liver retractor; the other three ports are for robotic instruments and can be either 8 mm or 5 mm in size depending on the size of the robotic hand instruments available. An additional port can be placed on the far left for the fourth arm to assist in retraction.

Bariatric Surgery

Roux-en-Y Gastric Bypass

Robotic technology has become increasingly prevalent in bariatric surgery. The first robotic Roux-en-Y gastric bypass (RYGB) was reported by Horgan and colleagues in 2001. Since that initial report, several major large studies have compared robotic RYGB to the conventional laparoscopic approach. The largest study published to date, from the University of Texas at Houston compared 320 robotic RYGB to 365 laparoscopic RYGB. They noted the robotic group to have a substantially lower gastrointestinal leak rate (0% vs. 1.7%) and a major complication rate of only 2.8%. The robotic approach has been noted to facilitate a hand-sewn anastomosis and in a major systematic literature review comparing the laparoscopic approach with the robotic one, anastomotic strictures occurred at a lower rate in robotic patients with hand-sewn anastomoses. Interestingly enough, although cost has always been one of the greatest deterrents to robotic adoption, a study published by Hagen et al. in 2012 compared a laparoscopic RYGB using stapled anastomosis with robotic cases performed using a hand-sewn technique and found the robotic cases to be lower in cost. Furthermore, with regard to costs, extra overheads of the robot are absorbed by the hospital by increasing market share, and probably result in increased revenue when properly marketed as patients often seek out new technology. This fact is especially evident in bariatric surgery. Robotic-assisted RYGB has been demonstrated to be safe with similar if not better outcomes than laparoscopic surgery. The robot may shorten the learning curve and is not necessarily more

expensive than the laparoscopic approach.

Sleeve Gastrectomy

Robotic-assisted vertical sleeve gastrectomy has become more widely utilized as results of laparoscopic sleeve gastrectomy are confirming the long-term success of this surgical option in bariatric patients. The advantages of robotic technology have been described in super morbidly obese (BMI >60 kg/m^2) patients. It can liberate the surgeon from torque, which is often substantial in the laparoscopic approach because of the thickness of the abdominal wall. It can also decrease port site trauma because of the remote center technology; however, more studies are needed to adequately define the degree of this benefit. Particularly useful is the facilitation of hand-sewn staple line reinforcement which was reported to be an acceptable practice by the International Sleeve Gastrectomy Expert panel in 2011, although no consensus has ever been reached as to whether this practice does in fact decrease the incidence of bleeding or gastric leak.

Robotic sleeve gastrectomy was recently reported to be an excellent procedure to incorporate into resident education, since less than 10% of surgical residents today have any experience operating the robotic console despite the recent boom in robotic surgery. In a study by Ecker and colleagues in 2015, the learning curve of surgical residents was examined when they were the exclusive operator of the robot console, after completing online training. They were observed to have a very short learning period before initial plateau of only five cases despite it being their first exposure to the robotic interface. The total cost difference between a laparoscopic versus robotic sleeve gastrectomy was noted to be $349.00 in this study with comparable operative times after the initial five cases. The increased cost of utilizing the robot for this procedure should be weighed against potential for resident education and enhanced ergonomics.

Adjustable Gastric Banding

Cadiere and colleagues reported the first robotic gastric band placement in 1999. Utility of robotic assistance in adjustable gastric banding has been demonstrated in the super morbidly obese for some of the same reasons noted regarding robotic sleeve gastrectomy. However, the success of adjustable gastric banding in these patients compared to other operations such as sleeve gastrectomy or gastric bypass should be considered.

Colorectal Surgery

Minimally invasive colorectal surgery has evolved dramatically since the first reports of laparoscopic colorectal operations in 1991. Laparoscopic colectomy for both benign and malignant disease has been shown in numerous randomized studies to provide decreased patient morbidity, reduced hospital stays, lower surgical site infection rates, less postoperative pain, and faster recovery with improved cosmesis and patient satisfaction when compared to open operation. Despite these notable benefits, laparoscopic adoption across the country has been variable and relatively slow and a study by Stamos et al. in 2015 demonstrated an overall national implementation rate of 55%. This under-utilization of laparoscopic colectomy in spite of overwhelming evidence of its superiority is likely not due to lack of appropriate equipment as laparoscopy has become ubiquitous in all US hospitals, but rather due to inherent shortcomings of laparoscopy. These limitations include amplification of physiologic tremor, dependence on a skilled assistant, comparatively low-quality 2D imaging, reduced dexterity in dissection and suturing, and a relatively slow learning curve even with formal laparoscopic skills training.

In recent years, there has been a growing interest in robotic colorectal surgery, evidenced by the steady increase in the number of publications on this subject every year. The first robotic colectomy was reported in 2002 by Weber, and several studies soon followed touting reduced blood loss, decreased conversion rates, and shorter hospital stays with the robotic approach when compared to the conventional laparoscopy albeit at an increased cost. In a recent study by Pryor et al. comparing laparoscopic versus robotic-assisted outcomes of five major common general surgical procedures, colectomy was the only procedure noted to have a significantly higher rate of overall complications and length of stay in the laparoscopic group. There are several theoretical advantages to the robotic approach. First, stable camera positioning combined with 3D imaging, digital zoom, and articulating instruments provides excellent visualization without the crowding and clashing of instruments and camera that often makes dissection in the narrow confines of the pelvis quite challenging. Second, the fourth arm can act as a fixed retractor and is not subject to fatigue and tremor like a skilled assistant. Third, fine motion scaling and tremor filters enable the robot to simplify complex surgical maneuvers such as suturing or creation of an intracorporeal anastomosis.

Intracorporeal anastomosis has been reported to contribute to faster bowel recovery due to decreased visceral trauma and stretching, which may explain why this phenomenon has been observed in several robotic colectomy studies. Moreover, the robot also allows for a somewhat smaller extraction site, which could decrease surgical site infections and hernia rates with slightly improved cosmesis. For these reasons, while robotic-assisted colectomy adoption rates are still low nationwide, robotic colon resection has become the preferred minimally invasive operative approach at numerous academic institutions and community hospitals alike.

Robotic surgery in multiple abdominal quadrants was initially problematic and several early strategies for robotic left-sided colectomies supported a hybrid approach, taking down the splenic flexure laparoscopically first and then docking the robot. However, as robotic technology has improved with the release of *da Vinci Xi*, fully robotic left colon, total colon, and rectal cancer resections have been described without the need to move the robotic patient cart (Fig. 18.3).

Abdominal Wall Hernia Repair

Although repair of an abdominal wall hernia is one of the most commonly performed operations by general surgeons worldwide, utilization of robotic-assisted technology for these procedures has been largely overlooked until recently. Interest in robotic ventral and inguinal hernia repair has grown rapidly in the last decade. This growth in the utilization of robotics for hernia repair has been prompted primarily by several trends in the literature. First, with regard to ventral hernias, evidence is growing steadily that primary suture closure of the hernia defect prior to mesh underlay can reduce hernia recurrence rates. Laparoscopic transfascial suture placement to close these defects is often challenging, associated with increased pain, and at times impossible altogether in patients with large hernia defects. Robotic-assisted ventral hernia repair allows for precise and easy intracorporeal suturing in an ergonomically friendly environment. This allows the surgeon to close abdominal wall defects primarily using a running continuous suture to distribute tension evenly along the suture line as well as secure the mesh to the abdominal wall with suture obviating the need for a helical tacking device. Although more randomized-controlled data is needed, this should provide for lower recurrence rates with less pain along with improved visualization and ergonomics for the surgeon. Second, little has drawn more attention to

improvement of hernia repair in the last two decades than the popularization of the component separation technique. First introduced by Oscar Ramirez, MD, in 1990, anterior component separation utilized a release of the external oblique allowing for midline advancement to facilitate primary fascial closure. In 2006, Novitsky and Rosen developed a novel technique for posterior component separation using transversus abdominis release for repair of large complex ventral hernias. Although the technique was originally developed for open repair, surgeons quickly realized that the procedure could be performed in a minimally invasive fashion by using the robot. The robot enables the surgeon to dissect and suture at difficult angles, in confined spaces, and perform a component release without creation of large subcutaneous flaps or subcutaneous tunnels.

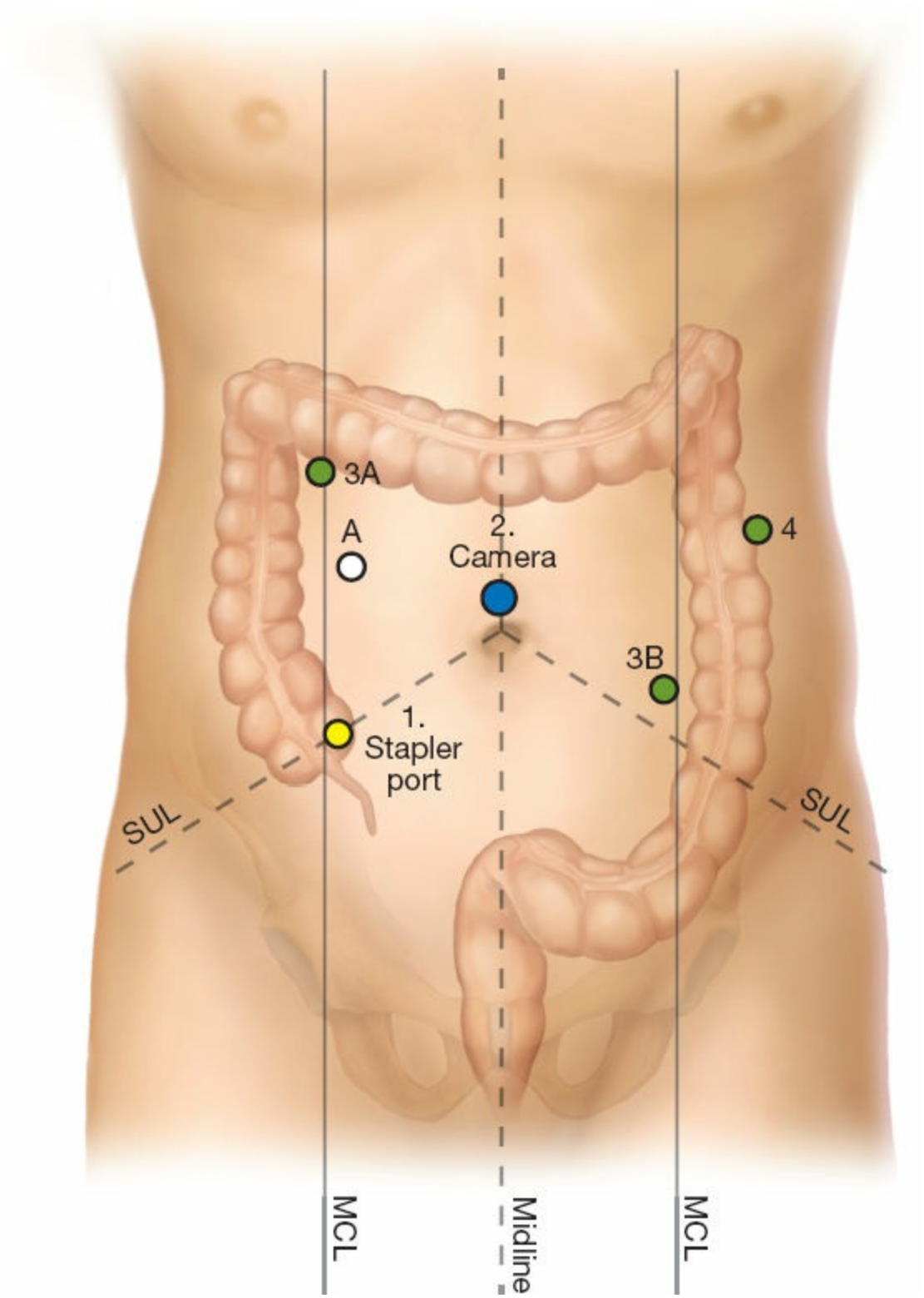

Figure 18.3. Potential port placement for robotic-assisted left colectomy. Numbers correspond to docking position of da Vinci arms. (Arm 1) 12 mm port to accommodate stapler. (Arm 2). Camera port. (A) assistant port. (3A) Position of arm 3 during mobilization of traverse colon, descending colon, and splenic flexure. Can also be used as assistant port once arm moved to 3B position. (3B) Position of arm 3 during pelvic dissection or

ascending colon mobilization. (4) Arm 4 is docked after descending colon and splenic flexure mobilization to aid in remaining dissection.

In regard to inguinal hernia repair, the benefits provided by the robotic platform are less pronounced. Robotic transabdominal preperitoneal inguinal hernia with suture fixation of the implanted mesh has been shown to be feasible in several reports, but no superiority to standard laparoscopic repair has ever been demonstrated. However, since a balloon dissector and tacking device are not used in the robotic approach when compared to the laparoscopic totally extraperitoneal approach, costs are very similar between the two with the robotic technique being much more ergonomically comfortable for the surgeon. Robotic inguinal hernia repair also presents a unique opportunity for resident education in that the procedure is not particularly challenging, costly, or time-consuming and residents can quickly become facile with robotic techniques and instrumentation without additional burden on the institution.

Thoracic Surgery

Noncardiac Thoracic Surgery

Minimally invasive thoracic surgery has come a long way since its inception. Several additional developments may change how we use robotics in the near future. These new technologies are still in an experimental stage but offer a glimpse of what the next generation of robots will offer.

Esophageal Surgery

Esophagectomy for benign or malignant disease can be associated with a high morbidity and mortality rate. Minimally invasive esophagectomy was first reported and popularized by Luketich et al. in 1998. Its role has been well established following multiple institutional series and systematic reviews which have shown its superior outcomes to open esophagectomy. It has always been a technically challenging operation and as surgical techniques have evolved, surgeons have begun to employ robotic assistance.

Horgan and colleagues reported their initial experience with a case of robotically assisted transhiatal total esophagectomy in 2003. The total operative time was 246 min and the patient lost <50 mL of blood. There

were no major perioperative complications. In their report, the authors comment that the 3D image and the articulating wrists allowed them to perform a nearly bloodless dissection of the esophagus. In addition, they found that they could mobilize the esophagus beyond the level of the carina through a transabdominal robotic approach. These surgeons felt that this was due to the fact that the robotic instruments are 7.5 cm longer than standard laparoscopic instruments. A thoracoscopic approach to complete esophageal dissection and mobilization was avoided in this case. The robotic-assisted transhiatal approach has also been validated by Gutt et al. for patients who are too ill to undergo an Ivor-Lewis approach with single-lung ventilation.

Kernstine and colleagues reported their experience using the robotic platform for the thoracic and abdominal portion of a three-field esophagectomy in 2007. However, they noted long average operative times of around 11 hours and were only able to complete the operation robotically in 8 of 14 patients.

Cerfolio et al. reported the first series of robotic cases with an intrathoracic anastomosis. The authors noted a significantly high morbidity and leak rate in the initial six patients undergoing a posterior stapled and anterior hand-sewn anastomosis. The remaining 16 patients in the study underwent a robotically hand-sewn anastomosis with substantially decreased morbidity and no leaks leading the authors to advocate this approach for robotic esophagectomy. Median operative time was initially 556 minutes, which dropped to 414 minutes for the last five cases.

The largest series of robotic-assisted Ivor-Lewis esophagectomy was published by de la Fuente et al. reporting their initial experience with this approach at the H. Lee Moffit Cancer Center and Research institute (Tampa, Florida). Fifty patients with esophageal cancer were included in the study. A median hospital stay of 9 days was observed, with two patients experiencing gastrointestinal leak. The authors noted a lower postoperative morbidity, higher lymph node yield, and higher R0 resection rates when compared with their historical reported outcomes. Median operative times were reduced from 479 to 414 minutes during the second 25 cases. The authors attributed the steep learning curve to a relative lack of standardization of robotic techniques.

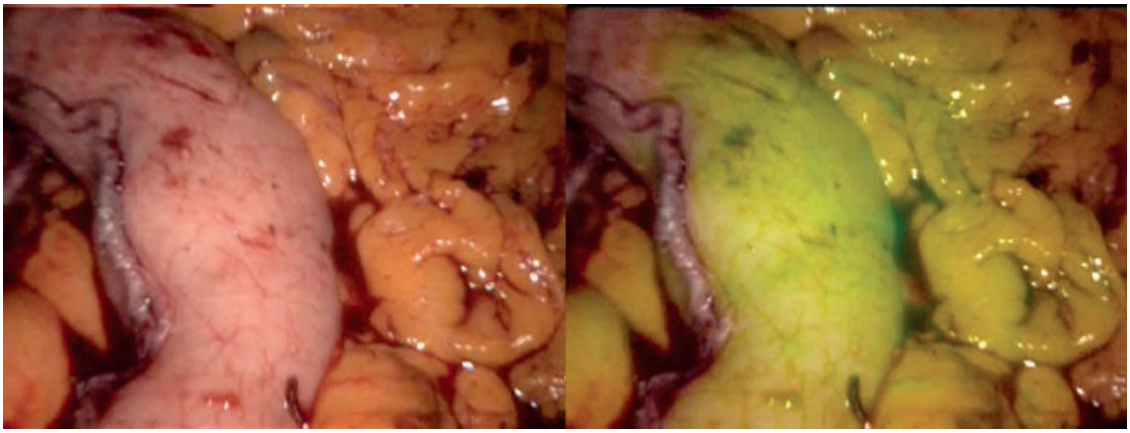

Figure 18.4. Florescent angiography demonstrating areas of perfused (shown in green) and un-perfused stomach during creation of gastric conduit.

A potential advantage of robotic assistance is the ability to assess gastric conduit and esophageal remnant perfusion in real time using fluorescence angiography. Intraoperative fluorescence angiography using near-infrared fluorescence imaging allows for the visualization of vascular structures and therefore organ perfusion after administration of indocyanine green (ICG) (Fig. 18.4). Near-infrared fluorescence imaging platforms are commercially available for open, laparoscopic, and robotic systems. However, in the robotic platform the technology is fully integrated and does not require purchase of additional equipment or require additional setup. A dramatic decrease in anastomotic leak rates from 20% to 0% was reported by Campbell et al. when ICG fluorescence angiography was performed to assess conduit perfusion using the SPY Elite System (LifeCell, Bridgewater, NJ) for open surgery. These results have yet to be duplicated in totally robotic groups. Feasibility studies out of Henry Ford and Memorial Sloan Kettering describe intraoperative fluorescence angiography as a useful adjunct to gastric mobilization and conduit formation that may help prevent unintentional injuries, especially early in a surgeon's learning curve.

Robotic-assisted esophageal surgery is still in its infancy and experience is limited, but its applications continue to expand. No prospective randomized data comparing robotic esophagectomy with open or laparoscopic procedures currently exists. However, current trials including a study by Sarkaria and Rizk at Memorial Sloan-Kettering Cancer Center (ClinicalTrials.gov: NCT01558648), and a Dutch trial known as the ROBOT trial (ClinicalTrials.gov: NCT01544790) are

accruing patients to assess outcomes comparing robotic-assisted esophagectomy with open esophagectomy. Robot-assisted esophagectomy appears to be at least as safe and feasible as a traditional laparoscopic or thoracoscopic approach. Robotic instruments that are long and multiarticulated may facilitate the completion of minimally invasive esophagectomy to a greater degree than conventional rigid laparoscopic instruments in some cases. Further research and clinical experience in this area will be necessary to answer these questions.

Anterior Mediastinum

The narrow confines of the anterior mediastinum represent an anatomic area ideally suited for robotic surgery, and there have been numerous reports on the value of robotic surgery for mediastinal diseases. The treacherous anatomy in this region accentuates the maximal advantage gained by the use of 3D, magnified stereoscopic cameras to allow safe identification of vital structures during delicate dissection with increased dexterity and articulating instruments.

Robotic-assisted resection of a mediastinal mass was first described by Yoshino et al. in 2001. Robotic thymectomy is the most published operation in the mediastinum with over 3,500 cases of robotic thymectomy registered with Intuitive Surgical since that time. Early studies demonstrated the feasibility of robotic-assisted thymectomy with decreased risk of postoperative wound complications. Caker et al. published the first study comparing minimally invasive robotic thymectomy with the open approach via median sternotomy touting decreased complications and length of stay in the robotic group. Weksler and his colleagues published similar results the following year additionally demonstrating decreased intraoperative blood loss with acceptable complete remission rates in myasthenia gravis patients. Thymectomy can be performed through either a left- or right-sided approach depending on the preference of the surgeon and his interpretation of the advantages and disadvantages of each approach. The largest series of robotic thymectomies was reported by Ismail and colleagues including 317 patients utilizing a left-sided approach with three ports in all patients except those with a thymoma on the right side. Robotic-assisted thymectomy was compared to videothoracoscopic thymectomy by Rucker et al. who observed no differences in operative time, conversion rates, or intraoperative blood loss. Several surgeons who have performed over 100 thymectomies with the assistance of robotic technology report that the

improved dexterity and articulated instrumentation simplifies and expedites radical dissection of all thymic tissue.

Tumors occurring less frequently within the anterior mediastinum and posterior mediastinum have also been removed robotically. Robotic excision of neurogenic tumors, germ cell tumors, ectopic thyroid and parathyroid, esophageal and bronchogenic cysts has all been reported.

Pulmonary Resection

Video-assisted thoracoscopic surgery (VATS) has been practiced since 1991 and has been shown unequivocally to be safe and effective. Despite the mountain of data that VATS offers reduced postoperative pain, shorter length of stays, reduced chest tube duration, and improved aesthetics, it has not been widely adopted by the thoracic surgical community. The benefits of minimally invasive surgery for this patient population should not be ignored. Recent reviews have shown that only 30% of stage I lung cancer operations are currently being performed by VATS in the United States and that number is closer to 10% in Europe. Successful thoracoscopic surgery is surgeon-dependent and there are several reasons why the outcomes being claimed by large-scale expert VATS groups are not being reproduced uniformly across the thoracic surgical community.

Minimally invasive surgery in the thoracic cavity can be very challenging due to the variable space between the ribs to place trocars and instruments with the ribs often acting as fulcrum points that increase torque on the surgeon's instruments which are rigid and nonarticulating. This lack of maneuverability coupled with suboptimal 2D vision, lack of depth perception, uncomfortable surgeon position, and lack of scaling down movements can make dealing with the delicate pulmonary anatomy quite demanding.

With the technological improvements afforded by the robotic platform, surgeons now have the ability to perform more complex procedures where conventional VATS might fail. Robotic thoracic surgery still has a steep learning curve, and a study by Veronesi et al. estimated that a surgeon needs to complete at least 20 cases to obtain competency. However, this is largely affected by the lack of standardization of robotic surgical techniques as well as underdevelopment of robotic instrumentation, and the authors felt that the length of the learning curve was still far superior to that of conventional thoracoscopic surgery. The recent development of wristed robotic staplers and energy devices as well as improved docking capability of the *da Vinci Xi* will undoubtedly decrease operative times and

the surgeons' dependence on a skilled assistant.

A recent meta-analysis by Velez-Cubian examined 23 robotic VATS series in combination with 600 cases performed by their own group. They concluded that robotic VATS was largely equivalent to conventional VATS with the caveat that the meticulous and detailed lymph node dissection provided by the robot improved the early detection of metastatic disease and resulted in a nodal upstaging rate of 19%. A comparative study by Kent et al. analyzing the State Inpatient Databases (SID) recently reported the superiority of robotic-assisted lobectomy and segmentectomy when compared with both open and conventional VATS. The overall complication rate, mortality, and average length of stay were all lower in the robotic group. Robotic VATS appears to be a safe and appropriate alternative to conventional VATS with similar improvements in outcomes when compared to open thoracotomy. Its increasing popularity will likely result in a broader acceptance and application of minimally invasive techniques by thoracic surgeons.

Cardiac Surgery

Cardiac Revascularization

Coronary artery disease remains the leading cause of death in the United States. Myocardial revascularization, traditionally performed via median sternotomy, is an effective strategy to prolong survival; however, the morbidities associated with sternotomy and cardiovascular bypass are not inconsequential. The heart was the first area that the robot was felt to be useful; but robotic endoscopic coronary artery bypass graft (CABG) is still only rarely performed at a small number of specialized centers due to its high cost, need for highly specialized equipment, lack of full reimbursement, and technical complexity.

Totally robotic cardiac bypass can be performed with or without cardiopulmonary bypass utilizing a left chest approach. The left internal mammary artery (LIMA) can be harvested and a LIMA to LAD anastomosis performed utilizing automatic anastomosis devices or polypropylene sutures. Robotic surgery off pump was only recently made possible by the development of robotic endostabilizers which transform a moving target into a static one. Due to the relative novelty of this procedure, data is still scarce and relatively limited in scope. Seco et al. recently published a systematic review of arrested heart and beating heart cardiac bypass procedures. Conversion to sternotomy was required in

approximately 10% of patients. Comparison to sternotomy, robotic CABG was limited by strict selection of elective low-risk patients for the robotic procedures. However, in selected analyses robotic CABG appears to be associated with lower mortality, shorter hospital stays, lower pain levels, and lower rates of new-onset atrial fibrillation at much greater initial costs.

With patency rates comparable to traditional techniques, robotic coronary artery bypass has the potential to further decrease the morbidity of cardiac surgery through utilization of the latest technology and techniques.

Valve Repair

Robotic-assisted mitral and tricuspid valve repair has been shown to be feasible and safe with low stroke risk and acceptable outcomes. In a study published by Yanagawa and colleagues in 2015, shorter length of stays was noted in robotic valve replacement patients which may offset the higher initial cost of robotic cardiac surgery. The role of robotic instrumentation in cardiac valvular surgery is still evolving, but initial results are promising.

Other Cardiac Surgery

As the techniques and durability of the robotic platform continue to be developed and accepted, the success of utilizing minimally invasive robotic techniques in cardiac surgery is growing. This includes, but is not limited to cardiac resynchronization, cardiac tissue ablation, atrial septal defect repair, aortic valve reconstruction or replacement, and pulmonary vein isolation or ablation.

Endocrine Surgery

Thyroidectomy and Parathyroidectomy

Many alternative approaches to the traditional open methods for thyroid and parathyroid surgery originally developed by Kocher in the 1800s have been pioneered over the years in attempts to avoid a neck incision. Robotic thyroidectomy was pioneered and developed in Korea and is now the preferred approach for the management of both benign and malignant thyroid and parathyroid disease in that country. Several large studies out of Korea have since confirmed its safety and feasibility in their patient population. The advancement of this approach is thought to be largely driven by the cultural aversion to a scar on the neck in many Asian

countries. Minimally invasive thyroidectomy and parathyroidectomy can be performed via a breast, axillary, posterior auricular, or transoral incision.

In the United States less than 1% of thyroidectomies are performed robotically and this is largely due to the controversy surrounding its safety and oncologic equivalence to the traditional approach. Several early studies out of the United States demonstrated higher complication rates, including hemorrhage, chest paresthesias, and nerve and trachea injuries in robotic-assisted thyroidectomy when compared to conventional thyroidectomy. These results are discordant with the Korean studies which report low incidence of recurrent laryngeal nerve and vascular injuries. This may be due to relative differences in body habitus in that American patients are typically larger and more obese resulting in greater technical difficulty. Additionally, most studies support a high-volume learning curve with a 40 to 50 case requirement to become comfortable and few centers in North America are performing that case volume. As a result, the adoption of minimally invasive robotic techniques for thyroid and parathyroid surgery has remained low in the United States and its role remains to be defined.

Adrenalectomy

Laparoscopic adrenalectomy has become the standard of care for the management of adrenal disease and both retroperitoneal and transperitoneal approaches have been well described. Robotic-assisted adrenalectomy was first reported in 1998 by Piazza utilizing the AESOP robotic platform. Since that time, several studies have compared robotic and laparoscopic adrenalectomy. A recent meta-analysis that examined nine such trials found that operative times and conversion rates were equal between the two groups. A slightly shorter length of stay and lower estimated blood loss were reported in the robotic group; however, although these results were statistically significant, they were not pronounced enough to be clinically significant. The author's did note that the robotic platform made surgery in obese patients much easier and the operation was able to be conducted without difficulty in patients with a BMI as high as 44 kg/m^2.

Pancreatectomy

Pancreatic cancer is associated with an abysmal prognosis, with yearly incidence and mortality rates that are nearly equivalent. Pancreatic

procedures, specifically pancreaticoduodenectomy, have always been linked with significantly high morbidity and mortality rates. Even with recent efforts by high-volume centers to improve and standardize surgical techniques and perioperative care, morbidity remains quite high and can approach 40%. Although laparoscopic surgical techniques have been very effective in reducing surgical morbidity for a variety of abdominal operations, the limitations of laparoscopy are only amplified when applied to highly complex pancreatic resections and thus adoption rates are extremely low. Even Pomp & Gagner, the progenitors of the laparoscopic pancreaticoduodenectomy, felt that the procedure was just too complex and time consuming to ever gain widespread acceptance or improve postoperative outcomes when they first described it in 1994. Some 20 years later, we see their predictions ring true.

With the emergence of robotics as both an adjunct and alternative to laparoscopic surgery, we are beginning to see some hope for minimally invasive techniques to improve outcomes in complex pancreatic surgery. Robotic distal pancreatectomy in capable hands has already been shown to be superior to laparoscopic distal pancreatectomy in several studies. The benefits of the robotic approach include reduced potential for blood loss, decreased conversion rates which result in shorter length of stay and ICU costs, as well as improved oncologic outcomes as evidenced by lower positive margin rates with improved lymph node yields.

Giulianotti et al. published the first report of robotic pancreaticoduodenectomy in 2003 and reported a mean operative time of 270 minutes which was far more promising than the initial laparoscopic reports. While robotic pancreaticoduodectomy is far from prevalent in the United States today it does represent an astute solution to the problem of how to improve on current outcomes, and reports of robotic pancreatic surgery are steadily increasing. The largest series to date on robotic pancreas resections was reported from the University of Pittsburgh in 2013 and analyzed 250 procedures including 132 robotic Whipple procedures. They reported a 30-day mortality rate of 1.5% and a clinically significant leak rate of 7.4% in their pancreaticoduodenectomy patient cohort. Conversion rates were also lower than laparoscopic historical controls and continually decreased with increasing experience. Surgeons have been much more welcoming of the robotic approach to minimally invasive pancreatectomy procedures, and this is likely because dissection and reconstruction techniques much more closely resemble those used in open

surgery due to the improved dexterity and visualization afforded by the robotic platform. This allows the procedure to be more easily reproduced and adopted by surgeons that already perform a high volume of open resections, which was certainly not the case with the laparoscopic approach. Robotic-assisted pancreaticoduodenectomy is associated with a reduction in length of stay and intraoperative blood loss and will likely be demonstrated to reduce overall complications in the near future. A truly meaningful comparison of two surgical approaches mandates that they both have reached a plateau phase which is not yet the case, but as robotic utilization for pancreas resection continues to increase, results are growing more and more promising.

Urologic Surgery

Prostatectomy

Urologists were unquestionably the first group of surgeons to generate interest in and popularize robotic surgery. Robotic prostatectomy for prostate cancer was truly the first robotic operation to gain widespread acceptance and penetrance in the surgical community. It is one of the few procedures today for which the robotic approach has become the standard of care.

Robotic prostatectomy for prostate cancer has indisputably been shown in numerous clinical studies and meta-analyses to provide lower positive surgical margin rates, reduced blood loss, reduced length of stay, decreased incidence of incontinence and sexual dysfunction, and greater overall patient satisfaction when compared to both open and laparoscopic prostatectomy. Additionally, robot acquisition has been associated in several studies with increased volume of prostatectomy at surgical centers around the word despite the ongoing debate over cost-effectiveness.

The reasons for the widespread adoption of robotic prostatectomy are as follows. Even the earliest versions of the *da Vinci* system were well suited to prostate surgery, and none of its early limitations which are rapidly disappearing prevented the early adoption of robotic prostatectomy. The instruments in fact are well designed for working in the tight space of the male pelvis and the magnified 3D, HD imaging allows for maximum visualization leading to minimal disruption of key neurovascular bundles. Additionally, while urologists in general have a reasonable minimally invasive surgery skill set in that they use endoscopy and basic laparoscopy routinely, only a minority of urologist are skilled enough to perform a

prostatectomy with standard laparoscopy which can be quite difficult so the complexity is high enough to justify the need for robotic precision. The balance of all of these factors led to an early adoption of robotic surgery among the urologic surgery community and has generated great confidence in the ability of robotic platform to improve the penetrance of minimally invasive surgery in other fields.

Nephrectomy and Partial Nephrectomy

Nephrectomy, partial nephrectomy, and nephroureterectomy have all been demonstrated to be feasible and safe. The morbidity associated with wide subcostal or midline incisions in an open approach is clearly mitigated by laparoscopic techniques. However, laparoscopic suturing of the bladder cuff such as in nephroureterectomy or in closure of renal parenchyma during partial nephrectomy can be a daunting task for any skilled laparoscopic surgeon. Recent evidence suggests that robotic partial nephrectomy holds the promise of better intraoperative outcomes and long-term nephron preservation. This appears to be due to the shorter warm ischemic time and reduced blood loss the robotic platform affords by making complex tasks like suturing quick and easy.

The relatively short learning curve of robotic surgery has provided a comparative advantage over laparoscopic techniques and is rapidly making robotics the minimally invasive modality of choice for urologists. Articles are already being published reporting quicker operative times with reduced redocking needs utilizing the latest fourth-generation robotic platform; the *da Vinci Xi.* With improvements in equipment and techniques, the measurable benefits of robotics for these procedures will only continue to grow.

Other Urologic Surgery

Feasibility of computer-enhanced robotic surgery has been demonstrated in cystectomy, pyeloplasty, and ureteropelvic obstruction. Long-term studies are still needed to demonstrate broad applicability of these operations relative to the current standards.

Gynecologic Surgery

Gynecology is another specialty like urology with high robotic usage when compared to general surgery for many of the same reasons. The robotic platform has always been well suited to pelvic surgery, and this fact along

with low surgeon endoscopic comfort with complex procedures has helped to drive its adoption among gynecologists. The benefits of a minimally invasive approach are clear, whether in regard to hysterectomy, sacrocolpopexy, salpingo-oophorectomy, retroperitoneal lymph node dissection, or other pelvic procedures. However, prior to the inception of robotic technology most patients received a laparotomy for the treatment of benign and malignant gynecologic conditions for a variety of reasons similar to those mentioned in the discussion on urologic surgery. Today, most cases of endometrial cancer are treated utilizing a robotic approach representing a swift transformation in surgical practice. Patients with endometrial cancer have seen the largest benefit from this transformation, because these patients are commonly obese with a high complication rate from laparotomy and their habitus often makes a traditional laparoscopic approach near impossible. Robotic-assisted surgery allows these high-risk patients to be afforded the benefits of minimally invasive surgery without the steep learning curve of laparoscopy.

Pediatric Surgery

The tremendous benefit of computer-enhanced robotic surgery is truly magnified in the pediatric patient. These patients' smaller size, confined operative fields, and demand for precision dissection are logarithmically enhanced with the robotic tools and enhanced visualization.

Fundoplication and pyeloplasty are the standout applications at present, accounting for around 50% of all pediatric robotic cases performed to date. Examples of other robotic pediatric procedures performed include small bowel resection, mediastinal mass resection, Ladd's procedure, proctocolectomy with pull-through, cholecystectomy, Kasai procedure, duodenal atresia repair, and many others. Limitations due to patient size are reported to become significant in patients below 3 kg. Although the platform has not yet gained significant penetrance among pediatric surgeons, those who are using it report that it is particularly well suited to hepatobiliary surgery and thoracic surgery especially with regard to solid chest tumors. Robotics is slowly enabling pediatric surgeons to perform complex procedures in a minimally invasive fashion where previously only an open procedure would have been possible.



Figure 18.5. The *da Vinci* Sp (single port) robotic system with fully articulating instruments and camera which fit through a single 25 mm cannula that is slated for release in the near future. (© 2018 Intuitive Surgical, Inc., Sunnyvale, CA, USA. Used with permission.)

Otolaryngology

Prior to the development of robotic technologies for the surgical management of oropharyngeal squamous cell carcinoma, these procedures were performed using comparatively morbid open techniques. Transoral robotic surgery was first pioneered in 2005 and since that time a few select studies have demonstrated its feasibility in the surgical management of obstructive sleep apnea, chronic tonsillitis, supraglottic laryngeal tumors, as well as pharyngeal and hypopharyngeal tumors. The recent development of unique retractors and lasers adapted for use with the *da Vinci* surgical system has facilitated transoral supraglottic laryngectomy, total laryngectomy, and hypopharyngectomy. The advancement of robotic transoral surgery has been somewhat limited by line-of-sight limitations associated with rigid endoscopy; however, new emerging technologies are being developed to overcome these barriers. Several systems which show tremendous promise are the Robotic Endolaryngeal Flexible Scope (Robo-ELF), as well as Titan Medical Incorporated's Single Port Orifice Robotic Technology (SPORT) system, and Intuitive's new flexible instrument single incision platform, the *da Vinci* Sp (Fig. 18.5). Although long-term data and outcome analysis are needed, minimally invasive surgical

techniques are likely to become much more commonplace in head and neck surgery in the near future.

CONCLUSION

Some of the current limitations of the robotic platform include lack of haptic feedback; however, the technology for incorporating haptic feedback does exist in other robotic systems and will likely be a part of future *da Vinci* robotic platforms. Another criticism of robotic surgery is its increased cost when compared to standard laparoscopy. These arguments are not unfamiliar and many are the same that were made against the adoption of laparoscopic cholecystectomy when minimally invasive surgery was still in its infancy. The fact is that comparing robotic-assisted surgery to laparoscopy is always likely to show an increased cost of robotics in this current era, but this assessment fails to capture the entire clinical situation. Innovation requires vision and procedure conversion to a minimally invasive surgical (MIS) approach increases procedure value, which can attract higher patient volume. It is widely understood and accepted that patients seek out the newest and most innovative treatments and techniques, but there is no good way to incorporate this fact into cost analysis. The alternative is to not take advantage of this rapidly evolving technology and all of its potential benefits, which is a truly self-defeating premise because increased utilization and improved patient outcomes will result in overall institutional savings.

The *da Vinci* Surgical System remains the only commercially available therapeutic robotic system currently available. It has allowed surgeons to perform procedures that previously were thought to be either too complicated or too risky to be performed in a laparoscopic fashion. New technology has since improved, allowing one to reach areas that could not be reached before and to perform operations without scars, such as natural orifice surgery. With the development of new types of devices that are smaller, cheaper, and based on more modular components, each device will be tailored to a given operation. New technologies are sure to follow along, and this field will not look the same in 10 to 15 years. It can be expected that we will continue to move toward more automation, more computer interface, and more mechanical assist and further away from the open surgical techniques that were pioneered in the years before. As technological advances occur, we will be challenged to assure appropriate training and credentialing on these new devices and technology.

Suggested Readings

Altieri MS, Yang J, Telem DA, et al. Robotic approaches may offer benefit in colorectal procedures, more controversial in other areas: a review of 168,248 cases. *Surg Endosc* 2016;30(3):925–33.

Ban EJ, Yoo JY, Won WH, et al. Surgical complications after robotic thyroidectomy for thyroid carcinoma: a single center experience with 3000 patients. *Surg Endosc* 2014;28:2555–63.

Ceccarelli G, Patriti A, Biancafarina A, et al. Intraoperative and postoperative outcome of robot-assisted and traditional Nissen fundoplication. *Eur Sug Res* 2009;43:198–203.

De la Fuente SG, Weber J, Hoffe SE, et al. Initial experience from a large referral center with robotic-assisted Ivor Lewis esophagogastrectomy for oncologic purposes. *Surg Endosc* 2013;27:3339–47.

Horgan S, Galvani C, Gorodner MV, et al. Robotic-assisted Heller myotomy versus laparoscopic Heller myotomy for the treatment of esophageal achalasia: multicenter study. *J Gastrointest Surg* 2005;9(8):1020–9; discussion 1029–30.

Kent M, Want T, Whyte R, et al. Open, video-assisted thoracic surgery, and robotic lobectomy: review of a national database. *Ann Thorac Surg* 2014;97:236–44.

Meehan JJ, Sandler A. Pediatric robotic surgery: a single-institutional review of the first 100 consecutive cases. *Surg Endosc* 2008;22:177–82.

Villamere J, Gebhart A, Vu S, et al. Utilization and outcome of laparoscopic versus robotic general and bariatric surgical procedures at Academic Medical Centers. *Surg Endosc* 2015;29:1729–36.

Yanagawa F, Perez M, Bell T, et al. Critical outcomes in nonrobotic vs. robotic-assisted cardiac surgery. *JAMA Surgery* 2015;150(8):771–7.

Zureikat AH, Moser AJ, Boone BA, et al. 250 robotic pancreatic resections: safety and feasibility. *Ann Surg* 2013;258:554–62.

EDITOR'S COMMENT

In this chapter on robotic surgery, Nussbam and Latzko do an excellent job of summarizing the many different surgical applications for the da Vinci surgical platform. Since the da Vinci Surgical System received approval from the FDA for use in General Surgery in the year 2000, the clinical application of robotic-assisted surgery has increased dramatically. In 2010, there were a total of almost 1,800 systems installed worldwide. In 2015, Intuitive Surgical reports 3,477 installed systems worldwide, with 2,344 in the United States alone. According to a 2015 ERCI Institute Report, one in four US hospitals has a da Vinci robot,

and 79% of all robotic procedures worldwide are performed in the United States. In 2014, there were 570,000 robotic procedures performed worldwide, a 178% increase since 2009. The number and variety of procedures performed per installed system continue to rise. The market share of robotic prostatectomy compared to laparoscopic and open prostatectomy is estimated to exceed 80% in the United States according to the manufacturer. Robotic surgical procedure growth in Urology and Gynecology seems to have levels off in the recent past, and much of the recent growth has been in General Surgery, especially hernia.

Specialty societies have attempted to examine the role of robotics in General Surgery at the current level of technology. The European Association of Endoscopic Surgeons (EAES) consensus statement of the use of robotics in General Surgery published in 2015 concludes that "…To date, in the vast majority of clinical settings, there is little or no advantage in using robotic systems in General Surgery in terms of clinical outcome." The Society of American Gastrointestinal and Endoscopic Surgeons (SAGES) Technology and Value Assessment Committee recently published a safety and efficacy analysis of the da Vinci Surgical System. SAGES concludes "gastrointestinal surgery with the da Vinci Surgical System is safe and comparable, but not superior to standard laparoscopic approaches. Although clinically acceptable, its use may be costly for select gastrointestinal procedures."

When the outcomes are at best equivalent, it is hard to justify a robotic approach when an established and readily available laparoscopic alternative exists. Emotional and subjective arguments about better precision and ergonomics with robotics need to translate into actual patient benefit. What is not often discussed is the impact that a lack of tactile haptic feedback has on the ability to perform fine dissection and delicate surgery when using the robotic platform. The robotic platform is an enabling technology for surgeons early in their learning curve or for those who lack an advanced laparoscopic skill set for very complex procedures (e.g., reoperative cases). This statement is in no way intended to imply that surgeons who use the robot preferentially for minimally invasive General Surgery are unskilled, but I personally become concerned when a surgeon feels empowered to take on a particularly difficult robotic case (e.g., a large recurrent paraesophageal hernia) when such a case is not something that he/she has experienced with otherwise and would not have attempted but for the availability of a robot. The complex surgery attempted robotically should be well within a particular surgeon's domain of expertise and experience.

According to the Intuitive Surgical website, "our business model is essentially a 'razor/razor blade' operation. Initially, we sell and install the da Vinci Surgical System into new customer accounts. Once systems are sold into accounts, we generate recurring revenue as our customer's use the system to perform surgery, and in the process buy and consume our EndoWrist instruments and accessory products. We also generate recurring revenue from system service." A survey of average quoted process for the da Vinci Surgical

System (Q2 2014–Q1 1015) reveals that the da Vinci Xi single console costs approximately $1.85 million and the Xi dual console sells for $2.31 million. Service contracts generally run at about 10% of the purchase price. Instruments cost approximately $2,000 and are programmed to only allow use for 10 cases. While there are various cost analysis and comparisons that have been published with regard to robotic surgery, in general it appears that robotic surgery is more costly than the laparoscopic counterpart in General Surgery. A systematic review of economic evaluations of robotic versus either open or laparoscopic surgery revealed that robotic surgery costs were consistently higher than open or laparoscopic surgery. The 2015 ERCI publication referenced above suggests that the incremental cost per robotic procedure is $3,000 to $6,000.

The argument that a hospital will recover any lost revenue from converting laparoscopic procedures to robotic ones by attracting patients who seek out this robotic approach becomes less valid as most competing hospitals in a market acquire a robot (currently the case in multiple markets across the country). The contention that patients will seek out surgeons who perform specific procedures robotically rather than laparoscopically could be addressed if hospitals were honest in their marketing efforts about the benefits of robotic surgery. A peer-reviewed article published in 2011 revealed that in a systematic analysis of 400 randomly selected hospital websites, that 41% described robotic surgery. Statements of clinical superiority were made on 86% of websites, with 32% describing improved cancer control, and 2% described a reference group. No hospital website mentioned risks. Materials provided by hospitals regarding the surgical robot were found to overestimate benefits, largely ignore risks, and were strongly influenced by the manufacturer.

In 2002, the Institute of Medicine published Crossing the Quality Chasm, an influential book that has framed recent discussions of quality health care. Among the six specific aims of quality health care defined was efficiency: care and service should be cost-effective. The proposed measure for this aim was to assess the cost of care by patient, provider, organization, and community. The Center for Medicare and Medicaid Services Value Based Purchasing Program bases their payments to hospitals for care provided to Medicare beneficiaries using various domains to assess quality. In fiscal year 2016, 25% of the quality assessment was based on efficiency or cost per Medicare beneficiary. Private insurers are driving patients to health care systems with the highest quality AND the lowest cost. Cost is becoming increasingly relevant to surgeons, and we need to ensure that the procedures we perform are of the highest possible quality and safety and as cost-effective and efficient as possible. For robotic surgery, we will need to demonstrate clear clinical benefit or create other cogent arguments to make any potential increased cost justifiable.

Despite how the above may appear, I believe that there is a prominent future for robotics in surgery and even in General Surgery. For certain complex procedures rarely if ever done laparoscopically (pancreaticoduodenectomy for example), we have seen that the introduction of robotics has enabled a

minimally invasive approach when the alternative was a laparotomy or even a thoracotomy. Patients are likely to benefit in these cases much like they do when a case can be performed laparoscopically rather than open. As the technology progresses, robotic surgical systems will become capable performing tasks not possible at the current time. Truly robotic surgical systems that can perform portions of a procedure autonomously (e.g., tying a knot or creating an anastomosis) are likely on the horizon. Tiny in vivo or endoluminal robots may make natural orifice surgery a real viable possibility in the future. New technologies may become integrated into robotic surgical systems that allow surgeons to do things like visualize tumor margins in real time, see tumors that cannot be visualized with current imaging technology (tumors deep in the parenchyma of the liver or an insulinoma not yet localized by current conventional methodology for example). As competing robotic surgical systems arrive on the market, the focus of robotic surgical companies will shift from utilization to enhanced capabilities and more cost-effective platforms. As outlined in the EAES consensus statement, "There is a severe lack of high-quality data on robotic surgery, and there is a great need for rigorously controlled, unbiased clinical trials. These trials should be urged to address the cost-effectiveness issues as well." From this same document, "Robotic surgery is still at its infancy, and there is a great potential in sophisticated electromechanical systems to perform complex surgical tasks when these systems evolve." I could not agree more.

Jon C. Gould

Suggested Readings

Barbash G, Glied A. New technology and health care costs—the case of robotic-assisted surgery. *N Engl J Med* 2010;363(8):701–4.

Jin LX, Ibrahim AM, Newman NA, et al. Robotic surgery claims on United States hospital websites. *J Healthc Qual* 2011;33(6):48–52.

Szold A, Bergamaschi R, Broeders I, et al. European Association of Endoscopic Surgeons (EAES) consensus statement on the use of robotics in general surgery. *Surg Endosc* 2015;29(2):253–88.

Tandogdu Z, Vale L, Fraser C, et al. A systematic review of economic evaluations of the use of robotic assisted laparoscopy in surgery compared with open or laparoscopic surgery. *Appl Health Econ Health Policy* 2015;13(5):457–67.

Tsuda S, Oleynikov D, Gould J, et al. SAGES TAVAC safety and effectiveness analysis: da Vinci® Surgical System (Intuitive Surgical, Sunnyvale, CA). *Surg Endosc* 2015;29(10):2873–84.

www.ecri.org/robotinfo

19 Surgical Energy

Edward L. Jones and Dean J. Mikami

INTRODUCTION

Surgical energy is an essential part of every operation; yet, the basic principles and application remain poorly understood among surgeons of all ages and experiences. Electrosurgical injuries account for over 5% of *all* laparoscopic complications and can result in severe disability or death as well as a source litigation. Public awareness of surgical energy complications significantly increased following the 2010 death of Pennsylvania Congressman John Murtha likely secondary to an electrosurgical injury. This event, combined with recent articles in the lay press and medical literature, has prompted a renewed interest in both research and education about energy use in surgery.

To combat the widespread lack of in-depth knowledge, the Society of American Gastrointestinal and Endoscopic Surgeons developed the Fundamental Use of Surgical Energy (FUSE) curricula and certification. The FUSE curriculum has proven robust especially when accompanied by an interactive component and is being rapidly accepted and applied internationally. The didactic content is freely available online and universal certification will eventually be required of all surgical trainees if not all surgical energy users.

This chapter seeks to provide the reader a strong basic understanding of energy use in the operating room but is not a substitute for FUSE certification which should be sought by anyone who uses energy in surgery. We will review the most common types of energy used, the eight patterns of injury as a result of energy use and lastly, provide a guide to selecting the best device for the desired tissue effect.

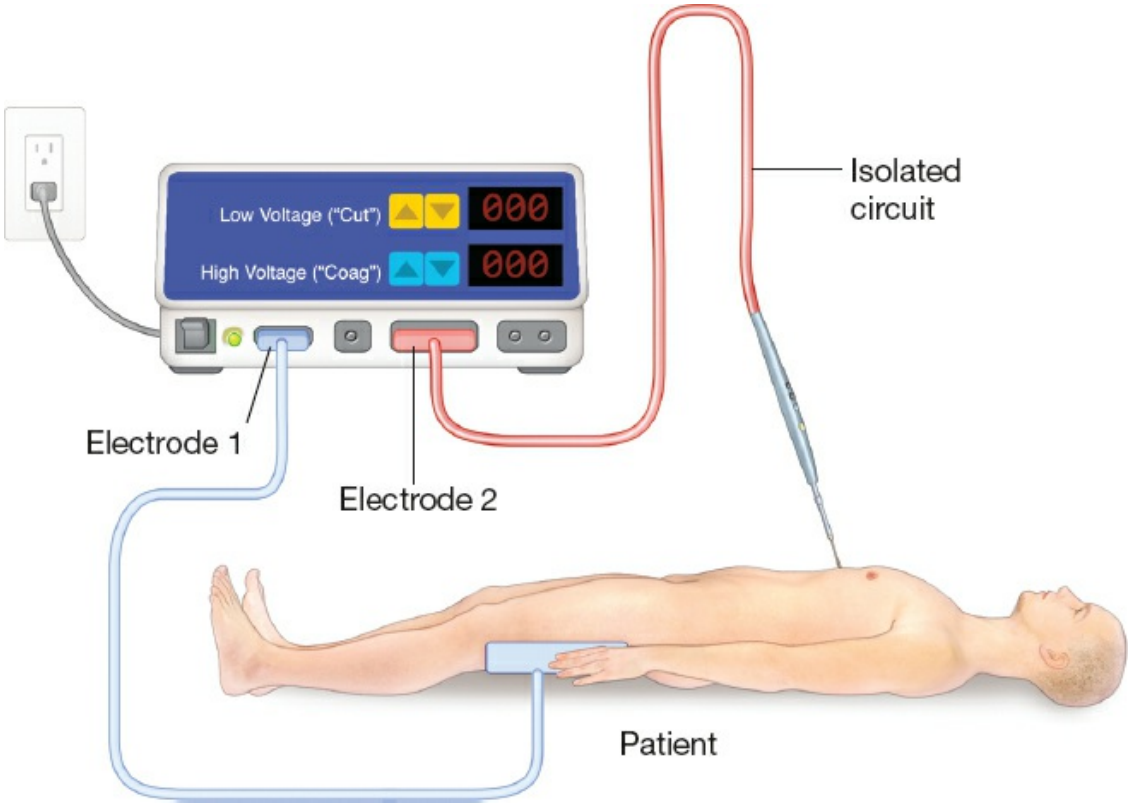

Figure 19.1. Monopolar radiofrequency energy circuit. Radiofrequency alternating current travels from the generator to the instrument tip and through the targeted tissue. It then passes through the patient and returns to the generator via the dispersive electrode.

TYPES OF ENERGY IN THE OPERATING ROOM

Monopolar Radiofrequency Energy

The most common device in today's operating room is based upon the monopolar device originally popularized by Dr. William Bovie and Dr. Harvey Cushing in the 1920s. The "Bovie," as it is commonly called in North American surgical suites, is a highly versatile device that is used in open surgery, laparoscopy, and endoscopy and permeates through all surgical specialties. When activated, the electrosurgical unit (ESU) converts 60 Hz alternating current from an electrical outlet to approximately 500,000 Hz of radiofrequency energy. This travels from the tip of the instrument, through the tissue, and into the patient and returns to the ESU via a dispersive electrode or "grounding pad" (Fig. 19.1). The most common modes of activation and surgical application techniques are discussed below.

Varying the duration of energy discharged (i.e., selecting "cut," "coag,"

or “blend” mode) from the generator as well as the proximity of the tip to the tissue (e.g., current density) creates three different clinic effects: vaporization, desiccation, or fulguration. To cut or vaporize tissue, a low voltage/high current mode is selected (i.e., cut mode). This is combined with a surgical technique that creates high current density (treating a small amount of tissue near the thin tip of the instrument) during activation. This focuses energy on a small area of tissue resulting in rapid heating of the cells to the boiling point. Linear movement of the instrument cuts tissue with less than 200 μm of lateral thermal injury (Fig. 19.2A).

To achieve more coagulative effect yet still move through tissue, a high voltage/low current mode is typically selected (coag mode) and the current density reduced by increasing the area of tissue contact with the instrument. This raises cell temperatures more slowly to 60° to 95°C which results in protein coagulation or “desiccation,” as opposed to vaporization (Fig. 19.2B). A “blended” mode is a combination of the cut and coag waveforms which seeks to maximize energy effectiveness by creating a safer, low voltage mode that can both cut and coagulate tissue.

Desiccation of tissue with the coag mode is an effective way to increase coagulation during dissection but should not be used for vessel sealing. This is better accomplished in cut mode while grasping and occluding the vessel with forceps. The apparent paradox (“cut” mode is more effective than “coag” mode for vessel sealing) is due to the fact that the continuous cut waveform more evenly heats tissues for a homogenous vessel seal as it cannot vaporize the cells due to the low current density created by the relatively large amount of tissue held between the tips of the tissue forceps.

Superficial coagulation or “fulguration” is achieved most commonly in a high voltage/low current flow mode (coag mode) while holding the instrument close but not contacting the tissue. Energy can then arc to the superficial tissues creating temperatures in excess of 200°C. The low current density rapidly heats and cools cells creating black eschar as a result of the breakdown of elements, especially carbon, into their atomic components. Thermal penetration is typically 5 mm or less (Fig. 19.2C).

The versatility and effectiveness of monopolar radiofrequency energy in surgery continues to increase as alternative modes and techniques of operation emerge. Energy devices and generators that continuously monitor tissue effect during activation are already available. When combined, these new devices and techniques all bring the surgeon closer to

the ultimate goal of energy application: the ability to utilize the smallest amount of energy possible to create the desired tissue effect.

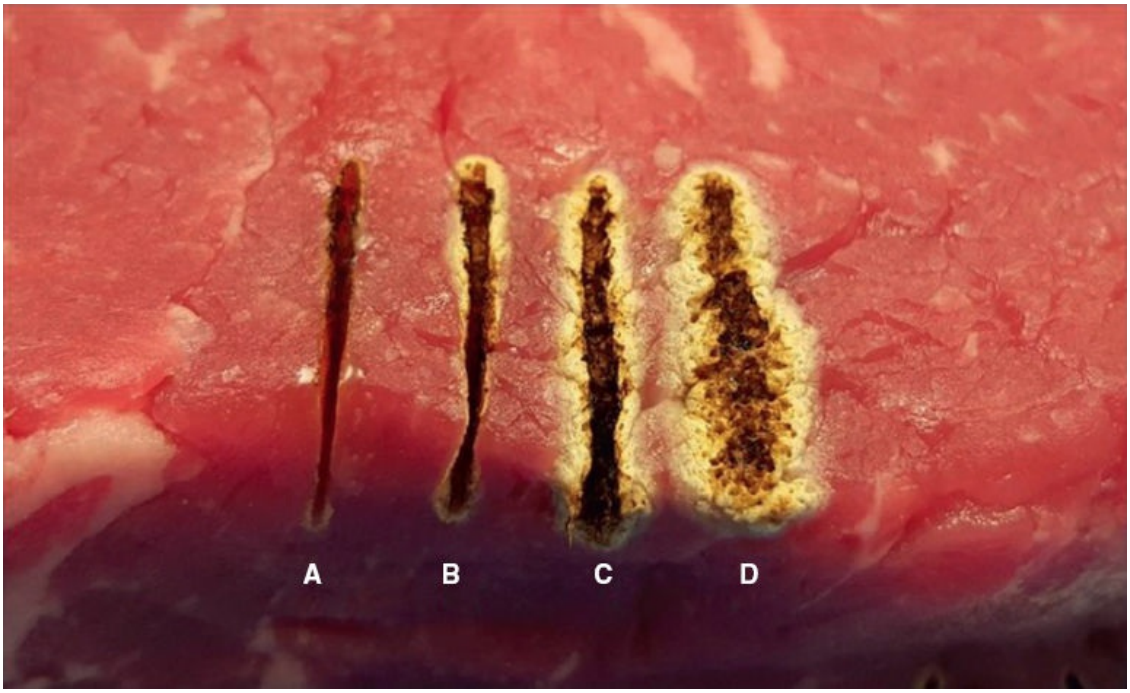

Figure 19.2. Monopolar energy tissue effect. Different tissue effects of monopolar radiofrequency energy: rapid tissue heating with high current density resulting in vaporization and minimal lateral thermal spread (“cut” mode) (**A**); rapid tissue heating with moderate current density and a blend of vaporization and dessication (a “blended” mode) (**B**); rapid tissue heating to 60° to 95°C with resultant desiccation and coagulation (“coag” mode set to “fulguration”) (**C**); spray energy arcing to tissue with rapid heating to >200°C with resultant fulguration and carbonization, depth of penetration typically <5 mm (coag mode set to “spray”) (**D**).

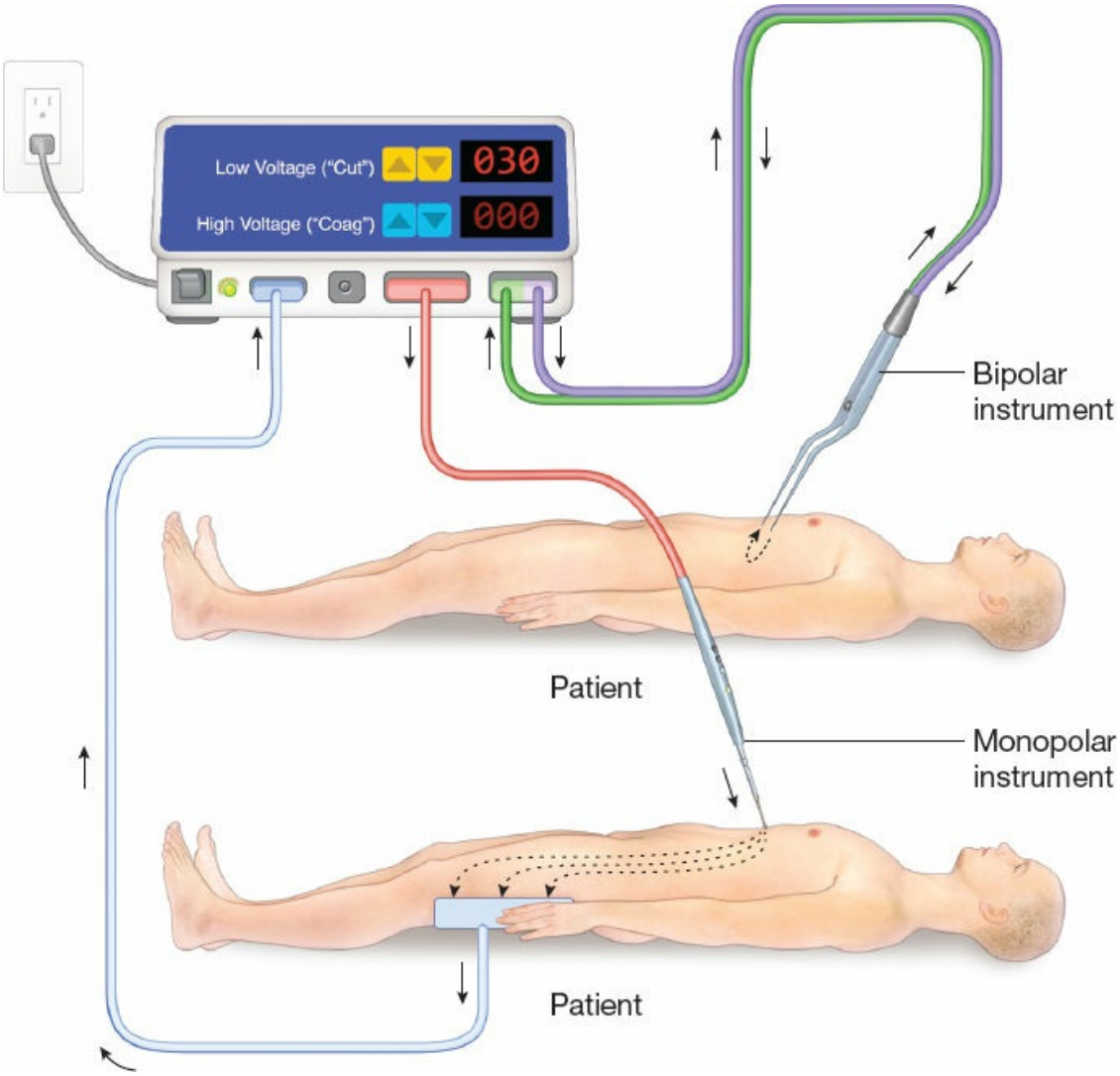

Figure 19.3. Bipolar energy circuit. Radiofrequency energy travels from the generator to the instrument and through the tissue between the instrument tips and back to the generator. This is in contrast to the monopolar instrument where energy must pass through the entire patient and return to the ESU via the dispersive electrode or "grounding pad."

Bipolar Radiofrequency Energy

Bipolar devices contain both limbs of the electrical circuit in a single device so as to focus radiofrequency energy solely on the tissue between the instrument's tips (Fig. 19.3). This reduces the required voltage from 1,400 to 9,000 V during monopolar energy use to approximately 100 to 200 V. Basic bipolar devices are designed for coagulation of tissue alone; however, newer devices are available that have added a cutting blade to transect tissue. These "advanced" bipolar devices often include tissue feedback mechanisms and audible tones to notify the surgeon when the

tissue is ready for transection. This slightly increase operative time and smoke production when compared to other devices but has the benefit of consistently sealing vessels up to 7 mm in diameter.

Ultrasonic Energy

Ultrasonic devices convert low-voltage radiofrequency energy into high-frequency (approximately 44,000 Hz) mechanical vibrations via piezoelectric crystals in the device handle. These rapid vibrations generate friction that heats tissue, denatures proteins (coagulates), and creates tissue separation (cuts) at temperatures below boiling. A transient mist is formed due to the cavitation effect of the vibration but minimal charring (tissue temperatures do not exceed 100°C) and lateral thermal spread is seen on low settings. This facilitates dissection and decreases operative time in contrast to monopolar and bipolar instruments. Ultrasonic devices can effectively seal vascular structures up to 3 mm in size although newer devices can reportedly seal larger vessels by increasing dwell time.

Plasma Energy

Radiofrequency energy can be applied in short, 40 μs bursts to create plasma energy along the edge of a device. Plasma energy can also be carried onto the tissue itself by an inert gas, most commonly, argon (Fig. 19.4). When combined with short bursts of high-voltage radiofrequency energy, plasma energy can provide tissue cutting and coagulation functions with minimal thermal spread. Argon plasma coagulators are thus designed for the superficial coagulation of diffusely bleeding tissue (e.g., cut liver or spleen). They are highly effective in a bleeding or debris-filled field and produce less smoke than monopolar or bipolar devices with a constant thermal spread of 2 to 3 mm. However, intravascular embolism of insoluble argon gas has resulted in cardiac arrest and death; thus, avoidance of direct tissue contact and minimal gas flow volume is recommended.

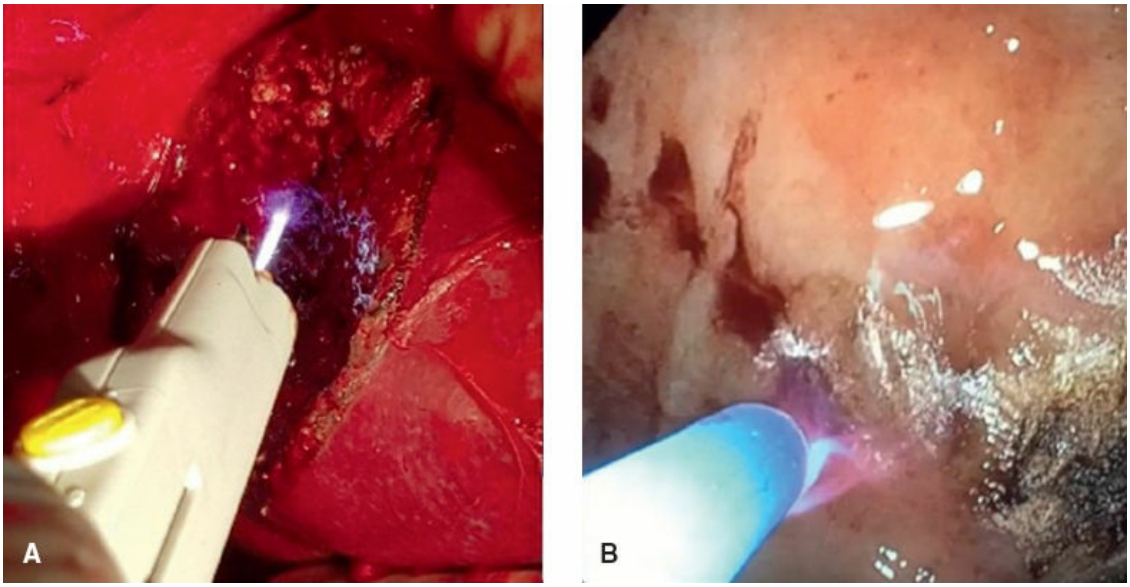

Figure 19.4. Plasma energy. Monopolar radiofrequency energy is conducted via inert argon gas to create plasma energy on the surface of tissue resulting in superficial coagulation. Argon gas is continuously insufflated during activation and so procedures within a closed space (e.g., laparoscopy, endoscopy) must be closely monitored and vented. **A.** Argon plasma coagulation during laparoscopy. **B.** Argon plasma coagulation during endoscopy.

Lasers

Lasers generate heat by focusing a concentrated beam of light on tissue. They can be used for both cutting and coagulating tissue and were quite common in the 1980s and early 1990s. Due to their high cost, need for specialized training and general increase in operating times lasers have been relegated to use in limited, specific scenarios. Precise control of the depth of penetration promotes their continued use in dental, eye, cosmetic, and gynecologic fertility procedures.

Microwave and Radiofrequency Energy Ablation

Microwave or radiofrequency energy can be applied directly to tissue to induce necrosis in either an open or percutaneous fashion. The goal of this directed use is typically tumor necrosis or arrhythmia ablation. Radiofrequency ablation devices take many different forms (bipolar, monopolar, internally cooled, etc.) and function via the principles of monopolar and bipolar energy discussed above. Significantly larger amounts of radiofrequency energy are used and extra care should be taken

to decrease the risk of electrosurgical complication.

Microwave ablation devices function within a different part of the electromagnetic spectrum (frequencies between 915 MHz and 9.2 GHz) and create tissue effect via dielectric heating. The microwave energy causes rapid alternation of the positive and negative poles within cells. The charged ions (especially water) rotate every time the positive and negative poles switch polarity (approximately 10^9 times per second) and this creates rapid and uniform heating of cells within the microwave field. No dispersive electrode is needed as no circuit is created—heating is a direct result of the microwave energy on the cells.

Both radiofrequency energy and microwave ablation are susceptible to nearby perfusion which can reduce complete ablation rates. Radiofrequency energy will follow the path of least resistance as it travels to the dispersive electrode so nearby vasculature, bile ducts, lymphatics, and so forth can serve as an “electric sink.” Microwave ablation can also be affected by nearby perfusion acting as a “thermal sink.” As no circuit is created, no electrons are stolen but the constant flow of liquid removes heat just as an automobile radiator cools an engine. A distinct benefit of microwave ablation is the ability to achieve high tissue temperatures (150°C) in contrast to the 60° to 100°C limit that guides energy flow during radiofrequency energy ablation. This can result in shorter ablation times (typically 4 to 10 minutes).

Both modalities can be successfully used to achieve complete tumor ablation and use is often guided by availability and experience. All surgeons should be aware of the different mechanisms of action in order to minimize the risk of electrosurgical complication. Due to each device’s complexity and relative rarity of use, utilization with imaging guidance and manufacturer assistance is recommended.

THE EIGHT REPRODUCIBLE PATTERNS OF ELECTROSURGICAL INJURY

Energy-based device have become ubiquitous in the contemporary operative room. Increasing use has resulted in more complications that adhere to eight common patterns of injury: fires, antenna coupling, insulation failure, residual heat, direct application interaction with electronic devices, direct coupling, and capacitive coupling. The authors have also included techniques to mitigate the risk of injury with each mechanism beginning with the most common and clinically relevant.

Fires

Operating room fires and explosions are fortunately rare events (550 to 650 per year) but can result in significant injury or death. To combat OR fires, the Joint Commission issued a sentinel event alert on fire prevention in 2003 and the most recent update (January 2015) to the hospital accreditation manual defines this as “fire, flame or unanticipated smoke, heat or flashes during an episode of patient care.” This results in mandatory hospital review of all such events even without patient injury.

Several professional organizations have published educational material to assist in the avoidance of OR fires including the SAGES FUSE training, the Association of peri-Operative Registered Nurses (AORN), the Emergency Care Research Institute (ECRI), the US Council of Surgical and Perioperative Safety (CSPS), and the Anesthesia Patient Safety Foundation (APSF). In order for a fire to occur, three elements must be present: (1) heat or an ignition source (i.e., surgical energy, patient or fluid warmer), (2) fuel (alcohol-based prep, surgical drapes, etc.), and (3) oxygen. The majority of surgical fires occur in the airway (21%) or around the upper chest, head, and neck (44%) likely due to increased oxygen content. Utilization of closed breathing circuits (i.e., endotracheal tube) as opposed to nasal cannula or mask oxygenation as well as maintaining oxygen content at ≤30% will minimize risk.

Should a fire or explosion happen the following steps should be immediately undertaken: (1) stop the flow of all airway gases and disconnect the patient from the breathing circuit including removing the endotracheal tube during an airway fire; (2) remove any burning or burned materials; (3) extinguish the fire from the burning materials by dousing it with saline, smothering it or utilizing a carbon dioxide fire extinguisher. If the fire is not contained by these steps then practitioners should follow the acronym RACE: Rescue; attempt to rescue the patient or staff. Alert; activate the fire alarm and alert nearby staff. Confine; isolate the fire by closing doors, shutting of medical gas and electrical power. Evacuate; evacuate the incident room and entire surgical suite if necessary.

Clinical Examples: (1) Surgical drapes are placed immediately after applying an alcohol-based prep resulting in a difficult-to-see blue flame fire as the alcohol ignites the drapes. (2) During a tracheostomy, the surgeon enters the airway with surgical energy resulting in an explosion both externally and within the patient’s airway. (3) While changing from the 10 mm laparoscopic telescope to the 5 mm, the fiber optic light cord is

left at 100% power and burns through the drape and onto the patient's skin.

Preventative Strategies: (1) Education of the surgeon and operating room staff on the three elements needed for fire creation taking special note of oxygen-rich environments such as the airway or under surgical drapes. (2) Do not place surgical drapes until alcohol-based preps are completely dry without pooling. (3) Enter the airway with cold surgical instruments with the patient on the minimal amount of oxygen enrichment necessary to maintain appropriate saturations (goal oxygen content <30%). (4) Maintain the fiber optic light in stand-by or "off" mode any time that it is not connected to the laparoscopic telescope. (5) Include a fire risk assessment in the preoperative timeout.

Antenna Coupling

Electrosurgical injury due to antenna coupling has only recently been elucidated but is thought to be a major source of thermal injury. Radiofrequency energy, most commonly from the wire/cable of monopolar devices, can be transmitted into the air (through intact insulation) and into nearby conductors (cables, instruments, or monitoring electrodes) similar to a radio station broadcasting music that is picked up by your car's antenna. Antenna coupling is one of the most ubiquitous sources of electrosurgical complications during monopolar energy use as any wire/cable that lay within close proximity of the "Bovie" cord (or return electrode cord) will pick up stray energy and can burn the patient.

Increasing amounts of stray energy are transferred with increased power settings (e.g., increasing power from 15 to 30 W nearly doubles energy transferred). Close proximity and parallel alignment of instruments/wires/cables has also been shown to increase tissue temperatures nearly 60°C. The forced parallel alignment and close proximity of Single Incision Laparoscopic Surgery (SILS) also increases antenna coupling and the resultant thermal injuries may be an explanation for the increased postoperative hernias and incisional pain. The simple maneuver of separating the cords has been consistently shown in benchtop and in vivo trials to reduce the incidence of antenna coupling.

Clinical Examples: (1) The monopolar "bovie" wire lays in parallel with a neuromonitoring lead during a spinal surgery and burns are noted at the insertion site due to energy transferred to the neuromonitoring lead via antenna coupling. (2) During a laparoscopic cholecystectomy the surgeon

bundles the camera, light, and bovie cords together and, when activating the “bovie,” energy transfers into the laparoscopic camera cord and then arcs from the tip of the telescope directly to the bowel. This happens outside of the surgeon’s view thus resulting in a missed bowel injury.

Preventative Strategies: (1) Separate the active electrode and dispersive electrode cords from other nearby wires/cords. (2) Minimize voltage by decreasing power, using lower power modes (cut or blend), or switching to lower power bipolar/ultrasonic devices. (3) Avoid use of monopolar energy during single incision laparoscopic surgery.

Insulation Failure

Electrosurgical injury via insulation failure is thought to be one of the most common causes of inadvertent thermal injury during laparoscopy. It may also be the most easily managed. Insulation defects can be found in up to 39% of monopolar instruments, typically near the instrument tip as the insulation begins to thin and taper. Interestingly, these defects (and resultant injuries) are more common during robotic surgery. Unfortunately, just 10% of insulation defects are visible to the naked eye; thus, some authors suggest routine use of porosity detectors during sterile processing of laparoscopic instruments.

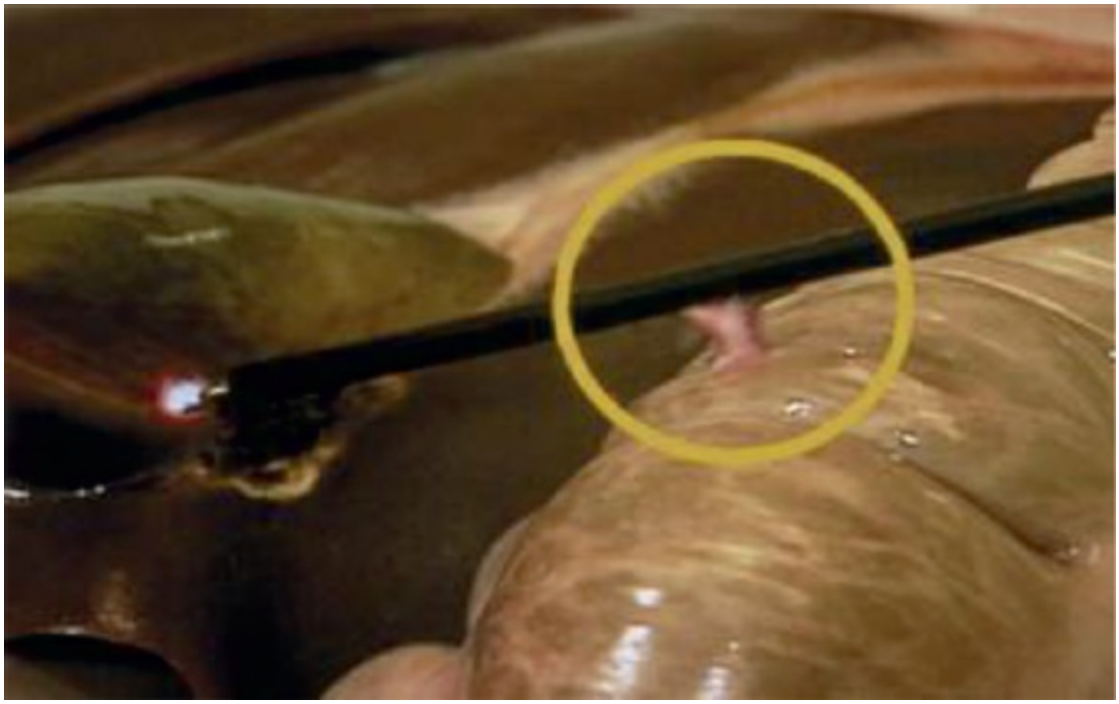

Figure 19.5. Insulation failure during laparoscopy. All electrosurgical devices should be carefully inspected for cracks or breaks in the insulation. However, only 10% of these can be

seen with the naked eye and so regular testing should be done as well as careful visualization of the entire instrument during activation. (Reprinted from Odell RC. Surgical complications specific to monopolar electrosurgical energy: Engineering changes that have made electrosurgery safer. *J Minim Invasive Gynecol* 2013;20(3):288–98. Copyright © 2013, with permission from Elsevier.)

Clinical Example: While using the monopolar "bovie" to remove the gallbladder from the fossa energy arcs from a break in the instrument shaft to nearby liver or bowel (Fig. 19.5).

Preventative Strategies: (1) Careful inspection of the instrument prior to use for obvious breaks in insulation. (2) Maximize visualization of entire instrument during activation to identify aberrant energy arcs. For laparoscopy and endoscopy this often requires pulling the telescope back into the port or out of the patient to see the "big picture." (3) Routine porosity detection of reusable laparoscopic instruments including any devices that may be connected to energy (e.g., L-hook, spatula, graspers, and/or scissors).

Residual Heat

Residual heat is defined as the increased instrument temperature after energy activation is completed. The rate of increase and maximal instrument temperature is unique to each device and causes injury when the tip touches tissue prior to complete heat dissipation. This is most commonly seen with ultrasonic devices which reach higher maximum temperature (>200°C) and remain hot longer than bipolar or monopolar devices (Fig. 19.6).



Figure 19.6. Residual heat. All energy devices are elevated to at least 60°C in order to effectively denature proteins and cool rapidly after activation is stopped. Ultrasonic devices commonly hit maximum temperatures ≥200°C and remain hot enough to cause full thickness injuries to bowel if the surgeon does not wait for the tip to cool before manipulating tissue. Instrument tip at approximately 253°C (*black arrow*).

Clinical Examples: During laparoscopic hemi-colectomy, the ultrasonic device is used to transect the transverse mesocolon and then immediately used to grasp/retract small bowel resulting in a full thickness injury and delayed perforation.

Preventative Strategies: Delay use of ultrasonic devices for grasping or dissecting until at least 5 seconds have passed after activation (2 seconds for advanced bipolar and monopolar devices).

Direct Application

Electrosurgical injury via direct application is a result of unintentional activation of any type of instrument while contacting tissue. A recent study of FDA's Manufacturer and User Facility Device Experience (MAUDE) database demonstrated that, of voluntarily reported injuries, the most common mechanism for thermal injury was direct application (84%). The

authors did not report the specific surgical techniques that resulted in injury; however, unintentional activation during device use or incomplete activation with inadvertent transection are likely mechanisms.

Clinical Examples: (1) While leaning against the patient, the surgeon unintentionally activates the monopolar device resulting in a burn to the patient at a site remote from the surgery. (2) The monopolar "bovie" is activated directly on the staple line of an intestinal anastomosis and focuses on a single staple resulting in enormous current density and melting of the staple with staple-line breakdown (Fig. 19.7).

Preventative Strategies: (1) Routine use of protective "holsters" or "sleeves" when devices are not in use. (2) Activate devices with the tips fully visualized and containing only the tissue intended to coagulate and/or cut. (3) Understand the activation cycle of each device.

Interaction With Electronic Devices

Radiofrequency energy transmitted through the air interferes with nearby monitoring devices such as ECG leads, neuromonitoring devices, and even implanted cardiac devices. The transfer of energy into monitoring cables hampers waveform interpretation and can cause direct thermal injury via antenna coupling. In addition, the transferred energy can interfere with implanted cardiac device sensing and cause malfunction. Just as separating the cords reduces antenna coupling, so does avoiding the energy vector of the pacemaker/defibrillator leads (Fig. 19.8). In addition, preferential use of low energy devices will also decrease the risk of stray energy transfer to implanted cardiac devices (Table 19.1).

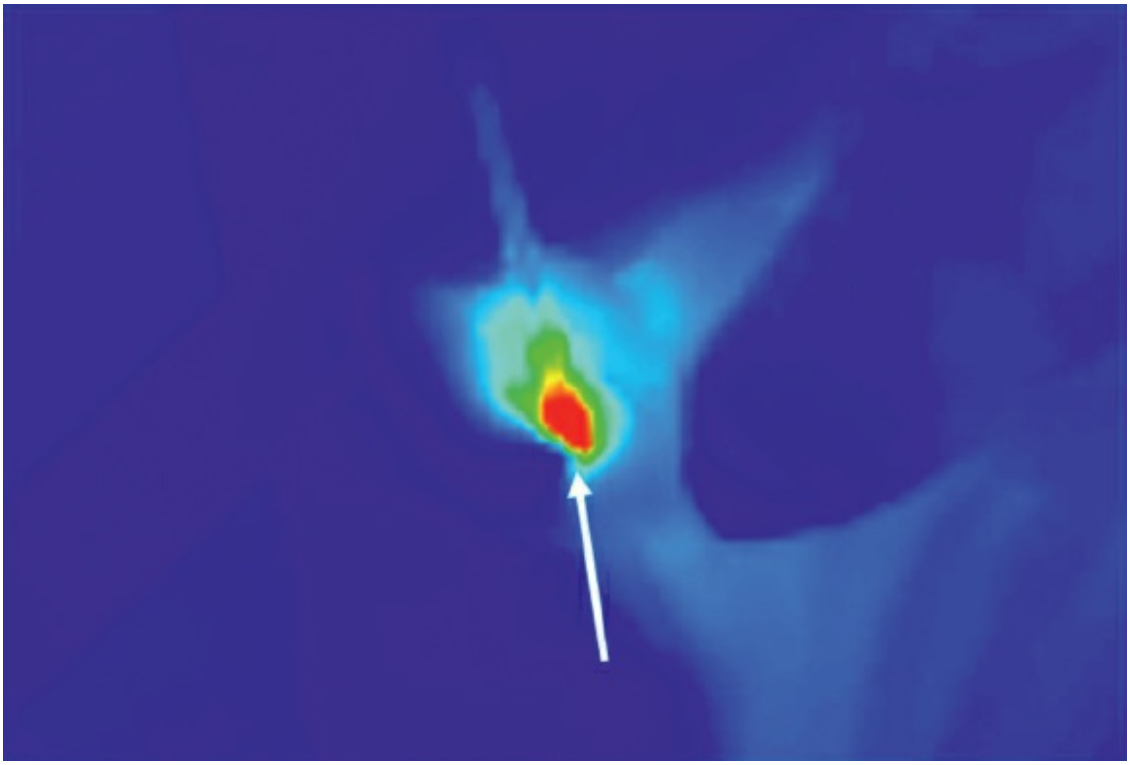

Figure 19.7. Direct coupling to a staple line. Direct coupling can result in astronomic temperatures if the current density is high as it is when activating monopolar energy on a staple line. The *white arrow* identifies the corner of a bowel staple-line where tissue temperatures exceeded the measurement capability of the thermal camera (≥200°C) and have been documented to hit temperatures nearing 1,000°C resulting in liquidation of the staples.

Clinical Examples: During activation of the monopolar "bovie" a cardiac defibrillator inappropriately senses cardiac dysrhythmia and administers a shock.

Preventative Strategies: (1) Utilize low power settings or low energy devices (bipolar, ultrasonic) when operating on patients with implanted cardiac devices. (2) Avoid use of energy devices near or parallel to the implantable device current vector.

Direct Coupling

Direct coupling is intentionally created when the surgeon touches the monopolar device to a forceps or other conductor while grasping tissue to coagulate. Complications arise when energy is unintentionally transferred to a nonelectrically active conductor.

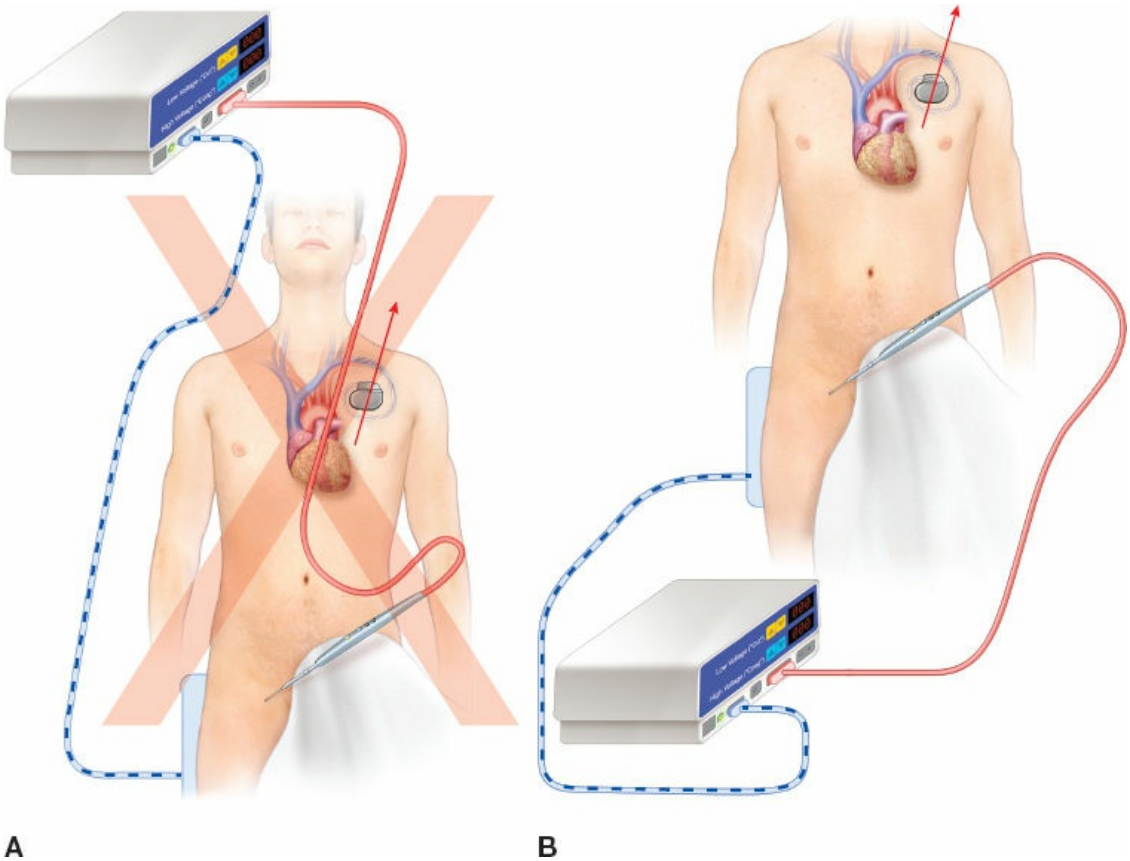

Figure 19.8. Energy vector of implanted cardiac devices. Pacemaker/defibrillator current vector (*red arrow*) is in parallel alignment with monopolar active electrode, "Bovie," cord (*blue*) (**A**) and dispersive electrode (*dotted blue*) cord which nearly doubles electromagnetic interference when compared to complete separation of the pacemaker/defibrillator current vector from the energy device cables (**B**).

TABLE 19.1 Surgical Energy-Based Devices and Electromagnetic Interference Occurring on Implanted Cardiac Devices

Low Risk EMI <0.2 mV	Intermediate Risk EMI 0.2–1 mV	High Risk EMI >1 mV
Traditional bipolar 0.01 ± 0.004 mV	Monopolar "bovie" 0.21 ± 0.07 – 0.92 ± 0.63 mV	Argon plasma energy 2.58 ± 0.34 mV
Advanced bipolar 0.00 ± 0.003 mV		Plasma energy 3.48 ± 0.78 mV
Ultrasonic shears 0.01 ± 0.004 mV		

All devices were activated for 5 seconds at a uniform location 2.5 cm inferior to the generator's lower edge. Traditional bipolar forceps were activated on a Force FX generator (Covidien, Boulder, CO) at 30 W bipolar mode. Advanced bipolar device (Ligasure; Covidien) activated on 3 "Bar" setting. Ultrasonic shears (Harmonic, Ethicon, Cincinnati, OH) activated on "Max" setting. Monopolar handheld "Bovie" was activated without tissue contact (least energy transferred), on 30 W coag mode and on 30 W blend mode (most energy transferred) creating the range of electromagnetic interference above. Argon plasma energy (Argon Beam Coagulator, ConMed, Utica, NY) was activated on 30 W coag mode. Plasma energy (Peak Plasma Blade, Medtronics, Minneapolis, MN) was activated on a "6" setting.

EMI, electromagentic interference.

Reprinted from Paniccia A, Rozner M, Jones EL, et al. Electromagnetic interference caused by common surgical energy-based devices on an implanted cardiac defibrillator. *Am J Surg* 2014; 208(6):932–6; discussion 935–6. Copyright © 2014 Elsevier.

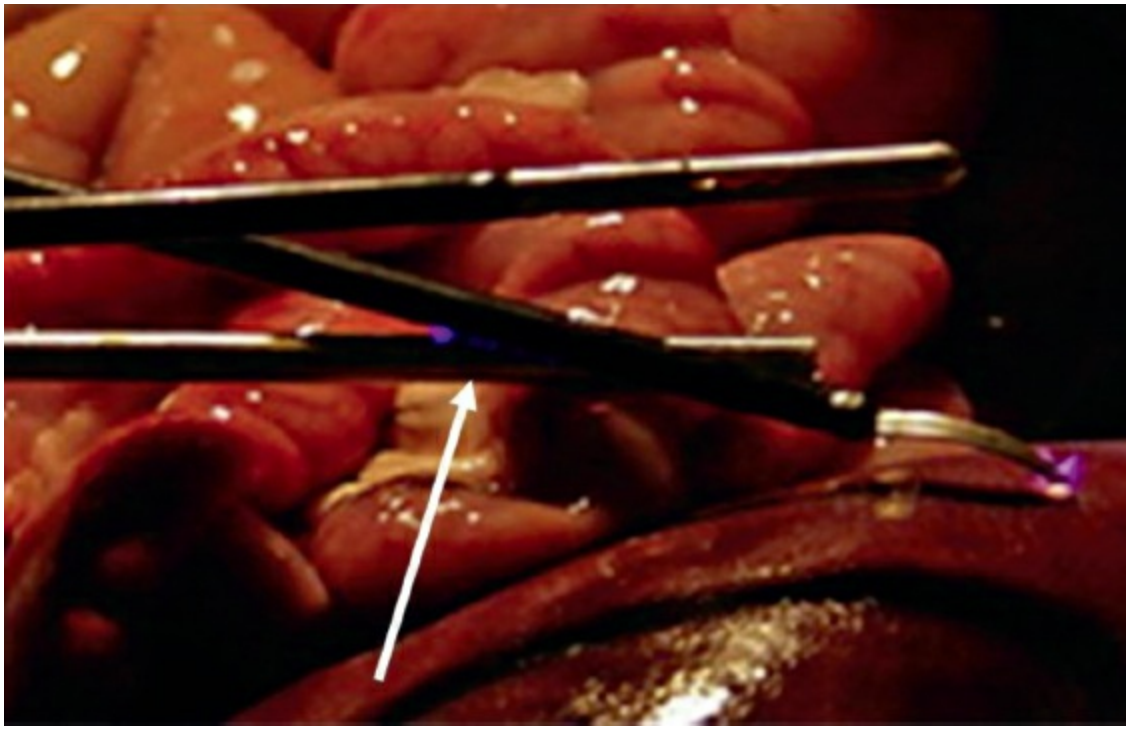

Figure 19.9. Direct coupling. Direct contact between the active electrode and nearby metal objects results in transfer of energy whether intentionally or unintentionally. The *white arrow* depicts unintentional transfer of stray energy to the laparoscopic suction device via direct coupling. (Reprinted from Odell RC. Surgical complications specific to monopolar electrosurgical energy: Engineering changes that have made electrosurgery safer. *J*

Minim Invasive Gynecol 2013;20(3):288–98. Copyright © 2013, with permission from Elsevier.)

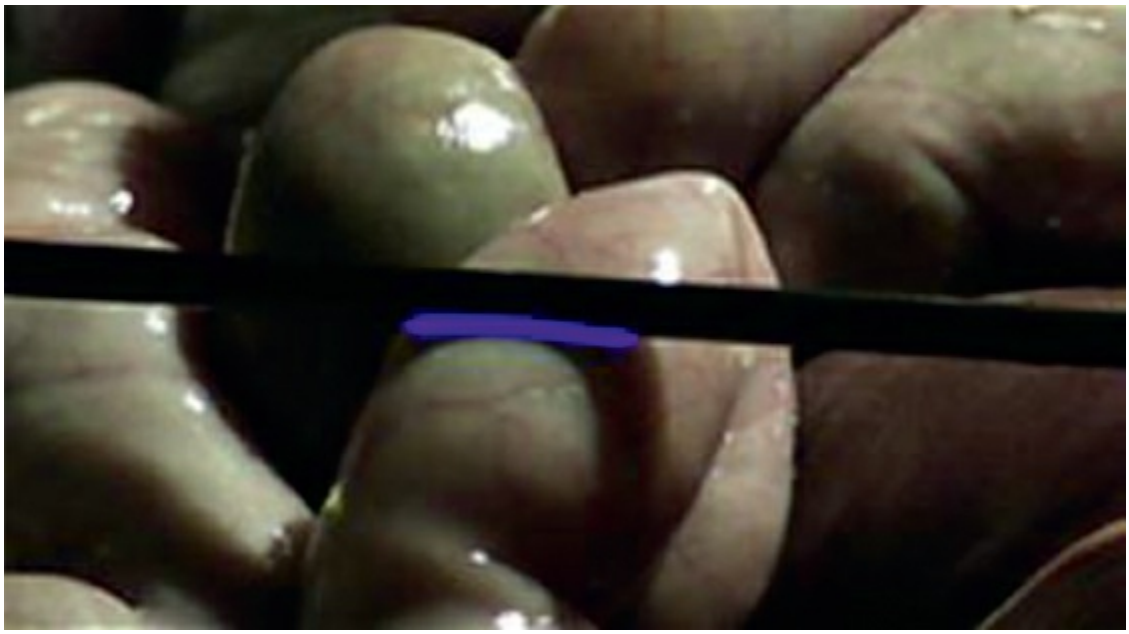

Figure 19.10. Capacitive coupling. Activation of monopolar L-hook with resultant transfer of stray energy directly to bowel via capacitive coupling. (Reprinted from Odell RC. Surgical complications specific to monopolar electrosurgical energy: Engineering changes that have made electrosurgery safer. *J Minim Invasive Gynecol* 2013;20(3):288–98. Copyright © 2013, with permission from Elsevier.)

Clinical Examples: (1) A monopolar instrument with an extension is activated in the pelvis while unintentionally touching a forceps that is retracting the ureter during a low anterior resection resulting in delayed ureteral injury. (2) A monopolar, laparoscopic L-hook is activated near the tip of the metal suction–irrigation resulting in energy transfer to the suction tip and into unintended tissue (Fig. 19.9).

Preventative Strategies: (1) Avoid contact with other conductive instruments prior to activation. (2) Maintain complete visualization of the monopolar electrode in contact with the tissue.

Capacitive Coupling

Capacitance is stored electric charge when two conductors are separated by an insulator. This stored energy can be transferred, through intact insulation, into nearby conductors (such as the bowel) resulting in thermal injury (Fig. 19.10). Capacitive coupling occurs almost exclusively with

monopolar energy use due to its high voltage. Open air activation (activation without touching tissue/completing the circuit) maximizes the risk of stray energy transfer to the patient via all mechanisms of unintentional energy transfer. The close proximity and parallel alignment of SILS also increases the risk of unintentional thermal injuries secondary to capacitive coupling.

Clinical Examples: (1) The laparoscopic monopolar L-hook is activated and capacitive energy is discharged directly into bowel contacting the insulated shaft of the instrument resulting in a delayed bowel injury (Fig. 19.10). (2) Prior to the development of video cameras for laparoscopy, surgeons looking directly through the eyepiece of the laparoendoscope would suffer burns to their eyes due to capacitive coupling.

Preventative Strategies: (1) Utilize lowest power setting to achieve effect or low energy devices (bipolar, ultrasonic). (2) Avoid the use of combined metal/plastic laparoscopic trocars. (3) Maintain complete visualization of instruments during energy activation.

SPECIAL CONSIDERATIONS

Endoscopy

Endoscopy is the standard tool for the evaluation and treatment of gastrointestinal disorders. The risk of major complications such as bleeding or perforation is less than 1:500. This risk increases to as much as 1:5 during complex procedures such as endoscopic mucosal or submucosal resections and large polypectomies, most of which cannot be completed without energy. Multiple studies have now defined the use of energy in any form during endoscopy as a risk for of postpolypectomy syndrome, bleeding, and perforation.

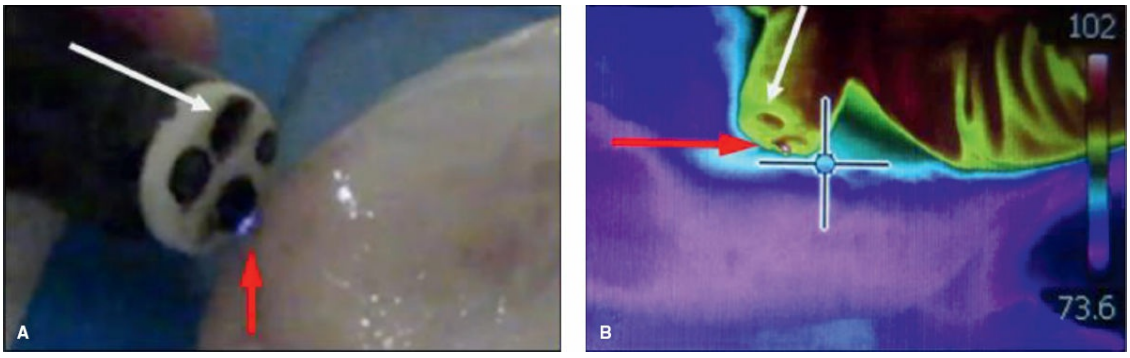

Figure 19.11. Stray energy transfer during endoscopy. **A.** Energy

is transferred directly to bowel from the endoscope camera lens (*red arrow*) when the monopolar snare is activated (retracted into the working channel) (*white arrow*). **B.** Thermal imaging by a separate camera demonstrating tissue temperatures in excess of 100°C (*red arrow*).

Monopolar energy remains the most common modality used during endoscopy and is vulnerable to the same mechanisms of stray energy transfer as open or laparoscopic surgery. Preliminary studies by the authors have demonstrated significant energy transfer within the endoscope itself secondary to antenna and capacitive coupling (Fig. 19.11). This likely results in energy transfer directly to the bowel wall from the endoscopic camera cord/lens that is not within the endoscopist's field of view and may be the source of increased complications with energy use during endoscopy (Fig. 19.12).

Another source of unintended bowel injury during endoscopy takes place via direct coupling. While activating the monopolar energy during polypectomy, energy can transfer through the polyp and into the opposing bowel wall if it is contacting, or near the tip of the polyp (Fig. 19.13). This can be avoided by fully insufflating the bowel during polypectomy to avoid any contact of the polyp to nearby structures. Alternatively, if complete insufflation is not possible, rapid movements or "wiggling" the polyp to avoid prolonged contact with the opposing bowel wall will decrease the risk of thermal injury.

One final situation bears special mention: the use of argon plasma devices during endoscopy. Plasma devices heat superficially, so perforation is rare; however, they utilize high voltage which places patients at increased risk for injury via stray energy transfer to the endoscopic camera cord and lens. In addition, continuous insufflation of argon gas can lead to significant organ distention, perforation, and gas explosion. Avoidance of prolonged argon plasma coagulator activation and use of the minimal power settings necessary for tissue effect are recommended.

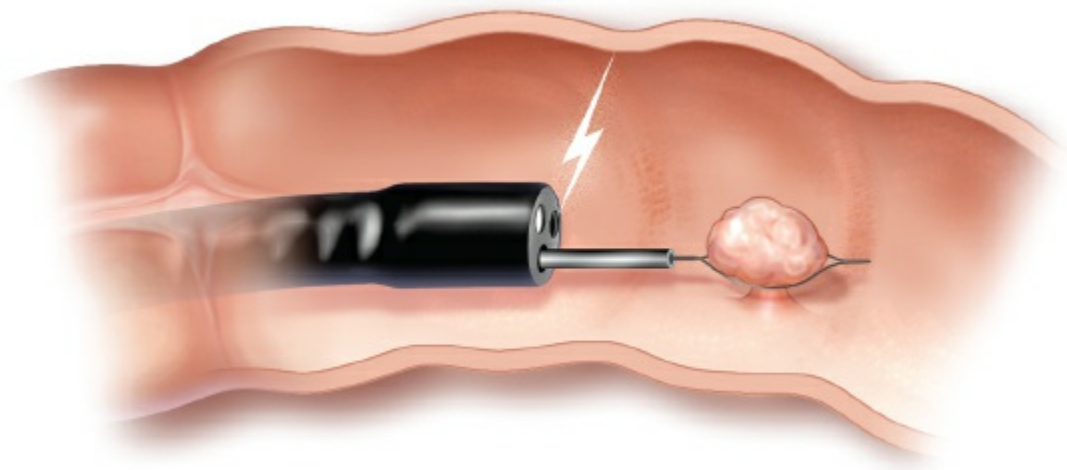

Figure 19.12. Stray energy transfer directly to bowel wall during endoscopy. Stray energy transferred within the endoscope may concentrate on the camera wire and discharge directly from the lens and into the bowel outside of the endoscopist's field of view. This may result in delayed bleeding and/or perforation as it is.

Pregnancy and Pediatric Surgery

Surgical energy can be used safely in patients of all ages and states. It bears special mention that children and infants have limited surface area to accommodate monitors, dispersive electrodes, and the surgical site. This can make adherence of the dispersive electrode difficult and smaller pads should be used for all children less than 13.6 kg (30 lb). Adult size dispersive electrodes should *never* be "cut to size" for small children and infants.

The high body surface area to volume ratio as well as elevated total body water content makes current flow less predictable in children than in adults. Similar redistribution of water in pregnant women warrants reduction in energy settings to only that necessary to generate tissue effect. Many clinicians use power settings at 50% of those in adults when operating on pregnant women or children. While specific studies have not been done, there appears to be no additional risk to the fetus at any point in gestation when using electrosurgical devices.

CONCLUSION

The best energy device for a particular patient and surgery is dependent on a multitude of factors. The characteristics of each energy device should be considered in addition to other factors such as device availability and user

experience which are not universally quantifiable (Table 19.2). Monopolar energy remains the most common and versatile instrument in the surgeon's energy armamentarium. However, that versatility brings the highest risks for electrosurgical complications and is inappropriate for certain applications such as sealing of large vessels. An industry-sponsored proliferation of advanced devices that seek to fill that gap complicates the surgeon's decision and limits the validity of blanket recommendations for a single device for every situation. Instead, the universal goal of decreasing the complications of stray energy can be had by following the summative strategies listed in Table 19.3.

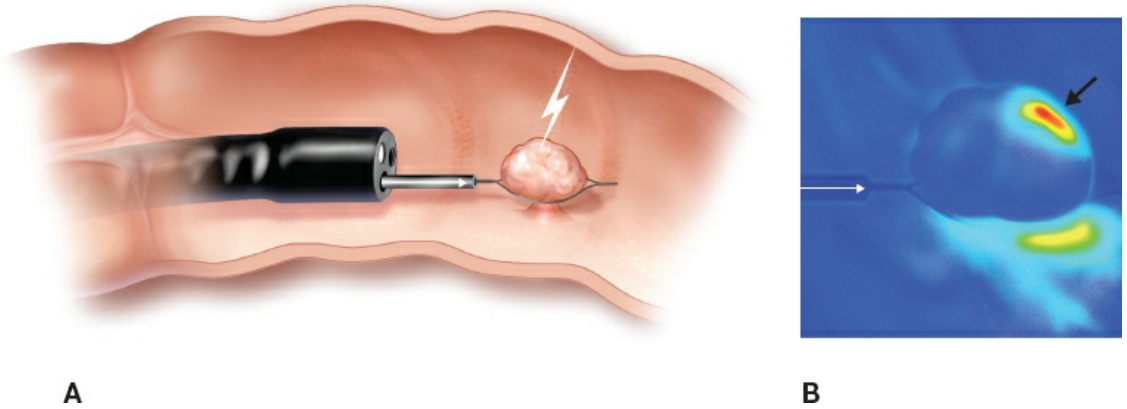

Figure 19.13. Direct coupling during endoscopy. **A.** During endoscopic polypectomy stray energy transfers directly through the polyp and into the opposing bowel wall. **B.** Thermal imaging demonstrating temperatures ≥98°C (red color at tip of *black arrow*) due to direct coupling to the bowel wall opposite the polyp (*white arrows* indicate the snare protruding from the endoscope).

TABLE 19.2 Common Electrosurgical Device Comparisons

	Monopolar	Bipolar	Ultrasonic
Energy ouptut	1,400–9,000 V	100–150 V	N/A
Cost	$10	$10—500	$500
Ability to incise skin	Excellent	Poor	Poor
Vascular sealing	≤2 mm	≤7 mm	≤3 mm
Smoke production	Low	High	Moderate
Electrosurgical Risk			
Insulation failure	**High**	Low	Low
Antenna coupling	**High**	Minimal	Minimal
Residual heat	Low	Moderate	**High**
Direct coupling	Moderate	Low	Low
Device interaction	**High**	Low	Low
Direct application	Moderate	Low	Moderate
Capacitive coupling	Moderate	Low	Low

Costs are based upon average operating room charge at a large academic center.

TABLE 19.3 Practical Steps to Minimize Risk of Electrosurgical Complications

Techniques to Minimize Risk of Electrosurgical Injury

- Reduce power setting to the lowest necessary
- Separate the active electrode ("Bovie") and dispersive electrode cord from all other cords
- Utilize low voltage cut or blended modes or low voltage devices (bipolar, ultrasonic)
- Avoid instrument activation when it is not completely within view
- Avoid instrument activation when not contacting tissue
- Maintain a low oxygen environment, especially when operating around the face or airway
- Always place the device in a sleeve or holster when not in use

Practice techniques to decrease risk of unintentional thermal injury when using electrosurgical devices.

It is everyone's responsibility in the operating room to understand how electrosurgery works and to take steps to ensure the patient's safety. As our understanding of surgical energy device function increases so should the safety of our operating rooms. Choosing the right tool for the job requires an evidence-based approach as well as lifelong learning. This chapter provides a basic understanding of the common devices and their applications but this should be supplemented with more in-depth training via FUSE certification and/or other energy-based curriculum.

Suggested Readings

Brunt LM. Fundamentals of electrosurgery part II: thermal injury mechanisms and prevention. In: Feldman L, Fuschshuber P, Jones DB, eds. *The SAGES Manual on the Fundamental Use of Surgical Energy (FUSE).* New York: Springer; 2012:61–80.

Crossley GH, Poole JE, Rozner MA, et al. The Heart Rhythm Society (HRS)/American Society of Anesthesiologists (ASA) Expert Consensus Statement on the perioperative management of patients with implantable defibrillators, pacemakers and arrhythmia monitors: facilities and patient management this document was developed as a joint project with the American Society of Anesthesiologists (ASA), and in collaboration with the American Heart Association (AHA), and the Society of Thoracic Surgeons (STS). *Heart Rhythm* 2011;8(7):1114–54.

Feldman LS, Brunt LM, Fuchshuber P, et al. Rationale for the fundamental use of surgical Energy (FUSE) curriculum assessment: focus on safety. *Surg Endosc* 2013;27(11):4054–9.

Feldman LS, Fuchshuber P, Jones DB, et al.; FUSE (Fundamental Use of Surgical Energy) Task Force. Surgeons don't know what they don't know about the safe use of energy in surgery. *Surg Endosc* 2012;26(10):2735–9.

Govekar HR, Robinson TN, Varosy PD, et al. Effect of monopolar radiofrequency energy on pacemaker function. *Surg Endosc* 2012;26(10):2784–8.

Harold HL, Pollinger H, Matthews BD, et al. Comparison of ultrasonic energy, bipolar thermal energy, and vascular clips for the hemostasis of small-, medium-, and large-sized arteries. *Surg Endosc* 2003;17(8):1228–30.

Jones EL, Dunn CL, Townsend NT, et al. Blend mode reduces unintended thermal injury by laparoscopic monopolar instruments: a randomized controlled trial. *Surg Endosc* 2013;27(11):4016–20.

Jones EL, Madani A, Overbey DM, et al. Stray energy transfer during endoscopy. *Surg Endosc* 2017 Feb 15. [Epub before print].

Jones EL, Overbey DM, Chapman BC, et al. Operating room fires and surgical skin preparation. *J Am Coll Surg* 2017;225(1):160–5.

Jones EL, Robinson TN, McHenry JR, et al. Radiofrequency energy antenna coupling to common laparoscopic instruments: practical implications. *Surg Endosc* 2012;26(11):3053–7.

Overbey DM, Townsend NT, Chapman BC, et al. Surgical energy-based device injuries and fatalities reported to the Food and Drug Administration. *J Am Coll Surg* 2015;221(1):197–205.e1.

Paniccia A, Rozner M, Jones EL, et al. Electromagnetic interference caused by common surgical energy-based devices on an implanted cardiac defibrillator. *Am J Surg* 2014;208(6):932–6; discussion 935–6.

Robinson TN, Barnes KS, Govekar HR, et al. Antenna coupling–a novel mechanism of radiofrequency electrosurgery complication: practical implications. *Ann Surg* 2012;256(2):213–8.

Robinson TN, Varosy PD, Guillaume G, et al. Effect of radiofrequency energy

emitted from monopolar “Bovie” instruments on cardiac implantable electronic devices. *J Am Coll Surg* 2014;219(3):399–406.

Schwaitzberg SD, Jones DB. Don’t get burned from lack of knowledge. *Ann Surg* 2012;256(2):219–20.

The Fundamental Use of Surgical Energy (FUSE), A SAGES Fundamental Program. http://www.fuseprogram.org/ Accessed August 15, 2015.

Townsend NT, Jones EL, Paniccia A, et al. Antenna coupling explains unintended thermal injury caused by common operating room monitoring devices. *Surg Laparosc Endosc Percutan Tech* 2015;25(2):111–3.

EDITOR’S COMMENT

Drs. Mikami and Jones have scripted a brilliant chapter on energy devices and safety. Critical is the basic understanding of the physics of an energy source for its best utilization in the operating room theater. It is even more important to ensure the safety of the patient and the staff alike. The fact that energy devices account for 5% of injuries in the operating room is incredible. The authors review the most common types of energy used, the most common patterns of injury (fires, antenna coupling, insulation failure, residual heat, direct application interaction with electronic devices, direct coupling and capacitive coupling) and provide a guide to selecting the best device for the desired tissue effect and avoiding a device-related injury. They admonish the reader that it is right and proper for everyone to obtain FUSE certification.

The FUSE didactics are available to everyone, free-of-charge at http://www.fusedidactic.org/ (accessed April 19, 2017). The curriculum is also available to take at the Society of Gastrointestinal and Endoscopic Surgeons (SAGES), American College of Surgeons (ACS), or at regional testing centers. One can obtain 6, Part I, self-assessment continuing medical education (CME) credits by taking the course. The curriculum covers the fundamentals of electrosurgery in more detail than Mikami and Jones in this chapter including physics of the electrosurgical generators and the biochemical effects on cells. The FUSE course further describes the circumstances, mechanisms, and prevention of injuries by a variety of instruments and in a mélange of situations. The FUSE curriculum also focuses on prevention strategies and how to report and handle adverse device events as well as meet regulatory requirements.

One area not mentioned in this chapter is the type of energy used to develop flaps for any procedure. In my practice, an important area is how one uses cautery or plasma energy devices in the development of skin flaps during a nipple skin–sparing mastectomy. It is critical to use the right energy or mode in developing such flaps. In my view, coag should be used sparingly as the heat generated in this mode can injure the vascularity of the flap and frequently cause flap necrosis and subsequent infection. When cauterizing a blood vessel

care should be used to aim the cautery parallel to the skin so the current does not arc and burn a hole right through the skin flap. As described in this chapter, it is better and more effective to pick up the blood vessel with forceps and use the cut or high current mode. The plasma blade is the coolest of these but should also be used parallel to the skin. As so aply put by the authors “the ultimate goal of energy application is the ability to utilize the smallest amount of energy possible to create the desired tissue effect.”

Radiofrequency ablation (RFA) is increasingly used in a number of surgeries today. Key to the more effective use of many of the electrosurgery instruments commonly used in the operating room is maximizing the use of current density to achieve the desired tissue effect as well as understanding the difference between using radiofrequency for electrosurgical use versus that of volumetric ablation. By manufacturing specifications it is safe to use RFA devices in the presence of a pacemaker or defibrillator but I perfer to turn them off and have an external device in the OR if necessary. However, as Mikami and Jones show any internal or external wires should not be in parallel with those of the RFA device. Grounding pads should be distant to any cardiac-related devices and any metal hardware. Compared with the other more common entities used for ablation (cryoablation, laser and microwave), RFA is by far and away the most reliable and consistent. We have also published a reliable Doppler method of following and determining the extent of ablation by RFA as well as help avoid the injuries described within this chapter. Microwave is the most inconsistent method of ablation and its use poses the greatest risk of injury. I use the analogy of putting a frozen hot dog in a home microwave. At the end of the allotted cooking time, half of the hot dog will still be frozen and the other half would have exploded because it got too hot. Research will help solve this issue in the future as focused ultrasound holds great promise for incisionless ablation.

This chapter is also very thorough in detailing the various mistakes one can make while performing endoscopy especially polypectomies. A risk of one in five is incredible but believable. How many of us have not been consulted for a perforation after an endoscopic polypectomy? The authors provide scenarios and illustrations on how these injuries happen and how to avoid them. In the case of laparoscopic injuries even some clues of where to look when injures occur.

The fact is that high energy devices are the most common cause of injury in operating room. There are also a major reason behind surgical fires and burns and the subsequent litigation. In a 33-year review of medical litigation from Mayo and Marshfield Clinic, Choudhry and colleagues review 139 cases. Most of these (82%) were operative burns and the rest surgical fires. One fourth of these were burns to the face. The most common source of the injury (43%) was a high energy device with death reported in two cases. Young age and the mention of a nonsurgical physician as a defendant both were shown to be independently associated with award payout which occurred in 60% of the cases. Median award pay-out was $215,000. The authors concluded that

understanding and addressing pitfalls in operating room may mitigate errors and hypothetically lessen impending liability. Surgery is a team approach and all members of the team should be knowledgable and empowered to make the operating room safe and avoid errors. Recent work by Molina and colleagues from the Brigham and Women's Hospital and Harvard demonstrated that even the perception of safety of surgical practice and respect among operating room personnel is associated with hospital-level 30-day postoperative death. A culture of safety is a priority for the whole team. It is incumbent upon the surgeon to lead this effort and do it in such a way that operating room personnel feel respected and invited to speak up on behalf of patient safety.

V. Suzanne Klimberg

Suggested Readings

The Fundamental Use of Surgical Energy FUSE, A SAGES Fundamental Program. http://www.fuseprogram.org./ Accessed April 19, 2017.

Choudhry AJ, Haddad NN, Khasawneh MA, et al. Surgical fires and operative burns: lessons learned from a 33-year review of medical litigation. *Am J Surg* 2017;213(3):558–64.

Klimberg VS, Ochoa D, Henry-Tillman R, et al. Long-term results of phase II ablation after breast lumpectomy added to extend intraoperative margins (ABLATE I) trial. *J Am Coll Surg* 2014;218(4):741–9.

Molina G, Berry W, Lipsitz SR, et al. Perception of safety of surgical practice among operating room personnel from survey data is associated with all-cause 30-day postoperative death rate in South Carolina. Presented April 21, 2017 at the American Surgical Association in Philadelphia, Pennsylvania. Submitted for publication in the Annals of Surgery.

SECTION III

THE HEAD AND NECK

20 Anatomy of the Head and Neck

Aaron Ruhalter

SURFACE ANATOMY

Surface anatomy is the relationship between structures that are visible and/or palpable with structures that are not visible and/or palpable. Visible and/or palpable structures in the neck include the following:

1. Sternocleidomastoid (sternomastoid) muscle that attaches to the superior aspect of the manubrium sternum by a tendinous head and from the medial third of the clavicle by a muscular head. It passes superiorly in a lateral, and then posterior, direction. Its superior attachment is to the mastoid process, and the lateral end of the superior nuchal line. Unilateral contraction of the muscle approximates the ear to the ipsilateral shoulder, while rotating the chin to the contralateral side. Bilateral contraction of the muscle can result in either flexion or extension of the head. If the head is slightly flexed, bilateral contraction will result in increased flexion. If the head is slightly extended, bilateral contraction will result in increased extension. The pulsation of the carotid artery is palpable, anterior to the edge of the muscle.
2. Trapezius muscle that has a very broad origin from the medial portion of the superior nuchal line, external occipital protuberance, ligamentum nuchae, spinous processes, and the supraspinous ligaments of the thoracic vertebrae. The muscle fibers converge and insert on the lateral third of the clavicle and the acromion process of the scapula. Because of the extensive origin of the muscle, differential contraction will create different movements. Contraction of the upper fibers will cause elevation of the scapula. Depression of the scapula is created by contraction of the inferior fibers. The middle fibers will cause the medial edge of the scapula to approach the midline. The external branch of the accessory nerve provides innervation to the trapezius and sternocleidomastoid muscles. Branches from the second and third cervical nerves provide added innervation.
3. Mastoid process.

4. Ramus of mandible.
5. Hyoid bone, palpable in the midline of the neck when the mandible is slightly depressed. It is located at the level of the third cervical vertebra. The greater horn of the hyoid bone can be traced to its lateral termination. This is the approximate level of origin of the lingual branch of the external carotid artery. The superior thyroid branch arises just inferior to this point, and the facial branch begins just superior to the same palpable landmark.
6. Fused laminae of the thyroid cartilage. The upper edge of this palpable structure is situated at the level of the fourth cervical vertebra. It represents the site of bifurcation of the common carotid artery.
7. Arch of the cricoid cartilage, palpable below the inferior end of the thyroid laminae. A small defect separates them. The cricoid cartilage represents an "anatomical bonanza" because it is a landmark for many anatomical occurrences. It may be referred to as the "cricoid plane."

   - The larynx ends, and the trachea begins.
   - The pharynx ends, and the esophagus begins.
   - The cricoid cartilage is at the level of the sixth cervical vertebra.
   - The intermediate tendon of the omohyoid muscle is found anterior to the carotid sheath.
   - The inferior thyroid artery passes posterior to the carotid sheath on its way to the lateral lobe of the thyroid gland.
   - The middle cervical sympathetic ganglion lies on the transverse mass of the sixth cervical vertebra.
   - The recurrent laryngeal nerve enters the larynx.
   - The ansa cervicalis is found anterior to the carotid sheath.
   - The vertebral artery enters a foramen in the transverse mass of the sixth cervical vertebra. This occurs at the apex of a muscular triangle formed by the anterior scalene and longus coli muscles. The base of the triangle is the first portion of the subclavian artery.
   - The superior pair of parathyroid glands is often found at this level.

8. Upper tracheal rings that are palpable between the cricoid cartilage and the superior edge of the manubrium sternum.
9. Superior edge of the manubrium of the sternum. It is at the level of the second thoracic vertebra.

STRUCTURE OF THE NECK

Skeletal Background

The cervical portion of the vertebral column creates the skeletal background. It is composed of seven cervical vertebrae, with a characteristic anterior convex curvature. Vertebrae C3 through C6 are considered to be typical cervical vertebrae. Vertebrae C1, C2, and C7 are atypical cervical vertebrae. C1 (atlas) has no body. C2 (axis) has incorporated the body of C1 in its structure. The combination of the two bodies results in a tooth-like projection called the odontoid process, or dens epistrophe.

This provides an axis of rotation for the skull on the atlas. C7 has a large transverse mass with a primitive foramen and a prominent spinous process (vertebra prominens). The typical cervical vertebrae have a bifid spinous process and a distinct foramen in the transverse mass. There are anterior and posterior tubercles related to the transverse mass. The first rib must be included in the skeletal background. Many of the neck structures are attached to, or pass over, the first rib. The superior surface of the first rib is flattened. This will avoid trauma to the neurovascular structures that travel over it. Midway between the vertebral and the sternal ends of this rib is the scalene tubercle, point of insertion of the anterior scalene muscle. A vascular sulcus is found on both sides of the scalene tubercle. The anterior sulcus provides passage for the subclavian vein. The subclavian artery passes over the posterior sulcus. The anterior scalene muscle attaches to the first rib between the subclavian vessels. The middle scalene muscle attaches to the first rib posterior to the groove for the subclavian artery. Therefore, the subclavian artery passes through the scalene triangle that is created by the anterior and middle scalene muscles. This area is referred to as the root of the neck. It will be described in more detail later in this chapter.

Ligamentous Background

The ligamentous background includes supporting structures for the atlanto-occipital and atlantoaxial joints. The anterior longitudinal ligament is found on the anterior aspect of the vertebral bodies. It extends from the atlas down to the upper sacral segment. It is attached to the intervertebral disc and that portion of the vertebral body lying just superior and inferior to the disc. The nuchal ligament covers the spinous processes of all the cervical vertebrae.

Muscular Background

The muscular background includes muscles that are attached to the anterior aspect of the vertebra (anterior vertebral) and muscles that are attached to the lateral mass of the vertebra (lateral vertebral). Both of these groups are combined and are referred to as prevertebral muscles. The longus coli and longus capitis muscles are anterior to the vertebral column. The longus coli is a complex muscle that is attached inferiorly to the upper thoracic portion of the anterior longitudinal ligament. These lower fibers pass superolaterally and attach to the transverse masses of the typical cervical vertebrae. Fibers of this same muscle then pass superomedially and attach to the anterior portion of the arch of the atlas. There are vertical fibers of this same muscle that lie between the two oblique portions laterally and the anterior longitudinal ligament medially.

The longus capitis muscle lies anterior to the superomedial fibers of the longus coli muscle. It passes from the base of the skull to the tubercles of the typical cervical vertebrae. The muscles that are lateral vertebral in position are the levator scapula, middle, and anterior scalene muscles. The levator scapula muscle is the most posterior of this lateral group. It arises from the posterior tubercles of the transverse masses of the first four cervical vertebrae, descends, and attaches to the superior portion of the vertebral border of the scapula. The middle scalene muscle is on a more anterior plane (Fig. 20.1).

The middle scalene muscle may be attached to the posterior tubercles of all cervical vertebrae. It descends and affixes to the superior flattened surface of the first rib, posterior to the groove for the subclavian artery. A few muscle fibers extend down to the second rib and create the posterior scalene muscle. The most anterior of the lateral vertebral muscles is the anterior scalene (Fig. 20.1). It arises from the anterior tubercles of the transverse masses of the typical cervical vertebrae and attaches below to the scalene tubercle of the first rib. It is in the same frontal plane as the longus capitis muscle. The anterior vertebral muscles will flex the cervical spine. The lateral vertebral muscles will cause lateral bending of the same area. Motor innervation is provided by ventral rami of cervical nerves.

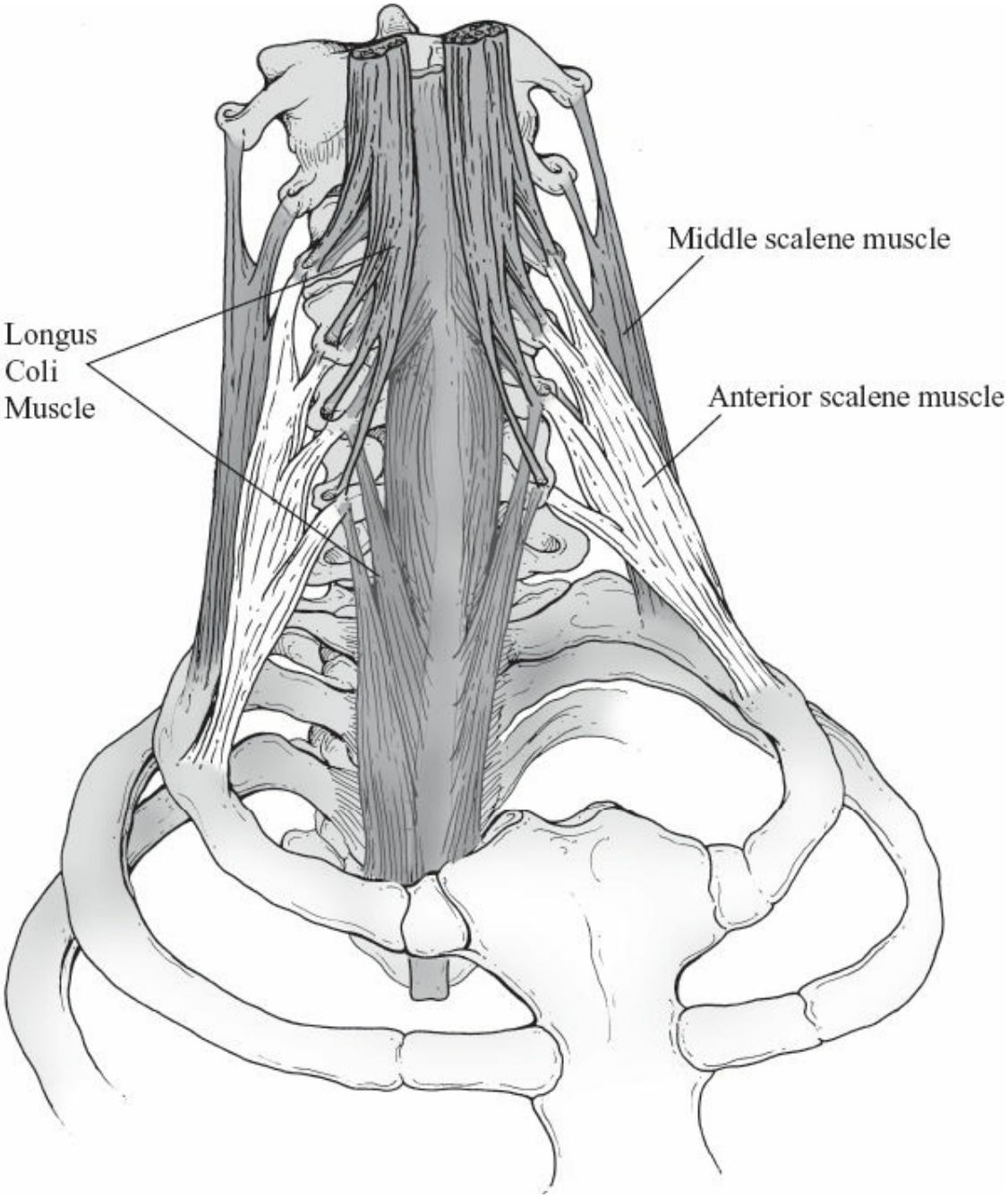

Figure 20.1. Structures of the Neck-1. Scalene muscles of the neck.

Nerve Background

The nerve layer should now be inserted. The nerves and the muscles are intimately related, so that the term “neuromuscular layer” is appropriate. The cervical and brachial plexuses and the cervical sympathetic chains are now encountered as we continue the reconstruction of the neck.

The cervical sympathetic chain consists of three ganglia with connecting branches. The superior ganglion is the largest, and it is found

on the transverse mass of the second and third cervical vertebrae. It is >1 in long and lies on the longus capitis muscle, posterior to the carotid sheath. The middle cervical ganglion is the smallest and lies on the transverse mass of the sixth cervical vertebra. The inferior cervical ganglion is related to the vertebral end of the first rib and the transverse mass of the seventh cervical vertebra. It frequently joins with the first thoracic ganglion to form a dumbbell-shaped structure called the cervicothoracic, or stellate, ganglion. Stellate refers to the star-like appearance created by the multiple branches that are emitted. It is posterior to the vertebral artery. At times, branches from the middle cervical ganglion will form a loop around the subclavian artery before entering the inferior ganglion. This is referred to as the ansa subclavia.

The cervical plexus is formed by the ventral rami of the first four cervical nerves. These nerves connect to each other by forming loops that lie in the interval between the levator scapula, or the middle scalene, muscle posteriorly, and the longus capitis or its inferior continuation, the anterior scalene muscle, anteriorly (Fig. 20.2).

Each of the first four cervical ventral rami receives a branch from the superior cervical ganglion. The cervical nerves lie within the prevertebral fascia. The cervical plexus provides muscular and cutaneous innervation. There are cutaneous branches from a superficial cervical plexus and muscular branches from a deep cervical plexus. The cutaneous branches will be described with the posterior triangle. Muscular branches innervate the prevertebral muscles. In addition, a branch from C1 travels with the hypoglossal nerve and gives rise to the superior limb (descending hypoglossal nerve) of the ansa cervicalis. Branches from C2 and C3 will form the inferior limb (descending cervical nerve). The two limbs unite and form the ansa cervicalis. This nerve loop is on the anterior aspect of the carotid sheath, in the cricoid plane. Branches arise from the ansa cervicalis that provide motor innervation to the strap muscles in the muscular triangle. Other branches of C1, traveling with the hypoglossal nerve, provide motor innervation to the thyrohyoid and geniohyoid muscles. A branch from C4 descends on the anterior surface of the anterior scalene muscle, within the prevertebral fascia. It is the phrenic nerve and it may receive branches from C3 and C5. It is, at first, seen on the lateral aspect of the anterior scalene muscle, but as it descends it passes obliquely across the anterior surface of the muscle and reaches its medial edge in the root of the neck. It then passes anterior to the subclavian artery and courses

medial to the internal mammary artery before entering the thorax. It provides sensory and motor innervation to the respiratory diaphragm (Fig. 20.2). There are some proprioceptive branches arising from the cervical plexus that pass to the sternocleidomastoid and trapezius muscles.

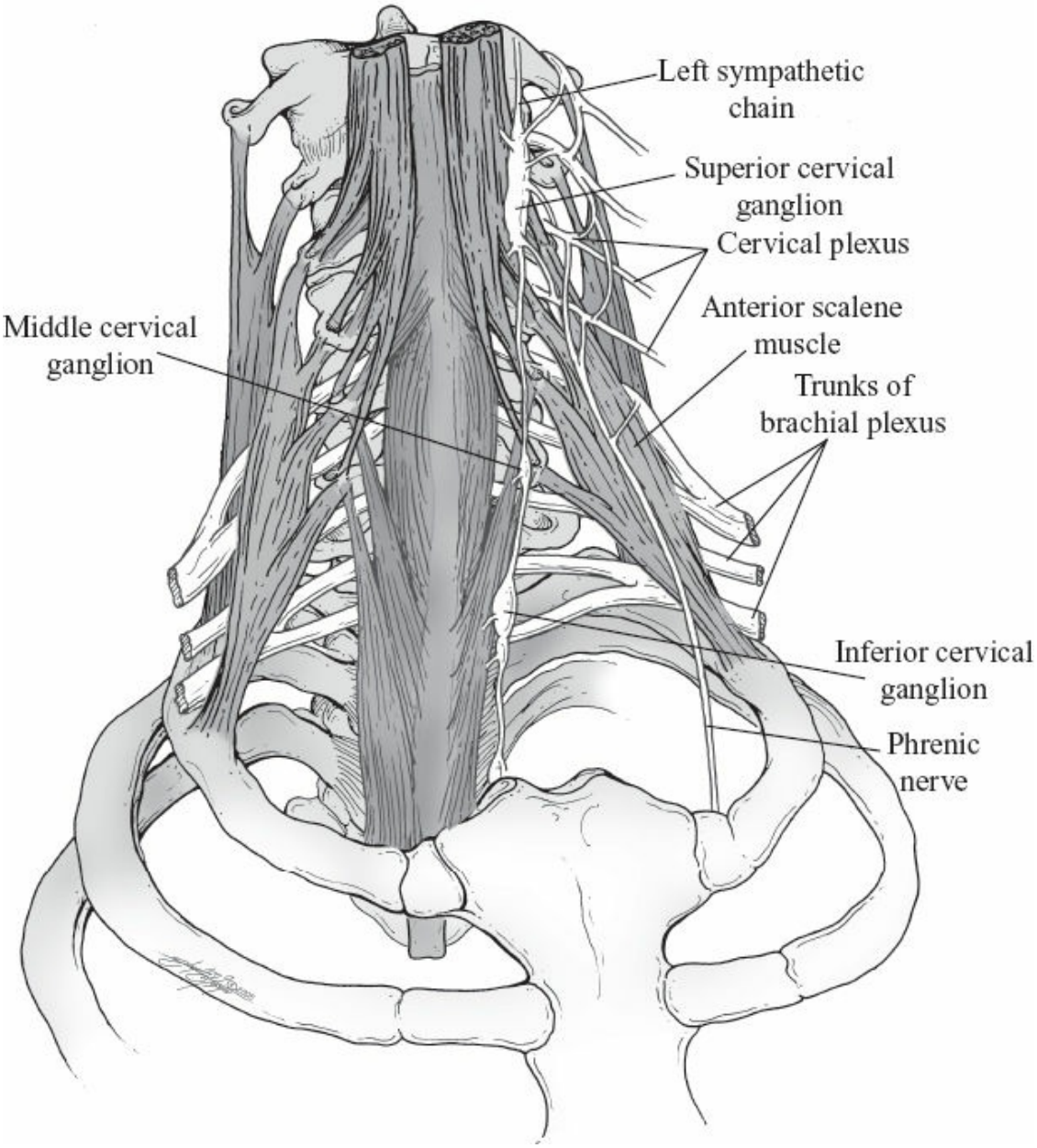

Figure 20.2. Structures of the Neck-2. Ganglia and cervical plexus structures.

As we pass inferiorly in the cervical region, the nerves now encountered will consist of the roots and trunks of the brachial plexus. The brachial plexus is created by the ventral rami of C5 through T1. These roots will form three trunks. C5 and C6 join to form the upper trunk. The

C7 root will become the middle trunk, and roots C8 and T1 will merge and form the lower trunk. These roots and trunks pass between the middle and the anterior scalene muscles. The lower trunk is draped over the first rib immediately posterior to the subclavian artery (Fig. 20.2).

The subclavian vein, unlike the accompanying artery, does not pass between the scalene muscles. It passes anterior to the anterior scalene muscle. Enclosing the skeletal background and the neuromuscular layer is the prevertebral portion of the deep cervical fascia. The neurovascular structures will pierce the deep cervical fascia and drag a portion of it along with them, creating the axillary, or cervicoaxillary, sheath.

Fascia of the Neck

The cervical fascia is composed of superficial and deep layers. The superficial fascia is not well developed and not easy to find. It consists of fat and some connective tissue. The platysma muscle is in the superficial fascia. It arises inferiorly from the fascia of the pectoralis major muscle and its fibers converge as they ascend to their insertion in the inferior part of the mandibular region. Some of the muscle fibers ascend and mix with the intrinsic depressor muscles of the lips. The cutaneous nerves and the superficial veins course below this muscle of facial expression. The cervical branch of the facial nerve innervates this muscle.

The deep cervical fascia consists of several layers. The superficial, or investing, layer of the deep cervical fascia splits to invest the trapezius and sternocleidomastoid muscles and the submandibular and parotid glands. It creates a complete tube that surrounds the neck. The deep layer of the deep cervical fascia, or prevertebral fascia, encloses the vertebral column and the attached erector spinae and prevertebral muscles and proximal portions of the cervical and brachial plexuses. It creates a complete tube.

The pretracheal fascia creates a tube that encircles the pharynx and esophagus, larynx and trachea, and the thyroid and parathyroid glands. The buccopharyngeal fascia is the posterior extension of the pretracheal fascia that covers the constrictor muscles of the pharynx. It is in contact with the anterior, or prevertebral, portion of the prevertebral fascia. This potential space between the prevertebral and the buccopharyngeal fascia layers extends from the neck down to the mediastinum. This retropharyngeal space can serve as a pathway for the spread of an infection from the neck to the thorax. The middle cervical fascia extends from the hyoid bone to the sternum. It encompasses all the strap muscles. This fascia layer extends

laterally to the omohyoid muscle and therefore is only related to the muscular and subclavian triangles.

The carotid sheath is a protective, tubular fascial sheath found between the base of the skull and the root of the neck. It receives tissue contributions from all layers of the deep cervical fascia and encloses the common carotid and internal jugular vascular conduits and vagus nerve. After the bifurcation of the common carotid artery, the internal carotid branch will assume its position in the sheath. The vein is anterolateral to the artery, except at the base of the skull, where the vein lies posterior to the artery. The vagus nerve is between, and slightly posterior to, the blood vessels. The ansa cervicalis is on the anterior surface of the sheath in the cricoid plane. The sympathetic chain is in contact with the posterior surface of the sheath.

ROOT OF THE NECK

The root of the neck is the anatomical intersection between the thorax, neck, and axilla. The superior thoracic aperture, or thoracic inlet, and axillary (or cervicoaxillary) sheath create a pathway for the neurovascular structures found in this area. Neck structures also contribute to the complexity of the anatomy in this important region. Passing between the clavicle and the first rib are nerves, arteries, and veins of the upper extremity. Narrowing of this costoclavicular canal can cause compression of these neurovascular structures. The thoracic inlet is created by the upper end of the manubrium anteriorly, the first rib and its costal cartilage laterally, and the first thoracic vertebra posteriorly. Structures passing through this area are medial or lateral in position. The esophagus and the trachea are medial as they enter the mediastinum. The thoracic duct lies just to the left of, and posterior to, the esophagus. In the root of the neck, at the level of C7, the duct passes laterally. It courses anterior to the left vertebral and left inferior thyroid arteries and posterior to the carotid sheath. It then travels anterior to the anterior scalene muscle. It is superficial to the prevertebral layer of the deep cervical fascia. The duct then descends anterior to the left subclavian artery and terminates at the lateral edge of the junction between the left internal jugular and the left subclavian veins (see Fig. 20.5).

The equivalent of the thoracic duct on the right side of the root of the neck is called the right lymphatic duct. It is much smaller and may be represented by several small ducts. It receives lymph from the right

hemithorax, right upper extremity, and right side of the head and the neck. Lymph from all other parts of the body is transported by the thoracic duct. The sympathetic chains are in contact with the head of the rib at this level. The recurrent laryngeal nerves, branches of the vagus (X) nerve, are also medial. The right recurrent laryngeal nerve arises in the root of the neck, loops around the right subclavian artery, and passes superomedially as it courses toward the tracheoesophageal groove. Its counterpart on the left arises in the mediastinum, loops around the aortic arch, and then ascends into the neck by way of the left tracheoesophageal groove. The right recurrent nerve, in the root of the neck, travels toward the right tracheoesophageal groove, but it may not yet have reached this protected position and is therefore more exposed to injury.

The apex of the cervical parietal pleura ascends to the neck of the first rib. The anterior end of the rib is lower than the posterior end; therefore, the apex of the lung can ascend out of the thorax into the root of the neck (Fig. 20.3). This ascension is most marked during deep inspiration and occupies the lateral portion of the superior thoracic inlet. This portion of the cervical pleura may extend above the superior edge of the clavicle. A tent-like thickening of the prevertebral fascia extends from the transverse mass of C7 to the first rib. It is called Sibson, or vertebropleural, fascia and provides some protection to the pleura when incisions are made in this area.

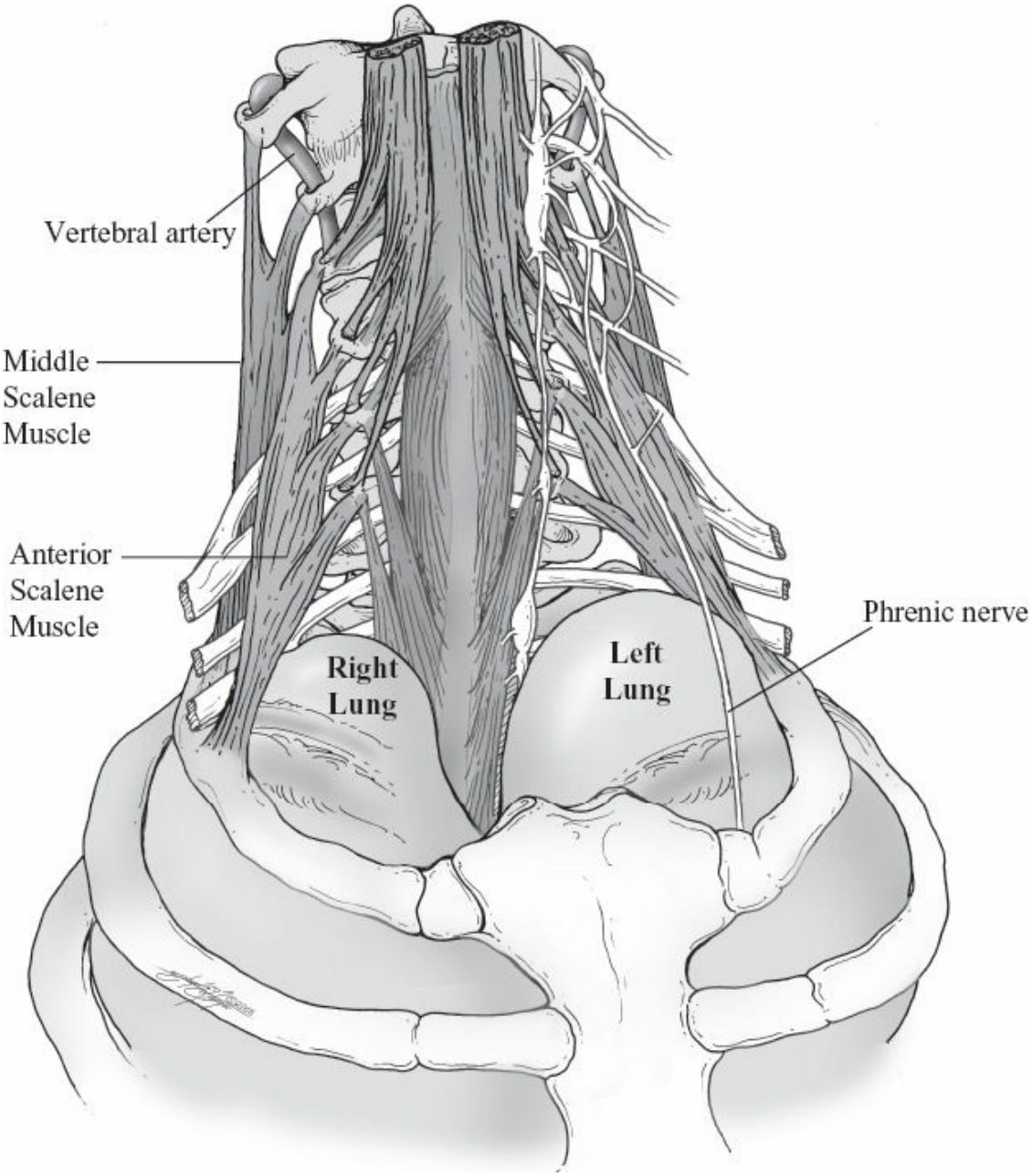

Figure 20.3. The apex of the lung ascends out of the thorax into the root of the neck.

Lateral structures include the subclavian artery and subclavian vein and their branches, and nerve branches from the cervical and brachial plexuses. The cervical or apical area of the lung is also found in the lateral portion of the root of the neck. The first rib and the scalene muscles have important spatial relationships with the anatomy in this area.

The brachiocephalic trunk is the first branch of the arch of the aorta (Fig. 20.4). It passes superolaterally and bifurcates at the level of the right sternoclavicular joint into the right common carotid and right subclavian arteries. The common carotid artery will pass superiorly on the right side

of the neck in the carotid sheath. It will be discussed in more detail later in this chapter. The next branch of the arch of the aorta is the left common carotid artery. The last branch of the aortic arch is the left subclavian artery (Fig. 20.4). The anterior scalene muscle divides the subclavian artery into three segments. The first portion extends from the origin of the vessel to the medial edge of the anterior scalene muscle. The second part lies behind the muscle, and the third segment extends from the lateral edge of the muscle to the lower edge of the first rib. Most of the branches of the subclavian artery arise from the first portion. The first and largest branch is the vertebral artery. It arises from the superior edge of the parent vessel, ascends vertically, and enters a foramen in the transverse mass of the sixth cervical vertebra. The accompanying vein covers it.

The foramen is situated at the apex of a muscular triangle created by the longus coli muscle medially and the anterior scalene muscle laterally. This is referred to as the triangle of the vertebral artery. The second branch is the thyrocervical trunk, which also arises from the superior surface and has a short course before it divides into the following branches. The inferior thyroid artery passes superiorly, anterior to the anterior scalene muscle. The phrenic nerve is within the prevertebral fascia as it passes inferiorly on the anterior surface of this muscle. The inferior thyroid artery is superficial to the prevertebral fascia. At about the level of the apex of the triangle of the vertebral artery the inferior thyroid artery passes medially, coursing posterior to the carotid sheath but anterior to the vertebral artery, and enters the substance of the lateral lobe of the thyroid gland. The transverse cervical and the suprascapular arteries are branches of the thyrocervical trunk that run transversely as they head for the lateral aspect of the neck. They cross the anterior scalene muscle and the phrenic nerve, but are superficial to the prevertebral fascia. The transverse cervical artery will divide into an ascending and descending branch when it reaches the margin of the trapezius muscle. The suprascapular artery will dip down below the clavicle after entering the posterior triangle, pass inferiorly, and contribute to the periscapular vasculature.

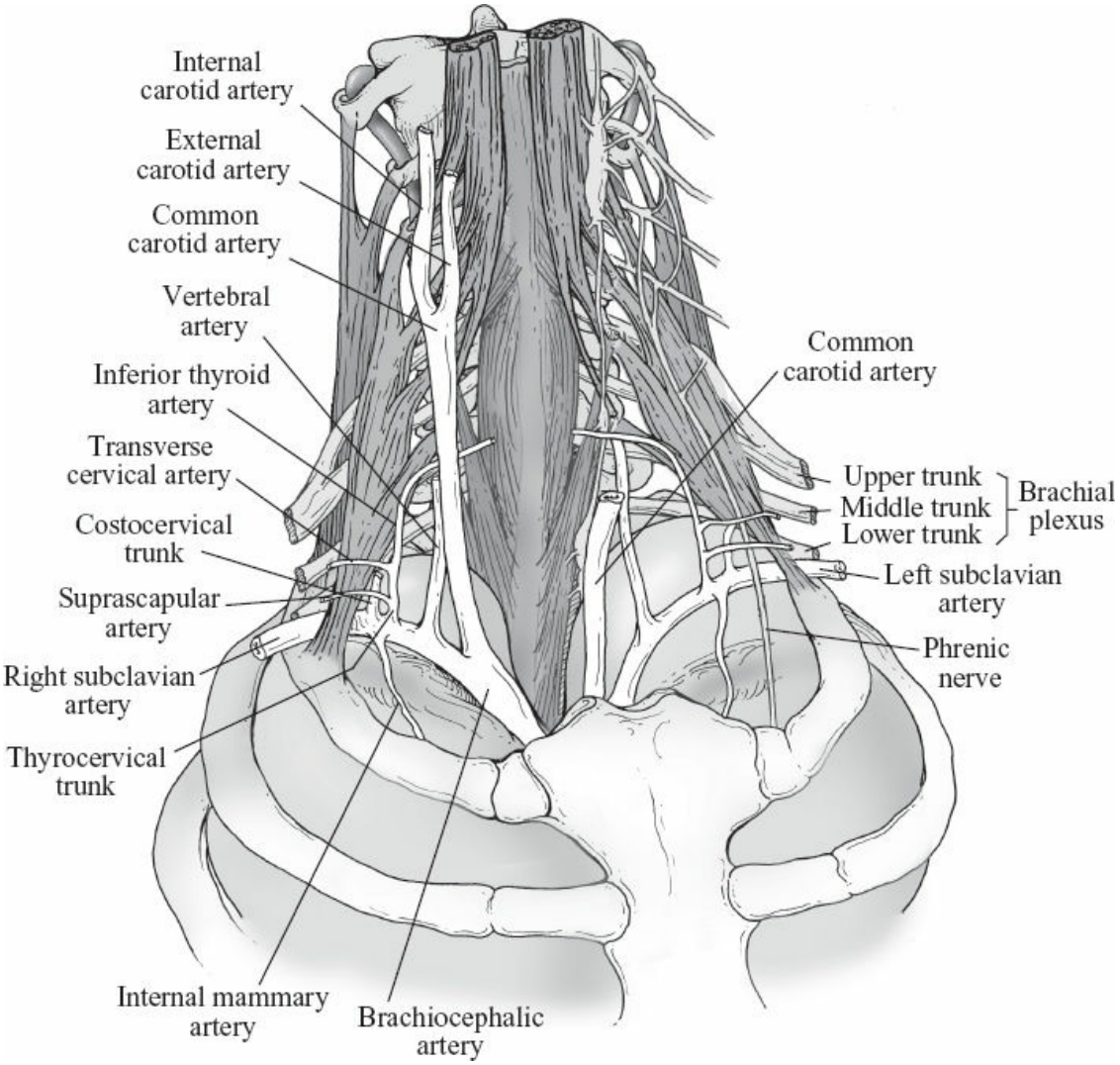

Figure 20.4. Structures of the Neck-3. Branch of the aortic arch.

The next branch originating from the superior aspect of the subclavian artery is the costocervical trunk (Fig. 20.4). It may arise from the second portion of the subclavian, and is therefore less at risk during surgical procedures. It arches over the cervical pleura and, when it reaches the neck of the first rib, divides into the deep cervical artery that passes up and supplies the muscles in the back of the neck and the supreme intercostal artery that creates the first and second posterior intercostal arteries. The first posterior intercostal vein that will enter the ipsilateral brachiocephalic vein, accompanies it.

The last branch of the subclavian artery is the internal thoracic or internal mammary artery. It arises from the inferior aspect of the subclavian artery across from the thyrocervical trunk. It passes inferomedially, courses posterior to the subclavian vein, and initially is in contact with the cervical pleura as it heads for the first costal cartilage. It

then assumes its characteristic location parallel to the lateral edge of the sternum. The subclavian vein begins at the outer end of the first rib and then passes anterior to the anterior scalene muscle (Fig. 20.5). It receives the external jugular vein before reaching the medial edge of this muscle.

When the vein is medial to this muscle, it is joined by the internal jugular vein, forming the brachiocephalic vein. The left brachiocephalic vein will pass to the right, just inferior to the superior edge of the manubrium sternum, and join with its right counterpart behind the right first costal cartilage to create the superior vena cava. Each brachiocephalic vein will receive the corresponding vertebral vein. Each vagus nerve passes anterior to the related subclavian artery. The left nerve then passes posterior to the left brachiocephalic vein. The right nerve is posterolateral to the related brachiocephalic vein.

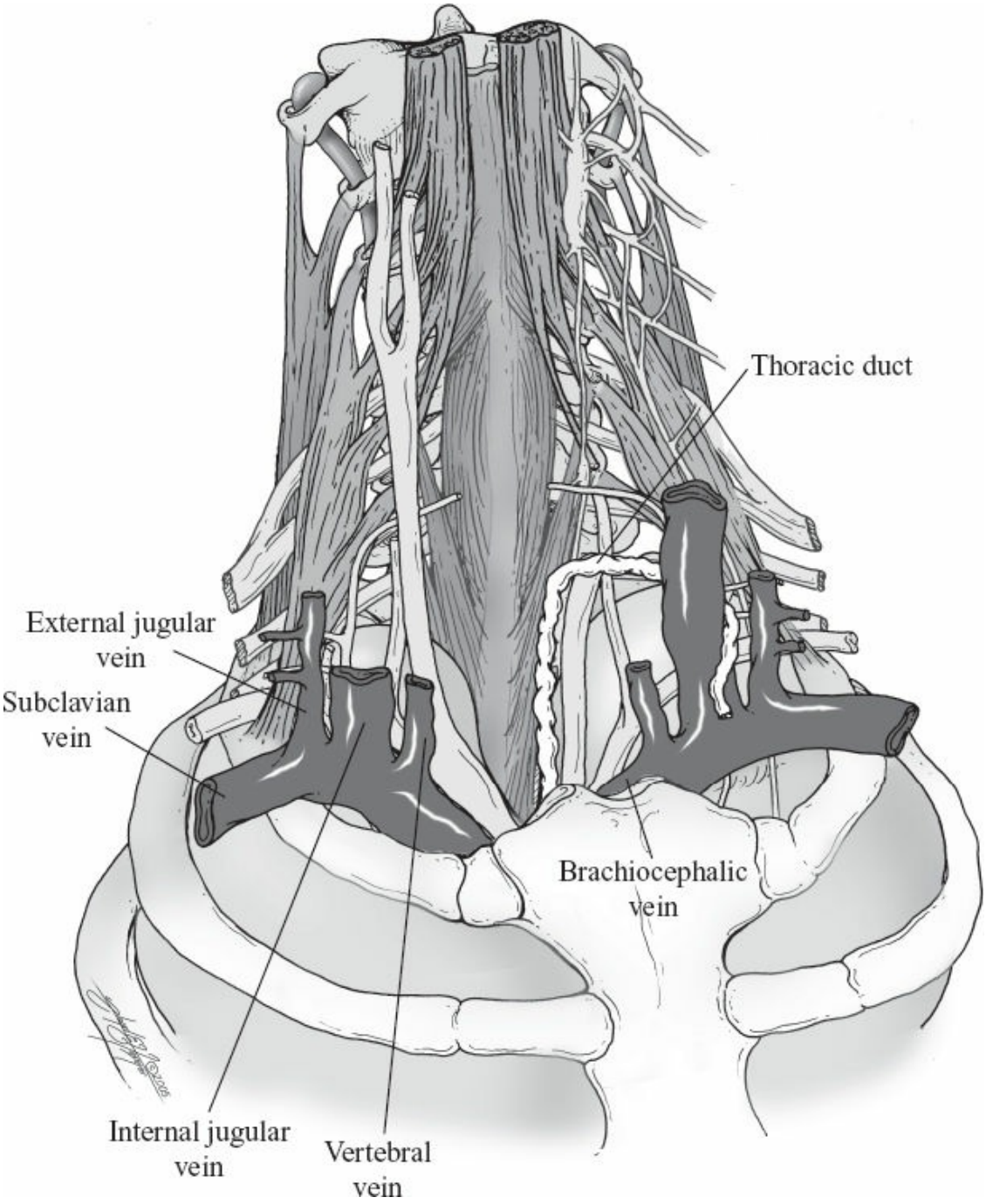

Figure 20.5. Structures of the Neck-4. Subclavian vein origin.

Anterior to this anatomical jungle is the thymus gland. It is largest during the childhood years, and then starts to regress with the onset of sexual maturation. The gland may extend from the thyroid cartilage above, to the pericardial sac below. Therefore, its superior portion is part of the medial, or anterior, aspect of the root of the neck. The gland is composed of two separate, asymmetrical lobes. The gland is contiguous with the large veins previously described. This explains why venous invasion is frequently seen with malignant disease of the gland.

The roots of the brachial plexus, C5 through T1, will create three trunks: an upper trunk (C5, C6), middle trunk (C7), and lower trunk (C8, T1) (Fig. 20.4). They will pass between the anterior and the middle scalene muscles on their way to the axilla. It is the lower trunk that is in direct contact with the upper surface of the first rib. It lies immediately posterior to the subclavian artery. The trunks pass through the posterior triangle. Each trunk will divide into an anterior and posterior division. These divisions, along with the accompanying subclavian vessels, will then pass through the costoclavicular space. The subclavian vein is the most medial of the structures passing through this space (Fig. 20.5). This vein is anteroinferior to the accompanying subclavian artery and can, therefore, be approached after the pulsations of the accompanying artery are palpated. The roots and trunks of the brachial plexus are within the prevertebral layer of the deep cervical fascia. As they head for the axilla, accompanied by the subclavian vessels, they drag some of this deep fascia along with them and create a protective tubular sheath for these neurovascular items called the cervicoaxillary, or axillary, sheath. These nerves and blood vessels, on their way to the axilla, pass under the insertion of the pectoralis minor muscle to the coracoid process of the scapula.

The Anatomy of the Root of the Neck Compression Syndromes

The root of the neck compression syndromes include the following:

Costoclavicular compression syndrome
Cervical rib syndrome
Anterior scalene compression syndrome
Pectoralis minor syndrome

If the space between the first rib and the clavicle should be decreased, there could be compression of the neurovascular structures traversing this area (Fig. 20.5). The subclavian vein is the most medial of the neurovascular structures passing through the costoclavicular space. The vein is in the narrowest portion of this space, and if additional narrowing occurs, venous outflow from the upper extremity may be impaired.

A cervical rib may present itself in several ways. It is frequently bilateral. It is an extension of the transverse mass of the seventh cervical vertebra and it may be a complete rib that articulates with the sternum. At times, it may fuse with the first rib or present as a fibrous band that attaches to the first rib. In some patients, it may have an anterior end that is

free. The subclavian vessels and the brachial plexus, especially the lower trunk, will be affected adversely when they try to pass over this additional obstacle.

The anterior scalene compression syndrome results from spasm, or hypertrophy, of the anterior scalene muscle, with resultant constriction of the neurovascular elements as they pass through the scalene triangle. If the clinician treats this condition by transecting the anterior scalene muscle near its insertion, the position of the phrenic nerve and the subclavian vein, passing anterior to the muscle, must be remembered.

The term “thoracic outlet compression syndrome” is frequently used when defining some clinical conditions encountered in the root of the neck. Thoracic outlet is a misnomer when used to identify the clinical problems in this area. The true anatomical thoracic outlet is the area related to the respiratory diaphragm. Correct terms for these conditions would include superior thoracic aperture compression syndrome or cervicoaxillary compression syndrome.

All of these compression syndromes can result in neurologic deficits and/or arterial and venous circulatory problems in the upper extremity.

Clinical Anatomical Applications

1. Cervical incisions should be made parallel to the skin lines (lines of Langer) for good cosmesis. The neurovascular structures lie deep to the platysma muscle. The muscle must be carefully repaired for the best cosmetic result.
2. The middle cervical ganglion block: this sympathetic ganglion is found anterior to the transverse mass of the sixth cervical vertebra. At the level of the cricoid cartilage, retract the carotid sheath laterally and inject the medication after the needle strikes the lateral mass of the vertebra.
3. Control of bleeding may be possible if the common carotid artery is compressed against the transverse mass of the sixth cervical vertebra. This is the cricoid plane.
4. Carotid angiography: the common carotid artery is palpable in the carotid triangle. It is partially covered by the sternocleidomastoid muscle. Lateral retraction of the muscle will facilitate insertion of a catheter into the palpable artery.
5. Internal jugular vein catheterization: the internal jugular vein accompanies the common and internal carotid vessels. They all lie within the carotid sheath. The vein is anterolateral to the palpable

artery.

6. The right internal jugular and right brachiocephalic veins, along with the superior vena cava, create a straight conduit to the right atrium and the inferior vena cava.
7. The subclavian vessels can be approached while passing through the costoclavicular space. The artery is palpable and the vein is situated anterior and medial to the artery. The vein is the most medial structure passing through the costoclavicular interval. A supraclavicular, or infraclavicular, technique can be used for catheterization.
8. The brachial plexus block approaches the nerves as they pass through the costoclavicular space. The subclavian artery is anterior to the branches of the plexus.
9. In cricothyroidotomy, the interior of the larynx is entered through the cricothyroid interval. The cricothyroid artery, a branch of the superior thyroid, pierces the cricothyroid ligament near the middle of the interval between the cricoid and the thyroid cartilages. A transverse incision, made close to the upper border of the cricoid arch, will avoid injury to this artery. The vocal ligaments are spared because they are superior to the point of entry.
10. For drainage of the retropharyngeal space, an incision is made at the level of the cricoid cartilage. The sternocleidomastoid muscle and carotid sheath are retracted posteriorly, and the lateral lobe of the thyroid gland is retracted anteriorly.
11. Using the external jugular vein as a conduit for central venous access, the external jugular vein is readily accessible because of its superficial position. It empties into the subclavian vein in the posterior triangle, but it may be difficult to negotiate the angle at the termination when attempting to introduce a device into the central portion of the circulatory system. Direct approach to the larger veins, right internal jugular or right subclavian, would eliminate this technical problem.

TRIANGLES OF THE NECK

The layer-by-layer recreation of the neck anatomy now requires the addition of the carotid sheath with the vascular contents and their branches, the last four cranial nerves, and the viscera of the neck, which includes the thyroid and parathyroid glands, pharynx, and larynx. The superficial cervical plexus will also be outlined. The cervical lymphatic pathways will then be described, and finally the superficial venous circulation will be examined. This information is presented with a

discussion of the triangles of the neck.

Anterior and Posterior Triangles

The sternocleidomastoid and trapezius muscles divide the neck into anterior and posterior triangles (Fig. 20.6; also see Fig. 20.13). The boundaries of the posterior triangle are the trapezius muscle posteriorly and the sternocleidomastoid muscle anteriorly. The middle third of the clavicle creates the inferior limit, and the apex of the triangle extends to the superior nuchal line. The triangle is spiral in shape. The inferior portion is anterior in the neck, but the apex is posterior. The anterior triangle includes the area between the anterior edges of the sternocleidomastoid muscles. The superior limit is the mandible and a line drawn from the angle of the mandible to the tip of the mastoid process. Two double-bellied muscles, omohyoid and digastric, subdivide the triangles. The inferior belly of the omohyoid muscle attaches to the superior transverse scapular ligament and a portion of the adjacent superior edge of the scapula. It passes superior to the clavicle and enters the lower portion of the posterior triangle. The intermediate tendon is in the cricoid plane, anterior to the carotid sheath, and is angulated by a fascial sling attached to the clavicle and the manubrium. The superior belly ascends to the hyoid bone.

The posterior triangle now consists of the large occipital and the smaller subclavian triangles. The digastric is the other double-bellied muscle that creates subdivisions of the anterior triangle. The posterior belly attaches just medial to the mastoid process. The intermediate tendon is tethered to the hyoid bone by a fold of deep cervical fascia. The stylohyoid muscle arises from the styloid process of the temporal bone and is in intimate contact with the anterior surface of the posterior belly of the digastric muscle. The tendon of insertion of the stylohyoid muscle to the hyoid bone is split and allows for passage of the intermediate tendon of the digastric muscle. The anterior triangle includes the submandibular and carotid triangles. They are separated from each other by median submental and muscular triangles.

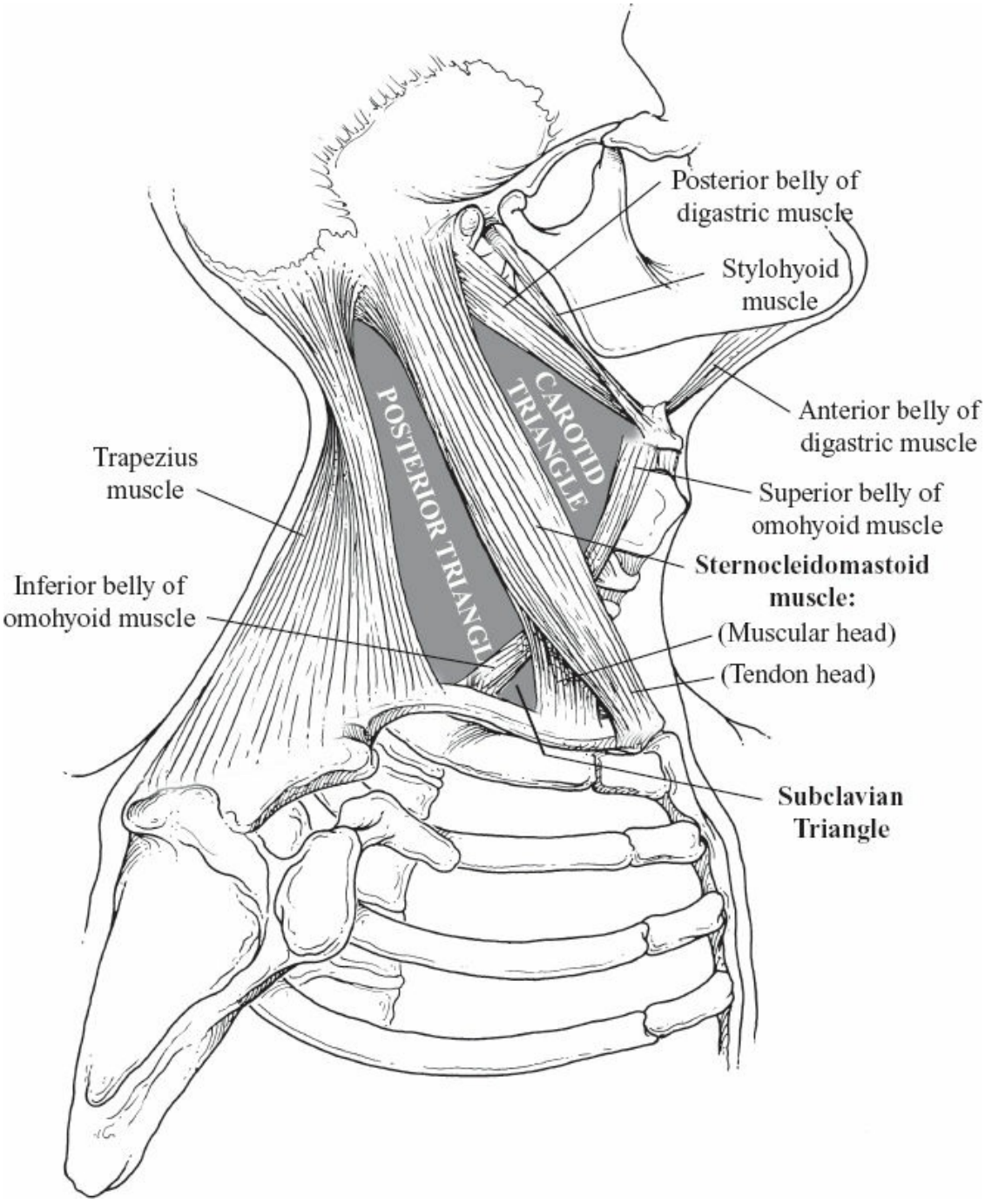

Figure 20.6. Boundaries of the triangles of the neck (see also Fig. 20.14).

The hyoid bone is a central structure in the neck. It is directly or indirectly attached to most of the muscular and membranous entities in the anterior triangle and in the floor of the mouth. If one considers the hyoid bone and the attached posterior belly of the digastric muscle, it is possible to divide the anterior triangle into suprahyoid and infrahyoid portions. The submandibular, or digastric triangles, and the submental triangle, are suprahyoid entities and are related to the floor of the mouth. They have

been discussed in another chapter. The carotid and the muscular triangles are found in the infrahyoid portion of the anterior triangle.

Carotid Triangle

The muscular boundaries of the carotid triangle are the sternocleidomastoid muscle posteriorly, the posterior belly of the digastric muscle anterosuperiorly, and the superior belly of the omohyoid muscle anteroinferiorly (Fig. 20.7). The greater horn of the hyoid bone is part of the anterior and superior segment of the floor of this triangle. The hyoglossus and thyrohyoid muscles are attached to this portion of the hyoid bone, and are part of the anterior portion of the muscular floor. A small portion of the thyrohyoid membrane is found just behind the thyrohyoid muscle and makes up a small area of the floor. The middle and inferior pharyngeal constrictor muscles create the posterior section of the muscular floor of the carotid triangle. The longus capitis, a prevertebral muscle, also contributes to the posterior portion of the muscular floor of this triangle. The pretracheal layer of the deep cervical fascia creates the fascial carpet. The investing layer of the deep fascia creates a fascial roof.

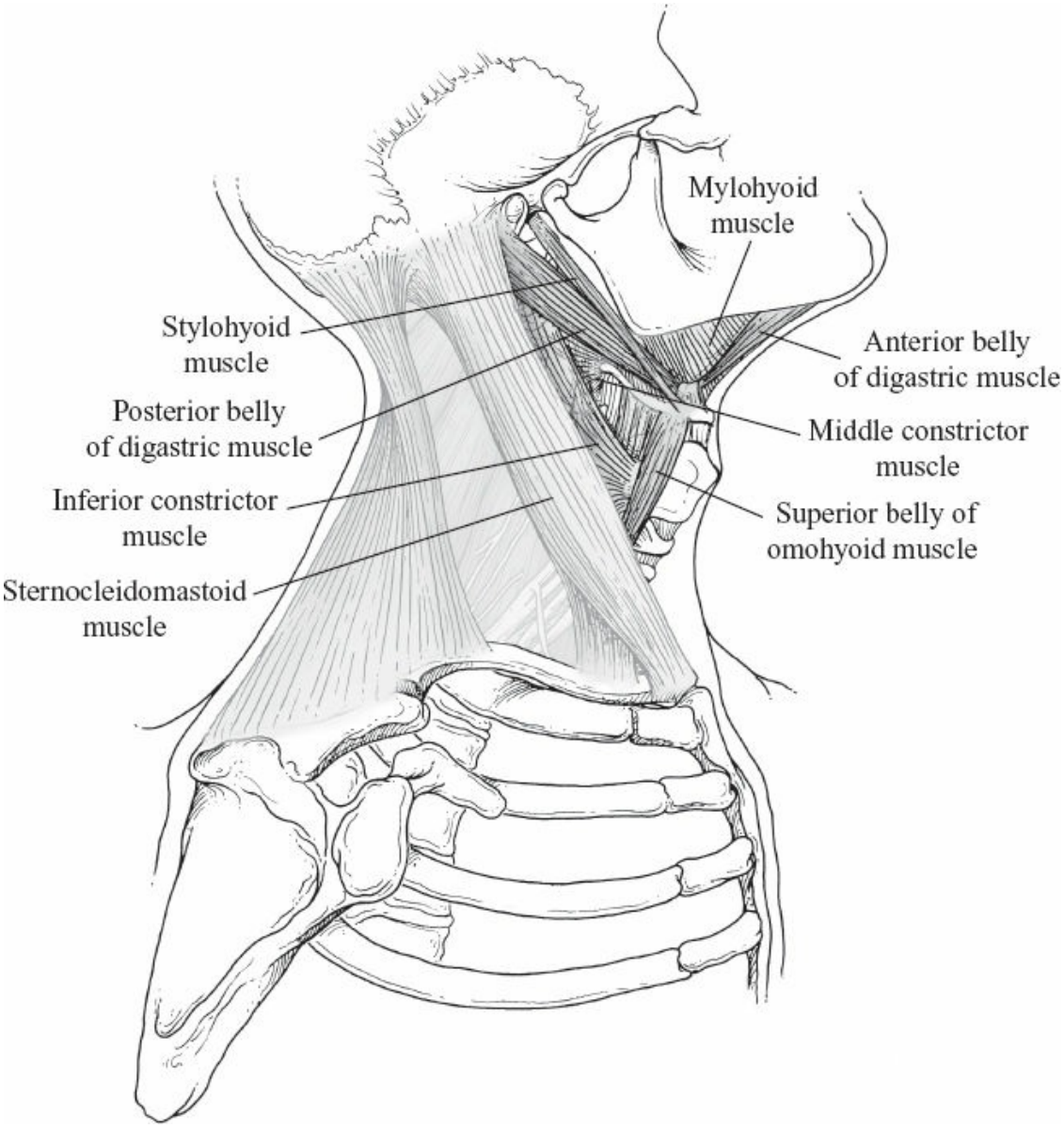

Figure 20.7. Muscular boundaries and muscular floor of the carotid triangle.

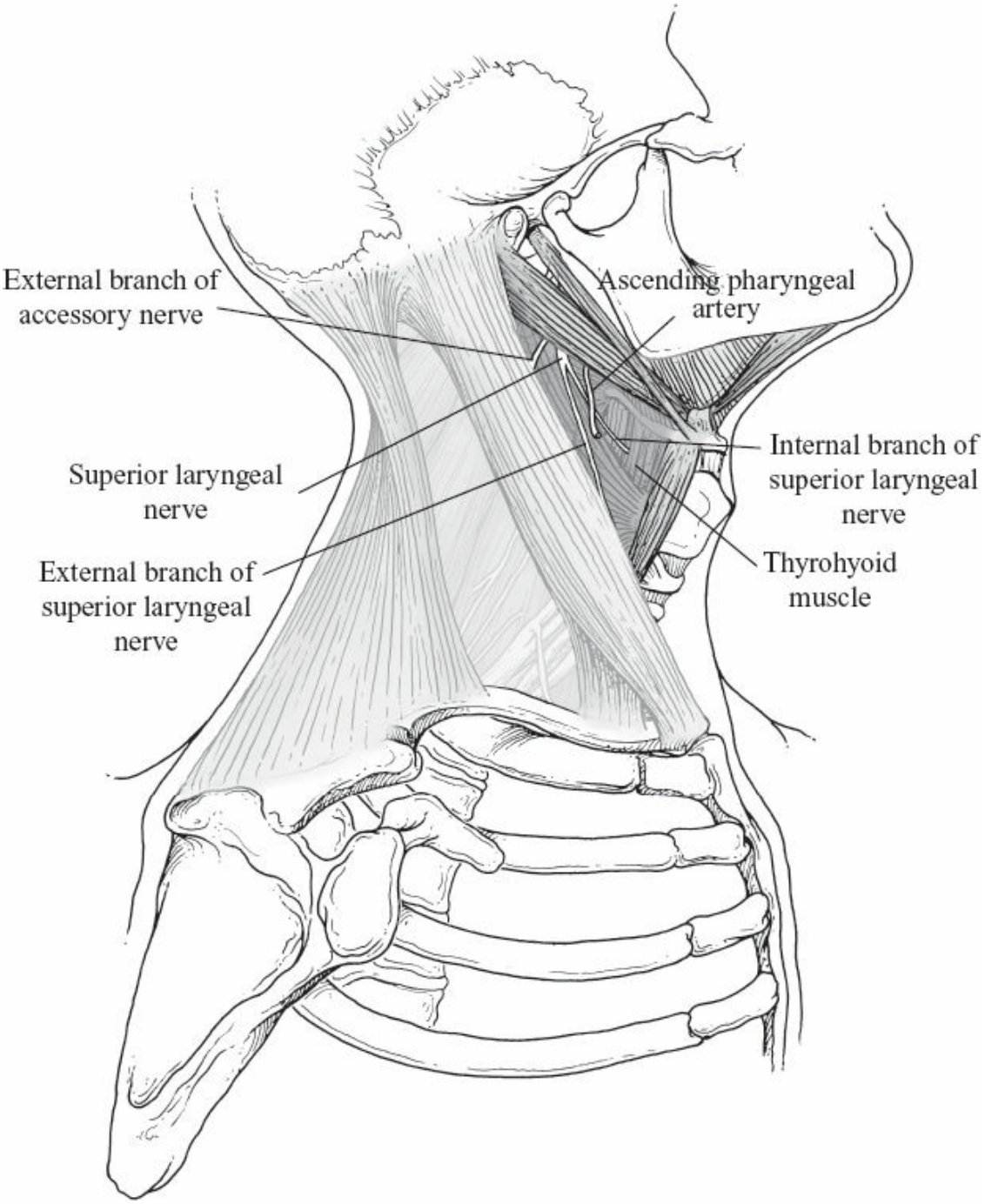

Figure 20.8. The deepest structures of the carotid triangle.

The contents of the triangle will be described beginning with the deepest structures (Fig. 20.8). The superior laryngeal nerve is a branch of the vagus nerve that is given off at the base of the skull. It travels inferiorly, in contact with the superior constrictor, courses deep to the internal and external carotid arteries, passes under the posterior belly of the digastric muscle, and is now in the carotid triangle. When it reaches the middle constrictor muscle, it creates an internal and external branch. The

internal branch enters the larynx after piercing the thyrohyoid membrane. It provides sensory innervation to the interior of the larynx above the vocal ligaments. The external branch passes inferiorly, in contact with the inferior constrictor, and gives some branches to this muscle. It also provides motor innervation to the cricothyroid, one of the intrinsic muscles of the larynx. This nerve, for a portion of its course just superior to the thyroid gland, is very close to the medial side of the superior thyroid vascular bundle. It should be located and swept medially in order to avoid its injury when ligating and dividing these blood vessels. In the superior part of this triangle, the spinal accessory nerve is seen as it passes inferolaterally, deep to the sternocleidomastoid muscle, and enters the posterior triangle.

The ascending pharyngeal artery, a branch of the proximal portion of the external carotid artery, ascends on the constrictor muscles as it heads for the base of the skull. The remaining contents of this triangle include the common carotid artery and its branches, the internal jugular vein and its branches, the cranial nerves X, XI, XII, and the ansa cervicalis of the deep cervical plexus.

The common carotid artery begins in the root of the neck and passes cephalad in the carotid sheath (Fig. 20.9). It is medial to the accompanying internal jugular vein. The vagus nerve (X) is between, but slightly posterior to, the blood vessels. At about the level of the superior aspect of the thyroid cartilage, the common carotid artery bifurcates and gives rise to the internal and external carotid vessels. The internal carotid artery, at its origin, has a small area of dilatation, the carotid sinus. It contains specialized nerve cells, which regulate blood pressure. This area receives autonomic, glossopharyngeal, and vagus nerve branches (Fig. 20.10). There is also an area of thickening in the arterial wall at the site of bifurcation of the common carotid artery. This is the carotid body, which contains chemoreceptor cells receiving branches from the glossopharyngeal nerve. The common and internal carotid arteries do not provide any branches in the neck.

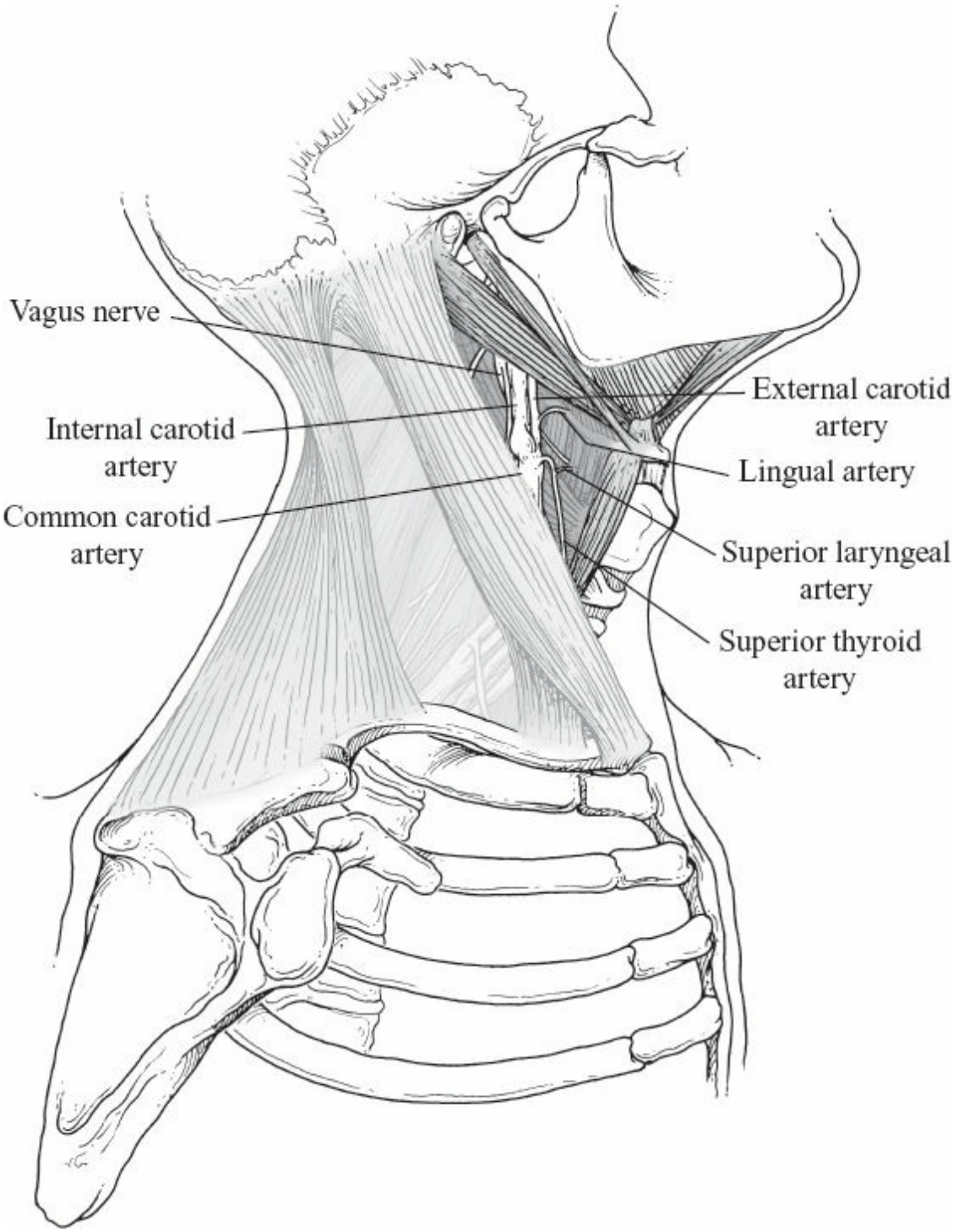

Figure 20.9. Common carotid artery and branches.

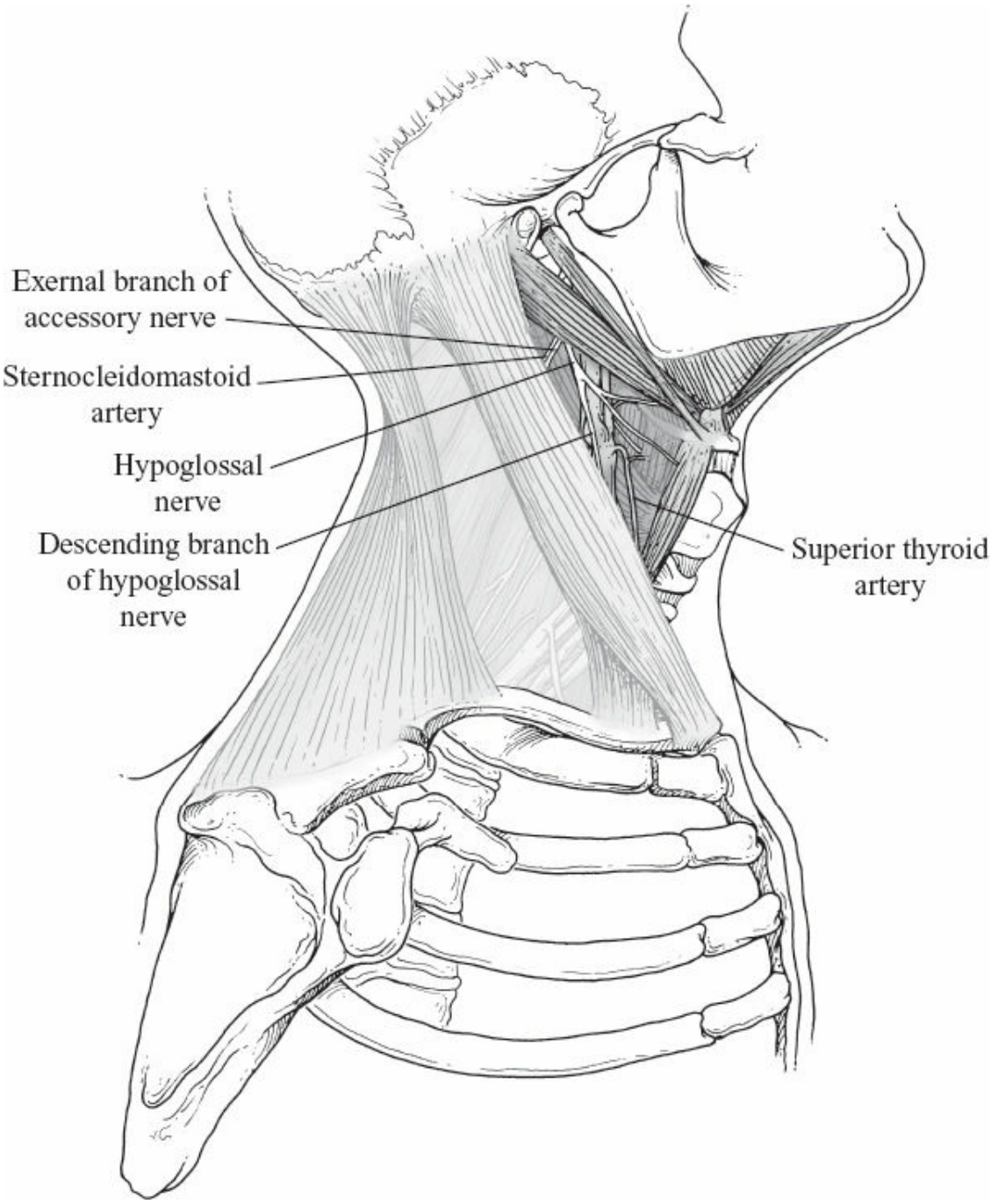

Figure 20.10. External carotid artery.

The external carotid artery leaves the carotid sheath and, at first, is anteromedial to the internal carotid artery. It will become anterolateral in position at a higher level, after passing superficial to the carotid sheath. It is the external carotid artery that provides vascular flow to the cervical structures. The branches are medial and posterior. The medial branches are the superior thyroid, lingual, and facial (external maxillary) arteries. The posterior branches include the ascending pharyngeal, occipital, and posterior auricular arteries. The occipital branch runs along the inferior

edge of the posterior belly of the digastric muscle. The posterior auricular branch follows a similar course on the superior aspect of this important muscle. The external carotid artery continues superiorly to the parotid region. At the neck of the condylar process of the mandible, the end branches arise. They are the superficial temporal and internal maxillary arteries.

The internal jugular vein begins at the base of the skull (Fig. 20.11). At this point, it is posterior to the internal carotid artery. The last four cranial nerves pass between these vessels and then head for their specific destinations. The vein passes inferiorly, quickly assuming a more anterolateral position to the internal and common carotid arteries, while in the carotid sheath. It receives the following branches: common facial vein, lingual vein, superior thyroid vein, branches from the pharyngeal venous plexus, and the middle thyroid vein. At its termination, it will receive the thoracic duct (left) and the right lymphatic duct (right). The vagus nerve (X) is found with the vascular structures in the carotid sheath. It lies between, and slightly posterior to, the artery and the vein. In the root of the neck, it will pass posterior to the large veins and enter the thorax. The spinal accessory nerve (XI) will pass obliquely across the superior part of the carotid triangle, continue under the sternocleidomastoid muscle, travel across the posterior triangle, and disappear under the trapezius muscle (Fig. 20.12). It provides motor innervation to both of those muscles. The hypoglossal nerve (XII) passes between the internal jugular vein and the internal carotid artery, and then descends below the posterior belly of the digastric muscle to enter the carotid triangle. It frequently hooks around a branch of the occipital artery, passes superficial to internal and external carotid arteries, and then leaves the carotid triangle by passing back under the posterior belly to reenter the submandibular triangle. The glossopharyngeal nerve (IX) is also found between the internal jugular vein and the internal carotid artery near the base of the skull. It passes inferiorly, travels between the internal and the external carotid arteries, and then enters the interval between superior and middle pharyngeal constrictors. The stylopharyngeus muscle accompanies this nerve. After penetrating the wall of the pharynx, the muscle attaches to the posterior free end of the thyroid cartilage lamina and is now part of the muscular wall of the pharynx. The cervical sympathetic chain lies on the prevertebral fascia. It is posterior to the carotid sheath.

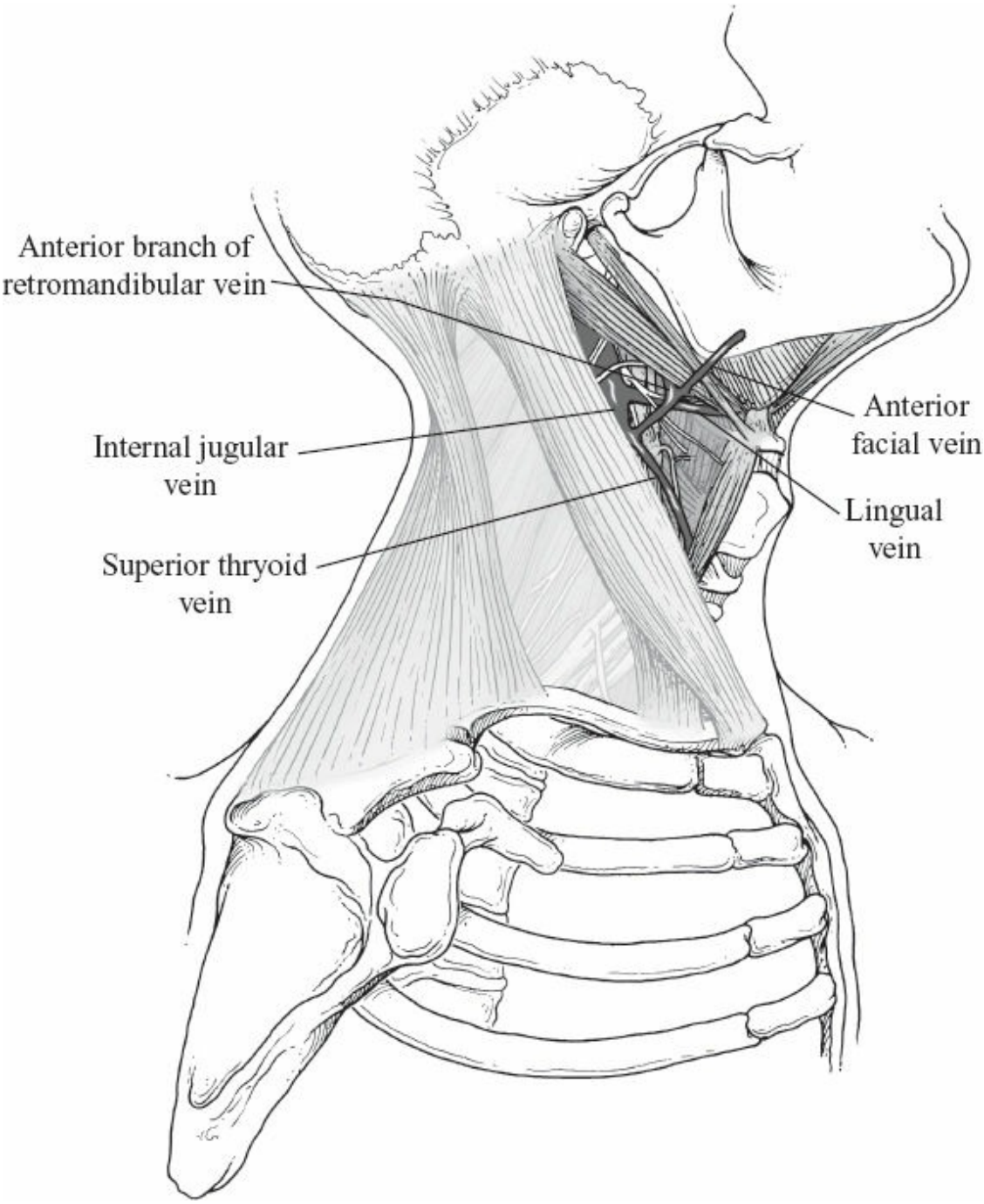

Figure 20.11. Internal jugular vein.

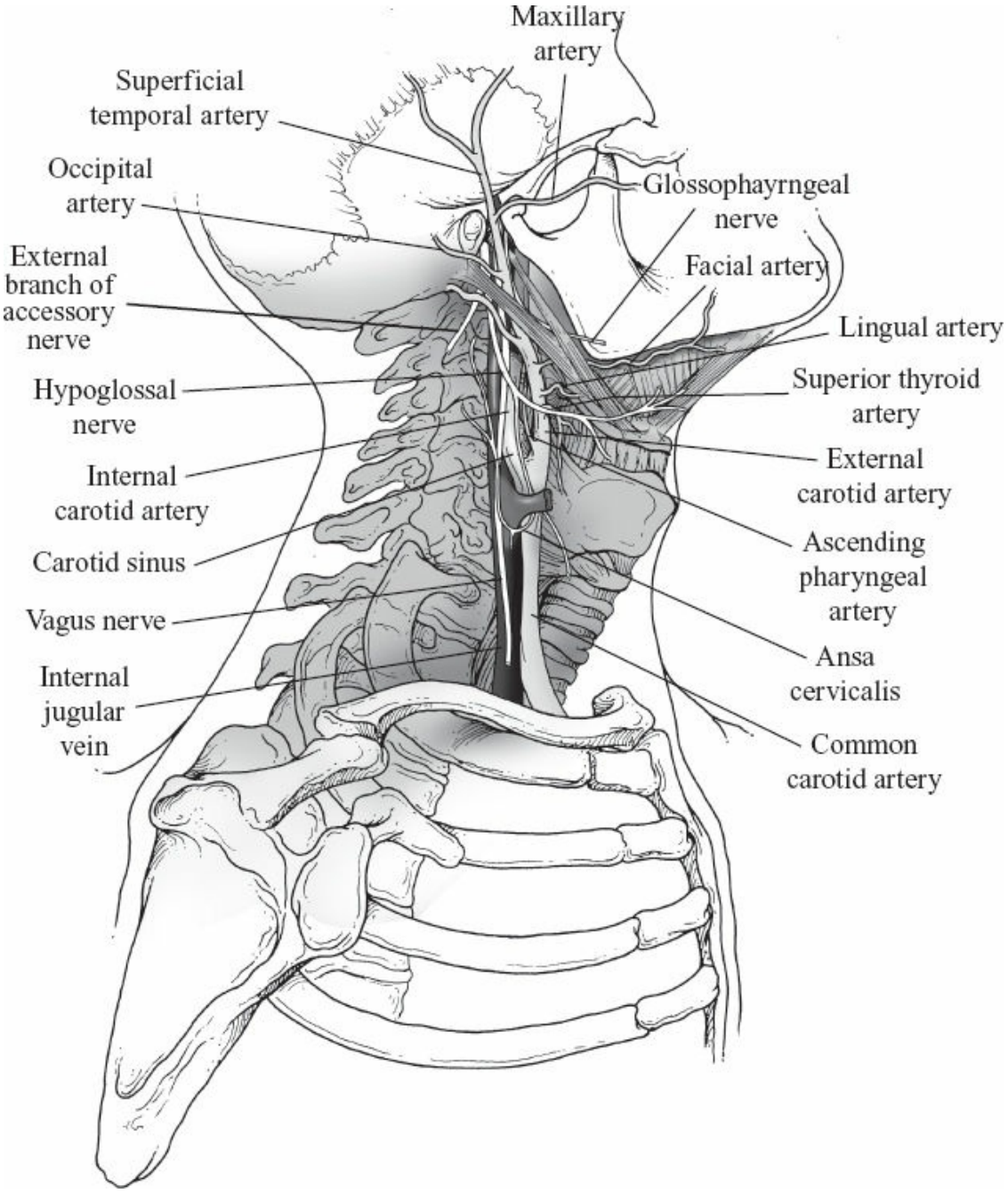

Figure 20.12. Carotid triangle with the sternocleidomastoid muscle removed.

The posterior belly of the digastric muscle plays an important role in this area. It is superficial to all of these neurovascular structures. It presses them against the pharyngeal wall. Incisions can be made on the posterior belly without risk of injury to nerves or arteries in this area. There may be some superficial veins and, occasionally, a low-lying cervical branch of the facial nerve found in the area superficial to this relatively safe landmark.

Muscular Triangle

The boundaries of the muscular triangle are the superior bellies of the omohyoid muscles superolaterally and the inferior part of the sternocleidomastoid muscles inferolaterally (Fig. 20.13). The hyoid bone is superior, and the upper edge of the manubrium sternum creates the inferior limit. The triangle contains the thyroid and parathyroid glands, larynx and trachea, and pharynx and esophagus. These cervical viscera are found below the muscular floor. The muscles are paired and referred to as the strap muscles. They are all infrahyoid in location and present in two layers. The superficial layer is composed of two long muscles. The omohyoid muscle is lateral and is composed of two muscle bundles that are separated by an intermediate tendon. The intermediate tendon is in the cricoid plane. The inferior belly is attached to the superior surface of the scapula. It subdivides the posterior triangle and then passes anterior to the carotid sheath. The intermediate tendon is tethered to the clavicle. The superior belly passes up to the hyoid bone. Medial to this is the sternohyoid muscle, which passes from the sternum to the hyoid bone. The deeper layer is composed of shorter structures. The sternohyoid muscle is attached inferiorly to the manubrium of the sternum, and extends up to the oblique line of the thyroid cartilage. This upper attachment is just superior to the lateral lobe of the thyroid gland, and prevents enlargement of the lobe from extending in a superior direction. The thyrohyoid muscle seems to be its superior continuation that passes from the oblique line to the hyoid bone. The inferior pharyngeal constrictor is also attached to the oblique line of the thyroid cartilage. The middle layer of the deep cervical fascia surrounds the strap muscles. It is not only found in the muscular triangle, but also extends laterally to the inferior belly of the omohyoid muscle. This belly creates the lateral boundary of the subclavian subdivision of the posterior triangle.

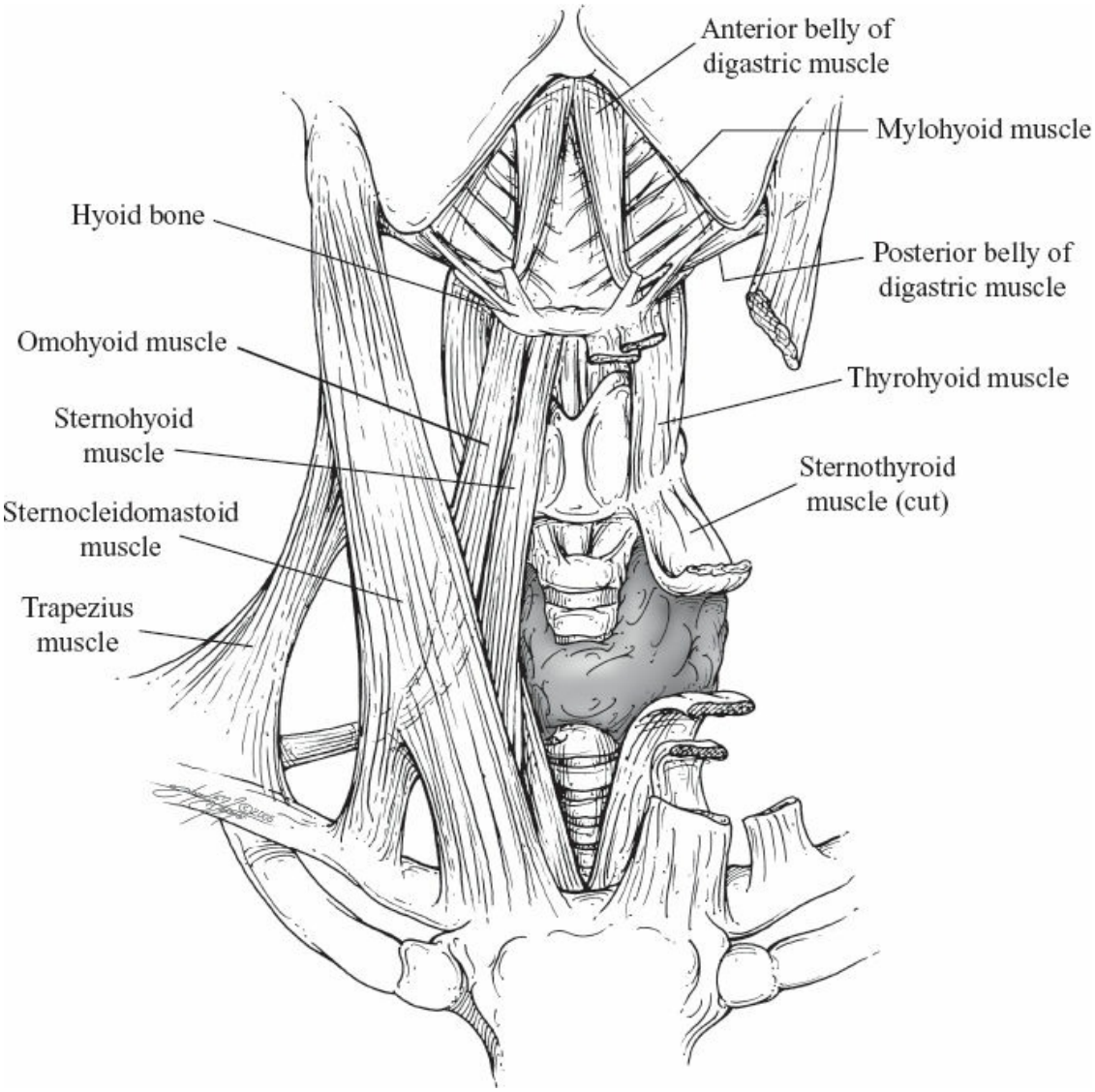

Figure 20.13. The boundaries of the muscular triangle of the neck.

All the strap muscles are depressors of the larynx. The nerve supply comes from the deep cervical plexus (C1, C2, and C3) by way of the ansa cervicalis. The nerves enter the inferior portion of the muscle. A branch of C1, which travels with the hypoglossal nerve, innervates the thyrohyoid muscle.

Clinical Anatomical Aids

1. Transection of strap muscles should be done closer to the superior end to preserve nervous innervation, which enters the muscle near its inferior end.
2. Proper entrance into the cleavage plane between the sternothyroid muscle and the thyroid gland provides excellent exposure of, and

facilitates surgical approach to, the gland.

Posterior Triangle

The boundaries of the posterior triangle are the anterior border of the trapezius muscle and the posterior edge of the sternocleidomastoid muscle, and the middle third of the clavicle is the base. The apex of this triangle is the superior nuchal line. This triangle, therefore, presents as a spiral as the base is anterior and the apex is posterior. The triangle is subdivided by the inferior belly of the omohyoid muscle into smaller entities that are named for the blood vessels found in them. There now is a larger, superior, occipital triangle, and the smaller, inferior, subclavian triangle. The muscular floor of the entire posterior triangle is composed mainly of three muscles whose fibers run inferolaterally. They are, from above down, the splenius capitis, the levator scapula, and the middle scalene muscles (Fig. 20.14). The anterior scalene muscle is not seen in the posterior triangle because the sternocleidomastoid muscle covers it. In the apex are seen a few vertically oriented fibers of the semispinalis capitis muscle. It is, along with the splenius capitis, classified as a back muscle.

The muscles of the floor are covered by prevertebral fascia, which creates a fascial carpet. There is also a fascial roof, generated by the investing layer of the deep cervical fascia. The contents of the triangle will be described layer by layer, beginning with the deeper contents found below the fascial carpet in contact with the muscular floor (Fig. 20.15). They include: (a) the occipital artery, which frequently exits the posterior triangle at its apex; (b) branches of the deep cervical plexus passing inferolaterally on the surface of the levator scapula muscle, destined to provide innervation to the inferior portion of the trapezius muscle; and (c) portions of the brachial plexus. The roots of the plexus combine deep to the sternocleidomastoid. The C5 and C6 roots combine to create the upper trunk, C7 becomes the middle trunk, and C8 and T1 create the lower trunk. The trunks are seen in the posterior triangle. There are branches arising from these roots and trunks that are seen in the posterior triangle. The dorsoscapular nerve (C5) pierces the middle scalene muscle and passes laterally toward the rhomboid and levator scapula muscles, which it innervates. The long thoracic nerve (C5, C6, and C7) courses inferiorly, passes deep to the other portions of the brachial plexus, and then passes over the first rib to reach the superficial surface of the serratus ventralis, where it innervates. Arising from the upper trunk of the plexus is the

suprascapular nerve, which is seen just above the upper trunk, passes across the posterior triangle to the scapula, and innervates the supraspinatus and infraspinatus muscles. The subclavius nerve is also seen in the posterior triangle. It arises from the upper trunk, passes inferiorly, and crosses the main portion of the brachial plexus superficially. It innervates the subclavius muscle.

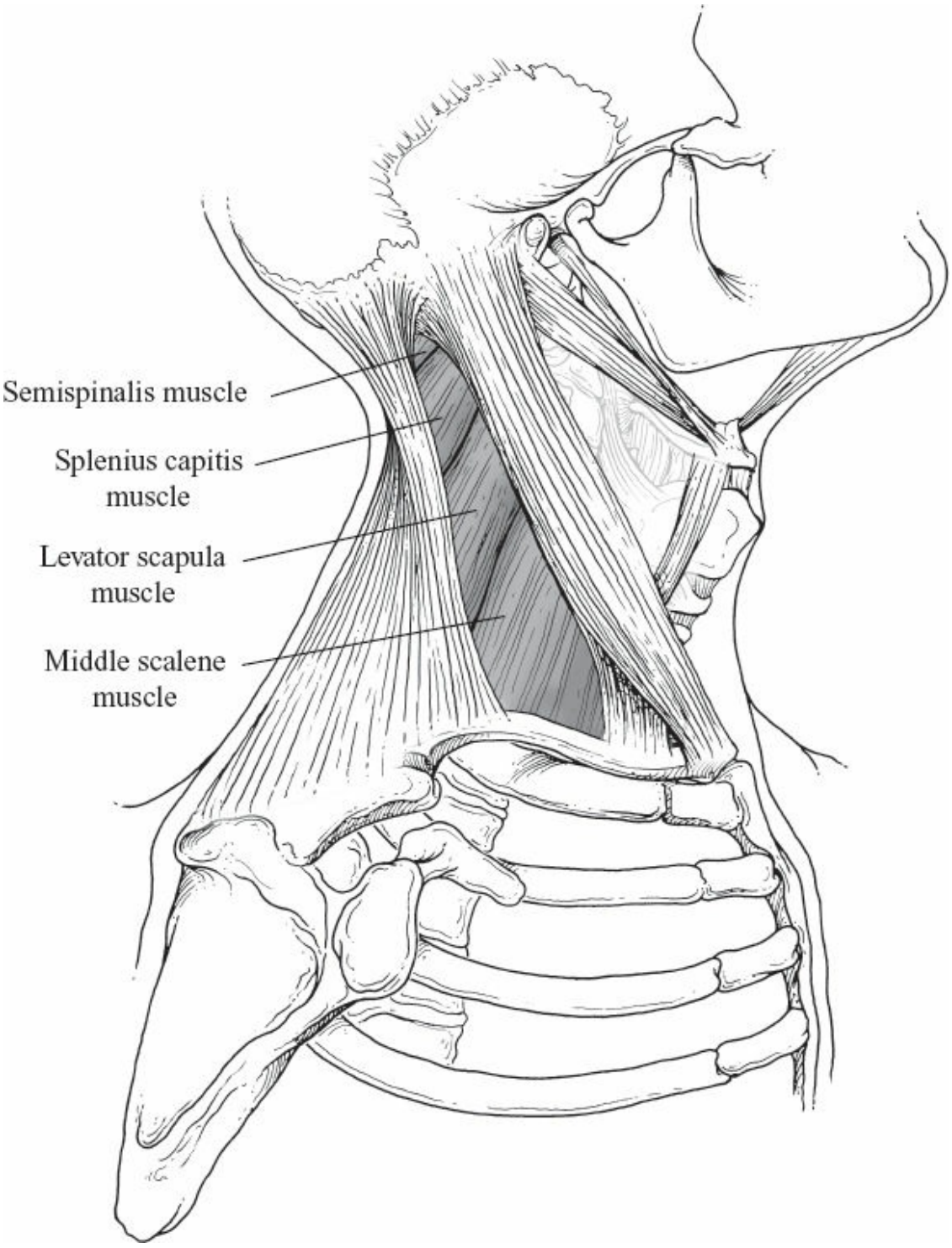

Figure 20.14. Muscular floor of the posterior triangle.

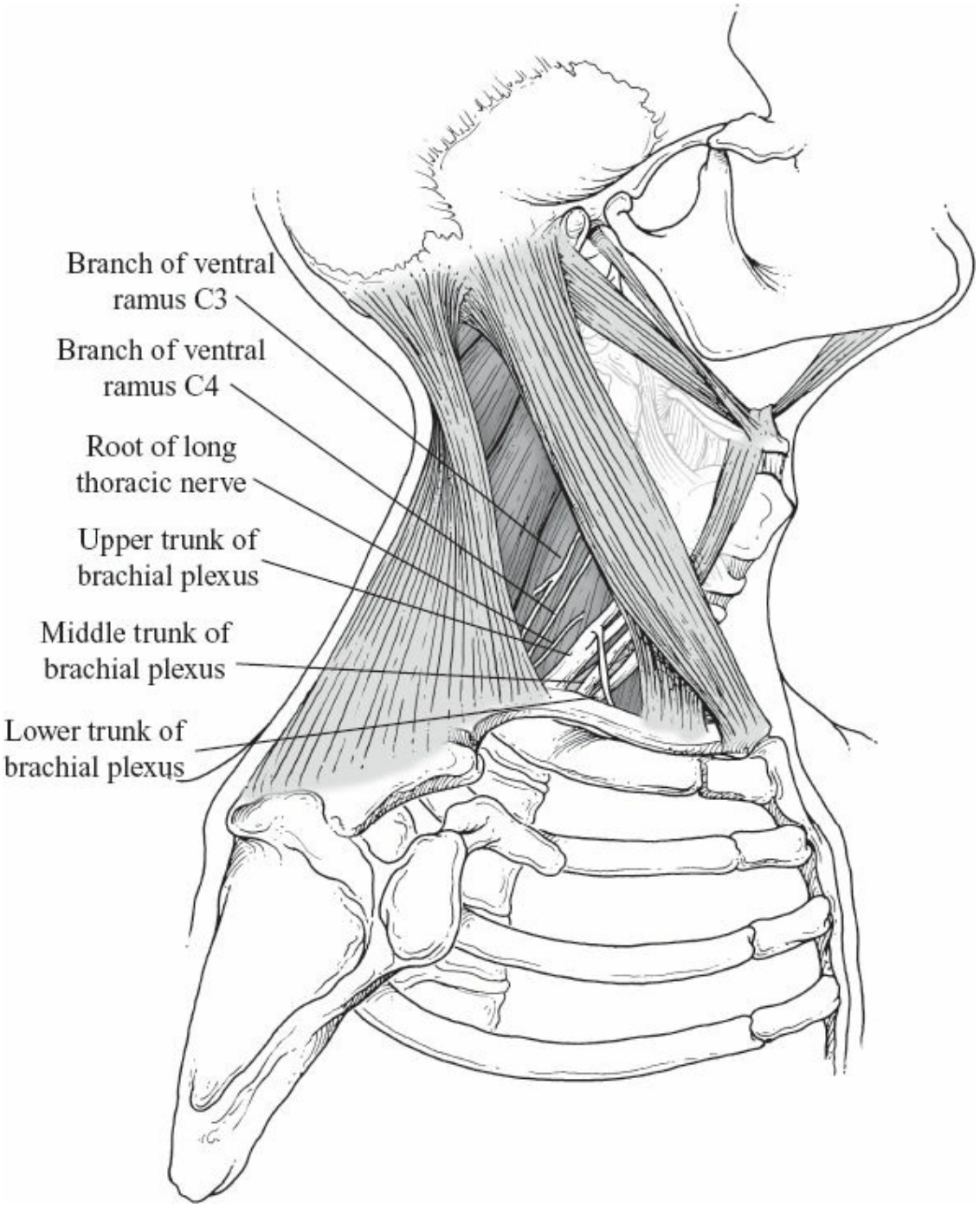

Figure 20.15. Structures below fascia floor of the posterior triangle.

The trunks create anterior and posterior divisions that will pass under the clavicle, and when reaching the axilla, create other combinations called cords. The cords will give rise to the named nerves of the upper extremity and the third portion of the subclavian artery is also related to the fascial floor of the posterior triangle. It can be palpated as it passes under the

midportion of the clavicle and over the first rib. The subclavian artery and the brachial plexus branches, after passing between the scalene muscles, will drag a portion of the prevertebral fascia along with them and create the cervicoaxillary sheath (Figs. 20.16 and 20.17).

Structures that pass between the fascial floor and the fascial roof include the transverse cervical and suprascapular (transverse scapular) branches of the thyrocervical trunk, originating from the first portion of the subclavian artery. They pass transversely across the anterior aspect of the anterior scalene muscle and are separated from the phrenic nerve by the prevertebral fascia. After entering the posterior triangle, the suprascapular artery will pass below the clavicle and participate in important collateral vascular channels that exist in the scapular region. The spinal accessory nerve (XI) as it traverses the posterior triangle. It is found on the anterior surface of, and runs with, the levator scapula muscle. It will disappear under the trapezius muscle about 2 in superior to the clavicle. There are some motor branches from the deep cervical plexus that travel with this cranial nerve. These nerves, and the spinal accessory nerve, are the only motor branches that are superficial to the prevertebral layer of the deep cervical fascia in the posterior triangle.

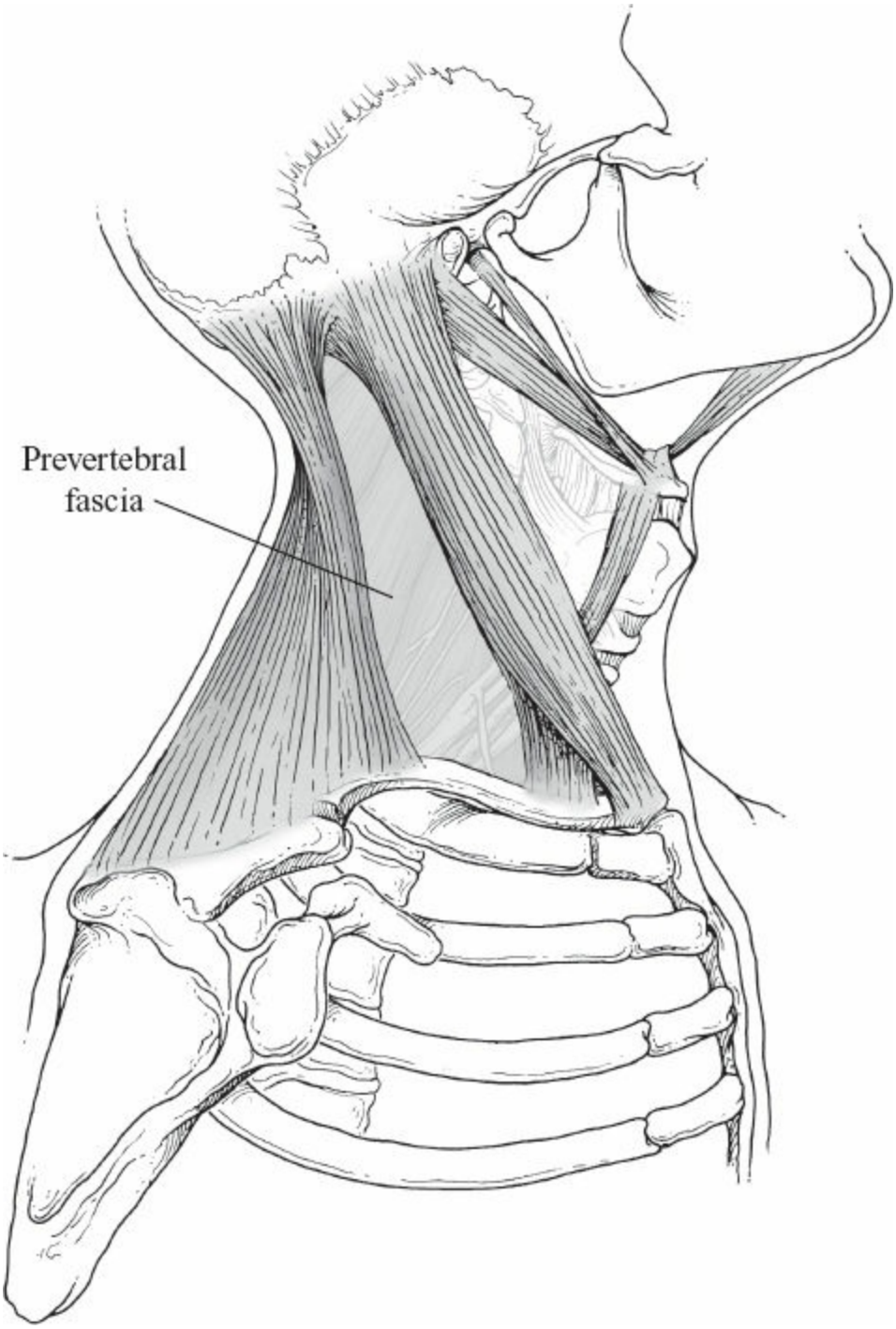

Figure 20.16. Fascial floor of the posterior triangle.

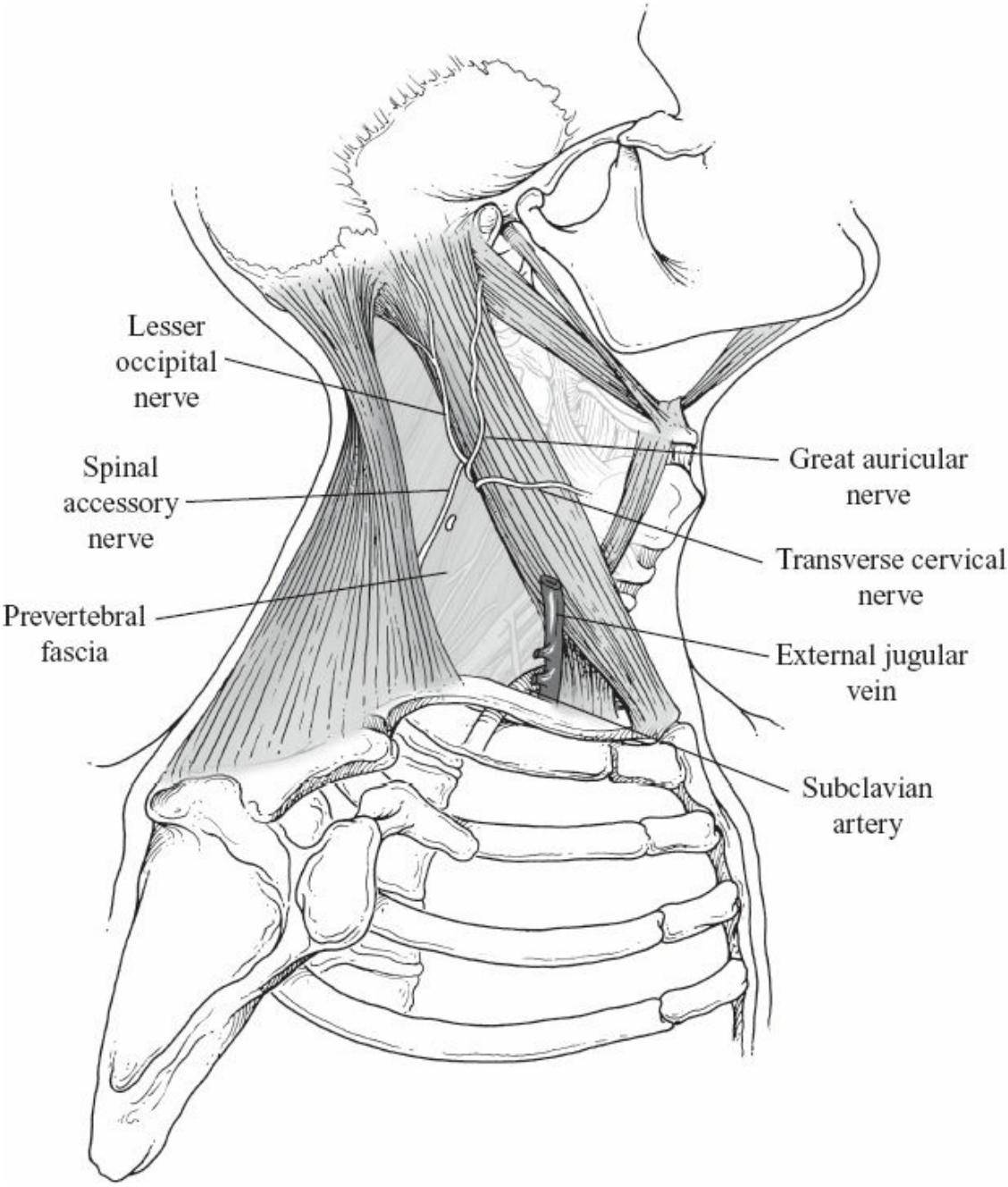

Figure 20.17. Structures superficial to fascial floor of the posterior triangle.

The external jugular vein, which passes obliquely across the sternocleidomastoid muscle, pierces the deep cervical fascial layers of the subclavian triangle, and ends in the subclavian vein. The transverse cervical, suprascapular, and anterior jugular veins are tributaries of the external jugular vein. The inferior belly of the omohyoid muscle creates the lateral boundary of the subclavian triangle. It is attached inferiorly to the superior surface of the scapula, courses anterosuperiorly, and passes deep to the sternocleidomastoid muscle, where its intermediate tendon is

angulated by attachments of deep cervical fascia to the clavicle. The superior belly continues to the hyoid bone. The superficial cervical plexus is created by the ventral rami of C2, C3, and C4. It includes the lesser occipital nerve (C2), which appears at the posterior edge of the sternocleidomastoid muscle just inferior to the spinal accessory nerve. It ascends near the posterior edge of the muscle and will provide sensory innervation to the external ear and the adjacent skin. The superficial cervical plexus also includes the great auricular nerve (C2, C3), which emerges from the cover of the sternocleidomastoid muscle just inferior to the lesser occipital nerve, hooks around the posterior edge of the muscle, and now lies on its superficial surface (Figs. 20.17 and 20.18). It then passes superiorly toward the parotid region and provides sensory innervation to the overlying skin and a portion of the ear. This nerve can frequently be found just posterior to the external jugular vein as it passes obliquely across the muscle. The transverse cervical nerve (C2, C3) also appears at the posterior edge of the sternocleidomastoid muscle in the vicinity of the other nerves of this plexus. It wraps itself around the posterior edge of the muscle and passes transversely across its external surface to reach the anterior triangle. It will then divide into ascending and descending branches that will provide cutaneous sensory innervation to the anterior triangle.

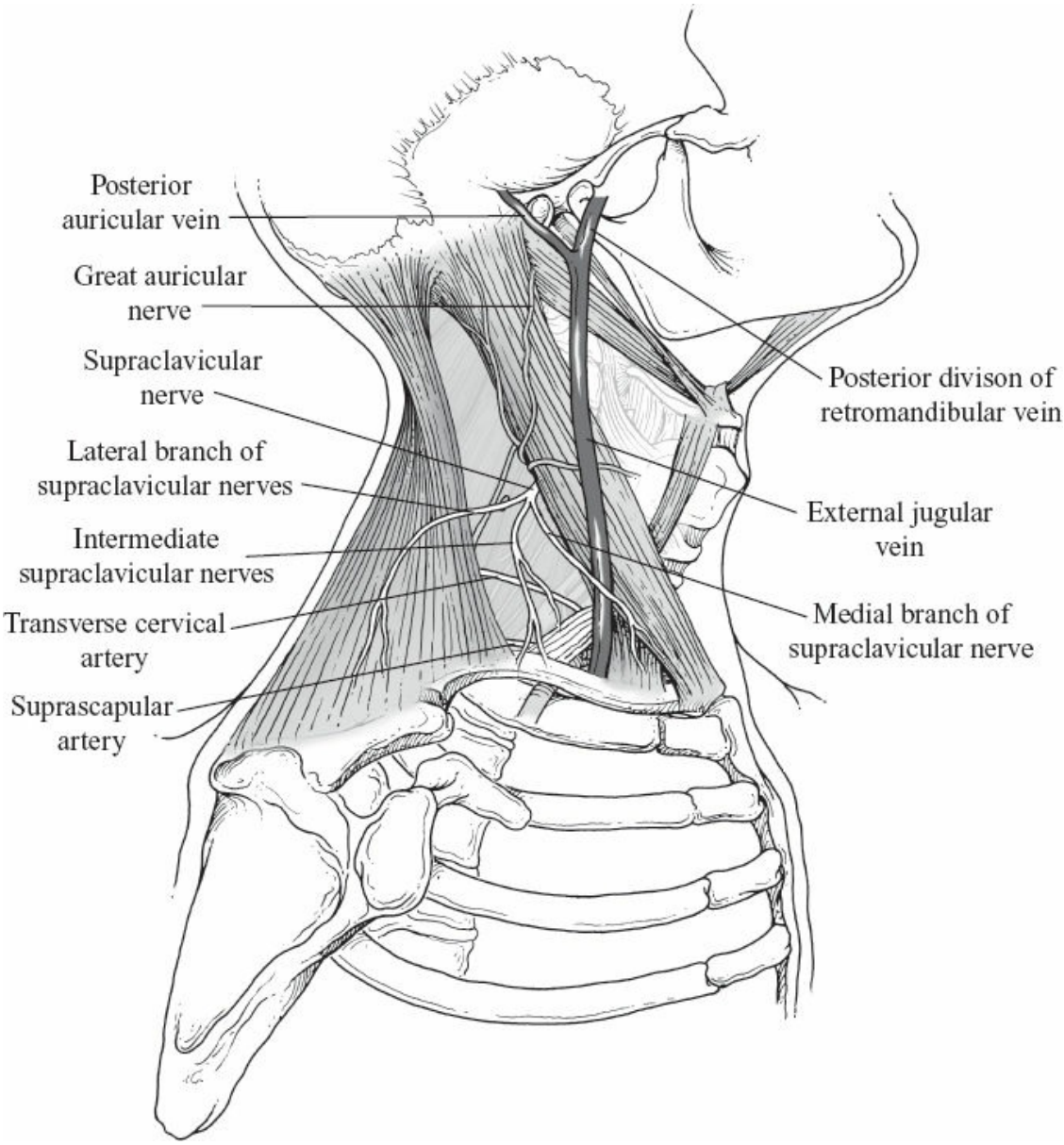

Figure 20.18. Superficial structures of the posterior triangle.

The supraclavicular nerves (C3, C4) first appear in the same area, just below the site of emergence of the other nerves, and then divide into medial, intermediate, and lateral branches. They provide cutaneous sensory innervation to the anterior aspect of the thorax down to the level of the second rib. All branches of the superficial cervical plexus, and the spinal accessory nerve, are quite close to each other as they first appear in the posterior triangle at the edge of the sternocleidomastoid muscle. If one divides the posterior edge of this muscle into thirds, at the junction of the middle and superior third is the site where all these nerves can be found gathered in a small localized area. This is referred to as the nerve point. They will then diverge as they head toward their specific destinations. As

the nerves pass through the posterior triangle, it will be seen that the spinal accessory nerve is the most superior of all the nerves that are in the triangle. Therefore, incisions that are made superior to the spinal accessory nerve are not likely to encounter any important nerves. This area has been referred to as the carefree area; whereas, an incision made below this nerve can injure major structures and is called the careful area.

Clinical Anatomical Aids

1. Superficial cervical plexus nerve block. The nerve point is located and the local anesthetic is injected in that region of the posterior edge of the sternocleidomastoid muscle. It can provide adequate anesthesia to the anterior triangle if bilateral nerve point injection is performed.
2. Catheterization of the subclavian artery or vein. The third portion of the artery is palpable as it passes between the midportion of the clavicle and the first rib. The accompanying vein is anteroinferior to the artery and is the most medial of the neurovascular structures that pass through the costoclavicular space.
3. Dissection can be performed safely in the posterior triangle in the area superior to the spinal accessory nerve (XI).
4. There are one or two motor branches for the trapezius muscle that originate from the deep cervical plexus. They run with, but are slightly inferior to, the spinal accessory nerve in the posterior triangle. In this area, these cervical nerves and the spinal accessory nerve are the only motor nerves that lie external to the prevertebral layer of the deep cervical fascia.
5. When veins pass through layers of fascia, the wall of the vein is adherent to the margins of the opening in the tissue being breached. If a vein is transected at the level of fascia penetration, bleeding may be prolonged because the attachments to the vessel wall may prevent it from going into spasm. Spasm of the cut end of a blood vessel assists in achieving hemostasis.

VISCERA OF THE NECK

Thyroid Gland

The development of the thyroid gland begins with the appearance of the foramen caecum (Fig. 20.19). This is a pit or depression that appears at the junction of the anterior two-thirds with the posterior third of the tongue. It continues inferiorly and creates the thyroglossal duct, which continues

caudad and becomes the thyroid gland. The duct is a midline structure down to the thyroid cartilage and then usually deviates to the left. The pyramidal lobe of the gland represents the distal portion of this embryologic structure. The duct has a tortuous U-shaped course around the body of the hyoid bone. Portions of this duct may remain patent and create thyroglossal duct cysts. These will be median in position, but closer to the gland they can deviate from the midline. Cysts found below the hyoid bone require excision of the central portion of this bone in order to include the tortuous portion of this persistently patent remnant of the thyroglossal duct. Accessory thyroid tissue may be found anywhere along the pathway of this developmental entity. The most frequent site is the posterior portion of the tongue near the foramen caecum.

The thyroid gland is composed of two pyramidal-shaped lateral lobes, connected by a transverse bridge of glandular tissue, that crosses anterior to the second, third, and fourth tracheal rings. This connection across the midline is the isthmus. There may be a superior extension of glandular tissue originating from the left portion of the isthmus. This is the pyramidal lobe, and it may be connected to the hyoid bone by a fibrous band. If there are muscle fibers in this band, it is called the levator glandulae thyroidea. The lateral lobe extends from the oblique line of the thyroid cartilage down to the sixth tracheal ring. The gland possesses a true capsule, created by condensation of the normal stroma, and is enveloped by the pretracheal layer of the deep cervical fascia, creating the false or surgical capsule. The pretracheal fascia surrounding the isthmus is adherent to the trachea. This deep cervical fascia also attaches the posteromedial aspect of the lateral lobe to the first and second tracheal rings. This is the ligament of Berry, which usually contains some small blood vessels. These attachments are responsible for superior and inferior movement of the thyroid gland during the act of swallowing. Medial relations of the lateral lobe include thyroid and cricoid cartilages, trachea, esophagus, cricothyroid and inferior constrictor muscles, external branch of the superior laryngeal, and the recurrent laryngeal nerves. The carotid sheath and inferior thyroid artery are posterior. The superior thyroid vessels and the external laryngeal branch of the superior laryngeal nerve approach the lobe from above. The sternohyoid, omohyoid, and sternothyroid muscles are anterior relations. The left lateral lobe is related to the thoracic duct as it travels superiorly, just to the left of the esophagus. It maintains this position until C7, where it arches laterally.

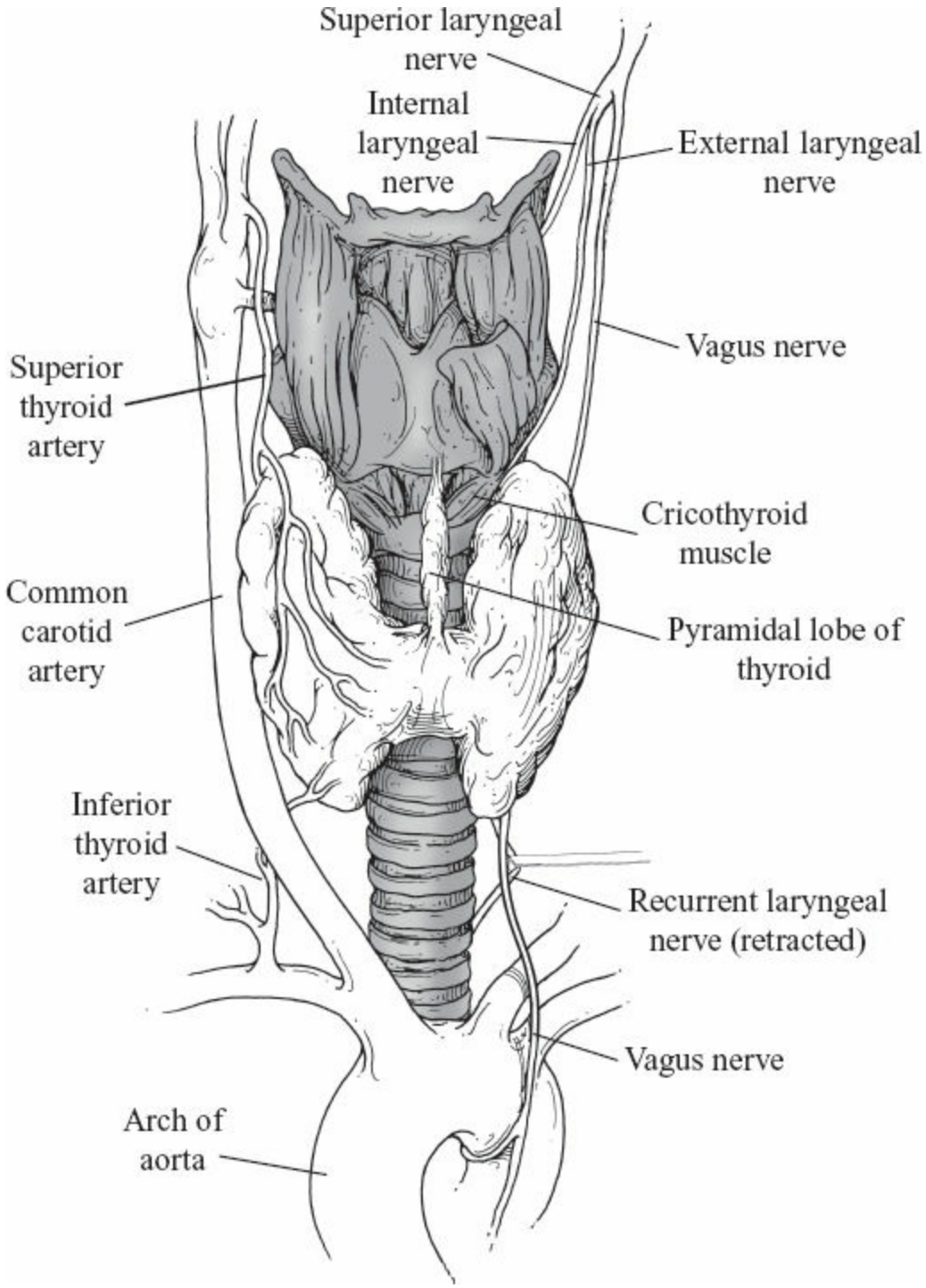

Figure 20.19. Thyroid gland anatomy.

The superior and inferior thyroid arteries provide the vascular supply (Fig. 20.20). In 8% to 10% of the individuals, a thyroid ima artery is present. It may be a direct branch of the arch of the aorta, appearing between the brachiocephalic and the left common carotid vessels. Occasionally, it may arise from the brachiocephalic trunk or the right common carotid artery. The superior thyroid artery is the first of the

anteromedial branches of the external carotid artery. It creates a superior laryngeal vessel that enters the larynx, after piercing the thyrohyoid membrane, along with the superior laryngeal vein and the internal branch of the superior laryngeal nerve. This nerve provides sensory innervation to the interior of the larynx above the vocal ligaments. The superior thyroid artery then passes vertically downward, accompanied by the superior thyroid vein, as it heads for the superior pole of the lateral lobe. Accompanying these blood vessels is the external branch of the superior laryngeal nerve. It is medial, and very close to the vessels. The nerve will turn medially, just superior to the upper pole of the lateral lobe, and head for the larynx. It provides motor innervation to the inferior part of the inferior constrictor of the pharynx and the cricothyroid muscle of the larynx.

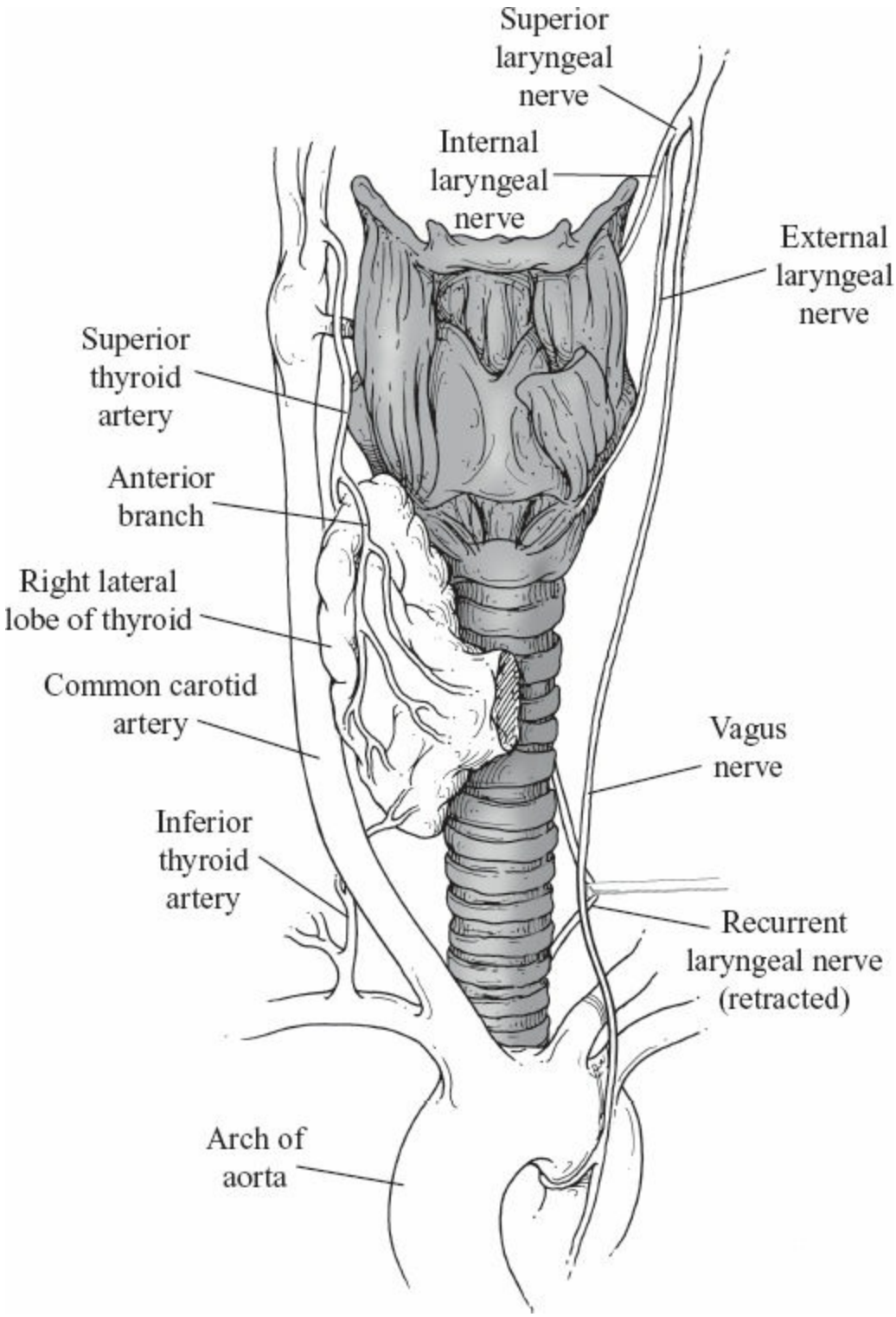

Figure 20.20. Vascular supply to thyroid gland.

The inferior thyroid artery arises from the thyrocervical trunk, a branch of the first portion of the subclavian artery (Fig. 20.21). It will ascend to the cricoid plane, passes posterior to the carotid sheath, and then passes inferomedially to reach the posterior surface of the lateral lobe. In this area, the artery is intimately related to the recurrent laryngeal nerve, a

branch of the vagus (X), providing motor innervation to all the intrinsic muscles of the larynx except the cricothyroid.

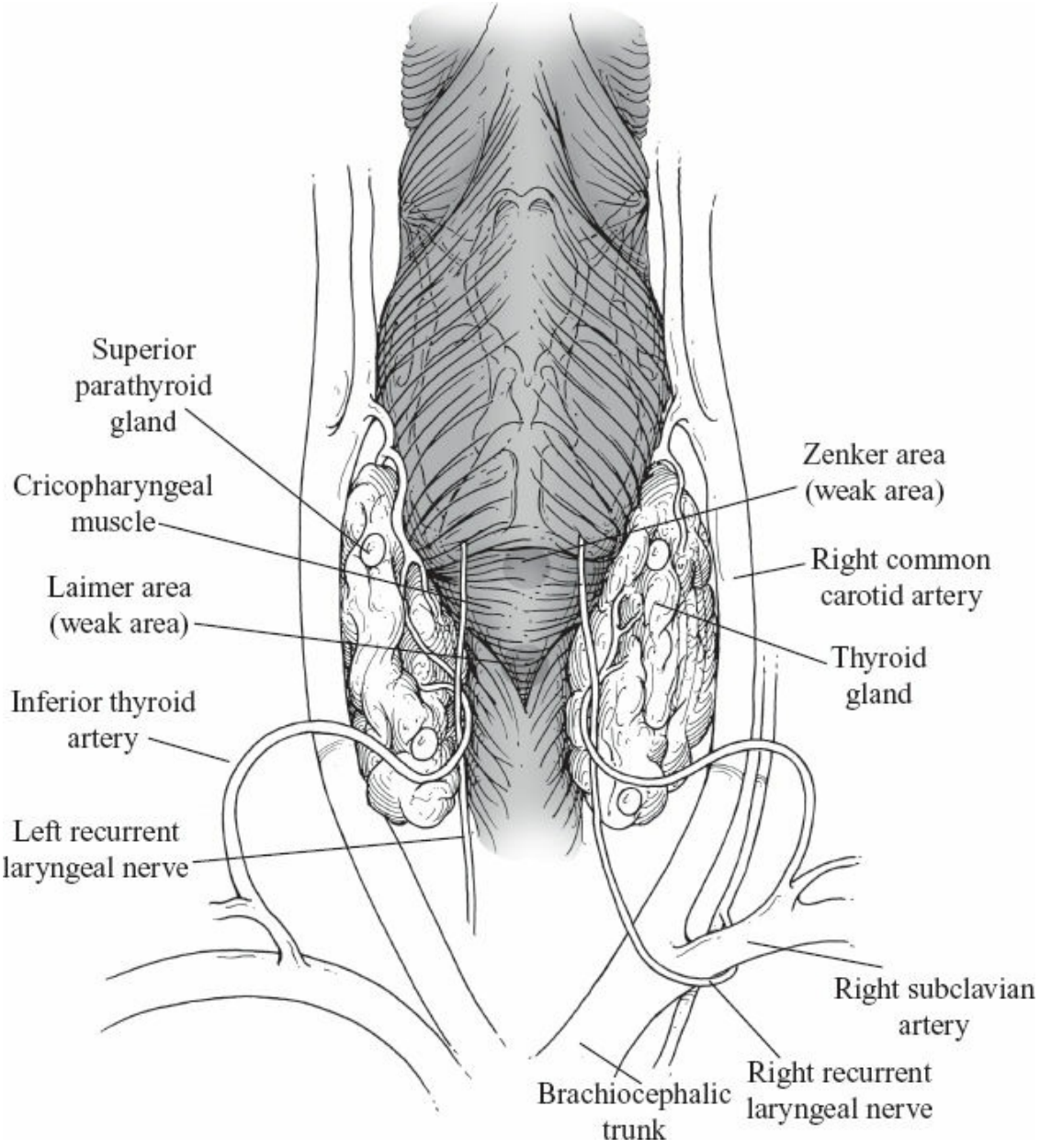

Figure 20.21. Posterior view of thyroid gland.

The superior thyroid artery will provide an anterior and posterior branch (Fig. 20.22). The anterior branch will communicate with its contralateral counterpart through branches that cross the midline by way of the isthmus. The posterior branch of the superior thyroid artery communicates with branches of the inferior thyroid artery. The venous drainage is *via* the superior thyroid vein into the internal jugular or common facial vein, the short middle thyroid vein into the internal jugular

vein, and the inferior thyroid veins into the brachiocephalic vein.

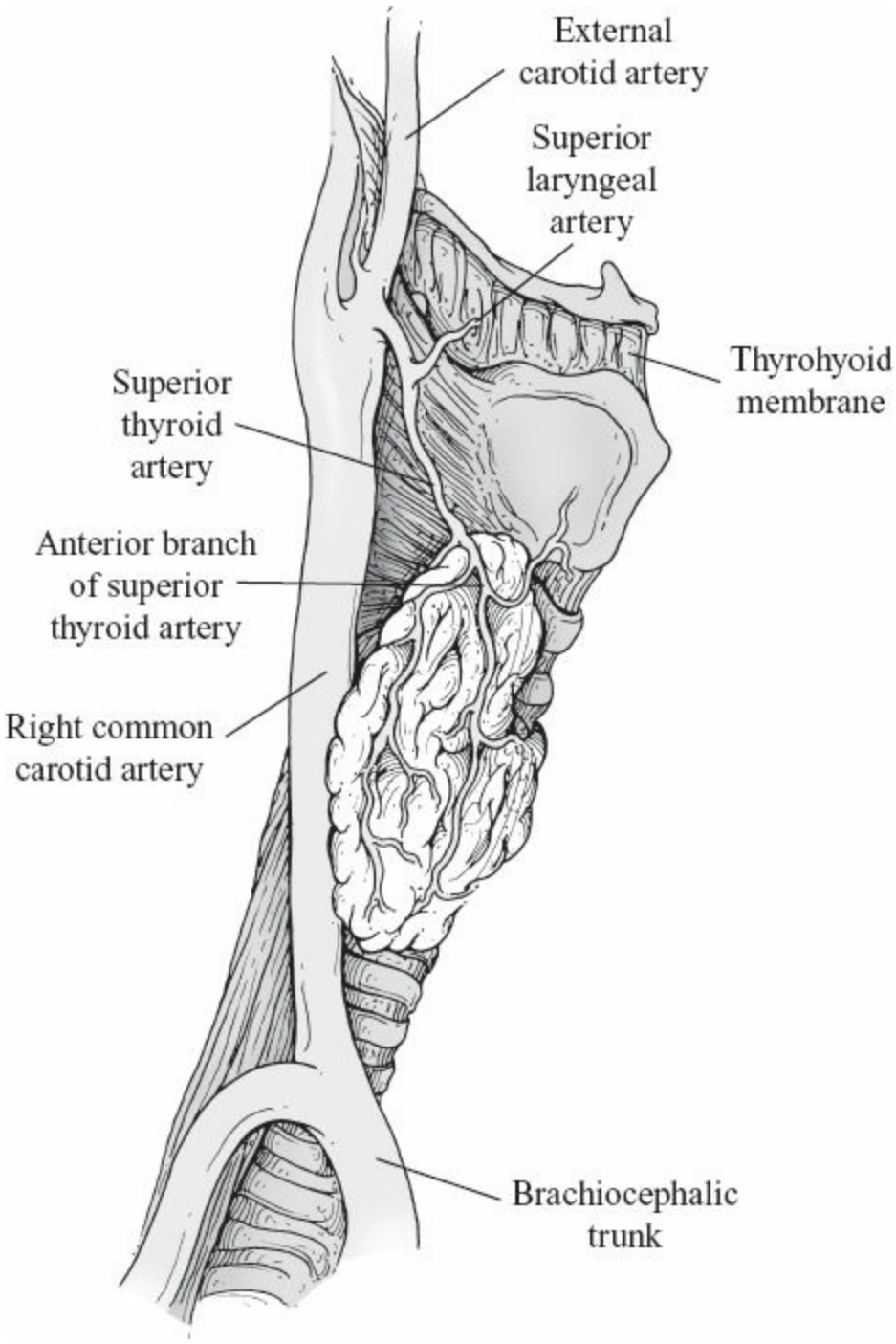

Figure 20.22. Right lateral view of thyroid gland.

The lymphatic drainage of the thyroid gland can be divided into superior or ascending, and inferior or descending pathways. They can be further subdivided into lateral and medial components. The superomedial pathway leads to the prelaryngeal or Delphian node found anterior to the cricothyroid membrane. The superolateral channels pass, with the superior

thyroid artery, to nodes situated at the bifurcation of the common carotid artery, or to the omohyoid nodes of the internal jugular chain. The inferomedial lymph vessels are related to nodes found anterior, and adjacent, to the trachea. The inferolateral lymph flow is to the supraclavicular nodes.

Parathyroid Gland

The parathyroid glands are found on the posterior surface of the thyroid gland between the surgical and the true capsule (see Fig. 20.21). They may also be situated outside the surgical capsule, or within the true capsule (intraglandular). There are usually four glands, and each one measures only 5 to 6 mm in diameter. The upper pair is found at the level of the cricoid cartilage and is frequently adjacent to a descending branch of the superior thyroid artery that anastomoses with an ascending branch of the inferior thyroid artery. They are yellowish brown and, therefore, distinguishable from normal thyroid tissue, which is reddish pink. The inferior pair of glands is found superior or inferior to the inferior thyroid artery, as this vessel passes transversely across the posterior aspect of the lower pole of the lateral thyroid lobe. They receive their blood supply from the superior and inferior thyroid arteries. Aberrant glandular tissue is not uncommon.

Clinical Anatomical Aids

1. A parathyroid gland may resemble a small lymph node, but the glandular tissue is softer when palpated, compared with the firmer feel of the node.
2. Superior enlargement of the thyroid lobe is prevented by the insertion of the sternothyroid muscle into the oblique line of the thyroid cartilage. Lateral expansion can occur.
3. Occasionally, there may be extralaryngeal branching of the recurrent nerve, resulting in loss of a single main trunk. This will usually occur superior to the inferior thyroid artery. Therefore, it is better to look for the main trunk of the nerve inferior to the artery.
4. The inferior thyroid artery will usually divide into two or three branches before entering the parenchyma of the thyroid gland. The recurrent nerve usually passes between these branches.
5. If the inferior thyroid artery is divided laterally, just after passing posterior to the carotid sheath, nerve injury is unlikely.
6. Anteromedial retraction of the lateral lobe of the thyroid gland will

displace the recurrent laryngeal nerve from its expected position in the tracheoesophageal groove, toward the posterolateral aspect of the trachea.

7. There may not be a recurrent laryngeal nerve found in the tracheoesophageal groove if there is a high origin of the nerve. This is referred to as a nonrecurring nerve.
8. A cricothyroidotomy provides access to the infraglottic space. This area of the larynx is below the vocal ligaments.

Pharynx

The pharynx is a muscular tube, approximately 5 in long, that extends from the base of the skull to the cricoid cartilage, where it is continuous with the esophagus (Fig. 20.23). An anterior wall is lacking where it faces the nasal and oral cavities and the larynx. This creates nasopharynx, oropharynx, and laryngopharynx subdivisions. The nasopharynx is between the soft palate and the base of the skull. The soft palate is attached to the posterior end of the hard palate. It is a soft tissue shelf, approximately 2 in long. A small grape-like swelling, the uvula, is attached to its free end. It contains the small, paired, uvular muscles. There are four additional paired muscles in the soft palate area: palatoglossus, palatopharyngeus, levator, and tensor palati. They narrow the oropharyngeal junction, tense the soft palate, and elevate the uvula in order for the oropharynx to be separated from the nasopharynx and oral cavity during deglutition. The posterior and lateral walls are immobile; therefore, the nasopharynx is always patent. In the lateral wall, at the level of the inferior nasal concha, is the opening of the auditory tube (eustachian). There is a bulge at the posterior end of the tube created by the cartilage in its wall. Passing inferiorly from this elevation is the salpingopharyngeal fold, created by the salpingopharyngeus muscle. Posterior to the bulge and the fold is the pharyngeal recess. On the posterior wall, there may be collections of lymphatic tissue referred to as pharyngeal tonsils, or adenoids. An anterior wall is created by the nasal cavity.

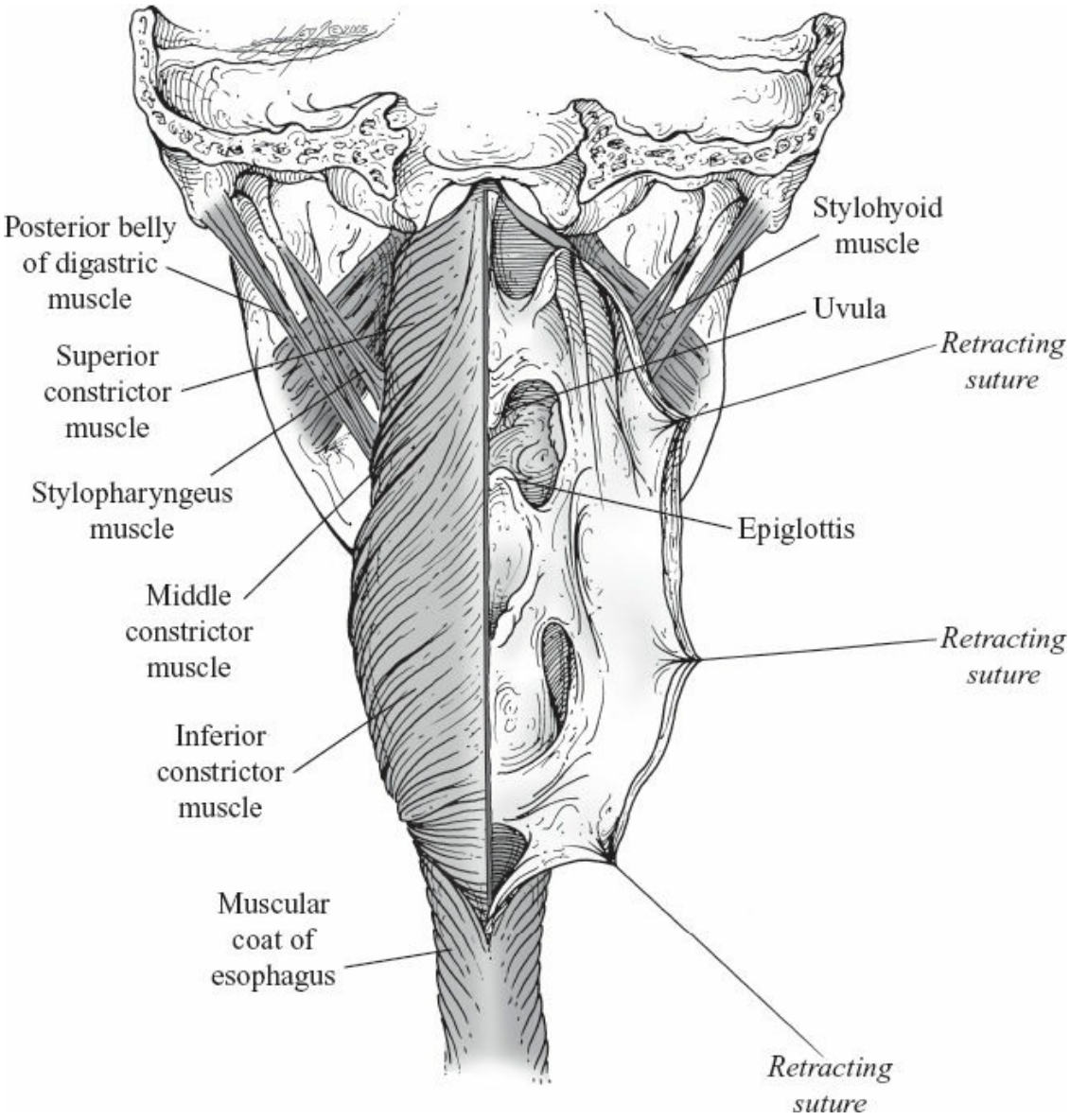

Figure 20.23. Posterior view of pharynx with right portion of constrictor muscle retracted laterally.

The oropharynx faces the oral cavity and the posterior surface of the tongue (Fig. 20.24). The palatoglossal arch is located at the junction between the mouth and the oropharynx. Posterior, and slightly lateral to this arch, is the palatopharyngeal arch. The arches are named for the muscles they enclose. Between the arches is the palatine or tonsillar fossa, a space for the palatine tonsil. The fauces is considered as the area between the oral cavity and the pharynx. The posterior third of the tongue contains lymphatic tissue called lingual tonsil. Behind the tongue is the upper free edge of the epiglottis. Its anterior surface and lateral edges are attached to the tongue by mucosal folds named glossoepiglottic folds. Shallow depressions between the folds are the valleculae. The buccopharyngeal

fascia covering the posterior aspect of the pharyngeal wall is in contact with the prevertebral fascia lying anterior to the upper cervical vertebrae.

The laryngopharynx receives, in its upper portion, products of the digestive and respiratory systems. Its lower segment is related only to the digestive system. The anterior wall is created by the entrance into the vestibule of the larynx, bounded laterally by the aryepiglottic fold, the arytenoid cartilages, and the lamina of the cricoid cartilage. The posterior wall is in contact with the prevertebral fascia situated anterior to the lower cervical vertebrae. The anterior and posterior walls of the distal segment of pharynx are in contact but are separated by the passage of food. The lateral wall is supported by the posterior free edge of the thyroid lamina. A small piriform recess is found between the thyroid lamina laterally and the aryepiglottic fold medially. This space receives sensory innervation from the internal laryngeal nerve, and if a foreign body, or a morsel of food, is trapped in this area, it will cause severe and persistent coughing.

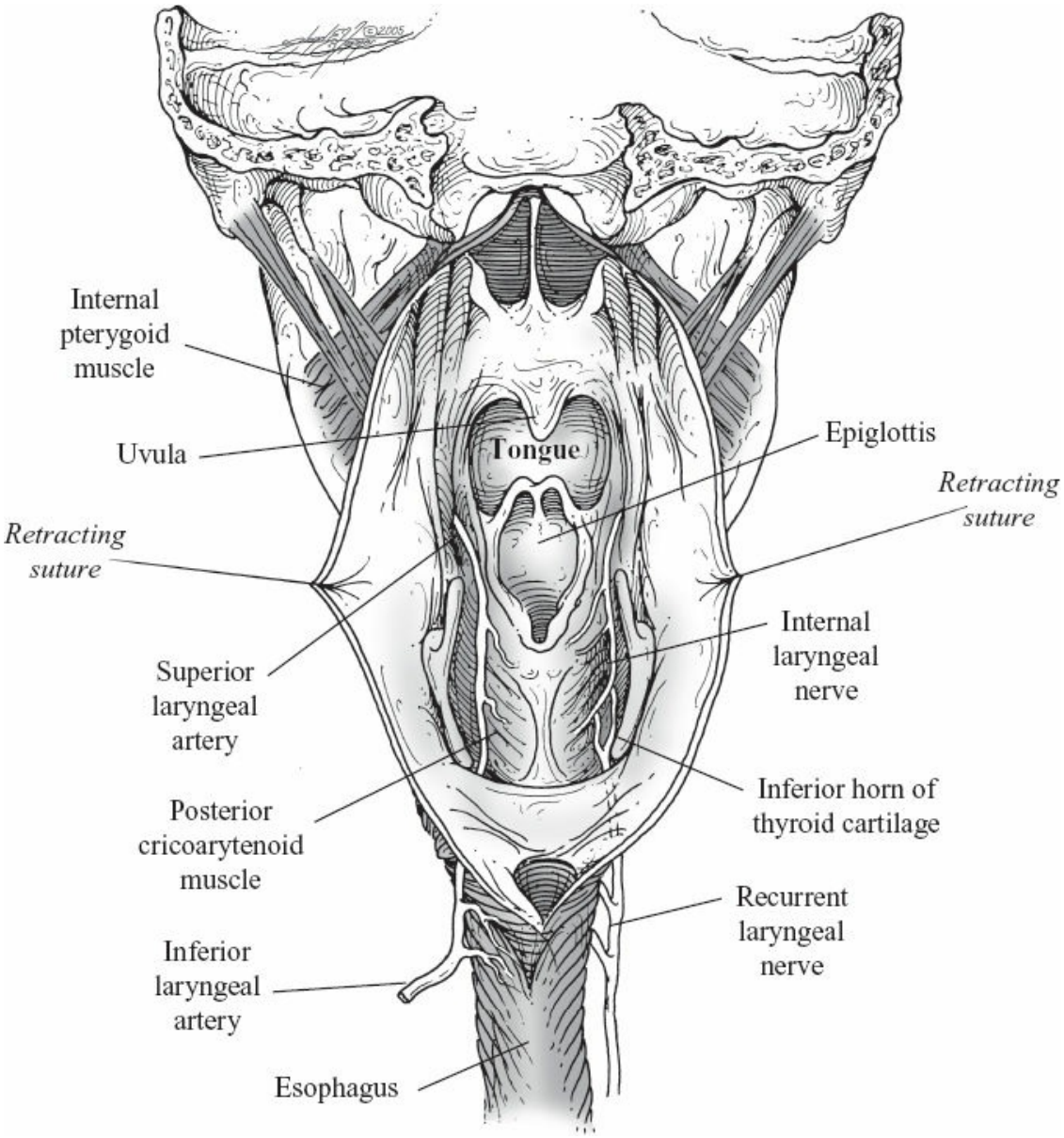

Figure 20.24. Interior view of pharynx.

Ligamentous Background

1. Stylohyoid ligament is found between the tip of the styloid process of the skull and the lesser horn of the hyoid bone (Fig. 20.25). It supports the hyoid, and through the thyrohyoid membrane is also responsible for suspension of the larynx.
2. Pharyngeal raphe is a fibrous seam, which represents the posterior site of attachment for the left and right constrictor muscles. It is attached superiorly to the pharyngeal tubercle found on the basal portion of the occipital bone, 1/2 in anterior to the foramen magnum. Inferiorly, it merges with the esophageal wall.
3. Pterygomandibular raphe is a fibrous structure between the pterygoid

hamulus and the mandible. It provides attachment for the superior constrictor and the buccinator muscles.

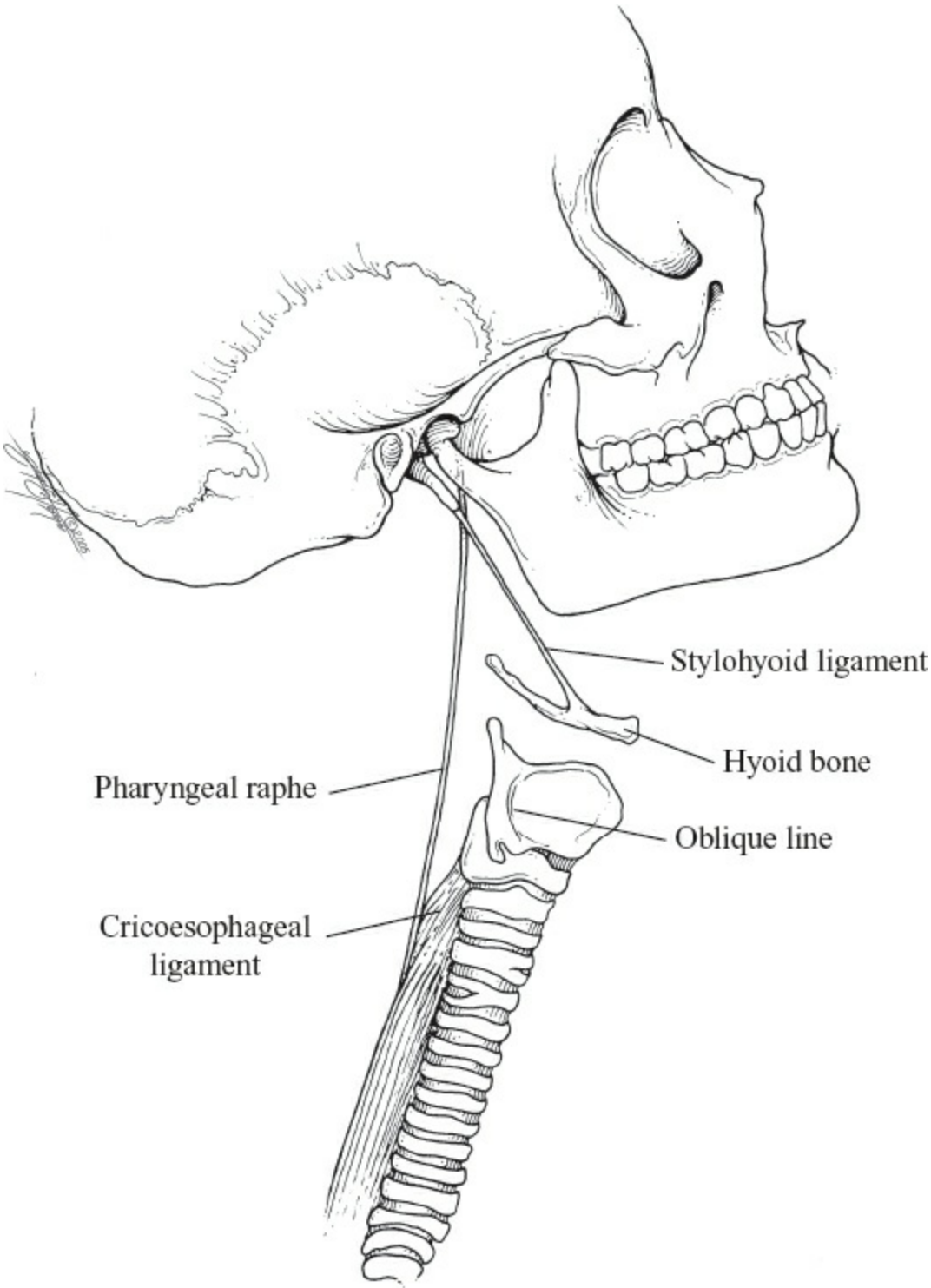

Figure 20.25. Skeletal framework of pharynx.

Muscular Background

There are five paired voluntary muscles contributing to the pharyngeal

wall. The superior, middle, and inferior constrictors create an external circular muscle layer (Fig. 20.26). The stylopharyngeus and the palatopharyngeus create an inner longitudinal muscle layer. Each constrictor muscle partially overlaps, externally, the inferior edge of the muscle above. The superior constrictor arises from the posterior edge of the lower part of the medial pterygoid plate, pterygoid hamulus, pterygomandibular raphe, side of the tongue, and the mylohyoid line of the mandible. The middle constrictor arises from the inferior end of the stylohyoid ligament and the lesser and greater horns of the hyoid bone. The inferior constrictor arises from the oblique line of the thyroid cartilage, the lateral aspect of the arch of the cricoid, and from the fascia overlying the cricothyroid muscle of the larynx. These muscles widen as they pass laterally and then posteriorly, where they insert into the posterior midline pharyngeal raphe. The lowest fibers of the inferior constrictor that arise from the cricoid cartilage create the cricopharyngeus muscle (Fig. 20.27). This is the superior esophageal sphincter, which can regulate flow into the esophagus. The upper fibers of the muscle pass superomedially and attach to the pharyngeal raphe, but the lower fibers pass transversely. There is a slight muscular defect between the transverse and the oblique portions of the cricopharyngeus muscle. This is Zenker area, a weak point, where pulsion diverticula may develop, and is a potential site for endoscopic perforation.

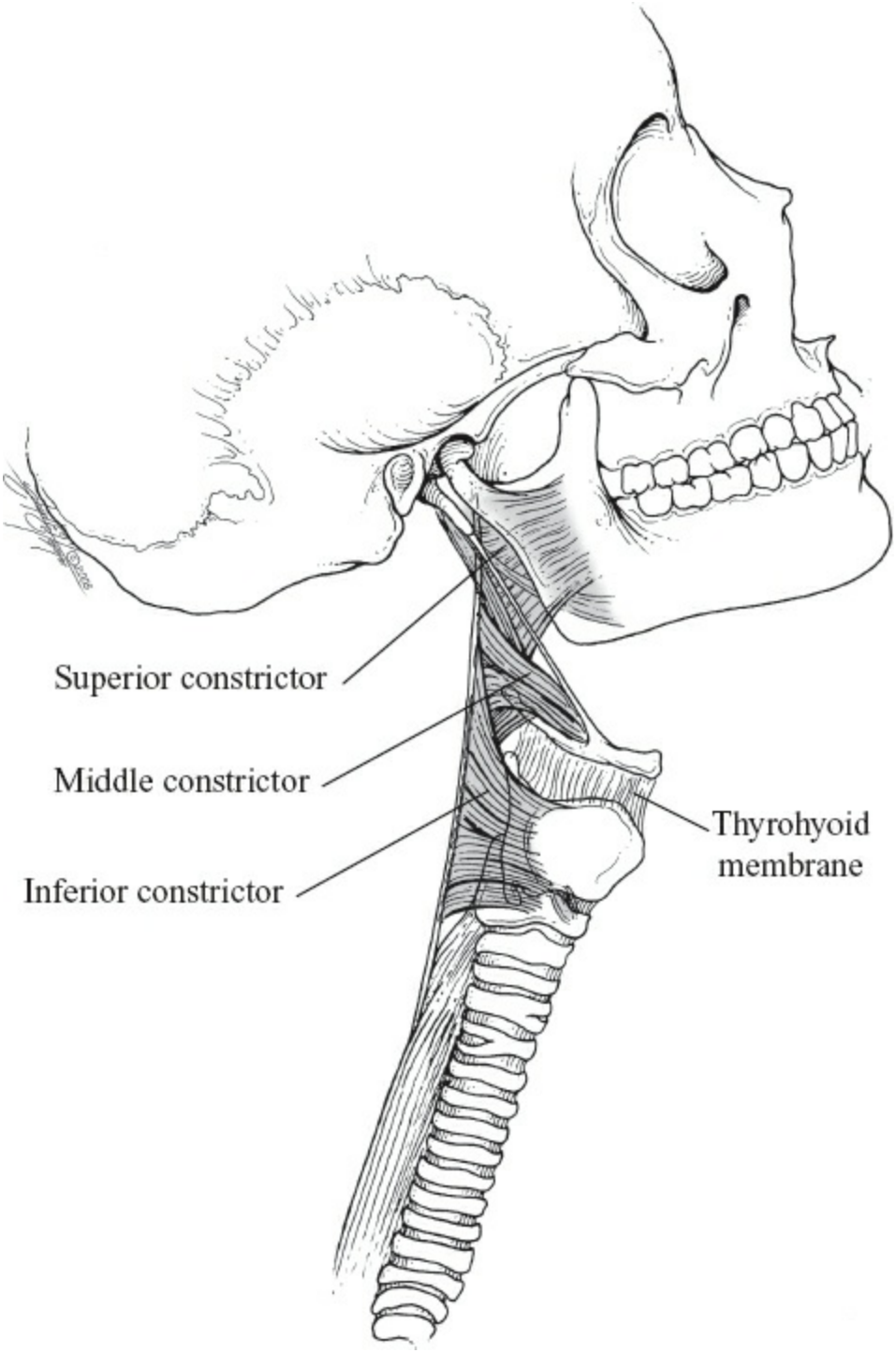

Figure 20.26. Constrictor muscles of pharynx.

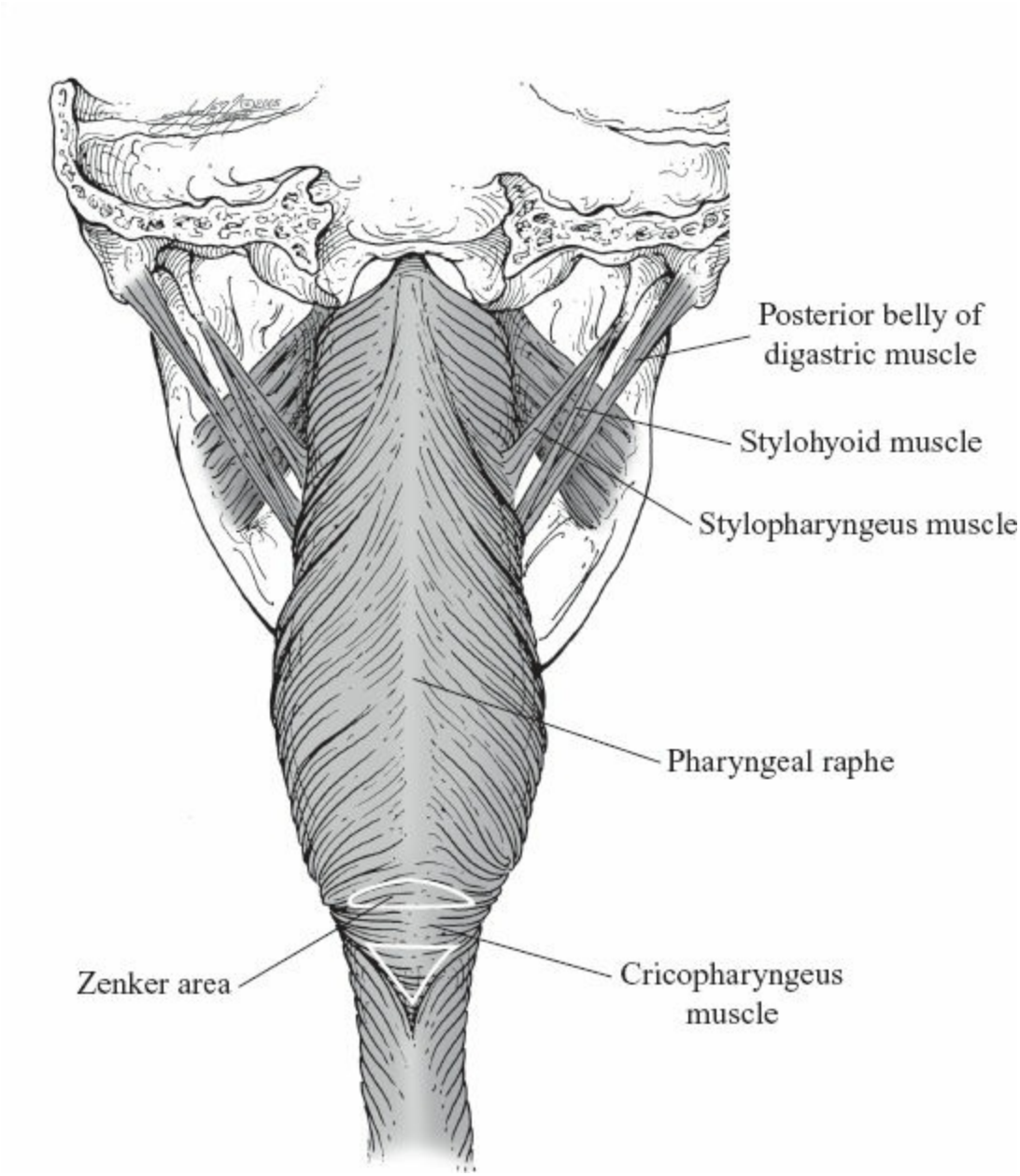

Figure 20.27. Posterior view of pharynx.

The stylopharyngeus and palatopharyngeus muscles create the internal longitudinal muscle layer. The stylopharyngeus muscle receives motor innervation from the glossopharyngeal nerve. The remainder of the muscular wall is supplied by the vagus and glossopharyngeal nerves *via* the pharyngeal plexus. The superior laryngeal nerve arises from the vagus at the base of the skull. It creates the external laryngeal nerve, which innervates the lower portion of the inferior constrictor, and the cricothyroid muscle of the larynx.

Completion of the Wall of the Pharynx

There are defects in the pharyngeal wall superior and inferior to the narrow origins of the constrictor muscles. There are structures that pass through these areas of muscular deficiency. Two layers of fascia close these openings: (a) buccopharyngeal fascia, which also creates an external covering of the constrictors, and (b) pharyngobasilar fascia, which is submucosal in position, and internal to the muscular wall.

The pharyngeal nervous plexus and the pharyngeal venous plexus are found between the constrictor muscles and the buccopharyngeal fascia. In addition, there are submucosal venous plexuses. The uppermost opening, between the base of the skull and the superior constrictor, provides passage for the cartilaginous portion of the auditory tube, levator palatine muscle, and small palatine vessels. The stylopharyngeus muscle and the glossopharyngeal nerve pass between the superior and the middle constrictor muscles (Fig. 20.28). The third gap, between the middle and the inferior constrictors, includes the area between the greater horn of the hyoid and the thyroid cartilage. The thyrohyoid membrane is found here and is penetrated by the superior laryngeal artery arising from the superior thyroid, the internal branch of the superior laryngeal nerve providing sensory innervation to the laryngeal mucosa above the vocal folds, and the superior laryngeal vein. Passing between the inferior constrictor and the esophagus are the continuation of the recurrent laryngeal nerve and the inferior laryngeal artery and vein (Fig. 20.24).

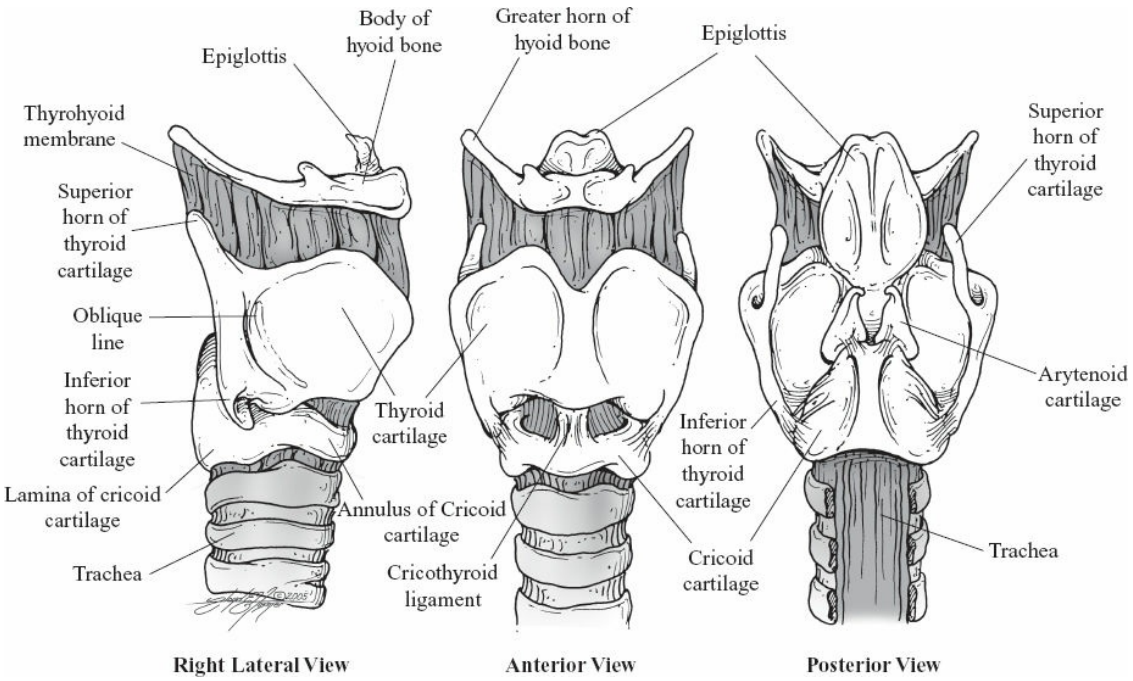

Figure 20.28. Cartilages of the larynx.

Innervation of the Pharynx

The pharyngeal plexus, created by the vagus (X) and glossopharyngeal (IX) nerves, supplies motor innervation to the pharyngeal muscles. The stylopharyngeus muscle receives motor innervation from the glossopharyngeal nerve. The superior laryngeal nerve arises from the vagus at the base of the skull. It creates the external laryngeal nerve that innervates the lower portion of the inferior constrictor and the cricothyroid muscle of the larynx. The remainder of the muscular wall receives motor innervation from the pharyngeal plexus. Sensory innervation is provided by the glossopharyngeal nerve *via* the pharyngeal plexus.

Larynx

The larynx is responsible for vocalization. The superior opening faces the laryngopharynx. The inferior end is at the cricoid cartilage, where it becomes continuous with the trachea. It is anterior to vertebral bodies C3 through C6. The anterior wall of the larynx is related to cervical fascia and skin. The strap muscles are anterolateral. The thyroid gland and the carotid sheath are lateral. The laryngopharynx separates the larynx from the vertebral column. It has some degree of rigidity and is composed of bone and cartilage that are held together by membranes, ligaments, and synovial joints. The hyoid bone is part of the anatomy of the floor of the mouth, but as it provides important support for the larynx, it will be discussed in this section.

Skeleton of Larynx

The hyoid bone is a U-shaped structure with a central body, measuring 1 in wide and 1/2 in high. It is continuous, on each side, with the greater horn that passes posterolaterally for approximately 1½ in. The free end of the greater horn is directly inferior to the angle of the mandible. The lesser horns are small, superior protrusions found at the junction of the body and greater horns. The stylohyoid ligament, which suspends the hyoid bone from the base of the skull, is attached here.

Laryngeal Cartilages

There are three unpaired and three paired cartilages (Fig. 20.28). The larger unpaired cartilages are the thyroid, cricoid, and epiglottis. The paired cartilages are the arytenoid, corniculate, and cuneiform.

The hyoid bone and the thyroid and cricoid cartilages provide the

principal support of the larynx. The thyroid cartilage is palpable 1/2 in below the body of the hyoid bone. It is composed of hyaline cartilage and formed by two laminae that fuse anteriorly. The anterosuperior point of fusion is incomplete, leaving a palpable V-shaped notch called the laryngeal, or thyroid, prominence. It is also referred to as Adam's apple, and is a more prominent structure in males. The posterior border of each lamina is free and creates projections called the superior and inferior horns. The superior horn extends up approximately 1/2 in toward, and is vertically inferior to, the tip of the greater horn of the hyoid. The inferior horn is only 1/4 in long, and extends down from the free edge of the thyroid lamina toward the posterior end of the arch of the cricoid cartilage. There is a ridge beginning at the root of the superior horn that extends inferomedially toward the lower edge of the fused thyroid laminae. This is the oblique line, and it represents the point of attachment of three muscles: sternothyroid, thyrohyoid, and the inferior constrictor of the pharynx.

The cricoid cartilage creates a complete ring. It is the only complete cartilaginous ring in the respiratory system. The anterior and lateral portion of the ring is narrow and creates the arch. The posterior part widens and creates the lamina. It does resemble a signet ring. The arch has been identified as the cricoid plane. This is the level that was referred to as an anatomical bonanza earlier in this chapter. The cricoid participates in two synovial joints: cricoarytenoid and cricothyroid. The epiglottis is the third of the unpaired cartilages. It is composed of elastic cartilage, which allows this racket-shaped structure to help seal off the entrance into the larynx during deglutition. Its lower pointed end is attached to the thyroid cartilage just inferior to the laryngeal prominence by the thyroepiglottic ligament. The superior edge extends above the body of the hyoid bone. The hyoepiglottic ligament attaches to the posterior aspect of the body of the hyoid. The anterior aspect is connected to the dorsum of the tongue by left, right, and median glossoepiglottic folds. Between the folds are depressions referred to as vallecula epiglottica. The superior edge of the epiglottis may be visible during oral examination if the dorsum of the tongue is depressed. The posterior surface of this cartilage is part of the anterior wall of the laryngeal vestibule.

The arytenoids are the largest of the paired cartilages. They lie on the superior border of the lamina of the cricoid cartilage and participate in the cricoarytenoid joint. They are pyramidal in shape and measure 1/2 to 3/4 in in height. The base is on the superior surface of the lamina of the

cricoid. The medial end of the base is prolonged anteriorly to create the vocal process. The posterolateral angle of the base is enlarged and forms the muscular process. The medial surface faces its partner. The anterolateral surface provides attachment for muscles inferiorly and the quadrangular membrane superiorly. The arytenoid is composed of hyaline cartilage, but the apex is created by elastic cartilage. The corniculate and cuneiform are small bars of elastic cartilage that lie within the aryepiglottic fold, just above the apex of the arytenoid.

Membranes and Ligaments

The thyroid cartilage is suspended from the body and greater horn of the hyoid bone by the thyrohyoid membrane. This membrane is thickened in the midline and at each edge, creating the median and lateral thyrohyoid ligaments. The median cricothyroid ligament is a midline thickening between the anterior aspect of the cricoid arch below, and the inferior end of the thyroid cartilage above (Fig. 20.28). Other strong fibers arise from the remainder of the arch of the cricoid and pass superomedially. The anterior fibers pass to the internal aspect of the thyroid cartilage below the thyroid notch (Fig. 20.29). The posterior fibers attach to the vocal process and the base of the arytenoids. The fibers between these anterior and posterior attachments are free and are called the vocal ligaments. The vocal ligaments are the superior free edge of the cone-shaped structure that attaches below to the arch of the cricoid cartilage. It is called the conus elasticus and encloses the infraglottic space of the larynx (Fig. 20.30). The cricotracheal ligament attaches the cricoid to the first tracheal cartilage. Above the level of the vocal ligaments is a thinner membrane, which passes from the anterolateral surface of the arytenoid cartilage to the lateral edge of the epiglottis, below its superior edge, and to the thyroepiglottic ligament. This is the quadrangular membrane. The lower edge, between the arytenoids and the thyroepiglottic ligament, is free, and forms the vestibular ligaments, or false vocal cords. The distance between the vocal ligaments and the more superiorly located vestibular ligaments separates the conus elasticus and the quadrangular membrane from each other inferiorly. The two structures create the fibroelastic membrane of the larynx. Both are cone-shaped and are aligned so that they resemble an hourglass.

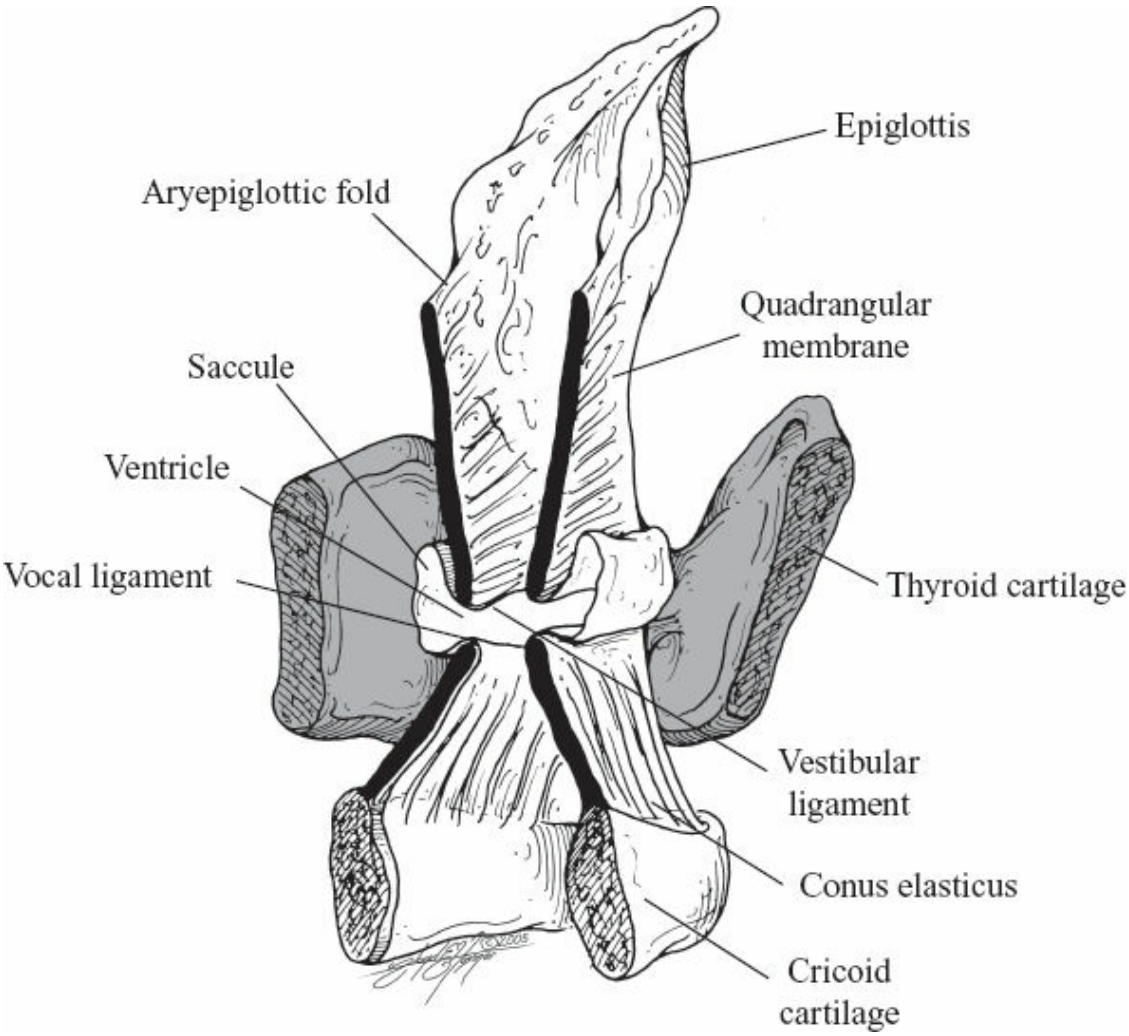

Figure 20.29. Membranes of the interior of the larynx.

Interior of the Larynx

The membranes and ligaments previously described are lined by mucosa. The larynx is divided into three portions (Fig. 20.29). The vestibule is superior and the infraglottic space is inferior. Separating these two areas is the ventricle. The vestibule is bounded anteriorly by the epiglottis. The quadrangular membrane is the lateral limit, and posteroinferiorly are the arytenoids and the interarytenoid fold. The mucosa covering the superior edge of the quadrangular membrane forms the aryepiglottic fold. The space between the aryepiglottic folds is the entrance into the vestibule. It is the laryngeal aditus. The mucosa covering the vestibular ligament creates the vestibular fold, which is the inferior end of the vestibule. The space between the vestibular folds is the rima vestibuli. Below the vestibular folds are the vocal folds. The mucosa covering the vocal ligaments creates the vocal folds. It is very adherent and has a white coloration. The mucosa of this fold is stratified squamous. The remainder of the laryngeal mucosa

is pseudostratified ciliated columnar. The space between the vocal folds is the rima glottidis. It is found 1/4 in below the rima vestibuli and is easily visualized by endoscopic examination through the wider rima vestibuli.

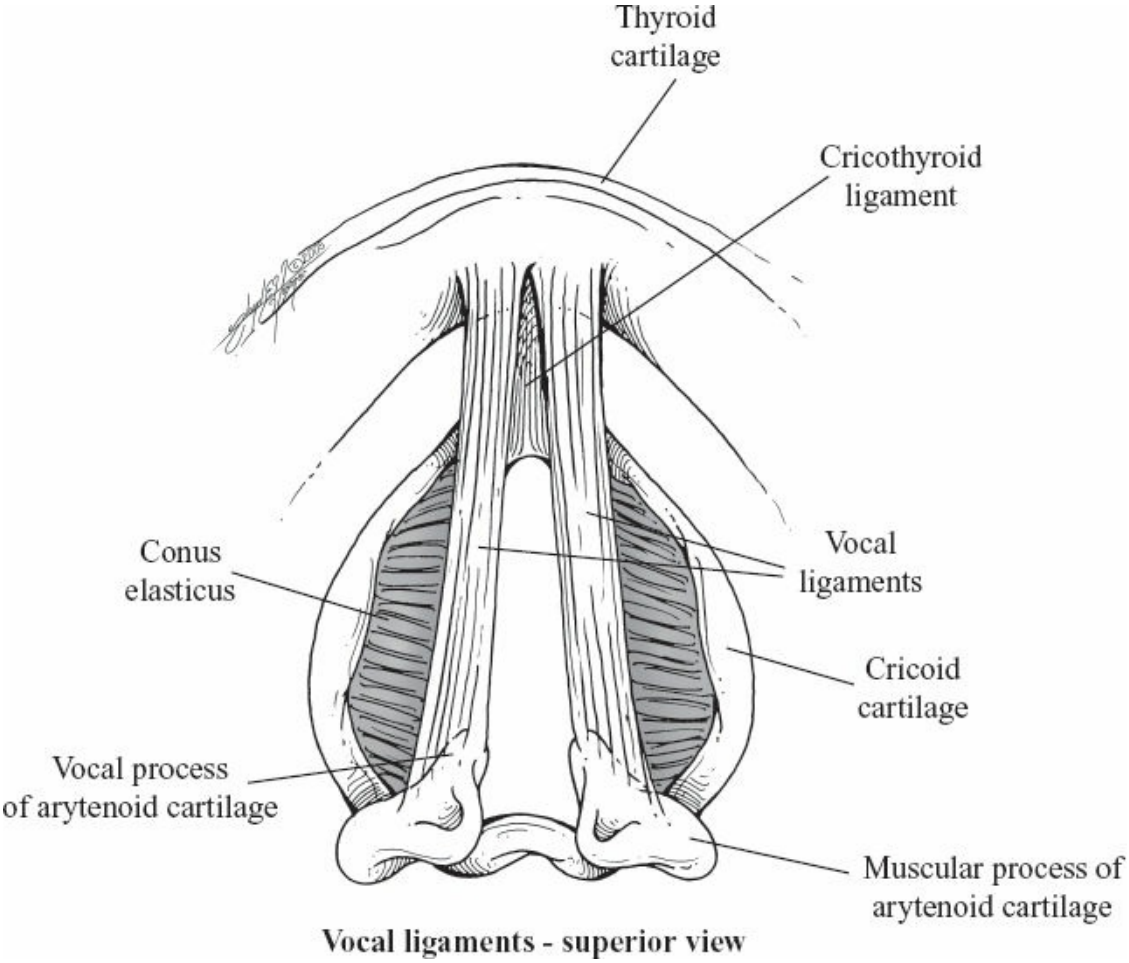

Figure 20.30. Superior view of the vocal ligaments.

The middle portion of the larynx is the ventricle. It separates the vestibule superiorly from the infraglottic space inferiorly. It is found between the rima vestibuli and the rima glottidis. The mucosa extends laterally between the vestibular and the vocal folds and creates the sinus. A small outpouching from this area ascends for a short distance, lateral to the vestibular fold, and creates the saccule. Numerous mucous-secreting glands are found here. The infraglottic space is internal to the conus elasticus and the cricoid cartilage. The rima glottidis is the upper limit, and inferiorly it is continuous with the lumen of the trachea.

Joints and Intrinsic Muscles of the Larynx

The cricothyroid and cricoarytenoid joints are synovial and created by

hyaline cartilaginous structures. The cricothyroid joint allows a pivoting movement, which elevates the arch of the cricoid cartilage while depressing the lamina and the arytenoid cartilages found on its superior surface (Fig. 20.30). This results in tensing of the vocal ligaments, which creates high-pitched sounds. The axis of rotation is transverse, through both cricothyroid joints. The cricoarytenoid joint permits two types of movements of the arytenoid cartilage. Rotation around a vertical axis passing through the arytenoids will result in adduction or abduction of the vocal ligaments. In addition, a gliding movement can occur, which allows the arytenoids to move toward, or away from, each other. The rima glottidis is triangular, and the base is the interval between the vocal processes. The transverse gliding movement, or the rotation of the arytenoids around a vertical axis, can result in either widening or narrowing of the rima glottidis. There are nine intrinsic muscles of the larynx, eight are paired and one is unpaired. Six of the paired and the unpaired act directly on the arytenoids, with resultant effect on the vestibular and vocal ligaments. The muscles can be divided into three functional groups. The first provides protection by sphincter-like activities. They are in the aryepiglottic fold. The aryepiglottic muscle passes from the posterior surface of the arytenoids to the lateral aspect of the epiglottis (Fig. 20.31). The thyroepiglottic muscle extends from the internal aspect of the thyroid lamina to the lateral aspect of the epiglottis. These muscles help close the laryngeal aditus. The second group of muscles tenses, relaxes, or adducts the vocal ligaments. The cricothyroid muscle, found between the arch of the cricoid and the internal aspect of the fused thyroid lamina, causes elevation of the arch of the cricoid and depression of the lamina. This results in tensing of the vocal ligaments. The thyroarytenoid muscle, which is found between the thyroid cartilage anteriorly, and the arytenoids oppose this action posteriorly. It pulls the vocal processes anteriorly and relaxes the vocal ligaments. Fibers from the medial aspect of this muscle attach directly to the vocal ligaments and can cause differential contraction and relaxation of portions of the vocal ligament. These specialized fibers are named the vocalis muscle. The lateral cricoarytenoid muscle, between the posterior portion of the arch of the cricoid and the muscular process of the arytenoids, is the main adductor of the vocal ligaments. The transverse arytenoid is the only unpaired muscle of the larynx; it passes between the arytenoids and causes narrowing of the rima glottidis and the rima vestibuli. The third group of muscles is

responsible for widening of the rima glottidis. The posterior cricoarytenoid muscle passes obliquely between the posterior surface of the cricoid lamina and the muscular process of the arytenoid. It widens the rima glottidis by abducting the vocal process of the arytenoid cartilage.

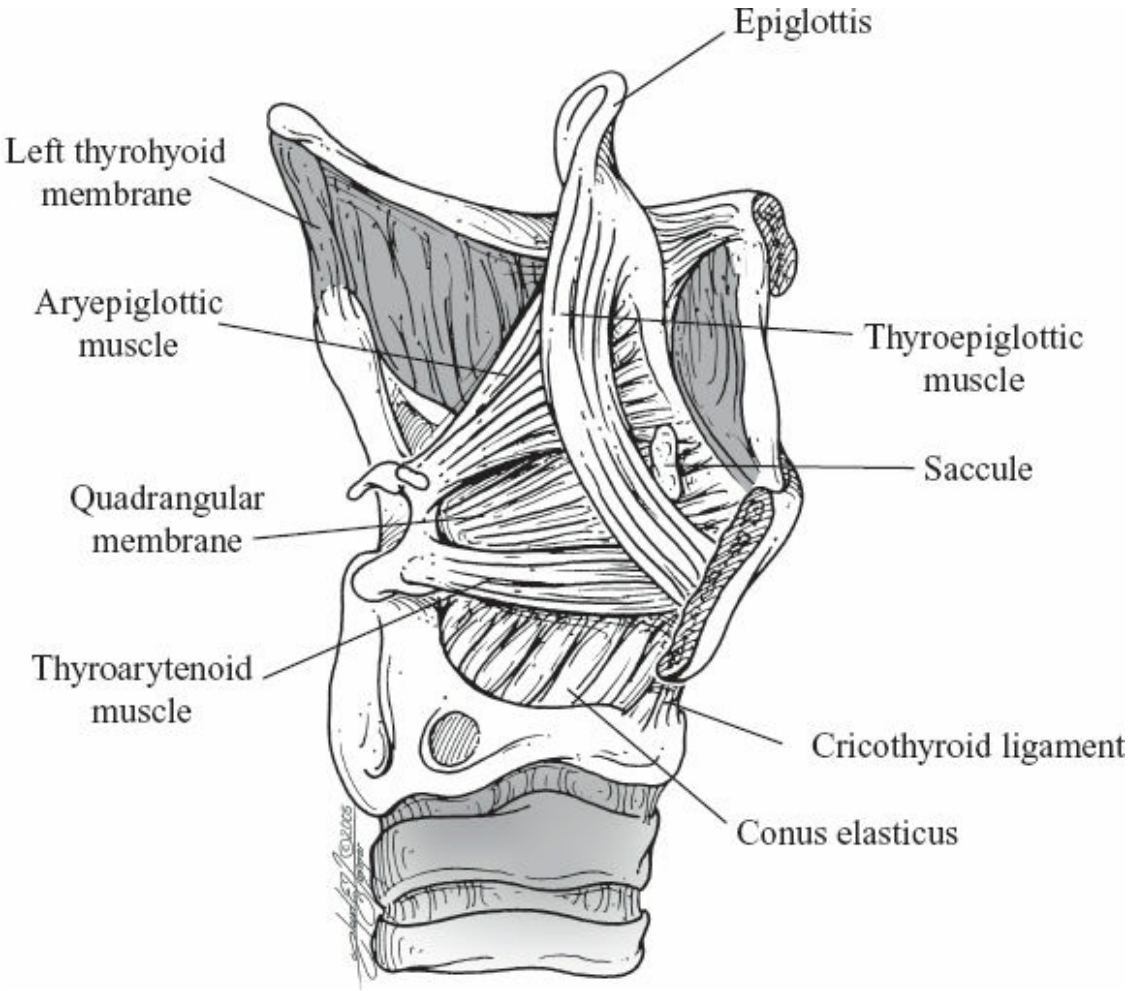

Figure 20.31. Interior of the larynx after the removal of the right portion of hyoid and thyroid cartilages.

Blood Supply and Nervous Innervation of the Larynx

The superior laryngeal branch of the superior thyroid artery provides vascular flow. It enters the larynx through the thyrohyoid membrane, along with the internal laryngeal nerve and superior laryngeal veins. Vascular inflow also occurs *via* the inferior laryngeal artery, a branch of the inferior thyroid that enters the larynx below the lower edge of the inferior constrictor muscle, along with the inferior laryngeal nerve. This nerve is the intralaryngeal continuation of the recurrent laryngeal nerve.

Vagus nerve branches provide all sensory and motor innervation. Sensory innervation, above the vocal folds, comes from the internal branch

of the superior laryngeal nerve. The inferior laryngeal nerve supplies sensory innervation to the infraglottic space and trachea. The external branch of the superior laryngeal nerve innervates the cricothyroid muscle. The inferior laryngeal nerve supplies all the other intrinsic laryngeal muscles.

Laryngeal nerve injury may occasionally occur during thyroid surgery. Knowledge of anatomy will allow the surgeon to perform any procedure, anywhere in the body, expeditiously and safely.

Division of the superior laryngeal nerve will cause loss of sensory innervation of the larynx above the vocal folds (internal laryngeal branch). The cough reflex will be lost. In addition, there will be loss of motor innervation of the cricothyroid muscle. The voice will become husky and unable to reach high tones.

Unilateral division of the recurrent laryngeal nerve will result in the vocal ligament being midway between adduction and abduction. This is the cadaveric position. The uninjured cord can cross the midline and approach its partner so that the voice changes may be minimal. If both recurrent nerves are cut, the vocal ligaments become lax, resulting in voice changes but no respiratory problems. Within several months, the voice will begin to reappear as a result of fibrotic changes and tightening of the vocal ligaments. This will also result in narrowing of the rima glottidis and the appearance of respiratory problems. If there is bilateral injury, created by crushing, stretching, or incorporation in a ligature, without transection, then a different set of symptoms may occur. Respiratory problems appear early. This may be explained by Semon's law, which states that in progressive disease of motor laryngeal nerves, the abductors are occasionally the only muscles affected. In addition, the unopposed action of the cricothyroid muscles, and narrowing of the rima glottidis and respiratory difficulties are to be expected.

SUPERFICIAL VENOUS SYSTEM

These veins and the other superficial neurovascular structures are deep to the platysma muscle.

1. Common facial vein is formed by the union of the anterior facial vein with the anterior division of the retromandibular (posterior facial) vein. It passes over the submandibular triangle and the posterior belly of the digastric muscle, and empties into the internal jugular vein in the superior portion of the carotid triangle.

2. External jugular vein is created by the union of the posterior auricular vein with the posterior division of the retromandibular vein. The vein passes inferolaterally, runs obliquely across the superficial aspect of the sternocleidomastoid muscle, pierces the deep cervical fascia in the subclavian division of the posterior triangle, and empties into the subclavian vein. The great auricular nerve (C2, C3) is posterior to this superficial vein in the upper part of the neck.
3. Anterior jugular vein begins in the suprahyoid portion of the neck and descends vertically, close to the midline, down to the clavicle. It then pierces the investing layer of the deep cervical fascia, passes deep to the sternocleidomastoid, and ends in the ipsilateral external jugular vein. It frequently gives a branch in the suprasternal area that crosses the midline and joins with the contralateral anterior jugular vein. This transverse communicating branch is referred to as the jugular venous arch.
4. Vein of Kocher arises in the submandibular area as a branch of the anterior facial vein, descends on the anterior edge of the sternocleidomastoid muscle, and terminates in the jugular venous arch, or the internal jugular vein.

LYMPHATIC PATHWAYS OF THE NECK

The lymphatic pathways of the neck (Fig. 20.32) can be divided into a superior horizontal group found at the junction of the head and the neck. It includes the submental, submandibular, parotid (preauricular), mastoid (postauricular), and occipital nodes. It creates a ring of lymph nodes in this area.

1. A vertical group that receives the lymphatic drainage from the superior horizontal components (Fig. 20.33). There are three pathways possible in this grouping. (a) The posterior cervical group consists of superficial nodes traveling with the external jugular vein and a deep group of nodes that journey with the spinal accessory nerve (XI). They are in the posterior triangle. (b) The jugular group is intermediate in position and is frequently referred to as the deep cervical group. This pathway is the most important. It consists of nodes at several levels, as this vertical channel descends with the internal jugular vein. There is a juguloparotid node located near the angle of the mandible, a jugulodigastric node where the posterior belly of the digastric muscle crosses the internal jugular vein, a jugulocarotid node near the bifurcation of the common carotid artery, and a jugulo-omohyoid node

where the omohyoid muscle crosses the internal jugular vein. The jugulodigastric node receives drainage from the tonsil. The jugulo-omohyoid node receives drainage from the tongue. (c) The visceral chain is the most anterior of the vertical pathways and drains all the cervical viscera. The individual components of this nodal chain are parapharyngeal, paralaryngeal, prelaryngeal or Delphian, paratracheal, and pretracheal. The Delphian node is a constant finding and receives lymphatic drainage from the larynx and the thyroid gland.

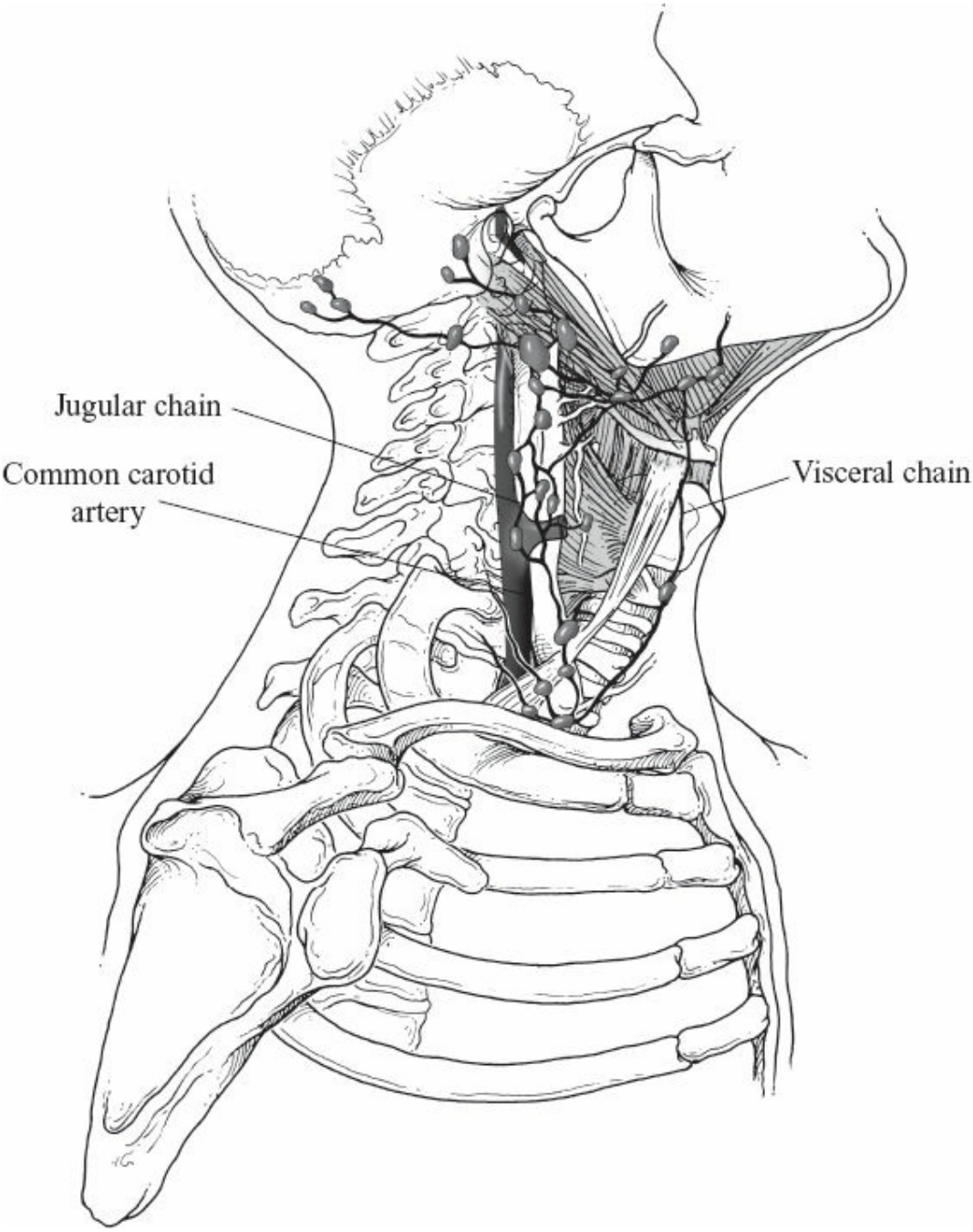

Figure 20.32. Deep lymphatic drainage.

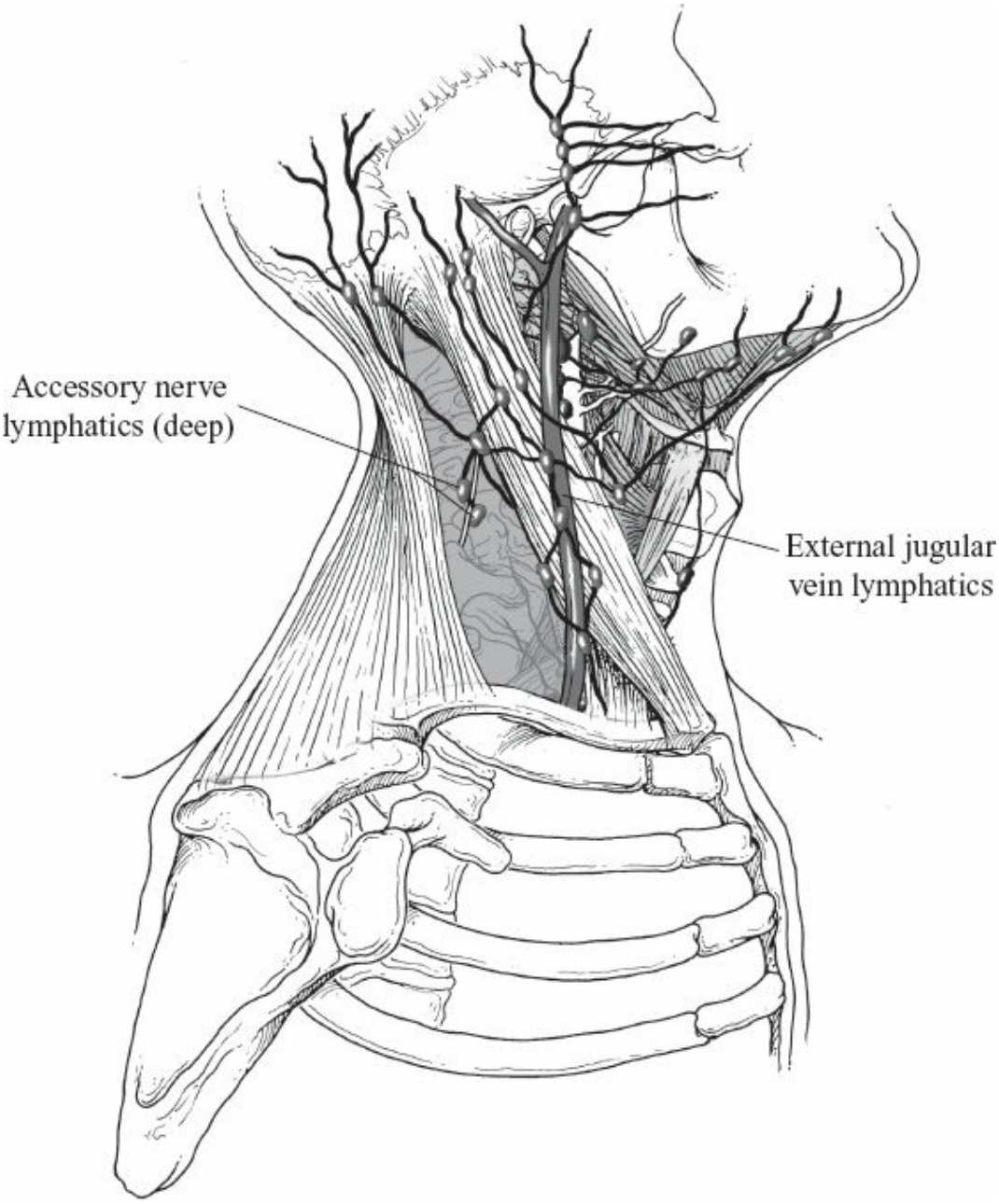

Figure 20.33. Lymphatic drainage.

2. An inferior horizontal group, called supraclavicular nodes, is found in the subclavian triangle. They receive lymphatic flow from the vertical cervical channels and the upper extremity, axilla, and the thoracic wall. They communicate, by way of efferent channels, with internal jugular and subclavian conduits. Some of these supraclavicular nodes lying anterior to the anterior scalene muscle are referred to as scalene nodes. They receive bronchomediastinal channels from the thorax and may be enlarged as a result of spread from an intrathoracic disease process.
3. The thoracic duct receives inflow from all lymphatics below the respiratory diaphragm, the left hemithorax by way of the left

bronchomediastinal trunk, the left side of head and neck *via* the left vertical cervical trunks, and from the left upper extremity through the left subclavian trunk. It empties into the venous system on the lateral aspect of the junction between the left internal jugular and the left subclavian veins. The trunks may enter separately into the venous circulation. On the right side, it is unusual for the bronchomediastinal, subclavian, and vertical cervical trunks to combine before entering the venous circulation. They frequently empty, as separate entities, into the vascular compartment.

Suggested Readings

Arnold M. *Reconstructive Anatomy: A Method for the Study of Human Structure.* Philadelphia: WB Saunders; 1968.

Healey JE, Hodge J. *Surgical Anatomy*, 2nd ed. Philadelphia: BC Decker; 1990.

Leeson CR, Leeson TS. *Human Structure: A Companion to Anatomical Studies.* Philadelphia: WB Saunders; 1972.

Thorek P. *Anatomy in Surgery.* Philadelphia: JB Lippincott; 1951.

EDITOR'S COMMENT

There is little attention paid nowadays to the neck. It is almost as if general surgeons are abrogating their responsibility and interest in the neck except in cases of diseases of the thyroid and parathyroid, and even in those circumstances, interest may be waning, or at least the interest of others such as otorhinolaryngologists seems to have increased. The reason for this is difficult to know.

1. Otorhinolaryngologists were liberated from the destructive surgery, for example, in mastoids and with otitis media, with the advent of effective antibiotics. In addition, pharyngeal neck abscesses from various colds and infections also vanished from the scene with effective antibiotics. Thus, they tried to reinvent themselves in the same area in which they were trained, but in which much of the destructive surgery based on infectious disease was not cared for with antibiotics. In those cases, they turned, as well as others, from destructive surgery to constructive surgery.
2. The rise of oral surgery. Oral surgery emerged as differentiated from dentistry some time in the early 1940s and gradually developed in the 1950s and 1960s. Carcinoma of the tongue, carcinoma of the tonsil, and pharyngeal maxillary cancer to a certain extent. This was also when submandibular cancer became part of the repertoire of the oral surgeon in some geographical areas.

3. General surgeons were held in sway by some leaders who didn't believe in the resection of nodes for thyroid cancer. A papillary carcinoma, of course, has a low mortality, and so it is difficult for some surgeons to believe that general surgeons, especially those taking care of thyroid cancer, should pursue the adenopathy, since mortality is so low. Others believed that carcinoma of the thyroid could be treated with psychiatry. In any event, this tide has turned, and at this point in time, most surgeons dealing with thyroid cancer have gotten much more aggressive at attacking the adenopathy with node dissections.
4. Other specialties began to concentrate on parathyroid surgery, which previously was the field of general surgery and endocrine services. In other chapters of this book, it does appear that the rates of success between ENT surgeons and general surgeons differ. In some of the well-recognized centers for parathyroid surgery, a success rate of 99% is expected. For those in the ENT field, it does appear as if perhaps a 95% or 96% rate of success in "curing" hypoparathyroidism is the norm.

In addition, medical schools stopped teaching anatomy. As medical schools became more research oriented, bragging rights was not about how well the students were taught but was about the NIH grants and the total number of NIH dollars appropriated to that school. In addition, in schools that have not given up anatomy, there were inappropriate instructors who were utilized to [make] up the funds that were [not] appropriated in their NIH grants. A classic example of this is to have acute abdomen taught by internists who were not called to the emergency room to see patients with acute abdomen. In many schools, surgeons are no longer asked to teach the acute abdomen. It is also now thought that medical students can learn in a truncated general surgery rotation, which is now increasingly shared with other surgical specialties, such as ophthalmology, in the time frame which in the past was solely utilized by general surgery. I am not criticizing ophthalmology in this statement, but I am just pointing out that those surgical specialties have now lost their own space to surgery time.

One appreciable thing about this chapter is that Professor Ruhalter is very well aware of clinical correlation and anatomic correlation. I just list these because I think they are of interest and have some clinical relevancy.

Anatomic goodies:

1. The cricoid bone is an anatomic bonanza, as is detailed in this chapter.
2. The superior surfaces of the first rib are flattened, so that neurovascular structures can travel over it without compression. This, of course, is true of thoracic outlet syndrome, in which the vasculature and sometimes the nerves are compressed.
3. The subclavian artery passes over the posterior sulcus of the scalene tubercle. The anterior scalene muscle attaches to the first rib between the subclavian vessels and, therefore, is in a position to compress the subclavian artery, giving rise to the thoracic outlet syndrome.

4. The cervical sympathetic chain has as its apex a “dumbbell-shaped structure, called the cervicothoracic, or stellate, ganglion.” The reason for it being called stellate ganglion is that it is star-like and gives out the multiple branches. The stellate ganglion, when invaded by a tumor at the apex of the lung on one side or the other, gives rise to the Horner’s syndrome and is often the first symptom or sign of the presence of that tumor.
5. The brachial plexus is formed by the ventral rami of C5 through T1. These nerve roots will form three trunks—C5 and C6 form the upper trunk, C7 root forms the middle trunk, and C8 and T1 form the lower trunk. These pass between the middle and anterior scalene muscles.
6. The lower trunk of the brachial plexus is draped over the first rib immediately posterior to the subclavian artery.
7. The fascia of the neck: The superficial fascia, which is often is not well developed, forms the platysma, which may or may not be very robust; the cervical branch of the facial nerve enervates the platysma, which contributes to facial expression.
8. The cutaneous branches and the superficial veins are below the muscles of facial expression, which are the platysma.
9. Deep cervical fascia: The superficial or investing layer of the deep cervical fascia splits to surround the trapezius and the sternocleidomastoid muscle and the submandibular and parotid glands.
10. The carotid sheath, which is part of the deep cervical fascia, surrounds the common carotid, the internal jugular, and the vagus nerve. The vagus nerve is between the common carotid and the internal jugular, which is somewhat posterior to the common carotid.
11. When the common carotid artery divides the internal carotid, it immediately goes anterior to the carotid, except at the base of the skull; the vein is anterolateral to the artery.
12. The sympathetic chain is in contact with the posterior sheath.
13. The thoracic duct is to the left of, and posterior to, the esophagus. It enters at the junction of the internal jugular vein and the subclavian vein.
14. The right lymphatic duct, which is the counterpart of the left thoracic duct, is not large as the thoracic duct and consists of several smaller lymphatics. It drains the right upper extremity and the upper right hemithorax.
15. The right recurrent laryngeal nerve loops around the right subclavian. The left recurrent nerve loops the aortic arch on the left. The right recurrent nerve is less well protected, as it comes up lateral to the tracheoesophageal groove, but, to get to the tracheoesophageal groove on the right, it is more superficial and more widely exposed.
16. Sibson’s fascia is at the apex of the lung and runs between C7 and the first rib. It is somewhat protective of the apex of the lung.
17. The inferior thyroid artery is superficial to the prevertebral fascia. It courses posterior to the carotid sheath and anterior to the vertebral artery.
18. The last branch given off by the subclavian artery, as it goes from medial to

lateral, is the internal mammary, which then travels behind the sternum and attaches to the sternum medial to the ribs.

19. The anatomy of the root-of-the-neck compression syndromes includes the following:
    a. Costoclavicular compression syndrome.
    b. Cervical-rib compression syndrome.
    c. Anterior scalene compression syndrome (thoracic-outlet syndrome).
    d. Pectoralis minor syndrome.
20. The following are the clinical anatomic applications, which are practical in the surgery of this area.
21. Cervical incisions should be made parallel to the skin lines for good cosmesis.
22. Control of bleeding may be possible, if the common carotid artery is compressed against the transverse mass of the sixth cervical vertebra, which is the cricoid plane.
23. The hyoid bone is the central structure of the neck. Most of the structures of the neck—muscular and membranous—attach to the hyoid bone. If one considers the hyoid bone and the attached posterior belly of the digastic muscle, it is possible to divide the anterior triangle into suprahyoid and infrahyoid portions.
24. The vagus nerve is behind and slightly posterior to the carotid and internal jugular vessels.
25. The posterior belly of the digastic muscle is superficial to the neurovascular structures and presses them against the pharyngeal wall. Therefore, owing to this structure, incisions can be made without the risk of injuring the nerves or arteries.
26. The intermediate tendon of the omohyoid between the two bellies is in the cricoid plane with a number of other venous and tendinous structures.
27. The transection of the strap muscles closer to the superior end will preserve the nervous innervation, since the nerve enters the muscle near the inferior end. Most individuals who divide the strap muscles to get at the thyroid do so at the interior end. Personally, I have never been taught that one divides the strap muscles at the superior end because the nerve enters inferiorly, but it is something good to remember, because one of the cosmetic difficulties following thyroid surgery is the denervation of the strap muscles, at times with a bulge in the lower neck.
28. When one enters the cleavage between the sternothyroid muscle and the thyroid gland, this provides excellent exposure of and facilitates surgical approach to the gland, which is avascular.
29. The long thoracic nerve originates from C5, C6, and C7 and courses inferiorly, passing to the other portions of the brachial plexus, and then passing over the first rib to reach the superficial surface of the serratus ventralis, which it innervates.
30. Dissection on the posterior triangle is safe in the area superior to the spinal

accessory nerve.

31. A good landmark for the upper thyroid glands is that they are usually at the level of the thyroid cartilage.
32. If there is a high origin of the recurrent laryngeal nerve, it may not be in the tracheoesophageal groove and it is called a nonrecurring nerve. Obviously, if there is a high origin, it is more exposed and not protected by not being in the tracheoesophageal groove.

The neck is a very hostile place from the standpoint of anatomy. We are very privileged to have an anatomist of Professor Ruhalter's skill and knowledge to keep us out of trouble.

J.E.F.

21 Surgery of the Major Salivary Glands

Carol M. Lewis and Michael E. Kupferman

INTRODUCTION

Surgery of the major salivary glands (parotid, submandibular, and sublingual) requires an understanding of the anatomy of a small region of the human body. Surgical knowledge of this area for either preservation or safe extirpation of critical structures enables the surgeon to determine appropriate indications for surgical intervention and to competently perform such procedures. This holds true for trauma, infection, obstruction, or neoplasm. This chapter focuses on the indications for surgery, as well as surgical approaches to the sublingual, submandibular, and parotid glands.

ANATOMY

The parotid gland extends from the zygoma superiorly, the external auditory canal posteriorly, the masseter muscle anteriorly, and lateral pharyngeal space medially. Inferiorly, the gland extends over the sternocleidomastoid muscle (SCM) and mastoid tip; this portion is called the tail of the parotid. The facial nerve runs through the gland, and surgically serves to separate the superficial from deep lobes, although these distinctions are not anatomic. The parotid gland empties into Stenson duct, which is located at the anterior superficial lobe roughly mid-way between the zygomatic arch and the corner of the mouth, and travels over the masseter, not uncommonly with accessory parotid tissue. It pierces the buccinator muscle and empties through a papilla opposite the maxillary second molar (Figs. 21.1 and 21.2).

The facial nerve exits the skull base through the stylomastoid foramen. Its main trunk can be found roughly 1 centimeter (cm) medial and inferior to the cartilaginous tragal pointer and 0.5 to 1 cm deep to the tympanomastoid suture line, at roughly the level of attachment of the posterior belly of the digastric muscle. The facial nerve can also be

identified intratemporally in the mastoid tip or peripherally with retrograde dissection. Within the parotid gland, the main trunk of the facial nerve splits into temporofacial and cervicofacial divisions at the pes anserinus, the temporofacial segment supplies the temporal, zygomatic, and buccal branches, while the cervicofacial segment supplies the marginal mandibular and cervical branches.

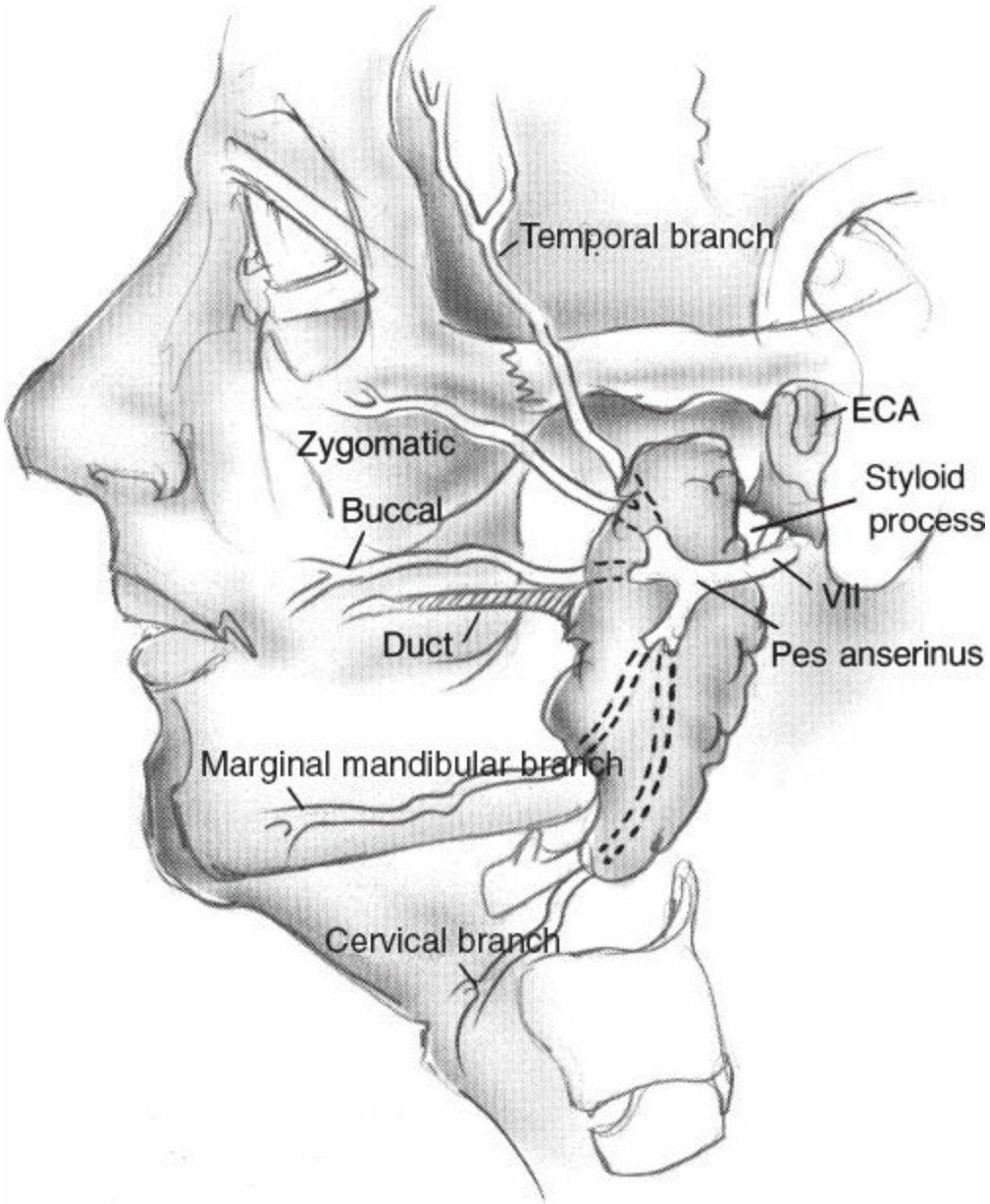

Figure 21.1. The parotid gland and the facial nerve. Note that the nerve exits the stylomastoid foramen lateral to the styloid process. Also, note the relationship of the nerve branches to the surrounding structures.

The mylohyoid muscle separates the sublingual space from the

submandibular triangle. The sublingual space is bounded anteriorly and laterally by the mandible, superiorly by the mucosa of the floor of mouth, and inferiorly by the mylohyoid muscle. This space contains the sublingual gland and associated connective tissue, the hypoglossal nerve, and the deep portion of the submandibular gland (Fig. 21.3).

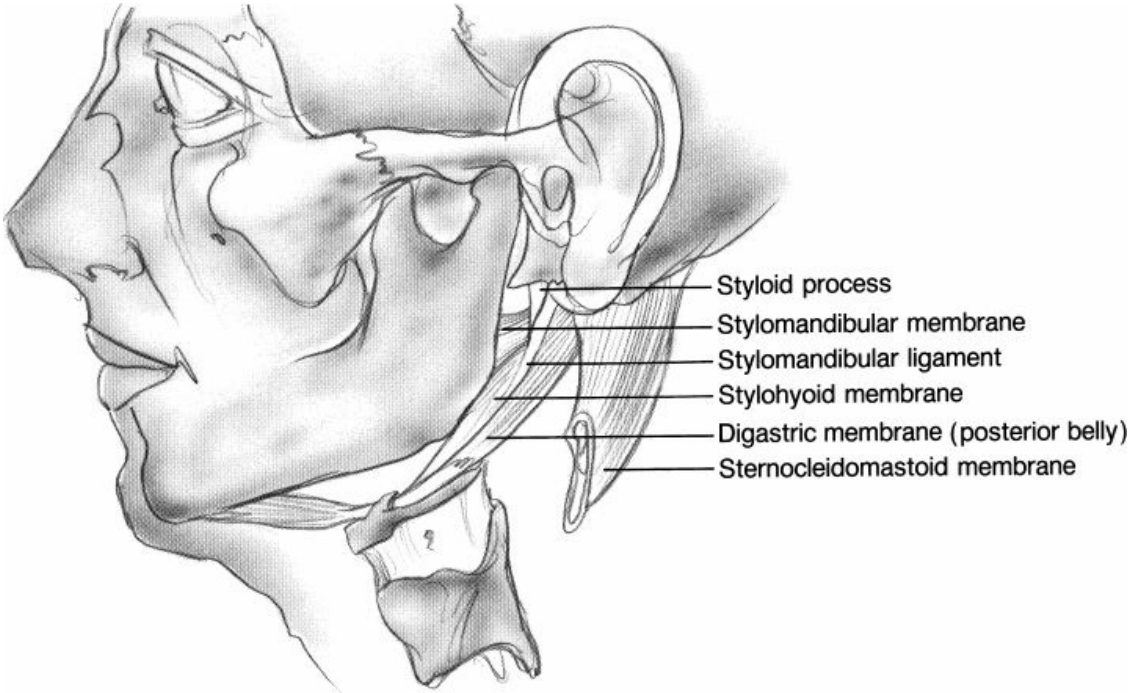

Figure 21.2. Stylomandibular membrane (deep layer of parotid fascia). Herniations of parotid tissue through this membrane can result in a parapharyngeal mass.

The submandibular triangle is bounded anteriorly by the anterior belly of the digastric muscle, superiorly by the inferior border of the body of the mandible and the mylohyoid muscle, inferiorly by the trochlea and posterior belly of the digastric muscle, and posteriorly by the posterior border of the submandibular gland (Figs. 21.3 and 21.4). This triangle contains the submandibular gland and associated Wharton duct, lingual nerve and submandibular ganglion, hypoglossal nerve, and neurovascular bundle to the mylohyoid muscle. It is imperative to be familiar with these structures and their anatomic relationships both in neutral and surgical positions.

CLINICAL, RADIOLOGIC, AND PATHOLOGIC EVALUATION

The evaluation of every patient begins with a thorough history and physical examination. Significant tenderness usually indicates acute infection, but can occasionally be attributed to neoplasms predisposed to perineural involvement, such as adenoid cystic carcinoma. Fluctuation of the size of the mass, most notably when eating, is a characteristic of an obstructed parotid or submandibular gland. Given the potential for disease metastatic to the lymph nodes of the parotid or submandibular triangle, any history of previous cancer is relevant; in addition to cancers of the upper aerodigestive tract or skin of the head and neck, breast, lung, gastrointestinal tract, or genitourinary tract can metastasize to this region. Occasionally, squamous cell carcinomas of the oral cavity can involve the sublingual or submandibular glands by direct extension.

Prior to the specific examination of the parotid or submandibular triangle, a thorough head and neck examination, including inspection of the upper aerodigestive tract and the skin of the head and neck, is mandatory. Cervical palpation should be performed to identify any associated lymphadenopathy or masses in other levels of the neck. Bimanual palpation is a useful diagnostic maneuver to evaluate the floor of mouth or submandibular triangle, performed with one finger palpating intraorally and the other hand assessing the mass from the neck. The mass should be evaluated for qualities such as tenderness, mobility, consistency (solid vs. cystic), and whether it is single, multiple, or lobulated. In addition, intraoral palpation allows for evaluation of calculi along Wharton duct or Stenson duct in cases of sialadenitis. Examination of the lateral oropharyngeal wall may reveal a tumor of the parapharyngeal space, which may be a deep lobe parotid mass. A cranial nerve examination with specific attention to the facial, trigeminal, and hypoglossal nerves is critical; cranial neuropathies are suggestive of malignancy.

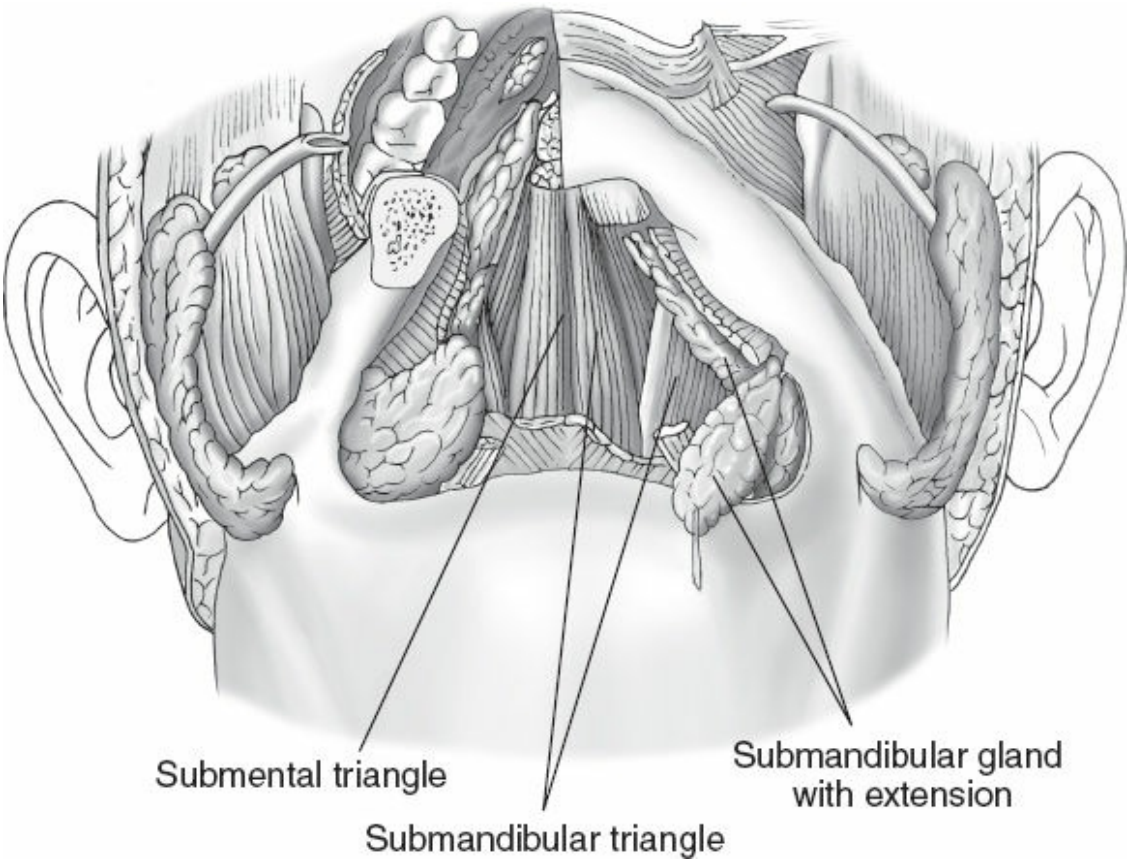

Figure 21.3. The submental triangle is bounded by the mandible, mylohyoid muscle (cut edge shown here), and superiorly by the oral mucosa.

The utility of fine-needle aspirate biopsy (FNAB), often performed in conjunction with an ultrasound, is controversial. While an FNAB may provide a preliminary diagnosis, some may argue that surgical removal will be necessary regardless. However, if the FNAB reveals a salivary gland malignancy, the surgical approach may require a comprehensive neck dissection. Further, the patient may need to be counseled on the role of cranial nerve resection, should a malignancy involve these structures. In addition, if the FNAB demonstrates carcinoma that is not of salivary gland origin, the work-up should involve identification of the primary tumor. Of note, FNAB is 80% to 90% sensitive for the diagnosis of salivary gland malignancies. Thus, FNAB findings may impact both work-up evaluation and surgical planning.

Axial imaging, most commonly computed tomography, can be helpful in determining if a mass is in, adjacent to, or invading the gland, as well as its cystic or solid qualities. It can also demonstrate other associated lymphadenopathy or, if the lesion is metastatic, the primary tumor.

Alternatively, ultrasound or magnetic resonance imaging scan may be performed. A sialogram is useful if obstructive sialadenitis is suspected. Metabolic imaging is indicated for suspected metastatic disease to other sites or metastatic disease to the salivary glands.

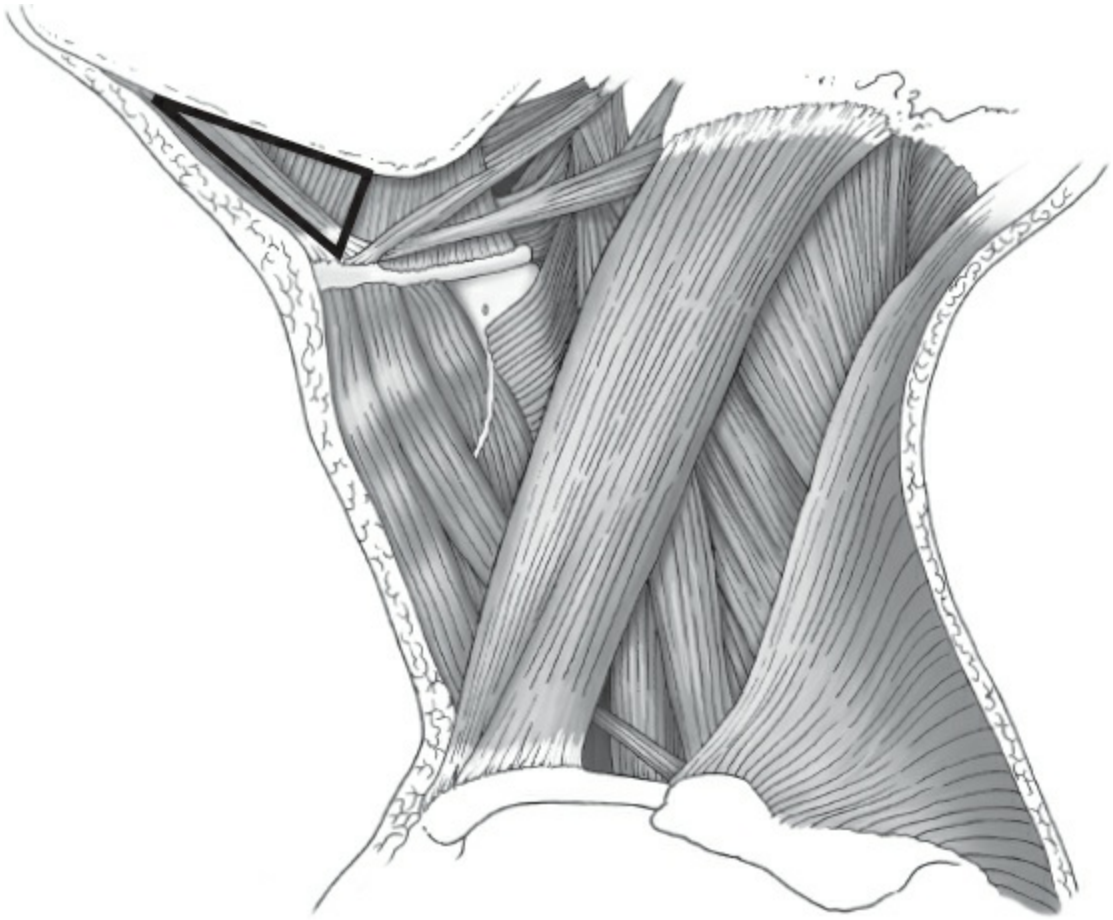

Figure 21.4. The muscular boundaries of the submandibular triangle.

INDICATIONS FOR SURGERY

The most common indications for removal of the parotid or submandibular glands are suspicion of neoplasm and chronic obstruction of Stenson duct or Wharton duct by calculi with resultant sialadenitis. Neoplasms of the sublingual gland are rare, with most sublingual gland excisions being performed for ranulas.

Neoplasm

The incidence of salivary gland tumors in the general population is 2.5 per 100,000, representing 0.3% of all cancers and 1% to 3% of all head and

neck tumors. There are various neoplasms that may involve the parotid, submandibular, and sublingual glands; submandibular and sublingual salivary gland neoplasms represent 70%, 7% to 15%, and <1% of all salivary gland tumors, respectively. Of these neoplasms, 25% of parotid, 40% to 50% of submandibular gland, and >70% of sublingual gland neoplasms are malignant. The more common neoplasms and their defining characteristics are detailed here.

Pleomorphic adenoma (benign mixed tumor) is the most common benign salivary neoplasm, accounting for roughly 80% of benign salivary gland tumors. Histologically, it contains mesenchymal, epithelial, and myxoid stromal components. This tumor is slow growing, nonpainful, and nontender, and can recur if not completely excised. It also has the potential for malignant degeneration (carcinoma ex pleomorphic adenoma), often heralded by rapid growth and/or neurologic symptoms.

Warthin tumor (papillary cystadenoma lymphomatosum) is the second most common benign salivary gland tumor, comprising roughly 10%. Warthin tumors are found predominantly in the parotid, and can be bilateral in 10%. These tumors have an association with smoking. These tumors may recur if not completely excised or if multifocal disease is not completely removed.

Adenoid cystic carcinoma is the most common submandibular gland malignancy, comprising 15% to 43% of malignancies at this site; 47% extend through the capsule on presentation. Ten to fifteen percent of adenoid cystic carcinomas occur in the parotid. A hallmark of this tumor is perineural invasion, such that postoperative radiotherapy is indicated with this diagnosis. Patients must have at least a 10-year follow-up due to the frequent occurrence of delayed recurrence or distant metastasis; a 39% 10-year survival is expected. There are three histologic varieties: cribriform, tubular, and solid; the solid variety carries a worse prognosis. This disease is associated with a high rate of local recurrence, and distant metastasis—most commonly, pulmonary occurs in approximately 50% of patients. These patients have a median survival of 3.5 years after the identification of distant disease.

Mucoepidermoid carcinoma is the most common salivary gland malignancy of the parotid, comprising about 70% of parotid malignancies. It is the second most common malignant tumor of the submandibular gland, comprising 17% of all submandibular malignancies. Histologically, it is composed of mucoid and epithelial elements; the higher the amount of

the epithelial component, the higher the grade of the tumor. Low-grade tumors have a good prognosis (71% 5-year survival); high-grade tumors are more aggressive and are associated with worse prognoses. The latter usually requires postoperative radiation and accompanying neck dissection at the time of primary tumor removal. Controversy exists regarding the outcomes of patients with intermediate-grade tumors, but emerging data suggests that these patients have favorable outcomes that approximate those with low-grade tumors.

Adenocarcinoma accounts for 16% to 20% of salivary gland malignancies. Histologic patterns include papillary, acinus, and solid; the amount of glandular elements determines the grade. These tumors are aggressive and tend to recur; intermediate- and high-grade histology usually indicates the need for postoperative radiotherapy.

Squamous cell carcinoma comprises 5% of salivary gland malignancies. The differential diagnosis should include high-grade mucoepidermoid carcinoma, metastases, and contiguous spread. There is a very poor prognosis (24% 5-year survival) associated with this disease and postoperative radiotherapy is generally indicated.

Malignant mixed tumor generally presents as a slowly growing mass that has a sudden increase in size, and accounts for 5% to 12% of salivary gland malignancies. The malignant component of the tumor may be undifferentiated carcinoma, adenocarcinoma, or squamous cell carcinoma. A 56% 5-year survival and 31% 10-year survival are to be expected.

Sialadenitis

A submandibular or sublingual mass is most commonly sialadenitis caused by sialolithiasis. Eighty percent, 5%, and 1% of salivary calculi occur in the submandibular, parotid, and sublingual gland, respectively. A single stone is the cause in 75% of cases. If the calculus can be palpated along the course of Wharton duct or Stenson duct intraorally, an incision may be made just above the stone to release it. Medical management includes frequent massage of the gland, sialogogues, and hydration; antibiotics may be indicated if purulence is expressed from the duct with gland massage. Multiply recurrent sialadenitis with calculi can be treated with lithotripsy, sialoendoscopy with basket retrieval of stones, or excision of the submandibular gland.

Other causes of sialadenitis include neoplastic obstruction and ductal stenosis. The latter can be addressed using sialendoscopy with sialoplasty

or with removal of the gland.

Ranula

The term *ranula* derives from the Latin word for *frog*, so named because of the appearance of patients with plunging ranulas. A simple ranula can be either a mucus retention cyst or pseudocyst from mucus extravasation that is confined to the floor of the mouth. A plunging ranula is a mucus extravasation pseudocyst arising from the sublingual gland that extends into the neck, either through the muscular dehiscence for the neurovascular bundle of the mylohyoid muscle or around the posterior border of the mylohyoid muscle. This usually presents as a soft, cystic neck swelling. If any portion of the suspected ranula is solid to palpation, the possibility of a neoplasm should remain in the differential diagnosis. Also, although rare, lymphatic malformations should remain in the differential diagnosis, particularly in children.

Drainage of the cyst, either spontaneously or by aspiration, usually results in recurrence. Observation is appropriate if the ranula is small and does not interfere with tongue function. Marsupialization of the cyst results in a 50% recurrence rate. The most definitive treatment of a ranula is excision of the sublingual gland with the pseudocyst; this reduces the recurrence rate to <2%. Most small ranulas can be excised with the sublingual gland transorally, taking care to identify and preserve the lingual nerve. The approach for a sublingual gland neoplasm that is suspicious for cancer should be done transcervically by retracting the mylohyoid muscle anteriorly for a more definitive procedure.

SURGICAL TECHNIQUE

Parotidectomy

Patients are positioned with their head turned to the side opposite the tumor and draped to expose the entire ipsilateral face for monitoring of facial nerve function during surgery. A shoulder roll should be placed if the need for a neck dissection is anticipated. A discussion with the anesthesia team beforehand should emphasize the need to avoid paralysis for facial nerve monitoring. Such monitoring may take the form of having an assistant observe the patient’s face for movement intraoperatively or more formal electromyographic (EMG) monitoring; the latter is most commonly used for revision surgeries or cases in which dissection is

anticipated to be difficult, such as a setting of chronic inflammation.

A modified Blair incision is most commonly used, extending vertically in a pre-tragal crease, curving posteroinferiorly around the earlobe and tail of parotid, and ending horizontally in a natural skin crease 2 or more cm below the angle of the mandible. Alternatively, the incision could continue posteriorly in the postauricular hairline (as a facelift incision), but this approach is generally reserved for known benign disease involving the tail or mid-parotid. A hatch mark should be made before incision to assist with proper alignment of the earlobe at closure. Skin flaps are elevated in a subcutaneous fascial plane to the anterior aspect of the parotid gland; care must be taken not to extent this dissection too far anteriorly over the masseter where distal facial nerve branches become superficial.

The tail of parotid is then elevated off of the underlying SCM. The greater auricular nerve is generally sacrificed, although postauricular branches should be preserved when possible. The posterior belly of the digastric muscle is identified at the anterior border of the SCM near the angle of the mandible and followed posteriorly to the mastoid. Overlying parotid parenchyma should be dissected off of these muscles. Superiorly, the parotid is the then dissected off the tragal cartilage in a supraperichondrial plane down to the palpable tragal pointer. The tympanomastoid suture line should be palpable at this point. Meticulous dissection using bipolar cautery for hemostasis should be used to identify the main trunk of the facial nerve as it exits the stylomastoid foramen; it is usually identified 1 cm inferomedial to the tragal pointer and 0.5 to 1 cm deep to the tympanomastoid suture line, at the level of the attachments of the posterior belly of the digastric muscle.

Once identified, the nerve is followed carefully into the gland with dissection proceeding over and parallel to the direction of the nerve, with division of overlying parotid parenchyma. Once the pes anserinus is encountered, dissection then proceeds in a stepwise fashion along the branches of the facial nerve in such a way that the superficial lobe and tumor are removed en bloc. The patient’s face should be closely monitored for movement to avoid injury to the facial nerve. Once adequate margins of parenchyma are obtained around the mass, the parotid and tumor are removed. Branches of the facial nerve should never be sacrificed unless there was a loss of function preoperatively or the nerve is encased in malignant tumor; every effort should be made to preserve nerves that are adherent to tumors, even in the case of malignancy. Nerve grafting should

be considered in cases where facial nerve sacrifice is expected.

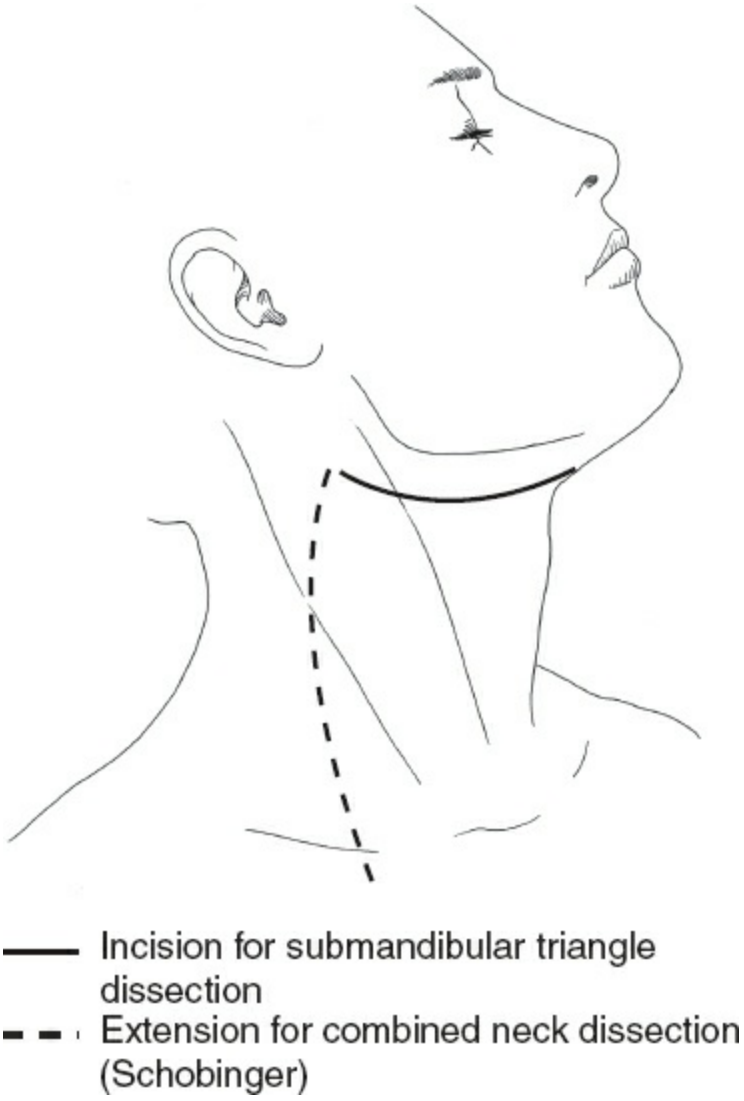

Figure 21.5. Incision site for a submandibular triangle dissection and extension for combined neck dissection.

The wound bed is then irrigated and hemostasis obtained with bipolar cautery. The incision is then closed in layers, after placement of a bulb suction drain.

The most common complication is hematoma. Infection is a rare complication, occurring in less than 5% of cases. Unintentional facial nerve injury has been reported in 3% to 5%; if the nerve has been left intact, however, full recovery should be expected. Sialoceles are rare when bulb suction drain is used; these are managed most often with repeat aspiration and compression dressings, and rarely with oral anticholinergics and Botox injection. Gustatory sweating (Frey syndrome) results from

aberrant regrowth of parasympathetic fibers into skin, possibly facilitated by excessively thin skin flaps; despite a high actual incidence, only a small percent of patients are symptomatic and can be managed with antiperspirants or topical anticholinergic agents, with Botox injection reserved for more severe cases.

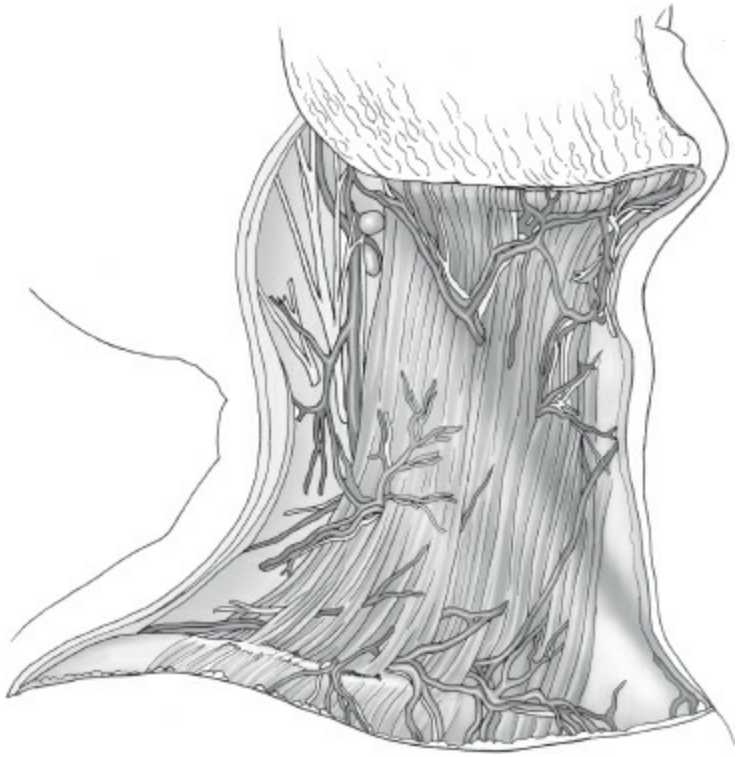

Figure 21.6. Skin flap raised superiorly with platysma muscle left in place.

SUBMANDIBULAR TRIANGLE DISSECTION

Lateral Transcervical Approach

This is performed through a curvilinear incision from the lateral hyoid to the anterior border of the SCM, approximately 3 fingerbreadths below the lower border of the horizontal ramus of the mandible (Fig. 21.5). The surgeon must make a determination as to whether the depth of the incision should be deep to the platysma muscle or superficial to it (Fig. 21.6); this is important if the procedure is being performed for a mass that is close to the skin such that including platysma in the resection provides an oncologic margin. In most cases, the flap is elevated in a subplatysmal plane (Fig. 21.7).

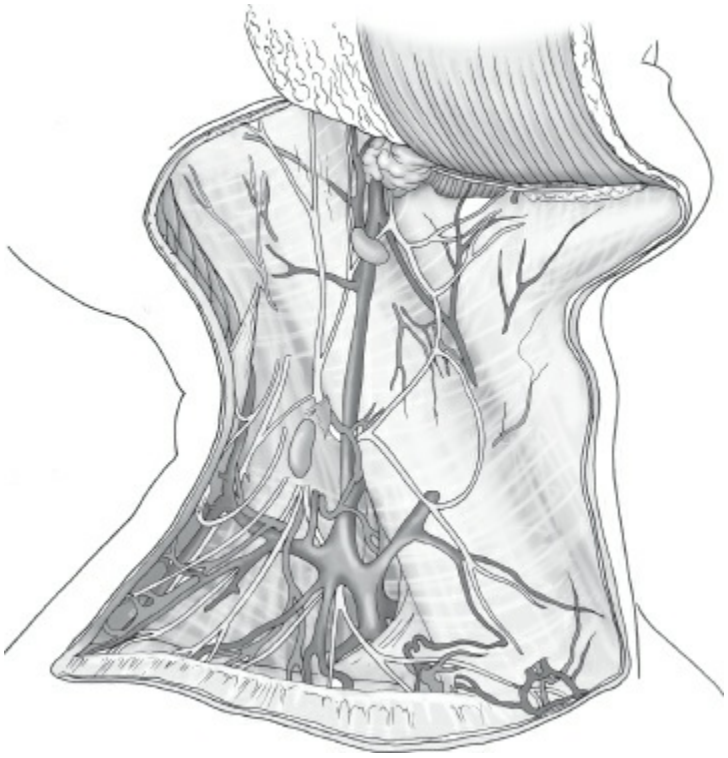

Figure 21.7. Skin flap raised superiorly in a subplatysmal plane.

As the flap elevation approaches the mandible, the surgeon must be aware of the course of the marginal branch of the facial nerve. It is important to identify this nerve and mobilize it for retraction superiorly; this allows the adjacent facial artery lymph nodes, which lie superior to the nerve as it courses lateral to the ramus of the mandible, to be removed with the mass while preserving the nerve (Fig. 21.8). The procedure of ligating the facial artery and vein at the lower border of the mandible and reflecting them superiorly (Hayes Martin maneuver) preserves this nerve, and also preserves the facial artery lymph nodes. Removing these lymph nodes is oncologically important if the mass is a metastasis or a primary tumor of the submandibular gland. The manipulation of this nerve, even if it is minimal, will undoubtedly result in some weakness of the ipsilateral corner of the mouth. Therefore, all patients should be informed of this preoperatively. In most patients, this weakness is temporary.

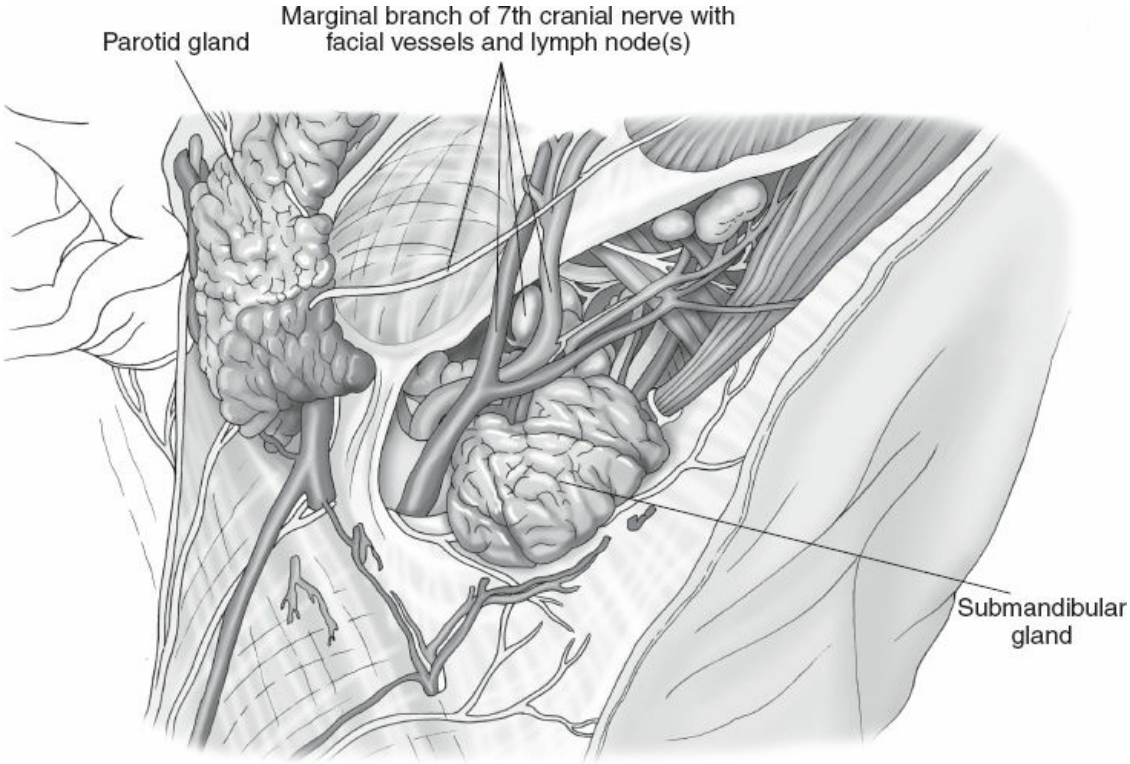

Figure 21.8. Marginal branch of the facial nerve and its relationship with the facial vessels. Note also the lymph nodes in the area of the marginal branch of the facial nerve and underneath the mandible on top of the mylohyoid muscle.

Once the nerve is retracted out of harm's way and the facial artery lymph nodes are retracted inferiorly, the facial vessels can be ligated. If the mass is fixed to the periosteum on the lower border of the mandible, this should be included with the specimen as an oncologic margin (Fig. 21.8). If the mass is not adherent to the periosteum, a plane of dissection should be developed along the free inferior edge of the ramus of the mandible from the midline to just posterior to the angle of the mandible. Dissection then continues, sweeping the fibrofatty lymph node packet inferiorly. This exposes the anterior belly of the digastric muscle and the nerve supplying the mylohyoid muscle. The latter must be divided in order to release the gland posteriorly. If the mass is malignant, pathologic examination of this nerve may be necessary, particularly if the mass is an adenoid cystic carcinoma; it is important to know if this nerve has been invaded because it defines the behavior and the extent of the disease, and may determine whether the patient requires postoperative radiation.

The surgeon can now proceed by dissecting the fibrofatty lymph node packet inferoposteriorly, exposing the anterior belly of the digastric muscle. Once this is accomplished, the anterior belly of the digastric

muscle can be retracted medially. All nodal and adipose tissues are removed from deep to this muscle down to the lateral surface of the mylohyoid muscle; this is particularly important if disease in the submandibular triangle represents extension of or metastases from a floor of mouth malignancy. Dissection should then continue along the lateral aspect of the mylohyoid muscle and will reveal the distal portion of the mylohyoid nerve and associated vascular bundle, which needs to be transected. Blunt dissection should then define the plane along the deep surface of the mylohyoid muscle, allowing it to be retracted medially. This exposes the hypoglossal nerve and associated veins inferiorly, the duct to the submandibular gland, and, superiorly, the genu of the lingual nerve with its attachment to the submandibular ganglion (Figs. 21.9 and 21.10). As with the nerve to the mylohyoid muscle, if malignancy is suspected, this nerve attachment should undergo pathologic examination. This nerve should be divided superior to the submandibular ganglion such that the ganglion is included with the specimen. If the mass extends under the mylohyoid muscle to the submucosa of the floor of the mouth, Wharton duct must be removed in its entirety with a portion of the surrounding floor of mouth mucosa (Fig. 21.10) as an oncologic margin.

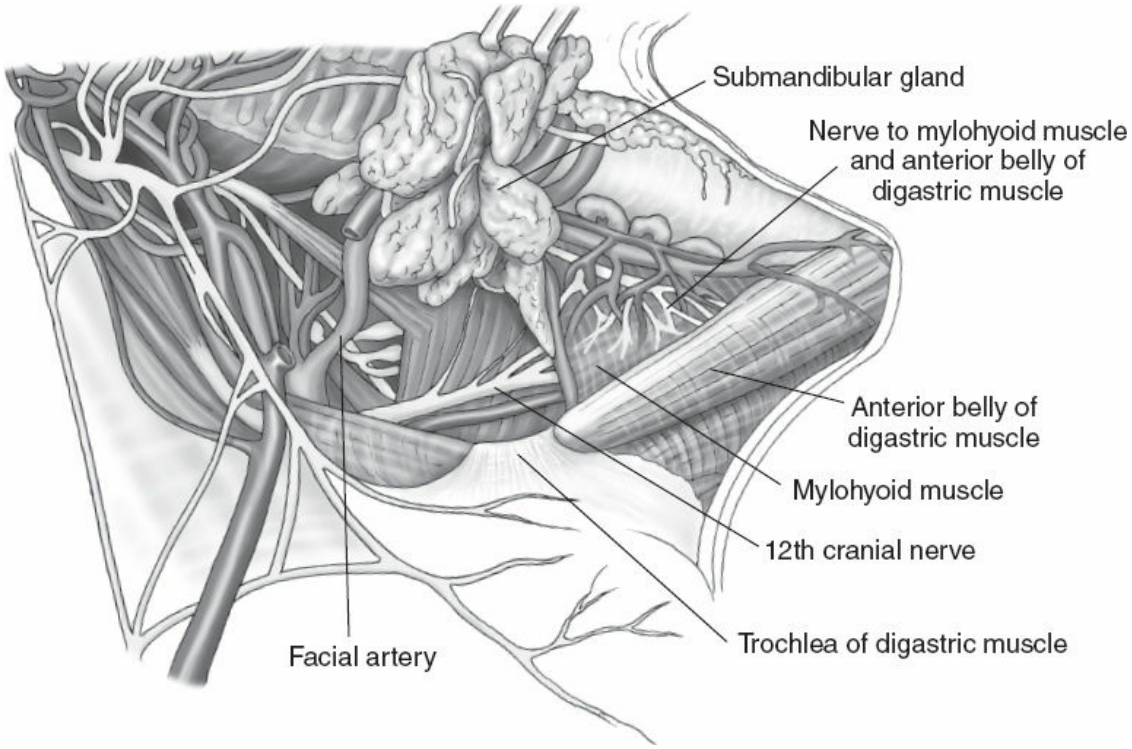

Figure 21.9. Detail of the submandibular triangle with the submaxillary gland resected superiorly, showing its duct going underneath the mylohyoid muscle. Note also the nerve to the

mylohyoid muscle, the anterior belly of the digastric muscle, the 12th cranial nerve, the facial artery, and the trochlea of the digastric muscle between the anterior and posterior belly of the digastric muscles.

Once the attachments to the submandibular gland have been released anteriorly and superiorly, the gland can be retracted posteriorly and inferiorly. If the mass is not adherent to the fascia overlying the hypoglossal nerve and associated venous plexus, the plane of dissection is very easily established superficial to these structures such that the entire gland with its preglandular and postglandular nodes can be elevated. With this elevation, the inferior aspect of the triangle should be dissected along the posterior belly of the digastric muscle, continuing posteriorly until the facial vein is encountered crossing over this muscle, where it should be ligated. As the remainder of the fibrofatty lymph node packet is dissected free along the deep plane, the last remaining attachment should be the facial artery, as it crosses deep to the posterior belly of the digastric muscle (Fig. 21.9). This should be ligated with at least a 1-cm cuff to prevent retraction under the muscle, thus releasing the contents of the submandibular triangle.

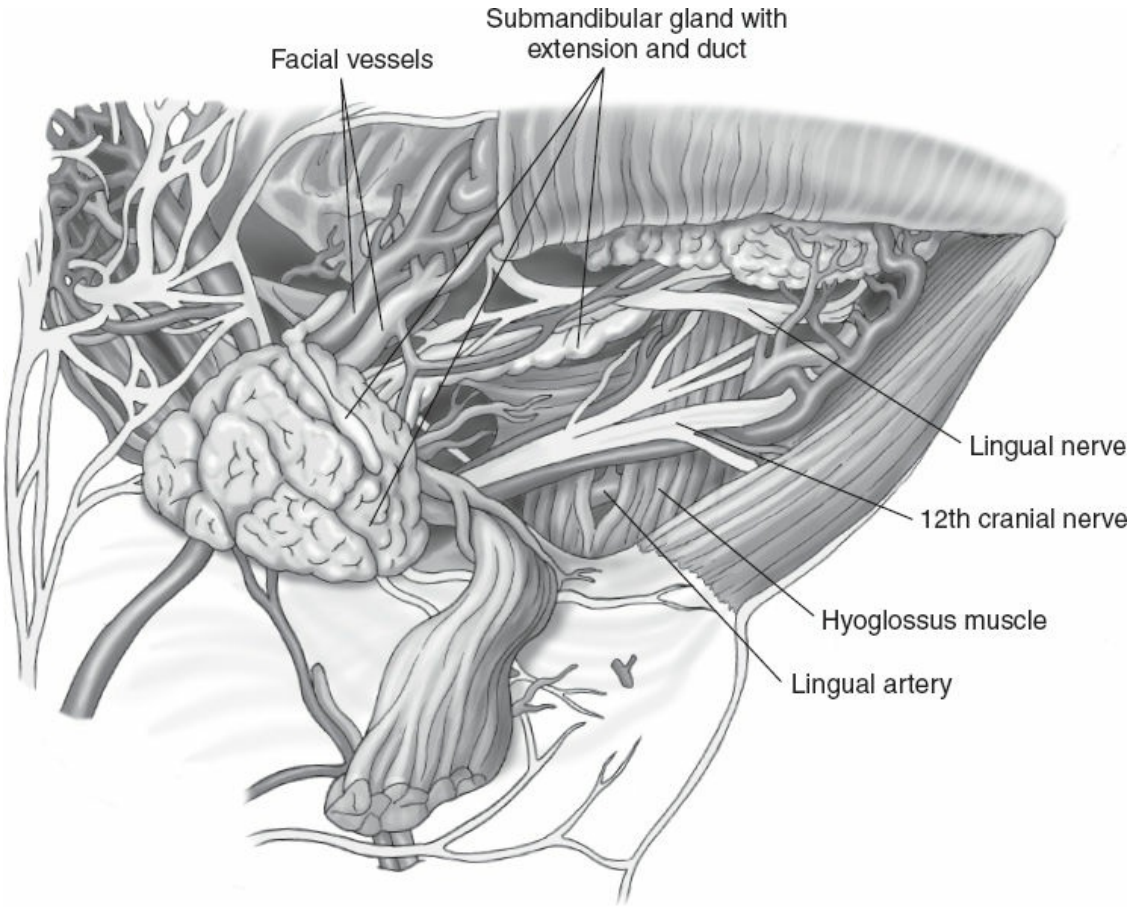

Figure 21.10. Facial vessels with the submandibular gland resected back. Note also the lingual nerve and the 12th cranial nerve.

The full indications for an associated neck dissection and adjuvant treatment are beyond the scope of this chapter. Briefly, if the mass is malignant and there is concurrent nodal disease in the neck, a selective neck dissection should be performed. If there is perineural or lymphovascular invasion, or if there are multiple positive lymph nodes in the resection specimen, postoperative radiation is indicated. Likewise, if the mass is a high- or intermediate-grade salivary gland malignancy, postoperative radiation is indicated for the dissected site and, in some cases, should include the entire ipsilateral neck to the clavicle.

Complications of a submandibular triangle dissection through a lateral transcervical incision include hematoma (2% to 10%), fistula formation (1% to 3%), wound infection (2% to 9%), injury to the marginal mandibular (7.7% to 36%), lingual (0% to 22.5%), and hypoglossal (0% to 7%) nerves.

Other Transcervical Approaches

Two other transcervical approaches have been described: submental and retroauricular. Neither of these is suited for complete submandibular triangle dissection and should be reserved for cases in which the pathology is confirmed preoperatively to be benign, requiring only removal of the submandibular gland. The reader should note that these are nonstandard approaches.

The submental approach occurs through a midline horizontal incision determined by the submental-cervical crease, usually at the level of the hyoid. Dissection proceeds posterolaterally in a subplatysmal plane until the gland is encountered. It is bluntly dissected free of fascial attachments, and the facial vessels are ligated. Lastly, the attachments of the submandibular ganglion and duct are divided, releasing the gland.

The retroauricular approach occurs through an incision placed in the lower portion of the postauricular sulcus, continuing posteriorly along the hairline, as in a facelift incision. Dissection, which can be extensive, continues in the plane superficial to the fascia of the SCM, taking care to preserve the external jugular vein and greater auricular nerve, continuing anteriorly in a subplatysmal plane. Extirpation of the gland then proceeds in a posterior to anterior direction.

Transoral Approach

As with the submental and retroauricular approaches, this nonstandard approach is only indicated in confirmed benign disease, as it only allows for extirpation of the submandibular gland and not the entire contents of the submandibular triangle. Complications associated with this procedure include abnormal tongue sensation in 43% to 74% and restriction of tongue movement due to scar contracture in up to 10%.

Briefly, an incision is made in the floor of the mouth mucosa from the papilla of Wharton duct to the retromolar trigone, leaving a cuff of mucosa between the incision and the gingival to limit postoperative contracture. The lingual nerve is identified and the submandibular ganglion and duct attachments are divided. The gland is dissected free of facial attachments, allowing for delivery into the wound using gentle transcervical pressure. The hypoglossal nerve is identified and preserved. The facial vessels are then divided, allowing removal of the gland.

Endoscopic Approaches

As with the previously described nonstandard approaches, endoscopic

approaches should not be undertaken when oncologic resection is indicated. Endoscopic-assisted approaches have been described for transoral and submental approaches, enabling successful extirpation of the submandibular gland through smaller incisions. Completely endoscopic approaches have only been described in animal models.

REVISION SURGERY

Often, there is a dilemma as to how best to proceed when a cancer has been previously "shelled out" of the parotid gland or submandibular triangle and the patient is referred for further treatment. If the previous resection margins are positive for tumor, but there is no residual disease by palpation or imaging, then there is nothing to be gained by further surgery and postoperative radiation is indicated. If gross residual disease is present, however, either clinically or radiologically, revision surgery is necessary, but is fraught with potential problems and the patient should be appropriately counseled. Not only are the critical structures at greater risk for injury, but many times, the extent of the procedure must be more radical and may involve resection of these structures to ensure an adequate oncologic margin. The type of incision used to accomplish this is dictated by the previous surgery; the existing scar should be excised and consideration should be given to extension along a modified Schobinger incision (Fig. 21.5).

Suggested Readings

Batsakis JG. Neoplasms of the minor and lesser salivary glands. *Surg Gynecol Obstet* 1972;135:289–98.

Baurmash HD. Marsupialization for treatment of oral ranula. *J Oral Maxillofac Surg* 1992;50:1274–9.

Beahm DD, Peleaz L, Nuss DW, et al. Surgical approaches to the submandibular gland: a review of the literature. *Int J Surg* 2009;7:503–9.

Bentz BG, Hughes CA, Ludemann JP, et al. Masses of the salivary gland region in children. *Arch Otolaryngol Head Neck Surg* 2000;126:1435–9.

Chiosea SI, Barnes EL, Lai SY, et al. Mucoepidermoid carcinoma of upper aerodigestive tract: clinicopathologic study of 78 cases with immunohistochemical analysis of Dicer expression. *Virchows Arch* 2008;452:629–35.

Cohen EG, Patel SG, Lin O, et al. Fine-needle aspiration biopsy of salivary gland lesions in a selected patient population. *Arch Otolaryngol Head Neck Surg*

2004;130:773–8.

Ettl T, Gosau M, Brockhoff G, et al. Predictors of cervical lymph node metastases in salivary gland cancer. *Head Neck* 2014;36:517–23.

Ichimura K, Nibu K, Tanaka T. Nerve paralysis after surgery in the submandibular triangle: review of the University of Tokyo Hospital experience. *Head Neck* 1997;19:48–53.

Koch M, Zenk J, Henrich I. Algorithms for treatment of salivary gland obstructions. *Otolaryngol Clin N Am* 2009;42:1173–92.

McGurk M, Brown J. Alternatives for the treatment of salivary duct obstruction. *Otolaryngol Clin N Am* 2009;42:1073–85.

Rice DH. Noninflammatory, non-neoplastic disorders of the salivary glands. *Otolaryngol Clin N Am* 1999;42:835–42.

Schobinger R. The use of a long anterior skin flap in radical neck dissections. *Ann Surg* 1957;146:221.

Spiro RH. Salivary neoplasms: overview of a 35-year experience with 2807 patients. *Head Neck* 1986;8:177–84.

Spitz MR, Fuegar JJ, Goepfert H, et al. Salivary gland cancer. A case-control investigation of risk factors. *Arch Otolaryngol Head Neck Surg* 1990;116:1163–6.

Weber RS, Byers RM, Petit B, et al. Submandibular gland tumors: adverse histologic factors and therapeutic implications. *Arch Otolaryngol Head Neck Surg* 1990;116:1055–60.

EDITOR'S COMMENT

Salivary gland tumors constitute an uncommon, heterogeneous group of neoplasms that vary considerably in their anatomical location, biologic behavior, and histology. Parotid gland remains the most common site of salivary gland tumors.

Approximately, 25% of parotid, 40% to 45% of submandibular, and 70% to 90% of sublingual gland tumors are malignant in nature (Guzzo M, Locati LD, Prott FJ, et al. Major and minor salivary gland tumors. *Crit Rev Onco Hematol* 2010;74:134–48). These malignant cancers compromise a broad range of histology, including mucoepidermoid, acinic, adenocarcinoma, adenoid cystic, malignant tumors, and squamous carcinoma. The most common malignant salivary gland tumors are mucoepidermoid and adenoid cystic comprising approximately one half of all the malignant salivary gland tumors. The primary squamous cell carcinoma of the parotid gland is rare; however, parotid gland is a common site of metastasis from skin cancers.

Recently, there has been rapid evolution of our understanding of salivary

gland lesions including description of new entities such as mammary analogue secretory carcinoma (MASC), hyalinizing clear cell carcinoma, and IgG4-related chronic sclerosing sialadenitis (Gupta R, Balasubramanian D, Clark JR. Salivary gland lesions: recent advances and evolving concepts. *Oral Surg Oral Med Oral Pathol Oral Radiol* 2015;119(6):661–74).

MASC is a low-grade neoplasm of the parotid gland described by Skalova et al. in 2010 (Skálová A, Vanecek T, Sima R, et al. Mammary analogue secretory carcinoma of salivary glands, containing the ETV6-NTRK3 fusion gene: a hitherto undescribed salivary gland tumor entity. *Am Journ of Surg Path* 2010;34(5)599–608). It is characterized by morphologic and molecular features similar to the secretory carcinoma of the breast and is known to occur in both men and women in both major and minor salivary tissues. Previously these tumors were categorized as zymogen granule-poor acinic cell carcinoma.

The major point of distinction between MASC and acinic cell carcinoma is the presence of intracytoplasmic zymogenic granules in acinic cell carcinoma and their absence in MASC. Although the prognostic information regarding these tumors is still evolving, these are usually considered as a low-grade malignant neoplasm.

Hyalinizing clear cell carcinoma have been described as “clear cell carcinoma, not otherwise classified” under World Health organization 2005 classification system. However, the presence of a specific translocation (EWSR1-ATF1 fusion t(12;22) (q13;q12)) indicates these tumors to be a rare distinct entity. These tumors are considered as low grade and most show an indolent course (Antonescu CR, Katabi N, Zhang L, et al. *Genes Chromosomes Cancer* 2011;50(7):559–70).

IgG4-related disease is a multiorgan inflammatory disease affecting many organs but most commonly involving salivary glands, pancreaticobiliary tree, lacrimal glands, and periorbital tissue (Deshpande V, Zen Y, Chan JK, et al. Consensus statement on the pathology of IgG4-related disease. *Mod Pathol* 2012;25(9):1181–92). Most patients with head and neck lesions present with bilateral, firm, nontender swelling of the salivary glands, especially submandibular glands. FNA is not useful and yields either lymphoplasmacytic or acellular aspirate based upon extent of sclerosis. Histology is considered as gold standard for the diagnosis. Most important differential includes carcinoma or lymphoma. IgG4-related chronic sialadenitis is usually managed by glucocorticoids. Prognosis depends upon extent of sclerosis and loss of the functional units.

Various factors like radiation exposure, smoking, viral infection (EBV, HIV, and HPV) and environmental exposure have been implicated in causation of salivary gland tumors. Radiation exposure has been linked with both benign and malignant tumors of salivary glands (Boukheris H, Ron E, Dores GM, et al. Risk of radiation-related salivary gland carcinomas among survivors of Hodgkin lymphoma: a population-based analysis. *Cancer* 2008;113(11):3153–9). Warthin tumors are known to have a strong association with smoking

(Pinkston JA, Cole P. Cigarette smoking and Warthin's tumor. *Am J Epidemiol* 1996;144(2):183–7). Rare lymphoepithelial carcinoma of salivary glands has been strongly associated with Epstein–Barr virus (EBV) in areas where this virus is endemic (Tumours of the salivary glands. In: Barnes L, Eveson JW, Reichart P, et al., eds. *Pathology and Genetics of Head and Neck Tumours.* Lyon: IARC/World Health Organization; 2005:209). Individuals with AIDS are reported to have high risks for lymphoepithelial carcinoma and squamous cell carcinoma of salivary glands (Shebl FM, Bhatia K, Engels EA. Salivary gland and nasopharyngeal cancers in individuals with acquired immunodeficiency syndrome in United States. *Int J Cancer* 2010;126:2503). Few studies have reported presence of high-risk serotypes of human papilloma virus in mucoepidermoid carcinoma (Isayeva T, Said-Al-Naief N, Ren Z, et al. Salivary mucoepidermoid carcinoma: demonstration of transcriptionally active human papillomavirus 16/18. *Head Neck Pathol* 2013:7:135–48). Occupation exposure such as rubber manufacturing and nickel compounds has been described to be associated with salivary glands tumors (Swanson GM, Burns PB. Cancers of the salivary gland: workplace risks among women and men. *Ann Epidemiol* 1997:7:369).

Most patients with salivary gland tumors usually present with a painless mass or swelling. Presence of neurologic signs and symptoms like facial nerve paralysis are almost always suggestive of a malignant tumor.

The preoperative definitive diagnosis of salivary gland lesions is critical for avoiding unnecessary surgery for nonmalignant lesions, and for therapeutic planning for malignant tumors. Fine-needle aspiration (FNA) is most widely used preoperative diagnostic technique for salivary gland lesions. However, FNA usually has relatively low sensitivity in comparison with its high specificity for diagnosing salivary gland tumors. According to a meta-analysis by Schmidt et al., the average sensitivity and specificity determined in 6,169 cases were 80% and 97%, respectively (Schmidt RL, Hall BJ, Wilson AR, et al. A systematic review and meta-analysis of the diagnostic accuracy of fine-needle aspiration cytology for parotid gland lesions. *Am J Clin Pathol* 2011;136:45–59). The low sensitivity of FNA can be ascribed to several factors including diversity and rarity of salivary gland carcinomas, and difficulty of diagnosing low-grade carcinomas by cellular morphology alone. In addition, pathologists' experience and expertise can affect the accuracy of FNA.

Core-needle biopsy (CNB) is a relatively new technique for diagnosing salivary gland lesions. It has many advantages over FNA, including the ability to attain a bigger specimen with preserved tissue architecture for possible immunohistochemical staining. A recent meta-analysis by Witt et al. included 12 studies to estimate the sensitivity and specificity of core-needle biopsy of salivary gland lesions. They reported 96% sensitivity and 100% specificity of core-needle biopsy for diagnosis of malignancy of salivary gland. There was no significant heterogeneity in accuracy between studies (Witt BL, Schmidt RL. Ultrasound-guided core needle biopsy of salivary gland lesions: a systematic

review and meta-analysis. *Laryngoscope* 2014;124:695–700).

Imaging studies like computed tomography (CT) and magnetic resonance imaging (MRI) may provide the clinicians with critical information to plan the type and extent of surgical intervention. With recent advances in imaging techniques, it may be possible to differentiate between malignant and benign salivary gland tumors using MR spectroscopy (Lee YY, Wong KT, King AD, et al. Imaging of salivary gland tumours. *Eur J Radiol* 2008;66:419–36).

The major therapeutic option for salivary gland malignant cancer is surgical resection. Surgical resection requires careful planning and execution. This is especially true in cases of parotid gland tumors because of the presence of the facial nerve in the gland. As a general principle, if the facial nerve function is normal preoperatively then every effort to preserve facial nerve function should be made during parotidectomy and if the facial nerve is scarified or incised intraoperatively then immediate microsurgical repair should be considered. Neck dissection should be considered for all malignant tumors of the parotid except for low-grade neoplasms. Adjuvant radiation is recommended for high grade or large tumors and/or those with preoperative facial nerve weakness, positive surgical margins, extracapsular spread, and perineural invasion (Sood S, McGurk M, Vaz F. Management of Salivary Gland Tumours: United Kingdom National Multidisciplinary Guidelines. *J Laryngol Otol* 2016;130(S2):S142–9).

Vishal Gupta

22 Anatomy of the Parotid Gland, Submandibular Triangle, and Floor of the Mouth

Aaron Ruhalter

ANATOMY OF THE PAROTID GLAND

The parotid gland is the largest of the paired salivary glands. The gland is wedged into the parotid space.

Parotid Space

The parotid space has a skeletal background created by the ramus of the mandible anteriorly, the styloid process medially, the mastoid process posteriorly, and the external acoustic meatus and the posterior part of the temporomandibular joint posterosuperiorly (Fig. 22.1). A soft tissue background is created by the muscles that are attached to these bony landmarks—the masseter, medial pterygoid, and temporalis muscles on the mandible; the stylohyoid, styloglossus, and stylopharyngeus muscles arising from the styloid process of the temporal bone; and the sternocleidomastoid and digastric muscles related to the mastoid process and the lateral portion of the posterior occipital line.

Parotid Gland

The superficial surface of the parotid gland is triangular in shape, with the apex pointing inferiorly (Fig. 22.2). The deep surface of the gland is wedged into this parotid space and presents anteromedial and posteromedial surfaces. The gland frequently extends beyond the limits of the parotid space. Glandular tissue may extend from the anterosuperior edge of the superficial surface, creating what is called the *facial process*, and is superior to the parotid duct. The extension of glandular tissue may be separate from the main portion of the gland. This isolated segment of gland (accessory parotid) has a duct that empties into the main duct. Frequently, extensions are found from the deep surface of the gland toward

the pharynx or the medial pterygoid muscle.

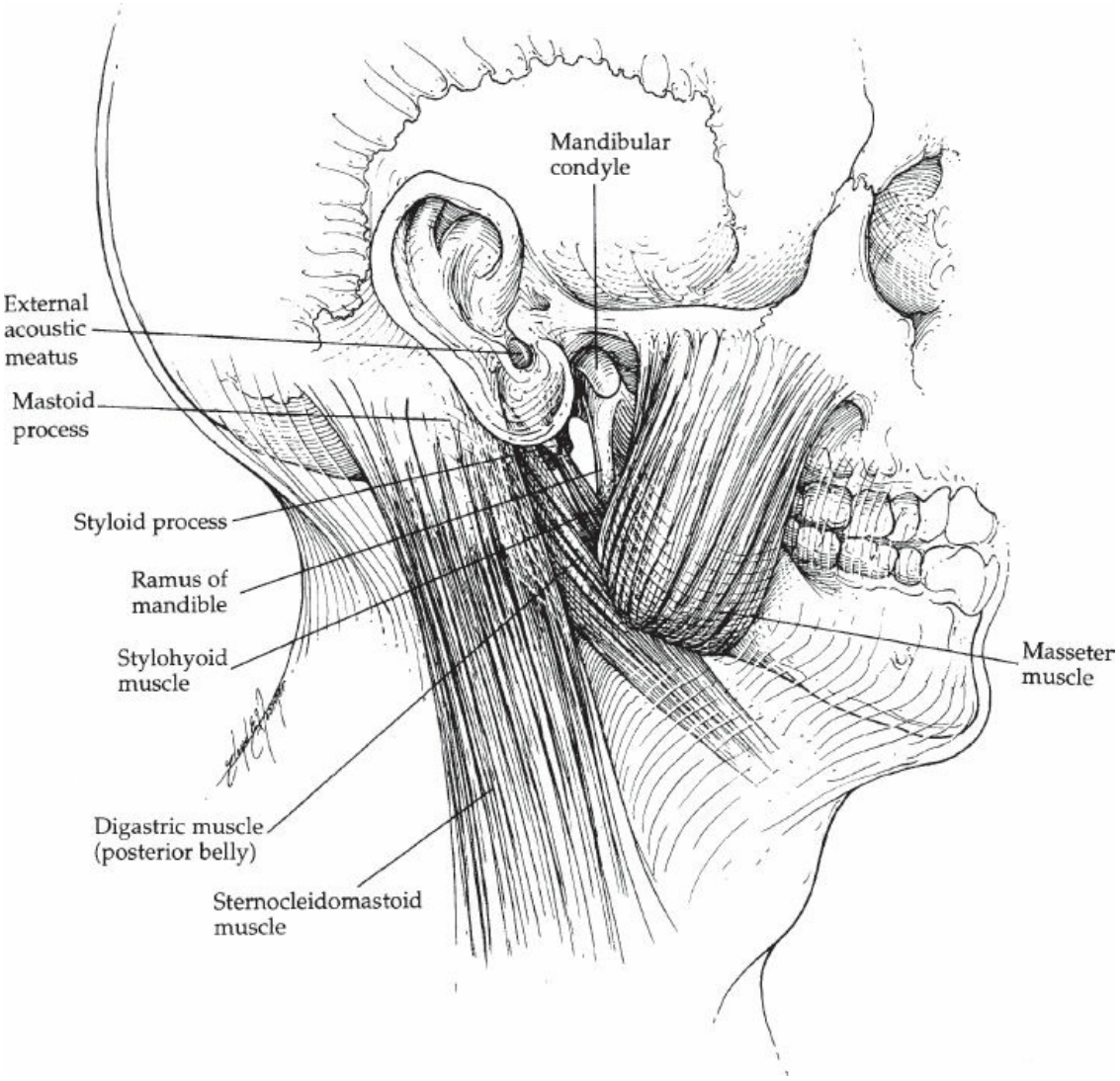

Figure 22.1. Parotid bed.

The parotid gland is somewhat artificially divided into two lobes by the facial nerve as it passes through. Endofacial (deep) and exofacial (superficial) portions are created. Multiple communications exist between the lobes, however, created by bridges of glandular tissue. A large area of communication, referred to as the *isthmus*, is related to the proximal part of the intraparotid portion of the facial nerve.

The parotid duct is approximately 5 cm long and lies on the superficial surface of the masseter muscle, approximately 1 cm below the zygomatic arch. The transverse facial artery is interposed between the duct and the arch, whereas the buccal branches of the facial nerve can be found inferior and superior to the duct. When this conduit reaches the anterior margin of

the masseter muscle, it turns sharply, penetrates the buccinator muscle, and ends in the vestibule of the oral cavity opposite the upper second molar tooth.

Fascial Relations

The gland is encased by a split in the investing layer of the deep cervical fascia. The deep layer passes superiorly and attaches to the base of the skull. A portion of this fascia between the tip of the styloid process and the angle of the mandible is thickened, creating the stylomandibular ligament. This ligament supports the temporomandibular joint and separates the parotid gland from the submandibular gland. The superficial layer of this fascial split is much thicker, invests the masseter muscle, and attaches to the zygomatic arch. Its thickness and unyielding nature are responsible for the severe pain that results from enlargement of the gland.

Neurovascular Relations

Neurovascular structures pass through the parenchyma of the gland and can conveniently be described in layers or planes. From deep to superficial are found the arterial, venous, and nerve layers.

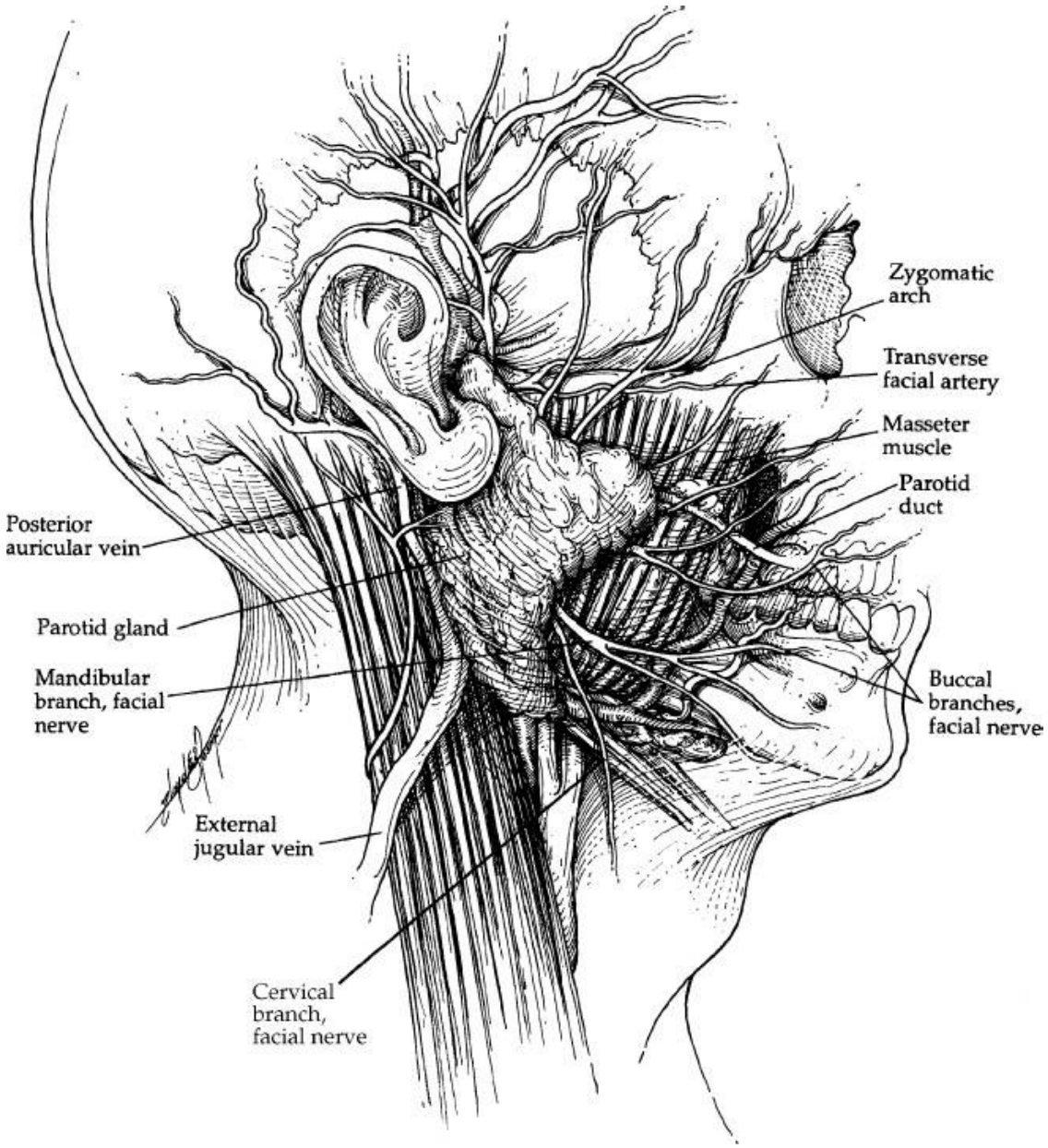

Figure 22.2. Superficial view of the parotid region.

Arterial Plane

The arterial layer includes the *external carotid artery*, which enters the parotid space after passing deep to the posterior belly of the digastric muscle (Fig. 22.3). At this point the external carotid artery gives rise to the *posterior auricular artery*, which gives off a *stylohyoid branch* that enters the stylomastoid foramen. This blood vessel is usually superficial to the facial nerve trunk as it exits from the skull by way of this same foramen. The posterior auricular artery then continues posteriorly, running under cover of, and parallel to, the superior edge of the posterior belly of the digastric muscle. One should note that this muscle passes superficial to and

protects almost all of the structures passing between the submandibular triangle superiorly and the carotid triangle inferiorly. This includes the *internal jugular vein* and the *internal carotid artery* in the carotid sheath, the last four cranial nerves, and the external carotid artery. The *retromandibular vein* or its branches, the *cervical branch of the facial nerve,* and the *greater auricular nerve,* however, pass superficial to the posterior belly of the digastric muscle.

The external carotid artery then pierces the medial surface of the parotid gland, and when it reaches the neck of the condylar process of the mandible it ends by giving rise to the *maxillary artery* and the superficial temporal artery. The maxillary artery passes medial to the condylar process of the mandible and enters the infratemporal fossa. The superficial temporal artery continues superiorly, accompanied by *superficial temporal veins.* The *transverse facial artery,* which arises from the proximal part of the superficial temporal artery, courses just superior to the parotid duct. The superficial temporal artery then enters the temporal region after passing between the external acoustic meatus and the temporomandibular joint. Accompanying these vascular structures at this level is the auriculotemporal nerve, which arises from the mandibular branch of the trigeminal nerve in the roof of the infratemporal fossa. It provides sensory innervation to the external acoustic meatus, external surface of the tympanic membrane, and temporomandibular joint, and cutaneous sensory innervation to the auricle and temporal scalp region.

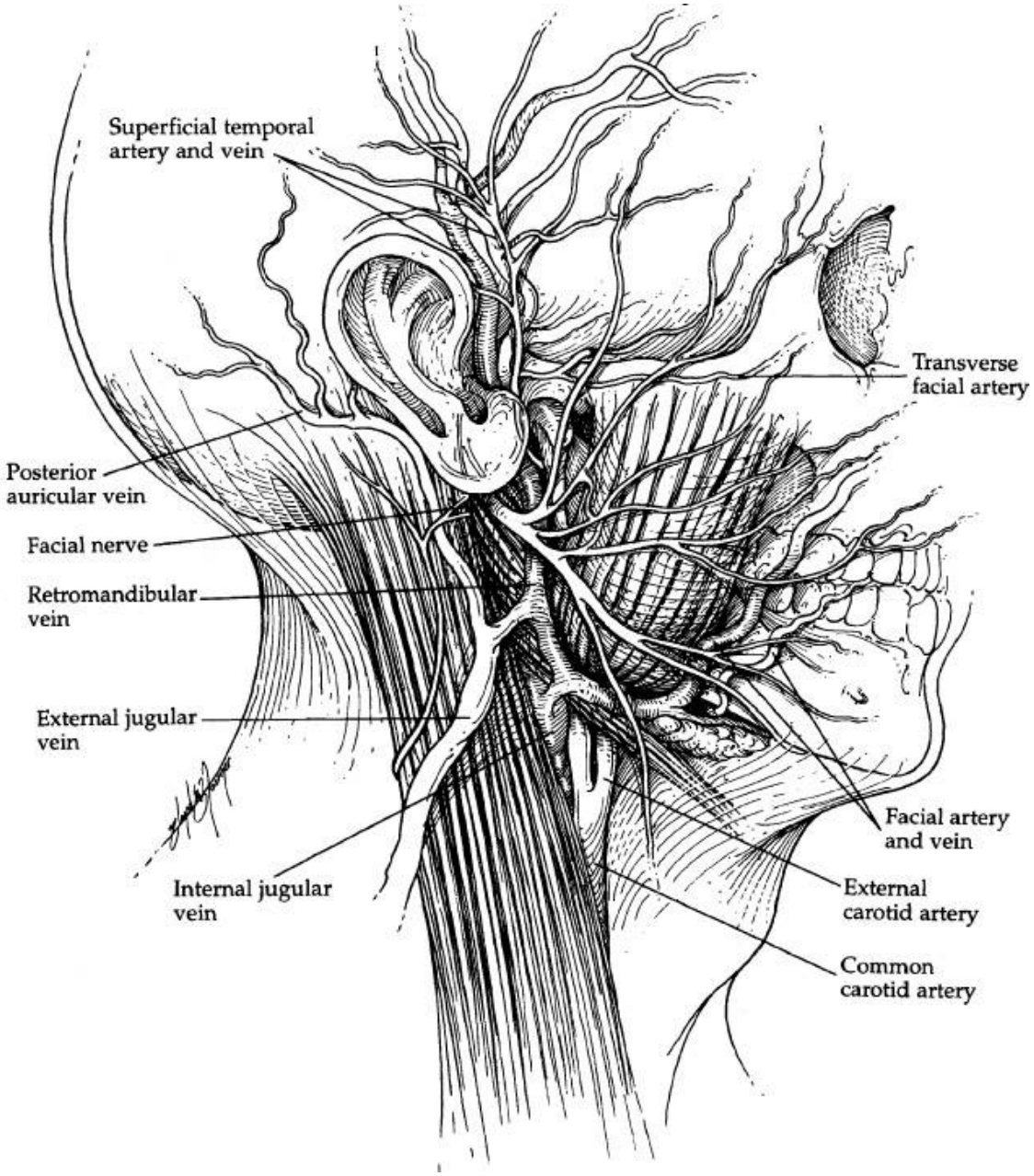

Figure 22.3. Vascular background.

Venous Plane

The venous plane is superficial to the arterial plane (Fig. 22.3). It includes the *retromandibular vein* and its branches. The retromandibular vein is created by the union of the superficial temporal and maxillary veins. The maxillary vein is formed by the union of veins that are part of a large plexus of veins surrounding the lateral pterygoid muscle. This venous plexus communicates with veins of the face as well as with the cavernous sinus within the skull. The parotid veins also communicate with the pterygoid venous plexus. This pterygoid venous plexus in turn represents a potential pathway for the spread of superficial cutaneous infections to the

cavernous sinus. This is a potentially lethal condition.

The retromandibular vein passes inferiorly through the substance of the parotid gland and is found between the branches of the facial nerve and the arterial layer. The retromandibular vein terminates at the lower edge of the gland by giving off anterior and posterior branches. The posterior branch joins with the *posterior auricular vein* to form the *external jugular vein,* which continues inferiorly, superficial to the posterior belly of the digastric muscle, then passes obliquely across the sternocleidomastoid muscle. It is frequently found just anterior to the great auricular nerve, which is on its way to the skin overlying the parotid gland. The anterior branch of the retromandibular vein unites with the anterior facial vein, forming the common facial vein. This passes inferiorly, superficial to the digastric muscle, to empty into the internal jugular vein.

Nerve Plane

The nerve plane is created by the facial nerve and its branches (Fig. 22.4). The *facial nerve* (seventh cranial nerve) exits from the skull through the stylomastoid foramen. At this point it is found with the stylomastoid branch of the posterior auricular artery, which enters the foramen and supplies the mucosa of the tympanic cavity, the mastoid cells, and the semicircular canals. The artery is usually superficial to the facial nerve. After emerging from the foramen, two branches arise from the facial nerve before it enters the parotid gland. The first branch, the *posterior auricular nerve,* provides innervation to the posterior auricular muscles and the intrinsic muscles of the auricle. The second branch, arising from the extraparotid portion of the facial nerve, provides motor innervation to the posterior belly of the digastric and stylohyoid muscles. This portion of the nerve, approximately 1 cm in length, then penetrates the posteromedial surface of the parotid gland. This nerve trunk passes forward in the glandular parenchyma for a distance of approximately 1 cm or less, then divides into two branches—a larger *temporofacial branch,* which creates *temporal* and *zygomatic* nerves, and a smaller *cervicofacial branch,* which gives rise to *buccal*, *marginal mandibular*, and *cervical nerves.* An isthmus of glandular tissue separates the temporofacial branch from the cervicofacial branch.

The facial nerve provides motor innervation to the muscles of facial expression. The platysma is included in this category of muscle. The nerve branches, as they pass through the parotid gland, divide it into two portions. The part of the gland that is superficial to the nerves is referred to

as the *superficial (exofacial) lobe*, and the portion of the gland that is internal to the nerve layer is referred to as the *deep (endofacial) lobe.* Multiple communications are found between the nerve branches as they pass through the gland. The zygomatic and temporal nerves are frequently multiple, whereas the mandibular and cervical branches are often single. The cervical and mandibular branches can extend below the mandible, whereas the cervical branch passes superficial to the posterior belly of the digastric muscle. The nerves become more superficial as they pass distally.

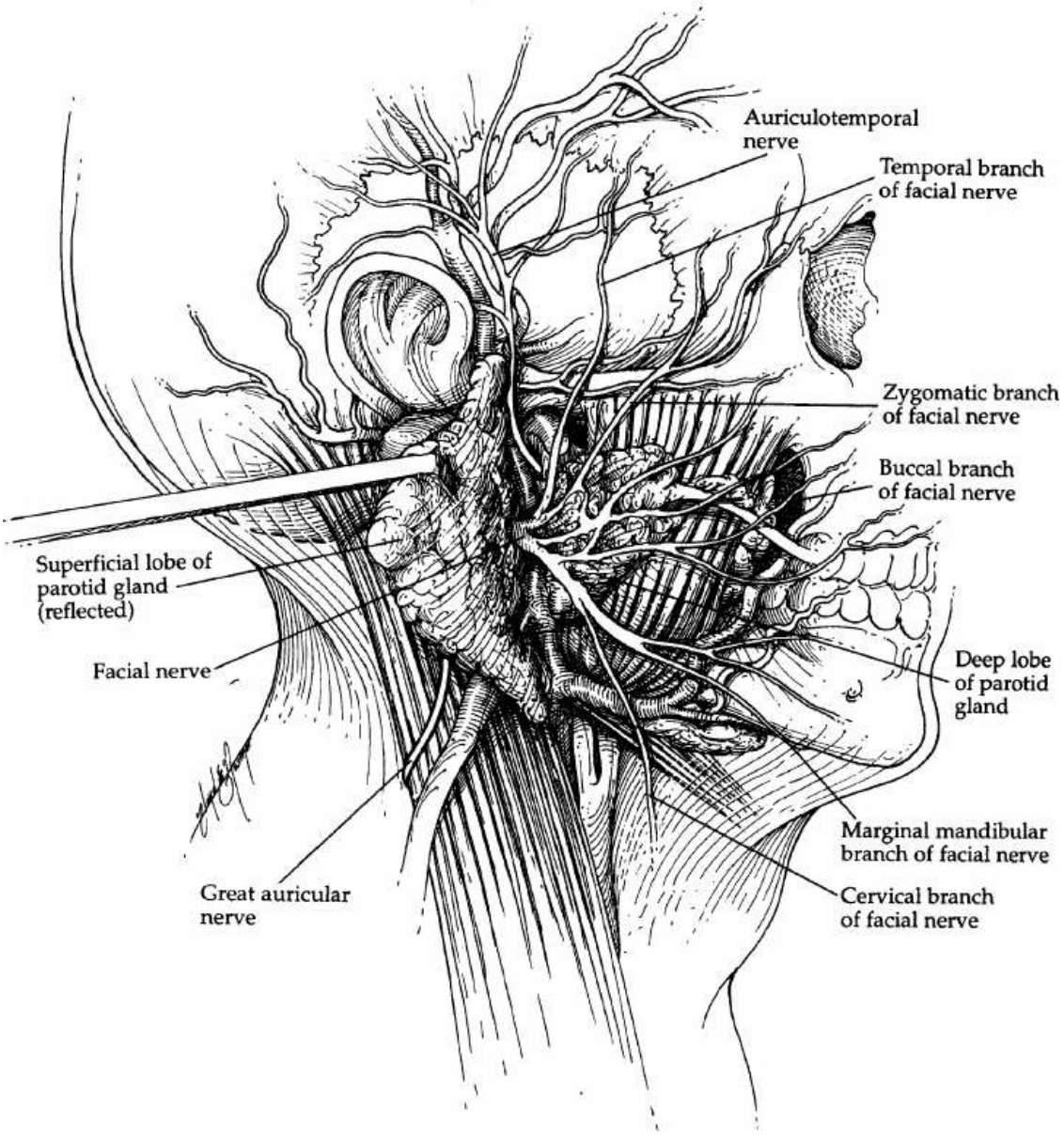

Figure 22.4. Nerve plane.

Innervation

The parotid gland receives postganglionic sympathetic fibers from a

plexus of nerves that travel with the external carotid artery. Secretomotor postganglionic parasympathetic fibers reach the infratemporal fossa by way of the lesser petrosal nerve, synapse in the otic ganglion, and then travel to the parotid gland by way of the auriculotemporal nerve.

Lymphatic Drainage

The lymphatic drainage of the parotid gland is related to two systems. Superficial nodes in the superficial fascia (preauricular) drain into the superficial system of cervical nodes. These are related to the external jugular vein and pass to the supraclavicular nodes in the posterior triangle. The second set of nodes is found within the fascial covering of the parotid gland. These nodes drain into the deep cervical nodes and the jugular chain.

Anatomic Aids

The main trunk of the facial nerve can be found by tracing one of its branches proximally. The mandibular and cervical branches are more frequently used because they are often single and more convenient to find.

The parotid duct is approximately 1 cm inferior to the lower edge of the zygomatic arch. The pathway of the duct can be recreated by a line between the lower end of the tragus of the ear and the commissure of the mouth.

Two nerves may be found with the superficial temporal vessels. The auriculotemporal nerve is posterior, whereas the temporal branches of the facial nerve lie anterior to these vessels.

The *great auricular nerve* is frequently found posterior to the external jugular vein. This nerve and vein travel together until the inferior edge of the parotid gland is reached. The nerve passes to the subcutaneous tissues superficial to the gland, providing sensory innervation to the skin overlying the parotid gland. The remainder of the face receives its sensory innervation only from the trigeminal nerve. The vein is seen to emerge from the substance of the gland.

The *external carotid artery* is related to the medial boundary of the parotid space. The *internal carotid artery* is slightly deeper. The two vessels should not be confused. One must remember that the internal carotid artery does not have any branches in the neck. Separating the external carotid artery from the internal carotid artery are the styloid process or stylohyoid ligament, the stylopharyngeus muscle, and the

glossopharyngeal nerve.

The stylohyoid muscle and the posterior belly of the digastric muscle diverge at their points of attachment to the skull. The main trunk of the facial nerve passes through this interval.

At the junction of the cartilaginous portion and the osseous portion of the auditory canal, a downward projection of cartilage frequently exists that points to the main trunk of the facial nerve.

When the external jugular vein is traced superiorly to its parent structure, the retromandibular vein, it leads to the interval between the superficial and deep lobes of the parotid gland. It is also a means of locating the cervical or mandibular branches of the facial nerve, because they pass superficial to the vein.

The stylomastoid branch of the posterior auricular artery enters the stylomastoid foramen and is superficial to the facial nerve trunk.

The internal jugular vein may be in contact with the deep surface of the gland.

ANATOMY OF THE SUPRAHYOID PORTION OF THE ANTERIOR TRIANGLE

The posterior belly of the digastric muscle and the hyoid bone divide the anterior triangle of the neck into suprahyoid and infrahyoid areas. The submandibular and submental triangles are suprahyoid in position, and are described in this chapter.

ANATOMY OF THE SUBMANDIBULAR TRIANGLE

The submandibular triangle is part of the anterior triangle of the neck and is suprahyoid in position. It is sometimes referred to as the *digastric* or *submaxillary triangle*.

Muscular Boundaries

The muscular boundaries of the submandibular triangle are the *posterior belly of the digastric* and *stylohyoid muscles* posteriorly, and the *anterior belly of the digastric muscle* anteriorly (Fig. 22.5). The inferior margin of the body of the mandible creates a superior boundary to this triangular area. The digastric muscle attaches posterosuperiorly to the *mastoid process* of the temporal bone, posterior to the stylohyoid muscle, which arises from the posterolateral surface of the styloid process. The two

muscles quickly approach each other and remain in intimate contact down to the region of the hyoid bone, where an intermediate tendon of this double-bellied muscle is found. This tendon passes through a split in the tendon of insertion of the stylohyoid muscle. The intermediate tendon is bound to the hyoid bone by a fascial thickening. The anterior belly then passes superomedially and ends by attaching to the internal aspect of the mandible near the midline. The digastric muscle elevates the hyoid bone and assists in depression of the mandible. The posterior belly of the digastric and the stylohyoid muscles is innervated by the facial nerve, and the anterior belly of the digastric muscle is innervated by the mylohyoid nerve branch of the inferior alveolar nerve. This latter nerve is a branch of the posterior division of the mandibular nerve.

Muscular Floor

The muscular floor of the submandibular triangle consists of four muscles (Fig. 22.5). The direction of the muscular fibers of each of the muscles is characteristic and allows for recognition of the boundaries between neighboring muscles. These muscles do not lie in the same plane. The anterior muscles are more superficial than those posterior, which creates a step-like pattern to this muscular floor of the submandibular triangle. Passing from anterior to posterior, one encounters the *mylohyoid* and then the *hyoglossus muscle.* The inferior portion of the *superior constrictor muscle* and the superior portion of the *middle constrictor muscle* complete the floor of the submandibular triangle.

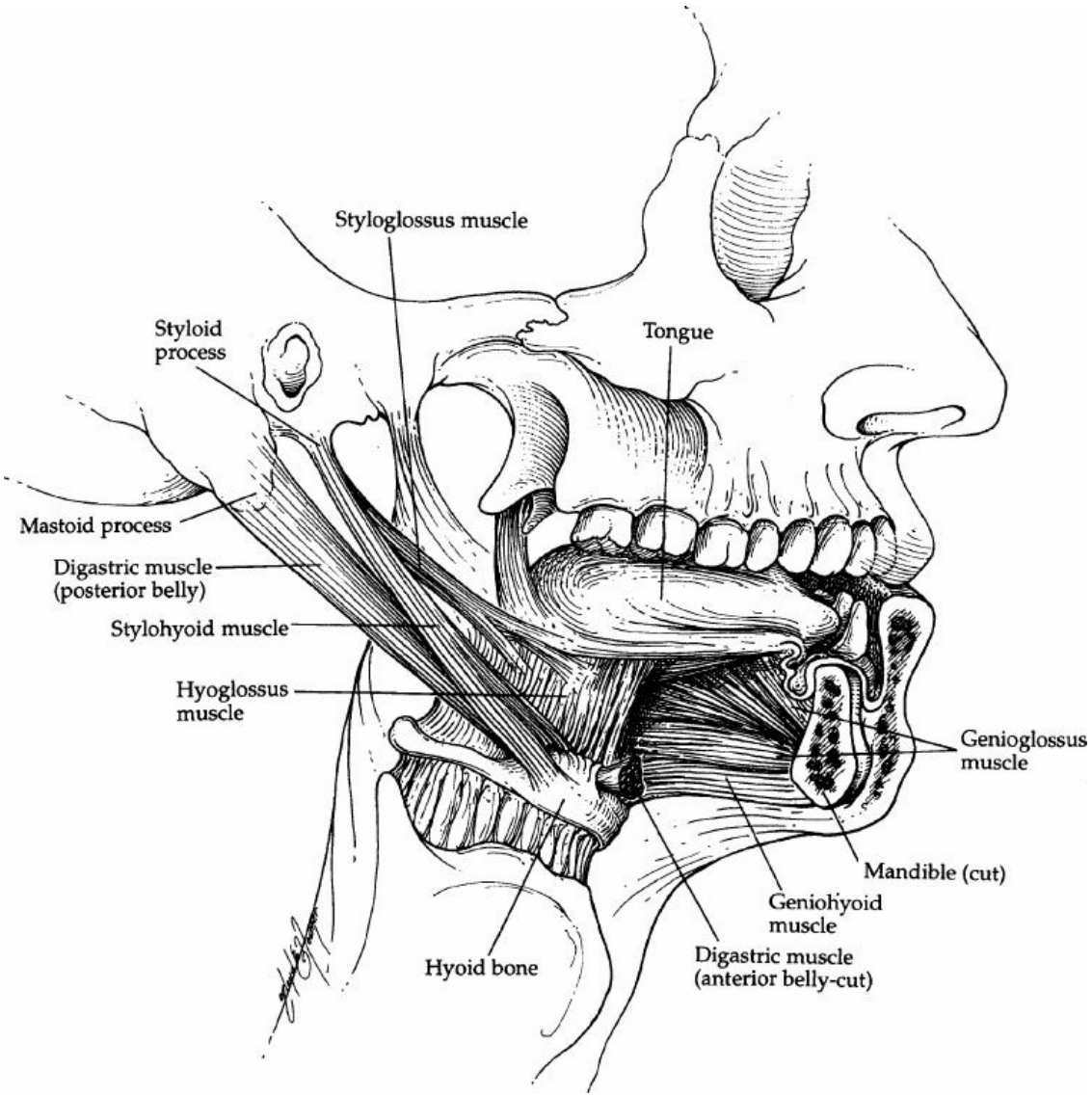

Figure 22.5. Musculoskeletal background and floor of the mouth.

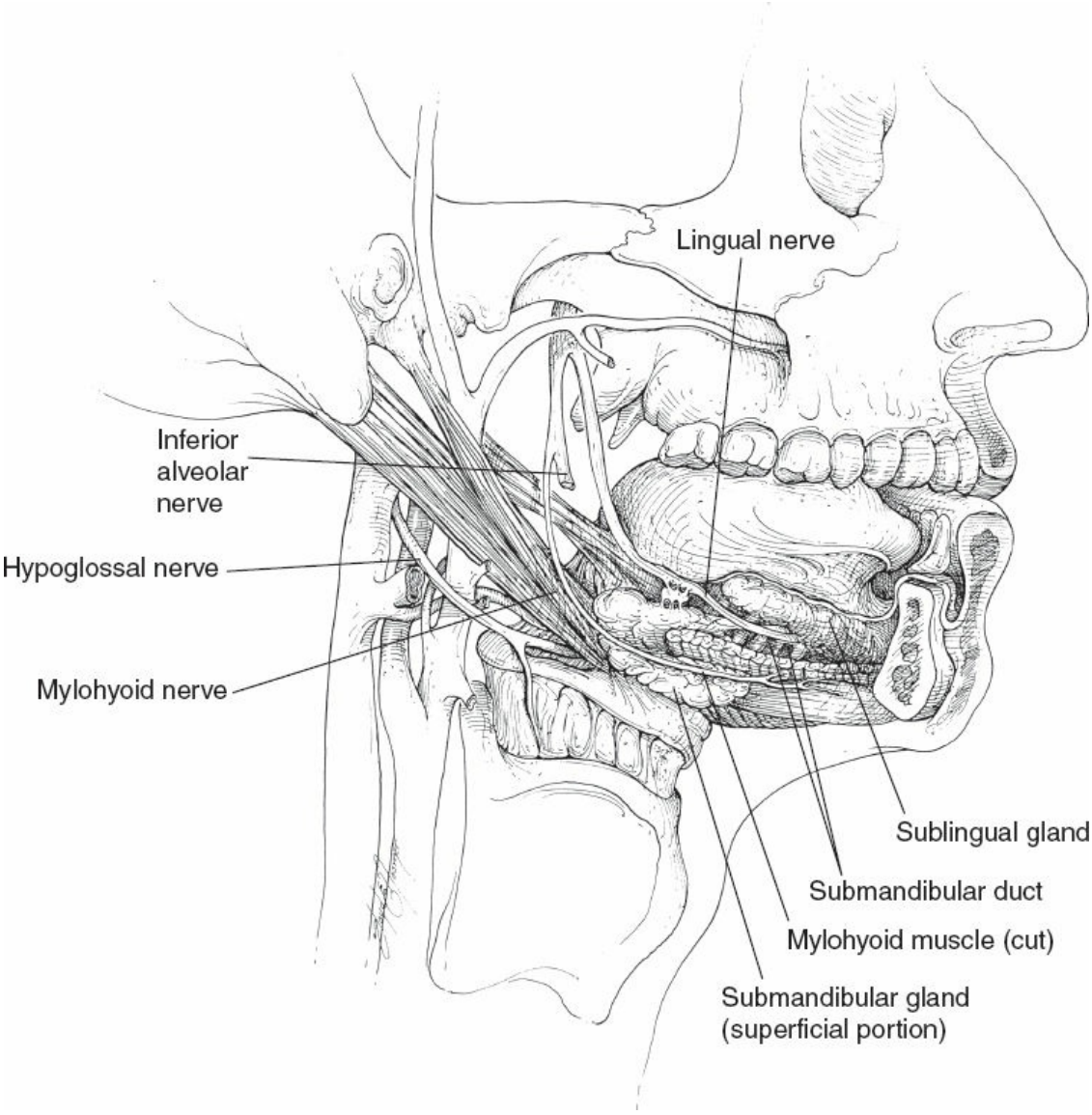

Figure 22.6. Submandibular triangle and floor of the mouth. This figure illustrates nerve contents and superficial and deep portions of the submandibular gland.

The mylohyoid muscle (Fig. 22.6) is the most anterior and superficial of the muscles creating the floor of the mouth. It arises from the inner aspect of the mandible, and the two halves pass inferomedially where the majority of the fibers insert into a midline fibrous raphe extending from the midportion of the mandible to the center of the body of the hyoid bone. The more posterior fibers insert into the body of the hyoid bone. The two halves of the muscle create a floor for the oral cavity. The mylohyoid muscle presents a posterior free edge. When this muscle contracts, it raises the floor of the mouth, causing elevation and posterior displacement of the tongue. This is an integral part of the swallowing mechanism.

The hyoglossus is a quadrangular muscle that arises from the entire length of the greater horn of the hyoid bone. It passes superiorly and attaches to the lateral surface of the tongue. Its deep relations include the *stylohyoid ligament*, the *glossopharyngeal nerve*, and the *lingual artery*. Passing superficial to the hyoglossus muscle are the *lingual nerve*, the *hypoglossal nerve* and its *two venae comitantes*, and the *submandibular duct*. Those structures that are superficial to the hyoglossus muscle become deep relations of the mylohyoid muscle when they reach the free posterior edge of the mylohyoid muscle and then travel in the interval between these muscles. The hypoglossal nerve innervates the hyoglossus muscle and the other extrinsic tongue muscles, as well as all of the intrinsic muscles of the tongue. The mylohyoid muscle and the anterior belly of the digastric muscle are innervated by the mylohyoid nerve, which arises from the inferior alveolar branch of the mandibular nerve.

Fascial Coverings

A fascial roof and carpet are created by the investing layer of the deep cervical fascia when it splits to invest the submandibular gland. The superficial layer attaches to the inferior edge of the mandible, whereas the deep layer attaches to the inner aspect of the mandible, just below the attachment of the mylohyoid muscle.

Contents of the Submandibular Triangle

Submandibular Gland

The submandibular gland is the main content of the submandibular triangle (Fig. 22.6). It actually overflows and extends beyond its boundaries. The gland wraps itself around the posterior free edge of the mylohyoid muscle. This creates a superficial lobe that lies on the external surface of the mylohyoid and a smaller deep lobe that lies internal to the mylohyoid muscle. The duct of the gland passes medial to the deep lobe and ends in the floor of the mouth at a small elevation just lateral to the frenulum. The lingual nerve at first is superior to the duct as they both pass superficial to the hyoglossus muscle. The hypoglossal nerve is at a more inferior level.

Neurovascular Structures

The structures that are superficial to the submandibular gland include the cervical branch of the facial nerve and the distal ends of the anterior facial vein and anterior branch of the retromandibular (posterior facial) vein (Fig.

22.7). These veins unite in the tissues overlying the submandibular triangle, creating the common facial vein, which passes inferiorly to empty into the internal jugular vein. Occasionally, the mandibular branch of the facial nerve descends below the inferior edge of the mandible and can be injured when incisions are made in this area.

Structures in the submandibular triangle found between the submandibular gland and the mylohyoid muscle include the facial artery and the mylohyoid nerve and vessels. The facial artery is the most superior of the vessels that arise from the anteromedial surface of the external carotid artery. It begins in the carotid triangle, just superior to the tip of the greater cornu of the hyoid bone, passes deep to the posterior belly of the digastric muscle, and enters the submandibular triangle. It passes superiorly and reaches a point well above and medial to the lower edge of the body of the mandible. It then passes over the superior and lateral surfaces of the gland and is adherent to these surfaces. It now arches superiorly in contact with the external surface of the mandible, creating a groove just anterior to the insertion of the masseter muscle. It gives a submental branch that runs along the inferior surface of the mandible in contact with the upper surface of the gland.

Appearing at the anterior edge of the gland are the mylohyoid nerve and vessels. The nerve arises from the inferior alveolar branch of the mandibular nerve. Neurovascular structures are found deep to the submandibular gland, but on the other side of (deep to) the mylohyoid muscle. They are located in the interval between the hyoglossus and mylohyoid muscles, and are responsible for tongue function and nutrition.

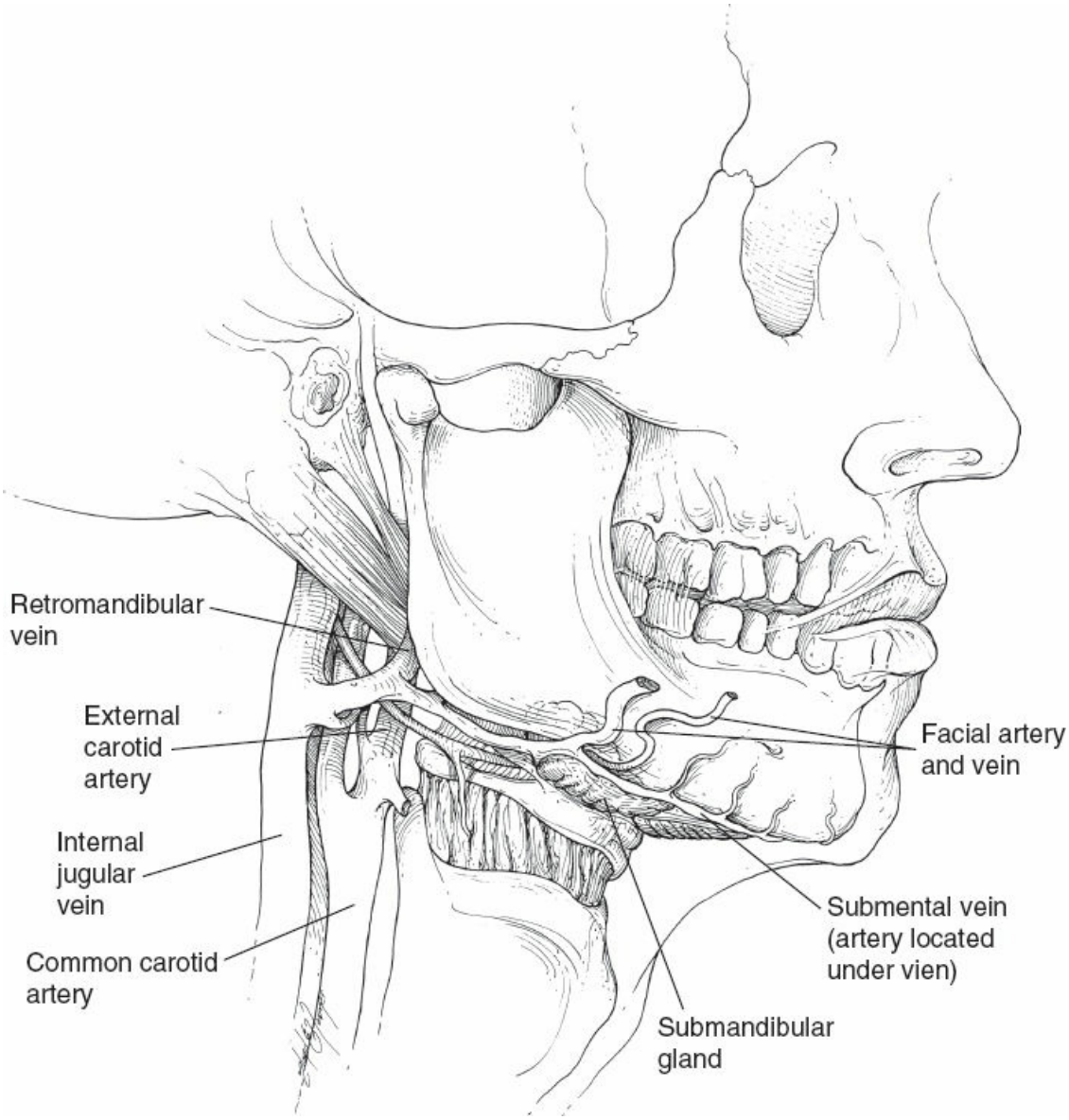

Figure 22.7. Submandibular triangle.

The lingual nerve, a branch of the mandibular nerve, passes through the interval until it reaches the anterior margin of the hyoglossus muscle. It then turns medially, after looping around the submandibular duct, and penetrates the tongue. It provides general sensation for the anterior two thirds of the tongue.

The chorda tympani (arising from the facial nerve) joins the lingual nerve in the upper part of the infratemporal fossa. It carries taste fibers from the tongue and brings preganglionic parasympathetic fibers to the submandibular ganglion. This ganglion is attached to the lingual nerve and is the site of synapse for these preganglionic fibers. Postganglionic secretomotor fibers then pass to the sublingual and submandibular glands. The hypoglossal nerve and lingual veins are also seen in this region.

Accompanying these neurovascular structures is the submandibular duct (Wharton duct). The deep lobe of the submandibular gland is also found internal to the mylohyoid muscle.

Lymphatic Drainage

The lymphatics of the submandibular gland are found within its parenchyma, whereas other lymph nodes are outside the fascial covering of the gland. The lymphatics of the mandibular region can be divided into horizontal and vertical systems. The horizontal chain runs along the mandible from the parotid gland to the midline, receiving afferent channels from the ipsilateral face and oral cavity. The lymphatics of the submental triangle also drain into this horizontal system. From this submandibular collecting area, vertical channels pass to the system of nodes related to the internal jugular vein (deep cervical nodes). Other vertical channels pass into the posterior triangle to the superficial posterior cervical system (found with the external jugular vein) and the deep posterior cervical system (found with the spinal accessory nerve). Named lymph nodes are located in the internal jugular channels, which are found where double-bellied muscles pass superficial to the internal jugular vein (i.e., jugulodigastric and jugulomylohyoid).

Anatomic Aids

The mandibular and cervical branches of the facial nerve may extend below the lower edge of the mandible. All other structures of concern lie deep to the posterior belly of the digastric muscle. Incisions can be made down to this muscle with little fear of injuring any vital neurovascular structures.

The fascial coverings of the submandibular gland are less adherent to the gland surface than are the coverings of the parotid gland. This allows for easier enucleation of the submandibular gland.

The facial artery is very adherent to the internal and superior surfaces of the gland and must frequently be removed with the gland after proximal and distal control is obtained.

The hyoglossus muscle is an anatomic landmark. It is superficial to the glossopharyngeal nerve and the lingual artery but is found internal to the lingual and hypoglossal nerves, the submandibular duct, and a deep process of the submandibular gland. The lingual veins are also superficial to this muscle and are closely related to the hypoglossal nerve.

The lingual nerve is superior to the deep process of the submandibular gland and its duct before forming a loop around the duct by passing lateral and then inferior to it before penetrating the framework of the tongue. The hypoglossal nerve and its venae comitantes are inferior to the duct.

The hypoglossal nerve crosses the internal and external carotid arteries superficially. The glossopharyngeal nerve, the pharyngeal nerves arising from the vagus, and the stylopharyngeus muscle pass between these same arteries, whereas the superior laryngeal nerve (arising from the vagus nerve near the base of the skull) passes deep to those arteries.

Small nerve branches arise from the lingual nerve and submandibular ganglion, which enter the submandibular gland. These must be transected during excision of the gland to prevent avulsion injuries to the lingual nerve.

ANATOMY OF THE SUBMENTAL TRIANGLE

This space is found in the suprahyoid portion of the neck (Fig. 22.8). It separates the submandibular triangles and contributes to the structure of the floor of the mouth. The anterior bellies of the digastric muscles create lateral boundaries of this triangle. The body of the hyoid bone is the base, and the apex is the symphysis menti. The mylohyoid creates a muscular floor. Its fibers arise from the mylohyoid line, on the medial aspect of the mandible; pass inferomedially; and attach to the body of the hyoid bone and a midline raphe found between the hyoid and the mandible. Contraction of the muscle will result in elevation of the floor of the mouth. The mylohyoid branch of the inferior alveolar nerve provides motor innervation. The investing layer of the deep cervical fascia creates a fascial roof. The only contents of the triangle are the submental lymph nodes, which drain the tip of the tongue, floor of the mouth, lower lip, and chin. Efferent channels pass to the submandibular nodes, or to jugular nodes of the vertical cervical chain. Anterior jugular veins are found in the tissues superficial to the submental triangle. Incisions made in this area will not injure major neurovascular structures.

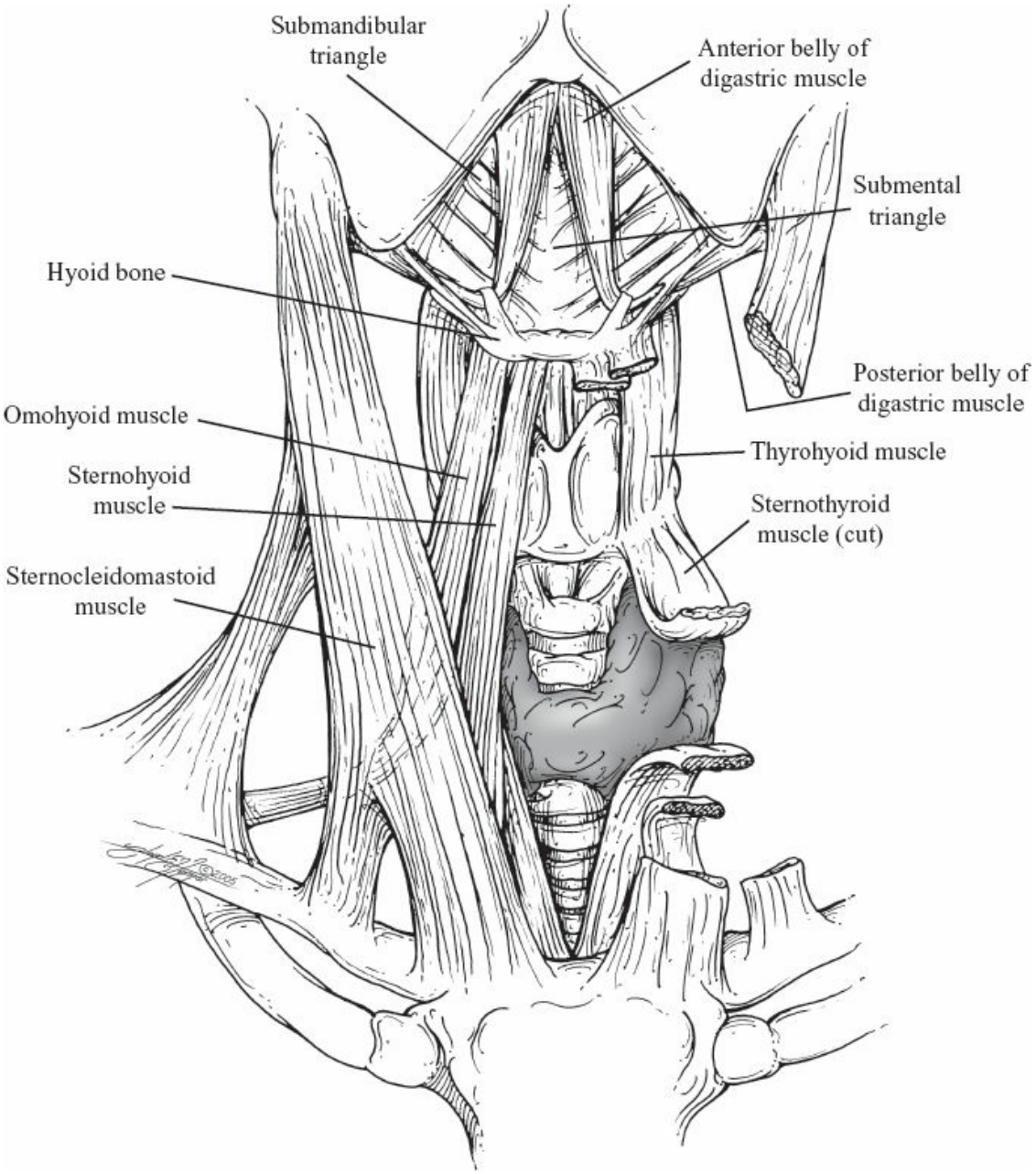

Figure 22.8. Submental triangle.

ANATOMY OF THE FLOOR OF THE MOUTH

The mylohyoid muscle is the anatomic structure that separates the oral cavity from the neck, and thereby creates the floor of the mouth. The attachments of this muscle have been mentioned previously. The hyoglossus muscle contributes a posterolateral boundary to this separation between the floor of the mouth and the submandibular triangle (part of the anterior neck). The floor of the mouth can also be defined as the area between the tongue and its lateral mucosal reflections, and the mylohyoid muscle.

Tongue

The tongue is a massive muscular structure that faces the oral cavity and the pharynx (Figs. 22.5 and 22.6). It is attached to the floor of the mouth, the mandible, and the hyoid bone.

Extrinsic Muscles

The extrinsic muscles of the tongue include the genioglossus, hyoglossus, styloglossus, and palatoglossus. The genioglossus muscle arises from the genial tubercles found on the internal aspect of the midportion of the mandible and passes to most of the dorsum of the tongue. The hyoglossus arises from the hyoid bone, passes superiorly, and attaches to the lateral aspect of the tongue. The styloglossus muscle arises from the tip of the styloid process and the proximal part of the stylohyoid ligament. Its fibers pass anteroinferiorly and attach to the lateral surface of the tongue, where they interdigitate with the fibers of the hyoglossus muscle.

Intrinsic Muscles

The intrinsic muscles of the tongue consist of longitudinal, horizontal, and vertical fibers that create an interlocking network.

Movements

Because of the extensive interdigitation of the muscles of the tongue, a wide variety of movements are possible. In addition, the mylohyoid muscle is displaced by movements of the hyoid bone. These movements are created by contraction of the suprahyoid and infrahyoid muscle groups. The mandible can be depressed by contraction of the mylohyoid, stylohyoid, digastric, and geniohyoid muscles if the hyoid bone is fixed in position by contraction of the infrahyoid musculature.

Innervation

All of the intrinsic and extrinsic muscles of the tongue receive their innervation from the hypoglossal nerve. The one exception is the palatoglossus muscle, which is innervated by the pharyngeal plexus of nerves. Sensory innervation of the anterior portion of the floor of the mouth is provided by the lingual nerve. Traveling with this nerve are fibers of the chorda tympani (seventh) nerve, which provides taste sensation for the anterior portion of the tongue, and preganglionic secretomotor fibers on their way to synapse in the submandibular ganglion before proceeding to the submandibular and sublingual glands. Sensation and taste for the

posterior one-third of the tongue are provided by the glossopharyngeal nerve.

Vascular Supply

The vascular supply to the tongue is provided by the lingual artery, which arises from the external carotid artery in the carotid triangle, passes into the submandibular triangle, and enters the region of the floor of the mouth after passing deep to the hyoglossus muscle. It gives a sublingual branch and then, as the deep lingual artery, passes to the apex of the tongue just lateral to the midline. Little communication exists across the midline between the left and right deep lingual vessels.

Contents of the Floor of the Mouth

Geniohyoid Muscle

The geniohyoid muscle originates just below the origin of the genioglossus and passes anteroinferiorly to attach to the body of the hyoid bone. The left and right parts of this muscle lie side by side. When they contract, the hyoid bone is displaced anteriorly and superiorly.

Salivary Glands and Their Ducts

The sublingual gland is found in the floor of the mouth, between the geniohyoid muscle and the mandible (Fig. 22.9). It is the smallest of the three paired salivary glands and frequently has two systems of ducts. One is composed of multiple ductules, which empty directly into the floor of the mouth. The second system consists of a duct (or ducts) of varying size emptying into the larger submandibular duct. In this same area is found the deep process of the submandibular gland and its duct. This deep process may be of significant size and may appear to blend in with the sublingual gland. The submandibular duct, lingual nerve and veins, and the hypoglossal nerve are medial to the sublingual gland. Anatomic flow exists between the submandibular triangle and the floor of the mouth (sublingual space), which allows for passage of the contents of one area into the domain of the other.

Lymphatic Drainage

The lymphatic drainage of the floor of the mouth is complex. Lesions from the central part of the floor of the mouth and the tip of the tongue can drain into submandibular glands on either side, or drain directly into submental nodes, and then into submandibular nodes (horizontal system). The

drainage is then directed primarily toward the deep cervical system, which is associated with the vertical system of lymphatics found with the internal jugular vein. Some spread may occur to the superficial posterior cervical system in the posterior triangle, which is found with the external jugular vein. The lymph drainage from the posterior part of the tongue is directly into the deep cervical nodes of either or both sides.

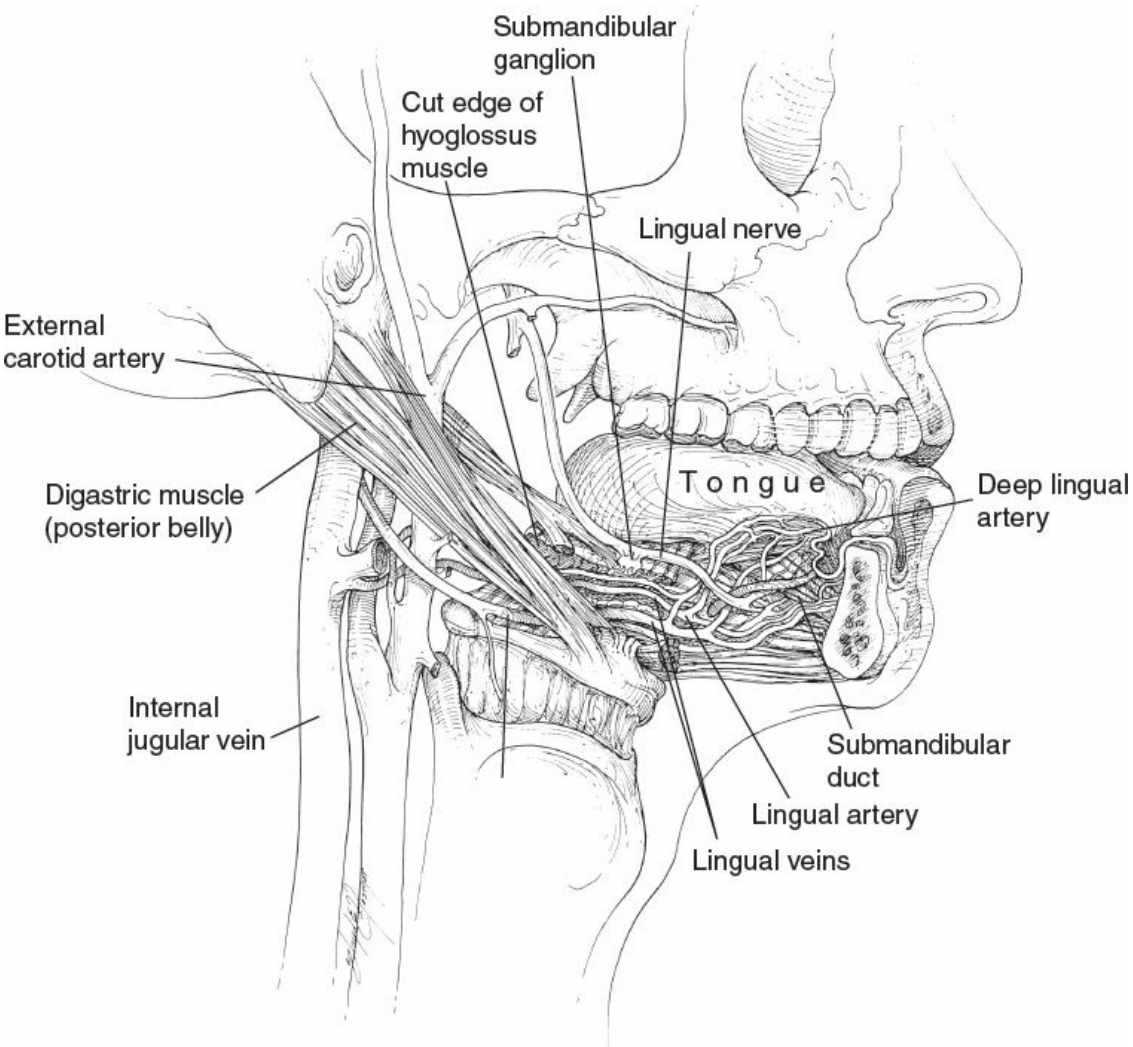

Figure 22.9. Submandibular triangle and floor of the mouth (deep structures).

Anatomic Aids

Little communication is found across the midline of the tongue between the deep lingual arteries. This limits blood loss at the time of hemiglossectomy.

Suggested Readings

Arnold M. *Reconstructive Anatomy,* 1st ed. Philadelphia: WB Saunders; 1968.

Delmas A. *Atlas Aide-memoire d'Anatomie (Rouviere).* Paris: Masson; 1991.

Hollinshead WH. *Anatomy for Surgeons.* 2nd ed. New York: Harper & Row; 1971.

EDITOR'S COMMENT

This is not an area in which general surgeons have a great deal of experience. Even the parotid gland which does appear every now and then in a busy surgical practice yields little familiarity to the average general surgeon. This may be different in the case of the rural general surgeon in which setting there is probably no ear, nose and throat surgeon and the area of tenderness may be beyond the expertise of the general practitioner or the family physician. While the general surgeon may have some familiarity with parotid disease in this case the most important aspect is to know the difference between a parotitis and some type of tumor, many of which are benign, in the case of the submandibular gland and the submaxillary gland there is even less familiarity with inflammation.

The most common malady that the general surgeon is called upon to treat is a chronic sialadenitis. It's commonly associated with an acute chronic inflammation and an obstruction of the excretory duct. But the differentiation between chronic sialadenitis and obstruction of the excretory duct is difficult even the best of circumstances. Stones are responsible for about 60–70% and may occasionally be palpated, stenosis in 15–25%, and inflammation of the duct alone in about 5–10%. Anatomic variations or foreign bodies (the latter difficult to comprehend) are only about 1–3%. In the past as Koch M, et al. (*Otolaryngology Clinics of North America* 2009;42:1173–1792) point out the operative removal of the gland was recommended as the therapeutic method of choice after unsuccessful non-operative treatment. As with many other things, minimally invasive techniques have led to tremendous differences in approach. Interventional sialography and other radiologically controlled methods such as ultrasound-guided techniques and sialendoscopy all have been developed lately and make the therapy of inflammation of the gland a much more direct and informed concept than just taking the gland out. If there is direct visualization of the findings without the use on contrast material and with lack of exposure to radiation, there is a high success rate. There are other gland preserving techniques such as transoral duct slitting or transcutaneous stone retrieval which likely will not be utilized by the average general surgeon. In this nicely authored article there is an algorithm for the treatment of various diseases of the salivary glands starting with the necessity of oral therapeutic diagnostic examination which include, as mentioned earlier, ultrasound and sialendoscopy. Ultrasound enables the presumptive diagnosis to make quickly, safely and cost effectively and in the hands of experienced people with great precision. Endoscopy serves

as a direct determination of the obstruction. Endoscopy controlled treatment such as interventional sialendoscopy also is a boon to non-destructive operations on the salivary glands.

Less than 5 mm stones and mobile stones located in the main excretory ducts and possibly even as far as the first and second branching ducts may be successful in the hands of the skilled endoscopist of which most general surgeon will not be. The stones may be fragmented during intervention and the fragments then retrieved by endoscopically controlled means. Micro-instruments also exist but probably will require a specialist. Radiologically controlled or fluoroscopic methods can be preformed with a success rate of up to 80%. Shock-wave lithotripsy represents a therapeutic alternative of the first choice in the parotid gland and the fragments may be extracted in an endoscopically controlled manner.

Stones are difficult to feel manually. I recently had a patient who had a neck procedure elsewhere and developed pain in her neck and it appeared as she pointed to the right side of the neck that she probably did have a sialadenitis of the submandibular gland with a sympathetic adenopathy going down the entire right neck. I had started her on antibiotics prior to seeing her because that what it sounded like and indeed she told me that an ENT person she had seen years ago that she had stones in her duct. I could not feel it nor could I milk anything out through the bottom of the mouth but I am certain that’s what she had. It subsided.

In the parotid gland which is not the subject of this particular exposition the 25% of all stones have an intraparenchymal location and therefore are more difficult to deal with.

Stenoses are another major cause of symptomatic sialadenitis and may be seen by endoscopy. However some stenoses may be multiple, they may be in difficult locations, they may be long and the tissue of the stenosis may be fibrotic. Sialendoscopy has the advantage of a direct assessment and does allow an inflammatory stenosis to be differentiated from a fibrous stenosis. The major of the inflammatory stenoses may be treated non-operatively with irrigation and intraductal steroid placement. In regard to the submandibular gland, symptom free stenosis, especially if one can recognize atrophy of the gland require no or exclusively conservative form of treatment. The basic treatment rule applies for symptomatic stenosis, as inflammatory stenoses are treated primarily non-operative whereas fibrous stenoses are operated on. This is an extensive paper and the detail that is contained in it is beyond the scope of what I wish to impart but it is readable and informative and the practitioner who deals with these may want to avail themselves of the wisdom in this particular paper.

Beahm, David D, et al. (*International Journal of Surgery* 2009;7:503–509) reviewed the surgical approaches to the submandibular gland. Surgical incision of the submandibular gland is commonly indicated in patients with neoplasm or occasional with chronic sialadenitis and ranula and drooling. In the past, traditional SMG surgery has involved a direct transcervical approach while

more recently alternative approaches through the submandibular gland excision have been described to avoid scarring and to offer minimally invasive options with better cosmetic results. In this paper the authors utilize dissection of cadavers which were dissection via both the transcervical and transoral approaches together with the use of endoscopic assistance when indicated. The authors conclude that while tradition submandibular gland excision (nobody seems to bother much with the submaxillary gland) a direct transcervical approach is what is preferred. The modes of excision include open, endoscopic and robotic-assisted dissections.

Ranulas, so named for frogs, may be the result of inspissated mucus and may not be an indication of malignancy or a situation which requires excision of the duct or the gland. Should such excision be required however Kauffman RM, et al., *Laryngoscopoe* 2009;119:502–507 propose a transoral surgical approach to excising the submandibular gland. They describe relevant anatomy and what to avoid. They describe nine patients in which this approach was attempted over the past ten years. Of the nine patients who underwent attempted transoral submandibular gland excision, eight operations were completed transorally and only one operation was aborted and converted to a standard external approach because of severe scarring. Six of the nine patients had chronic sialadenitis and three had obstructing sialoliths. Three other patients presented with other benign cystic lesions consistent with a ranula, an infected mucocele, and a cystic teratoma. The only complication with a patient with incisional breakdown and delayed healing because of a prior irradiated field. The lingual nerve, or hypoglossal nerves, were spared and there were no hemostatic complications. The authors conclude that this option actually is safe and there are no external scars. Obviously some skill and association with a thorough knowledge of anatomy is useful.

Finally Yu C, et al. *Journal of Oral and Maxillofacial Surgery* 2010;68:1770–1775) writing from the Shanghai 9th People's Hospital at Shanghai University report on endoscopy observation and management of obstructing submandibular sialadenitis. 128 cases, a very substantial number, were identified endoscopically and radiographically. They had three types of sialoliths in 114 or 89%, mucus plugs in 8 (6%) and stenosis in 5% (6). 47 were removed successfully for a success rate of 92% of 51 obstructions treated surgically. Of 63 patients treated using interventional sialendoscopy, 52 were removed with a success rate of 83%. The remaining unsuccessful cases were treated endoscopically or surgically. Obstructive symptoms were relieved in 12 of 14 patients without stones using dilation and irrigation under sialendoscopy. Of the 114 patients with a stone, the sialoliths of 67 (59%) in the distal region behind the first molar. It stands to reason that their conclusion that the more posterior the stone the more difficult it was to remove and that was correct. Three patients with treatment failure underwent resection of the gland. A basin-like structure in the hilus region was found in 67%. In 5 patients a fishbone was found surrounded by a sialolith. The authors conclude that this is a relatively

new technique and is sparing of the submandibular gland and holds great promise. I agree.

J.E.F.

23 Lip Reconstruction

Patrick C. Hettinger and Robert J. Havlik

Reconstruction of the lip may be required for a defect created from resection of malignancy, following traumatic injury, or as the result of a congenital anomaly. The incidence of oral/pharyngeal cancers in the United States is approximately 45,000 per year, with approximately 13,000 affecting the mouth directly. Approximately 25% to 30% of these malignancies involve the lips, thereby yielding a total annual incidence of approximately 4,000 cases. The number of traumatic injuries to the lips is difficult to determine accurately, but these injuries are not uncommon, and frequently occur following dog bites and motor vehicle accidents. The incidence of cleft lip, with or without cleft palate, in the United States is approximately 4,400 cases per year. While all of these patients will benefit from lip reconstruction, the majority of the latter group of congenital anomalies are cared for by specialized teams in children's hospitals, frequently follow more complex paradigms involving treatment of other facial structures in addition to the lip, and their treatment will not be discussed further here. Therefore, this chapter will focus on lip reconstruction following resection of lip cancer or traumatic injury—the principles involved in these reconstructions are similar.

Lip cancer is strongly associated with smoking, alcohol use, and sun exposure. Smoking and alcohol have significant "synergy" in the pathogenesis of all oral cancers and the effects together are multiplicative, noted to be as high as 20-fold the occurrence with either smoking or alcohol use. Unlike other oral and mucosal cancers, sun exposure is also a prime consideration in the pathogenesis of cancer of the lips. The upper lip has a more prominent position, projecting in front of the lower lip and shrouding the lower lip, but the vermillion surface is largely facing downward, away from the sunlight. It is the cutaneous surface of the upper lip that sustains the most significant exposure. The majority of lesions on the skin of the upper lip are basal cell carcinomas. In distinct contrast, the majority of lesions on the lower lip involve the vermillion and are the more aggressive squamous cell carcinomas. The lower lip vermillion is

facing upward and outward, and is prone to damage by direct sunlight. Actinic exposure is believed to play an important role in squamous cell cancer of the lower lip, as judged by association with occupation and geographic location.

Cancer of the lip differs from other cancers of the oral cavity in that the prominence of the lips in everyday activities often leads to early recognition of the presence of the lesion. Once the lesion has been recognized, diagnosis is made by surgical biopsy. A recent Cochrane review found that other alternatives for diagnosis (fine needle aspiration, etc.) were not as accurate as surgical biopsy. Clinical examination of the neck for involved nodes is crucial in staging this disease. Regional spread and nodal involvement at the time of diagnosis of lip cancer, unlike other oropharyngeal cancers, are relatively uncommon. The central portion of the lip drains to submental lymph nodes, whereas the lateral portion of each lip drains to the ipsilateral submandibular lymph nodes. Computed tomography (CT)/magnetic resonance imaging (MRI) may be warranted for evaluation for potential nodal involvement. However, a large number of patients with lip cancer will have nodal enlargement on the basis of inflammatory changes, which can be difficult to differentiate on digital scans. In follow-up of a large series of patients who had treatment of the primary lesion alone, only 8% to 10% will develop nodal disease. In addition, lymph node involvement seems to correlate with tumor stage: 4% in T1 lesions (<2 cm), 35% in T2 lesions (2 to 4 cm), and 63% in T3 lesions (>4 cm). If nodal disease does occur, it can be difficult to manage, with a 5-year survival of only 50% in these patients.

ANATOMY

Topographically, the lips dominate the lower third of the face. The lips have a number of surface landmarks that are important for successfully approaching reconstruction (Fig. 23.1). Accurate alignment of these landmarks is essential for an acceptable result—tolerances in discrepancies are a millimeter or less. As you pass from superiorly to inferiorly, the skin of the upper lip develops a slight prominence, the “white roll,” before transitioning across the linear mucocutaneous junction, or vermillion border, to the pink vermillion of the upper lip. The vermillion’s matte pink appearance is created by a dense network of blood vessels extending beneath a thin layer of nonkeratinizing epithelium. The dry appearing vermillion transitions to the wet appearing mucosa at the “wet line” where

the upper and lower lips meet. A similar transition of mucosa, vermillion, and skin occurs in the lower lip. In the upper lip, two ridges extend from the base of the columella of the nose to the peaks of the upper lip on either side of the midline, the philtral columns. These two philtral columns demarcate the central upper lip, and also serve as the lateral boundaries for Cupid's bow, the curved area of the transition between the skin and the vermillion border of the central upper lip. The philtral columns are created by the insertion of the largely transverse fibers of the orbicularis oris muscle fibers into the skin along the height of the columns. The central upper lip is aesthetically discrete from the adjacent lateral upper lip segments. The central upper lip is also anchored to the boney pyriform aperture. The labiomental crease is a depression in the cutaneous portion of the lower lip that is located roughly half-way between the vermillion border of the lower lip and the chin point.

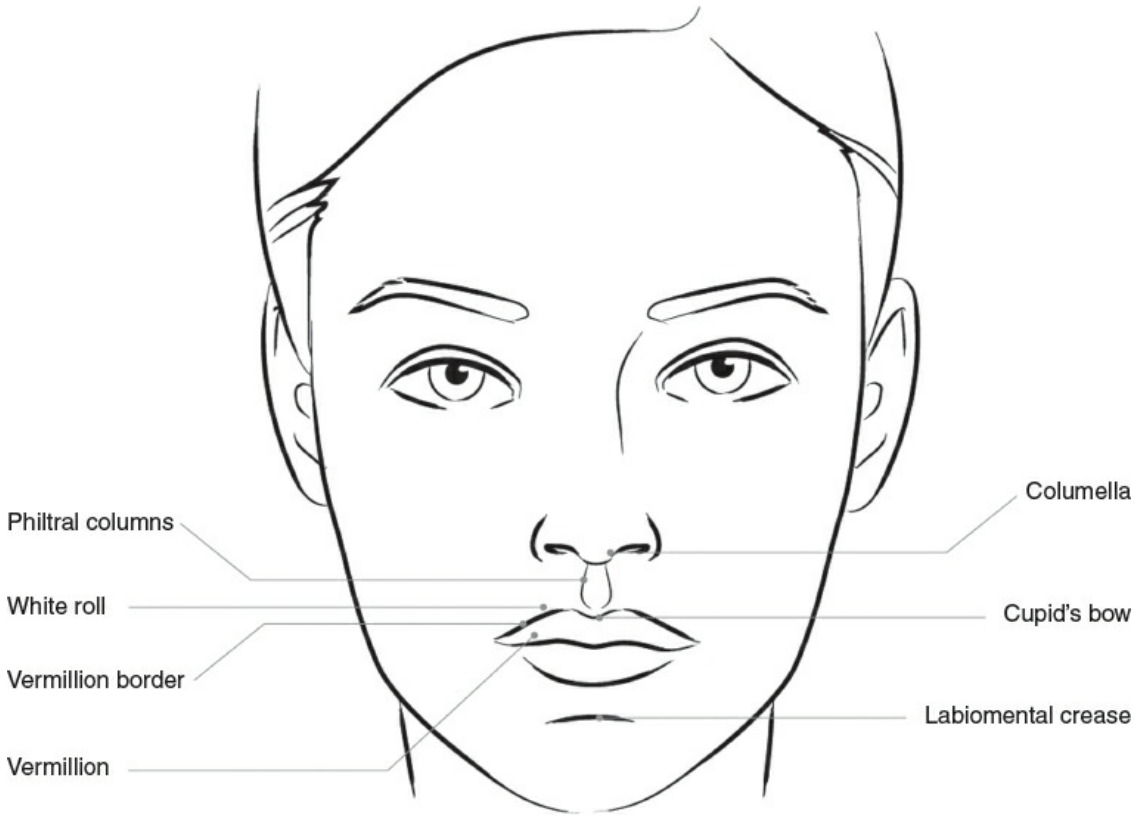

Figure 23.1. Surface landmarks of the lips.

Deep to the surface, the muscular architecture supports the lens-shaped oral opening (Fig. 23.2). Each side of the oral opening is known as the oral commissure. Just lateral to each oral commissure is the modiolus, a fibromuscular area of confluence of several muscles. This area is

noteworthy because it is a critical insertion point for many muscles that affect lip motion, and accordingly is also extremely difficult to reconstruct. Extending in an almost horizontal orientation across both the upper and lower lips is the orbicularis oris. The orbicularis oris muscle is responsible for the majority of the bulk of the lip. As noted above, in the upper lip some fibers of the orbicularis oris insert into the skin to create the ridge of the philtral columns, whereas in the lower lip all of the fibers pass transversely and horizontally and join with orbicularis oris fibers extending from the contralateral modiolus. In the upper lip, the levator labii superiorus, the zygomaticus major, and the levator anguli oris are the major lip elevators (Fig. 23.2). The levator labii superiorus arises from the inferior and medial orbital margin and wraps around the nasal ala and passes over the fibers of the orbicularis oris muscle to insert into the orbicularis oris fibers and the lower portion of the ipsilateral philtral column. The levator angulii oris arises just below the levator labii superiorus and inserts into the modiolus. The zygomaticus major muscle extends from the body of the zygoma to insert into the modiolus. There are several other muscles that arise from the pyriform aperture and the nose and can effect upper lip function, but are less significant in their overall impact, and will not be discussed here.

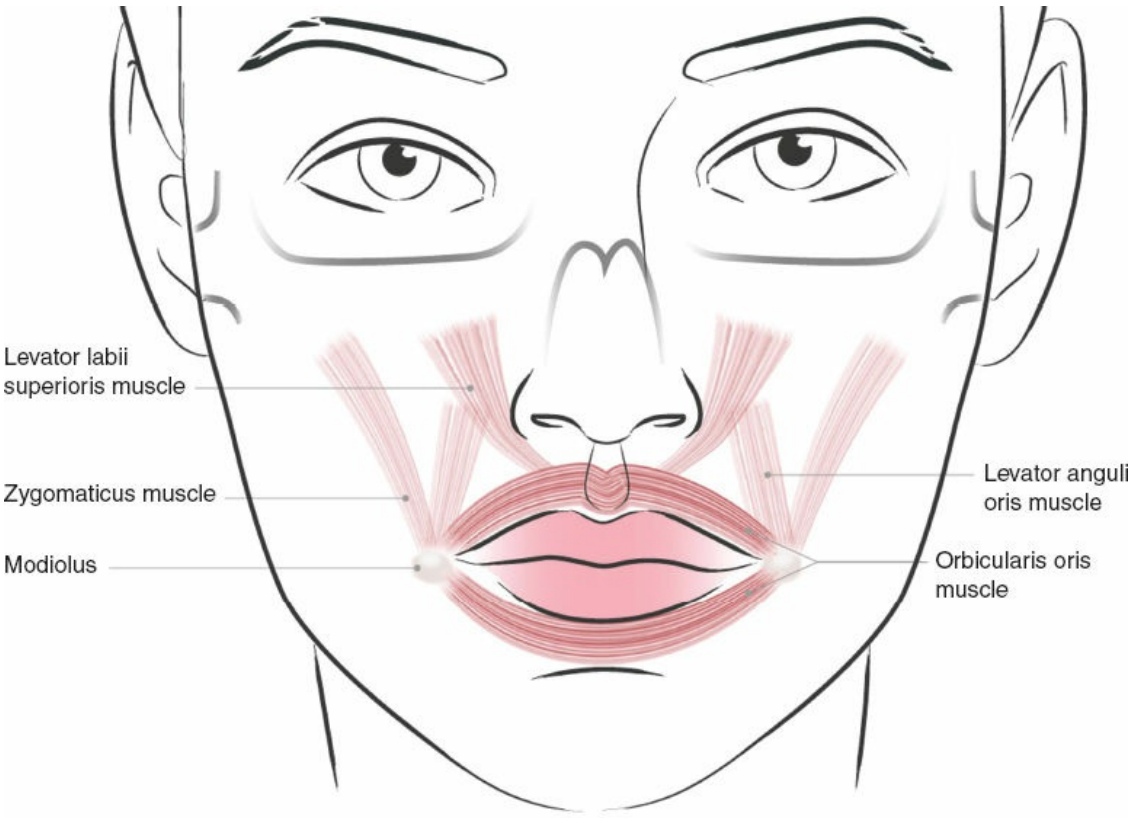

Figure 23.2. Muscles of the upper lip.

The buccinator muscle is the main muscle of the soft tissue wall of the cheek. It originates from the pterygomandibular raphe and maxillary and mandibular alveolar ridges of the posterior mouth and passes anteriorly, inserting on the modiolus and muscles of the upper and lower lips.

In the lower lip (Fig. 23.3), the depressor labii inferioris arises from the inferior border of the mandible from the area of the mental foramen to the symphysis and its fibers pass medially and superiorly and intermingle with the fibers of the orbicularis along the length of the ipsilateral lower lip. This muscle pulls the lower lip down. The depressor angulii oris arises inferior to the origin of the depressor labii inferiorus and its fibers pass laterally, superiorly, and superficial to the fibers of the depressor labii inferiorus to insert on the modiolus. The origin of the depressor angulii orus muscle interdigitates with the fibers of the platysma muscle, and these two muscles act to pull the modiolus (and the corner of the mouth) downward. The mentalis muscles originate from the parasagittal areas of the mandible below the vestibular sulcus, and pass inferiorly and toward the surface to insert into the skin. When they contract, they pull chin and the lower lip upward in the central area to facilitate lip closure and establish competence.

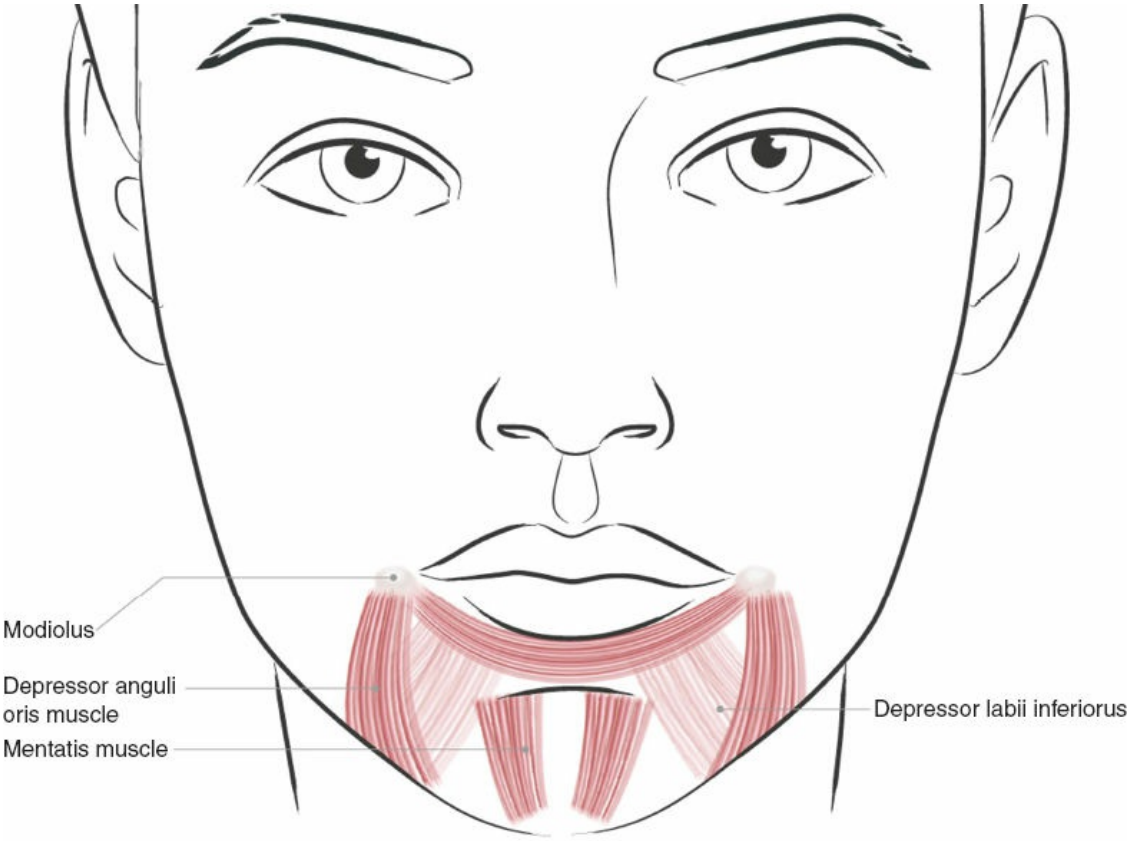

Figure 23.3. Muscles of the lower lip.

The motor innervation of the muscles of the upper lip is by the buccal branches of the facial nerve, whereas the lower lip muscles are innervated by the marginal mandibular branches of the facial nerve. Sensory innervation of the upper lip is provided by branches of the infraorbital nerve (V2), whereas sensory innervation of the lower lip is by branches of the inferior alveolar nerve (V3) via the mental foramen. The mental foramen is located at the level of the second mandibular premolar.

Of critical importance in reconstruction, the blood supply of the lips is provided by branches of the facial artery—the superior and inferior labial arteries (Fig. 23.4A). These arteries travel roughly parallel to the lip surface and connect with the superior and inferior labial arteries from the contralateral side, forming a ring around the mouth. The labial arteries are found at the level of the mucocutaneous junction horizontally, but closer to the mucosal surface than the skin (Fig. 23.4B). They are approximately 1 mm in diameter. These vessels not only assure a rich blood supply to the lips and anterior mouth, they also have adequate flow to serve as the basis for the regional flaps used in reconstruction of the lips.

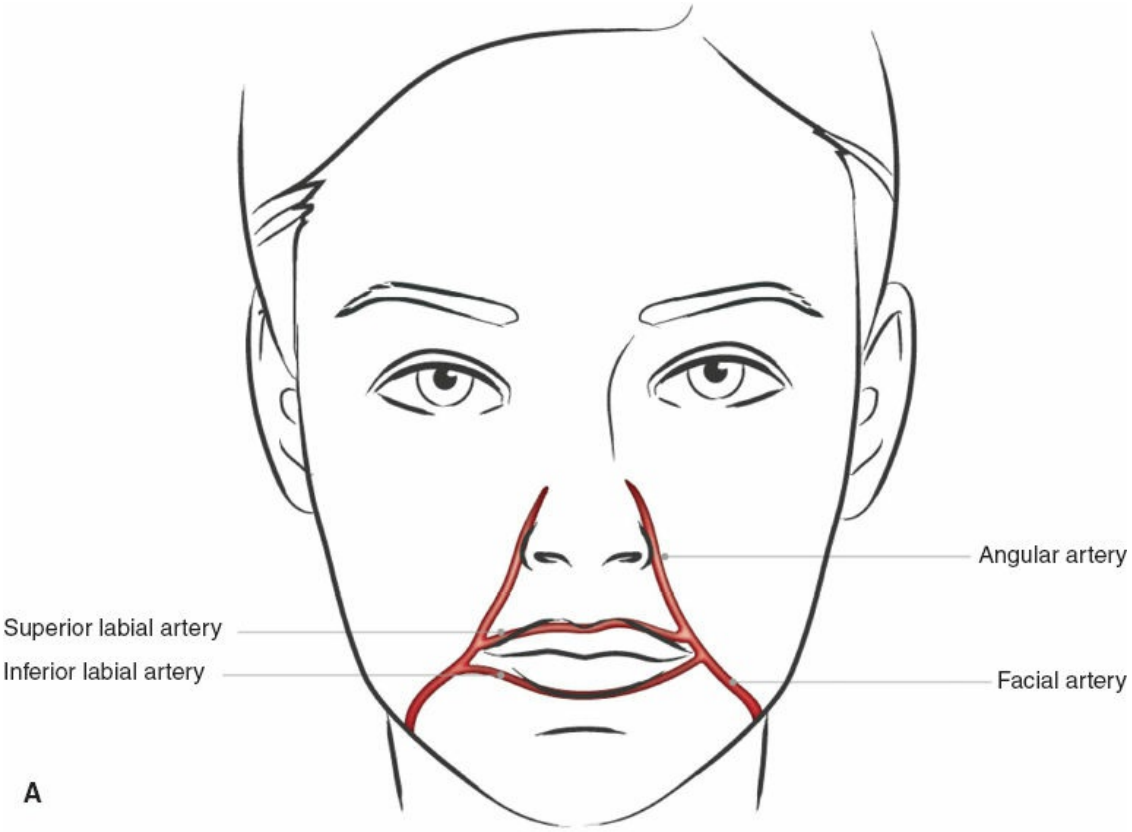

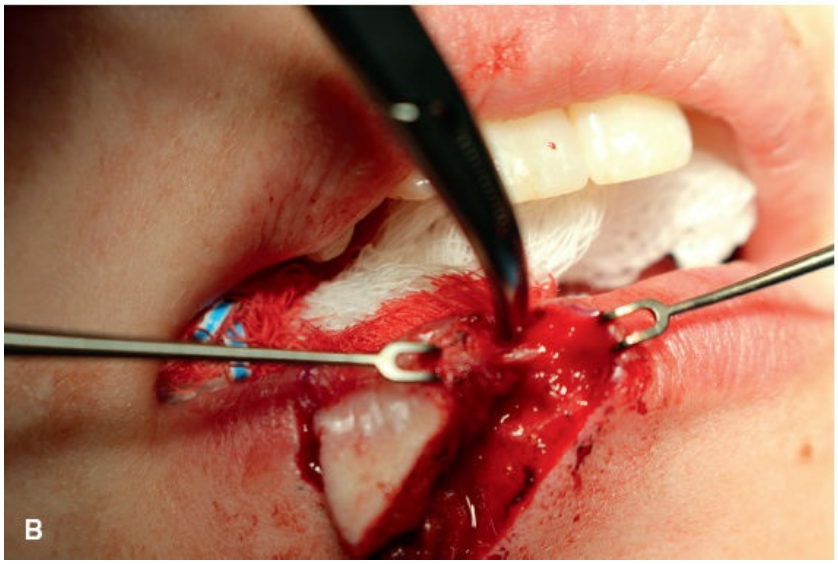

Figure 23.4. **A.** Arterial supply of the lips. **B.** Intra-op photo illustrating the position of the labial artery within the lip.

RECONSTRUCTION OF LIP DEFECTS

Reconstruction of the lip must address both aesthetic and functional concerns. The lips are a center point of the face, and serve a crucial role in facial aesthetics and beauty. They are a focal point of human interaction. Therefore, attention to principles in reconstruction is essential for an

optimal aesthetic outcome. Burget and Menick, in a major contribution, developed the principles of aesthetic subunits, and an understanding of these principles is essential for optimizing aesthetic results. The upper lip protrudes further in front of the lower lip, and partially drapes over the lower lip. Consequently, the upper lip has a more important role in facial aesthetics than the lower lip does. This is a critical feature for repair of upper and lower lips.

It is equally crucial to recognize that the lip serves as a barrier, or dam, to prevent the escape of oral contents. The lower lip is more important in this function than the upper lip. An essential goal in lip reconstruction is to restore this barrier function, and to prevent drooling. No matter how perfect the lip reconstruction, drooling is an unacceptable functional outcome and will need to be either avoided or corrected. The lips form a well-coordinated sphincteric mechanism to allow for oral intake, and control the passage of solids, liquids, and air. The latter is very important for the role the lips play in speech production.

Whether the defect in the lip is due to trauma or cancer extirpation, there are certain fundamental principles that need to be followed in lip reconstruction. The first principle is that healing by secondary intention is not an acceptable approach. The lips are soft and supple, which is important in their appearance and their sphincteric function, and healing by secondary intention leads to significant cicatricial change and fibrosis. Furthermore, an additional important consideration is that when the ring of muscle surrounding the mouth has been interrupted, the ends will pull apart, and healing by secondary intention will often lead to a larger defect. Therefore, all defects of the orbicularis oris muscle need to be repaired at the muscle level. The second basic principle is that the use of “like” adjacent tissue is preferable in lip reconstruction for two primary reasons. The color match of the adjacent tissue is superior to other options in reconstructing this aesthetically sensitive area. Furthermore, the use of adjacent tissue allows en bloc reconstruction of the trilaminar defect (skin, muscle, and mucosa) created in full thickness lip loss. Also, although the tissue at time of transfer/reconstruction may be denervated, there is a demonstrated ability for this tissue to become reinnervated and regain adequate sensation and reasonable function. Primarily for these reasons, local and regional flap reconstruction of the lip is preferred where possible. It is important to be aware that any reconstruction of the lower lip must have adequate depth of the lower lip sulcus, otherwise drooling may result.

This is very important.

PRINCIPLES OF LIP RECONSTRUCTION

- Complete skin covering and oral lining
- Semblance of a vermillion
- Adequate stomal diameter to allow mouth opening
- Sensation
- Competent oral sphincter
- Adequate depth of the lower lip sulcus
- Favorable color match is desirable

VERMILLION DEFECTS AND PREMALIGNANT LESIONS

Resection limited to the vermillion is used for superficial lesions and premalignant change. Occasionally, it can be used in actinic cheilitis, a dysplastic condition of primarily the lower lip. Following resection of the vermillion, a procedure known as a “lip shave,” the lower lip is reconstructed by either release of the mucosa in the labial sulcus and direct advancement and repair of the defect through the use of this bipedicle technique, or by undermining the mucosa of the lower lip into the sulcus and advancing this flap and closing the defect. The latter approach has significantly more swelling, but both are effective. Additionally (and importantly), the vermillion can be resurfaced through the use of V-to-Y advancement flaps, buccal mucosal flaps, or a two-stage operation using a mucosal flap from the ventral surface of the tongue, with subsequent division and inset.

UPPER LIP DEFECT LESS THAN 30% OF LIP LENGTH

The upper and lower lips are approximately 7.5 cm to 8 cm in width, so excision of a 1.5-cm lesion with 5- to 7-mm margin will fall into the upper limits of this category of a 30% defect. In the lateral upper lip (lateral to the philtral columns), excision of lesions that are this size or smaller can be accomplished with a V-shaped excision or laterally extended V-shaped excision. In smaller lesions, since the majority are basal cell cancers, it may not be necessary to perform full-thickness excision. In larger lesions, it is frequently necessary to perform full-thickness excision. Great care must be exercised to appropriately align the white roll, the vermillion

border, and the free border of the lip. In full thickness excision, prior to injection of anesthetic with epinephrine, it is necessary to “tattoo” the lip at the vermillion border/white roll with a full thickness through and through passage of a 30-gauge needle coated with methylene blue. When injected with topical anesthetic with epinephrine, the lip will blanch due to the vasoconstrictive effects of the epinephrine. This makes recognition of the landmarks and vermillion border difficult to detect and accurate repair exceedingly difficult. The methylene blue tattoo points facilitate accurate repair. In addition, care should be taken to design the incisions such that they cross the vermillion border at a 90-degree angle, perpendicular to the lip. This helps with accurate alignment in repair and favorable healing.

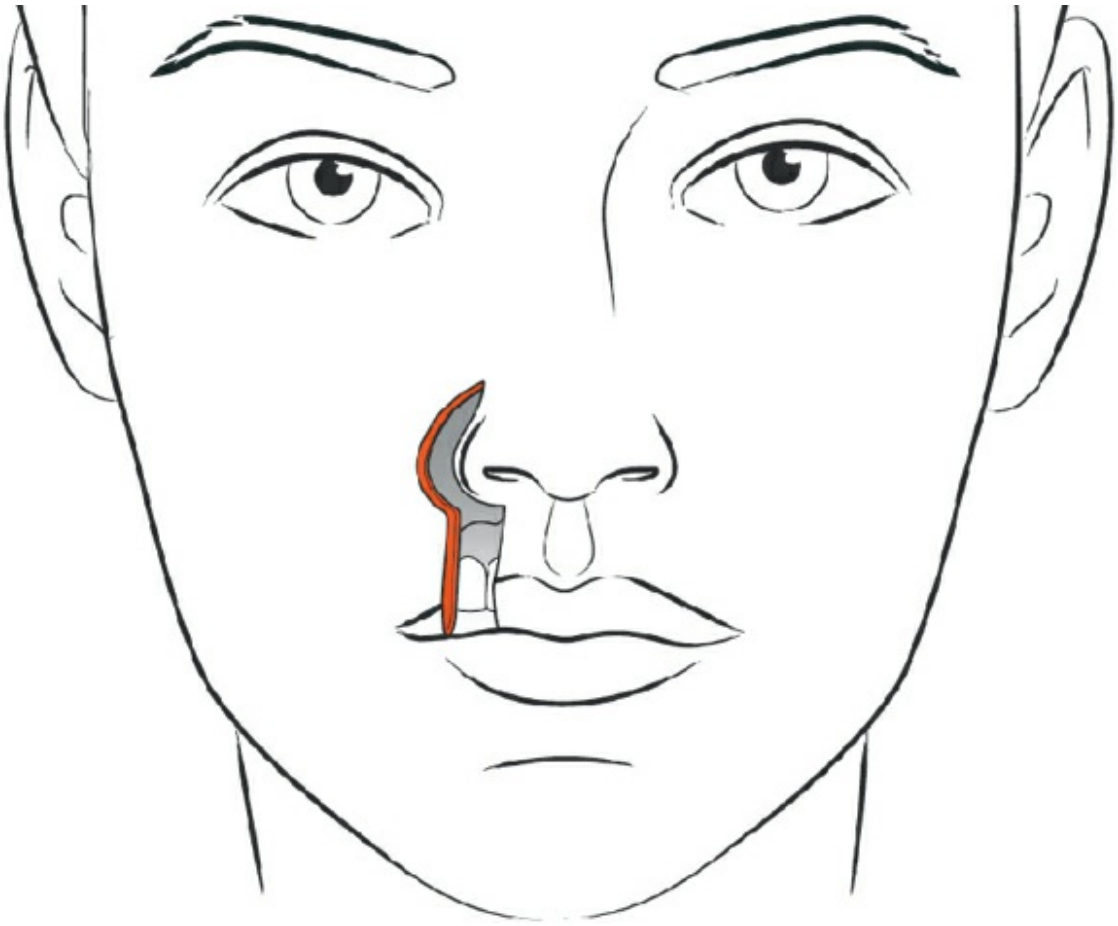

Figure 23.5. Peri-alar crescentic excision to facilitate lip closure.

It is important to understand that the upper lip will tolerate less of an excision than the lower lip before it appears and feels tight. Release of the tissue from the pyriform aperture by means of a full thickness incision through the upper labial sulcus can help, but displacement of the philtral columns and central upper lip must be avoided to prevent an unnatural

appearance. Webster described crescentic excision of peri-alar tissue in 1955 as an adjunct to lip excision, and this can also be performed to aid mobility of the upper lip flaps and improve the aesthetic result of the reconstruction by minimizing tension and deformity (Fig. 23.5).

If the site of the upper lip defect involves the majority of the central upper lip, repair can either utilize bilateral peri-alar excisions, or tissue can be transferred in from the lower lip through the use of an Abbe flap. The Abbe cross-lip flap is a workhorse in upper lip reconstruction that can minimize tightness of the upper lip, and can also lead to an improved aesthetic result. The disadvantage of the Abbe flap is that it requires a second stage for division and inset.

For reconstruction of the upper lip, the Abbe flap is based upon the inferior labial artery (Fig. 23.6A). The labial artery traverses the lower lip beneath the inner mucosal surface of the lip. It typically runs at the same horizontal level as the vermillion border, but in regard to depth lies more between the inner mucosal aspect of the lip and the center of the lower lip (Fig. 23.4B). The Abbe flap is designed such that the pedicle or hinge point is centered toward the edge of the excision on the contralateral lip. The flap should be designed to be approximately one-half the width of the upper lip defect, with the hinge point designed approximately one-half the way across the upper lip defect (again, very important). The flap is cut as a full thickness flap through skin, mucosa, and muscle. The dissection toward the labial artery from below the labial artery must be done meticulously. The hinge point/pedicle should be maintained at the full width of the vermillion to allow venous drainage and to provide strength to the pedicle to protect from the tension if the patient tries to open his mouth (Fig. 23.6B). The patient remains on a liquid diet.

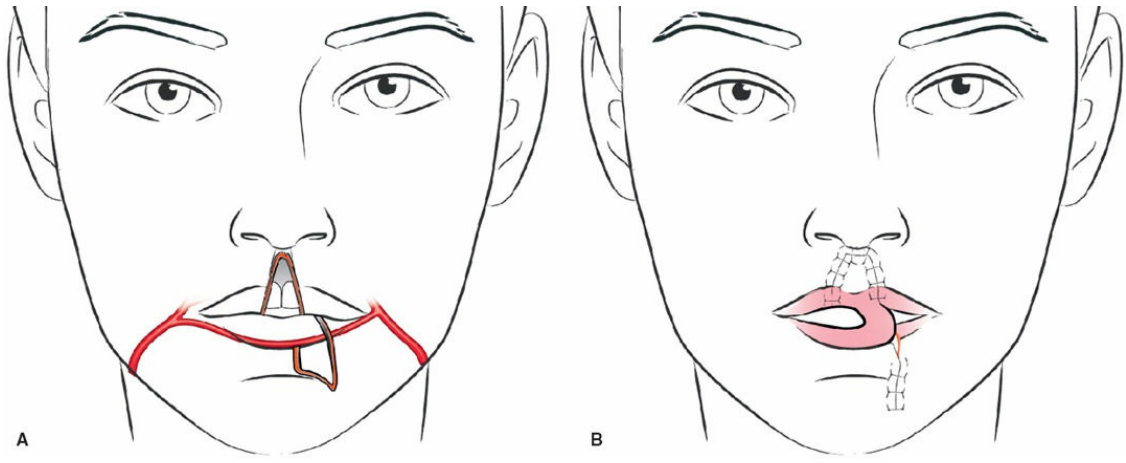

Figure 23.6. A. Abbe flap for reconstruction of central defect of

upper lip. **B.** Abbe flap following transfer and inset.

During the second stage, which occurs 2 to 3 weeks later, the labial artery is ligated and the pedicle completely divided. Care must be taken during the closure of the donor lip to align the vermillion border and the free border of the lip. This donor lip usually heals favorably. The inset of the flap in the upper lip is then undertaken, taking care to align the vermillion border. However, unlike the “donor” lip (lower lip in this case), it is frequently necessary to revise the inset. This can usually be accomplished under local anesthesia.

LOWER LIP DEFECT LESS THAN 30% OF LIP LENGTH

Unlike the upper lip, the lower lip does not have the discrete central area of Cupid’s bow and the philtral columns. If the defect in the lower lip is less than 30% of the lip width, V-shaped excision and direct closure is the preferable choice. The lower lip, however, does have the labiomental crease that is best avoided. An incision that violates the labiomental crease is prone to hypertrophic scarring and banding across the sulcus, a problem that is difficult to rectify in this area. The excision can be designed to create a V-shaped defect or a laterally extended V-shaped defect if the excision would cross the labiomental crease, since crossing this frequently leads to unfavorable hypertrophic scarring (Fig. 23.7). W-shaped excisions may also be used (Fig. 23.8). Again, like the upper lip, accurate alignment of the vermillion border is crucial, and the same techniques with methylene blue tattoo may be employed.

UPPER LIP DEFECT FROM 30% TO 60% OF LIP LENGTH

Moderate size defects of the upper lip can be reconstructed in three ways. Webster described the technique of peri-alar crescentic excision (Fig. 23.5). This is a powerful technique that allows cheek tissue to be swept in to reconstruct the upper lip defect. It enjoys favorable color match and favorable tissue characteristics, and yields very favorable aesthetic results. As the upper lip defect increases in size, it is frequently necessary to combine different options for optimal results. This frequently involves a pedicled local flap transfer. If the defect in the lateral upper lip segment involves more than 50% to 60% of the width of that lateral segment, the

reconstruction of the lateral segment can be accomplished with an Abbe flap (Fig. 23.6A,B). The Abbe flap, described above, can be used as an adjunct to peri-alar crescentic excision if the defect includes the central portion of the upper lip, or if the defect involves a greater extent of the upper lip and additional tissue is required to avoid tightness. Burget and Menick recommend completion of resection of the subunit of the lateral upper lip and transfer of a “block” of tissue as an Abbe flap to reconstruct the lateral upper lip.

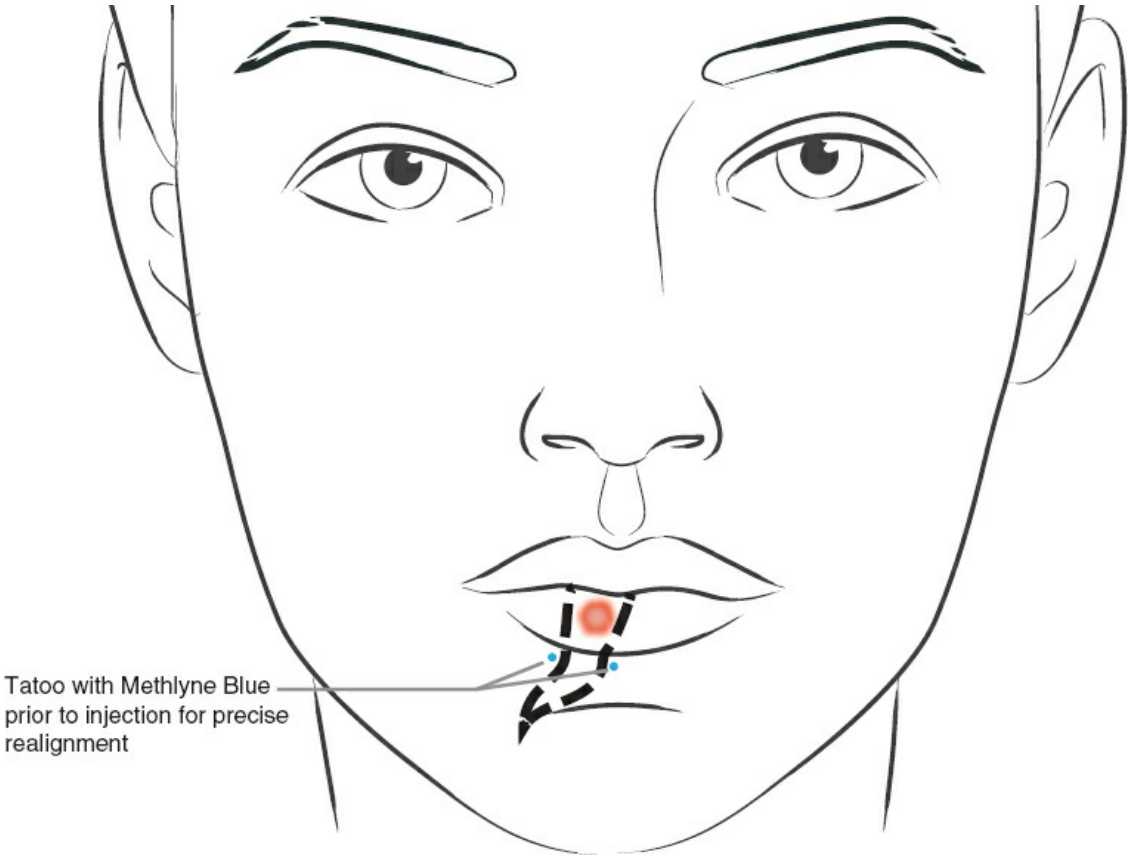

Figure 23.7. Laterally extended V-excision to avoid labiomental crease.

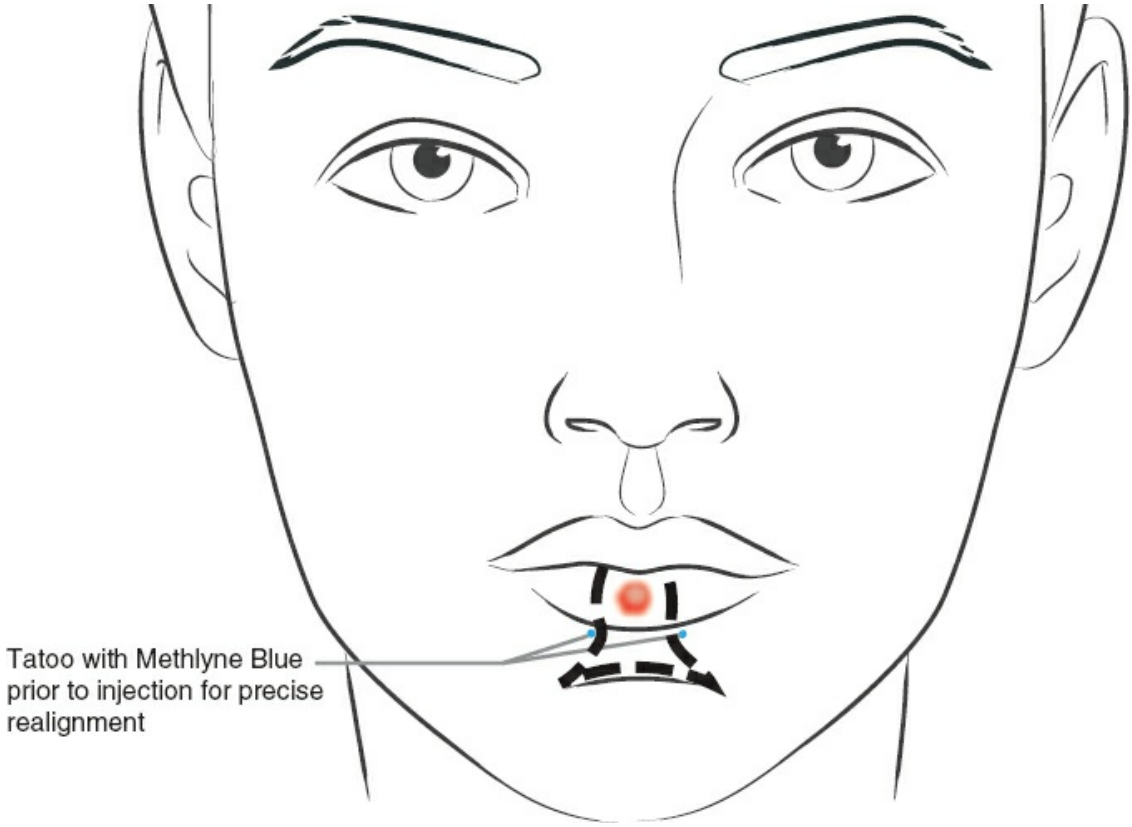

Figure 23.8. W-shaped excision of central lower lip.

LOWER LIP DEFECT FROM 30% TO 60% OF LIP LENGTH

As the lower lip defect approaches or exceeds 40% of the lower lip, simple excision and closure results in too large of a defect to allow closure without lower lip tightness. Fortunately, a number of options are available to help maintain oral competence and closure. In planning these operations, one must always be cognizant of incisions and denervation of tissue, since denervation can contribute to drooling and a loss of competence of the oral sphincter.

For central defects of the lower lip, the Schuchardt operation is analogous conceptually to the crescentic excisions around the alar bases, except that the crescents are taken around the chin. The crescentic excision provides for additional central movement of lateral lip elements to reconstruct a central lower lip defect (Fig. 23.9). The Bernard operation is an extension of the principle of the Schuchardt operation, but adds additional movement. The Bernard operation added full thickness excision of triangles of the upper lip along the nasolabial lines, enhancing movement and allowing larger defects to be corrected (Fig. 23.10).

Webster suggested a modification of this operation that included making only partial thickness nasolabial excisions (not full thickness), more extensive mobilization of the lower lip flaps, and using mucosal flaps to recreate a semblance of vermillion (Fig. 23.10).

Other options in lower lip reconstruction include the Estlander pedicle flap, which essentially is a modification of the Abbe flap that pivots around the intact oral commissure (Fig. 23.11). This flap allows a large block of composite tissue to be transferred to the lower lip, thereby restoring competence, and minimizing tightness of the lower lip. Like the Abbe flap, this flap should be designed to be approximately one-half the size of the lower lip defect. The Gillies fan flap is a modification of the Estlander flap that moves the commissure and causes some distortion because of this movement of the commissure (Fig. 23.12). McGregor described an alternative flap to the Gillies flap that pivots around the commissure, which causes less distortion (Fig. 23.13). However, the McGregor flap does change the axis of muscle fibers in the lip reconstruction, and this does interfere with sphincteric function, lessening the oral competence of this type of reconstruction.

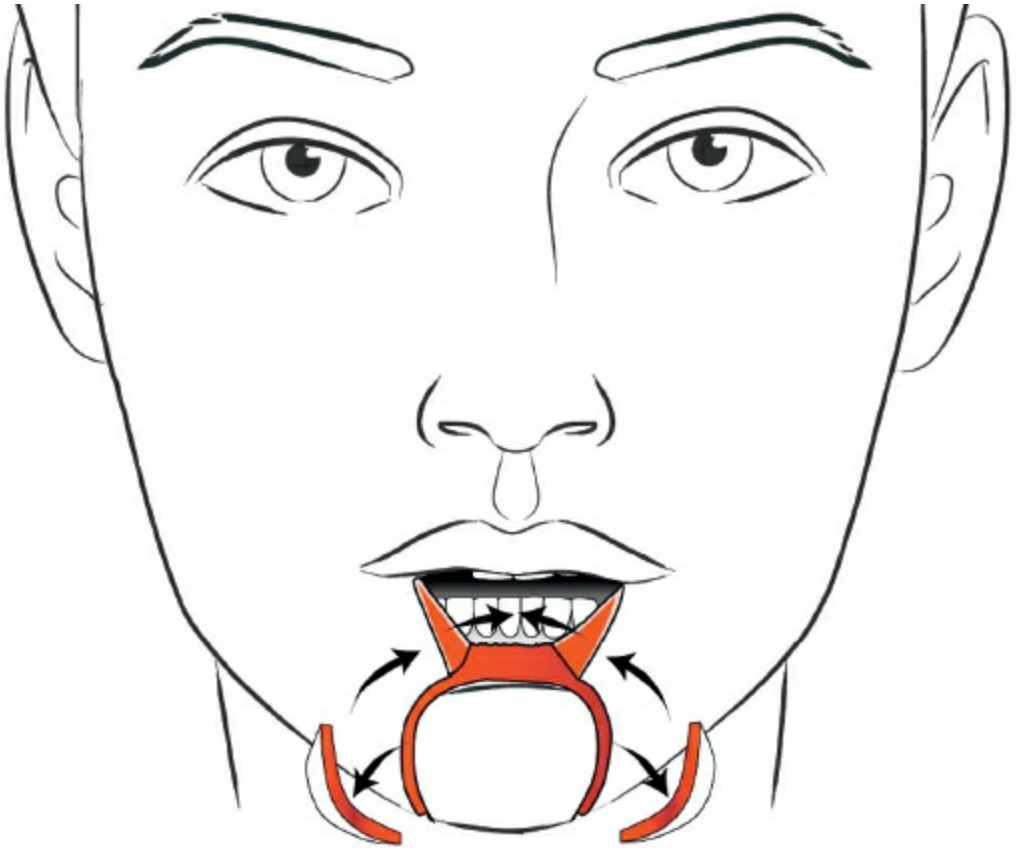

Figure 23.9. Schuchardt operation for closure of central lower lip defects.

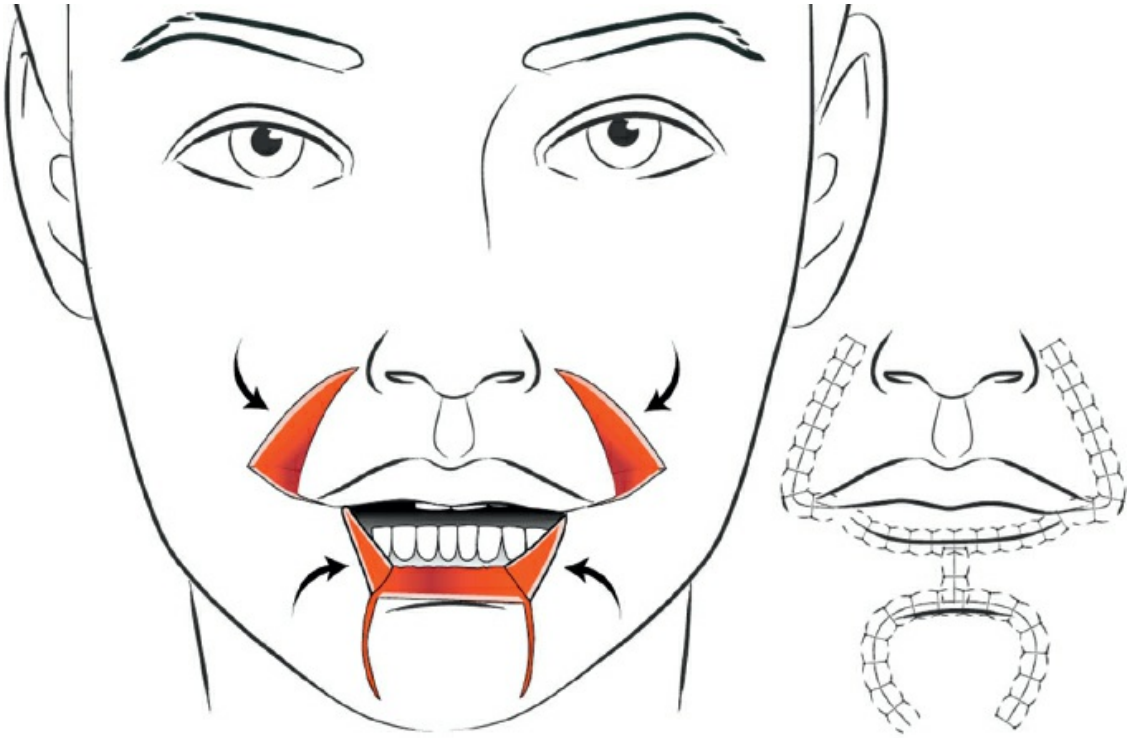

Figure 23.10. Bernard Webster operation for closure of large lower lip defects.

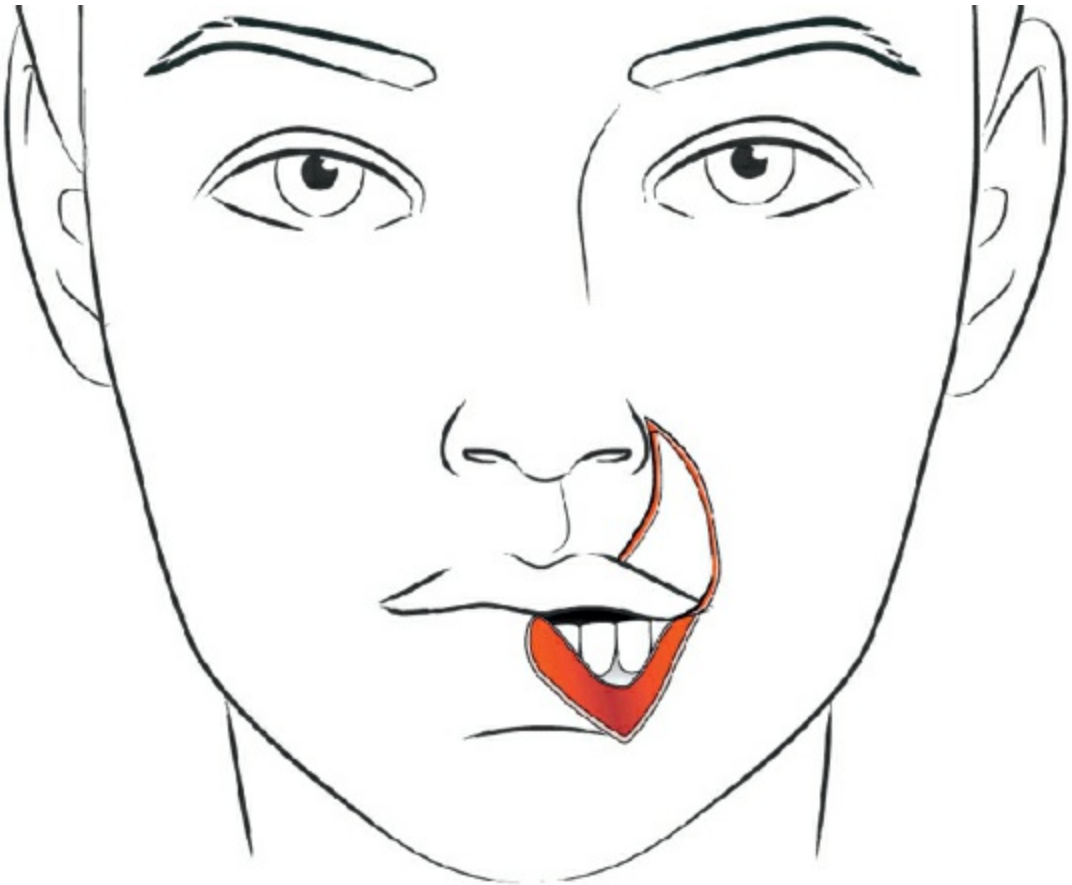

Figure 23.11. Estlander flap for reconstruction of lower lip defect.

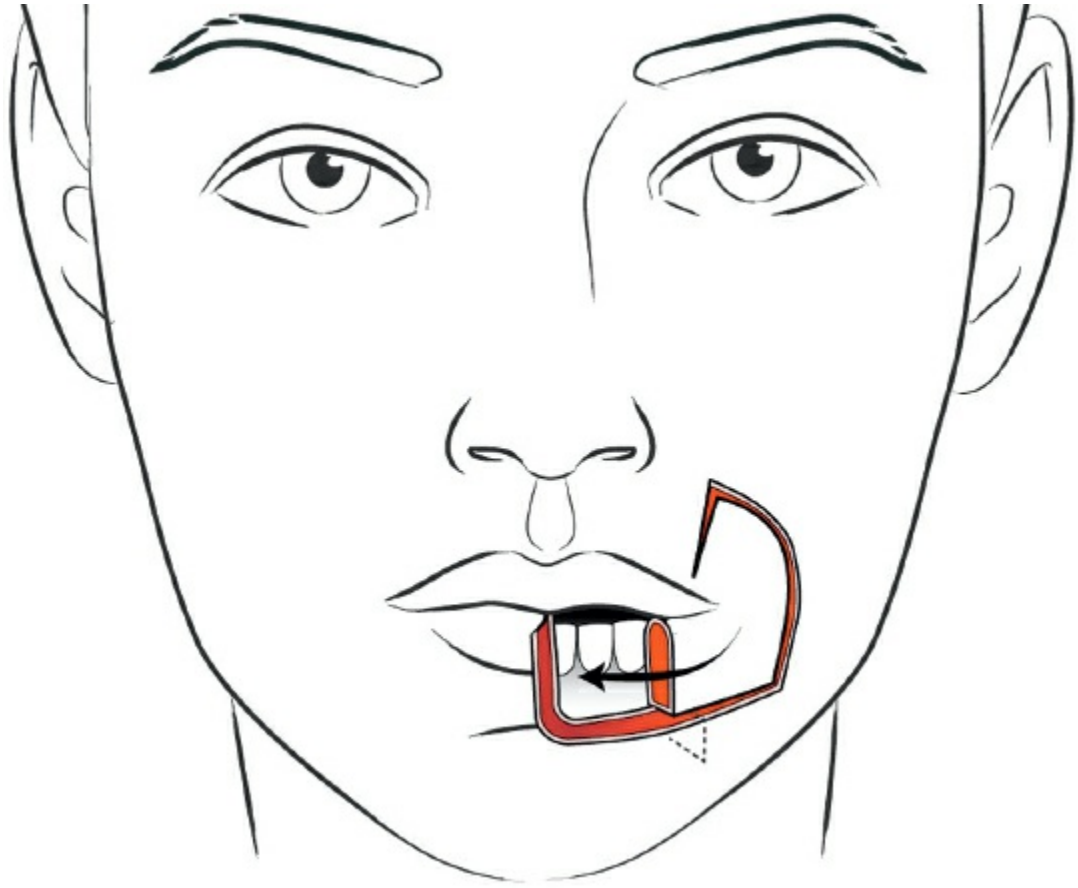

Figure 23.12. Gillies Fan flap for reconstruction of lower lip defect.

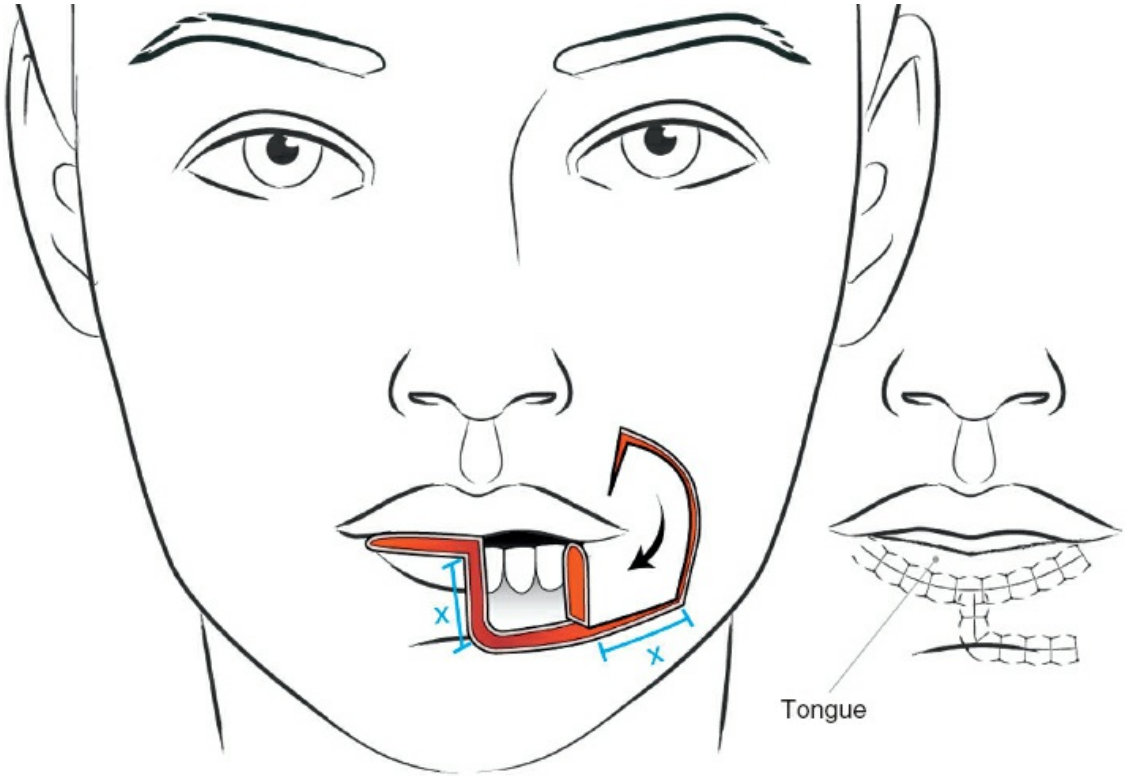

Figure 23.13. McGregor flap for reconstruction of lower lip defect.

UPPER OR LOWER LIP DEFECTS GREATER THAN 66%

If greater than two thirds of the upper lip or the lower lip has been lost, the ability to transfer local adjacent tissue and avoid microstomia is limited. There are two techniques for local tissue rearrangement that merit consideration. Karpandzic described a circumoral incision and release of the skin and muscle, preserving the neurovascular bundles to preserve blood flow and both motor and sensory innervation (Fig. 23.14). This is a challenging operation to perform because of the requisite identification of the nerve fibers, and can be assisted through the use of a nerve stimulator. The operation can be used in defects of up to 80% of the upper lip or the lower lip. The scars in the Karapandzic operation can be problematic, and microstomia is also a common complication.

Fujimori described the use of “gate flaps” for reconstruction of the lower lip, which essentially are inferiorly based pedicle flaps that harvest angular artery and the block of tissue between the nasolabial fold and the oral commissure and nasal ala, turning them medially for lower lip reconstruction (Fig. 23.15). The flaps are harvested with a contiguous flap of buccal mucosa, which are turned over and used to create a semblance of the vermillion. The flaps are insensate and lack effective motor function, but can provide an effective “dam” function. It should be noted that this technique also effectively denervates the upper lip to a large degree also.

When lip defects exceed 80%, local/regional flap transfer becomes limiting for many reasons—compromise of adjacent structures, microstomia, loss of sensation, and vascularity. It is at this point that reconstruction of the upper or lower lip often has to shift to free tissue transfer. Despite the fact that the transferred free tissue often has poor color match, lack of functionality, and compromised sensation, when lower defects become this large it is necessary to bring in tissue from elsewhere. An ideal tissue transfer that meets all the needs imposed by lip reconstruction (sensation, color match, functionality, tri-laminar construct) has yet to be identified. Reconstruction of the upper lip is perhaps easier to accomplish because the demands on the upper lip in providing lip competence are not as great as in the lower lip. If a static upper lip exists, then the lower lip can elevate and be brought into opposition. The

compromised sensation and significant demands imposed by the need to prevent drooling and maintain competence are not easily accomplished. The preferred choice by many surgeons for reconstruction of the upper or lower lip is the radial forearm flap, harvesting the palmaris longus tendon with the flap to serve as a sling for the free border of the upper or lower lip reconstruction. The ends of the palmaris longus tendon are anchored into either the modiolus, or an additional length of this tendon is harvested and the ends can be attached to the zygomas. If the tendon is inset too tightly, entropion of the lower lip can occur. A microneural anastomosis between the mental nerve and the lateral antebrachial cutaneous nerve can be performed to provide sensation, provided adequate length of the mental nerve exists following tumor resection.

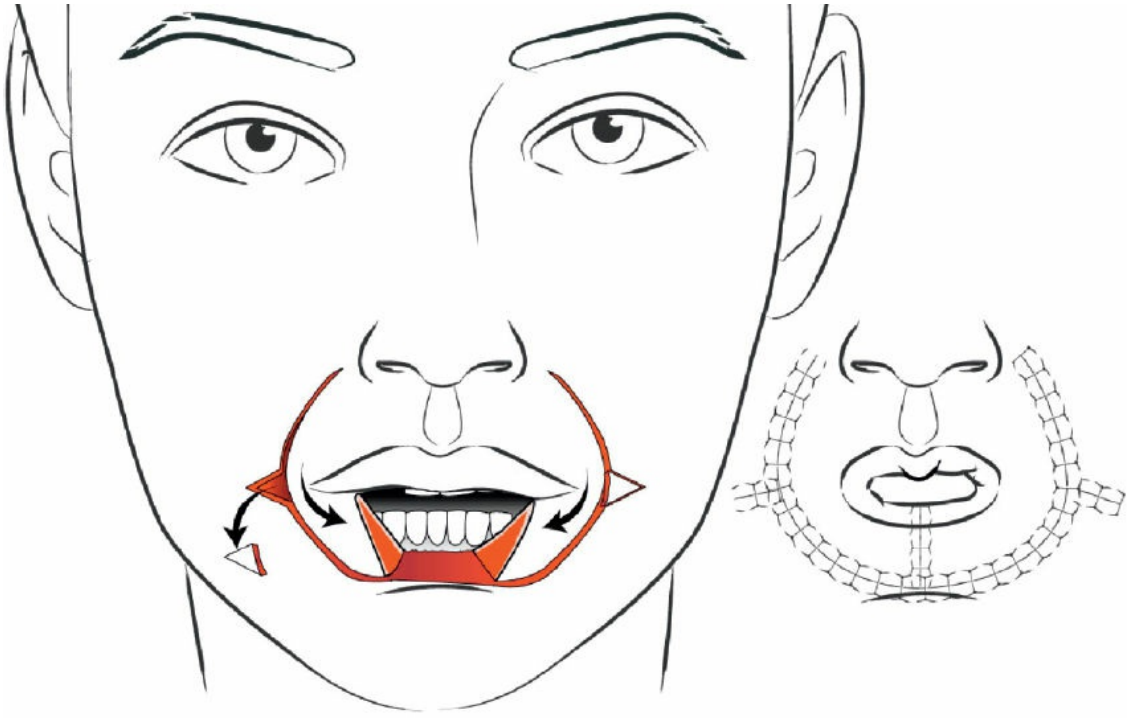

Figure 23.14. Karapandzic operation for reconstruction of larger upper and lower lip defects.

SUMMARY

Lip reconstruction must ideally attain two goals: reconstruction of an aesthetically acceptable lower face and reconstruction of the competence of the sphincteric function of the lips to prevent drooling. The upper lip is more important for aesthetic appearance, and the lower lip plays a larger role in lip function and competence to prevent drooling. Lip reconstruction for defects less than one third of the upper or lower lip is relatively straight

forward and can be readily accomplished with acceptable aesthetic and functional results. If the defect lies between one third and two thirds of the upper or lower lip, effective reconstruction relies upon labial artery vascular pedicle flap techniques, which may also be combined with adjunctive techniques (e.g., peri-alar crescentic excision and advancement). These techniques have the advantage of excellent color match and favorable aesthetic and acceptable functional results. As the defect begins to exceed two thirds of the upper or lower lip, the options for reconstruction begin to switch in favor of free tissue transfer for reconstruction. Common choices include the radial forearm flap or the parascapular flap. These tissues provide pliable reconstruction of the lip contours. In all cases, the tongue can be used to transfer mucosa for the pink vermillion and mucosa.

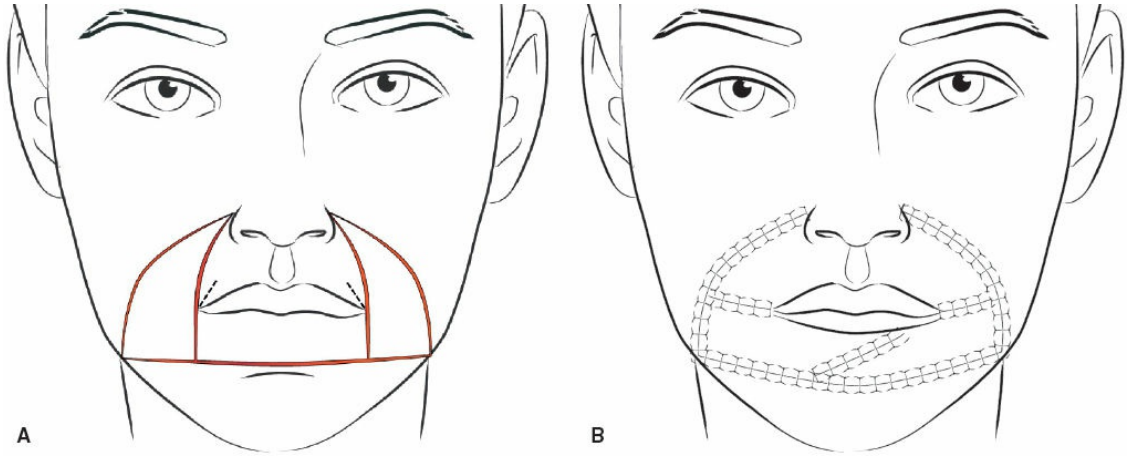

Figure 23.15. Fujimori “Gate Flaps” for reconstruction of larger lower lip defects.

Suggested Readings

Abbe RA. A new plastic operation for the relief of deformity due to double harelip. *Med Rec* 1898;53:477.

American Cancer Society. *Cancer Facts and Figures 2015.* Atlanta, GA; 2015:4.

Bernard C. Cancer de la levre inferieure opera par un procede nouveau. *Bull Soc Chir Paris* 1853;3:357.

Burget GC, Menick FJ. Aesthetic restoration of one-half of the upper lip. *Plast Reconstr Surg* 1986;78(5):583–93.

Estlander JA. Eine methode aus der einen lippe substanzverluste der anderen zu ersetzen. *Arch Klin Chir* 1872;14:622.

Fujimori R. Gate flap for the total reconstruction of the lower lip. *Br J Plast Surg*

1980;33(3):340–5.

Gillies H, Millard R. *The Principles and Art of Plastic Surgery*. London: Butterworth; 1957.

Heller K, Shah J. Carcinoma of the lip. *Am J Surg* 1979;138:600.

Karapandzic M. Reconstruction of lip defects by local arterial flaps. *Br J Plast Surg* 1974;27:93–7.

Luce EA. Carcinoma of the lower lip: treatment guidelines. *Surg Clin North Am* 1986;66:3.

Luce EA. Reconstruction of the lower lip. *Clin Plast Surg* 1995; 22(1):109–21.

Macey R, Walsh T, Brocklehurst P, et al. Diagnostic tests for oral cancer and potentially malignant disorders in patients presenting with clinically evident lesions. *Cochrane Database Syst Rev* 2015;5:CD010276.

Sadove R, Luce E, McGrath P. Reconstruction of the lower lip and chin with the composite radial forearm-palmaris longus free flap. *Plast Reconstr Surg* 1991;88:209–14.

Sakai S, Soeda S, Endo T, et al. A compound radial forearm flap for the reconstruction of lip and chin defect. *Br J Plast Surg* 1989;42:337–8.

Webster JP. Crescentic peri-alar cheek excision for upper lip advancement with a short history of upper lip repair. *Plast Reconstr Surg* 1955;16:434–64.

EDITOR'S COMMENT

Lip reconstruction is one of the most aesthetically and functionally important techniques in surgery. The lips are the focal point of the lower face and differences in anatomic alignment as little as 1 mm will be noticeable to others. Loss of lip function/oral competence results in drooling, difficulty eating, and social isolation greatly diminishing the quality of life for affected individuals. Successful reconstruction addresses both the aesthetic and functional deficits by following fundamental principles and first and foremost among them is that healing by secondary intent is not acceptable. The underlying muscles will pull the defect apart making it larger and the scar will not match and will distort the unique and delicate anatomy of the lips. Thus, there needs to be a plan for immediate lip reconstruction prior to taking the patient to the operating theater.

Detailed knowledge of the anatomy of the lips is essential to the planning and execution of a successful reconstruction. The lips have an outer layer of either skin and/or vermillion (dry mucosa) with the junction of the skin and vermillion highlighted by the white roll; a central layer consisting of the muscles, nerves, labial vessels, and salivary glands; and an inner layer or lining consisting of oral mucosa. All three layers must be repaired or replaced when

performing lip reconstruction. Since this anatomy is so unique, adjacent tissues provide the best match to replace like with like and are generally used for reconstruction. The goals of lip reconstruction are clearly stated in the chapter: (1) replacement of skin and oral lining, (2) vermillion reconstruction, (3) adequate size oral aperture to prevent microstomia, (4) sensation, (5) oral competence, (6) well-defined lower lip sulcus of adequate depth, and (7) color match of soft tissues. The unique anatomy, the contribution of lip appearance to self-image, and multiple operative goals to restore function and appearance make lip reconstruction a demanding surgical procedure.

The approach to lip reconstruction depends on the size and location of the defect. Defects less than 30% of the length of the lip can generally be closed primarily. However, defects of the central upper lip are frequently reconstructed using an Abbe flap, which entails transferring tissue from the lower lip to the upper lip, to preserve or reconstruct the philtral columns. This provides a better aesthetic result than direct primary closure. The most challenging lip reconstruction cases are defects that involve all three layers of the lips and exceed 66% of lip length. There are multiple flaps that have been described to reconstruct these full-thickness defects including the Karapandzic, Nakajima, Webster-Bernard and Gillies fan flaps; and free tissue transfer using radial forearm flaps with palmaris longus tendon for full length defects of the lower lip. All of these flaps have limitations regarding their ability to achieve *all* the goals of lip reconstruction. The search for an optimal surgical technique to reconstruct these defects continues.

A group from China published the largest reported case series of 87 patients who had total (n = 73) or near-total (n = 14) lip reconstruction in a single stage using a variety of flaps. The total lip defects were all full thickness. Patients were assessed with regard to drooling severity and aesthetic appearance. The paper includes an algorithm for flap selection (Bai S, Li R-W, Xu Z-F, et al. Total and near-total lower lip reconstruction: 20 year experience. *J Craniomaxillofac Surg* 2015;43:367–72). Gupta et al. described the repair of a full-thickness total lower lip defect use of bilateral apposing nasolabial flaps to create the lining and skin and then a bipedicle (bucket-handle) flap containing a portion of the orbicularis oris muscle and lip mucosa to reconstruct the vermillion and provide functional muscle for oral competence. The patient had oral competence and sphincteric function, adequate mouth opening, and a good aesthetic result (Gupta S, Chattopadhyay D, Murmur MB, et al. A new technique for one-stage total lower lip reconstruction: Achieving the perfect balance. *Can J Plas Surg* 2013 Spring;21(1):57–61). A British group reported a new technique for single-stage reconstruction of full-thickness lower lip defects in two patients with near-total (70% to 90%) lip defects. They used bilateral commissurotomy to create skin and mucosal flaps and mobilized the risorius, depressor angularis oris, and depressor labii inferioris to reconstruct the three layers of lips. The muscles were mobilized and approximated in the midline and then covered with the skin and mucosal flaps. The distance between the

commissures was maintained by suturing the lateral ends of the skin flaps to the buccal mucosa in the desired position. Both patients had full muscle and sensory function with oral competence, adequate oral opening, and an excellent cosmetic result (Sayan A, Paraneetharan S, Hsu DWK, et al. Reconstruction of the lower lip using bilateral commissurotomy and advancement of skin, muscle and mucosal flaps. *Br J of Oral and Maxillofac Surg* 2016;54:1012–5). Lip reconstruction continues to challenge surgeons, but each innovation in surgical technique moves us closer to achieving the optimal results desired for our patients.

Gayle Gordillo

24 Surgery for Cancer of the Oral Cavity

William R. Carroll

In 1893, the 24th President of the United States set sail on a clandestine cruise from New York to his summer home in Massachusetts. On board, physicians had transformed the deck to a makeshift operating room. Grover Cleveland was anesthetized and a malignant oral cavity tumor was resected. The President recovered and lived another 16 years. The operation was later described as a remarkable procedure for the time. Ulysses Grant, Sigmund Freud, George Harrison, and Sammy Davis Jr. all suffered from oral cancer.

INCIDENCE, MORTALITY, AND ETIOLOGY

Worldwide, oral cavity cancer is the sixth most common cancer type. The American Cancer Society estimated that 39,500 new cases of cancer of the oral cavity and pharynx would occur in the United States in the year 2015. Approximately 7,500 will die of the disease. The mean age at diagnosis is 62 years and over 70% of patients are male. The death rate has been decreasing over the last 30 years. These cancers are more than twice as common in men. Surveillance Epidemiology and End Results (SEER) data from the National Cancer Institute reveal that the overall 5-year survival rate is 61.2. Racial/ethnic disparity for oral cancer is among the most striking for all cancer types and is most evident among men. Five-year survival rates are 63.7% for white men, and 38.3% for black men. Causes of the disparate survival rates likely include comorbidities, later-stage disease at presentation, differences in treatment received, and possible biologic differences in the tumor and host.

Eighty to 90% of oral cancers are squamous cell carcinoma. Roughly 90% of patients use tobacco in some form and 75% use alcohol. The effect is synergistic and the relative risk of developing oral cancer is increased 16-fold for individuals who use both. The risk of developing a second primary tumor is also dramatically increased in those who continue to

smoke following initial treatment (37% vs. 6% risk).

Disturbing cases of oral cancer are also seen in patients without obvious risk factors. Other possible causes include prolonged minor trauma from poor dentition, a diet low in fruits and vegetables, immunosuppression, and exposure to the human papillomavirus (HPV). HPV types 16 and 18 are closely linked with cervical cancer and are responsible for approximately 75% to 80% of oropharyngeal cancers in the western world. A much smaller percentage of oral cavity cancers may also be caused by oncogenic HPV subtypes but the the majority are related to other risk factors. Cancer of the lip is classified with oral cancer and is strongly correlated with sun exposure in fair-skinned individuals. AIDS patients, transplant recipients, and others who are immunocompromised by disease or medical therapy are at increased risk for oral cancer. The cancers that occur in these individuals are unfortunately biologically very aggressive.

Genetic changes within the oral mucosa are measurable well before the development of invasive carcinoma. Chronic exposure to carcinogens damages DNA over the mucosal field. The “field effect” of altered mucosa may be evident as far as 7 cm from an established malignancy. These alterations may activate or amplify oncogenes that promote tumor cell proliferation and inhibit or inactivate tumor suppressor genes. Tumor cells are able to escape programmed cell death and proliferate self-sufficiently. It was found that 70% to 80% of oral premalignant lesions contain changes in chromosome 9p21, which encodes the tumor suppressor genes p16 and $p14^{ARF}$. The epigenetic process of methylation of these genes is the apparent mechanism of inactivation. Mutation of the p53 tumor suppressor gene has received much attention in the literature but is probably a later event in malignant transformation. p53 mutations at the margin of resection have also been correlated with increased rate of recurrence despite histologically clear margins.

ANATOMY AND CLINICAL PRESENTATION

The oral cavity extends from the vermillion border of the lips to the anterior tonsillar pillar (Fig. 24.1). For staging purposes, the following subsites are considered part of the oral cavity: lip, oral tongue (anterior two thirds), floor of mouth, buccal mucosa, upper and lower alveolus, hard palate, and retromolar trigone. The oral cavity has rich lymphatic supply, and regional nodal metastases are typically the first site of spread. The primary lymphatic drainage basins are the perifacial, upper jugular,

submandibular, and submental nodes. Sites close to the midline often drain bilaterally.

The most common symptom of oral cancer is a nonhealing ulcer in the mouth followed by persistent pain. Other common symptoms include a mass, persistent halitosis, or bleeding. Trismus, loose teeth, neck mass, and difficulty with speech or swallowing usually indicate more advanced disease. When symptoms persist longer than 3 weeks, a focused examination for oral cancer is imperative.

Oral cancer arises most commonly in the floor of mouth, followed by the lateral tongue. The distribution by site is summarized in Figure 24.1. Diagnosis is usually made in the office by simple physical examination and biopsy using local anesthesia. Oral cancer is often very curable when detected at an early stage. The same is not true of later-stage disease. The ease of examination and access for biopsy make late recognition of disease particularly regrettable.

STAGING AND DIAGNOSTIC WORK-UP

Oral cavity cancers are staged according to 7th edition (2010) American Joint Committee on Cancer (AJCC) guidelines. T1 to T3 tumors are staged only on the basis of size (Table 24.1). T4 tumors are subdivided into T4a and T4b according to the degree of invasion of surrounding structures and ultimate resectability. The TNM staging system does not yet include depth of invasion as a staging variable for oral cavity tumors. Many investigators have shown, however, that depth of invasion correlates directly with frequency of nodal metastasis. Most surgeons feel that a T1 tumor with a depth of invasion greater than 4 mm has a greater chance of developing nodal metastases than a T2 or T3 tumor that is very superficial.

The staging workup for oral cavity tumors includes a complete physical examination with focused mucosal examination of the upper aerodigestive tract and careful nodal examination. Careful palpation of the oral cavity is crucial in the staging workup as many of these tumors have unsuspected submucosal extension (particularly tongue cancers). Computed tomography (CT) scans of the primary site and neck may assist accurate locoregional staging. A search for distant metastases includes a chest radiograph and liver function tests at a minimum. CT scans of the chest and abdomen are indicated in patients considered to be at higher risk of distant disease. Positron emission tomography (PET) scans are not considered a routine part of the staging workup for head and neck cancer

at this time. Because second primary tumors are detected in about 10% of patients, an examination under anesthesia (direct laryngoscopy, esophagoscopy) is performed prior to treatment initiation. Bronchoscopy is recommended only for patients with evidence of subglottic disease, persistent cough, or suspicious chest radiography findings.

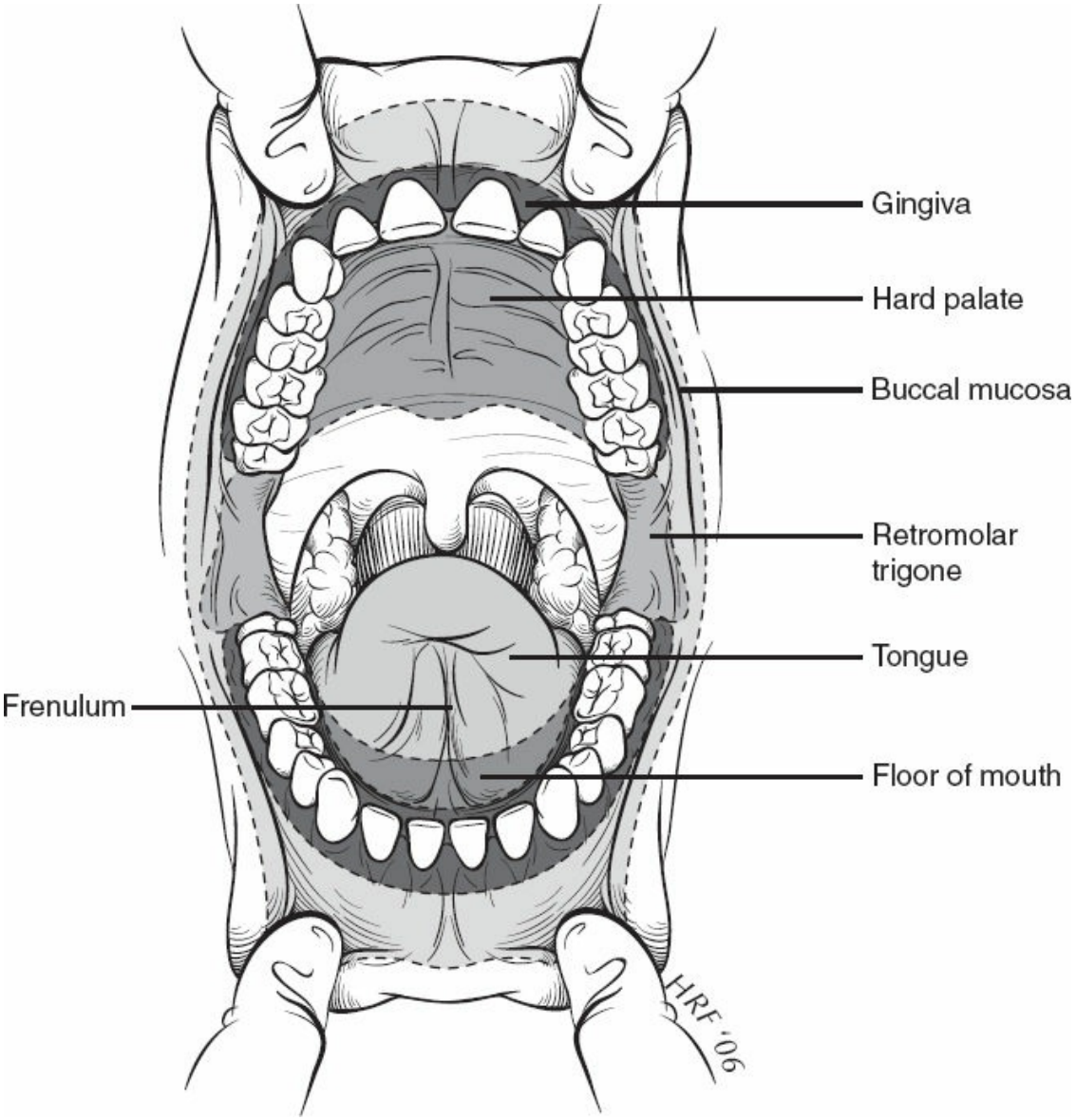

Figure 24.1. Subsites of the oral cavity.

TABLE 24.1 AJCC TNM Staging of Oral Cavity Cancer

T1: Tumor less than or equal to 2-cm diameter
T2: Tumor 2–4-cm diameter
T3: Tumor is greater than 4-cm diameter.
T4a: (Moderately advanced local disease)
Tumor invading adjacent structures (mandible, maxilla, extrinsic muscle of tongue, facial skin)
T4b: (very advanced local disease)
Tumor invading adjacent structures and in many cases considered unresectable (pterygoid plates, skull base, masticator space, carotid artery)

Imaging techniques designed to detect dysplastic changes in oral mucosa may ultimately improve early detection and margin control for oral cavity cancer. Confocal microscopy, radiolabelled antibodies to tumor markers, narrow band imaging, and multiwavelength fluorescence and reflectance technology are technologies designed to detect subclinical disease in at risk patients or to identify dysplasia at the margins of known cancers.

TREATMENT

Current treatment guidelines for head and neck squamous cell carcinoma are published by the National Comprehensive Cancer Network (www.nccn.org). The guidelines include staging information, recommendations for pretreatment assessment, and a balanced approach to treatment options for oral cavity cancers. Optimal treatment of head and neck cancer requires a multidisciplinary effort. Team members include a head and neck surgeon, reconstructive surgeon, radiation oncologist, and medical oncologist. Speech and swallowing pathologists rehabilitate function lost during multimodal therapy. Other important team members include dentists, prosthodontists, nutritionists, and social workers. For patients with advanced or recurrent disease, treatment recommendations are optimally considered in a multispecialty tumor-board format. A

coordinated team approach is essential.

In this chapter, treatment of oral cancer will be divided into two main sections: a general discussion of early-stage and locally advanced disease followed by specific recommendations for each subsite. The primary focus is surgical management. Alternative options will be included, but detailed descriptions are beyond the scope of this chapter. Treatment of metastatic neck disease is covered elsewhere in this text and is integral to proper management of the primary site.

Carcinoma in Situ or Microinvasive Carcinoma

Early, very superficial disease within the oral cavity is best treated by wide local excision. When disease is limited to carcinoma in situ on final pathology, an excisional biopsy with clear margins is adequate therapy. The site should be followed closely clinically with a low threshold for rebiopsy or reexcision. Microinvasive carcinoma should be excised with a 1- to 2-cm margin on the peripheral and deep aspects. Frozen sections are studied intraoperatively as severe dysplasia at the margin can be difficult to discern grossly (Fig. 24.2). Early-stage cancers of the floor of the mouth may involve the salivary ducts, and gain early access to the neck. The nodal status requires careful assessment.

Primary closure of the site is optimal if it can be accomplished without tethering the tongue or obliterating normal sulci. The surgeon should have little hesitation to allow these superficial defects to granulate. Healing by secondary intention is preferable to a closure that impairs mobility. Occasionally, a larger but very superficial lesion will be excised at the submucosal layer. A thin split-thickness skin graft will cover a larger area effectively and speed the recovery process. Commercially available dermal allografts have been uniformly unsuccessful in the oral cavity in our hands.



Figure 24.2. Leukoplakia of the lateral tongue. One nodular area contained microinvasive carcinoma.

T1 and T2 Carcinoma of the Oral Cavity

Five-year survival rates are 85% to 90% for stage I and 70% to 80% for stage II squamous cell carcinomas of the oral cavity. Single modality therapy is usually adequate. Surgery and radiotherapy are generally considered equally effective, but in most cases surgery is preferred for early-stage disease. Radiation therapy for early-stage oral cavity cancer is effective when delivered either by external beam or by brachytherapy. Xerostomia and dental disease are more commonly seen following radiotherapy, and there is risk of osteoradionecrosis of the mandible. Fewer studies have critically compared functional outcomes of radiation therapy with surgery. Whichever modality is chosen, treatment of the primary site and neck should be consistent. In other words, if the primary site is treated surgically and there is concern over micrometastases, the neck should be treated surgically as well. Likewise, if the oral cavity is treated with radiation, the lymphatics are treated similarly.

Surgical treatment for stage I and II oral cavity cancer is consistently recommended initially by our institution’s multispecialty tumor board.

Surgical treatment is effective and completed quickly with minimal impairment of form or function. The typical hospital stay is 1 or 2 nights, oral intake is resumed quickly, and patients typically resume full activity within 3 weeks. Even those individuals with occupations demanding precise oral function (attorneys, professors, salespersons) have typically enjoyed very favorable outcomes.

In planning resection, the surgeon must consider route of access, margin status, bone involvement, and whether or not lymphatics require treatment. Route of access is preferably transoral for smaller lesions. The margins must be clearly visible, however, and patients with full dentition or limited oral opening can present access challenges for even small lesions. A lip split and/or mandibulotomy may be required for adequate visualization of margins. Margins of 2 cm on all sides are ideal for these lesions.

As a word of caution, the first attempt at removing these lesions has the greatest chance of success. Each subsequent attempt at salvage has a decreasing yield. To withhold a full curative effort for a minimal cosmetic or functional benefit is a disservice to the patient.

Bone will not be grossly invaded in these early-stage I and II lesions, although dysplastic mucosa or the main malignancy may approach the teeth or mandibular periosteum. In general, the periosteum is an effective barrier if not previously radiated. If the tumor is freely mobile with relation to the bone, the periosteum is resected as a margin and the bone preserved. The alveolar surface of the mandible is vulnerable to microinvasion and allows access to the medullary cavity through the tooth sockets. The risk of microinvasion of the mandible is higher in an edentulous or previously radiated mandible. When tumor directly invades the periosteum, that segment of mandible should be resected with at least a rim mandibulectomy.

The risk of micrometastasis to cervical lymphatics is increased proportionally with the depth of tumor invasion. As a general rule, tumors that measure greater than 4 mm in thickness are at risk, and treatment of cervical lymphatics should be considered.

Sentinel Lymph Node Biopsy

Some centers, primarily in Europe, are using sentinel lymph node biopsy (SLNB) routinely in the management of early (T1 and T2) oral cavity cancers with clinically node-negative necks. (Clinically node-positive patients are treated with selective neck dissection.) Similar to SLNB in

melanoma or breast cancer, SLNB involves peritumoral injection with a radiocolloid, followed by lymphoscintigraphy and intraoperative gamma probe localization. The primary tumor is usually resected prior to lymph node localization so that radioactive “shine-through” from the primary site does not impede detection of radiotracer in adjacent lymph node levels. Most surgeons utilize SLNB in a staged fashion, allowing permanent analysis of sampled nodes before deciding if completion neck dissection is indicated.

In most studies, the negative predictive value of SLNB is 90% to 100% for oral cavity cancers. The serial sectioning and immunohistochemical analysis used in analyzing the sampled nodes improve predictive value and may upstage the nodal basin compared to traditional lymphadenectomy. SLNB may also identify unexpected patterns of lymphatic drainage, that is, nodes detected in levels that would not have been sampled in routine selective neck dissection. Authors have also demonstrated decreased wound complications and lower incidence of neuropraxia with SLNB compared to selective neck dissection.

SLNB has been primarily used in the setting of clinical trials in the United States. The National Comprehensive Cancer Network (NCCN) recognized the procedure in 2013 stating: “Sentinel lymph node biopsy is an alternative to elective neck dissection for the identification of occult cervical metastasis in patients with early (T1 or T2) oral cavity carcinoma in centers where experience for this procedure is available. Its advantages include decreased morbidity and improved cosmetic outcome.” Many surgeons remain concerned about the small numbers of false negatives (positive nodes become clinically evident at a later date). Others note that unlike melanoma or breast cancer, lymphadenectomy in oral cavity cancer has a distinct therapeutic role and is not primarily prognostic. These surgeons are concerned that SLNB may violate tissue planes adjacent to the great vessels and could allow recurrent disease to invade structures protected by undisturbed fascial barriers. SLNB is a procedure in evolution for oral cavity cancer. Elective node dissection or radiotherapy for at-risk patients with early-stage oral cancer in the United States remains standard for most US centers as of this writing.

T3 and T4 Carcinoma of the Oral Cavity

Large oral cavity cancers and those that deeply invade the tongue, bone, or adjacent spaces require multimodal therapy. Survival rates for T3 and T4

squamous cell carcinoma of the oral cavity are 50% to 65% in the absence of nodal metastases. Nodal metastases generally cut survival rates in half. Primary surgical resection remains the preferred initial treatment option. In contrast, advanced oropharyngeal malignancies are often treated initially with chemoradiation. When planning resection, the surgeon again must consider the lymphatics, access, bone involvement, and reconstruction as these defects can rarely be closed primarily.

Surgical treatment of the neck to control lymphatic disease and to provide access to the primary tumor is routine. Rarely can a T3 or T4 lesion be adequately resected by a transoral-only approach. Exposure of the neck allows preservation of important neurovascular structures and facilitates management of the deep margin of resection. Well-lateralized lesions that do not involve the deep tongue muscle may be adequately managed with a unilateral neck dissection. Clinically N0 necks are treated with a selective neck dissection, which carries very little morbidity (see Chapter 25). Edentulous patients with pliable perioral soft tissue may not require a lip split for access from the oral side. Again, if visualization of the margins is impaired, lip split or mandibulotomy is recommended as necessary to allow proper exposure. Complete tumor resection should be the primary concern.

Gross invasion of the mandible mandates a segmental resection. Whenever possible, the entire medullary cavity of the mandible should be resected. Tumor invading the mandible can spread widely through the loose cancellous bone. For example, if a lesion invades the midbody of the mandible, segmental resection of bone with a 2-cm margin is combined with rim removal of the remaining medullary cavity back to the sigmoid notch.

Reconstruction will often require more than primary closure. In some lateral composite resections, surprisingly large defects can be closed primarily when no bone reconstruction is planned. The disfigurement is pronounced, however, and most patients prefer immediate surgical reconstruction. Return of a more normal appearance and ability to chew are important aspects of quality of life. Large glossectomy and full-thickness buccal defects cannot be closed without supplemental tissue. Vascularized free tissue transfer has become the mainstay of surgical reconstruction for large oral cavity defects. Soft tissue defects are usually repaired with radial forearm, anterolateral thigh, or rectus abdominus flaps. Mandibular defects are managed with osteocutaneous flaps, the fibular flap

being the most common.

SITE-SPECIFIC SURGICAL MANAGEMENT

Floor of Mouth

The floor of mouth is the most common site for oral squamous cell carcinoma. The adjacent ventral tongue and lingual surface of the mandibular alveolus are involved early as the tumor enlarges. Anteriorly, floor-of-mouth lesions often involve the submandibular ducts and contralateral nodes are at risk. CT scans are useful in preoperative staging to assess tumor extent, nodal status, and early mandibular invasion.

T1 and T2 Carcinoma of the Floor of Mouth

T1 and T2 lesions of the floor of mouth are treated with wide local excision (Fig. 24.3). A margin of 2 cm is recommended and frozen section control of margins intraoperatively may avoid overlooking severe dysplasia in surprisingly normal-appearing mucosa. Lesions deeper than 4 mm have a higher incidence of nodal metastasis, and an elective selective neck dissection should be considered. Transoral access without lip split or mandibulotomy is often possible. Full dentition or poor oral opening can make access surprisingly difficult for small lesions. The patient should be prepared for mandibulotomy for access should this occur.

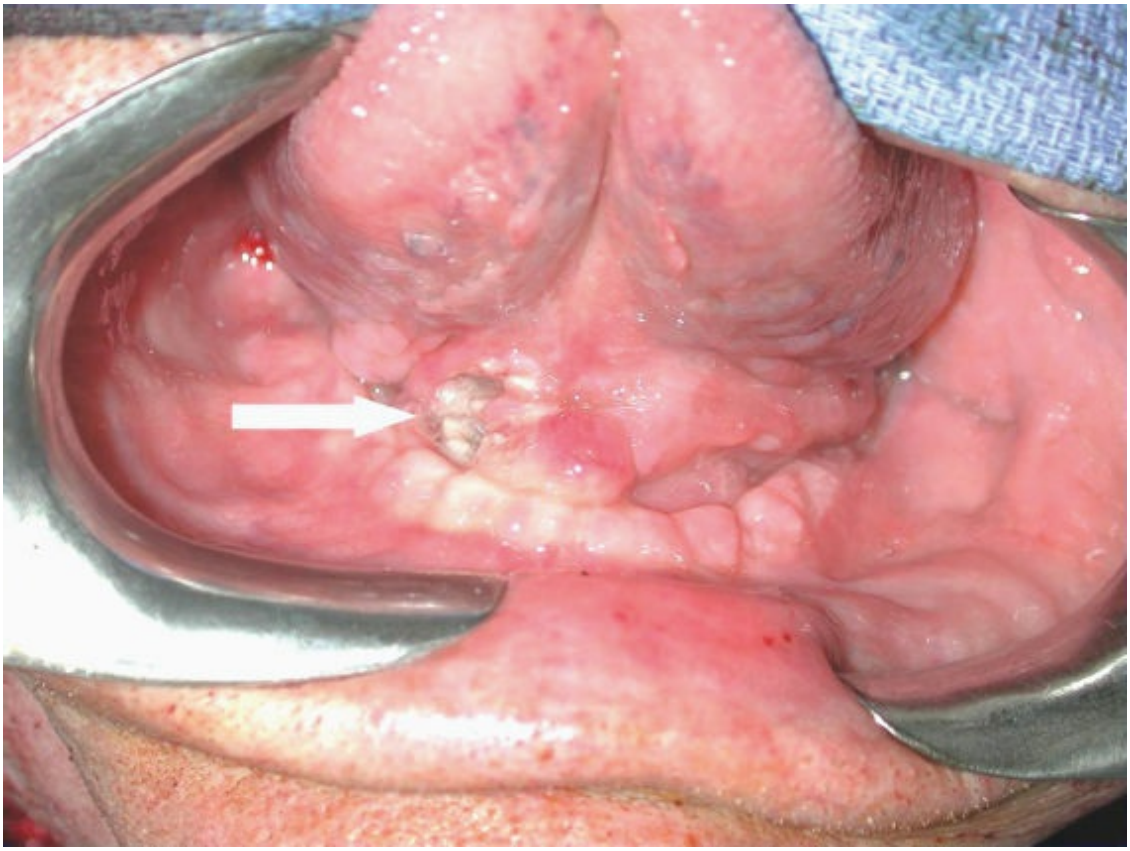

Figure 24.3. Early-stage carcinoma of the anterior floor of mouth.

When deep dissection in the lateral floor of mouth is combined with level 1 neck dissection, a through-and-through defect often results that can be surprisingly difficult to close. Pedicled flaps such as the platysma flap or submental island flap are useful to close these small defects. Radial forearm free flaps work very nicely as well. Pectoralis flaps are often too bulky for small defects in this site.

T3 and T4 Carcinoma of the Floor of Mouth

T3 and T4 floor-of-mouth lesions are usually resected in conjunction with cervical lymphadenectomy. A reasonable plan of surgical progression is outlined below. These steps will be adaptable for other subsites in the oral cavity as well.

1. Repeat examination under anesthesia. Assess size, depth, structures involved, and proximity to mandible. Finalize thoughts on access and bone invasion.
2. Tracheotomy in most circumstances.
3. Percutaneous gastrostomy. If a short period of tube feeding is anticipated, place a nasogastric tube at the conclusion instead.
4. Neck dissection. Extent determined by nodal status. See Chapter 25 for

details.

5. Approach primary. Split lip and perform stair-step mandibulotomy anterior to the mental foramen if necessary for access (Fig. 24.4). For large tumors with gross bone invasion, plan the mandibulotomy at the anterior margin of bone resection. Bend and apply reconstruction or fracture plates prior to cutting bone unless the tumor extends through the lateral cortex. This step optimizes dental occlusion postoperatively. If segmental composite resection is planned, tumor visualization will be easier if the posterior bone cuts are completed at this time as well.
6. For tumors that contact the mandible without gross bone destruction, perform a rim mandibulectomy to remove the occlusal surface and medullary cavity of the involved bone (Fig. 24.5). Take care in edentulous patients as the inferior mandibular remnant may be very thin and prone to pathologic fracture.

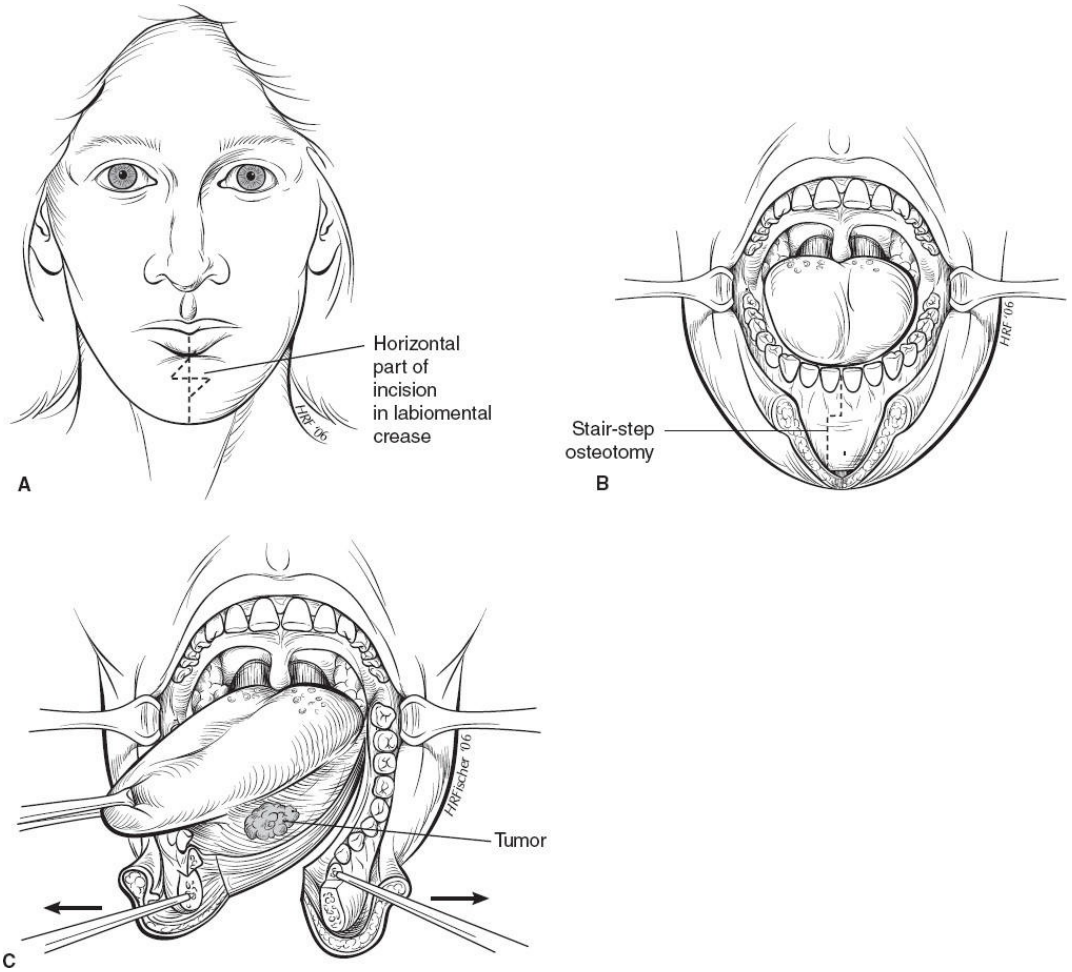

Figure 24.4. Transmandibular access to the floor of mouth. **A.** The lip split incision. The angles, based on the labiomental crease, prevent downward contracture from scarring. **B.** Stair-step osteotomy anterior to the mental foramen spares

sensation of the lip. **C.** Distraction of the segments allows exposure of the floor-of-mouth lesion.

7. Distract the mandible at the anterior osteotomy and visualize tumor margins. Make mucosal cuts 2 cm from obvious disease. As dissection progresses deeper, revisualize the hypoglossal nerve in the neck as it will often enter the tongue medial to the tumor and can be preserved. Control lingual artery branches with ligatures. Do not rely on cautery for the larger branches.
8. Remove the specimen and inspect. Orient the specimen for pathology. Check margins with frozen sections.
9. Inspect the defect and determine closure method. Avoid primary closure under tension or closures that will significantly tether the tongue. Often, the reconstructive team will have proceeded with flap elevation during the final phases of tumor extirpation.

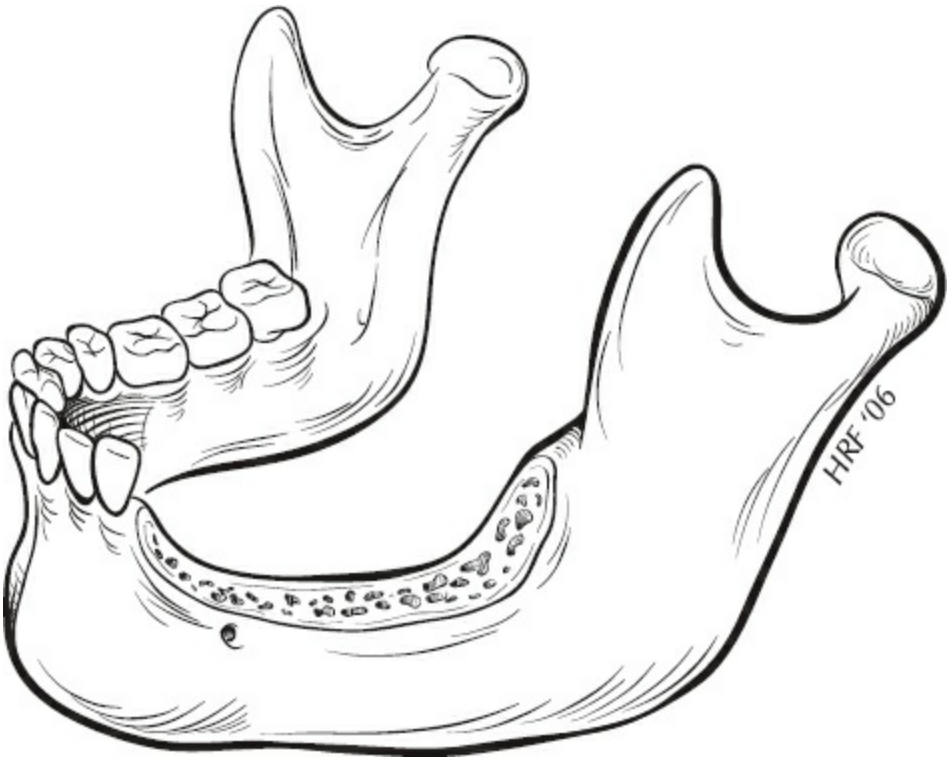

Figure 24.5. Rim mandibulectomy to resect disease involving periosteum or minimally invading the mandible. Resection includes the medullary cavity of the mandible.

Tongue

T1 and T2 Carcinoma of the Oral Tongue

Tongue cancers frequently have submucosal extension well beyond the

visible margin. Palpation and imaging studies are helpful in accurate staging. T2 and deep T1 (>4 mm) tongue cancers have occult metastatic rates approaching 30%. Treatment of the neck is usually recommended.

Small lateral tongue lesions can be widely excised with very little morbidity. These malignancies are generally more easily visualized than floor-of-mouth lesions and rarely require lip split or mandibulotomy. If possible, a deep wedge resection is designed in a vertical plane maintaining 2-cm margins at the peripheral and deep margins. The vertical resection allows closure of lateral tongue to corresponding lateral tongue and minimizes tethering (Fig. 24.6). Horizontal closure, in contrast, tethers the dorsal tongue to the floor of mouth and impairs mobility. Resection of superficial T2 tumors of the lateral tongue results in a defect involving most of the lateral surface (Fig. 24.7). These defects should be covered with a thin skin graft or allowed to granulate. The patient begins tongue mobility exercises early to prevent scar contracture and loss of function.

Dorsal tongue cancers are less common. These lesions are resected in a sagittal plane if possible and closed primarily. Function is usually excellent.

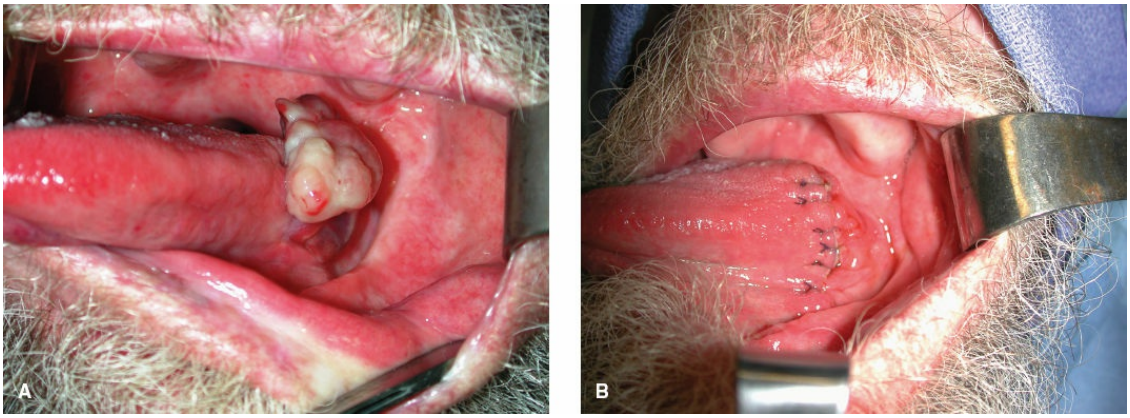

Figure 24.6. Resection of T1 carcinoma of the lateral tongue. **A.** Pedunculated lesion of the lateral tongue. **B.** Vertical excision and closure maintains optimal mobility.



Figure 24.7. Following resection of a T2 superficial lesion of the lateral tongue, primary closure is not feasible without severe restriction of motion. Options for closure include a split-thickness skin graft or healing by secondary intention.

T3 and T4 Carcinoma of the Oral Tongue

As noted, larger tongue cancers will require multimodal therapy. No treatment option has been found to be superior to surgery followed by radiotherapy for carcinoma of the oral tongue. These tumors may extend laterally into the adjacent mandible, or medially into the deep root of tongue musculature.

Large lateral tongue lesions are approached as described above under "Floor of Mouth." Osteotomies render the resection easier because the exposure is generous. These resections are the classic "commando" or "tongue–jaw–neck" procedures described for decades in the head and neck literature (Fig. 24.8). Primary closure of the buccal mucosa to the tongue remnant is often possible and speech and swallowing function are surprisingly good. The patient is unable to chew, however, and the appearance is dramatically altered. Immediate flap reconstruction is usually employed in modern resections.

For lesions that extend more centrally into the deep root of tongue musculature, an alternative pull-through approach to resection is required (Fig. 24.9). The steps are discussed below:

1. –3. Same as Floor of Mouth above.
4. Neck dissection should be bilateral for deep lesions extending toward the central tongue. A visor flap of the neck skin is raised to the inferior border of the mandible.
5. No lip split is usually required for access. The uninvolved floor-of-mouth mucosa is incised on the side of the tumor and continued onto the uninvolved contralateral tongue, maintaining 2-cm margins. Dissection will frequently extend across the midline. The mylohyoid muscle is transected from below. Working from above and below, the dissection progresses until the anterior and lateral cuts communicate from neck to oral cavity. The specimen is then delivered downward, under the intact mandible and into the neck. Following this maneuver, visualization of the posterior cuts is simplified and resection is completed (Fig. 24.10).
6. Assess margins grossly and by frozen section. Do not overlook deep tongue margins, which will extend down to the hyoid bone.
7. With an intact mandible, these lesions are nearly impossible to close without a pedicled or free flap.
8. If a large volume of tongue muscle is resected, the flap reconstruction should provide sufficient bulk to allow the neo-tongue to contact the palate. This will optimize speech and swallowing postoperatively. A radial forearm flap may not provide adequate volume in this setting.

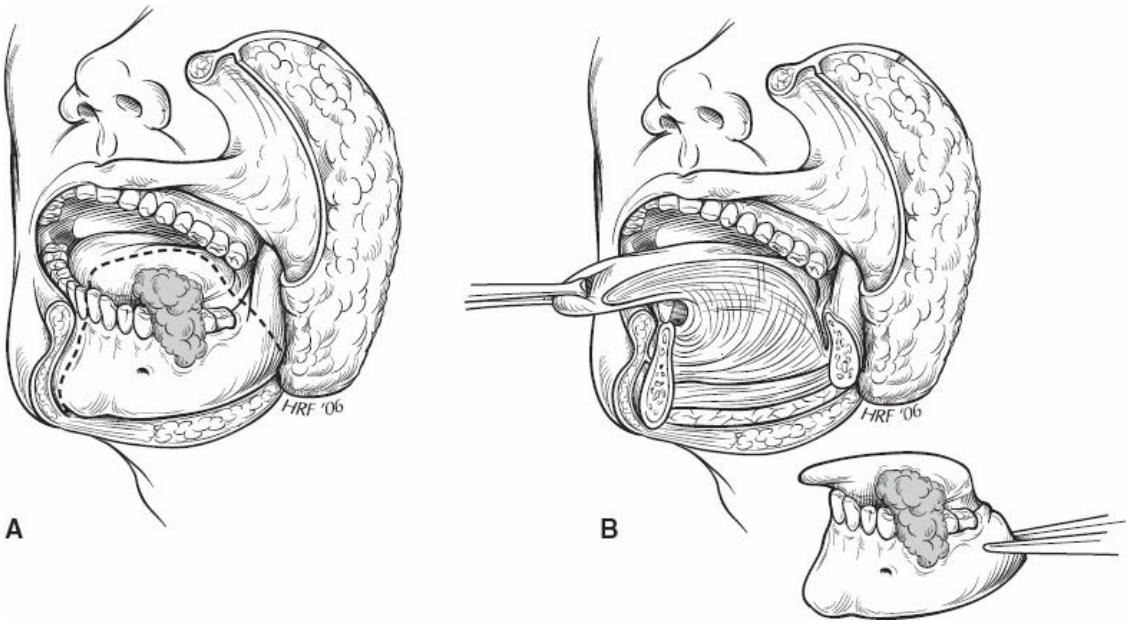

Figure 24.8. Composite resection for advanced oral tongue cancer involving the mandible. **A.** The cheek flap is reflected following a lip split. The bone cuts are positioned after

determining the location of tumor invasion. **B.** If the tumor does not extend lateral to the mandible, a reconstruction plate can be coapted prior to making the bone cuts.



Figure 24.9. Deeply invasive T3 carcinoma of the anterior tongue.

Large oral tongue lesions that arise more posteriorly warrant special mention. These lesions often involve the base of tongue extensively and/or may cross the midline anteriorly. Under these circumstances, surgical resection will require a near total glossectomy. The surgeon must carefully explain the functional implications of such a resection and ensure that the patient understands the alternative of concurrent chemotherapy and radiation with surgical salvage. In this particular circumstance, posttreatment function is probably superior with initial chemoradiation. The patient may wish to try nonsurgical treatment for organ preservation initially. Surgical salvage, if necessary, would still require a total glossectomy. Although no direct prospective comparisons exist for oral tongue primaries, case series data suggest that concurrent chemotherapy with surgical salvage should provide comparable cure rates to surgery and adjuvant radiation.

Buccal Mucosa and Retromolar Trigone

The buccal mucosa includes the pliable inner lining of the cheek, extending from the maxillary alveolus superiorly to the mandibular alveolus inferiorly. Posteriorly, the buccal mucosa is contiguous with the retromolar trigone. The mucosa of the retromolar trigone covers the ascending ramus of the mandible and extends posteriorly to the anterior tonsillar pillar at the start of the oropharynx. Carcinomas in this region usually are squamous cell and may be ulcerative, exophytic, or verrucous. Smokeless tobacco users are at higher risk of forming buccal cancer.

T1 and T2 Carcinomas of the Buccal Mucosa and Retromolar Trigone

Tumors of the buccal mucosa are relatively uncommon in the United States but are the most common site of oral cancer in countries of Southeast Asia (Fig. 24.11). In India, buccal cancer is the most common of all cancers occurring in men. Nodal metastases occur early (40% for T2 lesions in one meta-analysis). Early-stage carcinomas of this region are treated in a fashion similar to the floor of mouth. Wide local excision with 2-cm margins is recommended and primary closure for smaller defects is usually easily accomplished. Thin skin grafts also provide adequate coverage if the underlying buccinator muscle is intact. For all but the most superficial lesions, the buccinator should be taken as the deep margin of resection. Failure rates for early buccal carcinomas are high. Treatment of T1/T2 retromolar trigone (Fig. 24.12) lesions is similar.

T3 and T4 Carcinoma of the Buccal Mucosa and Retromolar Trigone

Large tumors of the buccal mucosa or retromolar trigine are difficult to manage (Fig. 24.13). The head and neck surgeon should keep the following facts in mind when planning treatment for advanced tumors in this region:

1. The layers of the buccal region are buccal mucosa, submucosa, buccinator muscle, subcutaneous fat, and cheek skin. Once a lesion is deep enough to invade the buccinator muscle, the overlying cheek skin is potentially involved. Resection frequently results in a through-and-through defect requiring at minimum local flap coverage.
2. Deep posterior invasion from both buccal and retromolar trigone tumors extends toward the masseteric space. Meticulous attention to this potential direction of spread is required to avoid local recurrence (Fig. 24.14).

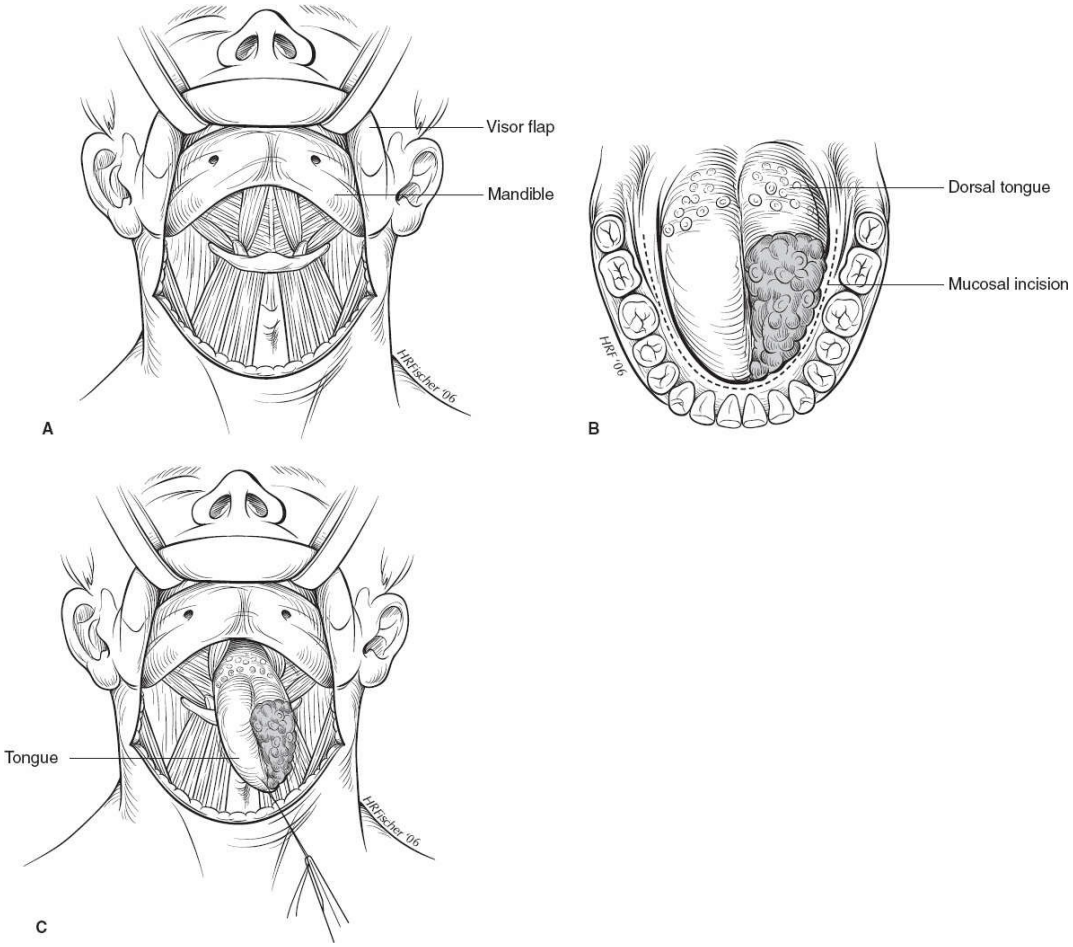

Figure 24.10. Pull-through approach for glossectomy. **A.** The skin flaps are elevated to the lower border of the mandible. **B.** Intraoral cuts along the uninvolved floor of mouth are connected with external cuts dividing the floor-of-mouth diaphragm. **C.** The specimen is pulled downward and into the neck, allowing visualization of more posterior cuts.



Figure 24.11. A patient demonstrates an early buccal mucosal carcinoma caused by smokeless tobacco use. Note the adjacent leukoplakia extending into the gingivobuccal sulcus.

3. The retromolar trigone mucosa provides reasonably thin cover over the ascending mandible. Larger tumors quickly invade the bone and continue into the masticator space as noted above.
4. Retromolar trigone tumors often extend posteriorly into the oropharynx. Many clinicians consider the biologic behavior to be more consistent with oropharyngeal carcinoma than oral cavity carcinoma. When there is bulky extension into the tonsil or soft palate, concurrent radiation and chemotherapy are given more consideration as first-line therapy to preserve speech and swallowing function. As is true for other oral cavity sites, however, no treatment has been proven superior to surgery and adjuvant radiation for buccal or retromolar trigone carcinomas.

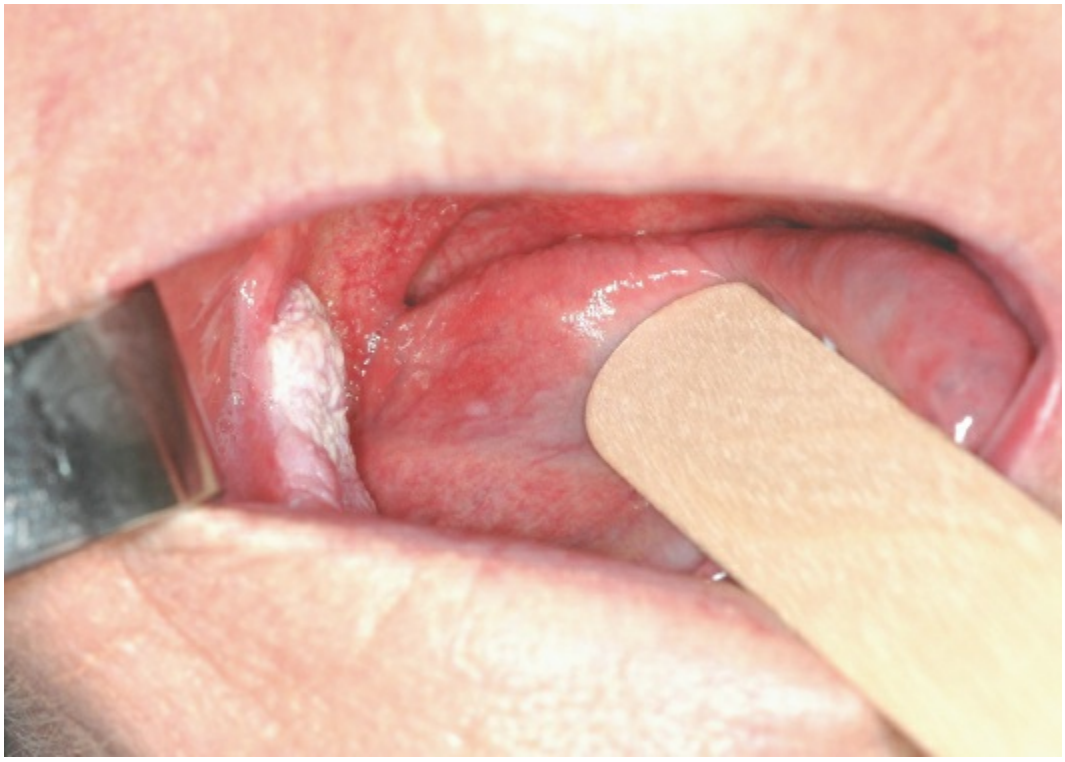

Figure 24.12. T1 carcinoma of the retromolar trigone. These lesions often invade the adjacent mandible or masseteric space early.

5. Perifacial nodes and parotid nodes are first-level nodal basins for these tumors.
6. Transoral exposure may be limited. Be prepared for a transfacial approach to improve access.

Hard Palate

T1 and T2 Carcinoma of the Hard Palate

Palatal carcinomas are uncommon. More nonsquamous cell cancers occur in the palate than any other oral cavity location. Minor salivary gland malignancies comprise the majority of other malignancies. All but the most superficial palatal lesions have the potential to invade underlying bone. The incisive and greater palatine foramina also provide pathways for perineural dissemination. Thin lesions of the hard palate may be managed with wide local excision. Peripheral margins are managed as discussed above. If uninvolved periosteum is interposed between the tumor and underlying bone, bone resection may be unnecessary. If any doubt exists, palatal bone can be drilled away down to nasal mucosa without creating an oronasal fistula. If a small fistula must be created, a rotational flap of

palatal mucosa or a buccinator myomucosal flap will usually close the defect effectively.

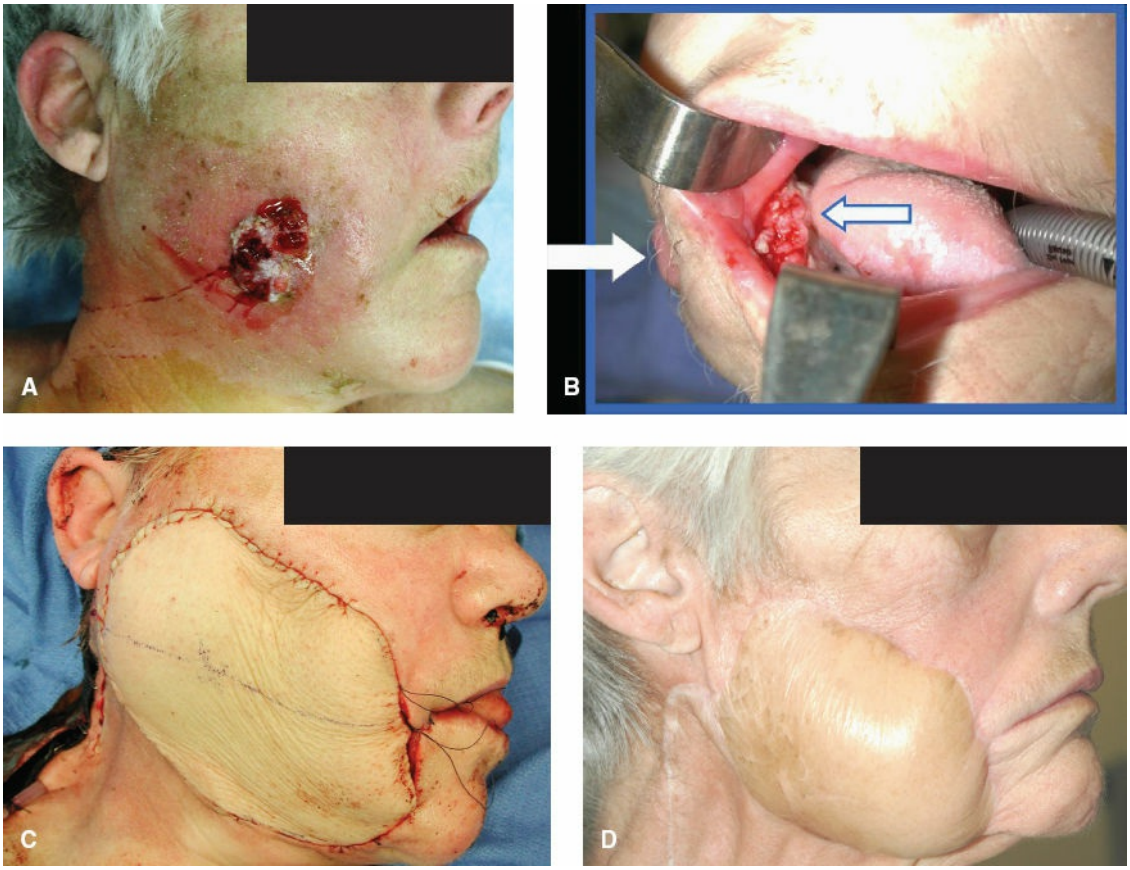

Figure 24.13. T4 carcinoma of the buccal mucosa with extension through overlying skin. **A.** Transbuccal extension. **B.** Extensive involvement of overlying skin. **C.** Wide resection to include most of the right cheek; rectus free flap reconstruction. **D.** Eighteen months postoperative. The patient was not interested in further flap debulking.

T3 and T4 Carcinoma of the Hard Palate

Larger palatal lesions characteristically involve bone. Preoperative CT scans are very helpful in assessing superior extension of disease into the nose or maxillary sinus (Fig. 24.15). An inferior maxillectomy is usually required for complete resection. These lesions may escape posteriorly into the pterygoid plates and pterygoid musculature and extend to the skull base. The pterygomaxillary space and foramen rotundum are sites of disease persistence in deeply invasive palatal carcinoma.

Reconstruction of palatal defects is essential for speech and swallowing. Reconstruction can be either prosthetic or surgical. A temporary dental obturator can be placed intraoperatively or after the first

postoperative visit around day 10. A final obturator can be fashioned a few months later when soft tissue contraction has stabilized (Fig. 24.16). The advantages are an open cavity for tumor surveillance and no additional surgical morbidity for the patient. The disadvantage is the requirement to maintain a well-fitting obturator in order to enjoy normal speech and swallowing. Many patients are frustrated by minor leaks or pain with an improper fit.

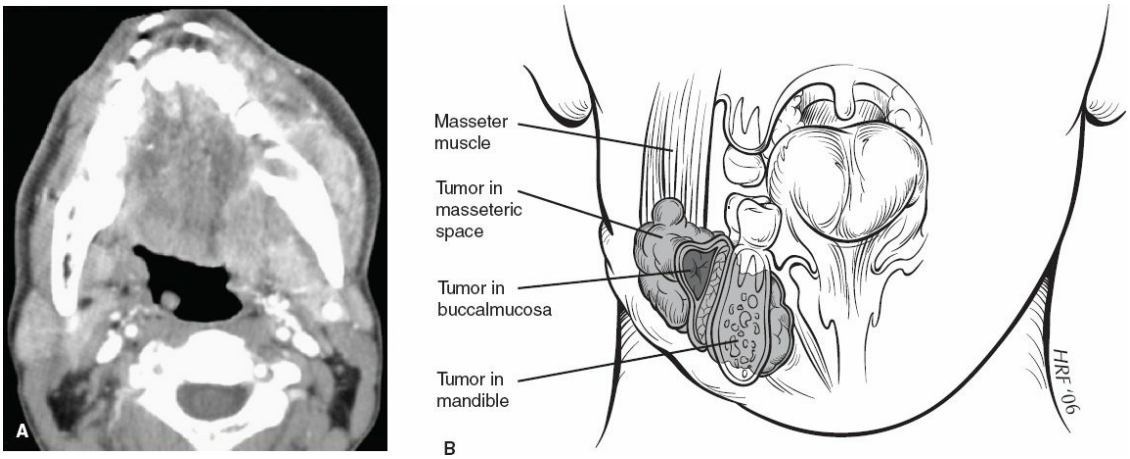

Figure 24.14. T4 carcinoma of buccal mucosa. **A.** Extensive involvement of masseteric space demonstrated by CT scan. **B.** The mandible and masseteric spaces illustrated here are the most common locations for failure of complete resection.

Surgical closure of larger defects typically requires free flap reconstruction. The option is worthwhile for younger patients who will not be forced to maintain a well-fitting prosthesis for the remainder of their lives. Flap reconstruction is usually offered at the time of primary excision. If doubt about margins remains, a temporary obturator can easily be fashioned and the defect reconstructed secondarily.

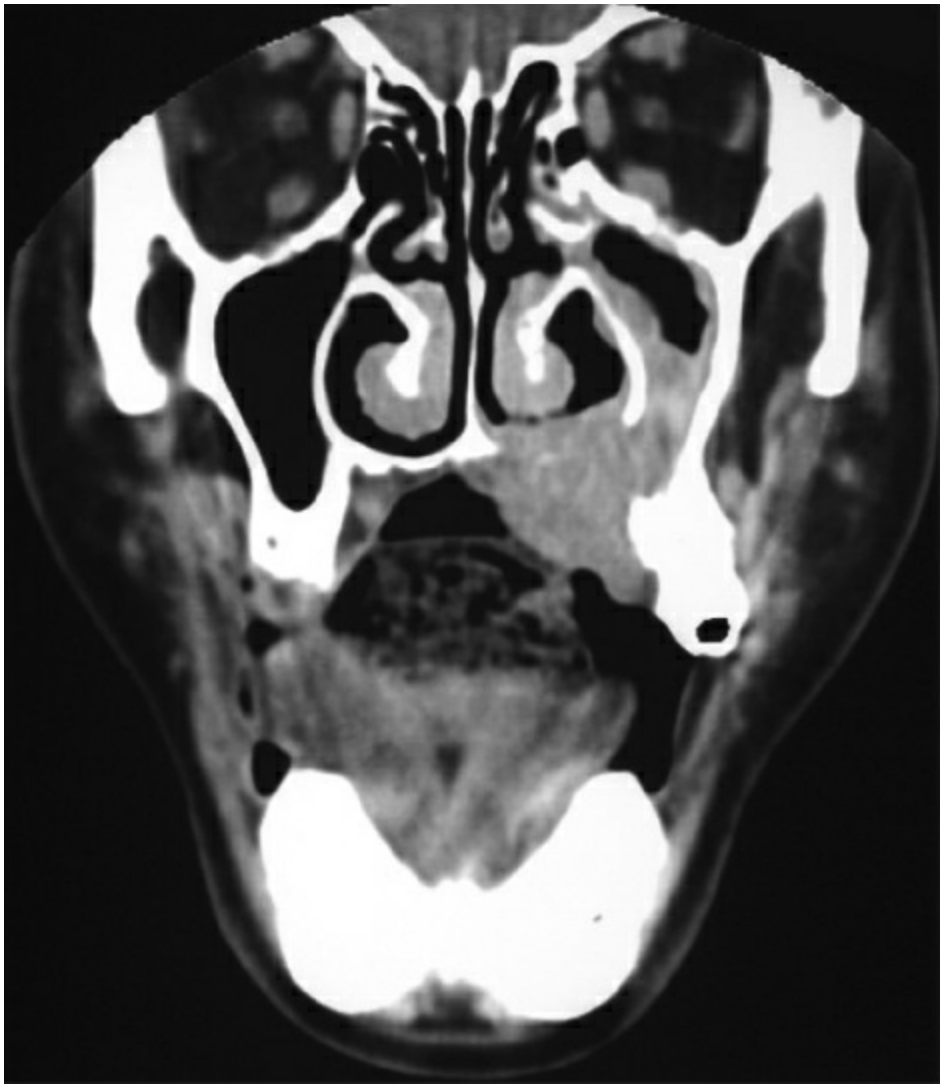

Figure 24.15. Carcinoma of the palate extending upward into the maxillary sinus and illustrating the importance of preoperative scanning in tumor staging.

POSTOPERATIVE CARE

Oral cavity cancer patients average 62 years of age at diagnosis and over 80% are long-term tobacco users. Cardiac disease, peripheral vascular disease, and COPD are common comorbidities that impact postoperative recovery and must be considered in the perioperative setting. While resections for advanced head and neck cancer may be tedious and time-consuming, recovery from surgery can also be surprisingly brisk. The fluid shifts and physiologic stress common to intra-abdominal and intrathoracic surgery are often less severe. Patients are typically encouraged to resume ambulation and enteral nutrition on the first post-operative day. Whenever the upper aerodigestive tract is surgically altered, however, the *airway*,

swallowing and *speech* require special consideration.

The oral *airway* is compromised by postoperative edema and added bulk from reconstructive flaps or gauze bolsters. Small lesions are typically removed with minimal alteration in airway patency. Larger resections, particularly when combined with neck dissection, have the potential to produce significant airway edema. Tracheotomy is preferred over prolonged intubation because the patient can be ambulatory immediately and the operative site more easily monitored. The surgical adage “If you think you might need a trach, do it…” remains relevant today.

There are two considerations related to *swallowing* that are important to consider. The first is when have the wounds healed adequately to resume oral intake. The second consideration is when can the patient swallow again without aspirating. If the resection has created an opening from the oral cavity into the neck, the patient is at risk for salivary fistula formation. If there is no evidence of a leak, oral intake may resume for most patients on post-op day 6 or 7. Even though an adequate seal is obtained, the swallow mechanism may still be impaired. Altered capacity to move food through the oral cavity and pharynx creates aspiration risk. Nasogastric or PEG tubes are commonly placed intraoperatively in anticipation of dysphagia. Speech pathology involvement early in the rehab process is recommended. Ultimate recovery of swallow function correlates inversely with the volume of normal tissue resected.

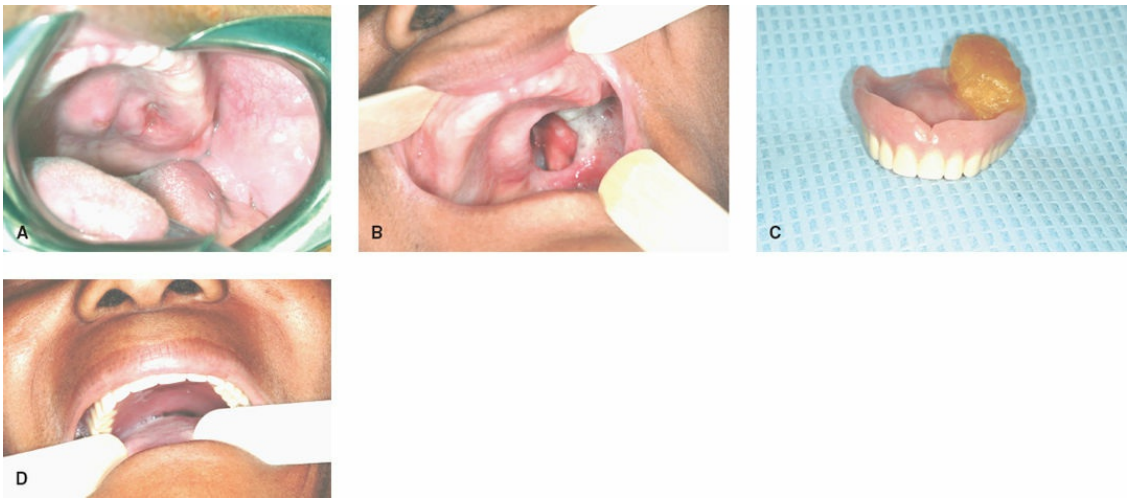

Figure 24.16. Minor salivary gland adenocarcinoma of the palate. **A.** Lesion involving left side of hard palate. **B.** Defect with clear margins. **C.** Initial obturator fashioned by prosthodontist to fill defect. **D.** Obturator in position allowing normal oral function.

Speech is also impacted by surgery for oral cancer. While speech is not a vital function, the patient should be prepared for the likelihood of speech difficulty and provided with a means of communicating post-op. Hospitalized patients who are trach tube dependent and cannot speak require special monitoring by nursing staff as they cannot use the “nurse-call” intercom system.

COMPLICATIONS

The best predictors of complications following surgery for oral cavity cancer are medical comorbidities, prior treatment with radiation/chemotherapy, and cancer-related cachexia. The common cardiovascular, pulmonary, renal, and wound-healing complications encountered in general surgical patients are seen in oral cancer patients as well.

Major complications in head and neck surgery occur in approximately 10% of patients. Major complications include those that require additional hospital stay, return to the operating room, or result in diminished recovery of function. The most common are wound infection, wound dehiscence with fistula formation, bleeding, and aspiration pneumonia.

With small oral cavity resections, delayed wound healing is a nuisance but not often lethal. With larger resections, particularly those in continuity with the neck, wound complications can be lethal. Salivary leak into the neck produces a poly-microbial infection manifesting as cellulitis, abscess, wound dehiscence, and potential hemorrhage from the great vessels. Steps to prevent wound complications include perioperative antibiotics, meticulous attention to obtaining a water-tight oral defect closure, and resumption of appropriate nutrition. The question of whether to delay surgery while improving nutrition remains controversial in head and neck surgery. Baseline nutritional parameters may improve with aggressive preoperative nutritional support. There are data from a chemoradiation trial, however, suggesting that those patients receiving pretreatment nutritional support had fewer complications of treatment but decreased overall survival; perhaps the nutritional support encouraged tumor growth. A reasonable is to establish nutritional support during the initial patient contact but not to delay treatment in the hopes of diminishing complications.

Previously radiated patients warrant special attention. Radiation dosages have escalated over the past decade and patients commonly

receive 70+ Gy—often with concurrent chemotherapy. Fistula rates as high as 70% are reported with salvage surgery for head and neck lesions following chemoradiation. Tension-free closure and liberal use of vascularized tissue from regional or free-flaps have been shown to diminish fistula rates in salvage situations. Fortunately, oral cavity cancers are less commonly treated with primary radiation and salvage surgery in a heavily radiated field is not required as often as laryngeal of pharyngeal primaries.

Suggested Readings

American Cancer Society. *Cancer Facts & Figures 2009.* Atlanta: American Cancer Society; 2009.

Beenken SW, Krontiras H, Maddox WA, et al. T1 and T2 squamous cell carcinoma of the oral tongue: prognostic factors and the role of elective lymph node dissection. *Head Neck* 1999;21:124.

Chhetri DK, Rawnsley JD, Calcaterra TC. Carcinoma of the buccal mucosa. *Otolaryngol Head Neck Surg* 2000;123:566.

Choi S, Myers JN. Molecular pathogenesis of oral squamous cell carcinoma: implications for therapy. *J Dent Res* 2008;87(1):14–32.

Cooper J, Pajak TF, Forastiere A, et al. Postoperative concurrent radiotherapy and chemotherapy for high-risk squamous-cell carcinoma of the head and neck. *N Engl J Med* 2004;350:1937.

Gillespie MB, Brodsky MB, Day TA. Swallowing-related quality of life after head and neck cancer treatment. *Laryngoscope* 2004;114(8):1362.

Govers TM, Hannink G, Merkx MA, et al. Sentinel node biopsy for squamous cell carcinoma of the oral cavity and oropharynx: a diagnostic meta-analysis. *Oral Oncol* 2013;49:726–32.

Horner MJ, Ries LAG, Krapcho M, et al. *SEER Cancer Statistics Review, 1975–2006.* Bethesda, MD: National Cancer Institute. http://seer.cancer.gov/csr/1975_2006/, based on November 2008 SEER data submission, posted to the SEER Web site, 2009.

Hunter KD, Parkinson EK, Harrison PR. Profiling early head and neck cancer. *Nat Rev Cancer* 2005;5:127.

Urken ML, Moscoso JF, Lawson W, et al. A systematic approach to functional reconstruction of the oral cavity following partial and total glossectomy. *Arch Otolaryngol Head Neck Surg* 1994;102:589.

EDITOR'S COMMENT

Cancer of the oral cavity is one of the most common malignancies, especially in developing countries but also in the developed world. As pointed out squamous cell carcinoma (SCC) is the common histology and the main etiologic factors are tobacco and alcohol use. Although early diagnosis is usually easy, presentation with advanced disease is not uncommon. As this chapter points out the standard of care is primary surgical resection with or without postoperative adjuvant therapy. Early diagnosis is key to improved prognosis. Although reconstructive methods have improved quality-of-life issue of function for these patients, prognosis for advanced-stage disease has been relatively constant for many years.

This commentary will discuss the issues of preoperative evaluation including tumor thickness as a major predictor of the risk of nodal metastasis, human papillomavirus as a driver of oral cavity versus oropharyngeal cancer, and the use of new methods for detection of nodal disease in the neck.

Tumor Thickness

The chapter states "most surgeons feel that a T1 tumor with a depth of invasion greater than 4 mm has a greater chance of development nodal metastases than a T2 or T3 tumor that is very superficial." In general there is support for this clinical judgment in the literature. Kane et al. suggested that depth of invasion is the most significant histologic predictor of subclinical cervical lymph node metastases in early squamous carcinomas of the oral cavity (Kane SV, Gupta M, Kakade AC, et al. Depth of invasion is the most significant histological predictor of subclinical cervical lymph node metastasis in early squamous carcinomas of the oral cavity. *J Cancer surgery* 2006;32:795–803). Patients with T1/T2 N0M0 cancer of the oral cavity were included in this study. All the patients received wide excision of the tumor with an elective supraomohyoid node dissection as the primary treatment. The margins of the primary tumor and the base of excision were assessed by frozen section and were revised if found close. Comparison of the depth of invasion with lymphovascular invasion was compared. Statistical significance was not achieved for a depth of 5 mm but most of the patients with metastases had correlation with tumor depth.

A more recent study compared oral cancer of the tongue and floor of the mouth sites. Results of retrospective comparison of depth of lesion with pathologically proven nodal metastases showed a difference for tongue and floor of mouth lesions (FOM). In contrast to the usual depth of 4 mm as being critical, FOM lesions crossed the 20% threshold of probability for nodal metastases between 1 and 2 mm versus 4 mm for tongue lesions. Such differences suggest why a recent meta-analysis suggesting that elective neck dissection improves the outcomes in patients with clinically negative necks is a reasonable clinical guideline (Fasunla AJ, Greene BH, Timmesfeld N, et al. A

meta-analysis of the randomized controlled trials on elective neck dissection versus therapeutic neck dissection in oral cavity cancers with clinically nod-negative neck. *Oral Oncol* 2011;47(5):320–4).

Human Papillomavirus in Oral Cavity Cancer

HPV is a causal and prognostic factor for oropharyngeal cancer but its role in squamous cell carcinoma of the oral cavity (SCCOC) is less clear. (HPV 16.) The increase in oral cancer in younger patients without the usual risk factors led to the first work implicating HPV in cancer occurrence. A recent study analyzed a large cohort of SCCOC from a single tertiary cancer center. Multiple HPV detection methods were used and positive and negative tumors were compared to evaluate whether they differed in clinical presentation and outcomes (Zafereo ME, Xu L, Dahlstrom R, et al. Squamous cell carcinoma of the oral cavity often over expresses p16 but is rarely driven by human papillomavirus. *Oral Oncol* 2016;56:47–53). (A very low incidence of true HPV-driven SCCOC). A 6% prevalence was found but clinical correlation raised some doubt as to whether even this small minority of patients had truly HPV-driven oral cavity tumors. Better methods of HPV detection would improve the data.

The clinical usefulness of HPV testing is discussed in another interesting paper (Mirghani H, Amen F, Moreau F, et al. Do high-risk human papillomaviruses cause oral cavity squamous cell carcinoma? *Oral Oncol* 2015;51:229–36).

In particular, the presence of HPV DNA alone is insufficient evidence for a causal association and E6/E7 oncogenes in oral cavity squamous cell cancer have been detected. Given the lack of specificity of assays the question as to why do HPV-driven cancers develop preferentially in the oropahrynx is crucial, but as yet incompletely answered.

New Methods of Lymph Node Detection

The importance of detection of occult neck metastases in treatment planning for patients is critical. There is a high rate of unnoticed neck involvement reported. So elective neck dissection in the clinically node-negative neck is usually performed. Preoperative evaluation of the cN0 neck by ultrasonography (US), fine-needle aspiration, computed tomography, and magnetic resonance imaging are available. In a meta-analysis the sensitivity and specificity were higher with US than with CT and MRI although the range of results were wide. A recent study found US a promising modality although lack of patient randomization and small sample size were weaknesses. The results of the study suggest that one third of elective neck dissections could be omitted in these cases.

This chapter is a useful compilation of current evaluation, management, and care of the patient with oral cavity cancer. The three areas highlighted in the commentary offer future ways to improve patient care by better diagnosis and choice of surgical methods.

Bruce Donoff

25 Neck Dissection

Ian Ganly and Jatin P. Shah

The single most important factor affecting prognosis for squamous cell carcinoma of the head and neck, the sixth most common cancer worldwide, is the status of the cervical lymph nodes. Metastasis to the regional lymph nodes reduces the 5-year survival rate by 50% compared with that of patients with early-stage disease (Fig. 25.1). The American Cancer Society has reported that 40% of patients with squamous carcinoma of the oral cavity and pharynx present with regional metastases (Fig. 25.2). Therefore, management of the cervical lymph nodes is an important component in the overall treatment plan for patients with squamous cell carcinoma of the head and neck.

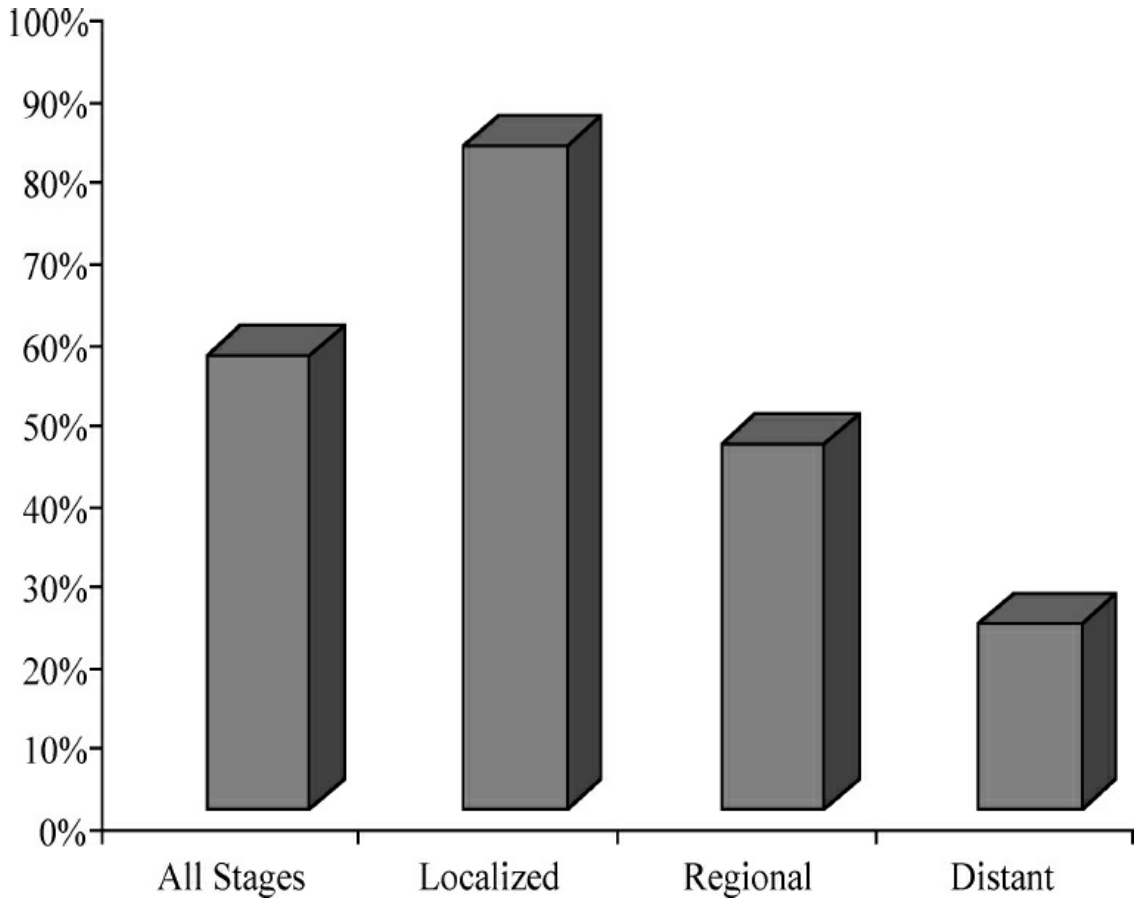

Figure 25.1. Five-year survival rates of squamous cell carcinoma of the head and neck in relation to extent of disease.

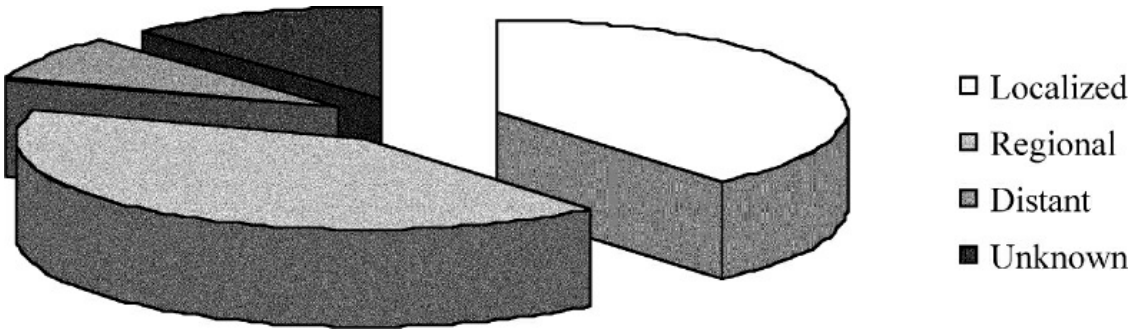

Figure 25.2. Distribution of patients with squamous cell carcinoma of the head and neck in relation to extent of disease at the time of initial diagnosis.

ANATOMY OF THE CERVICAL LYMPHATICS

Cervical lymph nodes are classified according to the system developed at Memorial Sloan-Kettering Cancer Center in the 1930s. This system divides the lymph nodes in the lateral aspect of the neck into five nodal levels, I through V, as shown in Figure 25.3. In addition, lymph nodes in the central compartment are categorized into level VI and those in the anterior superior mediastinum as level VII. Table 25.1 lists the clinical and surgical landmarks used to describe these levels. Recently, level I, II, and V nodes were subclassified into levels IA and IB, IIA and IIB, and VA and VB. Level IA includes the submental lymph nodes, whereas level IB includes the submandibular lymph nodes. Level IIA includes lymph nodes below the accessory nerve, whereas IIB includes nodes above the accessory nerve. The posterior triangle has been subdivided into levels VA and VB, with the dividing line being the accessory nerve in the posterior triangle. This subdivision is based on patterns of lymph node spread from various primaries. For example, level IA lymph node spread is rare except for tumors of the lower lip and anterior floor of mouth. Recent studies have shown that, in the patients with no level IIA nodes clinically, metastatic spread to level IIB nodes is rare. Similarly in thyroid cancer, studies have shown metastatic spread to level VA lymph nodes is exceedingly rare.

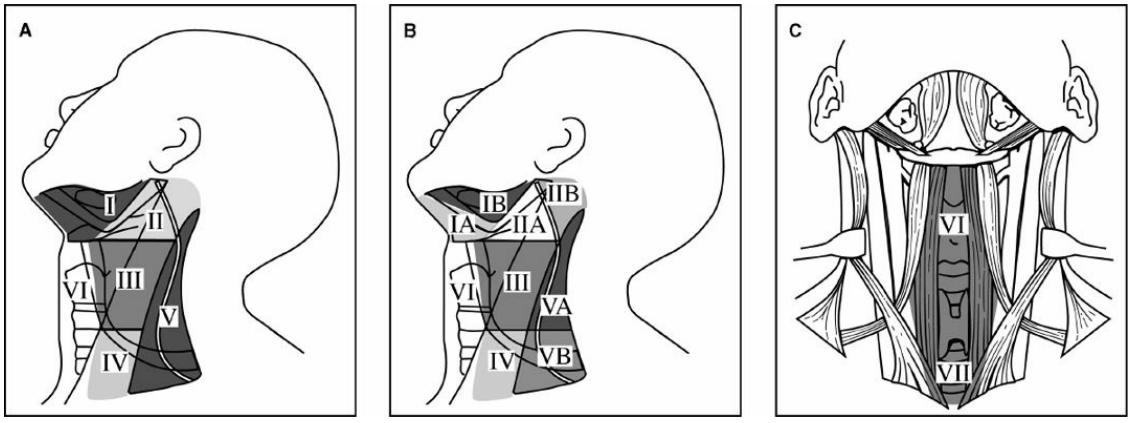

Figure 25.3. Memorial Sloan-Kettering Cancer Center leveling system of cervical lymph nodes (**A**); current modification of leveling system (**B**); and levels VI and VII (**C**).

TABLE 25.1 Clinical and Surgical Landmarks for Neck Node Levels

Node Level	Clinical Landmarks	Surgical Landmarks
Level I	Submental and submandibular triangles	Superior-lower border of the body of the mandible; posterior-posterior belly of digastric; inferior-hyoid bone
Level II	Upper jugular lymph nodes	Superior-base of skull; posterior-posterior border of sternocleidomastoid muscle; anterior-lateral limit of sternohyoid; inferior-hyoid bone
Level III	Middle jugular lymph nodes	Superior-hyoid bone; posterior-posterior border of sternocleidomastoid muscle; anterior-lateral limit of sternohyoid; inferior-cricothyroid membrane
Level IV	Lower jugular lymph nodes	Superior-cricothyroid membrane; posterior-posterior border of sternocleidomastoid muscle; anterior-lateral limit of sternohyoid; inferior-clavicle
Level V	Posterior triangle lymph nodes	Posterior-anterior border of trapezius muscle; anterior-posterior border of sternocleidomastoid muscle; inferior-clavicle
Level VI	Anterior compartment of the neck	Superior-hyoid bone; inferior-suprasternal notch; lateral-medial border of carotid sheath on either side
Level VII	Superior mediastinal lymph nodes	Superior-suprasternal notch; inferior-innominate artery

STAGING SYSTEM FOR METASTATIC SQUAMOUS CELL CARCINOMA OF THE NECK

A uniform staging system for regional metastases to cervical lymph nodes was established by the American Joint Committee on Cancer (AJCC) and the International Union Against Cancer. The staging system for squamous cell carcinoma has been recently updated by the AJCC. The 2016 staging system is now shown in Table 25.2 and Figure 25.4. The staging system for thyroid carcinoma is shown in Table 25.3. The staging system is based on both the size and the number of enlarged lymph nodes. Both of these factors have important prognostic significance. The prognosis worsens with increasing N stage. However, there are other nodal factors affecting prognosis that are not included in the staging system.

TABLE 25.2 Staging System of Regional Lymph Nodes (N Stage) for Squamous Cell Carcinoma of the Upper Aerodigestive Tract (AJCC-UICC 2016)

Nx	Regional lymph nodes cannot be assessed
N0	No clinical or pathologically positive node
N1	Single ipsilateral node <3 cm and extranodal extension ENE (–)
N2a	Single ipsilateral node >3 cm and ENE (–)
N2b	Multiple ipsilateral <6 cm and ENE (–)
N2c	Contralateral or bilateral ENE (–)
N3a	Single ipsilateral node >6 cm and ENE (–)
N3b	Single ipsilateral >3cm ENE (+) OR multiple ipsilateral, bilateral or contralateral nodes any with ENE (+)
Nodal staging for HPV+ve oropharynx cancer	
N0	No clinical or pathologically positive node
N1	1 or more ipsilateral nodes ≤6 cm
N2	contra or bilateral nodes, all ≤6 cm
N3	any node >6 cm
Nodal staging for nasopharynx cancer	
N0	No clinical or pathologically positive node
N1	Retropharyngeal (irrespective of laterality) Cervical: Unilateral, 6 cm, and above caudal border of cricoid cartilage
N2	Cervical: Bilateral, 6 cm, and [a]above caudal border of cricoid cartilage
N3	>6 cm and/or [b]below caudal border of cricoid cartilage (irrespective of laterality)

[a]Above caudal border of cricoid cartilage = Neck levels I, II, III, and/or Va
[b]Below caudal border of cricoid cartilage = Neck levels IVa-b, Vb-c

TABLE 25.3 Staging System of Regional Lymph Nodes (N stage) for Thyroid Carcinoma

Nx	Regional lymph nodes cannot be assessed
N0	No regional lymph node metastases
N1	Regional lymph node metastases
N1a	Metastases in central compartment lymph nodes
N1b	Metastases in unilateral, bilateral, contralateral cervical or superior mediastinal lymph nodes

NODAL FACTORS AFFECTING PROGNOSIS

Characteristics of regional nodes that affect prognosis include the presence of pathologically positive nodes, size of the metastatic lymph node, the number of lymph nodes involved, and the location of the lymph nodes. Involvement of the lower cervical nodes (level IV) and the lower posterior triangle lymph nodes has a very poor prognosis. Another important prognostic factor is the presence of extranodal spread where the capsule of the lymph node is ruptured, resulting in invasion of the surrounding soft tissues. This increases both the incidence of regional recurrence and also distant metastases. In a clinically positive N1 neck, there is a 30% incidence of extranodal spread, whereas in the clinically positive N2a/N3 neck, extranodal spread is present in 50% to 70%. Perivascular and perineural infiltration by tumor also has a negative effect on prognosis. All of these factors must be considered when planning adjuvant treatment following neck dissection.

RISK FACTORS FOR NODAL METASTASIS

The risk for cervical node metastases is influenced by characteristics of the primary tumor such as location, size, and histology. As a general rule, the risk for lymph node metastases increases for more posteriorly located tumors, such as those of the oropharynx and hypopharynx compared to lips and oral cavity (Fig. 25.5). For example, oropharyngeal cancers are at higher risk than oral cavity tumors. Lesions of the tonsil and base of tongue have a very high incidence of nodal metastases. Tumors of the

hypopharynx universally have lymph node metastases. The risk of nodal metastases is higher for tumors of the supraglottic larynx compared with the glottic larynx because of the relative absence of lymphatic vessels in the glottic larynx. The greater the T size of the primary tumor, the greater the probability of having lymph node metastases. For example, T1, T2, and T3 tongue cancers have an incidence of metastatic disease to the neck of 30%, 50%, and 70%, respectively. Pathologic features such as endophytic versus exophytic tumors, poorer degree of differentiation, depth of invasion, vascular invasion, and perineural invasion also determine the risk of cervical metastases.

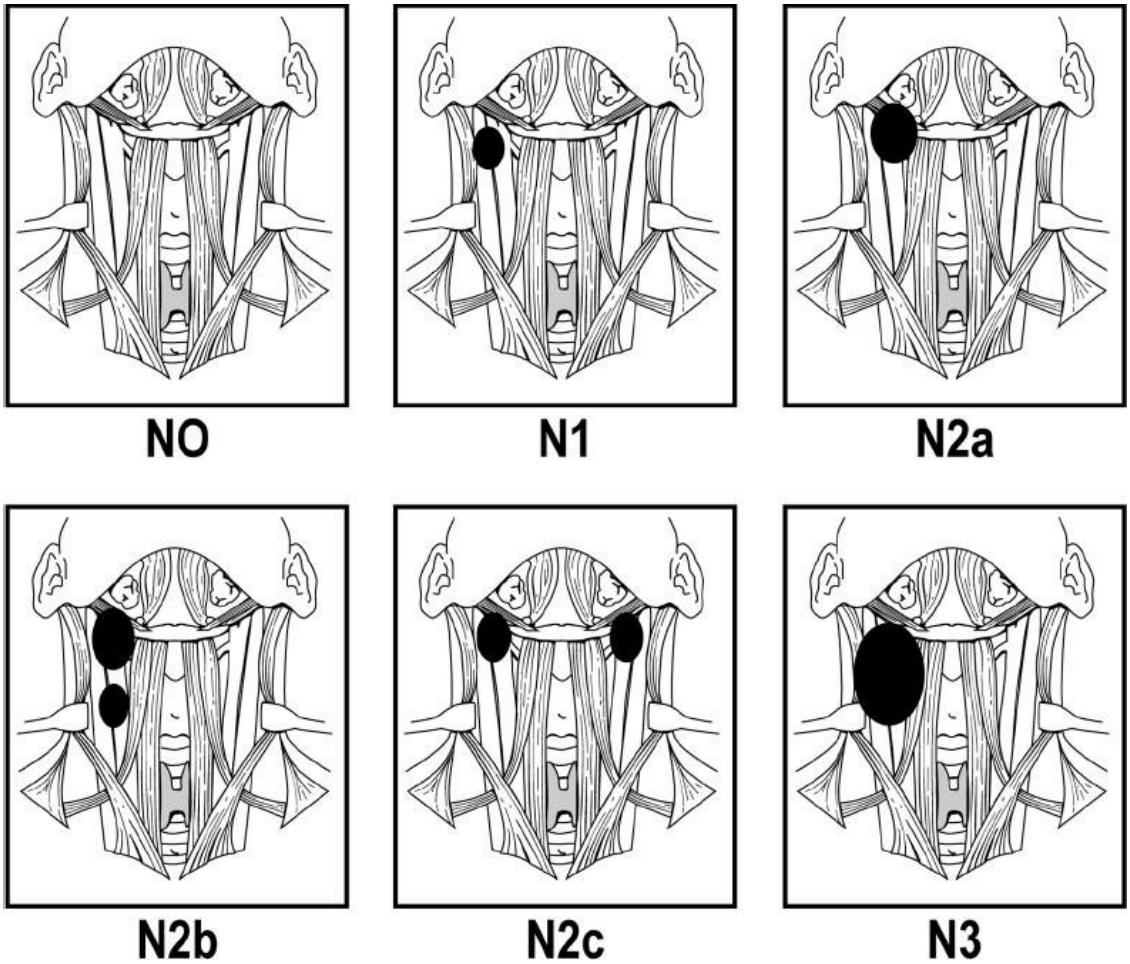

Figure 25.4. Staging system of regional lymph nodes (N stage) for squamous cell carcinoma of the upper aerodigestive tract, the nasopharynx.

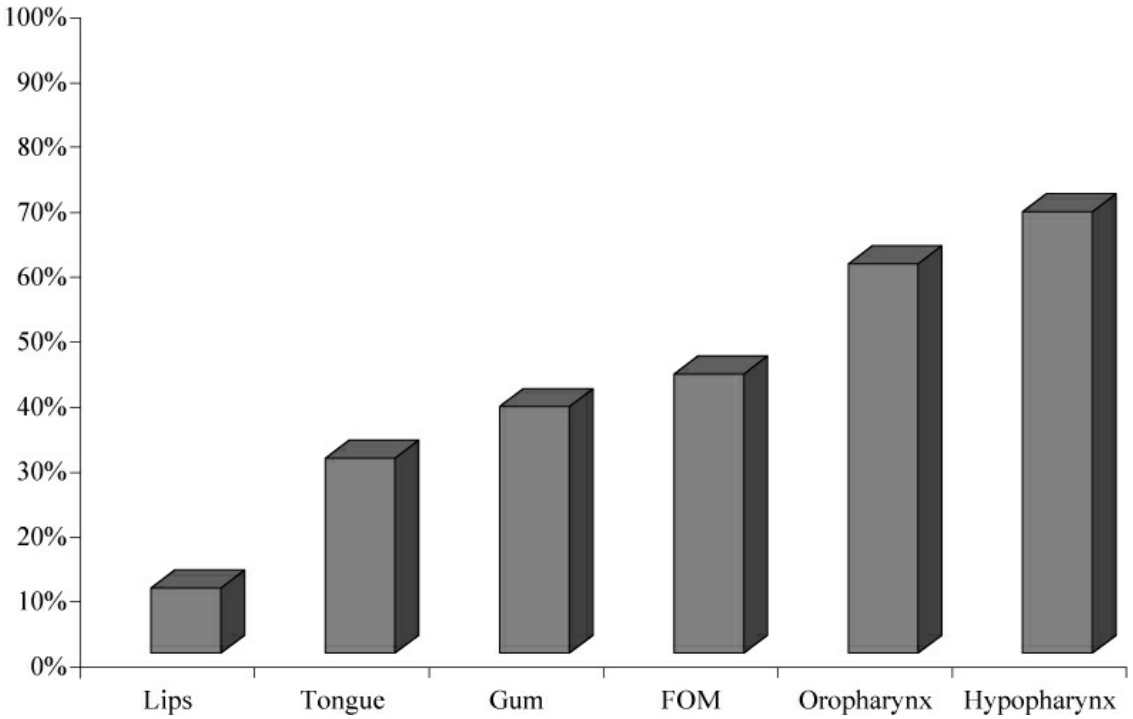

Figure 25.5. The risk of nodal metastasis increases in relation to location of the primary squamous cell carcinoma of the head and neck.

PATTERNS OF NODAL METASTASES

The location of metastases is mainly determined by the location of the primary site. Figure 25.6 illustrates the nodes typically affected by primary tumor location. Cancers of the oral cavity typically spread first to the nodes in levels I, II, and III, whereas cancers of the oropharynx, hypopharynx, and larynx spread first to the nodes in levels II, III, and IV. This observation is based on the philosophy that nodal spread of cancer proceeds in an orderly and predictable fashion as determined by the lymphatic drainage pattern in the neck. In 1972, Lindberg, from the M.D. Anderson Cancer Center, was the first to report that the lymph node groups most frequently involved in cancer of the oral cavity were level II/III, and in patients with cancer of the floor of mouth, oral tongue, and buccal mucosa, the nodes most frequently involved were located in the submandibular triangle (level IB). Lindberg also reported that cancers can metastasize to both sides of the neck and can skip the submandibular and jugulodigastric nodes metastasizing first to the midjugular nodes (level III).

The patterns of nodal metastasis were later well described by Shah, from Memorial Sloan-Kettering Cancer Center, in 1990. To determine

lymph node levels at risk from a particular primary site, Shah analyzed pathology specimens from 1,119 classic radical neck dissections (RNDs) for squamous cell carcinoma of the upper aerodigestive tract. This consisted of 343 RNDs for the clinically negative neck (N0) and 776 RNDs for the clinically positive neck. From these studies, the incidence of pathologically positive neck specimens was 82% for the clinically positive neck and 33% for the clinically negative neck. Tables 25.4 and 25.5 show the percentage of patients with pathologically positive nodes at each level for clinically positive and clinically negative disease.

In the clinically positive neck setting (Table 25.4), patients with primary oral cavity tumors had the majority of positive nodes in levels I to III; levels IV and V were involved in 20% and 4% of specimens, respectively. In patients with primary oropharyngeal tumors, the majority of positive nodes were in levels II to IV; levels I and V were involved in 17% and 11% of specimens, respectively. In patients with hypopharyngeal tumors, most positive nodes were in levels II to IV; levels I and V were involved in 10% and 11% of specimens, respectively. In patients with primary tumors of the larynx, most positive nodes were in levels II to IV; levels I and V were involved in 8% and 5%, respectively.

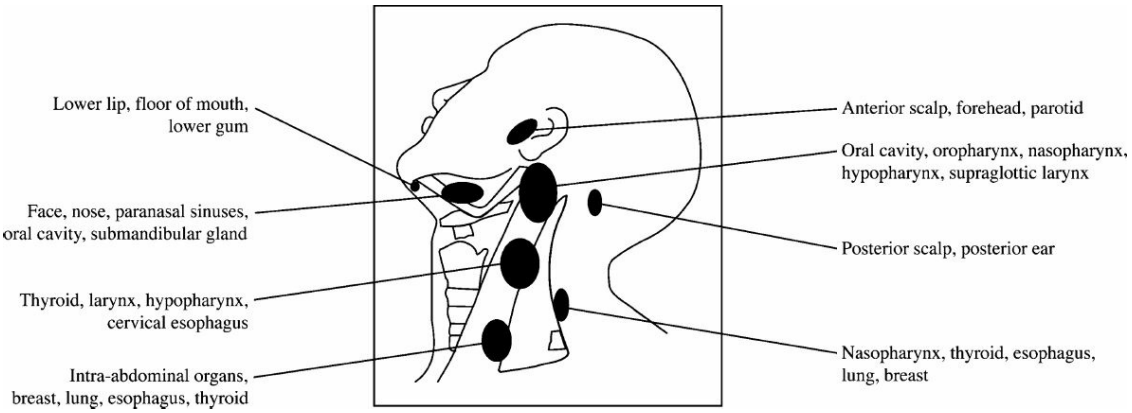

Figure 25.6. Regional lymph nodes draining at a specific primary site.

In the clinically negative neck setting (Table 25.5), patients with primary oral cavity tumors had the majority of positive nodes in levels I to III; levels IV and V were involved in 9% and 2% of specimens, respectively. In patients with primary oropharyngeal tumors, the majority of positive nodes were in levels II to IV; levels I and V were involved in 7%. In patients with hypopharyngeal tumors, most positive nodes were in levels II to IV; levels I and V were not involved. In patients with primary

tumors of the larynx, most positive nodes were in levels II to IV; levels I and V were involved in 14% and 7%, respectively.

The question of level V metastases was addressed in a separate study on 1,277 RNDs by Davidson et al. in 1993. Metastases were found in 40 (3%) patients. Level V metastases were highest in patients with hypopharyngeal and oropharyngeal primary sites (7% and 6%, respectively). Only 3 of 40 patients with a clinically negative neck had a positive level V lymph node. Therefore, the incidence of level V metastases is small and extremely unlikely in the clinically negative neck setting.

TABLE 25.4 Percentage of Positive Lymph Nodes in the cN+ Neck

Clinical N+ Neck					
% Positive Nodes at Each Lymph Node Level According to Primary Site					
Primary Site	I	II	III	IV	V
Oral cavity	61	57	44	20	4
Oropharynx	17	85	50	33	11
Hypopharynx	10	78	75	47	11
Larynx	8	68	70	35	5

CLASSIFICATION OF NECK DISSECTION AND INDICATIONS FOR NECK DISSECTION

History

The importance of the regional cervical lymphatics in oral cavity cancer was noted by Chelius in 1847 who commented, “the neighboring lymphatics become hard and painful” and “once the growth in the mouth has spread to the submaxillary gland, complete removal of the disease is impossible.” In 1847 Warren described the attempted removal of cancer in the neck through an incision from the masseter muscle to the clavicle, although this must have been an unplanned procedure, not based on any anatomical considerations. Kocher in 1880 described the removal of the tongue for cancer through the submaxillary triangle, first removing the lymphatics and submaxillary and sublingual salivary glands. He later proposed that the cervical lymphatics should be removed more widely and described the “Kocher” incision, a Y-shaped incision with the long arm running from the mastoid tip down the anterior border of sternocleidomastoid muscle to the omohyoid muscle, and the short limb

running at right angles to the submental region. Butlin in 1885 later described the removal of cervical lymph nodes for tongue cancer and even discussed the prophylactic removal of these “glands” for tongue cancer.

Solis-Cohen of Philadelphia, America’s first head and neck surgeon, later advocated the removal of cervical lymph nodes during total laryngectomy. However, most of the credit for neck dissection as a curative operation for cervical metastases belongs to George Washington Crile from the Cleveland Clinic. In 1900, he performed different types of neck dissections and subsequently described the classic operation of RND in his seminal article of 1905 published in the *Transactions of the Southern Surgical and Gynecological Association.* This operation is now considered to be the basic neck dissection, and all other procedures are considered to be modifications. George Crile later described his experience with 132 operations of RND in 1906. In this operation, all lymphatic tissues in the lateral neck from levels I to V are systematically removed in conjunction with the sternocleidomastoid muscle, internal jugular vein, the spinal accessory nerve, and the submandibular salivary gland. The operation was popularized by Hayes Martin from Memorial Sloan-Kettering Cancer Center, who described the stepwise procedure of RND in his classic article in 1951. However, this operation is not without morbidity, as it results in a cosmetic deformity and dysfunction of shoulder movement.

TABLE 25.5 Percentage of Positive Lymph Nodes in the cN0 Neck

Clinical N0 Neck					
% Positive Nodes at Each Lymph Node Level According to Primary Site					
Primary Site	I	II	III	IV	V
Oral cavity	58	51	26	9	2
Oropharynx	7	80	60	27	7
Hypopharynx	0	75	75	0	0
Larynx	14	52	55	24	7

This led to the development of modified/functional neck dissections. Oswaldo Suarez from Argentina was the first to describe functional neck dissection in 1963, now called modified radical neck dissection (MRND). He described the removal of all five lymph node levels in the neck while preserving the spinal accessory nerve, sternocleidomastoid muscle, and internal jugular vein to limit any functional disability in the shoulder.

However, his publications were in Spanish and therefore the technique was not popularized until Ettore Bocca, who learned the technique from Suarez, and published it in the English literature in 1967. Selective removal of regional nodal groups based on predictable patterns of lymph node spread was later popularized by Ballantyne from M.D. Anderson Cancer Center. In 1985, Byers from M.D. Anderson Cancer Center used the terms “anterior” and “supraomohyoid” neck dissection to describe the selective neck dissection procedure for cancers of the oral cavity and pharynx. These neck dissections were described for use in patients with clinically negative neck and were based on the philosophy that nodal spread of cancer proceeded in an orderly and predictable fashion. Unfortunately, the terms “modified neck dissection,” “functional neck dissection,” and “selective neck dissection” led to considerable confusion. Therefore, in 1991 the American Academy of Otolaryngology-Head and Neck (AAOHN) Surgery published an article classifying neck dissections into comprehensive and selective. This was later updated in 2002. Structures removed and indications for these different types of neck dissection are shown in Table 25.6.

Comprehensive Neck Dissection

Comprehensive neck dissections involve the removal of all lymphatic tissue in the lateral neck (levels I to V) and are generally carried out for the clinically positive neck (N+). They can be classified into radical and modified RND (Fig. 25.7), depending on what other structures are excised. RND involves the removal of lymph nodes in levels I to V, and also the sternocleidomastoid muscle, internal jugular vein, spinal accessory nerve, and submandibular salivary gland (Fig. 25.7A). MRND is divided into type I, II, or III, depending on the structures that are preserved. Type I MRND involves preservation of one structure, the spinal accessory nerve (Fig. 25.7B). Type II involves preservation of two structures, the spinal accessory nerve and the sternocleidomastoid muscle (Fig. 25.7C). Type III involves preservation of the spinal accessory nerve, internal jugular vein, and the sternocleidomastoid muscle (Fig. 25.7D). Type I MRND is the most commonly employed neck dissection for squamous cell carcinoma of the upper aerodigestive tract with clinically positive neck disease. Type III MRND is most commonly employed for metastatic-differentiated carcinoma of the thyroid.

Selective Neck Dissection

Selective neck dissection spares all nonlymphatic tissue, including the sternocleidomastoid muscle, internal jugular vein, and spinal accessory nerve. However, it does not remove all the lymphatic tissue on the involved side of the neck as does a comprehensive neck dissection, but rather uses the selective removal of nodal regions at risk. This is determined by the predictive pattern of metastases based on the location of the primary tumor. It is based on the clinical observation that squamous cell carcinoma of the upper aerodigestive tract metastasizes in a predictable and sequential pattern. Selective neck dissections are therefore generally carried out for the clinically negative neck (N0), where there is at least a 15% to 20% risk of occult metastatic disease. Additional indications may be situations in which surgical access to the primary extends to lymph node groups at risk of metastases. More controversially, it may be used for nodal metastases confined to the first-echelon nodes (usually N1) when the primary is being treated by surgery. However, it is important to point out that the neck requires postoperative radiation therapy in this setting.

TABLE 25.6 Classification of Different Types of Neck Dissection With Clinical Indications

Comprehensive	Nodal Levels Removed	Structures Preserved	Indications
Radical neck dissection	Levels I–V	None	N+ neck for SCC where SAN involved and/or extensive soft tissue disease with invasion of SCM and IJV
Modified neck dissection type I	Levels I–V	SAN	N+ neck for SCC where SAN free of disease
Modified neck dissection type II	Levels I–V	SAN, SCM	N+ neck for SCC or thyroid cancer where IJV involved but SAN free of disease
Modified neck dissection type III	Levels I–V	SAN, SCM, IJV	Metastatic differentiated thyroid carcinoma
Selective			
Supraomohyoid neck dissection	Levels I–III	SAN, SCM, IJV	N0 neck for SCC of oral cavity and oropharynx (include level 4); N0 neck malignant melanoma where primary site is anterior to ear (include parotidectomy for face and scalp)

Extended suprao-mohyoid neck dissection	Levels I–IV	SAN, SCM, IJV	N0 neck for SCC of lateral tongue
Lateral neck dissection	Levels II–IV	SAN, SCM, IJV	N0 neck for SCC of larynx and hypopharynx
Posterolateral neck dissection	Levels II–V, subocciptial, retroauricu-lar nodes	SAN, SCM, IJV	N0 neck malignant melanoma where primary site is posterior to ear
Modified lateral neck dissection	Levels II – V	SCM, IJV, SAN, Sub-Max gland	Therapeutic neck dissection for thyroid cancer with lateral neck nodes
Central compart-ment neck dissection	Levels VI and VII	N/A	Therapeutic dissection for central compartment nodes for thyroid cancer

SAN, spinal accessory nerve; SCC, squamous cell carcinoma; SCM, sternocleidomastoid muscle; IJV, internal jugular vein.

Common selective neck dissections are shown in Figure 25.8. These include the supraomohyoid neck dissection (SOHND), in which lymph nodes in levels I to III and the submandibular salivary gland are removed (Fig. 25.8A); the extended SOHND, in which lymph nodes in levels I to IV and the submandibular gland are removed (Fig. 25.8B); the anterolateral neck dissection (LND), in which lymph nodes in levels II to IV are removed (Fig. 25.8C); posterolateral neck dissection (PLND), in which lymph nodes in levels II to V and also the suboccipital and retroauricular lymph nodes are removed (Fig. 25.8D); and central or anterior compartment neck dissection, in which lymph nodes at level VI in the prelaryngeal, pretracheal, and paratracheal regions are removed (Fig. 25.8E).

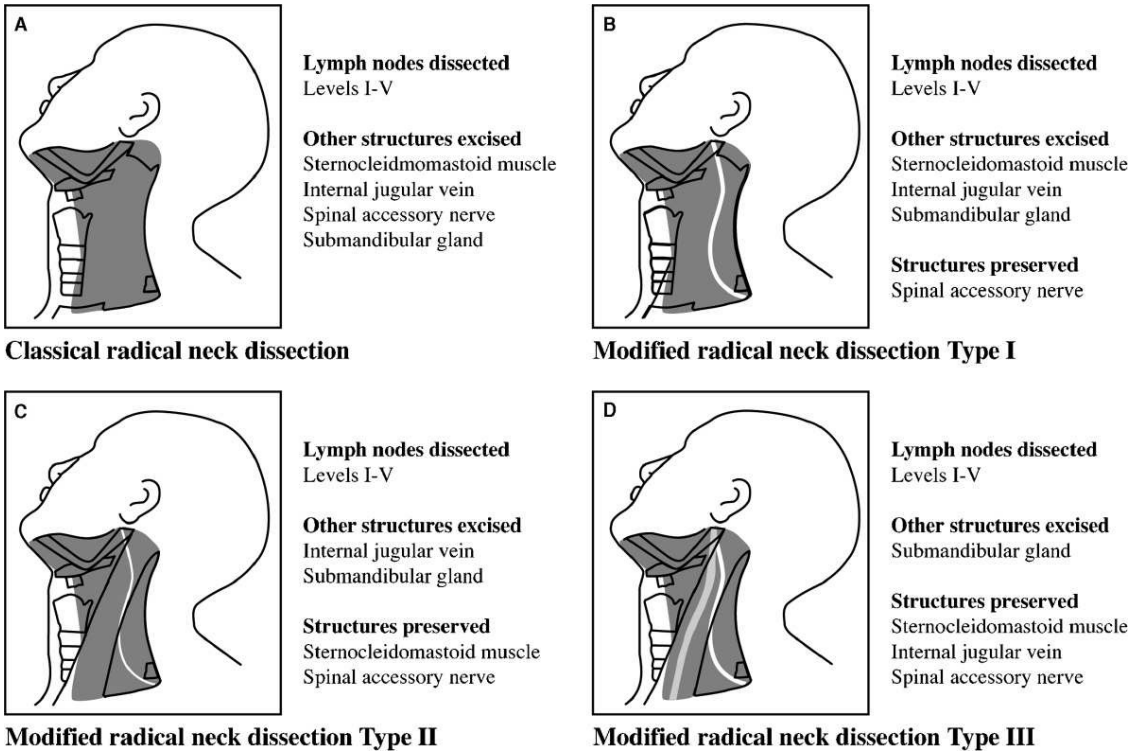

Figure 25.7. Classification of comprehensive neck dissections. **A.** Classical radical neck dissection. **B.** Modified neck dissection Type I. **C.** Modified neck dissection Type II. **D.** Modified neck dissection Type III.

SOHND is recommended for squamous cell carcinoma of the oral cavity with a high risk of micrometastases in a neck that is clinically negative for disease. Byers reported a recurrence rate of 5.8% in 154 N0 patients treated with SOHND. For node-positive disease, the results of selective SOHND are more variable. Byers reported a regional recurrence rate of 15%. In 1999, Byers reported that the regional recurrence rate was 36% in patients with pathologically positive N1 neck disease who had not received radiation therapy, but was 5.6% among those who had received postoperative radiation. For pathologically positive N2b disease, the failure rate was 8.8% with radiation and 14% without.

Extended supraomohyoid neck dissection is recommended for squamous cell carcinoma of the lateral tongue. This is based on the observation that patients with primary carcinoma of the lateral border of the oral tongue have a small but increased risk of skip metastases to level IV compared with other sites in the oral cavity. Therefore, selective treatment of the N0 neck in lateral tongue cancer should include level IV.

LND is recommended for squamous cell carcinoma of the larynx or pharynx with a high risk of micrometastases in a neck that is clinically

negative for disease. If the primary tumor crosses the midline, this procedure is carried out bilaterally. LND is indicated for cancer of the oropharynx when the primary tumor is treated with surgery in a neck that is clinically negative for disease. If postoperative radiation therapy is indicated, it is not necessary to perform bilateral LND because radiation alone is effective in treating the node-negative contralateral neck. Cancer of the hypopharynx frequently metastasizes to both sides of the neck. Therefore, bilateral LND is recommended in patients with a clinically negative neck setting. In supraglottic and advanced glottic cancer, bilateral neck dissection is generally recommended. LND is not indicated for early glottic lesions. In 1985, Byers reported efficacy data for recurrence rates following LND of 3.9% among 256 patients with pathologically negative neck (pN0) disease. He also reported a recurrence rate of 7.3% among 41 patients with pathologically positive neck disease (pN+) who underwent LND; 37 of the 41 patients received postoperative radiation. However, in patients with multiple positive lymph nodes, Byers reported a regional failure rate of 30% for those treated with postoperative radiation and 33% for those who were not. Selective neck dissection is therefore not indicated when there is evidence of multiple positive nodes.

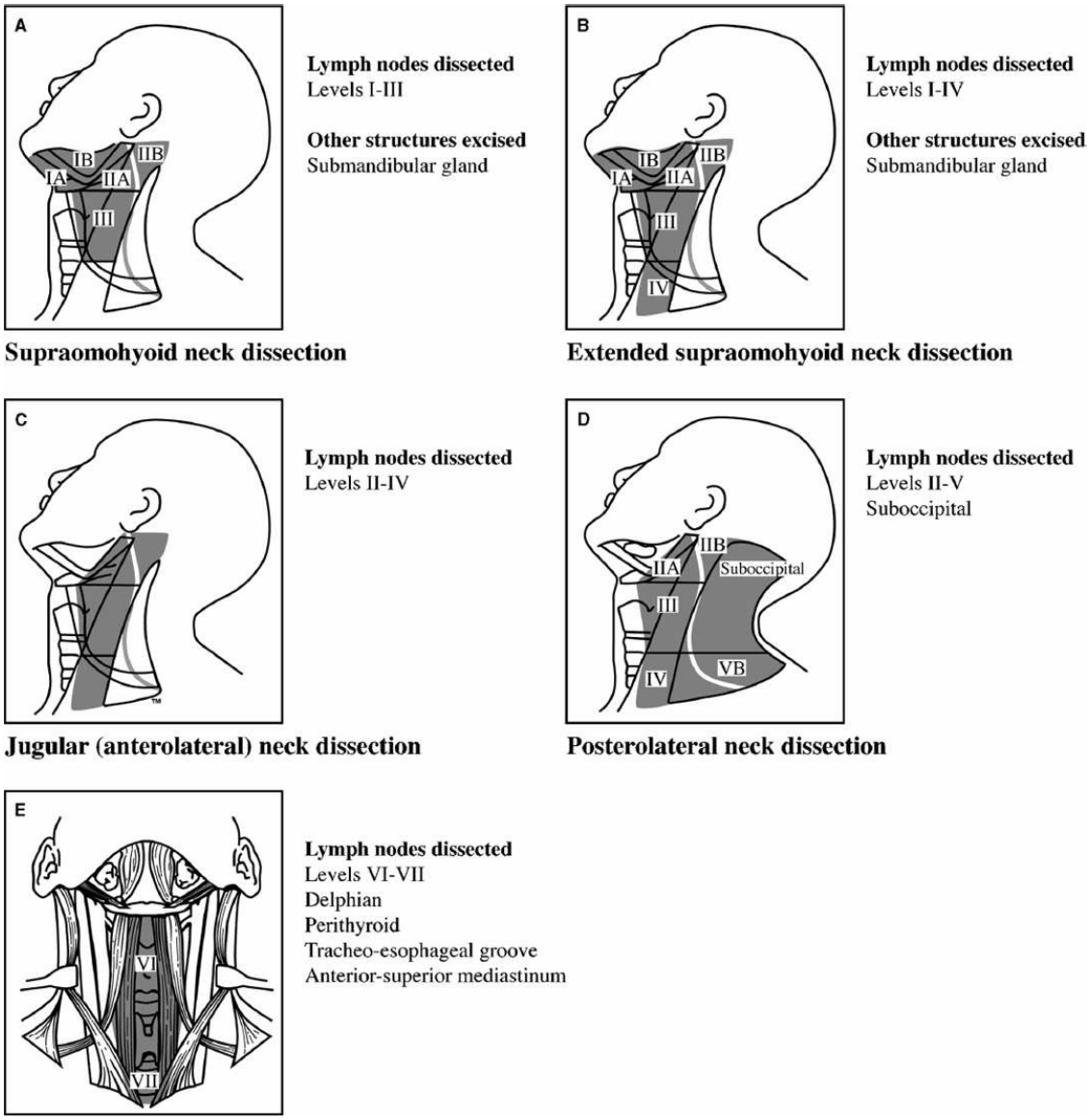

Figure 25.8. Classification of selective neck dissections. **A.** Supraomohyoid neck dissection. **B.** Extended supraomohyoid neck dissection. **C.** Jugular (anterolateral) neck dissection. **D.** Posterolateral neck dissection. **E.** Central compartment neck dissection.

PLND is recommended for primary cutaneous malignancies of the posterior scalp (e.g., melanoma and squamous cell carcinoma). *Central compartment neck dissection* is recommended for differentiated thyroid carcinoma in which the disease is limited to the pretracheal and paratracheal nodes.

Proposed New Neck Dissection Nomenclature

Recently a new neck dissection nomenclature has been suggested rather

than the American Association of Otolaryngology Head and Neck Surgery (AAO-HNS) current nomenclature. The nomenclature is as follows:

1. The symbol “ND” should be used to represent the term “neck dissection” and applied as the first component of the description. A prefix is included to denote the side of the neck using the abbreviation L for left, and R for right. If bilateral, both sides must be classified independently.
2. The second component of the description should be the neck levels and/or sublevels removed, each designated by the Roman numerals I through VII, in ascending order.
3. The third component of the description should be the nonlymphatic structures removed, each identified through the use of specified acronyms (symbols), all of which have been universally accepted.

Table 25.7 illustrates the new proposed nomenclature and how it relates to the current American Association Otolaryngology Head and Neck Surgery/American Head and Neck Society (AAO-HNS/AHNS) nomenclature.

Sentinel Node Biopsy

The sentinel lymph node is defined as the first echelon lymph node to which cancer spreads. The technique of sentinel lymph node biopsy (SLNB) allows focused examination of the lymph nodes at highest risk for metastases, so that neck dissection is performed only in patients with a positive node and the rest can be spared the morbidity of the operation. Identification of the sentinel node requires the use of preoperative lymphoscintigraphy using radioactive technetium and then blue dye injection (toluidine blue) at the time of surgery. The sentinel node is identified using a gamma probe and confirmed with the injection of blue dye at the time of biopsy. Pathology of the sentinel node requires both haematoxylin and eosin staining and also immunohistochemistry. The node requires serial sectioning at 150 micron sections for accurate analysis.

TABLE 25.7 Current and Proposed Nomenclature of Neck Dissections

AAO-HNS/AHNS Nomenclature	Proposed Nomenclature
Radical neck dissection	ND (I–V, SCM, IJV, CN XI)
Selective neck dissection (II–IV)	ND (II–IV)
Selective neck dissection (I–III)	ND (I–III)
Modified radical neck dissection with preservation of the SAN	ND (I–V, SCM, IJV)
Extended neck dissection with removal of the hypoglossal nerve	ND (I–V, SCM, IJV, CN XI and XII)
Selective neck dissection (II, III)	ND (II, III)
NA	ND (II–IV, SCM)
NA	ND (I–III, SCM, IJV, CN XI)
NA	ND (II–IV, VI)
Central compartment neck dissection or selective neck dissection (VI)	ND (VI)
Selective neck dissection (VI, VII)	ND (VI, VII)

Melanoma

Cutaneous melanoma is ideally suited to this technique because the primary tumor is easily visualized making injection into the tumor relatively straight forward. The usefulness and reliability of the technique have been well described in numerous publications since it was first reported in 1990 by Morton. In head and neck melanoma, SLNB is the most accurate way of staging the neck and is an important predictor of outcome. Patel et al. reported that the 2-year disease-specific survival for SLN-negative patients was 93% compared to 50% for SLN-positive patients (P = NS). If patients are SLN positive, they can be managed by either neck dissection or systemic therapy with immunomodulating agents such as interferon, interleukin, or vaccine-based therapy. A systematic review by Tanis et al. reported that there was no evidence to suggest that neck dissection in patients who are SLN positive improves overall survival compared to patients who did not have neck dissection. Whether or not to carry out a neck dissection in patients who are SLN positive is therefore an individual decision between surgeon and patient.

Mucosal Squamous Cell Cancer

The majority of oral cavity cancers are also easily visualized and are in general accessible to a direct injection. This has led to the suggestion that the sentinel node biopsy technique may be useful in neck management for oral cavity cancer. This technique for squamous cell carcinoma of the oral cavity was first reported in 2001 by Shoaib et al. where sentinel node biopsy was carried out prior to an elective neck dissection in patients with

a clinically negative neck. A report by Ross et al. examined SLNB in 57 clinically N0 necks in 48 patients and reported 15(35%) were upstaged by SLNB and 28 (65%) were staged SLN negative. With a mean follow-up of 18 months only one patient developed regional neck disease after being staged negative on SLNB. The overall sensitivity of the technique was 94%. However, this technique is still experimental and should only be carried out in centers with the necessary expertise and the appropriate volume of cases as it has been shown that centers who carry out this technique with less than 10 cases per year have a much lower sensitivity. Technical problems of "shine through," where the radioactivity level in the primary site potentially obscures the sentinel node, is one potential problem. The role of SLNB in advanced oral cavity cancers is limited due to false negatives resulting from obstruction of lymphatic flow caused by tumor and redirecting of flow to neighboring nodes.

Neck Dissection Post Chemoradiation

An increasing proportion of patients with advanced stage squamous cell carcinoma of the larynx and pharynx are treated with organ preservation protocols of Radiotherapy with Chemotherapy. Management of the cervical lymph nodes in these patients treated with a clinically positive neck remains an area of controversy. The neck may be managed in one of 3 ways; by observation, by planned neck dissection or by salvage neck dissection.

Observation

Observation of the neck can be done in patients who have a complete or near complete response to treatment. Evidence for this approach comes from studies by Corry et al. who have reported low regional recurrence rates. Corry et al. reported on 102 patients with N2/3 neck disease with a complete response clinically and radiologically at 12 weeks post chemoradiation where no planned neck dissection was done. With a median follow-up of 4.3 years, no patient had neck recurrence. Lau et al. reported that in patients who are observed following complete response post chemoradiation with N2/3 neck disease, the 2-year locoregional recurrence free survival was 95%. However, Rengen et al. reported on 65 patients who had a complete response to chemoradiation (CTRT) managed by neck observation. With a median follow-up of 9 years, there was a 10% to 15% incidence of neck recurrence. Patients who had a complete

response to induction chemotherapy were less likely to recur raising the suggestion that response to induction chemotherapy could be used as the indicator to who should have a planned neck dissection.

Planned Neck Dissection

Planned neck dissection is normally carried out in patients with N2 and N3 neck disease irrespective of the response to CTRT. The neck dissection is usually carried out 6 weeks after completion of chemoradiation; this has the advantage of carrying out the neck dissection before the onset of fibrosis, thereby making the neck dissection technically similar in complexity to a nonchemoradiation neck dissection. Evidence for a policy of planned neck dissection comes from studies that have shown the presence of tumor in neck dissection specimens in patients who have complete or near-complete radiologic and clinical response in the neck. Before the introduction of positron emission tomography (PET) scan, planned neck dissection was the conventional method for managing the neck following CTRT. Some groups still practice this policy due to limitations or nonavailability of PET. However, most groups now use a policy of salvage neck dissection.

Salvage Neck Dissection

Salvage neck dissection is normally carried out if there is clinical and/or radiologic evidence of neck disease after completion of chemoradiation. The use of fluorodeoxyglucose positron emission tomography (FDG-PET) has helped to identify patients at risk for residual cancer following CTRT allowing us to select patients who will benefit from a policy of salvage neck dissection. FDG-PET is usually carried out at 12 weeks following completion of CTRT to minimize any false-positive results from residual inflammation from CTRT. Salvage neck dissection in patients who have PET-positive nodes is therefore carried out after 12 weeks post CTRT. This has the disadvantage of making the operation technically more difficult due to the onset of fibrosis. This can result in increased morbidity in terms of shoulder dysfunction, wound complications, and quality of life compared to neck dissection carried out without chemoradiation. In addition, pathologic examination of specimen often fails to show evidence of disease outside of the positive nodes on the initial computed tomography (CT) scan. This has led many surgeons to question the need to carry out comprehensive neck dissection in this situation, and there are now several reports describing the use of selective or superselective

(removal of 2 or less contiguous neck levels) neck dissection to treat residual disease with no increase in regional recurrence.

Management of the Neck in Thyroid Cancer

In patients with a clinically negative neck, the incidence of occult micrometastases in the neck ranges from 30% to 70%. The incidence depends on the size of the primary (26% in tumors <1 cm and 66% in tumors >1 cm). Shaha reported on 1,038 patients at Memorial Sloan Kettering Cancer Center (MSKCC) and reported 56% of patients had a clinically positive neck at the initial evaluation. Given the fact that lymph node metastases are so common it may seem somewhat surprising that thyroid cancer has a 93% to 98% 10-year survival rate. There remains controversy about the impact of nodal metastasis on survival. Several studies suggest there is no decrease in survival in the presence of nodal disease, especially in the younger population of patients less than 45 years of age. Other studies report a reduced survival. Nodal size greater than 3 cm and extracapsular spread are poor prognostic signs. The management of the neck therefore is a controversial subject.

Management of the Clinically Negative Neck

Central Compartment Nodes

Because of the high incidence of occult metastases, many have recommended elective treatment of the central compartment lymph nodes. In a case control study of 195 patients having central compartment neck dissection, Tisell et al. reported that the 10-year survival was greater in the group having neck dissection compared with those who did not (98.4% vs. 89% to 92%). Other authors suggest that adjuvant radioactive iodine therapy may be an alternative treatment because central compartment dissection is associated with a high incidence of temporary and permanent hypoparathyroidism as well as increasing the risk of damage to the recurrent laryngeal nerves. As such, dissection of the central compartment should only be done if any nodes appear enlarged or suspicious.

Lateral Compartment Nodes

Even though occult metastases are seen in up to 40% of patients, studies have shown that in patients having a lateral neck dissection and those who do not, the regional recurrence rates were equivalent, suggesting that routine elective dissection of the lateral neck is not indicated. Radioactive

iodine therapy may be sufficient to treat occult metastatic disease. Elective treatment of the lateral neck is therefore not standard practice.

Treatment of the Clinically Positive Neck

If nodes are present in the central compartment, central compartment neck dissection is done. If nodes are present in the lateral compartment, then a lateral neck dissection should also be carried out. Patients who have positive lateral nodes but no nodes in the central compartment clinically (i.e., skip metastases) are treated with a combined lateral and central neck dissection as the incidence of positive nodes in the central neck is as high as 84%. The main debate is over what type of lateral neck dissection should be carried out. Several studies have shown that multiple neck levels are involved when the lateral neck is clinically positive. This is an argument against “berry picking” or superselective neck dissection as this may lead to a higher rate of missed disease and recurrent operations. It is recommended that a comprehensive MRND type III be carried out for the positive neck. In a 2006 study of 44 neck dissections in 39 patients, all patients had levels II to V dissected; the incidence of metastases was 52% in level II, 57% in level III, 41% in level IV, and 21% in level V. Another study by Roh reported 76% level IV and 70% level IIA and III nodes were involved, 17% of level IIb, 4% in level I, 16% in the infra-accessory compartment of level V but 0% in the supra-accessory nerve compartment of level V. These authors therefore recommended dissection of levels II to V including level IIb but sparing the supra-accessory compartment of level V.

Management of the Neck in Melanoma

Management of the Clinically Negative Neck

Regional nodal metastases are relatively rare in thin cutaneous melanomas (<1 mm in thickness) of the head and neck region and elective neck dissection is therefore not recommended. Thicker lesions (>4 mm) are associated with a high incidence of distant metastases, and therefore elective neck dissection is unlikely to impact on survival in this population. The role of elective neck dissection in patients with intermediate thickness (1.0 to 4 mm thick) melanomas continues to be debated, as only about 15% of patients will have histologically demonstrable metastatic nodes so that the remaining 85% may be considered to have undergone an unnecessary procedure. These patients

are selected for sentinel node biopsy to facilitate further management. Four randomized trials and a large, retrospective study in patients with intermediate thickness melanomas have failed to demonstrate any improvement in survival following elective neck dissection.

Management of the Clinically Positive Neck

Clinically apparent regional lymphatic spread to the parotid gland or to cervical lymph nodes should be managed with superficial parotidectomy and comprehensive neck dissection, with likely adjuvant radiation therapy. Originally believed to be a radioresistant tumor, cutaneous melanoma has a radiation response different from that of squamous cell carcinoma, demonstrating effective tumor cell death at a higher dose per fraction than that of squamous cell carcinoma. As a result, hypofractionation schemes utilizing large-dose fractions have been employed. Adjuvant hypofractionated radiotherapy has been shown to improve 5-year actuarial locoregional control rates for patients with stage II and III disease.

Management of the Neck in Salivary Gland Cancer

Management of the Clinically Negative Neck

Occult cervical metastases are uncommon in cancers of the major salivary glands. Armstrong et al. reported an incidence of occult metastases of 12% in 407 patients who were clinically node negative. Significant risk factors for occult nodal metastases from cancers of the major salivary glands include primary tumor size greater than 4 cm in size (20% vs. 4%), and high tumor grade (49% vs. 2%). Elective neck dissection should therefore be considered in patients with high-grade malignancies and T3/T4 tumors. Selective neck dissection for parotid cancer should encompass levels I, II, III, and IV. Alternatively, if it is anticipated that postoperative radiotherapy will be given to the primary site, then the ipsilateral neck can be treated by radiotherapy at the same time rather than by elective neck dissection.

Management of the Clinically Positive Neck

For clinically apparent nodal metastases, patients should be treated by parotidectomy, and comprehensive neck dissection followed by postoperative radiotherapy. Klussman et al. has reported that on multivariate analysis, lymph node involvement of level I was an independent predictor for poorer disease specific survival.

The benefit of adjuvant radiotherapy has been demonstrated in a matched-pair analysis of patients receiving combined surgery and postoperative radiotherapy compared to patients treated with surgery only. Five-year determinate survival for the combined therapy group was improved compared to the group undergoing surgery only (48.9% vs. 18.7%), and locoregional control was improved as well (69.1% vs. 40.2%). The benefit of postoperative radiation therapy was especially pronounced in patients with high-stage and high-grade primary tumors.

Management of the Neck in HPV-Positive Oropharyngeal Cancer

The incidence of oropharyngeal squamous cell carcinoma has increased dramatically over the past two decades. In a US study examining data from the Surveillance, Epidemiology, and End Results (SEER) program, the incidence of oropharyngeal cancers increased by 1.3% for tongue base cancers and by 0.6% for cancers of the tonsil for each year between 1973 and 2004. The reason for this increase is due to infection with human papilloma virus (HPV). The causal link between HPV and oropharyngeal cancer was first shown in a study by Gillison et al. It is now estimated that 70% of oropharyngeal cancers are associated with previous HPV infection. The high-risk HPV 16 subtype is found in 90% of these cancers with other high-risk subtypes 31, 33, and 18 identified in the other cases. Importantly, oropharyngeal cancers due to HPV have a different epidemiology, natural history, response to treatment, and outcome. Patients often present with smaller primary tumors but larger and cystic cervical nodal disease (Fig. 25.9). Therefore, patients often present with nodal disease, without typical head and neck cancer risk factors. The primary tumor is often a low T stage and can be small or not detectable by clinical examination or radiographic investigation.

There have been a large number of retrospective studies demonstrating patients with HPV-positive tumors of the oropharynx have a better prognosis than patients with HPV-negative tumors. The traditional TNM classification system has been reported to be less effective in predicting cancer-specific mortality in oropharynx cancers. Thus, the latest revision of the AJCC–UICC, TNM staging system has developed an entirely different staging system for HPV-positive oropharynx cancers (Ref: AJCC staging manual, 2016). Prognostic factors used in HPV-negative tumors such as margin status, lymphovascular invasion, pN status, and extra-

capsular spread were not predictive in HPV-positive tumors in a study reported by Iyer et al. In HPV-negative cancer, nodal stage has a very important predictor of outcome. However, the same is not true in HPV-positive disease. With the exception of N3 disease, nodal stage is not a predictor of outcome (Fig. 25.10). In patients with N2b disease, patients with >4 positive nodes had the same outcome as those with <4 positive nodes. Because these patients do so well, management of the positive neck in HPV-positive patients is more selective. Such patients may not require the traditional comprehensive neck dissection as advocated for HPV-negative disease. Rather, HPV-positive neck disease can be managed by a more selective approach with removal of levels 2, 3, 4 followed by adjuvant PORT.

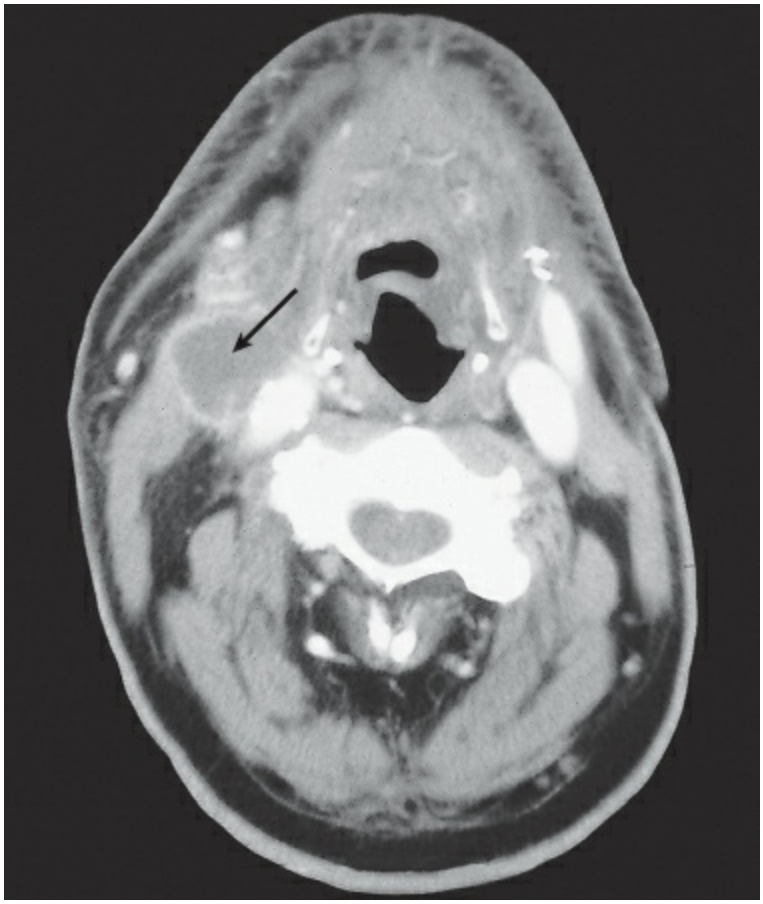

Figure 25.9. Typical cystic level II neck metastases as seen in patients with HPV-positive oropharynx cancer.

TECHNIQUE OF NECK DISSECTION

COMPREHENSIVE MODIFIED NECK DISSECTION: TYPE 1 (CMND TYPE 1)

This is currently the most frequently performed operation in patients with clinically positive neck disease (cN+) where the accessory nerve is not grossly involved by cancer.

Anesthesia

General endotracheal anesthesia with muscle relaxation is essential for performing a neck dissection. The patient is usually positioned in a supine position with the head elevated to 30 degrees. The neck is hyperextended and rotated to the opposite side.

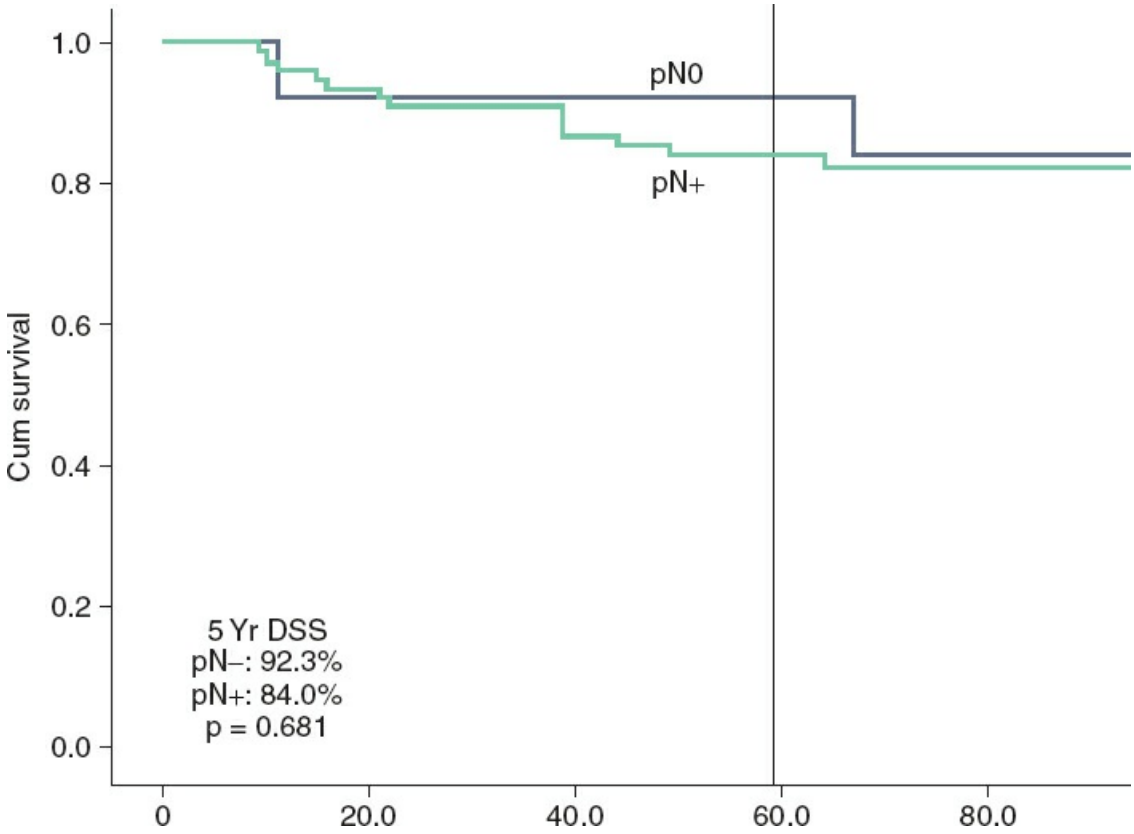

Figure 25.10. Impact of nodal disease on survival in patients with HPV-positive oropharynx cancer.

Incision

For CMND type I, a single trifurcate neck incision was the most frequently employed incision in the past. However, it is now possible that these operations can be carried out equally effectively with a single skin crease incision in the mid neck provided the incision is of sufficient length. Figure 25.11 illustrates different types of neck incisions that can be used in neck dissections.

Procedure

The dissection begins with elevation of the posterior skin flap. Skin is incised with the scalpel and then the remainder of the procedure is carried out using electrocautery. The skin incision is deepened through the subcutaneous tissue and then through the platysma muscle. The posterior flap is then raised in the subplatysmal plane by applying traction to the flap with skin hooks and countertraction of the deeper soft tissues. The flap is elevated up to the anterior border of the trapezius muscle (Fig. 25.12). During this elevation, care is taken not to enter the posterior triangle fat pad to prevent any injury to the spinal accessory nerve. The anterior border of trapezius muscle is skeletonized, and then care is taken to identify the spinal accessory nerve (Fig. 25.13). This can be done either by identifying it as it passes onto the undersurface of the trapezius muscle in the lower part of the neck, or by identifying it 1 cm superior to Erb point (which is a plexus of cervical cutaneous nerves on the posterior border of the sternocleidomastoid muscle ~6 cm from the inferior lobule of the ear). Once identified, the nerve is dissected out from its entry in the trapezius muscle up to the posterior border of sternocleidomastoid muscle. The nerve is then followed up through the sternocleidomastoid muscle, dividing the muscle with electrocautery while protecting the nerve with an Adson clamp under direct vision at all times.

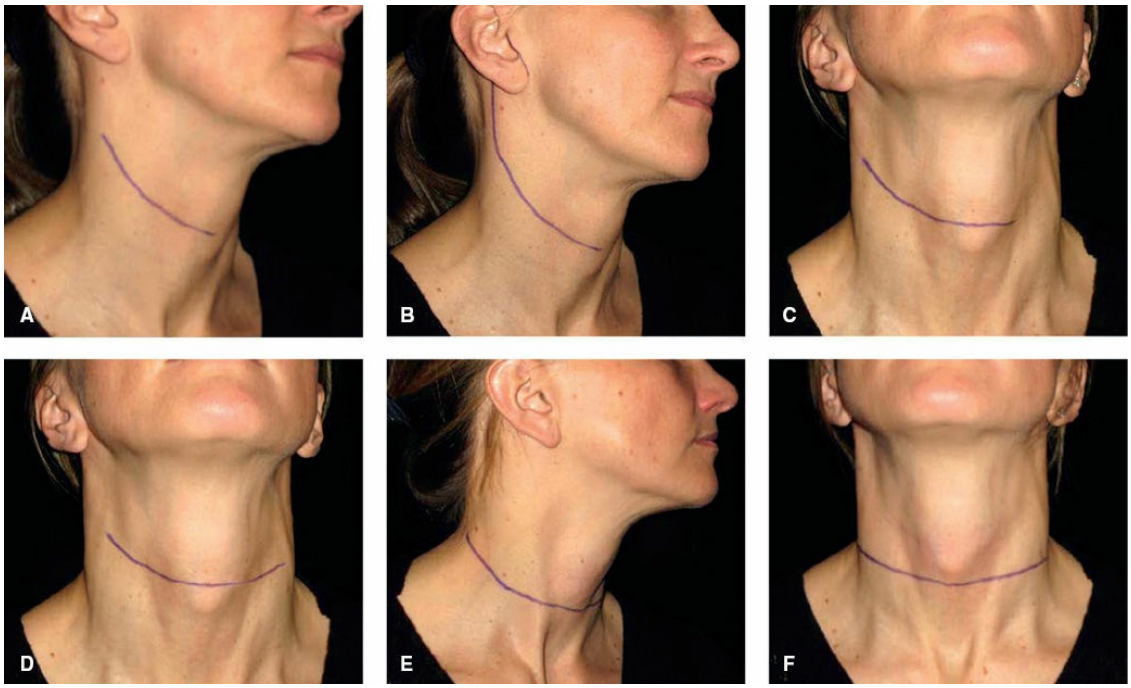

Figure. 25.11. Skin incisions for various types of neck dissections. **A.** Supraomohyoid neck dissection. **B.**

Supraomohyoid neck dissection with parotidectomy **C.** Supraomohyoid neck dissection with extension for submental dissection. **D.** Jugular node dissection **E.** Comprehensive neck dissection **F.** Comprehensive neck dissection with a thyroidectomy.

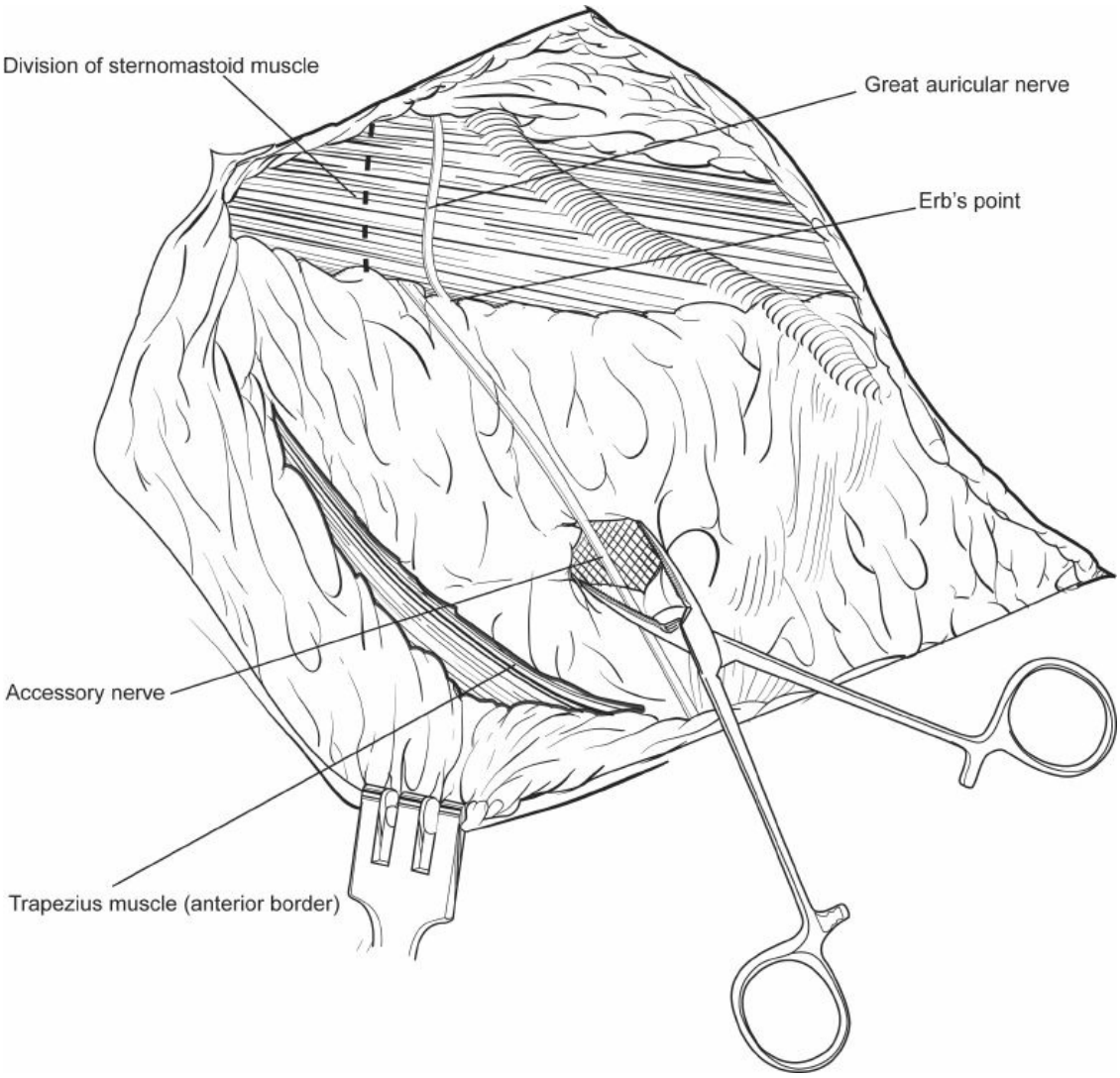

Figure 25.12. Elevation of the posterior skin flap.

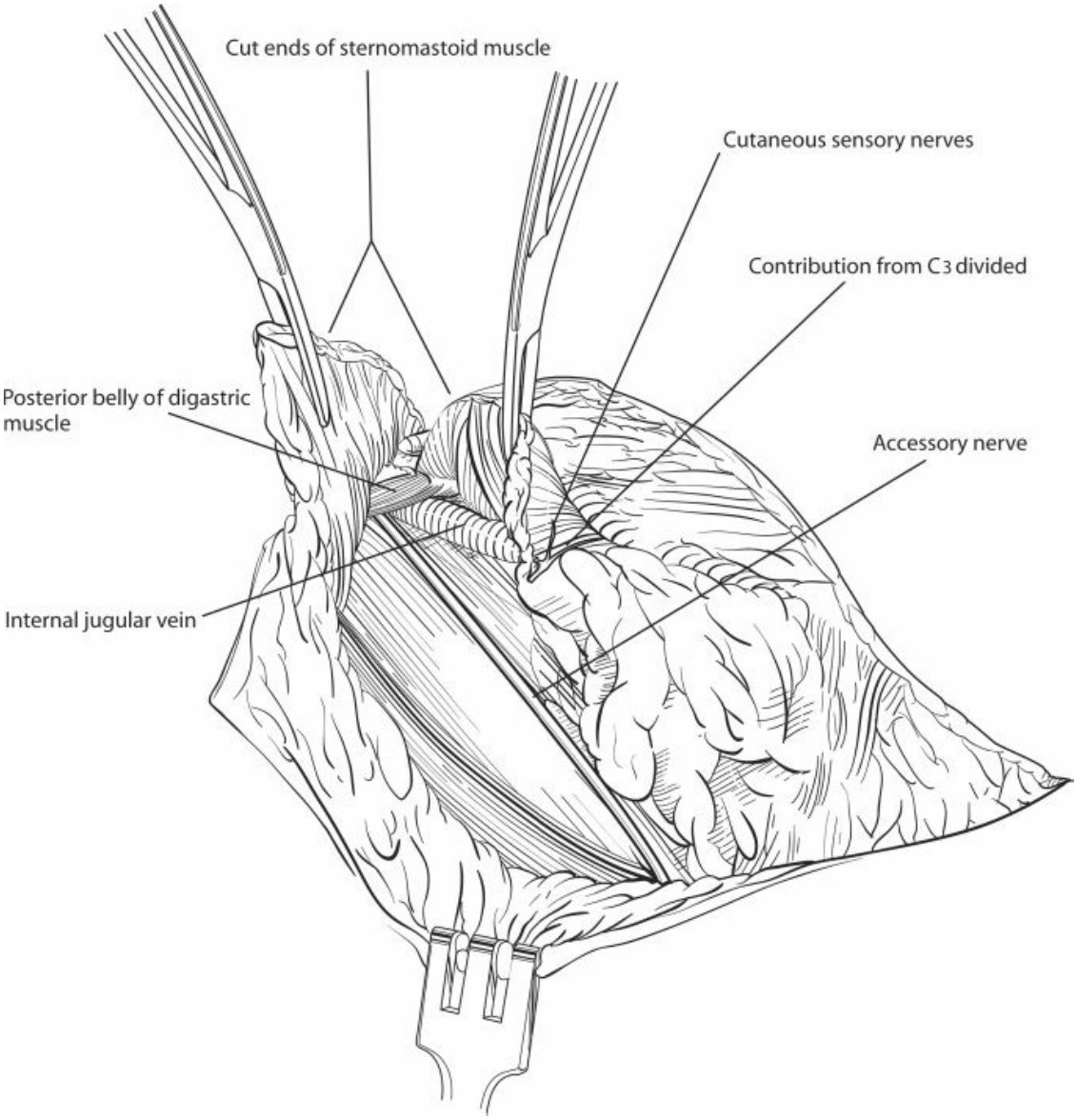

Figure 25.13. Identification of the spinal accessory nerve in the posterior triangle of the neck.

Retracting the anterior portion of the sternocleidomastoid muscle cephalad and the posterior portion caudad assists in the dissection of the nerve. The nerve is then carefully dissected out in a cephalad direction along the lateral border of the internal jugular vein up to its exit from the jugular foramen at the skull base under the posterior belly of the digastric muscle. Once this is done, the nerve is then carefully separated from underlying tissue using the Martin forceps and Reynolds scissors. The superior attachment of the sternocleidomastoid muscle is then detached from the mastoid process, and fibrofatty tissue lying in the supra-accessory triangle is dissected off the muscular floor, working from a lateral-to-medial direction. The tissue is sequentially dissected off the splenius

capitis muscle, followed by the levator scapulae muscle. At this point, the tissue is then able to be passed under the dissected accessory nerve and dissected off the rest of the muscular floor of the posterior triangle (Fig. 25.14). Working in a lateral-to-medial direction, the anterior border of each subsequent muscle is exposed. The posterior scalene muscle is exposed, and then the inferior belly of omohyoid muscle is divided at its attachment on the scapula. Transverse cervical vessels are encountered inferiorly and are divided between clamps and ligated with silk ties. This allows the specimen to be retracted medially, allowing further dissection of the muscular floor, first exposing the middle scalene muscle and then the anterior scalene muscle with the brachial plexus in between.

On the anterior surface of the anterior scalene muscle, the phrenic nerve is identified passing in a lateral-to-medial direction (Fig. 25.15). Care must be taken not to elevate this nerve with the overlying block of soft tissue. Once the phrenic nerve is identified and preserved, the dissection then continues in a cephalad direction, identifying the cutaneous cervical branches as they separate off the cervical rootlets. These branches are divided and the stumps of the nerve roots are ligated. This allows the specimen to be further retracted medially to expose the internal jugular vein, common carotid artery, and the vagus nerve.

At this point, the specimen is allowed to drop back into its natural position in the posterior triangle. Attention is then turned to the anterior skin flap. The transverse skin incision is completed from the trifurcation point up to its medial end. The skin, subcutaneous tissue, and platysma muscle are divided, and an anterior subplatysmal flap is elevated up to the midline superiorly and to the medial end of the sternocleidomastoid muscle at its attachment to the sternum inferiorly. A large loop retractor is used to increase exposure inferiorly. Using electrocautery with coagulating current, the sternal and clavicular heads of sternocleidomastoid muscle are divided. The muscle is then retracted in a cephalad direction, and loose areolar tissue is dissected to expose the carotid sheath. The lateral border of the strap muscles is retracted medially, allowing the carotid sheath to be fully exposed. The sheath is opened, and the common carotid artery, vagus nerve, and internal jugular vein identified and dissected. The internal jugular vein is then divided between clamps and doubly ligated with 2-0 silk ties (Fig. 25.16). A 3-0 chromic catgut transfixion suture is used to secure the distal end of the vein. Lymphatic tissue lying lateral to the internal jugular vein encompassing the thoracic duct on the left side and

unnamed lymphatics on the right hand side of the neck are carefully divided in clamps and ligated with silk ties to prevent chyle leakage. At this juncture, the proximal portion of the transverse cervical vessels is dissected, divided, and ligated with 3-0 silk.

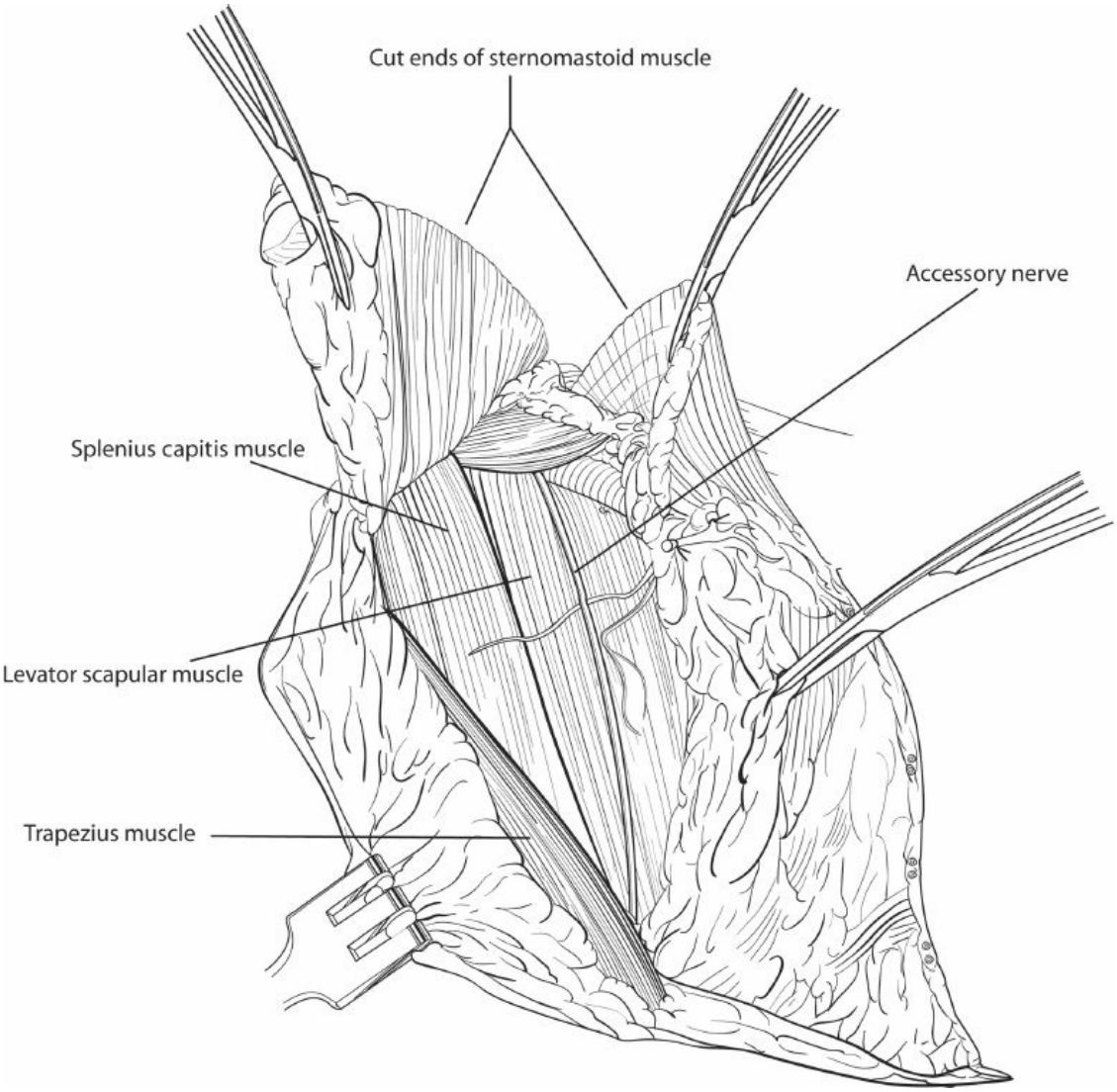

Figure 25.14. Dissection of fibrofatty tissue in the posterior triangle of the muscular floor proceeds in a lateral-to-medial direction.

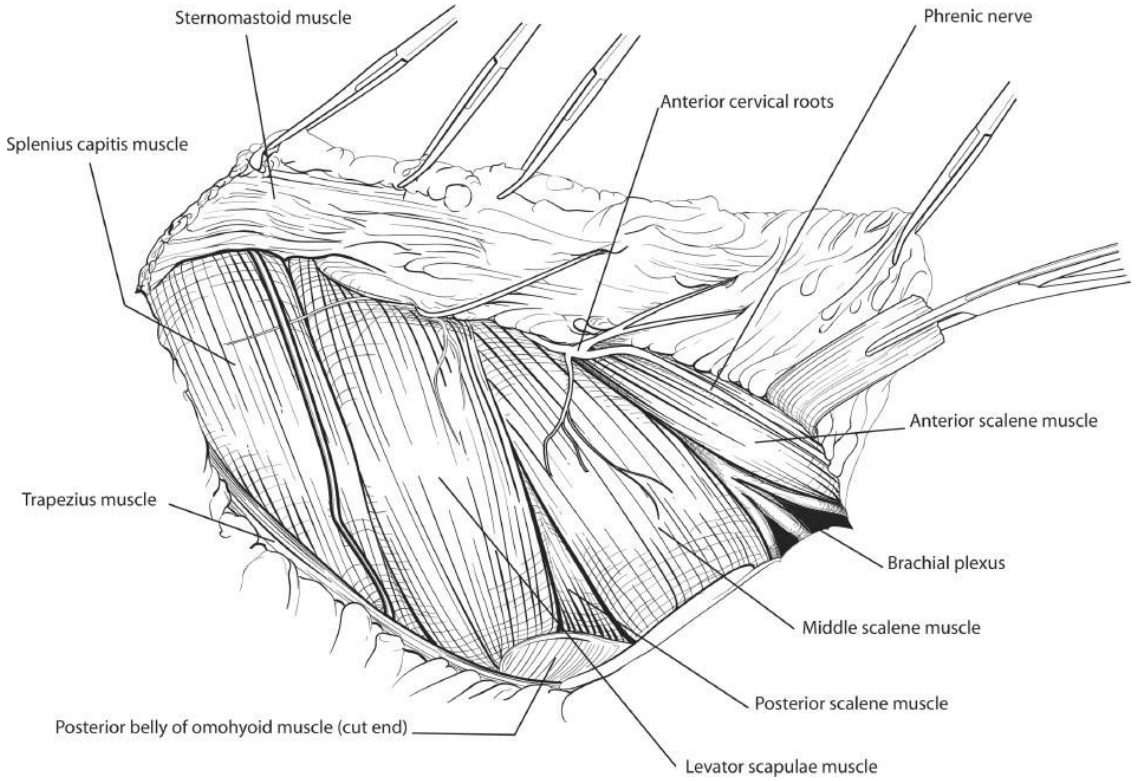

Figure 25.15. Identification of the phrenic nerve on the surface of the anterior scalene muscle.

The soft tissue, including sternocleidomastoid muscle and internal jugular vein, is now retracted in a cephalad direction and carefully dissected in the avascular plane off the vagus nerve and carotid artery (Fig. 25.17). The middle thyroid vein needs to be identified, divided, and ligated with 3-0 silk as it enters the medial aspect of the internal jugular vein. Working in a cephalad direction, the hypoglossal nerve is then identified beyond the bifurcation of the carotid artery. Additional medial mobilization of the specimen is obtained by dividing the superior cervical plexus. The anteromedial limit of the dissection is the anterior belly of the omohyoid muscle. This is incorporated into the specimen by dissecting it up to its attachment to the hyoid bone, where it is then detached. Careful dissection at this level allows identification of the superior thyroid vessels. The superior thyroid vein is divided and ligated, and the superior thyroid artery is preserved.

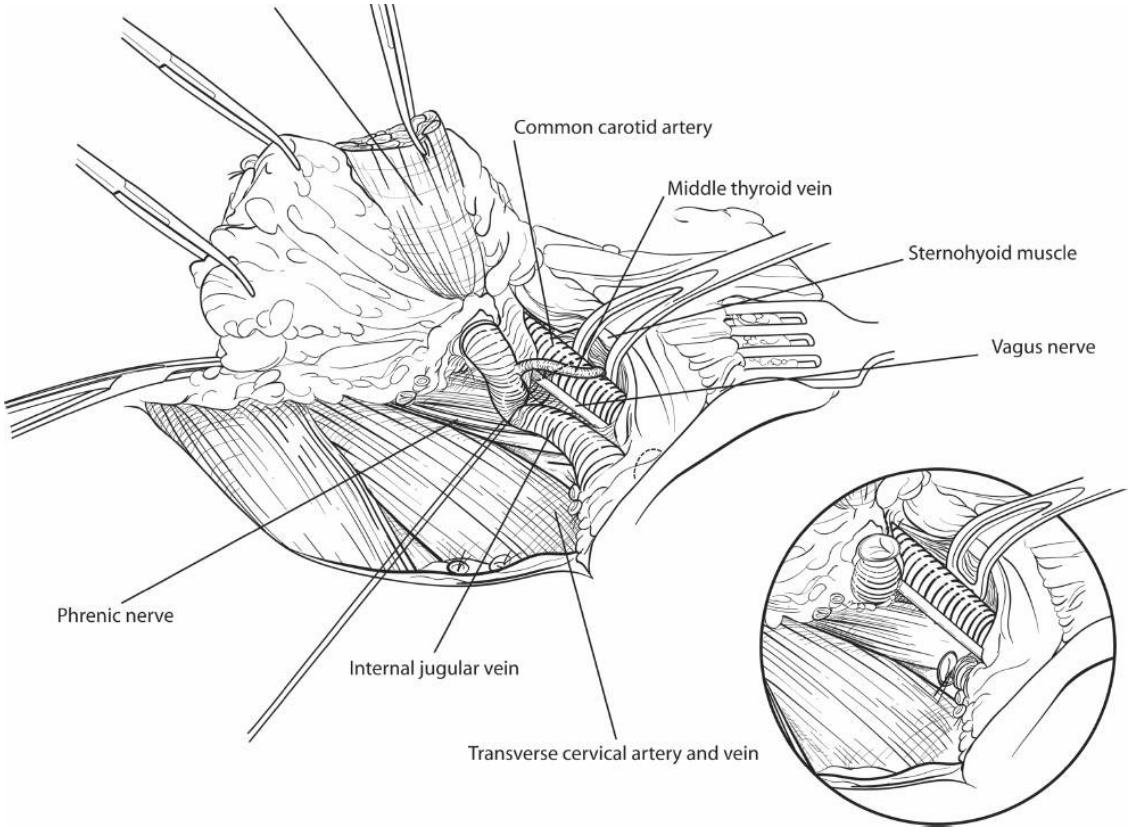

Figure 25.16. The lower end of the internal jugular vein is identified, dissected, and then divided between clamps.

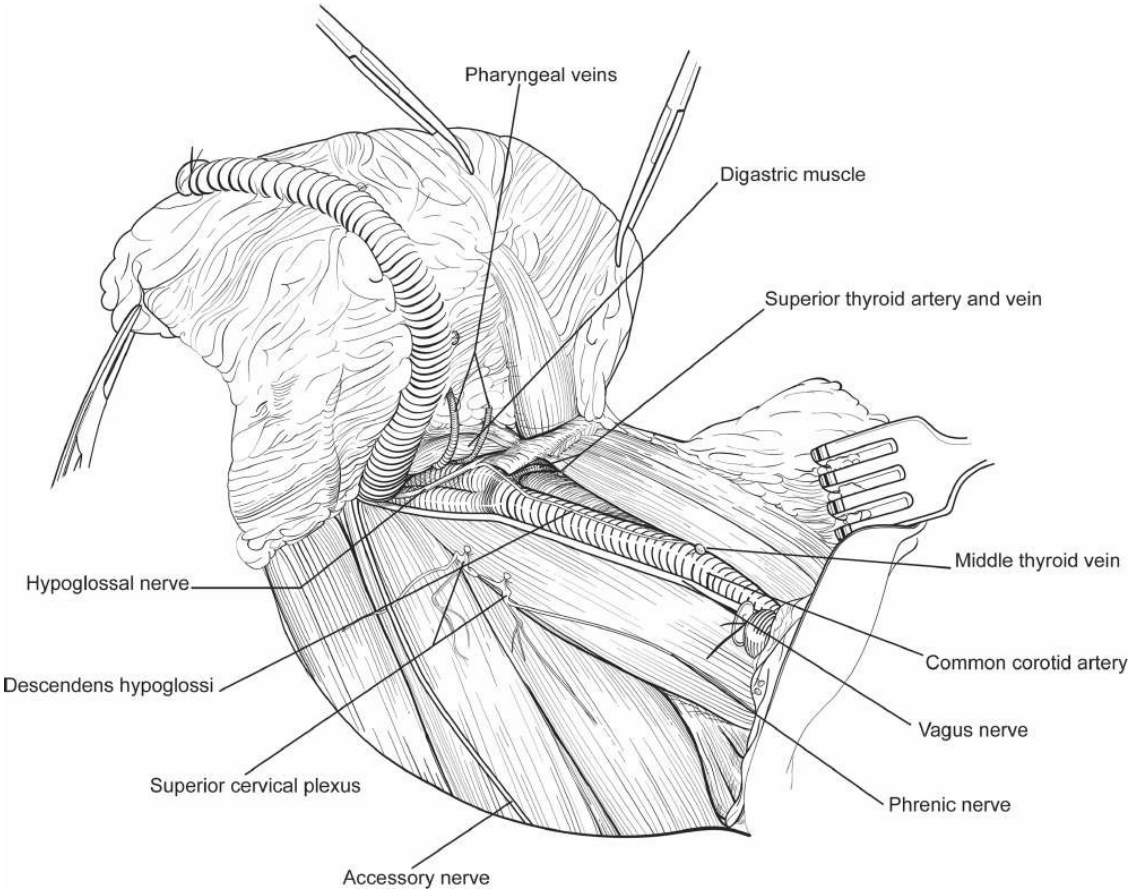

Figure 25.17. Dissection of the sternocleidomastoid muscle and internal jugular vein proceeds in a cephalad direction off the carotid artery and vagus nerve.

The superior skin flap is then elevated. Having divided the platysma muscle, the fascia on the inferior aspect of the submandibular gland is divided and dissected, allowing the superior skin flap to be raised in this plane. This allows the marginal mandibular branch of the facial nerve to be exposed, protected, and preserved. This nerve lies just anterior to the submandibular fascia and superficial to the posterior facial vein (Fig. 25.18). The vein is ligated and its upper stump retracted cephalad, protecting the marginal branch of the facial nerve (Fig. 25.19). Anteriorly, this dissection is carried out sharply, elevating the nerve with the skin flap. In performing this maneuver, the cervical branch of the facial nerve is identified and it may be divided distal to its separation from the marginal mandibular branch. Dissection now proceeds along the lower border of the mandible. The fascial attachment between the sternocleidomastoid muscle and angle of mandible is divided, and then dissection along the inferior border of the mandible allows the delivery of the prevascular facial lymph nodes. The facial vein and artery are divided at this point on the posterior superior aspect of the submandibular gland. Identification of the anterior belly of the ipsilateral and contralateral digastric muscles is then carried out. Nodal tissue in the submental triangle is dissected out, ligating vessels in the apex of the triangle with 3-0 silk ties.

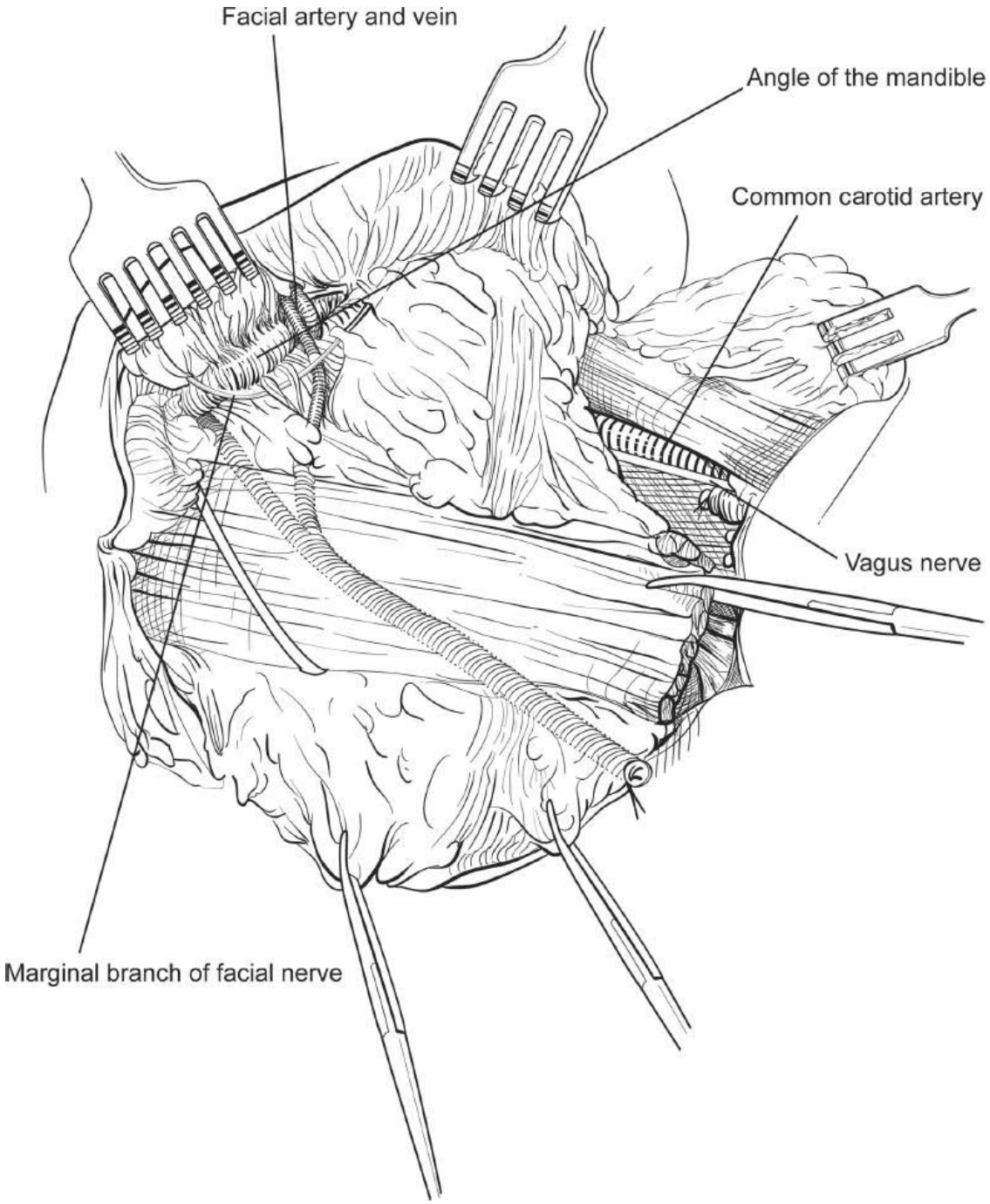

Figure 25.18. Identification of the marginal branch of the facial nerve anterior to the submandibular fascia and superficial to the posterior facial vein.

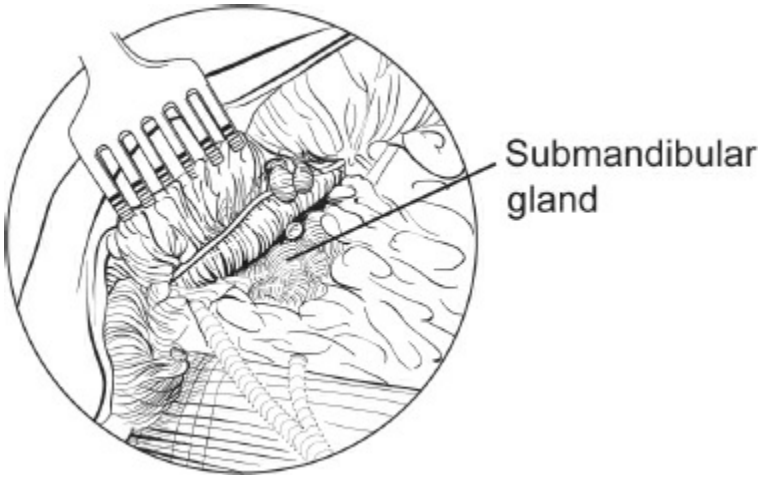

Figure 25.19. Ligation of the posterior facial vein with retraction of its upper stump cephalad to protect the marginal branch of the facial nerve.

The soft tissue from the submental triangle is then dissected off the ipsilateral anterior belly of the digastric muscle, followed by the mylohyoid muscle. The neurovascular bundle to the mylohyoid muscle is identified, divided, and ligated (Fig. 25.20). Several clamps are used to apply gentle traction on the submandibular gland, allowing it to be mobilized from its bed. A loop retractor is placed under the free edge of the mylohyoid muscle, retracting it superomedially. This maneuver allows exposure of the lingual nerve and the secretomotor fibers to the submandibular ganglion. These fibers are divided, taking care to protect and preserve the lingual nerve (Fig. 25.21). Following this, the submandibular duct is dissected, divided, and ligated. Care is taken not to enter the fascia of the hyoglossus muscle as it is in this plane that the hypoglossal nerve is located. The submandibular gland is now retracted laterally and separated from the posterior belly of the digastric muscle. The proximal portion of the facial artery is then identified on the posteromedial aspect of the posterior belly of the digastric muscle. It is divided in clamps and ligated with 3-0 silk (Fig. 25.22).

Following this, the tail of parotid is retracted cephalad, allowing access to the posterior belly of the digastric muscle. Several small pharyngeal veins need to be divided and ligated. After this, the posterior belly of the digastric muscle is retracted cephalad with a deep right-angled retractor. The occipital artery and vein lying superficial to the internal jugular vein are divided and ligated, allowing exposure of the upper end of the internal jugular vein at the base of the skull. The vein is then skeletonized

circumferentially and then doubly ligated with 2-0 silk (Fig. 25.23). The specimen is then able to be delivered.

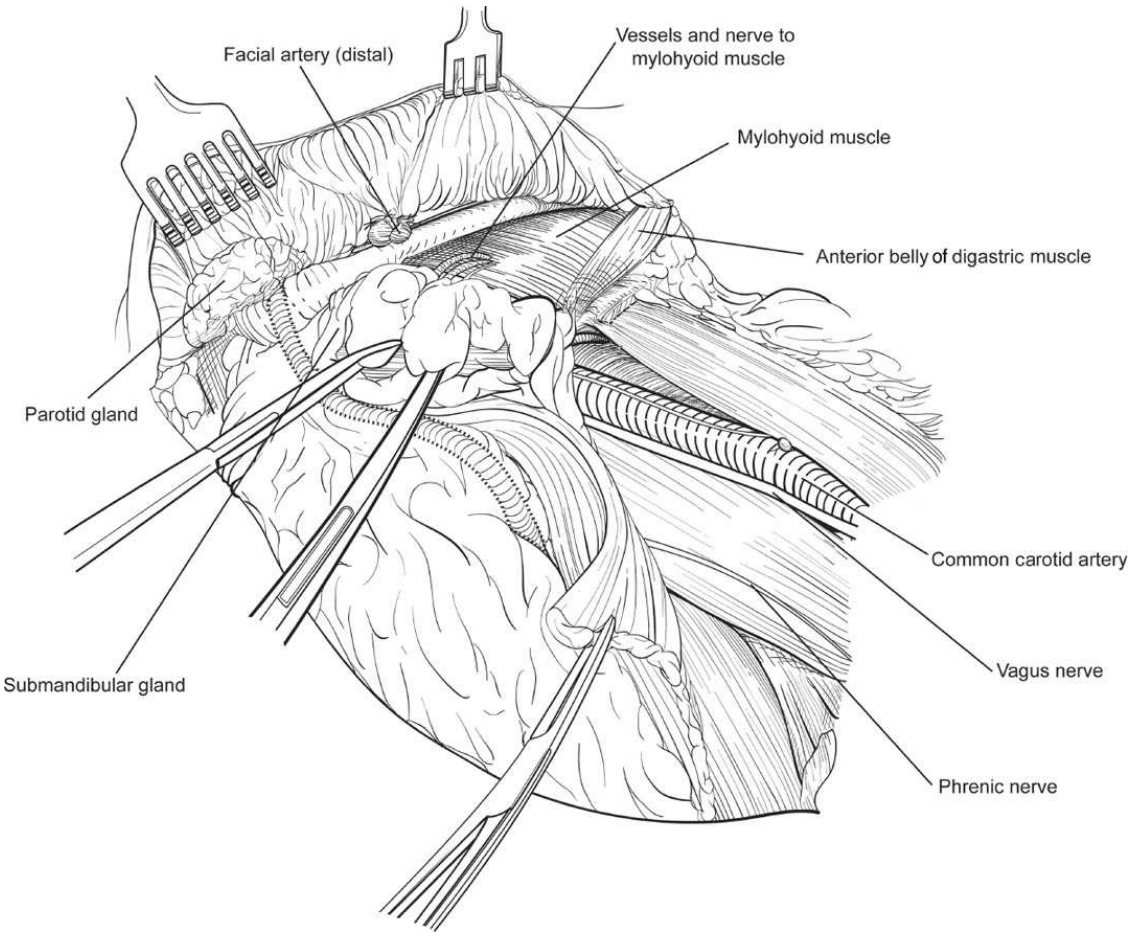

Figure 25.20. The neurovascular bundle to the mylohyoid muscle is identified, divided, and ligated.

Meticulous hemostasis is then secured with ligation or electrocautery and the wound irrigated with a plentiful amount of saline. Large suction drains are inserted through stab incisions in the lower skin flaps (Fig. 25.24). One drain is placed along the anterior border of the trapezius muscle and held in position with a loop of chromic catgut suture. An anterior drain is placed along the strap muscles, medial to the carotid artery, and again secured in place with a loop of chromic catgut suture. Both drains are secured to skin with a purse-string silk suture. The incision is then closed in two layers using 3-0 chromic catgut interrupted sutures for the platysma muscle and 5-0 nylon for skin.

Suction on the drains is maintained while the wound is being closed. An airtight closure is required to ensure adherence between the skin and deep structures of the neck. The drains remain in place for 4 to 7 days and

are removed only once minimal serous drainage is present.

SELECTIVE NECK DISSECTION

Supraomohyoid Neck Dissection (SOHND)

The skin incision used for the SOHND is a transverse incision in a skin crease approximately 2 fingerbreadths below the inferior border of the mandible (Fig. 25.11A). The skin incision is deepened through the platysma muscle with electrocautery. Care is taken to preserve the greater auricular nerve as it courses over the sternocleidomastoid muscle. The superior flap is raised first in the subplatysmal plane. Fascia overlying the submandibular gland containing the marginal branch of the facial nerve is incised, and this layer is raised along with the superior skin flap using blunt-end retractors. Dissection of the submental and submandibular triangles is then carried out in an identical fashion to that described for MRND type I. Dissection then proceeds to level II and III lymph nodes. An inferior skin flap is raised in the subplatysmal plane down to the posterior edge of the sternocleidomastoid muscle laterally and the sternal attachments of sternocleidomastoid muscle inferiorly. A loop retractor is used to retract the inferior flap. Fascia on the anterior border of the sternocleidomastoid muscle is incised, and the fascial attachments between the tail of parotid gland and sternocleidomastoid muscle are dissected, allowing exposure of the posterior belly of the digastric muscle. A large loop retractor is used to retract the sternocleidomastoid muscle laterally, dividing multiple small feeding vessels from the occipital and superior thyroid artery as they enter the sternocleidomastoid muscle.

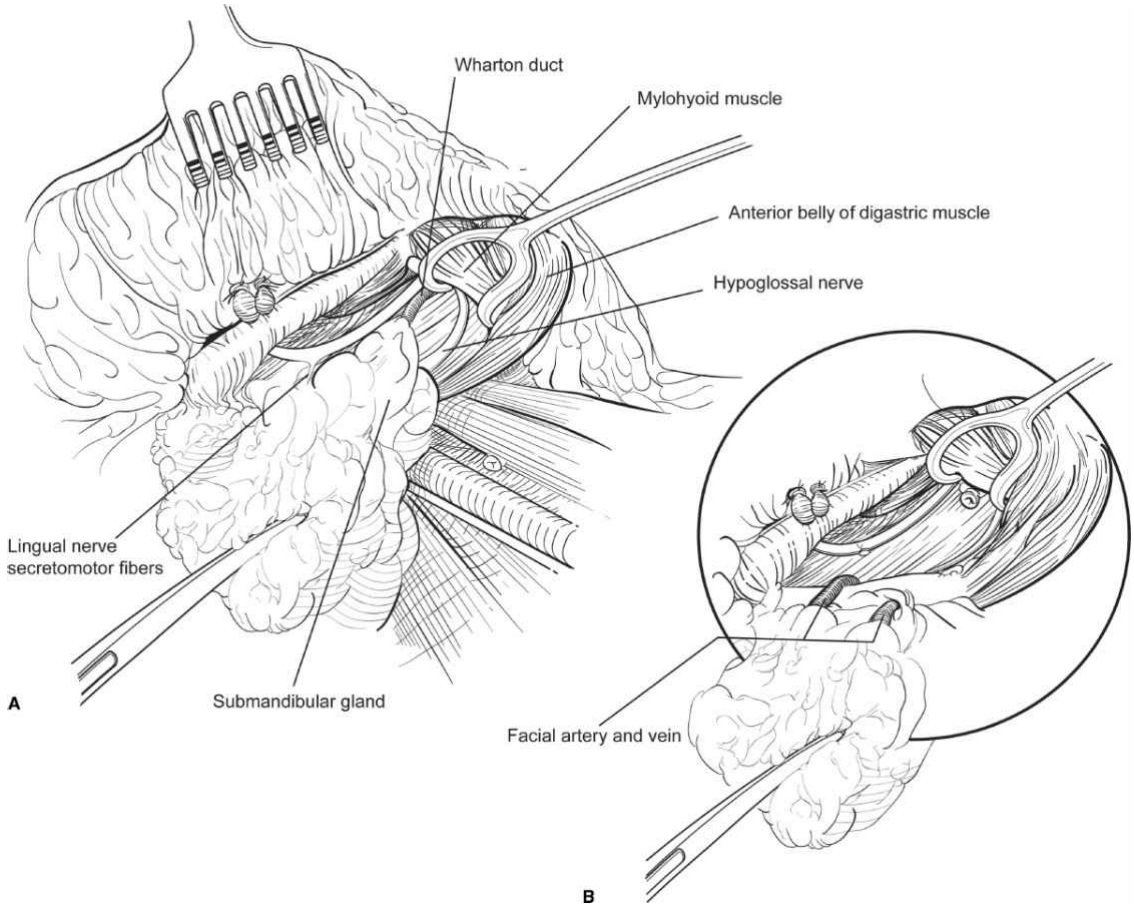

Figure 25.21. Exposure of the lingual nerve and the secretomotor fibers to the submandibular ganglion.

Next, the spinal accessory nerve is identified as it pierces the upper third of the sternocleidomastoid muscle. Using Reynolds scissors, the nerve is dissected out, up toward the proximal end of internal jugular vein and posterior belly of the digastric muscle. The fat pad and lymph nodes lying in level IIb are then carefully dissected out using electrocautery, taking great care not to damage the spinal accessory nerve. This tissue is then passed under the spinal accessory nerve and retracted in a medial direction using a clamp. With the sternocleidomastoid muscle retracted laterally using a Richardson retractor and countertraction on the soft tissue medially, the tissue overlying the cervical plexus of nerves is divided. Clamps are placed on the soft tissue and retracted medially, allowing the underlying nerves from the cervical plexus to be visualized.

Dissection then proceeds in a lateral-to-medial direction in a plane just superficial to these nerves. The lower limit of the dissection is the inferior belly of the omohyoid muscle lying in the inferior aspect of the posterior triangle. The phrenic nerve is then identified on the anterior scalene

muscle and carefully preserved. The carotid sheath fascia is divided, allowing exposure of the vagus nerve, carotid artery, and internal jugular vein. This is best done working from a cephalad-to-caudal direction using the Adson clamp to spread the fascial envelope for division with the electrocautery. Working from a lateral-to-medial direction, the soft tissue encompassing levels II and III lymph nodes is dissected off the internal jugular vein. The anteromedial limit of the dissection is the superior belly of the omohyoid muscle. The junction between this muscle, the sternocleidomastoid muscle, and the internal jugular vein is identified using a loop retractor. The soft tissue containing lymph nodes from the midjugular chain is then retracted in a cephalad direction and dissected off the internal jugular vein and superior belly of omohyoid muscle. Dissection is in a plane just superficial to the superior thyroid vessels. The superior thyroid artery is preserved but the vein needs to be divided and ligated on the medial aspect of the internal jugular vein. Superiorly, the common facial vein is then identified on the medial aspect of the internal jugular vein and divided in clamps and ligated with 3-0 silk. The hypoglossal nerve is identified and tissue lying lateral and inferior to it dissected. Several pharyngeal veins are encountered close to the hypoglossal nerve; these need to be individually ligated with 3-0 silk ties.

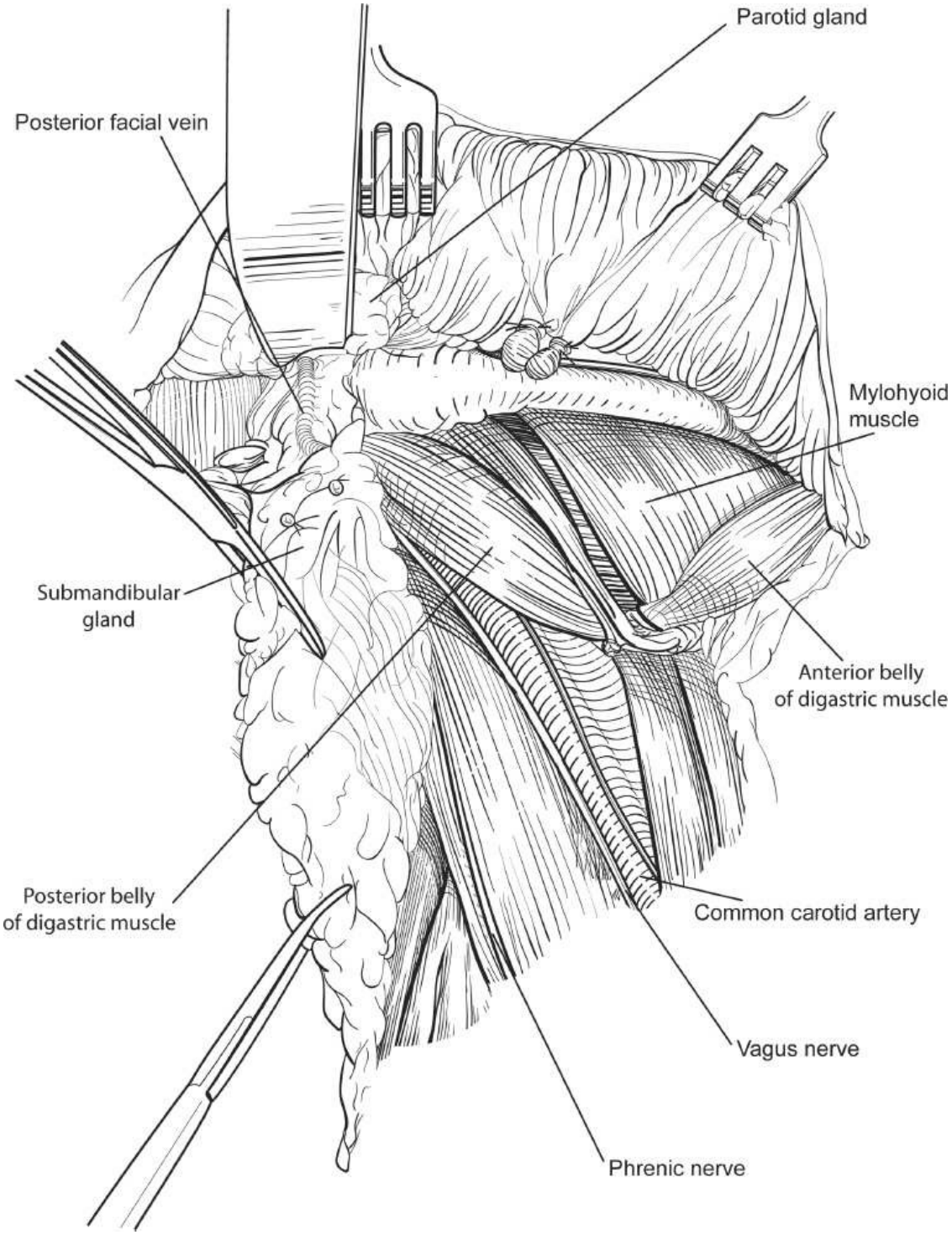

Figure 25.22. Separation of the submandibular gland from the posterior belly of the digastric muscle is achieved by ligating the proximal part of the facial artery.

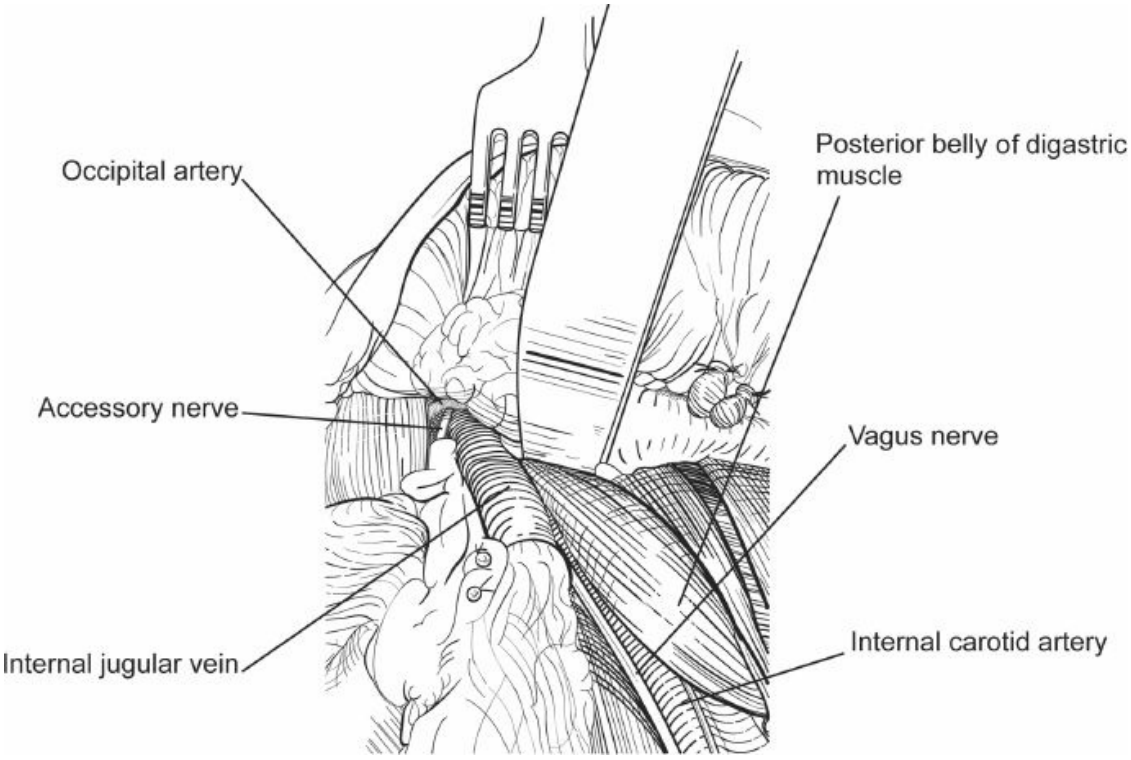

Figure 25.23. Exposure of the upper end of the internal jugular vein.

The specimen encompassing levels I, II, and III is then delivered. The wound is irrigated with saline, hemostasis obtained with electrocautery, and a single suction drain inserted via a separate stab incision and secured to skin with a purse-string suture. The incision is closed in two layers with interrupted 3-0 chromic catgut for the platysma muscle and 5-0 nylon for skin. The resultant functional and cosmetic deformity is insignificant.

Anterolateral Neck Dissection (Jugular Node Dissection)

This dissection is usually carried out as a staging procedure in conjunction with excision of primary carcinoma of the larynx or pharynx in a patient with a neck with clinically negative disease. The operation is now also acceptable for management of the positive neck in patients with metastatic neck disease from HPV-positive oropharynx cancer. This involves dissection of lymph nodes from levels II to IV. The incision is therefore planned according to resection of the primary tumor. This is usually a transverse incision at the level of the thyrohyoid membrane from the posterior border of one sternocleidomastoid muscle to the midline (Fig. 25.11D). Upper and lower skin flaps are raised in the subplatysmal plane. Fascia on the anterior border of the sternocleidomastoid muscle is incised

and elevated medially to expose the underlying jugular lymph nodes. The posterolateral extent of the dissection is the cervical nerve roots as they emerge from the vertebral column. The omohyoid muscle is divided inferiorly to allow dissection of level IV nodes. As in the SOHND, the accessory nerve is identified as it pierces the medial aspect of the sternocleidomastoid muscle and is traced superiorly. Lymph nodes in level IIb superior and lateral to the nerve are dissected as described for the SOHND.

Dissection again proceeds lateral to medial, identifying the anterior scalene muscle, phrenic nerve, and roots of the cervical plexus. The carotid sheath is opened to identify the vagus nerve, carotid artery, and internal jugular vein. Middle thyroid, superior thyroid, and common facial veins on the medial aspect of the internal jugular vein are divided and ligated with 3-0 silk to allow the specimen to be reflected medially. The specimen may be left attached to the primary tumor or may be removed separately. Insertion of drains and wound closure are as described previously.

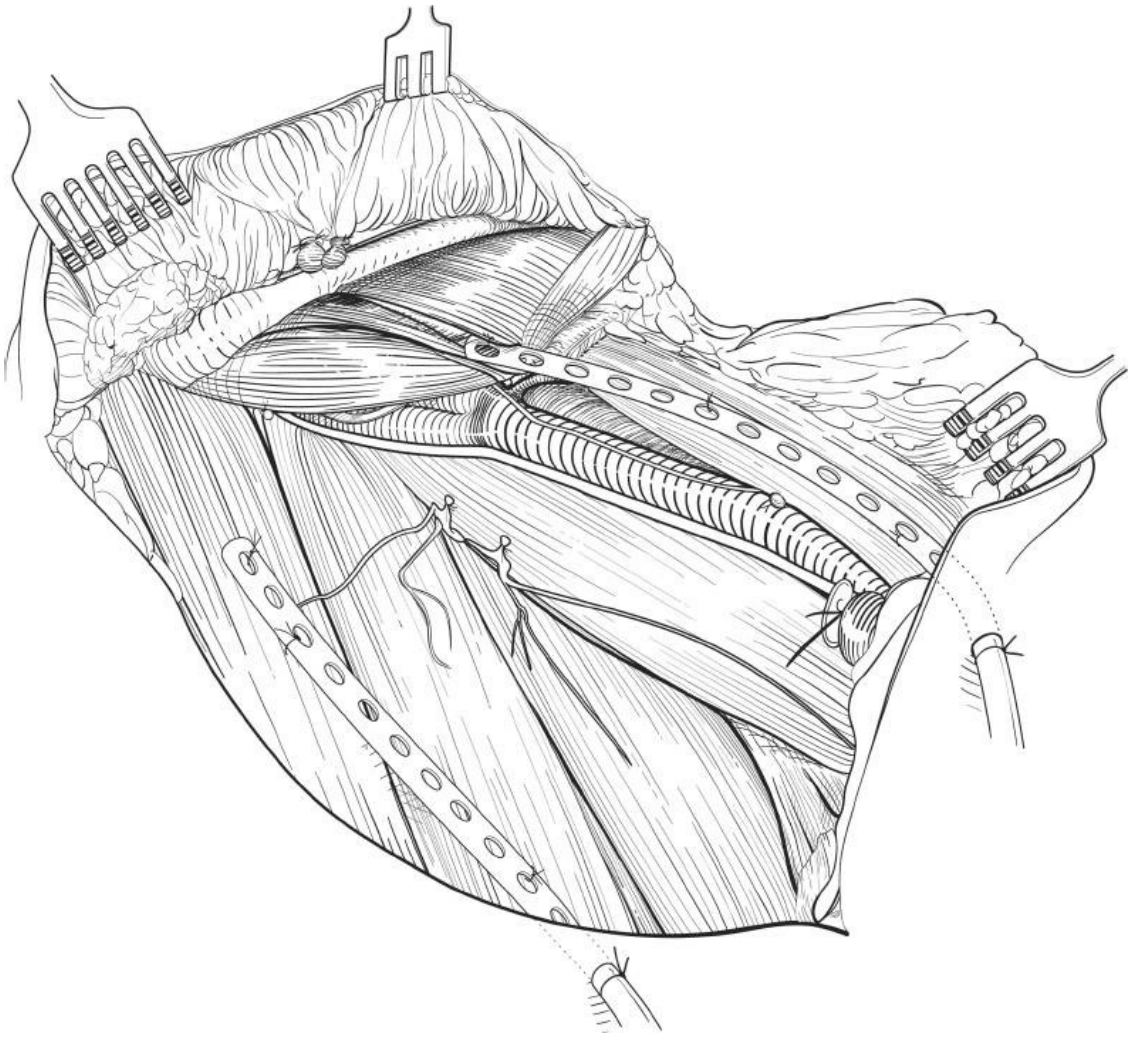

Figure 25.24. Suction drains are inserted through separate stab incisions in the lower skin flaps and positioned as shown.

Posterolateral Neck Dissection

This is carried out for clinically negative neck disease for either melanoma or squamous cell carcinoma of the posterior scalp. It involves the removal of lymph nodes in levels II to V, including the suboccipital and retroauricular lymph nodes. A hockey-stick incision is used, extending from the mastoid tip along the anterior border of the trapezius muscle and then curving anteriorly just superior to the clavicle. An anterior skin flap is elevated in the subplatysmal plane up to the anterior border of the sternocleidomastoid muscle. The spinal accessory nerve is identified in the posterior triangle as described previously and dissected out from the inferior aspect of the trapezius muscle up to the posterior border of the sternocleidomastoid muscle. Dissection of the posterior triangle lymph nodes proceeds as described previously. To dissect out the upper, middle, and lower jugular lymph nodes, the sternocleidomastoid muscle is retracted medially. The fascia of the carotid sheath is divided, identifying the carotid artery, vagus nerve, and internal jugular vein. Dissection of level II to IV lymph nodes proceeds in a caudal-to-cephalad fashion, and the specimen including the posterior triangle soft tissue is delivered. In order to include the postauricular and suboccipital lymph nodes, a lateral extension of the upper end of the skin incision from the mastoid process to the occipital tubercle is carried out. The trapezius muscle is then detached from its nuchal attachment, allowing exposure of lymph nodes in the suboccipital triangle, which are then removed as a separate specimen. Closed suction drains are inserted through a separate stab incision and the wound is closed in layers with 3-0 chromic catgut for the platysma muscle and 5-0 nylon for the skin.

Suggested Readings

Ang KK, Harris J, Wheeler R, et al. Human papillomavirus and survival of patients with oropharyngeal cancer. *N Engl J Med* 2010;363(1):24–35.

Armstrong JG, Harrison LB, Thaler HT, et al. The indications for elective treatment of the neck in cancer of the major salivary glands. *Cancer* 1992;69:615–9.

Armstrong JG, Harrison LB, Spiro RH et al. Malignant tumors of major salivary gland origin. A matched-pair analysis of the role of combined surgery and

postoperative radiotherapy. *Arch Otolaryngol Head Neck Surg* 1990;116:290–3.

Corry J, Peters L, Fisher R, et al. N2-N3 neck nodal control without planned neck dissection for clinical/radiologic complete responders—results of Trans Tasman Radiation Oncology Group Study 98.02. *Head Neck* 2008;30:737–42.

Gillison ML, Koch WM, Capone RB, et al. Evidence for a causal association between human papillomavirus and a subset of head and neck cancers. *J Natl Cancer Inst* 2000;92(9):709–20.

Iyer NG, Dogan S, Palmer F, et al. Detailed analysis of clinicopathologic factors demonstrate distinct difference in outcome and prognostic factors between surgically treated HPV-positive and negative oropharyngeal cancer. *Ann Surg Oncol* 2015;22(13):4411–21.

Klussman JP, Ponert T, Mueller RP, et al. Patterns of lymph node spread and its influence on outcome in resectable parotid cancer. *Eur J Surg Oncol* 2008;34:9320937.

Morton DL, Cagle LA, Wong JH, et al. Intraoperative lymphatic mapping and selective lymphadenectomy: technical details of a new procedure for clinical stage I melanoma. *Presented at the Annual Meeting of the Society of Surgical Oncology.* Washington DC: 1990.

O'Brien CJ. A selective approach to neck dissection for mucosal squamous cell carcinoma. *Aust N Z J Surg* 1994;64:236.

Patel SG, Coit DG, Shaha AR, et al. Sentinel lymph node biopsy for cutaneous head and neck melanomas. *Arch Otolaryngol Head Neck Surg* 2002;128:285–91.

Ross G, Shoaib T, Soutar DS, et al. The use of sentinel node biopsy to upstage the clinically N0 neck in head and neck cancer. *Arch Otolaryngol Head Neck Surg* 2002;128:1287–91.

Shah JP. Patterns of lymph node metastases from squamous cell carcinomas of the upper aerodigestive tract. *Am J Surg* 1990;160:405.

Shaha AR, Shah JP, Loree TR. Risk group stratification and prognostic factors in papillary carcinoma of thyroid. *Ann Surg Oncol* 1996;3:534–8.

Shoaib T, Soutar DS, MacDonald DG, et al. The accuracy of head and neck carcinoma sentinel lymph node biopsy in the clinically N0 neck. *Cancer* 2001;91(11):2077–83.

Tanis PJ, Nieweg OE, van den Brekel MW, et al. Dilemma of clinically node negative head and neck melanoma: outcome of watch and wait policy, elective lymph node dissection, and sentinel node biopsy-a systematic review. *Head Neck* 2008;30:380–9.

Tisell LE, Nilsson B, Molne J, et al. Improved survival of patients with papillary thyroid carcinoma after surgical microdissection. *World J Surg* 1996;20:854–7.

EDITOR'S COMMENT

In this chapter, Drs. Shah and Ganly provide rich historical perspective in addition to a masterful description of the technique of neck dissection, ranging from the comprehensive modified neck dissection to the many varieties of selective neck dissection. In contrast to the measured pace of refinements to the technique of neck dissection, the role of neck dissection in the management of regional disease across the entire gamut of histologies, from squamous cell carcinoma, to cutaneous melanoma, to papillary thyroid carcinoma, is evolving rapidly. As chemoradiotherapy (CRT) has become the cornerstone of the primary treatment of squamous cell carcinoma of the head and neck, there has been great debate as to the appropriate treatment of advanced nodal disease (stage N2 or N3) in these patients. Since up to 40% of patients who undergo neck dissection after CRT have residual disease identified in their cervical nodes and may enjoy a survival advantage from it, some authors have argued for a planned neck dissection after the completion of CRT (Brizel DM, Prosnitz RG, Hunter S, et al. Necessity for adjuvant neck dissection in setting of concurrent chemoradiation for advanced head-and-neck cancer. *Int J Radiat Oncol Biol Phys* 2004;58:1418–23). Yet owing to dramatic improvements in cross-sectional imaging—in particular the combined anatomic and functional imaging offered by a PET-CT scan—other authors recommend an image-guided, response-based approach, reserving neck dissection for only those patients who show an incomplete or equivocal radiographic response (Porceddu SV, Pryor DI, Burmeister E, et al. Results of a prospective study of positron emission tomography-directed management of residual nodal abnormalities in node-positive head and neck cancer after definitive radiotherapy with or without systemic therapy. *Head Neck* 2011;33:1675–82). However, until recently with the publication of the PET-NECK Trial, level I evidence in support of either approach was lacking.

The PET-NECK Trial was a prospective, randomized, controlled trial which sought to compare the clinical usefulness and health economic outcomes of planned neck dissection versus PET-CT–guided surveillance in patients with squamous cell carcinoma of the head and neck and nodal stage N2 or N3 disease who received CRT as primary treatment (Mehanna H, Wong WL, McConkey CC, et al. PET-CT surveillance versus neck dissection in advanced head and neck cancer. *N Engl J Med* 2016;374:1444–54). Specifically, they assessed the noninferiority of PET-CT–guided surveillance, performed 12 weeks after the end of CRT (with neck dissection performed only if PET-CT showed an incomplete or equivocal response), to planned neck dissection, and the primary endpoint was overall survival. From 2007 to 2012, a total of 564 patients were recruited from 37 centers in the United Kingdom. A total of 84% of the patients had oropharyngeal cancer, and 75% had tumor specimens which stained positive for the p16 protein, indicating that the HPV had a role in the

causation of the cancer. At a median follow-up of 36 months, the 2-year overall survival rate was 84.9% in the PET-CT surveillance group and 81.5% in the planned surgery group, indicating that surveillance was not inferior to planned neck dissection. Further, PET-CT surveillance resulted in fewer neck dissections (54 vs. 221)—and thus fewer complications—than seen in the planned neck dissection group, as well as a savings of approximately $2190 per person over the duration of the trial.

The desire to limit unnecessary neck dissections brings me to the topic of SLNB for squamous cell carcinoma of the head and neck. Note that approximately 50% of patients with oral squamous cell carcinoma present with early-stage disease, and the main prognostic factor is occult lymph node metastasis in the neck, which is present in some 20% to 30% of patients. For many years, elective neck dissection has been the gold standard treatment for these patients, but such a strategy results in the overtreatment of at least 70% of patients, as well as considerable morbidity. In a meta-analysis of 66 studies evaluating the diagnostic efficacy of SLNB in early (T1–2) oral squamous cell carcinoma, Liu et al. reported an SLN identification rate of 96.3%, a pooled sensitivity of 0.87, and a pooled negative predictive value of 0.94 (Liu M, Wang SJ, Yang X, et al. Diagnostic efficacy of sentinel lymph node biopsy in early oral squamous cell carcinoma: a meta-analysis of 66 studies. *PLOS One* 2017;12:e0170322). The authors concluded that SLNB is an ideal alternative to elective neck dissection in patients with early-stage oral squamous cell carcinoma.

Similar to that seen with oral squamous cell carcinoma, SLNB is able to accurately identify early nodal metastatic disease in primary cutaneous melanoma of the head and neck, and lymph node status is the strongest prognostic factor for these patients. For patients with a positive SLNB, the standard of care is completion lymph node dissection (CLND), though only 14% of patients will have additional positive nodes found at CLND (de Rosa N, Lyman GH, Silbermins D, et al. Sentinel node biopsy for head and neck melanoma: a systematic review. *Otolaryngol Head Neck Surg* 2011;145:375–82). This then begs the question of whether to routinely pursue a CLND in all patients with a positive SLN, especially for those patients with a very low volume of metastatic disease in the SLN (i.e., size of tumor deposit <0.2 mm), in which case the likelihood of identifying additional metastatic disease in the nonsentinel lymph nodes is almost certainly less than 10%. Though the current standard of care is to offer all patients with a positive SLNB a CLND, given the low likelihood of finding additional disease in the nonsentinel nodes and the questionable survival benefit conferred by a CLND, many surgeons have increasingly moved away from offering a CLND to patients with cutaneous melanoma of all primary sites, including those of the head and neck (Kingham TP, Panageas KS, Ariyan CE, et al. Outcome of patients with a positive sentinel node who do not undergo completion lymphadenectomy. *Ann Surg Oncol* 2010;17:514–20). We eagerly await the results of the MSLT-2 trial to determine

the wisdom of this approach. Importantly, for those patients with head and neck melanoma who do undergo CLND, the majority of positive nonsentinel nodes are found either within or immediately adjacent to the nodal level containing the SLN (Gyorki DE, Boyle JO, Ganly I, et al. Incidence and location of positive nonsentinel lymph nodes in head and neck melanoma. *Eur J Surg Oncol* 2014;40:305–10).

As transoral robotic surgery (TORS) has gained increasing popularity in the surgical treatment of thyroid and head and neck cancers (particularly oropharyngeal cancer), some surgeons have naturally extended the use of the robot to perform neck dissections. Song et al. recently compared their outcomes with robotic selective neck dissection (SND, ≥3 levels of II–V) with total thyroidectomy by a gasless unilateral axillary (GUA) approach versus the conventional transcervical SND with total thyroidectomy in the treatment of papillary thyroid cancer (Song CM, Ji YB, Sung ES, et al. Comparison of robotic versus conventional selective neck dissection and total thyroidectomy for papillary thyroid carcinoma. *Otolaryngol Head Neck Surg* 2016;154:1005–13). Compared with the conventional group (n = 41), patients in the robotic group were younger and more likely to be female. Not surprisingly, mean total operative time was longer in the robotic group than in the conventional group (298 vs. 236 minutes), but postoperative cosmetic satisfaction was superior in the robotic group. There were no differences in the rate of complications or in the number of harvested lymph nodes between the groups. Importantly, however, there was a significantly higher incidence of anterior chest wall pain and paresthesia in the robotic group for as long as 1 month after the procedure, perhaps due to the large dissected flap and tension on the flap due to the retraction necessary to complete the robotic procedure. In the end, the authors concluded that for those patients concerned about cosmesis and thus the desire to avoid a surgical scar in the neck, that the robotic approach to thyroidectomy and neck dissection is a reasonable one. We will no doubt hear a lot more about robotic surgery in the treatment of head and neck cancer in the years to come.

John T. Mullen

26 Congenital Lesions: Thyroglossal Duct Cysts, Branchial Cleft Anomalies, and Cystic Hygromas

Juan P. Gurria and Jaimie D. Nathan

Congenital lesions of the neck are the anatomical result of abnormal development of or persistence of immature embryonic structures through gestation. Their clinical manifestation varies from a nodule to a mass and from a skin pit to a sinus. The varying presentations are well defined and include thyroglossal duct cysts, branchial cleft anomalies, and lymphatic malformations. Prompt diagnosis and early identification along with appropriate workup and detailed surgical treatment are the key in the treatment of these congenital lesions. It is important to fully understand the embryologic differentiation of the structures of the neck to adequately plan a surgical therapy that correctly includes the tissues from which the structure is originating in order to prevent recurrence. These tissues can include midline abnormalities, as well as cartilaginous and branchial arch and cleft remnants.

THYROGLOSSAL DUCT CYST

Etiology and Pathophysiology

Thyroglossal duct cyst is one of the most common lesions in the midline of the neck and is found in around 7% of the population. It results from a remnant structure of the median thyroid anlage as it descends to a caudad position during the 3rd gestational week to fuse with the lateral thyroid anlage. During its descent into the neck, it passes most commonly through the hyoid bone process as it develops from the second branchial arch, and this represents a key factor during surgical resection. The thyroid diverticulum develops at the foramen cecum and remains connected to it as it descends. During weeks 4 to 8 of gestation, the thyroid gland develops and finds its final position in the neck, and it is by this time that the thyroglossal duct and its connection to the tongue usually obliterate.

When there is lack of obliteration of these structures, an abnormal structure can be located anywhere along its migratory course (Fig. 26.1). The tissue that forms during this process is lined with secretory epithelium that matures into a cyst once the epithelium becomes activated.

Clinical Presentation

The majority of thyroglossal duct cysts are diagnosed during the first decade of life, and over two thirds of the anomalies are diagnosed within the first 30 years of life creating a common encounter for the pediatric surgeon. The classic finding of this lesion is a midline structure at or just below the level of the hyoid bone (Fig. 26.2). It typically presents as a painless mass that moves with swallowing due to its remnant connection to the base of the tongue. The cyst may be found anywhere from the base of the tongue to a position behind the sternum and can sometimes present as a painful swollen erythematous mass if it has become infected.

Physical examination can be the only tool needed for diagnosis and should include a thorough evaluation of the mouth, tongue, neck, and lymph node basins. Specific examination of the mass is critical, as protrusion of the tongue and swallowing typically elicit vertical displacement of the cyst. The cyst is soft and nontender with smooth edges, and it is easily delineated from other structures. Because of its connection to the base of the mouth, thyroglossal cysts can become infected with oral flora and almost one third of patients will present with an infected cyst.

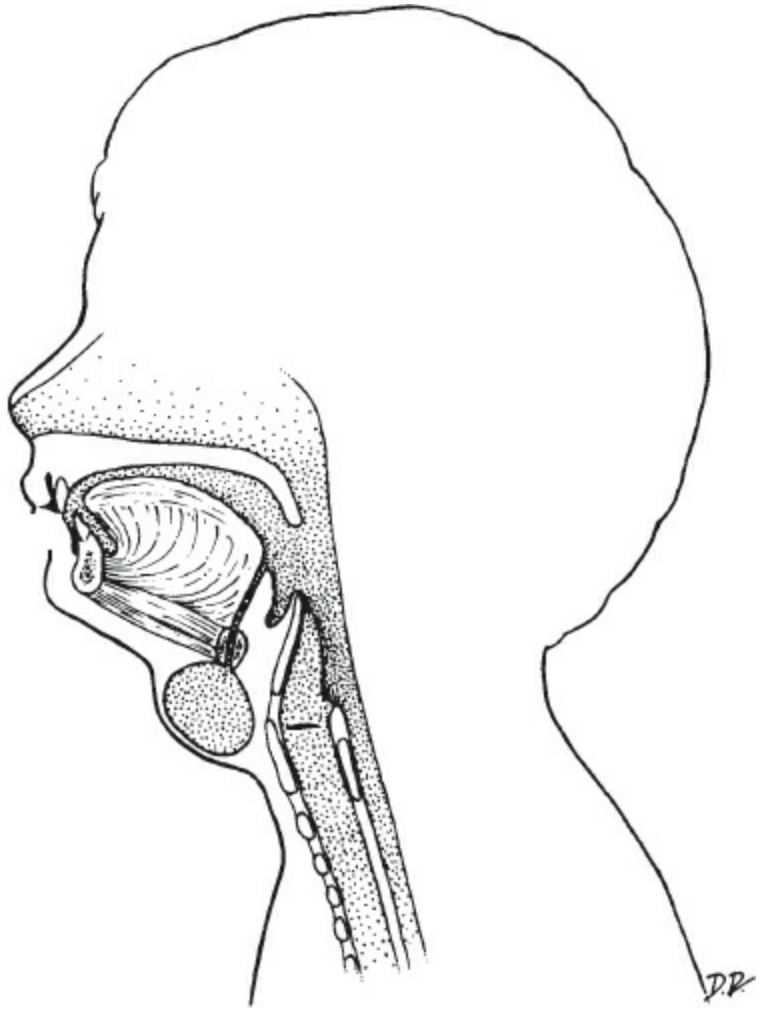

Figure 26.1. Thyroglossal duct cyst anterior to the hyoid bone with the thyroglossal duct tract passing through the hyoid bone and extending to the foramen cecum.

Indications and Contraindications

Surgical resection is indicated when a thyroglossal duct cyst is suspected and/or diagnosed after a thorough history and physical examination. Prior to operation, it is important to evaluate the thyroid function of the patient and perform additional imaging if results reflect hypothyroidism to exclude a median ectopic thyroid. Importantly, the presence of normal thyroid gland apart from the cystic structure must be confirmed, either by physical examination or by ultrasound study. There have been some documented cases of a thyroglossal duct cyst containing the only thyroidal tissue present in the patient, and in such circumstances, resection would cause permanent hypothyroidism. The incidence of ectopic thyroid tissue near the duct ranges from 10% to 40%. Surgical excision is recommended when a thyroglossal duct cyst is encountered to avoid both the potential

complication of infection and the less than 1% risk of developing malignancy within the cyst.

Preoperative Planning

History and physical examination will establish findings of uncomplicated versus infected thyroglossal duct cyst and will aid in ruling out thyroid gland abnormalities and malignancy. Ultrasonography is useful as the preoperative imaging modality of choice to evaluate the characteristics of the mass, to document the presence of normal thyroid gland, to rule out ectopic thyroid tissue, and to sample any abnormal tissue concerning for malignancy. Approximately 1% to 2% of patients with thyroglossal duct cysts will harbor their only thyroid tissue within this mass. The patient who presents with evidence of an infected thyroglossal duct cyst should be treated with needle aspiration of the cyst and antibiotic therapy directed against oral flora, prior to definitive surgical excision. Infected cysts managed with appropriately staged surgical excision 6 to 8 weeks following aspiration and antibiotic therapy can be resolved with an acceptably low recurrence rate, although recurrence risk is higher than in patients without prior history of infection.

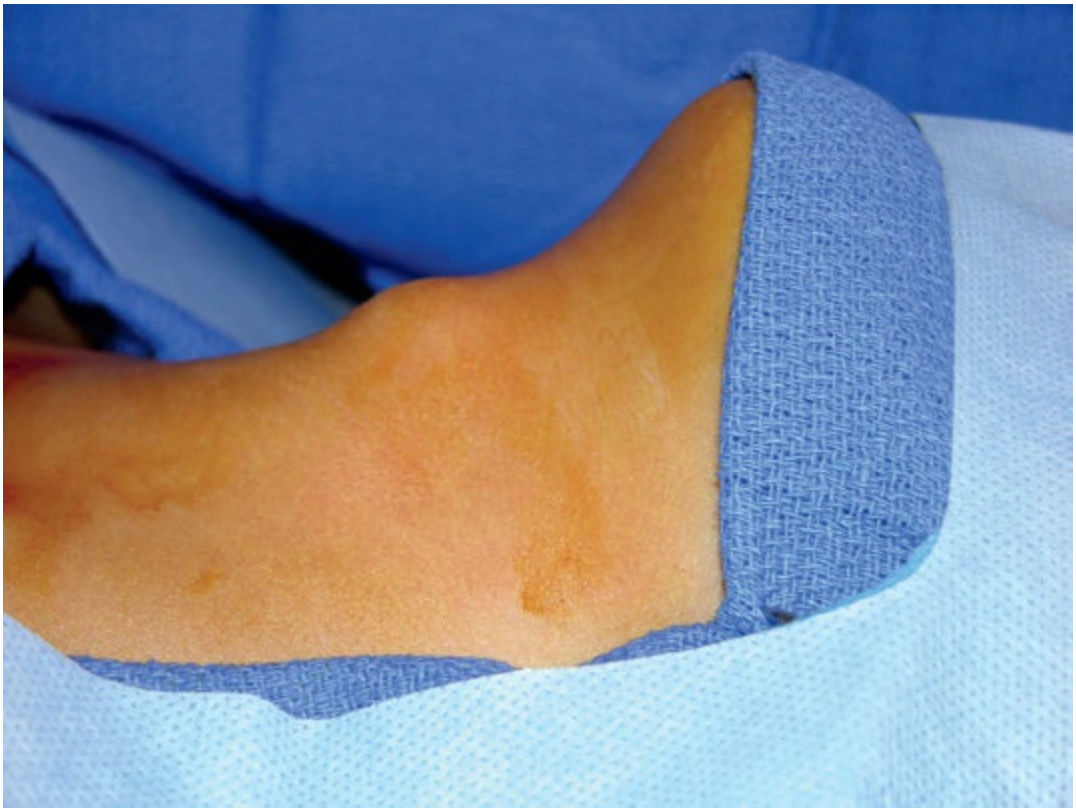

Figure 26.2. Photograph of a thyroglossal duct cyst.

Surgical Technique

Thyroglossal duct cysts are managed by elective surgical resection with the Sistrunk procedure with a recurrence rate of less than 5%. The procedure commences by placing the patient in the supine position with the neck slightly hyperextended. The addition of a back roll depends on the morphology of the patient and surgeon preference. Preoperative antibiotics should be administered covering both skin and oral flora. Methicillin-resistant *Staphylococcus aureus* (MRSA) should be covered if the patient has history of prior positive testing. A transverse incision is made in the skin overlying the cyst (Fig. 26.3), and the cyst is exposed by dissecting meticulously around the capsule with electrocautery. The duct is identified in a posterior and superior position to the cyst wall. Dissection is carried cephalad along the tissue surrounding the duct, including any accessory ducts thus minimizing the likelihood of recurrence, until the hyoid bone is reached. When a duct cannot be identified leading toward the hyoid bone, this suggests that the lesion is likely a dermoid cyst rather than a thyroglossal duct cyst. The muscle on both the superior and inferior edges of the hyoid bone is divided with electrocautery, and a bone cutter or angled scissors is used to transect the hyoid to remove a 1 to 1.5 cm segment of the central portion of the bone containing the duct (Fig. 26.4). The dissection continues cephalad to the base of the tract at the floor of the mouth. The duct and surrounding tissues are suture-ligated and divided at the foramen cecum (Fig. 26.5), and the specimen is removed. The dissection at this level may be made easier by inserting a gloved hand into the mouth to identify the most cephalad limit of the dissection. The wound is closed in layers with absorbable suture. The routine use of drains is unnecessary and not recommended.

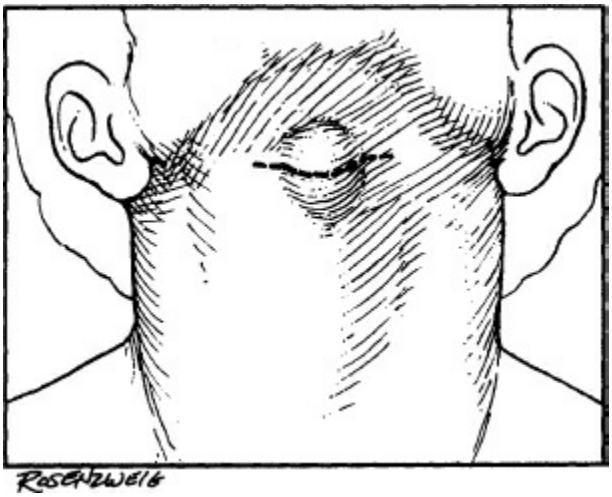

Figure 26.3. Thyroglossal duct cyst—technique of excision. Skin incision is made over the presenting cyst. No skin is excised.

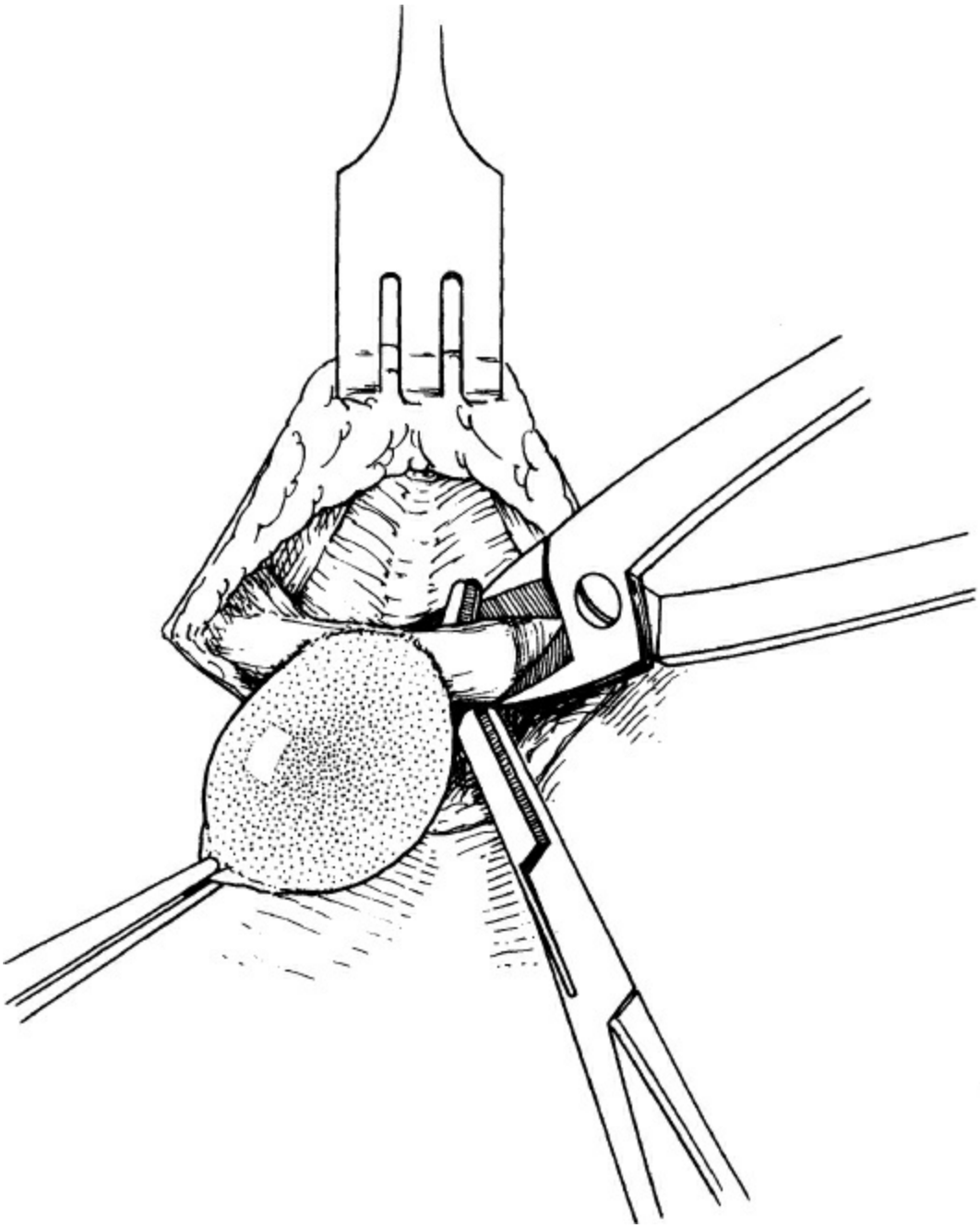

Figure 26.4. Thyroglossal duct cyst—technique of excision. The thyroglossal duct cyst has been dissected from surrounding tissues. The hyoid is exposed after division of the sternohyoid and thyrohyoid muscles at insertion. The bone is encircled with a short right-angle clamp 1 cm from its midpoint, where it is divided with a bone cutter or electrocautery.

Postoperative Care, Complications, and Their Management

The procedure can be performed as an elective operation on an outpatient basis. Diet can be started after the procedure and pain controlled by oral medications. Any procedure in the neck can have potential risk of airway compromise should a postoperative hemorrhage develop. While this complication is extremely rare, meticulous hemostatic dissection should be achieved during the procedure.

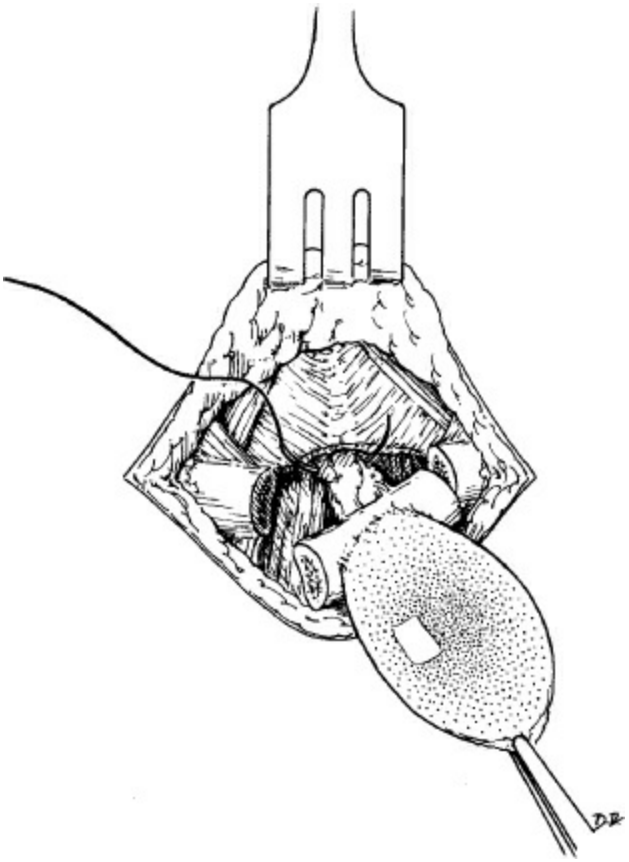

Figure 26.5. Thyroglossal duct cyst—technique of excision. Dissection proceeds cephalad to the foramen cecum where the tract and investing tissues are suture-ligated.

Dissection that violates the floor of the mouth or the tongue should be reapproximated with absorbable suture as part of a layered closure.

Outcomes

The risk of recurrence with complete excision including the central hyoid bone is low, approximating 2% to 5%, and usually manifests within the first year after operation with inflammation and sometimes drainage from the prior incision in the anterior neck. The recurrence risk is increased in patients who had an infection prior to initial resection or if the central

segment of the hyoid bone was left in place. The approach for this complication is to control the inflammatory process and infection with antibiotic therapy, followed by surgical re-excision. Reoperation should include wide excision of the previous incision and the inflamed tissue, a generous central hyoid bone resection, and excision of a core of tongue base musculature.

BRANCHIAL CLEFT ANOMALIES

Etiology and Pathophysiology

During the 4th and 5th gestational weeks, the head and neck structures develop from the branchial (or pharyngeal) arches, which consist of mesenchymal tissue bands separated by recesses known as pharyngeal clefts. Each arch is composed of muscle and cartilaginous components, as well as an artery and a cranial nerve. The pharyngeal clefts form on the outer ectodermal surface of the neck and line up with the pharyngeal pouches, which form on the inner endodermal surface. Any arrest in the embryologic process or failure of completion of the obliteration of these branchial clefts and pouches by mesenchyme will result in anatomical anomalies. Abnormalities of this complex structural process result in approximately 30% of congenital neck masses, and can present as cysts, cartilaginous remnants, sinuses, or fistulae.

It is critical to understand the anatomic patterns created by each of the arches and their relationships to neck structures. This will help predict the location of its associated abnormality. The different anomalies will be classified by the cleft or pouch of origin determined by the site of internal opening of the future sinus and its relationship to arteries, nerves, or muscles of the neck. These anomalies have contributions from clefts, arches, or pouches, and their presentation will differ depending on the site of failure. A sinus results from incomplete obliteration of a pharyngeal arch with communication with either the skin or mucosa. Failure of obliteration of both the cleft and the pouch will lead to a continuous communication between the mucosa and the skin, resulting in a branchial fistula. A cyst results from a pharyngeal cleft that forms an epidermis-lined cavity without the presence of a communication. Sinuses and fistulae will usually be lined by respiratory epithelium, whereas cysts will typically be lined by squamous epithelium.

The first branchial arch develops into structures of the middle ear and the facial nerve, leading to first branchial cleft anomalies that present as

either draining fistulae in the preauricular or postauricular areas, or as a fistulous tract or cysts near the facial nerve with involvement of the parotid gland in some circumstances. The second branchial arch forms the hyoid bone and the tonsillar and supratonsillar fossas, and anomalies arising from the second branchial cleft represent the most common branchial anomalies. Second cleft anomalies are located along the sternocleidomastoid muscle in the lateral aspect of the neck, and its associated fistulous tract usually enters the supratonsillar fossa. The third and fourth pouches form the inferior pharynx, and their anomalies will typically connect with the pyriform sinus. An externally seen cyst or a sinus will be located at the lower anterior border of the sternocleidomastoid muscle. These sinuses can course through the thyroid gland and can present as the cause of suppurative thyroiditis. Cysts and sinuses from the third branchial cleft are uncommon. Fourth branchial fistulae and cysts are also unusual and can present anywhere in the lower neck or upper mediastinum.

Clinical Presentation

In childhood, complete fistulae are more common than sinuses, and sinuses are more common than branchial cysts, unlike adults in which cysts are more commonly diagnosed due to absence of obvious drainage. All branchial remnants are congenital and are present at birth, and most are discovered within the first decade of life. Sinuses and fistulae are often found at birth due to obvious drainage. Cartilaginous remnants are usually palpated early in life, and cysts will commonly be found later in childhood. Up to one third of cases will present with signs and symptoms of infection with associated spontaneous mucous drainage along the edge of the sternocleidomastoid muscle. Overall, approximately 70% to 95% of cases are derived from the second pharyngeal arch structures with approximately 10% to 20% arising from first arch anomalies. The remaining lesions come from third and fourth pharyngeal arches.

A thorough clinical history and physical examination will help obtain an accurate diagnosis of branchial cleft anomalies and other abnormalities of the neck. Cysts and obstructed fistulae or external sinuses can present with infection. Skin tags or cartilage remnants commonly flag cutaneous openings harboring a sinus or a fistula. The tracts can be palpable with hyperextension of the neck as a cord-like structure, and usually mucoid drainage can be obtained with gentle compression of the tract.

Indications and Contraindications

A branchial cleft remnant should be surgically resected completely after a thorough investigation of its origin and contents. When the lesion presents with an acute infection, needle aspiration and antibiotics should be used before the excision, which should be delayed for 6 to 8 weeks. Debate exists for asymptomatic patients about the timing for surgery. Some surgeons prefer to excise the lesion upon diagnosis even in the neonatal period. Others advocate waiting until the child reaches 2 to 3 years of age. Both approaches are acceptable; however, waiting entails the risk of developing recurrent infections that will increase the risk of recurrence after surgical excision. Up to 20% of the lesions have been infected prior to excision. The surgeon should balance the risk of waiting, with the challenge of protecting vital structures during dissection on infants. General consensus suggests that dissection may be easier when the patient reaches 1 year of age.

Preoperative Planning

If a sinus or fistula tract is suspected but cannot be identified, upper endoscopy should be performed, and a third or fourth branchial cleft fistula can be identified entering the pyriform sinus. The tonsillar fossas should also be examined. A small feeding catheter can be used to cannulate the ostium and assist with the excision of the tract. Cysts can be more difficult to diagnose since they can be located near the edge of or under the sternocleidomastoid muscle. Although ultrasonography and magnetic resonance imaging (MRI) are useful in the evaluation of these lesions, computed tomography (CT) scanning is the imaging modality of choice for localization and for identification of the course of fistulous tracts in order to map the surgical resection. CT scanning can diagnose and delineate nearly 80% of sinus and fistula tracts.

Remnants of the second branchial cleft are the most common anomalies. Cysts represent about 65% of these lesions, and present as a lateral neck nodule adjacent to the sternocleidomastoid muscle (Fig. 26.6). It is important to rule out other neck masses, such as an enlarged lymph node, dermoid cyst, or lymphatic malformation. Sinuses represent about 30% of anomalies of the second branchial cleft. The tract of this sinus will pass between the internal and external carotid arteries just adjacent to the glossopharyngeal and hypoglossal nerves to finally reach the pharynx and tonsillar fossa (Fig. 26.7). For third and fourth cleft anomalies, endoscopy

and direct laryngoscopy should be performed prior to excision.

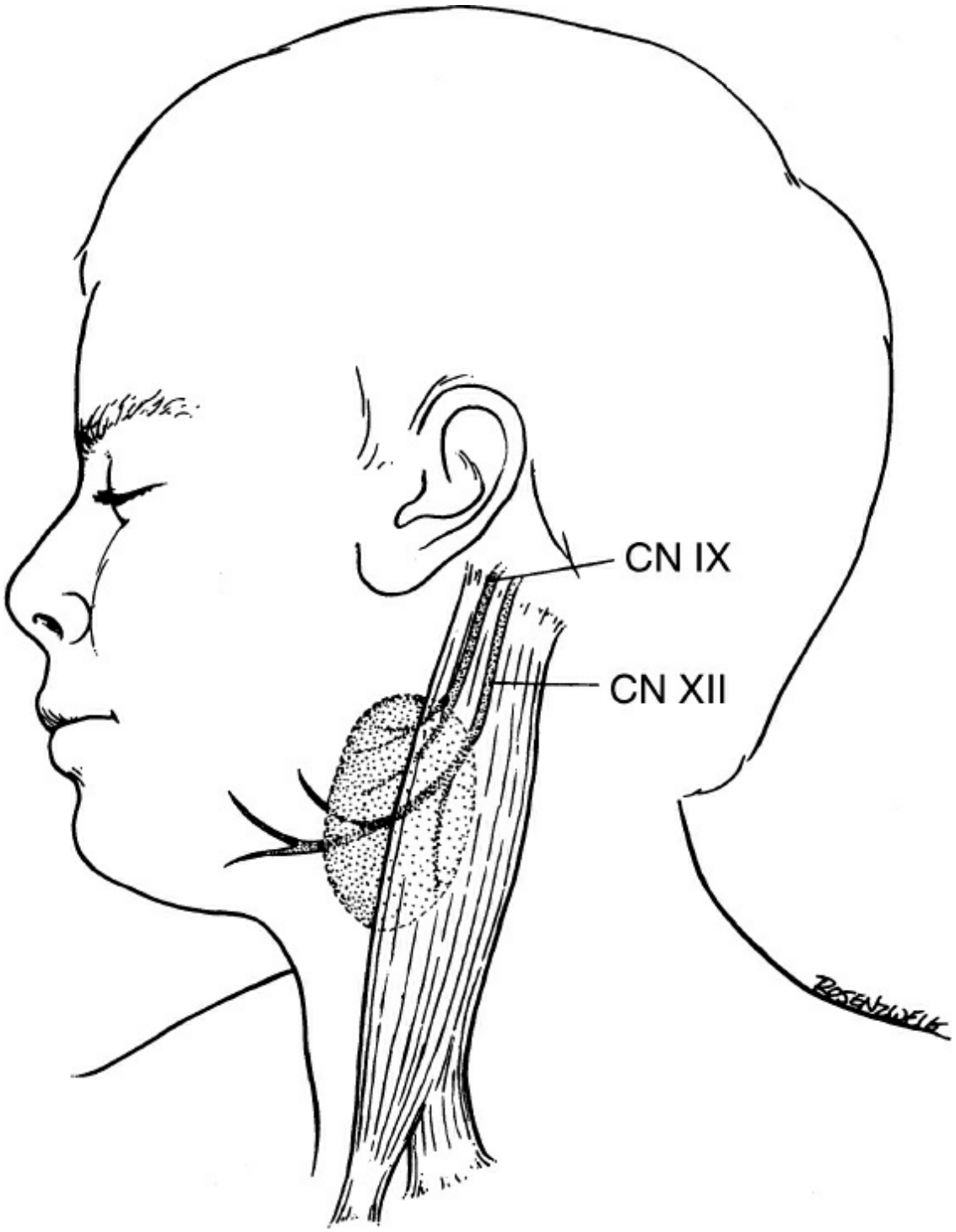

Figure 26.6. Typical location of a second branchial cleft cyst. The cyst is at the level of the carotid bifurcation. No external opening is present. Note the relationship to regional nerves. CN, cranial nerve.

Surgical Technique

Surgical resection is performed under general anesthesia, and perioperative antibiotics should be administered. The patient is positioned in the supine position with the head slightly tilted toward the opposite side of the lesion. An elliptical incision is made around the ostium previously identified with a lacrimal duct probe (Fig. 26.8). Dissection is carried deep to the cervical fascia from the inferior border of the incision so that the tract is identified from below to avoid transection. A small clamp or traction silk sutures are used as a handle to facilitate identification of the tract while precise sharp dissection with fine scissors or electrocautery is performed. Once dissection is carried cephalad enough that the tract can no longer be easily followed, a "ladder" counter incision higher in the neck is created and the tract is transposed cranially and exteriorized through it (Figs. 26.9 and 26.10). Dissection continues cephalad between the bifurcation of the carotid artery behind the posterior belly of the digastric and stylohyoid muscles, and in front of the hypoglossal nerve until the tonsillar fossa is reached in the pharynx. At this point, the fistulous tract should be resected and suture-ligated at its base with absorbable suture (Fig. 26.11). The incision is closed in layers with absorbable sutures. There is no need to use drains if resection is complete. Patients can usually be discharged home the same day.

First cleft anomalies are associated with facial deformities, including cleft lip and palate and internal and external ear abnormalities, and the lesions can present anterior or posterior to the earlobe or in a submandibular position. Resection often requires partial facial nerve dissection, superficial parotidectomy, and external auditory canal and middle ear dissection that often require staged procedures and require otolaryngology expertise and will not be described in this chapter.

Second branchial cleft cysts do not usually have a skin opening and should be excised via a transverse skin incision without entering the cavity to avoid recurrence. Of note, these lesions can be bilateral in up to 15% of patients.

Third and fourth cleft anomalies are removed in a similar fashion The associated fistulous tract can sometimes course through the thyrohyoid membrane to enter the pyriform sinus or through the thyroid gland and will require partial resection of the thyroid cartilage and thyroid lobectomy to achieve complete resection.

Postoperative Care, Complications, and Their Management

Patients can usually be discharged home the same day after surgery. The most common complications include infection that will require antibiotic treatment; bleeding that, despite being rare, in extreme cases requires operative intervention to protect the airway; injury to associated or nearby structures; and recurrence that will require re-intervention once diagnosed.

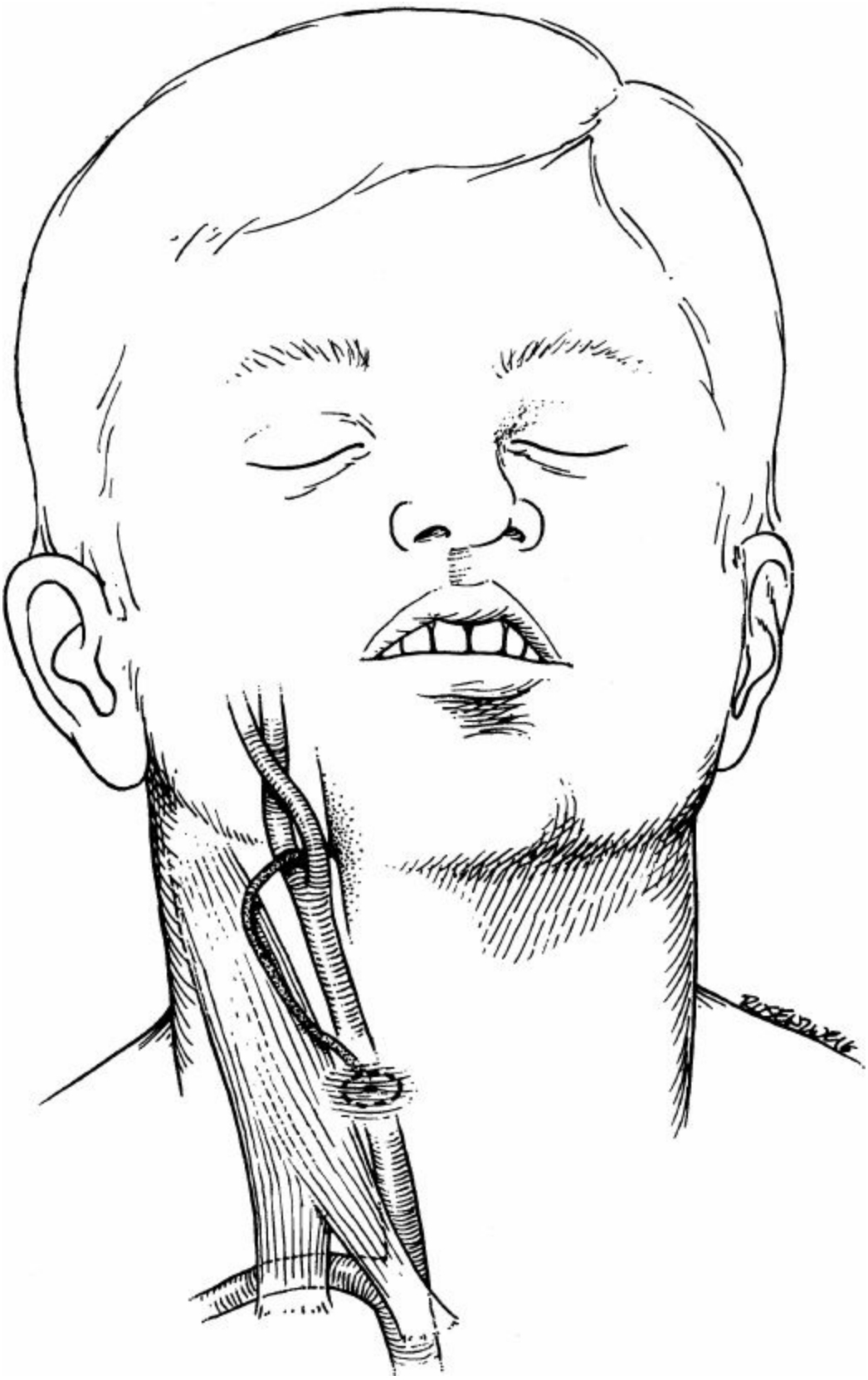

Figure 26.7. Course of a second branchial cleft fistula. The external ostium is at the anterior border of the sternocleidomastoid muscle. The fistula passes between the internal and external carotid arteries and enters the pharynx at

the tonsillar fossa.

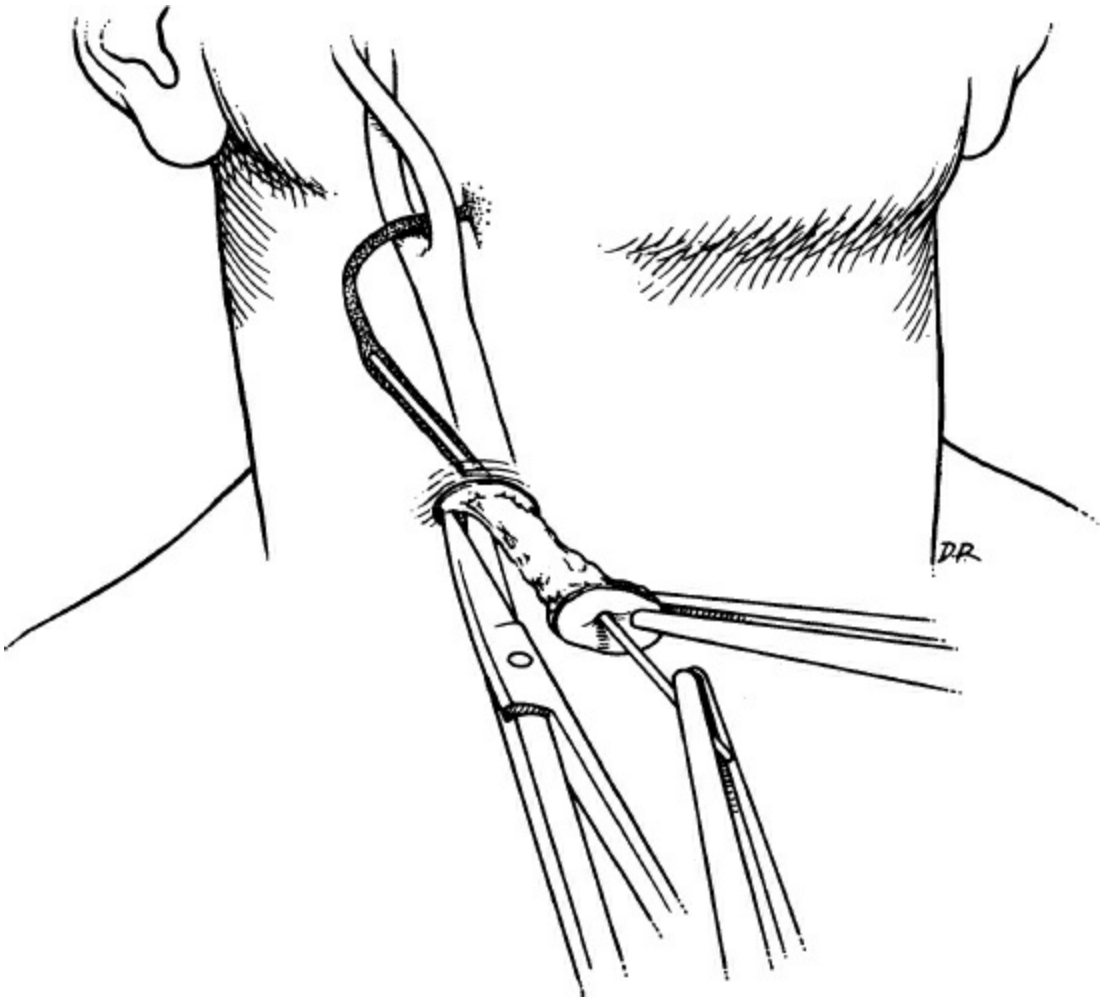

Figure 26.8. Technique of excision of second branchial cleft fistula. The skin ostium is incorporated in the elliptical incision. Note the lacrimal duct probe in the tract to facilitate its dissection.

Outcomes

Incidence of recurrence is overall low. Rate is increased in lesions that presented initially infected and were treated with incision and drainage, antibiotics, and staged excision. Recurrence is more frequent following resection of lesions arising from the first branchial cleft, probably due to incomplete removal due to its association with the facial nerve and parotid gland.

LYMPHATIC MALFORMATIONS

Etiology and Pathophysiology

The lymphatic system forms from lymph sacs present throughout the body, rich in endothelial cells, that merge into ducts to form a complex system that brings extravascular fluid back to the circulation in the form of lymph. During development, the lymphatic channels separate from blood vessels after a common embryonic derivation. A lymphatic malformation will occur when there is failure of the lymphatic vessels to fuse into complete channels. They originate from sequestration of lymphatic tissue from lymphatic sacs that fail to communicate with other channels.

Clinical Presentation

Most congenital lymphatic malformations present as painless soft compressible neck masses, and almost all are evident before 2 years of age. The malformation may also present with symptoms, such as respiratory distress, feeding difficulty, and fever, and sudden increase in size or infection in the lesion can exacerbate symptoms. They are classically located in the posterior or anterior triangles of the neck (Fig. 26.12), and sudden growth of the lesion can be precipitated by an upper respiratory infection. They are classified according to the size of the endothelial cysts that lie within them, from smaller to larger as: capillary lymphangioma, cavernous lymphangioma, and cystic lymphangioma (or cystic hygroma). Over two thirds of neonatal lesions can be associated with other anomalies, including Down syndrome, Turner syndrome, Trisomy 13, Trisomy 18, and Noonan syndrome.

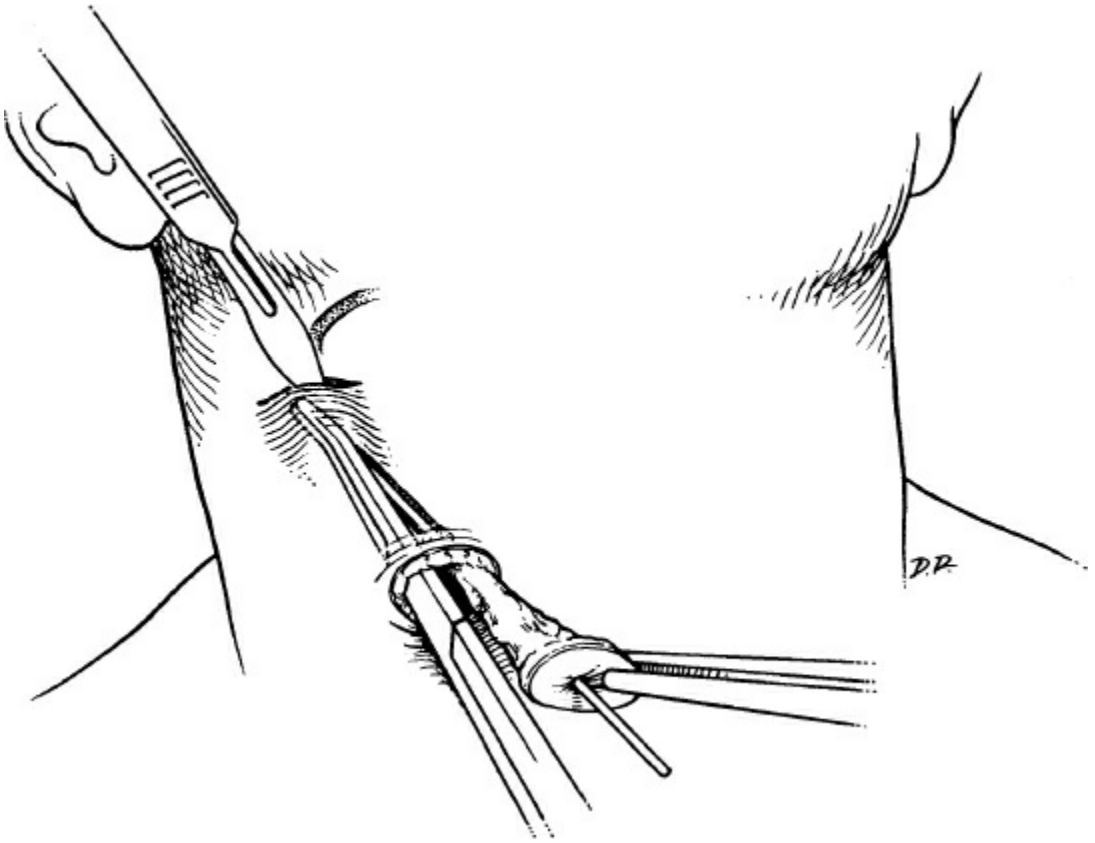

Figure 26.9. The extent of the tract of a second branchial cleft fistula eventually limits the dissection. A clamp is passed along the dissected tract to guide the creation of a counterincision or “stepladder” incision.

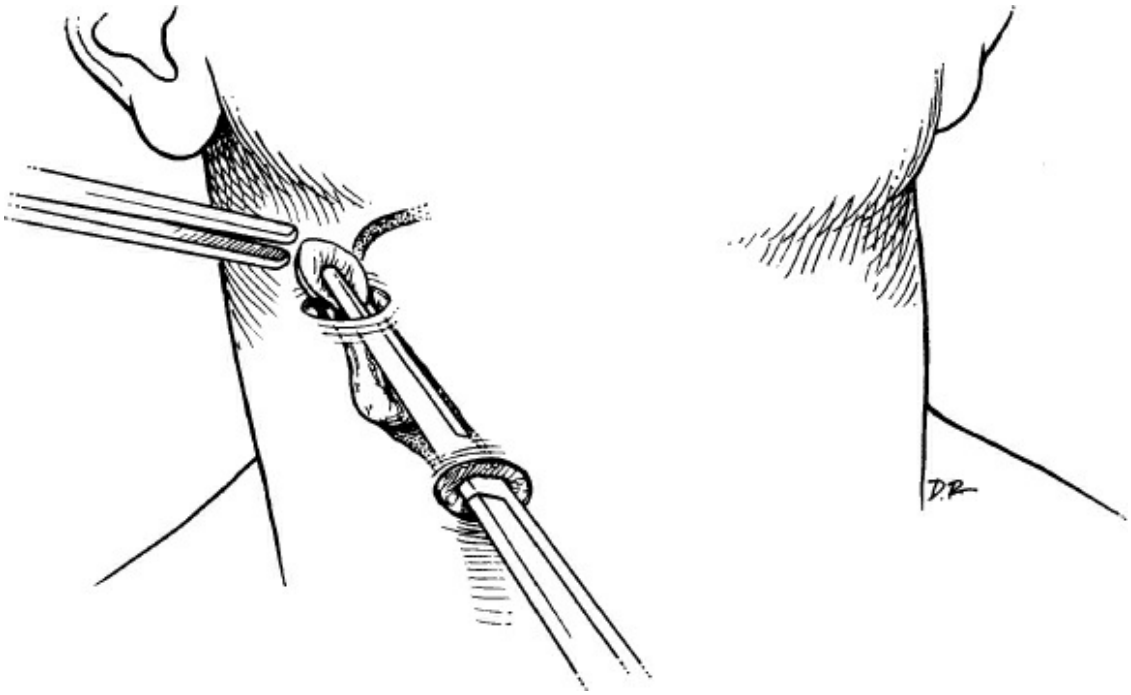

Figure 26.10. The previously mobilized second branchial cleft fistula tract is passed from the original incision to the

counterincision.

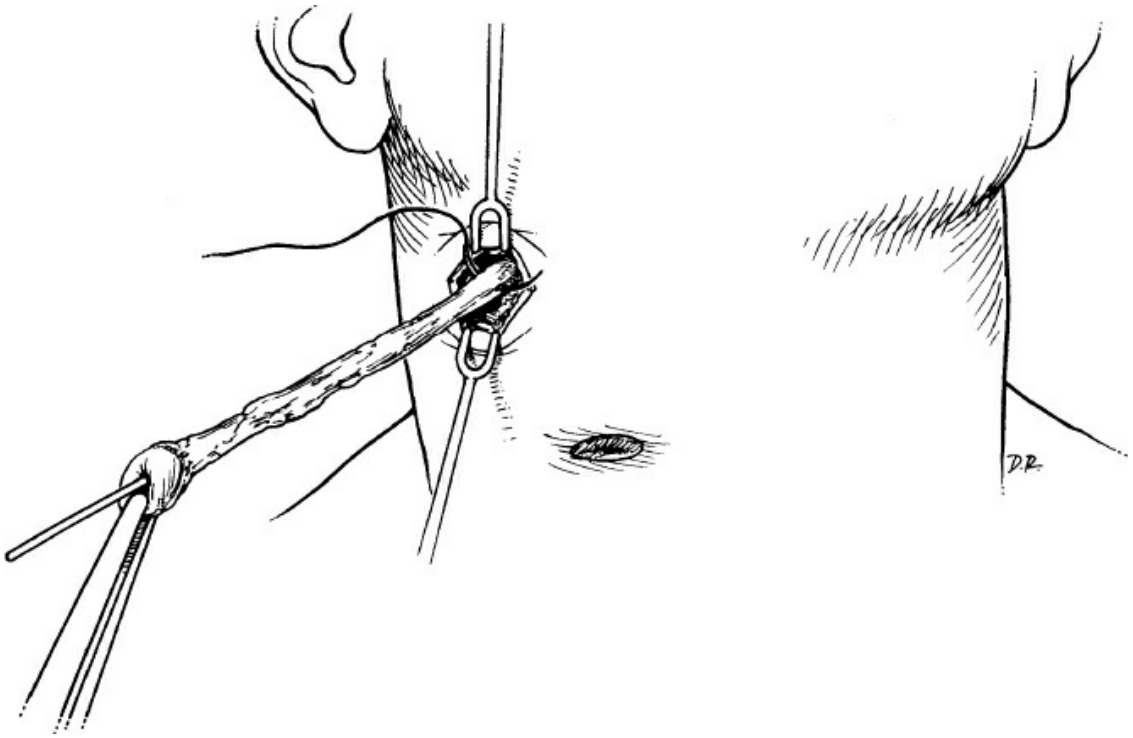

Figure 26.11. Passage of the previously mobilized tract to the counterincision facilitates further dissection of the tract in a superomedial direction to its termination at the tonsillar fossa, where it is suture-ligated and divided.

Indications and Contraindications

These lesions are benign; however, complete surgical resection is recommended upon diagnosis. Normal anatomic structures can lie adjacent to these lesions and should not be sacrificed to achieve complete resection. When a vital structure is identified within the lesion, it should be spared and protected during dissection or complete resection should not be attempted. Treatment options can include surgery, sclerotherapy, or a combination of both modalities. Newer modalities, such as laser therapy or radiofrequency ablation, are gaining attention and have been employed with variable results.

Preoperative Planning

MRI is the modality of choice to determine the extent of the lesion, delineate surrounding structures, and evaluate vital involvement by the malformation.

Surgical Technique

The procedure is performed under general anesthesia, with the administration of perioperative antibiotics. A transverse skin incision is made over the lesion following a skin crease line. Dissection is carried down through the platysma to reach the lesion. Careful dissection is performed around the lesion with sharp scissors, electrocautery or bipolar device, assuring avoidance of injury to adjacent vessels or nerves. Dissection of the lesion is facilitated by avoidance of entrance into the lesion, thereby preserving its distension. The mass is submitted for pathology evaluation, and hemostasis is assured in the dissection bed. Most surgeons prefer to leave a closed-suction drain at the completion of operation that remains until no output is observed.

Postoperative Care, Complications, and Their Management

Patients are usually admitted overnight when dissection has been extensive and to monitor drain output. The most common complications of surgical management of lymphatic malformations include bleeding, recurrence, infection, and injury to adjacent structures. Recurrent lesions are treated with sclerotherapy.

Outcomes

When complete resection is achieved, less than 10% of lesions will recur. This rate increases to 50% to 100% for lesions that have been incompletely resected. For this reason, in the case of complex lymphatic lesions with large cystic sacs insinuating around vital structures, emerging consensus is that initial management should be sclerotherapy, rather than surgery. Sclerotherapy can be successfully achieved with ethanol, bleomycin, doxycycline, or Picibanil (OK-432). It is usually performed under ultrasound guidance by aspirating the cyst and instilling the cavity with the sclerosant agent of choice for 10 to 15 minutes. This maneuver can be repeated as needed, especially for large and complex macrocystic cystic hygromas, in which excellent results can be achieved by sclerotherapy in over 80% of cases.

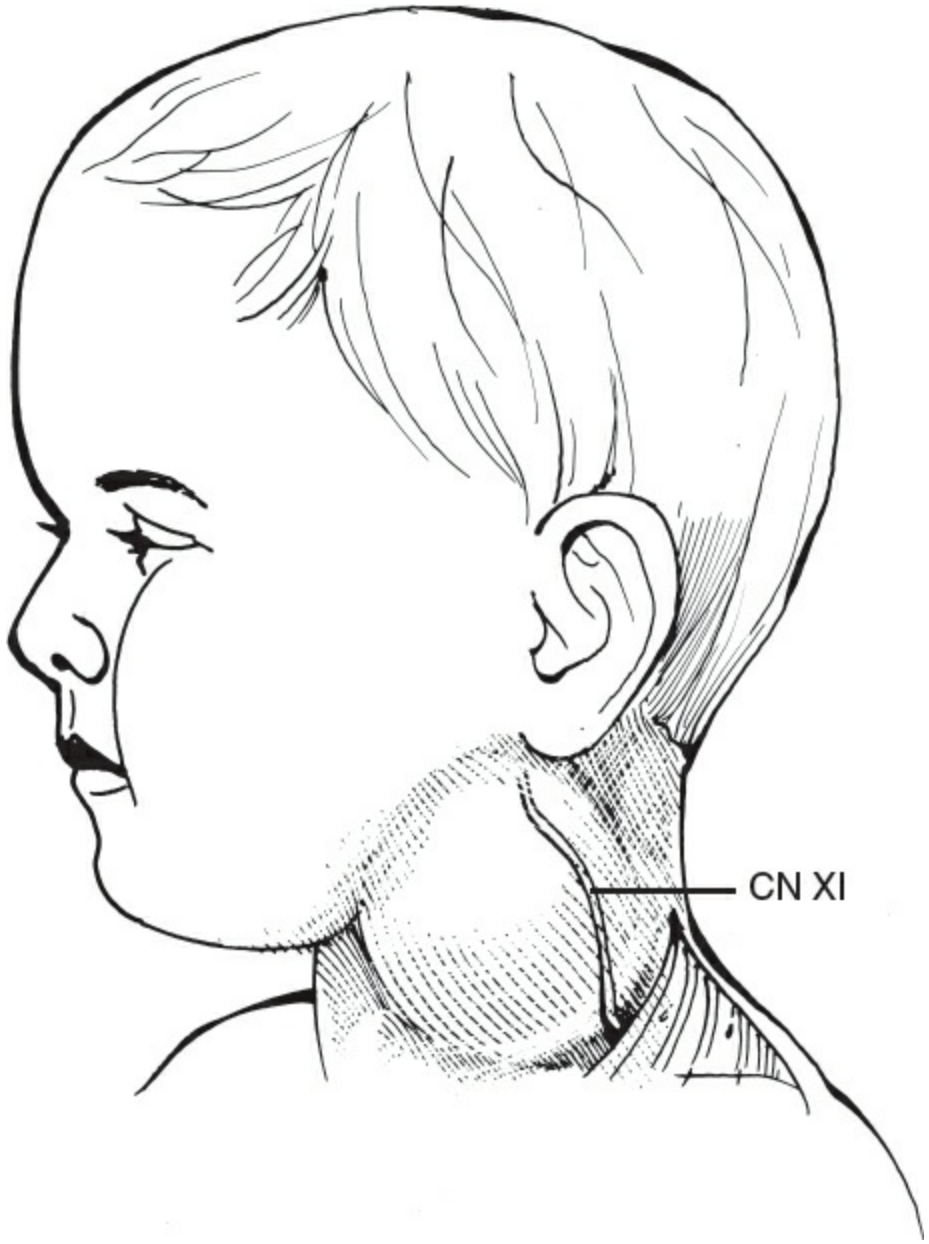

Figure 26.12. Depiction of a cystic hygroma. CN, cranial nerve.

Suggested Readings

Al-Thani H, El-Menyar A, Al Sulaiti M, et al. Presentation, management, and outcome of thyroglossal duct cysts in adult and pediatric populations: a 14-year single center experience. *Oman Med J* 2016;31(4):276–83.

Blei F. Congenital lymphatic malformations. *Ann NY Acad Sci* 2008;28:17–20.

Erikci V, Hoşgör M. Management of congenital neck lesions in children. *J Plast Reconstr Aesthet Surg* 2014; 67(9):e217–22.

Foley DS, Fallat ME. Thyroglossal duct and other congenital midline cervical anomalies. *Semin Pediatr Surg* 2006;15(2):70–5.

Goff CJ, Allred C, Glade RS. Current management of congenital branchial cleft cysts, sinuses, and fistulae. *Curr Opin Otolaryngol Head Neck Surg* 2012;20(6):533–9.

Ibrahim FF, Alnoury MK, Varma N, et al. Surgical management outcomes of recurrent thyroglossal duct cyst in children—a systematic review. *Int J Pediatr Otorhinolaryngol* 2015;79(6):863–7.

Kepertis C, Anastasiadis K, Lambropoulos V, et al. Diagnostic and surgical approach of thyroglossal duct cyst in children: ten years data review. *J Clin Diagn Res* 2015;9(12):PC13–5.

LaRiviere CA, Waldhausen JH. Congenital cervical cysts, sinuses, and fistulae in pediatric surgery. *Surg Clin North Am* 2012;92(3):583–97.

Mirza B, Ijaz L, Saleem M, et al. Cystic hygroma: an overview. *J Cutan Aesthet Surg* 2010;3(3):139–44.

EDITOR'S COMMENT

Thyroglossal duct cysts and branchial cleft remnants are common congenital lesions of the head and neck that are dealt with frequently by pediatric, general, and ENT surgeons. In contrast, cystic hygromas are less common and require multidisciplinary management as treatment strategies have evolved significantly. The authors present a concise overview of these three conditions. As the authors note, all three conditions are caused by developmental abnormalities of structures in the neck. Thyroglossal duct cysts are the residual of abnormal descent and formation of the thyroid gland, branchial cleft remnants are the residuals/arrest of branchial cleft/arch/neck formation and a cystic hygroma is an abnormality in the development of the lymphatic system.

Thyroglossal duct cysts are common and diagnosed most frequently in the pediatric population. Once diagnosed, the cyst should be excised as the risk of infection is high and if infection occurs, converts a straightforward procedure into a more technically challenging one with some morbidity. The authors nicely review the treatment options and the surgical approach. When performing surgical excision—the Sistrunk procedure—the most critical step is the removal of the central portion of the hyoid bone as if this is not resected recurrence rates are high (Rohoff D, Honings J, Theunisse HJ, et al. Recurrences after thyroglossal duct cyst surgery: Results in 207 consecutive cases and review of the literature. *Head Neck* 2015;37(12):1699–704). Although removal is required, the hyoid bone in patients with thyroglossal duct cysts can be abnormal in shape and excision must be done with some care as the trachea lies beneath the hyoid and overaggressive manipulation can cause inadvertent tracheal injury—a catastrophic complication. When the patient has an active infection, the best choice may be to stage the procedure where the cyst is either aspirated or incised and drained and the patient treated with a course of

antibiotics. If incision and drainage is performed, this can make the subsequent resection more difficult as anatomic planes will be less clear. We prefer aspiration with excision scheduled near the end of the course of antibiotics. This maintains the integrity of the cyst wall and will allow for a cleaner dissection of the duct up to the hyoid bone. When incision and drainage have been performed, typically prior to referral, we may observe the patient for a period of time as often, the cyst will reform allowing for a more straightforward resection. Postoperative recovery is usually uncomplicated. In the past, all patients were hospitalized overnight but now, we will only admit for 23-hour observation, children under 3 as given their smaller airways, the combination of intubation and anterior tracheal dissection may cause some stridor that can be alleviated with respiratory treatments.

Complications are rare with recurrence the most problematic. Recurrence has been linked to both pre- and postoperative infections. Recurrence, especially if a central hyoid resection was performed during the initial resection, can be challenged and may require an anterior neck dissection (O'Neill LM, Gunaratne DA, Cheng AT, et al. Wide anterior neck dissection for management of recurrent thyroglossal duct cysts in adults. *J Laryngol Otol* 2016;130 Suppl 4:S41–4).

As the authors note, on occasion the thyroglossal duct cyst will contain the patient's only thyroid tissue. Although ultrasound can be performed to help document cyst type and presence of thyroid tissue, physical exam can still delineate the presence of thyroid tissue even in infants. Resection should still be performed as the risk of malignancy precludes leaving the thyroid containing cyst in situ. Although disconcerting, especially as it can be a pediatric patient, maintenance on long-term thyroid replacement hormones without developmental impact can be readily achieved. Careful counseling of family of the risks of the procedure and treatment necessary should ectopic thyroid tissue be found is helpful to reduce postoperative anxiety.

Malignancy arising in a thyroglossal duct cyst although rare is usually found incidentally on pathologic analysis and has been reported in both pediatric and adult patients. Papillary and squamous malignancies have been reported. Treatment, should a malignancy be detected may not require anything more than surveillance. A retrospective pooled analysis by Patel et al. of 62 cases in the literature found that the Sistrunk procedure, if a clinically and radiologically normal thyroid gland was present, was adequate as in cases where the addition of total thyroidectomy was performed, no abnormalities were identified (Patel SG, Escrig M, Shaha AR, et al. Management of well-differentiated thyroid carcinoma presenting within a thyroglossal duct cyst. *J Surg Onc* 2002;79:134–9).

Branchial cleft anomalies are interesting anatomic abnormalities resulting from remnants of the closure of the branchial cleft arches. The authors provide an excellent review of the developmental and anatomic basis by which these remnants arise. The most common abnormalities arise from the first and second

branchial cleft with third and fourth remnants uncommon. The clinical manifestations of the remnants range from a small cyst to a cartilaginous containing nodule to a sinus to an actual fistula. The treatment is always surgical with careful preoperative mapping to ensure an understanding of the anatomy such that damage to critical structures of the neck can be minimized. Great care must be taken when excising first branchial cleft remnants as the facial nerve will be involved. Excision of the second branchial cleft remnants is technically straightforward. For fistulas, the placement of a fine lacrimal duct probe in the tract can facilitate dissection. Complications following branchial cleft remnant excision are uncommon.

Although branchial cleft remnants are common, surgeons should be aware of the Branchio-otorenal (BOR) syndrome, which is characterized by branchial arch anomalies, preauricular pits, hearing impairment, and renal malformations. As noted by the authors, most branchial cleft remnants are self-limited, however, in patients with a branchial fistula associated with external ear anomalies an additional workup should be performed to eliminate the possibility of BOR syndrome especially if there is a family history of either branchial cleft remnants, hearing loss, or kidney disease (Senel E, Kocak H, Akbiyik F, et al. From a branchial fistula to a branchiootorenal syndrome: a case report and review of the literature. *J Pediatr Surg* 2009;44(3):623–5).

Lymphatic malformations arising in the neck, termed cystic hygromas, are in addition to the author's concise review, discussed at length in the accompanying vascular malformations chapter. Treatment options have expanded beyond surgery as effective medical strategies have been developed. Multidisciplinary teams comprised of oncologists, interventional radiologists, pediatric ENT, plastics and general surgeons have developed and matured at multiple major children's hospitals focused on this cohort of patients. These teams have integrated medical management, interventional procedures, and surgery to address lymphatic and vascular malformations. Preoperative imaging is critical as treatment strategies are tailored to the size of the cystic lesions. mTOR inhibitors (sirolimus and everlimus) have been shown to be effective treatment options for microcystic lymphatic malformations (Ivars M, Redondo P. Efficacy of Topical Sirolimus (Rapamycin) for the Treatment of Microcystic Lymphatic Malformations. *JAMA Dermatol* 2017;153(1):103–5). Should medical management fail, sclerotherapy is an alternative and if neither successful, surgical excision can be considered but should not be performed at the expense of compromise of important structures especially nerves.

Gregory M. Tiao

27 Vascular Anomalies of Infancy and Childhood

Arin K. Greene and John B. Mulliken

INTRODUCTION

Vascular anomalies is a field involving several medical and surgical specialties. Lesions all look quite similar, in varying shades of red, pink, and blue. The field has been handicapped by its own confusing clinical and histopathologic terminology. The traditional diagnostic terms failed to guide management. The word “hemangioma” is the most egregious example; it has been used in a generic sense for any type of vascular lesion (Table 27.1).

A biologic classification of vascular anomalies, first proposed in 1982, was based on clinical findings, natural history, and cellular characteristics. This binary scheme was accepted by the International Society for the Study of Vascular Anomalies (ISSVA) in 1996. Vascular anomalies are broadly divided into two groups: *tumors* and *malformations* (Table 27.2). Vascular tumors are characterized by endothelial cell proliferation. Vascular malformations arise by dysmorphogenesis and have minimal endothelial cell turnover. Based on this classification, vascular anomalies can be diagnosed by history and physical examination in 90% of patients. Ten percent of patients require radiographical studies for diagnostic confirmation; histopathology is rarely necessary.

The most common vascular tumors are infantile hemangioma (IH), congenital hemangioma (rapidly involuting congenital hemangioma [RICH], noninvoluting congenital hemangioma [NICH]), kaposiform hemangioendothelioma (KHE), and pyogenic granuloma (PG) (Fig. 27.1). Malformations are divided into slow-flow lesions (capillary malformation [CM], venous malformation [VM], lymphatic malformation [LM]) and fast-flow anomalies (arterial malformations [aneurysm, ectasia, stenosis, fistulas] or arteriovenous malformation [AVM]) (Fig. 27.2). There are also combined vascular anomalies, often eponymous because of the physician credited for the initial description.

TABLE 27.1 Incorrect Terminology Commonly Used to Describe Vascular Anomalies

Tumors		Malformations	
Biologic Name	Incorrect Term	Biologic Name	Incorrect Term
Infantile hemangioma	"Strawberry hemangioma" "Capillary hemangioma" "Cavernous hemangioma"	Capillary malformation	"Port-wine stain" "Capillary hemangioma"
Congenital hemangioma	"Infantile hemangioma"	Lymphatic malformation	"Cystic hygroma" "Lymphangioma"
Kaposiform hemangioendothelioma	"Capillary hemangioma"	Venous malformation	"Cavernous hemangioma"
Pyogenic granuloma	"Hemangioma"	Arteriovenous malformation	"Arteriovenous hemangioma"

Patients with a vascular anomaly often wander from one specialist to another. Their problem seems to fall outside the purview of the general surgeon and vascular surgeon. Since most vascular anomalies present in the skin, these "medical nomads" are usually seen by a dermatologist or plastic surgeon, and sometimes an oncologist because their lesion is considered to be some kind of tumor.

The biologic separation of the two major categories, tumors and malformations, has stimulated the formation of vascular anomalies centers in the major referring hospitals. It is clear that no one specialist can have sufficient knowledge to care for these patients. The field of vascular anomalies insinuates among all the surgical specialties, many of the medical disciplines, as well as interventional radiology and pathology. Molecular geneticists are also involved. Causative genes for inheritable and somatic lesions have been discovered recently (Table 27.3).

This chapter was written as a primer, to encourage general surgeons to adopt the modern terminology of vascular lesions. Surgeons, who are curious and fascinated by these common and often insoluble disorders, are encouraged to join a vascular anomalies team.

TABLE 27.2 Classification of Vascular Anomalies

	Malformations		
Tumors	Slow-Flow	Fast-Flow	Overgrowth Syndromes
Infantile hemangioma Congenital hemangioma Kaposiform hemangioendothelioma Pyogenic granuloma	Capillary malformation Venous malformation Lymphatic malformation	Arteriovenous malformation	CLOVES Klippel–Trenaunay Parkes Weber Sturge–Weber

VASCULAR TUMORS

Infantile Hemangioma

Clinical Presentation

IH is a benign endothelial tumor that occurs in approximately 4% to 5% of Caucasian infants. The old terms “capillary,” “cavernous,” and “strawberry” hemangioma are imprecise and no longer used. IH is more frequent in premature children and in females (4:1). IH is typically single (80%) and involves the head and neck (60%), trunk (25%), or extremity (15%). The median age of appearance is 2 weeks; 50% of lesions are noted at birth as a telangiectatic stain or ecchymotic area. IH grows faster than the child during the first 9 months of age (proliferating phase); 80% of its size is achieved by 3.2 (±1.7) months. IH is red when it involves the superficial dermis. A lesion beneath the skin may not be appreciated until 3 to 4 months of age when it has grown large enough to cause a visible mass; the overlying skin may appear bluish. After 12 months, the tumor begins to regress (involuting phase); the color fades and the lesion flattens. Involution ceases in most children by the age of 4 years (involuted phase). After involution, one half of patients will have residual telangiectasias, scarring, fibrofatty residuum, redundant skin, or destroyed anatomical structures.

Head and Neck Hemangiomas

The majority of IH are small, harmless lesions that can be monitored under the watchful eye of a pediatrician. However, 10% of proliferating IH cause significant deformity or complications, usually when located on the head or neck. Ulcerated lesions may destroy the eyelid, ear, nose, or lip. IH of the scalp or eyebrow can result in alopecia. Periorbital hemangioma can block the visual axis or distort the cornea causing amblyopia. Subglottic hemangioma may obstruct the airway.

Multiple Hemangiomas

Approximately 20% of infants have more than one IH. Infants with five or more small (<5 mm) IHs have a 16% risk of having hepatic hemangioma which are typically asymptomatic. An ultrasonogram should be considered to rule out hepatic IH.

Hepatic Hemangiomas

The liver is the most common extracutaneous site for IH. Ninety percent of fast-flow hepatic lesions are IH. The differential diagnosis includes AVM, hepatoblastoma, and metastatic neuroblastoma which do not demonstrate significant shunting on imaging. There are three subtypes of hepatic

hemangioma: focal, multifocal, or diffuse. Although most hepatic IH are nonproblematic and discovered incidentally, large tumors can cause heart failure, hepatomegaly, anemia, or hypothyroidism. Focal hepatic hemangioma are usually asymptomatic and not associated with cutaneous lesions; they are often identified prenatally. Solitary hepatic hemangioma is a "rapidly involuting congenital hemangioma (RICH)." Occasionally this tumor can cause cardiac overload and thrombocytopenia; however, these symptoms resolve as the tumor regresses. Multifocal hepatic IH are often accompanied by cutaneous lesions. Although usually asymptomatic, multifocal lesions can cause high output cardiac failure which is managed by corticosteroid or embolization. Diffuse hepatic IH can cause massive hepatomegaly, respiratory compromise, or abdominal compartment syndrome. In addition, very large IH may cause hypothyroidism because the endothelium of hemangiomas produce type 3 iodothyronine deiodinase which inactivates circulating thyroid hormone; infants are at risk for hypothyroidism and irreversible brain injury. Consequently, patients with diffuse hepatic hemangiomas require thyroid stimulating hormone monitoring and, if abnormal, intravenous thyroid hormone replacement until the hemangioma begins to regress.



Figure 27.1. Vascular tumors of infancy and childhood. **A.** A 5-month-old male with superficial infantile hemangioma of cheek. **B.** A newborn infant with rapidly involuting congenital hemangioma (RICH) of lower extremity. **C.** An 11-month-old male with kaposiform hemangioendothelioma of trunk. **D.** A 23-month-old female with pyogenic granuloma of right lower eyelid.

Hemangiomas and Structural Anomalies

PHACE association affects 2.3% of patients with IH, and consists of a plaque-like IH in a regional distribution of the face with at least one of the following anomalies: *P*osterior fossa brain malformation; *H*emangioma; *A*rterial cerebrovascular anomalies; *C*oarctation of the aorta and cardiac defects; *E*ye/*E*ndocrine abnormalities. When ventral developmental defects (*S*ternal clefting or *S*upraumbilical raphe) are present, an "S" is

added (PHACES). Ninety percent of infants are female and cerebrovascular anomalies are the most common associated finding (72%). Because 8% of children with PHACE have a stroke in infancy, patients should have an MRI to evaluate the brain and cerebrovasculature. Infants are referred for ophthalmologic, endocrine, and cardiac evaluation to rule out these associated anomalies.



Figure 27.2. Vascular malformations. **A.** A newborn infant with capillary malformation of the trunk. **B.** A 9-year-old female with left facial lymphatic malformation. **C.** A 2-year-old female with upper labial venous malformation. **D.** A 14-year-old male with left facial arteriovenous malformation. **E.** An 18-month-old female with a combined capillary-lymphatic-venous malformation of right lower extremity and overgrowth (Klippel–Trenaunay syndrome).

LUMBAR association (*L*ower body IH, *U*rogenital anomalies, *M*yelopathy, *B*ony deformities, *A*norectal malformations, *R*enal anomalies) typically affects the sacral area or lumbar region. Ultrasonography (US) is obtained to rule out associated anomalies in infants less than 4 months of age. MRI is indicated in older infants or when ultrasound is equivocal.

Diagnosis

Most cutaneous IH are easily diagnosed by history and physical examination; these tumors are usually red, appear during the first 2 weeks of life, and grow rapidly during early infancy. Fast-flow is confirmed using a hand-held Doppler device. By formal US, IH appears as a soft tissue mass with fast-flow, decreased arterial resistance, and increased venous drainage. Involuting IH has increased lobularity and adipose tissue; the number of vessels and flow is reduced. Rarely, biopsy is indicated if malignancy is suspected or if the diagnosis remains unclear following imaging studies. Positive erythrocyte-type glucose transporter (GLUT 1) immunostaining differentiates IH from other vascular tumors and malformations.

Nonoperative Treatment

Most IHs are simply observed because 90% are small, localized, and do not involve anatomically important areas. During the proliferative phase 16% of lesions will ulcerate, most commonly on the lips, neck, and anogenital region. Other complications include bleeding and infection. IH is kept moist during the proliferative phase with hydrated petroleum to minimize desiccation as well as to protect against incidental trauma. IH may be further protected by using a petroleum gauze barrier. If an ulceration develops it is managed with local wound care; often healing takes 2 to 4 weeks.

Topical Pharmacotherapy

Topical corticosteroid is relatively ineffective; especially if IH involves the deep dermis and subcutis. Although lightening may occur, if there is deep component it will not be affected. Adverse effects include hypopigmentation and cutaneous atrophy. Topical timolol may be effective for superficial lesions, but will not affect IHs with a subcutaneous component.

TABLE 27.3 Mutations Associated With Vascular Anomalies

Condition	Mutated Gene	Inheritance
Capillary Malformation	*GNAQ*	Somatic
Venous Malformations		
Sporadic venous malformation	*TIE2*	Somatic
Verrucous venous malformation	*MAP3K3*	Somatic
Glomuvenous malformation	*Glomulin*	Dominant
Cutaneomucosal venous malformation	*TIE2*	Dominant
Cerebral cavernous malformation	*KRIT1*	Dominant
Lymphatic Malformations		
Sporadic lymphatic malformation	*PIK3CA*	Somatic
Familial congenital primary lymphedema	*VEGFR3*	Dominant
Lymphedema-distichiasis	*FOXC2*	Dominant
Lymphedema–hypotrichosis–telangiectasia	*SOX18*	Recessive
Hennekam syndrome	*CCBE1*	Recessive
Arteriovenous Malformations		
Capillary malformation-arteriovenous malformation	*RASA1*	Dominant
Hereditary hemorrhagic telangiectasia type 1 (HHT1)	*ENG*	Dominant
Hereditary hemorrhagic telangiectasia type 2 (HHT2)	*ACVRLK1*	Dominant
PTEN-associated vascular anomaly	*PTEN*	Dominant

Intralesional Corticosteroid

Problematic IHs that are well localized and <3 cm are best managed by an intralesional corticosteroid. Triamcinolone (not to exceed 3 mg/kg) will stop the growth of the lesion; two thirds will decrease in size. The corticosteroid lasts 2 to 3 weeks, and thus infants may require 2 to 3 injections during the proliferative phase. Intralesional corticosteroid may cause subcutaneous fat atrophy (2%). Blindness has been reported following injection of deep periorbital hemangioma due to embolic occlusion of the retinal artery.

Systemic Pharmacotherapy

Problematic IHs >3 cm are managed by oral prednisolone or propranolol. Prednisolone has been used to treat IH for over 45 years and has proven to be very safe and effective. Patients are given 3 mg/kg/day for 1 month; the drug is then tapered by 0.5 cc every 2 to 4 weeks until it is discontinued between 10 and 12 months of age when the tumor is no longer proliferating. The drug is given once a day in the morning, and infants have monthly outpatient follow-up. Using this protocol, all tumors will stabilize in growth and 88% will become smaller (accelerated regression). Twenty percent of infants will develop a cushingoid appearance that resolves during tapering of therapy. Approximately 12% exhibit decreased gain in height, but return to their pretreatment growth curve by 24 months of age.

Propranolol dosing typically is 2 mg/kg/day. Approximately 90% of tumors will stop growing or regress. Risks (<3%) include bronchospasm, bradycardia, hypotension, hypoglycemia, seizures, and hyperkalemia. Preterm infants and those <3 months of age are more likely to have adverse events. Patients usually have cardiology consultation, electrocardiogram, echocardiogram, glucose/electrolyte measurements, and frequent blood pressure, heart rate, and respiratory examinations. Inpatient initiation of treatment is used for premature or infants less than 3 months of age. Potential contraindications include asthma, glucose abnormalities, heart disease, hypotension, bradycardia, PHACES association. The drug should be discontinued if the infant is ill because reduced oral intake can increase the risk of hypoglycemia and seizures. Patients treated with propranolol experience later rebound growth compared to prednisolone, and thus may necessitate longer treatment. Recently, concern has been raised about potentially negative long-term neurocognitive effects of propranolol when given to infants.

Laser Therapy

There is little, if any, role for pulsed-dye laser treatment for proliferating IH. The laser penetrates only 0.75 to 1.2 mm into the dermis, and thus only affects the superficial portion of the tumor. Although lightening may occur, the mass of IH is not affected. Instead, patients have an increased risk of skin atrophy and hypopigmentation. The thermal injury delivered by the laser to the ischemic dermis increases the risk of ulceration, pain, bleeding, and scarring. Pulsed-dye laser is indicated during the involuted phase to fade residual telangiectasias.

Operative Treatment

Resection generally is not recommended during the proliferating phase. The tumor is highly vascular and there is a risk for blood loss, iatrogenic injury, and an inferior outcome, compared to excising residual tissue after the tumor has regressed. Approximately 50% of IH leave behind fibrofatty tissue or damaged skin after the tumor regresses causing a deformity. It is preferable to intervene surgically between 3 and 4 years of age (Fig. 27.3). During this period the IH will no longer improve significantly, and the procedure is performed before the child's long-term memory and self-esteem begin to form at about 4 years of age. Also, waiting until the IH is at its smallest will result in the shortest possible scar and the most favorable outcome. Circular lesions located in visible areas, particularly the face, are best removed by circular excision and purse-string closure (Fig. 27.4). This technique minimizes the length of the scar as well as distortion of surrounding structures. Lenticular excision of a circular IH results in a scar as long as three times the diameter of the lesion. In comparison, a two-stage circular resection followed by lenticular excision/linear closure will leave a scar approximately the same length as the diameter of the original lesion.

Congenital Hemangiomas

Clinical Presentation

There are rare hemangiomas that arise in the fetus, are fully grown at birth, and do not have postnatal growth. These congenital hemangiomas are red-violaceous with coarse telangiectasias, central pallor, and a peripheral pale halo. These lesions are more common in the extremities, have an equal sex distribution, and are solitary with an average diameter of 5 cm. There are two forms: RICH and NICH. RICH regresses rapidly after birth; 50% have

completed regression by 7 months of age. RICH affects the head or neck (42%), limbs (52%), or trunk (6%). RICH does not leave behind a significant adipose component, unlike IH. NICH, in contrast, does not undergo involution; there is persistent fast-flow. It involves the head or neck (43%), limbs (38%), or trunk (19%).

Treatment

RICH usually does not require resection in infancy because it undergoes accelerated regression. Occasionally, RICH is complicated by congestive heart failure which is controlled by corticosteroid or embolization as the lesion involutes. After regression RICH may leave behind atrophic skin and subcutaneous tissue. Reconstruction with autologous grafts (fat, dermis) or acellular dermis may be indicated. NICH is rarely problematic in infancy; it is observed until the diagnosis is clear. Resection of NICH may be indicated to improve the appearance of the affected area, as long as the surgical scar will be less noticeable than the lesion.



Figure 27.3. A 2-year-old female with involuting phase infantile hemangioma of the scalp resulting in fibrofatty residuum and alopecia: lenticular excision (**A**) and linear closure (**B**).

Kaposiform Hemangioendothelioma

Clinical Presentation

KHE is a rare vascular neoplasm that is locally aggressive, but does not metastasize. Although one half of lesions are present at birth, KHE may develop during infancy (58%), between age 1 and 10 years (32%), or after 11 years of age (10%). KHE has an equal sex distribution, is solitary, and affects the head/neck (40%), trunk (30%), or extremity (30%). The tumor is often greater than 5 cm in diameter, and thus larger than the typical IH.

KHE causes a visible deformity as well as pain. In addition, 50% of patients have Kasabach–Merritt phenomenon (KMP) (thrombocytopenia <25,000/mm^3, petechiae, bleeding). KHE partially regresses after 2 years of age, although it usually persists long-term causing chronic pain and stiffness.

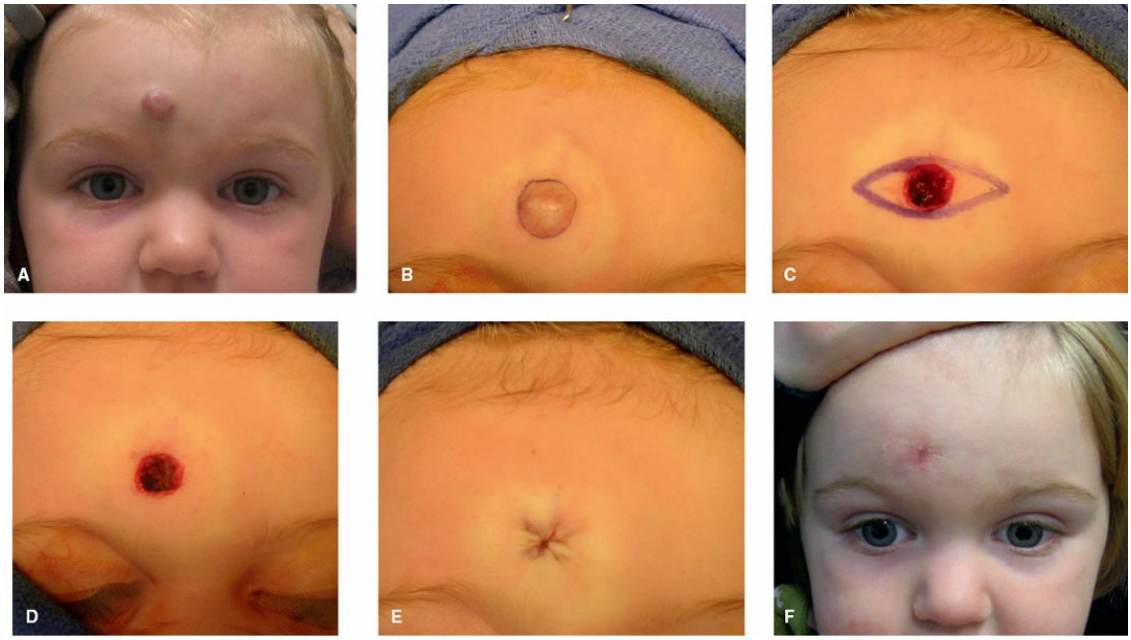

Figure 27.4. **A, B.** A 2.5-year-old female with frontal infantile hemangioma and fibrofatty residuum. **C.** Lenticular excision would result in a scar approximately three times the diameter of the tumor. **D, E.** Circular excision/purse-string closure. **F.** A small scar 3 months postoperatively.

Diagnosis

The diagnosis is established by history, physical examination, and imaging. Unlike IH, KHE is usually present at birth as a flat, reddish-purple, edematous lesion. It does not exhibit rapid postnatal growth; however, the tumor can expand with the onset of KMP. MRI is indicated for diagnostic confirmation and to asses the extent of the tumor. MRI shows poorly defined margins, small vessels, and invasion of adjacent tissues. There is T2 hyperintensity, postgadolinium enhancement, and signal voids also may be present. Histologically, KHE has infiltrating sheets or nodules of endothelial cells lining capillaries. Hemosiderin-filled slit-like vascular spaces with red blood cell fragments, as well as dilated lymphatics, are present.

Treatment

Most lesions are extensive, involving multiple tissues, and are beyond the limits of resection. Patients with KMP require systemic treatment to prevent life-threatening complications. Large, asymptomatic tumors without KMP are also managed with pharmacotherapy to minimize fibrosis and subsequent long-term pain and stiffness. Vincristine is first-line therapy, the response rate is 90%. Recently, patients have been treated with sirolimus with good efficacy. KHE does not respond as well to second-line drugs, interferons (50%), or corticosteroids (10%). Thrombocytopenia will not be significantly improved with platelet transfusion because the platelets are trapped in the tumor. Transfusion also worsens swelling and should be avoided unless there is active bleeding or a surgical procedure is planned. By 2 years of age, the tumor often undergoes partial involution and the platelet count normalizes.

Pyogenic Granuloma

PG is neither "pyogenic" nor "granulomatous." Some pathologists call it *lobular capillary hemangioma.* PG is a solitary, red papule that grows rapidly on a stalk. It is small, with an average diameter of 6.5 mm; the mean age of onset is 6.7 years. The male:female ratio is 2:1. PG is complicated by bleeding (64%) and ulceration (36%). PG primarily involves the skin (88%), but can involve mucous membranes as well (11%). PG is distributed on the head or neck (62%), trunk (19%), upper extremity (13%), or lower extremity (5%). In the head and neck region, affected sites include cheek (29%), oral cavity (14%), scalp (11%), forehead (10%), eyelid (9%), or lips (9%).

PGs require intervention to prevent ulceration and bleeding. Numerous methods have been described: curettage, shave excision, laser therapy, or excision. Because the lesion involves the reticular dermis, it is out of the reach of the pulsed-dye laser, cautery, or shave excision. Consequently, these modalities have a recurrence rate of 50%. Full-thickness skin excision is more definitive.

VASCULAR MALFORMATIONS

Capillary Malformations

Clinical Presentation

CM is now the accepted term for the familiar "port-wine" stain. Histopathologic examination shows dilated capillaries and venular vessels

in the superficial dermis. CM is most often solitary; it can be localized or extensive. The lesion is caused by a somatic mutation in *GNAQ*. Over time the stain darkens and exhibits fibrovascular overgrowth. It can be associated with soft tissue and skeletal hypertrophy. Sturge–Weber syndrome is characterized by CM in the ophthalmic (V1) trigeminal dermatome associated with ipsilateral ocular and leptomeningeal vascular anomalies. Leptomeningeal anomalies can cause seizures, contralateral hemiplegia, and delayed development. Patients are at risk for retinal detachment and glaucoma; they should be followed closely by an ophthalmologist.

Treatment

Pulse-dye laser (585 nm) therapy can improve the appearance of CM; the head and neck region responds better than the extremities. Outcome also is superior for smaller lesions and those treated at a younger age. Fifteen percent of patients achieve at least 90% lightening, 65% improve 50% to 90%, and 20% respond poorly. Multiple treatments, spaced 6 weeks apart, are often required until the CM no longer improves with additional treatments. After laser treatment, CM often redarkens over time.

CM can also be associated with soft tissue and skeletal overgrowth. Labial hypertrophy is improved by contour resection. Enlargement of the maxilla or mandible can result in an occlusal cant and malocclusion. Malocclusion may be corrected in adolescence by orthodontic manipulation and/or an orthognathic procedure. CM of the trunk or extremity may be associated with fatty overgrowth causing asymmetry and leg-length discrepancy. In severe cases, cutaneous thickening and cobblestoning can be resected and reconstructed either by linear closure, skin grafts, or local flaps. Facial asymmetry caused by overgrowth of the zygoma, maxilla, or mandible can be improved by contour burring.

Lymphatic Malformation

Clinical Presentation

LM is caused by an error in the embryonic development of the lymphatic system. LM is characterized by the size of the malformed channels: microcystic, macrocystic, or combined. Macrocystic lesions are defined as cysts large enough to be punctured by a needle and treated with sclerotherapy. LM is usually noted at birth or within the first 2 years of life. LM is most commonly located on the head and neck; other frequent

sites include the axilla, chest, and perineum. Lesions are soft and compressible. The overlying skin may be normal, have a bluish hue, or be studded with pink-red vesicles.

LM typically causes deformity and psychosocial issues, especially when it involves the head and neck. The two most common complications associated with LM are bleeding and infection. Intralesional bleeding occurs in up to 35% of lesions causing ecchymotic discoloration, pain, or swelling. Infection complicates as many as 70% of lesions and can progress rapidly to sepsis. Cutaneous vesicles can bleed and cause malodorous drainage. Oral lesions may lead to macroglossia, poor oral hygiene, and caries. Swelling due to bleeding, localized infection, or systemic illness may obstruct vital structures. Two thirds of infants with cervicofacial LM require tracheostomy. Bony overgrowth is another complication; the mandible is most commonly involved resulting in an open bite and prognathism. Thoracic or abdominal LM may lead to pleural, pericardial, or peritoneal chylous effusions. Periorbital LM causes a permanent reduction in vision (40%), and 7% of patients become blind in the affected eye. Generalized LM presents with multifocal or osteolytic bony lesions in association with pleural and/or pericardial effusions; so-called “lymphangiectasia” of the bowel with protein-losing enteropathy also may be present.

Diagnosis

Ninety percent of LM are diagnosed by history and physical examination. Small, superficial lesions do not require further diagnostic evaluation. Large or deep lesions are assessed by MRI to: (1) confirm the diagnosis; (2) define the extent of the malformation; and (3) plan treatment. LM appears as either a macrocystic, microcystic, or combined lesion with septations of variable thickness. It is hyperintense on T2-weighted sequences and does not show diffuse enhancement. Although US is not as accurate as MRI, it may provide diagnostic confirmation or document intralesional bleeding. US findings for macrocystic LM include anechoic cysts with internal septations, often with debris or fluid–fluid levels. Microcystic LM appears as ill-defined echogenic masses with diffuse involvement of adjacent tissues. Histologic confirmation of LM is rarely necessary. LM shows abnormally walled vascular spaces with eosinophilic, protein-rich fluid, and collections of lymphocytes. Immunostaining with the lymphatic markers D2–40 and LYVE-1 are positive.

Treatment

LM is a benign lesion; intervention is not mandatory. Small or asymptomatic lesions may be observed. An infected LM often cannot be controlled with oral antibiotics and intravenous antimicrobial therapy usually is required. Intervention for LM is reserved for symptomatic lesions that cause pain, significant deformity, or threaten vital structures.

Sclerotherapy

Sclerotherapy is first-line management for large or problematic macrocystic/combined LM. Cysts are aspirated followed by the injection of an inflammatory substance which causes scarring of the cyst walls to each other. Sclerotherapy has superior efficacy and a lower complication rate than excision. Several scleroscents are used to shrink LM: doxycycline, sodium tetradecyl sulfate (STS), ethanol, bleomycin, and OK-432 (penicillin/heat inactivated *Streptococcus pyogenes*). We prefer doxycycline because it is effective (83% reduction in size) and safe (less than 5% risk of skin ulceration). STS is our second-line agent. Ethanol is an effective sclerosant but has the highest complication rate. It can be used for small lesions, but large volumes should be avoided to reduce the risk of local and systemic toxicity. Ethanol can injure nerves and thus should not be used in proximity to important structures. The use of OK-432 is limited because it is not widely available.

The most common complication of sclerotherapy for LM is cutaneous ulceration (<5%). Ethanol is associated with additional systemic toxicity: CNS depression, pulmonary hypertension, hemolysis, thromboembolism, and arrhythmias. Extravasation of the sclerosant into muscle can cause atrophy and contracture. LM often re-expands over time; 9% recur within 3 years following OK-432 treatment and most will re-expand with longer follow-up. Consequently, patients often need repeated sclerotherapy over the course of their lifetime. If a problematic LM recurs and macrocysts are no longer present in the lesion, then resection is the next alternative. Recently, bleomycin sclerotherapy has shown efficacy for microcystic LMs. This modality can be considered for problematic lesions where resection would be unfavorable; approximately 10% reduction in the size of the lesion can be expected.

Resection

Attempts at extirpation of LM can cause significant morbidity: major blood loss, iatrogenic injury, and deformity. For example, resection of

cervicofacial LM can injure the facial or hypoglossal nerve. Excision is usually subtotal because LM involves multiple tissue planes and important structures; recurrence thus is common (35% to 64%). Resection is reserved for: (1) symptomatic microcystic LM causing bleeding, infection, distortion of vital structures, or significant deformity; (2) symptomatic macrocystic/combined LM that no longer can be managed with sclerotherapy because all macrocysts have been treated; (3) small, well-localized LM (microcystic or macrocystic) that may be completely excised. When considering resection, the postoperative scar/deformity following removal of the LM should be weighed against the preoperative appearance of the lesion.

For diffuse malformations, staged resection of defined anatomic areas is recommended. Subtotal excision of problematic areas, such as bleeding vesicles or a hypertrophied lip, should be carried out rather than attempting "complete" resection of a benign lesion which would result in a worse deformity than the malformation itself. Macroglossia may require reduction to return the tongue to the oral cavity or to correct an open-bite deformity. Bony overgrowth is improved by osseous contouring and malocclusion may require orthognathic correction, usually after skeletal maturity.

Bleeding or leaking cutaneous vesicles may be managed by resection if they are localized and the wound can be closed by direct approximation of tissues. Vesicles often recur through the scar. Large areas of vesicular bleeding or drainage are best managed by sclerotherapy or carbon dioxide laser; alternatively, wide resection and skin graft coverage is required. Microcystic vesicles involving the oral cavity respond well to radiofrequency ablation. Recently, sirolimus has shown efficacy for severe microcystic disease. Patients and families are counseled that LM can expand following any intervention, and thus additional treatments are often required in the future.

Venous Malformation

Clinical Presentation

VM results from an error in vascular morphogenesis; the anomalous channels are dilated with thin walls and abnormal smooth muscle. Consequently, flow stagnates, lesions expand, and clotting occurs. Lesions are blue, soft, and compressible; calcified phleboliths may be palpated. VM range from small, localized cutaneous lesions to diffuse

malformations involving multiple tissue planes and vital structures. VM is typically sporadic and solitary in 90% of patients; however, 50% have a somatic mutation in the endothelial receptor TIE2. Sporadic VM is usually greater than 5 cm (56%), single (99%), and located on the head/neck (47%), extremities (40%), or trunk (13%). Almost all lesions involve the skin, mucosa, or subcutaneous tissue; 50% also affect deeper structures (i.e., muscle, bone, joints, viscera).

Approximately 10% of patients with VM have multifocal, familial lesions. *Glomuvenous malformation* (GVM) is the most common type, *cutaneomucosal-venous malformation* (CMVM) is rare. GVM is an autosomal dominant condition with abnormal smooth muscle-like glomus cells along the ectatic veins. It is caused by a loss-of-function mutation in the *glomulin* gene. Lesions are typically multiple (70%), small (two thirds <5 cm), and located in the skin and subcutaneous tissue; deeper structures are not affected. GVM involves the extremities (76%), trunk (14%), or head/neck (10%). Lesions are more painful than typical VM.

CMVM are small, multifocal mucocutaneous lesions caused by a gain-of-function mutation in the *TIE2* receptor. The condition is autosomal dominant and less common than GVM. Lesions are small (76% <5 cm), multiple (73%), and located on the head/neck (typically tongue or buccal mucosa) (50%), extremity (37%), or trunk (13%).

Cerebral cavernous malformation (CCM) is a rare familial disorder with VM involving the brain and spinal cord; patients also may have hyperkeratotic skin lesions. The disorder results from mutations in CCM1/(*KRIT1*), CCM2, and CCM3 genes and patients are at risk for development of new intracranial lesions and hemorrhage.

Blue rubber bleb nevus syndrome (BRBNS) is a rare condition with multiple, small (<2 cm) VM involving the skin, soft tissue, and gastrointestinal tract. Morbidity is associated with gastrointestinal bleeding requiring chronic blood transfusions.

Verrucous venous malformation (VVM) (previously called “verrucous hemangioma”) is a low-flow vascular malformation that is similar to a hyperkeratotic VM. Lesions range from 2 to 8 cm and are located on an extremity (91%) or trunk (9%). VH involves the skin and subcutis, becomes more hyperkeratotic over time, and frequently causes bleeding. Recently, *MAP3K3* mutations have been found in VVMs. Treatment is carbon dioxide laser or resection.

Fibroadipose vascular anomaly (FAVA) shares features with

intramuscular VM and is caused by a *PIK3CA* mutation. It affects the calf most frequently followed by the thigh, forearm, gluteal area, and ankle/foot. It is differentiated from intramuscular VM by significant pain, contractures, and a nonspongiform venous cutaneous component (phlebectasia, CM, or lymphatic vesicles). On MRI FAVA exhibits fat and fibrosis, minimal signal on T2 images, and heterogeneous small channels. Sclerotherapy is not effective because FAVA is solid. Treatment is either corticosteroid injection, cryotherapy, or resection.

Complications of VM include pain, swelling, and psychosocial issues. Head and neck VM may present with mucosal bleeding or progressive distortion leading to airway or orbital compromise. Extremity VM can cause leg-length discrepancy, hypoplasia due to disuse atrophy, pathologic fracture, hemarthrosis, and degenerative arthritis. VM of muscle may result in fibrosis and subsequent pain and disability. A large VM involving the deep venous system is at risk for thrombosis and pulmonary embolism. Gastrointestinal VM can cause bleeding and chronic anemia. Stagnation within a large VM results in a localized intravascular coagulopathy (LIC) and painful phlebothromboses.

Diagnosis

At least 90% of VMs are diagnosed by history and physical examination. Dependent positioning of the affected region usually confirms the diagnosis. Small, superficial VM do not require further diagnostic workup. Large or deeper lesions are evaluated by MRI to: (1) confirm the diagnosis; (2) define the extent of the malformation; and (3) plan treatment. VM is hyperintense on T2-weighted sequences. In contrast to LM, VM enhances with contrast, often shows phleboliths as signal voids, and is more likely to involve muscle. US may be used for some localized lesions; findings include compressible, anechoic–hypoechoic channels separated by more solid regions of variable echogenicity. Phleboliths are hyperechoic with acoustic shadowing. CT is occasionally indicated to assess osseous VM. Histologic diagnosis of VM is rarely necessary.

Treatment

Patients with an extensive extremity VM are prescribed custom-fitted compression garments to reduce blood stagnation and thus minimize expansion, LIC, phlebolith formation, and pain. Patients with recurrent pain secondary to phlebothrombosis are given prophylactic daily aspirin (81 mg) to prevent thrombosis. Large lesions are at risk for coagulation of

stagnant blood, stimulation of thrombin, and conversion of fibrinogen to fibrin. LIC can become disseminated intravascular coagulopathy (DIC) following trauma or therapeutic intervention. The chronic consumptive coagulopathy can cause either thrombosis (phleboliths) or bleeding (hemarthrosis, hematoma, intraoperative blood loss). Low-molecular-weight heparin (LMWH) is considered for patients with significant LIC who are at risk for DIC. Patients who develop a serious thrombotic event require long-term anticoagulation or a vena caval filter.

Sclerotherapy

Intervention for VM is reserved for symptomatic lesions that cause pain, deformity, obstruction (i.e., vision, airway), or gastrointestinal bleeding. First-line treatment is sclerotherapy, which is safer and more effective than resection. Diffuse malformations are managed by targeting specific symptomatic areas; often the entire lesion is too extensive to treat at one time. Sclerotherapy is repeated until symptoms are alleviated or when injectable vascular spaces are no longer present. Although sclerotherapy effectively reduces the size of the lesion and improves symptoms, the malformation remains. Consequently, patients who have a mass or visible deformity after treatment, may be improved by resection. In addition, VM usually re-expands after sclerotherapy, and thus patients often require additional treatments.

The preferred scleroscents for VM are STS and ethanol; STS is most commonly used. Although ethanol is more effective than STS, it has a higher complication rate. Most patients, especially children, are managed under general anesthesia using US or fluoroscopic imaging. The most common local complication of sclerotherapy for VM is cutaneous ulceration (<5%). Extravasation of the sclerosant into muscle can cause atrophy and contracture. Posttreatment swelling may necessitate close monitoring. Compartment syndrome is a serious consequence of sclerotherapy for extremity VM. Systemic adverse events from sclerotherapy, including hemolysis, hemoglobinuria, and DIC, are more common if large lesions are treated. Consequently, patients with a large, diffuse VM have fibrinogen levels measured before sclerotherapy or resection. If fibrinogen levels are low, patients are given LMWH 14 days before and after the procedure. Anticoagulation is held for 24 hours perioperatively (12 hours before and after the intervention) to prevent bleeding complications.

Resection

Extirpation of VM can cause major morbidity; that is, blood loss, iatrogenic injury, and deformity. In contrast to sclerotherapy, resection is rarely primary treatment because: (1) the entire lesion is difficult to remove; (2) the risk of recurrence is high because channels adjacent to the visible lesion are not treated; and (3) the risk of blood loss and iatrogenic injury is greater. Resection should be considered for: (1) small, well-localized lesions that can be completely removed or (2) persistent mass or deformity after completion of sclerotherapy (patent channels are no longer accessible for further injection). When considering resection, the postoperative scar/deformity following removal of the VM should be weighed against the preoperative appearance of the lesion. Subtotal resection of a problematic area, such as labial hypertrophy, is indicated rather than attempting "complete" excision of a benign lesion that might result in a worse deformity than the malformation itself. Patients and families are counseled that VM can expand following excision, and additional operative intervention may be required in the future.

Almost all VMs should have sclerotherapy prior to operative intervention. After adequate sclerotherapy, the VM is replaced by scar and thus the risk of blood loss, iatrogenic injury, and recurrence is reduced. In addition, fibrosis facilitates resection and reconstruction. Because GVM are usually small and less amenable to sclerotherapy, first-line therapy for painful lesions may be resection. Nd:YAG photocoagulation can be an adjuvant to sclerotherapy for the management of difficult airway lesions. Gastrointestinal VM with chronic bleeding, anemia, and transfusion requirements are typically managed by resection. Solitary lesions can be treated by endoscopic banding or sclerotherapy. Multifocal lesions of BRBNS require removal of as many lesions as possible through multiple enterotomies, instead of bowel resection, to preserve the length of intestine. Diffuse, problematic colorectal VM may require colectomy, anorectal mucosectomy, and endorectal pull-through.

Arteriovenous Malformation

Clinical Presentation

AVM results from an error in vasculogenesis during embryonic development. An absent capillary bed causes shunting of blood directly from the arterial to venous circulation, through a fistula (direct connection of an artery to a vein) or nidus (abnormal channels bridging the feeding

artery to the draining veins). Genetic abnormalities cause certain types of familial AVM. *Hereditary hemorrhagic telangiectasia* (HHT) is caused by mutations in endoglin and activin receptor-like kinase 1 (ALK-1), which affect transforming growth factor-beta (TGF-β) signaling. *Capillary malformation-arteriovenous malformation* (CM-AVM) results from a mutation in *RASA1*.

The head and neck is the most common site of extracranial AVM, followed by the limbs, trunk, and viscera. Although present at birth, AVM may not become evident until childhood. Arteriovenous shunting reduces capillary oxygen delivery causing ischemia; patients are at risk for pain, ulceration, bleeding, and congestive heart failure. AVM also may cause disfigurement, destruction of tissues, and obstruction of vital structures. As AVM worsens over time, the lesion can be classified according to the Schobinger staging system (Table 27.4).

Diagnosis

Most AVMs are diagnosed by history and physical examination. If AVM is suspected, the diagnosis should be confirmed by US with color Doppler examination showing fast-flow and shunting. MRI also is obtained to: (1) confirm the diagnosis; (2) determine the extent of the lesion; and (3) plan treatment. MRI shows dilated feeding arteries and draining veins, enhancement, and flow-voids on T2-weighted imaging. In rare instances, diagnostic angiography is needed. Angiography also is indicated if embolization or resection is planned to determine the flow dynamics of the lesion. AVM exhibits tortuous, dilated arteries with venous shunting and dilated draining veins on angiogram. Often, a blush illustrates the nidus of the lesion. Histopathologic diagnosis of AVM is rarely necessary.

TABLE 27.4 Schobinger Staging of Arteriovenous Malformation (AVM)

Stage	Clinical Findings
I (Quiescence)	Warm, pink-blue, shunting on Doppler
II (Expansion)	Enlargement, pulsation, thrill, bruit, tortuous veins
III (Destruction)	Dystrophic skin changes, ulceration, bleeding, pain
IV (Decompensation)	Cardiac failure

Treatment

Because AVM is often diffuse, involving multiple tissue planes and important structures, cure is rare. The goal of treatment usually is to *control* the malformation. Intervention is focused on alleviating symptoms (i.e., bleeding, pain, ulceration), preserving vital functions (i.e., vision, mastication), and improving a visible deformity. Management options include embolization, resection, or a combination. Resection offers the best chance for long-term control, but the re-expansion rate is high and extirpation may cause a worse deformity. Almost all AVM will re-expand after embolization. Consequently, embolization is most commonly used preoperatively to reduce blood loss during resection, or sometimes for palliation of unresectable lesions.

Asymptomatic AVM should be observed unless it can be completely removed with minimal morbidity; embolization or incomplete excision of an asymptomatic lesion may stimulate it to enlarge and become problematic. Intervention is determined by: (1) the size and location of the AVM; (2) the age of the patient; and (3) Schobinger stage. Although resection of an asymptomatic Stage I AVM offers the best chance for long-term control or "cure," intervention must be individualized based on the deformity that would be caused by resection and reconstruction. For example, a large Stage I AVM in a nonanatomically important location (i.e., trunk, proximal extremity) may be resected without consequence, before it progresses to a higher stage where resection is more difficult, and

the recurrence rate is greater. Similarly, a small, well-localized AVM in a more difficult location (i.e., face, hand) may be excised for possible “cure” before it expands and complete extirpation is no longer possible.

In contrast, a large, asymptomatic AVM located in an anatomically sensitive area is best observed; especially in a young child who is not psychologically ready for major resection and reconstruction. Resection and reconstruction may result in a more noticeable deformity or functional problem than the malformation. Although the recurrence rate is lower when Stage I AVM is resected, it is still high, and thus even after major resection and reconstruction the malformation can recur. Some patients (17.4%) do not have significant morbidity from their lesion long-term.

Intervention for Stage II AVMs is similar to Stage I lesions. The threshold for treatment is lower if an enlarging lesion is causing a worsening deformity or if functional problems are occurring. Stage III and IV AVMs require intervention to control pain, bleeding, ulceration, or congestive heart failure.

Embolization

Embolization is the delivery of an inert substance, through a catheter proximal to the AVM, to occlude blood flow and/or fill a vascular space. Ischemia and scarring reduce arteriovenous shunting, shrink the lesion, and diminish symptoms. Embolization is used either as a preoperative adjunct to resection or as monotherapy for lesions not amenable to extirpation. Because the AVM is not removed, almost all lesions eventually re-expand after treatment. Stage I AVM has a lower recurrence rate than higher-staged lesions. Most recurrences occur within the first year after embolization, and 98% re-expand within 5 years. Despite the high likelihood of re-expansion, embolization can effectively palliate an AVM by reducing its size, slowing expansion, and alleviating pain and bleeding. Preoperative embolization also reduces blood loss during extirpation, but not the extent of resection.

Substances used for embolization are either liquid (n-butyl cyanoacrylate [n-BCA], Onyx) or solid (polyvinyl alcohol [PVA] particles, coils). The goal of embolization is occlusion of the nidus and proximal venous outflow. The embolic material is delivered to the nidus, *not* to the proximal arterial feeding vessels. Occlusion of inflow will cause collateralization and expansion of the AVM; access to the nidus also will be blocked preventing future embolization. For preoperative embolization, temporary occlusive substances (gelfoam powder, PVA, embospheres) that

undergo phagocytosis are used. Permanent liquid agents capable of permeating the nidus (n-BCA, Onyx) are used when embolization is the primary treatment. The most frequent complication of embolization is ulceration.

Resection

Resection of AVM has a lower recurrence rate than embolization alone and is considered for well-localized lesions or to correct focal deformities (i.e., bleeding or ulcerated areas, labial hypertrophy). Wide extirpation and reconstruction of large, diffuse AVM should be exercised with caution because: (1) cure is rare and the recurrence rate is high; (2) the resulting deformity is often worse than the appearance of the malformation; (3) resection is associated with significant blood loss, iatrogenic injury, and morbidity. When excision is planned, preoperative embolization will facilitate the procedure by reducing the size of the AVM, minimizing blood loss, and creating scar tissue to aid the dissection. Multiple embolizations, spaced 6 weeks apart, may be required prior to resection. Excision should be done 24 to 72 hours after embolization, before recanalization restores blood flow to the lesion.

Resection margins are best determined clinically, by assessing the amount of bleeding from the wound edges. Most defects can be reconstructed by advancing local skin flaps. Skin grafting ulcerated areas has a high failure rate because the underlying tissue is ischemic; excision with regional flap transfer may be required. Free-flap reconstruction permits wide resection and primary closure of complicated defects, but does not appear to improve long-term AVM control. Despite sub-total and presumed “complete” extirpation, most AVMs treated by resection recur. The majority of recurrences occur within the first year after intervention and 86% re-expand within 5 years of resection. Nevertheless, many of these patients remain asymptomatic. Patients and families are counseled that AVM is likely to re-expand following resection, and thus additional treatment may be required in the future.

Capillary Malformation-Arteriovenous Malformation

CM-AVM is a familial disorder; the prevalence is 1 in 100,000. CM-AVM is an autosomal dominant condition caused by a loss-of-function mutation in the *RASA1* gene. Patients have atypical CMs that are small, multifocal, round, pinkish-red, and often surrounded by a pale halo (50%). Thirty percent of individuals also have an AVM: Parkes Weber syndrome (PWS)

(12%), extracerebral AVM (11%), or intracerebral AVM (7%). PWS refers to a diffuse AVM in an overgrown extremity with an overlying CM. PWS involves the lower extremity approximately twice as often as the upper extremity; patients have microshunting in muscle. A patient presenting with multiple CMs, especially with a family history of similar lesions, should be evaluated for possible AVMs on physical examination. Because 7% of patients with CM-AVM will have an intracranial fast-flow lesion, brain MRI should be considered. Exploratory imaging of other anatomical areas is not necessary because extracranial AVM have not been found to involve the viscera. Although the CM is rarely problematic, associated AVMs can cause major morbidity.

Vascular Malformation Overgrowth Syndromes

CLOVES Syndrome

*C*ongenital *L*ipomatosis *O*vergrowth, *V*ascular malformations, *E*pidermal nevi, and *S*coliosis (CLOVES) represents a newly described overgrowth syndrome caused by a *PIK3CA* mutation. Many of these children previously were thought to have "Proteus syndrome." All patients have a truncal lipomatous mass, a slow-flow vascular malformation (most commonly a CM overlying the lipomatous mass), and hand/foot anomalies (increased width, macrodactyly, first web-space sandal gap). Patients also may have AVM (28%), neurologic impairment (50%), or scoliosis (33%). Treatment for the lipomatous lesions is resection, but the recurrence rate is high.

Klippel–Trénaunay Syndrome

Klippel–Trénaunay syndrome (KTS) denotes a slow-flow, capillary-lymphatic-venous malformation (CLVM) of an extremity in association with soft tissue and/or skeletal overgrowth. There is tremendous variability in the presentation of this disorder, from a slightly enlarged extremity with a capillary stain to a grotesquely enlarged limb with malformed digits. KTS affects the lower extremity in 95% of patients, the upper extremity in 5% of patients, and least commonly the trunk. Sometimes the contralateral foot or hand is enlarged, often with a macrodactylous component and frequently in the absence of a capillary stain. In 10% of patients with KTS, the involved limb is hypoplastic. Pelvic involvement is common with CLVM of the lower extremity. It is usually asymptomatic, although hematuria, bladder outlet obstruction, cystitis, and hematochezia can

occur. The CM is distributed in a geographic pattern over the lateral side of the extremity, buttock, or thorax. Whereas the CM is typically macular in a neonate, later it becomes studded with hemolymphatic vesicles. The venous component of CLVM manifests as abnormal drainage of the affected area. The lymphatic abnormalities are typically macrocystic in the pelvis and thighs and microcystic in the abdominal wall, buttock, and distal limb.

MRI is obtained to confirm the diagnosis and determine the extent of the anomalies. A large, embryonal vein in the subcutaneous tissue (the marginal vein of Servelle) is often located in the lateral calf and thigh and communicates with the deep venous system. Complications include thrombophlebitis (20% to 45%) and pulmonary embolism (4% to 24). Unlike some other hemihypertrophy syndromes, patients with KTS are not at increased risk for Wilms tumor and screening US is unnecessary. By 2 years of age, radiologic surveillance of leg length by plain radiography is indicated. If the discrepancy is >1.5 cm, a shoe-lift for the shorter limb can prevent limping and scoliosis. Epiphysiodesis of the distal femoral growth plate is typically done around 11 years of age. Enlargement of the foot may require a ray, midfoot, or Syme amputation to allow the use of footwear. Management of the VM component is conservative with compressive stockings for insufficiency and aspirin to minimize phlebothrombosis. Symptomatic varicose veins may be removed or sclerosed. Sclerotherapy may be necessary for focal macrocystic LM or to treat cutaneous vesicles. Excision and grafting is occasionally necessary for diffuse bleeding and/or oozing cutaneous vesicles. Circumferential overgrowth may be managed by staged contour resection. Venous insufficiency does not occur following staged subcutaneous excision or removal of the marginal vein of Servelle. A functioning deep venous system is present, although it is often difficult to visualize because of predominant flow in the superficial veins.

Parkes Weber Syndrome

PWS is a diffuse AVM in an overgrown extremity with an overlying CM. The disease can be caused by a mutation in *RASA1*. PWS involves the lower extremity approximately twice as often as the upper extremity; patients have microshunting in muscle. The malformation is evident at birth with symmetric enlargement and pink staining of the involved limb. The cutaneous stain tends to be confluent rather than patchy and is typically warmer than a banal CM. The diagnosis is confirmed by the

detection of a bruit or thrill. MRI is obtained to evaluate the extent of the malformation. Overgrowth in an affected extremity is subcutaneous, muscular, and bony with diffuse microfistulas. The enlarged limb muscles and bones exhibit an abnormal signal and enhancement. Angiography demonstrates discrete arteriovenous shunts.

Treatment is predicated on symptoms. In rare instances, an infant presents with high-output congestive heart failure secondary to shunting through arteriovenous fistulas. This situation mandates emergent embolization with permanent occlusive agents, often followed by repeated procedures. Children are observed annually with careful monitoring for axial overgrowth and development of cutaneous problems. Embolization may be useful for pain or cutaneous ischemic changes. Occasionally, amputation is necessary.

PTEN Hamartoma-tumor Syndrome

Patients with *PTEN* mutations, a tumor suppressor gene, have PTEN hamartoma-tumor syndrome (PHTS). This autosomal dominant condition is also referred to as Cowden syndrome or Bannayan–Riley–Ruvalcaba syndrome. Males and females are equally affected, and approximately one half (54%) of patients have a unique fast-flow vascular anomaly with arteriovenous shunting, referred to as a PTEN-associated vascular anomaly. Patients may have multiple lesions (57%), and 85% are intramuscular.

Suspicion of a PTEN-associated vascular anomaly usually is initiated after reviewing the MRI or angiographic study of a patient suspected of having an AVM. Unlike typical AVM, these lesions may be multifocal, are associated with ectopic adipose tissue, and have disproportionate, segmental dilation of the draining veins. If a patient is suspected of having a PTEN-associated vascular anomaly on imaging, a physical examination is performed. Patients with PHTS have macrocephaly (>97th percentile), and all males have penile freckling. In addition, PHTS is associated with mental retardation/autism (19%), thyroid lesions (31%), or gastrointestinal polyps (30%). Biopsy may aid the diagnosis of a PTEN fast-flow lesion. Histopathology shows skeletal muscle infiltration with adipose tissue, fibrous bands, and lymphoid aggregates. In addition, tortuous arteries with transmural muscular hyperplasia and clusters of abnormal veins with variable smooth muscle are present. Genetic testing is confirmative, although a germline mutation is not found in 9% of families clinically diagnosed with PHTS.

If physical examination is consistent with PHTS, molecular testing is necessary because this mutation is associated with multiple benign and malignant tumors which require surveillance. Patients are followed closely for the presence of tumors, particularly endocrine and gastrointestinal malignancies. In addition, the patient and family are counseled about the risk of transmitting the gene to their offspring. Symptomatic lesions are managed similarly to nonsyndromic AVM, with embolization or resection. It is our experience that the recurrence rate after these interventions is even higher than for nonsyndromic AVM, possibly because the loss of the tumor suppressor protein favors a more proliferative environment.

Suggested Readings

Chang LC, Haggstrom AN, Drolet BA, et al. Growth characteristics of infantile hemangiomas: implications for management. *Pediatrics* 2008;122:360–7.

Couto JA, Greene AK. Management of problematic infantile hemangioma using intralesional triamcinolone: efficacy and safety in 100 infants. *J Plast Reconstr Aesthet Surg* 2014;67:1469–74.

Couto RA, Maclellan RA, Zurakowski D, et al. Infantile hemangioma: clinical assessment of the involuting phase and implications for management. *Plast Reconstr Surg* 2012;130:619–24.

Drolet BA, Frommelt PC, Chamlin SL, et al. Initiation and use of propranolol for infantile hemangioma: report of a consensus conference. *Pediatrics* 2013;131:128–40.

Greene AK, Couto RA. Oral prednisolone for infantile hemangioma: efficacy and safety using a standardized treatment protocol. *Plast Reconstr Surg* 2011;128:743–52.

Greene AK, Liu AS, Mulliken JB, et al. Vascular anomalies in 5621 patients: guidelines for referral. *J Pediatr Surg* 2011;46:1784–9.

Hassanein AH, Mulliken JB, Fishman SJ, et al. Evaluation of terminology for vascular anomalies in current literature. *Plast Reconstr Surg* 2011;127:347–51.

Mulliken JB, Glowacki J. Hemangiomas and vascular malformations in infants and children: a classification based on endothelial characteristics. *Plast Reconstr Surg* 1982;69:412–22.

Mulliken JB, Rogers GF, Marler JJ. Circular excision of hemangioma and purse-string closure: the smallest possible scar. *Plast Reconstr Surg* 2002;109:1544–54.



Vascular anomalies are complex disorders encountered by virtually all disciplines of pediatric medicine and surgery. As these anomalies are optimally cared for by multiple specialties, collaboration between pediatricians, pediatric dermatologists, interventional radiologists, ENT, plastics and general surgeons are required. The authors present an excellent overview of a topic.

The nomenclature used to describe these disorders has been difficult to interpret and communicate across specialties. Hemangiomas or AVMs were used to incorrectly label virtually every vascular anomaly. A classification system proposed in 1982 by the senior author of the chapter formed the basis of biologic classification (Mulliken JB, Glowacki J. Hemangiomas and vascular malformations in infants and children: a classification based on endothelial characteristics. *Plast Reconstr Surg* 1982;69(3):412–22). This classification was adopted by the International Society for the Study of Vascular Anomalies (ISSVA). The classification system separated lesions into vascular tumors or vascular malformations. Vascular tumors are differentiated from malformations by the presence of growth. Vascular malformations are thought to be secondary to embryologic errors in the development of blood vessels: capillaries, veins, arteries, lymphatics, or combinations thereof. ISSVA adopted an expanded version of the classification. This revised system again classifies vascular anomalies into tumors and malformations but provides greater detail including newly named anomalies, clinical associations, and genes linked to lesions—further details can be found at the ISSVA website http://issva.org.

As the authors note, infantile hemangiomas (IHs) are the most common tumor of infancy and childhood, occurring in ~4% of children. Ulceration, the most common complication, occurs most frequently in perioral and perineal sites, and often comes to the attention of the pediatric surgeon for management. Patients with an IH should be screened for associated abnormalities. Two primary associations in patients with hemangiomas are noteworthy—the PHACES and LUMBAR syndromes (Metry D, Heyer G, Hess C, et al. Consensus statement on diagnostic criteria for PHACE Syndrome. *Pediatrics* 2009;124(5):1447–56; Iacobas I, Burrows PE, Frieden IJ, et al. LUMBAR: association between cutaneous infantile hemangiomas of the lower body and regional congenital anomalies. *J Pediatr* 2010;157(5):795–801). There is an increased incidence of airway hemangiomas in patients with the PHACES association therefore these patients may require an airway evaluation. For patients with a LUMBAR association, the presence of anorectal malformations and arterial anomalies will require the involvement of a pediatric surgeon. Hepatic hemangiomas are screened for when a patient has greater than 5 cutaneous lesions; however, can occur as solitary or diffuse lesions without cutaneous involvement. Some of these patients present in high output cardiac failure and if medical management fails, may require resection or in the worst case, liver transplantation. The first-line treatment of hemangiomas is no longer oral or intralesional corticosteroids as oral propranolol has been shown to be more effective (Drolet BA, Frommelt PC, Chamlin SL, et al. Initiation and use

of propranolol for infantile hemangioma: report of a consensus conference. *Pediatrics* 2013;131(1):128–40). Patients are treated with dosages of 1 to 3 mg/kg/day. At the initiation of therapy, glucose and vital sign monitoring are warranted. The duration of treatment is for the proliferative phase which is the first year of life. Surgical excision is reserved for lesions that are acutely affecting function or lesions that have involuted and contain fibrofatty residual tissue. Laser treatment can be used for ulcerations and residual telangiectatic vessels.

As the authors observe, lymphatic malformations encompass a wide spectrum of abnormalities and are categorized into three primary types: microcystic, macrocystic, and combined. Lymphatic malformations can be seen in any anatomical region but are more commonly seen the head and neck, axilla, mediastinum, groin, and retroperitoneum. With the significant advances in fetal imaging, the prenatal diagnosis of cervical lymphatic malformations has become common. Large anterior cervical and lingual lesions may be associated with airway obstruction and these patients may require the presence of a fetal surgical team capable of performing an ex utero intrapartum treatment (EXIT) where an airway is secured while the infant is still under maternal placental support (Laje P, Peranteau WH, Hedrick HL, et al. Ex utero intrapartum treatment (EXIT) in the management of cervical lymphatic malformation. *J Pediatr Surg* 2015;50(2):311–4). Treatment of a patient with lymphatic malformations depends on the clinical presentation, the size of the lesion, the anatomical location, and the presenting complications and is best managed by a multidisciplinary team. First-line medical management for complex lymphatic anomalies has become rapamycin (Sirolimus), an m-Tor inhibitor that has been shown to improve quality of life and decrease burden of disease (Adams DM, Trenor CC 3rd, Hammill AM, et al. Efficacy and safety of sirolimus in the treatment of complicated vascular anomalies. *Pediatrics* 2016;137(2):e20153257). Monitoring of rapamycin levels is warranted with a target therapeutic range of 8 to 10 ng/mL.

As the authors recommend, sclerotherapy using doxycycline, ethanol, or OK-432 if available, is the first-line interventional treatment for symptomatic macrocystic lymphatic malformations. Surgical intervention continues to play an important role in the management of lymphatic malformations especially in the resection of microcystic disease. Extensive lesions which involve deep structures of the neck, tongue, and mediastinum engender the risk of multiple complications, including fistula formation, infection, damage to vascular structures and nerves along with a cosmetic deformity therefore should be managed by experienced vascular malformation teams. Surgical debulking in patients with overgrowth secondary to lymphatic malformations can increase function and improve mobility. From a technical perspective, the judicious use of fibrin glue and long-term closed suction drains are critical to minimize the challenge of lymphatic leakage. The adjunctive use of rapamycin may assist in the timely removal of drains and decrease postoperative complications.

Lymphatic blebs that are present in the skin overlying lymphatic malformations represent dermal involvement and may occur within resection scars. They can be treated with CO_2 or KTP laser ablation reducing cellulitis. Recently, topical rapamycin cream has shown efficacy.

Vascular malformations are anomalies that are usually present at birth but may not become symptomatic until the child is older. Venous malformations (VMs) are common consisting of abnormal veins that can be localized or diffuse. VMs are comprised of mitotically inactive endothelium with scant mural smooth muscle and lack valves. As noted in the chapter, most VMs occur sporadically but genetic abnormalities such as the germline mutation in the endothelial cell tyrosine kinase receptor TIE2 must be tested for when multiple isolated VMs are noted, or in patients with a family history of VM (Boscolo E, Limaye N, Huang L, et al. Rapamycin improves TIE2-mutated venous malformation in murine model and human subjects. *J Clin Invest* 2015;125(9):3491–504). Coagulation abnormalities are common with VM. Patients develop pain secondary to the development of a localized LIC caused by stasis and abnormal venous endothelium. Patients with extensive VMs are prone to both bleeding and clotting. This may present as superficial clotting within the malformation or systemic clotting such as pulmonary emboli. When localized within superficial malformations, symptomatic treatment such as warm compresses and anti-inflammatories may be employed. For clots within larger deeper vessels, prolonged systemic anticoagulation is required. Patients should be carefully educated on the symptoms of pulmonary embolus as multiple deaths from PE in these patients have been reported (Huiras EE, Barnes CJ, Eichenfield LF, et al, Pulmonary thromboembolism associated with Klippel-Trenaunay syndrome. *Pediatrics* 2005;116(4):e596–600). Management strategies of VMs include custom compression garments, anticoagulants, sclerotherapy, glue embolization combined with surgical resection. Endovenous laser or radiofrequency ablation is used for ectatic anomalous veins to help prevent the risk of pulmonary embolism from these large capacity veins.

There are multiple subtypes of VM—one of particular interest to the surgeon is the Blue rubber bleb nevus syndrome, which is characterized by discrete VMs of varying size usually between 1 and 2 cm in size present within the skin and GI tract (Jin XL, Wang ZH, Xiao XB, et al. Blue rubber bleb nevus syndrome: a case report and literature review. *World J Gastroenterol* 2014;20(45):17254–9). Lesions within the GI tract may be associated with significant bleeding. These GI venous lesions are often numerous (hundreds of lesions) and are addressed by resection assisted by push enteroscopy.

The author’s present an excellent overview of the established vascular malformation overgrowth syndromes. For CLOVES and hemihypertrophy patients, it is important for the patients to undergo screening for malignancies (liver and kidney) until age 7 as they are at high risk of hepatoblastoma and Wilms tumor.

Great strides have been made within the field of vascular malformations as

an understanding of genetic basis has provided treatment options that were previously unrecognized. Multidisciplinary collaboration in highly specialized vascular centers are the ideal means of treating these complex patients as they do not fall in the purview of a single specialty.

Roshni Dasgupta and Gregory M. Tiao

28 Surgical Treatment of Laryngeal Cancer: A Legacy of Minimally Invasive Innovation and the Preservation of Airway, Swallowing, and Vocal Function

Steven M. Zeitels and John C. Wain

INTRODUCTION

Successful surgical management of laryngeal cancer requires that the clinician integrate a complex algorithm of interdependent host and tumor issues. The patient and surgeon must mutually consider the optimal treatment modality. This is based on the efficacy of cure along with the potential detrimental effects of those interventions on airway patency, voice, and swallowing. The functional outcomes must be assimilated into patients' age, vocal needs, and pulmonary reserve, as well as the skill sets of the surgeon, availability of technology, and prior oncologic history of the patient. These concepts were initiated in the 19th century and progressively established through the 20th century due to the increasing frequency of laryngeal cancer subsequent to the introduction of mass-produced cigarettes.

Remarkably, in the past decade we have observed a substantial change in the epidemiology in laryngeal cancer. New evidence suggests that glottic cancer is clinically and demographically metamorphosing. It is now commonplace for glottic cancer patients to present with morphologically papillary cancer as a result of human papilloma virus (HPV). Furthermore, frequently these individuals have never smoked and develop the disease at a younger age, which is distinctly different from conventional wisdom. It is likely evolving comparably to the experience encountered in HPV oropharynx cancer over the past decade, and similarly the lesions tend to be well-suited to endoscopic treatment. Unlike oropharynx cancer, there is a frequently encountered morphologically similar benign disease recurrent respiratory papillomatosis (RRP), which has been an omnitemporal

problem in laryngeal surgery over the past 150 years. This is of great concern because benign and malignant papillary glottal neoplasms frequently require vastly different treatment so that highly vigilant pathologic assessment is imperative.

The surgical treatment of laryngeal cancer during the last two centuries comprises a rich history chronicling the development of minimally invasive endoscopic laryngeal surgery, upper airway management, swallowing rehabilitation, and voice preservation. Independent and interdependent advances have led to current philosophies in which curative treatment is routine with serviceable airway and swallowing function while optimal vocal outcome remains a pursuit.

HISTORY AND DEVELOPMENT OF GLOTTIC CANCER TREATMENT: THE 19TH CENTURY

Horace Green: The First Direct Laryngoscopic Resection of a Laryngeal Neoplasm

The first endolaryngeal resection of a laryngeal neoplasm can be traced to the monumental achievements of Horace Greene (Fig. 28.1A,B) in the 1840s.

Having been first to routinely treat the trachea transorally, Green's skill and confidence mounted so that his next achievement became one of the most important in human airway management. He was faced with a child who had developed obstructive apnea with accompanying stridor. Using a bent-tongue spatula, along with sunlight for illumination, he performed the first direct laryngoscopy.

Having successfully viewed the laryngeal introitus directly, he observed a ball-valving fibroepithelial polyp that was obstructing the glottal aperture. He proceeded to use a curved forceps to remove the mass. This became the first visually controlled endoscopic resection of a laryngeal lesion, which predated the routine use of mirror laryngoscopy and mirror-guided endolaryngeal surgery.



Figure 28.1. A. Horace Green (1802–1866) was the "Father of American Laryngology." **B.** Green demonstrating blind intubation of the tracheobronchial tree. (From *Harper's Weekly: Dr. Horace Green and His Method.* 1859, February 5:88–90.)

THE EARLY CURES FOR LARYNGEAL CANCER

Remarkably, several years after Green's triumph, Garcia presented mirror laryngoscopy, which catalyzed the formal development of laryngology by Czermak and Turck. Laryngology became highly developed as a result of office-based indirect endolaryngeal diagnoses and procedures.

During this period, Solis Cohen (Fig. 28.2) likely achieved the first cure of laryngeal cancer by performing a laryngofissure and cordectomy for early glottic cancer (1869). To the best that the author can determine, he is the first surgeon to specialize in laryngology having been trained by Samuel Gross and serving the Union as a general surgeon for 4 years of the Civil War. Although there was intermittent use of laryngofissure and cordectomy with varied success in the late 19th century, the procedure was established by Semon, Butlin, and Jackson. Billroth (Fig. 28.3) performed the first total laryngectomy for laryngeal cancer (1874). Although Billroth successfully achieved the resection, Solis Cohen and Gluck perfected the procedure by suturing the trachea to the skin and separating the airway from the pharyngo-esophagus.



Figure 28.2. Jacob Solis Cohen (1838–1927). (Photograph circa 1868, courtesy of Thomas Jefferson University, Archives & Special Collections, Scott Memorial Library, Philadelphia.)



Figure 28.3. Theodor Billroth (1829–1894).



Figure 28.4. Bernhard Fraenkel (1836–1911).

In 1884, Koller and Jelinek introduced topical cocaine for mucosal anesthesia, which became a key chemical platform technology that greatly advanced office-based laryngeal surgery. Soon thereafter, Fraenkel (Fig. 28.4) performed the first successful transoral endoscopic resection of glottic cancer using mirror guidance. It is possible that this represents the first minimally invasive endoscopic cancer cure as well. There were further similar isolated reports over the next 30 years. This early endoscopic cancer treatment achievement did not significantly alter management strategies for glottic cancer, which were primarily composed of transcervical open laryngectomy procedures.

HISTORY AND DEVELOPMENT OF GLOTTIC CANCER TREATMENT: THE 20TH CENTURY

Formal Direct Laryngoscopic Treatment of Glottic Cancer

In 1895, Kirstein (Fig. 28.5) reintroduced direct laryngoscopy, described tracheoscopy, and established this technique as a routine surgical

methodology. It can be argued that this advancement was the most influential in the history of laryngology given the ensuing development of general endotracheal anesthesia, cardiopulmonary resuscitation, and critical care management. Pursuant to our specialty, direct laryngoscopy became the foundation for a majority endoscopic cancer treatment of the upper aerodigestive tract. Kirstein also predicted that Oertel's laryngeal stroboscope would be combined with direct laryngoscopy to enhance patient management of vocal-fold lesions. It was the promise of increased precision associated with direct laryngoscopy and commensurate advancements in anesthesia that subsequently promulgated the migration of direct endolaryngeal cancer surgery to the operating room, where most complex endolaryngeal surgery was done in the 20th century.



Figure 28.5. Alfred Kirstein (1863–1922).



Figure 28.6. Gustav Killian (1860–1921).

Killian (Fig. 28.6) acknowledged Kirstein's achievements and based on this work introduced rigid bronchoscopy and suspension laryngoscopy. After modifying the Killian suspension laryngoscope, Lynch (Fig. 28.7) published a series of 39 patients whose early glottic cancers were excised en bloc by suspension laryngoscopy. This became the first substantial series of endoscopic glottic cancer resections. He carefully selected lesions that were exposed adequately, of small volume, limited to a single vocal cord, and did not extend to the anterior commissure or vocal process. Because of the technical difficulties of suspension laryngoscopy without general endotracheal anesthesia, this approach remained obscure.



Figure 28.7. Robert Clyde Lynch (1880–1931).

Jako commenced experiments with laser technology to remove human tissue in the mid-1960s. By the early 1970s, Jako, Strong, and Vaughan were likely the first surgeons to remove human tissue with a laser and shortly thereafter employed this groundbreaking technology to resect glottic cancer. Thirty years later, Zeitels et al. introduced angiolytic laser treatment of glottic cancer based on Folkman's principles of neoplastic angiogenesis.

GLOTTIC CANCER

Disease Presentation and Philosophy of Management

In the United States, glottic cancer comprises ~6,500 of the new ~10,000 laryngeal cancer cases per annum. Hoarseness is the primary presenting symptom; however, with larger neoplasms, patients may also report airway

restriction, discomfort, hemoptysis, dysphagia, odynophagia, and referred ear pain (otalgia). Glottic cancer is unique as compared with other sites of the upper aerodigestive tract due to the low incidence of regional metastasis and the ease in which the disease is cured locally if the correct surgical procedure is selected.

The success of local control of the primary tumor arises from the fact that the anatomy of the larynx is a relatively isolated "box." It is bounded by a thick cartilaginous frame and dense connective tissue that are resistant to local and regional cancer spread while creating a series of self-contained compartments. This structural composition facilitates a variety of transoral (endoscopic) and transcervical (open neck) partial laryngectomy procedures that strive to preserve the three most critical functions of the larynx: (a) patent adequate airway caliber, (b) competent valve to preclude aspiration during deglutition, and (c) phonation and voice.

Glottic carcinoma is unique as the site of an organ cancer since very small lesions (2 mm) or even precancerous dysplasia can cause a discernable functional deficit, hoarseness. Furthermore, in the overwhelming majority of patients, voice loss is the sole or dominant symptom, which is easily recognizable to friends and family. Since local control is routine and aspiration can typically be avoided, the primary metrics for success in management are airway patency and voice restoration/preservation.

Because of the relative paucity of lymphatics in the true vocal folds, it is uncommon for patients to present with regional metastasis with T1 and T2 diseases. Therefore, small- to mid-sized glottic cancers are ideal for single-modality endoscopic minimally invasive treatment. Remarkably, even those with T3 and T4 lesions often do not have associated adenopathy. However, the surgical treatment majority of T3 and T4 glottic cancers require an open (transcervical) resection with removal of some or all of the cartilage framework (total laryngectomy).

Laryngeal cancer is staged using the standard TNM classification system (Table 28.1) based on the subsite affected (supraglottis, glottis, or subglottis). As with other cancers, the TNM staging has prognostic value for survival. As treatment decisions are often made based on the staging of the cancer, it is valuable to become familiar with this system.

Surgery Versus Radiation

The two definitive treatment modalities for glottic carcinoma are radiation

therapy (XRT) and surgery. Surgical therapy for glottic cancer can be divided into open or endoscopic techniques. Unlike radiotherapy, surgery treats only the areas of disease without ablating and distorting the remaining normal anatomy. Glottic cancer surgery can be done with millimeter margins, thereby decreasing surgical morbidity by sparing normal tissue several millimeters away from the tumor margin. Therefore, surgical resection of selected glottic cancer can be performed with phonosurgical techniques, which allow for precise control of disease with preservation of the vocal ligament, thyroarytenoid muscle, and the superficial lamina propria (SLP). Accordingly, postoperative voice results are excellent, especially when phonosurgical reconstruction is done. Other advantages of surgery include lower cost, diminished time of intercurrent disease, and a very low complication rate. Unlike XRT, endoscopic treatment preserves all treatment modalities, including further endoscopic management. Furthermore, vocal function resulting from angiolytic laser treatment of glottic cancer has resulted in the best voice results to date with continuing cure rates that are >90%.

Radiotherapy treatment of early glottic cancer successfully controls local disease in a majority of cases; however, this advantage is mitigated by the fact that XRT is a single-use treatment and patients with laryngeal cancer frequently have metachronous neoplasms. However, despite a century of success with higher cure rates employing transoral and transcervical function-sparing surgical procedures, glottic carcinoma is typically treated with external beam radiotherapy (XRT) in a majority of Western countries. T1 and T2 diseases are treated with radiotherapy alone, while T3 and T4 lesions are typically treated with XRT and chemotherapy. The primary advantage of this approach is uniformity of management not necessitating highly individualized skills, a key requisite of optimal surgical interventions.

For early disease, the disadvantages of XRT include damage to noncancerous glottal tissue including (e.g., contralateral vocal fold), which is the primary voice source as well as ablation of the saccular glands, which are vital for lubrication of the glottis to facilitate vocal-fold vibration. For advanced disease, it is commonplace for radiation and chemotherapy to cause airway swelling and/or stenosis requiring a tracheotomy as well as severe dysphagia and/or pharyngo-esophageal stenosis, both of which are usually not present pretreatment and extremely difficult to resolve.

Radiation also commonly causes chronic mucositis often masking recurrence while resulting in discomfort, dryness, and taste changes. Less common, patients develop frank osteoradionecrosis of the laryngeal cartilages resulting in any of the aforementioned functional symptoms as well as wound infections. Finally, it is well recognized that a majority of the undesirable effects of radiation therapy are long-lasting and usually irreversible.

In the later 20th century, radiotherapy became the mainstay of treatment for most stages of laryngeal cancer with chemotherapy used adjunctively. This was in part due to the fact that surgeons lack confidence that they could achieve optimal functional results. However, it has now been recognized that there is substantially diminished survival in a variety of stages if surgery is not employed as a primary initial treatment modality. Furthermore, complications and poor functional outcomes (voice, swallowing, and airway) from the nonsurgical regimens are being increasingly recognized. For both initial and salvage treatments, this has catalyzed new opportunities for surgeons skilled in endoscopic approaches for small- to mid-sized tumors as well as open partial techniques for larger tumors. The endoscopic methods for supraglottic primaries will likely be further advanced by robotic innovation due to frequent restrictions in optimal laryngoscopic exposure.

TABLE 28.1 TNM Staging of Laryngeal Cancer

Primary tumor (T)

- TX: Primary tumor cannot be assessed
- T0: No evidence of primary tumor
- Tis: Carcinoma in situ

Supraglottis

- T1: Tumor limited to one subsite of supraglottis with normal vocal cord mobility
- T2: Tumor invades mucosa of more than one adjacent subsite* of supraglottis or glottis or region outside the supraglottis (e.g., mucosa of base of tongue, vallecula, or medial wall of pyriform sinus) without fixation of the larynx
- T3: Tumor limited to larynx with vocal cord fixation and/or invades any of the following: postcricoid area, pre-epiglottic tissues, paraglottic space, and/or minor thyroid cartilage erosion (e.g., inner cortex)
- T4a: Tumor invades through the thyroid cartilage and/or invades tissues beyond the larynx (e.g., trachea, soft tissues of the neck including deep extrinsic muscle of the tongue, strap muscles, thyroid, or esophagus)
- T4b: Tumor invades prevertebral space, encases carotid artery, or invades mediastinal structures

Subsites include the following:

- Ventricular bands (false cords)
- Arytenoids
- Suprahyoid epiglottis
- Infrahyoid epiglottis
- Aryepiglottic folds (laryngeal aspect)

Glottis

- T1: Tumor limited to the vocal cord(s), which may involve anterior or posterior commissure, with normal mobility
  - T1a: Tumor limited to one vocal cord
  - T1b: Tumor involves both vocal cords

- T2: Tumor extends to supraglottis, subglottis, and/or with impaired vocal cord mobility
  - T2a: Tumor limited to one vocal cord
  - T2b: Tumor involves both vocal cords
- T3: Tumor limited to the larynx with vocal cord fixation, invades paraglottic space, and/or minor thyroid cartilage erosion (e.g., inner cortex)
  - T3a: Tumor limited to one vocal cord
  - T3b: Tumor involves both vocal cords
- T4a: Tumor invades through the thyroid cartilage and/or invades tissues beyond the larynx (e.g., trachea, soft tissues of neck, including deep extrinsic muscle of the tongue, strap muscles, thyroid, or esophagus)
- T4b: Tumor invades prevertebral space, encases carotid artery, or invades mediastinal structures

(The authors employ the (a, b) unilateral versus bilateral designation used for T1 lesions with T2 and T3 lesions as well)

Subglottis

- T1: Tumor limited to the subglottis
  - T1a: Tumor limited to one vocal cord
  - T1b: Tumor involves both vocal cords
- T2: Tumor extends to vocal cord(s) with normal or impaired mobility
  - T2a: Tumor limited to one vocal cord
  - T2b: Tumor involves both vocal cords
- T3: Tumor limited to larynx with vocal cord fixation
  - T3a: Tumor limited to one vocal cord
  - T3b: Tumor involves both vocal cords
- T4a: Tumor invades cricoid or thyroid cartilage and/or invades tissues beyond the larynx (e.g., trachea, soft tissues of neck, including deep extrinsic muscles of the tongue, strap muscles, thyroid, or esophagus)
- T4b: Tumor invades prevertebral space, encases carotid artery, or invades mediastinal structures

(The authors employ the (a, b) unilateral versus bilateral designation used for T1 glottic lesions with T1, T2, and T3 subglottic lesions as well)

Classical Endoscopic Glottic Surgery for Early Cancer

The overarching key to successful endoscopic treatment of laryngeal cancer is obtaining the best possible laryngoscopic exposure, which comprises optimal anatomic positioning along with the largest well-designed speculum and laryngoscope holder. Toward that end, we methodically described the key principles for success as well as designing a universal modular glottiscope and a new suspension gallows.

The goal of endoscopic treatment of early glottic cancer is eradication of the disease with maximal preservation of the normal layered microstructure. This approach results in the optimal postoperative voice without compromising oncologic cure. There are four basic procedures that are based on the depth of treatment (Fig. 28.8): (a) dissection just deep to the epithelial basement membrane and superficial to the SLP for

epithelial atypia and microinvasive cancer, (b) dissection within the SLP microinvasive cancer that is not attached to the vocal ligament, (c) dissection between the deep lamina propria (vocal ligament) and the vocalis muscle for lesions that are attached to the ligament but not through it, and (d) dissection within the thyroarytenoid muscle for lesions penetrating the vocal ligament and invading the vocalis. This approach can be fine-tuned further by performing partial resections of any of the layered microstructure.

In the classical surgical paradigm, if dissection is performed in the SLP, cold instruments facilitate precise tangential dissection around the curving vocal fold. This allows for maximal preservation of the SLP and for pliability of the regenerating epithelium. Dissection between the vocal ligament and the vocalis muscle can be performed equally well with cold instruments alone or with assistance by a laser. Dissection within the muscle is performed most precisely with a cutting laser, which allows for improved visualization because of hemostatic cutting properties.

Subepithelial saline–epinephrine infusion into Reinke space improves pre-excisional assessment of lesion depth. If the tumor has invaded the vocal ligament, the SLP at the perimeter of the lesion will distend creating a contour depression in the region of the cancer. The subepithelial infusion assists with the surgeon’s technical execution of the surgery in a number of other ways: (a) The infusion facilitates mucosal incisions by improving visualization of the lateral border of the lesion and by distending the SLP so that the overlying epithelium is under tension. (b) The infusion also increases the depth of the SLP, which facilitates less traumatic dissection in this layer and leads to regenerated epithelium that is more pliable. (c) The epinephrine and hydrostatic pressure of the infusion vasoconstricts the microvasculature in the SLP, and this improves visualization and precise dissection. (d) If a laser is used, the saline acts as a heat sink, which decreases thermal trauma to the normal vocal-fold tissue.

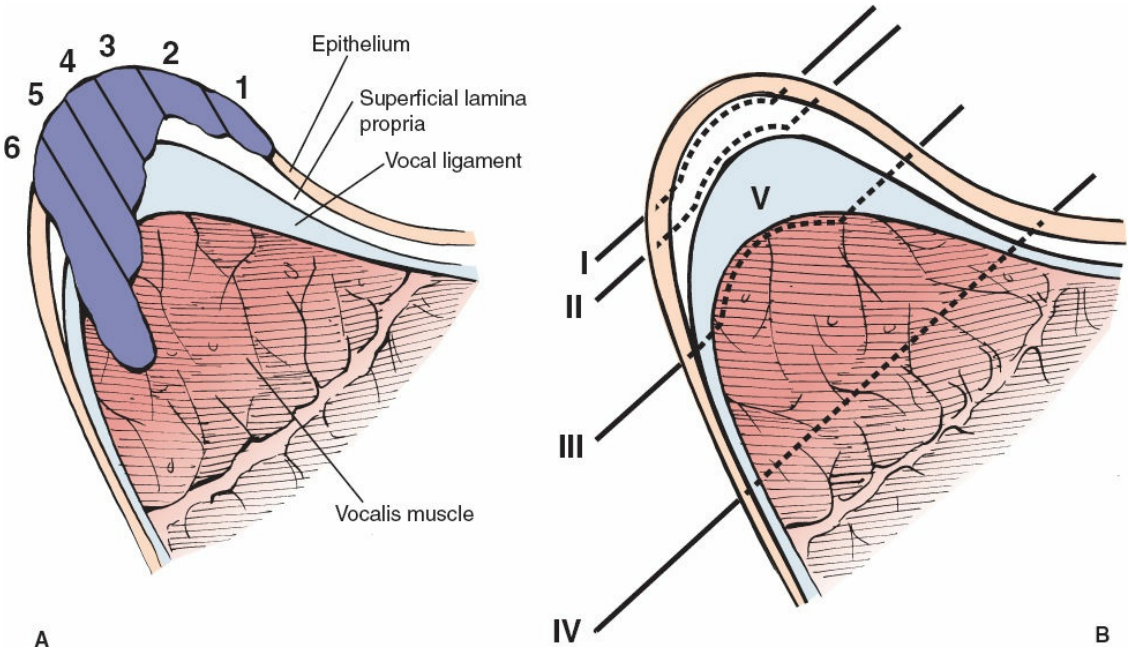

Figure 28.8. Coronal section of the mid-vocal fold displaying. **A.** Different potential depths of tumor invasion. **B.** Classification of different resection depths.

When substantial soft tissue of the glottis was resected, it was commonplace to have some vocal dysfunction due to aerodynamic glottal insufficiency. During the 1990s, we developed a variety of procedures to reconstruct the glottal valve, which were adopted domestically and abroad. The lost paraglottic soft tissue was augmented with fat and/or Gore-tex, and the anterior commissure tendon was reconstructed by means of an anterior laryngofissure and thyroid-lamina subluxation. However, restoring phonatory mucosal pliability remains a challenge.

After a decade of research, we have designed a promising vocal biogel and hope to commence human trials in 2012. This vocal biogel retains the possibility of restoring millions of voices, including hundreds of thousands hoarse laryngeal cancer patients. It will likely even facilitate voice enhancement in patients who have undergone partial or total laryngectomy. In the latter, the mucosal vibration associated with esophageal speech and phonation with tracheo-esophageal valve speech will be made more effective.

Endoscopic Angiolytic Laser Treatment of Early Glottic Cancer

Recently, the surgical resection model was developed further so that fiber-based angiolytic lasers were employed. We had introduced angiolytic lasers (585-nm pulsed-dye laser, 532-nm pulsed-KTP laser) to facilitate

microflap resection of glottal dysplasia in the late 1990s. Photoangiolysis of the subepithelial microcirculation allowed for extremely precise microflap epithelial resection, preservation of histopathologic architecture, and minimal collateral thermal damage to the perivascular SLP.

The promise of the angiolytic laser treatment of early glottic cancer was further supported by concepts of aberrant neovascularity described by Jako and Kleinsasser (Fig. 28.9) in 1966 and intralesional tumor angiogenesis (Figs. 28.10 and 28.11) established by Folkman shortly thereafter in 1971.

Over the past 12 years, >250 neoplasms have been treated by angiolysis with ~95% cure rate. It is likely that this is the first demonstration of employing nonionizing radiation without chemical enhancement (e.g., photosensitizing agents) to involute and treat cancer without resection or gross ablation. This approach combines elements of surgery and radiation to create a unique hybrid approach. The voice results that we have achieved in the cohort of patients herein are typically superior to what we have been able to achieve in the past. This is especially so for those patients who have bilateral disease. There are a number of reasons for the improved voices, all of which can be explained by improvements in posttreatment aerodynamic competency of the glottis and/or enhanced phonatory mucosal pliability through increased preservation of glottal soft tissue including noncancerous SLP, the layer necessary for glottal vibration.

Unlike prior microlaryngeal laser techniques that are used exclusively as a scalpel or indiscriminate ablating device (e.g., CO_2, continuous-wave KTP, and thulium), angiolytic lasers concentrate the energy within the dense aberrant angiogenic microcirculation of the tumors while not penetrating deeply into the normal soft tissue of the vocal fold. Thick tumors are vaporized in a continuous wave mode with simultaneous cooling until the interface with normal underlying soft tissue. The interface is treated in a pulsed mode, and frozen section margins are obtained from the patient to establish that the tumor has been removed. By confining the pulse width to ≤15 ms, the angiolytic laser induces selective heating of the lesions' intralesional/subepithelial microcirculation. This minimizes thermal trauma and fibrosis of the extralesional underlying normal glottal soft tissue, thereby optimally preserving vocal-fold soft tissue necessary for phonatory vibration. Photoangiolytic pulsed-laser treatment of early glottic cancer has the capability of preserving paraglottic-space soft tissue in deeper neoplasms as well as mucosal SLP in more superficial tumors

(Fig. 28.12).



Figure 28.9. **A.** Vascular pattern of normal arborizing microcirculation seen through the transparent epithelium and within the superficial lamina propria of the phonatory mucosa. **B.** Precancerous dysplasia of the epithelium obscures visualization of the subepithelial microcirculation. **C** and **D.** Invasive carcinoma is composed of aberrant disordered and dense microvasculature. (Used with permission of the American Medical Association. Jako GJ, Kleinsasser O. *Endolaryngeal Micro-diagnosis and Microsurgery.* Chicago, IL; American Medical Association. © Copyright American Medical Association 1966. All rights reserved.)

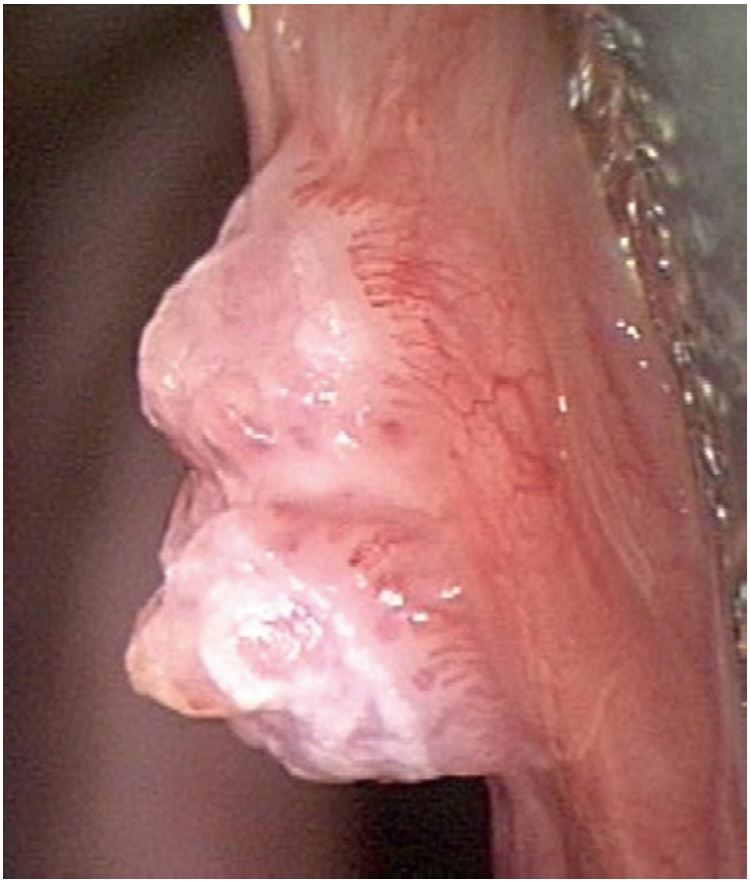

Figure 28.10. Early vocal-fold cancer demonstrating complex looping angiogenic microcirculation.

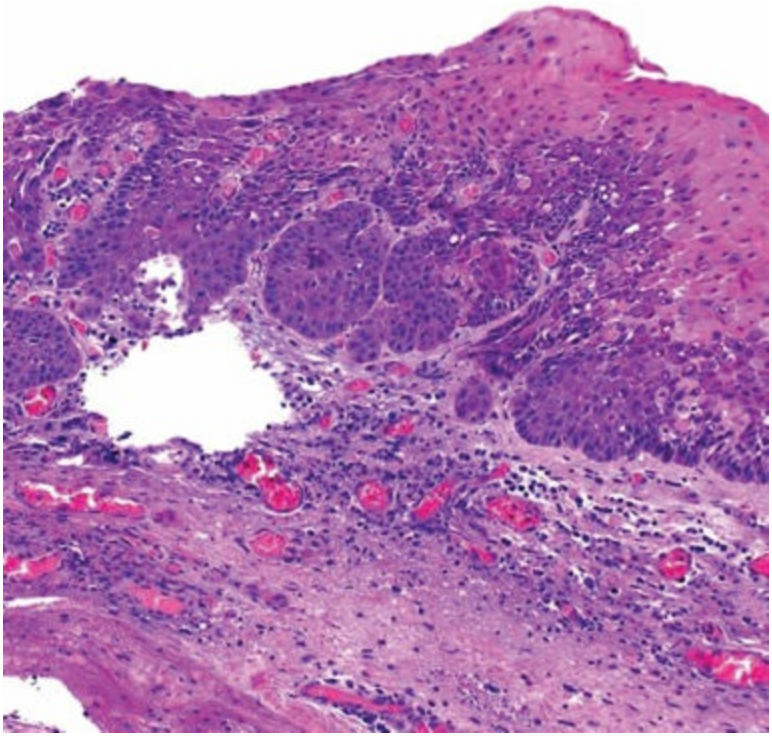

Figure 28.11. Histology of a T1 vocal-fold cancer. Note the vascular channels at the base of the nests of malignant epithelial

cells and the ingrowth of vessels within the neoplasm.

Cancer involvement of the anterior-commissure tendon and/or the arytenoid cartilage is not a contraindication to this technique if adequate laryngoscopic exposure can be obtained. Thyroid cartilage invasion is a contraindication to this approach and requires a transcervical removal of the thyroid lamina. To preserve the architecture of the anterior commissure, it is common to remove tumors with bilateral disease in two stages.

Two-staged pulsed photoangiolytic laser treatment by surgeons using nonionizing radiation retains elements of current phonomicrosurgery and radiotherapy models synthesizing key assets of both and comprises a significant revision of the typical surgical paradigm, which implies effective management as a solitary intervention. This is in contradistinction to radiotherapy and chemotherapy, which are incremental. For the promise of enhanced function, these nonsurgical cancer treatments have achieved acceptability despite the fact that patients have intercurrent disease during months of treatment. Moreover, it has been commonplace for decades for patients with *advanced* primary disease and regional metastasis to undergo incremental chemotherapy and XRT while intercurrent disease is left for 3 to 6 months. Considering this, and the fact that from microlaryngoscopic biopsy to completion of XRT is typically at least 2 months for early glottic cancer, there is no reason to believe that incremental staged endoscopic surgical treatment over the same time period will result in added risk to patients.

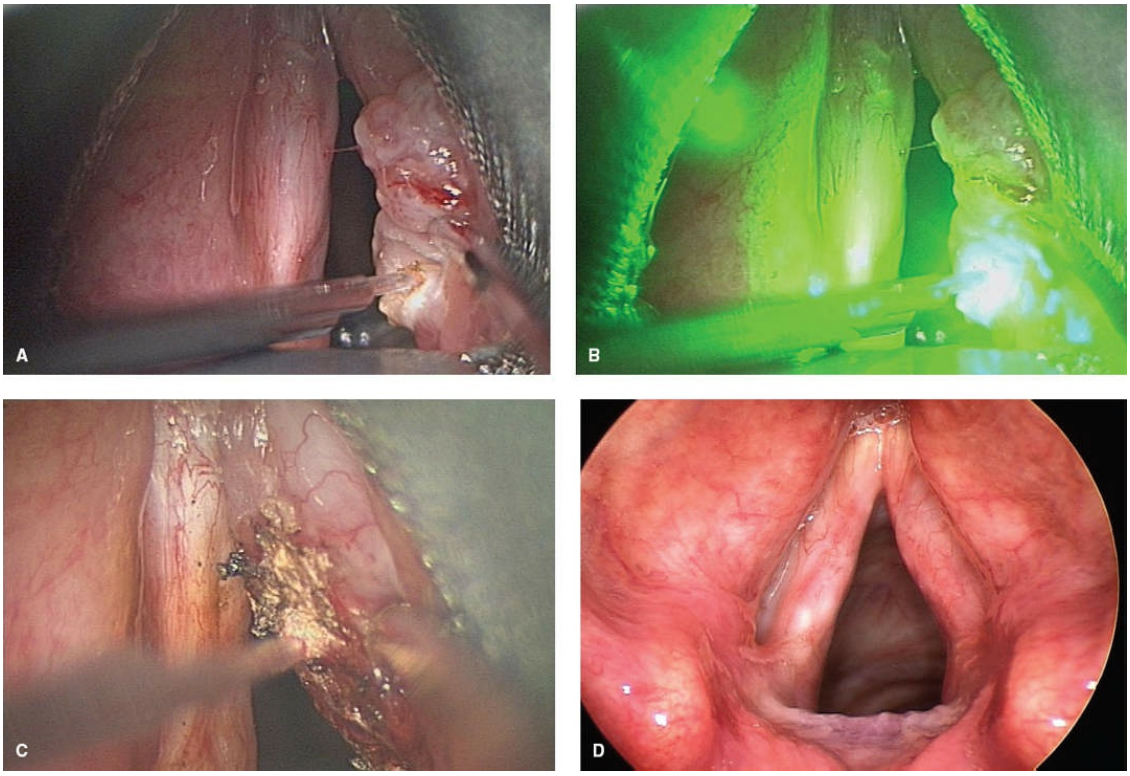

Figure 28.12. **A.** Microlaryngoscopic examination of a right vocal-fold cancer with a 0.4-mm KTP laser fiber directed at the tumor. **B.** A 15-ms pulse of green light is absorbed at the intralesional microcirculation. **C.** Toward the end of the cancer treatment. **D.** Office laryngoscopic examination after healing—the patient is over 4 years without recurrence.

Considering that the three conventional cancer treatments (surgery, radiotherapy, and cytotoxic chemotherapy) evolved from the primary basic sciences (biology, physics, and chemistry), anti-angiogenesis agents became the fourth cancer treatment. However, these agents are used as an adjuvant with other conventional treatment modalities. Based on discussions with Dr. J. Folkman (personal communication), pulsed-photoangiolytic laser treatment of the glottis is likely the first single-modality organ cancer treatment, which capitalizes on his philosophy and represents the fifth cancer treatment.

Endoscopic Angiolytic Laser Treatment of Cancer: Future Considerations

Vocal folds are a unique site to study localized minimally invasive cancer of the upper aerodigestive tract. As stated earlier, metastasis associated with early glottic cancer is extraordinarily rare so that intercurrent disease

is of minimal risk. This provides a unique window of opportunity to design novel strategies that accommodate the distinctive biomechanical and functional requirements of vocal-fold soft tissue. The impediment to future translation will likely be the cost of the instrumentation, which is ~ $850,000. Considering that ~60% of organ cancer is mucosal in origin, concepts developed for the vocal fold might be extrapolated to other sites such as the bladder, gut, tracheo-bronchial tree, and cervix. Furthermore, pulsed-laser photoangiolysis can be done during open procedures or endoscopic ones, and the small laser fibers can be introduced through rigid or flexible endoscopes. Angiolytic lasers could also be considered as a useful adjunct treatment at the perimeter of conventional resections if there are questionable close margins or in fields of condemned mucosa at resection margins.

The findings from the initial investigation support the fact that further research into developing laser technology that is capable of selectively ablating intralesional/sublesional tumor vascularity is a laudable goal. It is not difficult to envision that laser photoangiolytic treatment can be used as a single modality as in this report or it might serve as a cytoreduction and adjuvant treatment. Induction light treatment could be applied at the time of staging endoscopy. Given our office experience with the pulsed photoangiolytic laser treatment of glottal dysplasia with topical anesthesia, it is conceivable that further induction treatment could be continued in the clinic prior to full-course radiotherapy for larger primaries. Given the migration of many surgical interventions to be minimally invasive and/or office procedures, these prospects are not inconceivable.

Endoscopic Vertical Partial Laryngectomy

Endoscopic laser vertical partial laryngectomy can technically be done for a majority of T2 glottic lesions; however, it does require substantial experience. Steiner championed these techniques after visiting with the Boston University group (Jako, Strong, and Vaughan) in the late 1970s. These tumors often encroach or invade intrinsic glottic muscles in the paraglottic compartment. Three-dimensional geographic determination of tumors is done by means of careful staging endoscopy and imaging studies (CT scan or MRI). These resections may be done with a CO_2 laser, with or without a fiber, as well as the thulium and KTP lasers, which are both delivered with a fiber. The primary difference between endoscopic and open transcervical partial laryngectomy procedures is that the cartilage

framework is resected in open procedures. Although laryngoscopic procedures can usually be done without a tracheotomy, transoral procedures preclude immediate vocal reconstruction. After healing has taken place, various reconstructive procedures (previously mentioned) can be utilized (injection laryngoplasty with or without medialization thyroplasty) to restore a laryngeal phonation source. Because of the delayed reconstruction, some surgeons still opt to employ classic open partial laryngectomy techniques.

Open (Transcervical) Cancer Surgery: General Considerations

As reviewed earlier, there has been a rich history in surgical innovation for transcervical removal of laryngeal cancer. Many of the early designs for cancer resection procedures were based on surgeons' experiences in the management of penetrating trauma from hand-to-hand combat as well as homicides and suicides. Furthermore, the techniques for tumor removal and reconstruction have not substantially changed in decades. Furthermore, nuances in variation of the details of these methods are expansive with textbooks devoted to this subject and therefore well beyond the scope of this chapter. Finally, open partial laryngectomy is being done with decreasing frequency except for selected centers of excellence. Therefore, highlights of transcervical resection techniques (Fig. 28.13) will be provided with the reader being encouraged to review comprehensive specialized sources for details.

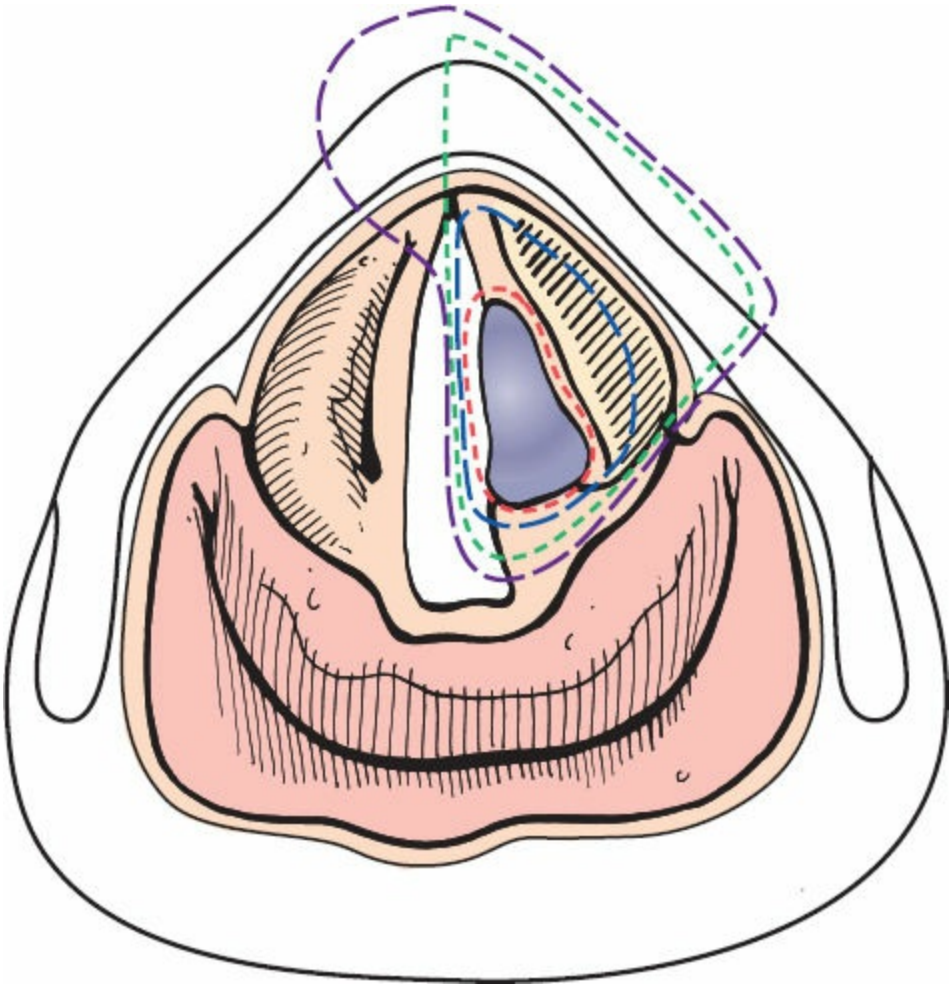

Figure 28.13. Different types of vertical partial laryngectomy procedures based on the size of the lesion to treat glottic carcinoma.

Transcervical Laryngofissure and Cordectomy

Open cordectomy can be used for patients with T1 and selected T2 lesions of the true vocal fold and subglottis who are not candidates for endoscopic laser resection because of limited laryngoscopic exposure. In this procedure, the thyroid cartilage is preserved. After exposing the laryngeal cartilage framework, a tracheotomy is performed prior to entering the larynx. Then thyroid cartilage is separated anteriorly without entering the airway. Next, the cricothyroid membrane is entered to view the glottic tumor from below to adequately resect it. Care is taken to preserve each side of the anterior-commissure tendon insertions. As the laryngofissure is opened, adequate visualization of the neoplasm is achieved; magnifying loupes can be helpful. Once the tumor has been resected, the false cord can be unfolded to reconstruct the resected glottic soft tissue. The thyroid lamina is reapproximated with two 2-0 prolene sutures above and below

the glottis. The strap muscles are reapproximated, and a subplatysmal penrose drain is placed, which helps prevent subcutaneous emphysema.

Transcervical Partial Vertical Laryngectomy

Vertical partial laryngectomy is typically used for T2 transglottic neoplasms extending through the ventricle to the lower false cords but not to the epilaryngeal regions. This initial procedure is similar to laryngofissure and cordectomy including a tracheotomy. However, the anterior thyroid lamina as well as the false cord, true cord, and subglottis are resected en bloc. The classical vertical partial laryngectomy can be extended to include the arytenoid, upper cricoid cartilage, and portions of the contralateral thyroid ala. The reconstruction is achieved by rotating local tissues such as the hypopharynx mucosa, epiglottis, posterior thyroid lamina, and extrinsic strap musculature. There are extensive variations in the use of these local tissues, which are beyond the scope of this chapter and detailed in dedicated texts for laryngeal cancer surgery. The primary goals are to preserve deglutition and when possible, to create an airway caliber that allows for removal of the tracheotomy tube. Until recently, tracheotomy decannulation was unlikely when substantial full-thickness segments of the cricoid cartilage require resection and/or one cricoarytenoid joint. Although a lung-powered laryngeal sound source is routinely achieved, the voice typically has limited pitch range and is often strained and breathy.

Supracricoid Laryngectomy With Cricohyoidopexy

Selected patients with T2 lesions of the glottis or T2 and T3 infrahyoid lesions of the supraglottis who have adequate pulmonary function (similar to horizontal partial laryngectomy patients) are candidates for supracricoid laryngectomy. Typically, the glottic tissue from the arytenoid forward along with the false cords and underlying thyroid laminae is removed. Initial postoperative aspiration is common as in horizontal partial laryngectomy patients. Preservation of both cricoarytenoid joints facilitates eventual tracheotomy decannulation and recover of swallowing function. The phonatory sound source is low-pitched and monotone; however, it is frequently quite strong and arises from oscillation of the peri-corniculate arytenoid mucosa and aryepiglottic folds.

Extended Open Partial Laryngectomy With Aortic Homograft

Reconstruction

Classical extended partial laryngectomy methods are often constrained by the balance of achieving an adequate oncologic resection with retaining enough structural cartilaginous scaffolding and internal soft tissues to achieve tracheotomy decannulation. Local soft tissues and/or regional flaps typically close the defect adequately, but also collapse and narrow the intralaryngeal airway lumen, frequently limiting the ability to decannulate the patient.

In 2009, we initiated wide-field reconstruction of extended partial laryngectomy defects with cryopreserved homograft aorta (Fig. 28.14). Preliminary results thus far are extremely promising, suggesting that this approach will provide new opportunities for organ and function preservation for patients with large laryngeal cancers. In the initial pilot group of seven patients, all of the patients had >40% of the cricoid cartilage removed along with >50% of the laryngeal thyroid cartilage. Four of seven patients had previously failed radiotherapy and five of seven were over 65 years of age. With aortic homograft reconstruction, there were no fistulas or significant complications, all patients resumed a full per-oral diet, and all cases have been decannulated. It is remarkable that there had been prior bench work using aortic homograft for tracheal reconstruction over 50 years ago and renewed interest in recent years.

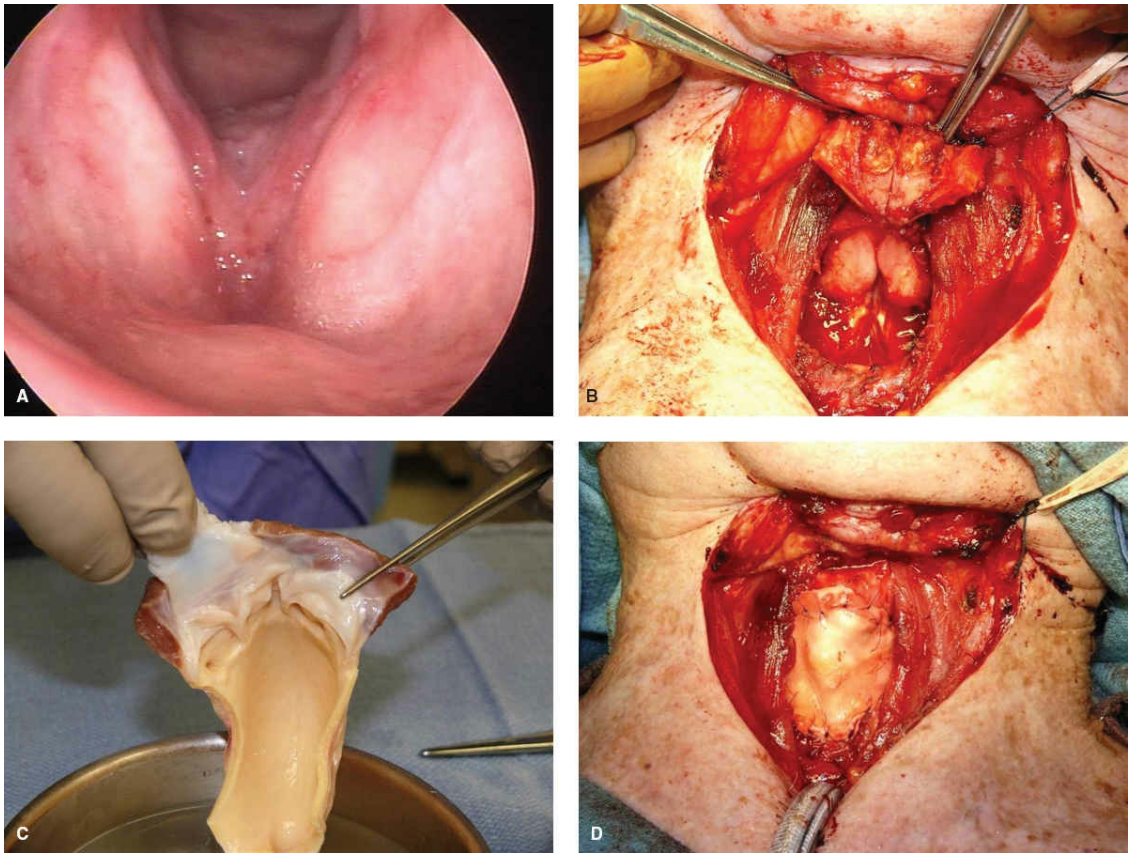

Figure 28.14. **A.** Clinic examination of a medium–large recurrence of a left glottic carcinoma with substantial extension to the subglottis and contralateral right vocal fold. **B.** The specimen is shown including the glottis and subglottis. The undersurface of the false cords is seen remaining in the patient. **C.** The arch of the aortic homograft will be used for the reconstruction. **D.** The aortic homograft is sutured in position to replace the resected areas of the cartilage framework.

Reliably replacing the aforementioned volume of laryngeal cartilage framework with consistent restoration of airway and swallowing function has not been achieved previously. The cryopreserved aortic homograft is unique in several aspects. It is essentially an acellular scaffold so that chemical immunotherapy is unnecessary. The aortic homograft is pliant and retains its rheology in a tubular form, which maintains the airway lumen. The graft is texturally robust so that it is easy to suture into place as a patch and its use requires routine surgical oncologic skills.

The aortic homograft appears to be extremely tolerant of exposure to upper aerodigestive tract reflux, barotrauma from coughing, and microbial flora. It maintains its structural integrity following implantation for prolonged periods of time. Based on our observations, there is ingrowth of

microcirculation from the soft tissues of the neck, which maintains the viability of the graft. However, there is a prolonged period of intraluminal granulation in the airway (2 to 4 months) prior to epithelialization that is similar to wide-field endoscopic resections. This is more substantial in previously irradiated patients but does not preclude decannulation during this period. In the future, it is likely that these grafts will be seeded with patients' mucosal epithelium retrieved in a clinic biopsy, prior to the cancer resection, to hasten epithelialization of the reconstruction, which we have observed to eventually occur.

Total Laryngectomy

Complete extirpation of the larynx has not changed dramatically over the past 125 years apart from diminishing the perimeter margins to preserve uninvolved pharyngo-esophageal soft tissue and developing innovative methods of pharyngo-esophageal reconstruction. Fortunately, this procedure with its attendant morbidity of a permanent tracheostomy and the loss of a lung-powered laryngeal phonation has become relatively infrequent in recent decades. The reason for this decline is multifactorial and includes extensive experience with endoscopic and transcervical partial laryngectomy techniques along with enhanced results with radiotherapy and chemotherapy. Despite these advancements, total laryngectomy remains a valuable treatment option that is often life-preserving in patients who have extremely large neoplasms or have failed prior treatments. A major concern of surgeons who must perform total laryngectomy in those who have failed prior radiotherapy and chemotherapy is the high incidence of severe pharyngo-cutaneous fistula formation. Vascularized nonirradiated flaps have only provided limited mitigation of this morbid routine outcome.

SUPRAGLOTTIC CARCINOMA

Disease Presentation and Philosophy of Management

Supraglottic cancer comprises approximately one third of new laryngeal cancer cases per annum in the United States. Discomfort and a neck mass are of the most common presenting symptoms; however, with larger neoplasms, patients may also report voice changes, airway restriction, dysphagia, odynophagia, hemoptysis, and referred ear pain (otalgia). Unlike glottic cancer, supraglottic cancer frequents presents with regional

metastasis, which is the primary determinant of survival. Similar to glottic cancer, controlling the disease at the primary site is typical with careful treatment selection and vigilant surveillance. However, achieving local control with preservation of optimal airway, swallowing, and vocal function remains as a challenge.

The general success of controlling supraglottic cancer locally is similar to glottic cancer. It is due to the fact that the anatomy of the larynx is composed of a thick cartilaginous frame and dense connective tissue that are resistant to local invasion outside the larynx, thereby creating a series of self-contained compartments. Like glottic cancer, this structural composition facilitates a variety of transoral (endoscopic) and transcervical (open neck) partial laryngectomy procedures.

Unlike the glottis, supraglottic carcinoma typically presents with advanced disease. Initial presentation of precancerous mucosa and early cancer are relatively rare since these lesions are unaccompanied by symptoms. They are typically identified because a patient is under surveillance for previous aerodigestive tract cancer. Pathologic assessment of tumors initially staged as T1 and T2 reveals that the largest majority are T3 and T4. Because of the rich lymphatics of the supraglottis, it is commonplace for patients with supraglottic cancer to present with clinical evidence of regional lymph-node metastasis or occult adenopathy discovered on elective neck dissection.

Preservation of laryngeal function can be a substantial challenge with advanced supraglottic primaries regardless of treatment modality. Smaller volume neoplsms are typically controlled locally with endoscopic removal, open supraglottic laryngectomy, or radiotherapy. Larger supraglottic tumors often require surgery and radiotherapy often including chemotherapy as well. Preservation of normal laryngeal function can be extremely difficult with large supraglottic cancers. Regardless of treatment selection of the primary site, neck lymphatics should always be considered carefully when designing a treatment regimen.

Endoscopic Resection of Supraglottic Cancer

Jackson described piecemeal endoscopic removal of supraglottic cancer over 70 years ago, and this philosophy is conformed to and deemed acceptable to the present. Vaughan championed this approach and performed the first endoscopic supraglottic laryngectomies in the 1970s when the Boston University Otolaryngology group introduced laser

technology to facilitate soft-tissue dissection and surgical oncology. Cutting the tumor into segments was done because the field of resection was substantially larger than the laryngoscope speculae. Steiner, who has been the primary proponent of this philosophy over the past two decades, visited Boston in the late 1970s and subsequently advanced this approach technically. Through steadfast perseverance as well as relentless lecturing and teaching, he has secured worldwide recognition of the effectiveness of endoscopic treatment of laryngeal cancer.

Endoscopic resection of supraglottic cancer provides several advantages over open supraglottic laryngectomy (Fig. 28.15). In most circumstances, a perioperative tracheotomy is not necessary. In addition, the superior laryngeal nerves are not cut so that critically important sensory function of the neosupraglottic valve is retained. This is a key determinant of posttreatment swallowing function in preventing aspiration. With endolaryngeal treatment, wound breakdown leading to fistula formation does not occur. Finally, supraglottic cancer, even in the deep compartments, is typically encased by a capsule, which enhances endoscopic feasibility and efficacy.

There have been two general approaches to endoscopic treatment of supraglottic cancer. This is composed of single-modality transoral resection and the use of endoscopic resection combined with postoperative radiotherapy. The logic of the latter approach is that treating most supraglottic cancers with radiation (alone or with chemotherapy) results in local failure in 25% to 40% of cases and subsequent total laryngectomy becomes necessary. If the primary cancer has been removed endoscopically prior to radiotherapy (induction surgery), local failure is <10%. This endoscopic approach mitigates functional deficits while maximizing larynx preservation. In accordance with this philosophy, our group now performs total or near-total endoscopic tumor removal with the angiolytic KTP laser.

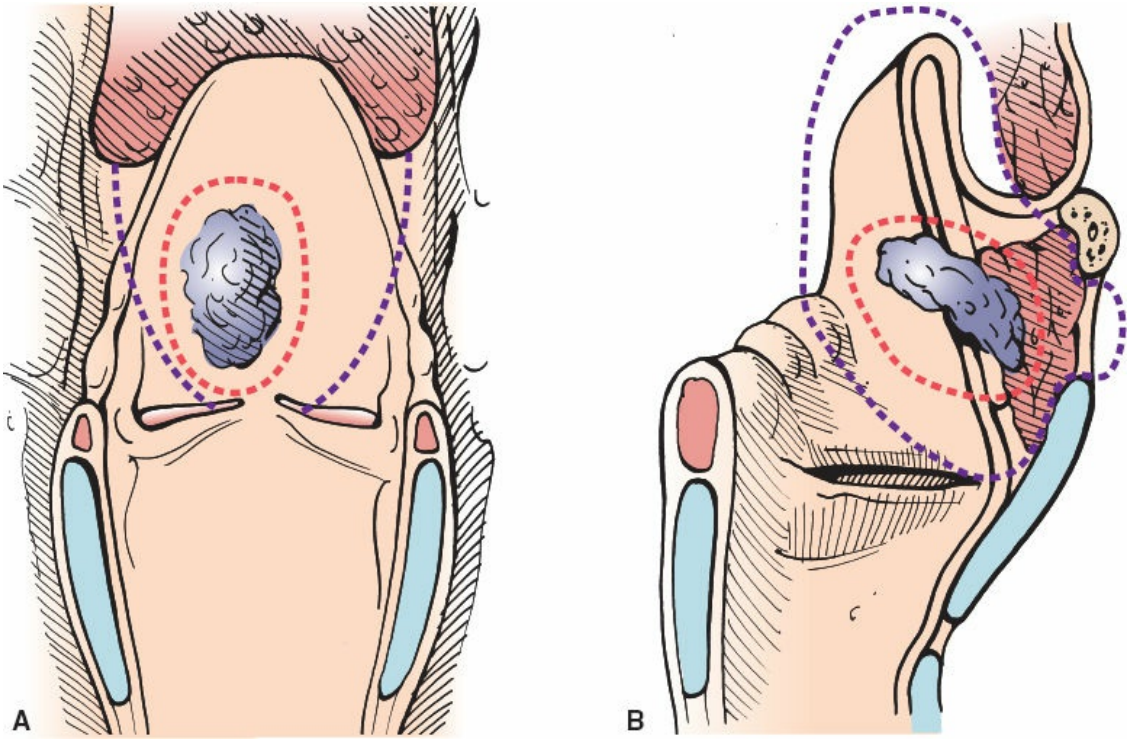

Figure 28.15. **A.** Infrahyoid epiglottic cancer demonstrating the resection boundaries for a wide-field supraglottic laryngectomy and a narrow-field tumor removal. **B.** The same tumor is seen on a sagittal. The piecemeal resection philosophy has always remained problematic for a majority of surgeons trained in classical techniques requiring en bloc removal of the tumor. To address this, over 20 years ago, Zeitels designed a wide bivalve adjustable supraglottiscope that would allow for en bloc supraglottic cancer resection. Despite the success in simulating en bloc open surgery through an endoscopic approach, the technique remained time-consuming and difficult. Remarkably, en bloc resection is being resurrected today with the technical advantages of transoral robotic surgery.

Open Horizontal Supraglottic Laryngectomy (Supraglottic Laryngectomy)

The horizontal supraglottic laryngectomy procedure was perfected in the mid-20th century for T1 to T3 carcinomas confined to the supraglottic soft tissues. This procedure can be extended in all directions to include portions of the tongue base, pyriform sinus, and glottis. Understandably, with wider swaths of pharyngeal and laryngeal soft tissue, there is increased difficulty preserving airway, swallowing, and vocal function. Since aspiration and pneumonia are common complications, patients must have adequate pulmonary reserve and will need to work with a speech language

pathologist postoperatively for swallowing rehabilitation.

A tracheotomy is necessary to perform a supraglottic laryngectomy. Once this is done, a pharyngotomy entry to view the tumor is performed in the oropharyngeal vallecula, glossoepiglottica, or in the pyriform sinus as a lateral pharyngotomy. In 1991, Zeitels described a reliable precise suprahyoid pharyngotomy technique that is valuable for a majority of cancers in the tongue base, larynx, and/or hypopharynx. It is useful to preserve some soft tissue of the supraglottis and its neurovascular pedicle if oncologically feasible since it can be valuable for reconstructing the neo-supraglottic valve for swallowing rehabilitation.

In a classic supraglottic laryngectomy, the upper thyroid laminae are resected with the tumor; however, often this is not necessary if the neoplasm is not adjacent to the cartilage. It is valuable to use magnifying loupes when it is necessary to preserve critical soft tissue such as the anterior-commissure infrapetiole region. To mitigate postoperative aspiration, it is important to resuspend the residual larynx by affixing the thyroid laminae to the hyoid bone with 0 prolene sutures. Complete mucosal closure is not typically feasible so that epithelialization occurs by regional approximation of soft tissues. The tracheotomy tube is removed when the perioperative edema diminishes to sustain an adequate airway lumen and when aspiration is mostly resolved so that tracheobronchial access is not necessary.

SUMMARY

The larynx retains the most complex neuromuscular function of any human organ, which supports human communication as well as balancing respiration and deglutition. Surgical treatment of larynx cancer has been recognized for over a century as an extremely effective treatment. Regardless of size, the overwhelming majority of larynx cancers are controlled locally with surgical removal if the tumor is removed with the correct procedure. Preservation of an adequate airway, as well as swallowing and voice function, becomes the key goal while performing larynx cancer surgery. Remarkably, transoral surgery of laryngeal lesions chronicles a 150-year development of minimally invasive surgery. Solis Cohen established that managing laryngeal disease required high-level skills in endoscopic and open surgery, and this continues to be a requirement of laryngeal surgeons today. These disparate skill sets are especially valuable for larynx cancer surgery. It is not surprising that Solis

Cohen was probably the first surgeon to become a laryngologist and he was also likely the first individual to cure larynx cancer.

Suggested Readings

Anderson R, Parrish J. Selective photothermolysis: precise microsurgery by selective absorption of pulsed radiation. *Science* 1983;220:524–7.

Barbu A, Burns JA, Lopez-Guerra G, et al. Salvage endoscopic angiolytic KTP laser treatment of early glottic cancer after failed radiotherapy. *Ann Otol Rhinol Laryngol* 2013;122:235–9.

Folkman J. Clinical applications of research on angiogenesis. *N Engl J Med* 1995;333:1757–63.

Fraenkel B. First healing of a laryngeal cancer taken out through the natural passages. *Archiv fur Klinische Chirurgie* 1886;12:283–6.

Friedman AM, Hillman RE, Landau-Zemer T, et al. Voice outcomes for photoangiolytic KTP laser treatment of early glottic cancer. *Ann Otol Rhinol Laryngol* 2013;122(3):151–8.

Green H. Morbid growths within the larynx. In: *On the Surgical Treatment of Polypi of the Larynx, and Oedema of the Glottis.* New York: G.P. Putnam; 1852:46–65.

Gussenbauer C. Ueber die erste durch Th. Billroth am Menschen, Ausgerfuhrte Kehlkopf Exstirpation und die Anwendungeines kunstlichen Kehlkopfes. *Archiv fur Klin Chir* 1874;17:343–56.

Hoffman HT, Porter K, Karnell LH, et al. Laryngeal cancer in the United States: changes in demographics, patterns of care, and survival. *Laryngoscope* 2006;116(9 Pt 2 Suppl 111):1–13.

Jako GJ, Kleinsasser O. Endolaryngeal micro-diagnosis and microsurgery. Reprint from the Annual Meeting of the American Medical Association, 1966.

Kirchner JA. What have whole organ sections contributed to the treatment of laryngeal cancer? *Ann Otol Rhinol Laryngol* 1989;98:661–7.

Kirstein A. *Autoscopy of the Larynx and Trachea (Direct Examination Without Mirror).* Philadelphia, PA: The F. A. Davis Co; 1897.

Kirstein A. Autoskopie des larynx und der trachea (Laryngoscopia directa, Euthyskopie, Besichtigung ohne Spiegel). *Archiv fur Laryngol Rhinol* 1895;3:156–64.

Kitamura T, Kaneko T, Togawa K, et al. Supracricoid laryngectomy. *Ann Otol Rhinol Laryngol* 1970;79(6):1027–32.

Lynch RC. Intrinsic carcinoma of the larynx, with a second report of the cases

operated on by suspension and dissection. *Trans Am Laryngol Assoc* 1920;40:119–26.

Martinod E, Seguin A, Pfeuty K, et al. Long-term evaluation of the replacement of the trachea with an autologous aortic graft. *Ann Thorac Surg* 2003;75(5):1572–78; discussion 1578.

Pressman JJ, Simon MB. Observations upon the experimental repair of the trachea using autogenous aorta and polyethylene tubes. *Surg Gynecol Obstet* 1958; 106(1):56–62.

Silver CE, ed. *Surgery for Cancer of the Larynx.* New York: Churchill Livingstone; 1981.

Solis-Cohen J. Clinical history of surgical affections of the larynx. *Med Rec* 1869;4:244–7.

Steiner W. Experience in endoscopic laser surgery of malignant tumours of the upper aerodigestive tract. *Adv Otorhinolaryngol* 1988;39:135–44.

Strong MS, Jako GJ. Laser surgery of the larynx: early clinical experience with continuous CO_2 laser. *Ann Otol Rhinol Laryngol* 1972;81:791–8.

Tucker GF. *Human Larynx Coronal Section Atlas.* Washington, DC: Armed Forces Institute of Pathology; 1971.

Vaughan CW. Transoral laryngeal surgery using the CO_2 laser. Laboratory experiments and clinical experience. *Laryngoscope* 1978;88:1399–420.

Weinstein GS, O'Malley BW Jr, Snyder W, et al. Transoral robotic surgery: supraglottic partial laryngectomy. *Ann Otol Rhinol Laryngol* 2007;116(1):19–23.

Zeitels SM. A universal modular glottiscope system: the evolution of a century of design and technique for direct laryngoscopy. *Ann Otol Rhinol Laryngol Suppl* 1999;108(Suppl 179):1–24.

Zeitels SM. *Atlas of Phonomicrosurgery and Other Endolaryngeal Procedures for Benign and Malignant Disease.* San Diego, CA: Singular; 2001.

Zeitels SM. Glottic cancer: a metamorphosing disease. *Ann Otol Rhinol Laryngol* 2015;125(6):452–6.

Zeitels SM. Jacob Da Silva Solis-Cohen: America's first head and neck surgeon. *Head Neck* 1997;19(4):342–6.

Zeitels SM. Phonomicrosurgical treatment of early glottic cancer and carcinoma in situ. *Am J Surg* 1996; 172:704–9.

Zeitels SM. Premalignant epithelium and microinvasive cancer of the vocal fold: the evolution of phonomicrosurgical management. *Laryngoscope* 1995;105(Suppl 67):1–51.

Zeitels SM. Transoral and transcervical surgical innovations in the treatment of

glottic cancer. *Otolaryngol Clin North Am* 2015;48(4):677–85.

Zeitels SM, Akst L, Burns JA, et al. Office Based 532 nm pulsed-KTP laser treatment of glottal papillomatosis and dysplasia. *Ann Otol Rhinol Laryngol* 2006;115:679–85.

Zeitels SM, Blitzer A, Hillman RE, et al. Foresight in laryngology and laryngeal surgery: a 2020 vision. *Ann Otol Rhinol Laryngol* 2007;116(Suppl 198):1–16.

Zeitels SM, Burns, JA. Oncologic efficacy of angiolytic KTP laser treatment of early glottic cancer. *Ann Otol Rhinol Laryngol* 2014;123(12):840–6.

Zeitels SM, Burns JA, Akst LM, et al. Office-based and microlaryngeal applications of a fiber-based thulium laser. *Ann Otol Rhinol Laryngol* 2006;115:891–6.

Zeitels SM, Burns JA, Dailey SH. Suspension laryngoscopy revisited. *Ann Otol Rhinol Laryngol Suppl* 2004;113(1):16–22.

Zeitels SM, Burns JA, Hillman RH, et al. Photoangiolytic laser treatment of early glottic cancer: a new management strategy. *Ann Otol Rhinol Laryngol Suppl* 2008;117(Suppl 199):1–24.

Zeitels SM, Davis RK. Cancer of the supraglottis: endoscopic laser management. In: Smee R, Bridger P, eds. *Laryngeal Cancer: Proceedings of the 2nd World Congress on Laryngeal Cancer.* Amsterdam: Elsevier; 1994:444–56.

Zeitels SM, Franco RA Jr, Dailey SH, et al. Office-based treatment of glottal dysplasia and papillomatosis with the 585-nm pulsed dye laser and local anesthesia. *Ann Otol Rhinol Laryngol* 2004;113(4):265–76.

Zeitels SM, Healy GB. Laryngology and phonosurgery. *New Engl J Med* 2003;349(9):882–92.

Zeitels SM, Hillman RE, Franco RA, et al. Voice and treatment outcome from phonosurgical management of early glottic cancer. *Ann Otol Rhinol Laryngol* 2002;111(Suppl 190):1–20.

Zeitels SM, Jarboe J, Franco RA. Phonosurgical reconstruction of early glottic cancer. *Laryngoscope* 2001; 111:1862–5.

Zeitels SM, Kobler JB, Heaton JT, et al. Carbon dioxide laser fiber for laryngeal cancer surgery. *Ann Otol Rhinol Laryngol* 2006;115(7):535–41.

Zeitels SM, Vaughan CW. A submucosal vocal fold infusion needle. *Otolaryngol Head Neck Surg* 1991;105:478–9.

Zeitels SM, Vaughan CW. Preepiglottic space invasion in “early” epiglottic cancer. *Ann Otol Rhinol Laryngol* 1991;100:789–92.

Zeitels SM, Wain JC, Barbu AM, et al. Aortic homograft reconstruction of partial laryngectomy defects: a new technique. *Ann Otol Rhinol Laryngol*

2012;121(5):301–6.

EDITOR'S COMMENT

Treatment of laryngeal cancer is multidisciplinary. Surgeons and therapists who deal with cancer of this condition have a particularly heavy burden. The challenge is that the patient may have significant comorbidities and present at an advanced stage of disease. Treatment is focused on organ preservation. The surgeon's role is attempt to cure the cancer while preserving the critical functions of the larynx and surrounding structures including voice, the ability to swallow, and maintain nutrition and respiration. The authors present the rich history of treatment of laryngeal cancer and most recent advances in larynx preservation including transoral endoscopic treatment employing the angiolytic laser with excellent voice preservation and up to 90% cure rates, partial laryngectomy, and phonosurgical reconstruction that preserve critical structures to retain voice function.

The incidence of laryngeal cancer decreased from over four cases per 100,000 persons to about three cases for 100,000. The epidemiology has changed dramatically as will be discussed below. The overall 5-year survival rate is 60.7% (http://seer.cancer.gov/statfacts/html/laryn.html, accessed September 26, 2016). However, the 5-year expected survival rates vary based on the site and stage. For supraglottic tumors, the 5-year survival is: stage 1, 59%; stage 2, 59%; stage 3, 53%; stage 4, 34%. For glottic tumors, including the vocal cords, the 5-year survival is: stage 1, 90%; stage 2, 74%; stage 3, 56%; stage 4, 44%. For subglottic tumors, the numbers are smaller, but the following represent expected 5-year survival: stage 1, 65%; stage 2, 56%; stage 3, 47%; stage 4, 32%.

NCCN Clinical Practice Guidelines in Oncology (NCCN Guidelines) are very helpful and should be reviewed (http://www.medsci.cn/webeditor/uploadfile/201505/20150518152341736.pdf, accessed September 26, 2016). Early-stage laryngeal carcinomas (stage I–II) are ideally treated with either radiation or surgical techniques (either endoscopic or open) that preserve laryngeal function. For carcinoma in situ or early-stage invasive glottic or supraglottic cancer, endoscopic surgical excision and radiation therapy are both equally effective with similar functional outcomes. Certain early-stage lesions may require more extensive resection, in which case open partial laryngectomy options exist that provide good oncologic control, although usually with worse voice outcomes than endoscopic surgery or radiation. Indeed, a recent review of the recent literature demonstrated a paucity of new reports of conventional conservation surgery as initial treatment for early-stage glottic and supraglottic cancer. (Silver CE, Beitler JJ, Shaha AR, et al. *Eur Arch Otorhinolaryngol* 2009;266(9):1333–52.) These authors reported that "transoral endoscopic laser microsurgery (TLS) and radiation therapy (RT)

with or without laser surgery or concomittent chemotherapy have become the standard initial treatments for T1, T2, and selected T3 laryngeal cancer." In addition they indicate "results of TLS are equivalent to those obtained by conventional conservation surgery, with considerably less morbidity, less hospital time, and better postoperative function and oncologic results of TLS and RT are equivalent for glottic cancer, but with better voice results for RT in patients who require more extensive cordectomy."

Whereas T1 and T2 lesions are amendable to a variety of endoscopic techniques, treatment of advanced laryngeal carcinoma may require multimodality treatment and in some cases total laryngectomy. However, it is evident that the role of open surgery for management of laryngeal cancer has been greatly diminished during the past decade. The development of transoral endoscopic laser microsurgery, improvements in delivery of radiation therapy and the advent of multimodality protocols, particularly concomitant chemoradiotherapy have supplanted the previously standard techniques of open partial laryngectomy for early cancer and total laryngectomy followed by adjuvant RT for advanced cancer. In these advanced lesions, induction chemotherapy may play a role as does radiation therapy. The optimal treatment of patients with T3 laryngeal carcinoma seems most controversial. The available options include open partial laryngectomy, transoral laser microsurgery, and radiation therapy alone or combined with chemotherapy. Treatment guidelines, experts' opinions, and clinical studies are highly contradictory. (Riga M, Chelis L, Danielides V. *Eur J Surg Oncol.* 2016 June 10.)

For T3 lesions, an alternative to conventional surgery is concomitant chemotherapy and radiation therapy. Current recommendations of the NCCN Guidelines for achieving laryngeal preservation in cases of locally advanced laryngeal cancer are concurrent radiation therapy and cisplatin 100 mg/m^2 on days 1, 22, and 43. Radiation therapy alone can be considered for patients who are medically unfit to undergo chemotherapy. Accelerated and hyperfractionated treatment schemes may improve the efficacy of radiation therapy. If the patient is not a candidate for the above, then for T3N0 laryngectomy and ipsilateral thyroidectomy are recommended. For T3N1 laryngectomy with ipsilateral thyroidectomy, ipsilateral neck dissection or bilateral neck dissection is indicated.

For T4a lesions, surgery or consideration of concurrent chemoradiation treatment followed by function preserving surgery is an option as is total laryngectomy with thyroidectomy and unilateral or bilateral lymph node dissection. More advanced lesions are usually not amendable to phonation preserving surgery.

The most significant change in our understanding of laryngeal cancer since the sixth edition of *Mastery of Surgery* is the changing epidemiology. Whereas in the past the patient with laryngeal and hypopharyngeal cancer was frequently a heavy smoker and user of alcohol and likely addicted to both, today there is an

increasing number of patients who are younger and never used tobacco products or alcohol but who have HPV infections. The association and clinical significance of HPV infections with a subset of head and neck cancers, particularly for oropharyngeal carcinoma, have been well established. Epidemiologic studies on HPV-associated cervical cancer have clearly demonstrated that HPVs are transmitted by sexual contact, and today there are several studies suggesting that HPV-positive head and neck tumors are also sexually transmitted. However, the involvement of HPV in laryngeal cancer has only recently been clarified. Investigators using several methods of detection have shown HPV DNA in benign (papillomatosis), indolent (verrucous carcinoma), and malignant (squamous cell carcinoma [SCC]) lesions of the larynx. Consistent with the known oncogenic risk of HPV infections, the prevalent HPV types associated with laryngeal neoplasms include those known to have an oncogenic relationship with other oropharyngeal neoplasms. Laryngeal papillomatosis is associated with low-risk HPV types 6 and 11, and neoplastic lesions (verrucous carcinoma and SCC) are more commonly associated with high-risk HPV types 16 and 18.

The larynx is among the most significant anatomic sites in terms of HPV involvement. This is because HPV infection is the etiologic agent of a clinically significant disease known as laryngeal papilloma (papillomatosis). Traditionally, four distinct entities of laryngeal papilloma were considered on the basis of the onset, clinical appearance, and natural history: (1) juvenile solitary, (2) juvenile multiple, (3) adult solitary, and (4) adult multiple. More recently, however, this nomenclature has been replaced by the term RRP, which more accurately describes the widespread extent of the disease and its tendency for repeated recurrence. The observed prevalence of HPV is 80% RPP and is almost as high as in genital condylomas and cervical cancer, which are well-established HPV-associated diseases. The vast majority of RRP are benign squamous cell proliferations induced by HPV types 6 and 11. Despite the basically benign character of these lesions, however, malignant transformation into laryngeal (tracheal, bronchial) SCCs occurs in a certain proportion of cases.

Laryngeal carcinoma may arise as a late complication of pre-existing RRP, but according to the literature the vast majority of these malignant lesions develop without any antedating papilloma, through cancer precursor lesions (dysplasia, intraepithelial neoplasia, carcinoma in situ). Meta-analyses have demonstrated that >25% of laryngeal SCCs harbor HPV infections, with common involvement of high-risk HPV types 16 (highest frequency) and 18. One such study reviewed published studies on HPV infection and laryngeal cancer and quantitatively summarized the prevalence of HPV infection and its association with the risk of laryngeal cancer by means of meta-analysis. (Li X, Li H, Gao J, et al. *J Inf Disease* 2012;10;1093). They included 55 eligible studies. The overall HPV prevalence in laryngeal cancer tissues was 28.0% (95% confidence interval [CI], 23.5%–32.9%). They observed that 26.6% of laryngeal cancer patients were infected with high-risk types of HPV. HPV-16

was most frequently observed with a prevalence of 19.8%. The meta-analysis based on 12 eligible case-control studies suggests a strong association between HPV infection and laryngeal SCC with a summarized odds ratio (OR) of 5.39 (95% CI, 3.25–8.94). Different magnitude of the association was observed for HPV-16 (OR = 6.07, 95% CI: 3.44–10.70) and HPV-18 (OR = 4.16, 95% CI: 0.87–20.04) ($p < 0.01$). Stratified analyses were performed with respect to HPV genotypes and characteristics of the study population.

The clinical implications of HPV-positive laryngeal carcinoma are not fully characterized. However, it may be similar to the prognosis for HPV-positive oropharyngeal cancer patients which is better than that for patients with HPV-negative tumors independent of treatment strategy, nodal status, age, stage, tumor differentiation, or gender. While it is still unclear whether tobacco is a risk factor for HPV-induced oropharyngeal tumors, smoking negatively impacts relapse rates and survival for the HPV-positive tumors. It is estimated that the risk of death and cancer relapse increased by 1% for each additional pack year of tobacco smoking.

Treatment of larynx cancer and epidemiology have changed dramatically over the past several years. HPV plays a role in the etiology. Novel modalities of treatment have been introduced as organ preservation has been developed. In addition, new targeted therapies have appeared; concomitant chemotherapy and improvements in radiotherapeutics and surgical techniques have been introduced. Treatment is multidisciplinary. The variety of treatment options is increasing local control rates and overall survival; however, selecting the most appropriate treatment remains a challenging decision. Organ preservation is a primary goal along with cancer control.

E. Christopher Ellison

29 Surgical Treatment of Pharyngeal Cancer

Bruce H. Haughey and Parul Sinha

The complexity of anatomical and physiologic structure makes pharyngeal cancer surgery one of the most challenging tasks for head and neck surgeons. Cancer originating in each of the pharyngeal subsites—nasopharynx, oropharynx, and hypopharynx—is unique in its biology, epidemiology, and response to treatment and merits a site-specific discussion of the appropriate surgical approach.

NASOPHARYNX

Etiology and Pathophysiology

Nasopharyngeal carcinomas (NPC) are rare head and neck neoplasms characterized by marked geographical, environmental, and ethnic variations. The most recent 2012 report of the International Agency of Research on Cancer estimated the worldwide age-standardized rate (ASR) for NPC to be 1.2 per 100,000. Higher rates have been observed in South East Asia, particularly Southern China, and in certain other ethnic populations like Alaskans and Greenland Eskimos. A genetic susceptibility conferred by alterations in human leukocyte antigen typing or chromosomal patterns and environmental risk factors including consumption of nitrosamine-rich salted fish have been postulated to play an important role in the etiology of NPC. Epstein–Barr virus (EBV) infection has also been documented as a strong oncogenic precursor.

Anatomy

The nasopharynx (Fig. 29.1) is approximately a 4 × 4 × 2 cm space behind the posterior apertures of the nasal cavities (opposite C1 to C2) bound superiorly by the body of sphenoid, petrous apices, and basiocciput and inferiorly by the upper surface of the soft palate. The mucoperiosteum of the roof merges with the posterior soft tissue wall. The posterior wall consists of four layers that run across the entire length of the pharynx—

from inside out, the mucosa, pharyngobasilar fascia, pharyngeal muscles, and bucco-pharyngeal fascia. The lateral walls of the nasopharynx contain the opening of the eustachian tubes (ET). Posterior and medial to the mucosal elevation formed by the ET opening (*torus tubarius*) is a deep recess, “fossa of Rosenmüller,” considered to be the commonest site for harboring NPC. The tumor may spread anteriorly from the fossa to block the ET opening. The proximity of this fossa to skull base structures and parapharyngeal space accounts for direct spread of disease across and through the skull base via invasion of the pharyngobasilar fascia. The nasopharyngeal mucosa is rich in lymphatics, with the lateral retropharyngeal group being the first echelon of nodes (uppermost known as *node of Rouvière*). The lymphatic disease spreads to the upper deep jugular nodes (level II) or the spinal accessory chain of nodes (level V). Lymphatics can also cross the midline to drain in the contralateral neck nodes.

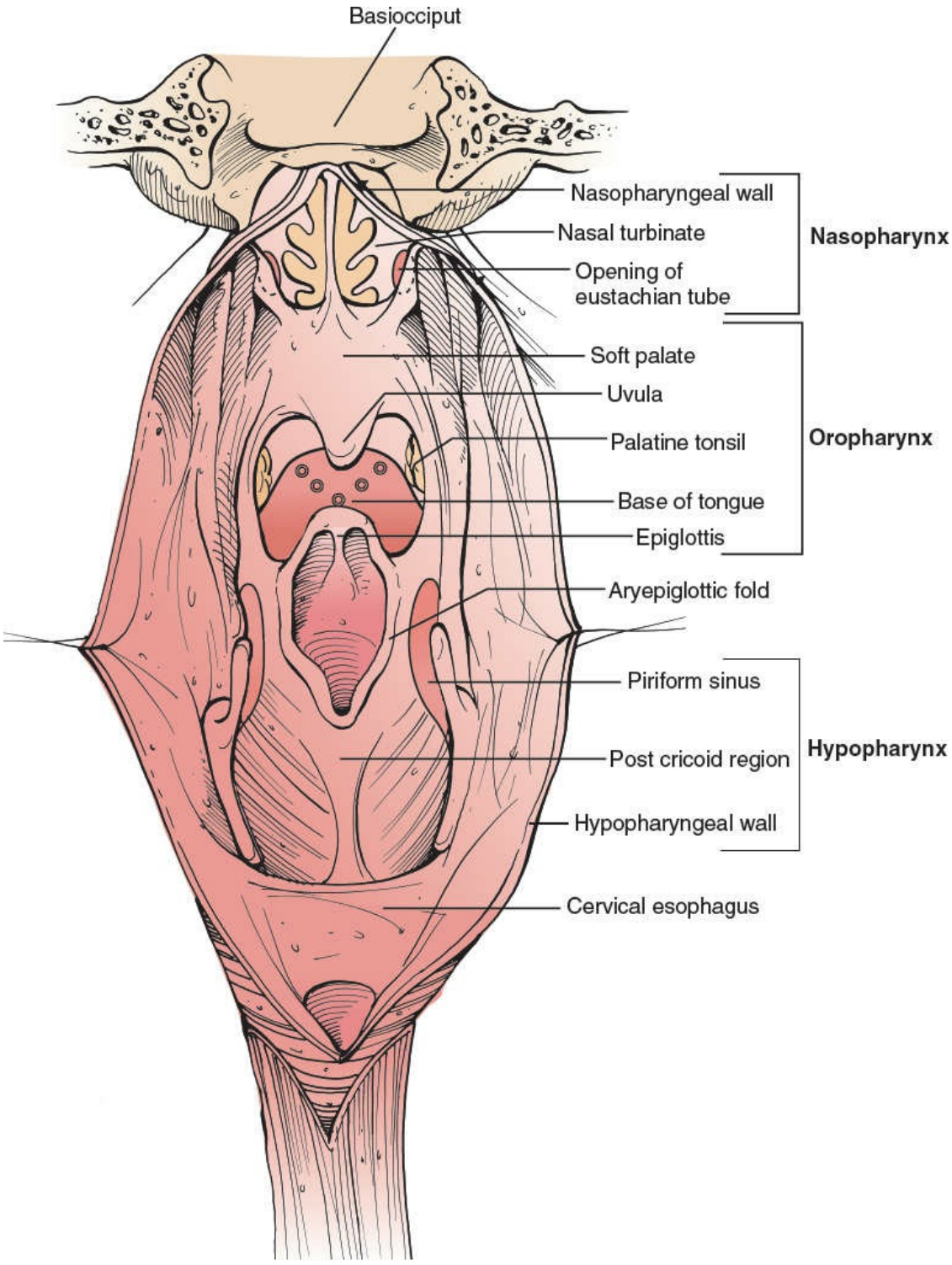

Figure 29.1. Posterior view depicting subdivisions of pharynx.

Clinical Presentation

Patients with NPC commonly present with painless metastatic neck mass(es); otologic symptoms, such as conductive deafness, aural fullness, otalgia or tinnitus; and nasal symptoms, including epistaxis or obstruction. Cranial nerve involvement can result in diplopia (VI, III, IV), facial pain

or dysesthesias (V), palatal and vocal cord paralysis (IX, X), or Horner's syndrome (sympathetic trunk). The characteristic symptoms of local tumor spread in NPC—conductive deafness, facial pain, and palatal paralysis—are collectively referred to as *Trotter's triad.*

Preoperative Planning

A complete head and neck evaluation including rigid or flexible endoscopy with careful assessment of the posterior nasal space along with the examination of the cranial nerves should be performed. Radiologic investigations including computed tomography (CT) and magnetic resonance imaging (MRI) are important to determine the extent and stage (Table 29.1) of tumor and also the appropriate surgical approach.

Treatment

The radiosensitivity of NPC and restricted surgical access owing to the proximity of vital structures have made nonsurgical therapy the primary modality of treatment. The role of surgery is limited to salvage of recurrent or persistent cancer at the primary site without any intracranial spread or neck dissection. The size, location, and extent of tumor as well as involvement of the adjacent soft tissue determine the appropriate surgical approach.

Surgical Technique

Endoscopic

Small lesions without any lateral extension may be amenable to transnasal endoscopic excision but often, the exposure is not sufficient for oncologic resection.

Transpalatal

Retraction or division of the soft palate can provide access to the nasopharynx. Wider exposure is achieved by detaching the soft palate from the hard palate or by incising the palate in midline, which allows retraction after elevating the mucoperiosteum over the hard palate. These approaches need minimal reconstruction but provide limited exposure. For lateral wall tumors, *surgical robot* has been combined with transpalatal approach to enhance visualization and maneuverability of the instruments.

Transcervical

An incision is made parallel to the lower border of mandible. Skin flaps are elevated and the mandible is retracted to expose parapharyngeal and nasopharyngeal space. A wider exposure is acquired through division of lip and mandibular symphysis.

TABLE 29.1 American Joint Committee on Cancer TNM Staging of Pharyngeal Cancer (2010)

Primary Tumor (T)	
TX	Primary tumor cannot be assessed
T0	No evidence of primary tumor
Tis	Carcinoma in situ
Nasopharynx	
T1	Tumor confined to the nasopharynx, or extends to oropharynx and/or nasal cavity without parapharyngeal extension[a]
T2	Tumor with parapharyngeal extension[a]
T3	Tumor involves bony structures of skull base and/or paranasal sinuses
T4	Tumor with intracranial extension and/or involvement of involvement of cranial nerves, hypopharynx, orbit, or with extension to the infratemporal fossa/masticator space
Oropharynx	
T1	Tumor 2 cm or less in greatest dimension
T2	Tumor more than 2 cm but not more than 4 cm in greatest dimension
T3	Tumor more than 4 cm in greatest dimension or extension to lingual surface of epiglottis
T4a	Tumor invades the larynx, extrinsic muscle of tongue, medial pterygoid, hard palate, or mandible[b]
T4b	Tumor invades lateral pterygoid muscle, pterygoid plates, lateral nasopharynx, or skull base or encases carotid artery
Hypopharynx	
T1	Tumor limited to one subsite of hypopharynx and/or 2 cm or less in greatest dimension
T2	Tumor invades more than one subsite of hypopharynx or an adjacent site, or measures more than 2 cm but not more than 4 cm in greatest dimension without fixation ofhemilarynx
T3	Tumor more than 4 cm in greatest dimension or with fixation of hemilarynx or extension to esophagus
T4a	Tumor invades thyroid/cricoid cartilage, hyoid bone, thyroid gland, or

	central compartment soft tissue[c]
T4b	Tumor invades prevertebral fascia, encases carotid artery, or involves mediastinal structures
Regional Lymph Nodes (N)	
NX	Regional lymph nodes cannot be assessed
N0	No regional lymph node metastasis
Nasopharynx	
N1	Unilateral metastasis in lymph node(s), 6 cm or less in greatest dimension, above the supraclavicular fossa, and/or unilateral or bilateral, retropharyngeal lymph nodes, 6 cm or less, in greatest dimension[d]
N2	Bilateral metastasis in lymph node(s), 6 cm or less in greatest dimension, above the supraclavicular fossa[d]
N3	Metastasis in a lymph node(s)[d] >6 cm and/or extension to supraclavicular fossa
N3a	Greater than 6 cm in dimension
N3b	Extension to the supraclavicular fossa
Oropharynx and Hypopharynx	
N1	Metastasis in a single ipsilateral lymph node, 3 cm or less in greatest dimension
N2a	Metastasis in a single ipsilateral lymph node more than 3 cm but not more than 6 cm in greatest dimension
N2b	Metastasis in multiple ipsilateral lymph nodes, none more than 6 cm in greatest dimension
N2c	Metastasis in bilateral or contralateral lymph nodes, none more than 6 cm in greatestdimension
N3	Metastasis in a lymph node more than 6 cm in greatest dimension
Distant Metastasis (M)	
M0	No distant metastasis
M1	Distant metastasis

[a]Parapharyngeal extension denotes posterolateral infiltration of tumor.
[b]Mucosal extension to lingual surface of epiglottis from primary tumors of the base of the tongue and vallecula does not constitute invasion of larynx.
[c]Central compartment soft tissue includes prelaryngeal strap muscles and subcutaneous fat.
[d]Midline nodes are considered ipsilateral nodes.

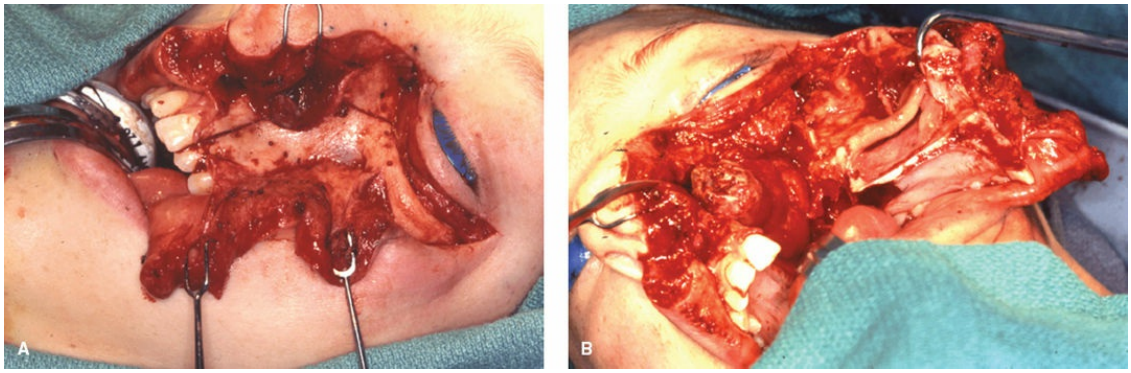

Figure 29.2. Maxillary swing approach: (**A**) elevation of left cheek flap, (**B**) lateral swing of left maxilla with attached skin flap to expose nasopharynx.

Maxillary Swing

First described by Hernandez Altemir (1986), this approach provides a wide exposure for resection of nasopharyngeal tumor. A cheek flap is elevated to expose the anterior wall of maxilla. The osteotomy cuts are made below the roof of orbit, across the zygomatic arch, medial wall of maxilla below the middle turbinate, and hard palate in the midline. The pterygoid plates are removed from the maxillary tuberosity, and after detaching all bony connections the whole maxilla is dropped inferiorly with the attached cheek flap for preserving vascular supply. The entire osteocutaneous complex is swung laterally to expose the nasopharynx for complete extirpation of tumor (Fig. 29.2).

Lateral

Fisch's lateral infratemporal fossa approach can be used to remove tumors in the lateral nasopharyngeal region. The procedure includes a radical mastoidectomy, delineation and mobilization of the facial nerve and internal carotid artery, and division and displacement of zygomatic arch and the mandibular condyle with the muscular attachments to expose the infratemporal fossa. The mandibular branch of trigeminal nerve is divided, and the bone at the middle cranial skull base is removed to access the nasopharyngeal space.

Complications

Palatal fistula may occur in transpalatal approaches, especially in irradiated patients. Maxillary swing approach can lead to ectropion, trismus, and/or malocclusion. The lateral approach is associated with significant functional morbidity, including hearing loss and damage to cranial nerves V and VII.

OROPHARYNX

Etiology and Pathophysiology

Cancer of the oropharynx constitutes about 10% to 12% of all head and neck cancers and annually accounts for about 10,000 cases in the United States. The growing recognition of a disparate shift in its epidemiology, particularly in the Western world, has made oropharyngeal malignancy an intriguing clinical entity among all head and neck sites. The numbers of newly diagnosed oropharyngeal squamous cell carcinomas (OPSCC),

mainly tonsillar and tongue base, are increasing in certain populations at an approximate rate of 4% and 2% each year, respectively. The rise is attributed to a strong etiologic association with oncogenic human papillomavirus (HPV) exposures. HPV-related OPSCC classically presents at younger ages and in persons with none or minimal tobacco exposure. The mode of HPV transmission is yet to be fully elucidated but high-risk sexual behaviors like orogenital contact and multiple lifetime partners are likely contributors.

Anatomy and Surgical Pathology

The oropharynx is anatomically subdivided into (a) base of tongue, (b) tonsils and faucial pillars, (c) soft palate, and (d) pharyngeal wall (Fig. 29.1). Anteriorly, the oropharynx is demarcated by circumvallate papillae, junction of hard and soft palate, and the anterior faucial pillars. The bucco-pharyngeal fascia in the posterior pharyngeal wall (PPW) acts as a natural barrier to prevent the posterior extension of carcinoma. Lateral pharyngeal wall, palatine tonsils, and the faucial pillars delineate the lateral limits of the oropharynx. Inferiorly the oropharynx extends to the vallecula and includes the glossopharyngeal and pharyngoepiglottic folds. Absence of anatomic barriers between the subsites allows oropharyngeal tumors to spread locally in contiguity without restriction. Tumor extending through the lateral wall can involve the parapharyngeal space, including the pterygoid muscles and the carotid sheath structures. Waldeyer's ring, a circumferential, mucosa-associated lymphoid tissue ring in oropharynx comprising the lingual tonsils, palatine tonsils, and inferior part of adenoids, may give rise to primary tumors that metastasize at an early stage and often present as *unknown primaries.* A rich lymphatic network is responsible for the high probability of cervical metastasis from the oropharyngeal tumors. The primary echelon of drainage is the jugulodigastric nodes in the upper jugular chain (level II) and the retropharyngeal and parapharyngeal nodes. Lymphatic spread may advance from level II to middle jugular (level III) and lower jugular nodes (level IV). The medial base of tongue and other midline structures often drain bilaterally.

Clinical Presentation

Oropharyngeal cancer tends to present at an advanced stage. Patients often present with a mass in the neck detected by direct observation or with

symptoms of fullness in the primary site such as sore throat, otalgia, dysphagia, or trismus by which time the tumor has usually progressed to a significant size (Fig. 29.3). A frequent presentation of OPSCC, particularly submucosal tongue base tumors, is in the form of an *unknown primary*, in which patients present with enlarged metastatic neck nodes but no clinically detectable or symptomatic primary tumor. OPSCC is also associated with a high incidence of distant metastases and synchronous primaries at the time of presentation.

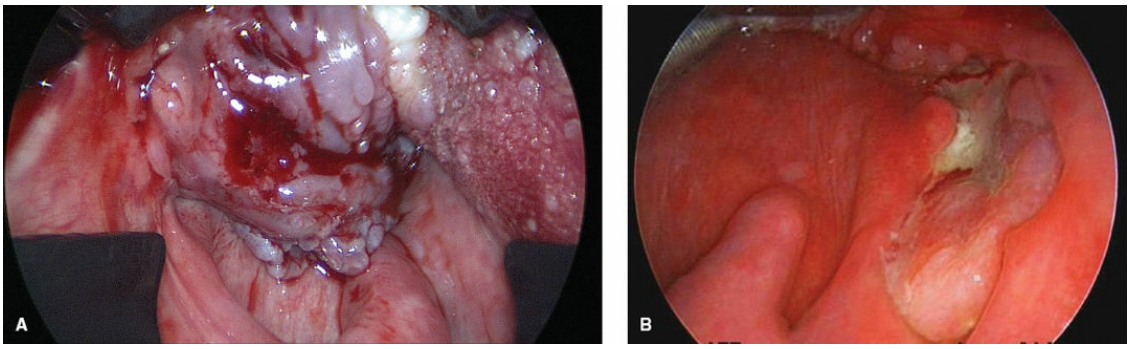

Figure 29.3. (**A**) Exophytic tumor of left tongue base, (**B**) endophytic tumor of right tonsil.

Preoperative Planning

A complete workup to assess the site and stage of primary tumor and presence of cervical lymphadenopathy is indicated. This includes history, physical examination, and a thorough head and neck evaluation including mirror examination, palpation, and office flexible fiberoptic laryngoscopy for direct visualization. Radiologic evaluation with a CT/MRI is performed to determine the extent of primary with greater accuracy as well as to assess the retropharyngeal metastasis. The cervical lymphadenopathy can be reliably assessed by Gray scale ultrasonography, supplemented by ultrasound-guided fine needle aspiration, if indicated. The latter is particularly useful in decision making for or against treating the contralateral neck. Chest radiography, CT, or positron emission tomography (PET) is used to evaluate distant metastasis or second primary tumors.

A systematic rigid pharyngolaryngoscopy examination under anesthesia (EUA) of the upper aerodigestive tract (UADT) along with photo documentation should be performed to assess the primary tumor, detect synchronous primaries, obtain biopsies, and decide the ideal surgical approach—transoral or open. This procedure forms a significant

component of tumor staging, treatment, and reconstruction planning. For patients with *unknown primaries*, a common mode of presentation for OPSCC, we employ transoral laser microsurgery (TLM) with traditional EUA, wherein the potential sites of occult primaries or other suspicious mucosal lesions are biopsied, followed by frozen section and finally by palatine and lingual tonsillectomies if no primary site is identified. The tumor is staged according to the American Joint Commission Cancer staging system based on all information gleaned from clinical, radiologic, and endoscopic evaluations (Table 29.1). An evaluation of the patient's dentition and necessary restorative dental procedures are also recommended prior to initiation of treatment.

Treatment

Definitive surgery with adjuvant radiotherapy has been the cornerstone of curative treatment for OPSCC. Issues of organ preservation and functional morbidity subsequent to conventional open *en bloc* surgery have instigated advocation of nonsurgical management of OPSCC with chemoradiotherapy (CRT), a modality associated with modest survival outcomes and a higher acute and long-term toxicity profile. Rapid advances in technology have shifted the paradigm of surgical management of OPSCC toward minimally invasive endoscopic transoral approaches (Fig. 29.4). These approaches allow primary tumor-targeted treatment, minimal blood loss, rapid wound healing, avoidance of tracheostomy except for extensive oropharyngeal resections with flap reconstruction, better functional preservation, shorter hospital stay, faster rehabilitation, and also facilitation of a less morbid, pathologically stratified, risk-based adjuvant therapy. Biofactors like presence of HPV or its surrogate marker, p16, are reported to confer a favorable prognosis in surgically managed OPSCC. Other independently prognostic variables in such reports of advanced OPSCC were T-classification, margins, and use of adjuvant radiotherapy. The decision for the optimal therapeutic modality is often made by a multidisciplinary team based on tumor site and stage, patient preference, comorbidity, performance status, and available technical expertise.

Transoral Procedures

Transoral Laser Microsurgery

Transoral carbon dioxide (CO_2) laser microsurgery can be used for

resection of both early and advanced stage tumor at all oropharyngeal subsites depending on the individual's surgical skills and training. The basic requirements for TLM include a competent surgical training, knowledge of pharyngeal and neck anatomy "from the inside out," good anatomic access, and strict enforcement of laser-specific precautions in the operating room. The core principles of TLM for oropharynx cancer, as first enunciated by Steiner, are summarized below:



Figure 29.4. Minimally invasive transoral laser microsurgery approach for oropharynx.

1. Utilization of microscope for adequate illumination and magnification of the operative field, and clear distinction between tumor and normal tissue.
2. Expeditious coring of large bulky tumors (with cautery or laser) to leave a thin rind of tumor.
3. Multiple transtumoral cuts to assess the deepest extent.
4. Multibloc resection with meticulous inking and labeling for orientation.
5. Securing clear margins with frozen section analyses; a 1- to 1.5-cm margin of normal tissue beyond the invading front of the tumor is recommended.

An optimum visualization of the operative site is paramount for TLM and is achieved with a combination of modified mouth gags, such as Dingman or Feyh–Kastenbauer, and laryngoscopes, such as Steiner or

Kleinsasser. The instruments may need repositioning during the procedure to obtain a satisfactory exposure; as exposure diminishes, the surgeon progresses from the expanding scopes to the smaller fixed-bore laryngoscopes. Transoral resection of OPSCC is performed with CO_2 laser via either microendoscopy or a handheld device, following the above-mentioned principles. Surgical techniques specific to an oropharynx subsite are described below. The contraindications to TLM include inadequate endoscopic access and tumor extent that may result in incomplete resection, for example, lateral extension through the infratemporal fossa with invasion of the great vessels. In the presence of inadequate access, the transoral approach can be combined with transhyoid or lateral pharyngotomy, using the same incision as neck dissection. The requirement of free flap reconstruction is not a contraindication to the TLM approach, and we have utilized techniques to accomplish suturing in free flaps through the mouth, with the vascular pedicle exiting to the neck through a small pharyngotomy.

Tonsil

Small (<10 mm), well-circumscribed, and truly superficial tonsillar lesions can be resected *en bloc* by performing a tonsillectomy. Larger tonsillar tumors require partial lateral pharyngectomy (Fig. 29.5). They are transected at multiple levels, and a dissection plane is developed deep to the pharyngeal constrictors into the parapharyngeal space and out to the medial pterygoid and/or styloglossus muscle more inferiorly. The tonsillar bed is excised thoroughly by continuing the dissection in the parapharyngeal space from superior to inferior. The superior loop of the facial artery is frequently transected here and requires clipping, also often exposing the lingual nerve and the posterior submandibular gland. The resection is extended to the base of the tongue as required and connected with a cut down the posterolateral pharyngeal wall, thus excising the posterior tonsillar pillar and completing the partial pharyngectomy. The lingual branch of the glossopharyngeal nerve may need to be sacrificed while working just deep to the inferior pole of the tonsil. In very deep tumors of the tonsillar fossa or lateral oropharyngeal wall, it is helpful to perform neck dissection prior to transoral resection since the internal carotid artery can be delineated and cottonoids inserted in the space between the artery and the pharyngeal wall for protection.

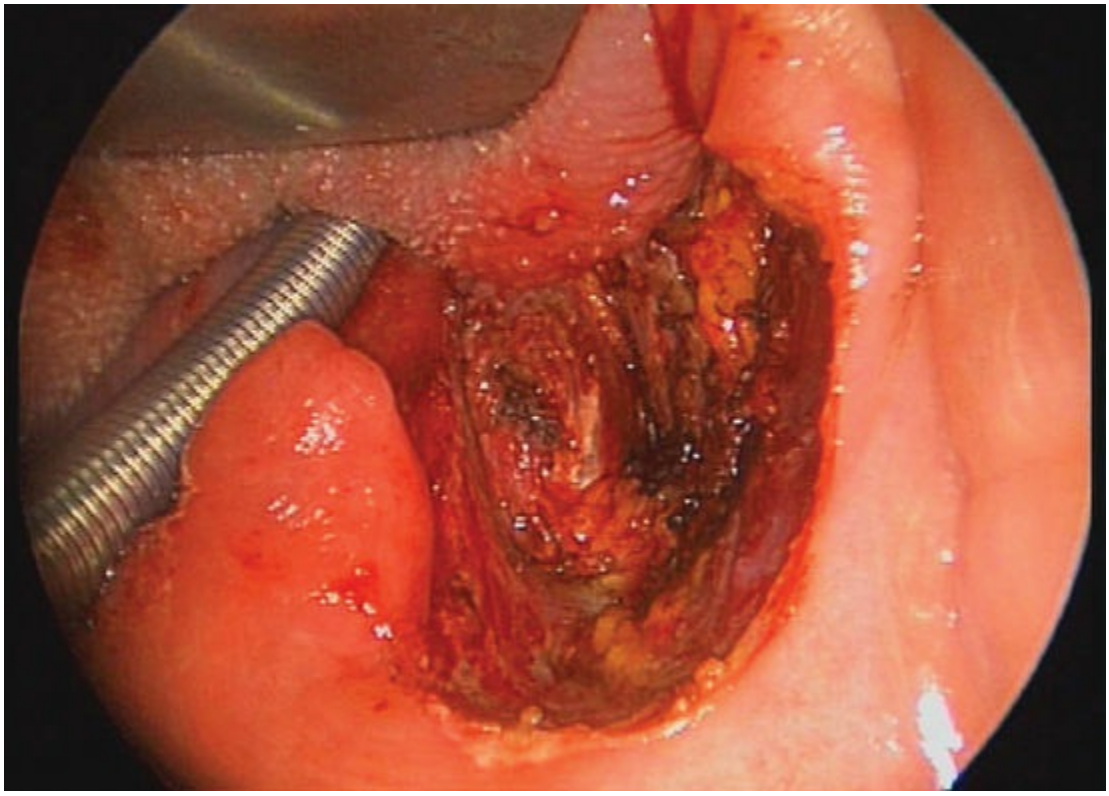

Figure 29.5. Limited partial pharyngectomy for tonsil primary—transoral laser microsurgery approach.

Base of Tongue

The significant intramuscular, submucosal extension of tongue base tumors requires a careful histologic analysis for margin negativity in all dimensions of the resected tumor segment. Achieving negative margins may require complete internal skeletonization of hyoid bone and exposure/excision of pre-epiglottic fat. The lingual artery or its branches need to be clipped if they are exposed, heat-injured, or transected during the dissection. Just lateral to this, from the inside out, is the hypoglossal nerve, which may be exposed or occasionally removed. When the tumor extends in an anterior direction, the lateral posterior floor of mouth needs to be accessed, which is usually accomplished with fixed-bore laryngoscopes. Here the lingual nerve and submandibular gland may be exposed.

Posterior Oropharyngeal Wall

Tumors of the PPW can be completely resected with the TLM approach. The superior and inferior extent of the tumor should be adequately exposed to secure clear margins. The tumors in this subsite and in the tonsil or soft palate may extend superiorly into the nasopharynx and their

resection may result in varying degrees of velopharyngeal incompetence or nasopharyngeal stenosis, which can be prevented by adequate reconstruction.

Hemostasis

It is important to achieve meticulous hemostasis at the completion of all procedures for oropharyngeal tumors, particularly tonsillar and tongue base lesions, because of proximity or transection of large named branches of the external carotid artery. If the lingual, facial arteries or their major branches are involved in the resection, the named vessel of origin is clipped in the neck during the neck dissection, obviating secondary hemorrhage, which can be catastrophic.

Transoral Robotic Surgery

Transoral surgery with robotic assistance (da Vinci Surgical system) is an emerging approach that has been found to be feasible for small oropharyngeal tumor resection with minimal disruption of function and structure (Fig. 29.6). Unlike TLM, the tumor is usually removed *en bloc* in transoral robotic surgery (TORS) with a cuff of normal tissue. The setup time, expense, access difficulty for rigid robotic arms, and compatibility issues of TORS with the routine operating requirements such as neck dissection currently confine it to select treatment centers and smaller, less deeply invasive primaries. The technique requires an assistant who has to perform suction and hemostasis around the three arms of the robot. The desired outcome of TORS is the same as for TLM, that is, a margin negative primary tumor resection accomplished entirely through the mouth. Technology improvements such as flexible delivery of the working tips, better robotic haemostatic capability, and miniaturization may promote more widespread use of the robot in future.

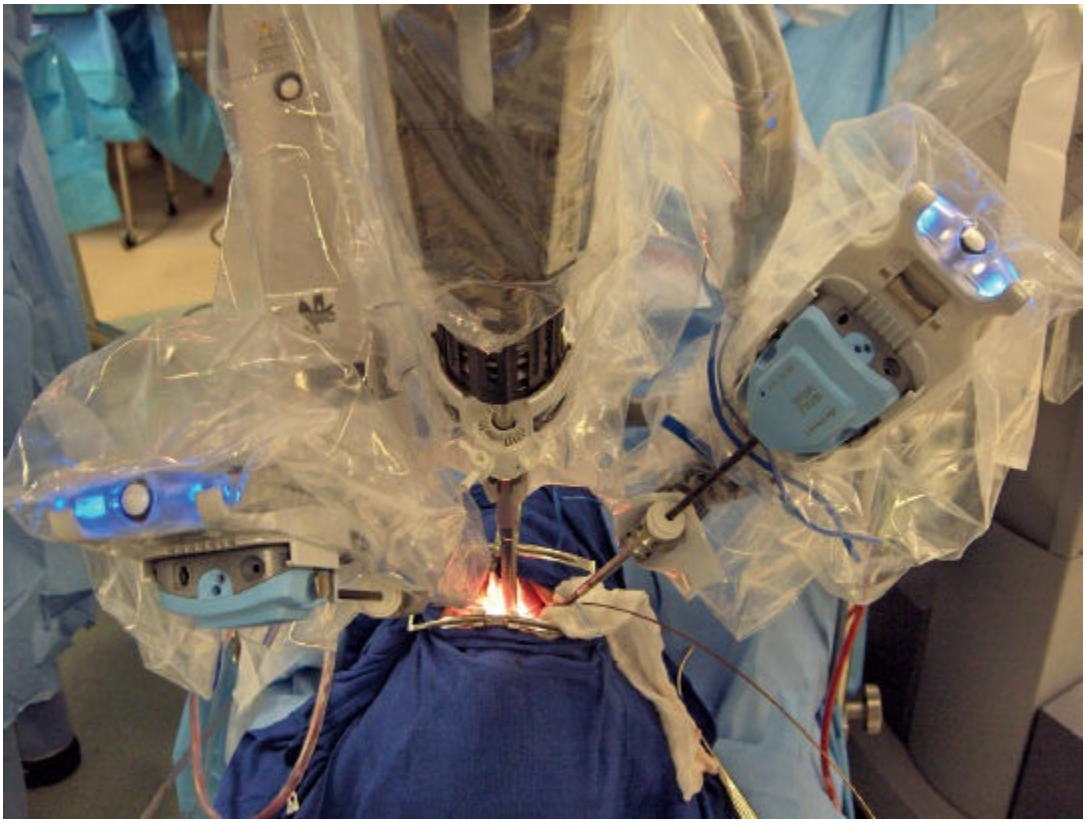

Figure 29.6. Transoral robotic surgery approach for oropharynx.

Transoral Approach to Unknown Primary

The oropharynx is a common site for detection of an occult, clinically undetectable primary tumor in patients presenting with metastatic neck nodes, which are HPV and/or p16-positive. Panendoscopy, tonsillectomy, and directed biopsies have been the traditional diagnostic procedures for an unknown primary. At Washington University in St. Louis, a TLM approach was developed for detection of unknown primary, which resulted in higher detection rates and an opportunity to simultaneously remove the primary to a negative margin. The TLM approach includes examination under anaesthesia followed by biopsy of pharyngeal sites with mucosal abnormalities as observed under the highly magnified view of an operating microscope, or the endoscopic camera of a da Vinci robot. In the absence of pathologic detection of a distinct primary site on frozen section of the biopsy, removal of the ipsilateral lingual and palatine tonsils is performed using the TLM technique. Similar approach to detection of unknown primaries has also been reported using TORS, although targeted primary resection is less common using robotic technology.

Open Procedures

Transhyoid Pharyngotomy

Small base of tongue tumors can be accessed through a transverse incision made at the level of hyoid. The suprahyoid muscles are divided from the hyoid bone, and the oropharynx can be entered through incision of the vallecular mucosa. Care should be taken to avoid injury to the superior laryngeal nerve, the hypoglossal nerve, and the lingual artery.

Lateral Pharyngotomy

A temporary tracheostomy is usually recommended in patients undergoing lateral pharyngotomy to prevent the potential airway obstruction secondary to postoperative pharyngeal edema. The skin incision is made at the level of the superior border of the thyroid cartilage extending from the midline to the posterior border of sternocleidomastoid. The suprahyoid muscles are detached from the hyoid above its lateral end, the mucosa is divided, and the pharynx is entered through the vallecula. A pharyngocutaneous fistula may develop as a complication in cases with significant mucosal resection, warranting a careful pharyngeal closure with inverting mucosal sutures.

Mandibular Swing

Advanced oropharyngeal tumors in patients with factors limiting transoral surgery may require an *en bloc* resection through the transmandibular approach (Fig. 29.7). A tracheostomy is performed prior to these procedures. A stepped skin incision is usually performed through the midline of the lip (full thickness) down to the mentum, and is continued into the neck dissection incision below the mandible. Inside the oral cavity, it is extended laterally in the gingivobuccal sulcus, leaving a cuff of approximately 5-mm mucosa for closure at the completion of procedure. As an alternative to the lip-splitting incision, a visor flap can be raised with a horizontal incision in the submandibular skin crease carried across to the angle of the mandible on either side. The soft tissues and periosteum are incised and elevated from the bone in the region of the mandibular split. At the site of intended osteotomy, fixation plates are placed and screw holes are drilled and sized to facilitate accurate alignment of bone during reconstruction. A stepped midline or paramedian mandibulotomy is performed using an electric saw, anterior to the mental foramen and through the middle of a tooth socket or between teeth. The floor of mouth mucosa, mylohyoid muscle, and other soft tissues are divided, preserving the lingual nerve medially, and the mandible is retracted laterally to expose the oropharyngeal tumor. Proper stabilization of the mandibular segments

and a close approximation of mucosa and soft tissue at the end of procedure are imperative to minimize complications with healing.

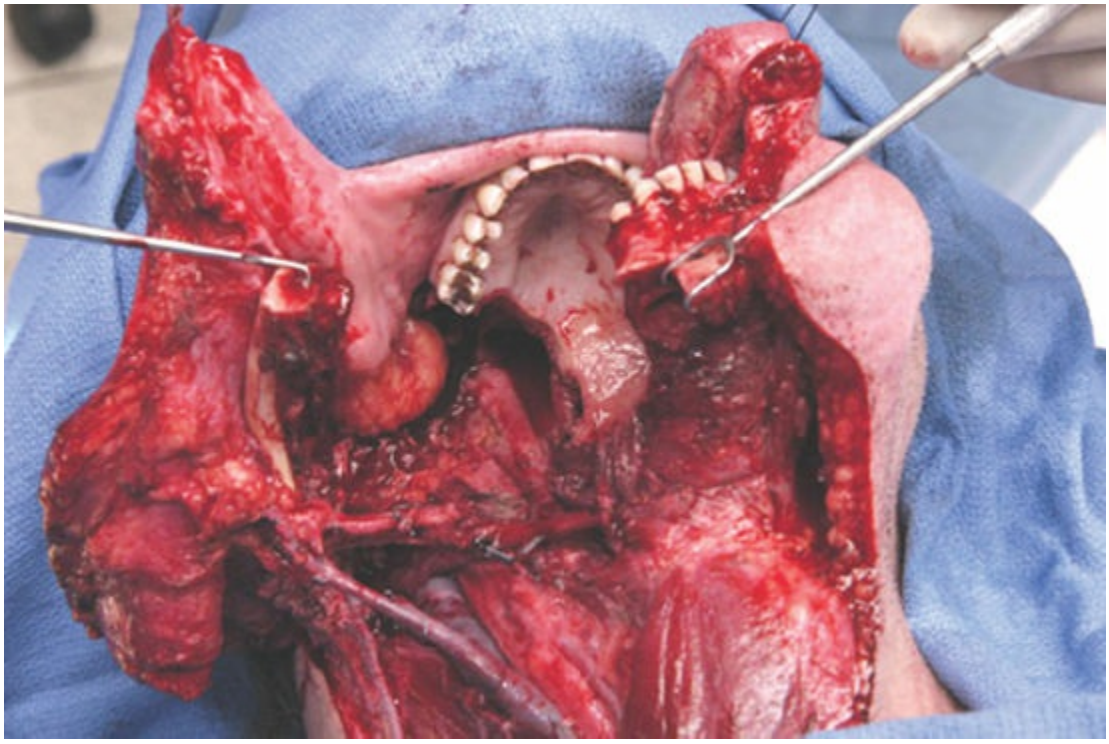

Figure 29.7. Mandibular swing access following *en bloc* resection of advanced oropharynx cancer.

Oropharyngeal Reconstruction

The oropharynx subserves the fundamental functions of swallowing, speech, and respiration; hence, oropharyngeal defect reconstruction should be in utmost consonance with the physiologic mechanisms underlying these functions. The size and site of defect as well as various patient- and surgeon-related factors determine the type of reconstruction.

Base of Tongue

Tongue base reconstruction is critical to deglutition and prevention of aspiration. Free fasciocutaneous flaps have become the standard technique of reconstruction for tongue base defects, with radial free forearm flap (RFFF) being the most commonly used followed by anterolateral thigh (ALT) flap. For RFFF, adequacy of radioulnar collaterals should be ascertained preoperatively with Allen's test. Free musculocutaneous flaps like innervated latissimus dorsi can provide adequate reconstruction for total glossectomy defect. Regional myocutaneous flaps are used for patients who are poor candidates for free tissue transfer.

Soft Palate

Large, full-thickness soft palate defects (50% or more) result in velopharyngeal incompetence, in turn resulting in nasal regurgitation and unintelligible speech. The aim of palatal reconstruction is to fabricate a functional velum and minimize unwanted communication between the nasopharynx and the oropharynx. Local flaps like uvulopalatal rotation flap, superior or inferior pharyngeal flap, and palatal island flap can provide adequate reconstruction for limited lateral palatal defects, but for through-and-through defects, RFFF is the technique of choice.

Tonsil and Pharyngeal Wall

Tonsillar and pharyngeal wall defects of less than 4 cm can be left to heal by secondary intention. Split skin grafting may be used for superficial pharyngeal defects. For larger defects with significant palatal involvement, we prefer use of a folded RFFF.

Management of the Neck

A selective or modified radical neck dissection is performed in patients with clinically positive necks. The ipsilateral clinically N0 neck should be addressed electively due to a high incidence of occult nodal metastases in oropharynx. Tumors of tongue base and tonsil approaching or extending across the midline present a rationale for contralateral elective neck dissection or radiation due to a greater risk of occult contralateral metastases.

Postoperative Care

A vigilant monitoring of vital signs, flap viability, nutritional status, and wound care is performed. A nasogastric tube is inserted for feeding in the immediate postoperative period. Swallowing recovers faster in patients undergoing TLM; however, a gastrostomy tube may be required in patients with extensive resection, slower recovery of swallowing, or in those planned for adjuvant therapy. Prophylactic antibiotics and mouthwashes are administered to maintain oral hygiene and prevent infections subsequent to salivary pooling or food retention in tongue base or vallecular wound defects.

Complications

Injury to blood vessels and cranial nerves V, VII, IX to XII; trismus; wound breakdown; dysphagia; and dysarthria may occur with the open

approach. Mandibular nonunion can result due to incomplete stabilization of the mandibulotomy site in open approaches. The complications rates are significantly reduced with TLM and skilled reconstruction techniques. Pain, bleeding, aspiration, dysphagia, or velopharyngeal insufficiency may occur following TLM resection, with a varying incidence for different oropharyngeal subsites.

HYPOPHARYNX

Etiology and Pathophysiology

Hypopharyngeal squamous cell carcinoma accounts for about 4% of all tumors in head and neck, with about 3,400 diagnosed cases in the United States, according to the most recent 2015 estimates of the American Cancer Society. It has been considered to portend a poor prognosis mostly due to the advanced stage of disease at presentation. Heavy alcohol and tobacco consumption are the two well-established risk factors. In Scandinavian regions, iron deficiency has been implicated in causation of postcricoid carcinoma in females with Plummer–Vinson syndrome.

Anatomy and Surgical Pathology

The hypopharynx extends from the level of hyoid to the lower border of the cricoid cartilage (opposite C3 to C6 vertebrae) and is subdivided into three regions—the pyriform sinus (PFS), the postcricoid area, and the PPW (Fig. 29.1). The PFS lies on either side of the larynx and extends from the pharyngoepiglottic fold superiorly down to the upper end of esophagus. It is bound by the thyroid cartilage laterally and the aryepiglottic fold and arytenoids medially. The postcricoid area extends from the level of arytenoids to the inferior border of cricoid. The PPW extends from the plane of floor of vallecula to the inferior border of cricoid. The lateral and medial wall of the PFS is continuous with the PPW and postcricoid area, respectively. The PFS is richly supplied by lymphatics that drain into the lower deep jugular chain (level IV); the inferior part along with the postcricoid area can also drain into paratracheal chain (level VI) nodes. The lymphatics from the PPW drain into the deep cervical lymph nodes bilaterally through the lateral pharyngeal or retropharyngeal nodes.

Extension of hypopharyngeal tumors beyond their subsite of origin is critical for surgical planning. PFS tumors tend to spread medially around

on to the postcricoid area and invade the posterior cricoarytenoid muscle. Laterally they extend around or invade the posterior border of the thyroid cartilage, to reach the neck and carotid sheath area. Postcricoid tumors tend to spread inferiorly and submucosally toward the esophagus, and likewise posterior wall tumors. The latter may also invade posteriorly outside the bucco-pharyngeal fascia into the prevertebral space.

Clinical Presentation

The chief presenting symptoms of patients with hypopharyngeal cancer include dysphagia, referred otalgia, neck mass, and sensation of lump in throat. Approximately two thirds of patients have nodal metastases at presentation, and most patients complain of weight loss consequent to impairment of swallowing. Other symptoms of hoarseness, aspiration, and hemoptysis may occur depending on the extension of the tumor.

Preoperative Planning

A complete head and neck examination with office fiberoptic laryngoscopy should be performed to evaluate the primary tumor and mobility of vocal cords and arytenoids. CT/MRI is required for assessment of tumor stage (Table 29.1) and extent in hypopharyngeal cancers, particularly inferior, extralaryngeal, and cartilage involvement. Ultrasound examination of neck is the preferred method for evaluating nodal metastases. Hypopharyngeal tumors are associated with high rates of distant metastasis ranging from 10% to 27% and need adequate investigation with chest x-ray, PET, and relevant laboratory tests. A direct endoscopic examination of the pharynx, larynx, and upper esophagus under general anesthesia is important for accurate evaluation of the tumor spread, for detection of synchronous primaries, and for obtaining both diagnostic and mapping biopsies. A careful endoscopic evaluation also serves to determine access for transoral approaches, criteria for partial operations versus total laryngopharyngectomies, and type of reconstruction of the pharyngeal defect following tumor resection. In patients possibly requiring a flap reconstruction, the adequacy of potential donor sites should be ascertained. Routine blood tests along with a preoperative baseline level for calcium and thyroid function are performed. The pulmonary function status should be assessed during preoperative planning of a conservation surgery since patients with inadequate pulmonary reserve are at a greater risk of aspiration.

Treatment

A combined therapy comprising surgical resection followed by adjuvant radiotherapy is the standard treatment for all stages of hypopharyngeal cancers as recommended by the United States National Cancer Institute. Conventionally, open neck procedures have been used to resect hypopharyngeal cancers, but in recent years, as an organ preserving minimally invasive strategy, the application of transoral approaches is increasing for early and selected advanced tumors of specific subsites such as PFS and PPW.

Transoral Procedures

Transoral Laser Microsurgery

Early stage hypopharyngeal tumors with minimal or no extension to the apex of the PFS or cricoid cartilage invasion can be adequately resected through transoral approach using CO_2 laser microsurgery as first described by Steiner (Fig. 29.8). The indications have expanded to include advanced PFS tumors in the hands of experienced surgeons depending on the extension of tumor, with some resections being possible down to the esophageal inlet. In comparison with open surgery, the TLM approach leads to avoidance of extensive reconstruction due to minimal resection of healthy tissues and also a diminished need of tracheotomy or dependency on feeding tubes.

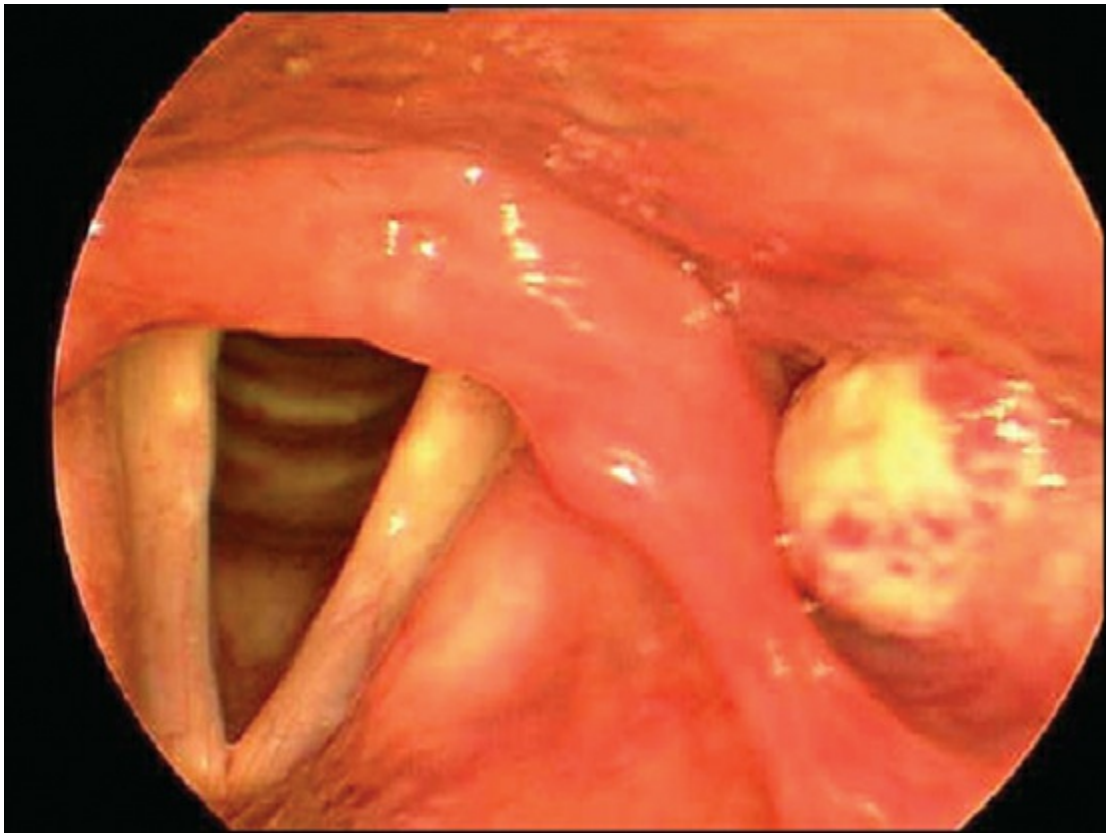

Figure 29.8. Tumor in left pyriform sinus.

The surgical principles for TLM of hypopharyngeal tumors are similar to those for resection of oropharyngeal cancer. The PFS tumors are transected to estimate the depth of tumor and resections are “multibloc,” until healthy tissue is identified and a negative margin achieved. For PFS tumors, resection is commenced laterally, from proximal to distal, and followed around the anterior extent toward the medial side. A margin of at least 5 mm for superficial small tumors and 5 to 10 mm for larger infiltrating tumors is recommended. If there is no frank invasion of the aryepiglottic fold, a relatively narrower margin can be kept for medial wall PFS tumors to avoid resection of arytenoids by carefully removing the mucosa alone in order to prevent impairment of swallowing. This precautionary technique also preserves the lateral cricoarytenoid muscle and the terminal recurrent laryngeal nerve.

Tumors confined to the postcricoid area and the posterior hypopharyngeal wall can also be excised by TLM, the former lesions being most suitable if they are superficial. Posterior wall lesions usually afford excellent access and are often ideal candidates for transoral approaches. Extension beyond the prevertebral fascia into the muscles and anterior spinal ligament are not limitations for TLM but may lead to

complications like vertebral osteomyelitis or abscess formation.

Open Procedures

Partial Pharyngectomy

Tumors of PPW that do not extend below the arytenoids inferiorly or into the PFS laterally can be excised through a lateral pharyngotomy. Smaller tumors in the lower part of PPW without any extension to postcricoid area can be adequately resected through a transhyoid partial pharyngectomy. The pharyngeal defects can be left to heal by secondary intention, or a split-thickness skin graft can be used.

Partial Laryngopharyngectomy

Partial laryngopharyngectomy is appropriate for PFS or PPW tumors, which can be excised adequately without compromising laryngeal or pharyngeal function. The tumor should not have any involvement of apex of PFS, base of tongue, postcricoid mucosa, or thyroid cartilage. The ipsilateral vocal cord and arytenoid should be fully mobile, and there should not be any transglottic laryngeal involvement. Inadequate pulmonary function is a contraindication to this procedure.

A transverse incision is made at the level of the thyrohyoid membrane. Skin flaps are elevated and strap muscles are divided for exposure of hyoid and thyroid cartilage. The suprahyoid muscles are separated from hyoid, and the pharynx is entered through the contralateral vallecula. The upper part of the thyroid cartilage is cut inferiorly and laterally with an oblique cut from the midline. Under direct view, tumor in the hypopharynx is resected, ensuring an adequate mucosal margin along with resection of the ipsilateral half of the supraglottic larynx by incising through the ventricle. A cricopharyngeal myotomy is performed, and the larynx is resurfaced by suturing the cut edges of hypopharyngeal mucosa to the edges of false cords. The base of tongue is impacted into the larynx by placing sutures between the muscles and the thyroid perichondrium to close the pharyngeal directly without tension. The cut ends of strap muscles are sutured to provide an additional layer of closure. For larger defects, a small free fasciocutaneous flap provides faster healing and better functional recovery.

Total Laryngectomy With Partial Pharyngectomy

This procedure is indicated for PFS tumors that extend to involve the apex

of PFS inferiorly, larynx medially, thyroid or cricoid cartilage laterally, or postcricoid mucosa posteriorly. A preliminary tracheostomy under local anesthesia is preferred at the onset. A long curvilinear incision is made from mastoid to mastoid, and skin flaps are elevated superiorly and inferiorly in the subplatysmal plane, exposing the sternocleidomastoid and strap muscles. The investing layer of deep fascia is incised longitudinally along the medial border of sternocleidomastoid on either sides, and the muscle is retracted laterally to identify the carotid sheath. The omohyoid tendon is divided, and the carotid artery is retracted laterally along with the internal jugular vein. The middle and inferior thyroid veins are divided, and the paracarotid tunnel is dissected down to the clavicle to allow adequate laryngeal mobilization on both sides. The strap muscles are divided inferiorly above the sternum, and are elevated to skeletonize the larynx and expose the thyroid gland. The superior and inferior thyroid pedicles are divided on the side on which ipsilateral thyroid lobectomy is to be performed. The contralateral thyroid lobe is dissected away from the larynx, and caution is exercised to preserve the inferior thyroid artery on the side. The superior laryngeal pedicle is divided on each side carefully, preserving the hypoglossal nerve and the lingual artery. The suprahyoid muscles are separated from the hyoid, and the inferior constrictors are divided from the posterolateral aspect of the thyroid lamina. The PFS mucosa is separated from the undersurface of the thyroid lamina. The tracheal wall is skeletonized and neck dissection is completed, ensuring removal of paratracheal, level IV, and VI nodes. The trachea is divided with an upward bevel about two rings inferior to the previously placed tracheostoma, following which the larynx is separated from below upward with a sharp dissection of the tracheoesophageal party wall. Intubation is continued through the newly created stoma.

The pharynx is entered through the contralateral vallecula by placing a Deaver retractor in the vallecula and making an incision at the site of its protrusion in the neck. The epiglottis is grasped through the pharyngotomy and pulled anteriorly. Lateral to the epiglottis, the pharyngeal mucosa is first resected on the less involved side, preserving maximal normal mucosa and progressing inferiorly toward the posterior part of the arytenoid. The pharyngeal wall on the side of the tumor is resected, ensuring adequate margins. The pharyngeal cuts are joined posteriorly inferior to the cricoarytenoid joint and the specimen is removed, followed by frozen section analysis of the pharyngeal margins.

For primary voice restoration, a tracheoesophageal puncture (TEP) is made between the upper esophagus and the tracheostome and a soft Silastic feeding tube is advanced through the tracheoesophageal party wall into the esophageal lumen. A primary closure in a T-shaped configuration is performed for a pharyngeal defect of less than one third of the circumference (sufficient mucosa to wrap around a 36 French dilator). Interrupted sutures between the tongue base and the pharyngeal wall form the horizontal segment of T and the vertical segment comprises interrupted/running extra mucosal inverting sutures between the edges of pharyngeal mucosae. Approximation of the strap muscles reinforces the pharyngeal repair. A tight pharyngeal closure may result in dysphagia and fistula formation and should always be avoided. For resections with greater pharyngeal defect, “patch” flap augmentation should be considered with a pedicled myocutaneous or a microvascular-free fasciocutaneous flap, for example, the ALT.

Total Laryngopharyngectomy/Total Laryngopharyngoesophagectomy

A total laryngopharyngectomy is indicated for circumferential postcricoid tumors, PFS tumors with posterior extension across midline, and advanced PPW cancer extending inferiorly below the arytenoids. The cervical esophagus may require resection in continuity. The initial steps are similar to total laryngectomy with partial pharyngectomy except that the PFS mucosa is not separated free from the thyroid lamina and the larynx and pharynx are mobilized together. Caution should be exercised to check for posterior extension into the prevertebral fascia. These patients may require microvascular reconstruction; thus, suitable arteries and veins should be preserved during the neck dissection. The pharynx is entered through the contralateral vallecula or a lateral pharyngotomy if the tumor has significant superior extension into oropharynx. Ensuring adequate margins, the pharyngeal cuts are made horizontally around the posterior wall to release the laryngopharyngeal unit followed by division of the trachea (Fig. 29.9).

Resection of cervical esophagus is indicated if hypopharyngeal tumors extend into the esophagus and complete oncologic clearance cannot be achieved with resection of hypopharynx alone (Fig. 29.10). This requires careful blunt dissection of esophagus to prevent injury of the posterior tracheal wall and absolute hemostasis of esophageal blood supply. Extensive esophagectomy will necessitate a gastric pull-up repair unless the upper esophageal stump is accessible for anastomosis to a tubed free

flap.

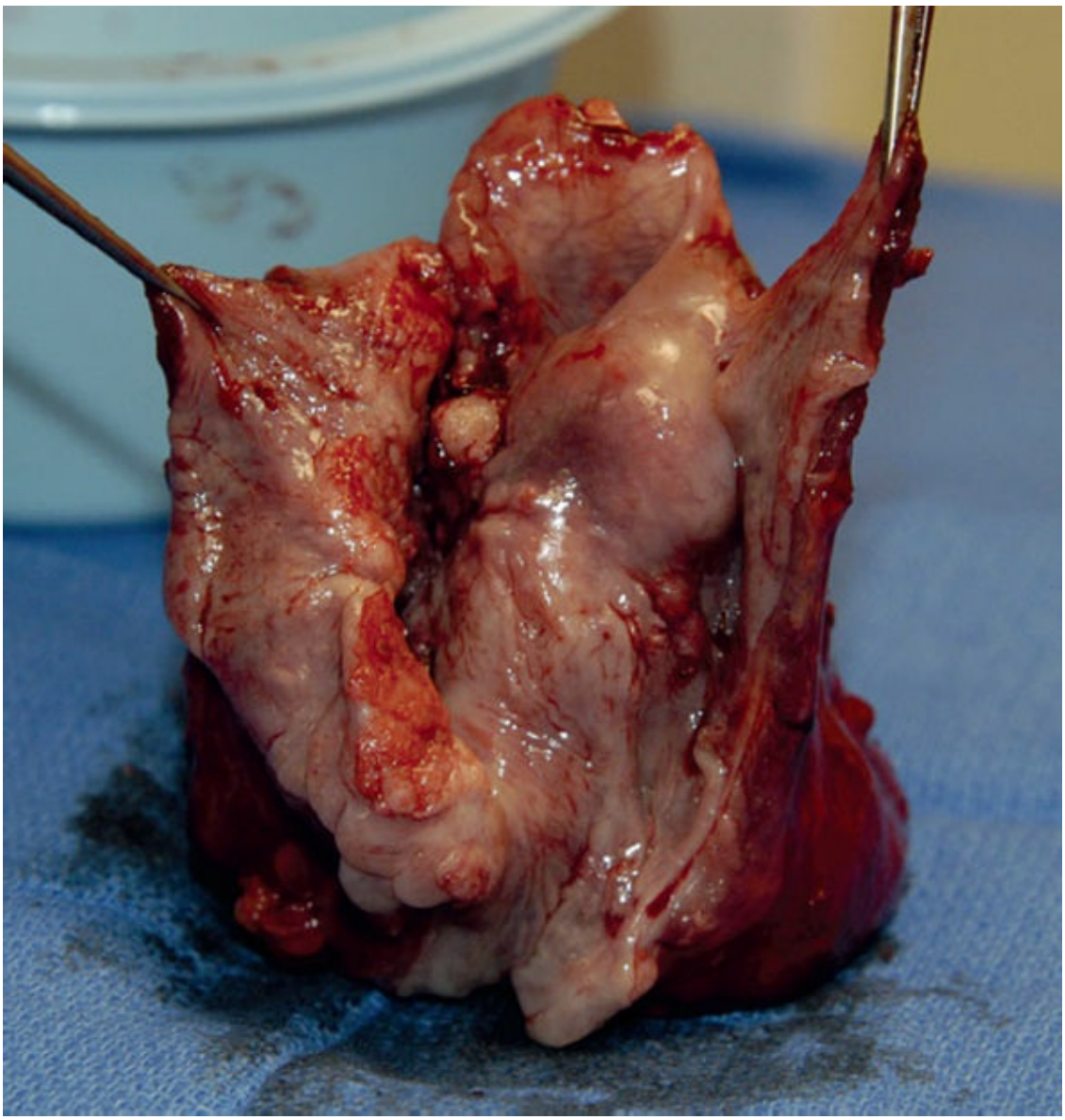

Figure 29.9. Specimen depicting total laryngopharyngectomy.

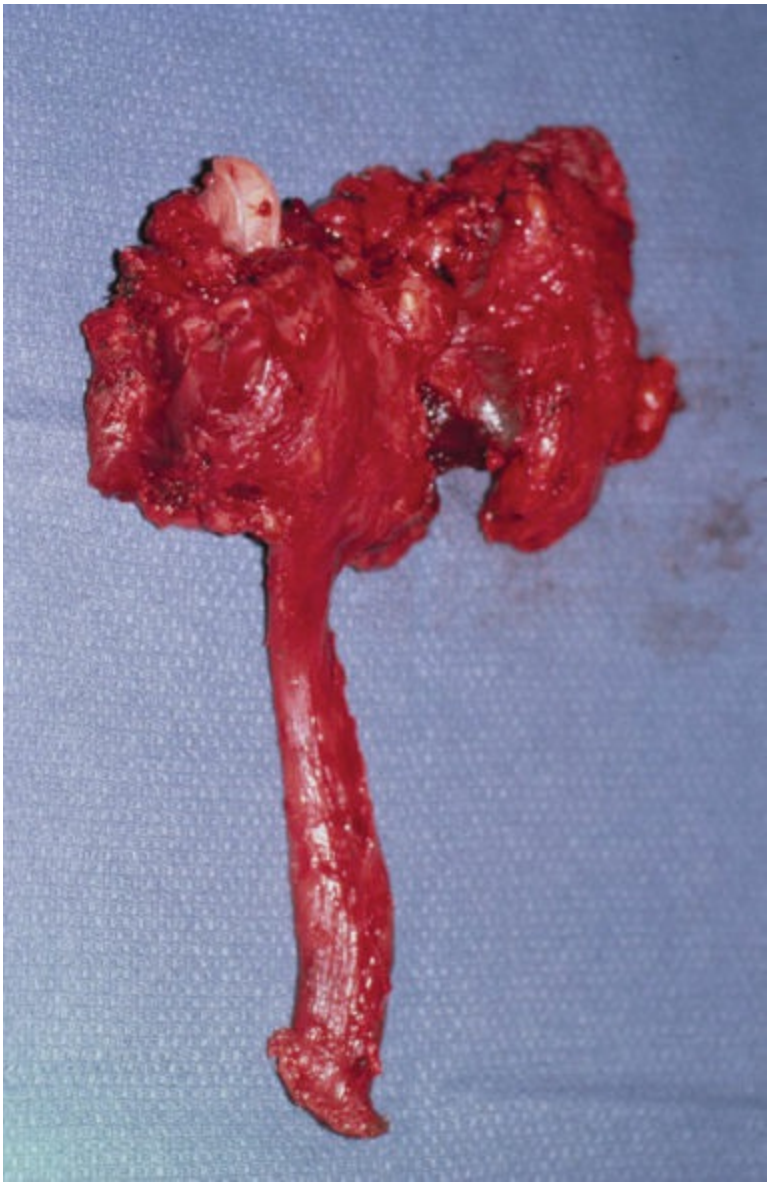

Figure 29.10. Specimen depicting total laryngopharyngoesophagectomy.

Hypopharyngeal Reconstruction

The hypopharynx represents a major functional conduit related to respiration and swallowing. Any treatment-related anatomical and physiologic disruption leads to varying severity of swallowing dysfunction and aspiration, emphasizing the importance of a competent reconstruction within any surgical procedure for pharyngeal cancers. A variety of techniques have been described for reconstruction of circumferential pharyngeal defects resulting from total laryngectomy with pharyngectomy. Free jejunal graft had been a popular option historically, but the association with donor site morbidity and poorer functional outcomes in

terms of dysphagia due to persistent muscular contractility and an unsatisfactory tracheojejunal voice shifted the focus over use of microvascular fasciocutaneous flaps (Fig. 29.11). The preferred option in our practice is a tubed radial forearm free flap. As compared with a pedicled pectoralis major myocutaneous flap, which is difficult to tube due to the muscle bulk, and enteric grafts with greater morbidity, use of a thinner, pliable tubed RFFF provides better functional reconstruction with minimal donor site problems. In patients unfit for RFFF, an ALT flap may be used if permitted by the patient's body habitus (Fig. 29.12). Free jejunal autografts are an option if none of the above techniques are feasible. Patients with total esophagectomy require a gastric pull-up procedure, which entails mobilization and thoracic transposition of stomach into the neck to restore continuity of the alimentary tract. The key surgical issues, herein, are a tensionless anastomosis at the junction between the oropharynx and stomach and an adequate pyloromyotomy for efficient gastric drainage in order to prevent postoperative regurgitation of food.

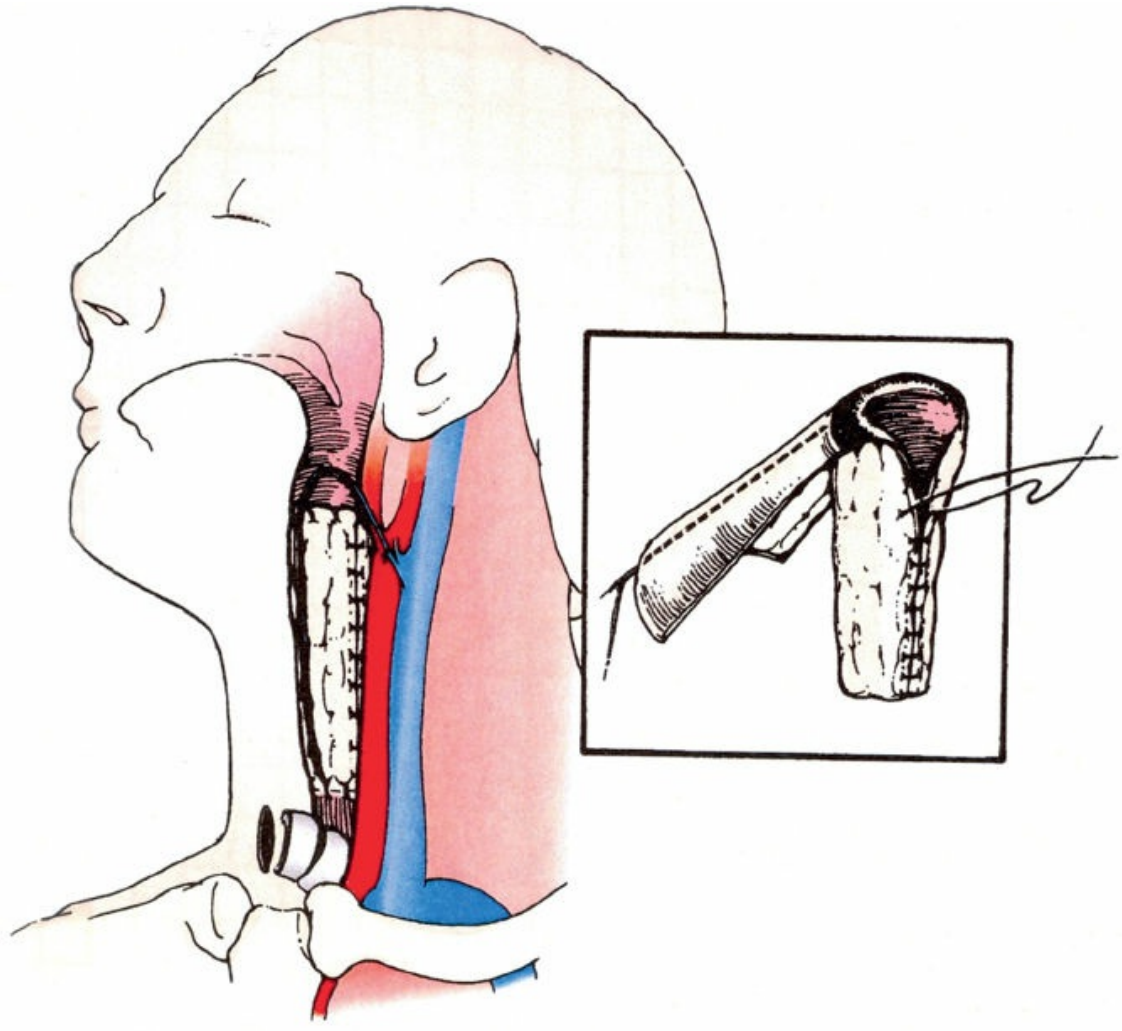

Figure 29.11. Hypopharyngeal reconstruction with a fasciocutaneous flap. Inset shows a tubed flap with an attached skin paddle that may be used for resurfacing any deficient neck skin along with pharyngeal reconstruction.

Management of Neck

A high incidence of occult metastases (30% to 40%) in hypopharyngeal cancer warrants addressing the N0 necks with selective neck dissection (level II, III, and IV). In clinically positive necks, a functional neck dissection clearing levels II, III, IV, and VI should be part of the neck management for PFS and postcricoid tumors, with inclusion of retropharyngeal nodes in the PPW. A contralateral selective neck dissection is recommended for circumferential tumors and tumors extending to or across the midline.

Postoperative Care

Patients are kept on negative pressure drains with perioperative antibiotics. Nasogastric alimentation is continued for 7 to 10 days in primary and 12 to 14 days in irradiated patients. Adequate fluid and nutritional balance, and wound and tracheostomy tube care are administered. Patients with flap reconstruction should undergo a vigilant monitoring of the flap viability along with care of the donor site. Calcium, parathyroid, and thyroid hormone levels should be assessed as indicated.

Complications

The early complications include hemorrhage, postoperative wound infection/dehiscence, pharyngocutaneous fistula, and complications related to neck dissection and flap necrosis if performed. Gastric pull-up procedures are associated with significant pulmonary complications. Late complications include stomal stenosis and dysphagia, which may be structural due to stricture formation at the inferior end of pharyngeal reconstruction or functional due to reconstruction-related dysmotility.

Rehabilitation

Swallowing and voice rehabilitation are major components of management in patients undergoing surgery for hypopharyngeal cancer. A primary TEP is the most commonly used technique for voice restoration. In patients undergoing total laryngopharyngectomy, we create the TEP in the inlet of the esophageal stump through to the infrastomal trachea, prior to

anastomosing the lower end of the flap to the esophagus. This eliminates any leakage around the prosthesis and leads to better voice outcomes. Other methods of voice rehabilitation include electromechanical devices and esophageal speech.

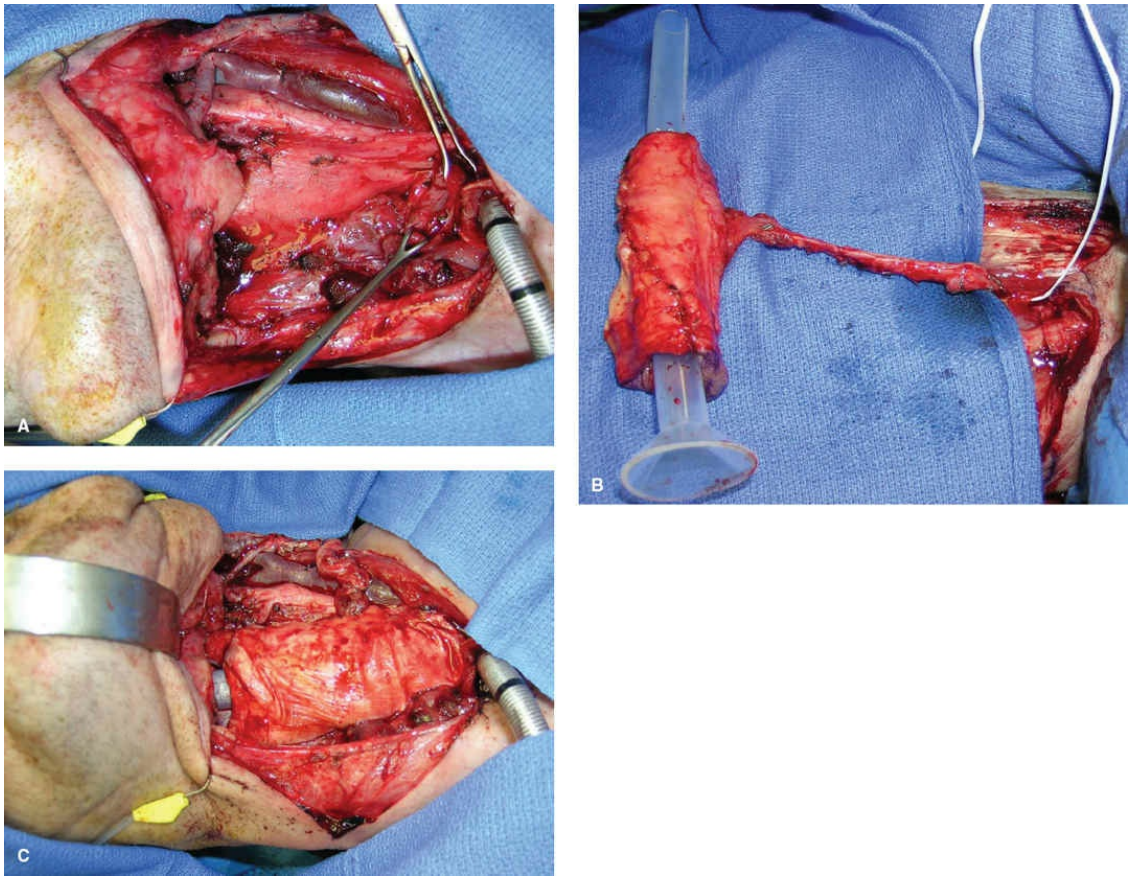

Figure 29.12. Hypopharyngeal reconstruction with an ALT flap: (**A**) surgical defect after total laryngopharyngectomy, (**B**) fabrication of a tubed ALT flap with vascular pedicle, (**C**) reconstructed hypopharynx after microvascular anastomosis.

Suggested Readings

Flint PW, Haughey BH, Lund VJ, et al., eds. *Cummings Otolaryngology Head and Neck Surgery*. Vol. 2. 5th ed. Philadelphia, PA: Mosby Elsevier; 2010.

Haughey BH, Colin WB. Pharyngoesophageal reconstruction. In: Gates GA, ed. *Current Therapy in Otolaryngology—Head and Neck Surgery*. 6th ed. St. Louis, MO: Mosby Publishing; 1998:285–8.

Haughey BH, Fredrickson JM, Sessions DG, et al. Vibratory segment function after free flap reconstruction of the pharyngoesophagus. *Laryngoscope* 1995;105:487–90.

Haughey BH, Hinni LM, Salassa JR, et al. Transoral laser microsurgery as primary

treatment of advanced stage oropharynx cancer: a United States multicenter study. *Head Neck* 2011;33:1683–94.

Karni RJ, Rich JT, Sinha P, et al. Transoral laser microsurgery: a new approach for unknown primaries of the head and neck. *Laryngoscope* 2011;121(6):1194–201.

Licitra L, Perrone F, Bossi P, et al. High-risk human papillomavirus affects prognosis in patients with surgically treated oropharyngeal squamous cell carcinoma. *J Clin Oncol* 2006;24:5630–6.

Martin A, Jäckel MC, Christiansen H, et al. Organ preserving transoral laser microsurgery for cancer of the hypopharynx. *Laryngoscope* 2008;118:398–402.

Moore EJ, Olsen KD, Kasperbauer JL. Transoral robotic surgery for oropharyngeal squamous cell carcinoma: a prospective study of feasibility and functional outcomes. *Laryngoscope* 2009;119:2156–64.

Steiner W, Ambrosch P. *Endoscopic Laser Surgery of the Upper Aerodigestive Tract: With Special Emphasis on Cancer Surgery.* New York: Thieme Medical Publishers; 2001.

Sturgis EM, Cinciripini PM. Trends in head and neck cancer incidence in relation to smoking prevalence: an emerging epidemic of human papillomavirus-associated cancers? *Cancer* 2007;110:1429–35.

Wei WI. Cancer of the nasopharynx: functional surgical salvage. *World J Surg* 2003;27:844–8.



EDITOR'S COMMENT

Dr. Haughey and Sinha have written an incredibly comprehensive and detailed chapter on pharyngeal cancer. As a general surgeon, I know relatively little about what is described in this chapter. I find pharyngeal cancer to be an interesting disease for a multitude of reasons. First off, the epidemiology of these tumors is of interest. Nasopharyngeal cancer (NPC) is relatively rare in the United States. According to the American Cancer Society, fewer than 1 in 100,000 people in North America develop this type of cancer. Epstein–Barr virus (EBV) is heavily implicated in the development of NPC. In fact, EBV was the first virus determined to cause cancer in humans—a fact I recall learning very early in medical school. EBV is one of the most common viruses worldwide. It is estimated that 95% of all people in the United States are exposed to this virus by the time they are 30 to 40 years old. In most people, EBV causes no harm. EBV infections trigger 200,000 new cases of cancer and more than 140,000 deaths worldwide each year. Interestingly, NPC is much more common in other parts of the world. In the southern regions of China, these types of cancer are quite common and account for as much as 18% of all cancers diagnosed. This high incidence of NPC may relate to the South East

Asian diet predominant in this part of the world that includes a diet heavy in salted vegetables, fish, and meat. Environmental influences (diet and exposure to certain carcinogens), EBV infection, and genetic predisposition or mutations all play a role in the development of NPC. EBV DNA levels have in fact been demonstrated to relate to overall prognosis and survival in NPC. A meta-analysis pooled 23 eligible studies including 10,732 patients with NPC. High expression levels of EBV DNA were found to predict poor prognosis in NPC.

In keeping with the theme of viruses causing cancer (seems to be most prevalent or best described in head and neck cancers), human papillomavirus (HPV) has been implicated in head and neck squamous cell carcinoma. HPV+ head and neck squamous cell carcinoma is increasing in incidence. More than 400,000 cases of oropharyngeal squamous cell carcinoma (OPSCC) are diagnosed each year worldwide. HPV-associated OPSCC affects younger patients and often presents at a higher stage; however, it is associated with a better prognosis. A recent systematic review included 56 articles and determined that HPV+ tumors had an improved prognosis and lower rates of adverse events when compared to HPV− head and neck squamous cell cancers. HPV− cancers had significantly worse outcomes when treated with primary radiation and compared to primary surgery.

Given the evolving understanding of the etiology of head and neck cancer and the emergence of new minimally invasive treatment options, the field seems to be undergoing a bit of a paradigm shift. The surgical treatment of pharyngeal cancer has historically been associated with major resections and reconstruction procedures that lead to significant potential morbidity and functional impairment. The emergence of chemoradiotherapy as an effective treatment option has made nonsurgical therapy the primary modality of treatment. The evolving understanding of the role that HPV status plays in outcome has led some surgeons to pursue minimally invasive surgical procedures as an alternative to chemoradiotherapy in select patients. Interventions have now evolved with computerized planning and intensity-modulated radiotherapy. Endoscopic head and neck surgery options are available and can provide the potential for decreased treatment-associated morbidity. Minimally invasive techniques are increasingly being used for resection of T1–T2 lesions with no evidence of distant metastatic spread instead of primary radiotherapy. A recent Cochrane review evaluated randomized controlled trials conducted in these kinds of patients to determine the evidence to support this approach. There were no completed studies that met inclusion criteria for the review, although two ongoing trials at the time fulfilled selection criteria but were not yet complete. The ORATOR trial (early-stage squamous cell carcinoma of the oropharynx: radiotherapy vs. transoral robotic surgery) is a phase II randomized controlled trial in small volume (T1–2, N0–2) OPSCC. It is estimated that this trial will be completed in June 2021. Another trial (European Organization for Research and Treatment of Cancer 1420) is a randomized study assessing radiotherapy compared to transoral robotic surgery/transoral laser microsurgery in patients

with T1–2, N0 OPSCC and squamous cell carcinoma of the base of the tongue. This trial was to begin accruing subjects in 2016. The authors of the Cochrane review concluded: "*The role of endoscopic head and neck surgery in the management of OPSCC is clearly expanding as evidenced by its more overt incorporation into the current National Comprehensive Cancer Network guidelines. Data are mounting regarding its outcomes both in terms of survival and lower morbidity. As confidence increases, it is being used in the management of more advanced OPSCC.*" It will be interesting to see if technological advances that have led to the proliferation of minimally invasive approaches to resection of OPSCC will result in surgery once again becoming the first line of therapy for many of these tumors.

As a general surgeon who performs abdominal robotic surgery, I am very interested in the transoral robotic approach to these oropharyngeal tumors. Otolaryngologists and head and neck surgeons had relatively little experience in robotic surgery prior to the introduction of transoral surgery. The concept of a learning curve when the techniques and technology are so novel to a surgical discipline is of interest. A recently published retrospective review of a single institutional series of 382 transoral robotic surgical resections performed by one of three surgeons examined the learning curve for this procedure. Positive margin rate and time of surgery were the two metrics used to define the learning curve. While the learning curve for transoral robotic resection of OPSCC was somewhat surgeon-specific, the inflection point (learning curve) was between 20 and 30 cases. When discussing robotic surgery, the issue of cost and cost-effectiveness is bound to come up. A microsimulation state transition model was developed to compare transoral robotic surgery to radiation therapy in OPSCC. Transoral robotic resection was associated with modest gains in quality-adjusted life years (QALYs). Radiation therapy yielded 10.43 QALYs at a cost of $123,410 per patient, whereas transoral robotic surgery yielded 11.10 QALYs at a cost of $178,480. This resulted in an incremental cost-effectiveness ratio of $82,190/QALY gained. The authors determined that transoral robotic resection may be a cost-effective alternative to radiation therapy in early OPSCC, but this was very sensitive to assumptions made in the model around quality of life after the two treatments.

Minimally invasive, transoral surgery has many limitations including difficult access to critical anatomic structures in a very confined space. The daVinci robotic surgical system provides several features that facilitate the transoral resection of early oropharyngeal cancers. These include three-dimensional and high-definition visualization, long robotic instruments that articulate at the tip and are capable of precise and complex maneuvers without tremor, and better ergonomics for the surgical team. If one were to design a robotic surgical system specifically for transoral surgery, the operating system would include smaller instruments with more flexibility and better hemostatic options for removing tumors from highly vascularized areas. There are numerous robotic surgical systems that should hit the market within the next 5

to 10 years that may address many of the shortcomings of the current system. As trials continue and experience with robotic techniques increases, it is likely that robotic transoral techniques for oropharyngeal cancer resection will become more commonplace if oncologic outcomes are proven to be equivalent to the current standard.

Finally, as a lifelong fan of Major League Baseball, I would like to take up a paragraph here examining the role of chewing tobacco and snuff on oropharyngeal cancer. Babe Ruth died from nasopharyngeal carcinoma in 1948 at the age of 53. It is said that his fondness for tobacco and liquor led to his cancer. More recently, Hall of Famer Tony Gwynn who played for the San Diego Padres his entire career died of parotid cancer. Although the link between chewing tobacco and parotid cancer is not clearly defined as it is for pharyngeal cancer, Tony and his family were convinced that more than 30 years of chewing tobacco led to his cancer. Other notable major league players to develop head and neck cancer most likely due to long-term abuse of chewing tobacco include Curt Schilling, Brett Butler, and Bill Tuttle. A recently published pooled analysis of 11 US case-control studies of oral, pharyngeal, and laryngeal cancers revealed that smokeless tobacco use appears to be associated with head and neck cancer, especially oral cancers, with snuff being more strongly associated than chewing tobacco. Among people who have never smoked, the odds ratio for developing oral cavity cancer with snuff was 3.01 (95% CI: 1.63, 5.55). An estimated 25% to 30% of Major League Baseball players chew tobacco. In 2016, Major League Baseball and the players union reached a collective bargaining agreement that bans chewing tobacco for new players. Current players were grandfathered in under the ruling.

Overall, this is an excellent and informative chapter on a topic about which I previously knew relatively little. I found this chapter to be extremely interesting and relevant. I highly recommend that surgeons take the time to familiarize themselves with the content of this chapter.

Jon C. Gould

Suggested Readings

Albergotti WG, Gooding WE, Kubik MW, et al. Assessment of surgical learning curves in transoral robotic surgery for squamous cell carcinoma of the oropharynx. *JAMA Otolaryngol Head Neck Surg* 2017. doi: 10.1001/jamaoto.2016.4132. [Epub ahead of print]

Hamilton D, Khan MK, O'hara J, et al. The changing landscape of oropharyngeal cancer management. *J Laryngol Otol* 2017;131(1):3–7. Epub 2016 Nov 29.

Howard J, Masterson L, Dwivedi RC, et al. Minimally invasive surgery versus radiotherapy/chemoradiotherapy for small-volume primary oropharyngeal

carcinoma. *Cochrane Database Syst Rev* 2016;12:CD010963.

Rodin D, Caulley L, Burger E, et al. Cost-effectiveness analysis of radiation therapy versus transoral robotic surgery for oropharyngeal squamous cell carcinoma. *Int J Radiat Oncol Biol Phys* 2017;97(4):709–17.

Wang MB, Liu IY, Gornbein JA, et al. HPV-positive oropharyngeal carcinoma: a systematic review of treatment and prognosis. *Otolaryngol Head Neck Surg* 2015;153(5): 758–69.

Wyss AB, Hashibe M, Lee YA, et al. Smokeless tobacco use and the risk of head and neck cancer: pooled analysis of US studies in the INHANCE consortium. *Am J Epidemiol* 2016 Oct 15. [Epub ahead of print]

Zhang J, Shu C, Song Y, et al. Epstein–Barr virus DNA level as a novel prognostic factor in nasopharyngeal carcinoma: a meta-analysis. *Medicine (Baltimore)* 2016;95(40):e5130.

30 Malignant Melanoma and Skin Cancer

Hiram C. Polk, Jr., Jane V. Carter, and Uri Netz

INTRODUCTION

An important, albeit underappreciated, part of a practicing surgeon's work is the diagnosis and treatment of skin cancers, mainly melanoma and squamous cell carcinoma. The most important change in the last 50 years has been the improvement in early diagnosis, resulting from better awareness of both patients and physicians to the results of exposure to the sun, and the importance of routine skin checkups and biopsies of suspicious lesions. This has led to an increasing number of patients being diagnosed at an earlier stage, and thus allowing more curative treatment and longer-term survival. The effect of early diagnosis has been made even more significant by a higher incidence of melanoma worldwide. This is probably related to increased exposure of the general population to the sun. The traditional victim, a family farmer who has been chronically exposed to the sun, has been altered politically and demographically to include nearly anyone. An important cause has been the increasing use of tanning beds. Indoor tanning beds, emitting mainly ultraviolet A (UV-A) radiation (>320- to 400-nm wavelengths), were previously believed to be safe, since UV-B (>280- to 320-nm wavelengths) radiations were believed to be the main risk factor for skin cancers. However, recent evidence has shown that tanning beds clearly increase the risk, especially with repeated exposure at young ages, with more than 10,000 melanoma cases and 450,000 nonmelanoma skin cancers said to be attributable to indoor tanning each year in the United States, Europe, and Australia. Although most melanomas are initially suspected and diagnosed in the offices of dermatologic specialists and family practitioners, the work-up and main treatment of potentially curative disease are in the hands of surgeons, thus stressing the importance of correct staging and treatment.

PATHOGENESIS

Some melanomas arise as changes in existing ordinary moles, while others appear to arise *de novo.* Risk factors for development of malignant melanoma are fairly well described. Particularly at risk are fair-complexioned people, often with blonde or red hair, and who typically reside between the Tropic of Capricorn and the Tropic of Cancer, predisposing them to heightened sun exposure and ultraviolet irradiation. Good examples of the prototypical high-risk population are individuals of Celtic heritage who emigrated to Australia over 100 years ago. Melanoma is more common in men who also have a worse prognosis. Another factor is the number of moles that exist in an individual patient, which may or may not be complicated by a history of sunburns. The tendency to have multiple small dark moles is frequently inherited. As such, parents as well as children of melanoma patients should be examined, not only to determine what the pattern of their moles may be, but also to look for new primary melanomas in an often unsuspecting population.

Sun exposure, particularly of the blistering type, during the period of teenage hormone bursts is especially important. Although the method by which data were collected is questionable, the reference to two or more blistering sunburns during teenage years as a causative factor has found its way into the literature, and is probably accurate. The use of sunblock containing a broad spectrum sun protection factor (SPF) protects the skin from harmful UV-A and UV-B irradiation. If sun exposure exceeds 20 minutes a day, we advise wearing sunblock of at least 30 SPF, and if used on a regular basis, may actually allow some repair of damaged skin.

It is commonly said that large birthmarks are not at risk for melanoma, including even bathing trunk nevi. This assertion is clearly untrue. An unknown proportion of these individuals acquires invasive melanoma at multiple sites within the large nevus at a later stage. When they begin to develop in such longstanding large pigmented lesions, melanomas are virtually impossible to detect by even the most attentive patients, family members, and specialist-physicians.

As stated earlier, maximum risk coincides with heightened hormonal periods, such as the teenage years and pregnancy. Pregnancy, in and of itself, has been debated as predisposing to the development or the overt clinical spread of existing melanoma. Recent data have demonstrated poorer outcomes for melanoma during pregnancy after adjustment for age and stage. The senior author has cared for at least five women who subsequently produced soon-to-be orphans, owing to progression of their

melanoma during their pregnancies. The elaboration of melanocyte-stimulating hormone (MSH) responsible for darkening of the nipple-areolar complex in pregnant women is believed to be a factor, although this remains largely unproven. This risk factor requires some very careful thought by the treating physician, particularly related to the tendency of women to have their first pregnancies at a later age, which naturally diminishes the opportunity to bear subsequent children. A current systematic review concluded that melanoma is not adversely affected by pregnancy; however, only 5 out of 304 papers were relevant and only 1 paper included melanomas beyond stage 1. Our own recommendation is that a woman who has, or had, a melanoma thicker than 1.5 mm, and/or is ulcerated or nodular, should not become pregnant during the first 5 years after such diagnosis. These alternative factors of thickness, ulceration, and conformation supervene to indicate that pregnancy avoidance or even termination becomes clinically more significant. Here lies a major test of a patient's trust in her melanoma surgeon. Fewer obstetricians are aware of this unusual risk. Whether or not pregnancy itself predisposes to melanoma is less clear. However, oral contraception is well known not to predispose to melanoma.

Overt immunosuppression, either as the result of cancer chemotherapy or as agents used to suppress host responses to solid organ or bone marrow transplants, also predisposes to new or recurrent melanoma. Obviously, physicians and patients do not undertake transplant immunosuppression lightly. However, in patients with previously diagnosed and treated melanoma, increased frequency of surveillance is warranted. Also, it appears that *de novo* melanomas can develop more readily in this scenario. The immunosuppressed patient warrants special attention, with at least annual examinations for a variety of skin cancers that include either new or recurrent melanoma and squamous cell cancer. Survivors of childhood cancers, especially those treated with radiation are also prone to develop melanoma later in life and should be screened annually.

The dysplastic nevus syndrome is a relatively rare phenomenon that generally consists of more than 100 moles, and, frequently, as many as a 1,000 on a fair-complexioned person. Here, the dominant pattern is a relentless conversion of these moles to invasive melanoma; again, these can be accentuated by the waxing and waning of hormones during teenage years or early adulthood. The optimum surgical management of these patients is unclear, although the senior author has never been able to clear

the number of lesions as rapidly as new primary melanomas appear to progress during the course of this illness once the first melanoma is detected.

CLINICAL PRESENTATION AND DIAGNOSIS

Diagnosis of melanoma has been simplified through the brilliant and imaginative work of the Queensland Melanoma Project led by the late Professor Neville Davis. “A-B-C-D” is a simple mnemonic that can be applied by virtually any physician or nurse practitioner to distinguish moles that possess malignant characteristics. Figure 30.1 demonstrates the different characteristics.

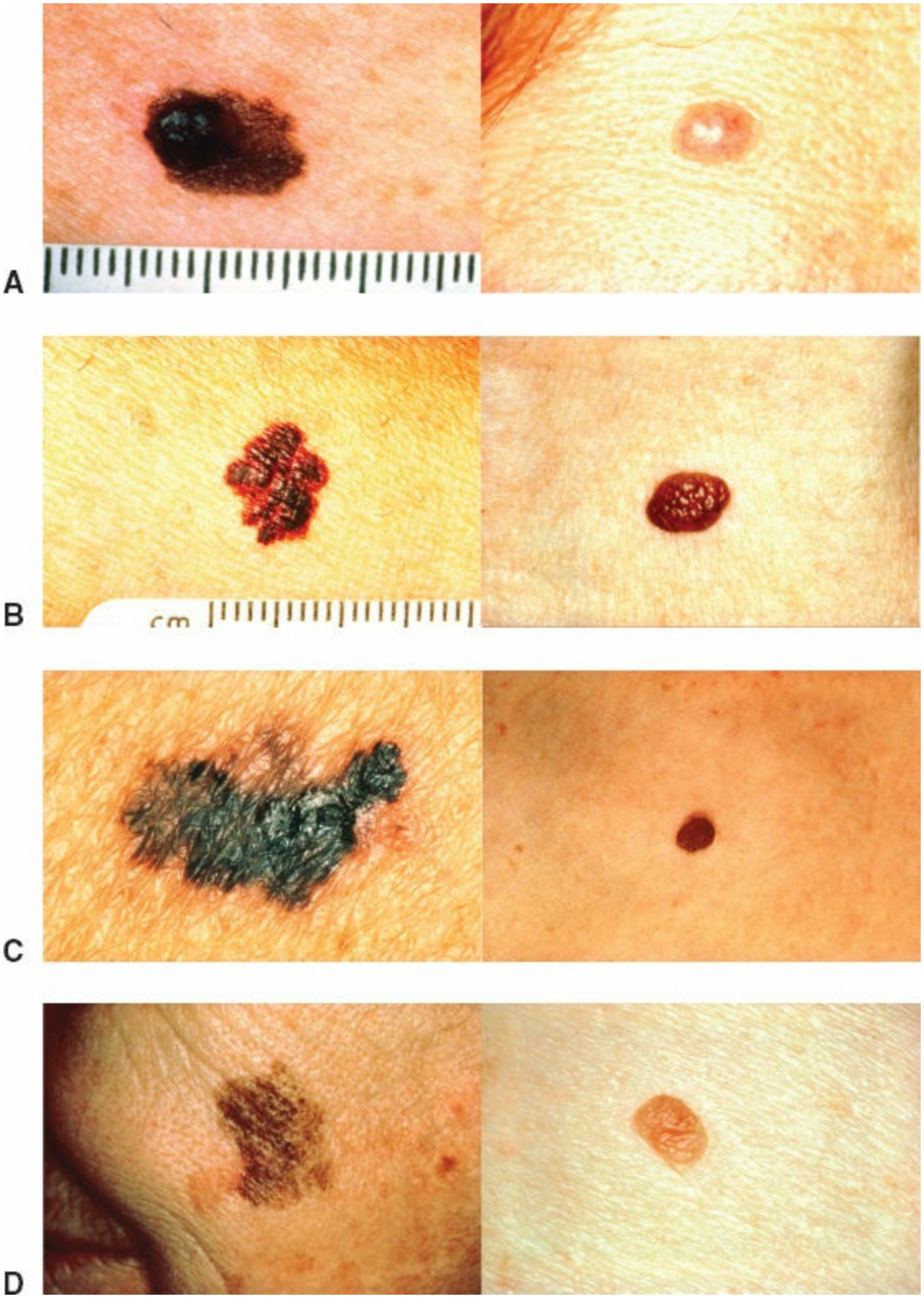

Figure 30.1. On the left are abnormal malignant melanomas as compared with benign moles for comparison on the right side. Moving from top to bottom shows asymmetry (**A**) within the malignant mole, irregular borders (**B**), different colors (**C**) within the melanoma (*black, brown,* and *tan*), and a diameter (**D**) greater than 6 mm, which is indeed suspicious.

A Asymmetry, where one half looks dissimilar to the other half.
B Irregular Borders are notched margins seen to occur in some relatively large moles.
C Uneven Coloration is especially characteristic of melanoma, with parts of the lesion often being light tan to brown to black.
D Finally, Diameters greater than 6 mm are more prone to be associated with melanoma, and are therefore suspicious.

As simple as this concept is, it is the backbone of early diagnosis by doctors, nurses, and other health care professionals. It can readily be applied to self-diagnosis through the distribution of simple patient education material. It should be part of the diagnosis for every melanoma, in both patients and their blood relatives. Since then, an **E** for Evolution has been added, inciting change in shape, size, symptoms, etc. Another useful concept is the "ugly duckling sign," implying heightened suspicion of lesions that do not match an individual's typical nevus phenotype.

There are two other variants of melanoma that remain very difficult to diagnose. The first is the amelanotic melanoma, which is difficult to differentiate among a variety of exotic dermatologic lesions, squamous cell cancer, and local fungal infections. A high degree of suspicion may be a trite word, but is virtually the only guide for any nonpigmented ulcerated skin lesion. The other lesion with this special difficulty in diagnosis is the subungual melanoma that occurs commonly on the feet. Inevitably, all patients have a history of having struck their toenails; many thoughtful physicians will have made a diagnosis of subungual hematoma. The nature of the subungual melanoma, however, is indicated by its tendency to push or elevate the nail, to bleed, and to be painful. Any question about the presence of a subungual melanoma needs to be followed by de-roofing of the lesion and an adequate incisional biopsy or curettage of the specimen.

The patient's signs or symptoms in these circumstances are enormously helpful to a physician who suspects melanoma. Lesions tend to itch, bleed, and change in size or color. Any of these is significant, particularly when combined with the observational "A-B-C-D-E" algorithm.

BIOPSY CONFIRMATION

The preferred biopsy, unless the lesion is very large, is a local excision with 1- to 2-mm margins, which will effectively deal with the occasional benign pigmented seborrheic keratosis, and, at the same time, provide an accurate thickness of melanoma and cell type, if it is present. In other

words, this should extend just into the full thickness end of the subcutaneous fat (Fig. 30.2). In part, because of the progressively earlier diagnosis of melanocytic lesions, errors of omission have begun to occur. It is sobering to recognize that nearly 2% of melanomas are not called such in North America. To some degree, the clinician can override such a potential effect by simply re-excising locally (1- to 2-mm margins) any suspicious or ambiguous lesions, and subsequently asking for a second, or even third, pathologic opinion. The minimal increase in scar or scarring is more than offset by an ultimate improved accuracy of pathologic diagnosis.

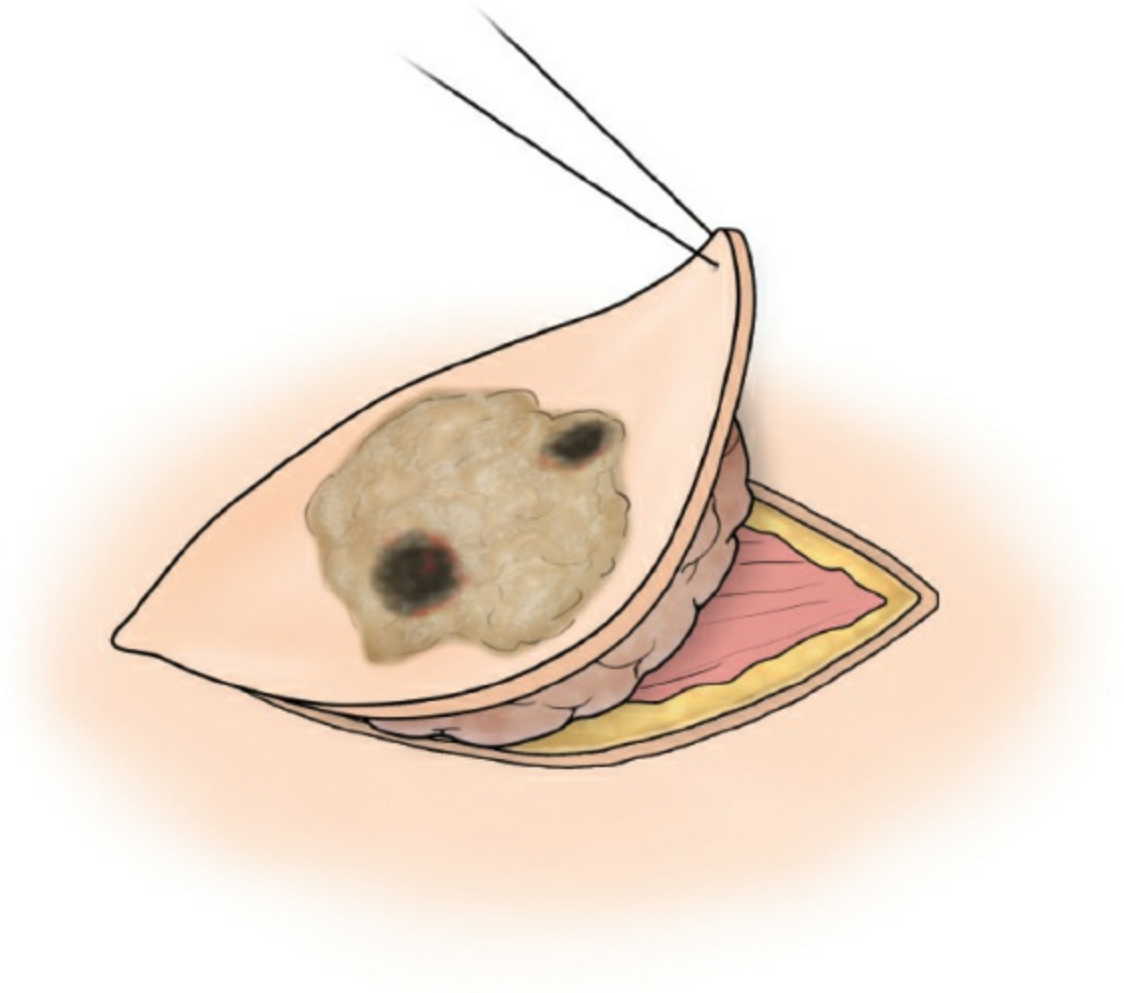

Figure 30.2. The preferred biopsy is a local excision with 1- to 2-mm margins, which will effectively deal with the occasional benign pigmented seborrheic keratosis, and, at the same time, provide an accurate depth of melanoma and cell type, if it is present. This should extend just into the full thickness end of the subcutaneous fat.

If the lesion is large or located on the face, one may opt to excise a simple 1- to 2-mm pie-shaped wedge from the edge of the lesion, choosing whichever edge by palpation is the more highly elevated. In fact, any ulcerated and/or elevated nonhealing skin lesion is at risk of being a malignant melanoma, squamous cell carcinoma, or basal cell carcinoma, and is properly treated with a 1- to 2-mm margin of excision. Depending on the location, once again, it is closed using simple closure with reconstructive methods, such as rotational flaps, used only where absolutely necessary.

Finally, the most important recommendation is take no chances; biopsy any lesion that is even remotely suspicious. The risks and discomfort are slim compared to the great advantage of early diagnosis on morbidity and mortality. For this reason, we tend to accept almost any type of tissue diagnosis, including shave biopsies. In fact, any piece of a melanoma that helps make the diagnosis is helpful. By accepting imperfect diagnoses, one helps promote an earlier biopsy on the part of practitioners, who for various reasons do not possess broader surgical skills. Actually, we have often said that the only form of biopsy that is absolutely contraindicated is cauterization; smoke under the microscope seldom looks like melanoma. As a result, this must be avoided at all costs.

LOCAL STAGING

There are three major factors affecting localized staging: depth, mitotic rate, and ulceration. The tumor-node-metastasis (TNM) system is the mainstay of clinicopathologic staging for melanoma and most other cancers. The initial observations by Clark and associates suggested that the depth of invasion of melanoma down into the skin and subcutaneous tissues was important prognostically. This observation was given much sharper focus by the work of Breslow, who simply quantified the depth of invasion, not by the various layers of the skin, but by depth of maximum melanoma invasion in millimeters. This latter figure is regularly interpreted accurately and has nearly a one-to-one relationship with prognosis. Prognostically, it is well known that melanomas less than 0.75-mm thick carry 99% cure rates with long-term survival. The senior author has only seen 2 of more than 1,000 such cases metastasize without explanation. Mitotic rate has been identified as an independent predictor of survival. In clinically localized melanoma, it has been found to be the second most powerful predictor of survival after depth. A threshold of 1

mitosis/mm^2 has been statistically correlated with decreased survival. Tumor ulceration also has a negative effect on prognosis. Survival rates of patients with an ulcerated melanoma are clearly lower per equivalent depth compared to nonulcerated cases.

TREATMENT OF THE PRIMARY LESION AND SURGICAL TECHNIQUE

The treatment of malignant melanoma focuses upon adequate local excision. In fact, this is true for most forms of cancer, but is especially important here. In general, the deeper the tumor, the wider the clinical margins needed (Table 30.1). In most cases, a peripheral margin of a centimeter per millimeter thickness is required according to the depth of the tumor. Margins of more than 2 cm have been said not to improve overall survival, regardless of the depth of the tumor; the senior author doubts this statement. It is important to measure and mark the required margins before beginning the incision in order to achieve the proper distance from the tumor in all directions. Proceeding via an elliptical incision in the line of skin creases allows for a generous wide local excision of the primary tumor and simple expansion of the resected margins as required. The elliptical wound permits simple wound closure, with or without flaps, and cosmetic defects are kept to a minimum especially when the wound can be closed in line with skin creases. Skin grafts are seldom required, unless lesions are in functionally important areas such as the hand, the ankle, and around the elbow. In general, a melanoma 1-mm thick or greater that occurs in the subungual position is best treated by digit amputation; few thin ones are detected.

TABLE 30.1 Recommended Margins of Resection According to Depth of Primary Tumor

Tumor Thickness	Recommended Excision Margins (cm)
In situ	0.5–1
≤1.0 mm	1
1.01–2 mm	1–2
2.01–4 mm	2 or more
>4 mm	2 or more

Republished (as modified), from Kimbrough CW, McMasters KM, Davis EG. Principles of surgical treatment of malignant melanoma. *Surg Clin North Am* 2014;94:973–88. Copyright © 2014, with permission from Elsevier.

LYMPH NODE CONSIDERATIONS

As the extent of tumor invasion progressively deepens, the risk of lymphatic spread increases. Patients with involved regional lymph nodes without distant metastases benefit from regional lymphadenectomy, improving survival. Clinical palpation of lymph nodes in the hands of surgeons who care for cancer patients is a process that is approximately 80% accurate. However, that is not sufficient, as many are still missed, and a significant proportion has micrometastases, which will be missed on imaging as well.

The practice of sentinel lymph node biopsy (SLNB) has arisen for melanomas and has been shown by our unit and others to be of increasing value toward the overall care of the patient. The number of lymph nodes involved correlates with overall survival, which decreases as the number of involved nodes increases.

Any patient who has a palpable lymph node in the immediate regional distribution in which the melanoma has developed needs to be considered for a lymph node biopsy and/or often a formal node dissection (based on palpation of the nodes) at the time when the primary lesion would be excised. There is no excuse for a limited operation on lymph nodes, that is, less than a full standard radical lymphadenectomy in the relevant body part, but complete excision of the primary tumor is the most important factor in survival. This applies particularly to the neck, in which a sternocleidomastoid muscle can be preserved, to the groin in which the deeper iliac nodes should generally not be excised, and to the axilla.

Surgeons must recall that lymph node dissection should be complete to fascial plane margins as described by Spratt et al. About one fourth of such patients can still be salvaged by a delayed complete regional lymph node dissection only.

Initially, SLNB was applied to melanomas with ambiguous drainage with respect to the dorsal and ventral surfaces of the body and/or the waistline. Occasionally, more than one lymph node basin will contain sentinel nodes in the same patient. This technique and many of its ramifications were developed by Morton, and subsequently perfected in our region by Edwards and McMasters. Its importance is evident in Table 30.2. Technical issues have been discussed repeatedly. It is important to realize how valuable the SLNB can be in the overall care of the melanoma patient. Obviously, melanomas less than 1-mm thick very rarely have node involvement, and rarely require SLNB. Such thin melanomas should, however, be considered for SLNB if the biopsy is suspected of being inadequate, ulceration is found, or high mitotic rates are present. Patients with melanomas thicker than 1 mm should have an SLNB, unless there is a compelling reason to the contrary. Lymph node involvement that is recognized by SLNB and followed by completion lymphadenectomy has been shown to improve survival in comparison to watchful waiting and performing lymphadenectomy only when overtly clinically positive nodes appear.

In general, the accuracy of the SLNB, using isosulfan blue dye and technetium-99m sulfur radioisotopes, exceeds 95%, with a capacity to detect micrometastases when combined with microscopic pathologic examination (Fig. 30.3). It is never perfect; the alert clinician should always be aware that the procedure is not infallible. For example, it is infinitely less helpful with head and neck melanomas, in which the distance between the primary lesion, which must be injected with radioisotope, and the pertinent nodes is very close. This is in contrast to a melanoma on the foot, which drains to the groin in virtual uniformity.

Although seldom emphasized, an important benefit of SLNB is the one that does *not* yield microscopic-positive melanoma but permits the psychological benefit gained in a patient who can avoid a high degree of anxiety, unnecessary testing, and the considerable side effects and expense of bio-chemotherapy. An individual with a 2-mm thick nonulcerated melanoma that has been adequately excised and treated and then has negative lymph nodes simply needs to see her or his surgeon on a regular

basis and be examined for local recurrence, not only at the site, but also in the regional draining lymph nodes. Palpation of the groin, axilla, and supraclavicular spaces in the head and neck is easily done and affords a high degree of accuracy. Depending on the thickness of the melanoma, this examination needs to be done relatively frequently in the early years following excision, and progressively less frequently across a follow-up period that should last for at least 5 and, in many cases, 10 years. Such follow-up must include an examination of all skin aspects. Have the patient, wearing minimal underclothes, stand and be inspected from head to toe, paying close attention to the soles of the feet and the backs of the thighs, which are spots frequently missed by most patients. A second primary melanoma occurs in at least 8% of patients who have been successfully treated for a first primary lesion. This is especially important, because these people with an early diagnosis favorable for primary melanoma have a high likelihood that other areas will also develop disease, as these areas will also have been similarly sunburned, similarly blistered, and at similar times. Nearly one third of patients who develop a second invasive melanoma will have a third melanoma, and the rate of metachronous primary melanomas continues to rise from there.

TABLE 30.2 Multivariate Hazard Ratios for Disease Recurrence and Death Among Patients With Intermediate-Thickness Melanoma Who Underwent Sentinel-Node Biopsy, According to Prognostic Indicator

	Disease Recurrence		Death From Melanoma	
Prognostic Indicator	Hazard Ratio (95% CI)	*P*-value	Hazard Ratio (95% CI)	*P*-value
Sentinel-node status (positive vs. negative)	2.64 (1.92–3.64)	<0.001	2.40 (1.61–3.56)	<0.001
Breslow thickness (per 1-mm increase)	1.62 (1.31–2.01)	<0.001	1.59 (1.21–2.09)	<0.001
Ulceration (present vs. absent)	1.40 (1.04–1.89)	0.03	1.79 (1.24–2.58)	0.002
Site of melanoma				
Arm or leg[a]	1.00		1.00	
Trunk	1.42 (1.03–1.94)	0.03	1.91 (1.26–2.88)	0.002
Head or neck	1.20 (0.77–1.86)	0.42	1.19 (0.65–2.16)	0.58
Sex (male vs. female)	0.94 (0.70–1.26)	0.66	1.22 (0.82–1.79)	0.32
Age (per 1-yr increase)	1.01 (1.00–1.02)	0.07	1.01 (0.99–1.02)	0.33
Clark level (IV or V vs. III)	1.27 (0.94–1.71)	0.12	1.07 (0.74–1.54)	0.73

[a]This group served as the reference group.
From Morton DL, Thompson JF, Cochran AJ, et al. Final trial report of sentinel-node biopsy versus nodal observation in melanoma. *N Engl J Med* 2014;370(7):599–609. Copyright © 2014 Massachusetts Medical Society. Reprinted with permission from Massachusetts Medical Society.

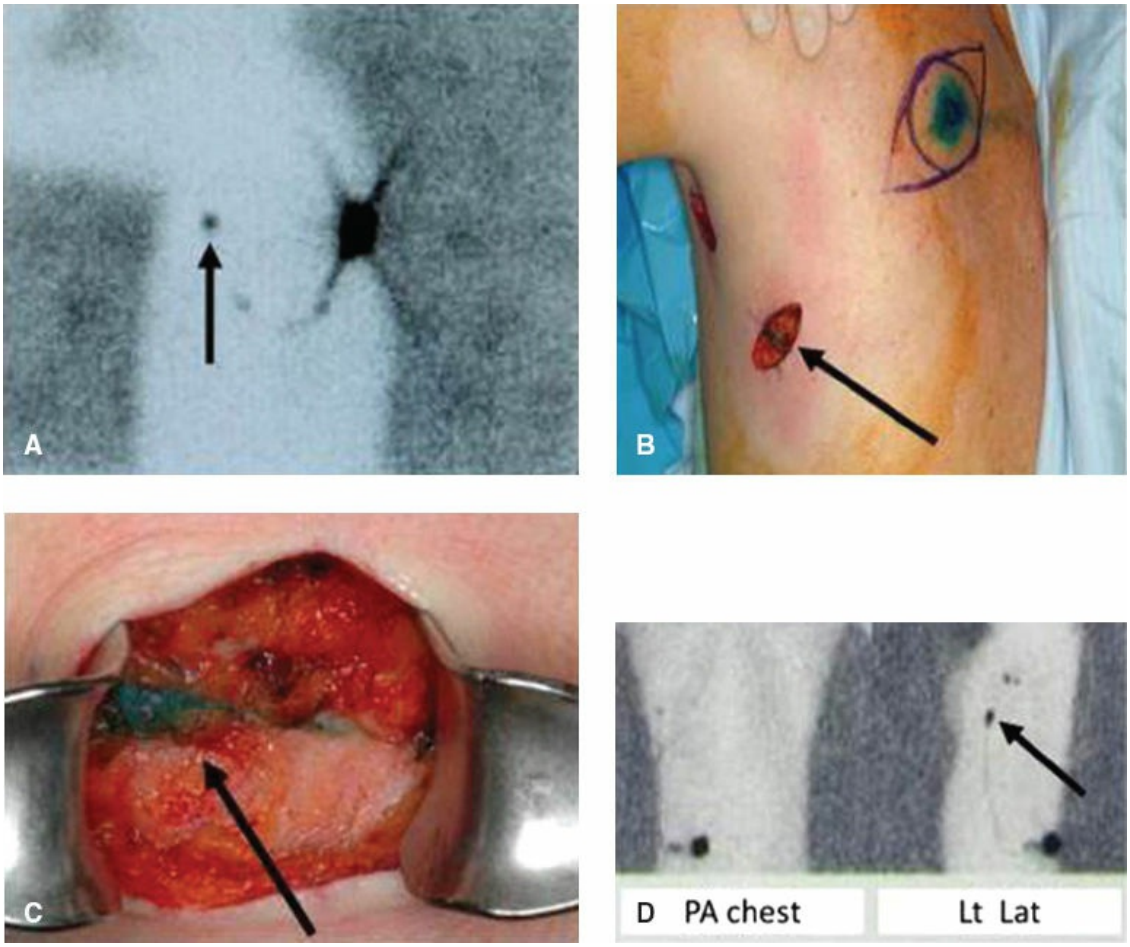

Figure 30.3. **A.** Lymphoscintigraphy demonstrating an in-transit node. **B.** Operative views demonstrate the node location in relation to the primary and draining nodal basin. **C.** With a blue node and afferent lymphatics evident on close-up view. **D.** A similar lymphoscintigraphy pattern with an in-transit node was seen in another patient. The arrow indicates blue lymphatic channels leading into a blue lymph node. (Reprinted from Ross MI, Gershenwald JE. Sentinel lymph node biopsy for melanoma: a critical update for dermatologists after two decades of experience. *Clin Dermatol* 2013;31(3):298–310. Copyright © 2013, with permission from Elsevier.)

In the current surgical literature, guidance on how to proceed with patients who have positive SLNB is not always apparent. In the first instance, understanding that these patients will require a standard or complete regional lymphadenectomy in the involved body part is critical. Once the procedure has been completed, one can, with confidence, provide pathologic data from the original lesion and regional draining nodes to medical and surgical oncologists for assessment of the need for additional systemic therapy. If there is only a single node involved, and the patient's

ability to tolerate the morbidity of therapy is impaired, then one could choose to withhold additional therapy. In general, multiple positive lymph nodes warrant systemic therapy of some sort. We continue to feel that the advantages are slightly in favor of treatment. However, the side effects of interferon alpha-2b are substantial. Many highly motivated patients do not complete their course of therapy because of significant side effects. Conversely, the value of systemic therapy in these patients continues to be debated. Systemic treatment is more frequently said to enhance 5- to 10-year survival in these patients. A recent review concisely and honestly debates the value of new and targeted systemic therapies. However, a substantial number of thoughtful patients may choose to decline such treatment and simply depend upon their surgeons for further regular follow-up, choosing to treat recurrent melanoma when and where found.

The outrageously expensive use of positron emission topography (PET) scanning for patients must be carefully considered before requesting such tests. It may become a collateral casualty of new broader health care insurance in the United States, which will inevitably pursue cost-cutting measures—a worthy casualty. PET scanning for melanoma, unless carefully applied to select genuinely, high-risk patients, yields as many false-positives as true-positives. It is well accepted that there is low yield of discovery of metastatic disease from PET in patients with stage I and II disease; however, the sensitivity and specificity of identifying metastases increase dramatically for patients with stage III or IV disease. It may also be enormously helpful in patients who have had previously positive lymph nodes, where it should be done annually initially after the primary resection. A major issue, aside from its expense, is that the positive PET scan often needs to be confirmed by tissue diagnosis, and that needs to be done in both a minimally morbid and yet definitive way. It should be assumed that the PET scan followed by biopsy confirmation creates a treatment environment that can be tolerated by the patient in order to proceed accordingly.

The majority of melanomas that recur either do so locally or in the body region initially involved and are detected on physical examination by the treating surgeon. Systemic disease occurs in well less than one third of patients treated surgically. As the tumor becomes progressively more favorable, the likelihood of systemic metastases decreases precipitously. Local recurrence, or in-transits, an “inner circle” name for intradermal lymphatic metastases, can be readily identified by physical examination.

In-transit lesions are more readily palpable than they are visible. Any nodular lesion that occurs on the body part from which the melanoma arose should be biopsied within a few weeks of its detection. When these lesions are confined to an extremity, hyperthermic isolated chemotherapeutic perfusion is a standard therapy that will stop progression permanently for about one third of patients, significantly arrest progression for another third, and have relatively little impact on the final third. We have experienced a large number of isolated extremity perfusions undertaken either for prophylaxis or for extremely unfavorable primary tumors (i.e., greater than 5-mm thick, positive regional lymph nodes, or in-transit recurrence). More than 400 such operations yielded two deaths and two amputations. One dozen patients developed significant leaks of the chemotherapeutic material, which resulted in leukopenia that required additional treatment. These patients all recovered, however. In-transit disease that is not amenable to perfusion can often be treated by simple but repeated local excision. The process through which the disease progresses is highly variable; simple local excision can allow some patients to remain lesion-free for long periods of time. There is clear evidence that the dermatotrophic variant of melanoma (i.e., those that are prone to recur in the skin or metastasize in the subdermal lymphatics) runs a very leisurely and seldom aggressive course, which adds an element of confidence to the conservative management of the patient.

NEW SYSTEMIC TREATMENTS AND ADVANCED DISEASE

Surgical excision with clear margins remains the primary curative treatment modality of melanoma. Almost all early-stage disease (in situ, I and II) and resectable stage III melanoma can be treated in this way in combination with evaluation of the regional lymph nodes. Patients who are at higher risk for recurrence, typically stage IIb and above, have been treated with adjuvant high-dose interferon alpha-2b or pegylated interferon. More recent evidence has suggested that neither of these medications improves overall survival in this group of patients, and currently newer therapies that have been shown to improve survival in recurrent and metastatic disease are being tested in clinical trials for use as adjuvant therapy. Isolated limb perfusion continues to be indicated as a treatment modality in patients with multiple lesions in a single extremity or recurrent disease in a single limb.

The treatment of more advanced disease such as unresectable stage III, stage IV, and recurrent melanoma is rapidly changing. Chemotherapy and palliative local therapy continue to be recommended as treatment for advanced or metastatic melanoma. Recent years have seen an emergence of novel therapeutic agents that show better efficacy than standard chemotherapy. Immunotherapy and signal-transduction inhibitors used as single agents, or in combination, have demonstrated increased overall survival. Currently, there are clinical trials investigating whether they can actually cure some cases of metastatic disease. An interesting dilemma, considering the heightened effectivity of the new systemic agents, is whether to treat earlier stage disease with adjuvant drugs to try to reduce recurrence or metastases. Using these drugs for cases that have had a potentially curative operation is a current subject of debate, considering their serious risks and side effects.

DISEASE RECURRENCE

There are at least two more unusual characteristics of melanoma. The first is the late recurrence of disease, which Morton called “dormant.” While unlikely, there is a variant of very late (some more than 25 years) recurrence of melanoma; in all those whom the senior author has seen, progression of disease was then rapid. This is easy to recognize and understand in patients who have been affected by systemic immunosuppression, such as that associated with organ transplantation. However, late recurrence does occur in otherwise unaltered patients and justifies some form of longer-term follow-up, either through the conscientious referring physician, or by the surgeon. Follow-up for such recurrence is, once again, easily conducted by thoroughly examining the undressed patient in good light. The other issue worthy of attention, of course, is management of a second primary. Interestingly enough, these tumors are only slightly prognostically, but not significantly, better than the first primary. One might assume that patients who have had one melanoma would demonstrate a heightened awareness to themselves using the “A-B-C-D-E” algorithms and looking for simple symptoms. One might also assume they would have the wisdom to stay out of the sun on Memorial and Labor Day holidays, with a complete avoidance of tanning beds. However, those assumptions about wise patient behavior are only infrequently true, and the informed physician’s attention to these patients is especially valuable.

What complicates this issue is the fact that 1% to 2% of all melanomas now identified in many states will have had the diagnosis missed by Board-certified pathologists. There is an ongoing argument between dermatopathologists (that is a specialty of dermatology) and pathologists skilled in skin lesions as to who identifies melanomas most accurately. In fact, as we have now advanced toward more in situ disease and the development of dysplasia, atypia, and otherwise normal moles, the pathologic landscape has become increasingly confusing. The fact that these lesions may be missed by even a good pathologist paradoxically simplifies their surgical management! If in doubt, any new lesion in a patient who had been treated for melanoma should be presumed to be a new primary, and a full-thickness local excision should be carried out by the treating surgeon, again, as guided by the body part involved and size of the lesion in question.

A further unusual characteristic relates to occasional reports that still appear about the extirpation of melanoma metastases to other viscera. In general, these are associated with a grave prognosis. Survival is approximately 100 days, and surgical approaches in treating such metastases are seldom successful. Among them are submucosal alimentary tract metastases that bleed or obstruct. Aggressive systemic therapy will arrest disease in only a few patients. However, one must also remember that malignant melanomas are on that curious list of tumors that undergo spontaneous regression for reasons that we do not understand.

THE UNKNOWN PRIMARY

From time to time, a surgeon caring for melanoma patients will see an individual who often has an isolated lymph node that, upon biopsy, shows malignant melanoma but without a visible primary lesion. Careful and detailed study of the vaginal, anal, nasopharyngeal, and oral mucosa is warranted. However, the most common unidentified primary lesions arise from the scalp, which incidentally may subsequently disappear. This is a good time to remember that melanoma may undergo spontaneous regression; it may be that there was an invasive melanoma that has regressed. A careful history about previous suspicious lesions that have either been treated or cauterized is critical in this setting.

In patients who present with single nodes associated with metastatic melanoma but without an obvious primary lesion, there is a substantial likelihood of their being cured by an isolated complete node dissection

confined to that particular body part. By doing so, at least a quarter of these patients are cured. In a self-selected way, they offer substantial salvage to the patient and to the surgeon. Systemic chemotherapy without evidence of metastases appears not to be of value in patients with unknown primary melanoma because, obviously, one simply cannot determine what is being treated.

After a diagnosis of melanoma has been made by an informed primary care physician or dermatologist, the first, second, and third consideration in the patient's care is adequate local and nodal excision and appropriate meticulous personal follow-up, with an emphasis on the potential for disease recurrence.

SQUAMOUS CELL CARCINOMA

The same sun exposure that predisposes toward melanoma appears to promote the likelihood of development of squamous cell cancer, especially in the head and neck regions. Basic lesions are usually diagnosed in doctors' offices. Biopsy strategies for squamous cell cancers are basically the same as for melanomas. Any elevated lesion or nonhealing ulcer on the skin of a patient, particularly in a patient over 50 years of age, and with sunburning, either presently or by history, warrants an excisional biopsy. In most cases, the biopsy can be a local excision with 1- to 2-mm margins, with simple repair of the wound.

In contrast to melanoma, the management of squamous cell cancer is extraordinarily simple, in that margins should generally be as noted above and consistent with the function of the body part. An adequate margin can often be as little as 1 microscopic millimeter with garden variety squamous cell cancers. In general, if the lesion is not in a functionally or cosmetically important area, somewhat wider margins are warranted; but also consistent with simple closure of the wound. Basal cell cancers or irritated seborrheic keratosis can be similarly managed. Metastases are very rare.

THE FUTURE

Whether or not one is a devotee of the "Green" movement, it is clear that the ozone layer has been impacted by some events, and it is less protective than it has been. If we continue a scenario where leisure time is enhanced, then the likelihood that more people will be exposed to the sun for longer periods of time without the protection of the natural ozone layer that benefited our generation will increase. When compounded by the liberal

use of indoor tanning beds, which today exist in an increasing variety of stores, including launderettes and gymnasiums, this leads to the inevitable conclusion that there will be more skin cancers, including both melanoma and squamous and basal cell cancer. We can only hope that the progress made in early diagnosis by dermatologists and other physicians is maintained by surgeons who respect the potential gravity of these diseases and, yet, at the same time, possess a healthy awareness of its biologic variation. The most important biologic variable in malignant melanoma is adequate excision of the primary lesion.

Suggested Readings

Azoury S, Crand Lange JR. Epidemiology, risk factors, prevention, and early detection of melanoma. *Surg Clin North Am* 2014;94:945–62.

Balch CM, Gershenwald JE, Soong SJ, et al. Update on the melanoma staging system: the importance of sentinel node staging and primary tumor mitotic rate. *J Surg Oncol* 2011;104:379–85.

Balch CM, Gershenwald JE, Soong SJ, et al. Final version of 2009 AJCCC melanoma staging and classification. *J Clin Oncol* 2009;27(36):6199–206.

Byrom L, Olsen CM, Knight L, et al. Does pregnancy after a diagnosis of melanoma affect prognosis? Systematic review and meta-analysis. *Dermatol Surg* 2015;41:875–82.

Byrom L, Olsen C, Knight L, et al. Increased mortality for pregnancy-associated melanoma: systematic review and meta-analysis. *J Euro Acad Dermatol Venereol* 2015;29:1457–66.

Davis NC. Cutaneous melanoma. The Queensland experience. *Curr Probl Surg* 1976;13(5):1–63.

Kimbrough CW, McMasters KM, Davis EG. Principles of surgical treatment of malignant melanoma. *Surg Clin North Am* 2014;94:973–88.

Morton DL, Thompson JF, Cochran AJ, et al. Final trial report of sentinel-node biopsy versus nodal observation in melanoma. *New Engl J Med* 2014;370:599–609.

Polk HC Jr. Surgical progress and understanding in the treatment of the melanoma epidemic. *Am J Sur* 1999;178:443–8.

Shah DJ, Dronca RS. Latest advances in chemotherapeutic, targeted, and immune approaches in the treatment of metastatic melanoma. *Mayo Clin Proc* 2014;89:504–19.

Spratt J. Groin dissection. *J Surg Oncol* 2000;73:243–62.

Wehner MR, Chren MM, Nameth D, et al. International prevalence of indoor tanning: a systematic review and meta-analysis. *JAMA Dermatol* 2014;150:390–400.

EDITOR'S COMMENT

With the second installment of this newly developed chapter for the seventh edition of the *Mastery of Surgery*, we were pleased Professor Polk and colleagues provided this eloquent presentation of the science, epidemiology, outcomes research, public and professional education, preventative medicine, and evolving molecular oncologic concepts for the management of skin cancers. Both melanoma and nonmelanoma skin cancers (NMSC–squamous cell carcinoma, and basal cell carcinoma) are inextricably linked to duration and intensity of sun exposure and its chronicity in the lifestyle of individual patients. Cancer of the skin remains the most frequently diagnosed cancer in America. Of epidemiologic importance, the NMSC cohort is difficult to estimate in occurrence frequency, as these neoplasms are *not* required to be reported to state cancer registries. The American Cancer Society estimated in the most recent study of NMSC (2006) that 3.5 million cases were diagnosed among 2.2 million patients. The cure rate for these NMSCs is the highest for all cancers reported. As emphasized by Dr. Polk and associates, invasive melanoma is an increasing public health liability; by 2015 the estimated lifetime risk for melanoma was 1:100,000 in blacks, 4:100,000 in Hispanics, and 25:100,000 in non-Hispanic whites. Projections estimated that new cases of melanoma would be diagnosed in nearly 73,870 patients in 2015 in the United States alone. This neoplasm has had the most rapid increase in the incidence of all cancers, which is attributed to sunlight and indoor tanning exposure, as a result of the lack of awareness and resultant risk-enhancing behavior of Americans (American Cancer Society. *Cancer Facts and Figures, 2015.* Atlanta, GA: Author; 2015). The exploitation and marketing of indoor tanning beds and their UV-A radiation emissions, formerly considered to be safe, were not only an erroneous scientific hypothesis, but together with sun exposure, have also increased the risk and the emergence of melanoma at earlier ages. Currently, over 10,000 melanoma cases and 450,000 nonmelanoma skin cancers are attributed to indoor tanning alone in Perth, Australia, and the United States. As noted by the authors, the management of melanoma with its varying anatomical, epidemiologic, and histologic presentations has remained at the core for reasoning of scientific and clinical arguments for management over multiple decades. While melanoma represents 2% of all skin cancer, it contributes as the principal cause of skin cancer-related mortality. As indicated by the authors, the management of squamous cell cancer and basal cell carcinoma is generally considerably much less complicated than that of cutaneous melanoma. Adequate margins of NMSCs are each defined in millimeters for garden variety squamous cell

carcinomas and basal cell lesions; in contrast, complex management is expected for advanced presentations of primary melanoma and subsequent recurrences.

Over the past three decades, advancing clinical, molecular, and epidemiologic research has focused intensely upon melanoma management, as advanced disease and widely metastatic melanoma predate a dismal prognosis. Furthermore, there has been a major paradigm shift over the past two decades, especially with the introduction by Morton and colleagues for the clinical implementation of intraoperative lymphatic mapping with lymphoscintigraphy and radioactive tracer introduced for early-stage melanoma at the 42nd Annual Meeting of the Society of Surgical Oncology (May, 1990). This presentation followed the original evidence for proof-of principle by the senior investigator's laboratory in 1977 (*Surg Forum* 1977;78:147–8). The technical details of intraoperative lymphatic mapping and use of vital blue dyes singularly or combined with technetium-99m sulfacolloid allowed scientific and clinical progress for management of this malignant cutaneous lesion, and the subsequent development for application in breast, and head and neck carcinomas.

Thus, the implementation of sentinel lymph node biopsy (SLNB) has dramatically shifted the method for detection and accurate pathologic staging of micro- and macrometastases within lymphatics; thereafter, the SLNB sharply impacted therapeutic management considerations for cutaneous melanoma. In what is considered current *standard* therapeutic management with biopsy and indicated dissection only for macroscopic disease, the paradigm shift from *elective* lymph node dissection (now obsolete) together with application of physical examination and radiologic (ultrasound/computed tomography [CT] diagnosis) staging, regional nodal management of melanoma has been profoundly and inextricably altered. As previously observed, fewer patients are subjected to elective nodal dissection as <1 in 5 melanoma patients (17%) will harbor nodal metastases for *lesions >1.0 mm* Breslow depth and *high-risk thin melanomas <1.0 mm depth.* In this selective cohort, high-risk is considered those melanoma lesions with ulceration, mitotic rate ≥1 per mm^2, and select histologic variants >0.75 mm but <1.0 mm (Wong SL, Balch CM, Hurley P, et al. Sentinel lymph node biopsy for melanoma: American Society of Clinical Oncology and Society of Surgical Oncology joint clinical practice guideline. *J Clin Onc* 2012(30);23:2912–8). As reiterated by Dr. Polk and the coauthors, the overwhelming majority of advanced cutaneous melanoma recurs either locally or within the anatomical body site/region initially involved by this cutaneous tumor and is usually first detected on physical examination by the treating physician/surgeon. While systemic disease occurs in *less than one third* of all patients with melanoma, systemic therapy (chemotherapy, biologic, or monoclonal) for the disorder remains largely ineffective, expensive, and often therapeutically toxic. Thus, therapeutic intervention has been principally that of aggressive surgical approaches with tumor resection and regional node dissection; this therapeutic principle provides the greatest potential for enhanced disease-free and overall survival. Moreover, in those high-risk lesions harboring

occult metastatic nodal disease, *early* intervention surgically has been shown to have measurable survival advantage over *delayed* therapeutic node dissections. To date, full (complete) lymphadenectomy in the setting of microscopic or macroscopic metastasis is considered the *standard* therapeutic approach with stage II or stage III disease. However, Bilimoria et al. (Bilimoria KY, Balch CM, Bentrem DJ, et al. Complete lymph node dissection for sentinel node-positive melanoma: assessment of practice patterns in the United States. *Ann Surg Onc* 2008;15(6):1566–76) have reported that only one half of all patients with known advanced local-regional disease receive *recommended* therapeutic approaches, which are principally surgical, with many patients being referred for other (alternative) treatment or no intervention of any type. These authors further emphasize the application of only inguinofemoral lymphadenectomy, rather than the preferred inguinopelvic nodal dissection, when clinically evident metastases are present, either clinically or radiographically (e.g., CT, MRI, PET, etc.). While the majority of surgeons consider axillary regional disease best managed with levels I, II, and III comprehensive dissection following removal of the pectoralis minor for adequate level III exposure, other surgeons limit this to incomplete therapy with dissection of levels I and II. Similar debates have been ongoing for decades and remain extant in our surgical lexicon. These debates have also emerged with the SLNB approaches, in that there is a prognostic variance between nodes that are detected clinically versus those detected by SLNB approaches. This disparity is further being defined by the *AJCC Staging System* to allow appreciation and distinction of methodologies for detection of occult nodal metastases.

In the final report of the Multicenter Selective Lymphadenectomy Trial (MSLT) Group (Morton DL, Thompson JF, Cochran AJ, et al. Final trial report of sentinel-node biopsy versus nodal observation in melanoma. *NEJM* 2014;370:599–609), no significant treatment-related differences were evident in the 10-year melanoma-specific survival rate for over 2,000 patients with primary cutaneous melanoma. Patients were randomly assigned to undergo wide excision and nodal *observation* with reservation of lymphadenectomy for nodal relapse (*observation group*), or wide excision and SLNB with *immediate lymphadenectomy* for nodal metastasis detected on biopsy (*the biopsy group*). This important work identified that biopsy-based staging of intermediate-thickness primary melanoma proved to provide prognostic data to identify patients with nodal metastases who would most appropriately benefit from *immediate* complete lymphadenectomy. This approach with biopsy-based management prolongs disease-free survival for all patients and that of distant disease-free survival and melanoma-specific survival for the patient with nodal metastasis from these intermediate-thickness lesions.

The lack of active and effective commercially developed immunotherapeutics and chemotherapeutics for the therapy of systemic melanoma has resoundingly intensified pharmacologic attention with the development and therapeutic evaluation of *new* active agents. Prior to 2011,

active therapy was limited to carboplatin, paclitaxel, interleukin-2, dacarbazine, temozolomide (Tomodar), and fotemustine. Importantly, no study confirmed any improvement in overall survival for these agents. However, the recent introduction of two FDA-approved agents, ipilimumab (Yervoy) and vemurafenab (Zelboraf), has confirmed improved survival in randomized phase III clinical trials. Of major progress with advancing biologic treatment, ipilimumab, as a fully humanized monoclonal antibody exploits signal-transduction of the immune system to eradicate primary cancer cells. This agent inhibits binding of cytotoxic T-lymphocyte antigen-4 to its ligands. This activity promotes T-cell response and antitumor immunity for melanoma. Data from phase III trials suggest that both vemurafenib and dabrafenib improve patient outcomes, with vemurafenib showing overall survival benefit together with dabrafenib. This trial confirmed improved median progression-free survival. While the immunotherapeutic ipilimumab together with the MAPK-targeted inhibitors (vemurafenib, dabrafenib, and trametinib) has considerably changed the rationale for the systemic immunotherapy of melanoma with these optimistic outcomes, these successes will likely open new vistas for therapeutic interventions. New objectives for success will require an enhancement of *durable* long-term improvement in patient outcomes. To date, traditional therapeutics as mentioned above have *not* provided sustained benefit, and have rapidly failed with time progression. Future research for this lethal neoplasm will continue on a molecular basis, and thus will yield new targeted therapeutics with more durable long-term enhancement for disease-free and overall survival (Yushak M, Kluger HM, Sznol M. Advances in the systemic treatment of metastatic melanoma. *Oncology* (Williston Park) 2013;27(5):374–81 and Olszanski. Current and future roles of targeted therapy and immunotherapy in advanced melanoma. *J Manag Care Spec Pharm* 2014;20(4):346–56).

Kirby I. Bland

31 Melanoma

Douglas Tyler and Kelly Olino

EPIDEMIOLOGY

According to the American Cancer Society in 2016 there were 76,380 new cases of invasive melanoma and 10,130 deaths in the United States. It currently represents 5% of all cancer in men and 4% of all cancers in women. In addition, in this same year it is estimated that there will be 63,770 cases of melanoma in situ. In contrast to many other cancers that have decreased in incidence over the past two decades, the incidence of melanoma has increased over this time.

GENETICS

Although most commonly melanoma arises out of a combination of accumulated somatic mutations, phenotypic risk factors (blue or green eyes, fair skin, red hair), and environmental exposures (sun burn, ultraviolet [UV] radiation), there are heritable genetic mutations that increase susceptibility to developing this cancer. Although rare, mutations in the CDKN2A gene are most commonly associated with familial melanoma and have a high penetrance when found. In kindreds with a member with multiple primaries or in cases where multiple (≥3) first-degree relatives are involved, consideration for genetic testing should be discussed. However, at this time there are no formal screening guidelines for this mutation given its rare occurrence. Although the relationship between the development of melanoma and multiple dysplastic nevi syndrome is currently controversial, patients with multiple dysplastic nevi are associated with having an increased risk of developing melanoma, specifically in cases of a family history of melanoma.

WORKUP OF SUSPICIOUS LESIONS

Suspicious skin lesions are usually identified using the common ABCDE method of evaluation for melanoma. A = Asymmetry; B = Border irregularity; C = Color variegation; D = Diameter >6 mm; E = Evolving

lesion. Figure 31.1 demonstrates several examples of pigmented lesions with the above characteristics that proved to be melanoma on biopsy. Once a suspicious lesion is identified, both the National Comprehensive Cancer Network (NCCN) and the American Academy of Dermatology recommend full thickness excisional biopsy (down to subcutaneous fat) with 1- to 3-mm margin. An alternative to full thickness excision is to perform a full thickness punch biopsy (as shown in Fig. 31.2) or incisional biopsy through the thickest portion of the lesion. The orientation of the incision utilized for the initial biopsy should be performed keeping re-excision or subsequent sentinel lymph node (SLN) mapping in mind. Increasingly, a shave biopsy is performed, particularly for lesions that have a low index of suspicion. Although upwards of 30% of melanoma lesions may have a positive deep margin when biopsied using this technique, shave biopsy has gained wide acceptance by dermatologists as it allows rapid, inexpensive information, and may lower the threshold to perform biopsies of suspicious lesions.

CLINICAL STAGE AND TREATMENT

Once a diagnosis of melanoma is secured, initial treatment decisions are based upon the clinical stage, which is determined by a combination of the initial biopsy results as well as evaluation of draining nodal basins by physical examination. If the initial history and physical examination suggest regional or metastatic involvement, appropriate imaging (computed tomography [CT], positron emission tomography/computed tomography [PET/CT], magnetic resonance imaging [MRI]) and biopsy should be obtained at the time of diagnosis.

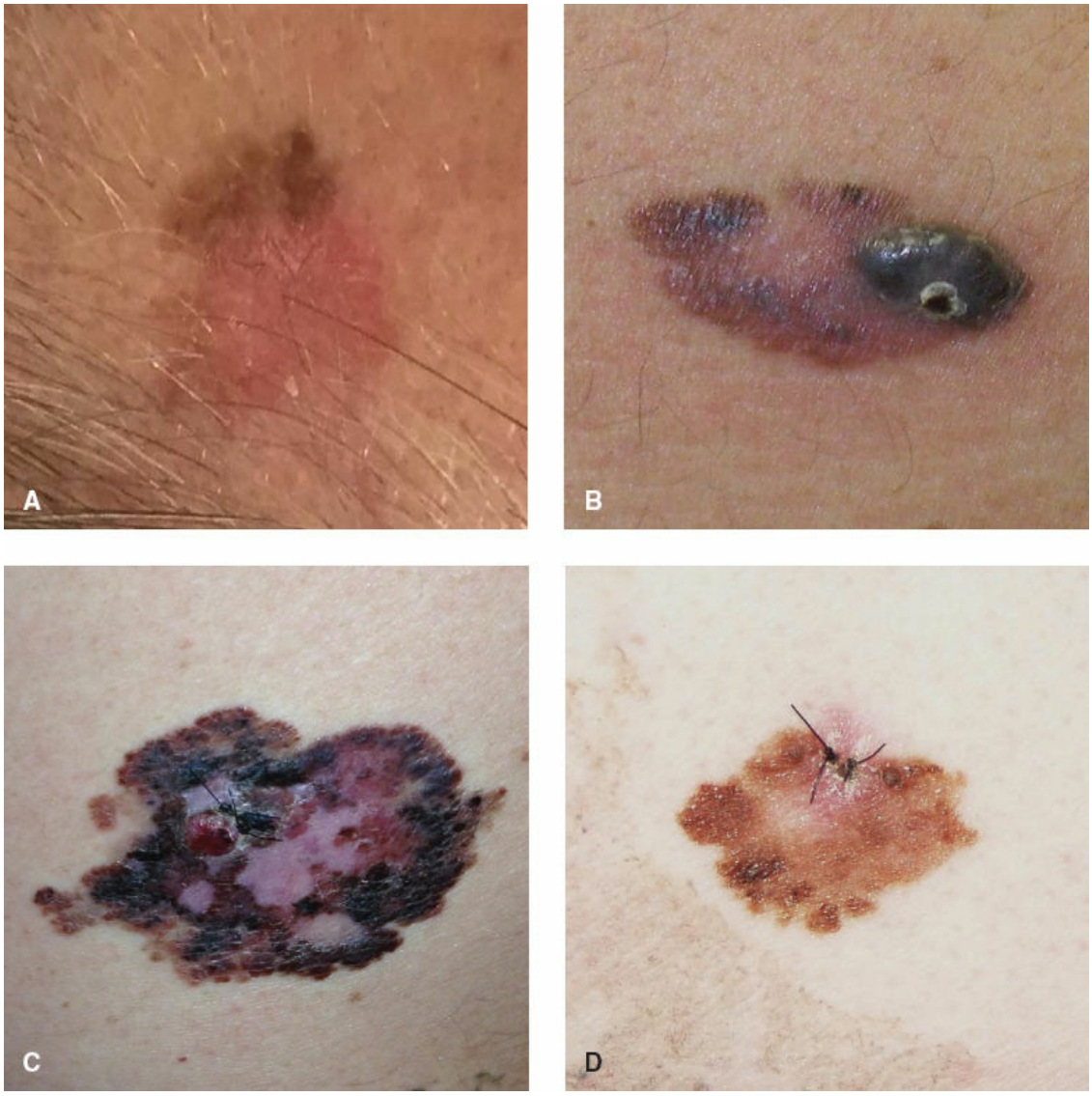

Figure 31.1. Examples of four pigmented lesions demonstrating the asymmetry, border irregularity, color variation, and size that are all concerning for melanoma. Panel **A** represents a lentigo maligna melanoma of the head and neck, Panels **B** and **C** demonstrate melanoma with nodular characteristics, and Panel **D** demonstrates a superficial spreading melanoma.

The initial biopsy specimen report should include the Breslow thickness, which as shown in Figure 31.3 is a measurement in millimeters from the top to the base of the tumor. Breslow thickness has replaced for the most part tumor staging using Clark levels, also shown in Figure 31.2, which refer to histologic levels of the skin to which the tumor has invaded. The Clark levels fell out of favor as they vary by location on the body, had more discordance among pathologists when reviewing a specimen, and were not as strongly correlated with the likelihood of metastasis as was the

Breslow classification. Other histologic characteristics that are factored into the staging system include ulceration status, margin status, and the mitotic rate. Melanoma in situ is confined to the epidermis (stage 0) and is treated by local excision with 0.5-cm margins. In some locations in situ disease may be challenging as tumor cells may extend out into the skin beyond where pigmented changes are present necessitating wider excisions to achieve negative margins. This tends to be more common with in situ disease on the sole of the foot and perianal area as well as in the head and neck area where it is frequently referred to as lentigo maligna melanoma. For invasive melanoma, the appropriate margin for re-excision of the primary site is based upon tumor thickness and has been vigorously studied in multiple randomized clinical trials (see Table 31.1). Based upon these trials, current guidelines (shown in Table 31.2) are for tumors ≤1 mm in thickness an excision with a 1-cm margin should be performed; for tumors that are 1 to 2 mm in thickness, a 1- to 2-cm margin should be obtained; and for tumors ≥2 mm in thickness, a 2-cm margin is performed. For lesions that are on the digits or under the nail bed, adequate margins are usually obtained by partial amputation of the digit at the joint space proximal to the melanoma.

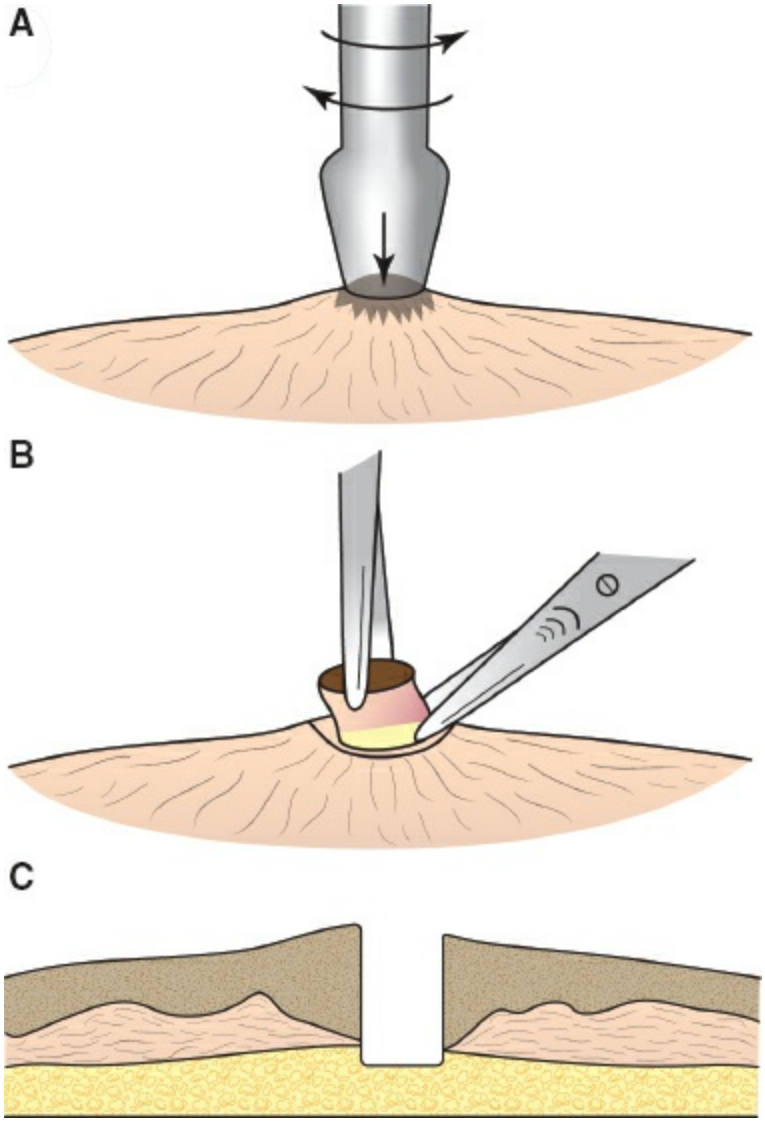

Figure 31.2. Schematic of the punch biopsy technique. Panel **A** shows the punch tool over the pigmented lesion with a twisting motion to cut through the skin. Panel **B** demonstrates the core of tissue that is elevated and cut at its base in the subcutaneous fat. Panel **C** demonstrates the full thickness skin defect left after the biopsy.

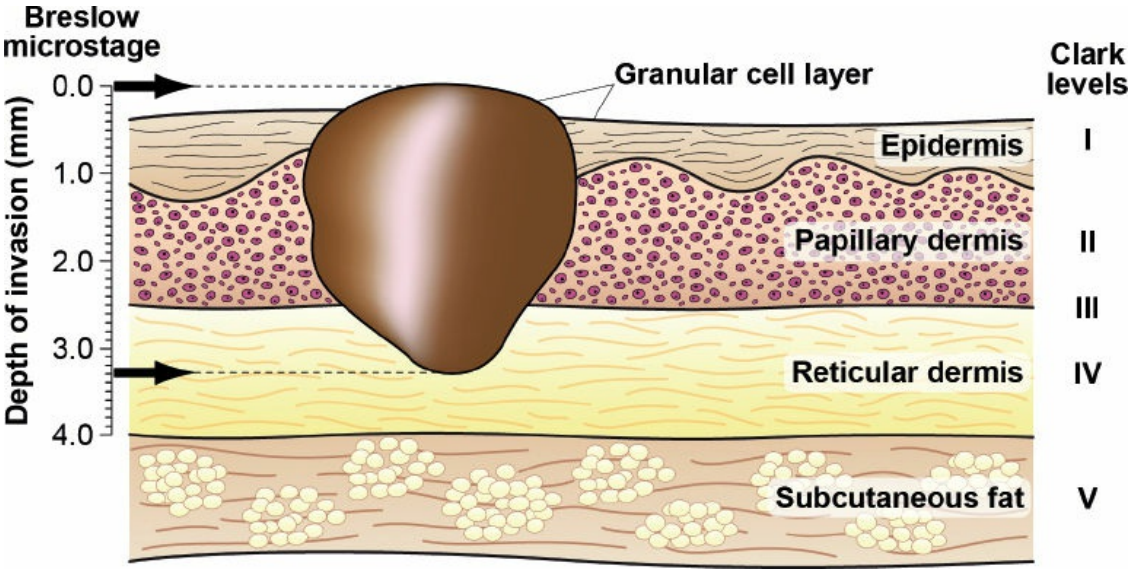

Figure 31.3. Schematic of primary tumor staging using the Breslow depth and Clark levels. The Breslow thickness is a measurement in millimeters from the top of the tumor to the base of the tumor as shown with the black arrows. The Clark level is the deepest layer that the base of the tumor invades into.

TABLE 31.1 Randomized Controlled Trials of Wide Local Excision of Melanoma

Trial	Year	N	Tumor Thickness	Arms	Outcome
WHO Melanoma Program	1988	612	<2 mm	1 cm vs. 3 cm	No difference in LR, DFS, or OS
US Intergroup Melanoma Trial	1993	486	1–4 mm	2 cm vs. 4 cm	No difference in LR, DFS, or OS
Swedish Melanoma Study Group	1996	989	0.8–2 mm	2 cm vs. 5 cm	No difference in LR, DFS, or OS
French Cooperative Study	2003	362	<2 mm	2 cm vs. 5 cm	No difference in LR, DFS, or OS
UK Melanoma Study Group	2004	900	>2 mm	1 cm vs. 3 cm	HR 1.26 for 1 cm vs. 3 cm for LR. No difference in DFS or OS
Scandinavian Study Group	2011	936	>2 mm	2 cm vs. 4 cm	No difference in LR, DFS, or OS

After determining the appropriate margin of resection, most lesions can be excised with excellent cosmesis by creating a fusiform incision with the ratio of 3:1 of the long:short axis. Small skin flaps can be created to aid in closure. For lesions on the head and neck or areas with less pliable skin, local rearrangement flaps can be used such as a rhomboid, V-Y or keystone advancement flap. For lesions on the sole of the foot, particularly in weight-bearing areas, reconstruction can be particularly challenging. Temporary placement of a VAC can be used prior to or following split thickness skin grafts. Good results have also been reported utilizing glaborous skin flap reconstruction.

Prior to the publication of the use of SLN biopsy to identify clinically occult nodes by Morton et al., management of the draining lymph node

basin in those who were clinically node negative was controversial. Although randomized controlled trials did not demonstrate a statistically significant benefit in overall survival for elective lymph node dissection, practitioners were performing the procedure based upon evidence from subgroup analysis of randomized trials and retrospective studies. After SLN biopsy became increasingly used, multiple studies were performed that correlated risk factors of the primary tumor with the risk of harboring nodal metastases. Conceptually, SLN biopsy is a technique where the primary tumor is injected with radioactive material and vital blue dye to help identify which regional draining lymph nodes drain the afferent lymphatics from the patch of skin where the tumor is located. In theory, tumor cells that leave the tumor would have followed the same channels that drain the radioactive material and vital blue dye, ending up in the first echelon or SLN in a given nodal basin as shown schematically in Figure 31.4. Figure 31.5 shows that some SLNs maybe in unusual locations such as the popliteal fossa for a posterior calf melanoma. Factors associated with an increased risk of a positive SLN include thickness of the primary tumor. For lesions <1 mm thick, there is <5% rate of a positive LN, which rises to >35% for tumors >4 mm thick. While there is general consensus for recommending SLN Bx for patients with tumors >1 mm thick, there is considerable controversy over which thin lesions might benefit from the procedure. Generally, SLN biopsy should be discussed in patients with thin melanomas that have characteristics that would push the primary tumor from being graded by AJCC criteria as a T1a (tumor <1 mm) to a T1b such as ulceration and/or high mitotic rate. These factors appear associated with a worse prognosis and a slight increase the probability of the SLN having metastatic disease.

TABLE 31.2 Recommended Surgical Margins for Local Excision of Melanoma

Tumor Thickness (mm)	Recommended Surgical Margin (cm)
In situ	0.5–1 cm (>0.5 for lentigo maligna or large in situ)
≤1.0 mm	1.0 cm
1.01–2.0 mm	1–2 cm
2.01–4.0 mm	2.0 cm
>4 mm	2.0 cm

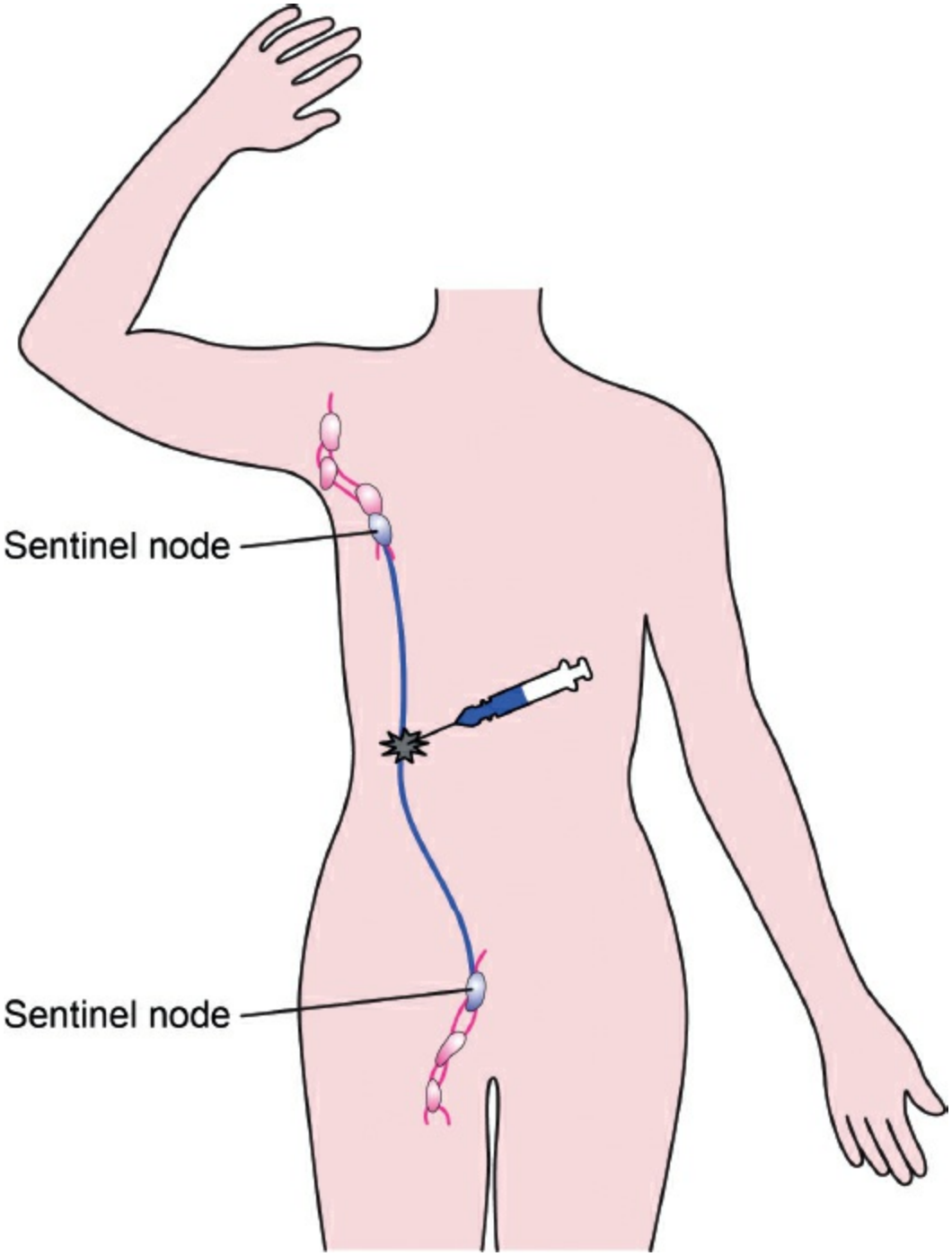

Figure 31.4. Schematic of the technique of lymphatic mapping. The blue dye is injected at the primary site, and the dye will drain to the lymph nodes that drain that area of skin. Since the lesion in the figure is in an ambiguous area of the trunk of the body, lymphatics from the primary site may drain to more than one basin. A lymphoscintigraphy that injects radiolabeled sulfa colloid at the primary site can also help facilitate identification of the sentinel lymph node.



Figure 31.5. Example of intraoperative lymphatic mapping of a posterior calf lesion that drained to a sentinel lymph node in the popliteal fossa. Panel **A** shows the operative field. Panel **B** shows the sentinel lymph node biopsy site with the nerves retracted, and Panel **C** shows the blue node that is removed.

The benefit of performing an SLN biopsy on survival was studied in a large randomized trial, the MSLT-1 Trial (Multicenter Selective Lymphadenectomy Trial). In this seminal study, 1,347 patients with melanoma 1.2 to 3.5 mm thick were randomized to undergo wide local excision with SLN Bx or wide local excision with nodal observation with clinical examination and ultrasonography. In patients who were found to have a positive SLN, a completion lymph node dissection was performed. The primary endpoint was melanoma specific survival with secondary endpoints including disease free survival and the development of nodal disease. Although there were no differences in overall melanoma specific survival between groups who underwent SLN biopsy compared to the observation-alone group, when subgroup analysis was performed there were differences seen among the intermediate thickness melanomas. For patients who had no nodal disease develop during observation, and for true negative SLN biopsies, 10-year melanoma specific survival was >85%. For patients who had a positive SLN and then underwent completion lymph node dissection, 10-year melanoma specific survival was 62%. Those who developed nodal disease in the observation arm had 10-year

melanoma specific survival of 41.5%, which was similar for those patients who were found to have a false negative SLN biopsy. Despite concerns about the validity of the subgroup analysis, these findings were interpreted to support the use of SLN biopsy. Interestingly, in this same clinical trial, for patients with thick melanoma, there was no observed difference on subgroup analysis between patients who underwent SLN biopsy followed by immediate completion LN dissection and those patients who initially underwent nodal observation and the subsequently developed nodal disease and underwent lymph node dissection.

Whereas the MSLT-1 trial has provided us with data to help shape the conversation of the benefit for performing a SLN biopsy, the MSLT-2 trial aims to answer the question whether in patients with a positive SLN, a completion lymph node dissection leads to improved melanoma specific survival when compared to observation of the nodal basin with ultrasound. This trial has completed accrual and is currently awaiting the data to mature before the first analysis is reported out. Multicenter retrospective studies have found that patients with a positive SLN who do not undergo completion lymphadenectomy that the local nodal recurrence is 15%, compared to <5% following completion lymphadenectomy. Given the morbidity associated with the extensive nodal dissection, controversy exists whether the risk is worth the potential benefit, particularly in patients with low burden of disease in a solitary lymph node.

The management of the axillae in the case of a completion lymphadenectomy requires a more extensive nodal dissection than is utilized in the management of breast cancer. Nodal dissection includes all of the nodes in levels I and II, skeletonizing the axillary vein and all fatty tissue surrounding the long thoracic and thoracodorsal bundle. For the treatment of melanoma, level III lymph nodes must also be removed following resection of level I and II nodes. The pectoris minor is retracted anteriorly in order to access the more proximal level III lymph nodes along the subclavian vein.

ADJUVANT THERAPY FOR STAGE III MELANOMA

At the current time, the prognosis for most SLN-negative patients with primary tumors <4 mm is very good and no additional therapy is recommend after surgery. Recent studies using a 31-gene expression signature have demonstrated an ability to identify patients with negative SLNs who have a high risk of distant disease recurrence. The role of this

test has yet to be determined as there are currently studies examining therapeutic interventions in those patients who have a positive test. For patients with thick primaries >4 mm or nodal metastasis, the prognosis is more guarded. High-dose interferon alpha therapy and anti-CTLA-4 therapy (Yervoy, Ipilimumab) are the only two FDA-approved adjuvant treatments for stage IIb and III disease in the United States, with low-dose interferon also approved in Europe. Interferon therapy has been evaluated in 14 separate clinical trials studying varying duration, doses including with pegylated formulations. Although most studies show a benefit in recurrence-free survival, there is no benefit in overall survival. Subgroup analysis points to patients with stage IIIa disease deriving the greatest benefit of treatment, particularly those with microscopically positive nodal disease. It also appears that the duration of treatment is related to relapse-free survival that may be due to a yet-to-be-described immunomodulatory mechanism of action, with some studies showing a benefit when continuing treatment up to 5 years. The marginal benefit of interferon treatment needs to be balanced with the high associated toxicity rates and high cost of treatment. Given this, there is a great variability among centers in the utilization of this therapy.

The success of anti-CTLA-4 treatment in the setting of metastatic disease and the lack of efficacy of other treatments in the adjuvant setting led to the EORTC 18071 trial, which equally randomized 951 stage III patients with nodal metastases following surgical resection of both the primary and regional lymph nodes to treatment with 10 mg/kg of ipilimumab (monoclonal anti-CTLA-4 antibody) or placebo. The study found an improvement in 3-year recurrence free survival of 46.5% in the ipilimumab group compared to 35% in the placebo group. Subgroup analysis revealed that patients with microscopically positive nodal disease and ulcerated primary tumors derived the greatest benefit of treatment. While the overall survival rates have yet to be reported, the marked improvement in median recurrence-free survival of 26 months for patients treated with ipilimumab compared to 17 months for patients receiving placebo has led the FDA to recently approve ipilimumab in the adjuvant setting.

Similar to treatment with adjuvant interferon alpha, the benefit of ipilimumab treatment has to be balanced with the toxicity. In this study, 54% of all patients treated with ipilimumab experienced a grade 3/4 toxicity with five treatment-related deaths. Grade 3/4 toxicity affected 25%

of the placebo group with no treatment-related deaths. Immune-associated toxicity was commonly related to colitis and hypophysitis. In this patient population when deciding whether to give adjuvant immunotherapy, great thought must be given to the potential benefit given the high toxicity as we still cannot predict who will derive benefit and whether any benefit in 3-year recurrence-free survival will translate into any benefit in overall survival.

SPECIAL SITUATIONS

Melanoma of Unknown Primary

In some situations, melanoma presents not as a pigmented lesion but as an enlarged lymph node or soft tissue mass. Despite an extensive skin exam, no obvious pigmented lesion is identified. While some feel that this may be related to the primary tumor undergoing regression, an extensive evaluation for the primary lesions needs to be undertaken before categorizing them as melanoma of unknown primary. Patients will need a careful eye exam to rule out an ocular melanoma, as well as an extensive evaluation of the nasopharynx and oropharynx to rule out mucosal melanoma. In addition to examining all the fingers and toes, an examination of the genitals for penile or vulvar/vaginal melanoma as well as the anorectal area to rule out anal melanoma is important.

If no primary is identified, and complete staging with PET/CT and brain MRI shows no additional metastatic disease, then surgical resection of the metastatic focus is indicated. If the focus is a lymph node, then a complete lymphadenectomy is recommended. If the lesion is a solitary lesion in the soft tissue that is not a lymph node, then simple surgical resection with negative margins is all that is required. In both scenarios, discussion of adjuvant therapy should take place. In general, the prognosis for patients with unknown primary is as good as those patients with a known primary, and in some cases it may be even better.

Melanoma Arising in Pregnancy

Melanoma can sometimes arise in women during pregnancy. In general, most groups currently recommend surgical excision of the primary lesion with appropriate margins under local anesthesia ideally performed in the second trimester but not totally necessary if local alone is used. The timing of the SLN biopsy if indicated for a T1b or greater lesion is more

controversial. While there are reports that lymphosyntigraphy and vital blue dye can be utilized during pregnancy especially after the first trimester, without ill effect to the mother or fetus, most surgeons still prefer to wait until after delivery to perform the SLN biopsy. In most cases, performing the wide local excision early will not impact the accuracy of the SLN biopsy. There are case reports of melanoma transmission to the fetus when mothers develop melanoma in pregnancy. As such it is important to make sure the placenta is evaluated histologically for metastatic melanoma at the time of delivery, which can be a strong predictor of spread to the child. Even in the absence of melanoma in the placenta, these children should be followed closely on the small chance metastases were missed.

Desmoplastic Melanoma

Desmoplastic melanoma is a histologic variant representing <4% of all melanomas. It commonly presents in patients >60 years old as a thick tumor, predominantly in the head and neck region. Given the heterogeneous histology associated with this diagnosis, there continues to be great difficulty in accurately securing not only the initial diagnosis but also in further delineating this diagnosis into histologic subtypes. Some centers have stratified desmoplastic melanoma into “pure” desmoplastic melanoma if >90% of the invasive melanoma was associated with stromal fibrosis, where as “mixed” or “combined” desmoplastic melanoma has >10% but <90% of invasive melanoma associated with stromal fibrosis.

Desmoplastic melanoma is thought to have a different underlying biology compared to conventional melanoma. This subtype rarely harbors BRAF mutations and when compared to similar thickness invasive melanoma, the incidence of harboring a positive SLN can be as much as 50% lower than in conventional melanoma. The decision whether to perform an SLN biopsy for staging in desmoplastic melanoma is further complicated by conflicting reports from retrospective single center case series where centers report rates ranging from 0% to 15%. Among the “pure” and “mixed” subtypes, there are also differences in reported rates of positive SLNs with “pure” ranging from 0% to 10% in various series and “mixed” ranging from 10% to 25%. Furthermore, reports also conflict as to whether the presence of a positive SLN or performing completion lymphadenectomy leads to any difference in melanoma specific survival. Given the controversy, we recommend patients with the diagnosis should

undergo pathologic re-review at an expert center to ensure appropriate diagnosis, and decisions regarding further lymph node staging be made on a case-by-case basis.

Local recurrence, particularly in thick head and neck desmoplastic melanoma, where obtaining wide local excision margins can be challenging, has led to some centers utilizing adjuvant radiation treatment either after the initial resection or in the setting of recurrent disease. Retrospective series have suggested a role for this therapy and is currently being investigated in a prospective clinical trial.

Head and Neck Melanoma Including Lentigo Maligna

Head and neck melanomas commonly arise on the face in adults over 70 years of age but can occur at all ages. The subtypes and the management of head and neck melanoma are similar to that of other locations on the body, but with additional consideration of lentigo maligna lesions that arise in pre-existing large freckles. Local excision is based upon the Breslow thickness and requires increased attention to cosmesis and reconstruction options. Several examples of melanomas in the head and neck region that highlight potential cosmetic issues and complex lymphatic drainage are shown in Figure 31.6. In the case of lentigo maligna melanoma, larger margins of resection may be required given its high incidence of subclinical involvement (see above). Lymphoscintigraphy with Technectium or a SPECT scan is vital given the variability in the location of draining SLNs in head and neck melanoma that can be bilateral, at different nodal levels in the neck, or in the parotid gland. During the operation, removal of the primary lesion is recommended to decrease the background noise as the SLN can be in close proximity. The SLN should be sent for permanent section. In the event that the SLN drains to the parotid gland, local expertise should dictate whether to perform a superficial parotidectomy or to perform a selective resection of the node alone. Following a positive SLN in the neck, selective lymphadenectomy of the involved nodal level should be performed as positive non-SLNs are usually located in close proximity. A parotidectomy is indicated in the case of a positive parotid lymph node. In the case of extensive nodal involvement, modified radical neck dissection should be performed. In the case of positive margins or extensive nodal disease, adjuvant radiation treatment should be considered.



Figure 31.6. Examples of melanoma of the head and neck region. Panel **A** is a scalp lesion, Panel **B** is a temporal area nodular melanoma, and Panel **C** is a lentigo maligna lesion of the left cheek. All of these lesions highlight some of the cosmetic issues that accompany management of head and neck melanoma lesions.

Hand and Foot Melanoma

Melanomas arising on the hands and feet can present difficult problems usually because they are usually mistaken for something else before a diagnosis is made. As a result, melanoma in these areas is usually more advanced than melanoma elsewhere on the body. The other problem with

the hands and feet is that generally the skin is not very mobile in these areas such that primary closure is usually impossible after a wide excision. Figure 31.7 shows examples of melanomas of the hands and feet. Diagnosis is made by biopsy as is elsewhere on the body but tumors arising under the nail bed require removal of the nail to gain access to the malignant tissue. Once a diagnosis is made, excision of the lesion in conjunction with a SLB biopsy is usually performed. When the tumors involve the digits, amputation at the joint space proximal to the tumor is usually the treatment of choice. Lesions on the palms and back of the hand can usually be skin grafted. Lesions involving weight-bearing parts of the foot usually need some type of tissue transfer as a skin graft may not prove durable enough especially in an active person. In some cases, tissue from a non–weight-bearing area like the arch of the plantar surface can be rotated to cover the defect and a skin graft placed on the non–weight-bearing donor site.



Figure 31.7. Examples of melanomas of the hand (Panels **A** and **B**) and foot regions (Panels **C, D,** and **E**). Reconstruction to optimize function is a challenge in these areas.

Pediatric Melanoma and Atypical Spitzoid Tumors

The incidence of pediatric melanoma is increasing in the United States, likely due to an increased awareness leading to more biopsies of atypical melanocytic lesions. Given that melanomas arise in different populations ranging from infants to older children to teenagers, the etiology underlying melanocytic lesions among these different age groups differs. Melanocytic lesions in children may not have the characteristic appearance of adult melanoma so when a suspicious lesion is identified, histopathology review of the biopsy should be sent for review at a center with experience in pediatric melanomas where molecular testing can also be performed. Several studies have demonstrated that comparative genomic hybridization can help distinguish between Spitz nevus and melanomas as melanomas will usually have significant changes in DNA copy number. Melanomas generally have frequent chromosomal aberrations whereas most melanocytic nevi, like Spitz nevi, will show no chromosomal aberrations

or have a restricted set of aberrations with no overlap with melanoma. Pediatric melanomas tend to have a lower incidence of local recurrence but higher rates of positive SLNs compared to equivalent thickness melanomas in adults. In fact, positive SLNs have also been found in atypical Spitzoid lesions despite the fact that they are unlikely to harbor distant metastases. The role of completion lymphadenectomy is controversial and should be decided on a case-by-case basis. Although there is an increased incidence of positive nodal disease, overall survival is usually better than in adults. The pediatric population, even in node negative patients, continues to have regional or distant recurrences past 5 years, so they should be followed for many years. Although there is no consensus, some centers favor the use of adjuvant interferon therapy for a year in cases of stage III disease, as the pediatric population tolerates this therapy better than in adults. The role of ipilimumab is under investigation with only one phase I clinical trial published. Given that pediatric melanomas tend not to be hypermutated, they might not be as immunogenic and may not be as responsive as adult tumors.

Anal Melanoma

Anorectal melanoma is rare, representing <1% of all cases of melanoma. It can present up to 20% of the time as an amelanotic lesion and usually presents with advanced disease at the time of diagnosis. Many times it is mistaken for a thrombosed hemorrhoid and diagnosed only after a “hemorrhoidectomy” is performed. Historically, treatment included abdominoperineal resection for loco-regional control. However, large case series showed equivalent overall and disease-specific survival for wide local excision with improved quality of life. Distant metastatic disease is common, with 5-year overall survival approaching 20%. Small case series have reported the use of adjuvant radiation therapy for local control. There is no role for prophylactic inguinal lymph node resection, with lymphadenectomy reserved for radiographic or clinically apparent disease. There are also case reports utilizing BRAF or c-kit inhibitors for targeted therapy as well as immunotherapy, but data are still lacking. Generally our practice is to locally excise small lesions and then use adjuvant radiation therapy postoperatively. For larger lesions, we treat with radiation neoadjuvantly. If the tumor shrinks, we perform a local excision; if it remains large and there is no metastatic disease, we perform a bigger circumferential operation that may require abdominoperineal resection if

the sphincters are involved. All patients with anorectal melanoma should be presented to a multidisciplinary tumor board that has expertise in managing melanoma patients.

Neoadjuvant Therapy

Increasingly, there are therapeutic options available for melanoma patients that can effectively shrink large tumors. In most solid tumors, neoadjuvant therapy is utilized to downsize a tumor to make it technically resectable or to allow preservation of an important structure like the anus. Melanoma is generally technically resectable even when it presents as a large lesion, so the reason why neo-adjuvant treatments are contemplated in melanoma is because there are concerns over the lesion having a very aggressive tumor biology. Currently, there are no systemic treatments that are approved for the neoadjuvant treatment in melanoma, and many of the reports in the literature are related to anecdotal case reports or pilot trials. Targeted agents like BRAF and MEK inhibitors as well as immunotherapy approaches targeting CTLA-4 and PD-1 (see below) have been tried with some marked responses. As such, patients with unusually large lesions or bulky lymphadenopathy should be presented at a multidisciplinary tumor board that has expertise in managing melanoma patients to consider this treatment approach.

In-Transit Disease

In-transit disease is a manifestation of dermal and subcutaneous metastasis usually related to lymphatic spread of tumor. As shown in Figure 31.8, it can present as multifocal satellite recurrences or as a single large lesion. The lesions can arise in all layers of the skin as well as in small lymph nodes that may be present outside the regional nodal basins. In-transit disease can occur secondary to melanomas that arise anywhere on the body from the scalp to the feet. Historically, the primary approach to in-transit small volume disease was surgical excision. The treatment of choice for larger volume disease confined to the extremities was treatment with regional chemotherapy using melphalan. Hyperthermic isolated limb perfusion (HILP), initially described in 1958, was the primary method used to regionally deliver melphalan (See Fig. 31.9). This technique utilized large bore vascular catheters surgically placed into the extremities, followed by isolation of the catheters with a tourniquet placed proximally on the extremity. The catheters were then connected to a pump oxygenator

allowing the drug to be circulated in the limb where acid base status and oxygenation were maintained in the physiologic range. More recently, a minimally invasive approach to deliver the chemotherapy through percutaneously placed catheters, called isolated limb infusion (ILI), has been popularized. This technique lacks a pump oxygenator, so chemotherapy circulates in a hypoxic acidotic environment (see Fig. 31.9). While HILP is more effective than ILI in achieving a complete response (50% vs. 30%), the durability of response is similar. However, HILP is associated with a higher toxicity rate, and there is no difference in overall survival in patients receiving either form of regional treatment. As such, ILI has become the preferred regional therapeutic modality in most centers that perform regional chemotherapy treatments given the increased toxicity of HILP and lack of survival benefit associated with HILP even though the complete response rate is higher. HILP is more commonly used for salvage therapy in select patients.

Although regional approaches are useful for extremity in-transit disease, they cannot be used in patients with in-transit disease on the trunk or head and neck region. Current advances in therapeutic options for melanoma patients in the last several years have changed the approach to patients with in-transit disease. There is now less consensus on the optimal way to manage patients with regionally advanced disease. Surgeons tend to have a bias toward regional treatments using surgery, intralesional therapies, or regional chemotherapy. This is mainly based on the observation that many patients can have regionally advanced disease for a prolonged period of time before it ever becomes systemic and that there appears to be a group of about 20% of patients who do exceptionally well with regional treatments such that they can be spared the toxicity of systemic therapies. Medical oncologists are more likely to consider systemic therapies early on in the course of treatment as they feel that that vast majority of patients with stage IIIB/C in-transit disease have distant micrometastatic disease. As such given the array of current treatment options and potential clinical trials that are open and available for this patient population, all individuals with in-transit disease should be discussed at a multidisciplinary melanoma tumor board. A brief summary of the various agents that are currently available are summarized below.

Regional chemotherapy: There are currently two trials exploring the combination of regional chemotherapy using ILI with ipilimumab. One trial (NCT01323517) explores the role of ipilimumab after ILI and the

other is a multicenter trial that explores the use of ipilimumab neoadjuvantly prior to ILI (NCT02115243).

Intralesional therapies: Many different intralesional therapies have been developed and generally are injected directly into the lesion as shown in Figure 31.10. While historically BCG was the intralesional treatment used by some centers, it has been replaced by newer therapeutic modalities that attempt to induce an immunogenic form of cell death that can elicit a regional and systemic immune response. These compounds include:

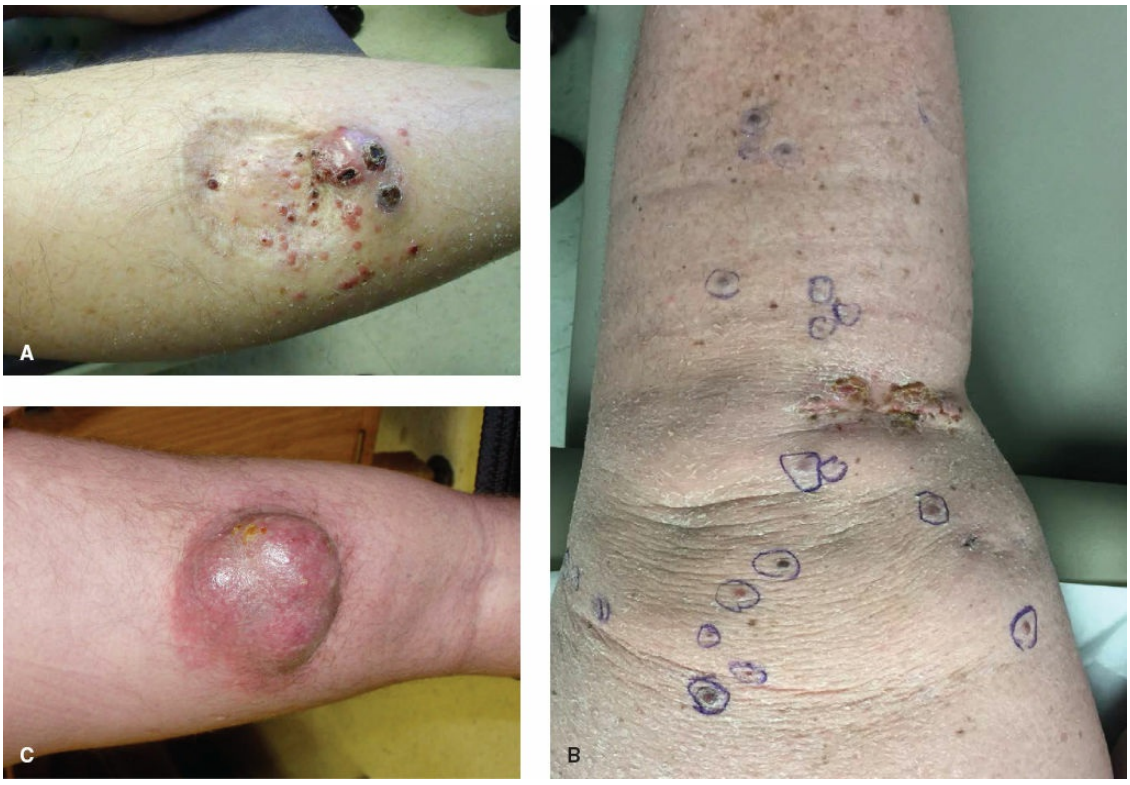

Figure 31.8. Examples of In-transit melanoma lesions that can appear as multifocal tumor deposits (Panels **A** and **B**) or large solitary lesions (Panel **C**). The size and multifocality of this pattern of disease can make management challenging.

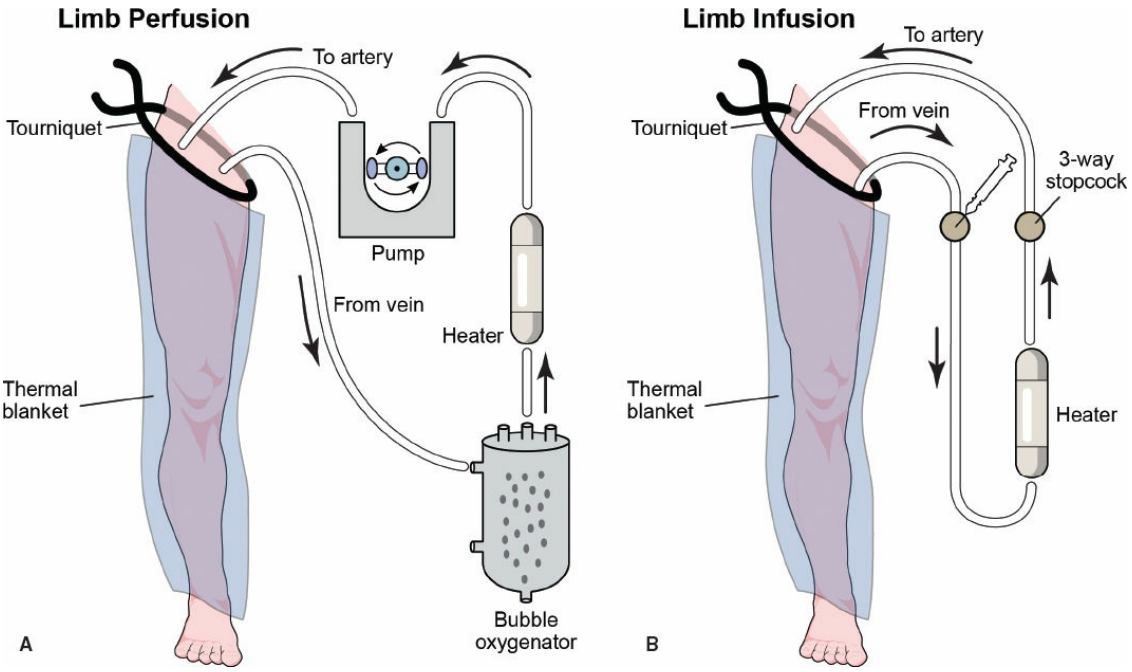

Figure 31.9. Schematic of regional chemotherapy set-ups. Panel **A** shows isolated limb perfusion (ILP) where limb oxygenation and acid/base status is maintained during chemotherapy delivery. Panel **B** shows isolated limb infusion (ILI) where the chemotherapy is delivered into a hypoxic acidotic environment.

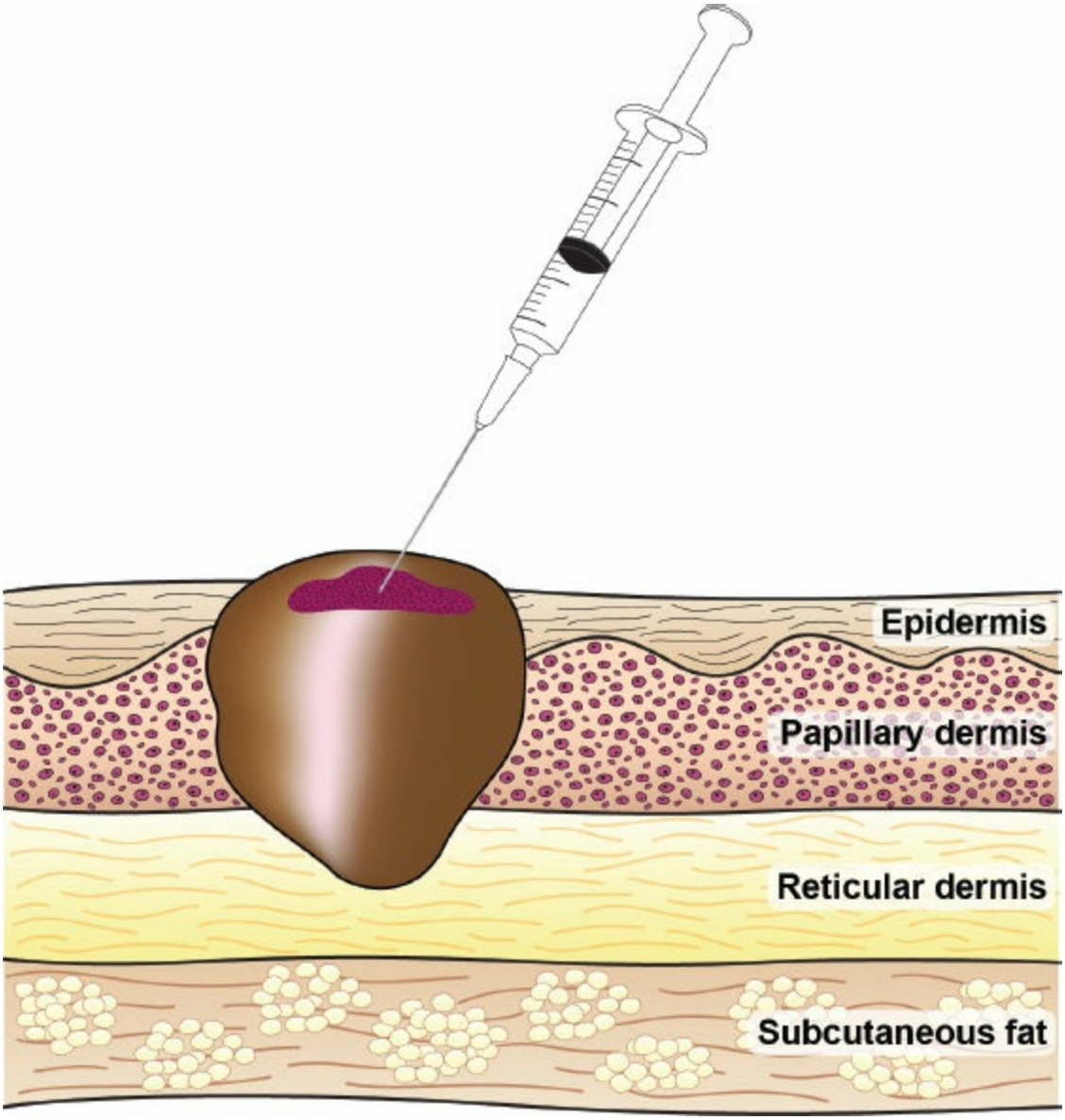

Figure 31.10. Schematic demonstrating the intralesional injection of a compound into a tumor to induce tumor cell death.

T-Vek: An oncolytic herpes virus that has been genetically altered to secrete GM-CSF. A randomized phase III trial has demonstrated improved local control but no survival advantage. The FDA recently approved this compound for the treatment of unresectable cutaneous disease.

PV-10: A vital dye that in a phase II trial has shown some ability to control disease. While these compounds have some effectiveness on their own, they are also currently being studied in trials with various combinations of agents.

Systemic therapies: Targeted and immunologic agents have revolutionized the therapeutic landscape for melanoma patients over the last 5 years. These compounds have demonstrated efficacy in stage IV

patients, and some of the trials have included patients with stage IIIB/C in transit disease.

Targeted therapies: BRAF inhibitors (vemurafenib and dabrafenib) and BRAF inhibitors plus MEK inhibitors (vemurafenib plus cobimetinib, and dafrafenib and trametinib) have proven beneficial in patients with a BRAF mutation. Response rates are in the 50% to 60% range, with progression-free survival of 6.9 months and median overall survival of 13.6 months. For combination therapy, median progression-free survival is 9.3 months and progression-free survival at 1 year ranges from 26% to 41%, depending on dose of MEK inhibitor.

Checkpoint blockade inhibitors: Ipilimumab is a checkpoint blockade inhibitor targeting the CTLA-4 protein. It is associated with a median overall survival of 10.1 months with a 24-month overall survival of 22%. Anti-PD-1 therapies include pembrolizumab, which targets the PD-1 checkpoint blockade protein and has a demonstrated objective response rate (complete plus partial responses) of approximately 20% to 25% and an overall 2-year survival rate of 49%. Nivolumab is another FDA-approved compound that targets PD-1 and has an objective response rate of 34% and an overall 2-year survival rate of 48%. Combination of anti-CTLA-4 and anti-PD-1 therapies has a very high response rate of 59% but is associated with great toxicity. As such, multiple combination regimens using different dosages and schedules are currently under investigation.

Metastatic Melanoma

Melanoma has a unique tumor biology such that selected patients can do quite well with surgical excision of their disease. While this has been recognized anecdotally for many years, it was a striking finding of Don Morton’s Canvaxin vaccine trial for patients with resected stage IV disease. In this trial, patients were randomized to receive surgery alone or surgery plus the Canvaxin vaccine. There was no difference in the survival of either group, and both groups had an approximate 50% five-year survival.

A number of case series document the survival of patients with resected disease by location. Generally surgery is reserved for patients with one to three lesions if all the disease can be removed and the morbidity of the surgery is not significant. The value of surgery is felt to decline as the number of lesions that need to be resected increases. Sites where surgical resection of solitary disease has been associated with favorable outcomes

include the brain, lung, gastrointestinal tract, and adrenal gland. Resection of metastatic disease may also be necessary for palliation secondary to significant symptoms associated with a tumor such as pain, skin ulceration, or bleeding. Surgery is also increasingly used to resect foci of metastatic disease that may not be responding to a targeted or immunologic systemic therapy especially when other lesions are responding. The current belief is that these nonresponding lesions may have tumor cells that are resistant to the targeted therapy or contain neoantigens not recognized by the immune system. Given the complexity of treatment options, patients with metastatic disease in whom surgery is being contemplated should be discussed at a multidisciplinary tumor board with expertise in managing melanoma patients.

SQUAMOUS CELL CARCINOMA

Definition

Primary cutaneous squamous cell carcinoma (SCC) is a malignant tumor that may arise from the keratinizing cells of the epidermis or its appendages. It is locally invasive and has the potential to metastasize to other organs of the body.

Incidence, Etiology, and Prevention

Actinic keratosis is the principal precursor to SCC. Actinic keratosis and SCC represent the same disease process at different stages of evolution, with neoplastic transformation of epidermal keratinocytes generally triggered by UV radiation. As the cells proliferate, they may extend into the dermis, at which point they are termed SCC. Other major risk factors for cutaneous SCC include chronically diseased or injured skin (e.g., ulcers, sinus tracts), exposure to iodizing or UV radiation, immunosuppression, and xeroderma pigmentosa. Increasingly, many SCCs are thought to be secondary to the human papillomavirus (HPV) especially in patients with depressed cell-mediated immunity. The HPV-16 and less so HPV-18 are the variants of the virus that is the most carcinogenic to humans and associated with SCCs. HPV-6 and HPV-11 are associated with most cases of genital warts. There are currently HPV vaccines that can prevent infection with these various subtypes of HPV, but there are no mature data to suggest that this leads to a decreased incidence of skin-related cancers. In addition, excessive sun exposure appears to increase

actinic keratosis that can evolve into SCC in sun-exposed areas of the skin.

Although the National Cancer Institute does not formally track the incidence and prevalence of nonmelanoma skin cancers, multiple longitudinal studies indicate that the incidence has risen sharply over the past two decades. It may develop de novo, as a result of previous exposure to ionizing radiation or arsenic, within chronic wounds, scars, burns, ulcers, or sinus tracts, and from pre-existing lesions such as Bowen's disease ("intraepidermal SCC"). Individuals with impaired immune function, for example, those receiving immunosuppressive drugs following allogeneic organ transplantation or those with lymphoma or leukemia, are at increased risk of this tumor; some SCCs are associated with HPV infection.

Clinical Presentation

SCC usually presents as an indurated nodular keratinizing papule or plaque, and may present as an ulcer without evidence of keratinization. Verrucous carcinoma is a less common but more invasive variant of SCC that often resembles a large wart.

Diagnosis

Initial tissue sampling for diagnosis of suspected nonmelanoma skin cancer is typically performed using a shave technique if the lesion is raised, or using a 2- to 4-mm punch biopsy of the most abnormal-appearing skin. Complete excision may be an appropriate initial diagnostic procedure for smaller tumors. Pigmented tumors or those eliciting any clinical suspicion of melanoma should always be evaluated using a full-thickness technique.

As part of establishing the diagnosis, the pathologist should report on the pathologic pattern; cell morphology; degree of differentiation; histologic grade; depth and the level of dermal invasion; and the presence or absence of perineural, vascular, or lymphatic invasion.

The preferred biopsy, however, unless the lesion is very large, is a local excision with 1 to 2 mm margins, which will effectively deal with the occasional benign pigmented actinic keratosis, and, at the same time, provide an accurate depth of melanoma and cell type, if it is present. The depth of the excision should extend into the subcutaneous fat. If the lesion is large, or located on the face, one may opt to excise a simple 1- to 2-mm pie-shaped wedge from the edge of the lesion, choosing whichever edge by

palpation is the more highly elevated. Given that malignant melanoma, SCC, and basal cell carcinoma are all managed in somewhat different ways, the ability to make an accurate diagnosis while preserving normal skin tissue will allow for optimal cosmetic results when definitive therapy is carried out.

Treatment

In contrast to melanoma, the management of squamous cell cancer is mainly focused on the primary lesion with the surgeon trying to obtain tissue margins that are free of tumor and consistent with the function of the body part from which the squamous cell cancer is being excised. Surgical excision, including Mohs micrographic surgery, is recommended as first-line treatment for most SCC. An adequate margin can often be as little as 1 mm with most squamous cell cancers.

Because SCC is typically sensitive to radiotherapy, this treatment option is recommended for tumors in high-risk, surgically difficult areas and offers favorable cosmetic results early on. Cosmesis can worsen with time, however, and radiotherapy usually is not considered for patients <55 years. A 2010 Cochrane Review found little evidence when comparing the effectiveness of different treatments for primary, nonmetastatic SCC.

Overall, the metastasis rate for SCC of the skin is 2% to 6%. In SCC >2 cm, the incidence of lymph node metastasis ranges from 10% to 30% and an SLN biopsy or imaging of the draining lymph node basins should to be considered. Marjolin's ulcers, aggressive ulcerating SCC that arise in the area of chronically inflamed, scarred skin such as burn wounds, post radiation scars, chronic venous ulcers, and ulcers from osteomyelitis, are also high risk for metastasis occurring 20% to 38% of the time. Therefore, an SLN biopsy is frequently performed to assess lymph node involvement.

The accumulated experience of treating cutaneous SCC by various methods has allowed some generalizations to be made about prognosis based on the original lesion. In general, SCC is highly curable when excised. Factors that influence metastatic potential include anatomical site, size, rate of growth, etiology, and degree of differentiation. Metastatic growth is most often seen at sites of chronic inflammation, the oropharynx, the nasopharynx, the genitals, and the anus. Metastatic disease isolated to nodal basins is managed by lymphadenectomy. Treatment for distant metastasis is more difficult as systemic therapies are currently not very effective.

Suggested Readings

Balch CM, Houghton AN, Sober AJ, et al. *Cutaneous Melanoma*. 5th ed. St. Louis, MO: Quality Medical Publishing; 2009.

Balch CM, Soong SJ, Bartolucci AA, et al. Efficacy of an elective regional lymph node dissection of 1 to 4 mm thick melanomas for patients 60 years of age and younger. *Ann Surg* 1996;224:255–63; discussion 263–6.

Balch CM, Urist MM, Karakousis CP, et al. Efficacy of 2-cm surgical margins for intermediate-thickness melanomas (1 to 4 mm). Results of a multi-institutional randomized surgical trial. *Ann Surg* 1993;218:262–7; discussion 267–9.

DeVita VT, Lawrence TS, Rosenberg SA. *Cutaneous Oncology*. 10th ed. Philadelphia, PA: Lippincott Williams & Wilkins; 2015.

Eggermont AM, Chiarion-Sileni V, Grob JJ, et al. Adjuvant ipilimumab versus placebo after complete resection of high-risk stage III melanoma (EORTC 18071): a randomised, double-blind, phase 3 trial. *Lancet Oncol* 2015;16:522–30.

Gillgren P, Drzewiecki KT, Niin M, et al. 2-cm versus 4-cm surgical excision margins for primary cutaneous melanoma thicker than 2 mm: a randomised, multicentre trial. *Lancet (London, England)* 2011;378:1635–42.

Morton DL, Wen DR, Wong JH, et al. Technical details of intraoperative lymphatic mapping for early stage melanoma. *Arch Surg* 1992;127:392–9.

Thomas JM, Newton-Bishop J, A'Hern R, et al. Excision margins in high-risk malignant melanoma. *N Engl J Med* 2004;350:757–66.

Veronesi U, Cascinelli N, Adamus J, et al. Thin stage I primary cutaneous malignant melanoma. Comparison of excision with margins of 1 or 3 cm. *N Engl J Med* 1988;318:1159–62.

EDITOR'S COMMENT

This is an excellent chapter on an increasingly common and in some cases devastating disease. Melanoma is the most dangerous type of skin cancer. About 9,730 people are expected to die of melanoma (approximately 6,380 men and 3,350 women). In the United States, the rates of melanoma have been rising for the last 30 years. Globally, in 2012 melanoma occurred as a new diagnosis in 232,000 people. In 2015 there were 3.1 million with active disease that resulted in 59,800 deaths. Australia and New Zealand have the highest rates of melanoma in the world.

According to the American Cancer Society, melanoma is more than 20 times more common in whites than in African Americans. Overall, the lifetime risk of getting melanoma is about 2.5% (1 in 40) for whites, 0.1% (1 in 1,000) for blacks, and 0.5% (1 in 200) for Hispanics. The risk of melanoma increases as

people age. The average age of people when it is diagnosed is 63, although melanoma is not uncommon even among those younger than 30. Melanoma is one of the most common cancers in young adult, especially young women.

Exposure to ultraviolet radiation (UVA and UVB) is one of the major contributors to the development of melanoma. Occasional extreme sun exposure resulting in sunburn is causally related to melanoma. I grew up in an era when we didn't really worry about sunscreen. Sunburns were a part of summer. An interesting and very large study conducted in Australia comparing native to Australian immigrants revealed that the risk of melanoma was related both to duration of stay in Australia and age at arrival. Immigrants had a lower rate of melanoma, and the older an immigrant at the time of arrival in Australia, the lower the melanoma risk. We now understand that exposure during childhood is a more important risk factor than exposure in adulthood. Exposure to tanning beds is also an important risk factor. Melanoma is most common in areas of sun exposure including on the back in men and on legs in women. Most melanomas arise as new lesions in the skin, although a significant fraction (25% to 40%) appears to arise from pre-existing nevi.

Lymphatic tumor spread and its implications for survival and treatment have been studied for centuries. Management of lymph nodes has been controversial since Snow first recommended elective complete lymphadenectomy for all patients with melanoma in the late 1800s. In patients without lymph node metastasis, this strategy results in overtreatment with associated morbidity and no survival advantage. Lymphatic mapping and sentinel node biopsy in melanoma were introduced in the 1990s. Sentinel node biopsy is a minimally invasive and low morbidity staging procedure performed with the use of blue dye and radiolabeled colloids. It identifies node or nodes (sentinel node(s)) in a regional node basin that receive lymph from the primary melanoma site. The tumor status of the sentinel node has been demonstrated to predict the tumor status of other nodes in the lymphatic basin. Results of a phase III trial of sentinel node biopsy versus nodal observation in melanoma was published in the *New England Journal of Medicine* in 2014 (Multicenter Selective Lymphadenectomy or MSLT-1). A total of 2001 patients with primary cutaneous melanoma were randomly assigned to undergo wide excision and nodal observation, with lymphadenectomy for nodal relapse (observation group), or wide excision and sentinel-node biopsy, with immediate lymphadenectomy for nodal metastases detected on biopsy (biopsy group). No significant treatment-related difference in the 10-year melanoma-specific survival rate was seen in the overall study population (20.8% with and 79.2% without nodal metastases). The 10-year disease-free survival rates were significantly improved in the biopsy group among patients with intermediate-thickness melanomas (1.20 to 3.50 mm) and those with thick melanomas (>3.50 mm). Biopsy-based management improved the 10-year rate of distant disease–free survival (hazard ratio for distant metastasis, 0.62; $P = 0.02$) and the 10-year rate of melanoma-specific survival (hazard ratio for death from melanoma, 0.56;

P = 0.006) for patients with intermediate-thickness melanomas and nodal metastases. The authors of this study conclude "Biopsy-based staging of intermediate-thickness or thick primary melanomas provides important prognostic information and identifies patients with nodal metastases who may benefit from immediate complete lymphadenectomy. Biopsy-based management prolongs disease-free survival for all patients and prolongs distant disease–free survival and melanoma-specific survival for patients with nodal metastases from intermediate-thickness melanomas." As discussed in the current chapter, the MSLT-2 trial aims to compare the strategies of completion lymphadenectomy versus monitoring with nodal ultrasound in patients with a positive sentinel node with regard to melanoma-specific survival. Estimated study completion date is 2022.

Significant progress has been made in adjuvant therapy for melanoma. As a surgery resident in the 1990s, I remember a patient admitted for interferon therapy for advanced melanoma. He experienced significant toxicity going through what we felt at the time was somewhat futile treatment—but really the only thing we had to offer him. In the current era, fundamental elements of the surgical, adjuvant medical, and systemic therapy of melanoma have led to improved outcomes. The intent of treatment for advanced melanoma has evolved from palliative to potentially curative. Targeted molecular therapy has been developed for many tumors including certain breast cancers, gastrointestinal stromal tumors, pancreas tumors, and melanoma. In melanoma, the cell growth signaling protein BRAF is present in an altered form (known as BRAF V600E) in many melanomas. Vemurafenib targets this mutant form of BRAF and is approved to treat patients with inoperable or metastatic melanoma that contains the altered BRAF protein. Targeted therapy, immunotherapy, chemotherapy, and neoadjuvant and adjuvant therapies for melanoma have advanced and so have the survival rates. Considering the rapid rate of progress in melanoma treatment over the past two decades, I predict we will continue to see more progress as our understanding of the disease continues to evolve. Most of these advances however are not likely to take place in the surgical approach to this disease, although surgical excision and possibly lymphadenectomy (and possibly not) will continue to occupy a central role in treatment.

Jon C. Gould

The evolution of melanoma treat which has the potential to cure is a great advance. The therapies that Dr. Gould describes is new and just the beginning. My sense is that this therapy will change the entire picture. All of us can look forward to better outcomes.

J.E.F.

Suggested Readings

Gorantla VC, Kirkwood JM. State of melanoma: an historic overview of a field in transition. *Hematol Oncol Clin North Am* 2014;28(3):415–35.

https://www.cancer.org/cancer/melanoma-skin-cancer.html. Accessed May 26, 2017.

Khlat M, Vail A, Parkin M, et al. Mortality from melanoma in migrants to Australia: variation by age at arrival and duration of stay. *Am J Epidemiol* 1992;135(10):1103–13.

Morton DL, Thompson JF, Cochran AJ, et al. Final trial report of sentinel-node biopsy versus nodal observation in melanoma. *N Engl J Med* 2014;370(7):599–609.

World Cancer Report 2014. World Health Organization 2014; Chapter 5.14. ISBN 9283204298.

32 Inguinal Lymph Node Dissection: Indications and Surgical Technique

Steven Agle and Douglas Tyler

Dissection of the superficial inguinal lymph nodes is currently a recommended treatment for patients who have evidence of nodal metastatic disease from a variety of malignancies. Generally, it is focused on patients who are presumed through staging to have stage III disease with tumor confined to the lymph node basin. The goals of surgery are locoregional disease control with the possibility of long-term cure. The most common clinical scenarios for consideration of superficial inguinal lymph node dissection currently arise in patients with melanoma who have a positive sentinel lymph node biopsy (SLNB). There are currently data from several retrospective studies and one prospective German study to suggest that for patients with low-volume nodal involvement in a sentinel lymph node, it may be unnecessary to perform a completion lymph node dissection. The rationale is that the sentinel lymph node often is the only lymph node to contain tumor when a completion lymph node dissection is performed; and if the patient has additional lymph nodes involved, then he or she frequently will also harbor distant metastatic disease. The Multicenter Selective Lymphadenectomy Trial-2 (MSLT-2 trial) that randomized melanoma patients with a positive sentinel lymph node to completion lymphadenectomy surgery or observation has completed accrual and is awaiting maturation of the data to help us better understand the role of completion lymph node dissection in melanoma. At the current time, most surgeons will still recommend a completion lymphadenectomy for patients with a positive SLNB in melanoma. SLNB is also occasionally utilized in patients with Merkel cell carcinoma, penile carcinoma, vulvar carcinoma, anal cancers, and some sarcomas like synovial cell sarcoma where if the SLNB is positive then lymphadenectomy is recommended. There will also be patients, with all of the above malignancies, who present with clinically evident inguinal nodal disease for whom a superficial inguinal dissection is also viewed as important for disease control and to potentially limit the spread of disease.

Inguinal lymph node dissection is associated with moderate morbidity. Several large centers have reported morbidity of 50% or higher related mainly to wound healing issues in the inguinal area. Skin edge necrosis can occur if skin flaps are made too thin, and lymphedema is common more so than is seen with neck or axillary nodal dissections. Many techniques have been reported to reduce postoperative lymphedema, such as preserving the muscle fascia, pedicled omentoplasty, and saphenous vein sparing inguinal lymphadenectomy. While few studies are large enough to conclusively state, systematic reviews and meta-analysis
appear to suggest that preserving the saphenous vein has the strongest evidence to help minimize leg edema and that a sartorius transposition does not prevent complications. As such our current approach to the inguinal lymphadenectomy is to preserve the saphenous vein and muscle fascia, and to not perform a sartorius muscle transposition to cover the femoral vessels.

Inguinal lymph node dissection can be performed through a standard 6- to 10-cm incision extending from 2 to 4 cm below the inguinal ligament and parallel to it (see
Fig. 32.1). While a horizontal skin incision has the least morbidity associated with it, a vertical incision is also sometimes used if one is trying to incorporate a vertically placed SLNB incision. With either incision, an attempt should be made to encompass the incision of any previous biopsy that was performed and to try and stay out of the biopsy cavity that may be present from a previous lymph node biopsy. Flaps are raised from the skin edges deep to Scarpa fascia to the adductor longus and Sartorius muscles. The saphenous vein is identified at the junction of the sartorius and adductor muscles inferiorly with care taken to preserve it. Small branches may need to be divided especially near the saphenofemoral vein junction to clear all the nodal tissue off the vessel. If tumor or the biopsy cavity is stuck to the vein, it can be removed by ligating it as it courses over the sartorius and oversewning the saphenofemoral junction with a 5-0 prolene suture. Flaps are then raised superiorly to the inguinal ligament, and medial to the pubic tubercle. The lateral cutaneous femoral nerve is identified at this point and preserved. It usually runs under the fascia of the sartorius muscle and becomes more superficial about 10 cm below the inguinal ligament where it divides into anterior and lateral branches. The femoral nerve, artery, and vein are identified within the femoral triangle. Dissection over the femoral triangle is accomplished in a lateral to medial

direction clearing the lymph nodes from the femoral nerve and femoral artery.

All the fibrofatty tissues extending from the external oblique aponeurosis 2 cm above the inguinal ligament to the medial border of the adductor longus muscle medially and sartorius muscle laterally are removed. The femoral canal is then explored to excise Cloquet node. Cloquet node is the first node of the deep system, and to get to it one must tease apart the lacunar ligament that runs medially between the inguinal ligament and the pectineal (Cooper) ligament (Fig. 32.2). One needs to be careful to avoid injuring the femoral circumflex vessels as the node is being dissected out. Once the node is removed, the defect in the lacunar ligament is repaired by using two simple 2-0 prolene stitches to pull the inguinal ligament down to the pectineal ligament. Care is taken not to close the space in a way that compresses the femoral vein. If performing a sartorius flap, the sartorius muscle is divided in its superior aspect and transposed medially over the vessels and secured to the fascia of the external oblique. Care must be taken if doing this as the blood supply to the sartorius is segmental; and if one is not careful, devascularization of the muscle will occur. A closed suction drain is then placed within the femoral triangle.

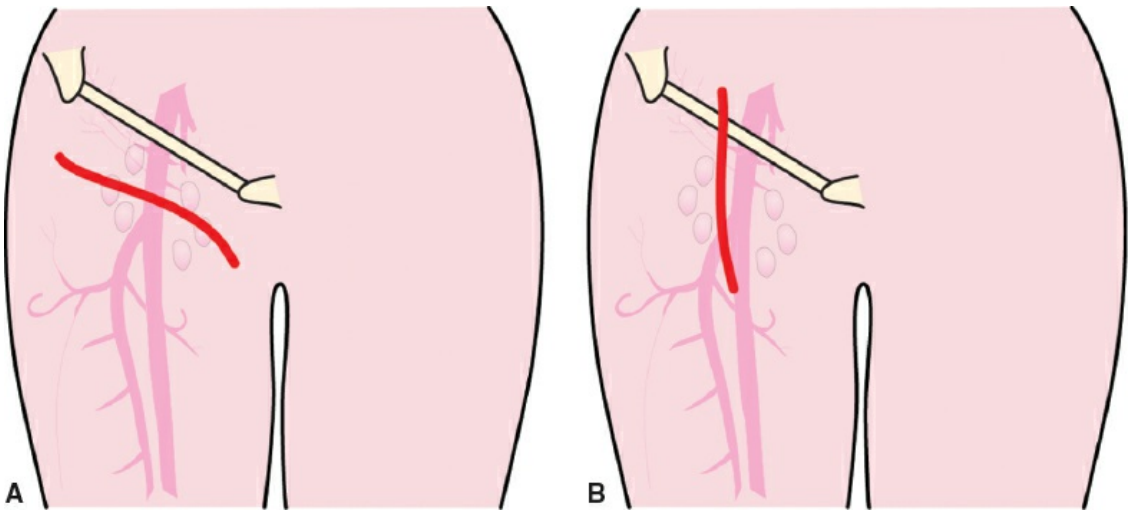

Figure 32.1. Schematic of two incision approaches to an open superficial groin dissection. Panel **A** is a horizontal incision, and Panel **B** is the vertical incision.

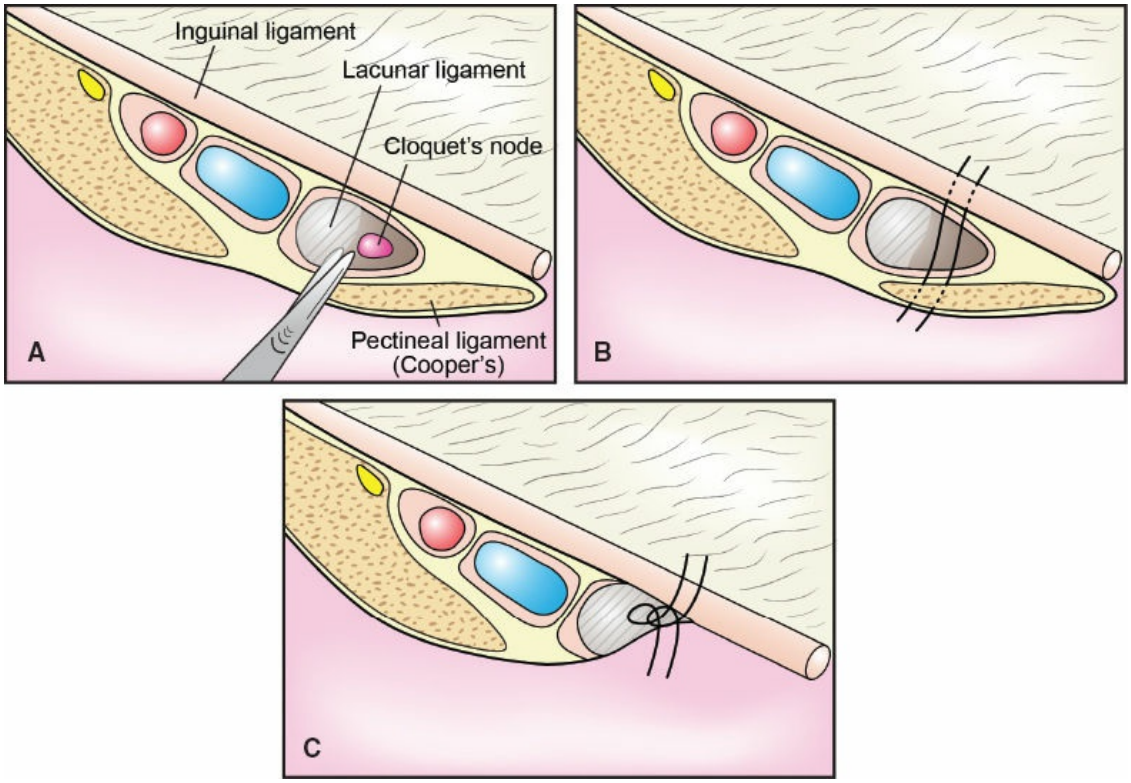

Figure 32.2. Schematic dissection of Cloquet node. Panel **A** is dissecting with a scissors to separate the lacunar ligament between the inguinal ligament and pectineal (Cooper) ligament. Panel **B** shows the node removed and two sutures placed between the inguinal ligament and Cooper ligament. Panel **C** demonstrates the sutures tied down medially to close the defect created and prevent a femoral hernia while avoiding compression on the femoral vein.

Iliac and hypogastric node dissections are generally performed for clinically or radiographically evident disease. Some individuals choose to perform a pelvic lymph node dissection if there is bulky disease in the superficial groin or four or more superficial inguinal nodes are positive due to the high incidence of pelvic nodal disease. Our preference is to only perform the deep nodal dissection if there is evidence by positron emission tomography/computed tomography (PET/CT) of disease or Cloquet node is positive. There are several ways to approach the pelvic lymph nodes. One can extend the superficial skin incision by making a lazy-S type of incision to incorporate the SLN incision en bloc. No flaps are needed on the skin overlying the pelvic dissection. Transecting the inguinal ligament is generally avoided because it increases morbidity and increases wound healing issues. Our preferred approach to provide access to the retroperitoneal space is to make a separate incision in the lower abdominal

musculature, leaving the inguinal ligament intact. External iliac vessels are exposed by blunt dissection and retraction of the peritoneum medially. Dissection of the iliac lymphatic tissue is extended up to the common iliac bifurcation. The obturator dissection is carried out by gentle mobilization of the external iliac vein medially and dissecting the obturator nodes off the obturator nerve and vessels.

Recently a new technical way of perfoming an inguinal lymphadenectomy has been described called a videoscopic inguinal lymphadenectomy. This procedure uses laparoscopic equipment to dissect out the lymph node tissue and uses very small skin incisions that are much further from the inguinal crease than the open incision. The initial studies suggest that there are significantly lower wound complications in these patients, but it comes at the expense of a longer operative procedure and longer lymphatic drainage postoperative. Given some of the technical challenges of this procedure and the decreasing incidence of nodal dissections, it remains to be seen if this method will become widely adopted.

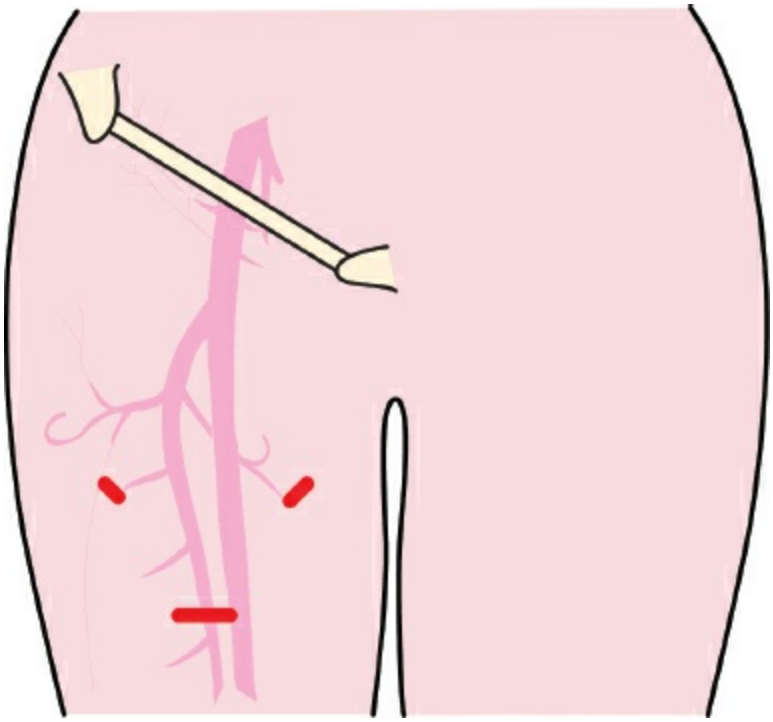

Figure 32.3. Schematic showing the location of the three incisions at the apex of the femoral triangle used when performing a videoscopic inguinal lymph node dissection.

Technically the videoscopic inguinal lympadenectomy is performed by

positioning patients supine on a split-leg table. The boundaries of the femoral triangle are mapped out with a surgical pen. The suprapubic region should be included in the field to monitor for crepitus. The surgeon is positioned between the patient's legs, and the assistant stands to the outside of the operative limb. Monitors are placed cephalad above each shoulder, with the laparoscopic tower strategically positioned on the side of the operative limb.

Trocar placement for a three-incision technique is shown in Figure 32.3 and includes a 12-mm port placed 3 cm distal to the apex of the femoral triangle. A scalpel is used to incise the skin and sharply dissect down through the Camper and Scarpa fascias. A space is then created with blunt-finger dissection, extending out 5 cm on each side from the incision. A balloon trocar is inserted into the 12-mm port site, and the dissected space is insufflated to 25 mm Hg for 10 minutes, then the pressure is decreased to 15 mm Hg to prevent end-tidal CO_2 elevation. Under direct visualization with a 0-degree scope, two 5-mm short bladeless trocars are inserted approximately a hand's breath from the visualization port. These are positioned 3 cm outside of the medial and lateral boundaries of the previously delineated femoral triangle.

At this stage, it is critical to ensure that dissection proceeds in the correct anterior plane. The dissection should be carried out just superficial to the Scarpa fascia. An energy device is generally used to complete the definition of the anterior working space between the fibrofatty node-containing packet and the superficial tissue.

Medial and lateral boundaries of the dissection consist of the adductor longus and sartorius muscle fascia, respectively, which should be correlated with the previous skin markings via transillumination. The fibrofatty packet may be rolled inward with an endoscopic sponge or Kittner continuing superiorly and inferiorly as much as possible to assist in defining the posterior tail of the node packet. Small perforating vessels and lymphatics are routinely encountered and should be divided with an ultrasonic dissecting scalpel or clipped. The deep thigh fascia constitutes the posterior boundary. Its violation is readily apparent when reddish muscle fibers are encountered.

The saphenous vein should be readily identifiable within the apex of the femoral triangle. Our practice has been to preserve it; but if it needs to be sacrificed, then it can be divided with the vascular load of an endoscopic linear cutting stapler. Careful dissection within the femoral triangle

enables identification of the femoral artery pulse as well as the medial femoral vein. Proceeding inferior to superior, the vessels are skeletonized along with all the tissue between the femoral vein and adductor longus.

Once the vascular dissection is complete, blunt dissection in the saphenofemoral junction is performed to identify the inferior edge of the saphenous vein as it enters the femoral vein. If the vein is going to be removed en bloc with the dissection, then a second vascular load of the endoscopic linear cutting stapler is then used to transect the vein at the saphenofemoral junction. Inferomedial dissection around the femoral vein will allow resection of the deep inguinal nodes (see Fig. 32.4). Complete node retrieval should be ensured by continuing the dissection to the level of the femoral canal until the pectineus muscle is visible. A biopsy of the Cloquet node can be done at this point. At this point, the nodal packet is free and is withdrawn in a laparoscopic specimen bag through the apical port. A drain is then placed through the medial port site and is usually left in place until the drainage is <30 mL over 24 hours.

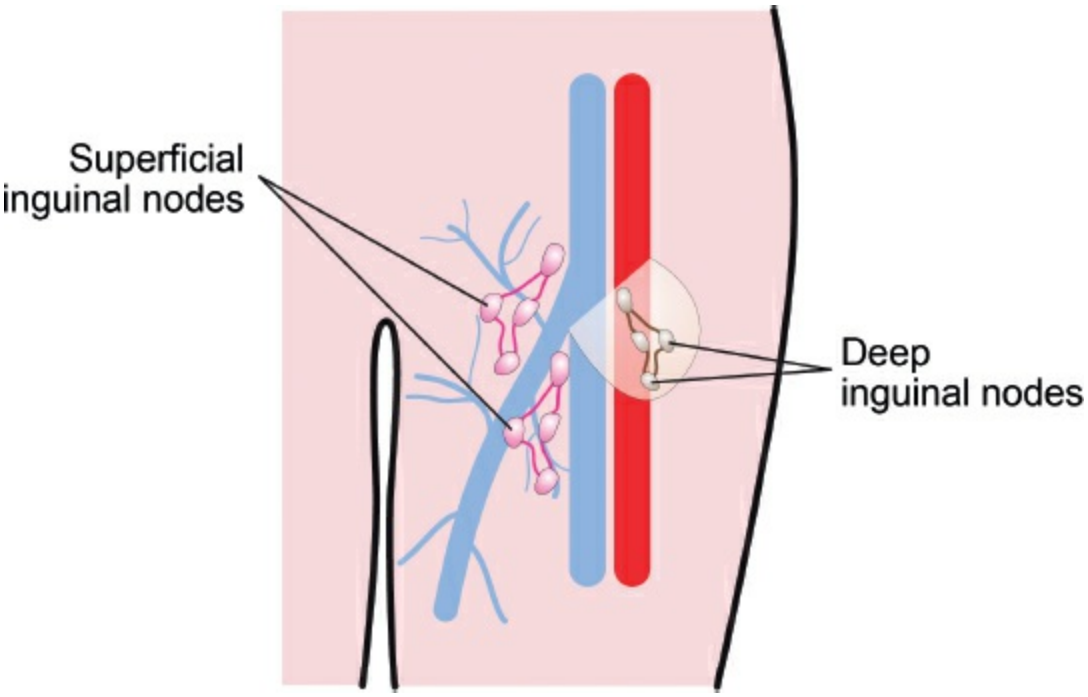

Figure 32.4. Schematic of the two levels of superficial lymph nodes present in a groin dissection. The superficial lymph nodes are generally located above the fascial layer and along branches of the saphenous vein and other tributaries of the femoral vein. The deep superficial lymph nodes are located around the anterior portion of the femoral vein and artery.

Suggested Readings

Abbott AM, Grotz TE, Rueth NM, et al. Minimally invasive inguinal lymph node dissection (MILND) for melanoma: experience from two academic centers. *Ann Surg Oncol* 2013;20(1):340–5.

Master VA, Jafri SM, Moses KA, et al. Minimally invasive inguinal lymphadenectomy via endoscopic groin dissection: comprehensive assessment of immediate and long-term complications. *J Urol* 2012;188(4):1176–80.

Spillane AJ, Haydu L, McMillan W, et al. Quality assurance parameters and predictors of outcome for ilioinguinal and inguinal dissection in a contemporary melanoma patient population. *Ann Surg Oncol* 2011;18(9):2521–8.

EDITOR'S COMMENT

Dr. Tyler and colleagues have nicely described the indications and their technique for groin dissection for appropriate patients with melanoma, Merkel cell carcinoma, penile carcinoma, vulvar carcinoma, anal cancers, and some sarcomas like synovial cell sarcoma. As they indicate, most surgeons will still recommend a completion lymphadenectomy for patients with a positive sentinel lymph node biopsy in melanoma. For melanoma, multiple randomized trials have failed to show any difference in overall survival for patients undergoing wide excision plus elective regional complete lymph node dissection versus wide excision plus observation, although there may be some survival benefit in certain subgroups (Balch CM, Soong S, Ross MI, et al. Long-term results of a multi-institutional randomized trial comparing prognostic factors and surgical results for intermediate thickness melanomas (1.0 to 4.0 mm). Intergroup Melanoma Surgical Trial. *Ann Surg Oncol* 2000;7:87–97). A comparison of the incidence of complications between completion lymphadenectomy undertaken immediately after identification of a positive sentinel node versus completion lymphadenectomy delayed until clinical appearance of regional node involvement has been performed (Faries MB, Thompson JF, Cochran A, et al. The impact on morbidity and length of stay of early versus delayed complete lymphadenectomy in melanoma: results of the Multicenter Selective Lymphadenectomy Trial (I). *Ann Surg Oncol* 2010;17:3324–9). Multicenter Selective Lymphadenectomy Trial-1 data showed a significant treatment-related difference in the incidence of lymphedema. Interestingly, the frequency and severity of lymphedema were greater when completion lymphadenectomy was delayed. The reason is unclear but might reflect blockage of lymphatics, or possibly a more extensive resection required for palpable nodal recurrence, although there was no difference in the number of nodes removed. Unfortunately, chronic lymphedema was seen in 20.4% of patients undergoing a delayed completion lymphadenectomy versus 12.4% of patients undergoing immediate completion lymphadenectomy.

These results are worth noting as the reported morbidity rates associated with groin dissection are significant. A recent report of a retrospective analysis of prospectively collected data in 240 patients who underwent an inguinal lymph node dissection in the University Medical Center Groningen between 1989 and 2014 analyzed four groups with different treatment protocols: A (≥10 days of bed rest with a splint), B (10 days of bed rest without a splint), C (5 days of bed rest), and D (1 day of bed rest). The effect of early mobilization, abolishment of the splint and postural restrictions, and the introduction of prophylactic antibiotics were analyzed. Of note, one or more wound complications occurred in 51.2% of the patients including wound infection (29.8%), seroma (21.5%), wound necrosis (13.6%), and hematoma (5%). In consecutive periods, respectively 44.4%, 60.3%, 44.9%, and 55.2% of the patients experienced wound complications. None of the instituted changes in protocols led to a decrease in wound complications. Furthermore, the authors demonstrated that disease-free survival and melanoma specific survival were reduced in those patients who developed a wound infection (Faut M, Heidema RM, Hoekstra HJ, et al. Morbidity after inguinal lymph node dissections: it is time for a change. *Ann Surg Onc* 2017;24:330–9).

Since changes in perioperative care protocols did not affect the rate of wound complications, it is not a large leap to infer that possibly a change in the surgical procedure itself could possibly lead to the necessary reduction of wound complications after inguinal lymph node dissection.

Replacement of the large inguinal incision by three smaller incisions away from the inguinal skinfold might offer a solution via a minimally invasive technique such as videoscopic inguinofemoral lymphadenectomy. As Dr. Tyler describes, this procedure is accompanied by a lower complication rate in some centers and has a comparable oncologic outcome (Delman KA, Kooby DA, Ogan K, et al. Feasibility of a novel approach to inguinal lymphadenectomy: minimally invasive groin dissection for melanoma. *Ann Surg Oncol* 2010:17:731–7; Jakub JW, Terando AM, Sarnaik A, et al. Safety and feasibility of minimally invasive inguinal lymph node dissection in patients with melanoma [SAFE-MILND]: report of a prospective multi-institutional trial. *Ann Surg* 2016:222:253–60; Martin BM, Etra JW, Russell MC, et al. Oncologic outcomes of patients undergoing videoscopic inguinal lymphadenectomy for metastatic melanoma. *J Am Coll Surg* 2014:218:620–6).

In the initial experience in 32 patients undergoing 45 procedures, 18 dissections (40%) were for melanoma, 19 (42%) for penile carcinoma, 4 (9%) for scrotal/urethral carcinoma, and 4 (9%) for other pathologies. The median patient age was 61 years (range, 16 to 87), and median body mass index was 30 kg/m^2 (range, 19 to 53). Eighty-nine percent of the patients with melanoma had primary disease located in the extremities, with a median Breslow depth of 2.8 mm (range, 0.6 to 9.9). Only two (4%) of the procedures were converted to an open approach. Wound complications occurred in 18% of patients. One patient (2.6%) experienced flap necrosis, which was conservatively managed with

negative pressure wound therapy. Mild to moderate lymphedema occurred in 7.8% of patients. Two of these required compressive stockings for symptomatic treatment. No episodes of wound dehiscence were noted following videoscopic inguinal lymphadenectomy (Delman KA, Kooby DA, Ogan K, et al. Feasibility of a novel approach to inguinal lymphadenectomy: minimally invasive groin dissection for melanoma. *Ann Surg Oncol* 2010;17:731–7). Although the collective clinical experience with this technique is much lower than for open inguinal lymphadenectomy, the early results reported with the videoscopic technique appear to demonstrate reduced complication. Since other adjustments in perioperative care and management have failed with the open approach, this videoscopic procedure might be a promising method for reducing wound complications after inguinal lymph node dissections.

It is possible that the results from the Multicenter Selective Lymphadenectomy Trial-2 may lead to a decrease in the need for inguinal lymph node dissection for melanoma, even in patients with a positive sentinel lymph node. Multicenter Selective Lymphadenectomy Trial-2 is a randomized phase III trial of sentinel lymph node biopsy plus regional completion lymphadenectomy versus sentinel lymph node biopsy plus ultrasound observation of the lymph nodes in patients with sentinel node metastases detected by histopathologic (H–E, immunohistochemistry [IHC]) or molecular (reverse transcriptase-polymerase chain reaction assay [RT-PCR]) techniques. The primary outcome from this trial is melanoma-specific survival, and it will generate findings that will help determine the clinical significance of sentinel node micrometastases and whether careful nodal observation enhanced by sensitive ultrasound monitoring might be an attractive alternative to complete lymphadenectomy in some patients with sentinel node metastasis (Morton DL, Cochran AJ, Thompson JF. Sentinel node biopsy in melanoma [letter]. *N Engl J Med* 2007;356:419–20; Morton DL on behalf of the MSLT-1 group. Overview and update of the Phase III Multicenter Selective Lymphadenectomy Trials [MSLT-I and MSLT-II] in melanoma. *Clin Exp Metastasis* 2012;29[7]:699–706).

Steven N. Hochwald

33 Evaluation and Repair of Common Facial Injuries

Branko Bojovic

INTRODUCTION

Facial trauma is a common occurrence that can be due to a myriad of etiologies and result in minimal to devastating injuries. It is a fundamental skill for the general surgeon to understand the constellation of injuries that are common in the spectrum of facial trauma. The principles and well-described techniques as it relates to facial trauma evaluation and management will be discussed herein so that the broadly trained general surgeon, along with those in subspecialty disciplines, will have a thorough and clearly defined understanding of common facial injuries and how to triage, treat, and, as necessary, refer such problems for appropriate, higher-level evaluation and management. What is clear is the fact that such injures typically occur not in isolation but in concert with other injuries that may be life-threatening. As such, a requisite understanding of Basic Life Support (BLS) and Advanced Trauma Life Support (ATLS) is to be expected and multidisciplinary cooperative care the goal. Team management with the involvement of trauma surgery, plastic surgery, neurosurgery, orthopedic surgery, otolaryngology, ophthalmology, and oral and maxillofacial surgery, to name a few, is the way to insure successful global evaluation and treatment. In addition, it must be recognized that timely evaluation and management of facial traumatic injuries will establish the best likelihood for outcomes that are both functionally *and* aesthetically optimal.

This chapter will provide the reader an overview of commonly encountered facial traumatic injuries and well-described techniques for addressing such injuries that are based on fundamental principles in surgery. There will be a focus on the critical aspects of the history and physical examination that will not only alert the reader to potential injures not obvious on primary or secondary survey but will also reinforce that which radiologic evidence suggests. A careful overview of appropriate

care for the soft tissue and bony injuries commonly encountered in facial trauma will also be discussed. The reader will also have an understanding for the more serious facial fracture patterns that can be seen in high-energy blunt and ballistic injuries commonly encountered in trauma surgical practice. In addition, the appropriate operative management of such injuries will be discussed. Finally, and something new to this chapter in the Mastery of Surgery series 7th edition, is the discussion of techniques available in the state-of-the-art treatment of facial scarring that is frequently seen as a lasting sequela of the myriad of facial injuries suffered by patients and the reminder these scars serve in the psyche of these patients. We have techniques available today that, once the fundamental goals of functional and aesthetic facial injury repair have been achieved, can *almost* erase the scars that have all too long been a painful reminder of the injury or injuries suffered in the past.

INITIAL EVALUATION

As was mentioned in the Introduction, facial traumatic injuries typically occur not in isolation but in concert with other injuries that may be life-threatening. As such, facial traumatic injuries, in and of themselves, are rarely life-threatening but that should not diminish the importance of the primary and secondary surveys in evaluating these patients. In every circumstance, the American College of Surgeons' principles of ATLS should be adhered to and appropriately utilized. Once the primary survey has been completed and an assessment of airway, breathing, and circulation performed satisfactorily with adherence to BLS principles, the secondary survey may begin. This is an appropriate time not only for facial traumatic injury assessment but also an excellent opportunity to assess level of consciousness. This is performed according to the Glasgow Coma Scale (Table 33.1) and should be documented in a baseline fashion with ongoing reassessment as appropriate, especially if closed head/traumatic brain injury is a concern.

As mentioned, the secondary survey is the appropriate time for closer and dedicated evaluation of obvious or occult facial trauma. During this time, critically important observations and even life-saving interventions can be made if the examiner were to discover life-threatening concerns. Namely, in addition to devastating closed head injury, airway obstruction or evidence of aspiration and life-threatening hemorrhage; all are vitally important findings that, if recognized, may be intervened upon

expeditiously and definitively so that such factors will not be allowed to compromise the injured patient's life. A familiar example of this is the multi-injured trauma patient who despite through primary and secondary surveys is still hypotensive and unresponsive to appropriate fluid resuscitation only to discover an occult or unrecognized dependent or posterior scalp laceration causing sustained and life-threatening hemorrhage. This is an example that need not be repeated if an appropriate, systematic, and completely thorough evaluation of the facial trauma patient is performed.

Table 33.1 The Glasgow Coma Scale

Eyes open	
Never	1
To pain	2
To verbal stimuli	3
Spontaneously	4
Best verbal response	
No response	1
Incomprehensible sounds	2
Inappropriate words	3
Disoriented and converses	4
Oriented and converses	5
Best motor response	
No response	1
Extension (decerebrate rigidity)	2
Flexion abnormal (decorticate rigidity)	3
Flexion withdrawal	4
Localized pain	5
Obeys	6
Total	15

From Jennet B, Teasdale G. *Management of Head Injuries.* Philadelphia, PA: FA Davis; 1981; and Oreskovich MR, Carrico CJ. Trauma: Management of the acutely injured patient. In: Sabiston DC, ed. *Textbook of Surgery,* 13th ed. Philadelphia, PA: WB Saunders, 1986:324.

One must be prepared to perform oral intubation if criteria dictate so or if concern for appropriate airway stability is apparent. In addition, if such a scenario were to present itself or develop in a rapid or deteriorating fashion, then emergent cricothyroidotomy and/or tracheostomy should be considered or performed if an oral or nasal airway cannot be established with certainty or safely. In line with this area of the evaluation, if there is evidence of concern for aspiration of a variety of things from oral secretions to blood/gastric contents to teeth or foreign bodies, then orotracheal intubation can serve as a preventive measure when clear concern or evidence for potentially compromised airway protection is

present.

Hemorrhage is also a significant concern, especially with devastating blunt or ballistic facial trauma. While there may be high index of suspicion for visceral or arteriovenous injury elsewhere, it should be noted that significant blood loss may occur from craniofacial injuries prior to and during presentation in the acute setting and as such should be evaluated and treated accordingly. Commonly encountered examples include scalp lacerations, including along the course of the superficial temporal artery and vein, facial lacerations of branches of the facial artery and vein, nasal hemorrhage that requires packing or balloon tamponade, oral cavity hemorrhage from Le Fort–type fractures, and bleeding from the cranial base or intracranial arteriovenous systems that can lead to devastating consequences if not recognized expeditiously. All the aforementioned, save the last example, may be dealt with by direct pressure or suture ligation-assisted hemostasis. However, it is important to recognize that the most appropriate place for such endeavors, in an ideal circumstance, is the operating room as critical neurologic structures may be injured iatrogenically, especially if suture ligation is performed at or near the areas of facial nerve trunks or branches. Exploration, direct visualization, and meticulous surgical technique is the safest and most predictable sequence to address many of the aforementioned hemorrhagic concerns.

It is beyond the scope of this chapter to discuss some of the more complex and infrequent occurrences of midfacial or cranial base injuries that may require temporary midfacial stabilization or possibly even interventional radiology selective arterial embolization other than to refer to some of the selected readings at the end of this chapter that discuss that thoroughly. Suffice it to say, in general, it should be at least something the reader is aware of when confronted with a scenario where thorough primary and secondary surveys have been performed and yet there is still a lacking explanation for significant hemorrhage. In such circumstances, urgent or emergent consultation with specialty colleagues in plastic surgery, otolaryngology, or oral and maxillofacial surgery should be obtained.

As discussed earlier, when the patient has been deemed to be stable and the examination now focused on careful evaluation and documentation of facial injury, the importance of a thorough and complete history during the physical examination cannot be understated. Various important facts can be obtained, if not from the patient or family members, then witnesses to

the injury or personnel present shortly thereafter, and the history can help to support the mechanism of injury suspected. In addition, important clues regarding possible substance abuse concerns can be vetted via toxicology screens and anything noted in the history including co-morbidities, allergies, medications, and immunization status will serve to complete the evaluation, so necessary interventions account for these important factors.

Careful clinical examination should begin with a thorough, reproducible, and consistent approach that will provide as much information as possible. This typically can be done by compartmentalizing the examination into soft tissue and bony considerations. In addition, if one can examine in a fashion that is consistent from patient to patient, this allows for the least likelihood that an important examination "checkbox" will be missed. Starting from the crown of the head and working in a caudal direction will typically be the easiest way to proceed. All obvious physical examination findings should be carefully noted and include ecchymosis, hematoma, puncture wounds, lacerations, asymmetry, contour irregularities, areas of tenderness to palpation or localized pain, gross visual acuity disturbances, and numbness or paresthesias, to name some of the most common findings. All soft tissue injuries encountered should be suspected to have concomitant or associated deeper, bony injuries until proven otherwise. The physical examination is a way to either raise suspicion as to what radiologic evaluation will uncover or confirm that which radiologic evaluation has already suggested or diagnosed.

As alluded to, the physical examination should be performed in a methodical and reproducible fashion. It typically is easiest to proceed with a "top-down" and "out-in" approach where careful examination starts from cephalad to caudad and from external to internal approaches. Firstly, a gross visualization of the entire craniomaxillofacial region is a very valuable way to get an initial assessment of the severity and complexity of what the presentation of injury may uncover. It should go without saying, but must be clearly understood, that part of the evaluation that frequently is done poorly or not at all is exposure and cleansing of the areas to be evaluated. Frequently, dried blood, debris, foreign bodies, or other objects such as bandages, dressings, clothing, jewelry, and so forth, can get in the way of a thorough examination. There is sometimes fear for exposing areas injured, understandably, but experience has shown that a thorough cleansing and exposure of areas of facial trauma can be safely done, unlikely to cause further injury, and will allow for a more accurate and

detailed examination that otherwise may go unnoticed by the novice examiner. It is absolutely necessary to perform an appropriate cleansing of all areas of concern and typically a warm solution of saline or a half strength solution of peroxide and warm saline functions well in that regard. A small forceps, scissors, and cotton-tipped applicator are all that is typically needed to accomplish this. Typically, most patients will tolerate this well without any need for local anesthesia as they are usually already suffering from diminished sensation at the initial evaluation and already have pain medication on board. For other areas, particularly intraorally, the use of a suction device or digital removal of debris or foreign bodies is helpful, paying particularly close attention to any loose or missing teeth, if encountered. Also, at this time, any evidence of central or midface mobility suggestive of maxillary alveolar or Le Fort–type injuries can be evaluated by bimanual palpation (Fig. 33.1). Using this technique, the maxillary alveolar ridge is manipulated with the dominant hand while the nondominant hand stabilizes the head while also being able to palpate the nasofrontal region.

Once the areas of concern have been fully exposed and cleansed, a palpation of the underlying bony structures can ensue. Generally, using the thumb or index finger, one can appreciate any irregularities, underlying foreign bodies, asymmetry, fluid collections, or what are commonly referred to as “step-offs” or focal areas where the facial skeleton may indicate evidence of fracture or displacement. Further palpation can identify loose or missing teeth, disturbances in the maxillary or mandibular dental arches, floor of mouth lacerations or hematoma, mandibular subluxation or dislocation, and presence of pain in the cervical vertebra area. All of these findings should be noted and documented carefully.

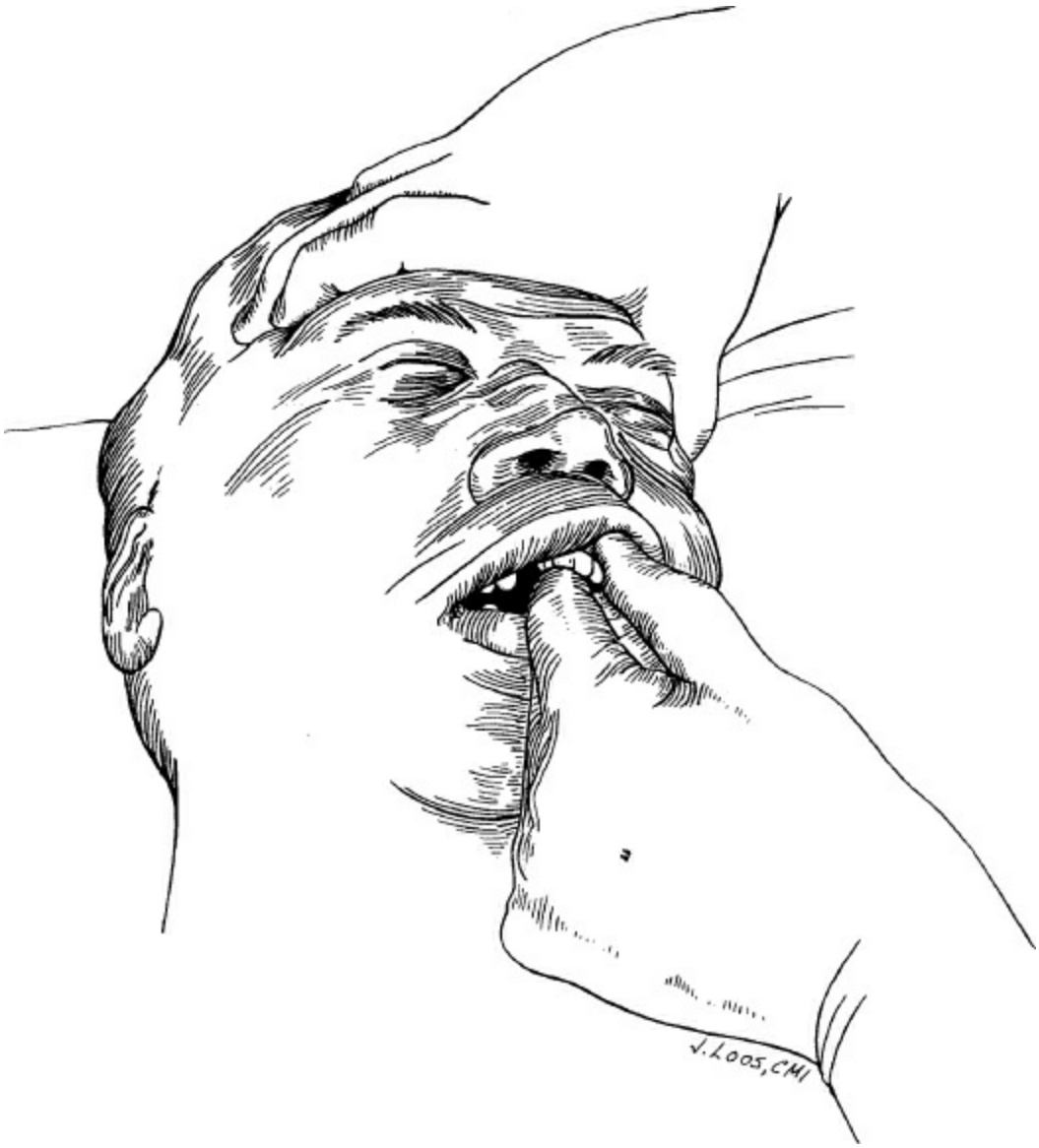

Figure 33.1. Bimanual palpation of the facial skeleton for the diagnosis of midface fractures.

Although only briefly mentioned thus far, the globe and periorbital region is of great importance and must be requisitely evaluated. If the eyelids are not swollen, then gross visual acuity and pupillary reactivity can be evaluated quickly. If needed, gentle digital or cotton-tipped applicator retraction of the eyelid(s) can be performed to facilitate the examination. Extraocular movements of the globe in all cardinal directions should be performed and any deficits noted or pain with movement documented. Ecchymosis in the periorbital region or blood in the scleroconjunctival region or anterior chamber between the cornea and iris (hyphema) will alert the examiner to high suspicion for orbital bony fractures or direct globe injury. Even with the aforementioned being

evaluated, a formal ophthalmologic evaluation should be considered when suspicion is high for periorbital injury. It should be mandatory if there is computed tomographic evidence of orbital fracture.

Once the examination has progressed to this point, it is a good time to document all relevant findings and begin thinking about adjunctive radiologic evaluation or preparing for review of any relevant radiologic imaging already performed. In addition, this is the appropriate time to start thinking about what soft tissue injuries may be able to be dealt with in the emergency room or trauma bay or whether these injures need more formal evaluation in the operating room setting.

This is especially important and relevant if there are lacerations to the periorbital region or frank trauma to the globe. Maneuvers, such as urgent or emergent lateral canthal tendon release should be considered if there is evidence of intraocular hypertension due to retrobulbar hematoma. In addition, this is also a good time to ascertain if there is evidence of injury to the lacrimal system, which will be discussed in more detail herein.

This is also an appropriate time to consider some of the deeper injuries that may not be obvious, including frontal or basilar cranial injuries. Such injuries classically present with clear fluid running out of the nose (also known as cerebrospinal fluid [CSF] rhinorrhea) or the ear (CSF otorrhea). This can be difficult to differentiate from blood or other secretions but if the index of suspicion is high, there are adjunct physical examination maneuvers that can attempt to provide clarity. One of these is the “halo” sign that can be observed when a drop or two of nasal discharge is placed onto a clean cloth and “double ring”–type effect or frank halo of CSF separates into the periphery from the center of where this fluid was placed. Additional laboratory testing in the form of serum electrophoresis can be performed to confirm the diagnosis. Furthermore, if radiologic imaging confirms pneumocephalus (air within the cranial cavity) or presence of blood in the cranial cavity then careful consideration must be given to serial neurologic examination, possible prophylactic antibiotic therapy if concern for development of meningitis is high, and close observation in an ICU-level setting to monitor progress or lack thereof. Thankfully, many of these injuries can be managed conservatively over the course of a number of days with observation.

RADIOLOGIC EVALUATION

When evaluating facial injuries, traditional radiographic workup frequently

included anteroposterior and lateral cervical spine imaging and a craniofacial imaging series with Waters view. Today, these are mostly of historic significance due to the highly sensitive and accurate rapid computed tomography (CT) scanners that are ubiquitous in most emergency or acute care facilities. In fact, CT scans provide a substantial and important amount of information and have been shown to be more cost-effective than radiographic series, especially in craniofacial trauma evaluation. In addition, superior imaging quality, the ability to have "cuts" in axial, coronal, and sagittal planes, and software available to "reconstruct" those images into three-dimensional (3D) imaging truly make craniofacial CT workup the "gold standard" for craniofacial trauma imaging. It should be noted that in most scenarios, a minimum slice size of 3 mm or less is ideal in evaluating the craniofacial trauma patient and in many cases 1-mm or 2-mm slice sizes are preferred.

It is worth mentioning that in isolated mandibular or maxillary trauma, a panoramic radiograph, also known as a Panorex, can be very valuable and in certain cases equal or superior to a CT. In these cases, injury severity and physical examination concordance with the Panorex will dictate whether further imaging is warranted. However, this is still a valuable tool and can be used with appropriate discretion.

Furthermore, 3D CT reconstructions, especially when formatted with fine slice imaging (2 mm or less/slice) can provide not only utility in operative management approaches to the surgeon repairing these injuries, but can also be used in planning of secondary reconstruction cases as more and more institutions acquire these high-speed and accurate CT scanners. It is also worth mentioning some institutions that perform a high volume of craniofacial trauma cases have intraoperative CT scanners available so that real time feedback can be obtained and intraoperative corrections made, if necessary, to areas of bony reduction and fixation, leading to fewer instances of operative revision surgery being necessary.

Even in light of the aforementioned, radiologic evaluation should serve as an adjunct to the traditional examination already discussed. "Laying on of the hands" on the patient will always be master to radiologic evaluation and a skill that will strengthen and refine over the course of a surgeon's career.

TREATMENT OF FACIAL SOFT TISSUE INJURIES

General Considerations

There is general agreement that once all of the aforementioned surveys and appropriate radiologic imaging is obtained, it is at this point in time that consideration be given to definitive management of injuries of the face. If, again, we compartmentalize these into soft tissue versus hard tissue, or both, it is obvious that there are multiple options available to provide treatment. If we look only at soft tissue injuries, then the acute setting in the emergency room, trauma bay, or even the office procedure room may serve as appropriate places for evaluation, exploration, cleansing and debridement, and meticulous closure if these injuries can be appropriately anesthetized with local anesthesia. This becomes more difficult in the highly anxious, uncooperative, or pediatric/adolescent patient and in such situations either monitored sedation or formal operative room treatment may be the best choice for the patient and the ease of management for the treating surgeon. There is consensus about tetanus prophylaxis and I refer the reader to the guidelines of the American College of Surgeons on those criteria (Table 33.2). As was mentioned earlier, it cannot be overemphasized that a commonly overlooked and frankly poorly performed initial and critical portion of any facial soft tissue injury treatment is the exposure/exploration, cleansing/debridement, and preparation of the wound(s) for definitive closure. It was once said by a plastic surgical mentor of mine “let the intern perform the flap portion of the procedure while I perform the debridement myself.” Those words underscore the importance and emphasis on appropriate wound evaluation and preparation prior to management and are just as true in the evaluation and management of common facial injuries as they are for anywhere else on the body.

Anesthesia

As alluded to, in an ideal scenario most soft tissue facial injuries are dealt with using local anesthesia optimized by utilizing well-described local nerve block techniques (Fig. 33.2). In such situations, limited amounts of local anesthesia, as little as a few milliliters, are needed and require less injection into the actual areas of injury which are already typically edematous and have areas of tissue that likely will not react favorably to the vasoconstrictive effects of epinephrine. In fact, I personally find that well-placed nerve blocks coupled with conservative placement of local anesthesia in a *topical* fashion works better than actually injecting it into the laceration or area of injury, especially when you are dealing with

aesthetically important areas including the perioral and periorbital regions.

TABLE 33.2 Recommendations for Tetanus Prophylaxis of the Committee on Trauma, American College of Surgeons

Age (Years)	Vaccination History	Clean, Minor Wounds	All Other Wounds
0–6	Unknown or not up-to-date on DTaP series based on age	DTaP	DTaP TIG
	Up-to-date on DTaP series based on age	No indication	No indication
7–10	Unknown or incomplete DTaP series	Tdap and recommend catch-up vaccination	Tdap and recommend catch-up vaccination TIG
	Completed DTaP series AND <5 years since last dose	No indication	No indication
	Completed DTaP series AND ≥5 years since last dose	No indication	Td, but Tdap preferred if child is 10 years of age
11 and older ([a]If pregnant, see footnote)	Unknown or <3 doses of tetanus toxoid containing vaccine	Tdap and recommend catch-up vaccination	Tdap and recommend catch-up vaccination TIG
	3 or more doses of tetanus toxoid containing vaccine AND <5 years since last dose	No indication	No indication
	3 or more doses of tetanus toxoid containing vaccine AND 5–10 years since last dose	No indication	Tdap preferred (if not yet received) or Td
	3 or more doses of tetanus toxoid containing vaccine AND >10 years since last dose	Tdap preferred (if not yet received) or Td	Tdap preferred (if not yet received) or Td

[a]Pregnant Women: As part of standard wound management care to prevent tetanus, a vaccine containing tetanus toxoid might be recommended for wound management in a pregnant woman if 5 years or more have elapsed since the previous Td booster. If a Td booster is recommended for a pregnant woman, healthcare professionals should administer Tdap.
From The American College of Surgeons. *The Advance Trauma Life Support Student Manual*. 10 Ed. 2017:409; an adaptation National Center for Environmental Health (NCEH)/Agency for Toxic Substances and Disease Registry (ATSDR), National Center for Injury Prevention and Control (NCIPC).

It should also be noted, and ideally already performed, that sensory (trigeminal) and motor (facial) nerve evaluation should be documented prior to local anesthetic infiltration in the face. In addition, taking advantage of anatomic nerve block techniques limits the need for direct or field block injections for the reasons mentioned. In fact, particularly in the perioral region at the vermilion border of the lips or the periorbital region of the eyebrow or eyelid, this is particularly useful so that limited distortion of these areas is performed. For example, a millimeter difference in approximation in these areas can be picked up by the human eye and it

is critical that these regions be meticulously reapproximated with limited local anesthetic infiltration if possible (Fig. 33.3).

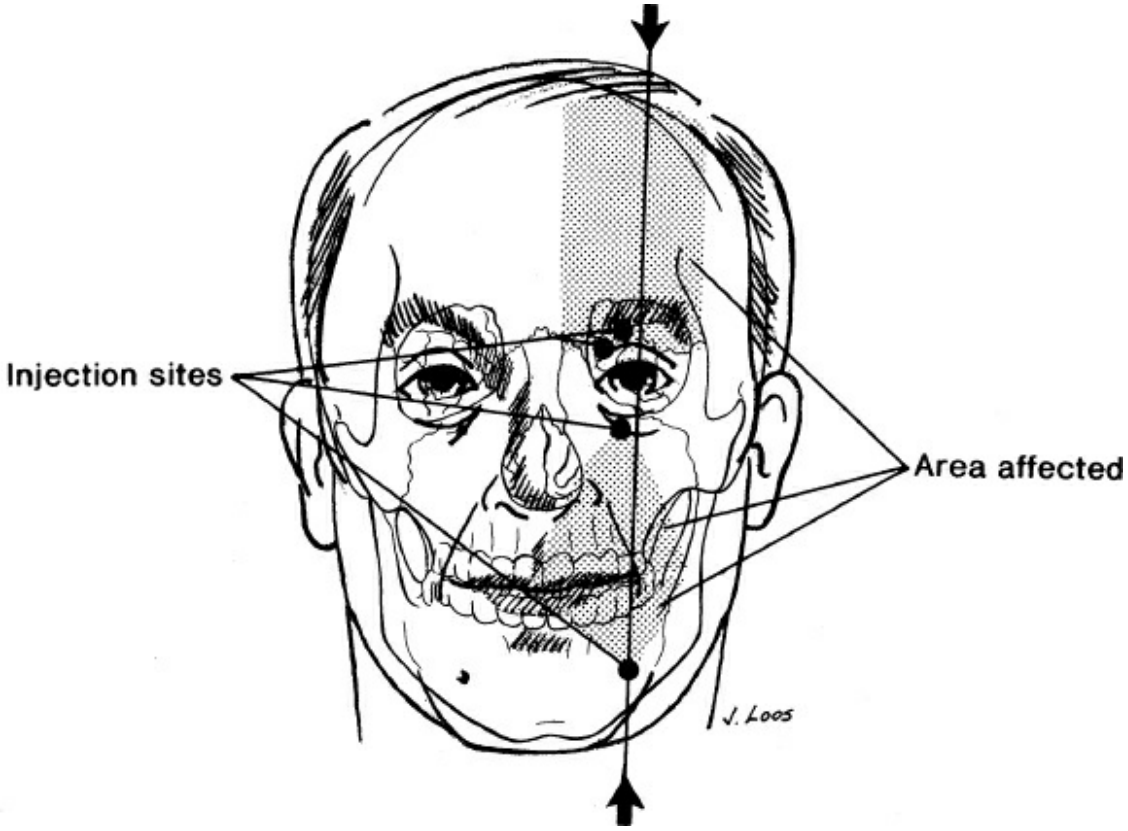

Figure 33.2. Sites for injection and affected areas for supraorbital, infraorbital, and mental nerve blocks.

Usage of bupivacaine or lidocaine is typically a personal preference but it is worth mentioning that the effects of bupivacaine can last up to 8 or more hours. This can be useful when a longer period of posttreatment pain control is needed. However, it must be remembered that accidental intravascular injection of bupivacaine can lead to asystole from its cardiotoxic effect; so when injecting using bupivacaine, use an appropriate technique with aspiration of the syringe prior to injection. In the same vein, when injecting in general, the same technique should be used to avoid inadvertent intravascular injection. There is also the potential of intraneural injection when performing the anatomic blocks mentioned. If there is extreme pain when such a block is being performed, there is a high likelihood the needle has found its way into the intraneural plane and the injection should be stopped and the needle immediately withdrawn. Finally, two areas of the facial region notoriously difficult to anesthetize without multiple areas of block or a formal ring or field block include the

nose and the ear due to overlapping regions of sensory innervation. In these cases, topical local anesthesia in the form of eutectic mixture of local anesthetics (EMLA) can be used to facilitate diminishing the pain from injecting multiple sites.

The best choice of anesthetic or the technique used can be further explored in the Suggested Readings section. Suffice it to say, that I have not personally found it useful to add sodium bicarbonate, as has been well described, to my local anesthetic of choice in attempts to make the injection less painful. While I have nothing personally against this technique, I have found the aforementioned pearls useful in limiting pain associated with injection and the additional step of adding bicarbonate practically not useful. I think that using a 1-mL tuberculin syringe with a 30-gauge needle is most effective and least painful and would encourage the reader to consider using that technique in his or her practice.

Finally, a word about conscious sedation deserves mentioning. I have found it to be very useful in some of the situations mentioned previously and feel that is an excellent option when appropriate anesthesiology or sedation-certified physician care is available with close monitoring throughout. This can sometimes save a trip to the operating room and should be used with appropriate discretion.

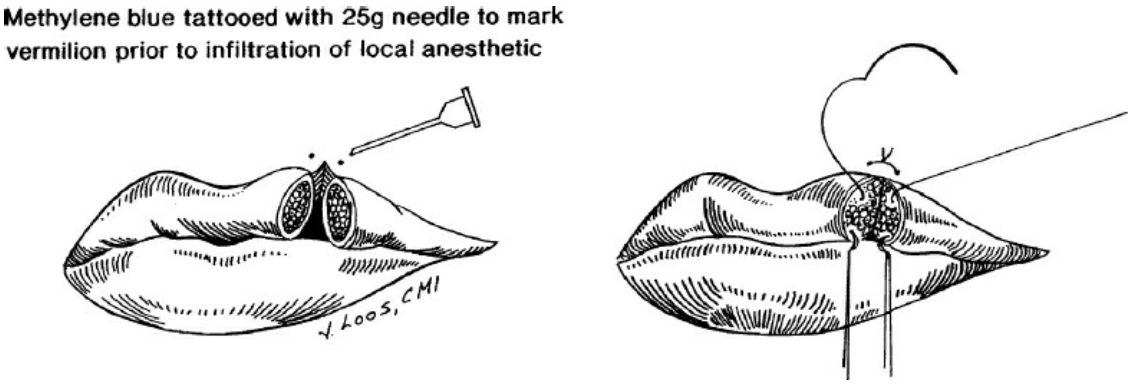

Figure 33.3. Marking the vermilion border before local infiltration of anesthetic aids precise repair of lacerations of the lip.

Wound Preparation

Wound preparation is an exercise in which multitasking is commonplace and a set routine an invaluable asset. Just as in the physical examination discussion, having a routine that one is comfortable with, reproducible, and allows for low likelihood of forgetting any steps is very useful. If the patient is awake, then wound preparation is also the time in which the

surgeon can work to calm any anxieties or fears and explain clearly, confidently, and in a step-by-step fashion what will be done.

I favor a wide exposure and preparation of the area to be intervened upon. It is extraordinarily useful to have, if possible, uninjured or contralateral landmarks available to guide your decision making and technical approach. I have found that *topically* applying local anesthesia to the wound be and giving it requisite time to take effect not only diminishes some pain the will experience with manipulating the wound prior to preparation but also leads to less local anesthesia needed overall for direct infiltration and including when anatomic blocks are performed.

Generally speaking, if overall debris or dried blood has not been removed by the time you have been asked to see the patient, please do this critical step. Then, a more formal cleansing of the wound, as has been discussed, may ensue. I do not hesitate, using clippers, to shave any areas of hair that may be obscuring the field, save for eyebrow hair which should be preserved in almost every circumstance. Solutions that are useful for cleansing include warm saline or a half-strength warm saline–hydrogen peroxide mixture. Use of betadine in the head and neck is safe and appropriate. Hibiclens solution or ChloraPrep should not be used in the head and neck under any circumstance due to mucosal and scleroconjunctival adverse effect concerns.

One of the most important things mentioned already is the concept of a thorough debridement of the areas of concern and interest. During the acute period during which most common facial injuries are suffered, this is unequivocally the best and perhaps only appropriate chance one will have to remove any foreign material, debris, devitalized tissue, and so on, that are so frequently encountered. If appropriate treatment is not able to be done under local anesthesia or even conscious sedation settings, then the operating theater should be used for definitive wound preparation, debridement, and management. The use of gentle scrub brushes can be an added asset. In addition, loupe magnification can assist with removal of small pieces of debris, especially if fine forceps are needed to individually remove various foreign bodies. Close examination of the injured areas will provide an assessment of how much, if any, sharp debridement will be necessary and if any margins of skin/subcutaneous tissue need to be removed. I would caution that, in my own experience, what may appear as marginal tissue at first many times will go onto survive and that one should be extremely conservative in debridement in the acute setting; this

is particularly important in the perioral and periorbital regions. In fact, it is easier to revise a wound months later under controlled surgical conditions once all areas have declared themselves and healed under minimal tension or stress than it is to revise a wound that has been unnecessarily or aggressively debrided, leading to increased wound tension during closure, surrounding distortion from the wound closure, and other numerous problems in the healing period that may develop under such circumstances.

With regards to closure, in general, a primary closure should be attempted when possible. Primary closure does not necessarily mean direct, linear closure. Applying a skin graft in the acute setting, for instance, is also a primary closure, just not a linear one. What matters is that when the circumstances are appropriate, direct closure is preferable for numerous reasons. However, if it is necessary to allow the wound to heal in by secondary intention or provide dressing changes as a bridge to delayed primary closure, this should be done at the discretion of the surgeon. Such circumstances are frequently encountered with animal bite wounds; deep, penetrating wounds that are difficult to thoroughly debride and drain; and in extraordinarily contaminated wounds where the risk of primary closure would predispose to a high risk of infection.

I favor layered wound closure when possible so that dead space is minimized and that multiple layers are able to serve to support the overall wound strength and stability. In the deeper layers, monofilament, absorbable sutures are preferred. In the more superficial layers, either an intradermal closure using absorbable monofilament suture or a more superficial placement of interrupted nylon or prolene suture is commonplace. For sutures in the head and neck, and certainly the face, skin sutures should be removed in 3 to 5 days, and preferably no longer than 7, to avoid the “hatching” or “track marks” so commonly seen as an iatrogenic sequela of sutures left in too long and the epithelialization of those suture tracts.

In the scalp, certainly staple usage is entirely reasonable and sometimes preferred. In the face, this is to be totally avoided. In the scalp, face, or neck, if there is dead space where concerns for postoperative fluid collection exist, either Penrose drains or closed suction drains placed for a few days can be a valuable tool to minimize such concerns. If concerns are present that critical structures of the face, including the lips or ears, are at risk for viability then subspecialty consultation should be immediately

obtained so that additional technical assistance may be provided, including microvascular repair or revascularization. In addition, if any anatomic parts are amputated, those should be wrapped in moistened-saline gauze, placed in a plastic bag, and then placed on ice while waiting for subspecialty consultation or, if not available, referral to an institution where such specialty services are available.

A quick word about adjuncts that are commonly available but frankly not that useful in facial injury repair, include the use of Histoacryl (n-Butyl-2 Cyanoacrylate) or Dermabond (2-Octyl Cyanoacrylate). While these have their unique areas of use, I have found in my practice that in the setting of craniofacial injury, they do not provide much practical help in this setting. In fact, many times they will seep into the wound and inhibit wound healing or cause an unintended reactive inflammatory response that is counterproductive. Frankly, Steri-Strips would be a more appropriate and suitable alternative if the treating surgeon feels an added amount of protection or support is needed for the area of repair and these can be placed longitudinally or perpendicularly and have the ability for fluid to egress through them as an added benefit.

Finally, a short discussion on the use of antibiotics is necessary to complete this section. In the elective setting, in clean or even clean–contaminated wounds, antibiotics are typically not used due to the robust blood supply of the face. However, an important caveat and still a controversial point of discussion is the use of antibiotics in the acute or traumatic setting. I think it is reasonable to provide at least one preprocedural/preoperative dose of appropriately selected antibiotics for skin flora coverage in these situations; typically a first-generation cephalosporin or appropriate substitute if patient allergy precludes. In fact, in cases of substantial contamination or devitalization, an additional 24 hours of antibiotic therapy is also entirely reasonable. This is especially the case in animal or human bites where multiple days of postoperative treatment may be indicated.

Special Considerations

There has already been discussion of several areas of particular importance in common facial injury management that deserve special mention. The face itself has areas of critical functional and aesthetic importance. The most important of these will be the motor and sensory nerves, which are frequently injured or at least affected to a degree in the majority of

commonly encountered facial injuries. If lacerations of the facial nerve trunk, its branches, and/or the branches of the trigeminal nerve are noted, these should be expeditiously explored in the operating room and repair attempted under the operating microscope. In addition, a frequently injured area due to lacerations in the region of a line drawn from the tragus of the ear to the lateral brow, is the frontal branch of the facial nerve. If this is unrecognized or not repaired, the frontalis muscle on the affected side will not function and lead to an inability to raise the brow and loss of rhytid lines, which can be distressing to the patient and require the use of chemodenervation on the unaffected side to restore symmetry. In fact, facial nerve injury should be suspected until proven otherwise when penetrating injuries occur on a line between the lobule of the ear and the lateral brow (Fig. 33.4). Again, physical examination and findings documentation is critical to exclude or recognize such injuries.

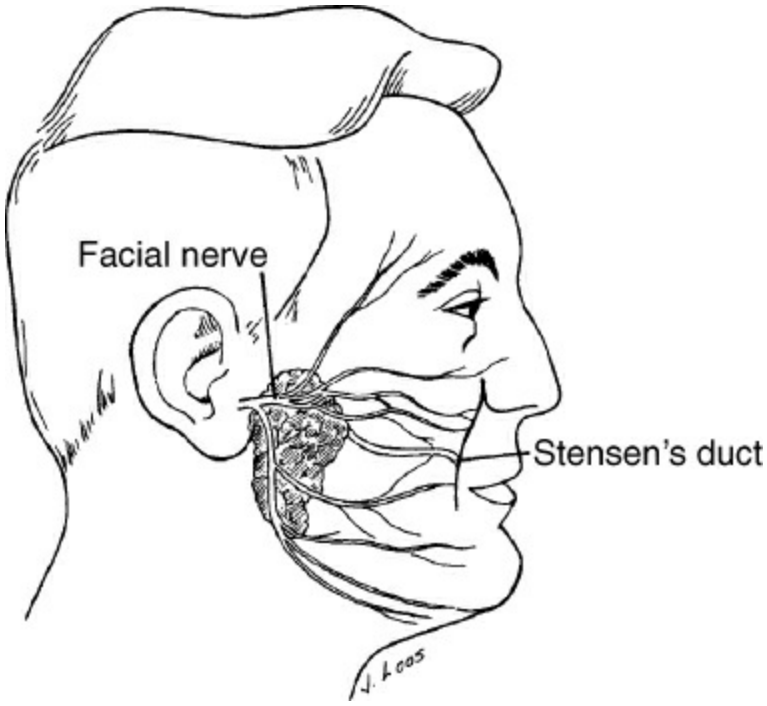

Figure 33.4. Location of the facial nerve and parotid duct (duct of Stensen).

The aforementioned is an excellent segue to discuss an injury that is not uncommonly suffered when concerns about facial nerve involvement arise. The parotid duct, also commonly referred to as the duct of Stensen, is anatomically located along the central divisions of the facial nerve as it branches from its main trunk and exits the parotid gland. Anatomically, it is located approximately 2.5 cm anterior to the tragus of the ear, at the

anterior margin of the parotid gland, to its termination intraorally visible as a small punctum near the maxillary second molar tooth. These are useful landmarks to remember as an injury along this course should alert one to parotid duct injury. If any injury is suspected, the intraoral punctum can be cannulated with a small, flexible angiocatheter and saline injected gently to see if it extravasates into a wound in that vicinity. If that is the case, exploration in the operating room should be performed to not only repair the duct but also to evaluate for high likelihood of facial nerve branch injury which can be supported by the physical examination findings. The selected readings section offers more specific information on the specifics of such evaluation and technical approaches to repair.

Fluid collections or hematomas can commonly develop in multiple areas of the face. The two most commonly encountered and important areas are the ear and the nasal septal area. If unrecognized, hematomas in these regions can lead to a disfiguring condition of the ear, commonly referred to as “cauliflower ear” or nasal septal cartilage destruction leading to a nasal septal fistula. In these cases, the fluid collection or hematoma should be incised and drained as soon as identified and the area stented or packed to prevent reaccumulation (Fig. 33.5). If other areas of the face harbor a fluid collection or hematoma, these should also be incised, drained, irrigated, and appropriately dressed with patient follow-up in the next few days to be sure that recurrence has not occurred. Occasionally, aspiration with an 18-gauge needle may be attempted but my personal experience with this has been disappointing and only as a temporizing maneuver until formal incision and drainage can be performed.

Finally, it is worth mentioning that high-energy–type wounds to the face, as is commonly seen in ballistic injures, deserve special mention. In these cases, the energy dissipation and subsequent injury may not immediately be obvious with regards to ultimate amount of tissue destruction that has declared itself. In these situations, once full BLS and ATLS, surveys, and patient clearance has been performed, it is typically necessary to perform serial examinations and debridements as the area of tissue involvement declares itself. This commonly translates into return to the operating room every 48 to 72 hours until this process has gone to completion, after which time definitive management of associated injuries can take place with lowest risk of infection or necrosis-related complications.

SOFT TISSUE INJURIES TO THE EYE, ORBIT, AND LACRIMAL APPARATUS

As was mentioned earlier, the periorbital region is of special importance for obvious reasons. I alluded to the fact that if one suspects frank globe injury or if evidence suggests orbital fracture, then consultation of ophthalmology is absolutely indicated and necessary. Once the globe(s) has(have) been appropriately evaluated and "cleared" it is then appropriate to deal with any lacerations in the periorbital region. Frequently, laceration to the eyelids is encountered and must be treated with meticulous technique (Fig. 33.6). The anatomic structures including the tarsus, eyelid margins and conjunctiva, and eyelash borders are repaired in layers. Typically, for the tarsus and conjunctival layers, a fine monofilament, absorbable suture is used in the form of 5-0, 6-0, or 7-0 suture size. The skin in these regions typically tolerates a monofilament such as nylon or polypropylene of the 6-0 or 7-0 size. In addition, noncutting, taper needles are my personal favorite in almost all situations on the face and frankly anywhere else on the body. These sutures are minimally traumatic and push nicely through delicate tissue rather than cutting through them. Once repair of the eyelid has been performed, suture ends should be protected with a fine Steri-Strip to prevent any corneal or scleroconjunctival irritation while healing occurs. As mentioned previously, leaving sutures in place for 3 to 5 days is ideal but certainly no longer than 7 days to avoid iatrogenic "hatch" or "track marks."

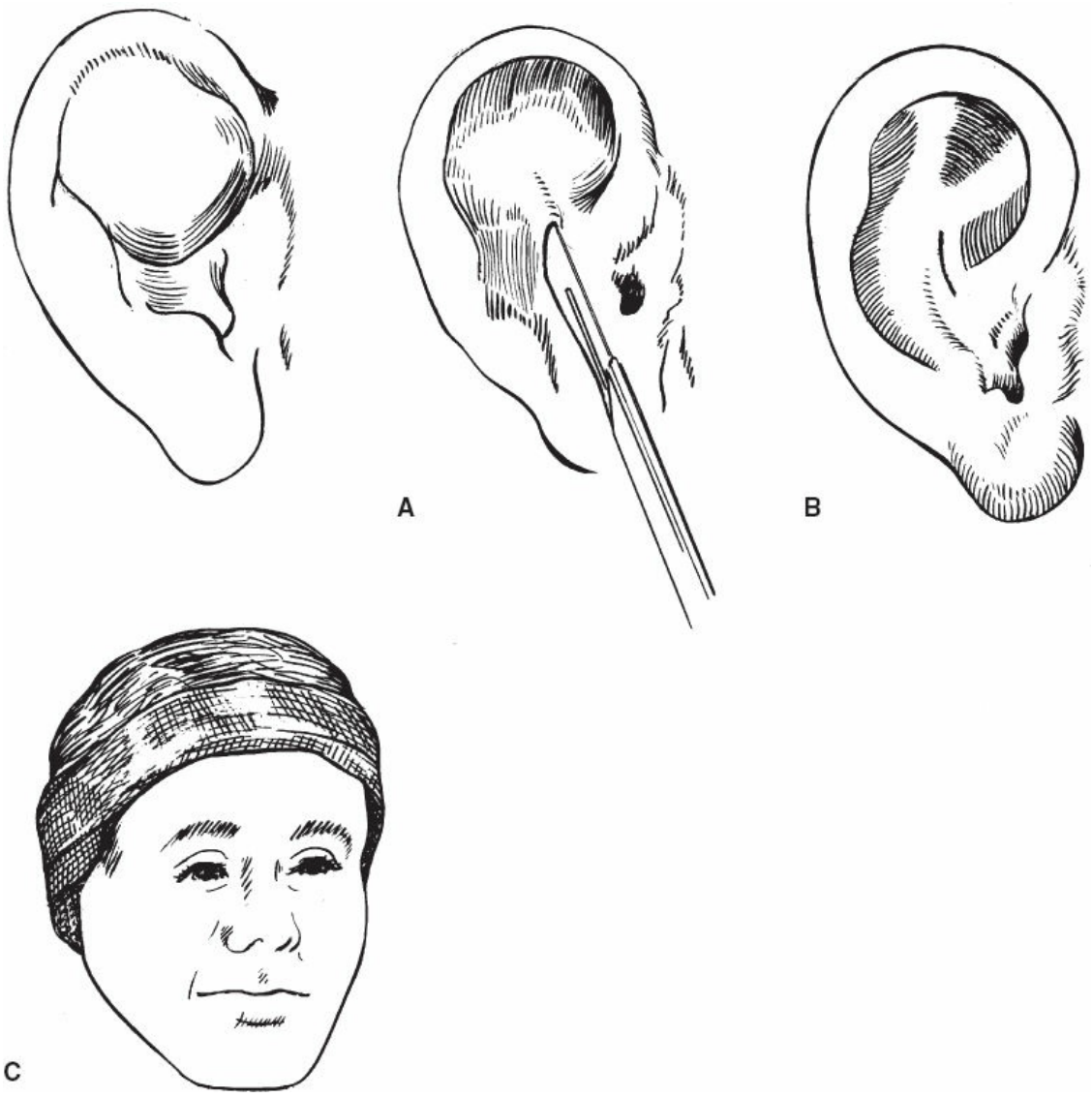

Figure 33.5. Evacuation of a hematoma of the external ear. **A.** An incision is made in a dependent position. **B.** The hematoma is evacuated and the anatomic detail of the ear is restored. **C.** A light compressive head dressing is applied.

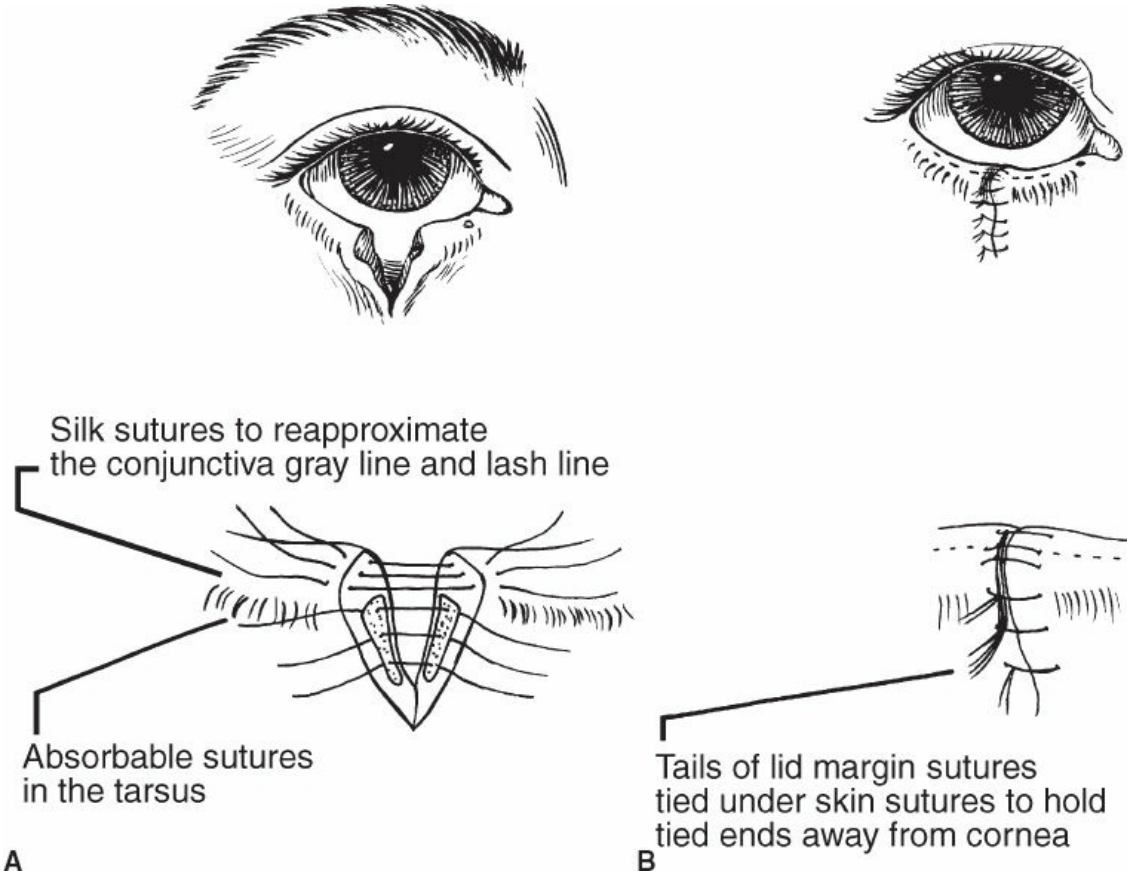

Figure 33.6. Repair of a laceration across the margin of the lower eyelid. **A.** The tarsal plate is reapproximated with fine absorbable sutures that do not penetrate the conjunctiva. **B.** The lid margin is reapproximated with fine nonabsorbable sutures anatomically. The ends of the lid margin sutures are tied under the first external suture to prevent corneal abrasion.

Another point worth discussing is lacrimal duct injury recognition, especially in the presence of lacerations in the medial eye and nasal sidewall regions (Fig. 33.7). If such injury is suspected, subspecialty consultation should be requested immediately. It is beyond the scope of this chapter to delve into the specific treatment of this injury but the selected readings section has a number of excellent resources that discuss this in great detail for those interested.

INJURIES TO THE EXTERNAL EAR AND NOSE

Much as was discussed in the previous section on eyelid repair, the same general concepts apply for the ear and its closely associated auricular cartilage (Fig. 33.8). The auricular cartilage can be approximated using absorbable, monofilament suture and the external ear skin using

nonabsorbable, monofilament suture using nylon or polypropylene in a 4-0, 5-0, or 6-0 size. The nose as well as its intimately associated cartilage and nasal septum can be also approached in a similar fashion using a similar technique and suture material (Fig. 33.9). In all cases, it is again ideal to limit any debridement, especially of cartilage, to that only necessary to preserve domain and anatomy as much as possible under presented circumstances. Much as was described already, any fluid collection or hematoma should be managed appropriately in these areas.

MANAGEMENT OF FACIAL FRACTURES

Facial fracture management has truly seen exciting and substantial advances in the last 30 years. There has been the important development and maturation of fundamental principles of management during that time as well. In the 1980s, rigid plate and screw fixation truly revolutionized facial fracture management, especially with the articulation of the concept of facial buttresses in Le Fort–type fracture management by Manson and colleagues. As time went on, the ability to perform aesthetically sound approaches to the facial skeleton for fracture management became easier due to the smaller footprint and better alloy composition of the rigid fixation materials being used, allowing for smaller incisions placed in aesthetically hidden skin creases. In 2005, facial transplantation became a reality and to date close to 40 such transplants have been performed as the ultimate reconstructive or, better stated, restorative operation for the most severely injured patients as a state-of-the-art option in select cases. In the selected readings section, there are excellent references that delve into this history further for the interested reader. What is critical to recognize is that, even in light of all the advancements made, facial fracture management still follows fundamental principles that have been shown to allow for excellent functional *and* aesthetic outcomes when followed and applied appropriately. In essence, goals of management can be listed in the following manner: (1) expeditious anatomic reduction of fracture fragments, (2) stabilization with rigid plate and screw fixation to restore anatomic fidelity and bony facial support for the soft tissues, (3) close attention paid to dental occlusal relationships and restoring as close to premorbid occlusion as possible, and (4) allowing the overlying soft tissues to heal over an appropriately reconstructed foundation of the facial bony skeleton to prevent any disfiguring secondary soft tissue abnormalities.

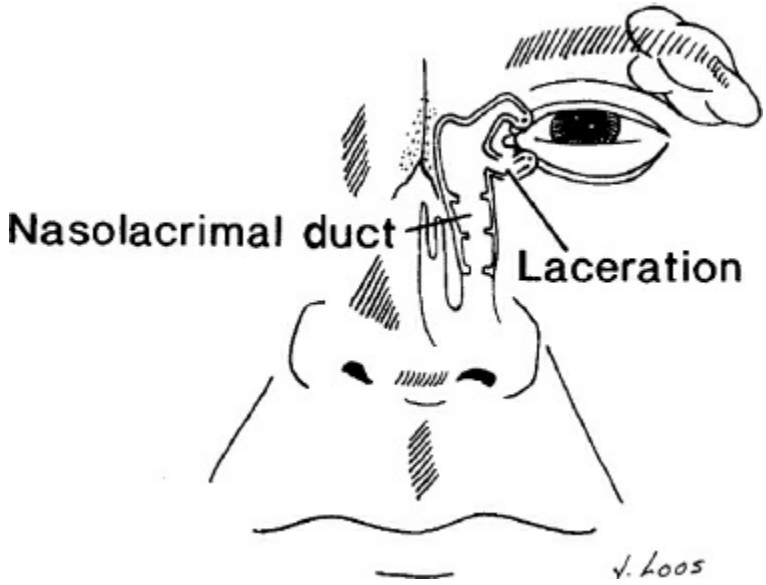

Figure 33.7. The nasolacrimal system.

A quick word about the most common facial fractures encountered is worth mentioning at this time. Nasal fractures are the most common injury seen, followed by orbitozygomaticomaxillary (OZMC) fractures, followed by mandibular fractures. Fractures of the midface (maxilla) or the frontal bones are less commonly encountered but still important to recognize. A thorough physical examination, as has been described, supplemented with appropriate radiologic imaging will allow one to essentially diagnose any facial fracture with certainty and confidence. In thinking about the facial skeleton, it is useful to divide the face into thirds: (1) upper third: frontal bone; (2) middle third: orbits, nasal bones, zygoma, and maxilla; (3) lower third: mandible. This also allows one to be systematic in his or her evaluation of the imaging obtained, so that the likelihood an injury could be missed is as low as possible. Once the constellation of facial fracture(s) is (are) identified, they may be classified and an operative plan developed to manage them. It is beyond the scope of this chapter to discuss the various classification systems that described the fracture patterns referred to previously but the selected readings section has within it the critical references that discuss the most important patterns including, frontal bone fractures, naso-orbito-ethmoid (NOE) fractures, all described Le Fort–type fractures (I, II, and III), and mandibular fractures.

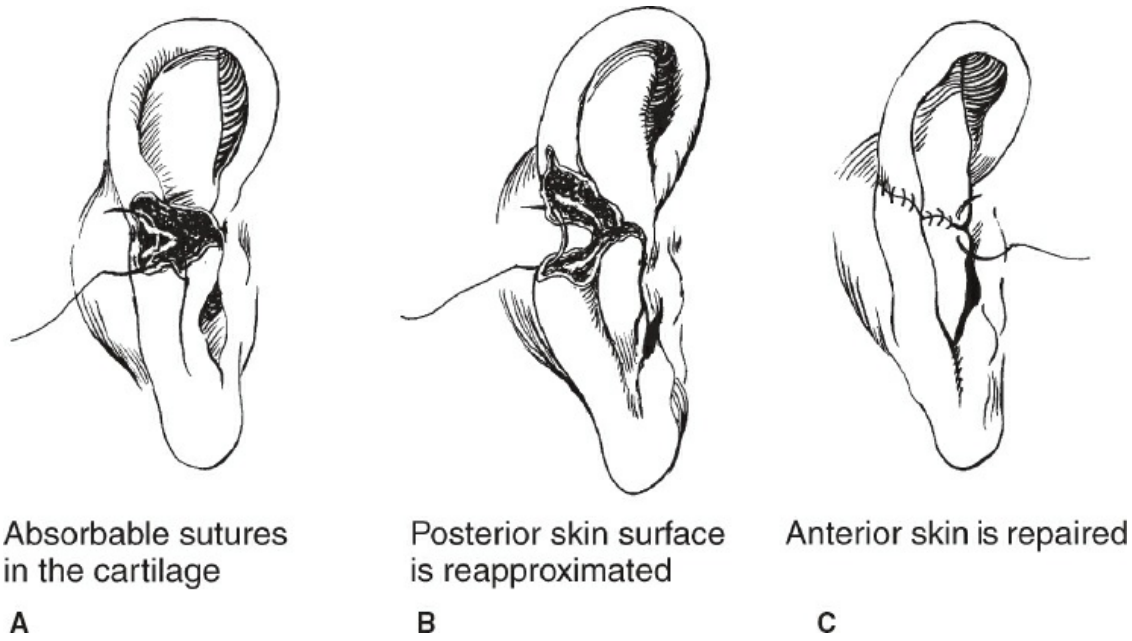

Figure 33.8. Repair of a laceration of the external ear. **A.** The cartilage is reapproximated with absorbable suture on a noncutting needle. **B,C.** The skin of the posterior and anterior surfaces is reapproximated with nonabsorbable sutures.



Figure 33.9. Repair of complex nasal laceration. **A.** The nasal mucosa is reapproximated with absorbable sutures. **B.** The cartilage is repaired with absorbable sutures on a noncutting needle. **C.** The skin is reapproximated.

As mentioned, in order of frequency, nasal fractures are the most commonly encountered and can be frequently diagnosed alone based on history and physical examination. Typically, these fractures are treated by closed reduction, ideally within the first 7 days of injury, and protected with nasal splinting (extranasal and intranasal) for about 10 to 14 days while the reduced fracture fragments heal in their anatomically reduced position. I personally do not favor attempts at nasal fracture reduction

anywhere but in the operating room with a secure airway under general anesthesia. Nasal fracture reduction can lead to a significant amount of nasal bleeding for a short period and this can be disastrous, even life-threatening, if the surgeon loses control in such situations. If there are additional nasal cartilaginous or soft tissue injuries, those can also be repaired definitively in the operating room. If elective nasal revisions are needed, waiting at least 6 months or more is appropriate due to the amount of time it takes for subtle nasal edema to resolve. In fact, it is typical that elective rhinoplasty patients have subtle edema present for up to a year after operative intervention and this fact serves as a good reference when thinking about nasal trauma after-effects.

OZMC and maxillary or Le Fort–type injuries are useful to combine in the same discussion (Fig. 33.10). The term *O*ZMC serves to alert the reader that, in fact and by definition, a zygomatic fracture involves the orbit, typically the floor, to some degree. This is important to understand not only in the anatomic sense of the fracture involvement but also that this pattern of injury always mandates a thorough globe examination and frequently ophthalmologic evaluation. There is still controversy in terms of how best to approach and treat OZMC fractures but it has become clear that the traditionally espoused 3- or 4-point fixation popularly advocated in the past is not necessary. In fact, many of these fractures can be approached from only an intraoral incision in the upper gingivobuccal sulcus and appropriately reduced and fixated with one plate with no need for an extraoral incision. In cases where the fracture is more comminuted or not easily or satisfactorily reduced via an intraoral approach, an upper blepharoplasty approach incision can be used to identify the zygomaticosphenoid articulation to confirm anatomic reduction. If needed, as some fractures will have enough orbital floor involvement that repair is needed in the orbit, a lower eyelid incision, typically transconjunctivally to avoid going through the eyelid skin and therefore avoiding a skin scar, can be used to plate the orbital rim and even place a plate to reconstitute an orbital floor defect.

Isolated orbital fractures also occur with enough frequency that a short discussion of this topic is necessary. These fractures are typically referred to as “blow-out” fractures and most commonly involve the orbital floor and medial orbital wall, as those bones are the most thin and fragile in the orbit and fracture first over the lateral and superior walls. Again, in these instances a careful evaluation of the globe is necessary and ophthalmology

consultation mandatory. Patients frequently have photophobia, diplopia, and even visual acuity abnormalities. It is paramount to be certain there are no pupillary abnormalities, there is no evidence of increased intraocular pressure, such as a retrobulbar hematoma, and that there is no restriction of any of the cardinal movements of the eye. This can all be quickly ascertained as part of the physical examination. Any of the aforementioned findings are surgical emergencies and typically mandate urgent or emergent operative intervention. The criteria for orbital fracture repair are controversial but a good rule of thumb is that if CT imaging shows orbital floor defects greater than 2 cm^2 or if the patient already has obvious muscle entrapment or a sunken in globe (enophthalmos), then operative repair should be pursued. However, many fractures of the orbit can be actually treated nonoperatively with close observation so long as the architecture surrounding the globe still maintains its “fibroligamentous sling” that will, in spite of remarkable medial orbital wall or orbital floor defects, still support the globe in its correct position, much as a hammock would function to keep its passenger in place even if the ground beneath was excavated into a deep hole. If operative intervention is pursued for the aforementioned indications, it is typically uncommon to need to do so immediately but rather it is a reasonable wait of 7 to 10 days to allow much of the orbital edema to subside so that it is technically less challenging to expose the important orbital contents. Blindness is an uncommon, but very real, risk of operative intervention on the globe and should be discussed with any patient undergoing orbital fracture repair as part of the informed consent process and as a standard of care consideration.

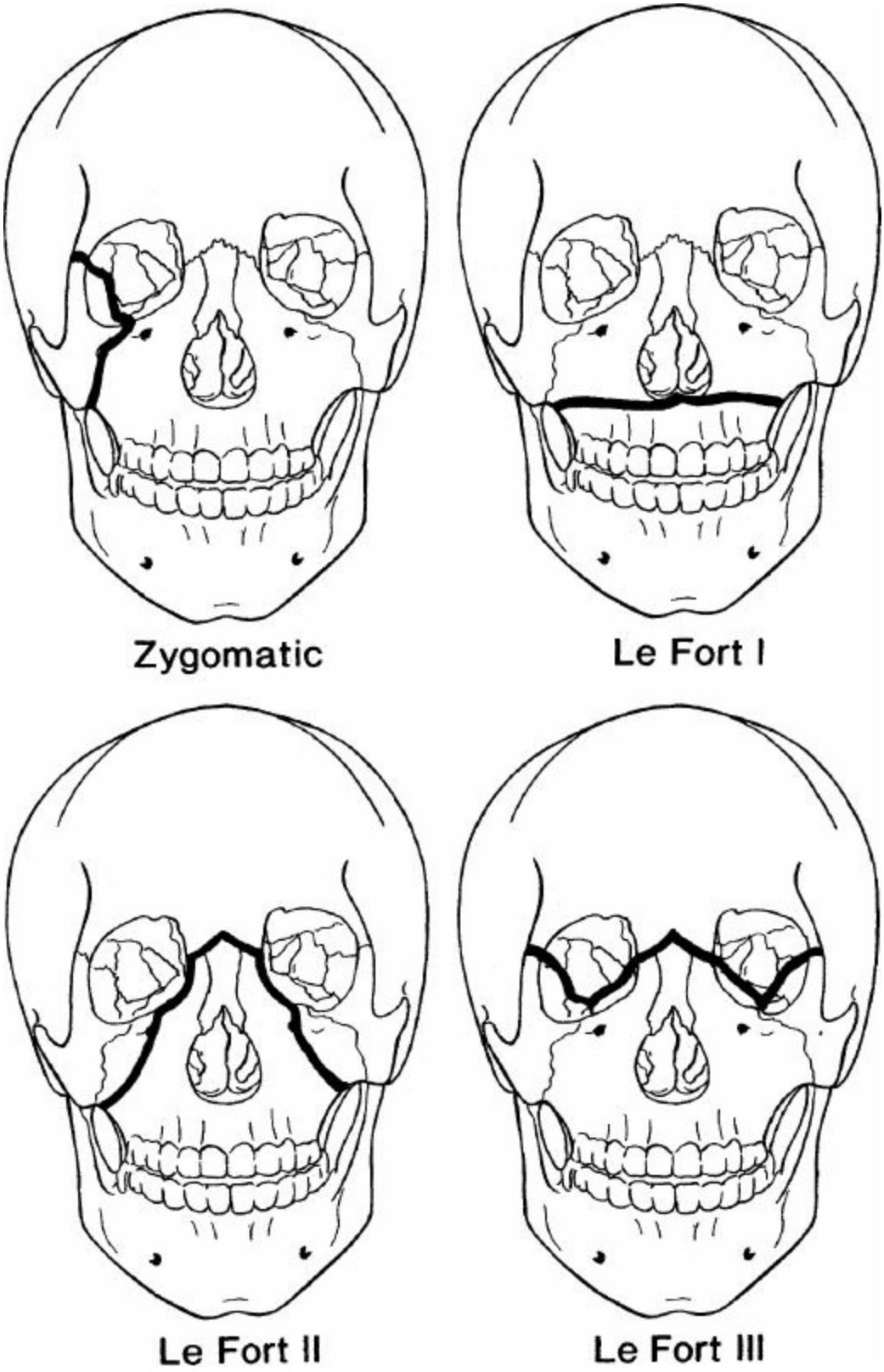

Figure 33.10. Maxillary fractures.

Mandibular fractures can occur frequently in isolation or in combination with other facial fractures and are important to recognize so that occult fractures are not missed. There are favorable and unfavorable

fracture patterns of the mandible which are useful to help guide treatment decision making (Fig. 33.11). In scenarios where there is a favorable fracture pattern and minimal to no displacement of fracture fragments, a liquid or pureed-type diet for 2 weeks may all be that is necessary to successfully treat these injuries. In more significant injuries to the mandible, including multiple fractures or involvement of the alveolar bone and teeth, these injuries frequently will need at least mandibulomaxillary fixation (MMF) to reduce the injured segments and allow for "jaw rest" so the fractures may heal. In other situations, formal operative exploration of the injuries with appropriate tooth salvage or removal, fracture debridement, and open reduction and internal fixation with rigid plates and screws is needed in addition to MMF. The selected readings section provides further information on the wide constellation of these injuries and appropriate treatment algorithms. One additional consideration that is worth mentioning with regard to mandible fractures involves fractures of the subcondylar region. These can be unilateral or bilateral and present with the classic finding on physical examination of an "open bite" wherein the patient looses mandibular height on one or both sides and has premature contact of the posterior molars and is unable to bring the anterior teeth into a normal occlusal relationship. Again, even consensus on the management of these types of fractures is controversial and is best served by subspecialty consultation, evaluation, and management.

Le Fort–type fractures were mentioned previously and deserve some further elaboration here. These fracture patterns were described in the early 1900s by a French surgeon named René Le Fort and were further characterized by Paul Manson and colleagues in 1980 by describing structural pillars of the facial skeleton and their importance in the management of Le Fort–type fractures (Fig. 33.12). There are many considerations in dealing with Le Fort-type I, Le Fort-type II, and Le Fort-type III fracture patterns but, suffice it to say, these fractures can be exposed and reduced and plated via a combination of the approaches already discussed. In fact, using gingivobuccal sulcus, upper blepharoplasty approach, and transconjunctival incisions, the surgeon can provide excellent exposure and treatment of these injuries with minimally obvious sequelae from a surgical scar perspective. Many of these injury patterns will require MMF for a period of time while all reduced and fixated fractures are allowed to heal, so it is common to use a prescription strength mouthwash on a twice or thrice daily basis as brushing of teeth

during this time is not practical and oral hygiene is of critical importance.

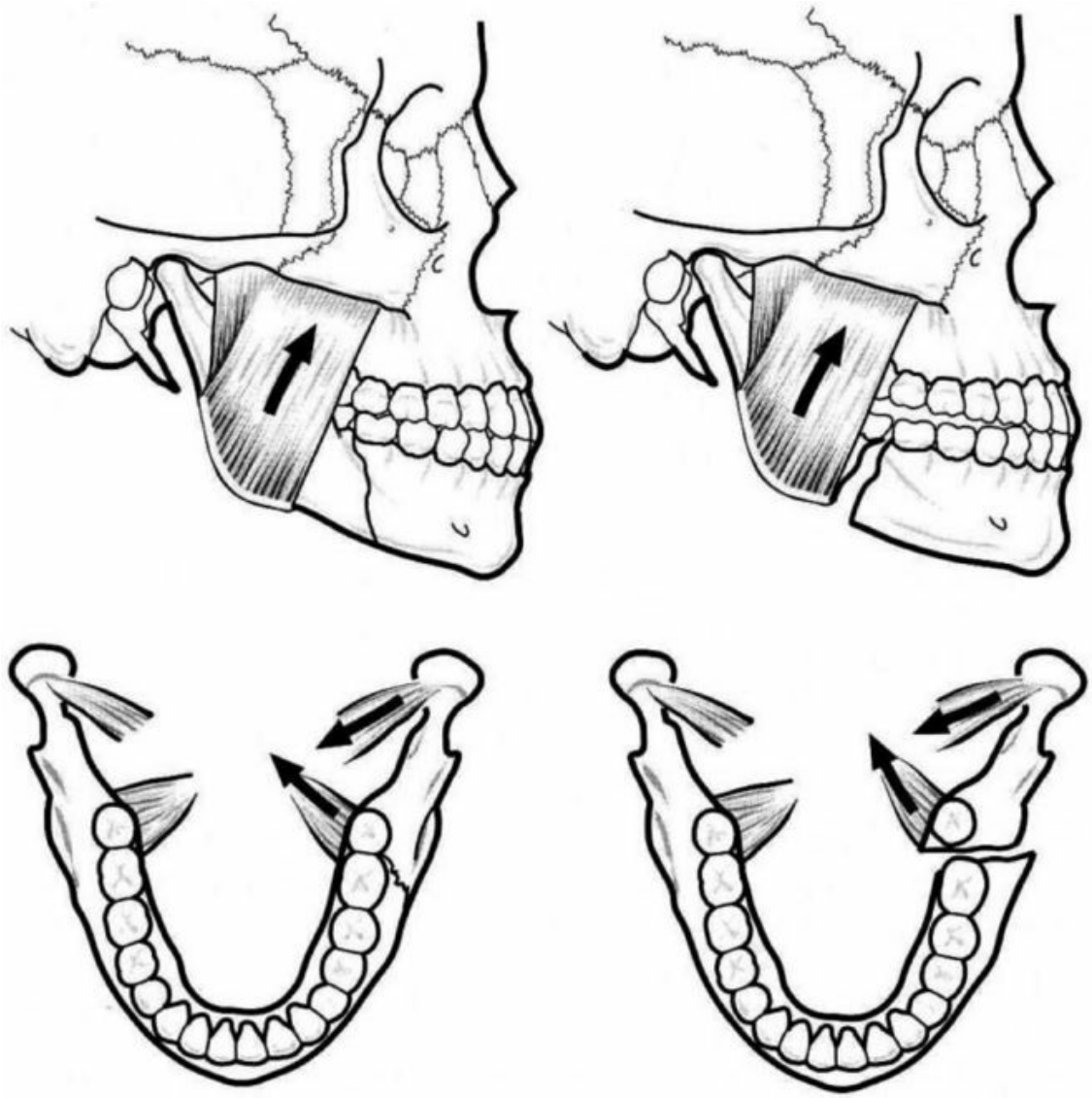

Figure 33.11. Favorable versus unfavorable mandible fractures. Favorable mandibular fractures (**left**), do not necessarily need to be plated as muscle pull impacts the fracture. In unfavorable fractures (**right**), muscle pull distracts the fracture. Rigid fixation is thus required. (From Booth PW, Schendel SA, Hausamen JE. *Maxillofacial Surgery,* 2nd ed. 2007;Vol. 1:38. Copyright © 2007 Elsevier.)

Another area mentioned in the earlier portions of this chapter was the frontal bone and its location in the upper third of the facial skeleton. It is important to recognize that injuries to the frontal bone, by definition, imply high velocity or high energy impact and should alert the surgeon to intracranial injury, cervical spine injury, and even occult carotid artery

injury that must be evaluated with CT scan evaluation of the brain, cervical spine, and even CT angiogram of the neck into the cranial base. Frontal bone injuries, also usually manifest as injuries to the anterior portion, posterior portion, or in combination. These are more frequently referred to as the anterior and posterior tables. While isolated frontal table injures can sometimes be managed nonoperatively, they can lead to significant deformities and secondary cosmetically undesirable sequelae. More importantly, frontal bone fractures, with concomitant frontal sinus involvement are a more serious and complicated matter that can lead to CSF rhinorrhea, frontal sinus mucoceles, and even meningitis depending on the amount of posterior table involvement. A general rule is that if the posterior table fracture depth of involvement exceeds the thickness of the posterior table then operative management should be considered and frequently becomes necessary. Approaches to the frontal bone can be direct, especially if an existing frontal skin laceration can be used, or via a bicoronal incision hidden in the hairline so that complete access to the frontal cranium as well as superior orbits is available for definitive surgical management. Again, it is beyond the scope of this chapter to discuss this in further detail but the selected readings by Rodriguez et al. provide a comprehensive and excellent overview of the matter.

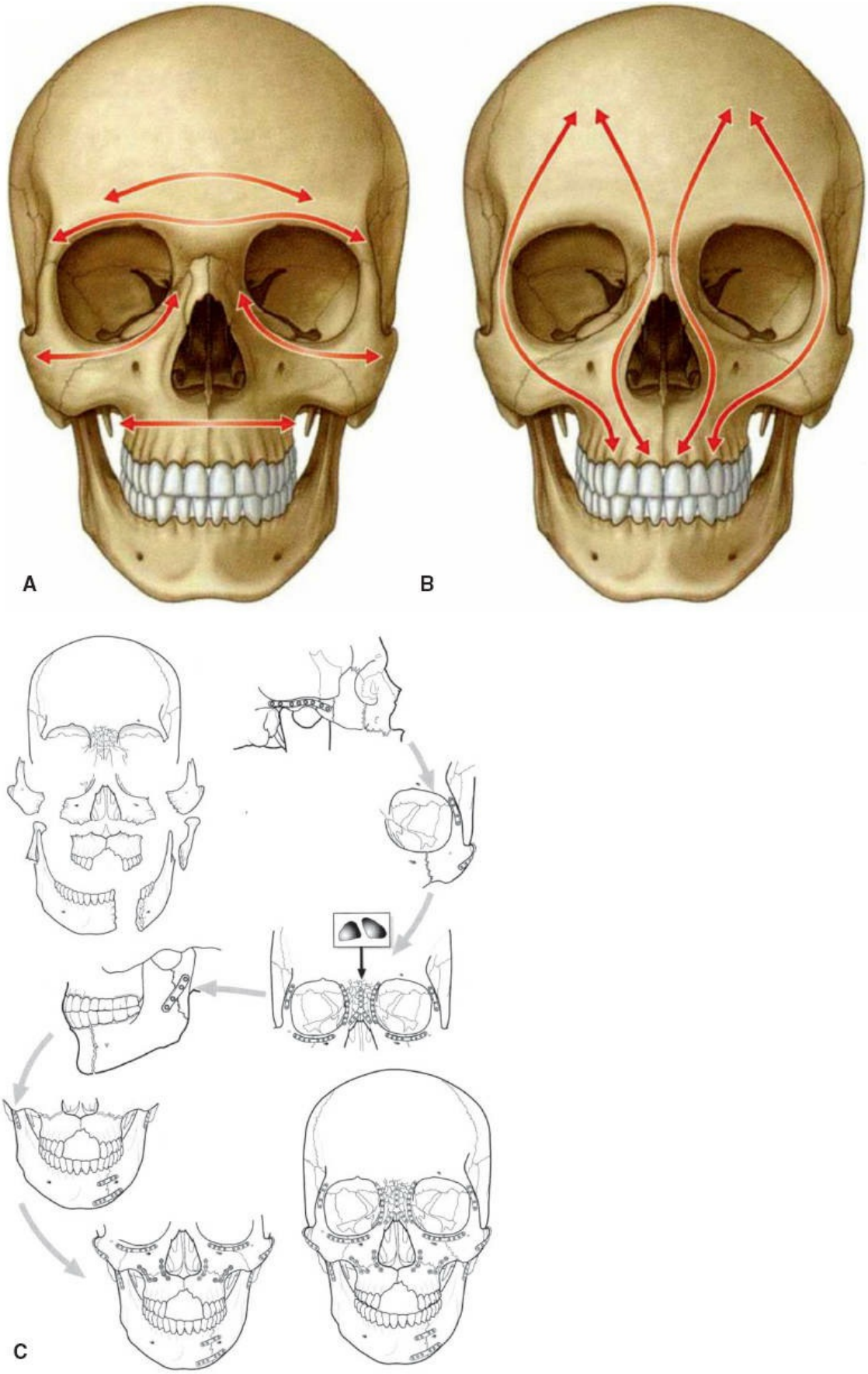

Figure 33.12. Approach to panfacial fracture management using

reconstruction of the horizontal and vertical buttresses as guiding principle. The horizontal (**A**) and vertical (**B**) facial buttresses are the support pillars of the face and overlying soft tissues. Disrupted buttresses must be reduced and reconstructed to optimize results. Nondisrupted buttresses adjacent to fracture sites serve as anchor points for fixation hardware. **C.** In panfacial fractures, buttresses are sequentially reconstructed by dividing the face into upper and lower units. Once reconstruction is complete in each unit, the two units are combined to complete reconstruction. (From Guyuron B, Eriksson E, Persing JA. *Plastic Surgery: Indications and Practice.* 2009;Vol. 1:633. Copyright © 2009 Elsevier and Booth PW, Schendel SA, Hausamen JE. *Maxillofacial Surgery.* 2nd ed. 2007;Vol. 1:38. Copyright © 2007 Elsevier.)

A final discussion about an uncommon, yet devastating, constellation of fractures is the involvement of all of the facial thirds that were defined earlier. This constellation is referred to as a “panfacial” fracture pattern. As mentioned in the frontal bone fracture section, the same high velocity and high energy impact concerns apply, even more so, in panfacial fracture patterns. This constellation is also seen in high-velocity gunshot wounds, many of which by mechanism are of the self-inflicted type. The best way to think about these injuries is a sum total of all the injury and fracture patterns discussed thus far. These types of fracture patterns are extraordinarily difficult and complicated to treat, even in skilled hands. However, it is important to recognize that the principles and fundamentals set forth thus far allow one to tackle such problems with expectations for restoring facial form, function, and appearance in a confident and high level of fidelity manner. In my personal training and, in fact, my preference is to treat panfacial fractures starting from the mandible and working my way cephalad. Using a “skull base up” approach has been a very well-described and consistent way in which panfacial fracture patterns can be dealt with appropriately and thoroughly. In such instances, subspecialty involvement is mandatory and it is frequently the case that such patients will require tracheostomy airway management and enteral access via percutaneous or open gastric tube placement as part of their immediate and postoperative course in their injury treatment.

POSTOPERATIVE MANAGEMENT

As was previously mentioned, cleansing and preparation of the wounds

commonly encountered in facial injuries was one of the important first steps in management of these patients. It needs to be reaffirmed as the completion of this chapter nears, that this is equally important in the postoperative management phase as well. In general, skin suture lines should be gently cared for on a daily basis for the first 2 to 3 days after operative intervention. Again, a half strength mixture of warm saline and hydrogen peroxide works well. Intraoral care typically involves 5 to 7 days of prescription strength oral mouth rinse and minimal instrumentation in the mouth with things like a toothbrush to allow for mucosal healing. Being observant of fluid collection or hematoma formation is also critical as these can be intervened upon easily and usually definitively if diagnosed early. Useful interventions such as head of bed elevation and cool compresses on the face facilitate edema management and resolution. Recommendations about return to activities of daily living, exercise, and recreational or contact sports are highly patient specific and individualized. I, in my own practice, have been very conservative about when I allow clearance for such activities as it makes little sense to not wait a reasonably requisite amount of time to allow the healing process to take its due course. Therefore, waiting days to weeks to even months to allow patients to resume normal activities should be a decision left to the surgeons' discretion and one that should never be hurried.

A discussion about the sequelae of facial injury apart from the many considerations already discussed would not be complete with focusing on something that many patients point out and have concerns about; namely, scarring. What we do know about the healing response and the maturation of scars is well described and frankly familiar territory, at least in the expectation we, as treating surgeons, have. Patients, understandably so, have constant reminders from their scars about the events surrounding the injuries they have suffered and anything that can be done to ameliorate or even "erase" those scars is welcome advice. I firmly believe that we do not do enough to provide counsel and assistance with this part of the postoperative management care spectrum. There are many well-described, well-documented studies that not only discuss topical treatment of scars, from high-quality topical Vitamin C or Vitamin A therapies, to facilitate their optimal maturation and healing but there is excellent, recent evidence that laser therapy of posttraumatic or hypertrophic/contracted scars is a present state-of-the art modality that is underutilized and underappreciated. In fact, for those surgeons who utilize lasers as part of their practice,

myself included, we now find very few indications, if any, for actual traditional surgical “revision” of scars. Scar revision is an oxymoron. Scars are dynamic entities not static ones, which can be stimulated and intervened upon to remodel and regenerate into a much more favorable and functionally and aesthetically pleasing state. Interventions such as z-plasties also facilitate scar improvement without the need of excising scars, rather rearranging them and releasing tension to allow more favorable conditions for ideal maturation. I have personally found lasers (of the pulsed dye and fractionated CO_2 variety) to be indispensable in my practice as it relates to traumatic and burn facial scar management. In the selected readings section, there is an excellent position paper by Anderson et al. on laser treatment of traumatic scars and should be required reading for our interns and residents in general surgical training. A paradigm shift is necessary in how we think about scars and the modalities we can offer patients today in facilitating ideal management and treatment.

CONCLUSIONS

The principles and fundamentals discussed in this chapter as it relates to evaluation and repair of common facial injuries should enable the broadly trained general or trauma surgeon to confidently and effectively manage many of the facial injuries described herein. Certainly, recommendations have been provided for instances in which subspecialty consultation is necessary and appropriate and it is my hope that the reader will understand that management of the facial injury patient is truly a team effort and facilitated certainly by the “quarterbacking” of a broadly trained and well-versed general or trauma surgeon with a fundamental, yet broad, knowledge base that will optimize patient triage, evaluation, and decision making in management and treatment. Working in a cooperative fashion and in a multidisciplinary environment will optimize outcomes for the patients we are so privileged to care for.

Suggested Readings

Anderson RR, Donelan MB, Hivnor C, et al. Laser treatment of traumatic scars with an emphasis on ablative fractional laser resurfacing: consensus report. *JAMA Dermatol* 2014;150(2):187–93.

Diaz-Siso JR, Rodriguez ED. Facial transplantation: knowledge arrives, questions remain. *Lancet* 2016;388(100052):1355–6.

Ellis E 3rd. An algorithm for the treatment of isolated zygomatico-orbital fractures. *J Oral Maxillofac Surg* 2014;72(10):1975–83.

Ellis E 3rd. Surgical approaches to the orbit in primary and secondary reconstruction. *Facial Plast Surg* 2014;30(5):537–44.

Fischer JE. On the uniqueness of surgery: William H. Harridge memorial lecture. *Am J Surg* 2005;189(3):259–63.

He D, Zhang Y, Ellis E 3rd. Panfacial fractures: analysis of 33 cases treated late. *J Oral Maxillofac Surg* 2007;65(12):2459–65.

Manson PN. Fractures of the zygoma. In: Booth PW, Schendel SA, Hausamen JE. *Maxillofacial Surgery,* 2nd ed. St. Louis, MO: Churchill Livingston Elsevier; 2007:120–54.

Manson P. Facial injuries. In: Mathes SJ. *Plastic Surgery,* 2nd ed. Philadelphia, PA: Elsevier, Inc. 2006.

Manson P, Clark N, Robertson B, et al. Subunit principles in midface fractures: the importance of sagittal buttresses, soft tissue reductions and sequencing treatment of segmental fractures. *Plast Reconstr Surg* 1999;103(4):1287–306.

Markovitz BL, Mandon PN, Sargent L, et al. Management of the medial canthal tendon in nasoethmoid orbital fractures: the importance of the central fragment in classification and treatment. *Plast Reconstr Surg* 1991;87(5):843–53.

Rodriguez ED, Stanwix MG, Nam AJ, et al. Twenty-six-year experience treating frontal sinus fractures: a novel algorithm based on anatomical fracture pattern and failure of conventional techniques. *Plast Reconstr Surg* 2008;122(6):1850–66.

Susarla SM, Bojovic B. Acute intraorbital hemorrhage following reduction of a displaced orbitozygomaticomaxillary complex fracture. *Craniomaxillofac Trauma Reconstr* 2015;8(3):221–7.

Zide BM, Swift R. How to block and tackle the face. *Plast Reconstr Surg* 1998;101(3):840–51.

EDITOR'S COMMENT

Facial injuries can result from a myriad of different mechanisms and result in many different combinations of injury. As the face plays the most important roll of our interaction with the outside world it is essential to restore both form and function. While the majority of more advanced facial trauma will require management by a surgical specialist (e.g., plastic, oromaxillofacial, or otorhinolaryngologic surgery), general and trauma surgeons play a key role in the management of facial trauma as they are the first-line providers responsible for the initial evaluation and management.

The initial management of patients with facial injuries needs to follow ATLS

and BLS guidelines. It is essential that airway be adequately assessed and secured if necessary in these patients. Complex and devastating facial injuries may make it difficult to secure the airway, and the general surgeon needs to be prepared to create a surgical airway in a moment's notice. One circumstance in which orotracheal intubation may actually be easier is in the self-inflicted shotgun blast patient. Often times the mandible and soft tissues of the oral cavity have been obliterated such that the posterior oropharynx is in full view. Once an airway has been established it is important to efficiently progress to the primary and secondary surveys. A methodical approach to assessment of the craniofacial skeleton, sensory and motor nerves, and soft tissues is key to avoid missing any injuries. In the obtunded patient examination of the extraocular eye muscles is not possible. As such it is recommended that all patients undergo a forced duction test to assess for entrapment of the extraocular eye muscles. Dr. Bojovic is accurate in stating that significant blood loss can occur from the scalp and oropharynx injuries and this needs to be recognized during the initial work-up. Rapid stapled closure of scalp lacerations can be achieved to stop ongoing blood loss.

CT examination of the maxillofacial skeleton is the gold standard for assessing bony injuries, and 3D CT reconstructions are essential with more complex facial fracture patterns. In the current era of cost containment it will be important to demonstrate that the use of 3D CT reconstructions reduces operating room times to offset the increased costs associated with obtaining these images. Regarding injection of local anesthetic, I also favor the use of directed nerve blocks to avoid distorting the normal facial landmarks, particularly in the perioral and periorbital regions. However, I would disagree with Dr. Bojovic in regards to the use of a buffering agent to reduce the pain with local anesthetic. The use of a buffering agent in my experience, as well as others (Welch MN, Czyz CN, Kalwerisky K, et al. Double-blind, bilateral pain comparison with simultaneous injection of 2% lidocaine versus buffered 2% lidocaine for periocular anesthesia. *Ophthalmology* 2012;119(10):2048–52), results in much less pain when compared to unbuffered local anesthetic.

Once an operative plan is developed it is important to get the patient into the operating room as soon as the patient is adequately resuscitated and all life-threatening injuries have been addressed. There are times when the patient is not stable enough to undergo transport to the operating room, which is problematic in the setting of gross contamination. In this circumstance, a thorough washout in an ICU setting under sedation should be performed.

I agree with Dr. Bojovic that adequate surgical debridement is of the upmost importance in achieving optimal functional and aesthetic outcomes. It is important that marginal soft tissues be given time to declare themselves rather than undergoing early debridement, as tissues that originally look marginal may completely recover. Excessive debridement, particular in areas with limited skin and soft tissues (e.g., nose, ears, eyelids), can have devastating functional and aesthetic results.

After adequate debridement soft tissue closure via appropriate techniques should be performed. In the pediatric population I prefer to use tissue adhesives (e.g., Dermabond) in repair of superficial lacerations as it may avoid the need for sedation in the pediatric patients with similar aesthetic outcomes to standard suture techniques (Farion K, Osmond MH, Hartling L, et al. Tissue adhesives for traumatic lacerations in children and adults. *Cochrane Database Syst Rev* 2002;(3):CD003326). Layered wound closure is reserved for deeper injuries. One note I would add to Dr. Bojovic's comments is that in closing intraoral lacerations it is essential to obtain a watertight closure, which prevents drainage of intraoral secretions that can break down subcutaneous tissues and lead to wound-healing complications.

Once stable soft tissue coverage is achieved fracture fixation and nerve repair can be performed. It is important to remember that in patients with an injury to the facial nerve that nerve repair needs to be performed within 72 hours of injury. After this time point the distal end of the nerve will not be able to be activated with the nerve stimulator due to degeneration of the motor end plates, which can make it very difficult to find the nerve for repair. Although acute nerve repair should be performed whenever possible delayed nerve repair can be attempted up to the point at which the motor end plates atrophy, which is typically around 18 months.

I agree with Dr. Bojovic's assessment that drainage of a hematoma in the ear and nasal septum should be performed as soon as the patient is hemodynamically stable. Saddle nose deformity is a devastating occurrence in unrecognized or untreated septal hematomas, which requires extensive reconstructive surgery to correct. When draining an ear hematoma my preference is to use xeroform bolsters and through and through nylon sutures to ensure direct approximation of the overlying skin to the underlying cartilage. Particular attention should be paid reestablishing the triangular fossa, the concha symba and concha cavum.

I am in agreement with Dr. Bojovic regarding high-energy wounds to the face. These are some of the most challenging wounds to address and require multiple trips to the operating room for debridement and assessment of the tissues. Once all wounds have been debrided and the defects defined one can then proceed with a clear plan in place. Fracture fixation, soft tissue reconstruction, and free tissue transfer are all aspects that may need to be utilized in this patient population.

Injuries to the eyelid and soft tissues of the orbit should in almost all instances be managed by a specialist comfortable in the anatomy in this region. Dr. Bojovic's comments about the use of a noncutting needle I would echo. Cutting needles tend to create additional tissue damage as well as lead to the possibility of bleeding from the wound edges. Debridement of precious auricular cartilage should be limited in most circumstances. Precise repair of both cartilage and the soft tissue envelope will result in the most aesthetic outcome.

Dr. Bojovic has done an excellent review of the management of facial fractures. His goals for management give the reader a stepwise manner in which to evaluate any facial fracture. The importance of accurate fracture reduction cannot be understated. Accurate fracture fixation provides the base upon which the soft tissues are draped and provides the form and function of the human face. Inaccurate fracture fixation can lead to abnormal human facies, and repairing inappropriately reduced facial fractures in a delayed fashion is challenging and results in increased complication rates.

To this end I would disagree with Dr. Bojovic that the OZMC fracture can be effectively addressed via an oral incision only. If these fractures are displaced then it is mandatory that the zygomaticosphenoid (ZS) suture be accurately aligned, which will ensure the remainder of the tetrapod in the appropriate anatomic alignment. Fracture fixation can then proceed in a manner moving top down (zygomaticofrontal → orbital rim → lateral buttress) (Birgfeld CB, Mundinger GS, Gruss JS, et al. Evidence-based medicine: Evaluation and treatment of zygoma fractures. *Plast Reconstr Surg* 2017;139(1):168e–180e). Soft tissue suspension should be paid particular attention in order to achieve the optimal aesthetic result with any fracture repair technique.

In managing pediatric orbital floor fractures one must remember that in children the orbital floor bone has much more pliability and that the fracture may “greenstick” resulting in entrapment of the rectus muscle with nondisplaced fractures on imaging. In this patient population it is of the upmost importance to have an accurate assessment of the patient’s extraocular eye muscle movement as missed entrapment can lead to permanent injury.

With regard to mandible injuries it is imperative that the cervical spine is cleared both clinically and radiographically as the incidence of cervical spine injury is 5% with isolated mandible fractures (Mulligan RP, Mahabir RC. The prevalence of cervical spine injury, head injury, or both with isolated and multiple craniomaxillofacial fractures. *Plast Reconstr Surg* 2010;126(5):1647–51). Manipulation of the cervical spine must be avoided in these patients and neurosurgical clearance should be obtained before proceeding to surgical repair. In the management of the pan facial fracture that fracture fixation should proceed from stable to unstable. If the mandible is stable or a simple fracture starting from the mandible and proceeding cranially is the best way to proceed.

Dr. Bojovic has performed an excellent review of the key elements in the evaluation and management of facial injuries, and he should be commended for making this complex subject matter digestible for all surgeons.

Ryan Gobble

34 Resection and Reconstruction of the Trachea

Natalie Lui, Harald C. Ott, and Douglas J. Mathisen

INTRODUCTION

Etiology

Tracheal resection is a relatively uncommon operation. The most common indication for surgical resection is tracheal stenosis resulting as a complication of prolonged intubation or as a consequence of tracheostomy. The injury from intubation results from an overinflated endotracheal cuff causing excessive pressure on the trachea and reducing blood supply. The ischemic injury can be mucosal or full thickness of the airway depending on the severity. Tracheostomy stomal injuries occur as a result of excessive damage of the trachea from technique, excessive traction on the tracheostomy tube or infection.

Symptoms

Patients with tracheal stenosis present with symptoms of shortness of breath of varying degrees. The degree of shortness of breath depends upon the diameter of the stenosis. Slow growing tumors may have an insidious onset with shortness of breath only noticed with extremes of exertion. Over time this progresses to symptoms at rest and frank stridor. Postintubation injuries usually present within days to weeks after extubation or decannulation. Recently extubated or decannulated patients who present with shortness of breath should be suspected of tracheal stenosis.

Those initially treating patients with tracheal stenosis are responsible for diagnosis, initial management and stabilizing the airway. In the nonemergent airway computerized axial, sagittal and coronal views of the trachea should establish the diagnosis in most patients. Initial management should include humidified oxygen and elevation of the head of the bed. Heliox administration can be effective in some patients who remain symptomatic. When a more urgent situation exists, it is best to secure the

airway in the operating room. Control of the airway can be achieved by balloon dilation of structures or dilation with bougies and rigid bronchoscopes. If a tumor exists, debridement may be required to establish a safe airway. Tracheostomy is a last resort. Care must be taken to place it in the proper position. Ideally through the damaged stenotic segment after dilation has been successfully achieved. This is to allow the most trachea for subsequent reconstruction. Ideally a thoracic surgeon is best suited to control the airway in a combination of anesthesiologists, pulmonologists, and general surgeons. Once stabilized, the patient should be transferred to a facility to deal with the problem.

INDICATIONS

The indications for tracheal reconstructive operations are (a) primary tumors, principally adenoid cystic and squamous cell carcinoma, and a wide variety of malignant, low-grade malignant, and benign tumors; and (b) secondary tumors, primarily thyroid carcinoma, bronchogenic, and, rarely, esophageal carcinoma. Benign conditions include (c) postintubation lesions, including cuff and stomal stenosis, tracheomalacia, tracheoesophageal fistula (TEF), and brachiocephalic arterial fistula, plus proximal stenosis including the subglottic larynx; and (d) stenosis of many causes, including trauma, prior surgery, tuberculosis, amyloidosis, relapsing polychondritis, congenital malformation, mediastinal fibrosis, idiopathic stenosis, and Wegener granulomatosis.

PREOPERATIVE PLANNING

Simple posteroanterior and lateral x-rays of the neck are satisfactory for seeing proximal lesions. The entire airway can be imaged with computed tomography (CT) and 3D reconstruction. Sagittal, coronal, and axial images are quite helpful in assessing the airway and are becoming the norm. CT adds data about potential mediastinal invasion by tumors. Knowing the extent of the uninvolved airway left for reconstruction is as important as defining the lesion itself.

Bronchoscopy is essential but can be performed at resection unless the problem is unusually complicated. When laryngeal abnormality is suspected, the examination is often carried out concurrently with an otolaryngologist. Rigid bronchoscopy with general anesthesia provides better visualization of anatomy, superior biopsy specimens, and the potential for airway management and improvement through maneuvers

such as dilatation or coring out of obstructive tumors. Furthermore, measurements that can be used in planning an operative procedure can be made using the rigid bronchoscope. These measurements are the distance from the carina to the bottom of the lesion, the length of the lesion, and distance from the top of the lesion to the vocal cords. The quality of mucosal inflammation can also be assessed. Care must be exercised in the outpatient setting when using flexible bronchoscopy to evaluate tracheal stenosis because of the possibility of precipitating airway obstruction.

Emergency tracheal resection is rarely performed. Critical obstruction can be relieved by dilatation of benign stenosis under anesthesia using rigid pediatric bronchoscopes and dilators. Tracheal obstruction by neoplasm requires removal of tissue via the rigid bronchoscope and biopsy forceps. An internal stent or T tube can also provide relief. Laser techniques have little use in the management of carcinoma except to debride tumor and relieve obstruction. Once the acute obstruction is relieved, careful diagnostic studies and examinations can be performed.

Patients must be in optimal preoperative condition to ensure a successful operation and recovery. Patients with postobstructive pneumonia or active mucosal inflammation, or those receiving high-dose steroids should undergo dilatation, and the condition should be allowed to improve. Repeated dilatations may be necessary in some circumstances. The need for mechanical ventilatory support would constitute a contraindication to resection. If the decision is made that a tracheostomy tube or T tube must be inserted to control the airway, placing the tube through the most damaged portion of the tracheal stenosis is mandatory to preserve the maximal amount of normal trachea for subsequent reconstruction.

ANESTHESIA

The maintenance of anesthesia can be achieved either with inhalational agents or with total intravenous anesthesia. Inhalational anesthesia in tracheal surgery is limited by the open airway during the procedure and periods when no anesthesia can be delivered. With total intravenous anesthesia, ventilation and anesthesia are uncoupled and there is the continuous delivery of anesthetic agents making it well suited for airway resections. This has become our preferred technique.

Prolonged paralysis of respiration is avoided because the desire is that the patient resume spontaneous respiration postoperatively without the

need for ventilatory support. After the trachea has been divided by either the anterior or intrathoracic approach, a sterile, flexible endotracheal tube with attached connecting tubing is introduced into the distal trachea for maintenance of ventilation. In carinal resections, ventilation is usually maintained through the opposite (usually the left) lung after the resection of the carina. With experience, the use of such tubes is not cumbersome. The alternative of high-frequency jet ventilation through a catheter works well and is used preferentially in special instances. Extracorporeal membrane oxygenation (ECMO) or cardiopulmonary bypass can be used for complicated carinal operations, but extensive manipulation of the lung while heparinized can lead to intrapulmonary hemorrhage and must be considered.

SURGICAL TECHNIQUE

Basic Principles

Although not all problems have been solved, standard and reliable methods for resection and reconstruction of the trachea have been developed. Because few patients with lesions requiring such operations are likely to be seen by one thoracic surgeon, close attention must be paid to basic principles and the special techniques of this type of operation. The rates of failure and complications in tracheal surgery remain unacceptably high when surgeons who only occasionally operate on the airway perform these operations.

Close attention to the basic principles of tracheal reconstruction will avoid many serious complications.

1. The trachea that is to remain must remain well vascularized. Extensive circumferential dissection of the trachea should not extend beyond the level of the resection. Preferably, no more than 1 cm of trachea should be circumferentially freed from lateral attachments beyond the line of resection.
2. Approximation must be performed without excessive tension. Levels of tension in grams beyond which dehiscence can be expected to occur have been measured precisely in the laboratory. Skilled surgeons, however, know whether they are attempting to pull the ends of the trachea together under excessive tension. Surgeons operating on the trachea must be familiar with all available techniques for mobilization of the trachea to lessen tension. They must also make a mature judgment in advance of resection as to whether sufficient trachea will

be left to construct a safe anastomosis.

3. Precise anastomotic technique is required. Lines of resection should be cut cleanly. Fine absorbable suture material must be used. We use 4-0 polyglycolic acid polymer (Vicryl, Ethicon, Inc., Piscataway, NJ) suture for all anastomoses in adults, and 5-0 polyglycolic acid polymer in small children. Stay sutures are 2-0 polyglycolic acid polymer and are usually left in place after tying to reduce anastomotic tension. All sutures are oiled to promote sliding of the suture through tissues.
4. A second layer of tissue coverage is required of all intrathoracic anastomoses, especially after carinal resection when the pulmonary artery is adjacent. The anastomosis should be airtight when tested under saline before coverage with a pedicled tissue flap.
5. The airway reconstruction should function satisfactorily at the conclusion of the operation. Internal stenting or protection by tracheostomy above, below, or through the anastomosis should not be required. If the anastomosis is not adequate at the conclusion of the operation, it is not likely to improve with time, with the exception of edema. If edema is suspected, a small, uncuffed endotracheal tube should be left in place for 48 hours. The patient should be given steroids for 24 hours, kept upright in bed, lasix, and fluid restricted to reduce edema. After 48 hours, the patient is returned to the operating room and extubation is attempted. If the patient is still stridorous, a small tracheostomy tube is placed two rings below the anastomosis and a pedicled strap muscle flap is placed over the anastomosis to protect it. Another exception is the traumatically divided cervical trachea in which both recurrent laryngeal nerves have been made dysfunctional and the glottic aperture is inadequate. In this case, a tracheostomy placed below the anastomosis is necessary. This will provide an adequate airway until the vocal cords recover function or further interventions are performed.

Anterior Approach

The anterior approach to the trachea is used for most benign strictures, even at the supracarinal level, and also for tumors of the upper and middle trachea. The patient is positioned supine with an inflatable thyroid bag beneath the shoulders, which allows for easy neck flexion during the case. The knee and hips are flexed to position the neck for the surgeon. A low collar incision is used and the upper flap is elevated to a point above the cricoid cartilage if no laryngeal involvement is present (Fig. 34.1). The

lower flap is carried to the sternal notch. The anterior surface of the trachea is exposed. The dissection may be difficult and tedious in postintubation stricture with prior or existing tracheostomies, or when prior operative procedures have been performed. The strap muscles are elevated. The thyroid isthmus is dissected away from the trachea, divided, and retracted laterally with sutures. An important principle is to keep dissection close to the trachea so that the operator does not injure the recurrent laryngeal nerves while working laterally around the area of disease, where scar tissue and inflammation are maximal. No effort is made to expose the nerves in instances of inflammation as this would likely lead to their injury. Circumferential dissection is carried only a short distance above and below the lesion to preserve the lateral blood supply of the proximal and distal trachea. The anterior surface of the trachea is freed bluntly as far as the carina to provide mobility.

With tumors, the dissection is not carried as close to the trachea as it is for other lesions. When the operation is for carcinoma, the recurrent laryngeal nerves are identified distal to the lesion and followed to the area around the lesion to provide a greater margin around the tumor. If the nerve is involved, it must be sacrificed, although at least one recurrent nerve should be preserved. Adjacent tissue occasionally has to be resected with the specimen to provide adequate margins. This may include a lobe of the thyroid gland or part of the esophageal wall. Adjacent lymph nodes should be removed with the specimen, but an extensive mediastinal node dissection cannot be performed without possible injury to the blood supply of the residual trachea.

With an upper tracheal lesion, it is important to identify the lesion. This can be obvious but if doubt exists the oral endotracheal tube should be pulled back, flexible bronchoscope inserted, the lesion identified by placing a needle through the suspected location and marked with a suture. I prefer to open the airway through the lesion so as not to sacrifice any usable trachea.

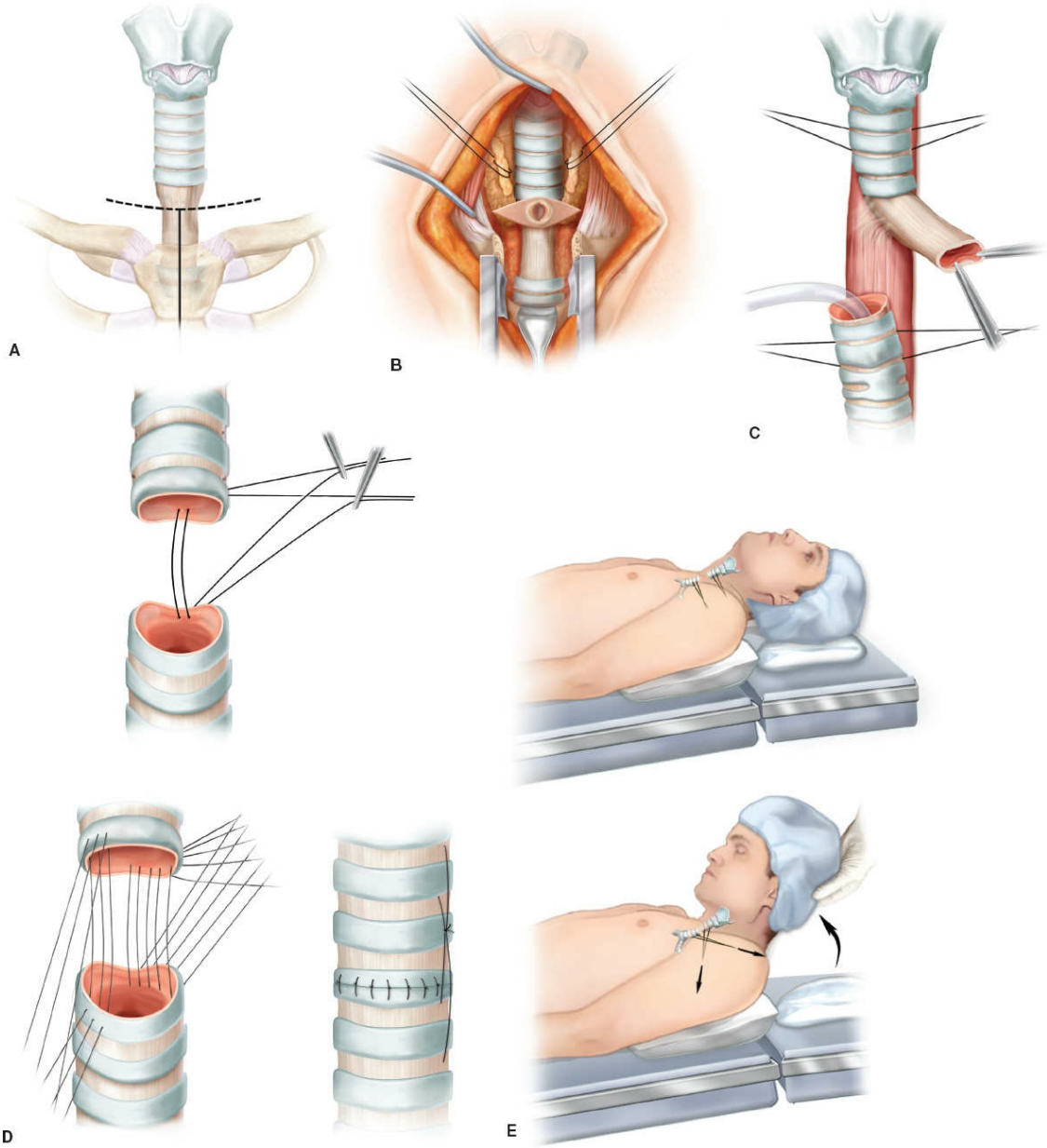

Figure 34.1. Reconstruction of the upper trachea. **A.** Collar incision and extension for upper sternotomy. Essentially, all benign strictures and upper tracheal neoplasms can be most easily resected through this approach. **B.** Dissection is carried anteriorly to the level of the carina. Nothing is gained by dividing the brachiocephalic vein. The brachiocephalic artery can be gently retracted downward. **C.** Circumferential dissection has been carried out only immediately beneath the lower-most level of the lesion, and the trachea has been divided. Traction sutures are in place and the patient has been intubated distally. The lesion is being retracted upward to facilitate dissection from the underlying esophagus. **D.** Details of anastomotic technique. The sutures are placed beginning posteriorly and working anteriorly. All the sutures are placed before the endotracheal tube is

advanced from above into the distal trachea. All the knots are on the outside. The diagram must be recognized as not indicating the complete circumferential dissection of the lengths of trachea shown. **E.** A greater amount of approximation is obtained by cervical flexion rather than upward traction on the carina in the anterior approach. (From Mathisen DJ, Morse C. *Master Techniques in Surgery: Thoracic Surgery: Transplantation, Tracheal Resections, Mediastinal Tumors, Extended Thoracic Resections.* 2014; Wolters Kluwer.)

Traction sutures (2-0 polyglycolic acid polymer [Vicryl]) are placed at the midlateral position of the trachea on both sides through the full thickness of the tracheal wall and at least 1 cm below the projected level of division. The trachea is divided and the oral endotracheal tube is withdrawn above the lesion. The distal trachea is intubated across the operative field with a flexible endotracheal tube and sterile anesthesia tubing. An assistant holds this tube in position by arrangement of the lateral traction sutures, which can be drawn on to pull the distal trachea away from the field of dissection. The specimen is grasped with forceps and elevated, which makes the dissection of benign stenosis from the esophagus much easier. It also gives access to tumors that have posterior extension. If the esophageal wall is involved, either the muscular portion can be resected or the muscular and mucosal layers removed. The esophageal wall is then closed with two layers of interrupted sutures. The narrowed esophagus can be dilated later, although it frequently dilates itself with the passage of food.

Lateral traction sutures are placed on either side of the trachea proximal to the level of the upper resection, and the specimen is removed. With upper tracheal stenoses or tumors, this means the lateral traction sutures are frequently placed in the substance of the cricoid. If the tracheal division is very high, a catheter is usually sutured to the end of the endotracheal tube so that it can be withdrawn out of the larynx to remove it from the field. The catheter remains as an aid for replacement of the endotracheal tube later in the operation.

In low lesions, division of the trachea is usually done as previously described. When the specimen has been fully dissected, distal traction sutures are placed and the specimen is divided inferiorly. If the lesion is a tight stenosis, it is dilated under direct vision after the trachea has been divided superiorly, and the endotracheal tube is placed through the

stenosis.

The surgeon and the assistant now pull the lateral traction sutures together on either side while the anesthetist flexes the patient's neck. This maneuver determines whether the ends can be approximated without excessive tension. If the ends can be approximated, the neck is allowed to fall back into extension and the anastomosis is begun. If the tension is excessive, a suprahyoid laryngeal release is performed. Although the skin flap can be elevated to the level of the hyoid bone, we find it more cosmetic and convenient to make a second transverse incision directly over the hyoid bone to perform the suprahyoid release. We have noted fewer early postoperative difficulties with deglutition and aspiration when this procedure is chosen in preference to the thyrohyoid release. After completion of the release, the upper incision should be closed with appropriate drainage because it becomes inaccessible when the neck is flexed later.

Anastomosis is performed with interrupted 4-0 polyglycolic acid polymer sutures placed approximately 3 to 4 mm back from the cut edge of the trachea and approximately 3 to 4 mm distant from each other. The sutures are placed so the knots can be tied outside the lumen. We prefer to place all the sutures before completing the anastomosis. We begin with the most posterior suture in the membranous wall in the midline, placing each successive suture until the lateral traction suture is reached on that side. This step is repeated on the opposite side to the level of the opposite lateral traction suture. The sutures are individually clipped with a hemostat, and further clipped to the drapes with a second hemostat in an orderly manner. The most posterior suture is clipped cephalad and each successive one follows. Care must be taken not to confuse the placement of the sutures. The sutures anterior to the lateral traction sutures are placed next, and these are fanned out on the operative drapes over the chest.

The divided distal trachea is suctioned frequently to prevent blood from seeping past the occluding cuff, which increases the risk of postoperative atelectasis and the need for ventilation. After all the sutures are placed, the tracheobronchial tree is suctioned thoroughly, the distal endotracheal tube is removed, and the endotracheal tube from above is passed into the distal trachea. The patient's neck is flexed and supported by blankets beneath the head. Next, the surgeon and the assistant tie the lateral traction sutures simultaneously so that the ends of the trachea are approximated. This permits the anastomotic sutures to be tied without tension.

The sutures are tied in the opposite order in which they are placed, with the anterior sutures between the two lateral traction sutures being tied first. The excess of each suture is cut after tying. As the assistant gently pulls one lateral traction suture to one side, the surgeon proceeds to tie the sutures posterior to the traction sutures down to the posterior midline in order. Again, each suture is cut after being tied. This procedure is repeated on the opposite side. The anastomosis is now complete. It can be tested for adequacy under saline solution. If the anastomosis is distal to the occluding cuff, the anesthetist can provide 30 cm of pressure to test the anastomosis. If the anastomosis is proximal, the airway cannot easily be occluded, and instead, the cuff of the endotracheal tube is deflated and the anesthetist provides 30 cm of pressure. Gas escapes through the larynx, but at that pressure the anastomosis should demonstrate an air leak under saline solution if there is a problem. The anastomosis should be airtight.

We leave the traction sutures in place even though they penetrate the wall of the trachea. We have observed no difficulty with absorbable sutures. The thyroid isthmus can be reapproximated and the strap muscles sutured over the trachea. A second layer is preferable over the cervical and mediastinal tracheal anastomosis to protect the anastomosis and provide coverage if superficial infection develops. If the brachiocephalic artery lies directly over the anastomosis, viable tissue must be interposed. We avoid exposing the artery and attempt to dissect on the surface of the trachea rather than on the surface of the artery. In reoperations in which the artery is necessarily exposed, or in tumors in which the arterial surface has been exposed, one of the strap muscles is sutured between the two structures.

Transthoracic Approach

The transthoracic approach is used for tumors of the lower trachea and carina (Fig. 34.2). We prefer a posterolateral right thoracotomy, entering the chest through the fourth interspace. The azygos vein is divided, the pleura is opened, and the trachea is exposed. The vagus nerve is divided as it crosses obliquely over the trachea. If the dissection is carried high in the chest, care must be taken not to injure the right recurrent laryngeal nerve as it courses around the subclavian artery. In the dissection of the lower trachea, care must be taken not to injure the left recurrent nerve as it passes on the other side of the trachea over the aortic surface. The principles of resection are the same as for the upper trachea. If the distal trachea is resected, cross-field intubation is generally done through the lower trachea

into the left main bronchus. This has the added advantage of collapsing the right lung. High-frequency ventilation can also be used. If intubation is used and partial pressure of oxygen (PO_2) begins to fall, a shielded vascular clamp can be placed on the right pulmonary artery to eliminate shunting through the unventilated lung. This is rarely necessary. An alternative is to continue high-frequency ventilation because this does not massively inflate the lung.

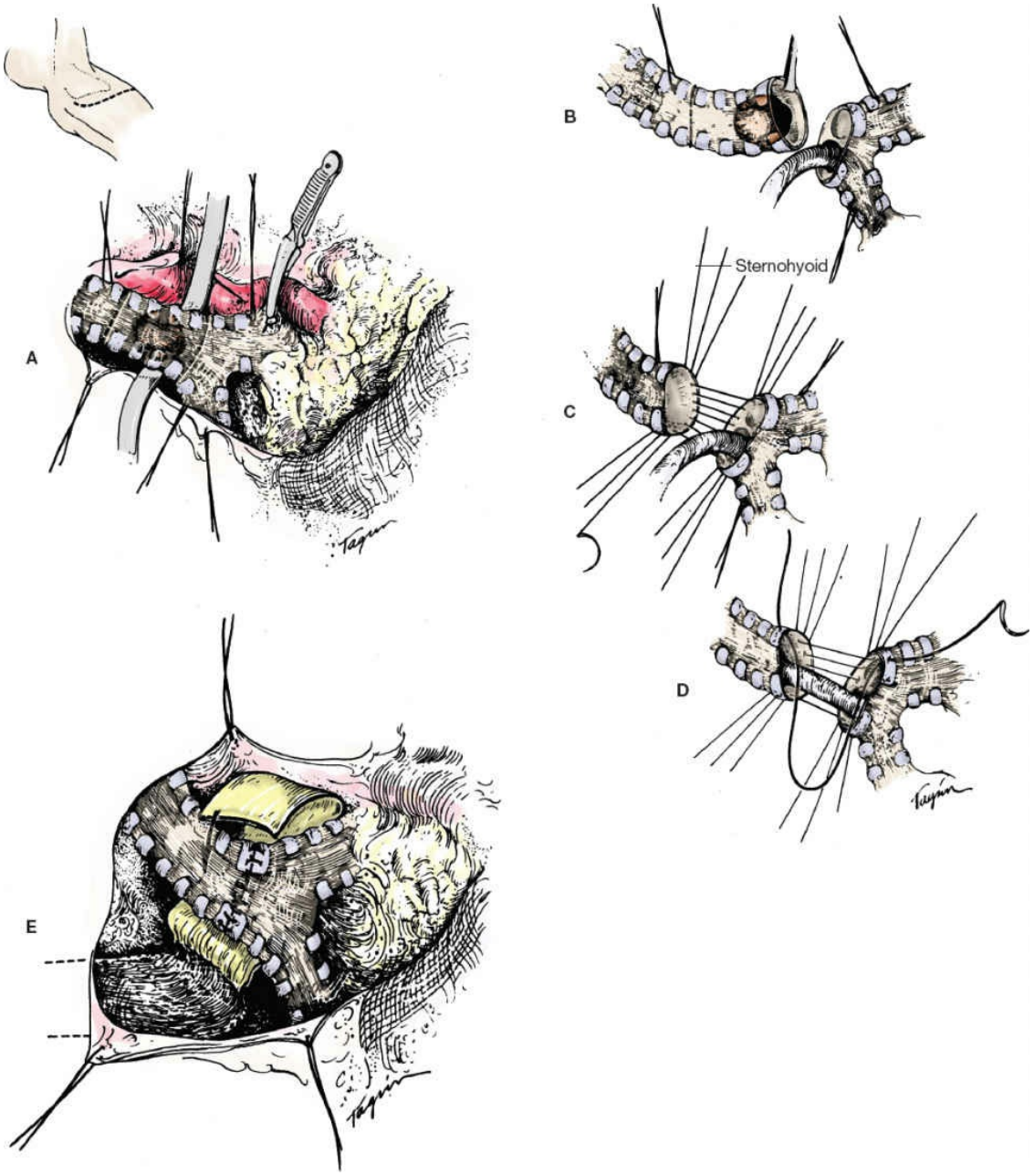

Figure 34.2. Transthoracic approach to resection of the lower trachea. **A.** As much mobilization as is thought to be necessary is done before division of the trachea. The drawing shows the placement of a clamp on the pulmonary artery, but clamps are not placed routinely. Proximal and distal traction sutures are placed as in the cervical procedure. **B.** The trachea has been divided just above the carina, and the left main bronchus has been intubated. **C.** Detail of anastomotic suture placement. **D.** The endotracheal tube from above is advanced distally and the balance of the sutures are placed. **E.** Once the anastomosis has been demonstrated to be airtight, a pedicled pleural flap or pericardial fat pad is placed on the anastomosis for security. (Reprinted from Grillo HC. Surgery of the trachea. *Curr Probl*

Surg 1970;7(7):3–59. Copyright © 1970, with permission from Elsevier.)

If it appears that tension will be excessive when the ends of the trachea are drawn together despite cervical flexion, intrathoracic intrapericardial mobilization should be used (Fig. 34.3). If this measure is required, it is easier to perform before resection of the tracheal lesion. The inferior pulmonary ligament is divided. A U-shaped incision is made in the pericardium just below and around the lower portion of the inferior pulmonary vein, the structure that most tethers the hilum. Often this degree of release is all that is required to provide sufficient upward movement of the hilum for anastomosis. If this release is not adequate, complete circumferential division of the pericardium around the hilum of the right lung can be performed. When the pericardium is so divided, we attempt to save the pedicle of vessels and lymphatics in the posterior hilum by looping a tape around them. Salvage of these lymphatics may be important for the early postoperative function of that lung. One must remember that the neck should be flexed during the anastomosis because this delivers a considerable amount of cervical trachea into the mediastinum. Laryngeal release does not help free the trachea for distal tracheal or carinal reconstruction.

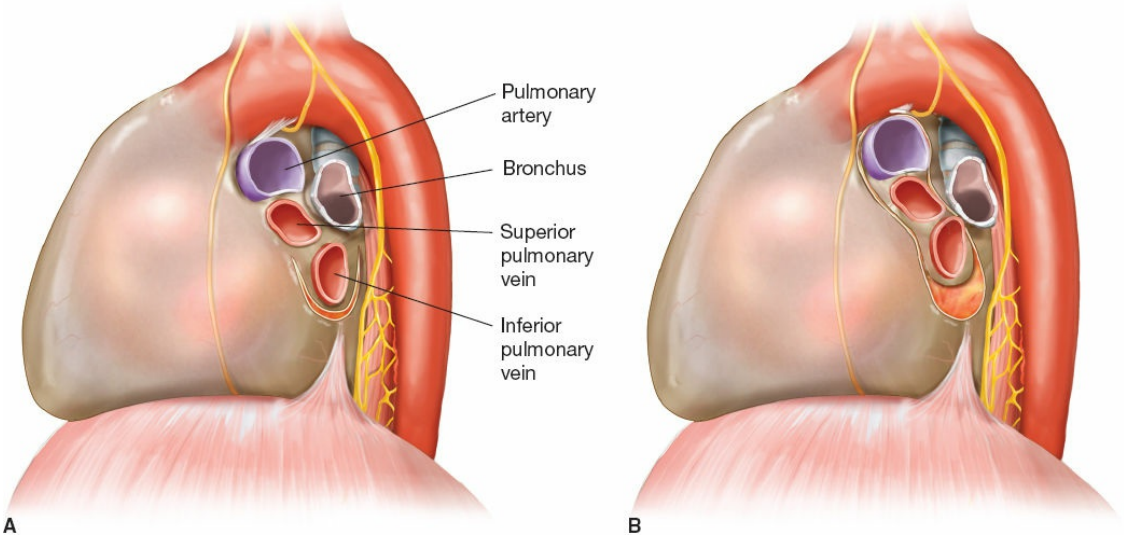

Figure 34.3. The left-side intrapericardial hilar release technique, showing the U-shaped pericardial incision, which allows 1 to 2 cm of upward hilar mobility to facilitate the creation of a tension-free anastomosis. (From Mathisen DJ, Morse C. *Master Techniques in Surgery: Thoracic Surgery: Transplantation, Tracheal Resections, Mediastinal Tumors, Extended Thoracic Resections.*

After the reconstruction is complete and tested under saline solution, second-layer coverage is provided with a broad-based pleural flap or pedicled pericardial fat carried in a circular manner around the anastomosis and sutured into place.

The distal trachea can also be approached through a median sternotomy using Perelman variation of the Abruzzini incision, in which the lower trachea and carina are exposed between the aorta and vena cava, and the pulmonary artery and the brachiocephalic artery are retracted. The pericardium is opened front and back. This is not a truly adequate incision for difficult or larger tumors, especially those that might involve the esophagus posteriorly. The exposure is also inadequate for complex anastomoses, such as those required for carinal reconstruction. It has the advantage, however, of allowing bilateral intrapericardial release if this is needed.

In complex procedures, such as operations for large tumors of the middle and lower trachea, we have sometimes used a “trap-door” incision, which consists of a collar incision and median sternotomy that angle to open the right fourth interspace. This incision provides access to the entire airway from the hyoid bone to the carina. In such circumstances, hyoid release and intrapericardial release both may be necessary.

Carinal Resection

Our preferred approach for resection and reconstruction of the carina is a right posterolateral thoracotomy. Anesthesia and dissection are carried out as described previously. The origin of the left main bronchus is easily accessible through the right hemithorax. The anatomical method of reconstruction is determined by the extent of the tumor and the amount of tissue removed. In a few instances, the medial walls of the right and left main bronchi can be sutured together to form a new carina, with this anastomosed to the distal trachea (Fig. 34.4). This procedure is rarely possible because fixing the right and left main bronchi together below the level of the aortic arch prevents upward movement. All the necessary length has to come from cervical flexion with downward devolvement of the trachea.

When more trachea has to be removed, we usually anastomose the trachea end-to-end to the left main bronchus (Fig. 34.5). The right main

bronchus is elevated and sutured into a side opening made in the trachea 1.0 cm above the end-to-end anastomosis. An ovoid opening is made in the lateral cartilaginous wall so that cartilage is all the way around the margin of the anastomosis. The anastomosis must be done with precision. Pericardial mobilization is often necessary to permit elevation of the right main bronchus.

If a greater amount of trachea has to be sacrificed, the trachea and left main bronchus will not reach one another. Under these circumstances, with full intrapericardial mobilization, the right main bronchus is elevated to the stump of the trachea and an end-to-end anastomosis is made. The end of the left main bronchus is anastomosed to an opening in the medial wall of the bronchus intermedius (Fig. 34.6).

In cases in which the right upper lobe also has been sacrificed because of tumor extension, or if a localized bronchogenic carcinoma of the right upper lobe extends to the carina, the bronchus intermedius or lower-lobe bronchus can be anastomosed to the trachea (Fig. 34.7) or to the left main bronchus, if it fails to reach the trachea.

In patients who have had prior pneumonectomies and who require carinal resection for residual or recurrent tumor in the bronchial stump, resection is usually done through the right chest, unless there is a long left mainstem bronchial stump (Fig. 34.8). After a left pneumonectomy, care is taken to maintain ventilation in the right lung. The surgeon retracts the lung gently to provide access to the carina without collapsing the lung. The anterior approach may be useful in some circumstances.

In a small number of patients, the approach has been made from the left side when a tumor involves a large length of left main bronchus but a small portion of the carina. In this situation, the left lung cannot be salvaged by any current technique. Tapes are placed around the base of the trachea and the right main bronchus to gain enough access to excise the carina and left lung. A direct end-to-end anastomosis of trachea to right main bronchus is done from the left side. We have tried dividing intercostal vessels and approaching the carina from the left posterior aspect to the aortic arch, but this has not proved to be of much help.

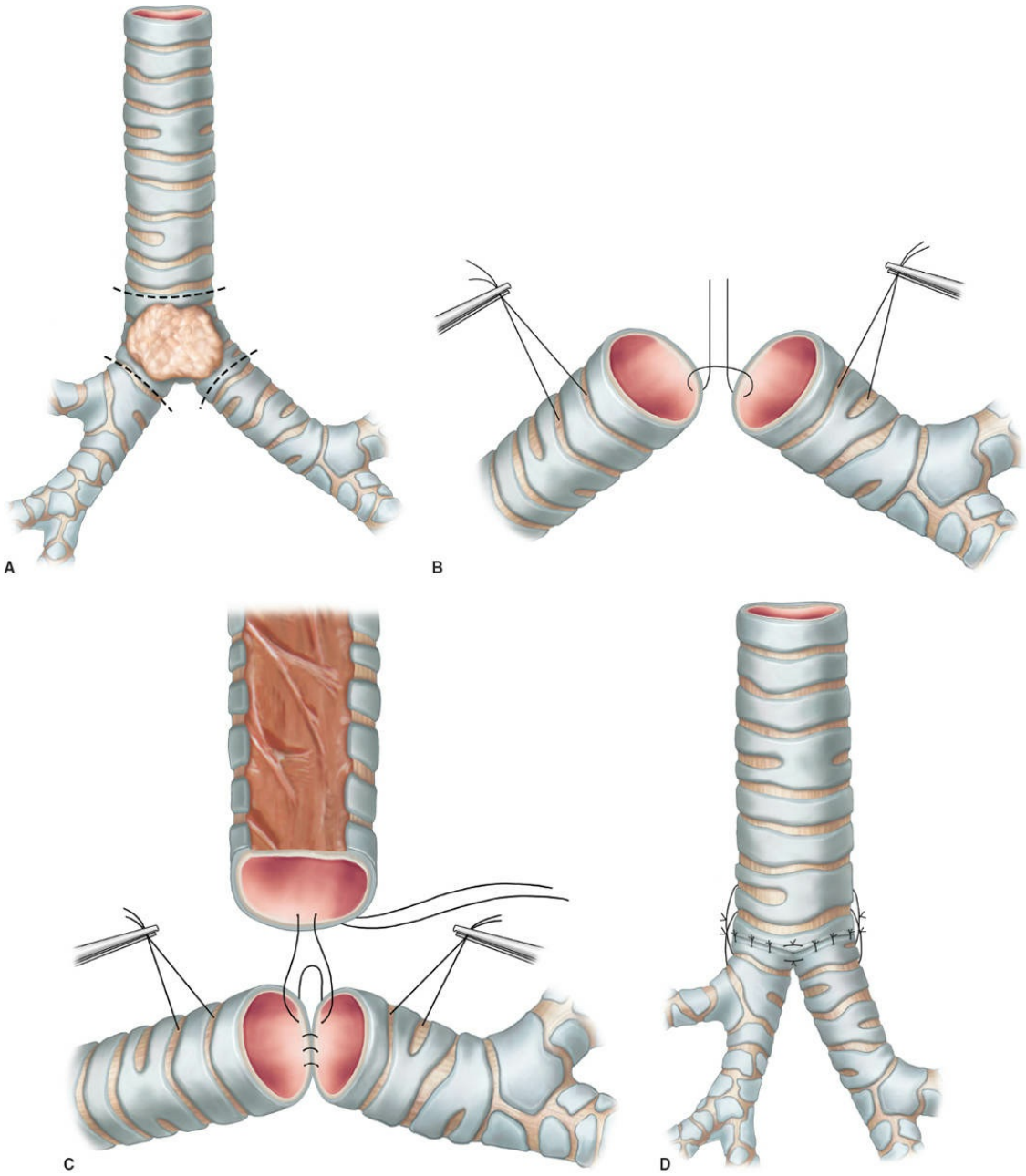

Figure 34.4. Resection with restitution of the carina. This technique is applicable only for small, centrally placed tumors. (From Mathisen DJ, Morse C. *Master Techniques in Surgery: Thoracic Surgery: Lung Resections, Bronchoplasty.* 2014; Wolters Kluwer.)

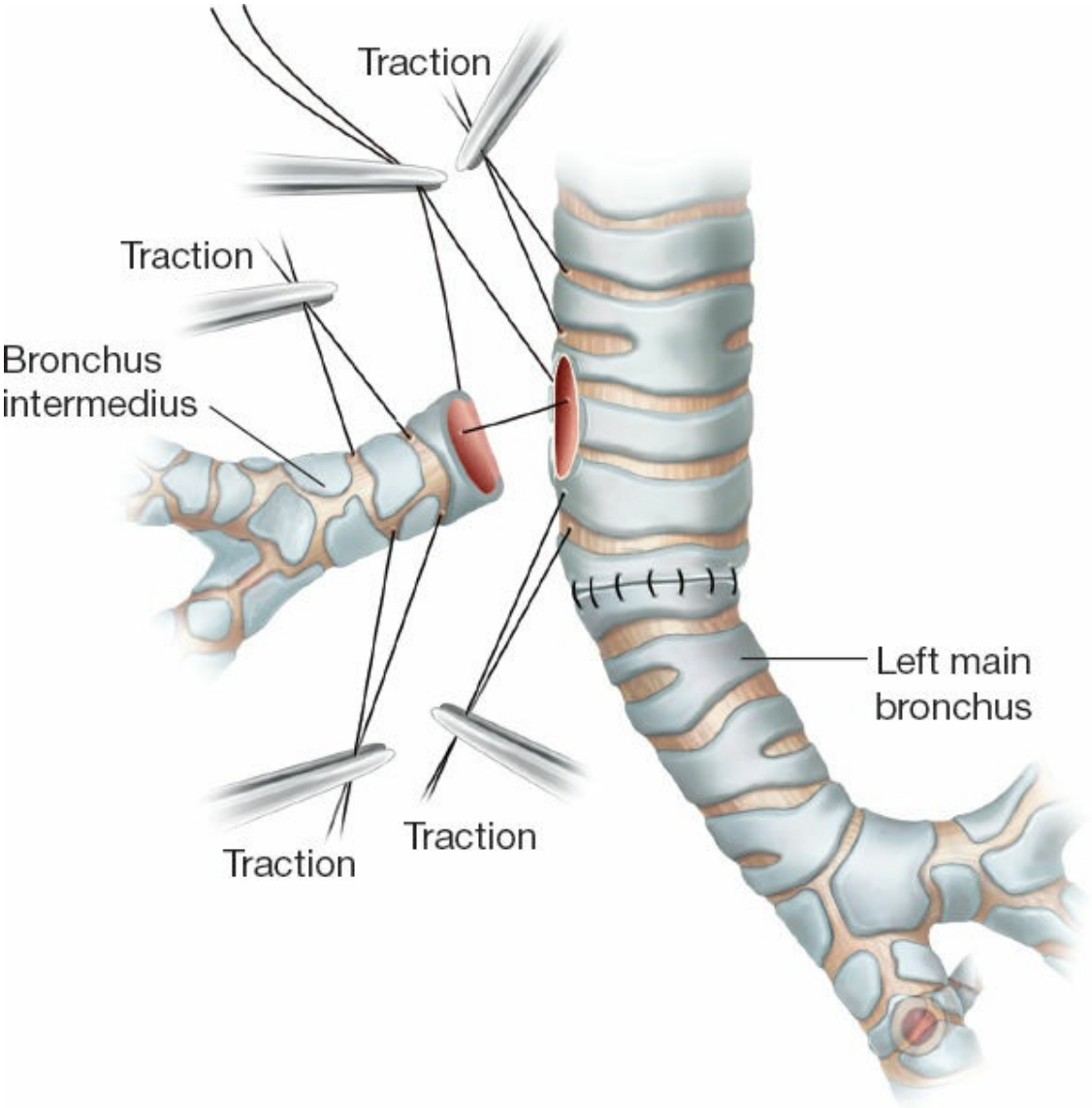

Figure 34.5. Carinal reconstruction after resection. The trachea is anastomosed end-to-end to the left main bronchus, and the right bronchus is placed into the lateral wall of the trachea above the first anastomosis. (Modified from Mathisen DJ, Morse C. *Master Techniques in Surgery: Thoracic Surgery: Lung Resections, Bronchoplasty.* 2014; Wolters Kluwer.)

A problem that has not been satisfactorily solved is how to approach a tumor involving a large amount of carina and a long segment of left main bronchus. If the approach is through the right chest alone, the tumor can be excised and the left main bronchus stapled off from the right side. Perelman proposed this procedure along with ligation of the left pulmonary artery to avoid shunting in the nonfunctional left lung. A left pneumonectomy can be done later. Another approach is bilateral thoracotomy. In patients who have satisfactory pulmonary reserve, the

approach has been through a bilateral anterior clamshell thoracotomy, crossing the sternum in the fourth interspace. This approach provides excellent exposure for resection, the anastomosis of the right main bronchus to the trachea, and the left pneumonectomy. However, bilateral thoracotomy is a physiologically demanding approach and may require postoperative ventilation in selected patients. An alternative is median sternotomy, which allows access for left pneumonectomy. Cardiopulmonary bypass or ECMO has been useful in certain large central tumors.

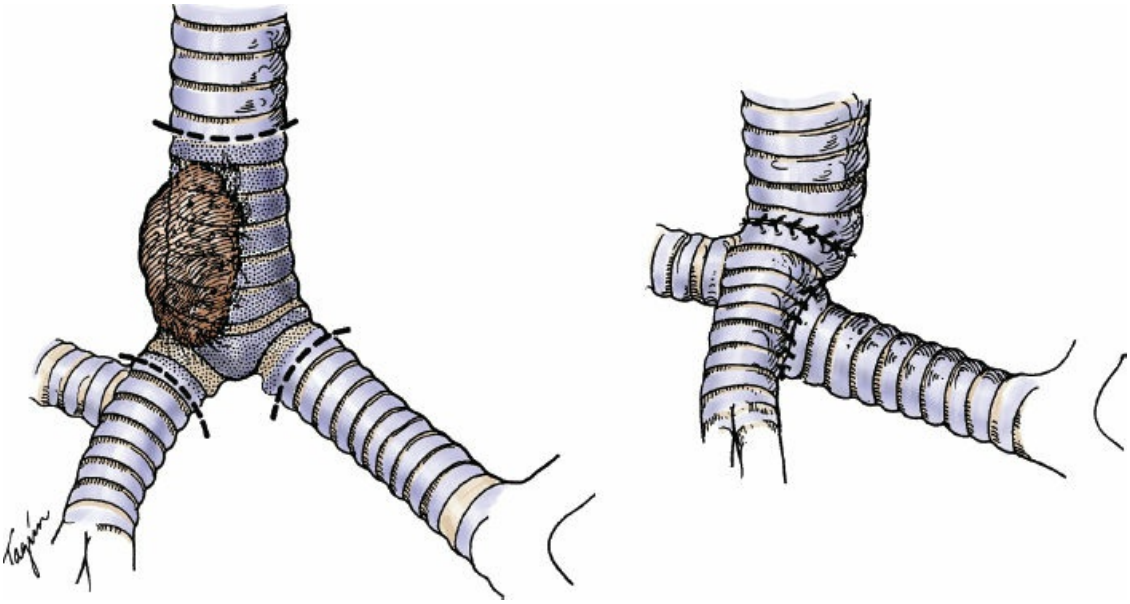

Figure 34.6. More extensive tracheal resection, with advance of the right main bronchus to the end of the trachea and implantation of the left main bronchus into the bronchus intermedius. (Reprinted from Grillo HC. Carinal reconstruction. *Ann Thorac Surg* 1982;34(4):356–73, with permission of the Society of Thoracic Surgeons.)

All suture lines are covered with flaps (pleural or pericardial fat) in carinal reconstructions. If a patient needs postoperative ventilation, it can be done safely with the cuff placed well above the anastomosis. The anastomosis can tolerate gas pressures but should not have a foreign body resting against it, which may cause injury. If secretions cannot be cleared by physiotherapy, flexible bronchoscopy should be used freely.

Laryngotracheal Resection in Benign Stenosis

If a subglottic stenosis stops short of the vocal cords so that a space exists

beneath the cords to which the trachea can be sutured, many of these lesions can be corrected while salvaging recurrent laryngeal nerve function. The lower anterior portion of the larynx involved by the stenosis is resected with the specimen. The line of resection begins inferior to the lower border of the midline of the thyroid cartilage (Fig. 34.9). The vocal cords are just above this level. The line of resection sweeps laterally downward on either side through the cricothyroid membrane in the line of the inferior margin of the thyroid cartilage. It then transects the lateral laminae of the cricoid cartilage and angles posteriorly, just below the inferior margin of the posterior plates of the cricoid cartilage. Dissection must be made with extreme care and must be very close to the cricoid cartilage to avoid injury to the recurrent laryngeal nerves, which enter the larynx medial to the inferior cornua of the thyroid cartilage.

If the intralaryngeal portion of the stenosis is entirely anterior, as it often is in stomal lesions because of either cricothyroidotomy or erosion by a high tracheostomy, the mucosa overlying the posterior plate of the cricoid cartilage may be intact. If, on the other hand, the stenosis is circumferential, as occurs from pressure secondary to a large endotracheal tube, then the scar that overlies the posterior plate also must be removed. The scar is excised down to the surface of the posterior cricoid plate leaving the cartilage intact. The upper line of mucosal division may lie just below the arytenoid cartilages. This bared cartilage must be resurfaced with the membranous wall of the distal trachea.

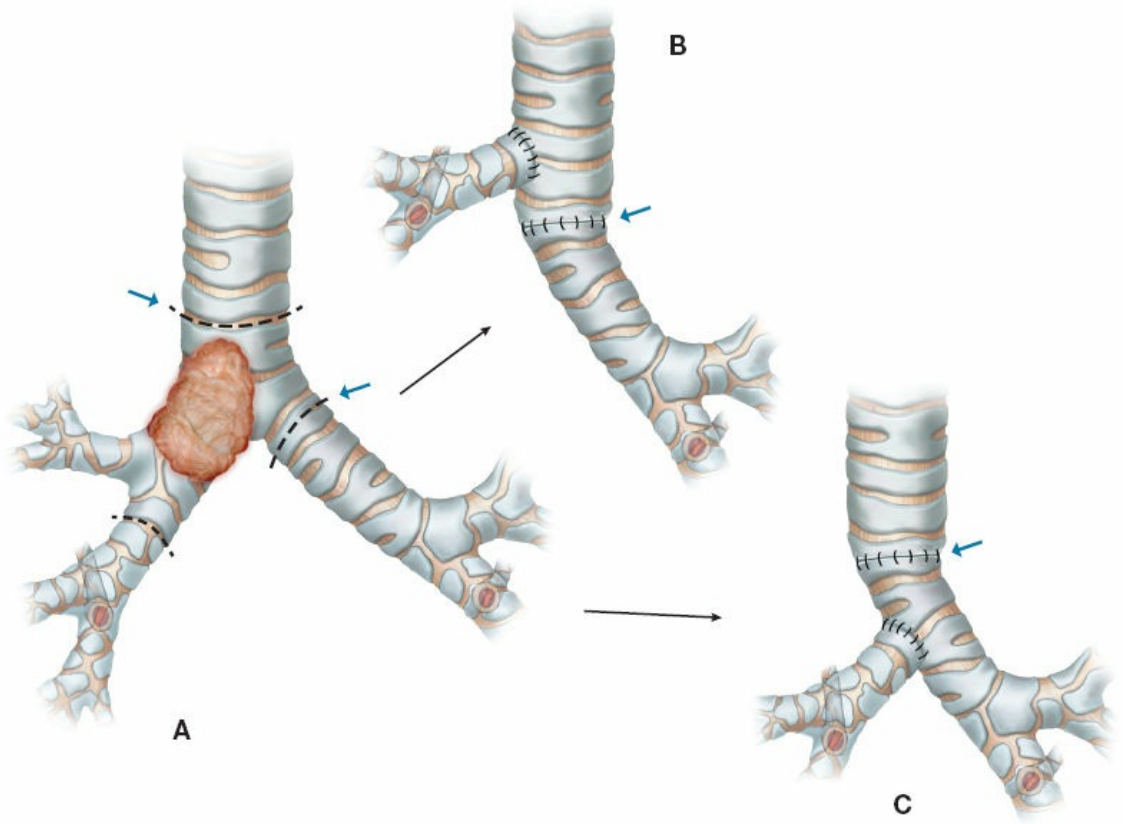

Figure 34.7. Carinal resection with right upper lobectomy. With mobilization, the bronchus intermedius is advanced to the side of the trachea and implanted above the anastomosis of the trachea and the left main bronchus. If it fails to reach the trachea, it is implanted into the side of the left main bronchus. (From Mathisen DJ, Morse C. *Master Techniques in Surgery: Thoracic Surgery: Lung Resections, Bronchoplasty.* 2014; Wolters Kluwer.)

Distally, the line of resection of the trachea is beveled backward along the thickness of just one cartilaginous ring so that a prow is formed. Posteriorly, the membranous wall can be transected horizontally if a mucosal flap is not needed to resurface the posterior plate of the cartilage. If the posterior plate has been bared by removal of scar, a broad-based flap of membranous wall is preserved, as indicated in Figure 34.9.

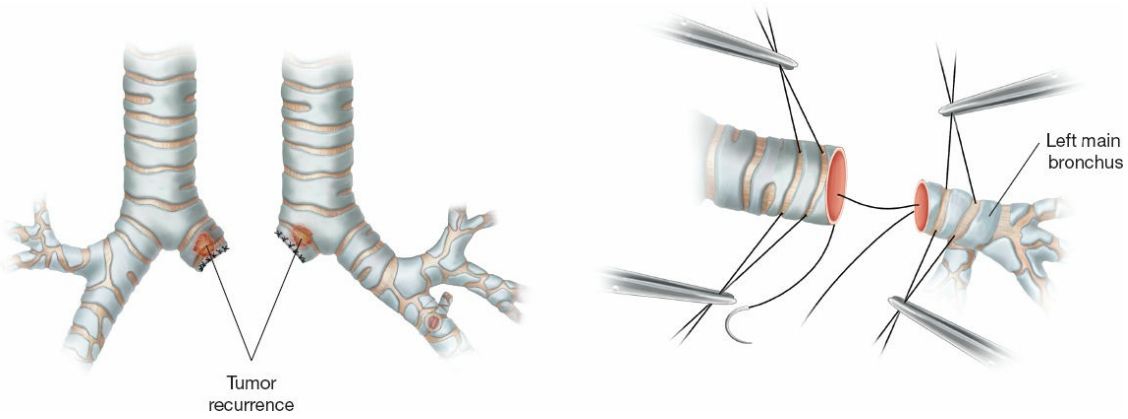

Figure 34.8. Carinal resection after prior pneumonectomy. Except in a patient who has a long residual left main bronchial stump, the procedures are carried out through the right hemithorax. (From Mathisen DJ, Morse C. *Master Techniques in Surgery: Thoracic Surgery: Lung Resections, Bronchoplasty.* 2014; Wolters Kluwer.)

When no posterior flap is to be inserted, the anastomosis is done in the conventional manner. When a flap must be inserted, we first place four sutures from the inferior margin of the posterior cricoid plate to a point approximately 5 mm down on the back of the membranous wall of the trachea so that the flap is free to cover the bared cartilage inside. These sutures are carefully marked but are not tied. The sutures on the membranous wall are placed in a vertical mattress fashion so that the knots are on the outside. After this step, all of the posterior anastomotic mucosal sutures are placed from the margin of the membranous wall flap to the mucosa within the posterior wall of the larynx. These sutures are placed so that the knots lie inside the lumen. The first few lateral anastomotic sutures go through the full thickness of the cartilage and mucosa of the trachea, and the mucosa and some of the cartilage of the lateral laminae of the cricoid. The lateral traction sutures are tied. The first four fixing sutures are tied and cut. The mucosal sutures inside the larynx are tied with the larynx open so that the surgeon’s finger can go into the larynx. After the posterior mucosal flap has been sutured into place, the balance of the lateral and anterior anastomotic sutures are placed in the usual manner and tying is continued.

In some patients with inflammatory disease, a considerable amount of submucosal thickening and edema remains in the subglottic larynx all the way to the undersurface of the vocal cords. In these instances, reconstruction has to accept a narrowed airway. If the airway is inadequate

after the reconstruction because of edema, a small, uncuffed endotracheal tube is placed well below the anastomosis for 48 to 72 hours. If airway obstruction is still present after the tube is removed, a small tracheostomy is placed in a previously marked area well below the anastomosis. With time, the edema usually regresses and the tracheostomy tube is removed.

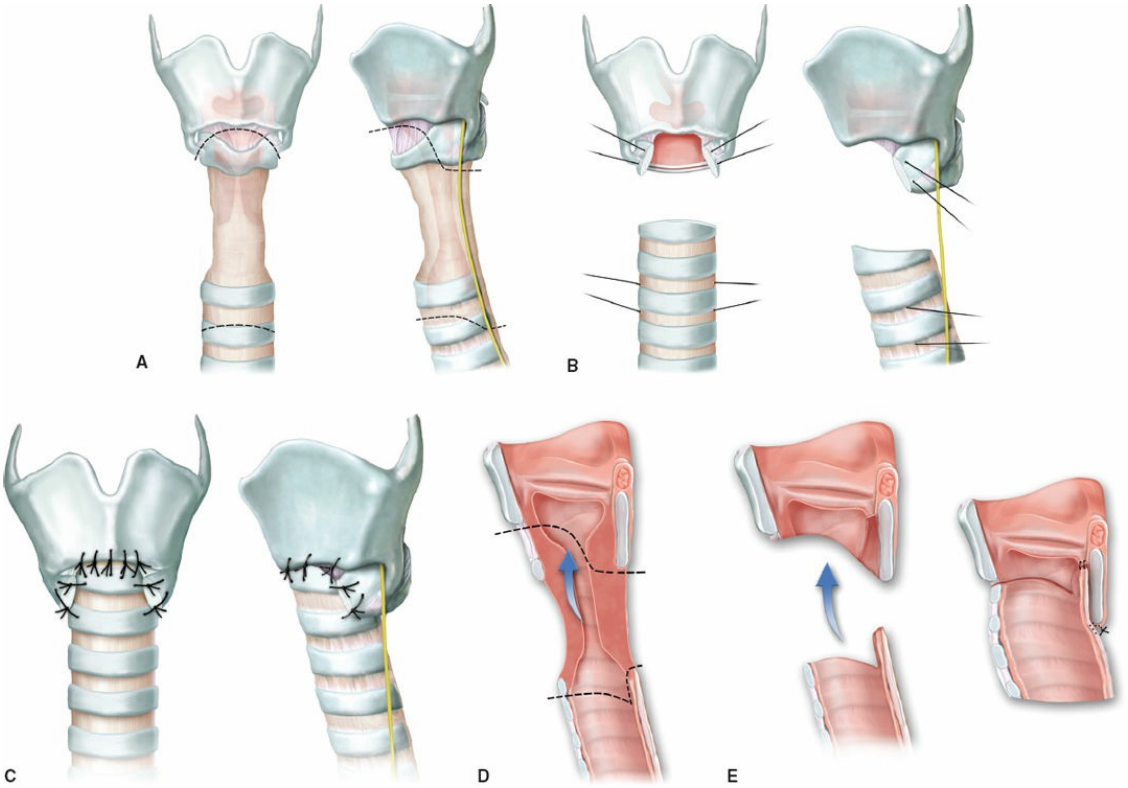

Figure 34.9. Operative repair of anterolateral stenosis of the subglottic larynx and upper trachea. **A.** Anteroposterior and lateral views showing the extent of disease and the ultimate lines of transection. **B.** Larynx and trachea after removal of the specimen. Recurrent nerves have been left intact. The mucous membrane of the larynx has been transected sharply at the same level of division as the cartilage. **C.** Anteroposterior and lateral views of the reconstruction. **D.** Resection and reconstruction of circumferential stenosis of the subglottic larynx and upper trachea. The external line of cartilaginous division of both the larynx and trachea is the same as in anterolateral stenosis. Interior view of the larynx and trachea demonstrate modifications necessary when stenosis involves mucosa and submucosa just in front of the cricoid plate. Superior *dotted line* indicates external cartilaginous division of the larynx. *Dashed line* against the anterior wall of the cricoid plate indicates that the mucosa with its scarring will be cut back to within a short distance of the arytenoid cartilage, if necessary. Inferiorly, the posterior

membranous wall has been retained as a broad-based flap. **E.** Resected specimen, leaving the bare area of the intraluminal portion of the lower part of the cricoid lamina. The flap of the membranous wall of the trachea is fitted into the defect to provide complete mucosal coverage, shown at the right. The mucosa of the larynx has been anastomosed to the mucosa of the membranous wall of the trachea. External to the lumen, connective tissue of the membranous wall has been fixed with four sutures to the inferior margin of the cricoid cartilage to assure that the flap stays firmly applied to the surface. (From Mathisen DJ, Morse C. *Master Techniques in Surgery: Thoracic Surgery: Transplantation, Tracheal Resections, Mediastinal Tumors, Extended Thoracic Resections.* 2014; Wolters Kluwer.)

Idiopathic subglottic stenosis is becoming a common reason for subglottic resection. Almost all patients are female and Caucasian. They present with progressive dyspnea on exertion that develops into stridor over several years. Possible etiologies such as gastroesophageal reflux, Wegener granulomatosis, and connective tissue disorders must be excluded. Typically there is a short stenosis that involves the first two or three tracheal rings, the cricoid cartilage, and the posterior cricoid mucosa. Patients will often undergo several procedures for palliation, such as tracheostomy, balloon dilatation, laser debridement, and cryotherapy. We prefer instead definitive treatment with single-stage resection and reconstruction, which almost always involves a buttressed anastomosis between the trachea and thyroid cartilage. Patients are almost always extubated immediately after the procedure, and rarely is a protecting tracheostomy required.

Laryngotracheal Resection for Tumor

Occasionally, a high primary tumor, such as adenoid cystic carcinoma, or a secondary tumor, such as differentiated but invasive thyroid carcinoma, involves the lower larynx. Often, one recurrent laryngeal nerve is already paralyzed. The line of resection is tailored to the particular tumor (Fig. 34.10). On the involved side, this line may lie beneath the vocal cord with a variable portion of the cricoid cartilage resected. The recurrent laryngeal nerve on the opposite side must remain functional. On the uninvolved side, the resection line is just below the lower margin of the cricoid cartilage. Frozen sections are used to check completeness of resection. The line of

tracheal resection is made to correspond to the line of laryngeal division so that the two structures can be mortised together. A protective tracheostomy usually is not necessary in these patients.

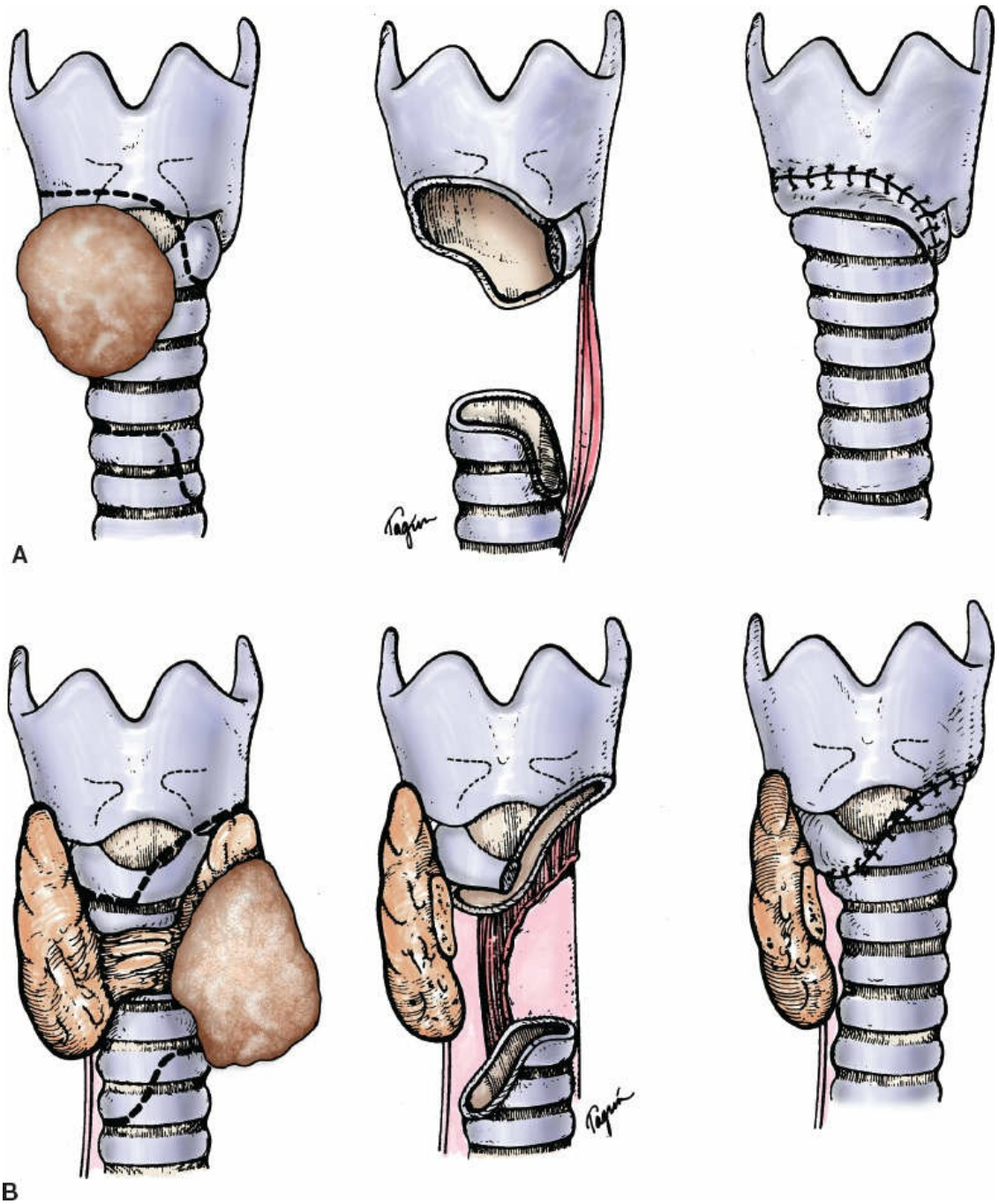

Figure 34.10. **A.** Resection of mixed papillary and follicular carcinoma after recurrence following total thyroidectomy. **B.** Mixed papillary and follicular carcinoma, not previously treated, is managed by complex resection, including removal of the anterolateral muscular wall of the esophagus. (Reprinted from Grillo HC, Zannini P. Resectional management of airway invasion by thyroid carcinoma. *Ann Thorac Surg* 1986;42(3):287–98, with permission of the Society of Thoracic Surgeons.)

Tracheoesophageal Fistula

TEF can arise from malignancy or mechanical causes. The most common location for tumor is the esophagus, but the precipitating carcinoma can arise from lung, trachea, or thyroid. The most common cause of nonmalignant TEFs is erosion by tracheostomy tubes that press against an in-lying, hard nasogastric tube. The common wall of the trachea and esophagus is destroyed between the two foreign bodies (Fig. 34.11A). However, because circumferential injury to the trachea is caused by the endotracheal cuff, simple tracheal repair is usually not sufficient, and adequate treatment involves a tracheal resection and reconstruction. We advocate a single-stage repair once the patient no longer depends on mechanical ventilation. However, the initial steps following the recognition of a TEF include removing the esophageal foreign body, using a low-pressure cuff in the distal trachea, and placing the cuff below the fistula. A gastrostomy tube is placed to drain the stomach and prevent reflux through the fistula, and a feeding jejunostomy is placed. Because of the location of most TEFs, proximal esophageal diversion is not feasible or practical. When the patient has been weaned from ventilation, a single-stage operation is performed via the anterior approach. The majority of TEFs that result from intubation can be repaired through a low-collar incision. If a tracheostomy stoma is present, it can be incorporated into the incision and resected. If the fistula is located near the carina, a right posterolateral thoracotomy may be used. The injured tracheal segment is resected along with the esophageal fistula (Fig. 34.11B). The esophagus is closed in two layers with fine interrupted sutures (Fig. 34.11C) and a pedicled muscle flap is placed over the esophageal repair (Fig. 34.11D). With a small fistula and otherwise normal trachea, tracheal resection may not be required. In this case, the fistula is dissected and divided from a lateral approach, cautiously avoiding the recurrent laryngeal nerves. The trachea is closed with fine absorbable sutures and the esophagus is closed in two layers. Again, a muscle flap is sutured over the esophageal closure to interpose healthy tissue between the esophageal and tracheal closures.

A TEF caused by malignancy has a particularly dismal prognosis, with few patients surviving more than 1 year. In the setting of continuous soiling of the tracheobronchial tree, a variety of treatment alternatives are available, including esophageal stenting, esophageal exclusion and palliative chemoradiotherapy.

Laryngotracheal Trauma

After the diagnosis of laryngotracheal trauma is made, control of the airway is critical. If any doubt exists about the status of the airway, emergency tracheostomy should be performed. Repeated attempts at oral intubation should be avoided for fear of losing airway control altogether. Examination of the traumatized airway is best done in the operating room with a flexible bronchoscope over which a small endotracheal tube has been passed to allow for intubation by using the flexible bronchoscope as a guide. Patients should be scrupulously examined for associated injuries, such as laryngeal, vascular, esophageal, and spine injuries. The presence of these injuries may influence management of the airway injury.

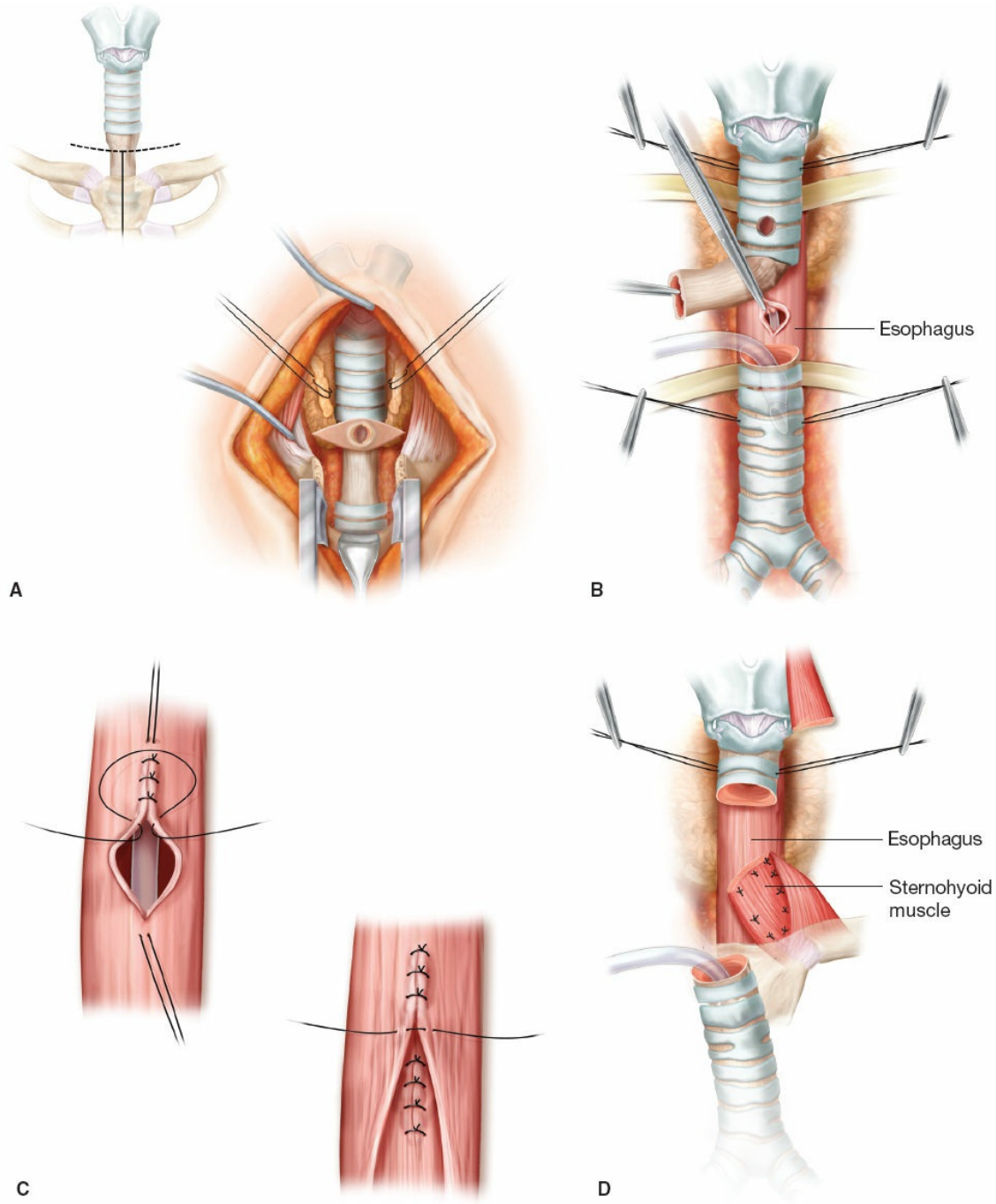

Figure 34.11. A. With tracheoesophageal fistulas, the common wall of the trachea and esophagus is destroyed. **B.** Because of circumferential tracheal damage, the injured tracheal segment is resected along with the esophageal fistula. **C.** The esophagus is closed in two layers with fine interrupted sutures. **D.** A pedicled muscle flap is placed over the esophageal repair. (From Mathisen DJ, Morse C. *Master Techniques in Surgery: Thoracic Surgery: Transplantation, Tracheal Resections, Mediastinal Tumors, Extended Thoracic Resections.* 2014; Wolters Kluwer.)

Simple lacerations should be repaired by interrupted, simple 4-0

polyglycolic acid sutures. Complex injuries require individual solutions. Placing a tracheostomy tube through damaged trachea to secure the airway with repair of associated injuries may be appropriate in some cases. One should stress that all viable trachea should be preserved for further reconstruction. Concomitant esophageal injuries should be repaired in two layers and covered by a pedicled strap muscle to separate the esophageal and tracheal suture lines (Fig. 34.12). Laryngeal injuries are best managed in conjunction with an otolaryngologist and often require a protecting tracheostomy. Complete transections of the airway are almost always accompanied by damage to one or both laryngeal nerves. A protecting tracheostomy is needed after repair of such injuries because of the risk of adduction of the vocal cords.

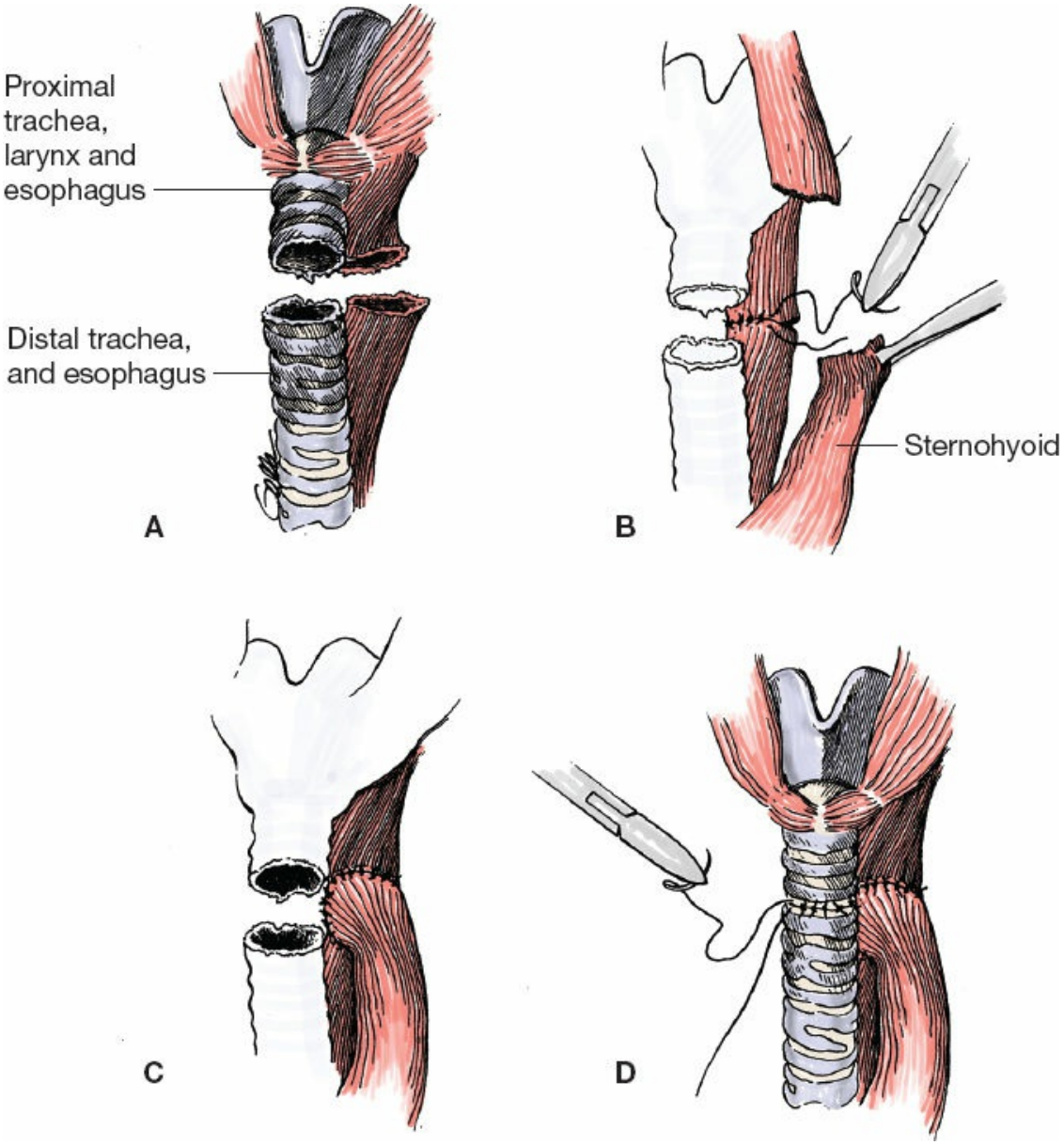

Figure 34.12. A. View of transected trachea and esophagus. **B.** Esophagus closed in two layers. **C.** Strap muscle interposed between the esophageal and tracheal suture lines. **D.** Completed repair.

Pediatric Tracheal Stenosis

Tracheal stenosis in children is an uncommon problem. When present, if the child is of sufficient size, resection and end-to-end anastomosis is the procedure of choice for correction. If the child is deemed too small, a tracheostomy or T tube is preferable until the child attains sufficient size. Congenital tracheal stenosis is even more uncommon. Short-segment tracheal stenosis is best managed by resection and end-to-end anastomosis. If long-segment stenosis exists and respiratory distress develops, two options are available. One option involves incising the stenosis (O rings) and inserting a pedicled pericardial patch. The second method, described by Goldstraw and Grillo, has been dubbed *slide tracheoplasty*. It involves dividing the stenosis at its midpoint. The anterior surface is incised in the distal segment and the posterior surface in the proximal segment (Fig. 34.13). The proximal and distal segment slide over one another and an anastomosis is performed, as described for tracheal reconstruction.

Reoperative Tracheal Surgery

Failure of primary tracheal resection and reconstruction may occur despite attention to technical details, and early restenosis poses a difficult challenge. Most important is the establishment of a secure airway. Dilatation is a temporary measure, as restenosis will occur within days to weeks, but it may be appropriate in some patients. Placement of a tracheostomy or T tube through the most damaged or stenotic portion of the trachea is the safest procedure. For definitive repair, the best approach is to wait 4 to 6 months before another attempt at reconstruction. This allows the inflammatory changes from surgery to subside and improves the mobility of tissues. Every effort should be made to discern the reason for failure and to correct any identifiable causes. Prior to any reconstruction, repeat bronchoscopy is essential to determine the amount of available airway and the condition of the tracheal mucosa. Surgery requires the same careful attention to detail. A laryngeal release is much more likely to be needed the second time around (25% of second operations vs. 6% of primary operations). Careful evaluation of patients, proper management of

the airway, correct timing of the operation, and strict attention to technical details can achieve success in more than 90% of patients selected for reoperation.

Subtotal Tracheal Resection

We do not recommend the use of tracheal prostheses or staged tracheal reconstructions using skin tubes or other tissues. Although success has been seen with both techniques, the number of complications and hazards are so great that these procedures seem unjustified. For a benign stenosis to require a resection that cannot be managed by primary reconstruction is extraordinarily rare unless the patient has had an inappropriate tracheal operation previously. In such situations, a safely placed silicone tracheal T tube performs the same function as a silicone prosthesis placed surgically, which has considerably more hazard.

Tissue-engineered tracheal replacement has gained some interest. Many problems still exist with this concept and cannot be recommended at present.

POSTOPERATIVE MANAGEMENT AND COMPLICATIONS OF TRACHEAL RESECTIONS

Following a tracheal resection, all patients have a “guardian suture” placed from the submental location to the angle of Louis. The suture is a reminder for the patient to maintain neck flexion, taking tension off the anastomosis. The patients are initially kept from food by mouth, but a diet is advanced slowly over the first several days. Warm, humidified oxygen helps mobilize secretions. Vomiting is best avoided in the early phase of recovery by the use of antiemetics. All patients are kept in the hospital until postoperative day 7, when repeat bronchoscopy is performed. At that time, if the anastomosis is intact with minimal edema, the guardian suture is cut and the patient is discharged. Edema when present is treated with 24 hours of dexamethasone. We use 10 mg IV initially, then 4 mg IV every 6 hours. This is often supplemented with heliox and diuresis. If stridor develops at any time postoperatively, the patient needs to be emergently evaluated and likely undergo bronchoscopy.

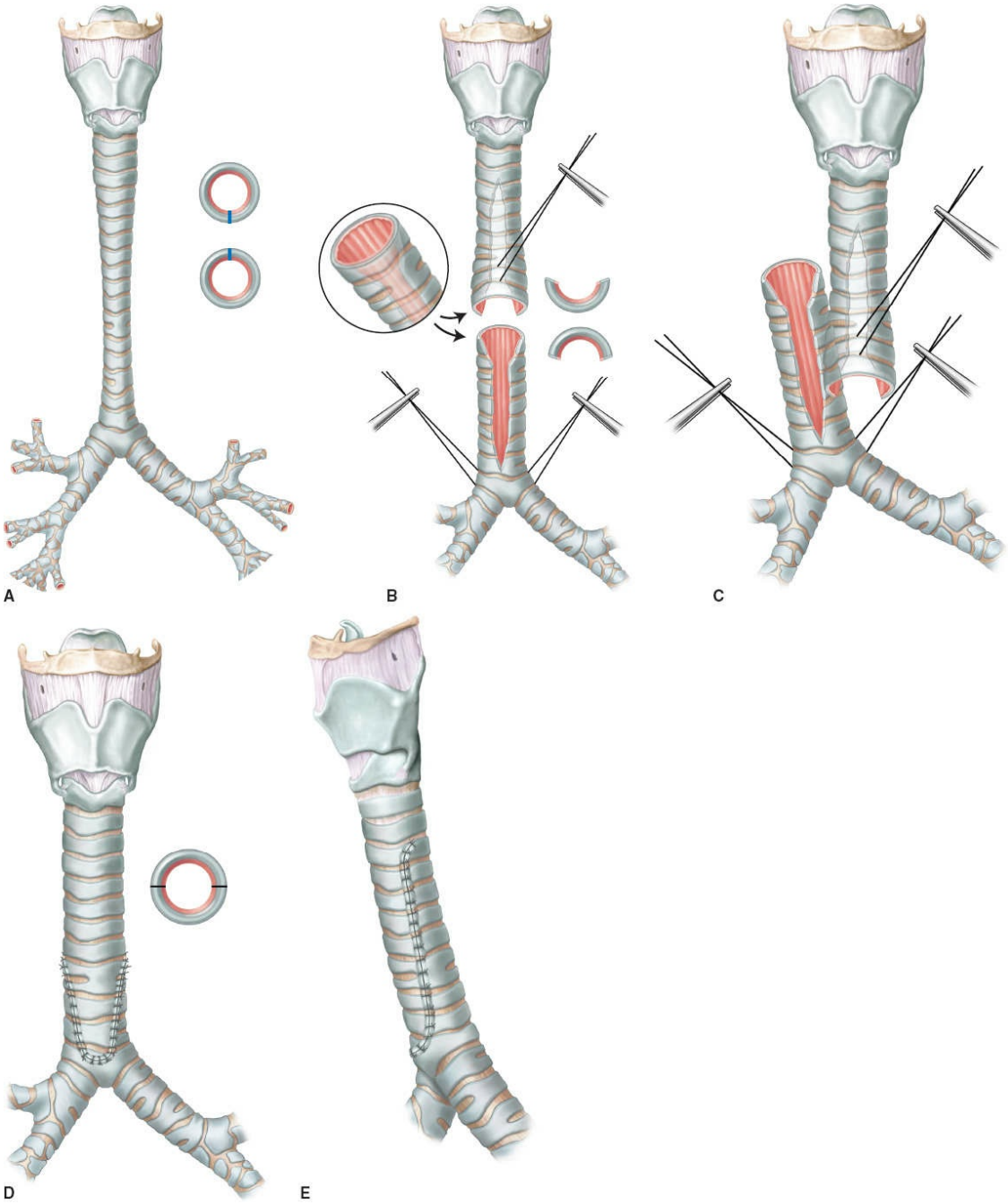

Figure 34.13. Technique of slide tracheoplasty. **A.** The extent of the stenosis is precisely identified. The stenotic segment is divided transversely in its midpoint after circumferential dissection at that locus only. The upper stenotic segment is incised vertically posteriorly and the lower segment is incised anteriorly for the full length of stenosis. **B.** The right-angled corners produced by these divisions are trimmed above and below. A stay suture near the top of the superior flap is helpful, as are traction sutures at the tracheobronchial angles or the main bronchi below. Minimal dissection of the lateral blood supply is performed. **C.** The two ends are slid together after placement of individual anastomotic sutures around the entire oblique circumference of the

tracheoplasty. **D, E.** The circumference is doubled, which results in quadrupled cross-sectional area. (From Mathisen DJ, Morse C. *Master Techniques in Surgery: Thoracic Surgery: Transplantation, Tracheal Resections, Mediastinal Tumors, Extended Thoracic Resections.* 2014; Wolters Kluwer.)

Anastomotic complications are rare following tracheal resections. Edema, granulation tissue, and complete separation of the anastomosis are all potential problems. Early diagnosis and intervention is important in the management of complications. With an unstable airway, the patients should be intubated from above with a small endotracheal tube and bronchoscopic guidance. If the airway is stable, a CT scan of the neck may be obtained to look for extraluminal air and fluid collections. Bronchoscopy can then be performed to evaluate the anastomosis. It is rare that an anastomotic separation can be repaired primarily, and these are best managed by either a T tube or tracheostomy. A T tube is preferred because it allows for speech and for the patient to clear secretions with humidification of air through the nose. As mentioned previously, one should wait at least 6 months before considering reoperation to allow for the resolution of swelling and edema.

In a small number of patients we have used hyperbaric oxygen therapy for partial necrosis of the tracheal cartilage. Fifteen to 20 treatments has been the norm. It has been used successfully to date. Patients must have a secure airway.

RESULTS

Careful patient selection and strict attention to technical details should result in very good results. First time tracheal resection and reconstruction should achieve a good to excellent result in over 90% of patients. Resection for tracheal tumors should have similar postoperative results. Carinal resection continues to pose technical challenges, but mortality rates are consistently less than 10% as extent of resection, better patient selection and better understanding of postoperative care have improved outcomes. Management of laryngotracheal trauma has improved as understanding of initial airway management and principles of repair have become more widely understood. Even the paralyzed larynx can be salvaged to provide an adequate airway and functional voice. TEFs are among the most challenging airway problems. The goal of fistula closure

can be achieved in over 90% of patients if principles of management and repair are observed. For more detailed analysis of results readers are referred to the selected readings.

Suggested Readings

Donahue DM, Grillo HC, Mathisen DJ, et al. Reoperative tracheal resection and reconstruction for unsuccessful repair of postintubation tracheal stenosis. *J Thorac Cardiovasc Surg* 1997;114:934–8.

Gaissert HA, Grillo HC, Mathisen DJ, et al. Long-term survival after resection of primary adenoid cystic and squamous cell carcinoma of the trachea and carina. *Ann Thorac Surg* 2004;78:1889–96.

Gaissert HA, Honings J, Grillo HC, et al. Segmental laryngotracheal and tracheal resection for invasive thyroid carcinoma. *Ann Thorac Surg* 2007;83:1952–9.

Grillo HC. Carinal reconstruction. *Ann Thorac Surg* 1982;34(4):356–73.

Grillo HC. Slide tracheoplasty for long segment congenital stenosis. *Ann Thorac Surg* 1994;58:613–9.

Grillo HC, Donahue DM, Mathisen DJ, et al. Postintubation tracheal stenosis: results of surgical treatment. *J Thorac Cardiovasc Surg* 1995;109:486–92.

Grillo HC, Mathisen DJ, Wain JC. Laryngotracheal resection and reconstruction for subglottic stenosis. *Ann Thorac Surg* 1992;53:54–63.

Liberman AM, Mathisen DJ. Surgical anatomy of the trachea and techniques of resection and reconstruction. In: Shields TW, LoCicero J, Reed CE, Feins RH, eds. *General Thoracic Surgery*. 7th ed. Philadelphia, PA: Lippincott Williams & Wilkins; 2009;946–67.

Liberman AM, Mathisen DJ. Tailored cricoplasty: an improved modification for reconstruction in subglottic tracheal stenosis. *J Thorac Cardiovasc Surg* 2009; 137(3):573–9.

Mathisen DJ, Grillo HC. Laryngotracheal trauma. *Ann Thorac Surg* 1987;43:254–62.

Mitchell JD, Mathisen DJ, Wright CD, et al. Clinical experience with carinal resection. *J Thorac Cardiovasc Surg* 1999;117:39–52.

Mitchell JD, Mathisen DJ, Wright CD, et al. Resection for bronchogenic carcinoma involving the carina: long-term results and effect of nodal status on outcome. *J Thorac Cardiovasc Surg* 2001;121:465–71.

Montgomery WW. The surgical management of supraglottic and subglottic stenosis. *Ann Otol Rhinol Laryngol* 1968;77:534–46.

Muniappan A, Wain JC, Wright CD, et al. Surgical treatment of nonmalignant

tracheoesophageal fistulae: a thirty-five year experience. *Ann Thorac Surg* 2013;95(4):1141–6.

Stock C, Gukasyan N, Muniappan A, et al. Hyperbaric oxygen therapy for the treatment of anastomotic complications after tracheal resection and reconstruction. *J Thorac Cardiovasc Surg* 2014;147(3):1030–5.

Wang H, Wright CD, Wain JC, et al. Idiopathic subglottic stenosis: factors affecting outcome after single-stage repair. *Ann Thorac Surg* 2015;100(5):1804–11.

Wright CD, Grillo HC, Mathisen DJ, et al. Anastomotic complications after tracheal resection: prognostic factors and management. *J Thorac Cardiovasc Surg* 2004;128:731–9.

EDITOR'S COMMENT

We are honored to have Professor Mathisen contribute this chapter. He is an international leader in this field. It is fitting that he holds the Hermes C. Grillo Professor of Thoracic Surgery, as we cannot talk about surgery of the trachea without mentioning Dr. Grillo. It is appropriate to digress at this point and share some facts concerning Professors Grillo and Mathisen.

Dr. Grillo was a great thoracic surgeon, who may have invented and popularized extensive resections of the trachea including the carina. He was born in Boston in 1923 and died at age 83 in Italy on October 14, 2006. He is considered the father of tracheal surgery. While in doing and working out the technique of resection of trachea and reanastomosis it became clear that 5 cm was the limit even with the Montgomery release, which he used to bring down the laryngeal structures and chin stitch, which I remember as a resident, that kept elevation of the chin from stretching the anastomosis. Dr. Grillo and I became very good friends.

Dr. Mathisen has been Chief of Thoracic Surgery at MGH since 1994 and was Chief of Cardiac Surgery during 2007–2011, and Program Director in Cardiothoracic Surgery since 1995. He has carried on the Grillo legacy.

Grillo successfully introduced and popularized tracheal resection and spawned a number of offspring, as it were, of which the senior author is one. It is only natural that attention would turn from being able to do tracheal repair to not being dependent on native trachea. Since the last edition, there have been substantial improvements or at least initial attempts, some successful, and improvement in substitutes for trachea.

One of the problems with trachea is that it has little in the way of specific vascular supply that one can identify and perform a microsurgical anastomosis. Thus, the reconstruction of a long segmental tracheal defect requires a vascularized allograft. The vascularity needs to be induced. In order to do so, the Belgium surgeon Delaere et al., from the KU Leuven Tracheal Transplant

Group (Tracheal allotransplantation after withdrawal of immunosuppressive therapy. Tracheal allotransplantation after withdrawal of immunosuppressive therapy *N Engl J Med* 2010;362:138–45), detail a profusely illustrated tracheal allograft, which was wrapped in the recipient's forearm fascia. At 4 months the tracheal chimera, which was now fully lined with mucosa that consisted of respiratory epithelium from the donor and buccal mucosa from the recipient, had begun to be placed once "revascularization was achieved." The recipient had been placed on immunosuppressive therapy, which was then withdrawn and then the tracheal allograft was moved to its correct anatomical position with an intact blood supply. This is a surgical tour de force. The patient reported was a 55-year-old woman who had been involved in a car accident and had undergone a tracheotomy with a long history of long tracheal stenosis. The fact that she is a woman and the cadaver donor was a male made it relatively easy to tell which cells in the allograft were which and indeed the 8-cm tracheal allograft from the recipient's forearm could be traced to having male donor respiratory cells as well as the tracheal allograft. Delaere's most recent review publication gave a state of art update and is offered as a resource to the reader (Delaere PR. Tracheal transplantation. *Curr Opin Pulm Med* 2012;18:313–20).

Replacing the trachea is not a new idea. In 1979, Rose et al. (Tracheal allotransplantation in man. *Lancet* 1979;1:433) reported the first allogenic tracheal transplant in a human. The donor trachea was originally implanted heterotopically, very much as here, in the sternocleidomastoidal recipient and transferred to the orthotopic position 3 weeks later. The recipient was not given immunosuppressive therapy, however. The report did not document the viability of the allograft, and no information has been made available about the long-term outcome. In addition, Klepetko et al. (Heterotopic tracheal transplantation with omentum wrapping in the abdominal position preserves functional and structural integrity of a human tracheal allograft. *Journal of Thoracic Cardiovascular Surgery* 2004;127:862–7) reported a preserved viability of a heterotopically revascularized allograft, which was revascularized in the omentum of a patient who ultimately received a lung transplant from the same donor. However, the tracheal transplant was not utilized but its viability was documented for at least 60 days.

There has also been some controversy surrounding tracheal replacement since the 6e. Debate and scrutiny surrounded the reports of the development of an artificial trachea created in a bioreactor and its implantation. At the present time this debate can be simply summed up that such techniques are not ready for prime time.

Another way of approaching the same problem is to use a scaffold of inert material. Janssen et al. (Tracheal reconstruction: mucosal survival on porous titanium. *Arch Otolaryngol Head Neck Surg* 2009;135:472–8) used a porous titanium scaffold and mucosa on a pedicled fascia flap created in rabbits utilizing a two-stage procedure. They noted normal mucosa in a submucosal layer and vital cells on top of the titanium. They also noted multiple blood

vessels from the muscle layer through the titanium strut. Cytokeratin expression was present in the suprabasal and basal layers of the mucosal epithelium. All animals survived the reconstruction. As far as I am aware, this type of experiment has not been tried in humans.

Another approach was tried by Hodjati et al. (Tracheal reconstruction by reinforced Gore-Tex in esophageal submuscular tunneling: An experimental study. *Ann Thorac Med* 2011;17–21) in which 10 adult mongrel dogs had a segment of seven tracheal rings resected circumferentially and a submuscular tunnel was induced between the muscular layers of the adjacent esophagus right next to the trachea. Implanted Gore-Tex passed through reinforcing the trachea and the anastomosis was made between distal ends of Gore-Tex and the trachea. Their criteria and end points were air tightness, good reepithelialization, and no limitation on esophageal length, which were all important. The Gore-Tex grafts were implanted and harvested 12 weeks after the implantation and the epithelialization that resulted was with mixed squamous/mucociliary metaplasia. It does seem as if this is another model that can be used for this important work.

Some newer experimental approaches which are being tested in animal models and in vitro include the use of cryopreserved tracheal allograft (Candas F, Gorur R, Haholu A, et al. Is tracheal transplantation possible with cryopreserved tracheal allograft and hyperbaric oxygen therapy? An experimental study. *Ann Thorac Surg* 2016;101:1139–44), the vacuum seeding BM-MNCs on nanofiber scaffolds for immediate implantation as tracheal interposition grafts to generate tissue engineered tracheal grafts in the lab of Chris Breuer (Clark ES, Best C, Onwuka E, et al. Effect of cell seeding on neotissue formation in a tissue engineered trachea. *J Pediatr Surg* 2016:49–55) and applications of chondrocyte-based cartilage engineering (Phull A, Eon S, Abbas Q, et al. Applications of chondrocyte-based cartilage engineering: an overview. *Biomed Res Int* 2016;2016:1879837).

Finally, in patients with tracheostomies, other than stenosis, a well-recognized complication is trachea-innominate arterial fistula. Tracheo-innominate artery fistula (TIF) is an uncommon but life-threatening complication after a tracheostomy. Rates between 0.1% and 1% after surgical tracheostomy have been reported, with a peak incidence at 7 to 14 days post procedure. Initial case reports of TIF resulted from surgically performed tracheostomies. This results in acute exsanguinating hemorrhage sometimes heralded by a sentinel bleed. I do not know how many of the readers have ever seen the rupture of a trachea-innominate artery fistula, but it is impressive. It is usually fatal unless treatment is instituted immediately. It may occur after percutaneous tracheostomy as well as a surgical tracheostomy. The literature describes methods of air way control, tamponade, and emergent ligation of the innominate artery. More recent publications describe percutaneous stenting as a way to provide initial treatment.

Prevention is the key as treatment outcomes are poor. To this end Sung et al.

(Is computerized tomography angiographic surveillance valuable for prevention of tracheoinnominate artery fistula, a life-threatening complication after tracheostomy? *J Korean Neurosurg Soc* 2011;49:107–11) focused on different measurements by CT angiography on 22 patients who had tracheostomies. They wished to evaluate the relationship between the tracheostomy tube and the innominate artery utilizing the proximal tube position on the cervical vertebra, the distal tube position, and the course of innominate artery and the gap between the tube and the innominate artery. After some complicated measurements they came to the conclusion that a low tracheostomy tube departure level was an indicator that some potential complication. Only 6 of the 22 patients were free of difficulties in these observations. These writings suggest that if one is concerned about this disastrous complication, there may be a way to avoid it.

Tracheal resection, reanastomosis, and the elimination of tracheostomy and tracheal stenosis are excellent advances in thoracic surgery. American surgery is pleased to have been able to call Dr. Hermes Grillo a friend and we are secure in the knowledge that Dr. Mathisen will carry on the tradition.

Josef E. Fischer and E. Christopher Ellison

35 Penetrating Neck Injuries

Alain Corcos and Andrew B. Peitzman

> but one spot lay exposed, where collarbones lift the neckbone off the shoulders, the open throat, where the end of life comes quickest
> Book 22: The Death of Hector, The Iliad

ANATOMY

Few areas of the body concentrate vital anatomy as in the neck. Notable structures include the pharynx; larynx; trachea; esophagus; common carotid artery; internal carotid artery; external carotid artery and its branches; the vertebral and subclavian arteries; the internal and external jugular veins and their tributaries; cranial nerves IX to XII (glossopharyngeal, vagus, spinal accessory, and hypoglossal); thyroid, parathyroid, and submandibular glands, and the bony spine and spinal cord. Thorough knowledge of the anatomy of this region is essential.

The platysma muscles spread subcutaneously as a sheet across the entire length of the lower border of the mandible down to and across the entire length of the clavicle below, distinguishing superficial from deep layers. Deeper fasciae envelope the infrahyoid “strap” muscles (sternohyoid, omohyoid, and sternothyroid) laterally and encircle the esophagus and trachea centrally. Palpable landmarks along the midline of the neck, which is not covered by platysma muscle, include the thyroid cartilage superiorly, the cricoid cartilage more caudally, and the suprasternal notch at the base of the neck between the clavicles.

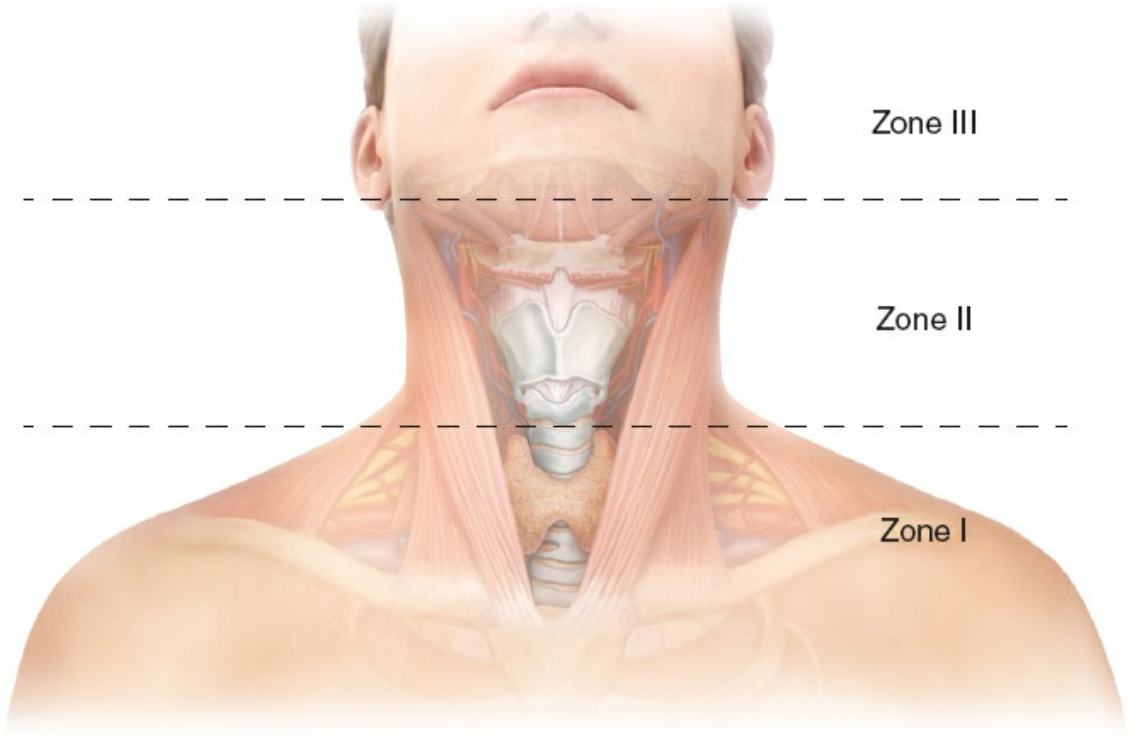

Figure 35.1. Anatomic zones of the neck.

Traditionally, anatomists divide the neck into triangular areas (Fig. 35.1), bordered by musculature and bony landmarks, while surgeons refer to Monson's three "zones" of the neck. The dominant muscular landmark of the lateral neck is the sternocleidomastoid muscle. Coursing obliquely from the skull base to the sternum and medial clavicle, the sternocleidomastoid separates anterior and posterior triangles. The anterior triangle is further bounded by the midline and lower border of the mandible and contains the "carotid bundle" (carotid artery and bifurcation, internal jugular vein, and vagus nerve) (Fig. 35.2). Zone I of the neck extends from the clavicle to the cricoid cartilage, zone II from the cricoid to the angle of the mandible, and zone III from the angle of the mandible to the skull base. Surgeons have historically favored the zone classification because it is useful to predict operative access. Injuries within zone II are readily exposed and repaired (Fig. 35.3); access to injury within zone I (the thoracic outlet) (Fig. 35.4) or III (the skull base) is far more challenging (Fig. 35.5).

CLINICAL PRESENTATION AND DIAGNOSIS

Patients who are in shock, have airway compromise, or other "hard signs" of visceral injury should undergo immediate exploration after penetrating

injury to the neck (Table 35.1). Without these hard signs on admission, the approach to penetrating neck injury has changed dramatically over the past several decades. Mandatory surgical exploration of injuries in zone II as practiced for decades traded ease and reliability for a high rate of negative and nontherapeutic operation. Over time, a more selective operative approach, based on findings from various arteriography or gastrografin/barium swallow and endoscopic studies, replaced this one-time standard. With the advancements in technology associated with the multislice helical CT, CT angiography (CTA) has emerged as the screening modality of choice for penetrating neck wounds in patients without hard signs for immediate exploration. CTA is the next step after history, physical examination, and chest radiograph—irrespective of the zone of injury (Fig. 35.6). It is easily accessible, well tolerated with minimal risk, sensitive for defining trajectory, and reliable for excluding significant arterial injury. Venous injuries which are not apparent on physical examination, meaning no evidence of active bleeding, generally do not require an operation (low pressure system). Nearly all tracheal injuries will have obvious signs or symptoms revealing their presence on admission (crepitance, sucking wound, etc.). Fortunately, aerodigestive tract injuries are uncommon, but are easily missed, and may not be apparent on clinical assessment alone. Abnormalities identified on CTA or trajectory suspicious for aerodigestive tract injury should be further evaluated with surgical exploration, laryngoscopy, tracheobronchoscopy, catheter-based arteriography, esophagoscopy, or esophagography as suggested by CTA, symptoms, or other findings. Soft signs mandate further evaluation of the patient with penetrating neck injury (Table 35.2).

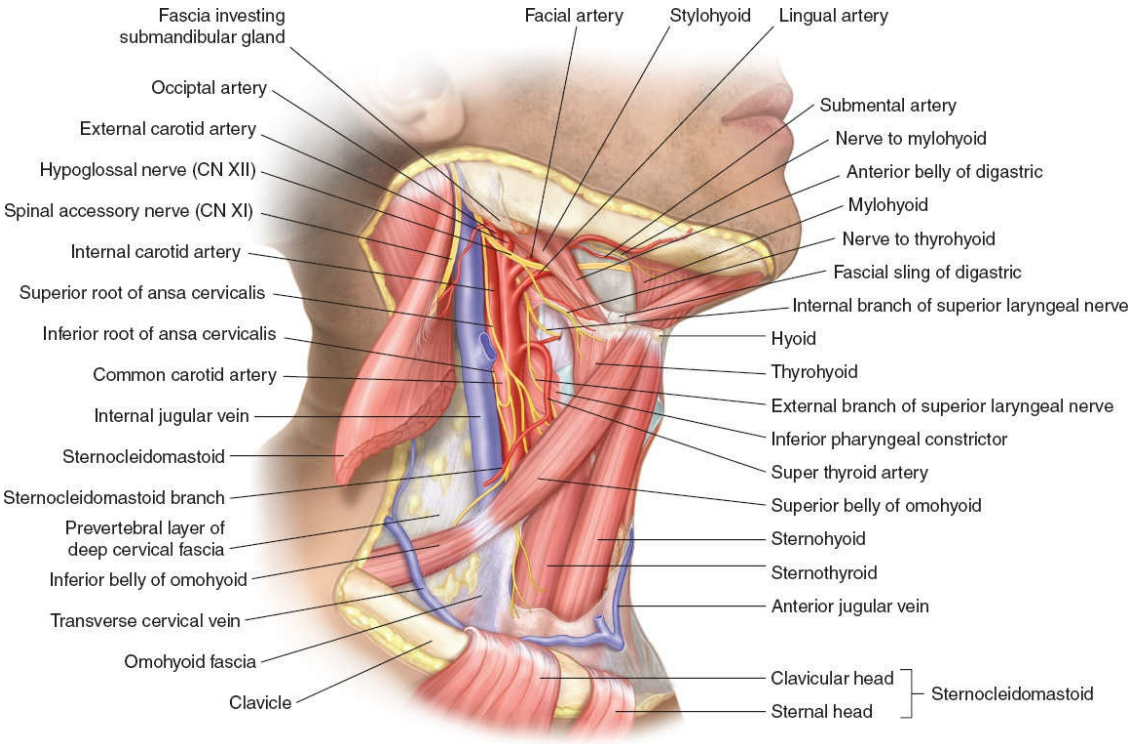

Figure 35.2. Deep dissection of the carotid triangle.

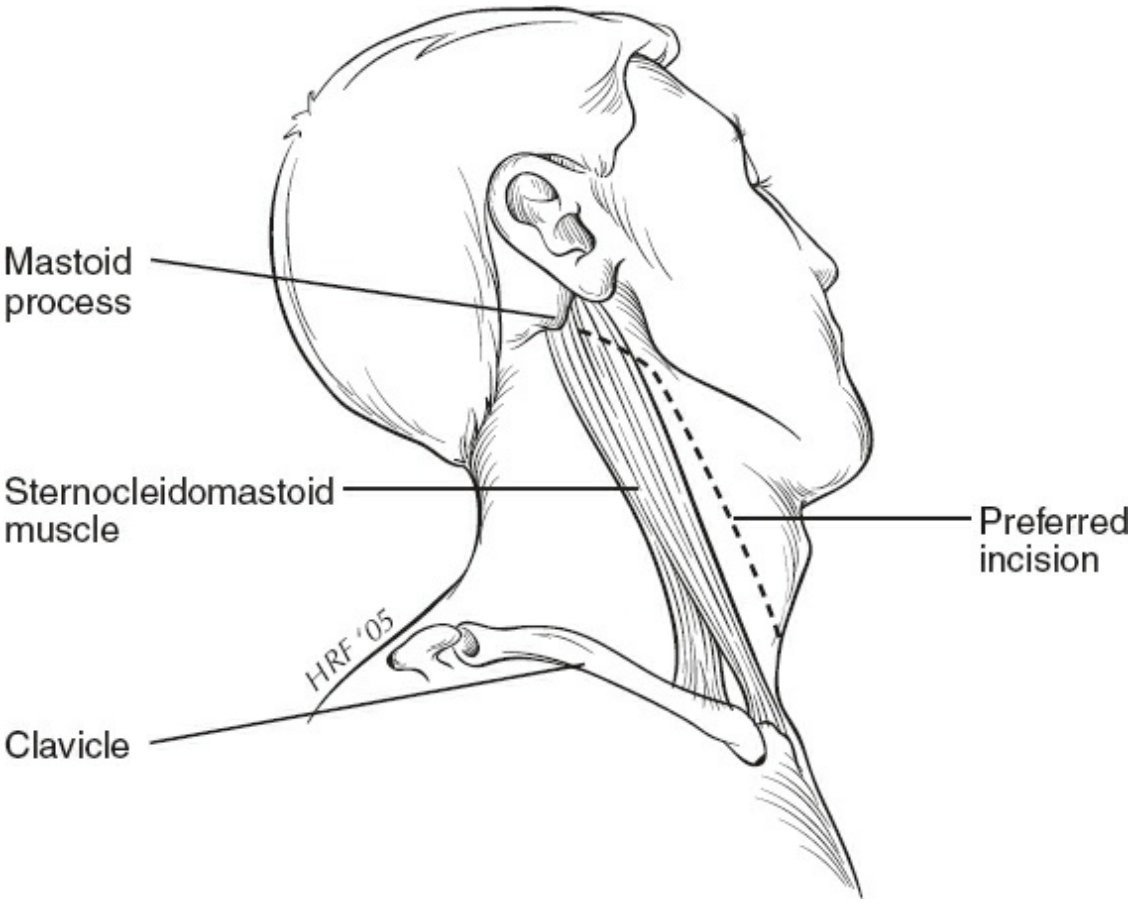

Figure 35.3. Incision for neck exploration is along the anterior border of the sternocleidomastoid muscle.

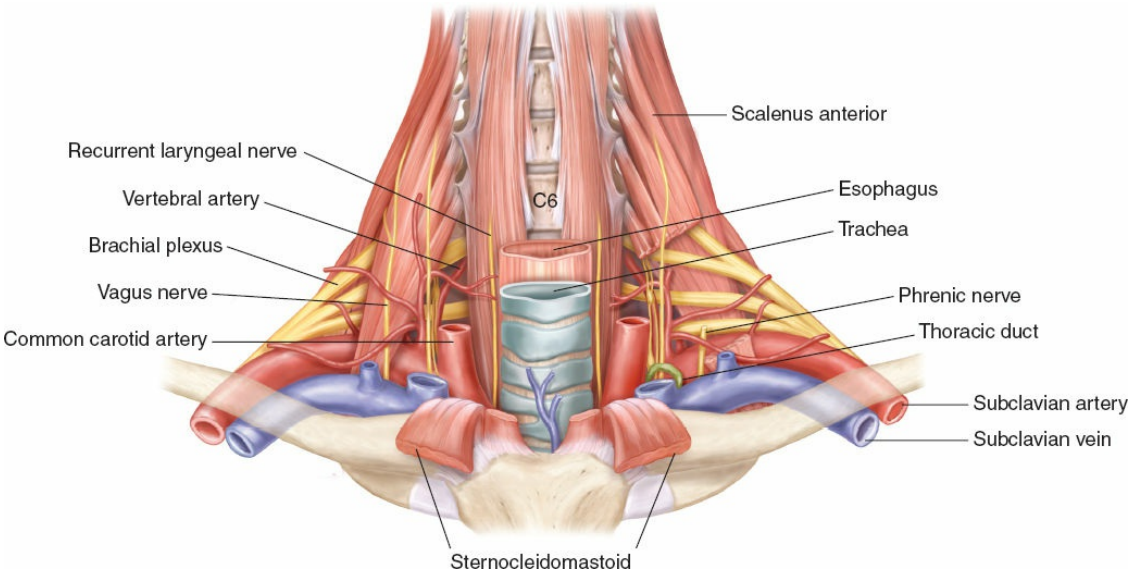

Figure 35.4. The surgical anatomy of the superior mediastinum and neck with its proximity of the vessels and nerves around the aerodigestive tract.

TABLE 35.1 Hard Signs: Mandatory Neck Exploration

Shock
Pulsatile bleeding
Expanding hematoma
Signs of stroke/cerebral ischemia
Unilateral extremity pulse deficit
Airway compromise
Extensive subcutaneous emphysema or bubbling wound
Stridor, hoarseness
Audible bruit/thrill (CTA first, if stable)

Several studies have reported that many of the patients who are asymptomatic after penetrating neck injury can be admitted and observed without further evaluation beyond history, physical examination, and chest radiograph (neck films if indicated). However, physical examination is unreliable to exclude aerodigestive tract injuries in the asymptomatic patient with penetrating neck wounds deep to the platysma muscle. A comprehensive literature review by the Practice Management Guidelines Committee of the Eastern Association for the Surgery of Trauma in 2008 concluded that “either contrast esophagography or esophagoscopy can be

used to rule out an esophageal perforation that requires operative repair." Furthermore, patients admitted for observation without further workup should be reexamined frequently by the same surgeon; this is labor intensive, difficult in a busy center, and may require a mean hospital stay up to 2.5 days. This may be useful in areas where technology is limited. In a busy trauma center with the resources, screening CTA allows more rapid triage, identification of injuries, and definitive treatment—this is our approach.

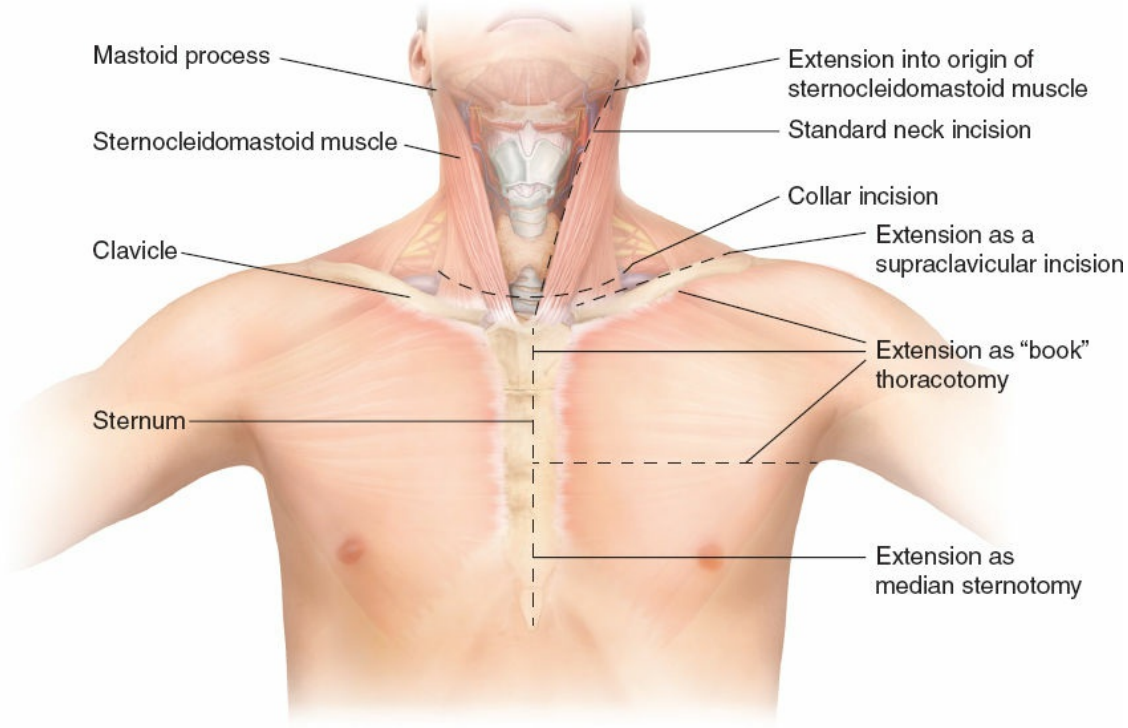

Figure 35.5. Incisions for exposure of penetrating neck injuries.

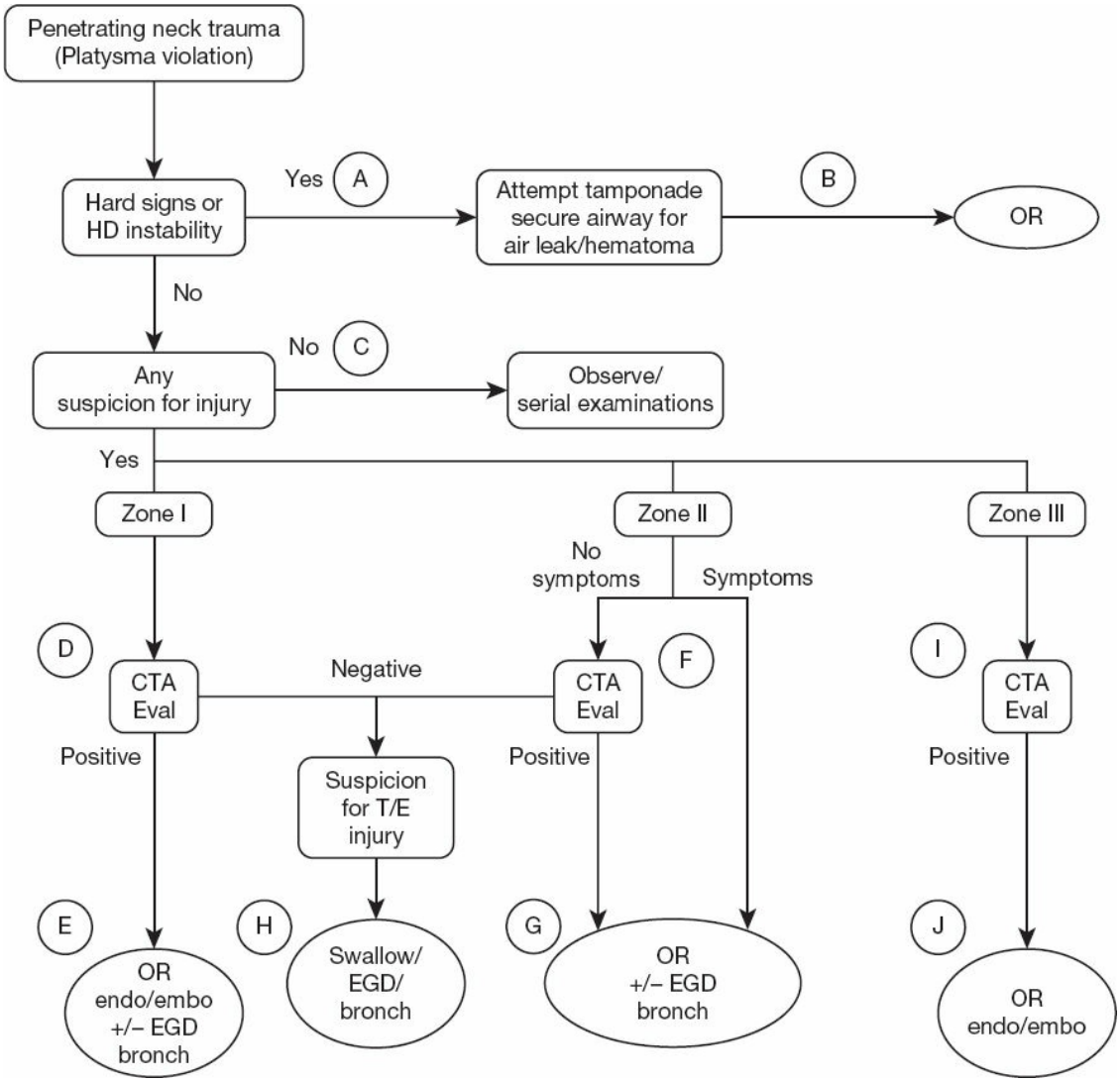

Figure 35.6. Western Trauma Association management algorithm for penetrating neck trauma. (From Sperry JL, Moore EE, Coimbra R, et al. Western Trauma Association critical decisions in trauma: penetrating neck trauma. *J Trauma Acute Care Surg* 2013;75(6); Figure 1, page 937; with permission from Wolters Kluwer Health, Inc.)

TABLE 35.2 Penetrating Neck Injury: Soft Signs

Dysphagia
Voice change
Hemoptysis
Hematemesis
X-ray finding abnormality
Crepitance
Hematoma of the neck
Peripheral neurologic abnormality

Primary Survey

As always, the principles set forth by Advanced Trauma Life Support guide the initial assessment of the patient with penetrating neck injury. Important historical information includes mechanism of injury and blood loss at the scene. Gunshot wounds have a significantly higher likelihood of vital-structure injury than stab wounds. The primary survey will identify patients in shock or with clear signs of vital-structure injury such as airway compromise, massive subcutaneous emphysema, sucking wound, active hemorrhage, expanding or pulsatile hematoma, carotid bruit or thrill (CTA may be helpful in a stable patient), neurologic defect, or absent/decreased radial pulse in the ipsilateral upper extremity. Immediate surgical intervention is indicated when any of these “hard” signs are documented (see Table 35.1).

Airway Management

Impending airway occlusion can occur with any tracheal or laryngeal injury, with compression from a large or expanding hematoma, or from intraoral hemorrhage. Control of the airway is a priority in these patients and may be accomplished by oral endotracheal intubation, cricothyroidotomy, or formal tracheotomy. If time allows, these airways are best managed in the operating room with full access to good lighting and surgical equipment. While blind nasotracheal intubation is contraindicated in this setting, fiberoptic bronchoscopy-assisted nasotracheal intubation can be helpful when tracheal deviation from large hematoma is present. Patients with significant intraoral hemorrhage often need to remain sitting rather than in the supine position to avoid essentially drowning in their own blood. Recognize these patients who are staying alive breathing on their own, but may not be able to be intubated after

rapid sequence intubation—and are now apneic. This uncommon patient will require awake intubation, or at times, a surgical airway with sedation.

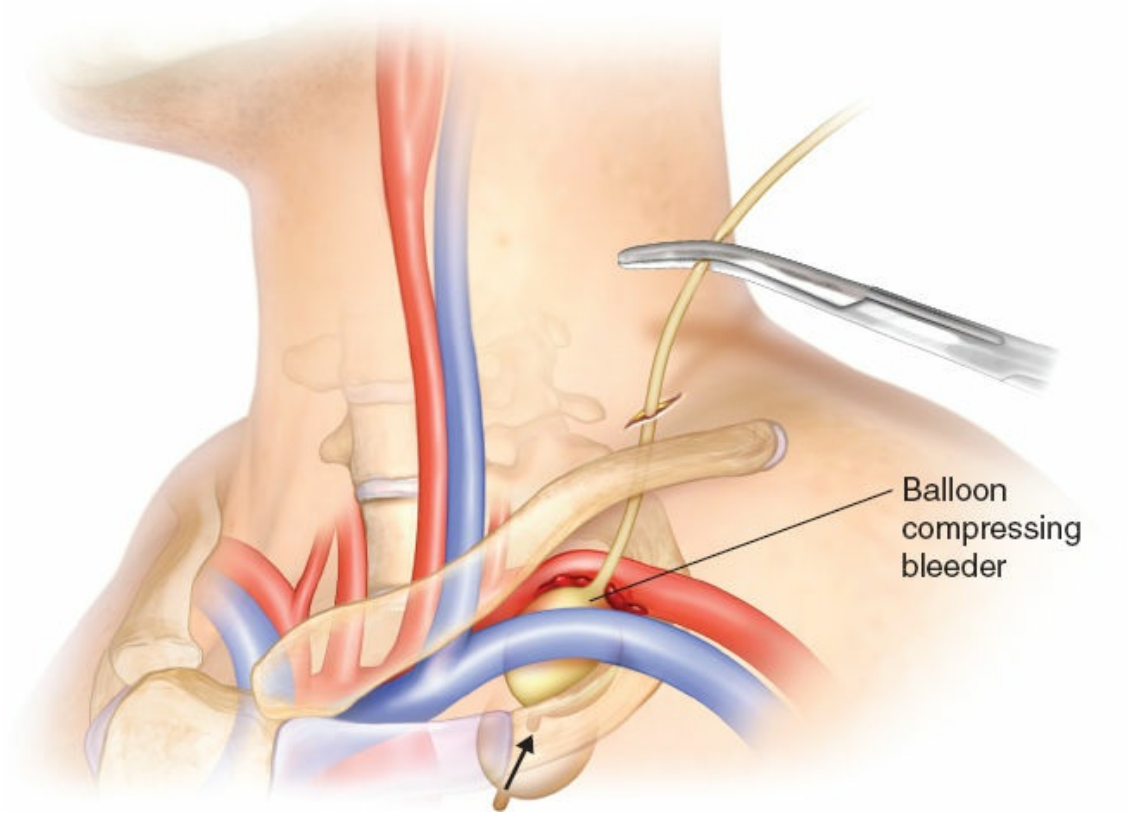

Figure 35.7. Balloon tamponade for bleeding control from the subclavian vessels. It can also be used for bleeding control from other zones in the neck.

Cricothyroidotomy is the quickest and most efficient way to access and secure the airway when oral intubation is unsuccessful. Understand that this operation is conducted with palpation more than visualization. Stay in the midline to avoid bleeding from the anterior jugular veins. If they are injured during the procedure, complete cannulation of the trachea and then control the venous bleeding. The operator should be on the patient's right side and should begin by palpating the superior and inferior aspects of the thyroid cartilage and securing this structure with the left hand between the thumb and middle fingers, leaving the index finger free to palpate the membranous space between the thyroid and cricoid cartilages. A vertical or transverse incision is made at this level, and the subcutaneous tissues are separated bluntly with a straight or curved clamp to the cricothyroid membrane, which is then incised with a No. 11 or 15 knife blade for direct access to the subglottic space. (Avoid cutting too deeply to protect the

posterior membranous trachea and more deeply located esophagus.) This should allow entry of the left index finger for control and dilatation. Alternatively, one can use the knife handle to dilate the space. A No. 6 endotracheal tube can then be positioned and secured. When a cricothyroidotomy is required, it should be converted to a tracheotomy at the earliest safe opportunity.

Circulatory Support

Large-bore peripheral venous catheters are adequate for circulatory support; however, avoid the ipsilateral upper extremity as an access site in patients with zone I (thoracic outlet) entry or trajectory. A plain radiograph of the chest should be obtained to assess for hemopneumothorax. Active hemorrhage from a wound in the neck in any zone is best managed by digital compression until the airway is controlled and surgical access can be obtained. If digital pressure fails to control the bleeding, insertion of a balloon catheter (Foley catheter) to control hemorrhage in the oral cavity or through the gunshot wound at the thoracic outlet may be necessary for temporary control of hemorrhage (Fig. 35.7).

PREOPERATIVE PLANNING

In the symptomatic patient who requires surgery without prior diagnostic testing, zone of entry and likely trajectory are important to plan exposure (see Fig. 35.5). The patient should be positioned supine, with arms tucked, neck extended, and head deviated slightly away from the side of injury; some surgeons find the beach chair position or reverse Trendelenburg helpful. A towel roll placed beneath the shoulders will extend the neck. The sterile preparation should include both sides of the neck from the temporomandibular joint to the lower lip down to and including the entire anterior chest. Zone II injuries are best approached via an oblique incision along the anterior border of the sternocleidomastoid muscle from the angle of the jaw to the clavicular head. With zone I entry, the surgeon should be prepared to perform a median sternotomy for access to and repair of structures in the thoracic outlet or base of the neck. In this circumstance the ipsilateral arm should be free and prepped to the elbow. A horizontal incision along the superior aspect of the clavicle will supply access to the proximal subclavian vessels and innominate vessels on the right. This incision may be independent or can extend an anterior sternocleidomastoid or median sternotomy incision when necessary. Clavicle resection may be

required on occasion. Access to the left subclavian artery at its origin can be difficult through a median sternotomy because of its posterior position on the aortic arch. Exposure here may require a third interspace left anterior thoracotomy (Fig. 35.8). Wounds in zone III may require a curvilinear posterior extension over the mastoid process to allow exposure of the distal internal carotid artery to the skull base. A horizontal "collar" incision can offer excellent exposure to multiple zones when subplatysmal flaps are developed. This incision is most useful for isolated laryngotracheal injuries that require a surgical airway or axial traverse gunshot wounds that require bilateral exploration.

SURGICAL TECHNIQUE

Standard Exposure (Zone II)

Injuries in zone II are both more frequent and more accessible than those at the skull base (zone III) or thoracic outlet (zone I). An incision along the anterior border of the sternocleidomastoid muscle offers the best access to all of the important vascular and aerodigestive structures of the neck (Fig. 35.4). As described above, this incision can also be extended to allow exposure to the thoracic outlet and skull base if needed (see preoperative planning). We prefer the semi-Fowler position with the neck extended and turned slightly away from the surgeon. The anterior chest should be prepared and accessible but may be draped. The ear lobe, chin, and entire lateral neck should be in the surgical field for easy orientation. On the left side we pay particular attention to trajectories that suggest zone I involvement as these patient will also have their left arm prepared to the elbow with the forearm and hand in a sterile wrap (i.e., self-adhesive Coban), so that the entire arm is free and mobile in the surgical field. With a towel roll elevating the shoulder, this preparation will facilitate exposure to the proximal left subclavian via a high anterolateral thoracotomy should that be necessary for control or repair (see exposure of the thoracic outlet). Separate right and left incisions may be made when bilateral exploration is required.

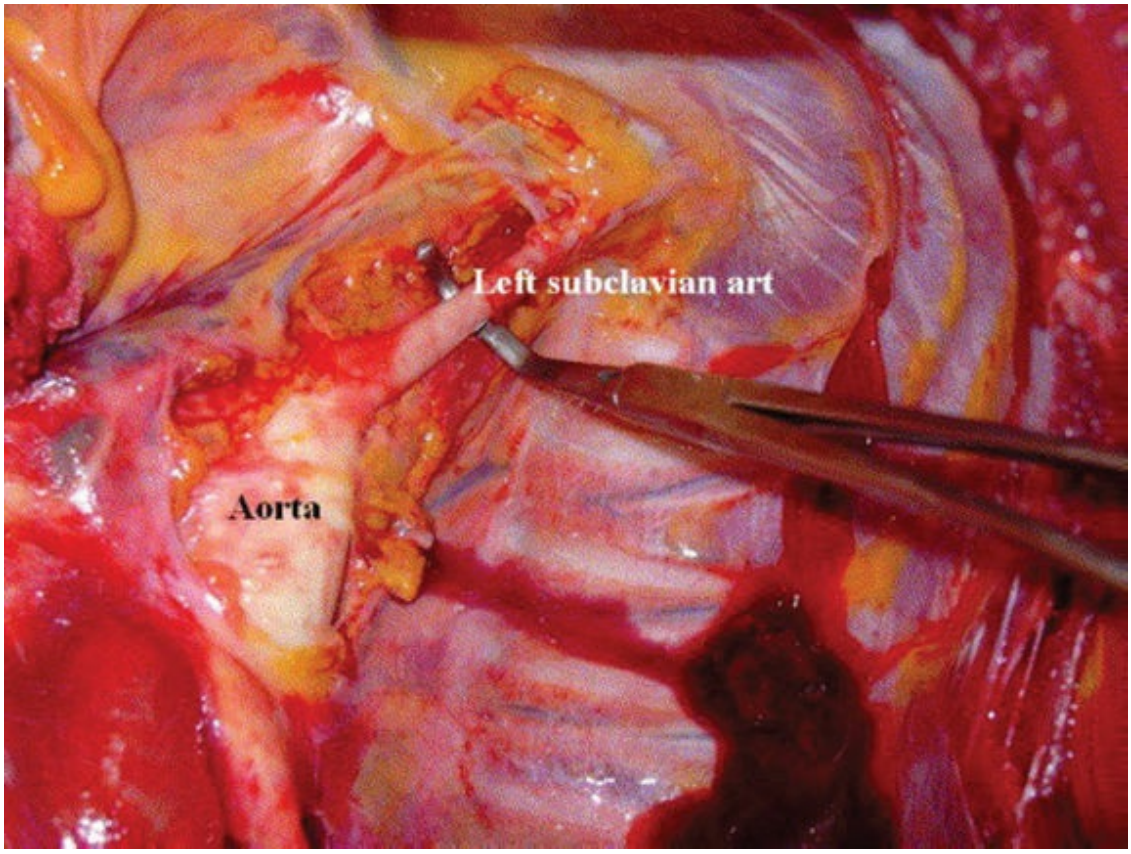

Figure 35.8. Bleeding from the left subclavian artery may be controlled in the apex of the hemithorax through a left thoracotomy. (Reprinted from Demetriades D, Salim A, Brown C, et al. Neck injuries. *Curr Problem Surg* 2007;44(1); Figure 19, page 64, with permission from Elsevier.)

The skin incision should begin near the angle of the jaw and extend down to the sternum. After incising the platysma muscle, a layer of investing fascia is encountered and taken (in line with the skin and platysma incisions) along with two cutaneous nerves (the greater auricular and anterior cervical) and the transverse portion of the anterior jugular vein. This vessel connects the external jugular (posterolateral) to the anterior jugular (anteromedial), is variable in location, and lies intimate to the undersurface of the platysma. It can be prominent and should be ligated when encountered. The plane along the anterior border of the sternocleidomastoid is now further developed, allowing posterolateral retraction and access to the carotid bundle. Two blunt Weitlaner self-retaining retractors positioned at the ends of the wound will open this space adequately. Alternatively, two right-angle retractors similarly positioned with retraction laterally by an assistant is sometimes less cumbersome. The internal jugular vein lies most prominently in this space

and obscures the carotid artery, which at this point in the dissection should be easily palpable. An injured internal jugular vein will stain this space and surrounding tissues with dark blood and clot but will also aid in the dissection. Digital manual pressure is the most effective initial maneuver, followed by ligation of the facial vein, which courses to the internal jugular directly over the carotid bifurcation from the midline, serving as a landmark for the surgeon (Fig. 35.2). The internal jugular vein can then be repaired or ligated as indicated (see treatment). Lateral retraction of the internal jugular will now reveal the carotid artery and vagus nerve and repositioning of the self-retaining or manual retractors will maintain exposure. The vagus nerve travels between the carotid and jugular and care must be taken when retracting the vein to protect this cranial nerve from injury.

As with any vascular injury, proximal and distal control should be obtained prior to entering a hematoma. However, this is often difficult in the tight confines of the lateral neck and proximal access alone will frequently suffice along with digital compression. Exposure of the proximal common carotid artery requires incision of the intermediate tendon of the omohyoid muscle (separating the superior and inferior bellies) along with the enveloping fascial sheath that tethers this muscle to the clavicle below (Fig. 35.2). A Kelly clamp introduced beneath the intermediate tendon along the course of the jugular vein facilitates development of this space allowing an assistant to incise the tendon without injury to the contents of the sheath. At a negligible cost to patient function, this release allows a more complete lateral eversion of the sternocleidomastoid muscle and should be a standard part of the dissection of the lateral neck for trauma. The proximal exposure can be even further enhanced by liberating the sternal head of sternocleidomastoid muscle. This muscular attachment can be freed from the bony sternum with electrocautery and serves as an excellent interposition muscle flap should one be required. The release of the sternal head of the sternocleidomastoid muscle also offers exposure to the proximal vertebral artery for ligation when required (see treatment). To this end, dissection is along the lateral border of the internal jugular vein with retraction of the bundle medially. This repositioning allows dissection into the posterior triangle to encounter the supraclavicular fat pad. Careful blunt dissection here will reveal the first stage of the vertebral artery deep in the thoracic outlet.

Exposure at the Skull Base (Zone III)

To expose the internal carotid artery at the skull base, a “hockey stick” extension curves the superior aspect of the skin incision toward the back of the ear along the mastoid process. Anatomy in this region is dense with cranial nerves that should be preserved. The glossopharyngeal nerve (cranial nerve IX) coursing anteriorly, and spinal accessory nerve (cranial nerve XI) coursing posteriorly, depart quite high, while the hypoglossal nerve (cranial nerve XII), as it swings down beneath the occipital branch of the external carotid artery en route to the tongue, is most vulnerable (Fig. 35.9A). The dissection here should begin with division of the posterior belly of the digastric muscle. The occipital branch of the external carotid and the less important ansa cervicalis (innervation to the strap muscles) can be sacrificed to preserve the hypoglossal nerve, which can now be retracted anteriorly (Fig. 35.9B). This maneuver alone can free up to 2 cm of internal carotid artery. Further exposure at the skull base can best be accomplished via a vertical ramus osteotomy, a procedure familiar to maxillofacial surgeons as a method to correct prognathism (extreme under-bite). Kumins et al. describe several advantages to this procedure over a temporomandibular subluxation. They describe it as follows:

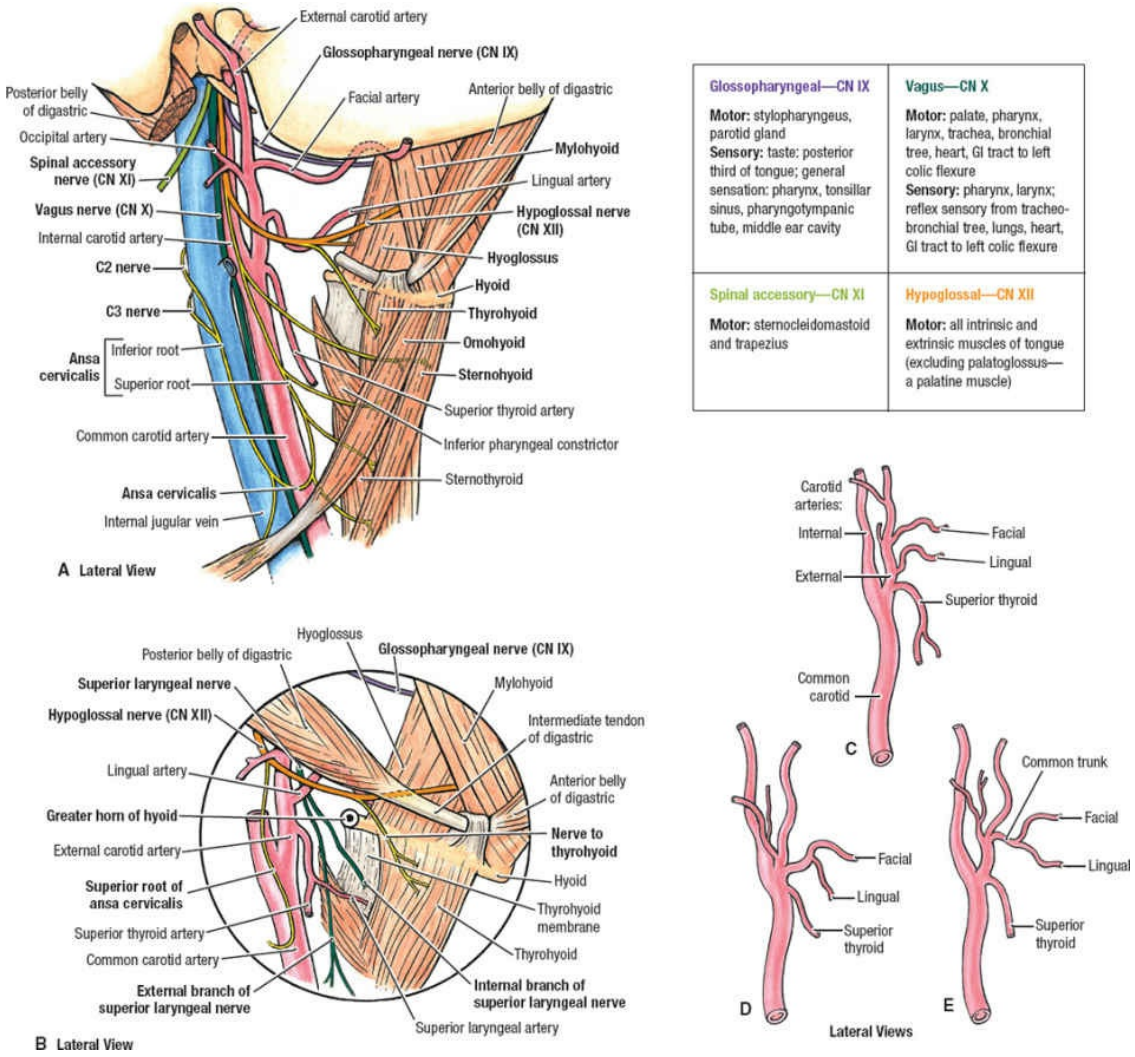

Figure 35.9. Anatomy pertinent to internal carotid artery exposure.

The ramus is approached by dissecting in a plane anterior to the masseter muscle and deep to the parotid gland. This exposure avoids injury to the branches of the facial nerve. The masseter muscle is elevated laterally from the mandibular angle to the sigmoid notch. A mark identifying the planned osteotomy is made with a small reciprocating saw. The osteotomy is designed to lie posterior to the entrance of the inferior alveolar nerve into the mandible. The bony transection courses vertically from the depth of the sigmoid notch to the angle of the mandible (Kumins et al., 2001).

Once the osteotomy is completed, the posterior segment is rotated anteriorly and superiorly. This provides access to the distal internal carotid artery up to the skull base. The mandible is repaired with miniature titanium plates that are positioned prior to the osteotomy to ensure realignment.

Hemorrhage Control at the Skull Base

Clearly, dissection at the skull base is a challenge even when structures are not obscured by active bleeding or hematoma. A more practical approach to exsanguinating hemorrhage from injury at this level of the internal carotid is to place a small thrombectomy catheter into the vessel through an arteriotomy in the common or proximal internal carotid artery and inflate the balloon at various levels until the bleeding is controlled. This technique can also control unrelenting bleeding from the vertebral artery when proximal ligation is insufficient. Dissection can then proceed, or, in the case of hemodynamic instability, the catheter can be left in place, sutured to the vessel and secured at the skin, for 48 hours. This approach is essentially equivalent to ligation of the internal carotid and should be reserved as damage control for patients in extremis.

Exposure at the Thoracic Outlet (Zone I)

Vascular injuries in the superior mediastinum often require exposure at the aortic arch. Again, an understanding of anatomy in this region is critical to obtain adequate access and exposure and avoiding iatrogenic injury. Important nerves to preserve include the vagus, phrenic, and recurrent laryngeal. On the right side, median sternotomy as an extension of the sternocleidomastoid incision will grant excellent access for control and repair of the brachiocephalic trunk (innominate artery), proximal subclavian artery, and first portion of the vertebral artery. On the left side, the left subclavian artery's posterior orientation as it emerges from the aortic arch renders it difficult to access and debate persists as to the optimal approach.

Patients in extremis with a zone I trajectory and massive ipsilateral hemothorax should have a Foley catheter placed into the wound and the balloon inflated for tamponade. If this is difficult or unsuccessful, they should undergo anterolateral thoracotomy in the emergency department and bimanual compression of the thoracic outlet with one hand inside the chest and the other outside at the base of the neck until optimal exposure can be achieved in the operating room. More often, thoracic outlet vascular injuries are contained in the superior mediastinum and some time is available to plan and optimize an approach. As described above, the ipsilateral arm should be prepared and freely mobile when approaching zone I injuries.

When a median sternotomy extends the standard neck incision (Fig.

35.5), the musculature attachments to the sternoclavicular joint (sternal head of the sternocleidomastoid, sternohyoid, and sternothyroid) are released at their insertion and the thymus and innominate vein are divided with suture ligature. A contained hematoma in the superior mediastinum should never be violated until proximal and distal control are achieved. For proximal control, this is accomplished by incising the pericardium to gain access to the arch of the aorta. The brachiocephalic trunk (innominate artery) can then be controlled with a vessel loop for injuries to the right side. For injuries to the left, the left common carotid artery is similarly encircled. Dissection can then proceed from the neck incision cephalad. With the innominate vein ligated, the right internal jugular vein is retracted laterally to further expose the vagus nerve, which at this level emerges from its posterior lie to cross the proximal subclavian artery anteriorly. Veins (brachiocephalic, innominate, right and left subclavian) reside more anteriorly in the thoracic outlet and like the internal jugular (see treatment), can be repaired if small and simple or ligated if large and complex. On the left, the thoracic duct joins the confluence of the left subclavian and left internal jugular veins and should be ligated when injured. The anterior scalene muscle is another important anatomical landmark in this area. The subclavian artery travels deep to it and the important phrenic nerve courses diagonally from lateral to medial just on top of it. If the anterior scalene muscle requires ligation the phrenic nerve must be identified and retracted away. The muscle should be divided sharply rather than with electrocautery as these important structures are intimate to the muscle and at risk for thermal injury. Release of the anterior scalene will grant access to the more distal subclavian artery, where the vertebral and internal mammary arteries emerge.

On the left side, a posterolateral thoracotomy offers the best exposure to the posterior aortic arch and origin of the left subclavian artery but requires lateral positioning, which is ill-advised in the trauma patient because zone II and the distal subclavian and axillary arteries become inaccessible. Consensus favors a left anterolateral thoracotomy incision (third interspace) for access to the take-off of the left subclavian artery paired with a separate supraclavicular, standard neck, or infraclavicular incision for access to the remainder of the left subclavian artery depending on what needs to be accomplished (Fig. 35.8). The proximal supraclavicular incision offers access via the anterior scalene release while the more distal infraclavicular incision is an excellent option if the axillary artery is

needed for distal anastomosis of an interposition graft. The laterally oriented pectoralis major musculature is split and retracted to reveal vertically oriented pectoralis minor muscle near its origin at the coracoid process. The pectoralis minor is then divided to expose the second portion of the axillary artery. Alternatively, a clavicle resection can be performed. A median sternotomy with left supraclavicular extension (Fig. 35.5) has also been described as a reliable option. Following the muscle release and ligation of the innominate vein, the left common carotid artery can then be retracted medially to expose the first stage of the left subclavian artery at a depth of 5 to 7 cm. The oft-mentioned "trapdoor" exposure joins an anterolateral thoracotomy to a supraclavicular incision via a limited sternotomy. We prefer the median sternotomy with supraclavicular extension for its ease and versatility; an additional anterolateral thoracotomy extension improves the traditional trapdoor. Although the subclavian artery has many branches, none besides the vertebral are essential. Relative to other arteries of similar size, the subclavian wall is thin and easily damaged. Important nerves are dense in this area. The brachial plexus forms from cervical nerve roots and travels through the thoracic outlet deep to the vasculature, while the phrenic and vagus nerves cross much more anteriorly. The recurrent laryngeal nerve (a branch of the vagus nerve) loops the subclavian on the right and the aortic arch on the left from anterior to posterior.

TREATMENT

Carotid Artery

Carotid artery injuries should be repaired except in rare circumstances. Primary repair, patch angioplasty, and interposition grafting are all options depending on the nature of the injury (Fig. 35.9). Small, clean wounds (i.e., stab wounds <2 cm) that can be approximated without significant narrowing should be repaired with nonabsorbable, monofilament suture (4-0, 5-0, or 6-0 polypropylene). Saphenous vein or polytetrafluoroethylene (PTFE) can be used for patch repair in cases where primary closure would narrow the vessel or as an interposition conduit when segmental resection is required and end-to-end repair is restricted by tension. PTFE as a conduit has not been shown to increase the incidence of thrombosis or infection when compared to saphenous vein (Table 35.3).

Common carotid artery injuries are usually easy to access and repair even when complex; however, they may be ligated in the extreme case that

associated injuries or severe hemodynamic instability prevent repair—although a temporary shunt would be preferable. Antegrade flow to the internal carotid via the external carotid is possible, and patients with adequate collateral cerebral blood flow (intact circle of Willis) will tolerate unilateral common carotid artery occlusion. External carotid artery injuries and injuries at the carotid bifurcation can be repaired when simple, but complex injuries can be ligated because collateral supply from the face and scalp is reliably ample. Injuries involving the internal carotid artery should be repaired when simple and the patient's condition permits, especially when patency is preserved. Controversy persists with regard to treatment of the injured and occluded internal carotid artery in the face of focal neurologic deficit or coma. The theoretical risk of reinstituting antegrade flow to the brain in the setting of cerebral ischemia is that of hemorrhage into the ischemic or infarcted area, aggravating brain injury. A reasonable approach to this dilemma is to base the decision to repair on the presence or absence of back bleeding from the distal internal carotid or obvious evidence of clot. Brisk blood flow from the distal end confirms adequate collateral cerebral flow, in which case repair should be safe. Aside from coma, which carries a dismal prognosis, neurologic deficits identified in patients with penetrating neck injury preoperatively are more likely to improve or remain unchanged with repair than with ligation.

TABLE 35.3 Principles of Repair of the Carotid Artery

- Systemic heparinization (100 U/kg) if complex repair (resection with end-to-end anastomosis or interposition graft) or repair at base of skull will be necessary
- No intraluminal shunt unless inadequate back-bleeding or prolonged repair at base of skull will be necessary
- Interrupted 6-0 polypropylene repair in children or in internal carotid artery in all patients
- Flushing sequence after verifying back-bleeding is externally, and then into the external carotid artery, and finally flow is reestablished into the internal carotid artery

From Feliciano DV, Vercruysse GA. In: Mattox KL, Moore EE, Feliciano DV, eds. *Trauma*. 7th ed. New York: McGraw-Hill; 2013:414–29. Copyright McGraw-Hill Education.

A heparin bolus, either systemic (5,000 or 10,000 units) or regional (10 to 15 mL of 50 units/mL concentration injected proximally and distally), should be administered when repair requires vascular occlusion. A completion angiogram should be obtained following interposition grafting. Internal shunting (Javid) will decrease arterial occlusion time and should

be considered as an adjunct during any interposition grafting that includes the internal carotid artery.

Injuries to the carotid artery that demonstrate contrast extravasation (pseudoaneurysm or arteriovenous fistula) on imaging studies are best repaired surgically when accessible (zone II). When similar injuries occur at the skull base or thoracic outlet, endovascular interventions, such as stent placement or embolization, should be considered. A tear or dissection of the intima that does not limit flow (as with blunt force injury) can be observed with repeat imaging after a 2-week interval on anticoagulation.

Internal Jugular Vein

Any venous structure in the neck can be safely ligated. Small, simple lacerations to the internal jugular vein should be repaired with a 4-0 nonabsorbable, monofilament suture. Larger lacerations can be repaired as well, provided the patient's clinical condition permits. When both internal jugular veins are injured, an attempt at repair of one should be made. Any neck-vein ligation should be done with a suture ligature to avoid postoperative bleeding from pressure-induced slippage of a simple tie.

Vertebral Artery

Vertebral artery injuries are much less common than carotid artery injuries and the vast majority are diagnosed by angiography (CT or catheter-based) in hemodynamically stable patients. Optimal treatment is coil or gel-foam occlusion via catheter-based angioembolization with repeat angiography at 2 weeks to rule out pseudoaneurysm or arteriovenous fistula formation. In the rare instance where active hemorrhage and associated shock prevent angiography, hemorrhage control must take place in the operating room. The vertebral artery travels within the bony transverse foramen of the cervical spine, and this portion of the posterior triangle is difficult to expose (Fig. 35.10). If packing the wound can decrease bleeding enough to achieve hemodynamic stability (we have found bone wax to be most effecting in this setting), the patient may be taken to angiography for embolization. Alternatively, control must be obtained by proximal ligation of the vessel at the thoracic outlet.

Subclavian Artery

Subclavian artery injuries diagnosed by angiography (CT or catheter-

based) in hemodynamically stable patients should be considered for endovascular repair. The vessel and injury may be accessed via the femoral artery and aortic arch (catheter-based angiography) or retrograde via a brachial artery cut-down (following CTA) for stent deployment. If hemodynamic stability becomes compromised during endovascular access, a balloon catheter can be inflated at or proximal to the injury for hemorrhage control until surgical exposure is obtained. Subclavian artery injuries should be repaired with PTFE interposition grafting. In the case of exsanguination and extremis, ligation may be considered as a life-saving option with a high risk of significant ischemic complications.

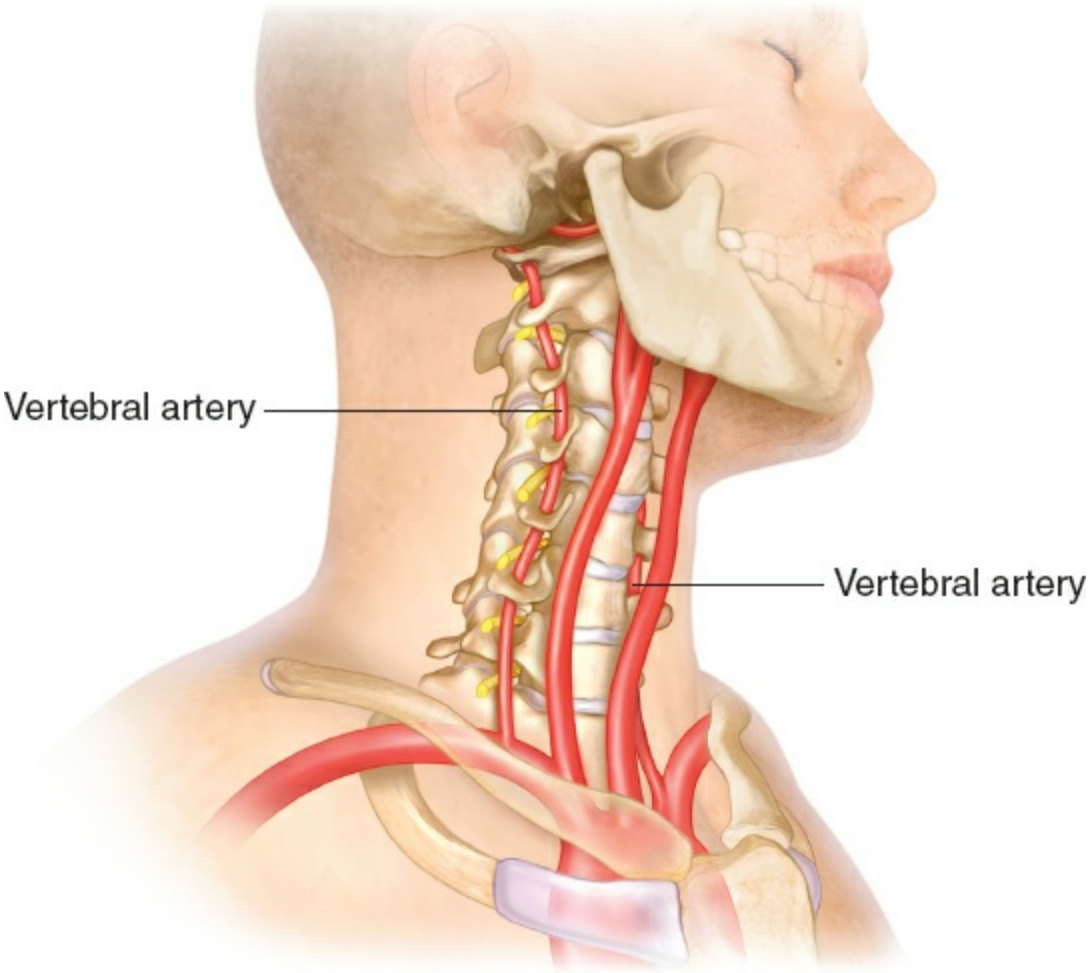

Figure 35.10. The vertebral artery (VA) is the first branch of the subclavian artery. Its takeoff is on the dorsosuperior aspect of the ascending subclavian artery.

Aerodigestive Injury

When considering injury to the pharynx or cervical esophagus, the importance of early diagnosis and repair cannot be overstated. A delay of

several hours can significantly increase the incidence of mediastinitis and empyema. All injuries should undergo repair as soon as diagnosed. All repairs should be drained with a closed-suction drain, which is left in place until a contrast esophagram at 1 week shows no extravasation and the patient is tolerating a diet. Inadequate or leaking repairs can heal without additional surgery as long as adequate drainage is maintained. Enteral nutrition can be administered via a soft feeding tube placed during surgery. Antibiotics appropriate for oral flora should be given postoperatively.

Esophageal Injury

Following exploration and repair of the carotid sheath structures, attention is next turned to evaluation of the aerodigestive tract. Begin with repositioning retractors so as to achieve displacement of the entire carotid bundle laterally. This will expose the pharynx and esophagus as well as the larynx, thyroid gland, and trachea inferiorly. This space has its own enveloping fasciae as well as many small perforating vessels, requiring careful dissection. The recurrent laryngeal branch of the vagus nerve travels in the groove between the esophagus and trachea and is an essential nerve. It should be identified and preserved as it is vulnerable to injury during dissection (Fig. 35.11).

Often flat and with a lie off-center to the left, the esophagus is best evaluated with a dilator, bougie, or rigid nasogastric tube inserted orally by the anesthesiologist. The esophagus is without a serosal layer and any necrotic muscle or mucosa should be debrided—but not excessively. Healthy tissue is then approximated with absorbable 3-0 or 4-0 suture in one or two layers (knots outside the mucosa) as needed to establish a watertight closure. The repair should then be reinforced with a buttress of muscle, usually the detached sternal head of the sternocleidomastoid muscle (Table 35.4). Ipsilateral superficial strap muscles (sternohyoid and the anterior belly of the omohyoid) are easily liberated and may be also be useful as interposition or reinforcement flaps. The blood supply to the strap muscles originates from cephalad origins; divide the strap muscle inferiorly and rotate them up as a muscular flap. As mentioned above, digestive tract repairs always require drainage. We prefer closed-suction drains (fully perforated Jackson-Pratt or Blake). Care must be taken to direct drains away from associated vital structure repairs as salivary enzymes are quite corrosive. Clean, uninjured muscle should interpose repairs and drain tracts.

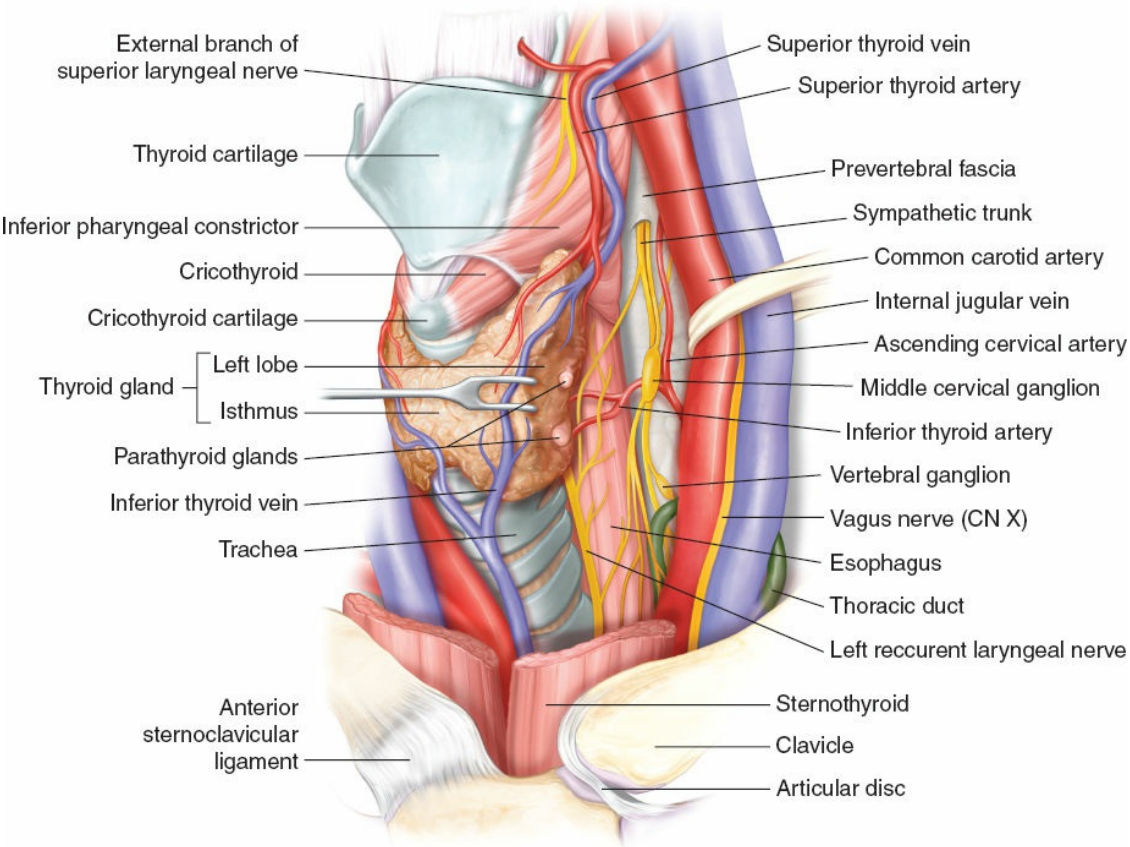

Figure 35.11. Alimentary layer of the visceral compartment.

TABLE 35.5 Principles of Repair of the Trachea

- No debridement is necessary.
- One-layer repair with absorbable suture if small or moderate-sized hole.
- When there is loss of a portion of the anterior or lateral wall, a tracheostomy tube is inserted into the defect. The sternocleidomastoid muscle is then detached inferiorly, mobilized, and sewn in an airtight fashion to the defect after the tracheostomy tube is removed.
- When there is loss of a portion of the membranous trachea, a three-sided rectangular longitudinal flap of pericardium based superiorly is sewn to the defect to create an airtight seal.

From Feliciano DV, Vercruysse GA. In: Mattox KL, Moore EE, Feliciano DV, eds. *Trauma*. 7th ed. New York: McGraw-Hill; 2013:414–29. Copyright McGraw-Hill Education.

Occasionally it is not possible (extensive tissue injury) or prudent (operative delay) to primarily repair the esophagus at the initial operation. Generally, these injuries are best treated with a large T-tube through the injury to create a controlled lateral esophageal fistula. A second option, if mobile enough, is to deliver the injured esophagus through the skin as an esophagostomy. (If needed, the efferent limb can be closed with a TA-

stapler.) A blind cervical esophageal stump should never be left in place. Either one of these treatments allows simple repair of the esophagus at a later date. Whenever possible, avoid esophagectomy, as ultimate reconstruction will be far more difficult. Cervical esophagostomy is always performed on the left side. If an end-esophagostomy is required, a subcutaneous tunnel should be developed over the sternocleidomastoid muscle, clavicle, and pectoralis so as to reach the anterior chest wall where an ostomy appliance can rest comfortably. The end is externalized through a 2-cm disc-shaped skin excision and sutured, full-thickness to the skin edges with interrupted absorbable sutures.

Tracheal Injury

Tracheal injuries require repair. Anterior injuries of appropriate size and location may be converted to tracheotomy. Exploration and repair of tracheal injuries may require division or retraction of the ipsilateral thyroid lobe for access. Formal lobectomy is rarely required, but division of the isthmus is generally necessary. For repair of tracheal injuries larger than 4 cm (three to four tracheal rings), mobilization of the trachea at the thoracic outlet inferiorly or the laryngeal complex superiorly may be required.

Head flexion is the simplest tension releasing maneuver; this may require suturing the chin to the chest wall for 10 to 14 days postoperatively. Minimize mobilization of the trachea to only what is essential. The blood supply to the trachea is at 3 o'clock and 9 o'clock positions and must be preserved. Thus, mobilization is safe only anterior and posterior to the trachea. To mobilize the trachea inferiorly, care should be taken to stay adjacent to the tracheal wall to avoid injury to the recurrent laryngeal nerve. The thyroid isthmus is divided along with the midline strap muscles (sternohyoid and sternothyroid). Blunt dissection is then all that is needed to separate the superficial and deep strap muscles and develop the pretracheal plane into the mediastinum. The suprahyoid release is a fairly complex procedure for the general surgeon and is ideally performed by otolaryngologists. It requires a separate, transverse incision over the hyoid bone followed by division of the superior muscular attachments and transection of the hyoid itself. Tracheal repair is performed in a single layer, using absorbable 3-0 or 4-0 monofilament suture, placed transversely (knot outside the lumen), in an interrupted fashion and incorporating the tracheal ring above and below the injury. A "protective" tracheostomy should be avoided, as there is little proven

benefit, as well as introducing a higher risk of infection (Table 35.5).

Larynx

When significant enough to compromise the airway, laryngeal injuries are typically discovered at surgical exploration during the creation of a tracheotomy or during the conversion of a cricothyroidotomy to a formal tracheotomy. Patients with less complex injuries found on CT scan or laryngoscopy should undergo tracheotomy to protect the airway. Laryngeal injuries often need reconstruction, internal fixation, or stent placement and are best treated semielectively by otolaryngologists. The surgeon should resist the temptation to widely debride these wounds when encountered at initial exploration. Although definitive treatment is usually deferred, consultation to otolaryngology at the time of exploration is important.

POSTOPERATIVE MANAGEMENT AND COMPLICATIONS

Patients who have undergone vascular repair should be monitored closely for hemorrhage and neurologic deficit in the immediate postoperative period. Any signs of bleeding or arterial thrombosis should prompt rapid return to the operating room for reexploration. Blood pressure and heart rate should be monitored particularly if there has been dissection or injury near the carotid bifurcation. A chest radiograph should be obtained to assess for pneumothorax. Antibiotics in the postoperative period should be reserved for esophageal injuries, and drains left routinely can be removed after 48 hours if the output is low (<20 mL). Injuries to the various cranial nerves can result in the following predictable deficits: facial droop (facial), aspiration (glossopharyngeal), dysphagia/dysarthria (hypoglossal), and vocal cord paralysis (recurrent laryngeal branch of vagus).

TABLE 35.4 Principles of Repair of the Esophagus

- Either one- or two-layer with absorbable sutures is acceptable, preferably in a transverse direction
- Loss of a portion of the wall in zone II and some patients with delayed diagnosis of perforation should be treated with a loop esophagostomy over a rod rather than an acute tenuous repair that is likely to dehisce
- Combined injuries with the trachea or carotid artery mandate a vascularized muscle buttress/separator such as sternocleidomastoid muscle

From Feliciano DV, Vercruysse GA. In: Mattox KL, Moore EE, Feliciano DV, eds. *Trauma*. 7th ed. New York: McGraw-Hill; 2013:414–29. Copyright McGraw-Hill Education.

Suggested Readings

Biffl WL, Moore EE, Feliciano DV, et al. Diagnosis and management of esophageal injuries: a Western Trauma Association critical decisions algorithm. *J Trauma Acute Care Surg* 2015;79:1089–95.

Demetriades D, Salim A, Brown C, et al. Neck injuries. *Curr Probl Surg* 2007;44:13–87.

Feliciano DV. Penetrating cervical trauma. *W J Surg* 2015;39:1363–72.

Feliciano DV, Vercruysse GA. In: Mattox KL, Moore EE, Feliciano DV, eds. *Trauma*. 7th ed. New York: McGraw-Hill; 2013:414–29.

Kumins NH, Tober JC, Larsen PE, et al. Vertical ramus osteotomy allows exposure of the distal internal carotid artery to the base of the skull. *Ann Vasc Surg* 2001;15: 25–31.

LeRoux D, Veller M. Carotid, jugular and vertebral blood vessel injuries. In: Velmahos GC, Degiannis E, Doll D, eds. *Penetrating Trauma*. Springer: Heidelberg; 2012:229–36.

Lyons JD, Feliciano DV, Wyrzykowski AD, et al. Modern management of penetrating tracheal injuries. *Am Surg* 2013;79:188–93.

Osborn TM, Bell RB, Qaisi W, et al. Computed tomographic angiography as an aid to clinical decision making in selective management of penetrating injuries to the neck. *J Trauma Acute Care Surg* 2008;64:1466–71.

Shiroff AM, Gale SC, Martin ND, et al. Penetrating neck trauma: a review or management strategies and discussion of the “no zone” approach. *Am Surg* 2013; 79:23–9.

Sperry JL, Moore EE, Coimbra R, et al. Western Trauma Association critical decisions in trauma: penetrating neck trauma. *J Trauma Acute Care Surg* 2013;75:936–40.

Tisherman SA, Bokhari F, Collier B, et al. Clinical practice guideline: penetrating zone II neck trauma. *J Trauma Acute Care Surg* 2008;64:1392–405.

EDITOR'S COMMENT

Dr.'s Corcos and Peitzman have written an incredibly detailed and comprehensive chapter on penetrating neck injuries. Penetrating neck trauma represents approximately 5% to 10% of all trauma cases that present to the emergency department. About 30% of these cases are accompanied by injury outside of the neck zones as well. The current mortality rate in civilians with penetrating neck injuries ranges from 3% to 6%. Higher mortality rates occur with injuries to large vessels, such as the carotid or subclavian arteries and veins. A recent review of the National Trauma Data Bank revealed that in children less than 14 years old, the incidence of penetrating neck trauma is 0.28%. Mortality rate in children was 5.6% in this NTDB review, and vascular injury and hypotension on presentation to the ED were both associated with an increased risk of mortality.

Penetrating neck trauma is an important area of trauma care that has undergone evolution in the recent past. Many changes have occurred in the treatment paradigm as new technologies have developed, and as surgeons have explored the outcomes from different treatment protocols. Therapy has evolved from no treatment (before effective anesthesia and instrumentation) to nonoperative management, routine exploration, selective exploration, and adjunctive invasive or noninvasive assessment. Penetrating neck injuries remain challenging, as there are a number of important structures in a small area, and injury to any of these structures may not be readily apparent.

Patients with penetrating wounds to the neck present with overt symptoms and signs of injury or are asymptomatic/mildly symptomatic. When there are overt signs and symptoms of injury, resuscitation and immediate operation is appropriate. In asymptomatic and mildly symptomatic patients, observation or a diagnostic evaluation is appropriate to avoid what is an approximately 45% rate of negative exploration in this cohort of patients. Asymptomatic patients with penetration of the platysma muscle but no signs of a visceral or vascular injury should undergo serial physical examinations for 24 to 36 hours before discharge. Noncontrast CT does not add to the accuracy of serial physical examinations. In stable patients with a variety of symptoms or signs possibly related to an injury to the carotid artery, CT-arteriography has become the diagnostic modality of choice. Patients with possible injuries to the cervical esophagus are often still evaluated with a Gastrografin swallow and a thin barium swallow prior to fiberoptic endoscopy. The addition flexible endoscopy to contrast studies can increase the diagnostic accuracy of detecting an injury to the cervical esophagus. Initial concerns about air insufflation during visualization for flexible endoscopy contributing to bacterial contamination in a perforation have waned. CT-esophagram is an evolving diagnostic modality that may replace the above tests in the screening algorithm in the near future. An unrecognized cervical esophageal injury can result in devastating complications

in a relatively short period of time. An intense necrotizing inflammatory response can result in the neck in the first 12 hours and worse if the mediastinum is involved. Unrecognized esophageal injuries significantly increase the mortality of these injuries.

Injuries to the trachea are usually apparent on presentation (over 85% present with overt symptoms and signs). In questionable cases, laryngoscopy and fiberoptic bronchoscopy can help confirm or rule out the diagnosis. These lesions should be repaired when identified. As for esophageal injuries, CT may replace bronchoscopy and laryngoscopy as diagnostic tests.

The optimal surgical management of the carotid artery injury is another controversy. The issues involve whether severe neurologic deficits (coma for example) and demonstrated absence of antegrade flow in the internal carotid artery contraindicate repair. In several studies, reestablishing antegrade flow has been suggested to be hazardous because it may convert an ischemic infarction into a hemorrhagic infarction. Many authors recommend repair of an injured carotid artery rather than ligation in all patients with a Glasgow Coma Scale >9. Patients with a GCS of 8 and below generally have an unfavorable outcome whether the carotid artery is revascularized or ligated. Options for management of a carotid artery injury include observation with or without anticoagulation, ligation, operative repair, or endovascular repair depending on the nature of the injury (and associated injuries) and the patient's neurologic status.

The utility of the traditional classification of neck injuries using the anatomic zones I through III has recently been questioned. In a recently published article, patients who sustained penetrating neck trauma from December 2008 to March 2011 were analyzed. All patients underwent structured clinical examination documenting the external zone where the wound(s) were located. All internal injuries were then correlated with the external wounds. An internal injury was defined as "unexpected" if it was located outside the borders of the neck zone corresponding to the external wound. In total, 146 patients sustaining a penetrating neck injury were analyzed. The mechanism of injury was stab wounds in 74 (51%) and gunshot wounds in 69 (47%). There was a high incidence of noncorrelation between the location of the external injury and the internal structures that were damaged in patients with hard signs of vascular or aerodigestive injury. The authors of this study concluded that the use of the anatomic zones and their role in the workup of penetrating neck injury are questionable. Another recently published discussion on the "no-zone" approach to management and evaluation of penetrating neck injury concludes that a comprehensive physical examination, combined with CT angiogram (CTA), is adequate for triage to effectively identify or exclude vascular and aerodigestive injury after penetrating neck trauma. "Zone-based algorithms lead to an increased reliance on invasive diagnostic modalities (endoscopy and angiography) with their associated risks and to a higher incidence of nontherapeutic neck exploration. Therefore, surgeons evaluating hemodynamically stable patients with penetrating neck injuries should consider

departing from antiquated, invasive algorithms in favor of evidence-based screening strategies that use physical examination and CTA."

Finally, recent military conflicts have led to an experience with penetrating neck injuries from bullets as well as blast injuries that have helped informed modern management of these injuries. Ramasamy et al. performed a retrospective medical record review of British military casualties from Iraq and Afghanistan who sustained penetrating neck injuries to determine the need for prehospital cervical immobilization, given current ATLS protocols requiring spinal precautions when a significant mechanism of injury may damage the cervical spine. Of 90 patients with a penetrating neck injury, 66 (73%) were from explosions and 24 (27%) were from gunshot wounds. In 20 (22%) patients, cervical spine injuries were present; only 6 (7%) survived to reach the hospital, and 4 of these 6 died within 72 hours of their injuries. Of 56 survivors that reached a surgical facility, only 1 (1.8%) had an unstable cervical spine injury requiring surgical stabilization, and this patient subsequently died due to a concomitant head injury. The investigators determined that it is unlikely that survivors of penetrating ballistic trauma to the neck will have unstable cervical spines; therefore, "not only is the risk/benefit ratio of mandatory spinal immobilization unfavorable, but cervical collars may also hide potential life-threatening conditions, in addition to putting medical teams at prolonged personal risk."

Penetrating neck injury is a potentially devastating problem. Surgeons who care for these patients need an in-depth knowledge of the neck anatomy and a clear understanding of the current approach to diagnosis and management. With modern diagnostic modalities, most of these injuries in stable patients can be managed nonoperatively. This chapter is an excellent review of a very important topic, whose management continues to evolve even today.

Jon C. Gould

Suggested Readings

Feliciano DV. Penetrating cervical trauma. *World J Surg* 2015;39:1363–72.

http://emedicine.medscape.com/article/433306-overview#a7. Accessed February 6, 2015.

Low GM, Inaba K, Chouliaras K, et al. The use of the anatomic "zones" of the neck in the assessment of penetrating neck injury. *Am Surg* 2014;80(10):970–4.

Ramasamy A, Midwinter M, Mahoney P, et al. Learning the lessons from conflict: pre-hospital cervical spine stabilization following ballistic neck trauma. *Injury* 2009;40(12):1342–5.

Shiroff AM, Gale SC, Martin ND, et al. Penetrating neck trauma: a review of management strategies and discussion of the "No Zone" approach. *Am Surg*

2013;79(1):23–9.

Stone ME, Farber BA, Olorunfemi O, et al. Penetrating neck trauma in children: an uncommon entity described using the National Trauma Data Bank. *J Trauma Acute Care Surg* 2016;80(4):604–9.

Woo K, Magner DP, Wilson MT, et al. CT angiography in penetrating neck trauma reduces the need for operative neck exploration. *Am Surg* 2005;71(9):754–8.

36 Neurosurgical and Neurologic Emergencies for Surgeons

Ekkehard M. Kasper, Yosef Laviv, Clark C. Chen, and Burkhard S. Kasper

TRAUMATIC AND NONTRAUMATIC HEAD AND BRAIN INJURY

Traumatic Brain Injury: Blunt versus Penetrating Trauma

Epidemiology of Traumatic Brain Injury (TBI)

Before we are committing ourselves to reviewing the management of traumatic brain injury (TBI), we need to understand that this problem remains a major public health issue in our times. To illustrate this point, I want to reiterate some facts about TBI in the United States as an introduction to the topic as reported by the Brain Trauma Foundation (www.BTF.org):

Brain injuries are most often caused by motor vehicle crashes, assaults, sports injuries, or even simple falls on the playground, at work or in the home. An estimated 1.5 million moderate to severe head injuries occur every year in the United States, and an additional estimated 1.6 million to 3.8 million sports-related TBIs occur each year. Every year, approximately 52,000 deaths occur from TBI. It is the leading cause of death and disability in children and adults from ages 1 to 44, and at least 5.3 million Americans (i.e., 2% of the U.S. population) currently live with disabilities resulting from TBI. In addition, moderate and severe head injuries are associated with an increased risk of developing Alzheimer's disease.

Males are about two times as likely as females to experience TBI, and hospitalization rates had increased from 79 per 100,000 in 2002 to 87.9 per 100,000 in 2003. Blasts are a leading cause of TBI among active duty military personnel in war zones, and veterans' advocates believe that between 10% and 20% of Iraq veterans, or 150,000 and 300,000 service members, have some level of TBI. Of note, 30% of soldiers admitted to Walter Reed Army Medical Center have suffered TBI.

Traumatic Head Injury Basics

What are the unique features of brain anatomy and physiology, and how do they affect patterns of brain injury?

The head is a rigid compartment filled with brain, cerebrospinal fluid (CSF), and blood.
Cerebral blood flow (CBF) in the healthy individual is autoregulated for SBP 80 to 160 to generate an adequate cerebral perfusion pressure (CPP).
If autoregulation is intact, CBF is maintained constant via a mean BP adjustment to generate a CPP of 50 to 60 mm Hg.
In moderate or severe brain injury cases, autoregulation is disrupted in a way that CBF varies greatly with mean BP.
The injured brain is more vulnerable to episodes of hypotension and metabolic imbalance that may cause secondary brain injury.

Intracranial Pressure (ICP)

Besides hemodynamic parameters and confining metabolic conditions, intracranial pressure (ICP) is the single most important determinant of neurologic function of the brain (Table 36.1).

Normal ICP is defined as the pressure (in cm H_2O) that is measured within the skull, either in subarachnoid fluid, ventricles, or parenchyma. It corresponds to the hydrostatic pressure that must be applied to prevent the emergence of fluid through a puncture needle from the CSF in the horizontal body position. Normal ICP should reside below 15 cm H_2O. An increase in ICP occurs when one of the intracranial compartments within the rigid skull is increased (1,500 to 1,700 mL total volume, which is made of ca. 80% brain parenchyma and 10% CSF and 10% blood). An acute increase in ICP above tolerance is fatal.

TABLE 36.1 Intracranial Pressure

Infants	0.5–2 mm H_2O
Children	2–10 mm H_2O
Adults	6–200 mm H_2O = Normal >200 mm H_2O = Abnormal >400 mm H_2O = Severe increase

Physiologic variations occur and show age dependence, with children having lower values than adults, fluctuation with each pulse-pressure wave, fluctuation with respiration, and a correlation with body weight (obese patient showing higher values).

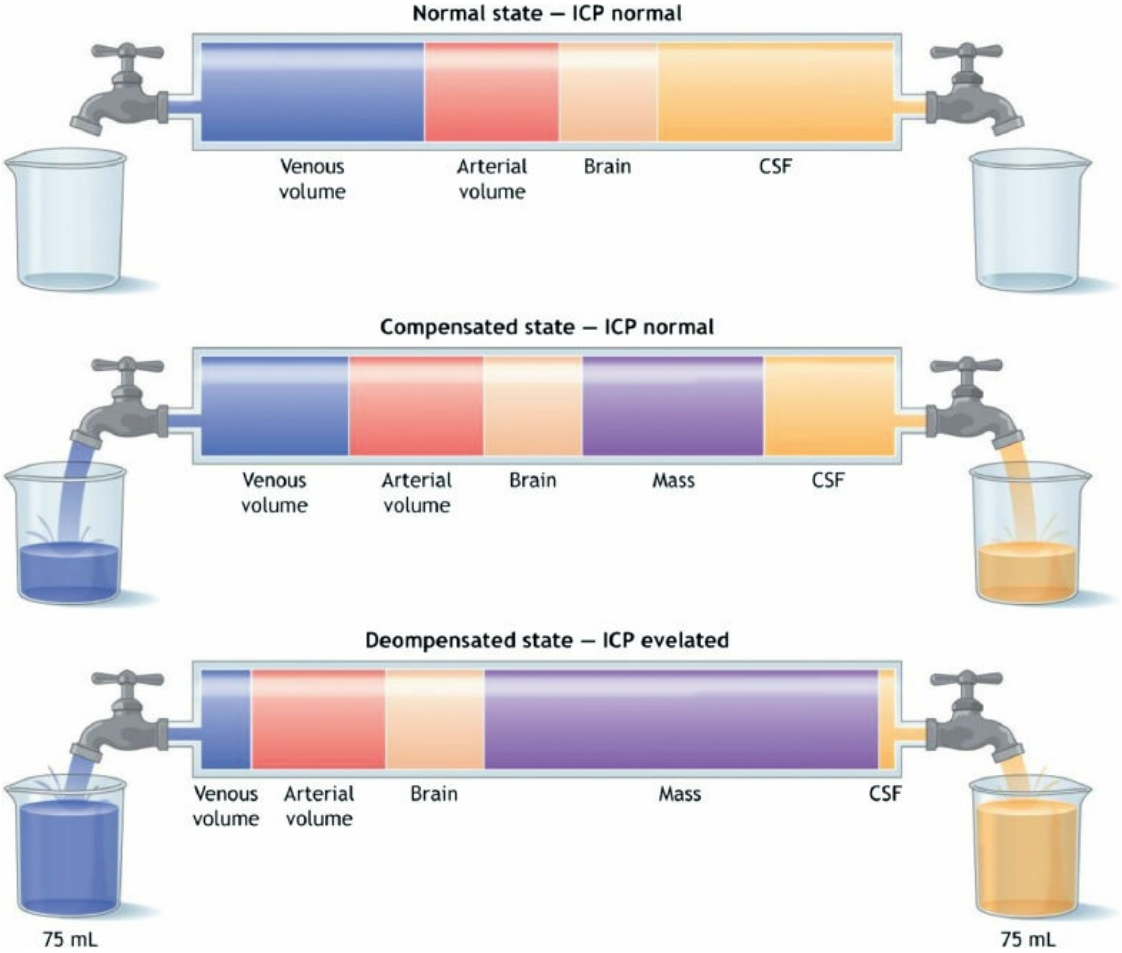

Figure 36.1. Monro–Kellie doctrine.

It must be noted that ICP can*not* be predicted based on imaging (head computed tomography [CT] or magnetic resonance imaging [MRI]).

The ***Monro–Kellie doctrine*** (Figs. 36.1 and 36.2) states that *the sum of all intracranial volumes will remain constant* and that *any increase in one of them or adding an intracranial mass will be offset by an equal decrease in one of its other components*; otherwise, it will cause an increase in ICP at the expense of the brain. *(This concept was introduced by both Monro and Kellie in the early 1800s.)*

ICP Impact

- In TBI, resulting increased ICP leads to decreased brain function and

poor outcome.

- Systemic hypotension and low O_2-saturation adversely affect outcome via poor CPP and hypoxia (Table 36.2).

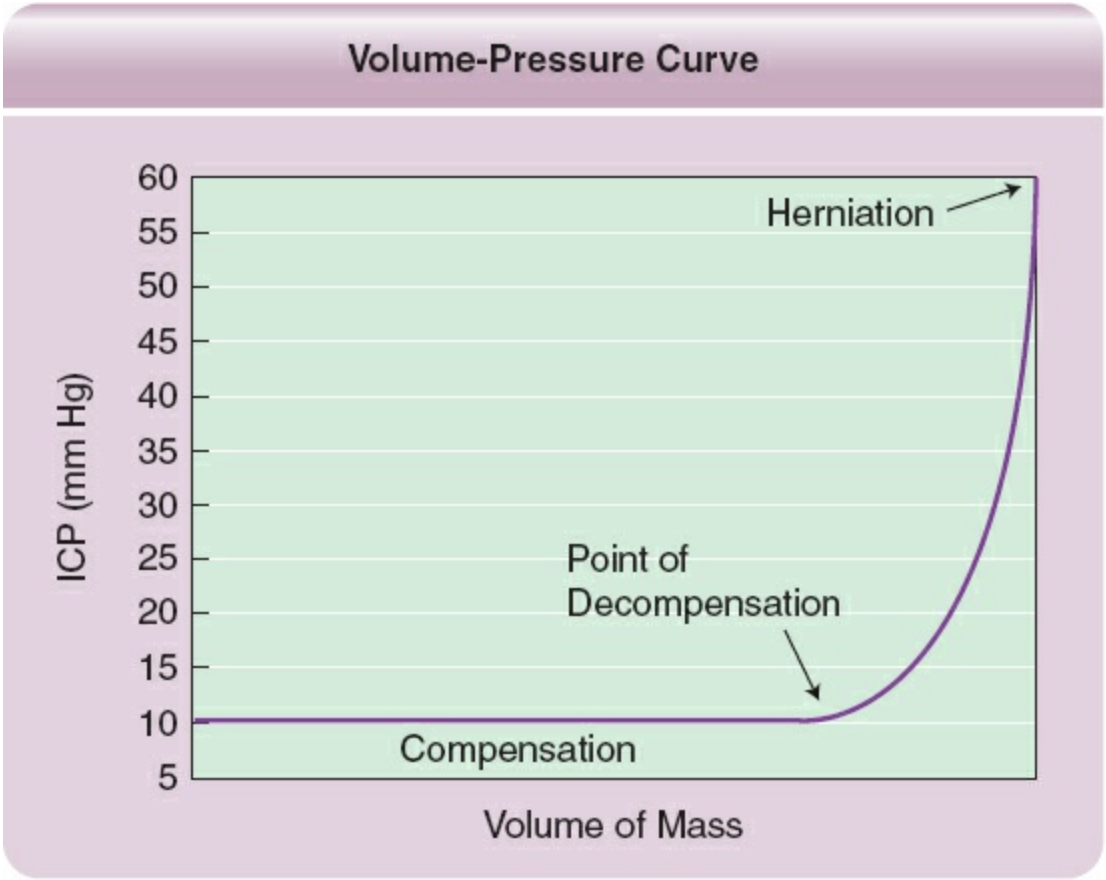

Figure 36.2. Volume–pressure curve.

TABLE 36.2 Cerebral Perfusion Pressure (CPP)

	MAP	– ICP	= CPP
Normal	90	10	80
Cushing Response	100	20	80
Hypotension	50	20	30

Primary and Secondary Brain Injury

Primary and secondary brain injuries are terms to classify brain injury processes. In TBI, primary injury occurs during the initial insult and results from the physical impact and energy transfer causing structural damage to the brain. Secondary injury is a consequence thereof. Its time

course is more gradual, reflecting the involvement of distinct cellular processes to which both primary and secondary injuries respectively will contribute. Primary and secondary injuries occur in other brain insults such as spontaneous hemorrhage, stroke, or mass lesions too.

In TBI, primary injury (Table 36.3) happens from energy transfer at the moment of trauma and it manifests as concussion (injury without visible correlate on CT), contusion (with damage to tissue and vessels), or diffuse axonal shear injury. Normal physiologic barriers (the blood brain barrier and connective tissue such as the meninges) can be damaged, and cells may die in a nonspecific manner. Certain areas of the brain are more susceptible to injury either by location (fronto-basis and temporal tip in head-on collision deceleration injuries) or by structural features (myelinated fiber tracts versus nonmyelinated fibers), and this type of structural injury is thought to be irreversible.

Since primary injury occurs at the moment of trauma, there is little that can be done for it; efforts to reduce disability and death from TBI are thought to be best aimed at secondary injury.

Secondary injury (Table 36.4) is delayed and results indirectly from the impact and comes via cellular processes as a consequence of the trauma. It is a well-known observation that many TBI victims do not die right away at the scene, but almost half of TBI patients deteriorate during their hospitalization as a result of secondary injury, which ultimately may cause raised ICP and brain herniation.

TABLE 36.3 Examples of Primary Brain Injury in TBI

Primary
■ Subarachnoidal hemorrhage ■ Epidural hemorrhage ■ Subdural hemorrhage ■ Parenchymal Hemorrhage ■ Concussion ■ Contusion ■ Diffuse axonal injury/or ■ Axonal stretch injury

TABLE 36.4 Causes for Secondary Brain Injury

Secondary
■ Edema ■ Change in cerebral blood flow (CBF) ■ Hypercapnia ■ Acidosis ■ Altered metabolism (free radical formation) ■ Change in neurotransmitters ■ Change in receptor activity ■ Excitotoxicity ■ Infection/abscess formation

Since secondary injury occurs over time, it can be prevented in part by taking measures to prevent complications and researchers are working actively to find drug therapies to limit or prevent the damage.

INITIAL DATA EVALUATION

It is crucial to obtain as much of the history upon arrival of the emergency medical services, and particular attention must be paid to mechanism of injury, initial on scene-exam, and time course of developing symptoms of concern.

Whenever there is significant impact, the index of suspicion of a life-threatening injury should be very high, even if the patient was doing rather well at the scene and looks good on arrival! Whenever there was significant injury to the head (e.g., enough to cause a fracture or bleed), the concern for associated cervical spine injury should be high. So actively search for neck pain and signs of radiculopathy or myelopathy! If the patient has sustained multisystem injury, the extent of injury and its initial management matter greatly for prognostic purposes.

Specific scenarios: In cases of motor vehicle accidents (MVA), questions about mechanism of injury should include a detailed account of vehicle speed (high/low), direction of impact (head on, rear ended, side/oblique impact), extend of external damage, possible passenger ejection, and death of or injuries to other participants. In cases of penetrating or blunt injury, ask about type of assault weapon (e.g., firearm versus golf club). Get as much information as possible from bystander accounts. It is important not

to miss the body temperature in this assessment since hypothermia may depress neurologic functions.

Examination

It may be of vital importance to obtain a description of the scenario and vital signs plus the first examination at the scene. When a patient is "found down," ask about circumstantial evidence (alcohol, drugs, observed blood loss). How long was the patient unaccounted for? Was there loss of consciousness (+LOC), evidence of seizure activity, or progressive obtundation? Did the patient act abnormally? Did the patient develop headache, nausea, vomiting, blurred vision, hearing loss, altered speech, or any other progressive symptom en route? If the patient became unconscious and arrives with a "blown pupil," ask when it happened. If bilaterally, ask which side went up first and when.

As in all other trauma case, a *full survey = primary trauma team assessment of ABC must be conducted first!*

Observe the primary survey by the trauma team as they gather vital signs and make sure all initial measures to limit secondary brain injury are being implemented (oxygen administered, adequate ventilation secured, and SBP >90 mm Hg maintained at all times).
Check for bradycardia, changes in breathing frequency, and hypertension (signs for increased ICP and Cushing's Response).
Make sure the patient is being treated with full spine precautions, a hard board is used, and the cervical spine is correctly immobilized with a hard collar or taped to the trauma board. Only in the setting of hypovolemic systemic shock (scalp blood loss can be massive!) and in cases of spinal cord injuries with florid neurogenic shock, you will see hypotensive responses despite increased ICP.

During the trauma-team assessment, get information about medications given during transport (paralytics, narcotics, sedatives).

Have a quick look at the pupils and check for size and reactivity. A side-difference >1 mm is considered nonphysiologic, unless caused by a preexisting condition. Classify the status of the pupils since *any newly dilated pupil >6 mm defines a neurosurgical emergency.* Rapid acquisition of head *CT-imaging in this setting* (e.g., penetrating Glasgow Coma Score (GCS) to the head) *takes precedence over a detailed secondary trauma survey!*

TABLE 36.5 TBI and GCS Scoring Table

Severity Level	GCS Score
Mild TBI (Concussion)	GCS 14–15 with LOC <5 min; impaired alertness or memory
Moderate TBI	GCS >9; focal neurologic deficit; possibly reversible; some residual possible
Severe TBI	GCS 5–8
Critical TBI	GCS 3–4; poor prognosis

Traumatic Brain Injury: The Glasgow Coma Scale

Once the trauma survey has been conducted, evaluate the patient rapidly yourself before other diagnostic studies are done: Check the patient's initial GCS to evaluate the patient's level of consciousness via motor response, eye opening, and verbal response. This score has predictive and prognostic value (Table 36.5).

If the patient is stable and in reasonable neurologic condition, obtain a focused exam:

1. *HEAD:* Observe the patient for external signs of trauma (*raccoon's eyes* = periorbital edema and hematoma, retro-auricular hematoma and ecchymosis = *Battle's sign* indicating a skull base injury). Check head and neck for wounds such as lacerations, abrasions, contusions, and palpate for possible fractures. *Do not probe lacerations concerning for open fractures* until in the OR and after adequate imaging has been obtained. Inspect and palpate the globes to assess possible rupture. Corneal reflexes can be used to assess CN 5/7 function in the comatous patient. A fundoscopic/ophtalmoscopic exam is less valuable in the adult, since ICP increase does not cause immediate optic nerve pallor and it is unlikely that one picks up a decrease in retinal venous pulsations in this ER setting. However, in pediatric patients and unclear mechanism of injury, evidence of retinal hemorrhage may point to abuse. *Pharmacologic dilatation must be avoided until ICP*

elevation has been ruled out. Check the external auditory canal (EAC) for hematotympanon and otorrhoea/liquorrhoea. Inspect also the nares for blood or CSF leakage/rhinorrhoea. Lower cranial nerve injury is rare in the acute trauma patients, and if noticed later during hospitalizations it needs attention to assess the risk of aspiration.

2. *BODY:* Check for motor response in all four extremities; if the patient has decreased level of consciousness, painful stimuli are applied to elicit an adequate response. Learn to recognize the posturing responses to be able to distinguish: decerebrate, decorticate, tripleflexion-withdrawal.

TABLE 36.6 Classification of Injury Patterns

- Concussion = mild TBI
  Altered MS with closed head injury
  Fully reversible
- Contusion = (e.g., deceleration injury)
  Structural changes; ME/MLS/swelling
  Possibly reversible, some residual
- Contre-Coup injury/second impact syndrome
- Diffuse axonal injury (DAI or shear injury)
  Microscopic/multiple structural lesions/+LOC severe; poor prognosis

In conversant patients also check the sensation from the head toward the toes and mark any possible level that correlates with a spinal cord injury. Check tactile stimulation as well as pain. You *must perform a rectal exam* to assess sphincter tone. In the comatous patient, this may be the only evidence for spinal cord injury. If the bulbo-cavernosus reflex is missing (reflecting acute myelopathy), the patient may show signs of spinal shock.

Check biceps and patellar reflexes as well as plantar responses (Babinski's). In acute spinal cord injury, the patient will present with dropped reflexes and mute toes. Only in rare cases of brain stem shear injury one can find hyperreflexia in the acute setting.

Serial neurologic examinations and serial imaging are necessary to diagnose delayed neurologic status change and deterioration from

secondary brain injury (Table 36.6).

INITIAL TREATMENT PLAN IN THE ER

Since TBI is a rather heterogeneous group of incidents, it has been extremely difficult to gather prospective randomized trial data and treatment recommendations from clinical studies in this scenario. However, a few fundamental and basic recommendations were derived from detailed analysis of retrospective data and prospective collection of data from cohorts that were followed long term.

Some priorities in guidelines are intuitive; for example, the systemically unstable patient needs to be treated first since systemic hypotension from hypovolemic shock in the multitrauma patient carries a poor prognosis in neurotrauma. Also, if there are any concerns for raised ICP or the GCS is <9, the patient should have treatment initiated *before* further and time-consuming diagnostic studies are undertaken (see below).

ICP Treatment
After systemic stabilization (make sure only isotonic solutions are used) administer mannitol (ca. 1 g/kg BW), Lasix (10–20 mg IV) and hyperventilate the patient (increase frequency and volume for goal pCO_2 = 30) before you run off to radiology/CT for further studies.

The current existing guidelines for management of acute head trauma are contained by a publication of the Brain Trauma Foundation and the American Association of Neurological Surgeons (AANS) and can be obtained from the AANS or found via web-link under:

http://www.guideline.gov/summary/summary.aspx?doc_id=10995

Some points of interest need to be described when accepting or signing out a patient: single versus multiple wounds; LOC at the scene, GCS at the scene, downtime until patient was found and treatment was initiated, seizures at the scene, any accompanying systemic injury. Then, focus on the actual neurologic injury.

Document mechanism of injury as *nonpenetrating blunt trauma* where the bony confinements remain intact (e.g., strike with a baseball bat) versus *penetrating trauma* where the bony integrity has been violated (GSW and stabs). It is helpful to realize that the energy transfer accounts for the devastation, so one should specify *"high-energy" versus "low-energy" injury*. Based on the initial GCS you can stratify the injury into

mild, moderate and severe (see Table 36.6 above).

Document morphology: **Surface and vault injuries:** *open versus closed, depressed versus nondepressed*, with and without translocated fragments. **Basilar injuries:** *with or without CSF leak*, with or without cranial nerve palsy.

Once a CT of the head as been obtained, classify the injury pattern into bony and parenchymal: epidural/subdural/subarachnoid/intracerebral/focal or diffuse (see below).

Upon arrival, the patient will undergo some ER-management in the hospital. Here are some conservative measures that can be initiated quickly and efficiently (Tables 36.7, 36.8 and 36.9).

TABLE 36.7 First Set of Conservative TBI Treatment Measures (Before Imaging)

- Optimize positioning: *elevate the head* of bed above the level of the heart to improve venous return and choose a level of ca. 30 degrees; if the spine is not cleared, *tilt the entire bed* into *reverse Trendelenburg position*; make sure the neck is not compressed by tapes from intubation or tight collars resulting in compromise to jugular venous return. Keep even the mild TBI patient initially at *bedrest* until the assessment has been completed
- Administer warm isotonic fluids (ns + 20 mM KCl) for volume resuscitation and give maintenance fluid to avoid secondary injury
- Avoid hypotension (SBP >90 at all times for sufficient CPP)
- Avoid hypothermia = cover the patient with warm blankets
- Intubation in all patients with GCS <8 who cannot protect their airway at all times; since facial and skull base fractures may be present, orotracheal intubation is the method of choice
- Keep the patient NPO and insert NGT for intubated patients
- Prior to imaging, provide assisted ventilation/hyperventilation
- If the patient arrives in poor neurologic condition and with a high suspicion for increased ICP, initiate osmoherapy (100 g mannitol + 20 mg Lasix) as you go to the CT-scanner, since it buys you time

Strategy in the Trauma Bay:

- Early intervention is the goal for all treatable conditions
  - Each patient with a significant impact or unclear story MUST be studied with imaging.
  - Comatous patients TBI patients (GCS 8 or less) with NORMAL CT scans: may be watched during further workup
  - All comatous TBI patients (GCS 8 or less) with ABNORMAL CT scans should receive invasive ICP monitoring

- This algorithm helps with earlier detection of intracranial lesions, to prognosticate recovery and it improves outcome

DIAGNOSTIC STUDIES

CT of the head is the study of choice in head trauma patients. All patients with a GCS of <15 should obtain a CT scan for proper assessment. Patients who look perfect, but had a significant mechanism of injury should also be imaged as well as patients on systemic anticoagulation and patients with syncopal events. *In all patients with a lateralizing or localizing sign, the radiographic workup must be obtained emergently*, since it is highly specific and sensitive for bony injuries as well as blood and gives a chance to assess intracranial injuries in a timely fashion. (Timely means: a significant head injury should be imaged within 15 minutes after arrival in the ER.) Most indications for surgical intervention can be made based on CT results alone and do not require MRI, which is only superior for prognostic purposes in patients with shear injuries and diffuse axonal injury (DAI) (Fig. 36.3; Tables 36.10 and 36.11).

TABLE 36.8 Second Set of Conservative TBI Treatment Measures (After Imaging)

A. *Invasive ICP monitoring* is indicated in all patients with a GCS <8 and/or signs of raised ICP on imaging (the only exception being the intoxicated patient with a normal head CT who has an obvious reason for depressed mental status and may recover in a short period of time in the ICU under constant observation); each patient should have an immediate repeat CT after placement of an EVD or ICPB to assess success and r/o complications. If the GCS is <8, but the patient shows 2 out of the 3 following signs: posturing, hypotension or age >45, monitoring is also recommended
B. *Anticonvulsants:* Once intracranial imaging has revealed a superficial focus of injury OR blood products, load the patient with prophylactic medication such as phosphophenytoin = dilatin 10–15 mg/kg BW = which equals about 1 g per adult load followed by 100 mg TID maintenance-dose for a blood serum level of 10–20 for a minimum of 10 days. Overall risk of seizures is low, even in severe TBI (ca. 1%) and less in mild TBI (ca. 0.1%), but their consequences can be dramatic, especially because they can exacerbate secondary damage. Newer data support the use of Leviracetam (Keppra) 1,000 mg p.o. BID, but the drug is still being evaluated
C. *Steroids:* Currently there is no indication for routine application of steroid therapy in trauma
D. *Antibiotics:* In patients with an obvious open scalp injury, provide skin flora coverage (e.g., Cephalosporin = Ancef 1 g Q8h × 3); if there is an obvious CSF leak or exposed brain tissue, provide triple coverage (gram+/gram– anaerobes; e.g., Vanco/Gent/Flagyl)
E. *Analgetics, sedatives, antiemetics* should be prescribed prn; mind you not to cloud your neuroexam by oversedation. See Table 36.9 for a guide on dosing

Plain XRT films are still acquired in some trauma patient for the initial series and in patient with possible cervical spine injury, patients presenting with myelopathy or focal spine symptoms, and in all comatous patients if a CT is unavailable. For any patient who is diagnosed with a traumatic spine fracture, a full spine assessment with CT is mandatory, since 15% of patients have one or multiple associated fractures. In any case of myelopathy with or without observed bony abnormality, an immediate MRI must be arranged for to rule out canal compromise from traumatic disc herniation, hematoma, tumor, or any other source.

A CT/*CTA of the head* is recommended in settings where the distribution of the blood does not match the mechanism of injury, or if the patient has experienced a thunderclap headache up to the trauma, since subarachnoidal hemorrhage (SAH) may well be caused by an underlying vascular lesion leading to a syncopal event that then presents as a trauma.

Other diagnostic studies such as MRI, conventional angiograms, electromyography (EMG), electroencephalography (EEG), and nuclear medicine studies are warranted in special circumstances only and go beyond the scope of this chapter. The interested reader should study publications related to the definition of brain death and high cervical spinal

injuries such as atlanto-occipital dislocations.

INDICATIONS FOR SURGICAL INTERVENTION

Any patient, who has a chance of recovery from TBI, who presents on imaging with a focal lesion that exerts mass effect, an expanding lesion that will predictably cause further damage, or a global injury that raises ICP or and puts the patient at risk *quo ad vitam* should undergo emergent intervention.

Surgical Goals for Craniotomy or Craniectomy

Debridement and closure for open wounds
Evacuation of hematoma and relief of pressure/MLS
Decompression for edema = craniectomy + duroplasty
Decrease in ICP
Bullet/bone fragment retrieval
Wound closure for CSF leak
Sinus repair

TABLE 36.9 Dosing Table for Medications

Medication	Mechanism	Dosage	Indication	Evidence Level
Mannitol	Osmotic	1 g/kg IV	GCS <9 in patients with a lateralizing motor deficit or unequal pupils	III
Dilantin	Antiepileptic	ca. 1 g IV load	Seizure prohylaxis ca. 100 mg TID for serum level	I
Kefzol	Antibiotic	1 g Q8h IV	Prophylaxis for G+ infections; scalp lacerations and open fractures	III

Possible Sources for CSF Leak

Traumatic CSF leaks occur in ca. 3% of all patients with significant head injury and up to 50% in penetrating injuries. Two thirds appear within days of the insult, 95% manifest within 3 months. Ca. two thirds of leaks stop spontaneously within 72 hours, most cease within 6 months. The incidence of associated meningitis is 5% to 10% in closed head injuries and its incidence increases with the length of a persisting leak.

The treatment recommendation remains controversial. We recommend

coverage for 72 hours post trauma to minimize the risk of meningitis until most leaks close spontaneously.

If a CSF leak persists for >2 weeks, surgical intervention is indicated.

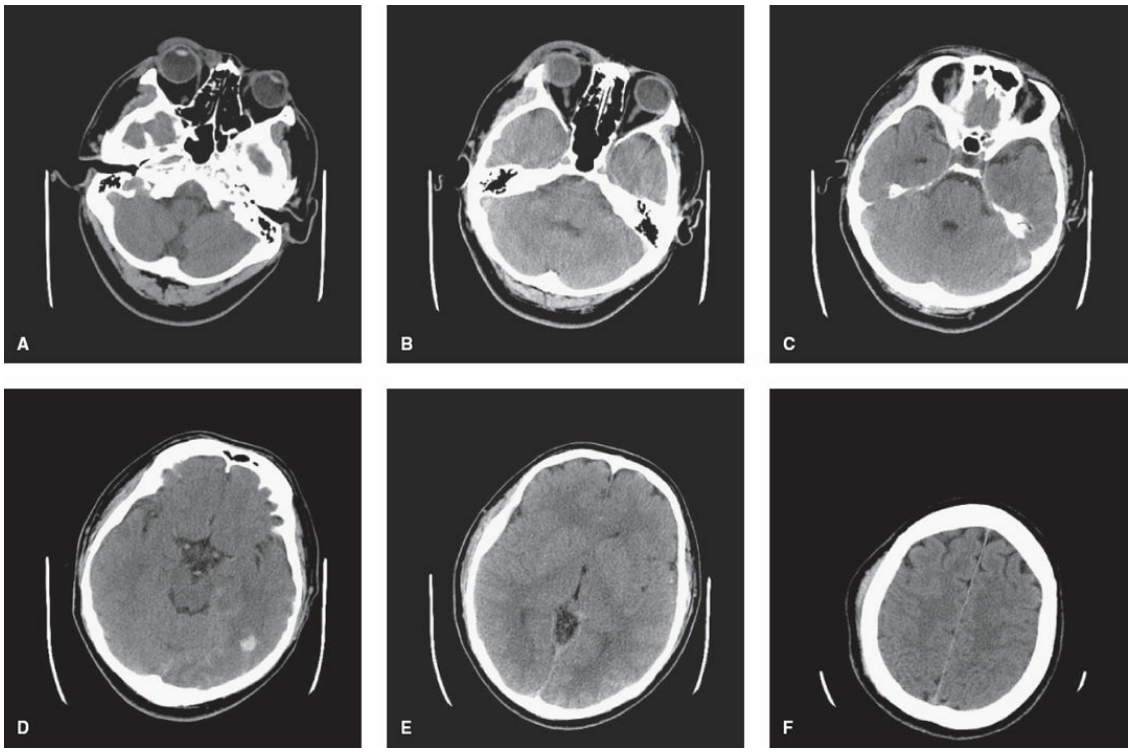

Figure 36.3. Slices of an emergent CT. **A.** Foramen-Magnum. **B.** 4th ventricle. **C.** Temporal lobe. **D.** Sylvian fissure. **E.** Midline/Ventricles. **F.** Superficial sulci.

Illustration of Specific Cases

Increased ICP From Global Injury; Emergent ICP-Bolt or EVD Placement (Fig. 36.4A–C)

Indicated in all comatous TBI patients with a GCS of 8 or less and an abnormal CT scan. The ICPB or EVD is placed in the ER/ICU/OR at Kocher's point (10 cm posterior and 3 cm lateral from the nasion).

It subsequently requires a management protocol written for ICP >20 cm >5 min

f/u CT needed immediately after placement

Epidural Hematoma (Fig. 36.5)

Characterized by convex, extra-axial, hyperdense mass, confined by sutures

Incidence among all TBI is about 3%

1/3 to 1/2 of patients are in coma on admission

50% present with classic lucid interval
Peak incidence: patients aged 20 to 30 years
Most frequently from meningeal arteries or veins, fx, or from sinus
10% require open surgery
Imaging shows incipient mass effect
Outcome correlates with Clot-location, Clot-thickness, Clot-volume, and MLS

- May be managed conservatively if: patient noncomatous, no focal deficits, thickness <15 mm, volume <30 cc, and MLS <5 mm or in a nontemporal location
- Indication for surgery: GCS <9 and/or volume >30 cc

Be aware: Time from deterioration to decompression correlates with outcome!

TABLE 36.10 Checklist for Interpreting a Trauma Head CT

A. Soft tissue windows

- Start at the level of the foramen magnum and work your way up to the vault
- Is the Foramen magnum open or crowded?
- Are the cisterns around the brainstem visible?
- Is the 4th ventricle visible? open? blood filled? in the midline?
- Is there a mass in the posterior fossa or cerebellum? is there a bleed or a stroke?
- Is the temporal lobe displaced medially? (pressing on the 3rd nerve?)
- Is the Sylvian fissure visible and open?
- Are the ventricles visible and midline (measure shift at the level of the Foramen Monroi)?
- Is there blood in the ventricles (check occipital horns in the supine pt)?

- Is there visible blood around the brain?
- Are there changes in the brain parenchyma (fronto-basal/ temporal tip contusions)
- Does the surface show visible sulci (indicating SAH or assessing ICP)

B. Bone windows

- Check for fractures. If at the surface, are they depressed? How much in mm? Is there a petrous apex/skull base fracture through the carotid canal (requires CTA)?
- Check the sinus and whether they are air-filled or opacified (= fluid-filled)
- Check for intracranial air indicating a CSF leak
- Check the orbit for fractures rule out compression of the optic nerve

TABLE 36.11 Radiologic Facts

1. Approximately 10% of initial head CT scans in patients with severe TBI do NOT show any abnormality
2. Significant new lesions and increased ICP may develop in 40% of patients with an initially normal head CT
3. Approximately 15% of patients with significant head injury may develop delayed deterioration (from hemorrhage or edema)

Clinical Case Vignette

- 26-year-old female patient s/p MVA with HA and dizziness and

intermittent confusion; transferred from OSH with initial CT: negative! Repeat Imaging for increased HA about 2 hours later showed a temporal fracture, and a new left 12 mm temporal EDH with incipient mass effect + uncal herniation

- Emergent L craniotomy for evacuation performed.

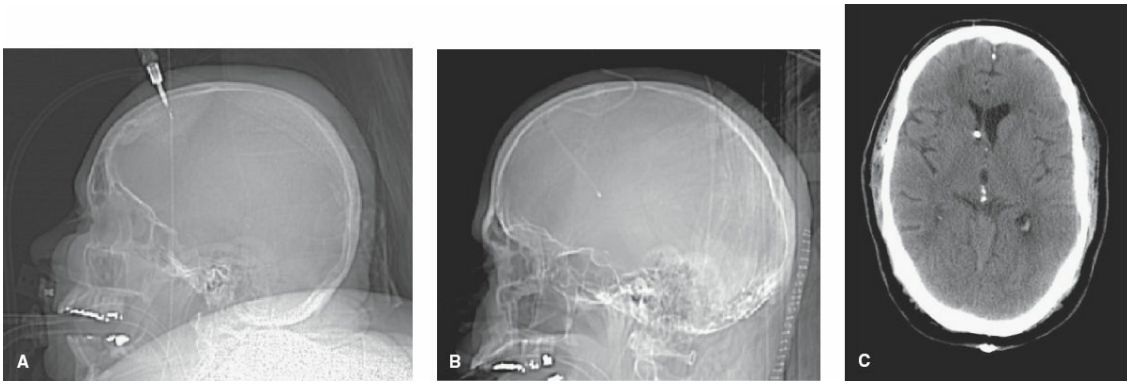

Figure 36.4. **A.** ICP-bolt insertion position on lateral XRT. **B.** Right frontal EVD placement. **C.** Postplacement CT scan: the soft tissue window shows the tip of the catherted at the level of the Foramen Monro.



Figure 36.5. Epidural hematoma.

Subdural Hematoma

Characterized as a crescentic, extra-axial, hyperdense mass on native head CT (Fig. 36.6), not confined by suture lines
Incidence among severe TBI patient is about 12% to 30%
1/3 to 1/2 of those patients are in coma on admission
Rarely patients present with a lucid interval
Peak incidence lies with patients aged 31 to 47 years, mainly men
Frequently from MVA, falls, fractures, assaults
35% to 80% of patients will present with GCS <9;
Poor outcome >age 60
Imaging shows incipient mass effect
Outcome correlates with clot-location, clot-thickness, clot-volume, and MLS
May be managed conservatively if: patient is noncomatous, without focal deficits, thickness <10 mm, volume <30 cc, and MLS <5 mm, nontemporal location; with ICPB
Indication for surgery: GCS <9, clot-thickness >10 mm, MLS >5 mm and/or volume >30 cc
Remember: Time from deterioration to decompression correlates with outcome!



Figure 36.6. Subdural hematoma.

Clinical Case Vignette

- 42-year-old male s/p fall from standing prior to admit and progressive hemi-paresis; h/o HTN and significant EtOH intoxication; Imaging revealed a Right acute SDH (Fig. 36.7)

Subarachnoidal Hemorrhage

Characterized as diffuse bleeding in the CSF space (looks like "sugar spilling" of extra-axial, hyperdense material on native head CT) not confined by suture lines. It is best visible in the sulci and fissures and in the occipital horns of the ventricles.



Figure 36.7. Right osteoplastic craniotomy for evacuation of hematoma.

Incidence among severe TBI patient is very high.
Patients may be in coma on admission (depends on mechanism of injury and impact), but it is very important to get a precise PMH.
Rarely patients present with a lucid interval.
Frequently from MVA, falls, fractures, assaults.
Imaging shows very little mass effect, if it occurs as an isolated injury.

Look carefully at the distribution of the blood and especially the basilar

cisterns and the Sylvian fissure. If there is any suspicion, that it could be aneurysmal in nature and the story does not make sense, it is mandatory to rule out that the SAH did not precede the TBI.

Intraparenchymal Hematoma

Traumatic parenchymal lesions occur in 10% of all TBI patients and in up to 30% of severe TBI patients

Smaller lesion may not require aggressive operative treatment, but additive mass effect may result in secondary brain injury and puts the patient at risk for deficit or death (Fig. 36.8)

All comatous patients with temporal or frontal lesions >20 cc or MLS >5 mm or any larger lesions >50 cc should be treated surgically

Early intervention is advocated with progressive neurologic deterioration

The threshold for decompression is a medically refractory ICP increase >25

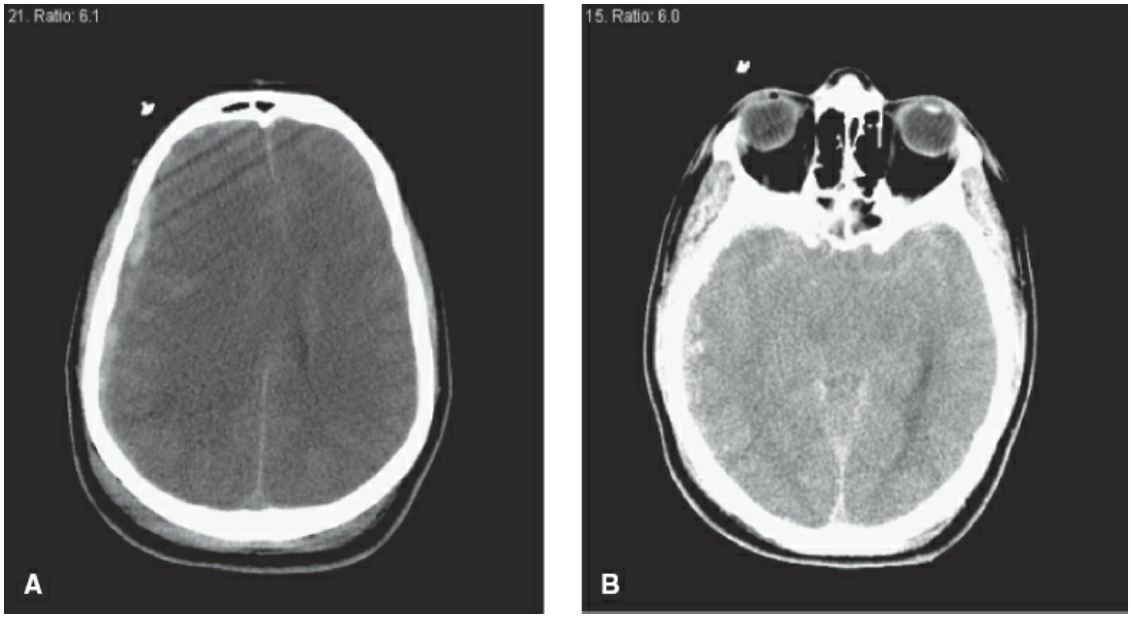

Figure 36.8. **A.** Small R SDH with global swelling. **B.** Right temporal hemorrhagic contusion adding mass effect.

Clinical Case Vignette

- 22-year-old male presented s/p snow board crash against brick wall; upon arrival he had a GCS 8 and a R 3rd palsy; Emergent CT revealed a small R acute SDH with a nondisplaced skull fracture, significant midline shift and multiple bilateral hemorrhagic contusions adding up to significant mass effect.

- Emergent R craniectomy, evacuation of SDH, and temporal lobectomy performed (Fig. 36.9)

Skull Fracture

Characterized by bone destruction to the skull and possible displacement, forming an extra-axial mass, not confined by sutures (Fig. 36.10)
Incidence among all TBI is about 6%
Because of the high impact, it is associated with high risk for intracranial hemorrhage and a significant neurologic deficit thus causing a poor outcome
Closed fractures can be fixed intraoperatively in one setting with craniotomy for exploration and bone fragment elevation and repair
All open fractures require a craniectomy with discarding of the bone, followed by delayed allograft cranioplasty. Most patients have to receive long-term antibiotics

Indications for surgery: if the depressed bone segment is thicker than the thickness of the overlying skull, they are unstable and require surgery.

Gun Shot Wounds (GSW)

GSW are the most frequent penetrating injuries (other are stabs/nailguns/falls into sharps) and account for one third of TBI trauma deaths in patients <45 years. The overall "proximal mortality" remains >90% (Fig. 36.11 and Table 36.12).

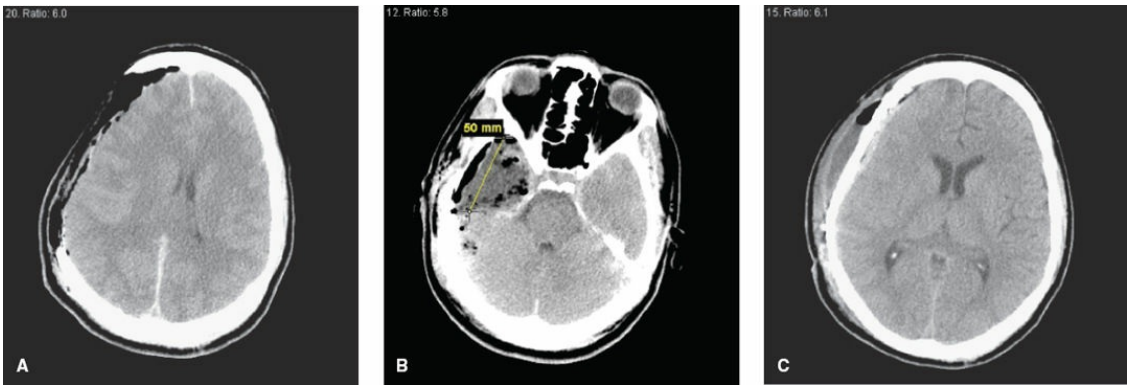

Figure 36.9. A. Right hemicraniectomy and evacuation of a SDH. **B.** R temporal lobectomy for performed to create space. **C.** Second stage R cranioplasty performed 8 weeks post trauma.

Hospital Course: Cardiopulmonary resuscitation (CPR) is likely to be performed in the field as necessary. Most patients will arrive per

emergency medicine services (EMS) in the hospital intubated and sedated. An expeditious trauma survey must be performed and additional injuries need to be identified and treated accordingly. Control bleeding from the scalp and other sites. DO NOT PROBE WOUNDS. Remember to keep MAP high during rescuscitation and avoid excessive hydration to avoid cerebral edema; standard spine precautions apply. Important: Describe entrance and exit wounds, unilateral injuries versus bullets crossing midline (very poor prognosis). Get 3D reformats from the CT done right away. If you have any chance to save the patient, act proactively and apply mannitol, lasix, hyperventilation as outlined and get the patient to the OR swiftly for decompression above.

Late complications: If the patient survives the initial insult and finally goes to rehab, a scheduled follow-up with full imaging is necessary to rule out delayed issues such as traumatic aneurysms, hydrocephalus, infections, and abscess. Keep the patient on anticonvulsants until reevaluation to protect him from secondary damage from seizures.

Outcome: GCS score and LOC (or the level of consciousness) at the scene and upon arrival in the hospital are the most relevant predictors of outcome. Most victims die at the scene. If the patient shows + LOC at the scene and upon arrival, 94% die and 3% survive with severest disabilities. Suicide attempts are more likely to be fatal. As in most TBI, young age and physical status are advantageous for improved recovery during rehabilitation, which should happen at an experienced TBI center.

NONTRAUMATIC EMERGENCIES

Mass Effect and Herniation

Background: Irrespective of detailed etiology and pathology, many CNS diseases directly or indirectly threat the patient's neurologic status and life by exerting force to functionally important and/or vital cerebral centers. Among the most dangerous conditions is brain herniation and its most critical final route of brainstem compression with consecutive death.

Brain herniation (Fig. 36.12) occurs when brain tissue inside the rigid skull is displaced or shifted by local pressure from its normal position toward another location with less pressure. It frequently happens as a direct consequence of hemorrhage (secondary to blood volume) or perifocal brain edema following ischemic stroke, CNS trauma, infection,

or inflammation, but is also commonly seen as vasogenic edema in the context of both primary and metastatic CNS tumors. It can also be caused by “global” problems such as hydrocephalus or generalized edema such as in malignant hypertension.

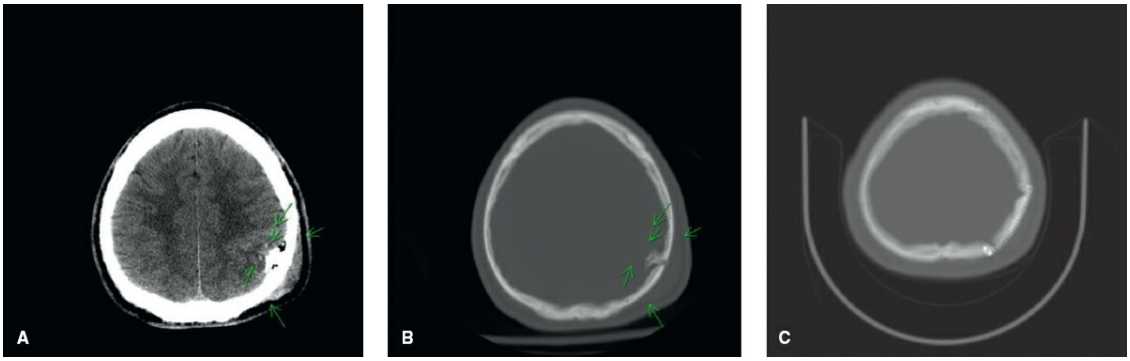

Figure 36.10. **A.** L frontal depressed skull fracture from a golf club assault. **B.** Bone window demonstrating internally displaced fragment. **C.** Post-OP CT of elevated calvarial fracture, which was repaired and augmented with titanium mesh.

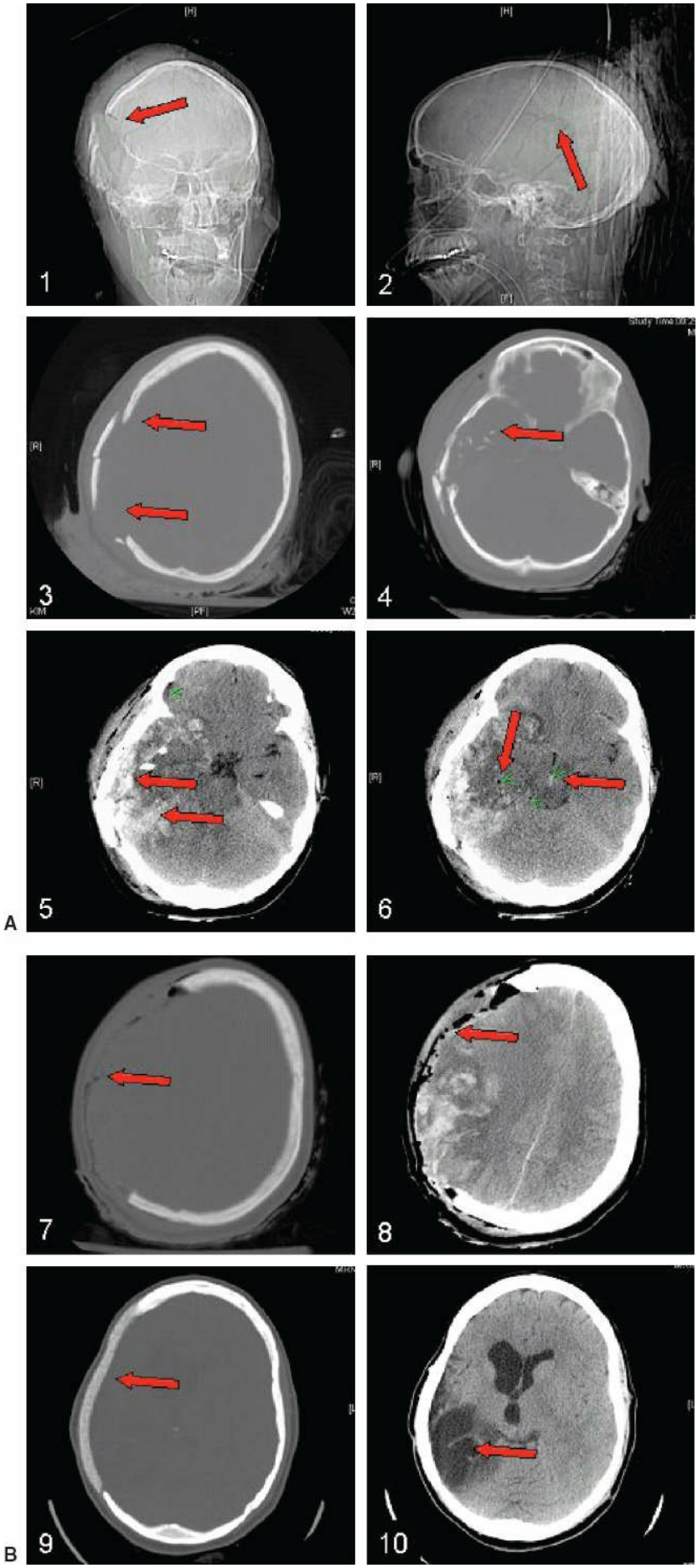
1
2
3
4
5
6
A
7
8
9
10
B

Figure 36.11. **A.** 1 to 6: R GSW to the head; extensive bone damage is visible with translocated fragments and extensive soft tissue injury. **B.** 7 to 10: Surgical decompression via wide hemicraniectomy (7/8) and delayed repair = 9, cranioplasty; 10: encephalomalacia.

TABLE 36.12 TBI From GSW Fall Into Two Categories: Primary and Secondary Injuries

Primary injury: Injury to soft tissue (scalp/face; bacteria translocation; pressure wave or gas); comminuted fracture to the bone; cerebral injury from missiles (direct path/ricochet/ fragments/coup & contrecoup)
Secondary injury (Early): Edema (ICP); cardiac output (MAP); DIC; hemorrhage; **(Late):** abscess/infection; Traumatic aneurysms; seizures; migrating fragments

Symptomatology: Any surgeon should know about the risks of herniation and anticipate and recognize the signs of impending or incipient herniation inherent to CNS disease potentially causing acute or delayed mass effect.

While the attribution of certain clinical signs to types and stages of herniation is puzzling, key symptoms of brainstem functional impairment in a patient at risk are as follows:

Dynamic decrease of the level of consciousness: somnolence → sopor → coma

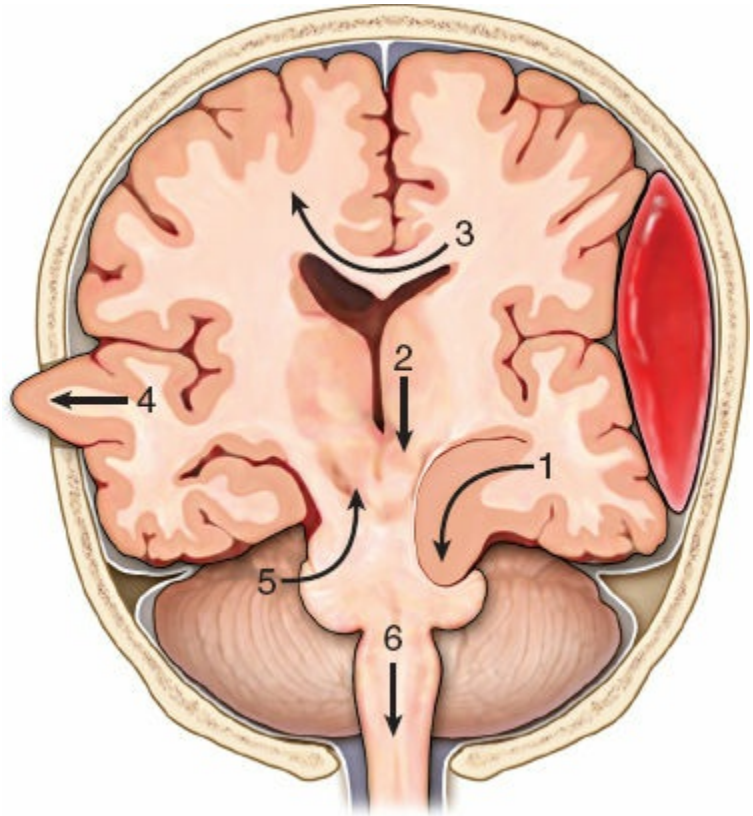

Figure 36.12. Brain herniation can occur from one compartment to another inside the skull. Subfalcine (3), uncal (1) and transtentorial herniation (2), upward herniation from posterior fossa (5), through a natural opening (tonsillar herniation at the foramen magnum (6)) or through bony defects such as the ones created during brain surgery (craniectomy sites (4)) or natural defects (encephaloceles).

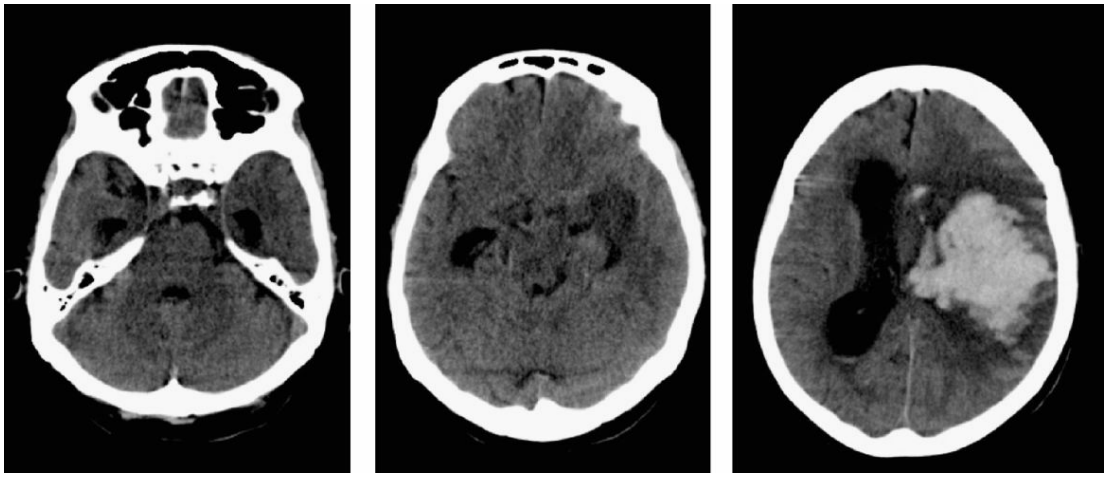

Figure 36.13. Hemorrhage into a left subtotal MCA infarction: Note radiographic signs b. to d. of transtentorial herniation as mentioned in the text. Note apparent shift of pons and associated changes in perimesencephalic cisterns.

Pupillary changes: especially bilateral small pupils, anisocoria, bilateral wide pupils
Pyramidal signs (especially Babinski group of signs)
Abnormal breathing patterns: pausing, hyperventilation, “machine breath”
Abnormal body posturing such decortication and decerebration
Abnormal motor reaction to painful stimuli
Development of hemiparesis

While often a developing hemiparesis is contralateral to the causative lesion (due to axial downward stress to ipsilateral peduncular long tracts before their decussation), an ipsilateral hemiparesis can develop by displacement of the upper brainstem leading to tentorial force on the contralateral cerebral peduncle (*Kernohan notch*). Thus, in case of a patient with primary left supratentorial mass lesion developing a left hemiparesis, Kernohan notch pressure during incipient herniation is the likely mechanism. Another traumatic mechanism leading to secondary damage is hemorrhage at the site of shearing force (*Durette hemorhage*).

Imaging features: CT and MRI need to be checked for signs related to early stages of progressive parenchymal shift indicating the risk of developing transtentorial herniation.

Noteworthy are the following: (a) principal basal cistern narrowing, (b) ipsilateral ambient cistern widening, (c) contralateral ambient cistern narrowing, and (d) contralateral temporal horn widening. Typical complications from herniation syndromes are usually detected on routine follow-up scans and include: anterior cerebral artery (ACA) infarction from transfalcine herniation in case of frontal lobe midline shift, or posterior vcerebral artery (PCA)-infarction due to transtentorial herniation (which may also occur from posterior masses). See Fig. 36.13.

Therapy: Intervention for increased ICP is either medical or surgical. Goal is to provide treatment that shrinks the brain and reduces associated tissue pressures. This includes such measures as improving venous outflow via elevation of the head, hyperventilation for vasoconstriction, osmotica for volume contraction, and steroids to decrease vasogenic edema in nontraumatic cases.

Surgical options depend on the scenario and patient eligibility and are aimed at: (a) eliminating the offending mass that creates such pressure and (b) forming a space by creating a skull defect to allow brain expansion to

occur and thus significantly lowering the resulting net tissue pressure and reducing midline shift and herniation.

Neurosurgical strategy, approach, and technique for decompression hence depend on the nature of the underlying lesion, the actual patient systemic status, and relevant imaging findings. One classic example is decompressing craniectomy for ischemic stroke, which will be discussed in detail below.

Ischemic Stroke (Malignant Media Infarction)

Acute occlusion of any major cerebral artery will result in significant ischemia to the brain secondary to the lack of adequate perfusion given that there is no functional collateral circulation. Resulting tissue death leads to the breakdown of the blood-brain barrier causing significant edema and raised ICP, which may result in herniation. Among strokes, large middle cerebral artery (MCA) territory or hemispheric infarction is often characterized by early and rapid clinical deterioration (*"malignant MCA infarction"*) and impending death unless a life-saving intervention is performed.

The clinical picture of total MCA infarction is characterized by severe sensorimotor hemisymptoms, head and eye deviation to lesion side, hemi-inattention and global aphasia (dominant hemisphere), accompanied by an early deterioration of conciousness and need of mechanical ventilation. Main causes are thromboembolic and atherothrombotic occlusion of proximal MCA or internal carotid artery (ICA). Such complete MCA infarction represents about 1% to 10% of all supratentorial ischemic strokes and occurs at an incidence of 10 to 20 per 1,000,000 per year; compared to other stroke types, it tends to affect women more likely and to occur at younger ages. It is associated with a significant mortality and morbidity rate of up to 80%.

Early diagnosis and initiation of aggressive therapy are determinants of outcome. In most cases, developing brain edema cannot be adequately treated by conservative means alone. Parenchymal edema is mainly due to ischemia resulting in cytotoxic cellular reaction. Its effect peaks approximately 1 to 5 days after the insult. The term "malignant" is used for such cases when brain swelling is starting early (within 24 to 48 hours) and results in significant mass effect. Extensive edema and marked elevation of ICP may cause secondary brain damage via ischemia of neighboring brain areas and can lead to "bystander-infarction," for

example, ACA-occlusion by transfalcian herniation or PCA-occlusion from transtentorial herniation.

The primary goal of surgical intervention is to save the patient's life, but also to limit the functional deficit. Several studies indicate that decompressive craniectomy limits the progressive evolution of effects on adjacent areas (e.g., secondary cerebral ischemia in the penumbra). For supratentorial strokes, it has been shown that early decompressive hemicraniectomy with durotomy/duroplasty is the most effective intervention in such circumstances, ultimately resulting in interruption of this vicious cycle. It not only reduces mortality, but it also improves outcome and reduces infarction size. It generates space, decreases ICP, alleviates mass effect, and increases cerebral perfusion to the penumbra allowing for perfusion via leptomeningeal collaterals. Metabolically compromised but viable parenchyma may thus survive. Optimal patient selection remains to be determined but preoperative clinical signs and timing of surgery seem to influence the prognosis.

Many retrospective clinical reports have indicated the significant effect of hemicraniectomy on survival of MCA infarction patients, several of them also pointing to positive results concerning functional outcome.

Data of several randomized controlled trials are currently available, i.e., DECIMAL, DESTINY, and HAMLET. All of them show significant rates of survival with respect to surgical versus nonsurgical treatment. According to a *pooled* analysis of these trials, the case fatality rate was significantly reduced comparing decompression (29%) versus conservative treatment (78%), the absolute risk reduction was 50%, and the functional outcome was significantly better. Age appears as the most important predictor of mortality, disability, and long-term functional dependence; further studies are running (DESTINY-2).

Currently there are only limited data reported as to the *optimal* time point for surgical intervention, but it shall be discussed early. More recently available imaging techniques, such as perfusion and diffusion MRI, may help to determine the time course of cerebral ischemia early after symptom onset, thereby allowing the clinician to decide on indication for surgical intervention. A similar approach needs consideration for expanding posterior fossa infarction, i.e, large cerebellar stroke.

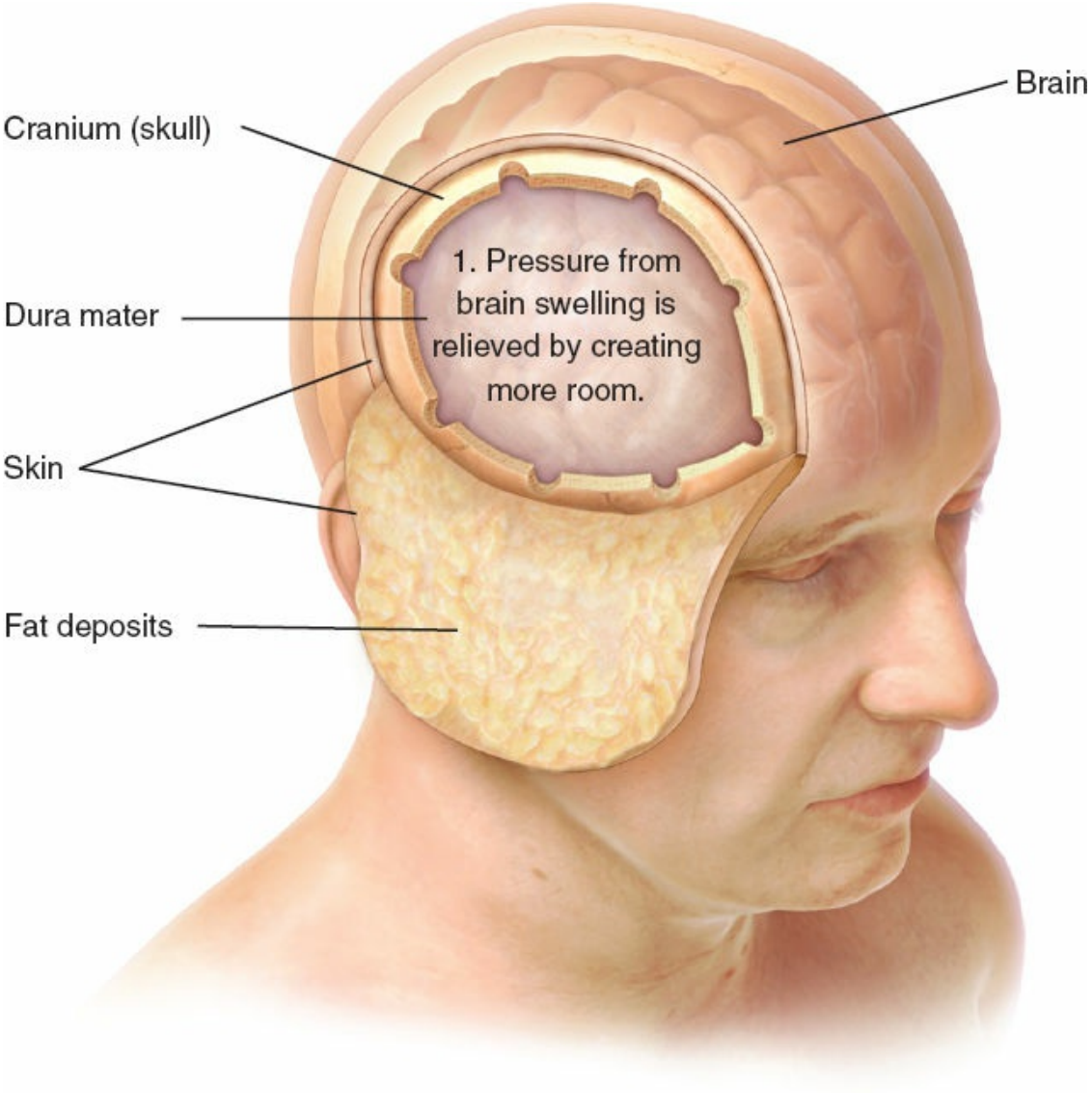

Figure 36.14. Hemicraniectomy.

Technical Considerations Concerning Hemicraniectomy

In order to give the brain parenchyma the maximum space for swelling and allowing for maximum decompression, the primary goal in a standard hemicraniectomy for MCA infarction is to remove a large bone fragment over one hemisphere (Fig. 36.14):

Trauma flap: fronto-parieto-temporal
Margins:
Anteriorly: superior border of orbital rim, avoiding frontal sinus
Posteriorly: 2 cm posterior to external meatus
Medially: 2 cm lateral to midline, avoiding superior sagittal sinus
Inferiorly: just above the ear cartilage = floor of middle fossa
Reflect temporal muscle anteriorly

Place several burr holes
Bone fragment can be stored in abdominal pouch or cryo-conservated
Remove sphenoid wing
Tack up dural edges to bony margins
Open dura via stellate or C-shaped incision
Perform duraplasty (periostium, temporal fascia)

This generates a 10 × 15 cm calvarial defect with a lower margin that should be extending <1 cm to the floor of the middle cranial fossa. If the bony opening is too small (<8 × 8 cm), it can lead to parenchymal injury from persistent pressure at the craniectomy margins with subsequent infarction. It must be emphasized that this type of emergent surgery is a dramatic event and only justified as a life-saving measure. It is to be noted that secondary to the significant compromise most of these patients sustained from their TBI, only 55% of the survivors answered "yes" to the question, "whether they would have liked the surgery being performed on them in this setting." Once the craniectomy has been successfully performed, one should plan on elective repair 8 to 12 weeks thereafter to reconstruct the calvarial defect.

Seizures: Status Epilepticus (SE)

Background

"Status epilepticus (SE)" is a term describing any type of prolonged, sustained or fast repetitive seizure activity and can occur in the setting of TTBI or not. It does represent a life-threatening emergency in many cases. Most relevant status types are as follows:

Generalized convulsive status epilepticus (GCSE, "Grand Mal"-Status)
Nonconvulsive SE (NCSE) and subtle status—SE without major motor activity; important cause of pronlonged impairment of conciousness or unexplained coma; often developing out of a GCSE, when epileptic activity on EEG outlasts the end of clinical motor activity. Special type: Absence Status
Simple partial SE—most frequently associated with certain conditions, for example, chronic focal encephalitis or other lesion. A special variant is Epilepsia partialis continua.

The International League Against Epilepsy (ILAE) classification of SE does not include a definite duration criterion for SE. GCSE has often been defined as >30 minutes seizure activity or a series of seizures without

return to full consciousness between the individual seizures. Notably, even a short period of seizure activity may cause neuronal injury and self-limitation is really rare after 5 minutes.

Epidemiology and Etiology

SE incidence is estimated to be 10 to 20 per 100,000 per year and is increasing with age. Approximately 50,000 to 200,000 cases occur per year in the United States. Males and females are affected nearly equally. SE affects all age groups but more frequently at the extremes of age (i.e., in neonates related to hypoxic injury or metabolic disease and in elderly people related to stroke).

Overall mortality rate is as high as 20%, but may exceed 50% in prolonged SE cases. Death often relates to underlying cause, unsuccessful treatment or SE complications.

Systemic SE complications are: (a) excessive catecholamine release leading to hypertension, tachycardia, cardiac arrhythmia, hyperglycemia and lactic acidosis; (b) hyperpyrexia promoted by excessive muscular activity; (c) hypoxia from impaired ventilation, pulmonary edema; (d) myoglobinemia due to muscular destruction with danger of renal failure.

Causes of SE may be roughly divided into three groups (Table 36.13):

Exacerbation of a known seizure disorder (irrespective of known or unknown etiology) occurs in up to 50% of the cases. Triggering factors include noncompliance; antiepileptic drug (AED) serum level drop caused by intercurrent disease (e.g., gastrointestinal) or pharmacologic interaction (after prescription of an interacting drug), intercurrent infection/febrile disease; complication acquired during a preceding seizure (intracranial hemorrhage, CNS trauma). So do not miss a new acute/subacute cause unrelated to pre-existing epilepsy!

TABLE 36.13 Causes for Status Epilepticus

Infection (e.g., meningitis, encephalitis, brain abscess)
Ischemic stroke
Subarachnoid hemorrhage
Neoplastic lesion (primary CNS tumor, metastasis)

Trauma
Systemic disease affecting the CNS, e.g., eclampsia
Toxic etiology (e.g., amphetamines)
Metabolic encephalopathies (e.g., hyponatremia, hepatic encephalopathy)

Hypoglycemia
A variety of medications, notably sympath-omimetics
Alcohol withdrawal
Hypoxic injury

First manifestation of an idiopathic/cryptogenic seizure disorder
Acute and subacute symptomatic CNS disease

Notably, any CNS disease may be associated with the development of acute seizures, including SE, which can be the first symptom also.

Given that such causes might also occur as secondary change (e.g., infarction due to vasospasms due to SAH, or intracranial infection after any open surgery, or generalized edema due to metabolic derangement due to sodium loss due to diuretic treatment) any of these scenarios must be considered regardless of primary cause of hospitalization.

Important Notes

Classic GCSE is easily recognizable at the bedside by the typical rhythmic tonic-clonic activity. Rarely, SE presents as persistent tonic seizure (postural, versive fits).
Rapid repeated and prolonged extensor and/or flexor movements or posturing may be confused with clonic activity, but rather characterizes nonepileptic attacks (“psychogenic status”). Typical is the “waxing and waning” character of motor symptoms. EEG is normal during the attack

(monitoring!).
Suspect persisting SE in any patient not regaining consciousness within the regular timescale after a witnessed grand mal seizure (subtle status or NCSE); here EEG is mandatory within 30 minutes (Fig. 36.15).
Suspect NCSE in all otherwise unexplained coma or significant disturbance of consciousness regardless of underlying primary cause, especially in the ICU. *NCSE not rarely is the cause of unexplained coma, especially in TBI patients.*



Figure 36.15. Characteristic rhythmic epileptic EEG activity from a case of NCSE.

Repetitive generalized myoclonus in a comatose patient following diffuse hypoxic brain injury may mimic generalized seizures; it poorly responds to AED treatment because its pathophysiology is likely not pure epileptic; it usually carries a poor prognosis.
Important seizure and SE-related injuries may include: severe tongue bites with the need of surgical therapy; joint dislocations and fractures (especially shoulder and spine); head and/or facial trauma;

rhabdomyolysis with danger of renal failure; and aspiration.

Since prolonged GCSE will cause severe CNS damage, it is paramount to diagnose and aggressively treat this condition from the very beginning in the general surgical population until a root cause has been identified or excluded.

Treatment

GCSE is a condition needing an intensive care setting.

General Notes

Determine and correct glucose level if necessary; consider substituting thiamine and folate (especially in alcohol withdrawal); optimize supportive care (blood pressure, oxygen); establish cardiovascular monitoring; measure AED levels in cases of preexisting epilepsy prior to acute treatment, perform extensive laboratory testing *early*, and consider CSF analysis.

Medical

It is recommended to establish a specific in-house standard algorithm. The general principles of SE, especially GCSE, drug treatment can be summarized as follows:

First line	benzodiazepines IV, especially lorazepam > diazepam > midazolam
Second/ Third line	phenytoin/fos-phenytoin versus valproate, levetiracetame, lacosamide; phenobarbital, propofol
Ultima ratio:	general anesthesia

Guidelines differ between countries and the United States and Europe, and, of course, strategies can incorporate the type of SE. Applying “third-line drugs” can be reasonable at stage 2; this field is in evolution. Notably, there is increasing usage of intranasal or intramuscular applications, for example, for midazolam.

Surgical Treatment

Besides surgical treatment of the primary cause of seizures, if necessary, and AED pharmacotherapy, a surgical intervention can be discussed in selected cases of refractory SE, for example in Rasmussen's encephalitis or malformation of cortical development. Repeatedly, successful surgical SE treatment has been reported, usually from partial epilepsy with strong semiologic, imaging, and electroclinical signs indicating the active area.

Suggested Readings

Andrews BT. Head injury management. In: Andrews BT, ed. *Intensive Care in Neurosurgery*. New York: Thieme Medical Publishers; 2003:12.

Centers for Disease Control and Prevention. Rates of hospitalization related to traumatic brain injury–nine states, 2003. *MMWR* 2007;56:167–70.

DeLorenzo RJ, Pellock JM, Towne AR, et al. Epidemiology of status epilepticus. *J Clin Neurophysiol* 1995;12(4):316–25.

Gennarelli GA, Graham DI. "Neuropathology": In: Silver JM, McAllister TW, Yudofsky SC, eds. *Textbook of Traumatic Brain Injury*. Washington, DC: American Psychiatric Association; 2005:27–33.

Greenberg, M. *Handbook of Neurosurgery*. New York: Thieme Medical Publishers; 2009.

Hatefi D, Hirshman B, Leys D, et al. Hemicraniectomy in the management of malignant middle cerebral artery infarction: lessons from randomized, controlled trials. *Surg Neurol Int* 2014;5:72.

Holtkamp M, Othman J, Buchheim K, et al. Predictors and prognosis of refractory status epilepticus treated in a neurological intensive care unit. *J Neurol Neurosurg Psychiatry* 2005;76(4):534–9.

Kasper EM, Luedi M, Kasper BS. Gunshot injuries to the head: Chapter 2.1. In: Velmahos G, Degiannis E, Doll D, eds. *Penetrating Trauma: A practical Guide to Operative Technique and Perioperative Management.* Springer: Berlin/Heidelberg; 2009.

Keenan T, Anthony J, Benson D. Noncontiguous spinal fractures. *J Trauma* 1990;30:489–91.

Kuchta J, Klug N, Ernestus RI. Noncunvulsant status epilepticus as a possible cause of coma in neurosurgical intensive care. *Current Eur Neurosurg* 2009;70:176–9.

Marion DW. Pathophysiology and treatment of intracranial hypertension. In: Andrews BT, ed. *Intensive Care in Neurosurgery*. New York: Thieme Medical Publishers; 2003;52–3.

Mayer SA, Claassen J, Lokin J, et al. Refractory status epilepticus: frequency, risk

factors, and impact on outcome. *Arch Neurol* 2002;59(2):205–10.

Narayan RK, Michel ME, Ansell B, et al. Clincial trials in head injury. *J Neurotrauma* 2002;19(5):503–57.

Scalea TM. "Does it matter how head injured patients are resuscitated?" In: Valadka AB, Andrews BT, eds. *Neurotrauma: Evidence-Based Answers to Common Questions.* New York: Thieme; 2005:3–4.

Teasdale G, Jennet B. Assessment of coma and impaired conscousness: a practical scale. *Lancet* 1974;2:81–4.



EDITOR'S COMMENT

Traumatic brain injury (TBI) is a major cause of morbidity and mortality worldwide. TBI accounts for nearly one third of all injury-related mortality and 2.2% of all deaths in the United States alone (Taylor CA, Bell JM, Breiding MJ, et al. Traumatic brain injury–related emergency department visits, hospitalizations, and deaths—United States, 2007 and 2013. *MMWR Surveill Summ 2017.* 2017;66(9):1–19). Data from the Centers for Disease Control and Prevention reveal that the number of TBI-associated deaths in the United States is increasing and over 70% of TBI-associated hospital admissions were due to falls (50.4%) or motor vehicle accidents (21.5%). TBI frequently occurs with and complicates the management of multisystem peripheral injuries. Nearly two thirds of multisystem trauma deaths have an associated brain injury. TBI in the context of multisystem trauma is associated with a significant increase in mortality (doubling of expected mortality for multisystem trauma patients with an associated moderate brain injury) (McMahon CG, Yates DW, Campbell FM, et al. Unexpected contribution of moderate traumatic brain injury to death after major trauma. *J Trauma* 1999;47(5):891–5). Consequently, it is critical to optimize TBI management in the multisystem trauma patient, as detailed by E. Kasper and colleagues.

Understanding of the mechanism of TBI through direct patient, first responder, and/or eye witness reports is essential to the evaluation and management of the patient (see the *Case Vignettes* demonstration of various injury mechanisms). Significant mechanisms of injury may result in delayed complications, suboptimal management, and impaired prognostication in patients. Careful assessment of vital signs before, at, and after admission can provide additional insight into intracranial complications and determine management strategy. Initial (after patient stabilization) and serial neurologic examinations are essential to the evaluation, management, and outcome estimation in all TBI patients. The Glascow Coma Scale (GCS) provides a succinct and broadly recognized grading scale for TBI patients that supplements the focused neurologic and physical examination. TBI severity based on GCS includes *mild* (GCS 13 to 15), *moderate* (9 to 12), and *severe* injury (3 to 8).

Computed tomography (noncontrast) provides the most efficient imaging assessment of intracranial injury. Early computed tomography scanning is critical in the assessment of the brain-injured patient immediately after stabilization, as well as for those patients with neurologic decline over their course of management. Magnetic resonance imaging can be used to supplement and better define subtle brain parenchymal injury (e.g., diffuse axonal injury) and the extent of edema/infarction as clinically indicated in patients. Patients with penetrating (e.g., gunshot wounds, knife wounds, other penetrating objects) or other nonpenetrating head injuries (e.g., skull fractures, anoxia, arterial dissection) that can be associated with possible vascular injury are assessed after stabilization/resuscitation with conventional angiography, computed tomography angiography, and/or magnetic resonance angiography.

Management strategies in TBI frequently follow injury severity as defined by the GCS. *Mild* injuries are typically managed by in-hospital or at-home observation (in *concussed* individuals). Signs and symptoms most often associated with mild head injury include headaches, nausea/vomiting, dizziness, forgetfulness/memory problems, blurred vision, fatigue, photophobia, and balance problems. Adult patients with *mild* injuries often improve at variable rates. While signs and symptoms frequently resolve in 2 weeks, some patients can remain symptomatic for several months. Symptomatic treatment and rehabilitation are used to manage refractory signs and symptoms. *Moderate* to *severe* injuries require hospitalization and careful serial observation in an intensive care unit until exam/imaging stabilize. *Severe* TBI patients require intracranial pressure monitoring and additional directed medical/surgical management to minimize TBI sequelae (see below) (Carney N, Totten AM, O'Reilly C, et al. Guidelines for the management of severe traumatic brain injury, fourth edition. *Neurosurgery* 2017;80(1):6–15).

Pathologic mechanisms of brain injury are defined as *primary* and *secondary* injury processes. Primary brain injury occurs at the time of the brain insult and is a result of the mechanical forces associated with the injury. The mechanism of primary injury can cause reversible and/or irreversible physiologic and anatomic changes. Because primary injury occurs at the time of injury, the treating physician cannot mitigate its effects. Secondary injury processes occur hours to days after injury and are due to cellular, physiologic, and anatomic alterations associated with the primary injury. Secondary processes frequently underlie delayed morbidity and mortality and can include hypoperfusion, increased intracranial pressure, hemorrhage, metabolic changes, excitotoxic injury, edema, infection, seizure, and hypercapnia. Because these processes can be minimized through careful management, they are the focus of care and guidelines development (see Guidelines for the Management of Severe Traumatic Brain Injury, Fourth Edition, 2017) (Carney N, Totten AM, O'Reilly C, et al. Guidelines for the management of severe traumatic brain injury, fourth edition. *Neurosurgery* 2017;80(1):6–15).

Two critical physiologic processes essential to mitigating secondary injury in

the *severe* TBI patient include optimizing cerebral perfusion (cerebral blood flow) and intracranial pressure. Cerebral perfusion pressure guidelines recommend a target of 60 to 70 mm Hg (cerebral perfusion pressure = mean arterial pressure − intracranial pressure) but target perfusion pressure can depend on patient autoregulatory status. (Carney N, Totten AM, O'Reilly C, et al. Guidelines for the management of severe traumatic brain injury, fourth edition. *Neurosurgery* 2017;80(1):6–15) Systolic blood pressure thresholds of 100 mm Hg or more in patients 15 to 49 years or over 70 years and 110 mm Hg or more in patients 50 to 69 years are recommended. Intracranial pressure guidelines recommend treating intracranial pressure greater than 22 mm Hg. (Carney N, Totten AM, O'Reilly C, et al. Guidelines for the management of severe traumatic brain injury, fourth edition. *Neurosurgery* 2017;80(1):6–15) Methods to reduce patient intracranial pressure can be patient specific (Carney N, Totten AM, O'Reilly C, et al. Guidelines for the management of severe traumatic brain injury, fourth edition. *Neurosurgery* 2017;80(1):6–15; Hutchinson PJ, Kolias AG, Timofeev IS, et al. Trial of decompressive craniectomy for traumatic intracranial hypertension. *N Engl J Med* 2016;375(12):1119–30) and include drainage of cerebrospinal fluid, removal of mass-occupying lesions (hematoma), diuretics/hyperosmolar therapy, decompressive craniectomy, short-term hyperventilation (to acutely reduce pressure), and barbiturates.

Other management guidelines (Carney N, Totten AM, O'Reilly C, et al. Guidelines for the management of severe traumatic brain injury, fourth edition. *Neurosurgery* 2017;80(1):6–15) that are critical parts of the multidisciplinary management of TBI patients with multisystem trauma, include nutritional and ventilator care. Latest TBI guidelines recommend caloric intake at replacement levels optimally by day 5 after injury and day 7 after injury at the latest. For patients unable to safely take oral nutrition, transgastric jejunal feeding is recommended to reduce risk of ventilator-associated pneumonia. Early tracheostomy is recommended in patients to minimize mechanical ventilation complications. The decision to place a tracheostomy in a TBI patient is made after weighing the procedural risk against the benefit. Steroids do not have a role in treating TBI-associated edema. Taken together, these medical and surgical management guidelines for TBI are continually evolving but provide a framework based on best available evidence.

E. Kasper and colleagues provide an expert review of TBI management in their chapter. The authors cover critical areas of exam, assessment, imaging, and management (including indications for surgical intervention). Surgeons frequently encounter trauma patients who have associated multisystem injuries that include the brain. These patients necessitate complex individualized multidisciplinary care to maximize outcome. The pathophysiologic features of the brain injury require strategies to minimize secondary injury. Further research remains critical to better define management strategies and develop new therapeutics.

Russell R. Lonser

37 Tracheotomy

Ryan Little and Jonathan M. Bock

INTRODUCTION

Surgical access to the airway follows three distinct approaches depending on the patient status and clinical situation. These are the open surgical tracheotomy, the emergency tracheotomy or cricothyrotomy, and the percutaneous dilatational tracheotomy (PDT). The first two have a wide range of described techniques each with advocates and detractors. Open surgical tracheotomy is often performed in cases of prolonged intubation and mechanical ventilation, or when the native airway is somehow obstructed or impaired above the level of the trachea. Narrowing of the airway at the level of a prior endotracheal tube (ETT) cuff or scarring of structures above this point can be seen after prolonged oral or nasal endotracheal intubation. An open surgical tracheotomy may also be utilized in preparation for major head and neck surgery or in the event of massive maxillofacial trauma.

Emergency airway access techniques include cricothyrotomy and “slash” tracheotomy, each done as quickly as possible in the context of an arrest with the single-minded indication being the preserving of the patient’s life. This technique is utilized when attempts to definitively secure the airway or temporize the situation are unsuccessful, including failed noninvasive ventilation, positioning techniques, oral or nasal airway, or transtracheal needle jet ventilation. Indications for securing a definitive airway include: apnea, inability to maintain a patent airway by other means, protection of the lower airway from aspiration of blood or vomitus (GCS <8), impending or potential compromise of the airway, inhalation injury, facial fractures, sustained seizure activity, closed head injury requiring hyperventilation, and failure to maintain adequate oxygenation despite supplemental oxygen via masking. While the surgical anatomy is relevant in the general sense, it is far less of an issue than getting a tube into the airway by whatever means as quickly as humanly possible. The main role of the surgeon in the emergency setting is to obtain access to the trachea for ventilation as quickly as possible, while being mindful and

protective of the laryngeal anatomy as much as possible.

PDT is a technique that has gained increased attention over the last three decades, and generally is performed at the bedside within the intensive care unit (ICU) with minimal surgical instrumentation and simple surface anatomy guidance. The process generally requires direct visualization of the airway with rigid or flexible endoscopic guidance to guide proper placement of the tracheotomy. It is indicated for any critically ill ventilated patient who would otherwise have to be taken to the operating room (OR) for an open surgical tracheotomy. Enthusiasm for PDT is tempered by some reports of increased bleeding risk and other complications, although evolving data in this regard is mixed.

OPEN SURGICAL TRACHEOTOMY

General Issues and Indications

The primary indication for tracheotomy is the bypassing of the larynx when prolonged intubation is necessary to reduce the risk of airway stenosis and secure airway access. Additional indications include definitive treatment of airway obstruction due to masses or obstructive sleep apnea, and protection of the airway in anticipation of extensive head and neck surgery or maxillofacial trauma. The timing of when to consider this operation in the context of prolonged intubation is fairly well established. Data support a 10- to 14-day window of intubation as the target for converting from orotracheal intubation to tracheotomy access, as risk of glottic and subglottic stenosis increases markedly on a daily basis after this time.

There are some areas of debate and variability in the timing of tracheotomy. Traumatic brain injury patients who are mobile and fighting their intubation can cause significant glottic injury. The pure physical erosion of the ETT against the posterior glottis can be very damaging to the larynx by causing granulation, mucosal erosion, cricoarytenoid joint inflammation and fixation, and subsequent posterior glottic stenosis. These patients may require tracheotomy in a timely fashion to prevent these devastating laryngeal injuries. Conversely, the comatose patient who needs no sedation and who has some chance of spontaneous recovery may have little endolaryngeal inflammation or injury even after 2 or 3 weeks of orotracheal intubation because they do not cough or swallow. Though these findings are common in these scenarios, it is our experience that laryngeal and tracheal injuries related to prolonged orotracheal intubation

remain quite variable, and the general maxim remains to perform tracheotomy early when prolonged intubation requirements are expected.

Patient medical factors can also influence the risk of glottic stenosis during periods of prolonged intubation. Laryngopharyngeal reflux (LPR) is known to contribute markedly to the potential laryngeal damage of prolonged intubation. Very short periods of intubation in patients with severe LPR can result in profound ulcerative laryngitis and edema which can increase rates of scarring and joint fixation. Other factors that can increase risk of airway edema and subsequent intubation-related injury are: immunosuppression; microvascular disease; diabetes mellitus; and history of recent airway instrumentation. In the context of these additional risks and unsuccessful attempts to wean or extubate, early tracheotomy to protect the larynx from further insult is highly recommended.

The surgically matured tracheostomy is useful in several specific clinical scenarios. The first is in a patient whose neurologic condition is so devastated that there is no reasonable chance for future removal of the tracheostomy tube, known as decannulation. Examples of such conditions include massive strokes, extensive brain injury, or high quadriplegia. Patients with intractable aspiration and laryngeal diversion surgery may need a permanent stoma to avoid airway obstruction if the cannula ever fell out or became plugged and had to be removed. Surgically maturing a tracheostomy may also be considered in cases of advanced head and neck cancer, wherein there is very advanced local invasion of the upper aerodigestive tract. In this scenario, a surgically matured stoma may be prudent in patients that are known to be a difficult orotracheal intubation should tracheostomy tube dislodgement or accidental decannulation occur in the immediate postoperative period. In addition, depending on the site of the primary tumor and staging, these patients may have a protracted course with multiple treatment modalities including surgery and/or chemoradiation, which may also have adverse effects on the airway. Lastly, a fully matured stoma is often appropriate for the morbidly obese patient or obstructive sleep apnea patient with significant pretracheal adipose tissue, as accidental decannulation in these patients can lead to life-threatening airway collapse and marked difficulty in the identification of the tracheal incision. In all of these cases, this technique allows a low maintenance stoma and the safety of a channel that will remain open for hours to days with no cannula at all in many cases. The main risk of a fully matured stoma is that if the clinical assessment is incorrect and the

person's condition does improve allowing for decannulation, the stoma will have most likely have to be surgically closed.

Open Tracheostomy Techniques

There are innumerable techniques for performing a tracheotomy and a tracheostomy (Fig. 37.1). The distinction between the two is of a surgically mature stoma in the latter, though both involve an opening or "otomy" into the trachea as an intrinsic feature of the operation. Vertical or transverse skin incisions are often debated. The vertical is more easily made with little risk of needing to ligate large anterior jugular veins but heals less well than a transverse incision that can be put into a skin crease. In an open surgical tracheotomy, most prefer to perform a transverse skin incision and simply ligate the anterior jugular veins if necessary. These vessels can be extensive in some patients, especially in those with a history of congestive heart failure. The deep dissection often includes the need to either divide or reposition the thyroid isthmus. Dividing the isthmus provides broad access to the trachea; however this may slightly increase the risk of bleeding postoperatively. Suture-ligation with a running baseball stitch or division with monopolar cautery is usually sufficient to control any potential hemorrhage. Another option if the isthmus is small and without cystic or nodular lesions is to move this above or below the tracheotomy entry site.

It is often wise to ask the anesthesia team to lower the ETT cuff pressure and advance the tube further into the airway prior to incision into the trachea. This allows for the tracheal incision to be made without damaging the ETT pressure cuff, which can cause significant respiratory compromise in patients who require large amounts of positive pressure to maintain appropriate ventilation. This allows for measured and careful stomal maturation prior to removal of the ETT under direct vision and placement of the tracheotomy cannula. The tube can even be advanced into the right mainstem bronchus temporarily if needed, as most patients can tolerate this for a minute or two while the stoma is developed. The type of tracheal incision is also an area of great controversy and varies between authors. Our recommendation is to perform an anteriorly based Björk flap wherein a wide transverse incision is made between the second and third tracheal rings, followed by parallel inferolateral vertical cuts to create an inferiorly based flap (Fig. 37.2). The free end of the cut tracheal ring is then secured to the dermis of the lower skin flap with 3-0 vicryl or chromic

sutures. This approach stabilizes the inferior aspect of the stoma to the neck skin, allowing for easier visualization of the tracheal airway in the event of accidental decannulation. Leaving one or two undisturbed rings below the cricoid is also beneficial to increase the protection to the cricoid, as inflammation of the cricoid ring can lead to cricoarytenoid joint fixation and subsequent airway compromise. A vertical incision is often done in children as the tracheal diameter is more narrow and floppy, and does not allow easy maturation of a Björk flap. Vertical tracheal incisions are also sometimes performed in an emergency situation as they allow for faster entry into the airway.

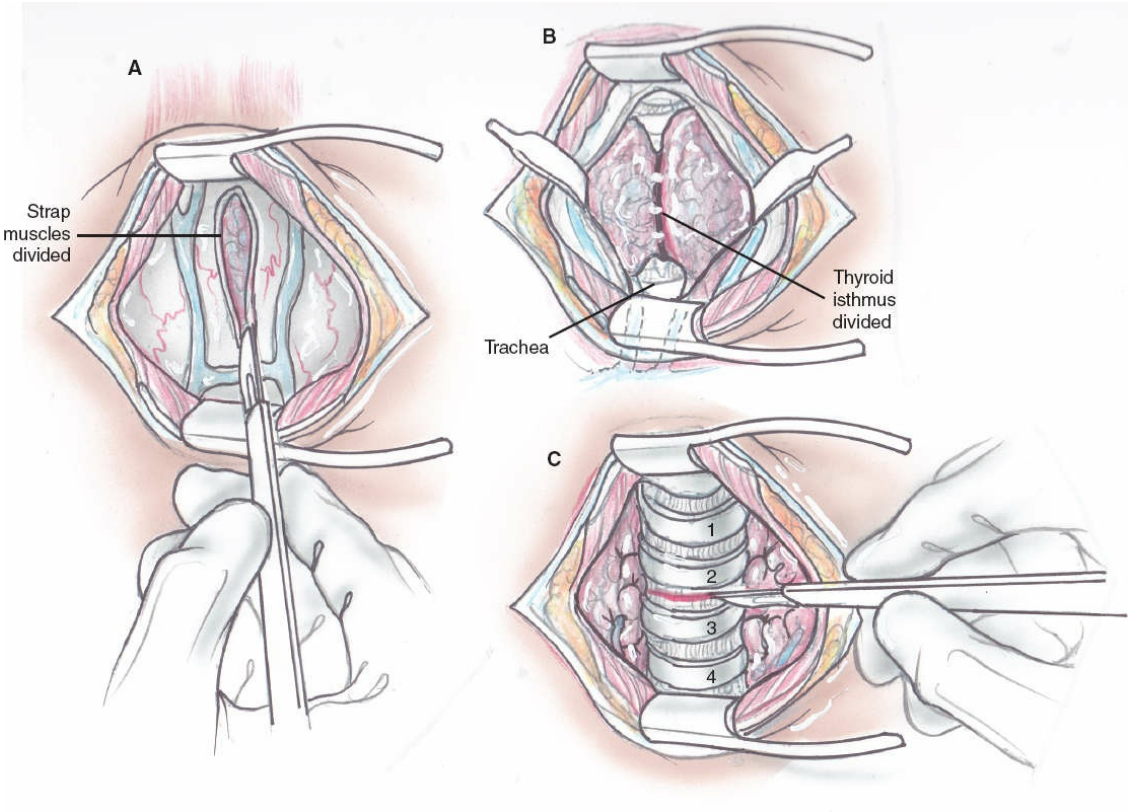

Figure 37.1. Steps of a typical open tracheotomy. The division of the thyroid isthmus is a common part of the procedure, though this may be avoided by mobilizing the isthmus and retracting it superiorly or inferiorly. This results in less potential for bleeding and tissue necrosis within the tracheotomy wound and less malodorous drainage. The hazard of preserving the isthmus is that you may not enter the airway in an ideal position, resulting in a stoma position that may make for a greater tendency for stenosis of the subglottis by injuring the cricoid cartilage. **A.** The strap muscles are divided along the midline raphe and retracted laterally. The trachea and thyroid gland are identified. **B.** The thyroid isthmus is retracted superiorly or divided, as required. **C.**

The first three or four tracheal rings are exposed. The trachea is entered between the second and third tracheal rings. (Modified from Kost KM. Advanced airway management—Intubation and tracheotomy. In: Johnson JT, Rosen CA, Bailey BJ, eds. *Head and Neck Surgery—Otolaryngology*, 5th ed. Philadelphia, PA: Lippincott Williams & Wilkins; 2014.)

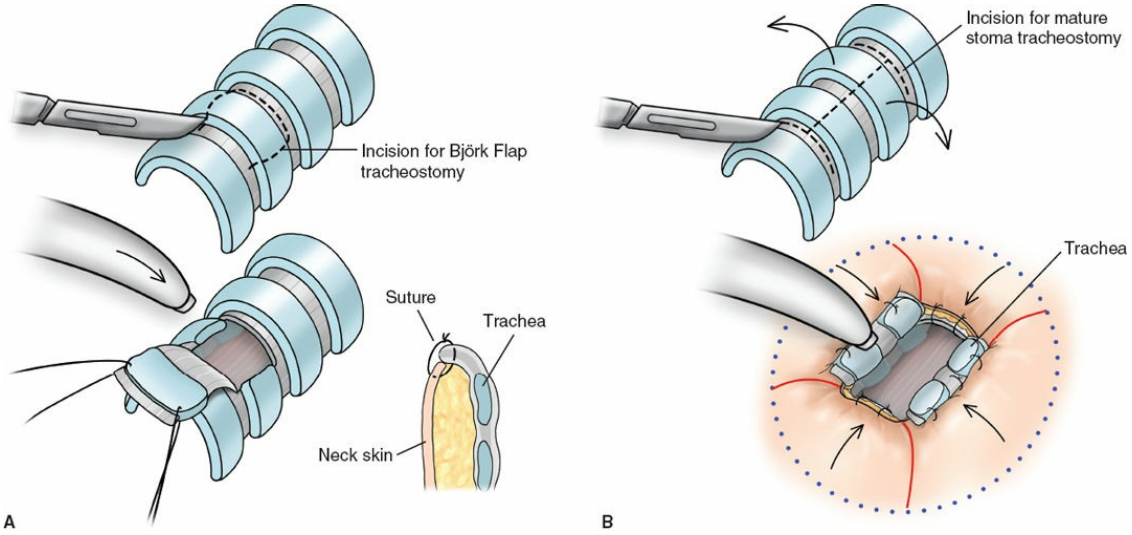

Figure 37.2. A. Generation of the "Björk Flap." **B.** The skin from the neck can be advanced to the trachea instead of the other way around, if additional security against the dislodgement of the cannula is needed. It takes only a small amount of additional effort to enable this. In fact, the same maneuver can be extended in the circumference of the tracheotomy to generate an appropriately named "tracheostomy" by advancing flaps of skin on the three sides of the opening suturing each to the corresponding part of the trachea with slowly absorbing buried monofilament sutures. (Modified from Weissler MC, Couch ME. Tracheotomy and intubation. In: Bailey BJ, Johnson JT, Newlands SD, eds. *Head and Neck Surgery—Otolaryngology*, 4th ed. Philadelphia, PA: Lippincott Williams & Wilkins; 2006.)

Obese patients or those with very short necks often have eventual issues with upward displacement of the tracheotomy tube after surgery. These body types promote the development of stenosis by the vertical upward force on the tracheostomy tube from their cervical pannus with consequent irritation of the anterior tracheal wall. These patients often develop a tracheotomy site with a dense vertical scar beneath it indicating that the initial entry point into the airway was far lower than it ended up (Fig. 37.3). A higher cannula placement point can therefore be justified in these

patients to help avoid this complication, although placement preference should always avoid contact with the cricoid cartilage if at all possible. Extensive anterior cervical defatting can allow for the tracheostomy tube to lay more flush against the skin, and development of skin flaps above and below the tracheotomy site can further facilitate this. Obese patients also are at increased risk of subglottic stenosis due to inappropriate ETT sizing prior to tracheotomy. Aggressive trach mask trials to remove the patients from ventilation and plugging trials to progress to decannulation as quickly as possible are highly recommended in the obese patient population.

The “mature stoma” tracheostomy in-volves the generation of laterally based cartilage flaps sewn to the skin by multiple buried absorbable sutures (PDS, chromic, or vicryl) (Fig. 37.4). A vertical incision through two rings in the midline of the trachea can be connected above and below by a generous transverse incision. This is termed an “I” flap by virtue of the shape of the capital letter “I.” The cartilage of each flap is supported by lateral axial blood and mucosa. An alternative approach is to make a tracheal window by simply excising the median portion of two tracheal rings. All the suture materials used to mature to stoma to the skin should be absorbable so as to avoid the need for suture removal from this difficult to access area. All sutures to mature the stoma are generally placed while the patient is still intubated to facilitate placement without a tube in the way of the surgeon (Fig. 37.5; see also Figs. 37.2 and 37.4).

Complications of Tracheotomy

There is no single technique that enables one to avoid all of the common complications of tracheotomy. These include inadvertent decannulation, or the loss of the airway from the separation of the trachea from the tracheotomy cannula; postoperative hemorrhage; local infection; stenosis or cicatricial scarring above, within, or below the airway entry point; cartilaginous or membranous tracheomalacia; and the potential of injury to the critical neighboring structures such as the esophagus posteriorly and the innominate artery anteriorly. The tracheotomy tube itself is a foreign body and can place pressure on the anterior or posterior tracheal wall, depending on the angle of placement and the patient’s neck anatomy. Erosion into the anterior or posterior wall may therefore occur over time, thus entering the adjacent structures including the esophagus or innominate artery (Fig. 37.6). The dilation that occurs, even in the absence

of erosion, can be its own disease in the form of tracheomalacia. This can make the process of decannulation laborious, long, and potentially unsuccessful. Other factors such as the patient's overall state of nutrition, the ventilatory pressures being used, and patient movements like repeated swallowing and coughing play a role in this erosive and dilatational process. Because of these host factors, potentially dire complications can occur even under the most meticulous attention. Severe and life-threatening complications of tracheostomy can be reduced by careful monitoring of the tracheotomy tube cuff pressure, maintaining it at the lowest possible pressure that allows proper ventilation. A slow increase in necessary cuff pressure and minute volume may indicate a gradual dilation of the trachea and may herald the damage that leads to complications. Proper sizing of the airway appliance can also be facilitated by flexible endoscopic evaluation of the airway through the tracheotomy tube.

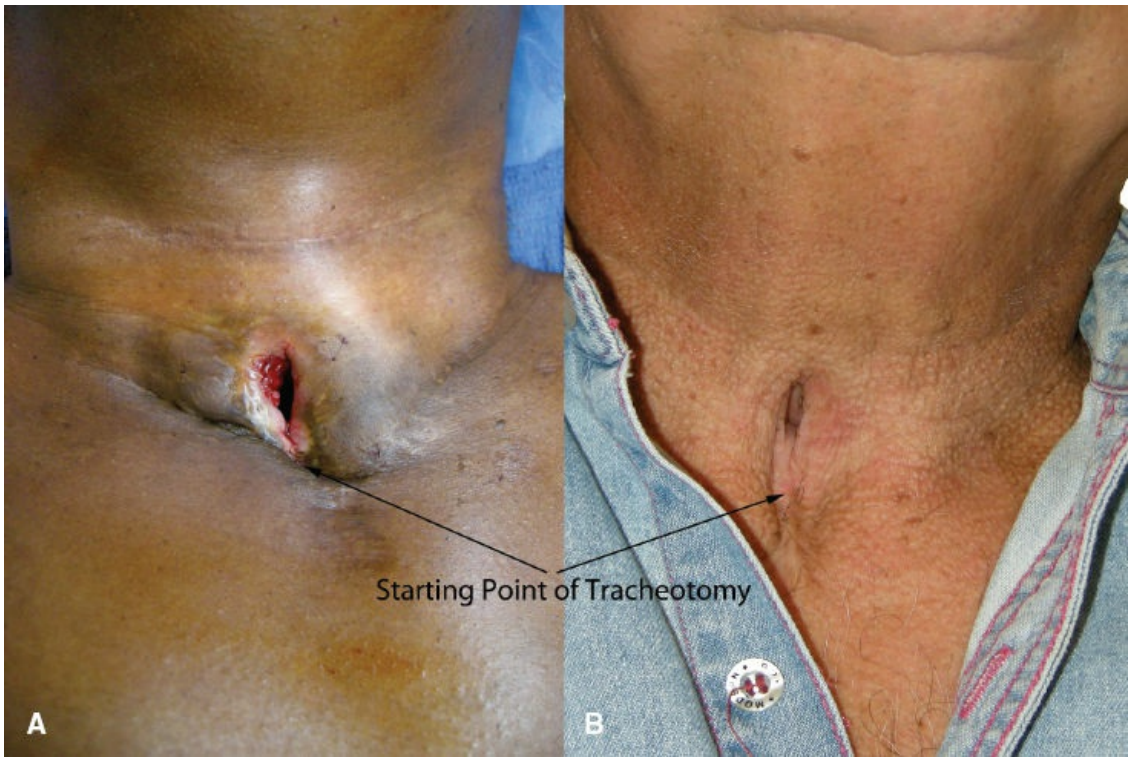

Figure 37.3. A. This stoma began at the level of the transverse scar and eroded upward. The jagged edges are made up of granulation tissue and cartilage that has lost it circular shape. **B.** This very old tracheostomy lacks obvious granulation tissue but clearly has eroded up from its original starting point near the thoracic inlet up to its ending spot below the larynx. Both patients experienced severe airway complications from the tracheotomies. "**A**" required a segmental tracheal resection prior to being able to be decannulated. "**B**" was able to be decannulated after a series

of minimally invasive procedures to widen his airway from the inside.



Figure 37.4. Incisions and dissection that are needed for a surgically matured tracheostomy, in the truest meaning of the term. The four divided skin segments sewn down to the airway on each of four sides bring them to the mucosa circumferentially. This promotes the generation of an “ostomy” that will be secure, require little local care, and will have to be surgically closed if it is ever no longer needed.

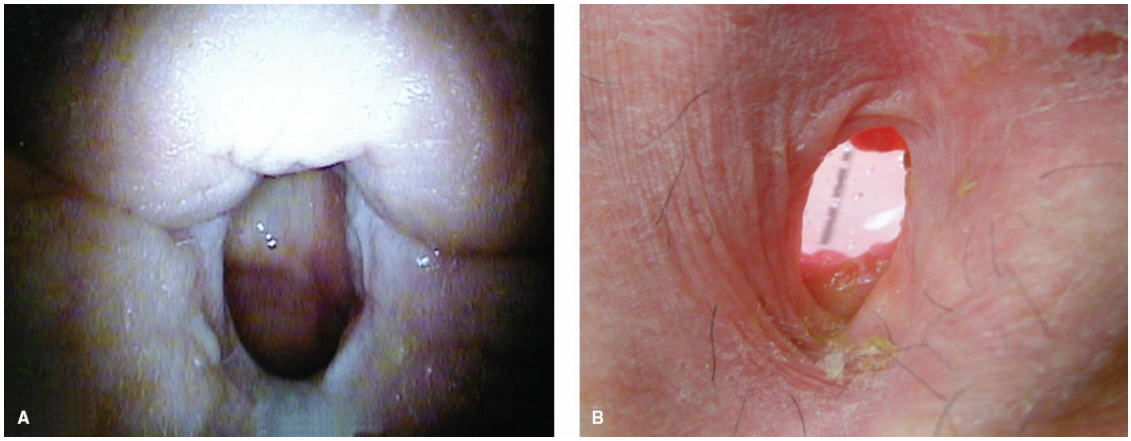

Figure 37.5. A. Video image of a stoma surgically "matured," in that skin flaps were sewn to the trachea to accomplish what can happen to a tracheotomy after it has had a cannula in place for several years depicted in "B." **B.** This image, taken during an endoscopy, provides internal illumination allowing the detection of the granulation tissue evident within the stoma that persists despite the fact that this stoma has been in place for several years. See Figure 37.4.

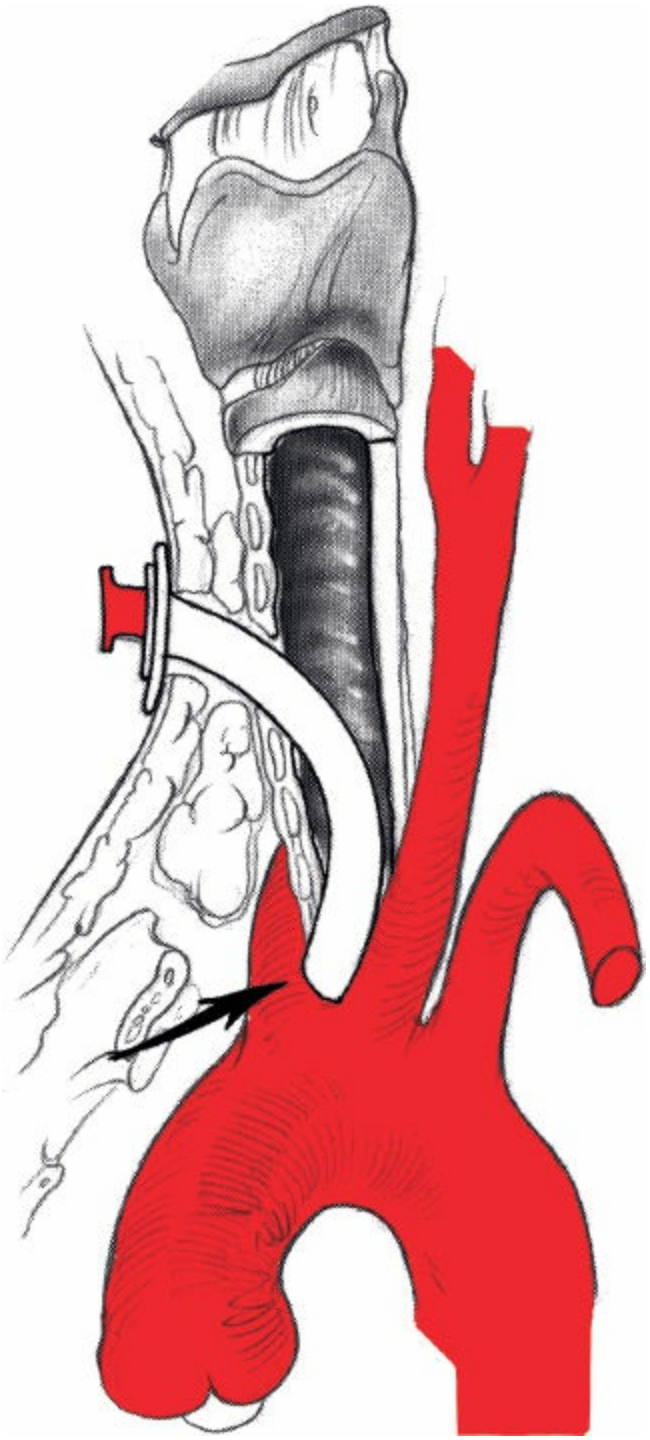

Figure 37.6. Diagrammatic rendering of the anatomical basis of tracheal erosion through the wall into the innominate artery. The curved shape of common tracheotomy cannulas is a common fit for most patients but not all. Common bleeding may indicate a poor shape match for a given patient. A brisk arterial bleed that stops spontaneously may be the so-called sentinel bleed of an innominate artery fistula. This is commonly a fatal complication of tracheotomy. (Modified from Weissler MC, Couch ME. Tracheotomy and intubation. In: Bailey BJ, Johnson JT,

Newlands SD, eds. *Head and Neck Surgery—Otolaryngology*, 4th ed. Philadelphia, PA: Lippincott Williams & Wilkins; 2006.)

Inadvertent decannulation warrants special mention as it the most likely cause of postoperative mortality in the tracheotomy patient. It tends to occur early after the procedure has been performed and before scar has formed to maintain the trachea in contact with the skin incision. This enables the tip of the cannula to fall out of the tracheostomy tract entirely or to sit within a false passage anterior to the tracheal lumen. The patient may be able to breathe, in the latter situation, through or around the cannula for a short time but loss of tidal volumes and decreased gas exchange will likely indicate the problem. If the driving pressures are increased or "bag ventilation" is employed enabling far higher air pressure and volume delivery, a pneumothorax soon follows and a dire downward spiral can result. A quick evaluation of the position of the tracheotomy tube with flexible endoscopy can confirm a view of the tracheal airway, and can also be used to advance the tracheotomy tube into the trachea using the Seldinger technique. The cannula can sometimes be replaced by "feel," if the problem is caught early and the tracheal wall is still widely open. If not, manipulating the cannula can fully close off the communication between the skin and the trachea. Intubation from above should be considered under such circumstances. If intubation from above is not successful, possible, or the patient has arrested, removal of the existing cannula and digital exploration of the wound should be attempted. The anterior tracheal wall may be palpated and the opening into the trachea found. If so, a small ETT (5.0 or less) can be used to reintubate the airway and provide for some degree of ventilation while chest tubes are being placed. The tracheotomy cannula can then be passed by Seldinger technique over a tube exchanger once the situation is stabilized. If the airway is not able to be cannulated but the tracheal opening is palpable, oxygen or Heliox can also supplied by high flow or jet through the open cervical incision into the distal trachea using a needle, IV catheter, or flexible suction. Depending on why the cannula became dislodged in the first place, it may be reasonable to introduce an extra-long cannula such as the Shiley XLT that comes with a proximal or distal extra-long segment (Mallinckrodt, St. Louis, MO). Stay sutures at all four corners of the tracheotomy tube can fixate the cannula base to the neck to secure it against inadvertent removal until the track has matured for 5 days, and also

decrease the rate of postoperative hemorrhage.

The most fearsome complications from tracheotomy, including tracheoesophageal fistula formation (TEF) and innominate artery fistula (IAF), should be mentioned but cannot be addressed definitively in a work of this scope. The critical issue is to avoid a tracheostomy in the context of a known TEF unless the fistula is very high and unlikely to be at or below the level of the entry point of the tracheotomy itself. It is possible that the cannula could be placed into the fistula and the esophagus will be intubated. Repositioning can be hazardous and ineffective. Dire scenarios are common in this setting. Esophageal stenting and rotational flaps in concert with thoracic surgery assistance are usually necessary to correct this problem, and decannulation can be challenging. IAF is highly morbid with over 50% mortality, and requires emergent intervention by cardiothoracic surgical intervention.

Infection is a known risk of tracheotomy but rarely causes life-threatening complications. The tracheotomy wound is open to the airway and by default contaminated with oral flora. The head and neck is famous for tolerating a high degree of contamination without infection because of the excellent blood supply and the vigor of the immune system built into our design. Nonetheless, tracheotomy sites are often oozing with foul mucopurulent secretions and blood caused by pooling of oropharyngeal secretions. Reflux of stomach acid including digestive enzymes and bile from the GI tract may also induce inflammation and a favorable environment for worsened scarring and stenosis of the larynx and subglottis. Prevention or reduction of reflux can be achieved by postural means with head of bed elevation, the use of gastrojejunostomy technology for post pyloric feeding, use of proton pump inhibitors, and vigorous irrigation and suctioning of the aerodigestive tract including the mouth and trachea if at all possible.

Another complication of tracheotomy or tracheostomy worthy of mention is an unwanted persistent opening into the trachea following decannulation, known as a tracheocutaneous fistula (TCF). When a stoma has been surgically matured as described in the technique section above, or when the cannula has been left in place for a prolonged period of time, a mucosalized tract forms between the surface skin and the trachea that may not spontaneously close. The TCF should be evaluated with flexible endoscopy by an airway clinician through the larynx and through the TCF, if it is wide enough. The surgery needed to repair airway stenosis of the

trachea is out of the scope of this work, but many options exist including minimally invasive techniques that could enable a safe and effective widening of the airway to restore adequate patency for ongoing decannulation. Following such care, the fistula could be closed as described below. Until such surgery is performed, it may be safest to replace a small cannula through the fistula tract to secure the patients airway. In some patients with a borderline airway, a persistent TCF may actually be favorable as even a tiny TCF can be dilated under local anesthesia to accommodate a small metal or cuffless plastic tracheotomy cannula.

If the airway is not narrowed on endoscopic evaluation, the TCF can be closed in a variety of ways. An initial attempt at treatment can include thorough cautery of the tract in clinic with silver nitrate, which can induce inflammation in the tissues and remodeling that can at times lead to TCF closure. Our surgical technique involves dissection around the TCF tract in a circular pattern down to the entry into the airway, followed by a Connell-type stitch to invert a small cuff of skin into the airway. The wound is then closed over three layers with reapproximation of the strap muscles to midline, deep dermal closure, followed by skin closure. It is our practice to perform these procedures under MAC with the patient spontaneously breathing, and to always place a small rubber band drain into the wound that remains in until follow-up in clinic. This drain functions as a pressure release valve if the patient should cough or sneeze, allowing egress of air out of the wound and preventing subcutaneous emphysema and possible pneumothorax. If a pinpoint TCF persists at the drain site in follow-up, this can often be treated with silver nitrate of simple suture overclosure.

Emergency Airway Surgery—Tracheotomy and Cricothyrotomy

Multiple techniques exist for emergency airway access, all with the expressed goal of stabilizing the emergent airway while minimizing laryngeal injury. It is certainly appropriate to perform an urgent awake or sedated tracheotomy under emergency circumstances in order to avoid cricothyrotomy and potential laryngeal injury. In an emergent airway scenario, the patient’s anatomy, overall condition, and/or surgeon experience may preclude tracheotomy and therefore emergent cricothyrotomy is an acceptable alternative for securing the airway in this circumstance. This decision is often based on the ability to maintain a mask airway during patient stabilization. Time lost in getting the airway

secured can cause profound anoxia and subsequent dire consequences. The finest operation in the world to gain access to the airway that is clean and well dissected but too slow to maintain a life is of no value in this circumstance. There is one goal and one goal only: to sustain the patient's life. The one which gets the clinician to that goal fast enough is the right choice.

Surgical neck access can be very challenging in the emergency airway patient. The maxim passed down from surgeon to surgeon in this situation is first to "take your own pulse," and keep a calm and deliberate demeanor. Once the decision has been made to establish a surgical airway, the airway surgeon should be able to obtain it in 1 to 2 minutes. The situation usually dictates that the patient is at points being mask ventilated, going through repeated efforts at intubation, and getting chest compressions. The surgeon may want to place their nondominant hand on the neck with the palm under the patient's chin to extend the head and draw the trachea out of the chest (Fig. 37.7). The same hand may then be used to stabilize the airway by putting the index and third fingers on either side of the trachea/larynx so as to put pressure on the paralaryngeal soft tissues and establish the midline of the neck. This also reduces the disruptive effect of the compressions on defining the surface landmarks of the airway. Once the airway is identified a midline vertical cut is used to open the skin over the CTM. This midline incision tends to avoid the anterior jugular vessels and may lessen hemorrhage. This also splays the edges of the incision laterally because of the pressure of the fingers of the nondominant hand applied to trap the airway. The dominant hand can then be used to palpate the laryngeal landmarks to verify what was felt through the skin. Note that in a male, the thyroid notch is the most prominent anterior laryngeal landmark, while in a female it is often the cricoid cartilage. The next knife cut is into the airway either through the trachea or the CTM. The channel is palpated and when performing a tracheotomy, the nondominant index finger is placed into the airway guiding the tube caudad. A hemostat is also very useful to open the airway widely and facilitate passage of a small ETT (5.0) into the airway. If passing the tube through the CTM is difficult, a tube exchanger or stylet can be used to accomplish this. The opening into the trachea or CTM can also be enlarged using a tracheal spreader or hemostat to allow the ETT to pass. In most emergency circumstances, a small ETT will be placed at the time of intervention, and the patient will be taken to the OR immediately for conversion to a standard tracheotomy.

In any emergency situation, the actions of the surgeon and anesthesia team are truly life-saving, and any subsequent injury or damage to the larynx in this situation are absolutely allowable secondary to preserving life.

Percutaneous Dilatational Tracheotomy

PDT is a newer technique in tracheotomy that is minimally invasive and kit based (Fig. 37.8). It is indicated for nonemergency situations and designed for bedside care in an ICU setting. It is commonly performed with bronchoscopic airway lumen visualization through the existing ETT. This approach has dramatically altered bedside airway care in many parts of the world and is rapidly gaining popularity in the United States and Asia. Regardless of the technique, taking a critically ill patient to the OR for a tracheotomy not only removes them from the location where he/she is best cared for, but also adds additional risks related to the need to transport them some distance away, rolling their IV pole(s) and their ventilator with them. The costs associated with OR tracheotomy are very high when OR time is taken into account along with the personnel costs of the transport team and those in the OR for the surgery itself. Bedside tracheotomy has the advantage of being performed in the ICU obviating all of the costs unrelated to the procedure itself. If done in the ICU by the open technique, there is the disadvantage of needing to essentially bring the OR to the bedside. With head lights and OR trays, a cautery device, and drapes; tracheotomy can be performed in a manner similar to that which is performed in the OR itself. According to the advocates of this approach, this is done in the event that a deep exploration of the neck is needed to control a bleeder that might retract into the surrounding tissues. There are some clinicians who also perform PDT in the operative setting due to the convenience and decreased operative time.

Kit-based PDT techniques, by contrast, are based on the surface incision of skin with the blunt dissection of the superficial tissues to gain access to the tracheal wall. The operating clinician navigates through the procedure by seeing on a video monitor the effect of the manipulation of the soft tissues overlying the airway. When performed by the typical PDT technique or T-PDT, a bronchoscope is used to get the existing ETT repositioned so that the tip of the tube is at or just above the likely entry point of the trachea as viewed from within the lumen of the airway. This is in reality, a controlled partial extubation and will limit the minute ventilation of some patients significantly. Most patients with high positive

end expiratory pressure (PEEP) needs or high minute ventilation needs will not tolerate this procedure due to this, and it may therefore be a contraindication to PDT. Inadvertent complete extubation can occur and may be followed by difficulty in finding the airway and the potential for dire consequences, even death. While complications on this scale are rare, the potential for this scale of adverse outcome has made the adoption of this otherwise safe and effective technique slow. This has been particularly the case by the one specialty most commonly involved in tracheotomy, the Otolaryngologists.



Figure 37.7. Emergency airway surgery handhold technique. **A.** Side view of the neck anatomy with markings indicating the relevant anatomy such as the thyroid notch, the cricoid, and the thoracic inlet. The vertical mark above the thoracic inlet is the planned skin incision. **B.** Lateral view of the handhold placed on the airway to stabilize it and isolate the trachea in the context of a resuscitation procedure. **C.** Oblique view identical to "B." **D.** *En face* view of the procedure as it could be performed with the scalpel ready to incise the trachea. The left hand could sit over a bag mask being used to ventilate the patient.

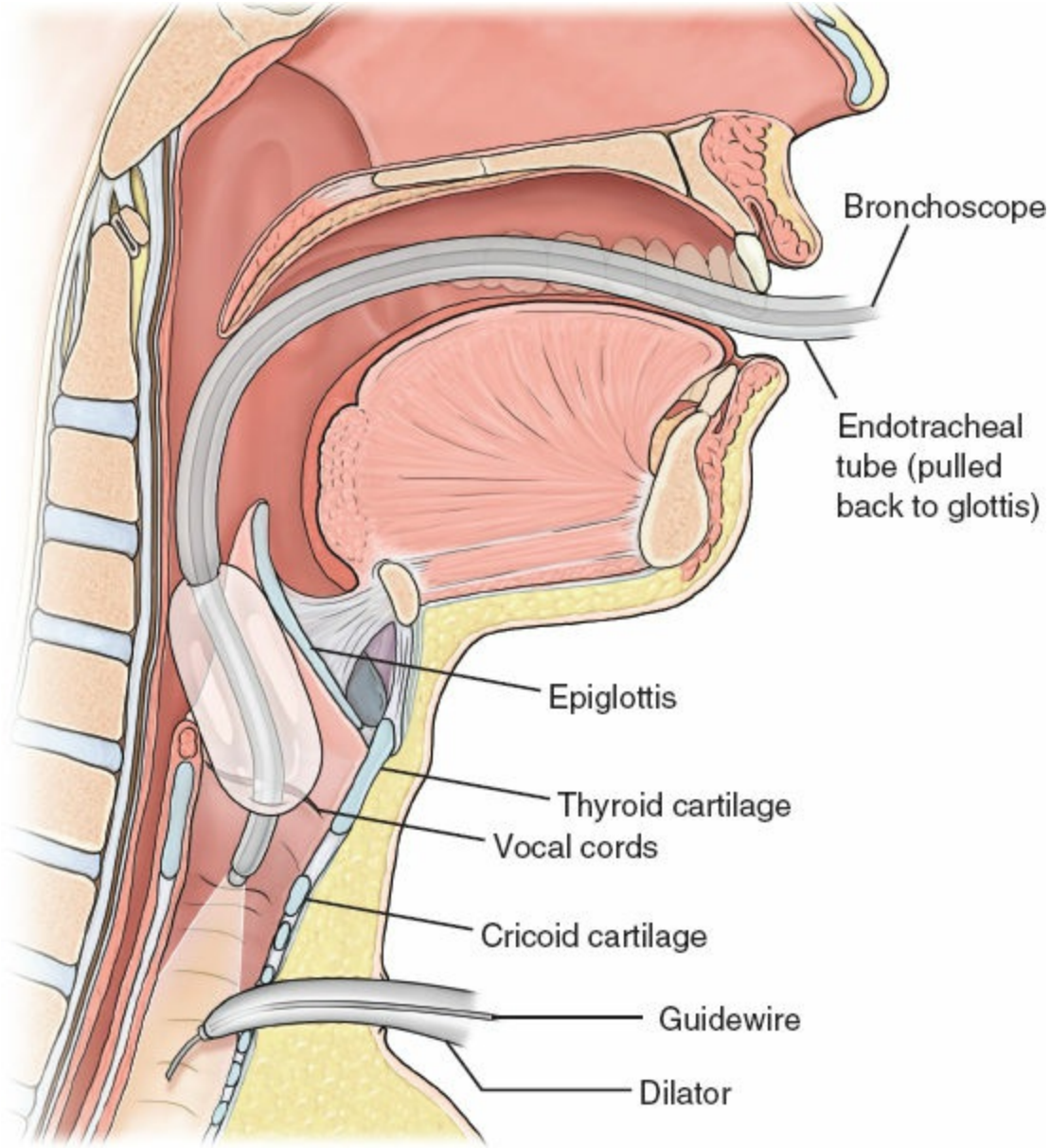

Figure 37.8. Anatomy and instrumentation of the typical or "traditional" percutaneous dilatational tracheotomy technique with the flexible bronchoscopic image of the inside of the airway, the guide wire entering the airway ahead of the dilator in the area that is transilluminated. (Modified from Weissler MC, Couch ME. Tracheotomy and intubation. In: Bailey BJ, Johnson JT, Newlands SD, eds. *Head and Neck Surgery—Otolaryngology*, 4th ed. Philadelphia, PA: Lippincott Williams & Wilkins; 2006.)

Numerous prospective cohort studies and randomized controlled trials have investigated the safety and efficacy of open surgical tracheotomy versus PDT techniques in critically ill patients. A recent Cochrane systematic review concluded that there appears to be some benefit in terms of PDT effectiveness and safety specifically as it relates to number of peri-

and postoperative non–life-threatening adverse events, rates of wound infection, and unfavorable scarring. There is no compelling evidence that PDT offers any advantage over traditional open techniques with respect to postoperative mortality, rates of serious postoperative life-threatening events, and rates of major bleeding. Unfortunately, many studies exclude patients with unfavorable anatomy or "difficult" anatomy, prior airway problems, coagulopathies, and those requiring emergent tracheostomy therefore limiting how generalizable these findings are for critically ill adults in an ICU setting. In practice, PDT is often reserved for patients who are assumed to be an "easy" tracheotomy due to body habitus, airway anatomy, and ventilator settings, and it is perhaps best used for that patient population.

Recently, a new approach to PDT known as suspension laryngoscopy-assisted PDT (SL-PDT) has been introduced to the Otolaryngology community (Fig. 37.9). This technique differs from T-PDT in that a suspension laryngoscopy system is used to secure the airway such that there is no way for the airway to be lost or the patient inadvertently extubated because of the very nature of suspension laryngoscopy. The airway is trapped by the orifice of a rigid laryngoscope and elevated with a device designed to fulcrum the scope against the maxilla and a second surface, commonly the patient's tray table. A new foreshortened (cut off at 20 cm) ETT is then passed into the airway through the rigid laryngoscope and the balloon is inflated within the scope and the upper larynx so as to seal the airway within the ventilatory circuit. This enables the delivery of the requisite tidal flow with the entire PEEP the patient needs. The internal view of the airway is accomplished by a 30 cm × 5 mm rigid telescope. Thus, the whole operation can be performed with the patient adequately ventilated. There is, therefore, no rush to locate the ideal position through which to enter the airway since there is no significant potential for desaturation. In addition, should the patient become unstable for any reason, the procedure can be safely aborted without any undue risk to the patient. A fresh full-length ETT can simply be placed into the laryngoscope beyond the airway entry point even if the airway has already been opened through the skin.

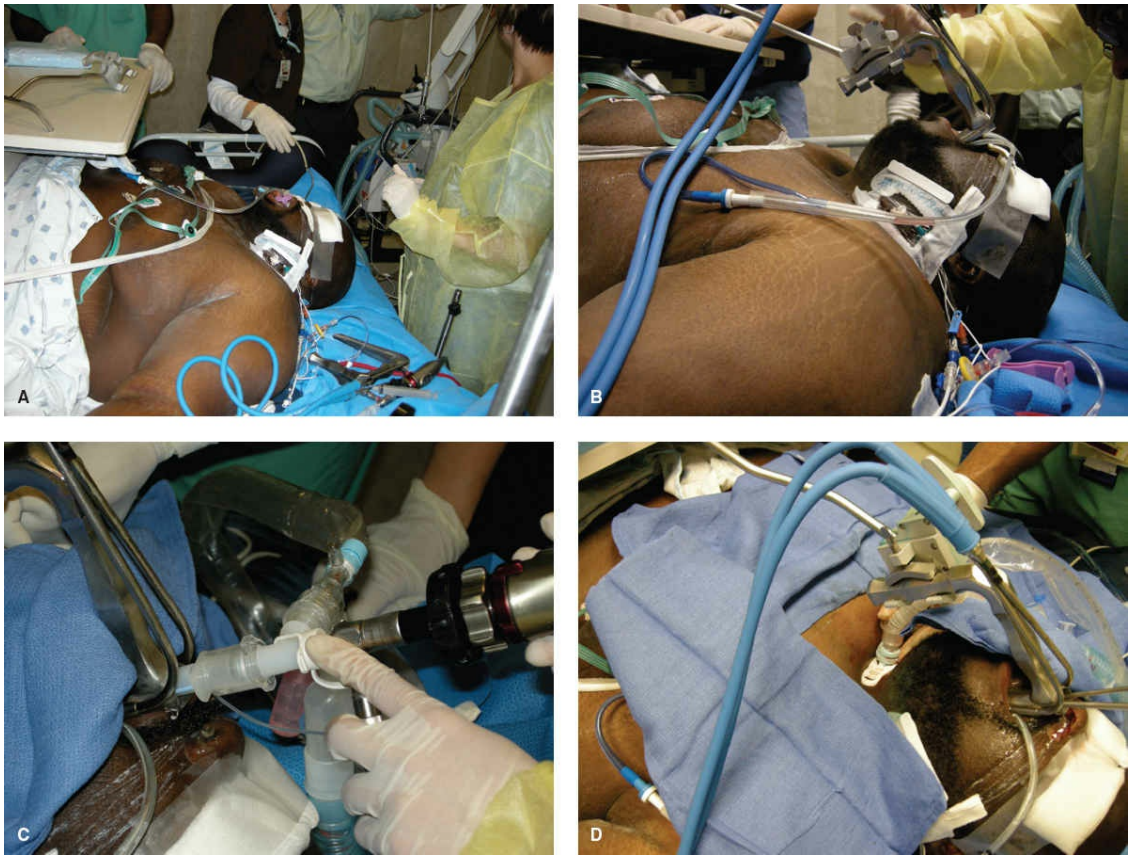

Figure 37.9. These images are of a morbidly obese patient, the type of whom who can be treated safely with this technique given sufficient expertise with the rigid laryngoscopy part of the procedure. This particular male was mechanically ventilated for several weeks but considered too unstable to be transported to the OR for his tracheotomy. It was performed uneventfully at bedside using the SL-PDT technique. **A.** The general view of his body habitus at bedside. **B.** The Storz Dedo laryngoscope in place and extending his neck backward and his airway closer to the surface. **C.** A close-up view of the laryngoscope, telescope, and ventilating endotracheal tube assembly. **D.** The #8 Shiley XLT Proximal extra length cannula in place ventilating the patient while the Dedo laryngoscope is still in place to make sure that there is no internal airway bleeding or other problems that need to be dealt with prior to the conclusion of the procedure.

Both the T-PDT and the SL-PDT techniques may have a role to play in a comprehensive multispecialty ICU airway program; T-PDT applying to roughly half of ICU patients who need a tracheotomy but have no special ventilatory needs such as high PEEPs, have easy-to-feel landmarks, have an easily accessible segment of trachea, and no history of challenging airway anatomy. The remainder of patients, including those with high

BMIs, poor landmarks, low larynges, prior neck surgery, and even neck tumors, anasarca, or other types of generalized edema and high/challenging ventilator may benefit from SL-PDT or referral to the OR for formal operative tracheotomy. The contraindications to SL-PDT include patients with trismus, uncertain C-spine disease or kyphoscoliosis, and/or the inability to tolerate a general anesthetic.

The main complications of PDT are well known, and have lessened ongoing enthusiasm for this approach among many otolaryngologists. The anterior jugular venous network can be extensive in some patients, and marked hemorrhage can be induced by PDT techniques requiring operative intervention. This is often due to repositioning of the PDT dilator or "second attempts" at passing the dilator wires into the trachea. Hemorrhage is also common from injury during transection of the thyroid isthmus without ability to provide direct cautery or vascular control. In addition, perforation through the posterior tracheal wall into the esophagus or nonmidline tracheal placement causing eccentric stenosis is also a possible issue. Careful visualization of the dilators and tracheotomy tube using either T-PDT or SL-PDT technique is of paramount importance to avoid these issues.

In conclusion, tracheotomy is a very important intervention to protect or establish the airway and there are many approaches, each of which has its advantages and risks. Open surgery in the OR is the best way to fashion a surgically matured tracheal "stoma." Emergency airway surgery has to be performed as quickly as it is performed effectively. The technique presented here is one that will enable this result. Tracheotomy in an ICU patient is best done at the bedside with a kit-based system and without leaving the unit. ICU patients with contraindications to T-PDT can safely have an SL-PDT operation and get a thorough airway evaluation in the process.

ACKNOWLEDGMENT

Acknowledgement for prior edition of this chapter: Dr. Paul F. Castellanos.

Suggested Readings

Brass P, Hellmich M, Ladra A, et al. Percutaneous techniques versus surgical techniques for tracheostomy (Review). *Cochrane Database Syst Rev* 2016;7:CD008045.

Jackson C. *The Life of Chevalier Jackson: An Autobiography*. Kessinger Publishing Company; 2008.

Johnson JT, Rosen CA, Bailey BJ, eds. *Bailey's Head and Neck Surgery—Otolaryngology*, 5th ed. Philadelphia, PA: Lippincott Williams & Wilkins; 2014.

Johnson-Obaseki S, Veljkovic A, Javidnia H. Complication rates of open surgical versus percutaneous tracheostomy in critically ill patients. *Laryngoscope* 2016;126(11):2459–67.

Myers EN, Johnson JT, eds. *Tracheotomy: Airway Management, Communication, and Swallowing*, 2nd ed. San Diego, CA: Plural Publishing; 2008.

White HN, Sharp DB, Castellanos PF. Suspension laryngoscopy assisted percutaneous dilatational tracheostomy in high risk patients. *Laryngoscope* 2010;120(12):2423–9.

EDITOR'S COMMENT

Almost any surgeon could be called upon to perform an emergency airway. About once a year or so I find myself in a room watching an anesthesiologist struggle to attain and to maintain the airway of a recently induced patient about to undergo surgery. These patients are often obese, and I find my mind wandering to recall what I know about the surgical landmarks of the neck and the best way to attain a surgical airway without haste. These are anxiety-provoking situations to say the least. While the vast majority of us will never need to perform an emergency airway, it is a great idea to be familiar with the techniques and pitfalls described so eloquently in the chapter by Dr.'s Bock and Little.

As a GI surgeon who deals mostly with patients undergoing elective surgery for benign disease, I rarely care for patients who have or ultimately need a tracheostomy. Most of my patients for whom we ultimately need to have a discussion about a new tracheostomy have experienced some sort of significant postoperative complication and will likely require prolonged intubation and ventilation as a result. For a surgeon dealing with the stress and anxiety that comes with a major complication in one of your patients, it can be difficult to wrap one's head around the fact that things are bad enough that a tracheostomy is the next step. In this chapter there is some excellent information and data to help those of us who occasionally struggle with these issues to understand the importance of considering and moving forward with a tracheostomy at the appropriate point in time.

The data on early versus late tracheostomy in critically ill patients is mostly equivocal. There have been quite a number of randomized, controlled clinical trials and several subsequent systematic reviews and meta-analysis of these trials. Metrics often evaluated in these trials include mortality, ventilator-associated pneumonia rates, duration of mechanical ventilation, and length of

ICU stay. Early versus late tracheostomy is variably defined, and 7 or 10 days are the most commonly used time points after laryngeal intubation used as cutoffs. A systematic review and meta-analysis published in 2015 in the Lancet Respiratory Medicine journal examined 13 trials in more than 2,400 patients to undergo early (<7 days), late (>7 days), or no tracheostomy. The primary outcome of interest was mortality and pneumonia. While an effect on mortality was not observed, the incidence of ventilator-associated pneumonia was lower in mechanically ventilated patients assigned to the early versus the late or no tracheostomy group (Odds Ratio 0.60, 95% CI 0.41–0.90; $p = 0.01$). Another systematic review and meta-analysis including nine trials and more than 2,000 patients published in 2016 used 7 days as the cutoff for early versus late tracheostomy. The results of this meta-analysis suggested that early tracheostomy might be able to reduce the duration of sedation but did not significantly alter the mortality, incidence of ventilator-associated pneumonia, the duration of mechanical ventilation, or the length of ICU stay. A Cochrane Database Systematic Review published in 2015 included eight randomized trials and nearly 2,000 patients. Early tracheostomy was defined as tracheostomy within 10 days. The authors of this review concluded "The whole findings of this systematic review are no more than suggestive of the superiority of early over late tracheostomy because no information of high quality is available for specific subgroups with particular characteristics." In other words, there are likely certain patients much more likely to benefit from early tracheostomy than others. There are several additional systematic reviews and meta-analysis examining this issue published between 2014 and 2016. For the most part, these studies found little difference in outcomes for early versus late tracheostomy.

Tracheostomy is one of the most frequently performed surgical procedures in ICU patients. As many as 10% of patients requiring at least 3 days of mechanical ventilation will eventually receive a tracheostomy for prolonged mechanical ventilation or airway support. In addition to minimizing the risk of laryngeal trauma as well as glottic and subglottic stenosis by converting an ETT to a tracheostomy, there is some data to support that a tracheostomy is more comfortable for patients, requires less sedation, and is easier to maintain. Nonverbal communication can prove frustrating for patients with prolonged respiratory failure. Patient communication can be greatly enhanced following tracheostomy by use of specialized appliances that utilize an additional small diameter tube that expels gas above the cuff of the tracheostomy tube when the proximal end has been manually occluded. Limitations of this device include the requirement for manual occlusion and the frequent inability to speak in complete sentences.

Otolaryngologists and general surgeons most often perform open tracheostomy. Many patients who require a tracheostomy are also ideal candidates for a percutaneous endoscopic gastrostomy (PEG) tube placement. Concurrent placement of a tracheostomy and a PEG tube is often performed in the OR to decrease the cost, anesthesia time, and procedural time that would

otherwise be associated with performing both of these procedures in a staged manner in the same patient. For this reason, in many institutions general surgeons perform the majority of the open tracheostomies. The option of a percutaneous dilatational tracheotomy (PDT) has led a variety of specialists in nonsurgical disciplines to perform tracheostomy. In some hospitals, anesthesiologists, pulmonologists, and cardiac surgeons routinely perform PDT on their patients.

Although there are concerns that PDT is essentially a "blind" tracheal tube placement and associated with an increased risk of bleeding and other serious complications, these concerns have not been validated in the published literature. In a recently published Cochrane review on PDT versus open surgical tracheostomy, 20 trials from 1990 to 2011 enrolling 1,652 participants fulfilled the inclusion criteria. When compared to surgical tracheostomy, PDTs significantly reduced the rate of wound infection/stomatitis (moderate quality evidence) and the rate of unfavorable scarring (low-quality evidence due to imprecision and heterogeneity). In terms of mortality and the rate of serious adverse events, there was low quality evidence favoring PDT. In terms of the rate of major bleeding, there was very low-quality evidence that nonsignificant positive effects exist for PDT. "However, because several groups of participants were excluded from the included studies, the number of participants in the included studies was limited, long-term outcomes were not evaluated, and data on participant-relevant outcomes were either sparse or not available for each study, the results of this meta-analysis are limited and cannot be applied to all critically ill adults."

A tracheostomy is one of the earliest described procedures, having first appeared in Egyptian artifacts dating to 3600 BC. As our capacity to keep sicker patients alive has improved in recent decades, tracheostomy has become more commonplace. Recent advances in tracheostomy include new techniques for percutaneous access to the trachea that can be performed safely at the bedside in many patients. This chapter on tracheostomy outlines the challenges, pitfalls, pros, and cons of several different options in a highly informative and well-organized fashion. Even those surgeons who do not perform routine tracheostomy should familiarize themselves with the content in this book chapter.

Jon C. Gould

Suggested Readings

Andriolo BN, Andriolo RB, Saconato H, et al. Early versus late tracheostomy for critically ill patients. *Cochrane Database Syst Rev* 2015;1:CD007271.

Brass P, Hellmich M, Ladra A, et al. Percutaneous techniques versus surgical techniques for tracheostomy. *Cochrane Database Syst Rev* 2016;20:7:CD008045.

Durbin CG, Perkins MP, Moores LK. Should tracheostomy be performed as early as 72 hours in patients requiring prolonged mechanical ventilation? *Respir Care* 2010;55(1):76–83.

Meng L, Wang C, Li J, et al. Early vs. late tracheostomy in critically ill patients: a systematic review and meta-analysis. *Clin Respir J* 2016;10(6):684–92.

Newhouse E, Ondik MP, Carr M, et al. Who is performing percutaneous tracheotomies? Practice patterns of surgeons in the USA. *Eur Arch Otorhinolaryngol* 2011;268:415–8.

Siempos II, Ntaidou TK, Filippidis FT, et al. Effect of early versus late or no tracheostomy on mortality and pneumonia of critically ill patients receiving mechanical ventilation: a systematic review and meta-analysis. *Lancet Respir Med* 2015;3(2):150–8.

SECTION IV

ENDOCRINE SURGERY

38 Surgical Anatomy of the Thyroid, Parathyroid, and Adrenal Glands

Clive S. Grant

Success in the surgical management of a patient can be conveniently divided into three phases: preoperative, intraoperative, and postoperative. Vitally important is the preoperative decision making and planning; an expertly performed operation for a wrong reason is still a bad operation. However, if the preoperative process is correctly conceived, at least in an elective procedure, a perfectly executed operation guarantees a smooth postoperative course in a high percentage of patients. The foundation for this operative success is a thorough knowledge of surgical anatomy. Anatomy to anatomists or pathologists is different from surgical anatomy. Because surgeons operate through limited incisions and must preserve function wherever possible, as well as control or prevent bleeding, the "anatomist's anatomy" must be applied from the surgeon's perspective. An attempt has been made to amalgamate the two forms of anatomy in the following sections to give a broad perspective (the anatomist's view as well as the perspective of the surgeon).

The surgical anatomy of the thyroid and parathyroid glands is so closely interrelated that much of what is important to one proves equally important to the other. Because of this overlap, the overall anatomic relationships of the region are covered in the Thyroid section, and the differences or additions as they relate specifically to parathyroid disease are noted in the Parathyroid section.

EMBRYOLOGY

From a median entodermal diverticulum on the ventral wall of the pharyngeal gut, in approximately the fourth week of embryologic development, the thyroid descends from the posterior tongue (foramen cecum) in front of the pharynx as a bilobed diverticulum. It initially remains attached to the pharynx by a hollow tube, the thyroglossal duct, which attaches to the foramen cecum. At the end of the second month, the

thyroid reaches its final position in front of the trachea; and the thyroglossal duct tissue, which has become solid, usually breaks up and disappears. Distal persistence of the solid duct is represented by the pyramidal lobe of the thyroid. If parts of the ductal epithelium persist, the secretion of the epithelium expands the remnant tube, which is closed at both ends, into a cystic mass filled with a colloid-like material—a thyroglossal duct cyst. It rarely has a connection either to the skin or the tongue unless it has been infected and drained or previously operated on. Cysts can develop anywhere along the course of the thyroglossal duct but are most typically found overlying the hyoid bone in the midline just above the thyroid cartilage. Adjacent to the primary persistent thyroglossal duct remnants, other smaller duct and mucus-secreting gland remnants are often found.

To prevent cyst recurrence, the duct and remnants can be encompassed in a core of tissues that should be excised from the cyst through the mylohyoid muscle to the base of the tongue, the site of the foramen cecum (Fig. 38.1). In addition, because the hyoid bone fuses in the midline in close proximity to the thyroglossal duct, the duct can pass either anterior or posterior, or even course through the bone. The central portion of the hyoid bone should, therefore, be excised as part of the operation for a thyroglossal duct cyst. Ectopic normal thyroid tissue or papillary thyroid carcinoma (PTC) can develop in a thyroglossal duct cyst or anywhere along the tract of the thyroglossal duct. Lingual thyroid represents a total failure of thyroid descent, in which the entire thyroid is located at the foramen cecum of the tongue, under the mucosa.

Contributing perhaps less than 1% of the eventual thyroid mass, yet critically important in considering thyroid malignancy, are the lateral thyroid anlagen. Originating from the fourth pharyngeal pouches, corresponding to the ultimobranchial bodies, they are responsible for production of calcitonin from the parafollicular or C cells. They fuse with the posterior and medial aspect of each thyroid lobe. Medullary thyroid carcinomas evolve from these small parts of the thyroid.

ANATOMY

An overall view of the anatomy relevant to thyroid and parathyroid operations is shown in Figure 38.2. For optimal surgical exposure, the patient is positioned with a small pillow placed between the scapulae, and the neck is hyperextended, bringing the thyroid gland as far anterior as

possible. The skin incision follows Langer lines transversely, optimally in a skin crease.

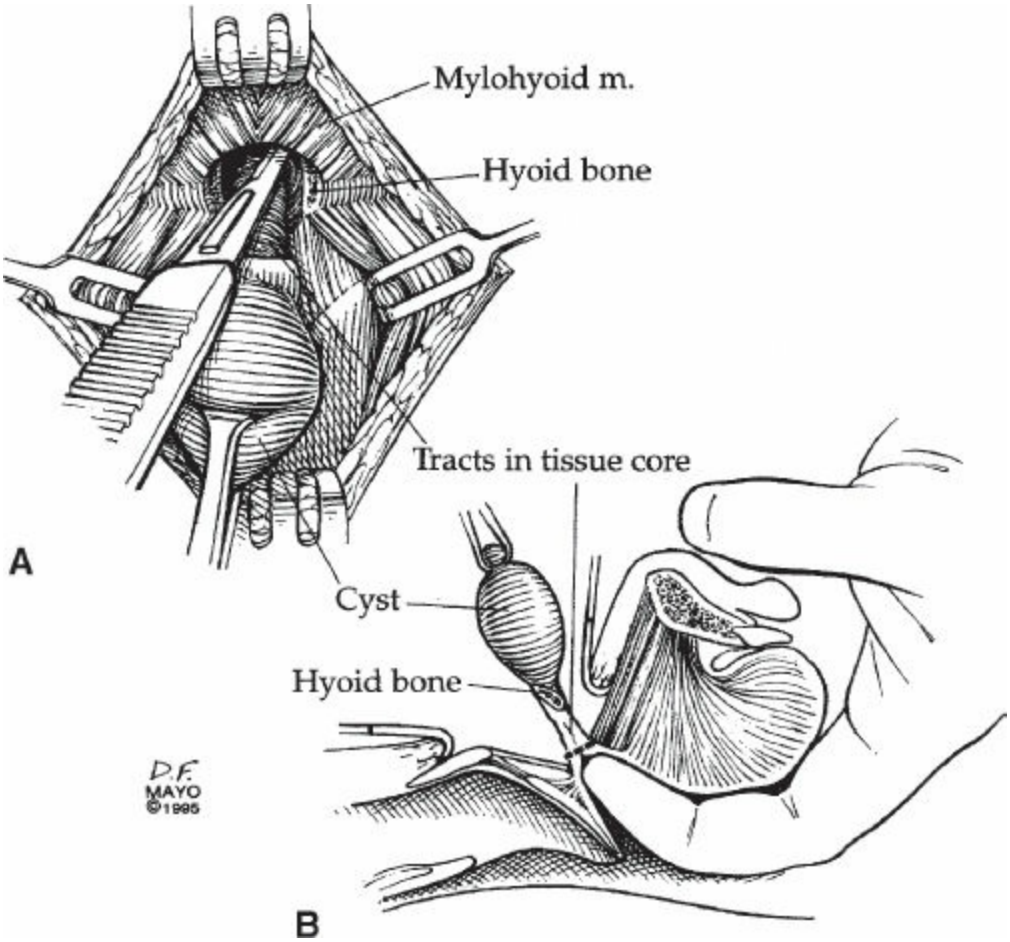

Figure 38.1. A: A thyroglossal duct cyst is excised from its usual location just above the thyroid cartilage, in the midline, overlying, or just inferior to the hyoid bone. The central portion of the hyoid bone is excised with the specimen, as is a core of muscle tissue encompassing duct tracts that lead to the former foramen cecum at the base of the posterior tongue. **B:** Lateral view showing the surgeon's finger through the patient's mouth positioned to assist excision of the tract at its origin.

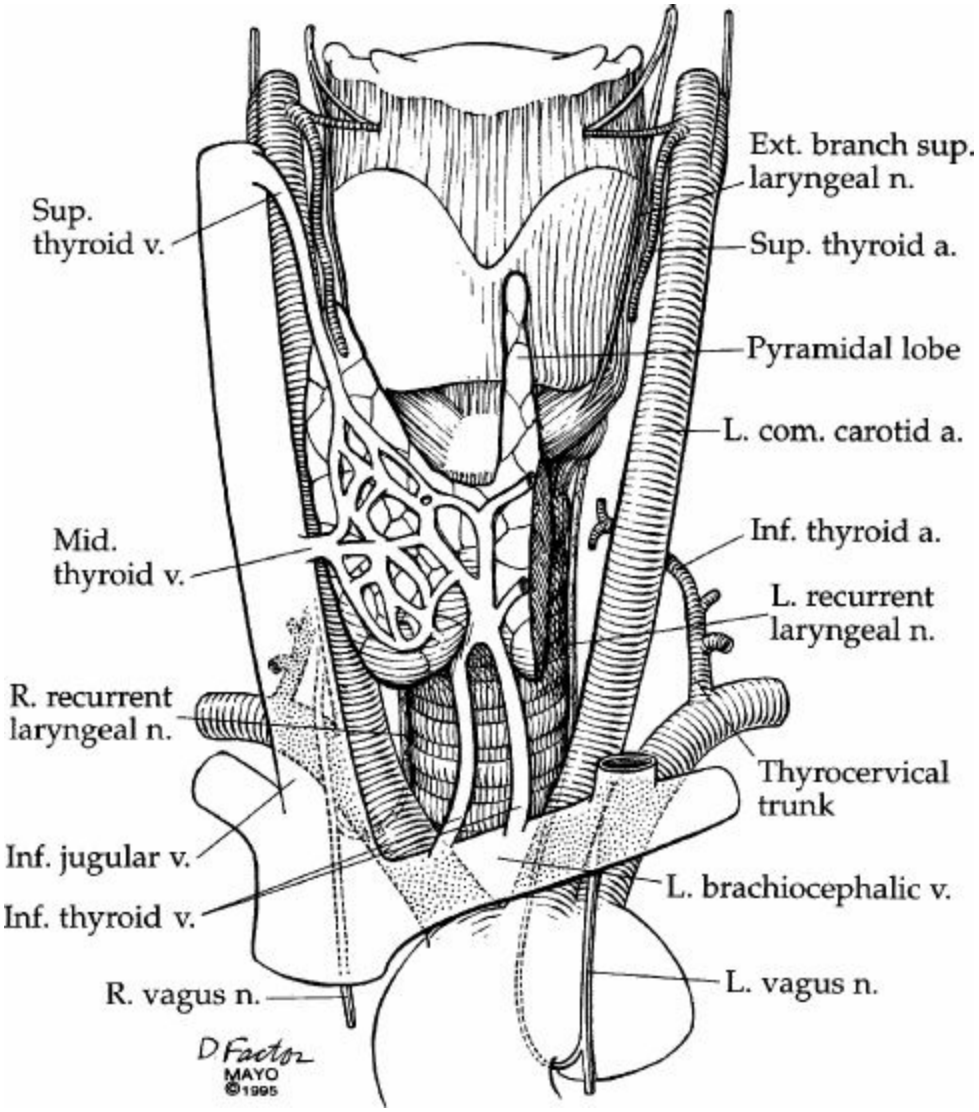

Figure 38.2. Overall anatomic relationships of the thyroid and surrounding structures. Note the course of the inferior thyroid artery, behind and perpendicular to the carotid artery. The superior thyroid artery and external branch of the superior laryngeal nerve run in close approximation.

Dissection of Muscles

Beneath the skin and subcutaneous tissue is the thin platysma muscle, under which is a relatively avascular plane. In this plane, the superior and inferior flaps can be raised with minimal blood loss. Once the flaps have been developed, the strap muscles—the sternohyoid and sternothyroid muscles—are exposed. The more anterior sternohyoid muscles lie close together, but the midline between them can be identified as a thin line of fat and avascular fascia. Dissection along this line to separate these muscles is facilitated by lifting the muscles anteriorly so as to avoid the

inferior thyroid veins, which course just below, running longitudinally over the trachea. Often bordering the midline along these muscles are the anterior jugular veins. These veins can be avoided but can be ligated as the need arises.

As the sternohyoid muscle is elevated, the underlying sternothyroid muscles are exposed. The fascia between these two muscles can be dissected for improved exposure. With the sternohyoid muscles retracted, as the sternothyroid muscle is dissected from the underlying thyroid lobes, care is taken to avoid the widely interconnecting venous network in the thyroid capsule. This caution is of particular importance in a larger goiter because the strap muscles can be thinned and splayed out across the bulging thyroid lobes and the large veins are in jeopardy. The insertion of the sternothyroid muscle into the thyroid cartilage can obscure the superior pole of the thyroid gland and can be partially transected for better exposure. Both the sternohyoid and sternothyroid muscles (as well as the omohyoid muscle) are innervated by the ansa cervicalis, derived from the hypoglossal nerve and C1 through C3. These muscles can be partially or completely removed as necessary for cancer operations without any significant disability. The cricothyroid muscles run obliquely from the cricoid cartilage to the thyroid cartilage and are innervated by the external branch of the superior laryngeal nerve. This muscle and nerve should be carefully preserved because they serve the important function of fine-tuning the voice.

VASCULAR ANATOMY

The principal arterial blood supply of the thyroid gland comes from the paired superior and inferior thyroid arteries, and, to a much lesser degree, the thyroidea ima (Fig. 38.2). Even when all these arteries are ligated, remnants of thyroid often survive from other small branches derived from laryngeal and tracheoesophageal arteries. The superior thyroid artery is the first branch of the external carotid artery and courses inferiorly to reach the superior pole of the thyroid gland. It often branches at this point, with the main branch running over the anterior surface of the superior pole of the thyroid and the other smaller branches entering more posteriorly. The inferior thyroid artery usually arises from the thyrocervical trunk, runs superiorly behind the carotid artery, and then arches medially to the thyroid gland, coursing either perpendicular to or in a recurrent path to the thyroid gland. The thyroidea ima artery is encountered in less than 10% of

patients and is almost never a relevant vessel except to ligate.

Dissection of Thyroid Lobe

Once the strap muscles have been dissected laterally, the thyroid gland is elevated anteriorly and medially, opening an areolar plane overlying the carotid artery and traversed by one or more small middle thyroid veins (Fig. 38.3). These veins are ligated and transected, and the space anterior to the carotid from the thyroid cartilage inferiorly to the base of the neck can be dissected safely. This step exposes the transversely directed inferior thyroid artery and the obliquely coursing recurrent laryngeal nerve (RLN), a branch of the vagus nerve, which, on the right, wraps around the subclavian artery and passes behind the carotid artery to ascend in the tracheoesophageal groove (Fig. 38.4). On the left, the RLN crosses the arch of the aorta, loops under it, adjacent and lateral to the ligamentum arteriosum, and ascends in the tracheoesophageal groove. Adjacent and mostly anterior to the RLN are the tracheoesophageal lymph nodes, which are a common site of metastasis in PTC and medullary thyroid carcinoma. Removal of these nodes requires care to protect the RLN; it should preserve not only the inferior parathyroid gland but also its blood supply, which usually crosses anterior to the RLN. Damage to the RLN on one side causes vocal cord paralysis and hoarseness and prevents complete closure of the vocal cords to protect the trachea. This incomplete closure results in choking, especially when the patient consumes fluids. Bilateral nerve injury jeopardizes the airway and usually requires at least a temporary tracheostomy. When the right subclavian artery anomalously originates directly from the aortic arch as its fourth branch, it passes behind the trachea and esophagus. The right recurrent nerve, therefore, does not recur around this artery and takes a direct course from the vagus nerve to the larynx (Fig. 38.5). In this instance, although it emerges posterior to the carotid artery, its perpendicular course mimics the usual course of the inferior thyroid artery and must be distinguished from it.

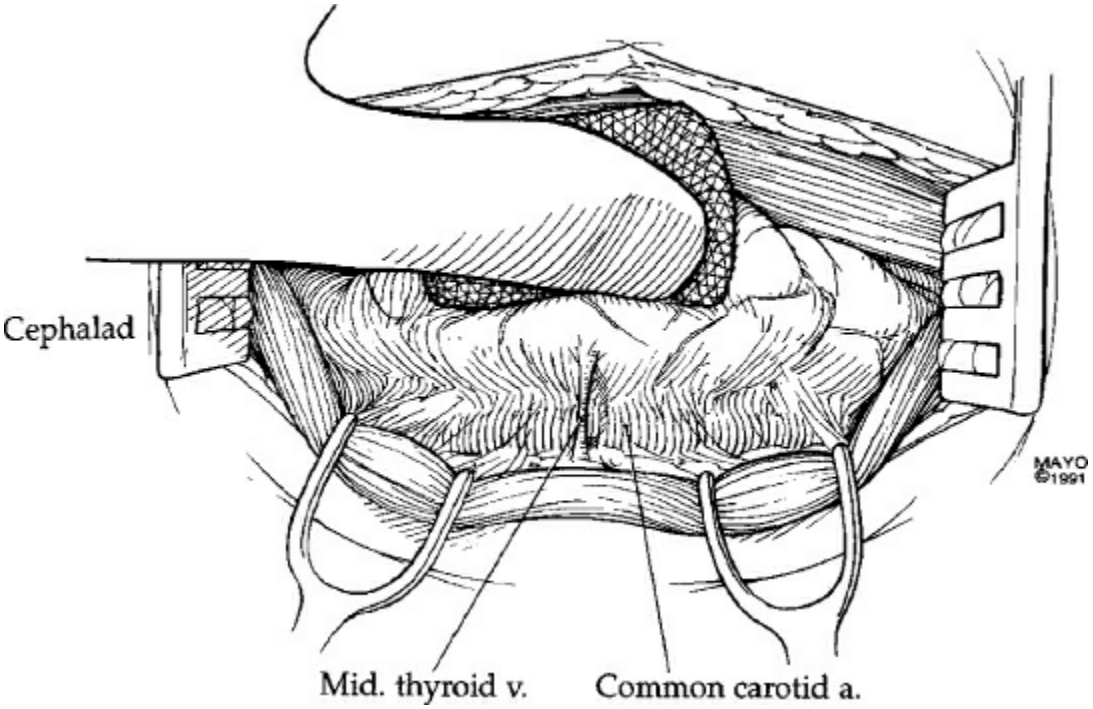

Figure 38.3. With traction laterally on the strap muscles that have been separated in the midline, but not transected, and countertraction on the thyroid medially, the middle thyroid vein is exposed. It runs anterior to the carotid artery and should be transected. (Republished with permission of John Wiley & Sons, Inc. from Grant CS, van Heerden JA. Technical aspects of thyroidectomy. In: Donohue JH, van Heerden JA, Monson JRT, eds. *Atlas of Surgical Oncology*. Cambridge: Blackwell Science; 1995:81–6; permission conveyed through Copyright Clearance Center, Inc.)

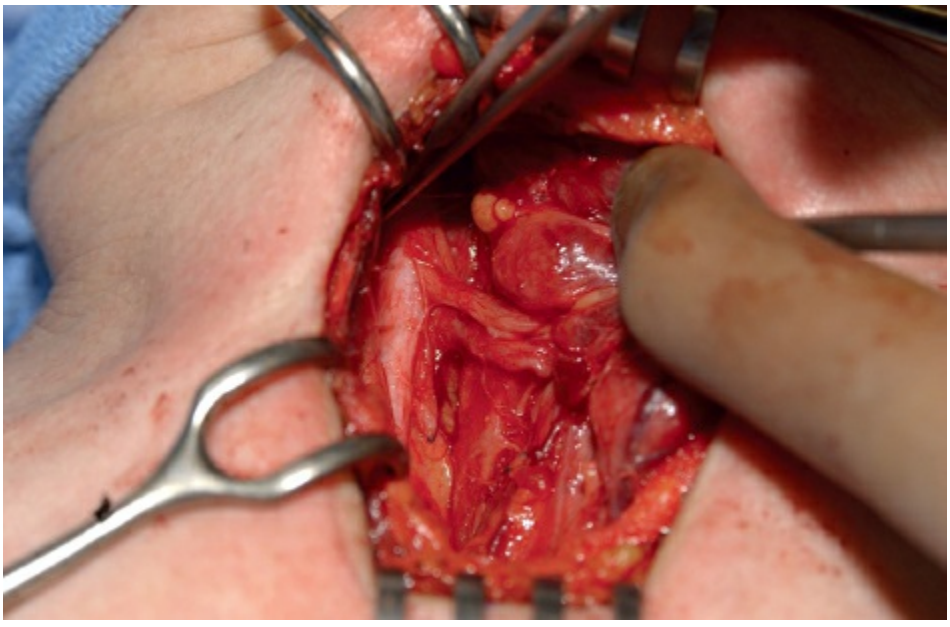

Figure 38.4. A nonrecurrent, recurrent laryngeal nerve (on the

patient's right side) courses directly from the vagus to its insertion at the cricothyroid membrane.

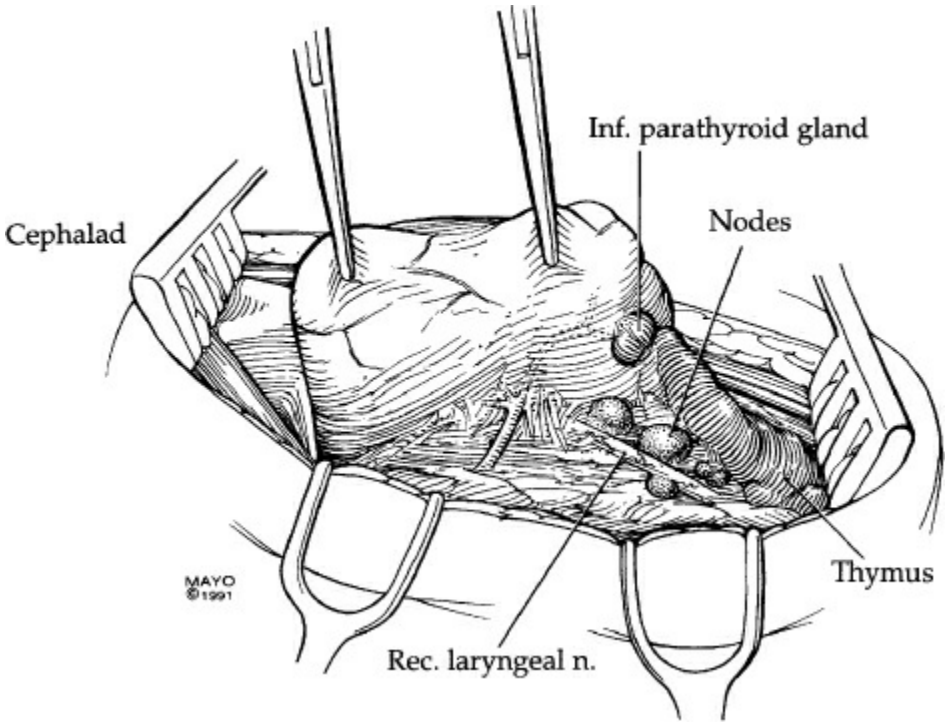

Figure 38.5. The right thyroid lobe is retracted anteriorly and medially, and the recurrent laryngeal nerve is exposed, coursing obliquely in the tracheoesophageal groove and surrounded by lymph nodes. The thymus lies anterior to the nerve and nodes and can contain or point to the inferior parathyroid gland. The superior parathyroid gland is not yet adequately exposed. The intersection of the inferior thyroid artery and the recurrent (rec.) laryngeal nerve is marked by branches of the artery, one crossing the nerve that serves the inferior parathyroid gland. (Republished with permission of John Wiley & Sons, Inc. from Grant CS, van Heerden JA. Technical aspects of thyroidectomy. In: Donohue JH, van Heerden JA, Monson JRT, eds. *Atlas of Surgical Oncology*. Cambridge: Blackwell Science; 1995:81–6; permission conveyed through Copyright Clearance Center, Inc.)

The inferior thyroid artery is usually the principal blood supply to both the superior and inferior parathyroid glands. These feeding vessels are small and fragile, often traveling in a course parallel, if not slightly anterior, to the parathyroid glands before reaching the vascular hila (Fig. 38.6). As the inferior thyroid artery intersects with the RLN, it usually branches into superior and inferior trunks. The superior trunk typically divides again with one branch anterior and another posterior to the RLN.

The inferior thyroid veins run vertically, anterior to the trachea, and are easily identified and controlled during the course of thyroidectomy. Accompanying these veins are the pretracheal lymph nodes, both infra- and supraisthmic (Delphian), which often contain metastatic thyroid cancer.

The superior thyroid artery and vein, which are sacrificed during thyroidectomy, must be separated from the external branch of the superior laryngeal nerve. Placing inferior and lateral traction on the superior pole of the thyroid gland usually distracts the artery away from the nerve, and the artery can be cleanly isolated and individually ligated (Fig. 38.7).

Once the vascular branches to the thyroid lobe have been transected and the nodes cleared, the posterior capsule of the thyroid is all that remains before the lobe is completely removed. To re-emphasize, a small vessel regularly courses in this dense posterior capsule (Berry ligament), and the RLN is also commonly tethered anteriorly. Gentle dissection will expose the vessel for ligation and push the RLN down and out of danger before the ligament is transected.

In addition to the pretracheal and tracheoesophageal lymph nodes already mentioned, thyroid cancer often metastasizes to lateral nodes. The routes of spread roughly follow the venous drainage. Cancers of the upper lobe, in addition to the primary drainage to the supraisthmic nodes, can involve the midjugular nodes, both anterior and lateral to the internal jugular vein (IJV), and occasionally extend superiorly along the vein to the base of the skull. Cancers of the mid- and lower thyroid lobes drain initially into the pretracheal and tracheoesophageal nodes, then to the mid- and lower jugular nodes and anterior mediastinal nodes.

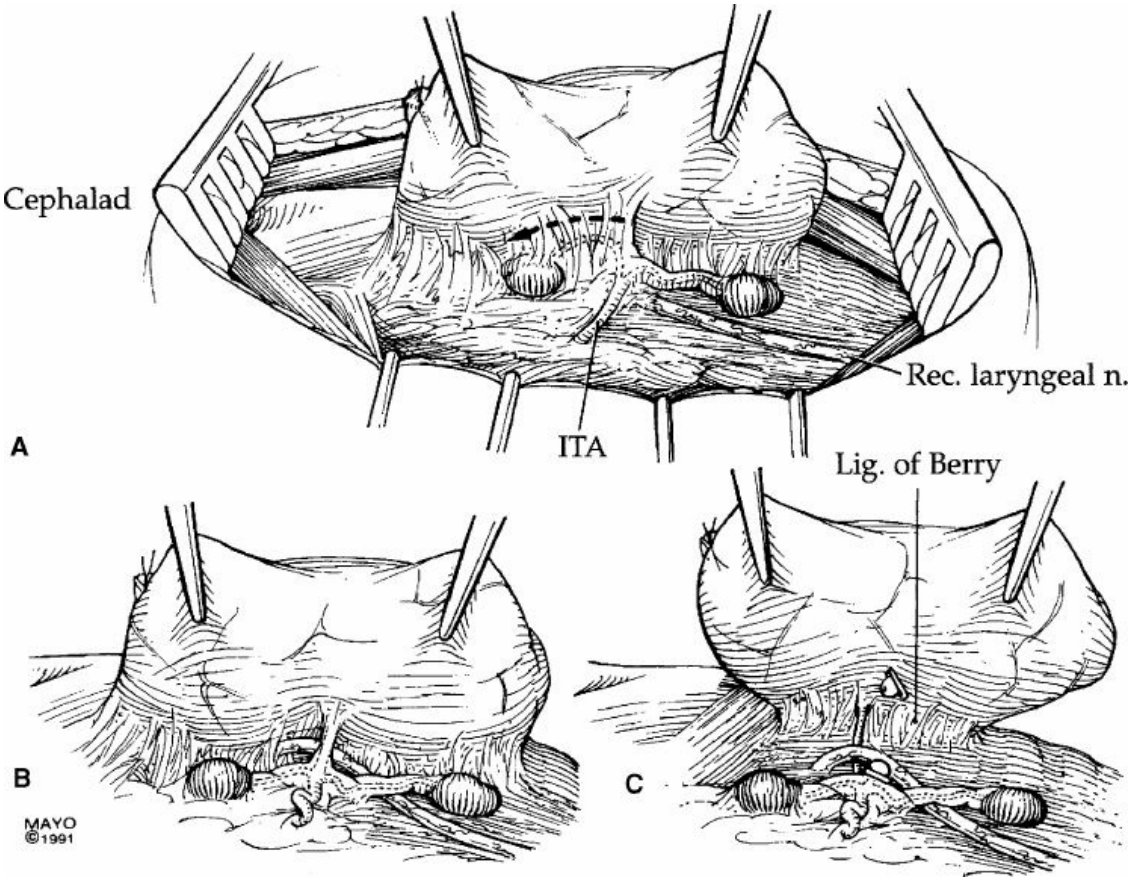

Figure 38.6. A: The small vessels feeding the parathyroid glands often run at least parallel if not slightly anterior to the glands. **B:** The surgeon can usually preserve these vessels by gently dissecting them and the parathyroid glands from the surface of the thyroid gland. **C:** Two significant branches of the inferior thyroid artery (ITA) are routinely present, one traveling anterior and the other posterior to the recurrent (rec.) laryngeal nerve. The coalescence of the dense posterior thyroid capsule constitutes Berry ligament (lig.), through which the posterior arterial branch courses. (Republished with permission of John Wiley & Sons, Inc. from Grant CS, van Heerden JA. Technical aspects of thyroidectomy. In: Donohue JH, van Heerden JA, Monson JRT, eds. *Atlas of Surgical Oncology*. Cambridge: Blackwell Science; 1995:81–6; permission conveyed through Copyright Clearance Center, Inc.)

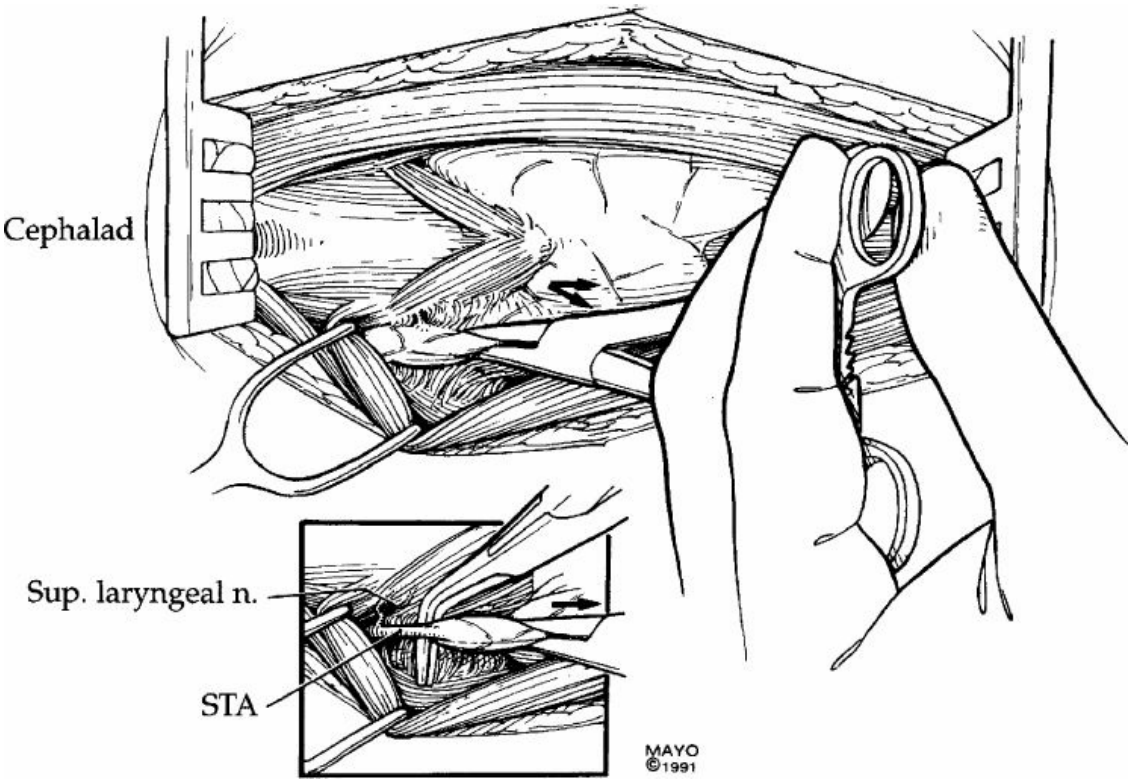

Figure 38.7. With traction inferiorly and laterally on the thyroid lobe, the superior thyroid artery (STA) can be displaced from its closely associated external branch of the superior laryngeal nerve. The artery is thereby transected individually, and the nerve is preserved (*inset*). (Republished with permission of John Wiley & Sons, Inc. from Grant CS, van Heerden JA. Technical aspects of thyroidectomy. In: Donohue JH, van Heerden JA, Monson JRT, eds. *Atlas of Surgical Oncology*. Cambridge: Blackwell Science; 1995:81–6; permission conveyed through Copyright Clearance Center, Inc.)

Modified Radical Neck Dissection

Important in the surgical management of papillary, medullary, and in some Hürthle cell carcinomas, lymph node metastases to the lateral internal jugular lymph nodes will necessitate a lymphadenectomy. Depending upon the extent of the dissection, various descriptive terms have been applied including regional, functional, selective, and modified radical neck dissection. Perhaps more important is the thorough, *en bloc* approach, and the neck *compartments* dissected. The anatomic boundaries of Compartments I to VI are summarized in Table 38.1, and graphically illustrated in Figure 38.8. Rarely used in thyroid cancer surgery is the classic radical neck dissection that implies sacrifice of the sternocleidomastoid muscle (SCM), IJV, and the spinal accessory nerve. In

addition, the submandibular triangle is virtually never dissected for thyroid cancer. Whereas in medullary thyroid carcinoma and node-positive Hürthle cell carcinoma, thorough dissection of Compartment VI is advised, controversy exists as to the extent and indications for this compartment dissection in papillary cancer.

Whether a standard collar incision is extended vertically along the anterior border of the SCM, or a separate transverse incision is made higher in the neck, extensive subplatysmal flaps are developed.

Compartments III, IV, and the Anterior Aspect of Compartment V

The dissection proceeds with dissecting the plane between the SCM and the strap muscles exposing the omohyoid muscle that is conveniently sacrificed (Figs. 38.9 and 38.10). This uncovers the lower aspect of the IJV and adjacent carotid sheath structures (carotid artery medially, IJV laterally, and vagus nerve posteriorly between the other two). The lymph nodes to be removed extend from the base of the neck inferiorly, behind the clavicle and slightly behind the IJV anteriorly, and laterally behind the SCM. Retracting the IJV anteriorly and medially (protecting the adjacent vagus nerve), areolar tissue is easily dissected laterally down to the floor of the neck onto the prevertebral fascia extending laterally as the fascia overlying the anterior scalene muscle (Figs. 38.11 and 38.12). Running vertically on the anterior scalene muscle is the phrenic nerve that is crossed low in the neck by the transverse cervical artery (Fig. 38.13A,B), a branch of the thyrocervical trunk. This artery may be sacrificed, but care must be taken to preserve the phrenic nerve. The lateral border of the IJV may be used as a guide to dissect inferiorly, but it will join the subclavian vein, and on the left side, the thoracic duct. This duct runs adjacent to the esophagus in the chest, coursing up behind the carotid sheath structures, and loops up a short distance from medial to lateral behind the IJV, and then enters the subclavian vein near its junction with the IJV. Nodes near the clear-fluid–containing duct are commonly involved in thyroid cancer, and the duct is very vulnerable to injury. In adults, if injured, the thoracic duct may be ligated without harm. The dissection across the base of Compartment IV at the level of the clavicle is usually safe with only relatively small veins requiring control. After releasing the inferior attachments, and with dissection superiorly along the lateral border of the IJV, and safely elevating the packet of lymph nodes from the anterior scalene muscle, the packet of nodes and soft tissue can be retracted anteriorly, putting tension on the posterior attachments behind the SCM.

Dissecting from inferior to superior, the cutaneous cervical plexus nerves (C2 to 4) will be encountered as substantial nerves coursing obliquely down behind the SCM (Fig. 38.14A,B). With care, these nerves can be preserved without jeopardizing a good nodal dissection. Deeply situated at the inferior and lateral aspect of the dissection, coursing from behind the anterior scalene and in front of the middle scalene muscles are the brachial plexus trunks. The superior border of Compartment III is defined as the level of the hyoid bone or carotid bifurcation. Not infrequently, lymph nodes, located anterior to the carotid artery at the level of the bifurcation, are metastatically involved and may be overlooked if not intentionally sought.

TABLE 38.1 Compartments of Neck and Levels of Cervical Lymph Nodes

Level (Compartment)	Location
I (Submandibular triangle)	Bounded by anterior and posterior bellies of digastric muscle and inferior ramus of mandible.
II (Upper jugular)	Extending from base of skull to bifurcation of carotid artery or hyoid bone. The posterior border of IA is the spinal accessory nerve (C. XI), and of IB is the sternocleidomastoid muscle. Anterior border of compartment is sternohyoid muscle.
III (Middle jugular)	Inferior border of Level II to omohyoid muscle or cricoid cartilage; anterior borders same as II.
IV (Lower jugular)	Inferior border of Level III to clavicle; anterior and posterior borders same as II and III.
V (Posterior triangle)	Bounded by clavicle inferiorly, trapezius muscle posteriorly, sternocleidomastoid anteriorly and medially.

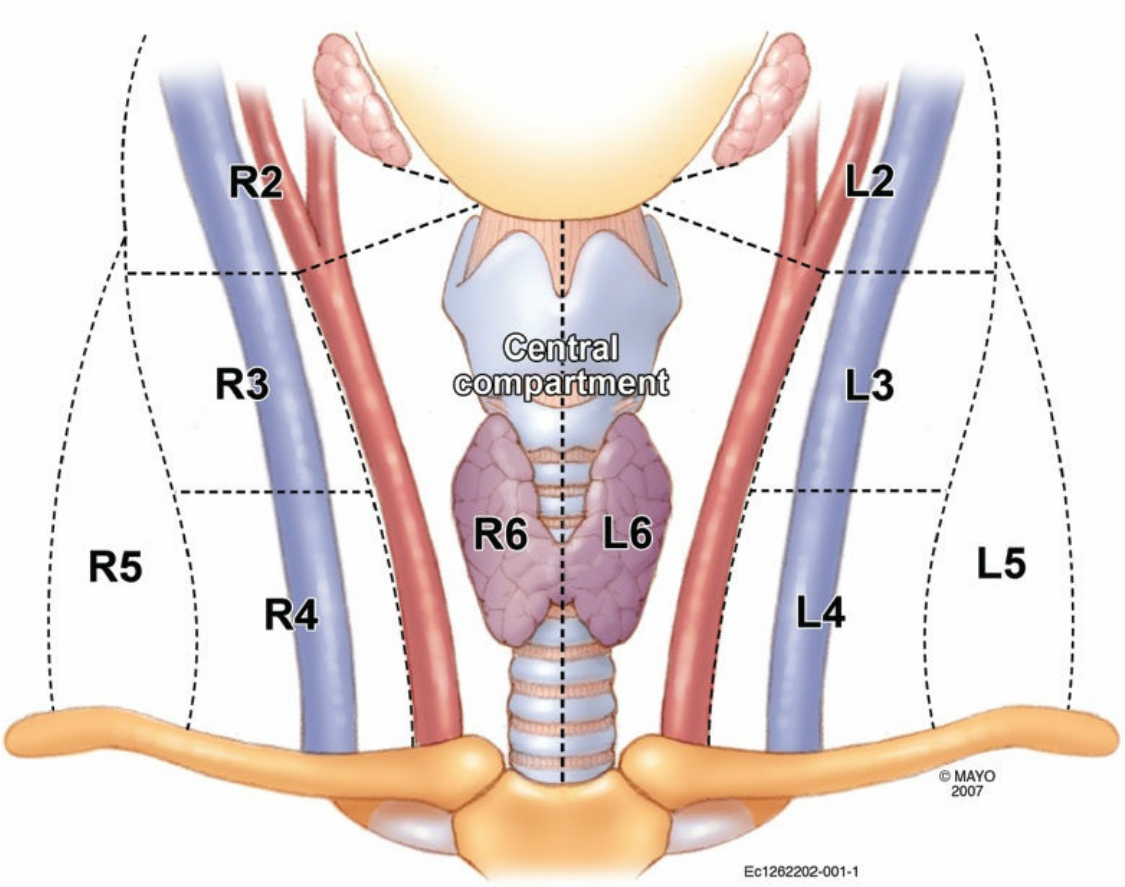

Figure 38.8. Anatomic compartments of the neck.

Compartment II

Superior to the cervical plexus nerves, coursing obliquely inferiorly and laterally from under the posterior belly of the digastric muscle is the spinal accessory nerve (Nerve XI). If dissection is carefully conducted with low-power cautery, stimulation of the nerve will cause contraction of the SCM and trapezius muscles with sudden movement of the shoulder. Further dissection with standard instruments will uncover the nerve where it can be traced cephalad and the associated lymph nodes cleared from Compartments IIA (anterior to the nerve) and IIB (posterior to the nerve), if necessary. At this level, several important structures emerge deep to the posterior belly of the digastric muscle. These include the carotid sheath structures, Nerve XI, the sympathetic chain behind the carotid artery, and the hypoglossal nerve (C XII) turning anteriorly, hooking under the arterial branch to the SCM off of the occipital artery. If dissection is kept along the lateral border of the IJV, C XII should not be encountered. Its descending branch, the ansa cervicalis (innervating strap muscles), descends anterior to the carotid artery and may be identified and sacrificed lower in the neck

(level of the omohyoid muscle).

EMBRYOLOGY

The parathyroid glands develop from Branchial Pouches III and IV. The superior parathyroid glands develop from Pouch IV, travel a shorter distance than the inferior glands, and are typically located along the posterior border of the thyroid gland at approximately 1 cm superior to the entrance of the inferior thyroid artery (Fig. 38.6A). Because of this location, when the superior glands descend further, they almost always remain posterior, in the tracheoesophageal groove or retroesophageal space (Fig. 38.15). Even when located quite low in the posterior superior mediastinum, they can still be retrieved through a collar incision.

In conjunction with the thymus, the inferior parathyroid glands develop from Pouch III and descend to the posterior aspects of the lower pole of the thyroid gland. This long descent gives rise to a much more variable position for the inferior parathyroid than for the superior gland. The location of the inferior gland can range from being high, anterior to the carotid artery (the so-called undescended parathymus), to being in the anterior mediastinum within the thymus, necessitating sternotomy for retrieval (Fig. 38.15). Inferior glands associated with the thyroid gland usually remain ventral to the RLN, whereas the superior glands are found dorsal to the nerve. The usual home for the inferior glands is on the posterolateral surface of the thyroid gland, just above, at, or within the attached remnant of the cervical thymus, the so-called thyrothymic ligament (Fig. 38.4). Rarely, this combined descent of parathyroid and thymus can be trapped within the carotid sheath, which might become relevant and evident only when the parathyroid gland is enlarged and hyperfunctioning. Moreover, because of the relationship between the thymus and the developing heart, these aberrant parathyroid glands can be located adjacent to the origin of the great vessels from the aorta.

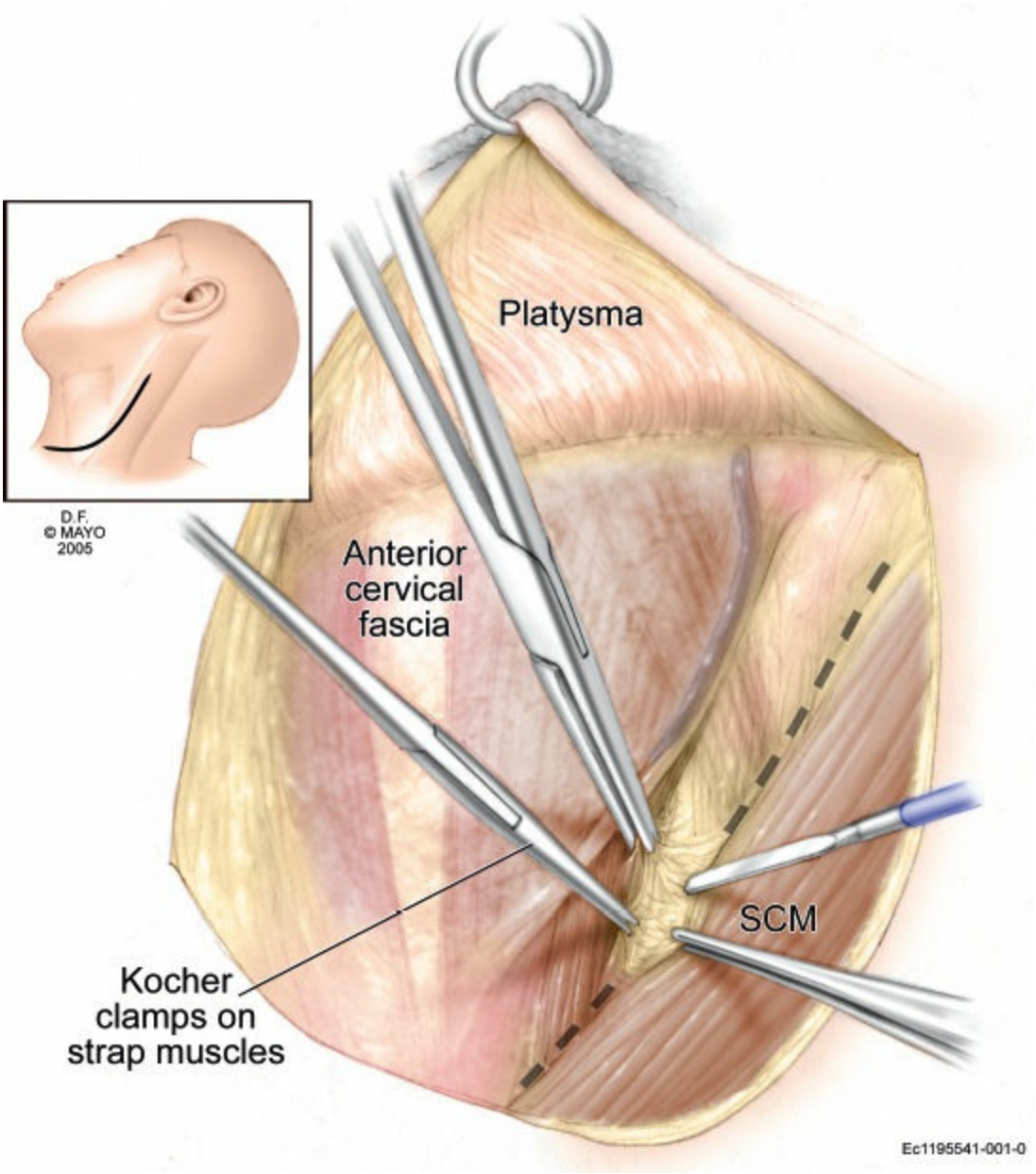

Figure 38.9. Modified radical neck dissection incision and dissection between sternocleidomastoid muscle (SCM) and strap muscles.

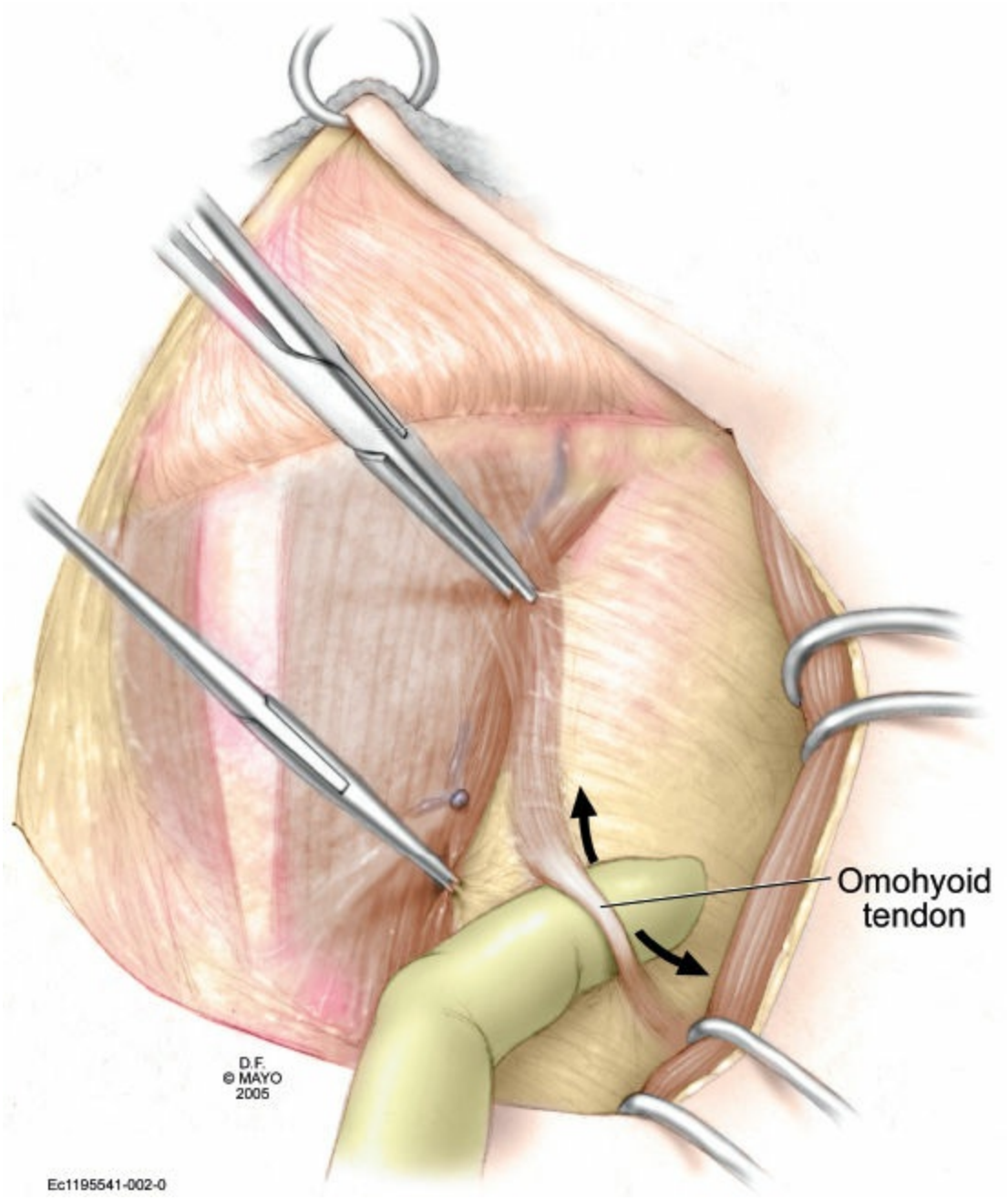

Figure 38.10. Isolation and resection of omohyoid muscle.

In very rare instances, the parathyroid glands can be found to be completely intrathyroidal. More commonly, they can be located on the surface of the thyroid gland, under the capsule but in clefts of the thyroid parenchyma. This location can seem intrathyroidal, particularly during reoperative parathyroid surgery, when the thyroid capsule is thickened with scar.

SURGICAL ANATOMY

Virtually everyone has at least four parathyroid glands, but at least 13% of the population has supernumerary glands. However, only one half of these supernumerary glands are proper glands; the others are tiny, rudimentary bits of parathyroid tissue, usually located near another normal gland. Supernumerary glands become important surgically in four situations: (a) hyperparathyroidism (HPT) caused by multiple endocrine neoplasia (MEN), especially type 1, and familial HPT, when all glands are abnormal; (b) secondary HPT, most typically that results from chronic renal failure, in which all glands are stimulated to enlarge and hyperfunction; (c) sporadic cases in which the four usual glands are normal and only the supernumerary gland is abnormally enlarged and responsible for hyperfunction; and (d) cases in which the supernumerary gland is enlarged in addition to another normal gland, which represents a double-adenoma situation.

Dissection of Parathyroid Glands

There are three important goals in parathyroid surgery: (a) recognition of normal parathyroid glands as well as removal of the abnormal glands; (b) safe searches in *predictable* locations for missing parathyroid glands; and (c) the preservation of parathyroid glands during thyroidectomy or the removal of other abnormal parathyroid glands.

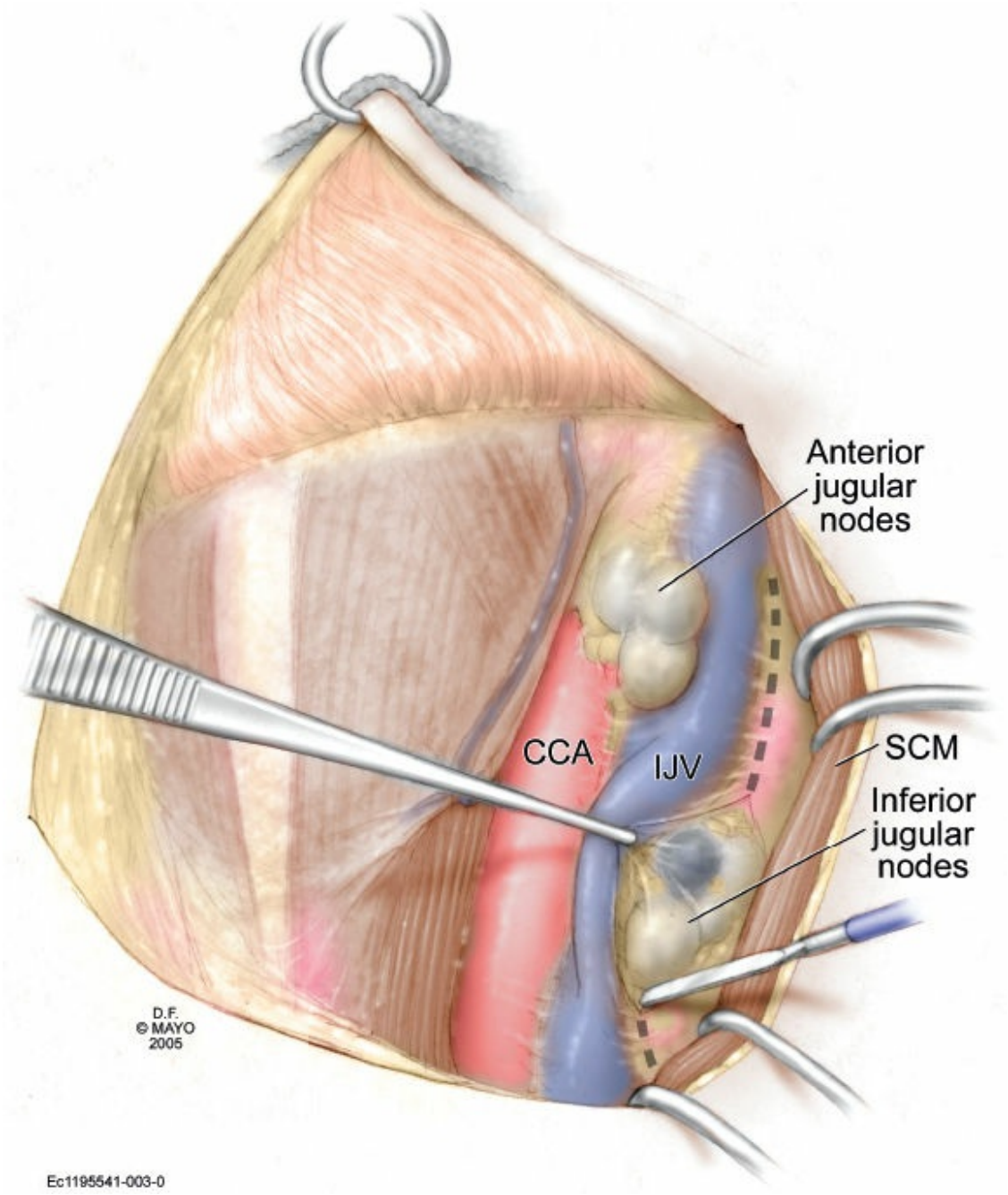

Figure 38.11. Initial dissection along lateral border of internal jugular vein (IJV) above level of clavicle. CCA, common carotid artery; SCM, sternocleidomastoid muscle.

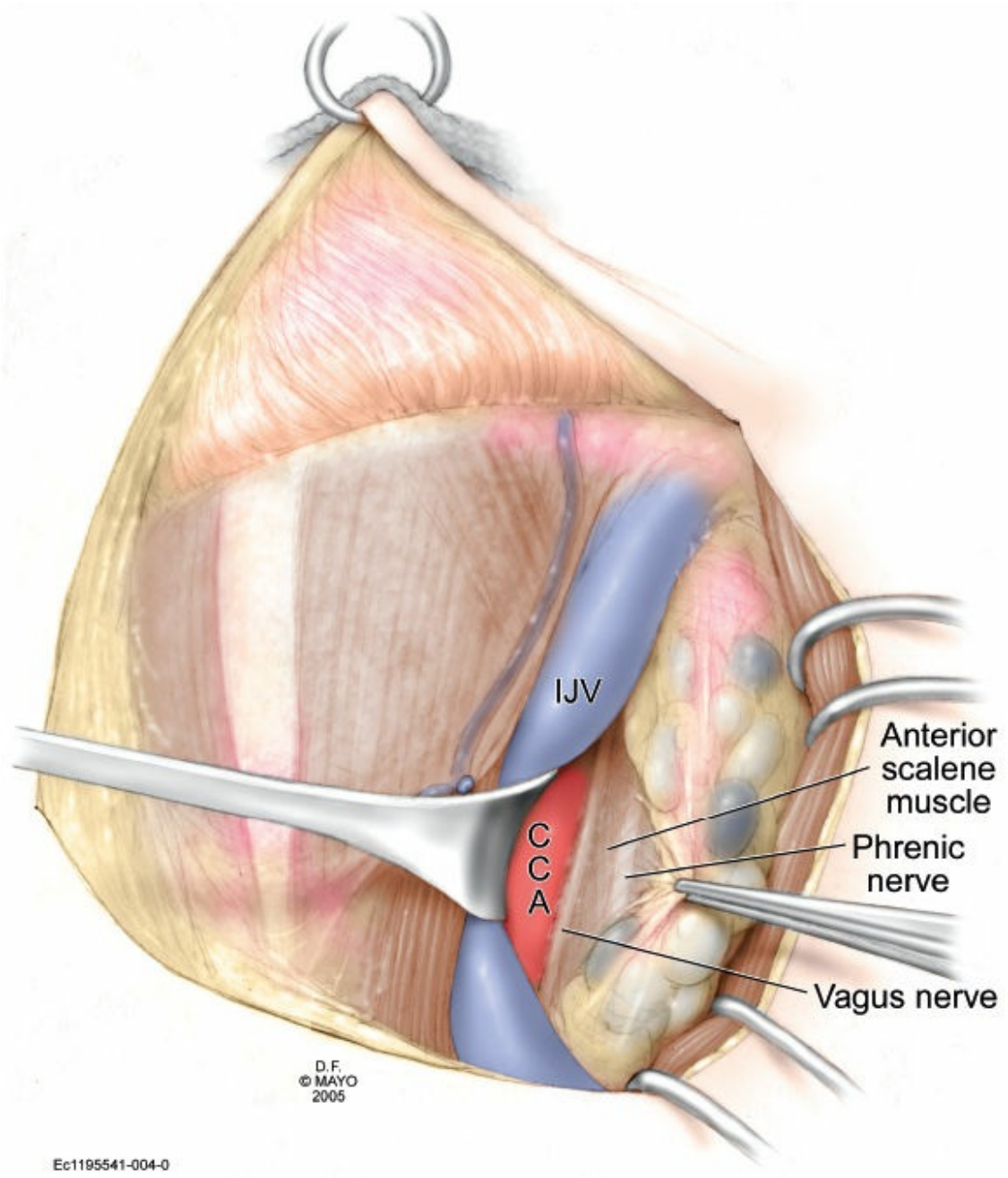

Figure 38.12. Exposure of anterior scalene muscle and phrenic nerve. CCA, common carotid artery; IJV, internal jugular vein.

The dissection of parathyroid glands proceeds similarly to the mobilization of a thyroid lobe, as described previously. In contrast, when HPT is the indication for operation, the arterial supply of the thyroid is usually preserved. Once the thyroid gland has been elevated (Fig. 38.4), the inferior parathyroid gland is usually sought first. It usually resides either on the posterolateral surface of the lower pole of the thyroid gland or at the tip of the cervical thymus or thyrothymic ligament. In fact, this ligament can be used to point to the gland or conceal it within its variably

atrophic and fat-replaced thymic substance. Similar to the superior gland, the inferior gland is often located in a lobule of fat, from which it can be distinguished by its reddish-yellow or yellowish-brown color. Normal glands are soft, pliable, and virtually nonpalpable, and can be present in differing shapes depending on whether the fascial layer that flattens it against the thyroid has been teased away to yield a more globular shape. When a tiny biopsy has been taken from the *nonhilar* portion of the gland, the entire parenchymal surface bleeds from pinpoint capillaries (in contrast to fat with its single bleeding vessel). Thyroid nodules and normal or diseased lymph nodes are firmer, not soft and pliable like normal parathyroid glands. The thymus can usually be distinguished by its pale, off-white color. If an inferior parathyroid adenoma is not found in the usual locations, it has almost universally migrated along an anterior path, following the course of or located within the cervical or mediastinal thymus. The sequence of searching for inferior glands not in the usual locations proceeds as follows: (a) the cervical and mediastinal thymus are drawn into the wound and searched or excised for pathologic review; (b) dissection is carried anterior to the carotid artery at least to its bifurcation to search for an undescended parathymus, as described previously; (c) the carotid sheath is opened, particularly if the cervical thymus is seen to deviate toward it; and (d) the lower pole of the thyroid is excised to exclude an intrathyroidal location.

The superior parathyroid glands are in a more constant location but are somewhat more difficult to expose than the inferior glands. They are usually found within a globule of fat located along the posterior border of the thyroid gland, 1 to 2 cm superior to where the inferior thyroid artery enters the thyroid gland (Fig. 38.6). Gentle dissection to strip thin fascial layers overlying the gland causes it to pop out directly, or the surrounding fat can be manipulated to expose the parathyroid gland. Initially, to identify probable locations for this gland, gentle prodding with an instrument causes the fat and contained parathyroid gland to float within the fascial envelope. They often directly overlie the RLN, although they are separated by a delicate fascial space. When a superior gland is not in the usual position, it tends to migrate posteriorly, behind the inferior thyroid artery, drawing its blood supply with it and descending in the potential space called the *tracheoesophageal groove*, which is almost the same as the retroesophageal or prevertebral space. Because the RLN is closely applied to the trachea and is located anterior to this dissection

plane, the retroesophageal space can be entered and widely dissected from the level of the larynx superiorly almost to as low as the tracheal bifurcation inferiorly. The only critical structure that crosses this plane is the inferior thyroid artery, which can be protected as it enters the thyroid gland or transected. Occasionally, exposure of the superior gland can be facilitated by mobilizing the superior pole of the thyroid gland by transecting the superior thyroid artery. Very rarely is a superior gland located within the thyroid gland. Superior and inferior glands are remarkably symmetric in their locations. Even in ectopic locations, with the exception of an inferior gland located low in the cervicomediastinal thymus, symmetry is often preserved.

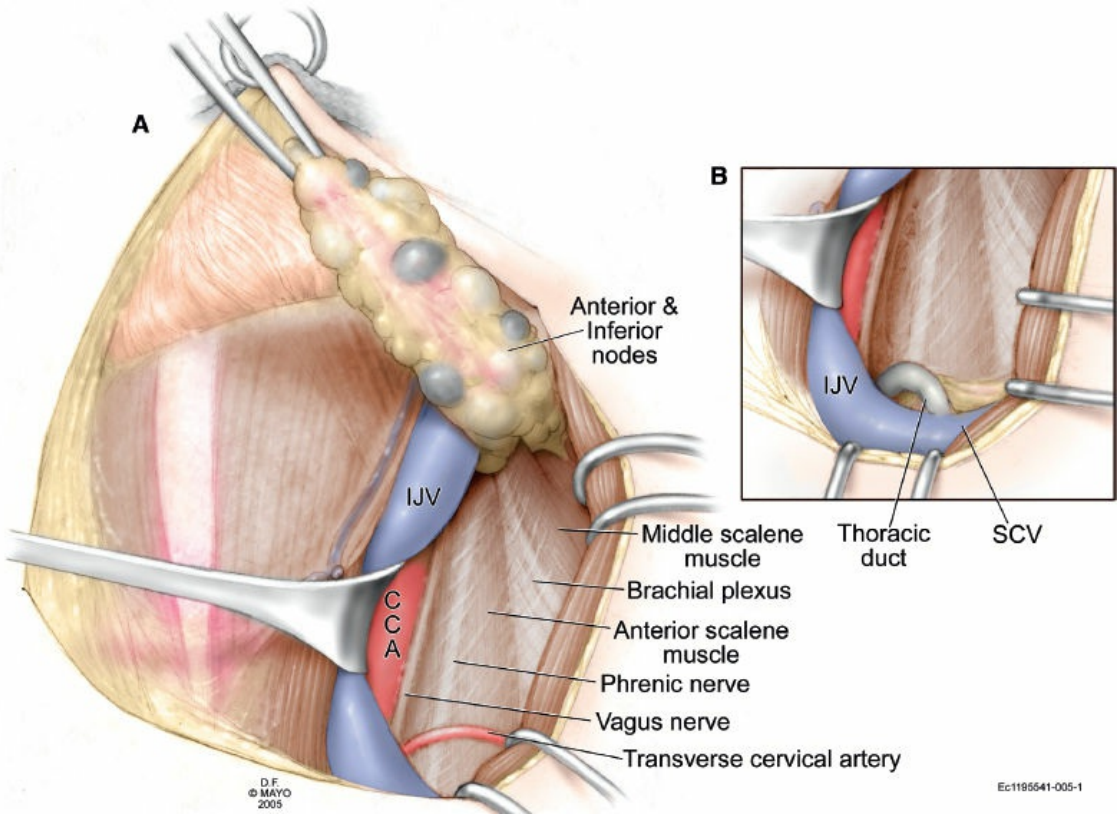

Figure 38.13. *En bloc* dissection of internal jugular vein (IJV) lymph nodes and exposure of floor of neck. CCA, common carotid artery.

Although the principal arterial blood supply to the superior and inferior parathyroid glands originates from the inferior thyroid arteries, other anastomotic vessels certainly provide a supplementary supply in most patients. However, when a total thyroidectomy has been performed, these supplementary sources are often interrupted. As a general rule during a

thyroidectomy, the inferior thyroid artery should be transected distal to the branches that supply the parathyroid glands. When an inferior gland is located within the substance of the thymus, it usually derives a satisfactory blood supply from thymic vessels.

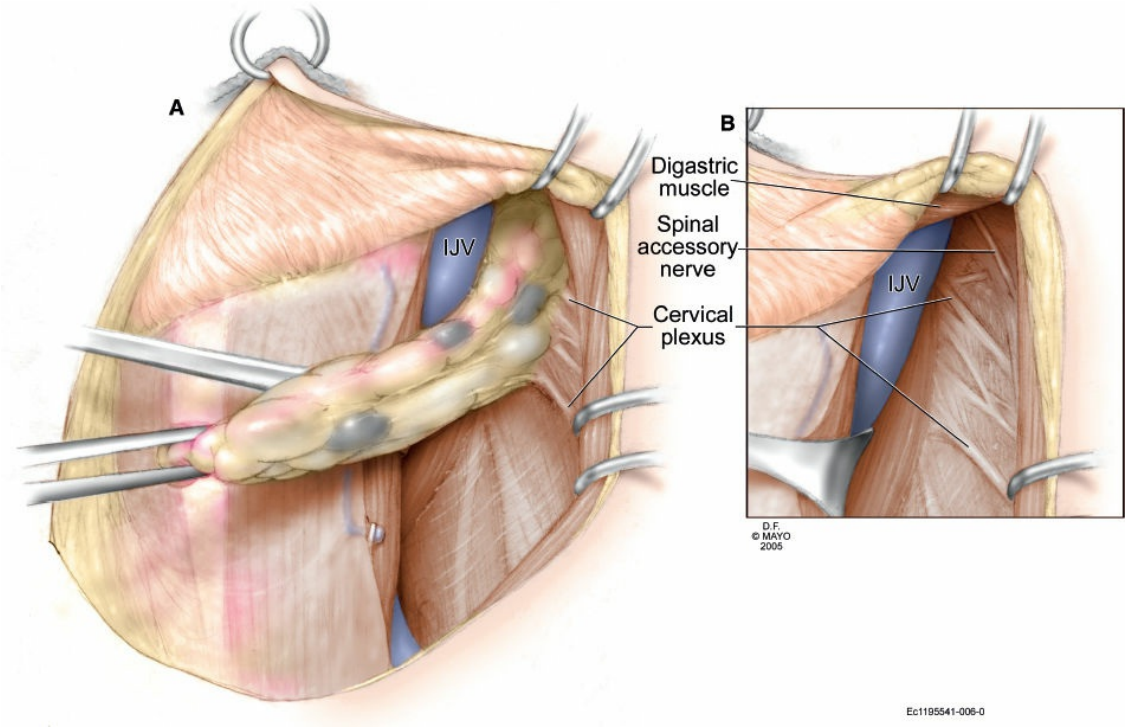

Figure 38.14. Cervical plexus (CP) and spinal accessory nerve dissection (extending to Level II). IJV, internal jugular vein.

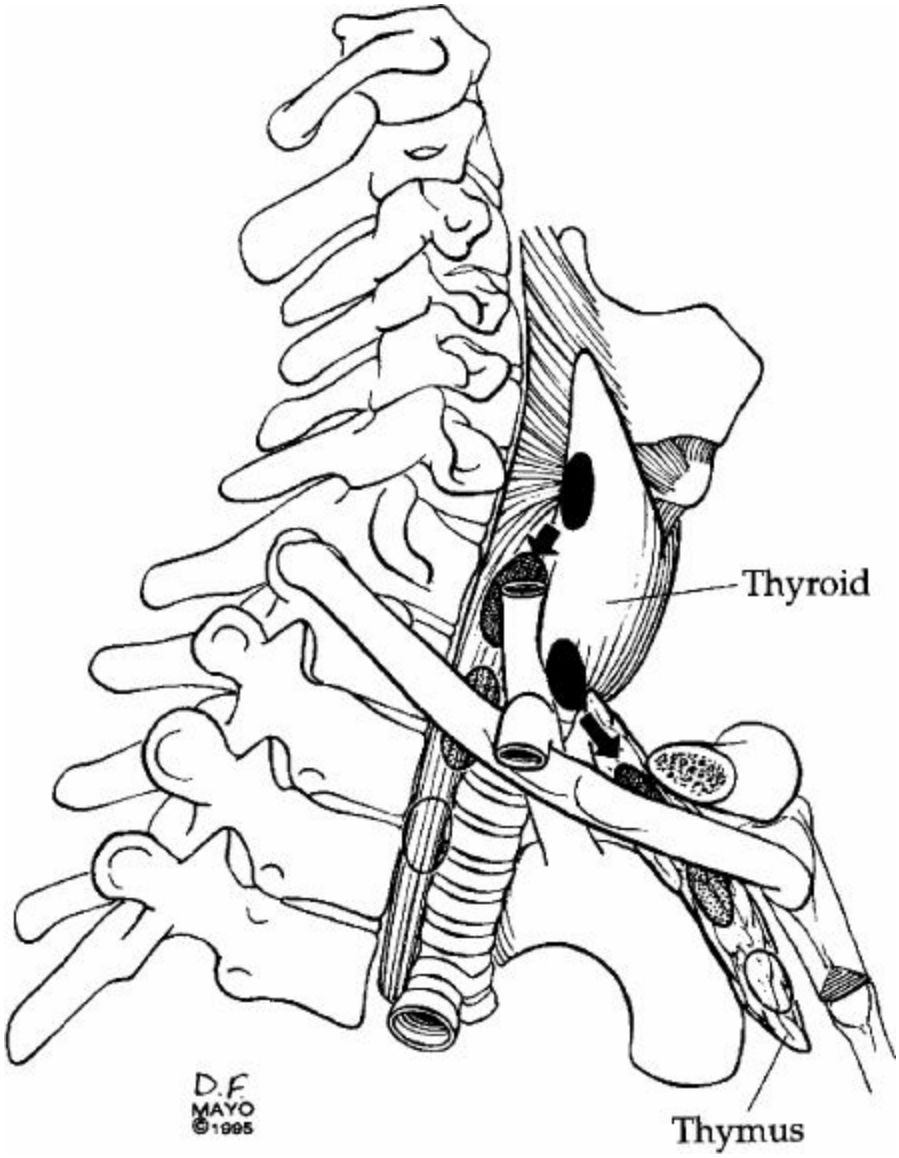

Figure 38.15. Owing to their embryologic origins, the parathyroid glands, particularly when enlarged, follow different, but often predictable, courses. The superior glands descend posteriorly in the contiguous tracheoesophageal groove or retroesophageal space, or into the posterior superior mediastinum. The inferior glands are less predictable but are usually found anteriorly in association with the thymus gland, either in the neck or in the anterior superior mediastinum.

Minimal-Access Parathyroidectomy

Application of minimal-access techniques that have swept across all disciplines of surgery have been applied to parathyroidectomy and, to a lesser degree, thyroidectomy. Two distinct methodologies have emerged: First, an open technique, which uses local anesthesia and a small incision and is directed by preoperative imaging and sometimes by intraoperative

rapid parathyroid hormone determination; and second, microendoscopic techniques. The feasibility of both techniques has been solidly established in the hands of experts, and the ultimate use of either or both awaits the assessment of the safety, cost-effectiveness, and, perhaps most important, the demands of patients.

Although perhaps only two thirds of patients with HPT are actually suitable for a limited exploration using present localization modalities, the surgeon must understand not only the anatomy of the parathyroid glands, but also the critical importance of his or her ability to interpret localization studies accurately.

Sestamibi Parathyroid Scan

Up to 80% of patients with sporadic HPT are demonstrated by sestamibi scan to have a single "hot spot" that represents a single enlarged parathyroid adenoma. This is probably the single most effective preoperative localization method currently available. Even if the hot spot is located as far inferior as the lower pole of the thyroid gland, it can still be a superior parathyroid gland, located posteriorly in the tracheoesophageal groove. Conversely, a hot spot superior to the superior pole of the thyroid gland is almost certainly an inferior gland—the undescended parathymus. Oblique views should be included in the scan technique to distinguish an anterior hot spot, which is most likely an inferior gland and rotates with the inferior pole of the thyroid gland (Fig. 38.16A). A posterior hot spot—a superior gland—moves to the midline in the opposite oblique view (Fig. 38.16B). Also, the level of the sternal notch should be noted, as the gland may reside within the mediastinal thymus in the anterior-superior mediastinum yet to be easily retrievable from a cervical incision. These ectopic but not unusual locations have been recognized for decades but need to be carefully considered to place a limited incision properly or to opt for a standard open exploration.

EMBRYOLOGY

The adrenal glands can be separated into two distinct areas, both histologically and physiologically: the cortex and the medulla. The cortex develops from mesodermic celomic epithelium of the posterior abdominal wall, at the cranial end of the mesonephros. The medulla develops from the neural crest in conjunction with the sympathetic ganglia. This group of neural cells migrates along the adrenal vein to invade the cortex and

becomes the completed adrenal gland. Other small masses of these cells, which stain brown with chromic acid (thus the name *chromaffin* or *pheochrome cells*), can persist throughout the life along the sympathetic chain as paraganglia. The most common location of a tumor (or paraganglioma) is at the origin of the inferior mesenteric artery on either side of the aorta, near the Zuckerkandl organ. Accessory adrenal tissue can be found occasionally in the connective tissue adjacent to the main gland but can also occur near a gonad, either ovary or testis.

ANATOMY

Because the adrenal glands are situated deeply in the retroperitoneum, and because primary diseases that require adrenalectomy are rare, surgeons tend to be less familiar with the anatomic relationships of these glands (Fig. 38.17). In addition, adrenal tumors can distort these relationships. On both sides, they cap the kidneys and derive arterial blood supply from the aorta and the inferior phrenic and renal arteries.

On the right, the upper part of the gland lies partially behind the inferior vena cava (IVC), against the bare area of the liver (to which it can seem somewhat adherent), and on the diaphragm. The principal venous drainage is through the adrenal vein, which is short and wide and which exits the gland just below its apex to enter the IVC on its posterior surface and is the only vein to enter the IVC posteriorly along its retrohepatic course.

The left adrenal gland lies on the diaphragm and is covered on its anterior surface by peritoneum superiorly and on its lower portion by the nonperitoneally covered pancreas. The adrenal *vein* exists near the lower border of the gland, often to join with the inferior phrenic vein to empty into the renal vein.

ANATOMY IMPORTANT TO VARIOUS SURGICAL APPROACHES

Anterior (Transabdominal)

Right

After the abdominal incision is made, the posterior edge of the liver should be dissected from the posterior peritoneum, which allows the liver to be lifted anteriorly and superiorly. This maneuver is also facilitated by transecting one or two small branches from the anterior surface of the IVC coursing to the caudate lobe of the liver. Neither the hepatic flexure of the

colon nor the duodenum usually needs to be mobilized unless the tumor is quite large. The arterial branch from the inferior phrenic artery is often located at the extreme superomedial aspect of the gland, higher than the adrenal vein, and requires careful control. Once this artery and the adrenal vein have been transected and the posterior peritoneal layer that covers the superior aspect of the adrenal gland has been incised, the gland can be retracted laterally as the IVC is retracted medially, which separates the plane between the two (Fig. 38.18). Control of the vessels from the aorta and renal vessels completes the dissection. With reasonable frequency, at least one small but significant accessory adrenal vein drains from the inferior aspect of the gland (especially important when large tumors are present that enlarge these veins) into the right renal vein. This situation is easily controlled when recognized. Care must be taken on this side as well as on the left to avoid ligating or injuring a small polar branch of the renal artery.

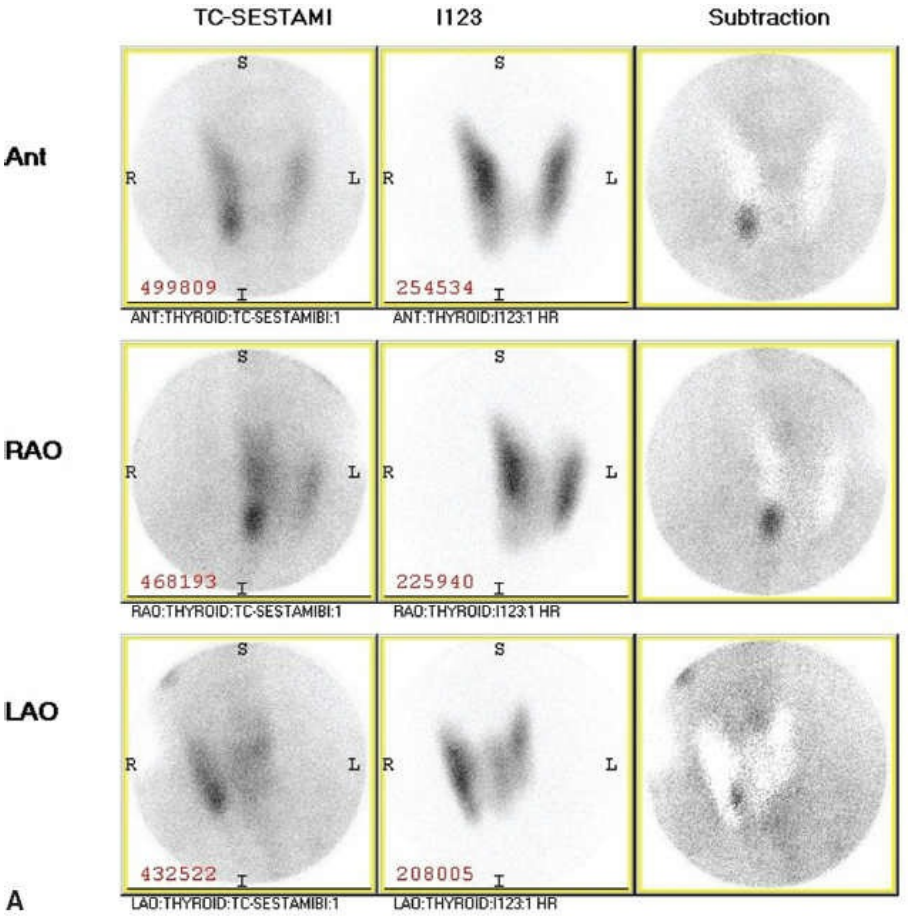
TC-SESTAMI
I123
Subtraction
Ant
RAO
LAO
A
499809
254534
468193
225940
432522
208005
ANT:THYROID:TC-SESTAMIBI:1
ANT:THYROID:I123:1 HR
RAO:THYROID:TC-SESTAMIBI:1
RAO:THYROID:I123:1 HR
LAO:THYROID:TC-SESTAMIBI:1
LAO:THYROID:I123:1 HR

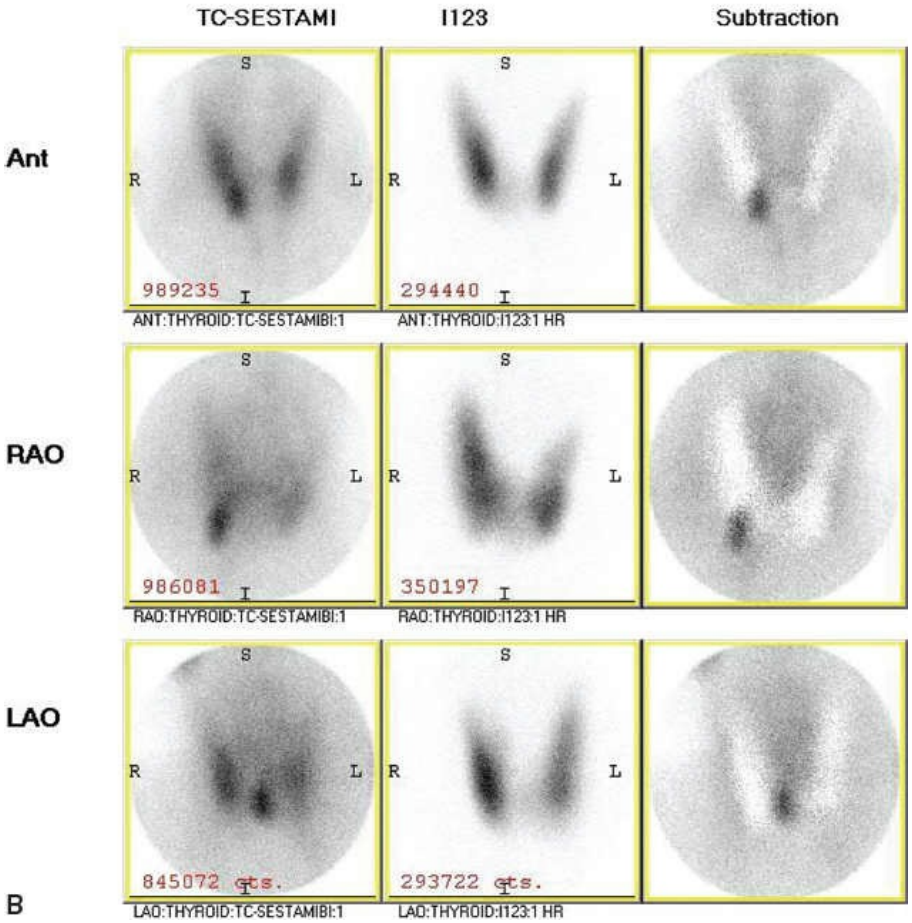
TC-SESTAMI
I123
Subtraction
Ant
RAO
LAO
B
989235
294440
986081
350197
845072 cts.
293722 cts.
ANT:THYROID:TC-SESTAMIBI:1
ANT:THYROID:I123:1 HR
RAO:THYROID:TC-SESTAMIBI:1
RAO:THYROID:I123:1 HR
LAO:THYROID:TC-SESTAMIBI:1
LAO:THYROID:I123:1 HR

Figure 38.16. **A:** The single “hot spot” is located at the inferior pole of the right lobe of the thyroid and moves with it in oblique views, indicating a right inferior parathyroid adenoma. **B:** The “hot spot” is located at the inferior pole of the right lobe of the thyroid, but moves into the midline in the left oblique view, indicating a right superior parathyroid adenoma (RS, left oblique view).

Left

Access to the left adrenal gland can be gained by dissecting the omentum from the colon, elevating the stomach, and dissecting the avascular plane under the pancreas to elevate it off the adrenal gland. The spleen does not need to be mobilized in this approach, but this exposure is adequate only for small to moderate tumors. For larger tumors, including adrenal cancers, the splenic flexure of the colon can be dissected and the spleen and pancreas mobilized from their bed (including ligation of short gastric vessels) to the patient’s right side (Fig. 38.19). This step exposes the adrenal gland or tumor inferomedially and eventually the most critical area of dissection on the left side. The adrenal vein and the arterial branches from the aorta and renal artery course in this space (Fig. 38.20).

Laparoscopic (Transperitoneal)

The laparoscopic approach has rapidly been adopted as the procedure of choice for removing all benign tumors, both functioning and nonfunctioning, with the upper size limit varying from 6 to 10 cm. Obviously, larger tumors require enlarging one of the trocar sites to accommodate removal, but most tumors “mold” somewhat into an oblong shape, allowing a much smaller transabdominal hole than might be expected. However, at present, most authors reporting a series of laparoscopic adrenalectomies prefer to remove adrenal malignancies using an anterior, open approach.

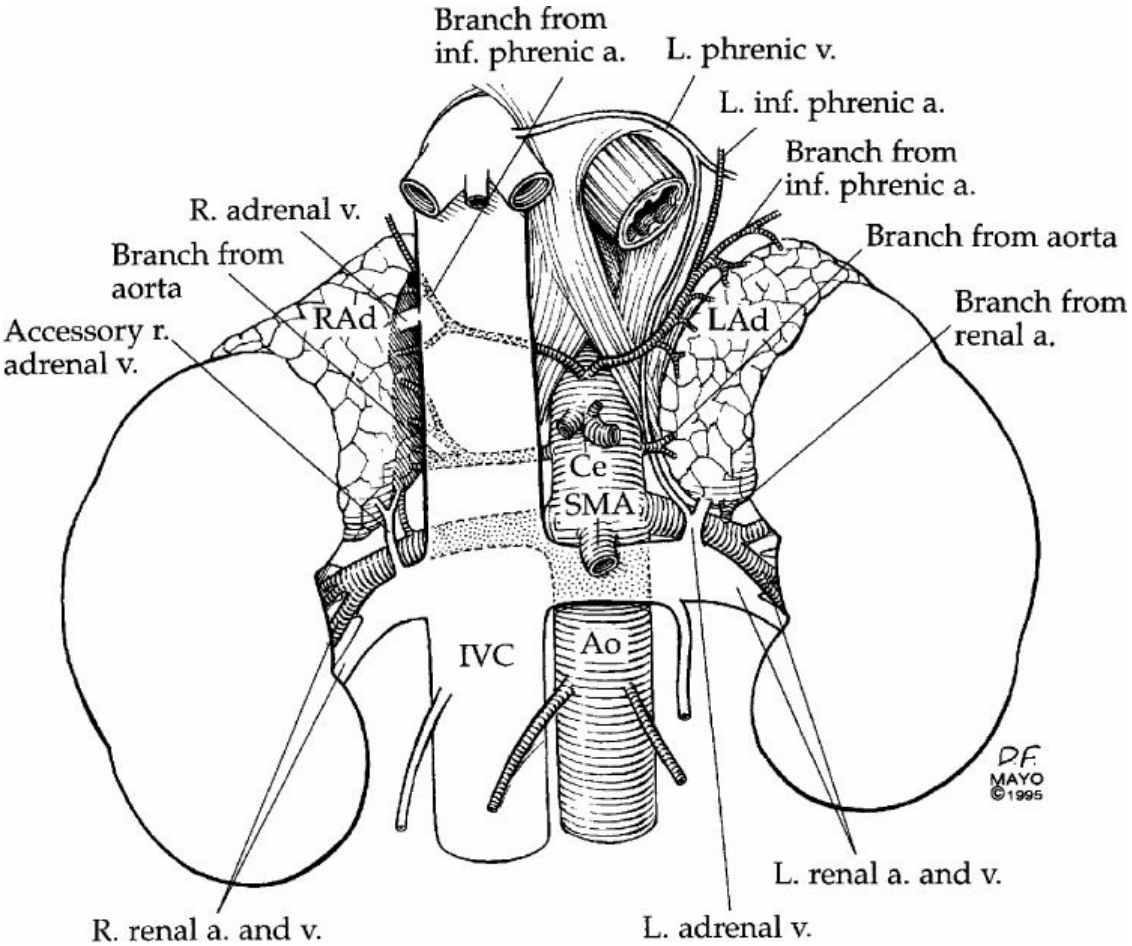

Figure 38.17. Overall anatomic relationships of the adrenal glands. Note the origins of the three main arteries: the inferior phrenic, aortic, and renal branches. Note also the single draining veins (except a small accessory right adrenal vein): the right, located superior and medial; and the left, found inferior and medial. Ao, aorta; Ce, celiac; IVC, inferior vena cava; LAd, left adrenal gland; RAd, right adrenal gland.

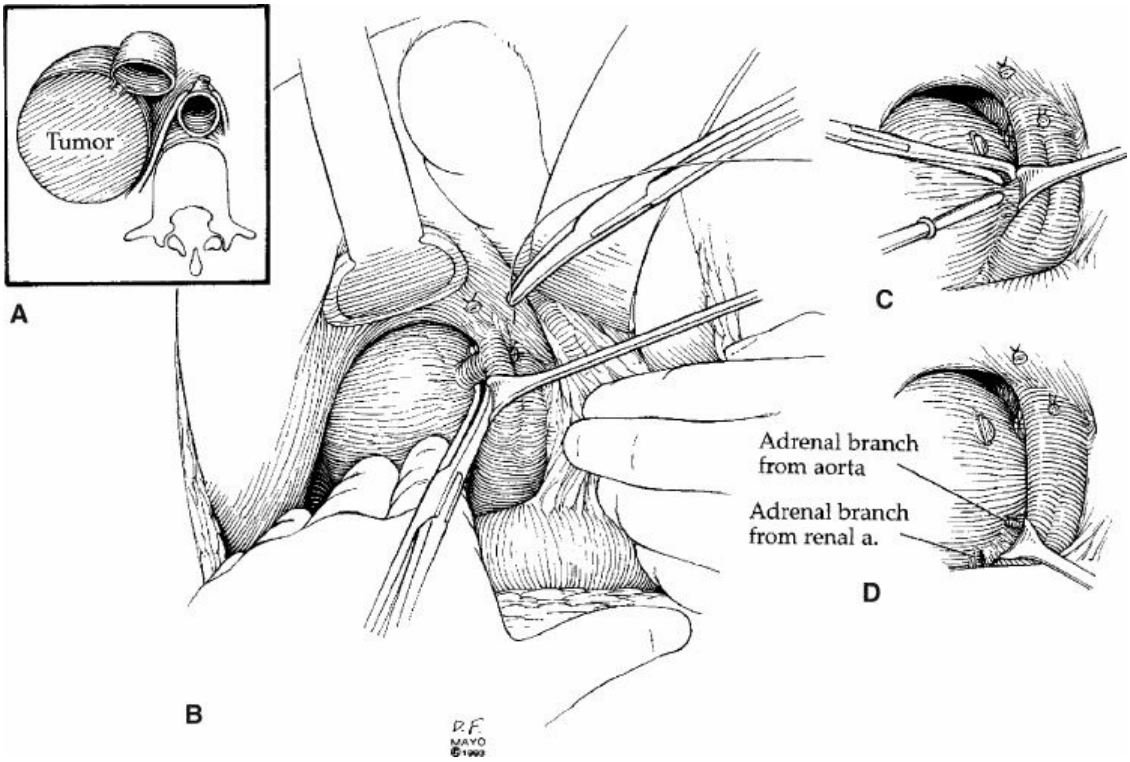

Figure 38.18. A: Cross-section of the anatomic relationships of the adrenal tumor, the inferior vena cava (IVC), and the right adrenal vein. **B:** With the liver elevated and the IVC retracted medially, the short, fat, right adrenal vein is exposed, coursing from the adrenal tumor to the posterior surface of the IVC. **C:** The vein has been clipped or ligated and transected, and the minimally vascular areolar tissues between the tumor and the IVC below the level of the vein are dissected. **D:** Along the medial inferior aspect of the tumor, the aortic and renal arterial branches that need to be controlled are found. (Republished with permission of John Wiley & Sons, Inc. from Grant CS, van Heerden JA. Technical aspects of thyroidectomy. In: Donohue JH, van Heerden JA, Monson JRT, eds. *Atlas of Surgical Oncology*. Cambridge: Blackwell Science; 1995:81–6; permission conveyed through Copyright Clearance Center, Inc.)

At least three different laparoscopic approaches have been described, including directly anterior with the patient positioned supine; retroperitoneal with the patient prone; and, most commonly, transperitoneal with the patient positioned laterally, with the side to be operated on elevated. “Breaking” the operating room table to distract and enlarge the distance from the costal margin to the iliac crest allows maximal space for placement of the trocars. Moreover, the most lateral trocar should be placed so as to avoid restriction of its inferior rotation by

the iliac crest. The anatomic considerations for a laparoscopic approach are not substantially different from the open operations, but some deserve special emphasis.

Right Adrenalectomy

Although the right side is potentially more dangerous of the two sides due to the short adrenal vein, the exposure is more direct and often easier than the left side. Four trocar sites are used, starting a few centimeters inferior to the right costal margin, somewhat medial to the midclavicular line, and coursing laterally. As much space as possible should be allowed between trocar sites to prevent the camera and instruments inserted through the cannulae from interfering with each other. The most medial cannula is used for retracting the liver, and the right triangular ligament should be divided to allow retraction of the liver, both medially and anteriorly, off the retroperitoneum. The retroperitoneal attachments to the liver should be lysed, exposing the IVC. The camera is usually best placed in the second cannula, and the two lateral cannulae are used for dissection and retraction by the surgeon. As the retroperitoneal covering is incised adjacent to the IVC, lateral retraction is placed on the adrenal gland to distract it from the IVC. Although the space between the gland and the IVC is limited, the camera magnification allows precise cautery dissection of the small vessels proceeding from the inferior border of the gland superiorly. We have not required direct retraction of the IVC. The incision in the retroperitoneal covering is curved laterally above the superior border of the adrenal gland, which allows further mobilization. Care must be taken to avoid unintentional trauma to the adrenal vein or the moderate-sized inferior phrenic artery, which can be transected at this stage. Gentle dissection of the adrenal vein, ensuring circumferential clearance, permits safe and precise control with endoscopic clips.

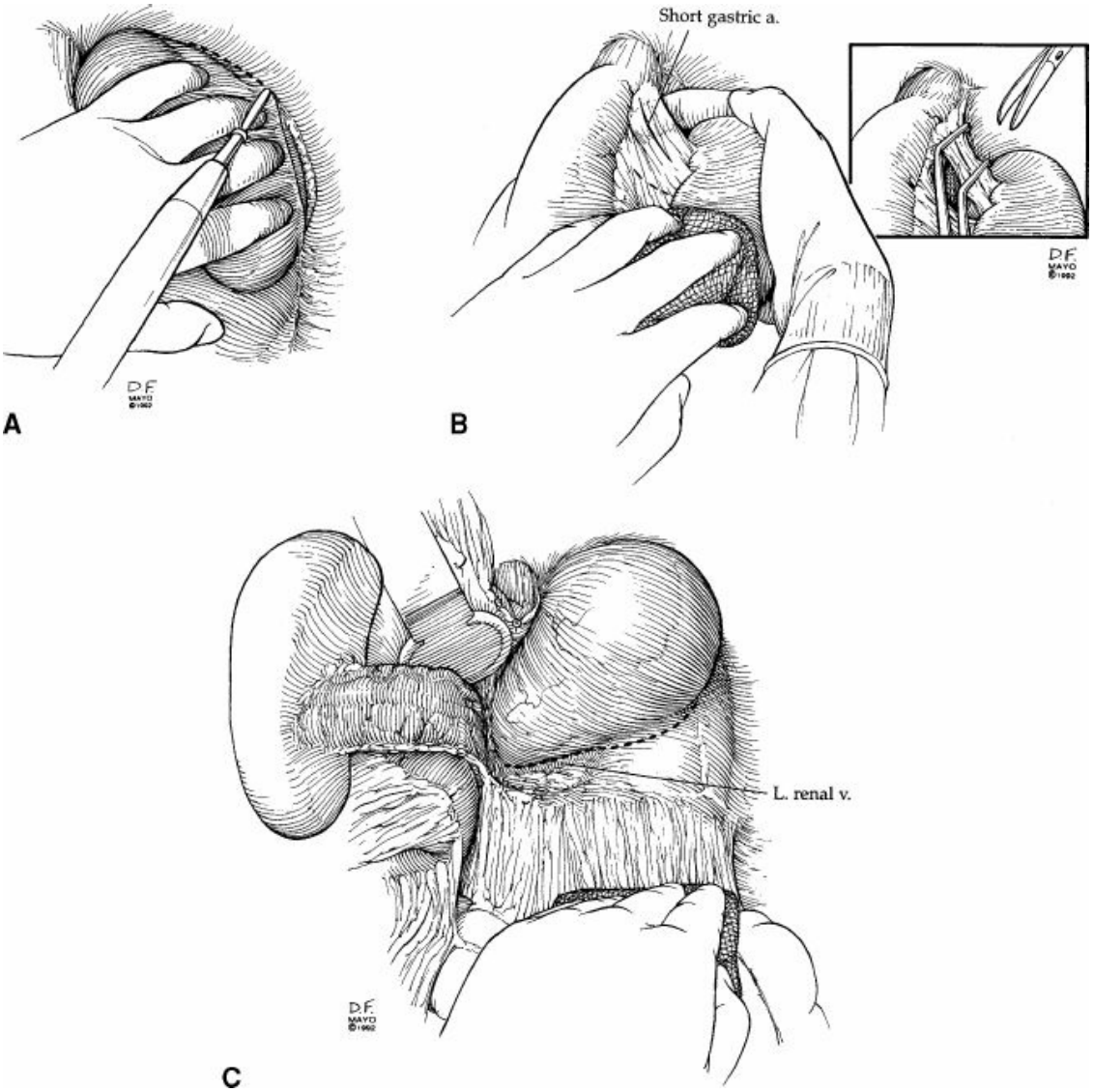

Figure 38.19. A: Retracting the spleen medially and inferiorly, the lateral peritoneal attachments are incised. **B:** The short gastric vessels are individually transected. **C:** With omentum dissected from the left transverse colon, the spleen and pancreas mobilized from their bed, and the short gastric vessels transected, these organs can be retracted into the patient's right upper quadrant, exposing a large adrenal tumor. (Republished with permission of John Wiley & Sons, Inc. from Grant CS, van Heerden JA. Technical aspects of thyroidectomy. In: Donohue JH, van Heerden JA, Monson JRT, eds. *Atlas of Surgical Oncology*. Cambridge: Blackwell Science; 1995:81–6; permission conveyed through Copyright Clearance Center, Inc.)

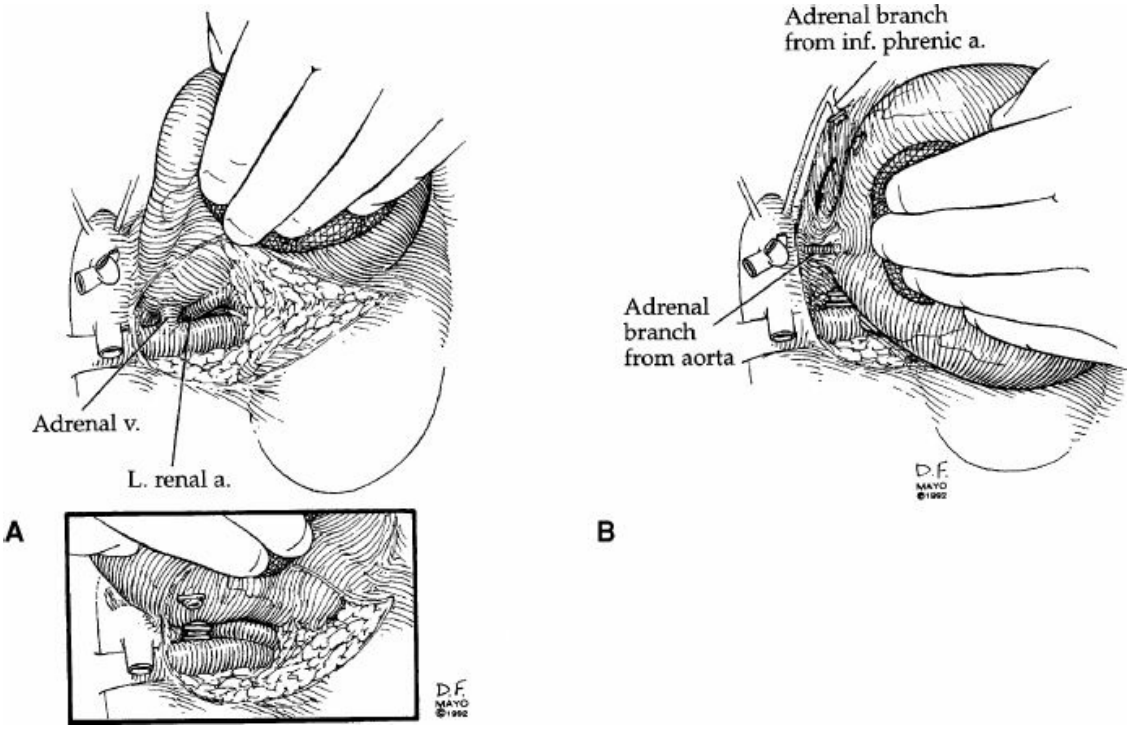

Figure 38.20. A: Along the inferomedial aspect of the adrenal tumor, the adrenal vein is identified, somewhat shorter than usual in the situation depicted. Care must be taken not to injure renal arterial branches coursing close by the vein as it is transected. **B:** The adrenal branches from the inferior phrenic and aorta can be seen in their typical locations. (Republished with permission of John Wiley & Sons, Inc. from Grant CS, van Heerden JA. Technical aspects of thyroidectomy. In: Donohue JH, van Heerden JA, Monson JRT, eds. *Atlas of Surgical Oncology*. Cambridge: Blackwell Science; 1995:81–6; permission conveyed through Copyright Clearance Center, Inc.)

As the dissection is carried around the inferior border of the gland, a thicker layer of fat is commonly encountered, and special attention must be taken, as in the open operation, not only to clip and transect the arterial branches to the adrenal gland but also to protect the arteries coursing to the underlying kidney. Particularly true of laparoscopic procedures, visualization is enhanced considerably by traction, and elevating the adrenal gland to facilitate dissection of the posterior attachments is most helpful. Placement of the adrenal gland into an endoscopic bag and withdrawal through one of the trocar sites completes the operation.

Left Adrenalectomy

Often, only three trocars are necessary for left adrenalectomy, because

once the spleen is mobilized, it usually does not require ongoing retraction. Trocar placement is planned in mirror image to the right side described previously. Before the third trocar is placed, the splenic flexure may need mobilization, sometimes extensively, to facilitate not only the placement of the trocar, but also the "dropping" of the transverse colon to gain exposure to the left adrenal vein later. The camera is usually placed in the lateral cannula (or third cannula if four are used—the most lateral to aid in retracting the kidney to expose the medial aspect where the adrenal vein drains into the left renal vein), but placement can be switched to another trocar as needed for optimal visualization. A blunt instrument is used to tip the spleen away from its retroperitoneal attachments; these then are incised relatively close to the spleen coursing superiorly, curving around the superior margin, and looking for and protecting the stomach as the dissection proceeds medially. The characteristic "fuzzy" areolar tissue posterolateral to the spleen that extends to the pancreas can be opened widely, exposing a variable thickness of fat and the adrenal gland. Locating the adrenal gland may be the most difficult portion of the procedure. During an operation for Cushing adrenal hyperplasia, with considerable overall obesity but particularly generous amounts of fat in the retroperitoneum, the marginally enlarged adrenal gland sometimes is engulfed by the fat. Along the medial border of the gland, as noted in the open procedure, the inferior phrenic vein may prove to be a valuable landmark. We often initially dissect the medial, superior, and lateral borders before visualizing and transecting the left adrenal vein, which is longer and generally more slender than its right-sided counterpart, and, when dissected, is easily clipped.

SPECIAL CONSIDERATIONS

There are several hot topics that have generated considerable interest and controversy relating to thyroid, parathyroid, and adrenal aspects of endocrine surgery that deserve special consideration. Without delving into great depth on these subjects or attempting to "answer" the controversies, the intent here is to highlight these contemporary issues, anticipating that perhaps a new set of topics will be covered in subsequent editions of Mastery of Surgery.

Thyroid

Papillary Thyroid Cancer

With the turn of the millennium, the goal of the endocrinologist seemed to be eradication of all evidence of disease, even down to molecular amounts. Facilitated by three new technologic advances—recombinant human TSH (rhTSH), high-resolution real-time cervical ultrasonography (US), and highly sensitive thyroglobulin (Tg)—postoperative disease as small as only a few millimeters, even submicroscopic size, could be discovered, that prompted either additional surgical intervention or administration of radioactive iodine (RAI). Of course patient's anxiety levels surged with discovery of this additional disease. Surgeons responded by obtaining preoperative US to identify subtle suspicious lymphadenopathy which was often combined with routine central neck (Compartment VI) lymphadenectomy. The result was a significant spike in recognizing either small volume metastatic disease preoperatively, or similar minimal disease residual postoperatively. Apart from these perioperative investigations, but closely related to the discovery of small volume disease, was an exponential rise in the diagnosis of thyroid cancer, specifically PTC. In large part attributed to increased use of sensitive imaging studies such as US, CT, and MRI, this explosive rise in the frequency of incidentally discovered PTC was principally comprised of papillary thyroid microcarcinoma (defined as ≤1 cm in largest size). Inevitably, questions arose as to the appropriateness of such exhaustive and expensive efforts to first identify then treat even minimal volume PTC surgically or with RAI ablation.

It appears that the pendulum of aggressive combined medical and surgical management is swinging back to a more moderate approach.

Japanese literature has convincingly demonstrated that the overwhelming majority of PTMC behave in a very indolent manner. In fact, in one large study, the Japanese have withheld treatment entirely, opting for only observation with ongoing US surveillance, and this management course has been shown convincingly to be safe.

Whereas the American Thyroid Association guidelines for therapy of PTC call for total or near-total thyroidectomy for all tumors >1 cm, data from large institutions indicate equivalent survival for lobectomy only in T1 to T2/N0 patients. Recent very large studies lend further support for lobectomy only to treat localized PTC even up to 4 cm.

Even though strong international data verify the safety and reduced lymph node recurrence rates of PTC following routine central neck lymphadenectomy, this is counterbalanced by more frequent temporary

hypoparathyroidism, and raises the very basic question of whether residual millimeter-sized PTC even requires any treatment. As a result, more recently, a greater tolerance for serial observation rather than intervention has evolved for mildly elevated postoperative Tg or image-detected, probable lymph node metastases <8 mm in the central compartment.

Following demonstrated lack of value of routine postoperative RAI in stage 1 PTC, its use nationally has finally turned on a downslope.

Intraoperative Neural Monitoring of the Recurrent Laryngeal Nerve

Following feasibility studies of intraoperative neural monitoring (IONM) prior to the year 2000, there has been increased investigation, modifications, enthusiasm, and usage of these techniques. The entire effort is directed to prevent unilateral and importantly bilateral RLN paralysis. The most important study on this topic was a multi-institutional, prospective, nonrandomized study of 16,448 patients with 29,998 nerves at risk. Comparing patients with routine visual identification of the RLN to those with both visual identification and IONM, there was no statistical difference in RLN injuries. While multiple studies and reports have been published on this topic, only a single major study has found IONM to improve outcome compared to visualization only, and that was only in rates of transient but not permanent RLN paresis. Even though its popularity has increased, given these data, IONM would certainly not be considered standard of care at this time.

Outpatient Thyroidectomy

In the last 10 years, increasing emphasis has been placed on outpatient surgery, including thyroidectomy. For this discussion, outpatient means same-day dismissal from the hospital or ambulatory surgical center (not to include 23-hour observation). Although a number of potential advantages have been cited, including potential to reduce hospital-acquired infections or management errors, the dominant reasons are patient-preference of a more familiar environment outside the hospital that is conducive to comfort and support, and cost reduction. However, these need to be balanced against the potential risk of postoperative complications that might be disastrous outside the prompt care available within a monitored hospital setting. When assessed by experts on behalf of the British Association of Endocrine and Thyroid Surgeons, they declared their opposition to the change: “Any financial benefits may be outweighed by

the exposure of patients to an increased risk of an adverse outcome." In the United States, several reports of safe outpatient thyroidectomy have been published, and the American Thyroid Association commissioned a task force to define eligibility criteria, preoperative, intraoperative, and postoperative factors to optimize safe outpatient thyroidectomy. As requested, thoughtful eligibility criteria, relative contraindications, operative surgical and anesthetic considerations, postoperative management, and discharge criteria were all enumerated. Perhaps paramount to this entire process would be a required clinical pathway incorporating all of the recommendations, necessitating adherence to it by all members of the team caring for the patient. Particularly highlighted were discharge assessment for any evidence of bleeding/hematoma, and 2-hour postoperative rapid PTH measurement or routine calcium and vitamin D supplementation to avoid these most significant potential complications. A cautionary note was emphasized in an editorial by Dr. Steward, "Outpatient thyroidectomy is clearly not for every patient, and perhaps not for every surgeon."

Parathyroid

Minimal Access Parathyroidectomy

Over the recent 15 to 20 years, "minimal access parathyroidectomy (MAC)" has become the favored approach by many if not most surgeons who perform this operation. This was facilitated by the development of technologic advances of high-quality Sestamibi scan to preoperatively localize parathyroid adenomas (sometimes augmented by the use of a γ-probe for intraoperative localization), and intraoperative parathyroid hormone (IOPTH) monitoring to verify cure. Coincidentally, across the nation and pertaining to all surgical disciplines, strong emphasis was being placed on "patient-centered" outcomes such as pain management, short-stay or outpatient procedures, small incisions, and local anesthesia. The convergence of these factors was further fueled by the explosion of information on the internet, readily accessible to patients, and particularly relevant to MAC—surgeon internet marketing. Over this time period, further attempts have been introduced to refine these techniques, trying to edge closer to perfection in surgical success for HPT. The nemesis has been the known occurrence in primary HPT of multiple gland disease. But strangely, even today, the frequency of this potential Achilles' heal of parathyroid localization and surgical success is still debated, and not

merely a few percentage point controversy. The original force behind use of IOPTH, George Irvin, found the frequency of single-adenoma to be nearly 95%, and surgical cure following single adenoma excision when postexcision IOPTH values dropped >50% from the pre-excision baseline. In contrast, an equally reputable leader in endocrine surgery, Allan Siperstein at the Cleveland Clinic, has pegged the multiple gland rate near 30%, with the use of IOPTH failing to detect 16% of abnormal parathyroid glands. He advocates bilateral, four-gland exploration as routine. Dr. James Norman, quoting exponentially greater surgical volume of parathyroid surgery than anyone else in the United States, and certainly the most powerful initial driving force in the use of MAP, initially touted success of nearly 100% with this technique. Recently, Norman has reversed his stance, now virtually never using a unilateral approach, preferring to explore all 4 glands, and finding multiple gland disease in 25%. Graphing his >15,000 case experience, he depicts improving his success rate from about 94% to >99% in his most recent 5,000 cases. He does utilize the γ-probe, but only a single planar Sestamibi scan preoperatively, and never uses IOPTH. To paraphrase his surgical strategy, he still performs the operation through a 2.5-cm incision, usually without intubation, never using nerve-monitoring, without need for SPECT, CT, 4D-CT, MRI, US, IOPTH, closing the incision in an average of 18 minutes, rarely keeping the patient more than 1 to 2 hours postoperatively. Most academic parathyroid surgeons continue to advocate a unilateral approach when preoperative localization and IOPTH indicate single-gland disease. Despite the initial simple “50% rule,” the details of IOPTH measurement are sometimes subtle but important.

Surgical Indication—Bone Mineral Density

A satisfying trend has emerged with increased acceptance and strong support favoring parathyroidectomy for patients with HPT, not only by surgeons, but also endocrinologists. Perhaps the most recent, persuading indication for recommending parathyroidectomy rather than observation, even in the “asymptomatic” patient, are the data regarding bone mineral density (BMD). Previously, at a 10-year follow-up of a prospective observational study of the natural history of PHP with and without surgical intervention, the unoperated, asymptomatic patients were found not to suffer a decline in BMD. In surgical patients, despite the 12% increase in lumbar spine BMD and 14% increase in femoral neck BMD at 10 years following surgical cure, observation was considered a reasonable option

for asymptomatic patients. However, the “permission” not to surgically intervene on the basis of stable BMD at 10 years seemed to crumble, as did the bones when the 15-year follow-up study was published. Cortical site (femoral neck and distal radius) BMD fell from 10% to 35%, and 37% of patients manifested BMD decline. From prior consensus conferences, women younger than 50 already had been recommended to undergo parathyroidectomy. Add to them a surgical recommendation for women older than 50 with osteoporosis, and it would seem with these newer data that we are on track in the future to add surgical recommendation for women not only with osteopenia, but any woman with declining BMD who has HPT.

Adrenal

Adrenal Incidentalomas

Although small adrenal tumors have been well recognized since they were first appreciated as a consequence of newly introduced CT imaging in the early 1980s, the management still remains somewhat controversial. Defined as an adrenal tumor >1 cm in size, without any obvious clinical evidence of hormonal hyperfunction, the prevalence increases with age, reaching about 7% in patients over 70 years of age. Once identified, the evaluation is intended to determine (1) if there is subclinical hormonal hypersecretion that would justify surgical resection, and (2) if the tumor represents a meaningful threat of malignancy. Measurement of simultaneous serum aldosterone and plasma renin activity (PRA) assesses for primary aldosteronism (abnormal aldosterone to PRA ratio is >20:1); a 1-mg overnight dexamethasone suppression test evaluates for subclinical Cushing syndrome (normal serum cortisol the following morning is <5 μg/dL); and a 24-hour urine collection for fractionated metanephrines and catecholamines to assess for pheochromocytoma. These tests have been quite well accepted as sensitive and cost-effective for assessment of hormonal hyperfunction. Criteria for assessing risk of malignancy have been weighted heavily on diameter size of the tumors. However, quite valuable in addition to tumor size are the imaging characteristics—the “imaging phenotype.” Adenomas are usually <3 cm, round or oval with smooth margins, homogeneous in texture, have a density on CT ≤10 Hounsfield units, have low-level vascularity and ≥50% washout of contrast medium at 10 minutes after injection. Their growth rate is slow, <1 cm/yr. In contrast, the small but real percentage of small adrenocortical

carcinomas (ACC) are usually >4 cm, with irregular margins, heterogeneous in texture with areas of necrosis and possibly calcification, >10 Hounsfield units in density with high vascularity and slower washout <50% at 10 minutes and hyperintense on T2-weighted image on MRI. Their growth rate is usually >2 cm/yr. Even though adrenalectomy now performed laparoscopically is quite safe, often requiring only an overnight hospitalization, used indiscriminately without careful attention to the imaging phenotype can be costly and unnecessary.

Laparoscopic Adrenalectomy for Small Adrenocortical Carcinomas

Only rarely are ACC smaller than 8 to 10 cm in size with no imaging evidence of surrounding tumor invasion—a situation that would seem suitable for potential laparoscopic resection. Between 1998 and 2004, 11 investigators had reported only 25 cases of primary ACC resected laparoscopically, with local recurrence or intraperitoneal dissemination in 40% of the patients. Subsequently, however, in the largest study of 152 patients, the German Adrenocortical Carcinoma Registry Group failed to demonstrate inferiority of the laparoscopic approach compared to open adrenalectomy either by matched pair or multivariate analysis. Consequently, the European Society of Endocrine Surgeons issued a position statement endorsing laparoscopic adrenalectomy for ACC with careful stipulations including an R0 resection, without capsule rupture, for tumors <10 cm in diameter. In sharp disagreement, citing increased frequency and more prompt local recurrence and peritoneal carcinomatosis, surgeons from the University of Michigan, MD Anderson, and France opposed the laparoscopic approach. Most of these studies have been small, including patients whose operations were performed somewhere other than the reporting institution, and many of the key operative and pathology details have been lacking. More information would be potentially beneficial, comparing patients matched for demographics and oncologic aspects of their cancers, but different only in the surgical approach. In retrospective review of our experience at Mayo Clinic of nearly 1,000 adrenalectomies, restricting ACA to <10 cm by imaging, with no surrounding soft tissue or organ invasion, only 20 were operated by open resection, and only 7 by laparoscopic or hand-assisted techniques. On follow-up, 5 of the 7 laparoscopically resected, and 5 of the 20 having undergone open resection were alive with no disease. Therefore, we would cautiously feel safe in initiating a laparoscopic approach, but convert to an open approach if necessary. While at first glance this overall

situation might seem to apply only to a tiny fraction of adrenalectomy patients, it actually must be considered in all patients undergoing adrenalectomy when the specific indication is to determine if a nonfunctioning adrenal tumor is benign or malignant—a significant proportion of adrenal resection patients.

Partial Adrenalectomy—Hereditary Pheochromocytoma

Hereditary forms of pheochromocytoma are rare, including MEN type 2 (MEN2) and von Hippel–Lindau disease (VHL), and often have bilateral but rarely malignant adrenal tumors. Particularly in MEN2 patients, the classic operation has been bilateral total adrenalectomies, since virtually 100% of the adrenal medullae are abnormal, featuring tumors which are frequently multicentric as well as bilateral, and associated with extratumoral medullary hyperplasia. Strong consideration has been given to preserve a portion of adrenal gland to avoid a permanent Addisonian state that can evolve into crisis in as many as 23% of patients. Furthermore, noncrisis symptoms of anxiety and mild adrenal insufficiency causes patients to restrict their activities resulting from the risk or actual need for supplemental cortisone. Even if a recurrent pheochromocytoma developed in an adrenal remnant, this could be discovered early—given the diligent follow-up necessary for associated conditions of either MEN2 or VHL—and reoperation could be performed safely. Two recent studies provide strong endorsement for partial adrenalectomy. When operating on small pheochromocytomas, cortical-sparing adrenalectomy showed only a 4% to 7% recurrence rate (12% after laparoscopic approach), no reduction in survival, and 57% to 64% of patients were steroid independent long term. Ideally, it is recommended to preserve 30% of the adrenal parenchyma to ensure cortical function, but less may still be successful, even sacrificing the adrenal vein. Interestingly, some of the strongest proponents of this advanced surgical method favor a posterior, retroperitoneal approach.

Suggested Readings

Brix D, Allolio B, Fenske W, et al. Laparoscopic versus open adrenalectomy for adrenocortical carcinoma: surgical and oncologic outcome in 152 patients. *Eur Urol* 2010;58:609–15.

Castinetti F, Qi XP, Walz M, et al. Outcomes of adrenal-sparing surgery or total adrenalectomy in phaeochromocytoma associated with multiple endocrine neoplasia type 2: an international retrospective population-based study. *Lancet*

Oncol 2014;15:648–55.

Dralle H, Sekulla C, Haerting J. Risk factors of paralysis and functional outcome after recurrent laryngeal nerve monitoring in thyroid surgery. *Surgery* 2004; 136:1310–22.

Grant CS. Pheochromocytoma. In: Clark OH, Duh QY, eds. *Textbook of Endocrine Surgery.* Philadelphia, PA: WB Saunders; 1997.

Grant CS, van Heerden JA. Technical aspects of adrenalectomy. In: Donohue JH, van Heerden JA, Monson JRT, eds. *Atlas of Surgical Oncology.* Cambridge: Blackwell Science; 1995.

Grant CS, van Heerden JA. Technical aspects of thyroidectomy. In: Donohue JS, van Heerden JA, Monson JRT, eds. *Atlas of Surgical Oncology.* Cambridge: Blackwell Science; 1995:81–6.

Gray SW, Skandalakis JE, eds. *Embryology for Surgeons*. Philadelphia, PA: WB Saunders; 1972.

Henry JF, Peix JL, Kraimps JL. Positional statement of the European Society of Endocrine Surgeons (ESES) on malignant adrenal tumors. *Langenbeck's Arch Surg* 2012;397:145–6.

Hodin R, Angelos P, Carty S, et al. No need to abandon unilateral parathyroid surgery. *J Am Coll Surg* 2012; 214:297.

Ito Y, Miyauchi A, Inoue H, et al. An observational trial for papillary thyroid microcarcinoma in Japanese patients. *World J Surg* 2010;34:28–35.

Miccoli P, Pinchera A, Cecchini G, et al. Minimally invasive video-assisted parathyroid surgery for primary hyperparathyroidism. *J Endocrinol Invest* 1997; 20:429.

Norman J, Lopez J, Politz D. Abandoning unilateral parathyroidectomy: why we reversed our position after 15,000 parathyroid operations. *J Am Coll Surg* 2012; 214:260–69; discussion 297–300.

Porterfield J, Factor D, Grant C. Operative technique for modified radical neck dissection in papillary thyroid carcinoma. *Arch Surgery* 2009;144(6):567–74.

EDITOR'S COMMENT

Dr. Grant has written an exceptional chapter on the surgical anatomy of the thyroid, parathyroid, and the adrenal gland. New in this addition of the chapter are some special considerations that highlight some very contemporary and evolving issues in the field of Endocrine Surgery. Endocrine Surgery as a defined surgical specialty has exploded in popularity over the past 20 years. It continues to amaze me that there are so many innovations and advances that have occurred recently in a field so focused on three very small endocrine

organs. The number of endocrine procedures being performed in the United States has been steadily increasing. In 2004, there were 80,505 endocrine surgery cases performed representing a 25% increase at the time in a span of 4 years. It has been estimated that 98,000 to 174,000 procedures will be performed annually by 2020. The steady increase in volume is attributable to improved imaging modalities, a rise in minimally invasive techniques and technologies, and an evolving understanding of the indications for surgery and the ramifications of leaving conditions like hyperparathyroidism undertreated.

High-volume endocrine surgeons are performing a large proportion of these surgical procedures, as are otolaryngologists. Unfortunately, the operative experience of endocrine surgery cases in a general surgical residency may not be adequate to properly prepare general surgeons to make endocrine surgery a routine part of their practice after training. This has contributed to the increase in endocrine surgery fellowship trained surgeons in recent years. A recent survey queried department chairs and determined that the average number of endocrine surgeons in their department increased from 1.3 to 2.2 over a 10-year period. A recognized endocrine surgery section exists in about half of all departments, and 39% of department chairs felt a likely need to recruit another endocrine surgeon in the next 2 years when this study was published in 2013. This is important because a clear volume outcome relationship has been demonstrated for endocrine surgical procedures in multiple studies. A review of the Nationwide Inpatient Sample over the years 2003–2009 stratified surgeons into low-, intermediate-, and high-volume categories for adrenalectomies. Surgeries performed by low-volume surgeons were associated with a higher risk of postoperative complications. Costs were greater for low-volume surgeons as well. An analysis from the same data source on thyroidectomy revealed that thyroidectomy procedures performed by low-volume surgeons were associated with a higher risk of postoperative complications compared with high-volume surgeons and that mean hospital cost was significantly associated with surgeon volume. Another meta-analysis showed that patients who received thyroidectomies performed by high-volume hospitals and surgeons had shorter length of stay and lower costs compared with those treated by low-volume hospitals and surgeons. In addition, in-hospital survival rates were better in patients treated by high-volume surgeons. A larger cross-sectional study using the NIS to examine thyroidectomy revealed a significant increase in cases during 2001–2008 compared to 1993–2000. The proportion of procedures performed for thyroid cancer increased from 28% to 34%. Cases performed by high-volume surgeons increased from 12% to 25% whereas cases performed by very–low-volume surgeons decreased from 51% to 34%. Review of practice patterns and outcomes revealed that high-volume surgeons were significantly more likely to perform total thyroidectomy and had a lower incidence of recurrent laryngeal nerve injury, hypocalcemia, and in-hospital death.

Dr. Grant discussed the evolving trend of outpatient or same-day thyroidectomy in his chapter. To investigate the practice patterns and outcomes

for same-day thyroidectomy in New York State, investigators recently turned to the 2004 New York State Inpatient and ambulatory surgery databases. A total of 6,762 thyroidectomies were identified; 17% were same-day thyroidectomies. Patients undergoing same-day surgery compared to thyroidectomy with admission were more often white, with private insurance and fewer comorbid medical conditions. Same-day surgery was performed more often by high-volume surgeons and at high-volume hospitals. Rehospitalization rates were similar for both approaches. In multivariate analysis, thyroidectomy by a high-volume surgeon was associated with a higher chance of same-day discharge. The authors conclude that there seem to be a few high-volume surgeons and centers with extensive same-day thyroidectomy experience, and that "*more research is needed to explore optimized patient triage and patterns of referral to centers of excellence*." As Dr. Grant discusses in his chapter, this is a controversial practice that should be selectively applied. In the current era of Milliman guidelines as well as payer and hospital pressure to convert procedures to outpatient and move them to low-cost ambulatory surgery centers, surgeons need to be acutely aware of the potential drawbacks to this approach.

Minimally invasive endocrine surgery is discussed at length in this chapter. Robotic thyroidectomy is not described in great detail however. The robotic approach to thyroid resection was pioneered in South Korea, primarily out of a desire to avoid a neck incision. In 2009, Intuitive Surgical began promoting the da Vinci robotic surgical system for use in thyroid surgery in the United States. In October 2011, the company announced in that it would withdraw promotion, training, and support in reaction to reports of complications and concern about whether Intuitive had received appropriate FDA approval for use of the device in thyroid surgery. Robotic thyroid surgery has not as of yet caught on in the United States, accounting for less than 1% of all thyroidectomies. Most of the published outcomes literature on this topic is from Asia. A recently published systematic review and meta-analysis of robotic thyroidectomy included 5,200 cases from 23 publications. Robotic thyroidectomy was associated with equivalent adverse event and complication rates. The "completeness" of surgical resection was also equivalent. Robotic thyroidectomy was demonstrated to be associated with less blood loss, fewer retrieved nodes, and better cosmetic satisfaction. In contrast, open thyroidectomy was associated with shorter operative time. The authors of this systematic review conclude "*robotic thyroidectomy is as safe as open thyroidectomy for the treatment of thyroid cancer. Based on the long-time follow-up and surgical completeness, the adverse events and complications, and recurrence rate of robotic thyroidectomy were comparable with open thyroidectomy.*"

An American Thyroid Association Statement on Remote-Access Thyroid Surgery sought to develop a simple classification of these approaches to thyroidectomy that are designed to avoid a neck incision, to describe the optimal patient selection criteria, to evaluate the outcomes objectively, and to define the barriers to adoption. Remote-access thyroid procedures can be

categorized into endoscopic or robotic. Approaches can include breast, bilateral axillo-breast, axillary, and facelift approaches. The experience in the United States involves the latter two techniques. Expert consensus was that in appropriate hands remote access thyroidectomy could be a viable option for patients with unilateral small nodules who wish to avoid a neck incision. "*These approaches require an additional level of expertise, and therefore should be done by surgeons performing a high volume of thyroid and robotic surgery.*"

A thorough understanding of the surgical anatomy described in this chapter is essential for surgeons who perform these operations. In the case of the thyroid and parathyroid, the critical anatomy is packed into a very small area and the potential for patient morbidity in surgeons who do not understand the nuances is high.

Jon C. Gould

Suggested Readings

Al-Qurayshi Z, Robins R, Buell J, et al. Surgeon volume impact on outcomes and cost of adrenal surgeries. *Eur J Surg Oncol* 2016;42(10):1483–90.

Al-Qurayshi Z, Robins R, Hauch A, et al. Association of surgeon volume with outcomes and cost savings following thyroidectomy: a national forecast. *JAMA Otolaryngol Head Neck Surg* 2016;142(1):32–9.

Berber E, Bernet V, Fahey T, et al. American thyroid association statement on remote-access thyroid surgery. *Thyroid* 2016;26(3):331–7.

Hinson A, Kandil E, O'Brien S, et al. Trends in robotic thyroid surgery in the United States from 2009 to 2013. *Thyroid* 2015;25(8):919–26.

Liang T, Liu S, Mok K, et al. Associations of volume and thyroidectomy outcomes: a nationwide study with systematic review and meta-analysis. *Otolaryngol Head Neck Surg* 2016;155(1):65–75.

Loyo M, Tufano R, Gourin C. National trends in thyroid surgery and the effect of volume on short-term outcomes. *Laryngoscope* 2013;123(8):2056–63.

Pan J, Zhou H, Zhao XX, et al. Robotic thyroidectomy versus conventional open thyroidectomy for thyroid cancer: a systematic review and meta-analysis. *Surg Endosc* 2017. doi: 10.1007/s00464–017–5433–0. [Epub ahead of print]

Shin J, Milas M, Mitchell J, et al. The endocrine surgery job market: a survey of fellows, department chairs, and surgery recruiters. *J Surg Educ* 2013;70(3):377–83.

Sosa J, Wang T, Yeo H, et al. The maturation of a specialty: workforce projections for endocrine surgery. *Surgery* 2007;142(6):876–83.

Tuggle C, Roman S, Udelsman R, et al. Same-day thyroidectomy: a review of

practice patterns and outcomes for 1,168 procedures in New York State. *Ann Surg Oncol* 2011;18(4):1035–40.

Zarebczan B, Rajamanickam V, Leverson G, et al. Training our future endocrine surgeons: a look at the endocrine surgery operative experience of U.S. Surgical residents. *Surgery* 2010;148(6):1075–81.

39 Biopsy, Lobectomy, Total Thyroidectomy, and Lymph Node Dissection for Thyroid Cancer

Randall Scheri, Sanziana Roman, and Julie Ann Sosa

ETIOLOGY AND PATHOPHYSIOLOGY

Patients may be seen in the surgery clinic for the evaluation of either structural (nodule, goiter, or malignancy) or functional (Graves' disease, toxic adenoma, or toxic multinodular goiter) thyroid disease. Thyroid nodules are very common and are present in approximately 50% of patients on screening ultrasound or autopsy studies. The overwhelming majority of thyroid nodules are benign and include colloid nodules, pseudonodules of thyroiditis, follicular, and Hürthle cell adenomas. However, thyroid cancer is the fastest increasing cancer in American men and women, with an incidence that has risen approximately 270% over the last three decades; malignant diagnoses include papillary, follicular, Hürthle cell, medullary and anaplastic thyroid cancers, primary thyroid lymphoma or (rarely) metastases to the thyroid, typically from breast, lung, or kidney primaries.

The etiology of benign nodules is unknown, but risk factors have been identified, including female gender, increasing age, and pre-existing thyroiditis. Thyroid goiters are described as endemic or nonendemic. Endemic goiters are secondary to iodine insufficiency. The etiology of nonendemic goiter is unknown; however, dietary and other environmental factors have been implicated. Family history of thyroid disease and radiation exposure particularly in childhood and adolescence from either therapeutic external beam radiation or environmental sources is well-established risk factors for papillary and anaplastic thyroid cancers. The thyroid cancer genetic analysis for well-differentiated thyroid cancer has identified BRAF, RAS, RET, NTRK1, and PAX8-PPAR mutations as potential driver mutations for thyroid cancer. Germline mutations responsible for familial thyroid cancer syndromes also have been identified. The RET proto-oncogene is responsible for multiple endocrine

neoplasia type 2 (MEN2A and B) syndrome and familial medullary thyroid cancer, conferring a nearly 100% risk of developing medullary thyroid cancer. The PTEN mutation is responsible for Cowden's syndrome, which is associated with a higher risk of nodular thyroid disease, follicular and papillary thyroid carcinomas. Adenomatous polyposis coli (APC) mutation is responsible for familial adenomatous polyposis, which is associated with a higher risk of developing the cribriform variant of papillary thyroid cancer.

Graves' disease is an autoimmune disease of the thyroid that is marked by the development of thyroid-stimulating hormone receptor antibodies (TRAb) that stimulate thyroid hormone synthesis and thyroid growth leading to hyperthyroidism. In addition to hyperthyroidism, patients with Graves' disease may experience ophthalmopathy, with periorbital edema and exophthalmos, as well as infiltrative dermopathy with pretibial myxedema. These features are also thought to be secondary to the TRAb. Risk factors for Graves' disease include a family history, female gender, patient age <40 years, and a history of autoimmune disease, pregnancy, and/or smoking. Toxic adenoma and toxic multinodular goiter are caused by hyperplasia of thyroid follicular cells that have become autonomous and are no longer regulated by thyroid-stimulating hormone (TSH).

CLINICAL PRESENTATION

History

A detailed patient history should evaluate for symptoms of hyper- and hypothyroidism, risk factors for thyroid cancer, family history of thyroid disease or other abnormalities of the adrenal, pancreas, pituitary, and parathyroid glands, and symptoms of local compression in the anterior neck. Symptoms of hyperthyroidism include weight loss, hair loss, anxiety, heat intolerance, palpitations, and increased frequency of bowel movements. Symptoms of hypothyroidism include weight gain, fatigue, cold intolerance, and constipation. Many patients with a thyroid nodule or thyroid cancer are asymptomatic, and the nodule is identified on physical exam or incidentally after radiologic imaging conducted for another indication. Risk factors for thyroid cancer include radiation exposure (for papillary and anaplastic thyroid cancers), a family history of thyroid cancer, or history concerning for a familial thyroid cancer syndrome, such as MEN 2. Symptoms of local compression, including a globus sensation, dysphagia, dysphonia, or dyspnea, can be related to large goiters or

nodules that compress surrounding structures. In the setting of a known or suspected cancer, these symptoms are concerning for locally advanced disease and should raise concern for invasion into surrounding structures. The rapid onset of symptoms or nodule growth is concerning for an aggressive, malignant disease process, such as primary thyroid lymphoma or anaplastic thyroid cancer. Pain over the thyroid is most likely related to thyroiditis, but an aggressive malignancy also should be on the differential.

Physical Examination

Physical examination should include a focused exam of the neck, including the thyroid and cervical lymph nodes. The thyroid gland is best palpated by standing behind the patient and asking the patient to swallow from a glass of water. The thyroid moves with swallowing, facilitating palpation of subtle thyroid nodules. Substernal extension of a goiter should be suspected if the inferior aspect of the thyroid gland cannot be defined, or there is a positive Pemberton's sign (facial congestion and respiratory distress with elevation of both arms above the head). Firm nodules and those with irregular borders are concerning for malignancy. Fixed nodules are concerning for a locally advanced malignancy, and enlarged lymph nodes are suspicious for metastases. The patient should also be evaluated for signs of hyper- and hypothyroidism. Signs of hyperthyroidism include tachycardia, tremor/tremulousness, muscle weakness, orbital edema, and exophthalmos. Signs of hypothyroidism include dry skin, coarse hair, and nonpitting edema.

SURGICAL INDICATIONS AND CONTRAINDICATIONS

Indications for thyroid surgery include indeterminate thyroid nodules, thyroid cancer, symptomatic nodules or goiters, Graves' disease, toxic adenoma, and toxic multinodular goiter. A TSH should be obtained to screen all patients for hyperthyroidism. For patients with hyperthyroidism, a thyroid uptake scan can be obtained to determine the etiology. Patients with Graves' disease will have diffuse increased uptake within the thyroid, while a toxic adenoma will demonstrate a solitary focus of increased uptake, with suppression of the remainder of the gland, and a toxic multinodular goiter will have increased uptake that is heterogeneous. Thyroid scan is not indicated for patients who are euthyroid. Thyroid ultrasound should be performed for all patients with a suspected nodule or goiter identified on physical exam or incidentally noted on other radiologic

imaging modality. Sonographic features of thyroid nodules that are suspicious for malignancy include microcalcifications, hypoechoic appearance, irregular margins, taller than wide nodule shape, rim calcifications with extrusive component, and evidence of extrathyroidal extension. Fine-needle aspiration (FNA) biopsy under ultrasound guidance is the procedure of choice for the evaluation of thyroid nodules and selection of patients who should undergo diagnostic or therapeutic surgery for a suspected or confirmed thyroid cancer.

FNA is a safe procedure that easily can be performed in the outpatient clinic. Ultrasound guidance is essential for nonpalpable nodules and is preferred in general because it improves accuracy and reduces the rate of nondiagnostic cytology. The patient is placed in a supine position with a pillow placed beneath the shoulder to slightly extend the neck (Fig. 39.1). The skin is prepped with an alcohol-based solution and the area is draped. A high-resolution (7.5 to 15 MHz) transducer is placed in a sterile cover and used for ultrasound. The nodule to be biopsied is identified with ultrasound, and 1% lidocaine is injected into the skin and subcutaneous tissue of the planned biopsy site. The transducer is placed directly over the nodule with the nondominant hand. Using the dominant hand, a 23- or 25-gauge needle with an attached 10 mL syringe is placed next to the transducer and advanced into the nodule perpendicular to the plane of the transducer. Once the needle is identified within the nodule, the FNA is performed using an aspiration or nonaspiration technique. The nonaspiration technique is preferred because it is less bloody. Using this method, the needle is moved back and forth within the nodule while rotating the needle on its axis until material is noted within the needle hub. For the aspiration technique, the needle is placed into various areas of the nodule and moved back and forth with suction applied; suction is released before the needle leaves the nodule. For cystic lesions, the aspirated fluid is sent for cytology, and repeat ultrasound is performed to evaluate for a solid component which, if present, should be aspirated. After the biopsy is completed, pressure is placed on the puncture site for 5 minutes, and a dressing is applied.

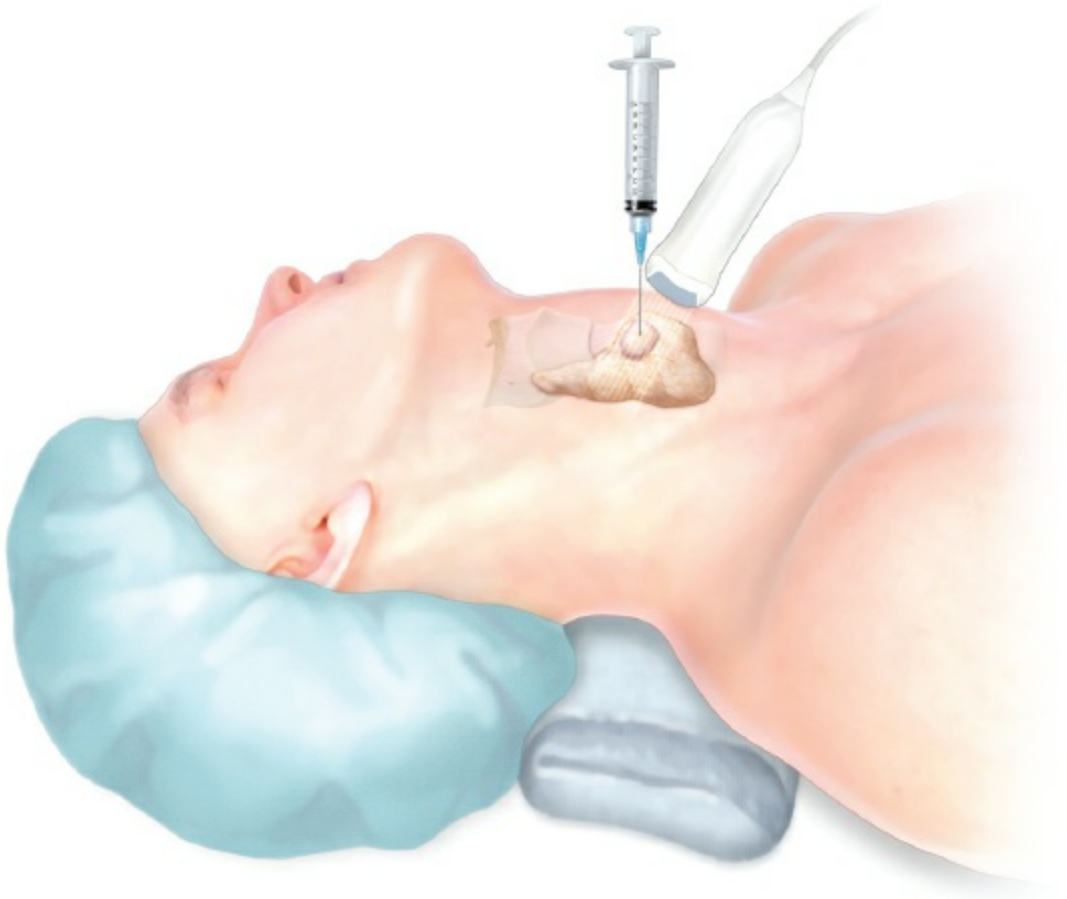

Figure 39.1. FNA biopsy with neck extended, nondominant hand holding ultrasound probe, and needle in dominant hand.

After the FNA is performed, the needle is detached from the syringe and reattached after the syringe is filled with air so that the needle contents can be expelled onto a glass microscope slide. A second slide is placed on top of the slide with the cellular contents, and the slides are pulled in opposite directions, thus creating two slides for evaluation. The slides can be placed in 95% ethyl alcohol or sprayed with fixative for Papanicolaou staining or air-dried for Giemsa staining. The specimen should be evaluated for adequate cellularity (if possible in the ultrasound suite in order to avoid the need for the patient to undergo a second ultrasound in the setting of an inadequate collection), and repeat FNA should be performed if the specimen is deemed to be inadequate. Typically, at least three passes are required. Complications from FNA are rare and primarily limited to bleeding or hematoma formation.

The results of the FNA should be reported using the Bethesda criteria. The possible results of FNA include a specimen that is nondiagnostic (Bethesda category I) for 2% to 3% of nodules, benign (Bethesda category

II) for 70% of nodules, indeterminate (Bethesda category II to V) for 20% to 25% of nodules, and malignant (Bethesda category VI) for 5% of nodules. A repeat FNA should be performed for nondiagnostic nodules. The cytologic results of the FNA guide therapy and surgical management for nodular disease.

Indeterminate and Benign FNA (Bethesda Criteria I and II)

Benign thyroid nodules do not typically require surgical resection unless they are symptomatic with associated symptoms of compression, or associated with hyperthyroidism. Asymptomatic benign nodules should be followed with serial ultrasound to evaluate for nodule growth. If the nodule increases in size significantly (2 mm in 2+ dimensions, or 50% increase in nodule volume), FNA should be repeated. Surgical resection of benign nodules is recommended if the nodules are symptomatic due to compressive symptoms, such as dysphagia or dyspnea, or for cosmetic reasons in the setting of very large nodules and patient preference. Surgery also should be considered for large thyroid nodules because FNA may be less accurate due to the greater potential for "sampling error." Several studies have shown that nodules >4 cm have a 10% to 15% risk of malignancy on final pathology after surgical resection. For nodules that have nondiagnostic cytology (Bethesda criteria I) after two biopsies, a diagnostic thyroid lobectomy should be done, as the risk of malignancy is similar to that of indeterminate nodules.

Suspicious or Indeterminate FNA (Bethesda Criteria III–V)

Indeterminate nodules are reported as follicular/Hürthle cell neoplasm or suspicious for follicular/Hürthle cell neoplasm (Bethesda category IV) or follicular/Hürthle cell lesion of undetermined significance or atypia of undetermined significance (Bethesda category III). Approximately 15% to 30% of FNAs that are reported as follicular neoplasm/suspicious for follicular neoplasm are follicular thyroid carcinomas or the follicular variant of papillary thyroid cancer (FVPTC). The FVPTC is more common than follicular thyroid cancer and is associated with a better prognosis. The encapsulated FVPTC is especially associated with an excellent prognosis, with a very low risk of metastases or recurrence. The diagnosis of follicular thyroid cancer is based on capsular or vascular invasion, so a final histologic diagnosis cannot be predicted by cytology alone, while the FVPTC has follicular architecture and cytologic features of papillary

thyroid cancer, sometimes permitting a diagnosis of malignancy based on cytology. The likelihood of follicular thyroid cancer versus FVPTC can be predicted based on patient and tumor characteristics. Follicular thyroid cancer is more likely in elderly male patients with large tumors. Patients with nodules suspicious for follicular thyroid cancer should be treated with a diagnostic lobectomy without frozen section, which is not helpful since it cannot assess well for capsular and vascular invasion, which are characteristics that separate benign from malignant follicular neoplasms; however, for patients likely to have a FVPTC, intraoperative assessment with frozen section/touch prep cytology may confirm malignancy, allowing a single stage thyroidectomy. A completion thyroidectomy would be indicated if final pathology revealed a follicular cancer/FVPTC with intermediate- or high-risk features. The completion thyroidectomy should be done either within 2 weeks of the initial surgery or after 2 to 3 months from the original surgery to avoid the worst inflammation and scar tissue. While surgery with a diagnostic lobectomy is the “gold-standard” for indeterminate nodules, molecular testing may be used to further differentiate these nodules into those that are likely malignant and should have surgery and those that are likely benign and can be safely observed. The ultrasound characteristics of the nodule, patient history and physical exam findings, and patient preference all should be taken into consideration when deciding whether to obtain molecular testing, and the type of molecular test to use. Two distinct types of molecular testing are available and can be classified as either a “rule out” or a “rule in” test. Molecular testing with the Afirma gene expression classifier (GEC) has been shown to effectively “rule out” malignancy. For negative test results on the Afirma GEC, the risk of malignancy is similar to that of a benign nodule, thereby potentially avoiding the need for diagnostic surgery. For results deemed to be “suspicious” on the GEC, the risk of malignancy is reported to be approximately 40%, so these patients frequently go on to a diagnostic thyroid lobectomy. It is important to note that long-term results have not been published demonstrating durability of the “benign” GEC result in thyroid nodules that have been surveilled. The “rule-in” test evaluates for a panel of somatic mutations and rearrangements. A commercially available 7 gene panel (BRAF V600E, BRAF K601E, KRAS, NRAS, HRAS, RET/PTC, PAX8/PPARG) is available which is highly specific, but lacks sensitivity to rule out thyroid cancer. If a mutation is identified, there is a high likelihood of malignancy (100%

BRAF or RET/PTC and 85% BRAF K601E, RAS or PAX8/PPARG), and definitive surgery should be performed. A diagnostic lobectomy can still be performed for a negative test, since malignancy is not excluded with the same confidence. Newer versions of the “rule in” test with a larger gene panel have been developed with a reported improved sensitivity and specificity, but additional validation studies are necessary. In the end, patients should be counseled about the strengths and weaknesses of molecular testing, as patient preference is critical in decision making regarding its use in specific cases.

An FNA revealing a Hürthle cell neoplasm/suspicious for Hürthle cell neoplasm implies a 15% to 45% risk of malignancy. Similar to follicular neoplasms, the diagnosis of malignancy is based on capsular or vascular invasion, such that cytology cannot reliably distinguish malignant from benign tumors. Accordingly, Hürthle cell neoplasms are treated similarly to follicular neoplasms, with a diagnostic thyroid lobectomy without frozen section analysis followed by completion thyroidectomy if an intermediate- or high-risk malignancy is found on final pathology. Unlike follicular neoplasms, large Hürthle cell neoplasms are more likely to be malignant than small Hürthle cell neoplasms, particularly in elderly patients. The risk of malignancy for tumors >4 cm exceeds 50%, so an upfront total thyroidectomy is often recommended for these large tumors. Molecular testing also may be employed for these nodules, but appears to be less effective than for follicular neoplasms.

A 5% to 15% risk of malignancy is implied when an FNA reveals a follicular/Hürthle cell lesion of undetermined significance or atypia of undetermined significance (Bethesda category III). For these patients, a repeat FNA with/without molecular testing or upfront diagnostic lobectomy is recommended. Upfront lobectomy should be considered for nodules with concerning imaging features or based on patient preference. If a repeat FNA is performed, recommendations are based on these results. Thyroid lobectomy is recommended for repeat indeterminate cytology or positive (“suspicious”) molecular testing. Alternatively, for patients with small nodules with indeterminate cytology that do not have suspicious ultrasound features, surveillance with serial ultrasound may be reasonable.

A nodule suspicious for papillary thyroid cancer (Bethesda category V) implies a 60% to 75% risk of malignancy; however, this may vary between institutions. Due to the high risk of malignancy, these patients may be treated similarly to patients with FNA diagnostic for papillary thyroid

cancer and have upfront thyroidectomy for any clinical or patient features that may indicate an intermediate- or high-risk tumor. A thyroid lobectomy may be planned as the definitive operation for patients with suspicious nodules anticipated to be at a low risk of malignancy. Alternatively, a diagnostic lobectomy with frozen section and touch prep analysis may be performed. If frozen section is positive for papillary thyroid cancer (which is typically a cytologic diagnosis), a total thyroidectomy can be performed during the same operation. If the intraoperative assessment is indeterminate, the operation should be terminated, and final recommendations for completion thyroidectomy are made based on permanent pathology.

Malignant FNA (Bethesda Category VI)

Patients with an FNA diagnostic of papillary thyroid cancer should be treated with either thyroid lobectomy or total thyroidectomy. The 2015 American Thyroid Association (ATA) guidelines for thyroid nodules and differentiated thyroid cancer recommend an individualized approach, taking into consideration patient and tumor characteristics and surgeon experience to determine the extent of surgery. Patients with intermediate- or high-risk tumors (including extrathyroidal extension/locally advanced disease, tumors >4 cm, multifocality, aggressive histologies, vascular invasion, nodal and distant metastatic disease) and patient-specific factors (e.g., history of familial thyroid cancer and head and neck irradiation) should be treated with total thyroidectomy to facilitate radioactive iodine treatment and close surveillance due to higher risk of recurrence. Tumors that are at low risk of recurrence and do not require treatment with radioactive iodine may be treated with thyroid lobectomy or total thyroidectomy. This recommendation is based on recent studies by our group and others showing that patients with 1 to 4 cm tumors have equivalent overall survival following either lobectomy or total thyroidectomy. Contralateral thyroid nodules, a history of cervical radiation exposure, family history of thyroid cancer, and patient choice may be criteria used to justify total thyroidectomy. Unifocal tumors <1 cm should be treated with thyroid lobectomy except if there is a history of cervical radiation, a family history of thyroid cancer, evidence of extrathyroidal extension, lymph node/distant metastases, or clear indications to remove the contralateral lobe. Emerging evidence suggests that surveillance with serial ultrasound might represent a nonoperative

alternative for a subset of patients with tumors <1 cm who are at low risk of developing tumor progression. A therapeutic level VI compartmental central lymph node dissection should be performed for patients when abnormal central lymph nodes are identified during surgery or preoperatively on physician examination, ultrasound, or other radiologic imaging. A prophylactic central compartment (level VI) lymph node dissection can be considered for high-risk tumors (T3, T4), clinically involved lateral compartment lymph nodes, or if the information would be helpful to plan further therapy. If suspicious lateral compartment cervical lymph nodes are identified, an ultrasound-guided FNA should be performed, and if it is positive for malignancy, a selective lateral compartment lymph node dissection of levels IIA, III, IV, and VB should be performed (Fig. 39.2).

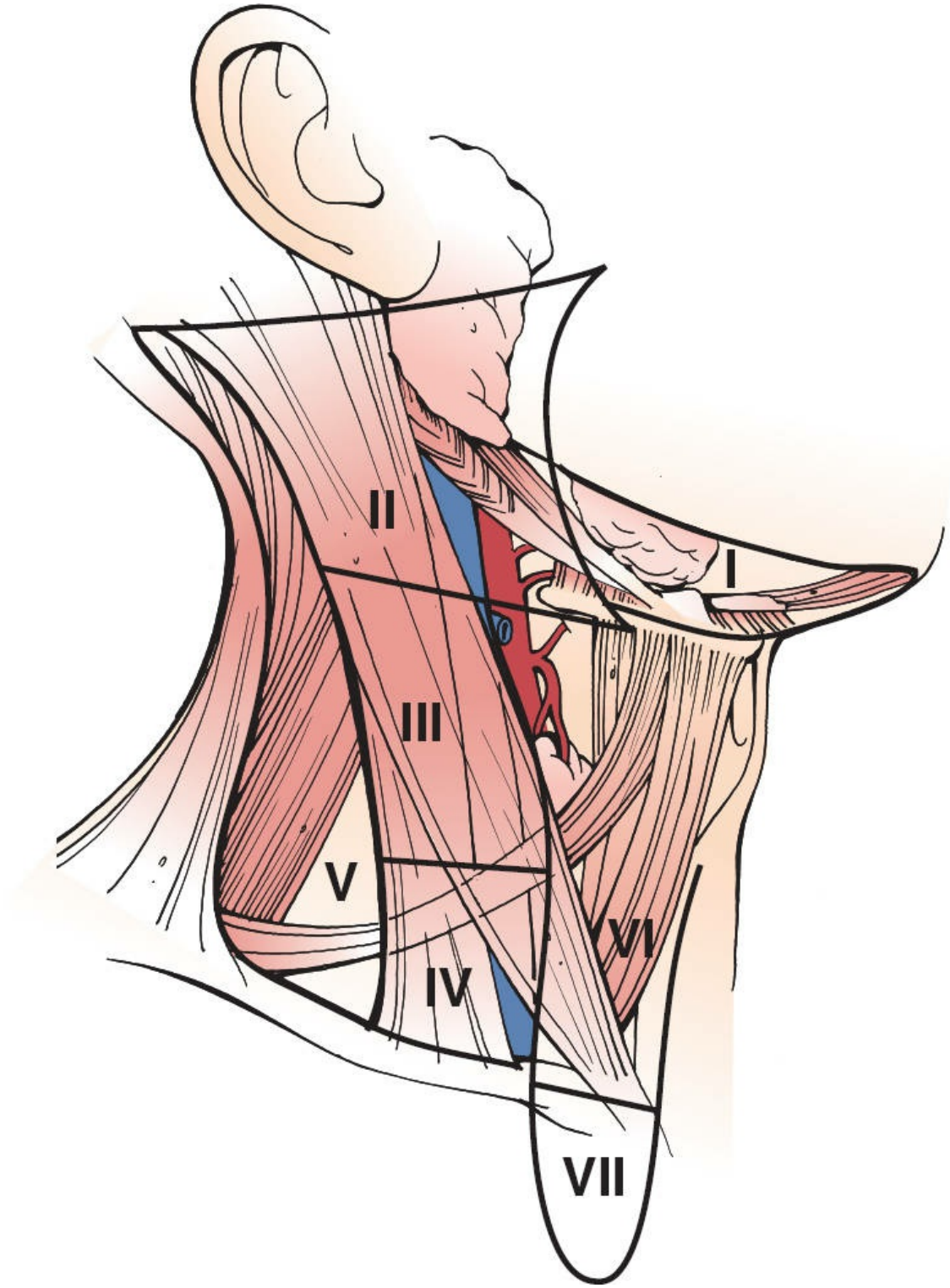

Figure 39.2. Nodal levels and their numbered compartments in the neck (I to VII).

Patients with an FNA diagnostic for medullary thyroid cancer should be treated with a total thyroidectomy and bilateral level VI central compartment lymph node dissection due to the frequency of lymph node metastases and the lack of effective adjuvant treatment. A selective lateral

compartment (levels II to V) should be performed for biopsy-proven lymph node metastases. The role of prophylactic lateral compartment lymph node dissection for patients with elevated calcitonin levels is controversial and is neither recommended for nor against by the 2015 ATA medullary thyroid cancer guidelines.

Patients with an FNA diagnostic for anaplastic thyroid cancer are usually not treated with surgery. They typically present with primary tumors that are locally advanced with/out extensive distant metastases and are treated with chemotherapy and external beam radiation. On rare occasions, anaplastic thyroid cancer is localized to the thyroid gland without local invasion or distant metastases (Stage IVA disease), such that thyroidectomy can be performed prior to chemotherapy and external beam radiation. Also, thyroidectomy can be performed to optimize local disease control in the setting of distant metastases if it may be accomplished with minimal morbidity and would not delay further treatment.

Primary thyroid lymphoma is uncommon but should be suspected with a rapidly expanding thyroid mass/goiter. The majority of these tumors are diffuse B-cell non-Hodgkin lymphomas. Symptoms of dysphagia, dyspnea, dysphonia, neck pain, and facial edema are common. Some patients may have systemic symptoms of lymphoma, including fever, night sweats, and weight loss. On physical exam, the thyroid is typically enlarged, firm, fixed, and may be tender to palpation; cervical lymphadenopathy is common. If primary thyroid lymphoma is suspected, FNA with flow cytometry should be performed to obtain a diagnosis. If FNA is nondiagnostic but suggestive of lymphoma or the clinical suspicion for lymphoma is high, a core biopsy is recommended to obtain sufficient tissue to confirm the diagnosis. Multiple core biopsies may be required if extensive tumor necrosis is present. An excisional biopsy is rarely necessary. Primary thyroid lymphoma is typically treated with chemotherapy and radiation; thyroidectomy is not recommended.

Hyperthyroidism

Hyperthyroidism can be treated with medication (thionamides), radioactive iodine, or surgery. The decision for the treatment should be individualized based on patient factors, disease process, and patient preference. Patients treated with thionamides should be reconsidered for radioactive iodine or surgery if hyperthyroidism persists after treatment for 12 to 18 months. In the special situation when hyperthyroidism is diagnosed during pregnancy,

thionamides are recommended (propylthiouracil 1st trimester, methimazole thereafter). Radioactive iodine is contraindicated, and surgery is only recommended for patients who fail medical management. In the United States, the majority of patients with Graves' disease are treated with radioactive iodine. However, surgery is the preferred treatment of some patients. Surgery is recommended for children, pregnant patients, nodules concerning or diagnostic of cancer, symptomatic or large goiters (>80 g), moderate-to-severe Graves' ophthalmopathy, or patient preference. Toxic multinodular goiter (Plummer's disease) may be treated with surgery or radioactive iodine. Surgery is recommended for patients with large goiters, evidence of low radioactive iodine uptake on thyroid scan, concern for malignancy, or patient choice. Total thyroidectomy is the surgical procedure of choice for Graves' and Plummer's disease because subtotal thyroidectomy is associated with a higher risk of recurrence with similar surgical morbidity. A toxic adenoma may be treated with radioactive iodine or an ipsilateral thyroid lobectomy. Both methods are effective; however, thyroid lobectomy offers rapid control of the hyperthyroidism and a lower recurrence rate than radioactive iodine.

Multinodular Goiter

Surgery is recommended for goiters that are symptomatic due to local compression, concern for malignancy, or for cosmetic reasons. Large goiters can compress the trachea and esophagus, leading to dyspnea or dysphagia. FNA of thyroid nodules may be indeterminate for malignancy, or innumerable nodules may be present that meet the criteria for biopsy, such that despite benign FNA of the most suspicious nodules, the patient or clinician may prefer surgery rather than undergo frequent/repeat FNAs indefinitely. Thyroidectomy also should be considered for mediastinal extension due to an inability to definitively rule out malignancy or since the mediastinal component may increase in size over time, making cervical excision more difficult; this would be a particular concern in a younger patient. Lastly, patients may be concerned about the cosmetic appearance of large goiters and elect for surgery.

Remedial Thyroid Surgery

Remedial thyroid surgery may be required for recurrent goiter, Graves' disease, or thyroid cancer. Prior medical records including operative reports and pathology slides should be obtained and carefully reviewed.

For patients with thyroid cancer, recurrence should be confirmed with FNA, and the extent of disease evaluated with imaging prior to initiating treatment. The decision for surgery is best derived after multidisciplinary evaluation, taking into consideration extent of disease and risk of complication, patient preference, and surgeon experience. Even in experienced hands, the risk of complication is significantly higher with remedial surgery. The majority of patients with thyroid cancer develop recurrence within regional cervical lymph nodes which are best treated with compartment-oriented central or lateral compartment lymph node dissection to remove all cervical disease. For patients with a prior compartment-oriented dissection by an experienced surgeon, a more selective approach using intraoperative ultrasound or wire localization of the disease may be used. Observation for patients with low volume disease is another option, especially in a reoperative field. For patients with distant metastases, surgical resection may be considered to protect the airway or facilitate radioactive iodine treatment directed to the extracervical disease. Prior to surgery, laryngoscopy and imaging with cervical ultrasound and selective use of CT are recommended to facilitate surgical planning and inform risk stratification. For patients who are not operative candidates due to medical comorbidities, high-risk disease location or a challenging reoperative field may be treated with radioactive iodine (if still iodine avid), ethanol ablation, radio frequency ablation, external beam radiation, or systemic therapy with tyrosine kinase inhibitors.

Contraindications

There are few contraindications to thyroid surgery, as long as the patient's overall health does not preclude general anesthesia. Surgery is not recommended for primary thyroid lymphoma and should be performed selectively for patients with anaplastic thyroid cancer when it can be performed with acceptable patient morbidity, as noted above. For differentiated thyroid cancer or medullary thyroid cancer, extensive invasion into the trachea, larynx, or esophagus is a relative contraindication for surgery, particularly in the setting of distant metastases. A limited resection of the trachea is well tolerated, and a more extensive resection to remove all disease in a young healthy patient may be warranted. Tumor involvement of the carotid artery or bilateral internal jugular veins is unresectable, while unilateral sacrifice of an internal jugular vein generally can be accomplished safely. The decision for

surgery in these complicated patients is best made in a multidisciplinary team setting, taking into consideration the patient's overall health, extent of metastatic disease, extent of surgery with attendant morbidity, underlying pathology, and the patient's goals. Distant metastases are not an absolute contraindication to surgery; indeed, palliative debulking surgery might be recommended to protect the aerodigestive tract, and in well-differentiated thyroid cancer facilitates more efficient radioactive iodine treatment.

PREOPERATIVE PLANNING

Preoperative Testing

All patients should have a TSH drawn to evaluate thyroid function. A calcium level should be obtained to evaluate for hyperparathyroidism. If hyperparathyroidism is identified, parathyroidectomy should be performed at the same time as thyroid surgery. Patients with medullary thyroid cancer should have calcitonin and carcinoembryonic antigen (CEA) tumor markers drawn, as well as a rearranged during transfection (RET) proto-oncogene tested, since one quarter of incident cases of medullary thyroid cancer will be inherited. Patients with unknown or positive genetic testing should also have biochemical testing to rule out pheochromocytoma (plasma fractionated metanephrines or 24 hour urinary catecholamines and metanephrines), and primary hyperparathyroidism (serum calcium and intact parathyroid hormone [PTH] levels) prior to surgery. Calcitonin and CEA levels correlate well with volume and extent of disease and can provide important prognostic information. Patients with locally advanced medullary thyroid cancer or serum calcitonin levels >500 pg/mL should have cross-sectional imaging to evaluate for extracervical metastatic disease, including neck/chest CT, liver MRI, and bone scan.

If not already performed, all patients should have a dedicated thyroid ultrasound to determine the size of the thyroid gland, size, number, and appearance of thyroid nodules, and the association of the nodules to surrounding structures. The 2015 ATA guidelines for thyroid nodules and differentiated thyroid cancer stratify nodules into risk categories by sonographic appearance. High-risk nodules are hypoechoic solid or partially cystic nodules with a solid hypoechoic component with one or more of the following features: microcalcifications, irregular margins, taller than wide nodule shape, rim calcifications with extrusive component, and evidence of extrathyroidal extension. Nodules with these features have

a 70% to 90% risk of malignancy. Intermediate-risk nodules are hypoechoic without any of the suspicious features mentioned above and have a 10% to 20% risk of malignancy. Low-risk nodules are hyper- or isoechoic and partially cystic nodules without suspicious features; they have a 5% to 10% risk of malignancy. Very low-risk nodules are spongiform in appearance and have a <3% risk of malignancy; finally, purely cystic nodules have a <1% risk of malignancy. Lymph node mapping with ultrasound to evaluate for lymph node metastases in the central and lateral neck compartments should be performed for all patients with cytologic or molecular findings diagnostic or suspicious for thyroid cancer. FNA of any suspicious appearing (cystic, microcalcifications, round shape, or peripheral vascularity) or significantly enlarged lymph nodes should be performed to evaluate for metastatic disease. Thyroglobulin or calcitonin washout of the FNA aspirate can be done for indeterminate cytology in order to increase the accuracy of FNA for differentiated or medullary thyroid cancers, respectively. CT with contrast is recommended for patients with suspected locally advanced disease, including advanced primary tumors or bulky/extensive lymph node involvement, ultrasound findings revealing posterior extension of tumor, inferior extension of tumor or inability to visualize the inferior extent of the tumor, voice changes, or vocal cord paralysis. CT with intravenous contrast is useful to identify invasion into surrounding structures, including the trachea, larynx, esophagus, muscle, major vascular structures, including the carotid artery and internal jugular vein, and extension into the mediastinum. Preoperative identification of any of these findings would significantly alter the surgical plan. The iodinated contrast from CT scanning should not delay radioactive iodine treatment of patients with normal renal function, since the iodine should be cleared prior to planned treatment. If there is any concern, urinary iodine concentration can be measured to assess for adequate clearance.

The 2015 ATA guidelines for differentiated thyroid cancer recommend preoperative voice assessment for all patients prior to thyroid surgery by the patient and physician. All patients with subjective or objective voice changes, a prior history of cervical or chest surgery, or locally advanced cancer (particularly with posterior extension) should be evaluated with laryngoscopy to assess vocal cord function. A paralyzed vocal cord significantly increases the risk of surgery and may alter surgical planning. Surgery on the side contralateral to the paralyzed vocal cord should be

undertaken with extreme caution because the patient would be placed at risk of bilateral recurrent laryngeal nerve (RLN) injury and potential tracheostomy.

Hyperthyroidism

Prior to thyroidectomy, a euthyroid state needs to be restored in patients with hyperthyroidism in order to avoid increased risk of thyroid storm during surgery. Treatment with methimazole, a thionamide, can typically accomplish this within 4 to 6 weeks. Propylthiouracil is no longer recommended due to a higher risk of side effects, including fulminant hepatic failure, except during the first trimester of pregnancy due to birth defects associated with the use of methimazole by the mother during that time. Methimazole is usually started with a dose of 10 mg one to two times/day and tapered based on patient response. Beta blockers can be added to control symptoms of tachycardia and tremor. Thyroidectomy can be safely performed once the patient's free T3 and T4 levels are normal; the TSH level usually lags behind and does not need to be normal at the time of surgery. For Graves' disease, super saturated sodium iodine (SSKI) with two drops three times daily should be started 7 to 10 days prior to surgery to decrease the vascularity of the thyroid gland and facilitate thyroidectomy by reducing blood loss. Patients who do not tolerate or are resistant to thionamides or who require urgent surgery can be prepared for the operating room within 1 week using a combination or SSKI (five drops every 6 hours), corticosteroids (300 mg loading dose then 100 mgs every 8 hours), and beta blockers (60 to 80 mg propranolol every 4 hours).

Patients with Graves' disease are at higher risk of postoperative hypoparathyroidism and hypocalcemia. To avoid this complication, patients can be started on calcitriol 0.5 mcg twice/daily 3 days prior to surgery. Alkaline phosphatase and 25OH vitamin D levels are obtained for risk stratification. For patients that are severely vitamin D insufficient or deficient or who have an elevated alkaline phosphatase level, surgery may be delayed to permit repletion of vitamin D and stabilization of bone disease. Preoperative calcium supplementation with 1,000 mg three times/day for 2 weeks prior to surgery also has been shown to decrease the incidence of postoperative hypocalcemia.

Informed Consent

Thyroidectomy is a well-tolerated procedure with infrequent complications

when performed by an experienced (high-volume) surgeon. Complications include the risk of an injury to the RLN which may result in hoarseness, change in voice, and/or aspiration. A bilateral RLN injury can result in loss of the airway, stridor, and even the need for tracheostomy. Injury to the external branch of the superior laryngeal nerve injury can lead to the patient's inability to reach high pitch and decreased voice volume. In some patients, nerve injury can be occult. The risk of transient and permanent nerve injury/hoarseness is 5% and 1%, respectively, for high-volume thyroid surgeons, but on average appears to be significantly more frequent for low-volume surgeons. Hypoparathyroidism may occur following total thyroidectomy, but not lobectomy, since only two parathyroid glands are at risk of injury. The risk of transient and permanent hypoparathyroidism is 10% to 20% and 1% to 2%, respectively. Transient hypoparathyroidism usually resolves within 1 to 2 weeks, but may take longer for some patients. Postoperative bleeding and hematoma are rare complications (<1%); however, they can be life threatening, with a rapid loss of the airway. Wound infection or other wound complications are uncommon. Complications of lateral compartment neck dissection include injury to the vagus nerve causing hoarseness; phrenic nerve leading to dyspnea and a weak cough; sympathetic chain injury leading to Horner's syndrome; spinal accessory nerve leading to shoulder weakness; brachial plexus leading to hand and arm weakness; marginal branch of the facial nerve injury leading to asymmetric smile; great auricular nerve, ansa cervicalis, and cervical plexus injury leading to numbness of the ear, neck, face, and upper chest; and lymphatic leak and thoracic duct injury potentially necessitating drainage, amendment of diet, or even reoperation.

Lifelong thyroid hormone replacement is required after total thyroidectomy and may be required after thyroid lobectomy. Only about 20% to 30% of patients will require thyroid hormone replacement after thyroid lobectomy. Risk factors for developing hypothyroidism following lobectomy include a high normal TSH preoperatively, a heterogeneous gland on ultrasound imaging, and a history of thyroiditis.

Anticoagulants should be stopped prior to thyroidectomy to minimize the risk of postoperative hematoma. For patients who are at increased risk of thromboembolic events, anticoagulation should be bridged with an agent with a short half-life and started cautiously after surgery. Antiplatelet therapy including aspirin should be stopped if possible before surgery; however, for patients who are at higher risk of thrombosis, low

dose aspirin may be continued.

A single dose of intraoperative corticosteroids prior to the start of surgery can be given to decrease postoperative pain, nausea, and vomiting. It may also improve postoperative voice function; however, studies have shown conflicting results leading to no recommendation for or against its use by the American Academy of Otolaryngology guidelines to optimize voice quality after thyroid surgery.

SURGICAL TECHNIQUE

Thyroid Lobectomy and Total Thyroidectomy

General anesthesia is induced, and the patient is intubated. The patient is kept in a supine position and centered on the operating table. A shoulder roll is placed lengthwise between the shoulders to extend the neck and permit adequate exposure to the thyroid. It is important to ensure that the neck is not overextended which can lead to postoperative discomfort and a slight risk of spinal cord injury. Patients with known cervical spine disease may need to be evaluated by neurosurgery or orthopedic surgery prior to thyroidectomy. A gel head ring should be placed to secure the head. The arms are tucked at the patient's side, and all bony protuberances padded, including the elbows, to prevent a nerve injury. The bed is placed in a beach-chair (semi-Fowler) position to reduce venous pressure/distention within the neck and minimize bleeding. Sequential compression devices are used for deep venous thrombosis prophylaxis. Perioperative antibiotics are not required, since thyroidectomy is a clean procedure. The surgical field is prepped with a Betadine- or chlorhexidine-based solution, and sterile drapes are applied. A surgical headlight improves visualization through small-sized thyroidectomy incisions.

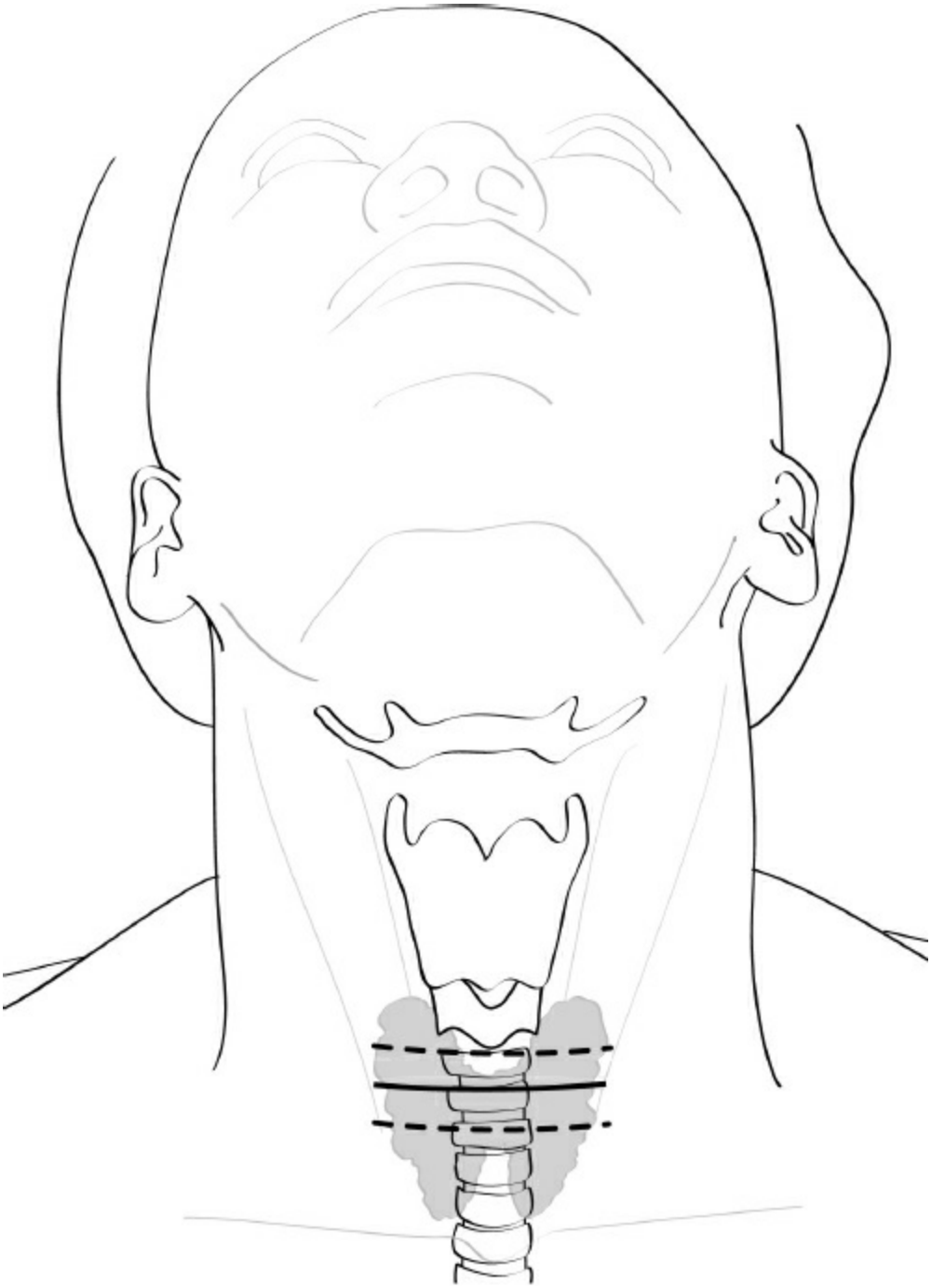

Figure 39.3. Site of incision in a skin fold about 1 cm below the cricoid. Surface anatomy with underlying anatomy shown to demonstrate why this location is optimal for thyroid surgery.

A slightly curved transverse incision is placed within a skin crease approximately 1 cm below the cricoid cartilage (Fig. 39.3). The length of the incision is based on the size of the thyroid gland, the patient's body habitus, and extent of surgery. A 3 to 4 cm incision is adequate for a normal-sized thyroid gland and small nodules. The incision should be created with a scalpel, deepened into the subcutaneous tissue and through

the platysma with electrocautery. Subplatysmal flaps are created using electrocautery. The superior flap is created by grasping the platysma and incising the natural bloodless plane posterior to the platysma and anterior to the anterior jugular veins and sternohyoid muscle (Fig. 39.4). The flap is extended to the thyroid cartilage. The inferior aspect of the platysma is grasped, and the inferior flap is created in a similar fashion in a caudal direction to the sternal notch. A self-retaining retractor can be placed to facilitate exposure (Fig. 39.5).

The sternohyoid muscles are separated in the midline raphe using electrocautery, exposing the anterior surface of the thyroid. The incision should be extended from the thyroid notch to the sternal notch to facilitate exposure. The ipsilateral strap muscles (sternothyroid and sternohyoid) are grasped, retracted laterally and dissected off the anterior aspect of the thyroid gland using blunt dissection with a Kitner or right angle clamp down to the level of the internal jugular vein along the entire length of the thyroid from the superior to inferior pole. If present, the middle thyroid vein is identified between the lateral aspect of the thyroid gland and internal jugular vein and divided between ties (Fig. 39.6). The strap muscles can be divided to provide additional exposure for large goiters. This should be done at the level of the cricoid cartilage to preserve the nerve supply, which enters inferiorly.

After thyroid exposure, the initial step is to divide the superior pole vessels in order to mobilize the superior thyroid pole. The superior thyroid pole is retracted in a lateral and inferior direction to facilitate exposure to the superior thyroid pole vessels. A retractor is used to retract the strap muscles laterally. Using a fine clamp, the cricothyroid space is opened, and the superior pole vessels are individually divided with either ties or a thermal sealing device close to the surface of the thyroid gland (Fig. 39.7) to prevent injury to the external branch of the superior laryngeal nerve. The nerve is very small and usually passes medially to the superior thyroid vessels; it can take a number of varied paths. Care should be taken not to injure the superior parathyroid gland, which may lie directly posterior to the superior thyroid pole. Thermal sealing devices have been shown to be safe and effective for thyroid surgery and may reduce operative time.

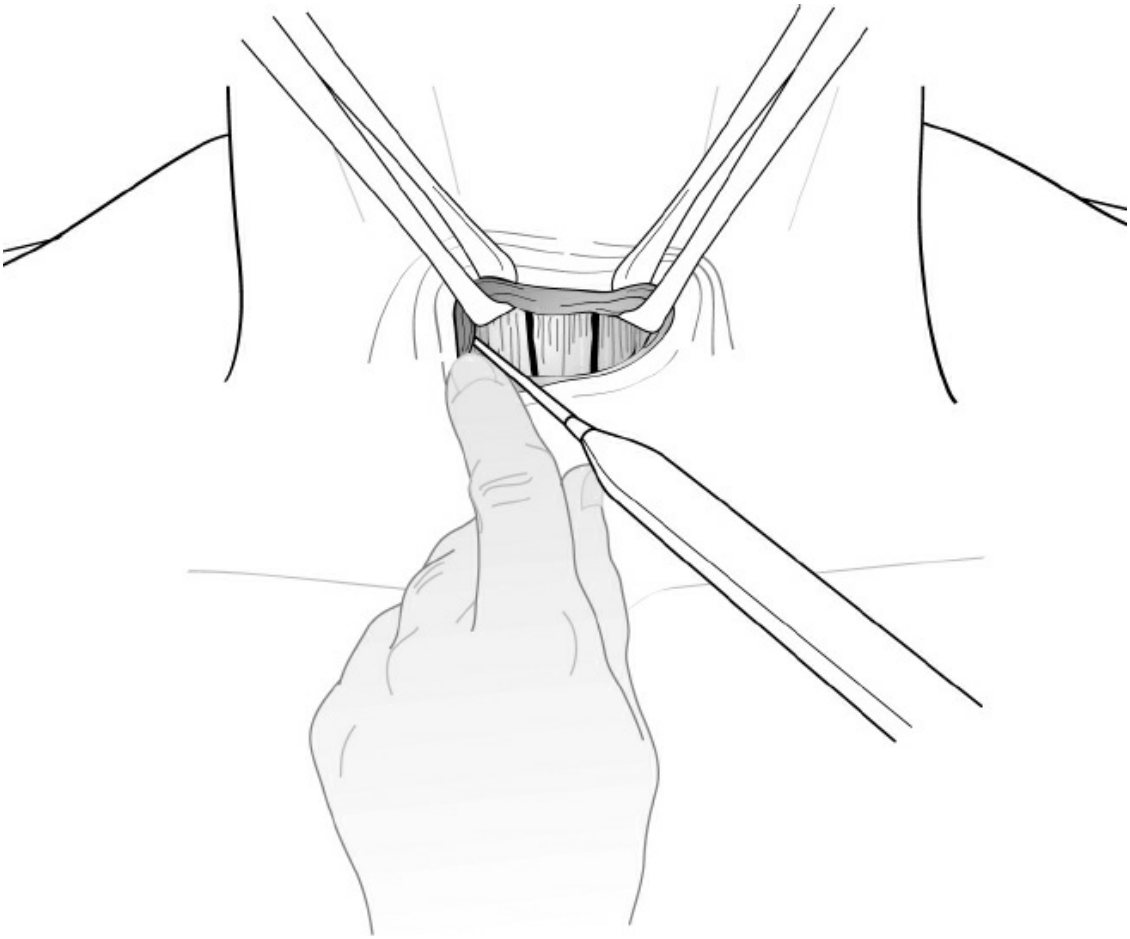

Figure 39.4. Creating superior flap—Allis clamps on platysma, countertraction with the surgeon's finger, and electrocautery, also demonstrating anterior jugular veins.

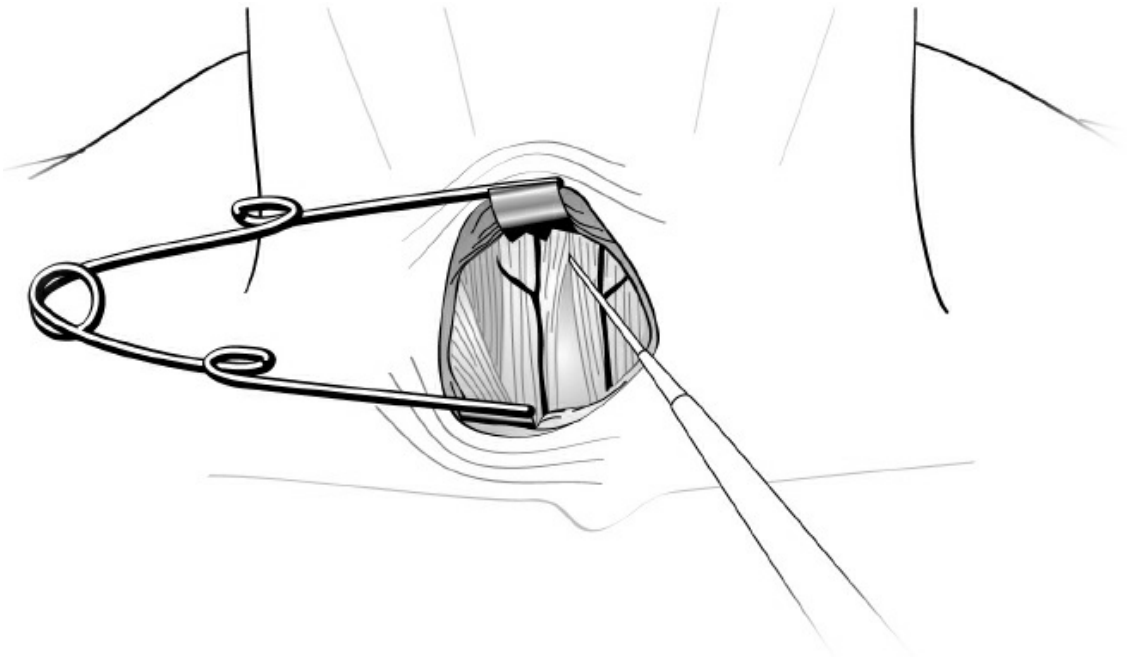

Figure 39.5. Dividing the strap muscles with electrocautery.

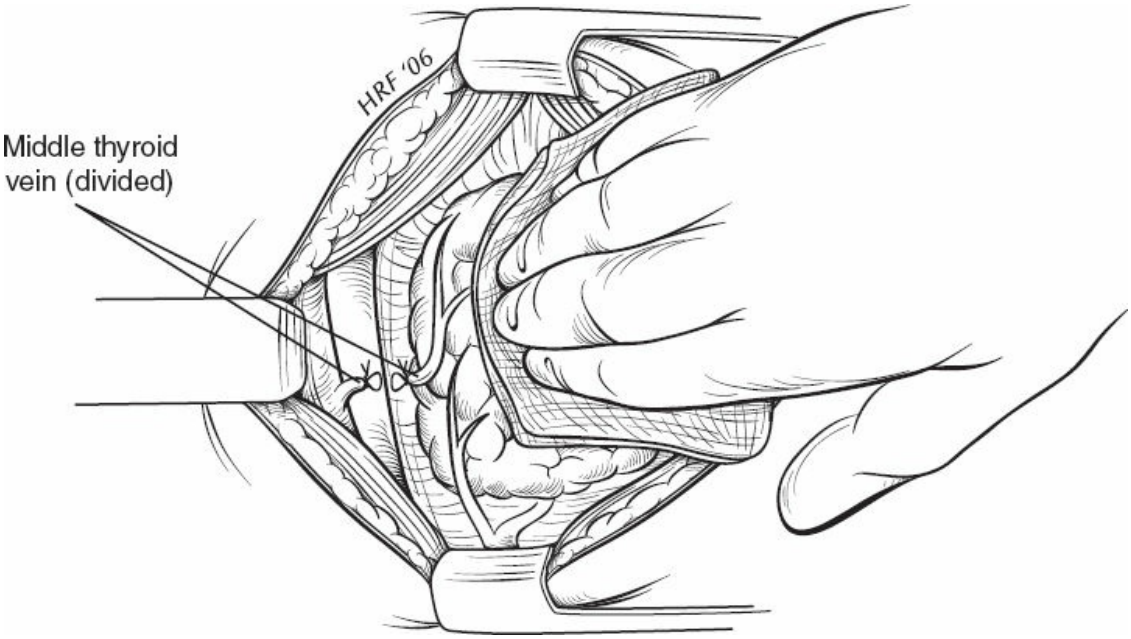

Figure 39.6. Medial retraction of thyroid with fingers covered with surgical sponge after division of the middle thyroid vein.

Once the superior pole is fully mobilized, the thyroid gland can be mobilized anteriorly and medially out of the operative wound. The thyroid is held in this position for the remainder of the procedure. In this position, the RLN and parathyroid glands can be identified, as the tracheoesophageal groove is well exposed (Fig. 39.8).

The parathyroid glands are usually within 1 cm of where the RLN crosses the inferior thyroid artery. The superior gland is typically located in a position that is superior and posterior to the RLN, and the inferior gland is usually inferior and anterior to the RLN. The superior parathyroid gland is frequently adherent to the posterior capsule of the thyroid near the tubercle of Zuckerkandl. A plane between the thyroid capsule and the superior parathyroid gland should be created, permitting the parathyroid gland to be swept off the thyroid out of the operative field while preserving its blood supply, which typically comes from the inferior thyroid artery.

The RLN should always be clearly identified and traced along its course during thyroidectomy. Routine visualization of the nerve has been shown to reduce the incidence of nerve injury. The left RLN travels in the tracheoesophageal groove throughout its entire course. The right RLN enters the neck more laterally and has an oblique course. The most reliable place to identify the nerve is just caudal to the inferior thyroid artery. If there is significant inflammation or scar in this area, the nerve can be

identified in a more caudal location. The RLN may pass posteriorly, anteriorly, or between branches of the inferior thyroid artery. A non-RLN coming directly from the vagus nerve may occur (right side) and should be suspected in patients with known aortic arch anomalies. Dissecting immediately anterior and parallel to the proposed course of the RLN facilitates identification. Branches of the inferior thyroid artery should not be ligated until the RLN and any of its branches are clearly identified to avoid inadvertent injury. Extreme caution should be exercised when dissecting the RLN to prevent inadvertent traction injury or division of the RLN or any branches that may occur prior to entering the cricothyroid muscle. Also, electrocautery should be used sparingly in proximity to the RLN to minimize the risk of a thermal injury. Once the RLN is clearly identified and protected, the end branches of the inferior thyroid artery are divided on the capsule of the thyroid gland to preserve the blood supply to the parathyroid glands. The inferior parathyroid gland is typically located in proximity to the inferior thyroid lobe and should be identified and preserved. Division of end branches of the inferior thyroid artery along the inferior surface of the thyroid gland permits the inferior parathyroid gland to drop away from the thyroid gland, thereby helping to preserve its blood supply. The final dissection through the ligament of Berry is where the RLN is most prone to injury (Fig. 39.9). The RLN should be visualized throughout the entire dissection to minimize the risk of injury. Once the anterior surface of the trachea is exposed, typically in an avascular plane, the thyroid can be dissected from the trachea with electrocautery. If a thyroid lobectomy is planned, the thyroid isthmus can be oversewn with a running suture, or divided with a sealant device (Fig. 39.10).

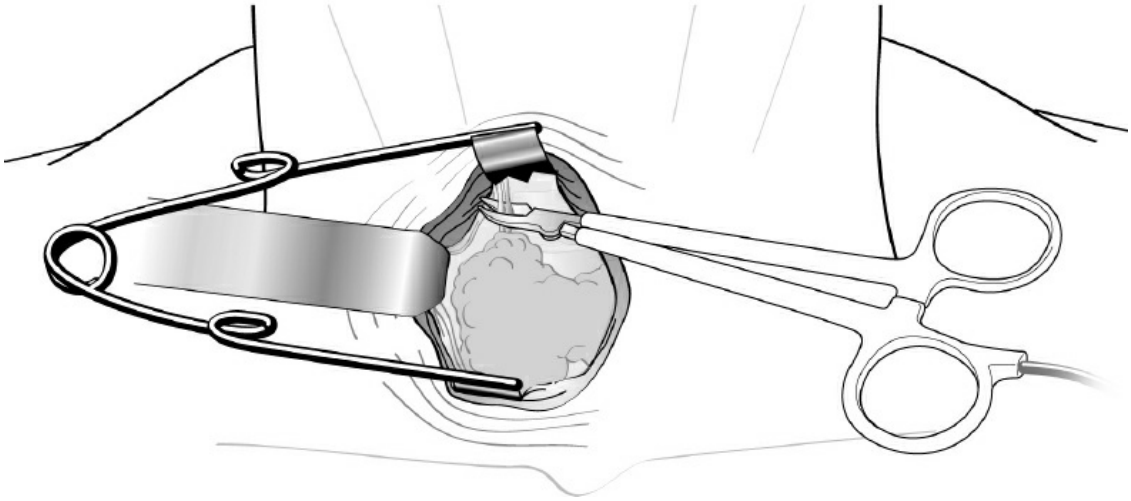

Figure 39.7. Division of the superior pole vessels with Ligasure.

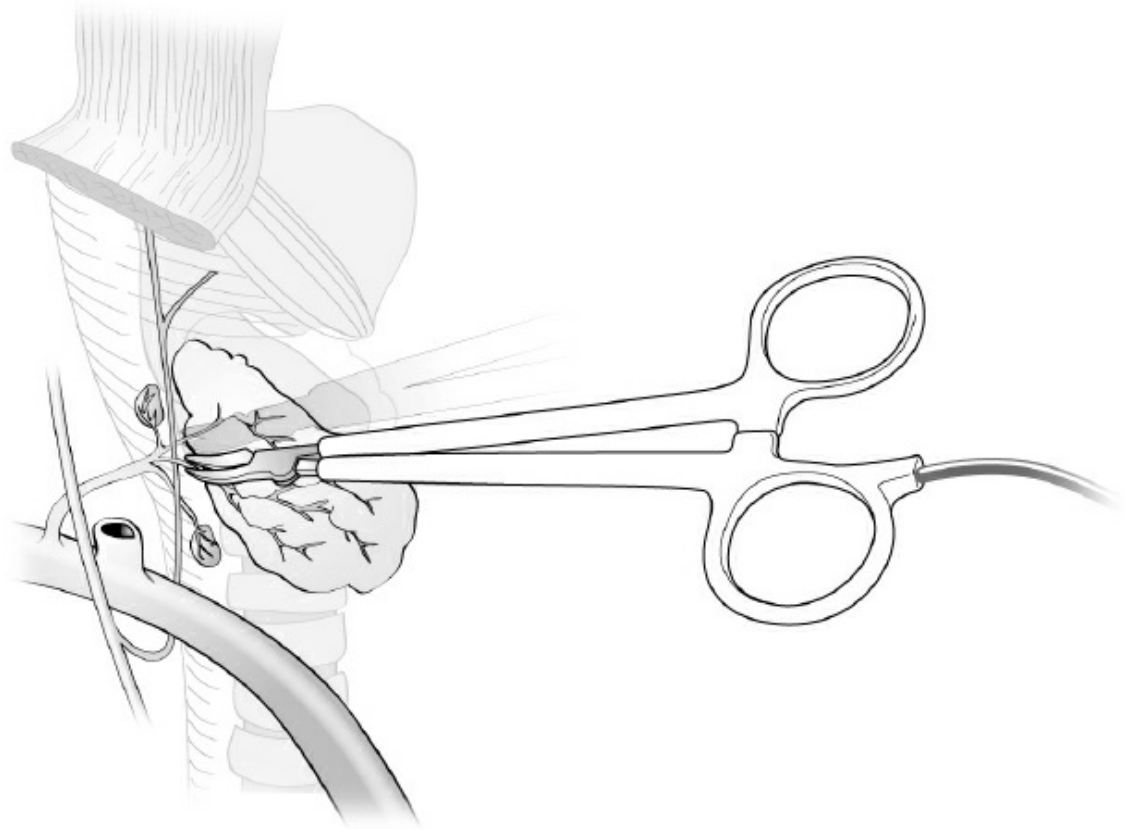

Figure 39.8. Anterior/medial retraction of thyroid, showing recurrent laryngeal nerve and parathyroid gland anatomy. Division of the distal branches of the inferior thyroid artery with Ligasure.

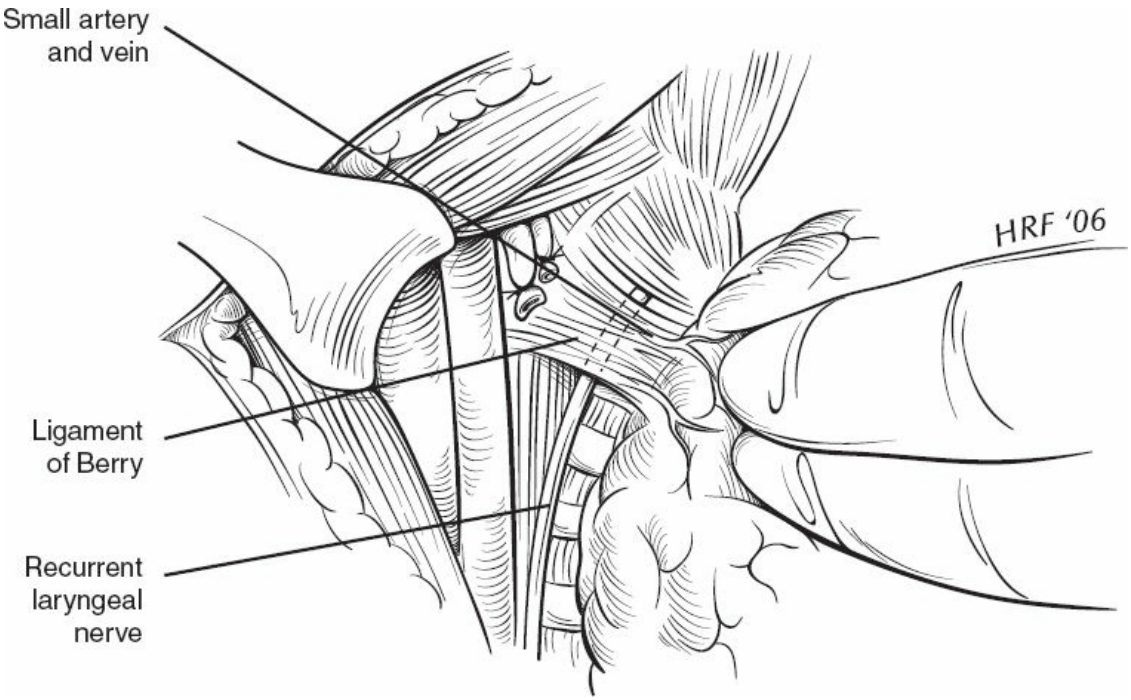

Figure 39.9. Dissection of the ligament of Berry depicting the course of the recurrent laryngeal nerve.

Intraoperative RLN monitoring may be employed during thyroidectomy; however, its use has not been shown to decrease the rate of permanent nerve injury. Proponents of nerve monitoring have advocated that it facilitates nerve identification, particularly for remedial surgery or challenging anatomy, such as advanced cancer or large goiters. Another perceived benefit of nerve monitoring is the ability to prognosticate nerve function at the conclusion of surgery. This would permit identification of a traction or blunt nerve injury and avoid the possibility of a bilateral nerve injury if surgery is terminated. Routine nerve monitoring may also be helpful because unusual anatomy and difficult surgery cannot always be predicted, and increased use permits improved familiarity with the device and potentially greater ability to troubleshoot problems. The American Academy of Otolaryngology and Head and Neck Surgery has published guidelines for improving voice outcomes after thyroid surgery. Based on an intermediate level of evidence from one randomized trial and multiple observational studies, the guidelines state that it is reasonable for surgeons to consider intraoperative nerve monitoring due to established benefit in complex and remedial cases, avoidance of bilateral nerve injury, and reduced operating time negating increased cost, suggesting value for bilateral surgery, remedial surgery, and surgery in the setting of pre-existing nerve injury.

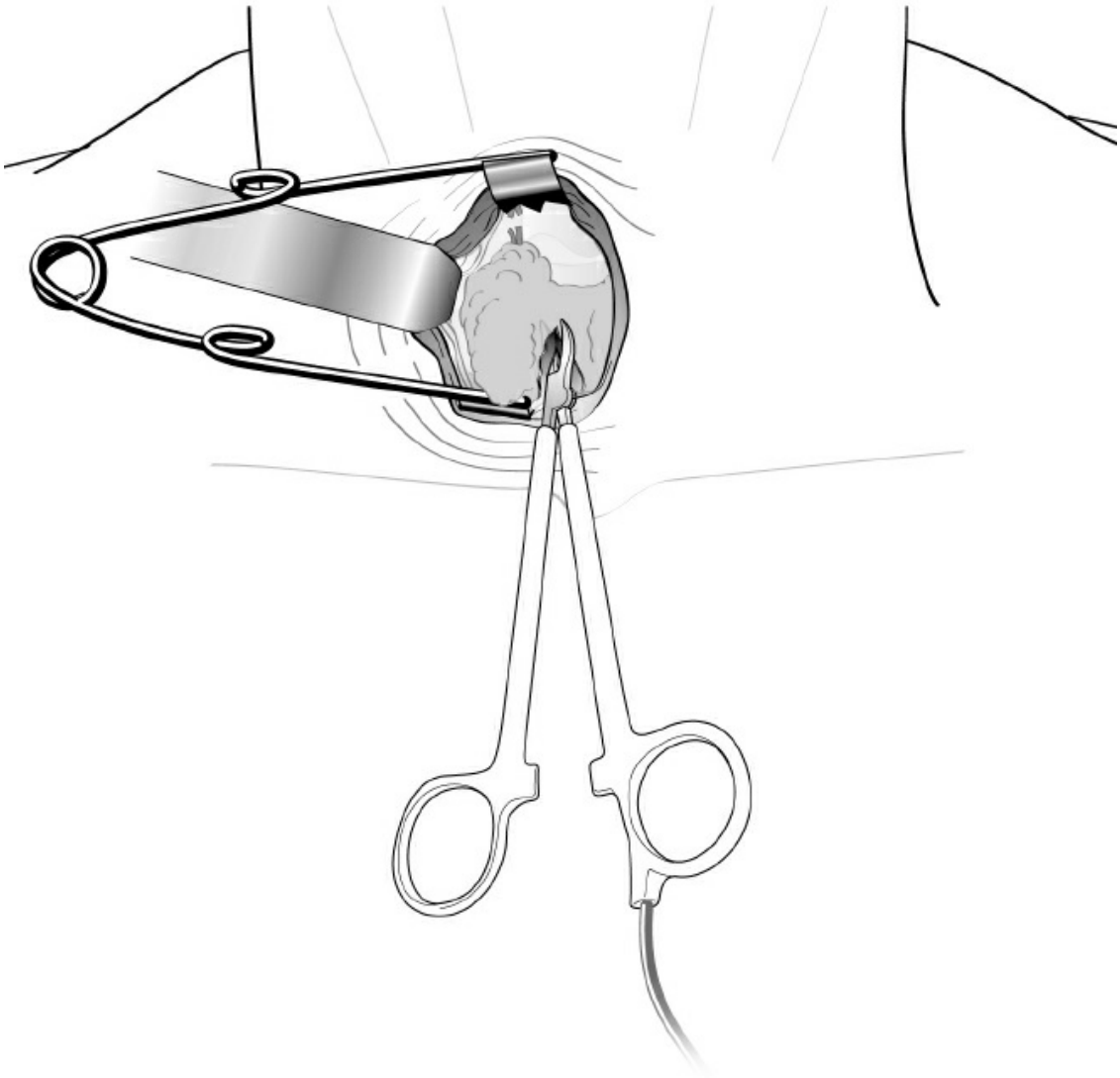

Figure 39.10. Dividing the thyroid isthmus with Ligasure during thyroid lobectomy.

A total thyroidectomy is essentially performing a thyroid lobectomy on each side. The thyroid should be resected as one specimen; however, the isthmus may be divided to facilitate exposure in large goiters. When a total thyroidectomy is planned, lobectomy should be done on the most abnormal side first. If there is an injury to the RLN during the first side, surgery should be stopped in order to preserve the contralateral RLN and prevent a bilateral nerve injury.

After the specimen is excised, it is carefully examined to determine if a parathyroid gland was inadvertently excised. If a parathyroid gland is present, it should be autotransplanted after confirmation that it is indeed parathyroid tissue (see parathyroid autotransplantation below). The operative wound is copiously irrigated, a Valsalva procedure is performed,

and hemostasis ensured. A small amount of topical hemostatic agent may be placed if there is oozing in proximity to the RLN, and pressure applied. The strap muscles are reapproximated with interrupted suture. The platysma is reapproximated with running suture, and the skin is closed with a running subcuticular monofilament suture and steri-strips.

Parathyroid Autotransplantation

Parathyroid glands should be treated as if each gland is the patient's last. If a parathyroid gland cannot be preserved in situ with ample blood supply, it should be excised, and a biopsy submitted for frozen section to confirm the presence of parathyroid tissue. While waiting, the parathyroid tissue should be placed in chilled saline. After confirmation, the parathyroid tissue is minced into small pieces and placed into pockets in the ipsilateral sternocleidomastoid or strap muscle. The pockets are closed with nonabsorbable suture and marked with clips to facilitate future localization if necessary.

Central Compartment Neck Dissection

A central compartment, level VI lymph node dissection should extirpate all prelaryngeal, pretracheal, and unilateral or bilateral paratracheal lymph nodes. A unilateral or bilateral compartment dissection may be performed. The anatomic boundaries of the central (level VI) compartment are the hyoid bone superiorly, the innominate artery inferiorly, and the carotid arteries laterally (Fig. 39.2). A standard thyroidectomy incision provides ample access to the central compartment. The entire course of the RLN should be identified from insertion into the cricothyroid muscle to where it enters the mediastinum. All lymphatic tissue should be carefully excised from around the RLN, and all lymphatic tissue within the central compartment excised. The parathyroid glands should be identified and preserved in situ if possible. Identification and preservation of the inferior parathyroid glands may be difficult. If all parathyroid glands cannot be readily identified, the excised lymphatic tissue should be carefully examined. Any parathyroid tissue that cannot be preserved in situ should be confirmed as parathyroid tissue and autotransplanted into the ipsilateral sternocleidomastoid or strap muscle.

Lateral Compartment Neck Dissection

The anatomic boundaries of the lateral compartment (levels II to V) are the base of the skull superiorly, the clavicle inferiorly, the carotid artery medially, and the medial border of the trapezius muscle laterally (Fig. 39.2). A lateral compartment lymph node dissection can be accomplished through a collar incision that is extended laterally to the lateral border of the sternocleidomastoid muscle on the affected side. Subplatysmal flaps are created superiorly to the hyoid bone and inferiorly to the clavicle. The marginal mandibular branch of the facial nerve is preserved along the superior flap. Heavy suture is placed through the platysma and secured to the drapes to provide exposure. The external jugular vein is identified and divided at the base and superior aspect of the neck dissection so that all lymphatic tissue may be removed. The dissection can be begun along the lateral border in the posterior triangle. The spinal accessory nerve is identified where it enters the trapezius using a nerve stimulator. The spinal accessory nerve is skeletonized of all lymphatic tissue from the insertion into the trapezius to the insertion at Erb's point under the sternocleidomastoid muscle. The greater auricular nerve and all sensory nerves emanating from Erb's point should be preserved if possible to avoid numbness of the ipsilateral ear lobe.

Attention is drawn to the medial border of the neck dissection. The plane between the sternocleidomastoid and the strap muscles is incised and extended inferiorly to the base of the neck and superiorly to the angle of the mandible. The sternocleidomastoid muscle is skeletonized of all fascia and lymphatic tissue and encircled with a Penrose drain to facilitate exposure. In muscular patients, the sternal and clavicular heads of the sternocleidomastoid muscle can be divided to permit visualization of the carotid sheath beneath. The omohyoid muscle is identified, dissected superiorly and laterally, skeletonized of all investing fascia and lymphatic tissue, and encircled with a Penrose drain, permitting exposure of the internal jugular vein, vagus nerve, and common carotid artery. The dissection along the lateral border of the internal jugular vein is initiated by incising the fascia just lateral to the vein approximately 2 to 3 cm cephalad to the clavicle. The internal jugular vein, carotid artery, and vagus nerve are encircled with a Penrose drain, and all lymphatic tissue surrounding these structures is extirpated. The sympathetic chain is identified posteriorly and preserved. The dissection is taken inferiorly and superiorly, such that the internal jugular vein can be retracted medially, exposing areolar tissue that extends down to the anterior scalene muscle.

Small branches of the internal jugular vein should be identified and ligated to prevent hemorrhage. The space between the lymphatic packet and the anterior scalene can be easily entered, and all lymphatics bluntly swept away from the jugular vein and anterior scalene muscle, thereby facilitating exposure of the phrenic nerve. The identity of the phrenic nerve can be confirmed with a nerve stimulator by eliciting movement of the diaphragm. The transverse cervical artery is identified on the anterior surface of the anterior scalene muscle and preserved. The dissection along the internal jugular vein is taken inferiorly to the base of the neck to where it joins the subclavian vein. On the left side, injury to the thoracic duct should be avoided where it loops up into the base of the neck and enters at the confluence of the internal jugular vein and subclavian vein. If injured, it should be ligated to prevent a chyle leak. Alternatively, it may be ligated routinely in adults. The dissection is taken from medial to lateral along the base of the neck just superior to the subclavian vein. The lymphatic tissue is divided between ties to prevent lymphatic leak. This will fully expose the anterior scalene muscle, and with further blunt anterior dissection of the lymphatic packet, the brachial plexus can be identified and protected.

The entire lymphatic packet is retracted anteriorly and medially. The phrenic nerve, brachial plexus, transverse cervical artery, accessory nerve, and vagus nerve should be easily visualized at this point and preserved (Fig. 39.11). Branches of the cervical plexus should be individually identified and preserved. Lymph nodes posterior to these nerves should be separated from posterior attachments and delivered in between branches. The spinal accessory nerve is identified and protected along its course deep and medial to the sternocleidomastoid muscle. The dissection is taken superiorly above the level of the carotid bifurcation, preserving the facial vein to the level of the posterior belly of the digastric muscle and salivary glands. Once the lymphatic packet is free, it is delivered from the operative field, oriented, and sent to pathology (Fig. 39.12A,B). For patients with differentiated thyroid cancer, excision of levels IIA, III, IV and VB is recommended. However, excision of levels IIB and VA lymphatic tissue superior to the spinal accessory nerve is recommended for medullary thyroid cancer, or patients with known involvement at these levels.

After the specimen is excised, the operative wound is copiously irrigated, a Valsalva procedure is performed, and hemostasis ensured. A small amount of topical hemostatic agent may be placed, and pressure applied if there is oozing. A closed suction drain is placed in the surgical

bed that exits below the clavicle. The cervical motor nerves should be assessed with the nerve stimulator at the conclusion of surgery to confirm their function is preserved. The anterior border of the sternocleidomastoid muscle is reapproximated to the lateral border of the sternothyroid muscle with interrupted suture. The platysma is reapproximated with running suture, and the skin is closed with a running monofilament subcuticular suture and steri-strips.

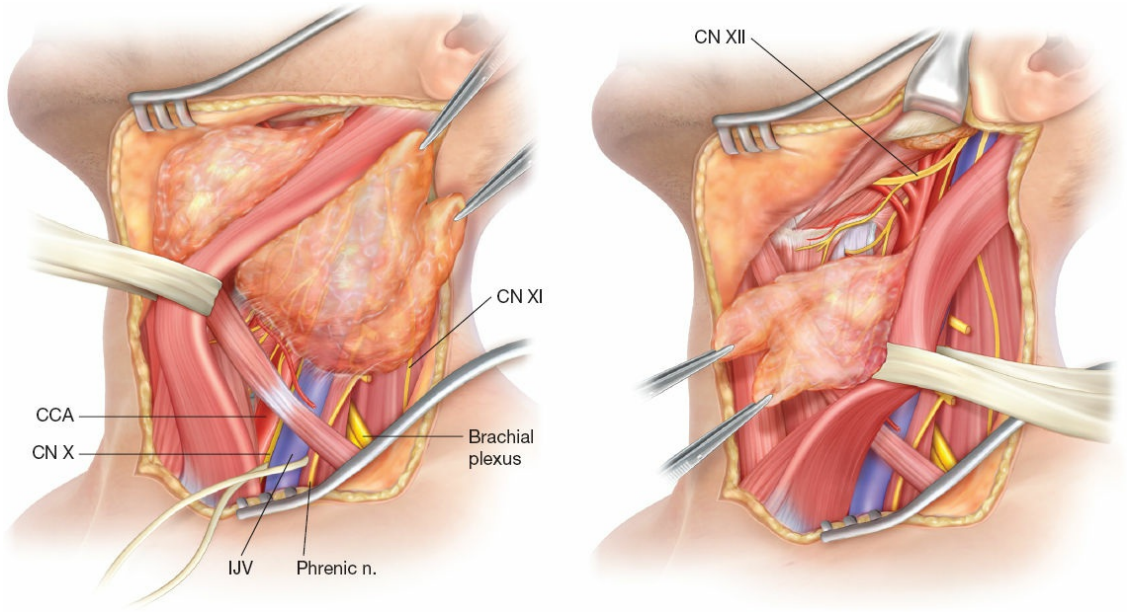

Figure 39.11. En bloc dissection of lateral compartment lymph nodes. CCA, common carotid artery; IJV, internal jugular vein; CN, cranial nerve.

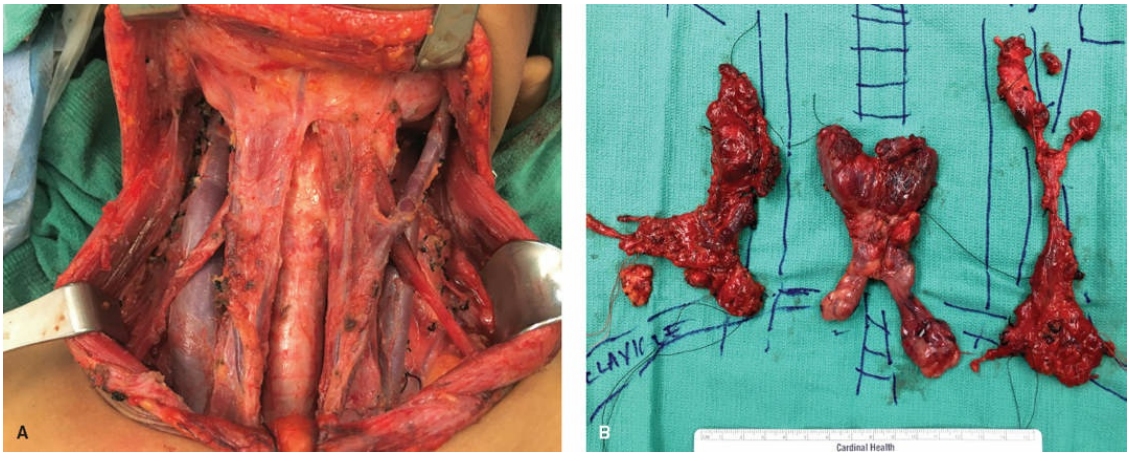

Figure 39.12. **A:** Total thyroidectomy, bilateral central and bilateral lateral modified radical neck dissections. **B:** Resected specimen oriented and marked for pathologic examination.

POSTOPERATIVE CARE

Thyroid Lobectomy

Thyroid lobectomy is frequently performed as an outpatient procedure. In 2013, the ATA published a statement on outpatient thyroidectomy. The statement recommended that patients should be observed in the recovery room for at least 2 hours and meet specific criteria prior to discharge, including the ability to take liquids, adequate pain control, and satisfactory postoperative evaluation without concern for hematoma, dysphonia, dysphagia, or dyspnea. Postoperative hematomas usually occur shortly after surgery, but may occur up to 3 days later, so patients should be counseled regarding symptoms of hematoma so that they can seek medical attention early in their postoperative course if necessary. If these criteria for discharge are not met, the patient should be admitted for overnight observation. Patients may be advanced from a clear liquid to regular diet as long as the patient is not nauseated. Postoperative pain is usually minimal and requires only a mild narcotic, such as acetaminophen with codeine, for no more than 1 to 2 days after surgery; frequently, acetaminophen alone is adequate. The dressing should be removed the day after surgery, and steri-strips left in place until they fall off. Patients may shower 2 to 3 days after surgery. Driving is permitted once the patient is no longer taking narcotic pain medication, and they can turn their neck without hesitating; this usually occurs 4 to 5 days after surgery. Normal activity may be resumed after surgery; however, patients should refrain from strenuous activity, including bending over and heavy lifting for 1 week. A postoperative appointment should be arranged 1 to 2 weeks after surgery to evaluate the patient for any voice changes, wound problems, and to review pathology with the patient. The half-life of levothyroxine is 7 days, so TSH is not obtained until 4 to 6 weeks after surgery to assess thyroid function. Communication between surgeon and endocrinologists/internal medicine physicians after surgery is imperative. It is essential to communicate operative findings, pathology, and intra- and postoperative events to facilitate transitions of care and treatment after surgery.

Total Thyroidectomy

After total thyroidectomy, most patients are admitted for 23-hour overnight observation. In select patients, some high-volume centers

perform thyroidectomy as an outpatient procedure. As mentioned above, the ATA published a statement for outpatient thyroidectomy in 2013. Relative contraindications to outpatient thyroidectomy were identified, including massive goiter, extensive substernal goiter, locally advanced cancer, challenging hemostasis, Graves' disease, severe thyroiditis, significant medical comorbidities, and social barriers to care. It is imperative that patients who have an outpatient thyroidectomy meet strict discharge criteria and can be easily evaluated for postoperative problems that require immediate attention should they arise.

Postoperative pain management, activity, wound care, and diet are similar for patients who undergo a thyroid lobectomy or total thyroidectomy. However, unlike thyroid lobectomy, hypoparathyroidism and hypocalcemia may occur after total thyroidectomy. Postoperative calcium levels usually nadir 3 days after surgery, so hypocalcemia should be identified early and supplemented prior to this time before symptoms occur. Selective or routine supplementation with calcium and calcitriol should be implemented to avoid this complication. Both methods have been shown to be effective for preventing postoperative hypocalcemia. Selective supplementation is based on either postoperative calcium or PTH levels. For selective supplementation based on calcium levels, serum calcium is checked in the evening after surgery and the following morning. Supplementation is based on the calcium value and change in the evening and morning values. Ionized calcium or calcium corrected for albumen more accurately reflect active calcium levels and may be useful in select patients. For selective supplementation based on PTH levels, serum PTH is obtained in the recovery room, and if >10 pg/mL, patients are given 1,000 mg calcium carbonate twice/day for 1 week; for PTH <10 pg/mL, patients are given 0.25 mcg calcitriol twice/day in addition to 1,000 mg of calcium carbonate three times/day. Our group and others have advocated routine supplementation for all patients following thyroidectomy, with calcitriol 0.25 mcg twice/day and 1,000 mg calcium carbonate three times/day, since routine supplementation has been shown to be more cost-effective than selective supplementation. All patients should be counseled to contact the surgeon for symptoms of hypocalcemia, such as perioral or distal extremity paraesthesias. If these symptoms occur, the supplementation may need to be increased. Calcitriol and calcium are titrated down over 1 to 2 weeks after surgery, as long as the patient does not experience symptoms of hypocalcemia.

After thyroidectomy, patients should be started on 1.6 mg/kg levothyroxine taken as a single dose on an empty stomach. Antithyroid medications for patients with hyperthyroidism should be stopped immediately after surgery and beta blockers weaned to off over 1 week. A TSH should be obtained 6 weeks after surgery to determine whether the patient is on adequate supplementation. The goal TSH should be within normal limits for patients with benign disease or low-risk thyroid cancer. A suppressive dose of thyroid hormone supplementation is recommended for patients with intermediate- or high-risk thyroid cancer.

Patients with differentiated thyroid cancer should be evaluated for radioactive iodine ablation (RAI). Treatment is selective and should be based on the risk of recurrence. The 2015 ATA guidelines for the management of differentiated thyroid cancer recommend RAI for patients with evidence of extrathyroidal extension or distant metastasis, regardless of tumor size. The guidelines also recommend that RAI be considered for other intermediate or high-risk tumor features, such as tumor size 1 to 4 cm with regional lymph node involvement or a combination of other high-risk features, such as larger tumor size, metastatic lymph nodes, and aggressive subtypes (tall cell, insular, diffuse sclerosing variants) of papillary thyroid cancer. RAI can be accomplished with either traditional thyroid hormone withdrawal or recombinant human TSH (rhTSH; Thyrogen). Both methods have been shown to be equally effective for the purpose of remnant ablation in randomized controlled trials. Thyrogen avoids the side effects of thyroid hormone withdrawal, improving quality of life for patients, so it should be used preferentially.

Lateral Compartment Neck Dissection

After lateral neck dissection with or without thyroidectomy, patients are observed in the hospital for one to two nights. Postoperative diet and wound management are similar to patients who have thyroidectomy. Patients may have more pain and require a stronger narcotic pain medication than acetaminophen with codeine. A drain in the surgical bed can be removed when there is less than 20 to 30 mL/day, typically after 2 to 4 days. Return to normal activities and driving may take longer due to increased pain or a sensation of tightness and neck stiffness. Occupational and physical therapy consultation and exercises can be beneficial to speed patients' recovery to baseline activity.

COMPLICATIONS AND THEIR MANAGEMENT

Hematoma

Hematoma requiring emergent surgical evacuation is a rare complication after thyroidectomy. Cervical hematomas can occur up to 72 hours after surgery and are characterized by a large firm mass directly posterior to the skin incision; they may be only mildly symptomatic when first identified. These are surgical emergencies, because symptoms may progress rapidly, leading to respiratory compromise. The patient should remain awake to protect the airway and be taken to the operating room emergently. The neck should be prepped, and the surgeon should be prepared to evacuate the hematoma or perform a surgical airway if the patient cannot be intubated. Once the airway is secured, the wound is opened and copiously irrigated to identify any bleeding source. It is important to use electrocautery carefully to avoid an inadvertent injury to the RLN or parathyroid glands. Overnight intubation and perioperative steroid treatment may be necessary to allow airway edema to resolve prior to extubation. A drain should be placed to evacuate any postoperative seroma or potentially identify a recurrent bleed.

Hypoparathyroidism

Hypoparathyroidism leading to hypocalcemia is the most common complication after thyroidectomy. Transient hypoparathyroidism is seen in 10% to 20% of patients, and permanent hypoparathyroidism is seen in 1% to 2% of patients after total thyroidectomy. Transient hypoparathyroidism usually resolves within 1 to 2 weeks, but may take as long as 6 months to evolve. Symptoms of hypocalcemia include perioral or distal extremity paraesthesias, with mild hypocalcemia progressing to muscle cramps and tetany with severe hypocalcemia. The threshold where patients experience hypocalcemic symptoms is highly variable and cannot be predicted based on calcium levels alone. Patients that experience symptoms usually can be managed with oral calcium and vitamin D supplementation with calcium carbonate or citrate and calcitriol. For patients already on supplementation, a dose increase may alleviate symptoms. For patients with persistent symptoms from hypocalcemia, treatment with intravenous calcium gluconate is required. The infusion should be started at 1 mg/kg/hour for 24 hours. The drip is slowly titrated off as long as the serum calcium level remains stable. At this point, the patient can be discharged home on an oral

supplementation regimen. The calcium and vitamin D supplementation can be weaned off as long as the patient does not experience symptoms of hypocalcemia.

Nerve Injury/Hoarseness

Postoperative voice changes may be due to irritation from the endotracheal tube, vocal cord edema/hematoma and arytenoid dislocation from intubation, or RLN injury. Transient RLN injury is seen in 5% of patients, and permanent RLN injury is seen in 1% of patients after thyroidectomy performed by experienced (high-volume) thyroid surgeons. Complication rates, on average, are higher when thyroidectomy is performed by less experienced, low-volume thyroid surgeons. An RLN injury should be suspected in patients with hoarseness, dyspnea, coughing, or symptoms concerning for aspiration that persist for more than 48 hours after surgery. Patients with significant dyspnea or symptoms concerning for aspiration should be immediately referred for laryngoscopy to evaluate for vocal cord paresis. These patients may require early intervention to prevent aspiration.

Most RLN injuries are transient and due to stretch or compression of the nerve, so they should resolve. Evaluation and treatment by a speech therapist can improve voice quality and reduce voice strain and patient anxiety until nerve function recovers. If vocal cord paralysis does not resolve by 6 months, it is usually permanent. Patients who have significant symptoms may undergo collagen injection into the paralyzed vocal cord, thereby medializing the cord. Medialization allows the contralateral cord to close the larynx during swallowing and phonation. If vocal cord function does not recover after 6 months and the patient remains symptomatic, a permanent medialization of the vocal cord may be performed.

Bilateral vocal cord paralysis is an uncommon but dreaded complication after total thyroidectomy. Patients typically present with difficulty breathing and stridor after extubation. Immediate intubation should be attempted, but may not be possible if the vocal cords are in a closed/adducted position. The surgeon must be prepared to perform a tracheostomy if the patient cannot be intubated or is unable to maintain an adequate airway.

Injury to the external branch of the laryngeal nerve may lead to inability to reach high pitches, voice fatigue, and decreased voice projection. These

injuries can be difficult to diagnose, except with electromyography. Most of these injuries are transient and should recover with time. Voice therapy is the mainstay of the treatment of permanent injury.

Spinal Accessory Nerve Injury

The spinal accessory nerve may be injured with a lateral compartment neck dissection. This leads to winging of the scapula, drooped shoulder, and shoulder weakness. Treatment focuses on physical therapy to strengthen the shoulder and improve range of motion.

Chyle Fistula

Chyle leaks and fistulas are caused by injury to the thoracic duct where it enters the junction of the left subclavian vein and internal jugular vein at the base of the left neck during a left lateral compartment neck dissection. Milky-appearing chylous drainage into the closed suction drain, or bulging of the left supraclavicular fossa with erythema over the area, are physical examination findings suspicious for leak. Most fistulas are low volume and can be treated conservatively with nonoperative management by placing the patient on a low fat diet, or NPO with TPN. High output fistulas (>500 mL/day) or those that are refractory may require surgical intervention.

OUTCOMES

In experienced hands, outcomes from thyroid surgery are superb. Surgery is well tolerated, and complications are infrequent. Recurrence of benign goiter and Graves' disease are rare after total thyroidectomy. The prognosis for patients with differentiated thyroid cancer is excellent, with a 5-year overall survival rate exceeding 95%. However, more than 30% of patients will develop recurrent disease. The most common site of recurrence is regionally in the cervical lymph nodes; it usually occurs within 10 years after initial diagnosis, but may recur later, thereby necessitating long-term surveillance. Treatment of patients with benign or malignant thyroid disease should be individualized and directed by easily assessed evidence-based guidelines published by professional societies in order to optimize patient outcomes. In areas where evidence is lacking, patient preference regarding treatment is essential. Overall, there is a trend toward less aggressive treatment of low-risk differentiated thyroid cancer with a careful consideration weighing the benefits against the real potential

risk of surgery and radioactive iodine. Treatment of patients continues to evolve, requiring a contemporary understanding of current literature.

Suggested Readings

Adam MA, Pura J, Gu L, et al. Extent of surgery for papillary thyroid cancer is not associated with survival: an analysis of 61,775 patients. *Ann Surg* 2014;260:601–5; discussion 605–7.

Bahn RS, Burch HB, Cooper DS, et al. Hyperthyroidism and other causes of thyrotoxicosis: management guidelines of the American Thyroid Association and American Association of Clinical Endocrinologists. *Endocr Pract* 2011;17(3):456–520.

Chandrasekhar SS, Randolph GW, Seidman MD, et al. Clinical practice guideline: improving voice outcomes after thyroid surgery. *Otolaryngol Head Neck Surg* 2013; 148(6 Suppl):S1–37.

Cibas ES, Ali SZ. The Bethesda System for Reporting Thyroid Cytopathology. *Thyroid* 2009;19(11):1159–65.

Englum BR, Pura J, Reed SD, et al. A bedside risk calculator to preoperatively distinguish follicular thyroid carcinoma from follicular variant of papillary thyroid carcinoma. *World J Surg* 2015;39(12):2928–34.

Ferris RL, Baloch Z, Bernet V, et al. American thyroid association statement on surgical application of molecular profiling for thyroid nodules: current impact on perioperative decision making. *Thyroid* 2015;25(7):760–8.

Haugen BR, Alexander EK, Bible KC, et al. 2015 American Thyroid Association Management Guidelines for Adult Patients with Thyroid Nodules and Differentiated Thyroid Cancer. *Thyroid* 2016;26(1):1–33.

Smallridge RC, Ain KB, Asa SL, et al. American Thyroid Association guidelines for management of patients with anaplastic thyroid cancer. *Thyroid* 2012;22(11):1104–39.

Terris DJ, Snyder S, Carneiro-Pla D, et al. American Thyroid Association statement on outpatient thyroidectomy. *Thyroid* 2013;23(10):1193–202.

Wells SA Jr, Asa SL, Dralle H, et al. Revised American Thyroid Association guidelines for the management of medullary thyroid carcinoma. *Thyroid* 2015;25(6):567–610.

EDITOR'S COMMENT

The incidence of thyroid nodules increases with age and is increased in women, in people with iodine deficiency, pre-existing thyroiditis, and after radiation

exposure. Many studies suggest a prevalence of 2% to 6% with palpation, 19% to 35% with ultrasound, and 8% to 65% in autopsy data. With widespread use of sensitive imaging in clinical practice, incidental thyroid nodules are being discovered with increasing frequency. As pointed out by the authors, ultrasonography is the most accurate and cost-effective method for evaluating and observing thyroid nodules. Current ultrasonography machines are relatively inexpensive, sensitive, and easy to operate. Most endocrinologists are now using ultrasound examination in the initial evaluation of a patient with known or suspected thyroid nodule. While the overwhelming majority of thyroid nodules are benign, the management of thyroid incidentalomas is a matter of controversy, particularly as the incidence of thyroid cancer has increased some 270% in the last three decades (Dean DS, Gharib H. Epidemiology of thyroid nodules. *Best Pract Res Clin Endocrinol Metab* 2008;22(6):901–11). It is the fifth most common cancer. In 2015, an estimated 64,300 adults (14,950 men and 49,350 women) in the United States will be diagnosed with thyroid cancer. As noted in the commentary in the 6th edition by Dr. Fischer, there was skepticism expressed by early endocrine surgeons (in particular Dr. Oliver Cope), in the mid-20th century about whether papillary thyroid cancer in particular was “a real cancer.” This was largely based on the indolent nature of some of the tumors. The 5-year survival for papillary thyroid cancer is: Stage 1 near 100%, Stage 2 near 100%, Stage 3 93%, and Stage IV 51%. The 5-year survival for follicular thyroid cancer is nearly 100% for Stage 1 and 2, and 71% for Stage 3, and 50% for Stage 4. For medullary carcinoma the survival is: Stage 1 near 100%, Stage 2 98%, Stage 3 81%, and Stage 4 28%. As evident in this chapter, we now appreciate the full malignant potential of thyroid cancer, have evolving evidence-based treatment guidelines and an understanding of specific sporadic and familial genetic mutations in the pathogenesis of this disease.

For the best outcomes, the surgeon must apply clearly defined evidence-based algorithm for the management of the incidental thyroid nodule. After screening for hyper- and hypothyroidism, fine-needle aspiration (FNA) biopsy under ultrasound guidance is the procedure of choice for the evaluation of thyroid nodules and selection of patients who should undergo surgery for a suspected or confirmed thyroid cancer. The technique has variable accuracy and that depends on the size of the lesion, skill of the person performing the biopsy, and the skill of the cytologist. FNA is recommended for nodules 1 cm or greater in size. In addition, there is difficulty in distinguishing some benign cellular adenomas, particularly follicular adenomas from their malignant counterparts. For nodules greater than 4 cm, the accuracy of the technique decreases presumably because of sampling error. Up to 15% of large thyroid nodules will contain a thyroid cancer. Analysis of recent data suggests a false-negative rate of thyroid FNA 1% to 11%, a false-positive rate of 1% to 8%, a sensitivity of 65% to 98%, and a specificity of 72% to 100%. The introduction of FNA has had a substantial effect on the management of patients with thyroid nodules.

The percentage of patients undergoing thyroidectomy has decreased by 25%, and the yield of carcinoma in patients who undergo surgery has increased from 14% to nearly 50%. In early series, FNA has been reported to decrease the cost of care by 25% (Gharib H, Goeliner JR. Fine-needle aspiration biopsy of the thyroid: an appraisal. *Ann Intern Med* 1993;118:282–9).

In this chapter, the authors describe the technique clearly. Using a 23 or 25 gauge needle will give superior sampling and accuracy. Although the technique may be done with or without aspiration, most thyroid surgeons favor the less traumatic nonaspiration technique.

"It is critical that cytopathologists communicate thyroid FNA interpretations to referring physicians in terms that are succinct, unambiguous, and clinically helpful" (Cibas ES, Syed ZA. The Bethesda System For Reporting Thyroid Cytopathology. *Am J Clin Pathol* 2009;132:658–65). Historically, the terminology used to describe the findings for thyroid FNA had been variable creating confusion in some cases.

The authors refer to using the Bethesda System for Reporting Thyroid Cytopathology (Bethesda Criteria) for categorizing thyroid nodules. In order to address terminology and other issues related to thyroid FNA, the National Cancer Institute (NCI) hosted the NCI Thyroid FNA State of the Science Conference: October 22–23, 2007. The conclusions regarding terminology and morphologic criteria from the NCI meeting led to the Bethesda Thyroid Atlas Project and formed the framework for the Bethesda Criteria. For clarity of communication, the Bethesda Criteria recommend that each report begin with one of six general diagnostic categories (Table 39.1).

As the authors point out, molecular tests are relatively new tools for further assessing nodules with atypical, suspicious, or indeterminate FNA cytology results. Combining cytology and molecular results may improve diagnosis. These tests can detect molecular alterations involved in the pathogenesis of thyroid cancer. Nodules with indeterminate cytology lacking these alterations are less likely to be malignant. Alternatively, more than 70% of papillary thyroid carcinomas have a point mutation in BRAF or RAS or a RET/PTC rearrangement, and >70% of follicular thyroid carcinomas (FTCs) harbor either RAS mutations or PAX8/PPARγ rearrangements. If a point mutation is identified, then definitive surgery is indicated. However, the reader is cautioned that RAS mutations may be found in benign thyroid lesions and hence may not be specific. In addition, sporadic and hereditary medullary thyroid carcinoma (MTC) are associated with point mutations in the RET gene.

In Chapter 39, the authors outline the appropriate treatment based on the Bethesda Criteria. For a lesion that has a high likelihood of malignancy, treatment depends on the cell type, patient and tumor characteristics as recommended by the 2015 American Thyroid Association guidelines (Haugenm BR, Alexnader EK, Bible, KC, et al. 2015 American Thyroid Association Guidelines for adult patients with thyroid nodules and differentiated thyroid cancer. *Thyroid* 2016;26:1–133). This evidence-based compendium of treatment

options for thyroid nodules is a phenomenal resource. It is clear that operations need to be individualized.

Lymph node metastases occur in 20% to 50% of patients with papillary thyroid carcinoma. Microscopic metastases are even more common and may be found in 90% of patients (Mazzaferri EL, Doherty GM, Steward DL. The pros and cons of prophylactic central compartment lymph node dissection for papillary thyroid carcinoma. *Thyroid* 2009;19:683–9). The central compartment of the neck (level VI) is most commonly involved. It is well documented that regional lymph node involvement is associated with increased rates of tumor recurrence and recurrence is more frequent in node-positive patients over the age of 45 years (Chisholm EJ, Kulinskaya E, Tolley NS. Systematic review and meta-analysis of the adverse effects of thyroidectomy combined with central neck dissection as compared with thyroidectomy alone. *Laryngoscope* 2009;119:1135–9). As the authors point out "a therapeutic level VI compartmental central lymph node dissection should be performed for patients when abnormal central lymph nodes are identified during surgery or preoperatively on physician examination, ultrasound, or other radiologic imaging. A prophylactic central compartment (level VI) lymph node dissection can be considered for high-risk tumors (T3, T4), clinically involved lateral compartment lymph nodes, or if the information would be helpful to plan further therapy. If suspicious lateral compartment cervical lymph nodes are identified preoperatively, an ultrasound-guided FNA should be performed, and if it is positive for malignancy, a selective lateral compartment lymph node dissection of levels IIA, III, IV, and VB should be recommended." In these situations, determination of FNA cytology thyroglobulin measurements may enhance the accuracy of FNA in diagnosing metastatic disease (Boi F, Baghino G, Atzeni F, et al. The diagnostic value for differentiated thyroid carcinoma metastases of thyroglobulin (Tg) measurement in washout fluid from fine-needle aspiration biopsy of neck lymph nodes is maintained in the presence of circulating anti-Tg antibodies. *J Clin Endo Metab* 2006;91:1364–9).

TABLE 39.1 The Bethesda System for Reporting Thyroid Cytopathology

Recommended Diagnostic Categories

I. Nondiagnostic or Unsatisfactory
- Cyst fluid only
- Virtually acellular specimen
- Other (obscuring blood, clotting artifact, etc.)

II. Benign
- Consistent with a benign follicular nodule (includes adenomatoid nodule and colloid nodule)
- Consistent with lymphocytic (Hashimoto) thyroiditis in the proper clinical context
- Consistent with granulomatous (subacute) thyroiditis
- Other

III. Atypia of Undetermined Significance or Follicular Lesion of Undetermined Significance

IV. Follicular Neoplasm or Suspicious for a Follicular Neoplasm
- Specify if Hürthle cell (oncocytic) type

V. Suspicious for Malignancy
- Suspicious for papillary carcinoma
- Suspicious for medullary carcinoma
- Suspicious for metastatic carcinoma
- Suspicious for lymphoma
- Other

VI. Malignant
- Papillary thyroid carcinoma
- Poorly differentiated carcinoma
- Medullary thyroid carcinoma
- Undifferentiated (anaplastic) carcinoma
- Squamous cell carcinoma
- Carcinoma with mixed features (specify)
- Metastatic carcinoma
- Non-Hodgkin lymphoma
- Other

Adapted from Baloch ZW. Overview of diagnostic terminology and reporting. In: Ali SZ, Cibas ES, eds. *The Bethesda System for Reporting Thyroid Cytopathology*. New York: Springer; 2010. Copyright © 2010, with permission of Springer.

The reader must be cautioned that the value of prophylactic central neck dissection is controversial in the absence of imaging showing abnormally enlarged nodes or palpable lymph nodes. Although regional lymph node metastases in papillary thyroid carcinoma do increase regional recurrence rates, they do not negatively impact survival rates. Pointing out the high risk of positive lymph nodes, better outcomes, and a lower morbidity rate associated with this as an initial operation some surgeons recommend prophylactic central neck dissection in order to prevent recurrence. Others argue that this procedure increases the risk of injury to the parathyroid glands and RLNs, without any demonstrable benefits in terms of long-term survival (Carling T, Long WD, Udelsman R. Controversy surrounding the role for routine central lymph node dissection for differentiated thyroid cancer. *Curr Opin Oncol* 2010;22:30–34). Central neck dissection does permit more accurate pathologic staging of the lymph nodes and treatment of the microscopic metastases. It is also argued that recurrence in this compartment is difficult to treat, while central lymph node dissection during the initial thyroidectomy can be performed within the standard collar incision.

Safely limiting hospitalization after thyroid surgery will reduce costs. The ATA guidelines refer to ambulatory thyroidectomy and specify contraindications to this approach. In this regard, of interest as is the role of PTH assay in the postoperative recovery unit in predicting the need for postoperative calcium supplementation.

Postoperative follow-up after surgery for thyroid cancer is necessary. Monitoring of serum thyroglobulin after thyroid surgery/ablation is a crucial part of follow-up for papillary thyroid cancer, follicular thyroid cancer, and Hürthle cell carcinoma. However, circulating antithyroglobulin autoantibodies may make these measurements unreliable in 20% to 30% of patients. Patients with medullary thyroid cancer are monitored to detect residual and recurrent disease using serum calcitonin and carcinoembryonic antigen measurements.

E. Christopher Ellison

40 Comprehensive Parathyroidectomy for the Treatment of PHPT, Including Intraoperative Parathyroid Hormone Assay–Guided Parathyroidectomy

Azadeh A. Carr and Tracy S. Wang

INTRODUCTION

The diagnosis and management of primary hyperparathyroidism (PHPT) has evolved considerably over the past several decades. From a once obscure disease, PHPT has become the most common cause of hypercalcemia in the outpatient population. A recent study of a large multiracial population in the United States identified an incidence of 66 per 100,000 person-years among women and 25 per 100,000 person-years among men. The reasons for the increased incidence of PHPT are multifactorial; first, the introduction of automated routine calcium testing in the 1970s led to a significant increase in the identification of hypercalcemia. Second, osteoporosis screening has also increased and practitioners have become more aware of the association of both osteoporosis and nephrolithiasis to PHPT, prompting additional evaluation in patients with these conditions.

Surgery remains the only curative treatment for PHPT. However, there is still wide variability in management of PHPT, with a high frequency of underreferral and undertreatment. Recent studies have shown that potentially less than 40% of patients with PHPT will undergo parathyroidectomy. This may be due to lack of recognition of diagnosis, lack of referral to endocrinology, lack of referral to surgery (especially if imaging obtained is nonlocalizing), as well as locoregional access issues. Due to this variability in evaluation and treatment recommendations for PHPT, several multidisciplinary committees have established standardized guidelines on the management of PHPT to guide providers on establishing the diagnosis of PHPT, and indications and timing of surgery.

Bilateral exploration of all four parathyroid glands, which will be referred to as comprehensive parathyroidectomy, was previously the standard method for parathyroidectomy. With the introduction of improved imaging techniques and intraoperative parathyroid hormone monitoring (IPM), there has been a shift in the technique of parathyroid surgery to minimally invasive techniques, which have become the preferred method when these intraoperative adjuncts are available. However, all surgeons performing parathyroid surgery must have knowledge and experience in comprehensive parathyroidectomy, as it may be required in patients with nonlocalizing preoperative imaging, when intraoperative adjuncts fail or are unavailable, and in patients with multigland PHPT. This chapter will focus on the method for comprehensive parathyroidectomy as well as introduce the use of IPM, which may be useful for both minimally invasive parathyroidectomy (MIP) and comprehensive parathyroidectomy.

ANATOMY AND PATHOPHYSIOLOGY

There are typically four parathyroid glands in most individuals, although autopsy study has identified five or more glands in up to 13% of people. Supranumerary parathyroids are most often located in the thymus. The possibility of having an unusual number or location of parathyroid glands has direct impact on the success of parathyroid surgery and the potential need for comprehensive parathyroidectomy.

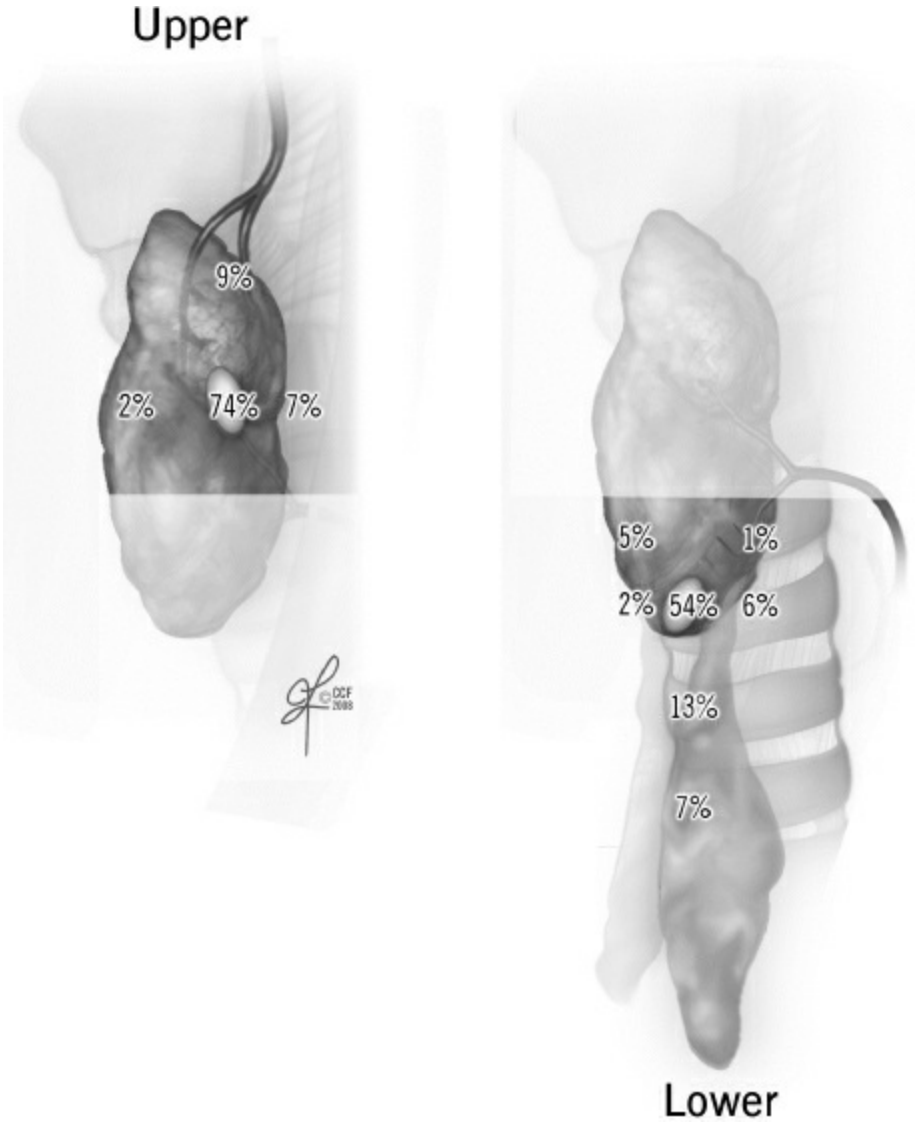

Figure 40.1. Normally expected distribution of upper and lower parathyroid glands. (Reprinted from Ritter H, Milas M. Parathyroidectomy: bilateral neck exploration. In: Terris D, ed. *Operative Techniques in Otolaryngology*. St. Louis, MO: Elsevier; 2009. Copyright © 2009, with permission from Elsevier.)

Embryologically, the upper parathyroids develop from the fourth branchial pouch and migrate caudally with the thyroid, while the lower parathyroid glands derive from the third branchial pouch and migrate with the thymus. The upper parathyroid glands have a narrow area of distribution and are fairly reliably positioned in the perithyroidal fat posterior to the superior pole of the thyroid gland and near the path of the recurrent laryngeal nerve as it enters the cricothyroid muscle. In contrast, the lower parathyroids are in an anterior plane with a long descent and more variable location around the lower pole of the thyroid gland,

thyrothymic ligament, and pretracheal fat. Symmetry is usually present between parathyroid locations in the left and right sides of the neck (Fig. 40.1). Migratory distribution of the parathyroids can lead to ectopic locations within the thymus, within the sheath encompassing the carotid artery, jugular vein, and vagus nerve even in high cervical locations, retroesophageally and even intrathyroidally (Fig. 40.2).

Calcium levels are closely regulated by interactions between parathyroid hormone (PTH) and vitamin D targeting bone, kidney, and gastrointestinal tract. In the normal state, PTH is released from chief cells in the parathyroid gland in response to low levels of ionized serum calcium, leading to resorption of calcium by the kidneys, hyperphosphaturia, increased renal synthesis of 1,25-dihydroxyvitamin D_3 (calcitriol) which increases interstitial calcium resorption, increased intestinal absorption of calcium and phosphate, and increased resorption of bone. PHPT refers to the inappropriate or unregulated secretion of PTH leading to abnormal calcium levels.

PHPT may be due to parathyroid adenomas, parathyroid hyperplasia, or rarely, parathyroid carcinoma. Parathyroid adenomas are most common, causing approximately 80% of cases of PHPT. Parathyroid adenomas are caused by a somatic DNA mutation in a parathyroid cell that provides a proliferative advantage and ultimately undergoes clonal expansion to produce the adenoma. Double adenomas may have an incidence of 2% to 15%, but may also represent a subset of patients with parathyroid hyperplasia. Parathyroid hyperplasia, present in 10% to 15% of patients with PHPT, is due to an increase in proliferation of parenchymal cells in all parathyroid glands. In PHPT, there is no biochemical stimulus for proliferation; this is in contrast to patients with secondary hyperparathyroidism, in whom parathyroid hyperplasia may be due to chronic low calcium levels or low vitamin D levels.

Most cases of PHPT are sporadic; however, PHPT may be associated with inherited syndromes in 3% to 5% of patients. These include familial isolated PHPT, multiple endocrine neoplasia type 1 (MEN1), multiple endocrine neoplasia type 2 (MEN2A), and hyperparathyroidism-jaw tumor syndrome (HPT-JT). PHPT is also linked to lithium use as it decreases the sensitivity of the parathyroid gland to circulating calcium and may also reduce urinary calcium excretion, which may ultimately lead to parathyroid hyperplasia. A history of radiation exposure, either environmental or cervical or whole body radiation for benign or malignant

conditions, is also a risk factor for developing PHPT. Parathyroid carcinoma is a very rare (<1%) cause of PHPT. It usually presents with significant hypercalcemia (>14.0 mg/dL) and frequently involves invasion of tumor into blood vessels, perineural spaces, soft tissue, or thyroid gland.

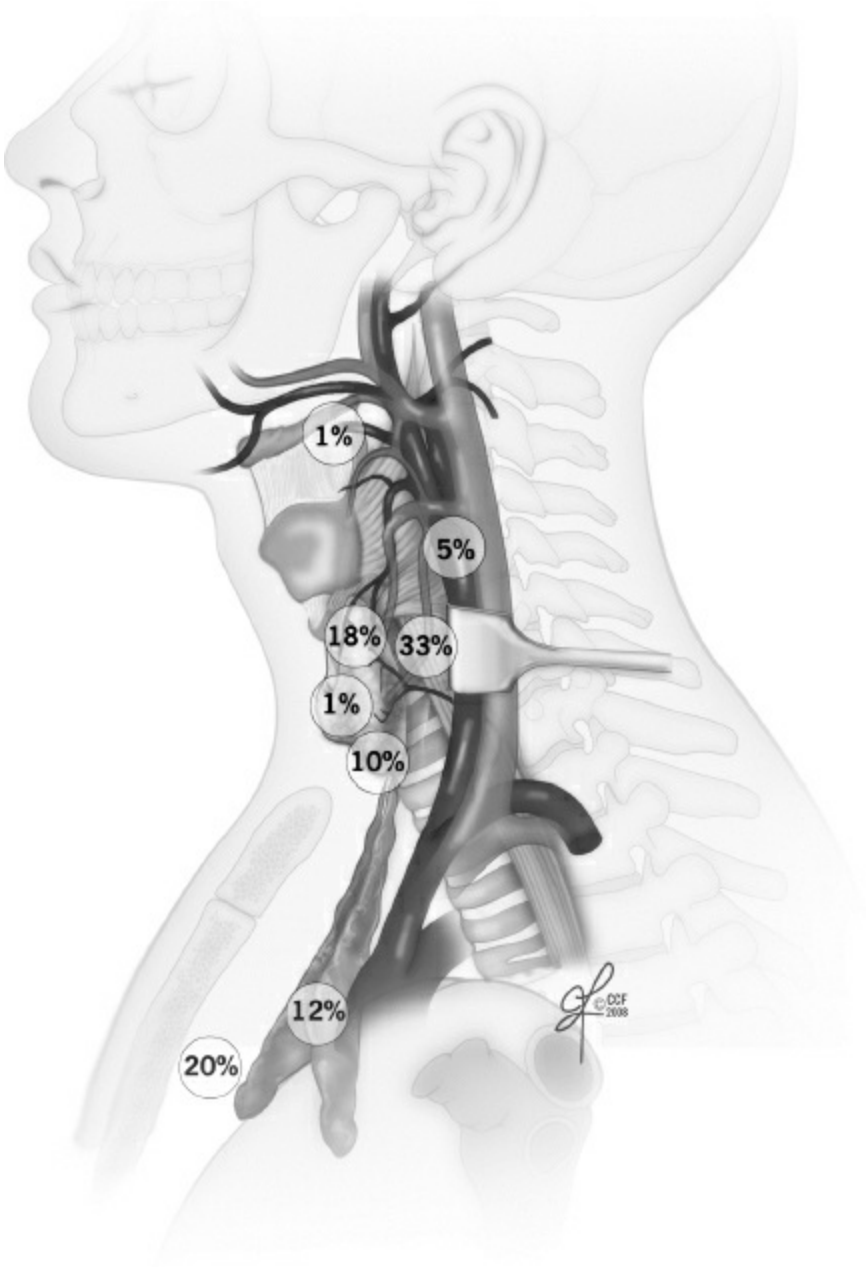

Figure 40.2. Distribution of ectopic parathyroid glands. (Reprinted from Ritter H, Milas M. Parathyroidectomy: bilateral neck exploration. In: Terris D, ed. *Operative Techniques in Otolaryngology*. St. Louis, MO: Elsevier; 2009. Copyright © 2009, with permission from Elsevier.)

TABLE 40.1 Signs and Symptoms of Primary Hyperparathyroidism

	Classical Signs and Symptoms	Potentially Unrecognized Signs and Symptoms
Neurologic	Lethargy Psychosis Coma	Anxiety Confusion Forgetfulness Fatigue Depression Poor sleep
Cardiovascular	Arrhythmia	Hypertension Ventricular hypertrophy
Musculoskeletal	Severe weakness Osteitis fibrosa cystica	Muscle weakness Bone pain Fractures Osteopenia/osteoporosis
Renal	Nephrolithiasis Renal insufficiency	Polyuria Polydipsia Nocturia
Gastrointestinal	Peptic ulcer disease Pancreatitis	Anorexia Constipation

CLINICAL PRESENTATION AND DIAGNOSIS

PHPT was first recognized as associated to parathyroid glands by Felix Mandl, who performed the first successful parathyroidectomy in 1925 in Vienna, Austria. At that time, patients often presented with advanced disease, and PHPT typically manifested as osteitis fibrosa cystica, characterized by generalized demineralization of bone, subperiosteal resorption, bone cysts, and brown tumors, or recurrent nephrolithiasis and kidney dysfunction. Patients also often presented with significant gastrointestinal symptoms including abdominal pain, peptic ulcer disease, and pancreatitis. Significant psychiatric and cognitive symptoms were also present, including generalized weakness, depression, and even coma. With the development of routine serum chemistry testing in the 1970s, the diagnosis of calcium abnormalities became more common and patients with few or no symptoms began to be diagnosed with PHPT. In the modern era, most patients do not present with advanced symptoms. However, many patients may have some unrecognized signs and symptoms related to the disease (Table 40.1).

In many patients, biochemical evaluation of PHPT is prompted by an incidentally identified elevated serum calcium level. In any patient with suspected PHPT, biochemical evaluation should include a serum total

calcium with simultaneous PTH, 25-hydroxyvitamin D, creatinine, albumin, and 24-hour urine calcium and creatinine levels. Table 40.2 details the recommended diagnostic studies. Calcium within plasma exists in the ionized (unbound) state, which is physiologically active and bound to other molecules, primarily albumin. Total serum calcium levels are a measure of bound calcium and are affected by albumin levels; therefore, total serum calcium should be corrected for albumin levels. In certain patients it may also be useful to obtain a simultaneous ionized calcium level, as some patients may have elevated ionized calcium levels but normal uncorrected total calcium levels. These patients are still considered to have PHPT. Vitamin D deficiency will increase PTH production, which is a type of secondary hyperparathyroidism; therefore 25-hydroxyvitamin D levels should be measured. However, patients with vitamin D deficiency alone will usually have normal or low calcium levels.

Some patients with PHPT may have elevated calcium levels with PTH levels within a normal range but inappropriately elevated in relation to calcium level. These patients should be considered to have PHPT and other workup and indications for surgery should be similar to classic PHPT. Another subset of patients may have normocalcemic PHPT, which is defined as consistently elevated PTH values and normal total and ionized serum calcium concentration without any secondary cause for the elevated PTH. Normocalcemic PHPT requires multiple measurements of total and ionized serum calcium and PTH values. The natural progression of normocalcemic PHPT is not certain although it has been suggested that normocalcemic PHPT may progress to classical PHPT with elevated serum and ionized calcium levels.

TABLE 40.2 Diagnostic Workup for Primary Hyperparathyroidism

Suspected PHPT

- Hypercalcemia or conditions related to PHPT (osteopenia, osteoporosis, kidney stones)
- History and Physical examination
  - Symptoms, prior head and neck irradiation, prior neck surgery, medication, other endocrine disorders, family history
- Laboratory testing: serum total calcium, serum ionized calcium, intact PTH, serum phosphate, 25-hydroxyvitamin D, 24-hour urine collection of urinary volume, creatinine, and calcium
- Diagnosis confirmed by: elevated serum total or ionized calcium or both with inappropriately elevated PTH and normal or elevated 24-hour calcium
  - If urine calcium is low (<100 mg/24 hrs) consider possible FHH, calculate urine calcium/creatinine ratio
    - Calcium Creatinine Clearance Ratio <0.01 suggestive of FHH

Suspected Normocalcemic PHPT

- Obtain multiple serum biochemical profiles—serum total calcium, ionized calcium, and PTH should be from same blood draw

- Correct vitamin D deficiency if present
- Eliminate other causes of secondary hyperparathyroidism

Other Causes of Hypercalcemia

- Bony metastases
- Sarcoidosis
- Multiple myeloma (check serum protein electrophoresis)
- PTH-RP-producing tumors such as breast, lung (squamous), head and neck (squamous), kidney, bladder, cervix, uterus, and ovary (check PTH-RP)
- Ectopic PTH-producing tumors (extremely rare)

Family History Present:

- Obtain genetic counseling/testing (Genes to be tested may include menin for MEN1, RET for MEN2, and CDC73 for HPT-JT)

PHPT, primary hyperparathyroidism; PTH, parathyroid hormone; FHH, familial hypercalcemic hypocalciuria; PTHrp, parathyroid hormone related protein; MEN1, multiple endocrine neoplasia type 1; MEN2, multiple endocrine neoplasia type 2; HPT-JT, hyperparathyroidism-jaw tumor syndrome.

Other causes for hypercalcemia or elevated PTH levels should be considered in patients undergoing evaluation for PHPT. Except for the rare case of ectopic PTH production, nonparathyroid causes of hypercalcemia will have suppressed PTH levels. The most common other cause of hypercalcemia is malignancy; if a malignancy is suspected, a parathyroid hormone-related peptide (PTH-RP) level can be obtained. Urine calcium levels are essential to exclude the rare condition of benign familial hypercalcemic hypocalciuria (FHH). Patients with this disorder have an inactivating mutation in the calcium-sensing receptor (CaSR) gene resulting in hypercalcemia with low urine calcium. These patients will not

benefit from parathyroidectomy. In patients with elevated PTH levels, medications and conditions associated with secondary causes of elevated PTH levels must be ruled out or accounted for. These may include the use of thiazide diuretics, bisphosphonates and lithium, malabsorption syndromes (including gastric bypass), and vitamin D deficiency (<20 μg/L) and insufficiency (20 to 30 μg/L).

A comprehensive family history must be obtained and patients with a family history should be considered for genetic counseling and/or testing. Current recommendations are for genetic counseling for patients <40 years of age with PHPT, those with multigland disease (MGD) (any age), and those with a family history or other disease processes associated with known syndromes such as jaw fibromas and uterine cancer (HPT-JT); pituitary and pancreatic tumors (MEN1); medullary thyroid cancer, and pheochromocytoma (MEN2A).

INDICATIONS FOR PARATHYROIDECTOMY

For patients with specific signs and symptoms related to PHPT such as kidney stones or fragility fractures, surgery is recommended. For patients with asymptomatic disease, in the current International Workshop on the Management of Asymptomatic Primary Hyperparathyroidism, a consortium of endocrinologists and endocrine surgeons, surgery is recommended for patients with: (a) serum calcium >1.0 mg/dL above the normal range; (b) osteoporosis (bone mineral density with T-score <−2.5 at lumbar spine, total hip, femoral neck, or distal 1/3 radius); (c) vertebral fracture; (d) nephrolithiasis by x-ray, ultrasound, or CT; (e) 24-hour urine calcium >400 mg/day and increased stone risk by biochemical stone risk analysis; or (f) age <50. Surgery may also be considered for patients for whom medical surveillance is not desired or not possible without any other contraindications. Parathyroidectomy is strictly contraindicated in patients with FHH as hypercalcemia will not improve. Patients with significant medical comorbidities who may have limited long-term benefit from parathyroidectomy may be considered poor candidates for parathyroidectomy.

Neurocognitive symptoms such as difficulty with concentration, cognition changes, sleep disturbances, depression, and reduced quality of life were not included in these guidelines, as indications for surgery in otherwise asymptomatic patients. However, studies have demonstrated that patients with PHPT suffer from these symptoms, although the symptoms

may overlap with other common diseases. Recent prospective studies using psychosocial assessment indices have found that patients may have improvement in symptoms within weeks after surgery with durable long-term effects. There have also been several randomized controlled trials of surgery versus observation which have found improvement in quality of life including lower anxiety and bodily pain, and improved general health after curative parathyroidectomy. However, the degree and area of improvement in neurocognitive symptoms have been varied among different studies; therefore, patients must be realistically counseled on potential benefits of surgery on neurocognitive symptoms.

Patients with otherwise asymptomatic disease may have unrecognized indications for surgery. Additional testing that should be performed include imaging to detect renal calculi, either abdominal x-ray, renal ultrasound, or noncontrast computed tomography (CT). Bone mineral density should also be evaluated by dual energy x-ray absorptiometry due to the increased bone turnover in PHPT. This should include evaluation of the forearm as it contains primarily cortical bone, which is most at risk for bone loss.

PREOPERATIVE PLANNING

Imaging

Once the diagnosis of PHPT has been established, imaging tests are recommended to attempt to identify abnormal gland or glands, if a MIP is planned. Nonlocalizing imaging studies do not preclude proceeding to parathyroidectomy, but may change the technique of parathyroidectomy. Cervical ultrasonography is the recommended initial test due to its cost effectiveness, lack of ionizing radiation, and its ability to assess concomitant thyroid disease (Fig. 40.3A). Evaluation of thyroid nodules, including fine needle aspiration, should follow current guidelines for evaluation of thyroid nodules. Cervical ultrasonography, whether performed by radiologists, endocrinologists, or surgeons, should be performed by a skilled ultrasonographer with knowledge of parathyroid anatomy. Ultrasonography is not as effective in identifying retroesophageal lesions and mediastinal parathyroid glands, secondary to depth of gland and poor transmission through gas-containing structures such as the trachea or esophagus. Meta-analyses have shown a sensitivity of 76% to 79% by trained ultrasonographers and a specificity of up to 96%. However, when MGD is present, sensitivity of ultrasonography to

identify all abnormal parathyroid glands does decrease significantly. Fine needle aspiration of suspected parathyroid glands is not recommended, as there have been concerns regarding potential seeding of parathyroid tissue (causing parathyromatosis) or that postbiopsy changes would affect interpretation of final histopathology.

Other imaging options include ^{99}Tmc-Sestamibi scan, preferably with single photon emission computed tomography (SPECT). ^{99}Tmc-sestamibi is normally distributed to the parotid and submandibular salivary glands, thyroid gland, heart, and liver, and not visualized in normal parathyroid glands. The rate of washout from hyperfunctioning parathyroid glands is slower; therefore, with delayed imaging the abnormal glands may be identified. Standard imaging obtains two-dimensional planar imaging with anterior views and possibly anterior oblique and lateral views. SPECT displays three-dimensional images with improved sensitivity, which may be even further improved when fused with CT. This allows for the combination of the three-dimensional physiologic information from SPECT with the anatomic information from CT (Fig. 40.3B). Sestamibi imaging has varied reported sensitivity and specificity due to institutional variability and use of varied protocols. A recent meta-analysis found the sensitivity of Sestamibi to be as high as 79%, while single institutions have reported sensitivities ranging from 45% to 92%. Sensitivity decreases significantly in patients with MGD and smaller parathyroid glands.

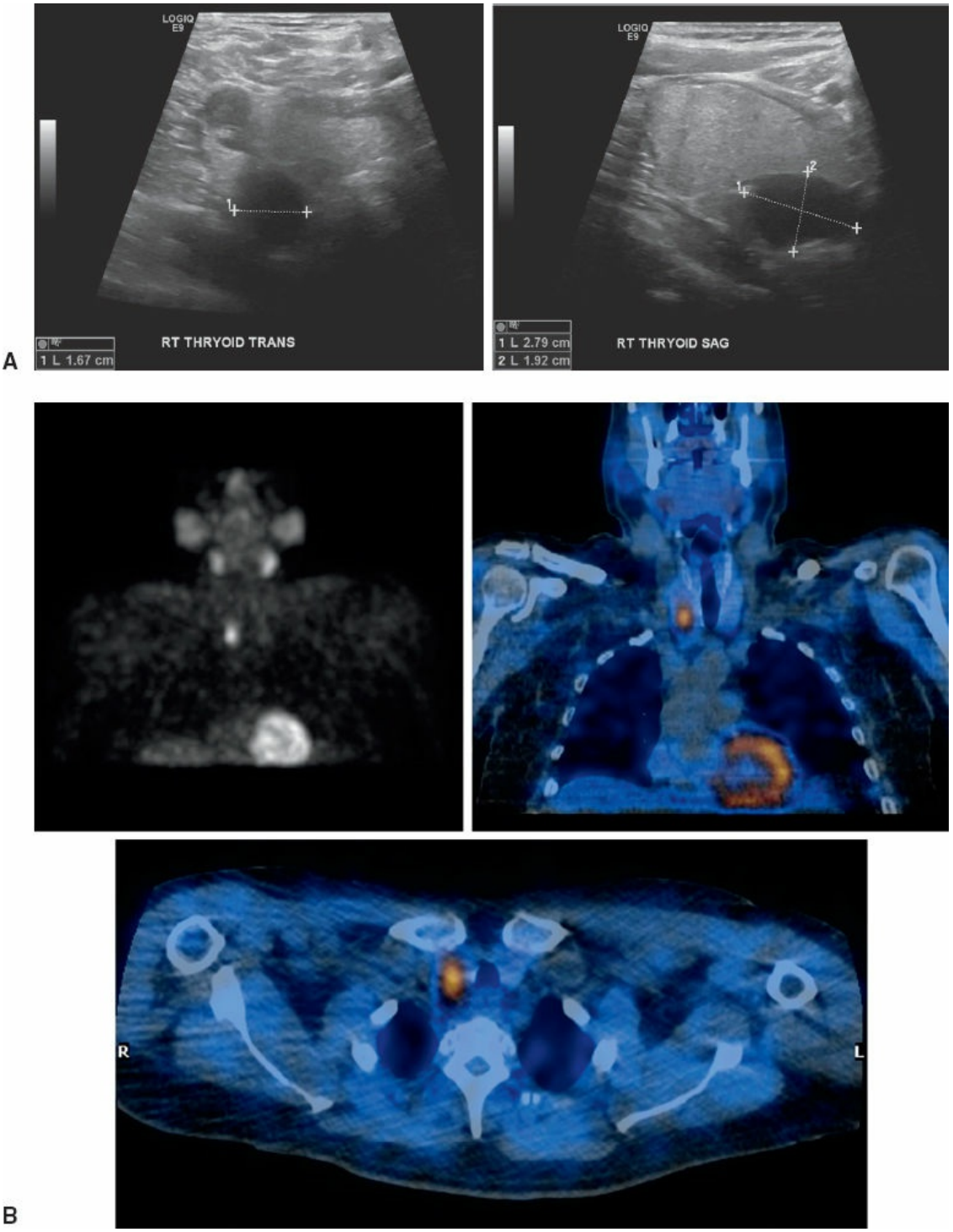

Figure 40.3. Preoperative imaging. **A.** Cervical ultrasound shows a 1.7 × 2.8 × 1.9 cm suspected parathyroid adenoma posterior to mid right thyroid lobe. **B.** The 99-Tc Sestamibi image shows an abnormality on the right side that is more precisely seen on the color SPECT.

4D-CT is a multiphase detector CT examination that combines the three-dimensional CT scanning with an added dimension from changes in

perfusion of contrast over time (Fig. 40.4). Parathyroid adenomas generally demonstrate a rapid uptake and washout compared to thyroid and adjacent tissue. On meta-analysis, 4D-CT has been found to have sensitivity as high as 89% and positive predictive value of 93.5%. Obtaining images does require having the appropriate imaging protocol as standard neck CT does not use thin sections or multiphase acquisition and may not yield equivalent results. Disadvantages include radiation exposure and need for iodinated contrast.

Preoperative ultrasound-guided differential jugular venous sampling may aid in localization of parathyroid disease in certain patients, especially in patients with persistent or recurrent disease. Whole blood is collected from each internal jugular vein and sent to the laboratory for PTH measurement. If the jugular venous PTH level on one side of the neck is 10% higher than the opposite side, the test is considered positive (localizing). Reported accuracy of this technique for abnormal parathyroid glands is 71% to 81% and may be a useful adjunct to other anatomical localization studies.

Overall, which imaging modality is obtained is generally based on surgeon preference and availability. The diagnosis of PHPT is based on biochemical evaluation and is not dependent on imaging. Imaging may be used to aid in preoperative planning but should not be used to select patients for surgical referral. For patients selected to undergo comprehensive parathyroidectomy, based on surgeon preference or other considerations, it is valid to consider whether imaging is necessary. However, preoperative imaging may help in comprehensive parathyroidectomy by allowing focused early dissection on the region of greatest suspected abnormality as well as the ability to identify concomitant thyroid disease, which may be addressed in the same procedure.

Other Considerations for Preparation for Surgery

In the evaluation and preoperative period, patients do not need to restrict their calcium intake and should maintain an intake in accordance with the Institute of Medicine guidelines, (1,000 to 1,200 mg calcium daily, via diet and supplements). It is not uncommon for patients to have low 25-hydroxyvitamin D levels; deficiency is typically defined as <20 ng/mL. There has been concern that vitamin D repletion in patients with PHPT may worsen hypercalcemia. However, this is rare and recent studies have

demonstrated that patients may be safely repleted without risk of hypercalcemia. Caution should be taken in patients with marked hypercalciuria, as this may be aggravated by vitamin D supplementation.

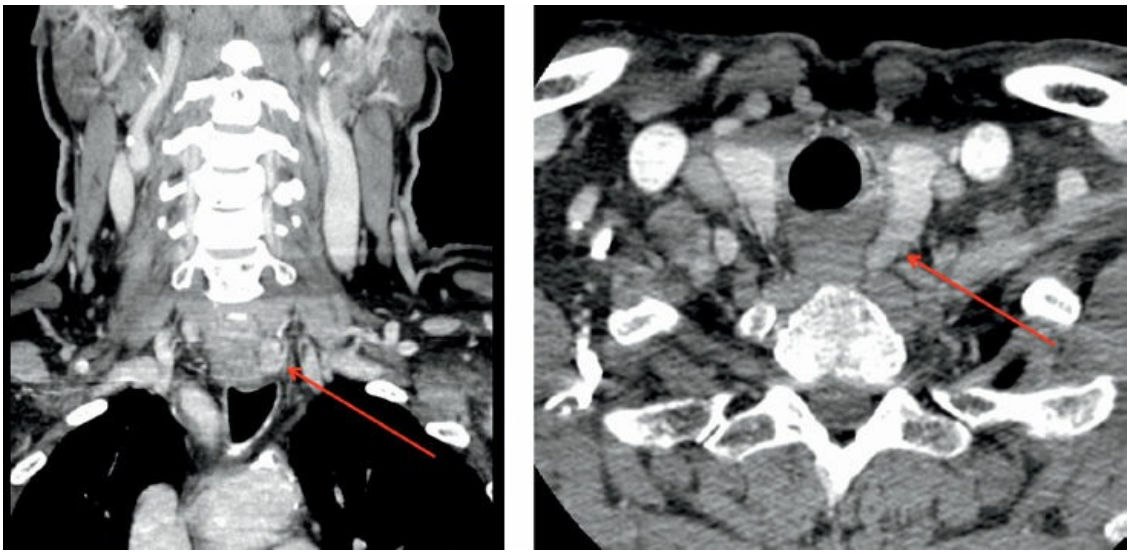

Figure 40.4. Preoperative imaging. 4D CT shows a 1.6 × 0.9 cm soft tissue lesion posterior and medial to the left inferior thyroid lobe consistent with parathyroid adenoma.

One of the most feared complications of parathyroid surgery is recurrent laryngeal nerve injury, although the incidence of permanent injury in parathyroid and thyroid surgery is <1%. The patient's voice should be examined as part of routine examination and in cases where subjective changes in the patients' voice, either by the patient or by the surgeon, are present or prior anterior cervical surgery (including thyroidectomy, previous parathyroidectomy, carotidectomy, cervical fusion, and/or thoracic procedures) has been performed with risk to the vagus or recurrent laryngeal nerves additional evaluation may be indicated. This may include indirect/direct laryngoscopy, sonographic evaluation of vocal cord motion, and/or videostroboscopy.

SURGICAL TECHNIQUE

Parathyroidectomy can be accomplished with minimal invasiveness and morbidity, gentle dissection. Most surgeons currently perform parathyroid surgery with general anesthesia, while some use local anesthetics supplemented by deep cervical nerve block and sedation. No antibiotics are needed except in reoperative cases, or in patients with other indications for prophylaxis. For prophylaxis of deep vein thrombosis, sequential

compression devices are adequate for most patients.

Traditional comprehensive parathyroidectomy requires bilateral cervical exploration with the identification of all four parathyroid glands and excision of all grossly enlarged glands, based on the surgeon's judgment. Normal parathyroid glands should be kept in situ. This method has been shown in large series to have success rates of 95% to 99% when performed by experienced parathyroid surgeons. However, curative rates are lower and risk of complications are higher when performed by inexperienced surgeons. Although comprehensive parathyroidectomy is a necessary skill for parathyroid surgeons, with contemporary techniques for preoperative imaging and the use of intraoperative adjuncts, such as IPM, operative cure can be obtained by directing the procedure to only the abnormal gland, MIP. Comprehensive parathyroidectomy may be performed based on surgeon preference, nonlocalizing imaging, suspicion for MGD, or when intraoperative PTH levels do not appropriately fall. Table 40.3 shows indications for comprehensive parathyroidectomy.

TABLE 40.3 Indications for Comprehensive Parathyroidectomy as the Initial Surgery for PHPT

Absolute Indications

- Coexisting thyroid cancer or bilateral goiter requiring total thyroidectomy
- Failure to find diseased gland at location indicated by imaging studies
- Intraoperative PTH fails to drop after resection of suspected single adenoma
- Imaging studies suggest multiple sites of disease
- Known or suspected multiple endocrine neoplasia syndromes (initial surgery)
- Finding more than one abnormal parathyroid during intended focal or unilateral neck exploration

Advisable Indications

- Negative or discordant parathyroid imaging studies
- Unavailability or malfunction of intraoperative PTH measurement
- Lithium-induced PHPT
- Non-MEN familial hyperparathyroidism
- Surgeon preference or experience

Comprehensive parathyroid exploration can be performed without the use of intraoperative adjuncts, although these may be helpful depending on the complexity of surgical findings, assessment of usefulness by the individual surgeon, or experience of the surgeon. Numerous intraoperative adjuncts have been described. Most notably IPM has become a fundamental part of modern parathyroid surgical practice and may be used

to confirm complete excision of hyperfunctioning glands. Other adjuncts include frozen section histology and needle aspiration of excised tissue for measurement of PTH as means of distinguishing parathyroid from nonparathyroid tissue. It is useful to recall that frozen section examination and permanent histology both cannot distinguish between single adenomas and multigland hyperplasia. Intraoperative gamma probe has been applied to in vivo localization of abnormal parathyroids and ex vivo measurement of radiotracer counts as markers of normal versus abnormal parathyroids. Near-infrared autofluorescence with use of a fluorescence system to distinguish parathyroid tissue is a newer method that is under investigation. These different methods may require specific equipment and have varying efficacy that has been documented or continuing to be elucidated in the literature. Ultimately the use of these different adjuncts may be surgeon and institution dependent and perhaps more often applied to MIP.

Technique

Once anesthetized, the patient is positioned with arms tucked at the side and head gently hyperextended, facilitated by placement of a roll or inflatable pressure infuser bag under the shoulders. Both arms are tucked and bed is placed in semi-Fowler position with the knees bent. Care to have vertical alignment of the patient’s chin, suprasternal notch, and center of the thyroid cartilage aids a symmetric incision. It may be useful to take note of natural skin creases when patient is awake and sitting upright to use as a site of incision. The authors prefer chlorhexidine for sterile prep because it is nonflammable and avoids potential irritation and staining of the face and neck.

A transversely oriented incision is made according to the optimal site marked. In most patients, this is 1.5 to 2 fingerbreadths above the suprasternal notch. The length of the incision varies with surgeon preference, and usually does not need to be longer than 4 to 6 cm. The incision is carried down by electrocautery through the platysma muscle that is about 2 to 3 mm thick (more visible in men) and relatively free of blood vessels. Deep to the platysma is an avascular plane just above the anterior jugular veins that should be developed to aid exposure, using a combination of electrocautery and blunt dissection. This subplatysmal plane is developed until the thyroid cartilage is palpable superiorly and the sternal notch inferiorly, but can be dissected less in thin patients.

Mobilizing these flaps offers optimal exposure through small incisions by increasing the ease of retraction.

The avascular midline raphe of the strap muscles is opened vertically along the midline to separate the muscles and expose the thyroid. Electrocautery is generally sufficient for tiny branches that may cross the midline. If preoperative imaging was obtained and a potential abnormal gland was identified on imaging, exploration should first begin on that side. Fine instruments based on surgeon's preference can be used for the dissection with the goal of maintaining a bloodless field with minimal manipulation of potential parathyroid tissue. If no imaging was obtained or it was nonlocalizing, laterality may not matter, although a systematic order of exploration, particularly if comprehensive parathyroidectomy is planned, can be useful. For comprehensive parathyroidectomy, a convenient strategy is to target exposure of the most abnormal parathyroid first, then the ipsilateral parathyroid, and finally explore the contralateral side. When all parathyroids have been identified, assessment about the disease process (single adenoma, double adenoma, or multigland hyperplasia) can be made and a decision about which parathyroids to remove and in what order can be determined.

Irrespective of planned extent of exploration, careful dissection should be performed staying close to the thyroid gland in expected location for superior and inferior glands. The sternothyroid muscle is bluntly separated from the undersurface of the sternohyoid muscle for a short distance, again to aid mobility in lateral retraction. The loose areolar tissue between the sternothyroid muscle and thyroid is taken down with cautery at low settings or with blunt dissection. It is important to separate these tissues or any pretracheal fat at the very edge of the sternothyroid muscle, to avoid unintentionally displacing parathyroid tissue laterally. Traction is exerted on the thyroid lobe by using a peanut or manually with 4 × 4 sponges, in order to elevate and medially rotate the lobe. This exposes the lateral and posterior thyroid surface, and brings the middle thyroid vein into view. This vein is always above the plane of the carotid artery, which should now be visible or palpable. The vein courses in a medial to lateral direction, similar and often parallel to the inferior thyroid artery, which in contrast, is always situated deep to the carotid artery. The middle thyroid vein can be isolated, ligated, and divided if necessary to facilitate exposure.

When an area of likely parathyroid abnormality is seen, careful blunt

dissection is done using a fine curved hemostat or right angle to separate the overlying fatty tissue looking for subtle color changes of the parathyroid. Normal parathyroid glands are small in size, weighing less than 50 mg. They generally have a yellow-brown color and are not detectable by preoperative imaging. A normal parathyroid will appear flattened and have a leaf-like vascular pattern absent in simple fat or thymus. It can be gently coaxed out of the areolar or fatty covering to determine its entire size and that it does not hide an enlarged segment (a "cap of normal" disguising an underlying parathyroid tumor).

Abnormal or enlarged parathyroid glands may display more prominent variable morphologic changes in size, shape, texture, and firmness. Abnormal parathyroid glands are generally fuller in all dimensions, have a darker brown or reddish-brown color, and do not compress easily or are significantly firm when gently probed. They will often appear as a mass bulging below thicker tissue, or have a sliding motion back and forth beneath a film of thin areolar cover ("float sign"). They may also have an irregular and knobby shape, more prominent vascular pedicles, or a plexus of vasculature. Glands of patients with secondary and tertiary hyperparathyroidism may be sclerotic and light in color from fibrosis. The abnormal parathyroid should also be separated from the encasing thin areolar tissue so that its only attachment is the vascular pedicle. Ideally, the dissection should free the enlarged parathyroid along its lateral and posterior aspects first, leaving the medially located pedicle along the thyroid last. Single or double adenomas should be treated with simple excision of the abnormal gland(s). We will discuss below the use of IPM.

Multigland hyperplasia is suspected when all four glands are enlarged and should be ideally treated with subtotal parathyroidectomy and parathyroid cryopreservation if available. Subtotal parathyroidectomy consists of removing 3.5 parathyroid glands. The most normal appearing of the four glands should be chosen and the remnant should be created first. This should preferably be an inferior gland as these are easier to approach in the future if reoperation is needed. The remnant should be about one to two times the size of a normal parathyroid gland, have a good vascular pedicle, and is ideally anteriorly located. It should be marked with a nonabsorbable suture or surgical clip. It is always easier to remove more tissue than to deal with a small remnant and potential hypoparathyroidism. This is where IPM can also be useful. More elongated or oval parathyroids with a discrete identifiable vascular pedicle are better suited for the

remnant. Subsequently the remaining hyperplastic parathyroid glands may be resected. Prior to resecting the final gland the remnant should be inspected. If there is concern that the remnant does not appear viable a remnant may be fashioned from the remaining gland.

If the initial examination of eutopic locations does not identify all four parathyroid glands or if the IPM reveals the presence of additional abnormal parathyroid tissue, then further exploration is needed. Important areas to examine are summarized in Figure 40.5. The most commonly missed location is a retroesophageal parathyroid that has sunken into the deep posterior space behind the tracheoesophageal groove, often lying on the anterior surface of the spine and below the main trunk of the inferior thyroid artery. This parathyroid is embryologically derived from the upper gland, although it often appears to have a position more inferior than the actual lower gland, both intraoperatively and on imaging studies (Fig. 40.6). The thymus should be retracted out of the mediastinum as far as possible without avulsion, carefully examined, palpated, and removed. The middle thyroid vein should be ligated and divided, if not already done, as this provides greater exposure of the trachea and esophagus. Mobilizing the upper thyroid pole as during thyroidectomy can occasionally disclose ectopic parathyroids without devascularizing the thyroid gland. Thyroid lobectomy on the side of the missing abnormal parathyroid may be justifiable even when no palpable abnormalities exist, but this circumstance can potentially be avoided if preoperative ultrasound describes a normal thyroid without nodules. Examination of the path along the carotid artery and jugular vein can be performed as widely as the incision allows. The skin incision can be enlarged to permit adequate exposure of any of these regions.

Parathyroid gland location is generally symmetrical and can aid in contralateral neck exploration. A parathyroid located at the posterior midpoint of the thyroid lobe could represent either a lower gland that sits higher than usual, or an upper gland that is more inferior than usual. Finding the other ipsilateral gland should take into account both possibilities. Double parathyroid adenomas, reported in 3% to 15% of patients, have a nonuniform distribution that favors enlargement of both upper parathyroids.

During parathyroidectomy, care should be taken to avoid injury to the recurrent laryngeal nerve, which may be found in the tracheoesophageal groove; the surgeon should note that the course of the recurrent laryngeal

nerve on the right side may be more variable than on the left. Its entire course does not need to be exposed but adequate identification should be performed to ensure its safety and as a potential guide to identification of parathyroid glands.

After exploration and resection are completed, the neck is irrigated with sterile water, which provides a clearer view of the surgical field than saline. Hemostasis is achieved. Each gland or remnant should be re-evaluated for viability. Some mild bruising and discoloration of the parathyroids is acceptable. If remaining parathyroid tissue has become completely black from ischemia or has questionable viability, it can be reimplanted into the ipsilateral sternocleidomastoid muscle. This is done by mincing the normal parathyroid tissue using a fresh blade and inserting the entire sample into a small window created within the sternocleidomastoid muscle. This window is sutured closed with a permanent prolene suture and can also marked with a clip in case there is need for identification and removal in the future. The strap muscles and platysma are reapproximated with absorbable suture, and the skin incision is closed. Drains are seldom, if ever, necessary. Our preferred technique uses a 5-0 prolene subcuticular stitch with long tails left in place and steristrips applied. The suture is removed on postoperative day 1. Absorbable monofilament (monocryl) may also be used.

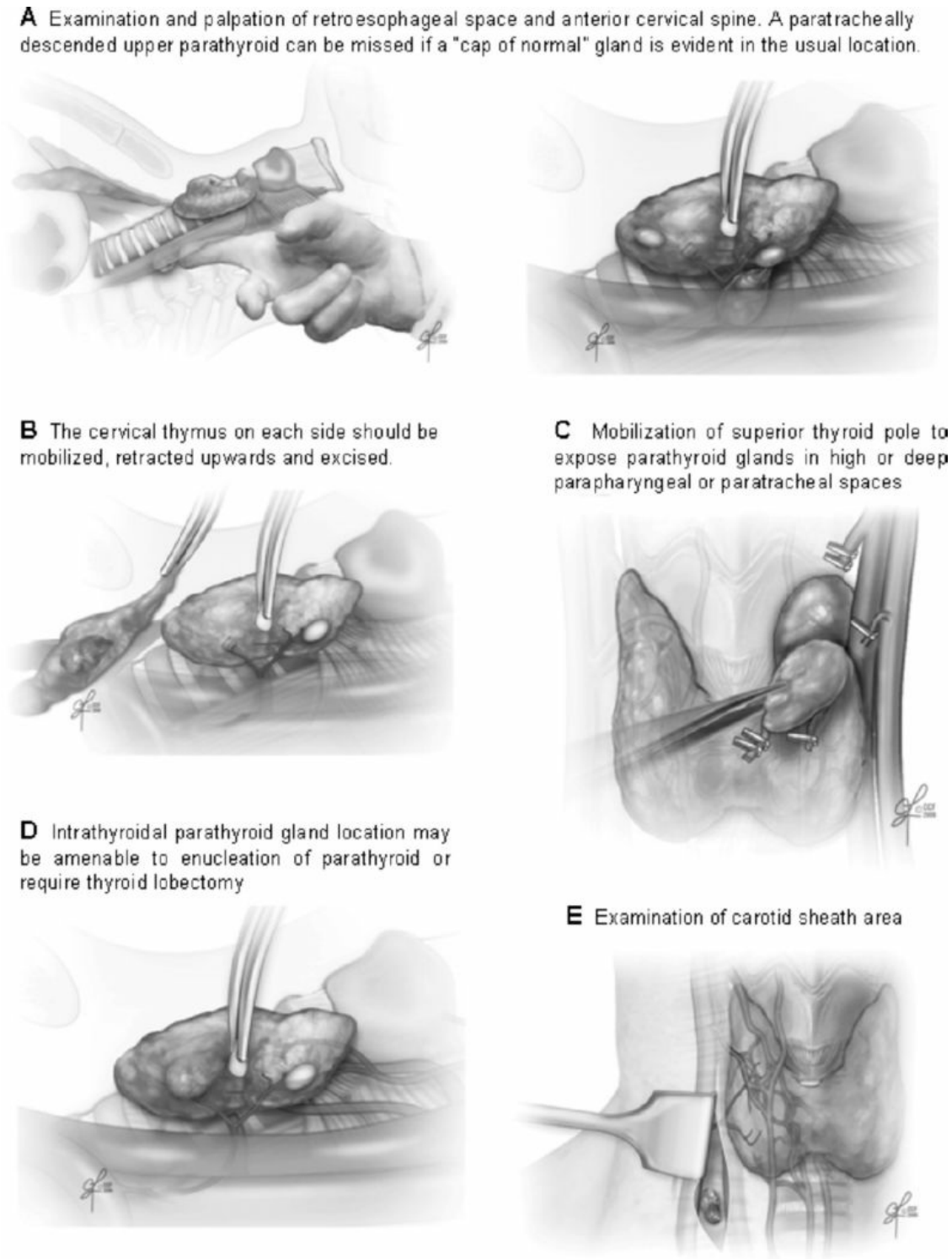

Figure 40.5. Secondary parathyroid survey examines areas of atypical or ectopic parathyroid location when initial exploration fails to reveal all pathologic glands.

Intraoperative Parathyroid Hormone Monitoring

IPM may be used as an intraoperative adjunct to confirm the complete excision of all hyperfunctioning parathyroid tissue. IPM is possible due to

the short half-life of PTH (3 to 5 minutes) and the use of a rapid immunochemiluminescence assay technique that runs for 8 to 20 minutes. Turnaround time may also be decreased by close proximity of the testing equipment to the operating room. A standard protocol should be used that the operating room staff and laboratory team are all well-informed of. It requires multiple blood collection samples that may be obtained from peripheral venous or arterial access. A central neck vein may also be used for blood samples although studies have shown levels may be higher then systemic levels and take longer to decrease. Central neck veins may be used to aid in lateralization as discussed below.

There are several intraoperative criteria that may be used to predict removal of a hyperfunctioning parathyroid tissue. The initially described protocol was developed at the University of Miami by George L. Irvin III, MD, and requires a “>50% drop in PTH” 10 minutes after resection of hyperfunctioning tissue to predict postoperative eucalcemia. Samples should be drawn at specific times during parathyroidectomy. The intravenous access is kept open with a slow infusion of saline, which must be discarded from the line before any blood sample is measured to prevent dilution. During the procedure, the anesthesiologist collects 4 mL of whole blood in an EDTA tube at specific times: (a) a “preincision” level before skin incision, (b) a “pre-excision” level collected after dissection and just before clamping the abnormal gland’s blood supply, (c) a 5-minute level, and (d) 10-minute level after excision of the suspected abnormal gland. When peripheral PTH values drop more than 50% from the highest either preincision or pre-excision level 10 minutes after the excision of all abnormal parathyroid gland(s), this criterion predicts normal or low calcium levels postoperatively with an overall accuracy of 98%. After this sufficient decrease occurs, the procedure may be terminated without any need for further parathyroid tissue excision. Conversely, if the hormone level fails to drop at the 10-minute interval following excision of a suspected hyperfunctioning parathyroid gland, the PTH assay signals that more hypersecreting tissue is likely to be present. Thus, the surgeon is directed to continue the exploration as a comprehensive parathyroidectomy with the above described protocol applied to each removed gland.

Other IPM criteria have also been developed. Our preferred criteria is the Normal range (or Dual Criteria) Protocol. Intraoperative criteria for a biochemical cure is met when the PTH level drops >50% from the highest value (preincision or preexcision) and falls into the normal range.

Additional levels beyond 10 minutes may be necessary to meet both criteria. If both criteria are not met this indicates residual hyperfunctioning parathyroid tissue and additional exploration is required. PTH levels are obtained as described above. We prefer to obtain the preincision level before entering the operating room to avoid any potential elevation from manipulation of parathyroid glands, particularly anteriorly located glands, during intubation or surgical prep. If comprehensive parathyroidectomy is planned and a clear adenoma is identified during initial exploration, either aided by imaging or not, resection of gland may be performed and levels obtained while completing exploration for remaining glands. However, if the initial gland appears only slightly enlarged or normal it is recommended to proceed with systematic exploration as described before resection of any glands.

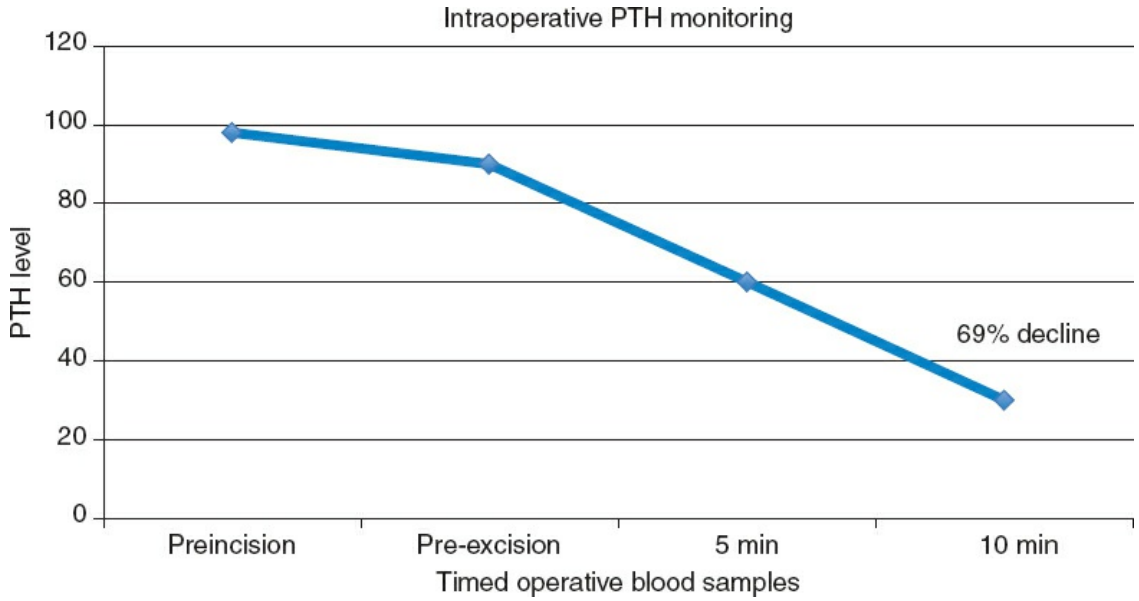

Figure 40.6. Intraoperative parathyroid hormone (PTH) dynamics after removal of a single parathyroid adenoma. At 10 minutes there was a 69% decline in PTH level from highest level (preincision), which is consistent with biochemical cure.

As an example, Figure 40.6 shows the PTH levels in a patient after excision of a single hypersecreting gland. The hormone dynamic shows an adequate >50% PTH drop at 10 minutes from gland excision from the preincision level, which was higher than pre-excision level, and into normal range. Conversely, if the hormone level fails to drop at the 10-minute interval after excision of a right inferior parathyroid adenoma, the persistently elevated PTH assay indicates that additional hypersecreting

tissue is likely present. Upon further exploration after identifying the three remaining glands, an additional adenoma is identified—a left inferior parathyroid adenoma (Fig. 40.7). Levels are obtained in a similar fashion starting with the pre-excision level and the IPM drops at the 10-minute interval appropriately indicating all hypersecreting tissue has been removed.

IPM criteria are not as effective when both preincision and pre-excision levels are not obtained. The pre-excision level may increase ("spike") significantly due to manipulation of abnormal gland(s) during exploration or dissection. In these instances, if only a preincision level is obtained, the PTH level may not drop >50% from this level at the 10-minute interval. This may lead to the need for additional PTH levels, potential prolongation of the procedure and occasionally unnecessary additional tissue excision. However, in some patients even when all hypersecreting tissue has been excised and all parathyroid glands have been identified, the dual criteria may not be met at 10 minutes. This may be more common when there is a PTH spike that is especially high (greater than three times the baseline). Recent analysis has shown that in these cases it may not be necessary to wait until the final PTH level is within a normal range as long as an appropriate decline of >50% has occurred. Ultimately the surgeon must use his/her best judgment and analysis of the hormone dynamics in deciding when to terminate the procedure.

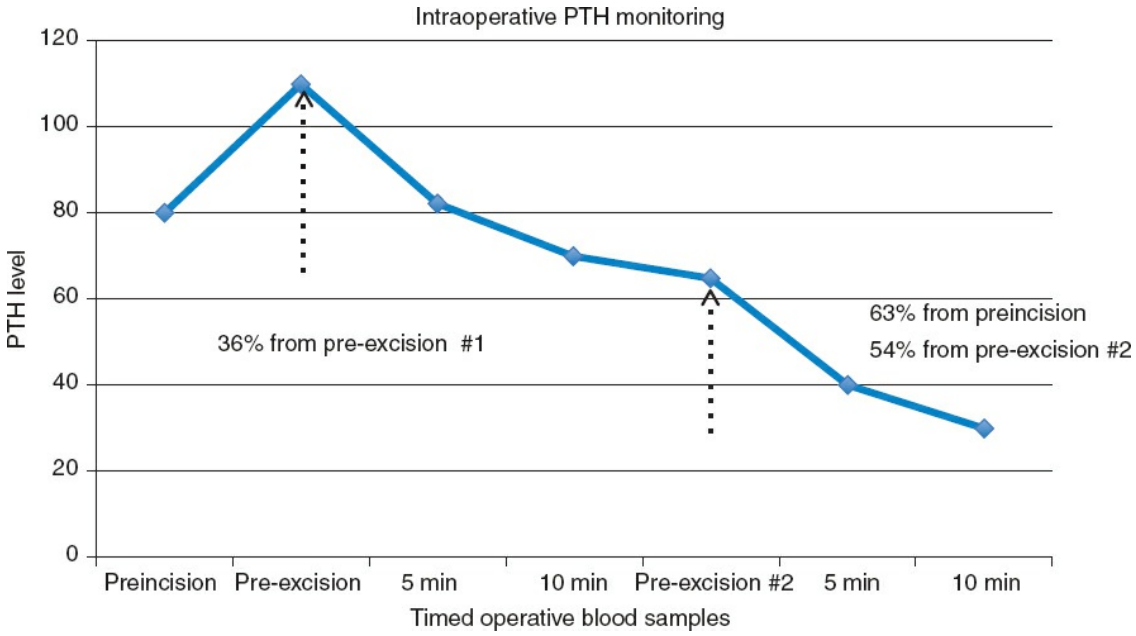

Figure 40.7. Intraoperative parathyroid hormone (PTH) dynamics in a patient with multigland disease. At time of right inferior gland

excision there is a mild increase (spike) in PTH level to 110 pg/mL. At 10 minutes there is only a 36% decline from highest value (pre-excision) indicating there is remaining hypersecreting parathyroid tissue. A left inferior parathyroid adenoma is also identified and repeat levels are obtained. At 10 minutes from the second gland excision the PTH level has dropped to 30 pg/mL which is a 64% decline from the preincision value and consistent with removal of all hypersecreting parathyroid tissue. The *dotted lines* indicate time of gland removal.

In certain situations, internal jugular venous vein sampling may aid in identifying the laterality of the abnormal parathyroid glands if initial bilateral cervical exploration does not demonstrate abnormal appearing parathyroid tissue or when one of the glands cannot be identified. If performed for this reason, samples should be taken from both right and left internal jugular veins, preferably as low as possible in the neck to account for all possible drainage, at the same time as a peripheral level is obtained. Lateralization is indicated by a PTH level 10% or higher than the opposite side. Further exploration may be further directed on the appropriate side. If both glands have been identified on the lateralizing side a supernumerary gland may be present. If both glands are not identified and PTH levels suggest lateralization, thyroid lobectomy or thymectomy should be considered.

Confirming Parathyroid Tissue

Intraoperative confirmation that the resected tissue is parathyroid tissue is recommended, especially if IPM is not being performed. The most frequently used method is frozen section. This has varied accuracy and may lengthen operative time and incur additional costs. However, it is widely available and most commonly used. Ex vivo aspiration of parathyroid and analysis for PTH levels is a point-of-care method that allows for rapid results where IPM is available with specificity and positive predictive values of up to 100%. In this method, presumed parathyroid tissue is aspirated with multiple passes of a 3 mL syringe prefilled with 1 mL of normal saline, using a 22-gauge needle. After aspiration an additional 1 mL of normal saline is aspirated directly through the needle to allow all aspirate material to be drawn into the syringe. Then the syringe may be passed off the sterile field to be tested for PTH level. Based on a recent study, a level of at least >1.5× above baseline is

indicative of parathyroid tissue, with typical levels being >5,000 pg/mL. Weight is a reliable distinguishing factor and should be part of the pathology report as well. Several studies have suggested that when the initial gland excised is <200 mg in size, it is more likely that MGD is present. Finally, the IPM results can help guide the surgeon in confirming that parathyroid tissue has been removed.

Reoperative Parathyroidectomy

Reoperative parathyroidectomy may result in unexpected challenges. Reoperative cases may be due to persistent or recurrent PHPT, or to initial parathyroidectomy in patients that have had prior thyroidectomy. In these cases, it is essential to obtain as much information as possible by study of prior operative and pathology reports. These will provide information on what, if any parathyroid tissue or other tissue was identified and/or resected. Without histologic confirmation of parathyroid tissue that was not removed, one cannot assume that the reported gland was actually identified. In the case of previous thyroidectomy, review of previous operative notes and pathology reports are critical to determining the status of the remaining parathyroid glands. It may be possible that the only functioning parathyroid gland is an abnormal gland in these situations and this must be considered intraoperatively.

Surgery in the reoperative field is more challenging due to tissue fibrosis, distortion of anatomy, and loss of natural tissue planes. The cure rates in reoperation, 82% to 98%, are lower than for initial parathyroidectomy and risk of complications are higher, with reported rates of 5% to 8% for postoperative hypoparathyroidism and up to 15% for recurrent laryngeal nerve injury. Therefore, most surgeons will apply stricter indications for surgery for these patients with more significant symptomatology and hypercalcemia. Imaging is essential in these cases and comprehensive parathyroidectomy is generally not recommended as the initial approach for reoperation. Surgery should be directed toward glands identified on imaging if possible. IPM may be useful in these cases to allow for monitoring of PTH levels after excision of identified abnormal gland. If PTH levels drop too low (<10 pg/mL), reimplantation of parathyroid tissue may be required. For this reason, all excised tissue should be kept on the operative field until the end of the procedure.

POSTOPERATIVE CARE

There are a number of essential issues in the immediate and long-term postoperative care of patients after parathyroidectomy. These include appropriate documentation of operative findings, observation for postoperative complications of hematoma or recurrent laryngeal nerve injury, calcium supplementation, monitoring for hypocalcemia and hypoparathyroidism, and long-term follow-up. Documentation of operative findings should be detailed and include specific description of all visualized glands including the relation to the recurrent laryngeal nerve, appearance, and management of the gland (removed, biopsied, transected, left viable in situ); all areas explored, any additional procedures (thyroidectomy, thymectomy, etc.), and results of IPM. These key points are essential for communication to other members of the care team and if there is need for future cervical or parathyroid surgery.

Complications from parathyroidectomy include hematoma, recurrent laryngeal nerve injury, transient or permanent hypoparathyroidism, and operative failure (persistent PHPT). Infections from parathyroid surgery are very rare. The rate of neck hematomas requiring operative evacuation is low at approximately 0.3%, while MIP has not reported to require reoperation for hematoma. Several large institutional studies have found that almost all cervical hematomas will be identified within 4 to 6 hours postoperatively. However, overnight observation is not essential for comprehensive parathyroidectomy; if multiple glands are removed we recommend one night observation. Signs and symptoms of postoperative hematoma include increasing swelling, neck pain, difficulty swallowing, respiratory distress, and voice changes. This is a potentially life-threatening complication and the treatment for neck hematomas should be immediate operative evacuation. The rates of permanent recurrent laryngeal nerve injury for initial parathyroidectomy are reportedly lower than with thyroidectomy (0.3% to 1.0%). Rates do increase with reoperative parathyroidectomy (2% to 9%). If nerve transection is noted during the procedure reinnervation should be attempted. For all patients if voice abnormalities are noted after procedure, formal evaluation by fiberoptic laryngoscopy or transcutaneous laryngeal ultrasound should be performed.

There is currently no standard for postoperative calcium management after parathyroidectomy. We recommend starting all patients on calcium supplementation postoperatively as relative and/or symptomatic hypocalcemia is common. This may be more frequent in patients with

vitamin D deficiency and/or malabsorption, and after comprehensive parathyroidectomy, especially with MGD. Calcium supplementation may vary based on preoperative calcium levels, adenoma size, rate of drop of IPM levels, and calcium levels in the perioperative period. Regimens may include calcium supplementation of 1,000 mg twice daily up to 2,500 mg three times daily, with as needed supplementation for symptoms. Additional activated vitamin D supplementation (calcitriol) may be necessary in patients with significant drops in PTH levels, calcium levels, or significant symptoms. IV calcium supplementation may be very infrequently necessary for parathyroidectomy for PHPT. The rate of permanent hypoparathyroidism for initial parathyroid surgery is low, 0% to 3.6%.

Patients should be seen in postoperative visit within 1 to 2 weeks after procedure. Laboratory testing including calcium and PTH levels should be obtained and calcium supplementation may be weaned down as needed. Subsequent testing may be obtained as needed. Patients should ultimately continue calcium and vitamin D intake levels according to the Institute of Medicine dietary recommendations. Successful parathyroidectomy is defined by normocalcemia at 6 months post procedure. Therefore, it is critically important that the patient have at least 6 months of postoperative follow-up, by either the surgeon or a member of the multidisciplinary team. Recommended laboratory tests at the 6-month timepoint include calcium, PTH, and 25-hydroxyvitamin D levels.

OUTCOMES

When performed by experienced parathyroid surgeons, the expected cure rate for initial operation for sporadic PHPT is >95% and for reoperation is >90%. With improved imaging modalities and the implementation of IPM, comprehensive parathyroidectomy is now one of two options for definitive treatment of PHPT. Comprehensive parathyroidectomy with bilateral neck exploration has a >95% success rate and low complication rates. All surgeons performing parathyroidectomy must be prepared for comprehensive parathyroidectomy in the situation of nonlocalizing imaging, suspicion for MGD, or when IPM levels do not appropriate fall during MIP. Recent observational studies have found that surgeon volume of cervical endocrine procedures inversely correlates with complications, cost, and length of stay. Hospital volume of parathyroidectomy has also been linked to outcome with low volume sites having higher rate of

complications, failed surgery, and need for reoperation.

With MIP, there is concern that even with meeting IPM criteria, there may be unrecognized enlarged glands that are identified and resected. Studies have identified increased incidence of MGD in comprehensive parathyroidectomy compared to planned MIP. Overall studies have shown conflicting results with some studies suggesting that MIP may not be as effective in identifying MGD and a trend to increased long-term recurrence rates with MIP. Cure of PHPT requires resection of all hyperfunctioning parathyroid tissue. Since in the immediate postoperative period there may be fluctuations in serum calcium and patients may be on higher doses of calcium supplementation, the long-established definition of cure of PHPT is normocalcemia at 6 months after surgery. Normalization of PTH levels is not required although preferred. There have been several studies showing PTH levels may continue to be elevated in patients cured of PHPT, potentially for varied reasons including vitamin D deficiency, mild renal insufficiency, and increased bone mineralization. However, due to the possible risk of recurrence, patients with normal calcium levels but elevated PTH postoperatively should be monitored at least annually for recurrence.

CONCLUSIONS

PHPT is an increasingly recognized disease that may only be cured by parathyroidectomy. The technique for comprehensive parathyroidectomy is an essential procedure that all surgeons performing parathyroidectomy should be prepared to perform. In skilled hands, comprehensive parathyroidectomy has an extremely high success rate. IPM is essential for MIP and may also aid in decision making and confirmation of findings during comprehensive parathyroidectomy. A careful approach to parathyroidectomy with understanding of the nuances of parathyroid location and analysis of IPM is essential to success.

Suggested Readings

Bilezekian JP, Brandi ML, Eastell R, et al. Guidelines for the management of asymptomatic primary hyperparathyroidism: summary statement from the fourth international workshop. *J Clin Endocrinol Metab* 2014;99(10):3580–94.

Carr AA, Yen TW, Wilson SD, et al. Using parathyroid hormone spikes during parathyroidectomy to guide intraoperative decision making. *J Surg Res* 2016; 209:162–7.

Cayo AK, Sippel RS, Schaefer S, et al. Utility of intraoperative PTH for primary hyperparathyroidism due to multigland disease. *Ann Surg Oncol* 2009;16:3450–4.

Coan KE, Yen TW, Carr AA, et al. Intraoperative ex vivo parathyroid aspiration: a point-of-care test to confirm parathyroid tissue. *Surgery* 2016;160(4):850–7.

Greene AB, Butler RS, McIntyre S, et al. National trends in parathyroid surgery from 1998 to 2008: a decade of change. *J Am Coll Surg* 2009;209(3):332–43.

Irvin GL, Dembrow VD, Prudhomme DL. Operative monitoring of parathyroid gland hyperfunction. *Am J Surg* 1991;162(4):299–302.

Lew JI, Solorzano CC, Montano RE, et al. Role of intraoperative parathyroid hormone monitoring during parathyroidectomy in patients with discordant localization studies. *Surgery* 2008;144(2);299–306.

Mcgill J, Sturgeon C, Kaplan SP, et al. How does the operative strategy for primary hyperparathyroidism impact the findings and cure rate? A comparison of 800 parathyroidectomies. *J Am Coll Surg* 2008;207(2):264–9.

Pasieka JL, Parsons L, Jones J. The long term benefit of parathyroidectomy in primary hyperparathyroidism: a 10-year prospective surgical outcome study. *Surgery* 2009;146(6):1006–13.

Patel KN, Caso R. Intraoperative parathyroid hormone monitoring: optimal utilization. *Surg Oncol Clin N Am* 2016;25(1):91–101.

Ritter H, Milas M. Parathyroidectomy: bilateral neck exploration. In: Terris D, ed. *Operative Techniques in Otolaryngology.* St. Louis, MO: Elsevier; 2009.

Solorzano CC, Carneiro-Pla D. Minimizing cost and maximizing success in the preoperative localization strategy for primary hyperparathyroidism. *Surg Clin North Am* 2014;94(3):587–605.

Wharry LI, Yip L, Armstrong MJ, et al. The final intraoperative parathyroid hormone level: How low should it go? *World J Surg* 2014;38:558–63.

Wilhelm SM, Wang TS, Ruan DT, et al. The American Association of Endocrine Surgeons guidelines for definitive management of primary hyperparathyroidism. *JAMA Surg* 2016;151(10):959–68.

Yen TW, Wang TS. Subtotal parathyroidectomy for primary hyperparathyroidism. *Endocr Pract* 2011; 17(Suppl 1):7–12.



EDITOR'S COMMENT

Drs. Carr and Wang have done a commendable job in detailing a comprehensive and in-depth review of "Comprehensive Parathyroidectomy for the Treatment of PHPT, Including Intraoperative Parathyroid Hormone Assay–Guided Parathyroidectomy." I would like to highlight some key points.

The recognition of PHPT increased in the 1970s with automated routine calcium testing, and prevalence continues to increase today. Incidence appears to increase with age and is two to three times higher in women. Primary hyperparathyroidism remains underdiagnosed and undertreated (Marcocci C, Cetani F. Primary hyperparathyroidism. *N Engl J Med* 2011;365:2389–97).

Genetic counseling should be performed for patients younger than 40 years with PHPT and MGD and considered for those with a family history or syndromic manifestations. Lithium-associated PHPT occurs in up to 15% of long-term users, with increased rates of MGD. Molecular alterations also affect the pathophysiologic mechanisms and rates of MGD. Germline-inactivating mutation of the *MEN1* gene causes multiple endocrine neoplasia type 1, and somatic events occur in sporadic tumors; germline-activating mutations of the *RET* proto-oncogene result in multiple endocrine neoplasia type 2; the somatic *PRAD1* rearrangement upregulates cyclin D1 in sporadic adenomas; and inactivating mutations of *CDC73* (formerly *HRPT2*) occur as germline alterations in hyperparathyroidism–jaw tumor syndrome and familial isolated hyperparathyroidism and as somatic events in sporadic parathyroid cancer (PCA) (Wilhelm SM, Wang TS, Ruan DT, et al. The American association of endocrine surgeons guidelines for definitive management of primary hyperparathyroidism. *JAMA Surg* 2016;151(10):959–68).

Imaging has no utility in confirming or excluding the diagnosis of PHPT. Imaging results should not be used to select patients for surgical referral. Patients with negative imaging results remain candidates for parathyroidectomy. There is a marked regional variability in imaging accuracy. When imaging with initially negative results is performed again at high volume centers, the sensitivity of localization improves to as high as 92%. Imaging is performed after deciding to proceed with parathyroidectomy and is performed for operative planning. Parathyroid imaging is significantly less accurate for MGD.

Four-dimensional computerized tomography (4D CT) combined with ultrasound is the imaging modality of choice at our institution. The ultrasound is more sensitive and specific to rule out any coexisting thyroid pathology. Our data and others have shown significantly higher positivity and accurate localization rate in single-gland parathyroid disease, significantly higher predictive value in multigland parathyroid disease, and significantly higher overall accuracy rate when compared with sestamibi. In addition, 4D CT minimizes unnecessary opposite-side exploration, provides excellent 3D reconstruction images, superior surgical planning, especially with ectopic glands (Kukar M, Platz TA, Schaffner TJ, et al. The use of modified four-dimensional computed tomography in patients with primary hyperparathyroidism: an argument for the abandonment of routine sestamibi single-positron emission computed tomography (SPECT). *Ann Surg Oncol* 2015;22(1):139–45).

Cohort data have demonstrated reductions in the risk of all fractures postparathyroidectomy. Surgery has also been shown to reduce the risk of renal

stones and offers a cure if successful. Similar benefits have not yet been demonstrated with the existing medical options available. Medical monitoring appears to be safe for individuals who do not meet surgical guidelines and is required for those with contraindications for surgery or who are unwilling to undergo surgery. Targeted medical therapy includes aminobisphosphonates for skeletal protection and cinacalcet for lowering serum calcium. There are no data showing fracture risk reduction with either antiresorptive therapy or with cinacalcet.

Future research should focus on the effects of PHPT on skeletal strength as well as pharmacologic approaches to lowering fracture risk. The effects of PHPT on cognition and the cardiovascular, gastrointestinal, and musculoskeletal systems in patients with mild asymptomatic disease require further evaluation with well-designed prospective cohort studies.

Moshim Kukar

41 Minimally Invasive Parathyroidectomy

Robert Udelsman and Tobias Carling

BACKGROUND

Approximately, 85% of patients with primary hyperparathyroidism (pHPT) harbor a single adenoma and are cured by excision of the incident gland. The remaining patients display double adenoma (3% to 5%) or four-gland hyperplasia (10% to 15%). Thus, with accurate preoperative localization, targeted surgery using unilateral neck exploration under regional or local anesthesia has been developed, evaluated over the past 10 to 20 years and has become the standard of care in an ever-increasing number of specialized centers. Unilateral surgery for pHPT was advocated in 1975, and the side to be explored was chosen based on palpation, esophageal imaging, venography, or arteriography.[1] If both an enlarged and normal gland were found on the initial side, then contralateral cervical exploration was obviated. Other authors advocated a similar approach, arguing that bilateral exploration increased the risk, cost, and morbidity of surgery for pHPT.[2] The Lund University surgeons advocated unilateral parathyroidectomy, which they defined as the removal of both an adenoma and ipsilateral normal parathyroid gland.[3] The excised tissue was studied microscopically during surgery with oil-red-O, and the decision to stop the operation at this stage was based on demonstration of a reduction in intracytoplasmic fat droplets in the excised adenomatous parathyroid tissue. Both techniques would fail, however, in the setting of a double adenoma on the contralateral side and if the essentially "random" choice of which side to explore was incorrect. Today, minimally invasive parathyroidectomy (MIP) is performed after preoperative parathyroid localization usually with high-quality sestamibi scans, ultrasonography, or four-dimensional CT (4DCT) scans, often under cervical block anesthesia during which a focused exploration is performed, and a rapid intraoperative parathyroid hormone (PTH) assay is employed to confirm an adequate resection.[4] These procedures are now often performed on an

outpatient basis.[4]

INDICATIONS

The indications for MIP are the same as those for traditional cervical exploration, that is, symptomatic patients or those with asymptomatic pHPT fulfilling the criteria established by the most recent consensus meeting.[5,6] In addition, there are now significant data to support more liberal use of parathyroidectomy for pHPT, since the disease has been associated with a number of "nonclassical" morbidities, some of which seem to improve postoperatively. These include neurocognitive impairments and cardiovascular abnormalities (extensively reviewed in reference).[6] Patients with persistent disease (previously failed parathyroidectomy) as well as other reoperative cases can also successfully be performed using the MIP techniques.[7,8] Minimally invasive techniques are rarely employed when preoperative localization of the parathyroid tumor was not performed, is negative, or is consistent with multiglandular enlargement. The role of MIP in the setting of familial HPT (i.e., multiple endocrine neoplasia type 1 [MEN1], MEN2A, the hyperparathyroidism-jaw tumor syndrome [HPT-JT], familial isolated hyperparathyroidism [FIHPT], and HPT occurring in patients with an underlying mutation in the calcium sensing receptor [CASR] gene) is evolving.[9] A conventional cervical exploration should be performed in the vast majority of these cases, although MIP may prove to have a limited role in specific instances of familial HPT. For instance, in HPT associated with MEN2A, HPT-JT, and FIHPT where uniglandular uptake is noted on preoperative imaging, MIP may be considered when combined with employment of an intraoperative PTH assay to confirm the adequacy of resection.[9,10] In rare cases when parathyroid carcinoma is diagnosed or suspected, a radical resection at the initial operation is required for optimal results.[11,12]

PREOPERATIVE PLANNING

The development and refinement of parathyroid imaging have been essential for the development of MIP techniques. Several noninvasive preoperative localization methods are available, including sestamibi-technetium-99m scintigraphy, ultrasonography, computed tomography (CT), magnetic resonance imaging (MRI), and thallium-201-technetium (Tc)-99m pertechnetate scanning. The most commonly used modality remains sestamibi with single photon emission computed tomography

(SPECT), which generates three-dimensional localization.[13–16] In 1989, it was first reported that the new agent Technetium-99m used for cardiac imaging also was avidly taken up by parathyroid tissue.[17] Parathyroid cells have a large number of mitochondria, which take up sestamibi/Tc-99m.[18] Sestamibi, a monovalent lipophilic cation, diffuses passively across cell membranes, concentrates in mitochondria, and accumulates in adenomatous parathyroid tissue because of increased blood supply, higher metabolic activity, and an absence of p-glycoprotein on the cell membrane.[19] Sestamibi imaging can be performed preoperatively to plan an MIP or on the morning of operation in combination with the use of a gamma probe in the operating room to guide the surgeon during surgery.[20] The sensitivity of sestamibi is limited in multiglandular disease. In a large study, scintigraphy localized at least one gland in all patients, but only 62% of the total number of hyperplastic glands.[21] SPECT, which allows localization of structures in the anterior/posterior plane, is particularly helpful in detecting smaller lesions and adenomas located posterior to the thyroid gland. The overall sensitivity for localizing adenomas <500 mg varies, from 53% to 92%.[22,23] A major limitation of sestamibi scans is related to the coexistence of thyroid nodules or other metabolically active tissues (e.g., lymph nodes, thyroid nodules, and metastatic thyroid cancer) that can mimic parathyroid adenomas, thereby causing false-positive results on sestamibi scans. This limitation can be overcome in part by using the double-tracer subtraction technique of sestamibi, in which both thyroid and parathyroid nodular abnormalities can be diagnosed simultaneously, or in combination with a neck ultrasound to preoperatively distinguish between thyroid lesions and parathyroid enlargement.[16,24] Sestamibi with SPECT does not provide detailed anatomical depiction, and can only detect double adenomas and multiglandular hyperplasia in a minority of cases.

Ultrasound is effective, noninvasive, and inexpensive, but its limitations include both operator dependency and being limited to application in the neck because it cannot image mediastinal adenomas. The normal parathyroid gland is generally too small to be visualized sonographically, whereas parathyroid enlargement seen in pHPT is often identified as a homogeneously hypoechoic extrathyroidal ovoid mass. Parathyroid adenomas are typically vascular, and an arterial branch can often be followed to the superior or inferior pole of the lesion.[25,26] An additional advantage of ultrasound is the ability to perform fine needle aspirates with

rapid PTH measurements of the aspirates. This technique should be reserved for select patients undergoing re-exploration.[13,27] By itself, ultrasound has approximately a 50% to 75% true-positive rate, with generally better rates for larger glands.[25,26] However, when combined with sestamibi, the true-positive rate approaches 90%, with few false-positives.[28] The ability of both ultrasound and sestamibi with SPECT to detect the parathyroid abnormality is reduced in milder forms of pHPT (i.e., only mildly elevated PTH and calcium levels) and in obese patients.[16]

The 4DCT scan is a promising, more novel parathyroid imaging technique. It is similar to CT angiography. The term is derived from 3-dimensional CT scanning with an added dimension referring to the changes in perfusion of contrast over time. Exquisitely detailed, multiplanar images are obtained that accentuate the differences in the perfusion characteristics of hyperfunctioning parathyroid glands (i.e., rapid uptake and washout), compared with normal parathyroid glands and other structures in the neck. The images provide both anatomic information and functional information (based on changes in perfusion) in a single study that the operating surgeon can easily interpret. In a recent series, 4DCT displayed improved sensitivity (88%) over sestamibi imaging (65%) and ultrasonography (57%), when the imaging studies were used to localize (lateralize) hyperfunctioning parathyroid glands to one side of the neck. Moreover, when used to localize parathyroid tumors to the correct quadrant of the neck (i.e., right inferior, right superior, left inferior, or left superior), the sensitivity of 4DCT (70%) was significantly higher than sestamibi imaging (33%) and ultrasonography (29%).[29] In a prospective consecutive cohort, the results at Yale University are similar. Moreover, 4DCT predicted multiglandular disease in 85.7% (6/7) patients.[30] Compared to sestamibi with SPECT, 4DCT is significantly less expensive but associated with higher exposure to ionizing radiation and thus should be used cautiously in children and young adults due to the theoretic risk of inducing thyroid carcinoma.[16,31] Moreover, because of the use of intravenous contrast it should be avoided in patients with renal insufficiency as well as in patients with concomitant well-differentiated thyroid carcinoma.[16,31] With the development of improved CT scanning, MRI is rarely used. However, since it does not involve the use of radiation it may be employed in select cases such as during pregnancy. Parathyroid adenomas may appear very intense on T_2-weighted images.

A subset of patients who require re-exploration will have negative,

discordant, or nonconvincing noninvasive localization studies. Current guidelines recommend that these patients undergo invasive localization procedures in the form of selective venous sampling (SVS) with measurements of PTH. Rapid PTH measurement is now being used in the angiography suite, because results are rapidly available on-site, and interventional radiologists can obtain additional samples from a region in which a subtle but potentially significant PTH gradient is detected.[32,33] In a recent study, we demonstrated that superselective SVS had a sensitivity of 90% for the correct localization of a parathyroid adenoma in remedial cases where other imaging was negative or inconclusive. All patients underwent reoperative parathyroidectomy and were cured.[33]

REGIONAL BLOCK ANESTHESIA TECHNIQUE

The majority of parathyroidectomies are performed under general anesthesia using either an endotracheal tube (ETT) or a laryngeal mask airway (LMA). We prefer local and regional block anesthesia with monitored anesthesia care (MAC). The regional block is performed by the surgeon in the operating room, and intravenous supplementation is administered by the anesthesia staff (Fig. 41.1). In most patients, 1% lidocaine containing 1:100,000 epinephrine is used and supplemented during the operation as required. Care is taken to aspirate before delivering the anesthetic to avoid intravascular administration. We have found that by also infiltrating along the anterior border of the sternocleidomastoid muscle, as well as a local field block, excellent analgesia is obtained in virtually every case (Fig. 41.2). The total cumulative volume of lidocaine administered is typically 18 to 25 mL. Intravenous sedation is used to minimize patient anxiety while maintaining an awake, conscious patient who can phonate. Propofol was thought to possibly interfere with the PTH assay, but a recent randomized trial has shown that the PTH assay can be employed during propofol sedation.[34]

Regional anesthesia avoids complications associated with general anesthesia, including endotracheal intubation, which has been reported to cause vocal cord changes in up to 5% of patients.[35] Furthermore, exploring a conscious patient permits intraoperative assessment of the superior and recurrent laryngeal nerve functions because the patient can vocalize during the procedure. We recently demonstrated that laryngeal physiology and voice acoustics are maintained after MIP.[36]

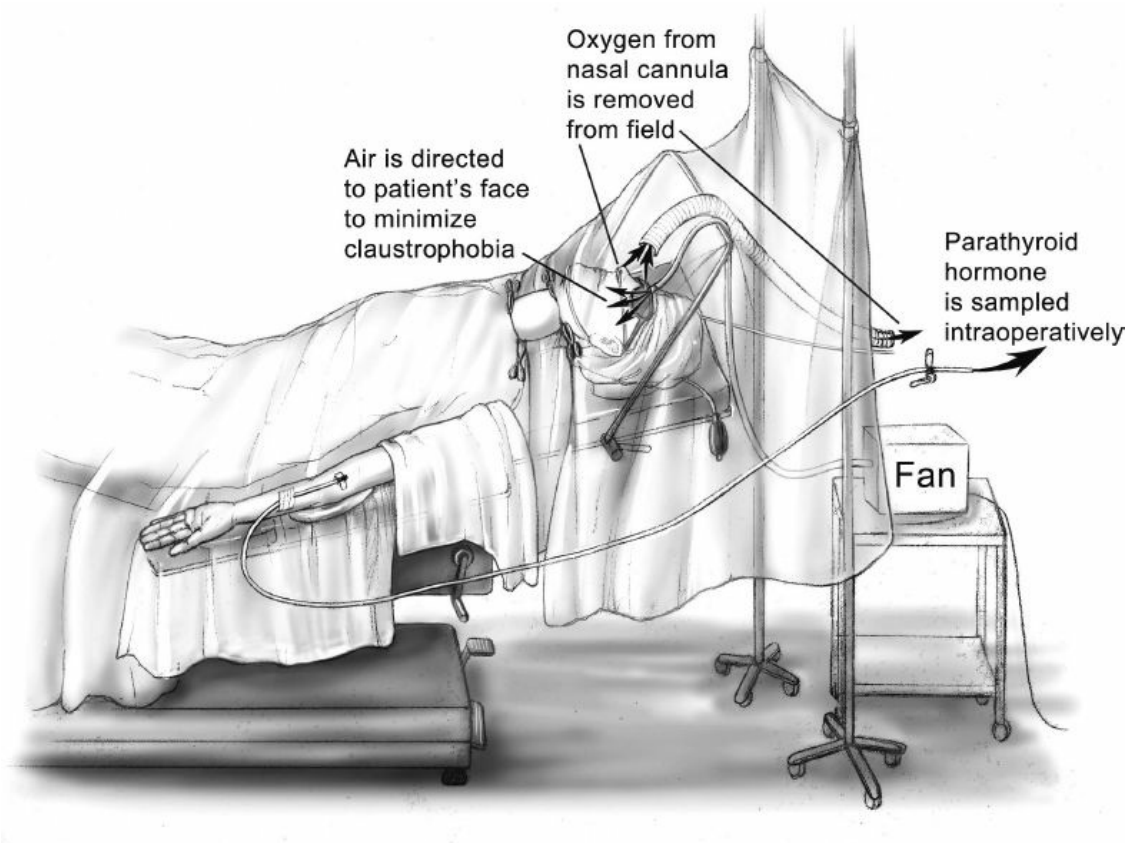

Figure 41.1. The patient has a large-bore peripheral intravenous line inserted, which is used for medication and fluid administration as well as sampling for parathormone (PTH) levels. The patient is awake, wearing protective eye glasses, and a fan is used to circulate room air gently toward his or her face to minimize the sensation of claustrophobia.

LoGerfo and colleagues have shown that bilateral neck exploration under regional anesthesia can be performed safely and effectively in patients with coexisting thyroid disease and a nonlocalized adenoma. In a series of 236 patients undergoing MIP, 62% had a nonlocalizing sestamibi scan preoperatively or no scan at all, but only 4 required conversion to general anesthesia. Twenty-three percent had a simultaneous procedure performed for thyroid disease, and 85% underwent a bilateral neck exploration.[37] We reported in 441 consecutive patients that 47 (10.6%) required conversion to general anesthesia.[38] In all instances, conversion was performed in a controlled fashion using neuromuscular blockade, endotracheal intubation, and maintenance of the original surgical field preparation. Table 41.1 summarized the reasons for conversion from regional block to general endotracheal anesthesia.

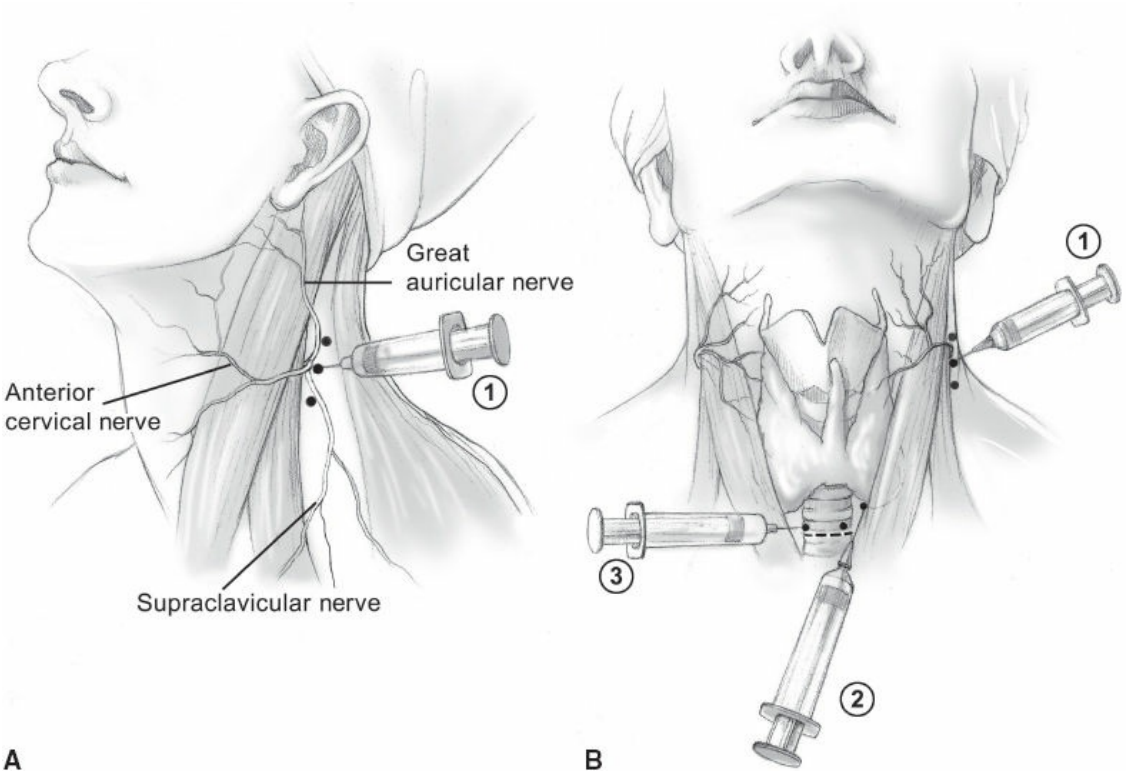

Figure 41.2. Cervical block anesthesia. **A.** A superficial cervical block is administered posterior and deep to the sternocleidomastoid muscle (SCM) (1). **B.** Local infiltration is also performed along the anterior border of the SCM (2), and a local field block (3) is performed.

TABLE 41.1 Reasons for Conversion to General Anesthesia From Cervical Block During Minimally Invasive Parathyroid Surgery in 47 (10.6%) of 441 Consecutive Patients

Indication	N (%)
Concomitant thyroid pathology	16 (34)
Multiglandular parathyroid disease	15 (32)
Technical considerations	8 (17)
Patient discomfort	5 (11)
Intraoperative diagnosis of parathyroid carcinoma	2 (4)
Toxic reaction to lidocaine	1 (2)

SURGICAL TECHNIQUE AND RESULTS

No preoperative imaging modality will replace the need for a well-trained, thoughtful parathyroid surgeon. Surgeons performing MIP must understand the embryology and anatomy of the parathyroid glands. The embryonic development and descent into the cervical neck of the parathyroids lead to a highly variable anatomy. Ectopic parathyroid tissue is commonly encountered within the thyroid, thymus, mediastinum, carotid sheath, and tracheoesophageal groove. Nondescended glands can be located along the carotid bifurcation or along the larynx.

The MIP technique used at our institution is individualized after the parathyroid adenoma has been localized. Typically, a 2.5 to 3.5-cm abbreviated Kocher incision is made, and the parathyroid adenoma is identified and excised after the creation of limited subplatysmal flaps and mobilization of the ipsilateral strap muscles (Figs. 41.3 and 41.4). Parathyroid surgery is a meticulous procedure and operative experience correlates with rates of recurrence and persistence as well as complications. The procedure is guided by intraoperative PTH measurements, which is used routinely.

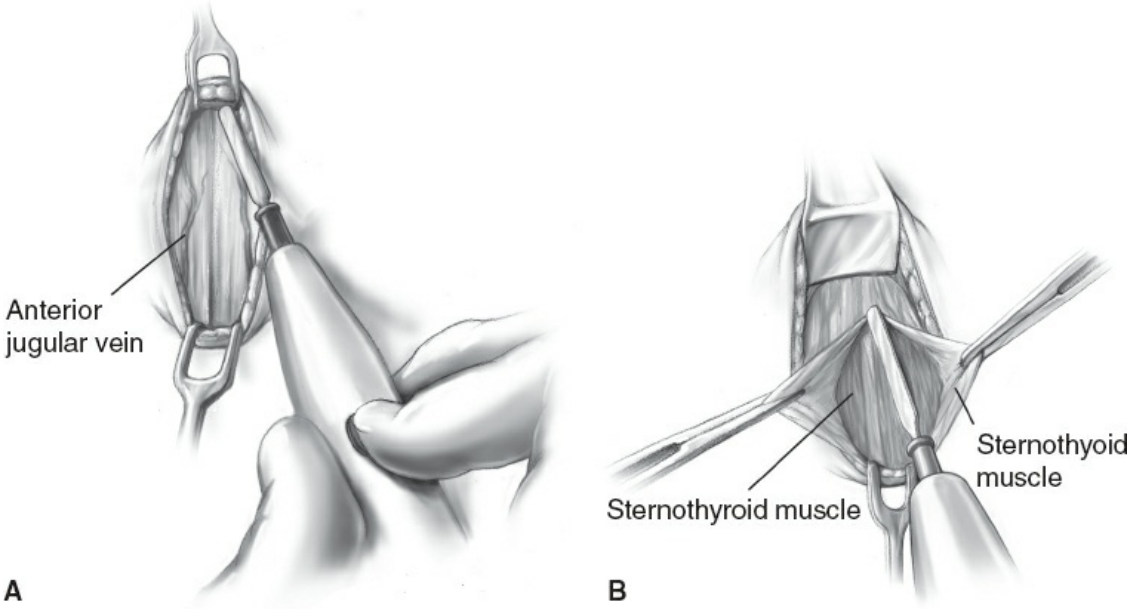

Figure 41.3. A. An abbreviated Kocher incision is made, the platysma is divided, and (**B**) the strap muscles are separated.

INTRAOPERATIVE PTH

Intraoperative PTH measurement is employed because although preoperative imaging can be sensitive for single adenomas, they fail to

identify 17% of a second (double) adenoma and 55% of hyperplastic glands. The circulating half-life of PTH is 3.5 to 4 minutes, and thus PTH levels are obtained prior to and 5 and 10 minutes after tumor extraction. Since the remaining normal parathyroid glands are suppressed by the hyperfunctioning parathyroid adenoma, a decline (>50%) in PTH is usually seen by 5 or 10 minutes, and the patient requires no additional exploration. Failure of the peripheral venous PTH level to adequately decline suggests remaining hyperfunctioning parathyroid tissue and additional surgery is indicated under either regional or general anesthesia.

Chapuis in France (1990) and Irvin in Miami (1991) independently described the use of intraoperative PTH monitoring to guide the surgeon during parathyroid surgery in patients with successful preoperative imaging.[39,40] These pioneers both concluded that intraoperative PTH monitoring could be reliably used during surgery to influence the extent of surgery and to determine the need for exploration of the contralateral side of the neck. At our institution, we have laboratory personnel and the analytical assay in the operating room, providing near real-time feedback to the surgeon.

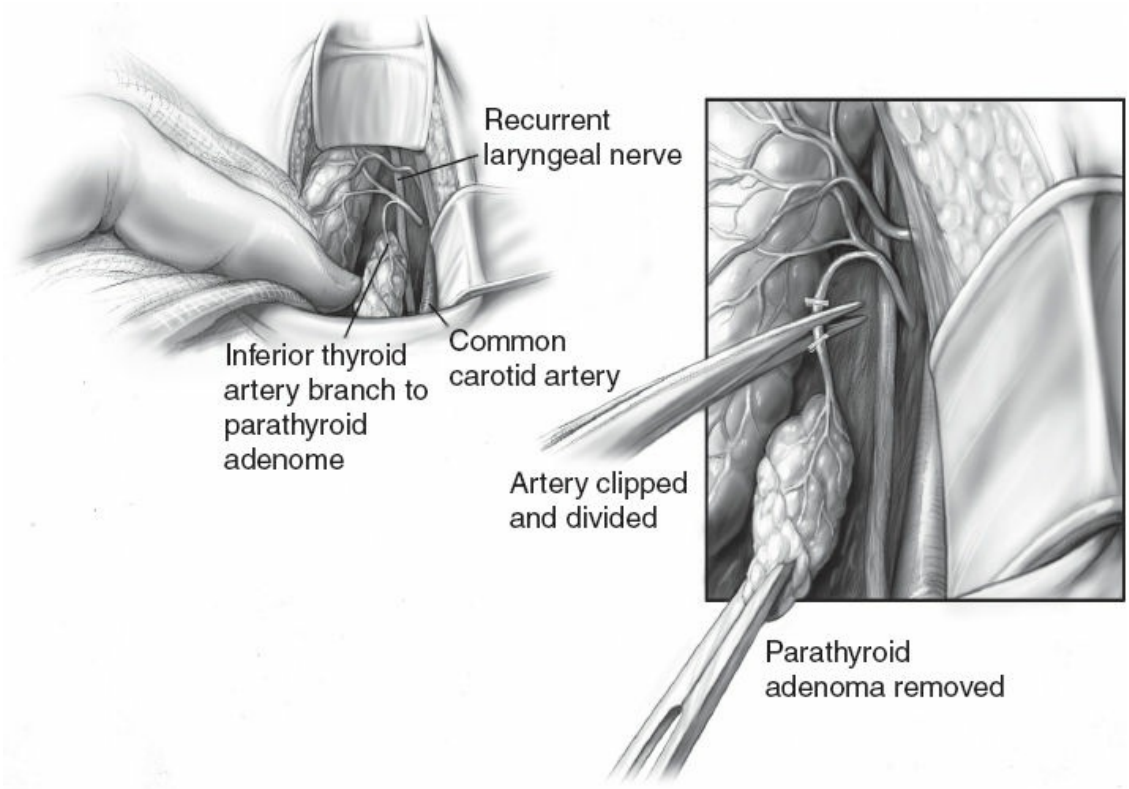

Figure 41.4. The parathyroid adenoma is identified, its end-arterial blood supply is ligated, the recurrent laryngeal nerve is protected, and the adenoma is removed.

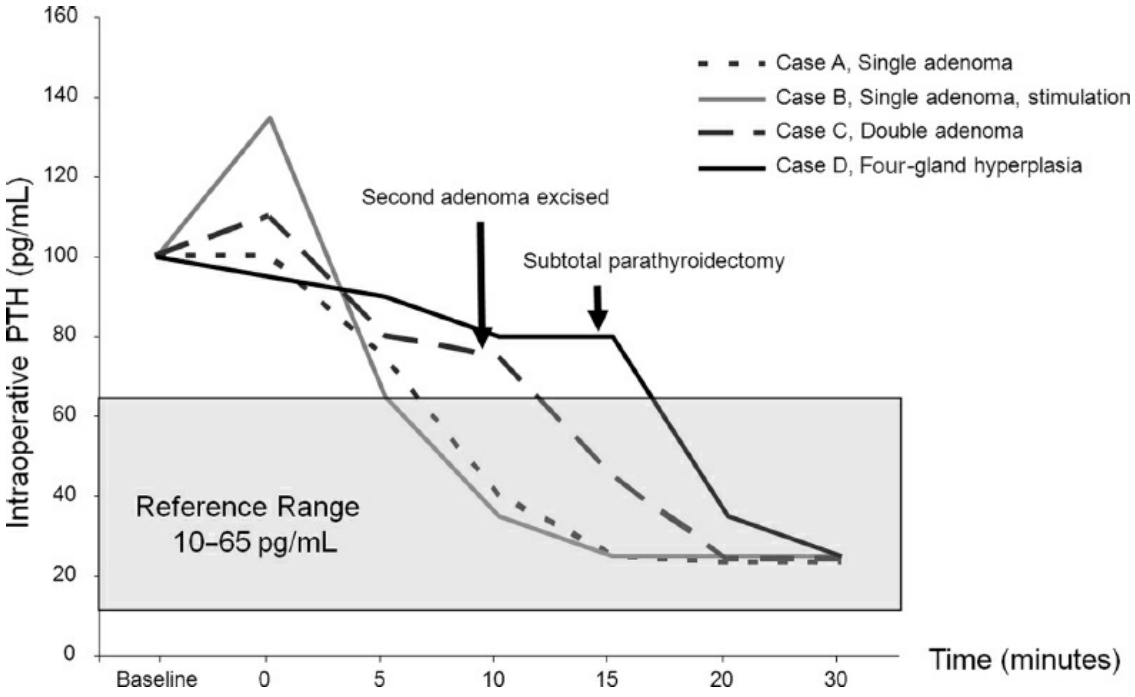

Figure 41.5. Interpretation of intraoperative PTH measurements. The graph illustrates typical findings in intraoperative PTH levels in four different scenarios. Case A shows the typical fall in PTH levels to below 50% of the preoperative baseline after excision of a single parathyroid adenoma, whereas case B illustrates an initial rise in PTH levels at time 0 minutes after resection, which is due to surgical manipulation. The patient in case C has pHPT due to double adenomas. Thus, although there is a slight reduction in PTH levels after the removal of the initial parathyroid gland at time 0 minutes, the PTH levels normalize only after excision of the second adenoma 10 minutes later. Case D shows typical findings of patients with pHPT due to hyperplasia of all four glands, and biochemical cure is not achieved until after subtotal parathyroidectomy.

Blood is collected from a peripheral vein, such as the antecubital vein, as blood sampled from the anterior or inferior jugular veins may not yield accurate results, because of their proximity to the parathyroid glands. To date, no standardized guidelines have been formulated regarding the timing and the number of PTH levels to measure during parathyroidectomy. It is important to measure a pre-incision baseline level as well as an immediate post-excision level, because frequently there will be a significant increase in PTH levels during surgical manipulation of the gland. If the manipulation level is not measured, the post-excision values may be difficult to interpret due to operative stimulation. Additional PTH levels are measured 5, 10, and occasionally 20 or 30 minutes following

excision of the targeted gland, the latter specimen being collected only if there is not an appropriate reduction in PTH levels at 5 and 10 minutes.

There is no universally adopted algorithm for interpreting the results of intraoperative PTH measurements. We advocate more stringent criteria than most, with a >50% reduction from the baseline with an absolute normalization of the PTH levels (Fig. 41.5). However, some surgeons advocate using a >50% reduction after parathyroidectomy, using the higher of either the pre-incision or the manipulation value. The rationality to use a more stringent criterion relates to the fact that patients may have multiglandular disease. We and others have advocated obtaining delayed measurements selectively (20 minutes or more after excision), especially in the setting of renal insufficiency, cystic parathyroid tumors, a significant manipulatory rise in the intact PTH, and multiglandular hyperplasia.[9,41] In the setting of familial HPT (especially MEN 1), a reduction in PTH levels >80% may be advocated prior to accepting adequate excision of parathyroid tissue.[9] Recently a computer algorithm has been developed to aid the surgeon in interpretation of intraoperative PTH data.[42]

In addition to being a valuable adjunct to confirming the completeness of parathyroid resection, the rapid PTH assay has been shown to be a useful adjunct to other aspects in the treatment of pHPT. We routinely perform, ex vivo, fine needle aspirations of tissue excised during parathyroid surgery with measurement of PTH. A positive aspirate will demonstrate PTH levels >1,000 pg/mL. This has eliminated the need for frozen section analysis in the vast majority of cases and saves time and expenses.

Although we rely heavily on the intraoperative PTH assay, it does not replace clinical judgment and the assay should be interpreted in this context.

CHALLENGING PATIENTS

Equivocal Imaging

Although the preoperative imaging of patients with pHPT has improved, approximately 10% to 15% of patients still present with equivocal or negative imaging results. We do not routinely perform additional imaging in the previously unexplored patients; rather, these patients are explored under cervical block anesthesia, or if the patients prefers, general anesthesia. Additional imaging techniques using ultrasound-guided fine needle aspiration (FNA) or SVS are reserved for patients undergoing

remedial cervical exploration.[32,33] Multiglandular parathyroid enlargement appears to be more common in patients with negative imaging studies. The intraoperative rapid PTH assay has been validated in the setting of multiglandular parathyroid disease in patients with either primary and secondary HPT.[43]

Static PTH Post-Excision

In about 85% of the cases, the rapid PTH assay demonstrates a >50% drop in the intact PTH level after excision of a single enlarged parathyroid gland, which is consistent with a diagnosis of a single parathyroid adenoma. In the remaining patients, failure of the PTH decrement suggests additional disease and further exploration is mandatory. Continued exploration unilaterally as well as bilaterally can be done under regional block in the vast majority of cases, but conversion to general anesthesia is sometimes needed.[38] Since the most advantageous time to cure pHPT is during the first surgical exploration, it is the obligation of the initial surgeon to perform a meticulous exploration evaluating both eutopic and ectopic sites. This exploration includes the retroesophageal space, thymus gland, carotid sheaths, and submandibular region for undescended glands. If the occult gland is still not identified, additional intraoperative adjuncts are used, including ultrasound and bilateral internal jugular vein sampling to determine if an ipsilateral PTH gradient is present. This technique has guided us to explore upstream and locate occult undescended or partially descended glands. Partial or complete thyroid lobectomy can be performed depending on the suspected location of the missing gland. We do not recommend sternotomy at the initial exploration unless imaging strongly suggests mediastinal disease that is not accessible by less invasive routes.[44] Despite all of these maneuvers, there still remains a subset of patients in whom the elusive parathyroid is not identified. In this setting, ligation of the blood supply to the missing parathyroid gland is performed. This usually involves ligation of the ipsilateral inferior thyroid artery but may also involve devascularization of other arterial branches.[7]

Coexistent Thyroid Disease

Coexistent thyroid disease is relatively common and may range from benign nodules to thyroid cancer. In patients undergoing a preoperative ultrasound showing thyroid lesions, appropriate work-up should be done prior to parathyroid exploration. In cases where a preoperative ultrasound

has not been performed, intraoperative recognition of coexistent thyroid disease is sometimes encountered. A thyroid lobectomy can be performed under regional block, but for more extensive thyroid resections conversion to general anesthesia is sometimes needed.[38] Patients with Hashimoto's thyroiditis, Graves' disease, or sarcoidosis often display significant cervical lymphadenopathy, which may cause difficulty in distinguishing enlarged lymph nodes from hypercellular parathyroid glands.

Previously Operated Patients

Despite the success rate of parathyroidectomy in the modern era, surgeons still encounter three groups of patients representing challenging management issues: (a) patients with persistent pHPT having failed initial exploration, (b) patients who develop recurrent pHPT having sustained a period of eucalcemia for >6 months after their initial operation, and (c) patients who have undergone previous neck explorations, particularly total thyroidectomy, who then develop pHPT. In each of these settings, remedial cervical explorations are associated with decreased success and increased complication rates.[7,45] Recently, we reported the experience with remedial surgery over the past 15 years in 130 consecutive operations (Fig. 41.6). Although the explorations were performed under general anesthesia in the majority of patients, MIP was employed in 23 patients. The cure rate was similar in the two groups, 94% and 96%, respectively. Again, meticulous preoperative imaging enhances the chance of operative success, and may include sestamibi scanning, ultrasound, 4DCT, venous localization, ultrasound combined with FNA of suspected enlarged parathyroid glands, or superselective SVS with rapid PTH measurements.

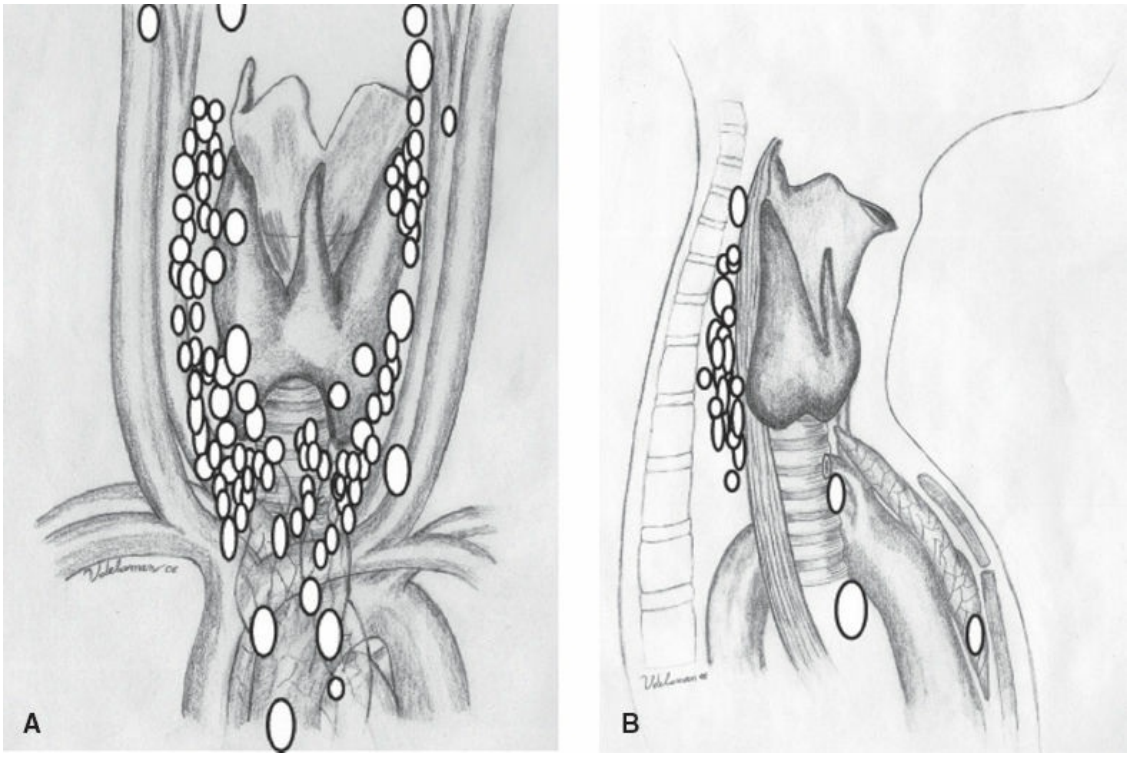

Figure 41.6. Location of enlarged parathyroid glands resected during remedial cervical exploration. Because of overlapping glands, the parathyroid glands are not drawn to scale. Some patients had more than one enlarged gland. Individual glands are depicted on one illustration only. **A:** Anteroposterior projection. **B:** Lateral projection.

POSTOPERATIVE CARE

Approximately 90% of cases are performed under regional cervical block anesthesia in the ambulatory setting at our institution. However, the patients are counseled that an overnight stay is a possibility. The most common reasons for admission to the hospital are multiglandular disease requiring subtotal parathyroidectomy, significant comorbidity, advanced age, or the lack of support at home. The majority of patients are monitored for 1 to 2 hours postoperatively, mainly to ensure absence of a neck hematoma. After curative parathyroidectomy, the patient is placed on oral calcium carbonate in the immediate postoperative period (2 to 4 weeks) to avoid symptoms of transient relative hypocalcemia. Since many patients suffer vitamin D deficiency as well, they are advised to adhere to current recommendations for calcium/vitamin D supplementation.

RESULTS AND COMPLICATIONS

The success of MIP has been confirmed by evidence of cure and complication rates that are at least as good as those achieved by conventional bilateral exploration. Specifically, in a series of 656 consecutive parathyroidectomies (of which 401 were performed in the standard fashion and 255 were performed with MIP) between 1990 and 2001, there were no significant differences in complication (3.0% and 1.2%, respectively) or cure rates (97% and 99%, respectively).[46] MIP was associated with an approximately 50% reduction in operating time (1.3 hours for MIP vs. 2.4 hours for standard operation), a seven-fold reduction in length of hospital stay (0.24 days vs. 1.64 days, respectively), and a mean savings in terms of charges of $2,693 per procedure. This represents a reduction by nearly one half in total hospital charges. A prospective randomized controlled trial comparing unilateral to bilateral neck exploration was recently published.[47] In this study of 91 patients, comparison was made between patients assigned to preoperative sestamibi localization and unilateral neck exploration with the rapid PTH assay versus patients assigned to bilateral neck exploration. Patients who underwent unilateral neck exploration had a lower incidence of early postoperative hypocalcemia necessitating calcium supplementation. There were no statistical differences between complication rates, costs, and operative time between the two groups. The study, which was not blinded, was encumbered by a high-crossover rate; only 62% of patients assigned to unilateral exploration actually underwent this operation. This may relate to the relatively low sensitivity (71%) of the sestamibi imaging in this population.

The complication rate of MIP is similar or lower compared to standard cervical approach. Recurrent laryngeal nerve injury may occur in 0.5% to 1.0% of the cases.[48] The risk of permanent hypoparathyroidism is absent if a single gland is explored and removed, but remains a concern in patients undergoing subtotal parathyroidectomy for multiglandular disease.

Suggested Readings

Bilezikian JP, Brandi ML, Eastell R, et al. Guidelines for the management of asymptomatic primary hyperparathyroidism: summary statement from the Fourth International Workshop. *J Clin Endocrinol Metab* 2014; 99:3561–9.

Kunstman JW, Kirsch JD, Mahajan A, et al. Clinical review: Parathyroid localization and implications for clinical management. *J Clin Endocrinol Metab* 2013; 98:902–12.

Lebastchi AH, Aruny JE, Donovan PI, et al. Real-time super selective venous sampling in remedial parathyroid surgery. *J Am Coll Surg* 2015;220:994–1000.

Leder SB, Donovan P, Acton LM, et al. Laryngeal physiology and voice acoustics are maintained after minimally invasive parathyroidectomy. *Ann Surg* 2013;257:968–70.

Mahajan A, Starker LF, Ghita M, et al. Parathyroid four-dimensional computed tomography: evaluation of radiation dose exposure during preoperative localization of parathyroid tumors in primary hyperparathyroidism. *World J Surg* 2012;36:1335–9.

Stalberg P, Carling T. Familial parathyroid tumors: diagnosis and management. *World J Surg* 2009;33(11):2234–43.

Udelsman R. Approach to the patient with persistent or recurrent primary hyperparathyroidism. *J Clin Endocrinol Metab* 2011;96:2950–8.

Udelsman R, Lin Z, Donovan P. The superiority of minimally invasive parathyroidectomy based on 1650 consecutive patients with primary hyperparathyroidism. *Ann Surg* 2011;253:585–91.

References

1. Roth SI, Wang CA, Potts JT Jr. The team approach to primary hyperparathyroidism. *Hum Pathol* 1975; 6:645–8.
2. Wang CA. Surgical management of primary hyperparathyroidism. *Curr Probl Surg* 1985;22:1–50.
3. Tibblin S, Bondeson AG, Ljungberg O. Unilateral parathyroidectomy in hyperparathyroidism due to single adenoma. *Ann Surg* 1982;195:245–52.
4. Udelsman R, Donovan PI, Sokoll LJ. One hundred consecutive minimally invasive parathyroid explorations. *Ann Surg* 2000;232:331–9.
5. Bilezikian J, Potts JJ, Fuleihan G-H, et al. Summary statement from a workshop on asymptomatic primary hyperparathyroidism: a perspective for the 21st century. *J Clin Endocrinol Metab* 2002;87:5353–61.
6. Bilezikian JP, Brandi ML, Eastell R, et al. Guidelines for the management of asymptomatic primary hyperparathyroidism: summary statement from the Fourth International Workshop. *J Clin Endocrinol Metab* 2014;99:3561–9.
7. Udelsman R, Donovan PI. Remedial parathyroid surgery: changing trends in 130 consecutive cases. *Ann Surg* 2006;244:471–9.
8. Udelsman R. Approach to the patient with persistent or recurrent primary hyperparathyroidism. *J Clin Endocrinol Metab* 2011;96:2950–8.
9. Stalberg P, Carling T. Familial parathyroid tumors: diagnosis and management. *World J Surg* 2009; 33(11):2234–43.
0. Carling T, Udelsman R. Parathyroid surgery in familial hyperparathyroid

disorders. *J Intern Med* 2005;257:27–37.
1. Carling T, Udelsman R. Parathyroid tumors. *Curr Treat Options Oncol* 2003;4:319–28.
2. Quinn CE, Healy J, Lebastchi AH, et al. Modern experience with aggressive parathyroid tumors in a high-volume New England referral center. *J Am Coll Surg* 2015;220:1054–62.
3. Carling T, Udelsman R. Advancements in the surgical treatment of primary hyperparathyroidism. *Probl Gen Surg* 2003;20:31–7.
4. Lavely WC, Goetze S, Friedman KP, et al. Comparison of SPECT/CT, SPECT, and planar imaging with single- and dual-phase 99mTc-sestamibi parathyroid scintigraphy. *J Nucl Med* 2007;48:1084–9.
5. Roach PJ, Schembri GP, Ho Shon IA, et al. SPECT/CT imaging using a spiral CT scanner for anatomical localization: impact on diagnostic accuracy and reporter confidence in clinical practice. *Nucl Med Commun* 2006;27:977–87.
6. Kunstman JW, Kirsch JD, Mahajan A, et al. Clinical review: parathyroid localization and implications for clinical management. *J Clin Endocrinol Metab* 2013;98:902–12.
7. Coakley AJ, Kettle AG, Wells CP, et al. 99Tcm sestamibi—a new agent for parathyroid imaging. *Nucl Med Commun* 1989;10:791–4.
8. Hetrakul N, Civelek AC, Stagg CA, et al. In vitro accumulation of technetium-99m-sestamibi in human parathyroid mitochondria. *Surgery* 2001;130:1011–8.
9. Mitchell BK, Cornelius EA, Zoghbi S, et al. Mechanism of technetium 99m sestamibi parathyroid imaging and the possible role of p-glycoprotein. *Surgery* 1996;120:1039–45.
0. Chen H, Mack E, Starling JR. A comprehensive evaluation of perioperative adjuncts during minimally invasive parathyroidectomy: which is most reliable? *Ann Surg* 2005;242:375–80; discussion 80–3.
1. Blanco I, Carril JM, Banzo I, et al. Double-phase Tc-99m sestamibi scintigraphy in the preoperative location of lesions causing hyperparathyroidism. *Clin Nucl Med* 1998;23:291–7.
2. Johnston LB, Carroll MJ, Britton KE, et al. The accuracy of parathyroid gland localization in primary hyperparathyroidism using sestamibi radionuclide imaging. *J Clin Endocrinol Metab* 1996;81:346–52.
3. Jones JM, Russell CF, Ferguson WR, et al. Pre-operative sestamibi-technetium subtraction scintigraphy in primary hyperparathyroidism: experience with 156 consecutive patients. *Clin Radiol* 2001;56:556–9.
4. Casara D, Rubello D, Cauzzo C, et al. 99mTc-MIBI radio-guided minimally invasive parathyroidectomy: experience with patients with normal thyroids and nodular goiters. *Thyroid* 2002;12:53–61.
5. Barczynski M, Golkowski F, Konturek A, et al. Technetium-99m-sestamibi

subtraction scintigraphy vs. ultrasonography combined with a rapid parathyroid hormone assay in parathyroid aspirates in preoperative localization of parathyroid adenomas and in directing surgical approach. *Clin Endocrinol (Oxf)* 2006;65:106–13.
6. Lo CY, Lang BH, Chan WF, et al. A prospective evaluation of preoperative localization by technetium-99m sestamibi scintigraphy and ultrasonography in primary hyperparathyroidism. *Am J Surg* 2007;193:155–9.
7. Maser C, Donovan P, Santos F, et al. Sonographically guided fine needle aspiration with rapid parathyroid hormone assay. *Ann Surg Oncol* 2006;13:1690–5.
8. Geatti O, Shapiro B, Orsolon PG, et al. Localization of parathyroid enlargement: experience with technetium-99m methoxyisobutylisonitrile and thallium-201 scintigraphy, ultrasonography and computed tomography. *Eur J Nucl Med* 1994;21:17–22.
9. Rodgers SE, Hunter GJ, Hamberg LM, et al. Improved preoperative planning for directed parathyroidectomy with 4-dimensional computed tomography. *Surgery* 2006;140:932–40; discussion 40–1.
0. Starker LF, Mahajan A, Bjorklund P, et al. 4D parathyroid CT as the initial localization study for patients with de novo primary hyperparathyroidism. *Ann Surg Oncol* 2011;18:1723–8.
1. Mahajan A, Starker LF, Ghita M, et al. Parathyroid four-dimensional computed tomography: evaluation of radiation dose exposure during preoperative localization of parathyroid tumors in primary hyperparathyroidism. *World J Surg* 2012;36:1335–9.
2. Udelsman R, Aruny JE, Donovan PI, et al. Rapid parathyroid hormone analysis during venous localization. *Ann Surg* 2003;237:714–9; discussion 9–21.
3. Lebastchi AH, Aruny JE, Donovan PI, et al. Real-time super selective venous sampling in remedial parathyroid surgery. *J Am Coll Surg* 2015;220:994–1000.
4. Sippel RS, Becker YT, Odorico JS, et al. Does propofol anesthesia affect intraoperative parathyroid hormone levels? A randomized, prospective trial. *Surgery* 2004;136:1138–42.
5. Stojadinovic A, Shaha A, Orlikoff R, et al. Prospective functional voice assessment in patients undergoing thyroid surgery. *Ann Surg* 2002;236:823–32.
6. Leder SB, Donovan P, Acton LM, et al. Laryngeal physiology and voice acoustics are maintained after minimally invasive parathyroidectomy. *Ann Surg* 2013;257:968–70.
7. Lo Gerfo P. Bilateral neck exploration for parathyroidectomy under local anesthesia: a viable technique for patients with coexisting thyroid disease with or without sestamibi scanning. *Surgery* 1999;126:1011–4; discussion 4–5.
8. Carling T, Donovan P, Rinder C, et al. Minimally invasive parathyroidectomy

using cervical block: reasons for conversion to general anesthesia. *Arch Surg* 2006;141:401–4; discussion 4.
9. Chapuis Y, Fulla Y, Icard P, et al. Peroperative assay of active parathormone 1–84 in surgery of primary hyperparathyroidism. *Presse Med* 1990;19:1461–2.
0. Irvin GL 3rd, Dembrow VD, Prudhomme DL. Operative monitoring of parathyroid gland hyperfunction. *Am J Surg* 1991;162:299–302.
1. Carling T, Udelsman R. Focused approach to parathyroidectomy. *World J Surg* 2008;32:1512–7.
2. Udelsman R, Donovan P, Shaw C. Cure predictability during parathyroidectomy. *World J Surg* 2014; 38:525–33.
3. Haustein SV, Mack E, Starling JR, et al. The role of intraoperative parathyroid hormone testing in patients with tertiary hyperparathyroidism after renal transplantation. *Surgery* 2005;138:1066–71; discussion 71.
4. Gold JS, Donovan PI, Udelsman R. Partial median sternotomy: an attractive approach to mediastinal parathyroid disease. *World J Surg* 2006;30:1234–9.
5. Jaskowiak N, Norton JA, Alexander HR, et al. A prospective trial evaluating a standard approach to reoperation for missed parathyroid adenoma. *Ann Surg* 1996;224:308–20; discussion 20–1.
6. Udelsman R. Six hundred fifty-six consecutive explorations for primary hyperparathyroidism. *Ann Surg* 2002;235:665–70.
7. Bergenfelz A, Lindblom P, Tibblin S, et al. Unilateral versus bilateral neck exploration for primary hyperparathyroidism: a prospective randomized controlled trial. *Ann Surg* 2002;236:543–51.
8. Udelsman R, Lin Z, Donovan P. The superiority of minimally invasive parathyroidectomy based on 1650 consecutive patients with primary hyperparathyroidism. *Ann Surg* 2011;253:585–91.

EDITOR'S COMMENT

Minimally invasive parathyroidectomy (MIP) has gained worldwide acceptance in the surgical treatment of sporadic hyperparathyroidism, replacing the gold standard of bilateral neck exploration in patients with a presumed solitary parathyroid adenoma. A survey distributed among members of the International Association of Endocrine Surgeons (IAES) found that MIP was offered to patients by almost two thirds of endocrine surgeons worldwide in 2002. (Sackett WR, Barraclough B, Reeve TS, et al. Worldwide trends in the surgical treatment of primary hyperparathyroidism in the era of minimally invasive parathyroidectomy. *Arch Surg* 2002;137:1055–9.) It is likely if queried today a greater percentage would opt for this techniques as the results are comparable to bilateral neck dissection. The contribution by Udelsman and Carling reviews the indications for the procedure, the use of various preoperative imaging

modalities, the type of anesthesia including an extensive discussion of application of regional block to parathyroid surgery, the role of intraoperative parathyroid hormone (IOPTH) assay, challenging patients, and outcomes.

What is MIP? The term means different things to different people. James et al. (James BC, Kaplan EL, Grogan RH, et al. What's in a name?: Providing clarity in the definition of minimally invasive parathyroidectomy. *World J Surg* 2015;39(4):975–80) try to provide some insight into a definition of minimally invasive parathyroid surgery. They performed a PubMed search using the terms: parathyroidectomy, minimally invasive, localized, focused, unilateral, radio-guided, video-assisted, and endoscopic. They analyzed 443 (44%) articles after applying specific exclusion criteria and identified 18 words that were used in 75 different combinations to describe MIP. The finding that there were 75 different definitions for MIP confirms that their hypothesis that the term is too generic to be useful. They established that there were four categories that encompassed all 75 definitions: (1) operative approach (incision size, including the specific technique as open; endoscopic; robotic; or video-assisted), (2) number of glands explored, (3) operative adjuncts, and (4) anesthesia type and recommend that these categories be used to specify an operation as MIP. They cite as an example "2-cm, single gland parathyroidectomy using IOPTH measurement, under general anesthesia" rather than using the generic MIP. This more granular approach will enhance the clarity of the operative report and provide better definition for subsequent patient care and data collection. In the United States, there is no specific CPT code for MIP. Rather the CPT code 60500 is currently used as a one size fits all. When guided by IOPTH assay, the 36500 code represents blood sampling for the PTH assay. For the use of adjunctive measures, it is recommended the 22 modifier be used.

The primary imaging modality for parathyroid localization is sestamibi-technicium-99m scintigraphy. Some surgeons use an intraoperative radioguided approach using a small gamma probe. The success of radioguided MIP is 96% to 98%. In this technique, the patient is injected with technetium sestamibi 1 to 2 hours prior to surgery. During the operation, a gamma probe is used to identify counts of the enlarged parathyroid gland relative to background counts. After excision of the parathyroid gland, the tissue is scanned and ex vivo counts are expressed as a percentage of background counts. According to Norman et al. if the ex vivo parathyroid count is >20% of the background, then frozen section is not needed. (Murphy C, Norman J. The 20% rule: a simple, instantaneous radioactivity measurement defines cure and allows elimination of frozen sections and hormone assays during parathyroidectomy. *Surgery* 1999;126:1023–28.) Inabet and colleagues reported that intraoperative radioguidance is not necessary (Inabet WB, Kim CK, Haber RS, et al. Radioguidance is not necessary during parathyroidectomy. *Arch Surg* 2002;137:967–70). Radioguidance is helpful but may not be necessary. Ultrasound may prove to be an important adjunct and may be used as the sole localizing test. Butt and colleagues (Butt HZ, Husainy MA, Bolia A, et al.

Ultrasonography alone can reliably locate parathyroid tumours and facilitates minimally invasive parathyroidectomy. *Ann R Coll Surg Engl* 2015;97(6):420–4) present an 8-year experience using ultrasonography alone to guide parathyroidectomy. Between April 2004 and December 2012, 100 patients with proven hyperparathyroidism underwent parathyroidectomy performed by a single surgeon. All patients underwent ultrasonography as the only localization test. The procedure included preoperative marking of the lesion by a single radiologist. The median age of all cases was 58 years (range: 19 to 90 years). Of the 100 patients (69% female) who underwent parathyroidectomy, 93 had MIP. Conventional surgery was indicated in 7 patients owing to the need for concurrent thyroidectomy. The median operative time was 30 minutes (range: 10 to 130 minutes). Ultrasonography localized the parathyroid adenoma correctly in 98% of patients. Outcome analysis at 6 to 8 weeks demonstrated that 86% of open cases (6/7) and 94% of MIP cases (87/93) were rendered normocalcemic. Although there is variability in the results of ultrasound owing to user experience and the quality of ultrasound probes, it is likely to gain increasing use as it may be more cost-effective and ultrasound is being more integrated into graduate medical education and clinical practice. In addition as pointed out ultrasound-directed FNA for parathyroid hormone (PTH) assay may facilitate parathyroid adenoma localization for recurrent disease or a failed operation.

The majority of procedures are performed under general anesthesia with an endotracheal tube for airway control and oxygenation. Udelsman and the Yale group have an extensive experience with parathyroidectomy under local anesthesia that was reported in 2006 (Carling T, Donovan P, Rinder C, et al. Minimally invasive parathyroidectomy using cervical block: reasons for conversion to general anesthesia. *Ann Surg* 2006;141:401–4). The advantages are readily apparent particularly in the elderly population, and it avoids voice changes caused by the effect of the endotracheal tube on the vocal cords. Adopting this technique requires a well-delineated protocol and a dedicated team.

If the localization procedures are so accurate, then why would one need to do IOPTH assays to guide the success of the procedure? As the authors note, double adenomas may occur in 3% to 5% of patients and 10% to 15% have parathyroid hyperplasia. Sestamibi scans are very sensitive for single adenomas, however fail to identify 17% of double adenomas and 55% of hyperplastic glands. Hence without IOPTH assay, there is a potentially greater risk of a failed operation. Kim and colleagues compared outcomes in 53 patients undergoing MIP with and without IOPTH assay. The overall cure rate of group 1 (without IOPTH) was 94.9% and that of group 2 (with IOPTH) was 100%. Hence as this study shows even though the localization studies are successful, IOPTH monitoring is essential to avoid a surgical failure in MIP. A paper by Vaid and Pandelidis (Vaid S, Pandelidis S. Minimally invasive parathyroidectomy: a community hospital experience. *Arch Surg* 2011;146:876–

8) ascertained the outcomes of MIP performed in a community hospital without the expense of measuring PTH intraoperatively. This was a retrospective review of 188 parathyroidectomies including 111 MIRP. The success rate of MIP was 98% with two failures. The authors indicate that higher preoperative PTH levels and gland weights had a direct correlation with the success of MIP. It is possible that patients with lower PTH levels and possible microadenomas underwent conventional parathyroidectomy. The safest course of action is to perform IOPTH assays. The goal is avoid failure and the need for a second operation.

What is the role of video-assisted parathyroid surgery? It is no surprise that video-assisted techniques have been applied to parathyroidectomy (Miccoli P, Materazzi G, Bonari G, et al. Minimally invasive video-assisted parathyroidectomy. *Operat Tech Otolaryngol Head Neck Surg* 2008;19:22–5). Barczynski and colleagues report a retrospective case-controlled study of video-assisted versus open MIP (Barczyn´ski M, Papier A, Kenig J, et al. A retrospective case-controlled study of video-assisted versus open minimally invasive parathyroidectomy. *Videosurg Miniinv* 2014;9:537–47). Of 455 patients with primary hyperparathyroidism and a solitary parathyroid adenoma on preoperative imaging, 151 underwent video-assisted MIP using the technique of Miccoli and 304 had open MIP. They reported that the following outcomes were superior for video-assisted versus open MIP: lower pain intensity during 24 hours postoperatively ($p < 0.001$), lower analgesia request rate ($p < 0.001$), lower analgesics consumption ($p < 0.001$), higher recurrent laryngeal nerve identification rate ($p < 0.001$), shorter scar length ($p < 0.001$), and better cosmetic satisfaction at 1 month ($p = 0.013$) and at 6 months ($p = 0.024$) after surgery. However, the video-assisted procedures had longer duration of surgery ($p < 0.001$), and were more expensive ($p < 0.001$) than the open technique. There were no differences noted in the conversion rate, length of hospital stay, and morbidity (including recurrent laryngeal nerve injury; 3/151 in the video-assisted group and 8/304 in the open group).

Robotic-assisted transaxillary parathyroidectomy using the da Vinci Si surgical system (Intuitive Surgical, Sunnyvale, CA) has been described recently in several case reports and small series, as well as robotic-assisted retroauricular parathyroidectomy. Overall, the data with robotic transaxillary parathyroidectomy in the literature are very limited. The robotic approach is more technically demanding than open or video-assisted MIP and will likely add unnecessary expense. A few series report that this procedure can be performed by surgeons experienced in robotic and conventional surgery safely, but with longer operating times compared to conventional approaches (Okoh AK, Sound S, Berber E. Robotic parathyroidectomy. *J Surg Onc* 2015;112:240–42). The candidates for this procedure are patients with a diagnosis of primary hyperparathyroidism and a single gland localized on ultrasound and/or sestamibi scan. Similar to robotic thyroidectomy, candidates should be thin (BMI <30) with an axillary to sternal notch distance of <17 cm, in order to facilitate transaxillary access. Absolute contraindications include previous neck

surgery, significant thyroiditis, or bulky thyroid disease. Based on the limited experience with this technique, more analysis is needed before the robotic approach can be widely applied.

There are some special considerations for the application of MIP. First is the reoperative neck. In these situations, MIP is not contraindicated as long as there is clearly identified single adenoma. These procedures are best performed under general anesthesia as the difficulty of the planned dissection and hence the time of the procedure is hard to predict. Although head and neck irradiation should not be considered a contraindication for MIP with single gland hyperparathyroidism, the surgeon should beware of the routine application in these inpatients. Wilson and colleagues (Wilson SD, Doffek KM, Wang TS, et al. Primary hyperparathyroidism with a history of head and neck irradiation: the consequences of associated thyroid tumors. *Surgery* 2011;150:869–77) found in 49 patients with hyperparathyroidism with previous head and neck irradiation that patients presenting for parathyroidectomy had marked increase in nodular thyroid disease: nearly one in two had concurrent thyroidectomy, and nearly one in four had thyroid carcinoma. High-resolution ultrasound prior to parathyroidectomy detects associated thyroid pathology and allows the surgeon to plan the extent of thyroid resection. MIP is likely not be appropriate if there is associated thyroid pathology.

E. Christopher Ellison

42 Secondary and Tertiary Hyperparathyroidism

Richard A. Prinz, Kaare J. Weber, and Shalini Arora

Secondary hyperparathyroidism is a physiologic attempt to maintain calcium homeostasis when calcium absorption is diminished. Its causes are varied and are related to gastrointestinal, genetic, vitamin D, and renal deficiencies (Table 42.1). Secondary hyperparathyroidism develops in nearly all patients with chronic renal failure undergoing long-term dialysis. These are the patients who may require surgery for secondary hyperparathyroidism. This discussion will focus on the etiology, diagnosis, and management of renal hyperparathyroidism. Even with the improvements that have been made in the medical management of chronic renal failure as many as 10% to 15% of patients with this problem may eventually require parathyroidectomy.

ETIOLOGY

Parathyroid hormone (PTH) and the active form of vitamin D (1,25-dihydroxy D_3) are the chief regulators of calcium metabolism. Their main target organs are the bones, intestines, and kidneys. As renal function decreases as reflected by a declining glomerular filtration rate, circulating levels of active vitamin D_3 decrease because of diminished hydroxylation by the kidney of 25-hydroxyvitamin D to 1,25-dihydroxyvitamin D. The resulting decreased intestinal absorption of calcium leads to a relative hypocalcemia. The calcium-sensing receptor which is highly expressed in parathyroid cells detects the change in calcium and causes a compensatory secretion of PTH to raise circulating calcium levels. Concurrently, hyperphosphatemia occurs due to impaired renal phosphate excretion. Both hypocalcemia and hyperphosphatemia stimulate the parathyroid glands to secrete PTH. Persistent stimulation leads to hyperplasia of all parathyroid glands in a compensatory attempt to raise serum calcium levels by increasing PTH levels. Continued stimulation results in polyclonal cell proliferation and enlargement of the parathyroid glands. As

the parathyroid glands enlarge, the parathyroid cells show a decreased expression of the vitamin D and calcium-sensing receptors. This causes resistance to medical treatment with vitamin D analogs and calcimimetics. With prolonged stimulation, the parathyroid glands may develop autonomous production of PTH which can persist even after the physiologic stimulus has been removed. This autonomous condition is termed tertiary hyperparathyroidism. Like primary hyperparathyroidism symptomatic tertiary hyperparathyroidism is treated with parathyroidectomy. A successful renal transplant should reverse the pathophysiologic effects of chronic renal failure on calcium metabolism so the parathyroid glands and PTH secretions should return to normal. However, if the parathyroid glands have become autonomous, a return to normal calcium metabolism does not occur. The incidence of this type of tertiary hyperparathyroidism that persists after renal transplantation and requires parathyroidectomy ranges from 0.5% to 5.6%.

TABLE 42.1 Differential Diagnosis of Secondary Hyperparathyroidism

Gastrointestinal/ Malabsorption	Gastric bypass
	Cystic fibrosis
	Pancreatic disease
	Calcium deficiency
	Liver/biliary disease
Kidney related	Chronic kidney disease
Vitamin D deficiency	Lack of sunlight exposure
	Inadequate dietary intake
Genetic	Pseudohypopara-thyroidism

CLINICAL MANIFESTATIONS

Secondary hyperparathyroidism can lead to a spectrum of bone disease referred to as renal osteodystrophy. The most common finding that patients with chronic kidney disease will have is low bone mineral mass. This increases the risk of fractures which are associated with substantial morbidity and even mortality. Patients can also present with generalized

weakness, myopathy, and bone pain. The extreme clinical manifestation of renal osteodystrophy is termed leontiasis ossea. The hyperostotic changes in the facial bones cause an expansion of the malar processes, a reduced nasomaxillary angle, widening of the nares, flattening of the nasal bridge and an increase of the interdental spaces. This gives the patient's face a characteristic lion-like appearance.

Uremic pruritus can have a major effect on quality of life and be quite debilitating. Its etiology is multifactorial. Secondary changes in calcium phosphate metabolism can lead to extra osseous calcium deposition in the dermis and sub-dermal tissue. Other factors include increased circulating PTH levels, anemia, and elevated aluminum levels. A high calcium phosphate product can also cause extraosseous calcification of the joints, soft tissue, and viscera that may cause pain and functional impairment.

Renal hyperparathyroidism is associated with an increase in cardiovascular morbidity and mortality. Hypertension, cardiomyopathy and hypertrophy, insulin resistance, and calcium phosphate deposition in small and large vessel walls all contribute to this accelerated development of cardiovascular complications.

Calciphylaxis is a rare but life-threatening complication of secondary hyperparathyroidism. Excessive calcium in the microvasculature causes ischemia and ulceration in atypical areas of the body. The ulcers can be quite painful and difficult to treat. Debridement and local wound care alone are often insufficient. When these wounds become secondarily infected the risk of sepsis and death are high.

Tertiary hyperparathyroidism is described as persistent hyperparathyroidism with hypercalcemia despite reversal of secondary hyperparathyroidism from chronic renal failure with kidney transplantation. The average time for PTH levels to return to normal after renal transplantation is 3 to 6 months but can continue for over a year. Most patients with tertiary hyperparathyroidism are asymptomatic. Symptoms of tertiary hyperparathyroidism are similar to those of primary hyperparathyroidism and include osteoporosis, nephrolithiasis, fatigue, and neuropsychiatric complaints. High calcium may also cause deterioration of graft function.

MEDICAL MANAGEMENT

In the United States, total Medicare expenditures for end-stage renal disease (ESRD) reached $34.3 billion in 2011 accounting for 6.3% of the

Medicare budget. About 1.4% of Medicare patients had ESRD in 2011. This accounted for 7.2% of Medicare spending. Medicare costs for ESRD were "$75,670 per patient per year."

The goal of medical treatment of secondary hyperparathyroidism is to inhibit excess parathyroid secretion by correcting vitamin D deficiency, hypocalcemia, and hyperphosphatemia. Calcium and vitamin D supplements, phosphate binders and dietary restrictions, and a calcimimetic are all used usually in combination. Calcimimetics limit the effect of extracellular calcium on the parathyroid glands. By occupying the calcium-sensing receptor on the parathyroid cells, they downregulate PTH release. Cinacalcet improves blood levels of PTH, calcium, and phosphorous. It has reduced the frequency of parathyroidectomy in ESRD patients from 5% to 1% per year. However, it has not improved overall cardiovascular mortality in secondary hyperparathyroidism. Cinacalcet increases the risk of nausea, vomiting, and hypocalcemia and patients may require more frequent testing of blood calcium levels. With calcimimetics there is a progressive decrease in the calcium-sensing receptors and vitamin D receptors which results in treatment resistance.

Tertiary hyperparathyroidism is characterized by the inappropriate autonomous hypersecretion of PTH. As such it does not respond to the treatments for secondary hyperparathyroidism. Calcimimetics are not approved for long-term treatment of tertiary hyperparathyroidism. Parathyroidectomy is the only proven treatment option for tertiary hyperparathyroidism.

INDICATIONS FOR SURGERY

Guidelines have been developed to improve the clinical outcomes for dialysis patients with metabolic bone disease from secondary hyperparathyroidism. The Kidney Disease Improving Global Outcomes (KDIGO) group proposed revised practice guidelines in 2009 which defined target ranges for serum calcium, phosphorous, and PTH levels. Calcium and phosphorous levels should be maintained within their normal ranges and PTH levels should be maintained within two to nine times the upper limit of the assay. When these targets are not obtained with maximal medical therapy, parathyroidectomy is recommended. Parathyroidectomy is generally advised when serum levels of PTH are greater than 800 pg/mL in association with hypercalcemia or hyperphosphatemia. A calcium × phosphate product of 55 or greater also implies failed medical treatment

and carries a risk of extraosseous precipitation of calcium salts. When the calcium and phosphate product exceeds 55, despite appropriate medical management, parathyroidectomy is indicated.

Parathyroidectomy is also indicated to relieve patient symptoms. These include bone and joint pain, muscle pain and weakness, intractable pruritus, progressive bone mineral loss, extra skeletal calcifications, and tissue loss from vascular calcifications.

There is controversy concerning the treatment of calciphylaxis. Because mortality rates can be as high as 90% once secondary infection of the ulcers and sepsis occurs, calciphylaxis seems best managed by parathyroidectomy which will promptly control the secondary hyperparathyroidism. After the biochemical abnormalities are reversed, the ischemic tissue and ulcerations are then managed with local wound care and systemic antibiotics as needed. Medical management with bisphosphonate therapy or sodium thiosulfate, a calcium chelator, has also been used to reverse arterial calcification in calciphylaxis. Hyperbaric oxygen has been used with some reported success in healing the ulcerations.

After successful renal transplantation, up to 5% of patients may ultimately need parathyroidectomy for tertiary hyperparathyroidism. The indications for parathyroidectomy in tertiary hyperparathyroidism include persistently elevated serum calcium, symptomatic hypercalcemia, increasing PTH levels, hypophosphatemia, decrease in bone mineral density, or a decline in kidney function associated with hyperparathyroidism. Generally parathyroidectomy is delayed for a year after the transplant. However, surgery can be performed as early as 3 months because most patients should recover or be moving toward normal parathyroid function by that time.

PREOPERATIVE IMAGING

Preoperative imaging has not been a standard recommendation for secondary and tertiary hyperparathyroidism. Unlike primary hyperparathyroidism, these diseases are usually not due to a single adenoma. Since all the glands have been affected by the adverse changes in calcium metabolism a bilateral neck exploration to identify all the abnormal glands is required. Routine imaging with SPECT 99mTc-sestamibi and cervical ultrasound identifies some but not all the abnormal glands in these patients with hyperplasia. Even though up to 10% of

patients with renal hyperparathyroidism can have supernumerary glands and up to 40% can have ectopic glands, most of these can be found and removed with a thorough cervical exploration including a thymectomy. We do recommend preoperative ultrasound to identify any associated thyroid pathology in these patients. Nodular thyroid disease is present in at least 10% to 20% of all patients with secondary hyperparathyroidism. The presence of thyroid pathology should be evaluated preoperatively using clinical parameters, ultrasound, and ultrasound-guided fine needle aspiration biopsy to determine if an associated thyroidectomy is necessary at the time of the parathyroidectomy.

For patients with persistent or recurrent secondary hyperparathyroidism preoperative localization studies are essential. At least two imaging studies should confirm and pinpoint the location of the missing gland or glands before undertaking a second operation. We start the localization process with ultrasound which is the least invasive and least expensive study. Ultrasound-guided fine needle aspiration biopsy for cytology and/or measurement of PTH can be done for conclusive identification of parathyroid tissue. We usually reserve this if the other noninvasive studies are not confirmatory. SPECT 99mTc-sestamibi scanning can provide both a functional and anatomic localization of an enlarged parathyroid gland. It is useful for identifying ectopic glands especially those in the chest and mediastinum. MRI and 4D CT scanning can also be helpful in localizing ectopic glands in the thorax. Selective venous sampling is rarely necessary for localization.

SURGICAL APPROACHES

There are three surgical procedures that are utilized for patients with secondary hyperparathyroidism who require parathyroidectomy. These include subtotal parathyroidectomy with 3½ gland removal, total parathyroidectomy with autotransplantation, and total parathyroidectomy alone. Surgical thymectomy should be included with all three approaches because of the high likelihood of ectopic and supernumerary glands in the thymus. Likewise, cryopreservation of parathyroid tissue should be considered with all three operations in case the remnant or transplant do not function or the patient develops difficulty to control hypoparathyroidism after total parathyroidectomy. All three techniques have achieved good and comparable results. There are no randomized prospective trials comparing the three approaches. Surgeons treating these

patients usually favor one method based on their experience and training. It is important to remember that parathyroidectomy does not cure secondary hyperparathyroidism. It is a temporizing procedure intended to control the pathophysiologic response that chronic renal failure has induced in the patient's calcium metabolism. Only a functioning kidney transplant can bring about normal calcium metabolism and parathyroid function.

Each operation utilizes a Kocher incision placed in a natural skin line in the mid to lower neck to achieve an optimal cosmetic result. A meticulous technique is needed to identify all the parathyroid glands and to avoid injury to the recurrent laryngeal nerves. Nerve monitoring should be considered but there is no proof that it decreases the rate of recurrent nerve injury with these operations. If all four glands are not identified the surgeon should perform a complete neck exploration guided by the knowledge of the embryologic development of the parathyroid glands. The carotid sheath should be opened, intrathyroid lesions can be evaluated with ultrasound, and the retroesophageal areas should be explored. A cervical thymectomy should be done even if all four glands have been found. The surgeon should do everything to ensure that no parathyroid tissue remains in the neck after their exploration except for the remnant if they are doing a 3½ gland subtotal parathyroidectomy. Care should be taken to avoid rupturing the capsule of the individual parathyroid glands when removing them. This can cause shedding of cells which can seed into the surrounding tissue. The implantation of parathyroid cells with resulting parathyromatosis is very difficult to treat. The surgeon should not rely on visual inspection alone to identify the parathyroid glands but should obtain frozen section confirmation by taking a small incisional biopsy from each. This is especially true for the gland that will serve as the remnant in a 3½ gland parathyroidectomy or will be transplanted or cryopreserved in the other procedures. All four parathyroid glands should first be identified before removing any.

The most normal appearing gland should be used as the remnant for a subtotal parathyroidectomy. A 30- to 50-mg well-vascularized portion of the gland should be left in place. There is a tendency to leave too much tissue for fear of hypoparathyroidism. The surgeon should remember that the operation does not reverse the pathophysiologic effects of renal failure and its continued stimulation, so hyperplasia of the remnant parathyroid tissue is likely over time. The remnant should be fashioned first before any

of the other parathyroid glands are removed. If the initial remnant does not look viable, another gland can then be used. The remnant is marked with a metallic clip or nonabsorbable suture in order to help locate it if a subsequent reexploration would ever be required. Another factor to consider when choosing which gland will be the remnant is the ease of subsequent removal if persistent or recurrent hyperparathyroidism develops. In other words the risk of injury to the recurrent laryngeal nerve or other structures at potential reexplorations should be considered. If too large a remnant or supernumerary glands are left in the neck, persistent or recurrent disease would necessitate a reoperation in a neck. During any future exploration, the surgeon will have to deal with the extensive scarring that potentially increases the morbidity especially for recurrent laryngeal nerve injury. We do use nerve monitoring when doing these reexplorations.

To minimize the chance of reoperative neck surgery, a total parathyroidectomy, transcervical thymectomy, and autotransplantation of normal parathyroid tissue is favored by some surgeons. Again the surgeon should select the most normal appearing parathyroid gland for autotransplantation. A biopsy should be taken for frozen section confirmation before any tissue is transplanted or cryopreserved. Preparation of the tissue and the site of the implant vary among surgeons. We mince a 30- to 50-mg piece of the chosen parathyroid gland with a fine scissors and place the resulting slurry in a pocket in the brachioradialis muscle. When possible the nondominant forearm is chosen especially if it does not contain the dialysis access site. A small skin incision is made and the muscle fascia is opened. The muscle fibers are gently spread apart being careful to avoid bleeding and hematoma formation which can jeopardize the viability of the transplant. The graft is placed in this pocket and the overlying fascia is closed with two metallic clips which also identify the site of the graft if reexcision of it is needed in the future. The advantage of this approach is that no parathyroid tissue should remain in the neck. If recurrence does occur, PTH levels can be sampled from both antecubital fossae. If the graft is the source of the persistent or recurrent disease there will be a marked gradient with very high levels above the transplant site. If there is no meaningful gradient, the graft is not the source of the recurrence so localization studies are needed to determine whether a supernumerary or ectopic gland is present in the neck or the chest. Other areas that have been used for placing the graft include the

subcutaneous and muscle tissue in the neck and in the upper chest. Some surgeons also place 1-mm pieces in individual pockets so that they can remove the individual pieces if recurrence occurs.

Total parathyroidectomy and cervical thymectomy alone without autotransplantation is advocated by some surgeons. Most patients who are managed this way do not seem to be hypoparathyroid. It is the exceptional patient who does develop difficult to manage hypoparathyroidism. Because there is concern about this possibility most surgeons favor leaving some parathyroid tissue either as a remnant in the neck or as a transplant elsewhere.

Permanent hypoparathyroidism occurs in up to 10% of all patients who have parathyroidectomy for renal hyperparathyroidism regardless of which of the three methods is used. Therefore, cryopreservation of parathyroid tissue, which can be done by the blood bank at most hospitals, is recommended with all three approaches. Success rates for autotransplantation at the initial operation with fresh parathyroid tissue exceed 90%, but only 50% to 60% of patients who receive cryopreserved tissue will have adequate parathyroid function.

The development of persistent or recurrent disease requires a thorough evaluation of the patient to determine if a reoperation is necessary. Localization of the abnormal gland is essential before considering reoperation. Imaging using ultrasound, parathyroid scanning, MRI, and 4D CT scanning is used as needed. Venous sampling is rarely necessary but can be helpful in select patients. At least two imaging studies should confirm the same exact location of the missing gland. If the gland is in the neck, a focused approach should be done to avoid unnecessary dissection that risks morbidity. If the gland has been located in the chest or mediastinum, it can be removed with a minimally invasive thoracoscopic approach. Intraoperative PTH monitoring is useful to limit and stop the dissection when performing these reoperations.

A subtotal parathyroidectomy or total parathyroidectomy with autotransplantation of parathyroid tissue to the forearm has been the traditional surgical approach for tertiary hyperparathyroidism. Since normal calcium metabolism has been restored by the normalization of renal function with the kidney transplant, it is desirable that the patient have functioning parathyroid tissue. Consequently total parathyroidectomy is not recommended in this situation. Again, parathyroid tissue should be cryopreserved in case postoperative hypoparathyroidism develops.

Because one third or more of patients with tertiary hyperparathyroidism have been reported to have a single or double adenoma as the cause of their disease, some surgeons are utilizing a minimally invasive focused approach. To avoid increased recurrence rates with the focused approach, intraoperative PTH monitoring should be used to guide the extent of resection for tertiary hyperparathyroidism. This technique has led to success rates that seem to be equivalent to the traditional four-gland exploration.

INTRAOPERATIVE PARATHYROID HORMONE MONITORING

PTH has a serum half-life of 2 to 4 minutes. Measurement of intraoperative PTH levels in primary hyperparathyroidism is routinely used to determine the complete removal of abnormal parathyroid glands. In primary hyperparathyroidism, a drop of the intraoperative PTH level of greater than 50% and to within normal limits 5 to 15 minutes after excision is indicative of a cure in greater than 95% to 98% of patients. This criteria for intraoperative PTH monitoring is well accepted for primary hyperparathyroidism.

The interpretation of intraoperative PTH monitoring in secondary hyperparathyroidism is complicated by the altered clearance of PTH breakdown products in renal failure patients. PTH is a single chain polypeptide consisting of 84 amino acids. The intact PTH assay measures both the 1 through 84 PTH and large C-terminal degradation products which are cleared by the kidneys. These products have a half-life that is five to ten times longer than that of the 1 to 84 PTH and may interfere with the assay interpretation. Newer bioactive assays measure only the active PTH and not the inactive C-terminal fragments and seem to be more specific in patients with renal failure.

The criteria to interpret intraoperative PTH levels in secondary hyperparathyroidism are not as clear cut as in primary hyperparathyroidism. We have reported a drop of 90% from baseline or return to normal level as an indication of a successful operation with removal of all parathyroid glands. Nephrologists prefer an absolute drop of a postoperative PTH level to 200 pg/mL or less postoperatively. Some surgeons have suggested that thymectomy may not be needed if the intraoperative PTH levels indicate an adequate resection before this is done. Again the assay can be quite helpful in guiding the extent and

success of parathyroidectomy in reoperations for secondary hyperparathyroidism and in primary operations for tertiary hyperparathyroidism.

Preoperative management of these patients requires a multidisciplinary approach. Patients should undergo dialysis the day prior to or on the day of the operation. There is a risk of intraoperative hyperkalemia especially in males who are younger than 40 years of age. The anesthesiologist should be aware of the potential complications of hyperkalemia. The PTH level should drop markedly with a successful operation with a resulting profound decrease in serum calcium postoperatively. Hypocalcemia is the intended effect of the procedure and should not be considered a complication. Both the surgeon and the nephrologist must be prepared to deal with possible life-threatening hypocalcemia. Patients can require up to 18 g or even 20 g of intravenous calcium in a 24-hour period. An intravenous calcium drip may be required in order to maintain serum calcium at a safe level in patients with severe bone hunger. Calcium must be given according to the patient's needs. Postoperative supplementation should include large amounts of oral calcium as well as the active form of vitamin D, calcitriol, since the lack of kidney function will not convert the 25-hydroxy vitamin D to its active form. Calcitriol is essential for maximizing intestinal calcium absorption. These patients should be dialyzed with a high calcium bath to prevent symptomatic hypocalcemia and maintain their serum calcium levels.

Platelet dysfunction in renal failure patients as well as the need for heparin during dialysis postoperatively raises the concern for hematoma formation. The patient should be monitored closely for any swelling in their neck during the postoperative period. Life-threatening hypocalcemia and airway compromise must be identified early to avert disaster. Patients will require hospitalization until they can maintain their serum calcium at a safe level for 24 hours with only oral calcium and vitamin D.

Patients who have had aluminum-containing phosphate binders may develop high circulating aluminum levels. Aluminum toxicity is associated with reduced symptom improvement in patients having parathyroidectomy for secondary hyperparathyroidism. The surgeon and nephrologist caring for these patients must be aware that serum aluminum levels should be kept lower than 20 μg/L.

Suggested Readings

Cheung SP, Lee JJ, Liu TP, et al. Parathyroidectomy improves symptomatology and quality of life in patients with secondary hyperparathyroidism. *Surgery* 2014;155:320–8.

Kidney Disease Improving Global Outcomes (KDIGO) CKD-MBD Work Group. KDIGO clinical practice guideline for the diagnosis, evaluation, prevention, and treatment of chronic kidney disease-mineral and bone disorder (CKD-MBD). *Kidney Int* 2009;(Suppl 113):S1–130.

Somnay YR, Weinlander E, Schneider DF, et al. The effect of cinacalcet on intraoperative findings in tertiary hyperparathyroidism patients undergoing parathyroidectomy. *Surgery* 2014;156:1308–14.

Sprague SM, Belozeroff V, Danese MD, et al. Abnormal bone and mineral metabolism in kidney transplant patients-a review. *Am J Nephrol* 2008;28:246–53.

Weber KJ, Misra S, Lee JK, et al. Intraoperative PTH monitoring in parathyroid hyperplasia requires stricter criteria for success. *Surgery* 2004;136(6):1154–9.

EDITOR'S COMMENT

Dr. Prinz and colleagues have written an excellent chapter describing an increasingly prevalent disease complex. According to the National Kidney Foundation, Chronic Kidney Disease affects 14.5% of the US population. Biochemical abnormalities including chronic kidney disease, mineral and bone disorder, and renal osteodystrophy are common in patients with advanced kidney disease. It was estimated in 2007 that between 2 and 4.7 million people with chronic kidney disease had elevated parathyroid hormone (PTH) levels and were candidates for treatment. It was further estimated that these treatments would cost up to $122 billion dollars per year. Although secondary hyperparathyroidism is a frequent complication of chronic kidney disease (some would state that this condition eventually develops in all dialysis patients), it remains underrecognized and undertreated in early kidney disease. The prevalence of secondary hyperparathyroidism increases rapidly with decreasing glomerular filtration rate. When detected in an advanced stage, secondary hyperparathyroidism is more resistant to dietary and medical therapy, and may persist following kidney transplantation (tertiary hyperparathyroidism).

The distinction between primary (autogenous secretion of PTH, most often by a parathyroid adenoma) and secondary hyperparathyroidism is important as these conditions are treated differently. As it turns out, primary and secondary hyperparathyroidism can be confused in certain circumstances. A parathyroid tumor can contribute to kidney damage. Chronically elevated calcium levels from primary hyperparathyroidism can lead to nephrocalcinosis and kidney failure. It is important to remember that early stage kidney disease (Stage III or less) is highly unlikely to lead to secondary hyperparathyroidism. Patients with secondary hyperparathyroidism are typically on dialysis or have had kidney

failure for years. Their calcium level is low normal or low. A patient with kidney disease not on dialysis, high PTH levels, and a high calcium level has primary hyperparathyroidism and needs resection of the parathyroid lesion.

Historically, approximately 5% of patients with secondary hyperparathyroidism undergo parathyroidectomy. With advances in medical management, this rate has steadily declined. As discussed in this chapter, medical treatments such as intravenous vitamin D analogues and cinacalcet has led to the steady decline in parathyroidectomy for secondary hyperparathyroidism over the past 10 years. A recent study conducted using data from the international Dialysis Outcomes and Practice Patterns Study (DOPPS) examined trends in PTH levels and secondary hyperparathyroidism therapies over the past 15 years. The association between PTH levels and clinical outcomes were reported in more than 35,000 patients on dialysis. The median PTH levels increased over time, the number of prescriptions for Vitamin D analogues and cinacalcet increased, and parathyroidectomy rates declined over time. Compared to PTH levels of 150 to 300 pg/mL, in adjusted models all-cause mortality risk was higher for patients with PTH levels between 301 and 450 (hazard ratio, 1.09; 95% confidence interval, 1.01 to 1.18) and 600 pg/mL (hazard ratio, 1.23; 95% confidence interval, 1.12 to 1.34). PTH levels over 600 pg/mL were also associated with higher risk of cardiovascular mortality as well as all-cause and cardiovascular hospitalizations. The authors of this study concluded, “In the absence of definitive evidence in support of a specific PTH target, there is an urgent need for additional research to inform clinical practice.” In the current day, parathyroidectomy rates for secondary hyperparathyroidism remain at around 1% to 2%. One of the factors that prevent a more routine approach to parathyroid resection for secondary hyperparathyroidism is the fact that mortality rates following surgery are between 1% and 3%. The single most preventable cause of death in the first 30 days following parathyroid resection is hyperkalemia. Acute hypocalcemia, cardiac complications, and respiratory complications can also lead to early postoperative mortality. Based on my reading, this remains a controversial topic with regards to secondary hyperparathyroidism. A very nice review on this topic published in Langenbeck’s Archives of Surgery concludes “*Specialized endocrine surgery offers efficient metabolic correction of renal hyperparathyroidism with very low surgical morbidity. The summarized data reveals that infrequently surgical treatment remains the last choice, a negative selection of severely comorbid patients with advanced intractable cardiovascular manifestation and calciphylaxis are offered surgery too late to benefit. From the surgical perspective, earlier cooperation between nephrologists and endocrine surgeon in the management of renal hyperparathyroidism is desirable and cooperative studies without industrial influence are needed to establish interdisciplinary consented guidelines for the role of surgery in renal hyperparathyroidism.*”

Tertiary hyperparathyroidism is an interesting disease. A kidney transplant

often cures secondary hyperparathyroidism. Only about 0.6% to 5.6% of patients to undergo a kidney transplant eventually require a parathyroidectomy for tertiary hyperparathyroidism. As I review the surgical literature on this topic, there appears to be a prevailing opinion that the actual rate of parathyroidectomy in this patient population should perhaps be higher. The rate of tertiary hyperparathyroidism necessitating surgery is directly related to how long a patient is on dialysis prior to receiving a kidney transplant. I completed my residency at a program with a very high volume of kidney transplants and in the era prior to the introduction of calcimimetics in this population. A review from this institution revealed 618 kidney transplant recipients over an 8-year period with tertiary hyperparathyroidism. Only 41 (6.6%) underwent parathyroidectomy. Patients with higher levels of serum calcium and PTH posttransplant were more likely to be referred for parathyroid resection. Importantly, those who underwent parathyroidectomy had serum calcium and PTH values distributed more closely to the normal range. After transplantation, poor follow-up of parathyroid function is common because normalization of parathyroid function is expected and there are other medical management issues in the first year after transplant that take precedence. Given the fact that persistent hyperparathyroidism in a posttransplant patient can be associated with significant morbidity and even allograft dysfunction, this is a topic that requires further investigation in the opinion of several authors.

Calciphylaxis is a devastating condition that can develop in patients with secondary and tertiary hyperparathyroidism. Between 1% and 4% of patients on chronic hemodialysis or peritoneal dialysis develop calciphylaxis. Calciphylaxis involves cutaneous gangrene and extremely painful skin ulcerations. I do not routinely care for patients with hyperparathyroidism, but I can vividly recall a patient with calciphylaxis I cared for in the burn unit when I was a resident. I am not sure I have ever seen a patient quite as miserable and uncomfortable as this patient. Besides renal hyperparathyroidism, obesity, systemic corticosteroids, and vitamin K antagonists have been identified as predisposing risk factors for calciphylaxis.

The rising prevalence of kidney disease, kidney transplants, and now calcimimetics has led to dramatic changes in the field of surgery for secondary and tertiary hyperparathyroidism in the past 10 years. This is a very interesting, detailed, and well-written chapter by some of the world’s experts on the topic. This chapter is a “must read” for surgical residents, general surgeons who perform parathyroidectomy, nephrologists, endocrinologists, and even endocrine surgeons.

Jon C. Gould

Suggested Readings

Kidney Disease: Improving Global Outcomes (KDIGO.) CKD-MBD Work

Group. KDIGO clinical practice guideline for the diagnosis, evaluation, prevention, and treatment of chronic kidney disease-mineral and bone disorder (CKD-MBD). *Kidney Int* 2009;76 (suppl 113):S1–130.

Kidney Foundation. K/DOQI clinical practice guidelines for bone metabolism and disease in chronic kidney disease. *Am J Kid Dis* 2003;42(S1).

Lou I, Schneider DF, Leverson G, et al. Parathyroidectomy is underused in patients with tertiary hyperparathyroidism after renal transplantation. *Surgery* 2016;159(1):172–9.

Pitt SC, Sippel RS, Chen H. Secondary and tertiary hyperparathyroidism, state of the art surgical management. *Surg Clin North Am* 2009;89(5):1227–39.

Smith DH, Gullion CM, Nichols G, et al. Cost of medical care for chronic kidney disease and comorbidity among enrollees in a large HMO population. *J Am Soc Nephrol* 2004;15:1300–6.

Tentori F, Wang M, Bieber BA, et al. Recent changes in therapeutic approaches and association with outcomes among patients with secondary hyperparathyroidism on chronic hemodialysis: The DOPPS Study. *Clin J Am Soc Nephrol* 2015;10(1):98–109.

Weenig RH, Sewell LD, Davis MDP, et al. Calciphylaxis: natural history, risk factor analysis, and outcome. *J Am Acad Dermatol* 2007;56(4):569–79.

43 Transsternal, Transcervical, and Minimally Invasive Thymectomy for Benign and Malignant Disease

Daniel P. McCarthy and Malcolm M. DeCamp

Thymectomy is one of the most common mediastinal procedures performed by thoracic surgeons. Myasthenia gravis (MG), an autoimmune disease characterized by weakness and fatigability following repetitive exercise, is the most common indication for thymectomy. Regardless of the etiology, malignant, benign, or autoimmune, complete resection of all thymic tissue is the key to state-of-the-art thymectomy. Thymectomy can be performed via a variety of operative approaches. The purpose of this chapter is to analyze the pathophysiology of thymic diseases, the indications for surgery in their treatment, and the available techniques of resection to achieve acceptable and durable outcomes.

HISTORY OF SURGERY OF THE THYMUS GLAND

The word *thymus* originates from the Greek word *thymos*, which has dual meaning. Although it is synonymous with heroic character and is associated with soul, spirit, courage, power, will, heart, and anger, it is also related to the herb thyme and to the thyme flower. Rufus (98 to 117 CE), who lived in Ephesus, a center of learning on the western shore of modern-day Turkey, is acknowledged as the first person to refer to the thymus gland in humans.

The thymus gland gained clinical importance once it was linked by the Swiss physician Platter in 1614 to the sudden death of a 5-month-old boy from suffocation. An autopsy was performed at the request of the father as two other sons had died similarly. This revealed a highly vascular mass compressing the mediastinal structures. This condition was subsequently called “mors thymica or thymic death.” More than two centuries later, Sir Astley Cooper in 1832 described the death of a 19-year-old woman from a malignant thymic tumor invading the major veins of the superior mediastinum and compressing the trachea.

The finding of thymic tumors in autopsies in 1889 by Oppenheim and in 1901 by Weigert first suggested an interrelation between the thymus and MG. Contemporaneous invention of X-rays by Wilhelm Roentgen in 1895 allowed diagnostic imaging of enlarged mediastinal structures. The first thymectomy for MG was performed in 1911 by Ernst Ferdinand Sauerbruch from Zurich. He used a radiogram to diagnose thymic enlargement, associated it with the patient's MG symptoms, and performed a successful transcervical thymectomy on a 19-year-old woman.

In 1936, Alfred Blalock became the first person to perform a transsternal thymectomy in a 19-year-old woman with persistent, severe MG and an anterior–superior mediastinal tumor that had only partially responded to three courses of radiotherapy. Beginning with this case, and encouraged by the neurologist Ford, Blalock also demonstrated the relation between MG and nonthymomatous thymus glands.

Sir Geoffrey Keynes followed Blalock in 1942 when he performed a thymectomy and completion thyroidectomy on one of his previous patients with severe MG and recurrent thyrotoxicosis 12 years after removal of a goiter. The subsequent smooth postoperative period encouraged Keynes, who reported a series of 281 thymectomies by 1956. His contributions to the evolution of thymectomy included the separate evaluation of the operative results of patients with thymomatous and nonthymomatous glands, and the precise documentation of surgical thymic anatomy.

The transsternal approach remained the "gold standard" for thymectomy until the early 1960s. After Carlens described mediastinoscopy in 1959, Crile in 1964 and Akakura in 1965 reported their experience with 24 cases of transcervical thymectomy. In addition to MG, the indications for thymectomy were extended to resection of thymic cysts or suppression of rejection in renal transplant recipients. In 1969, Kirschner reported on 21 cases with only 1 death, and suggested that transcervical thymectomy be adopted as the preferred approach to resection, exclusive of thymomas.

Other clinicians remained skeptical regarding completeness of transcervical thymectomy. Reported clinical failures following cervical excisions, in some cases necessitating a reresection, fueled the ongoing debate of the optimal approach to thymectomy for MG. These discussions became more complicated after the reports of Masaoka et al. in 1975 and Jaretzki in 1988 demonstrating the presence of extra glandular thymic

tissue in 74% of the cases. Investigators at the University of Pennsylvania have reported comparable results with transcervical thymectomy to transsternal thymectomy after using a specially designed sternal retractor that allowed extended dissection through the limited cervical incision. With this report, the scale again tipped in favor of less-invasive surgery in the debate of thymectomy for MG. The controversy continues with increased vigor in the modern era, as thoracoscopic and robotic approaches add to the available minimally invasive options for treating nonthymomatous disease.

ETIOLOGY AND PATHOPHYSIOLOGY

Embryology

The thymus gland, together with the inferior parathyroid glands, arises from the third pair of pharyngeal pouches (Fig. 43.1). Although the fourth pharyngeal pouches also give rise to a small amount of thymic tissue, these are usually vestigial masses and these latter primordia in humans are usually either absent or rudimentary. In the 6th week of gestation, epithelium of the third pouch proliferates to form a dorsal bulbar component, later becoming the inferior parathyroid gland, and an elongated ventral portion, which is destined to become a thymic lobe. The entire third pouch separates from the pharynx during the 7th week. These thymic primordia migrate in a caudal and medial direction. Originally hollow, thymic primordia rapidly become solid epithelial bars, and during the 8th week, the caudal ends of the paired components of the thymus fuse together to form what is generally a four-lobed gland that attaches to the anterior pericardium. The organ, then being attached to the growing pericardium, descends into the mediastinum behind the sternum and anterior to the great vessels. Incomplete migration may potentially leave islands of thymus anywhere along the course of the primordia. The lower capsule tends to be less distinct, and thymic corpuscles, as well as abundant lymphocytes, trail off into the surrounding mediastinal fat and nodal tissue. Because of either premature arrest of migration or deviation from its natural tract, the thymus gland itself may be found anywhere between the hyoid bone cranially and the xiphoid process of sternum caudally.

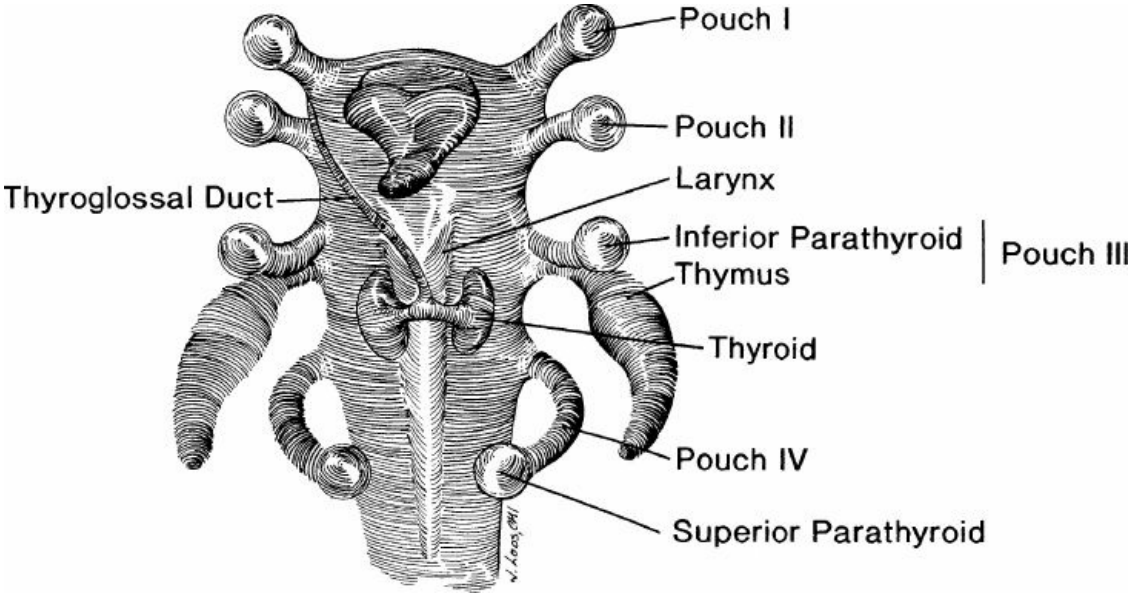

Figure 43.1. Embryologic development of the thymus and parathyroid glands from the third and fourth pharyngeal pouches.

Embryologic Development

Although the thyroid, parathyroid, and thymus glands arise from the pouches of the same primordial pharynx, they separate in later stages of embryonic life. As the thymus descends caudally, the parathyroid glands normally remain settled at the same level with and posterior to the lower poles of thyroid. The parathyroid glands are also called *parathymic* glands. In autopsy studies, as many as 20% of inferior parathyroid glands are found within the thymic capsule in the neck or in the mediastinum. Although more common for parathyroid tissue, thyroid tissue may also be present within the thymus gland.

Anatomy

In the newborn, the thymus weighs 10 to 12 g and continues to grow until puberty. Steinmann reported an average weight of 27.3 g with a standard deviation of 16.4 g within the 1st year of life. At puberty, the gland reaches its maximum weight of 20 to 50 g. Thereafter, it enters a gradual involution state, decreasing in mass to only 5 to 15 g in the elderly. At this time, the parenchyma is mostly replaced by fibro fatty tissue.

The thymus is a bilobed glandular structure; however, its two lobes are rarely symmetrical. The thymus is located predominantly in the anterior–superior mediastinum, where it anteriorly covers the great vessels, pericardium, and the base of the heart. It is also in close proximity with the

anterior surface of the innominate vein as it runs obliquely across the superior mediastinum to join the right brachiocephalic vein to form the superior vena cava (SVC; Fig. 43.2). The thymus may sometimes lie adjacent to either SVC on the right or the pulmonary artery on the left. One or both lobes may also lie behind the left innominate vein instead of in front of it. The two thymic lobes are fused in the midline, giving the gland its H-shaped configuration. The upper poles of each lobe reach into the neck where they join the thyroid gland by the thyrothymic ligaments on both sides. The lower poles lie on the pericardium anterior to the heart.

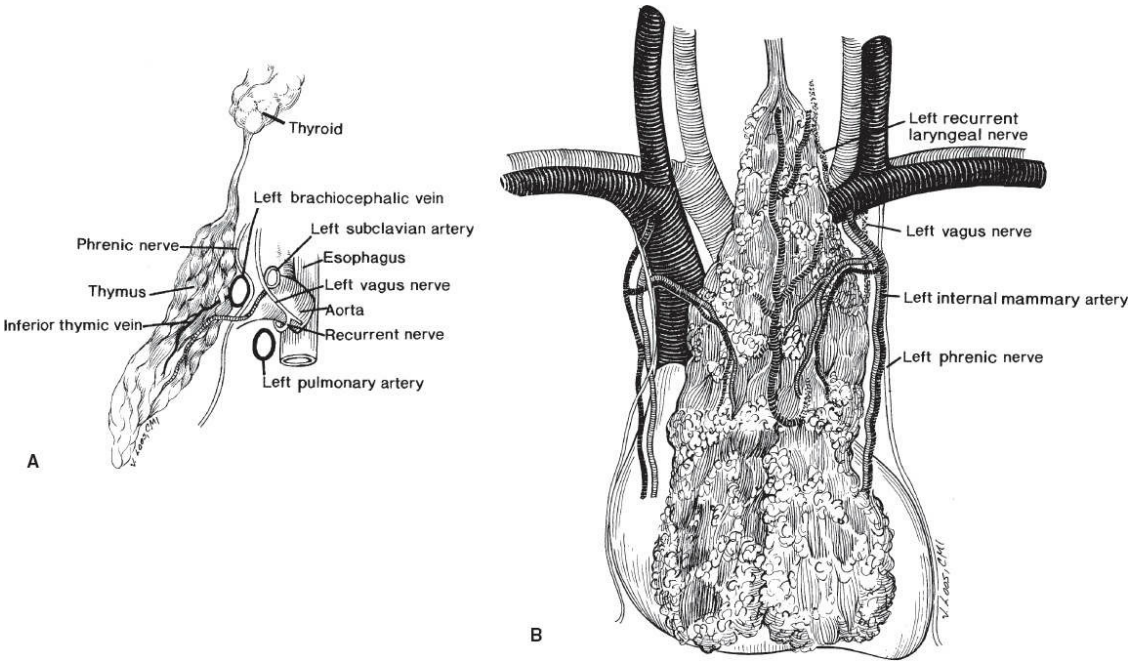

Figure 43.2. Anatomy of the thymus gland. **A.** Lateral view, showing the relationship to the left brachiocephalic vein, the inferior aspect of the thyroid gland, and the phrenic and recurrent laryngeal nerves. **B.** Anterior view, showing the relationship to the pericardium and great vessels. The major arterial supply originates from the internal thoracic (internal mammary) arteries, and the major venous drainage empties posteriorly into the left brachiocephalic vein.

Anatomy

The arterial supply of the thymus is chiefly derived from the internal thoracic arteries, although it receives branches from inferior thyroid arteries and pericardiophrenic arteries as well. There may be small draining veins traveling with the arteries from any of the three sources. However, the main venous drainage is through one or two major trunks,

formed by convergence of multiple tributaries from both lobes, running posteriorly between the lobes and draining into the anterior surface of the innominate vein. Although it is a major lymphatic tissue, unlike a lymph node, the thymus gland lacks afferent lymph channels. There are efferent lymph channels, which only drain the capsule and fibrous septa of the gland and drain into anterior mediastinal, pulmonary hilar, and internal mammary lymph nodes. Both sympathetic and parasympathetic nerve fibers are found in the thymus.

Numerous islets of thymic tissue, both macroscopic and microscopic, may be found in the neck, middle mediastinum, pulmonary hila, aortopulmonary window, retrocarinal fat, diaphragm, and even within the pulmonary parenchyma. Masaoka et al. reported 72% of cases had extracapsular microscopic collections of thymic tissue in the anterior mediastinum in 1975, and Fukai et al. came up with the same findings in 51.8% of cases in 1991. Jaretzki documented the variations of extra glandular thymic tissue found in different mediastinal locations in 1997 (Fig. 43.3). These publications form the basis for the ongoing debate on completeness and adequacy of thymectomy via various incisions.

Thymic Physiology

The thymus is a complex organ with epithelial and lymphoid components. During infancy, the thymus is essential for the development of cellular immunity. It is the main site for maturation of null lymphocytes into T cells. The majority of cells in the thymus are T lymphocytes and epithelial cells. These cells comprise the two main structural layers of the gland, the cortex and the medulla, respectively. Occasional lymphoid follicles with B cells and germinal centers can also be found. Although rare, myoid cells may also arise in the thymus. These cells act like skeletal muscle cells, including expression of the acetylcholine receptors (AChRs), and may be involved in the pathophysiology of MG.

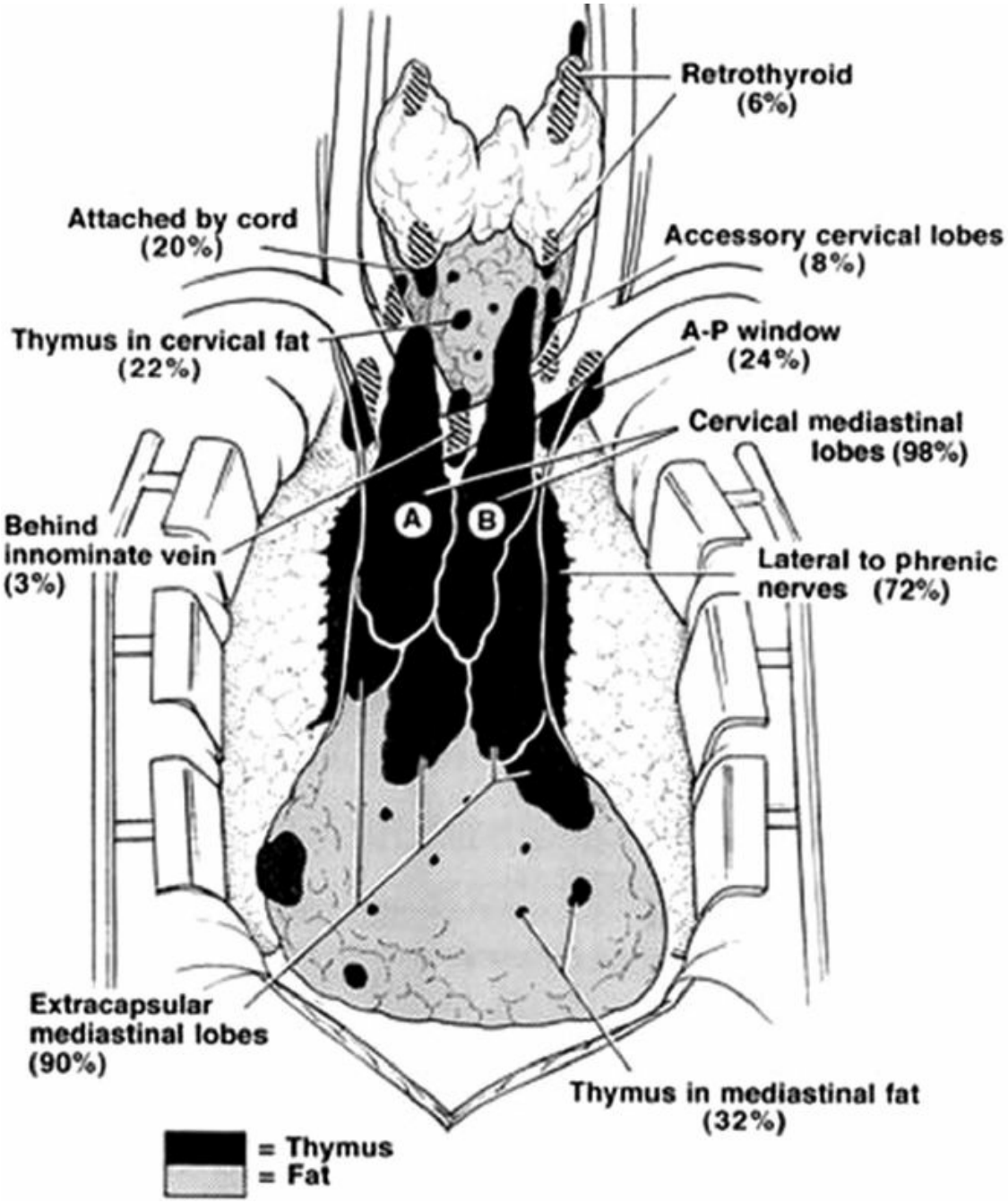

Figure 43.3. Locations of extraglandular thymic tissue. (Reprinted from Jaretzki A, Barohn RJ, Ernstoff RM, et al. Myasthenia gravis: recommendations for clinical research standards. *Ann Thorac Surg* 2000;70(1):327–34. Copyright © 2000, with permission from Elsevier.)

The proper function of the immune system depends on the normal simultaneous development of cellular and humoral components, and normal interaction between them. Thymus-centered T cells are responsible for differentiating self-antigens from intruders and producing cell-mediated immune reactions, as seen in delayed hypersensitivity reactions.

The bursa-dependent system, formed by the bursa, lymphoid follicles, and plasma cells, is responsible for the production of immunoglobulins (A, G, and M) and specific antibodies. Any disturbance in development of either system may lead to one of the various immunologic deficiency syndromes. Interestingly, some of these syndromes have been associated with various neoplasms of the thymus as well as with congenital thymic hyperplasia and agenesis. Some morphologic changes that the thymus can display have also been linked to hyperplasia, abnormal development, and infections.

Thymic Neoplasms

The epithelial subset of thymic neoplasms, namely, thymoma, is the most common tumor of the anterior mediastinum. It is fundamental in oncology that a successful therapeutic approach to a neoplasm be based on a definitive and prognostically reproducible classification and staging system. However, the classification of thymic tumors has been one of the most debated subjects of modern thoracic pathology, surgery, and oncology. There have been several classification proposals, focusing on one or more of histology, embryology, and biology of the tumors, in an attempt to establish an agreed-on nomenclature. Although lymphomas are far more common than thymomas in children and adolescents, the only role for surgery in their treatment is for diagnostic and staging purposes. Mesenchymal and germ cell tumors of the thymus are uncommon. The most common type is teratoma. Seminomas and nonseminomatous germ cell tumors also occur in the thymus, almost exclusively in men. Thymic carcinoids are extremely rare, often associated with endocrinopathies such as Cushing syndrome or inappropriate secretion of the antidiuretic hormone. They are typically invasive, often recur, are associated with extrathoracic metastases, and have a poor prognosis. The thymus can rarely be a site for metastasis as well.

Thymoma

Thymomas are rare tumors. Despite this, they account for 20% of all mediastinal neoplasms and comprise half of all primary tumors found in the anterior compartment. They may also be encountered in other areas of the neck and the thorax: along the pleura, inside the pericardial sac, over the diaphragm, within the lung parenchyma, and even as a polypoid lesion in the trachea. Thymomas are slow-growing tumors; however, they exhibit malignant potential as some demonstrate local invasion, pleural

dissemination, and systemic metastases without overt cytologic features of malignancy. They are more common between ages 40 and 60 and do not show predilection for either sex.

The clinical presentation of thymoma is extremely varied. In up to 50% of instances, these neoplasms are entirely asymptomatic, discovered incidentally on chest imaging or at autopsy. Approximately 30% of patients present with local symptoms related to pressure or direct invasion. In 20% to 70% of patients, thymoma is associated with systemic disorders that are primarily of autoimmune origin. When present, these concomitant diseases worsen the prognosis. The most common autoimmune disease associated with thymoma is MG. However, up to 28% of thymoma patients will present with an immune disorder other than MG. The most common disorders include pure red cell aplasia, lupus erythematosus, polymyositis, and hypogammaglobulinemia.

All thymomas originate from the thymic epithelial cells; however, only about 4% of them consist of a pure population of epithelial cells. Most have mixed populations of lymphoid cells, to a varying extent. There have been two major approaches to histologic classification of thymomas. In the 1960's Bernatz et al. from the Mayo Clinic divided thymomas into lymphocytic, epithelial, mixed, and spindle subtypes according to the lymphocyte-to-epithelial cell ratio in tumors. At that time, thymic carcinomas were not distinctly segregated, but grouped with thymomas. In 1978, Levine and Rosai proposed a new classification that proved to be of high clinical relevance. In this report, they divided the thymomas into benign (circumscribed) and malignant (invasive) types. Wick et al. in 1982 and Lewis et al. in 1987 proposed the separation of thymic epithelial cell neoplasms into thymomas and thymic carcinomas, which is now well accepted. Mixed thymoma cases with islets of thymic carcinoma behave clinically like typical thymomas more than thymic carcinomas. These findings support the theory that thymomas carry the potential for malignant transformation into malignant thymic carcinoma.

The Bernatz system remained the mainstay of thymoma classification until the mid-1980s. In 1985, Marino and Müller-Hermelink proposed a classification system based on the origin of the cells more than the cell type (i.e., cortical, medullary, or mixed subtypes). They differentiated the origin of epithelial cells found in the thymoma according to their resemblance to the normal epithelial cells in other parts of the thymic lobule and classified the tumor accordingly. This classification was

suggested to have independent prognostic implications. In their 80-patient series in 1990, Pescarmona and colleagues found that the Müller-Hermelink (M-H) classification reliably predicted prognosis. Medullary thymomas tended to be more encapsulated and clinically acted benign, but cortical ones were invasive and malignant in nature. When a modification of the Bernatz classification was used in the same 80-patient series, there was no correlation found between the subtypes and their prognosis. Wilkins (1995) also confirmed the M-H results, as he noted only a few recurrences in patients with medullary or mixed tumors, whereas the recurrence rate was much higher in cortical tumors.

The World Health Organization's (WHO) "Histological Typing of Tumors of the Thymus," reported by Rosai in 1999, reflected the consensus of the pathologists specializing in thymic tumors (Table 43.1). The cellular origins of the various neoplasms are emphasized in this classification, which is a successful synthesis of the most widely used classifications and resembles more the M-H classification. Currently, the WHO classification is the preferred classification method in thymic neoplasms. In this classification, type A represents atrophic adult-life thymic cells that are spindle or oval in shape, and type B represents bioactive thymic cells, of fetus and infants, with dendritic or epithelioid appearance. Type B thymomas are further divided into B1, B2, and B3 on the basis of increasing epithelial-to-lymphoid ratio and the emergence of atypia of the epithelial cells. Type AB thymomas display the common features of type A and type B lesions. Type C tumors are frankly malignant cells, and these lesions correspond to thymic carcinomas. There are at least nine subtypes of type C tumors, and they may be further subdivided into low-grade and high-grade malignant tumors.

TABLE 43.1 World Health Organization (WHO) Histologic Classification of Thymomas and Carcinomas of the Thymus

WHO Histologic Type	Previous Corresponding Terminology
A	Medullary thymomas; spindle cell thymoma
AB	Mixed thymoma
B1	Predominantly cortical thymoma; organoid thymoma; lymphocyte-predominant thymoma; lymphocytic thymoma
B2	Cortical thymoma
B3	Well-differentiated thymic carcinoma; epithelial; predominant epithelial; squamoid thymoma
C	Thymic carcinoma (with nine subtypes)

Besides the efforts of classifying the thymomas according to their histologic or morphologic features, Masaoka et al. in the 1980's proposed an anatomic classification based on the presence or absence of gross or microscopic invasion of the tumor capsule as well as its metastatic status. Medullary and mixed histology tumors are usually not invasive and therefore correspond to Masaoka stages I or II, whereas cortical thymomas are more commonly invasive and more likely to be Masaoka stages of III or IV. Later modifications of the Masaoka classification, as suggested by Koga et al. in the 1990's and Nakagawa et al. in the early 2000's have been more widely adopted (Table 43.2). These systems incorporated microscopic incomplete capsular invasion into stage I, leaving only transcapsular invasion in stage II.

As part of the WHO thymoma classification effort, it was suggested that a TNM scheme be used in staging of all malignant thymomas and thymic carcinomas. Because there has been so much controversy regarding tumor classification during the past four decades, no authorized TNM system has been adopted. The proposed WHO TNM schema is similar to the Modified Masaoka system but remains tentative, pending validation of its reliability, reproducibility, and predictive power.

To further enhance our understanding of thymic malignancies and provide support to patients and families with thymic cancer, the Foundation for Thymic Cancer Research (FTCR) organized meetings of international leaders in the field, resulting in collaborative initiatives. These efforts include several published meta-analyses, National Comprehensive Cancer Network (NCCN) guidelines for the management of thymic malignancies, and the creation of the International Thymic Malignancy Interest Group (ITMIG). The NCCN and ITMIG currently identify the Masaoka-Koga classification as the most widely used system for staging, and endorse the WHO system for histologic classification.

Myasthenia Gravis

The original description of MG dates back to the case report of the physiologist Sir Thomas Willis in 1672. The real recognition of the clinical syndrome came after the report by Wilks in 1877, in which he described a young woman who died of a respiratory paralysis. Autopsy did not reveal any central nervous system pathology that would explain the problem. In 1895, Jolly described the test now bearing his name, disclosing the easy fatigability in the affected muscle following repetitive stimuli. He then proposed the name *myasthenia gravis pseudoparalytica* for the disease. In 1899, the Berlin Society for Neurology and Psychiatry shortened the name to myasthenia gravis. However, only during the last two decades has the pathophysiology of this disorder become well elucidated as the experiments revealed the microstructure, physiology, and molecular composition of the nicotinic AChR.

TABLE 43.2 Modified Masaoka Clinical Staging of Thymoma and Thymic Carcinoma

I	Fully encapsulated tumor (a thymoma completely surrounded by a fibrous capsule of varying thickness that is not infiltrated by tumor growth in its full thickness)
II	Tumor infiltrates beyond the capsule into the thymus or mediastinal fatty tissue. Adhesion to the mediastinal pleura may be present
III	Macroscopic invasion into neighboring organs (i.e., pericardium, great vessels, or lung)
IVa	Pleural or pericardial dissemination
IVb	Lymphogenous or hematogenous metastasis

Data from Koga K, Matsuno Y, Noguchi M, et al. A review of 79 thymomas: modification of staging system and reappraisal of conventional division into invasive and non-invasive thymoma. *Pathol Int* 1994;44:359–67; and Nakagawa K, Asamura H, Matsuno Y, et al. Thymoma: A clinicopathologic study based on the new World Health Organization classification. *J Thorac Cardiovasc Surg* 2003;126:1134–40.

Pathophysiology of Myasthenia Gravis

The process of neuromuscular transmission in synapses is initiated with influx of calcium into the motor neuron, which in turn leads to release of acetylcholine (ACh) into the synaptic space. These ACh molecules diffuse across the synaptic cleft and bind to postsynaptic ACh receptors on the endplate of the muscle cell. In MG patients, this mechanism is blocked by an antibody-mediated attack on nicotinic AChRs on the muscle endplate. Clinically and physiologically, MG should be differentiated from the "myasthenic syndrome," which is also known as the Eaton–Lambert syndrome. It is a rare defect of neuromuscular transmission and is usually

associated with bronchogenic carcinoma. It is characterized by weakness and easy fatigability of proximal muscles of the extremities, with minimal or no bulbar symptoms and decreased or absent deep tendon reflexes.

The autoimmune attack on the AChRs appears to involve both cellular and humoral immune systems. Approximately 80% to 90% of MG patients have serum antibodies to the AChR. B-lymphocytes, which secrete anti-AChR immunoglobulin G, have been found in circulating blood as well as intrathymic germinal centers. Anti-AChR antibody and AChR interaction may occur in one of three ways: by accelerating the degradation of AChR through a cross-linking phenomenon, by directly blocking the receptor site, or by complement-mediated degradation of the receptor sites. Besides the amplified production of B cells in MG, antigen-specific T-helper cells are increased as well. AChR-specific T cells accumulate in myasthenic thymus glands regardless of the presence or absence of thymomas. The peripheral blood of myasthenic patients contains an increased amount of these autoreactive T cells, which in turn activate AChR-reactive B cells stimulating the anti-AChR antibody production.

Treatment is aimed at decreasing the circulating antibody levels, using either immunosuppression or plasmapheresis. This will result in clinical improvement in affected individuals as long as the treatment continues. In appropriately selected patients, the treatment that offers the best chance of complete remission is thymectomy. In this way, the source of autoimmunization is removed, depleting the specific T-helper cell population and normalizing T-cell function. B cells and helper T cells primed before thymectomy would theoretically remain in circulation, thus accounting for incomplete recovery in many patients who have undergone thymectomy as well as the relatively prolonged period (up to 2 years) between operation and remission in many patients.

CLINICAL PRESENTATION

Symptoms related to thymic disease are categorized as arising directly from the thymic lesion by either compression or invasion, symptoms associated with a previously described clinical syndrome (i.e., MG, red cell aplasia, or hypogammaglobulinemia), or nonspecific systemic symptoms such as anorexia and fatigue. Developmental anomalies can involve the location of the thymus or its structure. Failure of the thymus to descend into the anterior mediastinum might account for cervical thymic tissue, which can be mistaken for neoplasm, lymphadenopathy, or an

enlarged parathyroid. This aberrant tissue can cause compressive symptoms such as stridor or dysphagia. Lymphocyte count and tests of immunologic capacity may be diminished by thymectomy; however, no particular clinical problems have developed to correlate with these laboratory observations.

MG is the most common syndromic presentation of thymic disease. The prevalence of MG has been estimated at 43 to 64 per million persons. It has a predilection for females with a ratio of 3:2. Its peak age is 20 to 30 in women and more than 50 years in men. The disease is usually nonfamilial. The common presenting symptom of the disease is an insidious onset of generalized weakness. This is seen in 85% of the patients. It is usually symmetrical and becomes more intense at the end of the day. Muscles innervated by cranial nerves are often the first to be affected; however, any striated muscle in the body may be involved. Some patients may present with external ocular symptoms only, such as ptosis and diplopia. These symptoms may either spread to other muscle groups or remain confined to the eye, and may be so subtle that patients may go through several eyeglass prescriptions before they are diagnosed with MG. The worst type of disease occurs when the bulbar muscles are involved. The symptoms may include dysarthria with nasal tones caused by palatal paresis, diminished voice, and dysphonia. Often, patients can bite on the food but as they continue to eat, the mastication muscles weaken until they can no longer chew or close their jaws. Dysphagia may be associated with nasal regurgitation of liquids. Weakening of neck and back muscles may necessitate manual support of the head. Pelvic weakness may result in waddling gait. The most dreaded complication, however, is respiratory involvement. Weakness of respiratory muscles with paresis of intercostal muscles and the diaphragm may necessitate emergent medical attention. The Osserman and Genkins classification of MG is still very useful and widely adopted (Table 43.3). Standardized preoperative clinical staging has been recommended by applying the Myasthenia Gravis Foundation of America (MGFA) clinical classification (Table 43.4). Postoperative outcome can be characterized again in a standardized schema by following the De Filippi classification (Table 43.5).

Approximately 75% of patients with MG have thymic abnormalities; the majority having thymic hyperplasia. Although thymomas are present in 10% to 25% of MG patients, a higher proportion (30% to 60%) of patients with thymoma manifest some features of MG.

INDICATIONS AND CONTRAINDICATIONS

Thymectomy is indicated for the treatment of a resectable thymic neoplasm. Recent NCCN guidelines identify a “likely” thymic tumor as a well-defined anterior mediastinal mass in the expected location the thymus, with negative tumor markers, no mediastinal lymphadenopathy, and no continuity with the thyroid gland. Resectability must be defined by a thoracic surgeon and individualized to patient comorbidity. En bloc resections of pleura, pericardium, lung parenchyma, and even unilateral phrenic nerve may be safely performed. Innominate and SVC may be resected and reconstructed in appropriately selected patients. Direct myocardial involvement is rare but is a relative contraindication. Bilateral phrenic nerve involvement is generally avoided due to severe pulmonary morbidity.

Thymectomy is also indicated for nonthymomatous myasthenia gravis. The ideal patient for thymectomy is young with a short duration of symptoms and with significant disability and poor control with anticholinesterase medications. Conversely, elderly patients with nonthymomatous MG are generally not helped by thymectomy. In general, patients with mere ocular symptoms, or those whose condition is well controlled with acceptable medical treatment, are usually not first-line candidates for thymectomy. On the other hand, Shrager et al. reported an actual 50% complete remission, with a 5-year Kaplan–Meier estimate of complete remission of 57%, in patients with pure ocular MG. They also noted that as many as 50% of pure ocular MG patients historically deteriorate or develop generalized MG. In their ocular myasthenic patient group that had undergone thymectomy, the incidence of MG progression was zero.

TABLE 43.3 Osserman and Genkins Classification System of Myasthenia Gravis (MG)

I. Pediatric MG

A. Neonatal MG (1%)
- Seen in offspring of myasthenic mothers
- Self-limited (<6 weeks)
- Caused by transplacental transfer of circulating AChR antibodies
- Progression to juvenile or adult form is rare

B. Juvenile MG (9%)
- Onset any time between birth and puberty
- Tends to be permanent
- Nonmyasthenic mother
- MG disability is classified as in adult MG
- Familial involvement

II. Adult MG

Group I: Ocular MG (20%)
- Disease limited to ocular muscles
- 40% ultimately develop clinically generalized disease
- Electromyographic results may be positive in peripheral muscles
- Rarely progresses after 2 years of isolated ocular symptoms

Group IIA: Mild generalized disease (30%)
- Initial ocular symptoms progress gradually to generalized symptoms and involve cranial, limb, and truncal muscles
- Respiratory muscles are spared
- Good response to medical therapy, with low mortality

Group IIB: Moderately generalized disease (20%)
- More severe generalized involvement
- Bulbar symptoms are common, such as dysarthria, dysphagia, feeding problems
- Relative sparing of respiratory muscles
- Less responsive to medical therapy

Group III: Acute fulminating MG (11%)
- Rapid onset of severe generalized weakness
- Prominent respiratory symptoms
- Severe bulbar, limb, and truncal weakness
- Poor response to therapy
- High association with thymoma
- High mortality rate

Group IV: Late severe MG (9%)
- Patients with severe symptoms developing >2 years after onset of ocular or mild MG
- High incidence of thymoma
- Poor response to therapy

TABLE 43.4 Myasthenia Gravis Foundation of America Clinical Classification

Class	Description
Class I	Any ocular muscle weakness, other muscle strength normal
Class II	(IIa, IIb) Mild muscle weakness affecting limb, axial, oropharyngeal or respiratory muscles; any degree of ocular muscle weakness
Class III	(IIIa, IIIb) Moderate muscle weakness affecting limb, axial, oropharyngeal or respiratory muscles; any degree of ocular muscle weakness
Class IV	(IVa, IVb) Severe muscle weakness affecting limb, axial, oropharyngeal or respiratory muscles; any degree of ocular muscle weakness
Class V	Defined by intubation, with or without mechanical ventilation, except when employed during routine postoperative management

Adapted from Jaretzki A, Barohn R, Ernstoff RM, et al. Myasthenia gravis: recommendations for clinical research standards. *Ann Thorac Surg* 2000;70(1):327–34. Copyright © 2000, with permission from Elsevier.)

TABLE 43.5 De Filippi Postoperative Classification

Class	Description
Class 1	Complete remission, no medication
Class 2	Asymptomatic, decreased medication
Class 3	Improved, decreased symptoms or decreased medication
Class 4	No change
Class 5	Worsening symptoms

MG is unusual in childhood; however, one would expect the thymus to have a critical role in immunologic development. Although no deleterious effects of thymectomy have been shown in children older than 3 years of age, it is usually advisable to postpone pediatric thymectomies until puberty. In patients with MG and thymoma, the clinical course is influenced favorably by smaller tumor size.

PREOPERATIVE PLANNING

Comprehensive preoperative work-up for thymectomy includes attention to disease-specific considerations. Patients are screened for signs or symptoms of paraneoplastic syndrome. Serologic markers of germ-cell tumors, thyroid function tests, and anti-AChR antibodies may be useful.

Every candidate for thymectomy should undergo a preoperative contrast-enhanced computerized tomographic (CT) scan of mediastinum to accurately assess vascular relationships. CT defines the anatomic location, size, density, and extent of mediastinal tumors; identifies pulmonary and/or pleural-based metastases; and evaluates the status of contiguous mediastinal lymph nodes. Multidetector CT with multiplanar reconstructive capability may suggest local invasion of other mediastinal structures such as the chest wall, heart, pericardium, great vessels, central airways, or diaphragm and assists in surgical planning. Dedicated cardiac imaging protocols may be necessary when evaluating thymic tumors in close proximity to the pericardium. Most centers agree that magnetic resonance imaging (MRI) does not add much additional information to an optimally performed and reformatted contrast-enhanced CT. Rarely MRI may be used to better characterize soft tissue planes in an effort to discriminate between compression and local invasion. The utility of positron emission tomography in thymoma management is unknown. Additional neck imaging, and even thyroid scintigraphy, may be necessary to differentiate true thymic neoplasm from substernal goiter or ectopic thyroid tissue. A preoperative tissue biopsy is usually unnecessary, and a transpleural approach is contraindicated because of the risk of seeding the pleural space. Percutaneous core needle biopsy or surgical biopsy may occasionally be useful in the setting of significant diagnostic uncertainty with concern for a neoplasm that does not require surgical intervention (e.g., lymphoma). Fit patients who present with localized but marginal or unresectable disease should undergo core needle biopsy to confirm the histology followed by induction chemoradiotherapy in an attempt to allow subsequent resection. Unresectable thymic neoplasms should be biopsied prior to initiating definitive chemotherapy and/or radiation treatment.

Patients undergoing thymectomy for MG should not be rushed into the operating room until their medical condition is optimized. MG surgery is usually safe and well tolerated provided that a systematic, meticulous preoperative evaluation and preparation is performed. A team approach involving the anesthesiologist, neurologist, pulmonologist, respiratory therapist, intensivist, and thoracic surgeon is mandatory to minimize risk and achieve the desired outcome. The primary neurologist is charged with establishing an optimal medical regimen of anticholinesterases and immune-modulating drugs including corticosteroids. A preoperative spirometric workup is essential to forecast possible perioperative

respiratory complications. Various parameters including forced vital capacity, negative inspiratory force, maximum expiratory force, and maximum voluntary ventilation should be measured, both before and after application of cholinesterase inhibitors. Maximum expiratory force is useful for predicting an efficacious cough, and a measurement of less than 40 to 50 cm H_2O indicates a higher risk of postoperative respiratory complications. Vital capacity less than 2 L is another indicator of possible ventilatory compromise. Simple spirometric measures may be followed postoperatively as early indicators of impending respiratory compromise. Although data are limited in the perioperative population, forced vital capacity of less than 20 mL/kg and negative inspiratory force less than 30 cm H_2O have been identified as potential thresholds for elective intubation in patients with myasthenic crisis.

If the MG patient is unstable and/or symptoms are poorly controlled despite maximal maintenance therapy, intravenous immunoglobulin infusion or plasmapheresis is performed to diminish the circulating antibody levels. Plasmapheresis is also advisable prior to thymectomy in patients with bulbar symptoms even if they are well controlled on their current medical regimen. Three to five plasma exchanges, typically performed every other day, provide good preoperative preparation. As plasmapheresis is a nonspecific plasma exchange, other serum proteins such as clotting factors are depleted. To allow sufficient time for their resynthesis, surgery should be scheduled 2 to 3 days after the final pheresis session.

Anticholinesterase agents (pyridostigmine) should be discontinued 8 hours before the surgery. If these medications are discontinued any earlier, especially in severe cases, it may result in a myasthenic crisis. On the other hand, continuing the medications up until the time of surgery, especially in patients with mild symptoms, may cause a postoperative cholinergic crisis. Premedication in the operating room is usually minimal, consisting of atropine and a mild sedative. Long-acting muscle relaxants are avoided and deep anesthesia is maintained by inhalational agents and short-acting narcotics. Use of succinylcholine at induction is controversial. If possible, it is better to avoid it, but one should not hesitate to use it in case of a difficult intubation. First-generation cephalosporins are optimal for perioperative antibiotic prophylaxis. Aminoglycosides are to be avoided as they may increase neuromuscular blockade.

SURGICAL TECHNIQUE

Thymectomy is performed for benign and malignant thymic pathology. Thymectomy for MG, with or without thymoma, must be complete in order to obtain drug-free remission or at least significant improvement. This principle has fueled the endless debate between the enthusiastic proponents of the most extensive thymus and mediastinal fat resection and the defenders of thymic resection through a minimal incision.

Development of fiberoptic surgical tools, video applications in mediastinal and thoracic surgery, and specially designed sternal elevators improved direct mediastinal vision and the completeness of removed thymus from a small cervical incision. This in turn allowed the proponents of limited-incision approaches to improve the scope of their resections and report outcomes that had remission rates comparable with those of open extended or maximal thymectomies. The 1990s saw the advent of video-assisted thoracic surgery (VATS) followed by robotic-assisted thoracic surgery (RATS) a decade later, providing additional minimally invasive approaches to thymic surgery.

In the presence of clinical and radiologic evidence for a resectable thymoma, the surgical approach should be a full median sternotomy in order to obtain complete resection. There are, however, reports of video-assisted and robotic surgery approaches to resection of small thymomas (stages I and II). The goal of surgery remains a complete (R0) resection with inclusion *en bloc* of any adjacent structures involved by tumor such as pericardium, pleura, lung, or major vessels. Margins of resection include the thyroid gland superiorly, diaphragm inferiorly, and both phrenic nerves laterally. Microscopic (R1) and macroscopic (R2) incomplete resections are to be avoided but if unavoidable should be treated with adjuvant radiotherapy with consideration of chemotherapy as indicated by the NCCN guidelines.

Given the paucity of comparative studies, each of these approaches is in use today and will be discussed here.

Standard and Extended Transsternal Thymectomy

A standard thymectomy can be accomplished via either a full or partial sternotomy. For nonthymomatous MG, a partial sternotomy provides sufficient exposure. If a partial sternotomy is chosen, a T-shaped sternal incision through the fourth intercostal space facilitates excision of the inferior thymic poles. The technique used in standard thymectomy is the

same as for extended thymectomy except that there is a limitation in reaching caudally to the lower-most part of the anterior mediastinum and above the diaphragm because of the intact lower sternum. Extended transsternal thymectomy involves complete anterior mediastinal fat exenteration. This approach requires a full median sternotomy through either a midline or transverse submammary skin incision. It overcomes the shortcomings of standard thymectomy in removing all of the thymic tissue, beginning at the diaphragm and extending cranially together with any extraglandular thymic tissue found within the anterior mediastinal fat. It only lacks the accessory cervical incision used in the transsternal–transcervical (maximal) thymectomy. The patient is positioned supine with a transverse shoulder roll behind the scapulae and with the head in extension. A standard midline incision is made starting from one fingerbreadth below the suprasternal notch, extending down to below the xiphoid process. In the case of standard thymectomy, the incision is prematurely ended at the level of the fourth intercostal space. Because many of the patients are young women, either the transverse submammary or Y-shaped incision for sternotomy might be cosmetically preferable (Fig. 43.4). The presternal soft tissue and the fascia overlying the sternum are cut in the midline with electrocautery. Once the cleido-cleido ligament is divided with caution to avoid the vascular structures that may lie posterior to it, the space posterior to the manubrium is developed from the mediastinal tissues with blunt finger dissection. Similar digital dissection is carried out inferiorly behind the xiphoid process and the lower end of the sternum. The sternum is vertically split in the midline with a reciprocating or oscillating saw.

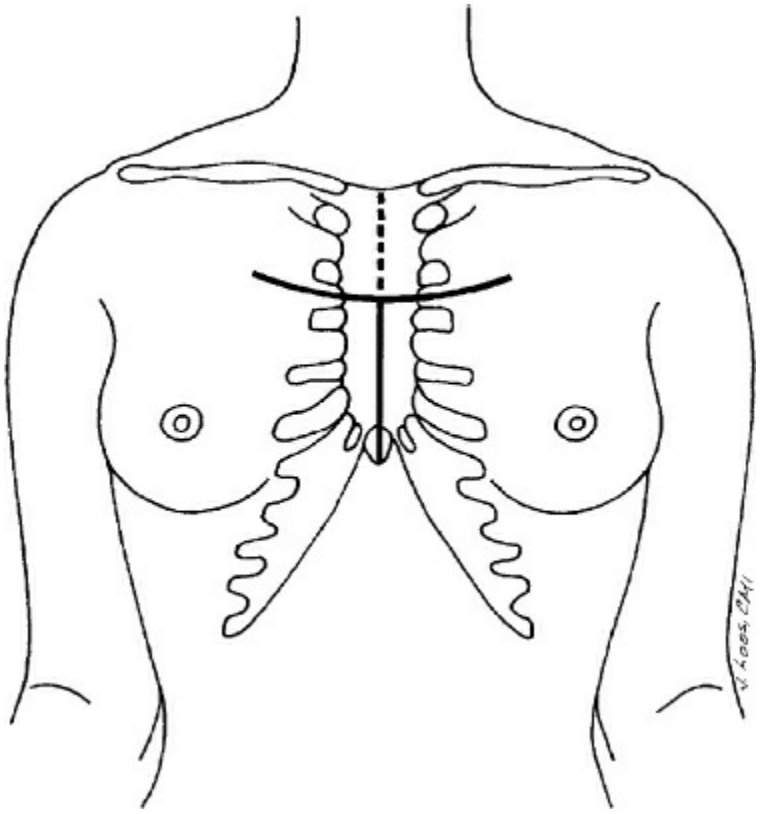

Figure 43.4. The Y-shaped skin incision, with a cephalad skin/subcutaneous flap, allows access to the entire sternum for midline sternotomy while maintaining cosmesis (especially in females) of the upper chest area.

Y-Shaped Incision

Because of its involution and since it is mostly filled with fibro fatty tissue, the thymus gland is often hard to distinguish from mediastinal fat in the adult. This is especially true in patients with long-term steroid use and in the presence of abundant mediastinal fat. *En bloc* resection of all mediastinal fat tissue, including both mediastinal pleural sheets, will ensure the inclusion of all of the thymic remnants in the resected specimen. Initially, both pleural spaces are opened and the phrenic nerves identified. Then, by using sharp and blunt dissection, the overlying mediastinal pleurae are pushed to the sides to bring the thymus and left innominate vein into view. Once the anterior surface of the gland is exposed, the mobilization starts at the diaphragm. The mediastinal fat, including the anterior pericardiophrenic fat pad, is elevated bilaterally and continued superiorly with the lower lobes of the thymus. The phrenic nerves should always be kept under direct vision to avoid injury. The lymph nodes and fat that course along the nerves are also separated and

included with the specimen. As the dissection moves cranially, the specimen should be elevated off the pericardium and sharp dissection should be carried strictly on the pericardium.

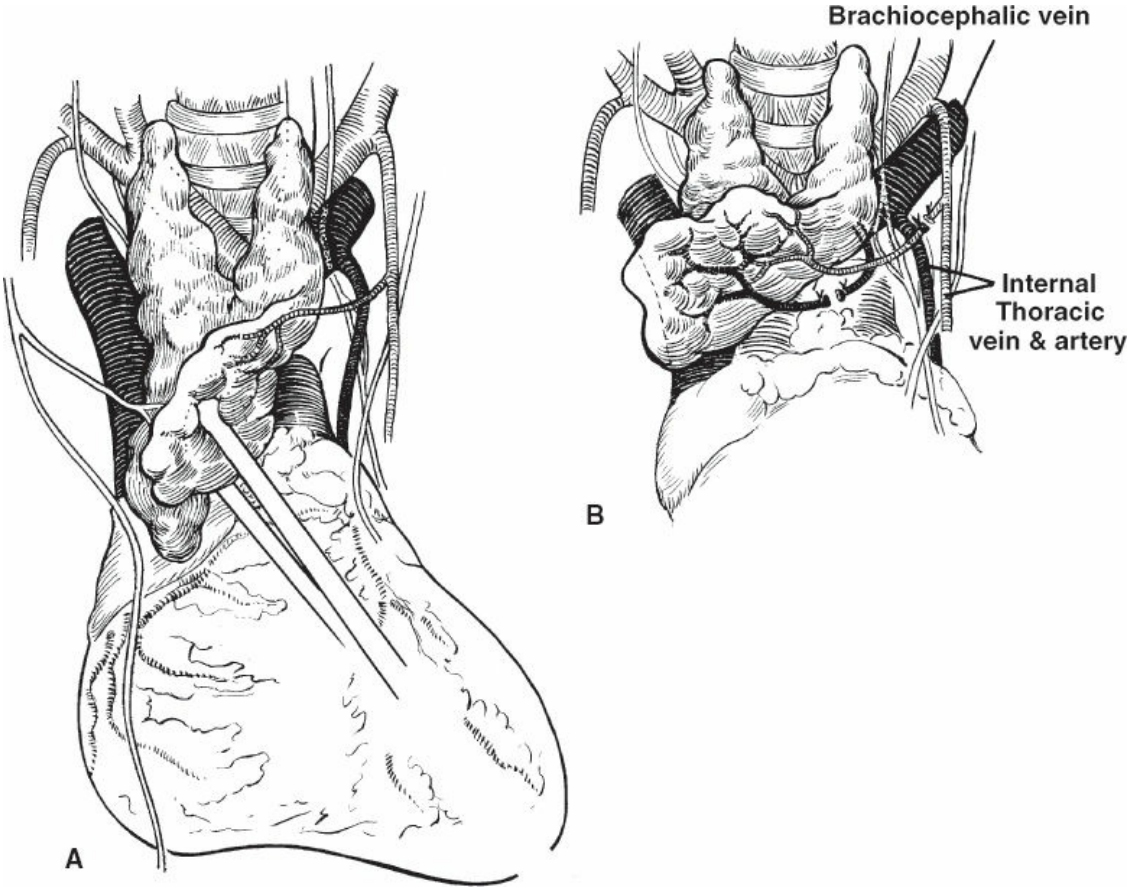

Figure 43.5. A. Division of the branches from the internal thoracic arteries allows the *en bloc* specimen to be rotated upward, exposing the undersurface of the gland and the draining veins. **B.** The brachiocephalic vein is exposed and the thymic veins are isolated and divided between ligatures or clips.

The arterial blood supply to the thymus gland extends laterally from the internal thoracic arteries. These branches are isolated and ligated appropriately. Once these anchoring vascular structures are divided, the gland can be rotated upward, exposing its posterior surface (Fig. 43.5). The thymic veins draining into the innominate vein are easily identified and safely divided as the inferior lobes are elevated. Once the dissection is completed on both sides up to the anterior borders of phrenic nerves, and the specimen is separated from the anterior surface of the innominate vein, the only attachment that remains would be the superior horns of the gland. This part of the dissection is carried out cautiously to avoid premature

disruption as the superior horns may be very delicate and extend well up into the cervical planes. Inferior parathyroid glands should be avoided and left with their blood supply intact if they are visualized. Venous tributaries between the thymic horns and inferior thyroid plexus should be ligated and divided. The fatty tissue between the SVC and aorta is swept anteriorly toward the mobilized thymus. Similarly, the lymphatic areolar tissue within the aortopulmonary window deep under the innominate vein is included with the specimen, completing the excision. Extra caution is needed during this radical anterior mediastinal lymph node dissection to avoid the left phrenic, vagus, and recurrent laryngeal nerves within the aortopulmonary window and along the left upper part of the dissection as such an injury would be devastating for a myasthenic patient.

En Bloc Resection

The presence of a thymoma mandates a thorough evaluation of resectability prior to embarking on thymectomy. The surgeon's assessment of local invasion is critical in defining the precise Masaoka stage, which in turn influences decisions regarding adjuvant treatments. A complete exploration includes inspection and palpation of both pleural spaces, the lung parenchyma, and the diaphragmatic and pericardial surfaces. Any tissue or organ involved by direct invasion with the thymoma should be included in the *en bloc* resection. Dense adherence of a thymoma to the pericardium requires that a portion of the parietal pericardium be included with the specimen. Direct invasion of the myocardium is rare. Droplet metastases along the pericardium and/or pleura should also be excised. In an adult, one but not both phrenic nerves can be resected if necessary. If the patient also suffers from MG, every effort to preserve diaphragmatic innervation should be made. Invasion of the innominate vein or SVC may require local resection. When possible, defects in these low-pressure vessels should be reconstructed with autologous tissue patches, transposition of the SVC or innominate vein to the right atrial appendage, or interposition with native vein or prosthetic grafts. If the right brachiocephalic to the SVC connection and the left jugulo-subclavian confluence remain intact, then an isolated resection of the innominate vein can be left unreconstructed.

Following resection of the gland, meticulous hemostasis is performed. Patients who underwent plasmapheresis prior to surgery may tend to bleed more postoperatively. A chest tube placed from the right inframammary

chest wall, across the mediastinum, and extended to the contralateral apex usually provides adequate postoperative drainage. For more extensive resections, the pleural spaces can be drained separately. The sternum is reapproximated with stainless-steel wires and the soft tissues with absorbable sutures in layers. Postoperatively, the patient is extubated in the operating room, the recovery room, or intensive care unit and is closely followed by the surgery, anesthesia, and neurology teams for signs of myasthenic crisis.

Patients are usually maintained on their preoperative medications as MG response to thymectomy is usually slow to evolve. Although the majority of myasthenic patients who undergo thymectomy experience significant improvement in their symptoms, drug-free remission is achieved predominantly in patients with earlier Osserman classes. This observation supports the recommendation for early thymectomy, as progression of symptoms was associated with an incomplete response to thymectomy.

TRANSCERVICAL THYMECTOMY

The original transcervical thymectomy described in the early 1970s involved removal of only the intracapsular thymus gland. Such a technique will not suffice as acceptable therapy for MG. In recurrent cases following basic transcervical thymectomy, transsternal reoperations revealed 2 to 60 g of retained thymic tissue, including thymomas. With specialized retraction, improved instrumentation, and illumination, the technique used in selected patients with thymic hyperplasia only has achieved results comparable with those of transsternal approaches. Moreover, proponents argued that patients with MG may choose transcervical removal of the thymus earlier in the course of their disease owing to its superior cosmetic results and lower morbidity. Because the duration of symptoms has an adverse effect on the MG response to thymectomy, an earlier commitment to surgery could provide better outcomes. Major contraindications to transcervical thymectomy are suspicion of thymoma and the patient's inability to fully extend the neck. Previous sternotomy or mediastinal surgery also precludes the transcervical approach.

Following the same preoperative preparation as for transsternal thymectomy, the patient is positioned supine on the operating table, with a roll behind the shoulders and the neck extended. Anesthesia equipment is positioned laterally in relation to the patient's head as the surgeon is seated

at the head of the bed. As there is always the possibility to convert to an open sternotomy in case of an emergency or unexpected finding (thymoma), the surgical field should be wide enough to expose such anatomic landmarks to allow this surgical conversion. The incision is a transverse curvilinear incision approximately 2 cm above the sternal notch. After the skin incision, the platysma is cut and both superior and inferior skin flaps are raised by electrocautery dissection. The strap muscles are separated and retracted laterally on both sides. The upper poles of the thymus gland are usually located at this tissue plane lying superficial to inferior thyroid vessels. Initially, the upper portion of the thymus gland and surrounding fat tissue is dissected off of the trachea, thyroid gland up to its isthmus, and inferiorly to the sternal notch (Fig. 43.6A). Ectopic thymus tissue should always be expected and searched for, deep to and superior to the upper horns on both sides. The recurrent laryngeal nerves and the inferior parathyroid glands are usually identified and preserved. If it becomes difficult to differentiate inferior parathyroid glands from the thymus tissue, or the ectopic thymus tissue, a frozen section can be sent for analysis and confirmation.

Cervical Dissection

Following the true cervical portion of the dissection, the cleido-cleido ligament is cut vertically and the prethymic plane is separated from posterior sternal plate by blunt finger dissection. The gland is palpated for nodular or invasive characteristics. A special narrow right-angled retractor is placed behind the sternum and attached to a self-retaining apparatus for upward traction (Fig. 43.6B). With the help of headlight illumination, the anterior mediastinum is then well visualized. The already mobilized upper half of the gland is lifted up and dissection is carried down posterior to the thymus until the innominate vein is exposed and the thymic venous branches isolated where they drain into the innominate vein. These branches are ligated and divided under direct vision. After this is accomplished, the remaining attachments of the gland and pericardial fat pad are dissected caudally with the combination of sharp and blunt dissection, as well as cranial traction, off of the pericardium and bilateral pleural surfaces. Although the dissection technique is almost identical to that of transsternal thymectomy, the major difference is the inability to keep the phrenic nerves under direct vision at all times. Therefore, utmost care should be paid to the anatomic landmarks and to staying away from

the possible course of the phrenic nerves. If there is any invasion of pleura, it should be resected *en bloc* with the specimen and may necessitate conversion to a sternotomy or VATS approach.

After removal of the specimen, the anterior mediastinum should carefully be inspected for satisfactory hemostasis. Unless the pleural spaces are opened, no chest tube is required. A red rubber catheter is placed into the mediastinum through the incision during closure of the layers. Once the strap muscles and platysma layers are approximated with absorbable sutures, and the lungs are fully expanded, the red rubber catheter is placed on suction and removed. The skin is closed with a running absorbable subcuticular suture.

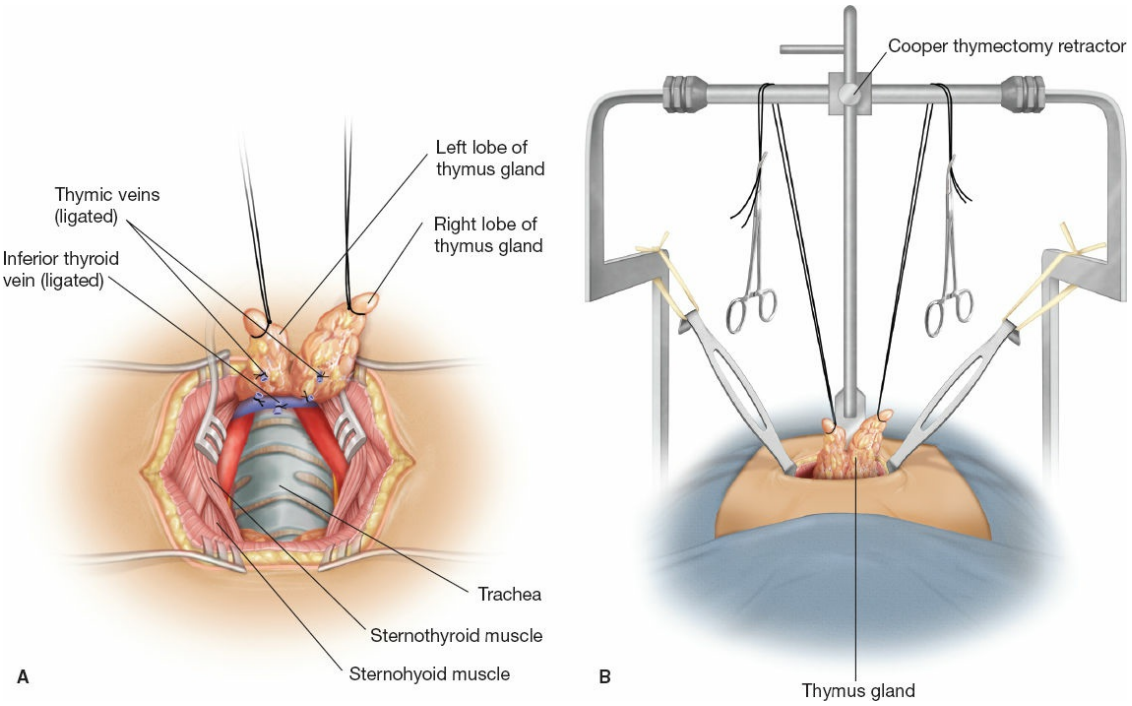

Figure 43.6. A. The cervical poles of the thymus gland have been dissected off the trachea, and are used to deliver the thymus up into the cervical incision and off of the posterior structures. **B.** After completion of the cervical dissection, a self-retaining retractor is used to bring the sternum anteriorly and facilitate better exposure of the anterior mediastinum. (Reproduced from Mulholland MW, Albo D, Dalman RL, et al. *Operative Techniques in Surgery*. Volume 1. Philadelphia, PA: Wolters Kluwer Health; 2015.)

VIDEO-ASSISTED THORACOSCOPIC THYMECTOMY

Thymectomy can be accomplished using VATS using a variety of

approaches. These include right- or left-sided VATS thymectomy, bilateral VATS thymectomy, bilateral VATS combined with a cervical approach for extended thymectomy (video-assisted thoracoscopic extended thymectomy [VATET]), bilateral VATS combined with a subxiphoid approach, and VATS thymectomy with sternal and anterior chest wall elevation. Both right- and left-sided approaches have their advantages and limitations. In left video-assisted thoracic thymectomy, it is easier to mobilize the left inferior pole and pericardial fat tissue lying laterally along the left ventricle. The aortopulmonary window is also more directly visualized. On the other hand, dissection along the innominate vein and visualization of the SVC can be quite challenging. The proponents of right-sided VATS thymectomy use the SVC as a helpful landmark, and can more easily identify the innominate vein. Combinations of transcervical, subxiphoid, and bilateral VATS thymectomy may allow for more extended thymic resection. Despite this, the complexity of multiple incisions is cumbersome, associated with postoperative pain similar to that following sternotomy, and lacks any evidence for therapeutic benefit. Currently, only right or left VATS approaches to thymectomy are performed with significant frequency to warrant a detailed description.

Technique for Right-Sided VATS Thymectomy

Following the initiation of general anesthesia with a double-lumen endotracheal tube, the patient is positioned in full left lateral decubitus position with the bed rotated 30 degrees to the right to allow the lung to fall away posteriorly. The port for a 0-degree or a 30-degree telescope is made at the fifth intercostal space along the posterior axillary line. The remaining working ports are located at the third intercostal space in the midaxillary line and fifth intercostal space in the anterior axillary line. If needed, another posterior port can be placed for lung retraction. The entire hemithorax is carefully examined for metastatic disease or for direct mediastinal pleural involvement. In case of a large thymoma or invasive disease, conversion to open sternotomy is recommended. The mediastinal incision starts from just anterior to the SVC, which is the cardinal landmark in the right chest. Once the pleura is opened longitudinally, the thymus is exposed. The plane between the anterior surface of the thymus and mediastinal fat pad and the posterior table of the sternum is dissected across the mediastinum to the contralateral side. The right inferior horn of the thymus is identified and dissected off the pericardium and aorta,

beginning at the diaphragm inferiorly and extending cranially to the innominate vein. Often, simple blunt dissection with anterior and cephalad retraction of the gland is sufficient. The thymic venous branches draining into the innominate vein are isolated, doubly clipped, and divided. The left inferior horn is dissected free using the same gentle combination of blunt dissection and cephalad retraction.

Once the two inferior poles are freed up to the isthmus and venous branches are divided, traction is applied anteriorly and inferiorly to allow the dissection of superior horns from the surrounding mediastinal and cervical tissue. If one or both superior horn(s) of the thymus gland pass behind the innominate vein, it/they should be carefully dissected off the vein before they can be freed safely from the neck. The descending blood supply within the inferior thyroid plexus may require clips for adequate hemostasis. Cautery should be avoided here to prevent injury to the recurrent laryngeal nerves. Once the thymus gland is completely free, it is removed in an endobag through the most anterior trocar incision, as this is usually the widest intercostal space.

In case of a clinical stage I or II thymoma, the dissection may be modified according to its size and location. If it is located to the left of the midline and is large, a left VATS thymectomy may also be performed. However, VATS thymectomy for thymoma is suggested only for stage I thymomas. After removal of the specimen, the bed is closely examined for bleeding and completeness of the resection. The brachiocephalic veins are skeletonized, and the junction where they form the SVC is clearly visualized. The pleural space is drained with a small chest tube or silastic drain and the port incisions are closed in layers.

Technique for Left-Sided VATS Thymectomy

Under general anesthesia via a double-lumen endotracheal tube, the patient is rotated 45 degrees toward the right lateral decubitus position. Typically, three or four thoracoscopic ports are used. The ports are located in the fourth intercostal space along the midclavicular line, a camera port in the fifth intercostal space at the anterior axillary line, and the other working ports in the fourth intercostal space approximately 2 cm lateral to the anterior axillary line, and in the sixth intercostal space between the anterior axillary and the midclavicular lines. The entire left hemithorax is examined to locate the important structures, such as aorta, subclavian artery, and phrenic nerve, and to look for tumor or thymic deposits on

pericardial, pleural, and diaphragmatic surfaces. If an invasive thymoma is found, the procedure is converted to a median sternotomy.

The dissection begins with left inferior horn and the pericardial fat pad, which is separated from the diaphragm inferiorly. The mediastinal pleura is incised along the course of the left phrenic nerve, leaving 1 cm of margin anteriorly. The adjuvant use of pneumomediastinum performed preoperatively or low-level (5 to 10 mm Hg) carbon dioxide insufflation intraoperatively has been reported to facilitate separation of the gland from the pericardium and posterior sternum. The dissection is then continued cephalad bluntly with pledget dissectors to the level of the innominate vein. Before proceeding above the innominate vein, it is advisable to dissect the thymus off the sternum anteriorly and complete the mobilization of the right lower horn. Utmost care should be given to avoid an injury to the contralateral phrenic nerve or to opening the opposite pleural space. The thymic veins draining into the innominate vein are then isolated, clipped, and divided. This is followed by the dissection of the superior horns up to the level of fascial attachments to the thyroid gland low within the neck. The intact thymus gland is extracted from the chest in an endobag through the most anterior access port. The surgical field is policed for bleeding, and any extra pericardial fat tissue is removed from the pericardiophrenic angles, aortopulmonary window, and aortocaval groove. Once the dissection is complete, the junction of both brachiocephalic veins where they form the SVC should be clearly visualized. The pleural space is appropriately drained and the port incisions are closed in simple layers.

Regardless of which VATS approach to thymectomy is used, there are shared benefits such as less postoperative discomfort, a shorter hospital stay, superior cosmesis, and acceptance of surgery by the patient earlier in the disease course. The thoracoscopic procedure is generally more time-consuming and requires additional technical expertise. The patient must be able to tolerate single-lung ventilation for a prolonged period of time. Although the response rates reported with VATS approaches are comparable with the results of more invasive approaches, the complete remission rates are still somewhat lower, at least partly because of shorter follow-up and limited accrual in reported series. The variety of approaches to resection and inconsistent use of adjunctive measures, such as pneumomediastinum or carbon dioxide insufflation, has hindered adoption of a standard approach to VATS thymectomy.

ROBOTIC THYMECTOMY

Incorporation of robotic surgical systems has been proposed by some to enhance maneuverability of instruments and precision of surgical dissection of the thymus when compared with conventional VATS thymectomy. While the feasibility and safety of RATS thymectomy has been proven, no additional benefits have been demonstrated over the VATS approach. Proponents of RATS suggest that robotic surgery is more suitable than VATS for either complete or extended thymectomy because of easier dissection of the upper horns, better control of the upper thymic veins, and improved unilateral access to the entire anterior mediastinum. Disadvantages of RATS include the initial expense of the equipment, lack of formal training, and a steep learning curve. Several groups have reported their experience with RATS, mostly for MG. The median operating time for the entire group of approximately 200 patients was 2 hours, with a range from 1 to 5.2 hours. The mortality for the group was 0%, the morbidity was 2% to 10%, and the length of stay was a median of 2 to 5 days. RATS has also been utilized for resection of small thymomas.

Technique of Robotic Thymectomy

RATS thymectomy can be performed through a right- or left-sided approach. Advantages of the left-sided approach include better access to the aortopulmonary window and lower possibility of phrenic nerve injury. The left-sided approach may allow a more extensive resection of ectopic thymic tissue than the right-sided approach and gives remission rates similar to maximal thymectomy in an early, highly selected clinical review. Advantages of the right-sided approach include easier identification of the innominate vein and a larger operative space for improved maneuverability of the instruments.

Placement of the incisions is, however, similar for both approaches. The patient is intubated with a double-lumen endotracheal tube for selective single-lung ventilation. For a left RATS thymectomy, the patient is positioned left side up at a 30-degree angle with a bean bag or with a roll along the left paraspinal area. The camera port for the 0-degree stereo endoscope is introduced through a 15-mm incision in the fifth intercostal space on the midaxillary line. Carbon dioxide insufflation is utilized to aid with exposure (6 to 10 mm Hg). Two additional ports are placed: one in the third intercostal space in the midaxillary region and another in the fifth intercostal space on the midclavicular line. Two arms of the robotic system

are then attached to the two access ports and a third arm is attached to the endoscope. The left arm controls an instrument for grasping of the thymus and the right arm has an endoscopic dissection device with an electrosurgical device (e.g., hook cautery). The dissection starts inferiorly at the left pericardiophrenic angle and continues along the anterior border of the phrenic nerve (Fig. 43.7). Care is taken to avoid current injury to the phrenic nerve by staying several millimeters away from the nerve. The dissection is continued cephalad toward the thoracic inlet at the point where the phrenic nerve crosses behind the left innominate vein. The thymic tissue is dissected from the pericardium by grasping the thymus and dividing the areolar tissue with electrocautery from the phrenic nerve toward the retrosternal area. At this point, the retrosternal plane of dissection is established by gently grasping the thymus downward and electrocautery is utilized to incise the mediastinal pleura away from the internal mammary vessels. This plane of dissection is carried from the midsternum toward the thoracic inlet until the prior plane of dissection is reached in front of the innominate vein. Retrosternal dissection is continued until the contralateral pleura is visualized and the underlying lung identified. The pleura is gently incised and entry to the contralateral pleural space is achieved. At this point, the dissection moves toward the thoracic inlet and the fat covering the innominate vein is dissected. The left innominate vein is identified and the dissection continues along the border of the vein to the point where the thymic veins are identified. These veins can be controlled and divided with electrocautery or clipped and divided. The left superior thymic horn is then identified and dissection performed by applying traction and gentle electrocautery until the entire horn is dissected from the thyroid attachments. Care is taken to avoid injury to the innominate vein or avulsing thymic venous branches. The right thymic horn is dissected in a similar fashion. The plane of dissection in the right hemithorax is then carried cephalad until the innominate vein is reached at the confluence with the SVC. The right phrenic nerve is usually protected by the SVC and care should be taken not to pull the nerve into the field of dissection (Fig. 43.8). The entire thymus gland, fatty mediastinal tissue, and the cervical extensions are resected and the specimen is placed in a bag. Following extraction of the specimen and complete hemostasis, a 24-Fr or 28-Fr chest tube is inserted through the lower port and directed transmediastinally so that the tip of the tube is in the right pleural space. The lung is reinflated and the incisions closed. The

patient is extubated in the operating room and after a period of observation in the recovery room, the patient is admitted to a regular surgical floor. The chest tube is typically removed the following day and the patient discharged on postoperative day 1 to 3.

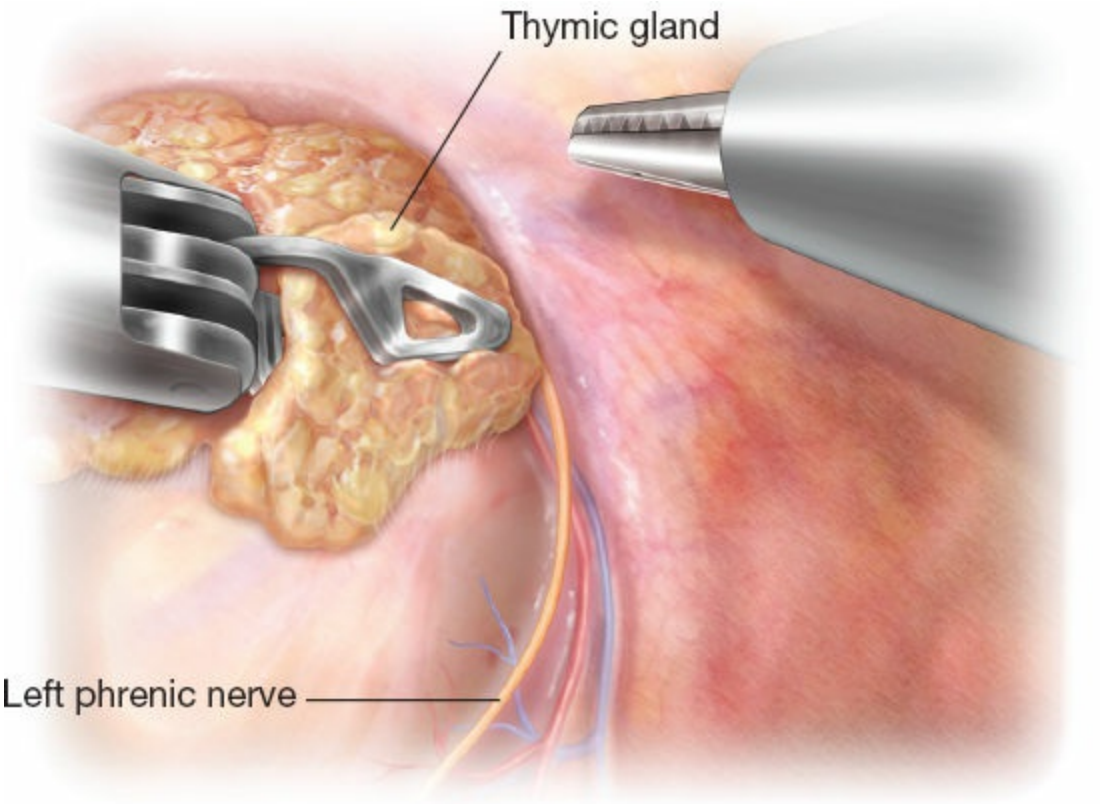

Figure 43.7. The thymus is mobilized along the left phrenic nerve from the pericardiophrenic fat pad to the level of the innominate vein. (Reproduced from Mathisen DJ, Morse C. *Master Techniques in Surgery: Thoracic Surgery: Transplantation, Tracheal Resections, Mediastinal Tumors, Extended Thoracic Resections*. 1st ed. Philadelphia, PA: Lippincott Williams & Wilkins; 2014.)

POSTOPERATIVE CARE

Following thymectomy, the majority of the patients can be extubated in the operating room or in the recovery area within a few hours. Frequent evaluations of the myasthenic patient by the anesthesiologist, surgeon, and/or neurologist with periodical measurements of negative inspiratory force and forced vital capacity may allow the extubated patient to be cared for on a standard postsurgical ward. Some authors strongly recommend that these patients be followed in an intensive care setting for at least 24

hours. Postoperative analgesia is maintained by administering small doses of intravenous morphine or by patient-controlled analgesia. It is advisable to start oral intake cautiously and slowly. Once the patient tolerates liquids without symptoms of choking, cough, or aspiration, the diet can be advanced. Following drain removal, parenteral analgesia is converted to an oral agent. Most patients are able to return to normal activity and work within 2 to 4 weeks following transsternal thymectomy and 1 to 2 weeks following transcervical, robotic, or video-assisted thymectomy.

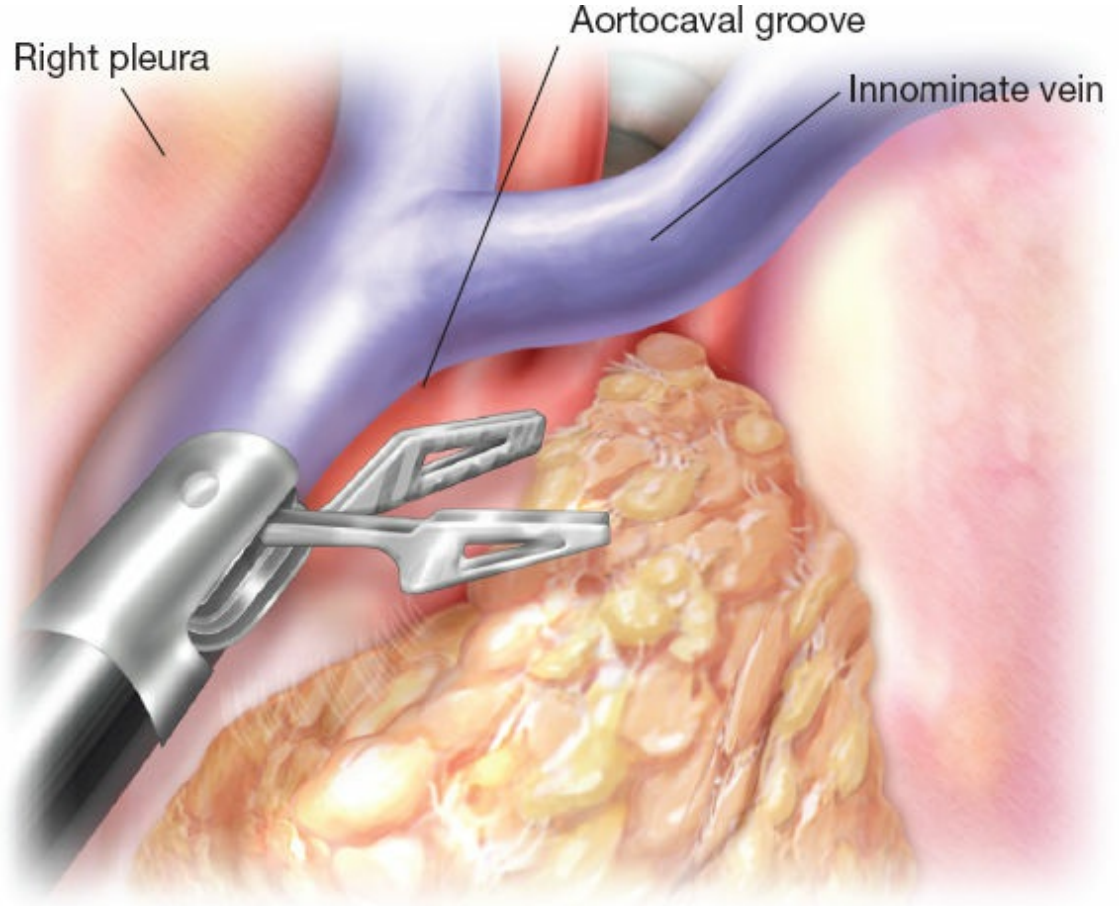

Figure 43.8. The right side of the gland is mobilized out of the aortocaval groove. The phrenic nerve is typically protected in its position lateral to the superior vena cava, but may inadvertantly be brought into the field with excessive traction. (Reproduced from Mathisen DJ, Morse C. *Master Techniques in Surgery: Thoracic Surgery: Transplantation, Tracheal Resections, Mediastinal Tumors, Extended Thoracic Resections*. 1st ed. Philadelphia, PA: Lippincott Williams & Wilkins; 2014.)

The care of a myasthenic patient requires teamwork, with an experienced neurologist involved throughout the perioperative period.

Immunosuppressive medications, such as azathioprine, mycophenolate, or cyclosporine, are usually continued in the postoperative period; however, the continuation of corticosteroids is controversial. In some centers, it is preferred to discontinue the steroids after surgery, whereas they may be given and weaned over varying durations in others. Most patients will not be completely asymptomatic soon after surgery. Typically, weaning of MG medications happens over time through close outpatient follow-up by a neurologist, and, for some patients, this may require years.

The most feared complication after thymectomy is myasthenic crisis with acute respiratory failure. It may be caused by weakness and fatigability of the respiratory muscles limiting ventilation or from oropharyngeal muscle dysfunction with inability to maintain an open airway free of secretions. Myasthenic crisis should be differentiated from other postoperative causes of respiratory failure such as phrenic nerve injury. The latter can be suspected by the presence of an elevated diaphragmatic contour in full inspiration on an upright chest radiograph. Phrenic nerve conduction studies or fluoroscopic or ultrasound evaluation of diaphragmatic movements may confirm isolated phrenic dysfunction. In the absence of some anatomic explanation for ventilator dependence, and if reinitiation of cholinesterase inhibitors and stress dose steroids does not stabilize the patient, plasmapheresis should be instituted and continued daily. Proper preoperative preparation of MG patients, especially those with bulbar symptoms, coupled with meticulous surgical and anesthetic management has vastly reduced the incidence of myasthenic crisis following thymectomy. When it does occur, consideration of early tracheostomy is appropriate.

OUTCOMES

Several series have reported acceptable outcomes with videoscopic, robotic, and transcervical approaches. Ye et al. retrospectively evaluated short-term outcomes in 125 VATS thymectomies and 137 transsternal thymectomies. They found similar complications rates, with reduced length of pleural drainage and shorter hospital length of stay in the VATS group. Ruckert et al. compared their VATS and RATS experience in a retrospective cohort study. With 42-month median follow-up, the cumulative complete remission rates were 39% for RATS thymectomy and 20% for VATS thymectomy. Longer outcome data are available for transcervical thymectomy. Cooper et al., in three different reports on the

transcervical approach, have presented complete remission rates of 52% at 3.6-year follow-up, 35% at 5 years, and 44% in 8.4 years. In the report by Shrager et al. on extended transcervical thymectomy, the actuarial complete remission rate was 43% at 4.6 years.

The most important criticism against minimally invasive techniques for MG is the higher likelihood of incomplete resection of the thymus tissue and, accordingly, a lower rate of complete remission. Jaretzki's report of combined, maximal transcervical–transsternal thymectomies demonstrated a 50% actuarial complete remission rate at 5 years. Masaoka reported a 46% remission rate at 5 years, 67% at 15 years, and 90% overall palliation for their nonthymomatous group. The same investigators noted only a 32% remission rate and 82% palliation rate for their thymomatous patient group.

Unfortunately, there are no definitive data establishing one thymectomy technique as the standard of care. There are no randomized trials comparing operative approach for either thymic neoplasia or myasthenia gravis. It is very difficult to make meaningful comparisons between the existing retrospective studies due to differences in technique, patient population (e.g., severity of disease, symptom duration, presence of thymoma), and definitions of outcomes (e.g., complete remission, medication reduction, symptom improvement).

Suggested Readings

Blalock A. Thymectomy in the treatment of myasthenia gravis: report of twenty cases. *J Thorac Surg* 1944;13:316.

Cooper JD, Al-Jilaihawa AN, Pearson FG, et al. An improved technique to facilitate transcervical thymectomy for myasthenia gravis. *Ann Thorac Surg* 1988;45:242–7.

Davenport E, Malthaner RA. The role of surgery in the management of thymoma: a systematic review. *Ann Thorac Surg* 2008;86:673–84.

Jaretzki A 3rd. Thymectomy for myasthenia gravis: an analysis of the controversies regarding technique and results. *Neurology* 1997;48(suppl 5):S52.

Masaoka A, Yamakawa Y, Niwa H, et al. Extended thymectomy for myasthenia gravis patients: a 20-year review. *Ann Thorac Surg* 1996;62:853.

Osserman KE, Genkins G. Studies in myasthenia gravis: review of a twenty year experience in over 1200 patients. *Mt Sinai J Med* 1971;38:497.

Ruckert JC, Swierzy M, Ismail M. Comparison of robotic and nonrobotic thoracoscopic thymectomy: a cohort study. *J Thorac Cardiovasc Surg*

2011;141:673–7.

Shrager JB, Nathan D, Brinster CJ, et al. Outcomes after 151 extended transcervical thymectomies for myasthenia gravis. *Ann Thorac Surg* 2006;82:1863–9.

Ye B, Tantai JC, Ge XX, et al. Surgical techniques for early-stage thymoma: video-assisted thoracoscopic thymectomy versus transsternal thymectomy. *J Thorac Cardiovasc Surg* 2014;147:1599–603.

EDITOR'S COMMENT

Thymectomy is often performed by thoracic surgeons for management of myasthenia gravis or surgical resection of a thymic neoplasm, such as thymoma or thymic carcinoma. Drs. DeCamp and McCarthy have written a very comprehensive chapter describing the history of thymic surgery and the current operative approaches utilized for resection of the thymus gland. The authors also cogently reviewed the embryology and physiology of the thymus gland. This commentary will focus on a very controversial and vigorously debated topic regarding thymic surgery. As reported in the chapter, Alfred Blalock performed the first transsternal thymectomy for a severe case of myasthenia gravis, which was the first time that myasthenia gravis was associated with the thymus gland. He reported a series of six patients who underwent transsternal thymectomy for nonthymomatous myasthenia gravis. Sir Geoffrey Keynes reported a series of 218 thymectomies in 1954 for patients with myasthenia gravis (Keynes G. Surgery of the thymus gland; second (and third) thoughts. *Lancet* 1954;263:1197–202).

In recent years there has been a proliferation of minimally invasive techniques for thymic surgery, such as VATS, RATS, and transcervical thymectomy. There is ample controversy regarding the use of these minimally invasive techniques for thymectomy in patients with myasthenia gravis which requires complete extirpation of all thymic tissues as well as extraglandular thymic tissues to achieve a clinical remission. As the authors describe, complete resection of the thymus gland requires dissection of all thymic tissues from phrenic nerve laterally to phrenic nerve down to the diaphragm and up to the inferior poles of the thyroid gland. There remains skepticism that minimally invasive thymectomy techniques can effectively achieve complete extirpation of all thymic and extrathymic tissues as described by Masoka and cited by the authors.

The transcervical approach for thymectomy was described my Kirschner in 1969 (Kirschner P, Osserman KE, Kark AE. Studies in myasthenia gravis. Transcervical total thymectomy. *JAMA* 1969; 209:906–10). This procedure involves the complete excision of the thymus gland through a cervical neck incision and requires extreme elevation of the sternum with customized

retractors (Cooper JD, Al-Jilaihawa AN, Pearson FG. An improved technique to facilitate transcervical thymectomy for myasthenia gravis. *Ann Thorac Surg* 1988;45:242–7).

The technique obviates the need for a sternotomy since the operation is performed in the retrosternal space. Shrager and colleagues reported a 35% remission rate for patients undergoing transcervical thymectomy for myasthenia gravis (Shrager JB, Nathan D, Brinster CJ, et al. Outcomes after 151 extended transcervical thymectomies for myasthenia gravis. *Ann Thorac Surg* 2006;82:1863–9).

VATS can be performed from a bilateral approach or unilateral approach. There are numerous nonrandomized single-institution studies reporting the results of VATS thymectomy. The authors all describe the advantages of the VATS technique over median sternotomy, which include less postoperative pain and shorter hospital length of stay. Ruckert and colleagues reported a series of 79 patients with myasthenia gravis who underwent a left VATS thymectomy with minimal morbidity (Ruckert JC, Swierzy M, Ismail M. Comparison of robotic and nonrobotic thoracoscopic thymectomy: a cohort study. *J Thorac Cardiovasc Surg* 2011;141:673–7). The complete stable remission rate was reported to be 20%. Tomulescu and colleagues reported a series of 107 patients with myasthenia gravis who underwent a bilateral VATS thymectomy (Tomulescu V, Ion V, Kosa A. Thoracoscopic thymectomy mid-term results. *Ann Thorac Surg* 2006;82:1003–7). The reported complete stable remission rate was 15%. Youssef and colleagues reviewed the results of minimally invasive thymectomy compared to sternotomy (Youssef SJ, Louie BE, Farivar AS, et al. Comparison of open and minimally invasive thymectomies at a single institution. *Am J Surg* 2010;199(5):589–93). The study had a small sample size with eight patients in each group. The average hospital stay for the minimally invasive thymectomy group was 2.4 days compared to 4.3 days for the sternotomy group. This study did not offer any results regarding the remission rates or symptom improvement after thymectomy.

In recent years, the prevalence of RATS has increased and proponents of the technology report that the three-dimensional optics of the DaVinci robot is superior to the VATS technique and is similar to the open median sternotomy approach. There are currently no randomized studies comparing the robotic-assisted thymectomy to the VATS or transsternal approach. There are numerous single-institution reports describing the results of robotic-assisted approach for thymectomy in patients with myasthenia gravis. Marulli and colleagues reported a series of 100 patients undergoing left robotic thymectomy for myasthenia gravis (Marulli G, Schiavon M, Perissinotto E, et al. Surgical and neurologic outcomes after robotic thymectomy in 100 consecutive patients with myasthenia gravis. *J Thorac Cardiovasc Surg* 2013;145:730–5). The reported complete stable remission rate was 28.5%. Ruckert and colleagues reported a series of 74 patients undergoing left robotic-assisted thymectomy for myasthenia gravis. The reported complete stable remission rate was 39.3% which was higher than

the remission rate reported for VATS thymectomy in the same study.

The Myasthenia Gravis Thymectomy Trial (MGTX) is a randomized prospective clinical trial published in the New England Journal of Medicine in 2016 (Wolfe GI, Kaminski HJ, Aban IB, et al. Randomized trial of thymectomy in myasthenia gravis. *N Eng J Med* 2016;375:511–22). A total of 126 patients with nonthymomatous myasthenia gravis were randomized to prednisone therapy alone or transsternal thymectomy with prednisone therapy. The inclusion criteria for this clinical trial were very rigorous and included a duration of myasthenia gravis symptoms for less than 5 years and serum acetylcholine receptor antibody levels greater than 1.0 nmol/L. The primary outcomes of the study were clinical status measured by the quantitative myasthenia gravis score and the time-weighted average required dose of prednisone over a 3-year period. The trial mandated that surgeons perform an extended transsternal thymectomy (median sternotomy) to insure that there would not be any variability in thymectomy technique. The results in this clinical trial demonstrated that extended transsternal thymectomy significantly improved the symptoms of patients with generalized myasthenia gravis. The patients who were randomized to extended transsternal thymectomy had significantly lower quantitative myasthenia scores and a significantly lower dose of prednisone was needed maintain improved neurologic symptoms. The importance of the MGTX cannot be overemphasized. The clinical trial provided level 1A evidence that extended transsternal thymectomy objectively improves the symptoms for patients with nonthymomatous myasthenia gravis. The results of the study also establish transsternal thymectomy as the gold standard approach for thymectomy in patients with myasthenia gravis.

In conclusion, the debate regarding the efficacy of minimally invasive techniques for thymectomy for myasthenia gravis will continue despite the paucity of randomized level 1A evidence to support their use in myasthenia gravis. Regardless of the surgical approach for thymectomy, the clinical efficacy of thymectomy for myasthenia gravis requires the complete excision of the thymus gland as well as all extra glandular thymic tissue within the anterior mediastinum.

Robert E. Merritt

44 Adrenalectomy—Minimally Invasive and Open

L. Michael Brunt and Arghavan Salles

Tumors of the adrenal gland may present in a variety of clinical manifestations depending on the underlying pathophysiology. Surgical resection is the preferred treatment for a primary adrenal mass that is hormonally functional or malignant. Accurate diagnosis and localization through a systematic approach with biochemical testing and imaging techniques are essential in selecting patients for operation. Several open and laparoscopic approaches are available to remove the adrenal gland, each with its own advantages in terms of exposure, degree of invasiveness, ability to explore the entire abdomen, and patient outcomes. Tumor size, functionality, bilaterality or extra-adrenal location, malignant potential, individual patient characteristics, and surgeon experience all play an important role in determining the type of procedure utilized. Patients with hormonally functional tumors should undergo adequate preoperative preparation to minimize intraoperative complications. Proper selection of patients for operation, a thorough knowledge of adrenal anatomy, and a meticulous and hemostatic extra-adrenal dissection technique are imperative to optimize outcomes, especially in the minimally invasive setting.

ETIOLOGY AND PATHOPHYSIOLOGY

The adrenal glands are retroperitoneal organs immediately superior to the kidneys. These glands are slightly nodular with a firm texture and are surrounded by a layer of areolar connective tissue. Each gland weighs approximately 4 to 5 g in the adult and has a golden yellow-orange color distinct from the pale yellow retroperitoneal fat. The left adrenal gland is bordered inferiorly by the left kidney and left renal vein, superiorly and posteriorly by the diaphragm, anteriorly by the tail of the pancreas, and medially by the spleen and aorta. The right adrenal gland is bordered inferiorly by the right kidney; superiorly, posteriorly, and laterally by the

diaphragm; anteriorly by the liver; and medially by the inferior vena cava (IVC; Fig. 44.1).

The arterial blood supply to the adrenal gland is derived mainly from the inferior phrenic and renal arteries as well as directly off the aorta. Occasionally, intercostal and ovarian vessels may contribute as well. Rather than one or two main arteries, the distribution is primarily one of multiple small branches that enter the superior, medial, and inferior aspects of the gland (Fig. 44.2). Venous drainage of the left adrenal is via the left adrenal vein, which arises from the inferomedial aspect of the gland and empties into the left renal vein. The inferior phrenic vein usually joins the left adrenal vein above its entry into the renal vein. Blood from the right adrenal gland empties directly into the IVC via the short central adrenal vein that arises from the medial aspect of the gland. Accessory adrenal veins entering the vena cava or hepatic veins may be present on the right side. Lymphatic drainage from the adrenal gland is into adjacent pericaval and periaortic lymph nodes, which is important during resection of a malignant tumor.

The adrenal gland is divided into two distinct components: the cortex and the medulla. The adrenal cortex is the site of production of mineralocorticoids (aldosterone), glucocorticoids (cortisone), and sex steroids. The medulla contains chromaffin cells that secrete the catecholamines epinephrine and norepinephrine and also dopamine.

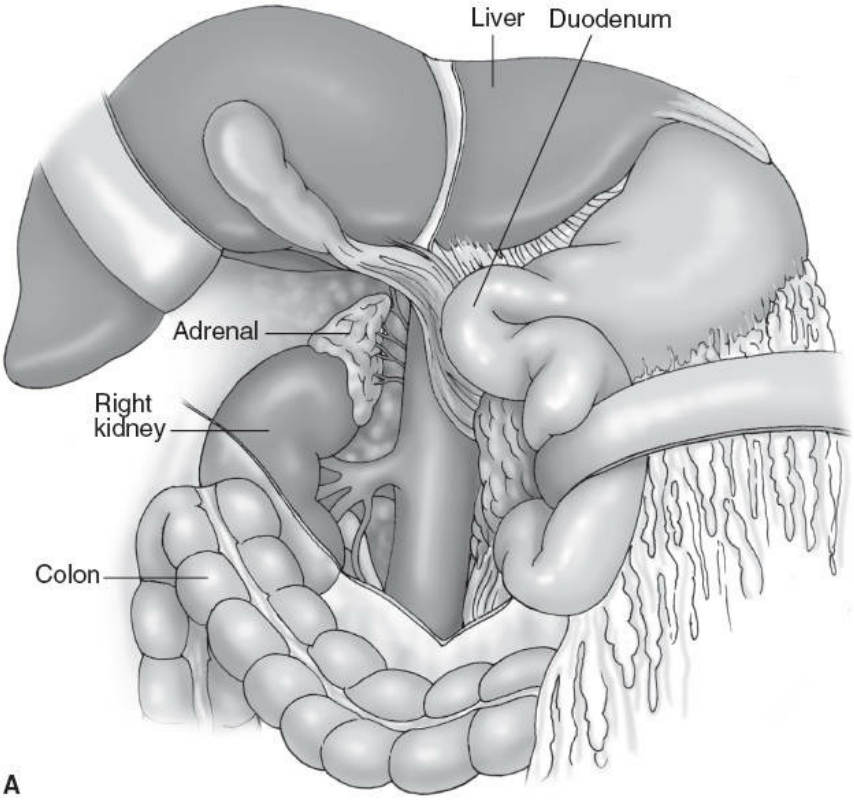
Liver
Duodenum
Adrenal
Right kidney
Colon

A

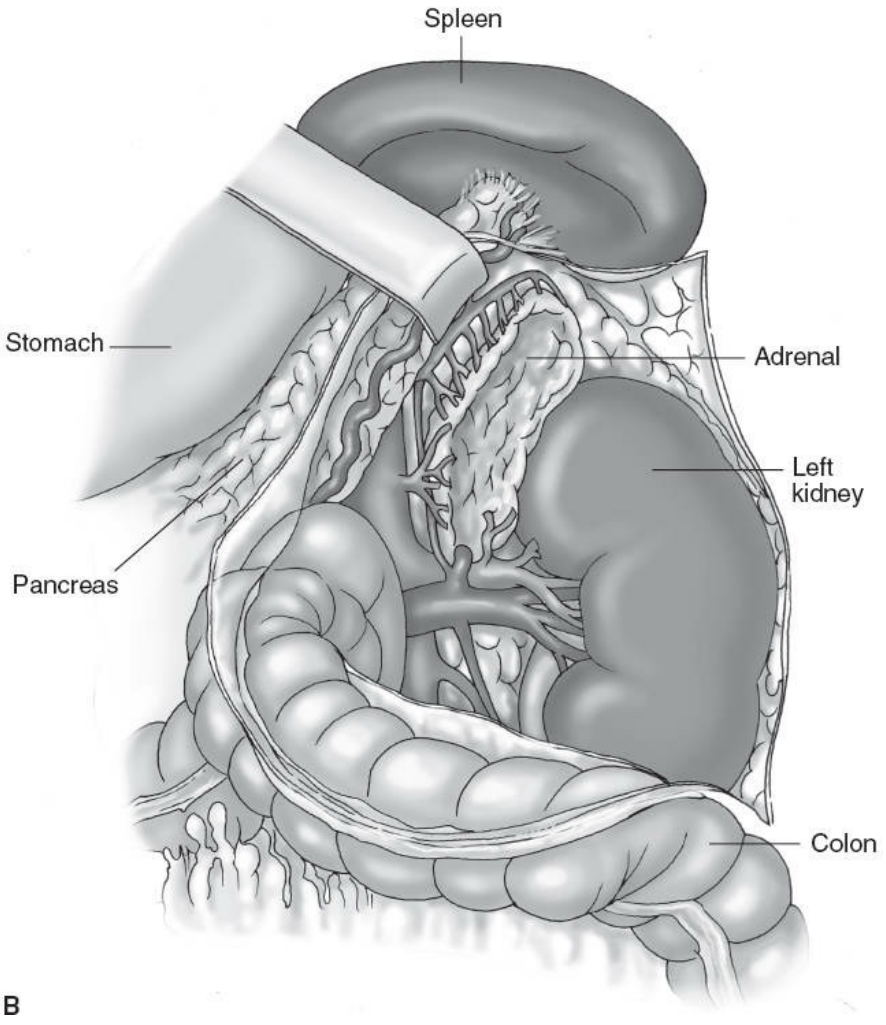
Spleen
Stomach
Adrenal
Left kidney
Pancreas
Colon

B

Figure 44.1. Anatomic relationships of the adrenal glands to surrounding structures.

CLINICAL PRESENTATION

Adrenal tumors may come to attention because of clinical signs and symptoms of hormone hypersecretion, because of local symptoms of pain due to a large mass, or as a lesion discovered incidentally during cross-sectional imaging done for other reasons. Appropriate diagnosis and localization are imperative for successful operative planning and treatment. The various indications for adrenalectomy are given in Table 44.1. Algorithms for biochemical testing as well as radiographic imaging are available for differentiating the various causes of adrenal lesions, including aldosteronoma, Cushing syndrome, pheochromocytoma, adrenal cortical carcinoma, metastatic disease of the adrenal glands, and adrenal incidentaloma. A summary of the biochemical evaluation and preoperative preparation used for the treatment of these adrenal lesions is described in Table 44.2.

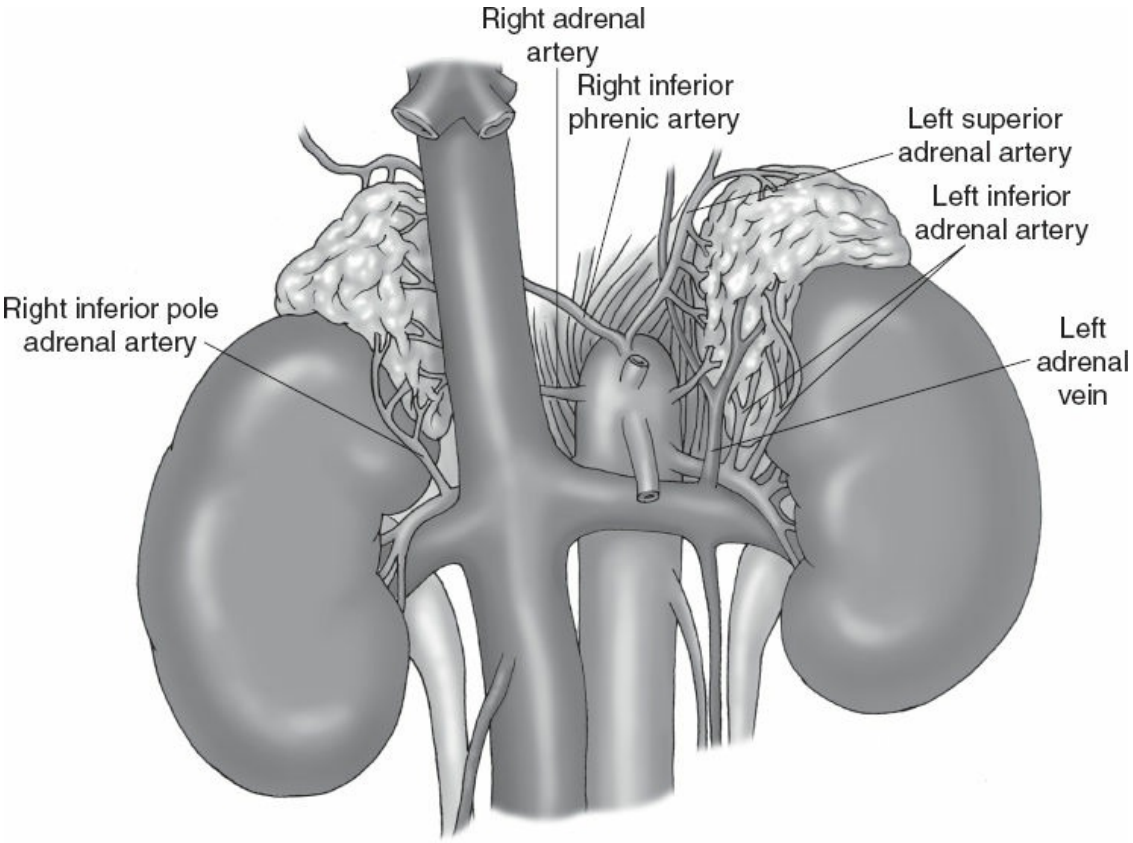

Figure 44.2. Blood supply to the adrenals.

TABLE 44.1 Indications for Adrenalectomy

Unilateral Adrenalectomy
Aldosteronoma
Cortisol-secreting adenoma (Cushing syndrome or subclinical Cushing's)
Unilateral pheochromocytoma (sporadic or familial)
Virilizing or feminizing tumors
Nonfunctioning unilateral tumor
Size >4–5 cm
Imaging features atypical for adenoma, myelolipoma, or cyst
Adrenocortical carcinomas
Solitary unilateral adrenal metastasis
Bilateral Adrenalectomy
Bilateral pheochromocytomas
Cushing syndrome from
Bilateral nodular adrenal hyperplasia
Ectopic ACTH-producing tumor unresponsive to primary therapy
Cushing disease (pituitary tumor) unsuccessfully treated by surgery or radiation

ACTH, adrenocorticotropic hormone.

Aldosteronoma

Primary hyperaldosteronism is the most common cause of secondary hypertension and has a much higher prevalence rate in the population than previously appreciated, occurring in 8% to 12% of hypertensive patients. Although the classic findings in primary hyperaldosteronism are hypertension and hypokalemia, many patients with this diagnosis have a normal serum potassium level. Therefore, any patient who has hypertension, with an early age of onset or that is difficult to control or refractory to medical management (especially if the hypertension is predominantly diastolic) should be considered for this diagnosis, regardless of the serum potassium level. Because endogenous

hyperaldosteronism suppresses renin secretion, biochemical screening entails simultaneous measurement of both plasma aldosterone and renin levels. A plasma aldosterone concentration (PAC)–to–plasma renin activity (PRA) ratio >20 to 25 in the setting of an absolute PAC >15 ng/dL is consistent with this diagnosis and should be evaluated further. Confirmatory testing consists of demonstrating elevated 24-hour urine aldosterone levels (>12 μg/24 h) while on a high-sodium diet or after intravenous saline loading. Other biochemical findings include an elevated urinary potassium excretion rate (>30 mEq/24 h).

TABLE 44.2 Diagnosis and Preoperative Preparation of Common Adrenal Tumors

Tumor Type	Biochemical Diagnosis	Preoperative Preparation
Pheochromocytoma	Plasma fractionated metanephrines and/or 24-h urinary catecholamines and metanephrines	Alpha-receptor blockade; hydration; beta-blockade only if persistent tachycardia or epinephrine-secreting tumor
Aldosteronoma	PAC and PRA; urinary aldosterone and potassium (on high-salt diet)	Replete hypokalemia, control hypertension
Cushing syndrome from cortical adenoma	24-h urine-free cortisol; overnight low-dose DMST; plasma ACTH	Perioperative stress steroids
Adrenal cortical carcinoma	24-h urine cortisol, plasma DHEA level	None unless tumor is cortisol secreting
Incidentaloma	Low-dose DMST, plasma fractionated	None unless biochemical screen positive metanephrines or urine catecholamines and metanephrines; PAC and PRA if hypertensive or hypokalemic

ACTH, adrenocorticotropic hormone; DHEA, dehydroepiandrosterone; DMST, dexamethasone suppression test; PAC, plasma aldosterone concentration; PRA, plasma renin activity.

The most common causes of primary hyperaldosteronism are aldosterone-producing adenoma (65%) and idiopathic cortical adrenal hyperplasia (35%). Aldosterone-secreting adrenal carcinomas are rare. Differentiation of these causes is critical in directing therapy since the preferred treatment of an aldosteronoma is adrenalectomy, whereas idiopathic hyperaldosteronism from cortical hyperplasia is treated medically with the aldosterone antagonist spironolactone. Adrenal cross-

sectional imaging with thin-cut (3-mm image slices) computed tomography (CT) is indicated once primary aldosteronism has been confirmed biochemically. Younger patients (under age 40 to 50) with a discrete unilateral macroadenoma (>1 cm) and a normal contralateral adrenal may undergo adrenalectomy without further testing. All other patients should undergo adrenal vein sampling for cortisol and aldosterone to determine if there is a lateralizing source of increased aldosterone production.

Most aldosteronomas are small (≤1 to 2 cm in size), with a golden orange color. These tumors are rarely malignant and can almost always be removed laparoscopically. Spironolactone may be given preoperatively to control hypertension but should not be administered until the biochemical evaluation, including adrenal vein sampling, is complete because it interferes with any subsequent testing including adrenal vein sampling. Patients should also have potassium levels repleted and, in long-standing cases, cardiac function and renal insufficiency should be assessed prior to surgery.

Cushing Syndrome

Cushing syndrome results from excessive cortisol secretion from a variety of pathologic processes that are not controlled by normal regulatory mechanisms. Overproduction of glucocorticoids may lead to development of characteristic features, such as truncal obesity, moon facies, plethora, hirsutism, abdominal striae, acne, and the presence of a “buffalo hump.” One of the most telling features that are distinct from patients with morbid obesity is prominence of the supraclavicular fat pads. Hypertension and diabetes are also commonly present.

Causes of Cushing syndrome can be divided into those that are adrenocorticotropic hormone (ACTH)-dependent and those that are ACTH-independent. Most ACTH-dependent cases are related to Cushing disease (due to excessive pituitary production of ACTH), while other cases may result from ectopic production of ACTH by other tumors. ACTH-independent causes include primary adrenocortical diseases, such as cortisol-producing adenoma, adrenocortical carcinoma, and adrenal hyperplasia. Suspected Cushing syndrome should be evaluated with measurement of 24-hour urine-free cortisol levels. A single-dose dexamethasone test can also be used to screen for Cushing syndrome. In this test, 1 mg of dexamethasone is given at 11:00 PM, and a morning (8:00

AM) cortisol level is obtained. Normal individuals are able to suppress plasma cortisol to <3 μg/dL, whereas patients with Cushing syndrome fail to suppress. Late-night (11:00 PM) salivary cortisol levels are also highly sensitive and specific in screening for Cushing syndrome and are increasingly being used by some groups.

Once Cushing syndrome is confirmed biochemically, plasma ACTH levels should be measured to differentiate ACTH-dependent from ACTH-independent causes. A low plasma ACTH suggests adrenocortical disease and should be evaluated further with CT. Patients with normal or elevated plasma ACTH levels should have pituitary imaging (pituitary magnetic resonance imaging [MRI], inferior petrosal sinus sampling) to evaluate for Cushing disease as the cause and to localize the tumor. Adrenalectomy is the treatment for Cushing syndrome from an adrenocortical tumor. Patients with Cushing disease who fail treatment of the pituitary lesion may benefit from bilateral adrenalectomy. It is important to administer stress doses of steroids to these patients in the preoperative period since they may not be physiologically capable of responding to stress with endogenous glucocorticoids. Patients undergoing bilateral adrenalectomy should also be given replacement mineralocorticoids postoperatively.

Subclinical Cushing Syndrome

Subclinical Cushing syndrome (SCS) is a condition in which there is autonomous secretion of cortisol but without the typical clinical signs of classic Cushing syndrome. SCS is most commonly identified in the setting of an adrenal incidentaloma. Laboratory findings include lack of suppressibility of cortisol secretion with dexamethasone, loss of the diurnal variation in cortisol secretion, low or suppressed plasma ACTH levels, and a blunted response of ACTH to corticotropin-releasing hormone. Elevation of 24-hour urine-free cortisol levels is seen in up to 50% of patients with SCS, but the degree of elevation is usually mild. Although patients with subclinical Cushing have a higher incidence of hypertension, obesity, and diabetes than controls, the natural history is not well characterized. In one study, progression to overt Cushing syndrome at 1-year follow-up was 12.5%. In the only randomized clinical trial to date comparing surgery to nonoperative management in patients with SCS, over the course of 15 years none of the patients managed nonoperatively developed overt Cushing syndrome. However, patients treated with surgical resection had higher rates of resolution or improvement of

diabetes, hypertension, and obesity than those treated nonoperatively, and those treated nonoperatively tended to have stabilization or worsening of their conditions.

Adrenalectomy is indicated for patients with this condition who are an acceptable risk for surgery. SCS is important to recognize in the setting of adrenal incidentaloma as these patients may develop adrenal insufficiency after adrenalectomy if glucocorticoid replacement is not administered.

Pheochromocytoma

Pheochromocytomas are rare tumors that arise from the chromaffin cells of the adrenal medulla. Approximately 10% of tumors in adults (up to 35% in children) arise in extra-adrenal locations, such as the area of the renal hilum, organ of Zuckerkandl, bladder, or rarely elsewhere along the sympathetic chain. While most pheochromocytomas are unilateral and benign, approximately 10% are bilateral in location (seen more commonly in hereditary endocrine syndromes) and up to 10% may be malignant. These tumors secrete excessive catecholamines including epinephrine, norepinephrine, and dopamine. Patients often present with symptoms of episodic spells consisting of headaches, diaphoresis, and palpitations in association with marked hypertension, although in recent years approximately 30% to 40% of pheochromocytomas have presented as incidentalomas.

Screening for pheochromocytoma consists of measurement of either plasma fractionated metanephrines or 24-hour urinary metanephrines and catecholamines (epinephrine, norepinephrine, and dopamine). Indications for screening for pheochromocytoma include refractory or accelerated hypertension, labile hypertension, hypertensive paroxysms during anesthesia or sedation, adrenal incidentaloma, paradoxic hypertension in response to beta-blockers, and familial screening for hereditary endocrinopathies. Patients with biochemical evidence suggestive of pheochromocytoma should undergo cross-sectional imaging. T2-weighted MRI sequences often show a bright appearance of the tumor that is characteristic for pheochromocytoma (adrenal mass/liver image intensity ratio >3.0). ^{123}I-metaiodobenzylguanidine (MIBG) scanning may occasionally be useful in localizing functional, extra-adrenal, or metastatic tumors. ^{123}I-MIBG is not warranted in patients with uncomplicated pheochromocytomas that are localized on CT or MRI, as it is expensive and rarely alters treatment in this setting.

Once the diagnosis of a pheochromocytoma is made, the patient should be placed on alpha-blockade with phenoxybenzamine to control hypertension and dilate the intravascular space and should be instructed to drink ample fluids. Alternatively, patients may be prepared with other selective alpha-1 blocking agents such as prazosin, terazosin, or doxazosin that blocks conversion of tyrosine to dihydroxyphenylalanine (dopa); metyrosine that inhibits catecholamine synthesis; and calcium channel blockers. Beta-blockade may be added if the patient develops tachycardia on phenoxybenzamine or has a predominantly epinephrine-secreting tumor. For further details, see the section on Patient Preparation below.

Adrenocortical Carcinoma

Adrenocortical carcinoma is a rare malignancy with an annual incidence of less than two cases per million individuals. It carries a poor prognosis as many patients (up to 40%) have advanced or metastatic disease at the time of presentation. Adrenocortical cancers are usually large tumors with an average diameter of around 12 cm and may be functional or nonfunctional. Malignancy should be suspected in any adrenal cortical tumor >6 cm in diameter, as the incidence of malignancy increases with increasing tumor size. Nonfunctional tumors may present with abdominal or back pain, weight loss, malaise, or hematuria. A majority of adrenal cancers (approximately 60%) are functional, however, with symptoms of Cushing syndrome, virilization, or both.

Preoperative considerations and preparation are similar to those for other functioning adrenal tumors. CT scanning or MRI is necessary to fully evaluate the extent of disease as well as possible involvement of major vascular structures and regional or distant metastases. Surgical resection remains the only potentially curative treatment.

Adrenal Incidentaloma

The most common adrenal mass encountered by the clinician is the adrenal incidentaloma discovered during abdominal imaging for a non–adrenal-related workup. The incidence of finding an adrenal mass on abdominal CT scanning ranges from 0.4% to 4.4%. The key factors in evaluating an adrenal incidentaloma are to characterize its size, functionality, and risk of malignancy. Functional masses should be removed regardless of size. Nonfunctional tumors 4 to 5 cm or larger (except for myelolipomas) should be removed, as should lesions in which the imaging characteristics

are atypical for an adenoma. The biochemical evaluation of the adrenal incidentaloma should include measurement of plasma fractionated metanephrines to exclude a pheochromocytoma and a single low-dose (1-mg) dexamethasone test to evaluate for subclinical hypercortisolism. Plasma aldosterone and renin levels should be done only if the patient is hypertensive or hypokalemic.

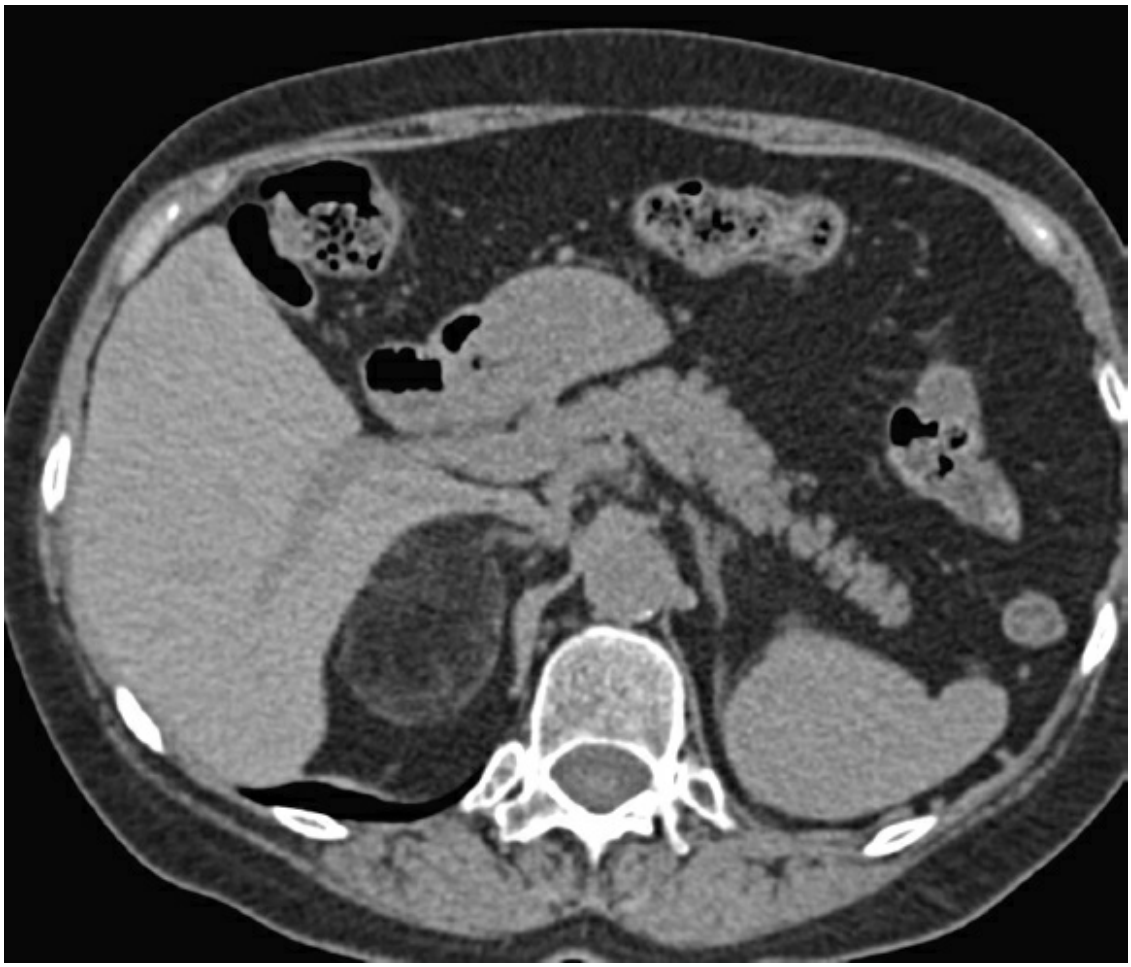

Figure 44.3. The typical radiographic appearance of an adrenal myelolipoma.

The most common adrenal lesion discovered as an incidentaloma is a nonfunctioning cortical adenoma. Adrenal myelolipomas are benign lesions composed of fat and bone marrow elements that can be diagnosed by their typical radiographic appearance (Fig. 44.3). They do not need to be removed unless they are enlarging or become symptomatic, such as from hemorrhage into the lesion. Nonfunctioning tumors <4 to 5 cm should be followed with serial imaging at 4 to 6 months initially and then at 12 months.

Occasionally other primary tumors such as lung cancer, breast cancer, renal cell carcinoma, and melanomas metastasize to the adrenal glands. In addition to CT or MRI, positron emission tomography (PET) should be done in potentially resectable cases to exclude metastatic disease in other sites. Surgical resection may be indicated for selected patients with an isolated adrenal metastasis. Percutaneous biopsy of suspected adrenal metastases should be reserved for patients who are not candidates for surgical resection and in whom the results of biopsy will impact therapy.

PREOPERATIVE PLANNING

Prior to adrenalectomy, patients should have electrolyte abnormalities such as hypokalemia corrected. Hypertension should be controlled medically, and patients with pheochromocytomas should receive 7 to 10 days of preoperative alpha-receptor blockade with phenoxybenzamine to avoid hypertensive exacerbations intraoperatively. Phenoxybenzamine is typically started in a dose of 10 mg twice daily and the dose is increased by 10 to 20 mg/day every 2 to 3 days until the blood pressure is well controlled and the patient is mildly orthostatic. Some patients with symptomatic pheochromocytomas in hypertensive crisis will need to be blocked while in the hospital, but for most patients the blockade can be managed on an outpatient basis. During this time, patients should be instructed to drink ample fluids to allow volume expansion as the alpha-blockade proceeds. Patients who are blocked while in the hospital should have monitoring of orthostatic vital signs and urinary output. A total dose of phenoxybenzamine of 60 to 80 mg/day is sufficient to block most patients. Intraoperatively, patients with vasoactive pheochromocytomas should have continuous blood pressure monitoring via an arterial line. Intraoperative fluid resuscitation is crucial to avoid hypotension after the tumor has been removed.

Patients with Cushing syndrome should receive intravenous steroids perioperatively and will require maintenance doses of steroids for 6 months or longer postoperatively. Mechanical bowel cleansing is not routinely given prior to adrenalectomy.

Indications and Contraindications

The retroperitoneal location of the adrenals makes them accessible via a variety of surgical approaches: transabdominal, retroperitoneal, or through the flank, and using either laparoscopic or open techniques. The choice of

surgical approach in a given patient depends on the size and functionality of the lesion, the degree of exposure needed, the likelihood that the tumor is malignant, and the surgeon's experience (Table 44.3). For most patients with an adrenal tumor, laparoscopic adrenalectomy should be the preferred approach. This approach has been associated with less pain, a shorter hospitalization, faster return to unrestricted activities, and less morbidity than open adrenalectomy. Late complications such as incisional hernia and chronic incisional pain are also less common with the laparoscopic approach.

Currently, the presence of local tumor invasiveness is the only absolute contraindication to laparoscopic adrenalectomy (Table 44.3). Large tumors >8 to 10 cm in size are more difficult to manipulate and remove laparoscopically and are associated with an increased rate of conversion to an open operation. Large pheochromocytomas are often benign and may be resected laparoscopically by highly experienced adrenal surgeons. In contrast, adrenal cortical tumors larger than 6 to 7 cm are likely to be adrenal cortical cancers and should be approached with great caution as some groups have reported higher local recurrence rates after laparoscopic excision. However, since the vast majority of patients with adrenal tumors have lesions that are <6 cm in size and have low malignant potential, open adrenalectomy is not often indicated. Prior major upper abdominal surgery on the planned side of the adrenalectomy, such as previous splenectomy, liver resection, or renal procedures, does not contraindicate a laparoscopic approach but does make the procedure more difficult. Laparoscopic adrenalectomy may also be more difficult in patients with large pheochromocytomas (because of the bulk and vascularity of these tumors) and in patients who have significant obesity, including those with Cushing syndrome.

TABLE 44.3 Indications for Various Surgical Approaches to Adrenalectomy

Laparoscopic

Nonmalignant primary unilateral or bilateral adrenal tumors <8–10 cm in size

Solitary unilateral adrenal metastasis[a]

Small adrenocortical carcinomas[a]

Retroperitoneal Endoscopic[b]

Previous upper abdominal surgery on affected side

Small adrenal tumor ≤5 cm

Bilateral adrenalectomy

Open Anterior

Any tumor with extra-adrenal extension or local invasion

Tumors with suspected regional lymph node metastases

Thoracoabdominal

Large tumor with major vascular invasion (e.g., inferior vena cava) that cannot be controlled intra-abdominally

[a]Controversial; depends on imaging features and laparoscopic surgical experience.
[b]More difficult in high BMI patients (≥35).

SURGICAL TECHNIQUE

The most common approach to laparoscopic adrenalectomy is the transabdominal lateral flank approach described by Gagner in 1992. The other laparoscopic approach that has been used increasingly is the retroperitoneal endoscopic approach. The retroperitoneal approach is the most direct route to the adrenals and avoids entry into the abdominal cavity. However, it has a smaller working space, which can present difficulties in patients with large tumors or significant amounts of retroperitoneal fat. It may also be more difficult to learn and to maintain orientation in the retroperitoneal space. Robotic posterior adrenalectomy has also been reported and may offer some potential advantages of using

wristed instruments for working in such a small space. In experienced hands, it can also be done in less time than a laparoscopic retroperitoneal adrenalectomy, although data on this approach are limited.

The transabdominal lateral flank approach carries several advantages, including good exposure and access to the superior retroperitoneum and a large working space. Because this approach is transperitoneal, the adjacent organs and anatomic landmarks are clearly identifiable even though the patient is in a lateral position.

Open adrenalectomy may be carried out via one of four approaches: anterior transabdominal, dorsal or posterior retroperitoneal, lateral flank, and thoracoabdominal approach. The anterior approach can be performed through a bilateral, subcostal, or midline incision. The benefit of this technique is that it allows for complete exploration of the abdomen and en bloc resection of the adrenal and contiguous structures in patients with large adrenal malignancies. The posterior approach gives more direct access to the adrenals, and although it has been associated with low morbidity, this approach has been completely supplanted by laparoscopic techniques. The flank approach provides reasonable exposure and access to major vessels, but it may be difficult to remove larger tumors or to perform en bloc cancer resections, and is also not commonly utilized. The thoracoabdominal approach provides the greatest exposure for difficult cases and large tumors. However, it potentially carries additional morbidity and increased patient discomfort; it is the rare tumor that cannot be resected via an abdominal incision.

Laparoscopic Adrenalectomy

Patient Positioning and Setup

The patient is placed supine on the operating table on a padded beanbag mattress. A urinary catheter is often used but may be unnecessary for uncomplicated cases and patients with small tumors. The patient is then turned into the lateral decubitus position with the affected side facing upward. The torso, the extremities, all pressure points, and the head are well padded, and the patient is secured with safety straps and the beanbag mattress. The table is then placed in reverse Trendelenburg position to allow abdominal contents to fall away from the upper abdomen and is flexed at the waist to lengthen the space between the costal margin and the iliac crest (Fig. 44.4). It can be helpful to mark the anterior and posterior axillary lines before draping the patient as these landmarks are useful in

determining initial port placement. The patient is prepped and draped with the midline of the abdomen exposed so that conversion to an open procedure can be performed if necessary. Monitors are placed at both sides of the head of the table.

A 5-mm incision is placed somewhat medial to the anterior axillary line, two fingerbreadths below the costal margin. Initial access to create the pneumoperitoneum can be achieved with a closed technique using a Veress needle through this incision or under direct vision via a larger open incision with a Hasson- or balloon-type cannula. Our preference is to use the closed Veress needle technique since open access through the overlapping muscle layers in the flank is more cumbersome. After establishing adequate pneumoperitoneum, a 5-mm optical trocar to directly visualize the insertion is placed at this site. The remaining ports are then placed under direct laparoscopic visualization at 5- to 7-cm intervals across the subcostal and flank region (Fig. 44.5). We generally use four ports for both right and left adrenalectomy, but the left side can be done with only three ports if the operating surgeon is experienced. One 12-mm port is used for insertion of a clip applier and for specimen extraction. The remaining ports can all be 5 mm in size. Additional ports may be added if needed for difficult cases. Care should be taken in determining port placement to allow enough spacing (minimum 5-cm apart) so that the instruments can move without impedance from the other port sites.

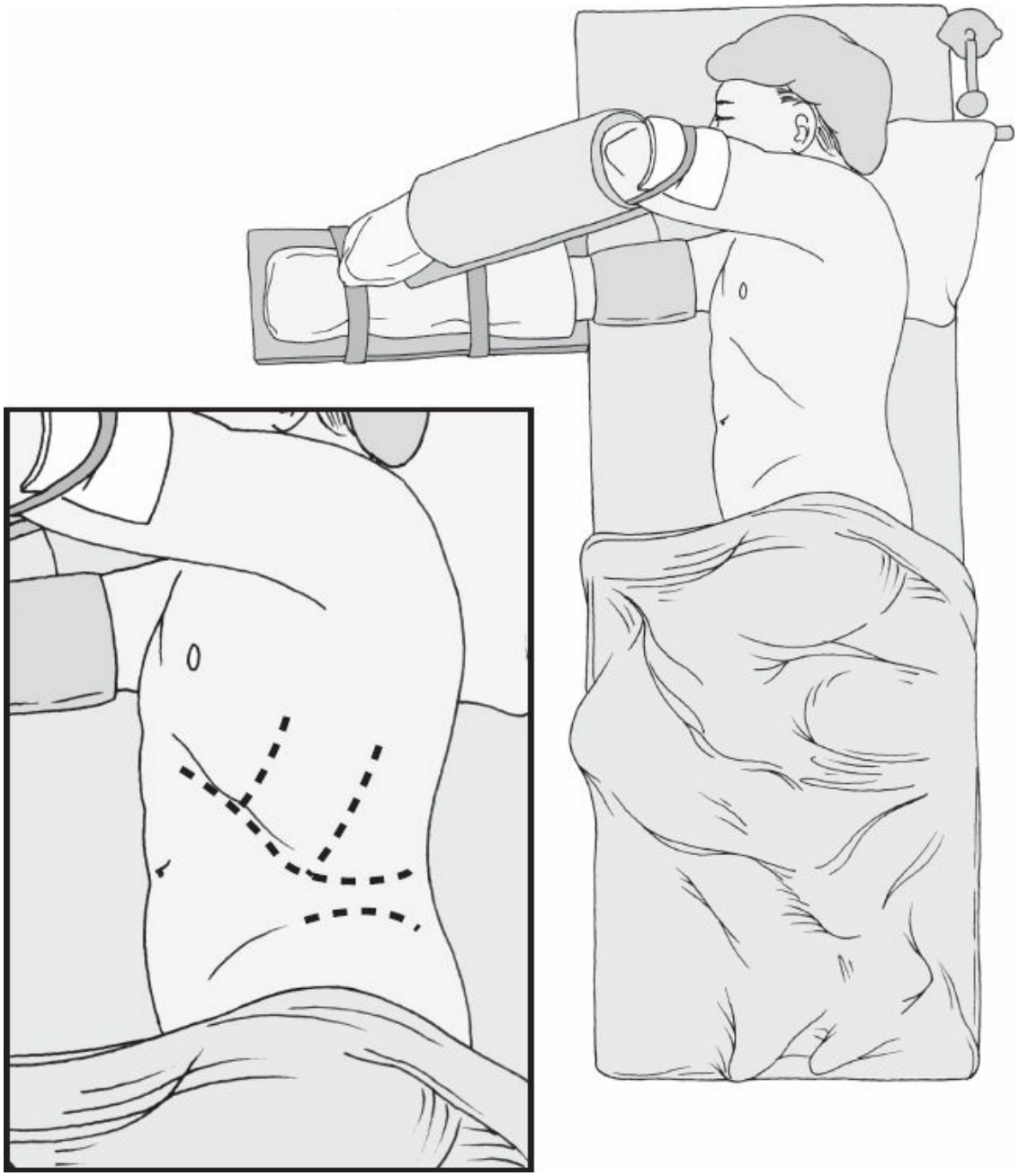

Figure 44.4. Patient position for laparoscopic adrenalectomy, left side.

Right Adrenalectomy

For right adrenalectomy, the patient is placed in the lateral decubitus position with the right side upward. The surgeon stands facing the patient's back (right side of the table), and the assistant and laparoscopic camera operator stand on the opposite side of the table. The sequential steps in the dissection are illustrated in Figure 44.6. After placement of all laparoscopic ports, the liver is first mobilized by incising the right triangular ligament. The hepatic flexure of the colon does not typically

need to be mobilized or retracted. It is key that the entire length of the triangular ligament be divided from the inferior border of the liver all the way to the diaphragm.

Once the liver has been mobilized, it is retracted medially with a 5-mm instrument placed through the most medial port. The adrenal gland and IVC should be visible at this point in the dissection (Fig. 44.6). The plane between the adrenal and IVC is then developed by incising the overlying peritoneum at the lateral border of the vena cava with an L-hook electrosurgical instrument. After identification of the gland, it is gently dissected away from the vena cava beginning along the medial border of the adrenal and continuing superiorly and inferiorly. Most of the arterial branches that enter the superior, medial, and inferior aspects of the adrenal are small and can be divided with monopolar electrosurgery, but there are often two or three larger branches that should be clipped. Alternatively, these vessels along with the remaining attachments can be taken with an ultrasonic or bipolar coagulating device.

The right adrenal vein is usually identifiable early in the dissection and is typically located at about the midportion of the adrenal; it enters the posterolateral aspect of the IVC. This vein should be carefully isolated with blunt dissection with a right-angle instrument and should be doubly ligated with clips. Alternatively, if the vein is large or if the tumor encroaches on it, a vascular stapler can be used to divide the vein taking the lateral “shoulder” of the IVC. Excessive traction on the adrenal vein is to be avoided as it may tear along the vena cava with resultant brisk hemorrhage. If there is major or uncontrolled bleeding from the vena cava, the patient should be immediately converted to an open procedure. Once the vein has been ligated and divided, the adrenal can be retracted away from the vena cava and all remaining medial attachments and small vessels can be divided. At this point, the diaphragm should be visible posteriorly and the dissection should stay on top of that plane. The dissection then continues along the inferomedial border of the adrenal and out laterally along the superior pole of the kidney. Some arterial branches are encountered here that may require ligation with clips or an advanced energy device. The dissection should not extend too low into the area of the renal hilum because of the risk of injuring a superior polar renal artery. Finally, the relatively avascular posterior and lateral attachments are divided.

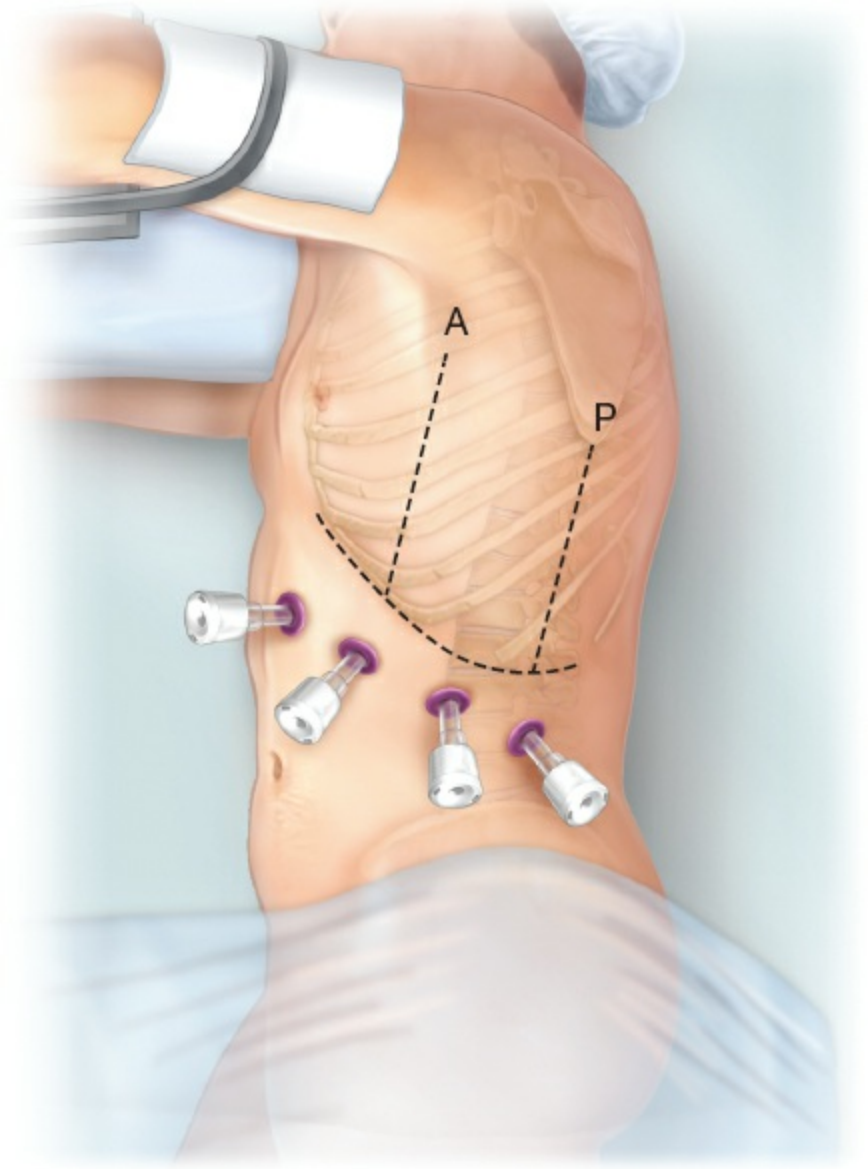

Figure 44.5. Port site placement for laparoscopic left adrenalectomy. The *dashed lines* indicate the anterior and posterior axillary lines and costal margin. The initial Veress needle access is usually achieved just medial to the anterior axillary line about two fingerbreadths below the costal margin. In most cases, a fourth port placed medial to the anterior axillary line is also used. A, anterior axillary line; P, posterior axillary line.

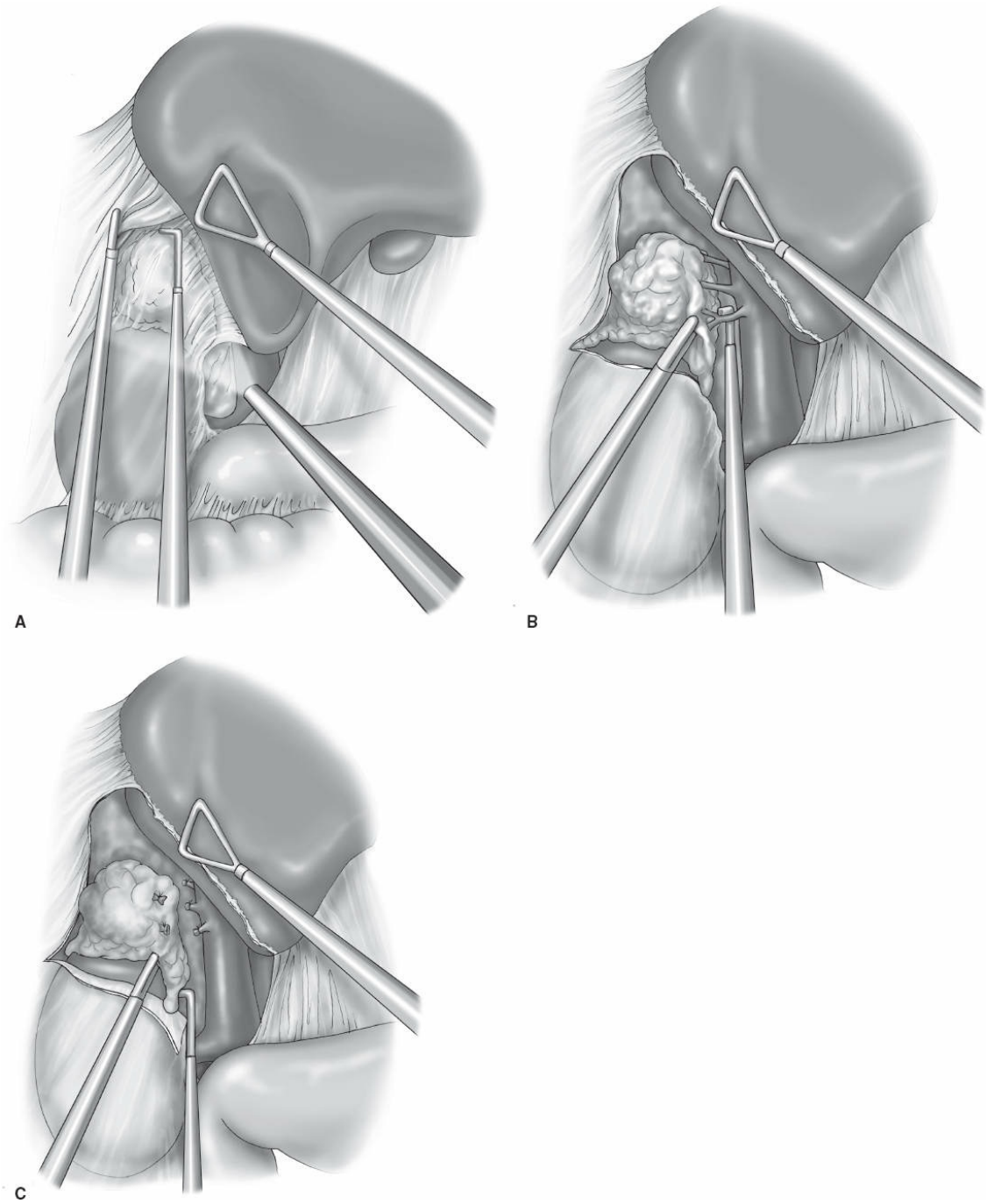

Figure 44.6. Sequential steps in laparoscopic right adrenalectomy. **A.** Mobilization of the right triangular ligament of the liver. A hook cautery is used to divide this ligament. **B.** Dissection of the plane between the adrenal and vena cava. The adrenal vein is ligated with clips and divided. **C.** Dissection of the inferior and posterior attachments of the adrenal. Note the exposure of the superior pole of the kidney.

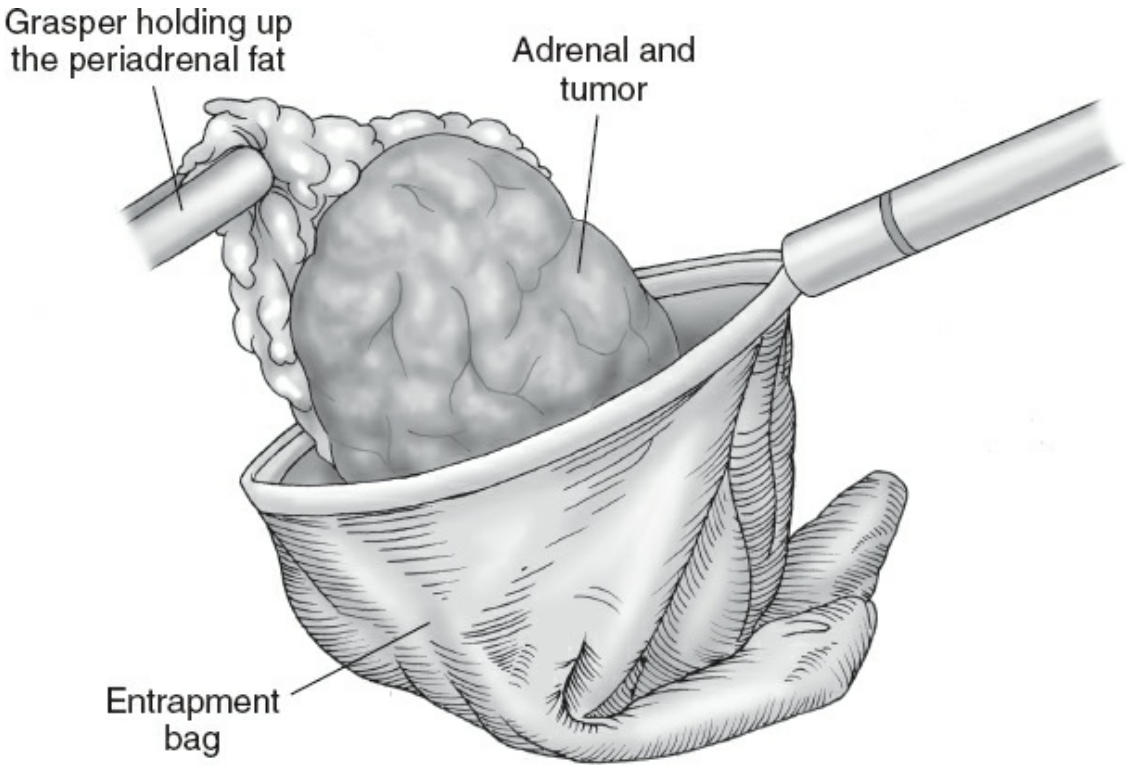

Figure 44.7. Specimen removal. The adrenal is placed in a secure entrapment bag for removal.

Care should be taken throughout the dissection to handle the adrenal and surrounding tissue in a gentle fashion, as aggressive retraction and blunt dissection can lead to bleeding or trauma to the adrenal gland or tumor with risk of tumor spillage. Direct grasping of the adrenal and tumor should also be avoided, but one can grasp the peri-adrenal fat and use that to elevate and move the gland around. Minimizing any retraction or pressure on the tumor may also serve to limit the release of catecholamines by a pheochromocytoma. Meticulous hemostasis is important to prevent blood from obscuring the visual field of dissection. Once the gland is free, it is placed into an impermeable bag for removal from the abdomen, and the retroperitoneum (Fig. 44.7) is irrigated and inspected for hemostasis and for security of the clipped vein pedicle on the vena cava. The gland is then removed at the 12-mm port incision, which usually will need to be enlarged somewhat. For large pheochromocytomas and other large noncortical tumors, the specimen may be morcellated within the entrapment bag to facilitate extraction. However, it is preferable to extract most cortical tumors and metastases intact for complete pathologic assessment. Finally, after the specimen is out, the abdomen is reinflated and the operative bed is reinspected. The extraction site is then closed in

two layers of 0-gauge absorbable suture for the fascia and an absorbable subcuticular layer or tissue glue for the skin. Steri-strip tapes are sufficient to approximate the other incision sites.

Left Adrenalectomy

For left adrenalectomy, the patient is placed in the lateral decubitus position with the left side facing upward. The surgeon and camera operator both stand on the side of the table facing the patient's abdomen and the assistant stands on the opposite side. The landmarks used for port placement are the same as for the right side. The key steps in left adrenalectomy are illustrated in Figure 44.8. After port placement, the splenic flexure of the colon is taken down from its lateral reflection to the inferior pole of the spleen to allow it to fall away inferiorly. The majority of the dissection is done with an advanced bipolar energy device, but an ultrasonic coagulator or electrosurgical scissors can be used alternatively. It is usually necessary to mobilize the splenic flexure before the most dorsal fourth port is placed. The length of the splenorenal ligament can then be divided to the diaphragm. This allows the spleen to be rotated medially with gravity using minimal retraction. A key step at this stage is to develop the plane between the tail of the pancreas and the left kidney using blunt dissection and cautery or an ultrasonic coagulator. The splenic artery and vein should be visible at this point as should the salmon-colored pancreas to the left side of the operative field (Fig. 44.9). This maneuver should lead directly to the adrenal gland, which is found in the perinephric fat in close proximity to the superior pole of the kidney, just superior and lateral to the pancreas and splenic vessels and cephalad to the renal vessels. It is important to positively identify the pancreas at this stage in order to avoid mistaking it for the adrenal.

In patients with small tumors or with large amounts of retroperitoneal fat, the left adrenal can sometimes be difficult to find. In such cases, laparoscopic ultrasound can be useful to image the adrenal and to identify its relationship to the kidney and renal vessels. The dissection starts along the medial and lateral borders to define those limits of the adrenal and then progresses inferiorly to locate the adrenal vein (Fig. 44.8C). On the left side, arterial branches enter the gland at the lateral–inferior aspect along the superior pole of the kidney, and also medially. The inferior border of the adrenal often sits adjacent to the renal vein and should be carefully dissected away from that structure. It is helpful to use the electrosurgical L-hook instrument for this part of the dissection because it allows

elevation and division of small amounts of tissue. The left adrenal vein courses along the inferomedial aspect of the gland to drain into the left renal vein and should be doubly ligated. The inferior phrenic vein empties into the adrenal vein just above this and may need to be ligated separately. Once the vein has been divided, the inferior border of the gland is elevated and the posterior attachments and remaining lateral and superior attachments are divided with advanced bipolar energy or an ultrasonic coagulator. Care must be taken to avoid injury to the superior pole renal arterial branches, which run cephalad to the renal vein and at the lateral aspect of the adrenal. The gland is then placed in an impermeable sac and removed as described for right adrenalectomy.

Hand-Assisted Laparoscopic Adrenalectomy

A hand-assisted laparoscopic approach to adrenalectomy may be considered for cases of large tumors or those in which there are intraoperative difficulties such as bleeding or failure to progress with the laparoscopic dissection. Access for hand port placement is usually carried out in the subcostal region or upper midline medial to the other ports. The hand port often replaces the most medial 5-mm port depending on where the incision is located. Although experience with this technique in patients with adrenal tumors is limited, its use in difficult splenectomy cases suggests that it may be of value in selected cases of adrenalectomy. Another benefit of this approach is that it greatly facilitates extraction of larger tumor specimens.

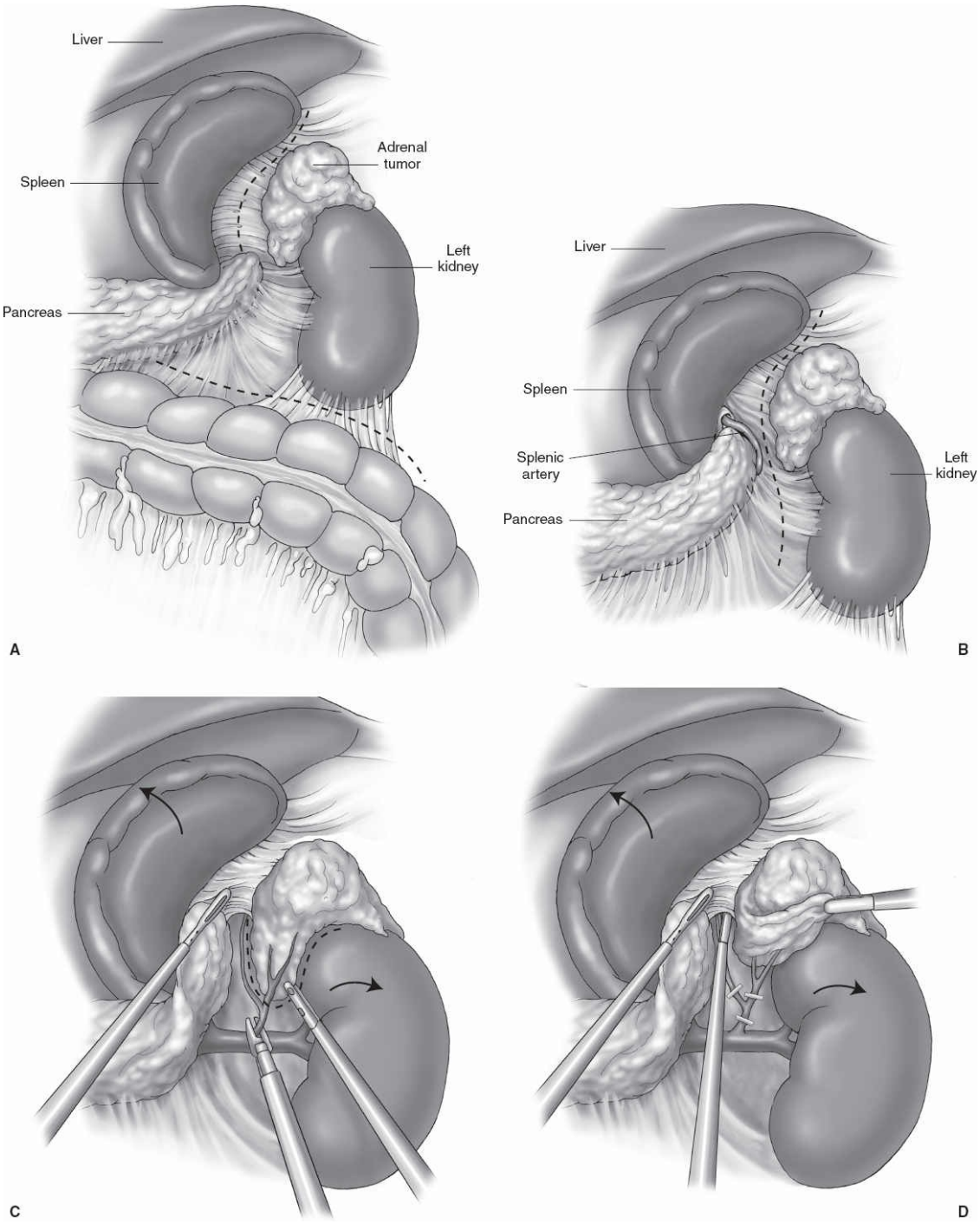

Figure 44.8. Sequential steps in laparoscopic left adrenalectomy. **A.** The splenic flexure of the colon is taken down, and the splenorenal ligament is divided (*dashed line*). **B.** The plane between the tail of the pancreas and kidney is developed to expose the adrenal gland. **C.** The medial, inferior, and lateral borders of the adrenal are dissected to expose the adrenal vein, which is clipped and divided. **D.** The posterior and superior attachments are divided to free the gland.

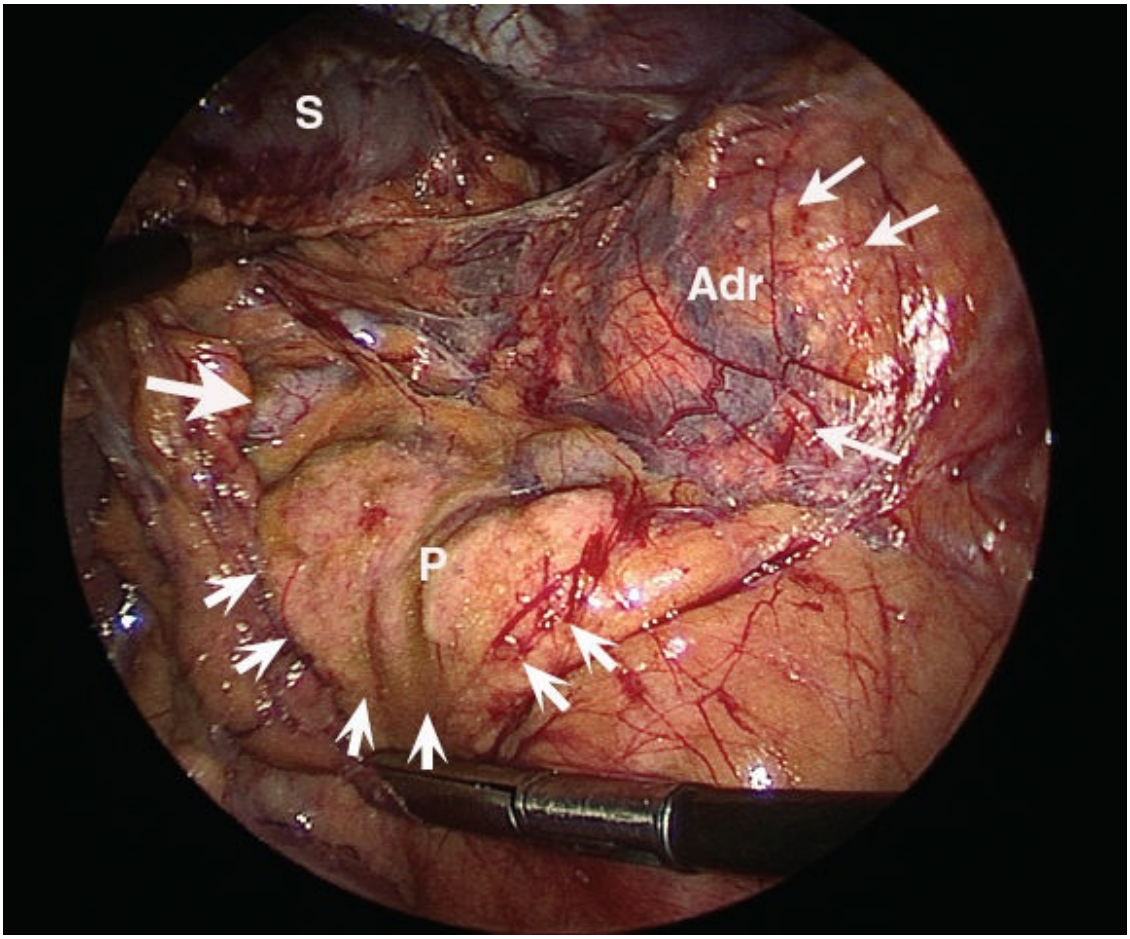

Figure 44.9. Operative photograph that demonstrates the relationships between the spleen (S), splenic artery (*large single arrow*), tail of pancreas (P and *arrows*), and left adrenal gland (Adr and *smaller arrows*) is shown.

Retroperitoneal Endoscopic Approach

The retroperitoneal approach to adrenalectomy is the most direct route to the adrenal glands and is becoming more popular for a number of reasons. Its advantages include avoiding intraperitoneal adhesions from prior operations, eliminating manipulation or retraction of intra-abdominal organs, and diminished bleeding due to the higher CO_2 pressures used. With experience, this approach can result in faster operating times; Walz has reported 560 adrenalectomies with this technique with average operating times of only 67 minutes. With the prone position, bilateral adrenalectomy can be performed without the need to reposition the patient between sides. The disadvantage of this approach includes a smaller working space, which makes removal of tumors >5 cm more difficult; also, the working space can be compromised if the peritoneum is opened. In addition, this approach can be more difficult to learn initially because

the anatomic landmarks and orientation are unfamiliar to most abdominal surgeons.

The retroperitoneal approach is carried out with the patient in a prone jack-knife position, although a lateral decubitus approach has also been described. In the prone jack-knife position, the patient is lying on a rectangular support, which allows the abdominal wall to hang freely to open up the retroperitoneal space (Fig. 44.10). Initial access to the retroperitoneal space is by direct visualization just below the tip of the 12th rib. The incision is extended through the muscle layers by blunt dissection with scissors into the retroperitoneal space, and this space is further developed with blunt finger dissection. A second trocar is placed under direct finger guidance 4 to 5 cm laterally below the 11th rib and a third trocar is placed 5 cm medially to the first port about 3 cm below the 12th rib (Fig. 44.10). A blunt balloon-tipped trocar is used at the open insertion site and the other ports may be 5 mm in size. Pneumoretroperitoneum of 20 to 25 mmHg is achieved, which increases the working space and decreases bleeding. The retroperitoneal fat beneath the diaphragm is pushed down bluntly to expose the upper pole of the kidney. The dissection should proceed lateral to medially to expose the adrenal gland. Laparoscopic ultrasonography can be used if there is difficulty locating the kidney and adrenal, but with experience, this is rarely necessary. The diaphragmatic and medial arterial branches are ligated with a bipolar energy device (or ultrasonic coagulator) as encountered during dissection. For right adrenalectomy, the vena cava is identified and dissected off the adrenal to expose the adrenal vein, which is ligated. For left adrenalectomy, the adrenal is elevated to expose the inferomedial aspect of the gland where the vein is identified and ligated. One should keep in mind that the orientation of the surgeon to the major vessels and the adrenal vein relative to the tumor is reversed compared with the conventional anterior approach (i.e., the right adrenal vein will be coming off the surgeon's left-handed view of the adrenal to enter the posterolateral vena cava). After the vein is taken, the adrenal gland is retracted caudally and the remaining attachments are divided. The gland is extracted and the incisions closed in the usual manner.

Open Adrenalectomy

Anterior Approach

Open adrenalectomy is most commonly carried out using an extended

subcostal incision. This incision can also be extended cephalad in the midline up to the xiphoid to allow better exposure for mobilization of the liver and other upper abdominal viscera, which is often necessary for very large (>10 cm) or invasive tumors. This incision also provides the exposure needed to perform periaortic lymph node dissection and en bloc resection of contiguous structures in patients with adrenocortical carcinoma. Exposure for this approach for right adrenalectomy may be facilitated by elevating the right flank somewhat and by placing a roll under the right side (Fig. 44.11). A midline incision is an option for the rare patient who requires bilateral open adrenalectomy.



Figure 44.10. Patient position and port site placement for the retroperitoneal approach to adrenalectomy.

After entering the abdomen, the liver and peritoneal surfaces are inspected for the presence of metastatic disease. On the right side, the liver is fully mobilized by dividing the triangular ligament as for the laparoscopic approach. With a large tumor, it may be necessary to mobilize the hepatic flexure of the colon and retract it inferiorly. The duodenum is also mobilized using a Kocher maneuver to expose the IVC (Fig. 44.11B). Inferior traction on the kidney exposes the adrenal gland. The dissection begins medially to develop the plane between the tumor

and the vena cava and to assess resectability. Periaortic lymph nodes should be assessed for involvement as well. The right adrenal vein is ligated, and the tumor is dissected away from the vena cava. A portion of the lateral wall of the vena cava may be taken along with the tumor if it appears involved. Once the medial side of the adrenal and the tumor are free, the dissection proceeds as described for the laparoscopic approach. For adrenocortical carcinomas that have invaded the kidney or liver, it may be necessary to perform an en bloc resection of the tumor along with these structures.

On the left side, the open operative approach is as described for the laparoscopic technique. The splenic flexure of the colon is mobilized from its attachments and the splenorenal ligament is divided. The tail of the pancreas and spleen are together reflected medially to expose the adrenal (Fig. 44.11C). If the spleen and pancreas cannot be mobilized away from the adrenal because of tumor involvement, then the lesser sac should be opened and the pancreas and splenic hilum accessed anteriorly. Large malignant tumors on the left may require en bloc resection of the spleen, tail of the pancreas, and even the kidney. These tumors should be removed along with a generous margin of retroperitoneal fat and Gerota fascia. In cases of primary adrenal cortical malignancies, periaortic lymph nodes medial to the adrenal should be removed along with the tumor.

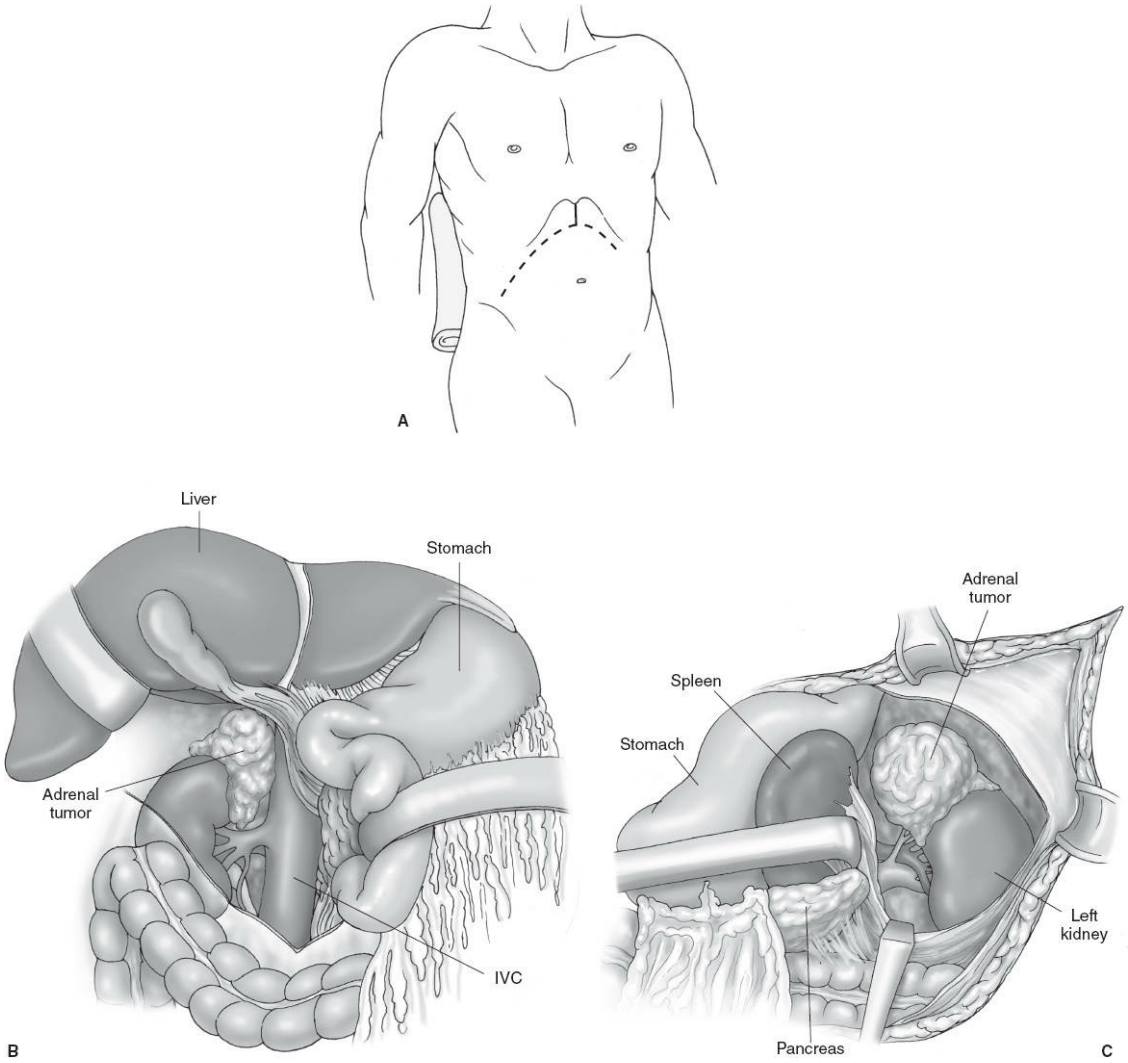

Figure 44.11. Incision and exposure for open adrenalectomy. **A.** Incision location. The incision can be extended into a bilateral subcostal incision or superiorly in the midline to improve exposure. **B.** Exposure for right adrenalectomy. **C.** Exposure for left adrenalectomy. IVC, inferior vena cava. (**B, C:** Modified from Scott HW Jr. Anatomy of the adrenal glands and bilateral adrenalectomy. In: Nyhus LM, Baker RJ, eds. *Mastery of Surgery*. Boston, MA: Little, Brown and Co.; 1992:1374.)

Posterior Approach

The posterior approach is rarely used today because there are fewer patients in whom this approach would be indicated who are not also candidates for laparoscopic adrenalectomy.

In the past, this approach was used primarily for bilateral adrenalectomy for Cushing disease or for small unilateral tumors. The patient is placed prone on two chest rolls with a pillow or roll under the hips and pillows under the legs and the table is flexed. A hockey stick–

shaped incision is made from the 10th rib extending first inferiorly and then laterally to the iliac crest (Fig. 44.12). The latissimus dorsi muscle is divided and the 12th rib is resected, preserving the intercostal nerve. Next the diaphragm with the pleura along its superior surface is exposed. The pleura is dissected off the diaphragm and reflected superiorly and the diaphragm is incised to expose the Gerota fascia. The adrenal gland is exposed by bluntly reflecting the fat away and retracting the kidney inferiorly. The remainder of the dissection is then as previously described for the endoscopic retroperitoneal approach. Once the adrenal is free, the wound is closed in layers with absorbable sutures, with care to avoid the neurovascular bundles of the ribs. If a pleural opening is created during the dissection, it can be treated by closing the incision over a small red rubber catheter placed in the pleural space and removing the tube as positive pressure ventilation is delivered after the space has been closed. A chest radiograph is obtained postoperatively to ensure that there is no residual pneumothorax.

Thoracoabdominal Approach

The thoracoabdominal approach is reserved for advanced adrenal malignancy with major vessel involvement (e.g., IVC) that requires exposure of the supradiaphragmatic vena cava. The options for access to the chest are to extend the bilateral subcostal incision in the midline into a median sternotomy or to make a classic thoracoabdominal incision. For the latter, the patient is placed supine and a roll is placed under the thorax to be incised. Either a midline or subcostal abdominal incision can be carried onto the chest for this approach. The thoracic portion of the incision is made along the 9th or 10th rib. The costal margin is divided and a portion of the costal cartilage is excised to prevent the costal margin edges from rubbing together after the incision is closed. The chest is entered through the 8th or 9th interspace, and the diaphragm is incised as the lung is retracted superiorly. Exposure of the vena cava above and below the tumor as well as the hepatic veins should be carried out. The dissection then proceeds as described above.

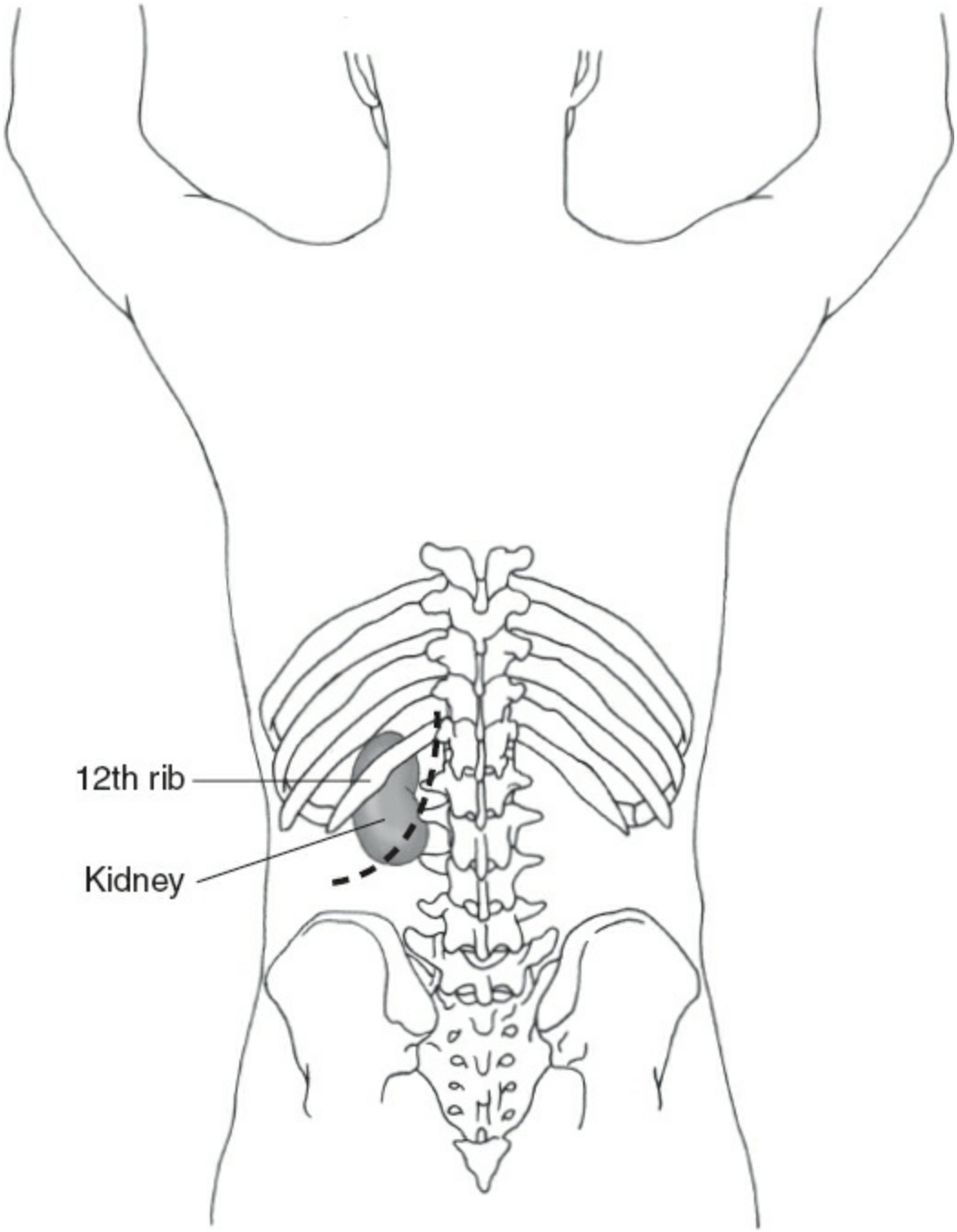

Figure 44.12. Schematic of incision for open posterior adrenalectomy.

POSTOPERATIVE CARE

A principal benefit of the laparoscopic approach compared with open adrenalectomy has been a reduction in the incidence of adrenalectomy-related complications. This lower complication rate has primarily been a result of fewer wound, pulmonary, and infectious complications with the laparoscopic approach. Although several complications can occur as a result of adrenalectomy, many of these can be avoided with careful

dissection principles, good hemostasis, and thorough knowledge of the surgical anatomy in this region. The most common operative complication is hemorrhage, which can occur from the adrenal vein, small arteries to the adrenal, the adrenal gland or tumor, hepatic veins, renal vessels, and the IVC or adjacent solid organs (spleen, pancreas, kidney, liver). Bleeding has also been the most common reason for conversion from the laparoscopic approach to open adrenalectomy. Minor bleeding during the procedure can usually be managed with tamponade of the area and then direct control of the bleeding site with an energy device or clips. Prompt conversion to an open procedure should be carried out if the bleeding is from a major vessel that cannot be immediately controlled. In addition to hemorrhage, vascular occlusion can also occur by inadvertent ligation of a renal artery branch or other visceral vessels. Other organs and structures in the vicinity of the dissection that may be injured (e.g., by electrosurgery) include the colon, spleen, pancreas, liver, stomach, kidney, and ureter, and these should be inspected carefully prior to closure. If there is any concern that the pancreatic parenchyma has been injured, a closed-suction drain should be placed. The diaphragm and pleura can also be injured with any of the various approaches, although this complication is less common with the laparoscopic approach.

The patient with a pheochromocytoma is at risk for intraoperative hypertensive crisis and arrhythmias if there has not been adequate preparation pharmacologically for surgery. Patients with an adrenal tumor causing Cushing syndrome should receive glucocorticoids as a stress dose in the perioperative period, which can then be tapered to an oral maintenance steroid dose until their hypothalamic–pituitary–adrenal axis has recovered, which may take up to 12 to 18 months. Patients undergoing bilateral adrenalectomy will require lifelong supplementation with both glucocorticoid and mineralocorticoid replacement.

Following resection of a pheochromocytoma, additional intravenous fluids may be required postoperatively due to intravascular volume expansion from phenoxybenzamine. These patients may also become hypoglycemic postoperatively due to loss of inhibition of insulin secretion by high levels of circulating catecholamines. Plasma-fractionated metanephrines or 24-hour urinary catecholamine levels should be checked at follow-up and on a yearly basis to evaluate for recurrence. Close follow-up is also required for patients with adrenocortical malignancy including periodic measurement of hormone levels and imaging with CT or MRI.

Local recurrences or solitary metastases may be treated with surgical resection in select cases.

Patients undergoing laparoscopic adrenalectomy usually require minimal parenteral analgesia and are often on oral pain medication on the first postoperative day, whereas patients undergoing an open procedure have a greater parenteral analgesia requirement often lasting more than 48 hours. Laparoscopic patients are started on a liquid diet early postoperatively and often can be discharged within 24 hours unless a longer period of observation is needed for blood pressure management or hormone replacement. Most patients can return to unrestricted activity within 7 to 10 days of operation.

Suggested Readings

Barczynski M, Konturek A, Nowak W. Randomized clinical trial of posterior retroperitoneoscopic adrenalectomy versus lateral transperitoneal laparoscopic adrenalectomy with a 5-year follow-up. *Ann Surg* 2014; 260:740–8.

Berber E, Tellioglu G, Harvey A, et al. Comparison of laparoscopic transabdominal lateral versus posterior retroperitoneal adrenalectomy. *Surgery* 2009;146:621.

Bittner JG, Gershuni VM, Matthews BD, et al. Risk factors affecting operative approach, conversion, and morbidity for adrenalectomy: a single-institution series of 401 patients. *Surg Endosc* 2013;27:2342–50.

Elfenbein DM, Scarborough JE, Speicher PJ, et al. Comparison of laparoscopic versus open adrenalectomy: results from American College of Surgeons-National Surgery Quality Improvement Project. *J Surg Res* 2012;184:216–20.

Gonzalez RJ, Shapiro S, Sarlis N, et al. Laparoscopic resection of adrenal cortical carcinoma: a cautionary note. *Surgery* 2005;138:1078–86.

Guerrero M, Schreinemakers JMJ, Vriens MR, et al. Clinical spectrum of pheochromocytoma. *J Am Coll Surg* 2009;209:727–32.

Kebebew E, Reiff E, Duh Q-Y, et al. Extent of disease at presentation and outcome for adrenocortical carcinoma: have we made progress? *World J Surg* 2006;30:872–8.

Perrier ND, Kennamer DL, Bao R, et al. Posterior retroperitoneoscopic adrenalectomy: preferred technique for removal of benign tumors and isolated metastases. *Ann Surg* 2008;248:666.

Sippel RS, Chen H. Subclinical Cushing's syndrome in adrenal incidentaloma. *Surg Clin North Am* 2004;184:875–85.

Stowasser M. Update in primary aldosteronism. *J Clin Endocrinol Metab*

2009;94:3623–30.

Tessier DJ, Iglesias R, Chapman WC, et al. Previously unreported high grade complications of adrenalectomy. *Surg Endosc* 2009;23:97–102.

Toniato A, Merante-Boschin I, Opocher G, et al. Surgical versus conservative management for subclinical Cushing syndrome in adrenal incidentalomas: a prospective randomized study. *Ann Surg* 2009;249:388–91.

Walz MK, Alesina PF, Wenger FA, et al. Posterior retroperitoneoscopic adrenalectomy—results of 560 procedures in 520 patients. *Surgery* 2006;140:943.



EDITOR'S COMMENT

The authors have made a nice outline of how to handle varied scenarios of known diseases and syndromes. Because of the frequent use or overuse of computerized tomography (CT) and positron emission tomography (PET) scans, the incidental finding of adrenal masses of unknown etiology has become all too frequent. These are the so-called incidentalomas, and this occurs about 4% of the time being less common in the younger than older patient (1% to 10%). Nonendocrine surgeons frequently have to deal with these as a part of their regular practice. The differential diagnosis requires a working knowledge of possible syndromes, their pathophysiology and biochemistry, and associated abnormalities. Bilateral cases occur about 10% of the time but are more common with genetic syndromes.

In my oncology practice, CTs are common place in the metastatic work-up. As with any patient, a thorough history and physical examination are the key to determining the origin of an adrenal mass(es) focusing on uncontrolled hypertensive and/or flushing episodes, a history of tachycardia, virilization or feminization, and pain. The presentation could be one of metastatic disease versus a functioning or nonfunctioning adrenal tumor. Pain and virilization are more often than not associated with malignancy where constitutional symptoms may be a sign of a functioning adrenal tumor. Even in the presence of a tumor, e.g., breast cancer, a functioning adrenal tumor must be ruled out. Serum metanephrines, cortisol, aldosterone, and renin (in presence of hypertension) are the initial biochemical tests. Often, however, these may come back high but in an equivocal range. In the setting of neoadjuvant chemotherapy, the surgeon cannot be sure what that means. If equivocal, then the next biochemical test would be 24-hour urine metanephrines.

CT scans can help elucidate the possibility of malignancy, size, and invasion into contiguous structures and possibility for resection. Pheochromocytomas have distinctive washout characteristics from intravenous contrast on fine-cut multi-phase CTs and require special alpha-blockade prior to any surgery. About 20% of pheochromocytomas will have intralesional calcifications. Pheochromocytomas also require work-up for associated tumors and genetic

mutations. Size makes a difference as well. Four centimeters is the cut-off because >4 cm has a proportional increased risk of malignancy. A nonfunctioning incidentaloma <4 cm in size with a Hounsfield unit (HU) of <10 and/or intralesional fat needs to be watched with serial CTs for growth but is almost never malignant. A HU >10 in a nonfunctional incidentaloma but with a washout >50% is also going to benign. Chemical shift magnetic resonance can also confirm malignancy with a sensitivity of >80% and a specificity of >90%. PET scans often the source of identification of incidentalomas should not be relied on to rule out malignancy as they have a false negative rate of >10%. Needle biopsy of an adrenal mass should only be performed for a nonfunctioning mass that is highly suspicious for metastatic disease. Primary adrenal tumors and benign adrenal cells are indistinguishable under the microscope when obtained by fine need aspiration and therefore should be avoided. Metastatic lesions to the adrenal should be referred back to the medical oncologists for appropriate treatment. Primary adrenal cancer can be suggested by local invasion or when presenting as distant metastases. In addition, bilateral nonfunctioning adrenal tumors should prompt consideration of hemorrhage (especially with associated pain), lymphoma, infection, and amyloidosis.

Nonfunctioning benign tumors need to be followed long term as up to 47% will become hormonally active within a 5-year period and 29% of cases will demonstrate worrisome imaging growth or characteristics requiring investigation for carcinoma. Recommendations are for yearly biochemical follow-up for a period of 5 years. Repeat imaging should be performed at 3 to 6 months, 1 year, and 2 years. An increase in size of greater or equal to 0.8 cm should prompt surgical intervention.

Functioning benign tumors can be managed by surgery. In the setting of an elsewhere primary malignancy (e.g., breast) especially with pheochromocytomas, the patient will need alpha blockade followed by beta blockade then adrenalectomy and fluid resuscitation. If bilateral (10%), an adrenalectomy of one side should be performed along with a cortical-sparing adrenalectomy on the contralateral side. Pheochromocytomas can recur and progress to a malignant pheochromocytoma and as such will need yearly biochemical follow-up.

Subclinical cortisol-producing adenomas are rare as 95% of cortisol-producing adrenal tumors will present as Cushing syndrome. Again a careful history and physical examination can help pick up this rare syndrome. However, this can be confusing because 70% of citizens in the United States are overweight, ~30% have diabetes (estimate of diagnosed and undiagnosed), hypertension (~29%), and osteoporosis (one tenth aged 60, one fifth aged 70, two fifths aged 80, and two thirds aged 90). The key is to consider this subclinical presentation and get the appropriate biochemical tests—a cortisol suppression test and baseline serum ACTH level. Surgery can alleviate the effects of hypercortisolemia especially in the young and as such should be pursued. Adrenalectomy should be considered for those presenting with a

primary cancer, especially, breast as cortisol may exacerbate tumor growth.

In the case of functioning aldosteromas, they can be quite small. Patients present with hypertension and chronic hypokalemia. A plasma aldosterone to renin level >20 is considered diagnostic. However, a falsely high ratio can be calculated if the plasma renin level is very low. A confirmatory saline suppression test can be used in a case like this. Nonsupression of aldosterone with administration of a 2-liter normal saline bolus confirms the diagnosis. Adrenalectomy can be curative.

The authors have described nicely the three main approaches to adrenalectomy, including open, laparoscopic, and retroperitoneal. Each technique has its own advantages and disadvantages. The open approach is recommended when cancer is known to be present as lymphadenectomy is required and it has the lowest rate of positive margins (including contiguous structures) and as such as the best chance for cure. Transabdominal laparoscopic cases have significantly less blood loss, better time to ambulation, postoperative pain, resumption of normal diet, and normal activities and length of stay compared to open. The retroperitoneal approach avoids the abdomen altogether and potential complication and also allows a bilateral approach. However, the retroperitoneal approach doesn't allow assessment of the peritoneal space, and if necessary the patient will need to be flipped, intraoperatively. A recent meta-analysis demonstrated statistically significant decreases in operative time, intraoperative blood loss, operative duration, length of hospital stay but not complications for the retroperitoneal approach over the laparoscopic approach.

V. Suzanne Klimberg

Suggested Readings

Chen W, Li F, Chen D, et al. Retroperitoneal versus transperitoneal laparoscopic adrenalectomy in adrenal tumor: a meta-analysis. *Surg Laparosc Endosc Percutan Tech* 2013;23(2):121–7.

Fassnacht M, Arlt W, Bancos I, et al. Management of adrenal incidentalomas: European Society of Endocrinology Clinical Practice Guideline in collaboration with the European Network for the Study of Adrenal Tumors. *Eur J Endocrinol* 2016;175(2):G1–G34.

Miller BS, Gauger PG, Hammer GD, et al. Resection of adrenocortical carcinoma is less complete and local recurrence occurs sooner and more often after laparoscopic adrenalectomy than after open adrenalectomy. *Surgery* 2012;152(6):1150–7.

Morelli V, Scillitani A, Arosio M, et al. Follow-up of patients with adrenal incidentaloma, in accordance with the European society of endocrinology guidelines: Could we be safe? *J Endocrinol Invest* 2017;40(3):331–3.

Terzolo M, Stigliano A, Chiodini I, et al. AME position statement on adrenal incidentaloma. *Eur J Endocrinol* 2011;164(6):851–70.

Wong KK, Arabi M, Bou-Assaly W, et al. Evaluation of incidentally discovered adrenal masses with PET and PET/CT. *Eur J Radiol* 2012;81(3):441–50.

45 Pancreatic Neuroendocrine Tumors

Michael P. Kim and Brian D. Badgwell

Pancreatic neuroendocrine tumors (PanNETs) comprise approximately 10% of all pancreatic lesions and represent a rare and heterogeneous subset of pancreatic tumors marked by indolence and latent presentation. Nonfunctioning PanNETs (NF-PanNETs) do not exhibit endogenous hormone secretion and comprise 40% to 91% of all PanNETs. Functioning PanNETs secrete hormones native to endogenous tissues; approximately 22% of patients with PanNETs have secretory disease symptoms. Among all functioning PanNETs, insulinomas are the most common and comprise 70%, whereas glucagonomas comprise approximately 15% of all functioning PanNETs. Less-common tumors include gastrinomas, VIPomas, and somatostatinomas, which together comprise approximately 5% to 10% of all functioning PanNETs. Primary considerations for surgical resection include tumor function, the presence of symptoms, size/mass effect, and the propensity for metastasis. The decision for formal surgical intervention should be made on an individual basis; patients with functioning PanNETs should generally proceed to surgical resection in the absence of clear contraindications or substantial risk of morbidity and/or mortality. Very small NF-PanNETs (<1 cm) may be selectively monitored in the absence of symptoms; most functioning PanNETs should be strongly considered for resection if location or mass effects are likely to result in anticipated complications such as an onerous or infeasible resection. Diagnosis of one or more PanNETs should also elicit consideration for an occult inherited genetic disorder such as multiple endocrine neoplasia-1 (MEN-1).

ETIOLOGY AND PATHOPHYSIOLOGY

The landscape of genetic mutations associated with sporadic PanNETs continues to evolve, but firm insight into the genetic nature of this disease is evident from their associations with genetic syndromes, e.g., MEN-1,

neurofibromatosis type 1, tuberous sclerosis, Von Hippel Lindau syndrome, and Li-Fraumeni syndrome. Somatic mutations in genes responsible for chromatin remodeling such as menin (MEN1), death-domain-associated protein (DAXX), and α thalassemia/mental retardation syndrome X-linked (DAXX) have been identified in substantial numbers of patients with PanNETs, indicating a possible role in disease development. NF-PanNETs largely exert deleterious effects by distorting native anatomy via anatomic involvement and compromised organ function at primary and metastatic sites. Because of aberrant hormone production, functioning PanNETs may result in profound symptoms despite a diminutive size that is often not amenable to localization despite highly detailed imaging.

PanNET STAGING

The clinical management of PanNETs largely depends on the location(s) and extent of tumor burden. Accordingly, staging of PanNETs is determined by criteria composed of tumor size and extension (T), tumor involvement of regional lymph nodes (N), and the presence of distant metastasis (M). Surgical management hinges on the ability to accurately identify and characterize primary lesion(s), and to assess regional and distant sites for disease. Initially, high-resolution CT or MRI should be obtained to accomplish these upfront goals. If insufficient, adjunct imaging modalities such as EGD/endoscopic ultrasound (EUS), somatostatin scintigraphy, and positron emission tomography (PET) may be employed to diagnose and stage PanNETs.

Somatostatin Scintigraphy

The majority of neuroendocrine tumor cells, including nonfunctioning tumors, express high levels of somatostatin receptors on the cell surface. High expression of somatostatin receptors on tumor cells may therefore help to identify PanNETs through the selective binding and detection of radio-labeled somatostatin analogs to somatostatin receptors. While advancements in the resolution and contrast timing protocols of CT and MRI have largely obviated the use of somatostatin scintigraphy, it does retain well-defined roles in: (1) the identification of small lesions not detected by other imaging modalities, (2) predictive value in the therapeutic response to the clinical administration of somatostatin analogs, and (3) to establish a baseline of tumor burden for monitoring of disease

progression. Ongoing treatment with somatostatin analogs should be suspended prior to somatostatin scintigraphy as they exhibit competitive binding to somatostatin receptors and can attenuate or obfuscate positive signals.

EGD/Endoscopic Ultrasound

The primary benefit of EGD/EUS is to identify and enumerate PanNETs, and to obtain a tissue diagnosis prior to surgical decision making. This aspect of preoperative planning is arguably the most important as the degree and nature of any intended resection may be completely altered by the presence of additional lesions not appreciated prior to surgical exploration and/or resection. Among PanNETs, gastrinomas are notorious for being multifocal and elusive; EGD/EUS may provide a powerful adjunct to high-resolution imaging to clarify imaging abnormalities or to discern anatomic relationships between tumors and critical structures. In nonfunctioning PanNETs, EGD/EUS may readily secure a histologic diagnosis of pancreatic lesions and significantly affect clinical management.

METASTATIC DISEASE

The decision to surgically resect metastatic PanNETs is directed by the feasibility of curative resection, control of symptoms, and/or the progressive nature of disease. Oligometastases that would permit an R0 resection along with the primary tumor should undergo upfront surgical resection with curative intent. Patients in whom all disease may be removed at the time of operation have the greatest potential for long-term and disease-free survival and therefore benefit from an aggressive surgical approach, including en bloc resections with other organs and/or sound vascular resection and reconstruction. Generally, patients with oligometastatic disease tend to require a lesser extent of resection with fewer postoperative complications. Patients with more extensive metastatic disease that precludes R0 resection may selectively undergo debulking operations to alleviate symptoms related to mass effect or associated hormonal syndromes. However, such debulking should be undertaken under careful consideration of the benefits derived from surgery versus systemic therapies. Ideally, surgical candidates with extensive metastatic disease will have tumors that are symptomatic and unresponsive to medical therapies, i.e., hormonal syndromes, and demonstrate stable, slow-

growing tumors. Following tumor debulking, symptom improvement and a prolonged period of disease progression may justify the risks associated with surgery and incomplete tumor resection. Accordingly, patients with large-volume, rapidly progressive metastatic disease are not likely to derive benefit from surgical resection and should undergo treatment with nonsurgical therapies.

Nonsurgical Therapies

Somatostatin Analogs

All patients with symptoms related to excessive hormone secretion by PanNETs should undergo treatment with somatostatin analogs. The two most common somatostatin analogs are octreotide and lanreotide; mechanistically, both bind and activate somatostatin receptors, thereby dampening the secretion of hormones from normal glands and from PanNETs. Somatostatin analogs are widely considered first-line agents to treat symptomatic hormone hypersecretion and have less side effects than other drug therapies. Notably, patients who receive somatostatin therapy are at high risk for gallstone and gallbladder sludge formation due to delayed emptying of the gallbladder. If long-term treatment with somatostatin analogs is anticipated for remnant disease or anticipated recurrence, a cholecystectomy should be performed at the time of surgical resection or debulking of primary and metastatic PanNETs to mitigate the chances of cholecystitis or symptoms related to diminished gallbladder contractility.

Cytotoxic Chemotherapy

Optimal chemotherapeutic regimens for PanNETs continue to be defined but are largely reserved for patients with unresectable, metastatic, or rapidly progressive disease. Toxicity of cytotoxic therapy is prevalent among patients commonly experiencing renal toxicity and myelosuppression. The use of streprozocin plus 5-FU or doxorubicin has led to objective responses and stabilization of disease. Dacarbazine and its less toxic analog, temozolomide, have also been shown to effect responses in patients with PanNETs, although toxicity continues to limit its use. Bevacizumab and everolimus have been administered in conjunction with temozolomode with a 33% and 40% response rate in PanNETs, respectively. FOLFOX plus bevacizumab have also demonstrated an overall response rate of 50%, with 50% of patients also demonstrating

stable disease.

Targeted Therapies

Preclinical studies in PanNETs have demonstrated the activation of signaling pathways downstream of numerous growth factors and their cognate receptors. Tyrosine kinase receptors including those belonging to the vascular endothelial growth factor (VEGF) receptor family and the mammalian target of rapacmyin-Akt (mTOR-Akt) have been targeted in PanNETs with some degree of success. Sunitinib, a tyrosine kinase inhibitor with broad inhibitory activity against VEGFR 1, 2, and 3 as well as PDGFRs (alpha and beta) and c-KIT, demonstrated an overall response rate of 9.3% but resulted in numerous toxicities and no improvement in overall survival. Everolimus, an mTOR inhibitor, has been shown to improve the median progression free survival (11 months from 4.6 months) with an increase in partial responses compared to placebo (5% vs. 2%). Overall, targeted therapies in PanNETs demonstrate less overall and partial responses compared to cytotoxic chemotherapy and are generally administered in conjunction with octreotide or lanreotide in patients with progressive metastatic disease.

INSULINOMAS

Insulinomas are the most common PanNET and represent approximately 70% of all functioning PanNETs. However, they are quite rare with an estimated occurrence in only 4/1,000,000 people. Approximately 10% of insulinomas demonstrate a proclivity for metastasis, and the vast majority are considered benign. Generally, insulinomas are distributed evenly throughout the head, body, and tail of the pancreas. Most sporadic insulinomas are solitary tumors (～87%); 7% are multifocal and approximately 6% are malignant with metastases. The spectrum of symptoms related to insulin overproduction ranges from the absence of symptoms to the necessity for continuous intravenous glucose administration in extreme cases. The presence of synchronous lesions should be ruled out preoperatively and at the time of surgical exploration. If multiple lesions are encountered, the possibility of MEN-1 should be strongly considered since insulinomas are among the commonest PanNETs encountered in patients with MEN-1.

Clinical Presentation

The majority of patients with insulinomas present with neuroglycopenic symptoms: diaphoresis, palpitations, anxiety, confusion, and behavioral changes. The median age of affected patients is approximately 50 years with a slight predilection for females (57% to 70%). The disease should be confirmed via biochemical evaluation, and exogenous insulin administration should be excluded prior to an extensive workup. A formal diagnosis of insulinoma is rendered from a 72-hour fast during which patients are monitored for neuroglycopenic symptoms. The development of hypoglycemia (serum glucose <40 mg/dL) in the presence of neuroglycopenic symptoms and high insulin levels (>5 μU/mL) confirms the diagnosis. C-peptide and proinsulin levels should also be tested, as subsets of insulinomas produce large amounts of proinsulin with attenuated symptomatology relative to insulin-secreting tumors.

Preoperative Planning

Once a diagnosis of insulinoma has been rendered, high-resolution computed tomography (CT) or magnetic resonance imaging (MRI) should be obtained to localize tumors and to stage active disease. Pancreas protocol imaging may reveal small lesions and inform anticipated operations and patient counseling. If tumors are not identified or well-characterized on cross-sectional imaging, we recommend proceeding with EUS, which is highly successful in identifying PanNETs (82% of cases). However, proceeding with EUS for initial localization is not recommended, as high-resolution CT or MRI is required for staging and may adequately localize tumors without the need for EUS. Patients with a biochemical diagnosis of insulinoma without identifiable tumors by conventional imaging modalities may undergo selective arterial calcium stimulation for localization. Calcium gluconate is sequentially injected into the superior mesenteric artery, gastroduodenal artery, and splenic artery, and hepatic venous outflow is sampled, and insulin levels are measured. Arteriography is also performed and used to establish specific perfusion to different regions of the pancreas. As calcium gluconate selectively stimulates insulin secretion from insulinomas, the general region of the pancreas containing the tumor may be identified through increases in detected insulin (>2-fold increase) when each source of arterial inflow undergoes calcium infusion. If all attempts at preoperative tumor localization are unsuccessful, laparotomy with careful inspection and palpation of the pancreas, coupled with intraoperative ultrasound, may be

needed to localize the tumor(s).

GASTRINOMAS

Gastrinomas secrete supra-physiologic levels of the hormone gastrin, resulting in a clinical syndrome (Zollinger-Ellison syndrome [ZES]), whereby the hypersecretion of gastric acid results in peptic ulcer disease and diarrhea. Common locations for gastrinomas are in the pancreatic head and duodenum, although extra-anatomic tumors may arise in 5% to 15% of cases. The gastrinoma triangle, defined by the junctions of the (1) cystic common bile duct, (2) neck and body of the pancreas, and (3) second and third portions of the duodenum, therefore encompasses the majority of gastrinomas (Fig. 45.1). Pancreatic gastrinomas comprise 25% of all gastrinomas, and most (50% to 88%) arise in the duodenum, most often in the first portion of the duodenum. There is a predilection for males with ZES; approximately 20% of cases occur in association with MEN-1, and the remaining 80% are sporadic.

Clinical Presentation

Patients typically present between the ages of 20 and 50 years with complaints of abdominal pain and chronic diarrhea. Sources of abdominal pain include reflux and peptic ulcer disease from acid hypersecretion; gastrointestinal bleeding may also occur in up to 25% of patients. Persistent acid hypersecretion into the gastrointestinal tract may also result in the inactivation of pancreatic enzymes with resultant steatorrhea and diarrhea. When persistent acid hypersecretion is refractory to treatments with H2-blockers or proton pump inhibitors, a diagnosis of gastrinoma should be considered, and additional workup should be planned.

Preoperative Planning

The diagnosis of gastrinoma is primarily established from elevated fasting gastrin levels in the setting of a gastric pH less than 4. Other clinical entities related to antral cell hyperplasia, prior gastrectomy, gastric outlet obstruction, proton pump inhibitor therapy, etc. may also result in an elevated serum gastrin level and should be excluded. Most patients (～2/3 of patients), however, have a serum gastrin level less than 1,000 pg/mL, requiring additional diagnostic evaluation in the form of a secretin stimulation test. During this test, secretin is administered intravenously

and serum gastrin levels are measured. Gastrinoma cells inappropriately secrete gastrin in response to secretin stimulation. Caution should be used in administering this test in patients with profound symptoms from suspected ZES and maintenance on proton pump inhibitor therapy. Sudden discontinuation of proton pump inhibitors may lead to gastrointestinal hemorrhage and profound diarrhea with subsequent dehydration. Localization of gastrinomas should initially be performed with high-resolution imaging focused within the gastrinoma triangle. Pancreas protocol, triple-phase CT imaging should be performed to identify suspicious lesions. Co-localization with somatostatin receptor scintigraphy and/or endoscopy/EUS may further confirm the diagnosis. In the absence of demonstrable lesions on imaging, selective arterial stimulation with secretin may assist in identifying the relative location of gastrinomas. Biochemical tests that strengthen the diagnosis of gastrinoma in questionable cases include serum chromogranin A. Last, exploratory laparotomy, manual palpation of the duodenum, intraoperative ultrasound, and endoscopic trans-illumination may be employed to identify and resect gastrinomas. The duodenum may be opened to facilitate visual and manual inspection if difficulty is encountered in the identification and localization of tumor(s).

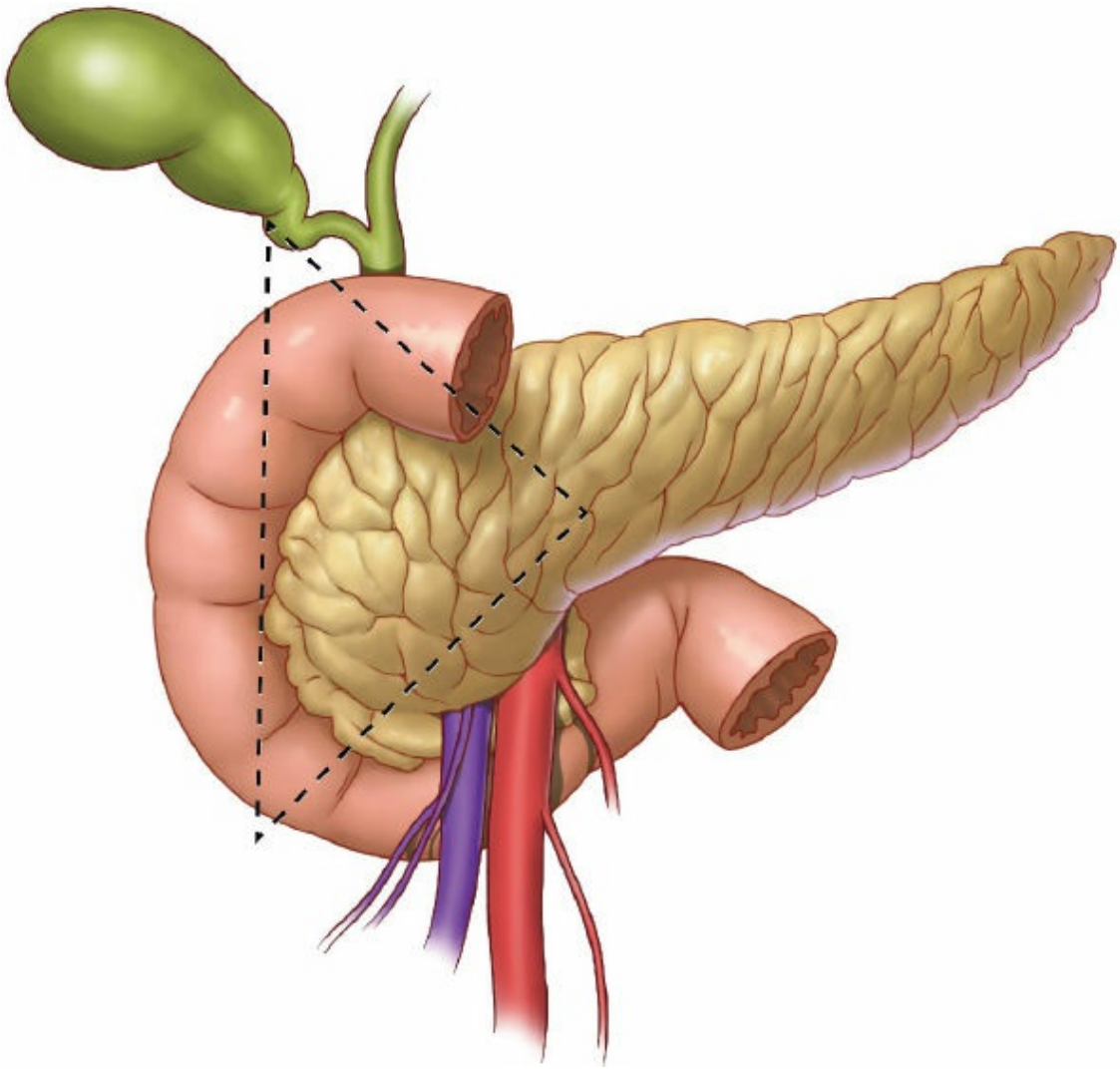

Figure 45.1. The gastrinoma triangle is defined by the junctions of the (1) cystic common bile duct, (2) neck and body of the pancreas, and (3) second and third portions of the duodenum. The vast majority (80%) of gastrinomas may be found within the anatomic confines of this triangle. (Image © 2015 The University of Texas MD Anderson Cancer Center.)

GLUCAGONOMAS

Glucagonomas are rare tumors marked by high metastatic proclivity; 50% to 80% of patients have metastatic disease at the time of diagnosis. Glucagonomas comprise 15% of all functional PanNETs, and the lesions are confined to the pancreatic tail in the majority of patients. Most glucagonomas present as solitary lesions in the fifth decade of life without a predilection for males or females. Owing to the malignant behavior of the majority of glucagonomas, surgical resection is strongly recommended when clearance of all tumor may be achieved. Up to 20% of patients with

a diagnosis of glucagonoma may have MEN-1 and therefore should be thoroughly evaluated within the context of management and surgical planning, if indicated.

Clinical Presentation

Two clinical features largely characterize patients with glucagonoma: weight loss and necrolytic migratory erythema (NME). Autonomous glucagon secretion produces nonspecific symptoms but promotes catabolic processes that result in significant weight loss. Approximately 80% of patients display weight loss at the time of presentation. Hyperglycemia and glucose intolerance are present at equal frequencies, although formal diabetes mellitus is present in approximately 40% of patients. NME is present in 70% of glucagonoma patients and manifests as painful, pruritic, erythematous papules/plaques on the face, perioral region, mucous membranes, and extremities. Formal diagnosis of NME is made through serial biopsies that show necrolysis of the epidermis and infiltration with lymphocytes. Last, deep venous thrombosis and/or pulmonary embolism may occur in up to 33% of glucagonoma patients, requiring treatment with anti-coagulants even prior to surgery and thereafter.

Preoperative Planning

Many glucagonomas present in late stages as sizable primary lesions. As such, diagnosis is usually made in the majority of cases via the presence of a pancreatic mass in the setting of elevated serum glucagon levels. Serum gastrin levels of >1,000 pg/mL are virtually diagnostic of glucagonoma, although levels above 500 pg/mL strongly indicate the diagnosis. Dedicated triple-phase CT imaging should be performed to identify suspicious lesions, intrapancreatic and otherwise, with a sensitivity of almost 100%. MRI may be employed to further characterize suspicious lesions or to confirm the presence of metastases, a finding that may drastically alter clinical management. In rare cases in which glucagonoma is suspected but not visualized on high-resolution, multiphase imaging, EUS, somatostatin receptor scintography, and angiography may be used to identify small lesions leading up to laparotomy, pancreatic palpation, and intraoperative ultrasound.

NONFUNCTIONING PanNETS

The majority of PanNETs are nonfunctioning and therefore do not produce symptomatic, hypersecretory, hormonal syndromes. Consequently, patients may present with advanced disease with latent onset of symptoms that may signal the presence of an underlying tumor. NF-PanNETs do secrete minute quantities of hormones such as pancreatic polypeptide, chromogranin, neuron-specific enolase, and ghrelin, which should be measured at presentation and used to monitor patients for recurrence and/or disease progression. Patients with NF-PanNETs commonly present with abdominal pain (35% to 78%), nausea/vomiting, and significant weight loss. At least a third of patients have metastatic disease at the time of diagnosis. Initial efforts should focus on ruling out active hormone secretion, alleviating symptoms, and staging disease prior to consideration for surgical resection. Owing to the occult nature of NF-PanNETs, patients often present with imaging studies demonstrative of a pancreatic mass. Once extensive biochemical workups fail to reveal hormonal hypersecretion, endoscopic biopsy should be performed to confirm the histologic diagnosis of a tumor of pancreatic endocrine origin. Distinguishing NF-PanNETs from pancreatic adenocarcinomas via tissue diagnosis is imperative, as both diseases may have similar patient presentations and imaging characteristics. High-resolution CT or MRI imaging should also be obtained prior to surgical resection to delineate anatomic relationships between tumors and critical, surrounding structures, particularly in cases of large, bulky NF-PanNETs.

SURGICAL MANAGEMENT OF PanNETS

The decision to proceed with surgical resection of PanNETs depends on the presence of resectable lesions in patients in whom the risks associated with surgery are justified and adequately mitigated. Patients with other malignancies in their family or personal history in whom genetic syndromes may be suspected should be adequately screened, and synchronous tumors should be excluded. This is particularly true for MEN-1 patients as the sequence of surgeries if multiple lesions are found directly affects the scope or sequencing of surgery.

Laparotomy for lesions of the pancreas is dictated by the anticipated operation, patient body habitus, location of the lesion(s), and surgeon preference. Generally, an upper midline incision that is extended inferiorly past the umbilicus, if needed, is adequate for exposure of the entire pancreas. A subcostal incision extended medially past the midline or into a

bilateral subcostal (chevron) incision may be particularly efficient for exposure and to mitigate wound complications in significantly obese patients. Laparoscopic resection of PanNETs may be considered in clinical settings with adequate volume and experience; enucleation of lesions may also be attempted for smaller lesions with low malignant potential. It should be emphasized that the surgical management of PanNETs rests almost entirely on their identification. Therefore, intraoperative exposure and uninhibited access to all indicated aspects of the pancreas are mandatory to evaluate the tumor involvement and extent of required resection and to exclude synchronous lesions.

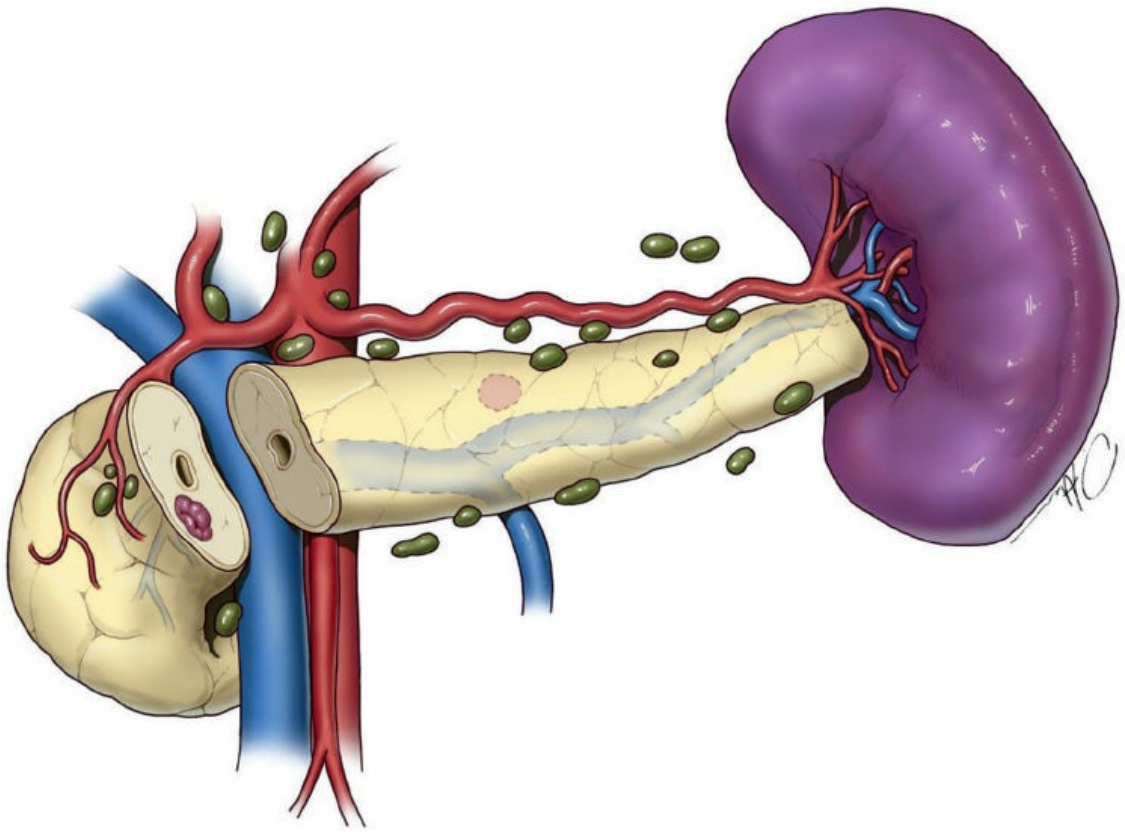

Figure 45.2. The planned operation to resect PanNETs depends on the location of tumor within the pancreas and its proximity to the pancreatic duct. Tumors located next to the pancreatic duct or that displace a significant volume of pancreatic parenchyma (>2 cm largest dimension) are not amenable to enucleation and require formal pancreatic resection. In such cases, PanNETs located with within the head of the pancreas require a pancreaticoduodenectomy and associated regional lymphadenectomy. PanNETs located within the pancreatic neck, body, or tail require a distal pancreatectomy and possibly a splenectomy, depending on the identity of the primary tumor. The

pancreas is typically divided along the pancreatic neck following the establishment of a clear plane between the posterior aspect of the pancreatic neck and the superior mesenteric vein. (Image © 2015 The University of Texas MD Anderson Cancer Center.)

The surgical approach to the resection of PanNETs is dictated by the physical location of the lesion(s) within the pancreas. Adherence to sound oncologic principles to maximally excise disease burden, obtain staging information, and dictate additional adjuvant therapies is mandatory to optimize patient outcomes. PanNETs deep within the pancreatic head or of sufficient size (generally >2 cm) require pancreaticoduodenectomy with lymphadenectomy of peri-pancreatic lymph nodes for regional clearance of disease. PanNETs located within the pancreatic neck or body require distal pancreatectomy and splenectomy (Fig. 45.2); regional lymphadenectomy is inherently achieved with this operation to control any potential locoregional disease. A central pancreatectomy, involving resection of the pancreatic neck and a small volume of adjacent pancreatic parenchyma, may also be performed in patients intolerant of the complications associated with formal pancreaticoduodenectomy or in whom removal of the majority of pancreatic parenchyma entailed in distal pancreatectomy is not desired. However, if locoregional disease is suspected, a central pancreatectomy does not permit significant lymphadenectomy and should be avoided except with the most benign of lesions. When possible, enucleation of PanNETs may be performed, usually when the lesion is smaller and the main pancreatic duct is not involved. As leakage of pancreatic fluid may result from enucleation(s), intraoperative drains should be strategically positioned to evacuate dependent fluid that may accumulate in the postoperative period (Fig. 45.3).

The entire length of the pancreas may be visualized when exposed through the lesser sac (Fig. 45.4). Access to the lesser sac is achieved either through direct division of the gastrocolic ligament or through division of the avascular fusion plane between the posterior surface of the omental apron and the transverse colon. In the latter approach, the stomach and omentum are reflected cephalad with a retractor, offering abundant access to the lesser sac. In cases where inspection or resection of the pancreatic head is required, the hepatic flexure may be mobilized and extended with a Cattell and Braasch maneuver to expose the pancreatic head, duodenum, and superior mesenteric vessels up to the ligament of

Treitz (Fig. 45.5). The duodenum and pancreatic head may then be thoroughly inspected following an extended Kocher maneuver that entails the division of the peritoneum overlying the C-loop of the duodenum (Fig. 45.6). Physical palpation and intraoperative ultrasound may be performed to identify PanNETs within the pancreatic head parenchyma (Fig. 45.7). Manual palpation and ultrasound assessment of the pancreatic body and tail may be performed once the pancreas is identified in the lesser sac. However, posterior tumors located within the deep substance of the pancreas are most thoroughly assessed following the division of the peritoneum along the superior and inferior borders of the pancreas and partial mobilization of the distal pancreas (Fig. 45.4).

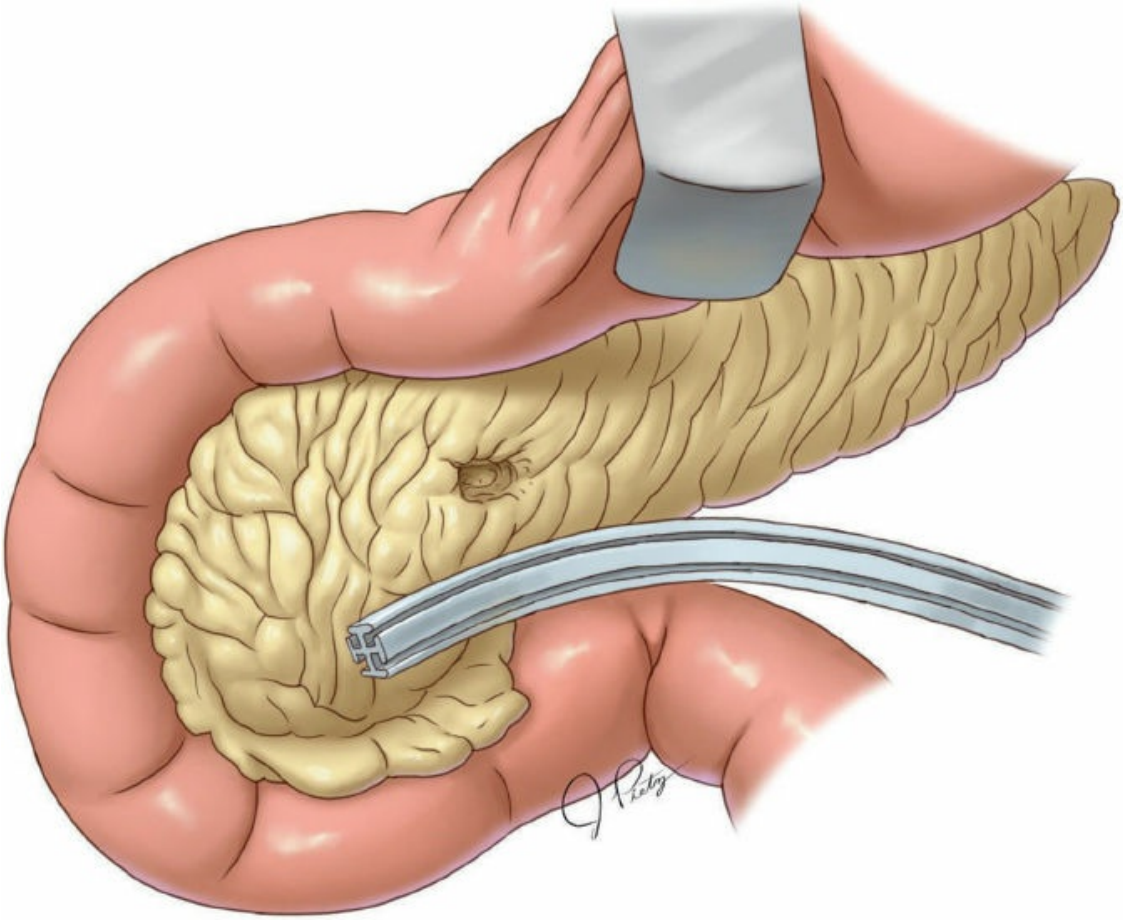

Figure 45.3. Placement of a closed suction drain to evacuate accumulated fluid following enucleation of PanNETs is recommended to prevent an uncontrolled pancreatic fistula or formation of a pancreatic abscess. The drain should be placed along the inferior border of the pancreas to optimally remove dependent fluid. Postoperatively, suspicion for a pancreatic leak may be supported through evaluation of closed drain suction fluid for amylase. (Image © 2015 The University of Texas MD

Anderson Cancer Center.)

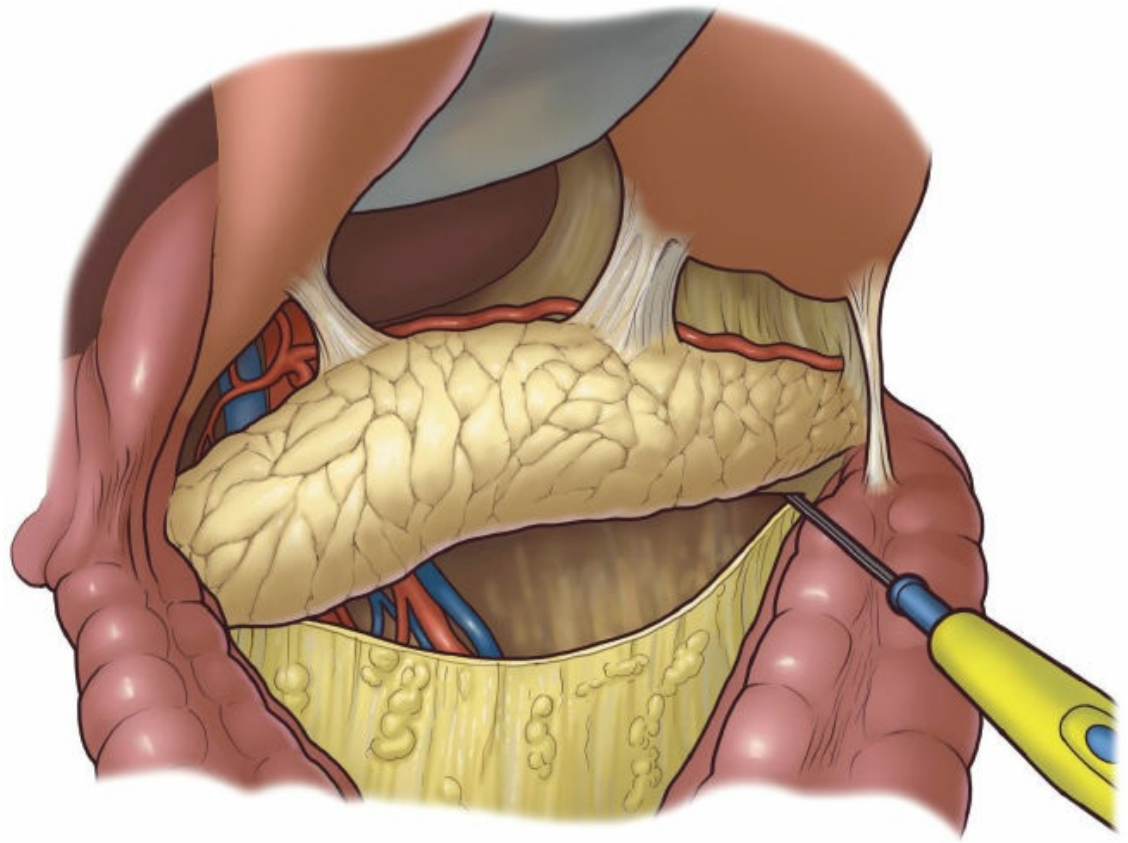

Figure 45.4. The length of the pancreas may be visualized and exposed for anticipated procedures through the lesser sac. Entrance into the lesser sac is commonly achieved following the division of the gastrocolic ligament with cephalad retraction of the stomach and caudad retraction of the omentum/transverse colon. Alternatively, dissection may proceed through the avascular fusion plane between the omental apron and transverse colon with subsequent cephalad retraction of the greater omentum and stomach and caudad retraction of the transverse colon. The latter approach offers unfettered access to the entire pancreas and facilitates subsequent mobilization of the pancreatic head without ligation of the gastroepiploic vessels. Consequently, we favor this approach when close evaluation or resection of the pancreatic head is anticipated. (Image © 2015 The University of Texas MD Anderson Cancer Center.)

Access to the pancreatic neck for division is required when performing either a pancreaticoduodenectomy or a distal pancreatectomy. The gastrocolic trunk and middle colic veins identified during operative exposure of the pancreatic head may be ligated to enhance exposure or to

prevent inadvertent avulsion and blood loss. Peritoneum covering the infrapancreatic neck may be carefully incised to mobilize and gain access to the posterior portion of the pancreatic neck. Likewise, removal of the hepatic artery lymph node provides an access point through the peritoneum that may be extended to the posterior aspect of the superior pancreatic neck. A dissection plane may then be slowly developed between the posterior aspect of the pancreatic neck and the anterior surface of the superior mesenteric vessels. Depending on the location of the tumor(s) and the ability to obtain negative margins, the pancreatic neck may be divided and the indicated operation performed.

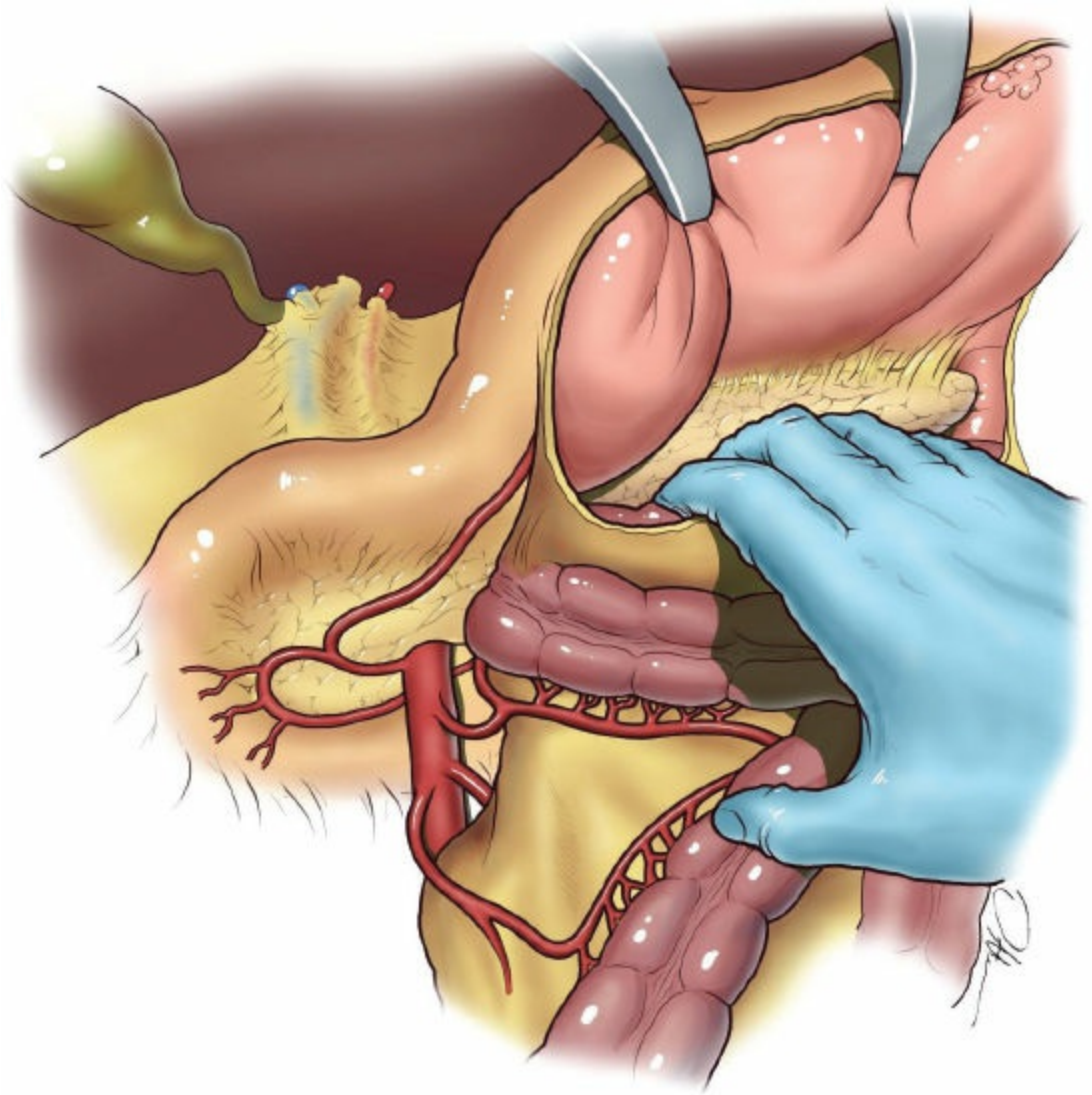

Figure 45.5. Complete exposure of the pancreatic head and mesenteric vessels is achieved following mobilization of the hepatic flexure and completion of a Cattell and Braasch maneuver. Controlled division of the gastrocolic trunk and/or middle colic veins, located along the anterior surface of the

infrapancreatic superior mesenteric vein, may be performed to prevent inadvertent rupture or to facilitate additional access to the pancreas or mesenteric vessels. Extended exposure of the pancreatic head and duodenum further facilitates their subsequent mobilization, if needed. (Image © 2015 The University of Texas MD Anderson Cancer Center.)

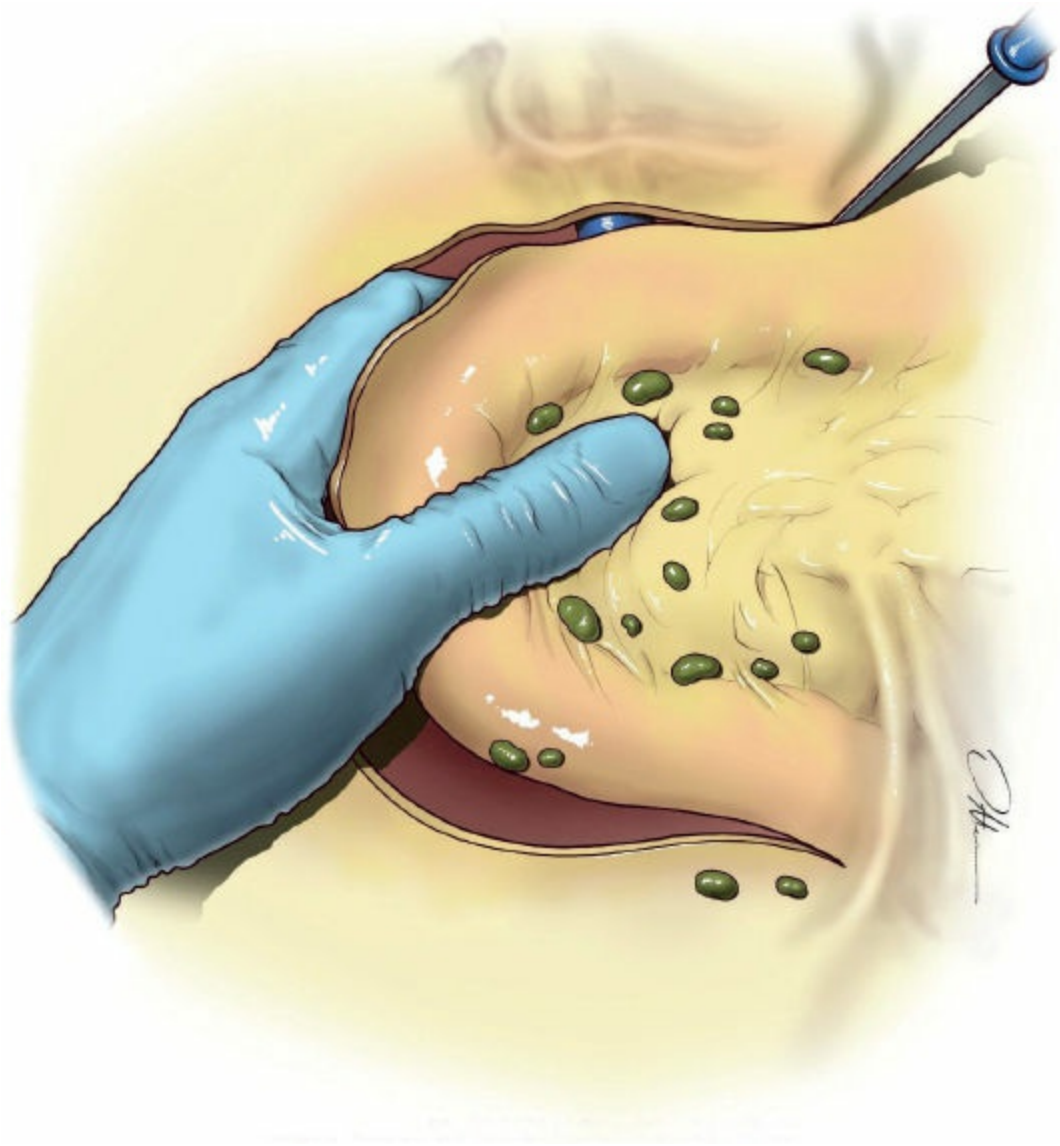

Figure 45.6. An extended Kocher maneuver is performed through incision of the peritoneum overlying the duodenum. Gentle retraction of the duodenum and pancreatic head in an anterolateral direction, to the left of the patient, exposes the underlying, avascular plane between the posterior aspects of the pancreatic head/neck and the inferior vena cava/aorta. Dissection should proceed until the left renal vein is visualized. Generous mobilization of the pancreatic head greatly enhances visual, manual, and ultrasound evaluation of the pancreatic head and

duodenum for PanNET identification and greatly facilitates subsequent dissection and/or resection of the pancreatic head and duodenum. (Image © 2015 The University of Texas MD Anderson Cancer Center.)

Special Considerations for Insulinomas

The vast majority (90%) of functional insulinomas are benign and therefore may be enucleated largely without fear of metastasis or recurrence. In familial syndromes, insulinomas are also commonly multifocal; in such cases, the liberal mobilization and assessment of the pancreas by palpation and intraoperative ultrasound are requisite to identify and remove all tumors. Three factors dictate whether an insulinoma may be enucleated: (1) involvement with surrounding structures, (2) tumor size, and (3) proximity to the pancreatic duct. As tumor size increases, so too does its involvement with normal pancreatic parenchyma and proximity to the pancreatic duct, necessitating a formal pancreatic resection. Tumors that are exophytic or located in the periphery of the pancreas, as evident on intraoperative ultrasound, may be enucleated regardless of their location along the length of the pancreas. Tumors located adjacent to the pancreatic duct should undergo a formal pancreatectomy. Likewise, formal pancreatectomy should be performed when enucleation of superficial tumors that extend deep into the pancreatic parenchyma might result in pancreatic duct damage or extensive disruption of pancreatic parenchyma. Intraoperative, closed-suction drains should be placed in locations where dependent drainage from enucleation sites might occur.

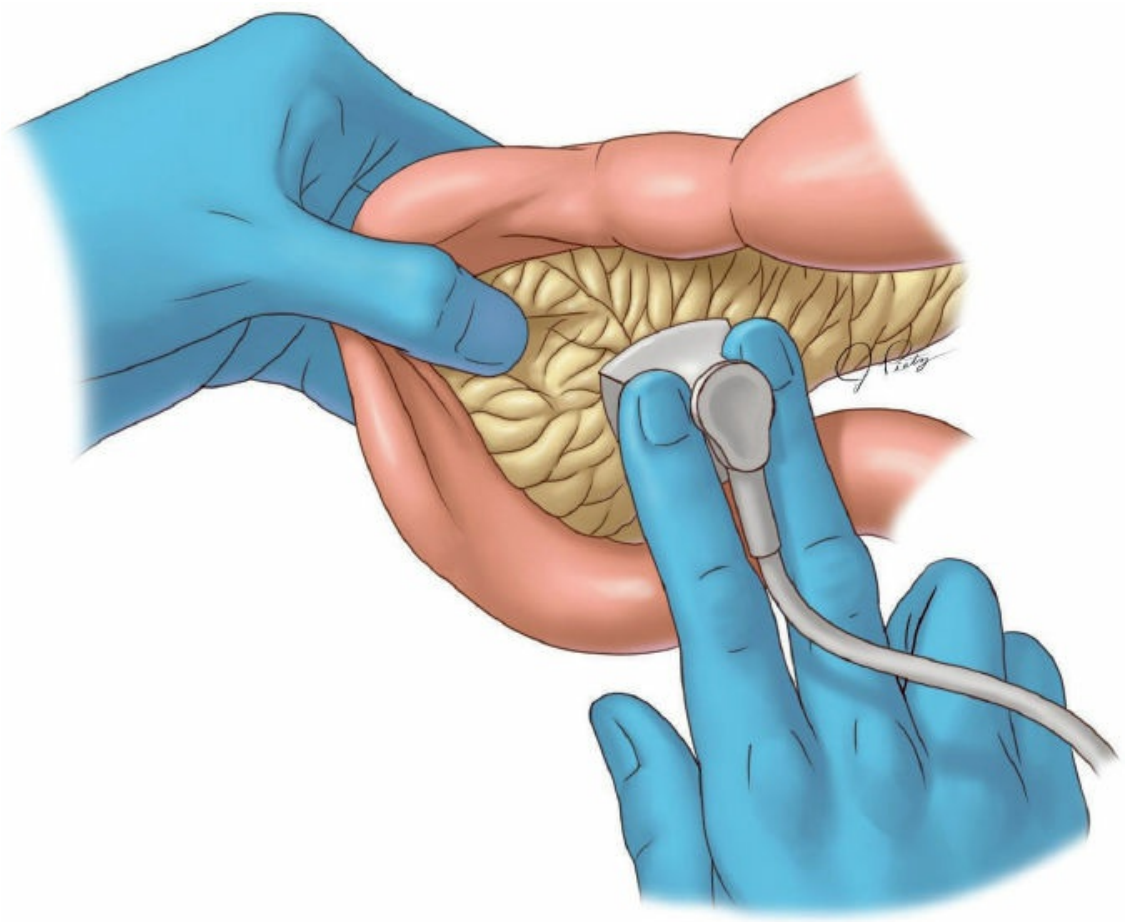

Figure 45.7. Intraoperative ultrasound may be utilized to localize PanNETs within the pancreatic parenchyma and to evaluate their proximity to the pancreatic duct. Many PanNETs may be enucleated when located in the peripheral pancreatic parenchyma and not adjacent to the pancreatic duct. Mobilization of the pancreatic head greatly enhances inspection and ultrasound evaluation of PanNETs, particularly for tumors located in the posterior pancreatic head or deep within the pancreatic parenchyma. (Image © 2015 The University of Texas MD Anderson Cancer Center.)

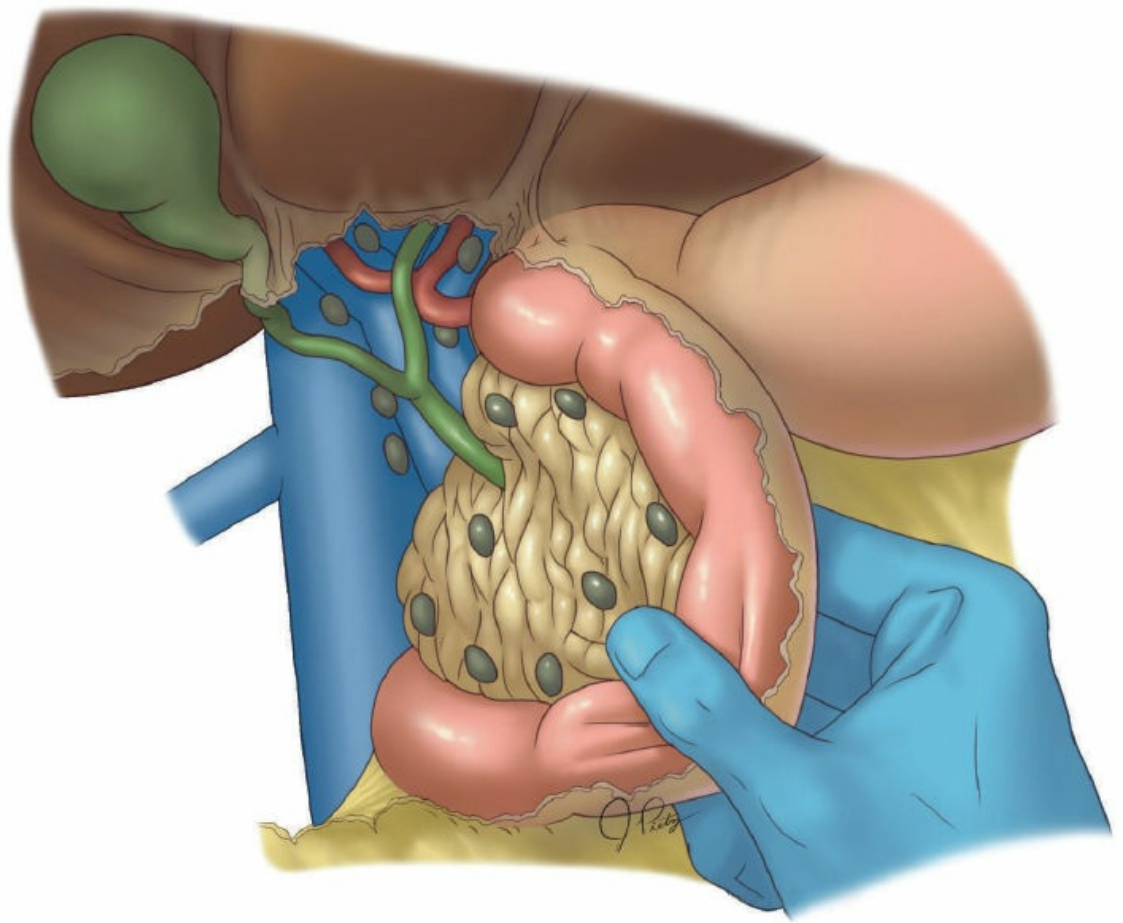

Figure 45.8. Regional lymphadenectomy is a critical technical point in the resection of PanNETs with a high propensity for metastasis. During pancreaticoduodenectomy, peripancreatic and periduodenal lymph nodes are largely adherent to the resected pancreatic head and duodenum. Extension of the lymphadenectomy into the porta hepatis is necessary to achieve complete clearance of periportal and perihepatic lymph nodes that may contain nodal disease. However, skeletonization or aggressive lymphadenectomy of structures far up the porta hepatis is not recommended and can result in devascularization of the common bile duct. (Image © 2015 The University of Texas MD Anderson Cancer Center.)

Special Considerations for Gastrinomas

Distinguishing factors that inform the resection of gastrinomas are their small size and frequent location in the duodenum. Metastatic disease should be excluded both radiographically and by visual inspection of the peritoneal cavity, liver, and diaphragm. Similar to insulinomas, enucleation may be performed for pancreatic head lesions that are peripheral and located away from the pancreatic duct. Regional lymph

node dissection inclusive of periportal, periduodenal, perihepatic, and celiac lymph nodes should be performed for all lesions in the head of the pancreas that undergo enucleation or pancreaticoduodenectomy (Fig. 45.8). Tumors in the distal pancreas are managed with distal pancreatectomy, with or without splenectomy, as this also provides an adequate lymphadenectomy for clearance of disease and prognostic information. This fundamental surgical concept is necessary given the frequency of regional nodal metastasis (~50%) associated with gastrinomas.

The most common primary site of gastrinomas is the duodenum. As such, mobilization of the duodenum with an extended Kocher maneuver is important to fully palpate and identify gastrinomas that may be located in the duodenum. Intraoperative ultrasound may be combined with manual palpation of the duodenum to localize gastrinomas for resection. If no tumors can be located at the time of laparotomy, intraoperative esophagogastroduodenoscopy may be performed to evaluate the duodenal mucosa for suspicious lesions. As light is less able to penetrate tumor and specifically tumors thicker than the surrounding bowel wall, trans-illumination of the duodenum with an endoscope may also assist in the identification of gastrinomas (Fig. 45.9). If the tumor(s) cannot be identified via transmural palpation, intraoperative ultrasound, and endoscopic evaluation/trans-illumination, some groups advocate incising the duodenal wall to facilitate palpation of the mucosal surface and bowel wall to better palpate and identify tumors. Typically, intramural gastrinomas of the duodenum are locally resected with a margin of normal tissue, and the defect is primarily repaired. A keen awareness of the location of the ampulla is necessary to prevent injury during duodenotomy and subsequent resection of the tumor.

Special Considerations for Glucagonomas

Surgical management of glucagonomas is based largely on their biologic propensity for metastasis, requiring thorough lymphadenectomy for disease clearance and staging. Accordingly, enucleation or formal pancreatectomy must be coupled with regional lymph node dissection. As most glucagonomas are located in the distal pancreas, distal pancreatectomy and splenectomy should be performed with lymphadenectomy of the celiac and perisplenic lymph nodes (Fig. 45.2). Small lesions in the distal pancreas are uncommon but may be enucleated

if they are smaller than 2 cm and located in the peripheral pancreas. Glucagonomas in the head of the pancreas are rare but almost always require formal pancreaticoduodenectomy owing to their size and the need for appropriate removal of periduodenal, retroperitoneal, perihepatic/celiac, and periportal lymph nodes.

Special Considerations for Nonfunctioning PanNETs

Most NF-PanNETs should undergo surgical resection, although lesions smaller than 1 cm may be closely monitored for patients who have relative or strict contraindications or unacceptable surgical risk. Small NF-PanNETs have a relatively small risk for metastasis; tumors 1 to 2 cm should undergo enucleation or formal pancreatectomy with or without regional lymphadenectomy. In cases of distal pancreatectomy, the spleen may be conserved. NF-PanNETs larger than 2 cm should undergo surgical resection, either pancreaticoduodenectomy or distal pancreatectomy and splenectomy, with corresponding regional lymphadenectomy similar to gastrinomas and glucagonomas.

POSTOPERATIVE CARE/COMPLICATIONS

Postoperative mortality for patients undergoing enucleation is lower than that of patients undergoing pancreaticoduodenectomy or distal pancreatectomy, owing in part to the preservation of pancreatic tissue and the avoidance of complications of pancreatic and bowel anastomoses. The morbidity rate of enucleation, however, is similar to that of formal pancreatic resection owing to the equivalent frequency of pancreatic fistula. Pancreatic fistulas associated with enucleation tend to be less severe. Moreover, blood loss is lower and hospitalization duration is shorter in patients undergoing enucleation. Closed-suction drains are helpful in patients who undergo enucleation to identify and manage postoperative pancreatic leaks, although postoperative drain placement is an area of active controversy in pancreatic surgery. Other complications include pseudocyst formation, abscesses, and the typical risks of major abdominal procedures. Laparoscopic resection is associated with reduced pain and shorter hospital stays but does not appear to provide benefit over open surgery for the risk of pancreatic fistula. The use of octreotide and, more recently, pasireotide to prevent pancreatic fistula formation varies among surgeons. Drains, if placed, should be maintained until the patient can tolerate a regular diet with no evidence of pancreatic leak.



Figure 45.9. Intramural PanNETs, specifically gastrinomas, may be identified and biopsied through preoperative endoscopic evaluation. Intraoperatively, an endoscope may be passed into the duodenum to trans-illuminate the duodenal wall to aid in the localization of small tumor(s). Because of their increased density and attenuated transmittance of light, tumors identified in this manner will appear as dark spots surrounded by illuminated, pink bowel. Localized resection of tumor may then proceed, limiting the resection of involved bowel wall. (Image © 2015 The University of Texas MD Anderson Cancer Center.)

OUTCOMES

Pan-NETs have a diverse range of outcomes based on their clinical and histologic features. As outcomes are classified according to stage, the inherent diversity and wide spectrum of clinical behavior of islet cell

tumors can represent a challenge in applying a universal staging system to these tumors. Pan-NETs are not included in the American Joint Committee on Cancer (AJCC) Neuroendocrine Tumor staging system. Pan-NETs are rather included in the AJCC Exocrine and Endocrine Pancreas category. Although survival rates are much better for patients with endocrine tumors than for those with exocrine histology, inclusion in this category has been shown to have good discrimination among stages and to correlate well with overall survival. In addition, inclusion within the pancreas stage group allows for improved data collection and hopefully for the identification of future prognostic factors. The 5-year overall survival rates for patients in the National Cancer Database who underwent resection of Pan-NETs, classified according to AJCC stage, were 61% for stage I, 52% for stage II, 41% for stage III, and 16% for stage IV. A similar staging system has been proposed by the European Neuroendocrine Tumor Society and also has demonstrated good prognostic differentiation among stages for overall survival.

Single-institution reports, from tertiary centers, of patients with Pan-NETs have reported higher rates of 5-year overall survival, on the order of 90%, 85%, 80%, and 60% for AJCC stages I, II, III, and IV, respectively. Grade is also highly prognostic for survival. When patients are categorized according to grade alone, 5-year survival rates are approximately 75%, 60%, and 10% for low-, intermediate-, and high-grade tumors, respectively. The outcomes for these tumors are perhaps best categorized according to their function, although their rarity limits cohort size to relatively small numbers of patients. In reports from high-volume centers, the 10-year disease-specific survival rate for patients with insulinoma who undergo resection approaches 100%. Gastrinomas have a lower cure rate with 5-year survival rates of approximately 40%. Patients with nonfunctional pancreatic NETs and localized disease who undergo resection can obtain 5-year survival rates of 70% to 80%. Accurate survival predictions for the rarest functioning tumors are even more difficult. Patients with VIPomas have a 5-year survival rate of approximately 70%, whereas patients with glucagonoma have lower rates of survival, approximately 50% to 60%.

Acknowledgments: Markeda Wade, for editorial assistance.

Suggested Readings

Eldor R, Glaser B, Fraenkel M, et al. Glucagonoma and the glucagonoma

syndrome—cumulative experience with an elusive endocrine tumor. *Clin Endocrinol (Oxf)* 2011;74:593–8.

Halfdanarson TR, Rabe KG, Rubin J, et al. Pancreatic neuroendocrine tumors (PNETs): incidence, prognosis, and recent trend toward improved survival. *Ann Oncol* 2008;19:1727–33.

Hill JS, McPhee JT, McDade TP, et al. Pancreatic neuroendocrine tumors: the impact of surgical resection on survival. *Cancer* 2009;115:741–51.

Isenberg JI, Walsh JH, Grossman MI. Zollinger-Ellison syndrome. *Gastroenterology* 1973;65:140–65.

Khashab MA, Yong E, Lennon AM, et al. EUS is still superior to multidetector computerized tomography for detection of pancreatic neuroendocrine tumors. *Gastrointest Endosc* 2011;73:691–6.

Kulke MH, Anthony LB, Bushnell DL, et al. NANETS treatment guidelines: well-differentiated neuroendocrine tumors of the stomach and pancreas. *Pancreas* 2010;39:735–52.

National Comprehensive Cancer Network (NCCN). NCCN guidelines in oncology for neuroendocrine tumors. Version 2. 2016.

Panzuto F, Boninsegna L, Fazio N, et al. Metastatic and locally advanced pancreatic endocrine carcinomas: analysis of factors associated with disease progression. *J Clin Oncol* 2011;29:2372–7.

Strosberg JR, Cheema A, Weber JM, et al. Relapse-free survival in patients with nonmetastatic, surgically resected pancreatic neuroendocrine tumors: an analysis of the AJCC and ENETS staging classifications. *Ann Surg* 2012;256:321–5.

Yao JC, Eisner MP, Leary C, et al. Population-based study of islet cell carcinoma. *Ann Surg Oncol* 2007;14:3492–3500.



EDITOR'S COMMENT

The authors present an up-to-date overview of neuroendocrine tumors. Pancreatic neuroendocrine tumors are very rare. As a surgeon, you may see a patient or two in your life time. They have an incidence of 1 to 5 per million per year and make up only 1% to 2% of pancreatic neoplasms. Autopsy studies suggest a greater frequency, occurring in 0.5% to 1.5% of the population. They are categorized as functional and nonfunctional. From the most to the least frequent, the order of frequency of these tumors is nonfunctional, insulinoma, gastrinoma, glucagonoma, VIPoma, somatostatinoma, and others (Metz DC, Jensen RT. Gastrointestinal neuroendocrine tumors: pancreatic endocrine tumors. *Gastroenterol* 2008;135:1469–92 and Grozinsky-Glasberg S, Mazeh H, Gross DJ. Clinical features of pancreatic neuroendocrine tumors. *J*

Hepatobiliary Pancreat Sci 2015;22:578–85). Functional pancreatic neuroendocrine tumors are so classified on the presence of a specific clinical syndrome and measurement of the related hormone in the serum. It is not based on immunocytohistochemical staining. Both the functional and nonfunctional tumors may secrete peptides. Some such as pancreatic polypeptide cause no associated syndrome. The peptides secreted from rare pancreatic endocrine tumors include luteinizing hormone, erythropoietin, insulin-like growth factor II, enteroglucagon, renin, glucagon-like peptide, and secretin.

After establishing the biochemical diagnosis, initial treatment should be directed at the clinical syndrome. For gastrinoma acid hypersecretion may be controlled with proton pump inhibitors. Somatostatin analogs may be effective in eliminating diarrhea and hence hypokalemia in VIPoma and the metabolic effects of glucagonoma. Somatostatin is frequently ineffective in insulinoma as these tumors do not predominantly express the somatostatin 2 receptor. Somatostatin is not a first-line therapy in gastrinoma, but has been shown to decrease serum gastrin levels and reduce acid hypersecretion.

Tumor localization is critical for the initial surgical management. The U.S. Food and Drug Administration approved Netspot® on June 1, 2016. This was the first kit for the preparation of gallium Ga 68 dotatate injection, a radioactive diagnostic agent for positron emission tomography (PET) imaging. This radioactive probe will help localize somatostatin receptor positive neuroendocrine tumors. DOTA-TATE is an amide of the acid DOTA, which acts as a chelator for a radionuclide, and (Tyr3)-octreotate, a derivative of octreotide. The latter binds to somatostatin receptors, which are found on the cell surfaces of a number of neuroendocrine tumors.

A recent study evaluated the diagnostic and management role of 68Ga-DOTATATE PET imaging in patients with neuroendocrine tumors and negative or equivocal findings on standard somatostatin scintigraphy (Srirajaskanthan J, Srirajaskanthan R, Kayani I, et al. The role of 68Ga-DOTATATE PET in patients with neuroendocrine tumors and negative or equivocal findings on 111In-DTPA-octreotide scintigraphy. *Nucl Med* 2010;51:875–82). The authors reported that 68Ga-DOTATATE PET was positive in 41 of these 47 patients (87.2%). No false-positive lesions were identified. 68Ga-DOTATATE PET identified significantly more lesions than 111In-DTPA-octreotide scintigraphy (168 vs. 27 respectively, $p < 0.001$). Another group reported the impact of 68Ga-DOTATATE PET/CT for imaging neuroendocrine and other somatostatin expressing tumors and compared it to Octreoscan and conventional imaging. They demonstrated that 88% of 68Ga-DOTATATE PET/CT studies were abnormal and in 83% of patients provided additional information not available on standard imaging (Hofman MS, Kong G, Neels OC, et al. High management impact of Ga-68 DOTATATE (GaTate) PET/CT for imaging neuroendocrine and other somatostatin expressing tumours. *J Med Imaging Radiat Oncol* 2012;56:40–7).

Insulinomas are usually benign as noted by the authors and are amendable to

enucleation unless the pancreatic duct is involved or in close proximity in which case resection is warranted. Enucleation is facilitated by using a bipolar device or ultrasonic energy. The tumors are very vascular and use of energy will allow better control of bleeding.

Whereas prior to 1980, total gastrectomy was the only certain way to control the ulcer diathesis associated with the Zollinger-Ellison syndrome, today gastric surgery of any kind is rarely indicated as the acid hypersecretion can be controlled with pharmacologic inhibition with proton pump inhibitors(preferred) or H2 antagonists. Gastrinomas are unique in that the primary may be in the duodenum or pancreas. It is critical to perform duodenotomy in all patients who are explored to accurately identify primary duodenal gastrinomas. At least 50% of such tumors will go unrecognized if the duodenum is not opened. This technique was championed by Norm Thompson and Jeff Norton. The authors note a 5-year survival of 40% in gastrinoma. This is low compared to our experience and that of Norton and colleagues at the National Institutes of Health and the University of Michigan group. In our experience, disease-specific survival is 60% to 80% at 10 years and is related to stage and whether an R0 resection was carried out. Long-term survival is independent of biochemical cure. Patients who are initially cured with gastrinoma resection have a recurrence rate of about 30% within 8 years after surgery. Hence, careful follow-up must be undertaken.

Glucagonomas are rare F-PNETs, with an incidence of 0.04 to 0.12 per million per year. Glucagonomas are typically diagnosed in the fifth decade and are equally distributed between the sexes. All glucagonomas occur in the pancreas, but are most frequently identified in the tail of the pancreas. The tumors are invariably malignant and frequently metastatic at diagnosis. The glucagonoma syndrome has been called the 4-D Syndrome (dermatitis, diabetes, depression, and deep vein thrombosis).

VIPoma is another rare tumor, with an incidence of 1 per 10 million per year. VIPomas are most often sporadic, solitary lesions usually larger than 3 cm. Eighty-five percent to 95% are located in the pancreas, with 75% found in the pancreatic tail. VIP-secreting tumors have also been found in the bronchus, colon, adrenals, and liver. In children, VIPomas occur as extrapancreatic ganglioneuromas. In adults 70% to 90% are malignant, and 60% to 80% are metastatic at diagnosis. Regardless of the location, VIPomas produce a clinical syndrome known as Verner-Morrison syndrome, WDHA syndrome (watery diarrhea, hypokalemia, and achlorhydria), or the pancreatic cholera syndrome. The hallmark of the syndrome is secretoty diarrhea with stool volumes from 700 to 3,000 cc/day. This is associated with profound hypokalemia that may result in temporary paralysis and dehydration. Achlorhydria is present in 30% to 75% of patients. Metabolic acidosis may occur. Although VIP is the dominant hormonal cause of the syndrome, secretin may also be the causal agent as suggested by Robert Zollinger (Zollinger RM, Tompkins RK, Amerson JR, et al. Identification of the diarrheogenic hormone associated with non-beta islet

cell tumors of the pancreas. *Ann Surg* 1968;168:502–18) and later verified by William Chey (Chey WY, Frankel WL, Roy S, et al. Primary pancreatic secretinoma: further evidence supporting secretin as a diarrheogenic hormone. *Ann Surg* 2016. [Epub ahead of print]). The syndrome responds well to somatostatin analogs.

Somatostatinomas are exceedingly rare, occurring in less than one in 40 million people. About 50% of the reported tumors are in the duodenum or jejunum. The other half are in the pancreas. And these are more likely to cause the characteristic syndrome of gall bladder disease, weight loss, diarrhea, steatorrhea, and anemia. Periampullary tumors may occur in neurofibromatosis. If a duodenal somatostatinoma is found, then genetic screening for Neurofibromatosis 1 is suggested as this syndrome accounts for >40% of all duodenal somatostatinomas.

An interesting phenomenon may occur with highly malignant tumors. Although most tumors in this class have a dominant hormone and syndrome, it is known that highly malignant lesions may produce multiple hormones. ACTH is one such hormone, and it may induce a Cushing-like state.

Although these tumors are rare, the surgeon should be aware of their peculiar nature and generally better survival than adenocarcinoma of the pancreas. In addition, about 20% to 25% of these tumors may occur in multiple endocrine neoplasm type 1 syndrome. Hence genetic screening may be warranted particularly in gastrinoma.

E. Christopher Ellison

SECTION V

THE BREAST, CHEST, AND MEDIASTINUM

46 Embryology and Anatomy of the Breast

Kirby I. Bland

With embryonic development in utero, primordially derived breast tissue anatomically matures as a modified sweat gland. The maturation of mammary parenchyma (ductal, lobular, and connective tissues), represents a unique feature of the mammalian species. Embryologically, the paired mammary glands synchronously develop within the “milk line” (Fig. 46.1); this anatomical linear plane which extends between the limb buds of the primordial axilla distally to the inguinal area. The number of paired glands varies widely among the various mammalian species, but in humans and most primates, a single pair of glands normally develops in the pectoral region, one gland on each side. In approximately 1% of the female population, supernumerary breasts (polymastia) or nipples (polythelia) may develop. Supernumerary appendages principally develop anatomically within the milk lines. While there is normally minimal additional development of the mammary gland during postnatal life in the male, extensive growth and development are evident secondary to hormonal stimuli in the female. Postnatal development of the female mammary gland is related to pubertal development of the organ and is principally regulated by hormones (estrogens and progesterones) which also regulate reproductive function. The greatest development of the breast is attained by the age of 20 years, and atrophy begins premenopausally at approximately the age of 40 to 45 years with waning estrogenic support of ductal–lobular matrix of the breast. During pregnancy and lactation, striking variants occur in both the amount (volume) of glandular tissue and the functional activity of the breast. Structural changes are also observed during menstrual cycles that result from variations in ovarian hormone levels (estrogens/progesterone). During menopause, with reduction in the hormonal secretory activity of ovarian function, the mammary gland undergoes involution and is primarily replaced by fat and connective tissue, and thereafter, diminishes its structural volume, form, and contour.



Figure 46.1. Mammary Milk line. After development of the milk bud in the pectoral area of ectodermal thickening, the “milk streak” extends from the axilla to the inguinal areas. At week 9 of intrauterine development, atrophy of the bud has occurred except for the presence of the supernumerary nipples of breast.

FUNCTIONAL ANATOMY OF THE BREAST

The glands of the breast are located within the superficial fascial compartment of the anterior chest wall. This organ consists of 15 to 20 lobes of tubuloalveolar glandular tissue, fibrous connective stroma that supports the lobules, and the adipose tissue that resides within parenchyma that intercalates between the lobules. Subcutaneous connective tissue typically does not possess a distinctive capsule around breast components;

rather, this tissue surrounds the gland and extends as septa between the lobes and lobules, providing longitudinal and gravitational support to the glandular elements. The deep layers of the superficial fascia that lie upon the posterior surface of the breast fuse with the deep (pectoral) fascia of the chest wall. A distinct space, the *retromammary bursa*, can be identified anatomically on the posterior aspect of the breast and resides between the deep layer of the superficial fascia and the deep investing fascia of the pectoralis major and the contiguous muscles of the thoracic wall (Fig. 46.2). The retromammary bursa contributes to the laxity and mobility of the breast on the rigid chest wall. Fibrous thickenings of supportive connective tissue interdigitate between the parenchymal tissue of the breast and extend from the deep layer of the superficial fascia to attach to the dermis of the skin. These dense fibrous suspensory structures, known as *Cooper ligaments*, are located perpendicular to the delicate superficial fascial layers of the dermis. These ligaments allow remarkable mobility of the gland while providing structural support and breast contour.

The postpubertal mature female breast extends from the level of the 2nd or 3rd rib inferiorly to the inframammary fold that is located at the level of the 6th or 7th rib interspaces. Laterally, the breast extends from the lateral border of the sternum to the anterior or midaxillary line. Breast parenchyma extends commonly into the anterior axillary fold as the axillary tail of Spence. The upper half of the breast, principally the upper outer quadrant, contains a greater volume of glandular tissue than the remainder of the breast. The posterior or deep surfaces of the breast reside upon portions of the fasciae of the pectoralis major, serratus anterior, and external oblique muscles; the gland also resides on upper portions of the anterior rectus sheath.

ANATOMY OF THE AXILLA

The anatomical boundaries of the axilla represent a pyramidal compartment that is tightly invested between the upper extremity and the thoracic wall; this structure has four boundaries inclusive of a base and an apex (Fig. 46.3). The curved oblong base consists of dense axillary fascia which is an investure of the axillary musculature. The apex of the axilla represents an aperture that extends into the posterior triangle of the neck via the cervicoaxillary canal. Most structures that course between the neck and the upper extremity enter this anatomic passage, that is bounded anterior/cephalad by the clavicle, medially by the 1st rib, and posteriorly

by the lateral margin of the scapula. The anterior wall of the axilla is composed of the pectoralis major and minor muscles and their associated fasciae. The posterior wall is formed primarily of the subscapularis muscle, located on the anterior surface of the scapula; the floor of this boundary is the teres major and latissimus dorsi muscles. The lateral wall of the axilla is the bicipital groove, a thin strip of condensed muscular tissue between the insertion of the musculature of the anterior and posterior compartments. The medial wall is composed of the serratus anterior muscle.

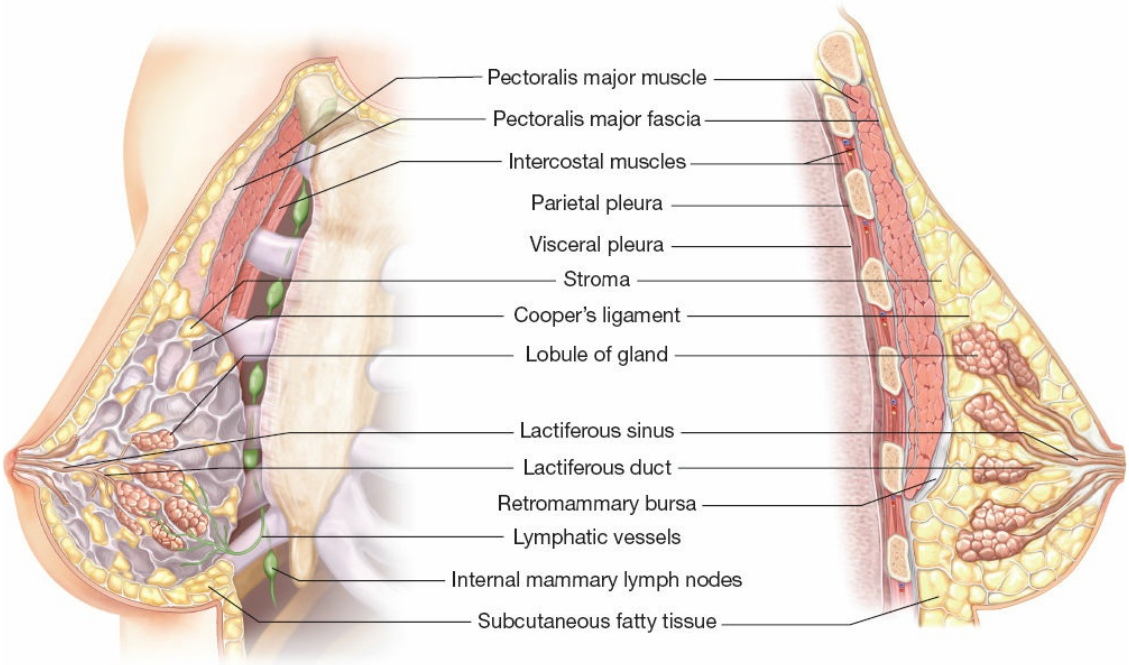

Figure 46.2. A tangential view of the breast on the chest wall and a sectional (sagittal) view of the breast and associated chest wall. The breast lies in the superficial fascia just deep to the dermis. It is attached to the skin by the suspensory ligaments of Cooper and is separated from the investing fascia of the pectoralis major muscle by the retromammary bursa. Cooper ligaments form fibrosepta in the stroma that provide support for the breast parenchyma. From 15 to 20 lactiferous ducts extend from lobules comprising the glandular epithelium to openings located on the nipple. A dilation of the duct, the lactiferous sinus, is present near the opening of the duct in the subareolar tissue. Subcutaneous fat and adipose tissue distributed around the lobules of the gland give the breast its smooth contour and, in the nonlactating breast, account for most of its mass. Lymphatic vessels pass through the stroma surrounding the lobules of the gland and convey lymph to collecting ducts. Lymphatic channels ending in the intercostal

muscles. The parietal pleura, attached to the endothoracic fascia, and the visceral pleura, covering the surface of the lung are shown.

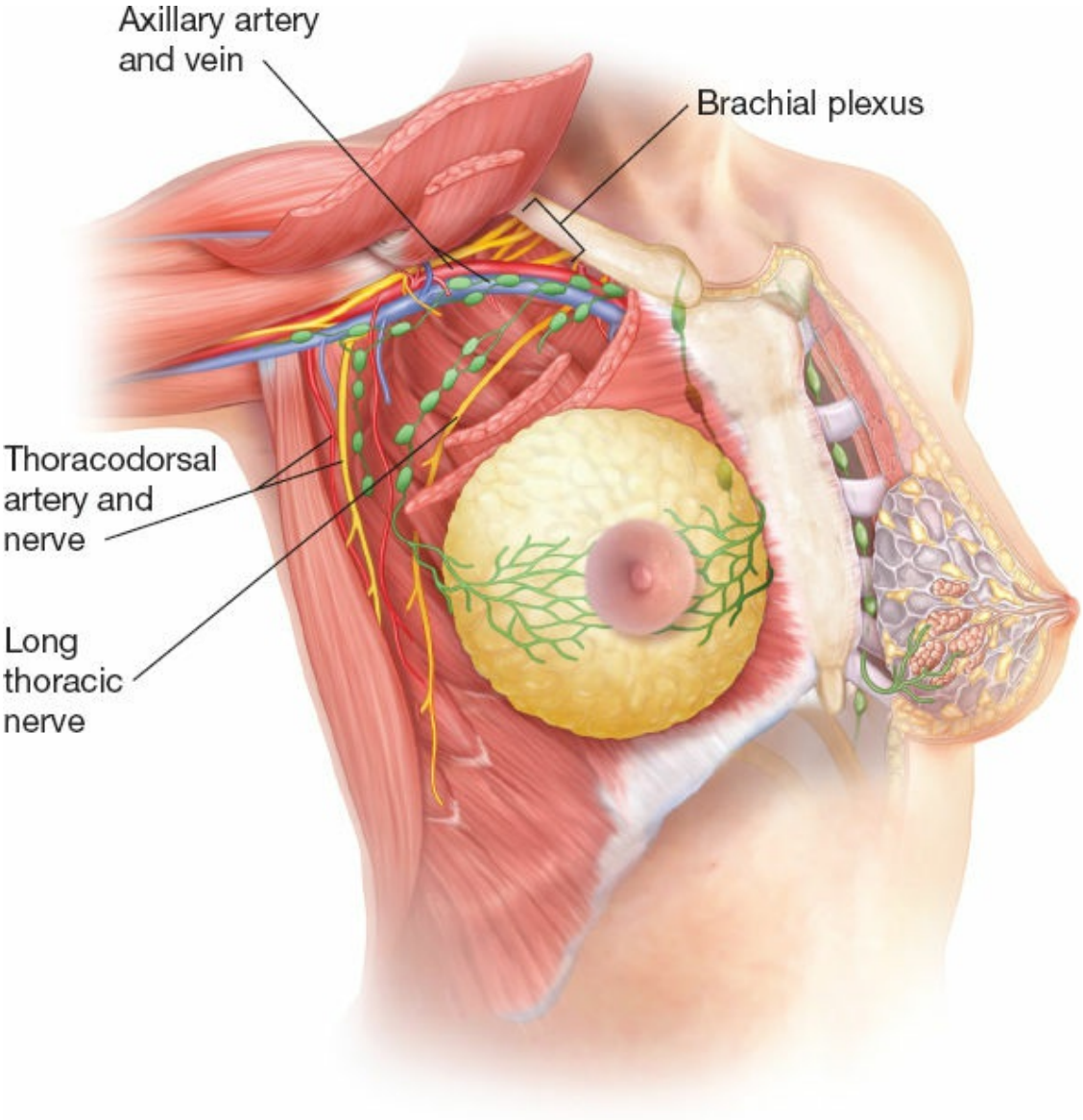

Figure 46.3. The anterior chest illustrating the structure of the chest wall, breast, and axilla. See text for details of the structure of the axilla and a description of its contents. On the right side, the pectoralis major muscle has been cut lateral to the breast and reflected laterally to its insertion into the crest of the greater tubercle of the humerus. This exposes the underlying pectoralis minor muscle and the other muscles forming the walls of the axilla. The contents of the axilla, including the axillary artery and vein, components of the brachia plexus, and axillary lymph node groups and lymphatic channels, are exposed. On the left side, the breast is cut to expose its structure in sagittal view. The

lactiferous ducts and sinuses can be seen. Lymphatic channels passing to parasternal lymph nodes are also shown.

The fascia of the pectoralis major and minor muscles are evident in two distinct planes: the superficial layer, called the *pectoral fascia*, invests the pectoralis major muscle; whereas the deep layer, called the *clavipectoral* or *costocoracoid fascia*, extends from the clavicle to the axillary fascia in the floor of the axilla and encloses the subclavius and the pectoralis minor muscle (Fig. 46.4).

The costocoracoid membrane represents the upper portion of the clavipectoral fascia and is pierced by the cephalic vein, the lateral pectoral nerve, and branches of the thoracoacromial trunk. The *medial pectoral nerve*, whose origin is the medial cord of the brachial plexus, does not penetrate the costocoracoid membrane, but rather, enters the deep surface of the pectoralis minor and passes through the anterior investing fascia of the pectoralis minor to innervate the pectoralis major muscle. Caudad portions of the clavipectoral fascia, which are anatomically inferior to the pectoralis minor, are sometimes referred to as the *suspensory ligament of the axilla* or the *coracoaxillary fascia*. Many surgeons refer to this anatomic landmark as *Halsted ligament*, which represents a dense condensation of the clavipectoral fascia that extends from the medial aspect of the clavicle, attaches to the 1st rib, and invests the subclavian artery and vein as each traverse the first rib. Surgical division intraoperatively is essential to complete the level III (cephalad) axillary dissection and allows full, safe exposure of the axillary vein anatomically.

Within the axilla are the great vessels and nerves of the upper extremity, which, together with the other axillary contents, are encircled by loose connective tissue. These vessels and nerves are anatomically contiguous and are enclosed within an investing layer of fascia referred to as the axillary sheath. The *axillary artery* can be divided into three anatomical segments within the axilla proper:

1. Located medial to the pectoralis minor muscle, the *first* segment gives rise to one branch, the *supreme thoracic*, which supplies the upper thoracic wall inclusive of the first and second intercostal spaces.
2. The *second* segment of this artery, located immediately posterior to the pectoralis minor, gives rise to two branches, the *thoracoacromial trunk* and the *lateral thoracic artery*. Pectoral branches of the thoracoacromial and lateral thoracic arteries supply the pectoralis

major and minor muscles (Fig. 46.5). Identification of these vessels during surgical dissection of the axilla is imperative to provide safe conduct of the procedure. The lateral thoracic artery gives origin to the lateral mammary branches.

3. The *third* segment of this vessel, located lateral to the pectoralis minor muscle, gives rise to three branches. These include the *anterior and posterior humeral circumflex arteries* that supply the upper arm, and the *subscapular artery*, which is the largest branch within the axilla. After a short course, the subscapular artery gives origin to its terminal branches, the *subscapular circumflex* and the *thoracodorsal arteries.* The thoracodorsal artery, which courses with its corresponding nerve and vein, crosses the subscapularis muscle, providing its substantial blood supply, as well as that of the serratus anterior and latissimus dorsi muscles.

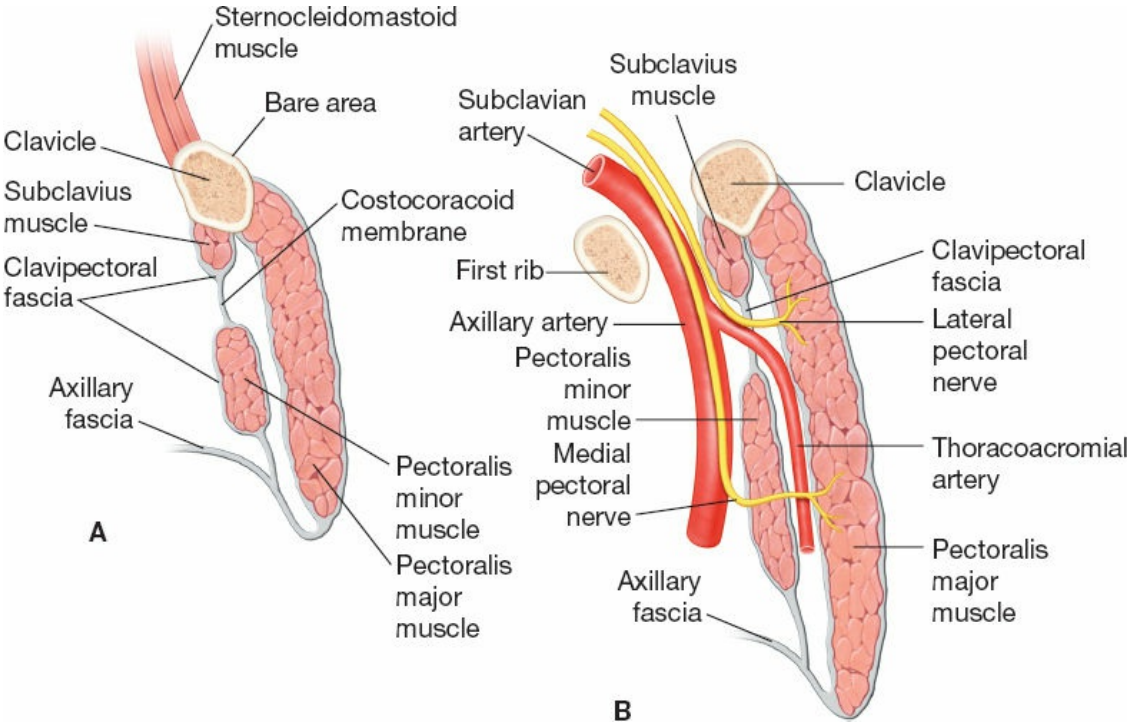

Figure 46.4. Sagittal sections of the chest wall in the axillary region. **A:** The anterior wall of the axilla. The clavicle and three muscles inferior to it are shown. **B:** Section through the chest wall illustrating the relationship of the axillary artery and medical and lateral pectoral nerves to the clavipectoral fascia. The clavipectoral fascia is a strong sheet of connective tissue that is attached superiorly to the clavicle and envelops the subclavius and pectoralis minor muscles. The fascia extends from the lower border of the pectoralis minor to become continuous with the axillary fascia in the floor of the axilla.

Tributaries of the axillary vein follow the course of the branches of the axillary artery, usually in the form of venae comitantes, paired veins that follow the course of the artery. The cephalic vein passes in the groove between the deltoid and pectoralis major muscles, and thereafter enters the axillary vein after piercing the clavipectoral fascia.

The *axillary artery* is anatomically contiguous with various portions of the brachial plexus throughout its course in the axilla. The cords of the *brachial plexus* are named according to their structural and positional relationship with the axillary artery—medial, lateral, and posterior—rather than their anatomic position in the axilla or on the chest wall. Thus, the *medial pectoral* nerve is laterally positioned; the *lateral pectoral* nerve is medial in the axilla.

There are three nerves of principal interest to surgeons that are located in the axilla (Fig. 46.3). Preservation of the *long thoracic nerve*, located on the medial wall of the axilla is imperative with axillary dissection. This nerve arises in the neck from the 5th, 6th, and 7th cervical roots (C5, C6, and C7) with entry in the axilla via the cervicoaxillary canal. This medially placed nerve lies on the lateral-most surface of the serratus anterior muscle and is invested by the serratus fascia such that it might be accidentally divided together with resection of the fascia during surgical dissection (sampling) of lymphatics of the axilla. The long thoracic nerve, although diminutive in size, courses a considerable anatomic distance to supply the serratus anterior muscle; injury or division of this nerve results in the "winged scapula" deformity with subsequent denervation of the muscle group and the inability to provide shoulder fixation. The *thoracodorsal nerve* takes origin from the posterior cord of the brachial plexus and innervates the laterally placed latissimus dorsi muscle. Injury or division is inconsequential to primary shoulder function; however, preservation of this nerve is essential to allow transfer survival and motor function preservation for the myocutaneous flap used for the latissimus dorsi musculocutaneous reconstruction. The *intercostobrachial nerve* is formed by the merging of the lateral cutaneous branch of the *second intercostal nerve* with the medial cutaneous nerve of the arm; this nerve provides sensory innervation of the skin of the apex and lateral axilla and the upper medial and inner aspect of the arm. The second intercostobrachial nerve may sometimes merge with an anterior branch of the *third lateral cutaneous nerve*.

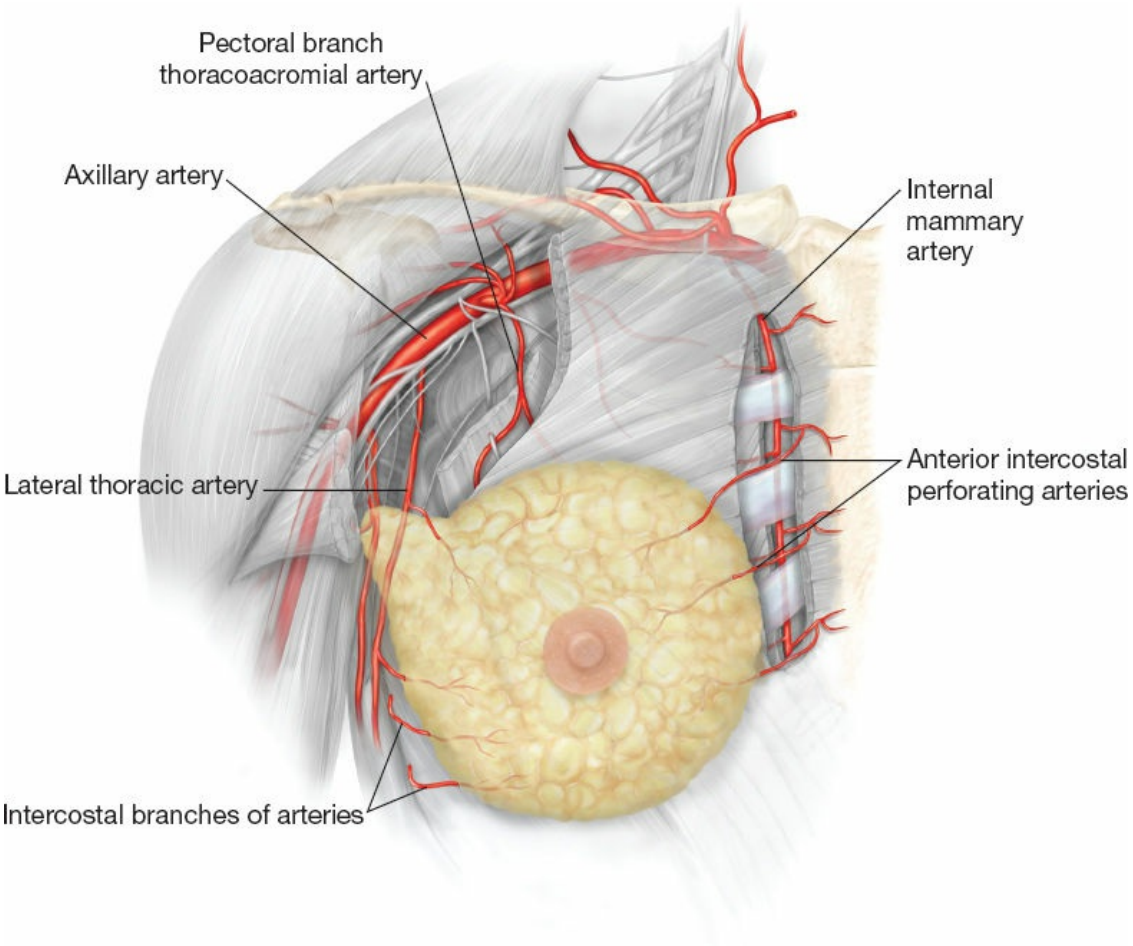

Figure 46.5. Arterial distribution of blood to the breast, axilla, and chest wall. The breast receives its blood supply via three major arterial routes: (a) medially from anterior perforating intercostal branches arising from the internal thoracic artery; (b) laterally from either pectoral branches of the thoracoacromial trunk or branches of the lateral thoracic artery (the thoracoacromial trunk and the lateral thoracic arteries are branches of the axillary artery); and (c) from lateral cutaneous branches of the intercostals arteries that are associated with the overlying breast. The arteries indicated with a *dashed line* lie deep to the muscles of the thoracic wall and axilla. Many of the arteries must pass through these muscles before reaching the breast.

BLOOD SUPPLY OF THE BREAST

Blood supply to the mammary gland is derived from perforating branches of the *internal mammary artery*, lateral branches of the *posterior intercostal arteries*, and several branches of the *axillary artery*. The latter vessels include the highest thoracic, lateral thoracic, and pectoral branches of the *thoracoacromial artery* (Figs. 46.4 and 46.5). Branches from the

second, third, and fourth anterior perforating arteries pass to the breast as medial mammary arteries.

The *lateral thoracic artery* branches allow perfusion to the serratus anterior muscle, both the pectoralis muscles, and the subscapularis muscle, and also supply the axillary lymphatics and supporting fatty tissues. The posterior intercostal arteries give rise to mammary branches in the 2nd, 3rd, and 4th intercostal spaces.

Although the *thoracodorsal branch of the subscapular artery* does not contribute to the primary blood supply of the breast *per se*, this vessel is intimately associated with the *central, subscapular, and lateral lymph node groups* of the axilla as it courses through the axilla. This fact should be taken into consideration during axillary node dissection, as postoperative bleeding can result when unidentified penetrating branches of this vessel are severed.

Principal venous outflow of the gland has preferential directional flow toward the axilla, with the veins principally paralleling the path of the arterial distribution. The superficial venous plexus of mammary parenchyma has extensive anastomoses that may be evident through the overlying skin. Circumscribing the nipple, superficial veins form an anastomotic circle, the *circulus venosus.* Veins from this circle and from deeper aspects of the gland converge to drain blood to the periphery of the breast, and thereafter into vessels that terminate in the *internal mammary, axillary, and internal jugular veins.*

Venous return from the gland is derived from three principal groups of veins providing drainage of the breast and the thoracic wall and include (a) perforating branches of the *internal mammary vein*, (b) tributaries of the *axillary vein*, and (c) perforating branches of *posterior intercostal veins.* The posterior intercostal veins lie in direct continuity with the *vertebral plexus of veins (Batson plexus)* that surround the vertebrae and extend from the base of the skull to the sacrum. This plexus has great importance clinically, as these veins may provide an important conduit for hematogenous dissemination of breast cancer. This vertebral venous plexus may physiologically account for metastases to the skull, vertebrae, pelvic bones, and central nervous system in the absence of pulmonary metastases.

INNERVATION OF THE BREAST

Neurosensory innervation of the gland is primarily supplied by the lateral

and anterior cutaneous branches of the 2nd through the 6th *intercostal nerves* (Fig. 46.6). These sensory nerves of the breast originate *principally* from the 4th, 5th, and 6th intercostal nerves, although the 2nd and 3rd intercostal nerves may provide cutaneous branches to the cephalad aspect of the breast. Cutaneous sensory supply is further augmented by nerves arising from the cervical plexus, specifically the anterior or medial branches of the supraclavicular nerve; these nerves supply a limited region of the skin of the upper portion of the breast. Collectively, these nerves convey sympathetic fibers for innervation to the breast and the overlying skin.

The *lateral branches* of the intercostal nerves exit the intercostal space via the attachment sites of the slips of the serratus anterior muscle. These nerves divide into anterior and posterior branches as they exit the muscle. Anterior branches of the intercostal also supply the anterolateral thoracic wall. The third through the sixth branches, known as the *lateral mammary branches*, supply the majority of the surface of the breast. As noted above, the *intercostal brachial nerve*, a large and constant sensory nerve, takes origin from the lateral branch of the second intercostal nerve. The intercostal brachial nerve courses through the fascia of the floor of the axilla to commonly join the *medial cutaneous nerve* of the arm. This nerve is of little functional significance; however, with injury to the intercostal brachial nerve during axillary dissection, the principal consequence for the patient is modest loss of cutaneous sensation in the upper medial aspect of the arm and axilla. No motor loss is evident after injury or division of the intercostal brachial nerve but prolonged hypoesthesia and/or paresthesia can be expected. This physiologic consequence is the genesis of principle somatic morbidity in the postoperative patient.

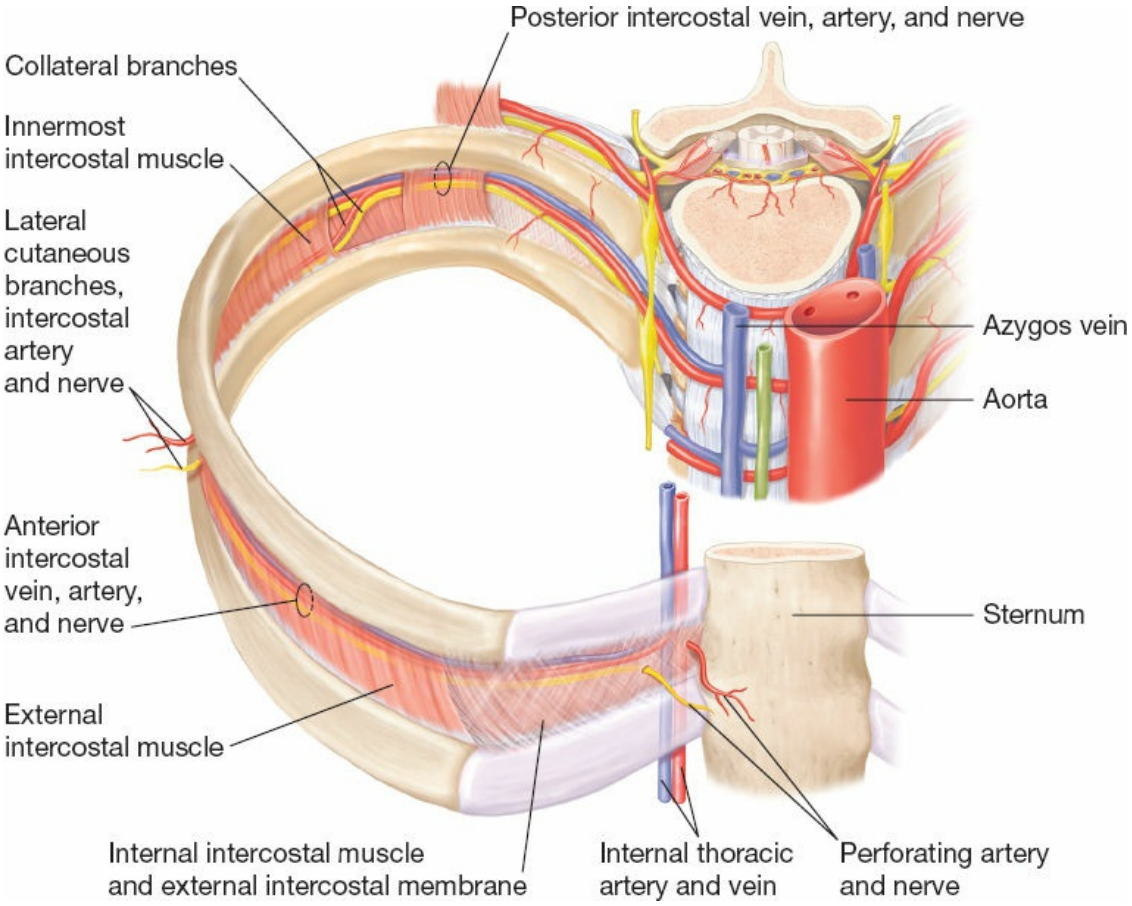

Figure 46.6. A segment of the body wall illustrating the relationship of structures to the ribs. Two ribs are shown as they extend from the vertebrae to attach to the sternum. The orientation of the muscle and connective tissue fibers is shown. The external intercostal muscle extends downward and forward. The muscle layer extends forward from the rib tubercle to the costochondral junction, where the muscle is replaced by the aponeurosis, called the external intercostal membrane. The internal intercostal muscle fibers with the opposite orientation can be seen through this layer. The innermost intercostal muscle fibers are present along the lateral half of the intercostal space. The intercostal nerve and vessels pass through the intercostal space in the plane between the internal and innermost (or intima of the internal) intercostal muscle layers. Anterior intercostal arteries arise from the internal thoracic artery; anterior intercostal veins join the internal thoracic vein. Posterior intercostal arteries arise from the aorta; posterior intercostal veins join the azygos venous system on the right and the hemiazygos system on the left. Lymphatics follow the path of the blood vessels. Anteriorly, lymphatics pass to parasternal (or internal mammary) nodes that are located along the internal mammary vessels; posteriorly, they pass to intercostal nodes located in the intercostal space near the

vertebral bodies.

The anterior branches of the intercostal nerves exit the intercostal space near the lateral border of the sternum to allow arborization of branches medially and laterally over the thoracic wall. The branches that course laterally innervate the medial aspect of the breast and are referred to as *medial mammary branches.*

LYMPHATIC DRAINAGE OF THE BREAST

Lymphatic drainage of the breast is primarily via the laterally positioned axillary lymph node groups, (levels I, II, III) (Fig. 46.7). There have been considerable variations in nomenclature for the lymph node groups of the axilla as the boundaries of these nodal groups are not well demarcated. These variations are particularly evident in level I nodal groups. Historically, anatomists have described four principal levels (groups) of axillary lymph nodes; whereas, surgeons typically identify six groups inclusive of three anatomic levels. The most commonly used terms to describe the axillary nodes are as follows:

1. The *axillary vein group,* usually identified by anatomists as the *lateral group,* consists of four to six lymph nodes that lie lateral and posterior to the axillary vein and at level I. This group is well identified at the anatomic confluence of the lateral vein with the latissimus dorsi. These nodes receive the majority of lymphatic contents from the upper extremity and ipsilateral back with the exception of lymph that drains into the deltopectoral lymph nodes, a group also referred to as the *infraclavicular nodes* (Fig. 46.8).
2. The external mammary group (Fig. 46.8), usually identified by anatomists as the *anterior or pectoral group,* consists of four or five lymph nodes positioned along the lower and lateral border of the pectoralis minor muscle contiguously associated with the lateral thoracic vessels. These nodes receive the principal volume of lymph drainage from the breast parenchyma and are positioned, as well, at level I. From these nodes, lymph drains primarily into the central lymph nodes (see below). However, lymphatics may interconnect with direct passage from the external mammary nodes, to the subclavicular lymph nodes, and to Rotter's (interpectoral) nodal group (all level II).
3. The *scapular group* (Figs. 46.7 and 46.8), usually identified by anatomists as the *posterior or subscapular group,* consists of six or

seven lymph nodes positioned near the posterior wall of the axilla in juxtaposition to the lateral border of the scapula and contiguous with the subscapular vessels near the "axillary floor." This group also occupies level I nodal group. These nodes receive lymph primarily from the lower aspects of the neck, the posterior skin and subcutaneous tissues of the trunk (as low as the iliac crest), and posterior portions of the shoulder region. Lymph from the (sub)scapular nodes drains into the central and subclavicular nodes.

4. The *interpectoral* or *Rotter's group* (Figs. 46.7 and 46.8), usually identified by surgeons but not by anatomists, consists of one to four small lymph nodes located *between* the pectoralis major and minor muscles. This group in level II is contiguous with pectoral branches of the thoracoacromial vessels. Lymph from these nodes enters the central and subclavicular nodes.
5. The *central group* (Figs. 46.8 and 46.9), considered to be centrally positioned by both anatomists and surgeons at level II, and consists of three or four large lymph nodes that are embedded in the fat of the axilla, usually behind the pectoralis minor muscle. These level II nodes receive lymph from the preceding nodal groups (lateral axillary, external mammary, and (sub)scapular nodal sites; all level I) and may also receive afferent lymphatic vessels directly from the breast parenchyma. Lymph from the central group, which may lie directly upon the ventral and anterior aspects of the axillary vein, and thereafter, drain directly into the *subclavicular* (apical, level III) nodes. This group is often placed superficially beneath the skin and the fascia of the mid axilla, and it is centrally located between the posterior and anterior axillary folds. This *superficial* nodal group is the most easily palpable with evident axillary adenopathy. This is the most numerous of axillary lymphatics; anatomically its superficial position may provide accurate clinical assessment of metastatic disease.
6. The subclavicular group, identified by anatomists as the apical group, consists of 6 to 12 lymph nodes that are located in part posterior and partially above the upper border of the pectoralis minor muscle. This nodal group extends into the apex of the axilla along the medial aspect of the axillary vein and is anatomically a level III group (Figs. 46.8 and 46.9). These nodes receive lymph from all other axillary lymph node groups. Thereafter, these efferent lymphatic vessels from the subclavicular lymph nodes unite to form the subclavian trunk. The course of the *subclavian trunk* is highly variable anatomically. It may join and directly enter the internal jugular vein or the subclavian vein,

or their junction. On the right side of the subclavian trunk, the right lymphatic duct may enter this structure, whereas on the left side confluence with the *thoracic duct* is common. Efferent vessels from the subclavicular lymph nodes may also pass to the deep cervical lymph nodes.

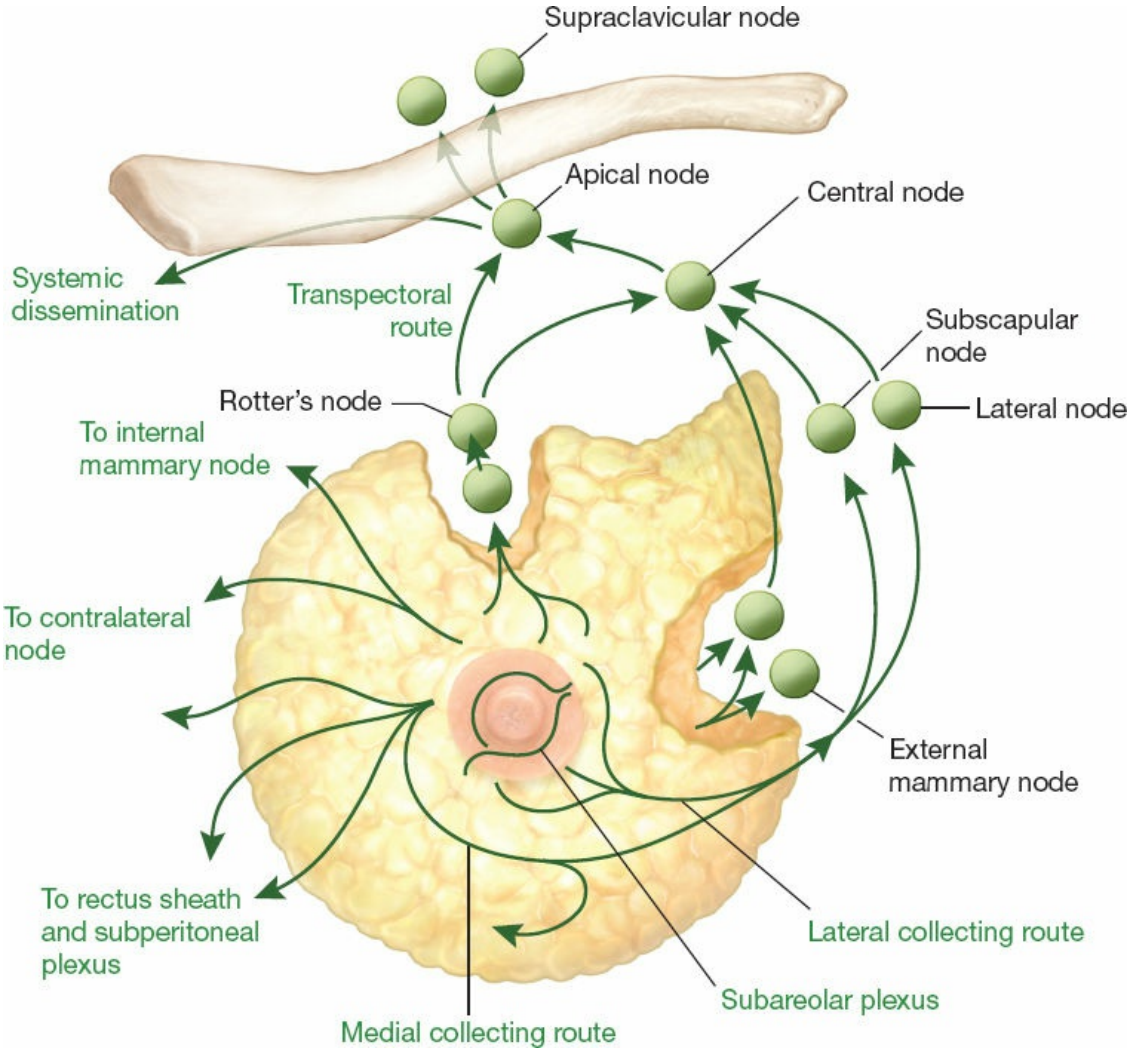

Figure 46.7. Schematic drawing of the breast identifying the position of lymph nodes relative to the breast and illustrating routes of lymphatic drainage. The clavicle is indicated as a reference point. See the text and Figure 8 to identify the group or level to which the lymph nodes belong. Level I lymph nodes include the external mammary (or anterior), axillary vein (or lateral), and scapular (or posterior) groups; level II, the central group; and level III, the subclavicular (or apical). The *arrows* indicate the routes of lymphatic drainage (see text).

As detailed above, axillary lymphatics are divided into three distinct levels according to their lateral and medial (surgical) anatomic

relationships with the pectoralis minor muscle. These nodal groups are identified as *levels I through III* (Figs. 46.8 to 46.10). *Level I nodes* are located lateral to or below the inferior border of the pectoralis minor; this level includes the *external mammary*, the *lateral axillary vein*, and the *scapular lymph node groups. Level II nodes* are located deep upon the ventral/caudad surface of the axillary vein *OR* behind the pectoralis minor and include the *central lymph node group* and possibly the lateral *subclavicular* lymph node group. *Level III nodes* are located superomedial to the upper margin of the pectoralis minor and include the *subclavicular (apical) lymph node group* (Figs. 46.7 to 46.10). This nodal group is contiguous with the axillary venous entry into the subclavian vein, entering between the 1st and 2nd ribs, bilaterally.

The British surgeon W. Sampson Handley is credited with the recognition of metastatic spread of breast carcinoma to the *internal mammary nodes* as a primary route of systemic lymphatic dissemination. As an anatomist, Handley provided extensive clinical and anatomic research to confirm that central and medial breast lymphatics pass medially and parallel to the course of major blood vessels, to perforate the pectoralis major muscle, and terminate in the internal mammary nodal chain.

Internal mammary nodes are located within the retrosternal interspaces between the costal cartilages, approximately 2 to 3 cm within the sternal margin (Figs. 46.7 to 46.10). This nodal group traverses and parallels the internal mammary vasculature and is invested by endothoracic fascia. The internal mammary lymphatic trunks terminate in the subclavicular nodal groups (Figs. 46.6 to 46.10). The right internal mammary nodal group drains into the right lymphatic duct, whereas the left enters the main thoracic duct (Fig. 46.11).

There are three *interconnecting groups* of lymphatic vessels that drain the breast:

1. A primary set of vessels originate as channels within the gland in the interlobular spaces and parallel the robust accumulation of lactiferous ducts of the breast parenchyma.
2. The vessels draining the glandular tissue and the overlying skin of the central part of the gland pass directly into the subareolar plexus, an interconnecting network of vessels located beneath the areola.
3. The rich lymphatic plexus lies upon the deep surface of the breast to communicate with minute vessels that parallel the deep fascia

underlying the breast. Along the medial border of the breast, lymphatic vessels within the substance of the gland anastomose with vessels that pass to parasternal nodes.

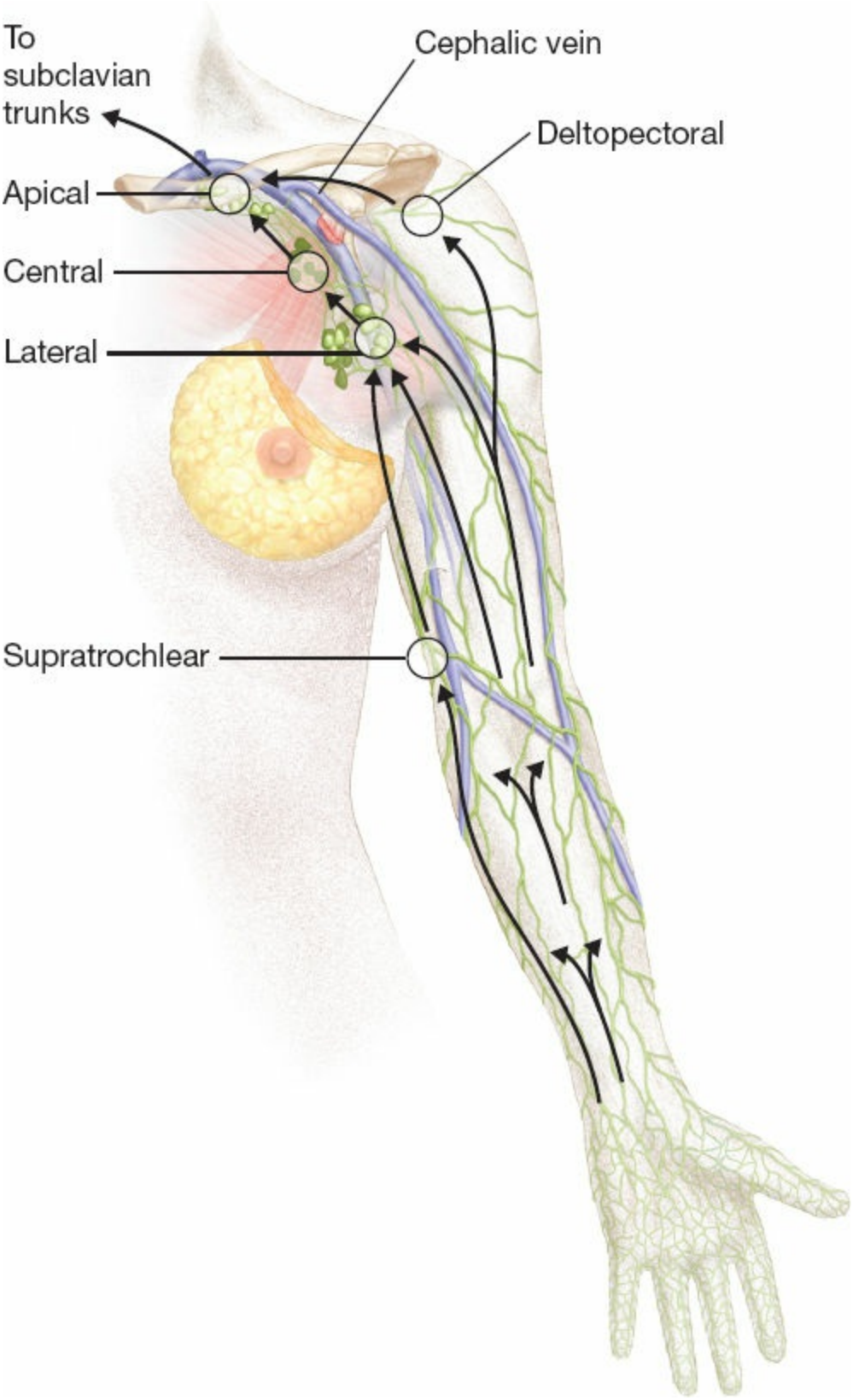

Figure 46.8. Schematic drawing illustrating the route of lymphatic drainage in the upper extremity. The relationship of the drainage to the major axillary lymph node groups is indicated by the *arrows.* All the lymph vessels of the upper extremity drain directly or indirectly through outlying lymph node groups into the axillary lymph nodes. The outlying lymph nodes are few in number and are organized into three groups: (a) supratrochlear lymph nodes (one or two, located above the medial epicondyle of the humerus adjacent to the basilic vein); (b) deltopectoral lymph nodes (one or two, located beside the cephalic vein where it lies between the pectoralis major and deltoid muscle just below the clavicle); and (c) variable small isolated lymph nodes (few and variable in number: may be located in the cubital fossa or along the medial side of the brachial vessels). Note that the deltopectoral lymph node group drains directly into the subclavicular, or apical, lymph nodes of the axillary group.

The key and operative word for lymphatic flow in this organ is *multidirectional* however, greater than 75% of lymph flow directly enters the axillary lymph nodes. The residual medial (nonaxillary) lymph will egress to parasternal nodes, following the course of the internal mammary artery and vein. This anatomic feature provides support for the rationale of the sentinel lymph node biopsy (sampling) of the axilla, popularized and scientifically advanced by Donald L. Morton in the 1990s, to determine the (accurate) histologic status of these nodes and, hence, valid pathologic staging. Although some authorities have suggested that the parasternal nodes receive lymph primarily from the medial part of the breast, others report that both the axillary and the parasternal lymph node groups receive lymph from all quadrants of the breast, with no definitive probability for any quadrant to drain medially or laterally. This observation allows surgeons to use sentinel nodes procured in the axilla to be the principal determinate of pathologic staging, regardless of the quadrant of anatomic presentation of the index tumor. The skin of the breast also drains via the superficial lymphatic vessels to the axillary lymph nodes. The anterolateral chest and the upper abdominal wall cephalad to the umbilicus show a striking unidirectional flow of lymph toward the axilla. Lymphatic vessels near the lateral margin of the sternum pass through intercostal spaces to the parasternal lymph nodes that course with the internal thoracic vessels. In the upper pectoral region, small numbers of lymphatic vessels pass over the clavicle to inferior deep cervical lymph nodes.

Within the fascial and muscular structures of the thoracic wall, lymphatics drain primarily into three groups of lymph nodes: the *parasternal, intercostal,* and *diaphragmatic lymphatics.* The *parasternal (internal thoracic) lymph nodes* are a group of smaller lymphatics positioned approximately 1 cm lateral to the sternal border in the intercostal spaces along the internal mammary vessels. These nodes reside in the areolar tissue just beneath the endothoracic fascia bordering the space between the adjacent costal cartilages.

The *intercostal lymph nodes* (Fig. 46.11) represent a small group located in the posterior portion of the thoracic cavity within the intercostal spaces near the origin of the ribs. One or more nodes are found in each intercostal space with contiguous relationship to the intercostal vessels. These nodes receive deep lymphatics from the posterolateral thoracic wall, including lymphatic channels from the breast. Upper efferent lymphatics from the intercostal lymph nodes on the right side terminate in the right lymphatic duct, whereas the efferent lymphatics from the corresponding nodes on the left side terminate in the thoracic duct.

The *diaphragmatic lymph nodes* consist of three groups of small lymph nodes located upon the thoracic surface on the diaphragm. The anterior group includes two or three small lymph nodes, also known as *prepericardial nodes,* located behind the sternum at the base of the xiphoid process. The efferent lymphatics from the anterior diaphragmatic nodes pass to the parasternal nodes. The lateral set of diaphragmatic lymph nodes is composed of two or three small nodes on each side of the diaphragm, adjacent to the pericardial sac, where the phrenic nerve innervates the diaphragm. These nodes lie near the vena cava on the right side and near the esophageal hiatus on the left. The posterior set of diaphragmatic nodes consists of a few lymph nodes located near the crura of the diaphragm. These nodes receive lymph from the posterior aspect of the diaphragm and convey the same to posterior mediastinal and lateral aortic nodes.

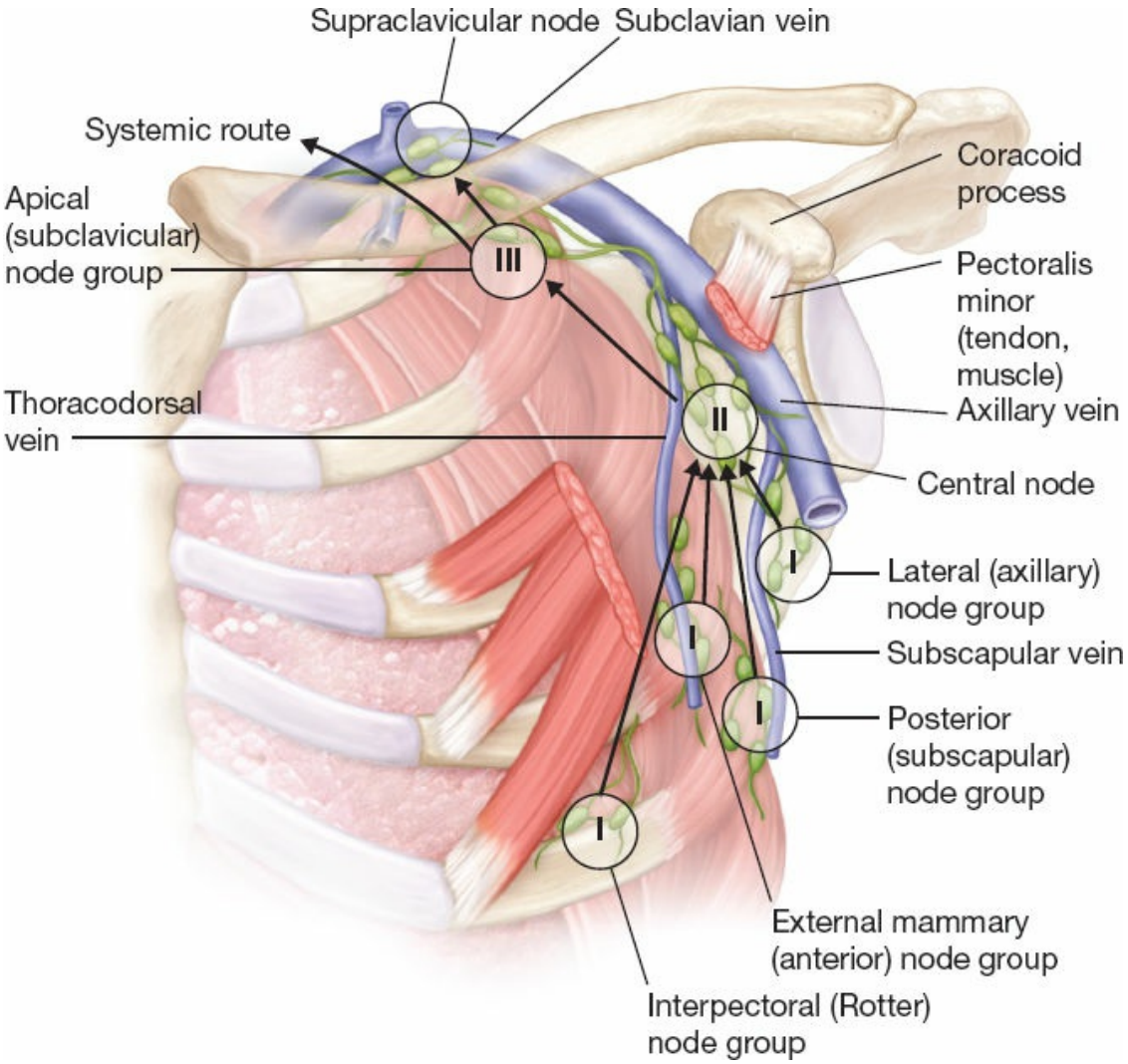

Figure 46.9. Schematic drawing illustrating the major lymph node groups associated with the lymphatic drainage of the breast. The roman numerals indicate three levels or groups of lymph nodes that are defined by their location relative to the pectoralis minor. Level I includes lymph nodes located lateral to the pectoralis minor; level II, lymph nodes located deep to the muscle; and level III, lymph nodes located medial to the muscle. The *arrows* indicate the general direction of lymph flow. The axillary vein and its major tributaries associated with the pectoralis minor are included.

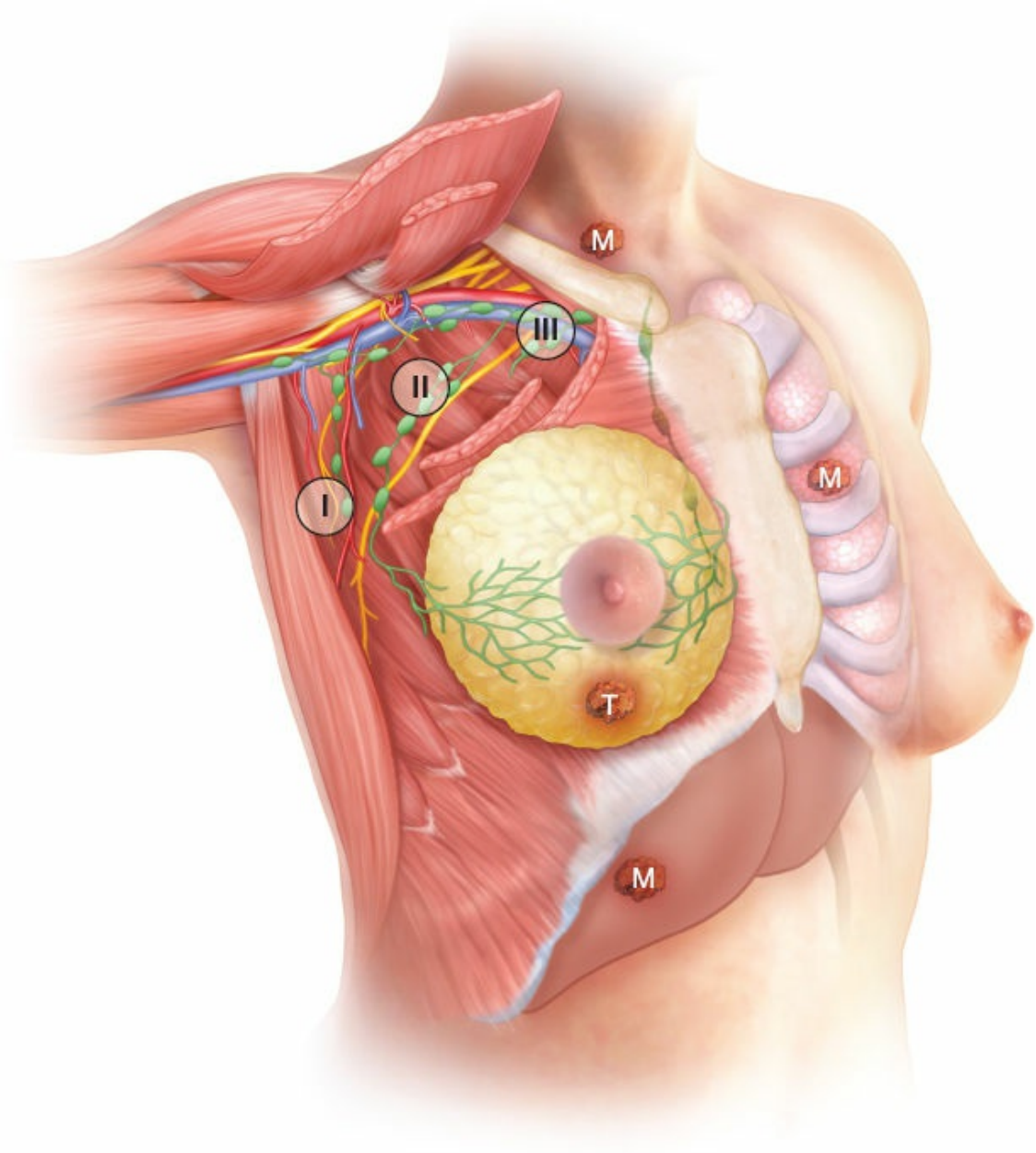

Figure 46.10. Lymphatic drainage of the breast. The pectoralis major and minor muscles, which contribute to the anterior wall of the axilla, have been cut and reflected. This exposes the medial and posterior walls of the axilla, as well as the basic contents of the axilla. The lymph node groups of the axilla and the internal mammary nodes are depicted. Also shown is the location of the long thoracic nerve on the surface of the serratus anterior muscle (on the medial wall of the axilla). The scapular lymph node group is closely associated with the thoracodorsal nerve and vessels. The roman numerals indicate lymph node groups defined in Figure 46.9. M, metastases; T, tumor.

MICROSCOPIC ANATOMY OF THE BREAST

Embryologically, the parenchyma of the mature mammary gland is composed of 15 to 20 irregular lobes of branched tubuloalveolar glands. These lobes, separated by fibrous bands of connective tissue, radiate from the mammary papilla (or nipple) and are further subdivided into multiple lobules. The fibrous bands that support the parenchyma and attach to the cutis reticularis of the dermis are termed the *suspensory ligaments of Cooper*. These tubuloalveolar glands lie within the subcutaneous tissues. Each lobe of the primary gland terminates in the lactiferous duct, 2 to 4 mm in diameter, and empties into the subareolar ampulla via a constricted orifice at the terminus of the nipple (Fig. 46.1). Beneath the areola at the termination of each duct is a dilated portion that is termed the lactiferous sinus. These lactiferous ducts are populated near their openings with stratified squamous epithelium. The epithelial lining of the duct has evidence of gradual transition to two layers of cuboidal cells in the lactiferous sinus, thereafter becoming a single layer of columnar or cuboidal cells distributed throughout the remainder of the ductal system.

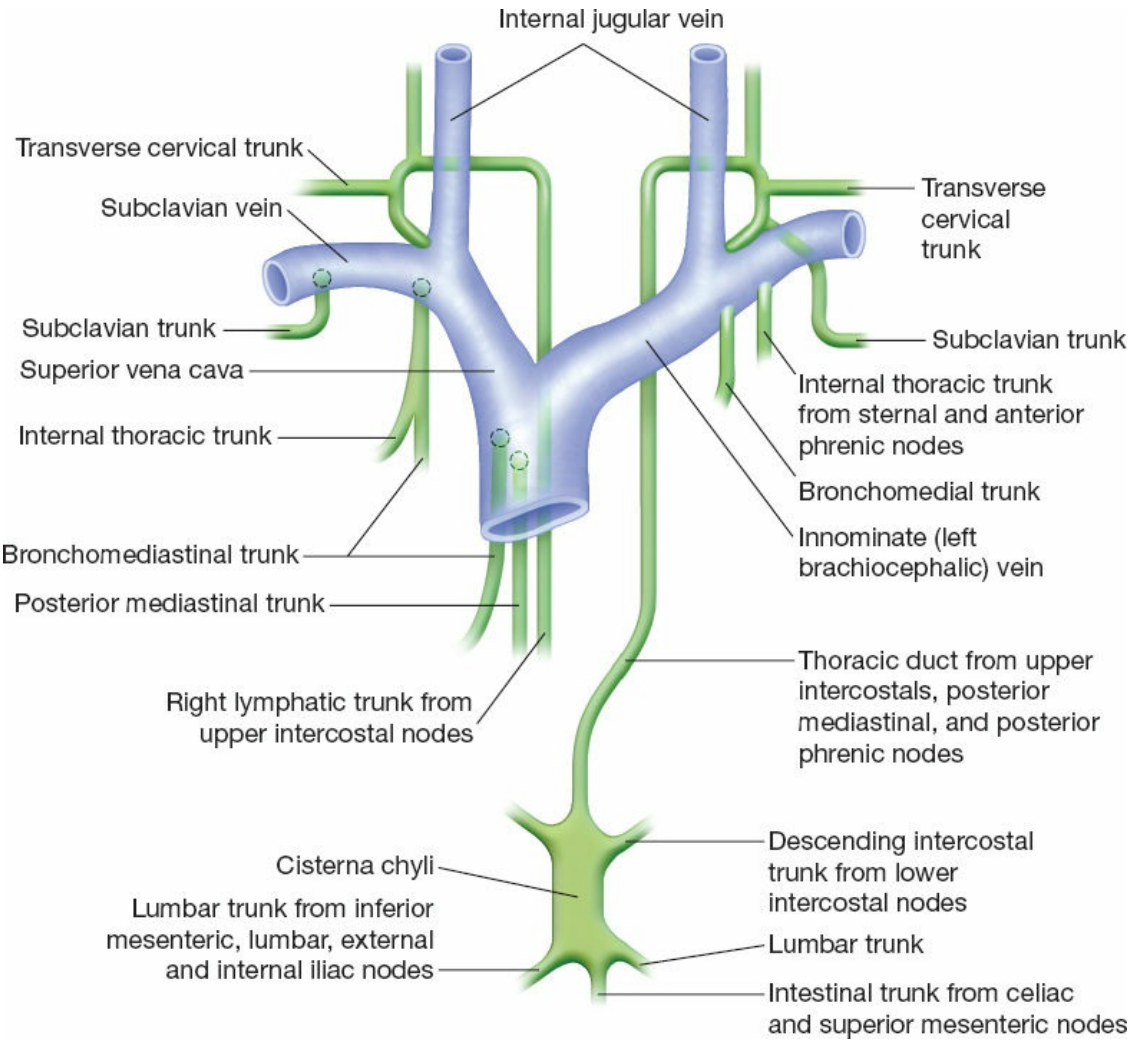

Figure 46.11. Schematic of the major lymphatic vessels of the thorax and the root of the neck. The thoracic duct begins at the cisterna chyli, a dilated sac that receives drainage from the lower extremities and the abdominal and pelvic cavities via the lumbar and intestinal trunks. Lymph enters the systemic circulation via channels that join the great veins of the neck and superior mediastinum. The lymphatic vessels demonstrate considerable variation as to their number and pattern of branching. A typical pattern is illustrated here. Most of the major trunks, including the thoracic and right lymphatic ducts, end at or near the confluence of the internal jugular with the subclavian veins.

Morphology of the secretory portion of the mammary gland varies significantly with patient age and has physiologic and anatomic variance with pregnancy and lactation. The glandular component of the breast is sparse in the inactive (nonpregnant) premenopausal gland and consists predominantly of duct elements. The inactive organ undergoes slight cyclical changes throughout the menstrual cycle. During pregnancy, the gland is altered in size and secretory function with dramatic proliferation inclusive of cellular hypertrophy, lactation, and development. These physiologic events are accompanied by relative diminution in the volume of connective and adipose tissue. With pregnancy, the epidermis of the nipple and areola becomes deeply pigmented and somewhat corrugated. It is covered thereafter with keratinized, stratified squamous epithelium. The areola contains sebaceous glands, sweat glands, and *accessory areolar glands of Montgomery*, which are intermediate between true mammary glands and sweat glands in their structure. These accessory areolar glands present as small elevations on the surface of the areola. Sebaceous and sweat glands are distributed along the margin of the areola. The apex of the nipple contains numerous free sensory nerve endings and Meissner (tactile) corpuscles in the dermal papillae, whereas the areola contains few of these terminal sensory structures. Neuronal plexuses are also present around hair follicles in the skin peripheral to the areola. Pacinian (pressure) corpuscles are present in the dermis and in the glandular tissue. Anatomically and functionally, the rich sensory innervation of the nipple–areolar complex is of great significance to allow lactation and breast feeding.

Suggested Readings

Anson BJ, McVay CB. Thoracic walls: breast or mammary region. In: Anson BJ, McVay CB, eds. *Surgical Anatomy,* 6th ed. Philadelphia, PA: Saunders; 1984:352–65.

Batson OV. The function of the vertebral veins and their role in the spread of the metastases. *Ann Surg* 1940;112(1):138–49.

Bland KI, Copeland EM 3rd, eds. *The Breast: Comprehensive Management of Benign and Malignant Diseases.* 4th ed. Philadelphia, PA: Saunders Elsevier; 2009:21–38.

Comen EA, Norton L. Breast cancer tumor size, nodal status, and prognosis: biology trumps anatomy. *JCO* 2011;29(19):2610–12.

Cunningham L. The anatomy of the arteries and veins of the breast. *J Surg Oncol* 1977;9:71–85.

Gray H. The lymphatic system. In: Clemente CD, ed. *Anatomy of the Human Body,* 30th ed. Philadelphia, PA: Lea & Febiger; 1985:866–932.

Haagensen CD. Anatomy of the mammary glands. In: Haagensen CD, ed. *Diseases of the Breast,* 3rd ed. Philadelphia, PA: Saunders; 1986:1–46.

Henriques C. The veins of the vertebral column and their role in the spread of cancer. *Ann R Coll Surg Engl* 1962;31:1–22.

Holm J, Humphreys K, Li J, et al. Risk factors and tumor characteristics of interval cancers by mammographic density. *JCO* 2015;33:9:1030–7.

Hunt KK, Robertson JFR, Bland KI. The breast. In: Brunicardi F, ed. *Schwartz's Principles of Surgery,* 10th ed. New York: McGraw Hill; 2015:497–564.

Mitchell MD, Klimberg S, Ochoa D, et al. Advanced locoregional therapies in breast. *Ann Surg Oncol* 2014;21(10):3198–203.

Romrell LJ, Bland KI. Anatomy of the breast, axilla, chest wall, and related metastatic sites. In: *The Breast: Comprehensive Management of Benign and Malignant Diseases.* 4th ed. Philadelphia, PA: Saunders Elsevier; 2009:21–38.

Sakki S. Angiography of the female breast. *Ann Clin Res* 1974;6(Suppl 12):1–47.

Sykes PA. The nerve supply of the human nipple. *J Anat* 1969;105(Pt 1):201.

Tan MP. Breast lymphatic anatomy and implications for sentinel lymph node biopsy. *Ann Surg Oncol* 2008;15(8):2345–6.

Turner-Warwick RT. The lymphatics of the breast. *Br J Surg* 1959;46:574–82.

Van Deventer PV, Page BJ, Graewe FR. Vascular anatomy of the breast and nipple–areola complex. *Plast Reconstr Surg* 2008;121(5):1860–1.

EDITOR'S COMMENT

Dr. Bland has superbly described the embryologic development of and the anatomical relationships of the tissue, vasculature, and lymphatics of the breast and axilla. Recent developments in oncoplastic procedures of the breast make breast anatomy more important than ever. One of the first of these that I would like to emphasize is total or nipple skin sparing mastectomy (NSSM). When developing flaps for this relatively new procedure, the surgeon must stay in the correct subcutaneous plane. If too thin the surgeon will strip the subcutaneous plexus that lies below the dermis along with the blood supply and the skin flaps will become necrotic. If too thick one risks leaving breast parenchyma behind. The surgeon wants to be right at the level of the superficial fascia of the breast. As this layer is of different thickness dependent on body habitus, Boneti and colleagues have described a dilation technique to determine this layer for the individual patient and consistently achieve viable flaps. The other anatomical consideration in NSSM is the preservation of the blood supply to the skin of the nipple areola as the nipple areolar complex (NAC) proper is removed. This is dependent on preserving the interconnecting network of vessels surrounding the areola within the subcutaneous tissue to feed the otherwise devascularized skin of the nipple and areola. In addition, when taking the NAC it is removed down to the dermis of the nipple. As Dr. Bland has pointed out the lactiferous ducts here are lined with squamous epithelium making the risk of leaving cancer behind in the ducts very low and ultimately assuring that NSSM is safe.

The other point of anatomy that I would like to bring out and that is less understood is the lymphatic anatomy of the axilla. Dr. Bland has done a superb job of describing the traditional concept of where and how the breast drains and similarly the upper extremity. However, it is less clear how the respective lymphatics intermingle within the axilla. This becomes important as we evolve our treatment of the axilla toward mitigating the complication of lymphedema. Using the concept of axillary reverse mapping (ARM), Boneti and colleagues have described variations in the location of the lymphatics draining the arm that include sling and apron patterns that are as much as 4 cm below the vein and in harm’s way during an axillary lymph node dissection or even a sentinel lymph node biopsy. The issue is how often do these coalesce with the lymphatics draining the breast and can they be separated and preserved. ARM is a technique of split mapping (mapping the breast with radiocolloid and mapping the arm with blue dye) and has shown an extremely low rate of coalescence which only occurs in patients with N2 or higher disease. Using this technique, Ochoa and colleagues have shown an extremely low incidence of lymphedema when ARM is added to sentinel lymph node biopsy or axillary lymph node dissection with an equally low rate of axillary recurrence. Further, Ochoa and colleagues describe reanastomosing/reapproximating lymphatics severed during lymphadenectomy with great success and an extremely low rate of lymphedema.

V. Suzanne Klimberg

Suggested Readings

Boneti C, Korourian S, Bland K, et al. Axillary reverse mapping: mapping and preserving arm lymphatics may be important in preventing lymphedema during sentinel lymph node biopsy. *J Am Coll Surg* 2008;206(5):1038–42; discussion 1042–4.

Boneti C, Yuen J, Santiago C, et al. Oncologic safety of nipple skin-sparing or total skin-sparing mastectomies with immediate reconstruction. *J Am Coll Surg* 2011; 212(4):686–93; discussion 693–5.

Gennaro M, Maccauro M, Sigari C, et al. Selective axillary dissection after axillary reverse mapping to prevent breast-cancer-related lymphedema. *Eur J Surg Oncol* 2013;39:1341–5.

Kuusk U, Seyednejad N, McKevitt EC, et al. Axillary reverse mapping in breast cancer: a Canadian experience. *J Surg Oncol* 2014;110:791–5.

Ochoa D, Korourian S, Boneti C, et al. Axillary reverse mapping: Five-year experience. Axillary reverse mapping: five-year experience. *Surgery* 2014;156(5):1261–8.

Piper M, Peled AW, Foster RD, et al. Total skin-sparing mastectomy: a systematic review of oncologic outcomes and postoperative complications. *Ann Plast Surg* 2013;70(4):435–7.

Tausch, C, Baege A. Dietrich D, et al. Can axillary reverse mapping avoid lymphedema in node positive breast cancer patients? *Eur J Surg Oncol* 2013;39:880–6.

47 Benign Disease and Breast Pain

Amy C. Degnim and Karthik Ghosh

WHAT IS BENIGN BREAST DISEASE

A woman is diagnosed with benign breast disease (BBD) when a radiologic or palpable abnormal area in the breast is subject to biopsy and the pathology is benign. BBD presents clinically with one of two scenarios: (1) a screening breast imaging test shows an abnormality that leads to a benign breast biopsy, or (2) a patient may present with a palpable finding in the breast (with or without suspicious imaging findings) and a biopsy shows benign results. If the findings are benign and concordant with imaging, the woman is diagnosed with BBD. Understanding BBD is important for patient care because multiple studies have reported elevated risk of breast cancer for these women, with varying levels of risk depending on the specific histologic findings that are present (see below). The risk associated with various BBD lesions is an important piece of information to include when estimating a woman's long-term risk of developing breast cancer, which is also influenced by other factors such as family history/genetics, hormonal exposures, mammographic density, and lifestyle factors.

Core Biopsy Is the Standard of Care for Diagnostic Approach

National Comprehensive Cancer Network (NCCN) guidelines indicate that if an abnormality is noted in the breast that warrants diagnostic tissue biopsy, the preferred approach to obtain tissue is with percutaneous core needle breast biopsy. Generally, this is an image-guided biopsy performed under ultrasound, stereotactic, or magnetic resonance imaging guidance. In the uncommon situation of a suspicious palpable abnormality and negative imaging findings, freehand core needle biopsy can be performed. Excisional biopsies are rarely performed as the initial diagnostic procedure, because the majority of mammographic lesions are benign, reducing healthcare costs and risks of surgical excision while still achieving excellent diagnostic accuracy. Furthermore, if cancer is

diagnosed by core needle biopsy, there is a far greater chance of successful treatment with only one operation compared to cases where cancer is diagnosed with surgical excision.

Imaging and Pathology Concordance

All percutaneous needle biopsies should be followed by imaging-pathology concordance evaluation. Assessment of concordance involves review of the clinical and imaging findings to determine if they are consistent with the pathology features of the tissue, in which case concordance is established. In other words, the pathology findings must be plausible to explain the imaging features of the lesion in that individual case. This concordance review and assessment requires multidisciplinary input from the treating clinician (usually a surgeon), the radiologist, and the pathologist. If discordant, such as when the imaging suggests a "suspicious finding" classified as Breast Imaging Reporting and Data System (BI-RADS) 4 or 5 but the pathology is benign, concern exists that the targeted lesion may have been missed at biopsy. Surgical excision of the lesion is the recommended approach to manage discordant breast lesions, as well as other benign lesions diagnosed on core needle biopsy that are shown to have an increased risk that cancer may be present within the lesion but can only be diagnosed accurately with complete surgical excision (so-called "borderline" or "high-risk" lesions). In these situations where adequate diagnosis is best made with complete surgical excision of the lesion, there is a significant risk that cancer will be found at the time of surgical excision and thus the diagnosis will be "upgraded" to cancer (see section below on Management of Benign Breast Disease). The term "high-risk lesion" has also been used to describe breast lesions that confer a long-term increased risk of breast cancer (generally atypical ductal hyperplasia [ADH], atypical lobular hyperplasia [ALH], and lobular carcinoma in situ [LCIS]). Information is presented below for various types of noncancerous breast lesions, along with their management.

Benign Breast Lesions—Histopathology, Management After Core Needle Biopsy, and Long-Term Associations With Breast Cancer Risk

Here we define categories and specific histologic entities of BBD, as well as their management. In order to understand how these benign lesions differ, some basic terminology is necessary regarding the microscopic

anatomy of breast tissue. Breast tissue consists of a branching series of ductal structures designed to channel the flow of milk from the milk-producing units of the breast, called the terminal duct lobular units (TDLUs) also referred to as lobules. This ductal and glandular structure is supported within a stroma of fibrous tissue. Like a cluster of grapes at the end of a vine, the TDLUs contains microscopic sacs called acini (singular form is *acinus*) that are lined with epithelium surrounding a central lumen. In the lactating state, the epithelium produces milk that flows into the central lumen and via the ductal system out the lactiferous ducts of the nipple. BBD includes abnormalities of both epithelial and stromal elements, although most BBD is classified according to the degree of the epithelial abnormality (which also correlates with long-term breast cancer risk).

The three major categories of BBD lesions are based on the degree of epithelial proliferation and abnormality as follows: (1) nonproliferative disease (NPD), (2) proliferative disease without atypia (PDWA), or (3) atypical hyperplasia (AH), as described by Dupont and Page. Multiple studies have demonstrated increasing risk associations across these three categories, with relative risk (RR) increased minimally for women with NPD (RR, 1.3), twofold for women with PDWA (RR, 1.9), and fourfold for women with AH (RR, 4.2) (see Table 47.1).

TABLE 47.1 Classification of Benign Breast Disease

Benign Breast Disease Category	Specific Lesions	Relative Risk of Breast Cancer
Nonproliferative disease	Mild duct hyperplasia Cysts Fibroadenomas Columnar cell change Apocrine metaplasia Duct ectasia Benign phyllodes Pseudoangiomatous stromal hyperplasia	1.2
Proliferative disease without atypia	Ductal hyperplasia (more than mild) Radial scar Sclerosing adenosis Flat epithelial atypia Papillary lesions	1.8
Atypical hyperplasia	Atypical ductal hyperplasia Atypical lobular hyperplasia	4.2
Lobular carcinoma in situ		10

Nonproliferative disease: Includes breast tissue changes such as cysts, fibroadenomas, pseudoangiomatous stromal hyperplasia (PASH), columnar cell change, and mild ductal hyperplasia.

Proliferative disease without atypia: Includes moderate and florid duct hyperplasia, papilloma, radial scar, sclerosing adenosis, columnar cell hyperplasia, and flat epithelial atypia (FEA).

Atypical hyperplasia: Includes ADH and ALH. *Lobular neoplasia* is a term that refers globally to both ALH and LCIS.

Nonproliferative Disease

This group of lesions indicates only mildly increased risk (RR, 1.3) of breast cancer and includes cysts, fibroadenomas, columnar cell change, and mild ductal hyperplasia.

Fibroadenoma

Fibroadenomas are common breast tumors that may present as a palpable mobile, well-defined breast mass or they may be incidentally detected as a mass on mammography. On ultrasound, they are round to oval circumscribed masses with homogenous echotexture, often without posterior shadowing. Histologically, fibroadenomas are predominantly stromal lesions, composed of collagenous stroma containing compressed epithelium that is not proliferative. Fibroadenomas are either simple or

complex, with the latter being based on the finding of sclerosing adenosis, calcifications, or papillary hyperplasia within the fibroadenoma.

Management

Fibroadenomas can sometimes be diagnosed presumptively based upon benign appearing imaging features in a young woman who may elect to follow the lesion rather than undergo diagnostic needle biopsy. However, once diagnosed by core needle biopsy, these lesions do not need to be surgically excised unless there is discordance with imaging or AH identified, in which case surgical excision is recommended to rule out malignancy. Fibroadenomas diagnosed presumptively (without core biopsy) need to be followed clinically every 6 to 12 months and excised in the event of rapid growth, generally defined as a doubling in size over 6 to 12 months. In general, fibroadenomas that are proven on core needle breast biopsy do not require any further evaluation or treatment. However, surgical excision is recommended for a fibroadenoma that is symptomatic, or enlarging, or measures over 2 cm.

Pseudoangiomatous Stromal Hyperplasia

PASH is a benign breast entity that is often noted clinically as a breast mass or on imaging as an asymmetric density or breast mass, leading to a core needle breast biopsy. Histologically, PASH is a stromal abnormality without epithelial proliferation, seen as a diffuse dense fibrosis between lobular units, where the proliferation of fibroblasts results in slit-like spaces resembling blood vessels. PASH is not associated with a significant increase in long-term breast cancer risk.

Management

If the imaging lesion has been adequately sampled, a finding of PASH is considered concordant with imaging and no further intervention is needed. However, if further clinical growth of the breast mass occurs, this suggests a possible sampling error in which case the lesion should be surgically excised.

Columnar Cell Change

Columnar cell change (also called columnar cell alteration) describes an abnormality of the breast epithelium in which the cells exhibit a columnar shape. Although the acini within lobules may enlarge in size and demonstrate larger lumens, there is very little to no epithelial proliferation,

as this condition is defined by only one or two layers of epithelial cells.

Management

Unless discordance or atypia are present (see Flat Epithelial Atypia below), columnar cell change identified on core biopsy does not require surgical excision. Columnar cell change without hyperplasia and without atypia does not confer an increase in long-term risk of breast cancer.

Mild Ductal Hyperplasia

Mild ductal hyperplasia (also called “usual ductal hyperplasia”) refers to an increase in the number of epithelial cells above the basement membrane within the TDLU acini, with the epithelial cells having a normal appearance. In mild usual duct hyperplasia, there are three to four layers and the cells do not completely fill or cross the lumen of the involved acinus.

Management

Mild or usual ductal hyperplasia found on core biopsy does not require surgical excision unless there is concern of discordance. This change is considered NPD and is associated with no significant increase in breast cancer risk.

Proliferative Disease

This group of lesions indicates an approximate twofold increased long-term risk (RR, 1.9) of breast cancer and includes moderate/florid ductal hyperplasia, radial scar, complex sclerosing lesion, sclerosing adenosis, papillary lesions, columnar cell hyperplasia, and FEA.

Moderate/Florid Ductal Hyperplasia

Moderate or florid hyperplasia is similar to usual ductal hyperplasia, with overgrowth of normal appearing epithelial cells that completely fill the lumen of the ductal structure and portray a streaming pattern microscopically. Despite the overgrowth of epithelial cells, the cells have a normal cytologic appearance.

Management

Moderate ductal hyperplasia found on core biopsy does not require surgical excision unless there is concern of discordance. However, this change is considered proliferative disease and is associated with an

approximate twofold increase in breast cancer risk.

Radial Scar/Complex Sclerosing Lesion

Radial scar and complex sclerosing lesions are the same histologically and distinguished only by their size, with lesions >1 cm termed complex sclerosing lesions. This is a benign breast lesion that may present as a palpable mass or on breast imaging and radiologically mimics breast cancer due to its spiculated appearance, prompting diagnostic core needle biopsy. It is composed of a dense collagenous core with epithelial components trapped in this core, mostly benign epithelium, but in some instances there can be atypical epithelium within the radial scar.

Management

Radial scar can often be an incidental histologic finding seen with benign proliferative breast changes on core needle biopsy. In that case, surgical excision is not warranted. However if atypia is present within a radial scar, these lesions should be excised due to an approximate 30% risk of upgrade to cancer. In addition, if the lesion is >1 cm in size, if there is discordance, or the sampling of the lesion is judged to be inadequate, surgical excision should also be performed. Alternately, if radial scar was biopsied with a larger gauge (11-gauge) vacuum biopsy technique with 12 or more cores obtained at biopsy, and no atypia is present, the upgrade rate is likely 5% or less and short-term follow-up mammogram in 6 months is reasonable to assure stability. In the long-term, radial scar and complex sclerosing lesions (without atypia) confer a twofold increased risk of breast cancer.

Sclerosing Adenosis

Sclerosing adenosis is a benign breast condition that is characterized by an increase in the number of lobular acini and myoepithelial cells. This lesion may present as a mammographically detected mass or architectural distortion with calcifications leading to a core needle biopsy.

Management

If the imaging is highly suspicious, and the finding of sclerosing adenosis is discordant with imaging, surgical excision would be advised to rule out malignancy. However, if concordant with imaging, no further work-up would be needed, and routine breast screening recommended. As a proliferative breast lesion, the long-term risk of breast cancer is increased approximately twofold.

Papillary Lesions

Papillomas are a heterogeneous group of lesions that include benign solitary intraductal papillomas, atypical papillomas, and papillary cancer. These are lesions with an epithelium-lined, branching, fibrovascular stalk. They may present clinically with nipple discharge or a breast mass that may be noted radiologically. Imaging often may demonstrate an intraductal mass that is then evaluated with core needle biopsy.

Management

Papillary lesions can be challenging to diagnose with percutaneous core needle biopsy. If atypia is present, then surgical excision is required due to an upgrade rate of approximately 25% to 30%. In addition, papillary lesions that present as a mass over 1.0 cm in size, or if there is imaging and pathology discordance, are also managed with surgical excision. In situations with imaging and pathology concordance and no atypia or associated high-risk lesion, observation is reasonable with a low risk of missed cancer. If observation is planned, clinical and radiologic follow-up in the short term is recommended to assess stability of the finding. Papillary lesions without atypia are a form of proliferative breast disease and are associated with an approximately twofold increase in long-term breast cancer risk. There is a fourfold increased risk of breast cancer for women with papillary lesions containing AH, similar to the risk associated with ADH or ALH alone.

Columnar Cell Hyperplasia and Flat Epithelial Atypia

Columnar cell hyperplasia refers to an abnormality of the breast epithelium in which the cells exhibit a columnar shape and appearance, with hyperplasia defined as more than two cell layers thick. When this is also accompanied by cytologic atypia in the epithelial cells, the condition is termed FEA. FEA is an uncommon entity that is seen in about 5% of percutaneous breast biopsies.

Management

Columnar cell hyperplasia found on core needle biopsy does not require surgical excision, and as a proliferative lesion carries a twofold increase in the long-term risk of breast cancer. The management of FEA is more controversial. Published studies on upgrade rates for FEA diagnosed on core needle biopsy show that at surgical excision approximately 8% to 10% of women are found to have cancer. In addition, approximately 20%

to 25% are found to have AH. Therefore, due to the risk of finding either cancer or AH at excision, both of which would change management compared to FEA alone, surgical excision is recommended for FEA diagnosed on core needle biopsy. As always, surgical excision should be performed in any case of discordant findings. Regarding long-term risk and FEA, due to its cytologic atypia, concern exists that it may portend an increase in long-term breast cancer risk similar to AH. However, a recent study of 282 women in the Mayo Clinic Benign Breast Disease cohort showed that FEA has a risk similar to other proliferative lesions without atypia. However, approximately half of the women with FEA also had AH. In these women with both FEA and AH, their risk was defined by the presence of AH (RR, 4), and the FEA did not further increase risk. In general, women with FEA and no AH or malignancy are not offered chemoprevention on the basis of the FEA finding alone, as the risk elevation is not considered large enough to justify the side effects of the medication. At this time, the recommendation is that if surgical excision shows no evidence of AH or malignancy, the patient can resume yearly breast screening with mammography.

Atypical Hyperplasia and Lobular Carcinoma In Situ

Atypical Hyperplasia (Atypical Ductal Hyperplasia and Atypical Lobular Hyperplasia)

AH refers to both ADH and ALH, lesions characterized by an epithelial proliferation with atypical cytologic changes in the TDLU. In ADH, there is a monomorphic epithelial proliferation that fills the acinar lumens, often with cribriform architecture and secondary “punched out” lumens. The cytologic atypia and architectural changes of ADH are similar to ductal carcinoma in situ (DCIS), but unlike ductal carcinoma in situ, ADH involves only 1 to 2 ducts and measures less than 2 mm. As a result, core needle biopsy can result in underdiagnosis of cancer (especially ductal carcinoma in situ) in 10% to 30% of cases. In ALH, the atypical epithelial cells have a monomorphic and discohesive appearance and distend and enlarge the lobules.

Management

Due to the frequent finding of cancer at surgical excision of ADH found on core needle biopsy, surgical excision is the standard of care. For ALH found on core needle biopsy, the need for surgical excision is less clear,

with multiple published papers showing widely varying rates of cancer upgrade. Although current NCCN guidelines recommend surgical excision of ADH and ALH lesions diagnosed by core needle biopsy, several recent publications suggest that an approach of selective excision may be safe with a low risk of missed cancer. This is more accepted in cases of ALH on core needle biopsy where the ALH was an incidental finding, there is radiologic-pathologic concordance, and no other high-risk lesion is seen microscopically. In that event, an observation approach is reasonable with imaging follow-up at 6 and 12 months. For ADH on core needle biopsy, criteria for avoiding excision are still in evolution but will likely include a lesion size less than 1 cm, near complete removal of the lesion mammographically, and only 1 or 2 foci of ADH microscopically.

Women with AH have a significantly increased risk of future breast cancer, estimated as an absolute risk of breast cancer of 1% to 2% per year, and risk is similar for ADH and ALH. Research suggests that long-term risk in these women is stratified by the number of separate foci of AH found at the time of biopsy, with risk increasing in stepwise fashion for 1, 2, and 3 or more foci of AH. In these women, closer screening is warranted, with annual mammography starting at age 40 (possibly earlier depending on other risk factors for breast cancer such as family history and mammographic density). Similarly, supplemental screening can be considered with breast magnetic resonance imaging if overall lifetime risk is estimated to be at least 25%. Furthermore, women with ADH or ALH should be counseled about lifestyle changes to reduce risk (see below) and the use of prevention medications, which reduce breast cancer risk by 50% to 70%.

Lobular Carcinoma In Situ

LCIS most often presents as an incidental finding seen on breast biopsy. Histologically it is similar to ALH with expanded acini in the TDLUs and a monomorphic discohesive cytologic appearance. LCIS differs from ALH in that the TDLUs is completely involved (LCIS) instead of partially involved (ALH), and the degree of expansion of the acini and the TDLUs itself is much greater with LCIS. Studies of mastectomy specimens have shown that LCIS is often multifocal in nature and can be present in both breasts.

Management

The need for surgical excision is controversial for LCIS observed on core

needle breast biopsy. Published studies show wide variation in upgrade rates to cancer, but similar to ALH, recent studies support an approach for imaging surveillance rather than surgical excision with a <5% risk of missed cancer with the following criteria: LCIS is an incidental finding, radiologic-pathologic concordance is confirmed, and there are no other high-risk lesions that would indicate surgical excision. Long-term risk of breast cancer is substantial in women with LCIS, estimated as an eightfold increase in RR. In terms of absolute risk estimation, recent data show that women with LCIS have a long-term risk of ~2% per year. Therefore, long-term management of women with LCIS should include more intensive imaging surveillance, as well as thorough discussion of risk reduction options, including prevention medications as well as surgical risk reduction with bilateral mastectomy (see below).

Phyllodes Tumors

Phyllodes tumors of the breast present most commonly as a palpable breast mass and less commonly as circumscribed, lobulated masses on mammography. They are also known to increase in size over time and often present as large masses, sometimes up to 20 cm in diameter. Histologically, phyllodes tumors have a hypercellular stroma that is out of proportion to the epithelium. These lesions generally do not have proliferative epithelial changes and therefore are not classified according to the typical range of BBD categories. Phyllodes tumors are categorized as benign, borderline, and malignant based on World Health Organization (WHO) classification that accounts for stromal cellularity and atypia, stromal overgrowth, mitotic activity, and tumor margin.

Management

For phyllodes tumors diagnosed on core needle biopsy, wide local excision remains the mainstay of surgical management of phyllodes tumors, whether benign, borderline, or malignant. For benign phyllodes tumors, complete surgical excision to negative margins is adequate treatment with a low risk of local recurrence, with larger margins desired for borderline and malignant lesions. Local recurrence occurs in about 15% of patients with phyllodes tumors and is more common after inadequate excision. Studies have shown that local recurrence is lower for women who have wide local excision with >1 cm margin compared to resection with less than 1 cm margin for all types of phyllodes tumors. However, this is more important for women with borderline and malignant tumors. Margin over 1

cm may not be necessary for women with benign phyllodes especially if wide excision will be disfiguring for the patient. For patients with borderline and malignant phyllodes, local recurrence was reduced when margin-negative excision was followed by radiation therapy when compared to excision alone.

Risk Reduction Strategies

Lifestyle

A healthy lifestyle with regular exercise, healthy low fat diet, maintaining a healthy weight, avoiding smoking, and avoiding or limiting alcohol are measures that can be associated with up to 25% reduction in breast cancer risk.

Medications

Medications including tamoxifen, raloxifene, exemestane, and anastrozole have been studied and demonstrated to have benefit in reducing breast cancer risk. These agents are offered to women with a 5-year breast cancer risk over 1.66% as estimated by various risk prediction models, and also should be offered to women with AH or LCIS on breast biopsy. Risk reduction of 50% is noted for most women, with up to 70% risk reduction in women with AH. In addition to the benefits, the side effects and precautions have to be clarified with the patient. Discussing the pros and cons and taking a shared decision-making approach based on risk assessment and patient preferences is the recommended approach.

Risk Reduction Mastectomy

Risk reducing mastectomies are not generally required for women with BBD as the lifetime risk of breast cancer is not as high as noted with for women with deleterious breast cancer susceptibility gene germline mutations. However, in select cases, based on patient values and preferences, risk-reducing surgery may be offered to women with AH or LCIS who have had multiple breast biopsies, or for women who have a strong family history of breast cancer. When considering bilateral mastectomy, women need to be well informed that this is a personal decision that needs to be made with complete information of the pros and cons of the procedure, changes in body image and sexuality, risks of the intervention itself, as well as other options for risk reduction, so that they are satisfied with the ultimate outcome.

Summary of Benign Breast Disease

Women diagnosed with BBD have a wide range in long-term risk of breast cancer, with some lesions associated with no increased risk such as benign cysts or fibroadenomas to others with substantially increased risk such as women with LCIS or multiple foci of AH. Surgical excision needs to be considered for some lesions diagnosed with core needle biopsy in order to ensure that cancer is not missed. Clarifying the pathology finding, ensuring imaging and pathology concordance, and multidisciplinary approach is needed to guide management. Tailoring therapy based on these features, the patient's other risk factors for breast cancer, and taking into account the patient's preferences will ensure the most optimal management of this condition.

BREAST PAIN

Breast pain (or mastalgia) is a common concern for women and may necessitate a clinical visit for evaluation. In a 10-year study of a health maintenance organization, breast pain was the indication for 47% of breast-related clinical visits.

Etiology/Pathophysiology

Breast pain may often be physiologically related to hormone effects on breast tissue. However, evaluation is needed to determine whether the cause is due to a benign condition or malignancy. Mastalgia can be classified as cyclic or noncyclic based on its relationship with the menstrual cycle. Cyclic mastalgia occurs in premenopausal women, who experience mastalgia most prominently in the second half of the menstrual cycle and that resolves with the onset of menstruation. Noncyclic mastalgia is unrelated to the menstrual cycle and may be related to conditions such as breast infection or mastitis, breast lumps such as fibroadenomas, or hematoma from breast trauma. An uncommon entity, thrombophlebitis of the breast (Mondor disease), can present with mastalgia. Other conditions that can present as mastalgia but are nonbreast related include chest wall pain from costochondritis, radiculopathy, cardiac etiology, or gastro-esophageal reflux disease (GERD). Although there are many benign conditions that can cause mastalgia, breast cancer is in the differential diagnosis for breast pain and is the primary diagnosis that should be ruled out. When pain is due to breast malignancy it is usually

noncyclic in nature, but there can be a cyclic component in premenopausal women.

Clinical Presentation

A detailed history and examination are important components of the evaluation. The patient history should include location of pain, duration, intensity, timing related to the menstrual cycle, radiation of pain to or from another site, aggravating or relieving factors, recent trauma, and medication changes especially related to hormone use; these can all provide clues to the etiology of pain (Table 47.2). On examination, it is important to pinpoint the location of the pain, especially focal pain such as in a specific breast location, or parasternal pain as with costochondritis, or pectoral muscle pain.

TABLE 47.2 Benign Causes of Breast Pain

Cyclic:
Fibrocystic changes
Use of hormones: oral contraceptives, post-menopausal estrogen therapy
Noncyclic:
Mastitis
Superficial thrombophlebitis (Mondors disease)
Hematoma from breast trauma
Breast lumps—fibroadenoma, lipomas
Chest wall pain such as costochondritis, pectoral myalgia
Coronary artery disease
Gastrointestinal—related to hiatal hernia, gall bladder disease
Neurologic such as radiculopathy

Evaluation

Breast imaging with mammography and targeted ultrasound is reasonable for patients aged 30 or older with a palpable abnormality or focal breast

pain to rule out an underlying cyst or mass contributing to the symptom. For women younger than 30 years, targeted ultrasound alone is reasonable.

Persistent breast pain despite treatment also warrants reassessment.

Management

Women with mastalgia and no abnormality on examination or imaging can be reassured of the absence of malignancy and for many patients, no further intervention is needed. In addition, conservative management approaches can be discussed.

Use of a fitted bra has been offered for patients with breast pain as breast tissue can pull on the chest wall if the tissue is unsupported or inadequately supported. Using a well-fitting bra for physical activity such as running is also recommended.

Methylxanthines including caffeine found in coffee, tea, chocolates, and some respiratory medications have been thought to cause breast pain. However, research in this area does not provide strong evidence of an association. Although controversial, many patients report benefits with discontinuation of caffeine, and being an inexpensive and noninvasive therapy, it is reasonable for the patient to try to see if it helps symptoms. A low fat diet has also been reported to help symptoms. Gentle massages, stretching exercises for upper body, and use of nonsteroidal anti-inflammatory medications may also be helpful.

A few research studies have evaluated the use of medications to help with breast pain. For women on postmenopausal estrogen therapy, stopping the medication can result in pain relief. Another approach to reduce estrogen stimulation on the breast tissue is to use tamoxifen, a selective estrogen receptor modulator, which has been shown to provide relief of breast pain. Benefits of tamoxifen have to be assessed keeping the side effects in perspective, and it should be used only for short periods such as 3 to 6 months for symptom relief. Side effects include hot flashes, vaginal symptoms, and more serious but infrequent concerns of deep vein thrombosis, pulmonary embolism, stroke risk, and uterine cancer risk. The only medication that has been Food and Drug Administration (FDA) approved for breast pain is danazol. However, the significant androgenic side effects of the medication make it a less attractive option for symptom management unless the patient is refractory to all other nonsurgical options. The dopamine agonist, bromocriptine has also been studied for breast pain management. Although therapeutically effective, the

medication is rarely used due to the significant side effects of nausea and vomiting, and headache. Evening oil of primrose and vitamin E have been reported to relieve breast pain symptoms but a randomized, double blind, placebo-controlled study failed to report benefit of either of these agents when compared with placebo. In a meta-analysis report on agents used for treatment of mastalgia, bromocriptine, danazol, and tamoxifen were shown to result in significant pain relief while evening primrose oil had no benefit.

Surgical procedures, such as excisional biopsy of a tender area or mastectomy for mastalgia, should only be done as a last option and if requested by the patient, ensuring that the patient is well informed and understands that the surgery may not relieve the pain symptom.

Summary of Breast Pain

In summary, a detailed history and examination, targeted imaging as needed, and if no abnormality, conservative management with plan for reassessment for persistent or worsening pain is recommended.

Suggested Readings

American Society of Breast Surgeons. Position Statement on Concordance Assessment of Image-Guided Breast Biopsies and Management of Borderline or High-Risk Lesions Aug. 5, 2011, https://www.breastsurgeons.org/statements/PDF_Statements_Concordance_Assessr Accessed March 20, 2012.

Barton MB, Elmore JG, Fletcher SW. Breast symptoms among women enrolled ina health maintenace organizationd: frequency, evalaution, and outcome. *Ann Intern Med* 1999;130(8):651–7.

Berg JC, Visscher DW, Vierkant RA, et al. Breast cancer risk in women with radial scars in benign breast biopsies. *Breast Cancer Res Treat* 2008;108(2):167–74.

Coopey SB, Mazzola E, Buckley JM, et al. The role of chemoprevention in modifying the risk of breast cancer in women with atypical breast lesions. *Breast Cancer Res Treat* 2012;136(3):627–33.

Dupont WD, Page DL. Risk factors for breast cancer in women with proliferative breast disease. *New Engl J Med* 1985;312(3):146–51.

Grady I, Gorsuch H, Wilburn-Bailey S. Long-term outcome of benign fibroadenomas treated by ultrasound-guided percutaneous excision. *Breast J* 2008; 14(3):275–8.

Hartmann LC, Sellers TA, Frost MH, et al. Benign breast disease and the risk of

breast cancer. *New Engl J Med* 2005;353(3):229–37.

King TA, Pilewskie M, Muhsen S, et al. Lobular carcinoma in situ: A 29-year longitudinal experience evaluating clinicopathologic features and breast cancer risk. *J Clin Oncol* 2015;33(33):3945–52.

Lewis JT, Hartmann LC, Vierkant RA, et al. An analysis of breast cancer risk in women with single, multiple, and atypical papilloma. *Am J Surg Pathol* 2006; 30(6):665–72.

Pruthi S. Vitamin E and evening primrose oil for management of cyclical mastalgia: a randomized pilot study. *Alt Med Rev* 2010;15(1):59–67.

Said SM, Visscher DW, Nassar A, et al. Flat epithelial atypia and risk of breast cancer: A Mayo cohort study. *Cancer* 2015;121(10):1548–55.

Srivastava A, Mansel RE, Arvind N, et al. Evidence-based management of mastalgia: a meta-analysis of randomized trials. *Breast* 2007;16(5):503–12.

Swapp RE, Glazebrook KN, Jones KN, et al. Management of benign intraductal solitary papilloma diagnosed on core needle biopsy. *Ann Surg Oncol* 2013; 20(6):1900–5.

Tan PH, Thike AA, Tan WJ, et al. Predicting clinical behaviour of breast phyllodes tumours: a nomogram based on histological criteria and surgical margins. *J Clin Pathol* 2012;65(1):69–76.

Visscher DW, Nassar A, Degnim AC, et al. Sclerosing adenosis and risk of breast cancer. *Breast Cancer Res Treat* 2014;144(1):205–12.

EDITOR'S COMMENT

Degnim and colleagues have given a very detailed explanation on benign and high-risk lesions with advice on when further surgical investigation is necessary. A few clarifications are necessary. Any lesion with atypia in the name should be treated as any other atypia. Surgical excision should be performed secondary to the risk of associated breast cancer. When dealing with small (less than 2 cm) probable benign lesions, every attempt should be made to percutaneously excise them making close follow-up unnecessary. Percutaneous excision of such a mass can be done at the time of the core biopsy for diagnosis and takes only a few minutes more to completely excise such a mass at no extra cost.

Breast pain often does not receive the attention it should. After all, it is one of the most common presenting complaints of women. In a recent survey two thirds of women complained of breast pain with one fifth of these cases being severe. It can be normal up to 5 days prior to the start of the menstrual cycle if mild. As with most of medicine a good history and physical can help sort out not only the cause of mastalgia but determine how to treat it. Severity can be

assessed by how much the mastalgia affects the patient's habits of daily living including work, sex, and sleep. Dietary intake of caffeine, fats, and medication should be assessed including cardiac and antihypertensives (digoxin, methyldopa, minoxidil, spironolactone, and other diuretics), hormone replacement therapy, psychiatric medications (selective serotonin reuptake inhibitors, venlafaxine, haloperidol, and other antipsychotics), antimicrobials (ketoconazole, metronidazole), antacids (e.g., cimetidine and related medicines), cyclosporine, domperidone, penicillamine, and methadone. A recent history of stress or trauma should lead one to consider the very common cause of breast pain, shoulder bursitis. This is especially true in the postmenopausal patient where endogenous hormones would not play a factor. Mild cases are easily treated with heat to the scapulothoracic bursa and analgesics. More severe cases can be treated with steroid trigger point injections. Because stress itself can raise prolactin levels mild cases can be treated with obtaining a normal mammogram and reassurance.

Age appropriate work-up should be undertaken of the breast pain patient because as much as 22% of breast cancer is associated with pain and as much as 7% of breast cancer can present as pain alone. The old myth that breast cancer does not hurt is simply false. However, no study has reported an increased risk of breast cancer with cyclical mastalgia. Cysts can be diagnosed with ultrasound and can cause severe pinpoint pain which can be treated with aspiration when small or percutaneous excision when large.

As might be predictable, there is a long list of suggested treatments for such a pervasive and variable symptom whose cause is, most of the time, unknown and whose relationship to benign and cancerous breast disease is so poorly understood. There are many treatments for mastalgia that have been proven by randomized clinical trials to be moderately effective for mastalgia including abstinence from methylxanthines like caffeine (83% effective), analgesics (92% effective), danazol (an attenuated androgen, 64% to 92% effective, 30% side effects), luteinizing hormone releasing hormone (LHRH) agonist (67% effective, 37% side effects), thyroid replacement (73% effective), molecular iodine (65% effective, 11% side effects), and tamoxifen (56% to 90% effective, 65% side effects). Placebo-controlled trials are necessary to prove the effectiveness of such agents as breast pain has a high spontaneous resolution as well as a high placebo effect. What has not been well controlled for in these studies is the cause of the breast pain. For example, if the cause of breast pain is bursitis then abstinence from caffeine is not helpful but as your bursitis improves over time it may appear to work. However, dietary changes including decreased caffeine ingestion and a low fat diet have been shown to decrease the fibrocystic changes in the breast as assessed with mammography as well as breast pain. An unfaultable, prospective study that accurately assesses methylxanthine intact paired with reliable dependent variables to assess pain has yet to be performed. Dietary manipulation is difficult to achieve but costs nothing to try. Ineffective treatments include diuretics, progesterone, vitamins

E, AB1, and B6.

Initial studies indicated that women with mastalgia have abnormally low blood levels of gamolenic acid, an essential fatty acid which can affect prolactin levels. Early clinical experience with evening primrose oil (EPO), a source of gamolenic acid, produced a good response rate. However, two more recent multicenter randomized controlled trials have not supported or contradicted this earlier evidence of the efficacy of EPO or antioxidants in the treatment of breast pain. A meta-analysis reviewing the data from all randomized controlled trials using EPO revealed no significant beneficial effect over placebo.

The exact influence of iodine on breast tissue is not understood. Eskin and colleagues demonstrated that iodine is involved particularly in the breast which has receptors for iodine. Absence of iodine may render the epithelium of the terminal intralobular ducts more sensitive to estrogen stimulation. Objective improvement was noted in 72% of those receiving molecular iodine as first-line therapy. Molecular iodine was found to be nonthyrotropic, without side effects, and beneficial for breast pain. Thyroid hormones may work in a similar way and may antagonize the effects of estrogen at the pituitary receptor levels of thyroid releasing hormone (TRH), although there is no conclusive support for this. Relative estrogen dominance is suggested as a cause for the increase in prolactin responsiveness to TRH in patients with mastalgia. Testing for hypothyroidism and replacement as necessary may also be helpful in some patients and relatively innocuous. Bromocriptine is effective through an antiprolactin mechanism and has been associated with a significant clinical response in patients with cyclic mastalgia. However, its use has been associated with seizure and death and is no longer recommended for mastalgia.

It is clear that estrogen and progesterone play a causative role in premenopausal breast pain. Therefore, various androgen formulations have been tried to treat mastalgia. The major problem has been side effects. Danazol is an attenuated androgen and therefore has less side effects. Danazol competitively inhibits estrogen and progesterone receptors in the breast, hypothalamus, and pituitary; multiple enzymes of ovarian steroidogenesis; the midcycle surge of LH in premenopausal women; and reduces gonadotropin levels. It is the only medication approved by the FDA for the treatment of breast pain. Danazol is usually started at 200 to 400 mg/day in divided doses. To prevent androgen-related side effects, danazol is weaned within a few months or even given only in the second half of the menstrual cycle. Eventually, danazol can be discontinued in those women with a complete response. Gestrinone is another androgen derivative with less data and is similarly effective to danazol with perhaps less side effects.

For those with severe mastalgia LHRH agonist can be tried to induce ovarian ablation and extremely low levels of ovarian hormones. Monthly injections of an LHRH analog can result in an overall response rate of more than 81% in patients with both cyclic and noncyclic mastalgia. Because LHRH can induce osteoporosis only short courses of LHRH analogs should be used and only for

severe refractory cases of mastalgia. Likewise tamoxifen, an estrogen agonist–antagonist, 20 mg per day were associated with a 75% reduction in mean pain scores in patients with cyclic mastalgia in a double-blind, controlled, crossover trial. However, tamoxifen is associated with major side effects including hot flashes, vaginal dryness, and rarely uterine cancer. Because of side effects tamoxifen as well as toremifene, 4-hydroxytamoxifen, centchroman, and other selective estrogen receptor modulators should only be used for refractory mastalgia.

Breast pain can present as a referred pain from the shoulder or other spinal abnormalities. When pain is mild heat on the scapula and nonsteroidal analgesics may be effective. Trigger points can be found along the medial scapular border. Injections containing a mix of lidocaine, bupivacaine, and steroids are used in the trigger point(s). The short-acting lidocaine is diagnostic if at least some relief occurs within 15 minutes. Relief is continued because of the long-acting bupivacaine allowing time for the steroid to decrease inflammation in the scapulothoracic bursa. Daily heat to the scapula and nonsteroidal analgesics accentuate the anti-inflammatory effect and result in long-acting relief. Patients should become aware of what caused the bursitis (e.g., heavy lifting) and avoid it.

In summary, a good history and physical is key to the accurate diagnosis of pain and ultimately its treatment.

V. Suzanne Klimberg

Suggested Readings

Barton MB, Elmore JG, Fletcher SW. Breast symptoms among women enrolled in a health maintenance organization: Frequency, evaluation, and outcome. *Ann Intern Med* 1999;651–7.

Boneti C, Arentz C, Klimberg VS. Scapulothoracic bursitis as a significant cause of breast and chest wall pain: underrecognized and undertreated. *Ann Surg Oncol* 2010;17(Suppl 3):321–4.

Hinton CP, Bishop HM, Holliday HW, et al. Double blind controlled trial of danazol and bromocriptine in the management of severe cyclical breast pain. *Br J Surg* 1986;40:326–30.

Iddon J, Dixon JM. Mastalgia. *BMJ* 2013;347:f3288.

Johnson AT, Henry-Tillman RS, Smith LF, et al. Percutaneous excisional breast biopsy. *Am J Surg* 2002;184:550–4, discussion 554.

Kataria K, Dhar A, Srivastava A, et al. A systematic review of current understanding and management of mastalgia. *Indian J Surg* 2014;76(3):217–22.

Kessler JH. The effect of supraphysiologic levels of iodine on patients with cyclic mastalgia. *Breast J* 2004;10:328–36.

Minton JP, Abou-Issa H. Nonendocrine theories of etiology of benign breast disease. *World J Surg* 1989;13:680–4.

Pirti O, Barlas AM, Kuru S, et al. Mastalgia due to degenerative changes of the spine. *Adv Clin Exp Med* 2016;25(5):895–900.

Rajswaroob U, Kannan R, Kannan NS, et al. Effectiveness of centchroman on regression of fibroadenosis and mastalgia. *J Clin Diagn Res* 2016;10(10):PC10–4.

Scurr J, Hedger W, Morris P, et al. The prevalence, severity, and impact of breast pain in the general population. *Breast J* 2014;20(5):508–13.

Watt-Boolsen S, Andersen A, Blichert-Toft M. Serum prolactin and oestradiol levels in women with cyclical mastalgia. *Horm Metab Res* 1981;13:700–2.

48 Diagnostic Approach to Breast Abnormalities

Catherine Caldwell Parker, Heidi Umphrey, Helen Krontiras, and Kirby I. Bland

Breast cancer accounts for 26% of all female cancers (excluding nonmelanoma skin cancer and in situ cancers). Despite significant strides in the treatment of breast cancer, 232,340 women were diagnosed with invasive breast cancer and 39,620 women died of the disease in 2013 alone. The highest incidence rates of breast cancer occur in non-Hispanic white females; however, the death rates for breast cancer are highest among African-American females. Breast cancer awareness has increased dramatically over the years. Therefore, women presenting with breast complaints are anxious about the possibility of being diagnosed with breast cancer. Clinicians evaluating these women should provide a comprehensive, efficient, and timely consultation in order to relieve anxiety with either a benign diagnosis or initiate an appropriate treatment plan should a cancer be diagnosed.

HISTORY AND PHYSICAL EXAMINATION

A thorough history and physical examination are essential components of the diagnostic evaluation of a breast abnormality. Key features of the history include details about the presenting symptom, history of previous breast disease or prior breast surgery, as well as, risk factors for breast cancer including a menstrual history and other contributing past medical history. Initial questions should focus on the presenting symptom, which could include a breast mass, nipple discharge, palpable adenopathy, pain, or abnormal imaging. As in any history, questions should be asked regarding the length of time the abnormality has been present, associated pain, change in size or texture of the breast or overlying skin over time, and the relationship of the pain or change in size of the breast or mass to the menstrual cycle. In addition, it is important to ascertain whether the patient has noticed any associated nipple discharge, nipple changes or

inversion, axillary adenopathy, or skin changes. If the patient reports nipple discharge, it is important to inquire whether the discharge is spontaneous or occurs only with manipulation, as well as, the color of the discharge, clear, green, white, or bloody. A patient may also notice staining of spontaneous discharge on her bra or bedclothes.

Identification of risk factors responsible for increasing a woman's likelihood of developing breast cancer is important in the daily practice of clinicians caring for women of all ages. Risk factors for developing breast cancer can be divided into several categories: gender, age, endocrine factors, family history, Ashkenazi Jewish heritage, genetic or inherited factors, breast density, and previous breast disease. Female gender is the most common risk factor for breast cancer. A woman living in the United States has 12.3% or 1 out of 8 lifetime risk of being diagnosed with breast cancer. Male breast cancer accounts for less than 1% of all breast cancer. A patient's risk for developing breast cancer increases with age. A woman in the sixth decade has a 1 in 24 chance of developing breast cancer, compared with 1 in 257 for a woman in her third decade. Endocrine risk factors for breast cancer include endogenous estrogen exposure as well as exogenous exposure to estrogen and progesterone. Early menarche, late menopause, late parity, and nulliparity all increase exposure to endogenous estrogen. In women posthysterectomy, documentation of concomitant oophorectomy should be obtained. It may be difficult to accurately determine the date of menopause, and often questions about menopausal symptoms may be helpful. Studies have indicated that long-term hormone replacement therapy (with estrogen and progesterone) can increase risk for breast cancer.

Previous personal history of breast cancer increases risk for subsequent breast cancer by approximately 0.7% per year. A previous breast biopsy also increases risk although to a much smaller extent, and this risk is further elevated if the pathology includes atypical hyperplasia or lobular carcinoma in situ. Table 48.1 lists the pathologic classification of benign breast disease and the risk associated with each category. A family history of breast or ovarian cancer consistent with genetic or inherited breast cancer significantly increases risk. A history of prior thoracic irradiation in women in their second and third decades of life carries a risk of subsequent breast cancer of approximately 35% by age 40. A summary of risk factors is listed in Table 48.2. It is important to note, however, that 60% of women with newly diagnosed breast cancer have no identifiable

risk factors. Thus, the decision to evaluate a breast abnormality should not depend on the presence or absence of risk factors. Moreover, the presence or absence of risk factors does not influence the probability that a breast abnormality is malignant.

TABLE 48.1 Pathologic Classification of Benign Breast Disease and Associated Risk

Lesion	Relative Risk
Nonproliferative Breast Disease (No Increased Risk)	**None**
Cysts and apocrine metaplasia	
Duct ectasia	
Mild ductal epithelial hyperplasia	
Calcifications	
Fibroadenoma	
Proliferative Breast Disease (Mild Increased Risk)	**1.5–2.0-fold**
Sclerosing adenosis	
Radial and complex sclerosing lesions	
Florid ductal hyperplasia	
Benign intraductal papilloma without atypia	
Flat epithelial atypia	
Proliferative Disease with Atypia (Moderate Increased Risk)	**4.0-fold**
Atypical ductal hyperplasia	
Atypical lobular hyperplasia	
Lobular carcinoma in situ	**6–10-fold**

The physical examination should be performed with respect for patient privacy and comfort without compromising the complete evaluation. The examination begins with inspection. The breasts are visually observed and compared with the patient upright for any obvious masses, asymmetries, or skin changes. The nipples are also inspected for the presence of retraction,

inversion, or excoriation. Thereafter, patients are then asked to place their hands on their hips and then raise their arms above their head for a more careful inspection of the lower half of the breasts. This maneuver also highlights any subtle skin retraction that is not readily visible with the arms in the relaxed position. Palpation of the regional nodes should then follow to include the cervical, supraclavicular, infraclavicular, and axillary nodal basins bilaterally. Finally, the breast is palpated in a systematic manner with the patient upright with arms relaxed and then again in the supine position with the ipsilateral arm raised above the head.

TABLE 48.2 Risk Factors for Breast Cancer

Gender

Age

Genetic risk factors
- *BRCA1* or *BRCA2* gene mutation
- Bannayan–Riley–Ruvalcaba syndrome
- Li–Fraumeni syndrome
- Cowden syndrome

Family history of breast cancer

Personal history of breast cancer

Previous breast biopsy
- Proliferative breast disease without atypia
- Atypical hyperplasia
- Lobular carcinoma in situ

Previous thoracic radiation

Endocrine risk factors
- Early menarche
- Late menopause
- Late parity
- Nulliparity
- Long-term hormone replacement with estrogen and progesterone

Lifestyle factors
- Alcohol
- Obesity

A dominant mass is defined as being three-dimensional (3D), distinct from surrounding tissues, and asymmetric relative to the contralateral breast. True masses will persist throughout the menstrual cycle. If a dominant mass is identified, it should be measured, and its location, mobility, and character should be documented in the medical record. If uncertainty remains regarding the significance of an area of nodularity in the absence of a dominant mass in a premenopausal woman, a repeat examination at a different point in the menstrual cycle may clarify the issue.

In patients who present with nipple discharge, the nipple discharge is

often elicited during palpation of the breast. The character, color, and location of the discharging duct or ducts should be documented. If the discharge is not grossly bloody, a Hemoccult test may be used to detect occult blood. Pathologic discharge, which is defined as unilateral, uniduct, spontaneous, and/or bloody discharge, should be evaluated initially with breast imaging and followed by surgical duct excision.

Male breast cancer is uncommon, accounting for less than 1% of all breast cancers. The most common male breast complaint is gynecomastia. Gynecomastia is a benign hypertrophy of breast tissue. In older men, the hypertrophy is often unilateral. The patient usually presents with a discoid mass symmetrically placed beneath the areola, which may be tender to palpation. There are a myriad of benign causes of gynecomastia. Many medications are associated with gynecomastia. Gynecomastia is easily distinguished from breast cancer in that breast cancer is asymmetrically located beneath or next to the areola, and may be fixed to the overlying dermis or the pectoral fascia (Fig. 48.1). If breast cancer is suspected, imaging followed by biopsy should be pursued.

IMAGING

Patients referred from another facility should provide prior imaging so that the consulting surgeon may examine the images as part of the complete patient evaluation. Imaging of inadequate quality should be repeated, and additional images should be performed as necessary depending on the specific complaint.

Mammography

Breast cancer incidence increased between 1980 and 1987 due to the widespread use of screening mammography. Since mammography can detect lesions too small to be palpated, cancers can be diagnosed 1 to 3 years earlier than would have been in the absence of screening.

Mammography allows for a description of breast density defined by the Breast Imaging Reporting and Data System (BI-RADS) outlined in Table 48.3. Breast density is not discernable by palpation on physical examination. Instead, density is a mammographic indicator of the amount of glandular and connective tissue relative to fatty tissue in the breast. Breast density is relevant since it is a risk factor for developing breast cancer. Women with very high breast density (BI-RADS Category D) (Fig. 48.2A) have a 4- to 6-fold increased risk of breast cancer compared to

women with the least dense breasts (BI-RADS Category A) (Fig. 48.2B). A number of factors influence breast density, such as age, menopausal status, the use of certain drugs (hormone replacement therapy), pregnancy, and genetics. The percentage of breast density is generally lower among women with higher body weight due to the higher proportion of fatty tissue, and usually breast density decreases with age. While women with denser breasts have been shown to be at increased risk for breast cancer, the etiology remains unclear and researchers often disagree. It is acknowledged that the sensitivity of a mammographic examination for the detection of breast cancer is decreased in patients with dense breast tissue. Due to this, some states have laws requiring that women be informed if they have heterogeneously (Category C) or extremely dense (Category D) breast compositions. At this time, however, there is no expert consensus on what other imaging tests, if any, should be done in addition to annual screening mammography for breast cancer screening in average risk women with dense breasts.

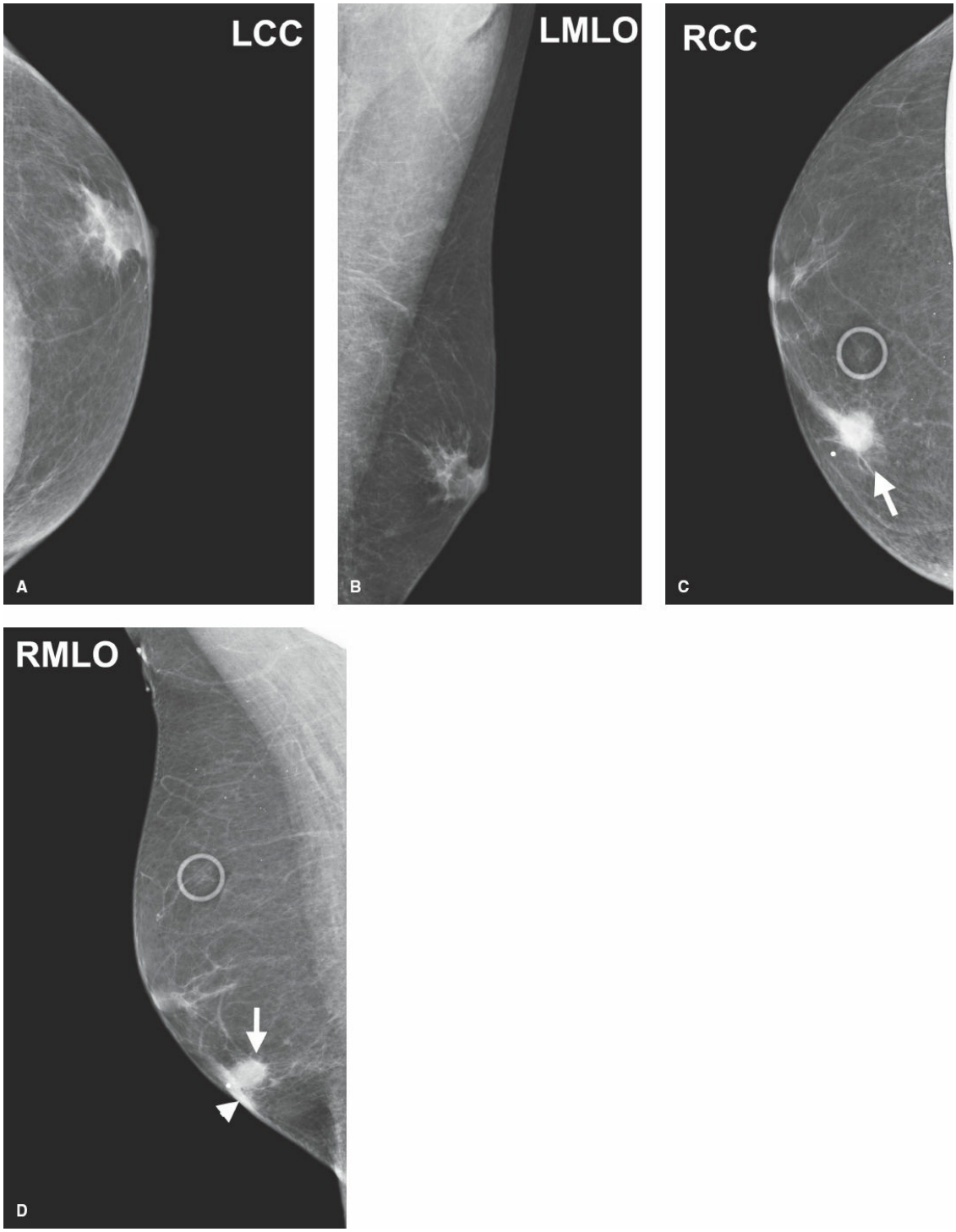

Figure 48.1. Left craniocaudal (LCC) (**A**) and left mediolateral oblique (LMLO) (**B**) views demonstrate left subareolar focal asymmetry, male gynecomastia. Right CC (RCC) (**C**) and right MLO (RMLO) (**D**) views demonstrate a well-circumscribed hyperdense round mass (*arrows*) with associated skin thickening (*arrowhead*), invasive ductal carcinoma. Radiopaque skin markers denote nevi.

TABLE 48.3 BI-RADS Breast Composition Categories

	Description
A	The breasts are almost entirely fatty.
B	There are scattered areas of fibroglandular density.
C	The breasts are heterogeneously dense, which may obscure small masses.
D	The breasts are extremely dense, which lowers the sensitivity of mammography.

Reprinted with permission of the American College of Radiology (ACR). No other representation of this material is authorized without expressed, written permission from the ACR. Refer to the ACR website at www.acr.org/Quality-Safety/Resources/BIRADS for the most current and complete version of the BI-RADS® Atlas.

Screening mammography is used to detect cancer in asymptomatic women when cancer is not suspected. It usually consists of at least two views of each breast in the craniocaudal (CC) and mediolateral oblique (MLO) projections (Fig. 48.3).

The American Cancer Society recommendations on breast cancer screening include:

Annual mammograms starting at age 40
Clinical breast examination (CBE) about every 3 years for women in their 20s and 30s and annually for women 40 and over
Breast self-examination (BSE)—Women should have baseline knowledge of how their breasts normally look and feel in order to report any breast changes to a health care provider right away.
Diagnostic mammography is used to evaluate patients with breast symptoms or complaints, such as nipple discharge or a palpable mass. It is also valuable in the work-up of patients who have had abnormal results on screening mammography. The diagnostic mammographic examination is tailored to the patient's specific abnormality. The

radiologist is present on site during performance of diagnostic mammography to facilitate the assessment process.

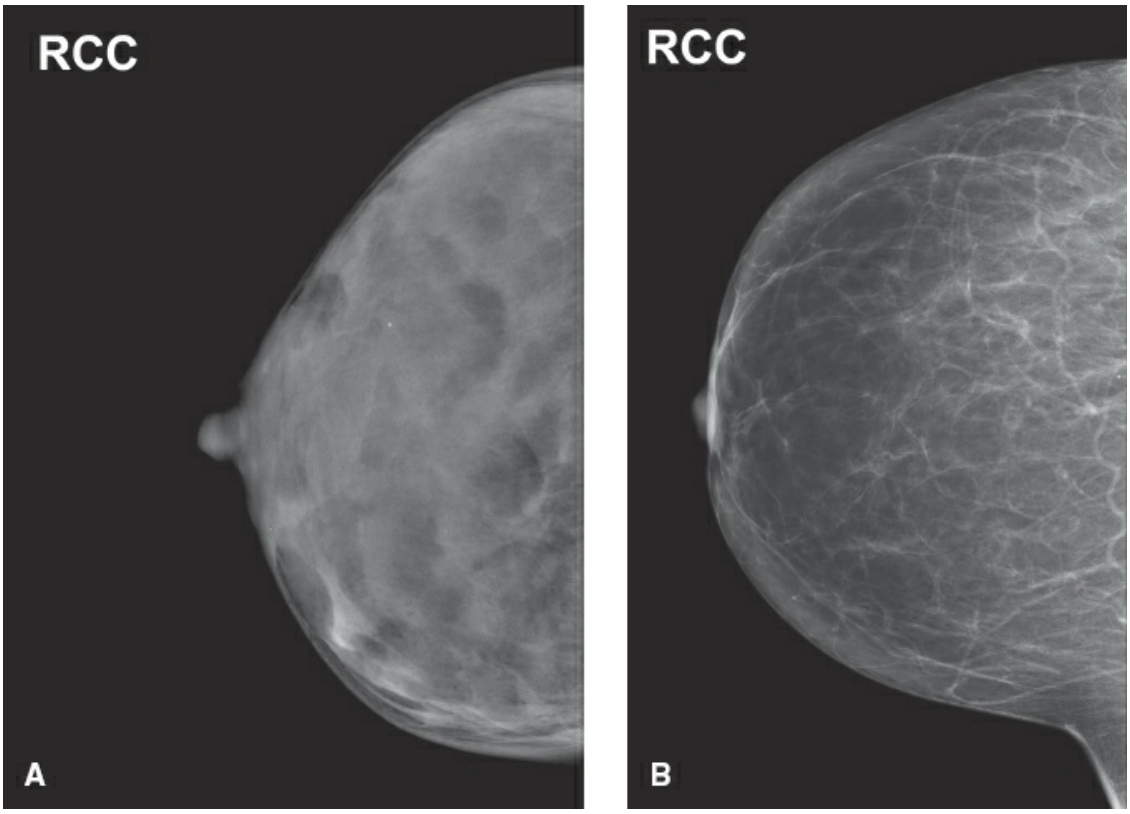

Figure 48.2. A. Right craniocaudal (CC) view demonstrates an extremely dense breast. **B.** Right CC view demonstrates an almost entirely fatty breast.

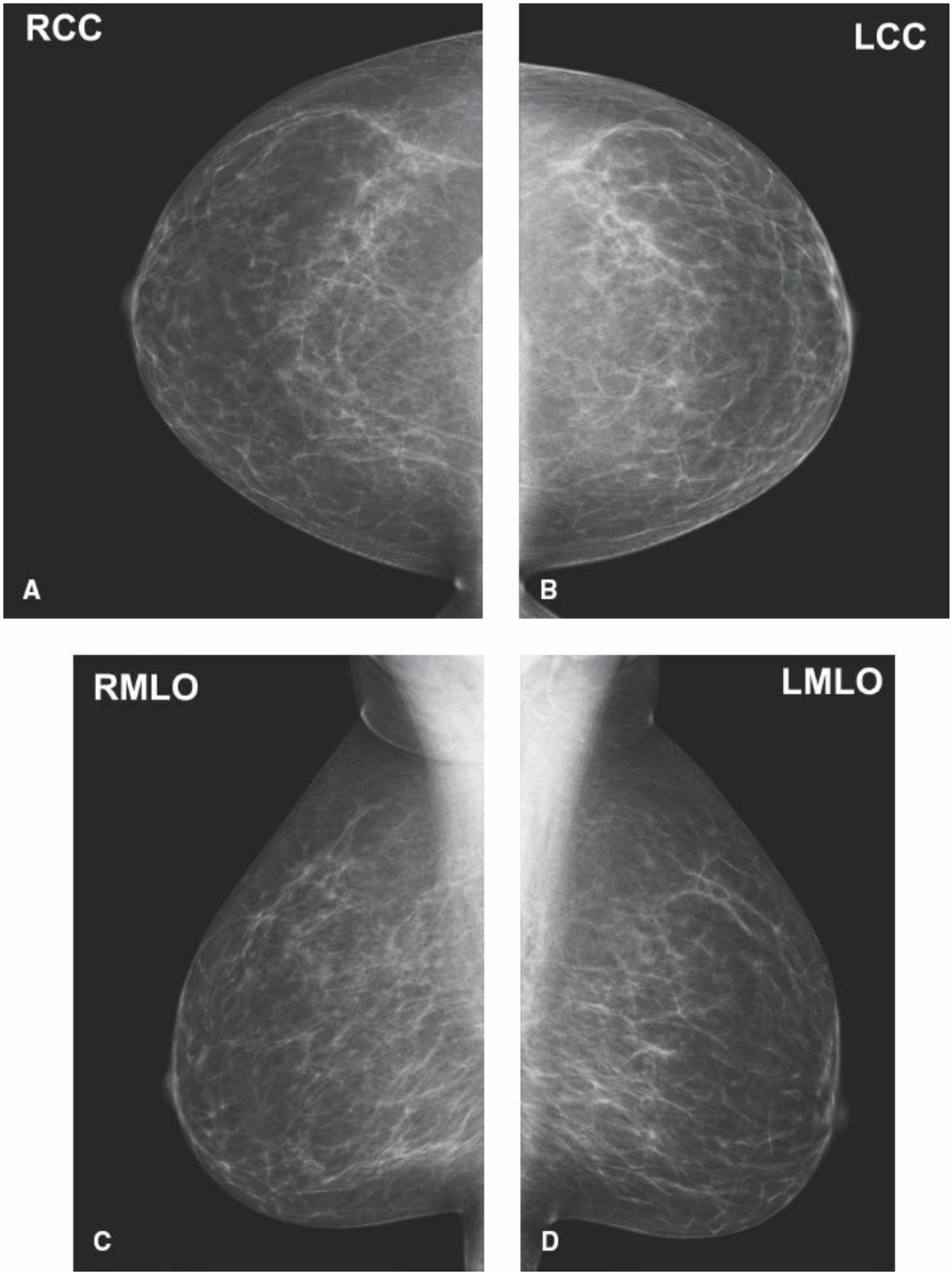

Figure 48.3. Screening mammography consists of craniocaudal (CC) (**A, B**) and mediolateral oblique (MLO) (**C, D**) views. Markers denoting view and laterality are placed near the axilla.

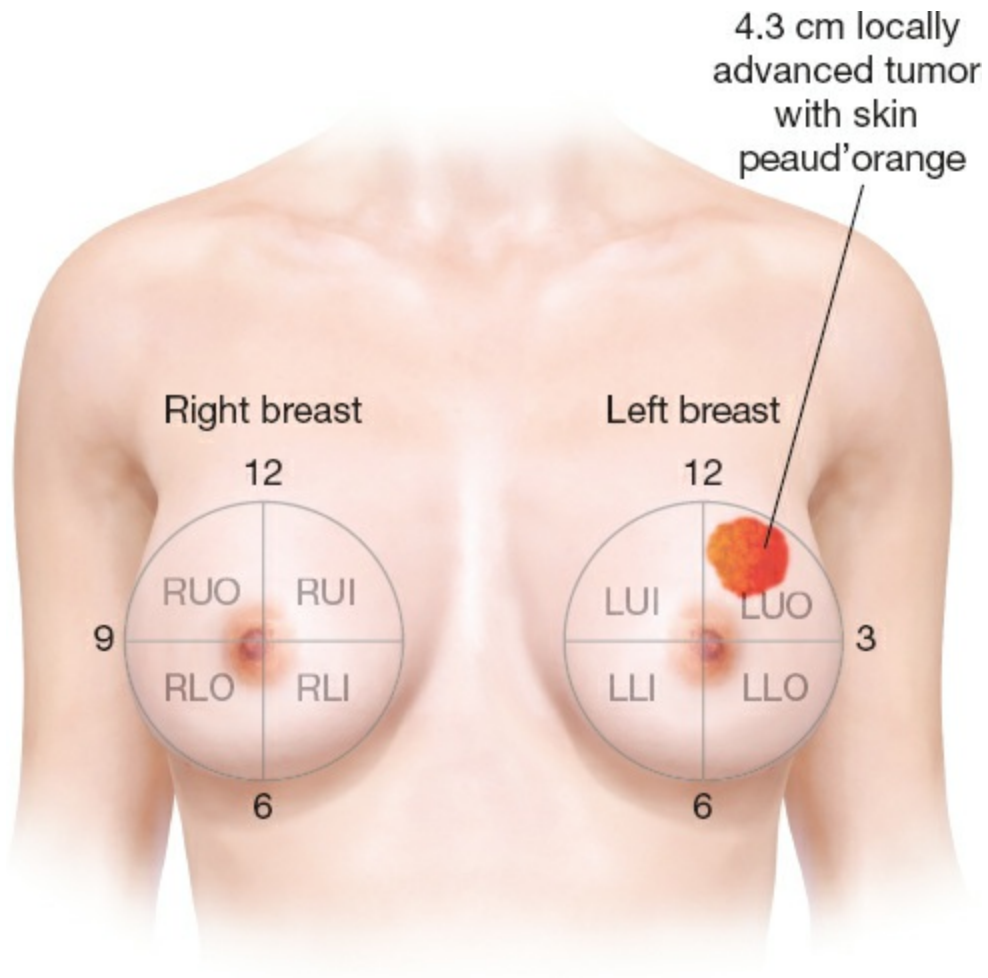

Figure 48.4. Lesions are localized by an o'clock designation with the physician facing the patient.

Screen-film mammography records the image on film, and digital mammography records the image in digital format that can be archived in a picture archiving and communication system (PACS). Images are reviewed for masses, asymmetries, calcifications and changes over time when temporal data is available. Right and left views are examined side by side so that asymmetries can be detected. A magnifying glass or magnification tool may be necessary for a thorough evaluation. The description of the abnormality should include the location of the lesion including laterality, quadrant, (o'clock) position (with the physician facing the patient) (Fig. 48.4), distance from the nipple, and depth.

After analyzing the mammographic images, radiologists describe the finding and subsequently classify the finding into a final assessment category. The BI-RADS final assessment classification was developed by the American College of Radiology to standardize mammographic reporting. The BI-RADS classification is listed in Table 48.4. Follow-up

recommendations are made based on the final assessment category. BI-RADS 0 or “incomplete” final assessments require additional imaging to further assess an abnormality seen on screening examinations. Magnification views, spot compression views, or other additional views are used to define or resolve the abnormality. Spot compression may be used to differentiate an area of summation artifact from a true abnormal lesion. Magnification views may be used to more clearly evaluate calcifications (Fig. 48.5). These techniques may also be used together.

Most mammographically visible cancers present as masses, calcifications, architectural distortion, or a combination of the three. Masses and calcifications account for about 90% of all breast cancers. A mass is a space-occupying lesion that can be detected in two projections. If a finding is only seen on one projection, and has concave margins it is referred to as an asymmetry. An asymmetry may or may not prove to be a real finding after directed diagnostic imaging. Masses are characterized by their shape, margin, density, and associated features (calcifications, distortion, and skin or nipple findings) to determine the probability of malignancy.

The shape of a mass can be described as round, oval, or irregular (Fig. 48.6A–C). Round or oval masses are usually benign. Masses that are irregular imply a greater probability of malignancy. Margin assessment is important because of the infiltrative nature of most breast cancers. Margins can be described as circumscribed, obscured, microlobulated, indistinct, or spiculated. A circumscribed margin that sharply delineates a mass from the surrounding tissue is commonly a benign finding, as seen in a fibroadenoma (Fig. 48.7) or a cyst. A mass with spiculated margins is highly suspicious for malignancy (Fig. 48.8).

TABLE 48.4 BI-RADS Assessment Categories

Assessment	Management	Likelihood of Cancer
Category 0: Need additional imaging evaluation and/or prior mammograms for comparison	Recall for additional imaging and/or comparison with prior examination(s)	N/A
Category 1: Negative	Routine mammography screening	Essentially 0% likelihood of malignancy
Category 2: Benign	Routine mammography screening	Essentially 0% likelihood of malignancy
Category 3: Probably benign	Short-interval (6-month) follow-up or continued surveillance mammography	>0% but ≤2% likelihood of malignancy
Category 4: Suspicious	Tissue diagnosis	>2% but <95% likelihood of malignancy
Category 5: Highly suggestive of malignancy	Tissue diagnosis	≥95% likelihood of malignancy
Category 6: Known biopsy-proven malignancy	Surgical excision when clinically appropriate	N/A

Reprinted with permission of the American College of Radiology (ACR). No other representation of this material is authorized without expressed, written permission from the ACR. Refer to the ACR website at www.acr.org/Quality-Safety/Resources/BIRADS for the most current and complete version of the BI-RADS® Atlas.

Calcifications are a common mammographic finding. Most calcifications are not associated with malignancy. When identified, the shape or morphology, location, number, and distribution of the calcifications should be noted. Malignant-appearing calcifications are usually fine linear branching or fine pleomorphic. Malignant-appearing calcifications are usually in a grouped, linear, or segmental distribution (Fig. 48.5). Benign calcifications are more likely round, milk of calcium, rim or coarse popcorn-like calcifications (Fig. 48.9).

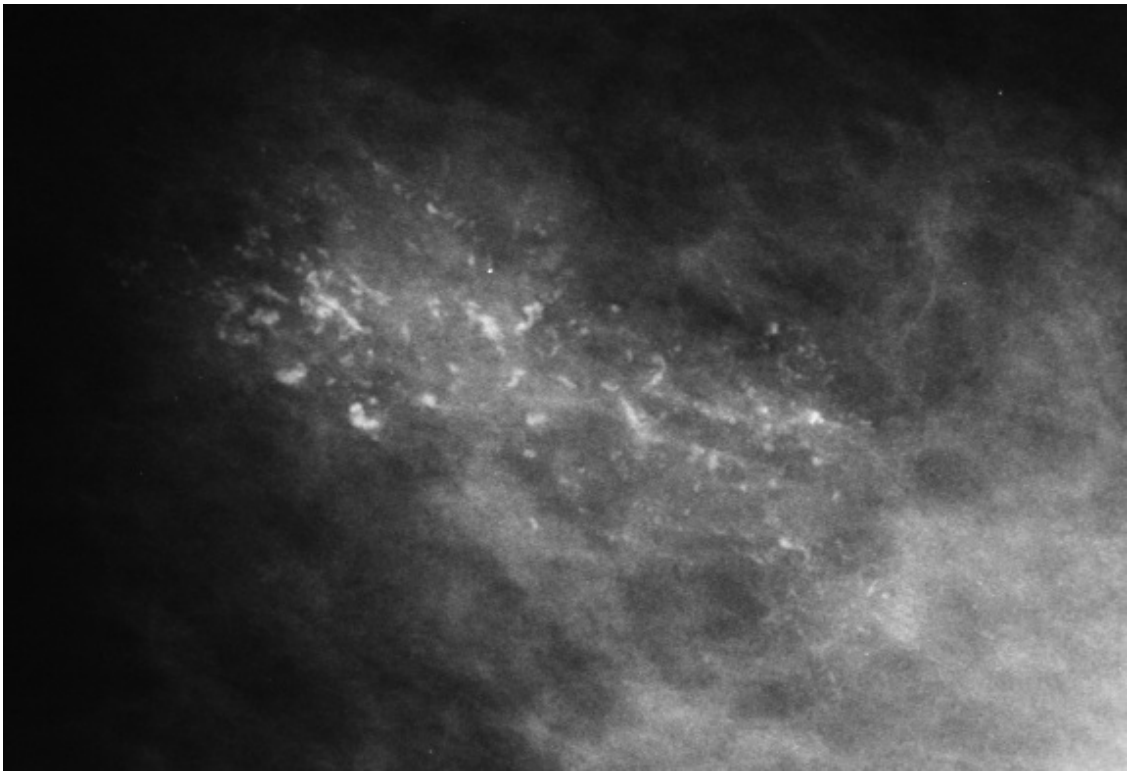

Figure 48.5. Magnification mediolateral (LMML) view reveals fine-linear branching and fine pleomorphic calcifications in a segmental distribution, ductal carcinoma in situ (DCIS).

Fat necrosis is becoming more common and can potentially pose a challenge to clinicians and breast imagers. Fat necrosis results from accidental breast trauma or most commonly seen after surgery (lumpectomy, breast augmentation, or reduction) or radiation therapy. Fat necrosis can present as oil cysts, rim or dystrophic calcifications, focal asymmetries, calcifications, or even spiculated masses (Fig. 48.10). Early evolution of fat necrosis may prove challenging and prompt a biopsy or short-term follow-up.

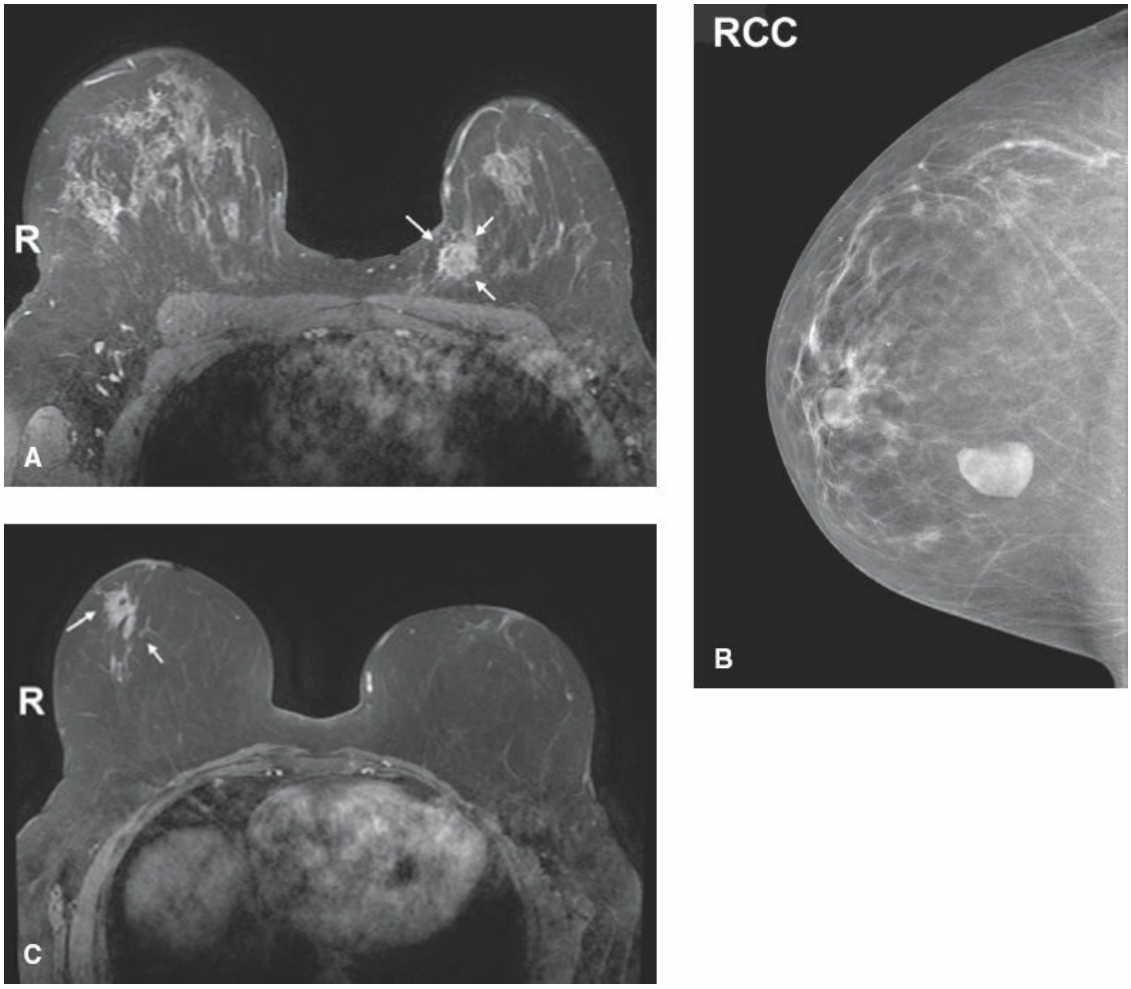

Figure 48.6. Mass shape classification. **A.** Axial T1 fat saturated image demonstrates a round mass in the left upper inner breast with microlobulated margins, invasive medullary carcinoma. **B.** Right craniocaudal (CC) view demonstrates an oval low density mass in the right medial breast with circumscribed margins, pseudoangiomatous stromal hyperplasia (PASH). **C.** Axial T1 fat saturated image demonstrates an irregular enhancing mass with spiculated margins, invasive ductal carcinoma.

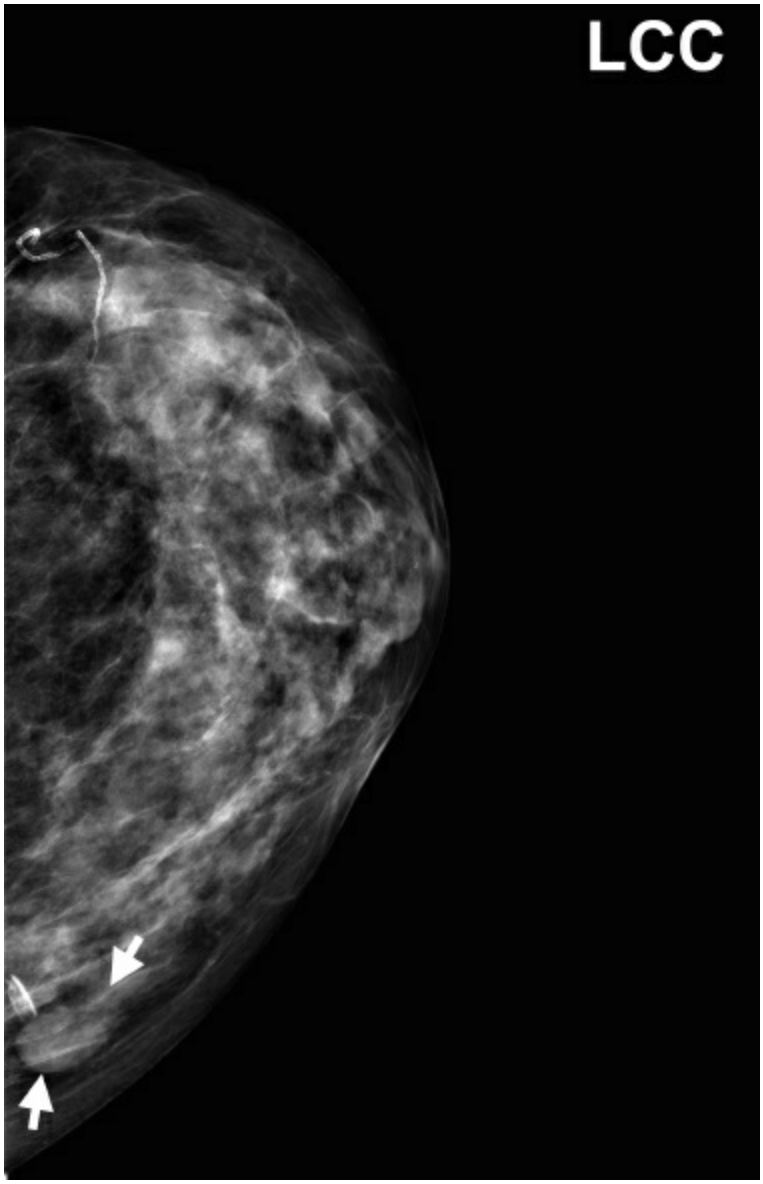

Figure 48.7. Left craniocaudal (CC) view shows an equal dense oval circumscribed mass (*arrows*) in the medial breast, fibroadenoma.

Ultrasound

Ultrasound was initially used to differentiate solid masses from cystic masses, but it has become an important adjunct to mammography and is an excellent method for guiding interventional procedures. Accurate breast ultrasonography requires high-resolution real-time ultrasound equipment that is properly maintained and calibrated. A 7-MHz linear array transducer is the minimum frequency that can be used for ultrasound of the breast, although 10- to 15-MHz linear transducers are preferable. Operators should be trained in breast anatomy and pathology, as well as

basic ultrasound technology and mammography. The patient is positioned so that the depth of tissue penetration needed for imaging by the ultrasound beam is minimized.

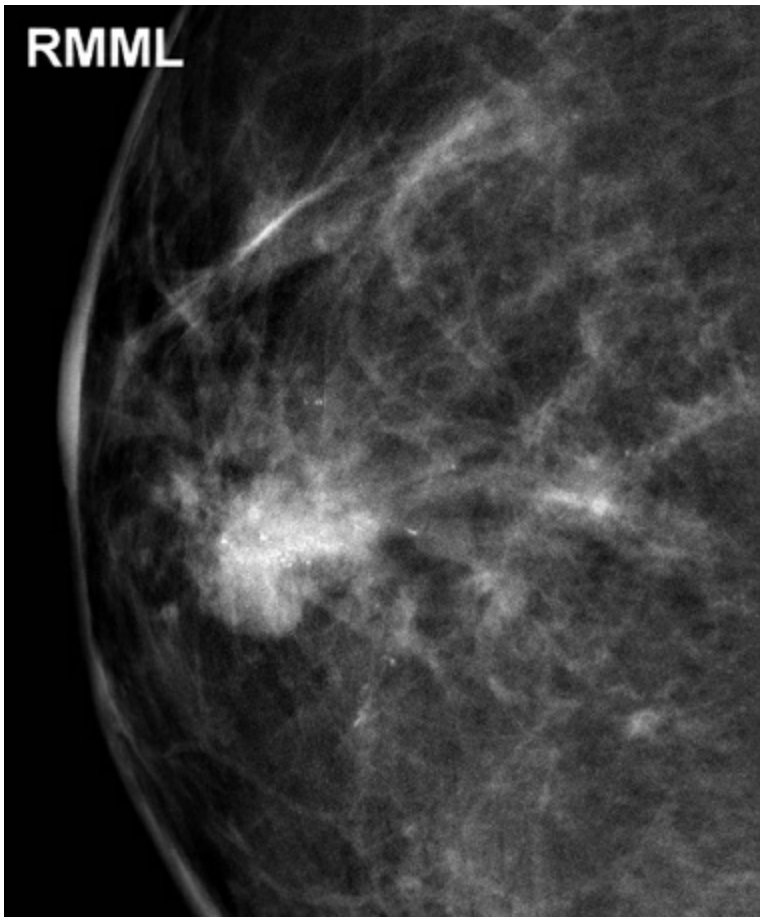

Figure 48.8. Right magnification mediolateral (RMML) view demonstrates a round hyperdense mass with spiculated margins and associated pleomorphic calcifications, invasive ductal carcinoma (IDC).

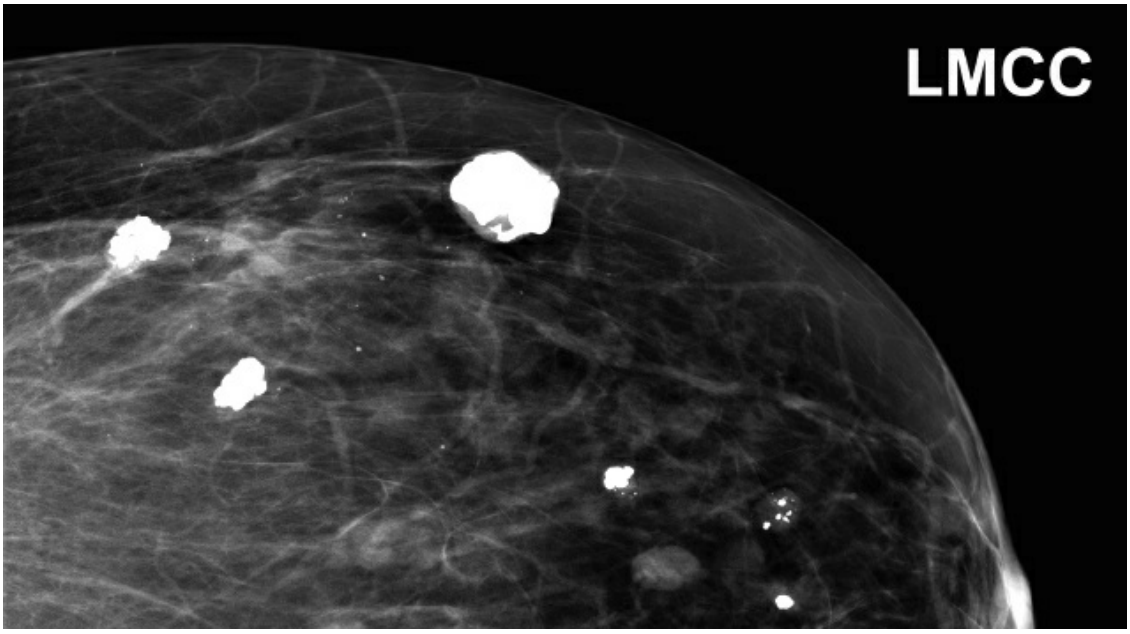

Figure 48.9. Left magnification craniocaudal (LMCC) view demonstrates multiple oval, well-circumscribed masses some with coarse-popcorn calcifications, hyalized fibroadenomas. Additional scattered round benign calcifications are noted.

Cystic masses are readily identified with ultrasound. Cysts are anechoic, oval, or round lesions with well-circumscribed margins that lack internal vascularity (Fig. 48.11). Because the cyst contents will transmit the ultrasound wave, posterior acoustic enhancement is frequently visualized. When the above features are present, the diagnostic accuracy of ultrasound in evaluating a simple cyst approximates 100%. Solid masses may have benign or malignant features. Malignant features of a solid mass on ultrasound include irregular margins, hypoechoic to the surrounding fatty lobules, and posterior acoustic shadowing. Malignant-appearing masses usually have a vertical growth pattern that disrupts the tissue planes (“taller than wide”) (Fig. 48.12). Benign features include ellipsoid shape, hyperechogenicity, and smooth, well-circumscribed margins (Fig. 48.13).

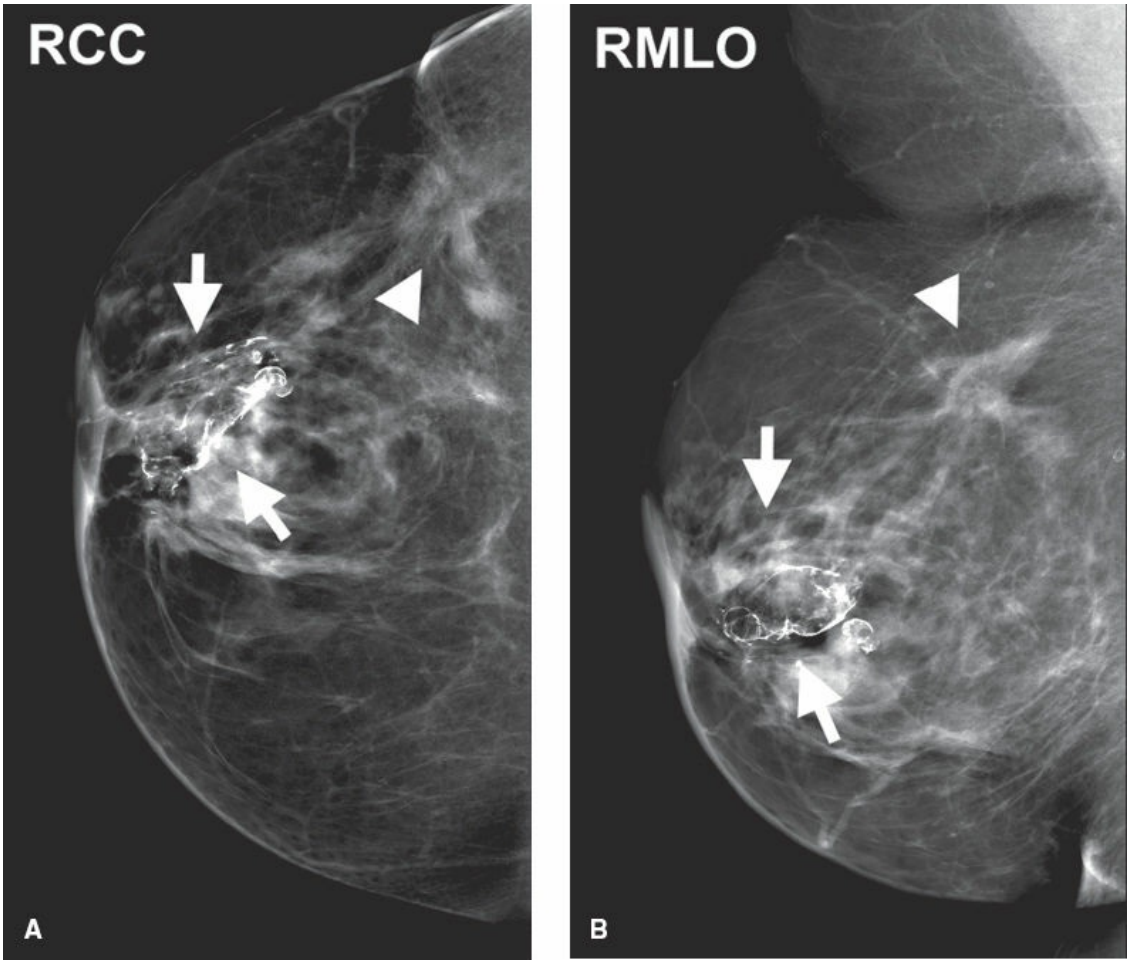

Figure 48.10. Right craniocaudal (CC) (**A**) and mediolateal oblique (MLO) (**B**) views demonstrate architectural distortion consistent with prior lumpectomy site (*arrowheads*) in the upper outer right breast and fat-containing architectural distortion with rim and dystrophic calcifications in the right subareolar breast, fat necrosis.

Ductography

Ductography is the injection of contrast into a discharging duct to identify a filling defect or other intraductal irregularity (Fig. 48.14). It can be useful in those presenting with nipple discharge without an underlying mass or mammographic or sonographic abnormality. If an abnormality is found, it may enable a directed excision of the presumed abnormality causing the discharge. A negative ductogram does not obviate the need for surgical excision of pathologic discharge.

Digital Tomosynthesis

Tomosynthesis is similar to mammography; however, it creates a 3D

picture of the breast using various projections obtained. In 2011, digital tomosynthesis was approved by the U.S. Food and Drug Administration (FDA) in combination with standard digital mammography; however, this radiographic technique is not yet considered the standard of care for breast cancer screening. Full field digital mammography depicts the breasts in two views; thus allowing for two-dimensional (2D) imaging that may allow for summation artifact that may increase recall rates and for tissue overlap that increases false-negative rates in patients with dense breasts. Digital tomosynthesis attempts to address some of these limitations. Multiple images of each breast are taken from several angles. The breast is positioned in the same way as conventional mammogram with appropriate compression. The tube moves in an arc around the breast while several images are taken over time. The information is then sent to a computer, where it is assembled to produce clear, highly focused 3D images throughout the breast. Single-institution studies have shown that adding tomosynthesis to mammography increases cancer detection and reduces false-positive results; however, there are limitations with tomosynthesis. Total radiation dose when tomosynthesis is added is approximately two times the current dose for digital mammography though still below the limits defined by the FDA.

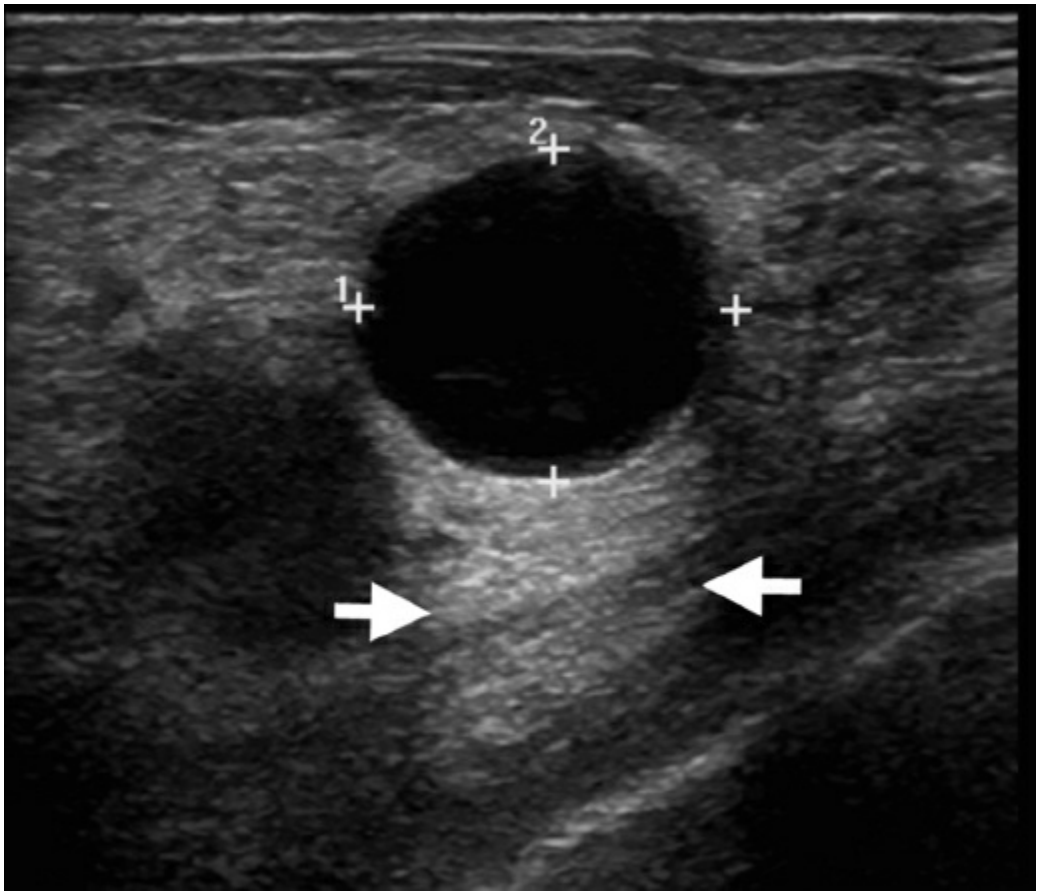

Figure 48.11. Grayscale ultrasound image demonstrates an anechoic round lesion with circumscribed margins (designated by calipers) and posterior acoustic enhancement (*arrows*), simple cyst.

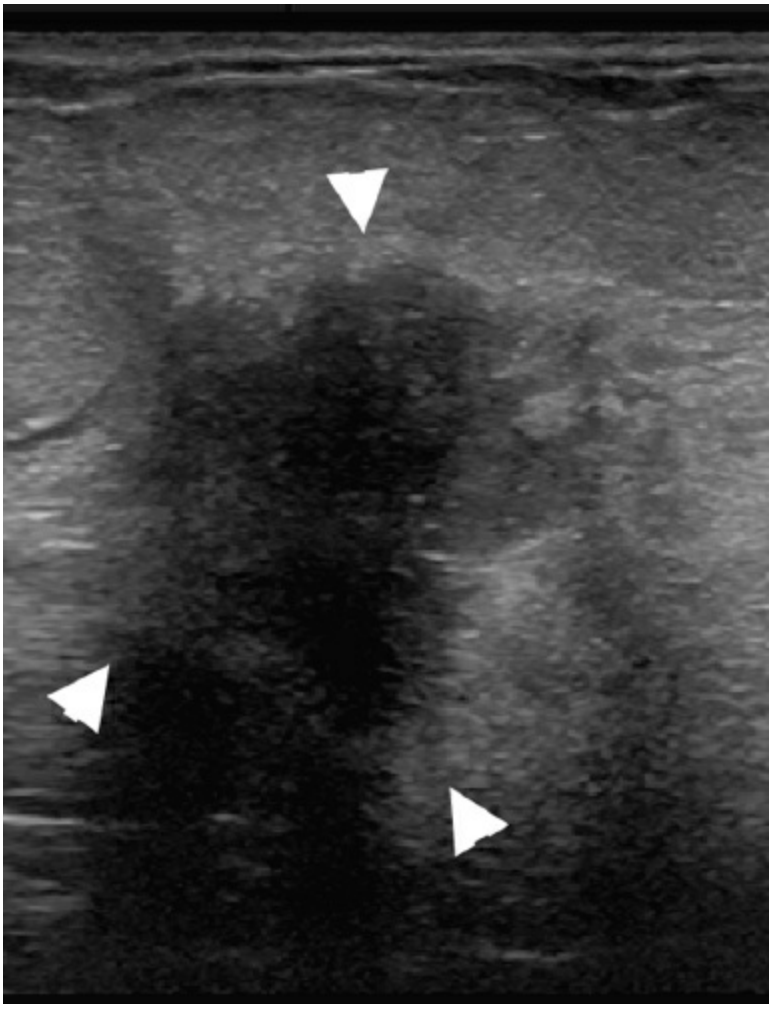

Figure 48.12. Grayscale ultrasound image demonstrates a hypoechoic irregular mass, taller than wide with posterior acoustic shadowing, invasive mammary carcinoma.

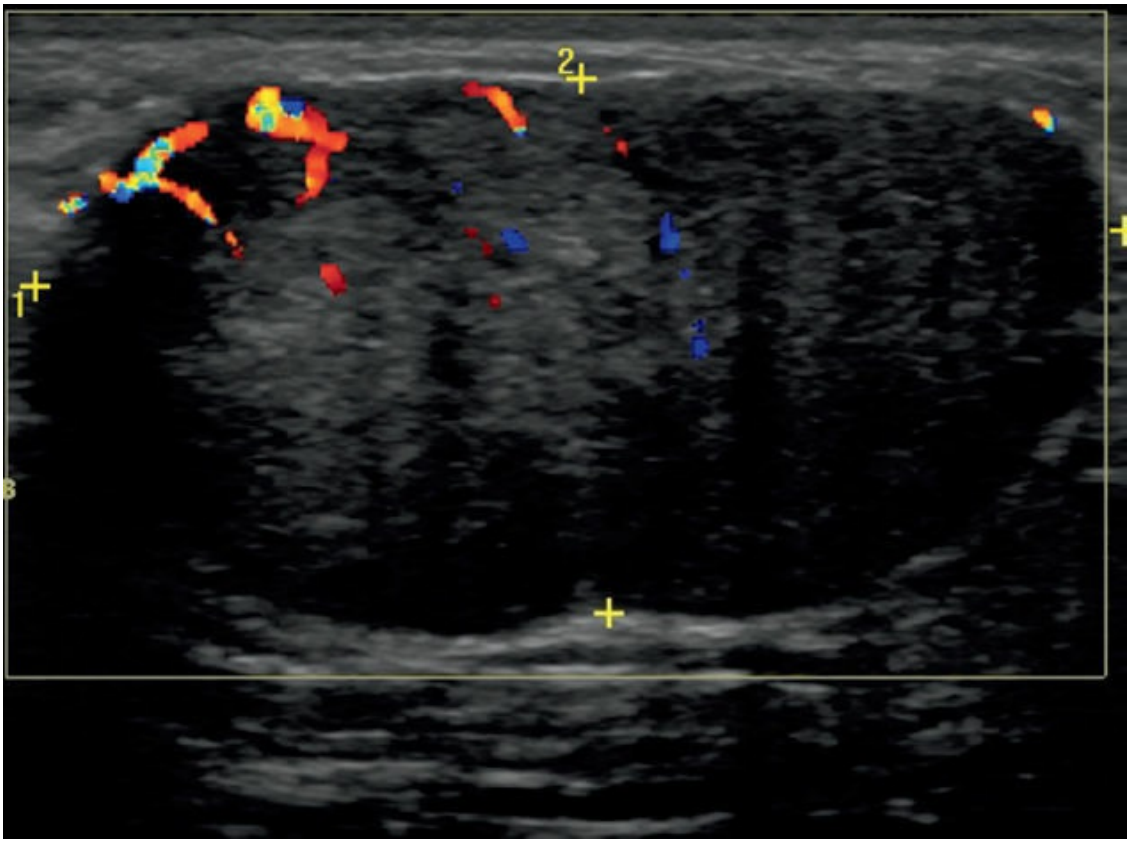

Figure 48.13. Color Doppler ultrasound image demonstrates an oval well-circumscribed hypoechoic mass with internal vessels, fibroadenoma.

Molecular Breast Imaging

Molecular breast imaging (MBI) is a nuclear medicine technique that utilizes small semiconductor-based γ-cameras in a mammographic configuration in order to provide high-resolution functional images of the breast. Current studies with MBI have used Tc-99m sestamibi, which is an approved agent for breast imaging. The scan procedure includes a single injection of 20 mCi Tc-99m sestamibi with imaging of the breast starting about 5 minutes postinjection. The breast is lightly compressed between two detectors, then two 10-minute images are obtained of each breast in the CC and MLO projections, total imaging time of 40 minutes or greater depending on breast size. MBI has shown promise with potential applications ranging from evaluation of the extent of disease to a role as an adjuvant in screening patients with dense breasts and or high-risk patients. The disadvantages of MBI, however, include the long imaging time and the radiation dose associated with the injection of the Tc-99m sestamibi.

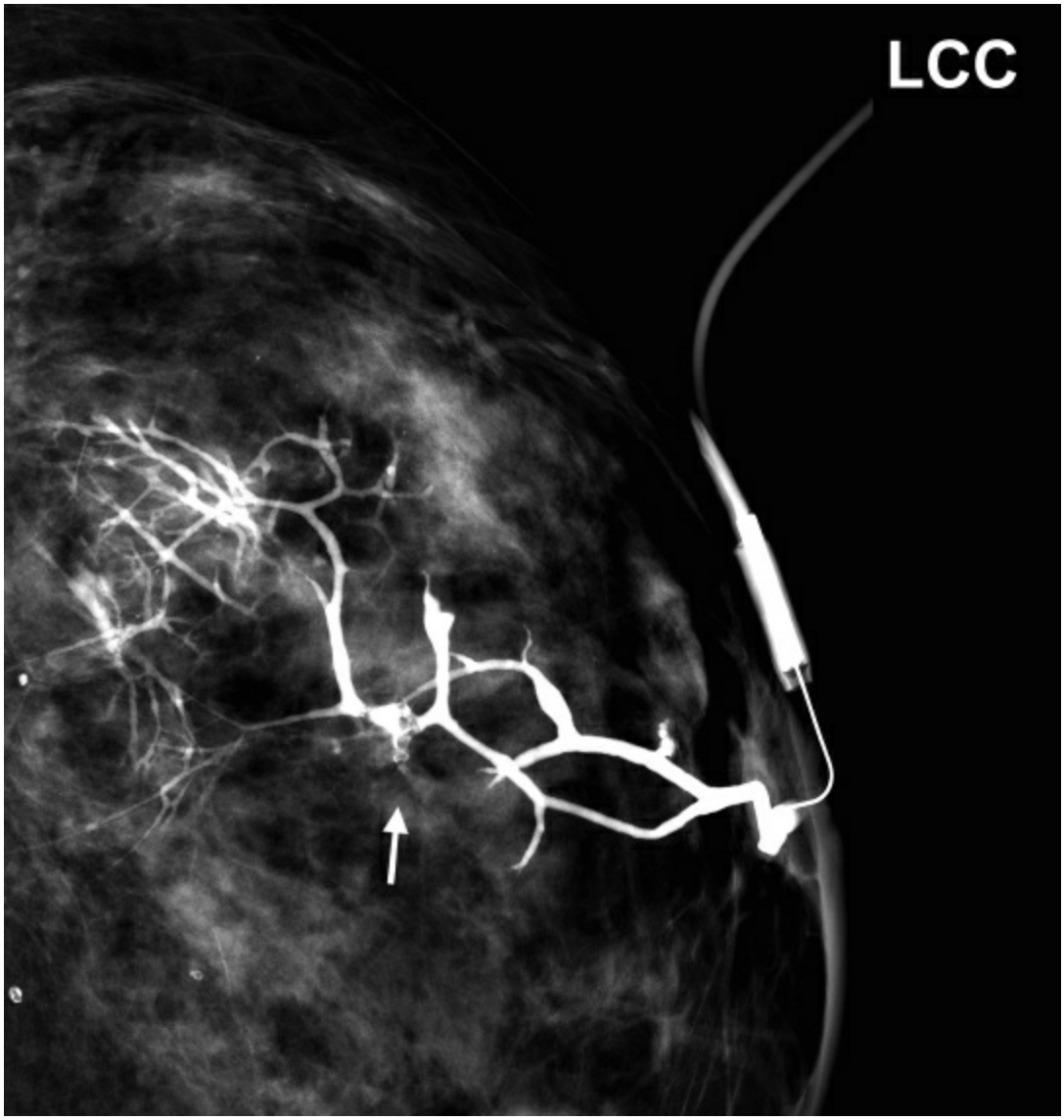

Figure 48.14. Left ductogram demonstrates an opacified ductal system with an intraductal filling detect (*arrow*), intraductal papilloma.

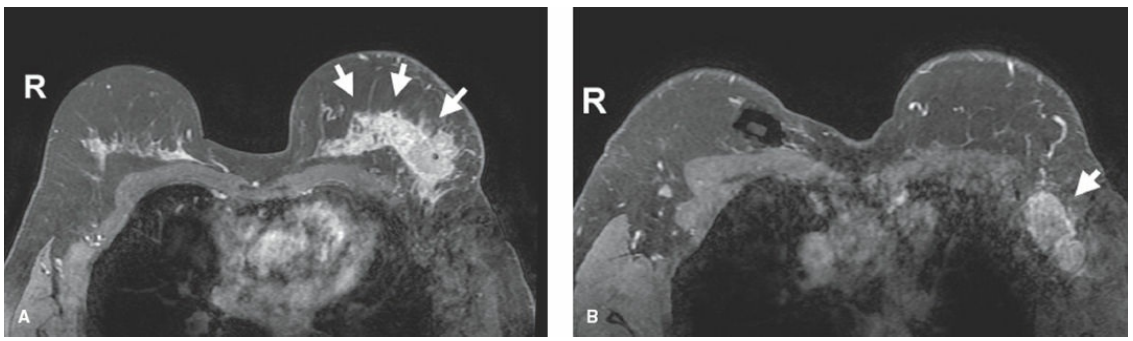

Figure 48.15. **A.** Axial T1 postcontrast fat saturated image demonstrates an enhancing irregular mass with indistinct margins and heterogeneous internal enhancement involving the left upper inner and upper outer quadrants (*arrows*), multicentric invasive

ductal carcinoma. **B.** Image through the axillary region demonstrates left axillary nodal involvement with extracapsular extension (*arrows*).

Magnetic Resonance Imaging

Magnetic resonance imaging (MRI) is being used with increasing frequency for screening and diagnosis of breast cancer in certain cases. While mammography remains the "gold standard," MRI is emerging as an important modality for evaluating breast disease. MRI has several advantages. There is no ionizing radiation to the patient with MRI. MRI is not limited by breast density and is an excellent tool for the screening of young women with increased risk for the development of breast cancer. Breast MRI is useful is determining extent of disease (Fig. 48.15) in certain patients with breast cancer and may also be a valuable tool in determining response to neoadjuvant therapy in certain patients. MRI allows for assessment of silicone implant integrity. In patients with indeterminate mammographic or ultrasonographic findings, MRI may be used for problem solving or clarification of imaging but should not replace biopsy for clinically suspicious lesions. Disadvantages of MRI are cost, limited availability, and specificity resulting in false positive biopsies. Patients with MRI-incompatible implantable devices, certain metallic clips, or prostheses may not undergo MRI. MRI should be performed in a breast imaging center with a 1.5-T magnet or greater. Patients lie prone with the breasts suspended in a dedicated breast imaging coil. Patients who are claustrophobic may require sedation prior to examination. Images are obtained before and after the administration of gadolinium, an MRI-contrast agent. The images are then evaluated for breast abnormalities with evaluation of enhancement and kinetic curves. Lesions suspicious for cancer will have malignant morphologic features with suspicious enhancement characteristics (Fig. 48.16).

DIAGNOSTIC BIOPSY

Nonpalpable Lesions

The widespread use of mammography and other breast imaging has resulted in the detection of increasing numbers of suspicious but clinically occult lesions of the breast. Such lesions represent more than half of the detected cancers in screening clinics and account for a substantial

proportion of breast tumors investigated with biopsy. Nonpalpable breast lesions are generally discovered on routine screening mammography, or incidentally with computed tomography or MRI performed for other reasons. Biopsy of these nonpalpable lesions can be performed utilizing various methods of image guidance.

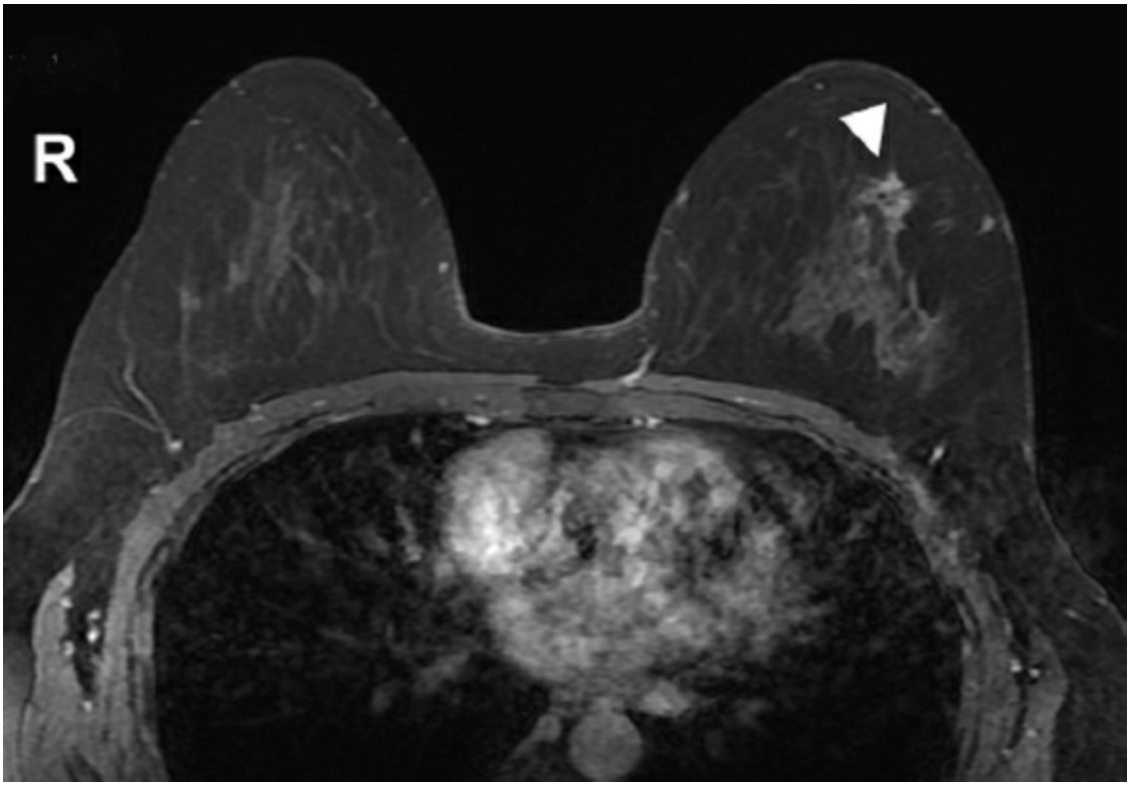

Figure 48.16. Axial T1 postcontrast fat saturated image demonstrates a heterogeneously enhancing irregular mass with indistinct margins in the left upper outer breast (*arrowhead*), invasive ductal carcinoma.

Aspiration

A simple cyst is a common finding and thought to arise from dilation of the terminal duct lobular units. Simple cysts diagnosed with ultrasound need not be aspirated unless the cyst causes the patient pain or anxiety regarding the finding. If the fluid aspirated is greenish or yellow-brown and the mass resolves sonographically, a benign diagnosis can be virtually confirmed and the fluid may be discarded. Follow-up is necessary within 4 to 6 weeks to ensure that the cyst has not recurred. Biopsy may be indicated if the cyst recurs. If the fluid aspirated is bloody, cytologic analysis should be performed to rule out malignancy, which occurs in a very small percentage of cases. Cysts that yield bloody fluid should not be

aspirated completely as the cyst may be difficult to localize either by physical examination or by imaging localization as histologic sampling is usually required in this situation. Complicated cysts, as defined by thin septations, debris within the cyst, rim enhancement (Fig. 48.17), or a cluster of microcysts may require short-term follow-up or aspiration for cytology or histologic biopsy as indicated. A solid component may indicate a papillary lesion and a cystic-solid lesion should undergo tissue diagnosis with biopsy. In addition, a presumed simple or complicated cyst that does not resolve with aspiration necessitates tissue diagnosis as well.

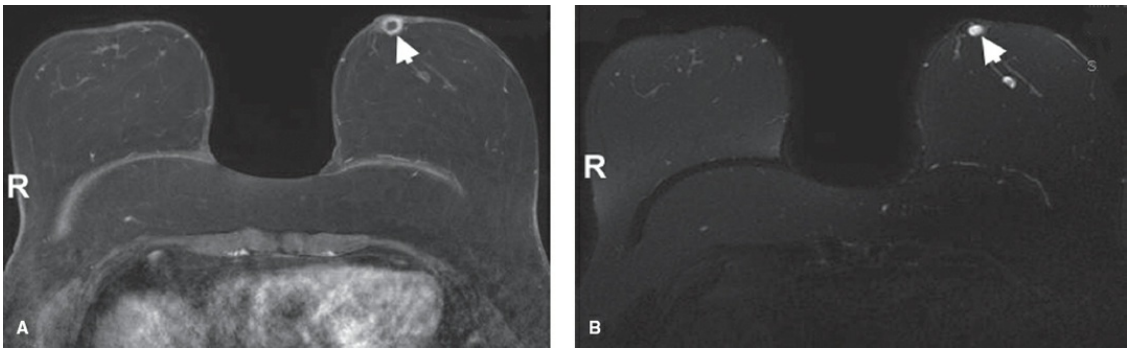

Figure 48.17. A. Axial T1 postcontrast fat saturated image demonstrates a rim-enhancing fluid collection at the base of the nipple suggesting inflammatory cyst versus abscess. **B.** Axial T2 image reveals increased T2 signal centrally consistent with fluid. Aspiration revealed an acute abscess.

Fine Needle Aspiration Biopsy

Cytologic analysis of a solid mass by fine needle aspiration (FNA) biopsy can be obtained rapidly, and often the patient can be informed of the results the same day (Fig. 48.18). The technique can be performed using imaging guidance or by palpation. The diagnostic accuracy of FNA biopsy of breast masses approximates 80%. When the specimen is properly prepared and reviewed by an experienced cytopathologist, the false-positive result is rare. False-negative results occur in approximately 15% of cases and thus a lesion that is suspicious clinically or by imaging must be further investigated with core biopsy. When physical examination, imaging, and FNA yield benign concordant results, the probability of a lesion being benign approaches 95%. Suspicious axillary lymph nodes may also be assessed with FNA during a breast cancer staging evaluation.

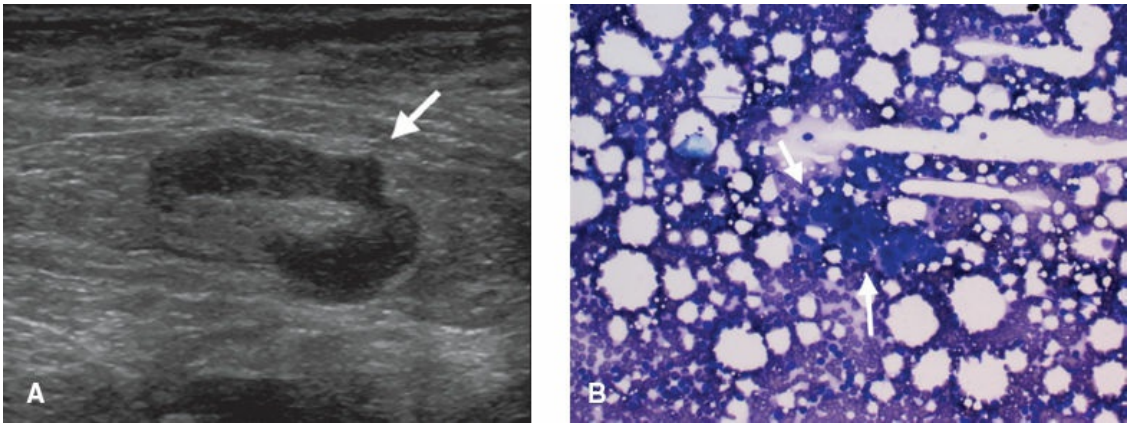

Figure 48.18. A. Grayscale ultrasound image reveals an axillary lymph node with focal nodularity (*arrow*). **B.** Cytologic specimen from ultrasound-guided fine needle aspiration revealed metastatic carcinoma (*arrows*).

Core Needle Biopsy

Core biopsy is the preferred method of evaluating an indeterminate or suspicious solid mass. Core biopsy obtains several tissue specimens for histologic evaluation. This can be performed using a variety of image-guided techniques or by palpation. The value of a core biopsy over an FNA is the ability to obtain hormone receptor and HER2 status, which is essential for personalized medicine.

Stereotactic Core Biopsy

Stereotactic mammographic devices use the principle of triangulation, which allows the precise location of a breast lesion to be determined in three dimensions. The procedure consists of placing the patient sitting upright or prone on the stereotactic table with the breast suspended through an opening in the table. The breast is compressed within the mammographic unit. A scout image is obtained and subsequently, two images are obtained and displayed on a digital monitor. The views obtained are taken at +15-degree and −15-degree angles from the plane perpendicular to the image receptor. These views are evaluated by the radiologist and the lesion is marked in both views. The needle is calibrated to the coordinates determined by the computer. The skin of the breast is sterilized, and the skin and underlying soft tissue are anesthetized with local anesthesia. A small incision is made in the skin using an 11-blade scalpel. A vacuum-assisted device is used to obtain several cores of breast tissue. Stereotactic biopsies performed for calcifications should be

evaluated with a specimen radiograph of the cores obtained to confirm the presence of the calcification within the sampled tissue (Fig. 48.19). A biopsy clip is then placed at the biopsy site via a hollow biopsy needle to facilitate locating the area should all of the imaging abnormality be removed with the biopsy. A postprocedure mammogram should be obtained to document clip placement and satisfactory sampling of the targeted lesion. Pathology results should be reviewed to determine concordance and appropriate follow-up. Patients who cannot lie prone or cannot tolerate breast compression may not be candidates for stereotactic breast biopsy. In addition, if the breast compresses to less than 3.5 cm, as in women with very thin breasts, stereotactic biopsy may not be technically feasible due to the possibility of piercing the opposite edge of the breast with the needle. The complication rate is low and most patients tolerate the procedure quite well. Most procedures can be completed within 30 minutes.



Figure 48.19. Specimen radiograph demonstrates vacuum-assisted core biopsies containing fine pleomorphic calcifications, ductal carcinoma in situ (DCIS).

Ultrasound-Guided Biopsy

Ultrasound-directed biopsy is performed for those lesions that are identified with ultrasound. Ultrasound-guided core biopsy is technically easier than stereotactic-guided biopsy as real-time imaging allows the surgeon or radiologist to visualize the biopsy as it occurs. Using sterile technique and local anesthesia, a small skin incision is made with an 11-blade scalpel and the needle is inserted into or abutting the lesion parallel to the chest wall. The position of the needle is visualized by ultrasound (Fig. 48.20). Once again, a handheld 11- or 8-gauge vacuum-assisted

needle or an 18- to 14-gauge spring-loaded automated large-core biopsy gun is used to remove several cores of tissue and in some instances completely remove the lesion. A biopsy clip is then placed at the biopsy site to facilitate locating the area should all of the visible abnormality be removed with the biopsy.

MRI-directed biopsy allows those lesions seen only with MRI to be biopsied under MRI guidance usually with vacuum assistance, and once again, it is important to place a postbiopsy clip to facilitate localization if surgical excision is indicated based on pathology.

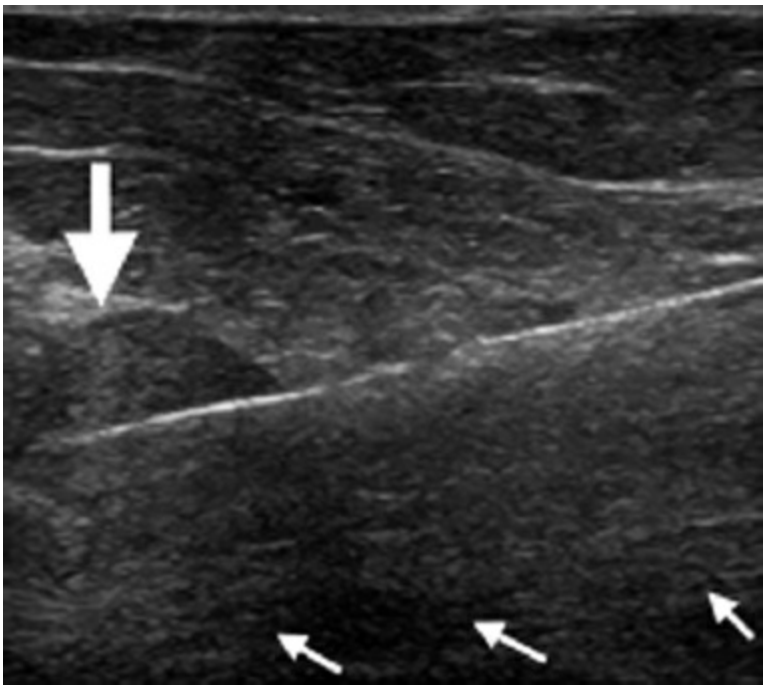

Figure 48.20. Grayscale ultrasound image demonstrates 16G needle through round hypoechoic mass (*large arrow*). Note needle is parallel to chest wall (*small arrows*).

If the core biopsy result is benign and is concordant with imaging findings, continued surveillance is acceptable. If the result is indeterminate or image-discordant, surgical excision is indicated to rule out malignancy. In addition, surgical excision is indicated for a core biopsy that demonstrates certain high-risk lesions including atypical hyperplasia (and some advocate for lobular carcinoma in situ as well) as the incidence of coexisting ductal carcinoma in situ or invasive carcinoma may be as high as 50% because of potential undersampling. Additional lesions requiring excisional biopsy also include atypical papillary lesions, mucocele-like lesions to exclude mucinous carcinoma, and cellular fibroepithelial lesions

to exclude phyllodes tumor.

Needle Localization Biopsy

Despite the frequency and simplicity of mammographic identification of suspicious lesions, intraoperative localization with subsequent adequate excision presents challenging technical problems because the shape and position of the breast during compression mammography may be quite different from that seen by the surgeon in the operating room. This has led to the development of several methods for preoperative localization of nonpalpable lesions. The aim of these methods is to facilitate complete removal of the lesion at first attempt excision while simultaneously minimizing the size of the resected specimen and shortening the duration of anesthesia. Radiologically guided, invasive preoperative localization of nonpalpable lesions is a safe, simple, and established procedure that allows for accurate and expeditious biopsy or excision. A specimen radiograph is mandatory to document the removal of the suspected area and to facilitate histologic examination because often these lesions remain nonpalpable even upon examination of the resected specimen.

The self-retaining wire localization was first described by Frank, Hall, and Steer. This technique utilizes a flexible, hooked wire within the localizing needle (Fig. 48.21). The hook lodges, ideally, within or adjacent to the suspicious lesion. The hook prevents dislodgement of wire within the breast prior to excision. The wire may be placed in most circumstances using mammography or ultrasound guidance, although MR-guided wire localization can also be performed. Mammographic images are obtained with the wire in place and are transported with the patient to the operating room for surgical excision. Incisions should be cosmetically placed using the natural skin lines, or Langer lines (Fig. 48.22). Utilizing the mammographic images, the surgeon begins the dissection. Some wires are labeled with regard to length or possess a change in caliber to direct the excision. The direction of the dissection and dimensions of the specimen are determined by the lesion size and the relative proximity of the wire to the lesion. If the incision does not pass though the entry site of the wire, it is necessary to identify the shaft of the wire proximal to the lesion and retract it into the wound (Fig. 48.23).

Once the specimen is removed, it should be oriented for the pathologist. A variety of orienting techniques can be used, including sutures or indelible ink (paint). The specimen is then sent for specimen radiograph to

conclusively confirm full excision of the suspicious/malignant lesion. The presence of the lesion within the specimen is documented mammographically and immediately relayed to the surgeon (Fig. 48.15B). The specimen should then be sent for pathologic analysis.

Radioactive Seed Localization

Radioactive seed localization (RSL) is an alternative for guiding surgical excision of nonpalpable breast lesions. The RSL uses radioactive seeds previously approved for the treatment of other cancers. Typically, iodine-125 and palladium-103 seeds between 200 and 300 μCi/seed are implanted into the breast lesion using a standard 18-gauge needle. The seeds can be implanted using mammography or ultrasound guidance, but seeds are not MRI compatible. The seeds are then surgically removed between 1 and 5 days postimplantation. In the operating room, radioactive seeds are located with appropriate instrumentation and removed with similar techniques surgeons use for sentinel lymph node biopsy. The advantages of RSL over wire implantation includes the bracketing of lesions and the postlocalization of mammograms is not impeded by wires, and procedure can be performed up to 5 days before surgery, minimizing schedule conflicts. The amount of radiation is similar to a screening mammogram. The seed or seeds are then disposed of in accordance with 10 CFR 35.92 or the equivalent Agreement State regulations. A successful radioactive seed program requires the combined efforts across multiple disciplines including surgery, pathology, radiology, radiation safety, and nuclear medicine.

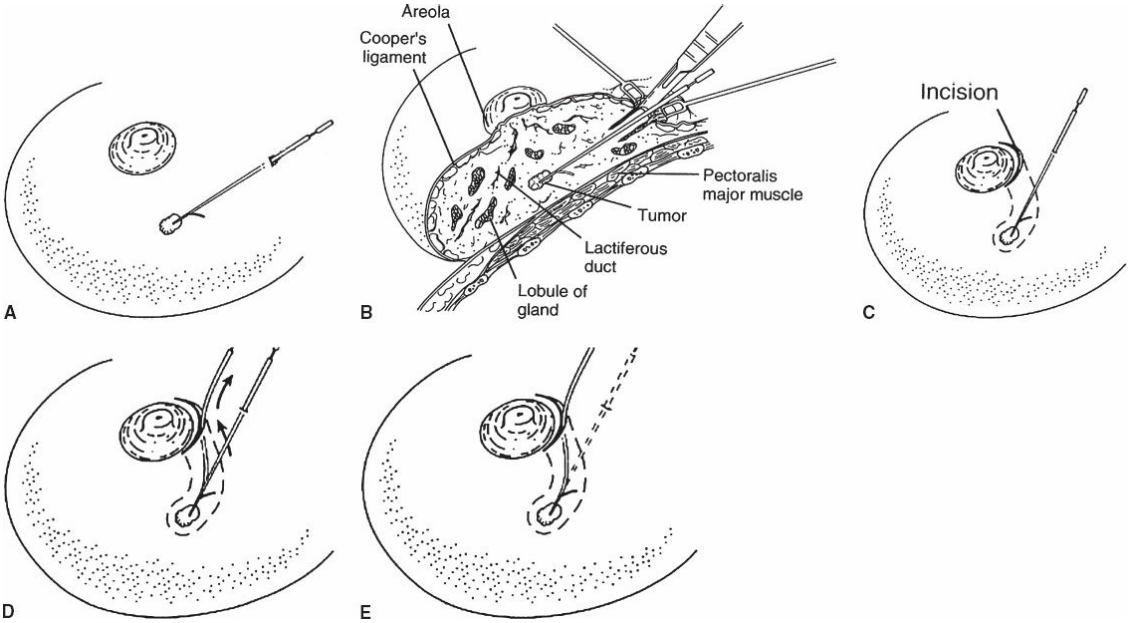

Figure 48.21. Operative technique for needle localization biopsy of a deep subareolar lesion. The suspicious lesion is “localized” on the mammogram immediately before surgery. **A.** During the operation, the needle serves as a guide for the surgeon to perform the biopsy. **B.** Development of tissue planes parallel to the localization wire. **C.** Deeply localized, suspicious lesion approached via a circumareolar incision. **D.** Wire is repositioned from the percutaneous localized position and retracted into the wound. **E.** Dissection completed parallel to wire. (Reproduced with permission from Bland KI, Edward M. *The Breast: Comprehensive Management of Benign and Malignant Diseases.* 3rd ed. Philadelphia, PA: WB Saunders, 2004.)

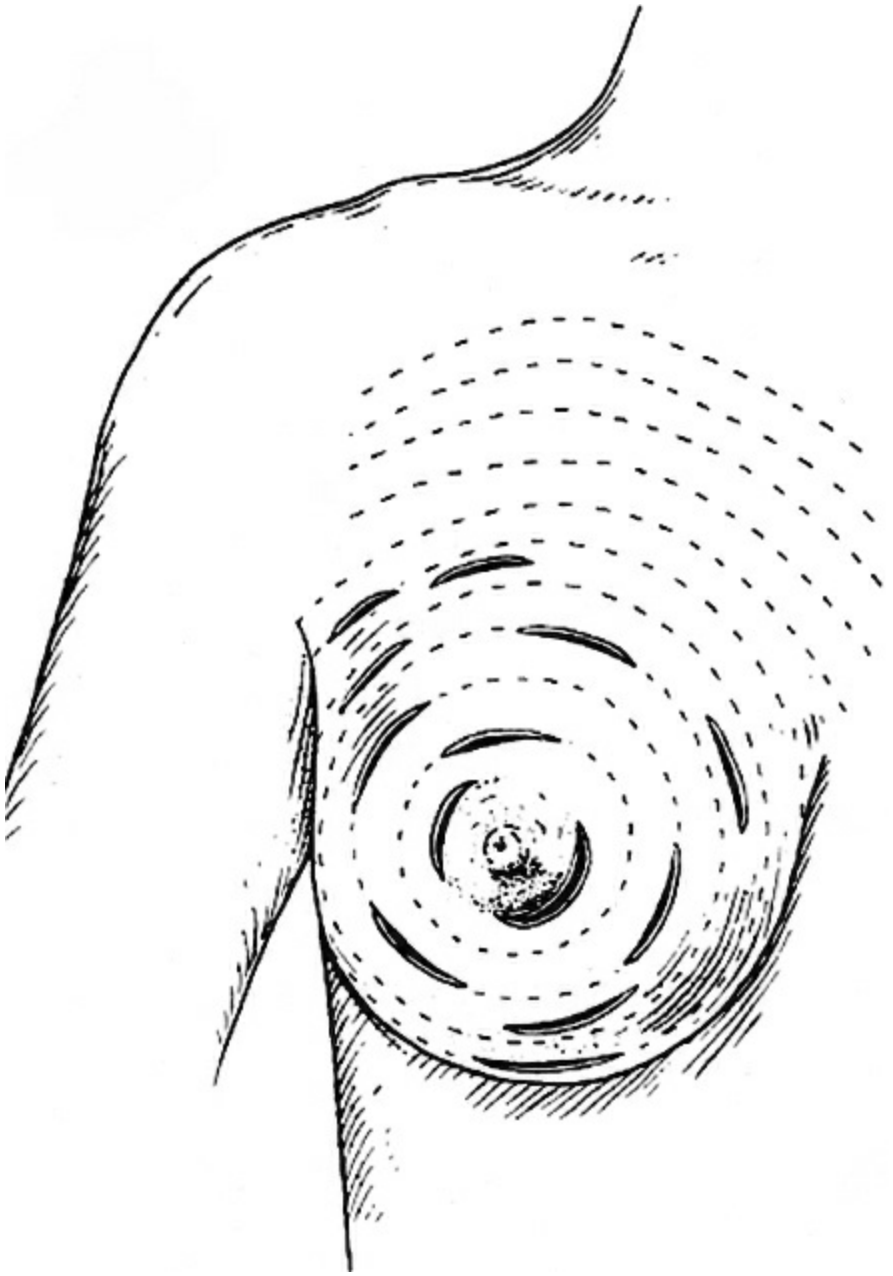

Figure 48.22. Recommended locations of incisions for performing needle localization lumpectomy. The most cosmetically acceptable scars result from incisions that follow the contour of Langer lines. (Reproduced with permission from Bland KI, Edward M. *The Breast: Comprehensive Management of Benign and Malignant Diseases.* 4th ed. Philadelphia, PA: WB Saunders, 2009.)

Palpable Masses

Ultrasound evaluation is the preferred method of evaluation of a palpable mass, but practitioners without ultrasound readily available may use aspiration to distinguish a solid mass from a benign cystic lesion. Details

of cyst aspiration were discussed previously. If a solid mass is confirmed, FNA biopsy may be performed to obtain a cytologic diagnosis (Fig. 48.24). An FNA, however, does not distinguish between in situ and invasive disease. Obtaining a core biopsy prior to proceeding to the operating room for a breast lesion is preferred and accepted as standard today. In 2003, the National Comprehensive Cancer Network identified core needle biopsy as “preferred” over surgical excision for breast diagnosis, and more recently the National Accreditation Program for Breast Centers established “palpation-guided or image-guided needle biopsy as the initial diagnostic approach rather than open biopsy” as a clinical management standard by which breast centers are measured. Obtaining a cancer diagnosis via core biopsy allows for better planning of the cancer treatment by obtaining hormone receptor status and avoiding multiple surgeries.

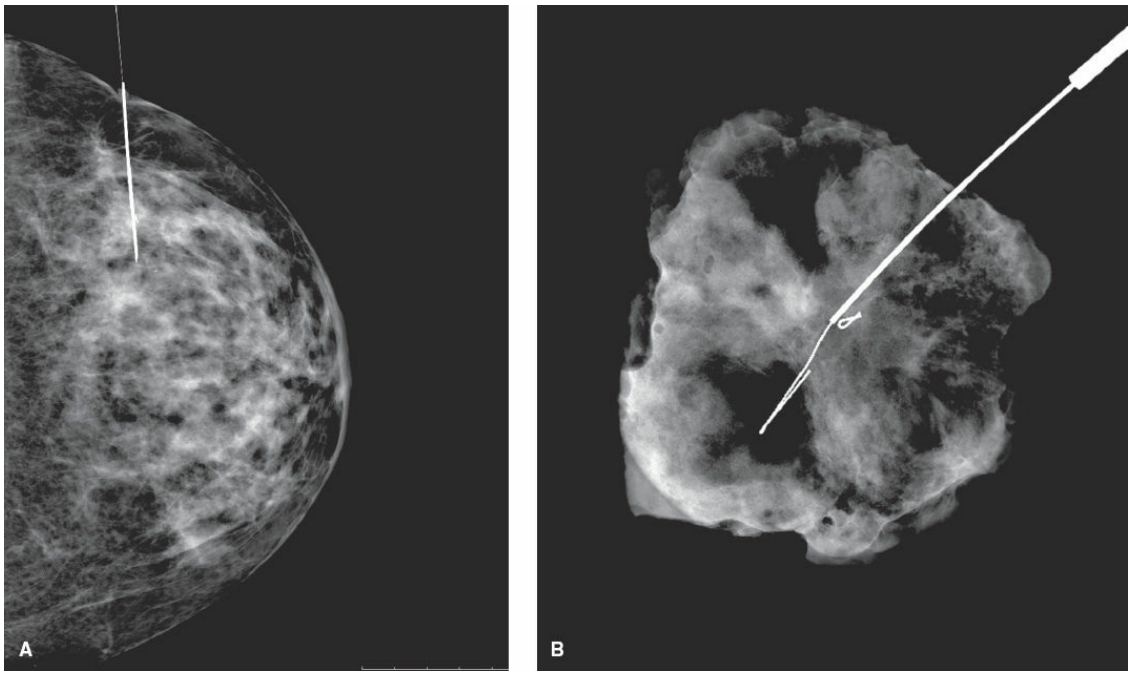

Figure 48.23. Needle localized lumpectomy. **A.** Right craniocaudal view demonstrating wire localization needle in excellent position for targeting biopsy clip and mass. The write is deployed through the needle and postwire placement craniocaudal and lateral views marked for the surgeon. **B.** Specimen radiograph demonstrates successful excision of biopsy clip and mass targeted for removal and retrieval of localization wire.

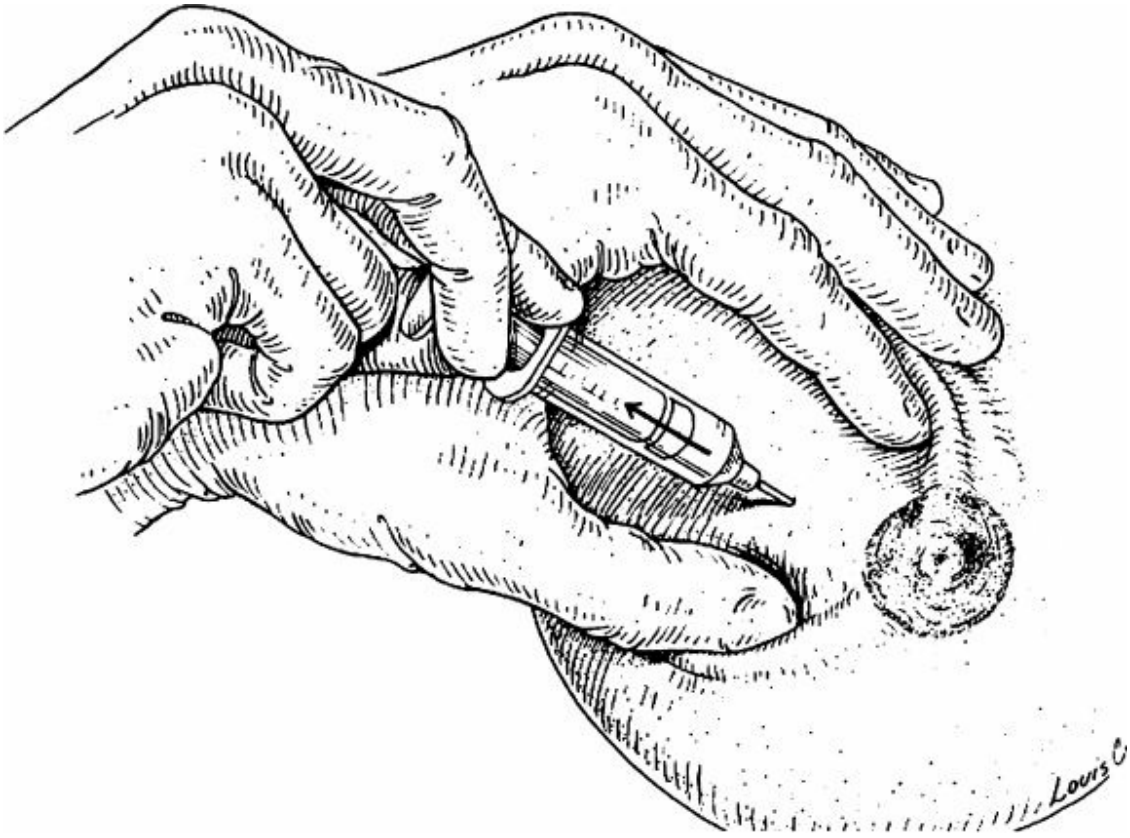

Figure 48.24. Technique for FNA of a breast mass. (Reproduced with permission from Bland KI, Edward M. *The Breast: Comprehensive Management of Benign and Malignant Diseases.* 3rd ed. Philadelphia, PA: WB Saunders, 2004.)

Punch Biopsy

While the diagnosis of inflammatory breast cancer is made largely clinically, histologic confirmation of cancer cells within the dermal lymphatics is pathognomonic for inflammatory breast cancer. In patients who present with skin changes, including erythema and/or peau d'orange, a 3- to 5-mm punch biopsy can be performed in the office using local anesthesia. The biopsy should be full thickness through the most suspicious area. Most inflammatory breast cancers do not present with a palpable mass, but if present, a core biopsy can then be obtained through the punch biopsy site to provide more tissue for receptor assays.

SUMMARY

The use of mammography and developing technology has revolutionized our ability to diagnose and treat breast abnormalities. While in the past most patients underwent surgical excision, we now have the capability to

perform less invasive procedures for both diagnosis and treatment of benign disease. In addition, a cancer diagnosis from an image-guided core biopsy allows for optimal patient management in this time of precision medicine.

Suggested Readings

American College of Radiology. *Breast Imaging Reporting and Data System (BI-RADS).* 5th ed. Reston, VA: American College of Radiology; 2013.

Bassett L, Winchester DP, Caplan RB, et al. Stereotactic core-needle biopsy of the breast: a report of the Joint Task Force of the American College of Radiology, American College of Surgeons, and College of American Pathologists. *CA Cancer J Clin* 1997;47(3):171–90.

Bland KI, Copeland EM, 3rd, eds. *The Breast: Comprehensive Management of Benign and Malignant Diseases.* 4th ed. Philadelphia, PA: Elsevier; 2009.

Fine RE, Staren ED. Updates in breast ultrasound. *Surg Clin North Am* 2004;84(4):1001–34, v–vi.

Harness JK, Wisher DB. *Ultrasound in Clinical Practice: Basic Principles and Clinical Practice.* New York: Wiley-Liss; 2001.

Hughes LE, Mansel RE, Webster DJT. *Benign Disorders and Diseases of the Breast: Concepts and Clinical Management.* Philadelphia, PA: WB Saunders; 2000.

Jackson VP. Diagnostic mammography. *Radiol Clin North Am* 2004;42(5):853–70, vi.

Lee CH. Problem solving MR imaging of the breast. *Radiol Clin North Am* 2004;42(5):919–34, vii.

Liberman L. Percutaneous image-guided core breast biopsy. *Radiol Clin North Am* 2002;40(3):483–500, vi.

Morrow M, Schnitt SJ, Norton L. Current management of lesions associated with an increased risk of breast cancer. *Nat Rev Clin Oncol* 2015;12:227–38.

National Comprehensive Cancer Network. *The complete library of NCCN clinical practice guidelines in oncology. Breast Cancer.* Jenkintown, PA: National Comprehensive Cancer Network; 2015.

Sharek D, Zuley ML, Zhang JY, et al. Radioactive seed localization versus wire localization for lumpectomies: a comparison of outcomes. *AJR Am J Roentgenol* 2015;204(4):872–7.



Nearly 8 billion is spent on diagnostic breast biopsies each year. Nearly half of that cost is the result of false-positive biopsies. Nearly 80% of biopsied lesions result in negative pathology. However, it is the standard of care to get a preoperative diagnosis before going to the operating room. First it allows for planned staging of the patient prior to surgery and of the axilla at surgery. It is also well documented that knowing the presence of cancer at surgery results in obtaining a higher likelihood of negative margins. Occasionally, one can get a significant bleed from an ultrasound-guided or stereotactic-guided core needle biopsy. In such a case, we use a pediatric Foley inserted in the needle track. A Doppler US can see the bleeder and the balloon can be inflated to produce tamponade. It can save the patient a huge hematoma.

In addition, the diagnostic procedure allows marking of the lesion for removal by a number of different methods. It is standard of care to leave a marker behind at the biopsy site. This is especially true in the case of neoadjuvant chemotherapy as a complete pathologic response may make the original lesion difficult or impossible to localize. In addition to the standard titanium clips of all shapes and sizes, innovations in markers have proliferated with coils, gels, radio-guided and magnetic markers which have added greatly to the cost and complexity of breast surgery localization. Wires and special clips and radio-markers all require an additional procedure to mark the site for lumpectomy while the patient is awake. However, there are a couple of situations when a second procedure is not necessary. The first instance is that of a lesion that is visible on ultrasound.

The fully developed technique of US-guided excision has evolved and been developed over time by multiple researchers. Breast ultrasonography is performed intraoperatively using a 7.5- or 10-MHz linear array transducer while the arm is abducted. After sterile preparation, the abnormality is localized in the standard two planes, longitudinal and transverse. After the incision was made, the transducer was placed inside the incision and the lesion was again visualized. Dissection is performed using a “line-of-sight” technique. This technique was adapted from and mimics the use of the gamma probe in sentinel lymph node surgery. The transducer is then placed perpendicular to the lesion and parallel to the chest wall to assess the adequacy of the deep margin. Tissue is excised around the lesion in a block fashion down to the ascertained depth. Ex vivo ultrasonography is performed on the specimen. Margins felt to be inadequate on specimen ultrasonography are reexcised at the time of the initial surgery. The remaining cavity is reassessed for residual disease both by palpation and ultrasonography.

A recent development presented at the 2017 American Society of Breast Surgeons is another localization procedure that does not require a second localizing procedure to remove the index lesion. We developed *F*luoroscopic *I*ntraoperative *N*eoplasia and *N*ode *D*etection or FIND after a needle from an NLBB was inadvertently removed at surgery. Barring waking the patient up and relocalizing the lesion, we used the fluoroscope which easily found the clip. We

wondered why no one had used this before as all surgeons are familiar with the use of fluoroscopy whether it be with placing a central line or performing and intraoperative cholangiogram. As it turns out not all clips are visible by fluoroscopy. The ribbon clips and collagen clips don't show up well at all. The bar clips and the newer circular clips are easily seen. We cut the dose of the fluoroscopy by three-fourths and we still easily saw the clips. Probably the most cumbersome thing about this procedure is the need to wear protective lead aprons. This innovation can easily be implemented in practice. In fact, walking out of the auditorium where we presented our work, a surgeon stopped us and said they'd already called their operating room and posted a case utilizing FIND. This allows cases to be done without a second localization and obviates scheduling issues. Care must be taken to note any post-clip placement migration. The surgeon can bill for the utilization of fluoroscopy as intraoperative interpretation. You will also be your mammographer's new best friend as (s)he will no longer have to get up early and torture patients with an NLBB. They hate them as much as the patients and we do.

Recent developments in oncoplastic procedures of the breast make breast texture and anatomy and localization technique more important than ever. In determining how to approach the breast, location, location, location is all important. For nearly any lesion in the breast a Benelli or donut deepithelialization can be performed and a flap raised over the index lesion. The closure produces a periareolar scar and if warranted the deepithelialization can be widened to perform a lift or a reduction. In a very large-breasted women (e.g., 54H) a bat-wing reduction can be performed to remove an upper quadrant lesion. Radial incision should be avoided in the upper pole of the breast but work well in the lower pole especially if they are tangential to the areola. Excision of lesions can be incorporated into a wise pattern reduction incision. With upper pole lesion, the nipple can emanate from an inferior pedicle. In the case of a lower pole lesion, the nipple should be on a superior pedicle. Both of these should come from the medial side as the blood supply to the nipple is based mainly on the internal mammary perforators.

When choosing a localization technique or procedure, it is best to choose one that does not require second preoperative localizations.

V. Suzanne Klimberg

Suggested Readings

Arentz C, Baxter K, Boneti C, et al. Ten-year experience with hematoma-directed ultrasound-guided (HUG) breast lumpectomy. *Ann Surg Oncol* 2010; 17(Suppl 3):378–83.

Denham F, Wilson B, Klimberg VS, et al. Fluoroscopic intraoperative neoplasia and node detection. https://www.breastsurgeons.org/docs2017/2017_ASBrSFinalProgram.pdf

Gadgil PV, Klimberg VS. Management of percutaneous core biopsy tract bleeding. *Ann Surg Oncol* 2013;20(10):3348.

Klimberg VS, Rivere A. Ultrasound image-guided core biopsy of the breast. *Chin Clin Oncol* 2016;5(3):33.

Langhans L, Tvedskov TF, Klausen TL, et al. Radioactive seed localization or wire-guided localization of nonpalpable invasive and in situ breast cancer: a randomized, multicenter, open-label trial. *Ann Surg* 2017;266(1):29–35.

Tummel E, Betzold R, Gallagher K, et al. The CUBE technique: continuous ultrasound-guided breast excision. *Ann Surg Oncol* 2014;21(10):3354–5.

49 Breast-Conserving Surgery

J. Michael Dixon

BREAST-CONSERVING SURGERY IN INVASIVE BREAST CANCER

The aim of local treatment of breast cancer is to achieve long-term local disease control with the minimum of local morbidity. The majority of women presenting symptomatically to breast clinics or who are diagnosed as having breast cancer through screening programs have small breast cancers that are suitable for breast-conserving surgery (BCS). Breast-conserving treatment (BCT) consists of BCS followed by whole breast radiotherapy. The major advantages of BCT are that it produces

an acceptable cosmetic appearance in the majority of women.
lower levels of psychological morbidity with less anxiety, depression, improved body image, sexuality, and self-esteem than mastectomy.
equivalence in terms of disease outcome for BCT and mastectomy, as shown by two systematic reviews.

One of these reviews analyzed data from six randomized controlled trials comparing BCT with mastectomy. A meta-analysis of data from five of these six trials, which included 3,006 women, found no significant difference in the risk of death at 10 years (odds ratio, 0.91, 95% confidence interval [CI], 0.78 to 1.05). The sixth randomized trial used different protocols. In the second systematic review, nine randomized control trials involving 4,981 women randomized to mastectomy or BCT were included in the analysis. A meta-analysis of these nine trials found no significant difference in the risk of death over 10 years (relative risk reduction [RRR] for BCS when compared with mastectomy was 0.02, 95% CI −0.05 to +0.09). There was also no difference in the rates of local recurrence in the six randomized control trials involving 3,107 women for whom data were available (RRR mastectomy vs. BCT, 0.04, 95% CI −0.04 to +0.12). The Milan Group published their 20-year follow-up results and, although they showed a significant difference in local recurrence within the ipsilateral breast of 2.3% in the mastectomy group

and 8.8% in the BCT group, the disease-specific survival was similar between the two groups, with rates of death from breast cancer being 24.3% in the mastectomy group and 26.1% in the BCT group.

Originally it was thought that local therapy had little influence on overall survival, but it is becoming clear that local therapy is responsible, at least in part, for some patients developing metastatic disease. It is thus important to minimize local recurrence and at the same time achieve a good cosmetic outcome.

More recent studies have confirmed the safety of BCT. One large cohort study from California indicated that BCT was associated with superior survival in all groups compared with mastectomy alone. Two other large European studies confirmed that women treated with BCT do better than women treated by mastectomy. A study from New York showed equivalent outcomes for BCT and mastectomy in triple negative breast cancer. Another study showed event free and overall survival is equivalent when comparing BCT and mastectomy in young women.

INDICATIONS AND CONTRAINDICATIONS TO BREAST-CONSERVING TREATMENT

Traditionally single cancers measuring 4 cm or less, without signs of involvement of skin or chest wall, have been managed by BCT (Table 49.1). Different units have different size criteria, and many units have a tumor size cut off for BCS of 3 cm. Increasing tumor size, however, does not mean increasing local recurrence rates, and this approach is therefore illogical. Clinical tumor size overestimates actual tumor size. There is a better correlation between pathologic tumor size and the size measured on imaging, with magnetic resonance imaging (MRI) assessment being more accurate than ultrasound or mammographic measurements. MRI has not been shown to be of value in improving the rate of successful BCT or reducing rates of recurrence (COMICE). It is the balance between tumor size as assessed by imaging and breast volume that determines whether a patient is suitable for BCT. Patients with tumors measuring clinically larger than 4 cm can be treated by BCT if the patient has large breasts. Conversely, in a patient with small breasts, excision of even a 1-cm tumor may produce an unacceptable cosmetic result. Options for patients with tumors considered too large relative to the size of the breast for BCT include neoadjuvant systemic therapy to shrink the tumor or an oncoplastic procedure, involving either transfer of tissue into the breast or surgery to

reduce the size of the breast usually combined with synchronous contralateral reduction.

Because of an initially high reported incidence of in breast recurrence, patients with multiple tumors in the same breast had not been previously considered good candidates for BCT. This view has changed and provided that the cancers can be excised to clear margins even if they are far apart and a satisfactory cosmetic outcome produced, then BCT is feasible. In some patients who have large areas of the breast involved, BCT may be possible if one or both breasts are made smaller by a mammaplasty procedure. If there is widespread ductal carcinoma in situ (DCIS) alone or associated with an invasive cancer, then most of these women are best treated by mastectomy, combined with immediate reconstruction in appropriate patients. Patients with two tumors close to each other on mammograms, or who have multisite disease identified only by the pathologist, are good candidates for BCT provided that all disease can be excised and the cosmetic outcome is not compromised. Patients with bilateral small cancers can also be treated by bilateral breast conservation.

TABLE 49.1 Indications and Contraindications for Breast-Conserving Surgery

Indications
- T1, T2 (<4 cm), N0, N1, M0
- T2 >4 cm in large breasts
- Single clinical and mammographic lesion

Contraindications
- T4, N2, or M1 (some localized T4 disease and some patients with limited metastatic disease may be suitable for breast-conserving surgery)
- Patients who prefer mastectomy

Relative contraindications
- Large or central tumors in small breasts[a]
- Clinically evident multifocal/multicentric disease[a]
- Collagen vascular disease
- Women with a strong family history of breast cancer or BRCA1 and BRCA2 mutation carriers

[a]Now common for these women to be offered BCS (see below).

CLINICAL AND PATHOLOGIC FACTORS

Clinical and pathologic factors have previously influenced selection of patients for BCT because of their perceived impact on local recurrence. They are no longer considered as contraindications for BCT. These include young age (<35 to 39 years), the presence of an extensive in situ component associated with an invasive tumor, grade 3 histology, and widespread lymphatic/vascular invasion (LVI). Another relative contraindication to BCT has been the presence of a collagen vascular disease, as radiotherapy may create problems in such women. Experience is emerging that most of these women can be treated by BCT without significant problems. Central tumors were initially considered a relative contraindication to BCT as the cosmetic result can be suboptimal. Most patients with small central tumors, however, are candidates for wide local

excision with or without nipple/areolar excision and/or rotational flap advancement as described later in this chapter.

Young women with a strong family history of breast cancer or known carriers of BRCA1 or BRCA2 mutations are probably better served by bilateral mastectomy instead of BCT as they are at higher risk of developing either a recurrent cancer or a new cancer in the treated or opposite breast. Young women without a gene mutation can be managed by BCT, and their outcomes are not improved by mastectomy.

PREOPERATIVE PLANNING

Patients are currently staged according to the International Union against Cancer TNM (Tumor, Nodes, Metastasis) classification, but this method of staging is of no real value in breast cancer. Clinical assessment of tumor size usually overestimates tumor size, although there is some correlation between clinical tumor size and final pathologic measurement. Decisions on treatment are thus best based on size estimated by imaging. Clinical examination is unreliable in determining whether the axillary nodes are involved with metastatic breast cancer. For this reason, in most units nodes are assessed by ultrasound.

In early operable breast cancer (Tl to 2, N0 to 1), there is no current evidence to support routine screening for metastatic disease in asymptomatic women. Patients with symptoms suggestive of metastases at a particular site require appropriate investigation. The incidence of asymptomatic metastases increases as the T and N stage increases. If it will affect treatment, patients with more advanced but operable disease (T3 and multiples N1 nodes or N2 disease clinically or on imaging) should be considered for investigations to exclude distant metastases.

All patients with a breast mass should have a careful clinical examination, and the mass should be measured accurately and recorded. The presence or absence of any signs of local advancement such as inflammation, peau d’orange, ulceration, satellite nodules, direct chest wall involvement, and fixed axillary nodes should be noted and recorded. All patients should have good-quality bilateral mammograms with magnification views of any visible indeterminate calcification. Ultrasound of the whole breast is recommended to assess the extent and size of the tumor, and ultrasound of the axilla should be performed to assess the presence of any metastatic lymph nodes and ultrasound-guided fine-needle aspiration biopsy or core biopsy performed of any lymph nodes with

features suggestive of metastatic spread. Routine use of breast MRI is unnecessary, but in certain patients it can provide useful clinical information on disease extent.

Patients should be informed prior to surgery that there is up to a 35% chance that BCS will not remove all disease and that these women need reexcision or sometimes a mastectomy to obtain clear margins and excise all disease. Patients should also be informed of other common complications, including bleeding, infection, scars, skin healing issues (two to three times more common in smokers), and of the likelihood of seromas. Prior to operation, patients should sign a consent form that includes these complications and have the side and site of surgery marked with an indelible pen.

The patient's imaging should be inspected before operation and excision planned to include the whole of the abnormal area. Some invasive carcinomas have surrounding noninvasive disease that is visible as microcalcification on mammograms. These microcalcifications should be excised and may require preoperative localization.

SURGICAL TECHNIQUE OF WIDE LOCAL EXCISION

Two breast-conservation surgical procedures have been studied extensively and described: quadrantectomy and wide local excision. Quadrantectomy is based on the belief that the breast is organized into segments, with each segment draining into its own major duct, and that invasive cancer spreads down the duct system toward the nipple. The evidence is that both of these premises are incorrect. Studies have also shown that both invasive and noninvasive diseases are no more likely to extend toward the nipple than in any other direction. One of the early studies of BCT randomized patients to lumpectomy or quadrantectomy. A significantly greater number of patients who had lumpectomy had incomplete local excisions. Not surprisingly, therefore, local recurrence was greater after lumpectomy than after the more extensive quadrantectomy, although survival was no different. Other nonrandomized studies have shown similar rates of local recurrence for quadrantectomy and wide local excision, provided margins of excision are clear. Quadrantectomy is no longer advocated because it removes substantially more breast tissue and produces a significantly poorer cosmetic outcome than wide local excision. The consensus view is that the majority of patients having BCT can be adequately treated by wide local excision.

The majority of wide excisions of palpable and impalpable cancers are performed under general anesthesia, although it is possible to perform wide excision under local anesthesia with or without sedation. A meta-analysis of studies of prophylactic antibiotics in breast surgery has shown a small but significant reduction in postoperative infections if intravenous antibiotics are administered during induction of general anesthesia, so many surgeons give a dose of intravenous antibiotics to cover the operative period. Our practice is to use 1.2 g of co-amoxiclav or a cephalosporin. The lack of a clear advantage for antibiotics in randomized studies means that not all surgeons give them.

Incisions

The aim of wide local excision is to remove all invasive and any DCIS with a 1-cm macroscopic margin of normal surrounding breast tissue. It is important to place the incision in a position that will obtain the optimal cosmetic result. Langer described the predominant orientation of collagen fibers in the skin and around the breast, and these lines are essentially circular (Fig. 49.1A). Kraissl later demonstrated that the lines of maximum resting skin tension run in a more transverse orientation across the breast (Fig. 49.1B). In general, scars placed in the lines of maximum resting skin tension (parallel to Kraissl lines) produce the best cosmetic incisions with least hypertrophy and keloid formation. Incisions that are at right angles to both the orientation of collagen fibers and the lines of maximum resting skin tension, such as radial incisions in the upper outer quadrant, generally produce the worst cosmetic results. Circumareolar incisions heal well. Radial incisions can produce a satisfactory cosmetic result in some circumstances, and a vertical incision at 6 o'clock that is used as part of most therapeutic mammaplasty procedures usually gives a reasonable scar. Radiation reduces the rate of hypertrophic scars, so most incisions used for breast-conserving incision produce satisfactory cosmetic results. Increasingly, remote incisions, including submammary, circumareolar, and axillary incisions, are used as they produce the best cosmetic outcomes. Excising skin directly overlying a cancer is only necessary if the carcinoma is very superficial and/or the skin is tethered. Skin should not be excised routinely.



Figure 49.3. After having dissected around three sides of the cancer, it is grasped with finger and thumb of the nondominant hand before completing the excision at the other margins.

The cosmetic result after BCT is influenced by the amount of skin excised. The poorest outcomes are seen in those patients who have the most skin removed. Limiting the length of the incision is important as in general the longer the incision the poorer the cosmetic outcome. The length of the scar is less of an issue if the scar is hidden as for example in a sub- or inframammary incision.

Excising the Cancer

After making a skin incision, the skin and subcutaneous fat are dissected off the breast tissue. This can be facilitated by injecting a 1 in 500,000 adrenaline (epinephrine) solution in saline into the plane between the breast and subcutaneous fat. This solution should be left a few minutes for the epinephrine to work and restrict local blood flow. When elevating skin, it is important not to disrupt the subcutaneous fat as thin skin flaps give a poor cosmetic result. The skin flaps should be elevated 1 to 2 cm beyond the edge of the cancer. This allows the fingers of the nondominant hand to be placed over the palpable cancer and the breast tissue can then be divided beyond the fingertips (Fig. 49.2); the line of incision through the

breast tissue should be 1 cm beyond the limit of the palpable mass. The breast tissue is divided 1 cm deep to the deepest aspect of the tumor and then breast tissue under the cancer is divided. It is usual but not always necessary to remove full thickness of breast tissue because this ensures that there is an adequate clearance deep to the cancer. In the majority of patients, in order to completely excise the cancer at the deep margin, it is necessary to continue the dissection through the breast tissue down to the pectoral fascia. The cancer and surrounding breast tissue are then lifted off the pectoral fascia. It is not necessary to excise pectoral fascia unless it is tethered to the tumor. If a carcinoma is infiltrating a chest wall muscle, then a portion of the affected muscle can be removed beneath the tumor in order to get clear tissue at the deep margin. For very superficial cancers in parts of the breast with significant depth, it is possible to clear the deep margins without removing full thickness of breast tissue.

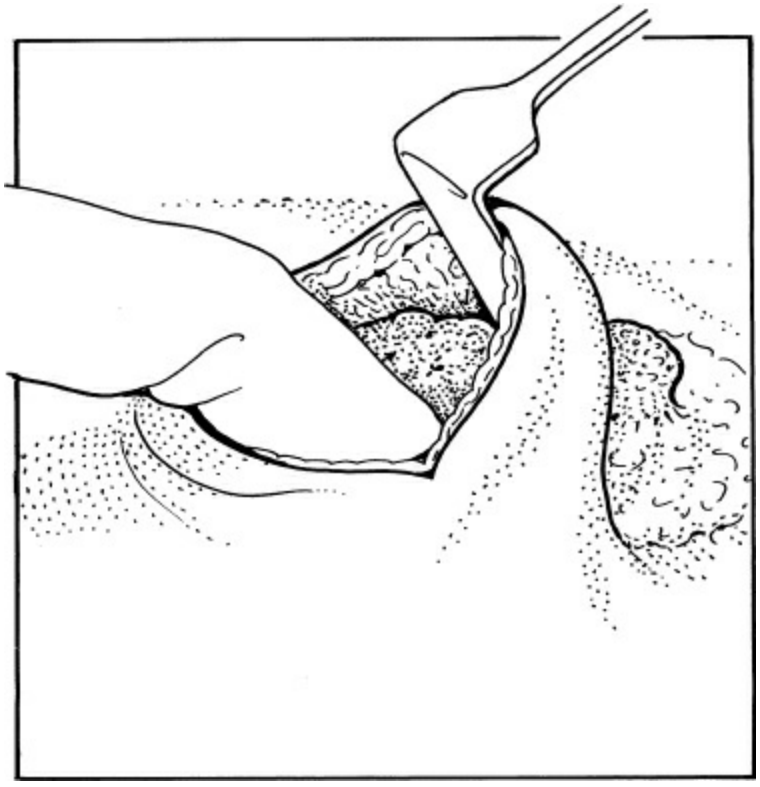

Figure 49.2. Finger of nondominant hand is placed over palpable cancer and breast tissue is divided beyond the fingertips.

Having lifted the tumor and surrounding breast tissue off the chest wall muscles, the cancer and surrounding tissue can then be grasped between the finger and the thumb of the nondominant hand and excision is completed at the other margins (Fig. 49.3). The specimen is immediately

orientated with sutures, ligaclips, or metal markers (Fig. 49.4). Using metal markers and ligaclips or attaching the specimen to an orientated grid has the advantage of allowing orientated anteroposterior-intraoperative specimen radiography to be performed. This helps the surgeon to determine first that the target lesion has been excised and second allows assessment of completeness of excision at the radial margins (medial, lateral, superior, and inferior). If inspection of the specimen radiograph shows that the cancer or any associated microcalcification is close to a radial margin, then the surgeon should remove further tissue from the margin of concern. Having excised this extra tissue, the surgeon should orientate this tissue, and send it for pathologic evaluation (Fig. 49.5A,B).

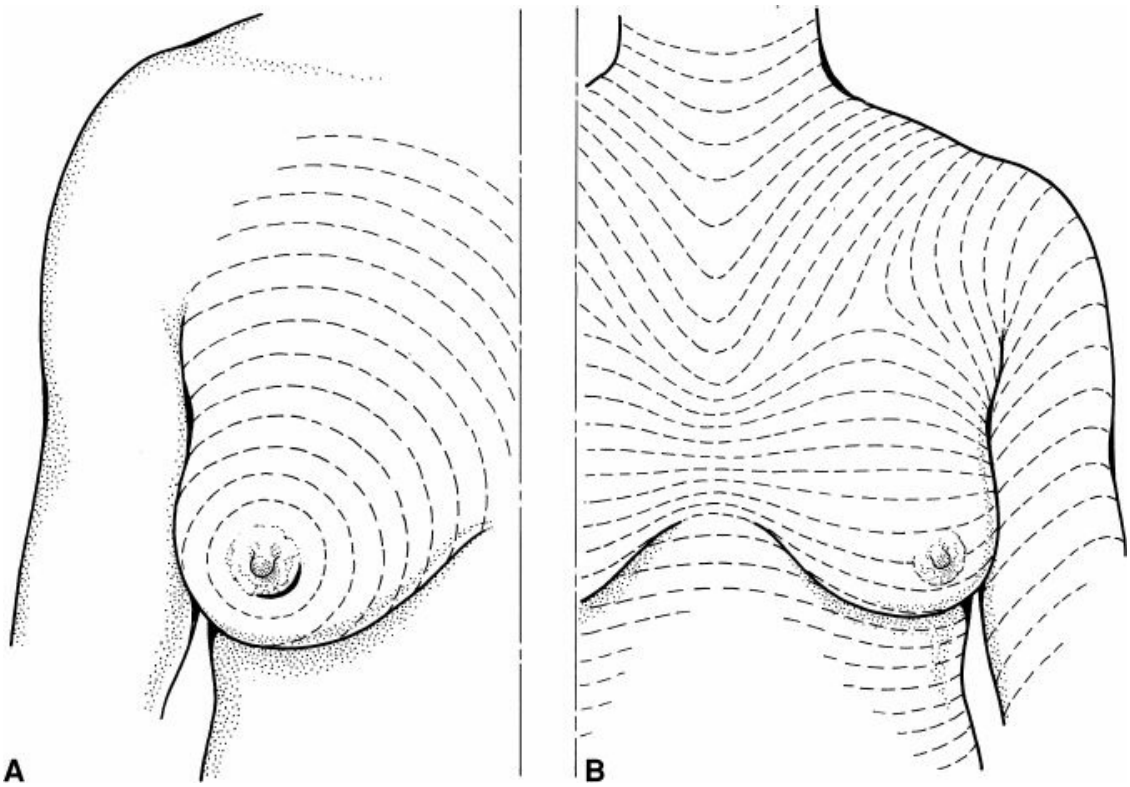

Figure 49.1. The direction of Langer lines (**A**) and the lines of maximum resting skin tension in the breast (the so-called dynamic lines of Kraissl) (**B**).

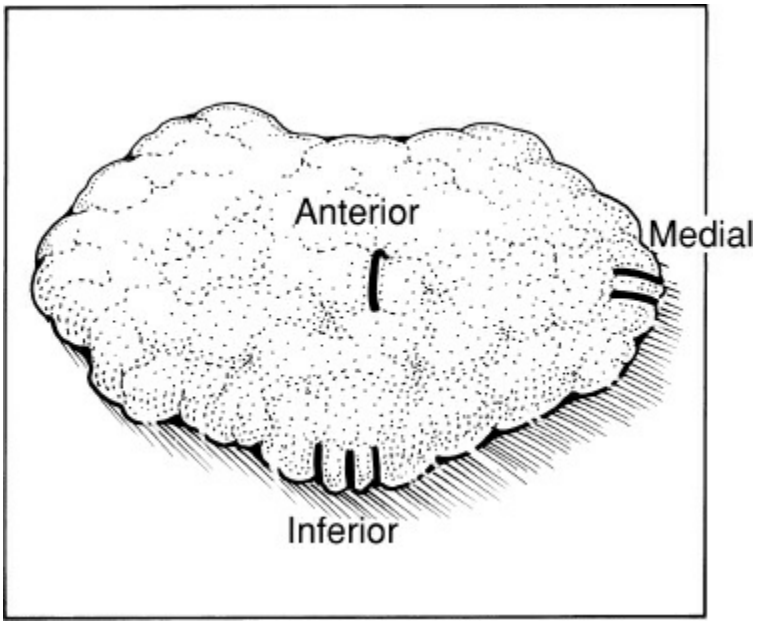

Figure 49.4. Orientation of the specimen. In our unit, we use one ligaclip for the anterior margin, two ligaclips for the medial margin, and three ligaclips at the inferior margin.

Controversy surrounds the use of routine cavity shavings or margin reexcision. Studies have demonstrated that the major factor that increases incomplete excision rates is DCIS out with the invasive cancer not imaged by mammography and ultrasound. The greater the volume of tissue excised, the more likely the margins will be clear. A recent study showed that shaving the margins can marginally reduce the rate of reexcision but the volume of excision increased from 74.2 cm^3 to 1115.1 cm^3 as a result of shaving of all margins. This is consistent with the view that the more tissue you excise, however you do it, the lower the rate of incomplete excisions, but larger excisions yield poorer cosmetic outcomes. It is difficult to believe that routine shaving of all margins is justified. Selective shaves of margins of concern is more logical. New devices in clinical trials are being used to assess margins intraoperatively, and these show promise but are not yet suitable for routine use.

Having excised the cancer from the breast, suturing the defect in the breast without mobilization of breast tissue usually results in distortion of the breast contour. Small defects (<5% breast volume) can be left open and can produce a good final cosmetic result. Larger defects in the breast should if possible be closed by mobilizing the surrounding breast tissue from the overlying skin and subcutaneous tissue. I do not usually find it necessary to undermine tissue from the chest wall unless the defect is

large. If such large defects (>10% breast volume) are not closed, they fill with seroma, which later absorbs; and as scar tissue forms, this contracts, often producing an ugly, distorted breast. The extent to which breast tissue can be mobilized depends on breast density. Soft fatty breast tissue cannot be mobilized extensively and fatty breast tissue cannot be easily sutured. Extensive mobilization of fatty breasts thus produces a very poor final cosmetic result. In contrast, dense fibrous breast tissue can be mobilized widely to allow defects to be closed and heals well. Having mobilized breast tissue from the subcutaneous tissue and if necessary the chest wall, it is usually possible to close the defect in the breast with a series of interrupted absorbable sutures. Larger defects can be filled by local flaps, or more major breast reshaping as part of a unilateral or bilateral therapeutic mammaplasty. Immediate lipofilling is being used in a few units, but it remains experimental and its use cannot as yet be recommended.

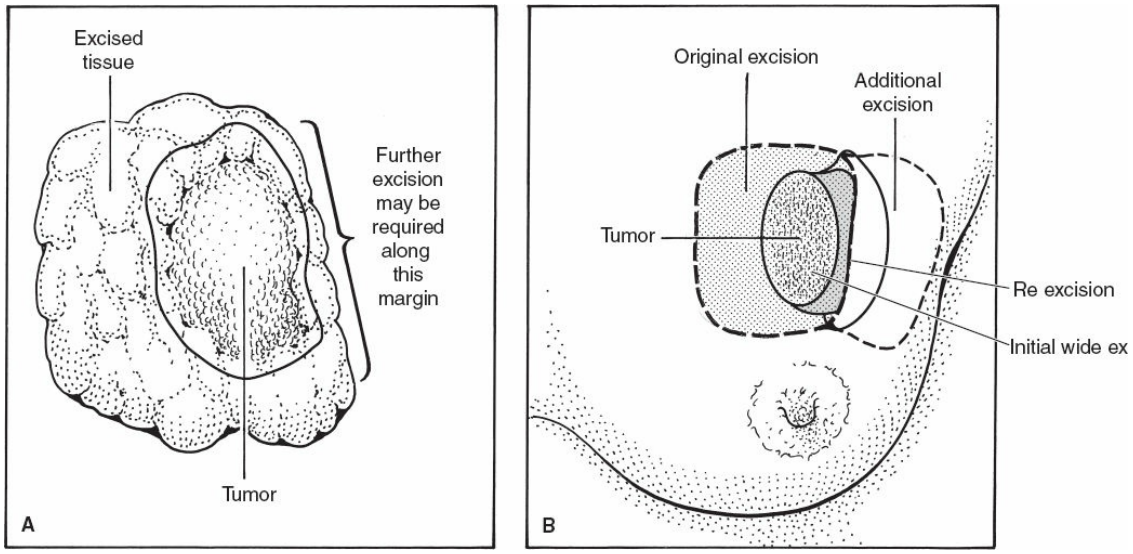

Figure 49.5. A. Specimen after removal and inspection showing that the cancer is close to a margin. **B.** A further excision is required to obtain clear margins.

Drains are not necessary following wide local excision and should not be used routinely. They do not protect against hematoma formation and increase infection rates. Breast skin wounds should be closed in layers with absorbable sutures, finishing with a subcuticular suture. Staples and interrupted sutures are not an acceptable method of wound closure in the breast. Long-acting local anesthetic should be infiltrated into the wound as it reduces postoperative pain, unless other anesthetic nerve blocks are

used.

PLACING MARKERS AFTER BREAST-CONSERVING SURGERY

Most young patients and selected older patients treated by radiation after BCS will have a local tumor bed boost. To help facilitate this boost and as an aid in further follow-up, most surgeons place four clips at the superior, inferior, medial, and lateral margins of the wide excision cavity.

AVAILABLE TECHNIQUES FOR WIDE LOCAL EXCISION OF CENTRAL TUMORS

Central cancers, if they are close to but do not involve the nipple, can be removed by a standard wide excision preserving the overlying nipple skin. If the lesion is very superficial and there is tethering, inversion, or invasion of the nipple, then the nipple and/or areolar complex needs to be excised. The nipple may need to be removed, but in some all or part of the areola can be preserved. Not all women with blood-stained nipple discharge require excision of the nipple. In between 25% and 50% of patients, the nipple can be preserved as the margin under the nipple will be clear on histologic assessment. A preoperative biopsy or an initial duct excision can be used to assess the safety of nipple preservation in such women. In women with large breasts, the nipple–areolar complex can be incorporated into a vertical wedge mammaplasty incision and the cancer excised in continuity with the nipple/areolar skin. Although this does alter the breast shape, acceptable results can be obtained in women with larger breasts. Following nipple–areolar excision, one option is to close the circular wound with a purse-string closure, or a series of radiating scars. The final cosmetic result is variable but can sometimes produce an excellent long-term cosmetic outcome. An alternative approach for such cancers involves removal of the nipple–areolar complex with underlying breast tissue and reconstructing the defect with a skin and breast tissue flap rotated in from the lower outer quadrant of the breast. To do this, an island of skin is identified and marked (Fig. 49.6A). The flap of tissue to be rotated to fill the defect is defined and, apart from the circle of skin that will close the central cutaneous defect, the rest of the skin is deepithelialized (Fig. 49.6B). The breast tissue is incised and divided (Fig. 49.6C) so that the flap can rotate and allow the island of skin to lie in the position of the

areola (Fig. 49.6D). The flap is sutured in situ with absorbable sutures. In patients with large breasts, a skin and breast flap can be advanced from tissue and skin that would normally be excised as part of a breast reduction.

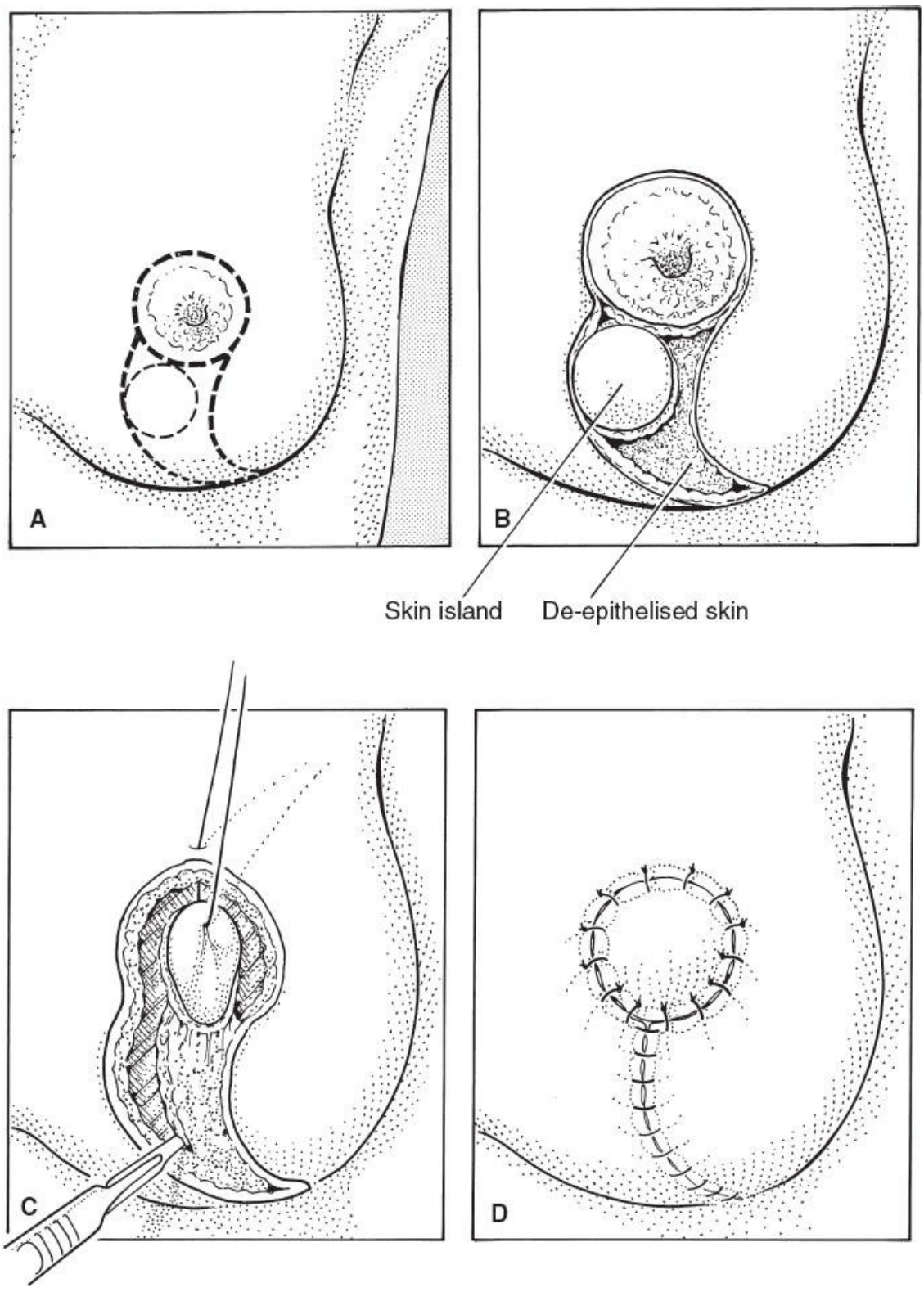

Figure 49.6. How to excise a central cancer under the nipple and get a satisfactory cosmetic outcome without major breast distortion. This procedure has also been called a *central quadrantectomy.* **A.** The nipple–areolar complex is excised and a portion of skin inferior to it is marked out. **B.** An incision around the circular skin island is made, and the remaining skin around

the island is deepithelialized. **C.** A full-thickness incision is the made in the breast, and the skin island is rotated to fill the central defect. Staples are useful to position the flap. **D.** When the flap is deemed to be in an optimal position, the staples are removed and the wound is closed in two layers with absorbable sutures.

TECHNIQUE OF EXCISING IMPALPABLE CANCERS

Impalpable lesions can be localized prior to surgery using a number of different techniques, including skin marking, injection of blue dye, carbon, or radioisotope, radioactive seed, or insertion of a hook wire with postlocalization mammograms (Fig. 49.7), or use of intraoperative ultrasound by the surgeon. Excising an impalpable cancer is easier if the skin incision is placed close to the cancer. Increasingly however such lesions are being excised through remote excisions. If the lesion is being localized by ultrasound, the skin directly over the cancer should be marked along with an indication of the depth of the cancer below the skin by the radiologist or radiographer performing the localization. If the lesion is only visible on a radiograph, then from a true lateral and craniocaudal mammogram, it is usually possible for the surgeon to estimate the likely position in the breast. An appropriate-sized skin incision is made and deepened (Fig. 49.8). If a wire is in place, dissection continues toward the wire so that it can be located where it enters the breast (Fig. 49.9).

If a remote incision is being used, hydrodissection with elevation of the skin and subcuteaneous fat allows identification and delivery of the wire through the skin into the breast. Localization wires with markings, which change diameter or have a guide that can be placed over the wire, help the surgeon know exactly how far down the wire the lesion is situated. Some surgeons use multiple wires to bracket a lesion. This can be helpful and improves the rate of complete excision in more difficult widespread calcifications. The direction of the wire on the preoperative mammograms is only a guide to the actual path of the wire through the breast, and can be misleading. Having found the wire as it enters the breast, do not cut it at its entry into the breast but deliver some of the wire outside the breast and only then cut the wire. This ensures sufficient wire is palpable and can be seen entering the surface of the breast. The aim is to remove the mammographic lesion with a clear radiologic margin (Figs. 49.10 and 49.11). Many so-called impalpable lesions can be palpated once it is clear where the lesion is situated within the breast parenchyma. Be cautious

when placing tissue forceps on the breast tissue. They distort the breast and can affect histologic assessment, and if used they are best placed at the edge of the lesion to be excised. Radio-guided occult lesion localization is a newer technique for localization of impalpable lesions. Under mammogram or ultrasound control, technetium-labeled human serum albumin, sulfur colloid, or an iridium seed is injected into the tumor. The surgeon then uses a handheld gamma-detecting probe intraoperatively to locate the lesion to guide excision. There is some evidence that this technique may be easier than hook wire localization, but no evidence to show it increases the rate of complete excision or reduces the volume excised. Radio iodine seeds are showing promise as they can be inserted days or even weeks prior to surgery. Iron is also being used to localize breast masses and to locate sentinel nodes. The iron in the cancer or the node is located with an intraoperative magnetometer. The use of intraoperative ultrasound has been evaluated in a number of studies. It has been used for removal of both palpable and impalpable lesions. Ultrasound performed by the surgeon during operation allows greater surgical autonomy and obviates the need for radiologist-led tumor localization, although it is greatly dependent on the training and experience of the surgeon. Most, but not all, studies using intraoperative ultrasound have reported high rates of complete excision and low rates of reexcision. It is clear that the major factor in incomplete excision is the presence of DCIS out with the invasive cancer that is not visualized by current imaging techniques. It is difficult based on this observation to believe that application of a technique to image disease that is not visualized by preoperative ultrasound will increase excision rates. Perhaps by ensuring that the lesion is more centrally situated and optimizing the excision with a consistent margin width all around the cancer will allow some of those patients with DCIS around the invasive cancer to have a complete excision. Newer techniques employing newer technologies to assess margins of excision during operation are showing promise.

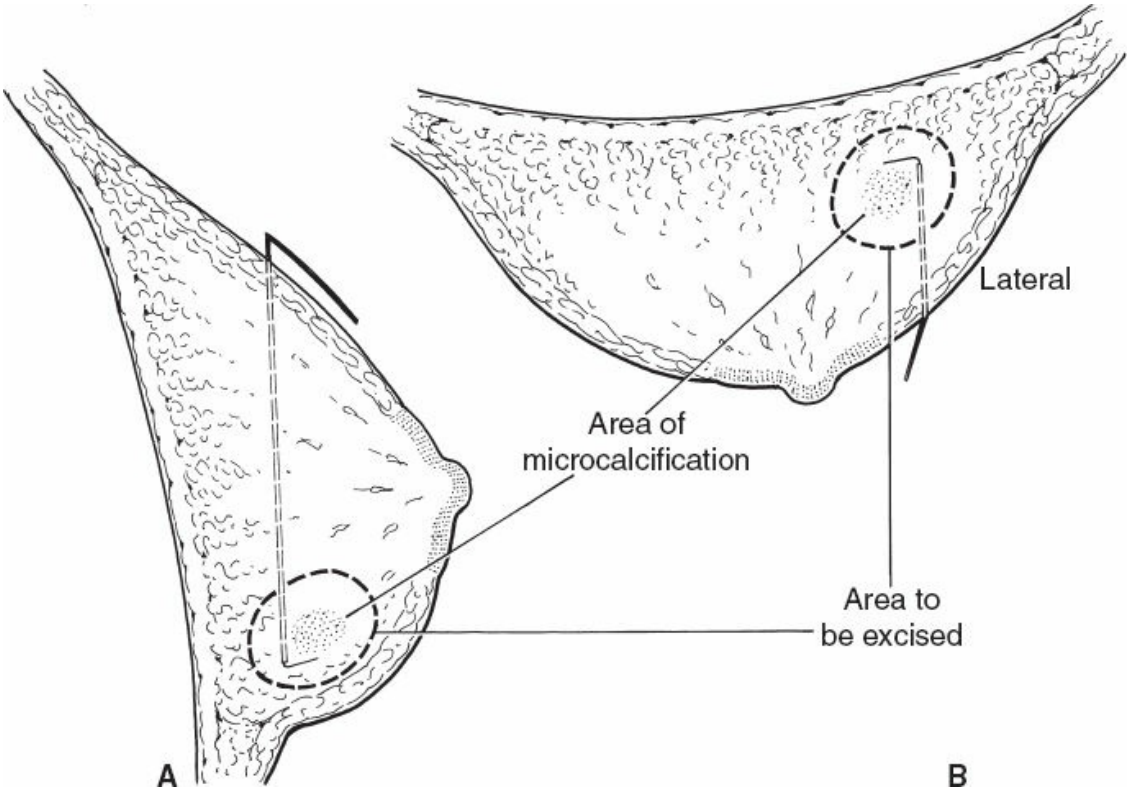

Figure 49.7. Diagrammatic representation of mammograms illustrating the position of a hook wire in relation to the area of microcalcification. **A.** Lateral view. **B.** Craniocaudal view.

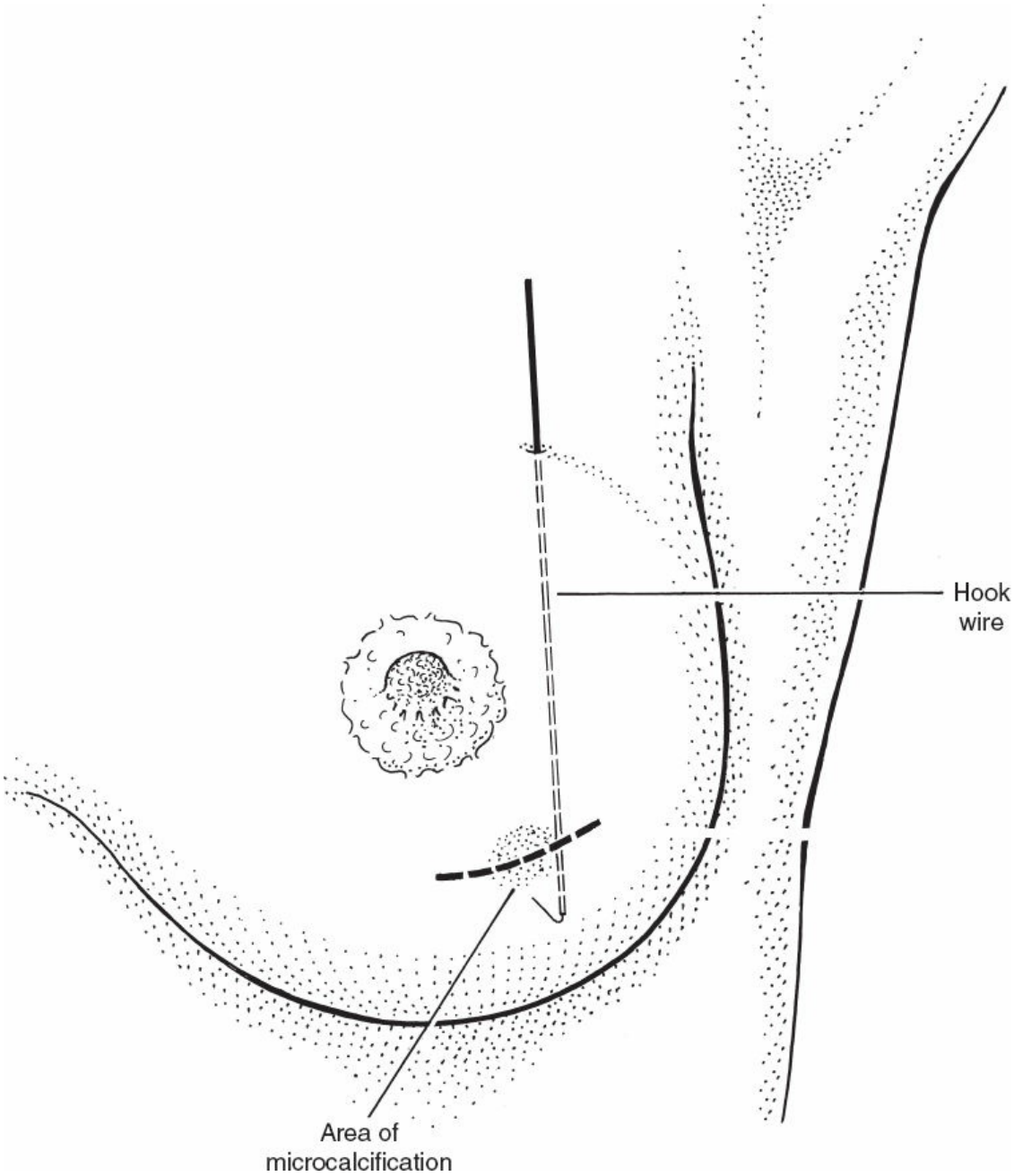

Figure 49.8. Planned incision over area of microcalcification.

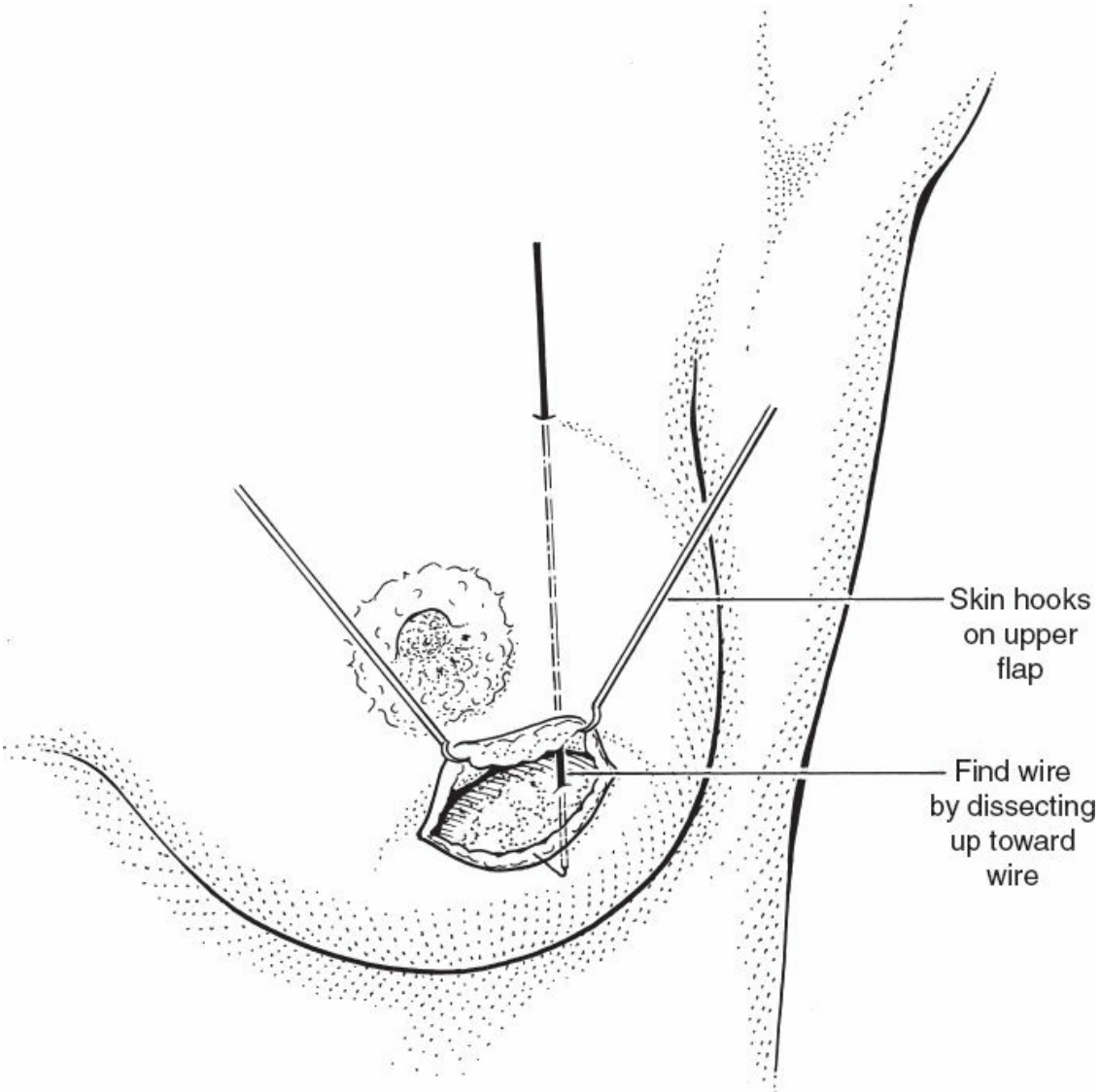

Figure 49.9. Dissection toward the hook wire to locate its entry site into the lesion.

Core biopsy itself causes a hematoma in some patients, although the hematoma is not always directly surrounding the cancer. So-called hematoma-directed and ultrasound-guided wide excisions have been reported. This has the potential to avoid wire localization in some patients. Hematomas do result in increased blood flow, so whereas some prefer to operate early, others wait until the hematoma and any increased blood flow to subside.

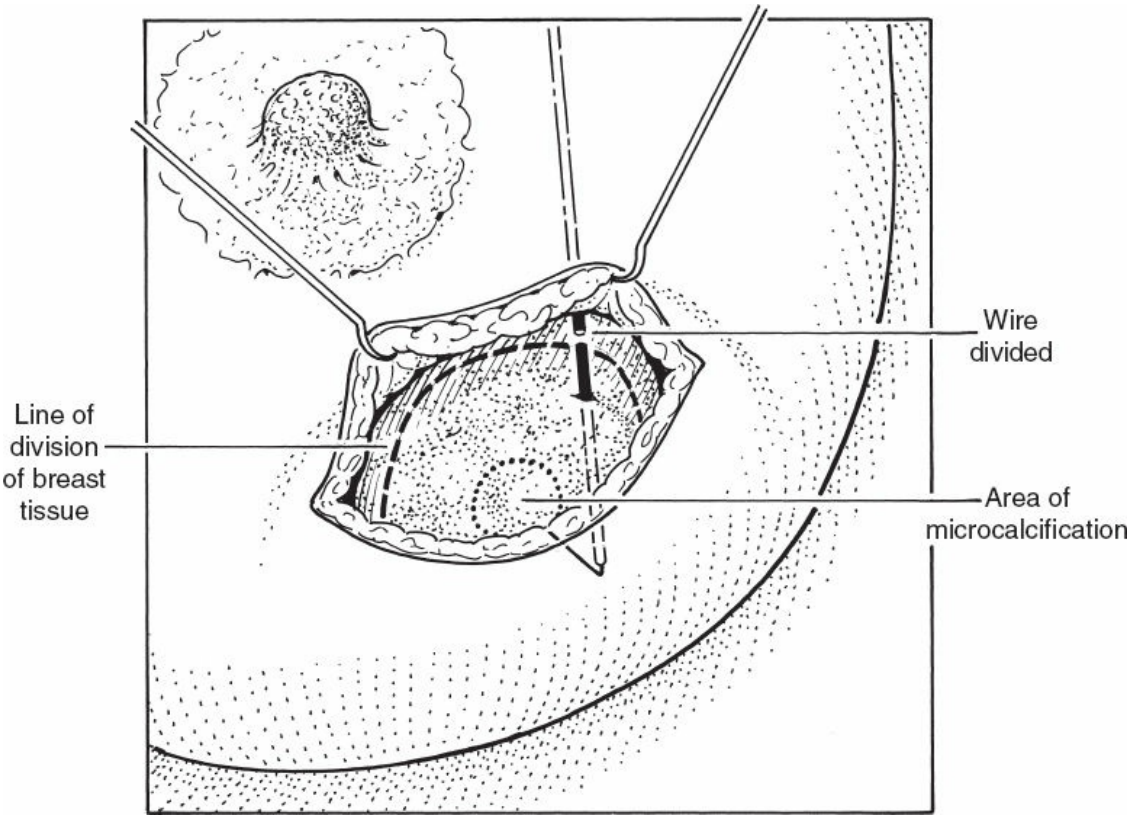

Figure 49.10. The goal of excision is to remove the lesion with a 1-cm clear radiologic margin.

Once the specimen has been excised, it should be orientated with ligaclips or metal markers, or secured to an orientated grid so that an orientated-specimen radiograph can be obtained. Orientated-specimen radiographs improve the rate of complete excision of impalpable cancers. The patient should remain anesthetized until the specimen radiograph has been reviewed and it has been confirmed that all radiologically visible suspicious areas have been removed before the patient.

BREAST-CONSERVING SURGERY AFTER NEOADJUVANT THERAPY

Significant numbers of patients with large and locally advanced breast cancers are treated with neoadjuvant chemotherapy (NAC) and then become suitable for BCS. Surgeons are poor at assessment of disease extent after NAC, and decisions on operability should be based on imaging. All patients having NAC should have all areas of disease marked at diagnosis with radiopaque markers or radioactive seeds. Up to 40% of patients with triple negative breast cancers, up to 60% with HER2 positive cancers, but only 10% of patients with ER-rich (Estrogen Receptor [ER])

breast cancers achieve a complete pathology response. More patients after chemotherapy than after endocrine therapy have a diffuse pattern of response and have a reduction in cellularity but little reduction in volume. Patients undergoing NAC should be warned of this.

The aim of BCS after NAC should be to excise the clip or clips and any palpable disease or disease marked by calcifications or visible on imaging. The surgery should focus on what is left, not what was present at diagnosis (Fig. 49.12A,B). Large volume excisions defeat the whole purpose of using NAC. Limit the surgery to the disease visible on imaging or palpable at surgery.

POSTOPERATIVE COMPLICATIONS

Breast Conservation

Complications of wide excision include bleeding with hematoma formation, infection, incomplete excision, and poor cosmetic results. Incomplete excision rates vary between 15% and 40% depending on what is defined as an involved margin. Hematoma requiring evacuation should be rare and occurs in less than 2% of patients. Rates will be higher in patients who have had greater tissue mobilization. Infection requiring treatment affects up to 5% of patients and is more common when BCS is combined with an axillary dissection. A common problem following BCS is a poor cosmetic result. Factors influencing cosmetic outcome are listed in Table 49.2.

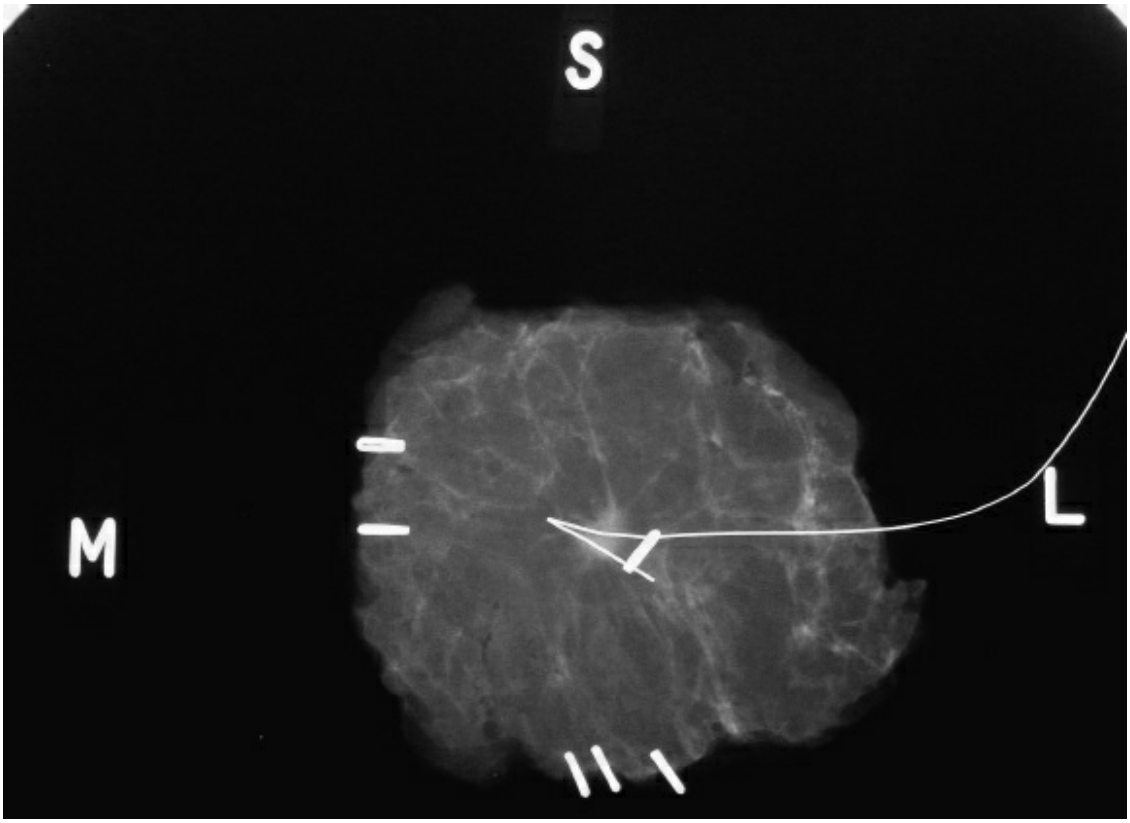

Figure 49.11. Specimen x-ray of small cancer. Note the clips orienting the specimen. Two clips are medial and three inferior.

There is a variation in different series in the number of patients getting good to excellent cosmetic results after BCT. The importance of good cosmetic results is demonstrated in a study from Nottingham, which showed that there was a significant correlation between cosmetic outcome and levels of anxiety, depression, body image, sexuality, and self-esteem. The extent of surgical excision (weight of excision) or the volume of resected breast tissue is the single most important factor affecting cosmesis. The inferior cosmetic results obtained with quadrantectomy compared with wide excision, even in the most experienced hands, are well documented. Even more critical is the percentage of the breast excised. Excisions less than 10% of breast volume are generally associated with a good cosmetic outcome in 95% of patients, whereas excisions of more than 10% produce poor cosmetic results in up to 50% of patients. When more than 10% of the breast volume needs to be excised to remove the cancer completely, then reshaping or volume replacement using local flaps, lipofilling, an oncoplastic reduction procedure, neoadjuvant drug therapy, or a mastectomy with or without immediate reconstruction should be considered.

INDICATIONS FOR REEXCISION

The current surgical practice is to aim for microscopically disease-free margins. In the United States, this is defined as no ink on tumor, but in other countries 1 mm is defined as a free margin based on the finding of two meta-analyses. What is clear is that there is no advantage in terms of local recurrence in having wide margins. Anterior and posterior margins matter much less than radial margins if full thickness of breast tissue has been excised. Regardless of how a negative margin is defined (no ink on tumor or ≥1 mm), there is an increased rate of local recurrence in patients with positive or involved margins. There remains controversy on the use of shaving of margins. Taking shavings reduces reexcision rates but does so at the expense of removing more tissue.

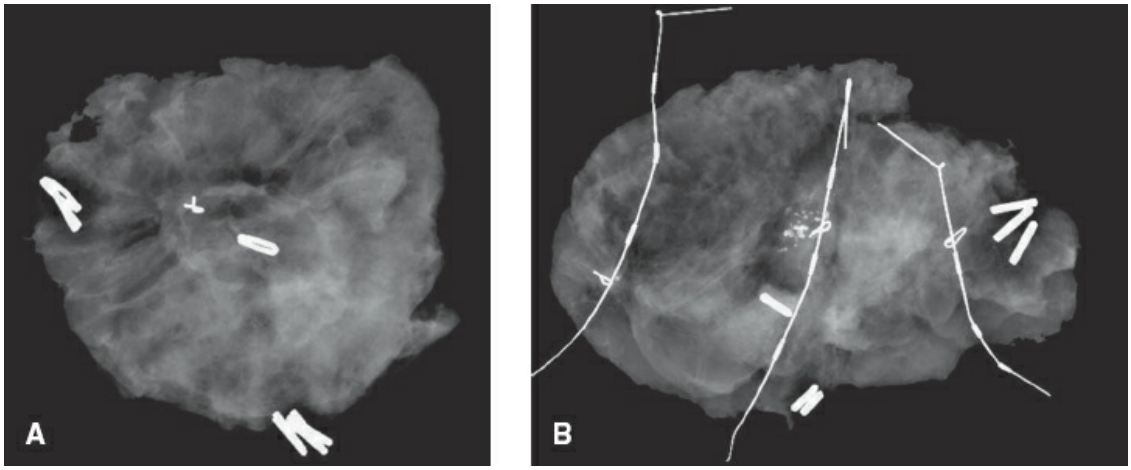

Figure 49.12. **A.** Specimen x-ray. Mass had disappeared after chemotherapy but no mass lesion leaving clip and this was localized. Pathology showed scar tissue with a complete pathologic response. **B.** Specimen x-ray. Patient had three masses adjacent with calcification in central mass. Clips were placed before chemotherapy. All three clips were localized and excised. Pathology showed all three cancers had a complete pathology response.

TABLE 49.2 Factors Resulting in Poor Cosmetic Outcome After Breast-Conserving Surgery

Large breasts
Increasing tumor size
Central tumor position
Increasing volume of breast tissue removed
Reexcision procedure
Increasing scar length
Postoperative complications
Associated axillary dissection
Increasing dose of radiotherapy, especially use of a boost
Chemotherapy

Neither lobular carcinoma in situ (LCIS) nor atypical ductal hyperplasia (ADH) at the margins increases local recurrence rates; consequently, there is thus no need for a surgeon to reexcise if the pathologist reports these features alone at any of the margins of excision. Patients with a positive radial (medial, lateral, superior, or inferior) margin for DCIS or pleomorphic LCIS should have a reexcision. Patients with a positive anterior or posterior margin do not appear to require reexcision providing full thickness of breast tissue has been taken and a radiotherapy boost is given.

Surgical Technique: Reexcision

When performing a reexcision, the old scar is opened and there is no need to excise the scar. The breast is opened and the site of the previous wide excision is identified. The involved margin is then excised to a thickness of approximately 1 cm. The outer margin of the reexcision is marked for the pathologist (we use a ligaclip) and the tissue is sent for pathology. A specimen radiograph of the reexcision is performed if there is a residual mammographic abnormality. Postoperative bleeding can be a problem following reexcision, so meticulous attention to hemostasis is required. The breastplate can be mobilized in patients with dense breast tissue from the subcutaneous fat +/− chest wall and the defect closed with absorbable sutures if at all possible. The wound is then closed as described previously in layers with absorbable sutures and infiltrated with local anesthetic. Drains are not required.

RECURRENCE AFTER BREAST-CONSERVING SURGERY

Local recurrence rates following BCS and adjuvant radiotherapy for invasive carcinoma of the breast vary widely between different centers but nowadays should be less than 0.5% per annum. Approximately half of in breast tumor recurrences are new primary cancers, and the remainder are true recurrences. The rate of true in breast local recurrence has fallen dramatically over the last two decades. Factors that affect local recurrence rates after BCT can be divided into patient-, tumor-, and treatment-related factors.

Patient-Related Factors

In breast tumor recurrence (IBTR) in the treated breast following BCT can be either a true recurrence (at the site of the previous cancer) or a second primary (usually elsewhere in the breast). IBTR is significantly more common in younger patients and is much less of a problem in older patients (>65 years). This may be because women who develop breast cancer at a young age are more likely to carry a mutated gene that predisposes them to develop another cancer in the treated breast. Family history of breast cancer, and, in particular, carriage of a mutation in one of the known breast cancer predisposing genes, is associated with a significantly increased rate of in breast tumor recurrence. If these women undergo a prophylactic oophorectomy, then local recurrence rates fall close to that of the general population.

Tumor-Related Factors

Tumor Grade

A number of studies have looked at the relationship between tumor grade and local recurrence. Grade 1 tumors have the lowest rates of local recurrence. Some series, although not all, report a higher recurrence rate in grade 3 compared with grade 2 cancers. The relative risk of local recurrence between grade 1 and grades 2 and 3 cancer is approximately 1.5.

Histologic Type

A few studies have correlated histologic tumor type and in breast recurrence. Data indicate that invasive lobular cancer is not associated

with a higher recurrence rate than invasive ductal carcinoma. Patients with invasive lobular cancer are more likely however to have incomplete excision than patients with invasive ductal carcinoma of no special-type, so patients with invasive lobular cancer identified on core biopsy should be warned of this.

Lymphatic/Vascular Invasion

Local failure rates were reported in many, but not all, early series to be higher in patients with histologic evidence of LVI. Recent studies have shown that LVI is a marker for recurrence after mastectomy but now is associated with little increased in patients having BCS and whole breast radiotherapy.

Extensive In Situ Component

Early reports indicated that local recurrence rates were higher in patients who had cancers with an extensive in situ component, but the majority of these studies undertook simple tumor excision rather than a wide local excision. If clear margins are obtained, there appears to be no increased rate of local recurrence in patients with an extensive in situ component.

Multiple Tumors

A patient with macroscopic multiple cancers (multisite disease) was until recently considered to be more likely to develop local recurrence following BCT than a patient with a unifocal cancer. It has long been recognized that if multisite disease is identified only by the pathologist or there are two cancers that are adjacent, then acceptable local recurrence rates can be obtained by BCT, provided that all margins of excision are clear of disease. More recent data indicate that multisite cancers can be treated safely by BCS provided all disease can be excised to clear margins and that any BCS performed will produce an acceptable cosmetic outcome. Multisite disease may be associated with a small increase in the risk of local recurrence, but is no longer a contraindication to breast conservation.

Tumor Size

Tumor size is not considered important in relation to local recurrences.

Other Factors

Tumor location, the presence of skin or nipple retraction, the presence or absence of axillary node involvement, and hormone receptor status of the

cancer have not been consistently shown to exert any influence on breast recurrence after BCT.

Treatment-Related Factors

The most important treatment-related factors are completeness of excision and the use of systemic therapy and appropriate doses of radiotherapy. Margins need to be clear of both in situ and invasive disease. In the United States, no ink on tumor is accepted, whereas in other countries ≥1 mm is defined as a clear margin. Some use a margin index to determine whether reexcision is required. Margin index is defined as the margin in millimetres multiplied by 100, divided by the tumor size in millimeters. When the index is ≥5, residual disease is present in less than 3% of reexcisions. This suggests that the bigger the tumor the bigger the margin needed. However, not all studies support this and reexcising based on margin status alone independent of the size of the cancer does not seem to be unreasonable based on the literature. Radiotherapy significantly reduces the rates of local recurrence and improves overall survival. Ongoing studies are evaluating whether localized radiotherapy delivered either during or within a few days of surgery is as effective as whole-breast radiotherapy. Following whole-breast radiotherapy, increasing the local dose of radiotherapy by giving a dose to the tumor bed reduces local recurrence rates, particularly in younger women (<50 years). There are a group of older patients with low-risk cancers (completely excised, node-negative, hormone receptor-positive on hormone treatment) in whom the rates of local recurrence without radiotherapy are low.

Adjuvant tamoxifen, chemotherapy, and trastuzumab all reduce local recurrence after BCT. In the absence of radiotherapy, however, tamoxifen or chemotherapy alone does not provide satisfactory local control. The interval between surgery and both radiotherapy and systemic therapy may be important, and there are suggestions that the rates of local recurrence are increased if radiotherapy or systemic therapy is delayed for many months.

Treatment of in Breast Tumor Recurrence

In breast tumor recurrence rates vary widely in the literature, but rates of less than 0.5% per year after BCT should be achievable by all units. Approximately half of in breast recurrences are second primaries. Although an isolated local breast recurrence does not appear to affect

survival, breast recurrence can be a predictor of distant disease. Isolated recurrences in the breast can be treated by excision or mastectomy. Excision alone is associated with a greater rate of subsequent local recurrence if the initial recurrence develop within the first 5 years of treatment. Local recurrence within the first 5 years is also associated with a worse long-term survival than recurrence thereafter. Ninety percent of local recurrences following BCT are invasive. The majority of in breast events that develop in the treated breast after 5 years represent a second primary cancer rather than a true local recurrence. Mastectomy is the most commonly used treatment for in breast recurrence after BCT and can be combined with immediate breast reconstruction. Excision of the recurrence combined with a change of systemic therapy or excision together with further radiation are also options. Care is needed when performing a further excision or mastectomy after breast radiotherapy as the complications of wound healing problems, necrosis of the skin flap edges, and development of postoperative seromas are more common following prior radiotherapy than in untreated patients.

MANAGEMENT OF CARCINOMA IN SITU AND PROLIFERATIVE LESIONS OF THE BREAST

Classification of noninvasive and proliferative lesions is difficult and challenging. Carcinoma in situ is separated into two groups: DCIS and LCIS based on cell type and pattern of disease. DCIS is the most common form of noninvasive disease and represents a heterogeneous group of neoplastic lesions confined to breast lobules and ducts. DCIS diagnoses have increased in frequency as a consequence of the widespread use of screening mammography. DCIS makes up 3% to 4% of symptomatic and 20% to 25% of screen-detected breast cancers.

Epidemiology

The overall incidence of DCIS increased from 5.8 per 100,000 women in the 1970s to 32.5 per 100,000 in 2004 and then reached a plateau. The risk of developing DCIS, like invasive cancer, increases with age. Death following a diagnosis of DCIS is rare and is less than 3% at 20 years. Risk factors for DCIS include family history, increased breast density, obesity, and late age at first birth. DCIS is seen in BRCA1 and 2 mutation carriers and tends to occur at a younger age in these women. Tamoxifen given to

high-risk women reduces the number of women who develop DCIS.

Clinical Presentation

Prior to mammographic screening, most women with DCIS presented with a mass, nipple discharge or Paget disease of the nipple. Now more women with DCIS are diagnosed following mammography. Ninety percent of women with DCIS have microcalcifications, and DCIS accounts for 80% of all cancers that have microcalcification without a mass lesion or distortion. Linear branching or segmental pleomorphic calcifications are characteristic of high-grade DCIS. Fine granular calcifications are seen more commonly with low- and intermediate-grade DCIS. Mammography often underestimates the size of DCIS, particularly in low-grade disease. The role of MRI in DCIS is unclear. It can visualize DCIS, particularly high-grade disease but can underestimate and overestimate size. There is no role for the routine use of MRI in DCIS management.

Diagnosis and Histology

The diagnosis is established by core biopsy typically guided using stereotaxis. Large core vacuum-assisted devices are favored as they remove more tissue and are more likely to sample sufficient calcification to establish the diagnosis. It is essential when performing core biopsy to ensure that adequate numbers of calcifications are retrieved and that these are identified by the pathologist in the histologic sections. For large lesions, core biopsies should be performed from each end of the lesion to establish the extent of disease. After core biopsy marker clips should be placed because sometimes most or all the calcifications are removed by the biopsy. Check films should be performed after marker deployment to check that markers are on target.

Histology

DCIS is classified into three main groups based on nuclear grade: high, intermediate, and low grade. Pathologists often separate DCIS into different patterns, such as solid, cribriform, micropapillary, and comedo, but these descriptions have little direct clinical significance. The presence of necrosis is a feature that has some prognostic significance. Approximately 50% of high-grade DCIS and 75% of low- and intermediate-grade DCIS overexpress the estrogen receptor and are classified as ER-positive. Approximately 40% of DCIS overexpress HER2

and are classed as HER2 positive.

Natural History

Approximately 30% to 40% of women with untreated low-grade lesions were reported to develop an invasive cancer over a 30-year period in studies performed almost 40 years ago. Newer evidence indicates that many low-grade DCIS lesions are indolent and some may not need any treatment and that the rate of breast cancer development if untreated is much lower than that reported in older studies and is closer to 10% to 20%. The rate of progression of high-grade DCIS to invasive cancer is much higher with a 30% or greater lifetime risk.

Treatment

The objective of treatment is to prevent recurrence or progression of DCIS to invasive cancer.

Surgery

The options are BCS or mastectomy.

Breast-Conserving Surgery

Outcomes with BCS are improving, and local recurrence rates have fallen over time and are now less than 0.5% per year. There is no size limit for offering BCS other than the balance between the extent of disease and breast size. When over 10% of the breast volume is excised, the cosmetic outcome is more frequently poor than when lower volumes are excised. In general, it is difficult to excise lesions over 5 cm except in women with larger breasts when a mammaplasty is an option. In such women once the the DCIS is excised, the breast is reshaped and made smaller, and usually the opposite breast is reduced to match. Wide excision is performed in an identical manner to that for invasive breast cancer. As DCIS is usually impalpable, the disease needs to be localized by one or more hooked wires or another method of localization such as using isotopes. As for invasive cancer, DCIS needs to be excised to clear margins. There is less uniformity in what constitutes a negative margin; ≥1 mm or ≥2 mm is the most frequently used margin, but some try to excise DCIS with wide margins ≥10 mm. There seems little scientific basis for using different margins for invasive cancer and DCIS given that most recurrences after BCS for invasive cancer is from residual DCIS. Up to 20% of excisions for DCIS show the presence of invasive cancer on histologic assessment. Such

patients usually require a later sentinel node biopsy. Rates of upgrade to invasive cancer are less if lesions have been sampled with a large core vacuum-assisted device.

Preoperative Assessment

This is similar to that for invasive cancer. Patients need to be warned of the 20% risk that invasive cancer may be diagnosed after excision and warned that if invasion is diagnosed they may need a subsequent sentinel lymph node biopsy (SLNB). Surgical Technique is similar for excision of impalpable invasive cancers. Complications are similar to that for invasive cancer.

Mastectomy

Mastectomy is a highly effective treatment for DCIS, but may be overtreatment for many women particularly those with small low- and intermediate-grade lesions that may never have become symptomatic within a patient's lifetime. Most women with DCIS are suitable for a skin sparing mastectomy approach with immediate breast reconstruction. While recurrence rates have been traditionally low after standard mastectomy, in younger patients with high-grade DCIS who have close margins much higher rates of recurrence of invasive cancer have been reported. Patients who have mastectomies for DCIS should have the breast X-rayed to assist the pathologist in localizing the disease. Studies have shown high rates of recurrence in young women with high-grade DCIS who have margins less than 1 to 2 mm after mastectomy. For this reason, in skin-sparing mastectomies particular care must be taken when dissecting the area over the DCIS. Taking extra tissue from the flaps and sending this separately for assessment increase the likelihood of obtaining a clear anterior margin. Given the 20% rate of invasive cancer evident on histologic assessment after excision of patients diagnosed on core as DCIS, sentinel node biopsy is often combined with mastectomy. The isotope +/− blue dye is injected centrally.

Radiotherapy

Multiple randomized trials have shown that radiotherapy reduces the rate of in breast tumor recurrence following BCS for DCIS by approximately 50%. In an overview of randomized trials radiotherapy reduced the absolute 10-year risk of any ipsilateral event (i.e., recurrent DCIS or invasive cancer) by 15.2% (SE 1.6%, 12.9% vs. 28.1% $p < 0.001$). The

proportional reduction in events was greatest for younger women. Even for women with negative margins and small low-grade lesions, radiotherapy showed a significant reduction in local events (12% vs. 30% $p = 0.02$). Despite this large effect, there is no current evidence that radiotherapy improves survival.

Not all women following BCS for DCIS require radiotherapy. A variety of algorithms and a new genomic index have been used to identify those who are most likely to benefit from radiotherapy. Younger women, with more extensive high-grade DCIS with comedo necrosis that is close to margins appear at greater risk of local recurrence and so these women may benefit from radiotherapy. In contrast, older women with small low- and intermediate-grade DCIS, excised adequately appear to benefit least and so many of these women can potentially avoid radiotherapy. A new genomic index that measures RNA for seven tumor genes and five reference genes has been developed and validated. In the first cohort patients classed as low risk had a 10.6% rate at 10 years of any in breast event and a 3.7% rate of invasive breast cancer development at 10 years. The figures for intermediate risk lesions were 26.7% and 12.3% for DCIS and invasive cancer, and for high-risk DCIS 25.9% developed further DCIS and 19.2% developed invasive cancer. This index does potentially identify a low-risk group who can potentially avoid radiotherapy after excision.

Endocrine Therapy

Two studies have shown a benefit of tamoxifen in reducing both the rates of DCIS recurrence and invasive cancer development following BCS. The effects were greatest in women with ER-positive DCIS with up to a 60% reduction in the number of in breast events. Studies with aromatase inhibitors have also shown reductions in the number of in breast events. Raloxifene has also been shown to reduce DCIS and invasive cancer events but appears less effective than tamoxifen.

The issue surrounding the use of endocrine therapy is how much benefit is necessary to justify their use. There is no evidence that any of these agents improve survival and all are associated with significant morbidity. Endocrine treatment is an option for both pre- and postmenopausal women following excision of DCIS and appears of greatest value in younger women with ER-positive DCIS where not only the rates of recurrence are higher, but the reductions in events with endocrine therapy have been greatest in the studies published to date.

Treatment for Low-Grade DCIS

A recent study has suggested that surgery for low-grade DCIS has no effect on subsequent outcomes. There is clear evidence from screening studies that between 11% and 19% of screen-detected cancers (including many DCIS lesions) are overdiagnosed and thus overtreated. Over diagnosis means that if left untreated they would never have caused problems in the patient's lifetime. Studies are now these studies are investigating doing less for low-grade DCIS and treating such patients without initial surgery and investigating the role of observation or endocrine therapy rather than surgical excision +/- radiotherapy.

Atypical Ductal Hyperplasia

ADH is defined as a localized intraductal proliferation having some but not all microscopic features of (low-grade) DCIS. It is usually seen most commonly in biopsies for calcification seen on breast screening. ADH is part of a spectrum and poses a challenge for the pathologist because it can be difficult to distinguish usual duct hyperplasia from ADH and low-grade DCIS. Histologically ADH is an architecturally complex proliferation of monotonous luminal-type cells forming bridging structures and "crisp" secondary lumens. ADH is distinguished from low-grade DCIS using a combination of qualitative and quantitative criteria: generally, there is less cytologic atypia in ADH than in DCIS. ADH is limited to fewer than three contiguous ducts or a size less than 0.2 cm. As sampling by core biopsy produces small fragments of tissue, it is not always possible to distinguish ADH from low-grade DCIS. On average 10% to 20% of ADH cases diagnosed on core needle biopsy are "upgraded" to DCIS or invasive carcinoma on subsequent excision, although the reported upstaging rates to DCIS or invasive carcinoma vary from 11.5% to 62%. If ADH is diagnosed on a core biopsy, then more tissue needs to be sampled at that site either by large bore vacuum-assisted biopsy or open surgical biopsy.

The relative risk of atypical hyperplasia for development breast cancer is between 3.9 and 13.0. Most have reported relative risks at the lower end of this range between 3.1 and 4. Risk increases in women with a strong family history of breast cancer. Various risk models are available to calculate individual risk. In the National Surgical Adjuvant Breast and Bowel Project (NSABP) P-1 study, there was a 57% increase in invasive cancer compared to patients without atypical hyperplasia (10.11 events per 1,000 patients vs. 6.44 events per 1,000 patients) at a mean follow-up of

47.7 months (Fisher).

ADH is a risk lesion, and options for management include chemoprevention with tamoxifen or raloxifene in premenopausal women and tamoxifen, raloxifene, or an aromatase inhibitor in postmenopausal women. Tamoxifen reduced the risk of breast cancer in patients with atypical hyperplasia patients by 86% in the NSABP P-1 prevention study. The other main option is regular breast screening with mammography with or without MRI. Performing risk reducing mastectomies based on ADH alone is not recommended.

Lobular Carcinoma *In Situ* and Atypical Lobular Hyperplasia

LCIS is rare. It was first described in 1941 and was originally treated in a similar way to invasive cancer by mastectomy. LCIS is a proliferative lesion of the terminal duct lobular unit characterized by lobules expanded by neoplastic cells that are regular in shape and size and have regular rounded nuclei. LCIS-like invasive lobular cancers lock e-cadherin—an adhesion molecule. Between 0.5% and 2% of all core biopsies contain LCIS, and it is seen most commonly in postmenopausal women and is often an incidental finding.

Atypical lobular hyperplasia (ALH) is a histologic continuum with LCIS and has similar but less developed features. The lobules are expanded with the same cell type with the cells having lost e-cadherin but not all the spaces in the lobule are expanded. Because of the difficulties in distinguishing between ALH and LCIS, the term *lobular intraepithelial neoplasia* (*LIN*) has been introduced to include both LCIS and ALH. Like LCIS, ALH is often an incidental finding and is most commonly diagnosed in core biopsies performed for calcification even though the ALH is not often associated with calcification.

Management

Studies of patients with LCIS on core biopsy have reported upgrade rates to invasive carcinoma or DCIS following surgical excision of between 25% and 38% of patients. Little data exist on upgrade rates for ALH alone, but studies of LIN (LCIS and ALH) have reported upgrade rates of 13% to 20%. Current NCCN and UK guidelines recommend that patients who have LCIS or ALH on core biopsy should have surgical excision. There are however huge problems with studies that have reported upgrade rates of LCIS and ALH on core biopsy. All such studies have contained small

numbers of patients, and there has been a wide reported variation in the upgrade rate. More recently, there has been an attempt to correlate radiology and pathology, and two groups have been identified. The first group is the concordant group where the histologic findings on the core biopsy are consistent with the radiology. The second is the discordant group where the findings on core biopsy do not adequately explain the radiology findings. A recent prospective study enrolled 79 patients, and of these 74 had LIN as the worst histologic lesion. The histology and radiology were concordant in all these 74 patients. There was no upgrade on surgical excision in 73 (73/74) of these concordant cases with just one upgrade to DCIS on excision. This is consistent with findings in the literature where a total of 335 cases combined from 5 different publications had histologic and radiologic concordance. In these 335, there were just six upgrades (1.8%). Of these six, five were upgraded to DCIS and one was a 2-mm grade 1 cancer. There is now growing evidence that it is possible to avoid excision biopsy in women diagnosed by LIN on core biopsy where there is concordance between pathology and imaging. As yet this change has not been incorporated into guidelines.

Pleomorphic LCIS

The clinical significance of pleomorphic lobular carcinoma in situ (PLCIS) is unclear. Currently management is inconsistent. One review analyzed nine studies involving a total of 176 patients and included five management guidelines (from United Kingdom, United States, Australia, and pan-European). This review found that 46 of 93 (49%) patients had PLCIS associated with concurrent invasive disease. They reported that 11 of 117 (9.4%) patients developed a recurrence of PLCIS, although no patient developed invasive disease or DCIS when they recurred. There were no studies assessing long-term outcomes of PLCIS. The Association of Breast Surgery (United Kingdom) and the National Breast and Ovarian Cancer Care (Australia) do not mention PLCIS. The National Comprehensive Cancer Network (United States) indicates that PLCIS should be excised to negative margins. The NHS Breast Screening Programme (United Kingdom) and the European Society of Medical Oncology (pan-European) recommend PLCIS should be treated in an identical manner to DCIS. Although high-quality evidence to guide management of PLCIS is lacking, the current consensus is to treat PLCIS in a similar manner to DCIS. If PLCIS is found on core biopsy, then

excision is required as the rate of upgrade to invasive cancer or DCIS is reported as between 17% and 46% in three small series.

AXILLARY SURGERY

The two main aims of axillary surgery in patients with operable breast cancer are to stage the axilla by SLNB and to treat any axillary disease by axillary clearance or axillary dissection. The presence or absence of axillary lymph node involvement is an important predictor of survival in patients with breast cancer, and important treatment decisions are based on it. The number of involved lymph nodes and the level of lymph node involvement are predictors of survival of patients with breast cancer. Figures 49.13 and 49.14 illustrate the levels of the axillary lymph nodes.

Indications for SLNB:

operable breast cancer (T1, T2)
clinically node-negative
imaging axillary node negative.[1]

Indications for axillary dissection[2]:

patients with histologically or cytologically proven involved axillary lymph nodes after freehand or ultrasound-guided fine-needle aspiration biopsy/core biopsy or after sentinel node biopsy.

MANAGEMENT OF THE INVOLVED AXILLA

For patients with involved axillary nodes in whom it is considered that the axilla requires treatment, there are two options: axillary dissection and axillary radiotherapy. A randomized trial AMAROS (After Mapping of the Axilla: Radiotherapy Or Surgery) showed after an average of 6.1 years an axillary recurrence rate of 0.43% after axillary lymph node dissection (n = 744) versus 1.19% after axillary radiotherapy (n = 681). There was no difference in disease-free or overall survival but an approximate doubling of the lymphoedema rates for lymph node dissection compared with axillary radiotherapy.

Sentinel Lymph Node Biopsy

The aim of SLNB is to identify patients who are node-negative or who have limited volume axillary disease. The premise behind SLNB is that the sentinel lymph node(s) is the first lymph node(s) to drain the cancer. If

sentinel lymph nodes are identified and removed and these do not contain metastatic disease, then the remainder of the axilla is likely to be negative, and complete axillary dissection and its sequelae can be avoided.

In the 1830s, Sappey injected mercury into the lymphatic channels of the breast. From these experiments, he concluded that breast tissue drains centripetally into the subareolar plexus before draining into the axilla. More recent studies of lymphatic channels in mastectomy specimens found no common subareolar plexus, but did identify one or two major lymphatic channels that drained the breast terminating in lymph nodes in the lower axilla. Tracer to identify sentinel nodes can be injected into the subareolar region, intradermally into the skin overlying the tumor, or around the tumor. The density of lymphatics is greater in the skin than in breast parenchyma, so uptake in the axillary nodes is greater with intradermal injection than other sites. Injection into skin can allow visualization of lymphatic channels, which may aid sentinel lymph node identification and can help to distinguish between first-echelon and higher-echelon lymph nodes. Peritumoral injection of tracer is preferred by some but the “shine-through” effect of injecting radio isotope in upper outer quadrant cancers can impede detection of the sentinel lymph node in the axilla. One study showed a 100% concordance between intradermal patent blue dye injection and peritumoral radioactive tracer injection. Intradermal injection has a higher rate of identification of the sentinel lymph node and a comparable false-negative rate when compared with peritumoral injection of tracer. Subareolar injection of tracer has advantages over peritumoral injection in patients with multisite or nonpalpable cancers. One review of 3,961 patients found that with subareolar and periareolar injection, the sentinel lymph node identification rate was 99.3% and 95.6%, respectively, compared with 91.1% for patients with peritumoral tracer injections. They concluded that subareolar and periareolar injection was superior, and this adds support to the hypothesis that lymphatic drainage of the breast, regardless of the site of injection, is through the same sentinel lymph nodes.

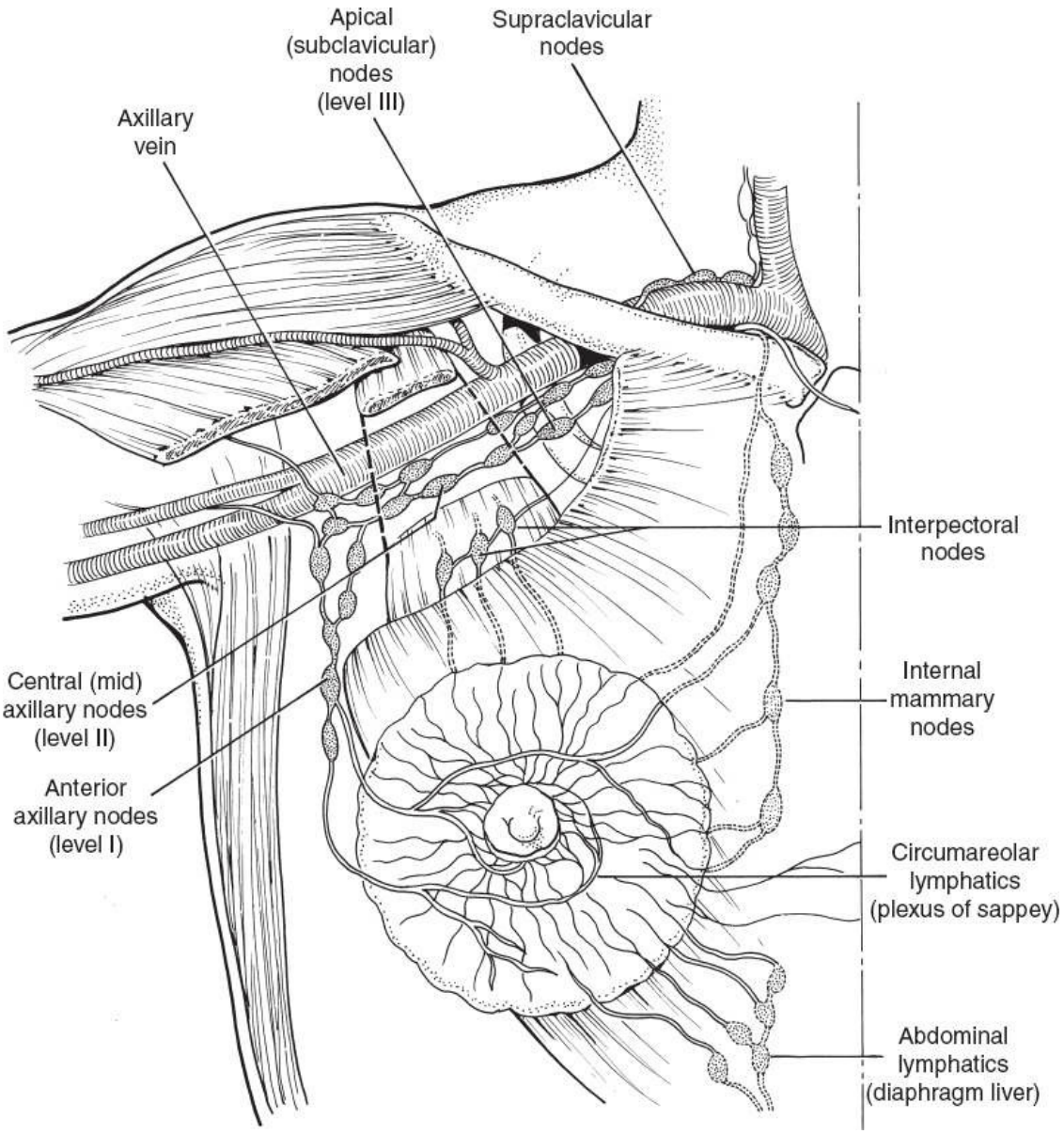

Figure 49.13. Lymph nodes and lymphatic drainage of the breast.

The two tracers in common use are technetium-99M-labeled albumin or sulfur colloid, and a blue supravital dye such as patent blue V, isosulfan blue, or methylene blue. Early studies of sentinel lymph nodes in breast cancer used a blue dye alone. In these studies, the rate of sentinel node identification was 66%, and no sentinel lymph nodes outside the axilla were identified with blue dye alone. The blue color appears in the axillary lymphatics and nodes within a few minutes of injection and can be visualized during operation. Injecting a gamma-emitting radiopharmaceutical around the primary tumor, into the skin over the tumor, or into the subareolar or periareolar area allows preoperative

visualization of any draining nodes using a gamma camera. The sentinel lymph node identified on scintiscans is in the internal mammary chain in up to 6% of patients. Internal mammary node uptake is dependent on the site and depth of injection. Peritumoral injections, particularly if placed deep in the breast, are more likely to drain to the internal mammary nodes. Using a handheld gamma probe, the surgeon can locate the node with the highest uptake of radioisotope and allow the surgeon to make a skin incision directly over it. This limits dissection and the associated morbidity of SLNB.

Following injection of a radioisotope, radioactivity can be identified in sentinel lymph nodes within a few minutes. Results from Milan demonstrated a 97.5% accuracy of SLNB using radioisotope alone. In their series of 250 women, only 10 patients did not have a sentinel lymph node identified. The average number of sentinel nodes was 2 (range 1 to 5) with less nodes being identified when larger colloid particles were used. Of the 240 patients who had sentinel lymph nodes removed, 108 had involved sentinel lymph nodes and 132 had negative sentinel lymph nodes. Of the 132 patients with a negative sentinel lymph node, 126 were node-negative following a full axillary clearance. The remaining 6 patients had a negative sentinel lymph node but had other involved nodes identified in the full axillary dissection specimen, a false negative rate of 6/108 (6%). The group from Memorial Sloan Kettering Cancer Center reported a detection rate with blue dye of 90%, compared with 98% for radioactive colloid. They recommended using both modalities to enhance sentinel lymph node detection.

Currently, radioactive colloid is used in most women with blue dye being used only for patients who do not have a sentinel node visualized on scan or nodes detectable by a handheld gamma probe. There are a range of reasons why blue dye is not used in all patients. First, and most importantly, blue dye is associated with a small but not insignificant rate of severe anaphylaxis. Allergic reaction to isosulfan blue or patent blue V has been reported in between 0.07% and 2.7% of patients. Methylene blue appears safer with no cases of anaphylaxis identified by one literature review. A second reason to avoid blue dye is that regardless of where it is injected the breast can remain discolored for months and even years after surgery. Other options are being explored including fluorescent tracers such as indocyanine green and injection of iron particles. The fluorescent tracers can be visualized intraoperatively in subcutaneous lymphatic

channels by ultraviolet light. Iron injected in the breast, like isotope and blue dye, migrates to nodes, and this iron can be identified by a handheld intraoperative magnetic device known as a magnetometer.

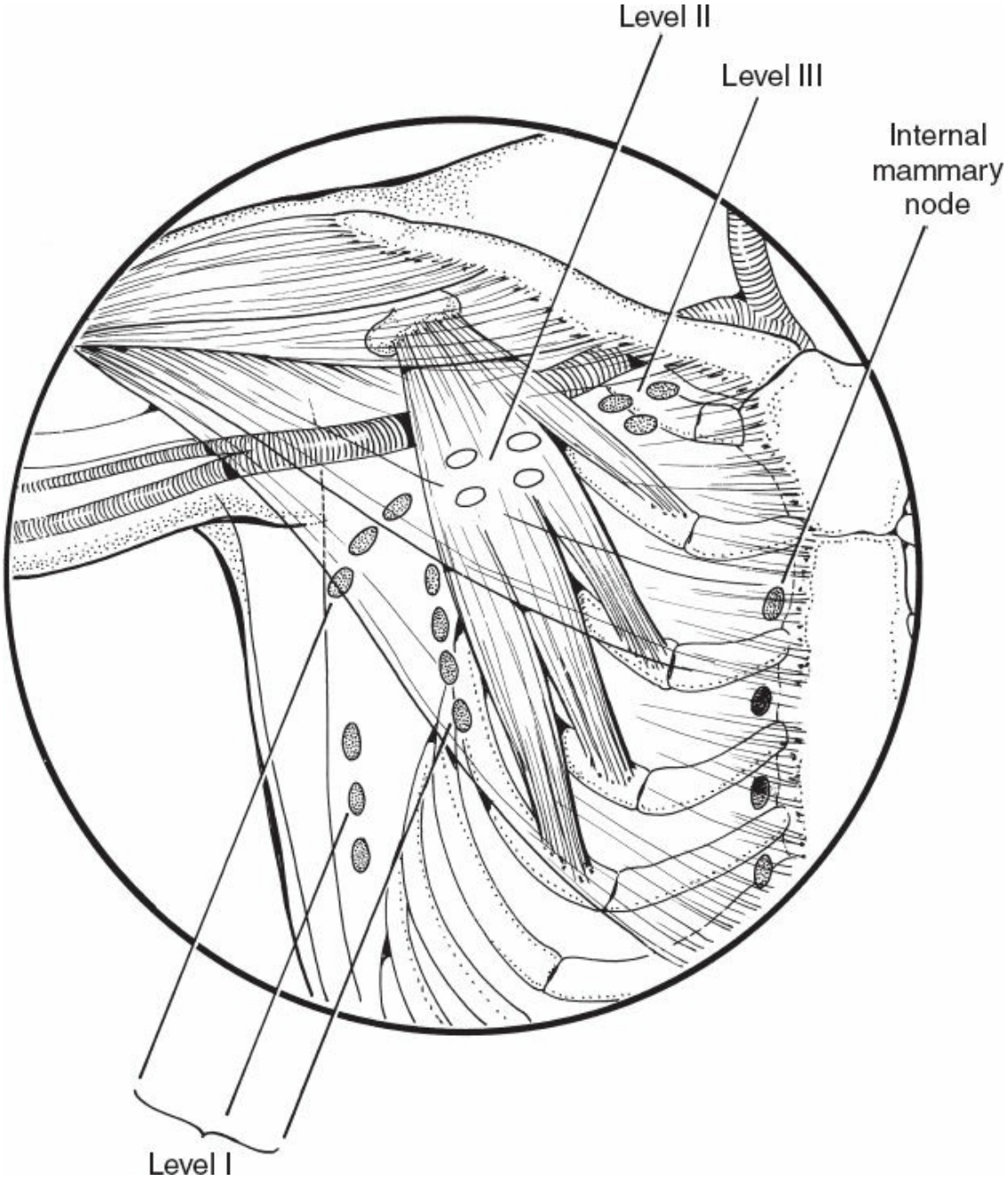

Figure 49.14. Levels I to III of the axillary lymph nodes.

Numbers of Sentinel Nodes

The false negative rate depends on the tracer used and the number of nodes retrieved. The false negative rate varies from 8.6% for dye alone, 7.5% for radioactive tracer alone, and 5.9% when both are used. There is no significant difference related to location in the breast. The false negative

rate in the largest study published to date (NSABP B-32) was 17.7% if one sentinel node was removed, 10% for two sentinel nodes, 6.9% for 3 nodes, and 5.5% for four nodes. Given that anatomical studies show the majority have two draining lymphatics ending at either the pectoral node, situated medially behind the pectoralis major muscle, or a second node laterally situated just above the axillary tail, then the average number of sentinel nodes a surgeon should be removing to limit the false negative rate is between two and three, and should include nodes at these two locations.

Despite the apparent high false negative rate overall in NSABP B-32 of 9.8%, the numbers of patients who developed axillary recurrence over the next decade was small validating the safety of this technique.

Technique of Sentinel Lymph Node Biopsy

The technique used in Milan is to inject 1 mCi of technetium-99M-labeled albumin around the tumor into the breast parenchyma on the day prior to surgery. This is equivalent to approximately 37 MBq of technetium. Most American studies have used technetium-labeled sulfur colloid. Doses of between 450 mCi and 1 Ci have been injected 1 to 6 hours before the operative procedure. Although the optimum volume has yet to be found, when using radioactivity, between 0.5 and 6 mL of technetium-labeled albumin or sulfur colloid in saline is used. The dose I use is 25 to 28 mBq of technetium on the day of surgery or 40 mBq if injected the day before. When using dye, between 2.0 and 7.5 mL of isosulfan blue, patent blue V, or methylene blue is injected just before the skin is prepared for surgery.

My practice is to inject a radioactive tracer together with blue dye into the breast in the anesthetic room following induction of anesthesia. The isotope is injected either intradermally or in the subareolar region. I dilute 2 mL of patent blue V with 3 mL of saline, making a total of 5 mL, and inject this into the subareolar region in those patients in whom a handheld gamma probe does not detect a sentinel node in the axilla. The injection site is then massaged for 1 minute. During surgery, the gamma-detecting probe is used to identify the site of the sentinel lymph node in the axilla. I do not perform scintigraphy and the UK Training Program recommends scintigrams only in the learning phase. A skin crease incision is made over the site of maximal radioactivity and this is deepened. The sound emitted by the probe is used as a guide to find a node, and the tissues are divided down through the fascia anterior to the axillary fat and then the fat of the axilla is separated to the point of maximum impulse intensity. Where there is no radioactive node visible on scan or detected by the probe, then a skin

crease incision is made in the lower axilla between the edges of the pectoralis major muscle anteriorly and the latissimus dorsi muscle posteriorly (Fig. 49.15). During dissection, blue lymphatics are usually visible and the tissue around these lymphatics is divided and the blue lymphatic is followed to a sentinel lymph node. The two classical sites for sentinel nodes are in the subpectoral region—low and medial—and in the low lateral axilla just above the axillary tail of the breast. Two or more sentinel nodes are usually evident, and all the nodes identified with the handheld probe containing significant isotope (10% or more of the radioactivity of the hottest node) or stained blue should be removed and sent for histologic evaluation. Routine intraoperative assessment of nodes is no longer recommended. Some units still use intraoperative assessment by frozen section or one stop nucleic acid amplification (OSNA) for patients having mastectomy. Given the alternative options of no further treatment for low volume axillary nodal disease or axillary radiation in patients with more extensive disease, intraoperative assessment of nodes is rarely indicated in patients having BCS.

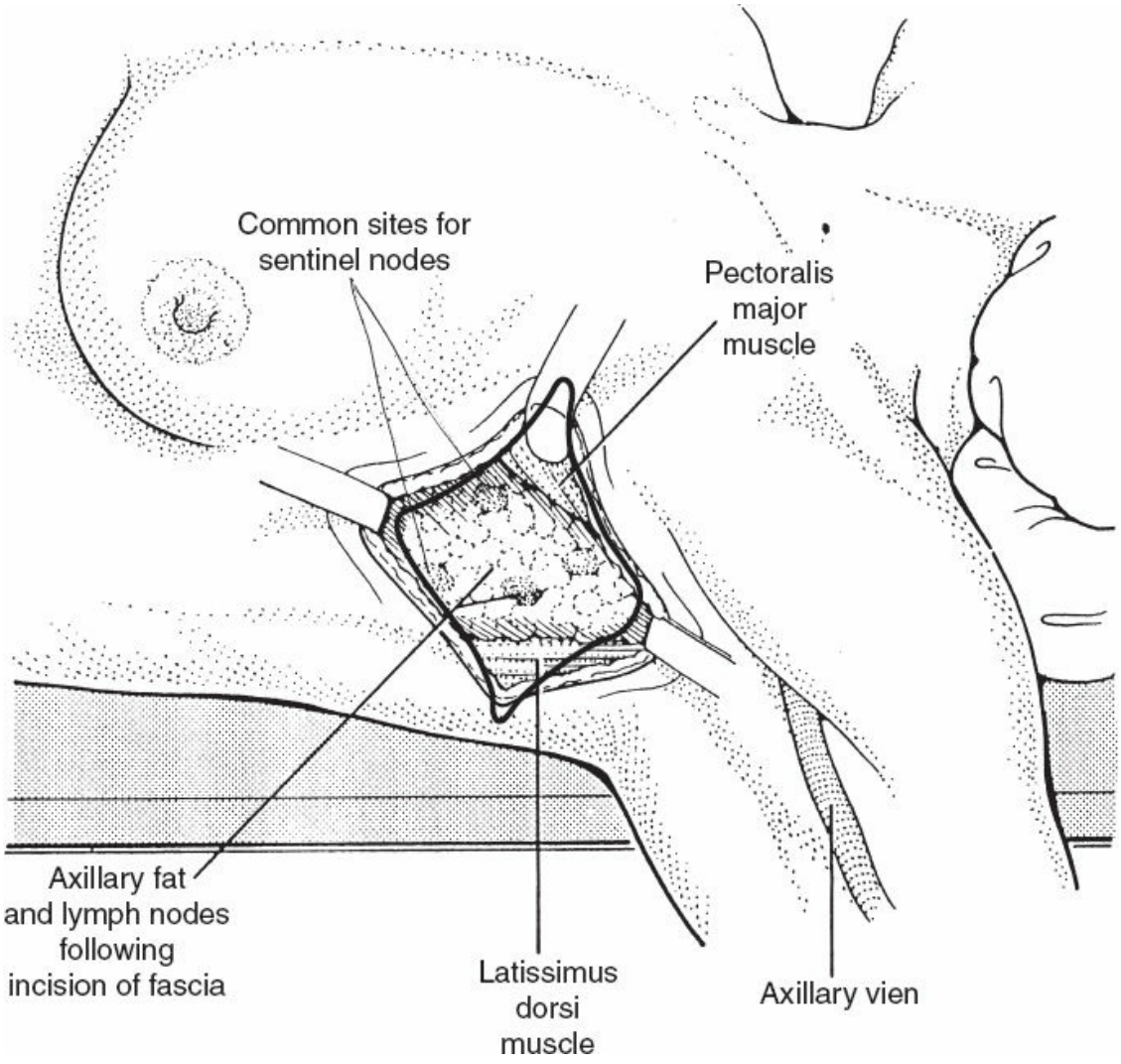

Figure 49.15. Diagram showing lower axilla, where sentinel lymph node(s) is commonly found.

Following a check to ensure that all nodes with residual isotope >10% of the hottest node and all blue nodes have been removed then, the wound is closed in layers with absorbable sutures before infiltration of the axilla with local anesthetic. Some slim women have a large number of nodes containing isotope and/or blue dye. In these patients, I remove only the three or four hottest and bluest nodes; these are usually the closest nodes to the breast. The most widely used method of assessing sentinel lymph nodes is by paraffin-section histology. Studies from the American College of Surgeons and the NSABP have not shown any advantage to staining nodes using immunohistochemistry to detect metastases not evident on routine H&E staining.

Axillary Reverse Mapping (ARM)

The lymphatics of the arm can be mapped with blue dye at the same time as the sentinel nodes are mapped with radioisotope during axillary lymph node dissection. Blue dye is injected into the upper arm and during axillary surgery lymphatics and lymph nodes draining the arm can be identified because they are stained blue and these lymphatics and nodes can be preserved providing there is no evidence that these nodes are clinically involved by metastatic disease or that they contain isotope indicating they are a sentinel node of the breast. Fluorescent dyes are an alternative to blue dye. The success of ARM has not yet been determined in randomized trials, but it seems logical.

Internal Mammary Node Biopsy

In patients who have a preoperative scintiscan, there is drainage to the internal mammary chain in 6% or more depending on exactly where in the breast and how deep the isotope was injected. There is no consensus as to whether these nodes should be excised if visualized on scintiscan. It is true that a small number of women do have involved internal mammary nodes in the absence of axillary node involvement but the exact percentage remains a topic of discussion. Recent studies of internal mammary node and supraclavicular node irradiation have shown a small survival advantage (82.3% 10-year survival with radiation vs. 80.7% without radiation [$p = 0.056$]), although the rate of skin and lung toxicity was higher with radiation. The role of preoperative scintigraphy and excision of all nodes visualized on the scan is best established for patients having a sentinel node biopsy performed when excising a recurrence, be that after mastectomy or BCS, in patients who have had a prior SLNB.

Technique of Axillary Dissection

Exposure is facilitated by placing a wedge or sandbag under the ipsilateral shoulder so as to elevate the axilla. The ipsilateral arm can be prepared and draped separately, and this allows the arm to be moved above the patient's head during surgery. The skin of the arm up to and above the elbow is prepared, and the lower arm and hand are wrapped in a sterile drape and secured with a stockinette (Fig. 49.16). A skin crease incision just distal to the hair-bearing skin of the axilla is made (Fig. 49.17A). This allows satisfactory exposure in patients with an adequate anteroposterior diameter, but in very small or thin patients, the length of this incision may be inadequate. A lazy S incision is an alternative, placed between the

pectoralis major and latissimus dorsi muscles (Fig. 49.17B). An anterior axillary fold incision can also be used (Fig. 49.17C). The skin incision is deepened through the superficial fascia, and skin flaps are developed deep to the superficial fascia. The axilla is protected by an anterior layer of fascia, and this should be identified. Dissection is anterior to this axillary fascia, and using skin hooks it is possible to elevate superior, medial, and inferior skin flaps in the plane deep to the subcutaneous fat but in front of this axillary fascia fat. Dissection continues with the aid of gentle retraction with a swab. Medially the edge of the latissimus dorsi is identified and laterally the pectoralis major muscle is palpable and dissection should continue to it.

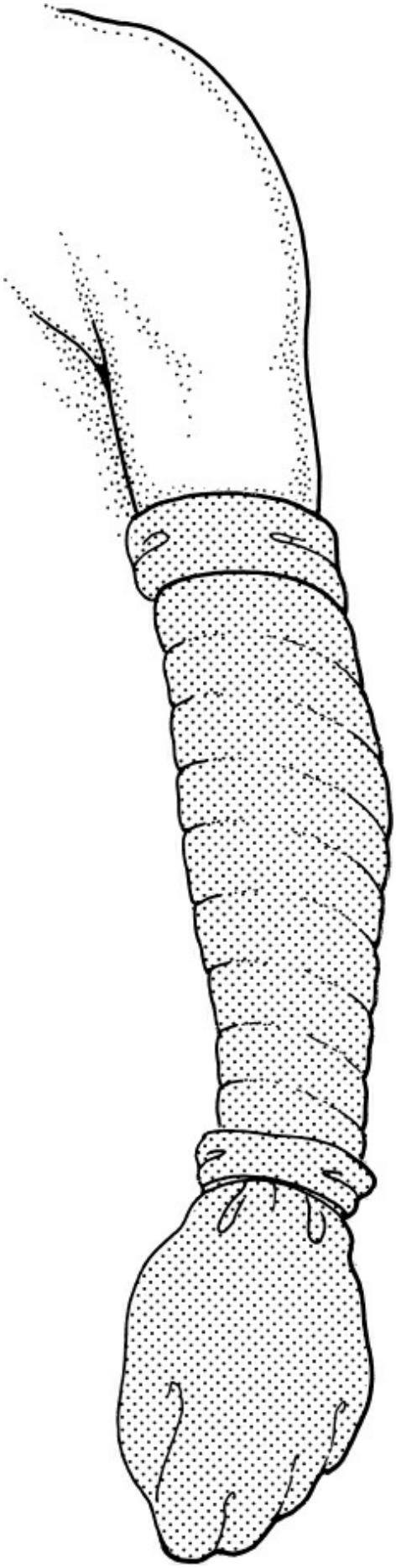

1889

Figure 49.16. Skin of the arm up to and above the elbow is prepared, and the lower arm and hand are wrapped in a sterile drape and secured with a stockinette.

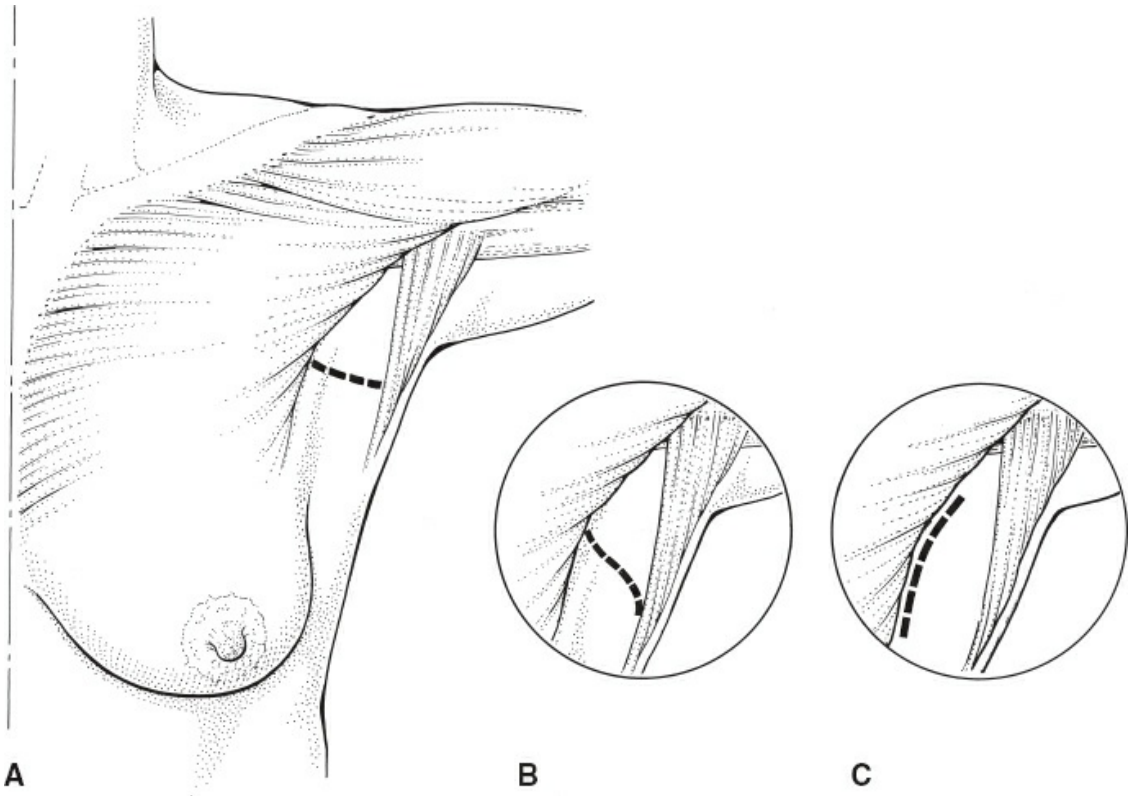

Figure 49.17. Incisions for axillary dissection. **A.** Skin crease incision distal to the hair-bearing skin of the axilla. **B.** Lazy S incision placed between pectoralis major and latissimus dorsi muscles. **C.** Anterior axillary fold incision (*dashed line*) placed parallel and posterior to lateral border of the pectoralis major muscle.

Retractors replace skin hooks, and the lateral edge of the pectoralis major is carefully cleared. Care is taken to identify and preserve the medial pectoral nerve and vessels that pass into the lateral border of the pectoralis minor muscle from the pectoralis major: these innervate both and supply the pectoralis minor and the lower lateral third of the pectoralis major muscle (Fig. 49.18). While retracting the pectoralis major and minor muscles, the elbow can be bent and the arm moved upward behind the patient's head (Fig. 49.19). This makes retraction of the pectoral muscles easier. Care must be taken when the arm is retracted not to overstretch the brachial plexus. With the pectoralis major and minor muscles retracted medially, it is possible to identify the nodes under the pectoralis minor

muscle. Beyond the medial margin of the pectoralis minor muscle and covered by the stretched clavipectoral fascia lies a small conical depression of adipose tissue containing a small number of lymph nodes. The upper limit of this depression is defined by the axillary vein, and the subclavius muscle forms its medial limit. Nodes in this adipose tissue comprise the third axillary level, as described by Berg. There remains conflict as to what comprises an adequate axillary dissection. Some surgeons perform a level I/II dissection, others remove levels I and II, and some remove all nodes to level III routinely. An empirical approach based on the findings at operation seems reasonable. Fewer patients require removal of level III nodes and only where there is obvious involvement of nodes up to level III should they be removed.

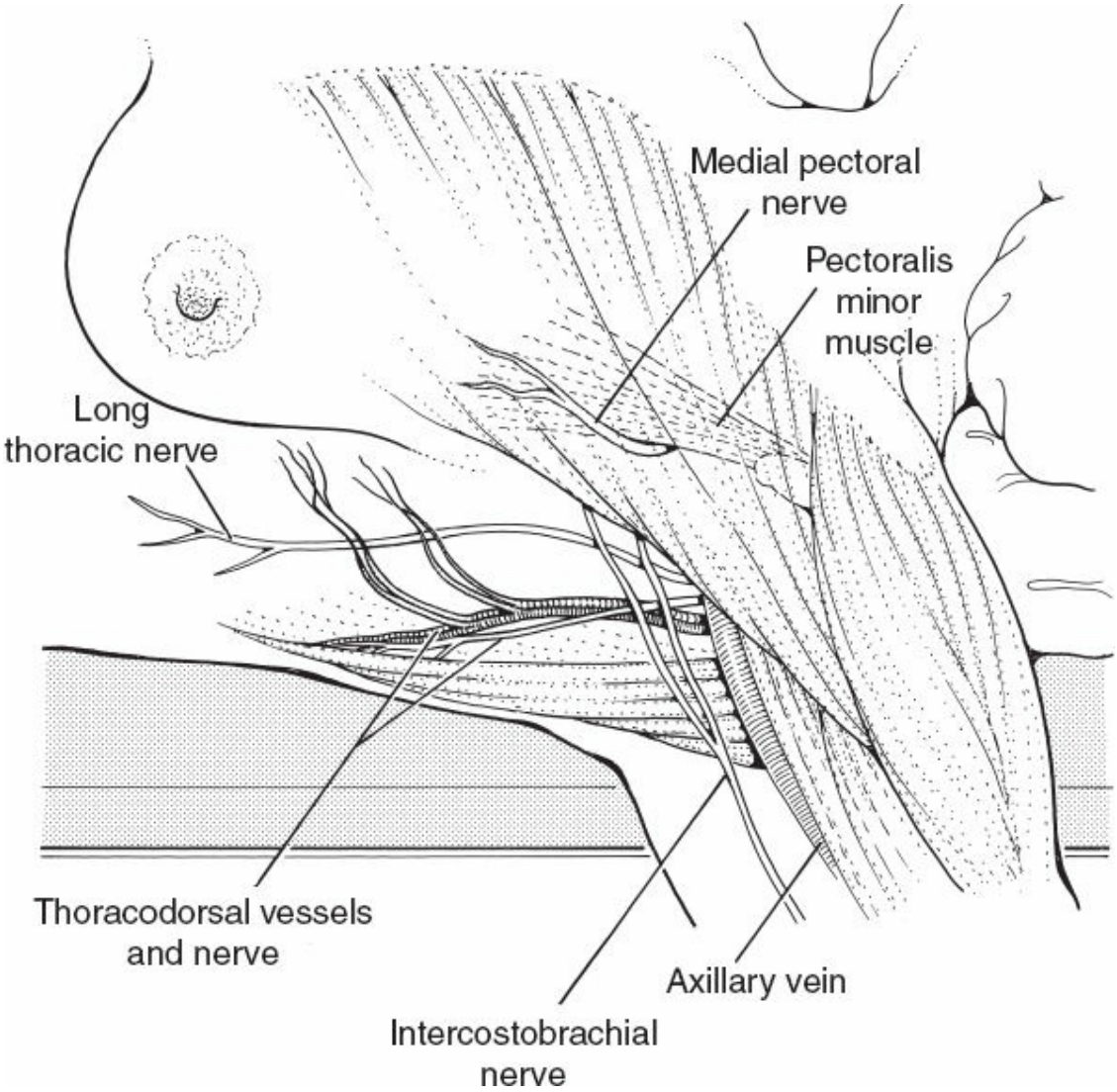

Figure 49.18. Major neurovascular structures to be preserved in an axillary clearance/dissection.

There are two surgical approaches to removing potentially involved nodes at level III, depending on whether the pectoralis minor muscle is spared or divided. This muscle should only be divided if there is extensive node involvement evident at surgery and a more radical dissection is to be performed. If the muscle is to be divided, then the lateral edge of the pectoralis minor is identified and a finger placed around the pectoralis minor as it passes over the axillary vein. The muscle can be traced up to the coracoid process and, with a finger around the pectoralis minor muscle, the tendon is divided from the coracoid process without damaging surrounding structures. Once the muscle has been divided, the pectoral fascia that covers the vein is also divided and swept downward. Care should be taken to divide and ligate the small vessels that drain into the axillary vein at level III as bleeding from these vessels high in the axilla is not easy to stop. If the pectoralis minor muscle is spared, as is now usual practice, the muscle is elevated and retracted. When elevating the muscle, care should be taken not to damage the medial pectoral nerve and vessels. Branches from these vessels pass laterally, and these branches should be divided and clipped or coagulated. The axillary vein, as it passes to the apex of the axilla, can then be dissected free from the adipose tissue containing lymph nodes. Sometimes, the vein is partially covered by fat or lymph nodes are adherent to the adventitia of the vein and it may be necessary to strip away this adventitia.

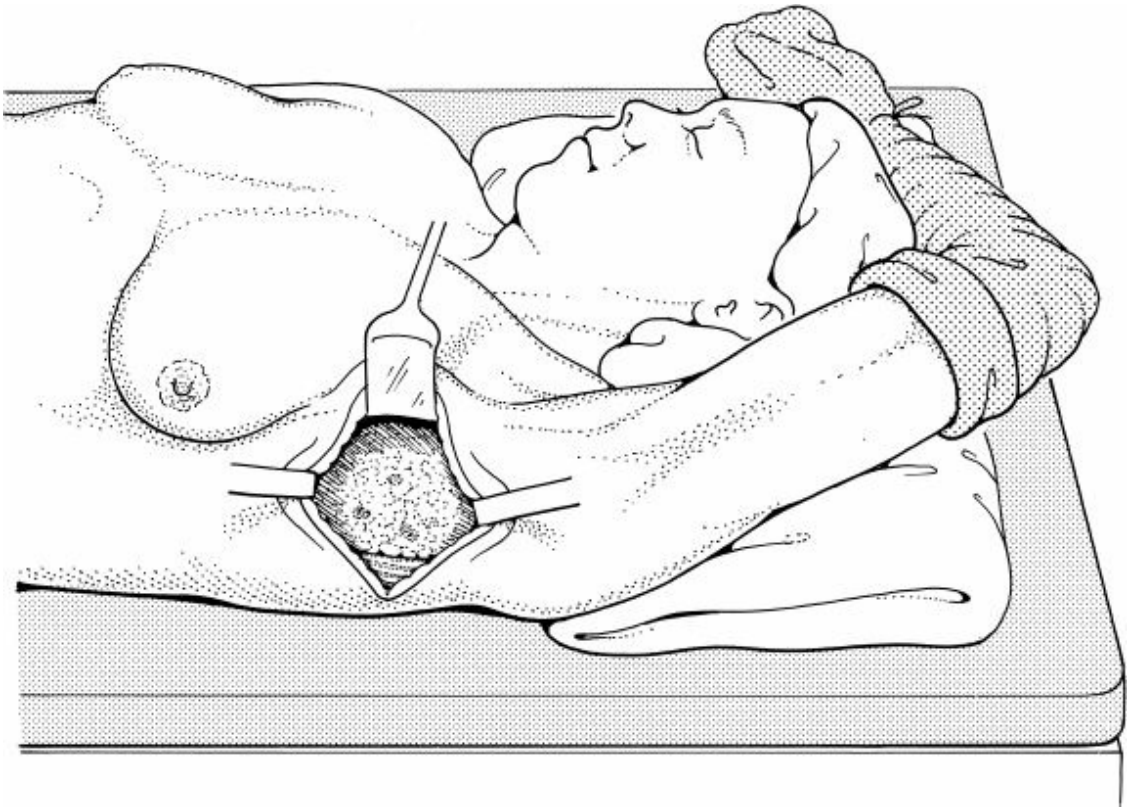

Figure 49.19. The ipsilateral elbow is flexed and the arm is moved over the patient's head to facilitate retraction of pectoral muscles and exposure of the axilla.

Dissection should continue until the vein meets the tendon of subclavius, which marks the medial limit of a level III dissection. In most patients, lymphatic vessels passing beyond the apex of the axilla can be seen, and these should be divided and ligaclipped or coagulated. At the end of this level III dissection, the apex of the axilla should be completely clean. As outlined above, care should be taken to preserve the vessels supplying the pectoralis major muscle (Fig. 49.20). When all the tissue from level III has been removed, the pectoralis major muscle should be lifted with a retractor and the thoracoacromial vessels, which supply the pectoralis major muscle, identified and palpated. Along these vessels lie the interpectoral nodes, and any palpable nodes in this area should be removed by incising the fascia on the undersurface of the pectoralis major muscle, and individual lymph nodes should be dissected out separately. Having removed all the tissue at level III, dissection then continues underneath the pectoralis minor muscle to remove the level II nodes. If level III nodes are not being removed and only level I and II nodes are being removed, then the medial border of the dissection is the medial border of the pectoralis minor muscle. Having cleared the nodes from

under pectoralis minor up to the axillary vein dissection on the medial wall continues inferiorly. This defines the medial margin of the dissection. Dissecting medially the inferior limit is the axillary tail of the breast. The edge of the latissimus dorsi muscle defines the lateral border of dissection. The intercostobrachial nerve traverses the axilla and passes from the chest wall and crosses the lateral edge of the latissimus dorsi muscle and can be damaged if the lateral edge of the latissimus dorsi muscle is dissected with cautery or a knife up to the level of the axillary vein, so the lateral dissection should not be performed until this nerve has been identified.

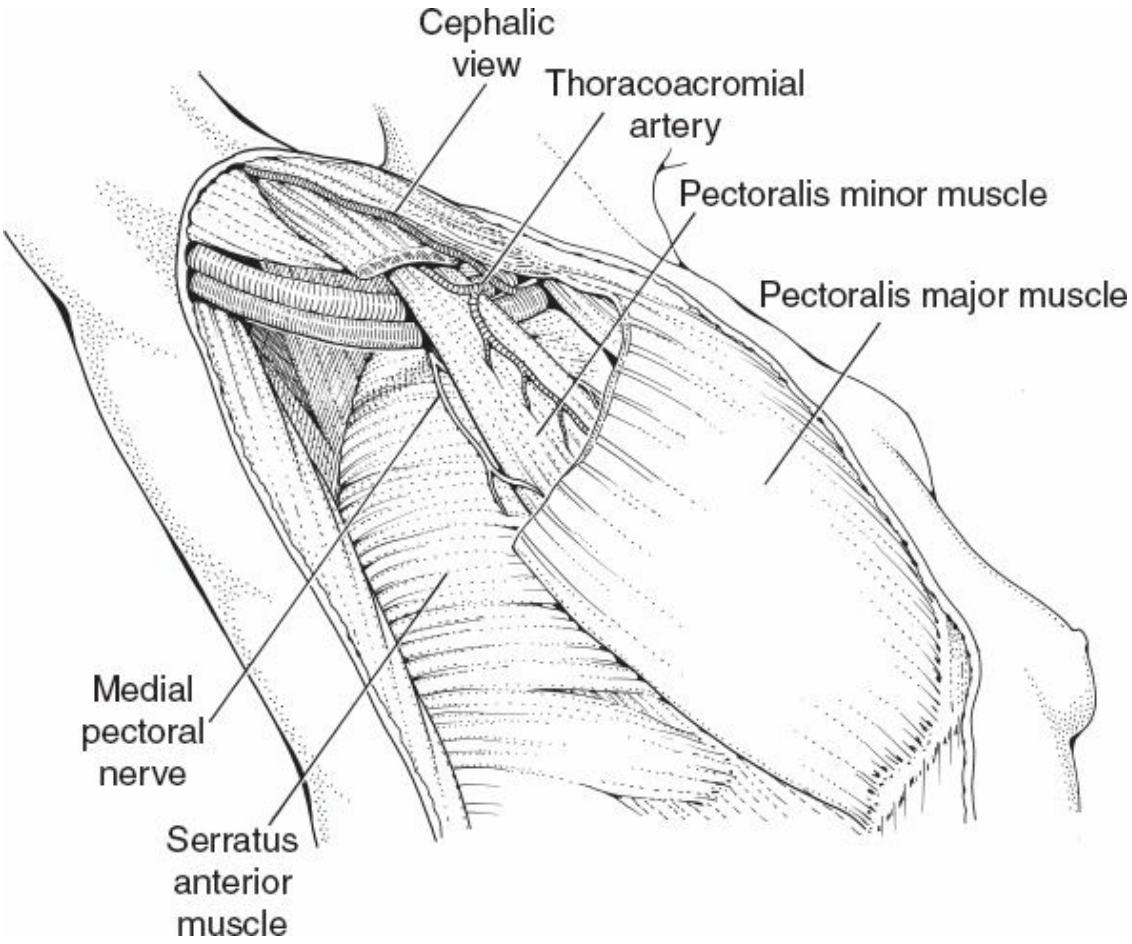

Figure 49.20. Vessels supplying the pectoralis major muscle.

By this point of the operation, the medial border, the inferior border, and the lower half of the lateral border have been defined. The next step is to develop dissection from the pectoralis minor laterally by a combination of sharp and blunt dissection and clear the tissue inferior to the central part of the axillary vein. The lower border of the axillary vein represents the superior limit of the dissection. The tissue below the axillary vein is dissected from the vein all the way to the edge of the latissimus dorsi

muscle. Veins that drain into the axillary vein on its anterior surface are divided between ties and ligaclips. The fat and lymph nodes are teased away by blunt dissection, and the intercostobrachial nerve is identified as it leaves the chest wall medially. This is usually in the second intercostal space but can be in the first. Dissecting out the whole of this nerve as it courses across the axilla can be tedious, but it is worthwhile as it avoids the annoying numbness and occasional pain or hyperesthesia that affects the skin of the upper inner arm when this nerve has been divided.

The anatomy of the intercostobrachial nerve is variable. Although there is usually one major intercostobrachial nerve that comes out of the chest wall, it divides laterally into a number of branches. Some of these branches pass into the axillary tail of the breast and can be sacrificed. Once this nerve is identified passing across the axilla and dissected from surrounding structures, it can be retracted superiorly. The next step is to identify and preserve the long thoracic nerve. This nerve can be identified by retracting the axillary contents laterally, although the long thoracic nerve has a tendency to be pulled out laterally with the axillary contents. It is situated approximately 2 cm posterior to the intercostobrachial nerve. Blunt dissection in the valley between the serratus anterior muscle and the axillary contents usually identifies this nerve. Once it has been identified, it is freed and pushed medially toward the chest wall and preserved. Certain identification and protection of this nerve is one of the most important principles in this operation. Vessels run with the nerve, and these should not be damaged as this can interfere with nerve function.

Dissection along the lower border of the axillary vein continues in a deeper plane in a medial-to-lateral direction. The next structures to be identified are the thoracodorsal nerve and vessels. The thoracodorsal vessels are situated posteriorly about two thirds of the way across the axilla from medial to lateral. The vein is often the first structure to be identified as it drains into the posterior aspect of the axillary vein; the nerve is the most medial structure of this neurovascular bundle. Having identified and protected the thoracodorsal vessels, the valley on the subscapularis muscle between the long thoracic and thoracodorsal nerves is cleaned with a cranial-to-caudad dissection. As fat, lymphatic vessels, and blood vessels pass underneath the axillary vein, these structures are divided and ligated or cauterized. Dissection then continues inferiorly, and branches passing from the thoracodorsal vessels into the axillary fat are identified; these vessels can cause troublesome bleeding, so they should be

identified and ligated or ligaclipped ensuring that the main vessels are not narrowed. Dissection continues laterally, removing tissue lateral to and around the thoracodorsal vessels to the lateral margin of the latissimus dorsi muscle. This allows completion of the lateral part of the operation. Care should be taken not to stray beyond the latissimus dorsi. Nodes at the top of the arm should be preserved to reduce the chances of lymphedema. If the arm lymphatics and lymph nodes have been mapped with blue dye, then care should be taken during dissection to preserve lymphatics and lymph nodes stained blue, ensuring that at the same time all pathologic nodes are removed.

The valley between the thoracodorsal vessels and the long thoracic nerve is cleared, taking care not to damage any branches from the thoracodorsal vessels that pass across to the serratus anterior muscle as damage results in troublesome bleeding. The thoracodorsal vessels and the long thoracic nerves remain in the axilla, while the axillary nodes and fat are retracted anteriorly. The inferior margin of the dissection is completed by dividing the axillary tail of the breast under direct vision. Any vessels passing into the tail of the breast should be cauterized or ligated. A single suction drain can be placed into the cavity and brought out through a separate stab incision. If possible, the skin flaps are sutured to the chest wall as results from small trials of axillary quilting have shown that this decreases the subsequent seroma rate. Finally, the wound is closed in layers with absorbable sutures before infiltration with local anesthetic.

POSTOPERATIVE COMPLICATIONS

Axillary Surgery

Complications of SLNB and axillary node sampling include bleeding, hematoma, and wound infection. Seroma formation requiring aspiration develops in 5% to 10% of patients after sentinel node biopsy. Lymphedema was reported after SNLB in 8% in NSABP B-32. Damage to the intercostobrachial nerve is rare after SLNB (0% at 6 months in the UK ALMANAC study with SLNB compared with 48% after axillary lymph node dissection). With careful attention to technique therefore, damage to the nerve can usually be avoided in SLNB.

Complications of axillary dissection/clearance include those mentioned for SLNB. Seroma formation is more of a problem with axillary clearance. Factors known to be related to increased or prolonged drainage include obesity, involved axillary nodes, a recent breast biopsy, and an extensive

axillary dissection. The results of studies investigating the effects of early shoulder mobilization are confusing. There is early evidence that there is less seroma formation in patients who do not perform early shoulder exercises after surgery and patients who have prolonged high-volume drainage generally have been more active in their shoulder movement. Early shoulder exercises, however, protect against frozen shoulder, which can develop as a consequence of decreased shoulder movement following axillary surgery. I encourage early shoulder mobility as I believe frozen shoulder is a worse problem than seroma. Patients who develop shoulder problems should be seen urgently by the physical therapist. Some patients after axillary surgery are said to develop scapulothoracic bursitis. Studies have shown improvement with local anesthetic and steroid injections. Despite looking for this, I have not found this problem in a significant number of patients.

Lymphedema develops in up to 40% of patients who undergo axillary dissection, and can develop many years after axillary clearance. In AMAROS, lymphedema rates were twice as common after axillary dissection than after axillary radiotherapy. At 5 years, observed or treated lymphedema was present in 28% of the axillary dissection group versus 13.6% after SLNB and radiotherapy. Lymphedema can occur following infection in the soft tissues of the ipsilateral arm. Infections in treated arms are usually caused by Gram-positive cocci and require prompt treatment. No adequate remedy exists for chronic lymphedema. Paresthesiae of the upper, inner arm from division of the intercostobrachial nerve is present in at least half of patients having axillary lymph node dissection and produces annoying symptoms. If neuroma formation develops, this can result in acutely painful areas that are difficult to manage. Sparing of this nerve, although tedious, is worthwhile. Damage to the thoracodorsal nerve resulting in atrophy of the latissimus dorsi muscle may cause problems if this muscle is to be used later for breast reconstruction, but otherwise has little or no functional consequence. The most significant injury is that to the long thoracic nerve, which, if damaged, results in a winged scapula. This results in a functional deficit and a cosmetic deformity.

POSTOPERATIVE MANAGEMENT FOLLOWING BREAST-CONSERVING SURGERY OR AXILLARY SURGERY

If the patient is feeling well and is mobile after BCS, she can be

discharged home on the same day. For patients having an axillary clearance, they may need education on drain management. Some units keep some mastectomy patients and those having an axillary clearance in overnight. A community nurse can visit the patient daily to record 24-hourly output from the drain and to check the wound. One option is to remove the drain at a fixed time after surgery, regardless of volume, as studies have shown that the rate of infection increases if drains are left in longer than 1 week. Some surgeons do not use drains. Patients should see a physical therapist and be given shoulder exercises to carry out several times a day. A surgical follow-up visit is organized for 1 to 2 weeks after operation, when the wounds are checked and the histologic evaluation report is available. Seromas may occur particularly if a significant defect has been left in the breast and are common after mastectomy or extensive axillary surgery. Aspiration is usually not painful and is performed using a needle attached to a nonreturn valve and a syringe. Repeat aspirations may be necessary until there is no more fluid accumulation. Persistent seromas can occur particularly in patients who have had extensive surgery. Recurrent seromas can be treated by aspiration to dryness and instilling 10 to 40 mg of triamcinolone acetonide (Kenalog).

FOLLOW-UP

Regular clinical examination after BCS or mastectomy has not been shown to be of value. Patients should be seen for 1 to 2 years to check the wound has healed and the cosmetic result is acceptable. Defects at the site of wide excision can be improved with lipofilling or lipomodelling. There is evidence that annual mammography is cost-effective and worthwhile. Regular MRI screening in younger women and women whose cancer was not visible on mammography also appears cost-effective.

Suggested Readings

Abner AL, Connolly JL, Recht A, et al. The relation between the presence and extent of lobular carcinoma in situ and the risk of local recurrence for patients with infiltrating carcinoma of the breast treated with conservative surgery and radiation therapy. *Cancer* 2000;88:1072.

Anderson SJ, Wapnir I, Dignam JJ, et al. Prognosis after ipsilateral breast tumor recurrence and locoregional recurrences in patient treated by breast-conserving therapy in five national surgical adjuvant breast and bowel project protocols of node-negative breast cancer. *J Clin Oncol* 2009;27:2466.

Arentz C, Baxter K, Boneti C, et al. Ten-year experience with hematoma-directed ultrasound-guided (HUG) breast lumpectomy. *Ann Surg Oncol* 2010;17(Suppl 3):378–83.

Asgiersson KS, McCulley SJ, Pinder SE, et al. Size of invasive breast cancer and risk of local recurrence after breast-conservation therapy. *Eur J Cancer* 2003;39:2462.

Bartelink H, Horiot JC, Poortmans P, et al. Recurrence rates after treatment of breast cancer with standard radiotherapy with or without additional radiation. *N Engl J Med* 2001;345:1378.

Cao JQ, Olso RA, Tyldesley SK. Comparison of recurrence and survival rates after breast-conserving therapy and mastectomy in young women with breast cancer. *Curr Oncol* 2013;20(6):e593–601.

Chagpar A, Martin RC III, Chao C, et al. Validation of subareolar and periareolar injection techniques for breast sentinel lymph node biopsy. *Arch Surg* 2004;139:614.

Chagpar AB, Killelea BK, Tsangaris TN, et al. A randomized, controlled trial of cavity shave margins in breast cancer. *N Engl J Med* 2015;373(6):503–10.

Cochrane RA, Valasiadou P, Wilson AR, et al. Cosmesis and satisfaction after breast-conserving surgery correlates with the percentage of breast volume excised. *Br J Surg* 2003;90:1505.

Derossis AM, Fey J, Yeung H, et al. A trend analysis of the relative value of blue dye and isotope localization in 2,000 consecutive cases of sentinel lymph node biopsy for breast cancer. *J Am Coll Surg* 2001;193:473.

Fischer B, Anderson S, Bryant J, et al. Twenty-year follow-up of a randomized trial comparing total mastectomy, lumpectomy, and lumpectomy plus irradiation for the treatment of invasive breast cancer. *N Engl J Med* 2002;347:1233.

Fisher B, Costantino JP, Wickerham DL, et al. Tamoxifen for the prevention of breast cancer: report of the national surgical adjuvant breast and bowel project P-1 study. *J Natl Cancer Inst* 1998;90:1371–88.

Fleissig A, Fallowfield LJ, Langridge CI, et al. Post-operative arm morbidity and quality of life: results of the ALMANAC randomised trial comparing sentinel node biopsy with standard axillary treatment in the management of patients with early breast cancer. *Breast Cancer Res Treat* 2006;95:279.

Gentilini O, Botteri E, Rotmensz N, et al. Conservative surgery in patients with multifocal–multicentric breast cancer. *Breast Cancer Res Treat* 2009;113:577.

Hofvind S, Holen A, Aas T, et al. Women treated with breast conserving surgery do better than those with mastectomy independent of detection mode, prognostic and predictive tumor characteristics. *Eur J Surg Oncol* 2015;41(10):1417–22.

Houssami N, Macaskill P, Marinovich ML, et al. Meta-analysis of the impact of surgical margins on local recurrence in women with early-stage breast cancer treated with breast-conserving therapy. *Eur J Cancer* 2010;46(18):3219–32.

Hwang ES, Lichtensztajn DY, Gomez SL, et al. Survival after lumpectomy and mastectomy for early stage invasive breast cancer: the effect of age and hormone receptor status. *Cancer* 2013;119(7):1402–11.

Krag DN, Anderson SJ, Julian TB, et al. Technical outcomes of sentinel-lymph-node resection and conventional axillary-lymph-node dissection in patients with clinically node-negative breast cancer: results from the NSABP B-32 randomised phase III trial. *Lancet Oncol* 2007;8(10):881–8.

Krekel NM, Lopes Cardozo AM, Muller S, et al. Optimising surgical accuracy in palpable breast cancer with intra-operative breast ultrasound—feasibility and surgeons' learning curve. *Eur J Surg Oncol* 2011;37(12):1044–50.

Kuenen-Boumeester V, Menke-Pluymers M, de Kanter AY, et al. Ultrasound-guided fine needle aspiration cytology of axillary lymph nodes in breast cancer patients: a preoperative staging procedure. *Eur J Cancer* 2003;39:170.

Martin Martinez MD, Veys I, Majjaj S, et al. Clinical validation of a molecular assay for intra-operative detection of metastases in breast sentinel lymph nodes. *Eur J Surg Oncol* 2009;35:387.

Pesek S, Ashikaga T, Krag LG, et al. The false-negative rate of sentinel node biopsy in patients with breast cancer: a meta-analysis. *World J Surg* 2012;36(9):2239–51.

Pierce L, Levin A, Rebbeck T, et al. Ten-year outcome of breast-conserving surgery (BCS) and radiotherapy (RT) in women with breast cancer (BC) and germline BRCA 1/2 mutations: results from an international collaboration. *Breast Cancer Res Treat* 2003;82:S7.

Saadatmand S, Bretveld R, Siesling S, et al. Influence of tumor stage at breast cancer detection on survival in modern times: population based study in 173,797 patients. *BMJ* 2015;351:h4901.

Singletary SE. Surgical margins in patients with early-stage breast cancer treated with breast conservation therapy. *Am J Surg* 2002;184:383.

Temple WJ, Russell ML, Parsons LL, et al. Conservation surgery for breast cancer as the preferred choice: a prospective analysis. *J Clin Oncol* 2006;24:3367.

Turnbull L, Brown S, Harvey I, et al. Comparative effectiveness of MRI in breast cancer (COMICE) trial: a randomised controlled trial. *Lancet* 2010; 375(9714):563–71.

Veronesi U, Cascinelli N, Mariani L, et al. Twenty-year follow-up of a randomized study comparing breast-conserving surgery with radical mastectomy for early breast cancer. *N Engl J Med* 2002;347:1227.

Xing Y, Foy M, Cox DD, et al. Meta-analysis of sentinel lymph node biopsy after preoperative chemotherapy in patients with breast cancer. *Br J Surg* 2006;93:539.

Zumsteg ZS, Morrow M, Arnold B, et al. Breast-conserving therapy achieves locoregional outcomes comparable to mastectomy in women with T1–2N0 triple-negative breast cancer. *Ann Surg Oncol* 2013;20(11):3469–76.

EDITOR'S COMMENT

The current standard of care is to offer breast conservation therapy (BCT) to patients with early-stage disease. BCT includes excision of the tumor with a rim of normal tissue (i.e., lumpectomy) and adjuvant treatments including radiation therapy, most commonly whole breast radiation therapy (WBXRT), to treat residual disease. BCT offers equivalent survival to mastectomy (removal of the whole breast) with similar local recurrence rates. Furthermore, BCT is less invasive and has favorable cosmetic and psychological outcomes compared to mastectomy.

However, BCT has limitations. Approximately 24% of BCT patients undergo at least one additional surgery due to inadequate negative margins on the initial lumpectomy (83.2% of these additional surgeries are mastectomies) at a total cost of $234 million per year to the US healthcare system. In addition, BCT patients undergo 25 to 30 adjuvant WBXRT sessions over 6 to 7 weeks, introducing adverse effects, high costs, and inconvenience. The Canadians have championed a hypofractionated regimen that completes the radiation in 3 weeks. With WBXRT patients may experience burns, breast shrinkage, pneumonitis/pulmonary fibrosis, edema, secondary solid cancers, and ischemic heart disease. Patients also often endure lengthy travel and significant expenses ($13,000 to $47,000) to access WBXRT facilities, leading many that may prefer breast conservation to elect mastectomy. Unfortunately, 36% of women who elect mastectomy are actually eligible for BCT.

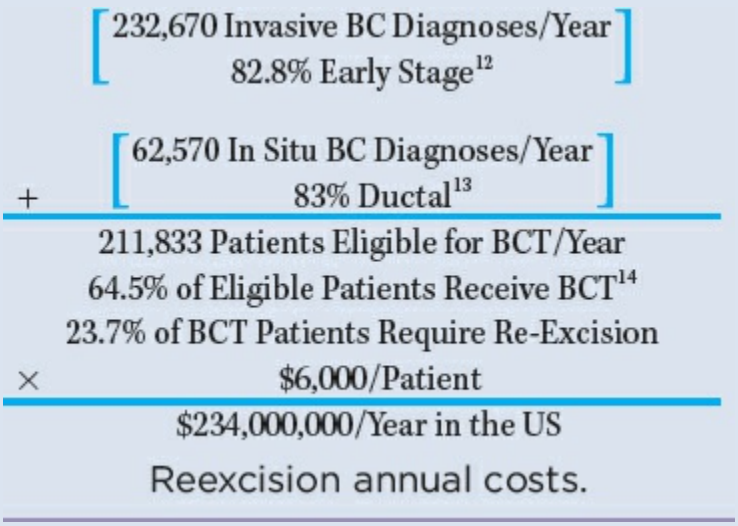

Because of the challenges of WBXRT, 14% to 26% of BCT patients skip WBXRT entirely. Patients refusing completion radiation lead to trials testing whether older patients (>70 years old) with favorable tumors received significant benefit from radiation. While the initial results looked favorable, the most recent follow-up of the CALGB (Cancer and Leukemia Group B) 9343 demonstrated that at 10 years that 98% of patients receiving tamoxifen plus WBXRT were free from local and regional recurrence compared to only 90% of those receiving tamoxifen alone. Survival was equivalent. This is tempered, however, with the fact that the Early Breast Cancer Trialist Group that reviewed data from over 42,000 women from 78 randomized studies demonstrated that at 15-year follow-up, for every four recurrences there was an associated increase of one death that could be avoided.

Issues surrounding WBXRT have led to the development of several alternative partial breast irradiation (APBI) technologies that are able to deliver biologically equivalent doses of radiation twice daily for 5 days to the approximate 1-cm region around the lumpectomy site where up to 90% of recurrences occur. These technologies can be divided into applicator-based brachytherapy devices and external-beam XRT. In addition, single-dose intraoperative radiation has become a viable option, although the cost of running such a program is untenable for many centers. All of these techniques will make BCT much more attractive. These will be reviewed in the Chapter 50.

It is my feeling that incorporating intraoperative ultrasound (US) techniques will allow even more patients to be eligible for BCT with increasingly better cosmetic results. The fully developed technique of US-guided excision has evolved and been developed over time by multiple researchers. Breast ultrasonography is performed intraoperatively using a 15 MHz linear array transducer while the arm is abducted. After sterile preparation, the abnormality is localized in the standard two planes, longitudinal and transverse. After the incision is made, the transducer was placed inside the incision and the lesion is again visualized. Dissection is performed using a “line-of-sight” technique. This technique was adapted from and mimics the use of the gamma probe in sentinel lymph node surgery. The transducer is then placed perpendicular to the lesion and parallel to the chest wall to assess the adequacy of the deep margin. Tissue is excised around the lesion in a block fashion down to the ascertained depth. Ex vivo ultrasonography is performed on the specimen to confirm adequacy of margins. Margins felt to be inadequate on specimen ultrasonography are reexcised at the time of the initial surgery. The remaining cavity is reassessed for residual disease both by palpation and ultrasonography. Recent studies show that if the margins from the main mass are greater than 1 cm, then 90% of excisions are successful. Advantages touted for intraoperative US include immediate documentation of removal of the suspect lesion, no additional discomfort to the patients, and no need for preoperative localization. It allows the entire procedure to be performed in the operating room, does not require radiation, and can be used to immediately assess margin status. With the use of

intraoperative US, the incision at the time of surgery is always closer to the lesion and the cosmetic results may be improved. Disadvantages include the equipment and additional required expertise on the part of the surgeon. As Dr. Dixon comments, in most series, positive margins were attributed to ductal carcinoma in situ (DCIS). DCIS is not commonly visualized by US. A specimen mammogram should be performed in addition to US in all lesions especially those with microcalcifications or spiculations that go beyond as well as to confirm clip removal. Use of intraoperative stand-alone surgical specimen radiography systems is now available in the operating room that have much improved visualization of specimen calcifications and can help direct reexcision. Most importantly, the specimen should be marked by the surgeon with pathological ink. Marking with sutures or clips is just not adequate. As most breast specimens don't hold their shape, the surgeon should immediately mark all sides for the most reliable pathology assessment.

Intraoperative US can also be used in localizing and guiding the excision of post-core or stereotactic biopsies viz a viz the hematoma-filled biopsy cavities. Needle-localization has been the most widely used tool available for excising lesions that require further evaluation after performing stereotactic core needle biopsy (SCNB). However, now there are a variety of methods that have been developed that can assist in removing nonpalpable lesions. All but one requires a second localization procedure to place a clip that can be visualized by ultrasound or that is radio-opaque. Traumatic hematomas after SCNB can be seen by US most of the time and utilized to locate the lesion, thus making the stereotactic procedure not only a diagnostic procedure but a localizing procedure as well. This has been deemed the HUG procedure (Hematoma-directed US-guided).

Oncoplastic techniques have become more widely used as surgeons are taken bigger margins and submitting shaved margins and certainly have allowed more patients to undergo BCT. These techniques range from the very simple such as using a parallelogram to improve simple excisions to those that incorporate reduction mammoplasties. Most oncoplastic surgeries can be performed by all surgeons without specific plastic surgery training. Cadaver courses are now actively training surgeons on how to incorporate more advanced procedures into their practice. These procedures are needed when excising excess skin and reshaping the breast.

Finally, I would like to comment on the addition of axillary reverse mapping (ARM) to lymphadenectomy whether it be sentinel lymph node biopsy (SLNB) or axillary lymph node dissection (ALND). As we developed this technique, we hypothesized that mapping the lymphatic drainage of the arm with blue dye (ARM) during axillary lymphadenectomy decreases the likelihood of disruption of lymphatics and subsequent lymphedema. The technique uses lymphazurin in the upper inner volar surface of the index arm at the time of surgery. Using ARM, we have identified significant lymphatic variations draining the upper extremities and have used ARM to facilitate preservation. Metastases in ARM-

identified lymph nodes were acceptably low indicating that ARM is safe. We also found in our single-institution trial that we could lower lymphedema rates with SLNB from 8% to less than 1.7%. During ALND, we could lower rates from 23% to 2.4%% in our most recent 18-month median follow-up. Although slightly more tedious and time-consuming, ARM can be safely accomplished and affords the patient the reduced risk of lymphedema. To date we have seen only one axillary recurrence in our single institution prospective trial of breast cancer patients giving credence that ARM adding to lymphadenectomy is a safe staging and therapeutic procedure.

V. Suzanne Klimberg

Suggested Readings

Chagpar AB, Killelea BK, Tsangaris TN, et al. A randomized, controlled trial of cavity shave margins in breast cancer. *NEJM* 2015;373(6):503–10.

Goyal S, Chandwani S, Haffty BG, et al. Effect of travel distance and time to radiotherapy on likelihood of receiving mastectomy. *Ann Surg Oncol* 2015;22(4):1095–101.

Hughes KS, Schnaper LA, Bellon JR, et al. Lumpectomy plus tamoxifen with or without irradiation in women age 70 years or older with early breast cancer: long-term follow-up of CALGB 9343. *JCO* 2013;31:2382–9.

Klimberg VS. Intraoperative image-guided breast-conservation surgery should be the gold standard. *Ann Surg Oncol* 2016;23(1):4–5.

Kummerow KL, Du L, Penson DF, et al. Nationwide trends in mastectomy for early-stage breast cancer. *JAMA Surg* 2015;150(1):9–16.

Landercasper J, Whitacre E, Degnim AC, et al. Reasons for re-excision after lumpectomy for breast cancer: insight from the American Society of Breast Surgeons Mastery (SM) database. *Ann Surg Oncol* 2014;21(10):3185–91.

Losken A, Dugal CS, Styblo TM, et al. A meta-analysis comparing breast conservation therapy alone to oncoplastic technique. *Ann Plast Surg* 2014;72(2):145–9.

Ochoa D, Korourian S, Boneti C, et al. Axillary reverse mapping: five-year experience. *Surgery* 2014;156(5):1261–8.

The American Cancer Society. What are the key statistics about breast cancer? 2014 09/25/14 [cited 2014 11/11/14]; Available from http://www.cancer.org/cancer/breastcancer/detailedguide/breast-cancer-key-statistics.

Wilke LG, Czechura T, Wang C, et al. Repeat surgery after breast conservation for the treatment of stage 0 to II breast carcinoma: a report from the National Cancer Data Base, 2004–2010. *JAMA Surg* 2014;149(12):1296–305.

50 Radiation Treatment, Whole and Partial Breast and Intraoperative Irradiation

Julia White

OVERVIEW AND HISTORICAL PERSPECTIVE

Of the nearly 260,000 breast cancers diagnosed within the next year, more than half will be considered eligible for breast-conserving therapy and the majority of these will receive radiation. Numerous phase III randomized clinical trials with over 25 years of outcome data have established that overall survival is equivalent for women treated with breast conservation compared to mastectomy. Over the past three decades, there has been extensive clinical research focused on improving the results of breast conservation that included defining the ideal suitable patient population, proper surgical resection margins, best systemic therapy, and optimal use of radiation. Advancements in surgical and radiation methods as well as more effective systemic therapy agents have now resulted in a gradual decline in local regional recurrence rates. Large registry-based analyses that have used propensity risk-based analysis to minimize bias now reflect that breast-conserving therapy delivered in a more modern era may even have improved cancer outcomes compared to mastectomy. This is good news for women with breast cancer who otherwise are good candidates for breast-conserving therapy but are considering mastectomy for "peace of mind" about their cancer control.

For invasive cancer, roughly 70% receive breast radiation following lumpectomy and somewhat less for those who have a ductal carcinoma in situ (DCIS) diagnosis. Radiation to the entire breast using 25 to 28 fractions (or treatments) of 1.8 to 2 Gray (Gy) of radiation to a total dose of 45 to 50.4 Gy was the conventional standard for decades (see Table 50.1 for common radiation terms). Often, a "boost" or additional dose of radiation is focused just on the breast tissue in the vicinity of the surgical cavity anticipated to be at a higher risk of recurrence. The boost delivers 5 to 8 fractions of 2 Gy to a total dose of 10 to 16 Gy so that this region

receives a cumulative total dose of 60 to 66 Gy over 30 to 33 fractions. This is the method of breast radiation used in the landmark clinical trials that established breast conservation therapy in invasive disease and DCIS. The other hallmark of conventional whole breast radiotherapy is that treatment planning was two-dimensional (2D), based on a single axial plane representing the patient external breast contour at about the longitudinal mid-plane of the treatment field that was established with fluoroscopy. This conventional approach to breast radiation has decades of documented efficacy and was technically simple so that all levels of radiation centers could become equally competent in its delivery.

Conventional whole breast radiation therapy also has known limitations. The protracted treatment time is one of the major drawbacks. Radiotherapy is delivered Monday through Friday, 5 days a week so that the 30 to 33 fractions for whole breast treatment require 6 to 7 weeks. Not long after breast conservation became validated as an effective treatment it was noted that its adoption into clinical practice varied widely across the United States and abroad; in part because of communities where women lived a far distance from a radiotherapy facility. A recent analysis of the National Cancer Database (NCDB) from 1998 to 2011 confirms this barrier persists as utilization for breast conservation was higher for woman residing within a 27.8 km vicinity of a treatment facility. Conventional whole breast radiotherapy also resulted in significant toxicity in some patient populations. In particular, women with large body mass index or pendulous breasts had higher rates of poor cosmetic results due to excess breast scarring or fibrosis attributed to dose heterogeneity. Finally, conventional breast radiation provided only an approximated means of assessing the extent of radiation delivered to the ipsilateral lung or heart.

TABLE 50.1 Commonly Used Terms in Radiation Therapy for Breast Cancer

Radiation Term	Definition
LINAC	Linear Accelerator delivers external beam radiation
CT Simulation	Establishes treatment position and acquires CT images for planning
Verification Simulation	Confirms that the virtually designed radiation plan is clinically reproducible
CTV	Clinical Target Volume: tissue at risk for cancer recurrence
PTV	Planning Target Volume: margin around the CTV for setup variation
OAR	Organ at risk for radiation toxicity
Gy, cGy	1 Gray = 100 centiGray: units of radiation dose
MV	MegaVoltage or million volt photon beam
kV	KiloVoltage or thousand volt photon beam
MeV	Megaelectronvoltage or million volt electron beam
Fraction	One radiation treatment
DVA	Dose Volume Analysis: quantifies dose distribution to organs

The desire to reduce the burden and toxicity of treatment led to investigating alternatives to conventional whole breast radiation delivered over several weeks for breast conservation. As a result, there are now multiple effective options for breast radiation. This progress is due in large part to scientific advances in technology and radiobiology that occurred over the same time period that the biologic heterogeneity of breast cancer became better appreciated and its impact on cancer recurrence established. It is clear that while there are now multiple methods of breast radiation available for post lumpectomy treatment, the specific method to be used depends on the type and stage of breast cancer as well as the needs of the individual patient.

WHOLE BREAST IRRADIATION

Radiation of the whole breast remains the most common treatment method for breast conservation. However, conventional whole breast radiation has been modified significantly over the past decade through a series of clinical trials demonstrating that (1) computed tomography (CT)-based three-dimensional conformal radiation (3DCRT) or intensity modulated radiation therapy (IMRT) planning reduces toxicity, and (2) the use of moderate hypofractionation— meaning, 260 to 270 cGy per fraction—is safe and effective so that the overall treatment duration can be reduced to 3 to 4.5 weeks.

The introduction of CT dramatically changed the approach to radiation therapy. The American College of Radiology documented through a series

of surveys that CT simulation for whole breast radiotherapy planning was about 5% in 1994, 17% in 1999, and jumped to >90% by 2007. The use of CT for treatment planning individualizes the radiation to each patient. Once the CT of a patient in treatment position is acquired, it is loaded into a software program for modeling the radiation treatment. The breast to be targeted and organs at risk (OAR) of injury from radiation, such as the lung and heart, are delineated onto each axial (cross-sectional) CT image (Fig. 50.1). These can then be used to create reconstructed three-dimensional volumes. The optimal radiation beam direction and energy are selected, and the treatment field is shaped to conform to the breast target volumes and to provide shielding of OAR. Radiation plans are approved for patient treatment using a set of standardized quantifiable measures of target dose coverage (typically aim for 95% of the dose to cover 95% of the target), dose homogeneity (keep "hot spots" <108% to 110%), and that the minimal constraint dose to the smallest volume of the OAR was met with a Dose Volume Analysis (DVA). Prior to starting treatment, a verification simulation is performed on the linear accelerator (LINAC) confirming that the computer model is reproducible. Radiation treatment is delivered with a LINAC typically using 6 to 15 megavoltage (MV) photon beams. For daily treatment, patients are on the treatment table ~15 to 20 minutes and the beam on-time for the radiation treatment is on average 6 to 8 minutes. Using modern methods, 10-year local recurrence rates for lumpectomy and breast radiation range from 4% to 7% and grade 3 toxicity rates are <2% to 3%.

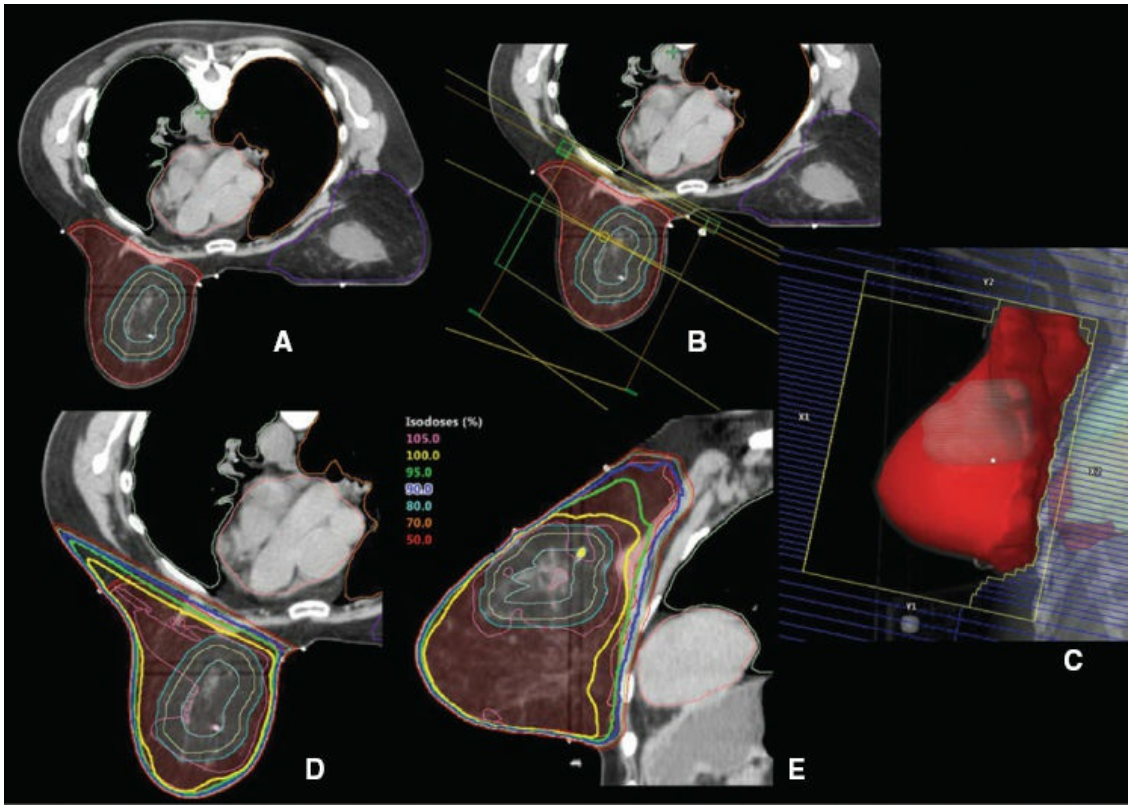

Figure 50.1. Steps in CT-based treatment planning for a left breast in the prone position. **A.** Targets and OAR are delineated after CT images are acquired at Simulation in the treatment position. **B.** Optimal beam arrangement is established. **C.** Treatment fields conform to targets and exclude OAR. **D.** Dose distribution in the axial. **E.** The sagittal reconstructions. A DVA will be reviewed and approved prior to Verification Simulation.

Several clinical trials have demonstrated reduced acute skin toxicity, less palpable firmness or fibrosis in the breast, and improved cosmetic outcomes when whole breast radiotherapy is delivered with CT-based 3DCRT or IMRT planning versus the simplified 2D approach. Despite the improved toxicity outcomes from integration of advanced treatment planning technology, large breast size has remained at relatively more risk for toxicity. One solution for this population is to treat in the prone position. In the prone position, gravity elongates and narrows the breast creating a more regular shape that has improved radiation dose homogeneity with fewer “hot spots” compared to the conical shape the breast takes in the supine position. In a clinical trial at the University of Ghent, Belgium, women with a C-cup bra or larger randomized to receive post lumpectomy breast radiation with IMRT in the prone position had significantly reduced desquamation, dermatitis, edema, and pain during

radiation, and a better cosmetic outcome was observed at 2 years.

Conventional fractionation for whole breast radiotherapy using 1.8 to 2 Gy per fraction for 25 to 28 treatments was based on the radiobiologic assumption that breast cancer is less sensitive to changes in the dose per fraction than the adjacent dose-limiting normal tissues. Therefore, delivery of a small dose per fraction such as 2 Gy or less to a higher total dose over several weeks was intended to spare the healthy tissues while effectively treating the breast cancer. On reevaluation, adenocarcinomas such as breast cancer appeared much more sensitive to changes in radiotherapy dose per fraction providing the opportunity to define a new larger fraction size that could preserve or improve cancer control, still minimize late toxicity, and shorten the treatment course. Three randomized trials have confirmed this shift in radiobiology to larger fewer fractions (hypofractionation) for whole breast radiation: the United Kingdom (UK) Standardization of Breast Radiotherapy (START) A (n = 2,236) and B (n = 2,215) trials, and the Ontario Clinical Oncology Group (OCOG) (n = 1,234) trial. Each of these trials demonstrated equivalent local regional cancer control and toxicity at 10 years from whole breast radiotherapy delivered with the shorter treatment course using moderate hypofractionation versus the conventional fractionation over several weeks. With adoption of hypofractionation, the treatment course for whole breast radiation becomes ~3 instead of 5 weeks. A sequential radiotherapy boost to the surgical cavity region still uses the conventional 2 Gy per fraction for 5 to 8 fractions to 10 to 16 Gy, but nevertheless the entire treatment course is reduced to 4.5 weeks instead of 6 to 7 weeks.

Indications and Recommendations

Whole breast radiotherapy is indicated for breast conservation in all cases of invasive disease or DCIS post lumpectomy. It is the treatment of choice in the following populations of breast cancer patients who have undergone lumpectomy: (1) triple-negative and HER2-positive breast cancer subtypes, (2) young premenopausal women (age <40) with invasive cancer or DCIS, (3) positive axillary lymph nodes from sentinel node biopsy or axillary dissection, or (4) those who received neoadjuvant chemotherapy prior to surgery. Standard treatment planning for whole breast radiotherapy should be based on CT scans using 3DCRT or IMRT and the dose distribution to contoured target and OAR volumes should be assessed with DVA. Hypofractionated whole breast radiotherapy post lumpectomy using

either 16 fractions of 2.66 Gy to a total dose of 42.56 Gy (OCOG) or 15 fractions of 2.67 Gy to a total dose of 40.05 Gy (START B) is indicated for most patients with node-negative invasive breast cancer. Increasingly, DCIS patients post lumpectomy are treated with hypofractionated whole breast radiation given the supporting radiobiologic and clinical outcome data for invasive disease. Young premenopausal patients ≤40 years of age comprised only 5% of the START A and B population and were not reported separately in the OCOG Trial. While deductively these women should be acceptable for hypofractionated radiotherapy, it is reasonable to treat them with conventional fractionation as well until more data are reported in this age group. So far, the protracted conventional fractionation (23 to 25 fractions of 2 Gy to a total dose of 46 to 50 Gy) for whole breast radiotherapy remains indicated for when the regional nodes (axilla, supraclavicular, and internal mammary) are simultaneously irradiated.

Many women receiving whole breast radiation post lumpectomy have indications for a “boost” or an additional few radiation treatments focused on a 1 to 2 cm expansions of breast tissue around the surgical cavity. The European Organization for Research and Treatment of Cancer (EORTC) Boost trial that enrolled 5,569 women reported that at 20 years after treatment those who were randomized to receive a boost had a 4% absolute improvement in cancer control in the breast and were less likely to undergo subsequent mastectomy by a similar percentage. The improvement in local control derived by a boost dose was largest in younger patients, or specifically in those ≤50 years of age where the boosted cases had 6% to 9% improvement in local control. The use of a boost resulted in a higher cumulative incidence of severe fibrosis at 20 years, 1.8% in the no boost group versus 5.2% in the boost group ($p < 0{\cdot}0001$). Typically, the boost portion of treatment is delivered with external beam radiation using either photons or electrons. Electrons are less penetrating than photons and are a good choice for when the lumpectomy cavity is in a more superficial location or within 3 to 4 cm from the skin surface. One of the challenges that arise is the identification of the surgical cavity if there is no seroma or other persistent postoperative changes present on CT treatment planning. The ability to target the boost is improved when surgeons mark the cavity with clips. Other radiation methods that have been successfully used to deliver the boost include brachytherapy, which is treatment with radioactive sources inserted into temporary implants or devices located in the breast, and intraoperative

radiotherapy (IORT), which is a single radiation fraction delivered in the operating room once the tumor has been removed and prior to surgical closure.

PARTIAL BREAST IRRADIATION

Rationale and Background

Shortly after breast conservation therapy was adopted, clinical patterns of failure emerged documenting that cancer recurrences in the breast after treatment were found in the vicinity of the original primary in roughly 75% to 90% of cases. This supported that recurrence risk is not constant across the entire breast post lumpectomy and that the breast tissue immediately adjacent to the surgical cavity is at the highest risk for cancer recurrence. This concept has had two important implications on radiation practice. First, this recurrence pattern serves as the scientific rationale for why a “boost” dose to the surgical cavity after whole breast radiation can improve local control. Second, it suggests that the major effect of post lumpectomy breast radiotherapy for many cases may really be from treating the high-risk breast tissue adjacent to the surgical cavity with much less gained from irradiating the remainder of the breast at lower risk. This is the underlying principle of partial breast irradiation (PBI) which delivers radiation solely to the high-risk breast tissue around the surgical cavity instead of the entire breast.

The first prospective trials evaluating PBI as the sole radiation method post lumpectomy yielded disappointing results with 19% to 37% 5-year local recurrence rates. On closer examination, the patients enrolled in these initial PBI trials had many adverse clinical pathologic features, including positive surgical margins, large tumors, positive nodes, and no systemic therapy. With more careful patient selection, the next generation of prospective trials studying brachytherapy for PBI yielded acceptable local recurrence rates of 5% at 10 years in 199 women treated at William Beaumont hospital and 2% at 7 years in 51 women treated at Oschner Clinic. Over the next decade, robust clinical investigation ensued and two approaches to PBI have been established: (1) accelerated partial breast irradiation (APBI) is delivered after lumpectomy when the final pathology is known, typically using 5 to 10 fractions of 3.4 to 6 Gy given once or twice a day over 5 to 10 elapsed days and (2) intraoperative partial breast irradiation (IPBI) delivers a single fraction of 18 to 21 Gy during surgery once the tumor has been removed and prior to surgical closure. Multiple

methods of APBI and IPBI have been developed, and each has advantages and disadvantages that are important to understand so that their use appropriately achieves acceptable outcome from breast conservation therapy.

ACCELERATED PARTIAL BREAST IRRADIATION

There are multiple methods for APBI post lumpectomy using either brachytherapy or external beam radiation that have been well-studied and are currently in clinical practice. Brachytherapy for APBI means the temporary insertion of either multiple narrow hollow catheters (multicatheter implant) around the surgical cavity or a device (single entry) into the surgical cavity (Fig. 50.2). Radiation is delivered internally by "after loading" the brachytherapy catheters or device with a radioactive source, typically Iridium 192. Initially, APBI with brachytherapy was with low dose rate (LDR) radiation using radioactive ribbons that were left in place in an implant for a few days to deliver a dose of 45 to 50 Gy at 0.5 Gy/hour while the patient remained in the hospital. This method has been replaced with the use of a high dose rate (HDR) radiation using single radioactive source that measures about 3 × 1 mm that robotically enters the implant or device and dwells for a matter of minutes to deliver the prescribed dose and can be delivered as an outpatient. The dose prescribed is commonly 10 fractions of 3.4 Gy HDR radiation given two times per day to deliver APBI as an outpatient. Prior to initiating treatment, CT-based treatment planning with DVA is done for brachytherapy to confirm dose distribution to targets and avoidance of OAR. The brachytherapy implant or device is removed after APBI is completed. External beam methods for APBI were developed after brachytherapy methods and are dominated by 3DCRT or IMRT. The steps for treatment planning of external beam APBI are similar to those outlined above for whole breast irradiation. There are multiple other external beam methods for APBI that are under investigation, including the use of protons, gamma rays, and stereotactic body radiotherapy for which mature data are pending.

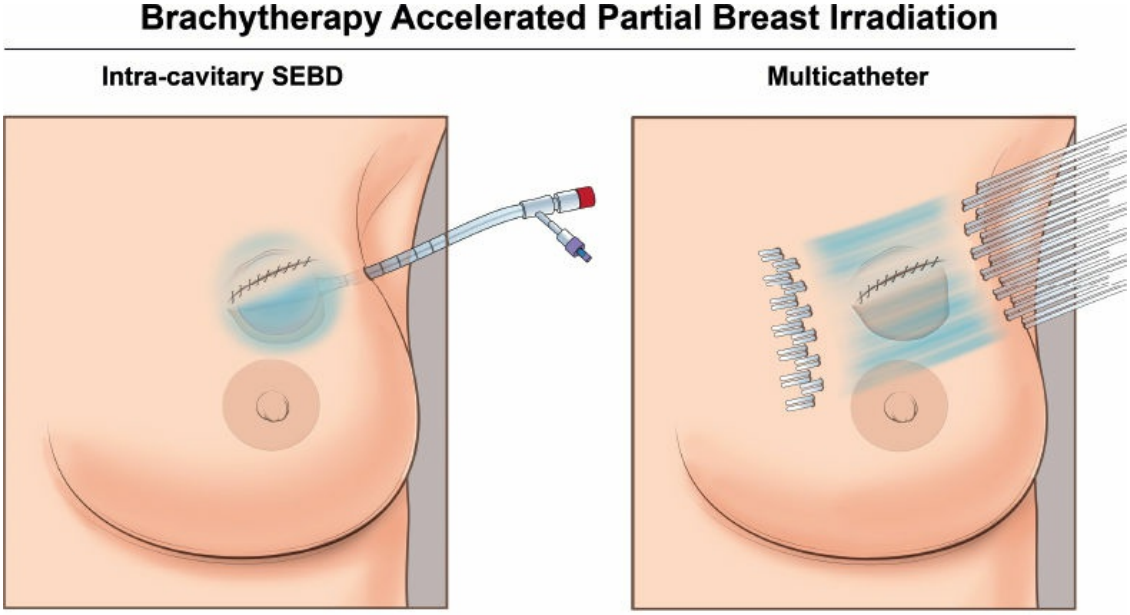

Figure 50.2. Brachytherapy methods for APBI are the multicatheter implant (**right**) and the single entry device (**left**). Each method has a characteristic radiation dose distribution (*blue*).

Multicatheter Brachytherapy APBI

Multicatheter (MCT) brachytherapy is one of the earliest methods of APBI developed and as a result has the longest track record documenting clinical outcome. When using MCT brachytherapy for APBI, the area targeted for radiation is the lumpectomy cavity plus a 1 to 2 cm expansion of breast tissue surrounding it comprises the clinical target volume (CTV). Rigid hollow needles are inserted into the breast under either ultrasound or CT guidance in 1 to 3 parallel planes to cover the extent of the CTV. An average size implant uses ~15 to 17 needles, typically within each plane are 5 to 7 needles set about 1.5 cm apart (Fig. 50.2). The distance between each plane of needles is also 1.5 to 2 cm to achieve optimal dose distribution. Once the total implant is completed, the rigid needles are replaced by narrow hollow flexible tubes that remain in place until the treatment is completed. A CT for treatment planning is done after the MCT implant is inserted and the dose distribution is confirmed by DVA. Treatment is outpatient and commonly the prescribed radiation dose with HDR is 34 Gy delivered in 10 fractions of 3.4 Gy twice daily, with a minimum of 6 hours between fractions. Each fraction lasts ~8 to 15 minutes depending on the Iridium 192 source strength. After the last fraction is delivered, the flexible tubes are removed.

Numerous clinical trials have reported local recurrence rates in the breast following MCT APBI of 2% to 6% at 5 to 10 years in the mostly stage 1 and hormone sensitive (i.e., tumor estrogen [ER] or progesterone [PR] receptors are positive) breast cancer cases that were enrolled. The durable local control results that are achievable are seen in an early phase II trial, RTOG 9517, where the median follow-up is 12 years for 100 women treated post lumpectomy with MCT APBI from 1997 to 2000 and the 10-year local recurrence is 6.2%. Similarly, a phase II German-Austrian Trial treated 274 women from 2000 to 2005 with MCT APBI resulting in a 5% 10-year local recurrence rate at 9.6 years median follow-up. Two phase III randomized trials have documented no difference in local control in women treated with MCT APBI versus standard whole breast irradiation post lumpectomy. The largest of these, the Groupe Européen de Curiethérapie of the European Society for Radiotherapy and Oncology (GEC-ESTRO) trial randomized 1,184 women with stage 1, 95% hormone sensitive breast cancer to MCT APBI versus whole breast irradiation post lumpectomy and reported 5-year in-breast recurrence risks of 1.42% and 0.92% respectively (p = 0.42) with a median follow-up of 6.6 years.

In addition to its established efficacy, the advantage of MCT brachytherapy for APBI is its technical adaptability to fit nearly any position or thickness of the breast by adjusting the number of planes or catheters used. The disadvantage of this method is that it is invasive, technically complicated, and requires significant training. As a result, it has limited availability in the United States, being practiced at only a minority of radiation facilities. This is reflected by the NSABP B39/RTOG 0413 phase III clinical trial that randomized 2,107 women to the APBI arm, of which only 5% were treated with MCT HDR brachytherapy.

Single Entry Device Brachytherapy (SEBD) ABPI

The emergence of single entry brachytherapy devices (SEBD) for APBI overcame the technical barriers of MCT brachytherapy. These are catheter-like devices inserted into the surgical cavity post lumpectomy through a single puncture site and once placed deliver HDR radiation through a single or multiple channels (Fig. 50.2). The first of these developed commercially (MammoSit) had a single central channel for radiation delivery that was enclosed in an expandable balloon used to secure the device in position within the cavity. There is a separate port on the catheter

to expand the balloon (typically with normal saline) after placement to fill the cavity and then radiation is delivered from the central channel to treat breast tissue that is within 1 cm from the balloon surface. The radiation CTV for this method of APBI is defined as an expansion of 1 cm from the surgical cavity edge. The most commonly used dosing is also 34 Gy in 10 fractions of 3.4 Gy HDR radiation delivered twice daily with a minimum of 6 hours between fractions, although investigation is ongoing to reduce this to 3 to 4 fractions over 2 days. It is important that the device fits well within the cavity so that the radiation reaches the targeted breast tissue. After the SEBD is placed, a CT is done to ensure it fits the cavity well and for radiation treatment planning. The radiation dose distribution, particularly to the skin and chest wall, is confirmed by DVA prior to starting treatment.

The initial SEBD (MammoSite) was approved by the Federal Drug Administration in 2001 and the prospective trial evaluating its safety for ABPI post lumpectomy included 42 node-negative breast cancer patients with a median tumor size of 1 cm that had no local breast recurrence events through 5 years of follow-up. The largest clinical experience is from the American Society of Breast Surgeons (ASBS) registry that includes 1,440 women from 93 institutions who were treated with APBI post lumpectomy from 2002 to 2004 using the one radiation channel SEBD (MammoSite). With a median follow-up of 5.4 years, it reported a 5-year rate for in-breast recurrence of 3.7% in 1,249 invasive breast cancer cases that were 97% node negative, 87% hormone sensitive with a median tumor size of 1 cm, and a 4.1% in-breast recurrence in 194 cases of DCIS with an average size of 9 mm. Despite the improved ease of use, the single channel SEBD for APBI delivery created a very heterogeneous dose distribution and prevented individualized dose adjustments resulting in excess toxicity when the balloon surface is too close (within 7 to 8 mm) to the skin or chestwall. Additional brachytherapy devices with more radiation channels were developed to overcome this limitation. Multichannel SEBD models have a central radiation channel and either three (MammoSiteML) or four (Contura) fixed surrounding radiation channels that expand after placement allowing more individualized modulation of the radiation dose at 1 cm from the balloon edge (Fig. 50.3). Another SEBD designed to more closely approximate the dose distribution of MCT brachytherapy is not encompassed in a balloon but instead has a central catheter with 6, 8, or 10 peripheral catheters (Fig. 50.3) that expand

to fill the cavity after insertion and permit even more individualized dose adjustment at 1 cm from the edge of the surgical cavity (Strut-Adjusted Volume Implant, SAVI). Early experience using the multichannel and multicatheter SEBD for APBI has demonstrated reduced dose to the skin and chest wall and similar efficacy. The various brachytherapy devices commercially available can accommodate a good fit in a range of lumpectomy cavity sizes, shapes, and locations.



Figure 50.3. Multichannel (**left**) and Multicatheter (**right**) Single Entry Brachytherapy Devices (SEBD) allow more modification of the dose to protect adjacent uninvolved normal tissue, like the

chestwall and skin.

The development of the SEBD really led to the broader utilization of APBI for breast conservation and acceptance in the surgical community. Examination of the National Cancer Database from 2003 through 2010 reveals that the use of APBI post lumpectomy increased from 3.4% in 2003 to 12.4% in 2010, and the largest increase was in brachytherapy methods (8.9% by 2010) likely reflecting the emergence of single entry devices. Surgeons place SEBD for APBI in the majority of cases, typically in an outpatient setting with the use of ultrasound guidance and local anesthesia. Initially the SEBD was placed at the time of lumpectomy, but insertion transitioned quickly to postoperative closed-cavity placement that permitted review of final pathology and was associated with fewer toxicity outcomes. Most often the entry site for the SEBD is separate in the lateral aspect of the breast, but some surgeons have entered through the prior lumpectomy scar if the cavity location is sufficiently deep. If APBI with a SEBD is an option, performing the lumpectomy in a way that will facilitate fit of the device should be considered. This includes bearing in mind cavity shape so that crevasses and irregular cavity walls are avoided when feasible to minimize poor device fit. There is a need for close cooperation between the surgeon who performs the lumpectomy and postoperatively places the SEBD and the treating radiation oncologist to ensure optimal cancer and cosmetic outcomes. The use of SEBD for APBI still has the drawback of being invasive and requiring the treating facility to have HDR radiation capability. Furthermore, so far there are no randomized data comparing SEBD APBI to standard whole breast irradiation post lumpectomy.

3DCRT and IMRT APBI

External beam radiation methods for APBI using 3DCRT or IMRT were developed after those using brachytherapy. When external beam radiation is used for APBI, the CTV to be irradiated is the surgical cavity plus a 1 to 1.5 cm expansion. In contrast to brachytherapy that is internally secured to the CTV, patient motion and set-up error must be taken into account for external beam radiation, so another 0.5 to 1.0 cm expansion is necessary for a planning target volume (PTV); this means the total expansion from the surgical cavity for this method is 1.5 to 2.5 cm. The most commonly used dosing regimen for 3DCRT or IMRT APBI is 38.5 Gy in 10 fractions

delivered twice daily with a minimum of 6 hours between fractions. The dosing scheme of 30 Gy in 5 nonconsecutive daily fractions at 6 Gy per fraction over 2 weeks of treatment has also been successfully used.

Several single institutions have completed phase II prospective trials evaluating 3DCRT APBI for breast conservation in predominantly stage 1 hormone sensitive breast cancer demonstrating in-breast recurrence rates of 1% to 5% at 5 years. A phase II multi-institution trial, RTOG 0319, studied 3DCRT APBI and reported a 5.9% rate of isolated local recurrence in the treated breast at 7 years with an 8-year median follow-up. A phase III randomized trial conducted at the University of Florence compared IMRT APBI versus whole breast irradiation in 520 women after lumpectomy who nearly all had stage 1, hormone sensitive breast cancer and with a median follow-up of 5 years reported very low rates of local recurrence at 5 years that were not significantly different by arm—1.5% versus 1.4%, respectively ($p = 0.86$).

The advantage of 3DCRT or IMRT APBI for breast conservation is its broad availability as every radiation facility has the technical capability to deliver external beam radiation. In fact, ~70% of the 2,107 women randomized post lumpectomy to the APBI Arm on the NSABP B39/RTOG 0413 clinical trial were treated using 3DCRT. Despite its accessibility, there is some caution with its acceptance as 10% to 15% higher rates of adverse cosmesis have been reported from 3DCRT APBI in comparison to whole breast radiation by the Ontario Clinical Oncology Group RAPID randomized trial. In contrast, the University of Florence trial reported improved physician assessed cosmetic outcomes at 5 years for women randomized to IMRT APBI compared to whole breast irradiation, $p = 0.045$. One of the main criticisms of external beam APBI is the extent of variation within this method—there are multiple definitions for the CTV and how much of the breast should be irradiated yet still be considered “partial”—in addition to inherent variation due to patient movement or technical set-up. It is likely that this variability explains the different toxicity and cosmetic outcomes reported so far from external beam APBI methods and will be addressed as clinical trial data mature and are more fully reported.

Indications and Recommendations

APBI is indicated for breast conservation in women with stage 1 hormone sensitive breast cancer who intend to complete the recommended adjuvant

endocrine therapy. Across all the clinical trials, registry, and cohort research that have reported efficacy of the different APBI methods, there has been an exceedingly consistent population of breast cancer patients studied. Nearly uniformly the population studied is breast cancer that has undergone lumpectomy with negative surgical margins, is node negative, hormone sensitive, with a tumor size <2 cm. Invasive cancers up to 3 cm have been included in these studies, but the prevalence of those >2 cm in size has been typically <10%. Similarly, the median age of women studied has been consistently 60 years or older with very few women <40 years evaluated. Endocrine therapy is likely an important component of the success of APBI in this population. This is illustrated well by the phase II German-Austrian MCT APBI trial where the 5-year local recurrence for hormone-sensitive patients (n = 264) with adjuvant endocrine therapy was 1.1%, and without was 12% (p = 0.0087).

Treatment outcomes from APBI for breast conservation in other breast cancer subtypes, including HER2 and triple negative, or with other adverse pathologic features have been reported relatively infrequently but in general have yielded poorer results. In particular, early-stage triple-negative breast cancer cases treated with APBI have had significantly higher in-breast recurrence at 5 years of up to 20% to 33% in prospective phase II trials. Other features that have been associated with significantly higher local recurrence after APBI, particularly when there are multiple present, include: estrogen receptor negative, grade III histology, involved surgical margins, age <50 years, and being premenopausal. The pending results of the NSABP B39-RTOG 0413 randomized trial may be able to clarify in the future the safety of APBI in other populations as it uniquely enrolled among its 4,216 accrued 19% who had triple-negative disease and 39% who were younger than 50 years old.

Numerous treatment guidelines and consensus statements have emerged to counsel when APBI is indicated for breast conservation therapy while data from the randomized trials are pending. The updated American Society of Radiation Oncologists (ASTRO) consensus statement identifies suitable candidates for APBI as women older than 50 years of age who have undergone lumpectomy with negative margins with either unicentric invasive breast cancers <2 cm in size, with negative nodes, estrogen receptor-positive disease, or low-risk DCIS. A detailed list of “cautionary” or “unsuitable” characteristics for APBI is also detailed by the ASTRO guidelines. The ASBS guidelines for women to be considered for APBI

include those age 45 years old or older for invasive cancer, age 50 years or older for DCIS, invasive carcinoma or DCIS, total tumor size (invasive and DCIS) ≤3 cm in size, negative surgical margins, and sentinel lymph node negative.

INTRAOPERATIVE PARTIAL BREAST IRRADIATION

IPBI refers to the delivery of a single fraction of radiation in a dose range of 18 to 21 Gy to the breast tissue surrounding the lumpectomy cavity following the removal of the tumor and prior to surgical closure. Delivery of IORT after surgical excision adds ~20 to 45 minutes to the case in the operating room. Currently, IPBI is delivered with either 4 to 12 mega-electron voltage (MeV) electrons delivered through a cone from a specialized mobile LINAC, or with low energy kilo voltage (kV) photons through a spherical applicator inserted into the cavity (Fig. 50.4). Brachytherapy methods for IORT are available but less commonly used.

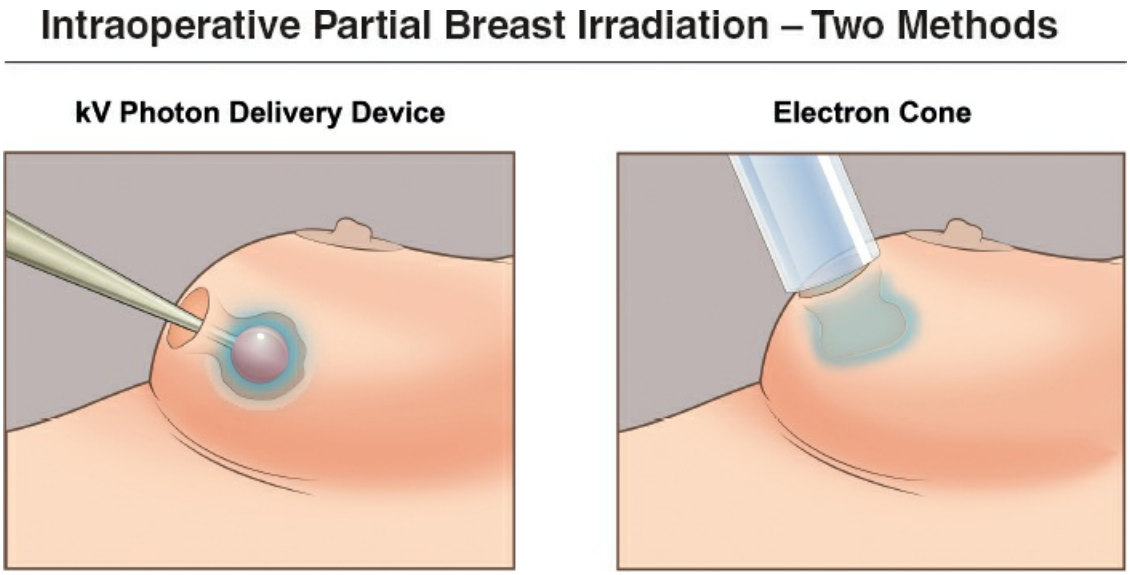

Figure 50.4. Methods for IPBI include the use of electrons (**right**) delivered via a cone from a small LINAC and kV photons delivered through a spherical applicator connected to a miniature LINAC. Each method has a characteristic radiation dose distribution (*blue*).

Electron IORT

The delivery of IORT became more feasible in the late 1990s with the development of small, mobile LINACS capable of delivering electron therapy in the 4 to 12 MeV range. These units can be moved into the

surgical suite and include self-shielding, so minimal modification to the operating room is required. Intraoperative PBI is delivered after the sentinel node biopsy and lumpectomy are completed. Following removal of the breast cancer, the tumor bed is identified and the depth of breast tissue to be irradiated measured. The skin is mobilized from the breast tissue in the affected region to allow entry of the LINAC cone and to exclude it from the radiation. The breast tissue can also be mobilized from the muscle fascia to allow a disc of aluminum-lead or Lucite to be placed below the glandular breast for radioprotection of the chestwall and intrathoracic organs. The edges of the lumpectomy cavity are approximated by sutures to bring it into the radiotherapy target volume deep to the cone. Based on the size and depth of the surgical cavity, the appropriate electron cone and energy for treatment are selected. Cones of 5 to 8 cm diameter and 6 to 8 MeV electrons (4 to 15 MeV) are commonly used to deliver the prescribed dose of 21 Gy to the cavity plus 1.5 to 2 cm of adjacent breast tissue and a depth of 1 to 3 cm.

Mature outcome date from electron IPBI for breast conservation is available from phase II and III trials. Two phase II trials have reported a range of local recurrence rates: 0.4% from the University of Verona trial of 227 women with a mean follow-up of 46 months and 9.2% at 6 years median follow-up in the Montpellier phase II trial that enrolled 96 women. The European Institute of Oncology (EIO) in Milan, instrumental in developing the electron methods for IORT (termed ELIOT) in breast cancer, conducted a phase III trial that randomized 1,305 women to receive either IPBI of 21 Gy during surgery versus standard adjuvant whole breast irradiation. Eligible cases had a clinical tumor size <2.5 cm and were between the ages of 48 and 75 years. On final pathology, 85% were T1 tumors, 90% were estrogen receptor positive, and 26% had positive nodes. An axillary dissection was performed in all cases with positive nodes. At a median follow-up of 5.8 years, the 5-year rate of local recurrence following IPBI was 4.4% versus 0.4% for standard adjuvant breast radiation (p = 0.001). The 5-year local recurrence rate exceeded 10% in the IPBI arm when there was a tumor size >2 cm, positive lymph nodes, grade 3 histology, ER negative, or triple-negative breast cancer. In a separate analysis, 1,822 cases in the ELIOT database that received IPBI were retrospectively categorized into the ASTRO APBI Consensus Groups of Suitable, Cautionary, or Unsuitable and were determined to have corresponding local recurrence risks of 1.5%, 4.4%, and 8.8%,

respectively ($p = 0.0003$).

kV IORT

For this form of IPBI, a miniature LINAC delivers low-energy x-ray radiation through a spherical applicator fitted into the cavity after the breast cancer has been removed (Fig. 50.4). The miniature LINAC accelerates the electrons to 50 kV and guides them through a narrow tube that ends within the spherical applicator. The electrons impinge on a gold target at the end of the narrow tube resulting in the generation of low-energy x-rays that distribute around the applicator surface. The spherical applicator is available in several sizes ranging from 15 mm through 50 mm diameter to accommodate a range of cavity sizes. The applicator should fit snugly within the cavity and one or two purse-string sutures are placed through the breast tissue around the cavity to appose it to the applicator. Care needs to be taken to prevent the skin from being too close to the applicator surface to minimize the radiation it receives. After positioning the appropriately sized applicator into the cavity, the radiation is delivered. A dose of 20 Gy is delivered to the surface of the applicator giving 5 to 7 Gy at 1 cm from the applicator surface.

The primary outcome data from kV IPBI are from a large phase III multi-institution trial, TARGIT A that randomized 3,451 women to receive either 20 Gy kV IPBI during surgery or standard adjuvant whole breast radiation therapy. For those randomized to the kV IPBI arm, radiation was considered “risk adapted,” meaning that adjuvant whole breast radiation was allowed if adverse pathologic features were present on final pathology and this indeed occurred in 15%. In addition, while 2,298 (66.5%) received kV IPBI after the cancer was removed during the first surgery or “pre pathology,” the other 1,153 (33.5%) had a second surgical procedure after initial lumpectomy or “post pathology” to specifically receive kV IPBI. On final pathology, 87% had tumors <2 cm, 93% were hormone sensitive, and 16% had positive nodes. With a median follow-up of 2.4 years, the 5-year risk for local recurrence in the conserved breast for kV IPBI was 3.3% versus 1.3% for standard adjuvant breast radiation ($p = 0{\cdot}042$). Patients treated with kV IPBI who received it “pre-pathology” had a 1% local risk at 5 years but 22% also received whole breast radiation, and those in the “post-pathology” group had a 3.7% local recurrence rate at 5 years with 3% also receiving whole breast radiation. The 2.4-year median follow-up on this trial is relatively short, and additional follow-up

is needed to confirm efficacy.

Indications and Recommendations

IPBI is best considered for breast conservation in those who are 50 years of age or older whose invasive tumor is <2 cm in size, hormone sensitive, HER2 negative, and expected to be node negative. Adherence to the ASTRO consensus guideline "suitable" category for patient selection is recommended. Careful workup of the axilla is warranted to reduce the likelihood of positive nodes at sentinel node biopsy.

The main advantage of IPBI is the convenience and efficiency of completing surgery and breast radiation by the time the patient exits the operating room. However, the main disadvantage is the risk of overtreatment and undertreatment as a result of not knowing the final surgical pathology. The IPBI could be considered medically pointless if the patient needs to undergo external beam radiation to the breast or regional nodes anyway due to adverse features on final pathology as seen in 22% and 5% respectively in the TARGIT-A and ELIOT phase III randomized trials. On the other hand, potential undertreatment can occur if patients with adverse pathologic features are treated with IPBI alone. Further research is warranted to improve patient selection that minimizes inclusion of high-risk features. Finally, the other disadvantage of IPBI is that it is not possible to confirm that the radiation dose distribution is being delivered accurately through individual treatment planning. Many of these issues will be addressed by additional follow-up from the large randomized trials and careful monitoring of outcome data as IPBI is used in practice.



EDITOR'S COMMENT

Professor White of the Department of Radiation Oncology, the Ohio State University Comprehensive Cancer Center, has included a technical and comprehensive overview of the role of whole and partial breast irradiation, as well as the intraoperative irradiation choices, available to the surgeon managing breast cancer. As Dr. White would embrace, radiation science is an art and technical feat that is not considered an exact science. The advancement of radiation technology and tools capable of delivering precise energy photons, electrons, and rads continues to be an emerging technical advance with increasing options for management of breast cancer patients as noted in the commentary made by Dr. White. All disciplines managing breast cancer require

advanced quality imaging inclusive of: ultrasonography, mammography, magnetic resonant imaging, and confirmatory CTs and staging, including positron emission tomography (PET) scans.

As noted, the original investigation by Agarwal et al. (Agarwal S, Pappas L, Neumayer L, et al. Effect of breast conservation therapy vs mastectomy on disease-specific survival for early-stage breast cancer. *JAMA Surg* 2014;149(3):267–74) provides emerging data that compare breast cancer-specific survival of patients who are undergoing breast conservation therapy (BCT) to mastectomy alone or mastectomy with radiation using contemporary cohorts in the investigation. Agarwal and associates confirm that patients undergoing BCT have a higher breast cancer-specific survival when compared with individuals treated with mastectomy alone or with mastectomy and irradiation. There are nearly four decades of data that date back with the NSABP of the 1970s that confirm BCT has equivalent cancer-specific survival to modified or radical mastectomies. Moreover, contemporary data suggest that BCT plus radiotherapy has an improved 10-year overall and relative survival when compared to mastectomy of these earlier era treatment protocols. Furthermore, 10-year distant metastases-free survival was enhanced with BCT plus RT when compared with mastectomy and the T1N0 subgroup cohorts. It would therefore be a conservative statement that BCT with radiotherapy is at least equivalent to mastectomy with respect to the overall survival and may influence therapeutic decisions (van Maaren MC, de Munck L, de Bock GH, et al. 10 year survival after breast-conserving surgery plus radiotherapy compared with mastectomy in early breast cancer in the Netherlands: a population-based study. *Lancet Oncol* 2016;17:1158–70). *This is a very important point. -JEF*

Mukesh et al. of Cambridge University Hospital National Health Service Foundation Trust, UK, reiterate that within the current era use of intensity-modulated radiotherapy (IMRT) clearly decreases late breast tissue toxicity; thus, control rates and cosmesis are enhanced as an additional equivalent in current radiation therapy protocols, and these outcomes are “practice-changing” parameters that will encourage university centers and population growth centers to increasingly utilize simple IMRT technology with two-dimensional RT to implement breast IMRT. (Mukesh MB, Barnett GC, Wilkinson JS, et al. Randomized controlled trial of intensity-modulated radiotherapy for early breast cancer: 5-year results confirm superior overall cosmesis. *J Clin Oncol* 2013;31:4488–95).

The European Organization for Research and Treatment of Cancer Radiation Oncology and Breast Cancer Groups suggested that the most commonly utilized techniques in postop whole-breast techniques with irradiation boost had no effect on long-term survival, but was implemented to confirm local control with the largest absolute benefit in the younger patient. It should be noted that this randomized controlled trial (Bartelink H, Maingon P, Poortmans P, et al. Whole-breast irradiation with or without a boost for patients treated with breast-conserving surgery for early breast cancer: 20-year follow-up of a randomised

phase 3 trial. *Lancet Oncol* 2015;16:47–56) confirmed this technology can improve local control with the largest absolute benefit in the younger patient, although the technique increases relative risk of moderate to severe fibrosis in these patients. Addition of a radiation dose was noted to possibly be avoided for the older patient (>60 years).

In the original dated trials that confirmed the value of whole-breast irradiation following BCT, 20 fractions of radiation at 50.0 Gy were given over an interval of over 5 weeks with daily fractions of 2.0 Gy. Whelan et al. (Whelan TJ, Pignol JP, Levine MN, et al. Long-term results of hypofractionated radiation therapy for breast cancer. *N Engl J Med* 2010;362:513–20) reported the 5-year results of a randomized trial with whole-breast therapy at this dose over a period of 35 days when compared to accelerated hypofractionated whole-breast radiation (42.5 Gy in 16 fractions over 22 days) following BCT with axillary lymph node-negative breast cancer. Of note, radiation-induced toxicity related to large doses per fraction that increased with time raises dubious concerns regarding the universal approach for hypofractionated radiation. Whelan and associates, thus, provide support for the use of accelerated hypofractionated whole-breast RT for select women who are node-negative following BCT. This abbreviated course of treatment was considered to be potentially less costly than standard therapy and could have an additional benefit to enhance the number of women who receive breast RT following breast-conserving surgery.

In the phase III randomized, noninferiority trial, by Strnad et al. of the European Society of Radiotherapy and Oncology (GEC-ESTRO) (Strnad V, Ott OJ, Hildebrandt G, et al. 5-year results of accelerated partial breast irradiation using sole interstitial multicatheter brachytherapy versus whole-breast irradiation with boost after breast-conserving surgery for low-risk invasive and in-situ carcinoma of the female breast: a randomised, phase 3, non-inferiority trial. *Lancet* 2016;387:229–38), the authors report this a phase III randomized trial for APBI with stages 0, I, and IIA breast cancer, which were compared with whole-breast irradiation. In finality of the report, the difference between treatments was below a relevance margin of 3 percentage points. Using multicatheter brachytherapy following BCT in patients with early breast cancer is *not inferior* to adjuvant whole-breast radiation relative to the 5-year occurrence of this patient population relative to overall survival, disease-free survival, and local control. Therefore, adjuvant APBI that utilized multicatheter brachytherapy was virtually identical to whole-breast irradiation and the risk of severe fibrosis at 5 years was 0.2% with whole-breast irradiation and 0% with APBI ($p = 0.46$).

The European Institute of Oncology (Milan, Italy) randomized trial with Intraoperative Radiotherapy versus External Radiotherapy for Early Breast Cancer (ELIOT) was a controlled equivalence trial. Veronesi et al. (Veronesi U, Orecchia R, Maisonneuve P, et al. Intraoperative radiotherapy versus external radiotherapy for early breast cancer (ELIOT): a randomised controlled

equivalence trial. *Lancet Oncol* 2013;14:1269–77) in this trial of 1,305 patients randomized to receive either external radiotherapy or intraoperative RT observed fewer skin effects in the intraoperative RT group than in the external RT group (p = 0.0002); although the result was within this pre-specified equivalence margin, the rate was significantly greater with external RT. Overall survival did *not* differ between the groups, and the authors conclude that improved patient selection could reduce the rate of ipsilateral breast tumor recurrence (IBTR) with intraoperative RT with electrons.

In the reported systematic search for the National Library of Medicine PubMed Database by Smith et al. (Smith B, Arthur D, Buchholz T, Accelerated partial breast irradiation consensus statement from the American Society for Radiation Oncology (ASTRO). *Int J Radiation Oncology Biol Phys* 2009;74[4]:987–1001), this multi-institutional trial report yielded 645 candidate research articles applicable to APBI versus whole-breast radiation. With his dated publication, taskforce proposed three patient groups: "*suitable*" group for whom APBI was acceptable outside a clinical trial, a "*cautionary group*" in whom concern should be applied when considering APBI outside a clinical trial and an "*unsuitable*" group where it is not generally considered warranted. The conclusion states that these patients in whom APBI therapy is being considered must be informed of the long-term database experience with whole-breast irradiation as an established therapy with known safeguards and effectiveness.

Finally in the randomized prospective phase III controlled trial from the University of Florence reported by Livi et al. (Livi L, Meattini I, Marrazzo L, et al. Accelerated partial breast irradiation using intensity modulated radiotherapy versus whole breast irradiation: 5-year survival analysis of a phase 3 randomised controlled trial. *Euro J Cancer* 2015;51:451–63), women older than 40 years affected with early breast cancer and tumor size that did not exceed 25 mm were randomized 1:1 with APBI using IMRT technique followed BCT to that of conventional whole-breast irradiation. Patients in the APBI arm received a total dose of 30 Gy to the tumor bed in 5 daily fractions; the whole breast irradiation (WBI) group received 50 GY in 25 fractions, following with boost to the tumor bed of 10 Gy in 5 fractions. Of 520 randomized patients equally divided between the two arms, this randomized study using IMRT for APBI delivery, no significant differences in terms of in-breast tumor reoccurrence (IBTR) and overall survival between the modalities were evident. Moreover, APBI had evidence of a significantly better toxicity profile than WBI.

These techniques and emerging RT technology embrace the improved outcomes with equivalent survival rates and superior cosmesis than the dated whole-breast irradiation technology.

Kirby I. Bland

EDITOR'S COMMENT

The current standard of care is to offer breast conservation therapy (BCT) to patients with early stage disease. BCT includes excision of the tumor with a rim of normal tissue (i.e., lumpectomy) and adjuvant treatments including radiation therapy, most commonly whole breast radiation therapy (WBXRT), to treat residual disease. BCT that is less invasive offers improved cosmesis, well-being, and equivalent survival to mastectomy (removal of the whole breast) with similar local recurrence rates. However, because of the challenges of WBXRT (time, travel, cost, and complications), 14% to 26% of BCT patients skip WBXRT entirely, and an additional 22% of women do not complete their treatment. This despite the knowledge that the risk of local recurrence is five times greater without the addition of radiation. Patients refusing completion radiation led to trials testing whether older patients (>70 years old) with favorable tumors received significant benefit from radiation. While the initial results looked favorable, the most recent follow-up of the CALGB (Cancer and Leukemia Group B) 9343 demonstrated a recurrence of 2% at 10 years in patients receiving Tamoxifen plus WBXRT and 10% in those receiving tamoxifen alone. Importantly, survival remained equivalent. On the other hand, most patients who get XRT don't benefit from it. That is, for example, in the CALGB study 90% of patient who didn't get radiation didn't recur. So that on 8 patients out of the 100 who got XRT actually benefited from it. One could conclude that we are vastly overtreating the majority of patients. Yet, recurrence remains important. The Early Breast Cancer Trialist Group, in review of data from over 42,000 women from 78 randomized studies, demonstrated that at 15-year follow-up, for every four recurrences there was an associated increase of one death that could be avoided.

Thirty-six percent of women who elect mastectomy are actually eligible for BCT. With variable rates of positive margins, a majority of women elect mastectomy after a failed first attempt at lumpectomy. Others fear the complications of radiation to the chest wall, including radiation dermatitis, breast shrinkage (moderate or greater decrease in size of the breast in 50%), pneumonitis/pulmonary fibrosis, edema, ischemic heart disease, and rare second lethal cancers like angiosarcoma. Rural patients and others cannot spare the time and/or cost of travel for treatment. These issues have been partially alleviated by the development of brachytherapy and accelerated partial breast irradiation (APBI) of which Dr. White nicely outlines the history. These techniques include a surfeit of devices and techniques developed for delivery of shorter courses of radiation administered only to the pericavitary breast tissue, including interstitial catheters, applicator-based brachytherapy, and external-beam XRT.

Partial breast irradiation (PBI) when added to lumpectomy demonstrates nearly equivalent local recurrence and equal survival when compared to whole

breast radiation. However, PBI can be delivered in much shorter time (5 days as compared to 3 to 6 weeks) and even intraoperatively as a one-time dose. This chapter describes the many alternative techniques available for delivering PBI.

One option for avoiding whole breast irradiation after breast conserving surgery is the use of three-dimensional conformal external beam radiation therapy (3DCRT) to deliver noninvasive APBI. This modality may be advantageous to brachytherapy in comparison due to its noninvasive nature, widespread availability of necessary resources, knowledge of final pathology at the time of treatment planning, and potential decrease in seroma formation and infection associated with catheter-based treatment. APBI is most commonly administered in a 38.5 Gy regimen divided into 10 fractions given twice per day for 5 days. Rodriguez et al. reported on the 5-year outcomes of 102 patients with early-stage breast cancer randomized to receive WBXRT or APBI. A median follow-up of 5 years found no local recurrences in either group, and physician assessment reported that >75% of patients had excellent or good cosmesis and remained stable over time. An interim analysis of the RAPID (Randomized Trial of Accelerated Partial Breast Irradiation) trial was performed by Peterson and colleagues to evaluate cosmetic outcomes of APBI compared to WBRT. The RAPID trial enrolled 1,108 patients; 539 were randomized to 3D external beam APBI and 569 were randomized to WBRT. Baseline posttreatment nurse assessment for adverse cosmesis was 19% in the APBI arm and 17% in the WBRT arm with 3-year evaluations increased to 29% with adverse cosmetic outcomes for APBI, but remained 17% for WBRT ($p < 0.001$). The National Surgical Adjuvant Breast and Bowel Project (NSABP) B-39/Radiation Therapy Oncology Group (RTOG) 0413 trial that randomized 3,000 patients to WBXRT or PBI has not yet matured. Most of the patients on the non-WBXRT arm have received 3DCRT.

In 2012, the consensus statement recommendations by the American Society for Radiation Oncology (ASTRO, 2009) that Dr. White reviewed delineating who was suitable for APBI was reviewed by a group examining 2,127 cases of APBI and comparing them with 206 of those patients having 3DCRT. At a median follow-up of 6.7 years, the recurrence rate in the tumor bed was 1.1% in the suitable group, 1.2% in the cautionary group, and 1.2% in the unsuitable group ($p = 0.2$). 3DCRT is easier on the patient, doesn't require an external device or device placement, and is readily accepted by the patient and physician alike. In addition, dose homogeneity can be assured. The complication rates tend to be less than with whole breast; but in my experience, when they do occur they tend to be worse with block fibrosis and pain. APBI has been associated with a fourfold higher rate of patients developing a palpable mass at the lumpectomy site and a 42% incidence of telangiectasia and/or other side effects. Dr. White is the PI for the phase III National Surgical Breast and Bowel Project (NSABP) B-39 comparing APBI and brachytherapy techniques with who breast radiation. Although the results of this trial are pending maturity, most of the patients in this trial receiving partial breast XRT did so via APBI.

The MammoSite (Hologic, Marlborough, MA) (the first balloon-based catheter) Registry of the American Society of Breast Surgeons has the largest collection of data with this device, which demonstrates comparable results to historical controls receiving WBXRT. The Registry has 1,449 patients with a median follow-up of 63.1 months with an actuarial ipsilateral breast tumor recurrence (IBTR) rate of 3.8% and axillary recurrence rate of 0.6%, which compares favorably to WBXRT. Cosmetic results are reported to be good to excellent in about 90% of the patients. Contura (SenoRx, Inc. Aliso Viejo, CA) makes a balloon that has multiple catheters as well as a vacuum port within the balloon with a total of 40 dwell positions. The multiplicity of catheters allows better treatment planning and is particularly useful in patients where the skin distance to the balloon is <7 mm. Multiple catheters make this and other balloons a bit stiffer and more uncomfortable for the patient. Most catheters have to be scanned with each treatment as they can rotate leading to incorrect dosing. The SAVI (Cianna Medical, Inc., Aliso Viejo, CA) device that also has multicatheters and has the advantage that it can be locked in place and comes in sizes such that the catheter can be custom-fitted to the lumpectomy cavity. ClearPath (Renata Medical, Irvine, CA) makes a similar device with multiple catheters that has the advantageous of laying flush with the skin and is a bit better-tolerated by the patient. Xoft, Inc (Sunnyvale, CA) has developed the Axxent electronic brachytherapy system that is an iridium seed-based single catheter radiolucent balloon impregnated with barium that emits low energy and can be turned on and off in the office setting. The EXIBT Electronic Xoft Intersocietal Brachytherapy Trial (EXIBT) registry recruited 400 patients and at 1- and 2-year follow-up demonstrated the safety and efficacy of Xoft as an adjuvant radiation therapy for early-stage breast cancer reporting no recurrences in 69 patients.

The major advantage of brachytherapy APBI is that the radiation therapy can be completed prior to systemic therapy. However, one must be careful. Starting chemotherapy too soon (<3 weeks) can result in the rare case of radiation recall that can be so severe as to necrose the overlying skin of the cavity.

As Dr. White discussed intra-operative radiation therapy (IORT) can provide effective long-term local control with equivalent recurrence rates to WBRT. IORT delivers a single large fraction over 2 minutes directly into the wound for increased dose delivery and decreased normal tissue exposure. IORT is more expensive because it requires radiation delivery equipment not available at most hospitals.

Using the Mobetron IORT device is a self-shielded, magnetron-driven, X-band linear accelerator Philippson and colleagues recruited 200 patients to a phase II trial who had favorable breast cancer ≤2 cm and no lymph node involvement, lymphovascular invasion or extensive ductal carcinoma in situ (DCIS). The patients received 21 Gy or intraoperative XRT. At a median follow-up of 23 months, the local regional recurrence was 0.5%, acute toxicity was 5.4%, and the late toxicity was 17.1%. Cosmetic outcome was good or very

good in 92.5% of patients. This technology is extremely expensive, and requires dedicated operating rooms and time and multidisciplinary interactive teams. The other disadvantage is the uncertainty of margins at the time of delivery of the dose.

The European ELIOT trial used a linear accelerator to deliver 21 Gy to the tumor bed via a collimator (4 to 9 cm) placed into the tumor bed after excision. The ELIOT trial compared WBXRT to intraoperative XRT comparing 1,205 patients presented with tumors 2.5 cm or smaller. In the intent-to-treat analysis, the 5-year ipsilateral breast tumor recurrence (IBTR) was 4.7% for ELIOT versus 0.5% for WBXRT. In subgroup analysis, low-risk women had a 5-year IBTR was 1.7%. ELIOT did report a higher rate of regional failure (1.0% vs. 0.3%, $p = 0.03$), but the overall survival was the same between the two arms at 5 years.

Zeiss (Carl Zeiss Meditec, Jena, Germany) has developed a low-cost low-energy electronic radiation source (IntraBeam) for intraoperative partial breast irradiation (IPBI) that requires minimal shielding and is much less expensive than other intraoperative devices. The applicators are solid and rounded and come in different sizes to place into the wound (2 to 5 cm). The appropriate size catheter is placed in the wound and the tissue cinched up around the catheter. The radiation oncologist must calculate an ~20 Gy one-time dose to be delivered at the surface of the applicator such that a dose of 5 Gy is delivered at a depth of 1cm from the cavity. The IntraBeam shares some of the same disadvantages as the IOERT devices but is much less expensive and has long-term data demonstrating noninferiority to WBXRT as well as a 2% survival advantage for cardiac events thought attributable to radiation. Silverstein and colleagues recently published a critical analysis and comparison of the two studies.

There is no doubt that radiation therapy reduces the risk of recurrence but only in the peri-cavitary bed and not for the majority of patients to whom it is given. Thus, future endeavors will minimize the treatment to the whole breast and develop better less toxic and less expensive methods to prevent recurrence at the tumor cavity site.

V. Suzanne Klimberg

This chapter has two commentaries and rightly so. Preservation of the breast (as much as possible) is extremely important to the female patient, thus the two commentaries. I have intentionally allowed this because of the importance of leaving as much breast as possible. Experienced breast surgeons know how important this is.

J.E.F.

Suggested Readings

Hughes KS, Schnaper LA, Bellon JR, et al. Lumpectomy plus tamoxifen with or without irradiation in women age 70 years or older with early breast cancer: Long-term follow-up of CALGB 9343. *JCO* 2013;31:2382–9.

Pan XB, Huang ST, Jiang YM, et al. Secondary malignancies after partial versus whole breast irradiation: a systematic review and meta-analysis. *Oncotarget* 2016;7(44):71951–9.

Radiation Therapy Oncology Group. NSABP Protocol B-39/RTOG Protocol 0413: a randomized phase III study of conventional whole breast irradiation (WBI) versus partial breast irradiation (PBI) for women with stage 0, I, or II breast cancer. Available at: http://www.rtog.orglinicalTrials/ProtocolTable/StudyDetails.aspx?study-0413

Shah C, Badiyan S, Ben Wilkinson J, et al. Treatment efficacy with accelerated partial breast irradiation (APBI): final analysis of the American Society of Breast Surgeons MammoSite® breast brachytherapy registry trial. *Ann Surg Oncol* 2013;20(10):3279–85.

Silverstein MJ, Fastner G, Wazer D. Intraoperative radiation therapy: a critical analysis of the ELIOT and TARGIT trials. Part 1—ELIOT. *Ann Surg Oncol* 2014;21(12):3787–92 and Part 2—TARGIT. *Ann Surg Oncol* 2014;21(12):3793–9.

Smith B, Arthur D, Buchholz T. Accelerated partial breast irradiation consensus statement from The American Society for Radiation Oncology (ASTRO). *Int J Radiation Oncology Biol Phys* 2009;74(4):987–1001.

Vaidya JS, Bulsara M, Wenz F, et al. Reduced mortality with partial-breast irradiation for early breast cancer: a meta-analysis of randomized trials. *Int J Radiat Oncol Biol Phys* 2016;96(2):259–65.

Vaidya JS, Wenz F, Bulsara M, et al. Risk-adapted targeted intraoperative radiotherapy versus whole-breast radiotherapy for breast cancer: 5-year results for local control and overall survival from the TARGIT-A randomized trial. *Lancet* 2014;383(9917):603–13.

51 Ablative Techniques for Benign and Malignant Breast Tumors

Sheldon Feldman and Margaret Chen

INTRODUCTION

Medical science and technology are rapidly progressing toward the goal of providing personalized, minimally invasive treatments, which are becoming increasingly effective and safe. An area of growth is the investigative use of thermal ablative techniques to treat breast tumors, either as a replacement for or as an adjunct to open surgical resection.

Thermal ablation of tumors is the in situ destruction of tumorous tissue by the local application of heat or cold. Heat-based modalities include radiofrequency ablation (RFA), interstitial laser therapy (ILT), microwave ablation (MWA), and high-intensity focused ultrasound (HIFU). Cryotherapy uses low temperature to ablate tissue.

Hyperthermia has been used to destroy tumor masses for over 4,000 years. Hippocrates describes that “if a tumor cannot be cut, it should be burned. If it cannot be burned, then it is incurable.” This concept is largely true today!

Hippocrates treated superficial tumors with direct ablative therapy. Around the middle ages, instruments were designed with shapes that would allow direct application of heat to kill tumors or cauterize bleeding. It was reported in 1900 that the first curative electrosurgery for cancer occurred when a man with a cutaneous carcinoma accidentally touched an electrical wire. Shortly thereafter, William T. Bovie and Harvey Cushing developed an electrosurgical device (The Bovie) that uses heat to reduce blood loss during surgery. This is used on a daily basis by surgeons around the world.

Hyperthermia has been used in combination with chemotherapy during isolated limb perfusion for melanoma and sarcoma. Targeted hyperthermia for tumor ablation has been used with increasing frequency for treating hepatic, pulmonary, renal, cervical and prostate disease. The use of hypothermia or cryotherapy has a much shorter history with evidence of

efficacy in treating prostate, liver, and renal tumors. It is a potentially very important modality for treating breast tumors as recent clinical trials have demonstrated.

This chapter showcases the most widely studied ablative techniques to treat breast tumors. Lumpectomy with radiation has a long history with excellent oncologic and esthetic outcomes, particularly with application of oncoplastic techniques. It is a low-risk, outpatient procedure with minimal associated complications, which allows for pathologic assessment of the completeness of resection. This experience sets the bar quite high for tumor ablation to perform as well, particularly in terms of safety, recurrence risk, and cost analysis. However, as technology advances ablation is becoming increasingly relevant. Patients are increasingly drawn to minimally invasive methods, which minimizes visible scars while maintaining normal appearance. Patient reported outcomes and patient satisfaction have becoming increasingly important measures of the success of therapy. In fact, there are patients who fear and thus procrastinate or decline traditional surgical treatment of breast cancer due to concern about scars and breast deformity. This often results in devastating outcomes. Nonsurgical ablation treatment may be particularly relevant to provide a less threatening option for this group. It is becoming increasingly clear that ablation techniques will become an important component to our armamentarium of local therapy tools.

The increased use of mammogram screening worldwide has enabled the diagnosis of smaller tumors. Breast conservation surgery remains the preferred approach for the majority of these patients. Screen-detected breast cancers are the most feasible for ablation since smaller tumor volumes can be more effectively treated in relatively shorter time, compared with larger tumors.

Advances made in breast imaging allow more precise targeting for nonoperative ablation. Presently, image-guided needle biopsy can fully characterize tumor biology and genomics. This information increasingly informs systemic therapy decision. Therefore, for most patients, it is no longer important to have tissue analyzed from tumor excisional procedures, such as lumpectomy, to guide subsequent management.

The role of axillary node evaluation for decision making in patients with small favorable subtype tumors is rapidly diminishing. Improved pretreatment axillary imaging with ultrasound allows many patients with nodal metastases to be identified. Thus, selecting out patients most likely

to be node negative will improve patient selection for a nonsurgical ablative approach.

Systemic therapy and radiation recommendations are increasingly be made based on tumor biology and genomics. Thus, it is likely in the near future that many patients will be fully staged and treated without any surgical intervention including sentinel node biopsy. The key to advancing nonsurgical ablation will depend on our ability to choose optimal patients and defining compete ablation without surgical excision.

In the breast, ablative approaches have been studied to treat benign fibroadenoma and cancer, as well as to extend lumpectomy margins intraoperatively. Compared with surgical excision, thermal ablation has the potential advantages of minimal scarring, decreased infection and bleeding, shorter recovery time, better cosmetic outcome, and treatment of patients who are not surgical candidates. Intracavitary hyperthermia using RFA to treat margins during lumpectomy adds an additional tumor-free zone and may reduce reexcision rate as well as obviate the need for radiation therapy. Disadvantages may include thermal injury, palpability, incomplete ablation, residual tumor, inability to assess margin, and disease recurrence.

There are no randomized trials comparing the outcomes of thermal ablation and surgical resection and radiation. Reports of spontaneous regression of untreated distant metastases after local thermal ablation of the primary tumor are generating research in immunomodulation, and may have implications for enhanced combinatorial treatment. There is growing evidence that ablation (whether hyperthermia or cryoablation) may have the additional benefit of altering the local tumor microenvironment and cause autovaccination against tumor antigens. This biologic effect may ultimately be exploited as a strategy to enhance the systemic benefit initiated by ablative local therapy, particularly with tumors with unfavorable biology.

TABLE 51.1 Comparison of Ablative Therapies of Breast Tumors

Characteristics	Radiofrequency Ablation	Cryotherapy	Laser	Microwave	High-Intensity Focused Ultrasound
Energy type	Heat	Cold	Heat	Heat	Heat
Invasiveness	Minimal	Minimal	Minimal	Minimal	Noninvasive
Image guidance	Ultrasound, open lumpectomy	Ultrasound	Ultrasound	Ultrasound	MRI, ultrasound
Target ablation temperature (°C)	100	−40	60	90	60–90
Ablation time (min)	<30	<30	<30	<30	≤120
Real-time monitoring	Yes	Yes	Yes	No	Yes
Procedural pain	Variable	Minimal	Variable	Variable	Variable
Complete tumor ablation rate (%)	44–100	36–93	13–91	0–90	24–100
Postablation MRI correlation with residual disease			High		High
Morbidity with breast and other tumor ablation (%)	2–10				
Mortality with breast and other tumor ablation (%)	0.3–0.8				
Postprocedural palpable breast mass	Yes	Yes	Yes	Yes	Yes
Unique features		Cryoshock phenomenon, immunostimulation, and paradoxical immunosuppression			

INDICATIONS AND CONTRAINDICATIONS

Data from ablative therapies of breast tumors are accumulating, and appear to demonstrate that each technique has a wide range of effectiveness, with low morbidities in appropriate patients. Each ablative technique has advantages and disadvantages, and currently, it is unknown whether one method is superior (Table 51.1). The selection of using a specific technique is determined by each patient's case and the vailable resources and experience with the modality.

Overall, clinical and pathologic criteria determine the selection of patients for thermal ablation (Table 51.2). Ablation is most successful when treating tumors measuring 2 cm or less in diameter, and is at least 5 mm away from the skin and chest wall to minimize thermal injury. Larger tumors have been treated and may require multiple treatments for complete ablation. Tumors are ablated using image guidance, and must, therefore, be well visualized on mammogram, ultrasound, or MRI. Prior to ablation, core needle biopsy is performed to establish definitive tissue diagnosis. It is critically important that adequate tissue be obtained by core biopsy so that complete evaluation of the tumor biology including genomic profiling is available. For cancer, most studies have treated small, well-characterized unifocal, invasive ductal carcinoma without extensive ductal carcinoma in situ, and excluded lobular neoplasm, recurrent, and uncommon malignancies.

PREABLATION PLANNING

Ablation of breast cancer is investigative and should be performed in the setting of a clinical trial. Trials require approval from institutional review board prior to starting treatment. For the ablation of benign fibroadenoma, laser ablation and cryoablation have received United States Food and Drug Administration 501 (k) clearance, and may be performed without trial participation. Prospective outcomes data are encouraged to share results and continually improve technique and patient selection.

TABLE 51.2 Indications and Contraindications for Thermal Ablation of Breast Tumors

Indications

- Patients 18 years of age or older
- Tumor measuring 2 cm or less
- Tumor at least 5 mm away from the skin and chest wall
- Tumor well visualized on imaging (mammogram, ultrasound, or MRI)
- Preablation pathologic diagnosis established by needle biopsy
- Benign fibroadenoma
- Invasive duct cancer
- No extensive ductal carcinoma in situ (<25% intraductal component)

Contraindications

- Pregnancy or breast feeding
- Women with strong family history of breast cancer or BRCA mutation carrier
- Large tumor measuring >2 cm in diameter
- Tumor not well visualized by imaging
- Phyllodes tumor
- Lobular neoplasm, metastatic cancer to breast, sarcoma, Paget's disease
- Recurrent breast cancer
- Neoadjuvant therapy

Appropriate patient selection is the key to successful ablation of breast tumors. Core needle biopsy of the tumor is required prior to any ablation procedure to establish diagnosis. A marker is often placed at the time of biopsy for localization. All patients should be carefully examined, and all imaging and pathology should be reviewed to ensure eligibility for inclusion.

ABLATIVE TECHNIQUES AND OUTCOMES

Patients who meet inclusion criteria and are eligible for ablation are treated, after discussion and informed consent. Treatment can be performed in the office or at an outpatient facility, under local anesthesia, conscious sedation, or general anesthesia depending on patient-related

factors.

Radiofrequency Ablation

Technique

RFA is a technology based on the principle of heating tumors or tumor margins to destroy tumor cells with heat. The RFA procedure was initially used for ablation of aberrant conduction pathways to treat cardiac arrythymias. It has evolved into use for ablation of solid tumors, since it causes a reproducible pattern of cell death in a predicable volume of tissue. For solid tumors, it was initially used for ablation of unresectable tumors, primarily in the liver and lung. Technical advances in RFA have led to increased ablation volumes, which have led to use for primary tumor ablation in the breast. None of the currently available devices have been specifically designed for use in the breast. They have been adapted for use in the breast.

RFA is usually performed under ultrasound guidance. Local anesthesia with mild sedation is generally adequate. There are several RFA devices commercially available. Newer bipolar cool-tip devices are being evaluated for ease of use and potentially reduce heat-related complications. The RFA device is percutaneously guided into the target tissue, and radiofrequency energy is transmitted into the target tissue where it produces heat and either shrinks or kills tumor cells depending on the size of the tumor. Following RFA, the ablated tissue shrinks and forms an internal scar. The ablation is monitored with duplex ultrasound so that the ablation zone can be identified.

While most studies involve ablation followed by surgical resection, some studies have investigated the safety of ablation only in patients who are poor surgical candidates or who have small well-defined tumors with favorable biology (Luminal A). RFA converts radiofrequency waves into heat by ionic vibration. The ionic vibration is created by passing a high-frequency alternating current from an electrode into surrounding tissues, which causes ions to vibrate as they attempt to follow the change in the alternating current. This vibration generates frictional heat. The heat causes coagulation necrosis and cell death in the tissue. The procedure is performed by placing the RF probe (which is connected to a generator) into the center of a tumor or the tumor bed under ultrasound guidance. The RF probe itself contains a small electrode, and a larger electrode grounding pad is placed on the patient’s thigh.



Figure 51.1. RFA cold water circulated in probe (2 different sizes).

Under imaging guidance, the RF probe is advanced with ultrasound guidance into the center of the tumor after local anesthesia has been administered. The goal is to obtain uniform temperatures throughout the tumor. Both multiprong and single needle probes are available (Figs. 51.1 and 51.2). The single needle probe has internal electrode cooling with circulating water or saline, to cool the tissue surrounding the electrode. The multiprong device has tines that are deployed within the tumor. The ablation involves activating the probe over at least 5 minutes to a target temperature of 100°C for 15 minutes. There is a 1-minute cool-down period before the probe is removed. Some protocols allow for repeat RFA if the cool down is too rapid. Temperature is monitored by sensors during the entire ablation. Thermal injury begins at temperatures above 42°C. Actual cell necrosis is identified at temperatures above 46°C. Irreversible cell death occurs above 60°C.

The ablation zone is most frequently visualized with ultrasonography with spectral Doppler. Doppler ultrasound signals can detect the creation of gas bubbles from tissue boiling. Doppler has the ability to record and visualize the “off gassing” of microbubbles that occurs when the tissue is heated by the RFA to 100°C (Fig. 51.3). Doppler ultrasound is used to determine the width and depth of ablation as well as to make sure that the skin is not injured. The RF probe should be maintained 1 cm away from any structure that is to be protected from ablation (skin or chest wall.) For percutaneous ablations, an aqueous solution can be injected between the skin and tumor or tumor and chest wall in order to achieve this 1 cm

distance.

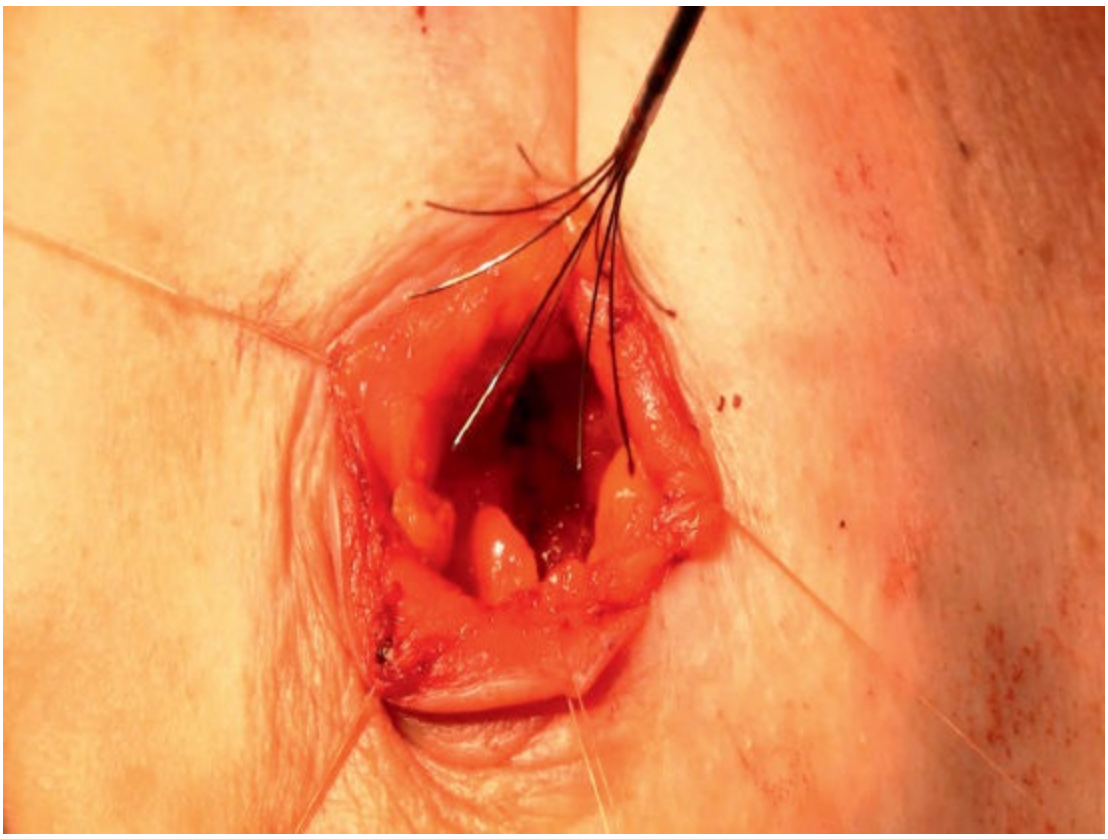

Figure 51.2. Starburst multi-tined RFA device.

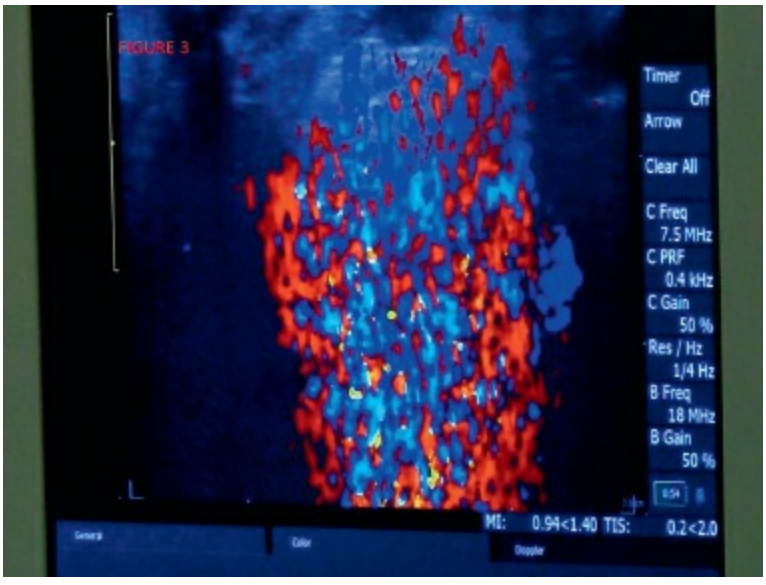

Figure 51.3. Dopplar ultrasound ablation zone.

A novel intraoperative approach is to use RFA for intracavitary ablation after surgical resection of a tumor. In fact RFA is FDA-approved for soft tissue ablation. This application has resulted in a trial known as the

ABLATE I and II Trials (RFA after Breast Lumpectomy Added To Extend intraoperative margins in the treatment of breast cancer). The goal is to assess intracavitary RFA to decrease surgical reexcision rates by extending the final margin after lumpectomy (Fig. 51.4). Primary goals are to estimate reexcision rate for close or positive margins, and to decrease local recurrence rates. Secondary goals of the trial include assessment of cosmesis and quality of life, monitoring the peri-cavitary zone of Doppler enhancement, monitoring complications and side effects, and monitoring ablation effects on postoperative imaging. Other potential benefits of RFA may be to obviate the need for postoperative radiation in the setting of breast conservation. This protocol included women with age ≥50 with invasive cancer or ductal carcinoma in situ (DCIS) with tumor <3 cm and clinically negative axillary nodes. A standard breast lumpectomy is performed with the incision placed over the tumor site. After achieving hemostasis, a purse string suture is placed in the cavity at the level of the previous tumor and brings the cavity together so that the opening is ~1 cm in diameter. A Starburst RFA probe is deployed in the tumor bed so that the tines enter the tumor bed to a depth of 1 cm. Skin is retracted with stay sutures (D). RF probe is activated to 100°C for 15 minutes (Fig. 51.5). Wait for 30 seconds and if the temperature goes below 55°C, an additional ablation at 100°C is performed for 5 minutes. Doppler ultrasound is used to determine the width of ablation zone (Fig. 51.3) and to monitor possible thermal injury to the skin. If necessary, the tines on the RF probe can be retracted to protect the skin. Once the ablation is complete, the RF probe is removed after a cool-down period. If the ablation is intraoperative in a lumpectomy cavity, the cavity is irrigated, hemostasis is obtained, and the cavity is closed.

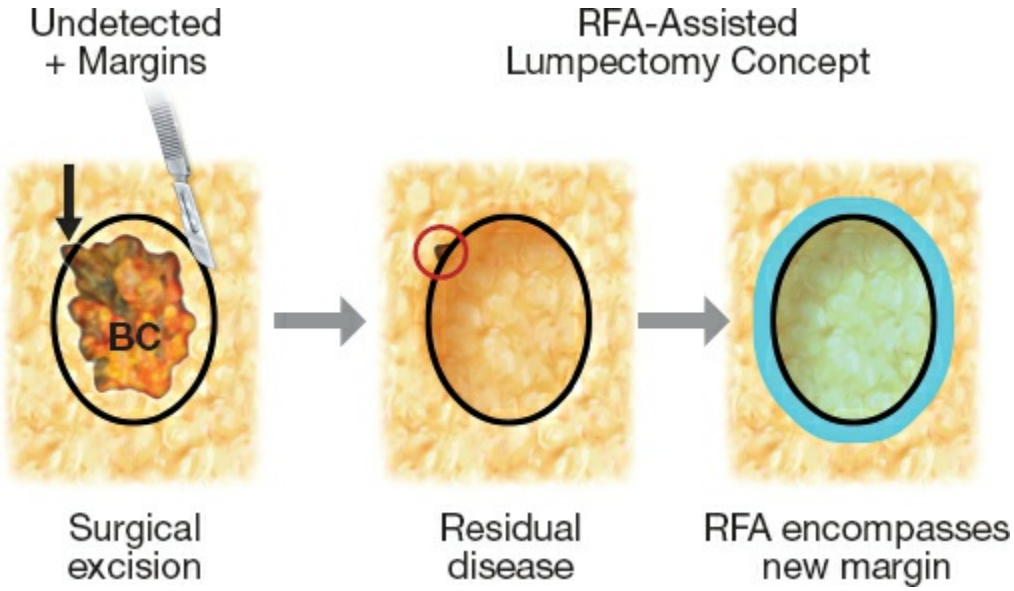

Figure 51.4. RFA-assisted lumpectomy concept.

The role of RFA for benign lesions has not been well-studied. In benign lesions, issues including margins or incomplete ablation are not as concerning and therefore RFA may be an alternative to surgical excision. However, the persistence of a palpable lump that may occur post RFA can be problematic for patients presenting for treatment with a palpable fibroadenoma.

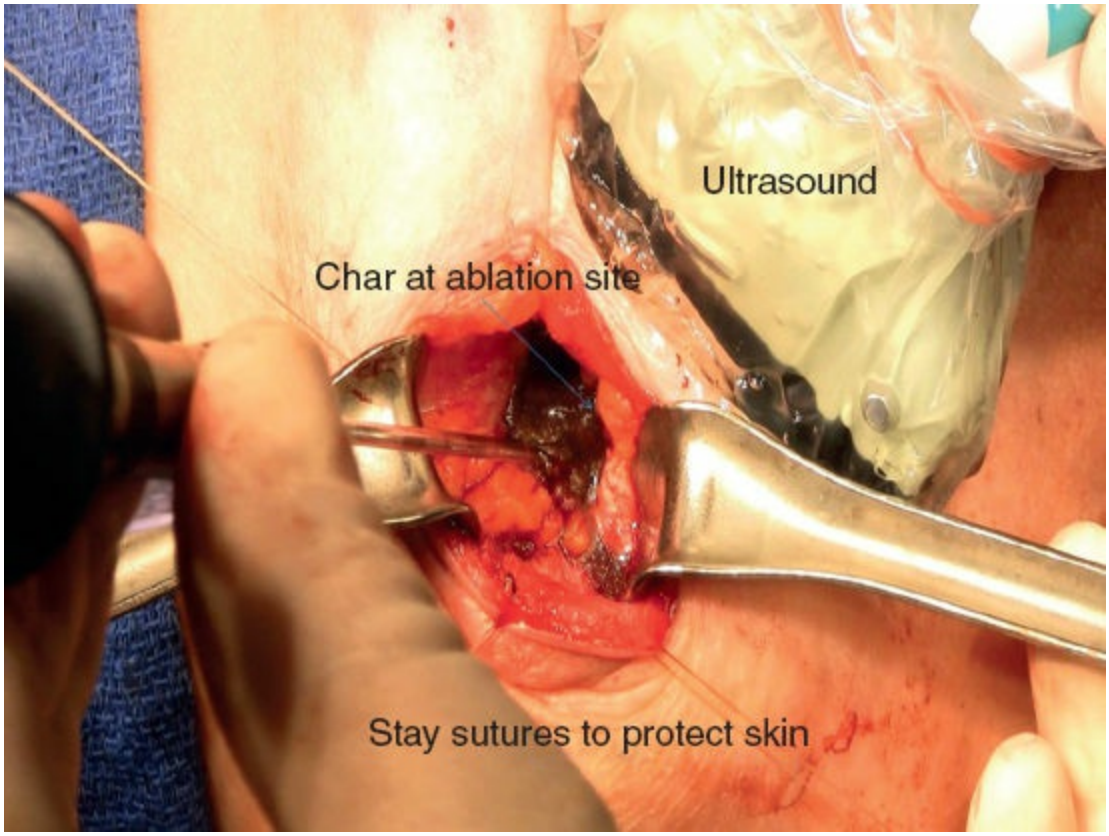

Figure 51.5. Intraoperative radiofrequency ablation of lumpectomy cavity.

Outcomes

Published studies of RFA for breast cancer involve RF for ablation of the tumor followed by either immediate or delayed surgical resection, or ablation of the primary tumor with clinical follow-up only. Some centers have performed RF and followed it with percutaneous biopsy techniques. The first clinical study regarding RFA of breast tumors was published in 1999 by Jeffrey et al. and consisted of 5 patients with locally advanced breast cancer (T3 lesions) who underwent RFA prior to immediate mastectomy. A portion of the tumor was treated, in order to evaluate the zone of RF ablation and the margin between ablated and nonablated tissue. This study was the first to demonstrate that RF ablation caused invasive breast cancer cell death. Subsequent studies (Table 51.2) investigated RF ablation followed by resection. Endpoints were either extent of ablation of target zone, which ranged from 90% to 96%, or extent of cell necrosis, which ranged from 61% to 100%. Cell viability can be assessed with nicotinamide adenine dinucleotide-diaphorase (NADPH) staining or proliferating cell nuclear antigen (PCNA) stains that enable detection of actively replicating DNA, so that absence of PCNA staining confirms cell death. These studies demonstrated that in appropriately selected patients, RF ablation could be done safely with minimal side effects. The patients with residual tumor cells at the tumor site were noted to have preoperative underestimation of tumor size on imaging studies. The efficacy of tumor ablation is dependent on tumor size, with RFA more likely to completely ablate tumors <2 cm. Tumors with extensive intraductal component (EIC) are more difficult to completely ablate. Preoperative MRI helps to select patients who are optimal for ablation. A number of investigators have performed RFA of small breast cancers without resection (Table 51.3). Patients underwent breast imaging follow-up with percutaneous needle biopsy of the ablation zone to assess residual disease or recurrence. Patients selectively received postablation radiation and systemic therapy. Local recurrence detected in 5 out of 125 patients with 15 to 50 months of follow-up. Cosmesis was described as excellent in 83% of cases, good in 12%, and fair in 6%. A palpable hard lump at the ablation site is noted in most patients, which gradually resolves. Infrequent complications of skin or muscle burn, pain, bruising, and pneumothorax have been reported.

Overall RFA outcomes are promising, and there is substantial research developing breast-specific RFA devices that likely will continue to advance this approach.

TABLE 51.3 Studies of Percutaneous RFA Without Resection (With or Without Radiation) and Periodic Biopsy of Cavity

Author/ Year	*N*	Patient Characteristics	RFA-Electrode	Assessment Ablated Lesion	Follow-Up	Outcome	Complications
Susni 2006	3	T1 >75 yo No adjuvant rx	Cool-Tip	US-guided core biopsy	18 months	No local recurrence	None
Marcy 2007	5	T1–2 >70 yo Endocrine and RT	Elecktrotom	Core biopsy	29 months	1 local recurrence	1 abscess
Oura 2007	52	T1 systemic therapy + RT	Cool-Tip	Fine needle aspiration 3–4 weeks postablation	15 months	No local recurrence	1 skin burn
Earashi 2007	7	T1 RT, some systemic Rx	Starburst	Core biopsy	4 months	No local recurrence	None
Brkljacic 2010	7	T1–2, elderly inoperable Endocrine and radiation	Bipolar	Core biopsy	29 months	No local recurrence	2 unrelated deaths
Yamamoto 2010	30	T1 RT and systemic some	Cool-Tip	Core biopsy	17 months	2 patients with viable tumor on core biopsy	None
Palous-siere 2012	21	T1–2, >70 yo Endocrine, no RT	LeVeen	Imaging only-core biopsy if finding	50 months	3 recurrences 2 breast cancer related deaths	None

Klimberg and colleagues published results of the ABLATE I trial in 2014. This was a prospective phase II trial where 100 patients with early-stage breast cancer underwent intraoperative RFA as an adjunct to lumpectomy. Of these, 15 patients had close or focally positive margins of which only 1 was reexcised, and 23 patient received adjuvant radiation. There were six postop complications, including hematoma and infection. With a median follow-up of 68 months, there were five local recurrences (three at the core biopsy site), two elsewhere, and one contralateral recurrence. These results suggest that a portion of breast conservation patients could potentially be managed without surgical reexcision for close margins and avoid radiation. Mammography follow-up (Figs. 51.6 and 51.7) demonstrates how the ablation zone appears post RFA and largely resolves with time and normal breast volume is maintained compared to post adjuvant radiation. The ABLATE trial II is planned that will include genomic profiling with Oncotype recurrence score to help define low-risk patients for this approach.

Cryoablation

Technique

Cryoablation is generally performed with ultrasound guidance in the outpatient setting with local anesthesia under sterile technique. Oral sedation may be necessary for some patients. There is limited experience with MRI-guided cryoablation. The key to successful ablation is having a well-defined visible mass by ultrasound. The long axis of the mass is identified with ultrasound and a 2-mm dermotomy is made with a No. 11 blade after local anesthesia is administered. A cosmetic location, either periarolar or inframammary or lateral skin crease, is chosen for the skin incision if possible. The entire track of breast tissue from the entry site to the mass is infiltrated with local anesthesia. Usually 10 to 20 ccs is adequate. Additional sterile normal saline can also be injected to separate the mass from the skin and/or chest wall if needed to avoid cold injury to those structures. The key to successful ablation is having a clearly visible mass by ultrasound. There has been limited experience with MRI-guided cryoablation. The probe is placed in the tumor under ultrasound guidance (Fig. 51.8), and positioning is confirmed by scanning in multiple planes. Final probe position is determined by the length of the cooling segment. Generally the tip of the cryoprobe will extend beyond the tumor depending on whether treating cancer or a fibroadenoma. The probe is insulated with the exception of the active tip, so there is no risk of cold injury to the skin at the insertion site. The current commercially available cryotherapy systems use liquid nitrogen for cooling, which circulates through a hollow, closed-end cryoprobe. The typical ablation protocol algorithm now involves a rapid freeze–thaw–rapid freeze protocol with target temperature of −160°C. Duration of the procedure depends on the tumor size, but generally is <30 minutes. It is important that the entire lesion is engulfed by the iceball that is confirmed by ultrasound. The treatment time can be extended during the procedure if the mass does not appear to be fully engulfed. The technique of cryoablation is similar for treating fibroadenomas or cancer. However, unlike cryoablation of fibroadenomas, where the engulfment of the lesion while minimizing ablation of surrounding tissue is the goal, protocols for cancer treatment involve treating the lesion and an additional 1 cm margin of normal tissue. Once the ablation is completed, the cryoprobe is removed and the entry site is compressed for 5 minutes. A steristrip is applied. The postprocedure bruising and discomfort are generally mild as the iceball provides some anesthesia and hemostasis. Patients are discharged with oral analgesics with office follow-up in 2 weeks. Imaging follow-up may include

ultrasound for ablated fibroadenomas or MRI and mammography for cancer if surgical resection is not performed.

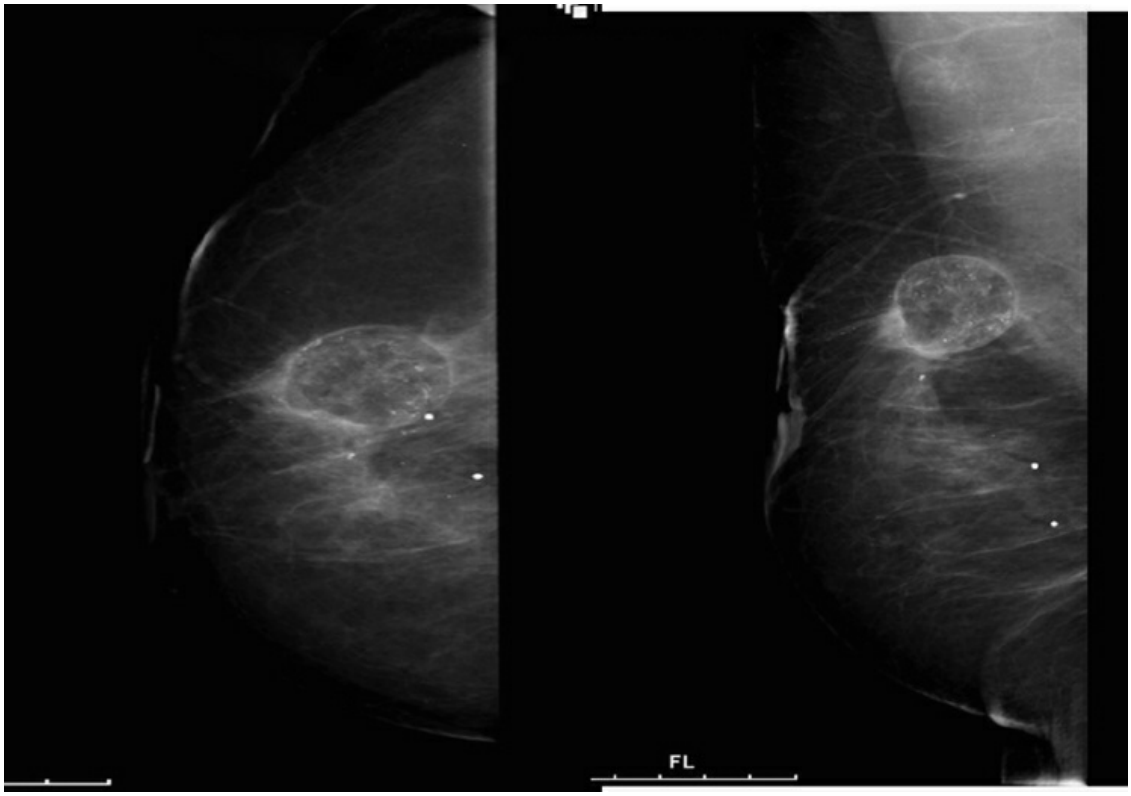

Figure 51.6. Ablation zone 6 months postop.

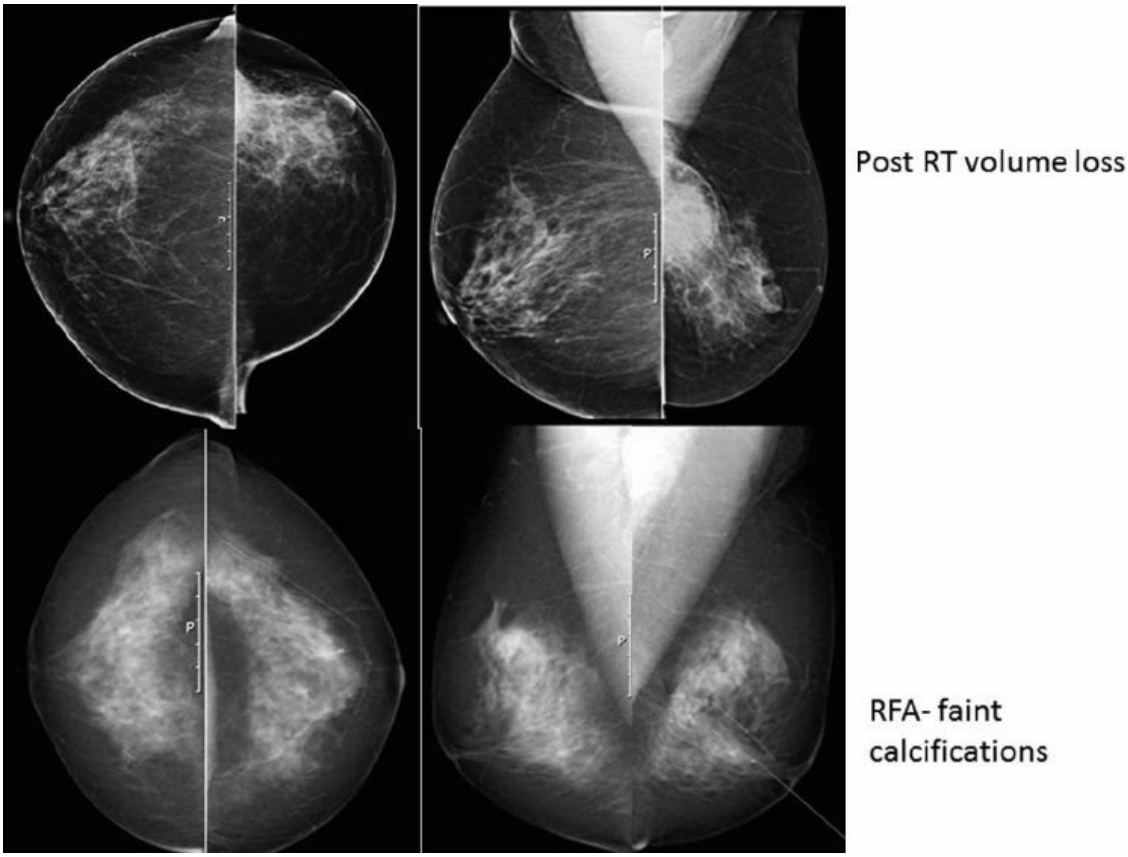

Figure 51.7. 5-year postop mammogram.

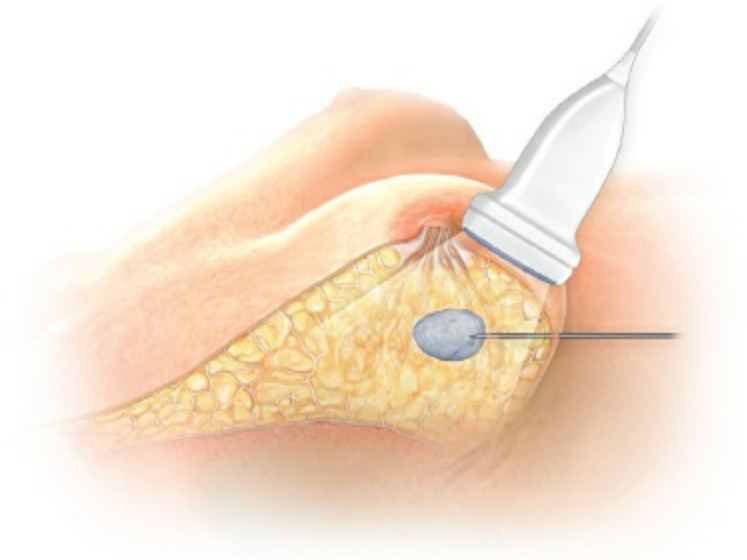

Figure 51.8. Cryoablation of fibroadenoma. **A.** Cryoprobe with ice ball. **B.** Ultrasound image ice ball.

Outcomes

Cryoablation causes cell death by several mechanisms. Closest to the probe, where the temperature is the lowest, there is intracellular ice

formation, cell membrane disruption, and intracellular ice formation. Further away from the probe, there is extracellular ice crystal formation with the increased osmotic concentration causing cell rupture with rehydration. In addition, freezing causes blood vessel endothelial cell, leading to vascular stasis and tissue ischemia, extracellular osmotic imbalance with cell lysis upon thawing, and blood vessel damage and ischemia. Many studies have shown that cells of various organs including breast tissue exposed to at least –40°C during two subsequent freeze thaw cycles are uniformly ablated. Cryoablation for breast cancer was described as feasible in mice by Rand in 1985. Subsequent case reports followed, suggesting that this could be an effective viable method for breast cancer treatment in humans. Sabel in 2004 reported the results of 29 patients treated by cryoablation using a single treatment probe. Tumor destruction was complete in cancers <1.0 cm in size. For tumors >1.5 cm, cryoablation was not reliable. Niu in 2007 reported similar results in 27 patients. In all series, residual DCIS was the most common reason for incomplete ablation. Morin in 2004 demonstrated a 52% complete ablation rate in 25 patients using an MRI-guided ablation approach. Manetti in 2011 reported complete ablation (confirmed by excision) in 14 of 15 patients with unifocal subcentimeter breast cancers. His patients underwent concomitant sentinel node mapping and node excision at the time of ablation to obviate potential concern about accuracy of lymphatic mapping as a secondary procedure after ablation.

Dr. Eisuke Fukuma from Kameda Medical Center in Japan reported his experience with nonsurgical cryoablation in 38 patients with luminal A phenotype, subcentimeter tumors at the American Society of Breast Surgeons meeting in 2012. All patients received whole breast radiation and antiestrogen therapy. At median 29-month follow-up, there were no local or distant recurrences or treatment-related adverse events. In addition, the preliminary results of a phase II ACOSOG Z1072 trial of cryoablation of breast cancer followed by resection were reported at the American Society of Breast Surgeons meeting in 2014 by Simmons et al. This was an ablate and subsequent resection protocol with the patients undergoing MRIs (Fig. 51.9) pre- and postablation. This was a multicenter trial with 87 patients treated at 19 centers. Overall complete ablation was achieved in 63% of patients. A 94% complete ablation rate was obtained in patients with tumors <1 cm. MRI correctly predicted the final ablation status in 75% of the patients.

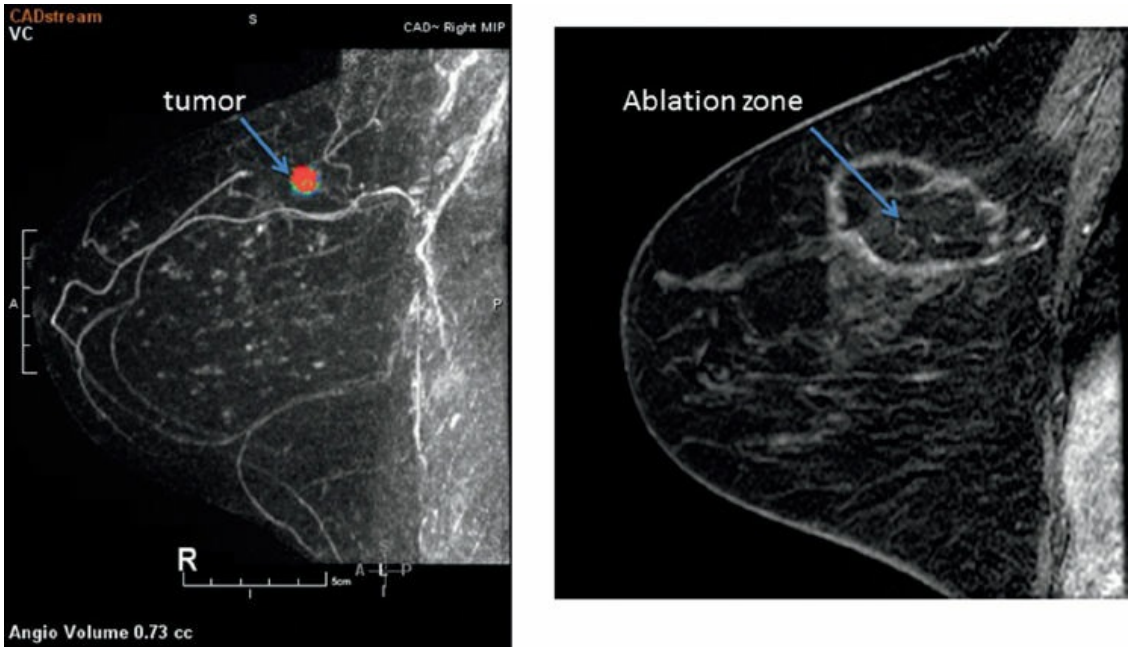

Figure 51.9. Cryoablation cancer (MRI).

There has been more extensive experience with cryoablation of fibroadenomas. Reported experience treating fibroadenomas up to 4 cm in diameter and multiple fibroadenomas shows a high degree of success. Series by Edwards, Caleffi, Kaufman, and Littrup with a total over 500 patients combined demonstrate a 73% to 97% volume reduction by ultrasound at 12 months postablation. Patient satisfaction was reported at >90%. Palpability of a fibroadenoma is often the reason that patients may seek treatment for a fibroadenoma. Postcryoablation there are some patients who do not have complete resolution of the palpable mass. This is more common with fibroadenomas over 2 cm. Ultrasound may demonstrate an ongoing cryolesion. A small number of patients request surgical excision due to ongoing concern about the mass.

Laser Ablation

Technique

Ultrasound-guided ILT (Novilase, Chicago, IL) is performed as follows. The patient is positioned supine or lateral decubitus on the examination table with ipsilateral arm raised and a roll under the chest, similar to positioning for needle biopsy. Ultrasound is performed to visualize the mass, measure maximal dimensions of the mass in both transverse and sagittal axes, measure the skin to mass distance to ensure a safe zone, and identify any neighboring blood vessels for potential heat sink effect.

The skin is sterilized using povidone-iodine; 1% lidocaine is infiltrated into the skin and along the track of the needle for prolonged anesthesia. Care must be taken not to inject excessive amount of lidocaine, which may obscure optimal visualization of the mass. A small incision is made. Under ultrasound guidance, the laser trocar needle is inserted into the breast and mass, with the needle tip at the center of the mass (Fig. 51.10). Its position is verified in both transverse and sagittal views. The trocar is replaced with a laser fiber that extends 2 mm beyond the laser needle tip. There is a thermal sensor at the tip that measures laser temperature. Normal saline tubing is connected to the laser needle, and saline is infused at a rate of 1 mL per minute to cool the laser tip, preventing extreme heating and charring, and to facilitate uniform heat radiation. A second incision is made. A temperature probe containing five evenly spaced sensors is inserted under ultrasound, alongside the needle probe, at the peripheral edge of the mass. The temperature probe measures and monitors peripheral temperatures throughout the ablation procedure to achieve complete tumor ablation.

Laser energy is activated, starting at the power output of 4 watts, and can increase to 8 watts. The rate of saline infusion is increased proportionally as power is increased. Additional lidocaine may be injected if the patient experiences pain. Ablation progress is monitored in real time using ultrasound and temperature readings. Temperature at the laser tip may rise up to 100°C, and shuts off automatically above 100°C for safety. Bubbling may be seen at the laser tip, indicating active heating. As the temperature rises, the tumor, initially appearing hypoechoic, becomes progressively replaced with hyperechoic ablation changes until the tumor outlines are no longer visible. Completion of ablation is determined by both ultrasound visual changes of tumor obliteration, formation of an ablation zone, and temperature criteria. Tissue necrosis is achieved when all five peripheral temperature readings show 60°C or higher, or 50°C for 2 minutes. With currently technology, laser ablation generally takes 1 minute per 1 mm of tumor and thus only small tumors can be ablated.

After ablation, both the laser and temperature probes are withdrawn. The patient remains for 30 minutes for monitoring, and is discharged on a regimen of ice packs and oral analgesics. Patients with ablated cancer return according to trial protocol. Patients who have ablation of fibroadenomas return for clinical examination and ultrasound assessment after 1 week, and at 1, 3, 6, and 12 months.

Outcomes

ILT is a newer technology compared to other ablative techniques, and thus has fewer reports. ABLATE (American Breast Laser Ablation Therapy Evaluation), a Web-based registry, was developed to monitor the effectiveness and safety of ultrasound guided ILT of fibroadenoma in the communities. As part of the registry, we performed laser ablation of biopsy-proven fibroadenoma among 39 patients at New York Hospital Queens, between 2009 and 2011: 56% Asian, 18% White, 5% Black, 18% other, and 3% unknown race. The mean tumor diameter was 10.5 (6 to 18.9) mm. Average treatment time was 14.2 minutes, at an average laser temperature of 60.3°C. Patients were followed for 1 year. Ablation was well-tolerated with a median pain score of 2/10. The median return time to normal activities was 24 hours. Thirty-seven of the 39 patients (94.9%) had complete ablation of fibroadenomas after one treatment as determined by ultrasound imaging. One patient with residual tumor was successfully treated after a second ablation. A second patient appeared to have a possible scar suggestive of residual tumor, which resolved without additional treatment. The most common patient's symptom after ablation was a painless, palpable lump, becoming less noticeable during the ensuing 6 months. Two patients had mild skin scalding, which resolved without significant scarring. Patient satisfaction was recorded on a scale of "Excellent," "Good," "Fair," and "Poor." On evaluation at 1 year, 100% patients reported Excellent-Good overall satisfaction, and 96.8% were satisfied with the cosmesis.

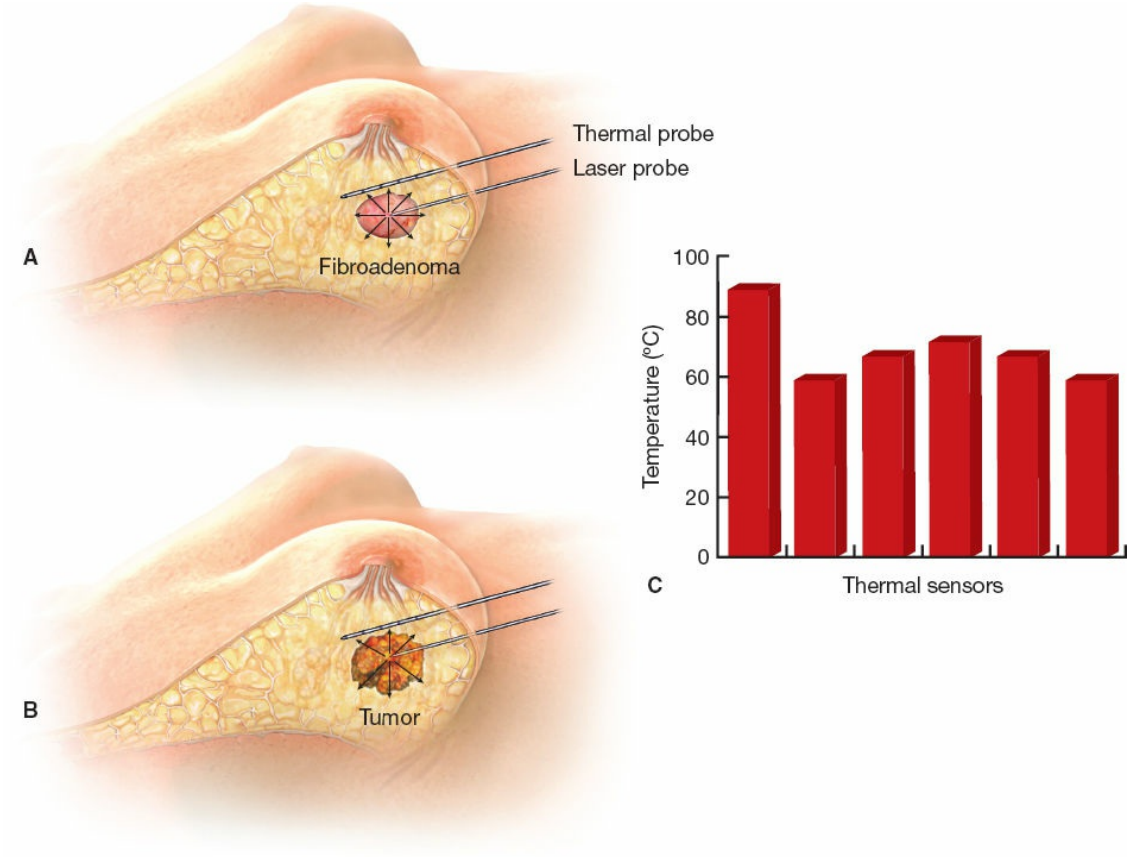

Figure 51.10. Laser ablation therapy of breast fibroadenoma (**A**) and cancer (**B**). Under ultrasound guidance, a laser probe is inserted into the center of the tumor. A thermal probe, containing evenly spaced thermal sensors (*dots*), is placed alongside the laser probe, at the peripheral edge of the tumor. Laser energy is activated and ablates tumor through heat radiation (*arrows*). Ablation progress and completion are determined in real time by observing ultrasound morphologic changes and temperature levels (**C**).

In 2002, Dowlat et al. reported stereotatically guided ILT for breast cancer among 54 patients—50 invasive and 4 in situ cancers, mean diameter 12 (5 to 23) mm. Forty-eight patients underwent excision following ILT. Overall complete tumor ablation was 70%. Incomplete tumor ablation was attributed to technical and procedural challenges during learning curve, such as inadequate laser energy, patient motion, malfunctioning thermal probes and fluid pump, suboptimal target visualization due to excessive fluid infusion or hematoma, and large tumor (2 cm). There were 2 patients who did not have excision and developed oil cysts 6 to 24 months after ILT that were aspirated.

We performed laser ablation of breast cancer at New York-

Presbyterian/Columbia University Medical Center as part of a multicenter trial. Collectively from all centers, 49 of the 61 patients treated had complete data for analysis. The mean tumor size was 11.3 mm, with mean laser time 15.7 minutes. Patients eligible for ILT had pre- and postablation mammograms, ultrasounds, and MRIs, followed by excision for pathologic correlation. Postablation tumor cell viability was determined by MRI and changes in CK8/18, Ki67, and ER. Seventy-three percent patients had complete tumor ablation, with 92% concordance between postablation MRI and pathology. Postablation MRI had 6% false negative with residual tumor <2 mm, and 2% false positive. ILT appears to be a promising method to treat breast tumors.

Microwave Ablation

Microwave Thermotherapy

Microwaves are a form of nonionizing electromagnetic radiation with a frequency higher than radio waves but lower than infrared light. Microwave ovens for heating food were first developed in 1947. Two methods of using microwave energy for breast tumor ablation have been described: focused microwave thermotherapy (FMT) and percutaneous microwave coagulation (PMC).

Focused Microwave Thermotherapy (FMT)

An FMT ablation system consists of three components: a generator, a power distribution system, and antennas. A cooling system is a crucial component of microwave systems to avoid thermal skin injury. MWA utilizes dielectric hysteresis to produce heat. Tissue destruction occurs when tissues are heated to lethal temperatures from an applied electromagnetic field, typically at 900 to 2,500 MHz. Polar molecules in tissue (primarily H_2O) are forced to continuously realign with the oscillating electric field, increasing their kinetic energy and, hence, the temperature of the tissue. Tissues with a high percentage of water (as in solid organs and tumors) are most conducive to this type of heating. Breast tumors have a much higher water content (mean, 74.3%) than benign fibrofatty breast tissue (19.1% to 58.5%) and thus microwave may preferentially destroy tumor cells.

Dooley et al. (2010) reviewed the clinical trials of FMT for preoperative treatment of invasive breast cancer. This method utilized a two-channel 915-MHz adaptive phased-array FMT system (model APA-

1000; Medifocus, Inc) (Fig. 51.11). An investigational device exemption (IDE) was obtained from the FDA for these studies. Using sterile technique, local anesthesia is injected into the breast skin and a 16-gauge catheter is placed percutaneously with ultrasound guidance into the center of the tumor to be treated. A single-use disposable (1.12-mm OD) combination electromagnetic-field focusing sensor and fiber-optic temperature sensor is inserted into the catheter to focus the microwaves and measure the tumor temperature during thermotherapy. The combination sensor has the fiber-optic temperature sensor at the probe tip, and the electromagnetic sensor is 1.5 cm from the tip. The patient is positioned prone with the breast dependent through a hole in the treatment table and the breast is compressed to a thickness of between about 4 and 8 cm, similar to a prone stereotactic biopsy table (Fig. 51.12). Temperature sensors are taped to the breast skin to monitor surface temperature during thermotherapy. Cooling the breast compression plates and skin with room-temperature airflow during FMT treatments helps reduce the potential for skin-surface hot spots. Compression immobilizes the breast tissue to avoid motion. The compression plates are composed of microwave-transparent acrylic plastic material (Fig. 51.13). This system uses transcutaneous opposing microwave waveguide applicators and produces a phase-focused microwave field in the compressed breast to heat and destroy high-water high-ion-content tumor tissue. The effective microwave radiation field encompasses an ~6 cm × 8 cm area in the breast tissue in a plane parallel to the breast compression plates. In the compressed breast thickness dimension, the effective microwave field extends ~1.5 cm on either side of the focal (target) point in the tumor. During treatment, the amount of breast compression, focused microwave power, and air cooling of the skin are adjusted from a computer console to provide patient comfort. Average ablation time is ~30 minutes. Experimental studies support the concept that tumor cell heating for 60 minutes at 43°C is tumoricidal. The period of time to kill tumor cells decreases by a factor of 2 for each 1°C increase in temperature above about 43°C. The cumulative equivalent minutes (CEM) thermal dose relative to 43°C is calculated from the measured temperatures recorded by the sensor in the tumor and also from the sensors on the skin and nipple. Once the desired tumor temperature range and target thermal dose are achieved during active microwave heating, the microwave power is reduced to zero and breast compression is maintained during a 5-minute cool-down period. Ultrasound images are obtained

postablation to assess for tumor shrinkage.

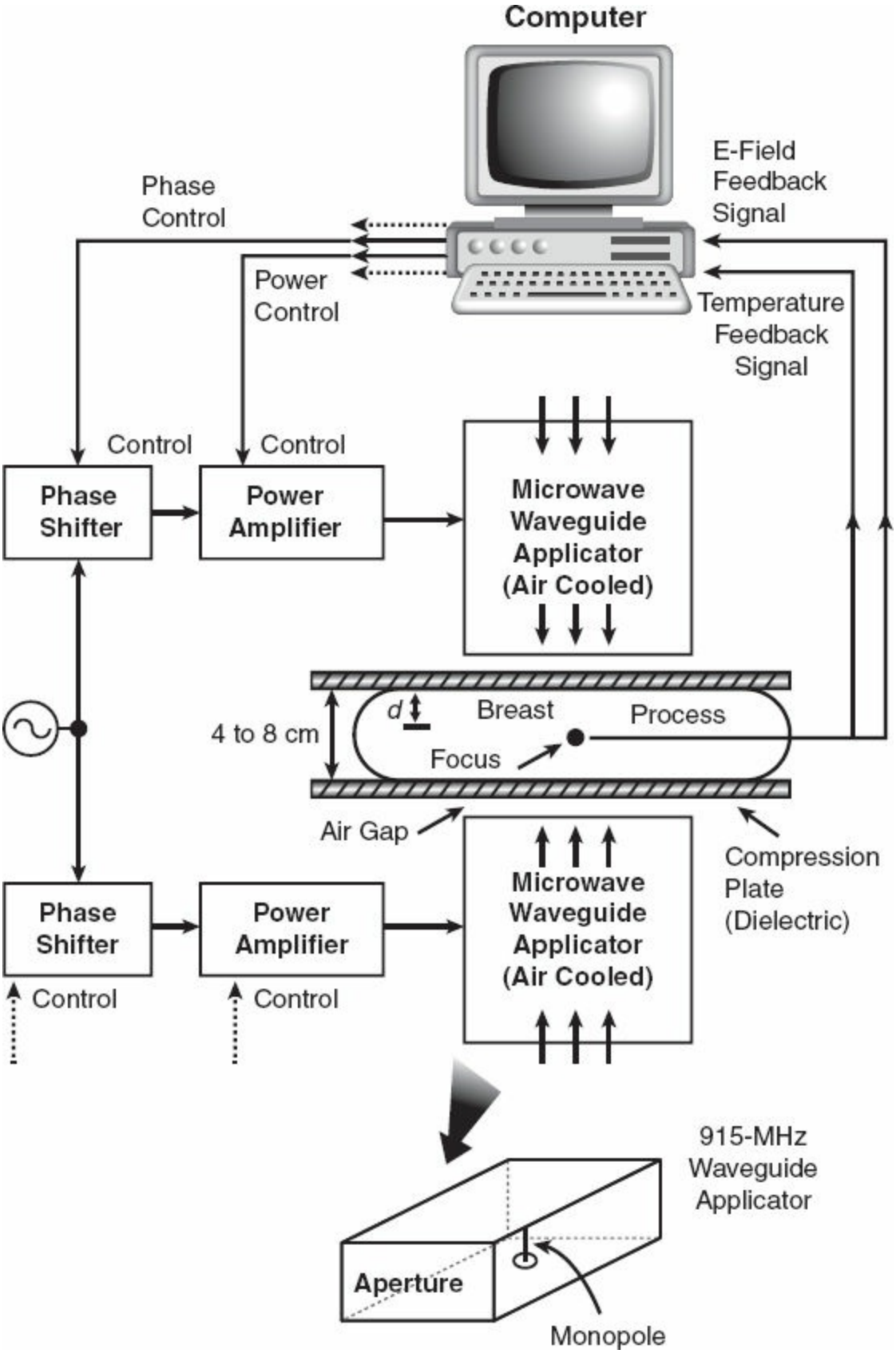

Figure 51.11. Diagram for a dual-channel adaptive microwave

phased-array thermotherapy system for treating breast cancer. The breast-compression plates are made of an acrylic material transparent to microwaves. Air cooling through the rectangular waveguide applicators is used to reduce the skin temperatures. The applicators generate a focused electric-field radiation pattern that will treat a large volume of breast tissue. (From Gardner RA, Vargas HI, Block JB, et al. Focused microwave phased array thermotherapy for primary breast cancer. *Ann Surg Oncol* 2002;9(4):326–32; with permission of Springer.)



Figure 51.12. Patient position on modified stereotactic biopsy table for microwave thermotherapy treatment.

In the first trial of FMT, this technique was used preoperatively prior to mastectomy. In this phase I study, 8 of 10 (80%) of patients with tumors 0.8 cm to 8.0 cm had a partial response as measured by ultrasound or pathology. For the second study, patients were randomized to preoperative FMT versus no preoperative ablation. The FMT thermal dose was increased, and patients were treated prior (5 to 27 days) to breast conservation surgery for early-stage breast cancer (average tumor size 1.7 cm). The results showed that 0 of 34 patients with preop FMT had

involved tumor margins compared to 4 of 41 (9.8%). Three of 34 patients (8.5%) experienced skin burns (<3 cm), and 8 of 34 patients (26%) experienced moderate to severe procedure-related discomfort. The final trial was a study of patients with larger tumors, who were randomized to FMT and neoadjuvant chemotherapy versus neoadjuvant chemotherapy alone. This demonstrated based on ultrasound measurements that there was a median tumor volume reduction of 88.4% (n = 14) for patients receiving FMT and neoadjuvant chemotherapy compared to 58.8% (n = 10) reduction in neoadjuvant chemotherapy alone arm. These studies have demonstrated that FMT can be safely administered with some evidence to support improvement in margin clearance and tumor volume reduction. Prospective randomized trials are required to further evaluate the safety and effectiveness of this promising experimental approach.

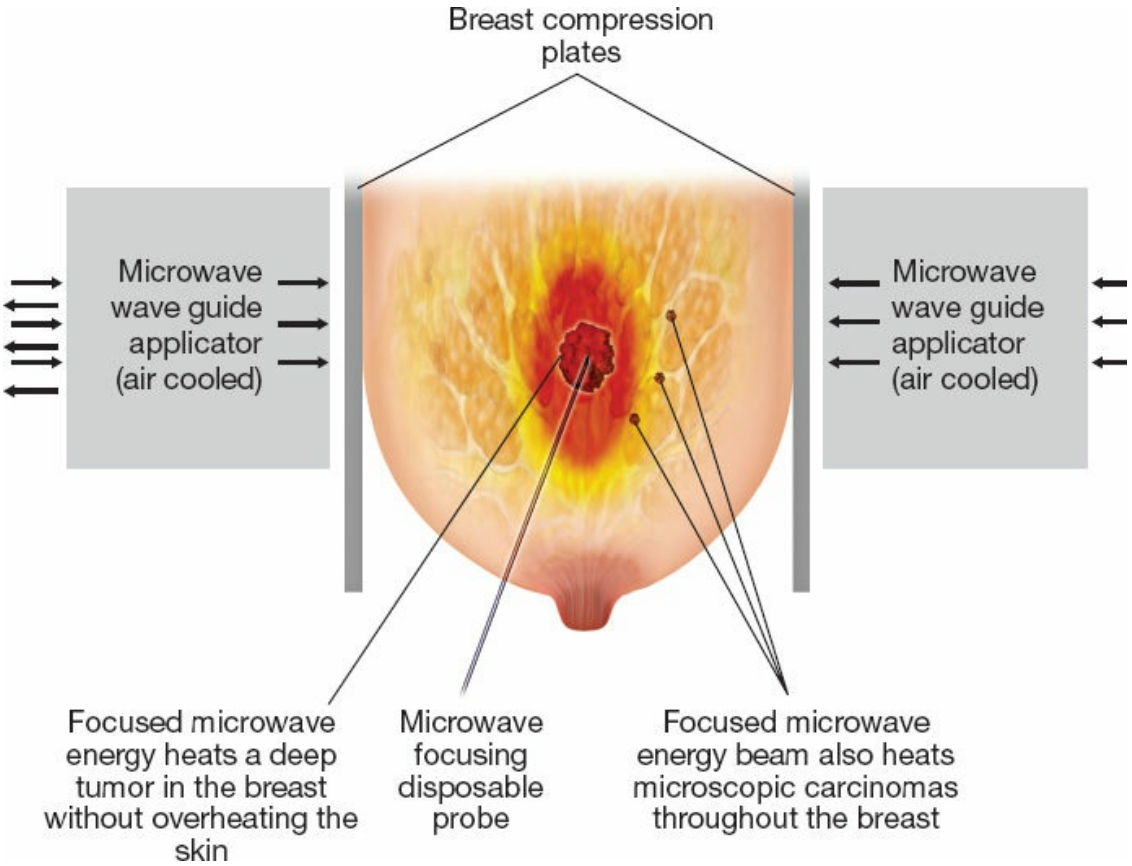

Figure 51.13. APA microwave breast thermotherapy concept.

Percutaneous Microwave Coagulation (PMC)

PMC has been described as an effective approach for the treatment of liver tumors and uterine myomas. It is an appealing method for tumor ablation since it potentially results larger ablation zones with shorter ablation times.

Zhou et al. from Nanjing, China, published the first experience with this method for breast cancer in 2012. This is a nonrandomized study of 41 with ultrasound-guided core biopsy-proven invasive ductal carcinoma <3 cm (mean 2 cm) in maximum diameter. Tumor must have an ultrasound distance of at least 1 cm from the skin and chest wall with patient in supine position. The procedure was performed in the operating room with patients under general anesthesia who underwent PMC followed immediately by mastectomy. A microwave generator with 2,450 megahertz irradiation frequency and 40 watt power output was used. A 2-mm coaxial cable with a water-cooled shaft antenna is inserted percutaneously along the long access of the tumor with ultrasound guidance into the center of the tumor (Fig. 51.14). It is a 2-lumen catheter that allows cooling water (4°C) circulation during the ablation. Peak temperature averages 91°C with completeness of ablation determined by ultrasound monitoring (Figs. 51.15 and 51.16). Ablation time was 3 to 10 minutes (mean 4.48 minutes). Completeness of ablation was determined using alpha NADH-diaphorase staining. Their results demonstrated that 37 of 41 pts (90%) had complete tumor ablation. It is noted that of the 4 patients with incomplete ablation, 2 had extensive DCIS and 2 had suboptimal positioning of the ablating antenna. One patient was noted to have a 1.5-cm skin burn and 2 patients had thermal injury to the underlying pectoralis muscle. Breast MRI was not used for patient selection and potentially could help select patients to avoid issue related to DCIS. Limitation of the study is that patient tolerability and long-term effects concerning pain, fibrosis, recurrence, and ongoing imaging artifacts could not be assessed. This study supports the feasibility of PMC ablation of small unicentric breast cancers. PMC appears to perform quite well compared to the other tumor ablation methods, including FMT, laser, cryo, RFA, and HIFU. Prospective randomized trials will be critical to further evaluate the safety and efficacy of PMC.

High-Intensity Focused Ultrasound Ablation

Technique

HIFU ablates tumors by two mechanisms. HIFU focuses acoustic waves onto a specific point within the tumor, causing focal tissue vibration, thus creating heat and coagulative necrosis. HIFU also causes acoustic cavitation that expands and contracts the gaseous nuclei in cells, leading to the collapse of cells and cell death (Fig. 51.17).

HIFU can be performed under MRI or ultrasound guidance. For MRI-guided ablation, an ultrasound transducer is fitted onto the MRI table top, and generates ultrasound beams that focus onto specific areas of tumor.

Compared with ultrasound, MRI has the advantage of producing more precise and reproducible images of breast tumors, thus facilitating better procedural planning and tumor targeting during ablation. MRI thermometry can also provide temperature measurements to monitor ablation progress. Disadvantages of MRI-guided HIFU include limited real-time imaging, injection of gadolinium, imaging complexity, and high cost that prohibit many surgeons from performing the procedure.

Ultrasound-guided HIFU (Echopulse, Paris, France) has been developed to treat breast fibroadenoma and thyroid and parathyroid nodules in Europe. This technology is currently being reviewed by the FDA for use in the United States.

For ultrasound-guided HIFU ablation of biopsy-proven fibroadenoma, the patient is positioned on the treatment table similar to other ultrasound-guided ablations (Fig. 51.11). An extracorporeal probe (Visualization Treatment Unit [VTU]), containing ultrasound imaging, acoustic treatment, and cooling systems, is applied to the patient's breast. The fibroadenoma mass is visualized. Full 3D treatment volume is calculated using both radial and antiradial slices through the tumor. Acoustic energy level is selected to begin ablation at the center of the tumor, and can range from 102 joules to 249 joules.

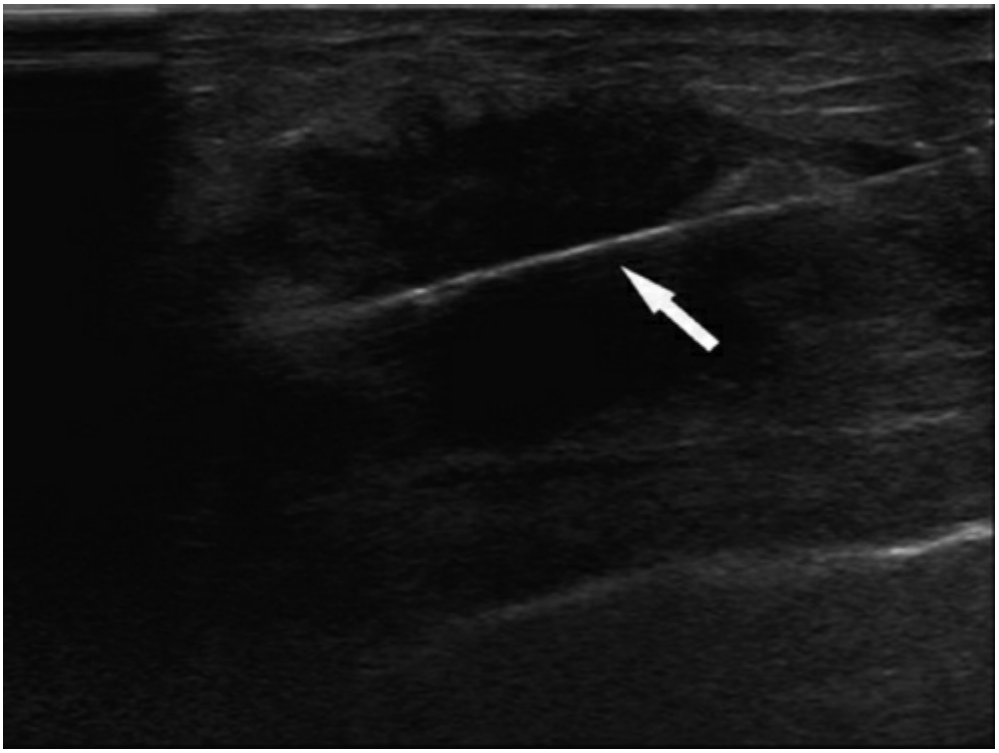

Figure 51.14. Longitudinal sonogram shows centrally placed antenna (*arrow*) in the tumor. (From Zhou W, Zha X, Liu X, et al. US-guided percutaneous microwave coagulation of small breast cancers: a clinical study. *Radiology* 2012;263:364–73. DOI: 10.1148/radiol.12111901.)

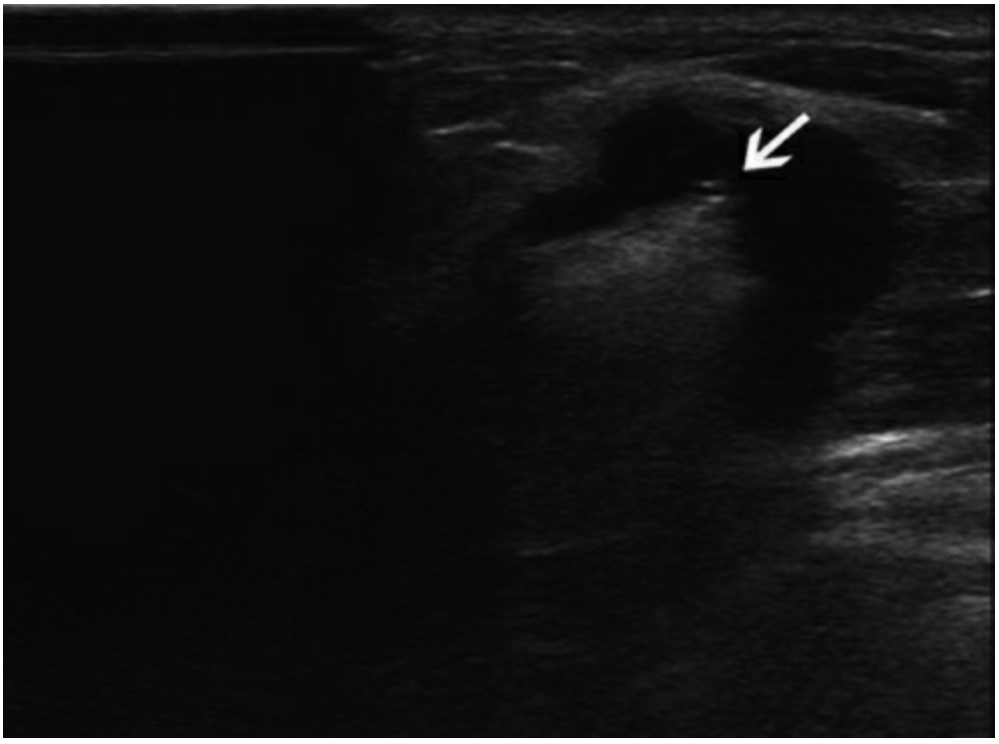

Figure 51.15. Sonogram shows the area with increased echogenicity covering approximately one half of the tumor (*arrow*)

in the middle of PMC session. (From Zhou W, Zha X, Liu X, et al. US-guided percutaneous microwave coagulation of small breast cancers: a clinical study. *Radiology* 2012;263:364–73. DOI: 10.1148/radiol.12111901.)

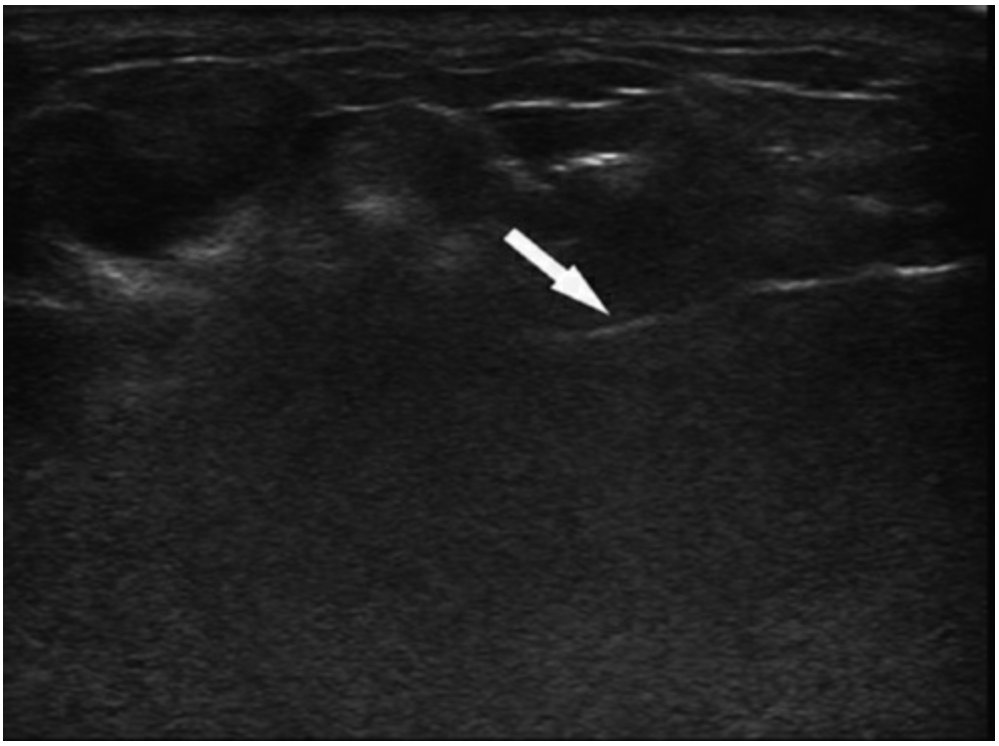

Figure 51.16. Sonogram shows the tumor obscured by an echogenic area, with the antenna (*arrow*) still clearly visible at the end of the PMC session. The sonograms show a gradual and diffuse increase in the echogenicity of the tumor from the irradiating segment to the whole tumor. (From Zhou W, Zha X, Liu X, et al. US-guided percutaneous microwave coagulation of small breast cancers: a clinical study. *Radiology* 2012;263:364–73. DOI: 10.1148/radiol.12111901.)

HIFU energy is activated and delivers the first pulses of treatment, and gradually increases until a hyperechoic mark (HEM) appears on ultrasound image corresponding to the localized boiling point of 100°C. Focal ablation endpoint is achieved by observing both HEM and reinforced interference pattern generated by the HIFU pulse on ultrasound image. Under computer control, the VTU repositions and successively treats other foci until the entire defined tumor volume has been ablated.

Outcomes

Similar to laser ablation, HIFU is a newer technology that is less well-

studied. Initial feasibility studies demonstrated variable complete ablation rates, ranging from 24% to 100%.[6] HIFU is the truly noninvasive treatment modality among all thermal ablations, and thus has the theoretical advantage of no risk of tumor seeding along the needle track, and no risk of bleeding.[7]

Complications of HIFU include burn, pain, and palpability associated with other hyperthermic ablations. Unlike other techniques, HIFU has technical limitations that require patients to be sedated consciously and remain motionless for the long procedure times.[3]

For treating breast cancer using HIFU, Peek et al. performed a systematic review of nine studies up to 2013 that showed complete cancer ablation rate of 46% (range 17% to 100%) on subsequent excision. Twenty-nine percent (range 0% to 53%) had <10% residual tumor, and 23% (range 0% to 60%) had residual tumor between 10% and 90%. Pre- and postablation MRI was found to successfully predict residual disease, with 82% (range 50% to 100%) patients whose posttreatment MRI showed no enhancement. Complications included pain (40%), edema (17%), skin burns (4%), and pectoralis major injury (4%).

Sheng et al. reviewed MRI- and ultrasound-guided HIFU in treating breast cancer between 2002 and 2010. A total of 173 patients whose tumors ranged from 0.5 cm to 6 cm were treated. Complete ablation was achieved in 71% patients determined by excision, 59% by MRI guidance, and 96% by ultrasound. These studies were small, and larger, prospective studies are needed.

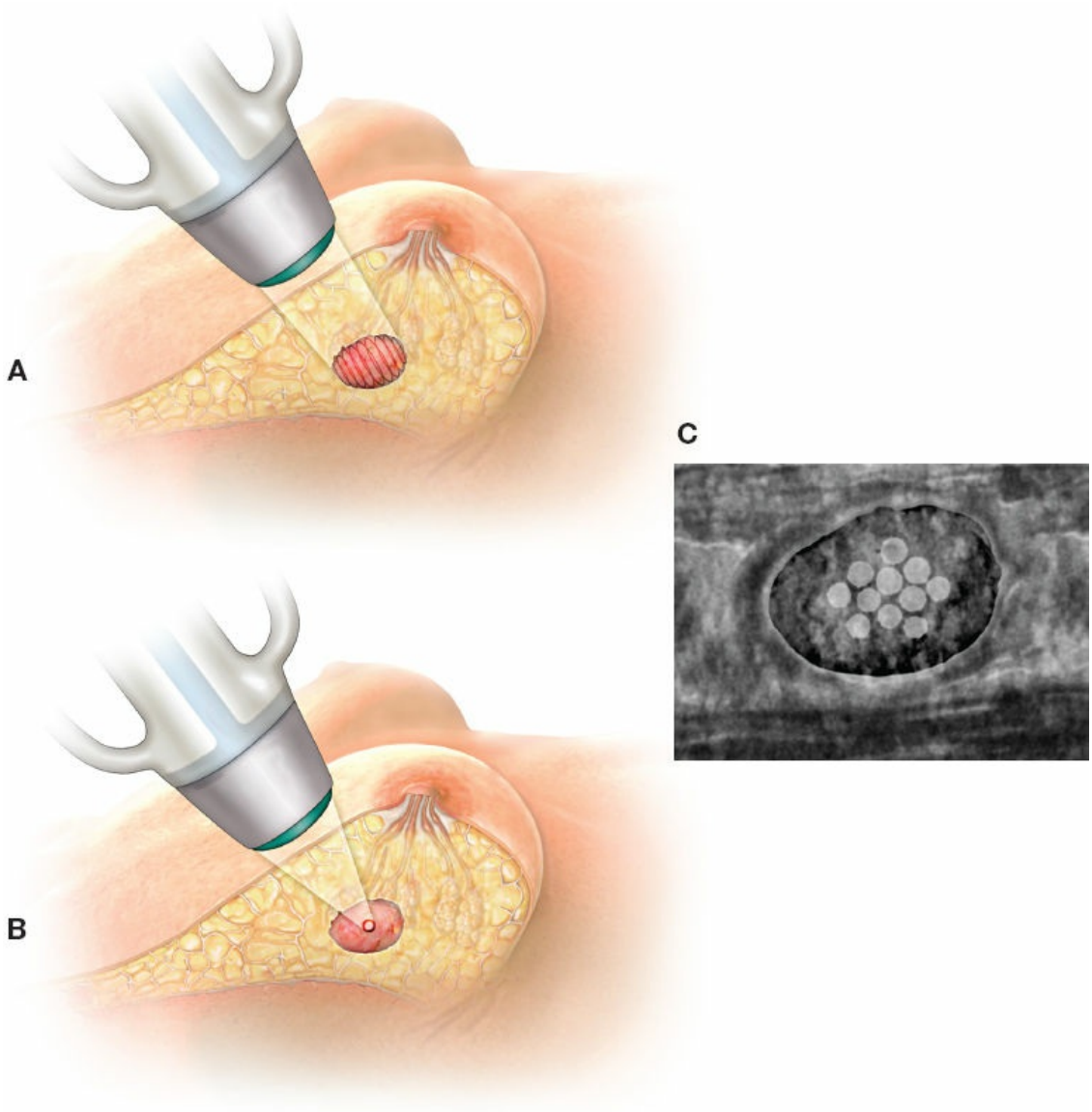

Figure 51.17. High-intensity focused ultrasound ablation of fibroadenoma. **A.** The Visualization Treatment Unit (VTU), containing ultrasound imaging, acoustic treatment, and cooling systems, is applied to the patient's breast to visualize the fibroadenoma. 3D treatment volume of the tumor is determined using both radial and antiradial slices (*ellipses*). **B.** Acoustic energy is focused at the center of the tumor, and is activated to cause tissue ablation. **C.** A hyperechoic mark (*white spot*) appears on ultrasound image after focal ablation. This process is repeated until the entire tumor volume is treated.

Like other ablative techniques, HIFU ablation of breast tumor seems feasible and safe. However, treatment time is longer, and complete ablation rate is variable, possibly due to occult multifocal disease, inadequate tumor volume calculation, and ablation margin imaging.

Continued research is needed to advance this technology and have wider applicability to potentially treat breast cancer.

SUMMARY AND FUTURE DIRECTIONS

The ablation techniques presented in this chapter represent a great deal of work by many dedicated researchers and clinicians toward the goal of improving treatment options for our patients. There is regulatory approval for the use of laser ablation and cryotherapy for the treatment of fibroadenomas in the United States. HIFU has been approved to treat fibroadenomas in Europe. The experience of using ablation to treat fibroadenomas has been as a proving ground toward using ablative methods for cancer. However, unlike fibroadenomas, most breast cancers do not have very well-defined borders and the implication of incomplete treatment can have serious consequences. If ablation fails, then the treatment of a selected favorable small tumor is compromised, so extreme caution in the attempt to advance ablation approaches is warranted. There are no randomized trials comparing ablation with lumpectomy. At the present time, all patients who are treated for breast cancer with ablative methods must be enrolled in clinical trials with informed consent and well-validated outcome measures. Refinement of patient selection criteria and adjunctive postablation therapies including radiation and systemic therapies need to be defined. The ultimate ablation method must be highly effective, well-tolerated by patients, cost-effective, and result in local recurrence rates at least as low as those achieved with breast conservation surgery. The modalities described in this chapter are incrementally moving toward this goal. Combination approaches such as intraoperative ablation to expand margins at the time of lumpectomy and prelumpectomy ablation supplemented with immunomoduling agents may have unique advantages. There is a great deal of work to do to optimize and ultimately define the role of ablation in the treatment of breast cancer. Long-term studies are needed to assess these growing techniques.

Suggested Readings

Chu KF, Dupuy DE, Thermal ablation of tumours: biological mechanisms and advances in therapy. *Nat Rev Cancer* 2014;14(3):199–208.

Dooley WC, Vargas HI, Fenn AJ, et al. Focused microwave thermotherapy for preoperative treatment of invasive breast cancer: a review of clinical studies. *Ann Surg Oncol* 2010;17(4):1076–93.

Fornage BD, Hwang RF. Current status of imaging-guided percutaneous ablation of breast cancer. *AJR Am J Roentgenol* 2014;203(2):442–8.

Han E, Johnson N, DelaMelena T, et al. Alternative therapy used as primary treatment for breast cancer negatively impacts outcomes. *Ann Surg Oncol* 2011;18(4):912–6.

Kennedy JE. High-intensity focused ultrasound in the treatment of solid tumours. *Nat Rev Cancer* 2005;5(4):321–7.

Li S, Wu PH. Magnetic resonance image-guided versus ultrasound-guided high-intensity focused ultrasound in the treatment of breast cancer. *Chin J Cancer* 2013;32(8):441–52.

Merckel LG, Bartels LW, Köhler MO, et al. MR-guided high-intensity focused ultrasound ablation of breast cancer with a dedicated breast platform. *Cardiovasc Intervent Radiol* 2013;36(2):292–301.

Nguyen T, Hattery E, Khatri VP. Radiofrequency ablation and breast cancer: a review. *Gland Surg* 2014;3(2):128–35.

Roubidoux MA, Yang W, Stafford RJ. Image-guided ablation in breast cancer treatment. *Tech Vasc Interv Radiol* 2014;17(1):49–54.

Webb H, Lubner MG, Hinshaw JL. Thermal ablation. *Semin Roentgenol* 2011;46(2):133–41.

Zhao Z, Wu F. Minimally-invasive thermal ablation of early-stage breast cancer: a systemic review. *Eur J Surg Oncol* 2010;36(12):1149–55.

Zhou W, Zha X, Liu X, et al. US-guided percutaneous microwave coagulation of small breast cancers: a clinical study. *Radiology* 2012;263(2):364–73.

EDITOR'S COMMENT

Breast conservation therapy (BCT) is the ideal, yet 35.5% of women choose mastectomy over BCT despite being eligible; 14% to 26% of women receiving BCT but never start XRT; and up to an additional 22% of women receiving BCT but not completing the XRT regimen. The successful demonstration of local therapy alternatives to whole breast radiation therapy (WBXRT) opens new opportunities for BCT patients to achieve positive outcomes without the cost, inconvenience, and morbidities associated with WBXRT or accelerated partial breast irradiation (APBI). APBI and intraoperative radiation therapy that aim to address whole breast XRT's limitations by giving a concentrated radiation dose to a local region, specifically the 1 cm region around the original lumpectomy site, where up to 90% of recurrences occur in a shorter amount of time, have limitations including high cost limiting outreach to smaller communities, variable results, and side effects. Because of this, many have

sought to use ablative tools to improve BCT and/or replace adjuvant radiation. The fact is, for patients with favorable tumors, 84% of patients do not benefit from radiation therapy. In the National Surgical Breast and Bowel Project (NSABP) B-21 patients were randomized to lumpectomy plus tamoxifen, lumpectomy plus WBXRT, or lumpectomy plus both WBXRT and tamoxifen. In the group that received lumpectomy plus tamoxifen and that did not receive WBXRT, the local recurrence rate at 8 years was only 16%. The local recurrence rate was lowered to about 4% if they received both tamoxifen and radiation. Thus, for every 100 women taking radiation, only a few benefit.

Of BCT patients, ~20% to 40% undergo at least one reexcision because an adequate negative margin was not achieved during the initial lumpectomy. Our group hypothesized that radiofrequency ablation (RFA) of breast tissue around the postlumpectomy cavity would reduce reexcision rates for patients with close or positive margins, as well as potentially provide local tumor control without radiation. Used for local control, RFA of the margin avoids damage to nearby organs including the heart and the lung that can occur with WBXRT. RFA is a method of inducing thermal tissue necrosis by using an applied sinusoidal voltage, oscillating between 400 and 800 kHz between electrodes and a dispersive grounding pad (in monopolar RFA) to generate ionic heating, and is currently utilized for the treatment of liver, lung, kidney, and bone tumors.

We initially investigated our RFA by performing lumpectomies in donor mastectomy samples, followed with RFA of the cavity to temperatures of 100°C. The procedure involves purse-string suturing the cavity to a ~1.0-cm volume, then the electrode tines of the radiofrequency probe are deployed into the cavity walls to achieve a circumferential ablation zone that after 15 minutes averages 10 mm in depth from the cavity wall. This preliminary investigation led to a 5-year 100-patient pilot trial including 22 patients with close or positive margins. Of these, 15 (two thirds) did not require reexcision per protocol. Upon follow-up, 2 of 68 patients who received a wide excision followed by RFA alone had a true in-breast recurrence (i.e., two elsewhere recurrences) and 3 had needle biopsy skin recurrences at the core entrance that were not classified as in-breast recurrence, but there were no tumor bed recurrences. Of these skin recurrences, all were successfully resected and WBXRT given. The 5-year disease-free survival rate was 88%. The postoperative complication rate was 6% (wound dehiscence, hematomas, or infection), and the cosmetic outcome on four-point scale was graded as excellent or good in 92% of patients. What was of the greatest interest is the high level of pain documented by patients even 5 years out who did receive WBXRT. This was virtually absent in the RFA-only group. Recently, we have just completed a 250-patient multicenter trial in patients with favorable tumors. An 18-month interval report demonstrated no recurrences with excellent cosmetic results. Final results will be reported as the trial matures.

During cryoablation, the size of the ablation as judged by the “ice ball” that develops can be judged by US. This ice ball has been used as an adjunct to

lumpectomy to try and improve margin excision but in a randomized trial showed no improvement over standard needle localization biopsy. One of the issues that had limited adoption of RFA in breast was the initial inability to determine the progression and size of the ablation zone. We developed a method of Doppler ultrasound that is currently utilized to observe nitrogen off-gassing from tissue motion in the tissue during ablation and therefore gives an estimation of the ablated zone. This is an essential component to the success of breast tumor ablation both primarily and secondarily that is excision followed by ablation. Accurate imaging of the ablated region is necessary for evaluating the clinical endpoint of these procedures, which is achieving a 1 cm region of necrosis around a tumor to avoid reexcision in case of close or focally positive margins as well as to mirror the equivalent area of radiation given during brachytherapy or APBI.

There is a desire to eventually be able to percutaneously ablate tumors. Promising yet experimental percutaneous techniques include RFA, cryoablation, laser, microwave therapy, focused microwave thermotherapy, percutaneous microwave coagulation, and high-intensity focused ultrasound ablation (HIFU). Most trials have <100% ablation of whole breast tumors and especially larger lesions and those that contain DCIS. RFA of breast cancer tumors without surgical removal has also been enthusiastically investigated. However, percutaneous RFA of primary breast tumors has met resistance and has found limited adoption by oncologists, breast surgeons, and patients because ablation of the primary tumor does not allow for complete histologic examination of the tumor and its margin, essentially eliminating tissue banking for molecular profiling and other future therapeutic and prevention options. In a different vain, my group used percutaneous excision of lesions ≤1.5 cm by vacuum-assisted device followed by percutaneous RFA versus laser as an alternative treatment to open lumpectomy. Twenty-one patients were enrolled onto a NIH pilot trial with 15 receiving RFA after percutaneous excision. In this manor, 100% ablation and negative margins were achieved. However, the laser arm was stopped secondary to unreliable ablation zones. Further follow-up studies are planned to determine if percutaneous excision followed by ablation is a reliable option for small favorable breast cancers. The main obstacle to this approach is the skill needed to accomplish both percutaneous excision and ablation and the select group of patients in which it can be accomplished.

Finally ablative techniques have found much more use for the time being in the management of bone disease in women with breast cancer and those with hepatic metastases.

V. Suzanne Klimberg

Suggested Readings

Fornage BD, Hwang RF. Current status of imaging-guided percutaneous

ablation of breast cancer. *AJR* 2014;203(2):442–8.

Klimberg VS, Boneti C, Adkins LL, et al. Feasibility of percutaneous excision followed by ablation for local control in breast cancer. *Ann Surg Oncology* 2011;18(11):3079–87.

Klimberg VS, Ochoa D, Henry-Tillman R, et al. Long-term results of phase II ablation after breast lumpectomy added to extend intraoperative margins (ABLATE I). *JACS* 2014;218(4):741–9.

Lane MD, Le HB, Lee S, et al Combination radiofrequency ablation and cementoplasty for palliative treatment of painful neoplastic bone metastasis: experience with 53 treated lesions in 36 patients. *Skeletal Radiol* 2011;40(1):25–32.

Manenti G, Scarano AL, Pistolese CA, et al. Subclinical breast cancer: minimally invasive approaches. Our experience with percutaneous radiofrequency ablation vs. cryotherapy. *Breast Cancer (Basel)* 2013;8(5):356–60.

Sadot E, Lee SY, Sofocleous CT, et al. Hepatic resection or ablation for isolated breast cancer liver metastasis: a case-control study with comparison to medically treated patients. *Ann Surg* 2015. [Epub ahead of print]

Seidensticker M, Garlipp B, Scholz S, et al. Locally ablative treatment of breast cancer liver metastases: identification of factors influencing survival (the Mammary Cancer Microtherapy and interventional approaches (MAMMA MIA) study). *BMC Cancer* 2015;15:517–29.

52 Sentinel Lymph Node Biopsy in Breast Cancer

Anthony Lucci, Sarah M. DeSnyder, and Oluwadamilola (Lola) Fayanju

INTRODUCTION

While there is some disagreement on the timing of the first description of the sentinel lymph node concept, there is general consensus that the first report of the modern technique of sentinel lymph node biopsy (SLNB) was made in 1992 by Alistair Cochran and Donald Morton as a less morbid alternative to full lymph node dissection in the staging of patients with early melanoma. It was subsequently adapted to and validated in the axillary staging of breast cancer by Armando Giuliano and colleagues at John Wayne Cancer Center, who published their experience in 1994. For breast cancer, SLNB relies on the principle that the breast drains predictably and preferentially to the axilla, and that within the axilla, there exist guardian or "sentinel" nodes that are the first to receive metastatic tumor cells in the case of dissemination beyond the breast mound (Fig. 52.1). Thus, these sentinel nodes may be seen as reliable surrogates for extent of disease in the axillary lymph node basin, thereby providing accurate axillary staging information without the associated morbidity of an axillary lymph node dissection (ALND). The accuracy of SLNB in the staging of early breast cancer has now been demonstrated in many trials, with false negative rates of <5% and rates of >95% for sentinel node identification reported in the literature. It remains the standard of care for axillary staging in patients with clinically node-negative breast cancer. But even in patients with SLNBs demonstrating metastatic disease, ALND is not always performed: the American College of Surgeons Oncology Group [ACOSOG] Z0011 trial demonstrated that ALND can be safely omitted in clinically node-negative patients found to have only 1 to 2 involved lymph nodes on SLNB, provided they go on to receive post-lumpectomy radiation as part of breast conservation therapy.

Furthermore, clinical determination of node-negative status has moved

beyond physical examination to also include image-guided axillary sampling techniques. Routine use of axillary ultrasound (AUS) has improved detection of microscopic metastatic disease in the axilla of patients with nonpalpable axillary disease. At our institution, sonographically abnormal lymph nodes are subjected to needle biopsy at the time of initial breast cancer diagnosis, thereby facilitating early assessment of nodal involvement that can inform decisions about neoadjuvant systemic therapy without the need for SLNB. However, the availability and accuracy of AUS remain heterogeneous, and SLNB is still recommended for axillary staging in patients with node-negative breast cancer based on physician examination in the absence of reliable axillary imaging.

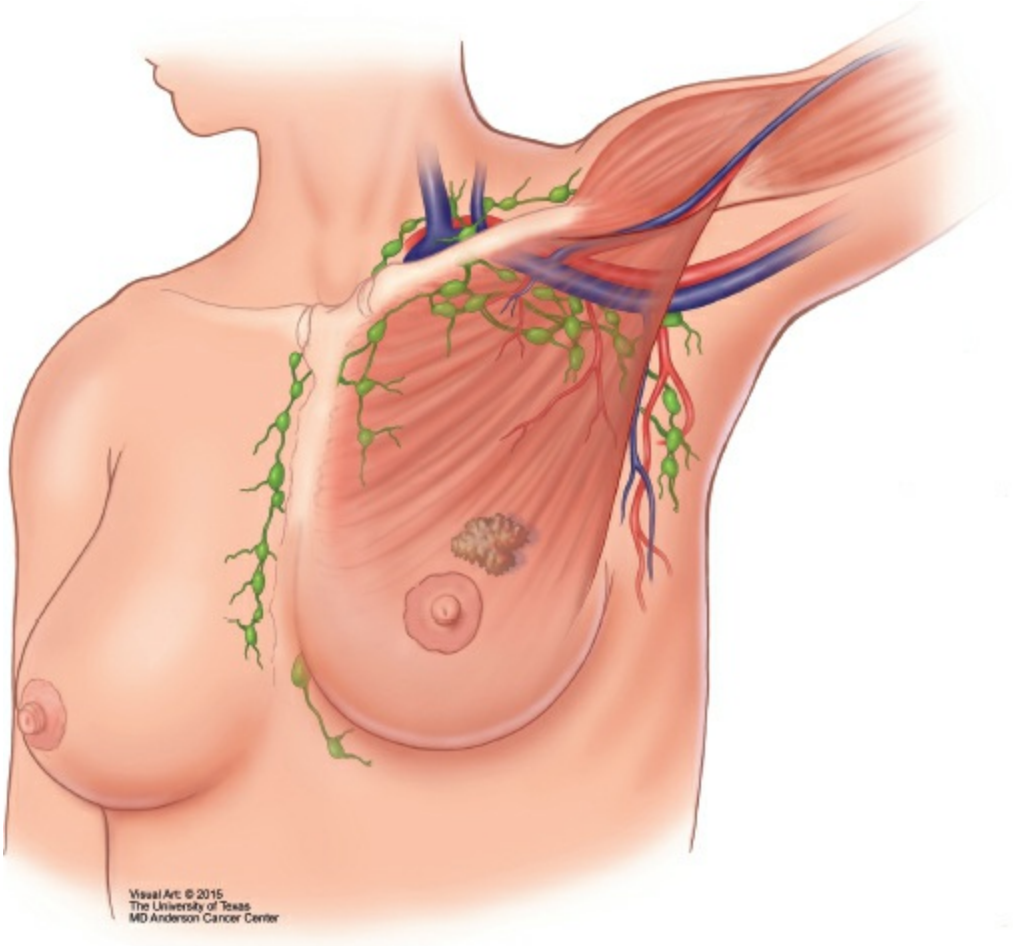

Figure 52.1. Illustration of axillary anatomy demonstrating lymphatic drainage of the breast. (Image © 2015 The University of Texas MD Anderson Cancer Center.)

INDICATIONS AND CONTRAINDICATIONS

SLNB is indicated for patients with nonmetastatic, T1-T3 breast cancer and no palpable lymphadenopathy. It is contraindicated in patients with inflammatory breast cancer or clinically palpable nodal disease regardless of response to neoadjuvant chemotherapy (NACT), though the timing of SLNB relative to systemic therapy remains controversial. At our institution, most patients with node-positive breast cancer receive NACT, but the accuracy of post-NACT SLNB continues to be investigated. Both the ACOSOG Z1071 trial in the United States and the SENTINA study from Austria and Germany demonstrated false-negative rates of >10% in patients with N1 disease prior to NACT, indicating that SLNB alone is not a reliable alternative to ALND in axillary staging after NACT. At institutions where ultrasound-guided needle biopsy of axillary lymph nodes is routinely performed, the results of needle-biopsy prior to NACT can guide therapy without the need for SLNB. If AUS-guided sampling is not available, SLNB can be performed prior to initiation of NACT to determine the likelihood of needing post-NACT ALND. Although there are ongoing trials to improve the selection of post-NACT patients with node-positive breast cancer who might be able to forego post-NACT ALND (see below under “Future Directions”), we continue to recommend that all patients with either needle- or sentinel-node biopsy-proven axillary disease prior to NACT undergo ALND after the completion of systemic therapy.

SLNB can be used in the work-up of early-stage, node-negative male breast cancer, though men are still more likely to undergo ALND as a result of later stage at presentation. There is also some evidence that men with positive SLNBs are more likely than women to harbor metastatic disease in the rest of the axilla. Neither previous augmentation nor prior mammoplasty is a contraindication to SLNB, though lymphatic drainage may be more aberrant, especially if either procedure is performed relatively soon prior to breast cancer diagnosis. Although sentinel node identification may be more challenging after previous axillary surgery due to scarring and aberrant drainage, SLNB can still be performed in patients who have undergone previous SLNB. This approach is associated with low false negative rates. In pregnant women, SLNB has usually been performed with radiocolloid only. Perioperative fetal exposure to radiation —which is already estimated to be very low with radiocolloid—can be further minimized by day-of-surgery injection with low-dose (0.5 mCi) isotope rather than high-dose (2.5 mCi) injection the day before surgery.

Both isosulfan blue and methylene blue are Class C (i.e., unknown teratogenic potential) drugs with regards to pregnancy, but there has been no clear linkage of birth defects associated with the use of either reported in the literature. However, because of the unknown teratogenic potential of the blue dyes, currently at our institution we use radiocolloid only for SLNB in pregnant patients. Pregnant women with breast cancer who are otherwise eligible for SLNB should, therefore, be offered SLNB in the context of extensive counseling as to the theoretical but as yet undemonstrated risks to the fetus.

SURGICAL TECHNIQUE

Successful mapping of the sentinel lymph node(s) is critical to ensuring identification of the sentinel lymph node(s) with minimal morbidity. When SLNB was first described for breast cancer by Giuliano and colleagues in 1994, intraoperative lymphatic mapping was performed using vital blue dye (1% isosulfan blue in the United States; patent blue V in Canada, Europe, or Australia). This blue dye was injected in the peritumoral location of the breast, and the lymphatic channels were identified and tracked to the sentinel lymph node(s). Lymphatic mapping can also be performed using radiocolloid material, most commonly technetium (^{99}Tc)-labeled sulfur colloid. In contrast to blue dye, injection of radiocolloid may occur either in the nuclear medicine suite on the day before or day of surgery or in the operating room on the day of surgery. If injection is performed in the nuclear medicine suite, lymphoscintigraphy can be performed using a gamma camera to document the presence of a “hot” node representing a sentinel lymph node. Infrequently, a sentinel node will localize only to the internal mammary position; given the difficulty of exposure at this site and the risks associated with this dissection, internal mammary SLNB should only be performed by surgeons experienced with this procedure, though in current practice many surgeons find this step unnecessary. Intraoperatively, a handheld gamma probe is used to transcutaneously localize the sentinel lymph node within the axilla. Dual agent mapping has been clearly demonstrated to improve the accuracy of SLNB, but some surgeons utilize these agents selectively. It is important to recognize that surgeon experience is critical to successful SLNB, and in the hands of a surgeon experienced in this technique, dual agent mapping may not be as critical as it would be to a less experienced surgeon. We believe that dual agent mapping is especially important for those patients

who have undergone neoadjuvant systemic therapy, patients who have undergone prior breast or axillary surgery, and patients with recurrent breast cancer.

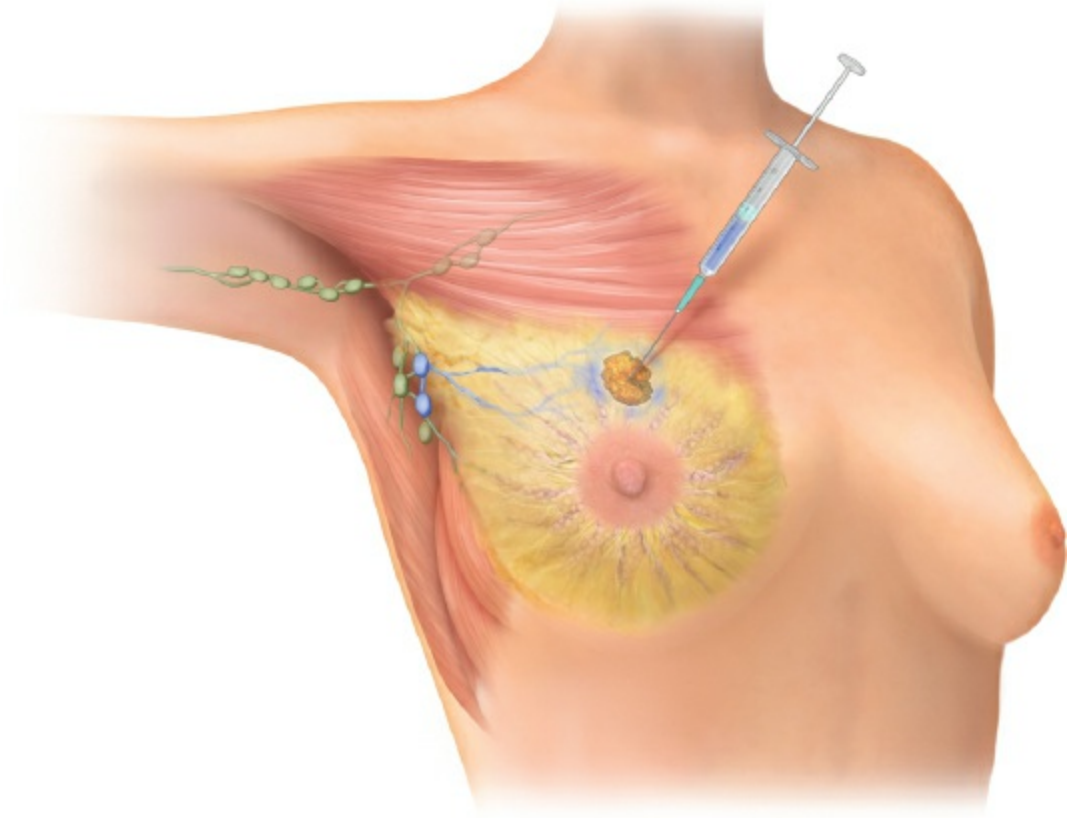

Figure 52.2. Peritumoral injection of blue dye using 25-guage needle.

General anesthesia is utilized for SLNB in our practice. However, this procedure can be performed using monitored anesthesia care consisting of local anesthesia with sedation and analgesia. Prior to injection of isosulfan blue (which is the preferred dye at our institution), the patient is administered a glucocorticoid, diphenhydramine (Benadryl), and famotidine as a prophylactic measure to minimize the severity of any allergic response the patient might have to the blue dye. After the patient is induced with general anesthesia, the breast, chest wall, and upper extremity are prepped and draped in standard sterile fashion with the arm in the field. If radiocolloid was not injected in the nuclear medicine suite, a 25-gauge needle is used to inject low dose ^{99}Tc-labeled sulfur colloid in divided aliquots around the peritumoral position. We use another 25-gauge needle to inject an additional 5 mL of blue dye in the peritumoral position (Fig. 52.2). It is important to inject the blue dye into the breast

parenchyma, as injection into the dermis may tattoo the skin. The breast is then massaged for 5 minutes to facilitate movement through the lymphatic channels to the sentinel node(s).

A small (~2 to 3 cm) transverse incision is made just below the axillary hairline, over the transcutaneous "hot spot" (Fig. 52.3). Dissection through the subcutaneous tissue is carried out using electrocautery and the clavipectoral fascia is opened. If blue dye is used, the blue superficial lymphatics are used as a guide to find the blue sentinel lymph node(s) (Fig. 52.4). A right angle clamp is used to dissect along the blue lymphatic. Care is taken to avoid disruption of the blue lymphatics and thus disruption of the blue guide. A lymph node is considered blue if the blue channel terminates at the node, if the hilum of the node is blue, or if the entire node is blue. When radiocolloid is used as a mapping agent, the gamma probe is used to detect the node(s) with the highest level of radioactivity, that is, the "hot" sentinel lymph node(s) within the axilla (Fig. 52.5). Care must be taken to focus the probe on the axilla and to direct it away from the breast so as to avoid shine-through from the site of peritumoral injection in the breast. The handheld probe is then used to guide the dissection within the axilla. In the event that the sentinel node(s) is located inferiorly or medially within the axilla, it may be helpful to raise the arm over the patient's head to bring the axillary contents to a more superficial position.

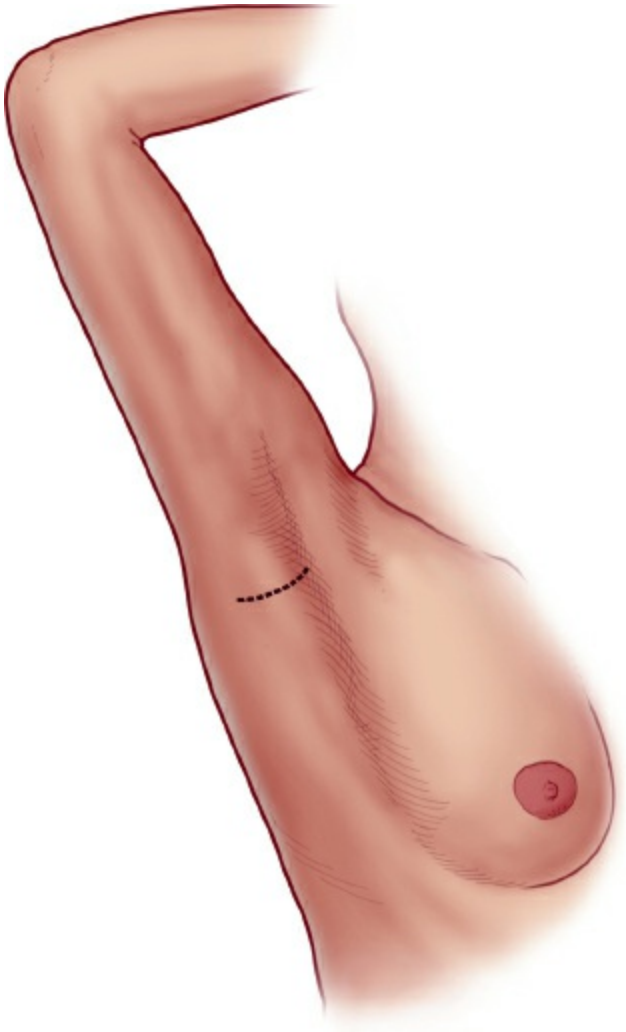

Figure 52.3. Ipsilateral arm is raised over the patient’s head. The incision site is represented by the dotted line.

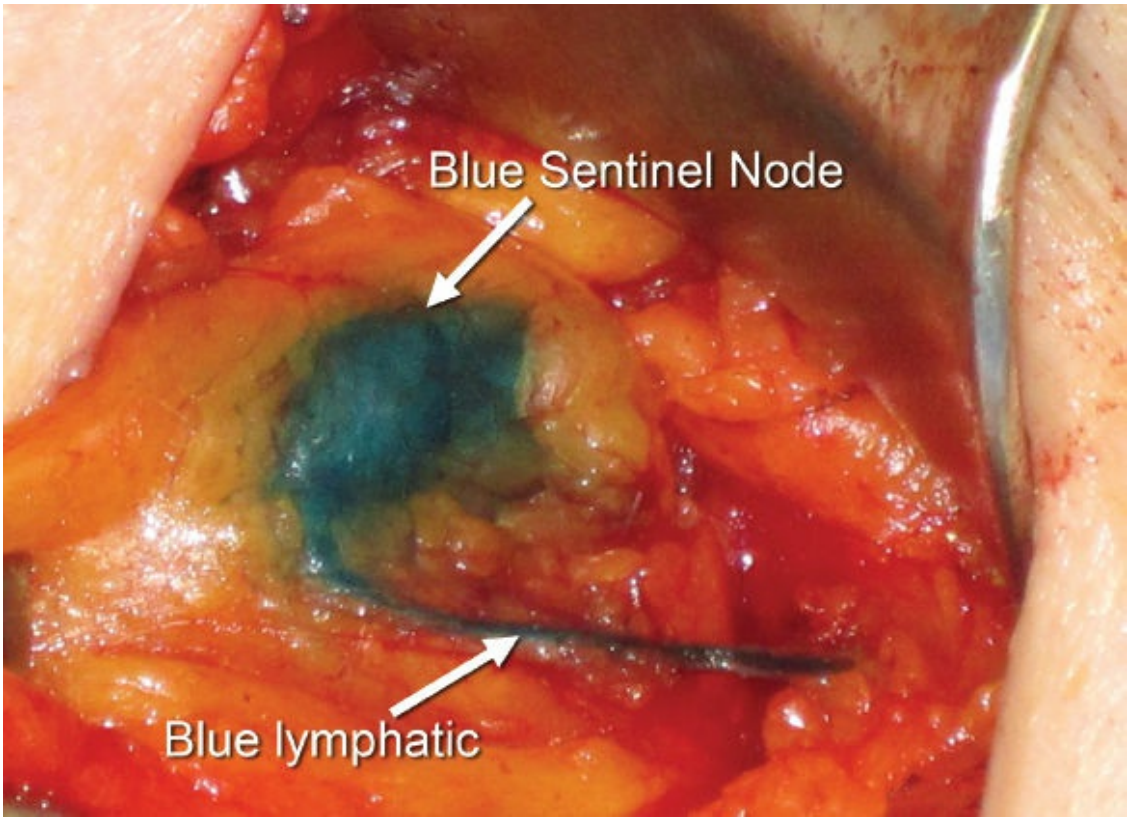

Figure 52.4. Visualization of blue-stained lymphatic traveling to the blue-stained sentinel node.

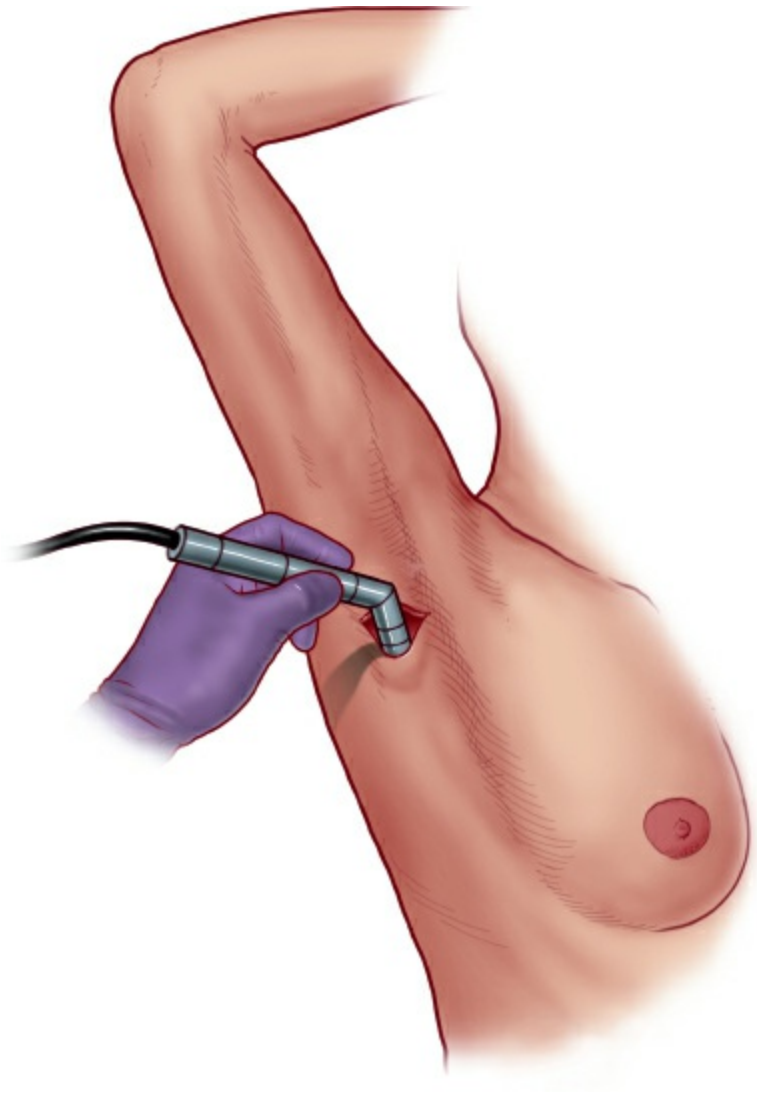

Figure 52.5. Handheld probe detects gamma rays and guides localization of sentinel nodes.

Sentinel node(s) are defined as those nodes that are either “hot” or blue. Nodes that are <10% of the highest ex vivo count with the gamma probe are not considered sentinel nodes. Palpable nodes that are neither “hot” nor blue are not usually considered sentinel lymph nodes, though at our institution we do remove and submit for pathologic evaluation any suspicious palpable nodes identified during the SLNB procedure. After all sentinel lymph nodes have been harvested, the axillary cavity is irrigated and checked carefully for hemostasis. The authors prefer to close the opened clavipectoral fascia with interrupted 3-0 vicryl sutures. The remainder of the incision is closed using 3-0 vicryl in an interrupted deep dermal fashion followed by 4-0 monocryl in a running subcuticular fashion. Dermabond is placed over the incision to complete the closure.

For patients undergoing breast-conserving therapy (and who will

receive whole breast irradiation), sentinel lymph nodes are sent for permanent pathologic examination. For patients with invasive carcinoma undergoing mastectomy, sentinel lymph nodes are sent to pathology for frozen section examination. In pathology, sentinel lymph nodes are bisected and examined by frozen section (for rapid intraoperative assessment) or embedded in paraffin (for permanent assessment), stained with hematoxylin and eosin, and examined for metastasis. If the sentinel lymph nodes are negative, no further surgery is needed. If metastases are identified, the size of metastasis may dictate the need for additional surgery. Nodal metastasis is reported as isolated tumor cells (<0.2 mm), micrometastasis (0.2 to 2 mm), or macrometastasis (>2 mm). Patients with isolated tumor cells require no further axillary surgery as this is considered N0(i+) disease in the American Joint Committee on Cancer staging system. For patients with T1/T2 primary tumors undergoing breast-conserving therapy with whole breast irradiation, patients with either micrometastases or macrometastases in one or two lymph nodes do not require additional axillary surgery as long as extranodal extension is absent. For patients undergoing breast-conserving therapy, patients with either micrometastases or macrometastases and extranodal extension present should undergo completion ALND. Patients undergoing mastectomy who have either micrometastases or macrometastases should undergo completion ALND. Many surgeons utilize a nomogram to determine the risk of additional nodal metastasis when counseling patients and making a decision about the need for additional axillary surgery.

COMPLICATIONS

Although SLNB confers significantly less morbidity when compared with ALND, it is, as with all surgical procedures, associated with some complications. Patients enrolled in the ACOSOG Z0010 trial who underwent SLNB alone had fewer complications, which included anaphylaxis after receiving blue dye for lymphatic mapping (0.1%), axillary wound infection (1%), axillary seroma (7.1%), axillary hematoma (1.4%), axillary paresthesias (8.6%), decreased upper extremity range of motion (3.8%), and objectively measured proximal upper extremity lymphedema (6.9%). Analysis of patients enrolled in the ACOSOG Z0011 trial revealed that patients who underwent SLNB alone had significantly fewer wound infections, axillary seromas, paresthesias, and subjectively reported lymphedema when compared with those who underwent

completion ALND. The Sentinel Node Biopsy versus Axillary Clearance (SNAC-1) trial from Australia and New Zealand also examined the morbidity of SLNB. Complications resulting from SLNB were similar to those seen in previous trials, but patients also had significant recovery from these complications. Notably, this trial included both subjective and objective measurements of arm swelling. The reported rate of lymphedema for patients undergoing SLNB in the SNAC-1 trial was 2.5%. Although the risk of developing it after SLNB is low, lymphedema is a dreaded sequela of any axillary surgery. It is important for patients to be educated not only about the signs and symptoms of lymphedema but also about who to contact if they develop them, as earlier diagnosis of lymphedema is associated with better outcomes after therapy. Stage 0 lymphedema occurs when patients experience symptoms of fluid build-up, such as fatigue, discomfort, and a sensation of heaviness in the absence of swelling. Stage I lymphedema is when swelling is noted, but the swelling can be alleviated with elevation of the arm. Stage II lymphedema is when swelling is present that cannot be relieved by arm elevation. Patients with stage II lymphedema also develop fibrosis of the tissue of the arm. Stage III lymphedema, also known as elephantitis, is when massive swelling is present with fibrosis of the arm tissue and thickening of the skin. The current standard of care for lymphedema is complete decongestive therapy. It is important to note that treatment of lymphedema is intensive, and care of the affected extremity requires a lifelong commitment for afflicted patients. Studies have been undertaken examining the role of axillary reverse mapping (ARM) in the prevention of lymphedema. The ARM technique involves injection of blue dye into the arm to determine if arm lymphatics can be successfully identified and spared during axillary surgery in an attempt to decrease the risk of lymphedema.

FUTURE DIRECTIONS

Preliminary studies are ongoing to determine if localization of the sentinel lymph node using radiocolloid and/or microbubbles followed by image-guided excision of the sentinel lymph node using vacuum-assisted core needle biopsy could provide accurate axillary staging. In addition, the possibility of omitting SLNB in patients with small breast tumors and a negative AUS is also being evaluated in the Sentinel Node versus Observation after Axillary UltrasouND (SOUND) trial.

SLNB remains the standard of care in patients with clinically node-

negative breast cancer, but controversy exists as to its accuracy following NACT, particularly in patients who convert from clinically node-positive to clinically node-negative after systemic treatment. ACOSOG Z1071 showed a false negative rate of 12.6% for SLNB in patients with clinical N1 disease after NACT. This trial resulted in much debate as to how the technique of SLNB in this subset of patients might be improved. Investigators at the University of Texas MD Anderson Cancer Center have published the results of a trial exploring the real-world accuracy of an enhanced form of selective, post-NACT axillary staging called targeted axillary dissection (TAD). Patients with axillary disease at presentation undergo placement of a clip within the node containing metastasis as determined by image-guided needle biopsy. Preoperatively, a radioactive I^{125} seed is placed within the clipped lymph node to facilitate localization at the time of surgery. During surgery, SLNB is performed in standard fashion and the clipped lymph node is also targeted for excision using a gamma probe. In patients who underwent TAD followed by completion axillary surgery, the false negative rate of this approach was 2%. This technique may allow for those whose systemic therapy eradicates their nodal disease to undergo a minimally invasive axillary operation that avoids the significant morbidity of completion ALND.

SUMMARY

SLNB biopsy is an accurate method of staging the axilla in patients with early-stage breast cancer. Patients who are found to have metastasis in the sentinel node(s) are then selected for additional axillary surgery as clinically indicated. Compared with ALND, SLNB is less invasive and associated with significantly less morbidity. Thus, SLNB has replaced ALND as standard of care for axillary staging in clinically node-negative patients. Ongoing studies may result in enhanced techniques that will allow SLNB to become an important component of axillary staging in patients with nodal metastasis at diagnosis who undergo neoadjuvant systemic therapy.

Suggested Readings

Boughey JC, Suman VJ, Mittendorf EA, et al. Sentinel lymph node surgery after neoadjuvant chemotherapy in patients with node-positive breast cancer: the ACOSOG Z1071 (Alliance) clinical trial. *JAMA* 2013;310:1455–61.

Caudle AS, Yang WT, Krishnamurthy S, et al. Improved axillary evaluation

following neoadjuvant therapy for patients with node-positive breast cancer using selective evaluation of clipped nodes: implementation of targeted axillary dissection. *J Clin Oncol* 2016;34(10):1072–8.

Giuliano AE, Hunt KK, Ballman KV, et al. Axillary dissection vs. no axillary dissection in women with invasive breast cancer and sentinel node metastasis: a randomized clinical trial. *JAMA* 2011;305:569–75.

Giuliano AE, Kirgan DM, Guenther JM, et al. Lymphatic mapping and sentinel lymphadenectomy for breast cancer. *Ann Surg* 1994;220:391–8; discussion 398–401.

Gropper AB, Calvillo KZ, Dominici L, et al. Sentinel lymph node biopsy in pregnant women with breast cancer. *Ann Surg Oncol* 2014;21: 2506–11.

Kiluk JV, Kaur P, Meade T, et al. Effects of prior augmentation and reduction mammoplasty to sentinel node lymphatic mapping in breast cancer. *Breast J* 2010; 16:598–602.

Krag DN, Anderson SJ, Julian TB, et al. Sentinel-lymph-node resection compared with conventional axillary-lymph-node dissection in clinically node-negative patients with breast cancer: overall survival findings from the NSABP B-32 randomised phase 3 trial. *Lancet Oncol* 2010;11:927–33.

Kuehn T, Bauerfeind I, Fehm T, et al. Sentinel-lymph-node biopsy in patients with breast cancer before and after neoadjuvant chemotherapy (SENTINA): a prospective, multicentre cohort study. *Lancet Oncol* 2013;14:609–18.

Lucci A, McCall LM, Beitsch PD, et al. Surgical complications associated with sentinel lymph node dissection (SLND) plus axillary lymph node dissection compared with SLND alone in the American College of Surgeons Oncology Group Trial Z0011. *J Clin Oncol* 2007;25:3657–63.

Maaskant-Braat AJ, Voogd AC, Roumen RM, et al. Repeat sentinel node biopsy in patients with locally recurrent breast cancer: a systematic review and meta-analysis of the literature. *Breast Cancer Res Treat* 2013; 138:13–20.

Mansel RE, Fallowfield L, Kissin M, et al. Randomized multicenter trial of sentinel node biopsy versus standard axillary treatment in operable breast cancer: the ALMANAC Trial. *J Natl Cancer Inst* 2006;98:599–609.

Morton DL, Wen DR, Wong JH, et al. Technical details of intraoperative lymphatic mapping for early stage melanoma. *Arch Surg* 1992;127:392–9.

Ochoa D, Korourian S, Boneti C, et al. Axillary reverse mapping: five-year experience. *Surgery* 2014;156:1261–8.

Raut CP, Hunt KK, Akins JS, et al. Incidence of anaphylactoid reactions to isosulfan blue dye during breast carcinoma lymphatic mapping in patients treated with preoperative prophylaxis: results of a surgical prospective clinical practice protocol. *Cancer* 2005;104:692–9.

Ruddy KJ, Winer EP. Male breast cancer: risk factors, biology, diagnosis, treatment, and survivorship. *Ann Oncol* 2013;24:1434–43.

Veronesi U, Paganelli G, Galimberti V, et al. Sentinel-node biopsy to avoid axillary dissection in breast cancer with clinically negative lymph-nodes. *Lancet* 1997;349:1864–7.

Wetzig N, Gill PG, Zannino D, et al. Sentinel lymph node based management or routine axillary clearance? Three-year outcomes of the RACS sentinel node biopsy versus axillary clearance (SNAC) 1 trial. *Ann Surg Oncol* 2015;22:17–23.

Wilke LG, McCall LM, Posther KE, et al. Surgical complications associated with sentinel lymph node biopsy: results from a prospective international cooperative group trial. *Ann Surg Oncol,* 2006;13:491–500.

EDITOR'S COMMENT

Sentinel lymph node biopsy (SLNB) was originally described by Krag et al. with unfiltered Technetium 99m sulfur colloid and then by Giuliano using blue dye. Since that time the injectate, method, timing, and patient selection have been a moving target and vary from country to country. Variation of ^{99}Tc includes filtered or unfiltered, nanocolloid or albumin. Isosulfan versus methylene blue dye have been used in Europe and the United States, and indigo carmine has been used in Asia. Lymphoseek® (technetium Tc99m tilmanocept) is a conjugation of the radioisotope and blue dye and seems to work well in small trials (Wallace AM, Han LK, Povoski SP, et al. Comparative evaluation of [(99m)Tc]tilmanocept for sentinel lymph node mapping in breast cancer patients: results of two phase 3 trials. *Ann Surg Oncol* 2013;20(8):2590–9). Others have successfully used fluorescent dyes that require near-infrared fluorescence imaging (just recently FDA-approved) and magnetic particles for sentinel lymph node (SLN) localization (SentiMag® in the United Kingdom, which is not yet FDA-approved). As yet the ideal injectate is not settled, nonradioactive methods will continue to be the subject of development.

Originally, peritumoral injection of radiotracer was used at least 30 minutes and up to 8 hours before surgery. Lymphoscintigraphy is not routinely performed in the United States and does not appear to be particularly valuable, although researchers have developed an intraoperative handheld camera (hybrid single-photon emission computed tomography/computed tomography [SPECT/CT]) that can be used for detecting intraoperative SLN drainage (Serrano-Vicente J, Rayo-Madrid JI, Domínguez-Grande ML, et al. Role of SPECT-CT in breast cancer sentinel node biopsy when internal mammary chain drainage is observed. *Clin Transl Oncol* 2016;18(4):418–25). I use ultrasound of the internal mammary lymph node chain when there is potential for significant aberrant drainage as is seen in recurrent tumors and large inner quadrant tumors with positive axillary nodes. Internal mammary node positivity

is rare when the axillary nodes are negative. Vital blue dye had the advantage of injection after induction of anesthesia. The original multicenter trial, using both blue dye and radioisotope methods, showed that all of the false negatives were in the upper outer quadrant of the breast. So we developed a subareolar injection that would avoid overlap with the zone of diffusion and decrease false negatives and showed it to be accurate and could be injected intraoperatively as well (Johnson CB, Boneti C, Korourian S, et al. Intraoperative injection of subareolar or dermal radioisotope results in predictable identification of sentinel lymph nodes in brest cancer. *Ann Surg* 2011;254(4):612–8). Others have injected dermally or intratumorally and up to the day prior to surgery. After a learning curve period and with experience of the surgeon, it appears that almost anything will work well. Thus, the drainage of the breast itself seems to be more important than where the tumor is sitting within the breast. We have also used axillary reverse mapping (ARM) or split mapping of the arm and the breast so that we can protect the arm lymphatics while performing an axillary lymphadenectomy with extremely low lymphedema rates (Tummel E, Ochoa D, Korourian S, et al. Does axillary reverse mapping prevent lymphedema after lymphadenectomy? *Ann Surg* 2016, May 9. (Epub ahead of print)).

Eleven quality indicators for the performance of SLNB have been identified by a consensus group and include: pathologic evaluation protocol, pathologic reporting by the American Joint Committee on Cancer (AJCC) guideline, protocol for injection of radiocolloid, proper identification of SLN, SLNB performance in eligible patients, SLNB concurrent with lumpectomy/mastectomy, completion of ALND for positive SLNB, SLNB performance in ineligible patients, axillary node positivity rate, number of nodes removed, and axillary recurrence rate (Quan ML, Wells BJ, McCready D, et al. Beyond the false negative rate: development of quality indicators for sentinel lymph node biopsy in breast cancer. *Ann Surg Oncol* 2010;17(2):579–91).

Since the first trials of SLNB, there has been ever-changing parameters of patient selection. According to the updated 2014 American Society of Clinical Oncology (ASCO) guidelines, SLNB is recommended with a limited or good level of evidence for DCIS (with mastectomy), T1 or T2 and multicentric tumors, pregnancy, older age, obesity, male breast cancer, evaluation of internal mammary nodes, prior excisional or percutaneous breast or axillary biopsy, prior nononcologic breast surgery (reduction or augmentation mammoplasty, breast reconstruction), and before or after preoperative systemic therapy. ASCO does not recommend SLNB for T3 or T4 tumors (as there is insufficient evidence although our group routinely uses it), inflammatory breast cancer, DCIS without mastectomy except for large DCIS (>5 cm) on core biopsy or with suspected or proven microinvasion, suspicious, or palpable axillary nodes. Although not mentioned by ASCO, there are just insufficient data on patients with lymphedema precox, extensive injuries or burns or extensive surgeries for hidradenitis who are not good candidates for SLNB. There are minimal data on patients with local recurrence especially in an irradiated field and most

recommend lymphoscintigraphy as this is the circumstance when abberant drainage is most likely to be seen. The risk of nodal metastasis in patients who are clinically node negative is 40%, ~60% if palpable but not suspicious, and ~85% if clinically palpable and suspicious. In my practice, patients with clinically palpable nodes undergo ultrasound and core needle biopsy if suspicious and are not considered candidates for SLNB until after neoadjuvant chemotherapy.

I do not recommend performance of SLNB during prophylactic mastectomies either for genetic mutation or for contralateral mastectomies. In a recent meta-analysis of 14 studies and 2,708 patients undergoing prophylactic mastectomy with accompanying SLNB, the frequency of occult invasive cancer was 1.8% and the rate of positive SLNs was 1.2% (Nagaraja V, Edirimanne S, Eslick GD. Is sentinel lymph node biopsy necessary in patients undergoing prophylactic mastectomy? A systematic review and meta-analysis. *Breast J* 2016;22(2):158–65). The rate of lymphedema for such a group would be 5% to 8% if everyone received an SLNB. The rate for selective ALND after a prophylactic mastectomy for an actual diagnosis of breast cancer would be <1% (1.8% × 11% = 0.198%). In addition, you should only put those patients at risk for lymphedema who might benefit from knowledge of nodal involvement or in prevention of axillary recurrence.

The future will bring additional changes regarding who will benefit from an SLNB only or not at all. Clinically node negative but SLNB positive patients may now be candidates for SLNB only when coupled with breast conservation whole breast irradiation. Ongoing is the Alliance 111202 trial in which patients who are node positive by core needle biopsy and have undergone neoadjuvant chemotherapy are randomized (if still node positive) to radiation versus axillary node dissection. In patients who are node negative, after chemotherapy they receive SLNB alone. Further in an European trial, in those patients who are node negative by palpation as well as ultrasound, the SOUND trial randomizes patients to SLNB versus follow-up alone without surgical intervention. The role of axillary surgery continues to evolve.

V. Suzanne Klimberg

Suggested Readings

Douek M, Klaase J, Monnypenny I, et al. The SentiMAG multicenter trial: sentinel node biopsy using a magnetic technique versus the standard technique. *Eur Surg Oncol* 2013;39:S85–S86.

Gentilini O, Botteri E, Dadda P, et al. Physical function of the upper limb after breast cancer surgery. Results from the SOUND (Sentinel node vs. Observation after axillary Ultra-souND) trial. *Eur J Surg Oncol* 2016;42(5):685–9.

Lyman G, Giuliano AE, Somerfield M, et al. American Society of Clinical

Oncology Guideline recommendations for sentinel lymph node biopsy in early-stage breast cancer. *J Clin Oncol* 2005;23:7703–20.

Lyman G, Temin S, Edge SB, et al. Sentinel lymph node biopsy for patients with early-stage breast cancer: American Society of Clinical Oncology clinical practice guideline update. *J Clin Oncol* 2014;32(13):1365–83.

Verbeek FP, Troyan SL, Mieog JS, et al. Near-infrared fluorescence sentinel lymph node mapping in breast cancer: a multicenter experience. *Breast Cancer Res Treat* 2014;143:333–42.

53 Lymphedema—Pathophysiology, Prevention, and Treatment

Sarah A. McLaughlin

Lymphedema is a dreaded, poorly understood, underestimated, and understudied long-term complication of surgery and cancer care. It occurs when protein-rich lymphatic fluid accumulates in the interstitial tissue causing swelling generally in an upper or lower extremity. Clinicians caring for cancer patients should understand the clinical manifestations, diagnosis, and treatment of lymphedema because of its relatively high frequency and significant negative impact on the overall patient functional status and quality of life. Lymphedema and other long-term consequences of cancer care remain key issues for the Institute of Medicine as the National Cancer Institute estimates the number of cancer survivors in the United States will increase by 31% from 14.5 to 19 million by 2024.

ETIOLOGY AND PATHOPHYSIOLOGY

The lymphatic system includes both lymphatic vessels and lymphatic tissue. Interstitial fluid composed of protein, water, fatty acids, cellular debris, and micro-organisms is absorbed from the interstitial space into the lymphatic vessels and transported to the venous system as lymph fluid. The superficial lymphatic system drains the skin and subcutaneous tissues and connects with perforating vessels to the deep lymphatic system, which course with the main arterial and venous vasculature. The lymphatic capillaries of the superficial system are larger and more permeable than blood vessel capillaries allowing absorption of interstitial macromolecules. These capillaries cover the entire skin surface but lack valves, therefore propelling fluid only in the direction of lower pressure gradients. The lymphatic fluid is transported via capillaries to pre-collector vessels that may have valves, to collector vessels that are similar in structure to veins, to lymph nodes or lymphatic trunks to the central veins or thoracic duct. The regional lymph nodes of the head and neck, thoracic and abdominal cavities, retroperitoneum, axilla, and groin are considered the major

regional lymphatic basins. The lymph nodes aim to filter and process lymphatic fluid and then produce an immune response.

In the normal state, the function of the lymphatic vessels is dependent on the relationship between lymphatic fluid volume and the vessel transport capacity. When transport volumes exceed capacity or lymphatic vessels are dysfunctional and capacity cannot be maintained, interstitial edema develops. Mechanical insufficiency prevents reabsorption of the interstitial protein and macromolecules leading to the progressive accumulation of fluid and thus lymphedema. Prolonged presence of increased interstitial fluid results in inflammatory skin changes, tissue fibrosis, and adipogenesis. Patients with chronic lymphedema are at risk for recurring soft tissue infections due to stagnant fluid accumulation and cutaneous angiosarcoma due to chronic skin changes.

Primary lymphedema, or Milroy's disease, results from a mutation in *VEGFR3* affecting initial lymphatic fluid absorption and drainage. Secondary lymphedema implies an external stimulus (surgery, radiation, trauma, parasitic infection) has interrupted the drainage pathways. Cancer treatment remains the most common cause of lymphedema in the developed world. Mechanistic obstruction however may be simplistic as the sole etiologic factor for lymphedema as research has demonstrated that women with lymphedema have higher peripheral lymphatic flow (not lower as expected) and this increased flow is witnessed even in the contralateral upper extremity after surgery. Together, these events suggest the development of lymphedema may be systematically driven. Regardless, other genes that may influence lymphedema development include *SOX18, CCBE1, GJC2, GATA2, KIF11,* and VEGFC; however, little is known about genetic influences or predisposition to lymphedema after mechanical trauma.

Advancements in molecular science and lymphedema pathogenesis currently focus on lymphatic endothelial cell specific targets and receptors like VEGF-C, VEGF-D, VEGFR-3, LYVE1, PROX1, and Podoplanin (D2–40). These markers have provided insight into how lymphatic vessels function. Whether these endothelial targets can become therapeutically beneficial or direct lymphangiogenesis remains unclear, but several animal models have exhibited promising results. A further relationship between lymphatic function, immunity, inflammation, fibrosis, and fat is suspected with extensive research into IL-6, CD4, fibroblast growth factor-2, and adipogenesis demonstrating alterations in lymphatic flow and vasculature

function, but the exact mechanisms are also unclear.

Incidence

The precise risk of developing lymphedema has been difficult to ascertain. This problem is complicated by the fact that lymphedema has prolonged periods of latency, months to years, requiring diligent follow-up and consistent reporting among patients and clinicians. In addition, as only a fraction of patients will develop lymphedema, large numbers of patients must be followed. The heterogenous body of literature addressing lymphedema incidence after breast cancer treatment highlights these specific limitations and inconsistencies. In general, the incidence of lymphedema after breast cancer treatment is primarily dependent on the extent of axillary surgery performed. A recent pooled analysis of 6,711 breast cancer patients undergoing sentinel lymph node biopsy (SLNB) found the incidence of lymphedema to be 6.3% with a range of 0% to 23%. A similar analysis of 5,354 patients undergoing axillary lymph node dissection (ALND) found a pooled incidence of 28% (range 11% to 57%).

The variations in incidence are also reflected in several recent therapeutic breast cancer randomized controlled trials. These trials were designed to evaluate disease-free survival and overall survival with respect to differing axillary management strategies. As secondary endpoints though, they each sought to evaluate the incidence of lymphedema (Table 53.1). The National Surgical Adjuvant Breast and Bowel Project B-32 trial identified lymphedema in 8% SLNB and in 14% ALND patients. The After Mapping of the Axilla: Radiotherapy Or Surgery? (AMAROS) trial reported lymphedema in 13% to 23% of patients after ALND and 5% to 11% after axillary radiation therapy when defined by objective or subjective measures, respectively. The National Cancer Institute of Canada-Clinical Trials Group MA.20 trial reported a much lower incidence of lymphedema with only 4.5% of patients developing lymphedema after ALND + standard whole breast radiation while 8.4% of patients having ALND + both whole breast irradiation and comprehensive regional nodal radiation therapy (RNI) developed lymphedema. The EORTC RNI trial had a design similar to MA.20 and found lymphedema rates of 10.5% and 12% respectively in the control and intervention RNI arms. Finally, the American College of Surgeons Oncology Group Z0010 trial found lymphedema in 12% to 24% of SLNB patients and 40% to 41% of ALND patients when using objective and subjective measures

respectively. Collectively, these trials outline the persisting controversies in lymphedema research and lack of consensus with respect to follow-up, diagnostic criteria, and objective and subjective measures as reviewed in Table 53.1.

TABLE 53.1 Incidence and Definition of Lymphedema in Recent Randomized Controlled Trials With Lymphedema as a Secondary Endpoint

	B-32	AMAROS	MA.20(12)	Z10
Definition	>10% RVC	Subjective or >10% RVC	unclear	Symptoms or 2 cm
Length of follow-up (yrs)	3	5	5	5
SLNB	8%		4.5%	Sx: 12% Obj: 24%
ALND	14%	Sx: 23% Obj: 13%		Sx: 41% Obj: 40%
Ax XRT		Sx: 11% Obj: 5%		
ALND and RNI			8.4%	

AMAROS, after mapping of the axilla: radiotherapy or surgery?; SLNB, sentinel lymph node biopsy; ALND, axillary lymph node dissection; AX XRT, axillary radiation; ALND+RNI, axillary lymph node dissection and regional nodal radiation; RVC, relative volume change; Sx, subjective; Obj, objective.

The strong advocacy movements surrounding breast cancer have pushed issues of survivorship like lymphedema to the forefront of clinicians' minds. It has also led to the inaccurate assumption that the risk of developing lymphedema is synonymous only with breast cancer treatment. In fact, lymphedema may occur anytime a lymph node basin is disturbed. Cormier et al. published the most comprehensive review on the incidence of secondary lymphedema after treatment for non-breast cancers. Table 53.2 highlights the incidence of lymphedema according to cancer type. Several conclusions can be made in reviewing these data. First, the incidence of lymphedema varies with cancer type even if the affected nodal basin is consistent. For example, the risk of lymphedema appears to be less after melanoma treatment in the upper extremity than after similar axillary surgery for breast cancer. Second, there seems to be a

higher incidence of lymphedema when the at-risk limb is a lower extremity but again rates differ between cancer types. Third, the overall number of subjects and published manuscripts on this subject matter is far fewer than those addressing breast cancer-related lymphedema (BCRL). As a result, they generally lack large numbers or long-term follow-up, both of which are imperative to accurately determining lymphedema incidence.

A large body of data regarding lymphedema after melanoma does exist and suggests a pooled incidence of lymphedema of 4.1% after SLNB, 3% after ALND, and 18% after inguinofemoral lymph node dissection. Hyngstrom et al. recently published the most contemporary prospective assessment of 182 melanoma patients followed for 12 months after therapeutic lymph node surgery. Using both objective and subjective assessment, similar to breast cancer data they found lymph node dissection resulted in an increased likelihood for lymphedema over SLNB (OR 3.18, $p < 0.01$) and evidence of borderline significance suggesting lower extremity lymph node procedures resulted in a higher risk for lymphedema than upper extremity procedures (OR 1.72, $p = 0.07$). When compared with patients with <5% volume change in their limb, those with >10% difference demonstrated seven to nine times increase in lymphedema-related symptoms of swelling, tightness, and tenderness. Data from the Multicenter Selective Lymphadenectomy Trial I (MSLT 1) prospectively randomized patients undergoing wide excision of a primary melanoma to SLNB or observation alone with the plan that those with a positive SLNB would complete immediate or early lymph node dissection. Those developing regional nodal recurrence would undergo delayed completion lymph node dissection. Again, results from this prospective trial suggest the timing and anatomical site of completion ALND may influence lymphedema risk. With a median follow-up of 5 years, the authors found patients proceeding with immediate/early lymph node dissection experienced less lymphedema than those undergoing delayed lymph node dissection (12.4% vs. 20%, $p = 0.04$). In addition when stratified according to lymph node basin, inguinofemoral dissection was significantly more likely to result in lymphedema than ALND (26% vs. 9%, $p < 0.001$).

TABLE 53.2 Prevalence of Lymphedema in Non-Breast Cancers

Cancer Site	No. of Studies	Incidence (Range)
Head/neck	3	4% (0–8)
Genitourinary	8	11% (1–23)
Gynecologic	22	25% (0–73)
Melanoma	15	9% (1–66)
Sarcoma	1	30%

RISK FACTORS

The etiology of lymphedema remains unclear. As a result, multitudes of studies have attempted to determine risk factors after breast cancer treatment but unfortunately they lack agreement regarding the exact factors and the strength of the association between the specific risk factor and the risk of lymphedema. The extent of nodal surgery, radiation, obesity, infection, and injury remain the most commonly reported risk factors. The ensuing discussion focuses primarily on patients treated for breast cancer as there is a paucity of robust data on lymphedema risk factors in non-breast malignancies. However, it is assumed that many of these principles can be extrapolated to those malignancies as well.

Tsai et al. have reviewed 98 studies and found that lymphedema was more likely after mastectomy compared to lumpectomy (RR, 1.42; CI, 1.15–1.76), ALND compared to no dissection (RR, 3.47; CI, 2.34–5.15), ALND compared to SLNB (RR, 3.07; CI, 2.20–4.29), radiation versus no radiation therapy (RR, 1.92; CI, 1.61–2.28), and for positive versus negative axillary lymph nodes (RR, 1.54; CI, 1.32–1.80). DiSipio et al. also performed a systematic review and meta-analysis of 72 studies published between 2000 and 2012 assessing lymphedema of which 29 met inclusion criteria for risk factor review. Similarly, extensive surgery such as mastectomy, ALND, greater number of nodes removed, or obesity exhibited strong level evidence supporting a relationship with lymphedema development. Collectively these studies used 11 different definitions of lymphedema and exhibited a wide range of follow-up (1 month to 30 years) both of which should temper enthusiasm for the results. Nevertheless, this serves as the most contemporary assessment.

The randomized controlled trials evaluating the efficacy of SLNB to accurately stage the axilla in breast cancer also clearly demonstrate the reductions in lymphedema after SLNB when compared to ALND reporting

rates of 0% to 7% and 12% to 16%, respectively. While the extent of axillary surgery may be the most commonly cited risk factor, this explanation may be overly simplistic. Data by Goldberg et al. suggest it may be the relative degree of lymphatic destruction of each patient's lymphatic anatomy that is more influential in lymphedema development. They prospectively followed 600 SLNB patients and stratified them by mean, median, or range of number of nodes excised and found no difference in the rates of lymphedema ($p = 0.93$) even when >10 nodes were excised at SLNB. Interestingly, when the subset of SLNB patients with >10 nodes removed was compared to women having 10 to 17 nodes removed at ALND, they identified 11% of the ALND and none of the SLNB patients had lymphedema ($p = 0.04$), suggesting that the relative extent of lymphatic damage may have been greater in the ALND group over the SLNB group despite a similar number of nodes removed.

Given that radiation frequently couples with nodal surgery for optimal oncologic treatments and that few studies include detailed descriptions of the radiation treatment fields, it can be difficult to extract the individual or incremental risk of radiation alone. The variations in lymphedema incidence seen in AMAROS and MA.20 (Table 53.1) attest to this fact. When reviewing simply radiation tangets alone, Cormier et al. performed a systematic literature review and reported the risk of lymphedema to be 14.5% after breast or chest wall radiation, 31.5% after breast/chest wall plus supraclavicular radiation, and 41.4% when a posterior axillary boost was added. Shah et al. also evaluated the impact of radiation on 1,861 breast cancer patients who completed breast conserving surgery and whole breast radiation. They found the risk of lymphedema was less than that reported by Cormier ranging from 8.3% to 14.7% according to whether supraclavicular, posterior axillary, or internal mammary nodes were treated. However, patients were significantly more likely to develop lymphedema if they had more nodes removed, extracapsular extension, advanced nodal status, grade III disease, or received adjuvant systemic therapy (all $p < 0.02$).

Less robust data suggest obesity and its associated comorbid conditions may increase the risk for lymphedema. A study of 455 patients treated for breast cancer found an overall rate of lymphedema of 27%. Among those with lymphedema, 92% were found to have an elevated body mass index (BMI) >25 kg/m^2 and their data concluded that obesity was an important risk factor for lymphedema ($p < 0.001$). Ridner et al. evaluated 138

patients with preoperative and postoperative measures in a prospective longitudinal study with 30-month follow-up. They found that breast cancer survivors who had a BMI >30 at the time of cancer treatment were 3.6 times more likely to develop lymphedema by 6 months than those with a BMI <30 (OR 3.6, 1.42–9.04, p = 0.007). Interestingly however, those with an increase in BMI to 30 or greater over the survivorship follow-up period were no more likely to develop lymphedema than those who maintained a BMI <30.

Many of the recommended and practiced preventative measures detailed below focus on reducing the risk of injury or infection to the at-risk extremity in an effort to reduce the future risk of lymphedema. Unfortunately injury and infection after nodal surgery have been difficult to capture and stratify as clear risk factors. Data evaluating patient injury or infection are primarily based on the patient's ability to recall an inciting event. Unfortunately this recall bias subjects the reported data to significant limitations as those affected with lymphedema are more likely to recall infection or injury.

While clinicians acknowledge many risk factors for lymphedema, it is clear that the development of lymphedema is likely multifactorial and includes not only clinical risk factors but also anatomical and genetic predispositions. Little effort has been put forth to individualize patient lymphedema risk, and therefore most preventative measures are widely applied to all at risk and more likely to be applied to those women with a history of breast cancer over other malignancies.

DIAGNOSING LYMPHEDEMA

Diagnosing lymphedema begins with a history and physical examination followed by one or a combination of the following objective and/or subjective measures. Many objective tools exist to measure lymphedema. The ideal tool would be easy to use, cost and time efficient, hygienic, reproducible, and noninvasive. Water displacement is the historic gold standard for limb volume measurement, and the tools are relatively inexpensive. However, it is cumbersome to incorporate into a busy clinical setting given infection control guidelines. More importantly, water displacement while considered sensitive and specific is unable to localize the lymphedema to a particular portion of the extremity (hand, forearm, upperarm, foot, calf, thigh).

Worldwide circumferential limb measurements are the most widely

used method of quantifying lymphedema. A nonstretch, flexible tape measure should be used to perform circumferential measures at specific anatomic points. These measurements are then used to calculate limb volumes using equations for a truncated cone or frustrum. There is no agreement as to the number of or distance between points needing to be measured or what constitutes a key measurement difference between limbs. The literature reports a heterogeneous collection of definitions ranging from 1 cm, 2 cm, and 3 cm differences at a specific point or 100 cc, 200 cc volume differences between limbs or relative volume changes of >10%, >20%. While inexpensive, this method suffers from significant inter-rater and intra-rater variability. As a result, it is ideal to limit the number of clinicians performing the measurements and ensure they undergo consistent training and quality assessment.

Perometry uses infrared light to measure the limb volume at various points. The machine is mounted on a table allowing for the open frame to be moved along the length of the extremity producing output points then creating a volumetric image of the limb. It allows for efficient segmental identification of the limb swelling with minimal to no patient discomfort.

Bioimpedance spectroscopy uses resistance to electrical currents to measure and compare the composition of extracellular compartments within affected and unaffected limbs. Elevations in extracellular fluid volume (including lymph fluid) result in a decrease in the impedance in the affected limb. The commercially available L-Dex device marketed by Impedimed is FDA-approved for the assessment of unilateral upper extremity lymphedema. Small EKG-like gel electrodes are placed on the skin between the areas of interest. The L-Dex device produces a ratio normalizing the contralateral/normal limb. An increase by >10 L-dex units from baseline measurement or a value outside of the normal range may suggest the diagnosis of early-stage lymphedema. The role for bioimpedance remains unclear, but it may be best suited for diagnosing early subclinical lymphedema as circumferential arm measurements or water displacement may have difficulty in detecting subtle changes in arm volumes <150 cc. However, a recent study suggests little correlation between volume displacement and bioimpedance ratios. Other imaging modalities have been suggested to aid in the diagnosis of lymphedema and include lymphoscintigraphy for assessment of lymphatic flow rates and high-frequency ultrasound; however, studies validating these techniques include very small numbers of patients and are generally used only in

research settings. Early data of lymphoscintigraphy suggest it may be reliable reporting sensitivity and specificity of 73% and 100%, respectively.

Several studies use patient-reported symptoms of heaviness or swelling to define and diagnose of lymphedema. Unfortunately little work demonstrates clear correlations between symptoms and objective measures. Patients may report a symptom without meeting a set objective measurement threshold or have measurements beyond the threshold and remain asymptomatic. Arm dominance and weight may contribute to this discordance. However, it could be argued that the patient's symptoms are the most important indicator of lymphedema as it may be these perceptions that will negatively impact quality of life.

Armer et al. sought to determine the best diagnostic method and definition for diagnosing lymphedema. She measured 118 women after breast cancer treatment with perometry, circumferential measures at 4 cm increments, and subjective assessment using validated questionnaires. She used four different definitions of lymphedema, including: 200-mL perometry limb volume change, 10% limb volume change, 2-cm circumferential arm increase, and subjective report of heaviness or swelling "now" or within the "past year" to define lymphedema. At 60-month follow-up, the incidence of lymphedema ranged from 43% to 94% with signs or symptoms or a 10% limb volume change being the most conservative definitions and 2-cm difference being the most liberal definition. These findings and the frequent lack of baseline findings in reported studies support the inability to identify one consistent "best" diagnostic technique or definition. Currently, the National Lymphedema Network does not recommend one measurement technique or definition over another but supports circumferential measures, bioimpedance, or perometry and emphasizes that baseline and follow-up ipsilateral and contralateral measures are critical.

Clearly choosing the method for lymphedema diagnosis can be challenging. Furthermore, clinicians must understand the advantages and limitations to the diagnostic modality chosen. Regardless, it is imperative that measurements begin preoperatively or pretreatment and continue at standardized intervals post treatment. In addition, measurements must be taken in both the ipsilateral and contralateral extremities for appropriate comparisons to be made and account for arm dominance and weight changes that may occur over time.

STAGING AND EARLY DETECTION

Various staging systems are in use to evaluate the severity of lymphedema in the limbs, but the Foldi scale and the International Society of Lymphology (ISL) scale are most commonly cited (Table 53.3). Figure 53.1 demonstrates severe clinical lymphedema. In general, the staging systems agree on the clinical signs and symptoms as well as on the presence of a latent or subclinical stage, whereby lymphatic transport is altered but does not result in clinical symptoms. Many researchers debate the significance of the stage 0 classification as this group may simply represent those at risk for the development of lymphedema. The surge in research devoted to identifying patients with stage 0 lymphedema underscores the trend in lymphedema specialists' perpetual effort to identify patients at the earliest stage possible. Several hypothesis generating studies suggest early diagnosis and intervention may halt or even reverse lymphedema progression. First, Stout-Gergich prospectively followed 196 women after breast cancer treatment setting an arbitrary threshold of 3% difference between arms. If a woman reached this threshold, she was treated with a compression garment for 4 weeks. This resulted in a >50% volume reduction in the affected arm at a mean of 4.8 months. Second, Bar Ad reported on the importance of mild lymphedema demonstrating that 48% of women with mild lymphedema were likely to progress to a more severe form within 5 years if not treated. The best way to diagnose subclinical or early lymphedema remains debatable. Barrio et al. prospectively followed 223 women treated for breast cancer for lymphedema assessing by both volume displacement and bioimpedance. At a median of 18.2 months, 4/25 women with abnormal biopimedance ratios developed lymphedema while 9 additional women developed lymphedema without a prior bioimpedance abnormality. The researchers found poor correlations between volume displacement measures and bioimpedance at 3 (r = 0.31) and 6 (0.21) months and acknowledge that most women with lymphedema did not have a prior abnormal bioimpedance value. As patients rarely exhibit symptoms in this latent phase, diagnosis of subclinical lymphedema without subjecting patients to a more invasive test like lymphoscintigraphy to document lymphatic flow rates is difficult.

TABLE 53.3 Common Staging Systems to Evaluate the Severity of

Lymphedema

Foldi Scale		International Society of Lymphology Scale		
	Clinical signs and symptoms		Clinical signs and symptoms	Severity
0	■ Latency ■ Asymptomatic	0	■ Latent; swelling not evident but altered lymphatic transport	Subclinical
I	■ Spontaneously reversible ■ Pitting edema	I	■ Early accumulation of fluid ■ May subside with extremity elevation	Minimal; <20% volume increase
II	■ Spontaneously irreversible ■ Extensive fibrosclerosis ■ Proliferation of adipose tissue ■ Not reduced with elevation	II	■ Limb elevation no longer reduces swelling ■ Pitting edema ■ Tissue fibrosis in late stage II	Moderate; 20%–40% volume increase
III	■ Elephantiasis	III	■ Lymphostatic elephantiasis ■ Tropchi skin changes ■ Acanthosis ■ Fat deposits ■ Wart-like overgrowths	Severe >40% increase in limb volume



Figure 53.1. Severe lymphedema right arm.

Specialized grading scales exist for the staging of head and neck lymphedema. These have been prospectively validated and similar to the extremity grading scales aim to categorize patients by the extent of swelling and fibrosis but also add the palpable consistency of the tissue as well.

PREVENTION

Prediction

As evidenced by the multitude of studies reporting various risk factors, diagnostic modalities, and definitions for lymphedema, it is no surprise that clinicians are unable to accurately predict which patients will develop lymphedema. As a result, women worry about lymphedema out of proportion to reported risks and long practiced risk-reducing strategies including avoidance of blood pressure, needle sticks, flying, heavy lifting, or tight clothing continue to be recommended to all patients without regard to their individual risk. Furthermore, clinicians lack high-quality evidence supporting or refuting the efficacy of these intuitive, well-intentioned physiologically based activities. The highest quality data regarding risk-reducing strategies come from a subanalysis of the prospectively randomized Physical Activities and Lymphedema (PAL) trial, which reviewed 30 different prevention practices and found only sauna use to be significantly associated with lymphedema risk on multivariate analysis. Regardless, educational strategies focus on all patients treated for breast cancer but are rarely discussed in the context of lymph node removal for non-breast malignancies creating further patient and clinician confusion.

In an attempt to refine and optimize delivery of prevention strategies, several studies have evaluated mathematical models to augment prediction. Bevilacqua et al. developed a nomogram after prospectively following 1,054 women who had ALND for treatment of breast cancer. Concordance indices for the three models when compared to the validation set were 0.70, 0.72, and 0.73 suggesting this may be useful. The nomogram is available for free at www.lymohedemarisk.com. Kim et al. identified the number of nodes removed, adjuvant chemotherapy, and supraclavicular radiation as the key independent risk factors for the development of lymphedema. Using these factors, they created a simple model to aid prediction showing that patients with 0–1 risk factors had a 5-year probability of 3%, 2 risk factors had a 19% probability, while 3 risk factors had a 38% probability of developing lymphedema at 5 years.

Campanholi et al. developed a similar model based in melanoma patients assigning points to individual risk factors, such as graft reconstruction, Breslow thickness >4 mm, ilioinguinal lymphadenectomy, and wound infection. The model score was found to have an area under the curve of 0.82 (95% CI 0.71–0.93) with a sensitivity of 70.8% and specificity of 80%. Although hypothesis generating, none of these models have been widely adopted in clinical practice.

Clinical Trials

The realization that modern systemic therapies reduce locoregional recurrences in addition to distant disease risk has fostered a new era in clinical trial development with respect to axillary surgery. Given that ALND seems to be the biggest driver for lymphedema, these recent clinical trials hypothesize that a tailored approach to axillary surgery or radiation may reduce axillary morbidity and specifically lymphedema without negatively affecting survival. The SLNB randomized trials reviewed above certainly attest to this movement. More recently, the ACOSOG Z0011 trial prospectively randomized women undergoing breast conserving surgery with one or two positive sentinel lymph nodes (SLNs) to either completion ALND or no further axillary surgery. They reported regional recurrence rates <1% in both arms and no differences between the overall survival (91.8% vs. 92.5%) and the disease-free survival (82.2% vs. 83.9%) between cohorts, concluding that SLNB alone in this population was not inferior to ALND. The ACOSOG 1071, SENTINA, and SN FNAC trials evaluated the accuracy and false negative rates of SLNB after neoadjuvant chemotherapy in patients with a positive axillary node at presentation. Collectively these trials find SLNB to be accurate with a false negative rate <10% when dual tracer mapping (blue dye and nuclear injection) is used and more than three SLNs are removed. Based on these data, the ALLIANCE 11202 and NRG B 51cooperative group trials are actively evaluating the role of selective ALND +/- axillary radiation in patients treated with neoadjuvant chemotherapy. Lymphedema is a secondary endpoint. Interestingly however, to date data from Z0011 have not demonstrated a difference in lymphedema rates between treatment arms.

Surgery

Emerging surgical techniques performed at the time of initial axillary

surgery seek to prevent lymphedema. The most widely reported is axillary reverse mapping (ARM), which hypothesizes that the upper extremity has lymphatic drainage pathways separate from the breast and that sparing the arm lymphatics will reduce lymphedema. By isolating the lymph nodes draining the breast with technetium and those draining the arm with blue dye, the surgeon attempts to preserve those draining the arm. Pioneering work done by Klimberg and Boneti has demonstrated variations in arm lymphatic pathways and their relationship to breast sentinel nodes (Fig. 53.2). To date nine studies with more than 50 patients published since 2011 have reported on ARM of which seven reported lymphedema rates, although the follow-up and definition of lymphedema vary (Tables 53.4 and 53.5). Concerns surrounding ARM have been focused on ARM identification rates and the risk of crossover lymph nodes/lymphatics where the breast SLNB is also an ARM node. Salvage of the efferent blue ARM lymphatics is critical to maintain drainage but may be challenging in axillae with heavy tumor burden. Review of the current literature suggests increasing rates of ARM node identification with ALND likely secondary to increased exposure and dissection when compared to SLNB. Currently reported ARM node crossover rates in ALND patients range from 7% to 49%. Most importantly, however, the rate of lymphedema appears to be <10% after ALND when the ARM nodes can routinely be saved. Although longer follow-up is critical to validate these findings, these results are optimistic.

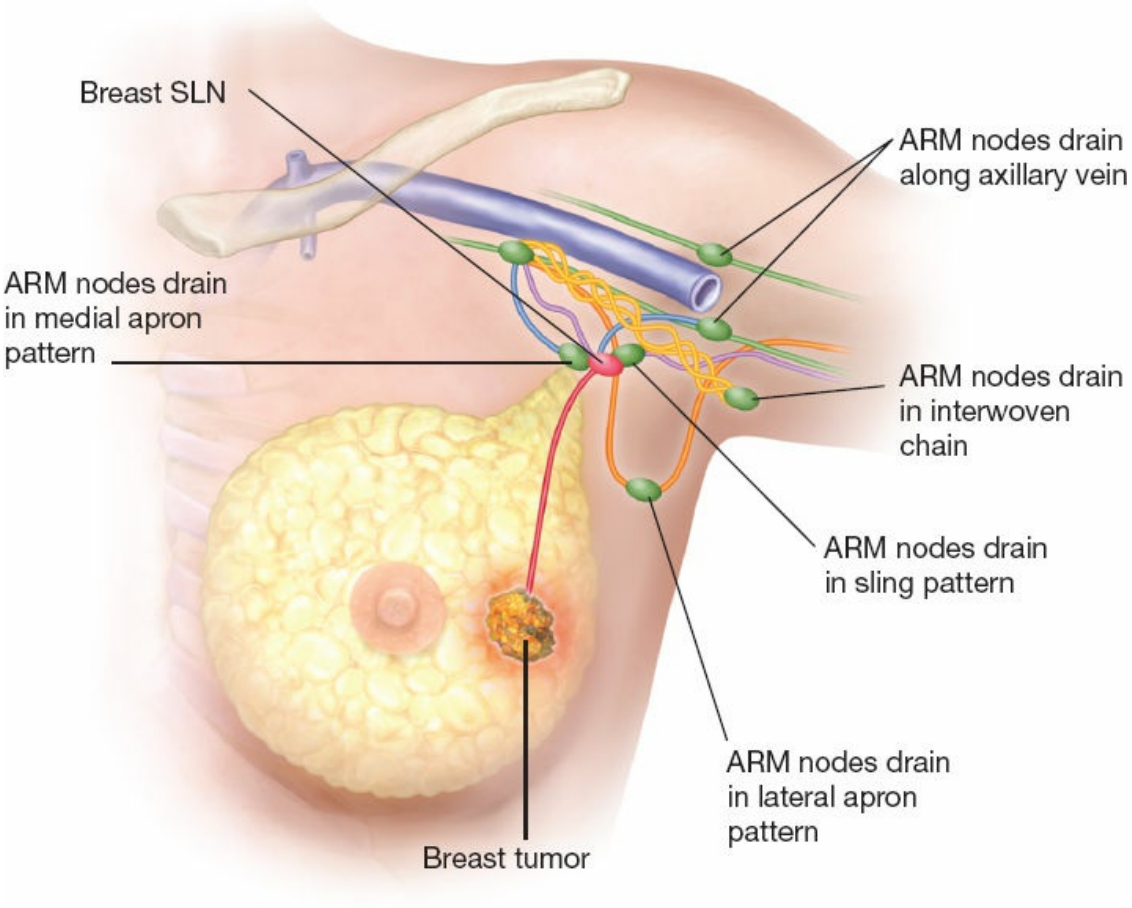

Figure 53.2. Five variations in upper extremity lymphatic drainage as demonstrated by axillary reverse mapping (ARM) and their relationship to the breast sentinel lymph node (SLN).

TABLE 53.4 Summary of Axillary Reverse Mapping (ARM) Outcomes in Patients Undergoing Axillary Lymph Node Dissection

Study	N	ARM Node Identification Rate	Crossover Rate[a]	Metastatic Disease in ARM Node	Lymphedema Rate[b]	Definition of Lymphedema	Follow-up (mos)
Ikeda	60	48/60 (80%)	NR	7/48 (15%)	NR	NR	NR
Han	83	70/83 (84%)	7/97 (7%)	2/17 (12%)	0	2 cm	96
Gobardhan	93	90%	NR	11/93 (12%)	NR	NR	NR
Connor	57	41/57 (72%)	10%	3/19 (16%)	NR	2 cm	NR
Gennaro	60	45/60 (75%)	NR	NR	9%	>2 cm or subjective	16
Tausch	143	112/143 (78%)	55/112 (49%)	17/115 (15%)	23%	>10%	19
Ikeda	98	81/98 (83%)	NR	NR	5/19 (26%)	2 cm	24
Ochoa	123	93/123 (75%)	4.3%	5/27 (18.5%)	4.8%	>20%	18
Yue	138	129/138 (93%)	NR	11 (8.5%)	7/118 (5.9%)	2 cm	20

[a]ARM node is also sentinel node.
[b]Lymphedema rate when ARM nodes spared.
NR, not reported.

TABLE 53.5 Summary of Axillary Reverse Mapping (ARM) Outcomes in Patients Undergoing Sentinel Lymph Node Biopsy

Study	N	ARM Node Identification Rate	Crossover Rate[a]	Lymphedema Rate[b]	Definition of Lymphedema	Follow-up (mos)
Deng	69	100%	6/69 (9%)	NR	NR	NR
Connor	155	47%	12%	3%	>2 cm	12
Sakurai	327	120/327 (37%)	76/327 (23%)	0/245	1–2 cm mild >2 cm severe	28
Ochoa	237	80/237 (34%)	4.3%	1.7%	>20%	18

[a]ARM node is also sentinel node.
[b]Lymphedema rate when ARM nodes spared.
NR, not reported.

While ARM aims to preserve arm lymphatics, surgeons performing lymphatic microsurgical preventive healing approach (LYMPHA) seek to identify arm lymphatics in the ALND field, then perform lymphatic to venous anastomoses via “dunking” microsurgical techniques in the presence of a competent venous valve (Fig. 53.3). Boccardo et al. first published this method in 2009 and recently reported their 4-year follow-up. Defining lymphedema volumetrically and with lymphoscintography, they demonstrated an ongoing lymphedema rate of 4% (3/74 patients) at 4 years follow-up after ALND that increased to 10.5% when they expanded their definition to include patients with transient postoperative lymphedema. Interestingly, lymphoscintography performed postoperatively demonstrated patent lymphovenous anastomoses in the remaining 71 patients at 1 to 4 years follow-up. Feldman et al. successfully completed LYMPHA in 24 patients and followed them for 26 months. They performed an average of 1.5 anastomoses per ALND patient and defined lymphedema as a combination of abnormal L-Dex bioimpedance ratios, arm measurements, and clinical symptoms. They reported an ongoing lymphedema rate of 8%, which increased to 12.5% when those with transient lymphedema were included. Regardless, this rate is much improved when compared to their own institutional historical cohort where 30% of women were diagnosed with lymphedema after ALND. Together, these studies suggest a benefit to immediate lymphovenous anastomosis (LVA) during ALND; however, the added cost, impact on operative time, and need for specialized microsurgical training must be considered for LYMPHA if the technique is to be adopted for all ALND patients.

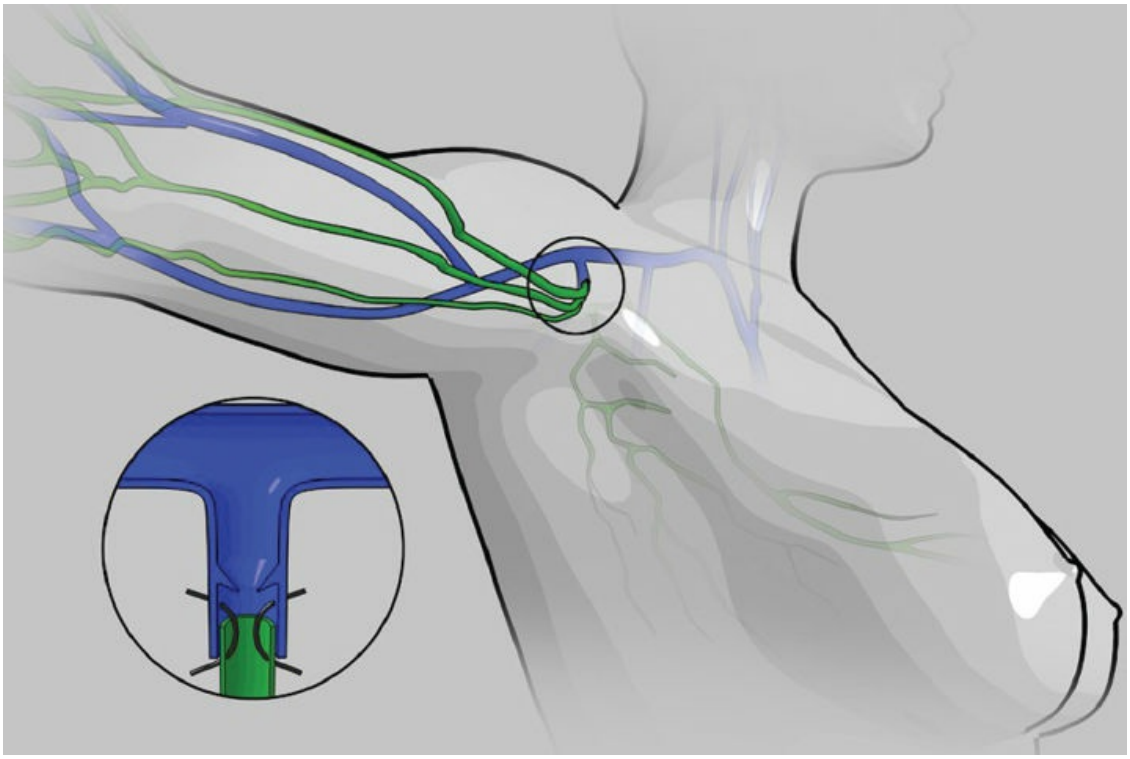

Figure 53.3. Technical aspects of lymphatic microsurgical preventative healing. The functioning lymphatics (green) draining the upper extremity are collectively gathered in the axilla and "dunked" and fixed into a vein tributary (blue) draining into the axillary vein. Illustrated by Peter Kuempel, Courtesy of Sheldon Feldman, MD Columbia University Medical Center.

The influence of breast reconstruction on the risk of lymphedema has been controversial with some purporting reconstruction to decrease risk of lymphedema. Review of five studies each with >300 patients compared subsequent lymphedema rates after any type of reconstruction (immediate or delayed, implant or autologous) finding significantly lower rates of lymphedema in the setting of breast reconstruction (3% to 9%) when compared to no reconstruction (9% to 18%). Unfortunately, these studies are limited by vague study design, short follow-up, and inability to stratify according to axillary surgery performed or other treatment characteristics. The most contemporary data however challenge these findings. Basta et al. performed a propensity matched analysis of breast reconstruction on the subsequent development of lymphedema. Using matched cohorts of 239 patients each, they found lymphedema in 19.2% of reconstruction patients and in 20.1% in no-reconstruction patients (p = 0.82) at >55 months follow-up. The authors concluded breast reconstruction did not appear to influence lymphedema rates either positively or negatively. Further study

into the relationship between breast reconstruction and lymphedema is warranted, although at present collective data suggest that breast reconstruction should not be withheld from patients based on concern for lymphedema.

TREATMENT

Complex Decongestive Therapy (CDT)

While treatment for lymphedema remains controversial and should be individualized, it is safe to say that the cornerstone of lymphedema therapy is still complex decongestive therapy (CDT). CDT is composed of manual lymphatic drainage (MLD), compression (both bandages and garments), skin care, and exercise. The first phase of CDT aims to reduce swelling, while the second phase aims to maintain limb volume reduction.

MLD aims to encourage lymphatic transport by rerouting lymphatic flow away from the obstructed lymphatics and toward normally functioning lymphatic basins. MLD is provided by a specially trained therapist who uses light massage strokes applying tension to the skin which in turn stimulates stretch in the superficial lymphatics and contraction in the deeper lymphatic channels. Patients then practice remedial exercises, and then compression bandages are applied to the arm. MLD is performed 5 days per week in the reduction phase. This cycle continues for 1 to 4 weeks until limb volume plateaus, then the maintenance phase begins. In the maintenance phase, patients wear compression bandages at night and compression garments during the day and continue to practice good skin care and remedial exercises daily. In an effort to standardize MLD and CDT treatments, the Lymphology Association of North America has established a standardized examination to certify lymphedema therapists. A list of certified therapists according to zip code can be found on the LANA Web site.

Compression bandaging and garments are key components to CDT and long-term lymphedema treatment maintenance. Compression bandages are short stretch bandages applied in multiple layers and designed to maintain volume reductions achieved through lymphatic drainage. These short stretch bandages have a low resting pressure and are therefore comfortable for patients to wear, but with increased muscular contraction these bandages maintain their integrity (high working pressure) enhancing lymphatic pumping, reducing capillary filtration, and preventing refilling of the tissue spaces cleared through MLD. Compression garments are the

most widely used form of compression as they are simpler to apply than bandages. They aim to limit re-accumulation of edema following reductions gained with MLD and bandaging. Their mechanism of action is unclear, but physiology suggests they may maintain an increased interstitial pressure and therefore interstitial fluid homeostasis.

A systematic review of 26 studies evaluating lymphedema management strategies supports the benefits of both MLD and compression bandaging with the greatest limb reductions identified when both therapies were used in combination. MLD alone for the specific intent of limb volume reduction is ineffective when used independently from CDT. A review published by Mosely et al. also supports these findings concluding that intensive treatment provided by health care professionals produced larger volume reductions than therapies performed solely by the patient. Overall it is estimated that CDT reduces limb volume by 30% to 70% with degree of volume reductions primarily linked to the baseline extremity volume, edema severity, and number of CDT sessions completed. MLD also significantly contributed to reductions in patient perceived symptoms of limb heaviness and tension especially when used in a palliative setting. Finally, MLD may be the best treatment option in patients with head and neck, genital or breast lymphedema when compression bandaging is not an option.

Despite significant gains in volume reduction achieved by CDT, recent randomized trials may temper enthusiasm for CDT. McNeelly et al. randomized women to 4 weeks of CDT versus compression garments alone. Patients participating in either study arm demonstrated significant limb volume reductions; however, the maximum volume reduction did not differ between trial arms (CDT: 46% vs. compression: 39%, $p = 0.22$). With a similar trial design, Andersen et al. also randomly assigned women to CDT or compression and also showed no significant difference in volume reductions between the two trial arms ($p = 0.66$). Finally, Dayes et al. performed the most rigorous randomized trial randomly assigning 103 women to CDT or compression bandaging but also standardized arm measurement techniques, required maintenance of diary logs, and actively performed monitoring to ensure treatment compliance. The groups were well-balanced with respect to BMI, duration of lymphedema, and oncologic treatments, although the CDT group did have a higher percentage of patients with larger limb volumes at commencement of treatment. They found no significant difference in percent volume

reduction at 6 weeks with a mean 29% reduction in the CDT and 23% in the compression groups, $p = 0.34$. This outcome was sustained to 52 weeks follow-up. Importantly, the authors also reported no difference in quality of life or symptoms between the groups. While these trials are limited by relatively small numbers and short follow-up, they provide enough evidence to establish the controversy surrounding the added value of CDT for first-line lymphedema therapy. That said, the impact of untreated lymphedema is significant and overall all these treatment strategies provide minimal morbidity.

Maintenance of volume reduction can be challenging as it requires strict adherence to treatment strategies with daily care performed by the patient or caregiver. Adherence with therapist-prescribed self-care modalities among women with breast care-related lymphedema has been documented to be variable. Brown et al. questioned 141 breast cancer survivors about their self-care practices of physical therapy exercises, bandaging, self-administered lymphatic drainage, pneumatic compression pump usage, compression garments, and taping. Over 12 months, they reported decreased prescriptions for therapist-administered treatments but still found 39% of women followed <50% of the recommendations with the trend of high adherence to low adherence over time. They concluded that adherence to self-care is suboptimal for this lifelong condition. Reasons for noncompliance may include patient difficulty with application of compression bandages, prolonged time commitment required for adequate daily therapy, or discomfort with bandaging in warm or humid climates. In addition, pumps, bandages, and sleeves can interfere with sleep or be cumbersome to use during daily activities. Finally, bandages and supplies must be replaced on a regular basis (at least twice annually). These costs frequently are not covered by private insurance or Medicare, which may deter adherence.

Exercise

Historically, patients with lymphedema have been discouraged from exercise and those at risk for lymphedema have been cautioned against certain sports or lifting activities fearing those behaviors may increase cellular waste products and lead to subsequent extracellular fluid accumulation causing lymphedema. However, as rates of obesity rise in cancer survivors and the acknowledgment that obesity may increase cancer recurrence in some settings, the NCCN has embarked on a campaign to

encourage healthy lifestyles in survivors, including maintenance of physical activity. Patients with lymphedema are considered at moderate risk of an exercise induced adverse event. Kwan et al. published a systematic review of 19 studies evaluating resistance and aerobic exercises in women at risk for or affected with BCRL. Evidence from this review suggests exercise can be safe in both populations when appropriately supervised and does not cause or exacerbate lymphedema. The largest randomized controlled trial evaluating exercise in women with lymphedema randomized 141 women to twice weekly weight training with compression garment or standard activity. The authors found no increase in lymphedema and interestingly found fewer and less severe exacerbations in the intervention cohort. The NCCN supports the concept that women with lymphedema should wear compression garments during exercise and begin supervised programs starting with low weights, low repetitions with gradual increases. Controversy remains surrounding the role of prophylactic use of compression garments during exercise in at-risk women and should be individualized.

Unfortunately little data exist regarding the risks or benefits of exercise in non-breast cancer survivors at risk for or affected by lymphedema. Specifically, data regarding lower limb lymphedema are sparse. One cross-sectional study of 213 uterine cancer survivors reported that patients with at least 18 MET hours per week of physical activity were less likely to develop lower limb lymphedema when compared with those with <3 MET hours (OR 0.32, 95% CI 0.15–0.6, p = 0.003). Given the paucity of additional validating studies, the authors concluded these findings should be viewed as preliminary but nonetheless can be viewed with cautious optimism. Clinicians should embrace exercise as being safe when performed under appropriate supervision in patients at risk for or affected by lymphedema.

Surgery

Advancements in microsurgical techniques have brought about the resurgence in interest of exploring surgery as a cure for lymphedema. While the concept of cure is enticing for such a chronic debilitation complication like lymphedema, enthusiasm for these surgical interventions should be tempered by the overwhelming lack of consensus surrounding lymphedema etiology, pathophysiology, definition, and diagnostic modalities worldwide. As a result of these limitations, the published

literature addressing surgery for lymphedema patients is very heterogeneous with regard to surgical timing and indications, hindered by short follow-up and small numbers, inconsistent reporting on quality-of-life outcomes, and frequently does not eliminate the need for CDT and/or compression to maintain volume reduction gains. Broadly, surgical procedures can be categorized as excisional or reductive, reconstructive, or tissue transfer.

Historically, surgeons performed the Charles procedure excising large areas of the affected fibrotic lymphatic tissues. In the modern era, specialized liposuction cannulas can be used to reduce limb bulk. This technique has been popularized by Brorson et al. Both techniques result in over 100% limb volume reduction, but strict adherence to posttreatment compression garments and therapy regimens is critical to maintaining reduced limb size. More importantly, excisional procedures fail to alter the underlying etiologic cause of lymphedema.

Surgeons performing lympholymphatic and lymphovenous anastomosis (LVA) use microsurgery to connect severed lymphatics or to divert lymphatic flow to the venous system. The technique requires multiple microsurgical anastomoses as targeted vessels range from 0.2 to 0.6 mm in diameter and surgeons seek to perform as many anastomoses as possible. Lymphoscintography is variably used to demonstrate functionality. Alternatively patient symptoms can be followed. Lymph node transfer (LNT) requires harvest of a small flap of lymphatic tissue containing lymph nodes, the vascular supply, and surrounding fat. The tissue is transferred to the affected lymphatic basin or extremity. Researchers hypothesize transferred lymphatic tissue promotes VEGF-C production encouraging lymphatic collateralization and regeneration. Animal studies support this hypothesis as transferred lymph nodes have demonstrated rapid infiltration of functional host lymphatics correlating with elevated endogenous VEGF C expression in the perinodal fat. Both LVA and LNT are likely most effective in early lymphedema as patients tend to have some remaining functional lymphatics.

Cormier et al. reviewed 8 LVA studies evaluating 990 patients and found a weighted limb reduction of 54%. They also reviewed 4 tissue transfer studies evaluating 61 patients and found a weighted limb reduction of 48%. However, little to no data are presented on the potential morbidity of the donor site in the LNT patients. Basta et al. reviewed 27 studies offering level III or IV evidence of which 22 studies evaluated LVA and 5

LNT. Overall, excess volume was reduced 56%, 91% reported subjective improvement, and 65% reported discontinuation of their compression garments. Unfortunately, 11.8% of patients had no change in their lymphedema and 35% experienced some kind of complication with the surgery. Many clinicians point to the largest LVA study to date to support surgery for lymphedema. This study reports on 1,800 patients treated with LVA over a 10-year period of time and notes a 56% limb reduction and 85% discontinuation of compression garments. While these results are exceedingly good, the methods and results section for this manuscript is shockingly brief limiting interpretation, not to mention that the authors fail to acknowledge the vast changes in surgical technique over the 10 years of the study.

The enthusiasm for surgery in lymphedema is growing in both the prevention and treatment arenas. Early data are encouraging. However, small numbers, short follow up, nonstandardized indications, techniques, and evaluation parameters hinder the ability to draw clear evidenced based conclusions. Finally, none of these procedures obviate the need for post-surgical compression therapy or CDT.

Suggested Readings

Ahmed RL, Prizment A, Lazovich D, et al. Lymphedema and quality of life in breast cancer survivors: the Iowa Women's Health Study. *J Clin Oncol* 2008;26(35):5689–96.

Armer JM, Stewart BR. A comparison of four diagnostic criteria for lymphedema in a post-breast cancer population. *Lymphat Res Biol* 2005;3(4):208–17.

Armer JM, Stewart BR. Post-breast cancer lymphedema: incidence increases from 12 to 30 to 60 months. *Lymphology* 2010;43(3):118–27.

Aschen S, Zampell JC, Elhadad S, et al. Regulation of adipogenesis by lymphatic fluid stasis: part II. Expression of adipose differentiation genes. *Plast Reconstr Surg* 2012;129(4):838–47.

Aschen SZ, Farias-Eisner G, Cuzzone DA, et al. Lymph node transplantation results in spontaneous lymphatic reconnection and restoration of lymphatic flow. *Plast Reconstr Surg* 2014;133(2):301–10.

Ashikaga T, Krag DN, Land SR, et al. Morbidity results from the NSABP B-32 trial comparing sentinel lymph node dissection versus axillary dissection. *J Surg Oncol* 2010;102(2):111–8.

Avraham T, Daluvoy SV, Riedel ER, et al. Tissue expander breast reconstruction is not associated with an increased risk of lymphedema. *Ann Surg Oncol* 2010;

17(11):2926–32.

Bar Ad V, Dutta PR, Solin LJ, et al. Time-course of arm lymphedema and potential risk factors for progression of lymphedema after breast conservation treatment for early stage breast cancer. *Breast J* 2012;18(3):219–25.

Barrio AV, Eaton A, Frazier TG. A prospective validation study of bioimpedance with volume displacement in early-stage breast cancer patients at risk for lymphedema. *Ann Surg Oncol* 2015;22(Suppl 3):S370–S375.

Basta MN, Fischer JP, Kanchwala SK, et al. A propensity-matched analysis of the influence of breast reconstruction on subsequent development of lymphedema. *Plast Reconstr Surg* 2015;136(2):134e–43e.

Basta MN, Gao LL, Wu LC. Operative treatment of peripheral lymphedema: a systematic meta-analysis of the efficacy and safety of lymphovenous microsurgery and tissue transplantation. *Plast Reconstr Surg* 2014;133(4):905–13.

Bevilacqua JL, Kattan MW, Changhong Y, et al. Nomograms for predicting the risk of arm lymphedema after axillary dissection in breast cancer. *Ann Surg Oncol* 2012;19(8):2580–9.

Boccardo F, Casabona F, De Cian F, et al. Lymphatic microsurgical preventing healing approach (LYMPHA) for primary surgical prevention of breast cancer-related lymphedema: over 4 years follow-up. *Microsurgery* 2014;34(6):421–4.

Boileau JF, Poirier B, Basik M, et al. Sentinel node biopsy after neoadjuvant chemotherapy in biopsy-proven node-positive breast cancer: the SN FNAC study. *J Clin Oncol* 2015;33(3):258–64.

Boughey JC, Suman VJ, Mittendorf EA, et al. Sentinel lymph node surgery after neoadjuvant chemotherapy in patients with node-positive breast cancer: the ACOSOG Z1071 (Alliance) clinical trial. *JAMA* 2013; 310(14):1455–61.

Brorson H, Ohlin K, Olsson G, et al. Breast cancer-related chronic arm lymphedema is associated with excess adipose and muscle tissue. *Lymph Res Biol* 2009;7(1):3–10.

Brown JC, Cheville AL, Tchou JC, et al. Prescription and adherence to lymphedema self-care modalities among women with breast cancer-related lymphedema. *Support Care Cancer* 2014;22(1):135–43.

Brown JC, John GM, Segal S, et al. Physical activity and lower limb lymphedema among uterine cancer survivors. *Med Sci Sports Exerc* 2013;45(11):2091–7.

Campanholi LL, Duprat Neto JP, Fregnani JH. Mathematical model to predict risk for lymphoedema after treatment of cutaneous melanoma. *Int J Surg* 2011;9(4):306–9.

Campisi C, Bellini C, Accogli S, et al. Microsurgery for lymphedema: clinical research and long-term results. *Microsurgery* 2010;30(4):256–60.

Card A, Crosby MA, Liu J, et al. Reduced incidence of breast cancer-related lymphedema following mastectomy and breast reconstruction versus mastectomy alone. *Plast Reconstr Surg* 2012;130(6):1169–78.

Chang DW, Kim S. Breast reconstruction and lymphedema. *Plast Reconstr Surg* 2010;125(1):19–23.

Cheung L, Han J, Beilhack A, et al. An experimental model for the study of lymphedema and its response to therapeutic lymphangiogenesis. *BioDrugs* 2006;20(6):363–70.

Connor C, McGinness M, Mammen J, et al. Axillary reverse mapping: a prospective study in women with clinically node negative and node positive breast cancer. *Ann Surg Oncol* 2013;20(10):3303–7.

Cormier JN, Askew RL, Mungovan KS, et al. Lymphedema beyond breast cancer: a systematic review and meta-analysis of cancer-related secondary lymphedema. *Cancer* 2010;116(22):5138–49.

Cormier JN, Rourke L, Crosby M, et al. The surgical treatment of lymphedema: a systematic review of the contemporary literature (2004–2010). *Ann Surg Oncol* 2012;19(2):642–51.

Crosby MA, Card A, Liu J, et al. Immediate breast reconstruction and lymphedema incidence. *Plast Reconstr Surg* 2012;129(5):789e–95e.

Dayes IS, Whelan TJ, Julian JA, et al. Randomized trial of decongestive lymphatic therapy for the treatment of lymphedema in women with breast cancer. *J Clin Oncol* 2013;31(30):3758–63.

Deng H, Chen L, Jia W, et al. Safety study of axillary reverse mapping in the surgical treatment for breast cancer patients. *J Cancer Res Clin Oncol* 2011 Dec;137(12):1869–74.

Deng J, Ridner SH, Wells N, et al. Development and preliminary testing of head and neck cancer related external lymphedema and fibrosis assessment criteria. *Eur J Oncol Nurs* 2015;19(1):75–80.

Denlinger CS, Ligibel JA, Are M, et al. Survivorship: healthy lifestyles, version 2.2014. *J Natl Compr Canc Netw* 2014;12(9):1222–37.

DeSantis C, Lin CL, Mariotto AB, et al. Cancer treatment and survivorship statistics, 2014. *CA Cancer J Clin* 2014;64(4):252–71.

DiSipio T, Rye S, Newman B, et al. Incidence of unilateral arm lymphoedema after breast cancer: a systematic review and meta-analysis. *Lancet Oncol* 2013; 14(6):500–15.

Donker M, van Tienhoven G, Straver ME, et al. Radiotherapy or surgery of the axilla after a positive sentinel node in breast cancer (EORTC 10981–22023 AMAROS): a randomised, multicentre, open-label, phase 3 non-inferiority trial.

Lancet Oncol 2014;15(12):1303–10.

Faries MB, Thompson JF, Cochran A, et al. The impact on morbidity and length of stay of early versus delayed complete lymphadenectomy in melanoma: results of the Multicenter Selective Lymphadenectomy Trial (I). *Ann Surg Oncol* 2010;17(12):3324–9.

Feldman S, Bansil H, Ascherman J, et al. Single institution experience with lymphatic microsurgical preventive healing approach (LYMPHA) for the primary prevention of lymphedema. *Ann Surg Oncol* 2015;22(10):3296–301.

Gennaro M, Maccauro M, Sigari C, et al. Selective axillary dissection after axillary reverse mapping to prevent breast-cancer-related lymphoedema. *Euro J Surg Oncol* 2013;39(12):1341–5.

Giuliano AE, Hunt KK, Ballman KV, et al. Axillary dissection vs. no axillary dissection in women with invasive breast cancer and sentinel node metastasis: a randomized clinical trial. *JAMA* 2011;305(6):569–75.

Gobardhan PD, Wijsman JH, van Dalen T, et al. ARM: axillary reverse mapping—the need for selection of patients. *Euro J Surg Oncol* 2012;38(8):657–61.

Goldberg JI, Wiechmann LI, Riedel ER, et al. Morbidity of sentinel node biopsy in breast cancer: the relationship between the number of excised lymph nodes and lymphedema. *Ann Surg Oncol* 2010;17(12):3278–86.

Han JW, Seo YJ, Choi JE, et al. The efficacy of arm node preserving surgery using axillary reverse mapping for preventing lymphedema in patients with breast cancer. *J Breast Cancer* 2012;15(1):91–7.

Hyngstrom JR, Chiang YJ, Cromwell KD, et al. Prospective assessment of lymphedema incidence and lymphedema-associated symptoms following lymph node surgery for melanoma. *Melanoma Res* 2013;23(4):290–7.

Ikeda K, Ogawa Y, Komatsu H, et al. Evaluation of the metastatic status of lymph nodes identified using axillary reverse mapping in breast cancer patients. *World J Surg Oncol* 2012;10:233.

Ikeda K, Ogawa Y, Kajino C, et al. The influence of axillary reverse mapping related factors on lymphedema in breast cancer patients. *Euro J Surg Oncol* 2014;40(7):818–23.

International Society of Lymphology. The diagnosis and treatment of peripheral lymphedema: 2013 Consensus Document of the International Society of Lymphology. *Lymphology* 2013;46(1):1–11.

Kim M, Kim SW, Lee SU, et al. A model to estimate the risk of breast cancer-related lymphedema: combinations of treatment-related factors of the number of dissected axillary nodes, adjuvant chemotherapy, and radiation therapy. *Int J Radiat Oncol Biol Phys* 2013;86(3):498–503.

Kim SJ, Park YD. Effects of complex decongestive physiotherapy on the oedema and the quality of life of lower unilateral lymphoedema following treatment for gynecological cancer. *Eur J Cancer Care (Engl)* 2008;17(5):463–8.

Kuehn T, Bauerfeind I, Fehm T, et al. Sentinel-lymph-node biopsy in patients with breast cancer before and after neoadjuvant chemotherapy (SENTINA): a prospective, multicentre cohort study. *Lancet Oncol* 2013;14(7):609–18.

Kwan ML, Cohn JC, Armer JM, et al. Exercise in patients with lymphedema: a systematic review of the contemporary literature. *J Cancer Surviv* 2011;5(4):320–36.

Lasinski BB. Complete decongestive therapy for treatment of lymphedema. *Semin Oncol Nurs* 2013;29(1):20–7.

Lee KT, Mun GH, Lim SY, et al. The impact of immediate breast reconstruction on post-mastectomy lymphedema in patients undergoing modified radical mastectomy. *Breast* 2013;22(1):53–7.

McLaughlin SA, Bagaria S, Gibson T, et al. Trends in risk reduction practices for the prevention of lymphedema in the first 12 months after breast cancer surgery. *J Am Coll Surg* 2013;216(3):380–9.

McLaughlin SA, Wright MJ, Morris KT, et al. Prevalence of lymphedema in women with breast cancer 5 years after sentinel lymph node biopsy or axillary dissection: patient perceptions and precautionary behaviors. *J Clin Oncol* 2008;26(32):5220–6.

McLaughlin SA, Wright MJ, Morris KT, et al. Prevalence of lymphedema in women with breast cancer 5 years after sentinel lymph node biopsy or axillary dissection: objective measurements. *J Clin Oncol* 2008;26(32):5213–9.

McNeely ML, Magee DJ, Lees AW, et al. The addition of manual lymph drainage to compression therapy for breast cancer related lymphedema: a randomized controlled trial. *Breast Cancer Res Treat* 2004;86(2):95–106.

Mellor RH, Bush NL, Stanton AW, et al. Dual-frequency ultrasound examination of skin and subcutis thickness in breast cancer-related lymphedema. *Breast J* 2004; 10(6):496–503.

Mortimer PS, Rockson SG. New developments in clinical aspects of lymphatic disease. *J Clin Invest* 2014; 124(3):915–21.

Moseley AL, Carati CJ, Piller NB. A systematic review of common conservative therapies for arm lymphoedema secondary to breast cancer treatment. *Ann Oncol* 2007;18(4):639–46.

Nakamura K, Rockson SG. Molecular targets for therapeutic lymphangiogenesis in lymphatic dysfunction and disease. *Lymph Res Biol* 2008;6(3–4):181–9.

Norman SA, Localio AR, Potashnik SL, et al. Lymphedema in breast cancer

survivors: incidence, degree, time course, treatment, and symptoms. *J Clin Oncol* 2009;27(3):390–7.

Ochoa D, Korourian S, Boneti C, et al. Axillary reverse mapping: five-year experience. *Surgery* 2014;156(5):1261–8.

Paskett ED, Dean JA, Oliveri JM, et al. Cancer-related lymphedema risk factors, diagnosis, treatment, and impact: a review. *J Clin Oncol* 2012;30(30):3726–33.

Poortmans PM, Collette S, Kirkove C, et al. Internal mammary and medial supraclavicular irradiation in breast cancer. *New Engl J Med* 2015;373(4):317–27.

Purushotham AD, Upponi S, Klevesath MB, et al. Morbidity after sentinel lymph node biopsy in primary breast cancer: results from a randomized controlled trial. *J Clin Oncol* 2005;23(19):4312–21.

Ridner SH, Dietrich MS, Stewart BR, et al. Body mass index and breast cancer treatment-related lymphedema. *Support Care Cancer* 2011;19(6):853–7.

Sakurai T, Endo M, Shimizu K, et al. Axillary reverse mapping using fluorescence imaging is useful for identifying the risk group of postoperative lymphedema in breast cancer patients undergoing sentinel node biopsies. *J Surg Oncol* 2014;109(6):612–5.

Schmitz KH, Ahmed RL, Troxel A, et al. Weight lifting in women with breast-cancer-related lymphedema. *N Engl J Med* 2009;361(7):664–73.

Shah C, Wilkinson JB, Baschnagel A, et al. Factors associated with the development of breast cancer-related lymphedema after whole-breast irradiation. *Int J Radiat Oncol Biol Phys* 2012;83(4):1095–100.

Shaitelman SF, Cromwell KD, Rasmussen JC, et al. Recent progress in the treatment and prevention of cancer-related lymphedema. *CA Cancer J Clin* 2015; 65(1):55–81.

Sharma A, Schwartz RA. Stewart-Treves syndrome: pathogenesis and management. *J Am Acad Dermatol* 2012;67(6):1342–8.

Showalter SL, Brown JC, Cheville AL, et al. Lifestyle risk factors associated with arm swelling among women with breast cancer. *Ann Surg Oncol* 2013;20(3):842–9.

Stanton AW, Modi S, Bennett Britton TM, et al. Lymphatic drainage in the muscle and subcutis of the arm after breast cancer treatment. *Breast Cancer Res Treat* 2009;117(3):549–57.

Stanton AW, Northfield JW, Holroyd B, et al. Validation of an optoelectronic limb volumeter (Perometer). *Lymphology* 1997;30(2):77–97.

Stout Gergich NL, Pfalzer LA, McGarvey C, et al. Preoperative assessment enables the early diagnosis and successful treatment of lymphedema. *Cancer* 2008 Jun 15;112(12):2809–19.

Szuba A, Cooke JP, Yousuf S, et al. Decongestive lymphatic therapy for patients with cancer-related or primary lymphedema. *Am J Med* 2000;109(4):296–300.

Tausch C, Baege A, Dietrich D, et al. Can axillary reverse mapping avoid lymphedema in node positive breast cancer patients? *Euro J Surg Oncol* 2013;39(8):880–6.

Ter SE, Alavi A, Kim CK, et al. Lymphoscintigraphy. A reliable test for the diagnosis of lymphedema. *Clin Nucl Med* 1993;18(8):646–54.

Teshome M, Ballman BK, McCall ML, et al. Long term incidence of lymphedema after sentinel lumph node dissection for early stage breast cancer: ACOSOG Z0010. Presented at the Society of Surgical Oncology 67th Annual Cancer Symposium. 2014 March 2–5, 2014; Phoenix, Arizona.

Tsai RJ, Dennis LK, Lynch CF, et al. The risk of developing arm lymphedema among breast cancer survivors: a meta-analysis of treatment factors. *Ann Surg Oncol* 2009;16(7):1959–72.

Ugur S, Arici C, Yaprak M, et al. Risk factors of breast cancer-related lymphedema. *Lymph Res Biol* 2013;11(2):72–5.

Veronesi U, Paganelli G, Viale G, et al. A randomized comparison of sentinel-node biopsy with routine axillary dissection in breast cancer. *N Engl J Med* 2003; 349(6):546–53.

Whelan TJ, Olivotto IA, Parulekar WR, et al. Regional nodal irradiation in early-stage breast cancer. *New Engl J Med* 2015;373(4):307–16.

Yamamoto R, Yamamoto T. Effectiveness of the treatment-phase of two-phase complex decongestive physiotherapy for the treatment of extremity lymphedema. *Int J Clin Oncol* 2007;12(6):463–8.

Yan A, Avraham T, Zampell JC, et al. Adipose-derived stem cells promote lymphangiogenesis in response to VEGF-C stimulation or TGF-beta1 inhibition. *Future Oncol* 2011;7(12):1457–73.

EDITOR'S COMMENT

The newly added chapter for the Seventh Edition of the *Mastery of Surgery* by Dr. McLaughlin of Mayo Clinic Florida was included in this edition to acknowledge the important morbidity of lymphedema, and its therapeutic expense, created as a consequence of surgical and radiation therapy management for neoplasms of the breast, extremities, and head and neck. Historically, etiologic factors that contribute to lymphedema of various organ sites are inclusive of (1) extent of the surgical resection of lymph node-bearing tissues and/or contiguous musculature, (2) irradiation, (3) obesity, (4) age, (5) inflammation and cellulitis, and (6) the anatomical length and site of the

surgical incision. Age is included in the aforementioned etiologic factors as lymphedema may be influenced by a relative lack of collateral lymphovenous anastomoses in older women. This process of neovascularization may be more evident in younger women postoperatively bridging lymphatic and vascular structures. Such lymphovascular anastomoses are less frequently observed in the aging population, especially those who are less physically active. Moreover, the occurrence of postoperative wound complications (e.g., infection, seroma/hematoma, flap necrosis) can be identified as independent variables that initiate early and late lymphedema of the ipsilateral neck or extremity. The extent of regional node dissection, that is, radical versus modified head and neck lymphadenectomy; levels I–II versus level III axillary LND for breast carcinoma, melanoma, and non-melanoma neoplasms; and superficial lymph node dissection versus combination with deep inguinal (radical) dissection each recognize that *extent of the dissection* is an important contributing factor, especially when combined with radiation therapy. The latter modality alone will increase the incidence of lymphedema from 20% to 52% (Sauter ER, Eisenberg BL, Hoffman JP, et al. Postmastectomy morbidity after combination preoperative irradiation and chemotherapy for locally advanced breast cancer. *World J Surg* 1993;17:237 and Copeland, *5th Annual General Surgery Forum Telluride, Colorado*). In dated publications authors have reported the risk of arm lymphedema to be as great as 37% for therapy of breast cancer when full axillary lymph node dissection (ALND) (levels I–III) was completed versus 8% when dissection was limited to levels I–II ALND. (Larson D, Weinstein M, Goldberg I, et al. Edema of the arm as a function of the extent of axillary surgery in patients with stage I-II carcinoma of the breast treated with primary radiotherapy. *Int J Rad Oncol Biol Phys* 1986;12:1575–82). This in-depth analysis found a correlation between the risk of lymphedema formation and the number of removed nodes; when >10 lymph nodes were removed in dissection, the risk of lymphedema is 28% versus 9% in the 1 to 10 nodal group resections.

The ascribed adverse observation of posttreatment weight gain and obesity (Petrek JA, Senie RT, Peters M, et al. Lymphedema in a cohort of breast carcinoma survivors 20 years after diagnosis. *Cancer* 2001;92:1368–77) suggests that this observation is an independent risk factor for lymphedema formation as well.

In the superb and detailed chapter included by Dr. McLaughlin, the incidence and even the definition of lymphedema in contemporary randomized controlled trials vary (Table 53.1). Implied in this context of the definition of risk/incidence is the variation of the prevalence for surgically induced lymphedema for non-breast cancers of four different sites (head/neck, genitourinary, gynecologic, extremity) and variable tumor types for management (melanoma, sarcoma, squamous cell, urinary tract epithelium, endometrial, and ovarian) (Table 53.2). Francis and Ahghari (Francis WP1, Abghari P, Du W, et al. Improving surgical outcomes: standardizing the reporting of incidence and severity of acute lymphedema after sentinel lymph

node biopsy and axillary lymph node dissection. *Am J Surg* 2006;192:636–9) describe common terminology criteria for adverse events (CTCAE) 3.0, which are detailed by the National Cancer Institute and have standardized reporting of adverse events and their inclusion to grade outcomes in clinical trials. These include lymphedema for extremities: levels I–IV that progress from: 5% to 10% (level I), 10% to 30% (level II), >30% (level III), and progression to malignancy (level IV). This incidence and the severity of post-op acute lymphedema were observed within the 1st year following sentinel lymph node biopsy (SLNB) and ALND. The incidence of lymphedema was 16.8% following SLNB and 47.1% after ALND. Acute lymphedema of severity level I was evident in 65% following SLNB and level II severity in 35%. This frequency for level II lymphedema escalated to 60% in the ALND group.

A large NSABP B-32 trial (Ahikaga T, Krag DN, Land SR, et al. Morbidity results from the NSABP B-32 trial comparing sentinel lymph node dissection versus axillary dissection. *J Surg Onc* 2010;102[2]:111–8) for postsurgical morbidity with treatment of breast cancer between patients with negative SLNB alone versus negative SLND and negative ALND confirms arm differences >10% at 36 months with reduction advantage with limited tumor burden for the SLND groups (8%) and ALND groups(14%). Numbness and paresthesias peaked at 6 months following ALND (49%, 23%) and for the SLND groups were 15% and 10%, respectively. Thus, in the node negative groups, the superiority of SLND was evident when compared with ALND groups to alleviate postsurgical morbidity with outcomes over a 3-year interval. This advantage is further emphasized in the radiotherapy or surgery of the axilla following positive sentinel lymph nodes in breast cancer (EORTC 10981–22023 AMAROS) (Donker M, van Tienhoven G, Straver ME, et al. Radiotherapy or surgery of the axilla after a positive sentinel node in breast cancer (EORTC 10981-22023 AMAROS): a randomised, multicentre, open-label, phase 3 non-inferiority trial. *Lancet Oncol* 2014;15[12]:1303–10) and was designed concurrently with the Z-0011 protocol of the American College of Surgeons Oncology Group (ACOSOG) trial for the evaluation and outcomes with ≤2 *positive* breast cancer lymph nodes. In the EORTC study, assessment of axillary radiotherapy to provide comparable regional control, together with its side effects, was evaluated. Axillary recurrence following axillary irradiation versus ALND were virtually equivalent; recurrence was evident in 4/744 patients in the ALND and 7/681 in the axillary RT group but appears to be statistically underpowered because of the low number of adverse events in the cohorts. Of interest, lymphedema in the ipsilateral arm was noted significantly more often following ALND (13% to 23%) than following axillary RT (5% to 11%) at 1 year, 3 years, and 5 years post treatment.

Whelan et al. (Whelan TJ, Olivotto IA, Parulekar WR, et al. Regional Nodal Irradiation in Early-Stage Breast Cancer. *N Engl J Med* 2015;373[4]:307–16) reported on the multi-institutional Canadian study for the National Cancer Institute of Canada (CT Group MA.20 trial). In this 10-year follow-up study of

1,832 women assigned to nodal-irradiation group or the control group (each arm = 916 patients), there was no significant difference in these groups for survival (82.8%) in the RT and in the control group (81.8%) (p = 0.38). The rate of disease-free survival was superior in the nodal RT (82.0%) group versus the control arm (77.0%) (p = 0.01). Nodal irradiation had higher rates of grade 2 or greater frequency of acute pneumonitis (1.2% vs. 0.2%, p = 0.01) and lymphedema was evident in 8.4% in the irradiated group versus 4.5% in the control (p = 0.001). Thus, the addition of whole breast irradiation to the ALND group for those receiving comprehensive regional nodal irradiation essentially doubled the frequency of lymphedema. While this approach of combination modality does not improve overall survival, this therapeutic methodology reduces the frequency of local-regional failure to enhance disease-free survival. This trend was further evident in the American College of Surgeons Oncology Group Z0010 trial (Teshome et al. 67th Symposium, Society of Surgical Oncology, March 2014) to confirm the considerable reduction in lymphedema for SLNB patients (20% to 24%) versus ALND patients (40% to 41%) combining both objective and subjective parameters. These data are detailed in Table 53.1 by the author of this chapter.

Since the original formulation of the physiologic principles of the sentinel node concept by Ramon Cabanas for penile carcinoma in 1977 (Cabanas RM. An approach for the treatment of penile carcinoma. *Cancer* 1977;456–66) with lymphangiograms and the technological progression with use of the technetium 99m pertechnetate and vital blue dye for the SLNB by Donald Morton in 1992 (Morton DL, Wen DR, Wong JH, et al. Technical details of intraoperative lymphatic mapping for early stage melanoma. *Arch Surg* 1992;127:392–9) for melanoma, the aforementioned articles apply the same considerations for breast SLNB. Guiliano et al. (Giuliano AE, Kirgan DM, Guenther JM, et al. Lymphatic mapping and sentinel lymphadenectomy for breast cancer. *Ann Surg* 1994;220:391–401) began development for adoption of these principles for breast lymphatic mapping in 1991. As melanoma requires a more comprehensive nodal dissection for axillary metasteses (levels I, II, III) versus breast (levels I, II), the extent of radical nodal resection is enlarged in the melanoma population for the axilla and in the groin. In addition, should Cloquet's femoral node be positive, deep ilioinguinal resection is recommended. Interval CT staging with contrast to evaluate subsequent development of deep ilioinguinal nodal progression is programmatically a follow-up recommendation. Hyngstrom et al. at UT MD Anderson Cancer Center (Hyngstrom JR, Chiang YJ, Cromwell KD, et al. Prospective assessment of lymphedema incidence and lymphedema-associated symptoms following lymph node surgery for melanoma. *Melanoma Res* 2013;23[4]:290–7) evaluated 182 patients at 12 months following therapeutic axillary inguino-femoral dissection with observation that there was a seven- to nine-fold increase in symptoms for patients with a significant limb volume change (LVC) >10% compared with those with LVC <5% (p < 0.05). With multivariant regression

analysis, therapeutic lymph node dissections at *both* anatomical sites versus SLND were more injurious with enhanced probability for lymphedema ($p < 0.01$); this was borderline significant for lower versus upper extremity procedures ($p = 0.07$) when associated with LVC >5%. These authors conclude that LVC >5% is common at 12 months following node dissection for melanoma and the risk of postoperative lymphedema should be an important component of informed consent for postsurgical morbidity.

In the meta-analysis for treatment factors for the risk of developing arm lymphedema in breast cancer survivors, Tsai et al. (Tsai RJ, Dennis LK, Lynch CF, et al. The risk of developing arm lymphedema among breast cancer survivors: a meta-analysis of treatment factors. *Ann Surg Onc* 2009;16:1959–72) further emphasize that the extent of the axillary dissection with irradiation and the presence of positive nodes increase the risk of developing arm lymphedema following breast cancer surgery treatment. This incidence of lymphedema after axillary surgery apparently increases up to 2 years following diagnosis of breast cancer, and the frequency increases in all studies in which preoperative direct measurements versus the control group arm dimensions were measured. DiSipio et al. (DiSipio T, Rye S, Newman B, et al. Incidence of unilateral arm lymphoedema after breast cancer: a systematic review and meta-analysis. *Lancet Oncology* 2013;14:500–15) also suggest that risk factors that enhance the frequency of lymphedema include: (1) extensive surgery with comprehensive nodal dissection, (2) greater number of lymph nodes procured with dissection at mastectomy, and (3) being overweight or obese are contributory. In the Phase III noninferiority Z-0011 trial of ACOSOG, Guiliano et al. (Giuliano AE, Hunt KK, Ballman KV, et al. Axillary dissection vs no axillary dissection in women with invasive breast cancer and sentinel node metastasis: a randomized clinical trial. *JAMA* 2011;305[6]:569–75) randomized patients with clinical T1–T2 invasive cancer and no palpable adenopathy between breast conservation surgery with one to two positive sentinel nodes following completion ALND versus no further axillary surgery. The authors concluded that there were no differences between overall survival (91.8%, 92.5%) and disease-free survival (82.2% vs. 83.9%), and that outcomes for SLNB are equivalent to ALND with two or fewer positive sentinel lymph nodes. Now beyond 6 years follow-up to date, the Z0011 trial has not demonstrated evidence of differences in lymphedema between the two randomized cohorts.

An important emphasis and therapeutic principle enunciated by Dr. McLaughlin includes that of complex decongestive physiotherapy (CDP). CDP in the treatment of lymphedema was studied by Kim and Park (Kim SJ, Park YD. Effects of complex decongestive physiotherapy on the oedema and the quality of life of lower unilateral lymphoedema following treatment for gynecological cancer. *Eur J Cancer Care* 2008;17:463–8) to determine quality-of-life (QOL) issues for lower extremity lymphedema following the therapy of gynecologic cancers. CDP was inclusive of manual lymphatic drainage, skin

care, remedial exercises, compression garments, pneumatic pumps, mercury compression, oral and topical benzopyrones, elevation, and microwave and laser therapies. These approaches have been emphasized by *The International Society of Lymphology* as objective measures that enhance control of lymphedema. In the analysis by Kim and Park, 57 gynecologic patients with unilateral lymphedema resulted in measurable change in edema and QOL; the percent excess volume correlated with change in QOL, and was significantly reduced following CDP ($p < 0.05$). QOL was significantly improved ($p < 0.05$) over baseline scores indicating that evident improvement of QOL was associated with enhanced physiologic function, social function, physical strength, body pain, and general health over parameters at baseline within 1 month ($p < 0.05$).

When the lymphatic system is partially or completely obliterated by either result of infection, malignancy, radiation or surgery, lymphatic fluid transport capacity is reduced. This consequence leads to the production of interstitial fluid that exceeds the rate of lymphatic return and therefore the stagnation of high-molecular-weight proteins leak into the interstitium. Kim and Park provide parameters for the patient's history and the measurement and documentation of lymphedema with the inherent problem for making objective and subjective assessments for improvement over baseline. This is particularly evident in those who have minimal lymphedema in the ipsilateral extremity.

The role of micro-surgery for lymphedema has periodically been approached by various international clinics and the largest series to date is that by Campisi et al. at San Martino, University of Genoa, Italy, in which 1,800 patients with peripheral lymphedema of various organ sites had treatment that was managed with microsurgical techniques. In this evolution of lymphonodal-venous microsurgery, surgeons used direct anastomoses with microvascular techniques for lymphatic vessel anastomoses directly to axillary and inguinal veins (Campisi C, Bellini C, Campisi C, et al. Microsurgery for lymphedema: clinical research and long-term results. *Microsurgery* 2010;30:256–60). The objective assessment was taken by water volumetry and lymphoscintigraphy. Objective volume changes confirmed an improvement in 83%, with an average volume reduction of 67% of excess volume. In follow-up, 85% have been able to continue use of conservative measures with an average follow-up of >10 years and an average reduction success limb volume of 69%. These results are not reproducible in all clinics and require an intensive long investment in the cost of expertise and experience to achieve these exceptional results.

The surgeon must be cognizant of the need for recognition of *early* lymphedema in the post-mastectomy and post-inguinal node dissection patient. Recurrent and detailed examination of the extremities and head and neck sites post therapy is essential to pre-empt progression of lymphedema. Implementation of the CDP measures enumerated above should be considered early in therapy. While salt restriction is appropriate in the elderly people, especially with heart failure, diuretics are of minimal benefit in the therapy of chronic lymphedema. Compression pumps, together with CDP measures,

currently represent the principle treatments that are the most beneficial medical management strategies. Together with physical massage taught by qualified therapists and compression sleeves “measured-to-fit” the extremity, advanced lymphedema may be avoided.

Kirby I. Bland

54 Modified Radical Mastectomy and Radical Mastectomy

Kirby I. Bland

HISTORY OF BREAST CANCER SURGERY

The anatomist, physiologist, and surgeon, Claude Galen, stated in the second century AD with his classical clinical observation of breast carcinoma: “We have often seen in the breast a tumor exactly resembling the animal, *the crab*. Just as the crab has legs on both sides of his body, so in this disease the veins extending out from the unnatural growth take the shape of a crab’s legs. We have cured this disease in its early stages, but after it has reached a large size, no one has cured it.” As advocated in the 18th century by Morgagni, father of modern pathology, surgical resections were more frequently undertaken, including early attempts at mastectomy and axillary dissection. Also in the 18th century, the surgeon Henri le Dran postulated that breast cancer was initially a local disease that progressed in stages to spread via skin and breast lymphatics to axillary lymph nodes. With surgery for breast cancer, le Dran routinely removed *en bloc* any enlarged axillary lymph nodes.

In the late 19th century, C.H. Moore, of the Middlesex Hospital, London, reemphasized complete resection of the breast for cancer and stated that palpable axillary lymph nodes should also be removed. In a presentation before the British Medical Association in 1877, Banks supported Moore’s concepts and advocated the routine resection of axillary lymph nodes even when palpable lymphadenopathy was *not evident*, recognizing that occult involvement of axillary lymph nodes was frequent. In 1894, William S. Halsted and Willy Meyer reported their operations for the radical treatment of breast cancer. By demonstrating superior locoregional control rates with radical resection, these surgeons established radical mastectomy (RM) as the benchmark procedure for that era. Both Halsted and Meyer advocated complete dissection of all levels of axillary lymph node levels (I, II, and III). Resection of the long thoracic nerve and the thoracodorsal neurovascular bundle with the axillary

contents was routine. This technical maneuver contributed significantly to the surgical management of the disease while enhancing surgical morbidity and limitation of postoperative function.

However, in 1943, Haagensen and Stout described the “grave-signs” of breast cancer, which included (a) edema of the skin of the breast, (b) skin ulceration, (c) chest wall fixation, (d) an axillary lymph node >2.5 cm in diameter, and/or (e) fixed axillary lymph nodes. Women with two or more signs had a 42% local recurrence rate and only a 2% 5-year disease-free survival. Based upon these observations, these investigators declared that patients with grave signs were beyond cure by radical surgery. Advocating this principle, approximately 25% of women were excluded from surgery based upon the criteria of inoperability. Presently, with comprehensive mammographic screening, approximately 10% of women are found to have advanced breast cancers.

The “modified radical” mastectomy was proposed in 1948, when Patey and Dyson of the Middlesex Hospital, London, provided a major technical and aesthetic advancement for the management of operable breast cancer. The technique espoused by Patey and Dyson included removal of the breast and axillary lymph nodes with preservation of the pectoralis major muscle. These surgeons confirmed that removal of the pectoralis minor muscle allowed access to and the anatomical dissection of axillary lymph node levels I to III (Patey modification). Today, the modification is frequently limited to severance of the origin of the pectoralis major muscle at the coracoid process of the scapula. Subsequent to the description of the Patey modification, Madden advocated a modified RM that preserved *both* the pectoralis major and minor muscles even though this approach prevented thorough dissection of the apical (level III) axillary lymph nodes.

The performance of the technique with frequency in the 1980s, allowed the modified RM to become the most frequently used procedure by American surgeons for the therapy of breast cancer. The transition from the Halsted RM to the modified RM acknowledged that (a) extirpation of the pectoralis major muscle was *not* essential for locoregional control in stage I and stage II breast cancer and (b) neither the modified RM nor Halsted RM procedures consistently achieved locoregional control of stage III disease. The National Surgical Adjuvant Breast and Bowel Project B-04 (NSABP B-04) conducted by Bernard Fischer and coinvestigators, thereafter, compared local and regional treatments of breast cancer. Life

table estimates were obtained for 1,665 women enrolled and followed for a mean of 120 months. This study randomized clinically node-negative women into three groups: (a) Halsted RM, (b) total mastectomy plus radiation therapy (TM+RT), and (c) total mastectomy alone (TM). Clinically node-positive women were treated with RM or TM+RT. With median follow-up of 10 years, there were *no differences in survival* between the three groups of node-negative women or between the two groups of node-positive women.

Additional prospective clinical trials comparing Halsted RM to the modified RM were the Manchester Trial, reported by Turner and colleagues, and the University of Alabama Trial, reported by Maddox and colleagues. In both studies, the *type* of surgical procedure did not influence recurrence rates for stage I and stage II breast cancer patients. Criteria for accrual to the Alabama Breast Cancer Project (1975 to 1978) included T1 to T3 breast cancers (Table 54.1) with absence of clinically apparent distant metastases. Patients underwent a radical or a modified RM. Node-positive patients received adjuvant cyclophosphamide, methotrexate, and 5-fluorouracil (CMF) chemotherapy or adjuvant melphalan. With median follow-up of 15 years, neither type of surgery, nor type of chemotherapy, was shown to affect locoregional disease-free or overall survival. Since the 1970s, considerable progress has been made in the integration of surgery, radiation therapy, and chemotherapy to control locoregional disease, to enhance survival, and to increase the possibility of breast conservation. Locoregional control is now achieved for approximately 80% of women with advanced breast cancers, following neoadjuvant chemotherapy.

TABLE 54.1 Definition of TNM

Definitions for classifying the primary tumor (T) are the same for clinical and for pathologic classification. The telescoping method of classification can be applied. If the measurement is made by physical examination, the examiner will use the major headings (T1, T2, or T3). If other measurements, such as mammographic or pathologic, are used, the telescoped subsets of T1 can be used

Primary Tumor (T)

TX	Primary tumor cannot be assessed
T0	No evidence of primary tumor
Tis	Carcinoma in situ
Tis (DCIS)	Ductal carcinoma in situ
Tis (LCIS)	Lobular carcinoma in situ
Tis (Paget's)	Paget disease of the nipple NOT associated with invasive carcinoma and/or carcinoma in situ (DCIS and/of LCIS) in the underlying breast parenchyma. Carcinomas in the breast parenchyma associated with Paget disease are categorized based on the site and characteristics of the parenchymal disease, although the presence of Paget disease should still be noted
T1	Tumor ≤2 cm in greatest dimension
T1mi	≤0.1 cm or less in greatest dimension
T1a	Tumor ≥0.1 but ≤0.5 cm in greatest dimension
T1b	Tumor ≥0.5 cm but ≤1 cm in greatest dimension
T1c	Tumor ≥1 cm but ≤2 cm in greatest dimension
T2	Tumor ≥2 cm but ≤5 cm in greatest dimension
T3	Tumor ≥5 cm in greatest dimension
T4	Tumor of any size with direct extension to chest wall and/or skin (ulceration of skin nodules)
T4a	Extension to chest wall, not including only pectoralis muscle adherence/invasion
T4b	Ulceration and/or ipsilateral satellite nodules and/or edema (including peau d'orange) of the skin, which do not meet the criteria for inflammatory carcinoma.
T4c	Both (T4a and T4b)
T4d	Inflammatory carcinoma

Regional Lymph Nodes (N)

Clinical

NX	Regional lymph nodes cannot be assessed (e.g., previously removed)
N0	No regional lymph node metastasis
N1	Metastasis to movable ipsilateral axillary level I, II lymph node(s)
N2	Metastasis to ipsilateral level I, II axillary lymph node(s) that are clinically fixed or matted; or in clinically detected* ipsilateral internal mammary nodes in the absence of clinically evident axillary lymph node metastases.
N2a	Metastases in ipsilateral level I, II axillary lymph nodes fixed to one another (matted) or to other structures
N2b	Metastases only in clinically detected* ipsilateral internal mammary nodes and in the absence of clinically evident level I, II axillary lymph node metastases.
N3	Metastases to ipsilateral internal mammary lymph node(s) with or without level I, II axillary lymph node involvement; or in clinically detected* ipsilateral internal mammary lymph nodes(s) with clinically evident level I, II axillary lymph node metastases; or metastases in ipsilateral supraclavicular lymph node(s) with or without axillary or internal mammary lymph node involvement.
N3a	Metastases in ipsilateral intraclavicular lymph node(s)
N3b	Metastases in ipsilateral internal mammary lymph node(s) and axillary lymph node(s)
N3c	Metastases in ipsilateral supraclavicular lymph nodes(s)
NOTES	*"Clinically detected" is defined as detected by imaging studies (excluding lymphoscintigraphy) or by clinical examination and having characteristics highly suspicious for malignancy or a presumed pathologic macrometastasis based on fine needle aspiration biopsy with cytologic examination.

Pathologic Classification (pN)

pNX	Regional lymph nodes cannot be assessed (e.g., previously removed, or not removed for pathologic study)
pN0	No regional lymph node metastasis identified histologically
pN0(i–)	No regional lymph node metastases histologically, negative IHC
pN0(i+)	Malignant cells in regional lymph node(s) no >0.2 mm (detected by H&E or IHC including ITC)
pN0(mol–)	No regional lymph node metastases histologically, negative molecular findings (RT-PCR)
pN0(mol+)	Positive molecular findings (RT-PCR)**, but no regional lymph node metastases detected by histology or IHC
pN1	Micrometastases; or metastases in 1–3 axillary lymph nodes; and/or in internal mammary nodes with metastases detected by sentinel lymph node biopsy but not clinically detected***
pN1mi	Micrometastases (>0.2 mm and/or >200 cells, but none >2.0 mm)
pN1a	Metastases in 1–3 axillary lymph nodes, at least one metastasis >2.0 mm.
pN1b	Metastasis in internal mammary nodes with micrometastases or macrometastases detected by sentinel lymph node biopsy but not clinically detected***
pN1c	Metastases in 1–3 axillary lymph nodes and in internal mammary lymph nodes with micrometastases or macrometastases detected by sentinel lymph node biopsy but not clinically detected

pN2	Metastases in 4–9 axillary lymph nodes; or in clinically detected****internal mammary lymph nodes in the absence of axillary lymph node metastases
pN2a	Metastases in 4–9 axillary lymph nodes (at least one tumor deposit >2.0 mm)
pN2b	Metastases in clinically detected****internal mammary lymph nodes in the absence of axillary lymph node metastases
pN3	Metastases to 10 or more axillary lymph nodes; or in infraclavicular (level III axillary) lymph nodes; or in clinically detected****ipsilateral internal mammary lymph nodes in the presence of one or more positive level I, II axillary lymph nodes; or in more than 3 axillary lymph nodes and in internal mammary lymph nodes with micrometastases or macrometastases detected by sentinel lymph node biopsy but no clinically detected***, or in ipsilateral supraclavicular lymph nodes
pN3a	Metastases in 10 or more axillary lymph nodes (at least one tumor deposit >2.0 mm); or metastases to the infraclavicular (level III axillary lymph) nodes
pN3b	Metastases in clinically detected****ipsilateral internal mammary lymph nodes in the presence of one or more positive axillary lymph nodes; or in more than 3 axillary lymph nodes and in internal mammary lymph nodes with micrometastases or macrometastases detected by sentinel lymph node biopsy but not clinically detected***
pN3c	Metastases in ipsilateral supraclavicular lymph nodes
NOTES	*Classification is based on axillary lymph node dissection with or without sentinel lymph node biopsy. Classification based solely on sentinel lymph node biopsy without subsequent axillary lymph node dissection is designated (sn) for "sentinel node," for example, pN0(sn) **RT-PCR: reverse transcriptase/polymerase chain reaction. ***"Not clinically detected" is defined as not detected by imaging studies (excluding lymphoscintigraphy) or not detected by clinical examination ****"Clinically detected" is defined as detected by imaging studies (excluding lymphoscintigraphy) or by clinical examination and having characteristics highly suspicious for malignancy or a presumed pathologic macrometastasis based on fine needle aspiration biopsy with cytologic examination.
Distant Metastasis (M)	
M0	No clinical or radiographic evidence of distant metastases
cM0(i+)	No clinical or radiographic evidence of distant metastases, but deposits of molecularly or microscopically detected tumor cells in circulating blood, bone marrow, or other nonregional nodal tissue that are no larger than 0.2 mm in a patient without symptoms or signs of metastases.
M1	Distant detectable metastases as determined by classic clinical and radiographic means and/or histologically proven >0.2 mm

Source: Modified from American Joint Committee on Cancer. *AJCC Cancer Staging Manual.* 7th ed. New York: Springer; 2010:349–60.

MASTECTOMY INDICATIONS

In contemporary surgical oncology, the type of therapy offered to the breast cancer patient is determined by the stage of the disease (Table 54.2). Survival rates for women diagnosed with breast cancer between 2003 and 2009 have been calculated based on Surveillance, Epidemiology and End Results (SEER) Program Data. The 5-year survival rate is diminished among women with advanced stage at diagnosis. Considering *all races*, 5-year relative-survival rate is 99% for *localized* disease, 84% for *regional* disease, and 24% for *distant* stage disease (Table 54.3). Race is highly correlative for the adverse effect and decreased survival of the underserved populations of American culture (Table 54.4).

Women at High Risk for Breast Cancer

Retrospective studies of women at high risk for breast cancer have found that prophylactic mastectomy can reduce their risk by >90%. Studies involving women who were carriers of BRCA-1 or BRCA-2 mutations found that the benefit of prophylactic mastectomy differed according to the breast cancer risk conferred by the individual mutations. For women with an estimated lifetime risk of 40% (approximately four times the population

risk), prophylactic mastectomy added almost 3 years of life, whereas for women with an estimated lifetime risk of 85%, prophylactic mastectomy added >5 years to survival based on genetic/familial risk of disease.

TABLE 54.2 TNM Breast Cancer Stages

Stage Grouping			
Stage 0	Tis	N0	M0
Stage IA	T1*	N0	M0
Stage IB	T0	N1mi	M0
Stage IIA	T0	N1**	M0
	T1*	N1**	M0
	T2	N0	M0
Stage IIB	T2	N1	M0
	T3	N0	M0
Stage IIIA	T0	N2	M0
	T1*	N2	M0
	T2	N2	M0
	T3	N1	M0
	T3	N2	M0
Stage IIIB	T4	N0	M0
	T4	N1	M0
	T4	N2	M0
Stage IIIC	Any T	N3	M0
Stage IV	Any T	Any N	M1
NOTES	T1 includes T1mi **T0 and T1 tumors with nodal micrometastases only are excluded from Stage IIA and are classified Stage 1B		

Source: Modified from American Joint Committee on Cancer. *AJCC Cancer Staging Manual.* 7th ed. New York: Springer; 2010:349–60.

TABLE 54.3

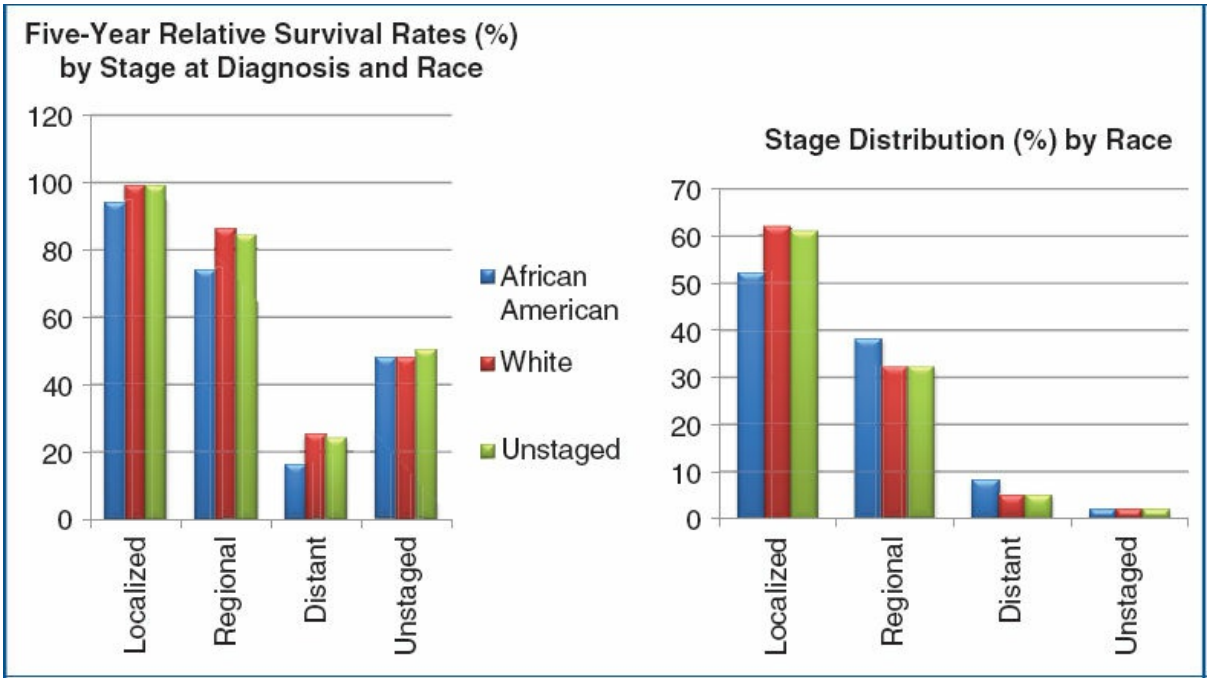

Source: Howlader N, Noone AM, Krapcho M, et al., eds. SEER Cancer Statistics Review, 1975–2010. Bethesda, MD: National Cancer Institute; 2013: http://seer.cancer.gov/csr/1975_2012/ based on November 2012 SEER data submission.

Variants of In Situ Breast Cancer (Stage 0)

Pathologists are cognizant that, on occasion, both lobular carcinoma in situ (LCIS) and ductal carcinoma in situ (DCIS) may be pathologically difficult to distinguish from atypia, atypical hyperplasia or from cancers with micro-invasion. Expert pathologic review is required in all cases. Since LCIS is considered a "marker" for increased risk rather than an inevitable precursor of invasive disease, the current treatment of LCIS is surveillance observation with or without antiestrogen therapy. The goal of treatment is to prevent or detect at an early stage the invasive cancer that subsequently develops in 25% to 35% of these women. Women with multifocal DCIS that is not amenable to lumpectomy and women with multicentric disease (involvement of two or more quadrants of the breast) require mastectomy. For women with limited disease, lumpectomy and radiation therapy is recommended. Sentinel lymph node biopsy is recommended for women with (a) multifocal DCIS, (b) multicentric DCIS, and (c) DCIS with comedonecrosis and tumor size ≥2.5 cm. In all cases, antiestrogen therapy is considered.

TABLE 54.4

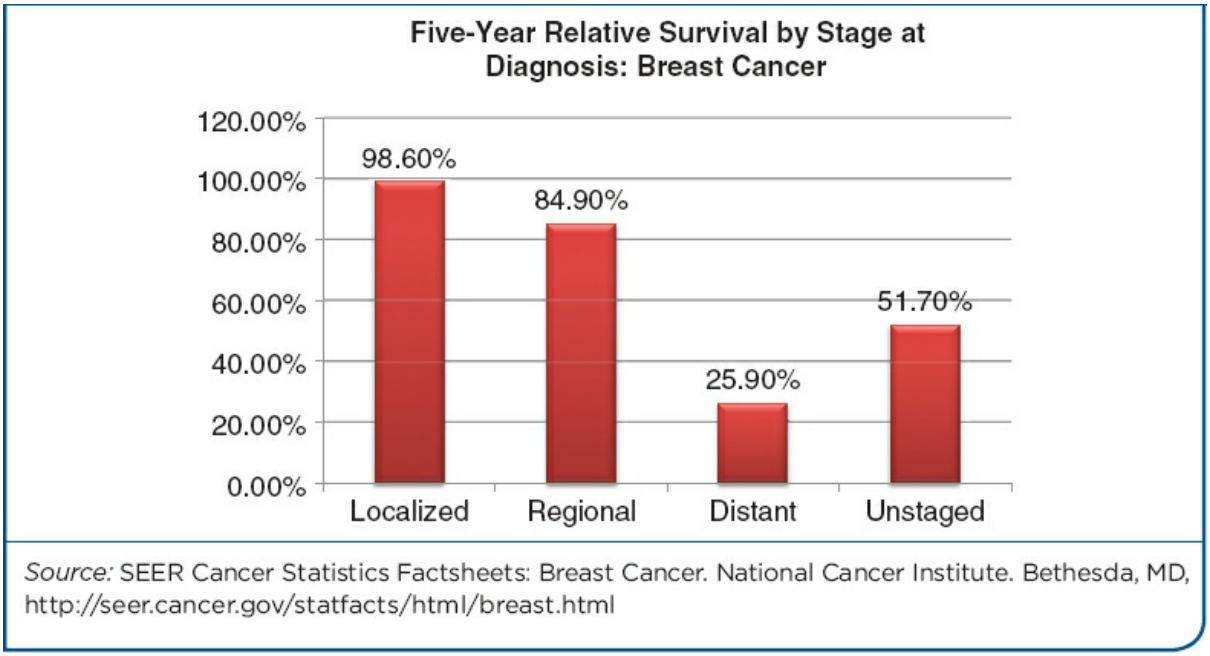

Source: SEER Cancer Statistics Factsheets: Breast Cancer. National Cancer Institute. Bethesda, MD, http://seer.cancer.gov/statfacts/html/breast.html

Early Invasive Breast Cancer (Stage I, IIa, or IIb)

NSABP B-06 represented a large, randomized prospective trial that compared TM with lumpectomy with or without radiation therapy for the treatment of stage I and II breast cancer. With 12 and 20 years of follow-up, the disease-free, distant disease-free, and overall survival rates for lumpectomy with or without radiation therapy were statistically equivalent to those observed after TM. However, the incidence of ipsilateral breast cancer recurrence (in breast recurrence) was higher in the lumpectomy group not receiving radiation therapy. The observations from this trial supported the routine recommendation of lumpectomy and radiation in the treatment of stage I and II breast cancer. Currently, (a) breast conservation (lumpectomy and radiation therapy with sentinel lymph node biopsy and/or axillary lymph node dissection) or (b) mastectomy with sentinel lymph node biopsy and/or axillary lymph node dissection should be the recommended treatments for stage I and II breast cancer. Breast conservation should be considered primarily for all patients because of the important cosmetic and functional advantages without compromise of overall cancer-related survival.

Relative contraindications to breast conservation therapy include: (a) *prior radiation therapy* to the breast or chest wall, (b) *involved surgical margins or unknown margin status* following reexcision, (c) *multicentric disease*, and (d) *scleroderma or other connective tissue disorders.* This recommendation pertains to the likely inability to utilize postoperative radiation therapy. In cases with three or more positive nodes,

lymphadenopathy or metastatic disease in a sentinel lymph node necessitates an axillary lymph node dissection (levels I, II) and/or regional node radiotherapy for disease control; both adjuvant techniques may apply in extranodal axillary metastases. In all cases with tumor size >0.5 cm, adjuvant chemotherapy and/or antiestrogen therapy is routinely considered.

Locoregionally Advanced Regional Breast Cancer (Stage IIIa or IIIb)

The patient presenting with stage IIIa and IIIb breast cancer has advanced locoregional breast cancer but does not have clinically or radiographically detected distant metastases (M0). In an effort to enhance optimal locoregional disease-free as well as distant disease-free survival for these women, surgery is integrated with radiation therapy and chemotherapy. Stage IIIa patients are divided into those who have operable disease and those who have inoperable disease (Fig. 54.1). Surgical therapy for women with operable stage IIIa disease is usually a modified RM, followed by adjuvant chemotherapy and adjuvant radiation therapy. Adjuvant chemotherapy is used to maximize distant disease-free survival, while radiation therapy is used to maximize locoregional control for disease-free survival. In *select stage IIIa* patients, initial (neoadjuvant) chemotherapy is increasingly utilized to enhance cytoreduction of the primary cancer and permit conservation surgery. For *inoperable stage IIIa* and for *stage IIIb* breast cancer, neoadjuvant chemotherapy is considered to decrease the locoregional cancer burden and may permit subsequent surgery to establish locoregional control. In this clinical scenario, the modified RM with/without the Patey modification or the infrequent (<2%) Halsted RM is followed by adjuvant chemotherapy and adjuvant radiation therapy.

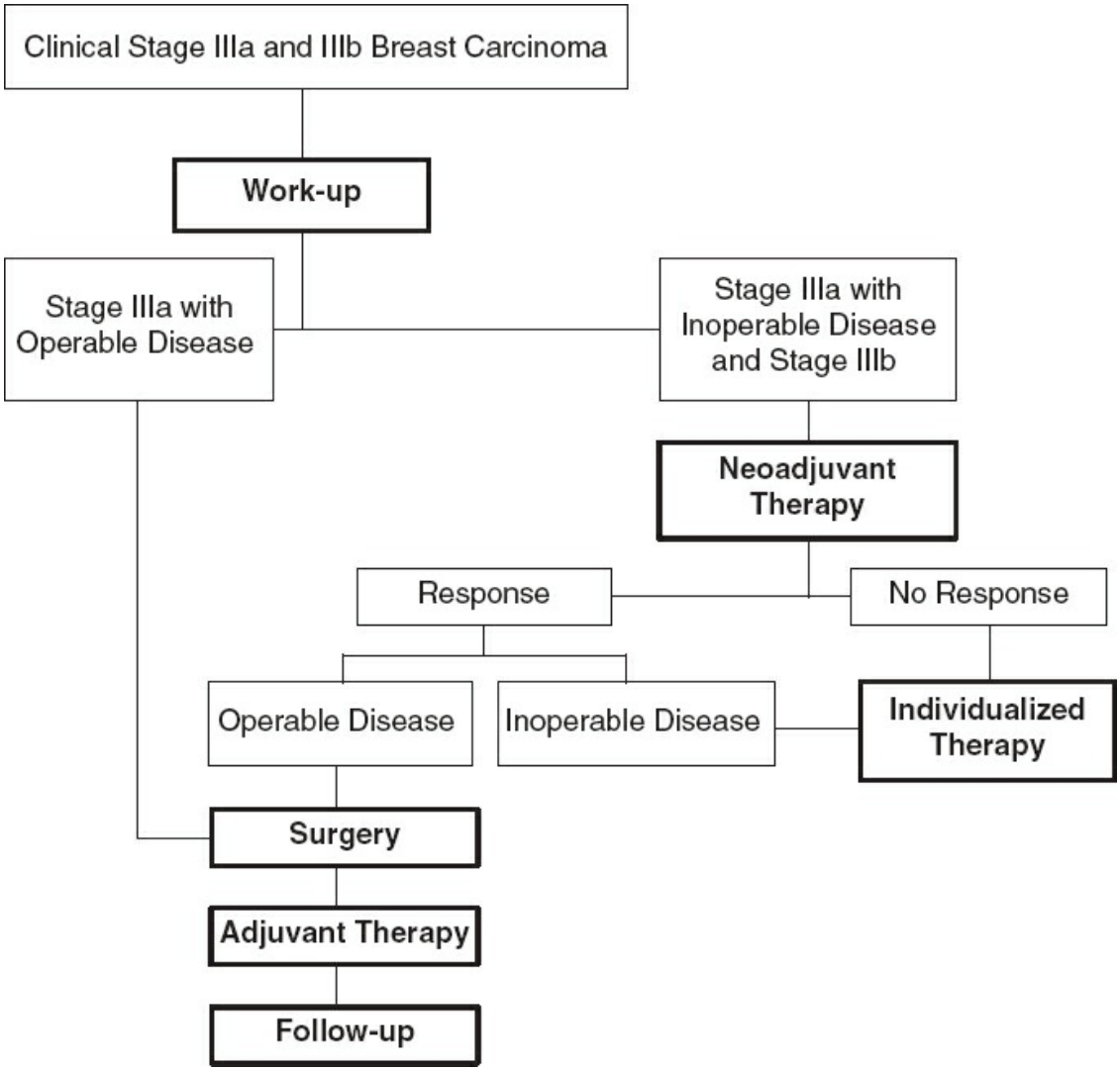

Figure 54.1. Treatment pathways for stage IIIa and stage IIIb breast cancer. (Adapted from Bland KI, ed. *The Practice of General Surgery*. Philadelphia, PA: WB Saunders; 2002. Copyright © 2002 Elsevier.)

Locoregional Recurrence of Breast Cancer

Therapeutic options for the patient with local recurrence of breast cancer is best separated into two groups: (a) those having had mastectomy completion and (b) those having had conservation surgery (lumpectomy). Patients who had prior mastectomy should undergo surgical resection of the recurrence and appropriate reconstruction. Chemotherapy and/or antiestrogen therapy are considered and adjuvant radiation therapy is given if the ipsilateral chest wall has not previously received breast irradiation. For patients having previous breast conservation, therapy should include mastectomy and appropriate reconstruction. Chemotherapy and/or antiestrogen therapy are considered. Women with recurrent disease

involving the axillary lymph nodes (regional recurrence) require axillary lymph node dissection followed by adjuvant chemotherapy.

MODIFIED RADICAL MASTECTOMY: SURGICAL TECHNIQUE

The increasingly popular *skin-sparing mastectomy* removes all breast tissue, the nipple–areola complex, and <1 cm of skin around excised scars. There is a recurrence rate of <2% to 4% when skin-sparing mastectomy is used for T1 to T3 cancers. A *total (simple) mastectomy* removes all breast tissue, the nipple–areola complex, and necessary skin without axillary sampling/dissection. An *extended simple mastectomy* removes all breast tissue, the nipple–areola complex, necessary skin, and the level I axillary lymph nodes. The *modified RM* removes all breast tissue, the nipple–areola complex, extensive skin, and the level I and II axillary lymph nodes. The *Patey modified RM* also removes the pectoralis minor muscle, to provide access for complete dissection of the apical (level III) axillary lymph nodes. *The Halsted RM* removes all breast tissue, the nipple–areola complex, necessary skin, the pectoralis major and (optionally) the pectoralis minor muscles, and the level I to III axillary lymph nodes. Currently, early diagnostic imaging and education—together with chemotherapy, hormone therapy, and radiation therapy—have existentially eliminated the need for the classical Halsted RM.

Positioning

The patient is positioned on the operating table in the supine position for induction of general endotracheal anesthesia (Fig. 54.2). Folded towels provide modest nonrestrictive elevation of the ipsilateral hemithorax and shoulder so that shoulder movement is not compromised. Positioning the patient at the edge of the operating table affords the surgeon and the surgical assistant ample access to the breast and axilla and avoids undue retraction on the pectoralis muscle groups or the brachial plexus. The arm and shoulder must be prepped into the surgical field to allow unrestricted access for dissection of the axilla. The ipsilateral breast, neck, shoulder, and hemithorax are prepped down to the operating table and across the midline of the chest. Folded towels are used to expose the prepped operative field, which includes the shoulder, lower neck, sternum, and upper abdominal musculature. The towels are secured in place with towel

clips or surgical staples. In addition, the ipsilateral axilla, arm, and hand are fully prepared within the operative field and the arm is positioned on an arm board that is placed perpendicular to the operating field. While alternative methods exist for including the arm and hand in the operative field, isolation of the hand and forearm with an occlusive cotton dressing (stockinette) is preferred. The stockinette is secured in place by applying an elastic or cotton bandage distal to the ipsilateral elbow, thereby ensuring free mobility of the ipsilateral elbow, arm, and shoulder.

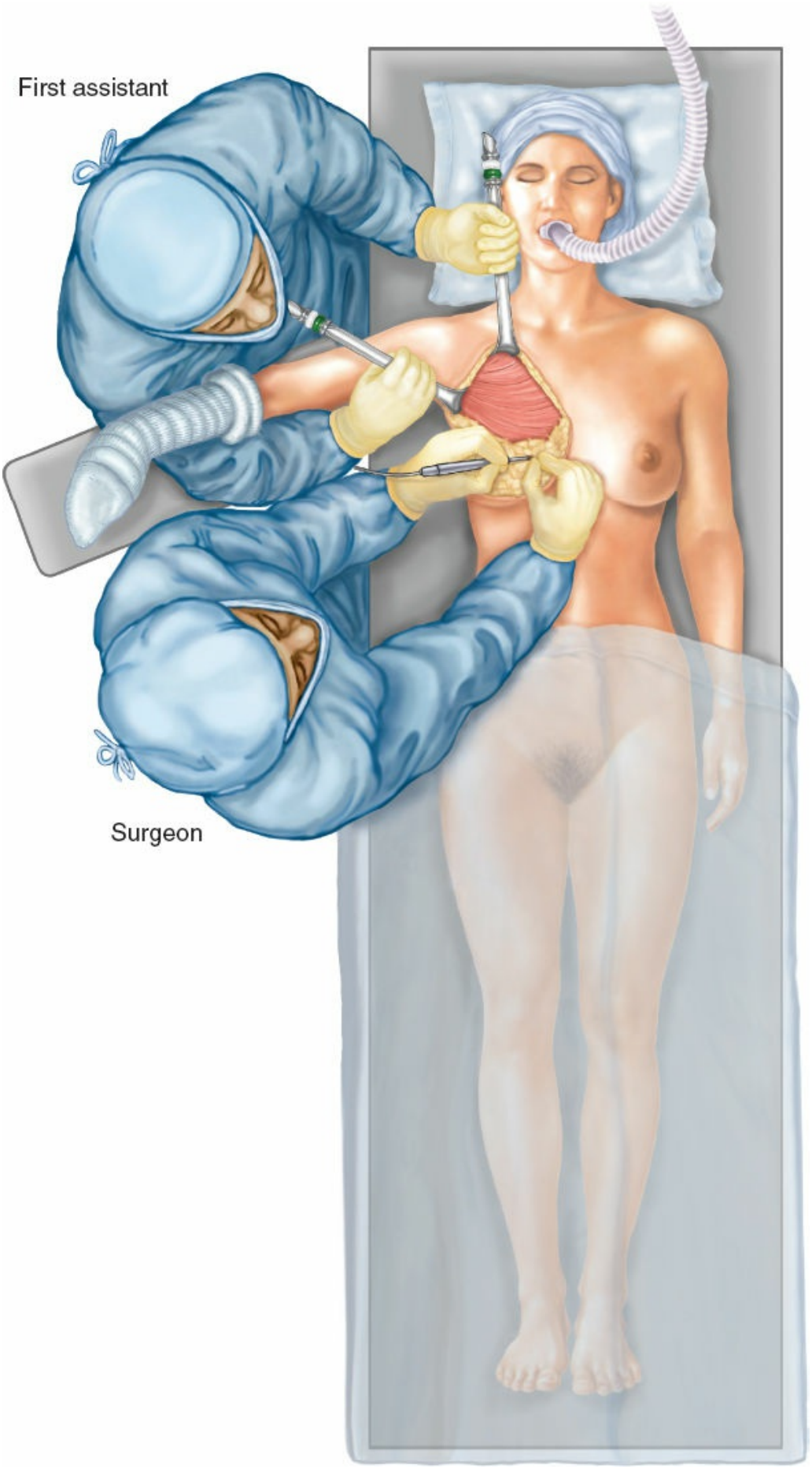
First assistant
Surgeon

Figure 54.2. Position of patient for left modified radical mastectomy at margin of operative table. The first assistant is cephalad to the arm board and shoulder of the patient to allow access to the axillary contents without undue traction on major muscle groups. Depicted is the preferential isolation of the hand and forearm with an occlusive Stockinette cotton dressing secured distal to the elbow. This technique allows free mobility of the elbow, arm, and shoulder to avoid undue stretch of the brachial plexus with muscle retraction. (Bland KI, Klimberg VS, eds. Breast surgery. In: Fischer JE, ed. *Master Techniques in General Surgery: a Series*. Philadelphia, PA: Wolters Kluwer; 2010, with permission.)

Prior to commencement of the procedure, the first surgical assistant is positioned cephalad to the shoulder of the ipsilateral breast, cephalad to the arm board (Fig. 54.2). This position permits the assistant to position the arm and shoulder and retract the pectoral muscles appropriately at the time of the axillary dissection. In an obese patient with large breasts, a second surgical assistant can be positioned on the contralateral side of the operating table to assist with exposure of the axilla during axillary dissection.

Planned incisions appropriate for cancers occupying various locations in the breast are depicted in Figures 54.3 to 54.9. The elliptical incision of the breast skin incorporates the nipple–areolar complex and skin overlying the breast cancer en bloc with skin margins that lie 1 to 2 cm from the cephalad and caudad extents of the cancer.

Utilizing electrocautery, “cold” or “harmonic” scalpel, all flaps are developed that extend to the boundaries of dissection for the modified RM and include: (a) the anterior margin of the latissimus dorsi muscle laterally; (b) the midline of the sternum medially; (c) the subclavius muscle superiorally; and (d) the caudal extension of the breast, which is 3 to 4 cm inferior to the inframammary fold, inferiorly (Fig. 54.10, *inset*). The skin edges are elevated at a right angle to the chest wall to adequately expose the superficial fascia (Fig. 54.10). Skin flaps include the skin and tela subcutanea and vary in thickness depending upon body habitus (Fig. 54.11A). The fascial envelope plane for skin flap elevation is variable and deep to the subcutaneous vasculature and superficial to the larger end-artery vessels of the breast parenchyma. The surgeon elevates the skin flap with consistent thickness to avoid creation of devascularized subcutaneous

tissues, which can contribute to wound seroma, skin necrosis, and flap retraction (Fig. 54.11B).

With development of skin flaps, the breast parenchyma and pectoralis major fascia are elevated from the underlying pectoralis major muscle in a plane consistently parallel with the muscle bundles as they course from their medial origin (ribs 2 to 6) to their lateral insertion on the humerus (Fig. 54.11B). Perforating vessels from the *lateral thoracic or anterior intercostal arteries* are end-arteries that supply the pectoralis major and minor muscles and breast parenchyma, are regularly encountered during elevation of the breast parenchyma and pectoralis major fascia. These vessels are individually identified and ligated with 2-0 or 3-0 nonabsorbable sutures. Elevation of the breast parenchyma and pectoralis major fascia is continued laterally until the lateral edge of the pectoralis major muscle and the underlying pectoralis minor muscle are exposed. The surgeon is aware of the anatomic location of the *lateral neurovascular bundle* in which the *medial pectoral nerve* (laterally placed with origin from the medial cord) courses to innervate the pectoralis major and minor muscles. If possible, this nerve is routinely preserved to prevent atrophy of the lateral head of the pectoralis major—a significant cosmetic and functional deficit (Table 54.5).

Following elevation of the breast parenchyma and pectoralis major muscle fascia from the underlying pectoralis major muscle, an incontinuity axillary lymph node dissection is performed (Figs. 54.12 and 54.13). The investing fascia of the axillary space is sharply divided (Fig. 54.12), the pectoralis minor muscle is defined, and lymph nodes, which may lie between the pectoralis muscles (Rotter's nodes), are cleared. As the axillary lymph node dissection proceeds, the loose areolar tissue of the lateral axillary space is elevated with identification of the lateral extent of the axillary vein in its course anterior and caudad to the brachial plexus and axillary artery (Fig. 54.12). (The axillary contents can also be removed in a medial to lateral direction.) The investing layer of the axillary vein is dissected sharply, with dissection allowing complete visualization of the anterior and ventral surfaces of the vein.

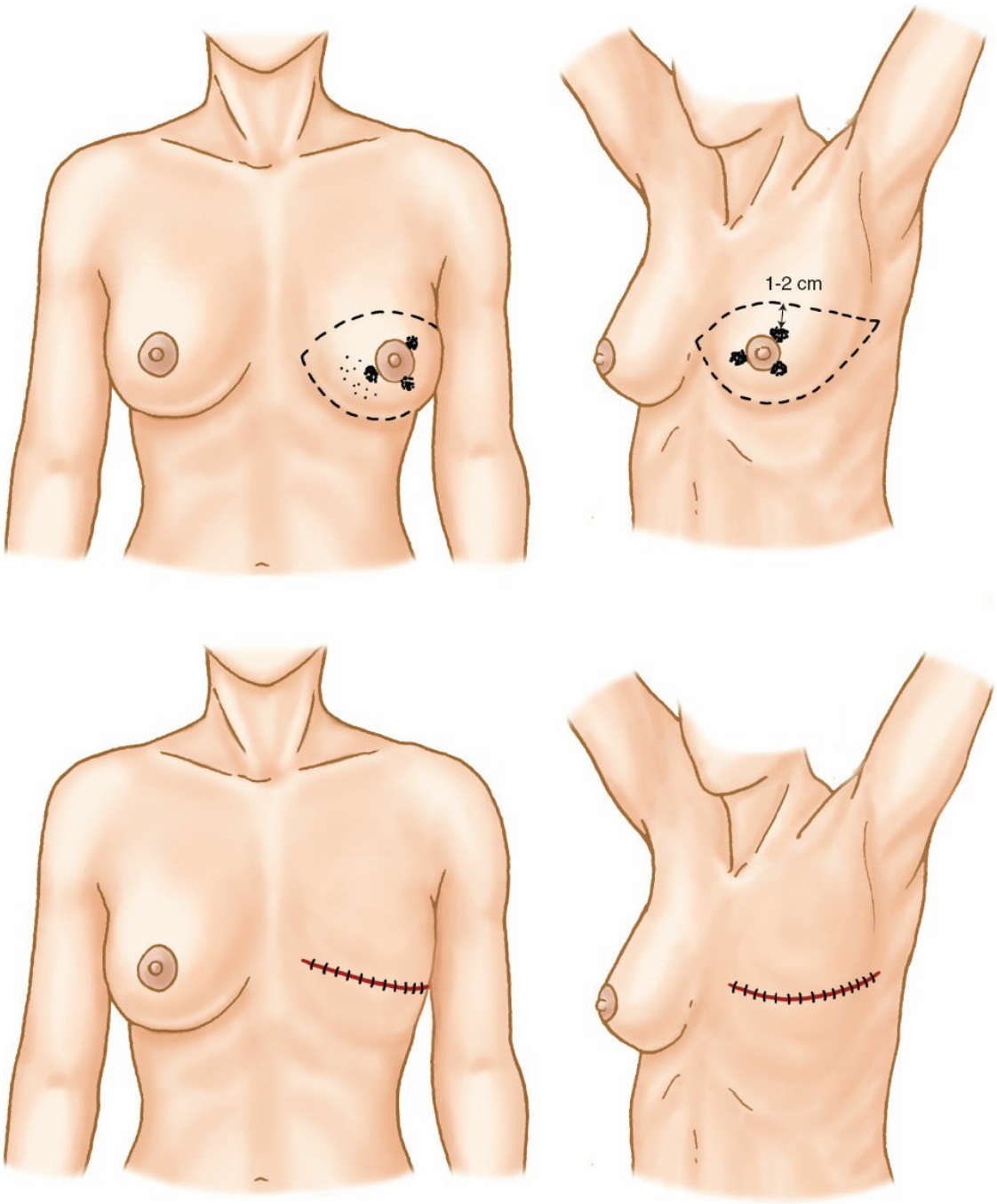

Figure 54.3. Design of the classic Stewart elliptical incision for central and subareolar primary lesions of the breast. The medial extent of the incision ends at the margin of the sternum. The lateral extent of the skin incision should overlie the anterior margin of the latissimus dorsi. The design of the skin incision should incorporate the primary neoplasm en bloc with margins that are 1 to 2 cm from the cranial and caudal edges of the tumor. (Bland KI, Klimberg VS, eds. Breast surgery. In: Fischer JE, ed. *Master Techniques in General Surgery: a Series*. Philadelphia, PA: Wolters Kluwer; 2010, with permission.)

Division and ligation of intervening venous tributaries is performed. Retraction of the superomedial aspect of the pectoralis major muscle exposes the lateral pectoral nerve, which originates from the lateral cord, and is protected to preserve innervation to the medial heads of the pectoralis major muscle (Figs. 54.12 and 54.13; Table 54.5). Dissection continues medially on the anteroventral surface of the axillary vein and the loose areolar tissue at the juncture of the axillary vein with the anterior margin of the latissimus dorsi muscle is swept inferomedially to include the lateral group of axillary lymph nodes (level I, see Fig. 54.12). The intercostobrachial nerves are infrequently visualized, except for the superior trunk that commonly divides close to the chest wall and courses through the level II axillary lymph nodes that lie below the axillary vein. Generally, no attempt is made to salvage the superior trunk and branches of the intercostobrachial nerve (Table 54.5).

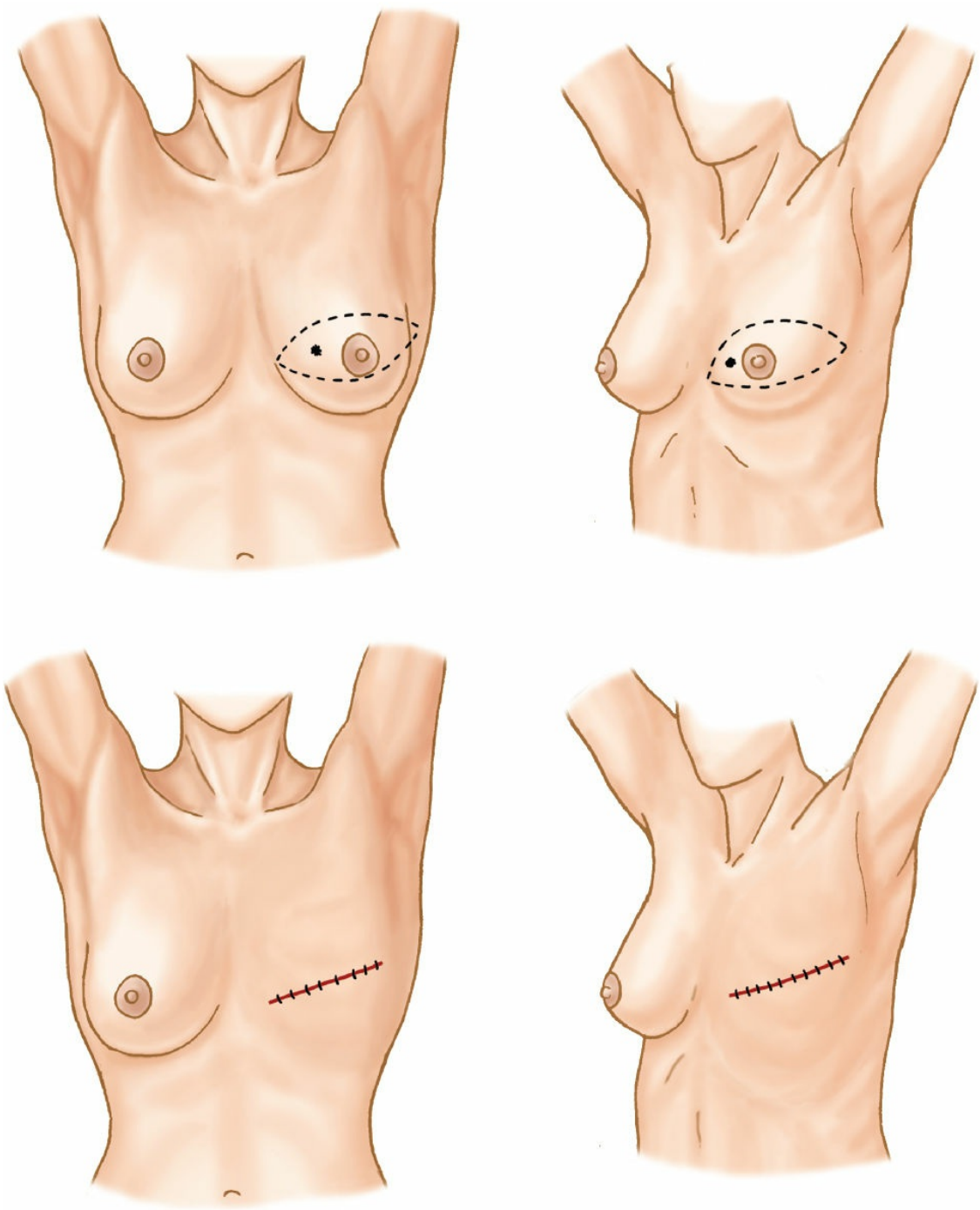

Figure 54.4. Design of the obliquely placed modified Stewart incision for cancer of the inner quadrant of the breast. The medial extent of the incision must often incorporate skin to the midsternum to allow a 1- to 2-cm margin in all directions from the edge of the tumor. Lateral extent of the incision ends at the anterior margin of the latissimus. (Bland KI, Klimberg VS, eds. Breast surgery. In: Fischer JE, ed. *Master Techniques in General Surgery: a Series*. Philadelphia, PA: Wolters Kluwer; 2010, with permission.)

The surgeon should be cognizant of preservation of the thoracodorsal artery, nerve, and vein, located deeply in the axillary space; this maneuver is advocated as these structures are invested with loose areolar tissue and the axillary lymph nodes of the lateral and subscapular groups (Figs. 54.12 and 54.13). The thoracodorsal nerve originates from the posterior cord medial to the thoracodorsal artery and vein and is visualized and protected along its variable inferolateral course en route to its distal innervation of the latissimus dorsi muscle. The lateral axillary lymph node group (Fig. 54.12) is retracted inferomedially and anterior to the thoracodorsal neurovascular bundle and dissected en bloc with the subscapular group of axillary lymph nodes (level I), which are medially located between the thoracodorsal nerve and the lateral chest wall. Dissection of the posterior contents of the axillary space exposes the posterior boundary of the axilla, allowing visualization of the heads of the teres major muscle laterally and the subscapularis muscle medially. Dissection then proceeds medially with extirpation of the central axillary lymph node groups (level II, see Fig. 54.12, *inset*). The superomedial aspect of the dissection specimen can be identified with a metallic marker or suture to provide anatomic orientation for the pathologist. The surgeon continues the dissection en bloc to avoid separation of nodal groups and disruption of lymphatic vessels in the axilla. With medial dissection, the surgeon encounters the chest wall deep in the medial axillary space and is able to identify and preserve the long thoracic nerve (Bell's respiratory nerve), which is constant in its location, anterior to the subscapularis muscle, and is closely applied to the investing serratus fascial compartment of the chest wall. The diminutive long thoracic nerve is meticulously dissected from cephad to caudad longitudinal to its course; dissection is terminated at the point of innervation of the serratus anterior muscle (Figs. 54.12 and 54.13). Damage to the nerve initiates permanent disability with a "winged scapula" deformity secondary to denervation of the serratus anterior muscle (Table 54.3). The axillary contents anterior and medial to the long thoracic nerve are then swept inferomedially with the dissection specimen. The surgeon ensures that the long thoracic and thoracodorsal nerves are completely visualized prior to division of the inferior extent of the axillary dissection contents.

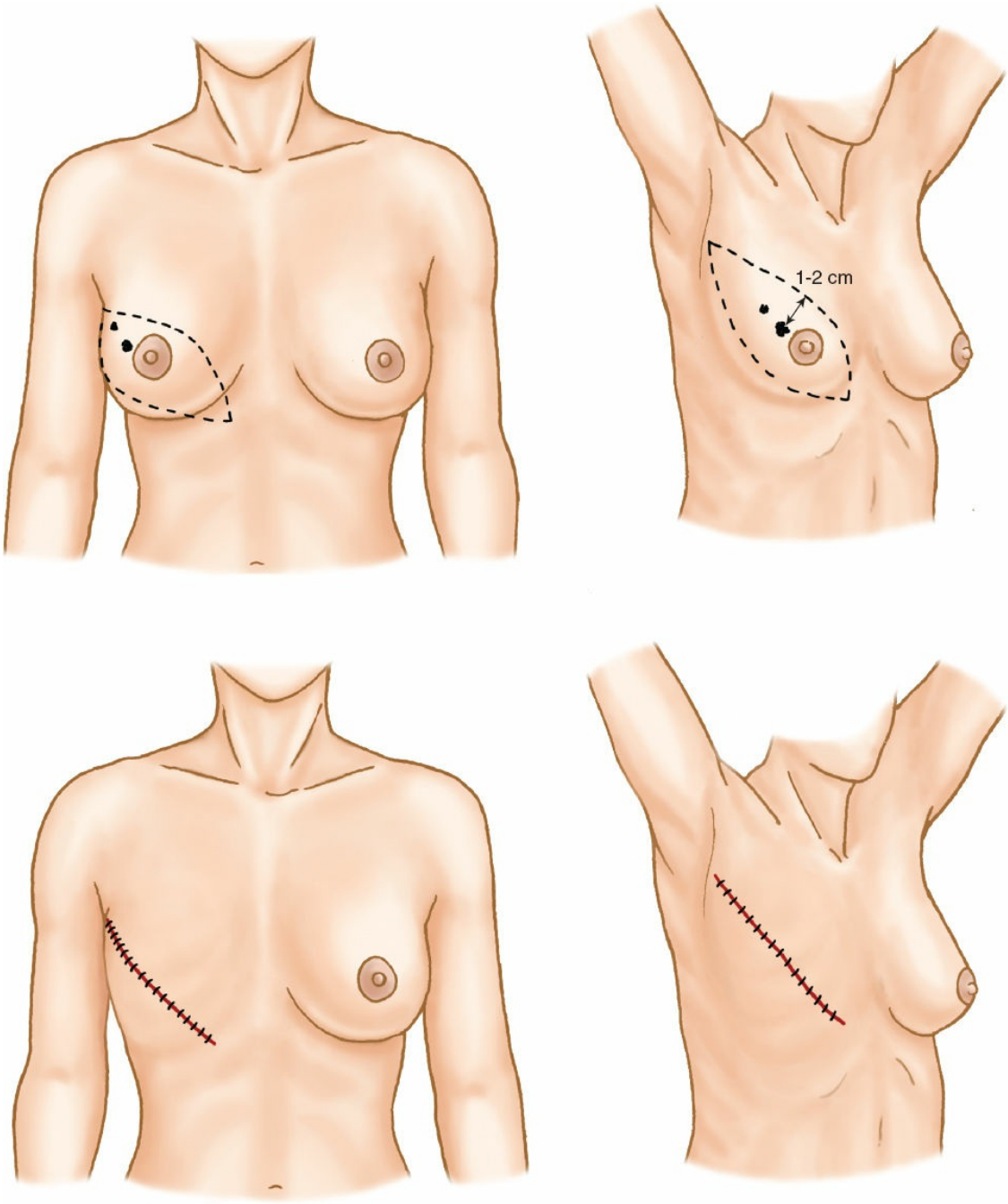

Figure 54.5. Design of the classic Orr oblique incision for carcinoma of the upper outer quadrants of the breast. The skin incision is placed 1 to 2 cm from the margin of the tumor in an oblique plane that is directed cephalad toward the ipsilateral axilla. This incision is a variant of the original Greenough, Kocher, and Rodman techniques for flap development. (Bland KI, Klimberg VS, eds. Breast surgery. In: Fischer JE, ed. *Master Techniques in General Surgery: a Series*. Philadelphia, PA: Wolters Kluwer; 2010, with permission.)

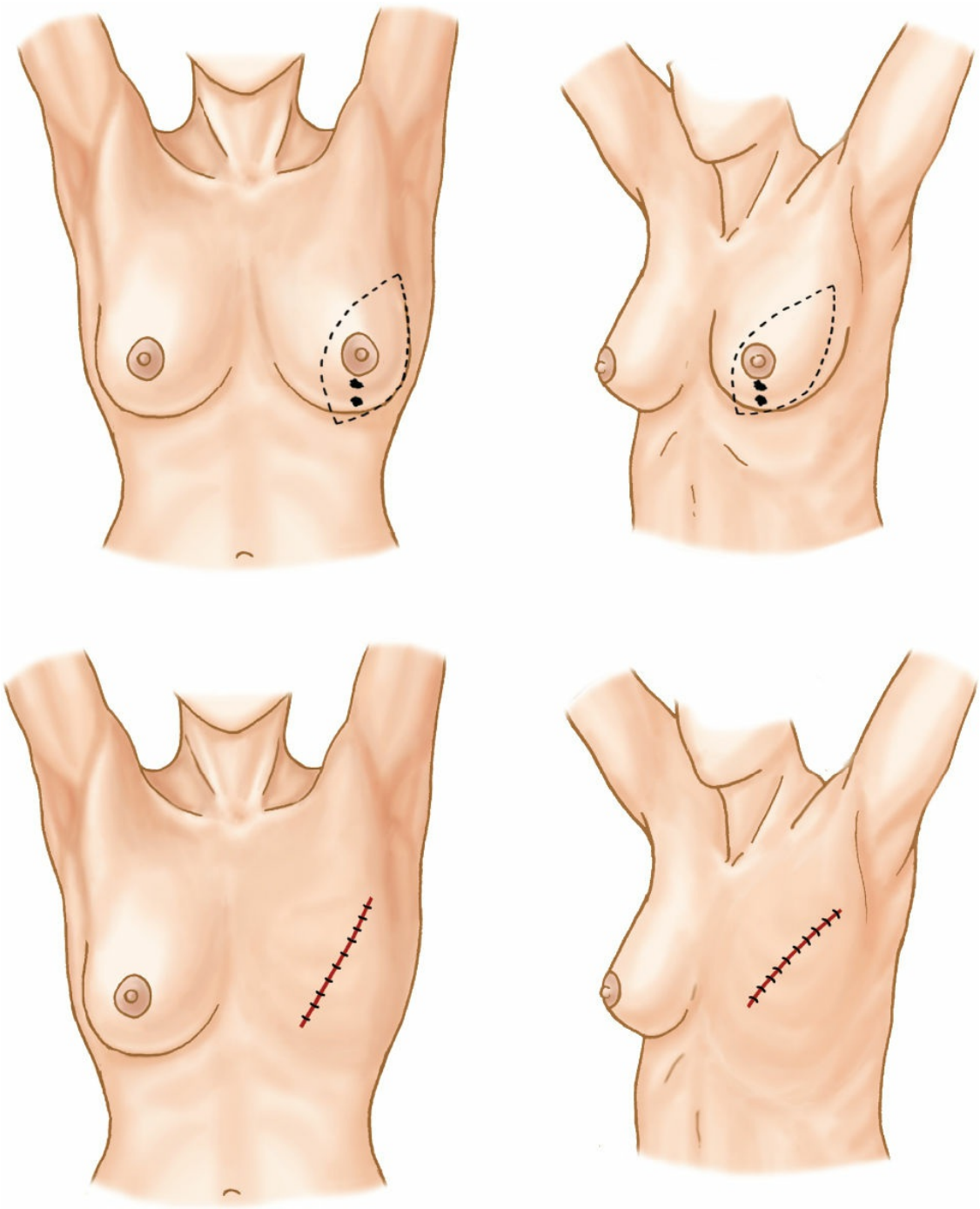

Figure 54.6. Variation of the Orr incision for lower inner and vertically placed (6 o'clock) lesions of the breast. The design of the skin incision is identical to that of Figure 20.4, with attention directed to margins of 1 to 2 cm. (Bland KI, Klimberg VS, eds. Breast surgery. In: Fischer JE, ed. *Master Techniques in General Surgery: a Series*. Philadelphia, PA: Wolters Kluwer; 2010, with permission.)

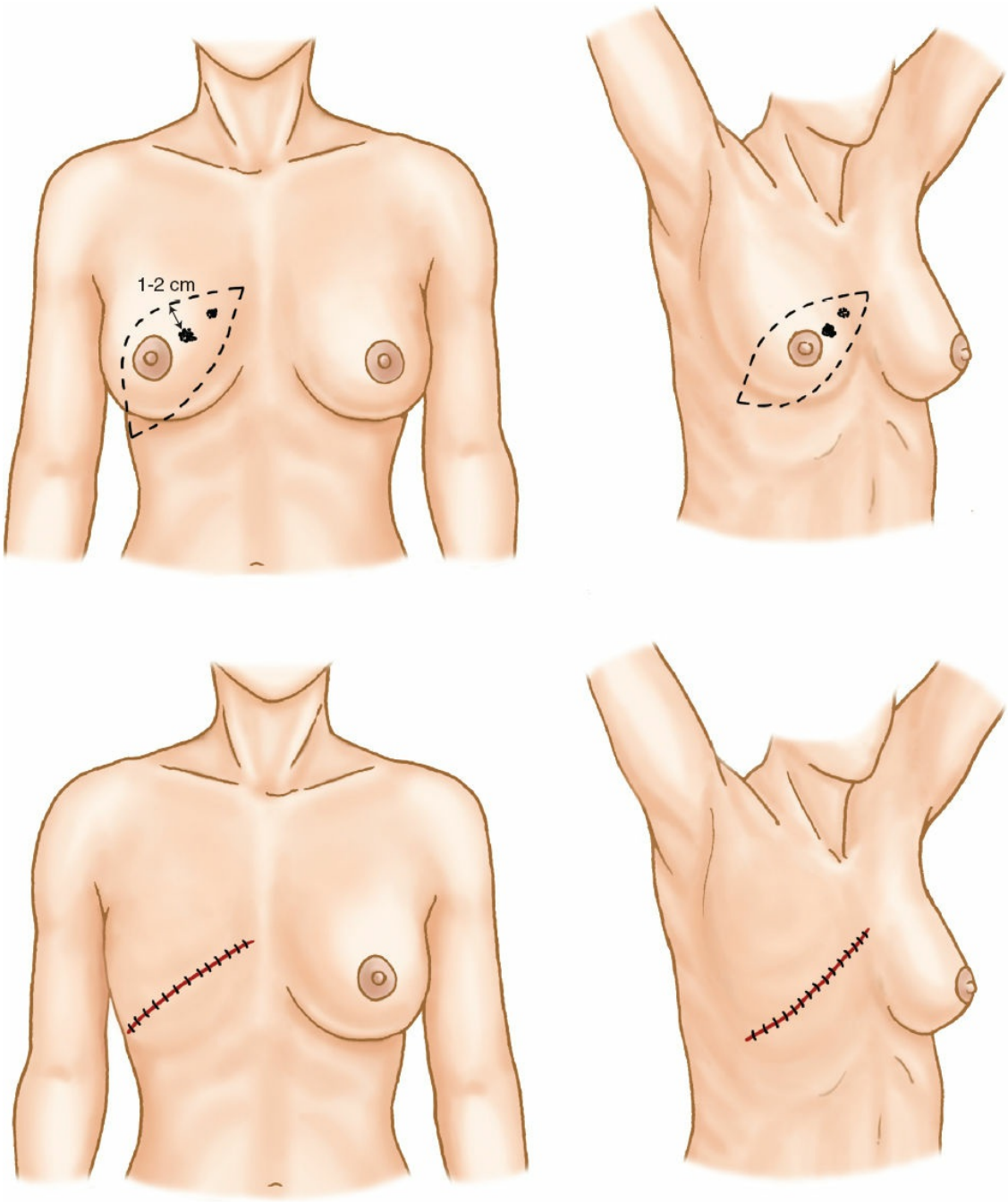

Figure 54.7. Design of skin flaps for upper inner quadrant primary tumors of the breast. The cephalad margin of the flap must be designed to allow access for dissection of the axilla. With flap margins 1 to 2 cm from the tumor, variation in the medial extent of the incision is expected and may extend beyond the edge of the sternum. On occasion, the modified Stewart incision can incorporate the tumor en bloc, provided that the cancer is not too high on the breast and craniad from the nipple/areola complex. All incision designs must be inclusive of the nipple/areola complex when total mastectomy is planned with primary therapy. (Bland KI, Klimberg VS, eds. Breast surgery. In: Fischer JE, ed. *Master Techniques in General Surgery: a Series*.

Philadelphia, PA: Wolters Kluwer; 2010, with permission.)

With the presence of level III lymphadenopathy, the Patey modification of the modified RM is employed to enhance locoregional control (Fig. 54.13). As the surgeon proceeds medially to complete dissection along the lateral margin of the pectoralis major muscle, abduction of the shoulder and extension of the arm along with finger dissection at the lateral margin of the pectoralis major muscle allow visualization of the insertion of the pectoralis minor muscle on the coracoid process of the scapula. The Patey modification involves division of the tendinous portion of the pectoralis minor muscle (Fig. 54.12) near its insertion on the coracoid process with/without removal of the muscle, which permits access to the apical axillary lymph nodes (level III) and visualization of the full extent of the axillary vein as it courses beneath the pectoralis minor muscle to its confluence with the subclavian vein beneath the costoclavicular ligament (Halsted ligament).

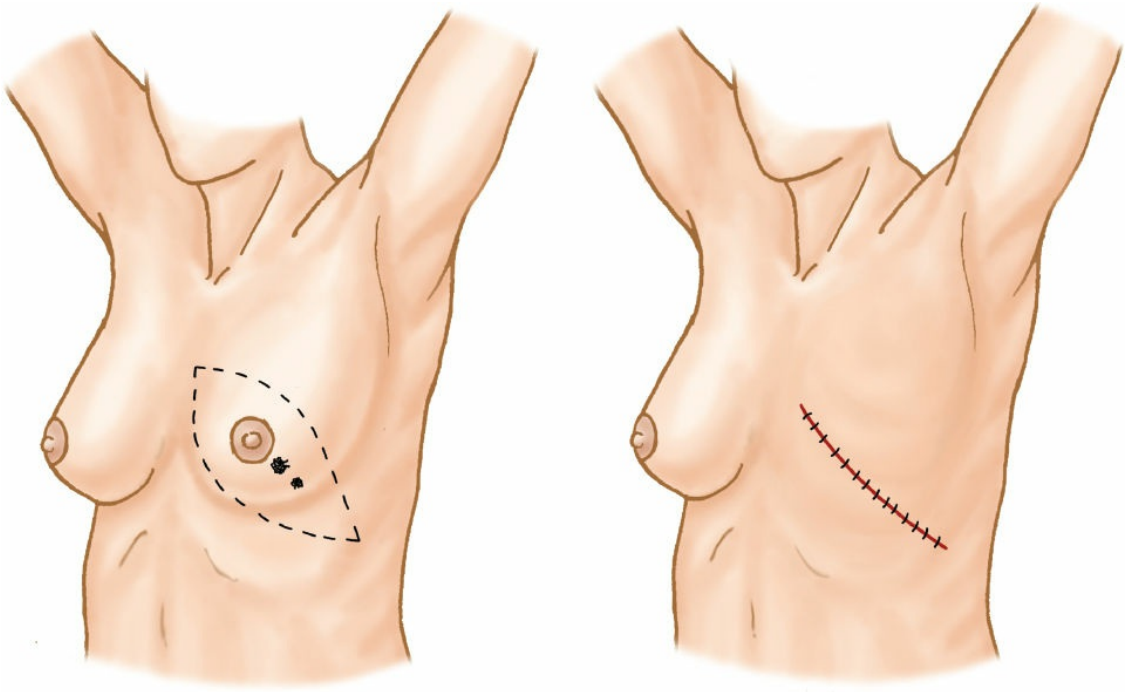

Figure 54.8. Incisions for cancer of the lower outer quadrants of the breast. The surgeon should design incisions that achieve margins of 1 to 2 cm from the tumor with cephalad margins that allow access for dissection of the axilla. The medial extent is the margin of the sternum. Laterally, the inferior extent of the incision is the latissimus. (Bland KI, Klimberg VS, eds. Breast surgery. In: Fischer JE, ed. *Master Techniques in General Surgery: a Series*.

Philadelphia, PA: Wolters Kluwer; 2010, with permission.)

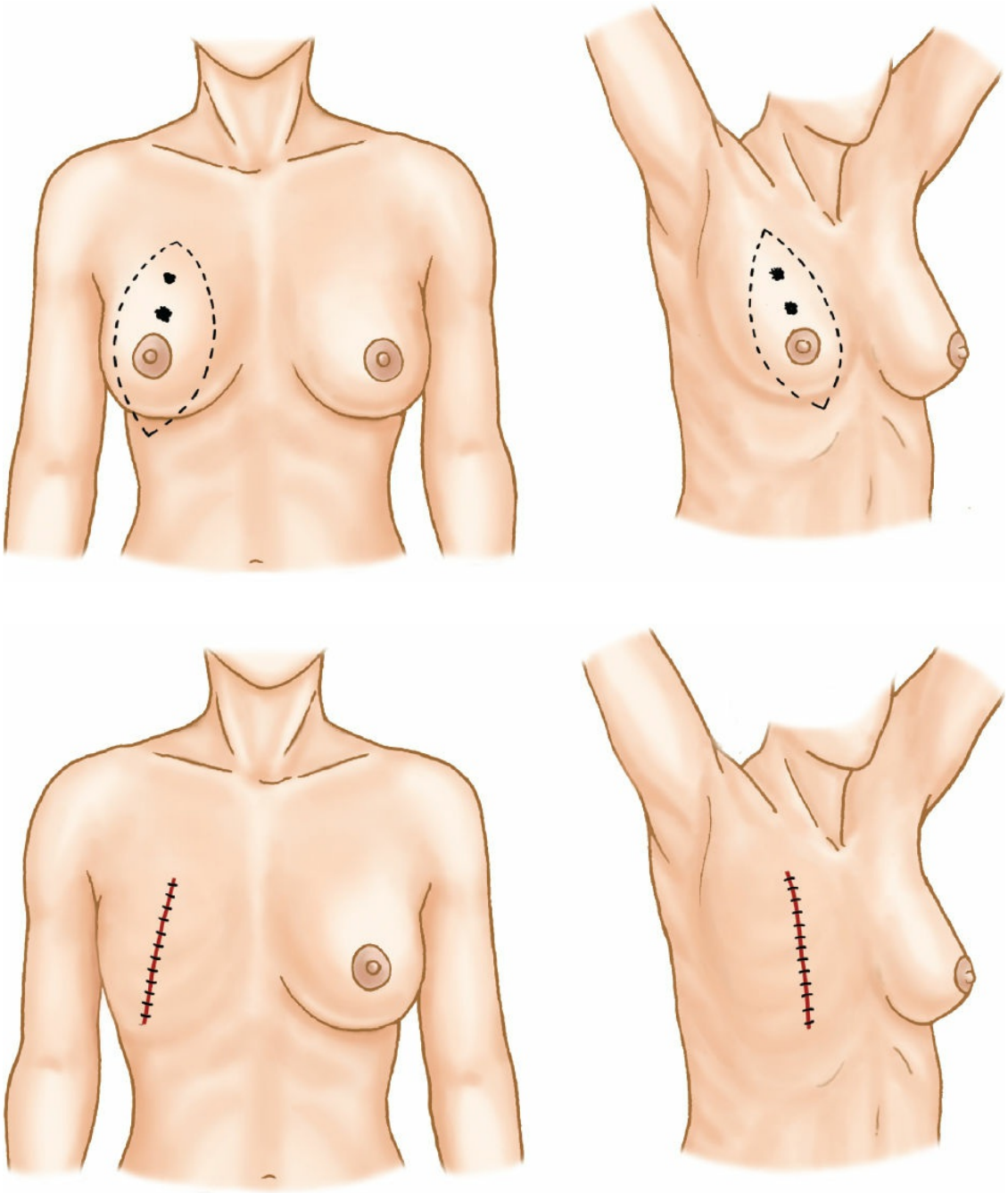

Figure 54.9. Depiction of skin flaps for lesions of the breast that are high lying, infraclavicular, or fixed to the pectoralis major muscle. Fixation to the muscle and/or chest wall necessitates Halsted radical mastectomy with skin margins of at least 2 cm. Skin grafting is necessary when large margins of skin are resected for T_3 and T_4 cancers. Primary closure for T_1 and some T_2 tumors is often possible. (Bland KI, Klimberg VS, eds. Breast surgery. In: Fischer JE, ed. *Master Techniques in General Surgery: a Series*. Philadelphia, PA: Wolters Kluwer; 2010, with

permission.)

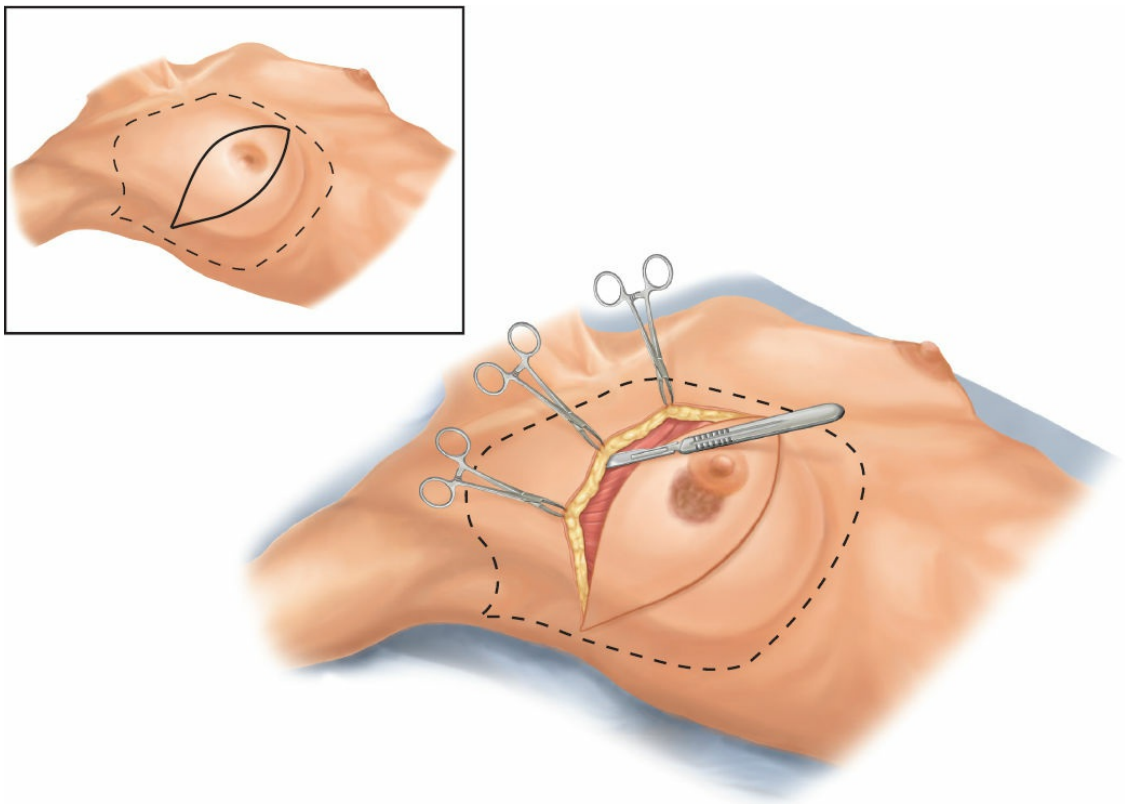

Figure 54.10. *Inset:* Limits of the modified radical mastectomy are delineated laterally by the anterior margin of the latissimus dorsi muscle, medially by the sternal border, superiorly by the subclavius muscle, and inferiorly by the caudal extension of the breast approximately 3 to 4 cm inferior to the inframammary fold. Skin flaps for the modified radical technique are planned with relation to the quadrant in which the primary neoplasm is located. Adequate margins are ensured by developing skin edges 3 to 5 cm from the tumor margin. Skin incisions are made perpendicular to the subcutaneous plane. Flap thickness should vary with patient body habitus but ideally should be 7 to 8 mm thick. Flap tension should be perpendicular to the chest wall with flap elevation deep to the cutaneous vasculature, which is accentuated by flap retraction. (Bland KI, Klimberg VS, eds. Breast surgery. In: Fischer JE, ed. *Master Techniques in General Surgery: a Series*. Philadelphia, PA: Wolters Kluwer; 2010, with permission.)

TABLE 54.5 Anatomical Complications of the Modified RM

Vascular Injury	The first and second perforating vessels are too large for cautery. They are ligated. The axillary vein, if torn, is repaired. Ligation may cause chronic edema.
Nerve Injury	
Intercostobrachial nerve	When cut, circumscribed numbness of the medial aspect of the ipsilateral upper arm results.
Long thoracic nerve	If cut, a "winged scapula" deformity results.
Medial and lateral thoracic nerves	If cut, the pectoralis muscles atrophy.
Thoracodorsal nerve	If cut, internal rotation and abduction of the shoulder is weakened.

Following completion of axillary node dissection (Fig. 54.13), the resection specimen is sent for histologic examination and for immunohistochemistry (ER, PR, Ki67, Her2-neu and appropriate prognostic genomic/proteomic analyses). The surgical bed is irrigated with sterile saline to evacuate residual tissue, blood clots, and serum. Bleeding points are identified, clipped, cauterized, or ligated. After this, the surgeon, surgical assistant, and scrub nurse don fresh surgical gloves and utilize clean surgical instruments to avoid implantation of exfoliated cancer cells in the surgical bed. Just prior to closure, closed suction silastic catheters are placed in the surgical bed and are brought out through separate stab wounds inferiorly (Fig. 54.13, *inset*). The laterally placed silastic catheter is positioned in the axillary space approximately 2 cm inferior to the axillary vein on the ventral surface of the latissimus dorsi muscle to provide drainage of the axilla. The medially placed silastic catheter is positioned under the skin flaps. Both catheters are secured to the skin with a 3-0 nylon suture and are maintained on low-pressure suction. The wound is closed in two layers with 3-0 absorbable sutures placed in the subcutaneous tissues, while the skin edges are approximated with staples or with 4-0 absorbable subcuticular sutures, in which case, short Steri-strips are applied perpendicular to the skin to closely approximate the skin edges. Noncompressive dressings can be applied.

Wound dressings are removed after 24 to 48 hours. The silastic catheters remain in place until drainage becomes serous or serosanguinous in character and decreases to ≤20 mL per 24 hours for a 48-hour period. Generally, the catheters are removed between postoperative days 5 and 7, but, when necessary for continued high-volume drainage, can remain until postoperative day 10. Range-of-motion shoulder exercises begin 24 hours

after surgery but are suspended for the 24-hour period following drain removal.

Development of a seroma beneath the skin flaps or in the axilla represents the most frequent complication of mastectomy and axillary lymph node dissection, reportedly occurring in as many as 30% of cases. Wound infections occur infrequently after a mastectomy and the majority occurs secondary to skin flap necrosis. Culture of the infected wound for aerobic and anaerobic organisms, debridement, and antibiotics are effective management. Moderate or severe hemorrhage in the postoperative period is rare and is best managed by return to the operating room with early wound exploration for control of hemorrhage and reestablishment of closed system suction drainage. The incidence of functionally *significant lymphedema* after modified RM is ≤10%. Extended axillary lymph node dissection (levels I to III), adjuvant radiation therapy, the presence of pathologic lymph nodes, and obesity contribute to an increased incidence of lymphedema. Individually fitted compression sleeves and intermittent compression devices considerably reduce the extent and palliate the symptoms of lymphedema.

RECONSTRUCTION OF THE BREAST AND CHEST WALL FOLLOWING MRM

The options for reconstructive surgery following mastectomy for breast cancer include: primary wound closure and prosthetic expanders/implants with transfer of skin and subcutaneous tissues for breast reconstruction. These techniques are either *initiated immediately* (Fig. 54.14) or *delayed* (Figs. 54.15 and 54.16). Reconstruction following prophylactic mastectomy or after mastectomy for *early invasive disease may be* performed concurrent with surgical resection of the neoplasm; however, reconstruction following surgery for *advanced breast cancer* is optimally delayed for 6 to 18 months after completion of adjuvant therapy to ensure that locoregional control of disease has been established. For most women, wound closure after mastectomy is accomplished with simple approximation of the wound margins. When more radical removal of skin and subcutaneous tissue is necessary, the split-thickness skin graft provides functional coverage but allows poor tolerance for adjuvant radiation therapy when required with more advanced disease. Thus, creation of large soft tissue defects should be covered with mycocutaneous flaps. Implants placed beneath the pectoralis muscle can be utilized for

reconstruction with or without the concomitant use of myocutaneous flaps. Various types of myocutaneous flaps may be employed, but the latissimus dorsi and the transverse rectus abdominis myocutaneous (TRAM) flaps are most frequently utilized and favored by the reconstructive plastic surgeon.

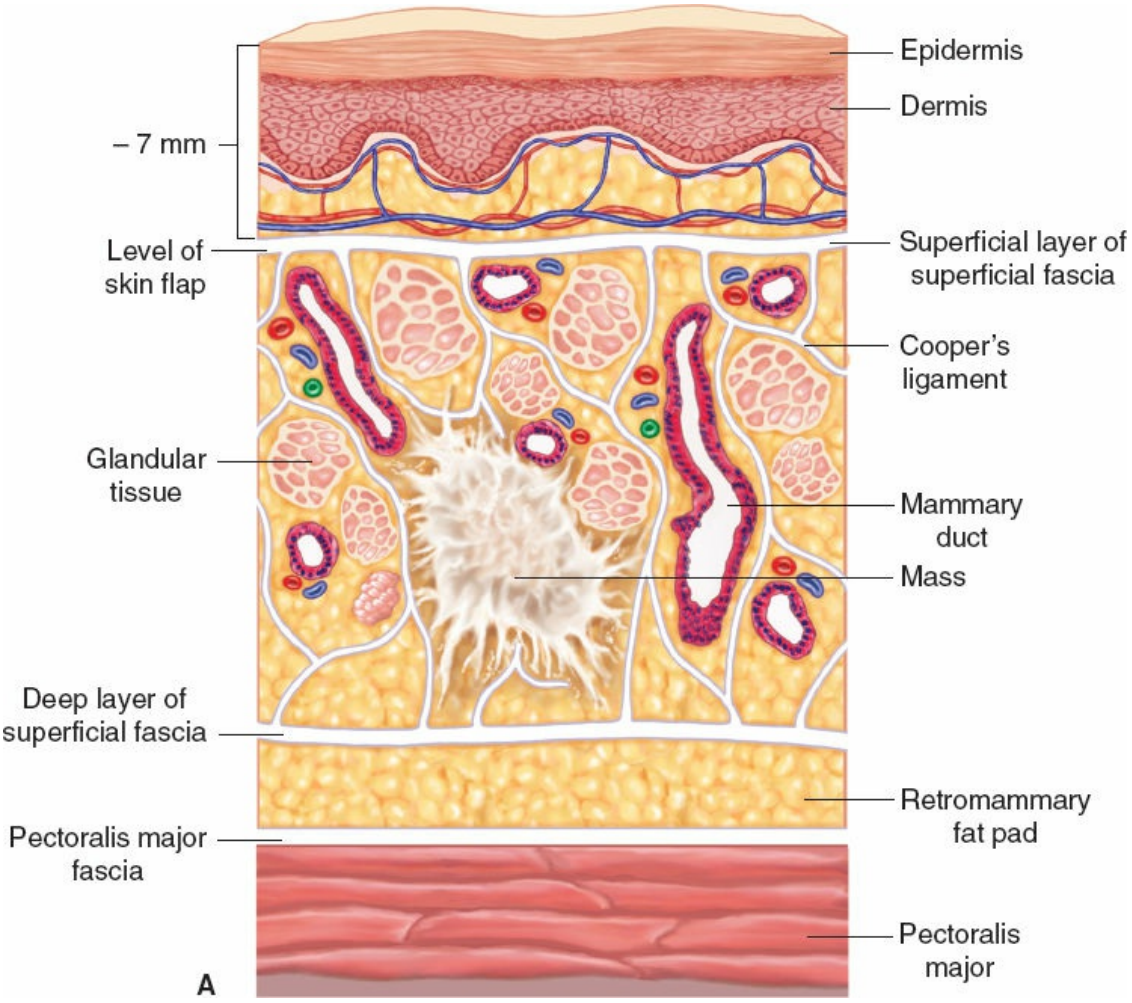

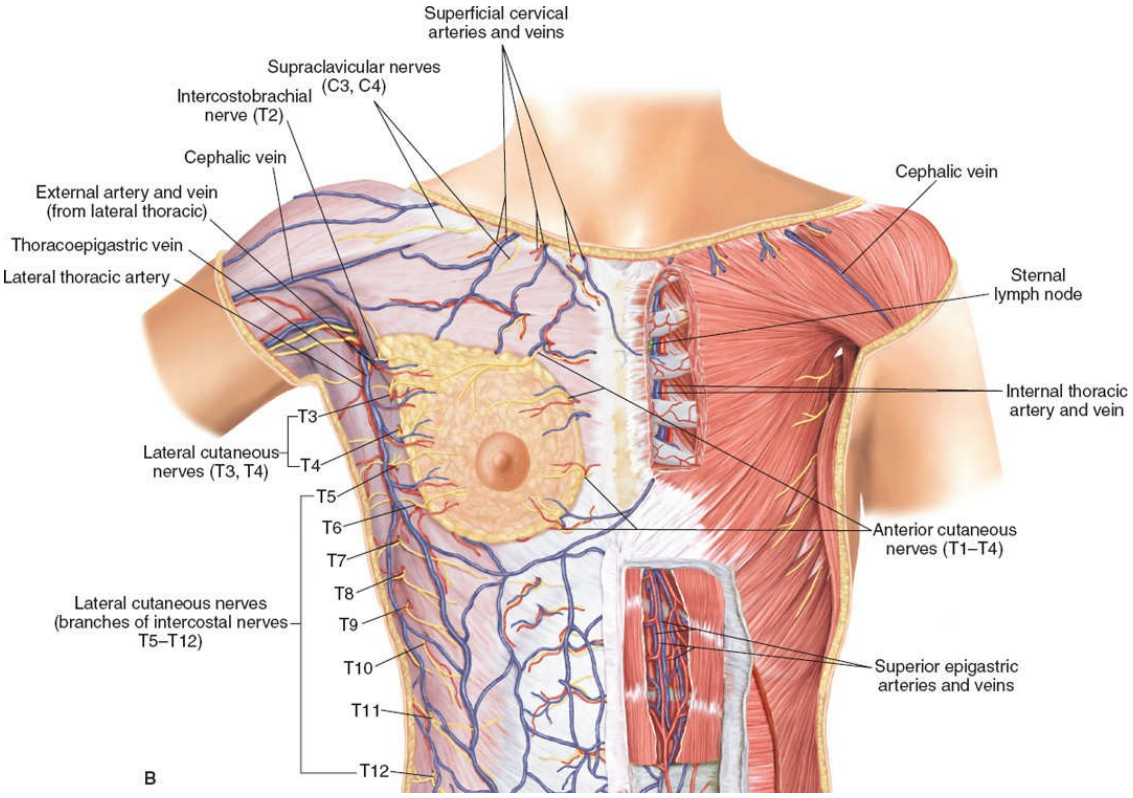

Figure 54.11. Development of the skin flaps. **A.** The skin flaps incorporate skin and the tela subcutanea and are elevated deep to the subcutaneous vasculature. The anterior border of the latissimus dorsi muscle and the innervation of the skin of the lateral chest and axilla by the lateral cutaneous branches of the intercostobrachial nerves are illustrated. **B.** Branches of these nerves also innervate the skin of the medial aspect of the arm. The intercostobrachial nerves are commonly divided during the axillary dissection. Elevation of the breast parenchyma and pectoralis major muscle fascia. The breast parenchyma and pectoralis major fascia are elevated en bloc from the underlying pectoralis major muscle in a plane parallel to the muscle bundles as they course from their medial origin (ribs 2 to 6) to their lateral insertion on the humerus. Perforating vessels from the lateral thoracic or anterior intercostal arteries, which are end arteries that supply the pectoralis major and minor muscles and breast parenchyma, are regularly encountered during elevation of the breast parenchyma and pectoralis major fascia. These vessels are individually identified and secured with 2-0 or 3-0 nonabsorbable sutures. Elevation of breast parenchyma and fascia continue until the full length of the lateral edge of the pectoralis major muscle is exposed. (Bland KI, Klimberg VS, eds. Breast surgery. In: Fischer JE, ed. *Master Techniques in General Surgery: a Series*. Philadelphia, PA: Wolters Kluwer; 2010, with permission.)

In the absence of metastic disease with bony chest wall invasion by locoregional disease, or with pretreated recurrent/primary disease, resection of portions of the bony chest wall en bloc is indicated. When one or two ribs are resected en bloc with the specimen, myocutaneous flap coverage is provided; reconstruction of the bony defect is usually not necessary as scar tissue will stabilize the chest wall. When more than two ribs are sacrificed, it is advisable to stabilize the chest wall with Marlex or other prosthetic mesh, which is thereafter covered with autologous soft tissues utilizing either the latissimus dorsi or TRAM myocutaneous flap.

For purposes of simplicity and function, the most pragmatic procedure for immediate breast reconstruction includes the placement of an implant beneath the pectoralis major muscle (Fig. 54.14). Candidates for this technique include patients with (a) early-stage breast cancer who require minimal skin excision, (b) a small-diameter nipple–areola complex, and (c) small- to moderate-sized breasts without ptosis. After completion of the mastectomy, an incision is made at the inframammary crease and a musculofascial flap involving the pectoralis major, serratus anterior, external oblique, and rectus abdominis muscles is elevated. An implant of appropriate size is then placed on the chest wall beneath the musculofascial flap and the incision closed with absorbable sutures. Capsular contraction is a complication of implant placement and can require reoperation.

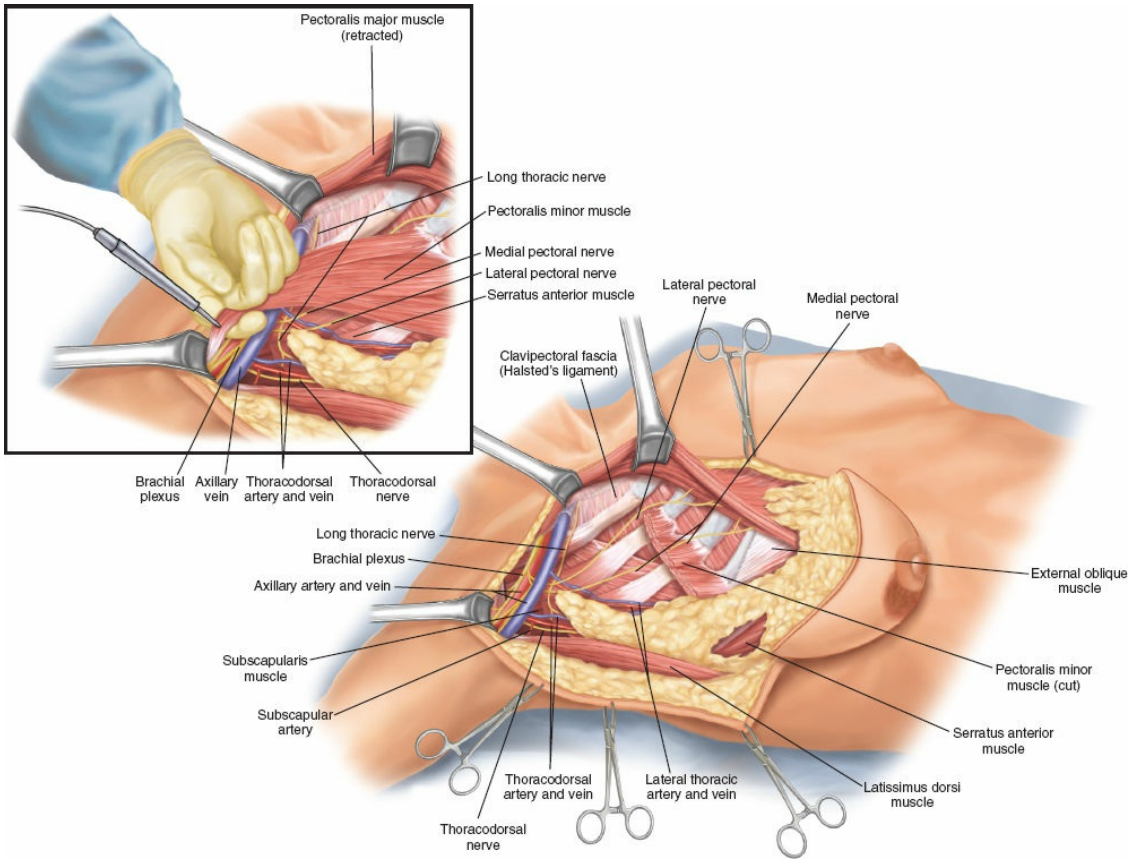

Figure 54.12. Exposure of the pectoralis minor muscle and incision of the investing fascia of the axilla. Upward retraction of the pectoralis major muscle reveals the underlying pectoralis minor muscle and an intervening compartment (Rotter's space), which may contain lymph nodes (Rotter's nodes). *Inset:* After incision of the investing fascia of the axillary space, the tendinous portion of the pectoralis minor muscle and underlying structures (axillary artery and vein, brachial plexus) are readily identified. Digital protection of the brachial plexus for division of the insertion of the pectoralis minor muscle on the coracoid process. All loose areolar and lymphatic tissues are swept en bloc with the axillary contents. Dissection commences superior to inferior with complete visualization of the anterior and ventral aspects of the axillary vein. Dissection craniad to the axillary vein is inadvisable, for fear of damage to the brachial plexus and the infrequent observation of gross nodal tissue cephalic to the vein. Investing fascial dissection of the vein is best completed with the cold scalpel following exposure, ligation, and division of all venous tributaries on the anterior and ventral surfaces. Caudal to the vein, loose areolar tissue at the junction of the vein with the anterior margin of latissimus is swept inferomedially inclusive of the lateral (axillary) nodal group (level 1). Care is taken to preserve the neurovascular thoracodorsal artery, vein, and nerve

in the deep axillary space. The thoracodorsal nerve is traced to its innervation of the latissimus dorsi muscle laterally. Lateral axillary nodal groups are retracted inferomedially and anterior to this bundle for dissection en bloc with the subclavicular (level 3) group. The superomedial most extent of the dissection is the clavipectoral fascia (Halsted ligament). This level of dissection with the Patey technique allows the surgeon to mark, with metallic clip or suture, the superiormost extent of dissection. All loose areolar tissue just inferior to the apical nodal group is swept off the chest wall, leaving the fascia of the serratus anterior intact. With dissection parallel to the long thoracic nerve (respiratory nerve of Bell), the deep investing serratus fascia is incised. This nerve is closely applied to the investing fascial compartment of the chest wall and must be dissected in its entirety, cephalic to caudal, to ensure innervation of the serratus anterior and avoidance of the “winged scapula” disability. Axillary lymph node dissection. The loose areolar tissue of the axillary space is elevated and the investing layer of the axillary vein is dissected sharply, with dissection continuing to allow complete visualization of the anterior and ventral surfaces of the vein, as well as ligation and division of intervening venous tributaries. The loose areolar tissue at the juncture of the axillary vein with the anterior margin of the latissimus dorsi muscle laterally is swept inferomedially to include the lateral group of axillary lymph nodes (level I). The thoracodorsal artery and vein, which are located deep in the axillary space and are invested with loose areolar tissue and the axillary lymph nodes of the lateral and subscapular groups, are preserved. The lateral axillary lymph node group is retracted inferomedially and anterior to the thoracodorsal neurovascular bundle and dissected en bloc with the subscapular group of axillary lymph nodes (level I), which is located medially between the thoracodorsal nerve and the lateral chest wall. Dissection then proceeds medially with extirpation of the central axillary lymph node groups (level II). The long thoracic nerve (Bell’s respiratory nerve), which is constant in its location anterior to the subscapularis muscle, and is closely applied to the investing fascial compartment of the chest wall, is identified and preserved. The axillary contents anterior and medial to the long thoracic nerve are then swept inferomedially with the dissection specimen. *Inset:* When level III lymphadenopathy is present, a Patey modification of the axillary dissection is performed, which involves division of the tendinous portion of the pectoralis minor muscle near its insertion on the coracoid process with/without removal of the muscle. This modification provides exposure for

dissection of the apical axillary lymph nodes (level III). Digital protection of the brachial plexus prior to division of the tendinous insertion of the pectoralis minor muscle at the corocoid process is illustrated.

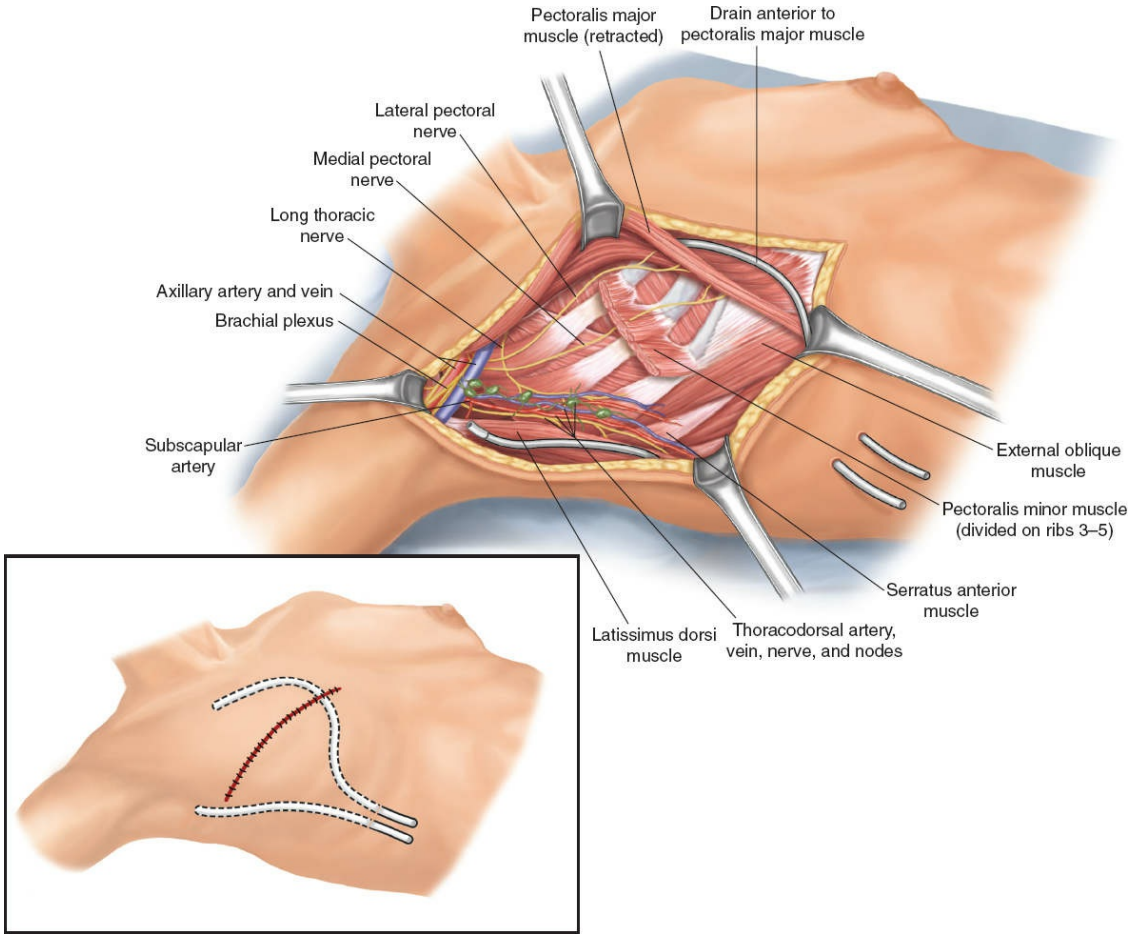

Figure 54.13. The completed Patey axillary dissection variant of the modified radical technique. The dissection is inclusive of the pectoralis minor muscle from origin to insertion on ribs 2 to 5. Both medial and lateral pectoral nerves are preserved to ensure innervation of pectoralis major. With completion of the procedure, remaining portions of this muscle are swept en bloc with the axillary contents to be inclusive of Rotter's interpectoral and the retropectoral groups. *Inset:* Following copious irrigation with saline, closed suction Silastic catheters (10 French) are positioned via stab incisions placed in the inferior flap at the anterior axillary line. The lateral catheter is placed approximately 2 cm inferior to the axillary vein. The superior, longer catheter placed via the medial stab wound is positioned in the inferomedial aspect of the wound bed anterior to the pectoralis major muscle beneath the skin flap. The wound is closed in two layers with 3-0 absorbable synthetic sutures placed in subcutaneous planes. Undue tension on margins of the flap must be avoided; it may necessitate undermining of tissues to reduce mechanical forces. The skin is closed with subcuticular 4-0 synthetic absorbable or nonabsorbable sutures. After completion of wound closure, both catheters are connected to bulb suction.

Light, bulky dressings of gauze are placed over the dissection site and taped securely in place with occlusive dressings. The surgeon may elect to place the ipsilateral arm in a sling to provide immobilization. (Bland KI, Klimberg VS, eds. Breast surgery. In: Fischer JE, ed. *Master Techniques in General Surgery: a Series*. Philadelphia, PA: Wolters Kluwer; 2010, with permission.)

The myocutaneous latissimus dorsi flap is appropriate for immediate breast reconstruction as a result of its favorable donor site and predictable wound repair (Figs. 54.15 and 54.16). The flap consists of a skin paddle based on the underlying latissimus dorsi muscle, which is supplied by the thoracodorsal artery with contributions from the posterior intercostal arteries. Alternatively, placement of an implant below the pectoralis major muscle may also be necessary to achieve a breast mound of adequate size and symmetry.

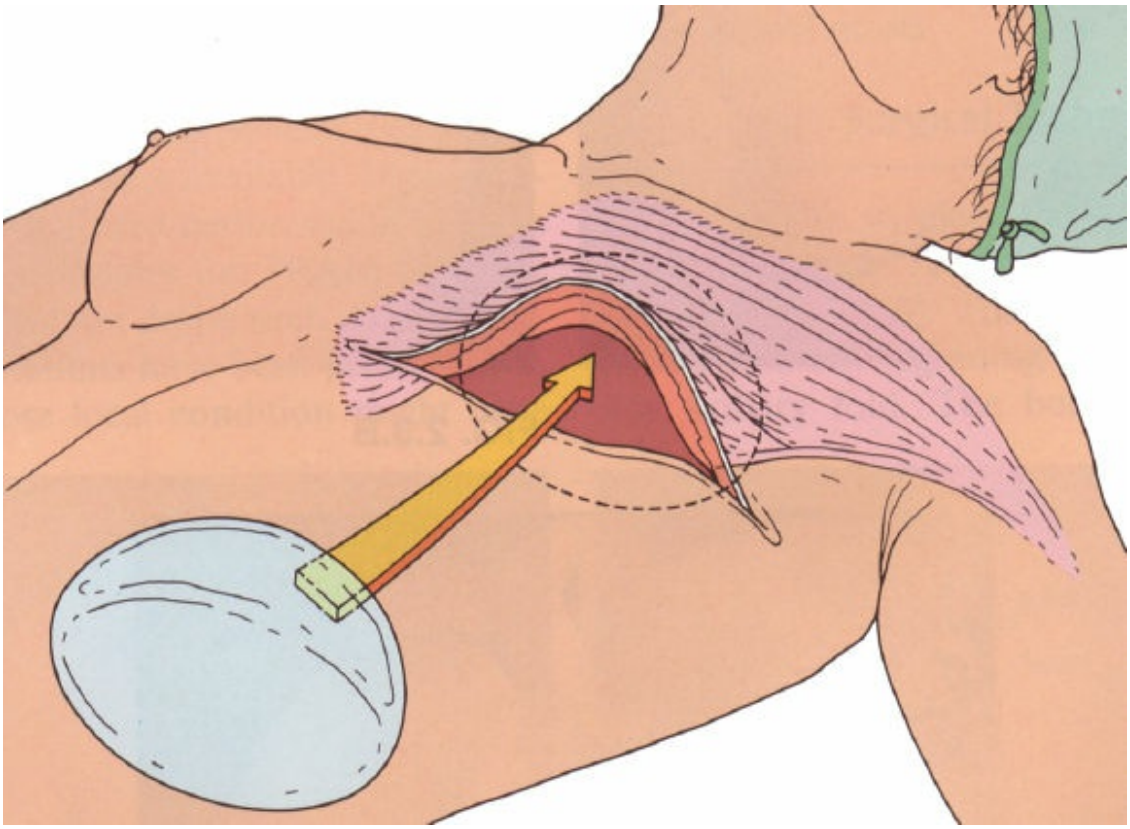

Figure 54.14. Implant placement beneath the pectoralis major muscle. An incision is made at the inframammary crease and a musculofascial flap involving the pectoralis major, serratus anterior, external oblique, and rectus abdominis muscles is elevated. An implant of appropriate size is then placed on the chest wall beneath the musculofascial flap (subpectoral flap) and

the incision closed with absorbable sutures. (From Bland KI, Copeland EM III, eds. *The Breast: Comprehensive Management of Benign and Malignant Disorders*. 4th ed. Philadelphia, PA: WB Saunders; 2009. Copyright © 2009 Elsevier.)

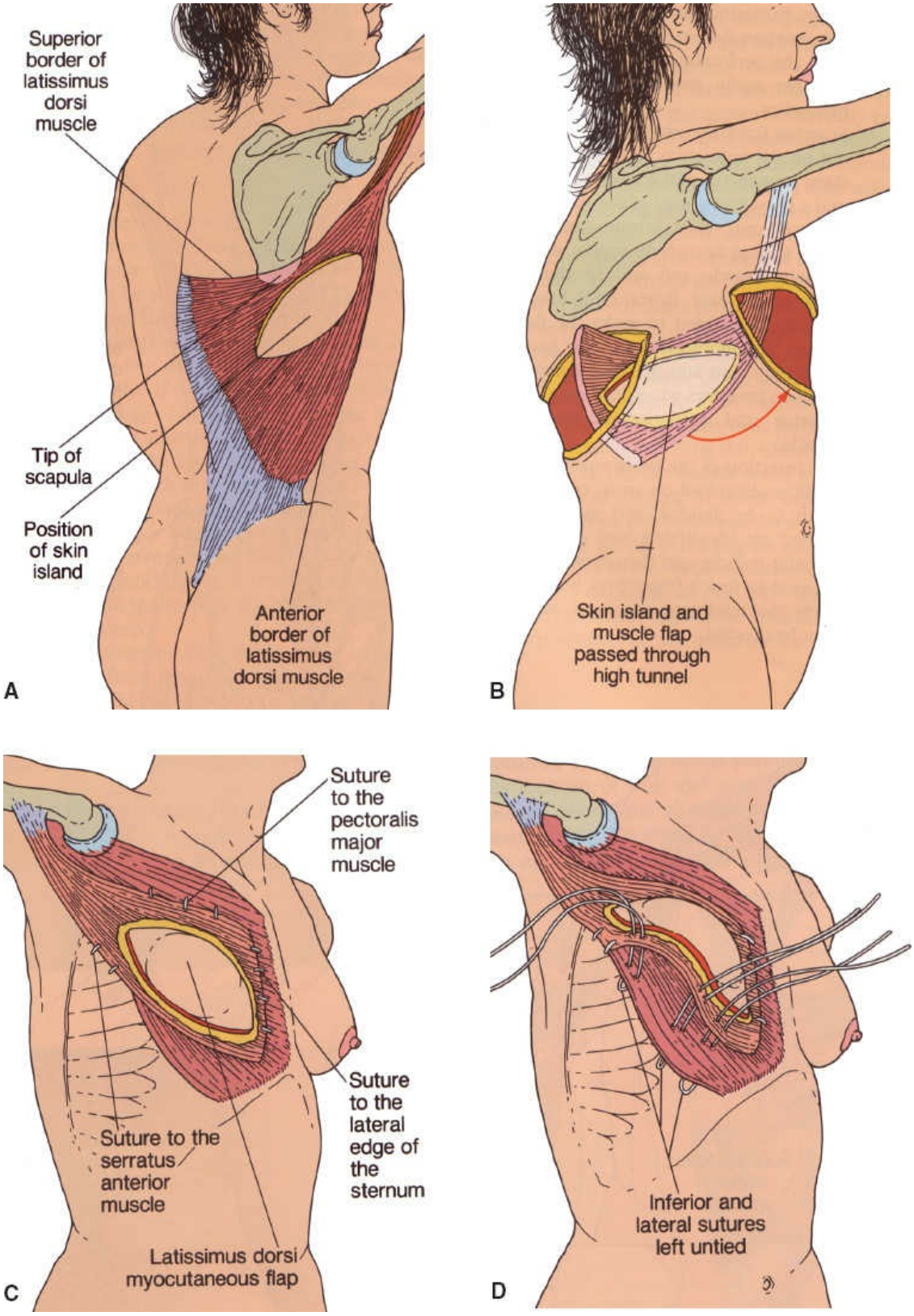

Figure 54.15. Anatomic relations of the latissimus dorsi myocutaneous flap. The latissimus dorsi myocutaneous flap consists of a skin paddle based on the underlying latissimus dorsi muscle, which is supplied by the thoracodorsal artery with contributions from the posterior intercostal arteries. **A.** Latissimus

dorsi muscle flap with skin island paddle delineated. **B.** The latissimus dorsi flap is being passed through a subcutaneous tunnel anteriorly to the breast defect. **C.** Inset of latissimus dorsi myocutaneous flap to reconstruct breast defect. **D.** Surgical dissection delineating elevated latissimus dorsi flap and its pedicle. (From Bland KI, Copeland EM III, eds. *The Breast: Comprehensive Management of Benign and Malignant Disorders*. 4th ed. Philadelphia, PA: WB Saunders; 2009. Copyright © 2009 Elsevier.)

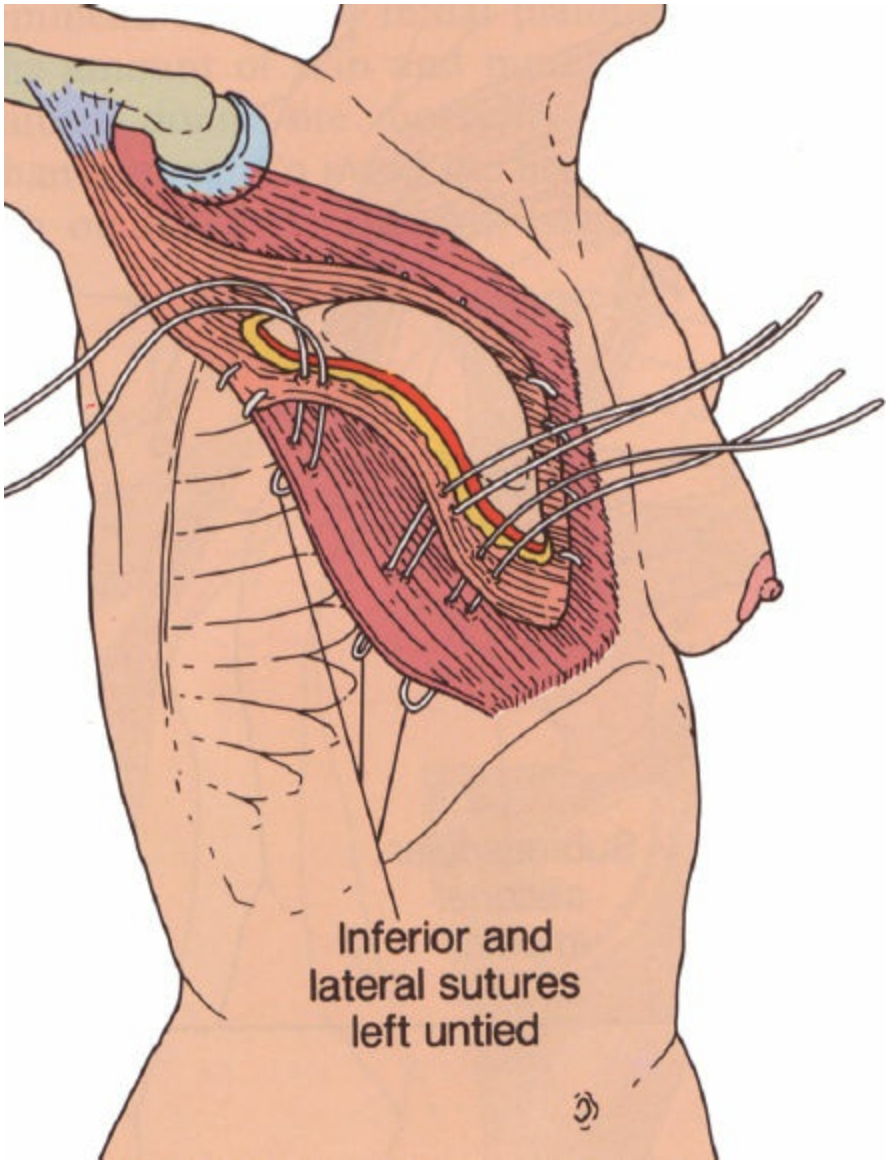

Figure 54.16. Inset of the latissimus dorsi myocutaneous flap for breast reconstruction. Breast reconstruction with a latissimus dorsi myocutaneous flap is appropriate for immediate reconstruction because of the favorable donor site and predictable wound healing. Occasionally, placement of an implant below the pectoralis major muscle may also be necessary to

achieve a breast mound of adequate size. (From Bland KI, Copeland EM III, eds. *The Breast: Comprehensive Management of Benign and Malignant Disorders*. 4th ed. Philadelphia, PA: WB Saunders; 2009. Copyright © 2009 Elsevier.)

The TRAM flap is internationally utilized for breast reconstruction and provides excellent symmetry relative to the contralateral breast. The TRAM flap can be pedicled or can utilize microvascular anastomosis to establish blood supply. It is composed of the rectus abdominis musculature, which is supplied by vessels from the deep superior and inferior epigastric arteries (Fig. 54.17), and the redundant skin and adipose tissue of the lower abdominal wall. After elevation from its bed, a pedicled flap (or two pedicled flaps for bilateral reconstruction; Figs. 54.17 and 54.18) can be rotated on its vascular pedicle and passed cephalad to the site of breast reconstruction through a subcutaneous tunnel where it is tailored for conformity with the contralateral breast and sutured to the pectoralis major muscle. The abdominal wall defect is closed in layers. Utilization of microvascular anastomotic techniques has made the free TRAM flap an excellent choice for immediate and delayed breast reconstruction. The harvested TRAM flap is tailored for conformity to the contralateral breast and receives its blood supply via microvascular anastomoses between the deep inferior epigastric vessels and the ipsilateral latissimus dorsi or internal mammary vessels. Utilization of the free TRAM frequently allows for one-stage breast reconstruction, but results in increased operative time, prolonged hospitalization, and more lengthy convalescence.

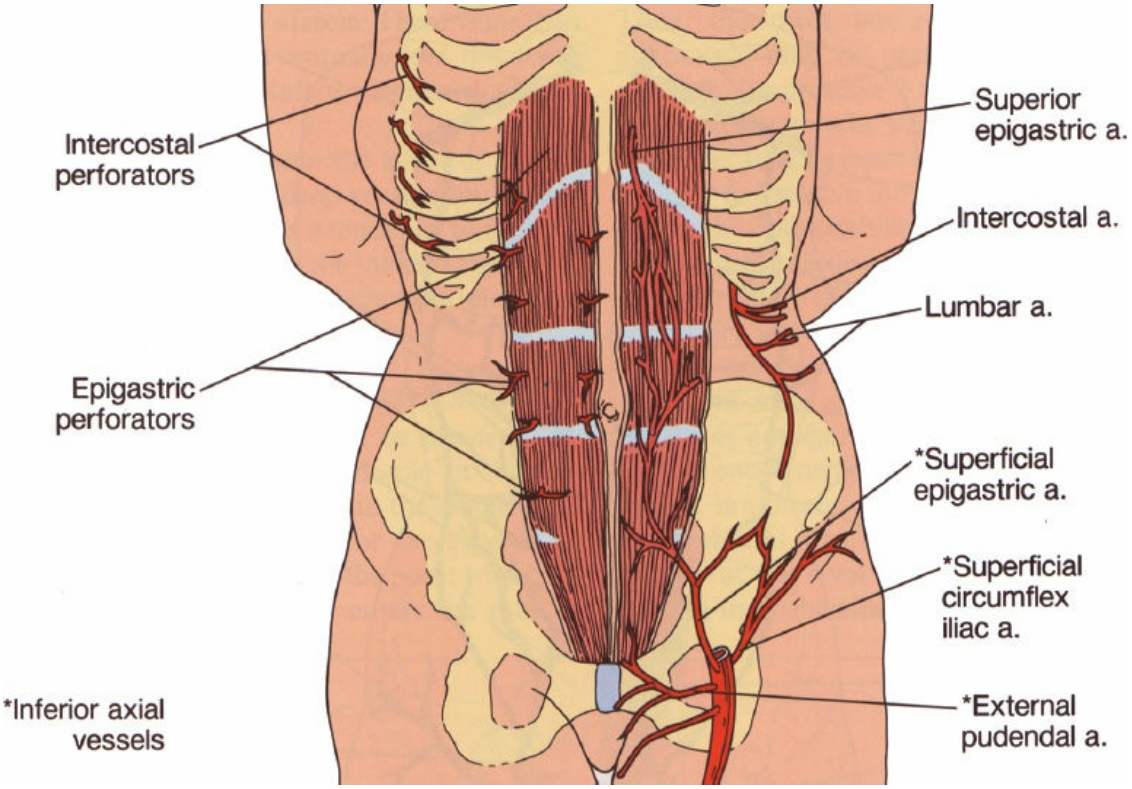

Figure 54.17. Superior and inferior epigastric artery axial blood supply to the rectus abdominus muscle and overlying skin. The transverse rectus abdominis myocutaneous (TRAM) flap is composed of the rectus abdominis musculature, which is supplied by vessels from the deep superior and inferior epigastric arteries, and the redundant skin and adipose tissue of the lower abdominal wall. (From Bland KI, Copeland EM III, eds. *The Breast: Comprehensive Management of Benign and Malignant Disorders*. 4th ed. Philadelphia, PA: WB Saunders; 2009. Copyright © 2009 Elsevier.)

HALSTED RADICAL MASTECTOMY

INTRODUCTION

In 1894 William Stewart Halsted of Johns Hopkins Hospital was credited with the tenets and development of RM. However, this result was the consolidated synthesis with the development and writings of multiple surgeons who preceded him and allowed Halsted to achieve unprecedented local and regional recurrence rates of 6% and 22%, respectively, with this innovative *en bloc* approach. Meyer noted similar reductions in local recurrence rates to 6% comparative to the extraordinarily elevated rates of 54% to 82% that were evident among European surgeons of the 19th century. The procedure was a masterful contribution to treatment of this

organ, as >80% of the patient population was stage III/IV in this time in surgical history. Moreover, only a radical surgical procedure was effectively therapeutic in the era, with absence of the advances in adjuvant chemo-hormonal and radiotherapy. Table 54.6 is a compilation of data provided by Hutchison which compares these operations completed by European surgeons during the Halstedian era. These data provide an accompanying 3-year estimated “cure rate” for breast cancer by surgeon, year, and case volume. The Halstedian procedure more than doubled the international 3-year “cure rates” of prior eras.

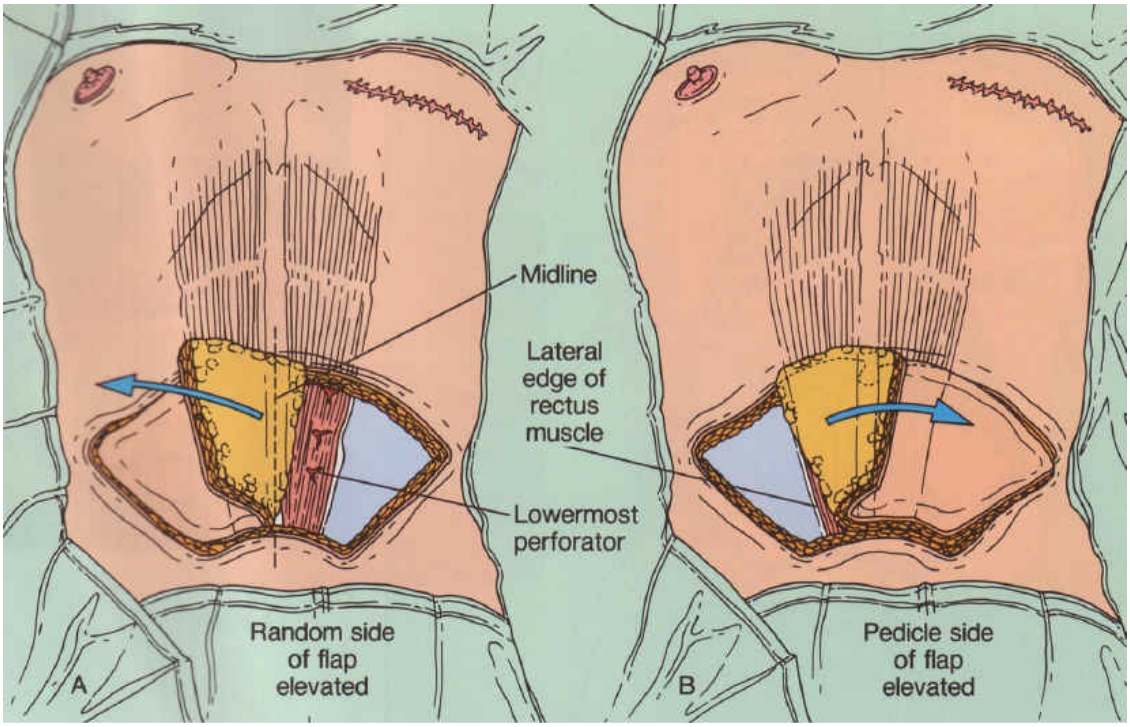

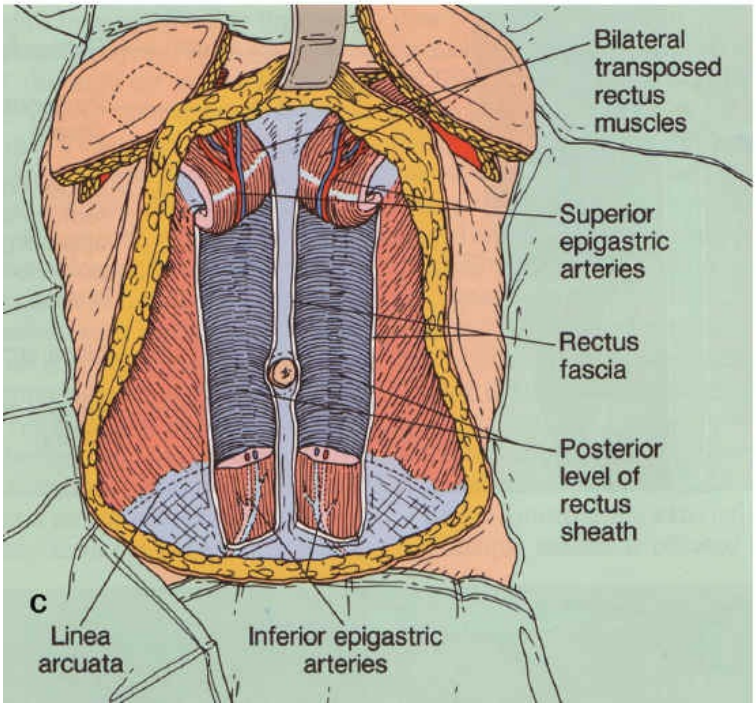

Figure 54.18. The TRAM flap. **A/B.** After elevation from the beds, two pedicled flaps are rotated on their vascular pedicles and passed cephalad to the sites of breast reconstruction through subcutaneous tunnels where they are tailored for conformity and sutured to the pectoralis major muscle. The abdominal wall defect is closed in layers. **C.** Diagrammatic depiction of bilateral transverse rectus abdominis myocutaneous (TRAM) flaps transposed on their superior epigastric pedicles. (From Bland KI, Copeland EM III, eds. *The Breast: Comprehensive Management*

of Benign and Malignant Disorders. 4th ed. Philadelphia, PA: WB Saunders; 2009. Copyright © 2009 Elsevier.)

Importantly, the advancement of *en bloc* resection techniques espoused in the Halstedian radical procedure by both Halsted and Meyer embodied the following tenets:

wide excision of the skin, covering the defect with Thiersch grafts;
routine resection of *both* pectoral muscles;
routine axillary dissection (levels I, II, III); and
resection of all tissues en bloc, providing wide skin and surgical margins for all margins of tumor growth.
Routine sacrifice of the long thoracic nerve and the thoracodorsal artery, nerve, and vein.

TABLE 54.6 Chronology of the Mastectomy for Treatment of Breast Cancer With Expectant (Average) 3-Year "Cure Rates"

Type of Operation	Study	Year	No. of Cases	3-Year Cures (%)
Simple mastectomy	Winiwarter (Billroth)[a]	1867–1875		4.7
Mean				4.7
Complete mastectomy and axillary dissection in most cases	Oldekop[b]	1850–1878	229	11.7
	Dietrich (Lucke)[c]	1872–1890	148	16.2
	Horner[d]	1881–1893	144	19.4
	Poulsen[e]	1870–1888	110	20
	Banks[f]	1877	46	20
	Schmid (Kuster)[g]	1871–1885		21.5
Mean				**18.1**
Complete (total) mastectomy, axillary dissection, removal of pectoral fascia, and greater or lesser amounts of pectoral muscle	Sprengel (Volkmann)[h]	1874–1878	200	11
	Schmidt[i]	1877–1886	112	18.8
	Rotter[j]	1887–1897	30	20
	Mahler[k]	1887–1893	150	21
	Joerss[l]		98	28.5
Mean				**19.9**
Modern radical mastectomy	Halsted[m]	1889–1894	76	45
	Halsted[n]	1907	232	38.3
	Hutchison[o]	1910–1933		39.4
Mean				**40.9**

[a]Data from Winiwarter V (Billroth). Beiträge zur statistik d. carcinome, Stuttgart, 1878 Gedruckt bei L. Schumacher.
[b]Data from Oldekop J. Statistiche Zusammenstellung von 250 Fällen von Mamma-Carcinom. *Arch F Klin Chir* 1879;24:536.
[c]Data from Dietrich G (Lucke). Beitrag zur Statistik des Mammacarcinom, *Duch Z F Chir* 1892;33:471.
[d]Data from Horner F. Ueber die Endresultate von 172 operierten Fällen maligner Tumoren der weiblichen Brust, *Beitr Z Klin Chir* 1894;12:619.
[e]Data from Poulsen K. Die Geschwülste der Mamma. *Arch F Klin Chir* 1891;42:593.
[f]Data from Banks M. A plea for the more free removal of cancerous growths. In Liverpool and Manchester Surgical Reports 1878:192.
[g]Data from Schmid H (Kuster). Zur statistik der mammacarcinome und deren heilung. *Dtsch Z F Chir* 1887;26:139.
[h]Data from Sprengel O (Volkmann). 131 Fälle von Brust-Carcinom. *Arch F Klin Chir* 1882;27:805.
[i]Data from Schmidt GB. Die Geschwülste der Brustdrüse. *Beitr Z Klin Chir* 1889;4:40.
[j]Data from Rotter J. Günstigere Dauererfolge durch eine verbesserte operative Behandlung der Mammakarzinome. *Berl Klin Wochenschr* 1896; 33:69.
[k]Data from Mahler F. Ueber die in der Heidelberger Klinik 1887–1897 behandelten Fälle von Carcinoma Mammae. *Beitr Z Klin Chir* 1900;26:681.
[l]Data from Joerss K. Ueber die beutige Prognose der Exstirpatio mammae carcinomatosae. *Dtsch Z F Chir* 1897;44:101.
[m]Data from Halsted WS[1].
[n]Data from Halsted WS[2].
[o]Data from Hutchison RG. Radiation therapy in carcinoma of the breast. *Surg Gynecol Obstet* 1936;62:653–64.

INDICATIONS/CONTRAINDICATIONS FOR THE

HALSTED RADICAL MASTECTOMY

Modern medical pharmacology allows application of cytoreduction of the advanced primary mammary neoplasm to provide the medical oncologists and surgeons a vast increase in the latitude of application of less radical procedures in the therapy of carcinoma of this organ. Although modern pharmacology and breast irradiation enhance the probability of these cytoreductive events, especially with the combinations of targeted chemotherapeutic agents, Halsted RM is only occasionally (<2%) indicated to achieve local–regional control of the breast, axilla, and chest wall. Quite simply put, contemporary adjuvant therapeutic advancements are the principle scientific tenets that allow *less radical* procedures to achieve enhanced local–regional control and survival without application of the Halstedian or modified radical techniques.

OPERATIVE PLANNING

Current indications for the use of the Halsted RM for patients presenting with advanced local–regional disease are depicted in Table 54.7. Historical developmental progress in breast cancer therapy has allowed a paradigm shift in application of more aggressive approach management tenets that replace contemporary management suggest:

Major transitions from the Halstedian approach for breast cancer therapy have occurred as a result of the equivalent local–regional control that is evident with alternative breast conservation principles.

With the increasing application of appropriate breast conservation surgery in eligible patients, there has been a redefinition for indications of the Halsted procedure.

RM may be indicated when disease *invades* the *pectoralis major* muscle and has been unresponsive to neoadjuvant therapy. Surgical dogma suggests that the Halstedian procedure represents a “salvage mastectomy” necessary for large, bulky recurrences, especially for posterior lesions that recur with fascial or muscle fixation. In the contemporary practice of surgical oncology, the medical or surgical oncologist should expect this event to occur in <2% to 5% of presenting patients following neoadjuvant approaches.

The radical surgical procedure may be the only available technique for local–regional control of locally advanced (fixed, ulcerated) disease, especially in patients who have received prior therapy with total breast irradiation and/or multimodality cytotoxic therapy.

Formerly advocated for medial quadrant lesions, *extended* RM (with internal mammary nodal dissection) has no indication in the contemporary practice of breast surgery.

TABLE 54.7 Relative Indications for the Halsted RM

Advanced locoregional disease with fixation to pectoralis major muscle (T_2, T_3, T_{4a-c}; stages IIIA, IIIB, IIIC), when refractory to induction chemotherapy and irradiation
Advanced locoregional disease with skin ulceration (T_{4b}; stage IIIb) unresponsive to radiochemotherapy
Recurrent advanced, locoregional disease (T_2, T_3, T_4) after partial (segmental) mastectomy with tumor fixation to pectoralis major muscle ("salvage" mastectomy)
For completion of the radical procedure with locoregional recurrence after modified/segmental mastectomy when tumor invades chest wall and is refractory to cytoinduction chemotherapy
High-lying advanced peripheral lesions near clavicle/sternum with tumor fixation to muscle (stages IIA, IIB; stages IIIA, IIIB)
All presentations of advanced locoregional disease should receive induction cytotoxic drug therapy, radiotherapy, or both before radical mastectomy. Staging to rule out systemic disease should precede induction therapy.

SURGERY POSITIONING

Following induction of general endotracheal anesthesia, the patient is carefully positioned with a cooperative anesthesiologist and surgeon to ensure that the patient is positioned supine on the operating table near its margin.

The ipsilateral and involved arm should have careful inspection such that the shoulder contour overlies the placement of a padded arm board and allows the ipsilateral hemithorax and shoulder to be slightly elevated on a sheet roll. This latter maneuver ensures avoidance of subluxation and abduction of the shoulder with potential stretch of the brachial plexus. Such stretch injury to the brachial plexus may initiate motor denervation (transient or prolonged) of the shoulder and arm. This complication is best avoided by padding the arm board to allow elevation of the forearm and hand, as well as by providing a relaxed anatomical position (Fig. 54.19).

The operator should confirm that the ipsilateral arm and shoulder have free mobility for adduction across the chest wall; moreover, the elbow should be easily flexed and extended without undue tension (Fig. 54.20).

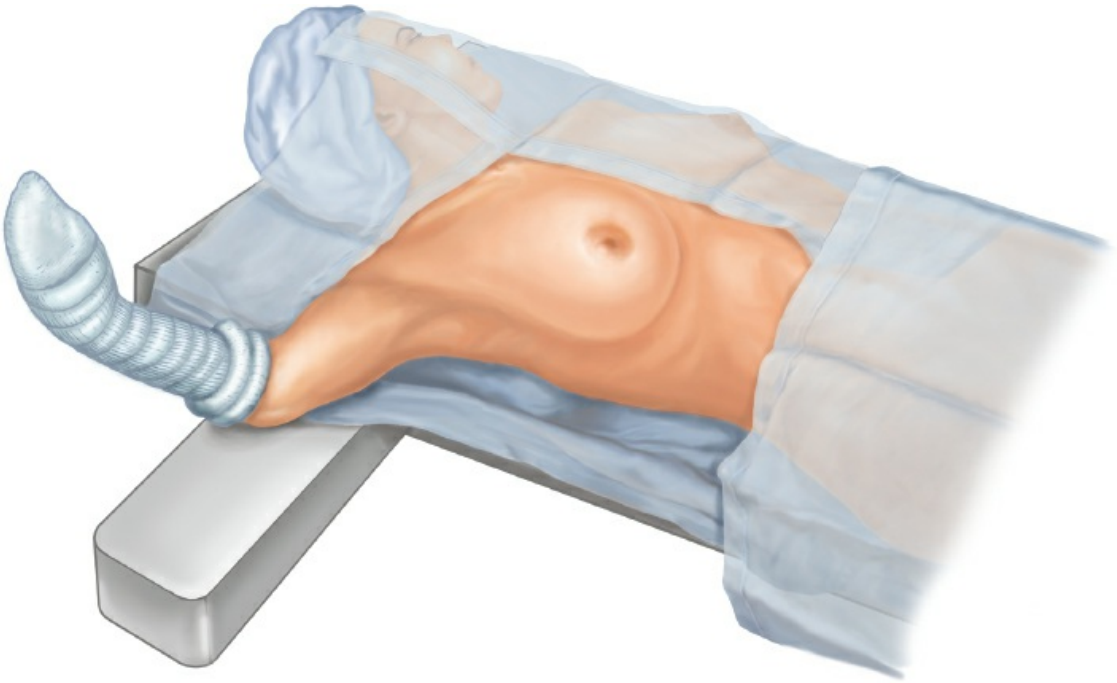

Figure 54.19. Typical position for draping patient for operations of cancer of the right breast. The ipsilateral hemithorax is positioned at the margin of the operative table with a sheet roll that provides slight elevation to the ipsilateral shoulder and hemithorax. This position potentially prevents subluxation and abduction of the shoulder with stretch of the brachial plexus. Draping of the periphery of the breast is inclusive of the supraclavicular fossa and the entire shoulder to allow adequate mobility for adduction of the shoulder and arm across the chest wall. The elbow should be easily flexed and extended without undue tension. (Bland KI, Klimberg VS, eds. Breast surgery. In: Fischer JE, ed. *Master Techniques in General Surgery: a Series*. Philadelphia, PA: Wolters Kluwer; 2010, with permission.)

TECHNIQUE

Prior to commencement of the surgical incision, the ipsilateral arm is placed in a relaxed, extended position on the arm board to allow proper planning of the incision. Incisions are made based upon the guidelines discussed in this chapter. The two most common incisions employed for Halsted RM are the *classical Orr* and *Stewart incisions* illustrated previously in Figures 54.6 and 54.7 of this chapter. Planned tissue dissections and flap elevations may be completed with electrocautery, cold scalpel, or aluminum garnet (Nd:YAG) laser scalpel.

The Halsted RM has decreasing usage in American surgery as noted in Table 54.8; this results from the increasing application of neoadjuvant

chemotherapy with tumor cytoreduction. However, tumors that are T2, T3, or T4 with gross fixation (involvement) of muscle and the skin overlying the pectoralis major muscle (Fig. 54.21), or peripheral high-lying lesions that are fixed near the clavicle to the pectoralis major, that are not otherwise candidates for radiation therapy, would be considered for the procedure. Furthermore, stages IIIa, IIIb, and IIIc would be candidates for Halsted RM when *refractory to induction chemotherapy and/or irradiation.* It is uncommon in conventional medical oncology to present with advanced local–regional disease and skin ulceration (T4b; stage IIIb) and tumors that are unresponsive to chemotherapy as replete publications in the dated medical literature suggest. Advanced local–regional disease with tumor fixation to the pectoralis major following segmental mastectomy and whole breast irradiation is an unusual presentation. Clinical and/or radiographic fixation to the pectoralis major muscle in this circumstance should have planned partial or total resection of the pectoralis major, even when radiographic evidence (mammogram, MRI) confirms evidence of cytoreduction.

The identification and exposure of the craniolateral humeral insertion of the pectoralis major muscle, with continuation of the dissection in a central superiomedial direction with muscular elevation, provide exposure of the pectoralis minor. The insertion of the pectoralis major on the humerus is transected and rotated medially. This muscle has origin on ribs 1 to 6 near the sternocostal junction. The surgeon must thereafter be aware of the anatomical position of the cephalic vein and the relationship to the deltopectoral triangle. Thereafter, the dissection commences medially with resection of the pectoralis major at its cranial clavicular attachments. This maneuver allows the surgeon direct exposure to the axilla. Thereafter, the tendinous portion of the pectoralis minor may be identified, encircled digitally, and stripped back to its insertion on the coracoid process of the scapula (Fig. 54.22). The pectoralis minor is similarly elevated digitally from the axilla with careful elevation from the axilla, taking care to avoid injury to the axillary vein. Division and ligature of perforating muscular branches from the thoracoacromial artery and vein must be ensured. The *medial* (anterior thoracic) *pectoral nerve* commonly penetrates the pectoralis minor en route to innervation of the pectoralis major and should be ligated and divided on its posterior surface of origin below the medial cord of the brachial plexus.

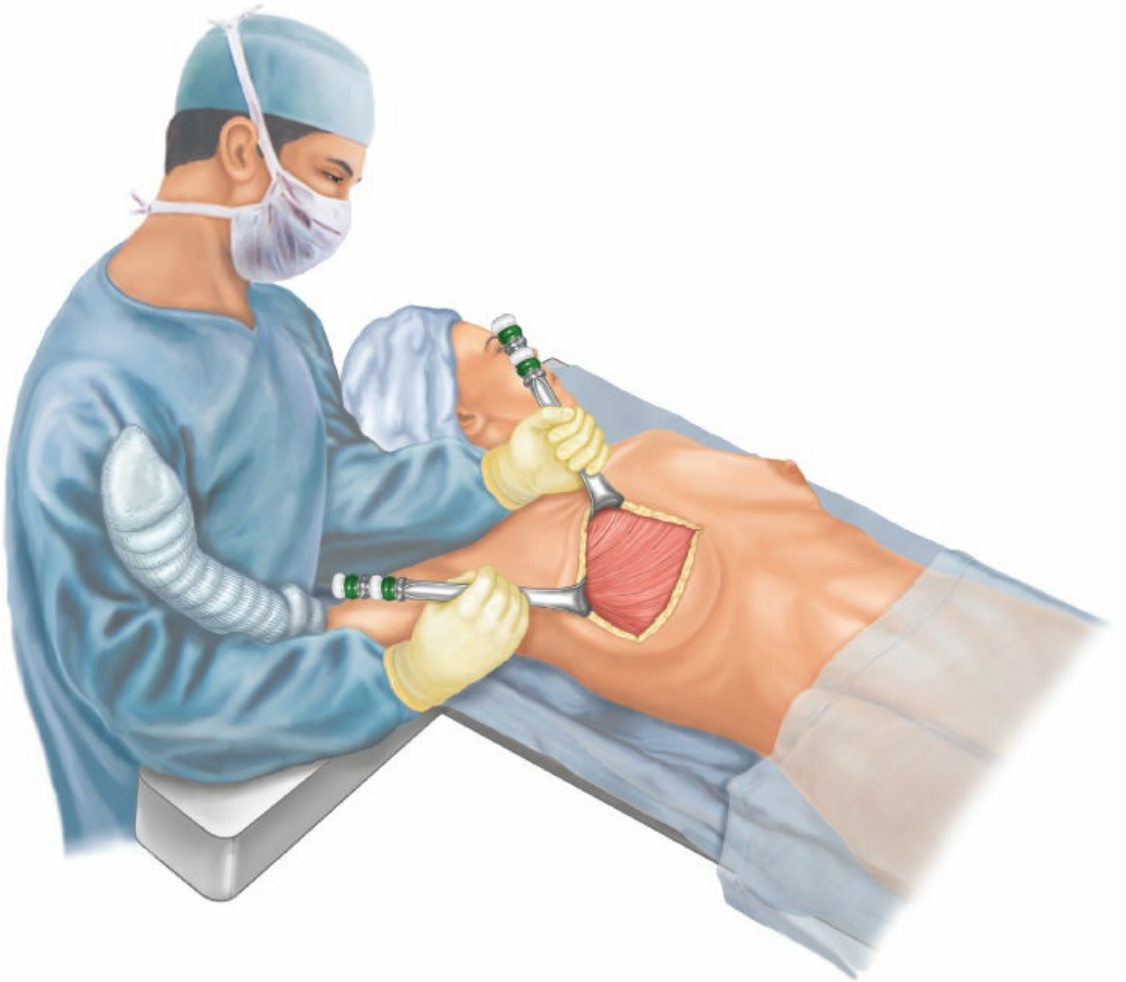

Figure 54.20. Position of the first assistant for right radical mastectomy. The surgical assistant, positioned cephalad to the arm board and shoulder, is able to provide traction, control, and protection of the arm and shoulder. Undue traction of chest wall musculature with potential damage to the brachial plexus can be avoided by ensuring free mobility of the shoulder and elbow that is being controlled by the first assistant. (Bland KI, Klimberg VS, eds. Breast surgery. In: Fischer JE, ed. *Master Techniques in General Surgery: a Series*. Philadelphia, PA: Wolters Kluwer; 2010, with permission.)

TABLE 54.8 Percentage of Breast Cancer Cases by Type of Surgery by Year of Diagnosis

Operation	1985	1988	1990
Radical mastectomy	1.9	1.5	0.6
Modified radical mastectomy	63.2	64.8	59.7
Total mastectomy	3.4	3.8	2.8
Partial (segmental) mastectomy	18.4	22.2	28.4
Subcutaneous mastectomy	0.5	0.5	0.5
Surgery type unknown	3.5	1	1.1
No surgery	7	5.4	4.5
Unknown if surgery done	2.1	0.8	2.4
Total	100	100	100
No. of cases	14,509	26,465	39,869

Reprinted from Winchester DP. Standards of care in breast cancer diagnosis and treatment. *Surg Oncol Clin North Am* 1994;3:85–99. Copyright © 1994 Elsevier, with permission.

Thereafter, medial rotation and resection of the pectoralis major and minor from the chest wall *en bloc* follow. As medial resection of the pectoralis major continues, the *lateral* (anterior thoracic) *pectoral nerve* with origin from the lateral cord (and is located medially in the neurovascular bundle) should be identified and ligated. We prefer to continue the dissection in the superiomedial aspect of the elevated flap such that the pectoralis major is divided from its medial origin at the costosternal junction of ribs 2 to 6 (Fig. 54.23). Resection of pectoralis musculature invariably allows the surgeon to encounter multiple perforator vessels (lateral thoracic, anterior, intercostal arteries) at its periphery and presents end arteries of the pectoralis major and minor muscles. Perforator branches from the intercostal muscles that take origin from the intercostal arteries and vein are also encountered. It is essential that the operator individually clamp and ligate with nonabsorbable 2-0 or 3-0 suture all divided tributaries with division of the pectoral muscles. With inferomedial traction of the specimen and the operator's hand posterior to the specimen lying on the chest wall, the axillary contents may be fully exposed. The origin of the pectoralis minor on ribs 2 to 5 is thereafter visualized and is divided, ideally with electrocautery, at its insertion into the sternocostal junction. With this maneuver, *Rotter's interpectoral nodes* are swept en bloc into the specimen and allow full visualization of the course of the axillary vein to the level of *Halsted ligament* (*costoclavicular*), which is recognized as a condensation of the *clavipectoral fascia.* Thereafter, *level III* (*apical, subclavicular*) *nodes* are dissected at this level and should be individually clipped or tagged to indicate the highest level of dissection.

With identification of the tendinous insertion of the latissimus dorsi muscle, the surgeon recognizes the anatomical juncture at which the dissection of the axillary vein commences; all tissues in this plane must be cleared of the *lateral* (*axillary*) *nodal group* (level I). Care is taken to preserve the thoracodorsal artery, nerve, and vein. The surgeon must be aware of the origin of the *thoracodorsal nerve,* which is uniformly medial to the thoracodorsal artery and vein. This nerve originates from the posterior cord and may run a variable course in the central axillary space and on occasion crosses anterior or posterior to the thoracodorsal artery and vein as it courses inferolaterally to innervate the latissimus dorsi muscle in its central muscular portion. As the axillary dissection commences, the operator will often encounter, at a minimal, two branches of the intercostobrachial nerves that traverse the axillary space at right angles to the latissimus and chest wall. These nerves, which are sensory to the medial arm and axilla with fibers from the lateral cutaneous branches of the second and third intercostal nerves, may be sacrificed without prolonged morbidity aside from paresthesia and hypesthesia of the axilla and medial arm skin.

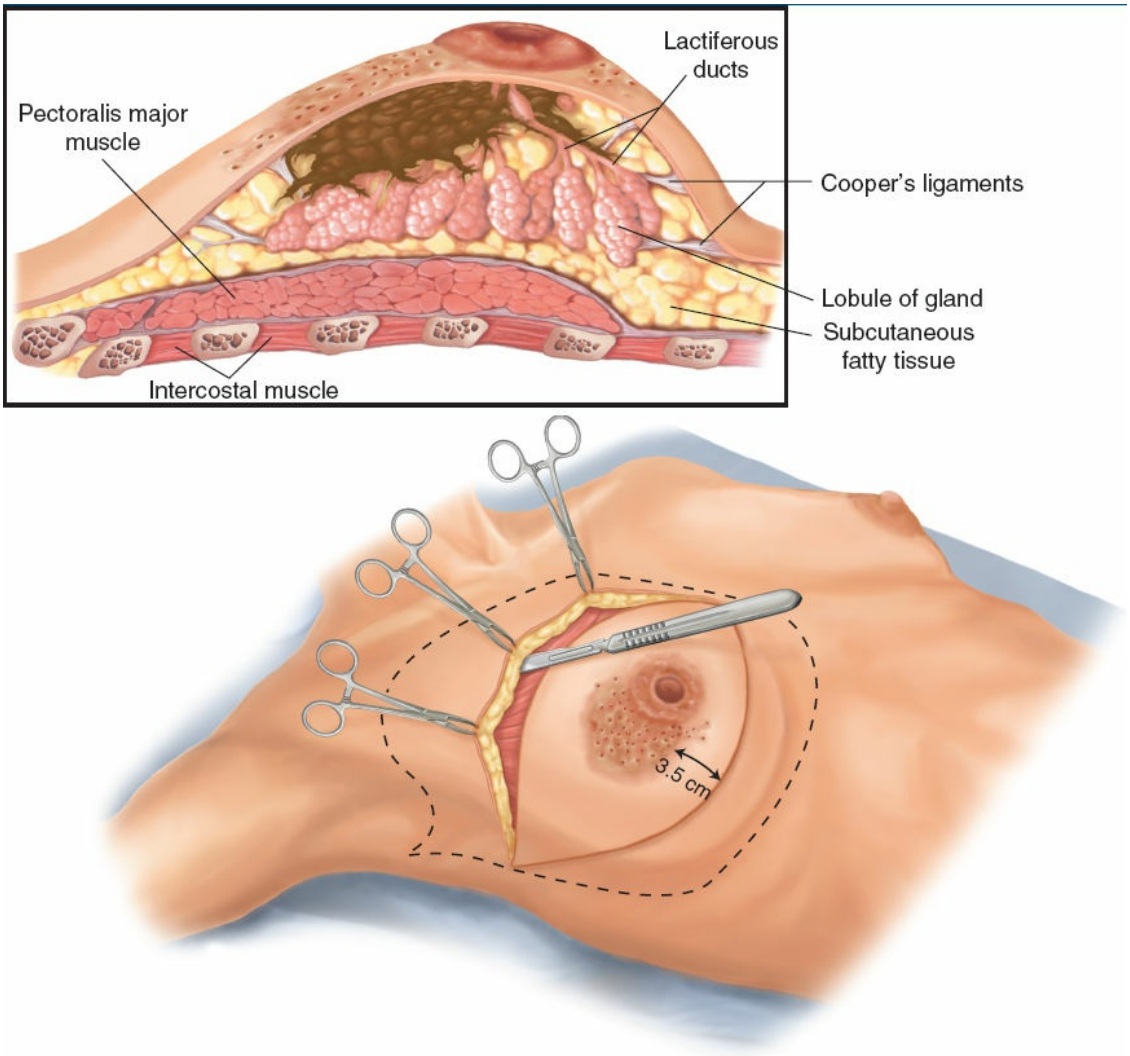

Figure 54.21. *Inset:* Large breast lesions (T2, T3, T4) may present with gross fixation to the skin and/or pectoralis major musculature. The radical mastectomy is designed to encompass wider skin flaps than the modified technique. The margins designed and developed should encompass normal skin and breast parenchyma 3 to 5 cm from the periphery of the tumor. This wider margin ensures tumor clearance and facilitates skin closure without redundancy of tissue flaps. The design of elevated flaps is inclusive of skin margins at the periphery of the breast on the chest wall. The broken line indicates the limits of the dissection and includes the following: superior, the inferior border of the clavicle at the subclavius muscle; lateral, the anterior margin of the latissimus dorsi muscle; medial, midline of the sternum; and inferior, the inframammary fold with extension of dissection to the cephalic extension of the aponeurosis of the rectus abdominis tendon. (Bland KI, Klimberg VS, eds. Breast surgery. In: Fischer JE, ed. *Master Techniques in General Surgery: a Series*. Philadelphia, PA: Wolters Kluwer; 2010, with

permission.)

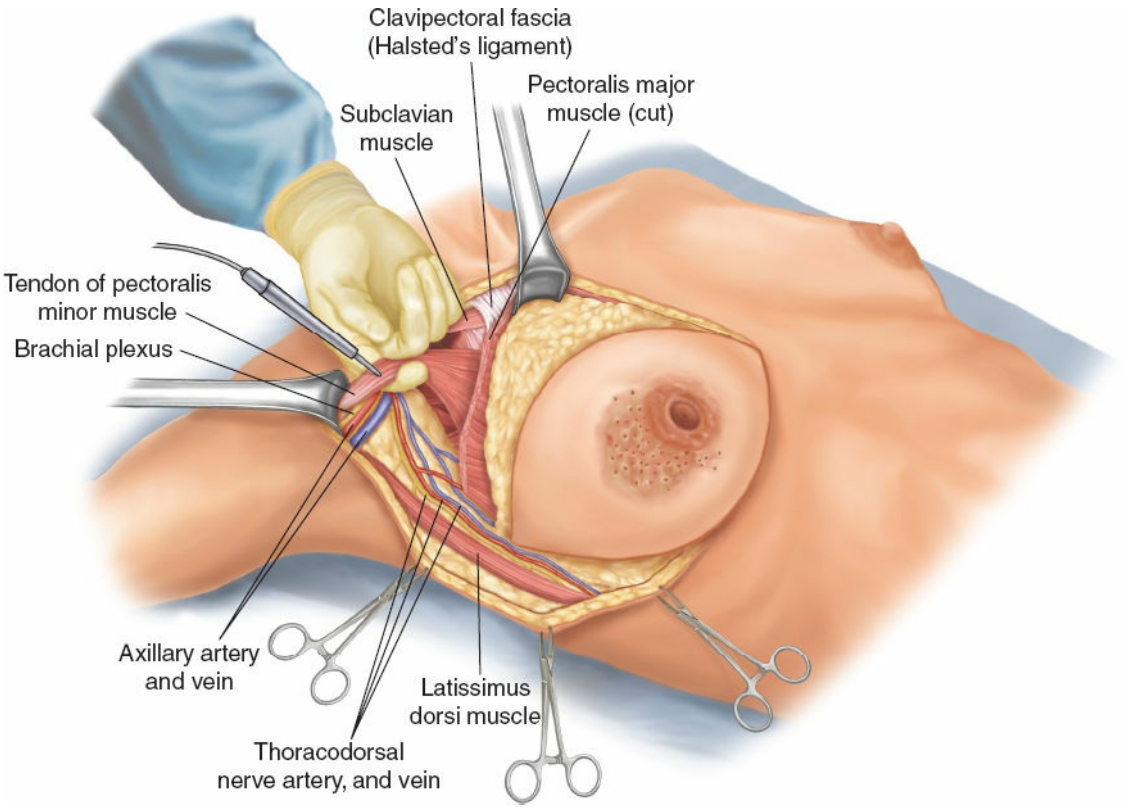

Figure 54.22. Exposure of the superolateral aspect of the mastectomy wound following division of the humeral insertion of the pectoralis major muscle. The insertion of the pectoralis minor on the coracoid process of the scapula is transected and rotated medially with en bloc dissection of Rotter's interpectoral nodes. Technically, the dissection commences on the anterior and ventral aspects of the axillary vein to incorporate level I to III nodes. Division of the pectoralis major and minor tendons allows the surgeon direct access to the floor of the axilla. (Bland KI, Klimberg VS, eds. Breast surgery. In: Fischer JE, ed. *Master Techniques in General Surgery: a Series*. Philadelphia, PA: Wolters Kluwer; 2010, with permission.)

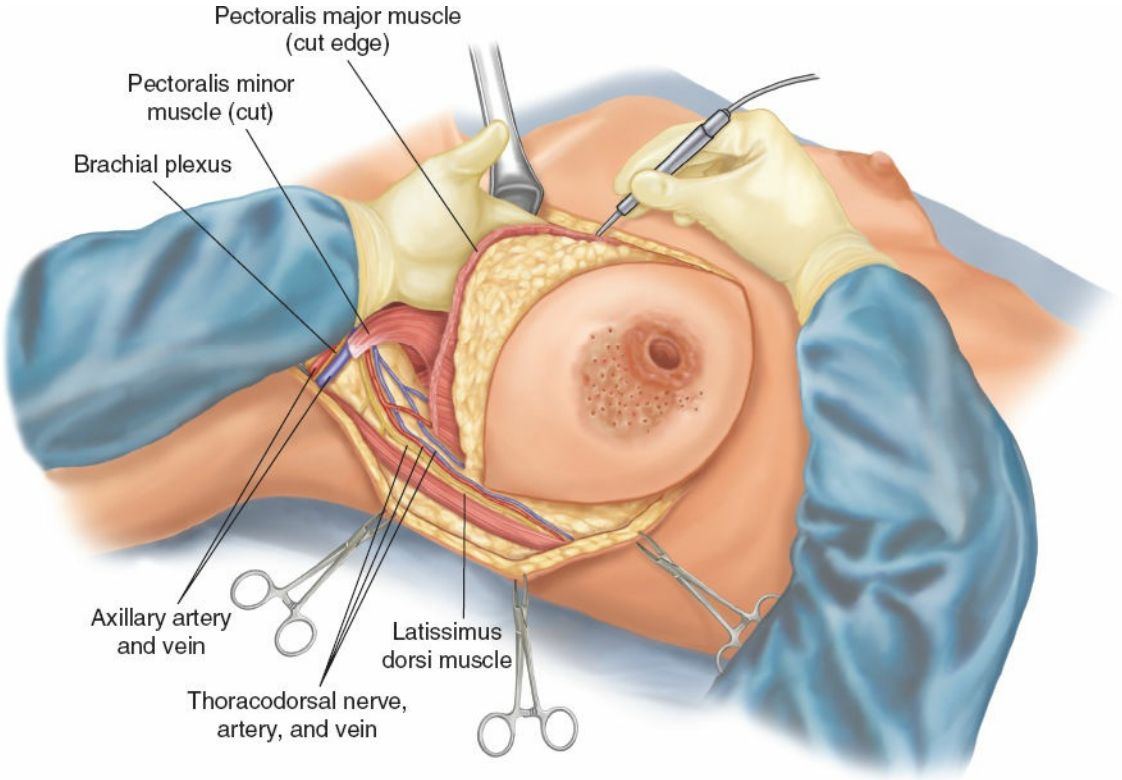

Figure 54.23. Superomedial dissection of the elevated pectoralis minor and pectoralis major muscles en bloc with the breast. The breast parenchyma remains intact with the pectoralis major fascia. Illustrated is the medial extent of the dissection along the costoclavicular margin with division of insertion of the pectoralis major on ribs 2 through 6 and the pectoralis minor on ribs 2 through 5. Multiple perforator branches from the intercostal muscles are encountered at the origin of the intercostal arteries and veins. Following superomedial and inferomedial dissection, the axillary contents are fully exposed to allow completion of the Patey axillary dissection of level I to III nodes. (Bland KI, Klimberg VS, eds. Breast surgery. In: Fischer JE, ed. *Master Techniques in General Surgery: a Series*. Philadelphia, PA: Wolters Kluwer; 2010, with permission.)

I recommend dissection of the *lateral* (*axillary*) *nodal group* in a caudad and parallel direction to the thoracodorsal neurovascular bundle and to be incorporated en bloc with the *subscapular nodal group* (*level I*), which is medially placed between the thoracodorsal nerve and the lateral chest wall. With dissection of these two nodal basins and its investing areolar tissues, the posterior boundary of the axillary space is delineated with exposure of the teres major and subscapular muscles. Medial dissection with clearing of the ventral surface of the axillary vein further

allows direct visualization of the subscapularis muscle, which is medially placed near the chest wall and medial to the teres. Inferior dissection of the *external mammary nodal group* of *level I* is deferred until completion of dissection of the *central nodal group* (*level II*) and the *apical* or *subclavicular level III nodes.*

Following clearance of the superiomedial nodal contents, the costoclavicular (Halsted ligament) area allows these nodal groups to be retracted inferiorly with the dissected muscles. Thereafter, nodal dissection begins on the chest wall with en bloc dissection of the *external mammary nodal group* (*level I*) that is medial and contiguous with the tail of Spence of the breast. The operator is reminded to dissect in the cephalad to caudad direction, parallel with the thoracodorsal neurovascular bundle, sweeping all contents en bloc. This maneuver is important in dissection to prevent neural injury and allows direct access to the venous tributaries posterior to the axillary vein. Thereafter, the surgeon will encounter the chest wall and exposure of the fascia of the serratus anterior. This maneuver is essential to allow high-level identification below the axillary vein of the *long thoracic nerve* (*respiratory nerve of Bell*), which provides motor innervation to the serratus anterior. This nerve courses consistently along the lower lateral chest wall, just superficial to the teres major over the subscapularis musculature. Following incision of the serratus anterior fascia, this nerve is dissected throughout its course in the medial axillary space from its superiormost origin near the chest wall to its innervation of the serratus anterior following proper exposure.

Following these maneuvers, the axillary contents anterior and medial to the long thoracic nerve are swept inferomedially en bloc with the specimen. The surgeon should defer division of the inferior boundary of the axillary content dissection until the preserved innervation of the long thoracic and the thoracodorsal nerves is definitively visualized.

Any points of origin of the pectoralis major from the first through the sixth ribs are left intact with the medial dissection are completely divided such that an en bloc resection of the pectoralis major is accomplished over the retromammary bursa. The surgeon continues the dissection in an avascular plane to sweep the breast and axillary contents toward the aponeurosis of the rectus abdominis muscle to complete extirpation of the specimen as an en bloc procedure (Fig. 54.24).

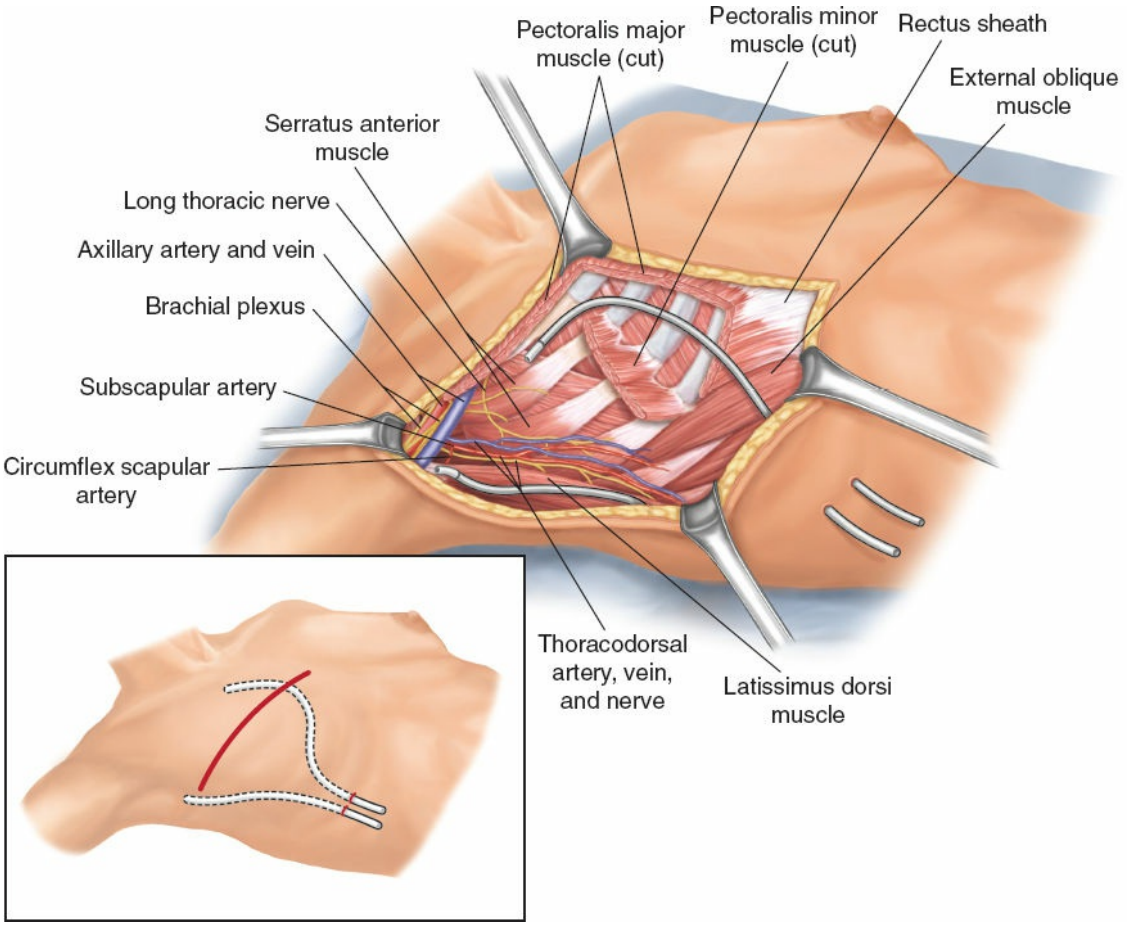

Figure 54.24. The complete Halsted RM with residual margins of the pectoralis major and minor muscles. Ideally, preservation of the long thoracic nerve ensures innervation of the serratus anterior. Innervation of the latissimus dorsi muscle is ensured with preservation of the thoracodorsal nerve that accompanies the neurovascular bundle of the posterior axillary space. Inset depicts position of closed suction catheters (18 to 20 French) placed through separate stab wounds that enter the inferior margin of the flap at approximately the anterior axillary lines. (Bland KI, Klimberg VS, eds. Breast surgery. In: Fischer JE, ed. *Master Techniques in General Surgery: a Series*. Philadelphia, PA: Wolters Kluwer; 2010, with permission.)

WOUND CLOSURE: Two closed suction catheters (flat 10-mm Jackson-Pratt) are placed via separate incisions that enter the inferior margin of the flap at approximately the anterior axillary line with the second lateral catheter placed approximately 2 cm below the axillary vein. Drains are secured at skin level with 3-0 nonabsorbable nylon sutures. Suction catheters should not be secured to the chest wall to abrogate the potential for muscle injury and hemorrhage with removal.

Before the surgeon initiates flap closure, skin margins are carefully inspected to evaluate for devascularization that results from trauma of dissection or tangential incisions that contribute to skin necrosis and wound dehiscence. We prefer closure with interrupted 2-0 absorbable synthetic sutures placed in subcutaneous tissues with purchase of the cutis reticularis of the skin without tension. Optionally, the skin may be closed with running subcuticular 4-0 synthetic absorbable sutures or stainless-steel staples. Steri-strips are applied across (perpendicular to) the incision when subcuticular sutures are used in closure. After irrigation, the closed suction catheters are connected and maintained on continuous low to moderate suction with large plastic vacuum reservoirs. Closure of dead space by suturing of skin flaps to underlying muscle combined with early removal of closed suction drainage has been reported to diminish incidence of seroma formation. We prefer to use light, bulky dressings applied with adherent sealed closure of the surgical incision. Typically, wound catheters may be removed when drainage becomes predominantly serous and each has decreased to a maximum of 20 to 25 cc during a 24-hour interval. Shoulder exercises are initiated on the day following removal of the drainage catheters.

ALTERNATIVE CLOSURE OF FLAP DEFECTS

Following completion of the classical Halstedian operation and sacrifice of large volumes of skin centrally, alternative measures are essential to close the central defect. However, with the conventional cytoreductive chemotherapeutic neoadjuvant principles used today, such maneuvers are rarely necessary and flap closure can usually be accomplished as a primary procedure. However, should defects be sizable and alternative closure essential, one could consider using either myocutaneous flaps (latissimus dorsi or rotational flaps) or the placement of skin grafts. In the latter circumstance, the defect may be grafted with split-thickness skin grafts (0.018 to 0.02 in) procured with a dermatome from the anterolateral thigh or buttock (Fig. 54.25).

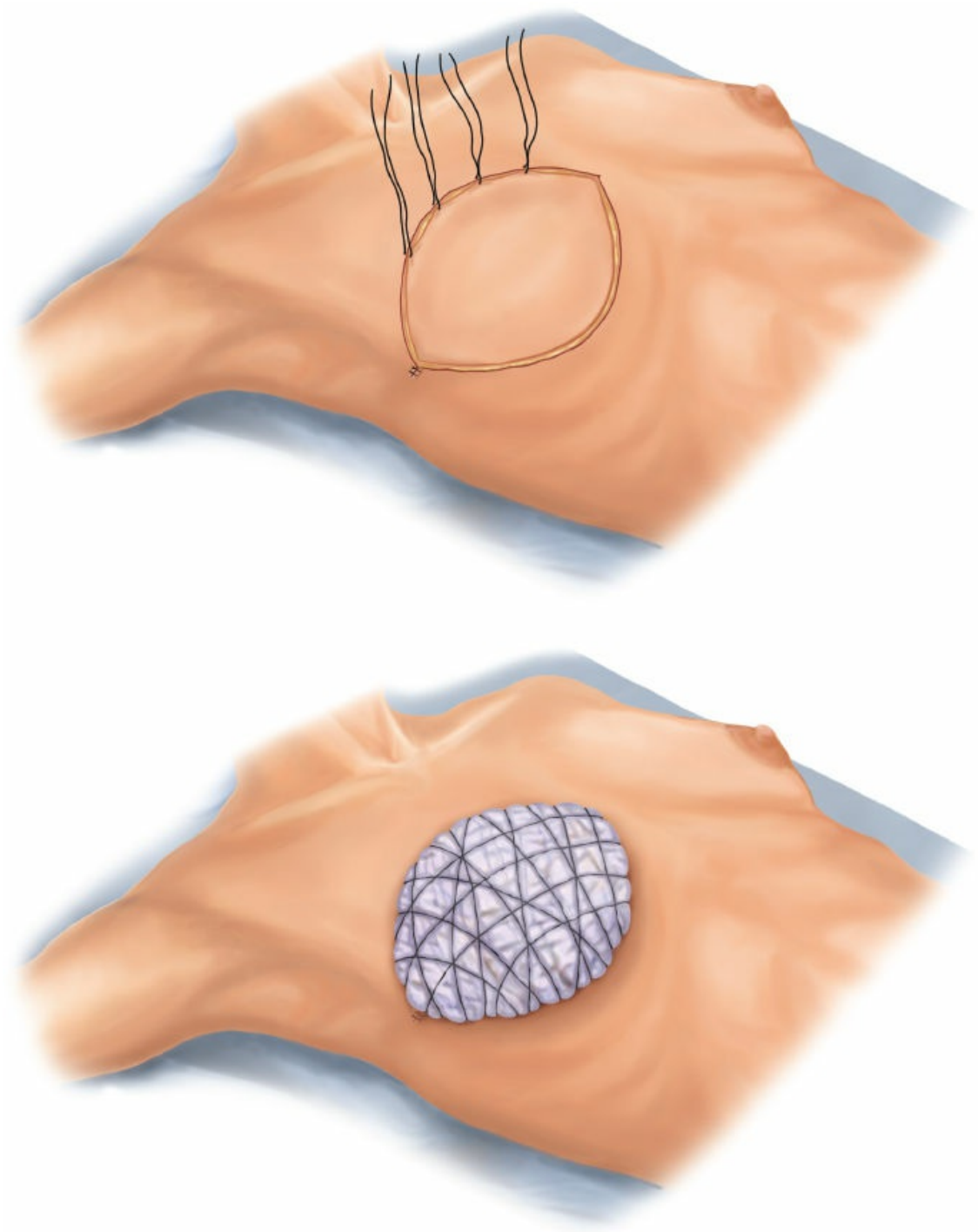

Figure 54.25. *Top,* Large defect that is expected with creation of large skin flaps inclusive of the periphery of the breast for T3 and T4 lesions with fixation to the pectoralis major. Such large defects must be grafted with split-thickness skin (0.018 to 0.020 in) that is preferably obtained through a dermatome from skin of the anterior/lateral thigh or buttock. An additional option for closure is the myocutaneous latissimus dorsi flap. *Bottom,* The partial-thickness skin graft held in position with a compression stent created with cotton gauze mesh. These large skin defects do not require catheter drainage. Alternatively, compression foam mesh

as the stent may be applied over the split-thickness skin graft. Foam mesh may be stapled in place at the margin of the skin defect. (Bland KI, Klimberg VS, eds. Breast surgery. In: Fischer JE, ed. *Master Techniques in General Surgery: a Series*. Philadelphia, PA: Wolters Kluwer; 2010, with permission.)

The surgeon should be cognizant of the necessity for immobilization of the skin graft to enhance the probability of adherence (with "graft take" to the chest wall); the partial-thickness graft is stented with bolsters (Fig. 54.25) or compression-foamed mesh, which may be stapled to the peripheral wound edges. In such closures, catheters are not necessary when skin grafts are applied to the defect. The stents placed over the split-thickness skin graft are not removed until day 5 or 6 postoperatively, unless undue drainage (serum, blood, suppuration) from beneath the grafts is evident. This practice increases the probability of graft adherence, which is further enhanced when postoperative shoulder immobilization for large defects is ensured.

Should postoperative irradiation be required following review of the operative pathology report, these patients may be offered breast reconstruction 6 to 18 months following the radical procedure. Breast reconstruction allows for cosmetic enhancement of the patient with maintenance of form and functional restoration. This alternative is being applied more commonly internationally. With the presence of adverse biologic features and the inexact probability of positive margins, the surgeon must often defer the reconstruction. Nonetheless, the Wells prospective trial conducted by Patel and associates with follow-up over 10 years suggests that an immediate reconstruction is widely applicable, technically feasible, and can be conducted with long-term outcomes that are not detrimental to local recurrence of metastatic disease. With the advancement and utility of myocutaneous reconstruction, with or without implants, the use of immediate reconstruction has increased between 1985 and 1995 from 3.4% to 8.3%. Considerations of the patient's decisions for reconstructive surgery include income, age, geographic location, hospital size and type, as well as tumor stage. Reports emphasize the importance of patient education as an essential component to address and provide proper patient consultation and information for options that include risk of reconstruction recurrence and projected morbidity.

Suggested Readings

Bland KI, Copeland EM. *The Breast: Comprehensive Management of Benign and Malignant Diseases.* 4th ed. Philadelphia, PA: Saunders; 2009.

Bland KI, Klimberg VS. Master techniques in surgery: breast surgery. In: Fischer JE, ed. *Series: Master Techniques in General Surgery.* Philadelphia, PA: Elsevier; 2011.

Bland KI, Menck HR, Scott-Conner CE, et al. The national cancer data base 10-year survey of breast carcinoma treatment at hospitals in the United States. *Cancer* 1998;83(6):1262–73.

Boneti C, Arentz C, Klimberg VS. Scapulothoracic bursitis as a significant cause of breast and chest wall pain: underrecognized and undertreated. *Ann Surg Oncol* 2010;17(3):321–4.

Boneti C, Korourian S, Diaz Z, et al. Scientific Impact Award: Axillary reverse mapping (ARM) to identify and protect lymphatics draining the arm during axillary lymphadenectomy. *Am J Surg* 2009;198(4):482–7.

Boneti C, Yuen J, Santiago C, et al. Oncologic safety of nipple skin-sparing or total skin-sparing mastectomies with immediate reconstruction. *J Am Coll Surg* 2011;212(4):686–93; discussion 693–5.

Cody HS 3rd, Laughlin EH, Trillo C, et al. Have changing treatment patterns affected outcome for operable breast cancer? Ten-year follow-up in 1288 patients, 1965 to 1978. *Ann Surg* 1991;213(4):297–307.

Fischer B, Anderson S, Redmond CK, et al. Reanalysis and results after 12 years of follow-up in a randomized clinical trial comparing total mastectomy with lumpectomy with or without irradiation in the treatment of breast cancer. *N Engl J Med* 1995;333:1456–61.

Fischer B, Anderson S, Bryant J, et al. Twenty-year follow-up of a randomized trial comparing total mastectomy, lumpectomy, and lumpectomy plus irradiation for the treatment of invasive breast cancer. *N Engl J Med* 2002;347:1233–41.

Fischer B, Bryant J, Wolmark N, et al. Effect of preoperative chemotherapy on the outcome of women with operable breast cancer. *J Clin Oncol* 1998;16(8):2672–85.

Giuliano AE, McCall LM, Beitsch PD, et al. ACOSOG Z0011: a randomized trial of axillary node dissection in women with clinical T1–2N0 M0 breast cancer who have a positive sentinel node. *J Clin Oncol* 2010;12(18).

Hartmann LC, Schaid DJ, Woods JE, et al. Efficacy of bilateral prophylactic mastectomy in women with a family history of breast cancer. *N Engl J Med* 1999;340:77–84.

Julian TB, Venditti CA, Duggal S. Landmark clinical trials influencing surgical management of non-invasive and invasive breast cancer. *Breast J* 2015;(21):60–6.

Kiyingi AK, Macdonald LJ, Shugg SA, et al. Harmonic dissection versus

electrocautery in breast surgery in regional Victoria. *ANZ J Surg* 2015;(85):358–62.

Meier P, Ferguson DJ, Karrison T. A controlled trial of extended radical versus radical mastectomy. Ten-year results. *Cancer* 1989;63(1):188–95.

Osborne MP, Borgen PI, Wong GY, et al. Salvage mastectomy for local and regional recurrence after breast-conserving operation and radiation therapy. *Surg Gynecol Obstet* 1992;174(3):189–94.

Patrizi I, Maffia L, Vitali CM, et al. Immediate reconstruction after radical mastectomy for breast carcinoma with a Becker-type expander prosthesis [Italian]. *Minerva Chir* 1993;48(9):453–8.

Roberston SA, Rusby JE, Cutress RI. Determinants of optimal mastectomy skin flap thickness. *BJS* 2014;(101):899–911.

Russell IS, Collins JP, Holmes AD, et al. The use of tissue expansion for immediate breast reconstruction after mastectomy. *Med J Aust* 1990;152(12):632–5.

Simmons RM, Adamovich TL. Skin-sparing mastectomy. *Surg Clin North Am* 2003;83(4):885–99.

Sweetland HM, Karatsis P, Rogers K. Radical surgery for advanced and recurrent breast cancer. *J R Coll Surg Edinb* 1995;40(2):88–92.

Veronesi U, Cascinelli N, Mariani L, et al. Twenty-year follow-up of a randomized study comparing breast-conserving surgery with radical mastectomy for early breast cancer. *N Engl J Med* 2002;347:1227–32.

Wickerham DL, Fischer B. Surgical treatment of primary breast cancer. *Semin Surg Oncol* 1988;4(4):226–33.

Winchester DP. Standards of care in breast cancer diagnosis and treatment. *Surg Oncol Clin North Am* 1994;3(1):85–99.

EDITOR'S COMMENT

Dr. Bland not only presents us with superb anatomical descriptions and diagrams but also provides us with a splendid historical account of surgical breast cancer treatment. The surgical evolution continues today as many advances in screening and early detection have led to innovations in the indications for and the way in which we perform mastectomies, lymphadenectomies, and reconstruction.

It is uncommon but not rare (especially in rural states) that there is an indication for radical mastectomy and usually only in the most advanced and/or resistant disease. Morbidity can be minimized by avoiding the use of a skin graft. In my practice, it is rare that one cannot rotate a skin flap in to cover the

defect. Often in these situations the defect is large and several rotational flaps can be performed for coverage. These types of flaps heal well as long as attention is paid to optimizing the nutritional status of the patient which is often poor. In my view anything is better than a skin graft. Skin grafts may or may not take and they do not radiate well at all. As an alternative a variety of pedicle or free flaps can be brought in for coverage. Healing with TRAM, DIEP, or Latissimus flaps are usually more slow and the complication rate higher than with rotational skin flaps but may be the only choice if the defect is large enough.

For locally advanced disease T4, especially T4d (inflammatory), one should consider neoadjuvant XRT as well as neoadjuvant chemotherapy as resection alone often results in recurrence if there is slow wound healing. Having said that radiation upfront will be met with decreased wound healing and prolonged seroma but less of a chance for chest wall recurrence.

Modified Radical is appropriately named because everyone has their own modification of it. Changes in this procedure continue even today. One of the major issues with a modified radical mastectomy as with a radical mastectomy is the occurrence of upper extremity lymphedema. One of the easy ways to mitigate some lymphedema is to try when possible to spare the intercostobrachial nerves as they have lymphatics that run with them. Taking these nerves can cause increased lymphedema particularly of the back. The best way to reduce lymphedema of the upper extremity is to add to the modified radical mastectomy the additional procedure of axillary reverse mapping (ARM). This procedure entails dual mapping of the breast with radioactivity and the upper extremity with vital blue dye. In doing so one can delineate what is draining the upper extremity from those lymphatics that drain the breast. This can be done via intraoperative injection making the procedure easy on the patient. Subareolar injection of the breast localizes within minutes as does the blue dye from the arm. This dual mapping is necessary as about 4% of the time the drainage colocalizes. In a case like this the so localized lymph node can be removed and the afferent and efferent lymphatics can be reapproximated or reanastomosed. The point is to keep incontinuity the lymphatics draining the arm and thus prevent lymphedema. We have shown in over 600 patients that lymphedema after axillary lymph node dissection is about 6% and nil if cut lymphatics are reanastomosed. Yu and colleagues have performed the only randomized trial of ALND with or without ARM and have similar shown upper extremity lymphedema rate of 6% with ARM and 33% without it.

Both chemotherapy and XRT increase the risk of lymphedema. Obesity, hypertension, and infection all increase the risk of lymphedema by 50%. Intermittent compression devices have now been shown not to be effective. Complete decongestive therapy with specialized upper extremity massage, compressive wrapping, and fitted sleeves is effective but constitutes a lifelong effort. Lymphovenous anastomosis and lymph node transfer may also be effective in treating lymphedema although more experience with these

techniques is needed.

Modified radical mastectomy includes an ALND. Neoadjuvant chemotherapy clears the positive axilla (via core biopsy) about 40% of the time. Several studies were designed to determine if an SLNB would be accurate after neoadjuvant chemotherapy and when negative avoid a concomitant ALND. Alliance 1071 and other trials showed that the false-negative rate of an SLNB with a known positive node before neoadjuvant chemotherapy was too high unless at least 3 nodes were obtained as well as the clipped positive node was also obtained. One of the next generation of trials is the NSABP 51. This trial examines in cN1 breast cancer patients who are node negative by SLNB the safety and efficacy of ALND versus XRT. The Alliance 111202 is going even further examining those patients who were node positive before and after neoadjuvant chemotherapy the safety and efficacy of XRT versus axillary radiation.

When performing an RM of MRM for recurrence a second sentinel lymph node biopsy has a high false-negative rate. If the axilla has been disturbed by prior surgery, then alternative drainage is likely to occur. Radioactive injection may or may not be able to locate such drainage especially in a patient that has been previously irradiated. The most likely occurrence would be in the internal mammary chain in the second and third intercostal spaces. If a lymph node in this area cannot be seen by ultrasound, it is unlikely to be significant. These are easy lymph nodes to retrieve and a recurrence in this chain is often difficult to treat.

Haagensen grave signs (p2) are no longer necessarily grave with the advent of neoadjuvant chemotherapy. Skin sparing and nipple skin sparing mastectomies can be performed on those patients with locally advanced disease with complete or partial responses to chemotherapy, previous radiation or expected post op radiation. The reported complication rates are only slightly higher when compared to those patients who did not adjuvant therapy prior to surgery. One must wait 4 to 8 weeks after chemotherapy to perform the mastectomy.

Contralateral mastectomies requested by patients have come under fire in recent years with societies advocating against them as such procedures have not been definitely shown to improved survival. However, survival is not the only parameter by which these procedures should be judged. The fear of recurrence and the actual recurrence itself which is 1% to 2% per year can be devastating for these patients. Symmetry especially for the patient with macromastia or those undergoing reconstruction is important. Informed patient choice should to be given every consideration.

Reconstruction for radical mastectomy requires a tissue reconstruction. By far, the most common type of reconstruction after modified mastectomy is implant under the pectoralis major usually with a dermal matrix to complete a sling-like pattern and natural look. Occasionally, for example, in the athlete the implant can be placed prepectoral within an envelope of dermal matrix.

Infection in this group of patients is serious and may cause the loss of the implant. Therefore I use adhesive drapes in these patients and prep before and after placement of the drapes. I give antibiotics per weight and redoes often. After closure I use skin glue instead of steristrips which has the added advantage of allowing the patient to take a shower. TRAM flaps can be performed and do well in the obese, previously irradiated patient or those at high risk of infection. However, the go to flap in centers where teams are available is the muscle sparing DIEP.

Postoperative pain control seems to receive little attention. In general, most complications can be mitigated if good pain control is obtained from the outset. Patients complain about the pain of drains more than any single area. Simply placing drains where you know the patient's skin is already numb with obviate this source of pain. I do intercostal rib blocks (2 to 6) and have published the value pectoral (major and minor) blocks with bupivacaine. When placing expanders, I also add botulinum toxin injected into the pectoralis major. We showed that attention to postoperative pain and using these techniques reduced the length of stay for reconstructive patients by 1 day. In addition, many of these patients have postoperative scapulothoracic bursitis from lying on the table so long. Pain from scapulothoracic bursitis radiates anteriorly and causes postoperative tightness and pain as well as decreased range of motion of the involved upper extremity. Trigger point injections under the scapula with a mixture of lidocaine, bupivacaine, and corticosteroids give good long-lasting pain relief. Heat and NSAIDs on the scapula are also helpful.

V. Suzanne Klimberg

Suggested Readings

Boneti C, Arentz C, Klimberg VS. Scapulothoracic bursitis as a significant cause of breast and chest wall pain: underrecognized and undertreated. *Ann Surg Oncol* 2010;17(3):321–4.

Boneti C, Yuen J, Santiago C, et al. Oncologic safety of nipple skin-sparing mastectomies with immediate reconstruction. *J Am Coll Surg* 2011;212(4):686–93.

Boughey JC, Ballman KV, Le-Petross HT, et al. Identification and resection of clipped node decreases the false-negative rate of sentinel lymph node surgery in patients presenting with node-positive breast cancer (T0-T4, N1-N2) Who receive neoadjuvant chemotherapy: results from ACOSOG Z1071 (Alliance). *Ann Surg* 2016;263(4):802–7.

Burdge EC, Yuen J, Hardee M, et al. Nipple skin-sparing mastectomy is feasible for advanced disease. *Ann Surg Oncol* 2013;20(10):3294–302.

Roderick J, Poage, E, Wanchai A, et al. complementary, alternative, and other

noncomplete decongestive therapy treatment methods in the management of lymphedema: a systematic search and review. *Physical Medicine and Rehabilitation* 2014;6:250–74.

Tummel E, Ochoa D, Korourian S, et al. Does axillary reverse mapping prevent lymphedema after lymphadenectomy? *Ann Surg* 2017;265(5):987–92. [Epub ahead of print]

Yue T, Zhuang D, Zhou P, et al. A prospective study to assess the feasibility of axillary reverse mapping and evaluate its effect on preventing lymphedema in breast cancer patients. *Clin Breast Cancer* 2015;15(4):301–6.

55 Oncoplastic Techniques for Breast Conservation Surgery

Kristine E. Calhoun and Benjamin O. Anderson

ETIOLOGY/PATHOPHYSIOLOGY

Breast conserving therapy was introduced as a surgical option for women with breast cancer beginning in the 1970s. Initially investigated in Europe and then the United States, clinical trials have since demonstrated equivalency in terms of overall survival between lumpectomy with radiation and mastectomy. For the appropriately selected individual, breast conserving therapy can offer adequate treatment, as well as the psychologic benefit of retention of the breast.

In a typical lumpectomy, an incision is made, the tumor removed, and the wound closed without any specific effort made to obliterate the internal cavity. Closing the pericavity fibroglandular tissue may result in cosmetic defects if alignment of the breast tissue is suboptimal. Often times, fibroglandular tissue that is sutured together at middle depth in the breast with the patient supine on the operating table results in a puckered, dimpled appearance with the patient upright. While such a "scoop and run" approach to lumpectomy may work well for smaller tumors, declivity of the skin and/or displacement of the nipple–areolar complex (NAC) may be the end result if the lesion is sizable or the breast small.

For breast conservation to be successful, the cancer must be resected with adequate surgical margins while simultaneously maintaining the breast's shape and appearance. Unfortunately, satisfying these dual goals can be challenging. In 1994, Werner P. Audretsch was one of the first to advocate the use of "oncoplastic surgery" for repair of partial mastectomy defects by combining the techniques of volume reduction with immediate flap reconstruction. Although initially used to describe partial mastectomy combined with large myocutaneous flap reconstruction using the latissimus dorsi or the rectus abdominis muscles (volume replacement), oncoplastic surgical techniques have evolved and the term currently refers to a series of surgical approaches that utilize partial mastectomy with

breast-flap advancement to address tissue defects following wide resection (volume displacement). Once 20% of the breast volume or more has been excised, the risk of significant long-term cosmetic deformity increases. The traditional lumpectomy generally removes 20 to 40 g of tissue, with adverse cosmetic outcomes typically seen when greater than 80 g are removed. In oncoplastic resections, volumes between 200 and 1,000 g can be removed without a significant negative outcome. Such resections allow oncoplastic techniques to broaden the application of breast conserving surgery (BCS) to patients with larger tumors who previously would have been automatically guided toward a mastectomy.

Given that there is considerable variability in oncoplastic techniques and many procedures are self-taught, some have attempted to define these procedures more completely. One such attempt was made by Clough et al. in their Quadrant per Quadrant Atlas for Oncoplastic Surgery, which divides oncoplastic approaches into level 1 (up to 20% breast volume resected, closure achieved primarily) and level 2 (20% to 50% of breast volume resected, closure achieved via the use of mammoplasty) techniques. Level 1 resections are performed without mammoplasty and are easily learned by most surgeons. Level 1 techniques include six basic steps and can be used in any quadrant—skin incision, skin undermining, NAC undermining, full-thickness excision, tissue reapproximation, and NAC repositioning (generally recommended). Level 2 techniques involve mammoplasty repairs and are much more advanced. We will focus on approaches more easily implemented and utilized by breast surgeons, including the parallelogram mammoplasty lumpectomy, batwing mastopexy lumpectomy, donut mastopexy lumpectomy, reduction mastopexy lumpectomy, and the central lumpectomy.

CLINICAL

A thorough understanding of normal breast anatomy is critical to planning an oncoplastic partial mastectomy. One of the fundamental challenges for the oncoplastic breast surgeon is appropriately determining how the target cancer is distributed within the breast and assessing whether the lesion can be resected as a single en bloc fibroglandular resection.

The modern anatomic analysis of ductal anatomy suggests that the number of major ductal systems is probably fewer than ten and that the size of ductal segments can be extremely variable. Not all ducts pass radially from the nipple to the periphery of the breast; instead some travel

directly back from the nipple toward the chest wall. As first described in the 1840s by the surgical anatomist Sir Astley Cooper, single ductal segments may radiate to the sternal (medial) and clavicular (superior) aspects of the breast, with two or three ductal branches layered upon each other, creating a fuller pad of fibroglandular tissue in the axillary (lateral) and abdominal (inferior) aspects of the breast (Fig. 55.1). Although the ductal branches appear to interdigitate with each other within the breast parenchyma, the segments do not communicate with each other via ductal anastomoses.

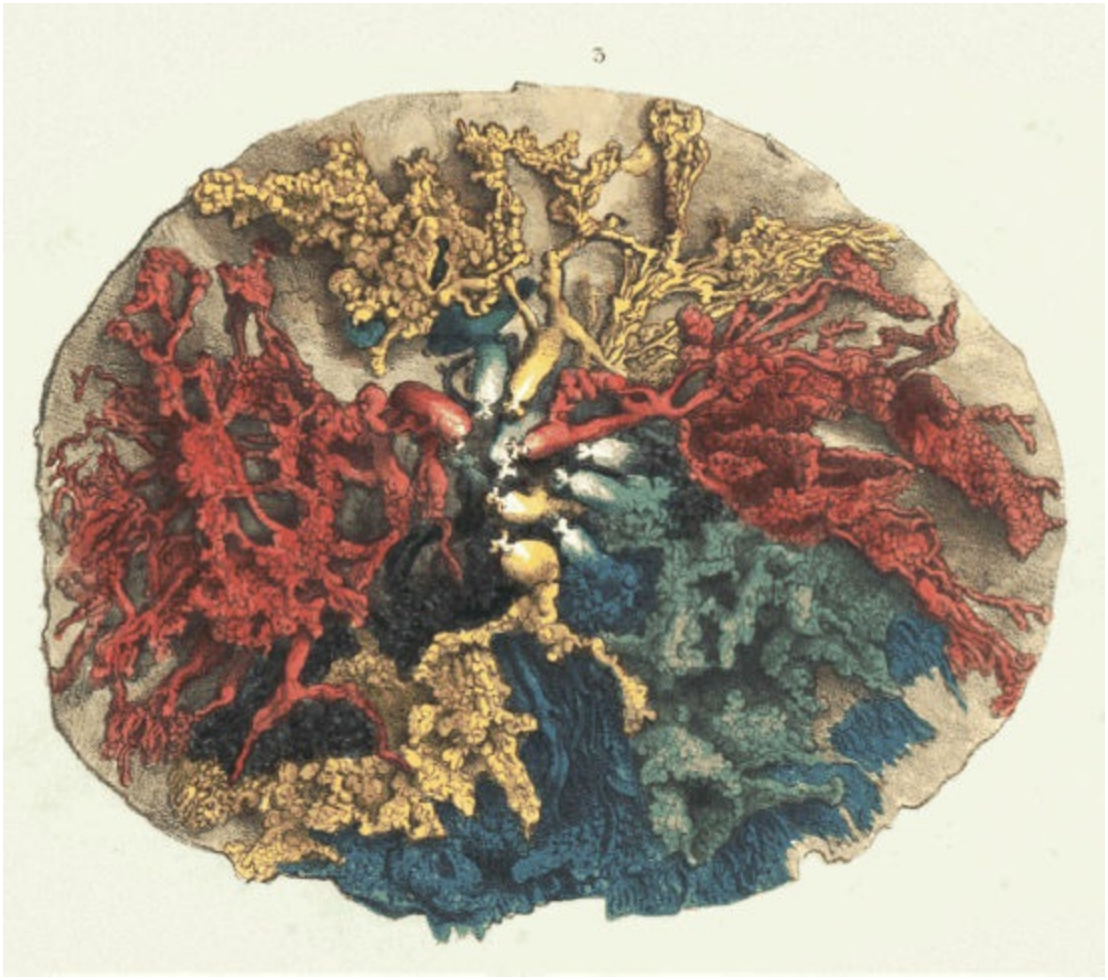

Figure 55.1. Ductal anatomy of the breast illustrating (1) the variability of segmental size and width and (2) how the lower breast has layered ductal segments creating a cushion while the upper breast ductal segments are single layered. (From Cooper AP. On the anatomy of the breast - Plate VI: Ducts and glandules (1840). Paper 16. http://jdc.jefferson.edu/cooper/16. Jefferson Digital Commons 2009. Courtesy of Thomas Jefferson University, Archives & Special Collections.)

In contrast to ductal anatomy, the fibroglandular tissue of the breast has an anastomotic circulatory bed that safely permits oncoplastic resection and mammoplasty fibroglandular advancement with minimal threat to tissue viability. By using volume displacement techniques where the surgeon simply shifts fibroglandular tissues en bloc along the chest wall, the surgeon is able to remodel large amounts of fibroglandular tissue within the skin envelope without major risk of breast ischemia. The axillary and internal mammary arteries are the most common origins of the arterial blood supply of the human. By maintaining communication with one of these two arterial connections, adequate blood supply to the breast parenchyma is maintained during tissue advancement and mastopexy closure.

INDICATIONS/CONTRAINDICATIONS

The use of oncoplastic surgical techniques allows for wider resection that minimizes the degree of subsequent tissue deformity, allowing surgeons to achieve wide surgical margins while preserving breast cosmesis. The indications, as well as the contraindications, for oncoplastic surgery are the same as those of traditional breast conserving surgery. In general, such techniques are offered to those patients otherwise believed to be breast preservation candidates, including patients with single quadrant disease and individuals who are candidates for postsurgical radiation therapy, including partial breast irradiation.

Clough et al. attempted to define selection criteria more by utilizing excision volume, tumor location, and breast density to determine which oncoplastic resection to use. Per their classification system, level 1 techniques are used when less than 20% of the breast volume will be removed, in any quadrant, and for dense breasts. More advanced level 2 resections and repairs are used when 20% to 50% of the breast volume needs to be removed and are preferred for fatty replaced breasts. In our experience, and in that described by Clough and others, tumor quadrant has a major bearing on the selection of technique.

The basic techniques described in this chapter are easily learned and implemented by breast surgeons, even those lacking formal plastic surgery training. In a review of 84 women who underwent partial mastectomy and radiation therapy, Kronowitz and colleagues showed that immediate repair of partial mastectomy defects with local tissues results in fewer complications (23% vs. 67%) and better aesthetic outcomes (57% vs. 33%)

than that with a latissimus dorsi flap, which some surgeons used for delayed reconstructions.

PREOPERATIVE PLANNING

Patients should undergo standard preoperative history and physical examination. Special attention should be given to any prior breast surgical history, including the presence of indwelling breast implants from previous augmentation. Tissue biopsy, preferably using percutaneous core needle sampling, should be performed to provide conclusive proof of malignancy. Excisional biopsy for tissue diagnosis should be avoided, as the resulting skin scar may complicate the placement of the subsequent lumpectomy incision.

Candidates for oncoplastic lumpectomy should undergo a standard preoperative breast imaging workup to establish the full extent of disease (EOD) in the breast. EOD workup typically includes a combination of mammography and ultrasound, with or without the supplemental use of breast MRI. Mammography may underestimate the EOD, especially DCIS, but is still warranted and is often the initial diagnostic study.

While it remains controversial, the use of MRI can contribute to the surgeon's ability to preoperatively determine the EOD present, especially when dealing with mammographically subtle or occult cancers in mammographically dense tissues. Compared with more traditional imaging modalities, the EOD seen on MRI may correlate best with the extent of tumor found at pathologic evaluation and MRI has the lowest false negative rate in detecting invasive lobular carcinoma. Although sensitivity is high, MRI unfortunately has a low specificity of 68% in the diagnosis of breast cancer before biopsy. Up to one third of MRI studies will show some area of enhancement that needs further assessment but ultimately prove to be a histologically benign breast tissue. A consensus statement from the American Society of Breast Surgeons supports the use of MRI for determining ipsilateral tumor extent or the presence of contralateral disease, in patients with a proven breast cancer (especially those with invasive lobular carcinoma), when dense breast tissue precludes an accurate mammographic assessment. For cancers containing both invasive and noninvasive components, a combination of imaging methods may yield the best estimate of overall tumor size.

While planning any lumpectomy, the surgeon needs to accurately identify the targeted area, which is often aided by the use of preoperatively

or perioperatively placed localization wires. Silverstein and colleagues have advocated for the preoperative placement of two to four bracketing wires to delineate the boundaries of a single lesion. In a study by Liberman and colleagues, wire bracketing of 42 lesions allowed for complete removal of suspicious calcifications in 34 (81%). Since single wire localization for larger breast lesions is more likely to result in positive margins, multiple bracketing wires may assist the surgeon in achieving complete excision at the initial resection.

Preoperative marking of skin landmarks with the patient in the upright, sitting position, with identification of the inframammary crease, the anterior axillary fold at the pectoralis major muscle, the posterior axillary fold of the latissimus dorsi muscle, the sternal border of the breast, and the periareolar circle is done. Identifying these structures with the patient in the sitting position is important to the final cosmetic outcome, because these landmarks may be challenging to accurately locate once the patient is asleep on the operating room table.

For all oncoplastic techniques, the patient should be supine on the operating room table with the arms abducted at 90 degrees or in a modified swimmer's position for the sentinel node biopsy portion of the procedure. Having both breasts prepped and draped into the field so that visual comparison with the patient in a beach chair position is possible as the wound is closed can help identify areas in need of immediate revision. Such an approach allows the surgeon to identify areas of unsightly tugging or dimpling inadvertently created during closure, so that they can be addressed at that time rather than at subsequent procedures.

SURGICAL TECHNIQUES

Parallelogram Lumpectomy

This technique, the most basic of the oncoplastic approaches, involves removal of the skin located directly superficial to the cancer, which insures that the two reapproximated skin edges will be equidistant at closure (Figs. 55.2 and 55.3). Parallelogram lumpectomy is most commonly used for superior pole or lateral cancers. Removal of the overlying parallelogram eliminates the existence of excessive, redundant skin after excision and helps prevent future declivity. The surgeon should be cautious when designing the skin ellipse, because removal of too broad of an island can cause substantial shifting of the NAC, thereby creating unintended asymmetry with respect to the contralateral breast. For upper inner

quadrant lesions, the skin island excisions should be small, or even avoided, since medial NAC shifting can create an unnatural appearance.

A rounded parallelogram with two equal length lines is drawn, marking the skin island to be excised in conjunction with the underlying target lesion and surrounding tissues (Fig. 55.2A). For lesions in the upper breast, incisions should be curvilinear, while lesions located within the lower breast, including the 3 o'clock and 9 o'clock positions, should have a radially placed parallelogram (see Lateral Segmentectomy).

After incision of the skin island (Fig. 55.2A), short distance skin flaps are raised along both sides of the wound to a width that encompasses the tumor. The dissection is then carried down through the breast tissue to the chest wall, maintaining a surgical margin around the tumor, and the specimen is then peeled off of the chest wall and removed in a full-thickness en bloc fashion (Fig. 55.2B,D). After the specimen is delivered through the incision and oriented with colored inks or sutures, 4 to 6 marking clips are typically placed at the base of the defect and within the surrounding fibroglandular tissue to mark the areas of tissue that were in closest proximity to the cancerous tumor. Once resection is complete and hemostasis obtained, the fibroglandular tissue at the level of the pectoralis fascia is widely undermined so that breast-tissue can be advanced to cover the exposed muscle without excessive tension. After tissues are mobilized, the margins of the residual cavity are shifted together by the advancement of breast tissue over muscle and sutured at the deepest aspect using 3-0 absorbable suture to close the surgically created defect (Fig. 55.3). The direction of tissue advancement can be adjusted depending upon the location of the fibroglandular defect and the excess tissue that can be shifted for closure. The goal of the mammoplasty (primary full-thickness closure of the fibroglandular tissue) is to perform as complete a closure over the pectoralis muscle as possible to discourage anterior (skin) and posterior (chest wall) tissue communication, thereby avoiding the classic and cosmetically undesirable "skin-pectoral adherence deformity." The superficial tissue layer is closed with interrupted subdermal absorbable sutures (we use 3-0 sutures), while the skin is closed by absorbable subcuticular sutures (we use 4-0 sutures) in routine fashion (Fig. 55.2E).

Lateral Segmentectomy

Essentially a variation of the above described parallelogram lumpectomy, the lateral segmentectomy is especially useful for lesions located within

the lateral breast at the 3 o'clock (left) and 9 o'clock (right) positions (Fig. 55.4A–D). The skin parallelogram is placed radially and positioned such that the closed incision will approach the NAC tangential to the periareolar line (Fig. 55.4A,B). This reduces deviation of the NAC toward the resected segment, gives more forward projection to the nipple, and avoids the downward-displacement that can be caused by a purely horizontal scar. The principles of resection and closure are otherwise the same as those described for the routine parallelogram lumpectomy (Fig. 55.4C,D).

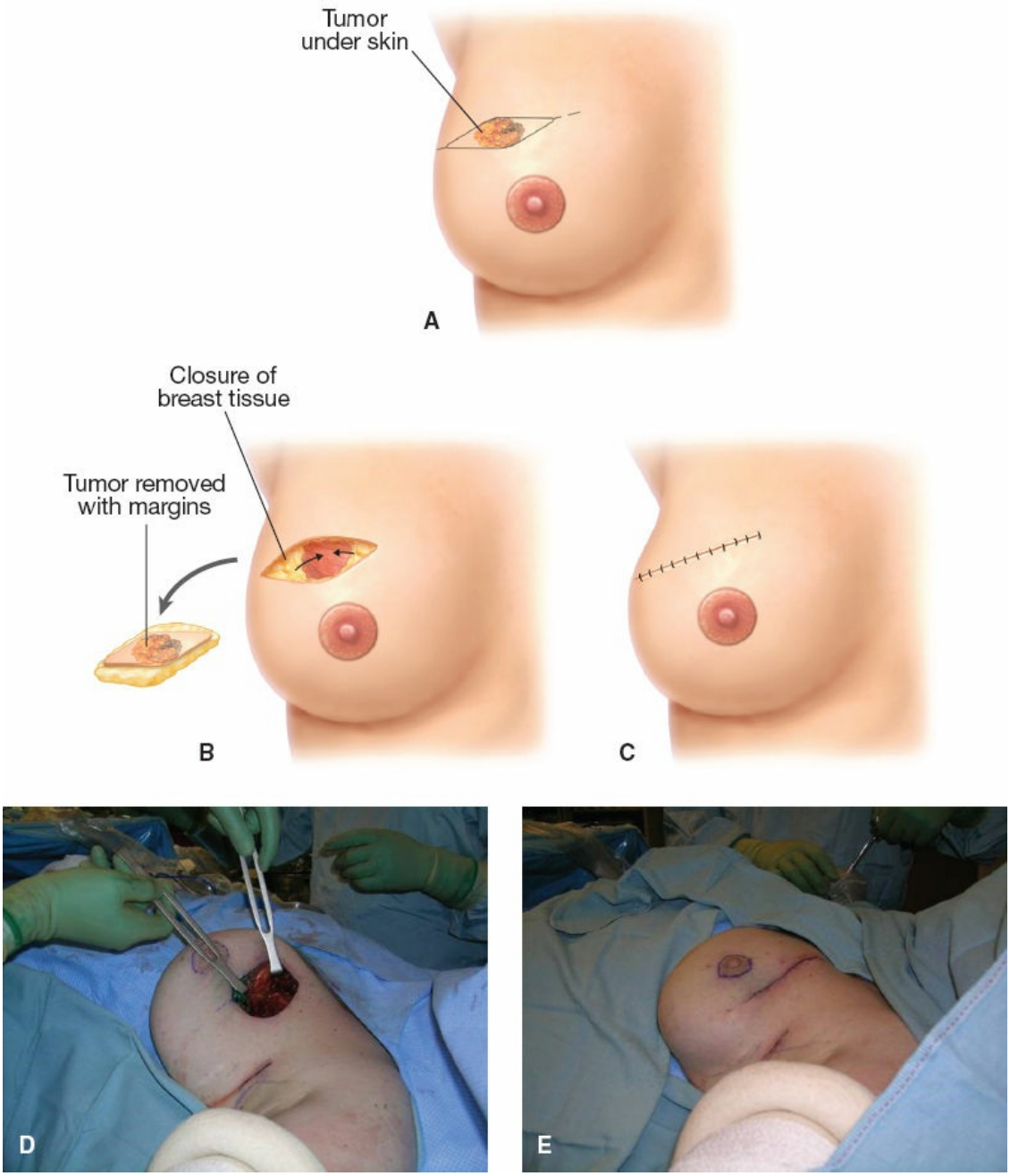

Figure 55.2. Parallelogram mammoplasty: incision design (**A**), full-thickness resection with open cavity prior to tissue

advancement (**B,D**), and final skin closure (**C,E**).

Batwing Lumpectomy

For cancers adjacent or deep to the NAC, but do not directly involve the nipple, lumpectomy can successfully be performed without sacrifice of the nipple itself (Fig. 55.5A–D). The batwing approach simultaneously preserves NAC viability while preserving the breast mound by using a mastopexy closure for the fibroglandular defect of the full-thickness resection. When the batwing incision is oriented laterally, a minor degree of lateral shifting of the NAC may result (Fig. 55.5D). When oriented at 12:00, this procedure may result in upward lifting of the nipple ("mastopexy" or "breast lift"), making a contralateral breast lift to achieve symmetry a distinct possibility.

Two similar semicircle incisions are made with angled "wings" on each side of the areola (Fig. 55.5A,B). The two half-circles are positioned to allow them to be re-approximated to each other at wound closure. Removal of these skin wings allows the semicircles to be shifted together without creating redundant skin folds at closure. Fibroglandular tissue dissection is carried down deep to the known cancer (Fig. 55.5C,D). In most situations, this dissection is carried down to the chest wall, with the breast gland lifted off the pectoralis muscle.

Central Lumpectomy

The cosmetic impact of NAC removal, which unfortunately is required when cancer involves the base of the nipple, likely accounts for the common use of mastectomy among these individuals despite the existence of the alternative option of central lumpectomy (Fig. 55.6A–C). The central lumpectomy is an alternative to total mastectomy that removes the NAC and underlying central tissues, but leaves behind a significant breast mound. The cosmetic outcome with central lumpectomy can range from good to outstanding, depending on the woman's body habitus, and may be better tolerated than mastectomy and subsequent reconstruction. Central lumpectomy can be particularly valuable in women with large breasts where unilateral total mastectomy may create prominent asymmetry. In central lumpectomy, the incision can be made in the pattern of a large parallelogram which encompasses the entire NAC (Fig. 55.6A). Rotating the NAC resection plane so that the incision results in an inverted T-incision may preserve breast shape and prevent flattening that can occur

with the more horizontally placed central lumpectomy incisions. The operative procedures and principles are the same as those of the parallelogram lumpectomy. The mammoplasty closure is performed as described above (Fig. 55.6B,C).

Reduction Mastopexy Lumpectomy

Typically indicted for macromastia and excessive breast ptosis, this procedure can also be adapted for resection of lesions in the lower hemisphere of the breast between the 4 o'clock and 8 o'clock positions (Fig. 55.7). For cancers in the lower pole of the breast, traditional lumpectomy using a circumareolar incision may result in unacceptable down-turning of the nipple due to scar contracture after radiotherapy. This unpleasant cosmetic outcome can be prevented by using the technique of reduction mastopexy lumpectomy. (The distinction between "mammoplasty" and "mastopexy" is that the latter procedure, in addition to closing the fibroglandular tissue to avoid soft tissue deficit and a possible visible divot, also moves the NAC on the skin envelope, thereby creating a breast lift.)

A reduction mastopexy keyhole pattern incision is made and the skin above the areola is de-epithelialized in preparation for skin closure (Fig. 55.7A). A superior pedicle flap is created by inframammary incision and undermining of the breast tissue off the pectoral fascia to mobilize the NAC and underlying tissues. For cancers located in the inferolateral or inferomedial quadrants, the keyhole pattern can be rotated slightly to allow for a more lateral or medial excision, while at the same time the NAC is moved in a direction opposite to that of the surgical defect. Commencing inferiorly and proceeding superiorly beneath the tumor, full-thickness excision of the lesion is accomplished, with at least a 1-cm macroscopic margin of normal tissue, and the skin overlying the lesion being removed (Fig. 55.7B).

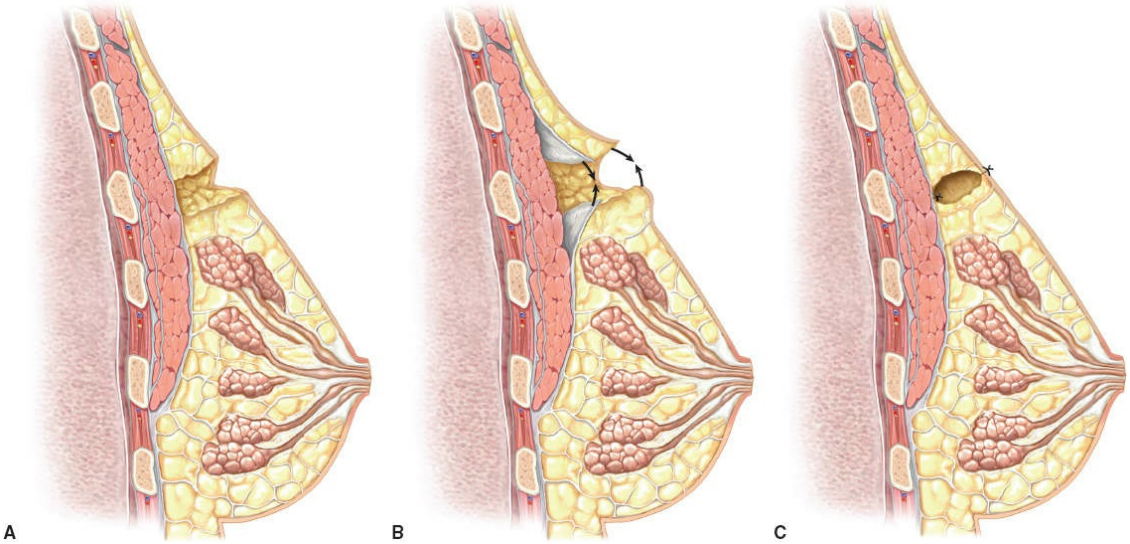

Figure 55.3. Volume displacement (mammoplasty) closure. After resecting the primary breast lesion in a full-thickness resection (**A**), the fibroglandular tissue is separated at the chest wall along the avascular pectoral fascia and advanced on the chest wall to close the fibroglandular defect created by full-thickness resection (**B**) prior to the final skin closure (**C**).

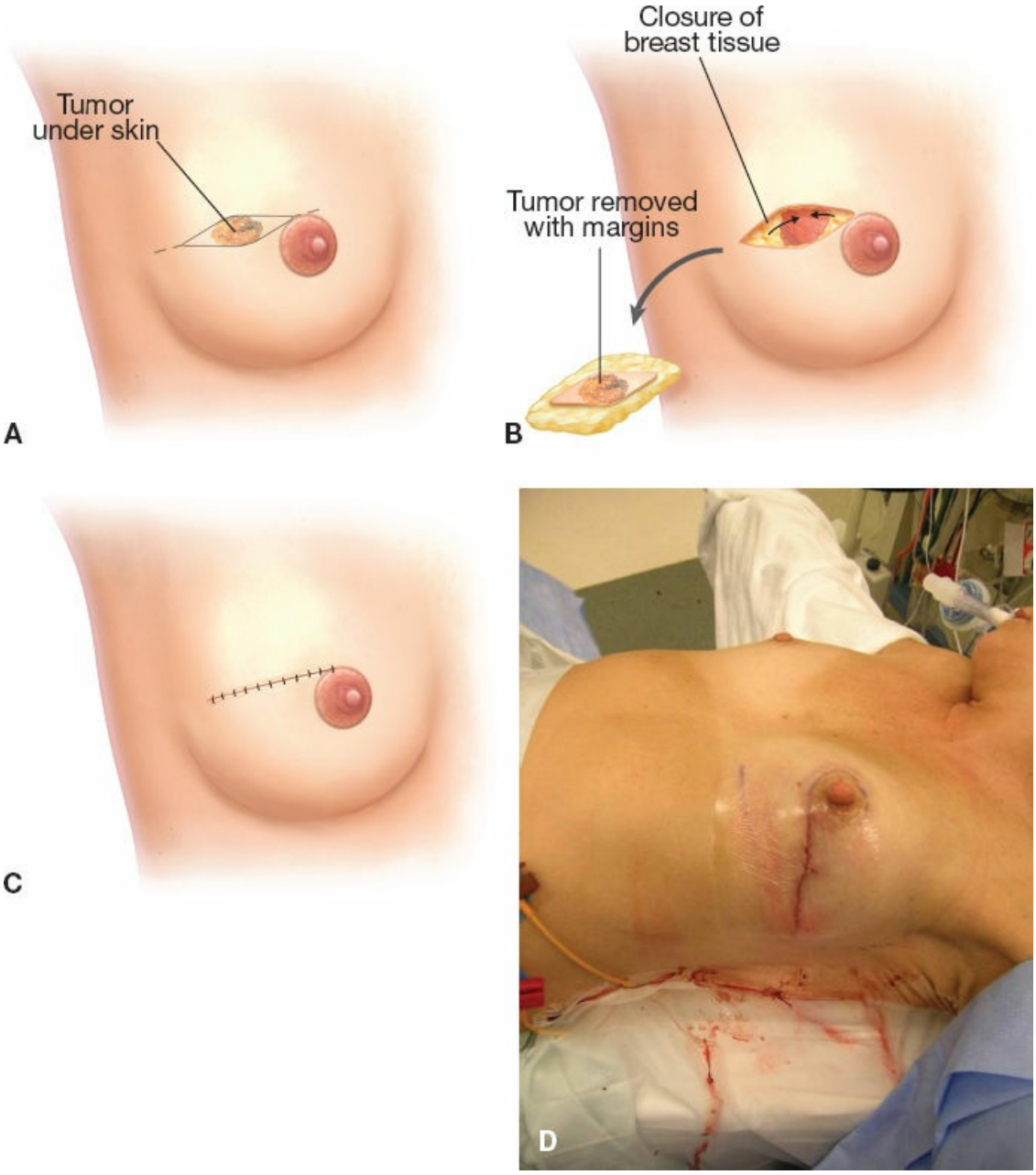

Figure 55.4. Lateral segmentectomy mammoplasty lumpectomy for laterally oriented, segmentally distributed cancers: incision design—noting the tangential approach that the skin incision makes with the nipple–areolar complex (**A**), full-thickness resection with open cavity prior to tissue advancement (**B**), and final skin closure (**C,D**).

Recentralization of the NAC is performed, with the medial and lateral breast flaps undermined and sutured together to fill the excision defect, leaving a typical inverted-T scar (Fig. 55.7C). Uplifting of the NAC by virtue of removal of the superior skin island helps restore a youthful appearance to the breast, but can create asymmetry with the contralateral

breast (Fig. 55.7D). For patients with macromastia, consistent positioning of the breast for radiotherapy may be difficult, resulting in dosing inhomogeneity and suboptimal treatment. These patients can benefit from reduction mastopexy lumpectomy using a unilateral or bilateral approach.

Donut Mastopexy Lumpectomy

The donut mastopexy lumpectomy is best utilized for segmentally distributed cancers located in the upper or lateral breast to achieve resection of long, narrow segments of breast tissue (Fig. 55.8A–E). The donut mastopexy avoids a visible long radial scar placed against Kraissl or Langer lines while allowing for adequate margin resection. In this procedure, two concentric lines are placed around the areola and a periareolar "donut" skin island is excised, with only a periareolar scar visible after this operation (Fig. 55.8A). Separation of this skin island from the underlying tissues is performed, taking care to avoid full devascularization of the areolar skin (Fig. 55.8B). The width of the "donut" skin island should be approximately 1 cm, but is somewhat dependent on the size of areola and expected extent of excision. Removal of this tissue ring is required to allow for both adequate access and exposure to the breast tissue and closure of the skin envelope around the remaining fibroglandular tissue that will reduce tissue volume overall.

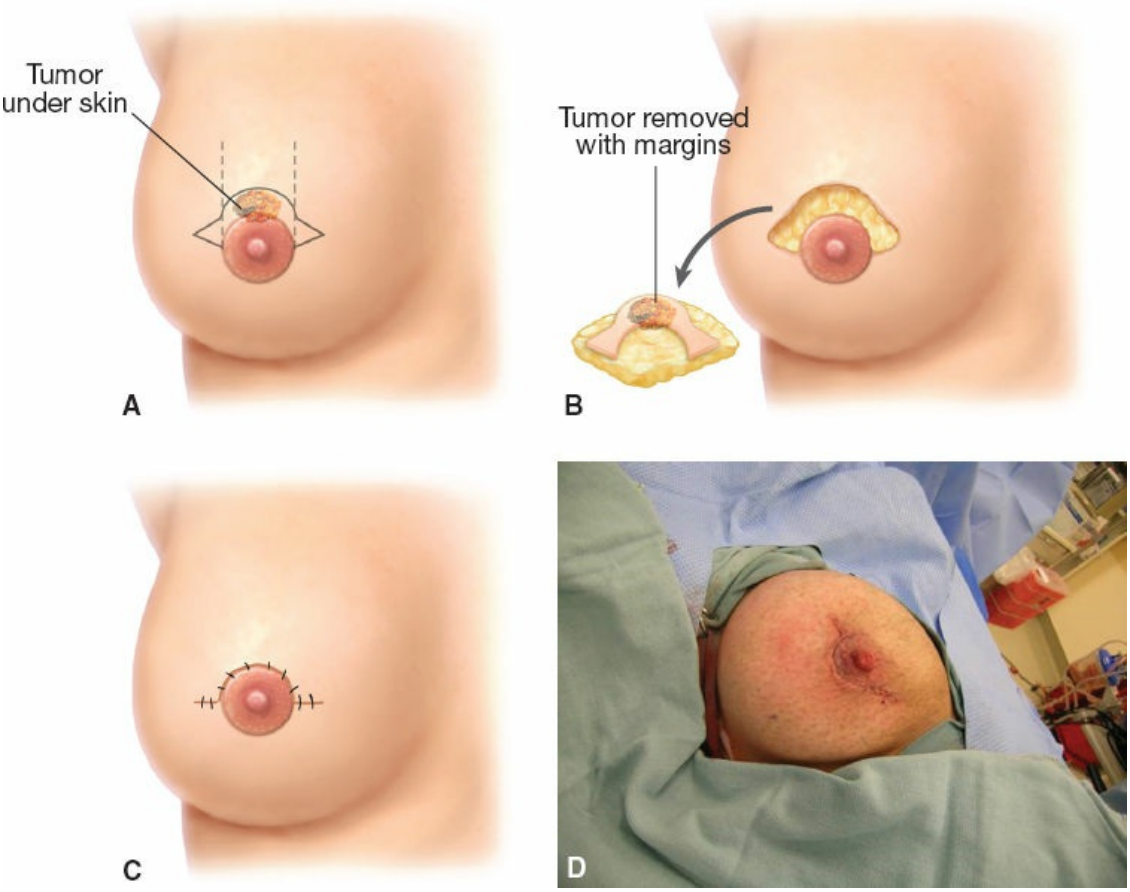

Figure 55.5. Batwing lumpectomy for centrally oriented cancers that do not directly involve the nipple–areolar complex: incision design (**A**) and skin incision (**B**), partial or full-thickness resection including dissection behind the nipple–areolar complex (**C**), final skin closure after mastopexy advancement of fibroglandular tissue behind nipple–areolar complex if needed (**D**).

A skin envelope is created in all directions around the NAC. The quadrant of breast tissue containing the target lesion is fully exposed utilizing the same dissection used for a skin sparing mastectomy. The full thickness breast gland is then separated from the underlying pectoralis muscle and delivered through the circumareolar. The segment of breast tissue with the tumor is resected in a wedge-shaped fashion, with the width of tissue excision balanced against the difficulty that will be created by virtue of an oversized segmental defect. The remaining fibroglandular tissue is returned to the skin envelope; the peripheral apical corners of the fibroglandular tissue are secured to each other and then anchored to chest wall (Fig. 55.8C). This anchoring maintains proper orientation of the mobilized fibroglandular tissue within the skin envelope during the initial phases of healing.

A purse-string using absorbable 3-0 suture is placed around the areola opening at a size that re-approximates the original NAC. Interrupted inverted 3-0 absorbable sutures are placed subdermally around the NAC, at which time the purse-string suture is tied and then 4-0 subcuticular sutures are used to close the wound (Fig. 55.8D). Uplifting of the NAC may create some asymmetry with the untreated breast, so if desired, a contralateral lift can be performed to achieve symmetry (Fig. 55.8E).

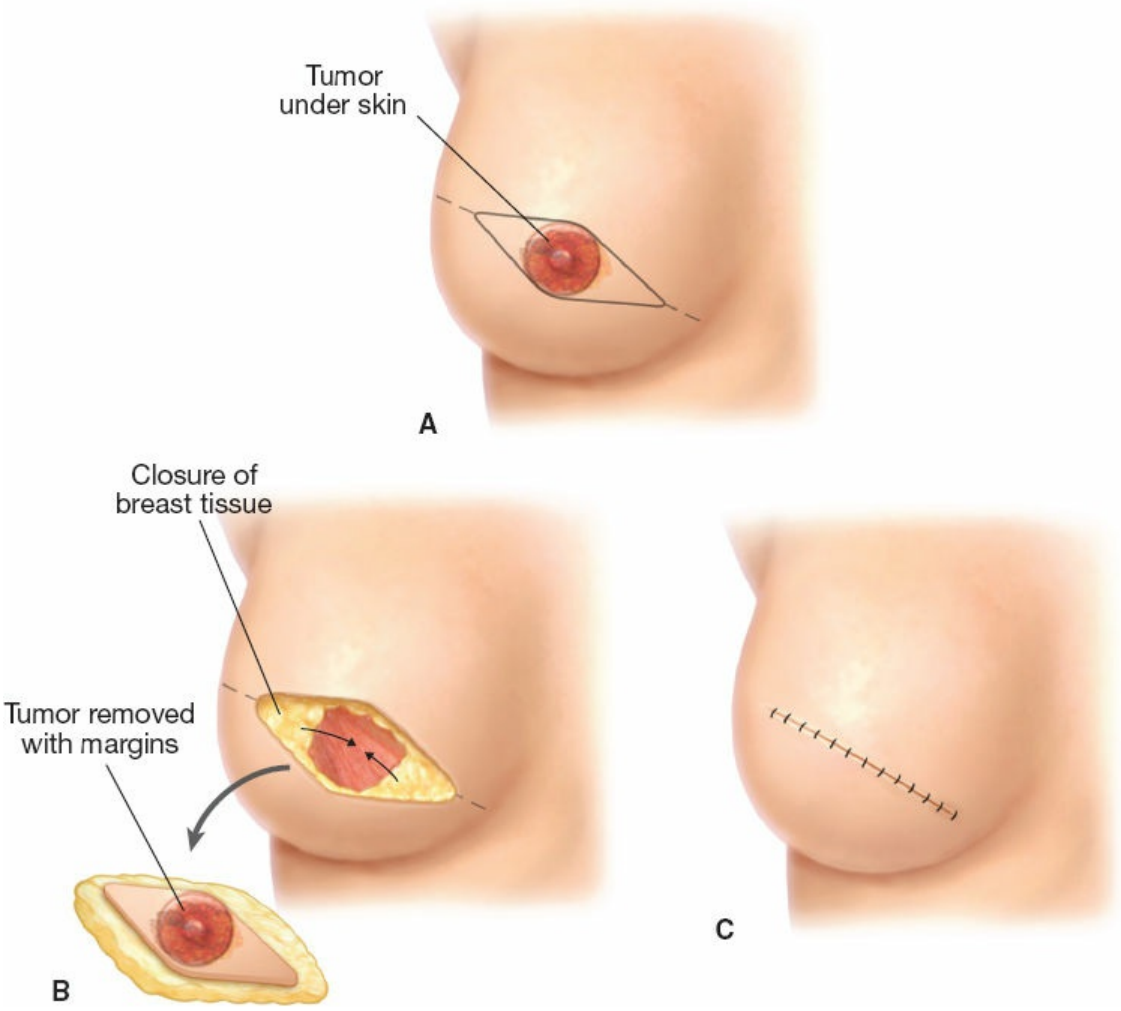

Figure 55.6. Central lumpectomy for centrally oriented cancers that do involve the nipple–areolar complex**:** incision design (**A**), resection (**B**), and final skin closure (**C**).

All oncoplastic procedures can be accompanied by axillary sentinel lymph node (SLN) dissection for staging purposes for those with invasive breast cancers. Consideration should be given to utilization of SLN for exceptionally large volume lumpectomies for ductal carcinoma in situ (DCIS), especially those in the upper outer quadrant, as such resections

may make subsequent lymphatic mapping difficult should surgical pathology reveal upstage to an invasive lesion.

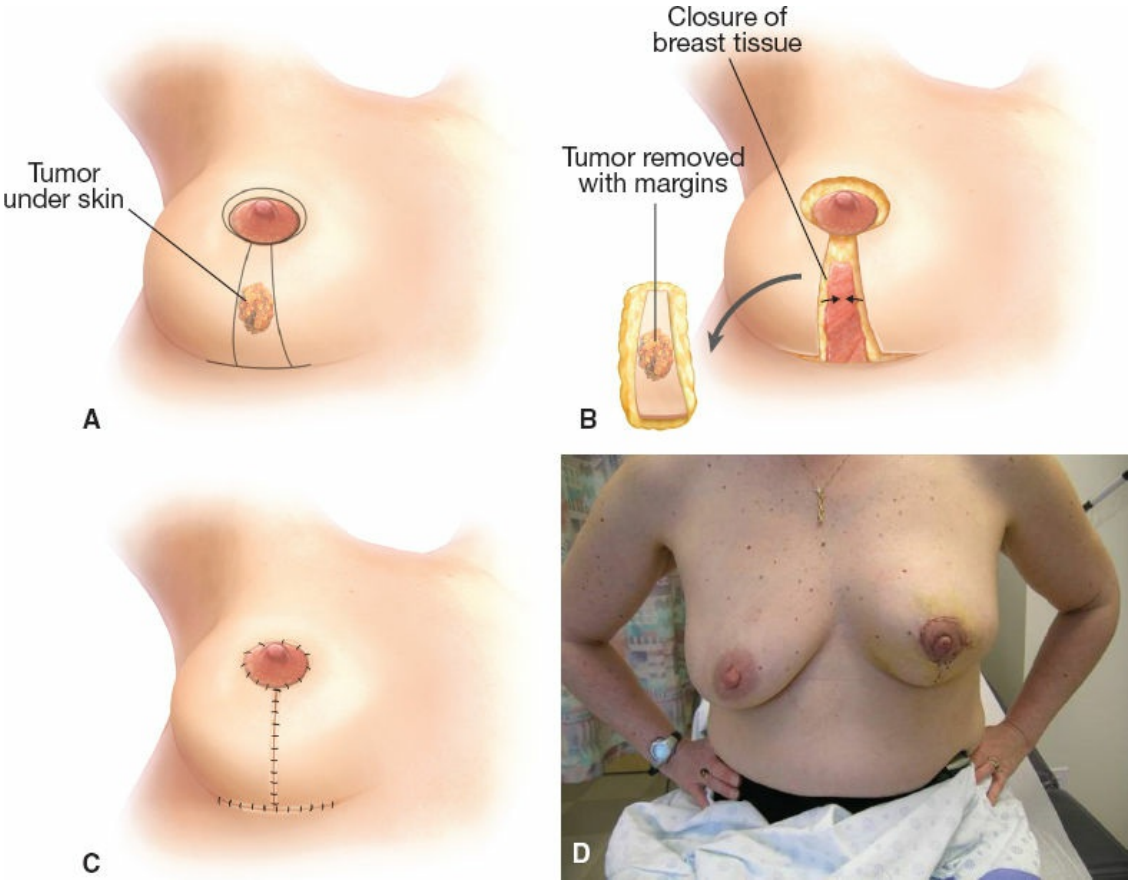

Figure 55.7. Reduction mastopexy lumpectomy for inferiorly 6:00 oriented segmentally distributed cancers: incision design (**A**), full-thickness resection back to chest wall (**B**), final skin closure after mastopexy medial and lateral advancement of fibroglandular tissue along chest wall (**C**). If this resection elevates nipple–areolar complex and creates asymmetry (**D**), a future contralateral breast lift could be considered.

POSTOPERATIVE CARE

Drains are rarely required in standard partial mastectomy cases, as any seroma will generally be reabsorbed. With more extensive dissections, such as the donut mastopexy lumpectomy, fluid accumulation can become more pronounced and may require postoperative aspiration on occasion. In recent years, we have started to occasionally place 15 French round Blake drains overnight to avoid excessive fluid accumulation in the dissected breast that might distort the oncoplastic closure. These drains are typically removed either prior to discharge if kept overnight, or on postoperative

day 1 in the clinic.

Despite more extensive resections and breast remodeling, postoperative care is very similar to that seen with more traditional lumpectomies. Patients are prescribed narcotic pain medication, but often transition to nonprescription medications quickly. We do not give antibiotics beyond the perioperative dose unless there is some pre-existing medical need.

COMPLICATIONS

When using oncoplastic approaches, surgeons without formal training must determine which procedures they are comfortable performing solo. In addition to standard potential postsurgical complications, wound infection, fat necrosis, and delayed healing in the more advanced reduction mastopexy lumpectomy have all been reported with oncoplastic resections. Clough et al. also caution against aggressive undermining of the skin or breast gland from the pectoralis when the native breast is fatty, as this type of breast increases the risk of glandular fat necrosis and subsequent wound complications. The blood supply of the external nipple arises from underlying fibroglandular tissue using major lactiferous sinuses rather than the collateral circulation from surrounding areolar skin, so nipple necrosis may occur if dissection extends high up behind the nipple.

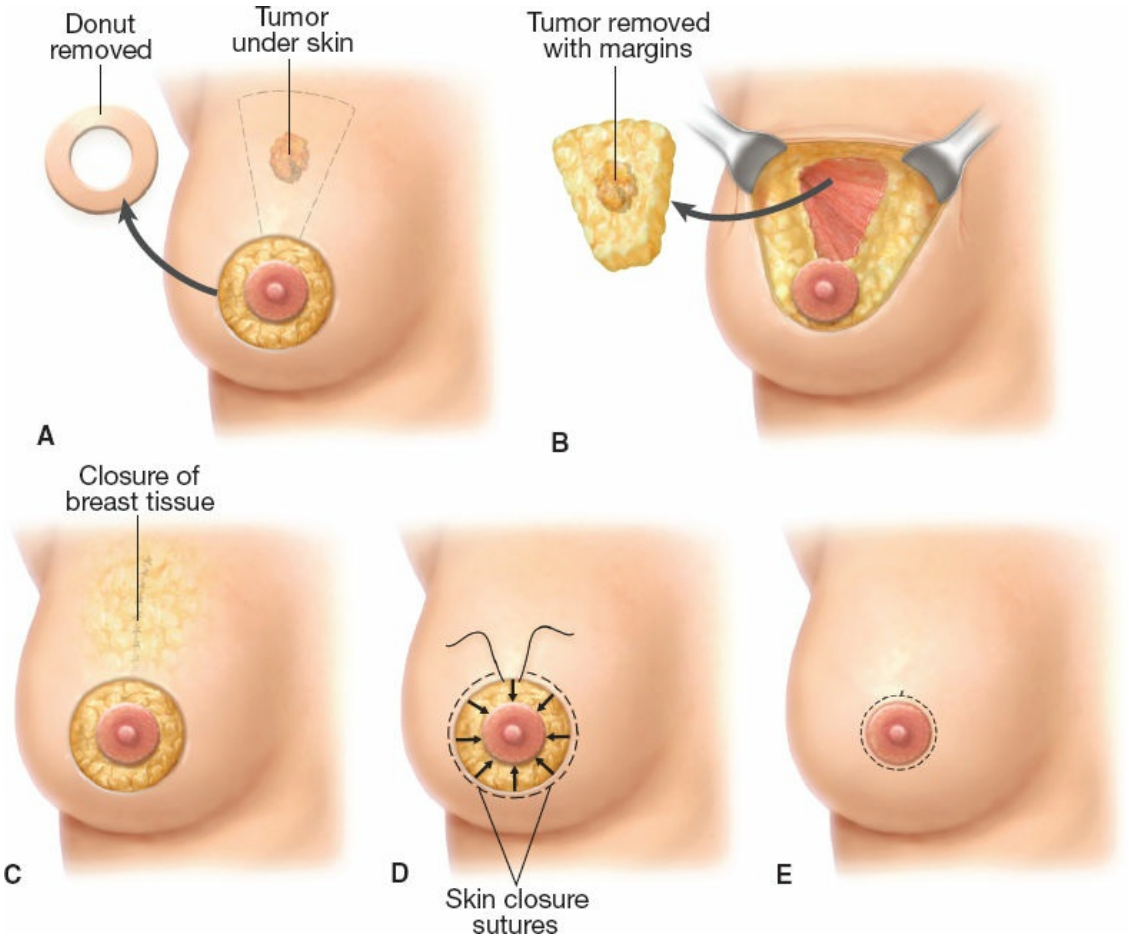

Figure 55.8. Donut mastopexy lumpectomy for upper pole segmentally distributed cancers: incision design and skin incision (**A**), full-thickness resection inside skin envelope (**B**), fibroglandular tissue closure inside skin envelope (**C**), purse-string skin closure to create a "neo-areola" (**D**), and final closure (**E**).

OUTCOMES

As with traditional lumpectomy, the main goal of all the oncoplastic approaches remains negative surgical margin resection. Excision of calcified lesions, masses, and the intended targeted lesion should be confirmed with specimen radiography during surgery. Additional oriented margins can be resected prior to mastopexy closure if specimen radiograph suggests inadequate resection, hopefully eliminating the need for a delayed re-excision.

While some centers utilize intraoperative analysis with frozen section or cytology to aid in decisions regarding the resection of additional segments of tissue, this is not our policy. What constitutes a true "negative margin" has been a topic of considerable debate. A recent consensus statement

from the Society of Surgical Oncology–American Society of Radiation Oncology has endorsed negative margins as being not at ink for invasive cancers and at least 2 mm for in situ lesions, which is now the standard of care at our institution. A recent review article reported a positive margin rate of 11.9%, despite a mean tumor size of 26 mm and a range up to 160 mm when oncoplastic resections are utilized.

If re-excision is needed for inadequate surgical margins, it can be done through the initial incision or possibly an angled “V” incision off of the initial incision to avoid cavitation of the scar. When the positive margin involves a minority of the specimen, only the involved margin(s) of the previous biopsy cavity need to be taken. When all the margins of resection are involved, mastectomy may be needed to attain satisfactory surgical clearance. In this instance, it may be technically challenging to include both the initial oncoplastic incision and the NAC in a subsequent total mastectomy and consultation with the plastic surgeon in the event of immediate postmastectomy reconstruction is mandatory. Cough et al. found that conversion to mastectomy was only necessary in 9% of the patients in the recent review, with 55% of those mastectomy specimens revealing residual disease.

Although there are few large studies of long-term outcomes specifically addressing the use of oncoplastic approaches in breast conservation, the results that are available are promising. One investigation from Europe followed 148 women for a median of 74 months (range 10 to 108 months) and only two were lost to follow-up. Among the 146 individuals available for analysis, there were only 5 (3%) women who suffered an ipsilateral in-breast cancer recurrence after 5 years and all had either T2 or T3 tumors at presentation. These authors argued that their recurrence rates for women with oncoplastic resections and concurrent radiation therapy were comparable, if not better, than the in-breast recurrence rates reported with standard breast conservation techniques. More recently, a meta-analysis comparing BCS alone to oncoplastic approaches found that patients treated with oncoplastic resections had lower rates of positive margins (12.3% vs. 20.6%), lower rates of re-excisions (4% vs. 14.6%), but higher rates of completion mastectomies (6.5% vs. 3.8%) when compared to their traditional BCS counterparts. This was accomplished with lower complication rates (15.5% oncoplastic vs. 25.9% traditional) and achieved lower rates of local recurrence (4.2% vs. 7% in BCS alone) over variable follow-up times, thus demonstrating the safety of these oncoplastic

procedures.

Suggested Readings

Anderson BO, Masetti R, Silverstein MJ. Oncoplastic approaches to partial mastectomy: an overview of volume-displacement techniques. *Lancet Oncol* 2005;6:145–57.

Audretsch WP. Reconstruction of the partial mastectomy defect: classification and method. In: Spear SL, ed. *Surgery of the Breast: Principle and Art.* 2nd ed. Philadelphia, PA: Lippincott Williams & Wilkins; 2006:179.

Bluemke DA, Gatsonis CA, Chen MH, et al. Magnetic resonance imaging of the breast prior to biopsy. *JAMA* 2004;292:2735–42.

Boetes C, Veltman J, van Die L, et al. The role of MRI in invasive lobular carcinoma. *Breast Cancer Res Treat* 2004;86:31–7.

Clough KB, Gouveia PF, Benyahi D, et al. Positive margins after oncoplastic surgery for breast cancer. *Ann Surg Onc* 2015;22(13):4247–53.

Clough KB, Kaufman GJ, Nos C, et al. Improving breast cancer surgery: a classification and quadrant per quadrant atlas for oncoplastic surgery. *Ann Surg Onc* 2010;17:1375–91.

Cooper AP. On the anatomy of the breast: Longman, Orme, Green, Brown, and Longmans (Special Collections, Scott Memorial Library, Thomas Jefferson university. Available at http://jdc.jefferson.edu/cooper/). 1840.

Fisher B, Anderson S, Bryant J, et al. Twenty-year follow-up of a randomized trial comparing total mastectomy, lumpectomy, and lumpectomy plus irradiation for the treatment of invasive breast cancer. *N Engl J Med* 2002;347:1233–41.

Kronowitz SJ, Feledy JA, Hunt KK, et al. Determining the optimal approach to breast reconstruction after partial mastectomy. *Plast Reconstr Surg* 2006;117:1–11.

Liberman L, Kaplan J, Van Zee KJ, et al. Bracketing wires for preoperative breast needle localization. *AJR Am J Roentgenol* 2001;177:565–72.

Losken A, Dugal CS, Styblo TM, et al. A meta-analysis comparing breast conservation therapy alone to the oncoplastic technique. *Ann Plast Surg* 2014;72:145–9.

Love SM, Barsky SH. Anatomy of the nipple and breast ducts revisited. *Cancer* 2004;101:1947–57.

Moran MS, Schnitt SJ, Giuliano AE, et al. Society of surgical oncology-American society for radiation oncology consensus guidelines for breast-conserving surgery with whole-breast irradiation in stages 1 and 2 invasive breast cancer. *Ann Surg Onc* 2014;21:704–16.

Rietjens M, Urban CA, Rey PC, et al. Long-term oncological results if breast conservation treatment with oncoplastic surgery. *Breast* 2007;16:387–95.

Silverstein MJ, Larson L, Soni R, et al. Breast biopsy and oncoplastic surgery for the patient with ductal carcinoma in situ: surgical, pathologic, and radiologic issues. In: Silverstein MJ, ed. *Ductal Carcinoma in situ of the Breast.* 2nd ed. Philadelphia, PA: Lippincott Williams & Wilkins; 2002:185.

The American society of breast surgeons consensus statement: The use of magnetic resonance imaging in breast oncology. Revised July 27, 2010. Available at www.breastsurgeons.org/statements.

EDITOR'S COMMENT

The 1990 Consensus Conference on Breast Cancer from the National Institutes of Health (NIH) stated that breast conservation therapy (BCT) followed by radiation is the preferred method of treatment for stages I and II breast cancer. The performance of the primary excisional biopsy as well as its pathologic evaluation is a key component in the successful implementation of BCT both cosmetically and medically. Cosmetically, as the best cosmetic results are obtained at the time of the initial operation and with a single excision. The volume of resected breast has been shown to be directly correlated with the ultimate cosmetic outcome. The volume of resected breast tissue is, in general, greater with a re-excision than with a single adequate primary excision of tumor mass. Medically, because several recent well-controlled retrospective studies have shown a significantly elevated local recurrence rate when even focally positive margins were not re-excised. Although all the studies looking at the margin issue are relatively small and by necessity retrospective, the bulk of the presently available evidence favors obtaining negative margins whenever possible. Despite this evidence most centers report a rate of positive margins between 20% and 55% on the initial diagnostic biopsy.

Intraoperative pathologic consultation for breast biopsy is among the most frequent (16% to 62%) as well as the most difficult. The problem is that there is no perfect way to examine margins, especially in the intraoperative setting. Pathologically, there is no standardized sampling method with most noncytologic methods assessing only 10% to 15% of the surface of a relatively rounded breast lesion; nor is there a standardized definition of what constitutes a "negative margin." de Mascarel has calculated that to go from a 90% probability of cancer detection to a 99% probability triples the number of blocks needed to be examined which is doubled again to approach 100%. Carter suggested that it would take 3,000 sections, 6 μm thick, to fully evaluate the margins of a 2 cm breast biopsy, an impossible task intraoperatively and a formidable and impractical task postoperatively. Thus presently available techniques provide only an estimation of margin status. Even when permanent

pathology shows a negative margin, re-excision may show disease in up to 25% of the cases.

Oncoplastic techniques have become more widely used as surgeons are taking bigger specimens and margins as well as submitting shaved margins and certainly have allowed more patients to undergo BCT. These techniques range from the very simple such as using a parallelogram to improve simple standard curvilinear excisions to those that incorporate reduction mammoplasties that leave the patient with more cosmetically pleasing breasts. Most oncoplastic surgeries can be performed by all surgeons without specific plastic surgery training. Cadaver courses are now actively training surgeons on how to incorporate more advanced procedures into their practice. These procedures are needed when excising excess skin and reshaping the breast.

One of my favorite tools after BCT is a scaffolding technique using a lattice of 3-0 prolene just under the skin to not only minimize the cavity but also buttress the skin so it does not sink in after a relatively big excision. There is also a new three-dimensional surgical implant made of a bioabsorbable material that can improve cosmesis as it fills the excision cavity and is absorbed over months. More importantly is its value in more accurately targeting accelerated partial breast irradiation and thus minimizing the dose of radiation with resultant improved cosmesis. The device is absorbed over time but the titanium clips remain permanent marking the cavity site for follow-up screening. The main drawback is the cost of the device.

Upper pole lesions of the breast can be removed with a variety of techniques: round block, crescent mastopexy, batwing resections. The upper inner quadrant is commonly known as no man’s land as it results in an unsightly scar along the cleavage. In my view, a round block technique is ideal for lesions in this area as the incision is made in the areola, a flap is raised over the lesion, and the index lesion removed. Crescent mastopexy requires de-epithelialization around the limbus of the areola and is used for correction in the position of the nipple. Lower pole lesion can be accessed easily from a reduction mastopexy or J or V plasty type of scar. A Benelli or double donut incision can be used to access any location in the breast with good cosmetic results as well as a lift. These advanced types of procedures require additional training and experience.

There is no prospective randomized trial comparing oncoplastic procedures with BCT alone. However, there is a recent meta-analysis that compared BCT (n = 5494) to oncoplastic reduction procedures and those that utilized oncoplastic flaps (n = 3165). All groups had similar percentages of in situ disease and positive nodes. Lumpectomy specimens were three to four times bigger with oncoplastic procedures and positive margins much less (12.2% for flap reconstruction and 12.4% for oncoplastic reduction versus 20% for BCT alone, $p < 0.0001$). Interestingly, complications were actually significantly less ($p < 0.0001$). Not unexpectedly satisfaction was significantly greater by about 10% ($p < 0.0001$). Recurrence was also reported as significantly less in the oncoplastic groups but the mean follow-up time for BCT was significantly

longer so it is unclear that this will remain so.

Pitfalls of oncoplastic surgery included dissection inferior to the inframammary fold which results in lowering the breast and poor cosmesis; dissection to medial resulting in a unibreast; unequal marking of the NAC resulting in asymmetry; incorrect marking of medial and lateral breast borders resulting in poor contour and dog ears and comprise of the nipple blood supply resulting in NAC ischemia and necrosis.

Advantages of oncoplastic surgery are that it allows major resections (20% to 50% of breast volume) without causing deformity, extends the indication for BCT without compromising oncologic goals or aesthetic outcome and avoids the need for secondary reconstruction.

V. Suzanne Klimberg

Suggested Readings

Clough KB, Benyahi D, Nos C, et al. Oncoplastic surgery: pushing the limits of breast-conserving surgery. *Breast J* 2015;21(2):140–6.

Clough KB, Gouveia PF, Benyahi D, et al. Positive margins after oncoplastic surgery for breast cancer. *Ann Sug Oncol* 2015;22(13):4247–53.

Gainer SM, Lee E, Lucci A. The suture scaffold technique for improved cosmesis in partial mastectomy defects. *J Surg Oncol* 2010;102(2):184–6.

Losken A, Dugal CS, Styblo TM, et al. A meta-analysis comparing breast conservation therapy alone to oncoplastic technique. *Ann Plast Surg* 2014;72(2):145–9.

56 Breast Reconstruction Following Mastectomy

James N. Long, John B. McCraw, Jorge I. de la Torre, and Luis O. Vásconez

As reconstructive surgeons, we are tasked with recreating that which has been lost. Indeed our history shows an unending search for the most ideal means by which to accomplish “restoration of form.” In the context of modern breast oncology, we are called on to recreate a breast mound that is aesthetic in its shape and contour while also achieving symmetry with the unoperated side. These goals must be accomplished without handicapping any future treatment for breast cancer while keeping the operation manageable, reproducible, and most importantly safe for the patient. Surgical changes in the modes of treatment for breast cancer have been dramatic since Halsted described his radical mastectomy. We now strive to diagnose disease in its earliest stages, which has made possible modern breast-conserving therapies. Modern breast reconstructive techniques are in a continuous state of evolution, attempting at every turn to improve the cosmetic appearance and function while reducing morbidity. Presently our task is made easier due to the smaller defects produced by newer ablative oncologic techniques. Until the late 1970s to early 1980s, reconstruction of breast was mostly done as a delayed procedure, months or even years after mastectomy. At that time, a number of concerns in performing immediate breast reconstruction existed. First and foremost among these concerns was the question of oncologic safety in immediate reconstruction, especially with the idea of reconstructed tissues hiding local cancer recurrence. In addition, there was concern over possible seeding of breast tumors throughout the chest or donor site. Some surgeons even posited that immediate breast reconstruction could interfere with adjuvant chemotherapy, whereas others feared these lengthy one-stage procedures would increase complication rates.

The advantages of immediate reconstruction are now quite clear and one very important improvement is found in not having to surgically reexpose the mastectomy site to achieve reconstruction. Furthermore, the

patient sustains an emotional benefit from the one-stage procedure, which also serves to diminish the total length of treatment. Many studies have now been completed that have sought to definitively address those concerns surrounding immediate breast reconstruction. From an oncologic safety perspective, most local recurrences are now known to occur either at the subcutaneous tissue margins or along the scar within about 3 years after mastectomy. This has been found to be true even in the patients who have received immediate breast reconstruction. Consequently, recurrences are usually detected with palpation or inspection in both reconstructed and nonreconstructed groups. To address concerns over putative seeding of the donor site, reconstructive surgeons, in cooperation with their oncologic surgery colleagues, have settled on a system, which uses separate surgical teams; this practice includes the use of different instruments, nurses, and surgical staff. To allay concerns over the prospect of immediate reconstruction causing delay in the initiation of adjuvant chemotherapy, a study was performed at the University of Alabama at Birmingham (UAB) comparing a group of 125 patients who underwent immediate reconstruction with a similar group of patients who did not undergo reconstruction. This study demonstrated that the great majority of patients who underwent immediate reconstruction were able to initiate adjuvant chemotherapy within 6 weeks of mastectomy and reconstruction. Counterintuitive to the initial presumption, a significant percentage of patients undergoing mastectomy without reconstruction experienced delayed initiation of adjuvant chemotherapy beyond 6 weeks as a result of the persistence of seromas along the axilla or from mastectomy flap necrosis. The overall complication rates for these two groups of patients were identical (18%).

Breast reconstruction was conceived to address defects of anatomy, and for this reason it is not accurate to consider its implementation as cosmetic surgery but rather as an endeavor to achieve “restoration of form.” Cosmetic surgery implies intent to enhance a patient’s normal appearance rather that to restore it. Of course, it is expected that any reconstructive breast procedure would serve to improve the appearance when referenced against an unreconstructed mastectomy site or radiation injury, but not when weighed against normal anatomy.

When we look to the past, we know that patients with breast cancer were not routinely considered for reconstruction at the time of mastectomy. Although sound rationale for this position existed then, such

as larger tumors and suboptimal methods of reconstruction, these concerns are not usually germane in the current era. We now practice in systems that offer both earlier diagnosis and improved methods of reconstruction that are consistently reproducible and yield satisfactory results. Most mastectomies today are performed for totally curable lesions such as in situ, multi-focal, and minimally invasive breast disease. Out of these advances, we now favor routine breast reconstruction at the time of mastectomy for the patients with stages 0, I, and IIa. Presently, this subset circumscribes the vast majority of patients undergoing mastectomy. Indeed, there presently exists no scientific basis for denying these patients' immediate reconstruction.

When immediate reconstruction is not offered in this current surgical era, it most typically occurs because of a lack of surgical resources at the facility or out of deference to now archaic conventions. Women remain no different from men in their desire to maintain their form; and now, due to the effort of countless patients and surgeons, it is increasingly rare that a woman who chooses to undergo breast reconstruction is denied such opportunity. In the past, many had argued that breast reconstruction was cosmetic and thus nonessential, since reconstructing the breast does not add to the patient's function. These attitudes have been replaced by an understanding that restoring the patients' form does have a significant positive impact on their self-perception, allowing greatly facilitated reintegration into their premorbid life. Since the advent of managed care, breast reconstruction in women has moved from having no financial justification to, in most cases, requiring none. When tumor extirpation causes a physical deformity, treating surgeons should routinely consider reconstruction, understanding that now it is of benefit to their patients and in most cases approved by third-party payers. While breast reconstruction serves as a critical component of the overall process of cancer rehabilitation, it is also vital to restore the patient physically, emotionally, and spiritually. In addition to the psychologic benefits realized from reconstruction, the methods used to achieve these aims have also shown themselves advantageous in the treatment and prevention of radiation injuries of the breast and chest wall. It is clearly recognized that radiation therapy causes a vasculitis that can progressively change skin, muscle, and bone over time. Higher radiation dosages, particularly when concentrated in a localized area, may result in fibrosis of the pectoralis muscle and ischemic necrosis of the costal cartilages and sternum resulting in late

disruption of the overlying skin. Though radiation injuries are less common now than in the past, they still occur in spite of continuous refinements in technique. This is important to consider because in younger women the progressive vasculitis of radiation therapy may cause problems 20 or 30 years after treatment. No matter how carefully performed, radiation therapy will produce a quantity of ulcers, lumpectomy-radiation failures, and other problem wounds that can be best corrected by resection of the irradiated area and coverage of the defect by introducing well-vascularized tissue. When resection of the chest wall is indicated, myocutaneous flaps are known to be indispensable in achieving a safe, durable closure of the wound.

THE IDEAL TOTAL MASTECTOMY

From the perspective of the reconstructive surgeon, the ideal total mastectomy should preserve the pectoralis major muscle and all of the skin that is not essential to tumor resection. When this approach is used, the functional preservation of the shoulder and soft tissue coverage of the ribs is achieved. Extensive skin excision results in a tight closure and is not shown to decrease local recurrence or enhance patient's survival. The removal of this redundant native tissue does however make reconstruction significantly more difficult. Tissue expanders cannot overcome a large skin deficit and the need for more complex autologous flap reconstruction is virtually assured when a mastectomy with radical skin resection is performed. The difference between laxity and tightness is usually a difference of about 2 cm of additional skin with each mastectomy flap. The addition of 4 to 6 cm of skin to the closure is remarkably helpful to any intended reconstruction and is often a determining factor in whether a myocutaneous flap will be required to correct the deformity.

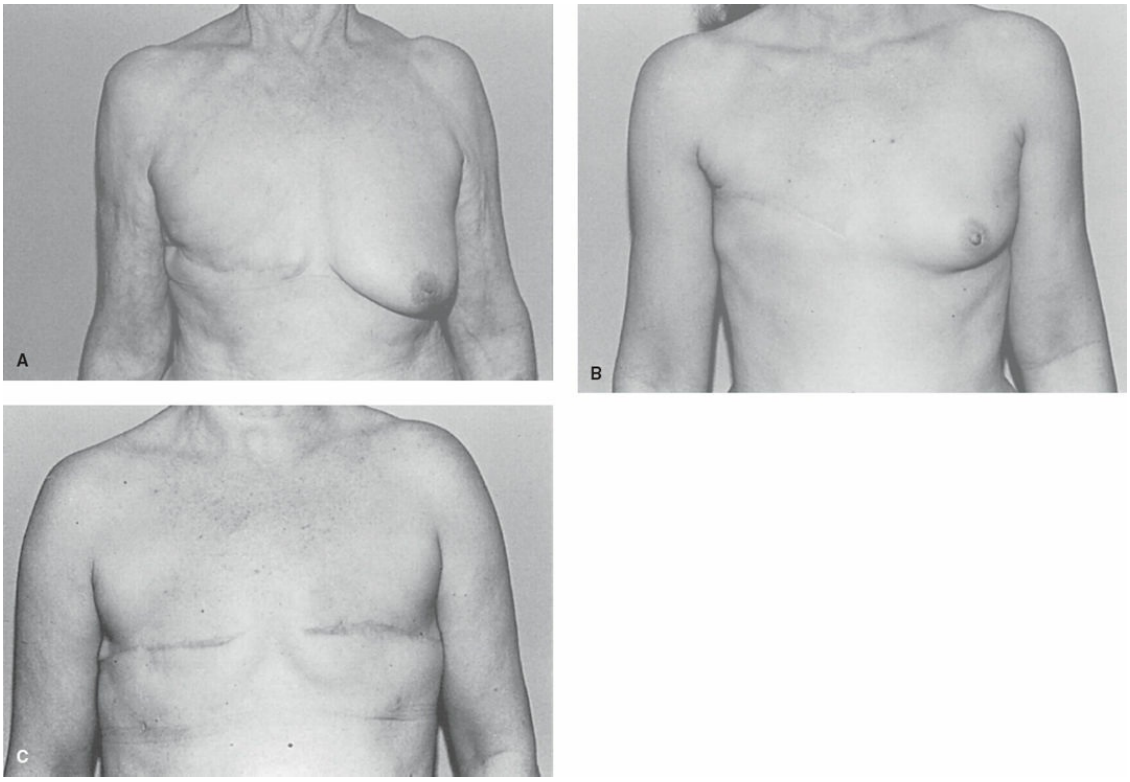

Figure 56.1. A comparison of favorable and unfavorable incisions. **A.** The most favorable low and oblique incision falls in a good line of skin tension and is well hidden. **B.** The high oblique incision, even though higher, is more easily expanded and gives a better scar since it rests in the lines of skin tension. Though inferior to the low oblique, it is still preferred over the common horizontal or Patey incision. **C.** The Patey horizontal incision offers the least favorable scar in terms of unreconstructed function while also limiting reconstructive options.

The placement of incisions is the other key factor that determines if mastectomy scars will be favorable. Here, the leading consideration should be placing incisions along the lines of skin tension. To identify the direction of these lines, pinch the skin, which accentuates the wrinkles native to the resting lines of skin tension. When incisions adhere to these lines precisely, healing occurs with the best chance of avoiding prolonged redness as well as widened or hypertrophic scarring. We favor the complete skin-sparing periareolar incision, with superior-lateral extension when needed and where practicable. When prior biopsy sites preclude the use of skin-sparing option, an elliptical incision is chosen to include the nipple, areola, and prior biopsy site. Either will provide adequate access for any mastectomy. Once complete with resection, we retain all skin redundancy in the closure to assist in any delayed reconstruction. The

worst choice for a closure in a patient who will eventually have a breast reconstruction is the transverse Patey incision. It is inelastic and unexpandable and results in the least attractive scars (Fig. 56.1A–C).

NIPPLE-SPARING MASTECTOMY

In selected patients, particularly those undergoing prophylactic mastectomies for BCRC 1 to 2 nipple-sparing total mastectomies are presently being performed. If this option is chosen, the breast tissue in the undersurface of the preserved nipple should be sent to pathology. In most series of nipple-sparing total mastectomies, the incidence of partial or total nipple necrosis approximates 20%, Although selected series show much less.

PARTIAL MASTECTOMY

Occasionally still unrecognized is that any partial breast deformity is preferable to a complete one. Replacement of up to 50% of the breast volume without the need for skin is a relatively simple reconstructive challenge. This can be accomplished with an autologous latissimus flap in a single stage. The usual skin defect of the non–skin-sparing mastectomy, which approximates 7 cm by 15 cm, can also be readily corrected with the latissimus flap. The favorable nature of the partial defect is a sound reason to choose lumpectomy and radiation when indicated by tumor size and location. When the planned lumpectomy is anticipated to cause breast deformity, even when planning to remove the nipple, breast-conserving therapy is still tenable with good aesthetic outcomes using the latissimus or its perforator variants. Although a partial central mastectomy will deform the breast, the deformity of a complete mastectomy will always be worse than this partial defect. The loss of the central breast and nipple are relatively simple to reconstruct and can be done before or after radiation.

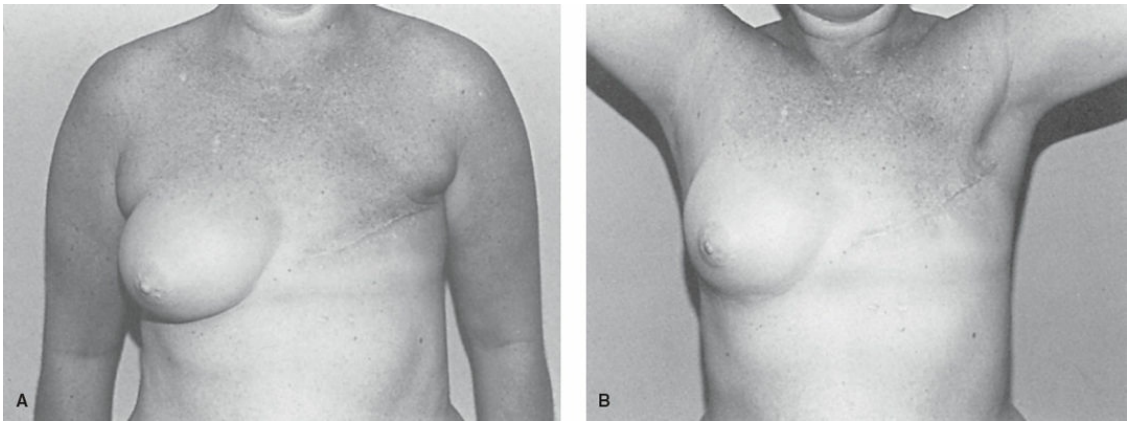

Figure 56.2. A, B. Typical modified radical mastectomy with extensive skin resection. The skin tightness is noticed at 90 degrees and limits shoulder motion beginning at 130 degrees. Because of the scarring, the skin between the incision and the inframammary fold cannot be used in the breast reconstruction and must be replaced by autologous tissue.

The skin-sparing mastectomy limits the skin excision adequate for tumor removal, which includes the nipple, the biopsy site, and any breast skin that is within 1 to 2 cm of the tumor. In most patients with stage I and IIa tumors, this approach is reasonable since tumors are more often deep than they are close to the skin. Even when the tumor lies beneath the nipple, a wide skin ellipse is usually unnecessary. In such cases, the periphery of the ellipse or the margin of tumor excision can be upward 10 to 15 cm, far in excess of that which is required to adhere to any treatment protocol. A circular excision of the nipple/areola complex will typically provide satisfactory margins and exposure with far less impediment to a reasoned reconstructive plan. Axillary sampling (Sentinel Node) is possible through the same circumareolar incision, although an additional axillary incision may be needed. Skin conservation facilitates reconstruction by all methods and greatly improves the aesthetic result that can be achieved by autologous tissue. Even in cases where reconstruction will never be performed, there is no reason to excise the skin widely, except to achieve oncologic clearance. The reconstructive surgeon should not be a solitary voice in encouraging skin conservation. It is in the patient's best interest to avoid radical skin excision when glandular resection and limited skin excision provides the same margin of safety.

MODIFIED RADICAL MASTECTOMY WITH EXTENSIVE SKIN EXCISION

Until the early 1990s when advocates for skin-sparing mastectomy began to be heard, the mastectomy skin excised with the modified radical technique differed little from the standard radical mastectomy. Extensive skin excision became a cornerstone of mastectomy when Handley promoted the permeation theory of centrifugal tumor spread in 1915. Some practicing surgeons today still model their modified radical mastectomy after the description of Patey, employing radical skin excisions with the primary closure—a perceived necessity also promoted by Auchincloss and Madden. Their preferred methodology closely followed the original description given by Moore in 1867. Patey espoused the belief that removal of the pectoralis major muscle contributed little to the cure of breast cancer since the tumor seldom invaded the muscle, except in the case of close margins. Instead, skin permeation with tumor became his primary concern in tumor extirpation and so he attempted primary closure in only about half of his cases. Compared with the radical mastectomy, the Patey mastectomy is less radical with regard to pectoralis major muscle but just as radical in elimination of skin.

In the normal breast, there exists no tightness of either the skin or pectoralis major muscle and 180 degrees of shoulder abduction is the normal full range of motion. By comparison, the skin closure of the standard modified radical mastectomy typically causes skin tension at 90 degrees of shoulder abduction followed by limitation in shoulder motion beginning at 130 degrees of abduction (Fig. 56.2). In practice, the elliptical skin excision usually measures 10 cm by 17 cm, which is easily sufficient to result in skin contracture across the chest. A horizontal skin ellipse has the most deleterious effect on shoulder motion when compared to other incisions because of tethering of normally expansile skin at a site between the inframammary fold and the axilla. The usual transverse skin closure is also the most unfavorable scar for breast reconstruction since it crosses the skin tension lines perpendicularly, usually resulting in scar hypertrophy and mastectomy flap stiffness. The low, oblique scar is much more favorable as the scar tethers at a site normally fixed to the chest wall, the inframammary fold. Though still suboptimal, the vertical closure is less restrictive than the transverse.

Reconstruction of a patient who has had a modified radical mastectomy with extensive skin excision is equal in difficulty to reconstructing the one with a radical mastectomy deformity. Reconstruction in these patients cannot be accomplished by means of an implant or even a tissue expander

alone since all surrounding skin has been “recruited” to achieve closure of the mastectomy defect. Autologous skin flaps are then required to replace lost breast skin as tissue expanders cannot overcome the tightness of the initial skin closure.

RADICAL MASTECTOMY

In the radical mastectomy, skin resection is always extensive and resultantly produces chest wall tightness, visible ribs, and compromise of shoulder mobility. Radical mastectomies are rarely seen today, thanks to earlier diagnosis and an improved understanding of the natural history of breast cancer. Nevertheless, patients still present with these massive deformities created years ago when it was considered the standard of care (Fig. 56.3). Because of the inadequate soft tissue cover, in most cases it is impossible for patients to wear an external prosthesis. Reconstruction of this deformity is clearly not possible by means of implant or tissue expander alone and they require autologous reconstruction. Even under ideal circumstances, it is very difficult to achieve satisfying aesthetic reconstructions from radical mastectomies.

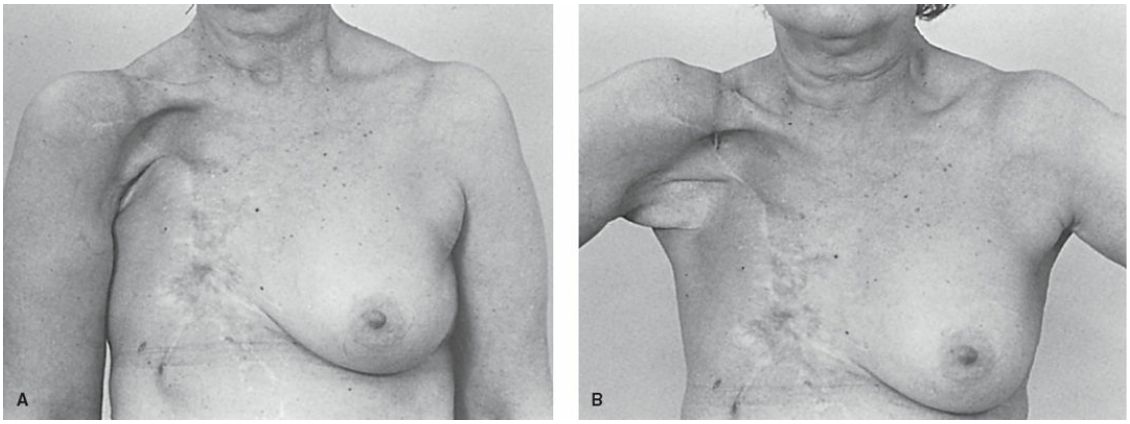

Figure 56.3. A, B. Classic Halsted mastectomy, which includes total resection of the pectoralis major and minor muscles, complete axillary dissection, and skin closure by secondary intention healing. This procedure was used into the 1980s because it was believed to prolong survival in patients with advanced disease.

MASTECTOMY AND RADIATION

When treatment includes postoperative radiation, the functional deformities caused by extensive skin excision are magnified. Radiation

causes scarring between skin and pectoralis major muscle as well as shrinkage of both skin and muscle; it may also have a direct causal effect on producing stiffness of the shoulder joint. Adding radiation to a modified radical mastectomy can extend the functional deficit to that of a radical mastectomy or worse. Because radiation causes persistent perivascular inflammation, it can act to damage the tissue permanently. For this reason, mastectomy flaps subjected to radiotherapy must be presumed to have poor vascularization. Therefore, much of the radiated breast skin must be discarded and replaced with autologous tissue. It is imperative to remove as much of the dyschromatic, visibly irradiated skin as possible. This discoloration provides the surgeon with visible evidence of tissue severely impacted by radiation damage. Though this skin may survive initial reelevation, ischemic necrosis can and often does develop many years later. Radiotherapy precludes an implant reconstruction in almost every instance since irradiated skin lacks pliability and is susceptible to late skin erosion from the underlying implant. Patients who have had augmentation can be considered for conservation therapy, which preserves the implant, but the value of this is unclear as these implants typically become firm because of the radiation, and mammography can also be impeded. Even with implants that are well positioned and intact, these factors combine to produce poor aesthetic results and arguably impaired surveillance.

HISTORICAL DEVELOPMENTS

The history of reconstructive breast surgery has several discrete periods, and the developments of each period have had a dramatic effect on the course of breast cancer surgery. From antiquity until recent times, healing of the mastectomy wound was the primary reconstructive concern in any extensive mastectomy procedure. Until skin grafting became tenable, radical mastectomies were allowed to heal by secondary intention. Small skin grafts were described as early as the 1870s but were not applied to the mastectomy deformity until the turn of the 20th century. Sheet skin grafting was developed in the late 1920s but was available in only a few major medical centers until after World War II. By 1950, only a few hundred surgeons were trained in sheet skin grafting, a technique that was not in general use until the Brown motorized dermatome became available. Elevation of breast skin flaps with primary closure of the mastectomy first appeared in the 1940s but was not accepted as routine until the 1960s. Breast reduction and nipple reconstruction were introduced in the late

1940s but did not gain popularity or safety until the 1970s. The first breast reconstructions were performed by means of tubed skin flaps or silicone implants starting in the early 1960s. In Europe, Tansini reported use of the latissimus dorsi myocutaneous flap for closure of radical mastectomy defects between 1900 and 1925. Alas, myocutaneous flap procedures were all but abandoned until their renaissance in the mid-1970s. Campbell reported his use of the latissimus dorsi muscle flap for chest wall reconstruction in 1950, but his method went unnoticed for another generation. By 1975, myocutaneous flaps were being used for delayed breast and chest wall reconstructions, but myocutaneous flaps were seldom used for immediate reconstructions prior to 1990. In the present, it is difficult to imagine oncologic breast surgery without the modern adjuncts of primary closure, skin grafting, and myocutaneous flaps.

PRIMARY CLOSURE

Extensive skin excision has been a past hallmark of radical, modified, and even simple mastectomies. In each method, breast skin was removed in anticipation this would improve the efficacy of the procedure. This practice was so accepted that it continued for 60 years before being subjected to scientific study. The various types of mastectomy are still differentiated by factors other than skin excision. For example, the modified radical mastectomy is a radical mastectomy in which the pectoralis major muscle is preserved and the simple mastectomy is a modified radical mastectomy without axillary node dissection. Patey's mastectomy is still considered less radical than the Halsted variant since pectoralis major muscle is preserved. However, Patey believed in extremely wide skin excision, in which only half of his mastectomies were primarily closed. Since the reports of Madden and Auchincloss in the early 1960s, primary closure was not considered harmful and thus achieved wide acceptance as the prevailing method. From the mid-1980s to early 1990s, extensive skin excision remained the standard of practice in mastectomy because of lingering suspicions that limited skin excision might be less effective in curing cancer, even though this belief had no scientific basis in fact. It will be interesting to see if our colleagues 50 years from now are as puzzled about our current practices as we are about the total breast skin excisions of the turn of the 20th century.

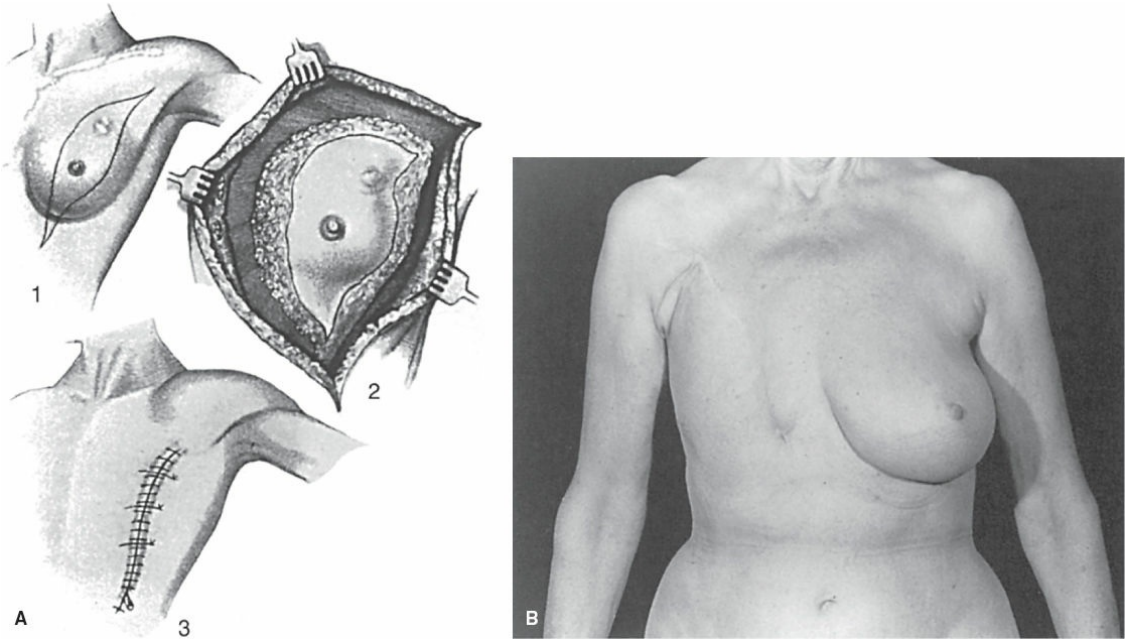

Figure 56.4. A. Illustration from Geschickter's diseases of the breast (1943). Note the extent of the proposed skin excision in this simple mastectomy making primary closure an obvious challenge. **B.** A 1979 clinical example of this mastectomy with a vertical closure demonstrates the same principles of wide skin excision, performed nearly 40 years later.

Primary closure in mastectomy surgery did not develop until the mid-20th century. The Halsted mastectomy, like other radical mastectomies in the early part of the 20th century, was rarely closed primarily. This procedure included resection of skin and breast tissue in a three-dimensional block (Fig. 56.4). This near-total removal of the breast skin was routinely used until the 1940s because elevation of breast skin flaps was believed to interfere with tumor resection by either spreading breast cancer or by leaving it within the tissues of the breast skin. At the time, it was presumed that the breast cancer permeated the entire breast skin, not just the part of the skin that was adjacent to the tumor. When total excision of the breast skin was eventually abandoned, it was replaced with such extreme resections of the skin in the modified radical mastectomy that primary closure remained the exception until the late 1960s.

SKIN GRAFTING

Primary healing of the radical mastectomy was rarely considered until sheet skin grafts became available in the 1920s. Until that time, very small, postage stamp–sized grafts were used. Beginning in 1870, small split-

thickness grafts and full-thickness grafts were used on the face. Most of these grafts were small since dermatomes had not yet been developed which would allow harvesting of larger grafts. In the 1920s, John Staige Davis popularized pinch grafts, which were harvested by shaving a “divot” of skin with a flat knife. This graft was a full-thickness graft in the center and a partial-thickness graft in the periphery to enhance the take of the graft. Even though these small grafts were available at the turn of the century, most mastectomies were nonetheless allowed to heal secondarily by scar epithelium.

Beginning in the late 1920s, Blair and Brown in the United States and Humby and Braithwaite in England popularized sheet skin grafts, which were taken with large handheld knives. These knives were variations on the straight razors of the day and required such dexterity that fewer than a hundred surgeons were trained in these techniques by the start of World War II. Most of these surgeons were those general surgeons who sought additional training in plastic surgery. In the late 1930s, calibrated drum dermatomes, such as the Padgett and Reese, were introduced. The motorized Brown dermatome was not developed until after World War II when it was conceived by Dr. Brown during his wartime imprisonment in Bataan. Even in the 1950s, only a few hundred surgeons in the world attempted skin grafting procedures, and very few of these were on mastectomy patients (Fig. 56.5).

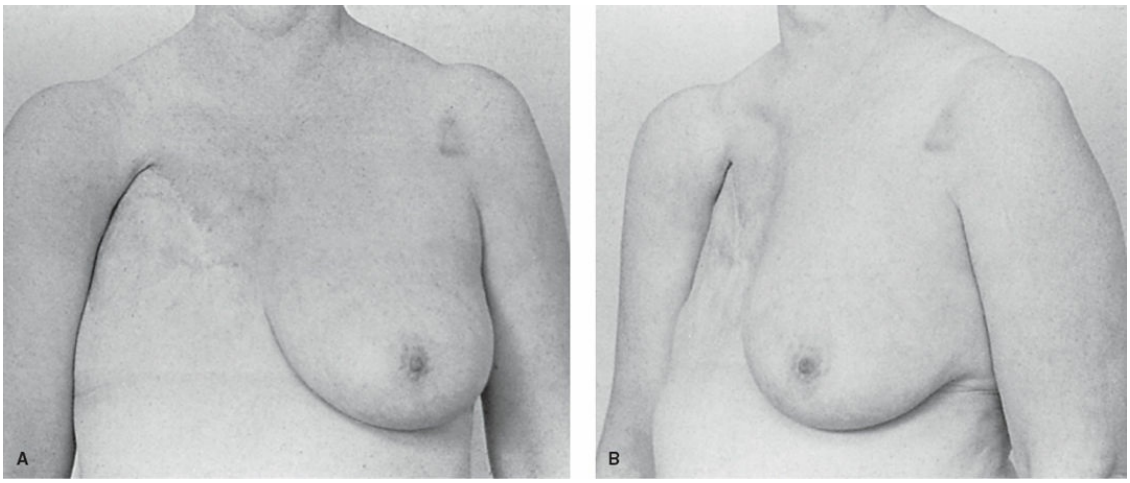

Figure 56.5. A, B. Example of a skin-grafted radical mastectomy done in 1978. The sheet skin graft was a major advance in healing the mastectomy wound.

EARLY FLAPS

In 1896 the latissimus dorsi flap was described by Igninio Tansini, a professor of surgery at the University of Pavia in Italy. In the early part of the 19th century, the breast was removed without elevation of skin flaps, which left a large circular defect taking a number of months to heal. The Tansini method used the same extirpative technique as the Halsted radical mastectomy, but the latissimus dorsi myocutaneous flap was transposed anteriorly to achieve wound closure. The purpose of the latissimus myocutaneous flap was to replace the pectoralis major and to provide skin from the back to close the breast wound primarily. Tansini's early 20th century description of the latissimus dorsi myocutaneous flap is virtually identical to that described independently by Olivari, McCraw, and Muhlbauer around the late 1970s. The Tansini method was the prevailing technique of mastectomy in Europe until about 1920 when Halsted made a grand tour of the European medical centers. Halsted said "Beware of the man with the plastic operation" because he thought that the latissimus flap was both "unnecessary and hazardous." At a time when intravenous fluids, transfusions, and anesthetics were in their early development, Halsted's statement was probably a reasonable one. Nevertheless, it sets back the legitimate use of myocutaneous flaps for breast or chest wall reconstruction for perhaps 50 years. Between 1920 and 1974, Tansini's procedure was abandoned and myocutaneous flaps were not used for immediate reconstruction of the breast until after 1980.

Because of the notable successes of Sir Harold Gillies in repairing World War I maxillofacial injuries, the tubed skin flap reconstructions he advocated became the dominant method of flap reconstruction until myocutaneous flaps were reintroduced in the mid-1970s. Tubed flaps were not applicable to immediate breast reconstruction because the transfer of the tube of skin from the abdomen to the breast consumed a period of at least a year and more than a dozen operations. Tubed flaps were impractical for use in treating radiation injuries since they did not carry an independent blood supply to the damaged area. Until the introduction of myocutaneous flaps, flap resurfacing of radiation wounds was seldom attempted because of high morbidity and frequent recurrence of wounds surrounding the flap. Even as late as the 1970s, tubed flaps were still being used for elective breast reconstruction (Fig. 56.6A–D).

SILICONE BREAST IMPLANTS

The introduction of silicone breast implants by Cronin and Gerow in 1964

was quickly followed by implant popularization led by a number of surgeons over the following 20 years. Their pioneering surgical work was conducted in collaboration with the Dow Chemical Company using polymers constructed from silicone.

Compared with previously available human breast implants, which were made of polyurethane foam, paraffin, or allogenic material, each of which had less than ideal characteristics, the silicone gel implants represented an historic medical breakthrough. This development also initiated the development of a completely new group of medical products derived from silicone, including silicone tubes, lubricants, and linings, which are relatively biologically inert. By the late 1960s, silicone gel implants had begun to find their way into the field of breast reconstruction. Early experience with these implants was not good because of fibrous encapsulation of the implant which occurred beneath the thin mastectomy skin flaps. The better soft tissue coverage of subpectoral placement improved results, just as the even better cover of autologous flaps improved it further. Over time, it became apparent that silicone implants were not as biologically neutral as had been hoped, and many local wound problems such as scarring, low-grade infection, and implant intolerance became causes for concern. Eventually, many of the early implant breast reconstructions failed because distortion produced an appearance known as the half-grapefruit shape, which accurately described the elevated, rounded, and firm implant (Fig. 56.7).

TISSUE EXPANSION

Tissue expanders were introduced in the early 1980s as an alternative to simple silicone implant breast reconstructions. These expandable implants were used to stretch the retained breast skin and create an oversized pocket with the goal of decreasing the encapsulation seen with the permanent silicone implant. Unfortunately, this method was initially applied in unfavorable candidates such as those who had undergone the Patey mastectomy with extensive skin excision; and it was the poor patient selection that gave the technique an initial but unwarranted bad reputation (Fig. 56.8). As experience was gained, the tissue expander became one of the predominant means of breast reconstruction in the patients who had not undergone extensive skin resections. The device is useful at the time of mastectomy to preserve the subcutaneous space, thus preventing primary contraction of mastectomy flaps. Over a period of weeks the device is

gradually inflated, which typically does not cause problems with wound healing. The ideal candidate for placement of an implant or tissue expander is one who is neither thin nor obese and who has a firm rounded and small opposite breast (or previous breast augmentation), a horizontal mastectomy scar with normal surrounding skin, and a well-preserved pectoralis muscle. These prosthetic devices should not be placed under tight, thin, or irradiated skin, even when placed beneath pectoralis muscle.

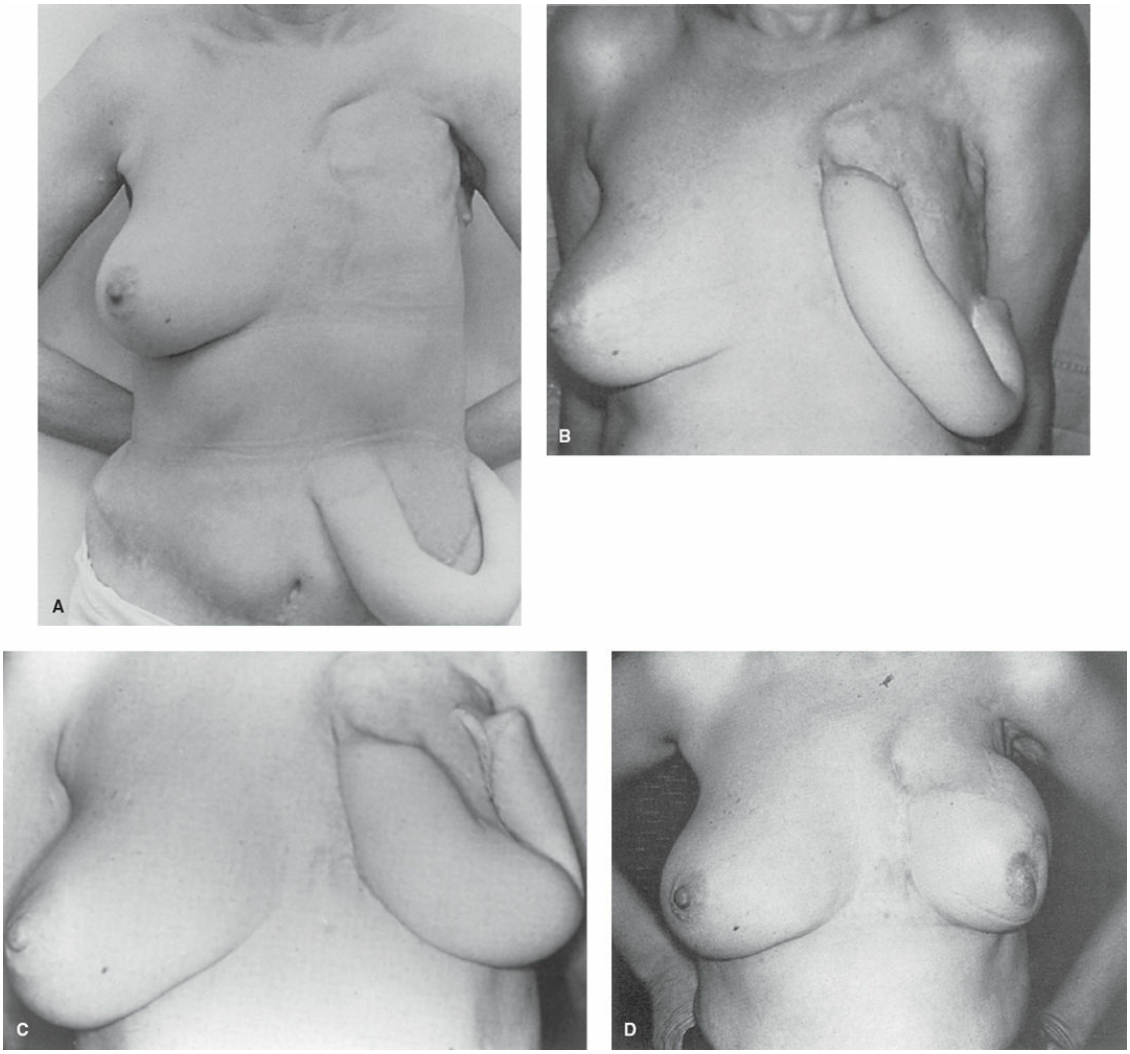

Figure 56.6. A–D. Correction of a radical mastectomy defect with a "waltzing" tubed flap created from abdominal panniculus. The flap, once created, is waltzed up the flank with periods of delay between each step until tissue is in proper position to craft a new breast mound.

Advantages of using implants and tissue expanders for breast reconstruction include simplicity, shortened operative times, and inpatient hospital stays. The disadvantages include the relatively high complication rates up to 30% to 40% that have been seen. Such complications include skin necrosis of the overlying flaps, exposure of the implant, disruption of the mastectomy scar, and, less commonly, infection. Regrettably, these complications in most cases lead to the removal of the implant. Even if successful expansion is achieved, the results can still be unsatisfactory. A fibrous capsule will form around all implants; and if a capsular contracture develops, it can result in both visible and painful deformities. Capsular contractures tend to cephalically displace the implant which produces a

rounded, nonptotic, and unnatural appearance. In addition, contractures lead to thinning of overlying muscle and skin. Despite these failings, tissue expansion continues to enjoy popularity among surgeons and patients throughout the United States. Selected surgeons and institutions have learned to achieve often excellent results using tissue expanders with acceptable complication rates.

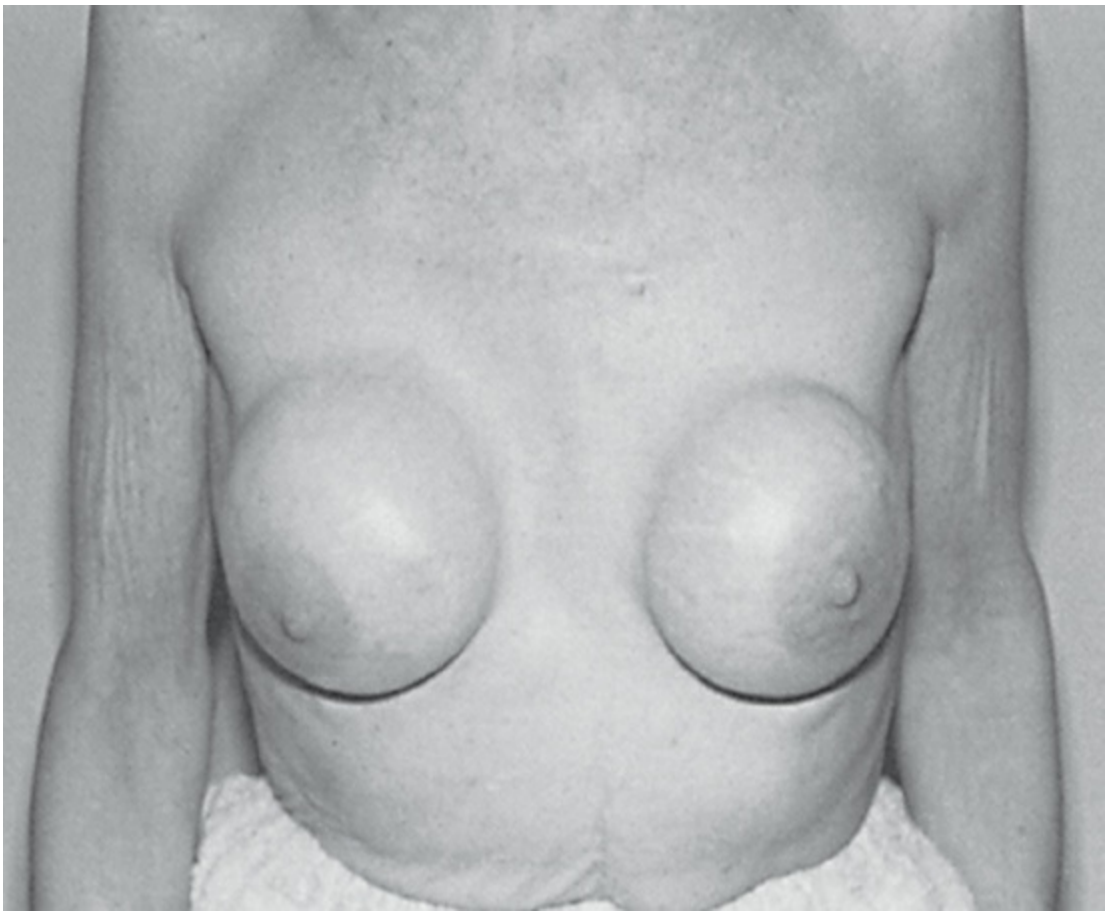

Figure 56.7. Silicone implant reconstruction of a subcutaneous mastectomy, a procedure popularized in the 1970s. The fibrous capsule around the silicone implant eventually constricts causing firmness, unnatural shape, and contour with elevation of the implant.

The most ideal circumstance in which to consider tissue expansion exists when a skin-sparing mastectomy has been performed and neither expansion nor recruitment of skin is required. After the desired dimensions are reached, the expander is removed and a permanent implant placed. Alternately, an autologous myocutaneous flap can be fashioned to reconstitute lost breast volume. As permanent implants are improved and skin-sparing mastectomies gain an even broader based acceptance, tissue

expansion has increased in its popularity. Presently this two-step type of breast reconstruction—expander and replacement with a silicone implant—is the most common method of breast reconstruction performed in approximately 70% of all reconstructions in the United States.

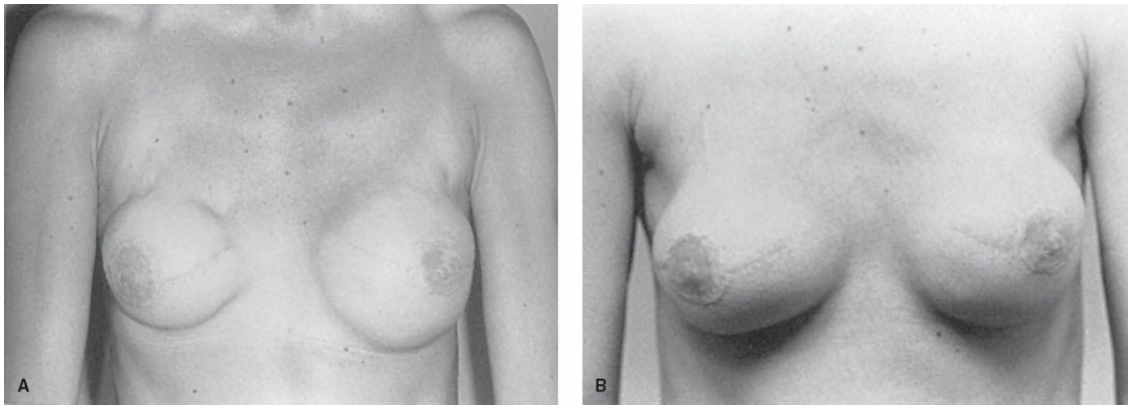

Figure 56.8. A, B. Encapsulated silicone implant reconstruction corrected by tissue expansion. The capsule is first excised then a tissue expander is used to create an oversized pocket for the implant.

MYOCUTANEOUS FLAPS

Subpectoral reconstructions were expected to solve the problem of periprosthetic scarring by placing implants beneath the pectoralis major muscle (as has been observed for cosmetic augmentation mammaplasties). This reduced the incidence of symptomatic capsular contracture from ~100% to <30% during the first 2 years. This marked reduction in contracture was due to a reduction in capsule formation around the implant. In retrospect, this phenomenon provided the first evidence of the protective effect of muscle in preventing periprosthetic scarring and thus capsular contracture (Fig. 56.9). Unfortunately, the skin defect of the modified radical mastectomy was too extensive to correct with an implant, even if capsule formed only beneath the pectoralis muscle.

The latissimus dorsi breast reconstruction was reintroduced in 1977 by Schneider, Hill, and Brown and was popularized by Bostwick, Vásconez, and Jurkiewicz, and others. The latissimus dorsi breast reconstruction offered several breakthroughs with immediate replacement of resected breast skin, replacement of the pectoralis muscle with the latissimus dorsi muscle, and complete muscle coverage of the implant needed for volume restoration. Replacement of the pectoralis major muscle, the anterior axillary fold, and the missing skin revolutionized the reconstruction of the

radical mastectomy defect (Fig. 56.10). The muscular coverage of the implant was anticipated to reduce the rate of capsular contracture to an acceptable level, which it did for 1 to 2 years. However, after 5 years, results were disappointing because of either firmness or contour deformities in at least one third of the patients treated. At the time, the latissimus dorsi myocutaneous flap gave the best aesthetic results with breast reconstruction following radical mastectomy. From the time of its description in 1977 to the height of its popularity in the early 1980s, the latissimus breast reconstruction was recognized as the standard by which all methods of breast reconstruction would be measured. By 1985, the standard latissimus reconstruction was nearly abandoned in favor of either tissue expanders or the transverse rectus abdominis myocutaneous (TRAM) flap reconstruction because of the problems of shape and softness caused by the implant over time. If new implant designs solve the problems with capsular contracture, it is clear that the latissimus myocutaneous flap reconstruction will regain its previous popularity. Presently, the latissimus muscle, with or without skin, is being used with increased frequency to provide cover to the lower half of an expander or an implant. Often it eliminates the previous use of an expander, allowing for a one-stage type of reconstruction.

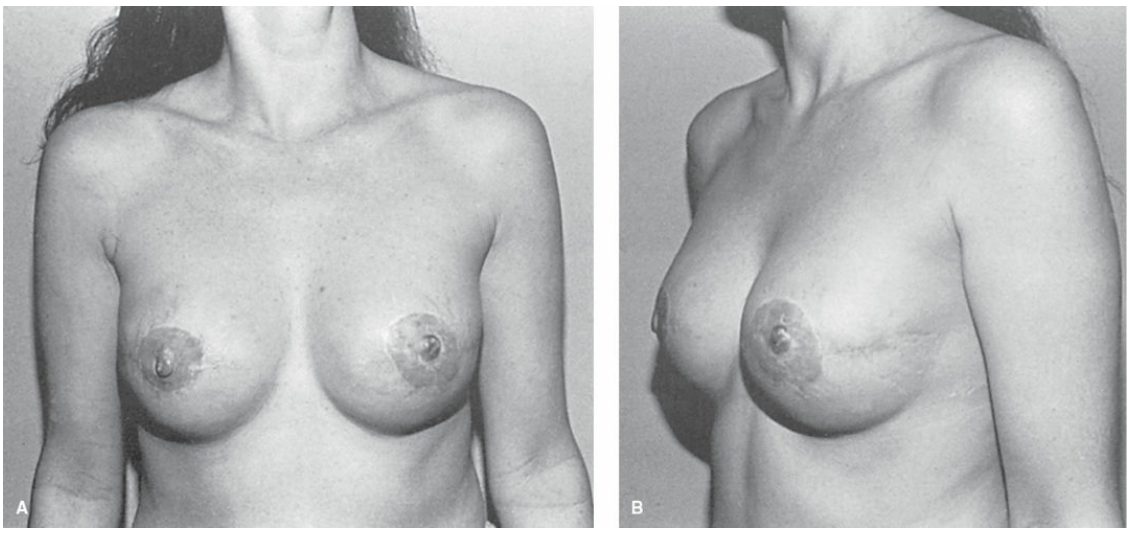

Figure 56.9. A, B. Placement of silicone implants beneath pectoralis major muscle at the time of a skin-sparing mastectomy. Reasonably good results can be seen with subpectoral implant reconstructions when the skin excision is kept minimal.

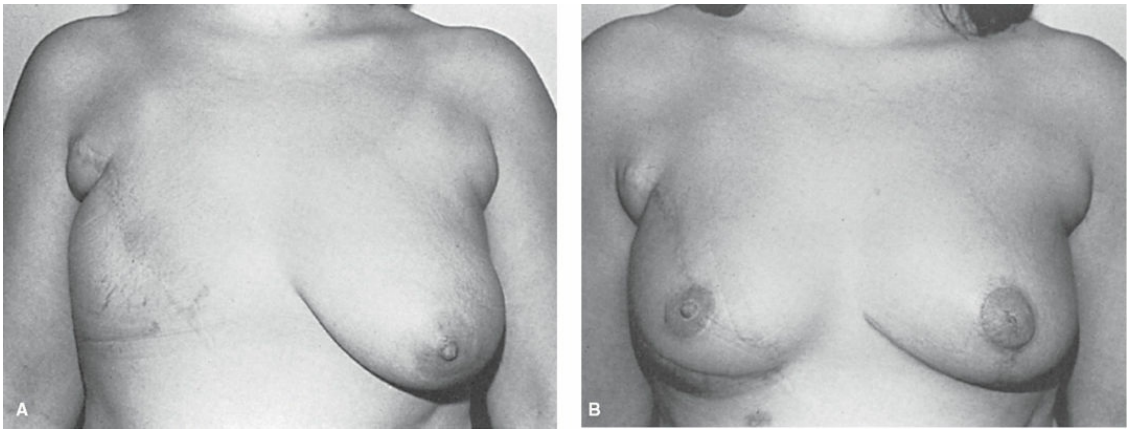

Figure 56.10. A, B. One of the first corrections of a radical mastectomy defect using the latissimus dorsi myocutaneous flap and reduction mammaplasty of the contralateral breast. The latissimus flap provides immediate replacement of lost breast skin and complete coverage of the implant. This allowed creation of a "tear-drop" shape and good symmetry for the first time in radical mastectomy reconstruction.

AUTOGENOUS MYOCUTANEOUS FLAPS

The era of autogenous myocutaneous flaps began in 1982 with the description by Hartrampf of the TRAM flap. This was the first breast reconstruction using only vascularized autologous tissue and it achieved the first uniformly good results with any type of mastectomy. Over a decade, this procedure reached a level of aesthetic excellence that was remarkable. In the late 1980s, the autologous extended latissimus flap was developed as an alternative procedure to the TRAM flap. In the 1990s, microvascular transfer of the TRAM flap including the sophisticated muscle-sparing or DIEP Flap (deep inferior epigastric) expanded indications for breast reconstruction to "high-risk" patients who were considered unacceptable candidates for pedicled TRAM flap reconstructions. High-risk patients included diabetics, smokers, obese, and those with prior radiotherapy. Looking to the future, as the socialization of medicine appears more clearly on the horizon, these complex and expensive procedures may be rationed or even lost for a time as was seen with Tansini's latissimus procedure.

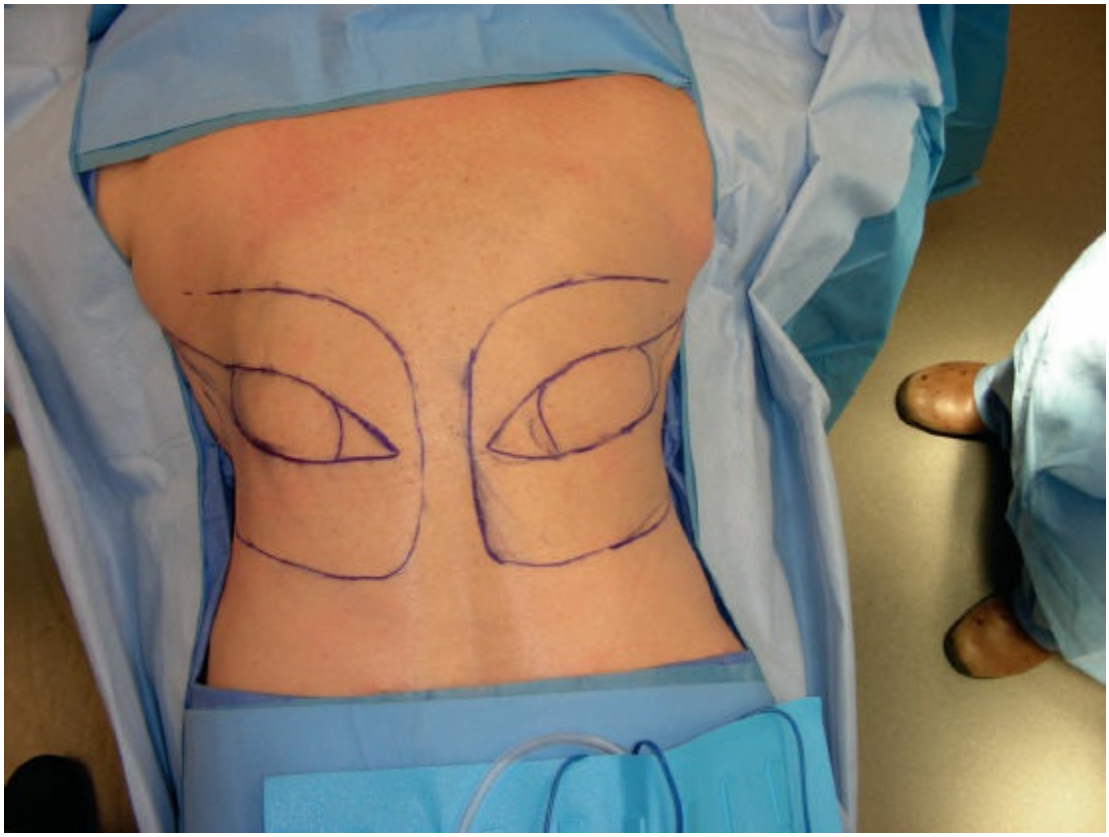

Figure 56.11. These markings, done preoperatively for planned immediate bilateral latissimus dorsi reconstruction with implants, show an outer line, which depicts the planned extent of muscle harvest. The inner ellipse represents the cutaneous portion of the flap harvest. The inner circles (within the ellipse) are the portion of the cutaneous paddle which will not be de-epithelialized in anticipation of this portion being used for reconstruction of the absent nipple–areolar complex and also nipple reconstruction. Note the transverse positioning of the cutaneous harvest which is designed to allow a closure which will fall beneath the back strap of the patient's brassiere.

The autologous extended latissimus breast reconstruction carries fat on the surface of the latissimus muscle to replace breast volume removed during mastectomy. In an average-sized patient, a 2-cm layer of fat on the surface of the latissimus dorsi muscle can provide 500 g of fat, and the skin paddle can carry an additional 300 to 500 g of fat. This total of 800 to 1,000 g is, in most cases, enough to replace the entire volume of breast tissue. If additional volume is needed, a small implant can also be used. The autologous latissimus dorsi flap can be raised at the time of the mastectomy, and an immediate reconstruction can be performed with only a modest increase in operative time (Figs. 56.10 and 56.11). With skin-

sparing mastectomy most reconstructions can be completed in a single stage. Delayed reconstruction, in contrast, requires a second operation producing less satisfactory outcomes than immediate reconstructions. The autologous latissimus dorsi reconstruction is particularly well suited for the modified mastectomy defect (Fig. 56.12). The autologous latissimus dorsi flap is also the procedure of choice for partial mastectomy defects over the more time-consuming and more morbid TRAM flap. If <50% of the breast volume is removed, the autologous latissimus flap can give excellent correction of lumpectomy-irradiation deformities and also in select patients that require mastectomy. Because of the excellent blood supply, the autologous latissimus dorsi flap is particularly useful in high-risk patients who have a history of smoking, diabetes, or marked obesity. Like the posterior-lateral thoracotomy scar, the donor site scar is usually very good. The functional loss of the latissimus muscle is unnoticed except in the most vigorous athletes. It is certainly possible to play golf and tennis and even climb ropes with the absence of latissimus function. It does leave a concave defect in the back. If done unilaterally, the opposite side may need corrective liposuction for symmetry.

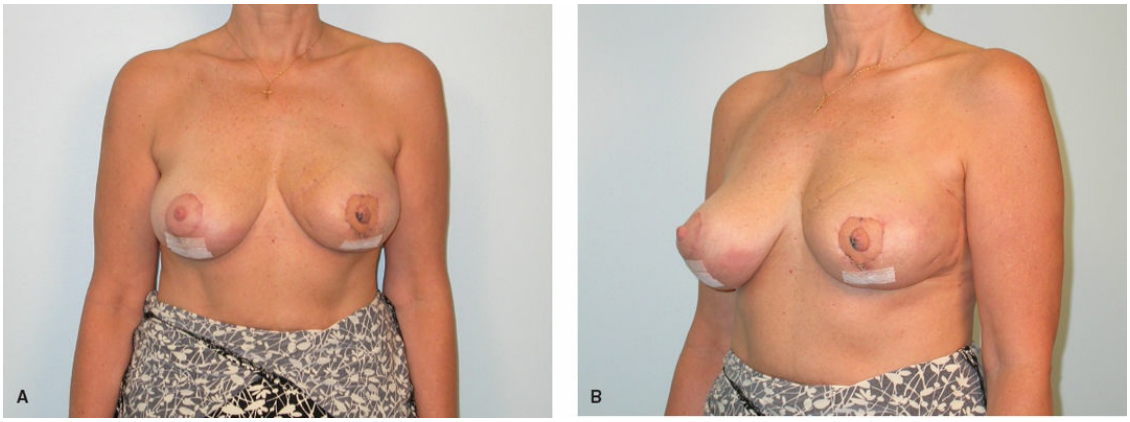

Figure 56.12. Photos (**A**) and (**B**) show a postoperative day #5 patient who underwent immediate reconstruction of the left breast after modified radical mastectomy (MRM) using a latissimus dorsi and implant reconstruction with nipple reconstruction done at the same time. The mastectomy was done through a mastopexy incision (drawn by the plastic surgeon) which gave the oncologic surgeon unparalleled access for MRM. Mirroring incisions were done on the right breast through which a concomitant right mastopexy for symmetry was also done in this patient whose desire was to avoid multiple operations. All that remains to be done on this patient is nipple–areolar complex tattooing on the left, which can be done in an office setting under local

anesthesia. The results seen here are from one operative event seen at POD#5.

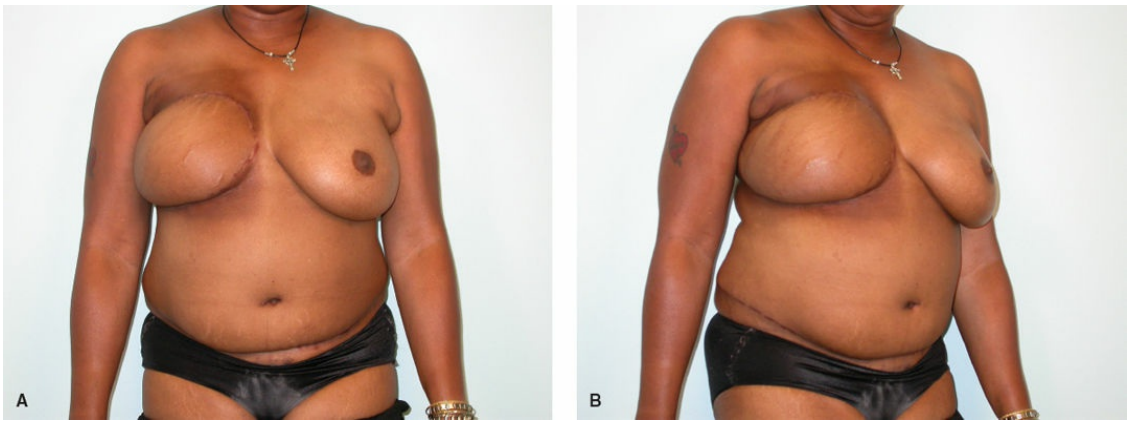

Figure 56.13. This photograph shows a patient who received radiation therapy to the right chest after mastectomy here at postoperative day 21 from a delayed ipsi-pedicled conventional TRAM. This photograph shows that large volume, single-pedicled conventional TRAM flaps are a reasonable option. This patient still needs nipple reconstruction on the right and a mastopexy/reduction on the left for symmetry.

The TRAM flap remains the gold standard of breast reconstruction. Since its description by Hartrampf in 1982, this procedure has gained worldwide acceptance as the procedure of choice for difficult reconstructions, particularly in mastectomies requiring extensive skin removal. In experienced hands, the TRAM flap is extremely reliable and gives predictably good results (Fig. 56.13). Although a long operative procedure, patients recover relatively quickly and can usually be discharged by the fifth postoperative day. Management of the abdominal closure with the TRAM flap is critically important since fascial bulges occur in 4% of the patients. The rectus muscle can usually be raised with only a small vertical strip of anterior rectus abdominis fascia (e.g., 2 to 3 cm in width) leaving a defect which can be easily closed primarily. Bilateral flaps are more difficult to close and synthetic mesh is frequently used as a tensioned onlay to carry the stress that would otherwise exist on the fascial closure. If patients are selected properly, true hernia formation is rare, with an incidence of 0.3% in 400 consecutive patients treated by Hartrampf. Overall, in most series, the incidence of hernia is 4%. The functional loss of a single rectus abdominis muscle is seldom noticed, and 95% of Hartrampf's patients believe their work performance and sporting

activities remained unchanged after surgery. Overall, the TRAM flap reconstruction is exceptionally well accepted by patients. When Hartrampf surveyed his first 300 patients, he asked two questions: “Was the operation worth the time and effort you have invested in it?” and “Would you recommend this method of breast reconstruction to other patients?” Both questions were answered affirmatively by 98% of the patients.

FREE TISSUE TRANSFERS

The modern era of plastic surgery has allowed free tissue transfers for breast reconstruction to gain acceptance in both immediate and delayed procedures treating extensive defects in high-risk patients (Fig. 56.14A–C). If the free TRAM flap is executed with a two-team approach, the operative time is similar to that required for pedicle TRAM flaps, and the free TRAM reconstruction has been shown to have a decreased complication rate and requires fewer revisions. Other free-flap donor sites are suitable and have begun to gain wide popularity over the past several years. These alternative flaps include the Superior Gluteal Artery Perforator (SGAP) flap, the Inferior Gluteal Artery Perforator (IGAP) flap, the Deep Inferior Epigastric Artery Perforator (DIEP) flap, the Superficial Inferior Epigastric Artery (SIEA) flap, and the transverse gracilis flap among others. Presently, the recipient artery for most microvascular breast reconstructions is the internal mammary artery. It provides an easier access, easier molding of the breast, and avoids the axilla, which invariably is subject to axillary sampling. The expense of these microvascular procedures may limit their practicality in a future dominated by cost benefit factors.

A clear description of the patient’s desires regarding breast reconstruction outlines the goals for reconstruction. As breast reconstruction techniques become more sophisticated and refined, so have the expectations of the well-informed patient. They desire a natural and symmetric appearance immediately after mastectomy. This may require ipsilateral or contralateral mastopexy, reduction, or even augmentation during surgery to fulfill these expectations.

Other factors that come into consideration when deciding on the type of breast reconstruction include the type of mastectomy (i.e., skin-sparing technique vs. the standard modified radical mastectomy), body habitus (thin women with scant abdominal donor tissue may not be suitable for TRAM reconstruction; obese women are more difficult to obtain a

satisfactory reconstruction with implants), contralateral breast size and shape, previous abdominal surgery, history of smoking, and of course the overall health of the patient.



Figure 56.14. **A, B.** Preoperative and postoperative views following a bilateral free transverse rectus abdominis myocutaneous flap breast reconstruction. **C.** The nipple reconstructions and tattooing are complete.

CONTRALATERAL PROPHYLACTIC MASTECTOMY

A number of patients elect to have a contralateral prophylactic mastectomy (CPM) at the same time of the mastectomy for cancer, even though it may not be warranted on purely oncologic grounds.

If a patient elects that option, immediate bilateral reconstruction is often performed. Possible reasons for patients to choose bilateral mastectomies include, cancerophobia; the fear of undergoing later a second mastectomy and even worse, chemotherapy for a second time; fear of frequent, involved medical checkups, including painful mammograms; and in a small part, the fact that reconstruction of the breast is a much improved procedure resulting often, in as good or better breasts than before (although without sensibility).

IMPLANTS AND EXPANDERS

Surgical technique for placement of im-plants and tissue expanders is relatively straightforward. The primary concern should be adequate muscular coverage as a tissue expander or implant placed subcutaneously will be fraught with complications. The pectoralis muscle is easily identifiable and provides muscular coverage for only the superomedial aspect of the implant. Dissection must continue inferolaterally beneath the serratus anterior and external oblique musculature. In addition, some of the fascia of the rectus muscle is elevated for coverage inferiorly. Submuscular dissection inferiorly is usually impossible to complete without separating some muscle fibers and fascia. Complete muscle coverage is often difficult or impossible.

Choosing the volume of the implant can be difficult. In such cases, the use of a postoperatively adjustable implant can simplify this task. A suction drain is placed, if felt needed, and the wound is closed in three layers. Perioperative antibiotics are recommended when placing prosthetic devices. Once the desired target volume is reached in the postoperatively adjustable implant, the adjustable prosthesis is replaced by a permanent implant of equal size.

Postoperatively, the surgeon’s main concern is for migration of the implant. During the first week after surgery, the spontaneous upward displacement of the implant may be partially controlled by light compressive dressings applied to the superior pole of the breast. This usually consists of an elastic bandage wrapped under the axillae to apply downward pressure on the implant. After 3 or 4 weeks, these maneuvers are no longer useful since at this time a capsule has formed around the implant and is not easily influenced by externally applied pressure. Because of that, most experienced surgeons place the implant 2 to 3 cm below the desired level, thus allowing for the assured capsular contracture, which will raise the implant.

Capsular contracture is a phenomenon over which surgeons have little control. It provides the advantage of shaping the skin to the implant but also the potential disadvantage of creating distortion. Because of this, it is impossible to predict the precise shape and volume of a breast reconstructed by means of an implant.

Patients who will not accept results that can change over time or who refuse major or multiple operations have been unsatisfied with this method. It should be stressed that implant reconstructions typically require

greater correction of the contralateral breast than do other methods of reconstruction, and this method is notably deficient in creating large and ptotic breasts. Because of this observation, it is often advisable to place a smaller implant in the normal breast to provide the desired roundness and fullness in the superior aspect of the breast, which matches the roundness of the reconstructed breast.

IMPLANTS AND EXPANDERS AND ACELLULAR DERMAL MATRIX

The pectoralis muscle provides coverage of only the upper half of an implant or expander. In an effort to provide coverage to the lower half of the implant, there are a number of maneuvers which can accomplish such coverage. They include a de-epithelializing thoraco-epigastric flap; using autologous dermis (obtained from the suprapubic area), a superficial epigastric flap; or with the use of allogenic dermis (ADM).

ADM is acellular cadaver dermis. It is made acellular and properly treated to decrease its antigenicity. It may come dehydrated or ready for use. An appropriate amount and size is patterned and sutured to the lower edge of the pectoralis major and to the chest wall inferiorly. The implant or expander is placed under the muscle and ADM. Drains are placed, because the ADM is associated with the production of considerable amount of fluid, seromas lasting several weeks in some cases. The ADM remains viable, and eventually attaches to the undersurface of the chest flap and is revascularized.

The technique is quite popular because of its simplicity and ease of availability of ADM. Seromas and infection are problems, as is the development of “redness syndrome” where the overlying skin appears quite red, simulating a superficial skin infection. Its cause is unclear, and it subsides spontaneously after a number of days. Nonetheless, surgeons may well treat with topical antibacterials such as silver sulfadiazine or systemic antibiotics for fear of missing an infectious process.

Recent modifications entail the introduction of a covered implant with ADM and its placement over the pectoralis major muscle in a one stage type of reconstruction. The one stage procedure with a number of modifications is gaining in popularity.

Prospective and comparative studies should be forthcoming to grade the effectiveness of the one- or two-stage procedure.

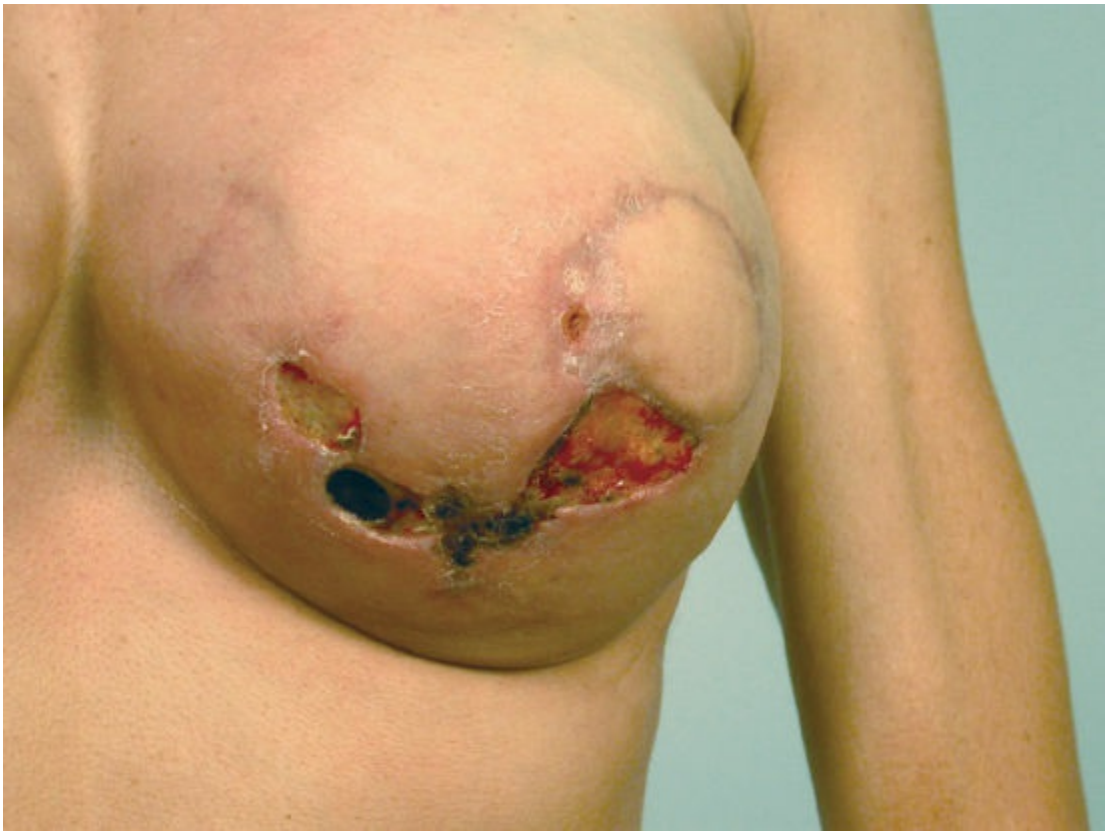

Figure 56.15. Wound healing problems in a patient who has undergone skin-sparing mastectomy, latissimus dorsi, and implant reconstruction with postoperative radiotherapy.

LATISSIMUS DORSI MYOCUTANEOUS FLAP

The patient is marked before mastectomy in the standing position. The skin island, which should be no more than 5 to 6 cm wide, is outlined transversely and in such a fashion so that the donor closure scar will be covered by the brassiere strap. If an immediate reconstruction is to be performed, the patient is placed on a beanbag and the oncologic surgeon performs the mastectomy. After the mastectomy, the patient is repositioned in the lateral decubitus position and maintained there with the use of the beanbag. If properly cleansed and the patient placed on a sterile drape over the bean bag, it is often unnecessary to cleanse and redrape. Alternately, the latissimus dorsi can be harvested first with the patient prone or in lateral decubitus position. The harvest site can be closed and the flap pocketed in the axilla. This minimizes the amount of patient repositioning intraoperatively.

After dividing the paraspinous origins of the muscle while preserving the thoracodorsal neurovascular bundle, the flap, which includes an ellipse of overlying skin, is carefully transposed on its humeral insertion toward

the anterior chest wall beneath a bridge of thoracic skin below the axilla (often, an axillary incision is needed, if not done for the axillary sampling). Once anteriorly, the latissimus dorsi flap can be sutured inferiorly to the anterior chest wall, and superiorly to the undersurface or the anterior aspect of the pectoralis major muscle to create a submuscular pocket within which an implant can be placed. It is imperative that the oncologic surgeon does not damage the thoracodorsal artery or vein during axillary dissection since this is the vascular axis to the latissimus dorsi myocutaneous flap when used as a pedicled flap for breast reconstruction. We suggest the preservation of the thoracodorsal nerve to maintain the volume of the muscle.

Postmastectomy patients who have received preoperative or postoperative radiation to the chest wall and axilla present an increased risk for skin slough and wound-healing problems (Fig. 56.15). The skin and scar of the anterior chest wall should be examined carefully for evidence of telangiectasia, dermal and subcutaneous atrophy, edema, and, in some cases, subcutaneous fibrosis.

Reconstruction is not contraindicated in irradiated patients if the latissimus dorsi flap used is healthy. Using the flap may provide the advantage of bringing a robust blood supply into a deficient region. However, irradiated skin is best excised if damage is considerable. Mastectomy skin flaps in these cases should be minimally elevated and in the submuscular plane. If an implant is used, it must be covered in its entirety with muscle. This method provides a margin of safety where if irradiated skin breaks down, the implant will be protected by the underlying muscle cover (Fig. 56.16A–D). There is a greater chance for severe capsular contracture in postradiated patients, but the latissimus dorsi myocutaneous flap is itself refractory to radiation-induced loss due to its rich blood supply.

TRANSVERSE RECTUS ABDOMINIS MUSCULOCUTANEOUS FLAP

The TRAM flap is the most common method of autologous breast reconstruction. It is an elegant technique that provides the greatest opportunity for symmetry with the contralateral breast while avoiding the use of implants, and when performed with skin-sparing mastectomy, it generally yields the most aesthetically pleasing result. The TRAM flap differs from every other myocutaneous flap in that its vascular supply is

more tenuous requiring much more delicate handling. Complications such as necrosis of the flap and development of a lower abdominal hernia can be troubling for both patient and surgeon. Nevertheless, the inherent characteristics of the flap are such that it provides versatility for the surgeon in restoring myriad defects as well as yielding lasting and gratifying results for patients.

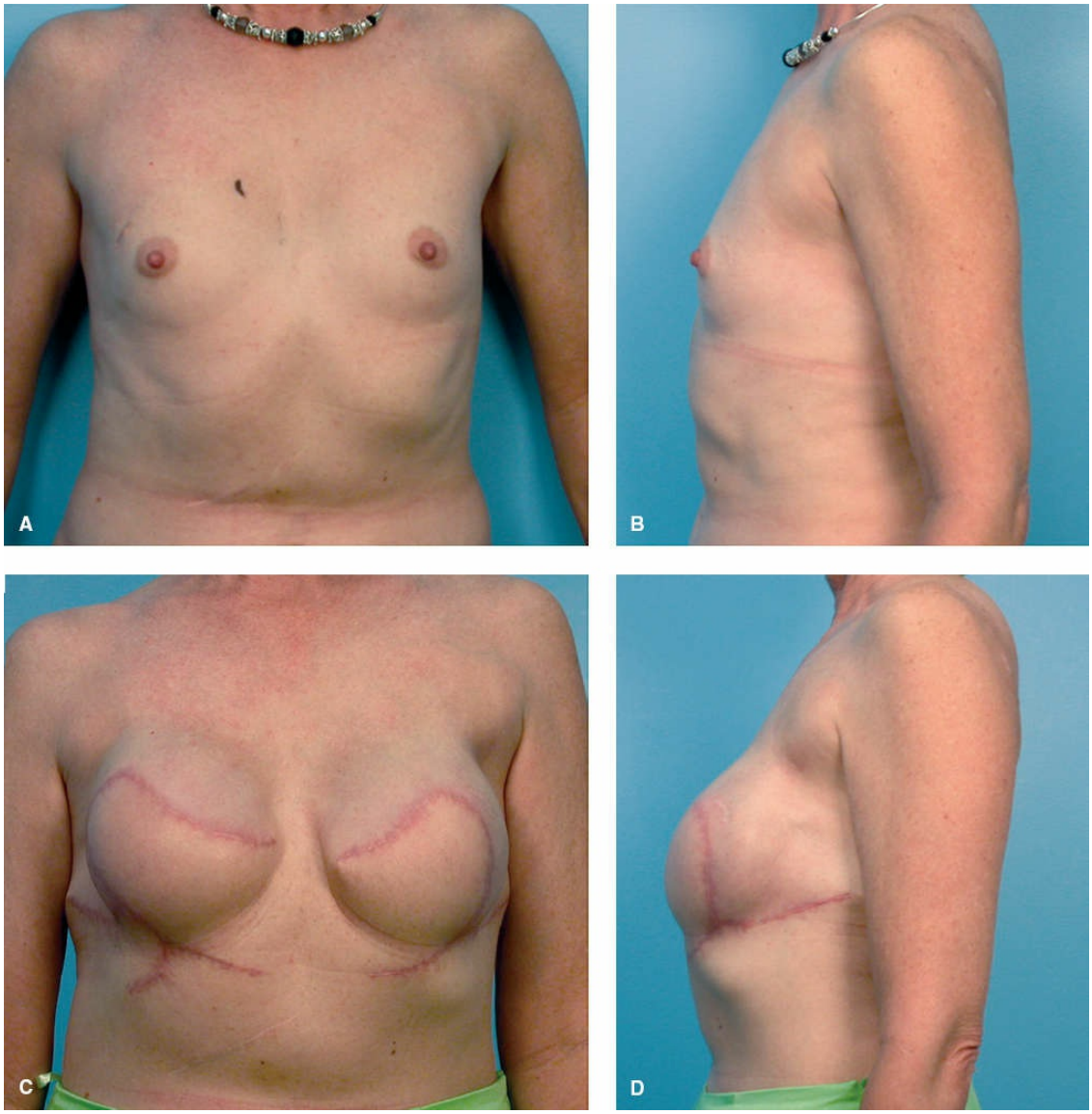

Figure 56.16. **A.** Frontal view of a patient where tissue expansion was attempted within a radiated field producing implant exposure. **B.** Lateral view of same patient, again note the implant exposure. **C.** Frontal view of same patient after latissimus dorsi and implant reconstruction which required partial skin grafting. **D.** Lateral view of the same patient after reconstruction; note the nipple has been reconstructed.

There are many variations of the TRAM flap, one of the reasons why it is considered to be so versatile, and so it is a procedure that can often be tailored to meet the needs of both patient and surgeon. The flaps are categorized by their blood supply. Pedicled TRAM flaps, also known as conventional (vs. free) TRAM flaps, can be based on either one or two pedicles, depending on the size of the flap that is required for reconstruction. These flaps are supplied by musculocutaneous perforating

branches from the deep superior epigastric artery and vein. The pedicled TRAM flaps can also be further categorized as either upper or lower, with the latter being far more common. In addition, the TRAM flap operation is an excellent alternative for reconstruction of the bilateral mastectomy defect. The flap is essentially divided into two, with each half delegated for use unilaterally.

The free TRAM flap utilizes the deep inferior epigastric artery and vein which are used as the axial pedicle for microsurgical transfer and it offers several distinct advantages. First, since the inferior epigastric artery and vein are of large caliber with only a short distance and with fewer choke territories to the tissues of the flap, the blood supply to this flap is considerably more robust than that to its pedicle counterpart. Compared with the pedicle TRAM flap, the free tissue transfer is associated with a lower incidence of fat necrosis, directly attributable to blood supply. Second, only a very small rectangle of rectus muscle which contains the musculocutaneous perforators to the flap needs to be harvested in flap elevation. This significantly decreases donor site morbidity. Further, the free flap does not require tunneling to reach the mastectomy defect. The absence of tunneling eliminates the bleeding than can occur during this portion of the conventional TRAM procedure. Conventional TRAM flaps can also be associated with an epigastric “bulge” as the muscle is turned from the abdomen over the lower costal margins toward the defect. This bulge may have the unwanted effect of obliterating the medial aspect of the inframammary fold.

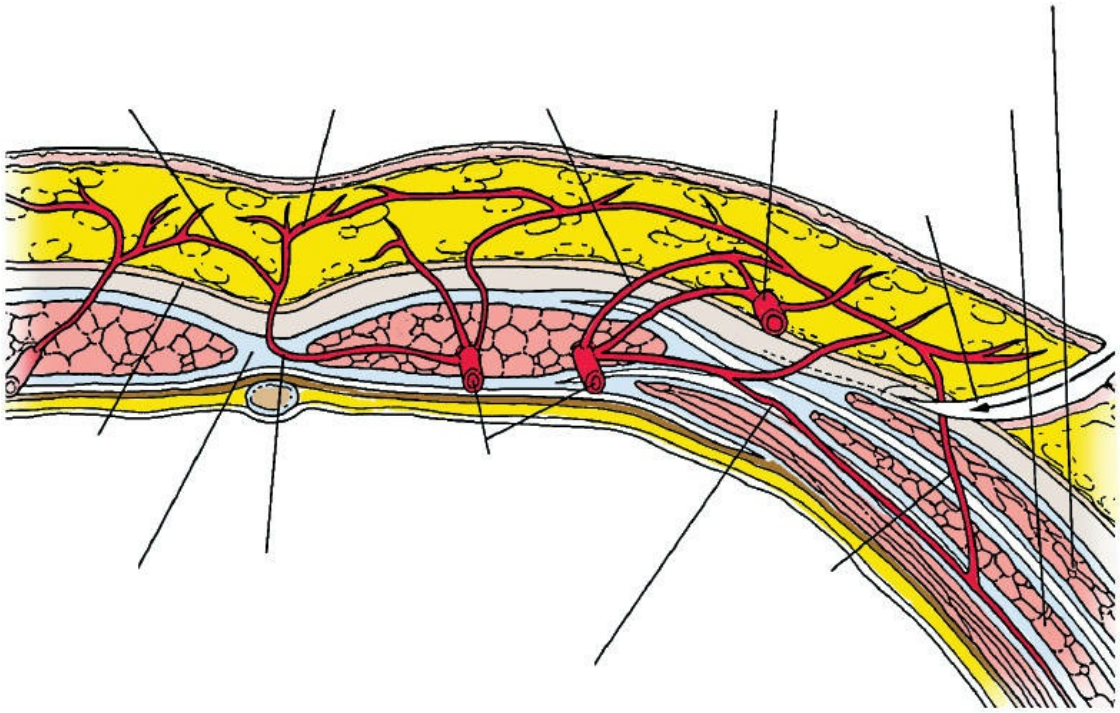

Figure 56.17. Cross-sectional pictorial depicting the musculocutaneous perforators supplying the transverse rectus abdominis myocutaneous flap.

However, the free TRAM flap has its disadvantages. Its proper execution is a greater technical challenge requiring longer operative times. In addition, postoperative monitoring of the flap is very important and must be done by skilled nurses who are trained in the postoperative care of free tissue transfers.

CONVENTIONAL TRAM FLAP

Anatomic Considerations

The TRAM flap is supplied by musculocutaneous perforating branches from the deep epigastric arcade that emerges dominantly in the periumbilical area (Fig. 56.17). There are two rows (medial and lateral) of perforating branches that supply the skin and subcutaneous tissues above. Venous return is essential. The course of the venous blood is through the superficial epigastric veins located above Scarpa fascia. These veins then perforate the fascia and eventually join the venae comitantes of the deep inferior epigastric artery.

Surgical Technique

The flap is outlined, with the upper incision placed at the level of the umbilicus, where it is critical to include the periumbilical perforators. The lower incision is placed suprapubically, as would be done for an aesthetic abdominoplasty, curving gently upward and laterally extending toward the Anterior Superior Iliac Spine (ASIS). The upper incision of the flap is completed and carried down to the anterior rectus sheath where care is used to avoid injury to the sheath. An upper abdominal skin and subcutaneous tissue flap is raised in a plane just superficial to the rectus abdominis sheath to the level of the lower costal margins just lateral to the linea semilunaris and above the xiphoid process in the midline. This fully exposes the anterior sheath of both rectus abdominis muscles above the outlined TRAM flap (Fig. 56.18A,B). A helpful safeguard at this point is to note the two rows of musculocutaneous perforators that are encountered while raising the upper abdominal flap. These provide a guide for the limit of elevation for the TRAM flap both medially and laterally.

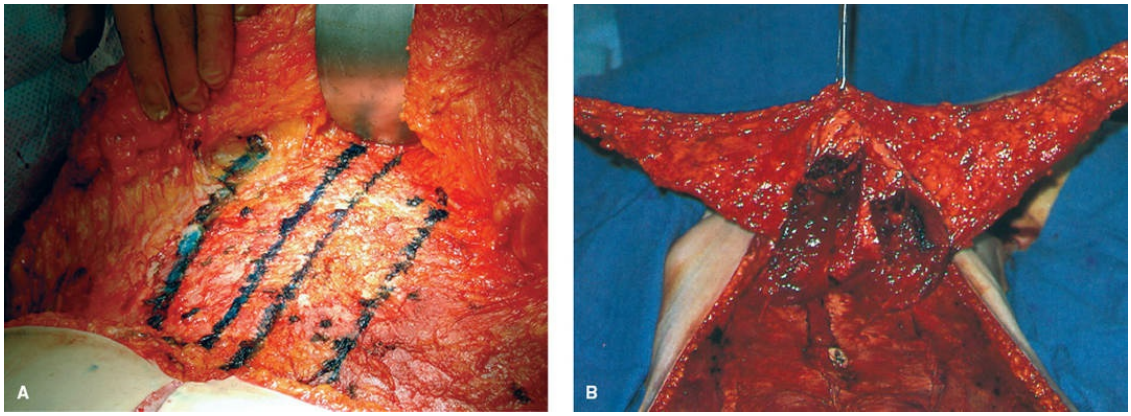

Figure 56.18. A. Photograph of development and elevation of bilateral transverse rectus abdominis myocutaneous flaps, showing marked in methylene blue the planned location of anterior rectus sheath fascial incisions and dots show locations of individual medial and lateral perforators which have been divided. **B.** Intraoperative photo of bilateral flap elevation.

The segment of anterior rectus sheath to be left intact with the muscle is marked. This segment is usually 3 to 4 cm in width, extending from above the costal margin to the upper margin of the TRAM flap. This fascial strip should overlie the medial and lateral rows of perforators. The lower incision on the TRAM flap is then made again down to the anterior rectus sheath. Next the TRAM flap is elevated, lateral to medial, with great care used in keeping the muscular perforators to the flap intact. Next, the

inferior epigastric artery and vein are identified and ligated leaving the muscle and skin paddle totally reliant on perfusion from the deep superior epigastric vascular axis. The rectus muscle is then divided inferiorly and the skin flap with the underlying rectus abdominis muscle is raised superiorly to the level of the costal margin, as the segmental intercostal vessels are divided.

After the TRAM flap is completely elevated, a tunnel must then be made to connect the mastectomy site to the superior-most aspect of the upper abdominal dissection plane which was created by elevation of the upper abdominal flap. The tunnel should be in the midline of the abdomen and then reach the mastectomy site. This allows the rectus muscle to enter the mastectomy defect medially, rather than entering the defect inferiorly, which can ablate the inframammary fold.

Once the TRAM flap is properly positioned, the surgeon shapes and molds the flap to resemble that of the contralateral breast. It is at this point that the poorly perfused and excess portions of the flap are discarded. The goal is to match the opposite breast by using only those portions of the flap with robust blood flow while achieving proper height, projection, and ptosis. The remaining flap skin easily covered by the mastectomy flaps is then de-epithelialized and buried. The flap is supported in position with sutures fixed superiorly and medially. The skin edges are approximated with absorbable deep dermal and running subcuticular sutures. If one is reconstructing immediately following a skin-sparing mastectomy, it is best to mold the pocket of skin and fill the flap to the pocket. To obtain a satisfactory molding of the pocket, one should mark the takeoff to the breast superiorly (from the contralateral breast) which will mark the superior aspect of the breast; close the axillary dissection to the anterior axillary line and place the inferior portion of the flap at the level of the inframammary fold.

FREE TRAM

Most free TRAM flap reconstructions are performed immediately after mastectomy since the recipient vessels (either thoracodorsal axis or the internal mammary axis or it perforators) are exposed by the oncologic surgeon by mastectomy and axillary node dissection. The free TRAM flap is designed on the lower abdominal wall in the same manner as is the conventional flap. The major difference being that the vascular axis for the free TRAM is the inferior epigastric artery and vein rather than the

superior epigastric axis. Since perfusion from the superior epigastric vessels is not required in the free transfer, the entire rectus muscle does not need to be elevated. Instead, only a small cuff of muscle containing the perforators must be included with the flap and its inferior epigastric vascular axis (Fig. 56.19). This confined donor site dissection decreases the donor site morbidity considerably. Once elevated and separated, the free TRAM is transferred to the site of mastectomy on the anterior chest wall where a microvascular anastomosis is performed on the internal mammary artery and vein; rarely to the thoracodorsal vessels which provide the sole blood supply to the flap (Fig. 56.20). Shaping the breast mound and closure are done as with conventional TRAM flaps (Fig. 56.21A,B).

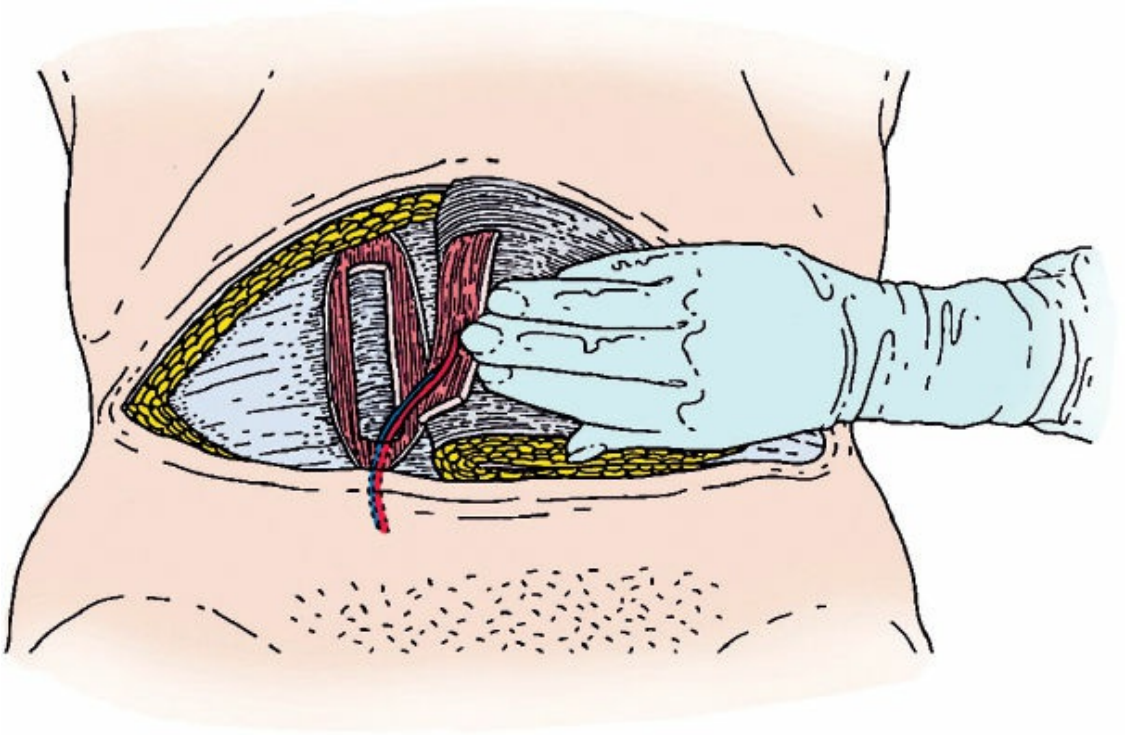

Figure 56.19. Free transverse rectus abdominis myocutaneous flap elevation using the inferior epigastric vascular axis. A small rectangular central portion of the muscle is harvested containing the musculocutaneous perforators. This technique minimizes donor site morbidity.

A sophisticated change in the microvascular type of breast reconstruction is the use of the deep inferior epigastric perforator (DIEP) flap. The dissection of the appropriate perforator and vena comitantes is safely done in experienced hands. The technique usually requires a

preoperative CT angiogram to evaluate the presence of an appropriate perforator.

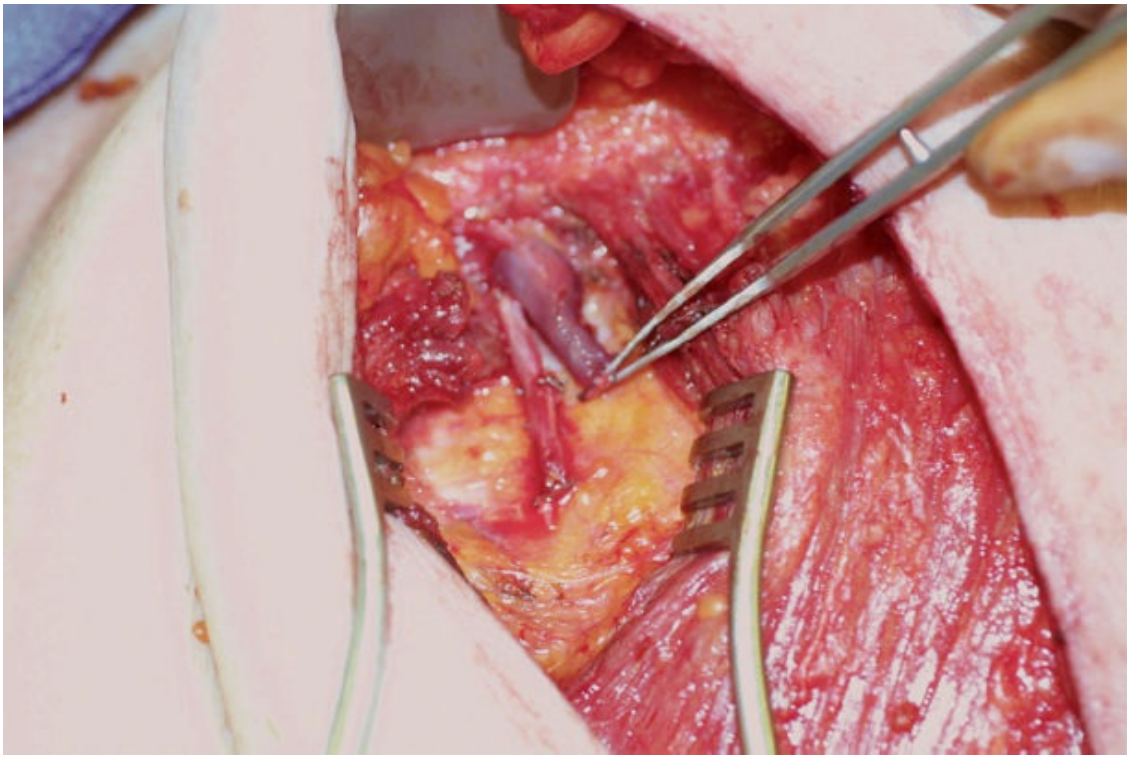

Figure 56.20. Photograph showing exposure and preparation of para-sternal perforators arising from the internal mammary vessels. These will be the recipient axis for free TRAM reconstruction.

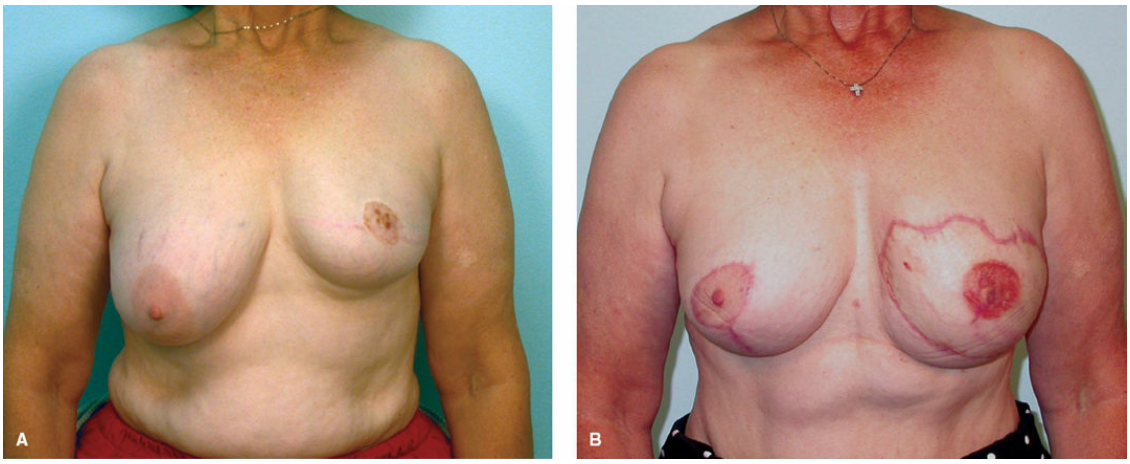

Figure 56.21. **A.** Preoperative view showing previously operated left breast with a ptotic, pendulous right breast. This patient is scheduled for left mastectomy. **B.** Postoperative view showing left TRAM reconstruction with nipple reconstruction complete and tattooing done. Also shown is the right breast reduced in order to achieve symmetry.

RECONSTRUCTION WITH FAT GRAFTING

Several centers are presently offering patients breast reconstruction with the injection of autologous fat.

Fat grating is practiced in almost every reconstructive case to fill a subclavicular hollow or rippling of the skin over an implant. It is particularly useful for the camouflage and filling of defects following lumpectomies. There is also clinical evidence that fat injection ameliorates the leatherly, stiff, inelastic post irradiated skin.

Recently, total breast reconstruction is being performed with autologous fat.

This method requires several injections done at intervals of approximately every 3 months each. Three or four injections are usually needed. Very satisfactory results are shown in selected and well-motivated patients.

Undesirable events include fat necrosis, infection, and inability to match the opposite large breast.

There is not a single, well-accepted method for obtaining the fat or for its injection.

Some plastic surgeons make use of a preinjection suctioning devise (“Brava”) which apparently helps in the creation of a subcutaneous space to allow fat injection as well as encouraging neovascularization of the injected fat.

ONCOPLASTIC RECONSTRUCTIVE SURGERY

For patients who elect lumpectomy and irradiation as the primary treatment of their breast cancer, there is the option of ameliorating the defect or hollowness of the breast by moving the remaining breast tissue around to recreate a rounded projected breast. This has been termed oncoplastic surgery.

It requires considerable knowledge of the blood supply to the breast as well as a thorough knowledge of reduction mammoplasty techniques.

Adequate margins are an imperative concern, since one does not want to move tissue around, until the margins have been cleared. Since most of these patients will also undergo radiotherapy, if the oncoplastic procedure is performed before the radiotherapy, the end result post radiation will be a smaller, thickened breast. If the oncoplastic procedure is done after radiotherapy, there is the increase risk on wound healing by operating on a postradiation tissue.

Of necessity, oncoplasty requires operating on the opposite normal breast in the form of a reduction mammoplasty or mastopexy to obtain symmetry.

OPPOSITE BREAST CONSIDERATIONS

Reduction Mammaplasty

Reduction mammaplasty involves the removal of breast tissue as well as excess skin. It also provides varying degrees of lift. Mastopexy, in contrast, corrects breast ptosis by elevating the breast mound and removing excess skin without removal of substantial breast volume. Each of these procedures can be performed without having an adverse effect on the clinical breast exam or impeding mammographic detection of breast masses. Reduction mammaplasty may be the only procedure indicated in mastectomy patients who do not desire reconstruction. A unilaterally large breast often causes more neck and back pain than bilateral enlargement because of a marked weight imbalance. In patients who undergo breast reconstruction, reduction mammaplasty and mastopexy procedures provide an invaluable tool in achieving symmetry. Both techniques are key in bringing about the restoration of form—the foremost reason for which reconstruction is sought. In the planning of a reduction mammoplasty for symmetry with the reconstructed breast, it is important to recognize the changes which occur with a chosen reduction mammoplasty procedure. For example, the inferior pedicle technique maintains in place the inframammary fold. On the other hand, the superomedial type of reduction mammoplasty raises the inframammary fold and narrows the width of the breast. The inframammary fold as well as the width of the breast should be at approximately the same level to obtain symmetry.

Augmentation Mammaplasty

Augmentation of the normal breast can be considered, but saline and silicone implants are densely radio-opaque and thus can obscure mammographic detection of breast tumors. Some newer implants have similar radiolucency to breast tissue and so even very small calcifications can be visualized through the implant. Subpectoral augmentation is generally preferred over prepectoral augmentation, which has the disadvantages of a higher rate of capsular contracture and greater interference with mammographic detection.

In breast reconstructions where an implant has been placed, the upper portion of the reconstructed breast appears rounded due to the capsule around the implant. In such cases, it is important to consider placing a smaller implant in the reduced or mastopexed normal breast for upper pole symmetry.

Prophylactic Mastectomy

Prophylactic mastectomy is rarely performed in the treatment of breast cancer, except when bilateral prophylactic mastectomies are indicated for those who are at elevated risk (genetic mutations or known familial disease). When a CPM mastectomy is performed, either contemporaneously or at a later date, it can significantly elevate the complexity of reconstruction. For example, thin patients may have adequate tissue for a single breast reconstruction but inadequate soft tissue for a bilateral procedure. To achieve adequate volume, implants must then be used and secondary flaps should be considered. Still, it is important for the reconstructive surgeon to consider that a contralateral mastectomy may be required in the future. If the risk is high that future contralateral mastectomy will be required, then the TRAM flap should be reserved as it is only available once.

NIPPLE RECONSTRUCTION

Nipple reconstruction represents a critically important part of breast reconstruction. Without the nipple, the breast lacks a key defining feature. Its absence alone makes the reconstructed breast look asymmetric—a fact that is unlikely to go unnoticed by reconstructed patients. Successful nipple/areola reconstruction restores the shape and projection of the nipple as well as the shape of the areola and the color to each. The shape of the areola is the foundation for the nipple and is created by a constricted circular closure of the autologous flap. The nipple is formed by local bilobed or trilobed flaps. The arms of these flaps are wrapped around themselves to form a standing cone. The tint of the nipple and areola are provided by imbedding pigments that are color matched to the contralateral side using a tattooing machine. The color of the nipple is usually slightly darker than that of the areola, which serves to provide additional spatial cues to dimensionality. Nipple reconstruction can safely be performed at the time of immediate reconstruction, but most typically it is performed at a later time once the reconstructed breast is has settled.

DELAYED RECONSTRUCTION

Although all patients treated for cancer do not survive, this is not a sound reason to withhold reconstruction from patients, except where reconstruction will interfere with synchronous adjuvant therapies. Existing treatment protocols use severity of the disease as the primary gauge for whether and when reconstruction should be performed. When, patients with ductal carcinoma in situ or minimal breast cancer are considered for immediate reconstruction, only 20% of the patients with invasive breast cancer undergo immediate reconstruction. Many patients are advised to wait until chemotherapy is complete before considering breast reconstruction. After the 6 traumatic months from the time of mastectomy through chemo and radiation therapy, many patients are overwhelmed and exhausted, lacking interest in secondary surgical procedures. The most common reason patients cite for refusing delayed breast reconstruction is a fear of additional procedures.

The commonly expressed goals of the patient seeking delayed reconstruction include the following:

1. Relief from negative feelings: Mastectomy patients come to accept the mastectomy and their diagnosis over time, but at some point they tire of the physical and emotional loss they have sustained. Feelings of “weariness” with the mastectomy deformity and the stigma of being seen as abnormal or different from other women are prevalent. This postmastectomy stigma is reinforced by those with good intentions who ascribe great strength to those who have been “afflicted.” These patients seek to be restored to that time prior to their diagnosis. They want to think, feel, and express themselves in the ways they did before the mastectomy. The problem can be perceived in many ways by these patients. Some see an anatomic deformity, whereas some feel a loss of femininity. No matter their perception, the mirror acts as a constant reminder for them.
2. Symmetry: Symmetry with the opposite breast is the goal of any mastectomy patient, whether stated or not. This goal is seldom obtainable without some form of autologous reconstruction. This decision must be reached by the patient, but we, as reconstructive surgeons, can help them in that process by providing them with the alternatives that can help them meet their goal.
3. Lasting result: The desire for a lasting result is a desire for closure. At some point, the patient wants to feel that the reconstruction is finished

and no more revisions will be required. The reason that implant reconstructions are not acceptable to many patients is that implants are far more likely to require revisions in the future.

4. Forgetting about the mastectomy: Putting the mastectomy in the past is the final goal of any breast reconstruction. In truth, most patients do not have unreasonable expectations. Often, they state that they just want to be able to dress in normal clothes or a similarly mundane activity. Mostly, patients want to return to their life as it was before cancer. They want to forget the trauma of surgery so that they can recover physically and emotionally. To provide for these patients' wishes, the reconstruction must be good enough so that the patients can walk by a mirror without being reminded of the traumatic experiences associated with their breast cancer. To meet this goal, reconstructions must appear natural and give symmetry while providing at least a semblance of natural feel. They should have a good nipple–areolar reconstruction and may require contemporaneous mastopexy or reduction of the contralateral breast. If a large amount of skin was removed with the mastectomy or if the mastectomy was accompanied by radiotherapy, then these goals can be more difficult to achieve. In such cases tissue expansion, implants, and revisions of the autologous tissue may be required.
5. Emotional recovery: The psychologic aspects of the recovery process are not well understood by most doctors since emotional healing has traditionally been left to outside groups such as Reach to Recovery. Though these groups usually function independently of the operating surgeon, they are quite effective because their members are the patients who have first-person experience with both the physical and emotional stresses of cancer treatment. Psychiatrists and psychologists, no matter how well intentioned, come to know these feelings secondhand and are not as effective in counseling mastectomy patients as are the women who have experienced the physical and emotional pain of losing a breast. Generally, breast reconstruction is useful adjunct to the late recovery process, at a time when self-esteem is high and life is viewed as worthwhile. At this point, patients and supporters see delayed reconstruction as healthy investment in a worthwhile life rather than as a way of denying unpleasant truths. It is clearly a mistake to proceed with plans for a breast reconstruction before emotional and psychologic issues have been resolved.

Both physicians and surgeons should be concerned about undertaking

reconstruction in patients who are poor candidates. It is always a disservice to undertake a complex reconstruction when a patient is still emotionally unstable, has unrealistic expectations, or is in poor health. Under such stressors, a truly informed consent cannot be obtained. The surgeon often accepts these patients at the request of their oncologic surgeon who recommends reconstruction as a means to bypass some of the trauma associated with mastectomy. However, it is not inappropriate for the reconstructive surgeon, in concert with the surgical oncologist, to refer such patients for counseling preoperatively. Selective serotonin reuptake inhibitors (SSRI) are among the medications prescribed to the patients in these depressed emotional states. When depressed, patients tolerate complications poorly and lawsuits can ensue since the surgeons are ready outlets for the patient's angst. It is critical to evaluate the emotional state of your patients preoperatively as in these cases it is in the patient's best interest to delay reconstruction until the time when emotional stability can be assured.

Experience from several large breast centers indicate that the complication rate of a delayed reconstruction with implants or expanders is much lower than if one did an immediate reconstruction (30% as compared to 5%). The increase rate in complications is related to: skin flap necrosis, exposure of the implant, infection, or marked asymmetry, if the reconstruction is performed at the same time as the mastectomy.

IMMEDIATE RECONSTRUCTION

Treatment of breast cancer and reconstruction of the mastectomy have been traditionally conceptualized as separate and unrelated issues—one necessary, the other optional. In contrast to other oncologic procedures, treatment is often completed before reconstruction is considered. In virtually all other cancer patients, the reconstruction is completed at the time of the extirpation. Although reconstruction may not be reasonable in a patient with a life span limited to 1 or 2 years, it is a reasonable consideration in any patient who is being treated for cure. Even in patients with advanced disease, immediate autologous reconstruction is reasonable and does not interfere with subsequent treatment or follow-up.

There are understandable historical reasons for the separation of treatment and reconstruction, which are as follows: (a) treatment protocols were developed before reconstructive procedures were available, (b) extensive skin resection has always been a hallmark of both radical and

modified mastectomies, (c) autologous flap reconstructions have become refined over just the past 20 years, and (d) the mastectomy and reconstructive procedures are performed by two different surgical specialties.

If autologous flaps had developed within the specialty of surgery rather than plastic surgery, it follows that they would have become routine at the time of mastectomy over a much shorter time period. Extensive skin resection would have sooner become the exception rather than the rule and reconstruction would likely have been viewed sooner as wholly compatible with adjuvant therapies.

For the foreseeable future, mastectomies will not be replaced by other forms of treatment as there are several conditions that are poorly accommodated by the lumpectomy and radiation paradigm; these include the following:

Familial breast cancer
Multicentric and multifocal breast disease
Central breast cancer that requires sacrifice of the nipple
Cancers that are too large for lumpectomy
Lumpectomy-radiation failures (an increasing number after 20 years of treatment)
Patients who cannot accept radiation.

Routine consideration for breast reconstruction at the time of mastectomy is now scientifically defended for patients with stages 0, I, and IIa. This subset describes the vast majority of patients who are undergoing mastectomy at present. As the safety of breast reconstruction has been demonstrated in careful studies, there is no reason to delay reconstructive measures. There are no data that support the idea that immediate reconstruction interferes with surgical treatment by spreading the cancer, hiding local recurrences, or negatively impacting patient survival. It is recognized that local recurrences are indicators of retained disease and that recurrences exist within retained breast tissue. The only remaining breast tissue following a mastectomy is either in breast skin or in breast tissue that was not removed with mastectomy. After reconstruction, what could have been a chest wall recurrence becomes a skin recurrence, since the skin is physically separated from the chest wall by the reconstruction. Recurrences are never seen within the substance of an autologous flap because the fat and muscle of the flap are poor recipients for the transplantation of breast cancer. Most of the local recurrences occur 2 to 3

years following mastectomy. More importantly, recurrences occur at the subcutaneous tissue level and around the scar. Thus, they are easily palpable during a physical examination.

A number of contemporary reports document the safety of immediate reconstruction. Wang and colleagues reviewed survival data in 172 immediate breast reconstructions performed between 1970 and 1990 and compared them with a control group of similar patients who had had only a mastectomy. In these groups, the flap reconstruction did not interfere with either diagnosis or treatment of the recurrence. There was no difference in 5- and 10-year disease-free survival and there was no difference in reconstructions performed with implants versus autologous flaps or immediate versus delayed reconstructions. Slavin, Love, and Goldwyn reported 161 immediate breast reconstructions, including 41 salvage mastectomies using myocutaneous flaps. Local recurrences that developed were consistent with the stage of the disease, and 76% of these local recurrences represented systemic disease. All local recurrences were found within the native breast skin rather than in relation to the flap. There were no cases of a delay in diagnosis or compromise in the timeliness of treatment. Godfrey, Godfrey, and Romita reviewed patients having immediate reconstruction with advanced disease and confirmed the findings of Slavin and his group that the reconstruction itself had no impact on the outcome of the cancer treatment. Noone and colleagues reported on 306 patients who had implant reconstruction with long-term follow-up. The local and distant recurrences in this group of patients were similar to those expected in patients with like disease. Kroll and colleagues collected 131 patients who had undergone immediate reconstruction, of which 104 had skin-sparing mastectomy. When compared with matched patients, the authors concluded that the skin-sparing mastectomy with immediate reconstruction had no impact on outcomes in this 5-year follow-up.

Although the postulated harmful effects of immediate reconstruction on local recurrence and survival have not materialized, concerns persist over the effect of breast reconstruction on adjuvant therapy. It is biologically important to begin chemotherapy within 28 to 40 days of extirpative treatment, so the reconstruction must be healed enough to tolerate initiation of chemotherapy by the end of the first month. Chemotherapy can be started while there is still a surface wound that has not yet epithelialized, but it cannot be started in the face of frank tissue necrosis,

seroma, or infection. When it is known in advance that the patient will undergo chemotherapy, the choices for reconstruction should include those flaps that are well vascularized and are known to heal with few complications as the first choice. Implants can be used, but if complications arise, it may be necessary to remove the device to facilitate healing and allow chemotherapy to begin. When radiation is planned, tissue expander and implant reconstruction should not be the first option selected because unsatisfactory firmness is the byproduct of implants which are radiated. Only autologous flaps offer a satisfactory solution in these patients and it is preferable to complete reconstruction at the time of mastectomy, again to avoid any delay in treatment. Radiation is usually performed for close margins or because the tumor is large or aggressive. In either case the cause of tumor recurrence or poor patient survival is disease stage, not immediate reconstruction. Should a flap hide a recurrence at a questionable chest wall margin, this could delay the diagnosis of systemic disease but it is so rare as to be a reportable event. Whether immediate reconstruction should be performed at all in stages IIb and III has become more of a social decision than a medical one. The survival in these patients will be poorer that in most patients, but it will not be negatively impacted by autologous reconstruction. If it can be ascertained preoperatively that the patient desires reconstruction, then immediate reconstruction serves the patients interest best. For a few hours added to the procedure, reconstruction can be completed, and the patient does not have to face a second major surgical procedure after chemotherapy. If the flap is placed immediately, radiation may decrease flap volume, but delayed reconstruction in the context of radiation is far more problematic in terms of radiation-induced skin and chest wall injury.

Contemporary oncologic practice guided by phase II/III clinical trials has been significantly refined allowing for multidisciplinary models of treatment that were inconceivable a generation ago. These models employ new combinations of chemotherapy, reconstruction, and radiation that continue their refinement by further study. The introduction of inductive chemotherapy to shrink large breast tumors does not preclude immediate reconstruction. It has been shown that wound healing is not significantly impaired.

Early in the 20th century, the surgeon stood alone in his responsibility for breast cancer treatment, a time when treatment existed only in the form of the radical mastectomy. Today, multidisciplinary support is the rule

rather than the exception and the surgical oncologist now stands as a leader with his colleagues in this coordinated effort. Helping the patient choose among these sophisticated treatment options requires the efforts and mutual cooperation of both surgical oncologist and reconstructive surgeon.

Suggested Readings

Bostwick J 3rd, Vasconez LO, Jurkiewicz MJ. Breast reconstruction after a radical mastectomy. *Plast Reconstr Surg* 1978;61(5):682–93.

Charvet HJ, Orbay H, Wang MS, et al. The oncological safety of breast fat grafting and contradictions between basic science and clinical studies: a systematic review of recent literature. *Ann Plast Surgery* 2015;75(4):471–9.

Hartrampf CR Jr, Bennett GK. Autogenous tissue reconstruction in the mastectomy patient: a critical review of 300 patients. *Ann Surg* 1987;205(5):508–19.

Medina-Franco H, Vasconez LO, Fix RJ, et al. Factors associated with local recurrence after skin-sparing mastectomy and immediate breast reconstruction for invasive breast cancer. *Ann Surg* 2002;235(6):814–19.

Mohan AT, Zhu L, Wang Z, et al. Techniques and perforator selection in single, dominant DIEP flap breast reconstruction: algorithmic approach to maximize efficiency and safety. *Plast Reconstr Surg* 2016;138(5):790e–803e.

Pittman TA, Fan KL, Knopp A, et al. Comparison of different Acellular Dermal Matrix (ADM) in breast reconstruction: The 50/50 study. *Plast Reconstr Surg* 2016 [Epub ahead of print].

Santosa KB, Chen X, Ballard TN, et al. Post mastectomy radiotherapy and two stage implant–based breast reconstruction: is there a better time to irradiate? *Plast Reconstr Surg* 2016;138(4):761–9.

Shimo A, Tsugawa K, Tsuchiya S, et al. Oncologic outcomes and technical considerations of nipple sparing mastectomies in breast cancer: experience of 425 cases from a single institution. *Breast Cancer* 2016;23(6):851–60.

Vásconez HC, Holley DT. The use of the TRAM and latissimus dorsi flaps in autogenous breast reconstruction. *Clin Plast Surg* 1995;22(1):153–66.

EDITOR'S COMMENT

In this chapter, Vasconez and colleagues have done a nice job of intertwining history and the evolution of breast reconstruction. Much of the story is tied to the evolution of skin preservation—from skin grafting the chest wall to skin sparing and today nipple skin-sparing mastectomy (NSSM) or total skin-sparing mastectomy. This evolution continues with novel reduction techniques, various incisions for improving cosmesis after an NSSM, techniques for reconstruction

of the pendulous breast and coverage of implants with dermal matrix or “autoderm” instead of extensive muscular dissection for coverage. As the ductal lining starts just a few millimeters from the skin, the oncoplastic safety of NSSM has challenged old dogma and demonstrates its safety even when the nipple–areolar complex is spared. Now there is little doubt that leaving the original skin envelope and filling it with tissue or an implant give the best and most immediate of reconstructions. When the nipple is involved as much skin can be spared as is free of cancer. In other words, the nipple is just another margin.

Importantly, the onus is on the cancer surgeon. First, a reconstruction-friendly scar should be made by the primary surgeon. The final result is very much dependent on the condition of the tissue that the cancer surgeon leaves for the reconstructive surgeon. The primary cancer surgeon should avoid the temptation to remove the fat pad superior to the breast mound so that the patient will not have a hollowed inframammary region. The breast tissue proper rarely goes above the first or second rib. Likewise, dissection too medial will result in synmastia. Dissection too inferior on the chest wall results in loss of the inframammary fold. The resulting asymmetry of the position of the breast on the chest wall is difficult to correct. In case the patient decides to have reconstruction later then the scar can be placed just above the inframammary fold saving as much skin superiorly as possible and de-epithelizing the lower flap and folding it under the upper flap (vest over pants) for later use by the plastic surgeon. This not only provides coverage for the implant later with natural tissue but allows the primary surgeon to reduce redundant tissue in laterally in the axilla.

Indications for offering breast reconstruction are broadening. Not offering or delaying reconstruction produces the greatest scar emotionally. I will have to disagree with the authors that reconstruction can only be limited to those with stage 0 to IIa in that recent studies have shown skin-sparing mastectomy to be safe even with locally advanced breast cancer. Systemic presurgical chemotherapy can be offered to the patients with more aggressive disease who will need radiation, or to those patients who need time to stop smoking. Patients with a recurrence after conservative breast surgery and radiation can also have good results using newer flap dissection techniques. Complication rates are higher in the obese, but some are more than willing to accept this for a chance to look and feel normal. Tissue reconstruction in these patients and the use of their own dermis can lower such complications. In addition, there is no doubt that contralateral prophylactic mastectomy (CPM) is on the rise, increasing from 0.4% in 1998 to 4.7% in 2007 to approximately one third in 2016. Why and whether CPM carries a survival benefit is controversial. Patients often elect CPM out of fear of recurrence or to lessen surveillance. The majority of average-risk women will obtain no oncologic benefit from a CPM with the risk of finding occult disease in a CPM of about 1.8%. Certainly sentinel lymph node biopsy of the CPM is not necessary as the risk of lymphedema is 5-fold

higher than the risk of finding an occult cancer. An individualized approach is necessary with thorough discussion of the risks and benefits but ultimately is decided by the patient.

The authors state that there is a 30% to 40% complication rate with implants; in fact, with the "living bra" concept of total implant coverage by chest musculature the explant rate secondary to pain is as high as 25%. Today implants are only partially placed behind the pectoralis major muscle and then a lateral and inferior sling of dermal matrix covers the implant laterally. This along with botulinum toxin to relax the muscle produces less contracture and good cosmetic results with implants and lessens pain. Marcaine can also be used to perform a pectoral block at the time of the open procedure with good results. Pain pumps left in at the time of surgery are not necessary, costly, and increase infection rates. Use of dermal matrix allows the ability to place the implant and finish the reconstruction at the time of the mastectomy with only a few hours added to the procedure and with lower complication rates than those offered by complete tissue reconstruction. Indeed, using such techniques, there is no delay in receiving chemotherapy and much more tolerance of the implant reconstruction to postsurgical radiation therapy with less contracture formation. Once the chest wall is radiated, tissue reconstruction is the only option. The main complication to be reckoned with is flap necrosis. This is a direct result of making the flaps too thin. Flap thickness is one of the most difficult techniques to master. Boneti and colleagues describe a dilation technique to determine the correct thickness of the skin flap and this can significantly decrease flap and nipple necrosis. Indocyanine green fluorescence has also been shown to be helpful.

The American Society of Plastic Surgeons practice surveys showed breast reconstruction is on the decline with a 29% reduction in breast reconstruction cases from 2000 to 2008 at a time when the demand for reconstruction is growing. Only ~6% of the cases submitted for the oral plastic surgery boards and also only ~6% of the cases submitted by plastic surgeons (in practice for 10 years) for Maintenance of Certification examination were breast reconstruction. The process that goes into making a decision to have reconstruction is complex—misperceptions about oncologic safety, difficulty in coordinating surgery schedules, and lack of enough or distribution of plastic surgeons to meet the demand are just a few of the problems. In a recent survey, fewer than one fifth of plastic surgeons perform autologous procedures for more than half of their breast cancer patients even though the results can be superior and more long lasting to implant. Deterrents are expertise, time, and reimbursement. The development of Breast Fellowships with the increasing emphasis on cosmesis has led to what is now termed oncoplastic surgery. However, proper training of such surgeons has lagged as plastic surgery is still only a minimal part of the oncologic breast surgery training. At present a multidisciplinary approach with the patient's best interest in mind seems the best solution coupled with an evolution of techniques and oncoplastic training

programs for the breast surgeon.

V. Suzanne Klimberg

Suggested Readings

Boneti C, Arentz C, Klimberg VS. Scapulothoracic bursitis as a significant cause of breast and chest wall pain: underrecognized and undertreated. *Ann Surg Oncol* 2010;17(Suppl)3:321–4.

Boneti C, Yuen J, Santiago C, et al. Oncologic safety of nipple skin-sparing or total skin-sparing mastectomies with immediate reconstruction. *J Am Coll Surg* 2011;212(4):686–93; discussion 693–5.

Boughey JC, Attai DJ, Chen SL. Contralateral prophylactic mastectomy consensus statement from the American Society of Breast Surgeons: Additional considerations and a framework for shared decision making. *Ann Surg Oncol* 2016;23(10):3106–11.

Kulkarni AR, Sears ED, Atisha DM, et al. Use of autologous and microsurgical breast reconstruction by U.S. plastic surgeons. *Plast Reconstr Surg* 2013;132(3):534–41.

Layeeque R, Hochberg J, Siegel E, et al. Botulinum toxin infiltration for pain control after mastectomy and expander reconstruction. *Ann Surg* 2004;240(4):608–13.

Noone RB. Thirty-five years of breast reconstruction: eleven lessons to share. *Plast Reconstr Surg* 2009;124(6):1820–7.

Yao K, Sisco M, Bedrosian I. Contralateral prophylactic mastectomy: current perspectives. *Int J Womens Health* 2016;8:213–23.

Yuen JC, Yue CJ, Erickson SW, et al. Comparison between freeze-dried and ready-to-use alloDerm in alloplastic breast reconstruction. *Plast Reconstr Surg Glob Open* 2014;7;2(3):e119.

57 Chest Wall Resection and Reconstruction for Advanced/Recurrent Carcinoma of the Breast

Kirby I. Bland, Cristiano Boneti, R. Jobe Fix, and Robert J. Cerfolio

INDICATIONS/CONTRAINDICATIONS

With improvements in patient awareness and imaging advancements (e.g., MRI, PET, PET/CT) the diagnosis at an earlier stage of breast cancer will provide enhancement of survival. Nevertheless, the incidence of local–regional recurrence following breast conservation surgery or mastectomy varies between 5% and 40%. The probability of recurrence correlates with the presenting pathobiologic characteristics of the primary neoplasm and/or the American Joint Committee on Cancer (AJCC) clinical tumor stage. Although no international standards for local recurrence have been fully defined, typically the combination of surgery, radiation therapy, chemotherapy, and/or targeted immunotherapy is directed for principal control. Following local–regional recurrence that defines a clinical and radiographically resectable tumor, protocol will typically embrace resection with pathologically negative margins followed by subsequent radiation therapy; many clinics will also utilize hormone-receptor markers (ER, PR, and HER2/neu status) to assist in therapeutic guidance.

For many clinics internationally, despite curability with isolated metastases, chest wall recurrences are left untreated. This rational is based upon previous surgical dogma suggesting that chest wall recurrences are the “harbinger of systemic disease.” However, this principle should not necessarily apply when the patient has been fully staged clinically and radiographically and only the isolated chest wall recurrence is evident.

PREOPERATIVE PLANNING

The authors have previously published guidelines at the University of

Alabama at Birmingham for resection of the chest wall in patients presenting with recurrence/advanced disease related to breast carcinoma. The indications for operation, as discussed, pertain only to an isolated disease that can be surgically managed with curative intent. The chest wall recurrence typically follows cytoreduction resection with neoadjuvant chemotherapy and ER-targeted therapies.

Individuals who have locally confined disease, with requirement of palliation for pain and/or nonhealing/ulcerative lesions related to postirradiation injury with pathologically negative ulcerative sites are included in this group.

It is incumbent upon the oncologic surgeon involved in the care of the patient to establish that there is absence of systemic disease and to exclude multifocally recurrent sites that are being considered for resection.

Relative contraindications include advancing age, short disease-free interval of recurrent disease, diminished pulmonary reserve, biopsy-proven extrathoracic disease, and existing systemic comorbidities (e.g., cardiac, hepatic, renal, and endocrine).

The preoperative evaluation and important preoperative considerations in the management of chest wall recurrence include:

Contemporary radiographic imaging is essential for all patients being considered for full-thickness chest wall resection and reconstruction. To properly evaluate chest wall anatomy and extent of tumor progression, we advocate dedicated chest wall magnetic resonance imaging (MRI) and/or computed tomography (CT) angiography as standard imaging modalities. Standard CT scanning with intravenous contrast also provides invaluable information. Many medical oncologists also consider positron emission tomography (PET) as a definitive test, but coexisting inflammatory sites, especially ulceration sites, with the associated false-positive and false-negative features of PET, do not allow use of this procedure as an exclusive screening modality. However, PET is extremely useful in evaluating systemic disease. Evidence of extensive direct lung invasion and pleural effusion are absolute contraindications for consideration of chest wall resection.

The principal site of focally recurrent disease typically presents between the 3rd and 6th rib interspaces; however, the recurrence location, as well as history of the patient’s operative procedure, is paramount.

Resection that extends beyond four ribs will routinely require rigid chest

wall reconstruction. This maneuver constitutes the creation of mesh with polypropylene that may be used as a singular sheet or with creation of a mesh "sandwiched" together with methyl methacrylate. Recently bioabsorbable materials are increasingly used and have some advantages over nonabsorbable material. The main advantage is that they do not need to be removed if the chest wall graft becomes infected. Myocutaneous flaps should be liberally used to cover the defects of these reconstructions. When defects are small and there is less probability for creation of the flail defect of the chest wall, mesh alone may be sufficient with this smaller area for coverage.

The most versatile and most commonly used flap is the latissimus dorsi pedicle flap. Ideally, flaps from previously irradiated fields should be avoided when possible.

Review of the surgical history is essential, especially if a transverse or vertical rectus abdominis muscle (TRAM) pedicle flap is being considered with prior abdominal operations, as the same will often affect the flap choice for defect coverage.

Lastly, preoperative planning between the surgical oncologist and reconstructive surgeons, following discussion with the medical oncologist, should define the indications, relative merits, and technical approaches essential for full oncologic resection (Table 57.1).

SURGERY POSITIONING AND INCISIONS

Following patient intubation with an appropriately endotracheal tube (a double lumen is not necessary for most operations) the patient is positioned in the supine or lateral decubitus position depending upon the recurrence site, planned resection, and flap choice. The area for harvest of the potential skin flap and graft-donor sites should also be prepped and draped into the operative field.

TABLE 57.1 Preoperative Considerations

- Indications for operation include isolated chest wall recurrence, curative intent, or palliation for painful, nonhealing, ulcerated lesions.
- Preoperative planning between oncologic and reconstructive surgeons should help elucidate flaps that will be available after oncologic resection.
- Absolute contraindications for resections with curative intent include systemic disease or multifocal recurrence.
- Relative contraindications include advanced age, short disease-free interval, poor pulmonary function, and high operative risk.
- Preoperative imaging and staging are essential for evaluation of chest wall anatomy, tumor invasion, metastatic disease, and preoperative planning. Magnetic resonance imaging, positron emission tomography, and computed tomography are standard imaging modalities. Bronchial washings may be appropriate to rule out direct lung invasion if suspicious by imaging.

Resection extending beyond four ribs will usually require rigid chest wall reconstruction with a mesh and methyl methacrylate sandwich. Mesh alone may be sufficient for smaller defects with less risk of flail chest.

Recurrence location, as well as patient's operative history, will affect flap choice for defect coverage. A latissimus pedicle flap is the most versatile and is usually the most readily available. Flaps from previously radiated fields should be avoided if possible.

From Howard JH, Tzeng CWD, Fix RJ, et al. Chest wall resection. In: Klimberg VS, ed. *Atlas of Breast Surgical Techniques.* Philadelphia, PA: Saunders; 2010, with permission.

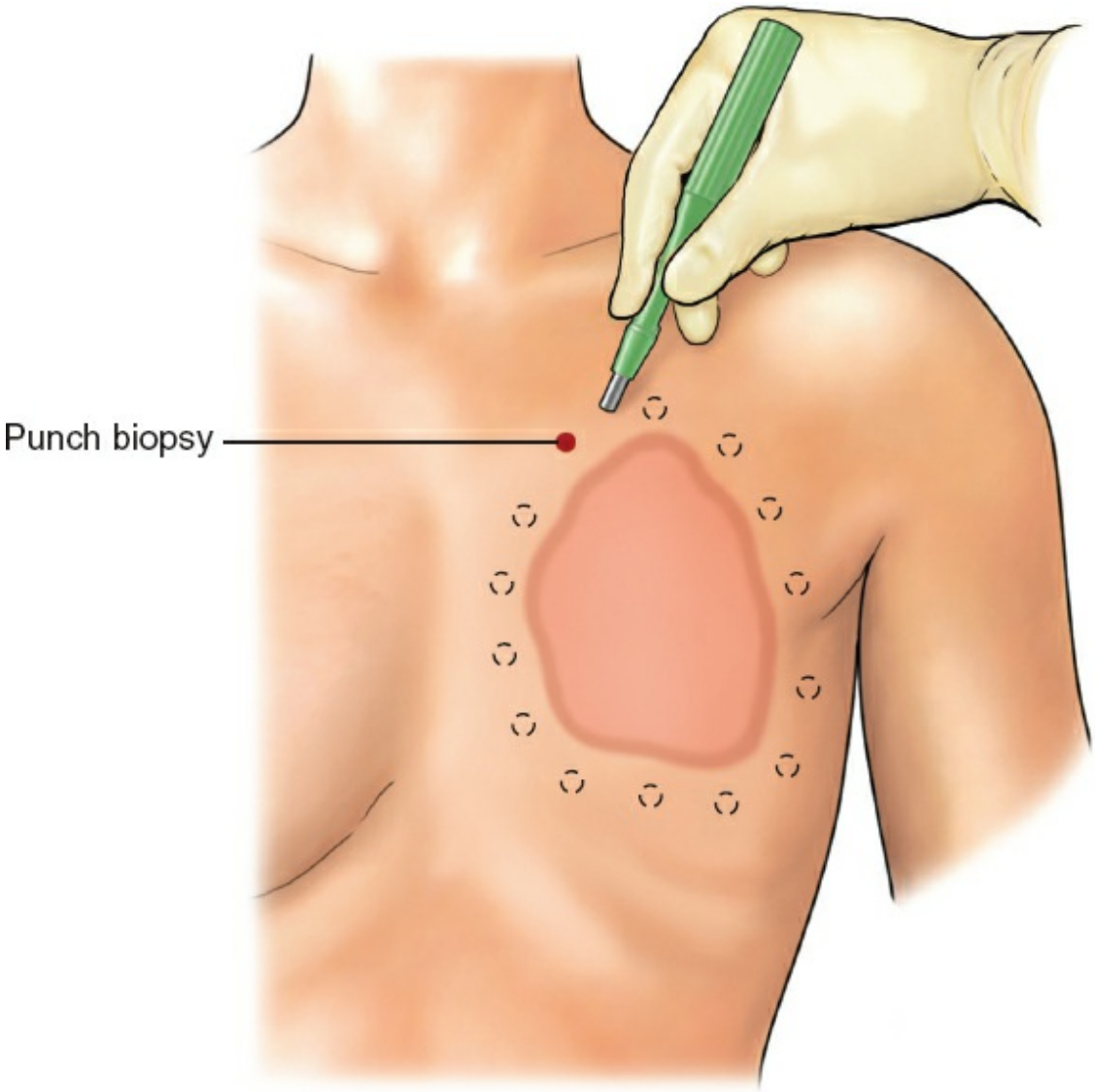

Figure 57.1. Chest wall topographic anatomy with outline of planned marginal clearance. Preferentially a minimal 2-cm margin developed 360 degrees about the periphery of the planned resection area is ideal. A punch biopsy (4 to 6 mm) should be taken approximately every 1 to 2 cm about the tumor margin resection to validate a negative pathologic margin before opening the chest. (From Bland KI, Fix RJ, Cerfolio RJ. Chest wall resection and reconstruction for advanced/recurrent carcinoma of the breast. In: Bland KI, Klimberg VS, eds. *Master Techniques in General Surgery: Breast Surgery*. Philadelphia, PA: Lippincott Williams & Wilkins; 2011.)

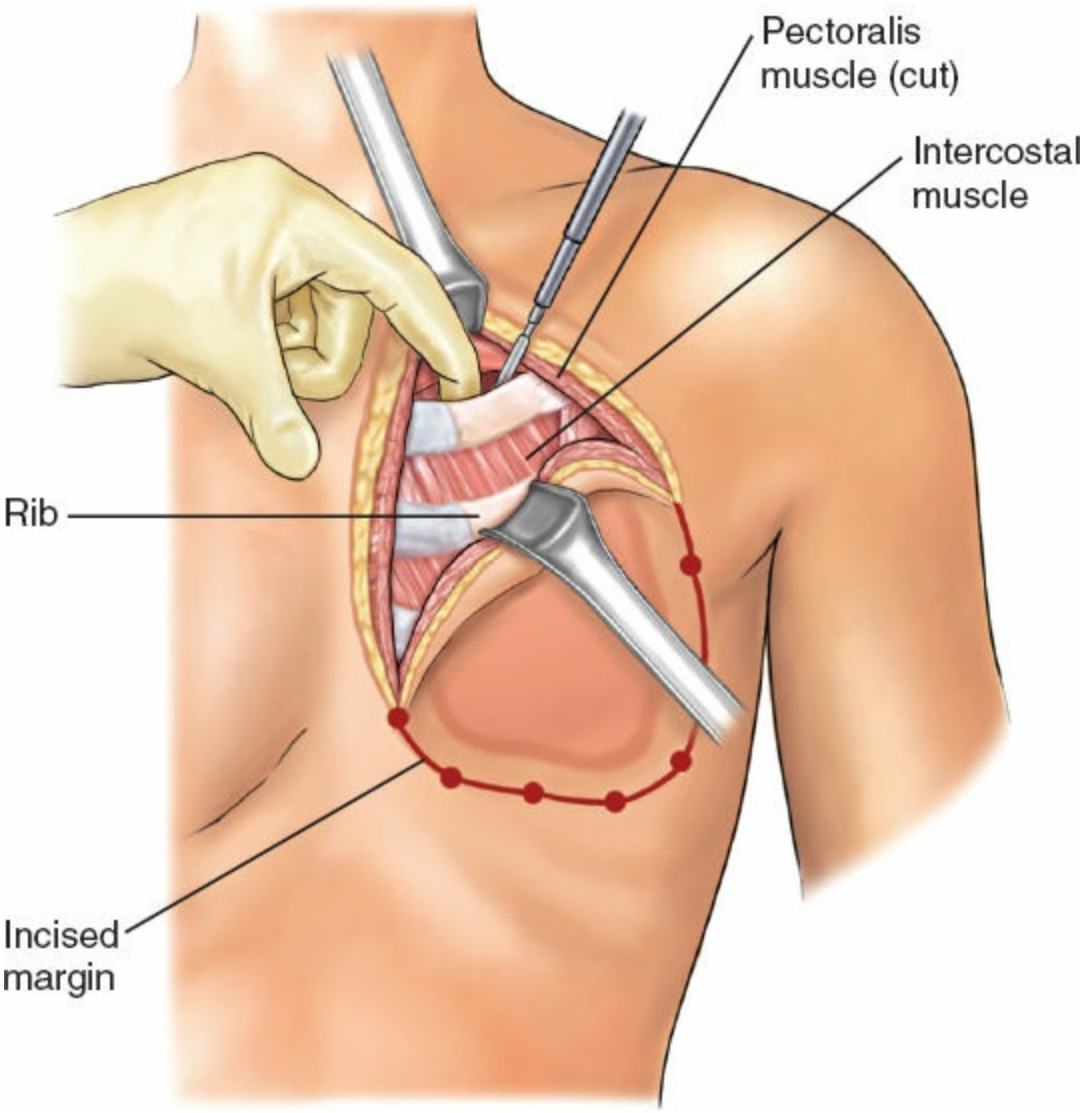

Figure 57.2. In the usual circumstance, incision above the cephalad-most rib with opening on its superior margin is preferable. Upon entering the thorax, prior pleural adhesions created by radiation therapy and/or surgery should be sharply dissected and the lung mobilized. Attention must be focused on the avoidance of injury to the visceral pleura of the lung and inadvertent damage to the pulmonary parenchyma. (From Bland KI, Fix RJ, Cerfolio RJ. Chest wall resection and reconstruction for advanced/recurrent carcinoma of the breast. In: Bland KI, Klimberg VS, eds. *Master Techniques in General Surgery: Breast Surgery*. Philadelphia, PA: Lippincott Williams & Wilkins; 2011.)

Preferentially, we prefer a minimal 2-cm margin developed 360 degrees around the periphery of the planned resection area (Fig. 57.1). We prefer a 2 cm margin for metastatic lesions and 4 cm for primary chest wall tumors. It is critical that both the oncologic surgeon and the plastic surgeon plan

the operative incision prior to skin incision, estimating the maximum cephalad, caudad, medial, and lateral extent of the tumor, such that the estimate for margins of resection can be discussed with the patient and family prior to the planned resection. Such estimates are simultaneously planned with radiographic imaging, if necessary.

Margins should extend, at minimal, one intercostal space above and below the tumor mass inclusive of the cephalad–caudad aspect of the planned rib resections at a minimum and more if a 2-cm margin is not obtained with just one rib space.

Circumferential full-thickness skin punch biopsies (6 mm) should be sent for frozen section analysis following skin prep and induction. These biopsies will validate a negative pathologic margin prior to incision (Fig. 57.1). Once negative margins are confirmed with pathology, the extent of the incision through the skin overlying the pectoralis major muscle may be completed using cold blade and, thereafter, electrocautery for subcutaneous and muscular tissues.

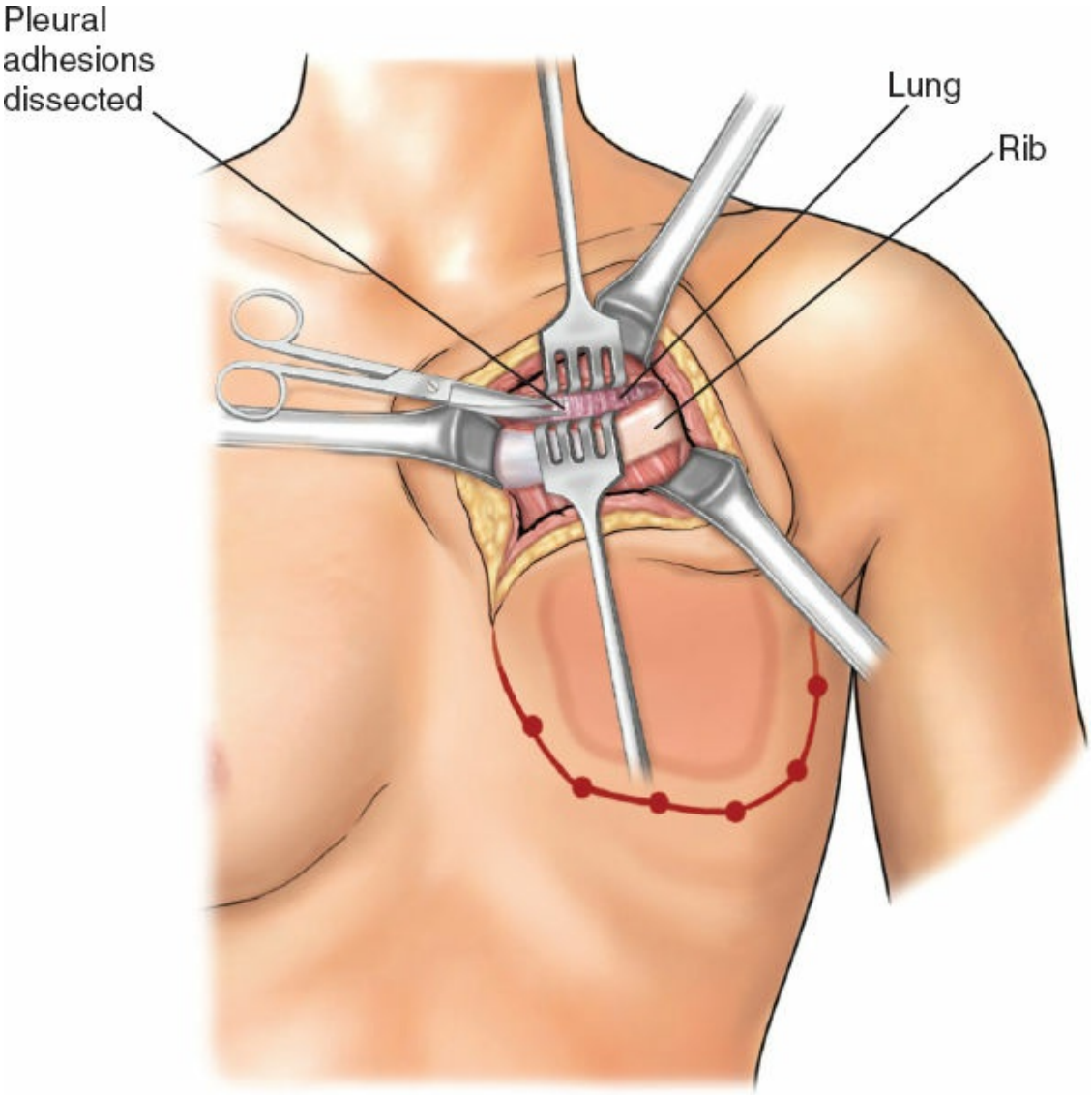

Figure 57.3. Extension of the incision around the periphery of the margins of the tumor mass through the intercostal muscles and via the outline of the punch biopsies that have been confirmed pathologically negative. (From Bland KI, Fix RJ, Cerfolio RJ. Chest wall resection and reconstruction for advanced/recurrent carcinoma of the breast. In: Bland KI, Klimberg VS, eds. *Master Techniques in General Surgery: Breast Surgery*. Philadelphia, PA: Lippincott Williams & Wilkins; 2011.)

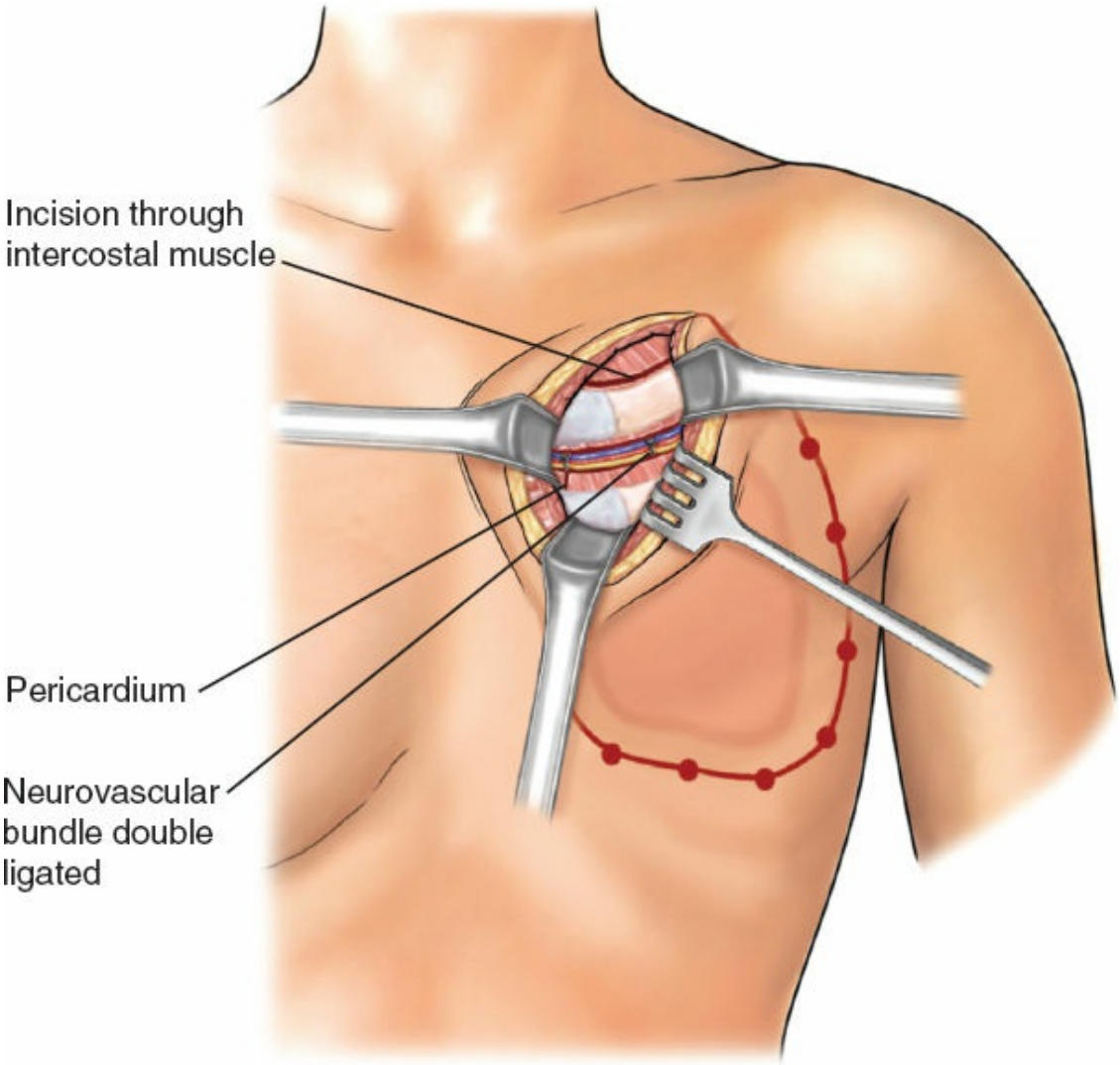

Figure 57.4. Planned line of resection of rib on cephalad-most extension with division on its medial surface following ligation of the neurovascular bundle. (From Bland KI, Fix RJ, Cerfolio RJ. Chest wall resection and reconstruction for advanced/recurrent carcinoma of the breast. In: Bland KI, Klimberg VS, eds. *Master Techniques in General Surgery: Breast Surgery*. Philadelphia, PA: Lippincott Williams & Wilkins; 2011.)

TECHNIQUE OF RESECTION

The pectoralis major and minor are incised outside the tumor-bearing area to the level of the chest wall; all ribs for planned resection are medially and laterally exposed. The incision will include all previous punch biopsied areas. In the cephalad-most extent of the planned rib resection, the rib is incised on its cephalad surface, and the ipsilateral lung is deflated by the anesthesiologist at the instruction of the surgeon. The thoracotomy should be initiated via the superior margin of the planned resection (Fig.

57.2). Upon entering the thorax, previous pleural adhesions created by prior radiation therapy and/or surgery should be sharply dissected and mobilized. Attention must be directed to avoidance of injury to the parietal pleura and inadvertent damage to the pulmonary parenchyma. When dissection is incomplete or inadequate, lysis of adhesions should be completed and performed with sharp dissection to avoid the formation of an alveolar–pleural fistula. With dense adhesions related to tumor invasion of the parietal pleura of the lung, complete pleurectomy with simultaneous segmental resection of the focally involved lung segment may be necessary. Repair of any parenchymal tears may be completed by stapling or suturing with a 3-0 absorbable polypropylene suture after adequate deflation of the lung without injury. The incision is thereafter extended around the peripheral margins of the tumor mass through the intercostal muscles (Figs. 57.3 to 57.6). The surgeon must be cognizant of ligation of the intercostal neurovascular bundles on the inferior margins of the rib with 2-0 silk suture ligatures (Fig. 57.5).

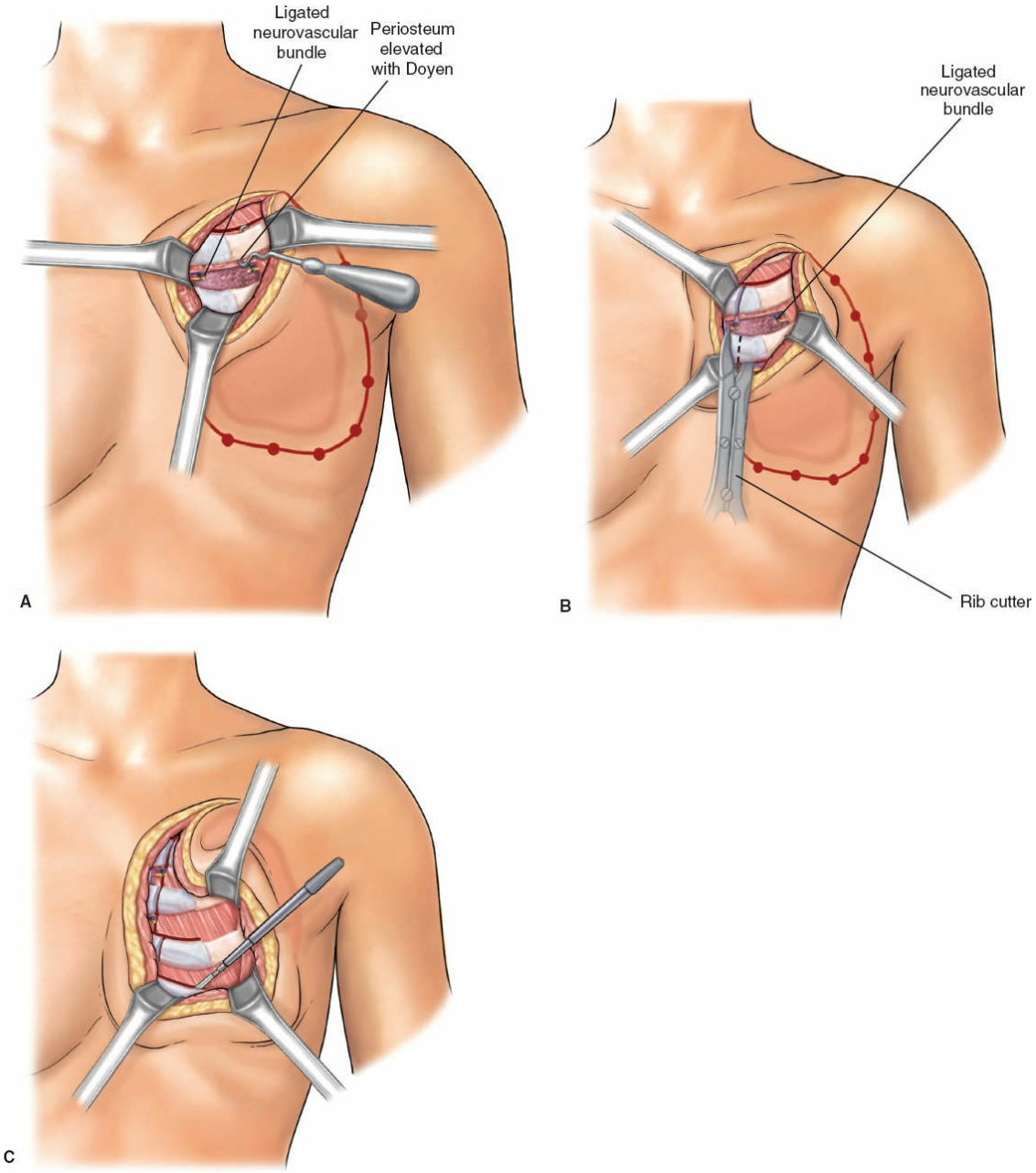

Figure 57.5. A. Isolation and ligation of both medial and lateral neurovascular bundles. **B.** Division of rib on its medial surface with rib cutter. **C.** Further extension of the medial cut with rib cutter to the third rib on its medial surface. (From Bland KI, Fix RJ, Cerfolio RJ. Chest wall resection and reconstruction for advanced/recurrent carcinoma of the breast. In: Bland KI, Klimberg VS, eds. *Master Techniques in General Surgery: Breast Surgery*. Philadelphia, PA: Lippincott Williams & Wilkins; 2011.)

As the incision is extended around the margins of the resection, the periosteum of the rib should be elevated with a Doyen retractor followed by a periosteal elevator prior to initiating rib division with a rib cutter (Fig.

57.5A). Following completion of the entire incision, the surgeon should be cognizant about including all the punch biopsy sites to ensure negative surgical margin.

When the tumor margin extends medially to the sternum, it may be necessary to utilize a sternal saw or osteotome to create a partial sternotomy up to and inclusive of the biopsied skin that establishes a clear surgical margin. Moreover, the incision should be extended to the sternocostal margin where the internal mammary artery (IMA) can be palpated, ligated, and divided. The sternum thereafter may be partially resected, but diligence must be exercised to protect the pericardium, which may be centrally adherent to the investing parietal pleura of the sternum, secondary to irradiation.

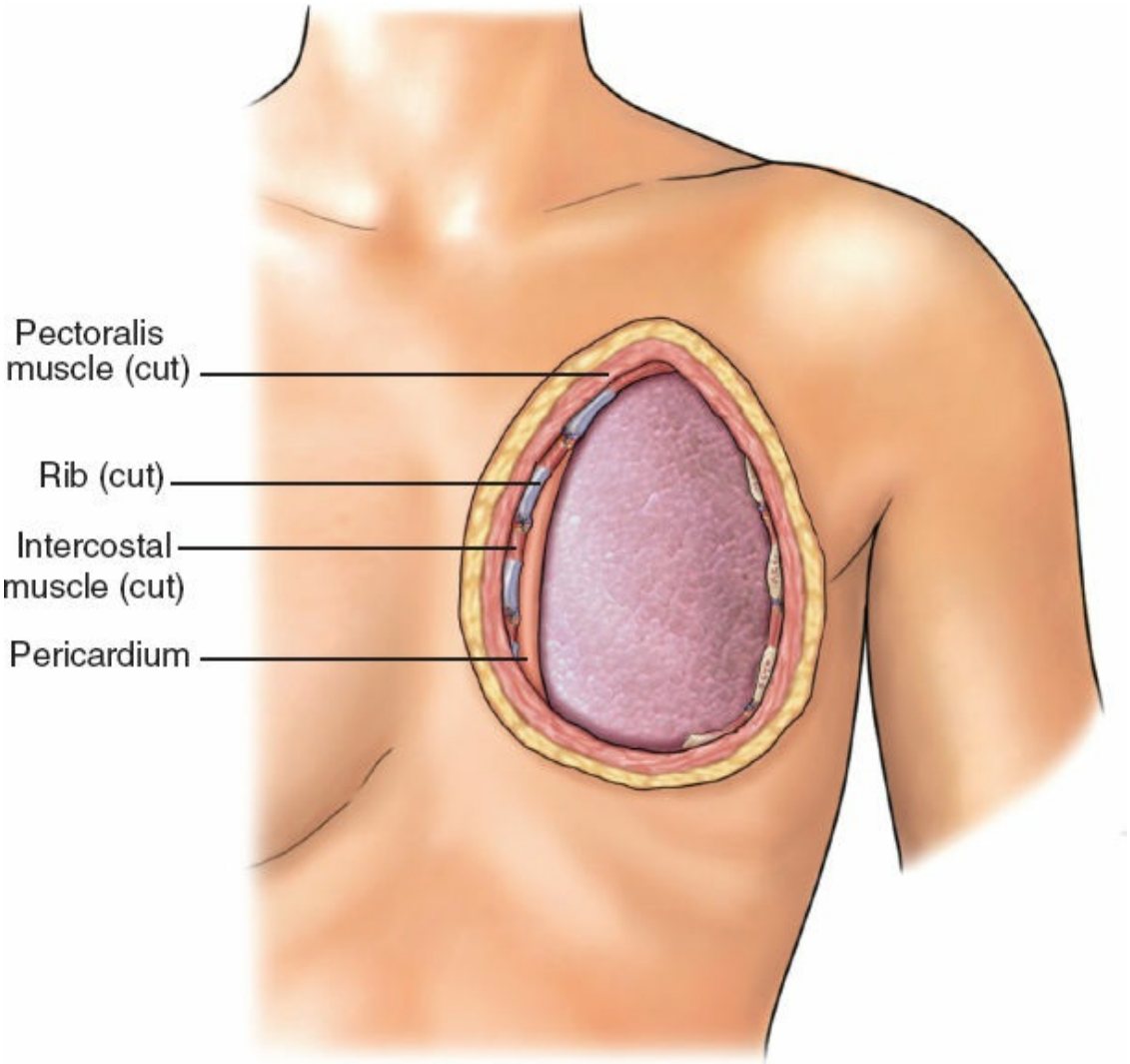

Figure 57.6. The completed resection both medially and laterally, including four ribs in the resection with exposure of the visceral pleural surface of the lung following resection of parietal pleura

with chest wall. (From Bland KI, Fix RJ, Cerfolio RJ. Chest wall resection and reconstruction for advanced/recurrent carcinoma of the breast. In: Bland KI, Klimberg VS, eds. *Master Techniques in General Surgery: Breast Surgery*. Philadelphia, PA: Lippincott Williams & Wilkins; 2011.)

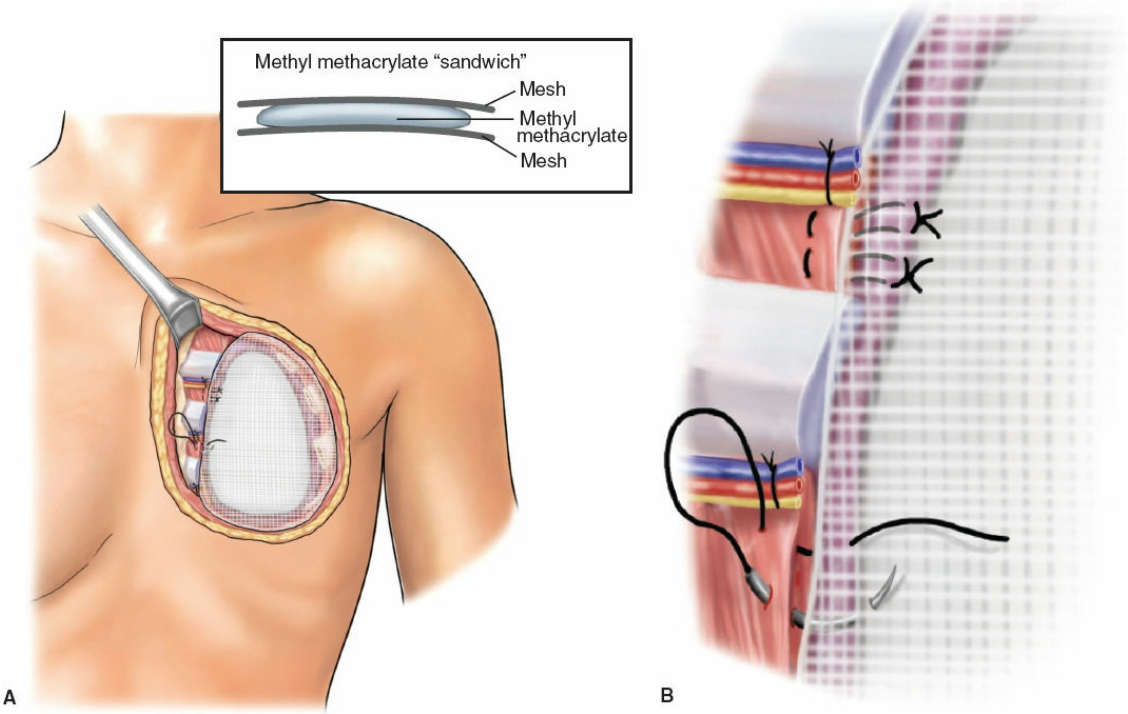

Figure 57.7. A. Inset identifies the optional creation of the methyl methacrylate "sandwich," in which methyl methacrylate interposes between two mesh surfaces of a nonabsorbable polypropylene mesh. The strut of this prosthesis is created with the folding in half of a large piece of polypropylene mesh to ensure coverage of the sandwich over the defect without undue tension. **B.** Suturing of the polypropylene mesh encircling the rib margin on its superior and inferior surface of the resection with creation of the planned suture knots external to the mesh with full-thickness purchase through the musculature of the chest wall. Neurovascular bundle has been separately ligated. (From Bland KI, Fix RJ, Cerfolio RJ. Chest wall resection and reconstruction for advanced/recurrent carcinoma of the breast. In: Bland KI, Klimberg VS, eds. *Master Techniques in General Surgery: Breast Surgery*. Philadelphia, PA: Lippincott Williams & Wilkins; 2011.)

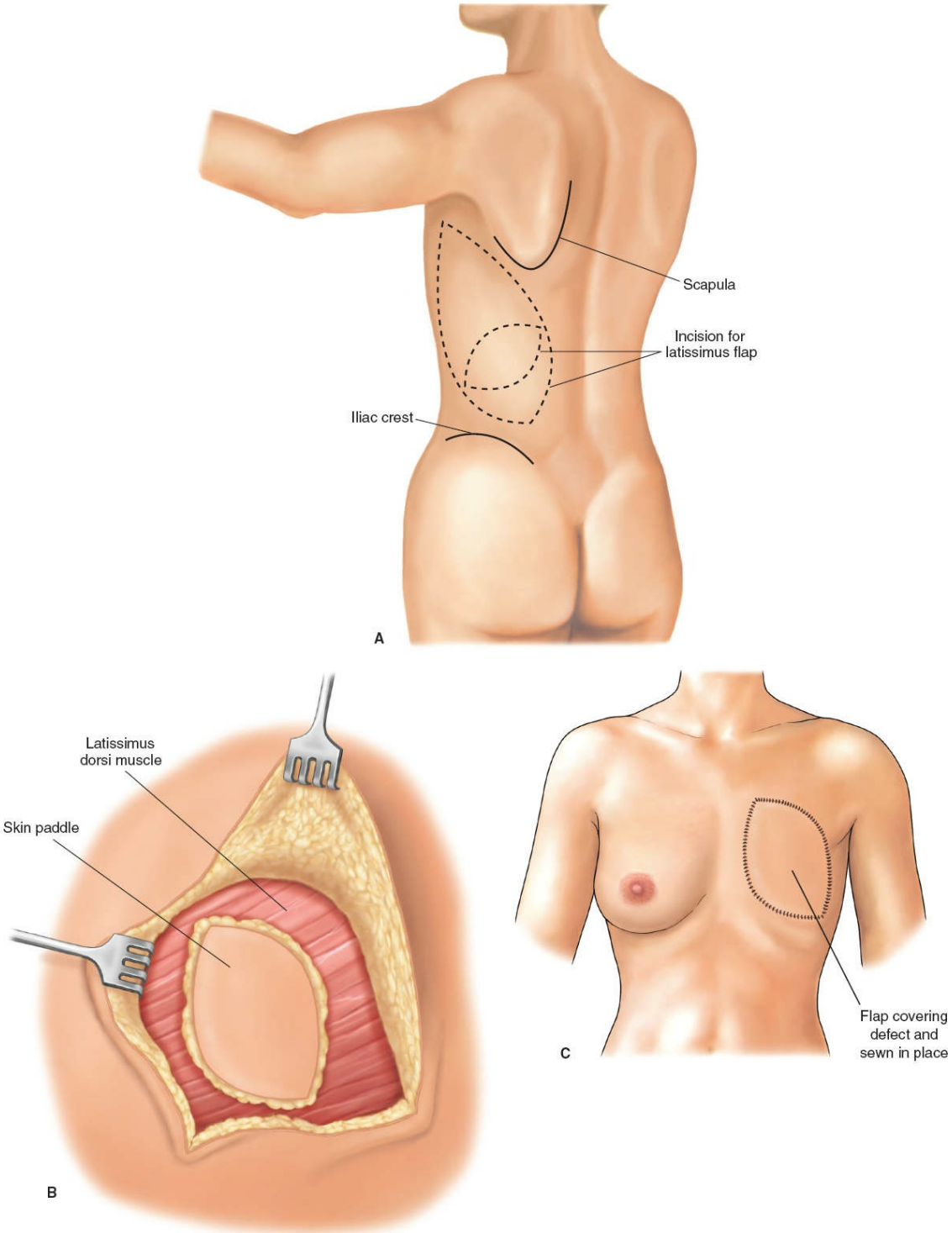

Figure 57.8. **A.** Design of the most commonly utilized and versatile flap reconstruction as a pedicled latissimus dorsi flap. **B.** Note that the flap is inclusive of a vascularized skin panel in the central inner outline, and in which the planned latissimus flap, together with the exposed latissimus muscle and skin panel, has been harvested. **C.** Identification of the completed inset of the vascularized latissimus dorsi pedicled flap following its in situ placement in the created chest wall defect.

In all circumstances, the specimen should be resected en bloc, thus exposing the chest wall defect with the exposed, inflated, protuberant lung. Insufflation of the underlying lung following resection of tumor invasion allows evaluation with visualization of alveolar–parenchymal leak; repair must be instituted for closure of such leaks. If invasive disease is detected grossly or with biopsy, the well-exposed lung can then be managed by a wedge resection of the involved lung with a stapler. Leaking defects should again be oversewn and tested for air leaks prior to tube placement and chest closure (Fig. 57.6). Air leak may increase the risk of infection of the material used to close the chest wall defect and a lung sealant can be applied as well if needed.

Prior to initiating chest wall reconstruction, an apical–posterior chest tube should be placed in the midaxillary line *inferior* to the defect. Only one chest tube is needed.

FLAP RECONSTRUCTION

The inset of Figure 57.7 confirms the methyl methacrylate mesh "sandwich" shaped and contoured for the chest wall defect. This reconstructive sandwich should be layered such that the methyl methacrylate is interposed between two layers of the polypropylene mesh.

The prosthetic strut may be created with the folding in half of a larger piece of polypropylene mesh that ensures coverage of the sandwich over the defect without undue tension. It is important that the methyl methacrylate does not contact the rib so as to avoid the pain of these rubbing against each other postoperatively.

With planning of surface area of the prosthetic strut to cover the defect, the mesh should be contoured beyond all margins of the resection such that it can be sutured to the resected rib edge. We prefer that the first layer of the mesh be sutured to the edges of the wound using nonabsorbable 0 or 1 polypropylene sutures (Fig. 57.7A). Figure 57.7B confirms that suturing should encircle ribs on the superior and inferior edges of the resection and that sutures are created external to the mesh, then full-thickness purchase through the musculature, exiting external to the musculature and incorporating the edges of the prosthetic strut, and are tied external to the mesh (Fig. 57.7A). Care must be taken to avoid entrapping the intercostal neurovascular bundle while securing the mesh. The neurovascular bundle should have previously been ligated in an isolated fashion. All sutures are tied external (anterior) to both folded edges of the mesh.

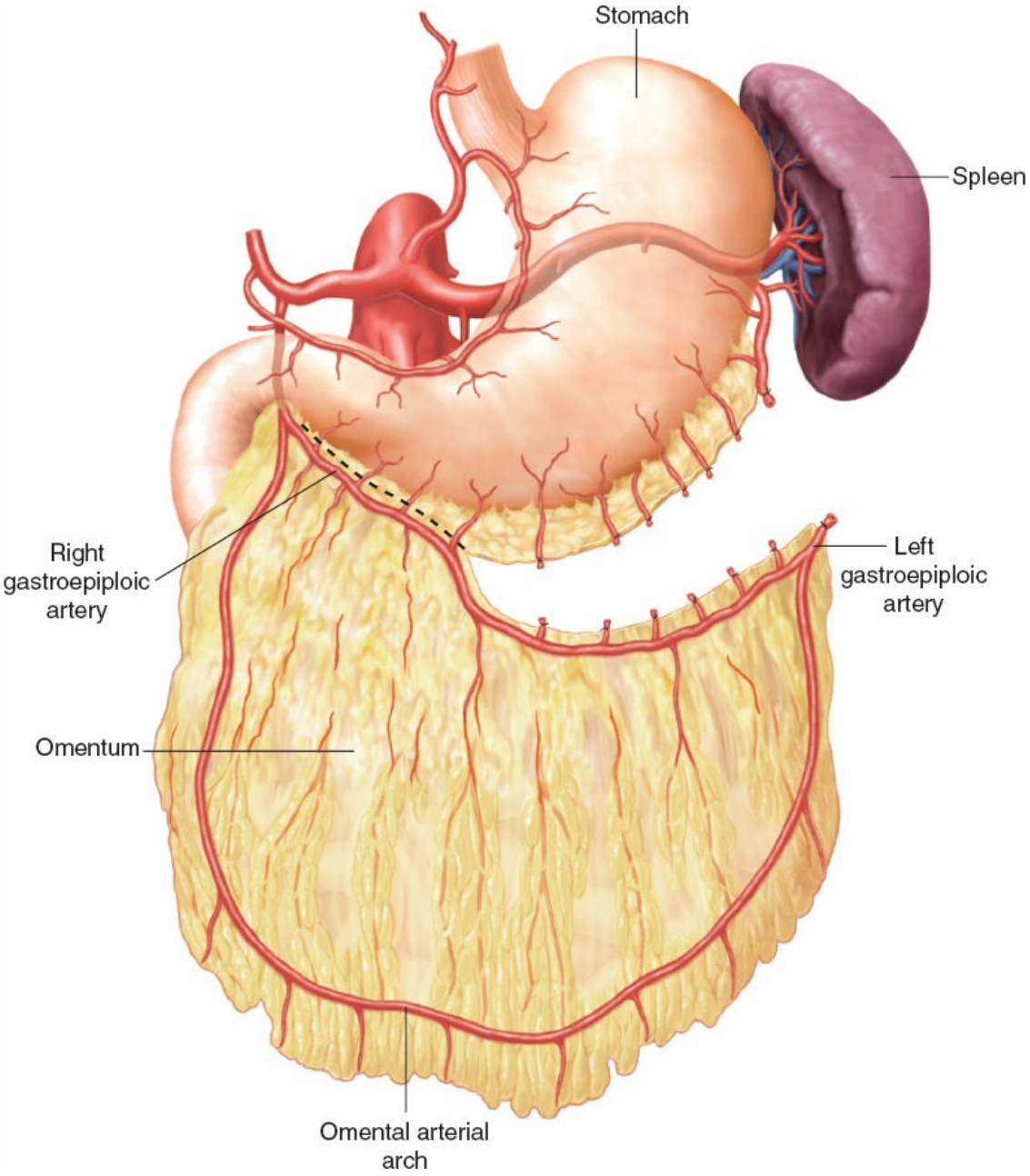

Figure 57.9. The intra-abdominal vasculature of the greater omentum, in which the selection of this approach requires upper midline laparotomy incision for access to the omentum. The omental flap approach by necessity enhances potential morbidity as it adds complexity to the chest wall defect with abdominal entry. Following division of the left gastroepiploic artery, vascular perforators (vasa brevia) to perfuse this arcade are ligated in continuity for revascularization purposes. (From Bland KI, Fix RJ, Cerfolio RJ. Chest wall resection and reconstruction for advanced/recurrent carcinoma of the breast. In: Bland KI, Klimberg VS, eds. *Master Techniques in General Surgery: Breast Surgery*. Philadelphia, PA: Lippincott Williams & Wilkins; 2011.)

Following placement and completion of suturing of the methyl methacrylate "sandwich," reconstruction of the soft tissue defect is initiated. Again, the most commonly utilized and versatile flap reconstruction of this area is the pedicled latissimus dorsi flap that is inclusive of a vascularized skin paddle. Such design and transfer of tissue is highlighted in Figure 57.8A in which the planned latissimus flap (Fig. 57.8B), together with the exposed latissimus muscle and skin paddle, has been harvested. Figure 57.8C confirms the completed inset of the flap following its in situ placement in the created defect.

Figures 57.9 to 57.11 highlight the omental flap, which designates an increase in potential morbidity as it adds complexity to the chest wall defect with abdominal entry. The omental flap is based upon the right gastroepiploic artery that is utilized for tissue coverage (Fig. 57.9). With selection of this approach, the upper midline laparotomy incision is utilized for access to the omentum. Figure 57.11 indicates that the omentum has been transected together with the splenocolic ligament, and divided from the inferior gastric surface from the splenocolic ligament to the base of the right gastroepiploic artery. Ligation and division of the vasa recta of the anterior and posterior omental leaves is performed using 3-0 nonabsorbable sutures (Fig. 57.11).

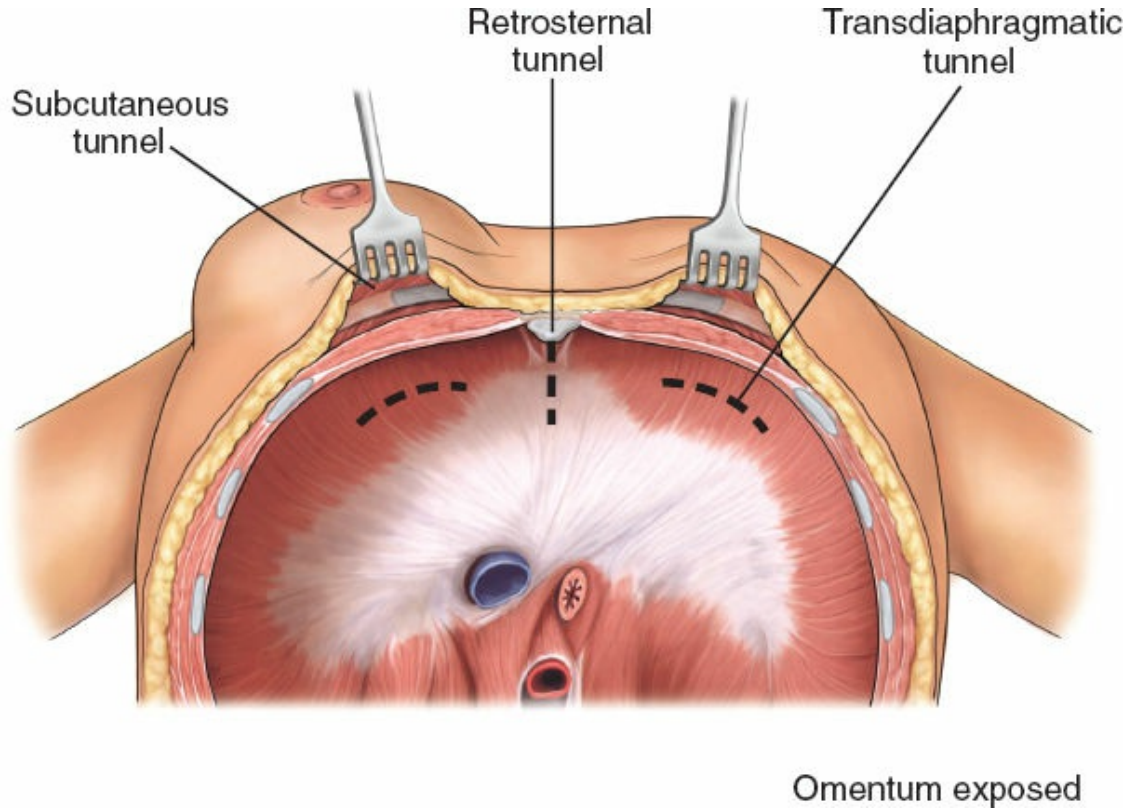

Figure 57.10. The anterior inferior diaphragmatic incisions that

require hepatic mobilization and creation of the transdiaphragmatic tunnel to the created defects of each side and thereafter placement in a subcutaneous tunnel. (From Bland KI, Fix RJ, Cerfolio RJ. Chest wall resection and reconstruction for advanced/recurrent carcinoma of the breast. In: Bland KI, Klimberg VS, eds. *Master Techniques in General Surgery: Breast Surgery*. Philadelphia, PA: Lippincott Williams & Wilkins; 2011.)

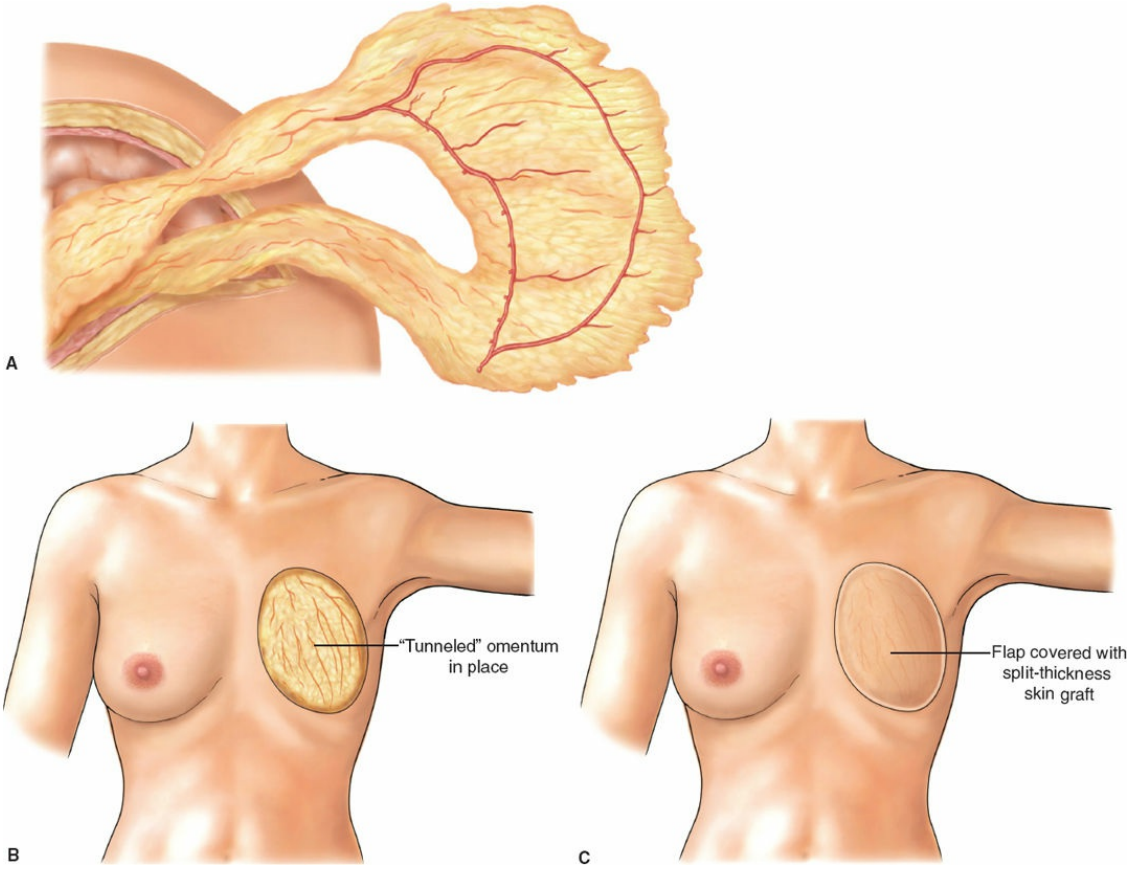

Figure 57.11. A. Mobilization of the omentum, together with the splenocolic ligament, and division from the inferior gastric surface from the gastrocolic ligament to the base of the right gastroepiploic artery. To maintain integrity of the vascular perfusion pedicle, the surgeon must be cognizant of inadvertent rotation of the omental pedicle and avoidance of vascular injury to the peripheral and central components of the pedicle. **B.** The omentum exposed and inserted into the tunneled subcutaneous space created with reconstruction of the defect. **C.** Placement of the optional split-thickness skin-graft coverage of the pedicle, which has been inserted in the patient as visualized at the time of a postoperative visit. (From Bland KI, Fix RJ, Cerfolio RJ. Chest wall resection and reconstruction for advanced/recurrent carcinoma of the breast. In: Bland KI, Klimberg VS, eds. *Master Techniques in General Surgery: Breast Surgery*. Philadelphia,

Options exist for transfer of the vascularized omental pedicle flap. After exiting the midline abdominal incision, the omentum may be transferred to the chest wall defect via a retrosternal, transdiaphragmatic, or subcutaneous tunnel as indicated in Figure 57.10. We prefer and almost exclusively use a transdiaphragmatic approach. To maintain the integrity of vascular perfusion, the surgeon must be cognizant of rotation of the omental pedicle to ensure preserved vasculature to its periphery and all the central components of the pedicle. Figure 57.11A confirms the omentum exposed, and Figure 57.11B confirms the adequately planned coverage of the defect prior to tunneling of the omental pedicle. Figure 57.11C confirms the optional skin grafting of the pedicle that has been inset in the patient as visualized at her postoperative visits.

A third option includes a pedicled free flap utilizing the TRAM flaps with skin paddles to bridge alternatives for covering these defects (Fig. 57.12). In addition, for heavily irradiated parasternal and chest wall tissues, most plastic surgeons prefer the free flap harvested as a TRAM reconstruction with anastomosis to the ipsilateral IMA that provides arterial and venous inflow/outflow to the vascularized graft.

A thoracoepigastric flap represents another option, especially for patients with excessive abdominal wall laxity. This versatile flap consists of the mobilization of the upper abdominal wall as a fasciocutaneous flap of variable sizes, according to the defect to be covered, based on the superior epigastric perforator. The donor site is closed primarily resulting in a “reverse abdominoplasty” as it mobilizes the abdominal tissues superiorly (Figs. 57.13 and 57.14).

For very large soft tissue defects, variations of the above-mentioned flaps provide reliable results. One of the described variations is the extended latissimus muscle flap, where a larger area of skin and subcutaneous tissue is rotated with the muscle flap. This results in a donor site defect that can no longer be closed primarily and will require a skin graft.

Another variation described for very large defects is the use of not only one rectus muscle flap, but rotation of *both rectus muscles* en bloc, on a bipedicle technique, providing additional bulk and skin surface to cover the defect.

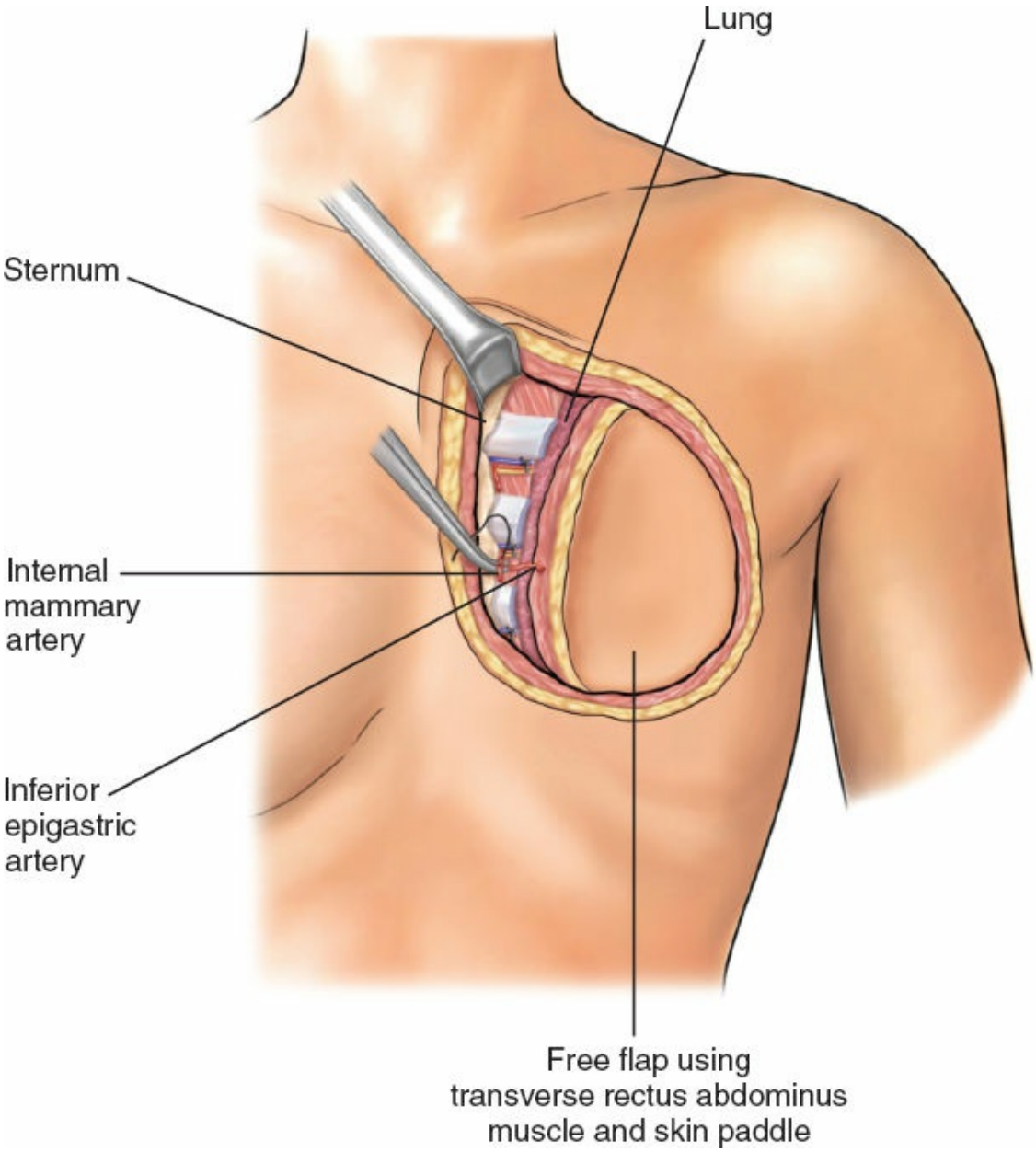

Figure 57.12. An additional option utilizing the pedicled free transverse or vertical rectus abdominis muscle (TRAM) flap as skin panels to bridge as the alternative for covering these defects. In the heavily irradiated parasternal and chest wall tissues, the pedicled free-flap TRAM represents the preferred harvested reconstruction and anastomotic technique. Anastomosis is completed for the vasculature (inferior epigastrics) of the free TRAM to the ipsilateral internal mammary artery (IMA) and provides both arterial inflow and venous outflow to the vascularized graft. (From Bland KI, Fix RJ, Cerfolio RJ. Chest wall resection and reconstruction for advanced/recurrent carcinoma of the breast. In: Bland KI, Klimberg VS, eds. *Master Techniques in General Surgery: Breast Surgery*. Philadelphia, PA: Lippincott Williams & Wilkins; 2011.)

The inset flap should be closed in two layers inclusive of a deep dermal layer that is sutured with 3-0 absorbable sutures. A running subcuticular closure with an absorbable 4-0 suture is used for the skin.

Chest tube drains are essential to evacuate the pneumothorax created with thoracotomy in these patients. In addition, we prefer large defects having subcutaneous closed-suction drains around the soft tissue reconstruction for avoidance of hematoma and seroma. Internal Doppler probes may be placed for monitoring purposes of the flap's arterial blood supply (Fig. 57.15).

POSTOPERATIVE MANAGEMENT

Immediately following operation, a chest x-ray is obtained to evaluate the potential of an existing and retained pneumothorax that is best drained by functional chest tubes. Proper suction drainage on the catheters is essential for vacuum decompression of the pneumothorax created with the opening of the chest. If the patient has an air leak, water seal is the optimal chest tube setting. Pulmonary management should include preventative care for ventilator-associated pneumonia.

COMPLICATIONS

Aggressive pulmonary toilet following extirpation is an essential part of care to prevent atelectasis and subsequent nosocomial pneumonia. Because of the considerable pain experienced with division of the ribs, postoperative epidural pain control should be considered, together with systemic analgesics and sedation.

Continual wound care and flap management are essential; monitoring for flap ischemia and necrosis are the requisite. Arterial supply can best be evaluated by an internal Doppler that is placed intraoperatively. However, the handheld external Doppler is commonly utilized together with visual inspection of capillary refill. Standard criteria are utilized in the management of chest tubes for the timing of removal of these tubes and subcutaneous drains. Removal is dependent upon complete resolution of the pneumothorax and decreasing subcutaneous serous wound drainage.

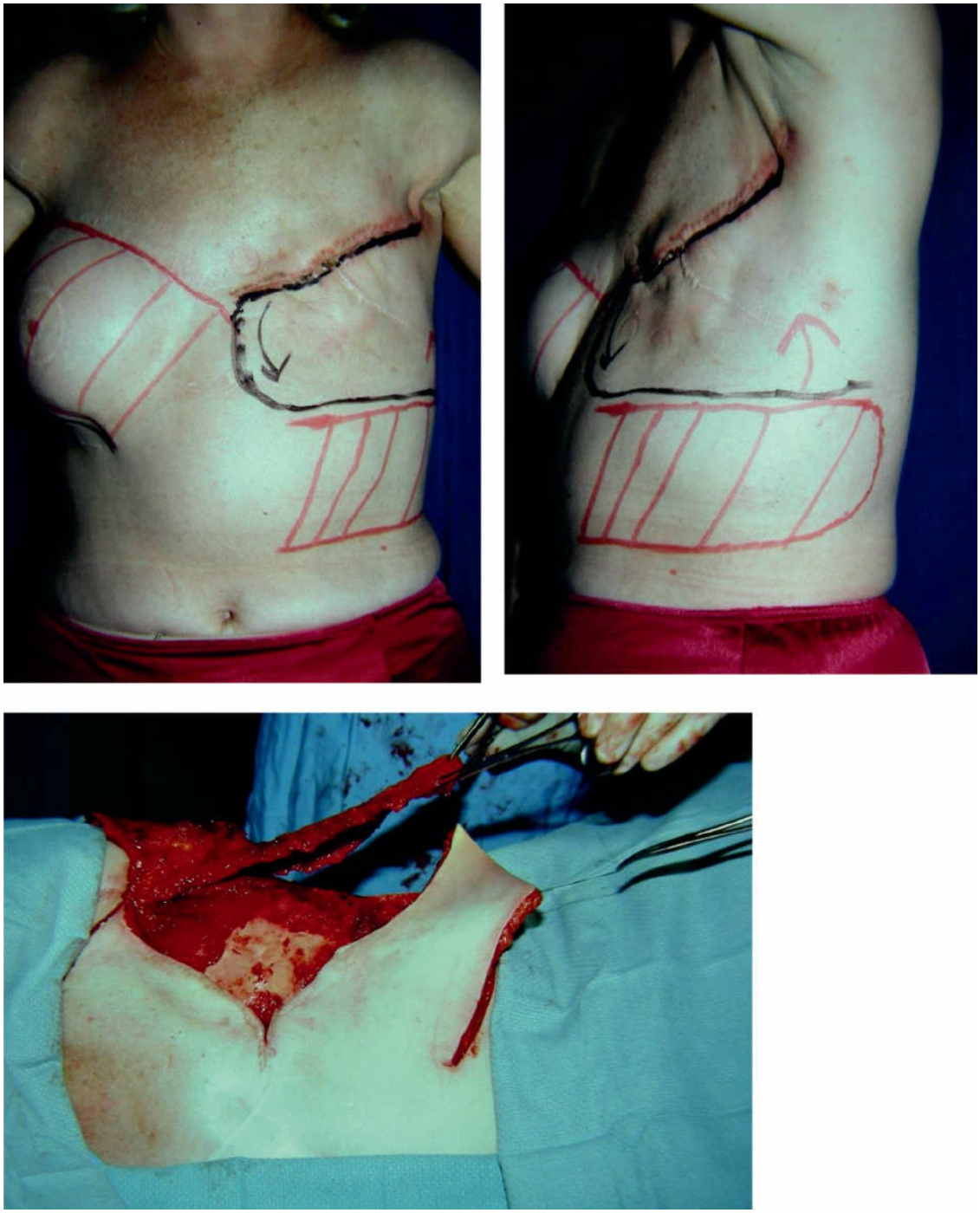

Figure 57.13. Depiction of thoracoepigastric flap where the upper abdominal skin, subcutaneous tissue, and fascia is elevated based on the superior epigastric perforators and rotated superiorly to cover the chest wall defect. The donor site is then approximated primarily.

Morbidity related to these wounds is experienced in virtually all patients. Complications have been reported in as many as 40% of patients and vary from 5% to 40%. The most common complications relate to wound dehiscence, separation and drainage, as well as pneumonia related

to deficient pulmonary toilet. Pulmonary complications also include the risk of reintubation, flail chest, and pleural infection. Wound complications include infection, delayed wound repair, and partial flap or skin-graft necrosis. The serious complications of advanced wound infection often require debridement of portions or all of the methyl methacrylate–polypropylene mesh repair and may include major portions of the reconstruction. Despite the significant morbidity associated with the resection, mortality for the procedure is less than 5%. The surgeon must have a low threshold to evaluate and treat suspected wound and pulmonary infections.

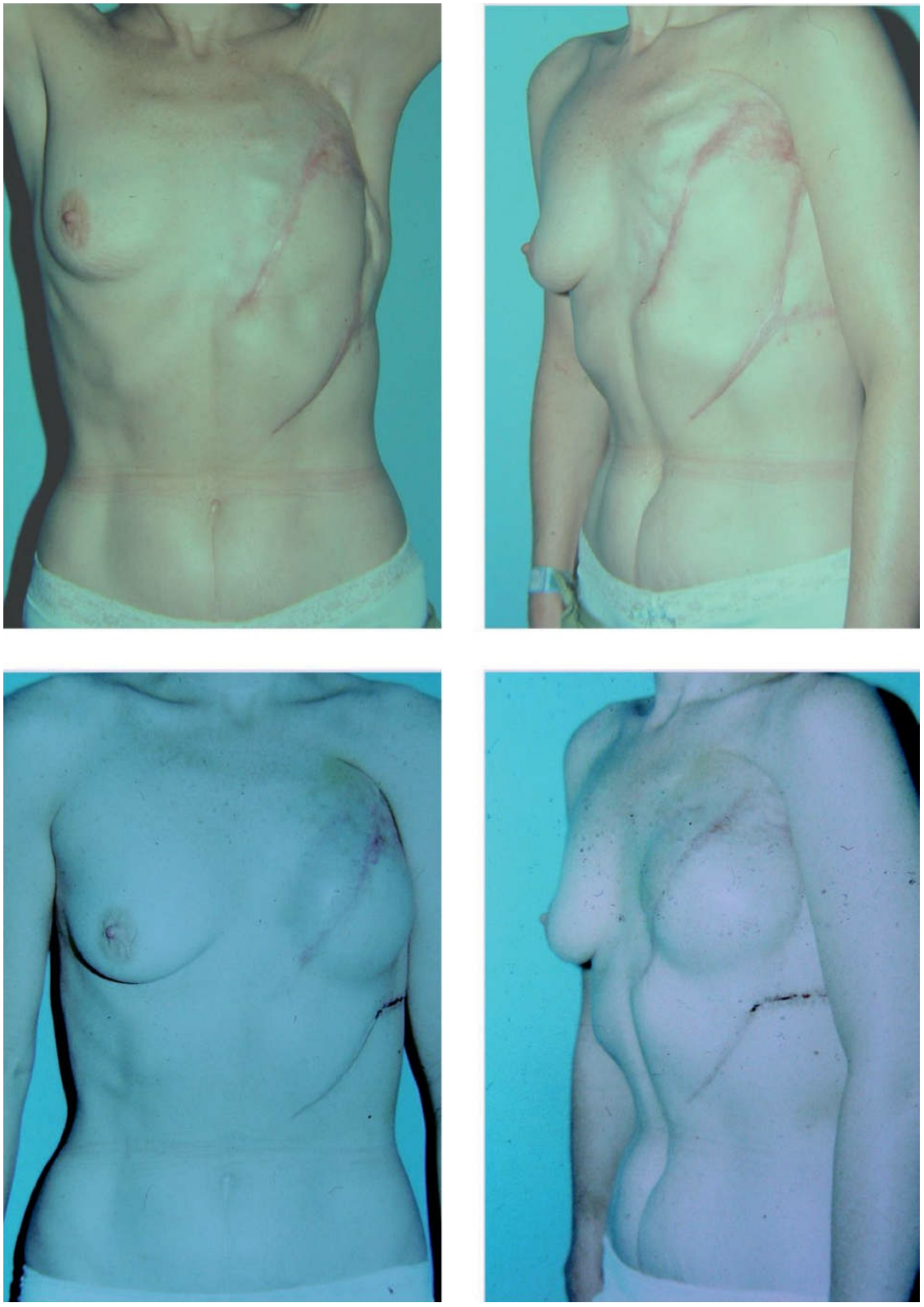

Figure 57.14. Post reconstruction thoracoepigastric flap procedure.

RESULTS

The contemporary surgical literature is devoid of prospective randomized

studies for selective patients undergoing full-thickness chest wall resections that are designed to eradicate locally recurrent/advanced breast carcinoma. Such procedures are regarded as highly mutilating interventions that harbor high morbidity and mortality. Moreover, the utility of plastic reconstruction of the full-thickness chest wall resection for recurrent disease is largely unknown and rarely utilized in surgical clinics. Friedel et al. report the largest series to date for advanced chest wall invasion related to recurrent breast carcinoma utilizing myocutaneous flap coverage. In this series, the cumulative 5-, 10-, and 15-year survival rates were 46%, 29%, and 22%, respectively (median survival, 56 months). When an R0 resection was possible, the 5-year survival was 50.4%. Similarly, outstanding results have been reported by Hanagiri et al., Hameed et al., Veronesi et al., Rivas et al., Cordeiro et al., Suryanarayana Deo et al., Chagpar et al., Kolodziejski et al., Santillan et al., and Pameijer et al.

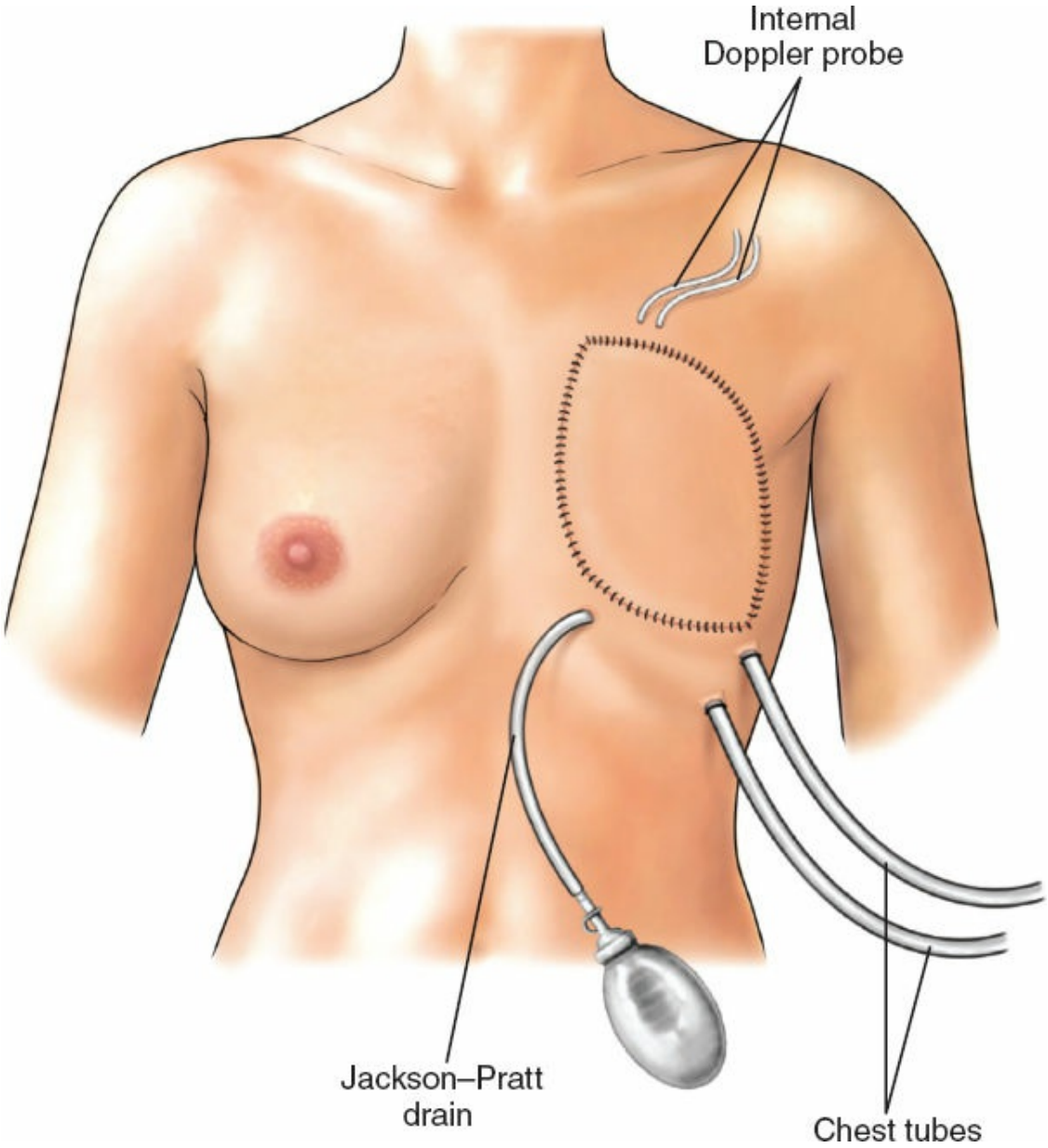

Figure 57.15. Depiction of the inset flap enclosure with completed closure of two layers of the deep dermal layer and a running subcuticular closure with absorbable suture. The opened thorax requires closed-suction chest tubes to evacuate the pneumothorax. In addition, the large defects require subcutaneous closed-suction drainage for evacuation of hematoma and seroma in the reconstruction site. The placement of internal Doppler probes over the vascularized free flap arterial blood flow provides continual monitoring of the patient. (From Bland KI, Fix RJ, Cerfolio RJ. Chest wall resection and reconstruction for advanced/recurrent carcinoma of the breast. In: Bland KI, Klimberg VS, eds. *Master Techniques in General Surgery: Breast Surgery*. Philadelphia, PA: Lippincott Williams & Wilkins; 2011.)

In the report by Pameijer et al. from the City of Hope National Medical Center, 71% of patients had an R0 resection; in this cohort, the 5-year disease-free survival was 67%. These reports suggest improvement in long-term palliation and potential cure for this select patient group with chest wall recurrence of breast carcinoma.

CONCLUSIONS

The pathobiologic character of the primary breast neoplasm and prior surgical technique with adjuvant/neoadjuvant approaches determines tumor recurrence.

Sine qua non to eligibility as candidate for chest wall resection is confirmation of the absence of systemic disease following staging.

A team approach with plastic and thoracic surgeons is essential with the oncologic surgeon to allow tissue transfer with reconstruction.

Confirmation of absence of skin/muscle involvement with "punch" biopsy technique enhances local control.

Resections that extend beyond four ribs will routinely require rigid chest wall reconstruction.

Disease-free survival in properly selected patients exceeds 50% at 5 years.

Suggested Readings

Bedwinek J. Natural history and management of isolated local–regional recurrence following mastectomy. *Semin Radiat Oncol* 1994;4:260–9.

Chagpar A, Langstein HN, Kronowitz SJ, et al. Treatment and outcome of patients with chest wall recurrence after mastectomy and breast reconstruction. *Am J Surg* 2004;187:164–9.

Cordeiro PG, Sanatamaria E, Hidalgo D. The role of microsurgery in reconstruction of oncologic chest wall defects. *Plast Reconstr Surg* 2001;108(7):1924–30.

Deo SV, Purkayastha J, Shukla NK, et al. Myocutaneous versus thoraco-abdominal flap cover for soft tissue defects following surgery for locally advanced and recurrent breast cancer. *J Surg Oncol* 2003;83:31–5.

Friedel G, Kuipers T, Dippon J, et al. Full-thickness resection with myocutaneous flap reconstruction for locally recurrent breast cancer. *Ann Thorac Surg* 2008;85:1894–900.

Hameed A, Akhtar S, Naqvi A, et al. Reconstruction of complex chest wall defects by using polypropylene mesh and a pedicled latissimus dorsi flap: a 6-year

experience. *J Plast Reconstr Aesthet Surg* 2008;61:628–35.

Hanagiri T, Nozoe T, Yoshimatsu T, et al. Surgical treatment of chest wall invasion due to the local recurrence of breast cancer. *Breast Cancer* 2008;15:298–302.

Howard JH, Tzeng CWD, Fix RJ, et al. Chest wall resection. In: Klimberg VS, ed. *Atlas of Breast Surgical Techniques.* Philadelphia, PA: Saunders; 2010.

Kolodziejski LS, Wysocki WM, Komorowski AL. Full-thickness chest wall resection for recurrence of breast malignancy. *Breast J* 2005;11(4):273–7.

Pameijer CR, Smith D, McCahill LE, et al. Full-thickness chest wall resection for recurrent breast carcinoma: an institutional review and meta-analysis. *Am Surg* 2005;71:711–5.

Rivas B, Carrillo JF, Escobar G. Reconstructive management of advanced breast cancer. *Ann Plast Surg* 2001;47(3):234–9.

Santillan AA, Kiluk JV, Cox JM, et al. Outcomes of locoregional recurrence after surgical chest wall resection and reconstruction for breast cancer. *Ann Surg Oncol* 2008;15(5):1322–9.

Veronesi G, Scanagatta P, Goldhirsch A, et al. Results of chest wall resection for recurrent or locally advanced breast malignancies. *Breast* 2007;16:297–302.

EDITOR'S COMMENT

Chest wall recurrence as well as locally advanced disease of the breast are associated with systemic disease in only about half the cases. Such a disease is associated with sometimes painful open wounds and odorous diseases. Therefore it is incumbent on the surgeon to be able to take care of such diseases. Not all chest wall recurrence is the same and therefore the treatment is not all the same (Moossdorff M, van Roozendaal LM, Strobbe LJ, et al. Maastricht Delphi consensus on event definitions for classification of recurrence in breast cancer research. *J Natl Cancer Inst* 2014;106(12)). Small (<2 cm) and late (>2 years from primary) chest wall recurrences may be handled with simple wide local excision. Depending on the age of the patient (premenopausal vs. postmenopausal) and extent of disease radiation may be added to the younger patient with muscular invasion. Because 50% of patients with recurrence have systemic disease, a metastatic workup is warranted and treat accordingly (Wadasadawala T, Vadgaonkar R, Bajpai J. Management of isolated locoregional recurrences in breast cancer: a review of local and systemic modalities. *Clin Breast Cancer* 2017. pii: S1526–8209(16)30416–5).

The second type of chest wall recurrence presents with multiple nodules of long-standing duration (>3 months) for which the patient has delayed treatment. When left alone these lesions infiltrate the chest wall and ulcerate the overlying

skin. These can also be resected with full thickness resection of the muscle. When infiltrating the deep chest wall they are rarely free of systemic disease. Still, local control is imperative. More often a full thickness involvement requiring rib resection is seen with rarer types of breast cancer such as phylloides or desmoids and do not necessarily have systemic disease. The authors detail in this and other chapters various muscular flaps that can be used to cover the mesh reconstruction. When the chest wall reconstruction is lateral and there is remaining pectoralis major, I have detached the inferior half of the pectoralis major from the ribs, freed it from the underlying pectoralis minor and rotated it to cover the mesh. This works quite well when possible, is easier on the patient and very quickly performed.

The third type of recurrence is inflammatory or carcinoma en cuirasse, that is, diffuse infiltration of the chest wall skin and subcutaneous tissue. Initial local excision in these cases is futile as they will recur almost immediately. In such cases, multimodality therapy is again required but in a different order. Primary systemic therapy is important. We have also reported successful use of subcutaneous injections of interferon in such cases. Photodynamic therapy has been used successfully but requires long procedures, results in ulcers, long healing times and can only be used in relatively superficial disease. When disease on the chest wall fails to respond to such treatment, radiation is a good next step especially when metastatic disease is already present. It can keep the chest wall in check. If there is no systemic disease then an attempt at resection and reconstruction after radiation is warranted. If surgery were to be prior to this radiation, recurrence will occur before the patient can fully heal. It is important prior to any surgical procedure that the surgeon makes every attempt to improve the commensurate poor nutritional status of all these patients. Most assuredly adding radiation prior to surgery will delay the wound healing and prolong drainage but these patients eventually heal with a higher chance of chest wall control. Paying attention to nutrition and prescribing the cofactors for collagen formation, Vitamins A, C and zinc, will aid in successful wound healing.

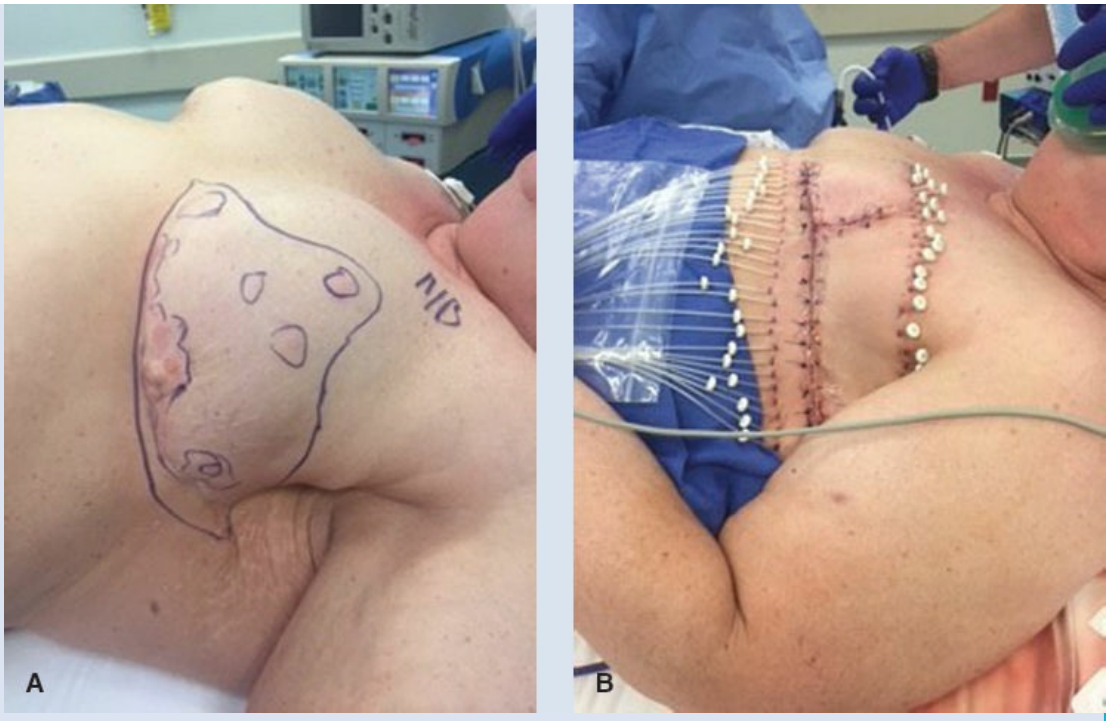

Figure 1. A. Recurrence on chest wall in a patient with reconstruction with implant and radiation. *Purple line* shows area to be resected. **B.** Patient postresection and placement of brachytherapy catheters for reirradiation.

The fourth type of recurrence is in an already irradiated field. Resection often has to be wide requiring flap reconstruction. The authors of this chapter have described extensive chest wall resection and various muscular flaps to cover the chest wall. The method for replacing the rib cage is what I use and is necessary to prevent paradoxical chest wall motion and is radiolucent as to allow radiographic follow-up. Mesh over bone cement has also been used (Rajesh A, Farooq M. Resection and reconstruction following recurrent malignant phyllodes–Case report and review of literature. *Ann Med Surg* 2017;16:14–8). In such cases, especially if the recurrence appears inflammatory or is incompletely resected, reirradiation may be necessary (Marta GN, Hijal T, de Andrade Carvalho H. Reirradiation for locally recurrent breast cancer. *Breast* 2017;33:159–65). These authors reported local control and complete response rates were reported to be 43% to 96% and 41% to 71%, respectively. Reirradiation in combination with hyperthermia suggested improved results (Jones EL, Marks LB, Prosnitz LR: Point: Hyperthermia with radiation for chest wall recurrences. *J Natl Compr Canc Netw* 2007;5:339–44). These cases are rare enough and present with such varied prior treatments, it is difficult to really judge success. At our institution, when chest wall recurrences present in a prior irradiated field, the first obligation is to bolster the patient's nutritional status. Then every attempt is made to resect the chest wall to clean margins. In such patients in order to avoid major flap reconstruction, as the complication rate is high, and if the patient has a remaining contralateral breast, one can perform a

skin-sparing mastectomy of the contralateral breast and fashion that skin into flaps to cover the ipsilateral skin defect. We like to use brachytherapy catheters placed at the time of resection to cover the area of recurrence. As such catheters have a more focused depth of radiation (～1 cm) then reirradiation of vital organs can be avoided. Figure 1A and B demonstrates pre- and postresection with brachytherapy catheters in place. One can except prolonged seroma drainage in such cases (～1 month) so that the surgeon should avoid removing catheters too early. When recurrence is in the sternum or more likely in the case of recurrent breast cancer in a mediastinal node eroding the sternum, major resection is and flap reconstruction is more involved and difficult for the patient (Cranenbroek S, van der Sangen MJ, Kuijt GP, et al. Diagnosis, treatment and prognosis of internal mammary lymph node recurrence in breast cancer patients. *Breast Cancer Res Treat* 2005;89:271–5). Reirradiation with gamma knife can be successful in controlling this disease and should be tried with or without resection. Overall prognosis for these patients is poor. Reconstruction of the sternum involves similar principles. There have been reports of the use of three-dimensional printing based on volumetric scans to provide hardware for reconstructing the sternum (Khalpey Z, Marsh KM, Ferng A, et al. First in man: sternal reconstruction with autologous stem cells. *ASAIO J* 2015;61(5):e31–2).

As one can see, there are as many operations as there are surgeons that can think of them. It is important to note there is not one correct answer except to say that this is a problem that only a multiple modality treatment (chemotherapy, immunotherapy, radiation therapy, surgery, and nutrition) can solve. With enough ingenuity, the passage of time, and technical skill, one can utilize a variety of muscles, skin, and prosthetic material that will give satisfactory coverage where one would not necessarily think it possible. In other words, do not give up if there is a recurrence of the chest wall; utilize your ingenuity and any kind of material, and finally you likely with enough persistence a good clinical result.

V. Suzanne Klimberg

58 Clinical Trials and Follow-Up for Breast Cancer

Michael S. Cowher, LaShondria Simpson-Camp, Eleftherios P. Mamounas, and Thomas B. Julian

PRIMARY SURGICAL THERAPY FOR INVASIVE BREAST CANCER

INTRODUCTION

Near the turn of the 20th century, breast cancer was a disease that carried a high mortality and had limited treatment options. Anecdotal reports from small series reported high levels of local recurrences (LR). In the 1895 *Annals of Surgery*, Halsted reported on 50 patients treated with radical mastectomy, with the LR rate of 6%. Although the Halsted radical mastectomy involving en bloc resection of the breast and surrounding chest wall musculature, skin, and axillary contents improved local control, mortality and morbidity remained high. Extensive belief in the value of the Halsted technique lasted into the later part of the 20th century when laboratory and clinical investigations challenged the hypothesis that breast cancer spreads primarily by a local contiguous process from the breast to the regional lymph nodes and eventually to distant sites. Instead, an alternative hypothesis postulated that breast cancer is a systemic disease from early on in its inception because breast cancer cells can reach distant sites through the blood stream without necessarily involving the regional lymph nodes. This paradigm change in the understanding of the biology of breast cancer progression led to the development and conduct of randomized clinical trials that eventually established the new standards for the surgical and adjuvant treatment of the disease.

Randomized clinical trials evaluated the use of less aggressive surgical techniques—with or without radiotherapy (RT)—and the introduction of adjuvant endocrine therapy and adjuvant chemotherapy. The results of these trials set the framework for the multidisciplinary approach to breast cancer and have led to a substantial decrease in breast cancer mortality

while improving the quality of life of breast cancer patients.

This chapter reviews key clinical trials that have led to improvements in breast cancer locoregional and systemic therapies.

National Surgical Adjuvant Breast and Bowel Project (NSABP) B-04

One of the first randomized surgical trials, introduced by the National Surgical Adjuvant Breast and Bowel Project (NSABP), the B-04 study accrued 1,765 patients with breast cancer between 1971 and 1974. Clinically node-negative (cN−) patients were randomly assigned to radical mastectomy, total mastectomy, or total mastectomy plus locoregional axillary RT. Clinically node-positive (cN+) patients were randomly assigned to radical mastectomy or total mastectomy plus axillary RT. With 25 years of follow-up, the B-04 trial continues to show no marked differences in overall survival (OS) between cN− patients who underwent radical mastectomy and those who underwent total mastectomy with or without axillary RT. In addition, for cN+ patients, there were no statistically significant differences in OS between those who had radical mastectomy and those who had total mastectomy with axillary RT. In the cN− patients who had axillary dissection as part of radical mastectomy, 40% had pathologically positive nodes. Despite this, the total mastectomy-only patients (who can be assumed also to have had approximately a 40% N+ rate) had an axillary failure rate of only 19%, suggesting that occult axillary disease may not always progress to clinical relevance and that omission of axillary dissection does not compromise outcome. The NSABP B-04 study began a trend of less extensive (and morbid) surgery for many patients with breast cancer, and was soon followed by studies questioning the need for mastectomy altogether.

Milan I

The Milan I study was an Italian prospective randomized clinical trial that played a critical role in the introduction of breast-conserving therapy (BCT), defined as quadrantectomy followed by RT, as an acceptable treatment option for women with small (<2 cm) operable breast cancers. Between 1973 and 1980, 701 women were randomly assigned to radical mastectomy or BCT. There were no appreciable differences in long-term survival between the groups, despite a higher cumulative incidence of recurrence at 20 years in patients treated with quadrantectomy plus RT. In-

breast tumor recurrence (IBTR) rates after 20 years of follow-up were 8.8% in the BCT group and 2.3% in the radical mastectomy group ($P < 0.001$). In addition, there were no substantial differences between the two groups in the rates of contralateral breast cancer, distant metastases, or secondary primary cancers, and survival.

NSABP B-06

Concurrent with the MILAN I trial, the NSABP B-06 trial compared partial mastectomy (lumpectomy) and axillary node dissection with and without breast RT to modified radical mastectomy (MRM) in patients with breast tumors <4 cm in largest diameter. A total of 2,163 patients were enrolled between 1976 and 1984 and were randomly assigned to one of three arms: MRM, lumpectomy (partial mastectomy) with axillary node dissection, or lumpectomy with axillary node dissection and whole-breast irradiation. With 20 years of follow-up, there continue to be no differences in OS, disease-free survival (DFS), or distant DFS between the mastectomy group and the groups treated with lumpectomy with or without whole-breast RT. BCT was associated with a marginal decrease in breast cancer deaths, but this was partially offset by an increase in deaths from other causes.

Although the lack of differences in OS in B-06 has led to the acceptance of BCT as a local treatment option for patients with operable breast cancer, it is important to note that there were differences in LR among the three arms. IBTR occurred in 39.2% of the lumpectomy-alone arm compared to 14.3% in the lumpectomy-plus-whole breast-RT arm. Chest wall recurrence occurred in 10.2% of the mastectomy group. The majority of ipsilateral recurrences in the lumpectomy-alone group occurred within the first 5 years after surgery; most ipsilateral recurrences in the irradiated and mastectomy arms occurred after 5 years.

The early results and subsequent long-term results of the NSABP B-06 and MILAN I trials have established BCT as the preferred treatment option for women with operable, early-stage invasive breast cancer. Further studies have sought to refine the indications and nuances involved in its appropriate implementation.

Cancer and Leukemia Group B (CALGB) 9343

Questioning the necessity of RT for all patients undergoing lumpectomy for invasive breast cancer, the CALGB 9343 study enrolled women aged

70 and older with clinical stage I (T1N0M0) estrogen-receptor–positive (ER+) breast cancer treated by lumpectomy. Patients were randomly assigned to receive tamoxifen (Tam) plus RT (TamRT) therapy or Tam alone. At 10 years, 98% of the women who received TamRT were free from local and regional recurrences, compared to 90% of those receiving Tam alone. The 10-year estimates of OS were 67% (95% CI, 62% to 72%) in the TamRT group versus 66% (95% CI, 61% to 71%) in the Tam-alone group. The study authors concluded that although RT (in addition to Tam) reduces locoregional recurrence (LRR), the impact of breast cancer in this select group of older women is much less than that of comorbid conditions. They noted that 3% of women in the study have died as a result of breast cancer, whereas 49% have died as a result of other causes. This study has allowed clinicians to consider the omission of RT for women >70 years with ER+ node-negative disease.

European Organisation for Research and Treatment of Cancer (EORTC) 1081

The EORTC 1081 study was a large, multicenter clinical trial designed to demonstrate the safety of BCT compared to MRM in patients with tumors 5 cm or smaller (T I-II) and axillary node-negative or node-positive disease. This study was open for accrual between 1980 and 1986 in the United Kingdom, the Netherlands, Belgium, and South Africa. There were 448 patients randomly assigned to BCT and 420 assigned to MRM. Patients who received BCT were treated with lumpectomy and complete axillary dissection followed by breast RT with tumor bed boost. At the 20-year follow-up, no clinical differences were noted for OS (44.5% in the MRM group vs. 39.1% in the BCT group) or time to distant metastasis. At 10 years, BCT was noted to have a higher LRR rate—20% versus 12% for MRM. In addition, factors associated with increased LRR were found to be dependent on biologic characteristics, including larger tumor size, lymph node metastasis, and receptor type. This study contributed to the earlier body of evidence from the B-06 and Milan I studies, both of which evaluated the safety and effectiveness of BCT for women with relatively small breast tumors. However, one of the main differences between those studies and the EORTC 10801 trial was that the latter generally included patients with larger tumors (80% had T2 tumors), and lymph node metastases (41%). Although tumor size >2 cm and positive lymph node status were found to increase risk for distant metastasis and death, this was

found to be independent from surgical intervention. Thus, the EORTC 10801 trial provided valuable data proving that BCT can safely be performed for patients with larger tumors and positive axillary lymph nodes.

Society of Surgical Oncology (SSO)/American Society for Radiation Oncology (ASTRO) Margin Consensus for Invasive Breast Cancer

Up until 2014, although BCT had become standard practice in the management of early-stage breast cancer, there was no accepted consensus on optimal negative margin width. The Society of Surgical Oncology (SSO) and the American Society for Radiation Oncology (ASTRO) convened a multidisciplinary expert panel to review the available evidence regarding margin width and IBTR and to issue recommendations on the appropriate margin width for patients treated with BCT. The panel used data from a recently published meta-analysis as well as results of randomized trials, reproducibility of margin assessment, and current patterns of multimodality care in order to conclude that (1) positive margins, defined as ink on invasive cancer, are associated with at least a two-fold increase in IBTR, but (2) negative margins (no ink on tumor) optimize IBTR and *the routine practice to obtain negative margins wider than no ink on tumor does not significantly decrease IBTR rates.* Although young age is associated with both increased IBTR after BCT and increased chest wall relapse after mastectomy, there was no evidence that increased margin width nullifies this increased risk in young patients.

PRIMARY SURGICAL THERAPY FOR NONINVASIVE BREAST CANCER

Ductal carcinoma in situ (DCIS) is defined as abnormal cancerous cells confined to the breast ducts. There has recently been considerable debate about the use of the term “carcinoma” in its description, as invasion is a “classic hallmark of cancer.” Regardless, since the advent of screening mammography, the incidence of DCIS has increased markedly, and its propensity to contain an invasive component at excision or to develop into invasive cancer in the future has driven surgical and adjuvant management recommendations. Although there has never been a randomized trial comparing BCT to mastectomy in appropriate patients with DCIS (as was

NSABP B-06 for invasive cancer), there have been several trials addressing the management of DCIS in a less invasive fashion.

NSABP B-17

In 1988, the NSABP began the B-17 trial to investigate BCT in the treatment of DCIS. This trial included 818 patients randomly assigned to receive lumpectomy alone or BCT. The addition of RT resulted in a drop of both the cumulative incidence of noninvasive IBTR from 14.6% to 8.0% ($P = 0.001$) and the incidence of invasive IBTR from 16.8% to 7.7% ($P = 0.00001$). The pathologic finding of moderate or marked comedo-necrosis was an independent risk factor for IBTR in both treatment groups. There was no statistically significant difference in OS between the two groups (86% vs. 87% $P = 0.80$). Updated 12-year follow-up data indicated that RT continues to decrease the rate of both invasive and noninvasive IBTR.

European Organisation for Research and Treatment of Cancer (EORTC) 10853

Similar in design to NSABP B-17, the EORTC 10853 study randomly assigned more than 1,000 women with DCIS to lumpectomy versus lumpectomy followed by whole-breast RT. After 15 years of follow-up, the study continues to show that RT reduced the risk of LR of any kind by 48% ($p < 0.001$). The 15-year invasive cancer LR-free rate was 84% in the lumpectomy group and 90% in the lumpectomy plus breast RT group. No differences were seen for breast-cancer specific survival or OS in either treatment arm.

Independent adverse prognostic factors for LR were age <40 years, symptomatic detection, solid or cribriform growth pattern, and involved margins. This study also found that patients who had an invasive recurrence had decreased survival compared with those without LR and the investigators were unable to identify a subgroup of DCIS patients in whom RT could be withheld.

Eastern Cooperative Oncology Group (ECOG) E5194

The ECOG E5194 trial accrued 670 patients between 1997 and 2002 who had lumpectomy for DCIS without RT. Thirty percent of patients took Tam. Patients were stratified into two groups: (1) low- or intermediate-

grade DCIS with lesions measuring 2.5 cm or less and (2) high-grade DCIS measuring 1 cm or less with margin widths of 3 mm or wider and no residual calcifications on postoperative mammograms. The low/intermediate DCIS group, with 565 eligible patients, demonstrated a 5-year IBTR rate of 6.1%, whereas the high-grade stratum, with 105 eligible patients, showed a 5-year IBTR rate of 15.3%. These results suggested that excision alone is inadequate treatment in patients with high-grade lesions, whereas patients with low/intermediate grade lesions may be treated without RT, given an acceptably low 5-year rate of ipsilateral breast events. However, at 12 years of follow-up, the rates of developing an IBTR continued to rise without a plateau effect: 14.4% for the low/intermediate risk group and 24.6% for the high-risk group with 12-year risks of invasive IBTR of 7.5% and 13.4%, respectively. This suggests that patient life expectancy and impact of RT and recurrence on quality of life should be considered when planning RT for DCIS treated with lumpectomy.

Solin et al. used results from the E5194 study to validate a DCIS recurrence risk score with the use of the Oncotype DX DCIS assay. This 12-gene recurrence score for DCIS is a modification of the 21-gene recurrence score used to predict the risk of recurrence for invasive breast cancer. The assay was evaluated in 327 patients from the E5194 study and was found to be an independent predictor of risk for IBTR (HR = 2.31; P = 0.02). The 10-year risk of any IBTR or invasive IBTR increased continuously as the DCIS Score increased. Patients with a low-risk DCIS Score had a 10-year risk of IBTR or invasive IBTR of 10.6% and 3.7%, respectively. Solin's study provided a new clinical tool using molecular taxonomy for individualized treatment selection for patients with DCIS. The utility of the DCIS recurrence score in predicting IBTR was further validated in another prospectively designed, population-based study that included 571 DCIS patients from Ontario, Canada, who received breast-conserving surgery alone with negative resection margins. In that study, the 10-year risk of IBTR according to DCIS Score risk group was similar to that from ECOG E5194: 12.7% for low-risk, 33.0% for intermediate-risk, and 27.8% for high-risk. DCIS Score was predictive of both invasive and DCIS IBTR (P = 0.03 and P = 0.002, respectively). In the multivariable analysis, the DCIS Score was an independent predictor of LR along with age, tumor size, solid or cribriform DCIS subtype, and multifocality.

NSABP B-24 and B-35

Following the B-17 trial, the NSABP directed attention to Tam as an adjuvant therapy for women treated with BCT for DCIS. The fact that Tam had been shown to markedly reduce IBTR as well as contralateral breast cancer events following BCT for invasive cancer made it an attractive option for patients with DCIS. In the early 1990s, 1,804 women with DCIS treated with BCT were randomly assigned to receive either Tam 20 mg daily for 5 years or placebo for the NSABP B-24 study. In contrast to the B-17 trial, patients were eligible regardless of margin status, and in fact 16% of patients had involved surgical margins. The addition of tamoxifen substantially improved DFS from 77.1% to 83.0% (P = 0.002), and the cumulative incidence of all ipsilateral and contralateral breast cancer events was reduced by 39%, with a reduction of invasive breast cancer events by 45%. Further retrospective analysis of Tam benefit by hormone-receptor status confirmed that the benefit was primarily seen in patients with ER-positive DCIS.

As the use of adjuvant aromatase inhibitors became more widespread for early-stage, invasive, ER-positive breast cancer, the NSABP B-35 study randomly assigned ER-positive, postmenopausal patients having BCT for DCIS to either Tam 20 mg per day or to anastrozole 1 mg per day. Follow-up data with a median of 9 years have recently shown that anastrozole provided a statistically significant improvement in breast cancer–free interval and DFS in the overall study population. Prespecified subset analysis of the treatment effect by age demonstrated that the anastrozole advantage was primarily seen in women younger than 60 years. There was also decreased incidence of thromboembolism in the anastrozole group, compared to the tamoxifen group, making this agent an attractive option for postmenopausal women who undergo BCT for DCIS.

NSABP B-43

DCIS is more likely to overexpress HER2/neu than is invasive cancer, and this overexpression is often associated with more aggressive subtypes of DCIS. Preclinical studies have shown that trastuzumab boosts the effectiveness of RT in xenograft models and in cell lines, without producing a detrimental effect on irradiated HER2-normal cells. Furthermore, several adjuvant trials in patients with invasive breast cancer have shown that trastuzumab added to adjuvant chemotherapy significantly improves DFS and OS. The above rationale led to the conduct

of the NSABP B-43 trial, which randomly assigned patients with DCIS treated with lumpectomy to RT alone or to RT plus two doses of trastuzumab given postoperatively during RT. The aim of this study was to determine if trastuzumab given during RT helps prevent the subsequent occurrence of IBTR or ipsilateral DCIS recurrence. This study has finished accruing patients, and it is currently on follow-up.

NEOADJUVANT CHEMOTHERAPY TRIALS

As BCT became an acceptable treatment for many women with operable breast cancer, the administration of systemic cytotoxic and/or antihormonal therapy was concurrently shown to have benefits for both DFS and OS in patients with positive as well as negative axillary lymph nodes. This benefit encouraged the development of trials demonstrating the use of preoperative systemic therapy for the downstaging of primary tumor size to allow more patients the option of breast conservation. It is important for surgeons treating breast disease to understand current research about optimal neoadjuvant chemotherapy regimens to maximize surgical options and outcomes for breast cancer patients.

NSABP B-18

From 1988 to 1993, NSABP B-18 randomly assigned 1,523 patients with operable breast cancer to surgery and then adjuvant chemotherapy (4 cycles of doxorubicin/cyclophosphamide—ACx4) or the same chemotherapy preoperatively and then surgery. The primary aim was to determine if the administration of neoadjuvant chemotherapy would more effectively prolong DFS and OS than standard adjuvant therapy.

Results on tumor response following neoadjuvant chemotherapy showed that 36% of patients had a complete clinical response (by tumor palpation) and 43% had a partial clinical response, for an overall clinical response rate of 79%. In addition, 13% of patients had no invasive cancer in the breast specimen following neoadjuvant chemotherapy, that is, a pathologic complete response (pCR). The neoadjuvant group with presumed cN+ disease also had a 37% down-staging rate of axillary lymph nodes. Patients who received neoadjuvant chemotherapy were also substantially more likely to have had lumpectomy (67% vs. 60%, P = 0.002).

Initial outcome results from the B-18 trial showed no statistically significant differences in DFS, distant DFS, or OS between the two

groups. However, patients who achieved pCR had statistically significantly better DFS and OS compared to those who had a clinical complete response but residual invasive tumor on pathology specimen, those who had partial clinical response, and those who had no clinical response. Even after adjusting for other known clinical prognostic factors such as nodal status, tumor size, and age, pCR remained an independent predictor for OS.

More recent results with 16 years of follow-up in the B-18 trial continue to show no clinically meaningful differences in DFS and OS between the two treatment groups; however, there are trends in favor of neoadjuvant chemotherapy for both DFS and OS in women younger than 50 years.

NSABP B-27

After the NSABP B-18 trial established the foundation of neoadjuvant chemotherapy in operable breast cancer, the B-27 trial was conducted to evaluate the role of taxanes pre- or postoperatively in addition to neoadjuvant adriamycin-cytoxan x4. From 1995 to 2000, a total of 2,411 patients were randomly assigned to adriamycin-cytoxan x4 followed by surgery versus adriamycin-cytoxan x4 followed by docetaxel x4 and then surgery, versus adriamycin-cytoxan x4, surgery, and then adjuvant docetaxel. All patients began Tam when initiating their cytotoxic therapy.

Although the addition of preoperative docetaxel increased the pCR rate from 13.7% to 26.1% ($P < 0.001$) and decreased the rates of pathologically positive nodes, it did not lead to an increase in the rate of BCT. Furthermore, the addition of neoadjuvant or adjuvant docetaxel to adriamycin-cytoxan x4 did not statistically significantly prolong DFS or OS in the B-27 trial.

NSABP B-40 and B-41

More recently, the NSABP conducted two neoadjuvant trials evaluating novel taxane chemotherapy combinations with or without bevacizumab (for HER2-negative patients) or with trastuzumab, lapatinib, or the combination of the two (for HER2-positive patients). NSABP B-40 randomly assigned patients to one of three chemotherapy regimens (docetaxel followed by adriamycin-cytoxan x4, docetaxel/capecitabine followed by adriamycin-cytoxan x4, or docetaxel/gemcitabine followed by adriamycin-cytoxan x4) with a secondary randomization to receive

bevacizumab or no bevacizumab. The primary aims were to determine if adding capecitabine or gemcitabine to docetaxel followed by adriamycin-cytoxan x4 would increase pCR rates in patients with operable HER2-negative breast cancer and also to determine the effect of bevacizumab on pCR. Although the addition of neoadjuvant bevacizumab was shown to increase the proportion of women having pCR, the addition of capecitabine or gemcitabine to docetaxel followed by adriamycin-cytoxan x4 did not. Further analysis showed that the addition of gemcitabine or capecitabine to neoadjuvant docetaxel followed by adriamycin-cytoxan x4 did not increase DFS or OS, whereas the addition of bevacizumab statistically significantly increased OS (HR 0.65; $P = 0.004$) but did not significantly increase DFS (HR 0.80; $P = 0.06$).

Small molecule tyrosine kinase inhibitors such as lapatinib have shown marked anti-tumor activity in patients with advanced breast cancer. The NSABP B-41 trial compared the addition of trastuzumab, lapatinib, or the combination of both to neoadjuvant paclitaxel given following four cycles of neoadjuvant adriamycin-cytoxan x4 to patients with operable HER2-positive breast cancer. B-41 has shown similar pCR rates for both the trastuzumab (52.5%) and lapatinib (53.2%) groups and a nonsignificant increase in the pCR rate for the combination group (62.0%). Future analysis will attempt to identify predictors of benefit for the combined anti-HER2 therapy.

NSABP B-51/Radiation Therapy Oncology Group (RTOG) 1304

The NSABP B-51/Radiation Therapy Oncology Group (RTOG) 1304 trial is a currently accruing phase III randomized clinical trial designed to evaluate the role of postmastectomy RT and regional nodal RT in patients with documented positive axillary lymph nodes prior to undergoing neoadjuvant chemotherapy, who subsequently convert to pathologically negative axillary nodes after neoadjuvant chemotherapy. The trial's primary endpoint is to examine if postmastectomy and/or regional nodal RT significantly reduces the rate of breast cancer recurrence-free interval. Node positivity has to be documented by either fine needle aspiration or core needle biopsy before the administration of neoadjuvant chemotherapy. Patients then undergo standard neoadjuvant regimens (with the addition of anti-HER2 therapy for patients with HER2-positive tumors) and if they are found at surgery to have negative axillary lymph nodes are eligible for randomization into the trial. Patients can have either

mastectomy or BCT; those undergoing mastectomy are randomly assigned to either no RT or chest wall plus regional-nodal RT, and those undergoing BCT will be randomly assigned to either whole breast RT or whole breast plus regional-nodal RT.

AXILLARY LYMPH NODE STAGING FOR PATIENTS WITH BREAST CANCER

The status of axillary lymph nodes remains the single most important prognostic factor for breast cancer recurrence. However, data as early as the NSABP B-04 trial demonstrated that elective axillary lymph node dissection (ALND) did not impact survival. For this reason, it has become accepted that elective axillary dissection is performed predominantly for staging purposes, to aid in selecting adjuvant systemic therapy, and for local control of axillary disease. Recent randomized trials have demonstrated a survival advantage with the addition of RT in node-positive patients. The appropriate extent of lymph node staging has therefore been the subject of much past and continuing research.

Sentinel Node Versus Axillary Clearance Trial (SNAC)

Originally proposed for penile cancer, the sentinel lymph node (SLN) biopsy principle hypothesizes that malignant cells from the primary tumor follow lymphatic channels to a single lymph node/group of nodes before spreading to further nodes within the basin. Early research applying the SLN biopsy to breast cancer sought to determine whether a negative sentinel node could obviate the need for completion ALND and associated morbidity, namely the development of lymphedema. The SNAC study randomly assigned 1,088 women with cN− early-stage breast cancer to receive either SLN or SLN followed immediately by ALND. The primary endpoint was an increase in arm volume from baseline; secondary endpoints included an increase in arm volume by 15%, early axillary morbidity (defined as arm dysfunction), or disability. Arm volume increased in the SLN group by 2.8%, and by 4.2% in the ALND group ($P = 0.002$). Lower rates of arm swelling ($P < 0.001$), symptoms ($P < 0.001$), and dysfunction ($P = 0.02$) were reported in the SLN group, and disability ($P = 0.5$) was not. The study showed that SLN had a sensitivity of 94.5%, a false-negative rate (FNR) of 5.5%, and a negative predictive value of 98%. The study concluded that SLN follows oncologic principles and

resulted in less morbidity than ALND.

NSABP B-32

The NSABP-32 trial was designed to evaluate SLN biopsy as an alternative to ALND in cN− breast cancer patients. From 1999 to 2004, 5,611 patients from 80 centers were randomly assigned into one of two groups: SLN biopsy followed by ALND or SLN biopsy with ALND only in the event of a positive sentinel node. There were 232 participating surgeons. The primary endpoints of this trial were OS, DFS, and regional control. The trial demonstrated an SLN identification rate of 97%, with 26% of patients having positive SLNs in each group. An FNR of 9.7% was seen in the SLND + ALND group, related to biopsy type and number of SLNs removed. OS, DFS, and LRR were statistically equivalent in both groups. Patients who underwent ALND reported greater morbidity outcomes, including lymphedema, range of motion, sensory defects, and chronic pain. The B-32 trial showed that SLN biopsy is a safe and effective treatment for cN− patients and that the addition of ALND with a negative SLN biopsy does not improve outcomes. On secondary pathologic IHC evaluation of patients diagnosed with negative SLNs by H&E staining, in approximately 16% of cases the SLNs harbored occult metastases. Although differences were demonstrated in OS and DFS between the group with occult metastases and the one without, the absolute difference of OS at 5 years was small, 94.6% (no metastases) versus 95.8% (occult metastases) leading to the conclusion that IHC staining yielded no clinical benefit in evaluating initially negative SLNs.

Axillary Lymphatic Mapping Against Nodal Axillary Clearance (ALMANAC)

The Axillary Lymphatic Mapping Against Nodal Axillary Clearance (ALMANAC) trial, a randomized multicenter trial of SLN biopsy versus standard axillary treatment in operable breast cancer, took the benefits of SLN biopsy in the cN− axilla one step further by demonstrating improved quality of life in patients undergoing SLN biopsy versus ALND. In this study, 1,031 patients were assigned to SLN biopsy or ALND. Those with an SLN-positive axilla were subsequently treated with delayed completion ALND or axillary RT. Such measures as usage of drains, length of hospital stay, and time to resumption of daily activities postoperatively were monitored. All were statistically significant and lower in the SLN group (*p*

< 0.001). Patient-reported quality of life and arm functioning scores were statistically significantly better in the SLN group as well ($p \leq 0.003$). From these results, it was concluded that SLN biopsy should be the treatment of choice for patients with early-stage breast cancer and cN− because it is associated with reduced arm morbidity and better quality of life when compared with ALND.

International Breast Cancer Study Group (IBCSG) 23–01

After SLN biopsy was established as the standard of care for cN− breast cancer by NSABP B-32, research efforts focused on node-positive patients in whom completion ALND could be avoided. The International Breast Cancer Study Group (IBCSG) 23–01 trial was a multicenter randomized trial that attempted to determine whether ALND was superior to SLN biopsy in patients with early-stage (T1–2) breast cancer who were cN− with micrometastatic deposits (<2 mm) in the SLNs. From 2001 to 2010, 934 patients with micrometastasis on SLN biopsy were randomized into two arms: ALND versus no ALND. The study found no meaningful difference in DFS, the study's primary endpoint, or OS. The axillary recurrence rate was 0.2% in the ALND group, versus 0.86% in the SLND-only group. Additional secondary endpoints included lymphedema and sensory and motor neuropathy, which occurred more frequently in the ALND group. These findings reinforced previous results showing a better quality of life for those in the SLN-only group.

American College of Surgeons Oncology Group (ACOSOG) Z0011

The ACOSOG Z0011 trial changed the approach to the axilla in patients with limited SLN involvement. This was a multicenter randomized noninferiority trial conducted from 1999 to 2004 that enrolled 891 patients with T1-T2 cN− invasive breast cancer who underwent lumpectomy and SLN biopsy. Patients with 1 to 2 positive SLNs were randomly assigned to undergo ALND or no further treatment. All patients received whole-breast irradiation, and there was little difference between the two groups in the delivery of adjuvant systemic therapy. The primary endpoint of the study was OS. The study found no clinical difference in 10-year OS, with rates of 86.3% in the SLN biopsy-alone group and 83.6% in the ALND group. Ten-year DFS rates were also similar for both groups. Complications such as wound infections, axillary seromas, and paresthesias were more

common in the ALND group. In addition, subjective but not objective reporting of lymphedema was higher in the ALND group. Z0011 findings highlight the importance of multimodality treatment in achieving locoregional control without the morbidity of an ALND and have altered clinical practice for select early-stage, node-positive breast cancer patients who may omit completion ALND.

EORTC 10981 After Mapping of the Axilla, Radiotherapy or Surgery? (AMAROS) Trial

The AMAROS trial was a phase III study comparing ALND with axillary RT in patients with proven axillary metastasis by SLN biopsy with a detection rate of 97%. The primary endpoint was axillary recurrence. This trial did not compare sentinel lymph node biopsy (SLNB) to ALND in the management of the diseased axilla; rather, it used SLN biopsy as a method for detecting the axilla that needs further treatment with ALND group axillary RT. With a median of 6.1 years of follow-up, 5-year axillary recurrence was 0.43% (95% CI 0.00 to 0.92) in the ALND arm versus 1.19% (0.31 to 2.08) in the axillary RT arm. However, the risk of lymphedema was twice as high (28% vs. 14%) in the ALND arm compared to the axillary RT arm at 5 years of follow-up.

ACOSOG Z1071

As neoadjuvant chemotherapy became increasingly used for women with early- and late-stage breast cancer, questions arose about the acceptability of SLN biopsy in women who were node positive prior to receiving chemotherapy but who converted to cN− after the administration of chemotherapy. The ACOSOG Z1071 trial was conducted to address this issue. The study determined the FNR for SLN biopsy following neoadjuvant chemotherapy in biopsy-proven, node-positive (before chemotherapy) patients. From 2009 to 2011, 649 patients with cN1 disease and 38 patients with cN2 disease underwent chemotherapy followed with both SLN biopsy and ALND. A pCR rate of 41% was achieved on pathologic examination of the SLNs and nodes removed on ALND. Of the remaining patients, 20.6% had residual nodal disease confined to the SLN only, 7.4% confined to the nodes removed on ALND, and 31.1% present in nodes from both SLN and ALND, yielding a false-negative SLN finding rate of 12.6%. The FNR decreased when SLN mapping was performed using both radiolabeled colloid and blue dye (10.8% in combination vs.

20.3% with single agent) and when three or more SLNs were examined (9.1% for ≥3 SLNs vs. 21.1% for 2). Investigators in the Z1071 trial concluded that because the FNR exceeded the prespecified study threshold of 10%, SLN examination should not be performed in patients with clinically node positive disease receiving neoadjuvant chemotherapy. However, dual agent mapping and three or more lymph nodes examined were associated with FNR similar to that found in the B-32 trial, <10%.

SENTinel NeoAdjuvant (SENTINA) Trial

Similar in focus to the Z1071 trial, SENTINA was a four-arm, prospective, multicenter cohort study of 1,737 patients designed to evaluate the role of SLN biopsy in patients who had undergone neoadjuvant chemotherapy for invasive breast cancer. Patients with cN− disease underwent SLN biopsy before the initiation of neoadjuvant chemotherapy. If the SLN was positive, a second SLN procedure and ALND was done after neoadjuvant chemotherapy. Women who were cN+ underwent neoadjuvant chemotherapy, and those who converted to being cN− also had SLN biopsy and ALND. For cN− patients who were pathologically confirmed to be SLN-positive prior to neoadjuvant chemotherapy, the FNR of SLN biopsy after chemotherapy was 51.6%, and for patients who converted from cN+ to cN− with chemotherapy the FNR of SLN after neoadjuvant chemotherapy was 14.2%. However, in the cN+ to cN− group, if both blue dye and radiocolloid was used, the FNR was 8.6% and the FNR decreased as the number of removed SLNs increased.

Alliance A011202

The Alliance A011202 trial is currently recruiting patients with clinically positive axilla (by FNA or core needle biopsy) and who, despite being cN− after neoadjuvant therapy, have a positive SLN at surgery. Patients are randomly assigned to either completion ALND or not. Both groups include RT to the breast/chest wall, un-dissected axilla, supraclavicular nodes, and internal mammary nodes in the first three intercostal spaces. The combined results from this and the NSABP B-51/RTOG 1343 trial should clarify the role of ALND and regional nodal RT for patients who convert from node positive to cN− status after the administration of neoadjuvant chemotherapy.

CONCLUSION

From anecdotal reports to the development and implementation of breast cancer clinical trials, improvements in the treatment and outcomes for breast cancer patients have been the result of a paradigm change in the biologic understanding and management of the disease. Breast cancer mortality has witnessed a steady decline since the mid-1980s. Patients now need not undergo extensive surgical procedures to achieve improved outcomes and as a result enjoy improved quality of life. Treatments based on genetic and genomic assays as well as targeted biologic therapies, along with focused molecular and hormonal treatments, provide a personalized approach in the modern era. Coupled with advanced RT techniques that have resulted in a more precise delivery of treatment with less toxicity, a multidisciplinary approach for each patient can be designed. These advancements are all in large part due to the results of clinical trials. The benefits of such trials have accelerated our understanding of breast cancer biology and have brought improved treatments, a better quality of life, and improved outcomes. Ongoing and new clinical trials will continue to refine this knowledge so that our patients can be better served.

Suggested Readings

Allegra CJ, Aberle DR, Ganschow P, et al. National Institutes of Health state-of-the-science conference statement: diagnosis and management of ductal carcinoma in situ September 22–24, 2009. *J Natl Cancer Inst* 2010; 102(3):161–9.

Allred DC, Anderson SJ, Paik S, et al. Adjuvant tamoxifen reduces subsequent breast cancer in women with estrogen receptor-positive ductal carcinoma in situ: a study based on NSABP protocol B-24. *J Clin Oncol* 2012;30(12):1268–73.

Bear HD, Anderson S, Brown A, et al. The effect on tumor response of adding sequential preoperative docetaxel to preoperative doxorubicin and cyclo-phosphamide: preliminary results from national surgical adjuvant breast and bowel project protocol B-27. *J Clin Oncol* 2003;21:4165–74.

Bear HD, Anderson S, Smith RE, et al. Sequential preoperative or postoperative docetaxel added to preoperative doxorubicin plus cyclophosphamide for operable breast cancer: National Surgical Adjuvant Breast and Bowel Project Protocol B-27. *J Clin Oncol* 2006;24(13):2019–27.

Bear HD, Tang G, Rastogi P. Bevacizumab added to neoadjuvant chemotherapy for breast cancer. *N Engl J Med* 2012;366:310–20.

Bear HD, Tang G, Rastogi P. Neoadjuvant plus adjuvant bevacizumab in early breast cancer (NSABP B-40 [NRG Oncology]): secondary outcomes of a phase 3, randomized controlled trial. *Lancet Oncol* 2015;16:1037–48.

Black DM, Hunt KK, Mittendorf EA. Long-term outcomes reporting the safety of breast conserving therapy compared to mastectomy: 20-year results of EORTC 10801. *Gland Surg* 2013;2(3):120–3.

Boughey JC, Suman VJ, Mittendorf EA, et al. Sentinel lymph node surgery after neoadjuvant chemotherapy in patients with node-positive breast cancer: the ACOSOG Z1071 (Alliance) clinical trial. *JAMA* 2013;310:1455–61.

Donker M, van Tienhoven G, Straver ME, et al. Radiotherapy or surgery of the axilla after a positive sentinel node in breast cancer (EORTC 10981–22023 AMAROS): a randomised, multicenter, open-label, phase 3 non-inferiority trial. *Lancet Oncol* 2014;15(12):1303–10.

Early Breast Cancer Trialists' Collaborative Group; McGale P, Taylor C, Correa C, et al. Effect of radiotherapy after mastectomy and axillary surgery on 10-year recurrence and 20-year breast cancer mortality: meta-analysis of individual patient data for 8135 women in 22 randomised trials. *Lancet* 2014;383(9935):2127–35.

EORTC Breast Cancer Cooperative Group and EORTC Radiotherapy Group; Bijker N, Meijnen P, Peterse JL, et al. Breast conserving treatment with or without radiotherapy in ductal carcinoma-in-situ: ten-year results of European organisation for research and treatment of cancer randomized phase III trial 10853—a study by the EORTC breast cancer cooperative group and EORTC radiotherapy group. *J Clin Oncol* 2006;24:3381–7.

Fisher B. The evolution of paradigms for the management of breast cancer: a personal perspective. *Cancer Res* 1992;52:2371–83.

Fisher B, Anderson S, Bryant J, et al. Twenty-year follow-up of a randomized trial comparing total mastectomy, lumpectomy, and lumpectomy plus irradiation for the treatment of invasive breast cancer. *N Engl J Med* 2002;347:1233–41.

Fisher B, Brown A, Mamounas E, et al. Effect of preoperative chemotherapy on local-regional disease in women with operable breast cancer: findings from national surgical adjuvant breast and bowel project B-18. *J Clin Oncol* 1997;15(7):2483–93.

Fisher B, Bryant J, Wolmark N, et al. Effect of preoperative chemotherapy on the outcome of women with operable breast cancer. *J Clin Oncol* 1998;16(8):2672–85.

Fisher B, Dignam J, Wolmark N, et al. Tamoxifen in treatment of intra-ductal breast cancer: national surgical adjuvant breast and bowel project B-24 randomised controlled trial. *Lancet* 1999;353:1993–2000.

Fisher B, Jeong JH, Anderson S, et al. Twenty-five-year follow-up of a randomized trial comparing radical mastectomy, total mastectomy, and total mastectomy followed by irradiation. *N Engl J Med* 2002;347:567–75.

Fisher B, Land S, Mamounas E, et al. Prevention of invasive breast cancer in women with ductal carcinoma in situ: an update of the national surgical adjuvant

breast and bowel project experience. *Semin Oncol* 2001;28:400–18.

Fisher ER, Wang J, Bryant J, et al. Pathobiology of preoperative chemotherapy: findings from the National Surgical Adjuvant Breast and Bowel (NSABP) protocol B-18. *Cancer* 2002; 95:681–95.

Galimberti V, Cole BF, Zurrida S, et al, for the IBCSG Trial 23–01 investigators. Axillary dissection versus no axillary dissection in patients with sentinel-node micrometastases (IBCSG 23–01): a phase 3 randomised controlled trial. *Lancet Oncol* 2013;14:297–305.

Gill G; SNAC Trial Group of the Royal Australasian College of Surgeons (RACS) and NHMRC Clinical Trials Centre. Sentinel-lymph-node based management or routine axillary clearance? One-year outcomes of sentinel node biopsy versus axillary clearance (SNAC): a randomized controlled surgical trial. *Ann Surg Oncol* 2009;16:266–75.

Giuliano AE, McCall L, Beitsch P, et al. Ten-year survival results of ACOSOG Z0011: a randomized trial of axillary node dissection in women with clinical T1–2 N0 M0 breast cancer who have a positive sentinel node. *J Clin Oncol* 2016;34(Suppl 15).

Halsted WS. The results of operations for cure of cancer of the breast performed at the John Hopkins Hospital from June 1889 to January 1894. *Ann Surg* 1894–1895; 20(5):297–350.

Hughes KS, Schnaper LA, Bellon JR, et al. Lumpectomy plus tamoxifen with or without irradiation in women age 70 years or older with early breast cancer: long-term follow-up of CALGB 9343. *J Clin Oncol* 2013;31(19):2382–7.

Hughes LL, Wang M, Page DL, et al. Local excision alone without irradiation for ductal carcinoma in situ of the breast: a trial of the eastern cooperative oncology group. *J Clin Oncol* 2009;27(32):5319–24.

Krag DN, Anderson SJ, Julian TB, et al. Sentinel-lymph-node resection compared with conventional axillary-lymph-node dissection in clinically node-negative patients with breast cancer: overall survival findings from the NSABP B-32 randomized phase 3 trial. *Lancet Oncol* 2010;11:927–33.

Kuehn T, Bauerfeind I, Fehm T, et al. Sentinel-lymph-node biopsy in patients with breast cancer before and after neoadjuvant chemotherapy (SENTINA): a prospective, multicentre cohort study. *Lancet Oncol* 2013;14:609–18.

Liang K, Lu Y, Jin W, et al. Sensitization of breast cancer cells to radiation by trastuzumab. *Mol Cancer Ther* 2003;2(11):1113–20.

Litière S, Werutsky G, Fentiman IS, et al. Breast conserving therapy versus mastectomy for stage I–II breast cancer: 20 year follow-up of the EORTC 10801 phase 3 randomized trial. *Lancet Oncol* 2012;13(4):412–19.

Mamounas EP. NSABP Protocol B-27. Preoperative doxorubicin plus

cyclophosphamide followed by preoperative or postoperative docetaxel. *Oncology (Huntingt)* 1997;11:37–40.

Mamounas EP, White JR, Bandos H, et al. NSABP B-51/RTOG 1304: Randomized phase III clinical trial evaluating the role of post-mastectomy chest wall and regional nodal XRT (CWRNRT) and post-lumpectomy RNRT in patients (pts) with documented positive axillary (Ax) nodes before neoadjuvant chemotherapy (NC) who convert to pathologically negative Ax nodes after NC. *Cancer Res* 2016;17(Suppl 4):Abstr OT2–02–02.

Mansel RE, Fallowfield L, Kissin M, et al. Randomized multicenter trial of sentinel node biopsy versus standard axillary treatment in operable breast cancer: the ALMANAC trial. *J Natl Cancer Inst* 2006;98:599–609.

Margolese RG, Cecchini RS, Julian TB, et al. Anastrozole versus tamoxifen in postmenopausal women with ductal carcinoma in situ undergoing lumpectomy plus radiotherapy (NSABP B-35): a randomized, double-blind, phase 3 clinical trial. *Lancet* 2016;387:849–56.

Moran MS, Schnitt SJ, Giuliano AE, et al. Society of Surgical Oncology–American Society for Radiation Oncology consensus guideline on margins for breast-conserving surgery with whole-breast irradiation in stages I and II invasive breast cancer. *Ann Surg Onc* 2014;21:704–16.

NCI Community Oncology Research Program. CTSU Alliance A011202: a randomized phase III trial evaluating the role of axillary lymph node dissection in breast cancer patients (CT1–3 N1) who have positive sentinel lymph node disease after neoadjuvant Chemotherapy [online]. (2014). https://clinicaltrials.gov/ct2/show/study/NCT01901094. Accessed May 4, 2016.

Piccart-Gebhart MJ, Procter M, Leyland-Jones B, et al. Trastuzumab after adjuvant chemotherapy in HER2-positive breast cancer. *N Engl J Med* 2005;353(16):1659–72.

Rakovitch E, Nofech-Mozes S, Hanna W, et al. A population-based validation study of the DCIS Score predicting recurrence risk in individuals treated by breast-conserving surgery alone. *Breast Cancer Res Treat* 2015;152(2):389–98.

Rastogi P, Anderson SJ, Bear HD, et al. Preoperative chemotherapy: updates of national surgical adjuvant breast and bowel project protocols B-18 and B-27. *J Clin Oncol* 2008;26:778–85.

Robidoux A, Tang G, Rastogi P, et al. Lapatinib as a component of neoadjuvant therapy for HER2-positive operable breast cancer (NSABP protocol B-41): an open-label, randomised phase 3 trial. *Lancet Oncol* 2013; 14(12):1183–92.

Rodrigues L, Mansi J, Griffiths J. Radiation enhances the antitumor effect of herceptin on c-neu/HER2 mammary carcinomas in transgenic oncomice (Abstr). *Proc Am Assoc Cancer Res.* 2003;Abstr 132a.

Romond EH, Perez EA, Bryant J, et al. Trastuzumab plus adjuvant chemotherapy for operable HER2-positive breast cancer. *N Engl J Med* 2005;353(16):1673–84.

Siziopikou KP, Anderson SJ, Cobleigh MA, et al. Preliminary results of centralized HER2 testing in ductal carcinoma in situ (DCIS): NSABP B-43. *Breast Cancer Res Treat* 2013;142:415–21.

Slamon D, Eiermann W, Robert N, et al. Adjuvant trastuzumab in HER2-positive breast cancer. *N Engl J Med* 2011;365(14):1273–83.

Solin LJ, Gray R, Baehner FL, et al. A multigene expression assay to predict local recurrence risk for ductal carcinoma in situ of the breast. *J Nat Can Inst* 2013; 105(10):701–10.

Solin LJ, Gray R, Hughes LL, et al. Surgical excision without radiation for ductal carcinoma in situ of the breast: 12-year results from the ECOG-ACRIN E5194 Study. *J Clin Oncol* 2015;33(33):3938–44.

Veronesi U, Zucali R, Luini A. Local control and survival in early breast cancer: the Milan trial. *Int J Radiat Oncol Biol Phys* 1986;12:717–20.

Weaver DL, Ashikaga T, Krag DN, et al. Effect of occult metastases on survival in node-negative breast cancer. *N Engl J Med* 2011;364:412–21.

Wolmark N, Wang J, Mamounas E, et al. Preoperative chemotherapy in patients with operable breast cancer: nine-year results from national surgical adjuvant breast and bowel project B-18. *J Natl Cancer Inst Monogr* 2001;30:96–102.

EDITOR'S COMMENT

Cowher and colleagues have shown that the history of breast cancer treatment is inextricably linked to the history of its clinical trials and so, I believe, is its future. Dr. William Thomas Beaver was the clinical pharmacologist at Georgetown University who drafted the initial regulations defining "adequate and controlled" clinical studies. "Clinical trials are systematic experiments performed on human beings for the purpose of assessing the safety and/or efficacy of treatments or care procedures. The function of the controlled clinical trial is not the 'discovery' of a new drug or therapy. Discoveries are made in the animal laboratory, by chance observation, or at the bedside by an astute clinician. The function of the formal controlled clinical trial is to separate the relative handful of discoveries which prove to be true advances in therapy from a legion of false leads and unverifiable clinical impressions, and to delineate in a scientific way the extent of and the limitations which attend the effectiveness of drugs."

Peter Drucker said that the only obstacle to progress is the thought that we already know the answer to the question. Much of the lack of progress or slow implementation of new or better techniques is related to busy clinical practices,

in and of itself and obstacle to clinical trial participation, as well as the surgeon's own bias. One of the trials that illustrate these issues best is the American College of Surgeons Oncology Group (ACOSOG) Z-0011. Proposed by Dr. Armando Guiliano, ACOSOG Z-0011s was a trial ahead of its time (Giuliano AE, Hunt KK, Ballman KV, et al. Axillary dissection vs no axillary dissection in women with invasive breast cancer and sentinel node metastasis: a randomized clinical trial. *JAMA* 2011;305(6):569–75). The hypothesis was, as was already demonstrated by NSABP B-04, that in patients undergoing breast conservation therapy removal of the axillary lymph nodes (ALND) would not negatively impact survival. Regional recurrence was also an endpoint. Unfortunately, the trial closed early due to poor accrual secondary not only to surgeon bias but also to patient bias. Patients often wanted a full ALND or they only wanted a sentinel lymph node (SLN) as they were sure that they were potentially being under- or overtreated depending on their bias, respectively. Unfortunately, the Z-0011 trial was underpowered and had a high percentage of nearly a quarter of patients lost to follow-up. In addition, radiation treatment was given to the undissected axilla that was a protocol deviation. Despite this, the trial did show no difference in survival between the groups at 5- as well 10-year follow-up (Bao J, Giuliano AE. Sentinel lymph node biopsy: from B04 to tumor genomics. *Ann Surg Oncol* 2016; 23(8):2380–82; Giuliano AE, Hunt KK, Ballman KV, et al. Axillary dissection vs no axillary dissection in women with invasive breast cancer and sentinel node metastasis: a randomized clinical trial. *JAMA* 2011;305(6):569–75). Local and regional recurrence likewise did not differ. The authors concluded that SLN biopsy only was adequate to stage the axilla and superior to full ALND. Based on this study, I would conclude either procedure, SLNB+XRT or ALND, would be acceptable as the objective lymphedema was not different between the groups, which is what the study was aimed at proving. This study did give rise to a multitude of other questions and interesting trials. Studies like SOUND (Sentinel node vs Observation after axillary Ultra-souND) have been started to assess whether one could not operate at all but rather follow the clinically node-negative axilla with ultrasound (Gentilini O, Botteri E, Dadda P, et al. Physical function of the upper limb after breast cancer surgery. Results from the SOUND [Sentinel node vs. Observation after axillary Ultra-souND] trial. *Eur J Surg Oncol* 2016;42(5):685–9).

The hypotheses of this trial are that:

- Avoiding axillary surgery and the absence of the pathologic information on the risk of recurrence given by nodal status do not worsen the outcome of patients with small breast cancers.
- Preoperative imaging of the axilla can identify patients with clinically relevant nodal burden.

The investigators at the European Institute of Oncology aim to verify that in the presence of a negative preoperative axillary assessment by physical examination and ultrasound (US), an SLNB can be spared and that the decision

on adjuvant medical treatment can be made based on the biology of the tumor without the prognostic information achieved by an SLNB on the nodal status. Gentilini and colleagues have just reported on the first 180 patients accrued to this trial. The first 180 patients were assessed using the *Quick*DASH (Diability ARM and Shoulder), which ranges from 0 (no disability) to 100 (complete disability). As expected, at 1 week the scores were higher for SLNB, which was 24.0% versus 10.6% for SLNB versus observation. At 6- and 12-month follow-up, these moved more toward baseline and were 4.5% versus 3.3% at 6 months, $p < 0.001$ (Gentilini O, Botteri E, Dadda P, et al. Physical function of the upper limb after breast cancer surgery. Results from the SOUND [Sentinel node vs. Observation after axillary Ultra-souND] trial. *Eur J Surg Oncol* 2016;42(5):685–9). Differences in regional recurrence or survival have not yet been reported.

But what about the clinically positive axilla? Two important trials that depend on the participation by surgeons are that of NSABP B-51 and Alliance 111202. Both enroll node-positive patients proven by US-guided biopsy with clip placement. Patients then undergo primary systemic therapy followed by surgery. If the SLNB is negative (must include the node with the clip), then the patient can be enrolled in the NSABP B-51 and randomized to nothing versus ALND. If the SLNB is still positive, then the patient is randomized on Alliance 111202 to radiation versus ALND. In terms of control of the axilla, my guess is that the recurrence rate in these studies will be equivalent. However, radiation is the gift that keeps on giving and so given a choice I would choose surgery every time. Long-term follow-up will be needed to determine the difference between the complications of radiation of the axilla versus those of definitive surgery.

Another alternative in the axillary treatment question is the addition of Axillary Reverse Mapping or ARM. In this concept, split mapping is used, that is, radioactivity in the breast and blue dye in the arm. This allows identification and separation of the breast lymphatics from those draining the arm and thus their preservation. Our recently published phase II prospective trial in 654 patients demonstrated lymphedema rates less than 1% for SLNB as compared to 5% to 8% in historical controls (Tummel E, Ochoa D, Korourian S, et al. Does axillary reverse mapping prevent lymphedema after lymphadenectomy? *Ann Surg* 2016;265(5):987–992). The lymphedema rate was ~6% for ALND, and if a primary approximation/anastomosis of the lymphatics was performed the rate of lymphedema was nil. A randomized trial to prove this concept is planned.

The authors have done a very nice job of laying out the history of randomized clinical trials. However, I would say one of the most important trials of the last decade that was not mentioned is that of the retrospective genetic analysis of prospectively collected blocks on patients enrolled in NSABP B-14 and B-20 that led to the development of the Oncotype genomic assay. The RT-PCR assay tests 21 genes, 16 of which tests hormone receptors, Her-2-neu genes or genes related to proliferation (Tang G, Cuzick J, Costantino JP, et al. Risk of recurrence and chemotherapy benefit for patients with node-

negative, estrogen receptor-positive breast cancer: recurrence score alone and integrated with pathologic and clinical factors. *J Clin Oncol* 2011;29(33):4365–72). It can be done on excisional biopsy blocks or on core needle biopsy specimens. The test gives a continuous recurrence score that strongly predicts for risk of recurrence as well as benefit or not from chemotherapy. With its use, it has prevented a majority of patients with node-negative hormonally sensitive tumors from having chemotherapy when the Oncotype test indicates a low recurrence score. The test is recommended in the published treatment guidelines of the American Society of Clinical Oncology (ASCO) and National Cancer Centers Network (NCCN). There are several other comparable tests (microarray, IHC, or FISH) that are available but have not been similarly validated. An ongoing trial (TAILORx) is a prospective trial to determine the efficacy of chemotherapy in those patients with a recurrence score via Oncotype in the midrange (18 to 31) where it is not clear as to whether chemotherapy is beneficial or not (Zujewski JA, Kamin L. Trial assessing individualized options for treatment for breast cancer: the TAILORx trial. *Future Oncol* 2008;4(5):603–10). Trial Assessing IndiviuaLized Options for Treatment for breast cancer (TAILORx) randomizes patients in this Oncotype midrange to either chemotherapy or hormonal therapy. The trial has completed accrual and is awaiting maturation to determine a more refined determination of the recurrence score of who really benefits from chemotherapy.

A similar retrospective analysis of blocks was performed on NSABP B-28, which enrolled node-positive patients (Wolmark N, Mamounas EP, Baehner FL, et al. Prognostic impact of the combination of recurrence score and quantitative estrogen receptor expression (ESR1) on predicting late distant recurrence risk in extrogen receptor-positive breast cancer after 5 years of tamoxifen: results from NRG Oncology/National Surgical Adjuvant Breast and Bowel Project B-28 and B-14. *J Clin Oncol* 2016;34(20):2350–58). Again the recurrence score when combined with nodal positivity (1 to 3 vs. ≥4 positive nodes) is predictive of in breast or chest wall recurrence. This may particularly be useful not only in prognosis but predictive in terms of determining the relative lack of benefit of chest wall irradiation in patients with a low recurrence score. This use of the Oncotype in node-positive patients has not gained wide acceptance and is undergoing prospective validation.

Only a properly planned and conducted trial with committed participation by surgeons can solve our tough issues. Surgeons are very important in this process as they are most often the gatekeeper to breast cancer care as well as key to obtaining appropriately preserved tissue for the vast array of markers now available as well as for studies in the future.

V. Suzanne Klimberg

59 The Deep Inferior Epigastric Perforator Flap for Breast Reconstruction

Robert J. Allen and James L. Mayo

INTRODUCTION

In 2013, 232,340 women were diagnosed with invasive breast cancer and 64,640 were diagnosed with in situ cancer. Of women who undergo surgical treatment, two thirds elect to undergo breast-conserving treatment (BCT), while one third elect to undergo mastectomy. With equal survival rates among both treatment modalities in the same tumor populations, the decision to perform mastectomy often is driven by either a desire for improved cosmesis in the setting of a larger tumor/smaller breast or a goal of most significant reduction in the risk of recurrence.

Of the 95,589 women who underwent breast reconstruction in 2013, 80% elected for tissue expander/implant based reconstruction versus 20% autologous reconstruction. Though the vast majority of breast reconstructions are implant-based, the senior author prefers autologous reconstruction for its ability to replace “like with like,” a lower long-term complication profile and more stable long-term patient satisfaction. A 2009 University of Michigan study demonstrated that, over the long term (>9 years), there is a significant decrease in patient satisfaction after implant-based breast reconstruction while patient satisfaction after autologous tissue breast reconstruction remains consistently high.

Autologous breast reconstruction celebrates a storied history centered around the abdomen as the most prolific donor site. Carl Hartrampf popularized the transverse rectus abdominis musculocutaneous (TRAM) flap in the early 1980s paving the way for an alternative to utilizing an implant for breast reconstruction. Unfortunately, this brought with it undesirable complications associated with removing a patient’s entire rectus abdominis muscle such as ventral hernia as well as an unnecessarily high rate of fat necrosis. In the late 80s, the senior author avoided these issues by basing an abdominal flap off of the superficial inferior epigastric

artery (SIEA) converting the flap to a free flap. Utilizing this flap for breast reconstruction was successful but, due to variable vascular anatomy, was not consistently available.

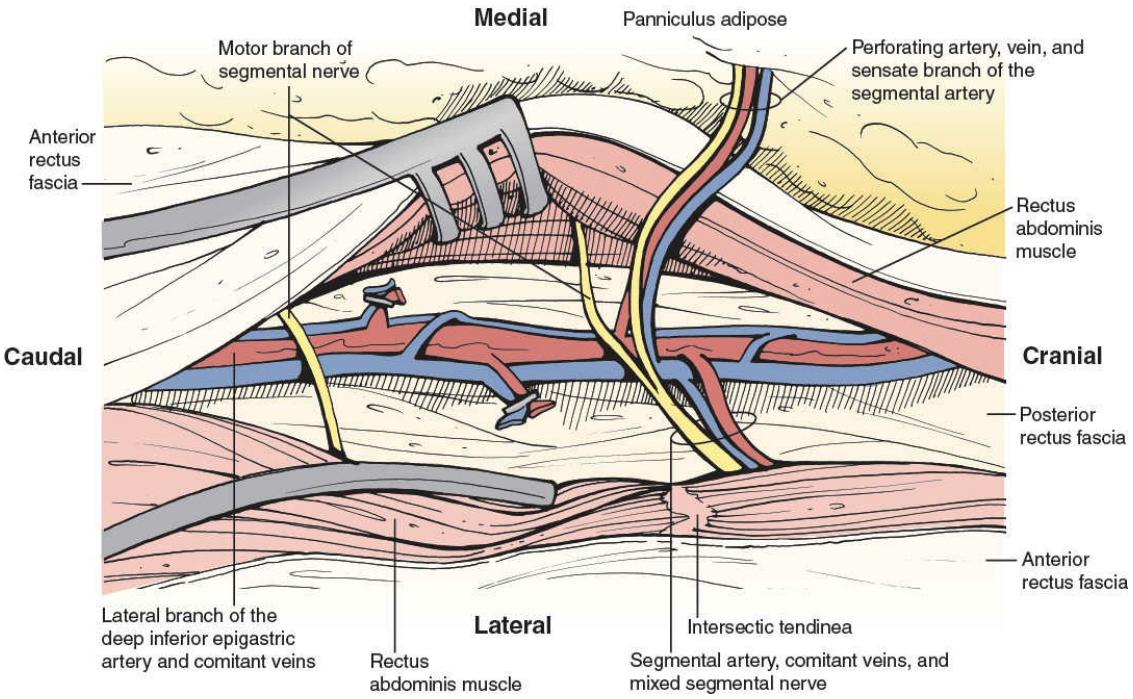

Figure 59.1. The DIEP flap is based on perforating vessels that originate from the deep inferior epigastric system, travel through the rectus abdominis muscle, pierce the anterior rectus sheath, and supply the overlying abdominal skin and fat.

In 1992, Robert Allen, Sr. first reported the use of the deep inferior epigastric artery perforator (DIEP) free flap for breast reconstruction. The DIEP flap is based off of perforators traveling through the rectus abdominis muscle to supply the skin and fat of the lower abdomen (Fig. 59.1). By dissecting these perforators through the rectus muscle to their origin at the deep inferior epigastric vessels, a plastic surgeon is able to spare the rectus muscle morbidity of the TRAM while providing advantageous flap volume and vascularity. The TRAM versus DIEP debate then ensued in the following year as many of the plastic surgeons in the community were still performing TRAM procedures due to lack of familiarity with microsurgical techniques. *The Mastery of Surgery*, 6th edition focused on the benefits of the DIEP versus the TRAM, and at the time of writing this chapter for the 7th edition, the DIEP is accepted as the standard of care first option for autologous breast reconstruction.

Currently, more appropriate debates center around a search for

additional autologous options when the abdomen is not available as a donor site. Numerous flaps have been described from gluteal to thigh-based flaps. The complete microsurgeon has these flaps in his armamentarium and now practices a patient-specific approach utilizing the area of the body that the patient has the most favorable donor site due to body habitus and personal preferences. Still, the clear front-runner for autologous breast reconstruction remains the DIEP flap, and after over 2,000 DIEP flaps with a 99% success rate, we are able to offer this procedure safely, efficiently, and with more aesthetic refinement than ever before.

INDICATIONS

The common indication for autologous (own tissue) breast reconstruction is simply an absent breast after mastectomy for breast cancer. The majority of women are candidates for some form of autologous reconstruction. This can be performed immediately during the same procedure as the mastectomy or in a delayed fashion, often after the patient has received radiation (Fig. 59.2). In the later cases, a tissue expander is often placed at the time of mastectomy to maintain the skin envelope during the interim. Another common indication for autologous breast reconstruction is failed implant-based breast reconstruction. About 25% of our breast reconstruction patients are women who have experienced problems such as infection, capsular contracture, implant displacement, and others after implant-based breast reconstruction. Particularly in women who have had to undergo radiation therapy as an adjunct to their breast cancer treatment, autologous tissue breast reconstruction can create a new breast mound that looks and feels natural while using the woman’s own tissues.

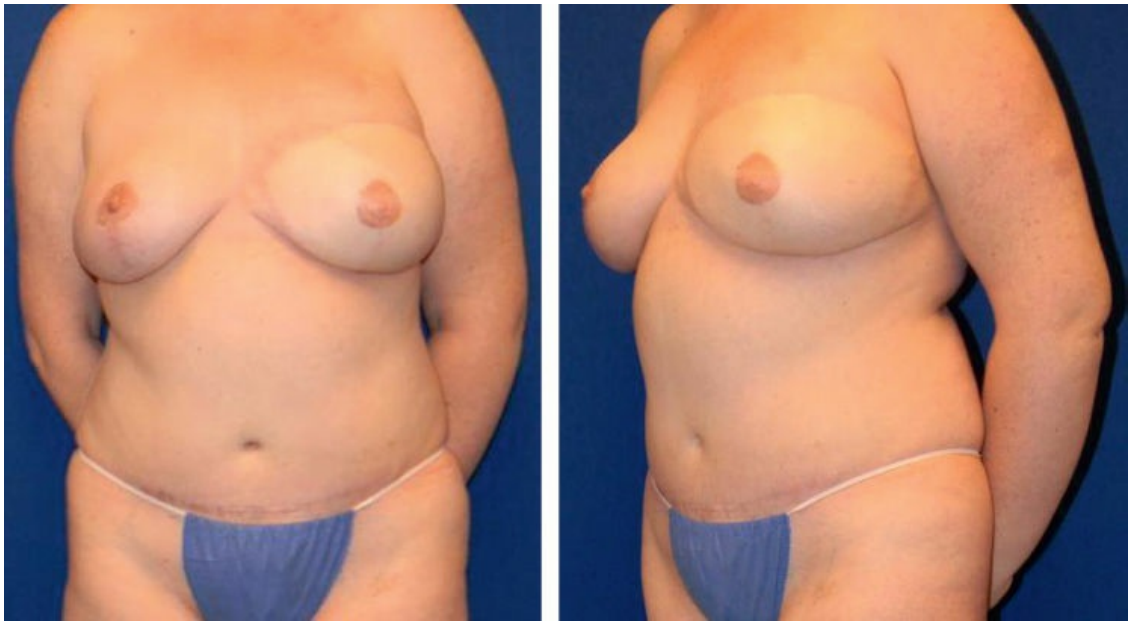

Figure 59.2. Postoperative views of a 45-year-old patient with history of left inflammatory breast cancer 5 years prior treated with left modified radical mastectomy, chemotherapy, radiation. She underwent delayed unilateral left DIEP free flap breast reconstruction followed by nipple reconstruction and areolar tattooing. She subsequently also underwent a right breast reduction mammoplasty for symmetry.

The deep inferior epigastric perforator flap is the first-line modality for autologous breast reconstruction. The best way to describe who is a candidate for DIEP free flap breast reconstruction is to outline who is not a candidate. Outside of medical comorbidities prohibiting surgery, the abdominal donor site characteristics precluding surgery would be insufficient volume of tissue or insufficient blood supply. The blood supply to the lower abdominal flaps can be compromised most commonly by previous surgery such as a previous abdominoplasty during which the perforators to the desired tissue have been transected or by other procedures that risk transecting the deep inferior epigastric vessels such as those requiring a lengthy pfannenstiel incision. Preoperative imaging via either CTA or MRA is standard in our practice as assessment of the abdominal vascularity in the above types of patients is paramount.

Other factors influencing surgical decision making include diabetes, cardiopulmonary disease, autoimmune disease, clotting disorders, obesity, and smoking. Active smokers should be counseled to abstain from tobacco and nicotine use for a minimum of 4 weeks prior to any reconstructive procedure. Liposuction is not an absolute contraindication to DIEP flap

breast reconstruction, but very thin women with no abdominal fat may not have enough subcutaneous tissue to recreate a satisfactory breast mound. If a woman does not have adequate abdominal fat for a DIEP flap breast reconstruction, she may still be able to undergo autologous tissue breast reconstruction, as previously alluded to, using either the thigh or the buttock as donor sites. In addition, our group has combined multiple flaps to achieve desired volume/aesthetics for a given breast reconstruction.

PREOPERATIVE PLANNING

All patients undergo a lengthy preoperative consultation aimed first at developing and understanding a patient's priorities and goals. Then after reviewing her medical/cancer details and performing a detailed physical examination, reconstructive options including short/long-term results and complications are discussed. Setting appropriate expectations and painting a realistic portrait of the perioperative period is very important for morale. On the day of surgery, the patient and surgeon should enter the operative suit confident in the choice of reconstruction as well as each other in performing his/her part. This includes the postoperative period, a vital time for active recovery and healing.

Often the topic of reconstruction begins with the breast surgeon as it is not uncommon for a patient to discuss general reconstructive options at the time of deciding on a mastectomy. Thus, developing a routine line of communication with breast surgeons is imperative to ensuring patient goals are both realistic and achieved through appropriate education and execution. Also, given the fact that some surgeons in the community are still not performing free flap breast reconstruction, offering other modalities such as TRAM flaps or latissimus dorsi/implant reconstructions, the breast surgeons benefit from knowing the reconstructive options as well as their advantages/disadvantages to ensure that each patient has access to the best care available in a given area.

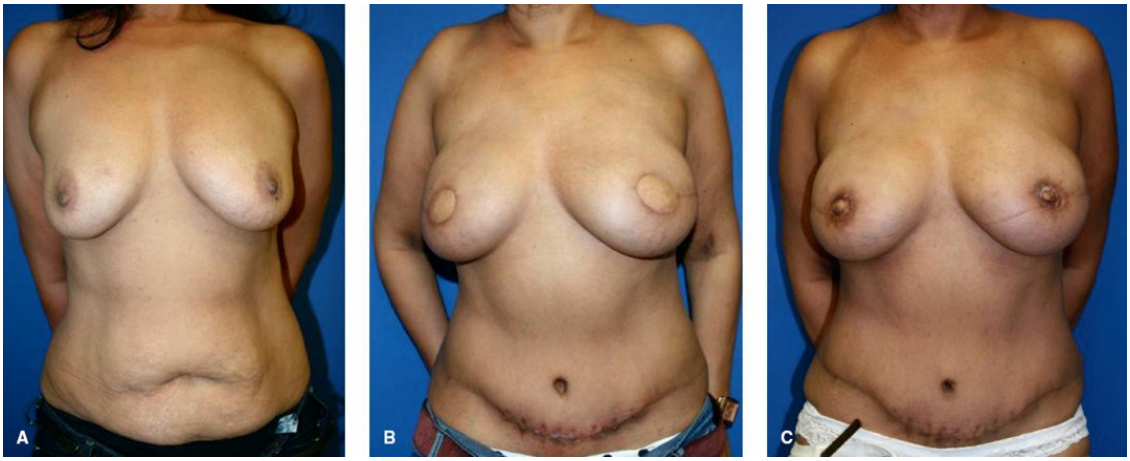

Figure 59.3. Left-preoperative picture of a 57-year-old patient prior to undergoing bilateral mastectomy. Immediately, she had tissue expanders placed which were later removed and bilateral DIEP free flap breast reconstruction performed. Center-postoperative picture after delayed DIEP free flap breast reconstruction. The areola skin is the abdominal flap skin which will be used for nipple reconstruction in the next stage of reconstruction. Right-postoperative picture after delayed bilateral DIEP free flap breast reconstruction followed by next stage nipple reconstruction with skate flaps and revision of the abdominal scar. (Pictures courtesy of Richard Klein, MD, FACS via Orlando Health/UF Health Cancer Center-Orlando.)

Another topic that often arises is the development of a plan for the contralateral breast. First and foremost, a patient should speak to her breast surgeon to discuss the implications of a contralateral prophylactic mastectomy on cancer risk in that breast. This should be weighed against potential complications, though often small, of performing an additional mastectomy. From a reconstructive perspective, a contralateral mastectomy allows for an easier aesthetic symmetry of reconstruction. However, this should not be the driving force. A patient should understand the full spectrum of risk/reward in considering a contralateral prophylactic mastectomy. Then move forward with an educated agreed upon decision.

During the initial reconstructive consultation, potential patients gain an understanding that DIEP flap breast reconstruction involves multiple stages (Fig. 59.3). The first stage centers on performing the actual breast reconstruction creating a new breast with the DIEP flap. This stage is the most extensive and with the longest recovery, though the senior surgeon has been able to get hospital stay to most commonly 3 days with a transition to nonnarcotic pain medicine by discharge. The second stage,

occurring ≥3 months after the initial surgery, involves numerous smaller procedures and is typically an outpatient procedure. At the second stage, nipples are reconstructed, the abdominal donor site is lowered, and the breasts aesthetics are improved. Improving the breast aesthetics can involve fat grafting, removing fat necrosis, and making minor adjustments to increase symmetry between the two breasts. If a unilateral reconstruction was performed, the nonreconstructed breast commonly requires a procedure such as reduction or lift (mastopexy). Second-stage procedures are outpatient with the patient going home the same day. Finally, tattooing of the nipple–areolar complex is performed in an office setting anytime after final healing of earlier stages.

Suitable patients who elect DIEP flap breast reconstruction undergo routine presurgical testing, including appropriate laboratory and diagnostic studies and anesthesia consultation. Blood typing and screening is not necessary. We routinely obtain preoperative imaging—either computed tomography angiography (CTA) or magnetic resonance angiography (MRA)—to delineate the topography of the key deep inferior epigastric perforators (Fig. 59.4). We find that preoperative imaging reduces our operative time by about 1 hour, and it also contributes greatly to patient safety as we are confident about exactly which perforating vessels will be the largest and most robust to use for the DIEP flap. We are able to plan the course of our dissection preoperatively, and we do not waste time guessing which perforating vessels to use while the patient is under general anesthesia.

ANATOMY

A full understanding of the vascular anatomy of the DIEP flap and its variances is crucial to offering consistently successful free flap breast reconstruction. The skin and fat of the DIEP flap are provided blood supply via perforators from the deep inferior epigastric artery. A perforator, simply stated, is a vessel arising from a source vessel and perforating muscle or fascia to supply a given territory (perforasome) of skin and fat. The perforators of the DIEP arise from the deep inferior epigastric vessels and then travel up through the rectus abdominis muscle to pierce the superficial fascia layer on their way to supply surrounding skin and fat of the abdomen. Each perforator bundle will have an artery, two veins, and sometimes a nerve. The deep inferior epigastric artery, after branching from the external iliac artery, travels from lateral to medial in

relation to the rectus abdominis muscle. Often, the vessels will branch into two rows, medial and lateral, each giving off perforators through the rectus abdominis muscle. At least one branch of the deep inferior epigastric artery will continue superiorly to anastomose with the superior epigastric arterial system.

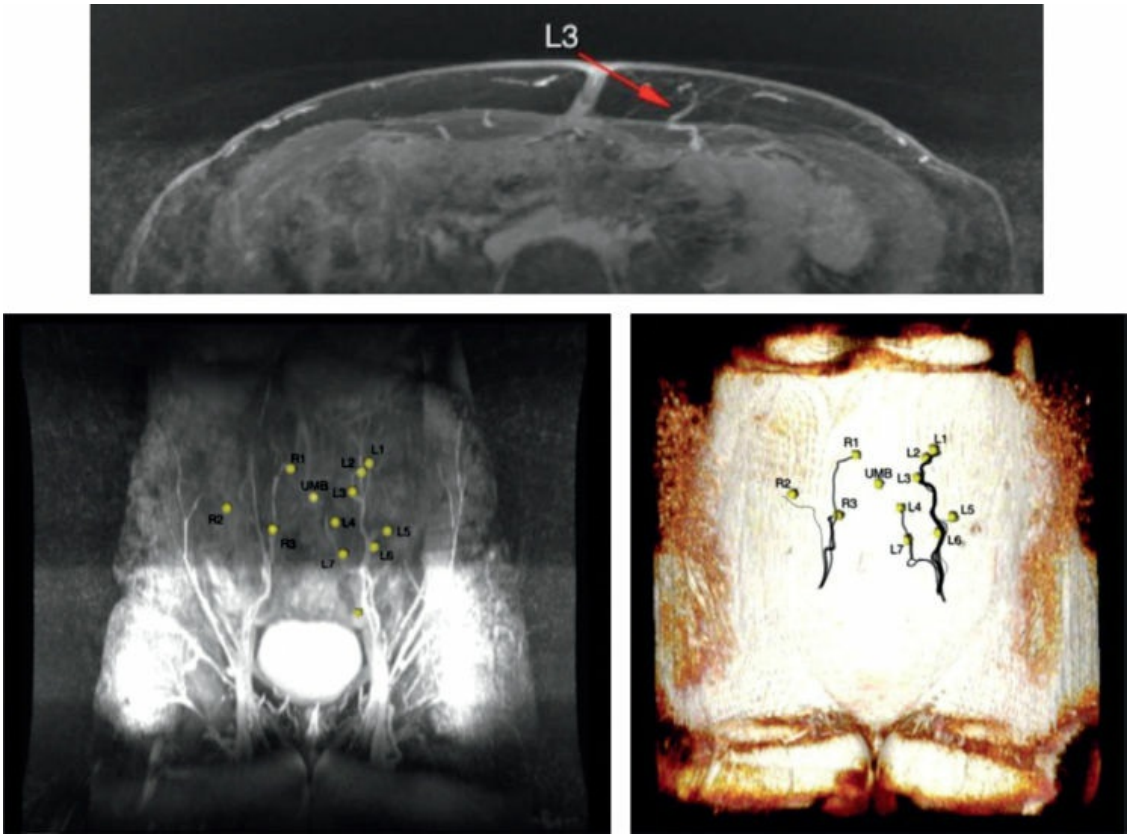

Figure 59.4. Superior MRA of the abdomen: *arrow* marks a perforator in the left hemi-abdomen as it courses deep through the muscle to its origin at the deep inferior epigastric vessels. Inferior left and right MRA images displaying the course of the deep inferior epigastric vessels and their perforators as they leave to perforate the muscle and ultimately supply the skin and fat of the abdominal wall. The preoperative imaging allows selection of the best perforators allowing the surgeon to proceed to the location of those vessels that will ultimately supply the free flap. The perforators are dissected to the origin deep inferior epigastric vessels dissecting inferior until adequate vessel caliber and pedicle length are reached.

The perforators best suited to supply a large area of the lower abdomen are commonly found in a periumbilical area. However, perforators can be located both medially and laterally in relation to the rectus abdominis

muscle, and all supply the surrounding tissue to some degree. The common flap design supplied by these perforators is a transverse, lower abdomen orientation which can be altered superiorly or inferiorly to adequately capture the key perforators. The lower the flap, the more hidden and aesthetically pleasing the resulting scar.

Using either CTA or MRA, the largest perforator(s) may be chosen preoperatively, and then mapped on an *X–Y* axis. The ideal perforator vessel is at least 2 mm in diameter with a short intramuscular course. In 8% of patients, a septocutaneous perforator may be found in which the dominant perforator vessel travels around the medial edge of the rectus abdominis muscle with no intramuscular course at all. This completely eliminates any intramuscular dissection and damage to the musculature, and the best way to identify a septocutaneous perforator is via preoperative imaging. Often, the best perforator vessels are around the umbilicus or slightly above the umbilicus. In these situations, we design our DIEP flap to incorporate the largest and most robust perforator vessels as seen on preoperative imaging.

SURGICAL TECHNIQUE

The day prior to surgery, the patient is seen in the office. After reviewing preoperative imaging and identifying the key perforator(s) supplying each hemi-abdomen, the proposed skin incision markings are placed (Fig. 59.5). First, the perforators are marked based on preoperative imaging coordinates. Some use a handheld Doppler probe to confirm the vessels that they choose preoperatively, and then identify them with direct visualization during flap harvest and perforator isolation. The upper incision is then marked to include the key perforators with the lateral extent of the flaps marked with the patient in a sitting position to avoid leaving excess flank skin after closing the abdomen. Finally, the lower incision is approximated based on lightly pinching the skin to ensure a low-tension closure. The lower skin incision can be adjusted during the operation to ensure a relatively low-tension closure. On the anterior chest wall, inframammary folds are outlined as well as suggested mastectomy skin incisions which vary based on tumor location, breast ptosis and whether or not the nipple areolar complex will be preserved.

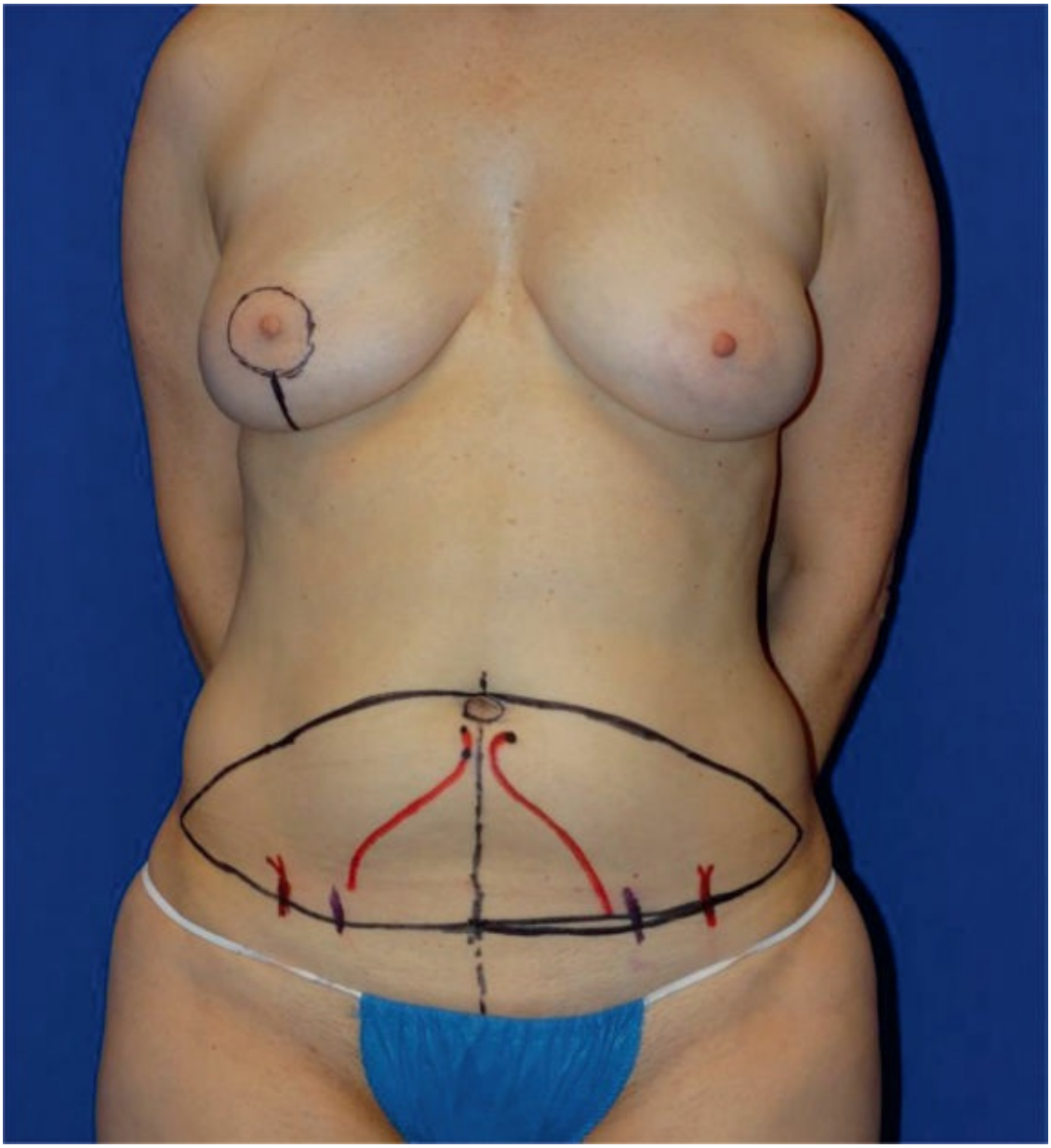

Figure 59.5. Typical preoperative markings showing the proposed incision for the breast surgeon to perform a skin-sparing mastectomy on the right. The abdomen is marked with flap outline as well as the perforators (2 on patient right, 1 on patient left). The lower lines represent the superficial inferior epigastric vein (medial) and artery (lateral).

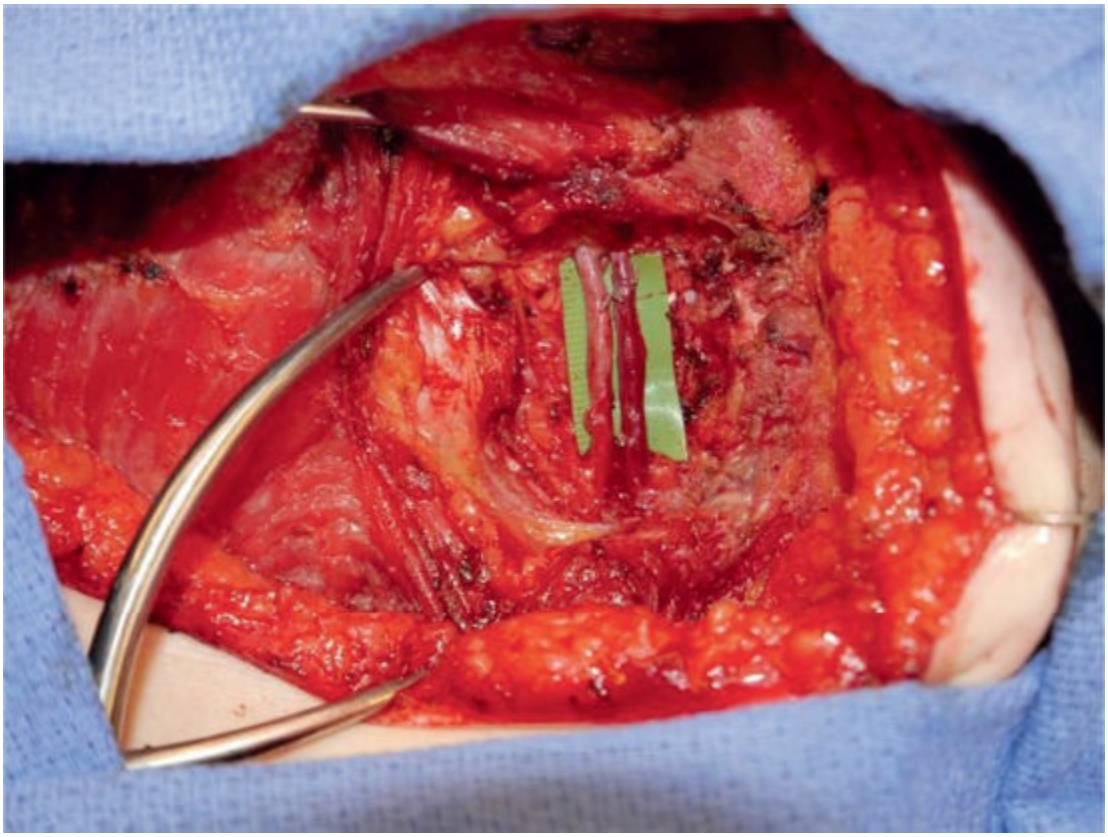

Figure 59.6. The internal mammary vessels (left artery, right vein) have been dissected out after removing the cartilaginous portion of the third rib allowing substantial exposure for vessel anastomosis. Removing a rib is not always necessary if the third or fourth intercostal space is wide enough for adequate exposure.

On the day of surgery, the patient is seen preoperatively to ensure no questions remain. In the operative suite, the patient is positioned supine on the operating table with the arms tucked unless the breast surgeon needs them untucked for the oncologic portion of the case, after which they are both tucked. Simultaneous abdominal flap harvest and preparation of the chest wall vasculature is carried out with a two-team approach. The internal mammary system is typically used as a recipient site (Fig. 59.6). The vessels are approached at the level of the third rib and in the interspace above or below it, depending on which interspace has the greatest width. The diameter of the internal mammary vessels usually increases in size more superiorly. The internal mammary vein often will split into two branches in this area as well, and preoperative MRA can identify the level of branching allowing the surgeon to harvest vessels just above this point. Ultimately, a balance is sought in level of vessel exposure in that one wants sufficient size of vessels but does not want to harvest the

vessels too high as to make exposure for vessel anastomosis cumbersome or to leave no room to expose more of the internal mammary vessels should an injury happen at the initial level of dissection.

First, the pectoralis muscle is split along its fibers over the third rib. It can also be separated from the sternum in a “T” or “L” manner for greater exposure. If necessary for exposure of vessels, the third rib is removed. The periosteum over the cartilaginous (medial) portion of the rib is then incised and stripped from the rib with a periosteal freer/elevator. The third rib is then removed to the sternum and the periosteum carefully excised. Bipolar cautery and sharp dissection are used in this area. Intercostal muscle fibers are excised to exposed a window to the fatty tissue and internal mammary vessels running longitudinally just lateral to the sternum. The vessels are skeletonized preparing them for anastomosis. Alternatively, a portion of the inferior third rib and superior fourth rib are resected to prevent removing a whole rib or, if the interspace is wide enough, no rib is removed, only intercostal muscle. Notably, literature has shown no physical deformity associated with removing the rib. Thus, our group has a very low threshold to remove a rib as a well set up microanastomosis is often key to success. It is important to note that if the vessels are injured during harvest, the recommended recourse is dissecting superiorly to virgin vessels even at the expense of removing another rib. Poor recipient vessels can lead to failure in reconstruction.

Harvesting of the DIEP flap begins with an incision at the upper marked line, dissection through the full thickness of the abdominal wall to the anterior fascia, and elevation of a superior abdominal wall flap. Dissection proceeds to the xiphoid process medially and then costal margin laterally. As much tissue laterally as possible is left undissected in order to preserve lateral perforators supplying the upper abdominal flap. The flap can then be brought down in a window shade fashion to estimate closure tension and adjust the inferior margin as necessary. The umbilicus is then incised. The inferior incision is then made and taken down to fascia. Care is taken to isolate and dissect length on the superficial inferior epigastric vein (SIEV) inferiorly. This vein is a key safeguard when performing DIEP free flap breast reconstruction as an alternative source of venous drainage. Some flaps drain preferentially via a superficial venous system, which can sometimes be recognized as a potential on preoperative imaging. Otherwise this is discovered due to a finding of congestion after the flap has perfused for a time with only the vena comitante providing

venous drainage. Alternatively, one of the perforators to the flap can be injured directly or via traction leaving adequate arterial inflow but insufficient venous outflow. The SIEV is a key bailout in these cases.

If the perforator has already been identified via preoperative imaging, then the dissection can continue directly to the chosen perforator. In a bilateral DIEP flap, the midline incision is made first. If the perforator is a medial row or a septocutaneous perforator, then the chosen perforator is isolated prior to elevating the lateral edges of the abdominal flap. Once the chosen perforator(s) has been identified, the dissection proceeds efficiently with elevation of the skin-fat flap from the underlying rectus fascia. The key perforators are isolated as they enter the anterior rectus fascia. The remainder of the perforators can be either ligated and transected if hindering exposure and dissection of the chosen perforators or left as a bailout should the chosen perforators be injured or inadequate.

Isolation of the DIEP flap proceeds under loupe magnification, and begins by opening the anterior rectus sheath around the selected perforator. Some surgeons incorporate a 1- to 2-mm cuff of the sheath around each perforator, but routinely, no fascia is harvested. Using a microsurgical scissor or bipolar electrocautery, the perforator is followed through the rectus muscle, carefully ligating and diving all small side branches with microsurgical clips. Bipolar electrocautery can be used for smaller branches. If a second or third perforator has been selected, particular attention must be paid to maintaining its continuity in line with the first. Ideally these additional perforators are along the same “row” as the primary, meaning medial or lateral. This will allow preservation of muscle as the perforators will all be along the same line when the muscle is split. If the perforators originate from both medial and lateral rows and are necessary for flap perfusion, a decision must be made to either transect a small portion of muscle or harvest a muscle-sparing type 2 TRAM removing a small portion of muscle between the two rows of perforators. This is rarely necessary.

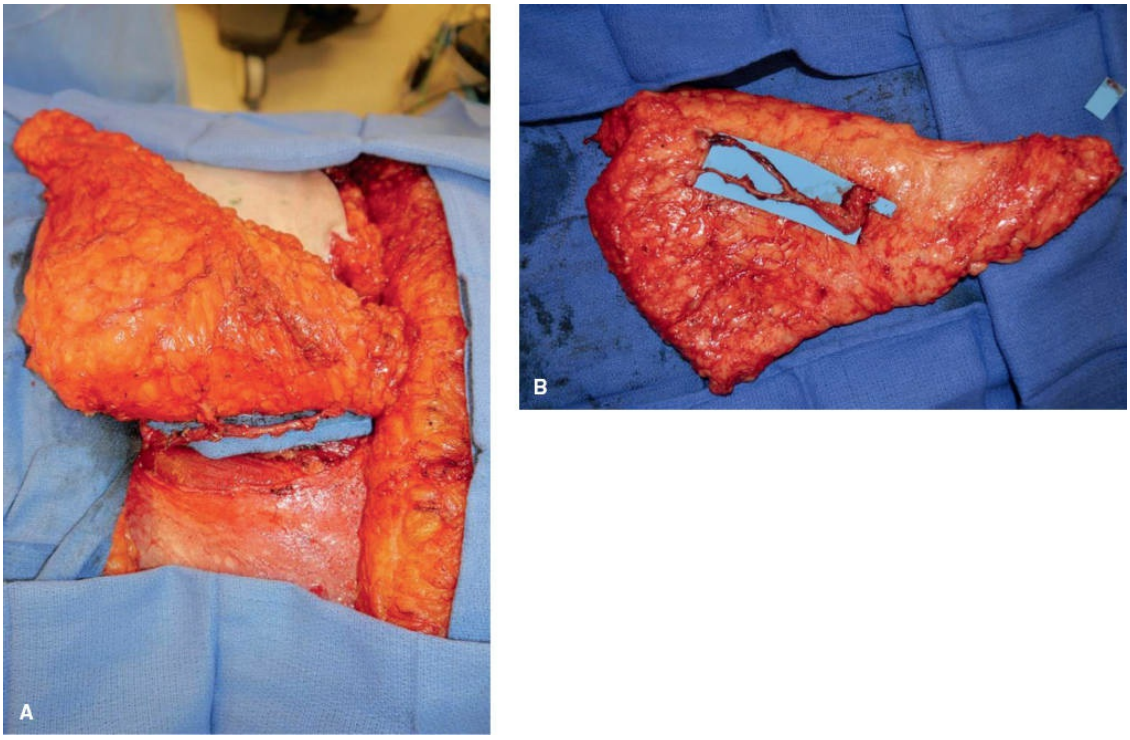

Figure 59.7. A: Deep inferior epigastric perforator artery flap harvested on two perforators. The perforators enter the deep inferior epigastric vessels were then course inferiorly. Below the blue background, the rectus abdominis muscle can be seen spared of any unnecessary trauma. **B:** DIEP free flap harvested. Pedicle seen resting on the blue background.

As dissection proceeds, the muscle is split along the direction of its fibers, preserving all intercostal nerves that do not lie between two perforators. The anterior rectus sheath is also split inferiorly, and the deep inferior epigastric vessels are eventually exposed. These are followed toward their origin from the external iliac artery and vein until adequately sized vessels are reached that match the caliber of the recipient vasculature. At this level, the resulting pedicle length is usually between 9 and 14 cm (Fig. 59.7).

The DIEP flap is then harvested by individually ligating and dividing the deep inferior epigastric artery and its two venae comitantes. It can be helpful to mark the anterior surface of the vessels with methylene blue prior to vessel division to prevent twisting of the pedicle. In addition, the smaller vena comitantes can be clipped, leaving the larger vena comitantes and artery open for anastomosis. The flap is weighed at this time to determine its comparability to the mastectomy specimen or implant. It is then transferred to the anterior chest wall and temporarily secured in

position. This can be done by suturing/stapling the flap to the chest wall or by wrapping the flap in a heparin-soaked lap sponge that is stapled to the chest wall. Routinely, the hemi-abdomen contralateral to the breast being reconstructed is utilized and rotated 90 degrees counterclockwise when transferring left hemi-abdomen to right breast, clockwise when transferring right hemi-abdomen to left breast.

The operating microscope is positioned at the recipient site and the pedicle prepared for microanastomosis, taking care to avoid twisting of the vessels. An end-to-end venous anastomosis is completed with a microvascular coupling device (Fig. 59.8). The end-to-end arterial anastomosis is hand-sewn with 9-0 nylon sutures usually in a running fashion if the vessel match is favorable, otherwise interrupted sutures are used. Once the anastomosis is completed, the vascular clamps are removed and the pedicle assessed for flow. There should be a palpable pulse in the pedicle. Next, the flap can be inspected for bleeding which should be a slow bright red ooze. Venous congestion will usually present slowly as the flap fills with blood and will include brisk dark red blood from the flap, decreased time of capillary refill and, over time, flap swelling.

The DIEP flap is then debulked, contoured, and inset to achieve the desired breast size and shape. At a minimum medial Vicryl sutures are placed to keep the flap from shifting laterally. These are placed to Scarpa fascia of the flap and the most medial chest wall. However, if the breast pocket is at all big, additional sutures can only help to contour an aesthetic breast mound. Areas underlying the native mastectomy flaps are deepithelialized in situ. A closed-suction drain is placed and brought out through the lateral edge of the skin closure or through a separate stab incision. After the flap has been shaped and inset, the skin is closed with 3-0 Monocryl deep dermal and running subcuticular sutures.

Ideally, closure of the abdomen begins as soon as the flap(s) are harvested, and is finished prior to the conclusion of the microvascular anastomosis. The anterior rectus sheath is closed with interrupted 0 V-lock suture. Since no fascia has been harvested, the use of mesh is not necessary. The remainder of the abdominal closure is in layered fashion, using 0 barbed suture to close Scarpa fascia, and 2-0 barbed suture for skin. Two closed-suction drains are placed in the abdomen and brought out through the lateral incision. We have also begun running barbed progressive tension sutures along the abdominal flap tacking the subcutaneous tissue to the anterior fascia of the abdominal wall. This has

allowed placement of only one drain. The umbilicus is brought through the abdominal wall at a predetermined site after removing a full-thickness elliptical core of skin and adipose tissue. It is secured in place using interrupted 3-0 Monocryl in the dermis and 4-0 subcuticular sutures for skin.

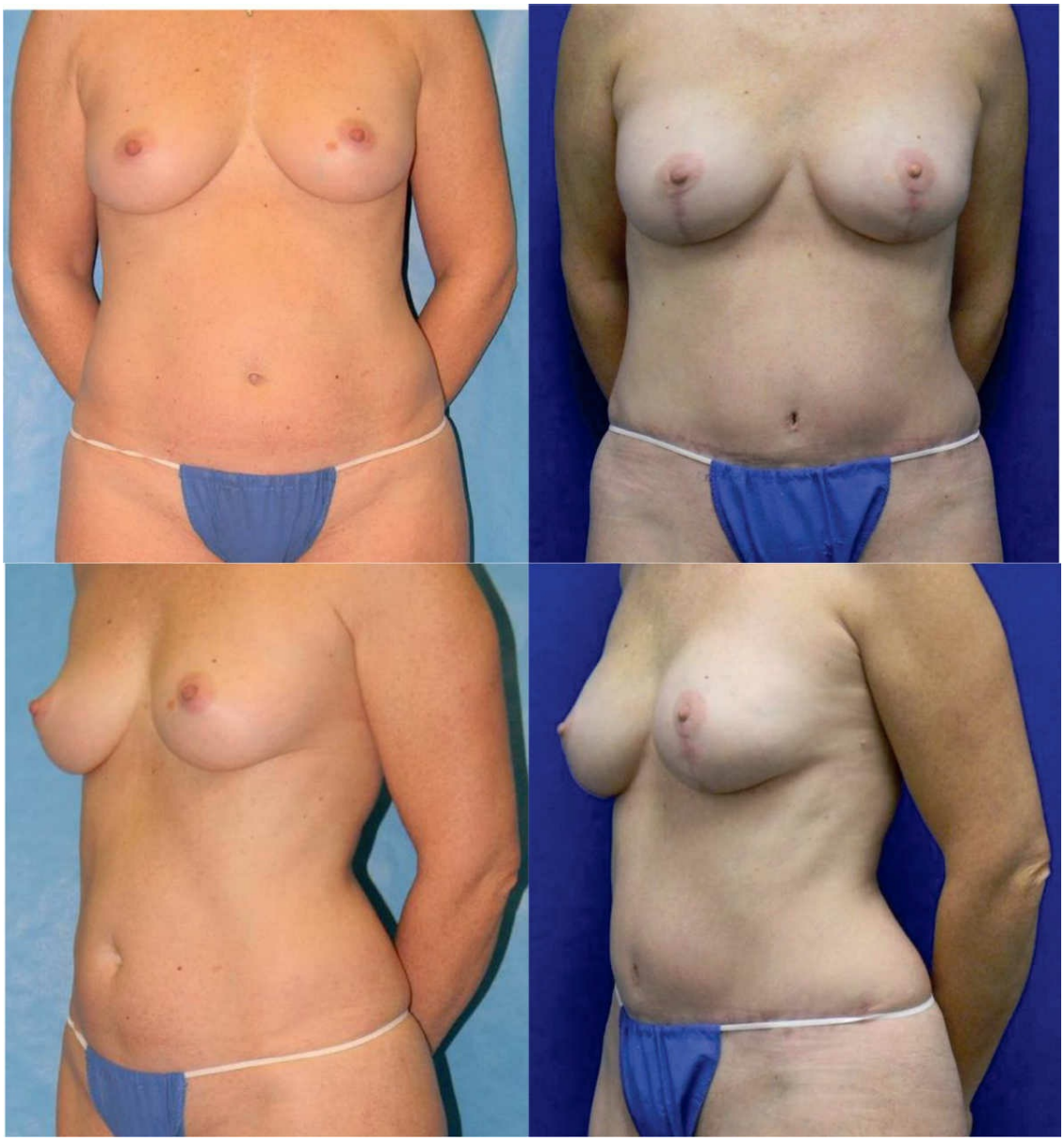

Figure 59.8. A 51-year-old patient who underwent bilateral mastectomy for prophylaxis with immediate DIEP free flap breast reconstruction. Left preop/Right postop.

Once all wounds are closed, the entire anterior body is cleansed and dried. Liquid skin adhesive is placed over the abdominal and breast incisions. A piece of Xeroform is placed within the umbilicus and the flaps are again checked for perfusion. Doppler signals are confirmed and marked with a 5-0 monofilament suture. The patient is usually given some form of IV nonnarcotic pain medicine such as ibuprofen, acetaminophen, or ketorolac then extubated and sent to recovery.

POSTOPERATIVE MANAGEMENT

The patient is monitored in the recovery room for 4 hours postoperatively. Flap checks are performed every 15 minutes during this time, and consist of assessments of skin paddle color, temperature, capillary refill, and Doppler signals. The patient is then moved to a regular private room, where flap checks are performed on an hourly basis overnight. The patient is out of bed to a chair sitting up the day of surgery. In the morning postoperative day 1, the Foley catheter and intravenous lines are removed. The patient is started on a regular diet, and is required to ambulate. Chemical deep vein thrombosis prophylaxis is started as well. Flap checks are continued every 4 hours while the patient is in the hospital. The patient is usually discharged home on postoperative day 3 or 4. After 4 to 6 weeks, patients are encouraged to gradually resume their preoperative levels of activity.

Complications

Much has been written comparing the DIEP with the traditional TRAM flap. It is imperative to meticulously review this literature as many factors confound the outcomes data including surgeon experience, definition of and quality reporting of complications such as fat necrosis, and even poor follow-up as is the case with many NSQIP-based studies. At present time, the DIEP is the gold standard for autologous breast reconstruction and a discussion of comparison to other abdominally based flaps will be brief given the DIEP's known superiority. Unlike the pedicled and free TRAM, the DIEP flap preserves the rectus abdominis muscle to maintain abdominal wall strength and minimize the risk of abdominal bulge or hernia. Preservation of the rectus abdominis muscle decreases abdominal wall morbidity, resulting in improved abdominal wall strength and contour. This translates into less postoperative pain, shorter hospital stays, and quicker recovery. In addition, the longer vascular pedicle allows greater freedom of design that optimizes the aesthetics of breast reconstruction.

DIEP flap breast reconstruction is not without complication maintaining a total complication rate of roughly 25%. Obese patients and smokers tend to suffer more donor site wound healing and mastectomy skin flap necrosis respectively. In our series of over 2,000 DIEP flaps beginning in 1992, the total complication rate compares favorably with other forms of autologous tissue breast reconstructions. Our complication rates include a 10.3% abdominal wound healing complication often associated with an

underlying seroma. We expect these rates to decrease as we have seen favorable results with progressive tension sutures.

Early complications included the need to return to the operating room in 5% of patients: 3.7% because of venous occlusion, 0.5% for arterial occlusion, and the remainder for hematoma. Adoption of a coupling device for venous anastomosis has decreased the take-back rate even further. The rate of total flap loss was 0.5%, with a partial flap loss rate of 2%. The most common complication following autologous breast reconstruction with abdominal tissue is fat necrosis. This is thought to arise in areas of deficient perfusion, often at the flap periphery farthest from the vascular supply. Although early experience with the DIEP flap led to initial reports of fat necrosis rates as high as 60%, improvements in perforator selection and operative technique have led to a significant decrease. It is important to keep this fact in mind when reviewing the available literature on the subject. A retrospective review of our DIEP free flap reconstructions reveal a 10% fat necrosis rate, which is significantly correlated with smoking, obesity, and postreconstruction radiotherapy. These rates are at or below the rates of fat necrosis for other forms of abdominally based free flap breast reconstruction. When performed routinely by an experienced microsurgeon, abdominal hernia is not seen after DIEP free flap breast reconstruction. We have seen a very small percentage of abdominal bulging without true hernia likely due to fascial laxity and this has been associated with the obese population.

CONCLUSION

The DIEP flap technique has expanded the pool of potential reconstructive candidates by allowing for autologous breast reconstruction in previously unsuitable patients, such as obese individuals or those with prior abdominal surgery. With the increasing use of preoperative imaging and a two-microsurgeon team, operative times are minimized and the procedure itself has become safer and more predictable. The DIEP flap represents the gold standard for autologous breast reconstruction using the abdomen and provides the best long-term aesthetic outcome (Fig. 59.8). The increased demand for microsurgical expertise is more than offset by the rewards of minimized donor site morbidity and increased patient satisfaction. DIEP free flap breast reconstruction should be accessible to all potential candidates for autologous breast reconstruction.

EDITOR'S COMMENT

Transverse rectus abdominis muscle (TRAM) flaps revolutionized breast treatment with the promise of reconstruction. The introduction of the deep inferior epigastric perforator (DIEP) flap allowed transfer of skin and soft tissue without the sacrifice of muscle with less morbidity (no sacrifice of rectus or fascia), abdominoplasty, reduced pain and recovery time and long-lasting results. Koshima and colleagues reported the first use of a deep inferior epigastric perforator (DIEP) flap in 1992 using a single periumbilical perforator which was used for mouth and groin reconstruction. At the same time Allen and Treece performed the first DIEP flap for breast reconstruction in order to use the fat and skin of the abdomen for breast reconstruction. The authors of this chapter go so far as to say that DIEP reconstruction should be accessible to all potential candidates for autologous breast reconstruction. This is said though without regard to the lack of availability of qualified surgeons and teams of surgeons or cost and without the discussion of acceptable alternatives. Implants are far and away the most utilized type of reconstruction (70%) in the United States. The patient can have a staged expander reconstruction or a direct to implant reconstruction with immediate results. Granted the cosmesis may not be as superior and deteriorates a bit over time. Implant reconstruction has been driven by, in this "McDonald's Society," immediate results, the low morbidity of implant reconstruction, short hospitalization and recovery and the back-up of tissue reconstruction should the implants fail.

DIEP flaps are indicated in anyone with amastia with or without contralateral reconstruction, lumpectomy-induced breast defect, failed implant reconstruction, or desired augmentation. Factors influencing surgical decision-making include diabetes, cardiopulmonary disease, autoimmune disease, clotting disorders, obesity, and smoking. DIEP flaps do better in such patients but still have a high complication rate, are much more costly (preoperative imaging, two microsurgeon team, long operative times and long recovery times) but with superior and long-lasting results and patient satisfaction.

Contraindications as is in all reconstruction include active smokers, prior abdominoplasty or liposuction. Relative contraindications include patients with prior scars including even an appendectomy scar. One contraindication to DIEP reconstruction that plagues plastic surgeons is the commonality of the presence of a midline scar. Gupta and colleagues have published a small series on the use of two hemi DIEP flaps stacked on each other with two separate anastomoses to the IM to create a breast of sufficient size. Magnetic resonance angiography (MRA) can be invaluable in patients with or without scars to preoperatively to determine perforator anatomy, location, size, and appropriateness which will result in a reduction in intraoperative time. Surgeons are also loathed to use DIEP flaps when a patient will require postoperative radiation therapy. In such situations, a nipple skin-sparing mastectomy can be performed, a short-term

expander placed above the muscle and radiation performed. Then the patient can return to surgery and the expander removed and the skin envelope filled with a DIEP flap thus avoiding the complication of severe fat necrosis created by radiating a flap.

The authors have given a very detailed description of DIEP reconstruction. The DIEP, like the TRAM flap, is based on the deep inferior epigastric artery and vein. The DIEP can also and was previously termed a muscle-sparing TRAM which dissects free the medial or lateral row of DIEP vessel down to the deep inferior epigastric vessels. Although any side can be used an ipsilateral DIEP is shaped/used if the recipient vessels are the thoracodorsal bundle and the contralateral DIEP is used when the internal mammary vessels are to receive the flap which is most of the time. Flap geometry, when there is an absent or an insufficient internal mammary (IM), may also dictate a change in recipient vessel. Use of the thoracodorsal vessel as a recipient vessel obviates the use of a latissimus musculocutaneous flap in case of failure of the DIEP flap. If the IM is used then the IM cannot be used in the future for coronary reconstruction.

Site of recipient vessel has been up to the discretion and preference of the plastic surgeon. Recently, Lhuaire and colleagues did a careful anatomical dissection of 80 cadavers to determine which recipient vessel, IM, circumflex scapular (CS) or thoracodorsal (LD) vessels and how well they matched the deep inferior epigastric vessels in the same cadaver. They found the best match was in the IM vessels, only a little better than CS, and was largest at the third rib. There was a perfect match in only about one third of cases for IM and CSA but one sixth of the time for LDA. Venous congestion is a common reason for flap failure but under studied. Lhuaire and colleagues showed that less than one quarter of the time was there a perfect match for the potential venous anastomoses. Although arteries of these vessels were singular this was not true of the venous vessels. Deep inferior epigastric and CS vessels were duplicative in 10% of cases. IM had two branches in 25% of cases. In this regard, TD vessels appear superior in that there is only one branch 99% of the time.

Advantage of using the IM for the DIEP recipient vessel is that it does have the size vessel matching the donor vessels, ease of inset, found to have a higher internal volume, no impediment to an axillary node dissection if necessary, ease of microscope set-up, and shorter donor pedicle procurement. It does usually require rib removal and as a result possible pulmonary complications. Some believe that respiratory movement puts undue strain on the microvascular anastomosis. If radiation has or is to be given then the quality of the IM can be affected. The CS is the second vessel with the highest vessel diameter match to the DIEP pedicle. The CS vessels are very constant in location, decreased operative time, avoids pulmonary complications and offers the possibility of a second or alternative vein anastomosis in case of insufficient outflow. Particularly important is that an anastomosis to the CS vessels does not affect IM or LD vessels. LD reconstruction then remains a back-up alternative Superficial Inferior Epigastric Perforators (SIEP) can be used when there is an

issue with DIEP. If there is a large SIEP then it portends that the DIEP vessels may be insufficient and then SIEP can be performed, 25% on one DIEP perforator, 50% on two and 25% on three.

Another newer and less established technique not discussed by the authors is preservation of the intercostal nerves to avoid muscle laxity that can mimic a hernia. Sensory nerves can be taken with the DIEP and reanastomosed to recipient nerves in the chest. In a more recent innovation, Yang and colleagues simultaneously combined TRAM/DIEP reconstruction with inguinal node donation to reconstruct patients who had received ALND and radiotherapy to improve postmastectomy lymphedema.

Complication rates with abdominal pedicled myocutaneous flaps to the deep inferior epigastric perforator free flap (DIEP) vary. These flaps vary in difficulty, time to perform, complication rate (roughly 25%), up to and including flap loss, donor site morbidity which is lessened in muscle sparing flaps. Early take back due to problems with arterial or venous occlusion (～5%) have been lessened with the adoption of vascular coupling devices. Tissue reconstruction does have the advantage of less complication in the obese which, in general, have a sevenfold higher risk compared to those who have a normal body mass index. In a systematic review and meta-analysis, Lee and Mun found that muscle sparing flaps like DIEP had less complications, flap loss and fat necrosis than the traditional free TRAM flaps. Zoghbi and colleagues examined the Nationwide Inpatient Sample Database (2010–2011) for all cases of DIEP and free TRAM reconstruction. They identified 15,836 cases. Although the DIEP cohort was much more likely to be obese the TRAM group had more complications including pneumonia, wound infection, and wound dehiscence which resulted in a relative risk of 1.6 in regard to length of stay but not flap loss. Despite this total charges for a DIEP flap were higher. Wade and colleagues showed that complications are much higher with bilateral DIEP reconstruction and total flap loss six times higher when comparing bilateral versus unilateral operations thought mainly due to venous congestion. Donor site morbidity with DIEP is also less when compared to the traditional free flaps. Egeberg and colleagues, in a recent meta-analysis of five studies that compared muscle sparing TRAM with DIEP flaps showed that the relative risk of hernia was halved with DIEP.

V. Suzanne Klimberg

This is an excellent commentary by Dr. Klimberg of various approaches to provide excellent cosmesis of the breast. Cosmesis is essential to make certain women have a satisfactory result to decrease the trauma of mastectomy.

J.E.F.

Suggested Readings

Allen RJ, Treece P. Deep inferior epigastric perforator flap for breast reconstruction. *Ann Plast Surg* 1994; 32:32.

Chang EI, Chang EI, Soto-Miranda MA, et al. Demystifying the use of internal mammary vessels as recipient vessels in free flap breast reconstruction. *Plast Reconstr Surg* 2013;132(4):763–8.

Das-Gupta R, Busic V, Begic A. Breast reconstruction in the presence of a midline vertical scar. *Journal of Plastic, Reconstructive and Aesthetic Surgery* 2006;59:675–6.

Egeberg A, Rasmussen MK, Sorensen JA. Comparing the donor-site morbidity using DIEP, SIEA or MS-TRAM flaps for breast reconstructive surgery: a meta-analysis. *J Plast Reconstr Aesthet Surg* 2012:65(11):1474–80.

Granzow JW, Levine JL, Chiu ES, et al. Breast reconstruction with the deep inferior epigastric perforator flap: History and an update on current technique. *Journal of Plastic, Reconstructive and Aesthetic Surgery* 2006;59:571–9.

Koshima I, Moriguchi T, Soeda S, et al. Free thin paraumbilical perforator-based flaps. *Ann Plast Surg* 1992; 29(1):12–7.

Lee KT, Mun GH. Effects of obesity on postoperative complications after breast reconstruction using free muscle-sparing transverse rectus abdominis myocutaneous, deep inferior epigastric perforator, and superficial inferior epigastric artery flap: a systematic review and meta-analysis. *Ann Plast Surg* 2016;76(5):576–84.

Lhuaire M, Hivelin M, Drame M, et al. Determining the best recipient vessel site for autologous microsurgical breast reconstruction with DIEP flaps: Anatomical study. *Journal of Plastic, Reconstructive and Aesthetic Surgery* 2017;70(6): 1–11. http://dx.doi.org/10.1016/j.bjps.2017.01.008

Wade RG, Razzano S, Sassoon EM, et al. Complications in DIEP flap reconstruction after mastectomy for breast cancer: A prospective cohort study comparing unilateral versus bilateral reconstructions. *Ann Surg Oncol* 2017;24(6):1465–1474. doi: 10.1245/s10434–017–5807–5.

Yang Z, Huang S, Wang J, et al. A retrospective study of lymphatic transverse rectus abdominis myocutaneous/deep inferior epigastric perforator flaps for breast cancer treatment-induced upper-limb lymphedema. *Sci Rep* 2017;7:80. doi:10.1038/s41598–017–00164–1

Zoghbi Y, Gerth DJ, Tashiro J, et al. Deep inferior epigastric perforator versus free transverse rectus abdominis myocutaneous flap: complications and resource utilization. *Ann Plast Surg* 2017;78(5):516–20. doi: 10.1097/SAP.0000000000000936.

60 Applied Anatomy of the Chest Wall and Mediastinum

Petros Mirilas, Michael E. Halkos, John D. Symbas, Panagiotis N. Symbas, and Lee J. Skandalakis

CHEST WALL

Embryogenesis

The *muscles of the chest* develop from the somites found in the mesoderm. About the 6th week, the somites differentiate into the sclerotomes and the dermatomyotomes. The myotomes elongate and invade the mesoderm of the wall of the embryonic thoracic and abdominal cavities. These myotomes divide into the epimere and the hypomere. The corresponding nerves give a dorsal and a ventral ramus, respectively. The hypomere in turn divides in three layers—outer, intermediate, and inner—that give the three layers of muscles of the chest, that is, the external intercostals, the internal intercostals, and the innermost intercostals; in the abdomen, the hypomere gives off the external oblique, the internal oblique, and the transverse abdominal muscles (Fig. 60.1). This arrangement explains the continuity of the three muscle layers in the thoracic and abdominal wall. The anterior edge of the hypomere gives the rectus abdominis, and, in the thoracic wall, its equivalent: the transverse thoracic muscle.

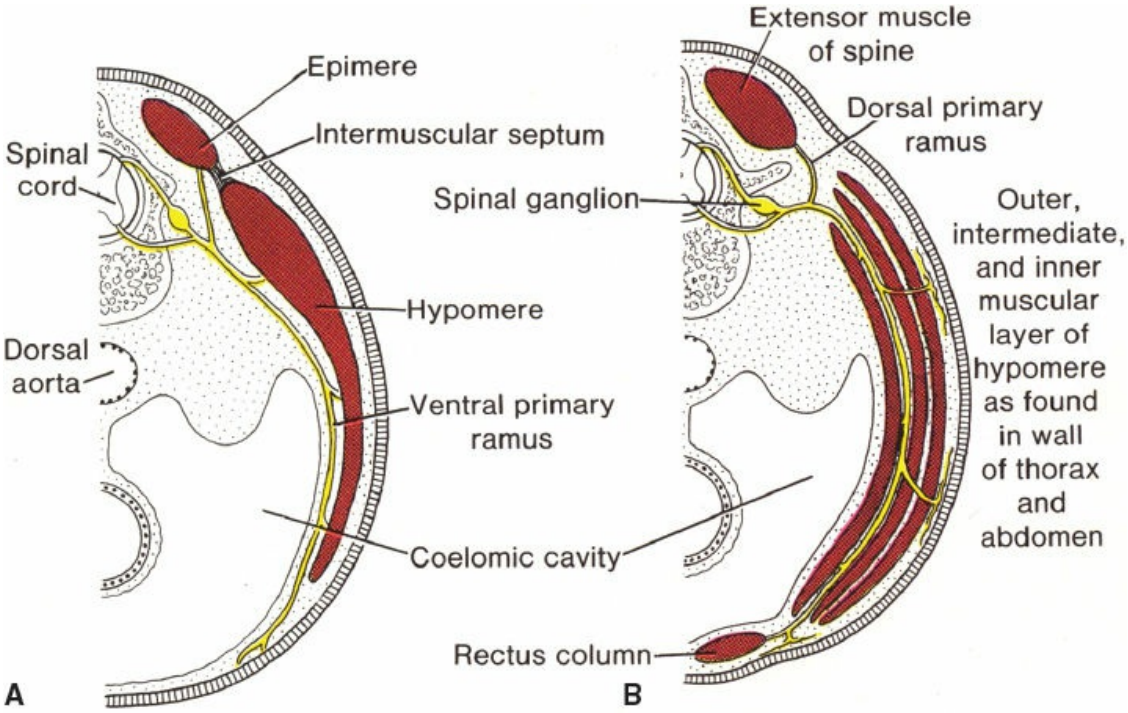

Figure 60.1. A: Transverse section through the thoracic region of a 5-week embryo. The dorsal portion of the body wall musculature (epimere) and the ventral portion (hypomere) are innervated by a dorsal primary ramus and a ventral primary ramus, respectively. **B:** Similar sections as in (**A**), at a later stage of development. The hypomere has formed three separate muscle layers and a ventral longitudinal muscle. (From Sadler TW. *Langman's Medical Embryology*. 10th ed. Baltimore, MD: Lippincott Williams & Wilkins, 2006, with permission.)

The *ribs* develop in the 5th week by the costal processes of the thoracic vertebrae (derivatives of the sclerotomes). They elongate in the same mesodermal layer with the thoracic muscles, and thus the investing fasciae of the intercostal muscles are continuous with the periosteum of the ribs. The embryonic ribs are cartilaginous; ossification takes place about the 9th week.

The *sternum* appears during the 6th week as paired bands of condensed mesenchyme. At the same time, the presternum, a cranial rudiment associated with the development of the shoulder, and two craniolateral pieces, the suprasternal cartilages, will join the two sternal bars, which "zipper" craniocaudally (Fig. 60.2). The manubrium is the result of subsequent ossification in the sternum.

Congenital Anomalies

Sternum deformities (Fig. 60.3): The *pectus excavatum* or funnel chest represents a depression deformity, with the apex at the lower end of the body of the sternum. The *pectus carinatum* or pigeon breast is a protrusion deformity. These deformities are often nonsymmetrical or mixed. *Sternal clefts* (upper, lower, or entire) may be the outcome of an anomaly of fusion of the two sternal bars; this deformity may be associated with ectopia cordis (cardiac ectopia), or, rarely, may be one of the constituents of Cantrell's pentalogy (sternal cleft, diaphragmatic defect, defect of the pericardium and communication with abdomen, cardiac defects).

Rib deformities: The spectrum of these rare anomalies includes unilateral absence, absence of cartilage, separation of cartilage and rib, combined costosternal anomalies, and part of a skeletal disorder combined with the absence of the pectoralis major muscle (Poland's syndrome).

Surface Anatomy

Sternum

Parts of the sternum point to the position of deep structures:

The superior border lies in the same horizontal level as the inferior border of the body of the second thoracic vertebra. McGregor and Du Plessis wrote about this border: A pin pushed back at the middle of the upper border of the sternum would transfix the inner border of the innominate artery just below its division. In the child the top of the aortic arch may reach the upper border of the manubrium, whereas in the adult it is about the level of the center of this bone.

The angle of Ludwig or of Louis, that is, the junction of the manubrium with the body of the sternum, lies on the same horizontal level with the fourth thoracic vertebra, the bifurcation of the aorta (one vertebra higher in the infant), the beginning and the end of the aortic arch, the site where the pleural sacs meet. The angle of Louis is useful for counting the ribs, because the second rib lies opposite to it.

The xiphisternal junction lies at the level of the disk between 9th and 10th thoracic vertebra.

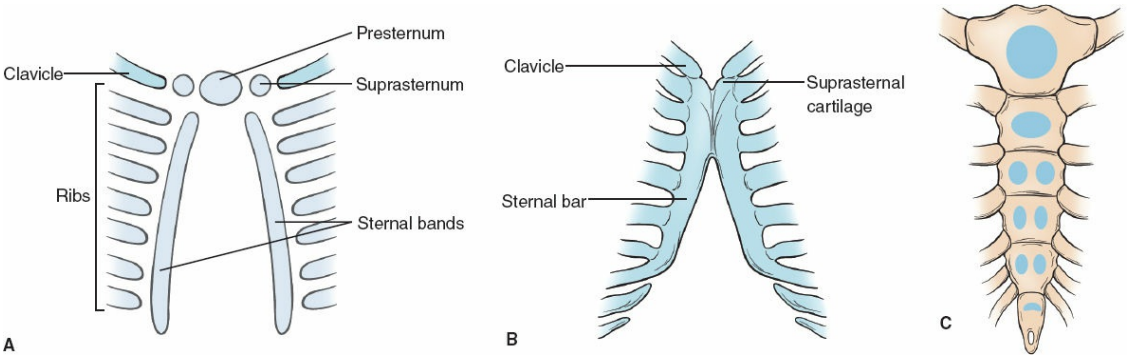

Figure 60.2. Development of the sternum. **A:** Mesenchymal stage (6th week). **B:** Cartilaginous stage (9th week). **C:** Ossification centers appearing after birth.

Lung and Pleura Projection

The classical teaching is that the inferior border of the lungs (defined by percussion) begins at the xiphisternal junction, then is found at the 6th rib in the midclavicular line, the 8th in the midaxillary line, and the 10th vertebra at the spine. The pleura is supposed to be found two spaces below at all these points; an empty *costodiaphragmatic recess* lies in between (Fig. 60.4). However, as O'Rahilly points out, it is not empty but occupied by a very thin part of the lung, which expands further in deep inspiration. Surgically, we must consider that the lung and pleura coexist. It is also important to know the exact levels of the *costomediastinal sinuses* (Fig. 60.4A) to gain transthoracic access to the pericardium, heart, and esophagus without producing pneumothorax; for example, the pericardium can be reached through the fifth and sixth interspaces without opening the pleura. Another must-know tip is the extension of the *cervical pleura* into the neck: the cupola of the pleura lies behind the sternocleidomastoid muscle, 2 to 3 cm or more above the medial third of the clavicle. This space is filled by lung. The subclavian artery, the internal thoracic vessels, the inferior ganglion of the cervical chain, the lower trunk of the cervical plexus all lie on the cervical pleura.

The lung, pleura, liver, stomach, spleen, colon, kidney, and peritoneal cavity extend higher to the periphery of the diaphragm and the inferior border of the lungs. A perforating trauma to the lower intercostals must be considered and treated as thoracoabdominal trauma.

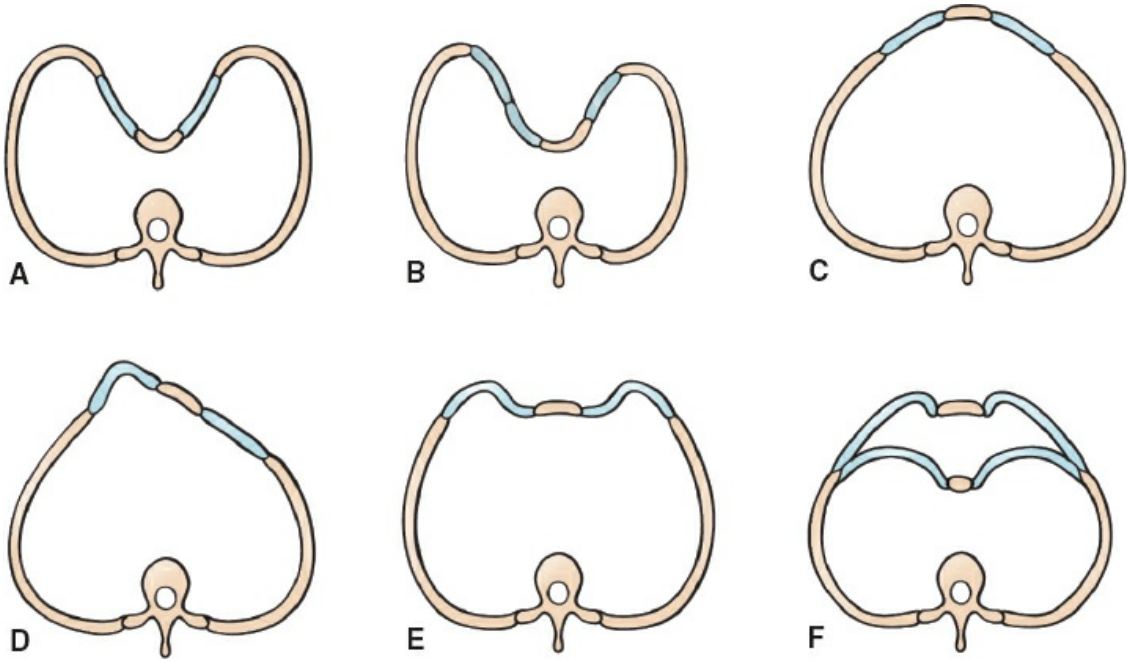

Figure 60.3. Varieties of chest deformities (in cross section). **A, B:** Depression deformities. **C, D:** Protrusion deformities. **E:** Bilateral protrusion. **F:** Chondromanubrial protrusion with gladiolar depression.

Bony Thorax

The thoracic cage includes the sternum, the ribs, and the vertebrae (Fig. 60.5). The sternum consists of the manubrium, the body, and the xiphoid process. The first seven pairs of ribs are the true ribs, and the last five the false ribs; of the last, ribs 8 to 10 articulate with the sternum via supervening costal cartilages, while ribs 11 and 12 do not articulate at all (floating ribs). Occasionally, the 12th rib is missing; a cervical rib is encountered in 1%, producing symptoms only in 10% of these.

A typical rib (Fig. 60.6) has a head, with superior and inferior articulation facets with the superior and inferior vertebra, respectively; a neck; an angle; and the shaft. The costal groove is located in the inferior internal surface of the rib and hosts the neurovascular intercostal bundle. Fracture of the rib due to compression is unusual, and happens at the apex of the curve, sparing the pleura. Otherwise, with direct injury, the fractured rib may traumatize the pleura, the lung, and the intercostal vessels, leading to pneumothorax, hemothorax, or even subcutaneous emphysema.

Muscles

Extrinsic Muscles

The thoracic cage is to a great extent covered by muscles that do not belong to the thorax, but to the shoulder, neck, back, or abdominal wall. The pectoralis muscles, major (lateral and medial pectoral nerve, C5 to C7) and minor, and the serratus anterior (long thoracic nerve) are the extrinsic muscles of the anterior and lateral chest wall (Fig. 60.7). The muscles of the anterior abdominal wall cover the lower ribs: the external oblique from the eight lower ribs (its slips interdigitate with the serratus anterior), the internal oblique (which attaches to the lower three ribs), the internal oblique from the inner surfaces of the eight lower costal cartilages, and the rectus abdominis (which inserts in front of the xiphoid process and into the fifth to seventh costal cartilages).

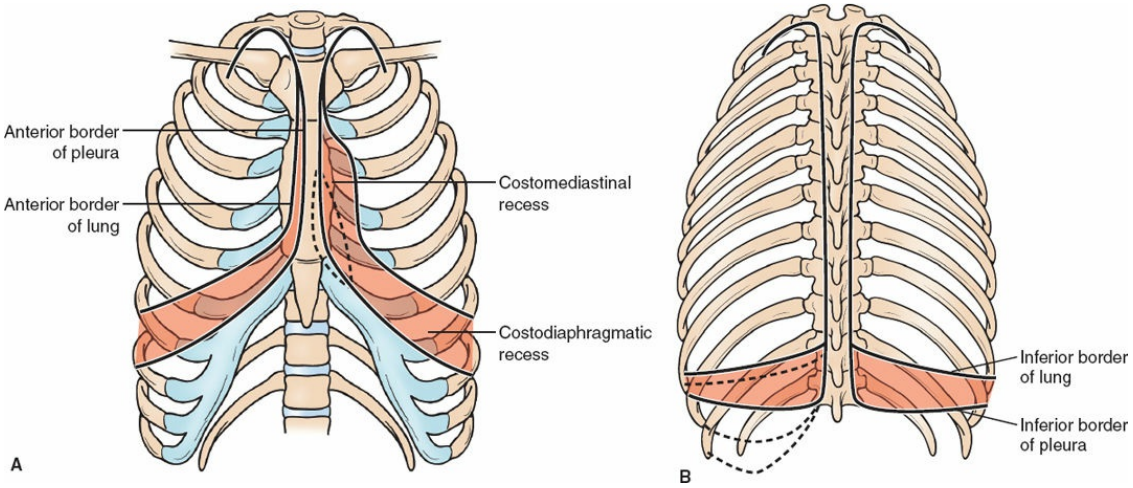

Figure 60.4. A: The pleurae from the front. The interrupted lines represent variants between which the left anterior border of the pleura lies in 70% of instances. The costodiaphragmatic and costomediastinal recesses are indicated in red. **B:** The pleurae from behind. The interrupted lines on the left represent common variations in the position of the inferior border of the pleura. The costodiaphragmatic recesses are shown in red.

The extrinsic muscles of the posterior thoracic wall are the trapezius (spinal accessory nerve, XI), the latissimus dorsi (thoracodorsal nerve), the serratus posterior superior and inferior (segmental rami), the rhomboids, and the levator scapulae (Fig. 60.8).

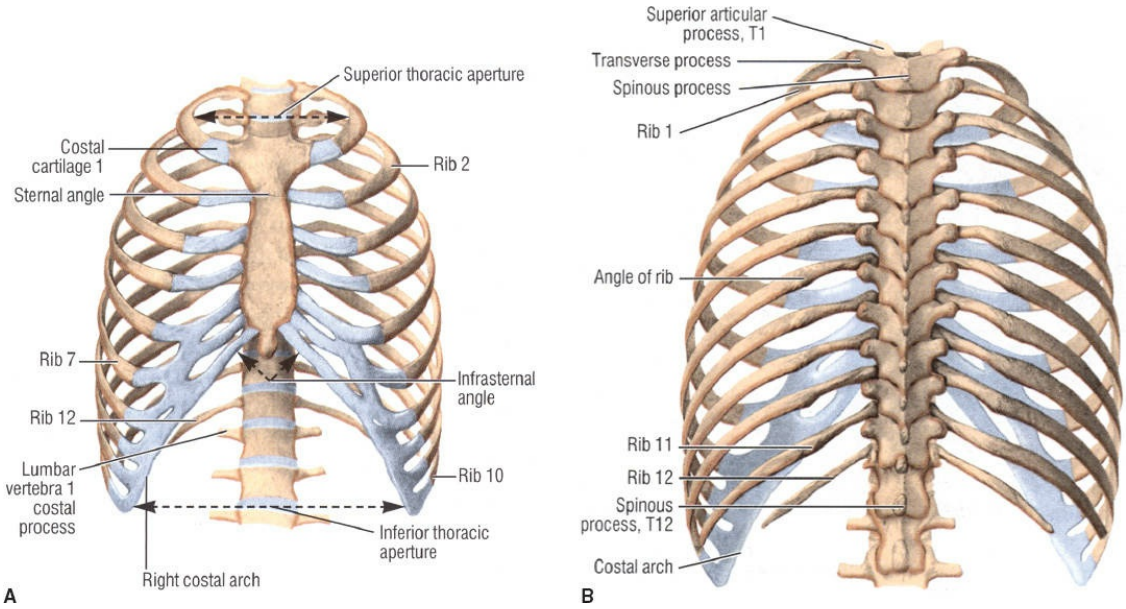

Figure 60.5. Thorax. **A:** Ventral aspect. **B:** Dorsal aspect. (From Colborn GL, Weidman TA, Mirilas P, et al. Thoracic wall and pleura. In: Skandalakis JE, Colborn GL, Weidman TA, et al., eds. *Skandalakis' Surgical Anatomy: The Embryologic and Anatomic Basis of Modern Surgery*. Athens GR: Paschalides Medical Publications, 2004, with permission. Modified from Frick H, Kummer B, Putz R. *Wolf-Heidegger's Atlas of Human Anatomy*. 4th ed. New York: Karger, 1990.)

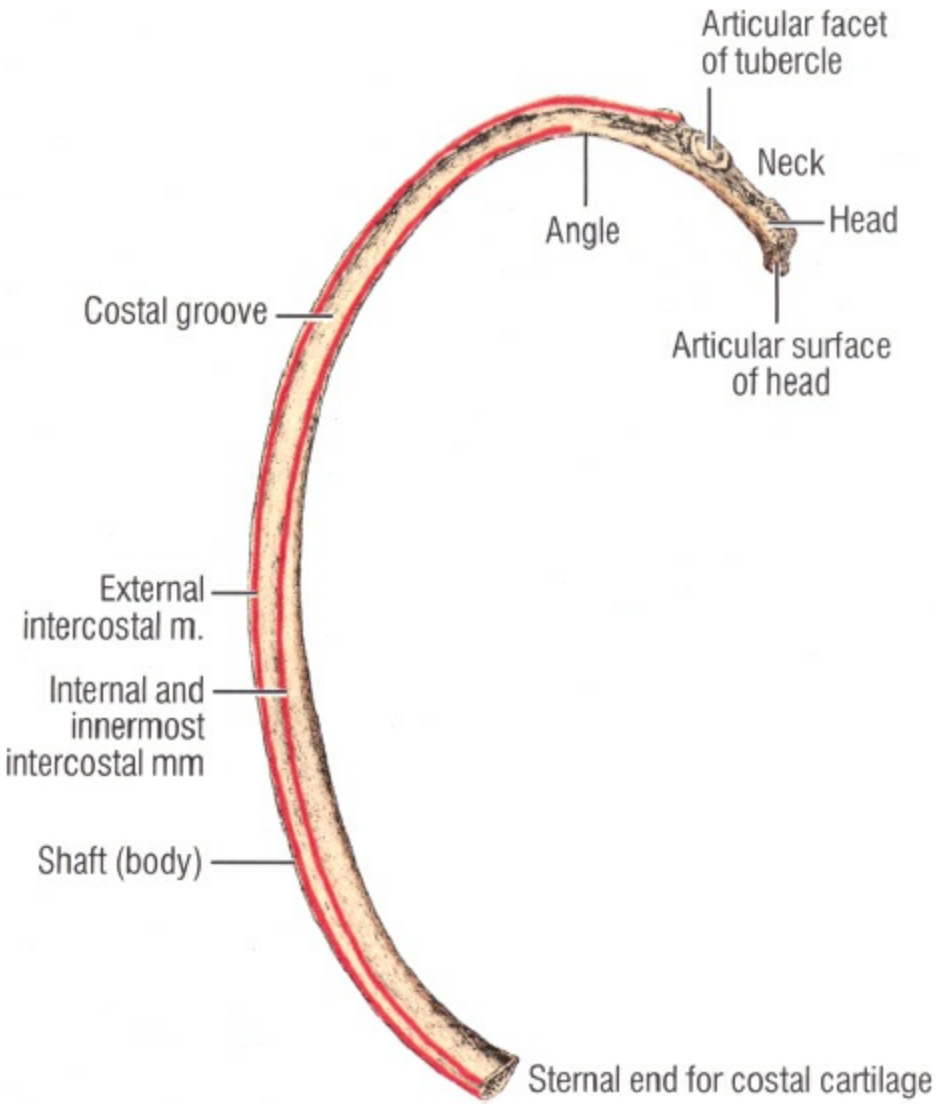

Figure 60.6. "Typical" rib. Surface features of left seventh rib (inferior view). (From Colborn GL, Weidman TA, Mirilas P, et al. Thoracic wall and pleura. In: Skandalakis JE, Colborn GL, Weidman TA, et al., eds. *Skandalakis' Surgical Anatomy: The Embryologic and Anatomic Basis of Modern Surgery*. Athens GR: Paschalides Medical Publications, 2004, with permission. Modified from Anson BJ, ed. *Morris' Human Anatomy*. 12th ed. New York: McGraw-Hill, 1986.)

Intrinsic Muscles

Similar to the abdominal wall, the thoracic wall includes three muscle layers (Fig. 60.9). The neurovascular bundle lies between the middle and internal layer.

The *superficial layer* consists of the *external intercostal muscles.* Their direction is downward and forward, similar to the external oblique abdominal muscle, with which the lower seven are continuous. They

extend from the tubercle of the rib to the costochondral junction, where they are replaced by the homonymous membrane.

The *middle layer* comprises the *internal intercostal muscles.* They extend from the medial ends of the ribs anteriorly to the angle of the ribs posteriorly, where they are replaced by the homonymous membrane.

The *internal layer* is noncontinuous around the inner surface of the chest wall and comprises the *innermost intercostals,* the *subcostals,* and the *transversus thoracis.*

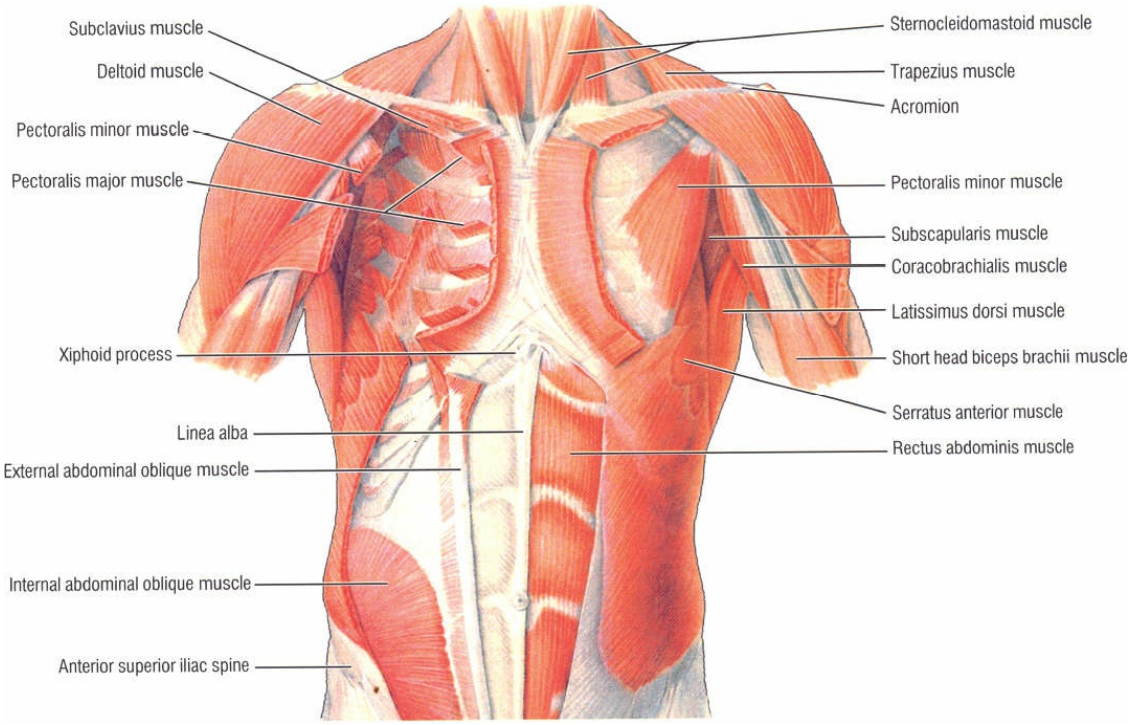

Figure 60.7. Musculature of the anterior body wall. Superficial and deep muscles. (From Colborn GL, Weidman TA, Mirilas P, et al. Thoracic wall and pleura. In: Skandalakis JE, Colborn GL, Weidman TA, et al. *Skandalakis' Surgical Anatomy: The Embryologic and Anatomic Basis of Modern Surgery*. Athens GR: Paschalides Medical Publications, 2004, with permission. Modified from Frick H, Kummer B, Putz R. *Wolf-Heidegger's Atlas of Human Anatomy.* 4th ed. New York: Karger, 1990.)

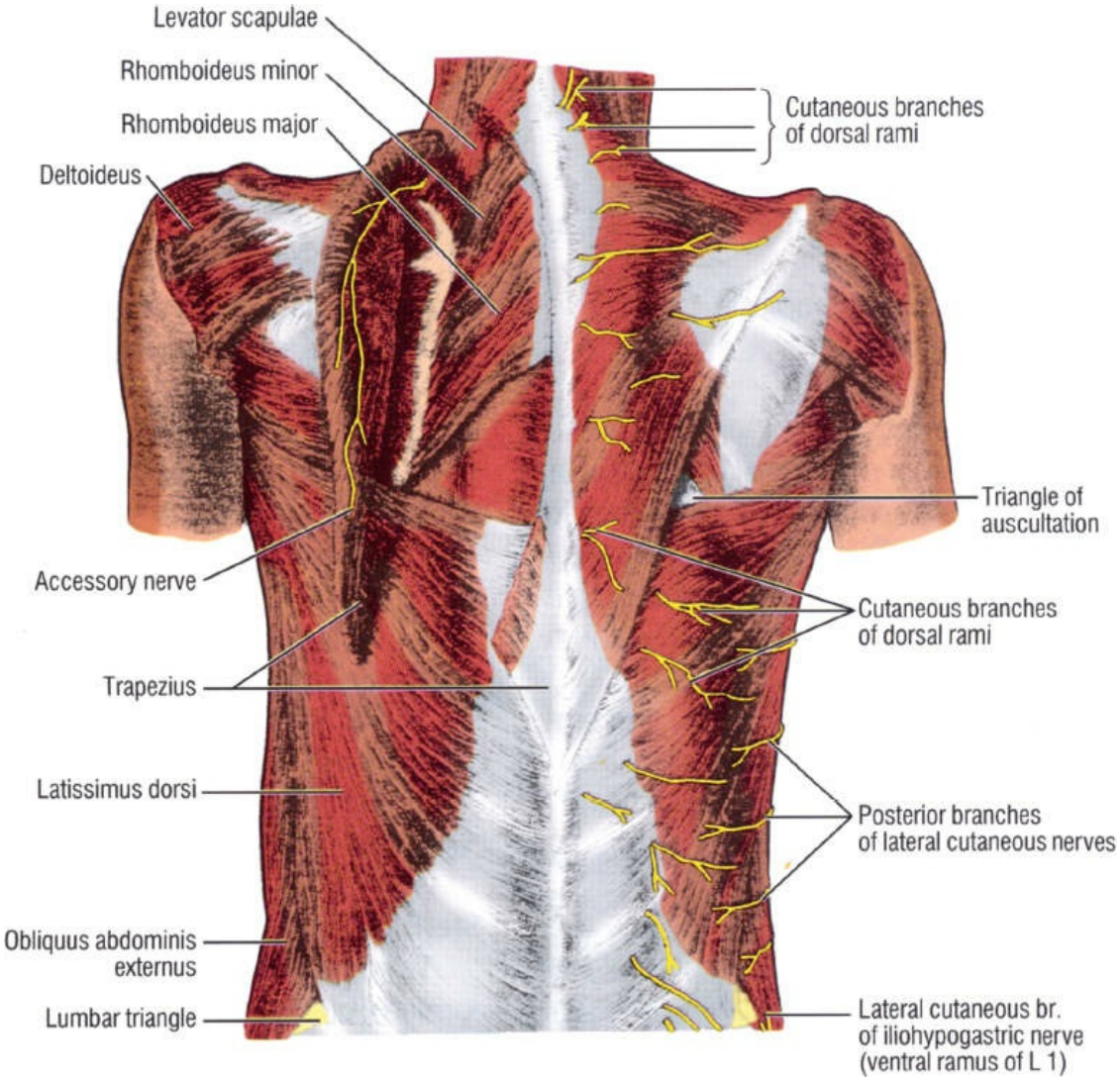

Figure 60.8. Superficial muscles of back and "triangle of auscultation." Trapezius muscle divided and reflected on the left side to show underlying structures. (From Colborn GL, Weidman TA, Mirilas P, et al. Thoracic wall and pleura. In: Skandalakis JE, Colborn GL, Weidman TA, et al. *Skandalakis' Surgical Anatomy: The Embryologic and Anatomic Basis of Modern Surgery*. Athens GR: Paschalides Medical Publications, 2004, with permission. Modified from Grant JCB. *An Atlas of Anatomy by Regions*, 4th Edition. Baltimore, MD: Williams & Wilkins, 1956.)

No fat is found between the endothoracic fascia (covering the internal surface of the internal muscle layer) and the pleura. In contrast, in the abdominal wall, preperitoneal fat is found between the endoabdominal fascia and the peritoneum.

Vessels

Arteries

The vascular supply of the chest wall is rich and originates from different sources. The chest wall is supplied by the posterior intercostal arteries arising from the aorta, the internal thoracic and the highest intercostals given off the subclavian artery, and the branches of the axillary artery (Fig. 60.10). Surgical mastery of this two-source arterial network (aorta-subclavian, and axillary arteries) can be reached if the surgeon studies the collateral circulation developing in aortic coarctation (Fig. 60.11).

The principal arteries are the (posterior) intercostals and the internal thoracic arteries. The first two or three pairs of the *intercostal arteries* arise from the highest intercostal artery, a branch of the costovertebral trunk of the subclavian artery. The remaining intercostal arteries are given from the back of the aorta. The right arteries pass in front of the vertebrae, and hence are longer than the left. The intercostal arteries lie behind the azygos and hemiazygos veins, the thoracic duct, and the sympathetic trunk (Fig. 60.10). The arteries course in the costal groove between the vein (above) and the nerve (below). This is true for the dorsal and lateral chest; anteriorly, vessels and nerve are exposed in the spaces. Therefore, in the dorsal and lateral chest, the surgeon must proceed along the superior margin of the lower rib when puncturing in order to aspirate or to perform surgical procedures. This relation with the bone explains the risk for vessel wound in rib fractures.

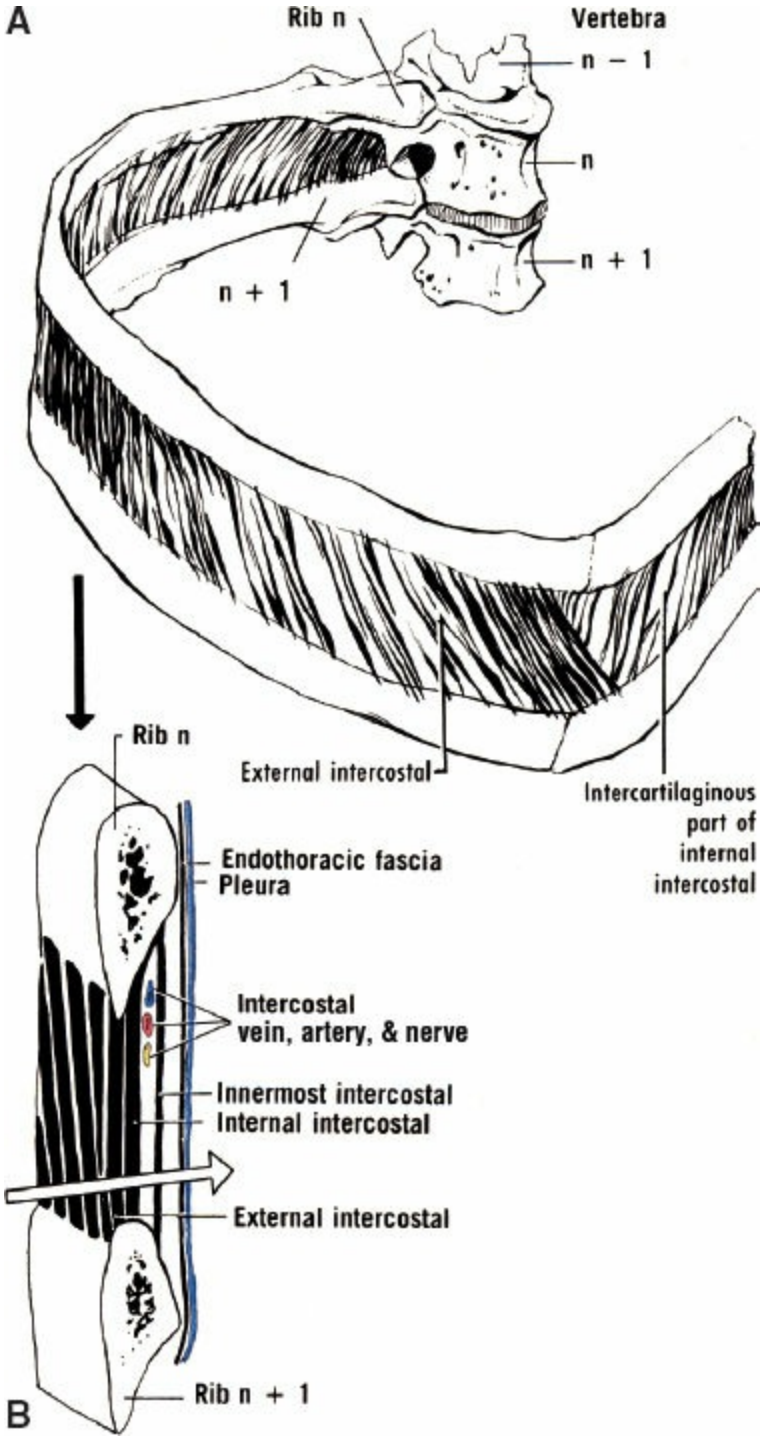

Figure 60.9. The intercostal muscles. **A:** Direction of fibers of the external and internal intercostal muscles. **B:** Vertical section through an intercostal space. White arrow represents path of a needle in pleura aspiration, avoiding the intercostal nerve. (Published in O'Rahilly R. *Gardner-Gray-O'Rahilly Anatomy*. Philadelphia, PA: WB Saunders, 1986. Copyright Elsevier.)

The intercostal artery gives off branches. One is the *dorsal* artery, muscular and spinal, which supplies the muscles and skin of the back.

Another branch is the *lateral cutaneous* for the overlying muscles; the third to fifth give small *mammary* branches. In most cases the intercostal artery, at the angle of the rib, gives off a *collateral* artery, which then travels anteriorly immediately above the lower rib. This vessel is much smaller than the main one. It is not unusual to disregard the presence of this vessel during paracentesis through a posterolateral part of an intercostal space; inserting the needle at the upper border of the lower rib to avoid the main intercostal artery and nerve can traumatize the collateral.

The *internal thoracic artery* arises from the first part of the subclavian artery (Fig. 60.12). It courses downward in the thorax just lateral to the sternum, behind the upper six costal cartilages and the internal intercostal muscles, and in front of the transverse thoracic muscle and the pleura. In the sixth space the internal thoracic artery divides into a lateral branch (the *musculophrenic artery*) and a terminal branch, feeding the rectus muscle (the *superior epigastric artery*). The rectus can be used in reconstruction of the breast as a flap reversed upward around the superior epigastric artery. Other branches are the *anterior intercostals arteries* and the *perforating arteries* in the upper six spaces; the latter in the second to fourth spaces supply the breast. The internal thoracic artery can be ligated —for example, in case of trauma resulting in a possibly fatal hemorrhage —in the third intercostal space; lower spaces are much narrower for this procedure.

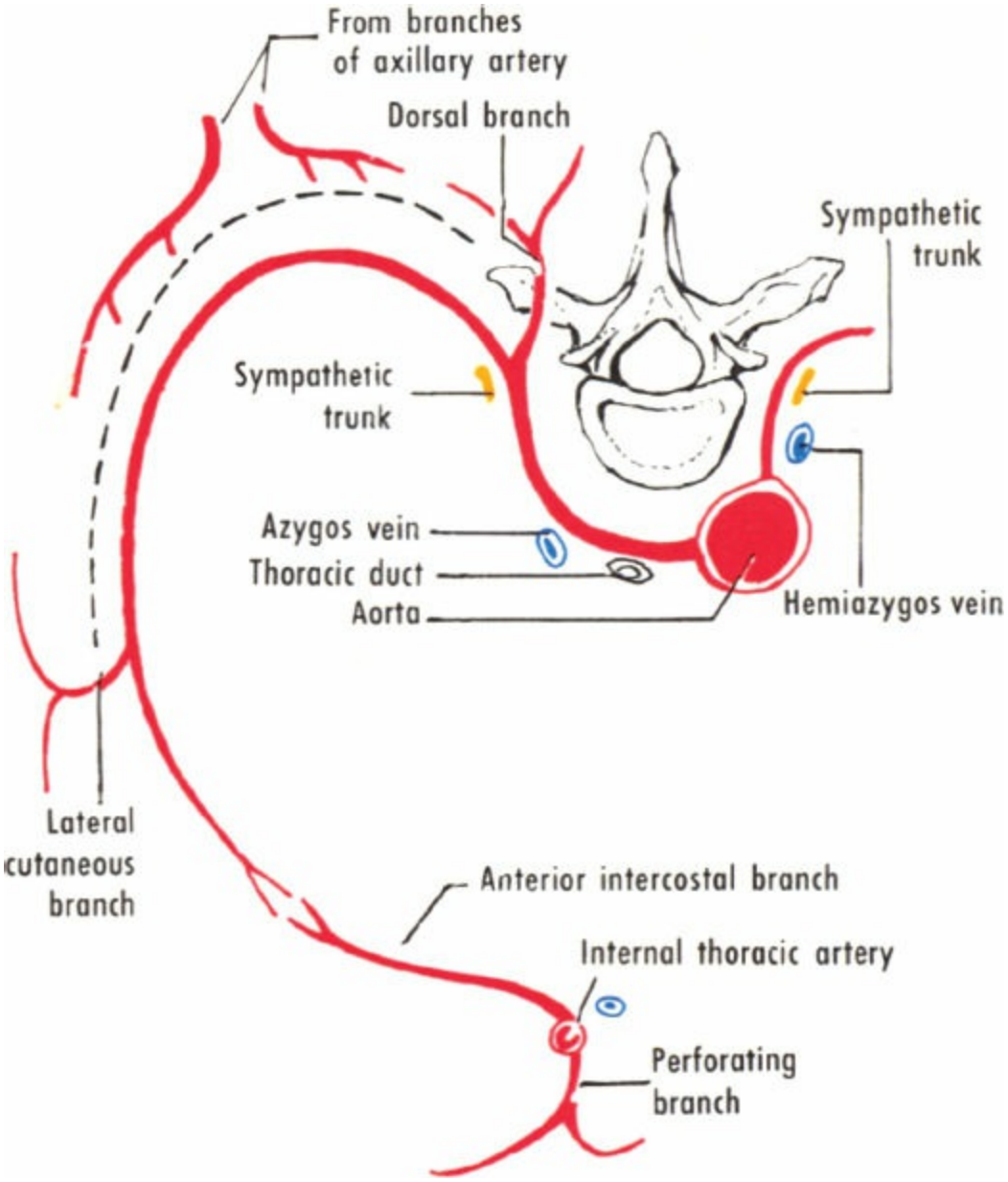

Figure 60.10. Arteries of the thoracic wall. Note that the intercostal vessels pass behind the longitudinally disposed veins and nerves of the posterior mediastinum. (Published in O'Rahilly R. *Gardner-Gray-O'Rahilly Anatomy*. Philadelphia, PA: WB Saunders, 1986. Copyright Elsevier.)

The anterior intercostal arteries are sometimes two (inferior and superior) in the respective intercostal space; sometimes the lower, traveling on the upper border of the lower rib, is the bigger. To perform paracentesis through an anterior intercostal space, the surgeon is advised to proceed in the middle of the space to avoid bleeding from the anterior intercostal arteries.

Veins

The *posterior intercostal veins* and the *subcostal veins* follow the posterior intercostal arteries in the costal grooves. The 1st posterior intercostal vein on either side empties into the brachiocephalic vein. The 2nd through 4th veins join the superior intercostal vein, which on the right joins the azygos vein and on the left the left brachiocephalic vein. The left superior intercostal lies next to the aorta and can be mistaken for aortic aneurysm. The rest of the intercostal veins (5th to 12th) empty into the azygos (right side) or into the hemiazygos and accessory hemiazygos on the left side (Fig. 60.13).

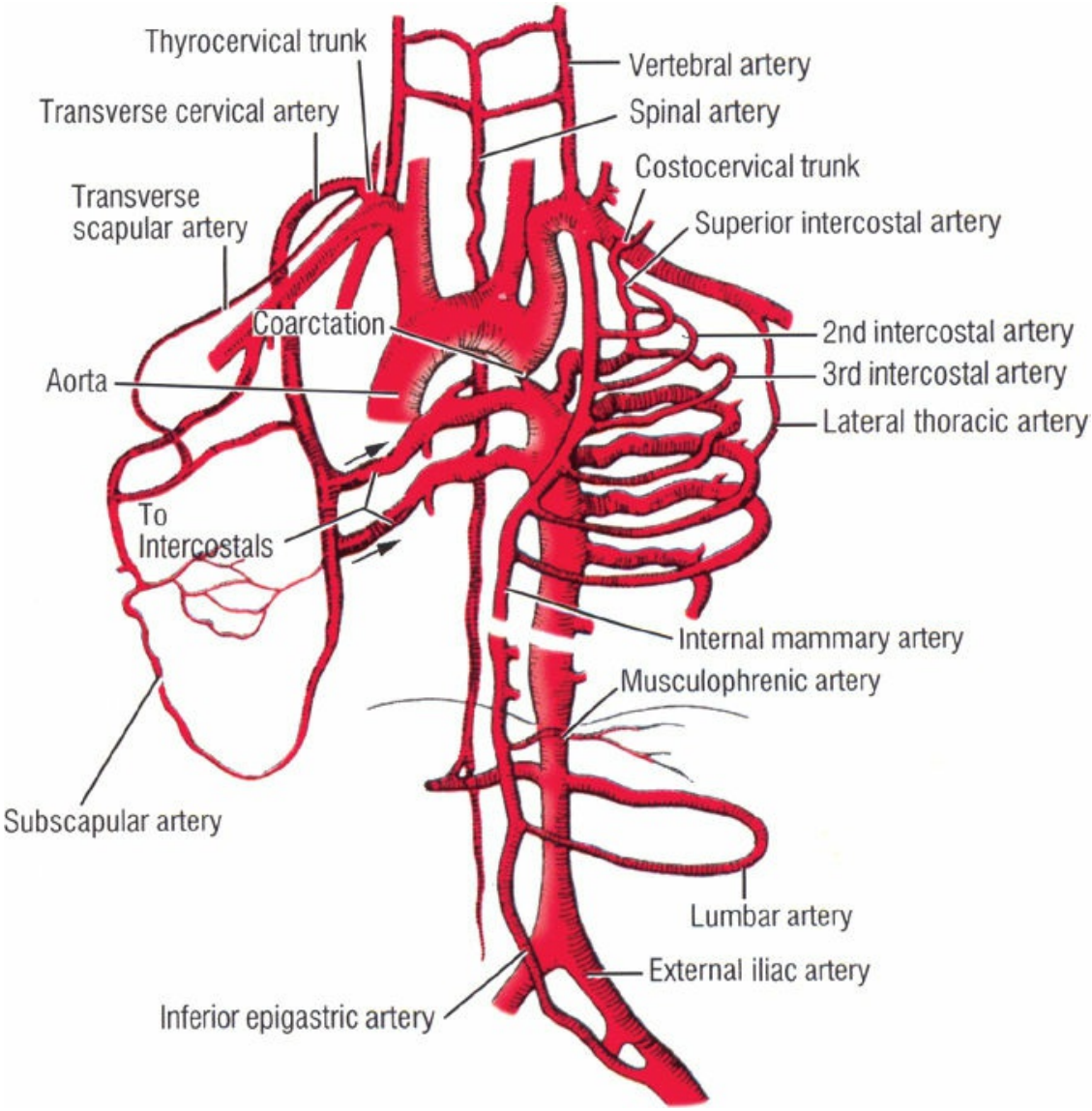

Figure 60.11. Collateral arterial channels in aortic coarctation. (From Edwards EA, Malone PD, Collins JJ Jr. *Operative Anatomy of the Thorax*. Philadelphia, PA: Lea & Febiger, 1972. Copyright Wolters Kluwer.)

The azygos veins are a paravertebral system paralleling the caval system, which not only drains the intercostal veins but also accepts the ascending lumbar veins. It serves most of the venous drainage of the abdominal and thoracic wall and offers an avenue for anastomoses between the superior and inferior vena cava. This system and the vertebral venous system, in effect, bypass the caval system. With increase of intrathoracic or intra-abdominal pressure (expiration, coughing, straining), blood flows in the vertebral system. This offers an avenue for metastases from pelvic, abdominal, and breast tumors. The collateral system is completed by the superficial thoracoepigastric veins, which connect axillary and femoral veins (Fig. 60.13).

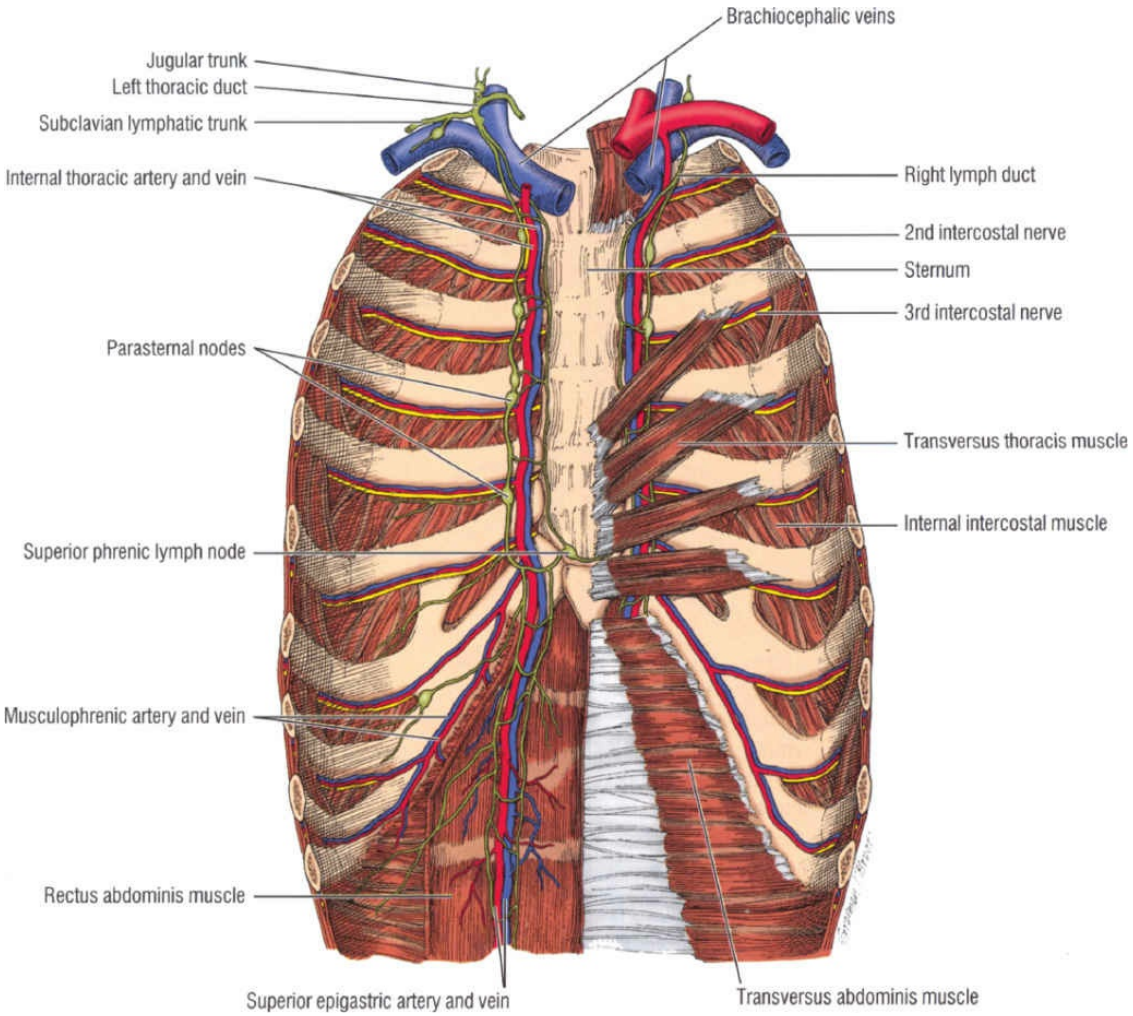

Figure 60.12. Anterior thoracic wall. Relations of vascular and lymphatic structures (dorsal view). Transversus thoracis muscle removed on left side to illustrate vessels more clearly. (From Colborn GL, Weidman TA, Mirilas P, et al. Thoracic wall and pleura. In: Skandalakis JE, Colborn GL, Weidman TA, et al. *Skandalakis' Surgical Anatomy: The Embryologic and Anatomic*

Basis of Modern Surgery. Athens GR: Paschalides Medical Publications, 2004, with permission.)

The *internal thoracic veins* accompany the homonymous artery and drain into the counterpart brachiocephalic artery. These veins offer another possibility for collateral circulation; for example, in case of superior vena cava obstruction the flow may follow the internal thoracic and iliac veins and return to the heart by the inferior vena cava and azygos system. The superior epigastric veins communicate with the inferior epigastrics; this is another way of connection between subclavian and femoral veins.

Breast cancer spread may follow a venous route for tumor emboli as follows: Perforating (anterior intercostal) veins empty into the internal thoracic vein and thus in the brachiocephalic vein, which is an avenue for metastases to the lungs. The axillary vein will follow the same pathway. The posterior intercostals will end in the same way via the azygos system. The communication with the vertebral system described above provides an understanding for metastases to the skeleton.

Lymphatics

Superficial

On either side, the anterior quadrant of the trunk above the umbilicus, via a large trunk, drains in the axilla, with the terminus in the pectoral nodes. Efferents of the dorsal upper quadrants terminate in the lateral, central, and subscapular axillary nodes.

Deep

The *internal thoracic (parasternal) nodes* (Fig. 60.12) are along the internal thoracic artery, at the anterior ends of the upper four or five intercostal spaces. They drain the medial part of the breast, the diaphragm, intercostal spaces, and costal pleura, and, partially, the pectoralis major muscle. Their efferents join the bronchomediastinal trunk. Clinically, parasternal nodes give a pathway for metastases from cancer of the breast to disseminate to the lungs, mediastinum, and liver (via connections of superior diaphragmatic nodes).

The *intercostal nodes* (Fig. 60.14)—one or two—are located at the paravertebral portion of each intercostal space. They drain structures along the corresponding intercostal vessels, and the pleura. The efferents of the upper intercostal nodes form the intercostal trunk, which ends in the thoracic duct on the left; on the right, it ascends behind the subclavian

vessels and either empties directly into the subclavian vein or joins the right lymphatic duct. The efferents of the lower nodes form a trunk that descends, passes through the diaphragmatic crura, and enters the cisterna chyli.

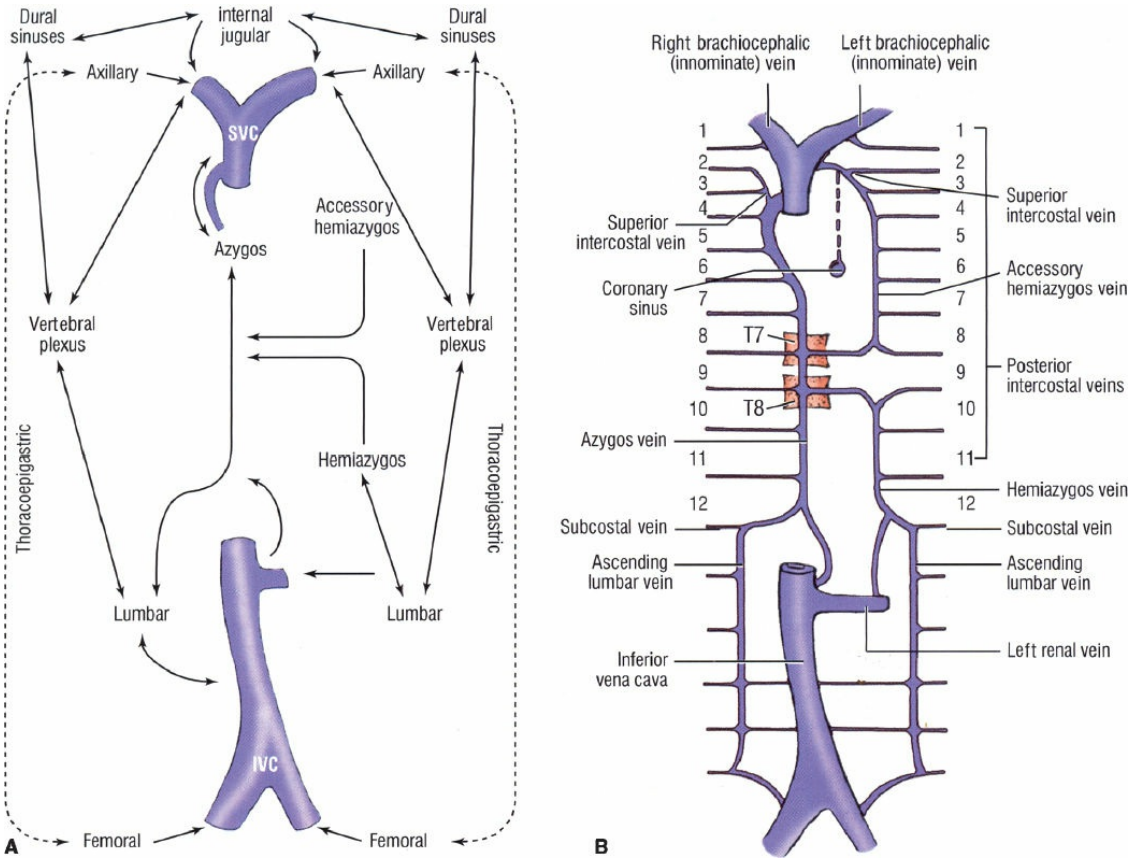

Figure 60.13. A: Main connections of azygos, caval, and vertebral systems of veins. **B:** Main connections of azygos, caval, and vertebral systems of veins. (Modified from O'Rahilly R. *Gardner-Gray-O'Rahilly Anatomy*. Philadelphia: WB Saunders, 1986. Copyright Elsevier.)

Nerves

Functionally, the thoracic nerves are motor (to muscles), sensory (from skin and deep tissues), and sympathetic (to vessels, sweat glands, and arrectores pilorum) (Fig. 60.15).

Anatomically, the *first three intercostal nerves* are special in morphology and in the fact that they supply the arm as well as the thorax. The 1st nerve divides into upper and lower parts. The upper part joins the C8 nerve of the brachial plexus. The lower part is a typical intercostal nerve, with the specific feature that its lateral cutaneous branch supplies

the axilla. The 2nd nerve is an otherwise typical intercostal nerve, except for the feature that its lateral cutaneous branch passes into the arm (intercostobrachial nerve). The 3rd nerve also gives a twig to the medial side of the arm from its lateral cutaneous branch.

The *typical intercostal nerve*s are the 4th through the 6th. They supply the thoracic wall and the overlay of extrinsic muscles. Each nerve emerges through an intervertebral foramen and divides into dorsal and ventral rami. The dorsal innervate muscle, bones, and skin of the back. The ventral connect with the sympathetic ganglia via rami communicantes, and innervate serosal membranes (parietal pleura), muscles, and skin of the wall. In fact, the intercostal nerves are the ventral rami, and this applies for all 11 thoracic nerves; the 12th is subcostal. Each intercostal nerve passes below the neck of the numerically corresponding rib and travels together with the intercostal vessels in the costal groove, between the second and third muscle layer. At the angle of the rib it gives a lateral cutaneous branch and a collateral branch that follows the collateral artery (see above for surgical importance). After it crosses the internal thoracic vessels it gives off an anterior cutaneous branch.

The intercostal nerves may be “anesthetized” by nerve block, that is, infiltration with anesthetics of the proper intercostal space, behind the posterior axillary line. This technique is useful in patients with thoracotomy, thoracostomy, or chest trauma who suffer severe pain with respiration and coughing.

The term *thoracoabdominal nerves* is reserved for the nerves 7th through 11th. These nerves surpass the anterior ends of the intercostal spaces behind the costal cartilages. They continue downward again in the same surgical layer between the second and third muscles (internal oblique and transversus abdominis) to reach the posterior wall of the sheath of the rectus abdominis, where they give anterior cutaneous branches. Their lateral cutaneous branches pierce the external oblique and give anterior and posterior branches. The thoracoabdominal nerves innervate the muscles of the abdominal wall, skin, and parietal peritoneum.

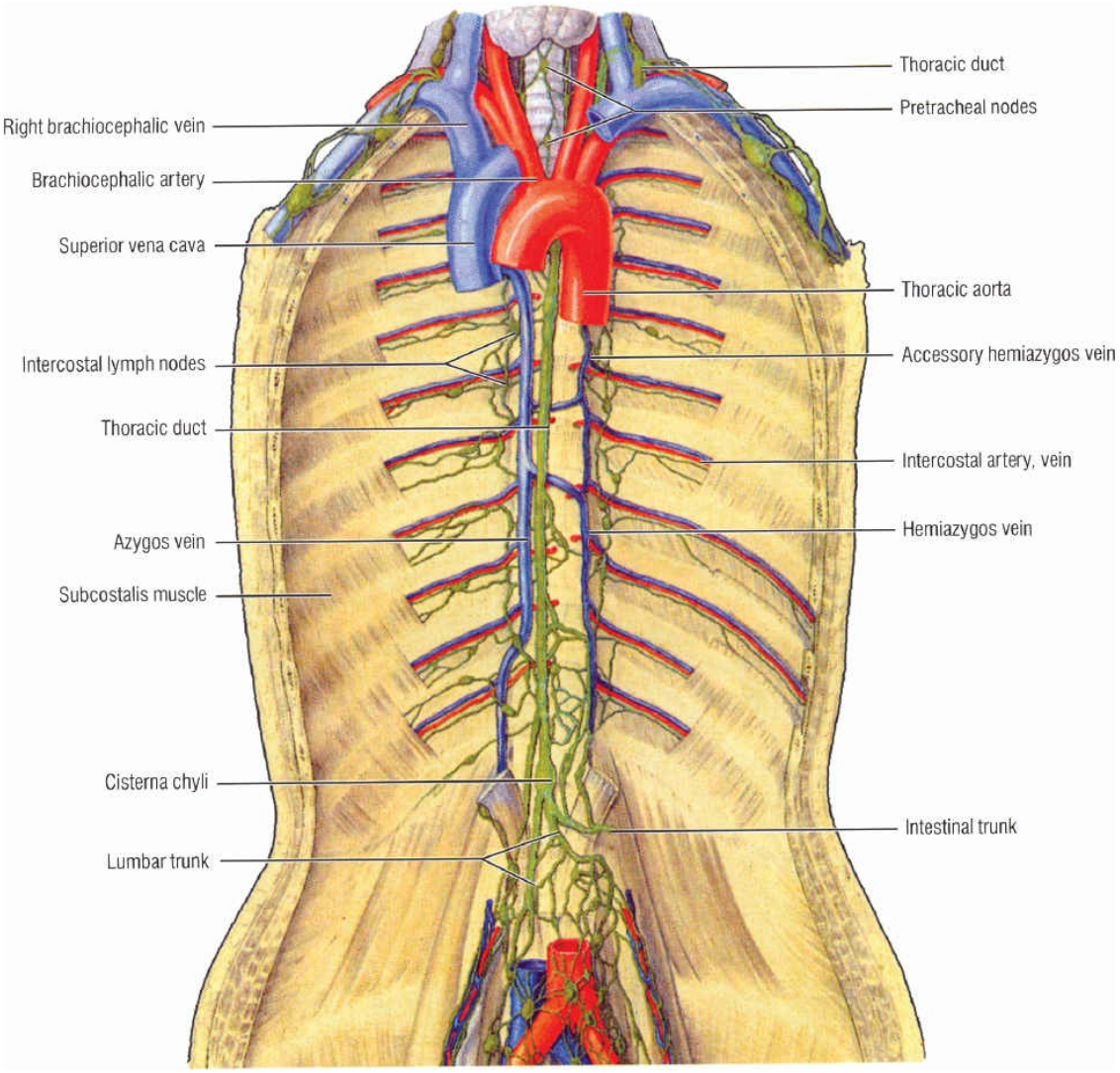

Figure 60.14. Lymphatic relations of the posterior thoracic region. Note the subcostalis muscles. (From Colborn GL, Weidman TA, Mirilas P, et al. Thoracic wall and pleura. In: Skandalakis JE, Colborn GL, Weidman TA, et al., eds. *Skandalakis' Surgical Anatomy: The Embryologic and Anatomic Basis of Modern Surgery*. Athens GR: Paschalides Medical Publications, 2004, with permission. Modified from Frick H, Kummer B, Putz R. *Wolf-Heidegger's Atlas of Human Anatomy*. 4th ed. New York: Karger, 1990.)

The distribution of the thoracic nerves (intercostal and thoracoabdominal) is segmental. Because there is much overlapping, one has to impair three nerves in order to see an effect of paralysis and anesthesia in the middle one of them. Although extensive thoracic and abdominal incisions are not contraindicated, caution must be exercised by the operating surgeon.

Some hallmarks of the segmental surface distribution are very useful in

practice: The thoracic wall is supplied by T2 to T6. The umbilicus is supplied by T10, and the supraumbilical part of the anterior wall by T7 to T9. The pubic tubercle corresponds approximately to T12 and the infraumbilical to T10 to T11.

Pain from intrathoracic and intra-abdominal splanchna (e.g., esophagus, heart, liver–bile system, etc.) projects on the thoracic or abdominal wall. This is what we like to call “cheating”: pain stimulus transported by the splanchnic thoracic nerves (major, lesser, least) reaches the corresponding sympathetic ganglia. Communication with the respective intercostal or thoracoabdominal nerves results in projection of the pain on the thoracic or abdominal wall.

Abdominal viscera have a characteristic surface distribution of pain. The foregut (esophagus, stomach, duodenum until the entrance of the bile duct) projects pain into the supraumbilical area. The midgut (the rest of the intestine and up to two-thirds of the transverse colon) projects into the umbilical area. The hindgut projects into the supraumbilical area.

MEDIASTINUM

Embryogenesis

The mediastinum arises from the mesentery of the esophagus. This statement may sound bizarre to the surgeon, who is brought up with the knowledge that the esophagus is deprived of serosal layer; that is, it has no mesentery. This misconception has to be changed.

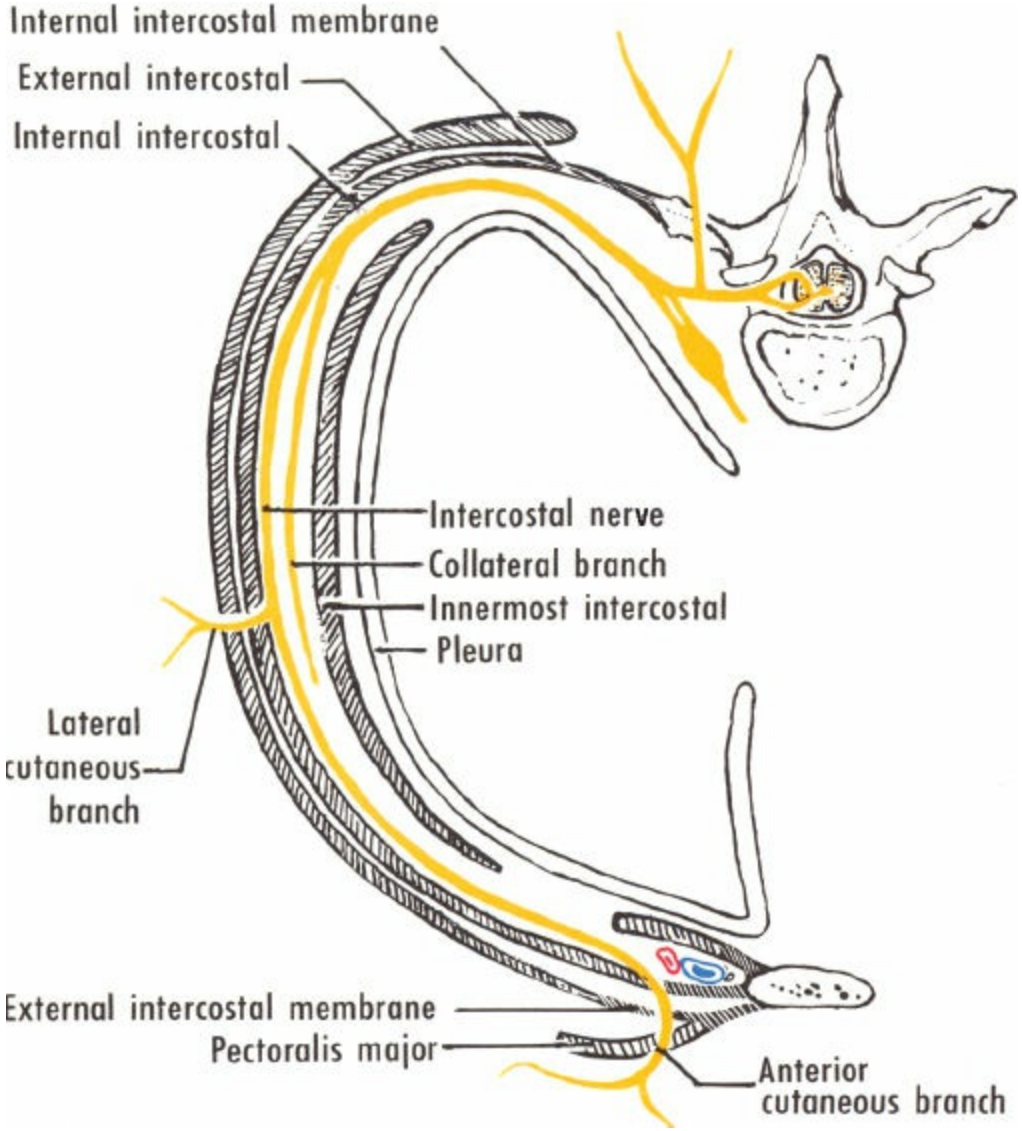

Figure 60.15. A typical intercostal nerve. (From O'Rahilly R. *Gardner-Gray-O'Rahilly Anatomy*. Philadelphia, PA: WB Saunders, 1986, with permission.)

In general, the mesentery of the intestine is defined as a double serosal layer that surrounds the viscus and carries the neurovascular bundle to and from it (arteries go in, veins and lymphatics go out, nerves go in and out); any functional tube (e.g., a duct) will also be packed in the mesentery, which also contains a variable amount of fat (Fig. 60.16).

The esophagus develops as part of the embryonic foregut, and initially has a mesentery. The trachea and the lung buds also develop from the foregut, as a diverticulum dividing in front and laterally to the esophagus (Fig. 60.17). The trachea and the lung buds push away the mesentery covering the ventral side of the esophagus. The proliferating lung buds project into the pericardial cavity, covered by serosa (splanchnic pleura)

given by the former mesentery of the esophagus (Fig. 60.18A).

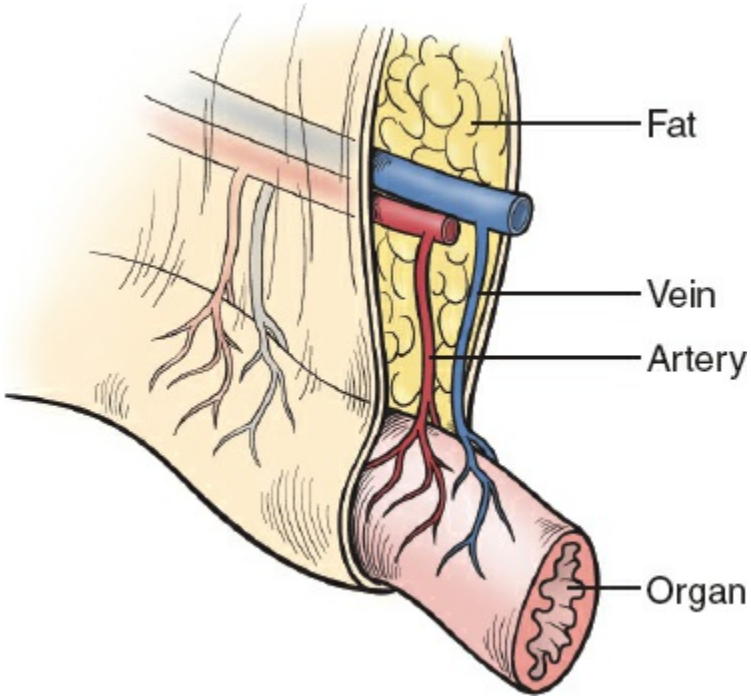

Figure 60.16. Diagrammatic representation of a mesentery.

Two lateral folds, the pleuropericardial folds, appear in the pericardial cavity, each serving as a mesentery for the cardinal vein; the phrenic nerve is also contained in the folds. The two folds unite and fuse with the root of the lungs. After transformations, the two cardinal veins form the superior vena cava. The thoracic cavity separates from the pericardial cavity, and divides into two pleural cavities. The pleuroperitoneal membranes form the fibrous pericardium, and the phrenic nerve finds its position on the pericardium. The developing lungs occupy the pleural cavities (Fig. 60.18B,C).

The communication of the pleural cavities with the abdominal cavity is interrupted by the development of the diaphragm from the septum transversum, the pleuroperitoneal folds, and the muscular components of the wall (Fig. 60.19). As a result of all the above developmental changes, a space is defined above the diaphragm, delineated anteriorly by the pericardium covered by pleura and posteriorly by the remaining mesentery of the esophagus (dorsal mediastinal pleura). The lateral walls of this space are covered by pleura with an opening for the root of the lung. This space is the mediastinum of the mature organism (Fig. 60.20). The mediastinal pleura reflects over the roots of the lungs and continues as visceral pleura. Posterior to the esophagus and aorta, the mediastinal pleura opens up

laterally as parietal pleura.

Compartments of the Mediastinum

To be consistent with most anatomy books and surgical teaching, it is best to divide the mediastinum into four compartments: superior, anterior, middle, and posterior. The latter three, without being explicitly named so, belong to the inferior mediastinum.

Borders

The border between the superior and inferior mediastinum is a plane defined by the angle of Louis (vide supra) anteriorly and the lower end of the fourth thoracic vertebra posteriorly (Fig. 60.21).
The anterior mediastinum lies between the sternum anteriorly and the pericardium posteriorly.
The middle mediastinum is delineated by the pericardium; adjacent structures of the roots of the lungs belong to this compartment.
The posterior mediastinum is located posteriorly to the pericardium.

The superior mediastinum can divided into anterior, middle, and posterior. The great vessels—whose roots are covered by pericardium in the inferior mediastinum—are used for this division, as occupying the middle division.

Contents

As already understood from the embryogenesis, the mediastinum as a whole contains all of thoracic viscera except for the lungs. All organs contained in this mesentery, and as happens with all mesenteries, are packed into loose areolar tissue, which suspends and connects them. A thickening of this tissue is the sternopericardial ligament.

Anterior Mediastinum

Anson and McVay write that the surgical importance of this space is that it is entered during cardiac procedures and during biopsy of the internal thoracic lymph nodes (through the 3rd or 4th space). The anterior mediastinum is the home of lymphomas, Morgagni hernia, or hematoma after sternal fracture. Ectopic goiter or parathyroids as well as thymoma can also be encountered in this compartment.

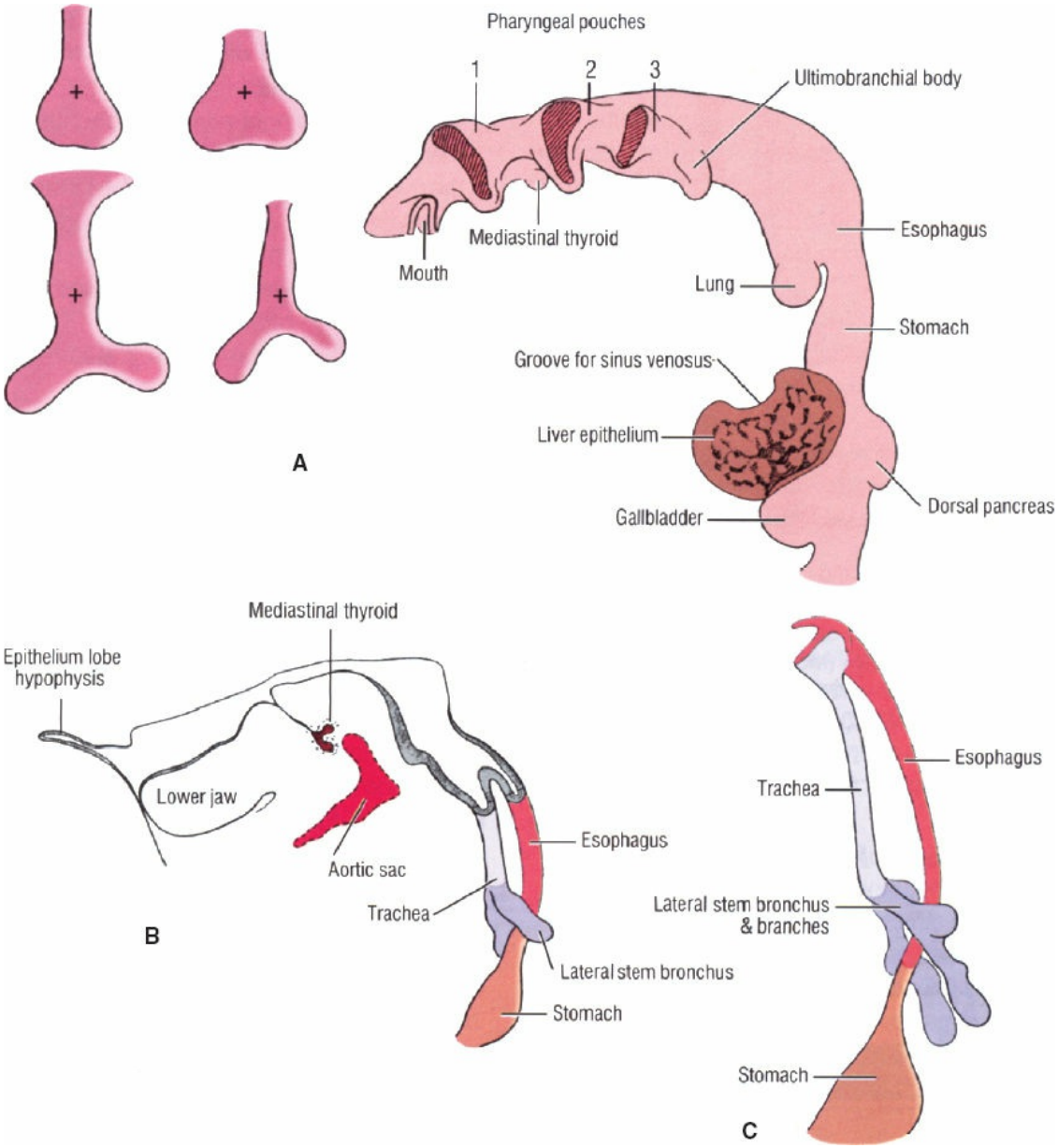

Figure 60.17. Development of trachea and bronchi. **A:** Four anterior and lateral views of lung buds at the end of the 5th week. **B:** Lateral view at the middle of the 6th week. **C:** Lateral view near the end of the 6th week. (From Skandalakis JE, Gray SW, Symbas PN. The trachea and lungs. In: *Embryology for Surgeons. The Embryological Basis for the Treatment of Congenital Anomalies*. Baltimore, MD: Williams & Wilkins, 1994, with permission. **A:** Modified from Streeter GL. Developmental horizons in human embryos: description of age group XIII, embryos about 4 or 5 mm long, and age group XIV, period of indentation of the lens vesicle. *Contrib Embryol Carnegie Inst Wash* 1945;31:27–63. **B,C:** Modified from Streeter GL. Developmental horizons in human embryos: description of age groups XV, XVI, XVII, and XVIII. *Contrib Embryol Carnegie Inst Wash* 1948;32:133–204.)

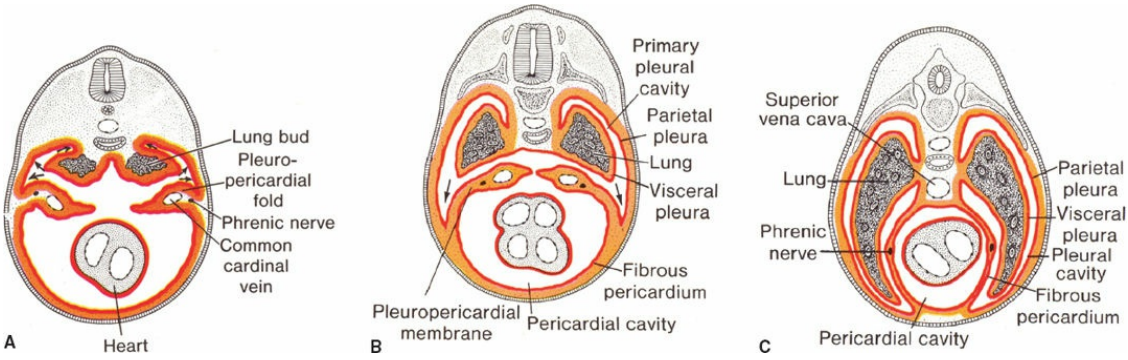

Figure 60.18. **A:** Growth of the lung buds into the pericardioperitoneal canals. Note the pleuropericardial folds. Arrows indicate the direction of expansion of the lung buds. **B:** Transformation of the pericardioperitoneal canals into the pleural cavities and the formation of the pleuropericardial membranes. Note the pleuropericardial folds with the common cardinal vein and phrenic nerve. The mesenchyme of the body wall is split into the pleuropericardial membrane and the definitive body wall. Arrows indicate direction of expansion of the primitive pleural cavity. **C:** Drawing through the thorax after fusion of the pleuropericardial folds with each other and with the root of the lungs. Note the position of the phrenic nerve, which is now in the fibrous pericardium. The right common cardinal vein has developed into the superior vena cava. (From Sadler TW. *Langman's Medical Embryology*. 5th ed. Baltimore, MD: Williams & Wilkins, 1985, with permission.)

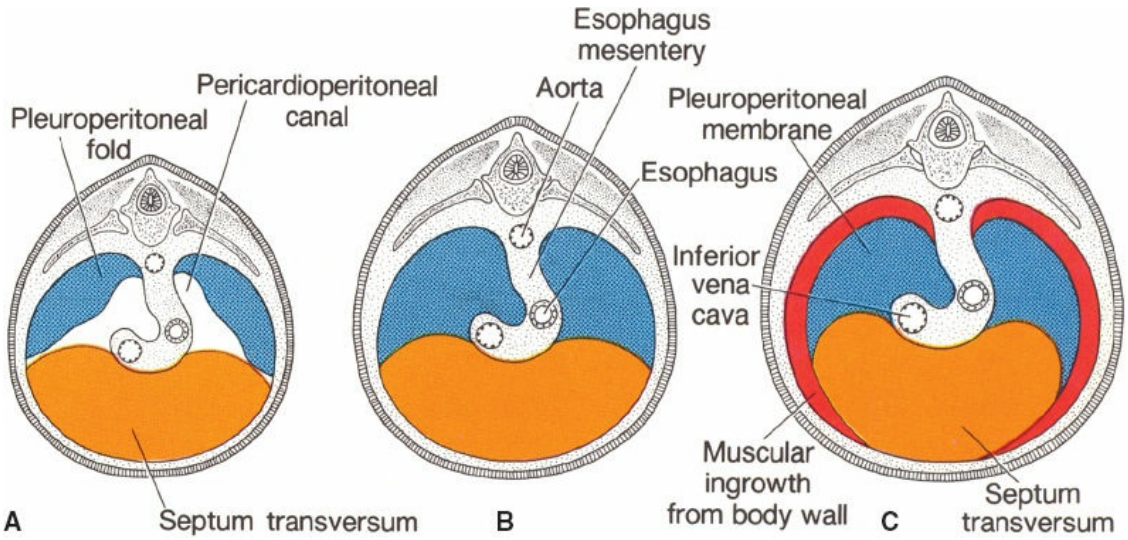

Figure 60.19. Development of the diaphragm. **A:** Pleuroperitoneal folds appear at the beginning of the 5th week. **B:** Pleuroperitoneal folds have fused with the septum transversum and the mesentery of the esophagus in the 7th

week, thus separating the thoracic cavity from the abdominal cavity. **C:** Transverse section at the 4th month of development. An additional rim derived from the body wall forms the most peripheral part of the diaphragm. (From Sadler TW. *Langman's Medical Embryology*. 10th ed. Baltimore, MD: Lippincott Williams & Wilkins, 2006, with permission.)

The chief content is the thymus (Fig. 60.22) (or its remnants), extending from the anterior superior mediastinum to the mediastinum proper. Originating from the 3rd pouch of the embryonic pharyngeal apparatus, the thymus descends together with the inferior parathyroids. Ectopic thymic tissue can be found along the path of descent, from the inferior side of the thyroid to the superior or inferior anterior mediastinum.

The superior part of the thymus lies anterior to the left brachiocephalic vein. A large thymus will cover the superior vena cava, and a large left lobe can reach the pulmonary artery. The inferior part of the thymus lies in front of the pericardium, in close relation with the costomediastinal recess, so that the latter has to be retracted together with the thoracic wall to be exposed during operation.

The vascular supply of the thymus is useful for the surgeon to know. There are small branches from the internal thoracic arteries or their pericardiophrenic branches. Veins from the two lobes unite to form a single vein, which travels on the posterior surface of the thymus and empties into the left brachiocephalic vein. Small venous twigs join the internal thoracic veins.

In the space between the anterior thoracic wall and the pleura run the internal thoracic vessels and accompanying lymphatics and lymph nodes. Here, for surgical reasons they are considered as belonging to the anterior mediastinum, although strictly anatomically they are in front of the pleura.

Middle Mediastinum

The surgical significance of the middle mediastinum centers on congenital anomalies or tumors that can be encountered in this space: congenital vascular anomalies, aneurysms, enteric or bronchogenic cysts, lymphomas, and so on.

Superior

After removing the thymus, one can appreciate the relations of the great vessels (Fig. 60.23). The *right brachiocephalic vein* courses in front and to

the right of the right subclavian artery. The phrenic nerve, after descending on the anterior scalene, passes behind the right brachiocephalic vein on the mediastinal pleura. The nerve then dives medially to find its position on the pericardium. The internal thoracic vessels lie laterally to it and then course anteriorly.

The *left brachiocephalic vein* starts from the left of the left carotid, much above the aortic arch, descends in front of the left subclavian artery and the ascending aortic arch, accepts thyroid veins, joins the right brachiocephalic vein, and forms the superior vena cava. The left phrenic nerve descends behind the left brachiocephalic vein, and then crosses the aortic arch and courses on the pericardium.

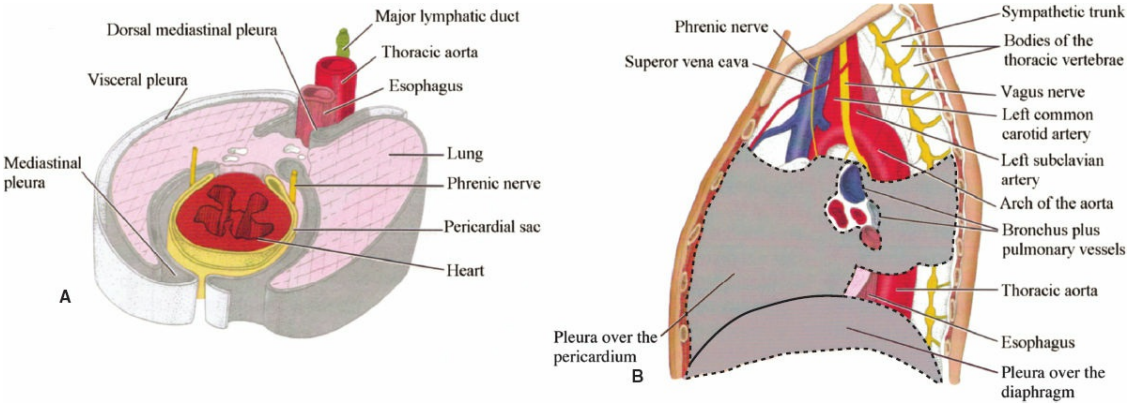

Figure 60.20. **A:** Drawing of a transverse section of the mediastinum of the mature organism. **B:** Schema of the lateral left view mediastinum; lungs are taken away. The dash line shows the border of the cut pleura; a small window is reflected to show the esophagus.

After removing the veins, one can realize relations of vagus nerves, branches of the aorta, and trachea (Fig. 60.24). The *aortic arch* lies in front of the trachea and the left bronchus. As a result, an aneurysm may produce respiratory symptoms. The esophagus (behind the trachea) and the recurrent nerve (in the groove between the trachea and the esophagus) may also be pressed, resulting in difficulty in swallowing and hoarseness; pressure of the sympathetic trunk will produce Horner's syndrome.

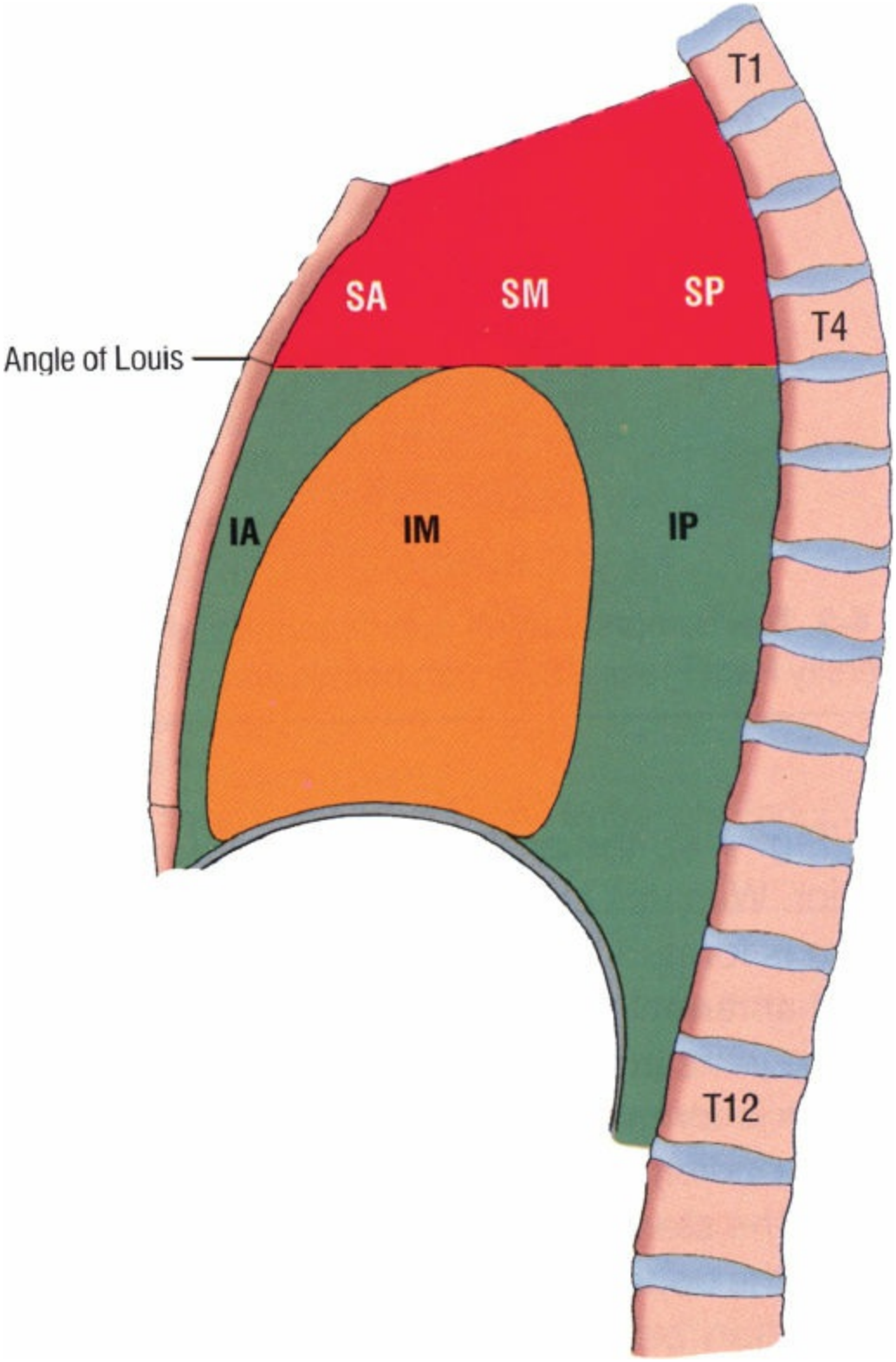

Figure 60.21. Anatomic divisions of the mediastinum. *S,* superior; *I,* inferior; *A,* anterior; *M,* middle; *P,* posterior. (From Colborn GL, Skandalakis JE, Mirilas P, et al. In: Skandalakis JE, Colborn GL, Weidman TA, et al. *Skandalakis' Surgical Anatomy: The Embryologic and Anatomic Basis of Modern Surgery*. Athens GR: Paschalides Medical Publications, 2004, with permission.)

The *brachiocephalic artery* is given off by the aortic arch on the right, subdividing into *common carotid* and *subclavian arteries.* On the left these arteries arise from the aortic arch.

The *pulmonary artery* is within the concavity of the aortic arch, but not readily seen because it is enclosed in the pericardium.

The *right vagus nerve,* after giving off the recurrent laryngeal nerve that loops around the right subclavian artery, continues behind the superior vena cava and the ascending aorta to reach the esophagus. The *left vagus* nerve descends between the left common carotid and the left subclavian artery, passes in front of the aortic arch, gives off the recurrent laryngeal nerve, and continues behind the hilum of the lung to reach the esophagus. The course of the phrenic nerves is shown in Figures 60.25 and 60.26.

Inferior

The inferior middle mediastinum contains the structures contained in the pericardium: heart and roots of the great vessels. The phrenic verves and the pericardiophrenic arteries, located on the pericardium and under cover of the mediastinal pleura, are considered contents of this compartment.

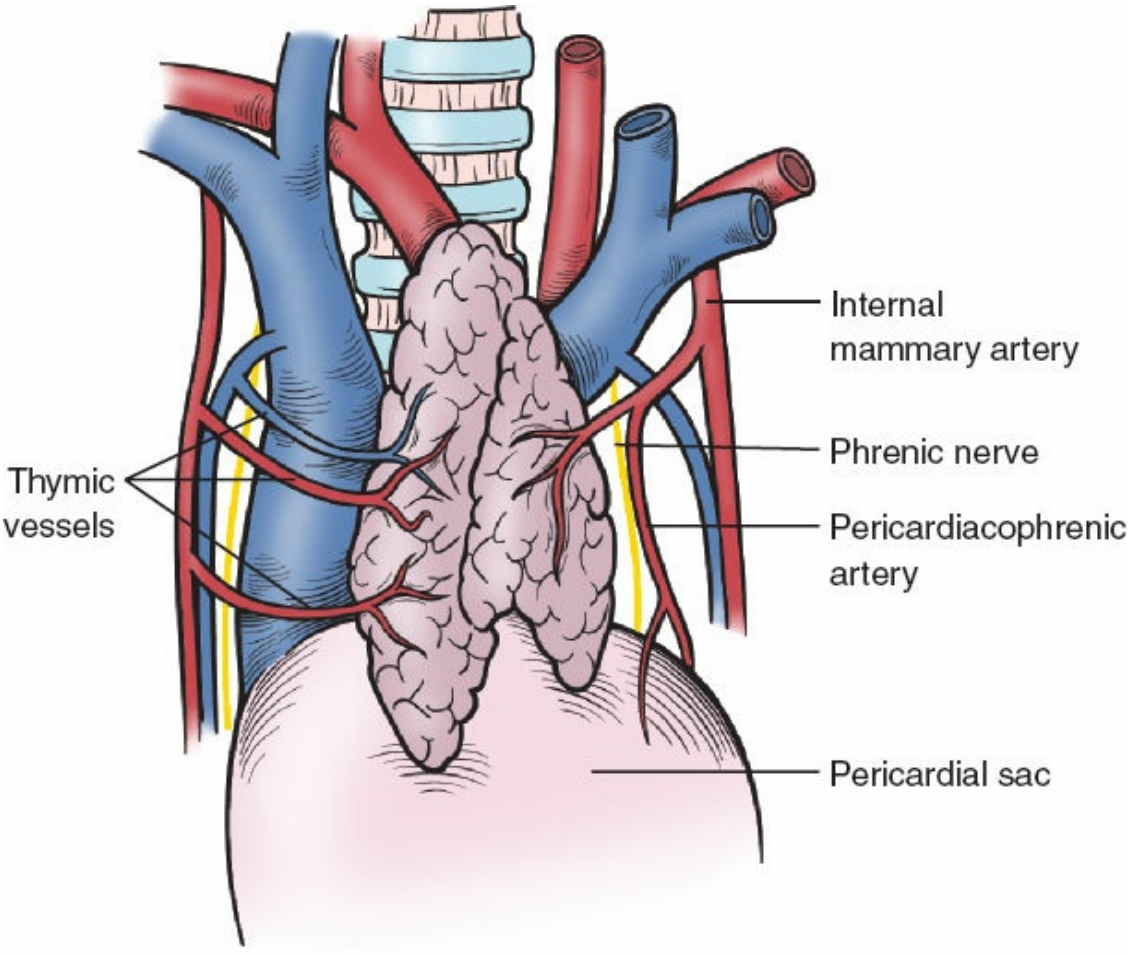

Figure 60.22. The thymus. The lungs and the pleura overlapping the thymus anteriorly are not shown. The chief vein of the thymus is not visible, as it lies behind that organ.

Posterior Mediastinum

The surgical significance of this compartment arises from the pathologic entities located in it: congenital anomalies like esophageal atresia, duplications, bronchogenic or enteric cysts; pathologies of the esophagus and aorta; lymphomas; mesenchymal origin tumors. Characteristic is the location of neurogenic tumors in this compartment.

This compartment of the mediastinum is the most complex and contains viscera traveling from the neck (trachea, esophagus) and continuing to the abdomen (esophagus, descending aorta), nerves (vagus, phrenic, sympathetic, and splanchnic), lymphatics, lymph nodes, etc. In this description, we consider the division into superior and inferior of didactic use only and will not follow it, as the surgeon will treat the compartment as a whole. The course of each entity and its relations can be followed in Figures 60.25 and 60.26. In the right side mostly veins and the esophagus can be seen (venous side) while on the left the aorta covers most other viscera (arterial side).

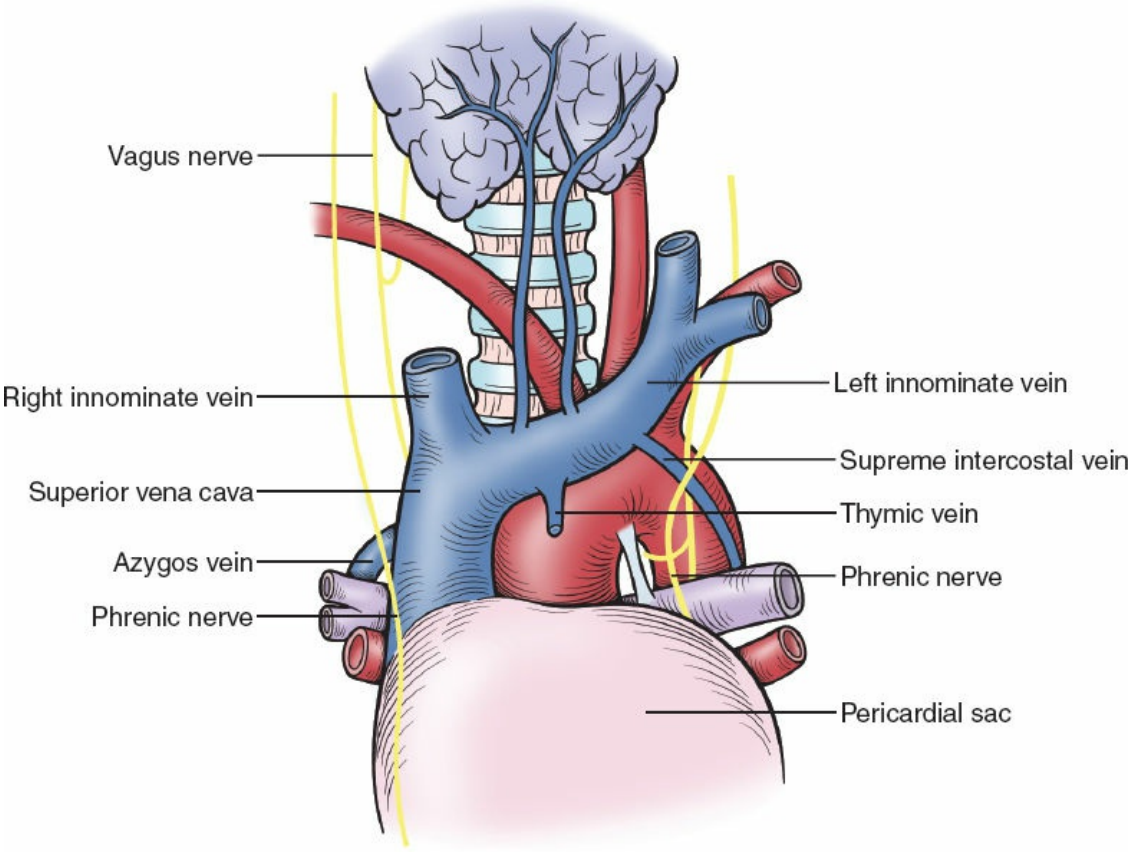

Figure 60.23. The superior mediastinum after removal of the thymus. The lungs and the pleura overlapping the thymus anteriorly are not shown.

The *trachea* is behind the ascending aorta and a bit to the left of it. The aortic arch lies anteriorly and to the left side of the trachea. The trachea is best seen in Figure 60.25. The right vagus nerve is on its right side, and they both descend under the arch of the azygos vein. Behind the trachea is found the *esophagus.* The trachea diverges slightly to the right at its lower end. Thus, the esophagus diverges to the left and passes behind the left bronchus. Then the esophagus turns to the right and descends toward the diaphragm, where it turns again to the left to reach the esophageal hiatus. The esophagus can be followed on the right side of the mediastinum (Fig. 60.25). Therefore, the intrathoracic esophagus is best proceeded from the right side. On the left, most of the esophagus is covered by the aortic arch and the descending aorta (Fig. 60.26). Only a superior part of the esophagus can be seen behind the left subclavian vein. Thus a cervical esophagostomy is performed on the left side of the neck. The *thoracic duct* descends just behind the upper esophagus and can been from the left. The lower intrathoracic esophagus is again seen at the lower end, as a triangular part between the pericardium and the aorta. The esophagus is in contact with the pericardium; this relation has led to development of the transesophageal ultrasound (combined with Doppler).

The *vagus nerves* in the superior mediastinum are well forward, and are best classified as contents of the middle mediastinum (see above). Then they enter the posterior mediastinum, travel on the trachea on the right side (Fig. 60.25), or pass in front of the aortic arch on the left side (Fig. 60.26). Above the hilum of the lung, after giving branches to the pulmonary plexuses, they deviate posteriorly, meet the esophagus, and converge to form a plexus on its wall. On the lower esophagus, the “left trunk” (the term is not strictly appropriate; the trunk is split into the plexus) becomes anterior, and the right, posterior.

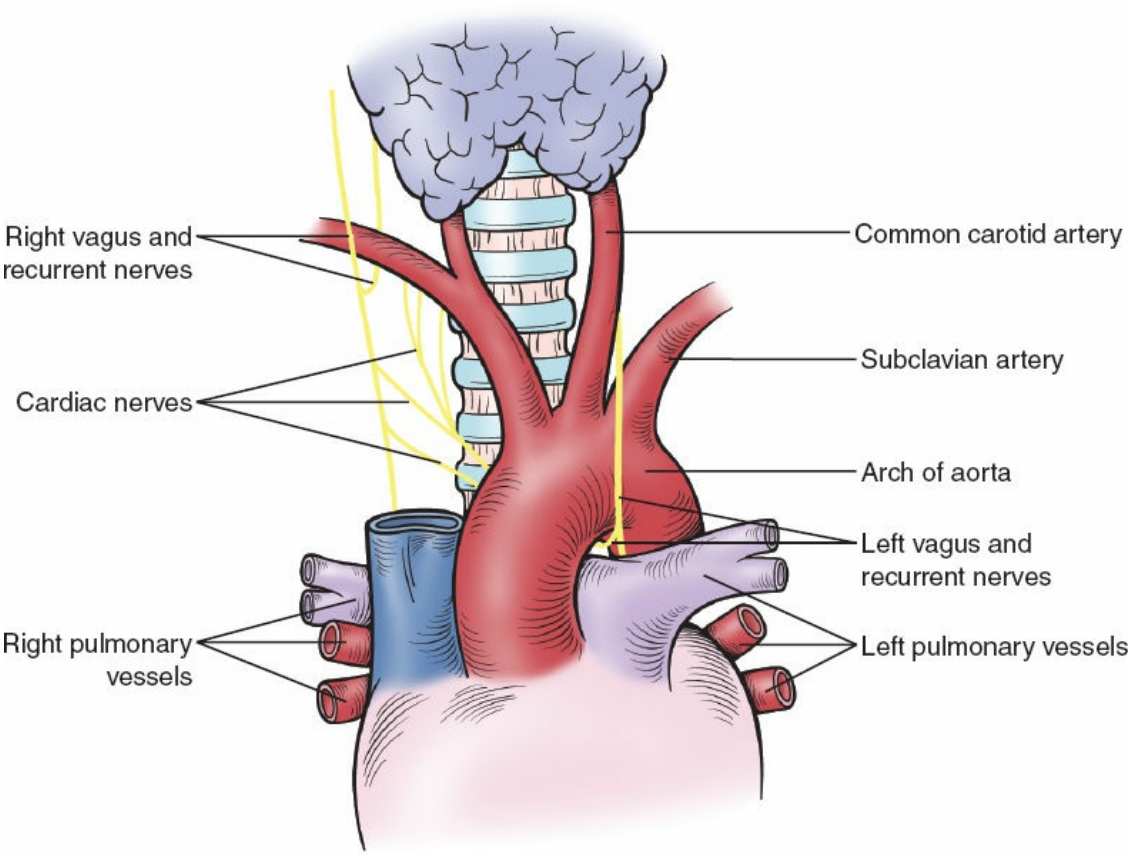

Figure 60.24. The superior mediastinum after removal of the great veins. The phrenic nerve and the pericardial sac have been removed. Portions of pulmonary vessels below the superior mediastinum are shown.

On the right side, *the azygos vein* accepts the *intercostal veins* and the *superior intercostal vein*, and arches over the hilum of the lung to empty into the superior vena cava. Lower on, the azygos vein is found posterior to the esophagus, always keeping a prevertebral location (Fig. 60.25). Ligation of the azygos can be done with impunity, and offers access to the esophagus (e.g., in esophageal atresia). On the left side, the superior intercostal vein crosses over the subclavian artery and the vagus nerve, and then empties into the left *brachiocephalic vein.* The *accessory hemiazygos vein* and the *hemiazygos vein* are located posterior to the aorta and accept intercostal veins (Fig. 60.26).



Figure 60.25. Right side of the mediastinum in an anatomical dissection of a human specimen. The pleura has been removed to display the underlying structures. 1, right subclavian artery; 2, sympathetic trunk and ganglion; 3, right phrenic nerve; 4, superior vena cava; 5, right recurrent laryngeal nerve; 6, right vagus nerve; 7, trachea; 8, esophagus; 9, azygos vein; 10, superior intercostal vein; 11, posterior intercostal vessels; 12, branches of the sympathetic trunk to greater splanchnic nerve; 13, pericardium. (Modified from: Abrahams PH, Hutchings RT, Marks SC. *McMinn's Color Atlas of Human Anatomy*. 4th ed. London: Mosby, 1998, p. 165. Copyright Elsevier.)

The *sympathetic trunks* descend from the neck in front of the posterior intercostal vessels, except for the superior intercostal vein, located anteriorly to the trunk. As described in the thoracic wall part of this chapter, the trunks communicate with the posterior intercostals nerves. Branches from the sympathetic trunks to the greater splanchnic nerve course anteriorly and forward in the paravertebral space (Fig. 60.25).

Mediastinal Lymph Nodes

The mediastinal lymph nodes are of tremendous surgical significance, as site of location of neoplasia or infectious disease. Strictly anatomically, the parasternal and the posterior intercostal nodes lie outside the pleura and belong to the thoracic wall, not the mediastinum. Surgically, however, it is important to have topographicoanatomic knowledge of these nodes:

The *parasternal nodes*: along the interval thoracic vessels. The *brachiocephalic or anterior mediastinal nodes* are found on the brachiocephalic veins. They drain the thymus, walls of the great vessels, the pericardium, and the heart.

The *posterior mediastinal nodes* are along the lower esophagus. They drain the esophagus and pericardium. They are joined by lymphatics to the phrenic nodes and the posterior intercostal nodes.

The *paratracheal nodes* are along each side of the trachea. Their efferents form the paratracheal trunks and join the efferents of the posterior mediastinal nodes to form the *bronchomediastinal* trunks. The right trunk empties into the right thoracic duct and the left into the thoracic duct.

The *nodes of the roots of the lungs* comprise, the pulmonary nodes (in the hilum) and bronchopulmonary nodes (in the root of the lung). They empty into the tracheobronchial nodes (above and below the bifurcation of the trachea). Their efferent trunks join the paratracheal trunks.

The *posterior intercostal nodes* are connected with lymphatics to the posterior mediastinal and phrenic nodes.

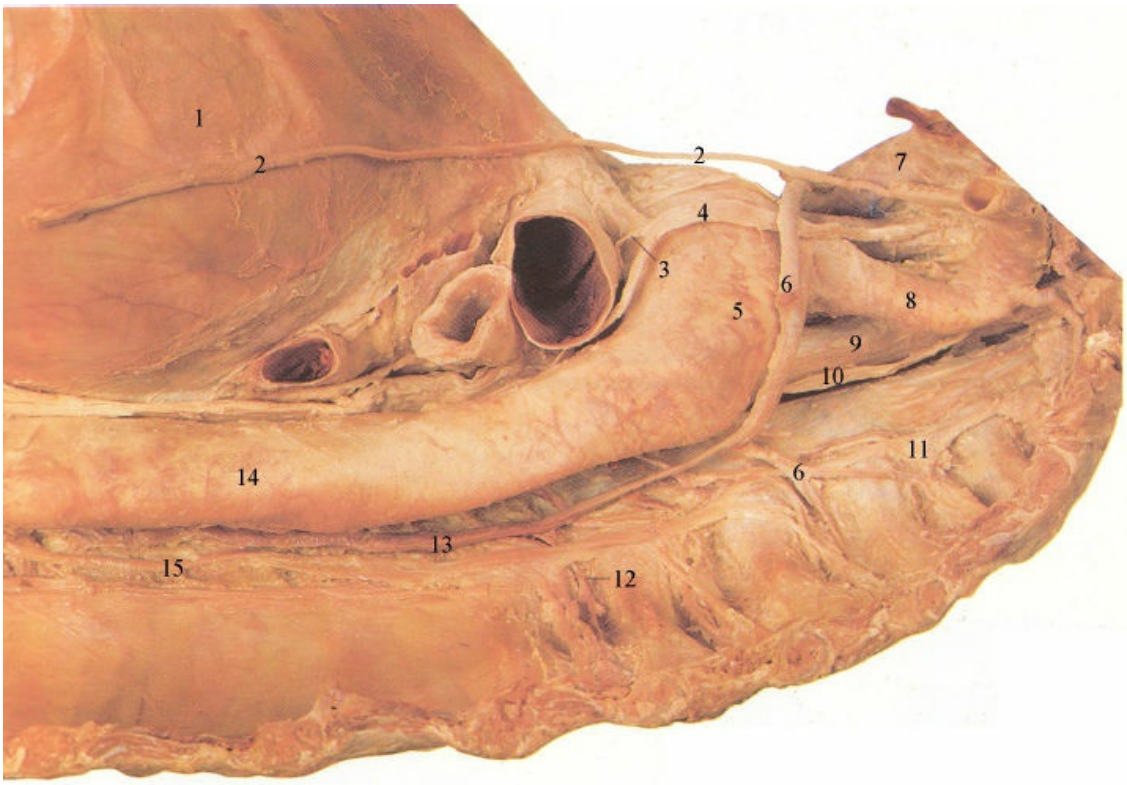

Figure 60.26. Mediastinum left side, anatomical dissection. Similar specimen to that of Figure 60.25. Most of the pleura has been removed to show the underlying structures. 1, pericardium overlying left ventricle; 2, left phrenic nerve; 3, left recurrent laryngeal nerve; 4, left vagus nerve; 5, arch of the aorta; 6, left superior intercostal vein; 7, left brachiocephalic vein; 8, left subclavian artery; 9, esophagus; 10, thoracic duct; 11, sympathetic trunk and ganglion; 12, posterior intercostal vein; 13, accessory hemiazygos vein; 14, thoracic aorta; 15, hemiazygos vein. (Modified from: Abrahams PH, Hutchings RT, Marks SC. *McMinn's Color Atlas of Human Anatomy*. 4th ed. London: Mosby, 1998, p. 167. Copyright Elsevier.)

We can describe the following lymph flow avenues in the mediastinum: (a) Along the internal thoracic vessels (parasternal nodes) toward the brachiocephalic nodes. (b) Along the pericardiomyophrenic artery (phrenic nodes) toward the bronchomediastinal trunks. (c) Along the thoracic duct (posterior mediastinal nodes) toward the bronchomediastinal trunks. (d) In the superior mediastinum, the bronchomediastinal (and the paratracheal) trunks course toward the right and left thoracic ducts. (e) In the inferior middle and posterior mediastinum the flow from intercostal, phrenic, and posterior mediastinal nodes may be downward to the celiac nodes of the abdomen. This is also valid for route (a) [vide supra], with lymph from

abdominal viscera reaching the parasternal nodes. Thus, there is a communication of lymphatics between the abdomen and the mediastinum, of great importance to the surgeon.

Suggested Readings

Colborn GL, Skandalakis JE, Mirilas P, et al. Thoracic wall and pleura. In: Skandalakis JE, Colborn GL, Weidman TA, et al. *Skandalakis' Surgical Anatomy: The Embryologic and Anatomic Basis of Modern Surgery.* Athens GR: Paschalides Medical Publications; 2004.

Colborn GL, Weidman TA, Mirilas P, et al. Thoracic wall and pleura In: Skandalakis JE, Colborn GL, Weidman TA, et al., eds. *Skandalakis' Surgical Anatomy: The Embryologic and Anatomic Basis of Modern Surgery.* Athens GR: Paschalides Medical Publications; 2004.

Hollinshead WH. *Anatomy for Surgeons. Vol 2. The Thorax, Abdomen, and Pelvis.* New York: Hoeber-Harper; 1956:1–39, 162–214.

Langebartel DA. *The Anatomical Primer: an Embryologic Explanation of Human Morphology.* Baltimore, MD: University Park Press; 1977:404–31.

McVay C. *Anson & McVay Surgical Anatomy.* Vol 1. Philadelphia, PA: WB Saunders; 1984:343–84, 385–476.

Meyerson SL, Harpole DA. Anatomy of the thorax. In: Shields TW, LoCicero J III, eds. *General Thoracic Surgery.* 7th ed. Philadelphia, PA: Lippincott Williams & Wilkins; 2009.

O'Rahilly R. *Gardner-Gray-O'Rahilly Anatomy.* Philadelphia, PA: WB Saunders; 1986:268–80, 329–43.

Shields TW. The mediastinum, its compartments, and the mediastinal lymph nodes. In: Shields TW, LoCicero J III, Reed CE, et al., eds. *General Thoracic Surgery.* 7th ed. Philadelphia, PA: Lippincott Williams & Wilkins; 2009.

EDITOR'S COMMENT

This is another excellent product from the Anatomy School at Emory with the tradition that the Skandalakis family has established, which has been so valuable to surgery in general and to American surgery in particular. Indeed, we have now a lot to consider about the chest, which we have not had to consider previously. This has not happened all at once, but it is an aspect of the development of thoracic surgery, of which the most recent chapter on pulmonary resection involves also the mediastinum. As time has gone on, the ability to treat patients with a number of chemotherapeutic agents, which have heretofore not been known to be effective against carcinoma of the lung, a very

complex—appropriately so—aspect of node numbers and where they are, and what kind of node dissections and node samplings are appropriate for whatever kind of operation is being done segmental, non-anatomical resections, lobectomy, or pneumorectomy. Not much has changed in the past five years—there are some additional dissections. Not as many dissections through the axilla are carried out as in the past, in which the intercostal brachial nerve, which is so nicely described, must be spared because of the numbness of portions of the upper arm and some of the other unfortunate side effects.

It is wise to remember where the arteries and nerves run. The intercostal artery accompanies the vein and the nerve in the costal groove beneath the rib. Thus, when one is doing a thoracentesis, one must insert the needle above the rib and stay close to the rib in order not to injure the intercostal artery and thereby get uncontrolled bleeding. I get very concerned about this, because of the fact that contemporary surgical residents don't have a great deal of experience in doing thoracentesis. They prefer to send these off to the interventional radiologists, and one shudders when one thinks of asking a contemporary young surgical resident like an intern to do a thoracentesis. Nonetheless, it does appear as if in certain programs things are beginning to turn around, and the residents are being asked to do procedures which we could do at a moment's notice. Can the contemporary resident do a thoracentesis without hitting the intercostal artery? I hope so, but I'm not exactly sure. Likewise, can one put in a chest tube? And, if one puts in a chest tube, with what facility can the resident, and specifically the intern, put in the chest tube without again hitting some of the vessels?

In the discussion of the mediastinum, the embryogenesis of the esophagus and the fact that the mediastinum arises from the mesentery of the esophagus are something we are usually unaware of. As the author says, this statement may sound bizarre to the surgeon who is brought up with the knowledge that the esophagus is deprived of the serosal layer, that is, it has no mesentery. This misconception has to be changed. One of the things I learned in this particular edition is that many of the spaces that we take for granted may have occurred embryologically from the spaces developing out of the mesentery that no longer exists. Thus, the statement that the mediastinum develops from the mesentery of the esophagus is something that not only is true but is something that most surgeons are unaware of. True, the esophagus has no mesentery at the present time, or at least it has no serosa, or, if it does have serosa, we are unaware of it; but the fact is that the mediastinum has developed from the mesentery of the esophagus.

For various endocrine surgeons, who have the occasion to go into the mediastinum looking for the wayward parathyroid or occasionally a thyroid remnant that ends up in the mediastinum, the cephalad extension of the anterior and visceral compartments is important. Three quarters of thyroidal goiters that extend to the mediastinum have their extensions limited to the anterior compartment, which is easy to get to, comparatively speaking; but the

remaining one quarter of the thyroidal-goiter extensions is in the visceral compartments. This can actually be forewarned, with a sestamibi scan or other imaging technology. The wayward parathyroid gland, which may end up anywhere between the hyoid bone and the superior level of the heart, has great variability, especially in the visceral compartment, as it develops from the mesentery of the esophagus, which is no longer present. This may require a sternal split or at least an episternal split looking at the horns of the thymus, where one usually finds a parathyroid gland when one is doing a thymectomy for myasthenia gravis. The neck and the anterior mediastinum, thus, must be regarded as components which "work together" and must be viewed as such. As the transhiatal esophagectomy has become more popular, we view esophageal neoplasms as a visceral-compartment organ. We may be aided in our approach to this disease by endoscopic ultrasound to at least define some of the visceral extensions of carcinoma of the esophagus. Despite the fact that it seems that an open thoracotomy, for dissection of the esophagus and its nodes, would give us cleaner dissection, this is not always the case and has been very difficult to prove. The reason for this is perhaps the fact that the adenopathy that occurs with carcinoma of the esophagus is not limited to the section where the carcinoma arises. For example, in carcinoma of the lower esophagus, there may be positive nodes in the upper one-third of the esophagus, that is, in the upper portion of the chest. In addition, there may be positive neck nodes in 20%. This probably is aided and abetted by the fact that there are no valves in lymphatics, and there are no segments to the esophagus or the esophageal nodes as we traditionally consider them. This is somewhat different from the adenopathy of pulmonary resections, in which the adenopathy associated with certain lobes and certain lungs and where to dissect is well known, as detailed very nicely in Chapter 54.

The final point that should be made here is that mediastinal infections are lethal. A perforation of the esophagus, which is not promptly treated, has no barrier, and within 24 hours, the entire mediastinum is filled with pus with an attendant high mortality. Whether it is the anterior compartment or visceral compartment, while theoretically these are separate compartments, in actual fact they do not act as such, there is free spread of pus up and down the mediastinum. Whether or not this is the result of an absent serosa, or whether or not this is because all of the compartments embryologically have fused when the mediastinum is developed is not clear, but this a high-mortality situation.

J.E.F.

61 Thoracic Trauma

J. Wayne Meredith and James Jason Hoth

INTRODUCTION

Trauma continues to be a significant source of patient morbidity and mortality, accounting for 140,000 deaths annually and is the leading cause of death in patients younger than 40 years of age. Although rarely isolated, thoracic injuries are a primary or contributing cause of death in up to 50% of all trauma-related deaths. Fortunately, the majority of thoracic injuries can be treated effectively, and often conclusively, by relatively simple maneuvers at the bedside such as tube thoracostomy. However, 10% to 15% of patients presenting with thoracic trauma have severe, life-threatening injuries that require definitive operative repair. In these patients, the timing of intervention and utilization of the appropriate surgical approach are crucial and should be based on a comprehensive knowledge of the location and nature of the injury. These extremes in injury severity are unique to the chest and require a correspondingly broad range of knowledge and skills on the part of the treating surgeon.

INITIAL EVALUATION

Initial evaluation and treatment of patients with thoracic injuries are guided by the same principles and priorities as initial evaluation and treatment of patients with other injuries. The first priority is to ensure an adequate airway and adequate ventilation. Patients with severe chest trauma commonly require nasotracheal or orotracheal intubation. It is frequently during this stage of evaluation that tube thoracostomy is required for life-threatening pneumothorax. The next priority is control of external hemorrhage and restoration of circulation. External hemorrhage is best controlled by direct pressure. Inadequate perfusion generally results from either hypovolemia or pump (i.e., cardiac) problems. Hypovolemia from hemorrhage, by far the most common cause of inadequate perfusion in the traumatic setting, often must be treated operatively as part of the resuscitative effort. Pump problems are signaled by distended neck veins

and are caused by one of four conditions: (1) tension pneumothorax, (2) pericardial tamponade, (3) coronary air embolism, or (4) cardiac contusion or myocardial infarction (MI). In most blunt trauma patients, urgent treatment of thoracic injury is accomplished during the primary survey because the most common blunt chest injuries can be controlled with endotracheal intubation or tube thoracostomy.

ED THORACOTOMY (EDT)

Emergency department thoracotomy (EDT) is a drastic procedure with limited utility. The therapeutic goals of EDT include control of hemorrhage, effective cardiac compression, cross-clamping the pulmonary hilum in the case of air embolism or massive bronchopleural fistula, relief of cardiac tamponade, and cross-clamping of the descending aorta for lower torso hemorrhage control.

Indications

When making a decision to perform an EDT, three factors must be taken into consideration: mechanism of injury, location of major injury, and signs of life. Better outcomes are seen when performed for penetrating (8% to 10%) injuries rather than blunt injuries (approximately 1%). Patients with isolated penetrating chest injuries have the greatest chance of survival, and the absence of signs of life (palpable pulse, pupillary or gag reflex, demonstrable blood pressure) or asystole on presentation must be considered. In general, the patients most likely to respond favorably to EDT include victims of penetrating trauma, particularly stab wounds, with signs of life either upon presentation to the emergency room or who lose signs of life within 10 minutes of arrival.

Surgical Technique

Once the decision has been made to intervene, the standard incision is a left anterolateral thoracotomy; however, extension across the sternum may be required. After evacuating blood from the chest, attention is directed to the injury. If a great vessel is injured and bleeding, pressure is utilized to staunch hemorrhage. If air embolism is encountered, the pulmonary hilum is clamped or the affected lung may be twisted 180 degrees and air in the aorta evacuated. When hemopericardium is present, the pericardium may be divided longitudinally, and once the hemopericardium is evacuated, the

heart is delivered from the pericardial sac and a temporary repair is then performed using suture or staples. After the cause of arrest has been addressed or in case of resuscitative thoracotomy for intra-abdominal sources of hemorrhage, a cross-clamp may be applied to the descending thoracic aorta once the mediastinal pleura has been carefully opened taking care not to injure the esophagus. Intravascular volume is restored and, if the patient responds, transported to the operating room for definitive repair of injuries.

SECONDARY EVALUATION AND DEFINITIVE DIAGNOSIS

The secondary survey should focus on more subtle evidence of injury that may be detected on physical examination and chest x-ray. Simple rib fractures, flail chest segments, pneumothorax, and hemothorax are often undetected during the primary survey but are common findings after patient workup. Because of continuing improvements in computed tomography (CT) scanning technology, this modality is increasingly being used in the evaluation of the thoracic trauma in stable patients. Indeed, chest CT angiography (CTA) is now routinely employed for definitive diagnosis of aortic and great vessel injuries, rendering standard angiography unnecessary in most cases. In addition, chest CT scanning is increasingly useful in the diagnosis of pulmonary contusion, and tracheobronchial and esophageal injuries. Furthermore, echocardiography can be an important adjunct for assessing proximity wounds to the heart or evaluating a new murmur.

INDICATION FOR URGENT OPERATIVE INTERVENTION

Indications for urgent operative treatment of thoracic injuries fall into five broad categories: (1) hemorrhage, (2) major airway disruption, (3) cardiac and vascular injuries, (4) esophageal disruption, and (5) diaphragmatic disruption. The extent and location of hemorrhage can sometimes be determined from open wounds but are more often established after chest tube insertion. It is important to understand that the pulmonary circulation is a low pressure system and complete re-expansion of the lung will tamponade parenchymal bleeding. In general, if 1,500 mL of blood or more is obtained initially or ongoing bleeding at a rate ≥300 mL/hr for 3

hours is noted, thoracotomy is generally indicated. Caveats to the use of chest tube drainage as an indicator for chest explorations are chest trauma with a delayed presentation and the presence of a coagulopathy. Massive air leakage and the presence of gastric or esophageal contents in the chest tube effluent also necessitate surgical intervention. A continuous air leak seen in conjunction with an inability to expand the lung completely or with inadequate tidal volumes is considered a massive air leak. These findings suggest major tracheobronchial injuries. The presence of cardiac tamponade, demonstrated on physical examination using a combination of findings (Beck's triad: muffled heart tones, distended neck veins, and hypotension) and more recently, by the presence of a pericardial effusion on FAST examination, demands further evaluation with pericardial window or median sternotomy. Lastly, air embolism, a rare entity associated with penetrating injury, occurs when a fistula develops between a bronchus and pulmonary vein and also requires urgent thoracotomy. Typically, the patient is stable until intubated and placed on positive pressure ventilation when sudden cardiovascular collapse and/or the onset of lateralizing neurologic symptoms occur.

CHOICE OF INCISION

Given the indications for chest exploration, selecting the appropriate chest incision is critically important. What makes this decision difficult is that four different compartments must be considered: the right chest, left chest, mediastinum, and in the case of concomitant abdominal injury, the peritoneal cavity. Several factors should be carefully assessed before making a decision. Information regarding missile or injury trajectory, a thorough working knowledge of thoracic/mediastinal anatomy, and the exposures offered by each different incision are vital to choosing the appropriate incision. For example, a left parasternal gunshot wound may injure both the anterior and posterior walls of the left ventricle. Of these two injuries, while the anterior injury is easily exposed and repaired through a median sternotomy or anterior thoracotomy, the posterior injury is more difficult to repair and is best approached with a left posterolateral thoracotomy. A summary of surgical approaches for common traumatic injuries to thoracic viscera is given at Table 61.1.

TABLE 61.1 Surgical Approaches for Traumatic Injuries to Thoracic

Viscera

Site	Sternotomy	Right Thoracotomy	Left Thoracotomy
R Atrium	+++	++	0
R Ventricle	+++	+	+
L Atrium	+++	+	+
L Ventricle	++	0	+++
SVC	+++	++	0
Azygos Vein	++	+++	0
IVC	+++	++	0
Aortic Root	+++	+	0
Aortic Arch	+++	0	++
R Subclavian	++	++	0
Proximal R Carotid	+++	+	0
Innominate	+++	++	0
L Subclavian	+	0	+++
Proximal L Carotid	++	0	++
Descending Aorta	0	+	+++
Main PA	+++	0	++
R PA	++	+++	0
L PA	++	0	+++
RUL	++	+++	0
RML	++	+++	0
RLL	+	+++	0
LUL	+	0	+++
LLL	0	0	+++
R Hilum	++	+++	0
L Hilum	++	0	+++
Pericardium	+++	++	++
R IMA	++	+++	0
L IMA	++	0	+++
Proximal Esophagus	0	+++	0
Distal Esophagus	0	++	+++
Proximal Trachea	++	+	+
Carina	0	+++	+
R Mainstem	0	+++	0
L Mainstem	0	++	++
R Hemidiaphragm	+	+++	0
L Hemidiaphragm	+	0	+++
CPB	+++	++	++

+++, preferred; ++, acceptable; +, with difficulty; **0**, not accessible; **R**, right; **L**, left; **SVC**, superior vena cava; **IVC**, inferior vena cava; **PA**, pulmonary artery; **RUL**, right upper lobe; **RML**, right middle lobe; **RLL**, right lower lobe; **LUL**, left upper lobe; **LLL**, left lower lobe; **IMA**, internal mammary artery; **CPB**, cardiopulmonary bypass.
From Ritchie WP, Steele G, Dean, RH, eds. *General Surgery*. Philadelphia, PA: JB Lippincott Co.; 1995, with permission.

Median sternotomy (Fig. 61.1) offers adequate exposure for the majority of parasternal stab wounds as these injuries do not typically

penetrate deeply and primarily involve the anterior mediastinum. Likewise, in the instance of right parasternal gunshot wound, a median sternotomy provides good exposure of structures that are likely to be injured, including the right atrium and ventricle, the superior vena cava, atrial appendage, right pulmonary artery, and lung. Furthermore, the incision for a sternotomy may be extended into the neck or supraclavicular fossa to enhance exposure of the great vessels (Fig. 61.1, inset). As previously stated, posterolateral thoracotomy provides superior exposure of the posterior heart and should be used in instances of left parasternal gunshot wound. In addition, for lateral wounds, depending on the side involved, a right or left posterolateral thoracotomy provides the best exposure as these injuries are more likely to be posterior. In cases of massive hemothorax, a posterolateral thoracotomy on the affected side will offer excellent visualization of the great vessels such as the subclavian artery or aorta. A left posterolateral thoracotomy (Fig. 61.2) is the incision of choice in instances of air embolism and massive air leak.

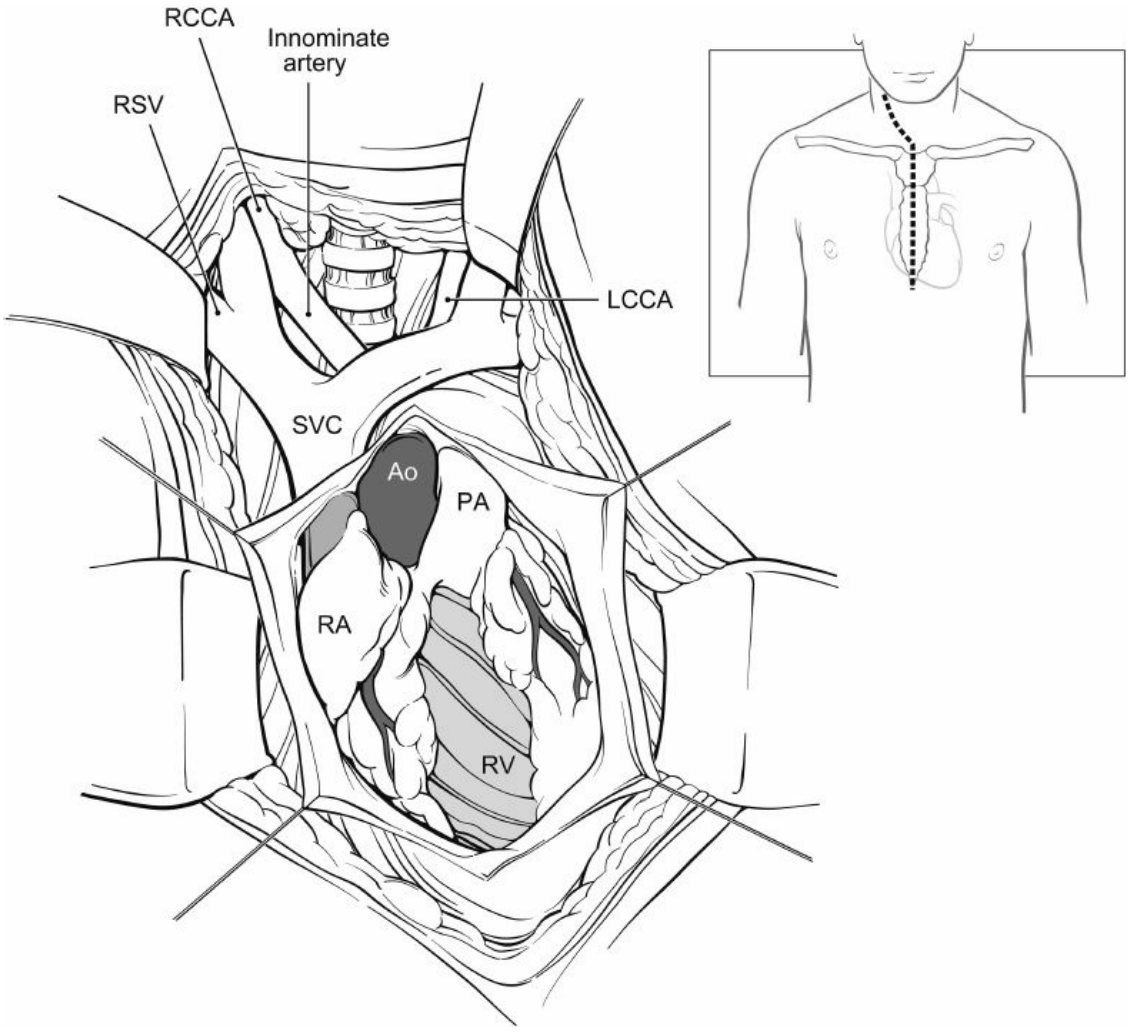

Figure 61.1. Median sternotomy with optional extension. A median sternotomy provides excellent exposure for the right atrium and ventricle, the superior vena cava, atrial appendage, right pulmonary artery, and lung. If necessary, the incision may be extended into the neck or supraclavicular fossa (see *inset*) to enhance exposure of the great vessels. Ao, Aorta; LCCA, left common carotid artery; PA, pulmonary artery; RA, right atrium; RCCA, right common carotid artery; RSA, right subclavian artery; RV, right ventricle; SVC, superior vena cava.

Right thoracotomy is an excellent approach for right lung, tracheal and proximal left mainstem bronchial injuries, a point that is often forgotten. Most upper and mid-esophageal injuries are best approached through a right thoracotomy except in cases of distal esophageal injuries that are best accessed through the left chest. Right heart structures such as the right atrium, right ventricle, atrial appendage, as well as the left atrium are also easily exposed with a right thoracotomy. Left thoracotomy provides adequate exposure of the left lung, left pulmonary hilum, the aorta, the proximal left subclavian artery, left heart chambers, distal esophagus, and distal left mainstem bronchus. A “clam shell” incision, formed by extending a thoracotomy incision transversely across the sternum using either the Lebske knife, a pair of trauma shears or a saw, provides excellent access but suboptimal exposure of every intrathoracic or mediastinal structure except the right ventricle and right atrium. When using this approach, the internal mammary arteries are divided and often do not bleed in the poorly perfused patient. However, once blood pressure is restored, significant hemorrhage from these vessels may result. A more stable closure of the transverse sternotomy may be achieved with sternal plates rather than wires.

CHESTWALL INJURIES

Rib Fractures

Clinical Presentation and Diagnosis

Rib fractures are the most common chest wall injuries resulting from blunt trauma. The main pathophysiologic consequences of rib fractures are pain, splinting, and prevention of adequate cough. The diagnosis should be suspected if pain or splinting occurs on deep inspiration, and it is confirmed by careful physical examination, consisting of anterior–

posterior and lateral–lateral manual compression. If an alert patient feels no pain when these maneuvers are done, clinically significant rib fractures can be excluded. Although rib fractures are often identified on routine chest radiographs, they are more likely to be undetectable on plain radiographs; however, chest CT identifies rib fractures with high sensitivity and specificity.

Treatment

Adequate pain control cannot be emphasized enough especially in those with greater than six rib fractures and over the age of 65. Pain from isolated rib fractures can usually be adequately controlled with oral analgesics, encouraging good pulmonary toilet, and use of thoracic epidural anesthesia in select patients. Increasingly, reports have demonstrated the feasibility of rib fracture repair using a variety of different methods; however, the patients who will benefit the most from these interventions have not been clearly identified. Potential indications for operative repair of rib fractures include flail chest, painful moveable rib fractures that are refractory to conventional management, chest wall deformity/defect, rib fracture nonunion, and during thoracotomy for other indications. Studies have demonstrated excellent outcomes for patients with flail chest of greater than three ribs; however, other indications for repair have not been as clearly defined. A reduction in ventilator days, pneumonia, ICU days, analgesic use, and other morbidities has inconsistently been demonstrated when rib fixation is undertaken. Most trauma surgeons feel there is a role for rib repair, but further clarification of the population of patients who will benefit remains an obstacle.

Sternal Fractures

Clinical Presentation and Diagnosis

The vast majority of sternal fractures result from motor vehicle crashes and may be associated with significant underlying thoracic and abdominal injuries. The diagnosis of sternal fracture is based on the presence of severe pain, often associated with instability, on sternal palpation. Sternal fractures are almost invariably transverse, with the majority occurring near the sternomanubrial joint.

Treatment

Initial management of a sternal fracture is directed toward resuscitation

and identification or exclusion of other life-threatening injuries. In patients with isolated sternal fractures, a normal electrocardiogram (ECG) and a normal chest radiograph suggest that associated serious injuries are unlikely. If the pain is controlled with oral analgesics, these fractures can usually be managed on an outpatient basis. The vast majority of sternal fractures heal with non-operative management. Those that are unstable or are displaced by more than 1 cm of overlap are more likely to exhibit mal-union or non-union and subsequent chronic pain; they may require treatment with open reduction and internal fixation.

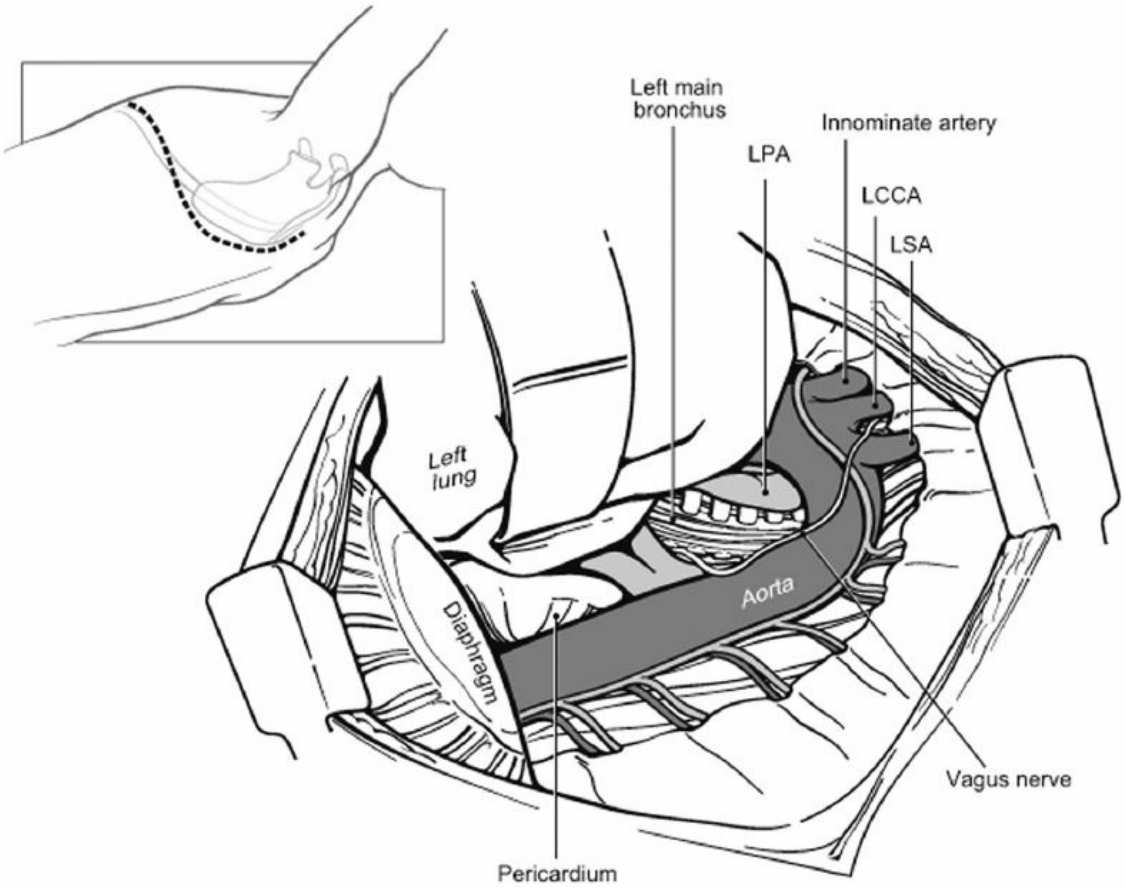

Figure 61.2. Left posterolateral thoracotomy. A left posterolateral thoracotomy (see *inset*) provides excellent exposure of the left pulmonary hilum, left lung, proximal left subclavian artery, descending aorta, distal esophagus, and left diaphragm. LCCA, left common carotid artery; LPA, left pulmonary artery; LSA, left subclavian artery.

Flail Chest

Clinical Presentation and Diagnosis

Flail chest is the most serious of the blunt chest wall injuries. It is common

after any form of blunt thoracic trauma, and though it may occur as an isolated finding, it is usually associated with other significant injuries. It involves fractures of adjacent ribs, each of which is fractured in two or more places so that with spontaneous respiration a panel of chest wall moves independently of, and in the opposite direction to, the remainder of the chest (i.e., paradoxical motion). A flail segment may be overlooked in a patient on positive pressure ventilation because there may be no paradoxical motion without inspiratory effort. The pathophysiology of flail chest consists of three components: alteration of chest wall mechanics impairing adequate ventilation; pulmonary contusion resulting in shunting to produce hypoxemia; and pain with associated splinting and inadequate pulmonary toilet, setting the stage for subsequent infection.

Treatment

Proper management of flail chest hinges on the recognition that the injury is an evolving process not a static condition. Frequent re-evaluation and timely, appropriate intervention are essential. Early and aggressive pain management is essential so to allow an adequate tidal volume and a forceful cough. Oral analgesics rarely suffice. Parenteral narcotics are effective, especially when administered in a patient-controlled analgesia (PCA) device. Intercostal nerve blocks occasionally provide dramatic pain relief, but only for short periods. However, thoracic epidural anesthesia is the mainstay of pain control in patients with flail chest. Epidural anesthesia provides immediate comfort, dramatically improves vital capacity and tidal volume, and most importantly, enables the patient to produce a forceful cough. Ambulation is encouraged, and frequent coughing is required. There is no role for antibiotic prophylaxis or steroid use in the management of patients with flail chest or pulmonary contusion. It is in this group of patients that operative repair of rib fractures has consistently been shown to be the most beneficial (see above) although not required in the majority of instances.

LUNG INJURIES

Lung injury requiring operative intervention is more common following penetrating rather than blunt injury. The majority of cases of pneumothorax or hemothorax can be adequately treated with accurate chest tube placement and full re-expansion of the lung. However, it is estimated that 20% to 40% of patients after penetrating injury and 15% to

20% of patients after blunt injury who require thoracotomy will need some form of lung resection. The vast majority of lung injuries that require thoracotomy can be successfully managed using lung sparing techniques such as non-anatomic stapled resections or tractotomies; however, trauma surgeons should be familiar with anatomic lung resection as well. Operative indications for lung injury tend to fall into one of two categories, hemorrhage or persistent air leak impairing ventilation. The incision of choice for lung injury is a fifth intercostal space posterolateral thoracotomy on the involved side. The most common procedures performed are simple suture repair of superficial lung lacerations or wedge resection of the injured lung using a stapling device.

Lacerations

Operative Indications and Approach

Operative indications for lung injury tend to fall into one of two categories, hemorrhage (>1,500 mL initially or >300 mL/hr for 3 or more hours) or persistent air leak impairing ventilation. The incision of choice is a fifth intercostal space posterolateral thoracotomy on the involved side. The most common procedures performed are simple suture repair of superficial lung lacerations or wedge resection of the injured lung using a stapling device.

Treatment

Bleeding pulmonary lacerations can be oversewn, resected, or explored via stapled pulmonary tractotomy. Bleeding from small or shallow lacerations can be controlled with an over-and-over repair using a continuous absorbable suture. Bleeding from deeper lacerations is controlled with resection or tractotomy. Most pulmonary resections for trauma should be stapled, non-anatomic resections; however, anatomic lung resection is required in rare instances. Mortality is proportional to the amount of lung tissue resected: with suture repair alone, mortality is 9%; with tractotomy, 13%; with wedge resection, 30%; with lobectomy, 43%; and with pneumonectomy, 50%.

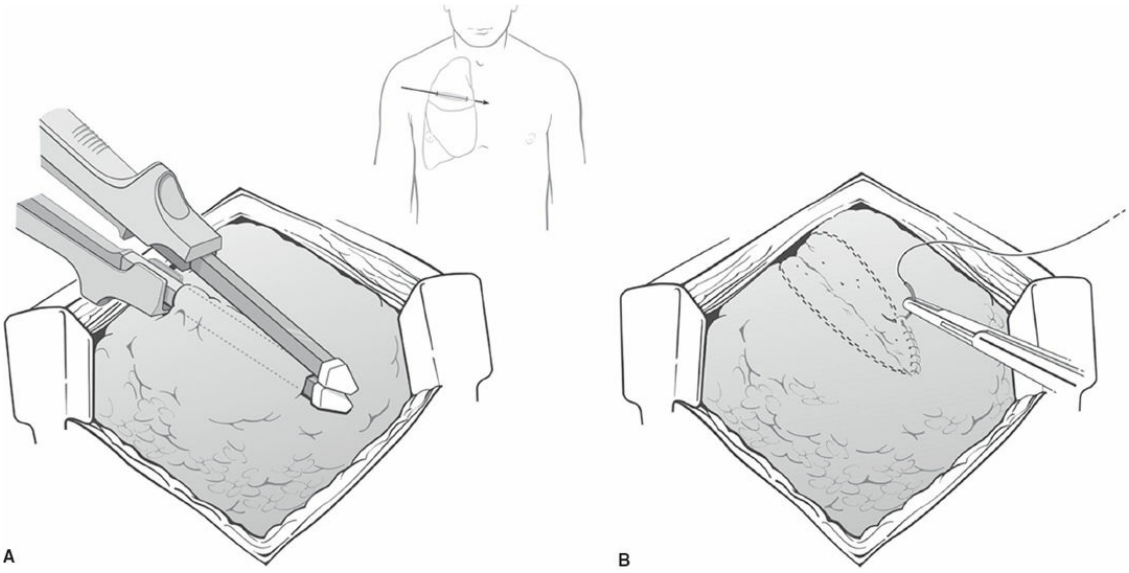

Figure 61.3. Tractotomy for nonhilar injuries. The principle of tractotomy is to open the tract of the bullet or knife wound (**A**, see *inset*) so that larger interior vessels may be identified and ligated individually (**A**). 3-0 polypropylene suture may be used to individually ligate the vessels or may be run along the length of the tractotomy (**B**). Oversewing penetrating lung injury is discouraged.

Tractotomy is especially useful for deep through-and-through injuries that do not involve the hilum. In this technique, the injury tract is opened with a linear stapler or between two aortic clamps (Fig. 61.3). If clamps are used, the cut lung edges are oversewn and the tract left open. Tractotomy exposes bleeding vessels and air leaks inside the tract and permits selective ligation. Occasionally, it exposes an injury to a major vascular or airway structure that must be treated with a formal resection. Because of the risk of exsanguination or excessive devitalization of lung tissue, tractotomy is not indicated when the injury traverses the hilum or when the entire thickness of a lobe will be cut.

The practice of simple oversewing of penetrating lung injuries should be discouraged. Oversewing entrance and exit sites may stop bleeding into the pleural cavity, but it does not stop intraparenchymal bleeding. Blood can then be forced into the tracheobronchial tree resulting in aspiration, pneumonia, acute respiratory distress syndrome (ARDS), and further worsening of the lung injury. Simple maneuvers such as tractotomy, wedge resection, and simple suturing are more commonly performed after penetrating lung injury since more proximal lung injuries are often associated with concurrent fatal mediastinal injuries.

Anatomic resections such as lobectomy and pneumonectomy are more commonly performed if resection is needed after blunt injury. Blunt traumas often result in a more severe and diffuse lung injury that is typically more difficult to treat surgically and has worse outcomes when compared to penetrating trauma. Patients with perihilar injuries are typically in shock or have extensive parenchymal injury (as seen commonly after blunt injury). Hilar control should be the initial maneuver upon entering the chest if profuse lung bleeding is encountered. This can involve placing a large clamp across the pulmonary hilum or dividing the pulmonary ligament to the level of the inferior pulmonary vein and twisting the immobilized lung. Occasionally, intrapericardial control of the pulmonary artery is required in cases of proximal injuries. If both the artery and vein are injured, pneumonectomy is indicated. At this point, lung amputation can be performed using a stapler or alternatively, the hilum may be oversewn. Traumatic pneumonectomy is associated with mortality rates of 50% to 100% and should only be considered if there is no alternative.

Contusions

Clinical Presentation and Diagnosis

Pulmonary contusions are bruises to the lung usually caused by blunt trauma to the chest but sometimes result from penetrating injury by high-velocity weapons. The contused segment of the lung has a profound ventilation-perfusion mismatch, which produces an intrapulmonary right-to-left shunt and hypoxia. The clinical sequelae of lung contusion may vary from simple shortness of breath to respiratory failure requiring mechanical ventilation.

Typically, the bruise is not completely appreciated on chest x-ray, but it is fully evident on chest CT. In fact, the size of the contusion as measured on chest CT is directly proportional to the risk of developing posttraumatic ARDS. Lung contusion is a significant risk factor for pneumonia, and the bruised lung also may serve later as a source of sepsis.

Treatment

Most pulmonary contusions that are not complicated by excessive attempts at resuscitation or by superinfection resolve over 3 to 5 days. Supportive care in the form of cardiovascular, and if necessary, ventilatory support, must be provided. In general, pulmonary contusion is treated in much the

same fashion as flail chest. Steroids are not indicated, because they have no effect on the development or resolution of the contusion and because they set the stage for subsequent infection. Diuretics and prophylactic antibiotics are also unnecessary.

CARDIAC INJURIES

Cardiac injuries may involve the myocardium, coronary arteries, valves, septum, or result in the late presentation of a ventricular aneurysm. Mortality rates range from 10% to 70%, reflecting a variety of presentations and injury mechanisms. Cardiac injuries usually cause either cardiac tamponade or hemorrhagic shock, depending on the nature of the pericardial injury and whether pericardial blood can escape into the pleural space. Pericardial tamponade results from the accumulation of fluid within the pericardial space that compresses the heart and prevents cardiac filling. The sac-like pericardium has poor compliance and as little as 50 mL of blood can effectively cause tamponade. The presence of cardiac tamponade is usually made based on clinical findings of a distinctive dusky, plethoric facial complexion associated with distended neck veins, hypotension, and evidence of pericardial effusion on ultrasound examination. It should be noted, however, that the sensitivity of ultrasound in the detection of hemopericardium is markedly diminished in the presence of a significant hemothorax where blood may be escaping from the injured heart directly into the thoracic cavity leaving only small amounts in the pericardium. Depending upon the hemodynamic status of the patient with tamponade, they should either undergo EDT or be taken to the operating room immediately for a pericardial window or formal chest exploration.

Penetrating

Clinical Presentation and Diagnosis

Patients with penetrating cardiac injuries generally present in one of three ways. In approximately 20% of patients, the injury is clinically silent, at least initially, and is subsequently diagnosed at operation or on diagnostic imaging. In approximately 50%, there is evidence of pericardial tamponade, including one or more of the signs in Beck’s triad (hypotension, distended neck veins, and muffled heart sounds). In the remaining patients, hemorrhagic shock develops after free bleeding from an atrial or ventricular wound into one or both hemithoraces.

Diagnosis of penetrating injuries to the heart often requires a high index of suspicion. Proximity wounds to the heart are defined as those that penetrate the chest wall in the area bounded superiorly by the clavicles, laterally by the midclavicular lines, and inferiorly by the costal margins. Any crossing of the anterior mediastinum by a missile or an instrument is also considered a proximity wound. Because cardiac injuries are present in 15% to 20% of patients who present with proximity wounds, these injuries must be definitively excluded.

As more surgeons become familiar with the use of ultrasonography in the trauma setting, two-dimensional surface echocardiography is gaining acceptance as a means of diagnosing cardiac injuries. When performed by appropriately trained surgeons, this modality detects blood within the pericardial sac with a sensitivity of 96% to 100% and a specificity of 100%, results essentially equivalent to those achieved with a pericardial window. Although cardiac ultrasonography has many advantages, the subxiphoid pericardial window remains the gold standard for diagnosis of cardiac injury. For otherwise stable patients with proximity wounds or suggestive signs and symptoms, a pericardial window should be considered when ultrasonographic findings are equivocal or are unavailable.

Operative Approach

In planning the surgical approach to the repair of cardiac injuries, the location of the entrance and exit wounds, the path of the wounding object, the type of wound created, the associated signs and symptoms, and the level of suspicion for other thoracic visceral injuries are important considerations (Table I). A median sternotomy is a logical extension of a subxiphoid pericardial window and provides access to all four chambers of the heart. It is appropriate for most precordial stab wounds and some low-caliber gunshot wounds. Its main limitations are that it does not allow repair or cross-clamping of the descending aorta or examination or repair of the esophagus and bronchi and that it provides limited exposure of the lower lobes of the lungs and the hemidiaphragms. A left thoracotomy is appropriate for patients who may require cross-clamping of the thoracic aorta and for those with suspected cardiac injuries in conjunction with other complex thoracic visceral injuries. Only occasionally is a right thoracotomy required; this incision generally does not provide optimal exposure of the heart.

Treatment

Atrial wounds are generally amenable to early control by finger pressure or by exclusion with a vascular clamp and simple oversewing. Right or left ventricular free wall injuries away from the coronary arteries may be treated by applying digital pressure over the entrance wound for hemostasis, then placing horizontal mattress sutures under the wound, reinforced with an epicardial continuous suture along the site of injury. Ventricular injuries adjacent to coronary arteries may be repaired in a similar fashion with care being taken not to narrow or occlude the artery. In some instances, especially with injuries near the proximal coronary artery or involving the left anterior descending artery, cardiopulmonary bypass may be required. Simple ligation may be entertained in desperate circumstances. All left ventricular wounds should be repaired with felt-pledgetted or pericardial-pledgetted sutures. Many right ventricular stab wounds can be closed primarily without pledgets if the sutures are tied accurately.

With all penetrating cardiac wounds, it is important to recognize the possibility of associated intracardiac injuries. The surgeon should palpate the heart along the pulmonary outflow tract for a thrill that would indicate a traumatic ventricular septal defect. Digital palpation through atrial wounds should be routinely employed to identify atrioventricularvalvular insufficiency or occasionally, an atrial septal defect. Intraoperative surface echocardiography and transesophageal echocardiography are also excellent at diagnosing intracardiac injuries.

Repair of intracardiac lesions usually can wait until the patient’s condition is stable and cardiac catheterization has been performed, although some patients experience such profound heart failure that immediate operative repair with cardiopulmonary bypass must be performed.

Blunt

Blunt cardiac injuries range from disruption of myocardium, septa, or valvular structures to cardiac contusion. Blunt cardiac injury typically involves a direct blow to the chest, usually sustained in a motor vehicle collision or a fall. Cardiac injuries generally are associated with sternal or rib fractures. The most common location of blunt cardiac injury is the anterior heart, which consists primarily of the right ventricle. A blow that causes the sternum to exert a direct impact on the myocardium may result

in direct injury to myocardial cells, sometimes leading to cell death, mechanical dysfunction, or dysrhythmias. In the rare patient with blunt cardiac rupture who presents to the hospital with signs of life, the most common injury is right atrial perforation. Other lesions seen in patients with vital signs, in order of decreasing incidence, are left atrial perforation, right ventricular perforation, atrial septal perforation, ventricular septal perforation, coronary artery thrombosis, and valvular insufficiency (most commonly involving the tricuspid and mitral valves).

Myocardial Contusion

Clinical Presentation and Diagnosis

The diagnosis of myocardial contusion is elusive. Many tests have been proposed, but none have proved definitive, except for direct visualization of the heart at surgery or autopsy. For practical purposes, the clinically significant sequelae of myocardial contusion are myocardial dysrhythmias and pump failure.

As an initial test, a 12-lead ECG should be obtained whenever blunt cardiac injury is suspected as in the case of a sternal fracture. If the ECG is normal, no further workup is required. If there is an ECG abnormality that does not necessitate treatment (e.g., nonspecific ST-T wave changes), the patient should undergo monitored observation for 12 hours. If there is a more serious ECG abnormality, the patient should undergo observation for at least 24 to 48 hours and may require further testing and treatment, depending on the sequelae of the abnormality. In patients with hemodynamic instability and suspected blunt cardiac injury, echocardiography should be performed promptly. There is no role for cardiac enzyme analysis or cardiac troponin assay in this setting. The latter test may detect myocardial injury, but this information does not complement ECG and echocardiographic findings and has no clinical utility. Similarly, there is no role for nuclear medicine studies.

Treatment

Pump failure associated with cardiac contusion is usually the result of right heart failure, in that most hemodynamically significant cardiac contusions are caused by injury to the anterior right ventricular free wall. Treatment of right heart failure from cardiac contusion consists of inotropic support and reduction of right ventricular afterload. Dysrhythmias secondary to cardiac contusion are treated in the same manner as dysrhythmias of any

other etiology.

TRACHEOBRONCHIAL INJURIES

Injuries to the trachea or main stem bronchi are uncommon in patients who survive to reach the hospital and may occur after blunt or less commonly, after penetrating injury with an estimated incidence of <2%. Regardless of mechanism, most of these injuries occur within 2.5 cm of the carina with main stem bronchial injuries in 86%, distal bronchial injuries in 9%, and complex injuries present in 8%. Associated intrathoracic or mediastinal injuries are common.

Clinical Presentation and Diagnosis

Symptoms depend on the location of the injury and whether the injury communicates with the pleural cavity. Thoracic injuries with pleural communication present with pneumothorax that may or may not be under tension. A pneumothorax that persists after chest tube placement or has a continuous air leak is indicative of tracheobronchial damage. In injuries with extrapleural communication, massive pneumomediastinum is typically encountered, occasionally without pneumothorax. In this case, the diagnosis is more difficult to make and other modalities are required to make the diagnosis. Nonspecific symptoms of tracheobronchial injury can include subcutaneous emphysema and hemoptysis. Most subcutaneous emphysema is due to lung lacerations without major bronchus injury. Subpleural rupture of alveoli is more commonly associated with mediastinal emphysema with or without neck subcutaneous emphysema. Hemoptysis is often a result of aspiration of blood from facial and pharyngeal injuries.

There are an increasing number of reports demonstrating the utility of CT technology in diagnosing tracheobronchial injuries with a sensitivity approaching 100%. Thus, because of its excellent negative predictive value, CT may be employed as a screening tool to look for these injuries in stable patients; however, at present, diagnostic bronchoscopy (rigid or flexible) remains the gold standard to reliably exclude the diagnosis of tracheobronchial injury when suspicion exists. That being said, rarely can one clear the cervical spine sufficiently to attempt rigid bronchoscopy during the initial resuscitation time frame. The injury may be initially missed and present later as tracheal or bronchial stenosis. Thus, the diagnosis of tracheobronchial injury is made based on clinical findings and

radiographic findings (both chest x-ray and CT), and is confirmed with bronchoscopy.

Preoperative Planning

Treatment of tracheobroncial injuries is directed at ensuring or establishing adequate ventilation. When safe, avoidance of positive pressure ventilation is recommended during the initial evaluation, but if necessary, bronchoscopic-guided intubation is suggested. Blind intubation in these patients is extremely hazardous.

Operative Approach

As most intrathoracic injuries occur within 2 cm of the carina, a right thoracotomy can be used to approach virtually all of these injuries except in cases of distal left mainstem bronchial injuries >3 cm from the carina where a left posterolateral thoracotomy is preferable. Primary emphasis should be placed on maintaining an adequate airway. This may require advancing the endotracheal tube under direct vision beyond the level of injury or passing a sterile endotracheal tube through the operative field into one or both lungs and ventilating with a sterile anesthesia circuit.

Treatment

Tracheobronchial injuries should be repaired primarily using interrupted or running absorbable suture with the knots placed on the outside of the lumen to reduce early secretion retention or late granuloma or stricture formation. When limited tracheal resection is required, up to 2 cm of trachea can be easily and safely excised and primary repair performed. Repairs should be buttressed with viable vascularized tissue, usually an intercostal muscle flap, pericardium, omentum, or rarely rhomboid or latissumus muscle flaps. Non-operative management is reserved only for highly selected patients who have lesions that involve less than one third of the bronchial wall with well-opposed edges and minimal tissue loss. In addition, the lung must fully re-expand with chest tube placement, the airleak should stop soon after chest tube insertion, and positive pressure ventilation is not required.

Postoperative Management

Postoperatively, barring other contraindications, a thoracic epidural

catheter should be placed to assist with pain control and ensure adequate pulmonary toilet. Patients on the ventilator should be extubated as soon as possible, ideally immediately after the operation is complete. Routine postoperative use of proton pump inhibitors is recommended as acid and pepsin exposure promotes granuloma formation at the site of repair.

ESOPHAGEAL INJURIES

These injuries are rare and primarily involve the cervical esophagus, typically as the result of gunshot wounds or iatrogenic trauma. Intrathoracic esophageal injuries are present in approximately 1% of gunshot wounds to the chest. Blunt esophageal injuries typically occur in the neck as a result of a direct blow or may occur in the chest just proximal to the esophagogastric junction. Blunt injuries are associated with increased intraluminal pressures against a closed glottis causing a bursting-type injury. Early diagnosis and treatment are of paramount importance as these injuries have significant morbidity and mortality when diagnosis is delayed.

Clinical Presentation and Diagnosis

These wounds are usually diagnosed at the time of exploration for other injuries or on diagnostic studies that are obtained in the stable patient because of the proximity of the wounding agent to the esophagus. Clinical manifestations may be present in 60% to 80% of patients depending on the location, size, amount of contamination, time to diagnosis, and the presence of associated injuries. Symptoms include odynophagia, dysphagia, and hematemesis. A small amount of mediastinal emphysema or small pleural effusion may be seen on chest x-ray. The presence of chest or back pain is also a clue to the presence of esophageal injuries. Tracheal and vascular injuries are often found as associated injuries.

The diagnosis can be definitively made at the time of surgical exploration, on endoscopy, or with esophagoscopy. An esophagram with barium rather than water soluble contrast is recommended for increased sensitivity, superior image quality, and decreased incidence of pneumonitis due to aspiration. Rapid diagnostic evaluation is desirable as the best surgical results are obtained when the duration of time between injury and repair is minimized.

Operative Approach

Upper and middle third thoracic injuries are optimally approached through a right posterolateral thoracotomy in the fourth or fifth interspace, depending upon the level of the injury. However, it is common for exposure of more urgent associated injuries to dictate the interspace selected. Distal third thoracic injuries are best approached through left posterolateral thoracotomy through the 6th intercostal space.

Treatment

Esophageal injuries should be treated early and aggressively. Once the wound is identified, the esophagus is mobilized sparingly to preserve its segmental blood supply but enough so that the injury can be completely defined. Most esophageal injuries when diagnosed and operated on within 24 hours lend themselves to primary repair with a single layer of absorbable monofilament suture.

Depending on the length of time prior to exploration, local inflammation, degree of contamination, and the severity of the injury, primary repair may not be feasible. In these patients, several temporizing techniques to control sepsis have been described in the literature, including esophageal diversion, esophageal exclusion, esophagectomy, and T-tube drainage with later definitive repair. If the patient is in extemis, wide drainage with a chest tube and placement of a nasogastric tube above the injury is a “damage control” option. Regardless, all esophageal repairs should be drained widely with a chest tube(s) and buttressed with viable, vascularized tissue (intercostal muscle flap, pericardial fat pad, gastric wrap or thickened pleura). Prior to initiating diet, a contrast study should be obtained to evaluate the integrity of the anastomosis.

GREAT VESSEL INJURIES

The great vessels of the aorta include the left subclavian, the left common carotid, and the innominate (brachiocephalic) arteries. Great vessel injuries are rarely encountered after penetrating chest trauma with a reported incidence of approximately 4%. The principle reason for this low incidence is that victims typically exsanguinate into the chest or externally prior to arrival at the hospital; however, with improved prehospital care and decreased transit times, these injuries are increasingly encountered at trauma centers.

Clinical Presentation and Diagnosis

The detection of the presence of a great vessel injury can be overt or subtle in presentation, depending on multiple factors including the mechanism and the vessel involved. The presence of a wound at the base of the neck or transmediastinal gunshot wounds should alert the clinician to the possibility of great vessel injury. The patient may be pulseless or moribund at presentation and diagnosis is confirmed at the time of EDT or urgent thoracotomy. Patients with proximal injuries may present with a massive hemothorax, pericardial tamponade, or external bleeding. Pulse deficits in the affected vessel's distribution, brachial plexus injuries, stroke or coma, and the presence of a thrill or bruit in the base of the neck also support the diagnosis of a great vessel injury.

In the stable patient or one who easily stabilizes with resuscitation, the diagnosis can be confirmed with angiography or CTA, if available. Chest x-ray may demonstrate the presence of an apical cap or widened mediastinum.

Operative Approach

After a diagnosis has been made, the patient should be taken to the operating room for exploration. If possible, the placement of a dual lumen endotracheal tube greatly facilitates exposure of these injuries. Many incisions have been described as providing adequate exposure for repair of great vessel injuries. For right subclavian injuries or right parasternal injuries, a median sternotomy with extension into the neck or a supraclavicular extension is recommended. A median sternotomy provides excellent exposure of the ascending aorta, the proximal right subclavian, the innominate, and the common carotid arteries. A left thoracotomy provides optimal exposure of the descending aorta and adequate exposure of the proximal left subclavian and the proximal left common carotid arteries. For distal control when dealing with left subclavian or left common carotid artery injuries, a supraclavicular or neck counter-incision is typically required. Alternatively, a mediansternotomy can be used to connect the incisions ("trapdoor" incision); however, this type of incision provides poor exposure and is associated with significant morbidity. Comprehensive knowledge of chest and neck anatomy is required when exposing these vessels to prevent injury to the phrenic, vagus, and recurrent laryngeal nerves that lie in close proximity to these vessels and to protect the thoracic duct when approaching the left subclavian artery.

Treatment

Once proximal and distal control is obtained, many of these injuries lend themselves to lateral repair or end-to-end primary anastomosis. Interposition grafts composed of polytetrafluoroethylene or knitted Dacron are the conduits of choice. When inflow control may not be achievable, as in cases involving injury at the thoracic outlet or the presence of a large hematoma, endovascular control of the proximal subclavian artery by means of a balloon catheter placed percutaneously through the femoral artery may be necessary.

There is a growing body of literature supporting endovascular management of great vessel injuries. Endovascular repair may be considered in stable patients with ateriovenous fistula or pseudoaneurysm. As with endovascular repair of blunt aortic injuries, concerns with this modality primarily center on the lack of long-term outcomes in a typically young patient population. Associated venous injuries (superior vena cava, internal jugular, innominate) are common, and if possible these should be treated by lateral repair or patch venography. Internal jugular or innominate injuries can be ligated with little ill effect except in patients with closed head injury. Vena cava injuries can be shunted if repair is not feasible and ligated only as a measure of the last resort.

TRAUMATIC AORTIC RUPTURE

Traumatic rupture of the aorta may account for as many as 10% to 15% of all traffic fatalities, and the majority of such injuries are fatal at the scene. Traumatic disruption of the thoracic aorta results from rapid deceleration and is produced by a rotation of the heart creating torsion or a shearing effect caused by differences in the mobility of the aorta above and below the point where the vessel is rotationally fixed. Most thoracic aortic disruptions in survivors occur at the aortic isthmus just distal to the origin of the left subclavian artery, where the aorta is fixed to a significant degree by the ligamentumarteriosum and intercostals.

Clinical Presentation and Diagnosis

Suspicion of an aortic injury is most often triggered by abnormal findings on a chest x-ray in a patient with a high-speed mechanism of injury and multiple other injuries. Most patients show no signs or symptoms on physical examination, but some complain of interscapular pain or

hoarseness, and some exhibit a difference in blood pressure or pulse fullness between the upper and lower extremities or between the right and left upper extremities. Accordingly, the diagnosis is usually made radiographically, often beginning with the recognition of mediastinal hemorrhage on a screening chest x-ray.

Numerous radiographic signs of a torn thoracic aorta have been described. Mediastinal widening is the most frequent indicator of mediastinal hematoma from a torn thoracic aorta. Other important signs are obscuration of the detail of the contour of the aortic knob, opacification of the aortopulmonary window, depression of the left mainstem bronchus, apical cap, deviation of the nasogastric tube, and displacement of the esophagus to the right. These signs may be present in any combination or may be entirely absent in up to 10% of affected patients. Currently, high-speed CT scanning with intravenous (IV) contrast is the diagnostic study of choice in all patients whose injury mechanisms produce a high degree of energy transfer. Using chest CT scanning, aortography may be eliminated in virtually all of these patients before surgical repair; the sensitivity and specificity of CT in this setting approach 100%. Aortography should continue to be used for equivocal cases or cases in which spiral CT is not available.

Indications

Essentially all aortic injuries associated with mediastinal hematomas should be repaired. The timing of repair, however, is less urgent than the timing of certain associated maneuvers that must be done, such as attainment of an adequate airway, control of external or cavitary hemorrhage, and evacuation of intracranial mass lesions. In general, if there is active bleeding from a blunt aortic injury, it will be massive; lesser amounts of bleeding from a chest tube often derive from associated injuries even in the presence of a torn thoracic aorta. If intra-abdominal bleeding is present, laparotomy is indicated before repair of the torn thoracic aorta and before aortography. Similarly, in patients with intracranial hemorrhage that necessitates operative evacuation, craniotomy should take precedence over repair of the torn thoracic aorta.

Preoperative Planning

While one is temporizing, stringent efforts must be made to prevent hypertension and reduce shear forces across the injury, ideally by means of

IV beta blockade. Esmolol, because of its short half-life, is the best agent to use in these patients, who are at risk for sudden hypovolemic episodes of hypotension. The goals of medical therapy are a heart rate <100 beats/min and a systolic blood pressure of approximately 100 to 120 mm Hg. Nitroprusside may have to be given to achieve these goals, but it should not be used until after adequate beta blockade is achieved because it can increase intravascular shear forces when used alone. With careful medical management of aortic injuries, the risk of rupture is low and allows the clinician to address other more life-threatening injuries prior to repair. In fact with certain low-grade or minimal aortic injuries, medical management may be all that is required.

Treatment

Traditional repair techniques include exposure of the aorta and arch through a left thoracotomy and direct repair or interposition graft placement. Although excellent results have been obtained with so-called clamp-and-sew techniques, most guidelines recommend use of some form of distal aortic perfusion (e.g., left atrial–distal aortic bypass or partial cardiopulmonary bypass with femoral cannulation). Systemic heparinization is required for full cardiopulmonary bypass and has been shown to be safe with respect to hemorrhagic complications. After the subclavin and the distal aorta have been controlled, the aortic arch is clamped between the common carotid and left subclavian arteries. It is unnecessary to control the carotid as it is proximal to the proximal clamp. An interposition graft is required for most of these injuries, although 15% to 20% can be treated with suture repair alone. With distal aortic perfusion, the risk of paraplegia is approximately 5% and is independent of clamp time; without distal aortic perfusion, ischemic times longer than 30 minutes are associated with an exponential rise in the incidence of spinal cord injury. Another potential advantage to using cardiopulmonary bypass is the ability to institute deep hypothermic circulatory arrest if needed. This technique may be useful for patients who have previously undergone thoracic aortic surgery or who have complex tears involving the arch.

An alternative modality for the treatment of aortic injury is endovascular stent grafting in which a stent graft is deployed that bridges the injury proximally and distally. Often the orifice of the left subclavian artery is occluded by the graft; however, carotid-subclavian bypass is infrequently required as limb ischemia is rare. The results of multiple

studies indicate endovascular repair to be superior to open repair in terms of mortality, incidence of spinal cord ischemia, renal injury, and graft infection. Thus, in the last decade, there has been a paradigm shift in the management of blunt aortic injuries in which medical management followed by endovascular repair has become the primary therapy rather than open repair. However, studies addressing long-term complications such as the incidence of late stent migration, collapse, erosion, thrombosis, and infection have not been performed. Furthermore, there remain some limitations with the current level of stent graft technology; however, this field is advancing rapidly to overcome these deficiencies, and reports on newer devices are encouraging.

RETAINED HEMOTHORAX AND POSTTRAUMATIC EMPYEMA

Clinical Presentation and Diagnosis

After blunt and penetrating chest trauma, when treating a hemothorax with tube thoracostomy, the goal is complete evacuation of blood from the pleural space and complete expansion of the lung. However, because of improper positioning of the tube, or obstruction of the chest tube, blood may not be completely evacuated from the pleural space and may become contaminated during tube insertion, from a pulmonary air leak or hematogenously.

A retained hemothorax is suggested by the presence of a persistent opacification in the pleural space in a patient with a known previous hemothorax. However, plain chest radiography can be misleading often underestimating the amount of fluid in the chest, and the radiodensity seen can be confused with adjacent pulmonary contusion or atelectasis. Chest CT confirms the diagnosis, providing information about the size and location of the hemothorax that can be used in preoperative planning.

Treatment

Because retained blood serves as a nidus for infection and empyema, aggressive attempts at removal are justified. Placement of additional chest tubes is rarely effective in removing clotted blood from the pleural space and may increase the risk of infection. When used early (<5 days after injury), video-assisted thoracic surgery (VATS) is a cost-effective method for managing clotted hemothoraces and free-flowing blood; however, in

patients who have ongoing bleeding, posterolateral thoracotomy is generally required. A dual-lumen endotracheal tube and single lung ventilation are usually necessary. With the patient in the lateral decubitus position, typically two or three incisions approximately 2 cm in length are used as chest ports and the clotted blood may be evacuated using suction catheters or ringed forceps. Thoracotomy is usually required in cases when the hemothorax has been present for longer periods of time and dense adhesions have formed to the visceral or parietal pleura. Often the hemothorax has become infected. A posterolateral thoracotomy on the affected side through the fifth intercostal space will typically provide adequate exposure. Decortication is necessary if the clotted hemothorax has a fibrous peel. Emphasis should be placed on completely removing the peel from the visceral surface of the pleural so that complete lung expansion may be obtained postoperatively. Ringed forceps or the scalpel may be required to remove the densely adherent peel from the lung, and moderate hemorrhage may be encountered during this part of procedure. Once decortication is complete and the retained hemothorax has been removed, wide drainage with chest tube is required to prevent re-accumulation of blood and facilitate re-expansion of the involved lung.

Postoperative Management

Postoperatively, every effort should be made to mobilize the patient and enhance pulmonary toilet. Toward this end, parental narcotics administered via PCA or thoracic epidural anesthesia will greatly assist with pulmonary toilet. Chest tubes should be discontinued as soon there is no air leak and drainage is <150 mL/day.

CONCLUSION

Thoracic trauma is a contributing factor in a majority of trauma-related deaths. With thorough physical examination and appropriate radiographic evaluation, the majority of these injuries can be identified early and appropriate therapy can be initiated. Most thoracic injuries do not require operative intervention and may be treated with simple life-saving bedside procedures. However, when considering surgical intervention, many variables must be considered in this decision process, and each injury has unique issues to be addressed. Once the need for intervention is apparent, the critical decision for an appropriate surgical approach is based on a complete understanding of the location and nature of the injury.

Suggested Readings

Cook CC, Gleason TG. Great vessel and cardiac trauma. *Surg Clin North Am* 2009;89:797–820.

Flagel BT, Luchette FA, Reed RL, et al. Half-a-dozen ribs: the breakpoint for mortality. *Surgery* 2005;38:17–23.

Karmy-Jones R, Wood DE. Traumatic injury to the trachea and bronchus. *Thorac Surg Clin* 2007;17:35–46.

Lee WA, Matsumura JS, Mitchell RS, et al. Endovascular repair of traumatic thoracic aortic injury: clinical practice guidelines of the Society for Vascular Surgery. *J Vasc Surg* 2011;53:187–92.

Marasco SF, Davies AR, Cooper J, et al. Prospective randomized controlled trial of operative fixation in traumatic flail chest. *J Am Coll Surg* 2013;216:924–32.

Meredith JW, Hoth JJ. Thoracic trauma: when and how to intervene. *Surg Clin North Am* 2007;87:95–118.

Miller PR, Kortesis BG, McLaughlin CA III, et al. Complex blunt aortic injury or repair: beneficial effects of cardiopulmonary bypass use. *Ann Surg* 2003;237:877–83.

Wall MJ Jr, Villavicencio RT, Miller CC III, et al. Pulmonary tractotomy as an abbreviated thoracotomy technique. *J Trauma* 1998;45:1015–23.

EDITOR'S COMMENT

Thoracic trauma is a significant cause of trauma-related mortality. It is estimated that 25% of traumatic deaths are related to injuries sustained within the thoracic cage. A recently published study analyzed data from more than 2.5 million injured patients entered in the National Trauma Data Bank Research Data Set from 2012 to 2014. Patients with torso injury were identified utilizing Abbreviated Injury Scale (AIS) for body regions 4 (Thorax) and 5 (Abdomen). A cohort of 42,000 patients with thoracic injury was analyzed. The overall mortality rate of the study population with thoracic trauma was 7.9% (3326/42,135). Torso AIS and pre-hospital time were noted to be strong independent predictors of patient mortality in all population strata of the analysis ($P < 0.05$). The data demonstrated a profound incremental increase in mortality in the early time course after injury associated with torso AIS ≥4. The authors of this particular study conclude, "Our data highlight the critical nature of pre-hospital time in patients with non-compressible torso hemorrhage. However, realizing that evacuation times ≤30 minutes may not be realistic, particularly in rural or austere environments, future efforts should be directed toward the development of therapies to increase the window of survival in the pre-hospital environment." The concept of a "golden hour" following trauma is

widely attributed to R. Adams Cowley, founder of Baltimore's Shock Trauma Institute, who in 1975 stated "the first hour after injury will largely determine a critically injured person's chances for survival." Based on these data, patients with severe hemorrhage from significant thoracic injuries likely have far less than a 60-minute window for definitive therapy before their outcome and survival are compromised.

ED thoracotomy is a dramatic, last-ditch effort to save the life of a patient in extremis due to a chest injury. As mentioned in this chapter, ED thoracotomy is most likely to lead to survival in patients with penetrating thoracic injuries (stab wound > gunshot wound) and signs of life upon presentation to the ED. The American College of Surgeons Committee on Trauma indications for ED thoracotomy include precordial wound in a patient with pre-hospital cardiac arrest, a trauma patient with cardiac arrest after arrival to the ED, or a patient with a truncal wound who is either unconscious or an operating room is unavailable. Relative indications include penetrating thoracic injury with traumatic arrest without previously witnessed cardiac activity, penetrating non-thoracic injury with traumatic arrest with previously witnessed cardiac activity, and blunt thoracic injuries with traumatic arrest with previously witnessed cardiac activity. One recent review of ED thoracotomies performed in a busy urban trauma center identified 180 ED thoracotomies performed over a 6-year period. There were 23 patients who survived ED thoracotomy and hospitalization neurologically intact (12.8%). Over the 6-year study period, several patients survived ED thoracotomy neurologically intact until hospital discharge despite having poor outcome predictors, including multiple GSWs, abdominal exsanguination, asystole or agonal initial cardiac rhythm, unobtainable vital signs, and undetectable signs of life. Because of these issues, many believe that the decision to perform an ED thoracotomy should be made on a case-by-case basis due to exceptions and reported survivors who exceeded the above thresholds. I am not a trauma surgeon and I completed my residency in a medium-sized Midwestern town without a lot of penetrating trauma. I can remember the two ED thoracotomies I performed as a resident with incredible detail despite the fact that these both happened 20 years ago. ED thoracotomy is a dramatic, adrenaline-fueled experience. Surgeons who take care of trauma patients should familiarize themselves with the techniques and approaches to ED thoracotomy described in this chapter given the remote chance that this is necessary, and that a life could be saved as a result. One of the patients I cared for had a penetrating cardiac injury. Staples to the cardiac injury are described in this chapter. My patient had a large hole, and we chose to temporize and stop the exsanguination until a more definitive repair could be performed. We inserted a Foley catheter into the hole, inflated the balloon, and withdrew the catheter until the wound was occluded. If this technique is deployed, it is important to clamp the catheter to prevent exsanguination through the catheter itself. Although my patient with the penetrating cardiac injury did not survive, the Foley catheter did stop the exsanguination and allow us to place a very large

bore IV directly into the right atrium for rapid resuscitation once relative hemostasis from the cardiac wound was attained. A technical note—when incising the pericardium, it is important to avoid injury to the phrenic nerve. The phrenic nerve is a tendonlike structure and can be difficult to visualize in the ED. This is the rationale for the longitudinal pericardiotomy to relieve hemopericardium described in this chapter.

Flail chest results in paradoxical chest wall movement, altered respiratory mechanics, and frequent respiratory failure. Despite advances in ventilator management, flail chest remains associated with significant morbidity and mortality. Operative fixation of the flail segment has been advocated as an adjunct to supportive care. A recently published systematic review and meta-analysis identified nine studies with a total of 538 patients who met inclusion criteria. Compared with control treatment, operative management of flail chest was associated with shorter duration of mechanical ventilation (pooled Effect Size: -4.52 days; 95% confidence interval [CI]: –5.54 to –3.50), intensive care unit length of stay (-3.40 days; 95% CI: –6.01 to –0.79), hospital length of stay (–3.82 days; 95% CI: –7.12 to –0.54), and decreased mortality (pooled Relative Risk: 0.44; 95% CI: 0.28 to 0.69), pneumonia (0.45; 95% CI: 0.30 to 0.69), and tracheostomy (0.25; 95% CI: 0.13 to 0.47). The authors of this study felt that although their findings suggest that operative management of flail chest is associated with significant effects on patient morbidity, mortality, and resource expenditure, that prospective evaluation is still required to determine optimal patient selection, timing, and surgical technique. Time to surgical stabilization in the nine studies included in this analysis varied from <24 hours to >8 days after admission. Multiple techniques were described in the included studies, including metal plates, absorbable plates, and intramedullary fixation. Several studies included patients undergoing fixation with multiple different techniques, and only three reported complications. There may be an optimal technique and fixation device for these injuries, and further study is needed. Current practice varies widely by institution, and opinions regarding the optimal patients and timing of intervention vary. A 2009 survey revealed that one third of surveyed surgeons reported that operative management of flail chest was indicated after failure to wean from mechanical ventilation in 7 days. Another 29% felt that operative management of flail chest was indicated after failure to wean in 14 days. Only 8% felt operative management of flail chest was indicated in patients who did not require mechanical ventilation.

Retained hemothorax is a potentially morbid outcome of traumatic hemothorax requiring tube thoracostomy. The exact incidence of retained hemothorax is difficult to define. Most studies use an estimated volume of 500 mL, the amount of retained blood that can be seen on a plain x-ray, as the threshold for defining and possibly intervening on a retained hemothorax. In one study of 328 patients with retained hemothorax from 20 trauma centers, the rates of empyema and pneumonia in retained hemothorax were 26.8% and 19.5%, respectively. Video-assisted thoracoscopic surgery (VATS) was the

most commonly used initial procedure in 33.5% of these patients, but 26.5% required two and 5.4% required three procedures to clear retained hemothorax or subsequent empyema. Thoracotomy was ultimately required in 20.4%. The strongest independent predictor of successful observation was estimated volume of retained hemothorax ≤300 mL. No relationship between timing of VATS and success rate was identified.

A 2011 guideline published by the Eastern Association for the Surgery of Trauma (EAST) on the management of hemothorax and occult pneumothorax describes current recommendations. With regard to management of hemothorax, attempt of initial drainage of hemothorax should be with a tube thoracostomy. Persistent retained hemothorax, seen on plain films, after placement of a thoracostomy tube should be treated with early VATS, not a second chest tube. A referenced prospective randomized trial demonstrated that patients who had retained hemothorax on plain films 72 hours after initial chest tube output benefited from early VATS instead of a second chest tube. Patients undergoing VATS had significantly shorter duration of chest tube drainage, fewer days in the hospital after the procedure, and lower hospital costs than putting in a second chest tube. In addition, 10 of the 24 patients who underwent a second chest tube required surgical intervention later in their hospital stay. EAST guidelines on retained hemothorax also recommend early VATS, done in the first 3 days to 7 days of hospitalization to decrease the risk of infection and conversion to thoracotomy. Intrapleural thrombolytic may be used to improve drainage of subacute (6- to 13-day duration) loculated or exudative collections, particularly in patients where risks of thoracotomy are significant. A randomized controlled trial designed to compare intrapleural streptokinase instillation to VATS in retained hemothorax enrolled 48 patients. Retained hemothorax resolved equally well in both study groups (72% VATS, 71% streptokinase) with no difference in morbidity.

This is an excellent chapter by Drs. Hoth and Meredith on thoracic trauma. An exceptional level of detail is provided along with a nice description about when to operate and when not to. When there are multiple possible thoracic injuries, the importance of selecting the right approach is appropriately emphasized and outlined. Surgeons who participate in the care of injured patients should be intimately familiar with the information presented in this chapter.

Jon C. Gould

Suggested Readings

Alarhayem AQ, Myers JG, Dent D, et al. Time is the enemy: mortality in trauma patients with hemorrhage from torso injury occurs long before the “golden hour.” *Am J Surg* 2016;212(6):1101–5.

DuBose J, Inaba K, Demetriades D, et al. AAST Retained Hemothorax Study

Group. Management of post-traumatic retained hemothorax: a prospective, observational, multicenter AAST study. *J Trauma Acute Care Surg* 2012;72(1):11–22.

Kumar S, Rathi V, Rattan A, et al. VATS versus intrapleural streptokinase: a prospective, randomized, controlled clinical trial for optimum treatment of post-traumatic Residual Hemothorax. *Injury* 2015;46(9):1749–52.

Leinicke JA, Elmore L, Freeman BD, et al. Operative management of rib fractures in the setting of flail chest: a systematic review and meta-analysis. *Ann Surg* 2013;258(6):914–21.

Mayberry JC, Ham LB, Schipper PH, et al. Surveyed opinion of American trauma, orthopedic, and thoracic surgeons on rib and sternal fracture repair. *J Trauma* 2009;66:875–9.

Seamon MJ, Fisher CA, Gaughan JP, et al. Emergency department thoracotomy: survival of the least expected. *World J Surg* 2008;32(4):604–12.

Working Group, Ad Hoc Subcommittee on Outcomes, American College of Surgeons. Committee on Trauma. Practice management guidelines for emergency department thoracotomy. *J Am Coll Surg* 2001;193(3):303–9.

62 Pulmonary Resection

Bryan M. Burt, Shawn S. Groth, and David J. Sugarbaker

HISTORY

The evolution of thoracic surgery parallels the development of endotracheal anesthesia and selective lung ventilation. These techniques permit safe operations to be performed in an open thoracic cavity. Pulmonary surgery has grown in scope and complexity from the simple management of pleural space infections and crude two-stage lobectomies for bronchiectasis via a thoracotomy in the early 1900s to formal anatomical resections for lung cancer via a video-assisted thoracic surgery (VATS) or robot-assisted approach in the present era.

After Dr. Graham successfully performed a pneumonectomy, pneumonectomy became the initial standard of care for all lung cancer patients. Since then, pulmonary resection techniques have gradually evolved. Building on the techniques learned from the treatment of bronchiectasis, Brunn, Blades and Kent, and Churchill developed the techniques for performing lobectomy for lung cancer. In the 1950s, when Churchill and colleagues demonstrated long-term survival after lobectomy for patients with early-stage peripheral lung cancer, lobectomy became widely accepted as the new standard of care. As the surgical techniques and the understanding of pulmonary anatomy improved, anatomic sublobar resection (segmentectomy) emerged. Ever since Jensik and colleagues reported a favorable survival rate in patients with stage I non–small cell lung cancer (NSCLC) undergoing segmentectomy for curative intent, controversy has existed regarding whether lobectomy or segmentectomy is the more appropriate operation for treating early-stage lung cancer, especially in patients who have small peripheral tumors or who are older. Nonetheless, the only published randomized controlled trial that has addressed this topic demonstrated higher local recurrence rates and lower survival rates for patients undergoing sublobar resection (nonanatomic wedge resection or anatomic segmental resection) as compared to lobectomy for stage I NSCLC. Since then, lobectomy and mediastinal lymph node dissection or sampling has remained the standard

of care for early-stage NSCLC. In the 1990s, as experience in minimally invasive techniques evolved, VATS and robot-assisted pulmonary resections for lung cancer emerged.

EPIDEMIOLOGY

Current estimates indicate that by 2017, there will be 222,500 new cases of and 155,870 deaths from lung cancer in the United States. The single most important risk factor for developing lung cancer is smoking, followed by radon and asbestos exposure. The risk for lung cancer is 10-fold higher for smokers than for lifetime nonsmokers (defined as a person who has smoked <100 cigarettes in their lifetime). The risk increases with the quantity of cigarettes, duration of smoking, and starting age. Smoking cessation results in a decrease in precancerous lesions and a reduction in the risk of developing lung cancer.

Lung cancer continues to be the leading cause of cancer-related mortality in this country. The 1- and 5-year relative survival rates for lung cancer are 44% and 17%, respectively. Only 15% of lung cancer patients are diagnosed at an early stage (I or II); 5-year survival rate for such patients is 54%. Greater than half of lung cancer patients (57%) are diagnosed with stage IV disease; the 1-year (26%) and 5-year (4%) survival rates are poor.

Lung cancer is divided into two major histologic groups: small cell lung cancer (SCLC) and NSCLC. NSCLC is more common (85% to 95% of new cases) than SCLC (10% to 15% of new cases) in the United States. There are three major NSCLC subtypes: squamous cell carcinoma (25% to 30% of all lung cancers), adenocarcinoma (40% of all lung cancers), and large cell (undifferentiated) carcinoma (10% to 15% of all lung cancers). In 2011, the International Association for the Study of Lung Cancer (IASLC), American Thoracic Society (ATS), and the European Respiratory Society (ERS), proposed a revised classification system for lung adenocarcinoma. A major contribution of this system is the parsing of lung adenocarcinomas into prognostic categories based upon the extent of pathologic tumor invasion. The term bronchioloalveolar carcinoma (BAC) is no longer used. Tumors previously classified as BAC would likely fall into one of three categories: adenocarcinoma in situ (AIS) which is a ≤3-cm lesion with lepidic growth and no invasive component, minimally invasive adenocarcinoma (MIA), which is a ≤3-cm lesion with lepidic growth and ≤5 mm of invasion, and lepidic predominant adenocarcinoma,

which demonstrates predominantly lepidic growth and >5 mm of invasion. AIS and MIA typically have significantly decreased frequencies of lymphatic spread and significantly improved recurrence-free and overall survival in comparison with other lung adenocarcinomas.

The 5-year survival from SCLC (6%) is significantly lower than from NSCLC (21%). Left untreated, SCLC has a median survival of 2 to 4 months. Although the standard of care for early-stage NSCLC patients is pulmonary resection, the treatment of SCLC is generally nonsurgical (with chemoradiation therapy). Nevertheless, SCLC is responsive to systemic chemotherapy with a median survival approaching 18 to 36 months.

In an effort to detect lung cancers at an earlier stage and improve cancer-specific survival rates, a number of screening trials have emerged. The National Lung Screening Trial (NSLT) reported that annual screening over 3 years with low-dose helical computed tomography (CT) in patients at high risk for lung cancer was associated with a 20% relative reduction in lung cancer mortality. Inclusion criteria for this trial included patients aged 55 to 74 years, 30 or more pack-years of smoking, and former smokers who quit within the previous 15 years.

STAGING OF NSCLC

The seventh edition of the lung cancer stage classification system was adopted in the United States on January 1, 2010. Having an accurate and reproducible staging system is critical for defining prognostic subgroups, planning treatment strategies, and analyzing the results of clinical trials. The Union for International Cancer Control (UICC) and the American Joint Committee on Cancer (AJCC) are the organizations that periodically review, refine, and define the stage classification systems. The TNM Classification of Malignant Tumors (TNM) stage classification system was developed to enable classification of tumor extension (TX to 4), nodal involvement (NX to 3), and distant metastatic spread (M0 to 1a,b).

TABLE 62.1 T, N, M Descriptors for the International Lung Cancer Staging System

T: Primary tumor	
TX	Primary tumor cannot be assessed, or tumor proven by the presence of malignant cells in sputum or bronchial washing but not visualized by imaging or bronchoscopy
T0	No evidence of primary tumor
Tis	Carcinoma in situ
T1	Tumor 3 cm or less without invasion of visceral pleura
T1a	Tumor 2 cm or less in greatest dimension
T1b	Tumor more than 2 cm but not more than 3 cm in greatest dimension
T2	Tumor more than 3 cm but not more than 7 cm; or tumor with any of the following features; involves main bronchus, 2 cm or more distal to the carina; invades visceral pleura Associated with atelectasis or obstructive pneumonitis that extends to the hilar region but does not involve the entire lung
T2a	Tumor more than 3 cm but not more than 5 cm in greatest dimension
T2b	Tumor more than 5 cm but not more than 7 cm in greatest dimension
T3	Tumor more than 7 cm or one that directly invades any of the following: chest wall (including superior sulcus tumors), diaphragm, phrenic nerve, mediastinal pleura, parietal pericardium; or tumor in the main bronchus less than 2 cm distal to the carina but without involvement of the carina; or associated atelectasis or obstructive pneumonitis of the entire lung or separate tumor nodule(s) in the same lobe as the primary
T4	Tumor of any size that invades any of the following: mediastinum, heart, great vessels, trachea, recurrent laryngeal nerve, esophagus, vertebral body, carina; separate tumor nodule(s) in a different ipsilateral lobe to that of the primary
N: Regional lymph nodes	
NX	Regional lymph nodes cannot be assessed
N0	No regional lymph node metastasis
N1	Metastasis in ipsilateral peribronchial and/or ipsilateral hilar lymph nodes and intrapulmonary nodes, including involvement by direct extension
N2	Metastasis in ipsilateral mediastinal and/or subcarinal lymph node(s)
N3	Metastasis in contralateral mediastinal, contralateral hilar, ipsilateral or contralateral scalene, or supraclavicular lymph node(s)
M: Distant metastases	
M0	No distant metastasis
M1	Distant metastasis
M1a	Separate tumor nodule(s) in a contralateral lobe; tumor with pleural nodules or malignant pleural or pericardial effusion
M1b	Distant metastasis

Adapted from Detterbeck FC, Boffa DJ, Tanoue LT. The new lung cancer staging system. *Chest* 2009;136:260–71. Copyright © 2009, with permission from Elsevier.

The most recent seventh edition of the International Lung Cancer Staging system is shown in Table 62.1. The two most common types of stage assessment are *clinical staging* (determined by using all the information available for pretreatment) and *pathologic staging* (determined after resection). Clinical stage is denoted by the prefix "c,"

and pathologic stage by the prefix “p.” Several important points regarding the seventh edition staging system deserve mention. While the *T* descriptor definitions maintain a size threshold of 3 cm as the cut point between a T1 and a T2 tumor, several new cut points have been identified at 2, 5, and 7 cm. Tumors >7 cm in size are classified as T3, since they have a survival rate similar to other T3 tumors characterized by invasion or central location. Another modification of the seventh edition is related to additional tumor nodules. Patients with additional satellite nodules *in the same lobe* as the primary tumor have survival rates similar to T3 and now are classified as $T3_{satell}$, where previously they were classified as T4. Patients with an ipsilateral nodule *in a different lobe* are classified as $T4_{IpisNod}$ or simply T4; they were previously classified as M1. The *N* descriptor categorization (i.e., N0, N1, N2, and N3) has not changed. The number of involved nodal zones does appear to have prognostic impact. Patients with single-zone N1 or N2 involvement have better survival than those with multizone N1 and N2 involvement (5-year survival rate of 48% vs. 35%, $P < 0.09$, and 34% vs. 20%, $P < 0.001$, respectively). Finally, after the above modifications, the cohorts remaining in the M descriptor were separated into two distinct prognostic groups. Patients with pleural dissemination are now classified as M1a, as their prognosis is statistically significantly worse than T4. M1a is reserved for patients with either pleural dissemination or contralateral pulmonary nodules. The M1b subgroup is reserved for distant metastases.

TABLE 62.2 Stage Groups According to TNM Descriptor and Subgroups

T/M	Subgroups	N0	N1	N2	N3
T1	T1a	IA	IIA	IIIA	IIIB
	T1b	IA	IIA	IIIA	IIIB
T2	T2a	IB	IIA	IIIA	IIIB
	T2b	IIA	IIB	IIIA	IIIB
T3	T3>7	IIB	IIIA	IIIA	IIIB
	$T3_{Inv}$	IIB	IIIA	IIIA	IIIB
	$T3_{Satell}$	IIB	IIIA	IIIA	IIIB
T4	$T4_{Inv}$	IIIA	IIIA	IIIB	
	$T4_{IpslNod}$	IIIA	IIIA	IIIB	
				IIIB	
				IIIB	
M1	$M1a_{ContrNod}$	IV	IV	IV	IV
	$M1a_{PlDissem}$	IV	IV	IV	IV
	M1b	IV	IV	IV	IV

Reprinted from Detterbeck FC, Boffa DJ, Tanoue LT. The new lung cancer staging system. *Chest* 2009;136:260–71. Copyright © 2009, with permission from Elsevier.

The revised TNM associations with corresponding stage groupings are shown in Table 62.2.

Noninvasive Staging

A standard posteroanterior and lateral chest radiograph can reveal discrete mass lesions as well as atelectasis and postobstructive pneumonia due to the presence of endobronchial tumors. Hilar and mediastinal adenopathy, along with pleural effusion, might also be noted. Chest CT is performed to evaluate surgical anatomy and assess for mediastinal and hilar lymphadenopathy, liver metastasis, and adrenal metastasis. The median sensitivity and specificity of CT scanning for identifying mediastinal lymph node metastasis are 55% and 85%, respectively. A lymph node is considered malignant when its shortest axis is at least 10 mm. The presence of pleural effusion, unresectable T4 tumors, and contralateral nodal involvement can be suggested by chest CT scan.

Positron emission tomography (PET) relies on the uptake and concentration of ^{18}F-2-fluorodeoxyglucose (FDG) in lung cancer cells. It is more sensitive and specific (approximately 90% sensitive and specific) for mediastinal nodal metastases than CT. Most importantly, the negative predictive value of PET CT is 93% to 94% for the detection of mediastinal nodal metastases. The four most common sites of distant NSCLC metastases (stage IV disease) are the brain, bone, liver, and adrenal glands,

and PET CT is also fairly sensitive in detecting metastatic disease (except the brain). PET has an overall sensitivity of 96% (range, 83% to 100%), specificity of 79% (range, 52% to 100%), and accuracy of 91% (range, 86% to 100%). False-negative results can occur in lesions smaller than 1 cm because a critical mass of metabolically active malignant cells is required for PET diagnosis. False negatives may also occur in tumors with a low metabolism, like carcinoid tumors, AIS, and MIA. False-positive FDG uptake is seen in inflammatory conditions, such as bacterial pneumonia, pyogenic abscesses, and aspergillosis; and in granulomatous diseases, such as tuberculosis, sarcoidosis, histoplasmosis, Wegener granulomatosis, and coal miner's lung. In these lesions the FDG uptake has been attributed to granulocyte and/or macrophage activity.

Because of the high rate of glucose metabolism by the brain, PET CT cannot accurately identify brain metastases. For this reason, brain MRI is recommended for patients with stage II, III, and IV diseases to rule out asymptomatic brain metastases if aggressive multimodality therapy is being considered. In the absence of central nervous or bony symptoms in patients presenting with small tumors, the incidence of a true positive finding will be less than 10%. If these sites are excluded, the disease is confined to the chest (stages I to IIIB).

Invasive Staging

Nearly half of patients with lung cancer have mediastinal disease at diagnosis, and these patients have significantly worse prognosis. Metastases to ipsilateral or subcarinal lymph nodes (N2) are classified as stage IIIA disease. Many centers treat patients with IIIA disease with multimodality therapy including radiation and chemotherapy, reserving surgery for selected patients with single-station N2 disease and for investigational protocols. Metastasis to contralateral mediastinal lymph nodes (N3) is classified as stage IIIB disease. The 5-year survival of patients with IIIB disease is <5%, and these patients are generally offered treatment with chemotherapy alone. Selected patients with T4 disease (direct mediastinal invasion) without mediastinal lymph node metastases are surgical candidates. Thus, accurate pretreatment staging of the mediastinum is critical for treatment and prognostic implications. Given the limitations of CT and PET CT, histologic confirmation of radiographic findings is often required.

Invasive methods of mediastinal nodal staging include cervical

mediastinoscopy, anterior mediastinoscopy (Chamberlain procedure), endobronchial ultrasound (EBUS) with transbronchial nodal aspiration (TBNA), endoscopic ultrasound (EUS) with TBNA and VATS. In the absence of M1 extrathoracic disease, a PET CT showing hypermetabolism in the mediastinum requires pathologic confirmation. At the time of this writing, invasive staging of the mediastinum in patients with early-stage disease (stages I and II) is recommended by the National Comprehensive Cancer Network (NCCN). Based upon a recent prospective trial of early-stage lung cancer patients, we suspect that these recommendations may be altered in the next version of the NCCN guidelines. In this trial, 90 patients with clinical stage T2N0 or T1N0 with standardized uptake value greater than 10 by PET underwent routine cervical mediastinoscopy before lung resection, and only 1 patient (1.1%) had occult metastases detected at mediastinoscopy suggesting that invasive staging of the mediastinum may have limited utility in certain patients with PET negative mediastinums who are being considered for lung cancer resection. The incidence of N2 disease is 18% to 24% in patients with cN1 disease and these patients should undergo invasive mediastinal staging.

Bronchoscopy

Before thoracotomy is performed, the surgeon should perform flexible fiberoptic bronchoscopy to evaluate for anatomic abnormalities, endobronchial tumor extent, and previously undetected lesions. Bronchoscopy is often performed at the time of invasive mediastinal staging.

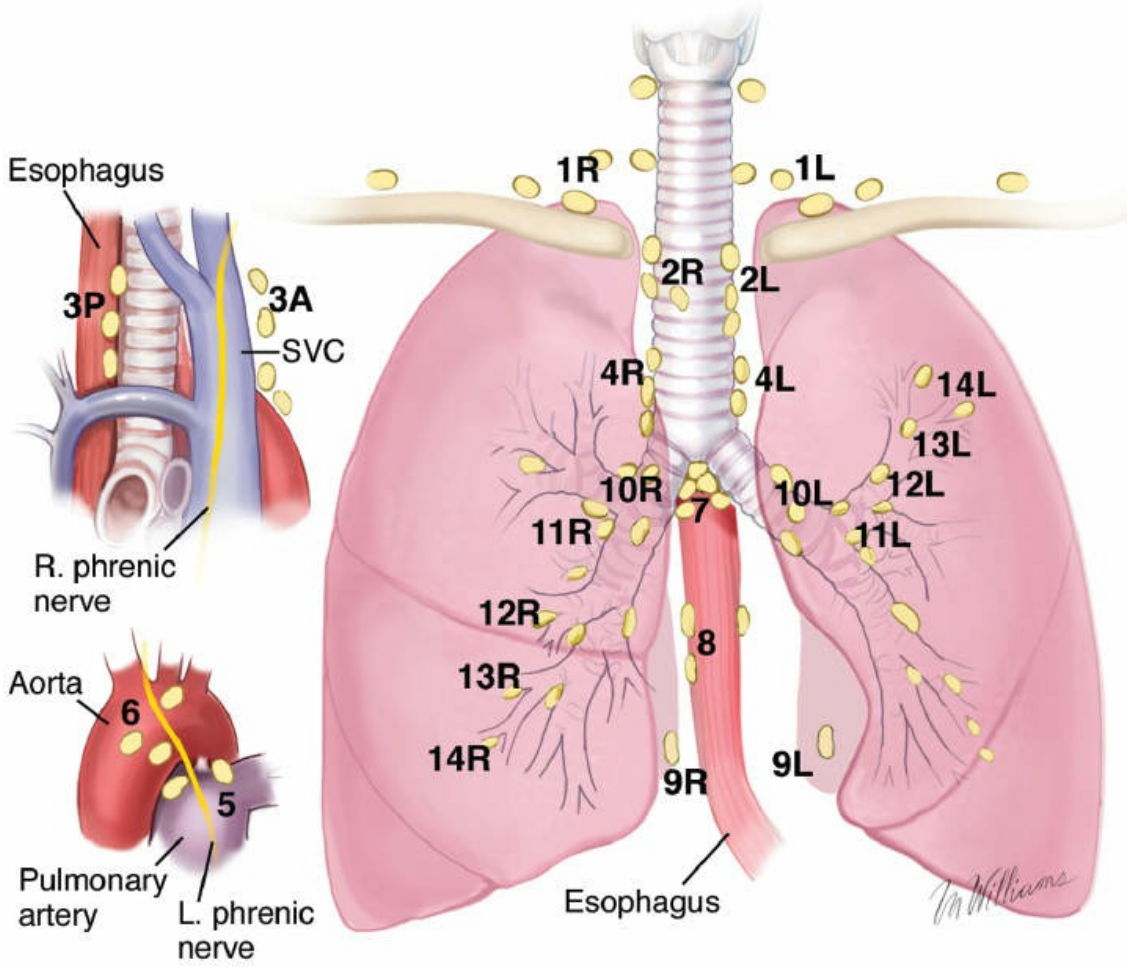

Supraclavicular Nodes
1 Low cervical, supraclavicular and sternal notch

Superior Mediastinal Nodes
2 Upper paratracheal
3 Prevascular and retrotracheal
4 Lower paratracheal

Aortic Nodes
5 Sub-aortic (AP window)
6 Para-aortic (ascending aorta or phrenic)

Inferior Mediastinal Nodes
7 Subcarinal
8 Paraesophageal (below carina)
9 Pulmonary ligament

N_1 Nodes
10 Hilar
11 Interlobar
12 Lobar
13 Segmental
14 Subsegmental

R – right, L – left
A – anterior, P– posterior

Figure 62.1. Lymph node stations in accordance with the IASLC.

Cervical Mediastinoscopy

Intrathoracic lymph nodes are divided into anatomic stations (Fig. 62.1). Mediastinal nodal stations are generally described as single digit nodal

stations, and hilar and parenchymal nodal stations are described using double digits. Cervical mediastinoscopy is a surgical sampling of the mediastinum that can access upper paratracheal nodal stations (2L and 2R), lower paratracheal nodal stations (2L and 4R), and the subcarinal nodal station. An adaptation of this procedure, called extended cervical mediastinoscopy (ECM), can reach the aortopulmonary (AP) window and paraaortic nodal stations on the left side, but this procedure has not been widely accepted into clinical practice.

Cervical mediastinoscopy is performed by positioning the patient supine with the neck fully extended. A small transverse incision is made one fingerbreadth above the sternal notch, and the tissue planes are dissected between the strap muscles down to the pretracheal fascia (Fig. 62.2). This plane is entered, and finger dissection is used to develop a plane along the anterior surface of the trachea posterior to the innominate artery down to the aortic arch (Fig. 62.3). Nodes cranial to the innominate vessels are termed *level 2 nodes.* Nodes caudad to the innominate artery are termed *level 4 nodes.* Subcarinal nodes are level 7. On the left, care is taken to identify and preserve the left recurrent laryngeal nerve as it courses medially to reach the tracheoesophageal groove. Cautery is generally avoided on the left side of the trachea to avoid injury to the nerve. Further dissection along each mainstem bronchus permits the surgeon to sample the tracheobronchial angle (level 4) nodes bilaterally.

Cervical mediastinoscopy is a safe procedure with mortality rates <0.1% and complication rates <1%, including paresis of the left laryngeal recurrent nerve, pneumothorax, pneumonia, injury to the azygos vein, perforation of the esophagus, mediastinitis, and hemorrhage. Bleeding is usually minor and can be controlled with packing. Major bleeding can be controlled with packing only, while one is getting ready to open the chest. Bleeding from major vessels, for example, superior vena cava, azygos vein, brachiocephalic artery, aortic arch, and pulmonary artery, will require expeditious median sternotomy. Small pneumothoraces can occasionally be managed conservatively. A chest x-ray with a new pleural effusion indicates blood draining into the pleural space and one should not hesitate to place a chest tube for drainage. Tracheobronchial injuries can result in a dramatic subcutaneous emphysema or air leak. Most of these injuries are small and will require observation only, but large injuries will require primary repair. Small, contained esophageal leaks can be managed conservatively. Large injuries will require complex repair and

management, which is beyond the scope of this chapter.

Anterior Mediastinoscopy

Anterior mediastinoscopy can be performed to biopsy lesions in the anterior and superior mediastinum that are inaccessible by cervical mediastinoscopy. For NSCLC tumors originating in the left upper lobe, the mediastinal lymph node stations most frequently involved are the paraaortic arch (level 6) and AP window (level 5) nodes. These nodes are generally difficult to access through a standard cervical approach and can be accessed by anterior mediastinoscopy; alternatively, a left VATS may be performed. To perform anterior mediastinoscopy, the patient is placed in the supine position and a 2- to 3-cm incision is made in the second intercostal space on the left side (Fig. 62.4). The pectoral muscle fibers are split to expose the intercostal muscles, the pleura is identified and divided, and the mediastinum is entered. The dissection is carried down gingerly onto the aortic arch and AP window. The internal mammary vessels are identified and swept medially or can be ligated. The mediastinal pleura is swept away laterally and the mediastinoscope is introduced through this incision into the mediastinum. Level 5 and level 6 lymph nodes are sampled, and care is taken to avoid the use of electrocautery near the recurrent laryngeal nerve, which arises from the left vagus nerve and travels under the aortic arch medially to the ligamentum arteriosum.

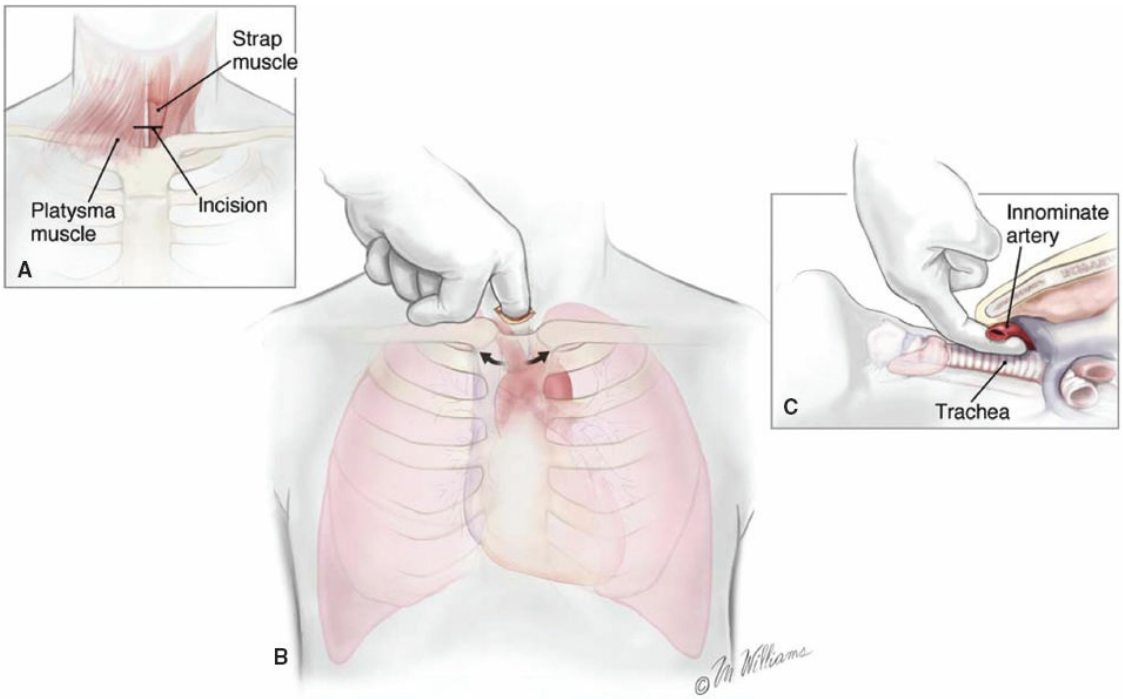

Figure 62.2. A. A 3-cm incision is made in the midline one

fingerbreadth above the sternal notch. **B.** Pretracheal plane fashioned with blunt dissection using the index finger. **C.** Dorsal aspect of the finger remains on the trachea while the volar aspect comes in contact with the innominate artery. (Reproduced with permission of The McGraw-Hill Companies, *Adult Chest Surgery,* 2009, edited by Sugarbaker et al., Figure 61–1, p. 526.)

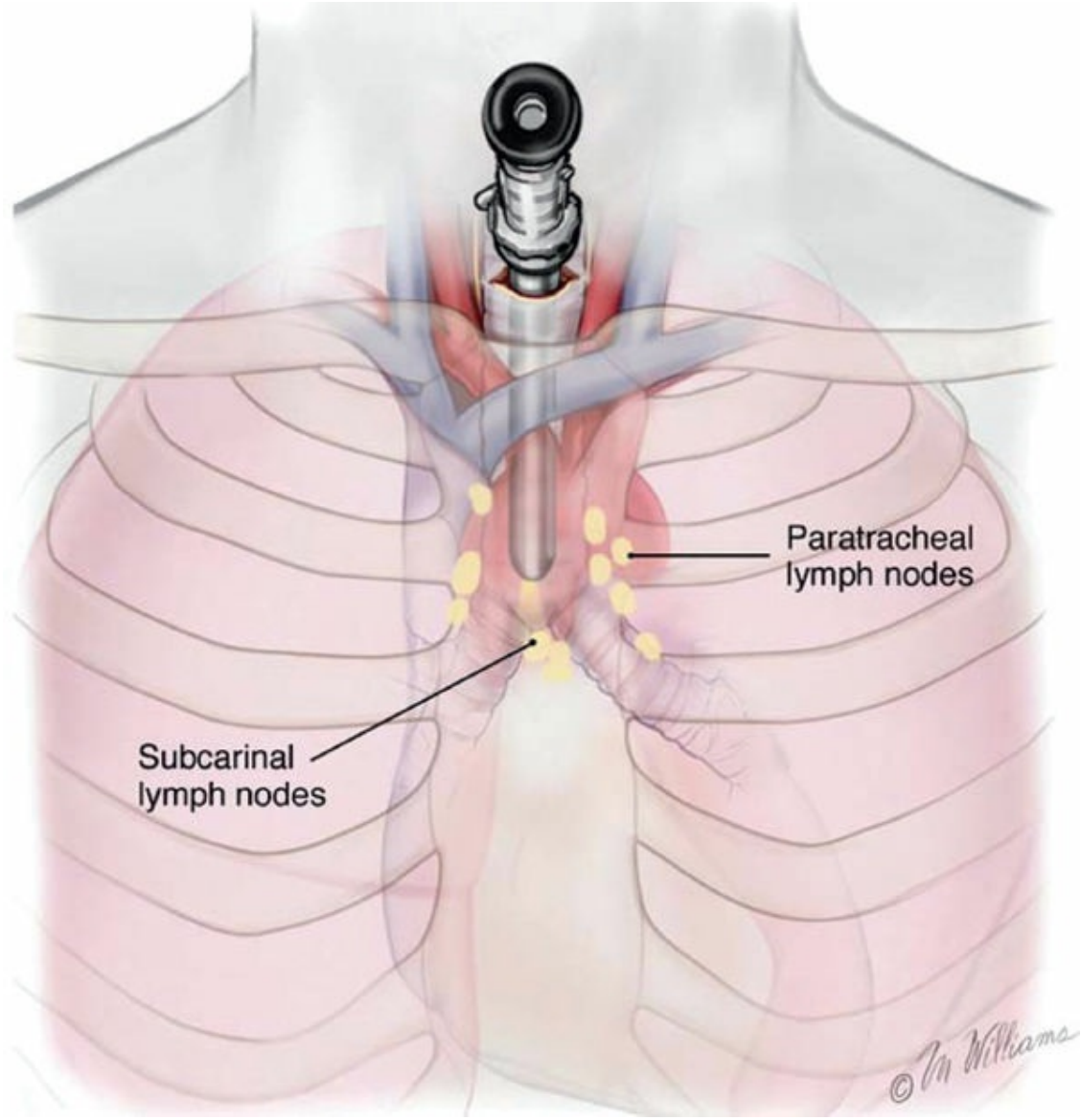

Figure 62.3. The mediastinoscope is introduced into the pretracheal tunnel with constant traction anteriorly and a slow rotating motion during the dissection. (Reproduced with permission of The McGraw-Hill Companies, *Adult Chest Surgery,* 2009, edited by Sugarbaker et al., Figure 61–2, p. 526.)

Thoracoscopy

Although cervical mediastinoscopy remains the procedure of choice,

especially for the higher mediastinal levels (2 and 4), in some situations cervical mediastinoscopy can be technically challenging (e.g., neoadjuvant chemoradiation and prior mediastinoscopy) or contraindicated (e.g., substernal goiters, previous laryngectomy, previous median sternotomy, aortic arch aneurysm, superior vena cava syndrome, or cervical spine disease that would preclude proper positioning). In such cases, thoracoscopic nodal sampling can be performed. Thoracoscopy can be used to sample stations 2R, 4R, 7, 8, and 9 for right-sided tumors and 5, 6, 7, 8, and 9 for left-sided tumors. In addition to evaluating N2 disease, thoracoscopy is particularly useful in ruling out unresectable T4 invasion in primary lung cancer and T3 invasion in high-risk patients.

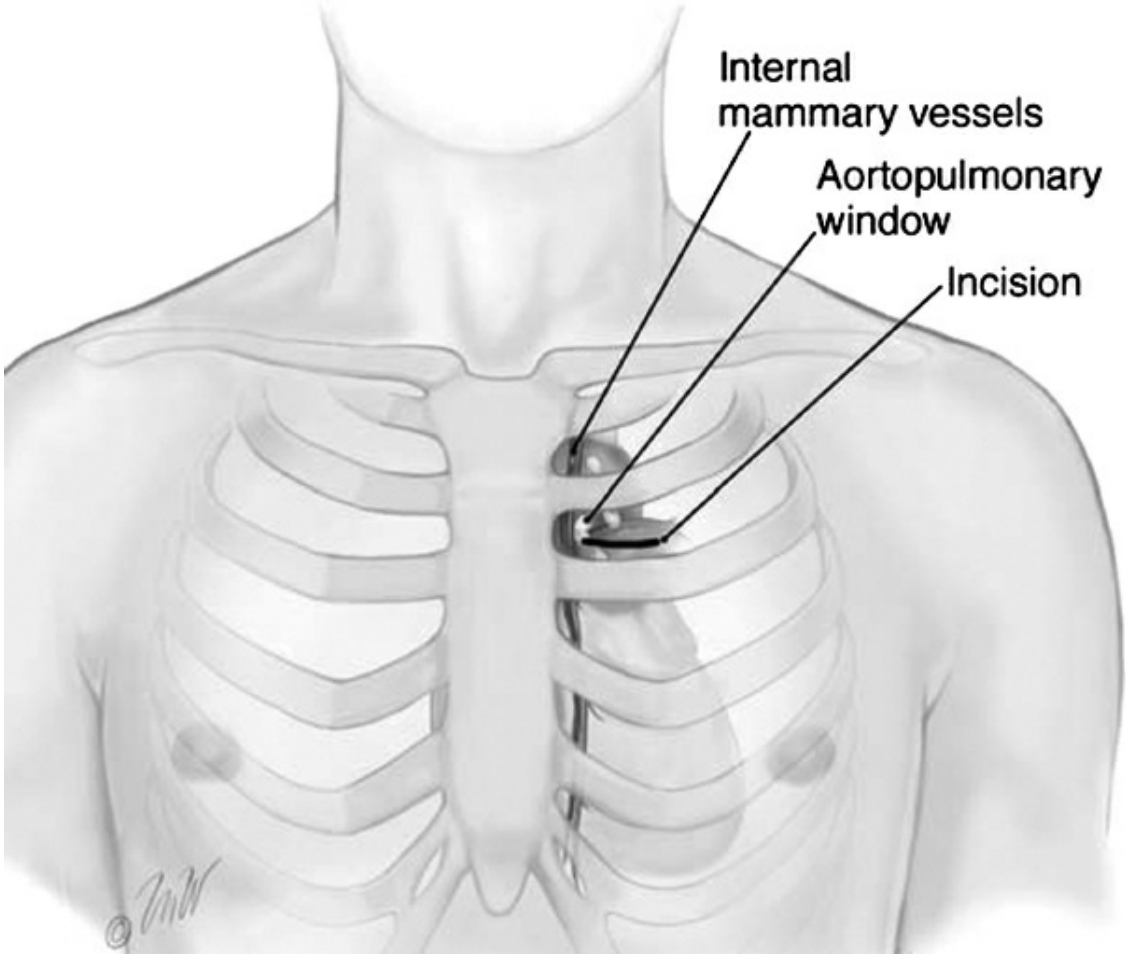

Figure 62.4. A classic 2-cm anterior mediastinotomy incision is made in the second intercostal space on the left side. (Reproduced with permission of The McGraw-Hill Companies, *Adult Chest Surgery,* 2009, edited by Sugarbaker et al., Figure 132–6, p. 1105.)

Endobronchial Ultrasound

EBUS is a technique that uses a bronchoscope equipped with either a curvilinear (60 degrees) or radial scanning (360 degrees) ultrasound probe to visualize the airway wall and adjacent structures, including lymph nodes. EBUS-guided transbronchial needle aspiration biopsy (EBUS-TBNA) allows fine-needle aspiration of lymph nodes and other lesions adjacent to the airway under ultrasound guidance (Fig. 62.5), and this technique has been gaining popularity for invasive staging of the mediastinum in patients with NSCLC. EBUS-TBNA can sample nodal stations 2, 4, 7, 10, 11, and 13. It has sensitivity greater than 90% in the staging of NSCLC. The sensitivity of EBUS-TBNA appears similar to mediastinoscopy with enlarged nodes but lower or similar with normal-sized nodes. False-negative rates with EBUS-TBNA are higher than with mediastinoscopy, so nonmalignant EBUS results may be unreliable. False positives have been reported in cases of central squamous cell carcinomas where carcinoma in situ led to contamination of the TBNA needle.

There are scenarios in which EBUS is preferable to mediastinoscopy, including pathologic confirmation of a PET positive mediastinal node. However, for routine staging of the upper mediastinum in NSCLC, the benefits of EBUS over mediastinoscopy remain unproven.

Endoscopic Ultrasound

Transesophageal EUS scanning is an endoscopic technique that provides high-resolution imaging of the mediastinum by using high-frequency ultrasound probes attached to the tip of a flexible endoscope. It offers the additional facility of endoscopic ultrasound-guided fine-needle aspiration (EUS-FNA) or tru-cut biopsy (TCB) under real-time ultrasound guidance. This technique allows sampling of mediastinal nodal stations 4L, 7, 8, and 9 as well as some enlarged station 5 nodes.

PREOPERATIVE EVALUATION

Patients considered for pulmonary resection often have existing pulmonary disease, which places them at a higher risk for postoperative morbidity and mortality. The preoperative physiologic assessment of the patient being considered for lung resection should begin with a cardiovascular evaluation and spirometry. Forced expiratory volume in 1 second (FEV_1) and diffusing capacity for carbon monoxide (D_{LCO}) are the most commonly used pulmonary function tests, and their values are inversely correlated with postoperative mortality, respiratory failure, and other

complications following pulmonary resection. Both FEV_1 and D_{LCO} should be measured, and predicted postoperative FEV_1 ($ppoFEV_1$) and D_{LCO} ($ppoD_{LCO}$) should be calculated. These predicted postoperative values have been shown to have stronger correlations of postoperative risk than their parent values. For calculation of $ppoFEV_1$ and $ppoD_{LCO}$ in patients who will undergo lobectomy or sublobar resection (segmentectomy or wedge resection), the anatomic method may be used, in which the percentage of remaining lung is calculated based upon the number of remaining segments, and this percentage is multiplied against the preoperative FEV_1 or D_{LCO} values.

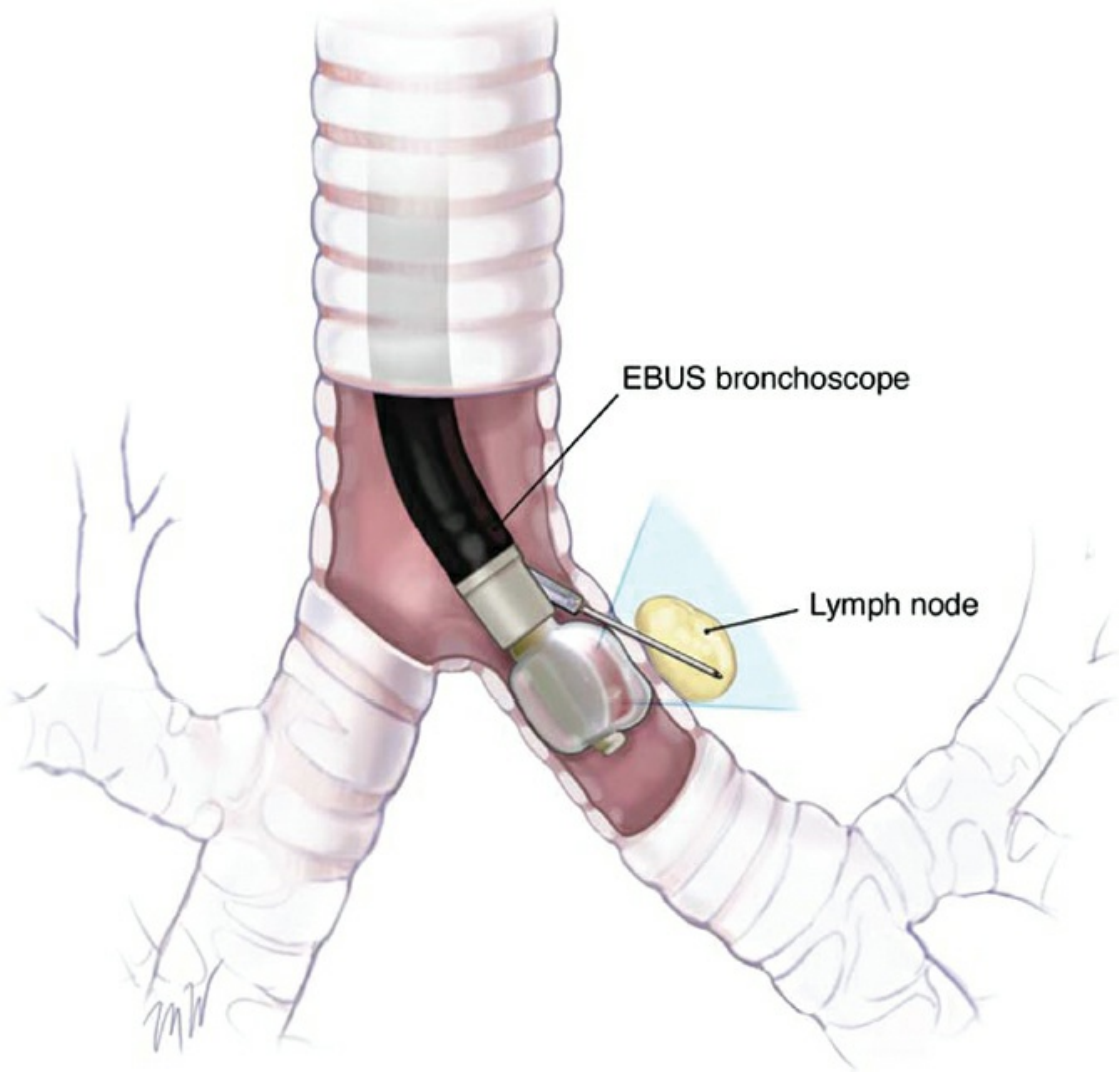

Figure 62.5. EUBS-TBNA. EBUS-guided TBNA procedure for sampling lymph node stations/lesions from the bronchi.

Anatomic Method

% Predicted postoperative FEV_1 = % preoperative FEV_1 − (preoperative FEV_1 × no. of segments to be removed/19), where 19 is the total number of segments in the normal lung.

For the calculation of these ppo values in patients undergoing pneumonectomy, the anatomic method loses accuracy, and a lung perfusion scan is required to calculate the ppo values.

The American College of Chest Physicians (ACCP) recommends that both ppoFEV_1% and ppoD_{LCO}% should be calculated in all patients being considered for lung resection, as it provides a useful preoperative risk stratification algorithm for patients being considered for lung resection. Patients with ppoFEV_1 and ppoD_{LCO} values both greater than 60% are considered at low risk for anatomic lung resection, and no further tests are indicated. Further preoperative risk stratification with a low technology exercise test (e.g., stair climb or shuttle walk test) is recommended for patients whose ppoFEV_1% or ppoD_{LCO}% is <60% predicted (but both above 30% predicted.) A formal cardiopulmonary exercise test is currently recommended for patients with a ppoFEV_1% or ppoD_{LCO}% of <30%.

With regard to ppoFEV_1 and ppoD_{LCO}, several preoperative scenarios deserve mention. An important consideration for risk stratification following pulmonary resection is whether a minimally invasive approach, which is associated with lower morbidity and mortality rate as compared with an open approach, can be offered and successfully accomplished. Moreover, it has been recently demonstrated that the decreased perioperative morbidity advantages of VATS lobectomy are amplified in patients with decreased pulmonary function, and this benefit further translates into decreased postoperative mortality rates for these patients. Patients with obstructed bronchi or nonfunctioning areas of lung can generally tolerate removal of that portion of lung, and these nonfunctioning segments should be accounted for when calculating ppoFEV_1 and ppoD_{LCO}. Patients with upper lobe predominant emphysema and upper lobe lesions may tolerate lung resection better than what would be anticipated based purely on the ppoFEV_1 and ppoD_{LCO} values, owing to the concomitant lung volume reduction benefits. Finally, for patients with small lung cancers and limited pulmonary function, sublobar resection can be performed in specialized centers in patients with very low FEV_1 and D_{LCO} with limited morbidity and mortality.

TREATMENT

The treatment of NSCLC depends upon clinical stage. Anatomic resection, namely lobectomy, is the current gold standard for patients with stage I NSCLC. Anatomic resection entails resection of an anatomic unit of the lung which encompasses all of the draining lymphovascular structures, that is, pneumonectomy, lobectomy, and segmentectomy. A wedge resection is performed to remove a portion of lung containing the lesion of interest and does not conform to an anatomic unit (e.g., a segment). It does not require separate dissection of the arterial supply, venous drainage, airway, and corresponding lymphatic drainage and lymph nodes. The benefit of anatomic resection is decreased local recurrence. For example, in the 1995 randomized trial of lobectomy versus limited resection of T1N0 NSCLC by the Lung Cancer Study Group, patients undergoing lobectomy indeed had decreased rates of local recurrence and a trend toward improved overall survival. To determine whether disease-free survival after sublobar resection (segmentectomy or wedge) is equivalent to that of a lobectomy for patients with small peripheral (≤2 cm) NSCLC, a randomized trial (CALGB 140503) is currently under way. For patients with small lung cancers who have limited pulmonary function, parenchymal-sparing sublobar resections (segmentectomy or wedge resection) can be offered. Similar results have been shown in patients undergoing anatomic sublobar resections (segmentectomy) compared with nonanatomic sublobar resections (wedge resections). For patients who are medically inoperable based upon comorbidities, stereotactic ablative radiotherapy (SABR) is a viable alternative.

Patients with stage II NSCLC are best treated with surgical resection followed by adjuvant chemotherapy, and adjuvant chemotherapy can also be considered in patients with stage IB tumors with high-risk features (size >4 cm, lymphovascular invasion, visceral pleura, invasion). Patients with stage IIIA disease are treated with multimodality therapy including neoadjuvant chemotherapy or chemoradiotherapy followed by surgery or by definitive chemoradiotherapy, depending upon patient and tumor characteristics. For example, patients with single station, nonbulky (<1 cm) N2 disease (IIIA) should be considered for neoadjuvant therapy followed by surgical resection, especially in the context of a clinical trial. Patients with multistation or bulky IIIA disease are probably best treated by definitive chemoradiotherapy. Resection of tumors with contralateral paratracheal nodal disease (IIIB) is generally contraindicated. Patients with

distant metastases (stage IV) are generally treated with systemic chemotherapy. Patients with resectable primary tumors and oligometastatic disease to the brain or adrenal gland may benefit from anatomic resection of the primary site and surgical or radiotherapy to the metastatic site.

ANESTHETIC CONSIDERATIONS

Optimal conditions for lung resection require lung isolation (i.e., deflation of the operative lung). This requires complete ventilatory support of the patient with the contralateral lung and can be achieved by one of two means. A double-lumen tube can be inserted into the trachea with its distal lumen in the long left main bronchus and the tracheal side port directed at the right main bronchus, known as a left-sided double-lumen tube. An inflatable cuff is present above each orifice, allowing for single-lung ventilation. Assurance of proper positioning requires the use of a small-gauge (pediatric) bronchoscope. In operations potentially involving the left main bronchus (left-sided sleeve resections or left pneumonectomy), a right-sided double-lumen tube may be used or a conventional endotracheal tube may be used and the ipsilateral main bronchus blocked with an inflatable “blocker.” Collapse of the lung depends on absorptive atelectasis and is generally longer with a blocker.

Proper perioperative pain control is essential for postoperative pulmonary toilet and to avoid mucous plugging, lobar atelectasis, and perioperative pneumonia. In patients undergoing thoracotomy, major lung resections, or even in patients with poor lung function undergoing lesser resections, effective pain control can mitigate perioperative respiratory complications. In these cases placement of a mid-thoracic-level epidural, tunneled catheter for continuous infusion of local anesthetic, or intercostal nerve blocks with long-acting (liposomal) bupivacaine should be considered. At the time of thoracotomy, dissection of a muscle flap in the interspace of interest and closure of the rib space by placing the sutures through (instead of around) the inferior rib results in improved pain control by avoiding strangulation of the intercostal nerve.

In patients with cardiac dysfunction, pulmonary hypertension, or when pneumonectomy is planned, central venous monitoring and access is often helpful. Arterial access is essential in patients with borderline lung function, and often helpful in any patient undergoing major pulmonary resection. Fluid administration should be judicious. Patients undergoing lobectomy, and especially patients undergoing pneumonectomy, should

receive less than 1,500 mL and, ideally, less than 1,000 mL, of fluid during the operation to minimize the risk of postoperative pulmonary edema.

PRINCIPLES OF PULMONARY RESECTION

Under general anesthesia, all patients undergo a flexible bronchoscopy to evaluate for synchronous endobronchial lesions and anatomic anomalies. For primary endobronchial lesions, a margin of at least 2 cm of grossly uninvolved mainstem bronchus is desired to ensure a curative resection. Second, prior to committing the patient to a thoracotomy, a thoracoscopic examination is performed and the chest cavity inspected for pleural and pericardial metastases, chest wall invasion, adhesions, and location of the lesion in relation to hilar structures as well as to determine the best location for entry into the chest. Once resectability has been established and the appropriate thoracotomy performed, the inferior pulmonary ligament is taken down and the hilum is opened, moving inferiorly to anteriorly and posteriorly, in a “Y”-shaped manner. Next, the major and minor fissures (right) are completed, exposing the pulmonary artery. Dissection in the interlobar fissures is performed carefully as this is the most common site of postoperative air leaks that prolong chest tube removal and hospital stay. Following resection, surgical margins are evaluated by frozen section and a thorough mediastinal lymph node dissection is performed.

Posterolateral Thoracotomy

A posterolateral thoracotomy can be employed for most open lung resections (Fig. 62.6). In this incision the latissimus dorsi muscle is divided, and the serratus anterior muscle is dissected from its underlying attachments and reflected anteriorly. The rib space of interest (typically 5 or 6 depending upon the planned resection) can be identified by counting the ribs by placing the hand beneath the scapula and counting down posteriorly from the first rib. The intercostal muscle is divided along its attachments to the inferior rib. A 2-cm segment of posterior rib can be divided with a rib cutter (“shingling”) to aid exposure and to avoid unintentional rib fracture that can result in chronic postoperative pain.

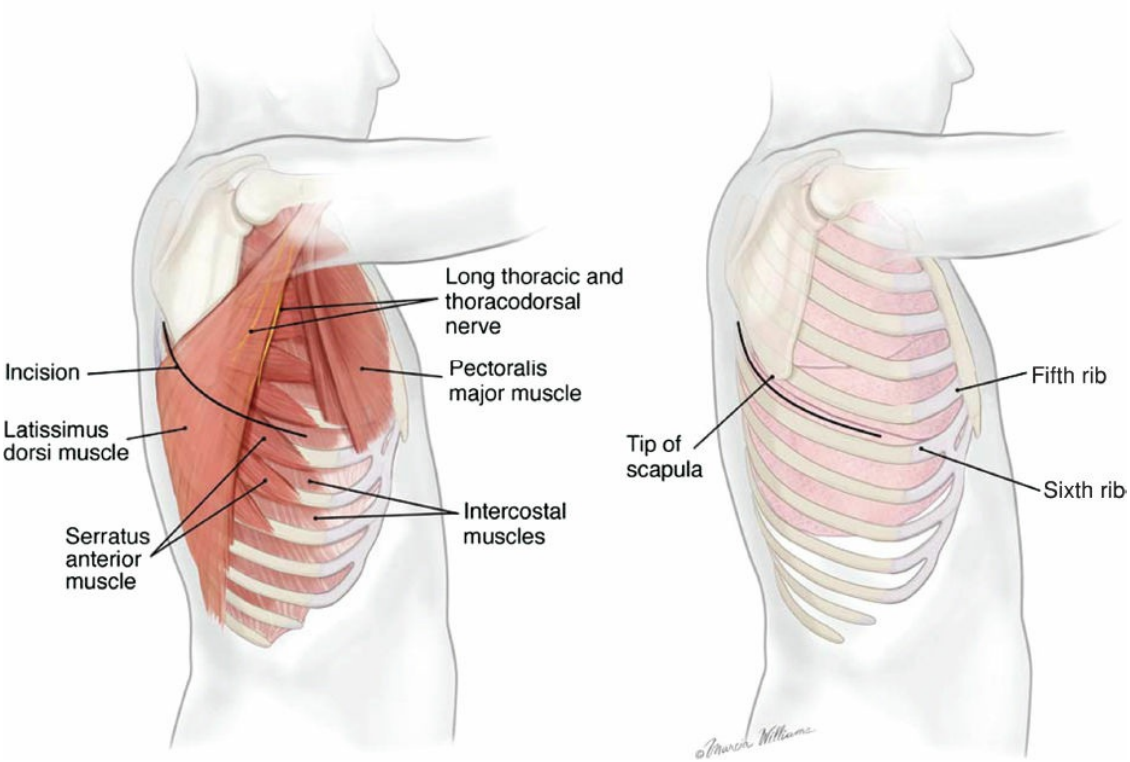

Figure 62.6. Standard posterolateral thoracotomy incision with extrathoracic musculature and surface landmarks. The incision wraps around the tip of the scapula and parallels the course of the sixth rib. (Reproduced with permission of The McGraw-Hill Companies, *Adult Chest Surgery,* 2009, edited by Sugarbaker et al., Figure 2–1, p. 6.)

Handling of the Pulmonary Artery

The pulmonary artery is a thin-walled and delicate vessel, much more so than the pulmonary veins. Operative identification and dissection of the pulmonary artery requires meticulous technique to avoid injury, and an intimate understanding of the anatomy of the main pulmonary artery and its branches is necessary for the safe performance of any anatomic resection (Fig. 62.7). Tears in the pulmonary artery can spread in retrograde fashion, at times compromising circulation to the entire lung. The pulmonary artery is encircled by a connective tissue sheath. On entering this sheath, dissection along the vessel can be achieved by gently pushing the sheath away from the pulmonary artery with a blunt instrument such as a metal tip sucker or the curved tips of a Pearson type dissecting scissors. The pulmonary artery itself is never grasped; rather, the connective sheath is grasped and the artery distracted from the sheath. Gentle handling of the lobar branches is important to avoid avulsion of the orifice from the ongoing pulmonary artery. Small tears or dissections of

the artery can often be controlled with simple application of pressure for several minutes as the pulmonary artery circulation is a low pressure system. Otherwise, arteriotomies in the pulmonary artery can be closed with fine (5-0) Prolene. In cases of central tumors with elevated risks for pulmonary artery injury, or for cases suspected to require pulmonary arterioplasty, proximal control of the pulmonary artery at the main pulmonary artery can be obtained early in the case using a vessel loop and tourniquet, and distal control can be achieved in a similar fashion following appropriate dissection.

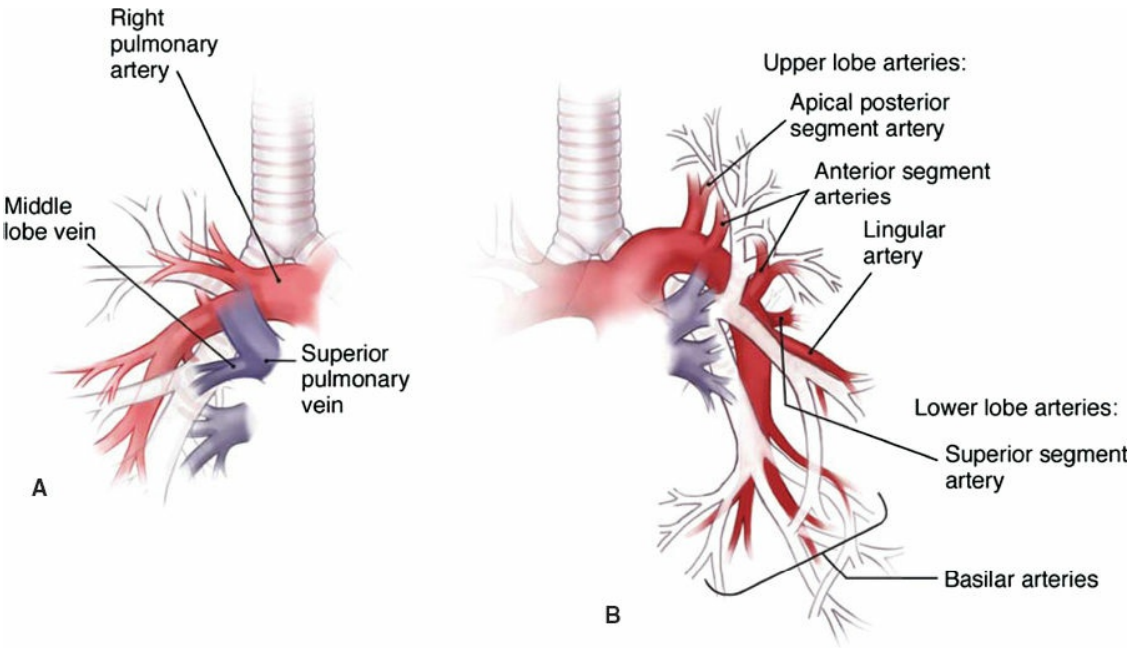

Figure 62.7. A. Right upper lobectomy, hilar exposure. If the superior vein lies anterior to the pulmonary artery, the middle lobe vein must be identified and preserved. **B.** Left upper lobectomy. Pulmonary arterial anatomy pertinent to left upper lobectomy, which can be approached anteriorly, superiorly, posteriorly, or inferiorly. (Reproduced with permission of The McGraw-Hill Companies, *Adult Chest Surgery,* 2009, edited by Sugarbaker et al., A is from Figure 62–2, p. 533. B is from Figure 62–14, p. 538.)

Closure of the Bronchus

Anatomic pulmonary resection requires division of the bronchus which can be done using a surgical stapler or with suture closure, typically with absorbable (e.g., Vicryl) suture placed in a single interrupted fashion. Surgical staplers are often employed for this step of the case as these

devices will facilitate minimally invasive approaches to anatomic resection and are a generally reliable means of bronchus closure. The bronchus should be closed as flush as possible to the airway from which it arises to avoid pooling of secretions, which potentially may lead to stump breakdown. Before staple closure of the bronchus, it is a good practice to re-evaluate airway anatomy. This can be done by either insufflating the operative lung to ensure that there is no impingement on the adjacent airway, or by video bronchoscopy through the double-lumen tube with a pediatric bronchoscope (generally by the anesthesiologist) to assure the remaining airways are open. If the tumor is close to the orifice of the bronchus, then the bronchus is divided with a knife and is closed with interrupted 3-0 Vicryl sutures. After any closure, the bronchial stump should be tested for leaks under water and with 25 cm H_2O of pressure. Pneumonectomy stumps, bronchial sleeve anastomoses, and postirradiation stumps are typically covered with live tissue flaps including intercostal muscle, pleura or pericardium, and vascularized thymic or pericardial fat.

OPEN LOBECTOMY

Lobectomy is currently the gold standard oncologic resection for most cases of NSCLC. Lobectomy involves resection of the involved anatomic lobe of lung parenchyma as well as a thorough nodal dissection. In addition to N1 hilar, interlobar, and segmental draining lymph nodes, a complete mediastinal (N2) lymph node dissection is performed.

Right Upper Lobectomy

After positioning the patient in the left lateral decubitus position, the right chest is typically entered through a serratus-sparing, limited posterolateral thoracotomy through the fifth intercostal space. We routinely shingle the fifth rib posteriorly, removing a 2-cm portion of the rib posteriorly, to allow for atraumatic exposure when spreading the ribs. After inserting the chest retractor, the lung and pleural cavity are inspected for any evidence of pleural disease, and the tumor is identified with palpation. Next, the inferior pulmonary ligament is divided to permit mobility of the remaining lung to fill the apex of the pleural cavity. The oblique and horizontal fissures are examined to assess the need for further dissection. The sequence in dissection and ligation of the pulmonary artery and vein is generally based on the anatomic setting and convenience. The dissection

typically proceeds initially at the anterior hilum. The phrenic nerve is seen coursing over the superior vena cava. The mediastinal pleura is divided posterior to the nerve at its junction with the visceral pleura of the lung anteriorly. This dissection plane is carried superiorly and posteriorly after gently elevating the upper lobe anteriorly. Blunt dissection at the posterior hilum is performed to clarify the right mainstem bronchus and the upper lobe origin with the bronchus intermedius coursing distally. Dissection typically begins at the superior pulmonary vein, which includes the venous drainage of the upper and middle lobe. The veins draining the upper lobe are identified and ligated with a vascular stapler, and care is taken to spare the venous drainage of the middle lobe vein lying inferiorly (Fig. 62.8). Division of the vein from the upper lobe exposes the pulmonary artery, which lays superiorly and behind the vein. A thin layer of fatty and lymphatic tissue can be divided with electrocautery, exposing the main pulmonary artery. The sheath of the artery is gently grasped and divided with blunt scissors. The sheath is retracted and the length of the artery is dissected locating the first branch, the truncus anterior, which supplies the apical and anterior segments of the upper lobe. This branch is isolated and ligated first, using a vascular stapler or suture ligatures (Fig. 62.9).

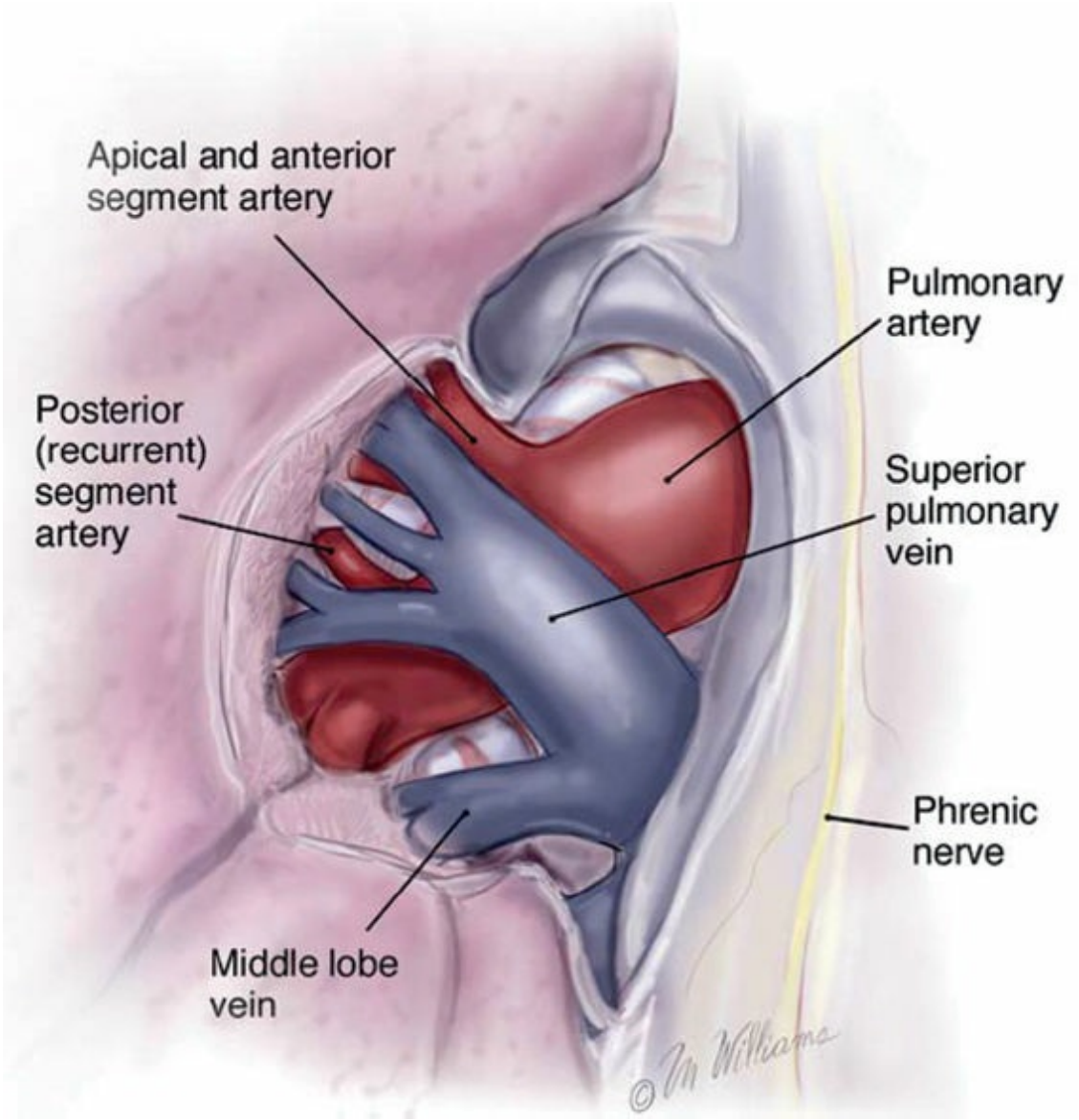

Figure 62.8. Right upper lobectomy, hilar exposure. If the superior vein lies anterior to the pulmonary artery, the middle lobe vein must be identified and preserved. (Reproduced with permission of The McGraw-Hill Companies, *Adult Chest Surgery,* 2009, edited by Sugarbaker et al., Figure 62–3, p. 533.)

Next, division of the right upper lobe bronchus is performed by developing a plane around this lobar bronchus first with scissors and then with a finger. Peribronchial lymph nodes should be harvested both for staging and to allow for stapler placement and closure of the bronchus. The bronchus can be divided either with a heavy tissue (green) load stapler or with scissors or blade and closed with interrupted absorbable sutures (Fig. 62.9). The divided distal bronchus is then grasped with an Allis clamp and retracted inferiorly, exposing the ascending pulmonary artery

branch to the posterior segment of the upper lobe (sometimes termed the *recurrent branch*), which is suture-ligated and divided. This approach is termed the *posterior approach to the ascending branch.* This artery can also be approached anteriorly (with the lung retracted posteriorly) by dissecting distally along the pulmonary artery after division of the truncus anterior. A middle approach to the artery can be performed through dissection of the major fissure which can also further clarify the pulmonary artery anatomy (Fig. 62.10). The specimen is now attached only by its remaining fissures and parenchyma, which are divided with a stapler to provide an airtight resection. After removing the specimen, the bronchial staple line is tested under water for integrity. We do not routinely cover nondependent stumps. In cases where the minor fissure is complete, and the right middle lobe is at risk of torsion, we anchor the right middle lobe to the right lower lobe with a noncutting stapler. A single chest tube is inserted through the anterior inferior incision that was used for thoracoscopic exploration if performed before thoracotomy. The wound is closed after irrigation of the chest and assurance of hemostasis.

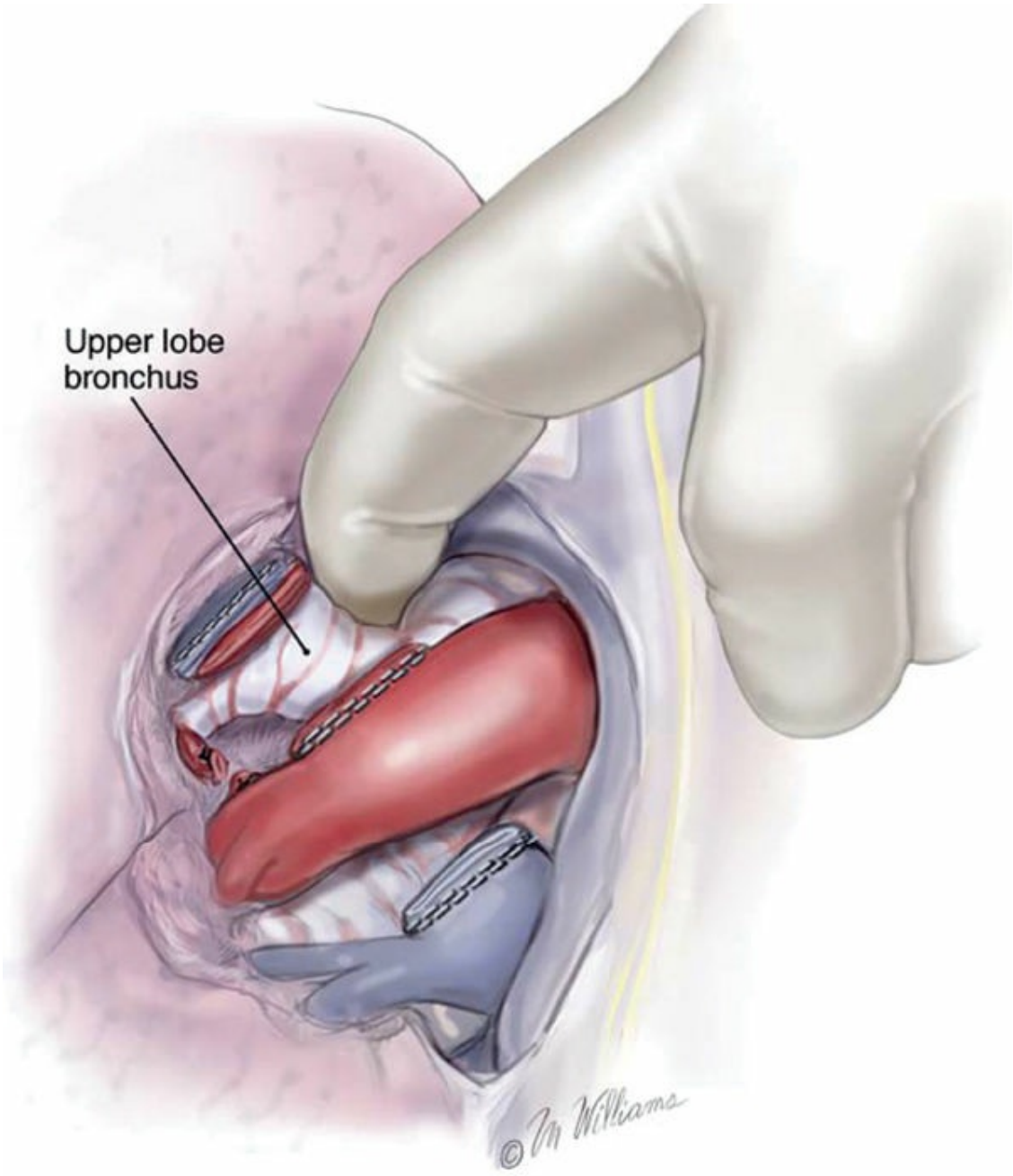

Figure 62.9. Right upper lobectomy. After the vasculature is controlled, the bronchus is resected. (Reproduced with permission of The McGraw-Hill Companies, *Adult Chest Surgery,* 2009, edited by Sugarbaker et al., Figure 62–4, p. 534.)

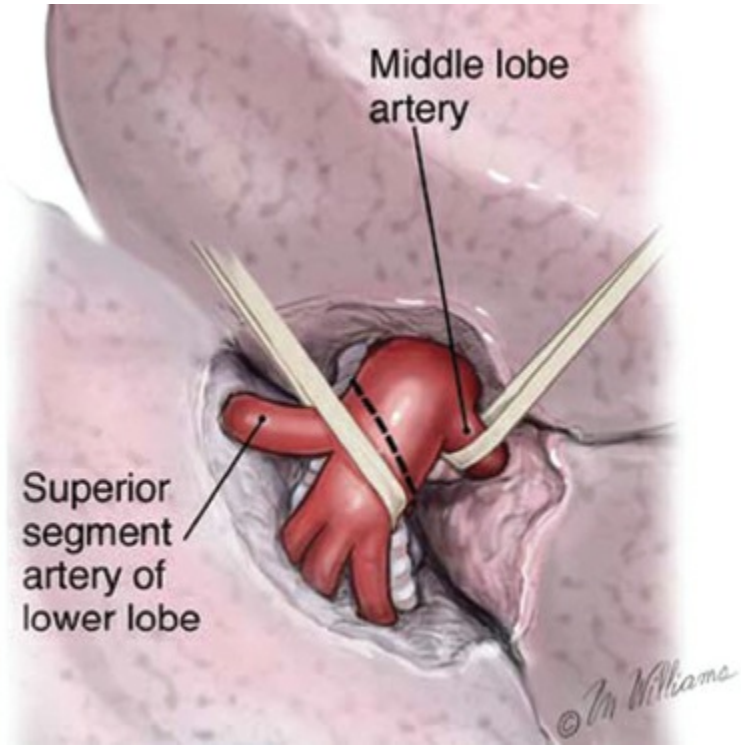

Figure 62.10. Right lower lobectomy. After identifying the middle lobe artery, which is preserved, the basilar segmental artery is encircled and divided. (Reproduced with permission of The McGraw-Hill Companies, *Adult Chest Surgery,* 2009, edited by Sugarbaker et al., Figure 62–9, p. 536.)

Right Middle Lobectomy

To perform a right middle lobectomy, we prefer an anterolateral thoracotomy through the fifth interspace. The dissection begins in the oblique fissure at its intersection with the horizontal fissure. The visceral pleura is opened and the interlobar pulmonary artery is identified in the fissure. With gentle traction anteriorly on the middle lobe, one or two middle lobe arteries are identified and ligated. If necessary, the horizontal fissure is completed with a stapler. The vein from the middle lobe is identified in the anterior hilum most commonly draining into the superior pulmonary vein as described above and ligated. The bronchus to the middle lobe can be identified and divided from the fissure after dividing the middle lobe pulmonary artery or from the anterior hilum after dividing the middle lobe pulmonary vein. Not uncommonly, the right middle lobe is involved by a tumor in the upper or lower lobe, thereby requiring bilobectomy for complete resection.

A standard fifth intercostal space posterolateral thoracotomy is employed for bilobectomy. In the case of the right middle and lower

bilobectomy, the bronchus intermedius can be divided just distal to the upper lobe bronchus takeoff. In the setting of the right upper and middle bilobectomy, the bronchi are divided separately.

Right Lower Lobectomy

A fifth intercostal space posterolateral thoracotomy is performed. The completeness of the fissures determines the ease of exposure of the pulmonary arteries to the right lower lobe. Typically, for a right lower lobectomy, the first step after gaining entry into the chest is to retract the upper and middle lobes anteriorly and the lower lobe posteroinferiorly, spreading open the oblique fissure. Dissection of the visceral pleura reveals the interlobar pulmonary artery. Identification of the middle lobe artery anteromedially aids in the detection of the superior segmental artery posteriorly and opposite the middle lobe artery. The artery to the superior segment of the lower lobe and the arterial trunk to the basilar segments of the lower lobe are isolated and ligated either individually or together, depending upon the vascular anatomy (Fig. 62.10). The inferior pulmonary vein is approached posteriorly. The inferior pulmonary ligament is divided to the level of the lower border of the vein, and level 9 lymph nodes within the ligament are collected. Division of the mediastinal pleura posteriorly allows for clearance of the inferior pulmonary vein away from the lower border of the bronchus and the superior pulmonary vein (Fig. 62.11). After freeing the inferior pulmonary vein anteriorly, a clamp is passed to aid in the stapling of the vein with a vascular stapler. Before division, anomalous middle lobe venous drainage into the inferior pulmonary vein (occurring 5% to 10% of the time) should be ruled out. If the oblique fissure is incomplete, a stapler is applied to separate the middle lobe from the specimen. The lower lobe is now attached by only its bronchi. Care must be taken not to divide the lower lobe bronchus in such a way as to narrow the orifice of the middle lobe bronchus. Not uncommonly, it is safer to divide the superior segmental bronchus separately from the ongoing bronchus to the basal segments. After dividing these bronchi with the 30-mm stapler, we will often cover the dependent stumps of the lower lobe bronchi with vascularized pericardial fat or parietal pleura (Fig 62.11).

Left Upper Lobectomy

The chest is entered through a fifth interspace posterolateral thoracotomy. The hilum is approached anteriorly by gentle lateral and inferior retraction

of the left lung. The mediastinal pleura is incised over the pulmonary artery as it courses beneath the aortic arch. The phrenic nerve is identified anteromedially and the vagus nerve with its recurrent laryngeal branch is identified coursing below the aortic arch from the boundaries of the pleural dissection (Fig. 62.12). Working from the top of the fissure posteriorly with the upper lobe retracted superomedially and lateral reflection of the lower lobe, the interlobar left pulmonary artery is exposed. The most common anatomic variability encountered is the number of segmental pulmonary arterial branches to the upper lobe. Most commonly, four branches (i.e., apicoposterior, anterior, superior lingular, and inferior lingular), one to each of the segments, are present. However, between three and seven pulmonary artery branches may supply the left upper lobe and require identification and ligation (Fig. 62.13). The first branch (truncus branch) to left upper lobe can take off quite proximal on the left main pulmonary artery. Given the relatively shorter length of the left main pulmonary artery (compared with the right main pulmonary artery) to the main pulmonary artery originating from the right ventricle, injury to the truncus branch of the left pulmonary artery can be a treacherous proximal pulmonary artery injury. Great care must be taken in identifying and dividing the truncus branch, and an approach from the anterior hilum can facilitate the approach to this branch. After arterial ligation is complete, attention is shifted to circumferential isolation of the upper lobe bronchus, which is carefully freed from the posterior surface of the superior pulmonary vein. The stapling device is used to divide the bronchus, and the superior vein is then exposed for similar ligation with a vascular stapling device.

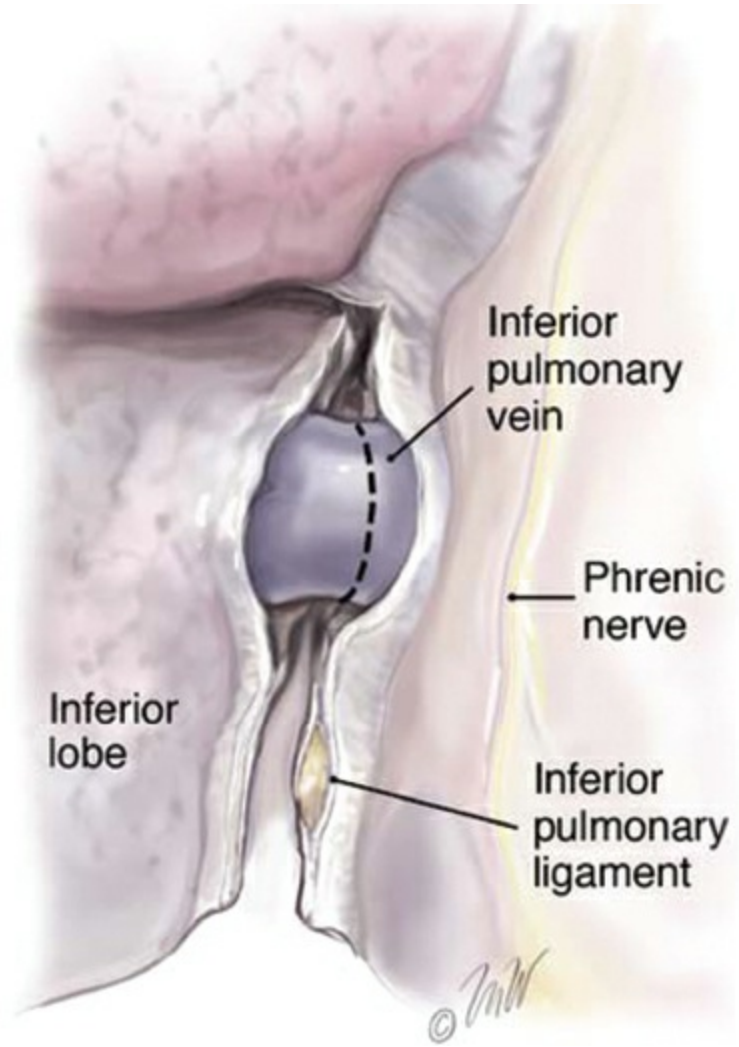

Figure 62.11. Right lower lobectomy. The inferior pulmonary ligament is taken down, with caution to avoid injury to the phrenic nerve, to expose the inferior pulmonary vein. This vein is encircled and divided or clamped and oversewn. (Reproduced with permission of The McGraw-Hill Companies, *Adult Chest Surgery,* 2009, edited by Sugarbaker et al., Figure 62–10, p. 537.)

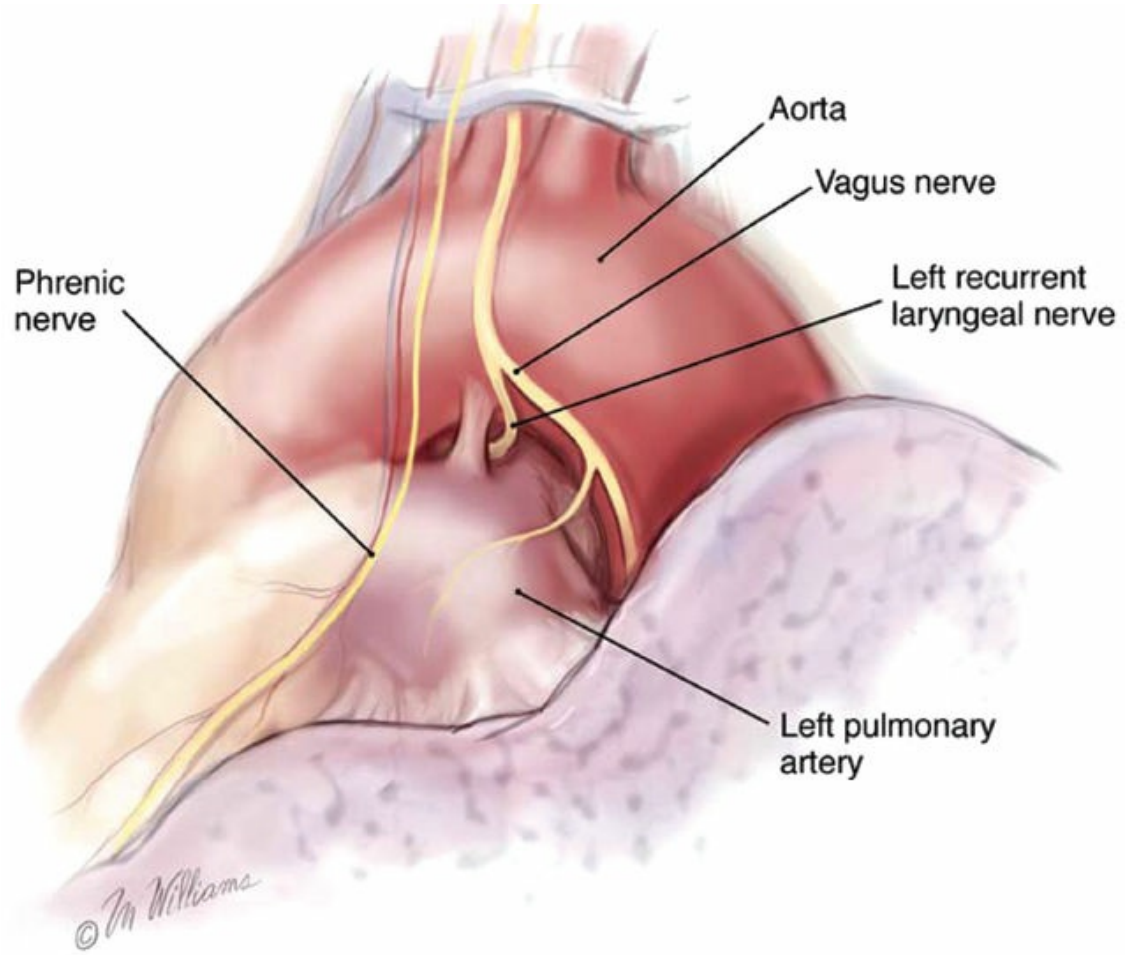

Figure 62.12. Left upper lobectomy. Owing to the proximity of the recurrent laryngeal and phrenic nerves, left upper lobectomy poses many obstacles to easy resection. (Reproduced with permission of The McGraw-Hill Companies, *Adult Chest Surgery,* 2009, edited by Sugarbaker et al., Figure 62–13, p. 538.)

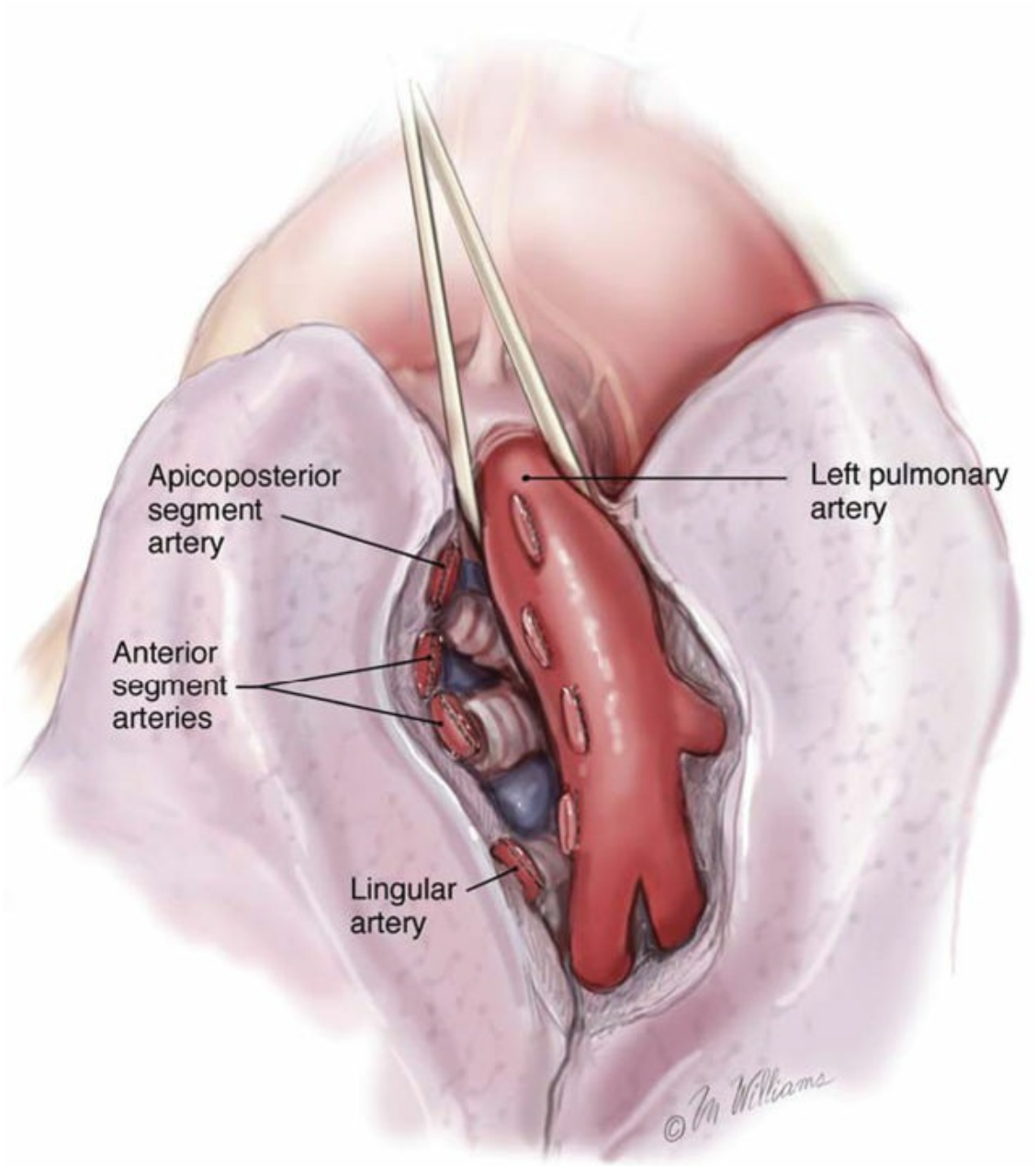

Figure 62.13. Left upper lobectomy. A superior approach to access a peripheral lung mass in the left upper lobe. The main pulmonary artery is encircled with tape to establish control, and the apicoposterior and anterior arterial branches are divided. (Reproduced with permission of The McGraw-Hill Companies, *Adult Chest Surgery,* 2009, edited by Sugarbaker et al., Figure 62–15, p. 539.)

Left Lower Lobectomy

The chest is entered through a fifth interspace posterolateral thoracotomy. The dissection for the left lower lobectomy begins posteriorly in the fissure with opening of the pleura and sheath over the main left pulmonary

artery. Reflection of the lower lobe posteriorly allows visualization of the artery to the superior segment of the lower lobe, which is isolated and ligated. Next, the basilar arterial branches are isolated and divided distal to the lingular artery. Similar to a right lower lobectomy, the superior segmental branches and basilar trunk can often be divided as one, if the arterial anatomy allows (Fig. 62.14). The inferior extent of the fissure can then be completed by applying a stapler. The lower lobe is reflected anteriorly and the inferior pulmonary ligament divided to the lower border of the inferior pulmonary vein. The posterior mediastinal pleural attachments to the inferior vein and the plane between the vein and the membranous bronchus are developed. The inferior pulmonary vein is freed circumferentially and then divided with a vascular stapler. The lower lobe is now attached only by its bronchus, which in most cases can be divided with a single stapler fired across the basal bronchi and superior segmental bronchus without compromising the left upper lobe bronchial orifice (Fig. 62.14). We generally will cover this dependent bronchial stump with locally derived vascularized tissue.

Mediastinal Lymph Node Dissection

Lymphadenectomy during pulmonary resection provides improved pathologic cancer staging and should be performed in all patients undergoing pulmonary resection for NSCLC. In addition to removing the hilar, interlobar, and segmental lymph nodes during the course of an anatomic resection, mediastinal nodal dissection should be performed. On the right side, lymph nodes from nodal stations 2R, 4R, 7, 8, 9, and 10R should be removed. A left-sided nodal dissection includes nodal stations 5, 6, 7, 8, 9, and 10L. Mediastinal dissection (removal of all lymph nodes) versus lymph node sampling from these nodal stations has been debated with respect to a survival advantage; however, mediastinal nodal dissection has proven to be safe and to upstage a number of patients with early clinical stage NSCLC.

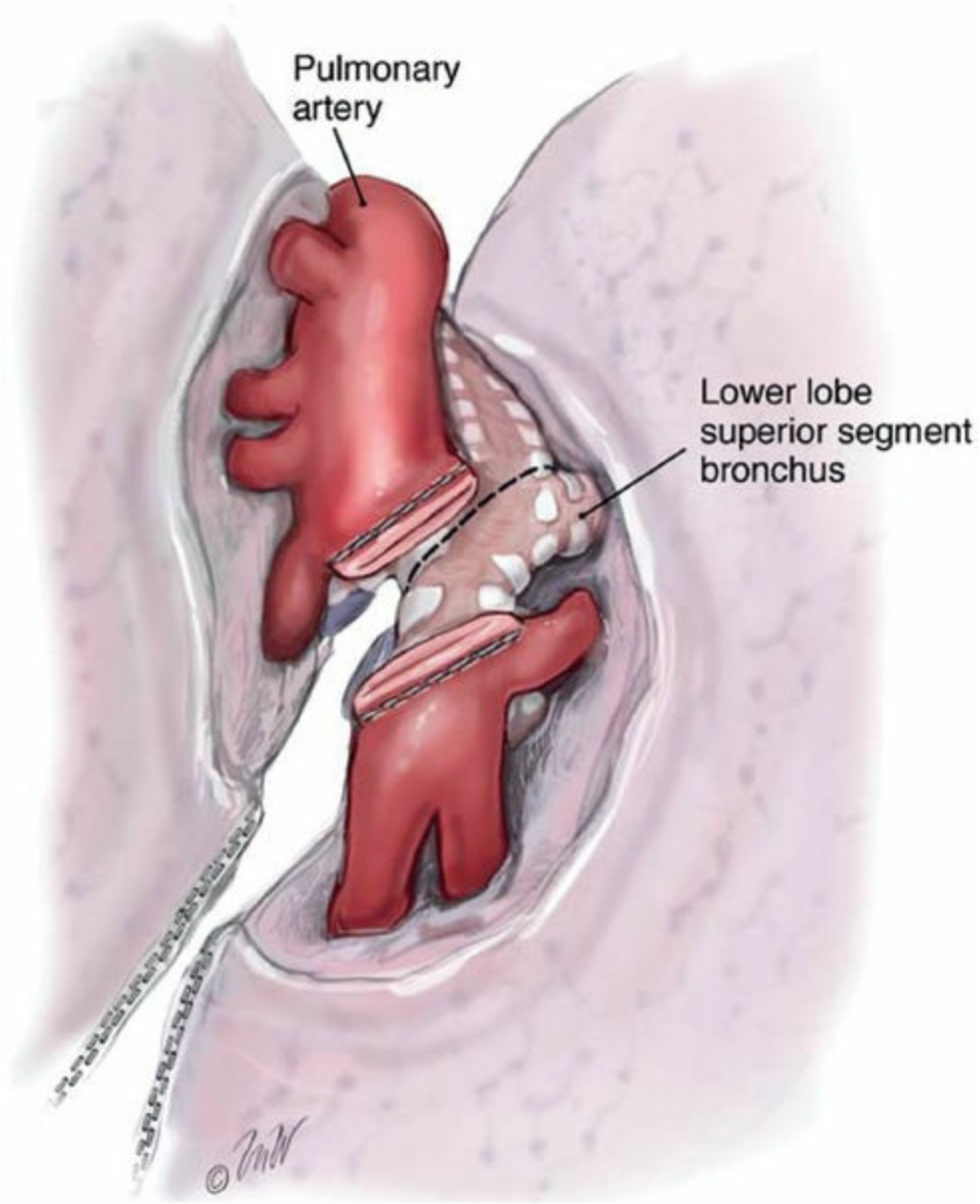

Figure 62.14. Left lower lobectomy. The lower lobe superior segment bronchus is closed with a stapler or interrupted absorbable sutures after the parenchyma between the upper and lower lobes has been divided. (Reproduced with permission of The McGraw-Hill Companies, *Adult Chest Surgery,* 2009, edited by Sugarbaker et al., Figure 62–17, p. 540.)

VIDEO-ASSISTED THORACOSCOPIC SURGERY

It is becoming increasingly evident that VATS lobectomy holds advantages over thoracotomy with regard to postoperative morbidity. For example, compared to matched patients undergoing thoracotomy and lobectomy, VATS lobectomy has lower incidences of arrhythmia, reintubation, and blood transfusion. Importantly, there are no compromises

in oncologic and long-term survival outcomes by VATS compared with open lobectomy, and patients with compromised pulmonary function should be preferably offered minimally invasive pulmonary resection, when possible.

The principles of anatomic resection by VATS do not differ from traditional open procedures. Hilar elements, such as arteries, veins, and bronchi, must be separately isolated and transected, and a complete lymphadenectomy is performed. To carry out a VATS pulmonary resection, two ports and an access incision are usually required. The access port is an incision 3 to 4 cm in size through which most of the vessel dissection is performed and through which the specimen is extracted at the conclusion of the resection. Rib spreading is avoided to minimize postoperative discomfort. The camera is placed in the seventh or eighth intercostal space in the midaxillary line for right-sided resections and the posterior axillary line for left-sided resections. The posterior port is generally positioned in the fifth to sixth intercostal space behind the tip of the scapula. The access incision is made in the fourth intercostal space in the anterior axillary line for right upper, right middle, and left upper lobectomies and in the fifth intercostal space in the anterior axillary line for lower lobectomies (Fig. 62.15). A standard hilar and mediastinal lymphadenectomy is performed as described above. All resected specimens are placed in a thoracoscopic specimen bag before removal from the thoracic cavity to prevent port-site seeding.

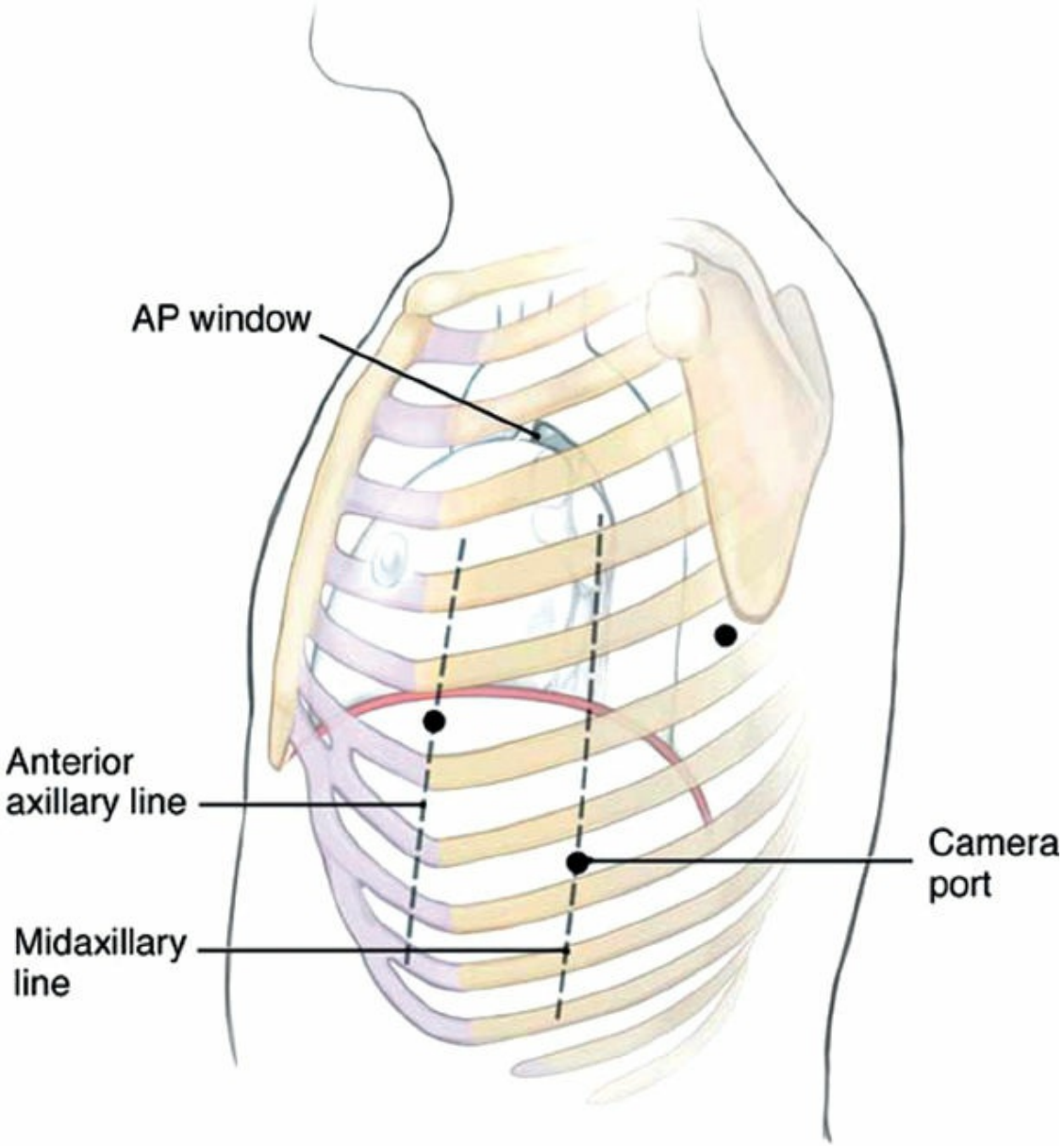

Figure 62.15. Port placement for the three incisions used for right upper lobectomy: inferior camera port, posterior working port, and anterior access/utility incision. (Reproduced with permission of The McGraw-Hill Companies, *Adult Chest Surgery,* 2009, edited by Sugarbaker et al., Figure 63–1, p. 544.)

Techniques for Specific VATS Resections

Right Upper Lobectomy

Once the ports are placed, the ring forceps is used through the posterior port to gently retract the upper lobe posteriorly. Dissection is performed from anterior to posterior beginning in the anterior hilum. Removal of hilar nodes defines the middle lobe vein and the upper lobe vein. The minor fissure can then be divided using an Endo GIA 30-mm stapler through the

access incision. The superior pulmonary vein is dissected circumferentially, and the upper lobe branches are identified and isolated, taking care to spare the middle lobe vein. To guide the stapler around the vessel, an 8-mm red rubber catheter attached to one anvil of the stapler is helpful; the flared end of the catheter dilates the passage and safely guides the stapler into position (Fig. 62.16). The truncus anterior branch of the right pulmonary artery and the posterior recurrent branch of the pulmonary artery are then identified, isolated, and transected using the endovascular stapler in a similar fashion (Fig. 62.17). The best angle for the articulated vascular stapler is often achieved via insertion through the low posterior port. The posterior hilum is opened and the right mainstem bronchus identified. The fissure between the superior segment of the lower lobe and the posterior segment of the upper lobe is completed and the right upper lobe bronchus is dissected free. The upper lobe is retracted anteriorly using ringed forceps placed through the access incision, and the right upper lobe bronchus is divided using the Endo GIA 30-mm stapler through the posterior port. The lobe is placed into a specimen bag and brought out via the access incision.

Right Middle Lobectomy

VATS middle lobectomy may at times be performed through entirely "thoracoscopic" (i.e., 2 cm or smaller) incisions because the middle lobe is small enough to fit through a 2-cm incision. Middle lobectomy begins with completing the minor fissure between the right upper lobe and the right middle lobe. Dissection of the anterior hilum and mobilization and transection of the middle lobe vein proceed using an endovascular stapler inserted through either the access incision or the posterior port. The middle lobe bronchus is identified lying posterior and slightly inferior to the vein. Through the access incision, the bronchus is dissected free. The middle lobe is then retracted posteriorly, and the bronchus is divided with an Endo GIA 30-mm stapler. This exposes the middle lobe artery that lies posterior and slightly superior to the bronchus. Through the posterior port, the middle lobe is retracted, and the artery is transected with the endovascular stapler passed through the access incision. The final step is completion of the minor fissure between the right middle and lower lobes using an Endo GIA stapler introduced through the access incision.

Right Lower Lobectomy

The first step is dividing the inferior pulmonary ligament with

electrocautery using the extended tip through the posterior port. Level 9 lymph nodes are also harvested at this time. The lower lobe is then retracted posteriorly using a ringed retractor, and the anterior hilum is opened. The inferior pulmonary vein is identified and divided with the endovascular stapler. The lower lobe artery must be isolated within the fissure and dissected free. This is done with blunt and sharp dissection through the access and posterior ports. Once the artery has been isolated, the lower lobe is retracted posteriorly and the artery divided using the endovascular stapler placed through the access incision. Alternatively, if the angle for the stapler via the access incision is not optimal, the stapler can be placed through the posterior incision. Care must be taken to avoid injury to the middle lobe artery. If there is insufficient room between the artery to the right middle and lower lobes, the superior segmental artery and basilar artery can be divided separately. After arterial transection is complete, attention is shifted to opening the posterior hilum and creating the fissure between the superior segment of the right lower lobe and the right upper lobe. This is done with the Endo GIA 30-mm stapler through the posterior port. The lobe can be displaced anteriorly to expose the bronchus, which is isolated with scissors and swab and divided with the Endo GIA 30-mm stapler. In cases in which the middle lobe bronchus is too close to the right lower lobe bronchus, the superior segmental bronchus and the basilar bronchus can be stapled and divided separately.

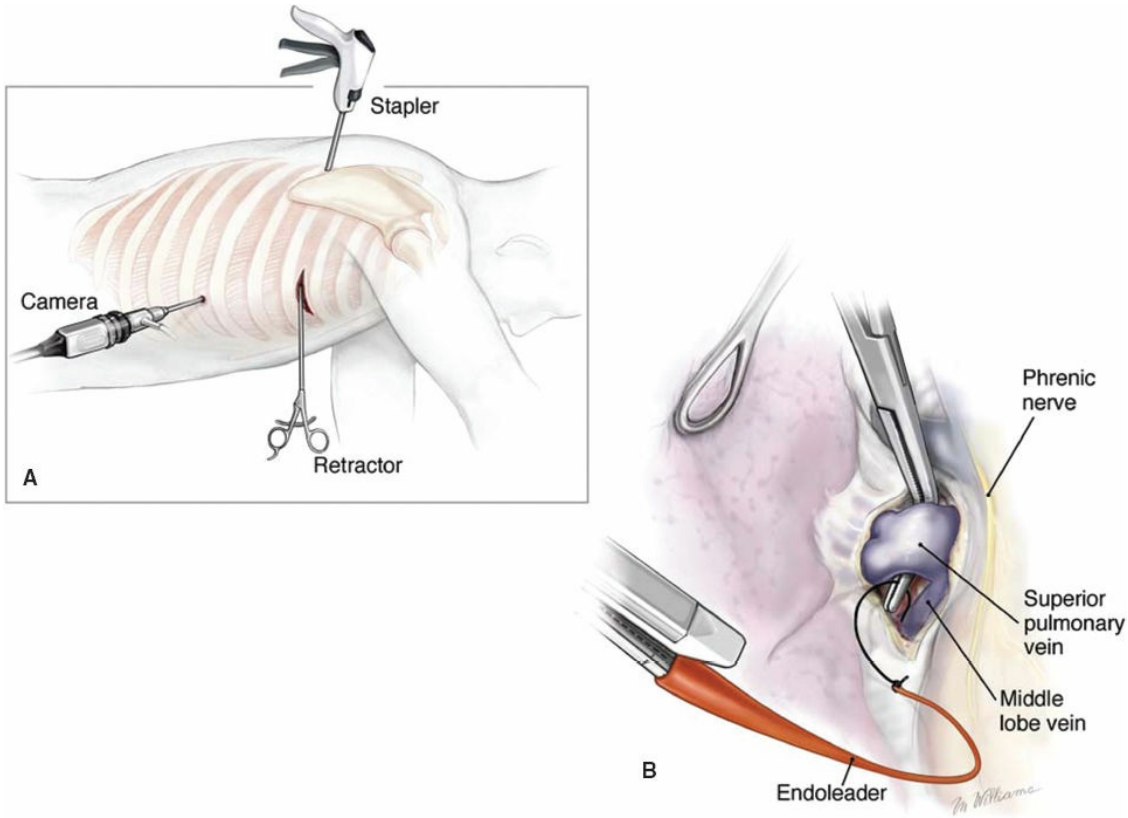

Figure 62.16. An oiled 2-0 silk suture is looped around the superior pulmonary vein, which is divided with an endovascular stapler, usually introduced through the posterior port, which provides the best angle. (Reproduced with permission of The McGraw-Hill Companies, *Adult Chest Surgery,* 2009, edited by Sugarbaker et al., Figure 63–2, p. 546.)

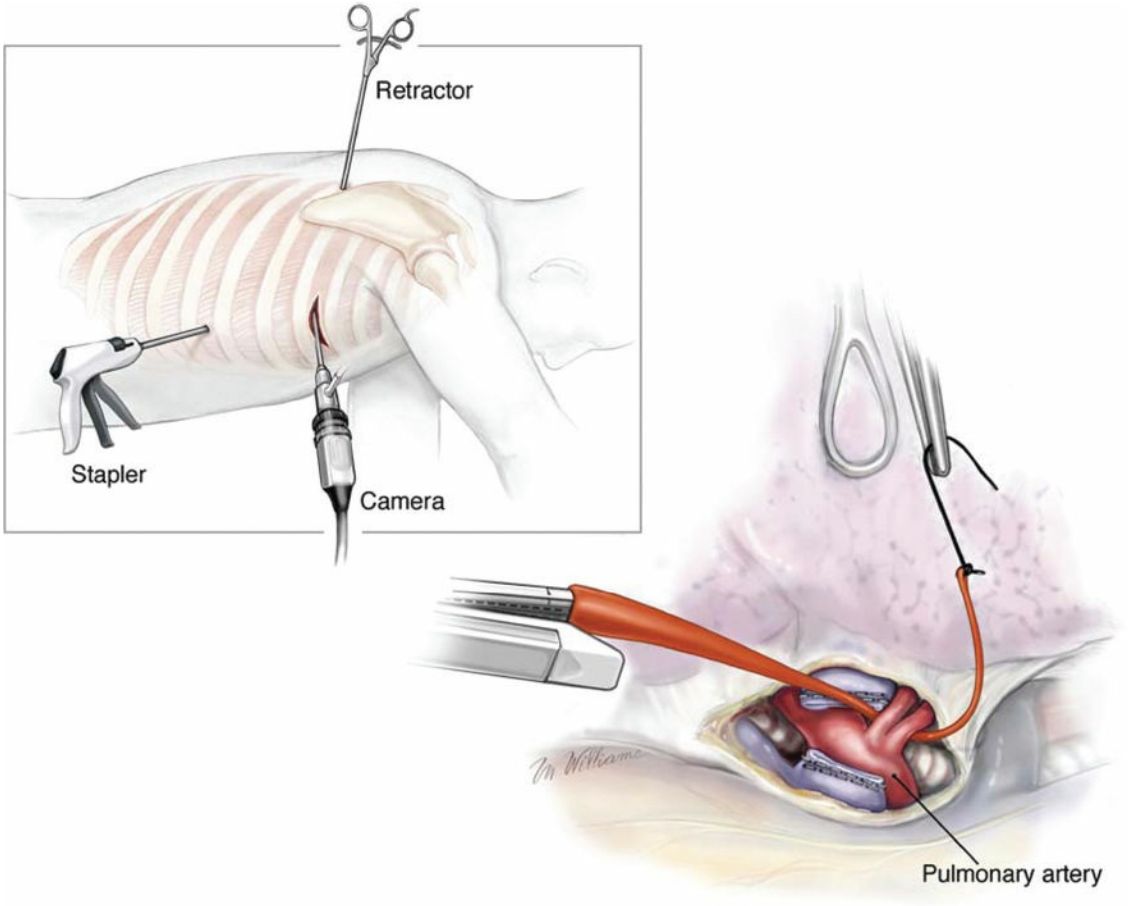

Figure 62.17. The truncus anterior and its variable number of branches are exposed, dissected free, and divided individually or as a trunk depending on configuration and accessibility. Before the arteries are divided, the camera is switched to the anterior access port for better visualization, and the stapler is placed in the inferior port (*inset*). An endovascular stapler fitted with a rubber "endoleader" for guidance is used to divide the vessels. (Reproduced with permission of The McGraw-Hill Companies, *Adult Chest Surgery,* 2009, edited by Sugarbaker et al., Figure 63–3, p. 547.)

Left Upper Lobectomy

Left upper lobectomy is technically the most challenging operation that can be carried out using VATS techniques because of the presence of arterial branches that originate from the fissure and those that originate from the proximal pulmonary artery. Furthermore, the pulmonary anatomy to the left upper lobe is variable. The operation is begun by opening the anterior hilum through the anterior access incision, and the superior pulmonary vein is dissected free. Before dividing the superior pulmonary vein, the inferior pulmonary vein must also be identified to assure that it is

spared from injury if an extrapericardial venous confluence is not fully appreciated. The upper lobe is retracted posteriorly and the vein divided with an endovascular stapler, via the access incision or through the posterior incision. Next, the posterior fissure between the superior segment of the lower and the upper lobe is completed with an Endo GIA stapler through the posterior port. The posterior hilum can be opened through the same port. The anterior pulmonary artery, which runs posteriorly between the upper and lower lobe, is carefully dissected free and divided using the endovascular stapler placed through the access incision. The posterior arterial branches and the branches to the lingula are divided through the posterior port with an endovascular stapler. Once arterial transection is completed, dissection continues on the anterior hilum through the access incision and the fissure between the lingula and the lower lobe is completed with the Endo GIA stapler. Finally, the left upper lobe bronchus is dissected free and divided with the Endo GIA stapler through the posterior port. Alternatively, after division of the superior pulmonary vein, the first one or two branches of the pulmonary artery can be divided with a vascular stapler passed through the posterior port. The upper lobe bronchus can then be divided, followed by the remaining branches to the upper lobe originating in the fissure. The fissure is completed last.

Left Lower Lobectomy

The technique for left lower lobectomy is similar to that used to perform a right lower lobectomy. The first step is dissection of the inferior pulmonary ligament and isolation of the inferior pulmonary vein. The lower lobe is grasped with ringed forceps through the access incision and retracted anteriorly. This puts mild tension on the ligament, which is then dissected up to the vein. The anterior fissure between the lingula and the lower lobe is created with an Endo GIA stapler. The lower lobe can then be retracted posteriorly, and the inferior pulmonary vein is divided with the endovascular stapler. Continuing, the posterior fissure is completed between the superior segment of the lower lobe and the upper lobe using an Endo GIA stapler. With sharp and blunt dissection, the pulmonary artery in the fissure is freed using the access incision and the posterior port. Through the posterior port, the superior segmental artery and basilar pulmonary arteries are divided with serial firings of the endovascular stapler. Once arterial ligation is complete, attention is shifted to isolation and dissection of the bronchus. The upper lobe is retracted anteriorly, and the lower lobe bronchus is dissected free from the posterior hilum and

divided using the Endo GIA 30-mm stapler placed through the posterior port.

PNEUMONECTOMY

Indications

In patients with a centrally located tumor, which is invading to hilar structures or involves extensive amounts of both upper and lower lobes, a pneumonectomy is often necessary for a curative resection. Operative mortality rates for pneumonectomy have been reported to be between 5% and 20%; morbidity and mortality rates are highest following neoadjuvant chemoradiation therapy.

Preparation

For left-sided lesions, a bronchial blocker or right-sided double-lumen endotracheal tube is positioned to aid in left lung deflation. For right-sided tumors, the standard left-sided double-lumen endotracheal tube is preferred. The patient is then placed in the lateral decubitus position, and the chest is prepared and draped.

Right Pneumonectomy

A standard fifth intercostal space posterolateral thoracotomy incision is performed as previously described. The sixth rib is marked, and the intercostal muscle flap along the superior border of this rib is harvested for bronchial stump coverage. The sixth rib is shingled posteriorly near the longitudinal ligament. After insertion of the chest retractor, the surgeon systematically evaluates the lung and mediastinum to document the extent of disease. A histologic diagnosis of NSCLC is made by biopsy, if tissue has not been obtained preoperatively. Pleural metastases or adherence to the spine or unresectable mediastinal structures (T4 lesions) should be ruled out. After documenting a localized lung cancer, the tumor is evaluated for resectability. This step requires a circumferential evaluation of the hilar structures with a goal of ligation and division of major vessels and the bronchus with clear margins. The pulmonary artery, veins, and bronchus must be inspected before proceeding with any ligation of these structures and committing the patient to resection. The lung is gently retracted posteroinferiorly to access the hilar structures (main pulmonary artery, right mainstem bronchus, superior pulmonary vein, and azygos

vein) (Fig. 62.18A). The adventitial sheath of the proximal pulmonary artery is dissected superomedially near the origin of the right upper lobe bronchial takeoff. Level 10 (main bronchial or hilar) lymph nodes should be swept up onto the specimen side, revealing the right mainstem bronchus in the space beneath the azygos vein. The vagal afferents to the bronchus are divided, and visible bronchial arteries are cauterized, clipped, or ligated.

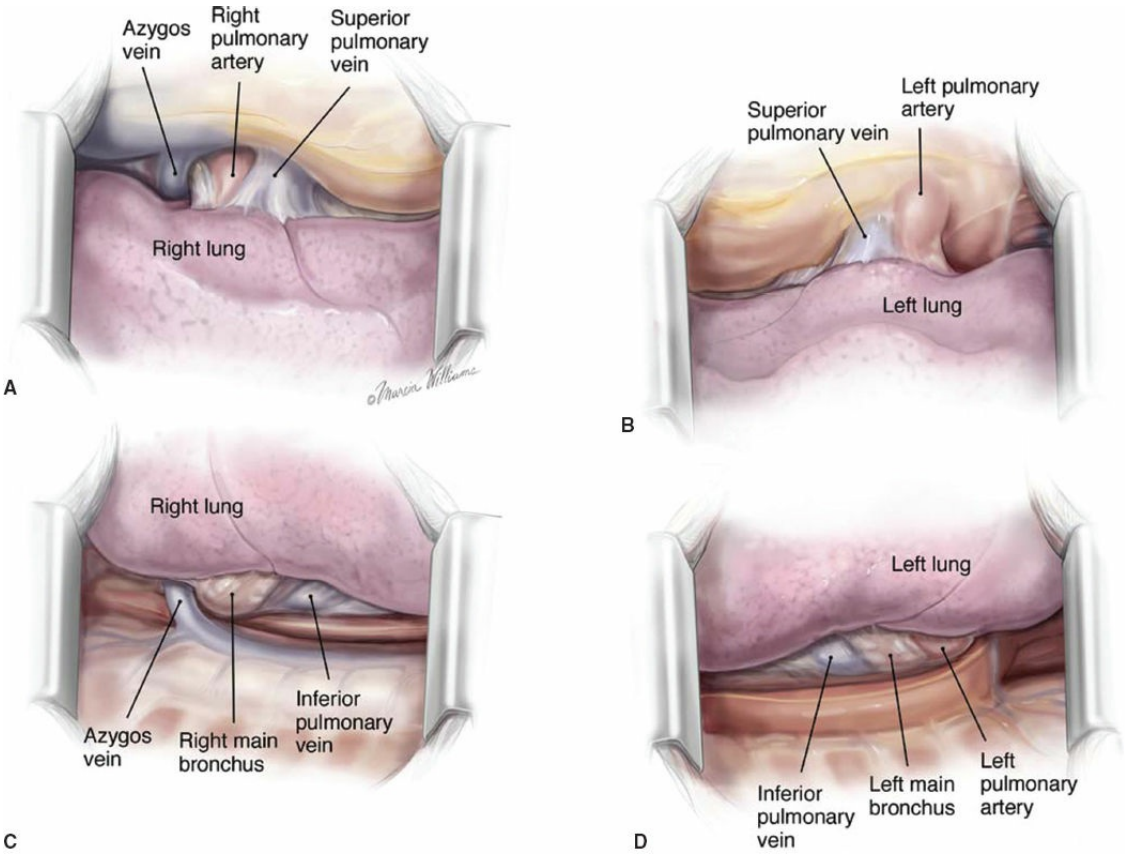

Figure 62.18. Anterior and posterior views of the hilum of the lung from a standard posterolateral thoracotomy. **A.** Anterior view of right lung. **B.** Posterior view of right lung. **C.** Anterior view of left lung. **D.** Posterior view of left lung. (Reproduced with permission of The McGraw-Hill Companies, *Adult Chest Surgery,* 2009, edited by Sugarbaker et al., Figure 2–4, p. 8.)

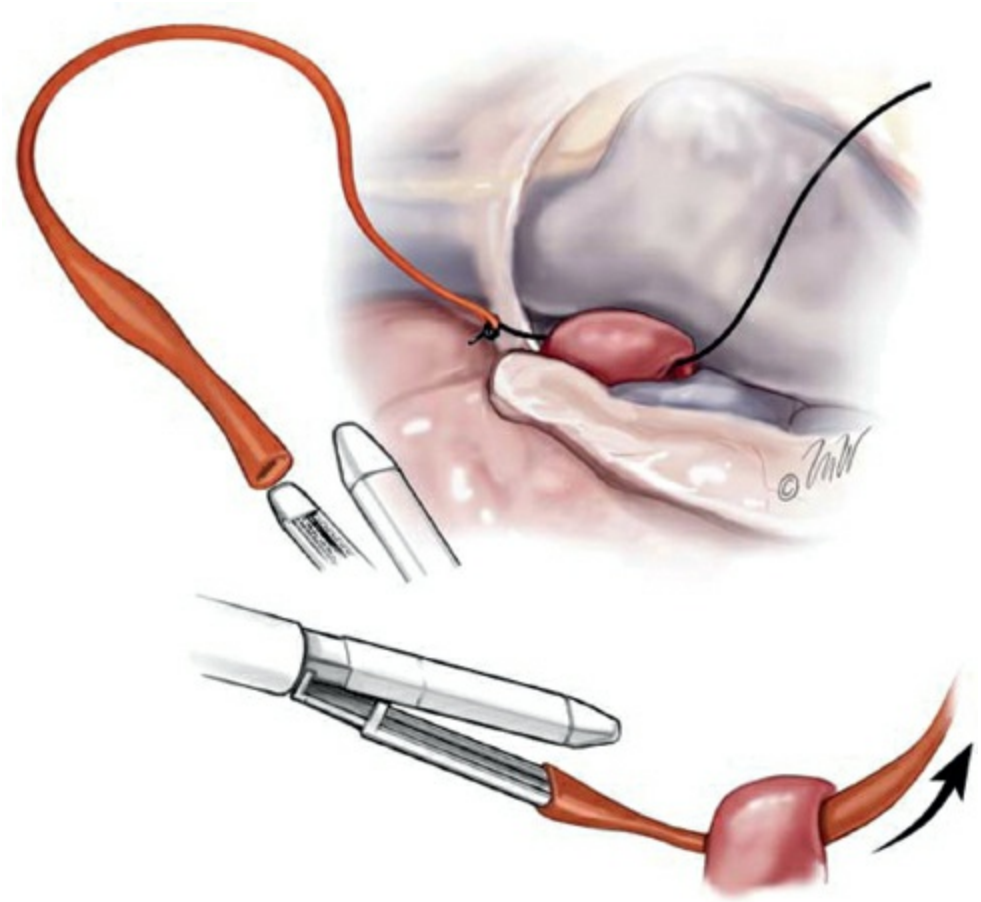

Figure 62.19. The endoleader is passed around the pulmonary artery to guide the safe passage of the endovascular stapler, and the right pulmonary artery is divided. (Reproduced with permission of The McGraw-Hill Companies, *Adult Chest Surgery,* 2009, edited by Sugarbaker et al., Figure 103–12, p. 874.)

The lung is then retracted anteriorly, exposing the right mainstem bronchus and subcarinal space (Fig. 62.18B). Level 7 subcarinal lymph nodes are removed, and a finger is passed behind the bronchus to ensure resectability. With the lung retracted superiorly, the inferior pulmonary ligament is divided to the edge of the inferior pulmonary vein and the level 9 lymph nodes are harvested. The lung is then retracted posteroinferiorly and the hilar pleura is opened posterior to the phrenic nerve. The main pulmonary artery and superior and inferior pulmonary veins are evaluated for resectability. The last question to be answered is whether a lesser resection, such as a lobectomy or sleeve lobectomy, can be performed. If not, then attention is directed toward division of the hilar structures. The order of division of the vascular structures or bronchus is not critical and usually proceeds along the lines of the ease of dissection. Our preferred

technique involves division of the right main pulmonary artery first. Other surgeons prefer to divide the inferior and superior pulmonary veins first. Dissection and division of the superior pulmonary vein aids in exposure of the main pulmonary artery, which traverses superior and posterior to the vein.

After sharply dividing the adventitial sheath of the main pulmonary artery, most of the isolation of the vessel can be carried out with gentle, blunt dissection. Occasionally, the truncus anterior branch of the pulmonary artery can be divided separately to provide more room for division of the right main pulmonary artery. If there is sufficient length to accommodate the surgeon's finger, we prefer to use an endovascular stapler to divide the artery (Fig. 62.19). Other surgeons prefer to ligate the artery with nonabsorbable sutures and suture-ligate the proximal end. After division of the artery is complete, the superior pulmonary veins are isolated by dissecting anteriorly in the groove of pericardial reflection between the superior and inferior pulmonary veins. These veins can be similarly divided with separate applications of the stapler. The lung is now tethered only by the bronchus. Reflecting the lung anteriorly affords access to the membranous side of the mainstem bronchus. The bronchus can be divided with suture closure or stapler. We staple the bronchus with a heavy wire 30-mm stapler (Fig. 62.20). The stump should be left as short as possible, flush with the carina, to avoid the dependent pooling of secretions and the higher likelihood of breakdown incumbent with a longer stump. The chest is then irrigated, and the stump is tested for air leakage with 20 to 30 cm H_2O of static positive-pressure ventilation. We routinely cover any pneumonectomy stump with vascularized tissue. A pericardial fat pad based on the superior thymic vessels can easily be mobilized to cover the stump in most instances (Fig. 62.21). The flap is anchored to the airway with absorbable sutures. Other local flap coverage options include an intercostal muscle flap, parietal pleura, pericardium, or omentum. The empty pleural space is examined for hemostasis and the wound is closed without the use of chest tube drainage. A catheter and syringe are used to evacuate 1,000 to 1,200 mL of air from the hemithorax after the patient is placed supine to aid in repositioning the mediastinum to the midline.

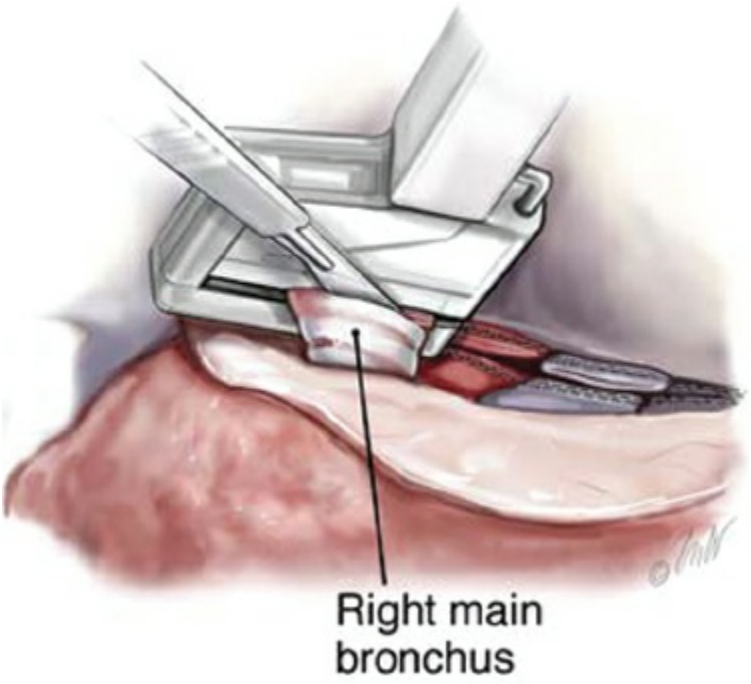

Figure 62.20. The right mainstem bronchus is encircled as close to the carina as possible before division with a heavy gauge wire bronchial stapler. (Reproduced with permission of The McGraw-Hill Companies, *Adult Chest Surgery,* 2009, edited by Sugarbaker et al., Figure 103–14, p. 875.)

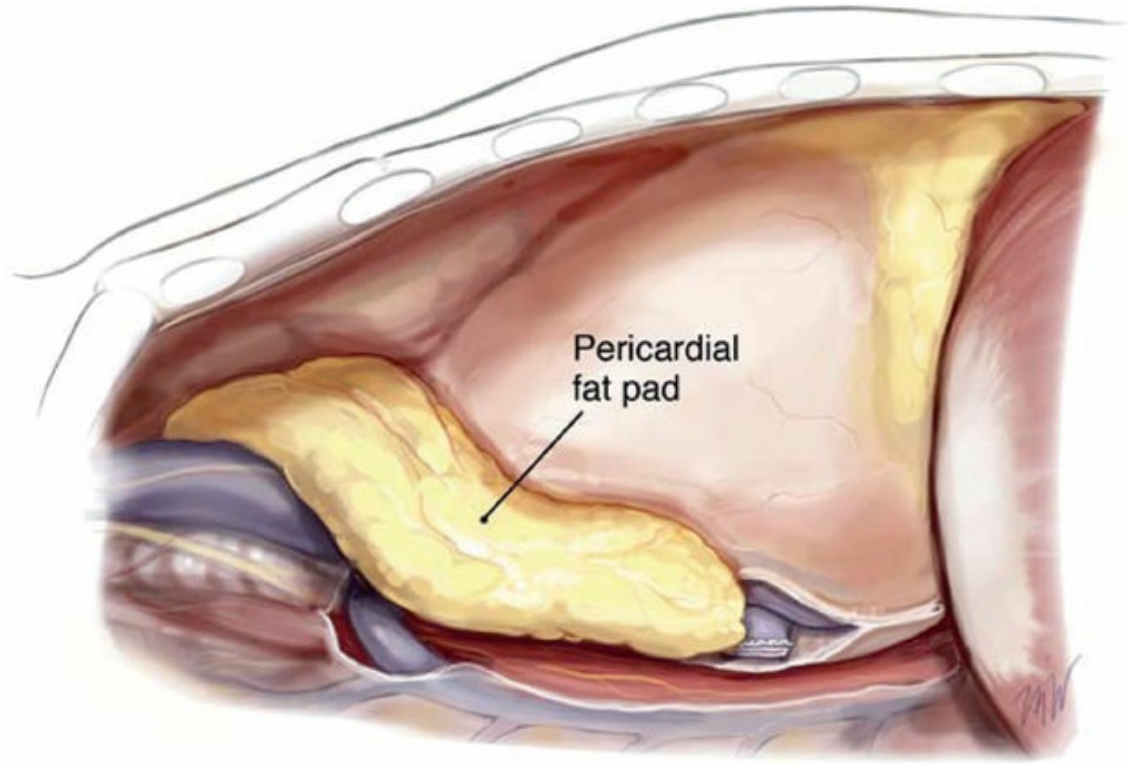

Figure 62.21. A pericardial fat pad is used as a bronchial buttress. (Reproduced with permission of The McGraw-Hill

Companies, *Adult Chest Surgery,* 2009, edited by Sugarbaker et al., Figure 103–16, p. 876.)

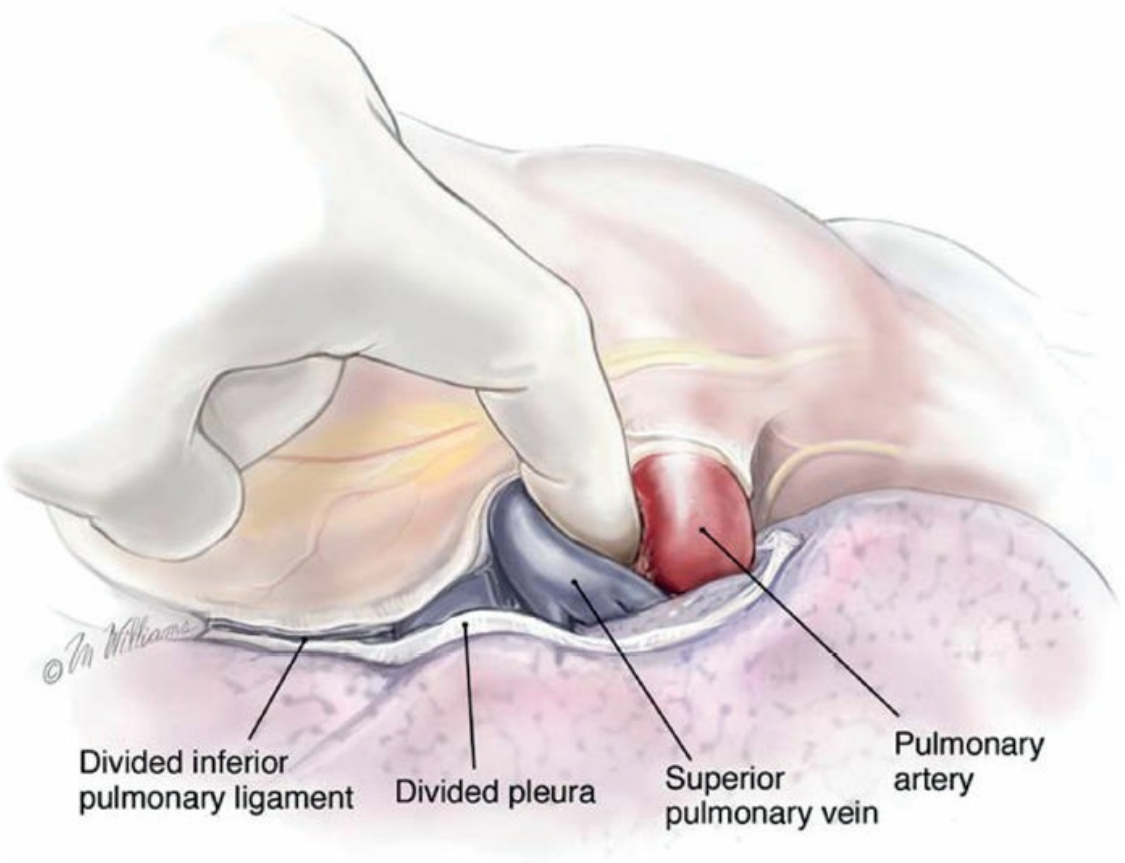

Figure 62.22. Left pneumonectomy. Using a combination of blunt and sharp dissection, the pulmonary artery is dissected away from the pulmonary vein anteroinferiorly. (Reproduced with permission of The McGraw-Hill Companies, *Adult Chest Surgery,* 2009, edited by Sugarbaker et al., Figure 64–1, p. 554.)

Left Pneumonectomy

The left pneumonectomy differs from the right mainly with respect to the anatomy near the aortic arch (Fig. 62.22). Level 5 AP window lymph nodes and the level 6 nodes over the anterior aortic arch are dissected and removed during the initial exploration. This maneuver gives better exposure to the proximal pulmonary artery. The recurrent laryngeal nerve branches off the vagus and courses anteriorly, then inferiorly, to the aortic arch. This structure should be protected except in instances of direct tumor involvement. All hilar structures are inspected and confirmation of tumor resectability is made before ligating or dividing these structures. The vessels are divided in a manner similar to the procedure described for the

right side. Dissection is first carried out in the anterior hilum (Fig 62.18C) then posterior hilum (Fig 62.18D). The left mainstem bronchus is significantly longer than the right, and attaining the desired short stump can be more challenging (Fig. 62.23). Tissue coverage of the stump remains important, and the pedicled pericardial fat pad is used when available.

Occasionally, in an otherwise resectable situation, the tumor involves the proximal hilum, where a safe margin cannot be obtained on the vessels. In this setting, the pericardium can be opened away from the tumor and an intrapericardial plane established for safe ligation of the pulmonary veins or main pulmonary artery of the involved side. In contrast to the right pulmonary artery, which has a long intrapericardial segment and can be easily divided within the pericardium, the left pulmonary artery is short and more difficult to isolate. Small pericardial defects need not be covered or closed, whereas larger defects require patch closure, usually using a surgical membrane, to prevent cardiac herniation into the empty thorax (Fig. 62.24). Such approaches do not increase operative mortality, although the incidence of postoperative supraventricular arrhythmias approaches 30%.

CONCLUSIONS AND GENERAL CONSIDERATIONS

Surgery is a cornerstone in the treatment of patients with NSCLC. Lobectomy is currently the gold standard for patients with early-stage NSCLC. Compared to open lobectomy, thoracoscopic lobectomy results in decreased morbidity and mortality for patients with lung cancer, and these benefits may be exaggerated in patients with decreased pulmonary function. Importantly thoracoscopic lobectomy has similar oncologic outcomes when compared to open lobectomy. In patients with small lung cancers and impaired pulmonary function, sublobar (segmentectomy and wedge resection) can be considered as parenchymal sparing approaches. For patients with tumors involving multiple lobes and central tumors involving hilar structures, pneumonectomy may be required for complete resection. In some cases of central tumors, sleeve resection of an airway and/or pulmonary artery may be possible to avoid pneumonectomy. Complete lymph node dissection is important for all patients undergoing pulmonary resection for NSCLC.

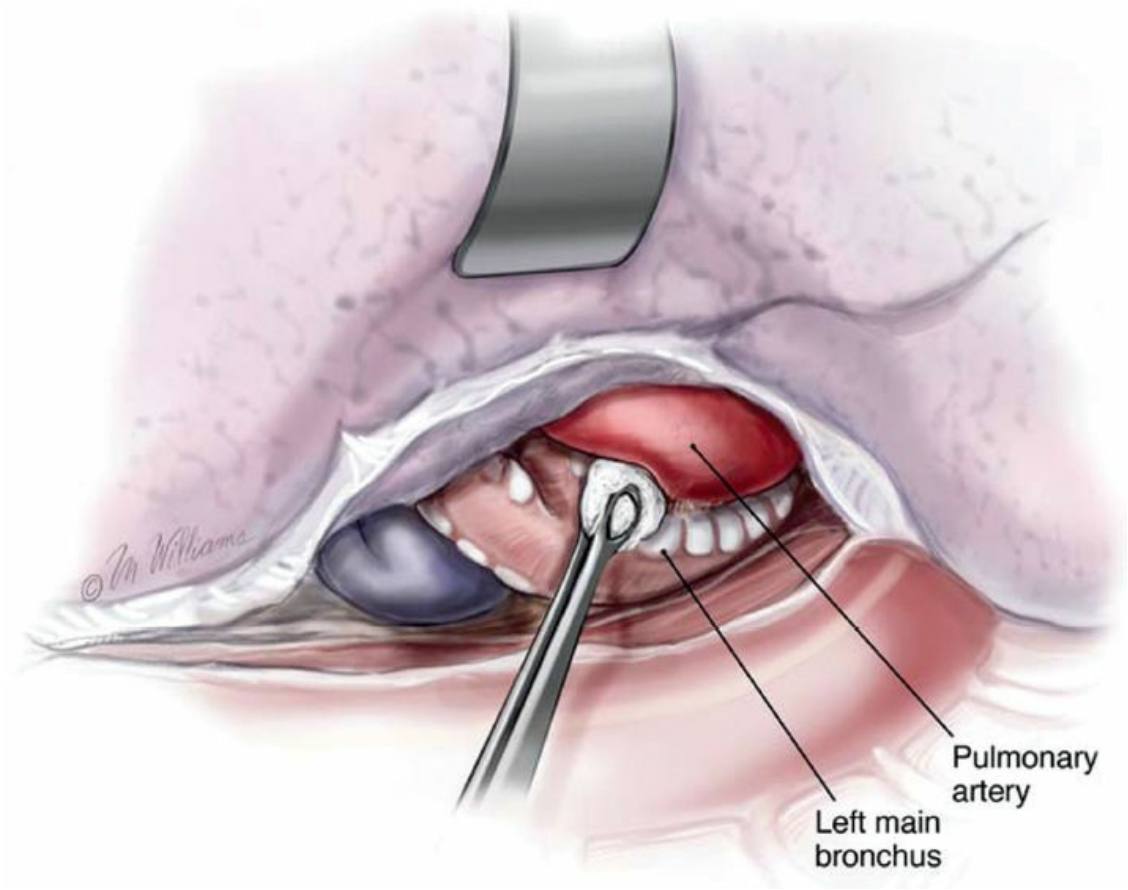

Figure 62.23. Left pneumonectomy. The bronchus is dissected away from the pulmonary artery posteriorly. (Reproduced with permission of The McGraw-Hill Companies, *Adult Chest Surgery,* 2009, edited by Sugarbaker et al., Figure 64–2, p. 555.)

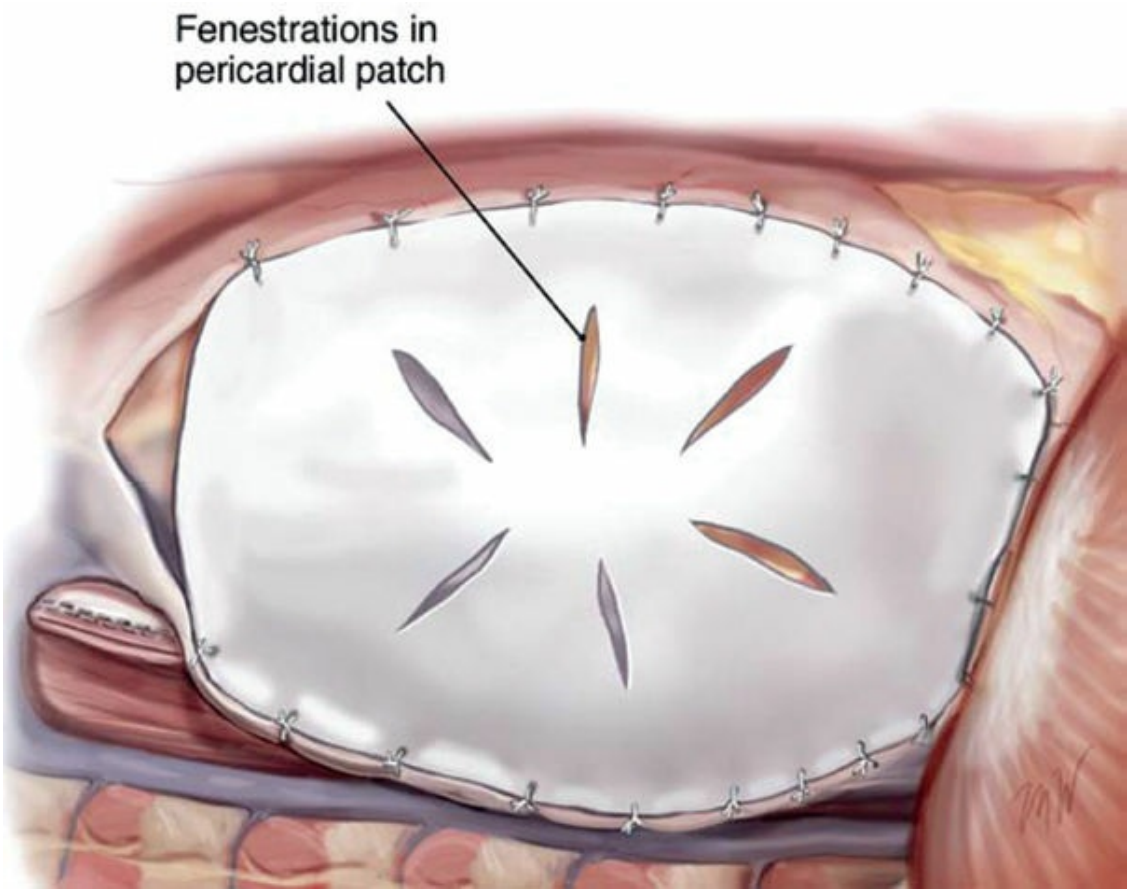

Figure 62.24. A pericardial patch is fenestrated and sewn to the pericardial edge to prevent herniation and rotation of the heart after pneumonectomy. (Reproduced with permission of The McGraw-Hill Companies, *Adult Chest Surgery,* 2009, edited by Sugarbaker et al., Figure 103–20, p. 878.)

ACKNOWLEDGMENTS

The authors wish to acknowledge the services of Marcia Williams for medical illustration, Ann Adams for editorial assistance, and Ellie Biaghoshi for assistance with chapter preparation.

Suggested Readings

Albain KS, Crowley JJ, LeBlanc M, et al. Survival determinants in extensive-stage non–small-cell lung cancer: the southwest oncology group experience. *J Clin Oncol* 1961;9(9):1618–26.

Brunelli A, Kim AW, Berger KI, et al. Physiologic evaluation of the patient with lung cancer being considered for resectional surgery: Diagnosis and management of lung cancer, 3rd ed: American college of chest physicians evidence-based clinical practice guidelines. *Chest* 2013;143:e166S–90S.

Burt BM, Kosinski AS, Shrager JB, et al. Thoracoscopic lobectomy is associated

with acceptable morbidity and mortality in patients with predicted postoperative forced expiratory volume in 1 second or diffusing capacity for carbon monoxide less than 40% of normal. *J Thorac Cardiovasc Surg* 2014;148:19–28, discussion 28–9 e1.

Darling GE, Allen MS, Decker PA, et al. Randomized trial of mediastinal lymph node sampling versus complete lymphadenectomy during pulmonary resection in the patient with N0 or N1 (less than hilar) non-small cell carcinoma: results of the American college of surgery oncology group z0030 trial. *J Thorac Cardiovasc Surg* 2011;141(3):662–70.

Detterbeck FC, Boffa DJ, Tanoue LT, et al. Details and difficulties regarding the new lung cancer staging system. *Chest* 2010;137(5):1172–80.

Ettinger DS, Akerley W, Bepler G, et al. Non-small cell lung cancer. *J Natl Compr Canc Netw* 2010;8:740–801.

Ettinger DS, Wood DE, Akerley W, et al. Non-small cell lung cancer, version 6.2015. *J Natl Compr Canc Netw* 2015;13:515–24.

Ginsberg RJ, Rubinstein LV. Randomized trial of lobectomy versus limited resection for T1 N0 non-small cell lung cancer. Lung cancer study group. *Annals Thoracic Surgery* 1995;60(3):615–22; discussion 622–3.

National Lung Screening Trial Research T, Aberle DR, Adams AM, Berg CD, et al. Reduced lung-cancer mortality with low-dose computed tomographic screening. *N J Medicine* 2011;365:395–409.

Paul S, Isaacs AJ, Treasure T, et al. Long term survival with thoracoscopic versus open lobectomy: propensity matched comparative analysis using SEER-Medicare database. *BMJ* 2014;349:g5575.

EDITOR'S COMMENT

Since the publication of the last edition, we have expanded our understanding of the staging and treatment of lung cancer. The reasons for this are multiple but can be grouped in at least four overall headings:

1. Most important is a clearer understanding of the types and staging of lung cancer. Key to this is the demonstrated value of positron emission tomography (PET) computed tomography (CT) which as Sugarbaker notes may make unnecessary staging mediastinoscopy and the trend to use EBUS and EUS.
2. In addition, outcomes are improved because of better patient selection and the application of enhanced postoperative recovery protocols including the use of thoracic epidurals for postoperative pain management.
3. Development of new technical expertise with minimally invasive surgery and the development of new instruments.

4. The importance of molecular analysis of tumors for the selection of chemotherapy.

The authors point out the mainstay of treatment for NSCLC is surgery and more explicitly lobectomy unless the indications exist for a pneumonectomy in patients with a centrally located tumor, which is invading to hilar structures or involves extensive amounts of both upper and lower lobes. Key to staging is the assessment of the mediastinal nodes. Furthermore there has been an increasing use of videoscopic lobectomy. PET CT is a standard part of the pretreatment evaluation of NSCLC.

Staging of the mediastinal and hilar lymph nodes plays a crucial role in identifying the best treatment option for patients with confirmed or suspected lung cancer and, in many cases, can simultaneously confirm a diagnosis of cancer. Noninvasive modalities, such as CT, PET and PET CT, are an important first step in this assessment. Ultimately, invasive staging is frequently required to confirm or rule out the presence of metastatic disease within the lymph nodes. The authors describe the various methods of mediastinal nodal staging in the absence of M1 extrathoracic disease, which include cervical mediastinoscopy, anterior mediastinoscopy (Chamberlain procedure), endobronchial ultrasound (EBUS) with transbronchial nodal aspiration (TBNA), endoscopic ultrasound (EUS) with TBNA and VATS.

At this point in time, PET CT showing hypermetabolism in the mediastinum requires pathologic confirmation. Currently invasive staging of the mediastinum in patients with early stage (stages I and II) has been recommended by the National Comprehensive Cancer Network (NCCN). However, as the authors note based upon a recent prospective trial in early-stage lung cancer patients, these recommendations may be altered in the next version of the NCCN guidelines. It is worth emphasizing that in the referenced trial of 90 patients with clinical stage T2N0 or T1N0 with standardized uptake value greater than 10 by PET who underwent routine cervical mediastinoscopy before lung resection, only 1 patient (1.1%) had occult metastases detected at mediastinoscopy if they had a negative PET CT.

Can mediastinoscopy be replaced by less invasive techniques? Several trials have compared endoscopic approaches with cervical mediastinoscopy which is considered the gold standard by many authorities. Yasufuku et al. (A prospective controlled trial of endobronchial ultrasound-guided transbronchial needle aspiration compared with mediastinoscopy for mediastinal lymph node staging of lung cancer. *J Thorac Cardiovasc Surg* 2011;142:1393–400) prospectively enrolled 159 patients with confirmed or suspected lung cancer and performed EBUS immediately followed by cervical mediastinoscopy under general anesthesia in all patients. They reported finding no significant differences in sensitivity (81% vs. 79%), NPV (91% vs. 90%), or accuracy (93% vs. 93%) between the two tests, but higher complications in the mediastinoscopy group. Annema et al. (Mediastinoscopy vs. endosonography

for mediastinal nodal staging of lung cancer: a randomized trial. *JAMA* 2010; 304:2245–52) reported a multicenter study in which 241 patients were randomly assigned to EBUS and EUS followed by mediastinoscopy if no nodal metastasis was identified versus mediastinoscopy alone. They found no difference in sensitivity and NPV between mediastinoscopy and combined EBUS and EUS. It should be noted that the majority of the published experience with EUS staging of lung cancer has included subjects with moderate or higher prevalence of mediastinal disease (>35%). Uncertainty remains with regard to application of this and other staging modalities in cohorts with lower prevalence of disease (e.g., CT- or PET/CT-negative mediastinum).

A study by Wallace et al. (Minimally invasive endoscopic staging of suspected lung cancer. *JAMA* 2008;299:540–6) compared EBUS and EUS and found identical sensitivity between the techniques in 150 patients with known or suspected lung cancer. Kang et al. (EBUS-centred versus EUS-centred mediastinal staging in lung cancer: a randomised controlled trial. *Thorax* 2014;69:261–8) found a significant improvement in sensitivity, accuracy and upstaging when EUS was followed by EBUS, while the converse was not observed. This study suggested that "EUS provides minimal additional diagnostic gain when EBUS is performed first, and that perhaps EBUS alone is sufficient for adequate endoscopic staging of the mediastinum when node stations #5, #8, and #9 are not suspected to be involved with disease on imaging."

Enhanced Recovery After Surgery (ERAS) protocols have been advocated for many operative procedures. The authors outline the details of operative techniques including thoracic surgery. Gimenez-Mila et al. (Design and implementation of an enhanced recovery program in thoracic surgery. *J Thorac Dis* 2016;8(Suppl 1):S37–45) reviewed recent literature on early recovery pathways specific to thoracic surgery. They found that ERAS programs were divided into the preoperative, intraoperative, and postoperative periods. A key part of these programs is promotion of physical activity promotion and educational programs that provide information about the surgery and the surgical pathway. In the perioperative management an optimal pain control strategy, antibiotic prophylaxis and protective ventilation were likewise essential. In addition, they recommended that minimally invasive surgery approaches should be applied if possible and combined with a prospectively designed postoperative care plan that is proactive rather than reactive. They showed that an early recovery program in thoracic surgery can facilitate early discharge from hospital and possibly reduce postoperative complications.

An example of an enhanced recovery (ER) protocol was the report of Scarci et al. (Enhanced recovery pathway for thoracic surgery in the UK. *J Thorac Dis* 2016;8:S78–83). They introduced a multi-disciplinary integrated perioperative pathway. In this study, 154 ER patients were compared with 171 controls from the year before ER was introduced. They found an 80% increase in same-day admissions, with a net gain of more than 300 patient bed-days. Increased use of

video-assisted procedures in the ER group (ER, 32.9% vs. 9.4%, $P = 0.0001$) and a lower rate of admission to the intensive care unit (ER, 5.8% vs. 12.9%, $P = 0.04$), a decreased length of stay (mean ER, 5.2 vs. 11.7 days, $P < 0.0001$), and higher patient satisfaction scores with reduced cost. Use of ER pathways has proven to be a safe perioperative management strategy to improve patient satisfaction and to reduce the length of hospital stay and cost after major thoracic surgery without increasing morbidity or mortality.

Although most lobectomies in the United States are done by an open approach there has been a trend toward application of video-assisted thoracoscopic surgery (VATS) and robotic techniques. Simple thoracoscopy to examine the pleural space and perhaps perform simple wedge resection has existed for years. The application of advanced thoracoscopy to anatomic lung resection began in the early 1990s. Initial reports were greeted with harsh criticism and skepticism. The randomized trial by Kirby et al. (Lobectomy–video-assisted thoracic surgery versus muscle-sparing thoracotomy. A randomized trial. *J Thorac Cardiovasc Surg* 1995;109(5):997–1001) was the beginning of minimally invasive thoracic surgery. In 2008, the number of lobectomies performed by VATS techniques has increased to at a 32% according to the Society of Thoracic Surgeons database (Boffa DJ, Allen MS, Grab JD, et al. Data from The Society of Thoracic Surgeons General Thoracic Surgery database: the surgical management of primary lung tumors *J Thorac Cardiovasc Surg* 2008;135:247–54) and this number has continued to increase as research comparing VATS lobectomy to the open procedure has confirmed the benefits of VATS in early-stage lung cancers with less blood loss, improved operative times, and fewer perioperative complications all favor the minimally invasive approach. The oncologic benefits are similar to open approaches with equivalent 5-year survival.

Robotic surgery was introduced at the end of 1990s in part to overcome the limitations of minimally invasive surgery. Robotic lobectomy has recently had significant focus with increasing numbers of cases. The main advantages of robotic technology over VATS are that natural movements of the surgeon's hands and wrists which are translated by the computer-assisted robotic arms into precise movements. Increasing experience shows the value of the robotic approach. The robotic approach is equivalent to VATS in terms of immediate postoperative results and oncologic results, but may be technically easier to learn. However, most of the studies show an increased cost with this technique. An excellent review by Veronesi is available (Robotic lobectomy and segmentectomy for lung cancer: results and operating technique. *J Thorac Dis* 2015;7(Supp 2):S 122–30).

Recent developments in the molecular analysis of lung cancer have led to developments in targeted and personalized therapy in advanced NSCLC (Coco S, Truini A, Vanni I, et al. Next generation sequencing in non-small cell lung cancer: new avenues toward the personalized medicine. *Curr Drug Targets* 2015;16:47–59). Indeed, as simple as it seems, not all lung cancers are the

same. The advent of next-generation sequencing (NGS) has dramatically revolutionized the molecular knowledge of cancer. The review by Coco et al. reports an overview of different applications of the NGS as novel approach to study NSCLC, and the techniques ability to provide information about the mutational spectrum of this cancer. An additional study (DiBardino DM et al. Next-generation sequencing of non-small cell lung cancer using a customized, targeted sequencing panel: emphasis on small biopsy and cytology. *Cyto J* 2017;14:7) further shows the power of NGS in NSCLC in small biopsy and even cytologic specimens. In this study, the genomic alterations found most commonly were in the *TP53, EGFR, EPHB1, MLL3, APC, SETD2, KRAS, DNMT3A, RB1, CDKN2A, ARID1A, EP300, KDM6B, RAD50, STK11*, and *BRCA2* genes. These can be targeted by novel therapeutic regimens.

E. Christopher Ellison and J.E.F.

SECTION VI

THE DIAPHRAGM

63 Surgical Anatomy of the Diaphragm

Petros Mirilas, Lee J. Skandalakis, Richard R. Ricketts, and Marios Loukas

EMBRYOGENESIS

Embryogenesis of the diaphragm comes from the following sources: transverse septum (ventrally), paired pleuroperitoneal membranes (posteriorly), skeletal muscle derived in situ from the body wall and from migration of cervical myotomes (peripherally) (Fig. 63.1). Some authors of the previous decades believed that the mesentery of the esophagus also contributed to the diaphragm.

Transverse Septum

The septum transversum is a mesenchymal bridge arising from the coelomic wall located between the pericardial cavity and the umbilical vesicle (Fig. 63.2). In early stages this mesenchyme mass separates ventrally the pleural and peritoneal cavities. It extends from the ventral body wall to the ventral border of the foregut.

The cranial part of the septum contributes to the connective tissue of the pericardium and is finally covered by pericardium and pleura. The ventral part of the septum constitutes a sagittal mesentery in which the liver develops. The septum transversum which originates at a cervical level gives genesis to the major part of the diaphragm (central tendon and ventral part). Therefore, the major innervation of the diaphragm is supplied from the phrenic nerve, derived from C3, C4, and C5.

Pleuroperitoneal Membranes

The pleuroperitoneal membranes close the right and left communication between the pleural and peritoneal cavities at approximately the 8th embryonic week. The pleuroperitoneal canals are closed by fusion of their edges. Growth of the adjacent adrenals brings the closing edges from posterolaterally to a more anteromedial final location. The right canal

closes earlier. Originally, the pleuroperitoneal membranes form a large part of the developing diaphragm, but relative growth of other elements reduces their contribution to a small area.

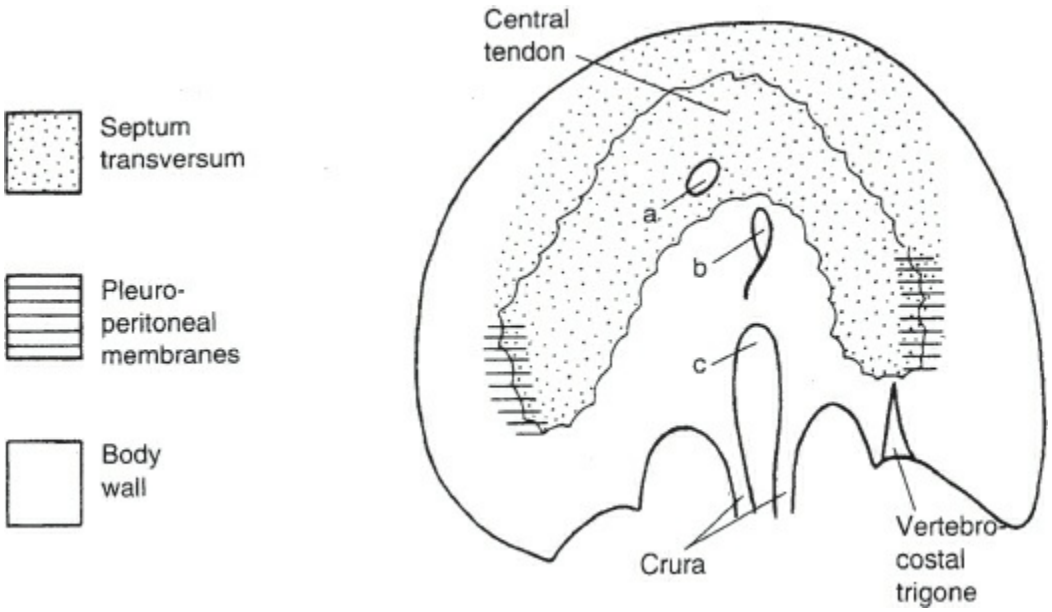

Figure 63.1. Scheme showing the probable origin of the diaphragm. Sharp boundaries are not justified. The vertebrocostal trigone does not mark the closure of the pleuroperitoneal canal. *a,* caval foramen; *b,* esophageal hiatus; *c,* aortic hiatus. Based on findings of Wells. (Republished with permission of John Wiley and Sons, Inc from O'Rahilly R, Müller F. *Human Embryology and Teratology.* 3rd ed. New York: Wiley-Liss, 2001; permission conveyed through Copyright Clearance Center, Inc.)

Muscles of the Body Wall

Myotomes of the 7th to 12th segments contribute the lateral component of the diaphragm by caudal excavation of the thoracic wall to form the costodiaphragmatic recesses. This process produces the final domed shape of the diaphragm, and explains innervation of the peripheral part of the diaphragm by the lower intercostals nerves.

Except from the in situ muscles of the body wall, cervical myotomes accompany the phrenic nerve, migrate, and contribute to the skeletal muscle of the diaphragm. This explains the innervation of the central part of the diaphragm by the phrenic nerve.

Descent of the Diaphragm

In the 3rd week, the transverse septum lies at the level of C3, and the developing diaphragm descends to its final position at the level of L1 by the 8th week (Fig. 63.3). The phrenic nerve, which originates from the third to fifth cervical levels, is carried caudad with the descending diaphragm.

Diaphragmatic Anomalies

A number of areas of the diaphragm can give way under pressure from the abdominal viscera. Most diaphragmatic hernias start in these small areas of weakness and enlarge with age. The specific hernias are described in the following sections and summarized in Table 63.1.

CONGENITAL ANOMALIES

Congenital Diaphragmatic Hernia

Congenital diaphragmatic hernia (CDH) is a displacement of abdominal organs into the thoracic cavity through a weak area or a defect in the diaphragm. It occurs in about 1 per 2,500 live births and accounts for about 8% of all congenital anomalies. CDHs usually occur through the posterolateral foramen of Bochdalek and rarely through the substernal foramen of Morgagni. They are more frequent on the left side (80%) and are very rarely bilateral. The two main pathophysiologic abnormalities in CDH are *pulmonary hypoplasia*, both on ipsilateral and contralateral sides, and *pulmonary hypertension.* Because of the high mortality rate, approximately 30% in live-born infants, the pediatric surgical community has been conducting research into the etiology and pathophysiology of CDH in hopes of affecting better survival rates. This research has been the backbone of the entire field of fetal surgery/fetal intervention.

Many theories have been proposed to explain the appearance of posterolateral diaphragmatic defects:

1. Improper development of the pleuroperitoneal membrane
2. Failure of muscularization of the lumbocostal trigone resulting in an area of weakness
3. Premature return of the intestines into the abdominal cavity when the pleuroperitoneal canal is still “open”
4. Abnormal persistence of lung in the pleuroperitoneal canal
5. Abnormal development of the early lung and posthepatic membrane
6. Abnormal muscle innervation by the phrenic nerve.

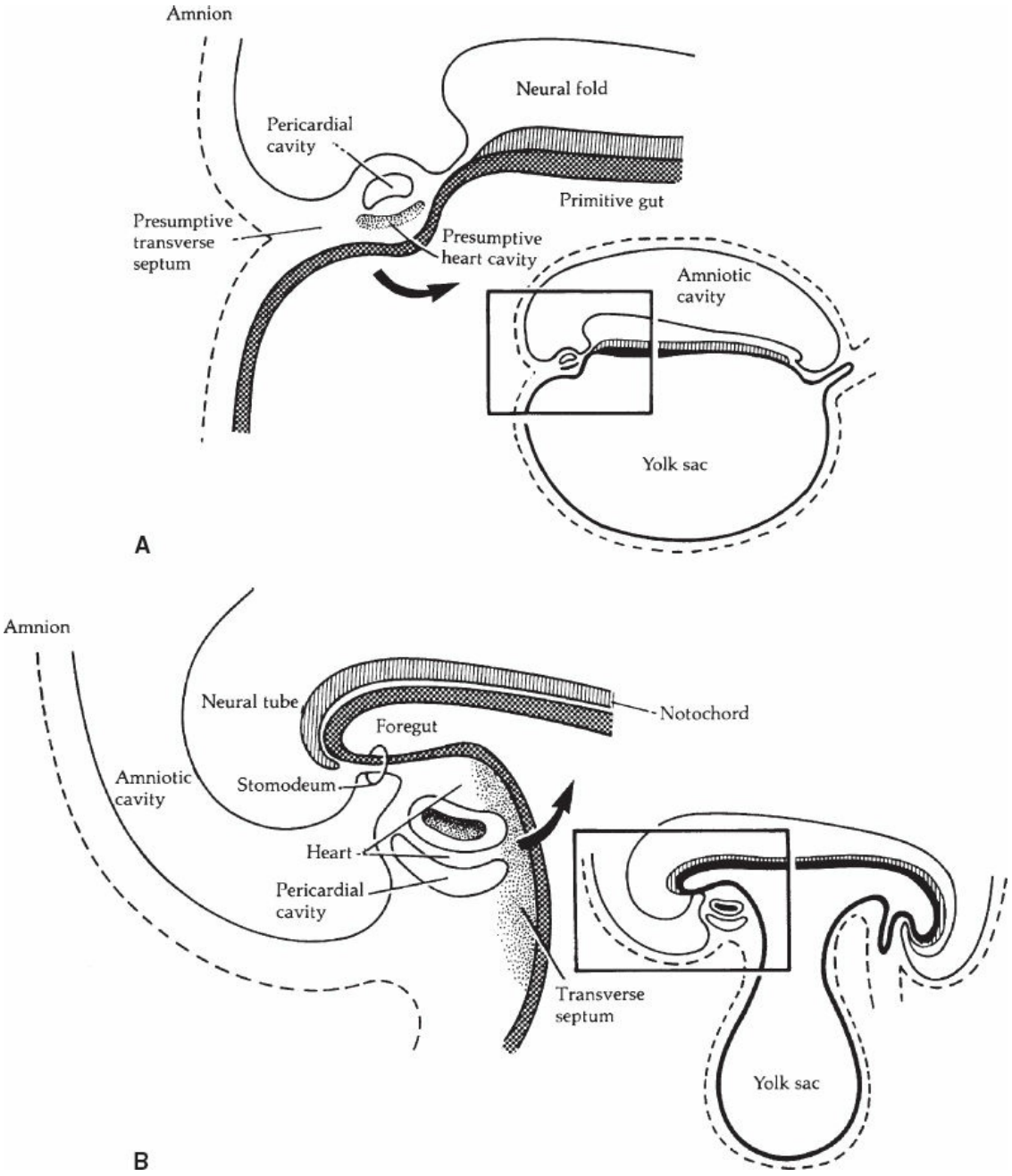

Figure 63.2. Formation of the transverse septum. **A.** The heart and pericardium from anterior to the head of the embryo in the 3rd week. **B.** Rapid growth of the head rotates the heart and the mesoderm, which become the transverse septum, in the direction indicated by the *arrows* in the 4th week.

The most popular theory is that the lung hypoplasia is *secondary* and a direct consequence of a *primary* diaphragmatic defect: inhibited or delayed closure of the pleuroperitoneal canal by 8 weeks of gestation allows the fetal intestine, returning from the extracoelomic cavity at 8 to 10 weeks, to enter the thoracic cavity and impair lung growth and development.

However, Kluth (1995) points out that this series of events has never been observed in embryos or fetuses.

Another popular theory is that the lung is primarily hypoplastic and that the hypoplastic lung in CDH is not the *result* but the *cause* of the diaphragmatic defect (Iritan, 1984).

Two experimental models have been developed to study the embryogenesis and pathophysiology of CDH. In the *murine nitrofen model*, pregnant rats are given 100 mg of nitrofen (a teratogenic agent) orally and then are sacrificed during gestation. The fetuses are examined at various points of development. In the *fetal lamb model*, diaphragmatic hernias are simulated or created in utero in fetal lambs early in gestation. The resultant pathophysiologic abnormalities are then studied at various points in gestation.

Using the experimental murine nitrofen model Kluth has found that the typical features of CDH and pulmonary hypoplasia cannot be explained by inhibited closure of the pleuroperitoneal canals, since these are never large enough to allow for herniation of the gut into the thorax. Also, the maldevelopment of the diaphragm begins early in the embryonic period (corresponding to the 5th week of gestation in humans), and the lungs of the nitrofen-fed rats are already significantly smaller than those of the controls by the end of the embryonic period (8 weeks in humans). He suggests that the murine nitrofen model does not accurately reflect the true pathogenesis of CDH since the manipulations are done in the fetal period of development rather than in the embryonic period. Kluth believes that the hypoplastic lung is secondary to the defect in the diaphragm and is caused by ingrowth of liver (not bowel herniation) into the thorax.

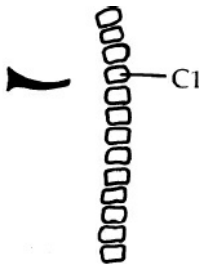

3 weeks

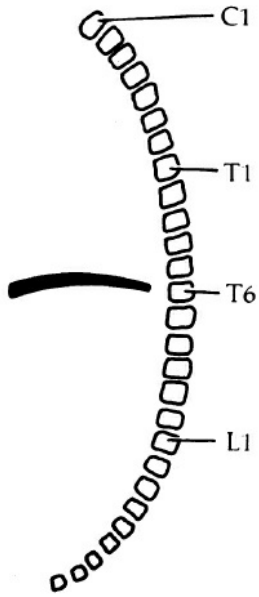

6 weeks

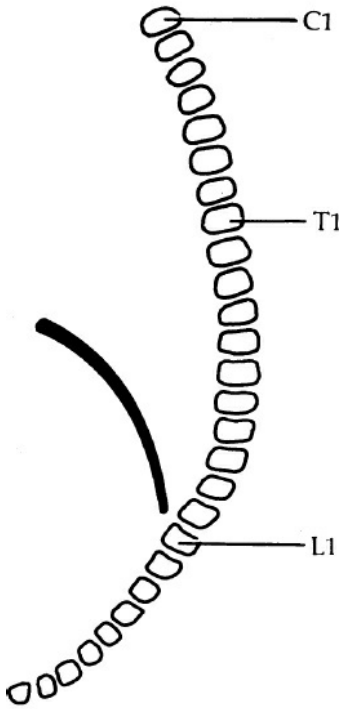

8 weeks

Figure 63.3. The descent of the diaphragm during development. The phrenic nerve arises from the 3rd to the 5th cervical segments and follows the diaphragm down to its final position.

TABLE 63.1 Characteristics of Diaphragmatic Hernias

Hernia	Anatomy	Sac and Herniated Organs	Remarks
Hernia through the foramen of Morgagni (retrosternal hernia, parasternal hernia, anterior diaphragmatic hernia)	Congenital potential hernia through muscular hiatus on either side of the xiphoid process. Usually on the right; bilateral hernias are known. Actual herniation usually the result of postnatal trauma.	Sac present at first. Can rupture later, leaving no trace. Contents: Infants: liver Adults: omentum Can be followed by colon and stomach later.	Rare in infants and children.
Hernia through the foramen of Bochdalek (posterolateral hernia of the diaphragm)	Congenital hernia through the lumbocostal trigone. Can expand to include almost whole hemidiaphragm. More common on left.	Sac present in 10–15%. Contents: small intestine (usual); stomach, colon, spleen (frequent). Pancreas and liver rare. Liver only in right-sided hernia.	Heart and mediastinum shifted to contralateral side. Ipsilateral lung collapsed but usually not hypoplastic. Secondary malrotation is common. Craniorachischisis, tracheoesophageal fistula, and heart defects are common.
Traumatic hernia	Acquired hernia. Tear, usually from esophageal hiatus across dome to left costal attachment of diaphragm.	No sac. Herniated organs: none at first. Spleen, splenic flexure of colon, stomach, left lobe of liver later.	
Peritoneopericardial hernia (defect of the central tendon, defect of the transverse septum)	Congenital hernia through central tendon and pericardium.	Sac rarely present. Contents: stomach, colon.	Has been seen in newborns and adults. Perhaps traumatic in adults. Rare.
Eventration of the diaphragm	Congenital hernia. Diaphragm is thin with sparsely distributed, but normal, muscle fibers. Either or both sides can be affected. Phrenic nerve appears normal. Acquired: paralysis of normal muscle resulting from phrenic nerve injury.	"Sac" is formed by the attenuated diaphragm. Contents: normal abdominal organs under elevated dome of hemidiaphragm. No sac.	Heart and mediastinum shifted to contralateral side. Ipsilateral lung collapsed, but normal. Malrotation and inversion of abdominal viscera are common. As above, without malrotation and inversion.
Hiatal hernia Sliding hiatal hernia Fixed hiatal hernia	Congenital potential hernia. The enlarged esophageal hiatus of the diaphragm permits the cardia of the stomach to enter the mediastinum above the diaphragm. The phrenicoesophageal ligament is attenuated and stretched. The gastroesophageal junction can be freely movable or fixed in the thorax.	Sac lies anterior and lateral to the herniated stomach. Contents: cardiac stomach.	A large hiatus (admitting three fingers) can be a predisposing factor; actual herniation usually occurs in late adult life. Has been seen in newborn infants.
Paraesophageal hernia	Congenital potential hernia. The cardia is in the normal position. The fundus has herniated through the hiatus, into the thorax.	Sac lies anterior to the esophagus and posterior to the pericardium. Contents: fundus of stomach. Body of stomach, transverse colon, omentum, and spleen can enter the sac later.	An esophageal hiatus larger than normal can be the predisposing factor. Actual herniation occurs in late adult life.
Short esophagus	Congenital hernia. The cardia of the stomach is fixed in the mediastinum.	No sac.	This lesion is rare. It appears to be the result of failure of the embryonic esophagus to elongate sufficiently to bring the gastroesophageal junction into the abdomen.

Baglaj and Czernik (2004) point out that caution must be taken in extrapolating data from murine nitrofen studies to humans because of the significant anatomical differences of this model with humans. In murine models CDH occurs on the right side in 50% of embryos and bilaterally in 30%, as opposed to the left-sided predominance in humans. In murine models, the posteromedial diaphragm is affected rather than the posterolateral area as in humans. All murine CDHs contain liver (infrequent in human), and small bowel loops appear late—too late to interfere with lung development. Furthermore, the intrathoracic murine liver appears to be an extra lobe, with the normal liver remaining in the abdominal cavity, rather than a herniation of normal liver into the thorax as is seen in humans.

The fetal lamb model is based on the concept that the pulmonary abnormalities (pulmonary hypoplasia and pulmonary hypertension) are the result of impaired lung growth secondary to the mass effect of the herniated viscera. This led to experimental and then clinical trials to reduce the viscera and close the diaphragmatic defect prenatally, in order to allow space for the lung to grow and develop during the rest of gestation (Harrison, 1991). Following years of experimental prenatal CDH repair (beginning in 1980), the first open prenatal CDH repair in a human was performed at the University of California in San Francisco (UCSF) in 1986. This therapy was only offered to patients who had a nearly 100% predicted mortality with the best available postnatal care. All of the initial infants died. The first successful fetal repair was reported in 1990 (Harrison, 1990). A randomized trial of open fetal repair versus advanced postnatal care showed that prenatal repair was unsuccessful in the most severe cases and did not reduce mortality in the less severe cases.

In the 1990s, it was observed that in congenital high airway obstruction syndrome (CHAOS), lung growth is accelerated and the lung becomes hyperplastic, because of the inability of the fetal lung fluid to exit the lung because of tracheal occlusion. In the fetal lamb CDH model, occlusion of the trachea resulted in reduction of the herniated viscera, increased lung volume, and improvement in gas exchange and compliance. Open fetal tracheal occlusion was first performed in a human in 1996. Technology advanced to the point that endoscopic occlusion through an intact uterus (in an attempt to prevent preterm delivery) became feasible by 1999 (“fetendo”). Initially a clip was applied to the trachea. Because of tracheal damage, current technology involves placing a detachable balloon inside

the trachea endoscopically. An NIH-sponsored randomized trial of Fetendo balloon occlusion versus postnatal care was started in 2003. After 24 patients were randomized, the study was stopped because there was no survival advantage to the fetendo group versus the controls (73% vs. 77%), and the experimental group experienced more premature rupture of membranes and preterm deliveries than the controls.

Hiatal Hernia

Ascent of the stomach into the thorax through the esophageal hiatus of the diaphragm is a common and poorly understood lesion. It has been found in stillborn infants. O'Rahilly pointed out that the anomaly may lie in a delay of the elongation of the esophagus. Thus the stomach is found in an abnormally high position and the hiatus is formed around the stomach instead of the abdominal esophagus. A congenital hiatal hernia predisposes to an adult hiatal hernia, especially with obesity, as fat accumulates in the mesentery of the esophagus.

As in the adult hiatal hernia, congenital hiatal hernia can be of two types: sliding and paraesophageal (Fig. 63.4). In sliding hernia the abdominal esophagus and the stomach move in the thorax. The two requirements for a sliding hiatal hernia appear to be an enlarged hiatus and a weakened phrenicoesophageal ligament. Because both conditions are exacerbated by the hernia, the opening is further dilated and the ligament further stretched.

A congenital paraesophageal hernia permits herniation of the fundus of the stomach into the thorax through the hiatus, usually anterior or sometimes beside the esophagus (Fig. 63.4B). There is a peritoneal sac anterior to the esophagus containing stomach and, in extreme instances, transverse colon and omentum. Obstruction of the distal esophagus or the stomach is the usual result. The two types of hernia can be combined: a paraesophageal hernia may be associated with a sliding hernia.

Congenital Short Esophagus

Congenital short esophagus can simulate hiatal hernia. It is present in children, although it might be asymptomatic. An overall incidence of 1.53% has been documented. The phrenicoesophageal ligament is normal, there is no hernial sac, and the left gastric artery is not displaced upward. The condition is often familial, and it is more common in males. It is sometimes associated with pyloric stenosis, malrotation, and Marfan

syndrome. The authors of this chapter believe that, although it is rare, short esophagus is a true congenital malformation.

There are controversies regarding the existence and incidence of short esophagus. Nyhus (1992) has stated that short esophagus is not congenital, and that the shortening is caused by secondary factors in an esophagus of normal length. He commented that infants who have chalasia develop peptic esophagitis and then shortening of the esophagus.

Barrett esophagus must be distinguished from the congenital short esophagus. Barrett esophagus is associated with reflux, columnar epithelium and to stricture cephalad to the gastroesophageal junction (GEJ). In the congenital esophagus, the distal esophagus is practically a gastric tube, which radiographically cannot be differentiated from hiatal hernia. In this case reflux is significant.

Two conditions must be considered:

1. Irreducible partially supradiaphragmatic true stomach. The stomach has herniated into the thorax through an enlarged diaphragmatic esophageal hiatus and become fixed. This condition is true fixed hiatal hernia. Occasionally, the fixed hernia is not congenital but acquired, with tissue adhesions.
2. Partially supradiaphragmatic true stomach existing from birth and not reducible. This condition is true congenital short esophagus and is very rare.

The congenital short esophagus is not associated with a hernial sac. Branches of the left gastric artery do not pass upward through the hiatus. The authors of the current chapter believe that only a small percentage of hiatal hernias belong to this group.

Horvath et al. (2000) provided an interesting commentary on the term “short esophagus”:

Most esophagi that are short based on preoperative imaging are actually of normal length. It is therefore helpful to think of the short esophagus, as evaluated in the operating room, as falling into three categories: a true, non-reducible short esophagus; a true but reducible short esophagus; and an apparent short esophagus. Perioperative endoscopic or radiologic studies document that all three groups have a GEJ located at or above the hiatus. Both the true reducible and nonreducible short esophagi have sustained enough chronic damage to the esophagus to lead to actual intrinsic shortening, whereas patients with an apparent short esophagus have a normal-length esophagus that is merely accordioned into the distal

mediastinum. The only way to differentiate between these types is surgical mobilization of the mediastinal esophagus. In most patients (i.e., true, reducible short esophagus and apparent short esophagus), it is possible to reduce the GEJ to at least 2.5 cm below the hiatus. However, in a few patients (i.e., true, nonreducible short esophagus), intra-abdominal reduction cannot be accomplished despite extensive transmediastinal or transthoracic esophageal mobilization.

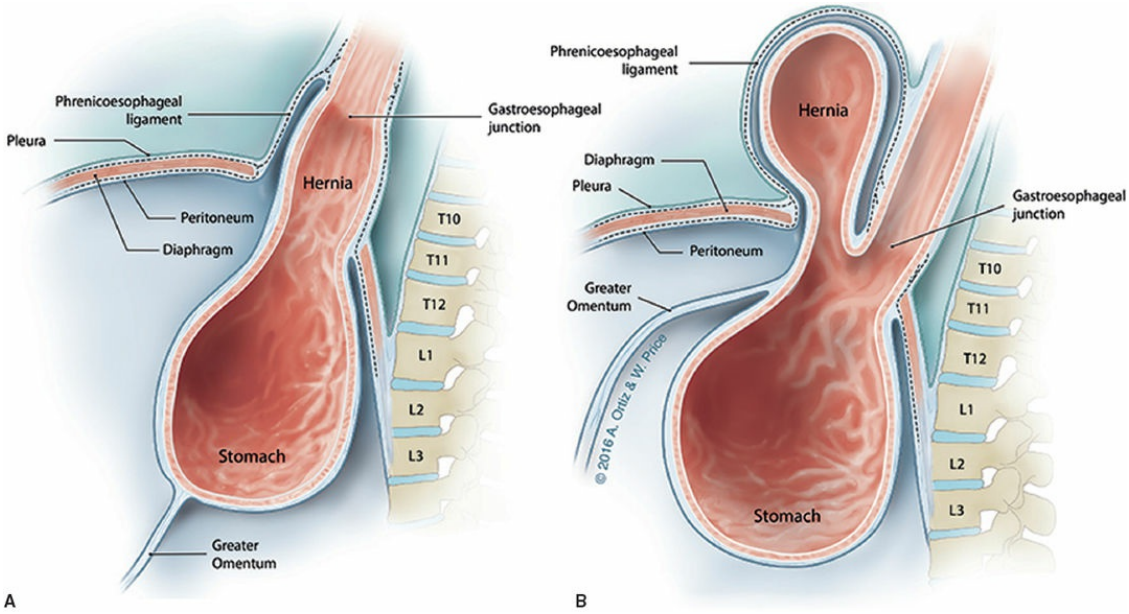

Figure 63.4. Hiatal hernias. **A.** Sliding hiatal hernia seen from the left. The gastroesophageal junction is in the thorax. **B.** Paraesophageal hernia seen from the left. The gastroesophageal junction is in its normal location; the fundus has herniated into the thorax through the hiatus anterior to the esophagus.

Posterolateral (Bochdalek) Defects

The posterolateral (Bochdalek) defect begins at the vertebrocostal trigone, above and lateral to the left lateral arcuate ligament (Fig. 63.5). At the time of intestinal return to the abdomen, this trigone is membranous, with few muscle fibers; even at maturity it is variable in size and degree of muscular development. Spreading of the muscle fibers permits a defect, the foramen of Bochdalek, to form and spread anteriorly on the dome of the diaphragm to include the site of the embryonic pleuroperitoneal canal.

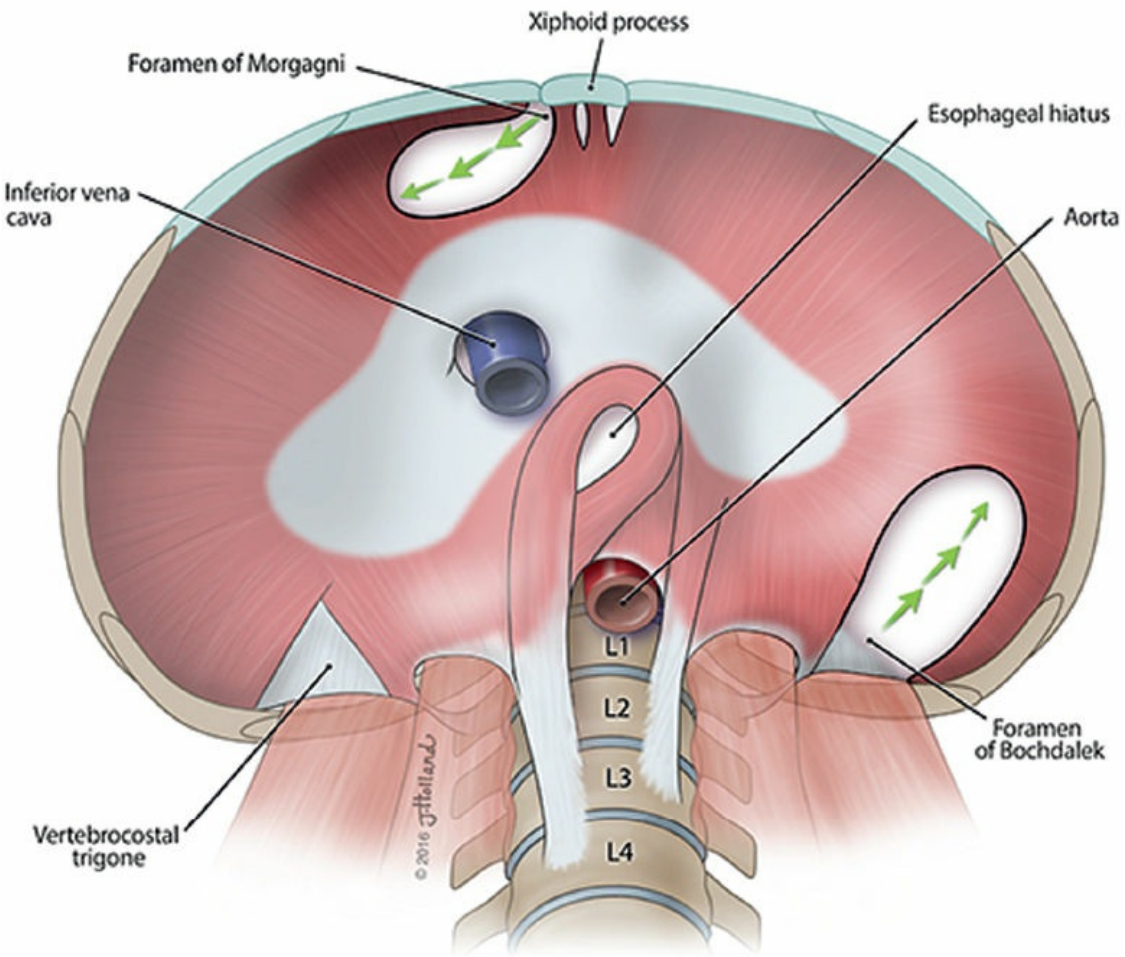

Figure 63.5. The diaphragm from below showing the foramen of Bochdalek and the foramen of Morgagni. Both are weak areas of potential herniation. *Arrows* indicate the direction of enlargement after herniation has begun.

The defect can be as small as 1 cm in diameter, or it might involve almost the entire hemidiaphragm. It is much more common on the left side. During an operation, usually no hernial sac is found. The small intestine, stomach, colon, or spleen can be present in the thorax at birth. The lung on the affected side is usually hypoplastic (Fig. 63.6).

Bilateral congenital posterolateral diaphragmatic hernia is extremely rare and difficult to diagnose.

Parasternal (Morgagni) Defects

Between attachments of the diaphragm to the xiphoid process and the 7th costal cartilage, there is a small gap in the musculature on either side of the xiphoid process (foramina of Morgagni). Herniation at these sites represents only approximately 3% of surgically treated hernias of the

diaphragm. The gaps are filled with fat, and the superior epigastric arteries and veins pass through them (Fig. 63.5).

Herniation through these muscular gaps is almost always the result of postnatal trauma. The hernia occurs more often on the right side, and the herniated organs are usually the omentum, colon, and, eventually, stomach. A sac can be present, or it might have ruptured and disappeared. There might be a predisposition to herniation in persons who have large foramina or more fat between muscle fibers, but this pattern has not been demonstrated. Omental herniation through the foramen of Morgagni has been reported. Laparoscopic procedures have been used to repair this defect.

The Vertebrocostal Trigone

The vertebrocostal trigone (Fig. 63.5) is rather a variation than an anomaly of the diaphragm. The term describes a defective area between the lumbar (vertebral) and costal attachments of the diaphragm. The weak area is usually on the left side. It is usually present but varies in size. The vertebrocostal trigone does not correspond to the site of closure of the pleuroperitoneal membrane (Fig. 63.1). It may be encompassed by a posterolateral defect.

Eventration of the Diaphragm

Congenital eventration describes the abnormal elevation of one leaf (side) of the diaphragm. The entire hemidiaphragm bulges upward, in contrast to the localized defect of a foramen of Bochdalek hernia (Fig. 63.7). The left side is affected more often than the right, and males are affected more often than females. The phrenic nerve appears normal, but the eventrated leaf can consist of a fascial layer with few or no muscle fibers between the pleura and peritoneum. The failure is of muscularization rather than fusion of embryonic components. Intestinal malrotation is often associated. The lung is usually partially collapsed but not hypoplastic; the mediastinum is shifted to the contralateral side, which further reduces ventilation.

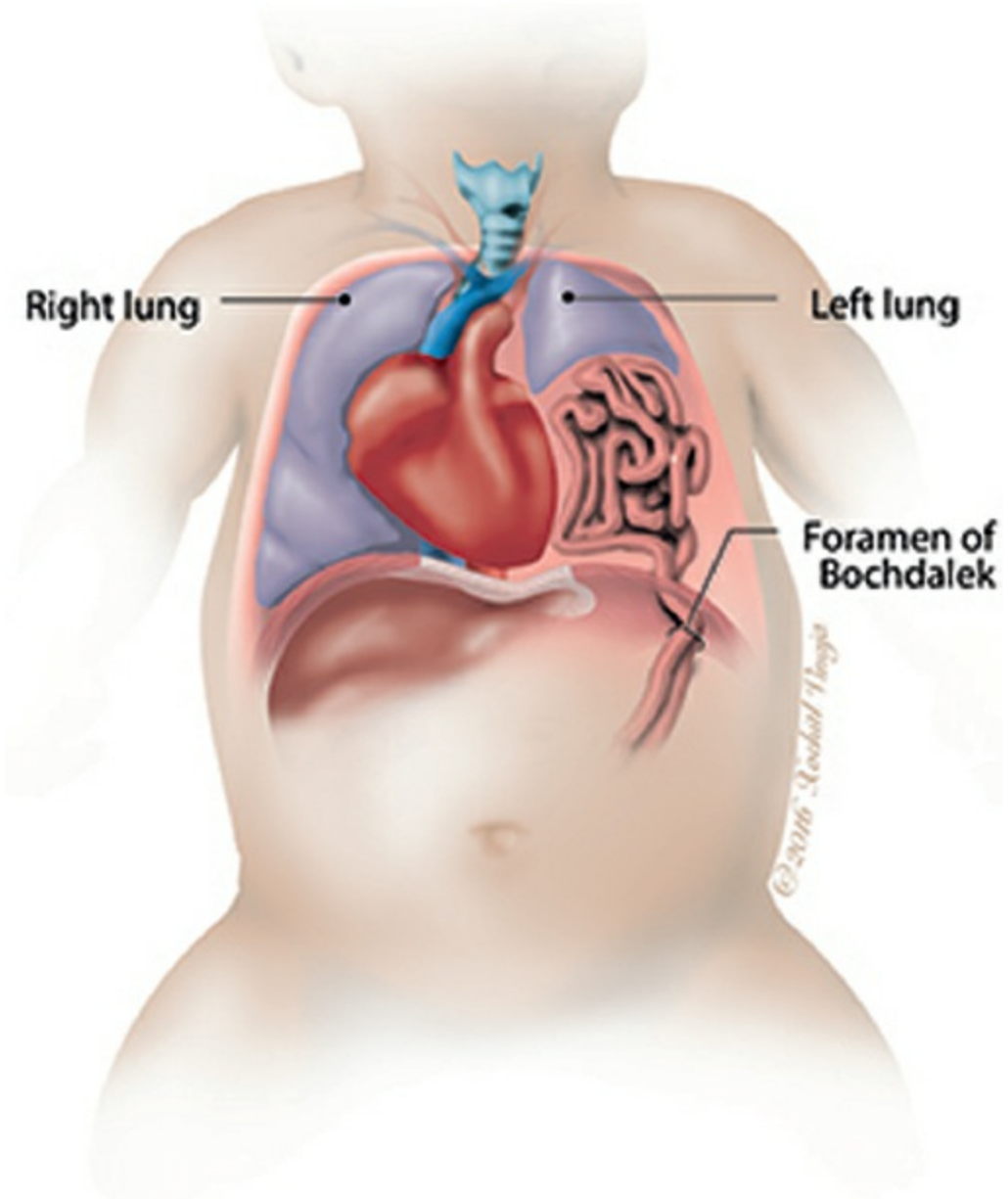

Figure 63.6. Herniation of intestines through the foramen of Bochdalek compressing the left lung. The mediastinum is shifted to the right, also reducing the volume of the right lung.

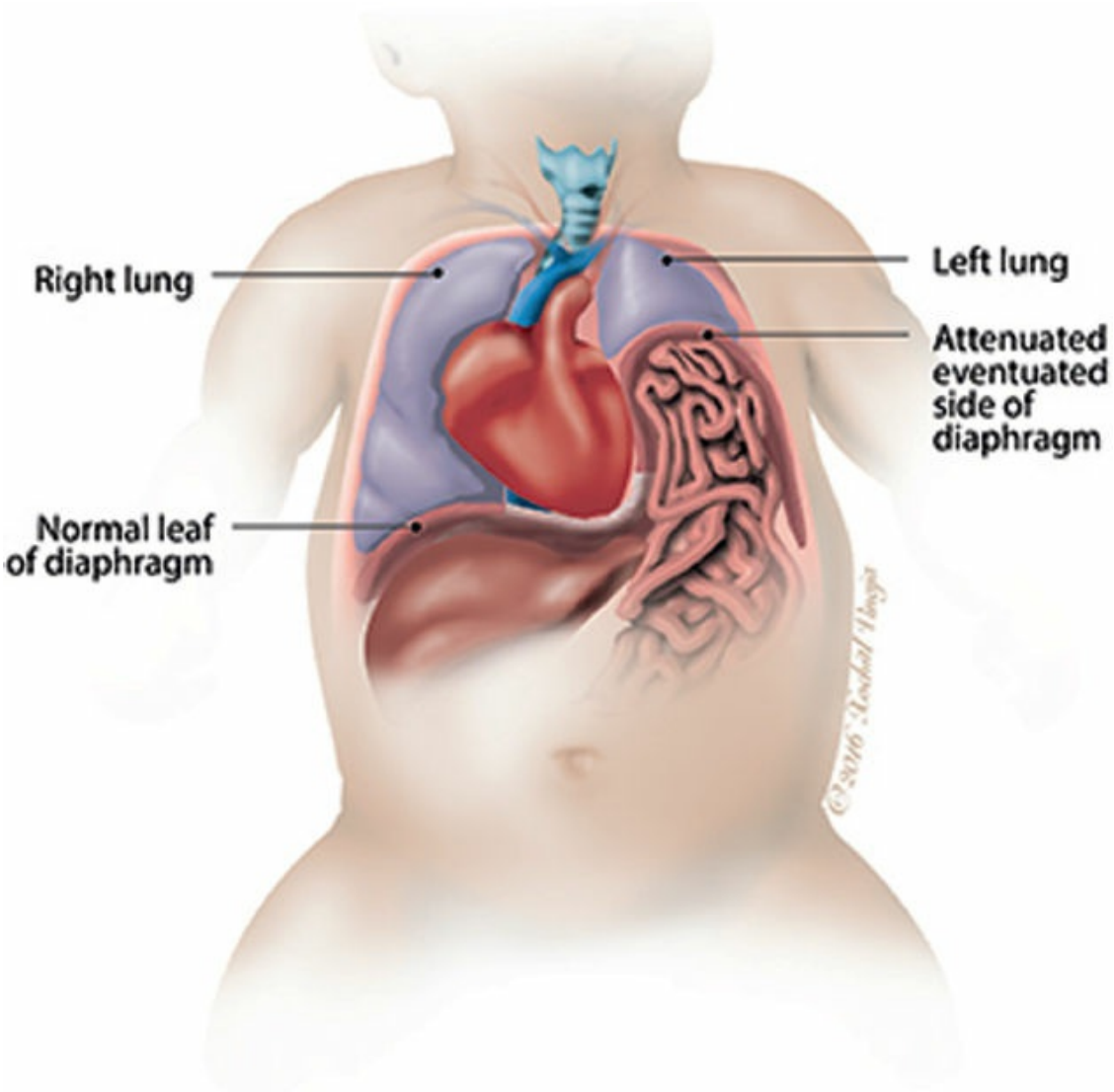

Figure 63.7. Eventration of the left diaphragm. The herniated abdominal organs remain beneath the attenuated but intact side of the diaphragm. Both lungs are compressed, and mediastinum is shifted to the right. Compare with Figure 63.6.

By contrast, *acquired eventration* is the result of phrenic nerve injury with normal musculature. The acquired lesion can be temporary; the congenital lesion is permanent unless repaired.

Eventration can be unilateral or bilateral and can rupture in later life. Eventration and acute gastric volvulus have been seen in pediatric patients.

A common but little-understood lesion that has been reported in stillborn infants is ascent of the stomach into the thorax through the esophageal hiatus of the diaphragm. Its congenital origin is not well established.

Peritoneopericardial Hernia

Peritoneopericardial hernia is a rare hernia that lacks a simple embryologic explanation. The authors of the current chapter believe that this hernia is produced by a residue of the pneumatoenteric recess (this recess give genesis to the lesser sac). Peritoneopericardial hernia has been reported in newborn infants and in adults. A hernial sac, or a trace of one, has been found in a few instances. Because it is in the central tendon and the overlying pericardium, the defect originates in that part of the diaphragm formed by the transverse septum.

Liver herniation into the pericardium through the central tendon has been reported. Investigators have found that symptoms of diaphragmatic hernia might not appear until viscera incarcerate in it years after a causal injury.

Other Anomalies Associated With Diaphragmatic Defects

Diaphragmatic anomalies can be associated with other congenital anomalies, such as Cantrell pentalogy, tracheal agenesis, genetic syndromes with omphalocele, gastroschisis, intestinal atresias and stenoses, and obstructive uropathies.

ANATOMY

Roentgenographic findings support the hypothesis that the cardiac mass is responsible for the caudad displacement of the related hemidiaphragm; this finding is contrary to the classic teaching that it is the liver that lifts the corresponding hemidiaphragm.

The function of the diaphragm, which is composed of skeletal voluntary muscle, is as automatic as the function of the heart, with the difference that the cardiac myocytes function as a syncytium. It has been suggested that the diaphragm is second in importance only to the heart in maintaining life.

Pediatric Diaphragm

The following observations have been made from anatomic and ultrasonographic studies of the diaphragm in newborn infants:

1. The diaphragm inserts only on the anterior costodiaphragmatic rib cage border.
2. From anterolaterally to posteriorly, the diaphragmatic insertion has

increasingly greater distance from the rib cage.

3. The dorsal diaphragm ends its free course at the 11th rib and continues caudally, ending between the 12th rib and the crista iliaca. The diaphragm in the newborn acts as a bellows moving mainly in the posterior part, whereas in the adult it acts as a piston. The diaphragm of the newborn, which has a flat curve because of its large angle of insertion on the rib cage and small area of apposition, has only one physiologic destiny—to suck in the rib cage rather than air. It is this rib cage action that reduces the area of apposition and results in an increase in chest volume.

Origins and Insertions of the Diaphragmatic Musculature

The diaphragm comprises a central tendinous area from which muscle fibers radiate in all directions toward their peripheral attachments (Fig. 63.8).

Sternal Portion

Paired slips of muscle originate from the xiphoid process and the aponeurosis of the transversus abdominis muscle. Small triangular spaces (foramina of Morgagni) separate those slips from the costal fibers and from each other (Figs. 63.5 and 63.8). These small triangular gaps are filled with connective tissue and transmit the superior epigastric vessels (end branches of the internal thoracic [mammary] arteries and veins) and lymphatics that run along them. The sternal portion of the diaphragm arises from xiphoid process and from the aponeurosis of the transversus abdominis.

Costal Portion

Muscle fibers arise from the cartilages of the 7th and 8th ribs, the cartilage and bony portions of the 9th rib, and the distal bony portions of the 10th to 12th ribs.

Lumbar Portion

Posteriorly, the diaphragmatic muscle arises from the crura and the medial and lateral arcuate ligaments (lumbocostal arches). Between the costal and lumbar portion of the diaphragm is the lumbocostal trigone (Fig. 63.5), filled in only with connective tissue.

Surgical Considerations

Hollinshead (1956) has pointed out that the sternocostal part of the diaphragm is in “intimate” relation to the transversus abdominal muscle. They blend and attach together to the lower six costal cartilages. Therefore, they can be separated together from the ribs. The transversal muscle, which is then made continuous with the diaphragm, could be utilized to help in closure of an anterior defect of the diaphragm.

The lumbar part of the diaphragm is in conjunction with the aponeurosis of the transversus muscle, which blends with the deep layer of the thoracodorsal (lumbosacral) fascia. The latter fuses with the anterior layer medially. Therefore, the latissimus dorsi can be of use in the closure of posterior defects of the diaphragm.

Crura

The crura arise from the anterior surface of L1 to L4 on the right, and L1 to L2 or L3 on the left, as well as from the intervertebral discs and the anterior longitudinal ligament. The crural fibers pass superiorly and anteriorly, forming the muscular arms that surround the openings for the aorta and the esophagus; they insert on the central tendon. The crura are tendinous at their origin on the vertebrae, becoming increasingly muscular as they ascend into the diaphragm proper (Fig. 63.9). In our studies of cadavers, we found the crura to be tendinous, posteriorly and medially, from their vertebral origins to the level of the 10th thoracic vertebra in 90% of cadavers. Sutures to approximate the crura should always be placed through the tendinous portions.

The pattern of the crural arms at the esophageal hiatus is variable. Loukas et al. (2008) classified the patterns of the right and left arms of the right and left crus forming the esophageal hiatus (Fig. 63.10). The most common type (Type I, 45%) formed the esophageal hiatus from muscular contributions arising solely from the right crus. In Type II (20%) the esophageal hiatus was formed by muscular contributions from the right and left crura. In Type III (15%), the right and left muscular contributions arose from the right crus with an additional band from the left crus. Type IV (10%) showed that the right and left muscular contributions arose from the right crus, with two additional (anterior and posterior) bands arising from the left crus. Type V (5%) demonstrated the contributions arising solely from the left crus. In Type VI (5%) the right and left contributions originated from the left crus with two additional bands, one from the right crus and one from the left crus.

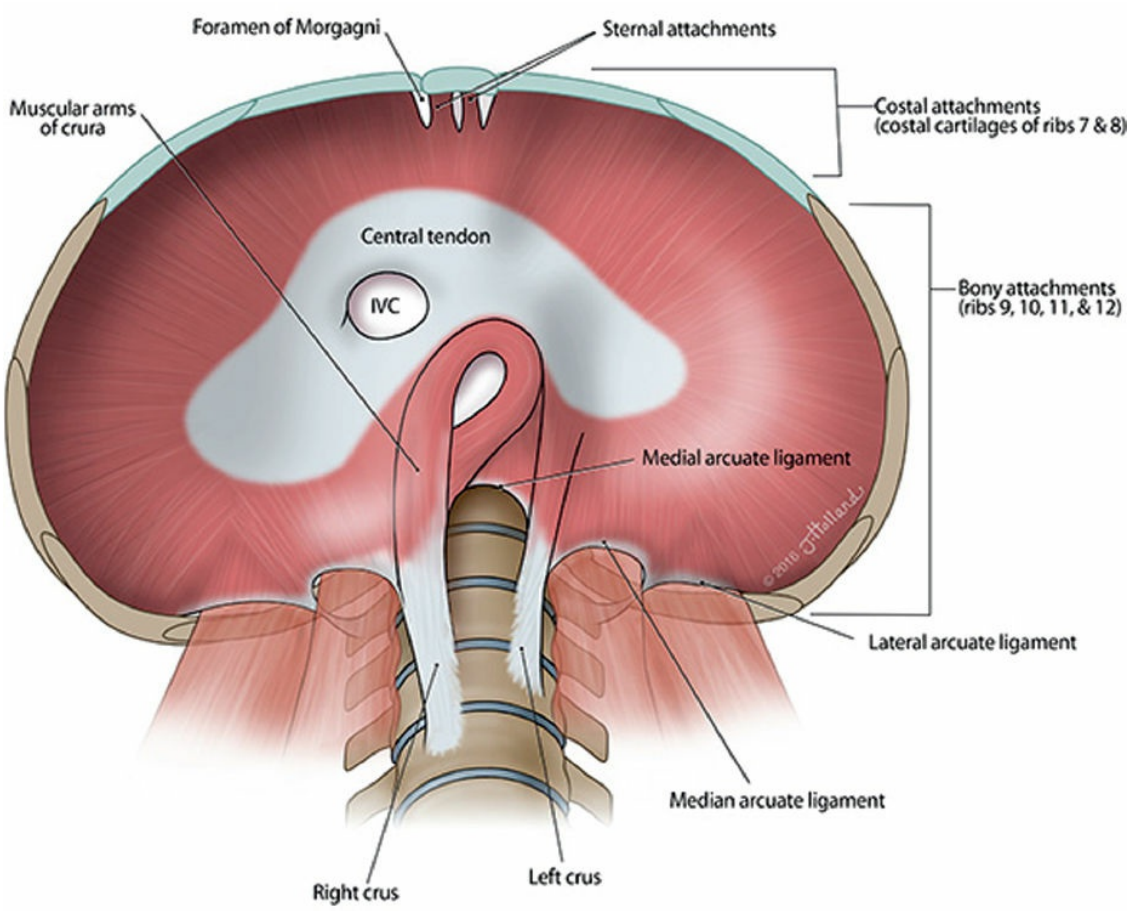

Figure 63.8. The attachment of the muscles of the diaphragm seen from below. IVC, inferior vena cava.

Arcuate Ligaments

The lateral arcuate ligaments (lumbocostal arches) are a thickening of the fascia on the anterior surface of the quadratus lumborum muscles, which attach to the 12th ribs laterally and to the transverse processes of L1 medially. The medial arcuate ligaments (medial arches) compose the similarly thickened fascia on the anterior surface of psoas muscles, which attach to the transverse processes of L1 laterally and to the body of L1 or L2 medially. The medial arcuate ligaments are separated from each other by the crura and the median arcuate ligament, described in the section "Median Arcuate Ligament." From these two pairs of arcuate ligaments on either side arises a portion of the muscle fibers of the posterior portion of the diaphragm (Fig. 63.8). The remaining portion of the diaphragm arises from the crura.

Central Tendon

All the musculature described so far inserts on the fibrous central tendon

of the diaphragm. The thickened portion anterior to the esophageal hiatus and to the left of the caval aperture is sometimes called the cruciform (transverse) ligament. Fibers on the superior surface of the central tendon blend with those of the fibrous pericardium. Patches of muscle are often present among the fibers of the central tendon.

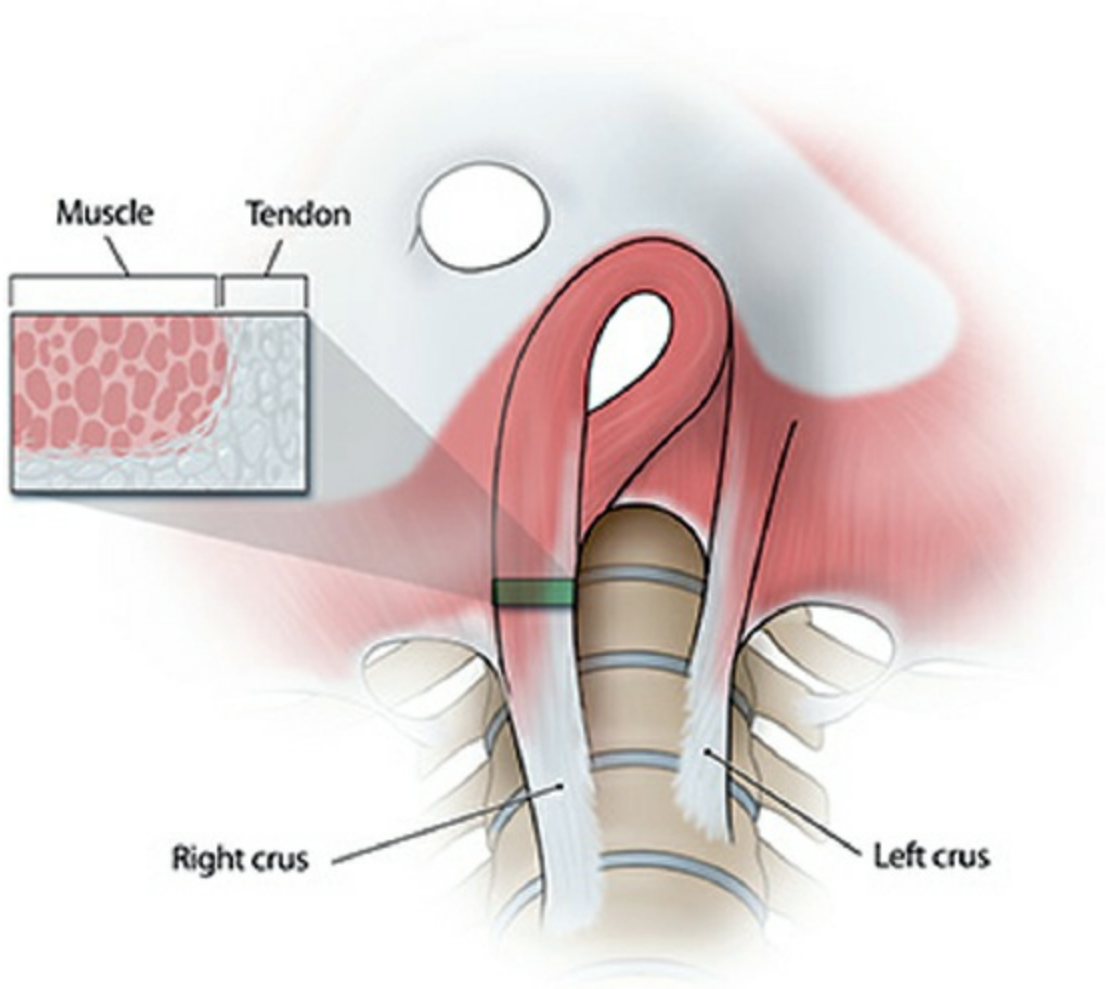

Figure 63.9. The crura consists of both tendinous and muscular tissue; only the tendinous portion holds sutures: 90% the medial edge of the crura is tendinous.

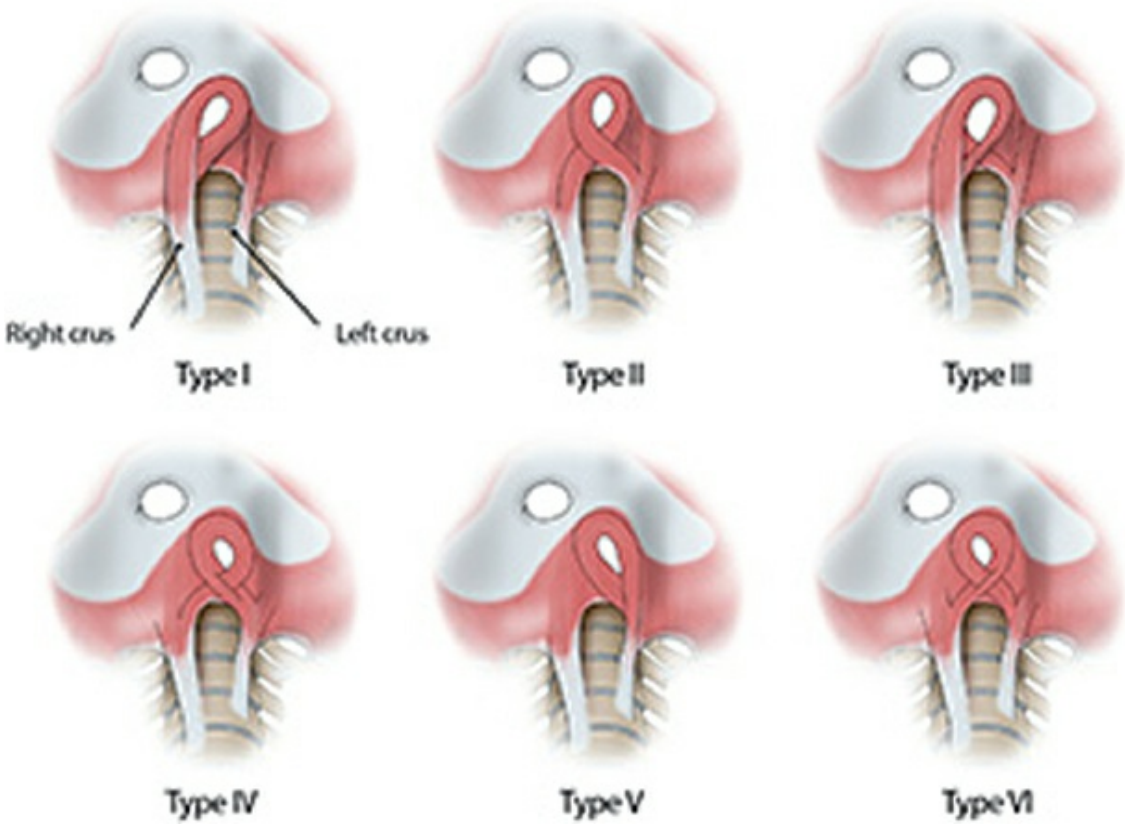

Figure 63.10. Representation of the different types of diaphragmatic crura. (Modified from Loukas M, Wartmann CT, Tubbs RS, et al. Morphologic variation of the diaphragmatic crura: a correlation with pathologic processes of the esophageal hiatus? *Folia Morphol* 2008;67:273–9; with permission.)

Loukas et al. (du Plessis 2015) reported a great variability in the morphology of the muscular and tendinous (central tendon) portions of the diaphragm, contributing unequally to the size of the diaphragm. The central tendon exhibited a V-shaped morphology in the majority of specimens and many displayed a left and right portion (leaflet), in addition to the central anterior leaflet (Fig. 63.11). In the majority of cases (56%), the ratio between tendon and muscle was 10% to 15%; the next often (25%) was tendon/muscle ratio <10%; specimens with high ratios were rarer. These measurements suggest a difference in “availability” of tendon and muscle, suggesting that diaphragmatic procedures would benefit from being tailored to the individual subject based on their specific musculotendinous classification. This information is useful to surgeries such as pericardiectomy following lung cancer resection, as shown in a case by Tamesue et al. (2005), in which the diaphragm is an excellent graft if used as a peddled flap.

OPENINGS OF THE DIAPHRAGM

Hiatus of the Inferior Vena Cava

The hiatus of the IVC lies in the right dome of the central tendon approximately 1 inch to the right of the midline and at the level of T8. The margins of the hiatus are fixed to the vena cava, which is accompanied by branches of the right phrenic nerve (Fig. 63.12).

The collagen fiber bundles forming the right margin of the caval hiatus cross inferiorly to the bundles forming the medial and posterior margins to form a fibrous limb that can be traced to the edge of the central tendon. The tendinous fibers forming the medial margin of the hiatus are attached to the muscle fibers of the right crus. This arrangement is often omitted in textbook illustrations of the caval hiatus. Whether this arrangement of fibers constricts or enlarges the caval hiatus during inspiration has been a source of controversy for many years.

Esophageal Hiatus

The elliptical esophageal hiatus is in the muscular portion of the diaphragm an inch or less to the left of the midline at the level of T10 (Figs. 63.12 and 63.13). The anterior and lateral margins of the hiatus are formed by the muscular arms of the diaphragmatic crura, and the posterior margin is formed by the median arcuate ligament (Fig. 63.8). The anterior and posterior vagal trunks and the esophageal arteries and veins from the left gastric vessels pass through the hiatus with the esophagus. In this region, the portal circulation (left gastric vein) communicates with the systemic circulation (esophageal branches of the azygos veins).

The esophageal hiatus is of great surgical importance and is considered in more detail in the “Median Arcuate Ligament” section.

Hiatal hernia can be defined as the protrusion of a portion of the stomach into the mediastinum through the esophageal hiatus of the diaphragm. A hernial sac is present. Hiatus hernias have been traditionally classified as sliding and paraesophageal. Today, an additional type, combined sliding and paraesophageal is recognized. Congenital short esophagus is also considered as a variant of hiatal hernia. The anatomy of esophageal hiatus in each of these abnormalities is shown in Figure 63.14A.

Sliding Hiatal Hernia

In a sliding hiatal hernia, the esophagus moves freely through the hiatus

with the GEJ being in the thorax or in the normal position at different times. It is usually found in the normal position at autopsy. Sliding hernias (Fig. 63.14B) constitute 90% of all hiatal hernias. Although these hernias do slide back and forth through the hiatus, they are called *sliding hernias* because the stomach composes part of the wall of the hernial sac. Thus, they are analogous with sliding inguinal hernias, which typically involve partially retroperitoneal organs.

A sliding hernia can become secondarily fixed in the mediastinum by adhesion. In such instances, the esophagus appears to be too short to reach the diaphragm because of contraction of the longitudinal muscle coat. This type is uncommon.

Paraesophageal Hiatal Hernia

In the paraesophageal hiatal type of hernia (Fig. 63.14C), the GEJ remains in its normal location. The gastric fundus and greater curvature bulge through the hiatus anterior to the esophagus. Volvulus of the herniated stomach is a major complication.

Combined Sliding and Paraesophageal Hernia

The GEJ is displaced upward as in a sliding hernia in combined sliding and paraesophageal hernia, and the fundus and greater curvature are herniated as in a paraesophageal hernia. Paraesophageal hernias usually are of the combined type (Fig. 63.14D).

Abdominal Esophagus

Anatomically, the last 0.5 to 4.0 cm of the esophagus lies below the diaphragm, forming the abdominal esophagus. With decrease in the length of the abdominal esophagus, the pressure necessary for competence of the sphincter rises exponentially. Normal lower esophageal sphincter pressure values vary from 14.5 to 34.0 mm Hg. Ninety percent of patients who have lower esophageal sphincter pressure below 5 mm Hg experience reflux, regardless of the length of the abdominal esophagus. Similarly, reflux occurs in 90% of patients if the length of their abdominal esophagus is less than 1 cm. Thus, sphincteric incompetence is the result of a low sphincter pressure, a short abdominal esophagus, or both.

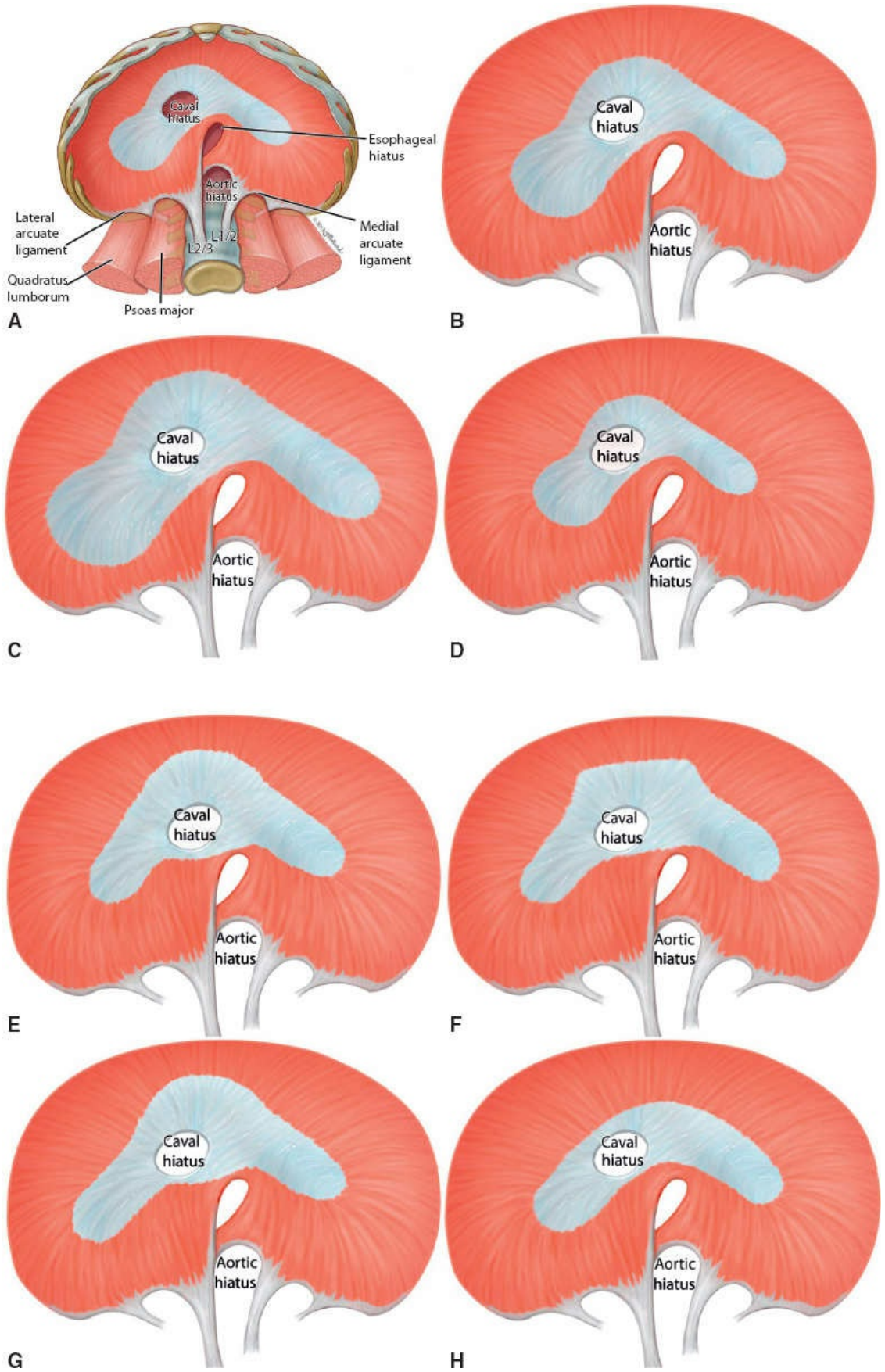

Figure 63.11. Schematic representation of the diaphragm and central tendon with the “normal” in situ anatomy (**A**), the medium

(**B**), large (**C**), and small tendon-to-muscle ratio's (**D**). Schematic representation of the diaphragm and central tendon that shows the morphology of the central portion of the tendon as oval shaped with left and right leaflets different sizes (**E**). The same shape is depicted in (**G**) but with the left and right leaflets of equal or close to equal size (**H**). The central portion has square shape while in h the tendon is elongated with no distinct demarcation between leaflets. (From du Plessis M, Ramai D, Shah S, et al. The clinical anatomy of the musculotendinous part of the diaphragm. *Surg Radiol Anat* 2015;37(9):1013–20; with permission of Springer.)

If the abdominal esophagus were the only factor governing reflux, all patients who have hiatal hernia would have esophagitis. This situation is not the case. If the hernial sac, carried up into the mediastinum, can transmit intra-abdominal pressure to the distal esophagus, it can support the sphincter. It seems clear that the abdominal esophagus plays a role in the prevention of reflux.

Phrenicoesophageal Membrane (Ligament)

A strong, flexible, airtight seal is necessary at the esophageal hiatus of the diaphragm. The seal is provided by the pleura above and the peritoneum below, whereas strength and flexibility are provided by the phrenicoesophageal ligament.

The major component of the ligament is collagenous, elastic fibers that arise as a continuation of the endoabdominal (transversalis) fascia beneath the diaphragm. Some of the elastic fibers penetrate to the submucosa of the esophagus. The transversalis fascia passes upward through the hiatus, forming a truncated cone that inserts in the adventitia and intermuscular connective tissue of the esophagus 1 or 2 cm above the diaphragm. The transversalis fascia also turns downward and inserts into the adventitia of the abdominal esophagus and the stomach. A weaker and less constant component can arise from the endothoracic fascia, passing upward to join the fibers of the endoabdominal fascia. The relations of these components of the phrenicoesophageal ligament are shown in Figure 63.15.

The phrenicoesophageal membrane inserts into the esophagus an average of 3.35 cm above the squamocolumnar epithelial junction. In 227 patients who had esophagitis, as noted by Bombeck et al. (1966), the insertion was only approximately 0.5 cm above the epithelial junction.

Fisher (2012) commented in the previous (6th) edition of Mastery of Surgery that the phrenicoesophageal ligament may have a role in stabilizing the distal esophagus in the esophageal hiatus and thus limiting the superior shift of the esophagus during periods of increased intra-abdominal pressure. In cases of an enlarged esophageal hiatus (e.g., hiatal hernia), the phrenicoesophageal ligament may limit the effect of increased intra-abdominal pressure on the distal esophagus. The phrenicoesophageal ligament was the basis of the Allison repair, which was the earliest repair for hiatus hernia.

The phrenicoesophageal ligament has been often called a “membrane.” Investigators have compared the anatomic and the histologic characteristics of the phrenicoesophageal ligament to the inguinal ligament and reported that the phrenicoesophageal ligament is a fascio-areolar structure, rather than a ligament. In addition, the phrenicoesophageal ligament gives elasticity rather than stability to the esophagus and therefore suggested that the term “lig. phrenicoesophagealis” be removed from the literature. Our histologic findings showed that the phrenicoesophageal ligament is a dense connective tissue formed by collagen and elastic fibers where the nuclei of fibroblasts were elongated in the direction of the collagen fibers and supplied with blood vessels, in all age groups. The collagen fibers were thick and organized in parallel fashion and the elastic fibers surrounded the collagen fibers tightly in the sections taken from younger specimens. Although the collagen alignment in the phrenicoesophageal ligament is not as straight as the alignment in tendons, it has a specific orientation that is regular and parallel. However, this organization is not as irregular as in dense irregular connective tissue. Thus, we suggest that since the phrenicoesophageal ligament also consisted of regularly oriented parallel bundles of collagen fibers, it could be defined as a “visceral ligament.” However, with older age, the number of collagen fibers decreased and became more irregularly arranged. The amount of adipose infiltration was also increased in these specimens.

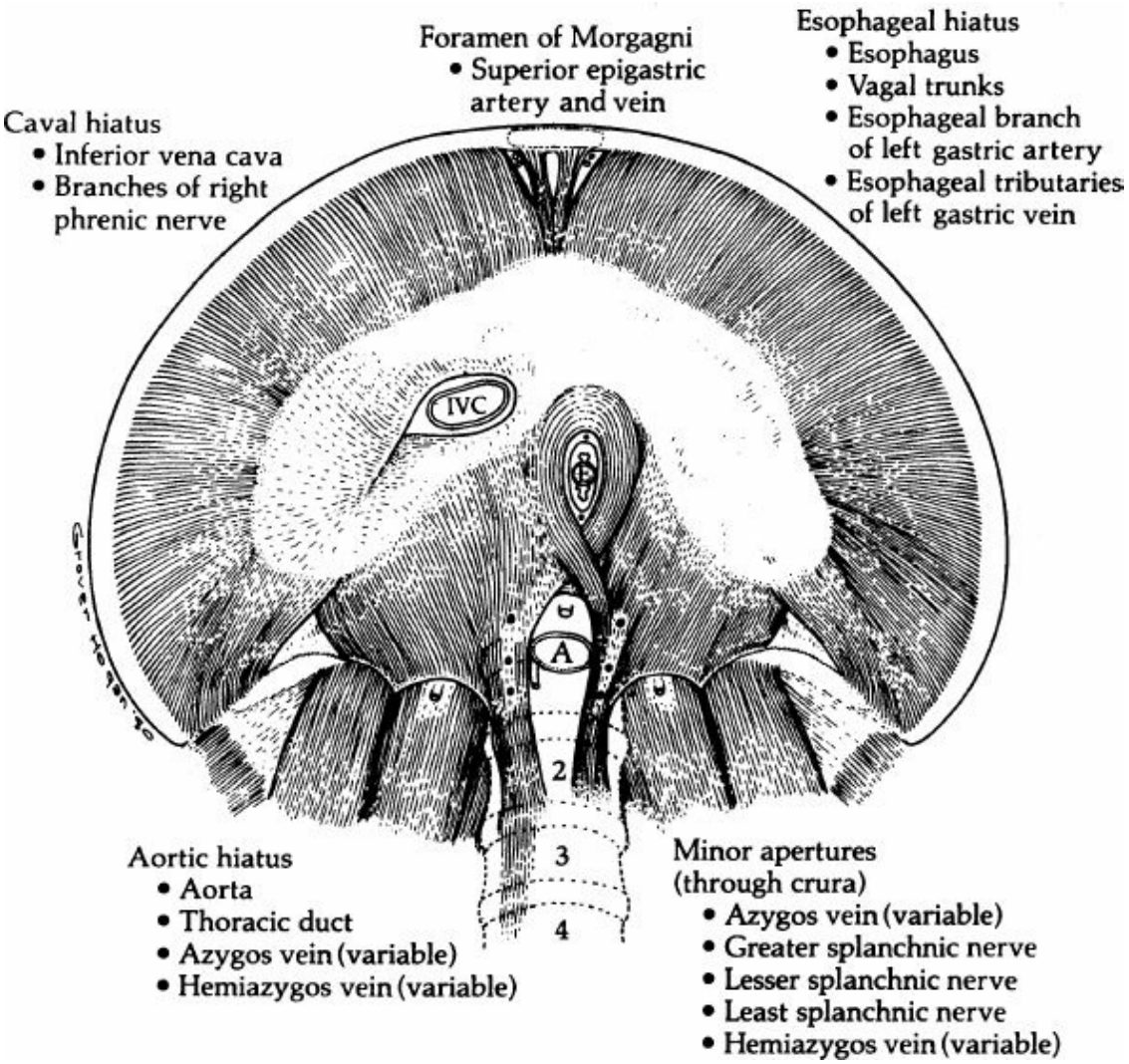

Figure 63.12. The apertures of the diaphragm seen from below and the structures transversing them. A, aorta; E, esophagus; IVC, inferior vena cava.

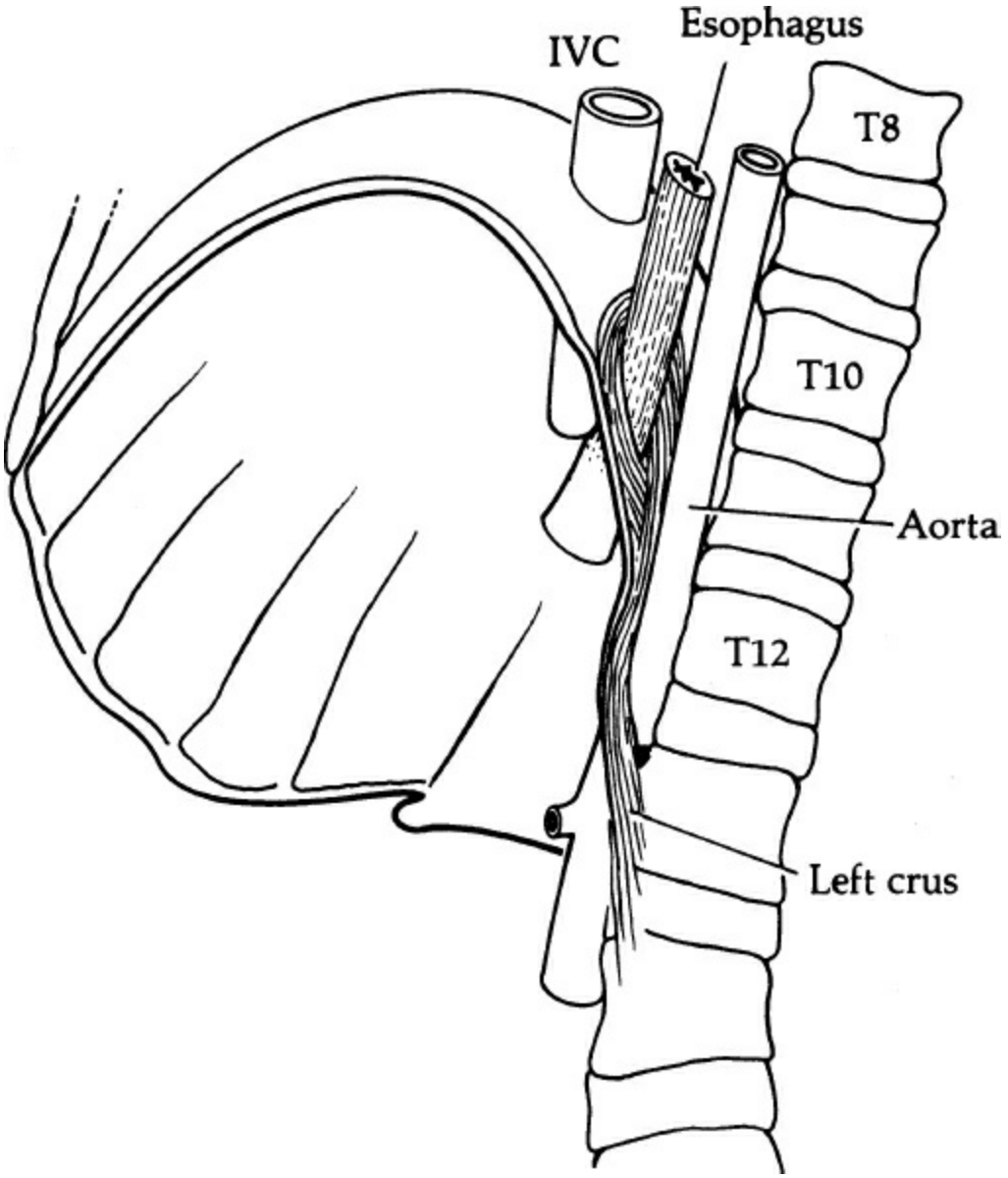

Figure 63.13. The diaphragmatic openings for the inferior vena cava (IVC), the esophagus, and the aorta, as seen from the left.

Descriptions of the phrenicoesophageal ligament vary because the tissue changes with age. In the fetus, the esophagus and diaphragm are tightly joined at the hiatus by connective tissue. With the onset of respiratory movements and swallowing in postnatal life, the two structures become less firmly attached, and the space between them fills with loose connective tissue and fat.

The development of the phrenicoesophageal membrane has been studied by Botros et al. (1983). They agree with Carey and Hollinshead (1955) that loose connective tissue with collagenous and elastic fibers arises from both surfaces of the diaphragm and attaches to the esophagus.

Between these fascial components, a layer of crural striated muscle is found in the 10-week-old fetus. With age, the muscle fibers undergo gradual regression and replacement with collagen fibers. Muscle fibers in the adult phrenicoesophageal membrane should be considered vestigial.

The natural course of the phrenicoesophageal ligament can be summarized as follows (Androulakis et al. 1966):

1. In newborn infants, the phrenicoesophageal ligament is present.
2. In adults, the ligament is attenuated and subperitoneal fat accumulates at the hiatus.
3. In adults who have hiatal hernias, the ligament for all practical purposes does not exist.

Aortic Opening

The oblique course of the aorta takes it behind the diaphragm rather than through it (Fig. 63.13). At the level of T12, the anterior border of the opening is the median arcuate ligament; laterally the diaphragmatic crura form its margins. The thoracic duct and (usually) the azygos vein accompany the aorta.

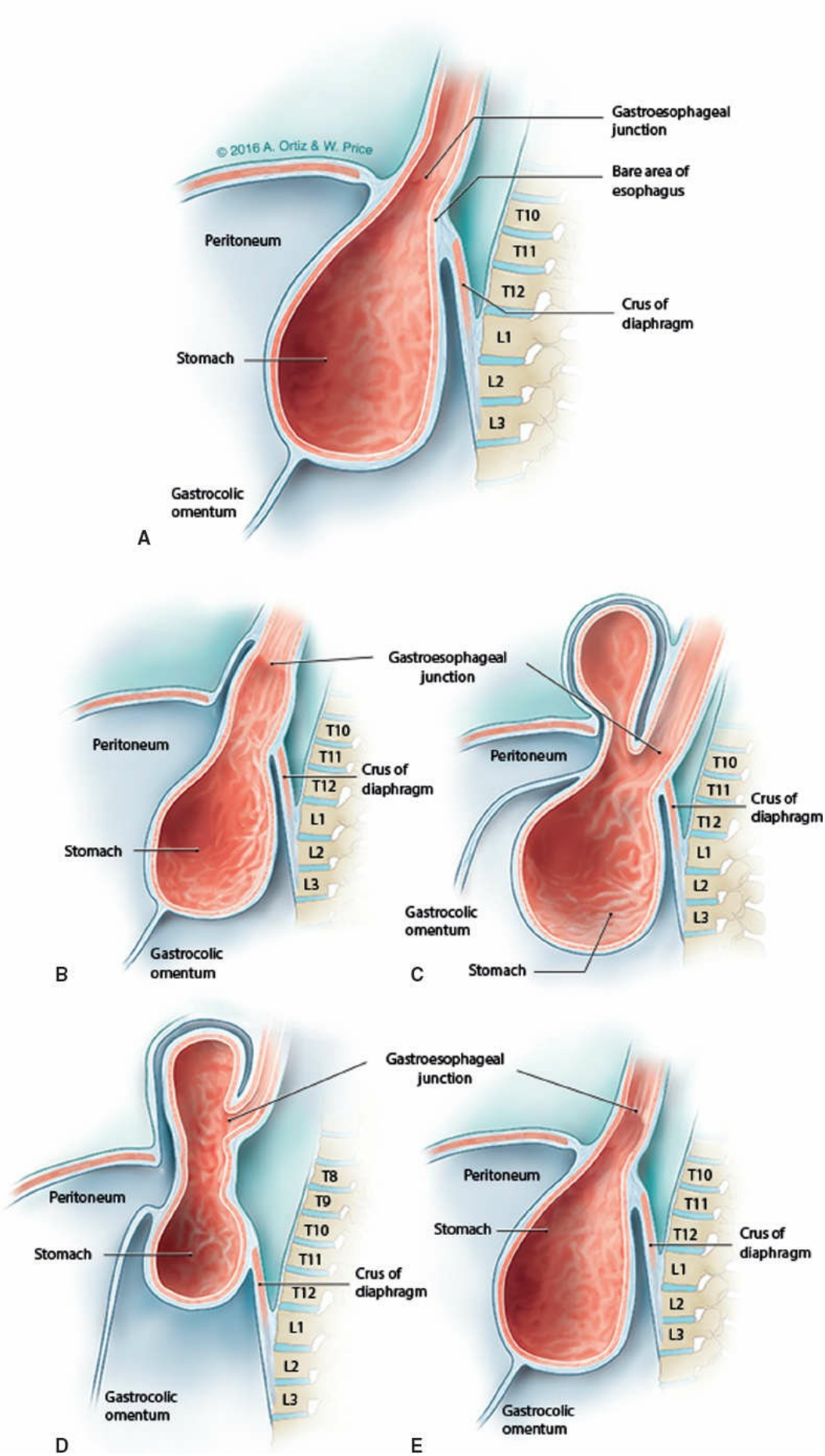
© 2016 A. Ortiz & W. Price
Gastroesophageal junction
Bare area of esophagus
Peritoneum
T10
T11
T12
Crus of diaphragm
L1
Stomach
L2
L3
Gastrocolic omentum
A
Gastroesophageal junction
Peritoneum
T10
T11
Crus of diaphragm
T12
L1
Stomach
L2
L3
Gastrocolic omentum
B
Gastroesophageal junction
Peritoneum
T10
T11
Crus of diaphragm
T12
L1
L2
L3
Gastrocolic omentum
Stomach
C
Gastroesophageal junction
Peritoneum
T8
T9
T10
Stomach
T11
Crus of diaphragm
T12
L1
L2
L3
Gastrocolic omentum
D
Gastroesophageal junction
Peritoneum
T10
T11
Stomach
T12
Crus of diaphragm
L1
L2
L3
Gastrocolic omentum
E

Figure 63.14. The esophageal hiatus in sagittal section with normal anatomy and the various abnormalities described in the text (**A**); sliding hiatal hernia (**B**); paraesophageal hiatal hernia (**C**); combined sliding and paraesophageal (**D**); and congenital short esophagus (**E**). (Modified from Gray SW, Skandalakis LJ, Skandalakis JE. Classification of hernias through the oesophageal hiatus. In: Jamieson GG, ed. *Surgery of the Oesophagus.* Edinburgh: Churchill Livingstone, 1988, with permission.)

Other Openings in the Diaphragm

Anteriorly, the superior epigastric vessels pass through the parasternal spaces (foramina of Morgagni). In the dome of the diaphragm, the phrenic nerves pierce the upper surface to become distributed over the lower surface between the muscle and the peritoneum.

The azygos vein can pass behind the diaphragm with the aorta, to the right of the right crus, or it can pierce the right crus. Also passing through the crura are the greater, lesser, and least splanchnic nerves (Fig. 63.12).

Median Arcuate Ligament

The median arcuate ligament is a rim of connective tissue that extends between the crura of the diaphragm and arches over the aorta (Fig. 63.16). In all dissections by Loukas et al. this rim was a constant finding irrespective of the configuration of the crura.

The median arcuate ligament passes in front of the aorta at the level of L1 just above the origin of the celiac trunk (Figs. 63.8 and 63.17). The celiac ganglia lie just below and lateral to the celiac trunk, in intimate juxtaposition. The median arcuate ligament and the origin of the celiac artery become slightly lower with increasing age. In 16% of patients, a low median arcuate ligament covers the celiac artery and can compress it. This clinical condition known as celiac artery compression syndrome (CACS) or Dunbar syndrome has proven controversial in definition and relevance. This condition was first described as chronic abdominal pain because of the mesenteric ischemia caused by extrinsic compression of the celiac artery. Dunbar and others presented surgical approaches to decompress the celiac artery by releasing the median arcuate ligament. Definitive answers have been sought to classify and relieve the clinical symptoms patients experience postprandially. Persistent symptoms following surgical

treatment for CACS have led investigators to question the existence of this disease. Advances in technology such as angiographic MRI and color duplex ultrasonography have refreshed the importance of considering compression of the celiac artery during differential diagnoses. Because of the varying anatomic etiologies of disease, it is not possible to pinpoint a single cause for CACS. Potential etiologies for compression of the celiac artery include a “high take off” origin of the celiac artery compressed by normal diaphragmatic crura and median arcuate ligament, a normal origin of the celiac artery with long diaphragmatic crura and median arcuate ligament, large bilaterally fused celiac ganglia (with or without the involvement of the superior mesenteric ganglia) compressing the celiac trunk, celiacomesenteric trunk compression by diaphragmatic crura and median arcuate ligament, or combinations of the above-mentioned entities.

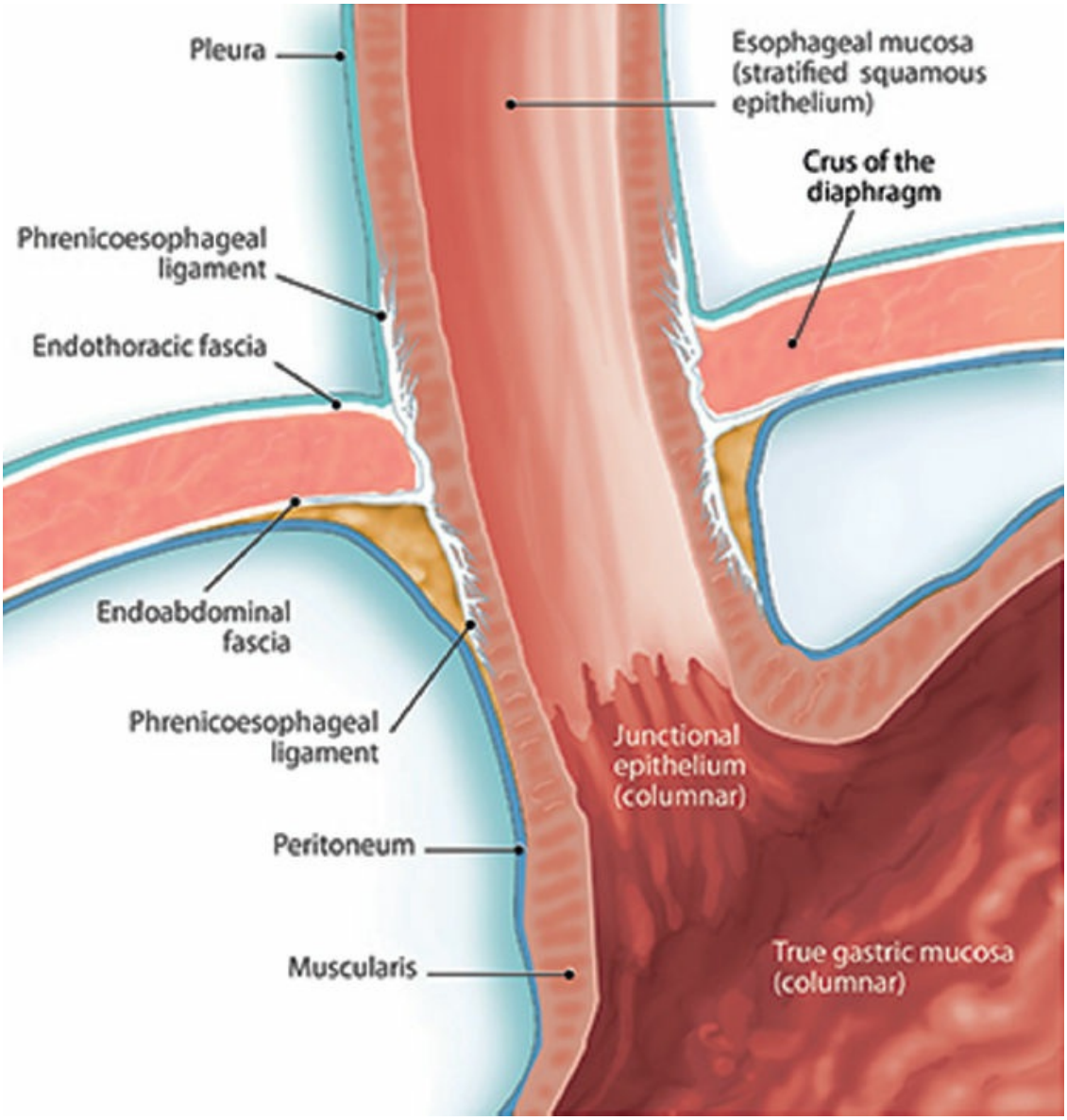

Figure 63.15. Structures at the gastroesophageal junction and the diaphragmatic hiatus.

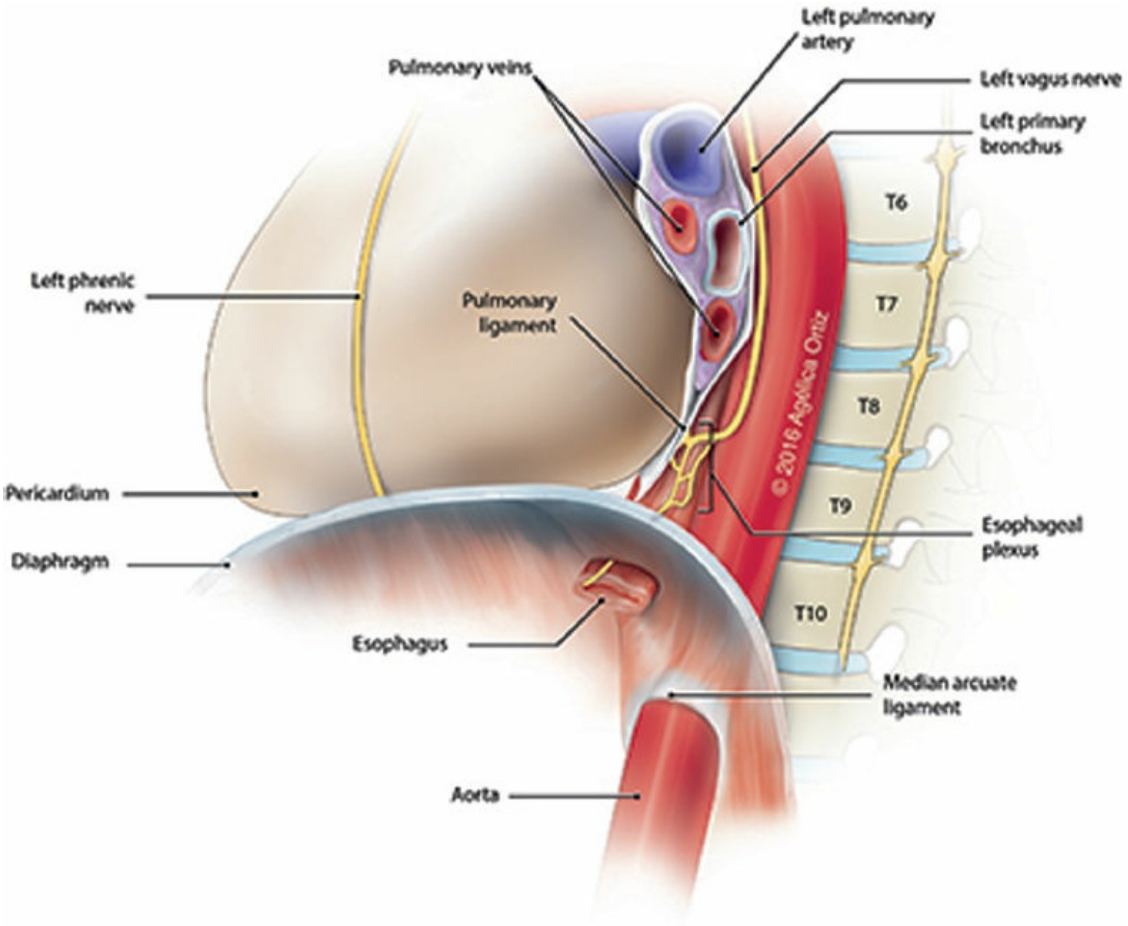

Figure 63.16. Structures in the inferior portion of the left mediastinum.

If there is no true median arcuate ligament, and the muscular arms of the crura are thinned by posterior extension of the esophageal hiatus, the aortic and esophageal openings can become practically confluent, although there is always some connective tissue between them.

In approximately half of the cadavers having hiatal hernia that we examined, the ligament was sufficiently well developed to use in surgical repair of the esophageal hiatus. In the remainder, there was enough preaortic fascia lateral to the celiac trunk to perform a posterior fixation of the GEJ. The celiac ganglion, just below the arcuate ligament, must be avoided.

DIAPHRAGMATIC, PLEURAL, AND MEDIASTINAL RELATIONS

Over much of the anterosuperior surface of the diaphragm, the fibrous tissue of the central tendon is continuous with the fibrous pericardium (Fig. 63.18).

In addition to the pericardium, the mediastinum on the right contains the IVC, the right phrenic nerve and pericardiacophrenic vessels, the right pulmonary ligament, the esophagus with the right vagus nerve and esophageal plexus, the thoracic duct, the azygos vein and azygos arch, the greater and lesser right thoracic splanchnic nerves, the right sympathetic trunk, and the right posterior intercostal arteries (Fig. 63.19).

In the left mediastinum are the pericardium, the left phrenic nerve and pericardiacophrenic vessels, the esophagus, the left vagal trunk, the descending aorta, the hemiazygos vein, the accessory hemiazygos vein, the highest intercostal vein, the greater and lesser left thoracic splanchnic nerves, and the left sympathetic trunk (Fig. 63.16).

The triangle (of Truesdale), formed by the pericardium, the aorta, and the diaphragm, contains the left pulmonary ligament and the distal esophagus. In sliding hiatal hernia, the stomach is in this triangle. The cardiophrenic space is located in the most central portion of the mediastinum and is bordered by the base of the heart, diaphragm, and chest wall. This area of contact between the heart and the diaphragm divides the cardiophrenic space into anterior and posterior. Most pathologic alterations are located in the anterior cardiophrenic space. In normal individuals, the cardiophrenic space is occupied by fat. An increase in the amount of normal pericardial fat is often seen in overweight individuals. The appearance of normal pericardial fat in the cardiophrenic space often simulates tumorous disease on plain chest radiographs. The absence of encapsulation or soft-tissue components is useful to differentiate prominent fat from lipomas or other fat-containing tumors.

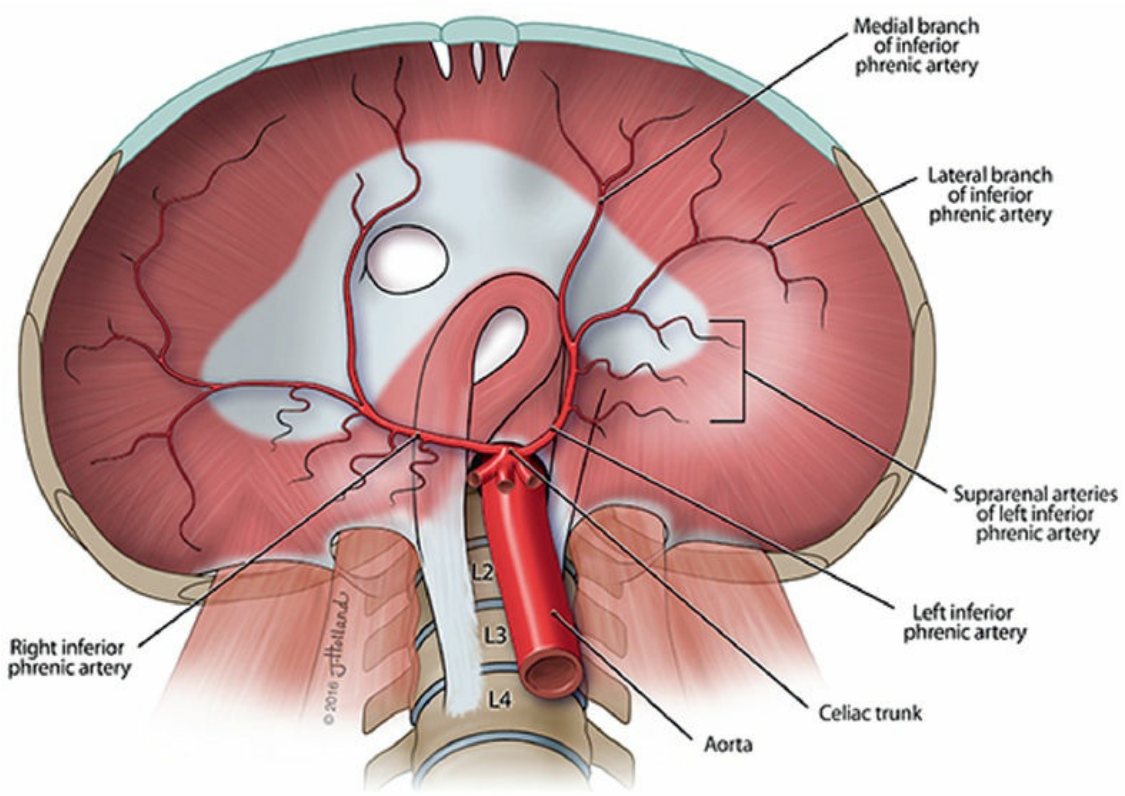

Figure 63.17. Arterial supply of the diaphragm from below. The inferior phrenic arteries can arise from the celiac trunk or directly from the aorta. E, esophagus; IVC, inferior vena cava.

The right pleura is in contact with the lower third of the esophagus almost down to the esophageal hiatus. This situation creates the risk of accidental entrance into the pleural cavity during abdominal operations on the esophageal hiatus. In spite of this proximity of the right pleura, the surgeon, working on the right side of the operation table, is more likely to produce a pneumothorax or hemopneumothorax on the left.

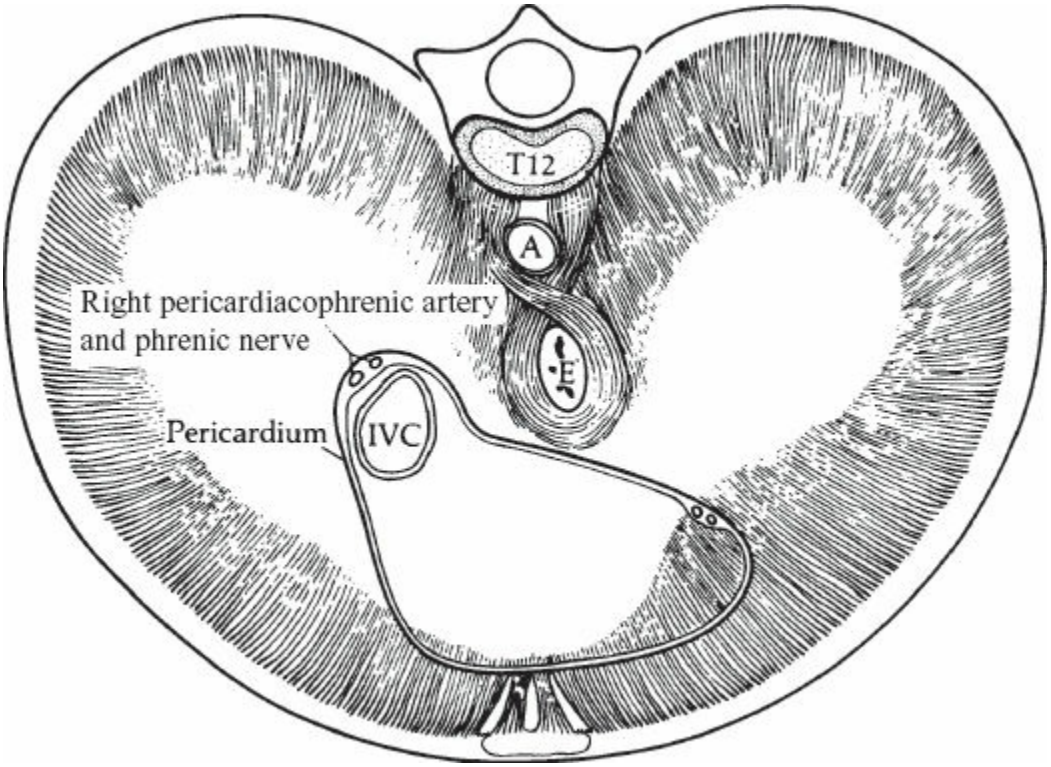

Figure 63.18. The diaphragm viewed from above. The area in contact with the pericardium is indicated. The pericardial fibrous tissue is continuous with that of the diaphragm. A, aorta; E, esophagus; IVC, inferior vena cava.

The diaphragmatic pleura is part of the parietal pleura, and covers all parts of the diaphragm except the part of the central tendon that is in contact with the pericardium. It is heavily fixed to the diaphragm through the phrenicopleural fascia of the endothoracic fascia in such a way that separation from the diaphragm is practically impossible. This situation is in contrast to the costal pleura, which can be stripped away along with the endothoracic fascia.

The costodiaphragmatic recess is located at the reflection of the parietal pleura from the ribs to the diaphragm. The phrenicomediastinal recess (lower part of the costomediastinal recess) is between the mediastinum and the diaphragm.

PERITONEAL ATTACHMENTS ON THE INFERIOR SURFACE OF THE DIAPHRAGM

The primitive dorsal and ventral mesenteries of the abdomen form a number of ligaments related to the diaphragm and the GEJ (Fig. 63.20).

Falciform, Coronary, and Triangular Ligaments

The falciform ligament, a remnant of the primitive ventral mesentery, arises from the anterior abdominal wall and extends to the anterior surface of the liver and the diaphragm. In its free edge encircles the round ligament of the liver, the obliterated left umbilical vein.

The leaves of the falciform ligament separate over the liver to form the anterior and posterior layers of the coronary ligament. Enclosing the bare area on the right, these leaves unite laterally to form the right triangular ligament. On the left, the leaves are in apposition to each other, forming the left triangular ligament. The lower leaf of the right and of the left coronary ligament continue to meet the esophagus. The latter, when entering the abdomen, is covered by peritoneum from infront, lower from infront and laterally, until lower in GEJ, where the esophagus is totally enveloped by the continuation of the lesser omentum. Thus behind the abdominal esophagus there is a bare area on the diaphragm (Fig. 63.20).

One approach to the GEJ is to section the left triangular and left portion of the posterior layer of the coronary ligament. In operating, one must be careful in mobilization of the liver, especially the left lobe, not to injure the left hepatic vein or the IVC.

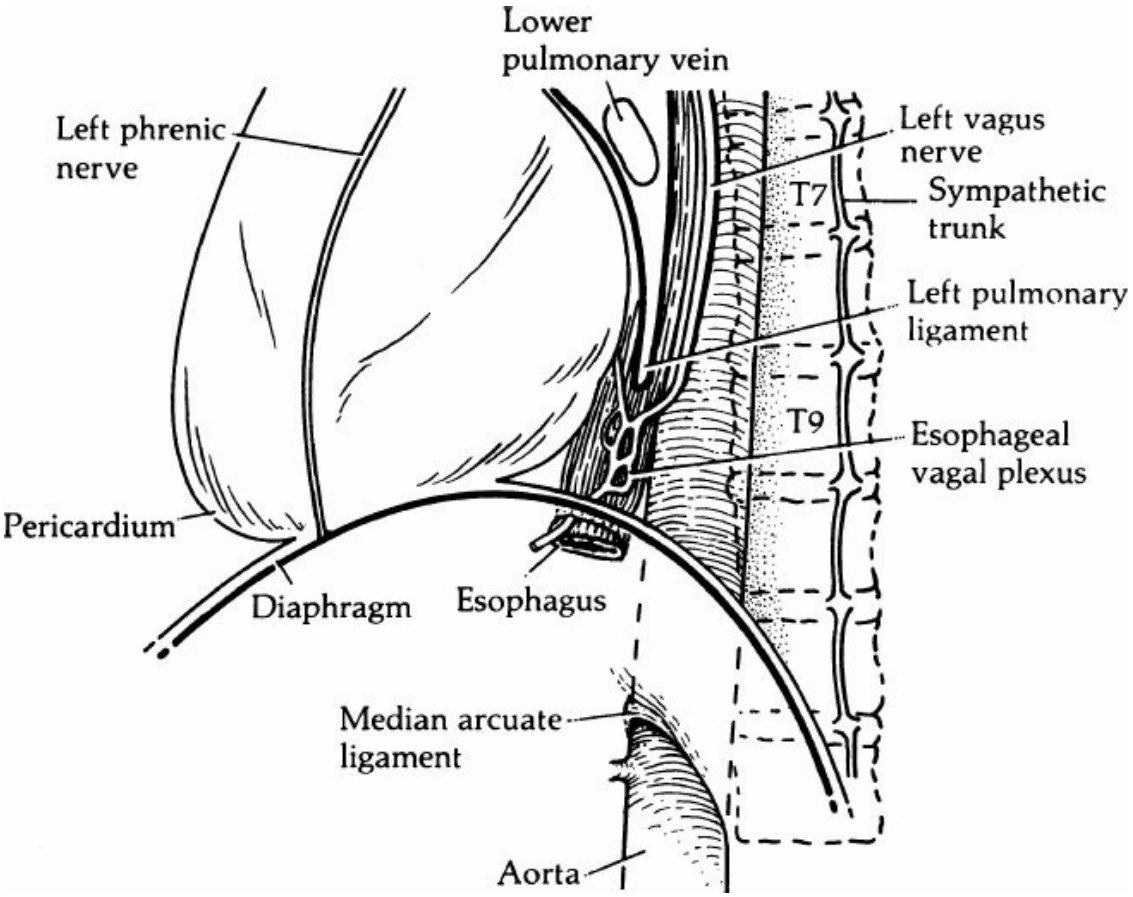

Figure 63.19. Structures in the inferior portion of the right mediastinum. IVC, inferior vena cava.

Gastrophrenic Ligament

The gastrophrenic ligament, the superior portion of the dorsal mesentery, arises from the greater curvature of the fundus and extends upward to the diaphragm (Fig. 63.20). The upper part is transparent and avascular, continuous with the posterior layer of the coronary ligament on the left. The lower part is continuous with the gastrosplenic ligament and contains some short gastric vessels and lymph nodes.

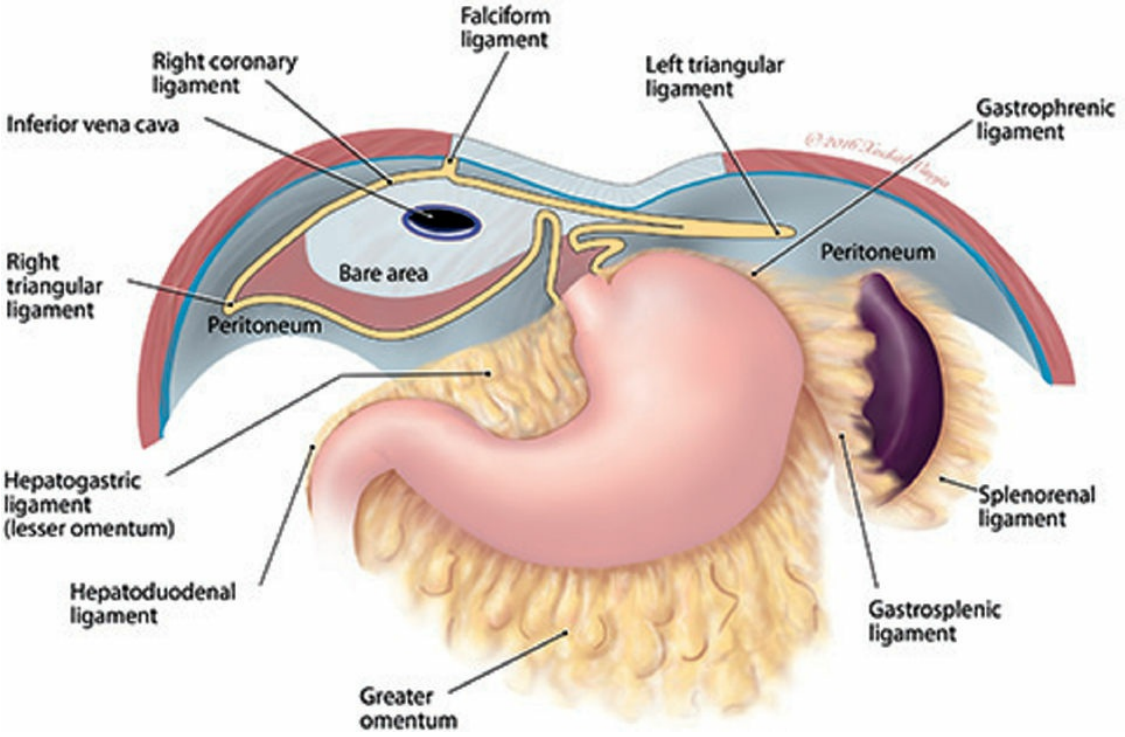

Figure 63.20. Peritoneal reflections of the stomach, gastroesophageal junction, and bare area of the diaphragm. The parietal peritoneum on the diaphragm is shown in *grey color.* The reflections of the parietal peritoneum toward visceral peritoneum are *bright yellow.* The stomach and spleen are covered by the visceral peritoneum. The liver that shares the bare area has been removed. The lower esophagus and lesser omentum have been cut in order to obtain view to the bare area and reflections of the peritoneum.

The upper, avascular area can be perforated by the surgeon's finger in order to insert a Penrose drain around the cardia. The surgeon can thus apply gentle traction on the endoabdominal esophagus and mobilize the GEJ.

VASCULARIZATION OF THE DIAPHRAGM

Arteries

The vascular supply of the diaphragm comes from several sources: (a) The inferior phrenic arteries, which are branches of the abdominal aorta or the celiac axis. (b) The superior phrenic arteries, which are branches of the thoracic aorta. These arteries are distributed to the posterior part of the diaphragm. (c) The pericardiacophrenic arteries, terminal branches of the internal thoracic (mammary) arteries; they follow the phrenic nerves and

supply the central area of the diaphragm. (d) The musculophrenic arteries, also terminal branches of the internal thoracic arteries, running laterally near the attachment of the diaphragm to the lower ribs. (e) The lower intercostal arteries, feeding the posterior periphery of the diaphragm.

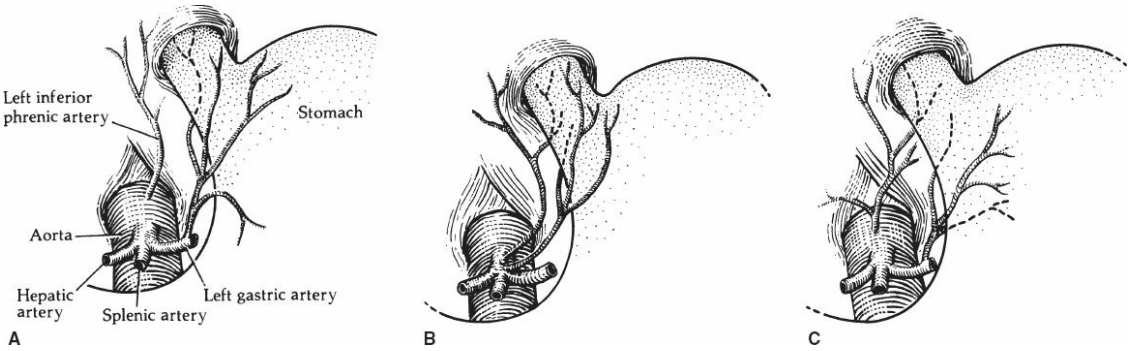

Figure 63.21. Variations in the blood supply to the distal esophagus and the esophageal hiatus. **A:** The inferior phrenic artery supplies the margin of the hiatus. An esophageal branch of the left gastric artery supplies the esophagus and anastomoses with thoracic esophageal arteries. The pattern is the most frequent one. **B:** The esophagus is supplied by esophageal branches of the left gastric and the inferior phrenic arteries without cranial anastomoses. **C:** The esophagus is supplied entirely by a branch of the inferior phrenic artery, which anastomoses with thoracic esophageal arteries. This pattern is rare. (From Skandalakis JE, Gray SW, Rowe JS Jr. *Anatomical Complications in General Surgery*. New York: McGraw-Hill, 1983, with permission.)

The major blood supply to the diaphragm comes from the inferior phrenic arteries (Fig. 63.17). Loukas et al. (2005) reported that the right inferior phrenic artery originated from the celiac trunk in 40% of their cadaveric specimens, the aorta in 38%, the right renal artery in 17%, the left gastric artery in 3%, and the hepatic artery proper in 2%. The left inferior phrenic artery originated from the celiac trunk in 47%, the aorta in 45%, the left renal artery in 5%, the left gastric artery in 2%, and the hepatic artery proper in 1%. The inferior phrenic arteries give rise to eight notable branches: ascending, descending, IVC, superior suprarenal, middle suprarenal, esophageal, diaphragmatic hiatal, and accessory splenic. In some persons, the lower esophagus which is supplied by the left gastric artery, receives twigs from the left inferior phrenic artery. In still others, branches of the inferior phrenic artery supply the lower esophagus;

branches of the left gastric artery are confined to the cardia and fundus of the stomach (Fig. 63.21). The margin of the hiatus is always supplied by a branch of the left inferior phrenic artery.

The surgeon must be aware of collateral circulation in several situations. According to Michels, in pathologic situations, such as a hepatocellular carcinoma, there is a possibility of collateral pathways between the arteries mentioned in the first paragraph of this heading. We add the anastomoses between the esophageal branches of the left gastric artery and the left inferior phrenic artery. Sources of collateral circulation for the liver could be branches of the right phrenic artery, and multiple branches in the bare area of the liver (passing from the diaphragm to the liver).

Veins

On the superior surface, small tributaries form the musculophrenic and pericardiacophrenic veins, which run with the corresponding arteries. Respectively, they empty into the internal thoracic and (perhaps) brachiocephalic veins. Posteriorly there is some local drainage into the azygos and hemiazygos veins.

On the inferior surface, the right inferior phrenic vein runs with the artery and empties into the IVC. Loukas et al. (2005) reported that the right inferior phrenic vein drained into the IVC inferior to the diaphragm in 90%, the right hepatic vein in 8%, and the IVC superior to the diaphragm in 2% of specimens. The left inferior phrenic vein drained into the IVC inferior to the diaphragm in 37%, the left suprarenal vein in 25%, the left renal vein in 15%, the left hepatic vein in 14%, and both the IVC and the left adrenal vein in 1% (Fig. 63.22). The branch draining into the vena cava passes in front of the esophagus closely enough to be injured. These findings may have clinical implications for the performance of endoscopic sclerotherapy and mobilization of the supradiaphragmatic segment of the IVC.

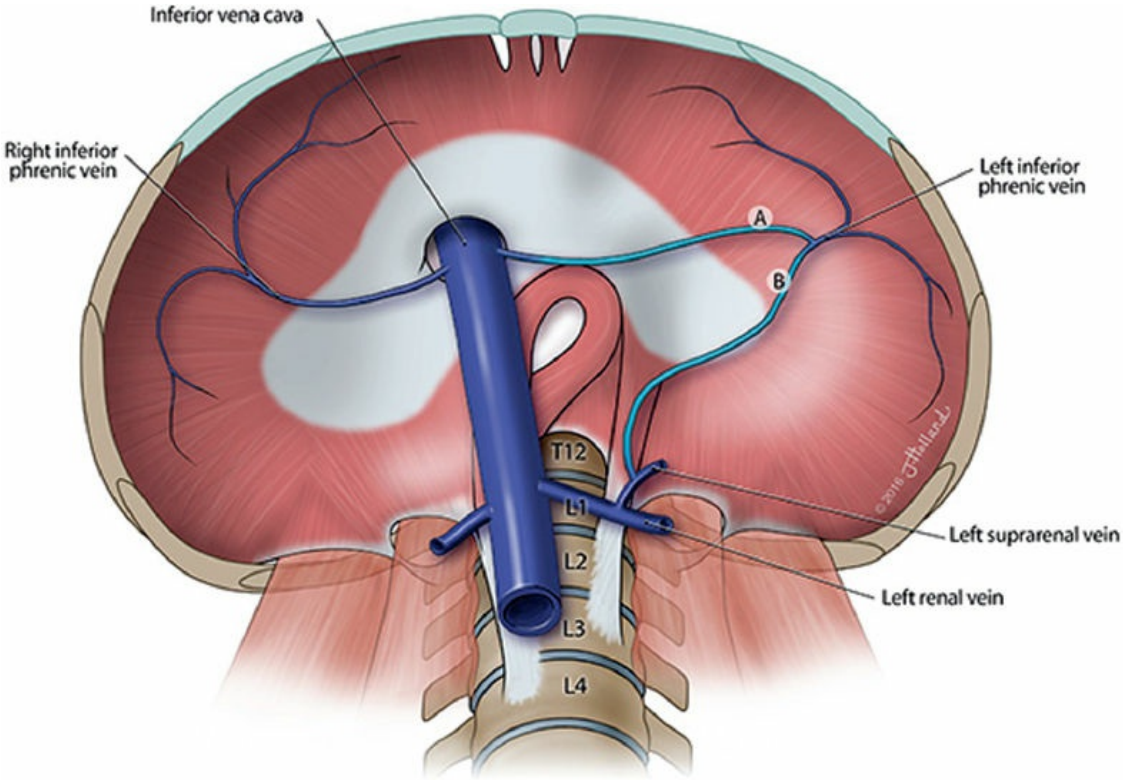

Figure 63.22. Venous drainage of the diaphragm from below. The left inferior phrenic vein may enter the inferior vena cava (IVC) (*A*), the left suprarenal vein (*B*), or both.

LYMPHATIC DRAINAGE OF THE DIAPHRAGM

Almost all the diaphragmatic lymph nodes lie on the superior surface of the diaphragm. These nodes can be divided into anterior, middle, and posterior groups (Fig. 63.23). They receive drainage from the upper surface of the liver, the GEJ, and the abdominal surface of the diaphragm. Efferent lymph vessels from these nodes drain upward to parasternal and mediastinal nodes anteriorly, and to posterior mediastinal and brachiocephalic nodes posteriorly.

The abdominal surface of the diaphragm is drained by lymphatics that direct to the supradiaphragmatic lymph nodes. However, in the abdominal surface there is some drainage via lymphatics that course retroperitoneally and join the renal and cisternal lymph nodes (Fig. 63.24).

The abdominal serosal surfaces of the diaphragm are active in the removal of fluid and cells from the peritoneal cavity. Pores between mesothelial cells from 4 to 12 μm in diameter open directly into the lymphatic vessels of the diaphragm. First seen in 1863 by von Recklinghausen, their existence has been confirmed by electron microscopy. Clinically, they may provide escape for tumor cells,

pathogens, and toxins from the peritoneal cavity. They also provide access for peritoneal dialysis in treating renal failure. All surgeons placing Tenckhoff peritoneal catheters take advantage of this function of the lymphatics in the abdominal surface of the diaphragm.

NERVE SUPPLY TO THE DIAPHRAGM

The right phrenic nerve enters the diaphragm through the central tendon just lateral to the opening for the IVC. Occasionally, it passes through that opening with the vena cava. The left phrenic nerve pierces the superior surface of the muscular portion of the diaphragm just lateral to the left border of the heart.

Both nerves divide or trifurcate at just above the diaphragm, and the branches travel together into the musculature. Small sensory branches are given off to the pleura and to the peritoneum over the central part of the diaphragm. The larger motor branches separate within the diaphragm into three or four major nerve trunks: sternal, anterolateral, posterolateral, and crural; the last two usually have a common trunk. These nerve trunks travel partly within the diaphragmatic musculature and partly on the inferior surface covered only by the peritoneum. The sternal branches of the two sides can anastomose behind the sternum (Fig. 63.25).

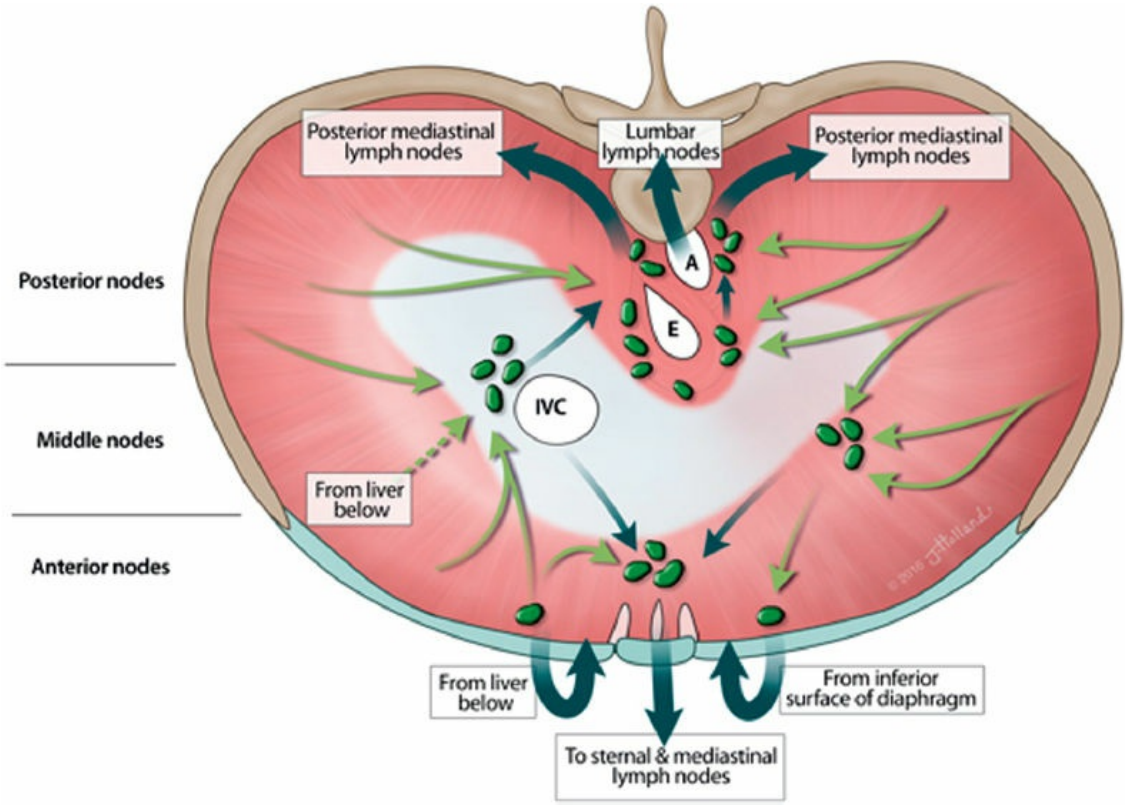

Figure 63.23. Lymphatic drainage of the diaphragm seen from above. The diaphragm receives lymph from the liver below and sends it to ascending sternal, anterior, and posterior mediastinal nodes. *A,* aorta; *E,* esophagus; *IVC,* inferior vena cava.

Recently, Loukas et al. (2016) reported that the right phrenic nerve was found inferior to the diaphragm in 98% of the specimens with 49.1% displaying a right phrenic ganglion. In 22.8% of the specimens there was an additional smaller ganglion (right accessory phrenic ganglion). Most specimens (65.5%) exhibited plexiform communications with the celiac ganglion, aorticorenal ganglion, and suprarenal gland. The left phrenic nerve inferior to the diaphragm was observed in 60% of specimens with 19% containing a left phrenic ganglion. No accessory left phrenic ganglia were observed. The left phrenic ganglion exhibited plexiform communications to several ganglia in 71.4% of specimens. Both phrenic nerves and ganglia were closely related to the diaphragmatic crura. Subdiaphragmatic phrenic nerves, ganglia, and their connections with autonomic ganglia are shown in Figure 63.26.

The presence of a classical phrenic ganglion in approximately 50% of human specimens suggests that this may constitute a potential source of extraphrenic innervation. The communication between the phrenic nerve, phrenic ganglion, and celiac ganglion provides structural evidence to suggest a flow of retrograde impulses via the celiac plexus and phrenic ganglia (peripheral control) for diaphragmatic function. The existence of these communications allows for the possibility of a viscerosomatic communication through which the respiratory function of the diaphragm may in part be controlled peripherally. These “peripheral controls,” if present, may prove particularly active during times when the action of breathing is regulated by variations in autonomic tone, such as sleeping. As reported in the paper by Loukas et al. (2016):

“Additional evidence for viscerosomatic regulation comes from reports describing neurogenic shock and respiratory paralysis following trauma to the epigastrium (Robinson, 1907; Furuya et al., 1979). By extension, if one considers the possibility of this viscerosomatic control, preservation of these fibers could prove particularly important during surgical procedures to the region. Owing to their location anterior to the diaphragmatic crura, the right phrenic ganglion, right accessory phrenic ganglion, and left phrenic ganglion could potentially be injured during operations for repair of diaphragmatic hernia and median arcuate ligament syndrome.

Conversely, if there is indeed sympathetic innervation of the diaphragm and its crura within these fibers, as proposed by Tubbs et al. a highly selective sympathectomy of the phrenic ganglia could be explored as a potential therapeutic alternative in the treatment of median arcuate ligament syndrome (Tubbs et al., 2008).”

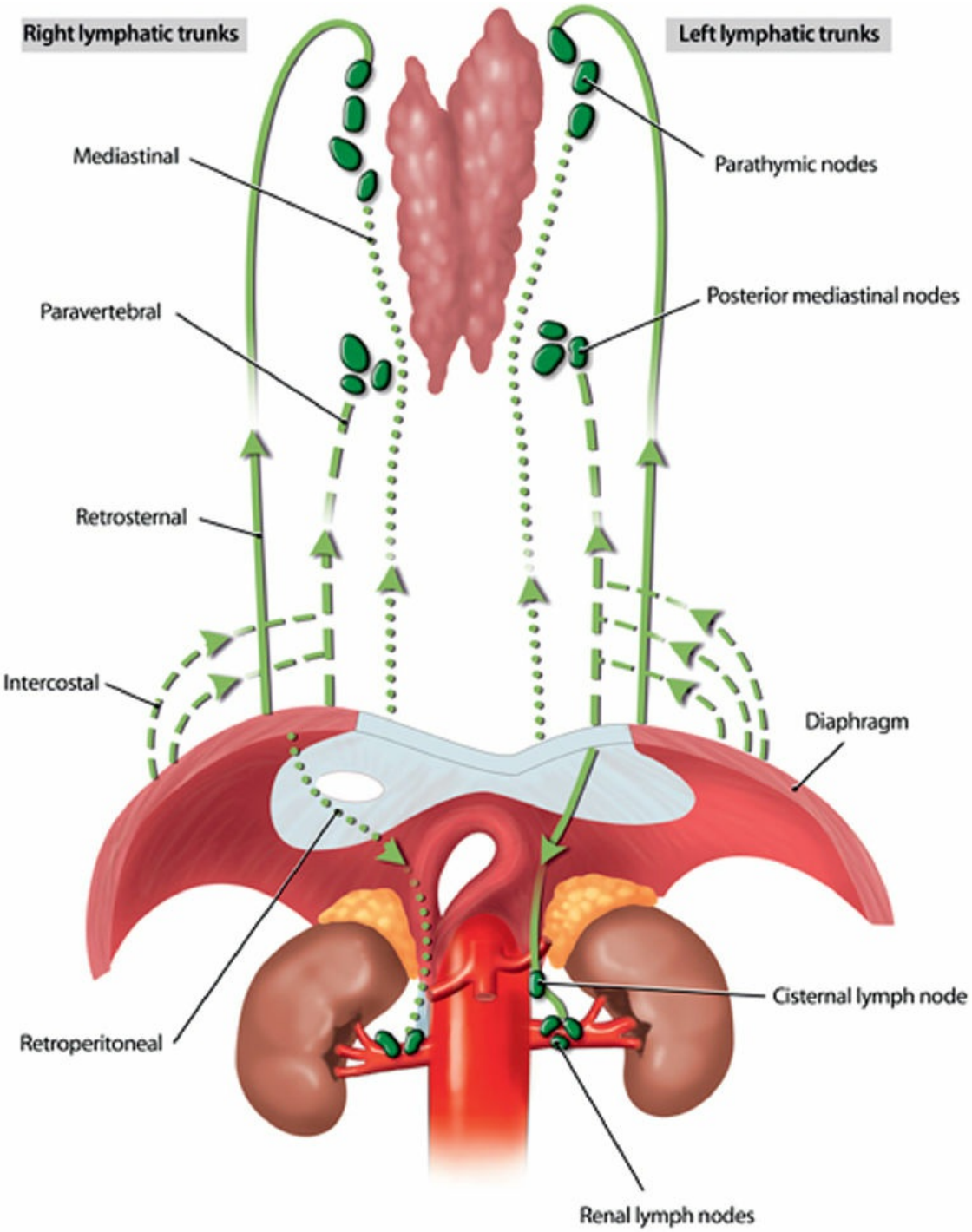

Figure 63.24. Diagram showing an anterior view of the lymphatic drainage routes of the diaphragm and their relative importance. The latter is judged on the basis of size, frequency, and intensity of coloration with ink:…, constant; –, usual; —, occasional. (Redrawn from Abu-Hijleh MF, Habbal 0A, Moqattash ST. The role of the diaphragm in lymphatic absorption from the peritoneal cavity. *J Anat* 1995;186:453–67; with permission from John Wiley and Sons.)

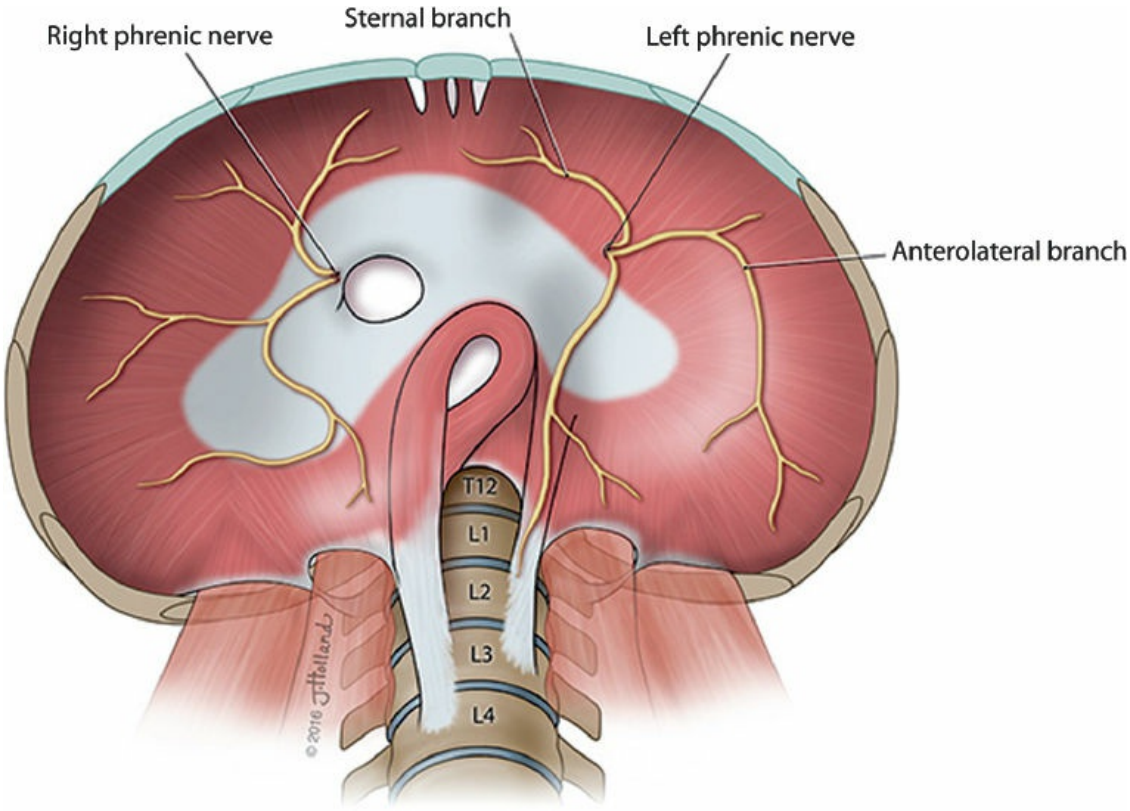

Figure 63.25. The major branches of the phrenic nerves from below. Each phrenic nerve divides just before entering the diaphragm from above.

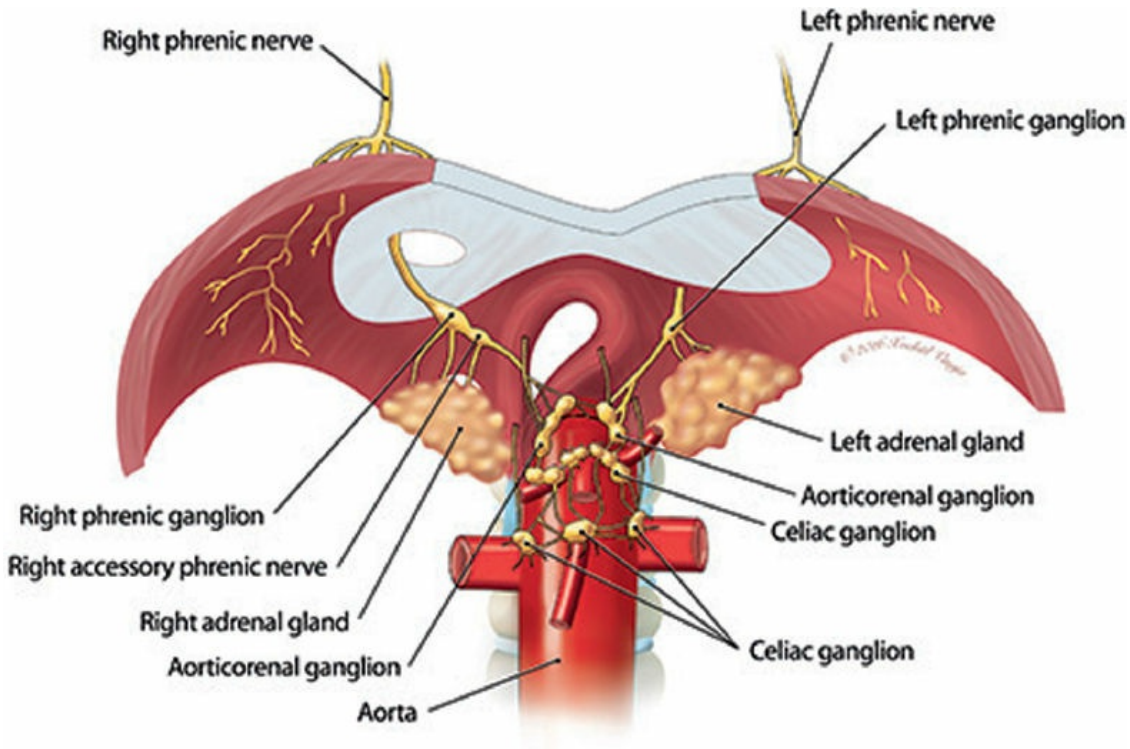

Figure 63.26. Diagrammatic representation of the right and left phrenic ganglia in relation to surrounding structures such as the

celiac, aorticorenal, and superior mesenteric ganglia and the greater and lesser splanchnic nerves. (Modified from Loukas M, Du Plessis M, Louis RG Jr, et al. The subdiaphragmatic part of the phrenic nerve – morphometry and connections to autonomic ganglia. *Clin Anat* 2015;29(1):120–8; with permission from John Wiley and Sons.)

The concept of peripheral autoregulatory functions was first described by Robinson in 1907, who used the term "Abdominal Brain" to describe the celiac plexus, including communications with the phrenic nerve. This idea is further supported through histologic examination of the right phrenic ganglion and right accessory phrenic ganglion by Tubbs (2008). The presence of multipolar autonomic neurons within these ganglia seems to suggest that autonomic innervation may be provided by way of these communications. On the other hand, Hollinshead stated that the diaphragm also receives sympathetic innervation from fibers of the phrenic nerves and of plexuses accompanying inferior phrenic arteries.

CELIAC GANGLIA

The celiac ganglia are closely adherent to the celiac artery at its origin from the aorta, and closely related to the crura of the diaphragm bilaterally. Sutures to approximate the crura must be placed above the ganglia and behind the celiac division of the posterior vagal trunk.

ACKNOWLEDGMENTS

The authors wish to thank the medical illustration team at St. George's University, Grenada, West Indies: Jessica Holland, MS, CMI; Angélica Ortiz, MScBMC; Charles Wesley Price, MS, CMI; and Xochitl Vinaja, MS; for the creation of color illustrations in this chapter, "Surgical Anatomy of the Diaphragm."

Suggested Readings

Abu-Hijleh MF, Habbal OA, Moqattash ST. The role of the diaphragm in lymphatic absorption from the peritoneal cavity. *J Anat* 1995;186:453–67.

Androulakis JA, Skandalakis JE, Gray SW. Contributions to the pathologic anatomy of hiatal hernia. *J Med Assoc Ga* 1966;55:295.

Baglaj SM, Czernik J. Nitrofen-induced congenital diaphragmatic hernia in rat embryo: what model? *J Pediatr Surg* 2004;39:24–30.

Bombeck CT, Dillard DH, Nyhus LM. Muscular anatomy of the gastroesophageal junction and role of phrenoesophageal ligament: autopsy study of sphincter mechanism. *Ann Surg* 1966;164(4):643–54.

Botros KG, El-Ayat AA, El-Naggar MM, et al. The development of human phrenoesophageal membrane. *Acta Anat* 1983;115(1):23–30.

Carey JM, Hollinshead WH. Anatomic study of esophageal hiatus. *Surg Gynecol Obstet* 1955;100:196–200.

du Plessis M, Ramai D, Shah S, et al. The clinical anatomy of the musculotendinous part of the diaphragm. *Surg Radiol Anat* 2015;37(9):1013–20.

Fischer JE. Editor's comment. In: Ricketts RR, Loukas M, Skandalakis LJ, et al., eds. Surgical anatomy of the diaphragm. In: Fisher JE, ed. *Mastery of Surgery.* 6th ed. Philadelphia, PA: Wolters Kluwer/Lippincott Williams & Wilikins; 2012:736–7.

Harrison MR. The fetus with a diaphragmatic hernia: pathophysiology, natural history, and surgical management. In: Harrison MR, Golbus MS, Filly RA, eds. *The Unborn Patient.* Philadelphia, PA: WB Saunders Company; 1991:295–319.

Harrison MR, Adzick NS, Longaker MT, et al. Successful repair in utero of a fetal diaphragmatic hernia after removal of herniated viscera from the left thorax. *NEJM* 1990;322:1582–4.

Hollinshead WH. *Anatomy for Surgeons*, Vol 2, *The thorax, Abdomen and Pelvis.* New York: Hoeber-Happer; 1956:17–25.

Horvath KD, Swanstrom LL, Jobe BA. The short esophagus: pathophysiology, incidence, presentation, and treatment in the era of laparoscopic antireflux surgery. *Ann Surg* 2000;251(5):630–40.

Iritan I. Experimental study on embryogenesis of congenital diaphragmatic hernia. *Anat Embryol* 1984;169:133–9.

Kluth D, Tander B, von Ekesparre M, et al. Congenital diaphragmatic hernia: the impact of embryological studies. *Pediatr Surg Int* 1995;10:16–22.

Loukas M, Du Plessis M, Louis RG Jr, et al. The subdiaphragmatic part of the phrenic nerve–morphometry and connections to autonomic ganglia. *Clin Anat* 2016; 29(1):120–8.

Loukas M, Hullett J, Wagner T. Clinical anatomy of the inferior phrenic artery. *Clin Anat* 2005;18(5):357–65.

Loukas M, Louis RG Jr, Hullett J, et al. An anatomical classification of the variations of the inferior phrenic vein. *Surg Radiol Anat* 2005;27(6):566–74.

Loukas M, Wartmann ChT, Tubbs RS, et al. Morphologic variation of the diaphragmatic crura: a correlation with pathologic processes of the esophageal hiatus? *Folia Morphol* 2008;67(4):273–9.

Nyhus LM. Editor's comment. In: Skandalakis JE, Gray SW, Rowe JS Jr, et al., eds. Surgical anatomy of the diaphragm. In: Nyhus LM, Baker RJ, eds. *Mastery of Surgery*, 2nd ed. Boston, MA: Little, Brown; 1992:395.

O'Rahilly R, Müller F. *Human Embryology and Teratology*. 3rd ed. New York: Wiley-Liss; 2001:276–80.

Skandalakis JE, Colborn GL, Weidman TA, et al. Diaphragm. In: Skandalakis JE, Colborn GL, Weidman TA, et al, eds. *Skandalakis' Surgical Anatomy: the Embryologic and Anatomic Basis of Modern surgery*. Athens: Paschalides Medical Publications; 2004:355–92.

Tamesue K, Hara K, Hara F, et al. Pericardial reconstruction using a pedicle flap of the diaphragmatic central tendon. *Jpn J Thorac Cardvas Surg* 2005;53:494–7.

Tubbs RS, Stetler W, Kelly DR, et al. Immunohistochemical study of the phrenic ganglion. *Anat Sci Int* 2008; 83:159–61.

EDITOR'S COMMENT

Dr. Mirilas and colleagues have written a detailed and interesting description of the Surgical Anatomy of the Diaphragm. As a surgeon with a lot of experience in operating on and near the diaphragm, I found many of the details informative and quite relevant.

Congenital diaphragm hernia (CDH) is a significant developmental anomaly that is quite interesting when considering the embryologic development of the diaphragm. Because this highly morbid condition can be diagnosed in utero, there is tremendous interest in intervening before birth when CDH is identified. A recent Cochrane review evaluated the antenatal administration of corticosteroids and in utero tracheal occlusion as strategies for addressing CDH in utero. There are relatively few small and retrospective studies available and the authors conclude that there is currently insufficient evidence to recommend in utero intervention for fetuses with CDH as a part of routine clinical practice. CDH is a great model for studying fetal surgery, and I suspect that in time in utero treatment of CDH will become a common procedure when identified at the appropriate stage of development.

Congenital hernias that present in adults are of interest to those of us who do not operate on infants. A Morgagni hernia is more likely to first present in an adult compared to a Bochdalek hernia. While Morgagni hernia represent only 3% of all repaired hernias of the diaphragm, the actual incidence is likely higher. I am a fairly high volume laparoscopic foregut surgeon, and I would estimate that once a year or so I encounter a small Morgagni defect incidentally in a patient in whom I am performing an unrelated procedure. Laparoscopic Morgagni hernia repair is well described and can be performed either primarily or with a mesh interposition.

The concept of a "short esophagus" is controversial. I am from the school of

thought described by Horvath et al. in this chapter who believes that a true short esophagus is an anomaly and highly unusual. Short esophagus is not easily identified prior to surgery and the incidence is directly related to the extent of the mediastinal dissection undertaken at the time of surgery. The reported incidence of short esophagus in the literature varies widely. A recent review article on the topic states "*[Short esophagus] has been reported to be as high as 60% and as low as 0% in older open and more recent laparoscopic series. If the need for a Collis gastroplasty is used as the most restrictive definition, then retrospective review of the literature indicates that between 1% and 5% of patients undergoing GERD-related surgery meet criteria.*" In the current chapter, a true congenital short esophagus is described as a partially supradiaphragmatic stomach existing from birth, not associated with a hernia sac, and not reducible. This is a truly rare condition. When most surgeons describe a short esophagus, they are likely referring to an acquired condition—most often associated with severe GERD or Barrett esophagus that leads to transmural scarring and shortening of the esophagus. In my opinion, in almost all patients in whom the diagnosis of short esophagus is suspected, the GEJ can be mobilized into the abdomen by circumferentially mobilizing the esophagus in the mediastinum, sometimes all the way to the aortic arch. The dilated hiatus often encountered in patients with preoperative concern for a short esophagus facilitates access to the high mediastinum. During high mobilization, surgeons should be aware of the position of the Vagus nerves (left anterior and right posterior, LARP) and the fact that the pleura becomes closely approximated to the esophagus the higher you go. While a pleural tear during high mediastinal dissection is usually of no consequence, in elderly frail patients with decreased cardiopulmonary reserve, there will likely be some compensatory adjustments that need to be made by both the anesthesiologist and the surgeon.

In large and complex paraesophageal hernia repairs, especially in elderly patients with poor tissue integrity and large hiatal defects, it can be exceedingly difficult to close the diaphragm primarily during surgery. Occasionally, a crural relaxing incision is needed to close the hiatus to the appropriate caliber. The description in this chapter on the innervation of the diaphragm is relevant in these cases, especially if a left-sided relaxing incision is considered given the typical location of the phrenic nerve in this area. In certain patients with diaphragm paralysis and the need for mechanical ventilation (especially cervical spine injuries), diaphragm pacing is an option that can lead to ventilator independence. A key part of this procedure is diaphragm mapping to reveal the location of the phrenic nerve, and this work has contributed to our understanding of the anatomy of the diaphragm.

The physiology of the lower esophageal sphincter and the relationship between anatomic abnormalities in this area and gastroesophageal reflux is important to understand. As correctly described in this chapter, reflux is common in patients with hiatal hernia and in patients with a short abdominal component of the lower esophageal sphincter. Fein and colleagues studied 375

consecutive patients with foregut symptoms and no previous foregut surgery. All patients underwent upper endoscopy, esophageal manometry, and 24-hour pH monitoring. The lower esophageal sphincter was considered structurally defective when the resting pressure was less than or equal to 6 mm Hg, the overall length was less than 2 cm, and/or the abdominal length was less than 1 cm. The presence of a hiatal hernia and a defective lower esophageal sphincter were identified as independent predictors of abnormal esophageal acid exposure. The anatomy of the lower esophageal sphincter and the contribution of abnormalities in this anatomy to the presence of pathologic GERD is important. I still struggle to convince gastroenterologists in my community that a patient without a hiatal hernia who suffers from medically refractory GERD symptoms is a candidate for antireflux surgery.

The median arcuate ligament is discussed in this chapter. This is an anatomic structure associated with compression of the celiac axis in some patients. However, the clinical significance and role of this anatomic finding in abdominal symptoms is controversial. A recent review of 20 years of the published literature revealed that median arcuate ligament syndrome involves a vague constellation of symptoms including epigastric pain, postprandial pain, nausea, vomiting, and weight loss. Extrinsic compression of the vasculature and surrounding neural ganglion is thought to be the cause of symptoms. Compression of the vasculature may also be a normal anatomic finding in patients without symptoms complicating the diagnosis. A multi-institutional review of 67 patients with presumed median arcuate ligament syndrome compared the symptomatic outcomes of patients treated surgically (median arcuate ligament release) to patients managed without surgery. After surgical treatment (which was significantly more effective than nonoperative therapy), 37% were asymptomatic and 56% were partially improved. Postexertional pain was predictive of improvement after surgery, while vomiting and unprovoked pain were predictors of poor surgical outcome. My personal results after 15 years as a surgeon and over a dozen patients treated are similar. I prefer to use intraoperative ultrasound and continue to divide median arcuate ligament fibers until the velocities in the celiac artery have normalized. The ligament in patients whose symptoms improve after surgery is often quite thick and can clearly be seen to compress the celiac artery. The use of ultrasound is helpful as this is a nerve-racking procedure and the temptation to quit dividing fibers is huge as the aorta and celiac trunk become more prominent during the release. As someone with a decent experience in these procedures, I wonder if part of the issue with regard to inconsistent symptomatic outcomes relates to my hypothesis than many surgeons do not do a complete release. Using ultrasound, I have routinely observed that when I think I am done dividing muscle fibers (or I want to quit), the ultrasound velocities have not quite normalized. With additional muscle fiber division, normalization of celiac flow velocities is almost always possible, unless there is an intrinsic lesion of the artery itself.

Finally, transitioning from the diaphragm and onto the ventral abdominal

wall, there is some interesting anatomy described in this chapter that is helpful for surgeons who embark on complex abdominal wall reconstructions for hernia. Ventral hernia repair has evolved significantly in the past decade. The trend currently is to use advanced techniques to bring the linea alba together and to reinforce the reconstruction with mesh in the retrorectus position. For larger and more complex hernias, this often requires some form of an abdominal wall component separation and reconstruction. A very popular technique associated with excellent outcomes at the current time is a transversus abdominis release to achieve a posterior components separation. For abdominal wall defects that extend to the sternum and subcostal area, the retromuscular plane is extended cephalad to the costal margin and dorsal to the sternum by sweeping the peritoneum/transversalis fascia off the diaphragm. This allows wide overlap of a large piece of mesh in the sublay position—both laterally and superiorly to the defect. This is an extremely useful technique for repair of complex and large ventral hernias and requires intimate knowledge of the anatomic relationships described so well in this chapter.

Overall, this is an excellent chapter that described anatomic principles and relationships of the diaphragm that are clinically relevant in many different disease states and surgical procedures. Any surgeon who operates on or near the diaphragm would be well served to have a thorough understanding of the concepts described in this chapter.

Jon Gould

Suggested Readings

Alshekhlee A, Onders RP, Syed TU, et al. Phrenic nerve conduction studies in spinal cord injury: applications for diaphragmatic pacing. *Muscle Nerve* 2008;38(6):1546–52.

Fein M, Ritter MP, DeMeester TR, et al. Role of the lower esophageal sphincter and hiatal hernia in the pathogenesis of gastroesophageal reflux disease. *J Gastrointest Surg* 1999;3(4):405–10.

Grivell RM, Andersen C, Dodd JM. Prenatal interventions for congenital diaphragmatic hernia for improving outcomes. *Cochrane Database Syst Rev* 2015;(11):CD008925.

Ho KK, Walker P, Smithers BM, et al. Outcome predictors in median arcuate ligament syndrome. *J Vasc Surg* 2017;S0741–5214(16)31858–4.

Kim EN, Lamb K, Relles D, et al. Median arcuate ligament syndrome-review of this rare disease. *JAMA Surg* 2016;151(5):471–7.

Kunio NR, Dolan JP, Hunter JG. Short esophagus. *Surg Clin North Am* 2015;95(3):641–52.

Novitsky YW, Elliott HL, Orenstein SB, et al. Transversus abdominis muscle

release: a novel approach to posterior component separation during complex abdominal wall reconstruction. *Am J Surg* 2012;204:709–16.

Schumacher L, Gilbert S. Congenital diaphragmatic hernia in the adult. *Thorac Surg Clin* 2009;19(4):469–72.

64 Congenital Diaphragmatic Hernia

Corey W. Iqbal

INTRODUCTION

Congenital diaphragmatic hernia (CDH) occurs in 1 in 2,200 to 5,000 live births. Given the lethality of this lesion and a high rate of in utero fetal demise, still birth, and early neonatal death prior to transfer to a tertiary referral center the true incidence is difficult to capture in epidemiologic studies and the incidence is likely closer to 1 in 2,200 pregnancies—this phenomena is referred to as the hidden mortality of CDH. No congenital anomaly has been more perplexing for pediatric surgeons, as surgical correction of the defect postnatally seems to have very little impact on survival.

Prior to 1940, there were few survivors of CDH. Gross and Ladd reported 9 out of 16 survivors with immediate surgical repair. This became the mainstay of therapy, as experts believed mediastinal compression from the herniated viscera was the inciting factor for mortality. However, survival, at best, was around 50%. In the mid 1980s, Dr. Stolar recognized the impact of pulmonary hypoplasia—a fixed defect that immediate decompression does not reverse—and introduced the idea of “gentilation” and permissive hypercapnia that led to a major paradigm shift. Currently expected survival for CDH may be as high as 70% to 80%.

EMBRYOLOGY

The diaphragm is a predominately fibrous dome that separates the abdominal cavity from the thoracic cavity. The central tendon comprises the majority of the diaphragm with muscular fibers on the periphery anchoring the diaphragm to the rib cage where it functions in ventilation by innervation from the phrenic nerve. The left and right crural fibers split where the esophagus and aorta pass from the thoracic cavity into the abdominal cavity. More than 85% of CDH occur on the left side as a posterolateral defect, classically referred to as the Bochdalek defect after his description in 1848. Right-sided defects and anterior defects

(Morgagni-type defect) occur with less frequency and are discussed in separate sections within this chapter.

In normal development, the fusion of four embryologic components gives rise to the diaphragm: the septum transversum, the pleuroperitoneal folds, the esophageal mesentery, and the body wall mesoderm. The septum transversum fuses dorsally with the body wall mesoderm and gives rise to the central tendon. The pleuroperitoneal folds close from the dorsal and lateral aspects completing separation of the fetal chest and abdomen by 8 weeks. The pleuroperitoneal folds are later replaced by a striated muscle. The esophageal mesentery forms the crural and dorsal fibers. When any of these structures fail to fuse, a diaphragmatic defect results.

The most commonly accepted theory behind the development of CDH is that the pleuroperitoneal folds incompletely fuse; the degree of incomplete fusion can result in a small defect or complete absence of the diaphragm—diaphragmatic agenesis. In 10% to 20% of cases, the pleuroperitoneal folds likely completely fuse, but there is failure of muscularization and a sack results.

Lung development occurs in five phases: embryonic, pseudoglandular, canalicular, saccular, and alveolar. Lung buds give rise to the lobar structures in the embryonic phase. During weeks 7 to 17, the pseudoglandular phase occurs and the bronchial structures develop. Primitive alveoli develop during the canalicular phase along with type I and II pneumocytes—this process occurs up to 24 weeks of gestation. In the setting of a CDH, herniated viscera impair this developmental process resulting in hypoplastic lungs.

It has been widely accepted that the herniated viscera compress the fetal lungs and impairs lung development resulting in pulmonary hypoplasia. However, pulmonary hypoplasia occurs bilaterally, despite a unilateral defect. Therefore, more recently some have proposed a dual hit theory of primary pulmonary hypoplasia affecting diaphragmatic development resulting in a CDH with additional pulmonary injury from compression. Either way, pulmonary hypoplasia results in pulmonary hypertension, inadequate gas exchange, and in many cases, death.

ASSOCIATED ANOMALIES

In 60% of cases, CDH occurs as an isolated event. However, there are often associated anomalies inherent to CDH or that can be a consequence of a CDH such as nonrotation of the intestines and esophageal ectasia. In

40% of cases, CDH occurs as part of a syndrome or in association with another congenital anomaly (nonisolated). Associated anomalies can include congenital heart disease, genitourinary abnormalities, intestinal atresia, bronchopulmonary sequestration, and neurologic defects.

The most common syndrome is Fryns syndrome, but multiple genetic disorders have been described in association with CDH such as trisomy, Beckwith–Wiedemann, and Pierre-Robin. When a genetic association is suspected, families should be tested and counseled accordingly. When CDH is part of a syndrome or nonisolated, the survival rates are less favorable. In fact 95% of stillborns with CDH have a chromosomal abnormality indicating the lethality of nonisolated CDH.

PRENATAL CARE

Diagnosis

As prenatal imaging modalities continue to improve, the detection of congenital anomalies in the prenatal period has become commonplace. The presence of abdominal viscera in the chest is clearly abnormal and readily detected by prenatal ultrasonography (US) in as many as 90% of CDH cases. The ultrasonographer may observe the gastric bubble is not in its normal anatomic position, the liver may be herniated into the chest, and there may not be any appreciable lung on the ipsilateral side. The presence of any abdominal viscera above the inferior tip of the scapula or at the level of the four-chamber view of the heart is abnormal and consistent with a CDH. Polyhydramnios can occur if the stomach is kinked causing amniotic fluid to build up. The finding of polyhydramnios should prompt the ultrasonographer to conduct a careful assessment of the fetal chest to rule out CDH.

Prognostication

The high mortality rate associated with CDH made it a driving force behind the advent of fetal surgery and the concept of in utero intervention for a high-risk congenital anomaly in order to improve the postnatal outcome. Intense investigation in this area has resulted in multiple prognostic measures for CDH in the hopes of identifying those cases at highest risk for death that could potentially benefit from an invasive in utero procedure.

US provides the most studied prognostic factors, although other

modalities such as fetal magnetic resonance imaging (MRI) and fetal echocardiography have also been studied. A detailed US should be obtained in any pregnancy where there is a suspicion for CDH. In addition, fetal echocardiography should be obtained to rule out any structural abnormalities of the heart, which has a significant impact on prognosis and will impact counseling. The routine use of MRI is more controversial. Fetal MRIs can be difficult to obtain if there is significant fetal movement but may offer more objective measures and have less interuser variability than US.

The presence of liver herniation reproducibly predicts a worse outcome for CDH. Therefore, position of the fetal liver should be routinely assessed during fetal US for CDH. The lung-to-head ratio (LHR) is another important prognostic indicator. It is obtained via US by measuring the right lung area at the level of the four-chamber view of the heart and dividing by the fetal head circumference. In multiple studies, an LHR <0.6 was associated with 100% mortality while an LHR >1.35 was associated with 100% survival.

A major criticism of the LHR has been that the fetal lung and head grow at different rates, especially up to 32 weeks of gestation when lung growth begins to level off relative to the head circumference. Consequently, LHR changes with gestational age. This prompted investigators to propose the observed-to-expected ratio for LHR (O/E LHR) based on what the mean expected LHR would be for a specific gestational age in fetuses not affected by CDH. In the original description of the O/E LHR for left-sided defects, O/E LHR of <25% was associated with an 18% survival; O/E LHR of 26% to 45% was associated with a 66% survival; and O/E LHR of >45% was associated with an 89% survival.

Fetal MRI has primarily been used to study lung volumes for antenatal prognostication of CDH. The most studied measurement by MRI is the percent predicted lung volume (PPLV)—also known as the observed-to-expected fetal lung volume (O/E FLV). This calculation is made by subtracting the mediastinal volume from the thoracic volume to determine the expected lung volume. The actual lung volume is then measured and divided by the expected lung volume to create a percentage.

Exactly how the PPLV should be interpreted is not agreed upon. In one study, 15% appeared to be the determinant of survival where those with a PPLV >20% had 100% survival whereas a PPLV of <15% was associated

with only 40% survival. In another study, the cutoff appeared to be 25% where PPLV <25% was associated with a 13% survival and a PPLV >35% was associated with an 83% survival. However, some have reported that PPLV is inferior to LHR in predicting outcomes. Other groups have looked at the raw FLV obtained by fetal MRI as a prognostic indicator. In a series of FLV at 34 to 35 weeks of gestation the investigators reported that survivors had a mean FLV of 35 mL, those requiring ECMO had a mean FLV of 18 mL, and nonsurvivors had a mean FLV of 9 mL. Use of these measures in prenatal counseling should be done judiciously and incorporates one's own institutional experience.

Fetal Interventions

Any fetal intervention carries a risk to both the fetus and a healthy mother. Fetal interventions are associated with fetal demise, preterm labor, the risk of premature rupture of membranes, chorionic membrane separation, chorioamnionitis, and bleeding. Open fetal procedures run the additional risk of uterine dehiscence and rupture with the current pregnancy and any future pregnancies. For these reasons, fetal intervention should be reserved for those situations where a clear benefit exists for the fetus.

In 1990, Dr. Michael Harrison and his team at UCSF published the first successful open fetal CDH repair. This was followed by a prospective trial comparing open fetal repair to postnatal repair that did not show survival benefit with open fetal repair. Open fetal repair has since been abandoned in favor of fetal tracheal occlusion (FeTO). When the fetal trachea is occluded, fluid normally made by the fetal lung parenchyma builds up and leads to pulmonary hyperplasia.

The initial trials investigating FeTO showed dramatic pulmonary hyperplasia but this was not associated with any survival benefit due in large part to the invasiveness of the fetal procedure, which was performed through an open hysterotomy, that resulted in preterm delivery. Consequently, fetoscopy with tracheal clip application was used in a subsequent study which compared fetoscopic FeTO (n = 8) to open FeTO (n = 8) and postnatal CDH repair (n = 13) in pregnancies at <25 weeks of gestation for isolated left-sided CDH with liver-up and LHR <1.4. Survival was greatest in the fetoscopic FeTO group (75%) followed by the postnatal repair group (38%) and the open FeTO group (15%).

Given these promising findings, a prospective randomized trial was initiated at UCSF for pregnancies complicated by isolated left-sided CDH

with liver-up and LHR <1.4. In addition, use of tracheal clips was abandoned in favor of tracheal balloon occlusion. Subjects were randomized to either fetoscopic bronchoscopy through a 5 mm port with tracheal balloon occlusion or postnatal care. The primary outcome was 90-day survival and the study was powered for a 77% survival rate in the FeTO group that required an enrollment of 40 patients. The study was terminated at 24 patients because no survival benefit was found. The nontreatment group had a survival rate much higher than historical controls and what had been expected in the study (77 vs. 73%, $p = 1.0$) that became a major criticism of the study. Yet this improved survival in the postnatal therapy group was likely a reflection of improved perinatal care and "gentilation" techniques introduced at that time. An additional criticism was the inclusion of LHR 1.0 to 1.4 as these defects were likely not as severe as if the study had been limited to an LHR <1.0.

In Europe, the consensus has been to move forward with FeTO and continue to investigate its potential for CDH. Currently the Eurofetus group is sponsoring a multicenter, prospective trial that is studying the optimal timing for FeTO. Investigators in North America have proposed a multicenter, prospective trial on FeTO for CDH as an extension of the Eurofetus trial but are still awaiting FDA approval for the balloon device currently in use throughout Europe.

In the absence of tracheal occlusion, some investigators have proposed that EXIT-to-ECMO may be a viable alternative to improve outcomes for unfavorable CDH. The theory is to provide cardiopulmonary support prior to the fetus becoming hemodynamically compromised. However, the largest experience with EXIT-to-ECMO, out of Boston, found no survival benefit for EXIT-to-ECMO (33% survival) compared to those CDH patients requiring ECMO but not undergoing an EXIT procedure (50% survival). Currently, there does not appear to be a convincing role for EXIT-to-ECMO.

PATHOPHYSIOLOGY

Initial Resuscitation

The underlying factors contributing to the pathophysiologic process of CDH are (1) pulmonary hypoplasia and (2) pulmonary hypertension. These two elements are closely related. Pulmonary hypoplasia results in limited surface area for adequate gas exchange—in some cases the extent of pulmonary hypoplasia is incompatible with life. Pulmonary hypoplasia

results in an underdeveloped pulmonary vasculature that impedes blood flow through the pulmonary circulation, that is, pulmonary hypertension. This further impairs adequate gas exchange by limiting blood flow across the alveolar surface and increases the afterload on the right heart leading to heart failure.

Lung volumes are fixed at birth, however pulmonary hypertension can be potentially managed. Acidosis, hypoxia, and hypercarbia have a significant effect on the reactivity of the pulmonary vasculature causing profound vasoconstriction that exacerbates pulmonary hypertension. Therefore, the initial resuscitation in the newborn with CDH should focus on avoiding hypoxia, hypercarbia, and acidosis. While, it is necessary to optimize ventilation through the existing lung parenchyma, overly aggressive ventilator strategies result in barotrauma that can be detrimental.

Recognizing the need to maintain adequate gas exchange without injuring the fragile lungs of a neonate with CDH, permissive hypercapnia with spontaneous ventilation has been advocated, as it is associated with improved survival. Preductal SaO_2 should be maintained above 85% and $PaCO_2$ up to 45 to 60 mm Hg can be tolerated as long as a pH of >7.3 can be maintained. PO_2 can be used as a guide as well with goals of the preductal PO_2 above 60 mm Hg and a postductal PO_2 above 40 mm Hg. Inhaled nitric oxide (NO) has been administered to facilitate pulmonary arterial vasodilation and treat pulmonary hypertension; however, clinical trials have failed to demonstrate any survival benefit with the use of NO.

If the diagnosis of CDH has been made prenatally, delivery plans should include the presence of a neonatal resuscitation team in a tertiary referral center. Once delivered, decompression of the neonate's intestinal tract with a nasogastric tube is important to prevent further compression of the lungs from air accumulating in the gastrointestinal tract. Intubation should be undertaken, especially for signs of respiratory distress (see Fig. 64.1). Arterial and venous access should be obtained—preferably a right radial arterial line to allow preductal measurements that reflect the cerebral oxygenation. An echo should be obtained early on to assess for pulmonary hypertension.

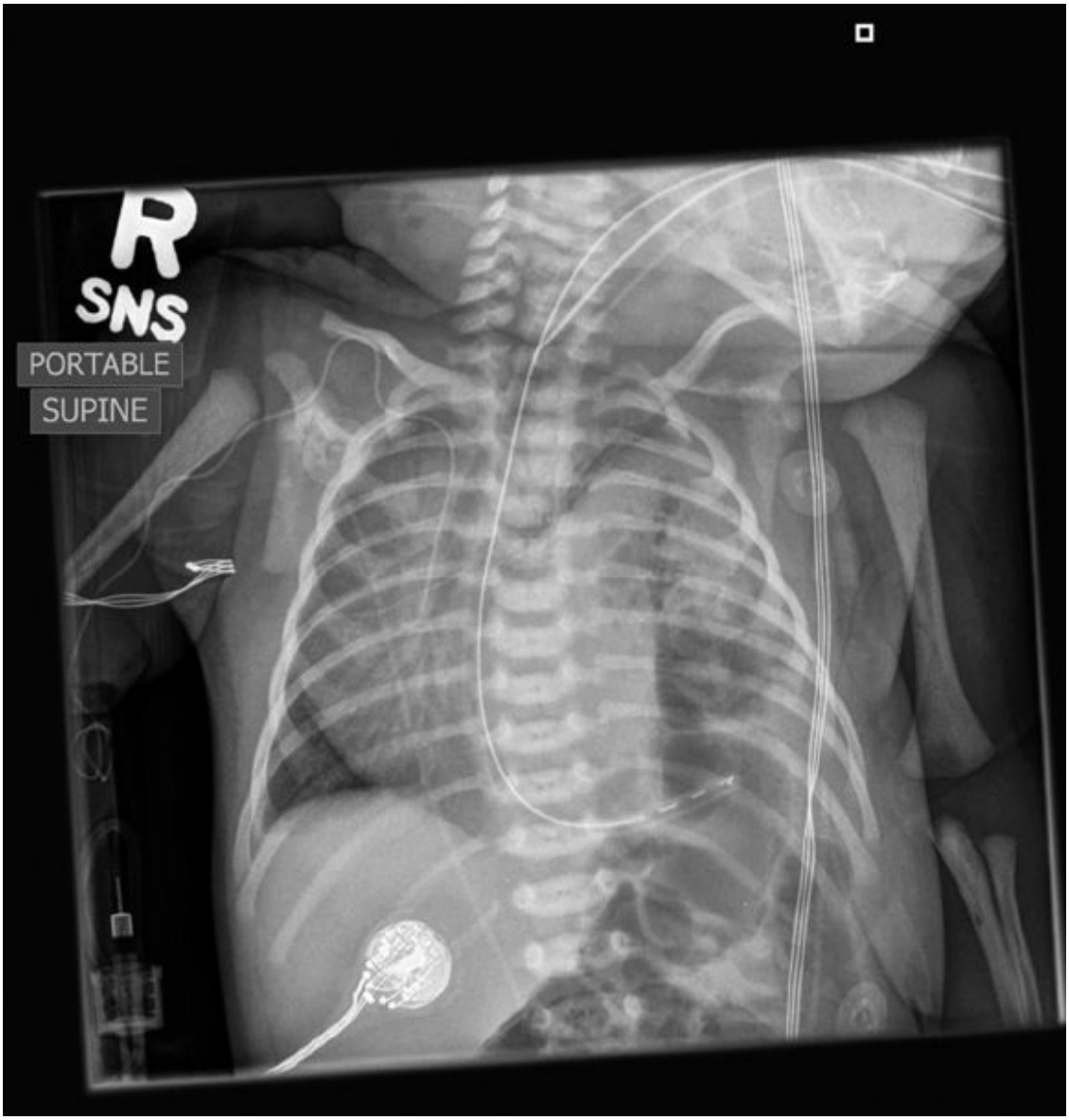

Figure 64.1. Left-sided congenital diaphragmatic hernia on postresuscitative radiograph.

Preoperative Planning

Immediate surgical repair does not correct the fixed lung volumes nor expedite vascular remodeling and subsequent resolution of pulmonary hypertension. Therefore, stabilization of the infant should precede operative repair which should be delayed until the pulmonary hypertension is controlled, which can be followed by echocardiography paying specific attention to right heart function.

In infants unable to maintain adequate gas exchange and with impending heart failure, extracorporeal membranous oxygen (ECMO) has been used as a salvage therapy. Generally speaking, infants ≥34 weeks of

gestational age and ≥2 kg are candidates for ECMO. A specific criterion for ECMO is that the underlying cause is reversible; therefore infants with lethal pulmonary hypoplasia should not be offered ECMO. Neonates who never achieve a preductal SaO_2 ≥90% for at least 60 minutes likely have lethal pulmonary hypoplasia and are poor candidates for ECMO.

For infants on ECMO, the timing of operative repair is controversial. Bleeding is a major complication with any intervention while on ECMO. It has been shown that bleeding complications can be minimized by repair within 24 hours of going on ECMO in conjunction with the administration of aminocaproic acid for 48 hours perioperatively. However, repairing the defect will not reverse the pulmonary hypoplasia and hypertension that necessitated ECMO; therefore, others advocate delaying repair until the infant has come off ECMO.

SURGICAL REPAIR

Multiple methods have been described for the surgical correction of CDH. The most commonly employed method is the open, transabdominal approach, although a minimally invasive thoracoscopic repair has also been described. Which operation is ideal depends on the experience of the surgeon, the clinical condition of the baby, and the suspected size of the defect.

Open Repair

The most common approach for a left-sided CDH is an open technique through a left, sub-costal incision. The incision can either be made transversely, or obliquely, one fingerbreadth below the costal margin. Once the abdominal cavity is entered, a self-retaining retractor is helpful to provide traction cephalad on the anterior chest wall. Using dry sponges, the viscera are gently reduced. Oftentimes a CDH will contain the liver and/or spleen; therefore, care should be taken to minimize trauma to these fragile structures and avoid life-threatening hemorrhage.

Once the hernia has been reduced, malleable retractors can be used to keep the viscera reduced and out of the operative field. In most cases, the defect is posterolateral; therefore, an anterior rim of diaphragm can often be identified and utilized in the repair (see Fig. 64.2). The anterior rim can be traced medially where there is often some diaphragm that will extend posteriorly. There is little need to mobilize the anterior and medial aspects of the diaphragm, however posteriorly the peritoneum can be opened to

help gain some mobility on the posterior leaf (see Fig. 64.3). As this dissection along the posterior rim is carried laterally, the diaphragm is usually lost at the lateral aspect. The surgeon then assesses the size of the defect and determines the most appropriate method of closure based on the defect size and available diaphragm. The CDH study group has created a classification of CDH defect size to help standardize reporting in the literature and this can be useful in describing the defect (see Fig. 64.4).

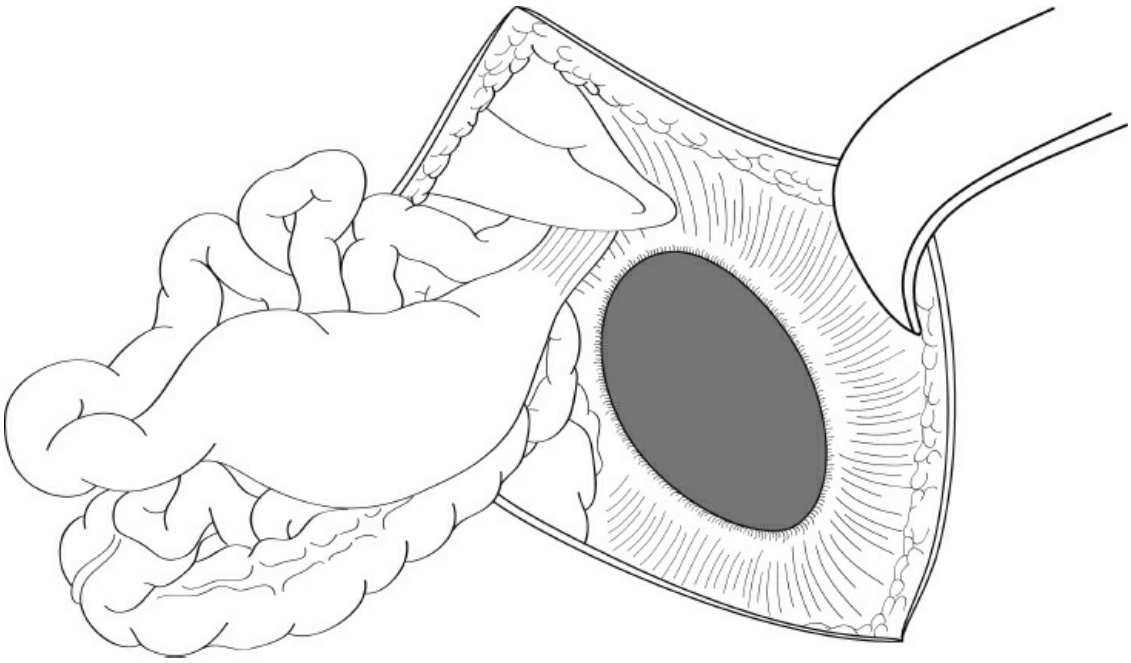

Figure 64.2. After the abdominal viscera are reduced back into the abdomen, the view of the diaphragmatic defect is evident.

If the diaphragm can be closed with minimal tension, then a primary repair can be performed. Most surgeons use nonabsorbable sutures and some advocate the use of pledgets to reduce damage to the tissues and promote scarring; however, there is no convincing data to support their routine use. If the defect is too large for primary closure then a patch must be used. Oftentimes, the medial aspects of the diaphragm can be closed primarily, but the lateral aspect lacks adequate tissue for closure and a patch is still required. There is mixed data on whether a permanent mesh such as stretched polytetrafluoroethylene (PTFE) or a bioprosthetic (of which numerous products are commercially available) is the most suitable patch. The potential advantages to a bioprosthetic are that they resist infection and support in-growth of autologous tissue that will potentially grow with the child reducing chest wall deformities and hernia recurrence. However, much of the patch is not in apposition to vascularized tissue that

most likely limits their efficacy, and current studies have not been convincing that bioprostheses are superior to a nonabsorbable mesh.

When using a patch, the patch is sewn to the diaphragmatic rim using nonabsorbable sutures, with or without pledgets. Securing the patch to the posterolateral chest wall can be challenging when there is little or no rim to sew to. In these cases, the patch is sewn directly to the chest wall by either suturing to the periosteum of the ribs, or passing the suture around the rib. In severe cases, medial diaphragm may be absent as well and the patch may need to be sewn to the adventitia of the aorta and the esophagus.

Recurrence after CDH repair can be as high as 35% and even higher if a patch was necessary. Therefore, more recently surgeons are beginning to go back to the muscle flap repair using the internal oblique muscle flap, which has been shown to reduce recurrence rates to as low as 4% in a single center experience from Utah. The advantage to this approach is that it utilizes autologous tissue that will grow with the child and potentially reduce the risk for recurrence. The disadvantages to a muscle flap are that the incision is made lower on the abdominal wall and can make exposure more difficult during repair; the decision to use the flap must be made prior to incision; and it also leaves the left abdominal wall with some degree of diastasis.

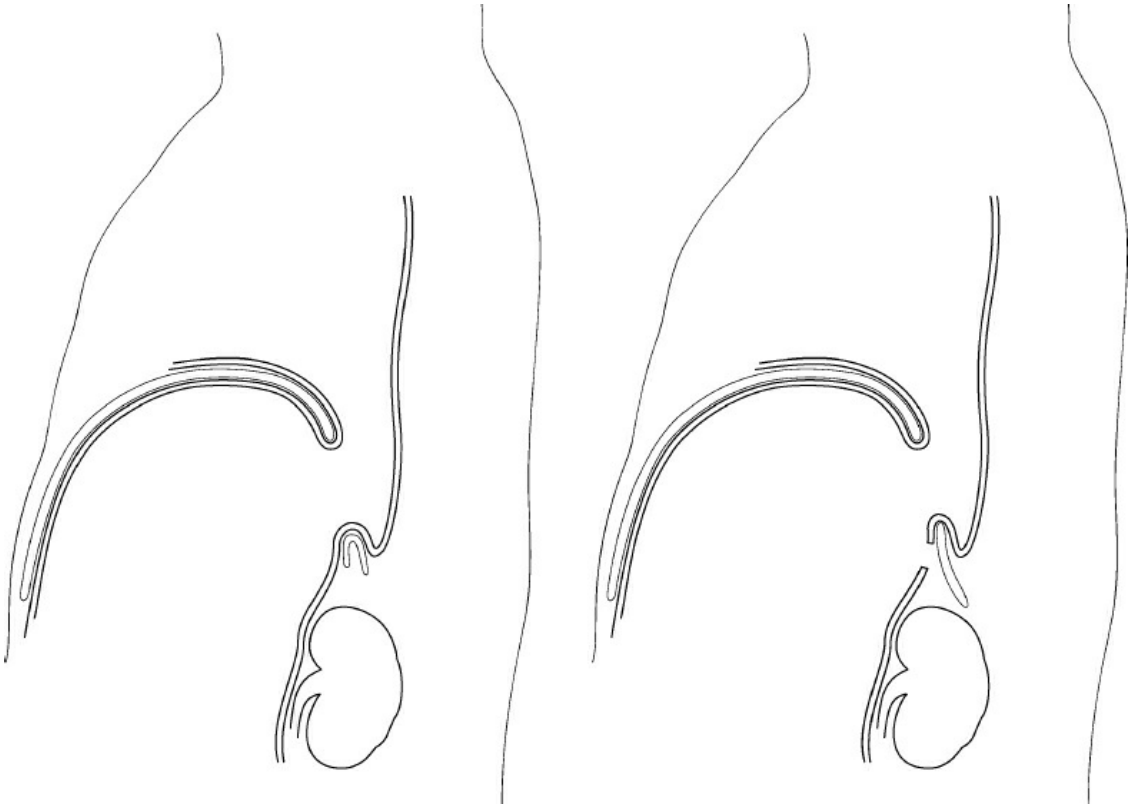

Figure 64.3. The posterior peritoneum can be seen covering the inferior leaf of the diaphragmatic remnant (**left**). Incision of the peritoneum either above or under the posterior rim of the diaphragm enables the diaphragm to be more fully mobilized and the defect can be repaired with less tension.

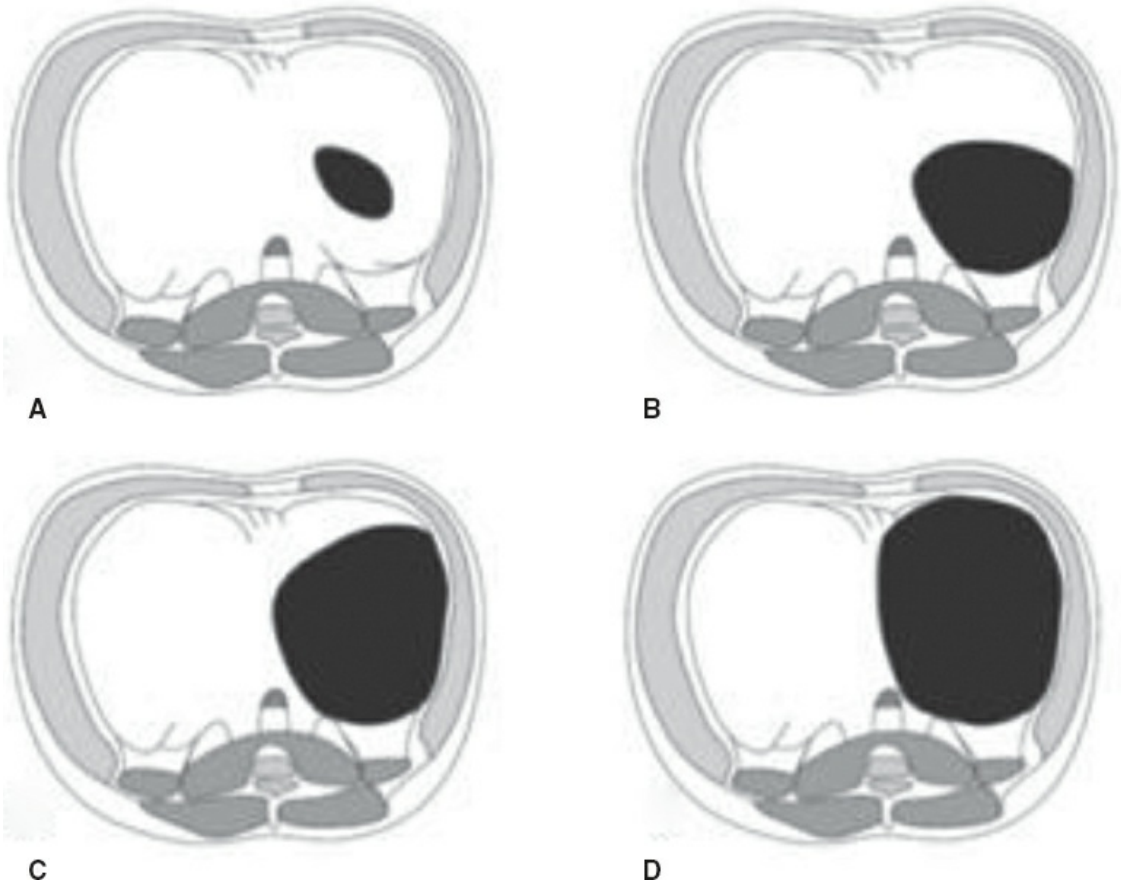

Figure 64.4. Congenital diaphragmatic hernia study group classification of diaphragmatic defect defined as types **A-D**. (Reprinted from Lally KP, Lasky RE, Lally PA, et al. Standardized reporting for congenital diaphragmatic hernia—An international consensus. *J Pediatr Surg* 2013;48(12):2408–15. Copyright © 2013, with permission from Elsevier.)

To perform a muscle flap repair, a bump is placed under the baby's left side to expose the entire lateral chest and abdominal wall. The incision is made at the level of the inferior most portion of the costal margin and extended medially. This lower incision makes it more difficult to retract on the costal margin and expose the defect, and it also leaves less abdominal wall to retract the abdominal viscera once they have been reduced, but it will allow full mobilization of the internal oblique muscle for an excellent muscle flap.

The external oblique muscle is divided carefully to avoid injury to the internal oblique. The plane between the divided external oblique and intact internal oblique muscles is then opened with cautery mobilizing this space up to the costal margin superiorly and down to the iliac crest inferiorly. Once this dissection is complete, the internal oblique muscle is released from its medial attachment to the rectus, from its inferior attachments along the iliac crest, and lastly from the retroperitoneum. Once mobilized, the muscle flap can be packed in warm sponges while the abdominal viscera are reduced and the diaphragm is mobilized. The muscle flap drops in to fill the defect like a garage door and is secured medially, posteriorly, and laterally with nonabsorbable sutures. Care must be taken anteriorly to ensure that there are no defects where the muscle flap folds back on the chest wall as early recurrence can occur in this location.

Once the defect is repaired, the abdominal wall is closed in layers with absorbable sutures. With a muscle flap, there is only one layer of fascia to close. A chest tube is not routinely necessary, and a postoperative pneumothorax is expected given the hypoplastic left lung and reduction of the hernia (see Fig. 64.5).

Thoracoscopic Repair

A minimally invasive approach to CDH repair has been described, although there is a significant amount of controversy associated with this approach with a moratorium on thoracoscopic CDH repair in some regions of the world. When utilizing a minimally invasive approach, the CDH is repaired through the chest with video-assisted thoracoscopic surgery (VATS). With the baby in a right lateral decubitus position, a 5-mm camera port is placed below the tip of the left scapula. The chest is then insufflated to help reduce the abdominal viscera through the defect. Two 3-mm stab incisions are made along the anterior chest wall and blunt graspers are used to fully reduce the hernia. Once reduced, the defect is assessed and either closed primarily or using a patch as discussed above. Even in cases of primary closure, this author prefers to reinforce the repair with a bioprosthetic mesh. A chest tube is not routinely needed after VATS CDH repair unless there is concern for injury to the lung parenchyma that will result in an air leak.

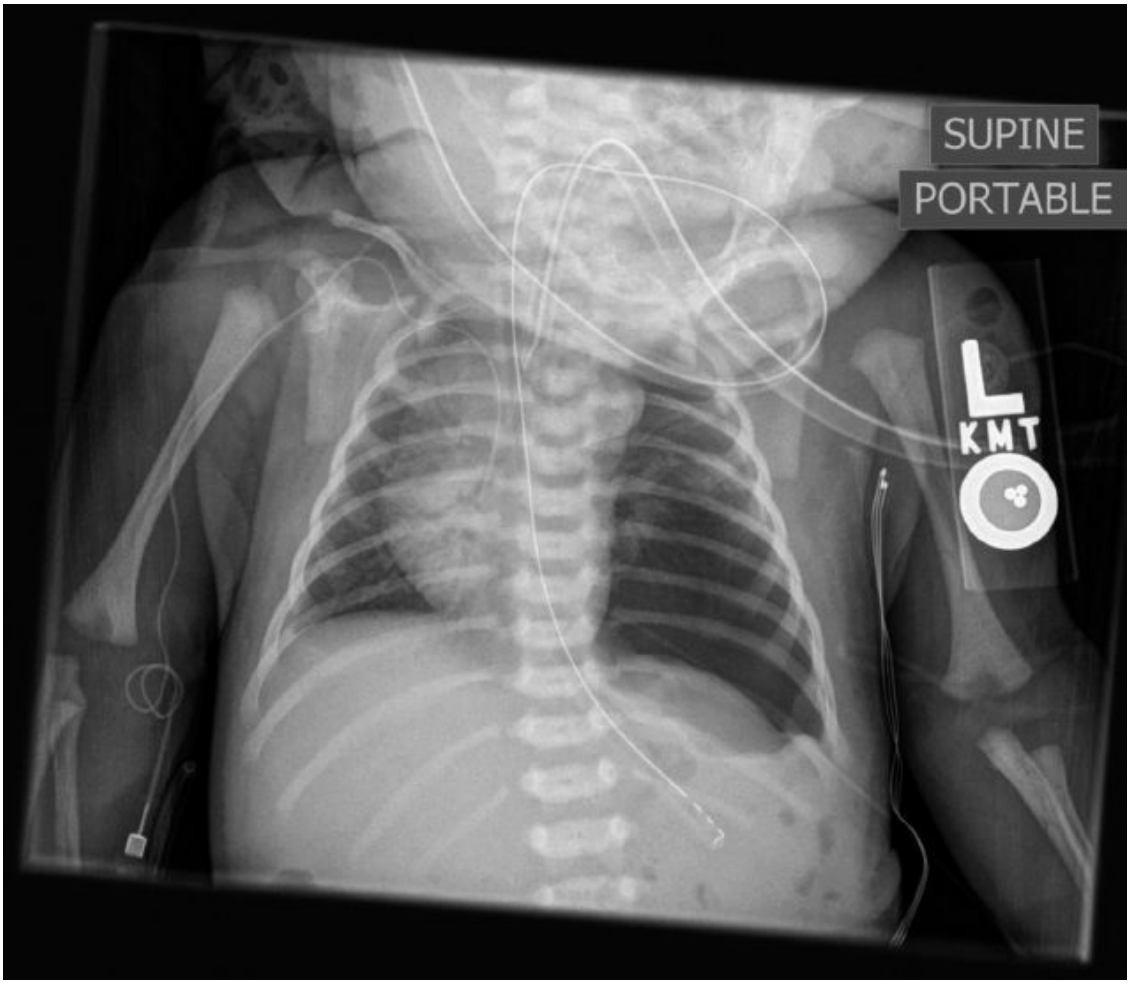

Figure 64.5. Postoperative radiograph after surgical correction of a left-sided congenital diaphragmatic hernia.

Controversy exists regarding this approach because of the potential effects of CO_2 insufflation. CO_2 is readily absorbed by the pleural and peritoneal surfaces—this property makes it ideal for endoscopic procedures. However, the absorption of CO_2 results in a metabolic acidosis that can exacerbate pulmonary hypertension. Hyperventilation to blow off CO_2 can lead to barotrauma and contribute to worse outcomes. It should be recognized, that not all babies with CDH are at the same risk for pulmonary hypertensive crisis, and it has been shown that select cases tolerate the VATS approach. The ideal candidate for a VATS approach, in this author's opinion, is the infant with minimal to no respiratory distress and no evidence of pulmonary hypertension—in most cases this is the CDH diagnosed postnatally.

Postoperative Care

Under ideal circumstances, pulmonary hypertension and gas exchange had stabilized prior to surgical repair. Stress at the time of repair can trigger pulmonary hypertension, and the baby should be closely monitored for this postoperatively. In the absence of any deterioration, ventilator support should be weaned as tolerated. Once there is return of bowel function, feeds can be initiated and advanced to goal.

LONG-TERM OUTCOMES

Overall survival is still quoted around 50%, and if the defect is prenatally diagnosed mortality may be as high as 75%. These reported values reflect a very heterogeneous patient population confounded by the fact that some patients die before they can be transferred to a tertiary referral center or some may have a delayed presentation to a tertiary center, which may explain why there are published survival rates as high as 90%.

Survivors of CDH are still at risk for other long-term problems. Prolonged ventilator dependence can lead to bronchopulmonary dysplasia in 33% and there is a higher rate of reactive airway disease in children with a history of CDH. Pulmonary function tests are normal in 50% to 70% of survivors; however, 25% will have evidence of obstructive airway disease even after 5 years. Abnormal pulmonary function tests can also show restrictive and mixed disorders of pulmonary function.

Sensorineural hearing loss can manifest later in life and requires routine follow-up. Children with CDH can be affected by cerebral palsy, delay in speech and verbal skills, vision loss, and seizure disorders. Neurologic sequelae are more commonplace if ECMO was necessary.

Gastroesophageal reflux can be a problem in up to 60%, of which 10% to 15% will require an antireflux procedure. Nutrition can be a problem for these children who can have respiratory symptoms during feeding contributing to poor growth and failure to thrive with 50% falling in the less than 25th percentile for height and weight. Fortunately, this delay in growth appears to normalize by 2 years, but one third will still require a gastrostomy tube for nutritional support. Growth can also be affected by chest wall deformities in 20% who will develop a pectus excavatum defect and 10% that will develop scoliosis.

Recurrence rates overall are reported to be as high as 35%; however, if a prosthetic patch was required, then recurrence is as high as 50%. The group in Salt Lake City has published favorable rates using an internal oblique muscle flap for large defects with a recurrence rate of 4% at a

median follow-up of 4 years. Recurrence with incarceration as well as adhesions and volvulus can contribute to intestinal obstruction that occurs in 20% of CDH patients.

RIGHT-SIDED CONGENITAL DIAPHRAGMATIC HERNIA

Isolated right-sided CDH accounts for 10% to 15% of CDH. Their lower incidence may be due to the fact that the right hemidiaphragm fuses earlier than the left and has more muscle. These babies are also at risk for pulmonary hypoplasia and require the same resuscitative efforts when prenatally diagnosed. In a single series, survival was reported to be as high as 95% for isolated right CDH. This series included postnatally diagnosed right CDH; however, when looking exclusively at prenatally diagnosed right CDH, overall survival is lower at 59% indicating that right CDH can be as lethal as left CDH.

Data on prognosis for right CDH is limited because it is less frequently encountered. In a single-center experience from UCSF, LHR appeared to have value in prognosticating for right CDH. All children with right CDH and an LHR ≥1.0 survived and none required ECMO. Gestational age did not seem to impact the LHR findings and so an LHR <1.0 for a right CDH can be considered high risk. In fact, tracheal occlusion has been offered to high-risk CDH and appears to have a survival benefit in the UCSF experience: 78% versus 52% survival. However, the numbers from that retrospective review are very small and should be interpreted with caution.

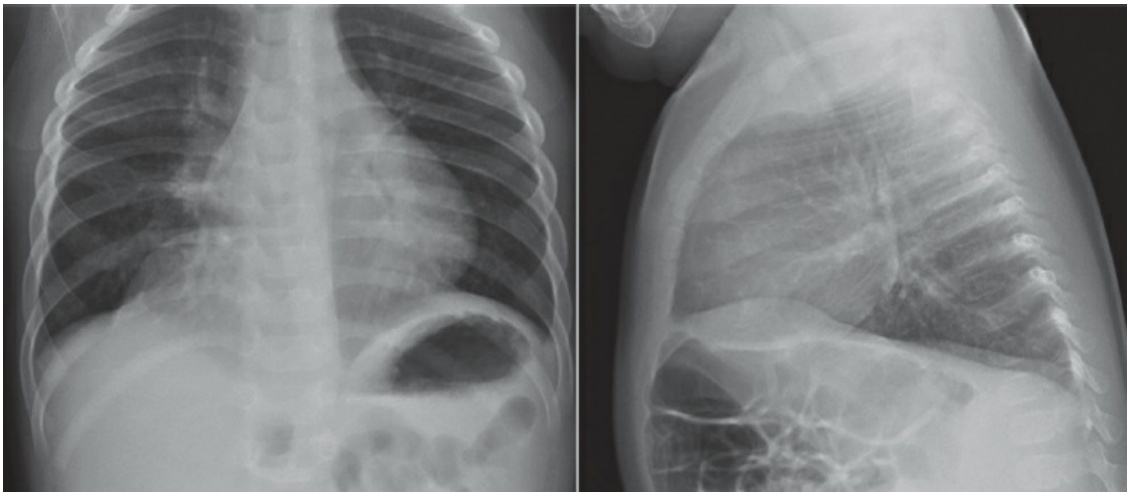

Figure 64.6. Two-view chest radiograph of a Morgagni hernia.

Right CDH are unique due to the involvement of the liver. The

approaches for repair are similar to left CDH except they are performed on the right side. Repair of the defect is similar: primary versus patch repair. Special considerations at the time of repair include caution when reducing the liver as kinking of the hepatic veins can lead to impaired preload and cardiac compromise. In addition, hepatopulmonary fusion can occur where the liver and right lung are fused. For this reason, some surgeons approach right CDH through a low thoracic incision.

MORGAGNI HERNIA

Morgagni hernia, also known as the retrosternal hernia of Morgagni, occurs when the diaphragm fails to fuse with the sternum or anterior chest wall. This type of hernia has not been associated with pulmonary hypoplasia. In fact, this hernia most often presents later in childhood as an incidental finding on a chest radiograph. Obtaining a lateral film in addition to an anteroposterior film helps confirm the diagnosis (see Fig. 64.6). The defect can contain liver if it is central or on the right and may also contain bowel.

This defect tends to be amenable to primary repair. The sack is excised and the diaphragm reapproximated with nonabsorbable sutures. In many cases, there is no diaphragmatic rim on the anterior, central aspect of the defect. In this area, the posterior rim of the defect can be sutured to the abdominal wall. If the defect is too large for primary repair, then a patch should be used.

The Morgagni-type defect is also amenable to laparoscopy. The sack can be excised with a hook cautery, and the defect closed intracorporeally with nonabsorbable sutures. If the anterior rim is lacking, a suture passer can be used through stab incision through the abdominal wall to secure the posterior rim of the diaphragm to the rectus muscles. When performed laparoscopically, the child should be permitted to eat immediately postoperatively with discharge to home the following day.

CONCLUSION

CDH is a frequently encountered congenital anomaly that spans a wide-spectrum of severity. The vast majority are left-sided defects. Improved prenatal diagnosis has led to the detailing of several prognostic parameters that are critical in counseling families and determining candidates for investigational fetal interventions. The pediatric surgeon should be able to provide valuable prognostic information prenatally that will guide families

as they decide what level of care they want for their baby who may ultimately benefit from a delivery plan that ensures the availability of appropriate resources. To date, the greatest impact on survival has been a strategy of gentilation and permissive hypercapnia and delayed surgical repair. Multiple options are available for repair, and are primarily determined by the defect size. Babies who survive CDH are at high risk for long-term problems and require close follow-up beyond the neonatal period.

Suggested Readings

Barnhart DC, Jacques E, Scaife ER, et al. Split abdominal wall muscle flap repair vs patch repair of large congenital diaphragmatic hernia. *J Pediatr Surg* 2012;47:81–6.

Boloker J, Bateman DA, Wung JT, et al. Congenital diaphragmatic hernia in 120 infants treated consecutively with permissive hypercapnia/spontaneous respiration/elective repair. *J Pediatr Surg* 2002;37:357–66.

Deprest JA, Hyett JA, Flake AW, et al. Current controversies in prenatal diagnosis: should fetal surgery be done in all cases of severe diaphragmatic hernia. *J Pediatr Surg* 2009;29:15–9.

Harrison MR, Bjordal RI, Landmark F, et al. Congenital diaphragmatic hernia: the hidden mortality. *J Pediatr Surg* 1979;13:227–30.

Harrison MR, Keller RL, Hawgood SB, et al. A randomized trial of fetal endoscopic tracheal occlusion for severe congenital diaphragmatic hernia. *New Eng J Med* 2003;349:1916–24.

Iqbal CW, Derderian SC, Lusk L, et al. Outcomes for prenatally diagnosed right congenital diaphragmatic hernia. *Fetal Diagn Ther* 2015. [Epub ahead of print].

Jani JC, Benachi A, Nicolaides KH, et al. Prenatal prediction of neonatal morbidity in survivors with congenital diaphragmatic hernia: a multicenter study. *Ultrasound Obstet Gynecol* 2009;33:64–9.

Nobuhara KK, Lund DP, Mitchell J, et al. Long-term outlook for survivors of congenital diaphragmatic hernia. *Clin Perinatol* 1996;23:873–87.

The Neonatal Inhaled Nitric Oxide Study Group (NINOS). Inhaled nitric oxide and hypoxic respiratory failure in infants with congenital diaphragmatic hernia. *Pediatrics* 1997;99:838–45.

Victoria T, Bebbington MW, Danzer E, et al. Use of magnetic resonance imaging in prenatal prognosis of the fetus with isolated left congenital diaphragmatic hernia. *Prenat Diagn* 2012;32:715–23.

EDITOR'S COMMENT

Despite significant advances in prenatal, neonatal, and surgical care, congenital diaphragmatic hernia (CDH) remains one of the most challenging congenital anomalies to manage. The mortality rate remains high even in developed countries. The author presents an excellent overview of the different components of this condition and its management. A CDH reflects an embryologic failure in closure of the pleuroperitoneal folds or the *septum transversum* generating a defect that communicates between abdominal and thoracic cavities that allows herniation of the abdominal viscera into the chest resulting in compression of the developing fetal lungs impairing growth. The pathophysiologic basis for impaired lung growth is thought to occur because of a loss of the paracrine effect of intrapulmonary fluid. During the canalicular phase of development, the fetal lung acts as a gland secreting fluid that is rich in growth factors that are essential for lung growth. When the developing lung is compressed, intrapulmonary fluid is extruded into the amniotic space impairing growth. Not only are the bronchiolar branching and the number of alveoli diminished, the development of the pulmonary vasculature is also affected resulting in decreased number of pulmonary distal arterioles that are "shorter, thicker, and narrower." The muscular media thickness augments pulmonary vascular reactivity and pulmonary hypertension.

The size of the diaphragmatic defect directly correlates with the presence of other anomalies and mortality rates. The Congenital Diaphragmatic Hernia Study Group (CDHSG) classified CDH defects into four types in increasing order from A—small defect that can usually be repaired primarily to D—diaphragmatic agenesis (CDHSG, Morini F, Valfrè L, et al. Congenital diaphragmatic hernia: defect size correlates with developmental defect. *J Pediatr Surg* 2013;48(6):1177–82). A large defect guides prenatal counseling and identifies patients most likely to benefit from fetal treatment.

Associated anomalies are found in as high as 40% of CDH patients with more than 50 different genetic abnormalities linked with a CDH. In addition to the syndromes listed by the author, one should be aware of Pallister–Killian syndrome (PKS) caused by an isochromosome 12p duplication (tetrasomy 12p) (Izumi K, Krantz ID. Pallister-Killian syndrome. *Am J Med Genet C Semin Med Genet* 2014;166C(4):406–13). PKS must be distinguished from Fryns syndrome, as the former is not hereditary, while the latter has been attributed to autosomal recessive inheritance. Once confirmed, appropriate counseling can be provided as to the risks of occurrence in future pregnancies.

From a diagnostic standpoint, the currently utilized antenatal testing and imaging tools are amniocentesis, conventional ultrasound and Doppler, tridimensional ultrasound, fetal echocardiography, and fetal MRI. The first indicator on screening ultrasound for the in utero presence of a CDH is malposition/shifted heart and the second more obvious sign is the presence of

the intestines in the fetal chest. The detection of a thoracic position of the gallbladder raises the possibility of a right-sided CDH.

Accurate prenatal prognostic stratification of the severity of a CDH is essential for following reasons: (1) appropriate counseling of parents of the likely outcomes including the consideration of comfort care in severe cases, (2) guidance of prenatal and postnatal care, and (3) consideration for fetal intervention. Most of the prenatal prognostic indicators such as LHR, O/E LHR, PPLV, TLV rely entirely on lung area or volume to predict the degree of pulmonary hypoplasia and do not always correlate with the severity of pulmonary hypertension. In a recent retrospective study, prenatal pulmonary hypertension index (PPHI) and modified McGoon index (MGI) were shown to predict the severity of pulmonary hypertension, the more critical determinant of the postnatal course (Vuletin JF, Lim FY, Cnota J, et al. Prenatal pulmonary hypertension index: novel prenatal predictor of severe postnatal pulmonary artery hypertension in antenatally diagnosed congenital diaphragmatic hernia. *J Pediatr Surg* 2010;45(4):703–8).

The treatment strategy for patients afflicted with congenital diaphragmatic hernias has changed dramatically, evolving from emergent operative repair to physiologic stabilization followed by delayed operative repair. The CDH cohort and its hidden mortality were the genesis of fetal treatment programs. The successful in utero open repair of a CDH in 1990 led to a prospective trial comparing open fetal repair to postnatal repair that did not demonstrate an outcome benefit of in utero repair (Harrison MR, Adzick NS, Bullard KM, et al. Correction of congenital diaphragmatic hernia in utero VII: a prospective trial. *J Pediatr Surg* 1997;32(11):1637–42). A frameshift changing observation that dramatically impacted current fetal intervention paradigms came with the recognition that in the fatal in utero condition of the congenital high airway obstruction syndrome (CHAOS), fetuses on postmortem examination had pulmonary hyperplasia (Silver MM, Thurston WA, Patrick JE, et al. Perinatal pulmonary hyperplasia due to laryngeal atresia. *Hum Pathol* 1988;19:110–3). This physiologic response has undergone intense study leading to the current paradigm of fetal tracheal occlusion (FETO). The goal with FETO is to retain intrapulmonary fluid, inducing lung growth, partially reverting hypoplasia. Although the UCSF-initiated prospective randomized FETO study was terminated early because of a lack of efficacy (due in large part to the improved survival of the postnatally treated cohort) (Harrison MR, Keller RL, Hawgood SB, et al. A randomized trial of fetal endoscopic tracheal occlusion for severe fetal congenital diaphragmatic hernia. *N Engl J Med* 2003;349(20):1916–24), in Europe, it has been demonstrated in a prospective nonrandomized study that included more than 200 cases of severe CDH cases treated, the survival rate of fetuses treated with FETO for left CDH increased from 24.1% to 49.1% and for right CDH from 0% to 35.3% (Jani JC, Nicolaides KH, Gratacós E, et al. Severe diaphragmatic hernia treated by fetal endoscopic tracheal occlusion. *Ultrasound Obstet Gynecol* 2009;34(3):304–10). The Eurofetus consortium is currently

conducting the Tracheal Occlusion to Accelerate Lung Growth Trial (TOTAL) which is comprised of two randomized prospective cohorts to determine if FETO improves survival of fetuses with severe CDH and decreases morbidity in fetuses with moderate CDH. Through the sponsorship of the North American Fetal Therapy Network, an IDE of the detachable balloon used for FETO has been approved by the FDA to allow several fetal therapy centers in North America to perform this intervention. Interestingly, a recent meta-analysis suggests that FETO is beneficial for severe CDH (Al-Maary J, Eastwood MP, Russo FM, et al. Fetal tracheal occlusion for severe pulmonary hypoplasia in isolated congenital diaphragmatic hernia: a systematic review and meta-analysis of survival. *Ann Surg* 2016;264(6):929–33). FETO remains an exciting intervention that could markedly alter the course of CDH patients; however, its role remains experimental and should be offered only at experienced fetal treatment centers.

As the author notes, in some patients with severe CDH, ex utero intrapartum procedure (EXIT) to ECMO is a treatment paradigm offered. The goal of EXIT-to-ECMO is to place the fetus on ECMO prior to severing of the umbilical cord allowing for a smooth transition into the postnatal period, avoiding barotrauma and hemodynamic instability. Although theoretically beneficial, the evidence in support of its efficacy remains uncertain with a recent nonrandomized study of 17 patients (8 EXIT-to-ECMO and 9 non-EXIT) finding it conferred no survival benefit (Shieh HF, Wilson JM, Sheils CA, et al. Does the ex utero intrapartum treatment to extracorporeal membrane oxygenation procedure change morbidity outcomes for high-risk congenital diaphragmatic hernia survivors? *J Pediatr Surg* 2017;52(1):22–5).

Postdelivery, we, as the author recommends, employ the combination of gentle ventilation or “gentilation,” permissive hypercapnia, aggressive management of pulmonary hypertension, and delayed surgical repair. Effective “gentilation” requires committed care with constant bedside attention. We employ a multidisciplinary team of pediatric surgeons and neonatologists who focus on this population. Unfortunately, many infants still require ECMO support. Once on ECMO, when to repair the CDH is of some controversy. In our practice, if a patient can be steadily weaned from ECMO, we proceed with CDH repair just before coming off ECMO. If the patient has severe prenatal prognostic indicators or is not making progress weaning from ECMO, we will repair the CDH earlier in the course with the goal of optimizing cardiopulmonary physiology.

How to repair a CDH varies according to surgeon preference. Whenever feasible, we prefer transversus abdominis muscle flap (TAMF). We have found that in majority of our patients, the TAMF is adequate with less degree of abdominal wall diastasis. It remains to be determined if autologous muscle flap repair will decrease scoliosis and chest wall abnormality when compared to synthetic patches. Abdominal wall repair using a patch may be necessary in patients with inadequate abdominal domain to accommodate the viscera. The

recurrence rate after CDH repair can be as low as 5%.

CDH patients require long-term follow-up. In addition to the issues discussed by the author, close monitoring in the first year for pulmonary hypertension is required with optimization of medical management. Patients with persistent pulmonary hypertension should be transitioned to oral antipulmonary hypertensive agents. Patients with severe pulmonary hypertension may require multiple treatment regimens, including intravenous vasodilators.

Advances in neonatal management and surgical intervention have improved the outcomes of patients who are afflicted with a CDH. Further research expanding our knowledge of the causes of CDH is required along with collaborative efforts developing innovative therapy encompassing all aspects of care such that survival rates and long-term quality of life improves.

Gregory M. Tiao

65 Eventration of the Diaphragm

Heather R. Nolan, Daniel von Allmen, and Foong-Yen Lim

Diaphragmatic eventration (DE) is a pathologic condition defined by a permanent elevation of an immobile hemidiaphragm that cannot participate actively in respiration. Peripheral muscular attachments are normal, the diaphragmatic apertures are sealed appropriately, and there is no interruption in the pleural or peritoneal layers as is seen with diaphragmatic hernias. Instead, a flap of lax diaphragmatic tissue inhibits appropriate muscular excursion with respiration and intrudes into the thoracic cavity displacing its contents along with the mediastinum. The defect can be unilateral, localized, or bilateral. DE may be a congenital anomaly caused by failure of muscularization of the dome of a hemidiaphragm or it may be acquired as a result of dysfunction of the phrenic nerve in cases such as neuromuscular disease, trauma, or iatrogenic injury. DE is most commonly diagnosed in pediatric patients and occurs in 10 of 100,000 live births, whereas the incidence in adulthood is low, estimated to be between 1 in 10,000 and 1 in 13,000. It is more common in males and affects the left hemidiaphragm more frequently. The effect on the pediatric population is more pronounced as infants and children rely on diaphragmatic excursion for respiration and physiologically their ribs are more horizontally oriented with weaker intercostal muscles. Asymptomatic patients with incidentally discovered eventration do not require any intervention unless the invagination is significant enough to cause compromised future lung growth. In those with recoverable phrenic nerve injury, watchful waiting is reasonable to assess for improvement in nerve function. Conversely, all symptomatic eventration is treated with operative management using a variety of techniques described in detail below.

ANATOMY

Congenital DE is an abnormal elevation of the diaphragm resulting from failure of muscle fibers to develop. Starting at week 4 of gestation, four components coalesce to form the diaphragm—the lateral body walls,

transverse septum, esophageal mesentery, and the pleuro-peritoneal membranes. During the eighth to tenth week of gestation, muscle fibers grow from the lateral body wall to form the membranous and muscular portion of the peripheral diaphragm while the pleuro-peritoneal membranes become a muscular trigone in each hemidiaphragm. Different etiologic factors have been postulated as causes of congenital DE such as failure of migration of myoblasts along normal phrenic nerve branches or from the peripheral chest wall, failure of normal innervation of the primordial diaphragm, congenital infection with *Toxoplasma* or *Cytomegalovirus,* and premature return of the midgut to the peritoneal cavity during development. The sparsely distributed muscle fibers are mechanically nonfunctional, resulting in a lax, thin, elongated membrane.

Normally the diaphragm projects from the 10th rib posteriorly up to the dome at the level of the 5th or 6th rib anteriorly. In the majority of patients, the dome of the left hemidiaphragm is one interspace lower than the right. Elevation of the diaphragm in cases of eventration results from arching of the diaphragm as the lax membrane is unable to withstand the relatively higher intra-abdominal pressures compared to its thoracic counterpart.

Eventrations are frequently unilateral; however, a few cases of bilateral eventration have been reported in the literature. Further categorizations relate to the segment of impaired diaphragm. Eventration is considered complete if the entire hemidiaphragm demonstrates thinning muscle or partial when it involves just a portion. Although a complete eventration of the hemidiaphragm is more common in males, and on the left side, partial eventration is more common on the right side and is of equal sex distribution. The most common site of partial eventration is seen more often in the adult rather than the pediatric population. A weakening in the anteromedial aspect of the right hemidiaphragm occurs commonly in patients over 60 years of age and is usually of no clinical significance.

Disorders that may accompany congenital DE are the same as those that may accompany congenital diaphragmatic hernia (CDH). These include facial (cleft lip and palate), cardiovascular (patent ductus arteriosus, aortic stenosis, ventricular septal defect, and coarctation of the aorta), gastrointestinal (malrotation, gastric volvulus, megacolon), situs inversus, tracheomalacia, genitourinary (horseshoe kidney), musculoskeletal (hemivertebrae, arthrogryposis, Werdnig-Hoffmann disease, and Ehlers-Danlos syndrome), and chromosomal (trisomy 18) abnormalities.

Therefore, when congenital disorders of the diaphragm are suspected, it is essential to evaluate the patient for possible coexistence of other anomalies.

Acquired or secondary DE is often due to pathologic or iatrogenic insult to the phrenic nerve resulting in paralysis of the diaphragm and DE. External trauma, inflammation (pleural, mediastinal, or pulmonary source), or neoplastic invasion of the nerve usually results in complete DE. With diaphragmatic paralysis, the muscle fibers are present but become atrophic with time. Histopathologically, eventration results in the characteristic findings of microscopically few muscle fibers and diffuse fibroelastic changes while paralysis or paresis of the phrenic nerve can lead to thickening of nerve fibers. Birth trauma is by far the most common cause of acquired DE and is usually related to breech presentation or shoulder dystocia resulting in a stretch injury to the C3 through C5 nerve roots. These nerves give rise to the phrenic nerve and brachial plexus and are responsible for motor innervation to the diaphragm. Fractures of the clavicle or humerus are often seen in association. If nerve roots are avulsed, no improvement in the DE is predicted, whereas lesser degrees of injury may potentially recover with time. Acquired DE is also seen after open cardiac procedures, due to surgical dissection, electrocautery, or ice placement. Again, recovery depends on the nature and completeness of the nerve lesion.

CLINICAL PRESENTATION

The anatomic diagnosis of DE is largely based on imaging studies but the clinical presentation is critical to the management algorithm and will vary slightly based on the age of the patient. Dyspnea is the primary presenting symptom and the degree to which it is clinically significant determines the need for surgical intervention. Pulmonary function test (PFT), when can be performed in older children and adults, will demonstrate a restrictive pattern with a decreased forced vital capacity (FVC) and forced expiratory volume in 1 second (FEV1). Lung volumes in the upright and supine position can help delineate the physiologic effect of the DE. PFTs and lung volumes can also be used postoperatively to quantify objective improvement from preoperative values.

Adults

Most adults with congenital DE are asymptomatic and do not require

surgical treatment. DE acquired during adulthood due to phrenic nerve insult results in atrophy and progressive laxity of the diaphragmatic muscle. These patients are likely to present with incidental findings on a chest radiograph obtained for unrelated reasons. When the patient is symptomatic, they typically present with signs and symptoms related to inadequate ventilation (e.g., dyspnea on exertion or with recumbency). In an adult with a previously asymptomatic DE, conditions that cause atelectasis or mild respiratory infection may result in respiratory distress, tachypnea, tachycardia, and even cyanosis. Chest pain, either spontaneous or provoked by flexion, or palpitations caused by cardiac arrhythmias can also be seen. Alternatively, abdominal symptoms including epigastric pain, dysphagia, dyspepsia, belching, and gastroesophageal reflux may be associated with displacement of the viscera into a large DE or secondary to a positional change in the esophagus creating a bend in the esophagus or obstructing the pylorus.

Infants and Children

DE commonly results in respiratory symptoms in infants and children similar in nature to a flail chest. This is due to a more mobile pediatric mediastinum shifting to the contralateral side. This results in compression of contents of both hemithoraces significantly compromising overall cardiopulmonary function. In addition, infants rely much more on diaphragmatic excursion than accessory muscles for respiration, resulting in a greater susceptibility to symptomatic DE. Less commonly, infants and children with DE may present with abdominal symptoms, the most catastrophic of which is acute gastric volvulus, requiring urgent operative intervention.

DIAGNOSIS

The diagnosis of DE is based on a combination of clinical and radiographic characteristics that are necessary to differentiate it from a diaphragmatic hernia or an underlying primary pathologic condition involving the lungs or chest wall. A thorough history is important to provide clues to the presence of other pathology as well as to document the degree of respiratory symptoms, which are the main determinant for surgical intervention. The findings from a physical examination are nonspecific but include dullness to percussion, decreased breath sounds on the affected side, and paradoxic movement of the chest wall with

inspiration.

Prenatal diagnosis of congenital DE is possible with high-resolution prenatal ultrasonography, or magnetic resonance imaging (MRI). DE and CDH may appear similar during fetal imaging, with a hypoplastic ipsilateral lung, and fetal stomach or liver seen in the same axial plane as the heart. With DE, polyhydramnios is relatively infrequent and abdominal circumference is normal or slightly smaller than gestational dates would indicate. Although the paradoxical movement of the diaphragm itself during fetal breathing may not be able to be visualized, paradoxical movement of intra-abdominal viscera can serve as a surrogate. Occasionally, a hypoechoic, thin diaphragmatic membrane can also be seen in cases of DE. One of the additional benefits of prenatal imaging includes an evaluation of the lungs in an effort to predict postnatal outcomes. Various methods and indices exist to categorize the degree of pulmonary hypoplasia including the lung-to-head ratio, observed-to-expected lung-to-head ratio, percent predicted lung volume, and observed-to-expected total fetal lung volume measurements.

Postnatally, the diagnosis is often first suspected based on marked elevation of the hemidiaphragm on a chest radiograph obtained to investigate respiratory distress. The subsequent workup is based on the clinical context. In the absence of a history suggesting phrenic nerve injury, investigations to elucidate the reason for DE should be conducted. In particular, occult neoplastic, infectious, and degenerative diseases of the cervical or mediastinal regions should be considered. Most can be excluded with a cervicothoracic computed tomography (CT) scan. Upper-abdominal CT is useful for excluding subphrenic abnormalities such as abscess or Chilaiditi syndrome that may be the causative factor of the diaphragmatic paralysis. Treatment would then focus on correcting the underlying cause rather than repair of the anatomic abnormality of the diaphragm itself.

While initial imaging often identifies the presence of hemidiaphragmatic elevation, to confirm the diagnosis of DE some form of dynamic imaging must be done to assess the function of the diaphragm. Fluoroscopy, ultrasound, or dynamic MRI can determine whether diaphragmatic movement is absent or decreased, or if the classic “paradoxical” movement of the diaphragm is present during spontaneous ventilation. Normal findings involve the downward motion of both hemidiaphragms on inspiration. Paradoxical motion is observed when

during inspiration paralysis or elevation of the involved hemidiaphragm is identified in conjunction with depression of the contralateral (normal) hemidiaphragm. This finding can be accentuated during fluoroscopic examination using the “sniff” maneuver which entails a fast inspiration through the nose with the mouth closed. Dynamic MRI is also gaining footing as an alternative mode of assessing function with the benefit of excellent anatomic visualization without the associated ionizing radiation. Other imaging modalities include ventilation-perfusion scanning which is less commonly used to demonstrate DE, but can show loss of ventilation on the involved side. Upper-gastrointestinal contrast study has also been described as a useful diagnostic modality to assess GI symptoms and can identify the anatomic location of intra-abdominal structures.

It is important to realize that characteristic physical examination and radiologic findings will not be evident in patients who are undergoing mechanical ventilation. Positive-pressure ventilation eliminates the diaphragmatic asymmetry that is used to secure the diagnosis in spontaneously breathing patients. For patients with history consistent with DE who cannot be extubated, fluoroscopy during brief discontinuation of mechanical ventilation may provide radiologic information to exclude or support the diagnosis of DE. In addition, DE must be considered in infants who have unexplained respiratory distress and require urgent intubation before baseline chest radiography can be obtained.

TREATMENT

Asymptomatic patients do not typically require operative intervention and may be observed. For those with symptoms, supportive therapy for respiratory dysfunction often precedes surgical treatment and includes supplemental oxygen, upright positioning, and treatment of respiratory infections. Rarely, emergency surgery is required due to the severity of respiratory compromise, gastric volvulus, or spontaneous rupture. Otherwise, operative intervention is the primary treatment for symptomatic eventration.

The goals of surgical therapy should be to (a) return the diaphragm to a normal location within the involved hemithorax, (b) reinstate normal capacity to the hemithorax to allow lung growth in infants and children, (c) restore normal visceral location in the abdomen, and (d) stabilize the mediastinum by eliminating paradoxical motion of the diaphragm. These goals have classically been achieved via open thoracotomy. First described

in 1923 by Morrison, the evolution of the open technique has involved either plication of the redundant diaphragm or resection of excess tissue with primary closure of the resulting diaphragmatic defect. More recently, minimally invasive approaches have been described using thoracoscopic or laparoscopic techniques. The obvious advantage of these methods is to reduce the operative morbidity of an open intervention, which may in turn reduce the threshold for pursuing surgical repair.

INDICATIONS

Indications for operative correction of either congenital DE or acquired DE include (a) progressive respiratory distress with atelectasis or pneumonia or (b) failure to wean from mechanical ventilation. In either of these settings, early operative correction, at the time of diagnosis, is warranted because of the limited morbidity of the operative correction and the often dramatic improvement with fixation. Conversely, for asymptomatic DE, surgical correction is generally not indicated.

A relative indication for operative intervention in an infant who has congenital DE is the presence of significant elevation of the hemidiaphragm. This is described as abdominal viscera occupying at least half or more of the volume of the hemithorax. This degree of diaphragmatic elevation results in compromised growth of the ipsilateral lung, and potentially the contralateral lung in cases associated with significant mediastinal shift, similar to that seen in CDH. The capacity for normal lung growth is restored after surgical repair of DE, thus suggesting that early operation in this setting is clinically warranted.

For patients in whom respiratory symptoms are less severe and the etiology is thought to be from recoverable phrenic nerve injury, a delay of several weeks to months to allow for improvement is justified. Lack of improvement or deterioration in respiratory function during observation is an indication for immediate operative repair. In patients with central nervous dysfunction confirmed by extensive neuromuscular testing, phrenic pacing shows promise for improvement of respiratory status through diaphragmatic stimulation.

Surgical correction of DE in older children or adults is less common. Infants have a more compliant chest and mediastinum which results in a reduced capacity to compensate for the physiologic aberrancies of DE compared to their older counterparts. In this population, phrenic nerve injury caused by cardiac or aortic surgery rarely results in clinically

significant respiratory insufficiency to require operative correction of DE. A more compelling indication for correction of acquired DE in older patients is the development of abdominal pain due to displacement of abdominal structures into the chest or cardiac arrhythmias related to cardiac compression. In addition, gastric volvulus or significant gastroesophageal reflux associated with DE should be seen as indications for surgical fixation. Treatment of DE caused by aggressive malignancy or other underlying pathology should be directed at the underlying cause.

SURGICAL TECHNIQUE

Open Operative Repair

The traditional operative approach utilizes a posterolateral thoracotomy. Right-sided DE is best approached through the chest and avoids complications associated with working around the liver. Left-sided DE can be approached via thoracotomy or laparotomy. Thoracotomy offers better anatomic exposure of the phrenic nerve branches. Bilateral eventrations, although rare, are best approached through the abdomen. Patients who present with gastric volvulus and eventration should undergo laparotomy for gastric fixation and diaphragmatic plication.

Historically, both diaphragmatic plication and resection have been described; however, plication is currently preferred over resection for both open and minimally invasive approaches. The open procedure can be performed through a standard posterolateral thoracotomy incision in the 7th to 8th intercostal space (ICS). The initial examination of the diaphragmatic tissue should concentrate on the identification of the phrenic nerve branches (Fig. 65.1). Preservation should be planned even though the potential for recovery is often limited.

The desired outcome of surgical intervention should be the construction of a rigid, flat hemidiaphragm that does not participate in or detract from ventilatory movement. This can be achieved by placing two rows of sutures to imbricate the redundant hemidiaphragm. The initial row is placed along the posterolateral one third of the diaphragm, beginning at the central portion of the diaphragm and proceeding toward the periphery. The sutures are placed parallel to the branches of the phrenic nerve. Each suture placed should incorporate several centimeters of tissue in two to three equally spaced bites. During this imbrication maneuver, the diaphragmatic tissue should be grasped and elevated to separate it from the underlying liver in the case of a right-sided DE, or from the stomach or

spleen in the case of left-sided DE (Fig. 65.2). The entire row of interrupted sutures is placed before they are tied sequentially to imbricate the diaphragm (Fig. 65.3). The suture material selected should be permanent, such as 2-0 braided nylon or monofilament nylon. The second row of sutures is then placed from the center of the diaphragm along the anterior one third of the diaphragm. After plication, the tissue should be taut and thus incapable of flail. If this is not achieved after the placement of both suture lines, the tissue along the suture lines can be plicated again over itself to remove the redundancy in the hemidiaphragm until proper correction is achieved (Fig. 65.4).

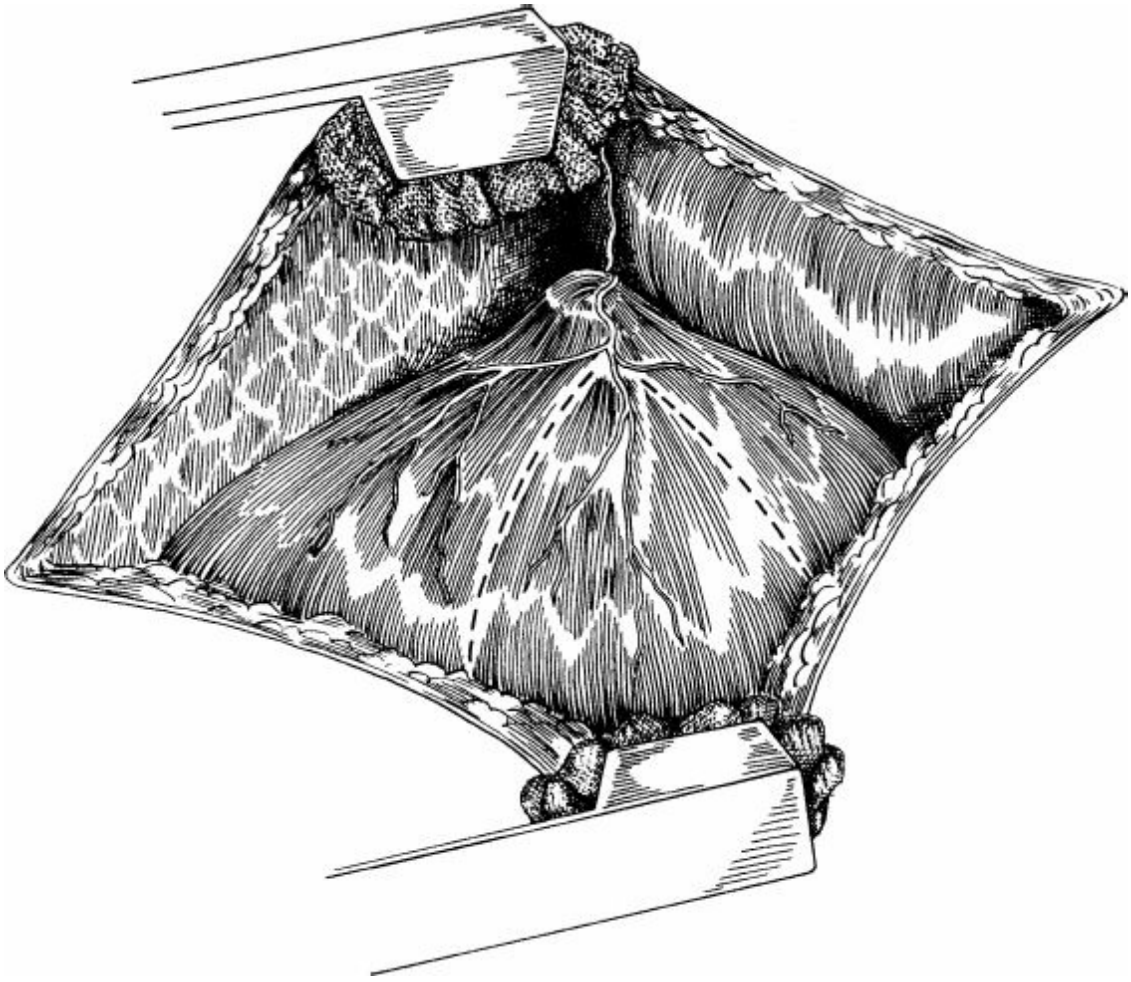

Figure 65.1. Phrenic nerve descending over the central dome of the diaphragm. Right posterolateral thoracotomy. *Dashed line* indicates site of the diaphragmatic plication.

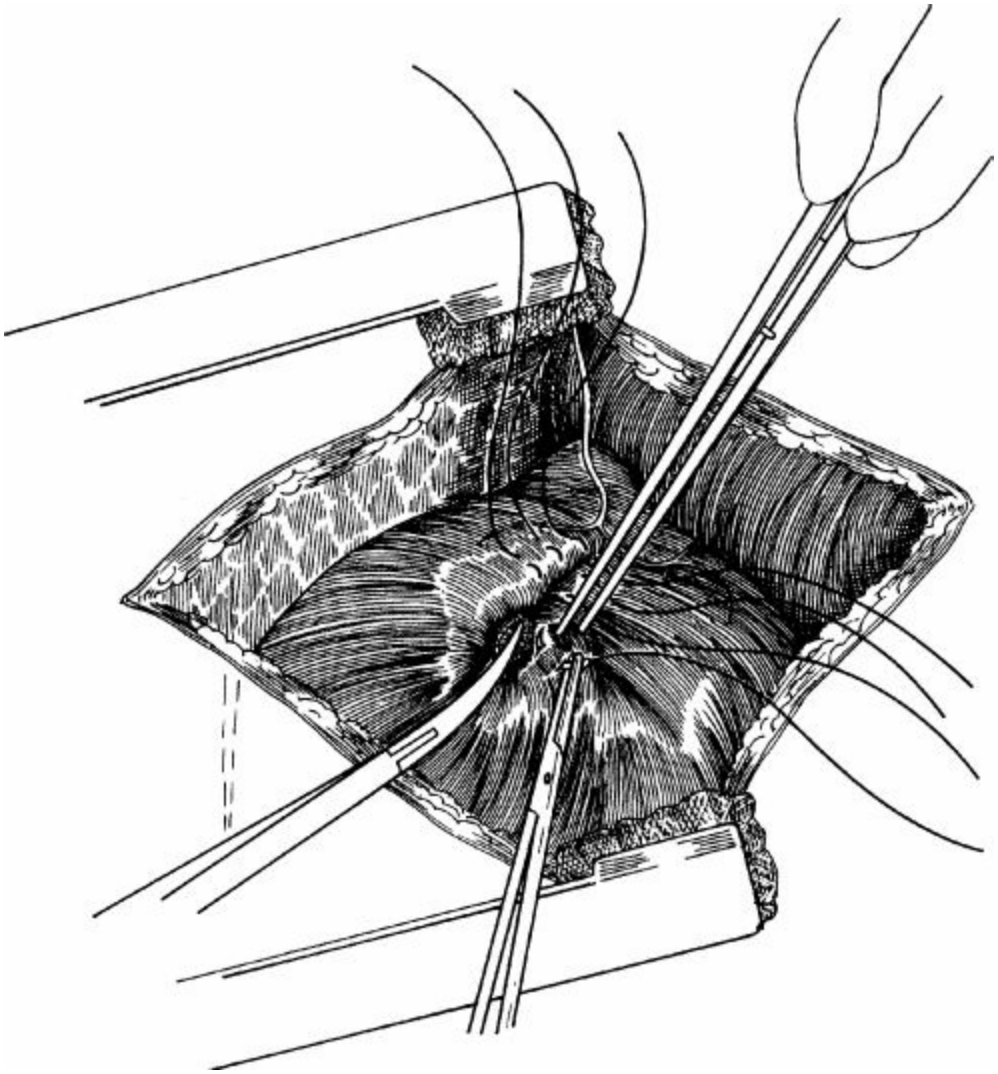

Figure 65.2. Multiple interrupted imbricating sutures are placed between the phrenic nerve branches at the site of the diaphragmatic plication.

Alternatively, one can resect the redundant portion of the diaphragm. A full-thickness ellipse of the central portion of the diaphragm is removed. The resected diaphragm should not include the major branches of the phrenic nerve, and care must be exercised to avoid abdominal visceral injury when the resection margins are established. A two-layer closure is achieved by first placing and then tying the first row of sutures to imbricate the diaphragm margins. To avoid injury to abdominal organs, the second row of sutures that secures the imbrication should not transgress the diaphragm (Fig. 65.5). This procedure also reconstructs a flat, noncompliant diaphragm.

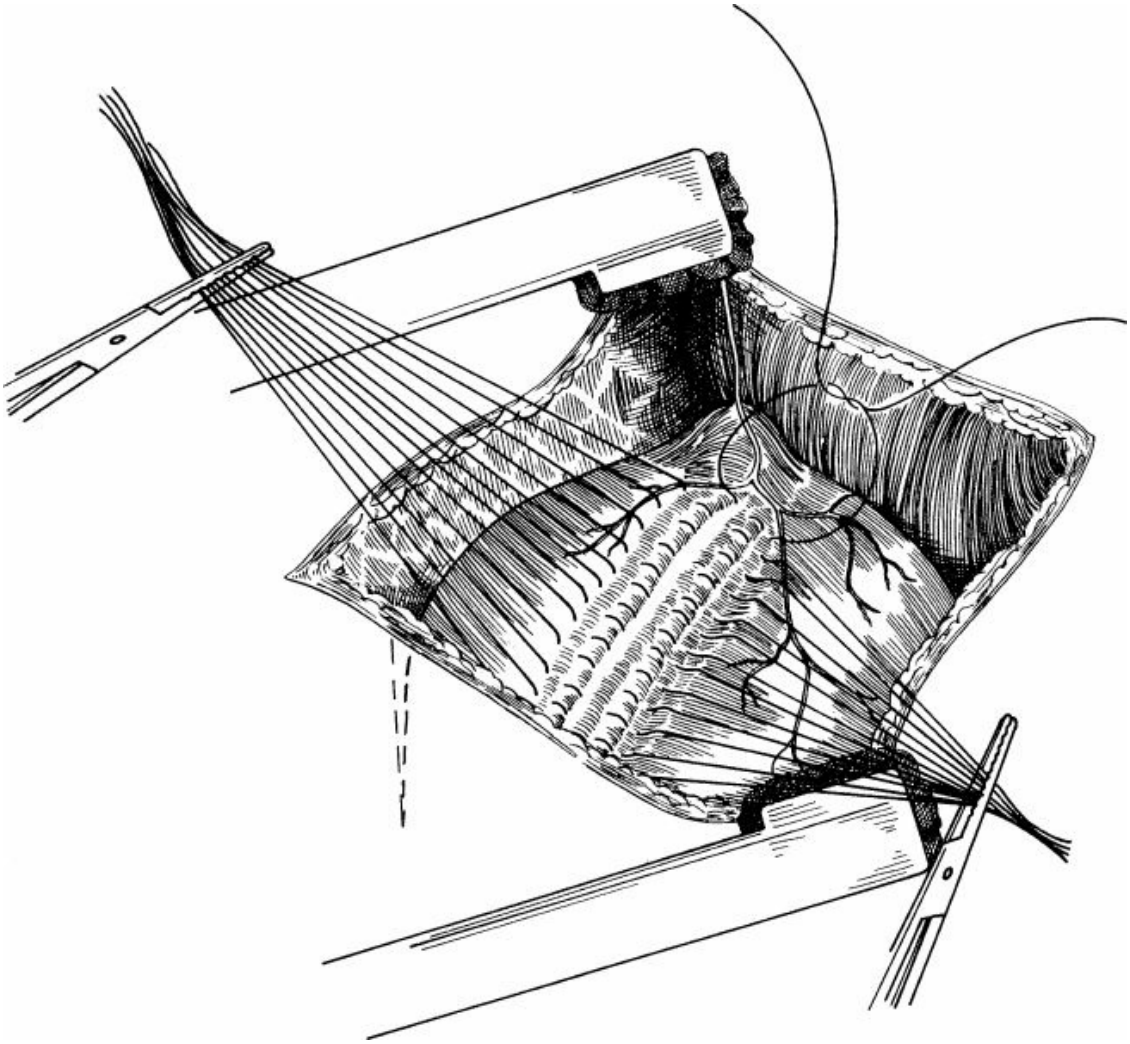

Figure 65.3. Completed suture placement before plication.

A thoracostomy tube is placed for pleural drainage. The patient can often be weaned from mechanical ventilatory support immediately after operation unless there is significant pulmonary hypoplasia. The chest tube is typically removed after 1 to 2 days and the patient is discharged home once they are stable from a respiratory standpoint.

Open abdominal intervention is also described and is typically contemplated for left-sided eventrations. The abdominal approach affords the ability to visualize intra-abdominal structures to prevent plicating bowel or other organs during diaphragmatic repair. The right-sided liver is rarely incorporated in the plication from the thoracic approach and additionally can impede visualization and working space in the abdominal approach.

The open approach, either transthoracic or transabdominal, provides an adequate repair with minimal recurrence. The benefits of minimally

invasive surgery, however, have persuaded many surgeons to employ endoscopic techniques. In the thorax, the video-assisted thoracoscopic surgery (VATS) intervention is associated with a significantly decreased operative time and length of stay, in addition to less postoperative complications and recurrence. Similar improvements in morbidity, mortality, and length of hospital stay in other thoracic and abdominal surgical interventions have prompted further research into endoscopic interventions. As such, the majority of recent literature on eventration revolves around minimally invasive techniques and outcomes.

Minimally Invasive Plication

Thoracoscopic Plication

Minimally invasive surgical techniques, both thoracoscopic and laparoscopic, offer a safe and effective alternative to open diaphragmatic plication. In the thoracoscopic approach, visualization is paramount and can be improved with several methods. In patients of adequate airway size and maturity to accommodate a double-lumen endotracheal tube or bronchial blocker, selective ventilation of the contralateral lung allows improved visibility of the affected diaphragm. In addition, insufflation of the ipsilateral pleural space with carbon dioxide at a pressure of 5 to 6 mm Hg can also optimize exposure. This is especially true in younger, smaller patients with limited space for observation and manipulation of the redundant diaphragm tissue. Recently, there are reports that demonstrate that carbon dioxide insufflation alone is sufficient and single-lung ventilation is not required to achieve adequate visualization.

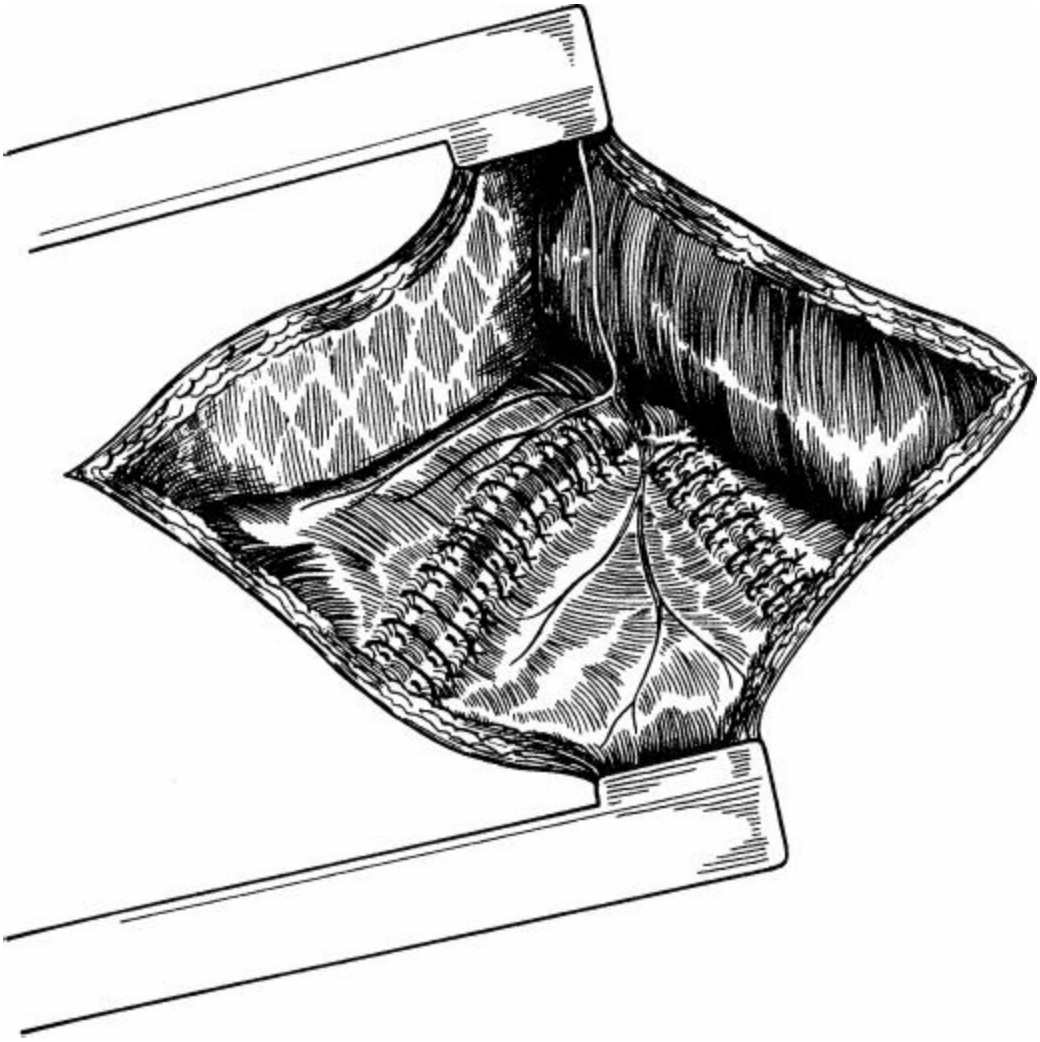

Figure 65.4. Completed diaphragmatic plication, removing the redundancy within the hemidiaphragm.

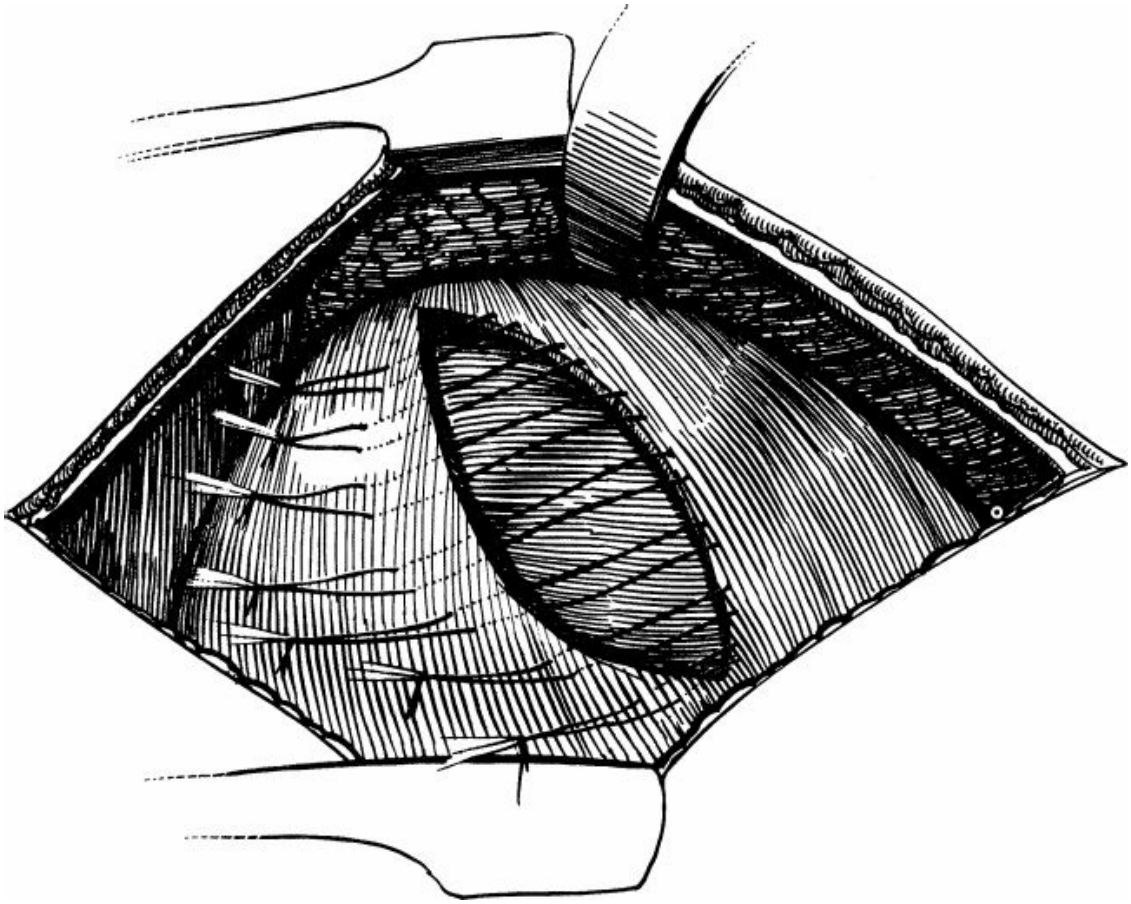

Figure 65.5. Removal of full-thickness ellipse of central portion of the diaphragm in the anteroposterior direction.

Thoracoscopic set-up varies within the literature and is largely based on surgeon preference. A lateral decubitus position or bump is used to help rotate and align the patient. Typically, three to four ports are used and are triangulated toward the target anatomy (Fig. 65.6). Some authors posit that higher trocar placement provides increased working space while others strive for fewer ports and use alternative means of plication. In smaller children and infants, 3-mm instruments can be passed directly through the chest wall without the use of a trocar.

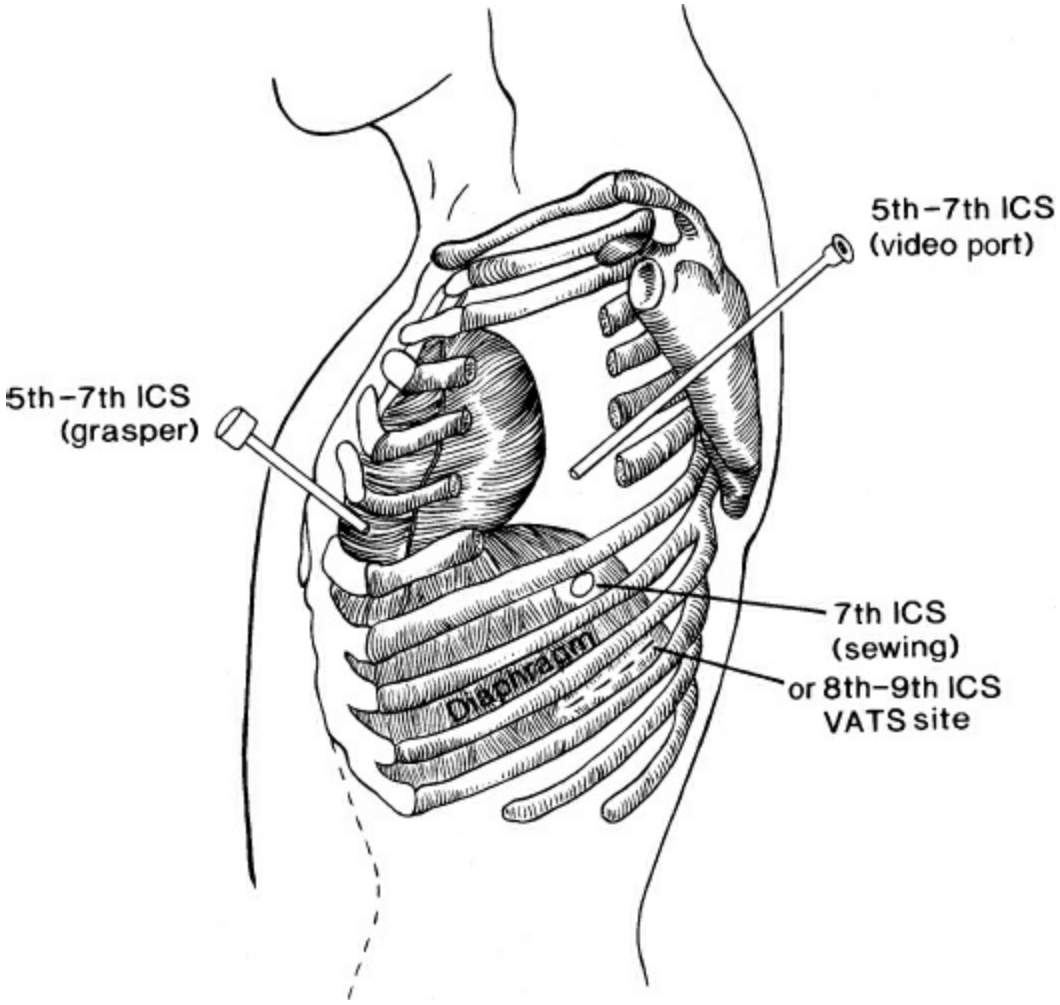

Figure 65.6. Schematic representation of trocar placement for minimally invasive correction of DE. VATS, video-assisted thoracoscopy.

Several techniques for plication have been described. The lax portion of the diaphragm can be folded over onto itself and secured with nonabsorbable suture through all three layers of the diaphragm (Fig. 65.7). Alternatively, the apex of the eventration can be invaginated and sutures passed between the muscular parts of the diaphragm to reapproximate the muscular edges (Fig. 65.8). This technique can be performed with or without a second row of imbrication suture. Similarly, the redundant diaphragm can be grasped with a long vascular clamp and pulled through the jaws of the clamp until laxity is removed. With the clamp applied, the base of the diaphragm is then safely sutured with a running horizontal mattress nonabsorbable suture. This may be repeated several times until the desired effect is achieved. Another method involves an accordion-like maneuver in which sequential bites of diaphragm are taken from one side of the diaphragm to the other producing pleats that recreate the tension of

the hemidiaphragm (Fig. 65.9). This technique has been described with intra- and extracorporeal tension on the suture and has also been demonstrated using a spinal needle to avoid difficult intracorporeal suturing in neonates and small infants. Lastly the use of an endostapler has recently been described and achieves repair through reapproximation along with resection of the redundant diaphragm (Fig. 65.10). The original description of this method required a larger port to accommodate the stapler but with the advent of smaller devices, the trocar size can be significantly diminished.

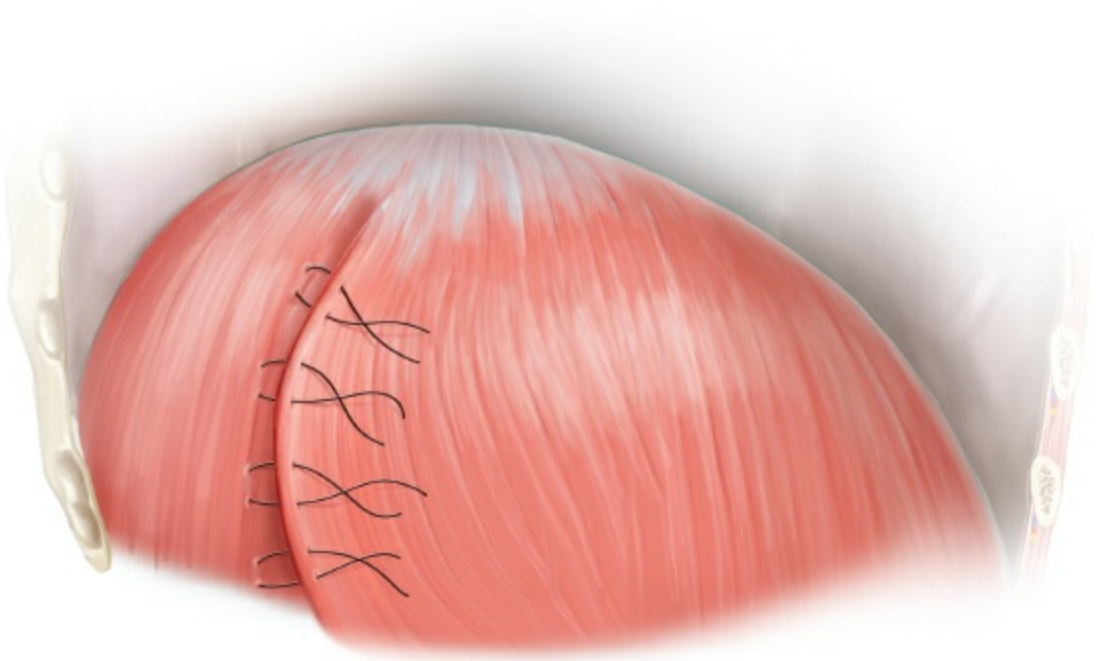

Figure 65.7. Folded plication technique with sutures through three diaphragmatic layers.

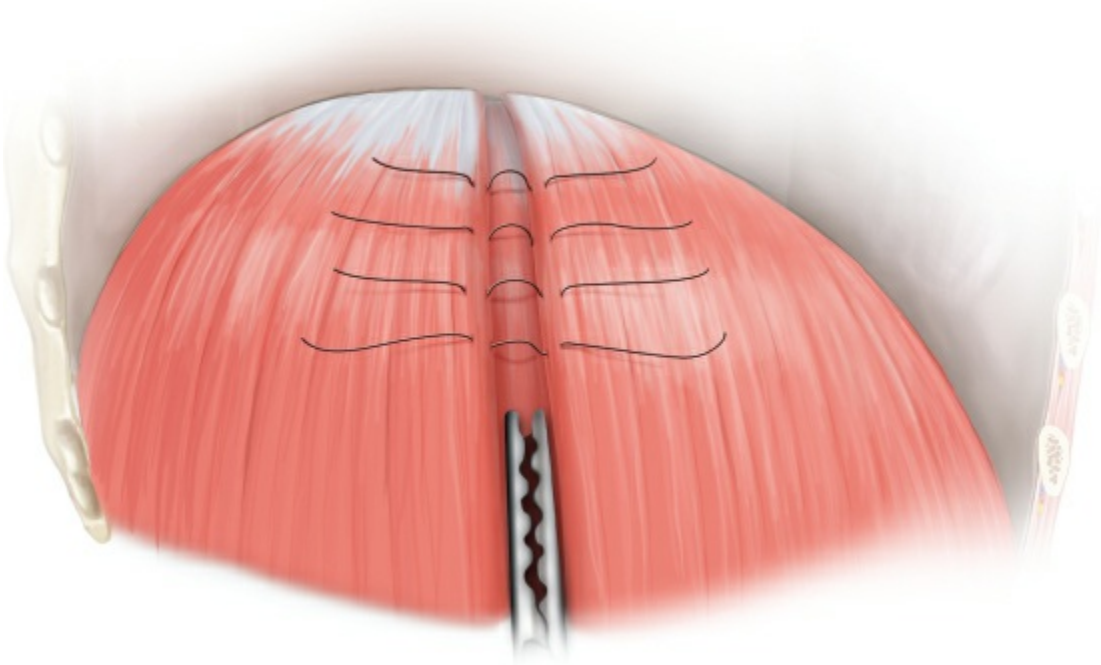

Figure 65.8. Invagination technique with reapproximation of the muscular portions.

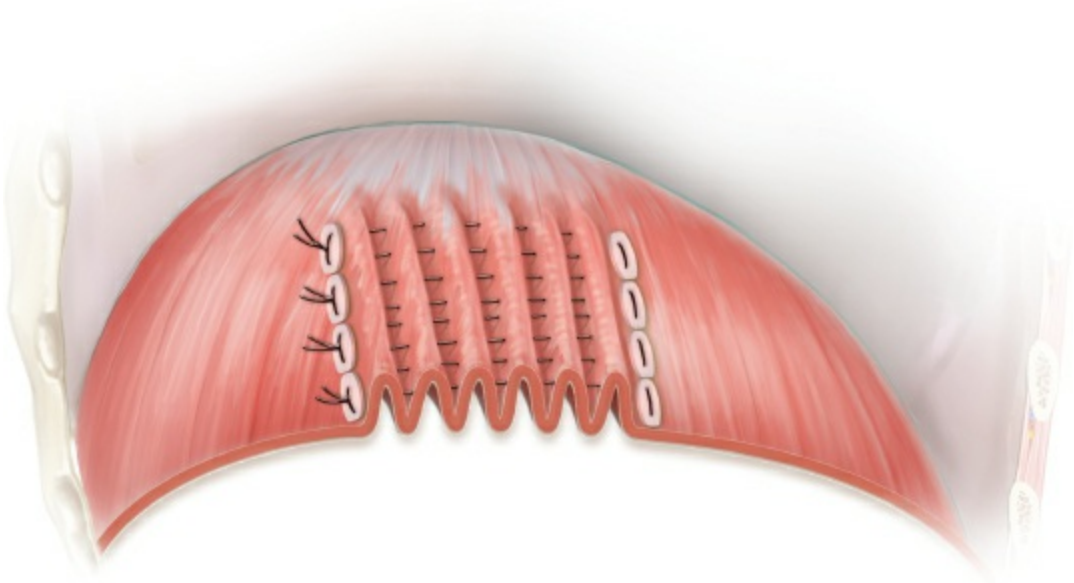

Figure 65.9. Accordion-type plication using a pledgeted u-stitch technique with multiple passes of suture in a linear fashion to create pleats in the lax portion of the diaphragm.

Adjuncts that may facilitate repair include knot-tying devices, fan retractors, and increasingly smaller instruments. In patients with fragile, friable diaphragmatic tissue the use of a stapler has been described to create a reinforced ridge that is used to hold the suture for plication. Visual

inspection confirms flattening of the plicated diaphragm as the induced pneumothorax is released. All carbon dioxide and air is aspirated from the pleural space. Use of a pleural tube varies with some surgeons advocating thoracostomy tubes in all patients, some in select patients, and some with no tube use at all.

In adults, robotic thoracoscopic interventions and single-port surgery have been described; however, the 8-mm robotic ports remain intrusive to the small surface area of the pediatric population and single site interventions require additional small incisions for suturing potentially negating the benefit of an isolated incision.

Laparoscopic Plication

The major advantages of an abdominal approach to plication are (a) the ability to utilize dual-lung ventilation, (b) the avoidance of injury to the lung parenchyma from retraction techniques, (c) a larger operative space in which to work, (d) less risk of injury to intra-abdominal viscera which cannot be directly seen thoracoscopically, and (e) a greater degree of freedom of trocar movement than is permitted with thoracoscopy. The laparoscopic approach also offers the ability to assess the intra-abdominal contents and/or to provide simultaneous additional surgery such as a feeding tube or fundoplication.

Laparoscopic plication of DE can be achieved using a single lumen endotracheal tube with the patient supine in reverse Trendelenburg position. Typically, four trocars (3 mm for infants and toddlers, 5 mm for older children and adults) are deployed, one in the umbilicus (scope) and three others in a half circle. It may be necessary to divide the triangular ligament of the left hepatic lobe to afford exposure to the left hemidiaphragm. Gentle downward retraction on the right hepatic lobe facilitates plication of right-sided DE. In the technique described by Andrade, hook electrocautery is used to make a small hole in the affected diaphragm, inducing an ipsilateral pneumothorax. This equalizes the pressures across the pleural and peritoneal cavities and allows the redundant diaphragm to be grasped and retracted down into the peritoneal cavity. Alternatively, a retraction suture may be placed at the apex of the DE to allow it to be pulled into the operative field and away from the underlying lung parenchyma. After invaginating or retracting the diaphragm, plication is then performed using pledgeted nonabsorbable sutures. Alternatively, the accordion or pleated repair and the stapled repair described previously in the thoracoscopic approach have also been

utilized in the laparoscopic technique. In cases of suture retraction, no further intervention or pleural tube is required. If a hole in the diaphragm is created prior to plication, the plication sutures are positioned in such a way as to incorporate the hole in the repair and a small thoracostomy tube is placed for 24 to 48 hours.

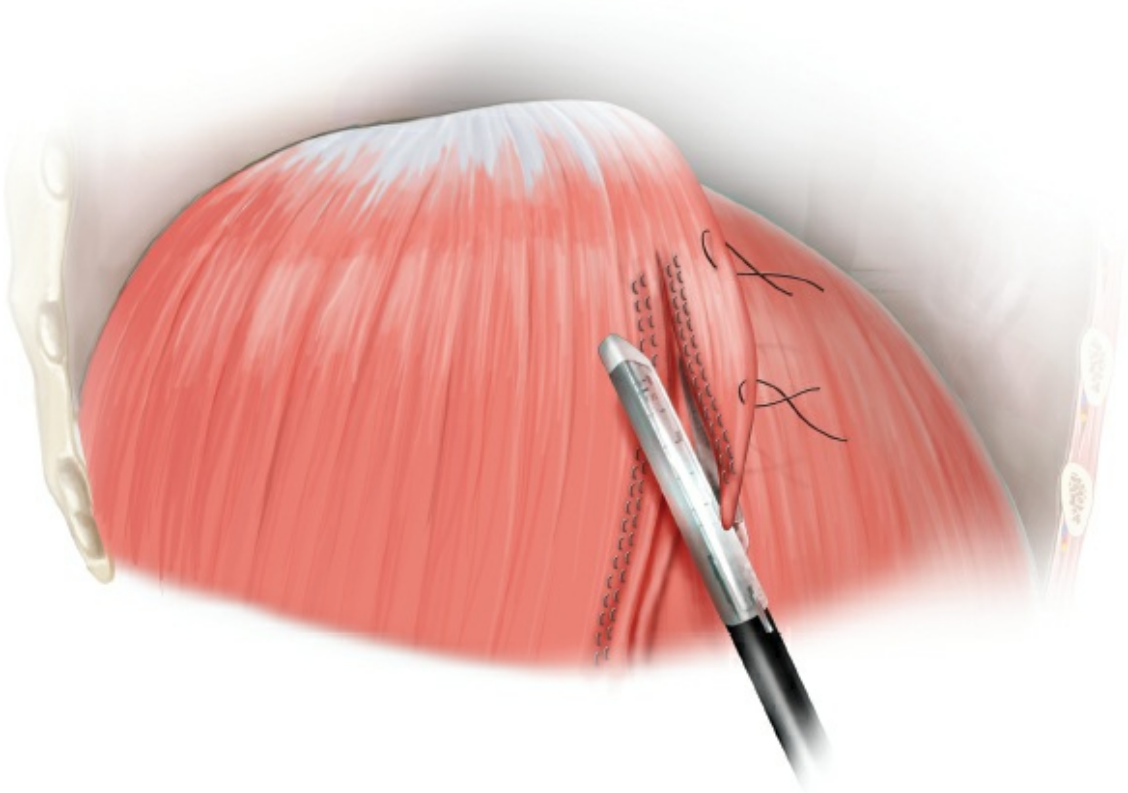

Figure 65.10. Use of an endostapler to simultaneously reapproximate and resect the redundant diaphragm.

Modifications of the laparoscopic technique have included robotic technology in adults and the use of a mesh or patch to augment repair. Tissue engineering to provide special biologic meshes to reinforce the plication repair are also undergoing early investigation.

Comparison of Laparoscopic and Thoracoscopic Plication

Two recent retrospective reviews directly compared laparoscopic and thoracoscopic plication. In a study by Miyano et al., 20 pediatric patients underwent operative repair: 13 in the laparoscopic group and 7 in the thoracoscopic group. Each technique had similar mean operating time, mean duration of postoperative ventilation, and mean time to resume feeding. The thoracoscopic group had one conversion to open procedure

with no major complications reported in either group. Mean intraoperative end-tidal CO_2 was higher in the laparoscopic group. Most notably, there were six cases of recurrence and all of these occurred in the laparoscopic cohort. In a study by Hu et al., 27 pediatric patients underwent plication with all left-sided eventrations repaired laparoscopically, and all right repaired via the thoracoscopic approach. No conversions were required in either group and there was no morbidity or mortality reported.

Two separate studies, Cao et al. and Fujisharo et al., evaluated the laparoscopic and thoracoscopic approach specifically in patients requiring plication after congenital heart surgery. Eighteen patients were reported in the laparoscopic study while only five were reported in the thoracoscopic study. Open conversion was not required in either group and neither study reported any recurrence. With the laparoscopic approach, operative time ranged from 45 to 105 minutes while the thoracoscopic approach was longer ranging from 92 to 169 minutes. Several concerns with the thoracic approach exist including management of adhesions from cardiac interventions and respiratory instability due to the pre-existing congenital heart disease. The patients described in the thoracoscopic study maintained sufficient peripheral tissue oxygenation and although they had adhesions these were able to be dissected thoracoscopically; however, this may account for the longer operative time compared to that reported in the laparoscopic study.

The optimal minimally invasive approach has yet to be conclusively identified. Surgeon preference remains a major determinant but a variety of other factors should also be taken into account including right- or left-sided location, cardiovascular status, and previous or concomitant interventions. Further larger randomized trials are required before definitive superiority is established.

POSTOPERATIVE MANAGEMENT

Postoperatively, there is no contraindication to extubation in the operating room or to immediate initiation of a ventilator weaning protocol. A postoperative plain chest radiograph should be obtained once the patient is breathing spontaneously to document the position of the affected diaphragm. Antibiotics are discontinued within 24 hours and if a chest tube has been placed, it may be removed as soon as the output has decreased appropriately based on the size of the patient. There are no dietary restrictions and the patient discharged as soon as these milestones are met.

COMPLICATIONS

Complications from both open and minimally invasive procedures are uncommon. Care must be taken when placing the plication sutures not to damage structures on the other side of the diaphragm. Pneumonias, deep venous thrombosis, and cardiac events are possible in elderly patients. Pleural effusions can require drainage if the chest tube is removed prematurely and the patient becomes symptomatic. Pneumothorax requiring additional chest tube drainage has also been described.

The recurrence rate for DE is unclear since asymptomatic patients may not be identified. Historically, a recurrence rate of 10% to 15% in adults has been reported; however, recent studies report rates as low as 0%. For the pediatric population, the majority of recent studies report a recurrence rate of 0% with only a handful documenting a low number of recurrences.

CONCLUSION

Plication of DE is a safe and feasible treatment that improves respiratory function. There are a variety of techniques reported in the literature; however, the majority involve small case series or are underpowered. No randomized controlled trials identify a definitively superior method of repair. As the incidence of symptomatic eventration is low, surgeons should rely on the existing evidence to formulate an operative plan. Minimally invasive techniques have shown proven benefits in other arenas and in pediatric eventration retrospective studies. With current advancements in technology it is reasonable to predict that improvements in minimally invasive platforms will assist in the technical feasibility of these procedures. Choice between abdominal and thoracic approaches is not clearly defined and should be left to surgeon preference based on patient presentation and needs.

Suggested Readings

Alamo L, Gudinchet F, Meuli R. Imaging findings in fetal diaphragmatic abnormalities. *Pediatr Radiol* 2015;45:1887–900.

Alshorbagy A, Mubarak Y. Open transthoracic plication of the diaphragm for unilateral diaphragmatic eventration in infants and children. *Korean J Thorac Cardiovasc Surg* 2015;48:307–10.

Cao GQ, Tang ST, Aubdoollah TH, et al. Laparoscopic diaphragmatic hemiplication in children with acquired diaphragmatic eventration after congenital

heart surgery. *J Laparoendosc Adv Surg Tech A* 2015;25:852–57.

Evman S, Tezel C, Vayvada M, et al. Comparison of mid-term clinical outcomes of different surgical approaches in symptomatic diaphragmatic eventration. *Ann Thorac Cardiovasc Surg* 2016;22:224–9.

Fujishiro J, Ishimaru T, Sugiyama M, et al. Thoracoscopic plication for diaphragmatic eventration after surgery for congenital heart disease in children. *J Laparoendosc Adv Surg Tech A* 2015;25:348–51.

Hu J, Wu Y, Wang J, et al. Thoracoscopic and laparoscopic plication of the hemidiaphragm is effective in the management of diaphragmatic eventration. *Pediatr Surg Int* 2014;30:19–24.

Kozlov Y, Novozhilov V. Thoracoscopic plication of the diaphragm in infants in the first 3 months of life. *J Laparoendosc Adv Surg Tech A* 2015;25:342–7.

Lao VV, Lao OB, Abdessalam SF. Laparoscopic transperiteonal repair of pediatric diaphragm eventration using an endostapler device. *J Laparoendosc Adv Surg Tech A* 2013;23:808–13.

Miyano G, Yamoto M, Kaneshiro M, et al. Diaphragmatic eventration in children: laparoscopy versus thoracoscopic plication. *J Laparoendosc Adv Surg Tech A* 2015;25:331–4.

Nason LK, Walker CM, McNeeley MF, et al. Imaging of the diaphragm: anatomy and function. *Radiographics* 2012;32:E51–70.

Podgaetz E, Diaz I, Andrade RS. To sink the lifted: selection, technique, and result of laparoscopic diaphragmatic plication for paralysis or eventration. *Thorac Cardiovasc Surg* 2016;64:631–40.

Shary TM, Hebra A. A simple technique for thoracoscopic treatment of diaphragmatic eventration. *Am Surg* 2013;79:893–5.

Skandalakis JE, Gray SW, Ricketts RR. The diaphragm. In: Skandalakis JE, Gray SW, eds. *Embryology for Surgeons*, 2nd ed. Baltimore, MD: Williams & Wilkins; 1994:511.

Tsao K, Lally KP. Congenital diaphragmatic hernia and eventration. In: Holcomb GW 3rd, Murphy JP, eds. *Ashcraft's Pediatric Surgery*, 5th ed. Philadelphia, PA: Saunders Elsevier; 2010:304.

Wu S, Zang N, Zhu J, et al. Congenial diaphragmatic eventration in children: 12 years' experience with 177 cases in a single institution. *J Pediatr Surg* 2015; 50:1088–92.

EDITOR'S COMMENT

Permanent elevation of the diaphragm, an eventration, is a pathologic condition

from which afflicted patients experience some degree of respiratory symptomatology; however, most do not require operative correction. The authors provide excellent overview of the condition. As they note, there are two primary causes of an eventration—congenital and phrenic nerve injury. For those patients who present with the congenital form, the etiology reflects a lack of appropriate diaphragmatic muscularis development resulting in an area of weakness. Although patients are born with the abnormality, they may not be diagnosed until respiratory symptoms are significant enough that an evaluation is begun.

In the infant population, differentiating an eventration from a congenital diaphragmatic hernia (CDH) with a hernia sac can be difficult. For both conditions, an afflicted infant will present with mild respiratory symptoms—often tachypnea—prompting a CXR. The majority of patients with a CDH will have loops of bowel that are visualized in the chest making the diagnosis obvious, but in a patient with a CDH that has a hernia sac, the diaphragm will be elevated and have an abnormal contour which mirrors the findings of an eventration, especially if it occurs on the right. Interestingly, patients with a CDH in which a hernia sac limits the egress of abdominal contents into the chest do not have the same degree of cardiopulmonary vasculature challenges as a patient with a CDH without hernia sac where pulmonary hypoplasia and pulmonary hypertension result in marked physiologic instability requiring diligent intensive care monitoring and often ECMO for stabilization and survival. Patients with a CDH that have a hernia sac, similar to a patient with an eventration, have limited respiratory symptoms and are quite stable. Often they are diagnosed incidentally or later in childhood after a CXR has been obtained for respiratory symptoms. Although we group CDH patients with and without a hernia sac under the same diagnosis, one wonders from a mechanistic process whether, given the marked difference in frequency of pulmonary hypertension, this should be the case. Perhaps, a CDH with a hernia sac and an eventration, even though the muscular defect arises in different parts of the diaphragm, are pathogenically more closely related.

A diaphragmatic eventration induced by traumatic injury to the phrenic nerve is a more readily understandable physiologic process. As the authors note, in infants, the most common cause of a phrenic nerve injury is traction occurring during a difficult delivery (shoulder dystocia with traction injury to C3–C5 nerve roots) resulting in a partial or a permanent phrenic nerve injury. In contrast, injury during congenital heart surgery, typically attributed to ice on the phrenic nerve, is another common cause that in theory should be a transient process that resolves. Pediatric surgeons will be consulted to address both of these etiologies, and if the patient is encountering significant respiratory challenges (failure to extubate, recurrent pneumonias, or persistent tachypnea) surgical intervention is warranted. Eventration diagnosed in an older patient is typically due to a pathologic process encompassing the phrenic nerve and should be investigated as such. Neurodegenerative disorders, infection,

malignancy, and autoimmune disease in the upper mediastinum are potential causes, and due diligence investigation for such possibilities should be completed.

As the authors note, the diagnostic evaluation of a patient with eventration is dependent primarily upon a dynamic study of the diaphragm. A series of options are available, including ultrasound and MRI; however, a simple fluoroscopic sniff test is what we recommend. In an infant and young child, performing a sniff test can be difficult, as their ability to comply with "sniffing" may be limited.

From a clinical standpoint, eventration-induced symptoms are related to pulmonary mechanics. Because the diaphragm does not contract properly, full lung expansion during inspiration may be reduced. In children, symptoms may be more significant as the mechanics of breathing are still in evolution. Additionally, a smaller thoracic cavity in theory could inhibit lung growth—although the mechanistic basis for this inhibition has not been defined. In older patients, the ability to compensate reduces the frequency of respiratory compromise. As the authors note, the indications to address eventration are limited to those patients who encounter significant respiratory challenges. Many patients can be supported with either minimal respiratory support (i.e., nasal CPAP) or postural positioning. Repair is indicated more frequently in the pediatric population, as the respiratory mechanics of a child is more dependent upon full diaphragm excursion.

The authors nicely summarize the treatment options to address diaphragmatic eventration. How to appropriately address an eventration falls into the two alternatives—a resection of the lax diaphragm with primary closure of the resected defect or diaphragmatic plication. Although the evidence in favor of either approach has not been analyzed in a prospective randomized fashion, the ease by which plication can be performed and the minimal morbidity of that approach has resulted in more surgical interest towards that alternative than diaphragmatic resection.

As in all of general surgery, minimally invasive approaches to repair an eventration have been developed and embraced—in the case of eventration this is justified. Both thoracoscopic and laparoscopic approaches have been described with the authors reviewing several recent studies where it has been shown that the thoracoscopic approach is more durable than the laparoscopic approach. This is understandable as with the thoracoscopic approach (which also applies to an open approach should that be considered), there is better visualization of the entire diaphragm and also allows maximal flattening of the diaphragm, which assists in the placement of plication sutures to maximize effect. We use the combination of CO_2 insufflation (pressures of 5 mm Hg) and single lung ventilation, as this has been shown to be helpful (Fujishiro J, Ishimaru T, Sugiyama M, et al. Thoracoscopic plication for diaphragmatic eventration after surgery for congenital heart disease in children. *J Laparoendosc Adv Surg Tech A* 2015;25(4):348–51). A novel, simple

thoracoscopic plication technique was recently reported, in which through a 3-mm camera port, a 3-mm instrument incision without a port, and an 18-gauge spinal needle, the procedure could be achieved (Snyder CW, Walford NE, Danielson PD, et al. A simple thoracoscopic plication technique for diaphragmatic eventration in neonates and infants: technical details and initial results. *Ped Surg Int* 2014;30(10):1013–6). The spinal needle is passed into the chest, and the excess diaphragm is plicated over the needle, after which a nonabsorbable suture is passed through the needle and tied extracorporeally. The needle is passed repeatedly until the desired degree of tension is achieved. Should resection of the diaphragm be chosen, great care must be taken not to further damage what residual phrenic nerve branches are available which would then further alter functional aspects of the diaphragm.

Diaphragmatic eventration is a condition that infrequently will require surgical repair; however, should it be necessary, the morbidity rates following such intervention should be minimal. It seems likely that open approaches will be abandoned as minimally invasive approaches become the primary route used to address this issue.

Gregory M. Tiao

66 Traumatic Injury to the Diaphragm

H. Leon Pachter, Chad T. Wilson, and Spiros G. Frangos

ANATOMY

The primary muscle responsible for breathing is the diaphragm, a musculoaponeurotic barrier that separates the thoracic and abdominal cavities. Muscle fibers originate higher anteriorly from the sternum's xiphoid process. Their origins laterally and posteriorly are more inferior, arising from the costal cartilages and osseous portions of the lower ribs and the lumbar vertebral bodies and their intervertebral discs (Fig. 66.1). These fibers all insert into the diaphragm's aponeurotic portion known as the central tendon. The right dome is naturally 2 cm higher than the left owing to the mass effect of the underlying liver.

Three major orifices—the caval, esophageal, and aortic—allow for the passage of major structures (Fig. 66.1). Located at the T-8 level, the aponeurotic caval opening allows the inferior vena cava and often the right phrenic nerve to traverse body cavities. The diaphragm's lumbar origin includes left and right crural fibers, which form the boundaries of the esophageal and aortic hiatus. The esophagus and the vagus nerves traverse the esophageal hiatus—a gap between the right crural fibers—at the T-10 level. The aortic hiatus, which is formed by the fibers of the left and the right crura, is located at the T-12 level and allows for passage of the aorta, thoracic duct, and variably the azygos and the hemiazygos veins.

The diaphragm's blood supply comes from inferior and superior phrenic arteries that arise directly from the thoracoabdominal aorta. Superior epigastric and intercostal arteries provide blood to the muscle's costal margins. Venous drainage is through phrenic veins directly into the inferior vena cava. The motor nerve supply of the diaphragm is through left and right phrenic nerves. The left phrenic nerve passes through the muscular diaphragm more anteriorly than the right phrenic nerve, which passes through the aponeurotic central tendon through or in close proximity to the caval opening. The two main trunks typically divide into three main branches: anterior, anterolateral, and posterior.

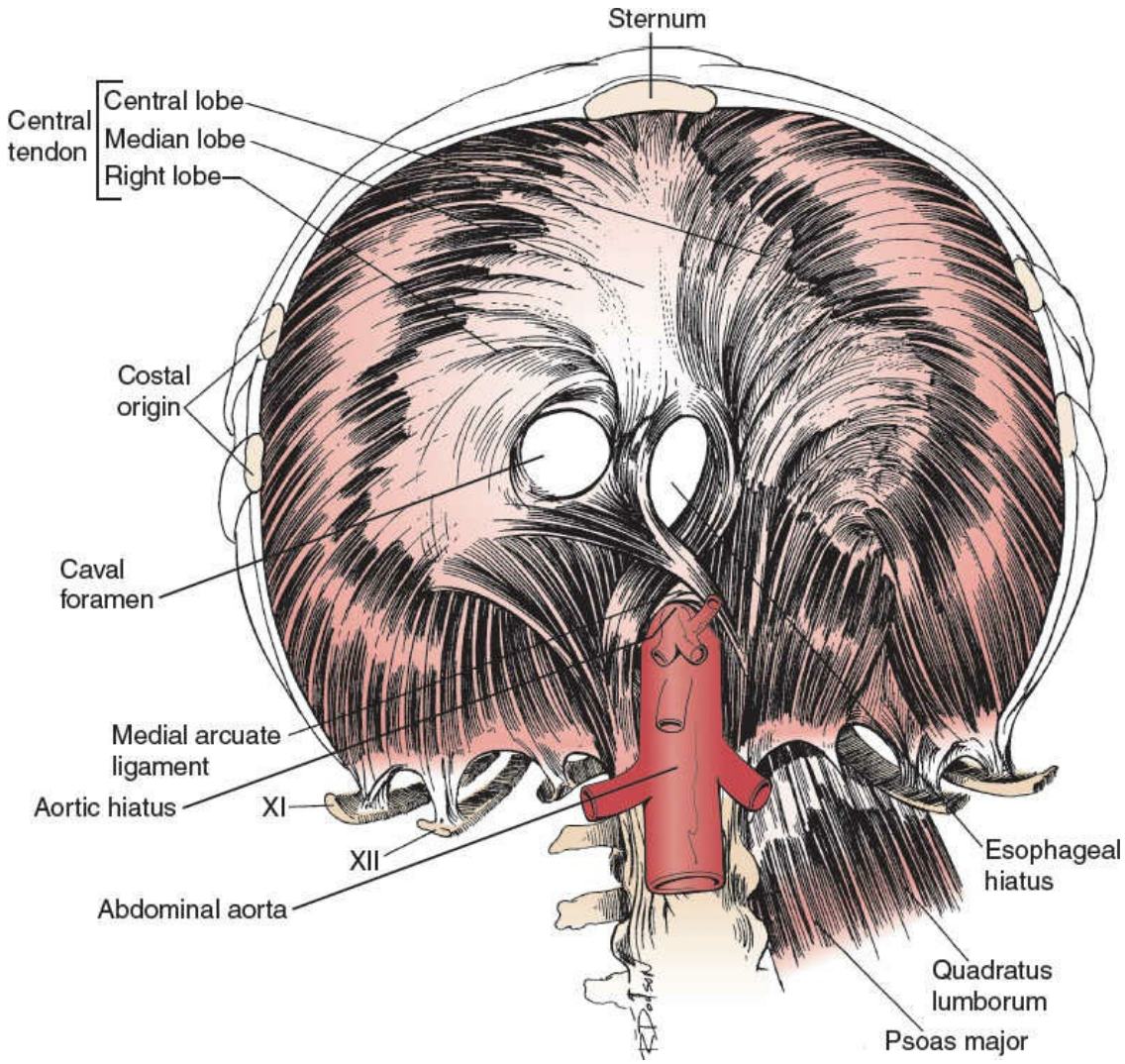

Figure 66.1. Anatomy of the diaphragm; view from below.

An understanding of diaphragmatic anatomy by surgeons who care for trauma patients is important to avoid missed injuries. In addition, the variable topography of the muscle—especially when assessing for trajectory in penetrating trauma—must be recognized. A patient's positioning (e.g., supine vs. erect) and phase and depth of ventilation affect the location of the left and right diaphragmatic domes, which can vary by as much as 10 cm. Each individual's natural build and pulmonary pathophysiology (e.g., chronic obstructive pulmonary disease) play a role in the muscle's topography, as may associated injuries (e.g., a liver hematoma that pushes the diaphragm superiorly). Furthermore, a firm grasp of diaphragmatic anatomy is important in minimizing iatrogenic phrenic nerve injury during operative repair.

ETIOLOGY AND PATHOPHYSIOLOGY

Large studies from the United States suggest that four out of five patients who sustain a diaphragm injury are men, and the mechanism of injury is penetrating two to three times as often as it is blunt. These findings vary among populations as a result of geographic and sociocultural factors.

Left hemidiaphragm injuries are diagnosed more commonly than right in blunt trauma, likely as a result of the force-distribution protection afforded by the extensive solid parenchymal mass of the liver. Penetrating injuries show less left-right bias, although it is plausible that the liver may afford a mild amount of anatomic barrier protection. The fact that right-sided injuries may be less aggressively pursued diagnostically given a lower likelihood of untoward sequelae (e.g., hernia) if missed certainly contributes to a diagnostic bias in comparing injury rates. Bilateral dome injury is uncommon regardless of mechanism as is herniation into the mediastinum. The American Association for the Surgery of Trauma (AAST) organ injury scale for the diaphragm is depicted in Table 66.1.

TABLE 66.1 AAST Organ Injury Scale—Diaphragm[a]

Grade	Injury Description
I	Contusion
II	Laceration ≤2 cm
III	Laceration between 2 and 10 cm
IV	Laceration >10 cm with tissue loss ≤25 cm^2
V	Laceration with tissue loss >25 cm^2

[a]Advance one grade for bilateral injuries up to Grade III.

CLINICAL PRESENTATION

The diaphragm is uncommonly injured in an isolated fashion. Diaphragmatic injury resulting from blunt trauma usually accompanies injury to local structures, including ribs, lung, and abdominal solid viscera, especially the liver and the spleen. Pelvic or long-bone fractures and traumatic brain injury are frequently seen concurrently in these patients, a

predictable association given the significant energy required to rupture a hemidiaphragm. Penetrating injury to the diaphragm is also usually accompanied by injuries to one or more nearby viscera, including the lungs, the liver, the stomach, the spleen, the kidneys, and the colon. Projectiles lead to a greater number of local visceral injuries than do stab wounds. A high index of suspicion for diaphragmatic injury is critical following penetrating thoracoabdominal or high-velocity deceleration mechanisms.

Penetrating Trauma

When evaluating for the possibility of a diaphragmatic injury, the location of the wound is important and can be readily inspected in the emergency department. It is however the trajectory of the foreign body relative to the diaphragm, which is more significant; unfortunately this is much more difficult to ascertain by history and physical examination. Penetrating injuries between the nipples and the lower costal margin place the diaphragm at risk for injury. Anterior and lateral thoracoabdominal penetrating injuries are more likely to lacerate the diaphragm than are those to the back along the same axial plane. Injuries to the diaphragm as a result of penetrating trauma are generally short (1 to 3 cm) lacerations without acute herniation. These patients rarely have any symptoms resulting from the diaphragm injury alone.

The incidence of diaphragmatic injury secondary to penetrating thoracoabdominal trauma is not well-delineated due to variability in the denominator data (i.e., the study population has occult injuries of uncertain clinical significance that may not be detected). Inclusion and exclusion criteria, including anatomical boundaries and indications for imaging studies or operative exploration, are inconsistent between studies.

Although penetrating injury to the diaphragm is more common than blunt, the diagnostic challenges of these smaller injuries are problematic and their natural history is unclear. This leaves clinicians with two vital questions: What is the incidence of occult, and therefore unrepaired, diaphragmatic injuries, *and* what percentage of these untreated patients go on to sustain complications (i.e., abdominal visceral herniation)? Lacking evidence-based answers to these questions, the optimal management of potential injuries is often left to a surgeon’s own experience and judgment.

Blunt Trauma

When considering blunt diaphragmatic injury, a thorough assessment of the severity of the event must be made as the potential for an injury is entirely related to mechanism. Injury frequently occurs as a result of significant deceleration mechanism or truncal impact, contributing to a rapid and abrupt increase in intra-abdominal pressure. For a victim of a motor vehicle collision, the approximate velocity of the incident must be considered because high delta-*v* (i.e., significant change in velocity) decelerations are more likely to lead to rupture of a hemidiaphragm. Occupant compartment intrusion and seat belt use may also play a role. For a victim of a fall, it is important to ascertain the height and the surface of impact to estimate the deceleration forces.

Injuries to the diaphragm as a result of blunt trauma are larger (i.e., usually longer than 5 cm) than penetrating lacerations and are commonly associated with acute herniation. These patients may have symptoms associated with the diaphragm injury, including shortness of breath or respiratory distress, especially with larger defects involving significant herniation. However, in light of the multi-organ system trauma (e.g., brain injury) frequently sustained by these critical patients, which may require therapeutic prioritizing, a delay in diagnosis or treatment of a diaphragm injury may be unpreventable. Because pulmonary symptoms associated with a blunt force diaphragmatic injury are nonspecific, a high index of suspicion is required.

Chronic Diaphragmatic Hernia

Patients with missed or untreated diaphragmatic injuries often present in a delayed fashion with symptoms related to intestinal herniation or strangulation. Over time, small diaphragmatic holes can increase in size as a result of the constant activity of the muscle, and the pressure gradient between pleural and peritoneal cavities can draw intraperitoneal organs into the chest. Presentations vary from mild nausea and vomiting due to intermittent bowel obstructions to pain from incarceration and ischemia to septic shock from strangulated, necrotic, or perforated viscus. Undoubtedly, the consequences of an untreated diaphragm injury can be devastating.

DIAGNOSIS

The diagnosis of diaphragmatic injury in a patient who does not otherwise warrant immediate thoracic or abdominal surgical intervention can be

challenging. Generally, the ability to make an accurate diagnosis outside an operating room (OR) relates to the size of the defect.

Physical Examination

The physical examination is unreliable for diagnosing diaphragmatic injury following blunt or penetrating trauma. There are no highly sensitive signs to detect an underlying injury. Following penetrating injuries, the trajectory of the knife or bullet is more important than the actual location of the skin wound, but trajectory is usually difficult to elicit accurately. Probing a thoracoabdominal wound, especially one overlying the ribcage, is generally discouraged for fear of creating or exacerbating a pneumothorax or intercostal bleeding. The careful insertion of a cotton applicator superficially by an experienced surgeon may however provide some indication of trajectory, and there are instances—e.g., in obese patients, for wounds to the back, for subcutaneous tangential tracts—where this maneuver, when applied cautiously, may be useful information in determining the probability of a deep visceral injury.

The physical examination lacks sensitive or specific signs of a diaphragm injury following blunt trauma as well. However, there are certain signs that are suggestive of injury, including unilateral decreased breath sounds, bowel sounds in the chest, and respiratory distress. Obviously, these are nonspecific findings, but their presence should not be discounted in assessing for diaphragm injury. The multiple associated injuries commonly found in patients with ruptured diaphragms may delay the diagnosis from being made prior to imaging studies.

Imaging

A chest radiograph is commonly performed but rarely diagnostic. This is especially true for penetrating trauma where diaphragm injuries are small and plain films are seldom helpful. A chest x-ray more commonly contributes to the diagnosis following a blunt mechanism and in these circumstances may appear dramatic. Examples of such radiographic evidence include air or an air–fluid level within a hollow viscus overlying the thorax or with the additional “classic” finding of the coiling supradiaphragmatic nasogastric tube. Suggestive findings include abnormality in the contour, shape, or position (e.g., elevation) of the hemidiaphragm, pleural effusion or atelectasis, and mediastinal shift. The chances of seeing these signs may be reduced in patients on positive

pressure ventilation as the contour of the lower lobes of the lungs, when expanded under pressure, mimics that of the intact diaphragm.

Contrast studies that were commonly ordered in the past are now infrequently performed in the acute setting. Most of these techniques rely on gastrointestinal herniation for diagnosis, which is especially rare in the acute period following penetrating trauma. They do still have a role in the evaluation of the patient with a chronic hernia. Diagnostic peritoneal lavage is an inadequate modality for diagnosing diaphragmatic trauma and should not be used for this indication. The detection of red cells, white cells, or bowel contents lacks any specificity and is simply unreliable in the work-up of the diaphragm. A focused assessment with sonography in trauma (FAST) scan is of limited sensitivity in diagnosing diaphragm injury; however, the presence of peritoneal fluid (especially in the concurrent setting of hemothorax or pleural fluid) can suggest diaphragm injury, in particular for penetrating mechanisms However, sonographic features of injury lack specificity and are generally visible with larger lesions.

With its greater sensitivity and specificity, computed tomography (CT) scan has replaced contrast studies. Suggestive findings using this modality include discontinuity of the diaphragm or a wound tract extending up to a hemidiaphragm, while conclusive evidence includes intrapleural abdominal contents. CT has a greater sensitivity for blunt trauma, where injuries tend to be larger, and is less helpful following penetrating mechanisms, where diaphragmatic defects are small and acute herniation rare. Penetrating diaphragm injuries also present a distinct spectrum of radiographic findings from those in blunt trauma with contiguous injury and transdiaphragmatic trajectory acting as best predictors. Diaphragmatic discontinuity, thickening, elevation, or segmental nonrecognition and intrathoracic herniation of abdominal viscera are strong predictors of blunt diaphragmatic rupture. CT scan is far from perfect and certainly may miss a small injury; therefore, a high index of suspicion is required. Advances in imaging technology including 64–slice multidetector CT with reformatted sagittal and coronal images have improved sensitivity further. Older studies suggesting a lower diagnostic accuracy for penetrating injury to the diaphragm are no longer applicable, and CT with multiplanar reformations currently represents the screening imaging modality of choice for diaphragmatic injury. Table 66.2 depicts CT findings associated with diaphragmatic injuries.

Magnetic resonance imaging (MRI) has superior soft tissue resolution compared to CT. However, it currently has a limited role in the acute trauma setting as it is more time-consuming and costly to perform. MRI is absolutely contraindicated in hemodynamically unstable patients.

Surgery

When multidetector CT scan is equivocal for diaphragmatic injury, especially following thoracoabdominal penetrating trauma, further investigation is warranted. Surgery remains the gold standard for diagnosing an injury to the diaphragm, although controversy exists regarding exactly which hemodynamically stable patients who have sustained thoracoabdominal trauma require operative evaluation.

Diagnostic laparoscopy is an excellent modality for evaluating the diaphragm and is the procedure of choice for assessing the diaphragm in patients who lack a clear indication for laparotomy. Although laparoscopy alone is sufficient to rule out a diaphragm injury, it is unclear which patients should undergo the procedure. Available data suggest that almost two thirds of diagnostic laparoscopies in stable patients with penetrating thoracoabdominal trauma will fail to reveal diaphragmatic injury. Exploring all patients would cause a great number to undergo negative explorations with their associated risks and cost. At present, there is no clear consensus as to what an acceptable percentage rate of negative laparoscopy should be in regards to diaphragmatic injury screening. In addition, the clinical significance of small diaphragm injuries is unknown and the diagnosis of a small injury may not have substantial merit. Despite this uncertainty regarding indications, laparoscopy is a reliable way to make the diagnosis when diaphragm injury exists, and for this reason has grown in popularity in the recent years.

TABLE 66.2 CT Findings Associated with Diaphragmatic Injuries

Finding	Sensitivity/Specificity in Blunt Mechanism	Sensitivity/Specificity Penetrating Mechanism
Herniation of abdominal viscera into the chest	75/99%	17/97%
Diaphragm discontinuity	50/95%	40/90%
Segmental nonrecognition of diaphragm	44/91%	–
Thickening of the diaphragm (curled diaphragm sign)	56/95%	48/70%
Elevated intra-abdominal organs	56/99%	–
Thoracic fluid abutting intra-abdominal viscera	31/100%	–
"Collar" sign[a]	62/100%	4/100%
Dependent viscera sign[b]	56/100%	0/100%
Hemothorax *and* hemoperitoneum/contiguous injury[c]	50%/95%	88/82%

[a]A waist-like appearance of herniated organs at the level of the diaphragm.
[b]Absence of interposition of lungs between the upper part of the abdominal organs and the chest wall.
[c]In penetrating, trauma contiguous injury can be blood above and below diaphragm or other findings like pneumoperitoneum below diaphragm and concurrent pneumothorax, or bullet cavitation that crosses diaphragm plane.
Data from Bodanapally UK, Shanmuganathan K, Mirvis SE. et al. MDCT diagnosis of penetrating diaphragm injury. *Eur Radiol* 2009;19:1875–81; and Nchimi A, Szapiro D, Ghaye B. et al. Helical CT of blunt diaphragmatic rupture. *AJR* 2005;184:24–30.

Laparoscopy, however, is not only excellent in its diagnostic accuracy, but it also carries a simultaneous therapeutic advantage in that an injury may be repaired. Laparoscopy provides excellent visual access as well as access for repair in areas that can be hard to see and reach through standard laparotomy. The surgeon must be cautious about introducing air into the pleural cavity during peritoneal insufflation and thereby creating a tension pneumothorax. For this reason, it is imperative to monitor airway pressures, oxygen saturation, end tidal CO_2, and mean arterial pressure as pneumoperitoneum is introduced. Insufflation pressures should not exceed 10–12 mm Hg until the abdominal surface of the diaphragm is evaluated and deemed free of injury. In draping such a patient for laparoscopy, the chest should be prepped in case a thoracostomy tube needs to be inserted if not already present at the time of laparoscopy. With a strategy of low pressure pneumoperitoneum, careful attention to ventilatory parameters, and early diaphragmatic inspection, an iatrogenic tension pneumothorax may be considered a rare event. Laparoscopy should not be used in hemodynamically unstable patients.

Higher level evidence and the development of protocols are necessary

to help delineate which patients would benefit most from screening laparoscopy for suspected diaphragmatic injury. What is clear, however, is that the use of laparoscopy significantly decreases nontherapeutic laparotomy rates and associated costs.

Akin to laparoscopy, thoracoscopy may be used for the diagnosis of diaphragmatic injury and is an exceedingly sensitive modality. Repair of the diaphragm through the chest can be accomplished without concern for creating a tension pneumothorax. However, because the diaphragm rarely gets injured in isolation, an intraperitoneal approach may be preferred in patients who would benefit from operative assessment for intra-abdominal injuries. Whereas the majority of pleural cavity injuries may be safely managed with a thoracostomy tube, a perforated intra-abdominal hollow viscus or hemorrhage emanating from a solid viscus injury requires a timely diagnosis and expeditious surgical intervention.

Prior to scoping techniques, diaphragmatic injuries were most commonly detected at laparotomy. This remains the current mode of diagnosis in patients who require immediate abdominal exploration for hemodynamic instability or peritonitis. In patients who are acutely hemorrhaging from a chest injury with an indication for thoracotomy, an injured diaphragm may be detected and addressed from the chest as well. Concomitant abdominal injuries may be ruled out via an additional abdominal procedure or, in rare selective cases, by a transdiaphragmatic approach to the upper abdomen.

In patients with chronic diaphragmatic hernias related to trauma, a proper history and physical examination may be suggestive. These missed injuries often present with alimentary tract obstruction, incarceration, or strangulation. They are almost always found on the left and the diagnosis can usually be made with plain radiography, although CT scan is frequently used to better delineate size, location, and visceral involvement.

TREATMENT

The treatment for an injured diaphragm is operative whether an injury is acute or chronic.

Regardless of mechanism, acute injuries can usually be repaired primarily. This is especially true for penetrating injuries, which are much smaller. Larger defects secondary to acute blunt mechanisms appear to be more common on the left and are generally amenable to primary suture reapproximation. Complex repairs including use of mesh are uncommonly

required in the acute setting. Rarely, a hemidiaphragm may avulse from the chest wall and may be reattached with nonabsorbable sutures.

Repair may be achieved via laparoscopy/laparotomy or via thoracoscopy/thoracotomy depending on a patient's hemodynamic stability and associated injuries and a surgeon's experience with minimally invasive techniques. Laparoscopic techniques continue to gain traction for definitive exploration and repair, especially for penetrating acute diaphragmatic lesions with fewer associated injuries. Conversion to laparotomy is frequently required when an acute blunt diaphragmatic rupture is diagnosed laparoscopically given the high likelihood of significant additional injuries. Laparotomy remains the most common operative approach for repair of both blunt and penetrating diaphragmatic injuries. Indications for thoracoscopic exploration remain undefined because intra-abdominal organs can rarely be adequately assessed operatively without an additional incision.

Surgery is indicated for chronic diaphragmatic hernias. Thoracotomy has a definite role in these patients since there is no concern for an associated intra-abdominal injury. In addition, reduction through the chest may be easier, as bowel adhered to lung can make for a tedious and difficult dissection trans-abdominally. A mesh repair is practically guaranteed for the treatment of a chronic hernia, where primary reapproximation of the diaphragm would likely involve tension and produce suboptimal results.

INDICATIONS AND CONTRAINDICATIONS

The indications for surgical intervention may be generalized rather simply: Most traumatic diaphragmatic hernias should be repaired. What is less clear and remains controversial is the natural history of the small peripheral diaphragmatic lesion or the right-sided defect abutting the dome of the liver. The actual percentage of these injuries that will go on to become clinically significant is unknown.

PREOPERATIVE PLANNING

Preoperative management in the acute setting involves the principles detailed in the Advanced Trauma Life Support course provided by the American College of Surgeons Committee on Trauma. The level of resuscitation, the adjunctive studies ordered, and the immediate treatments employed for these patients generally relate more to their associated

injuries than to any diaphragmatic lesion they may be harboring.

For chronic diaphragmatic hernias, a routine assessment for cardiac risk and medical clearance should be obtained as for any potentially involved elective surgical procedure.

SURGICAL TECHNIQUE

Laparoscopy

The patient is placed supine on the OR table. For penetrating trauma, if there is no evidence for a previously unrecognized significant hemorrhage, a thorough inspection of the diaphragm should be performed early. This is especially true for patients without a thoracostomy tube, as they may rapidly develop a tension pneumothorax from the CO_2 pneumoperitoneum. The upper abdominal viscera have to be retracted in a way that allows for the entire intraperitoneal diaphragmatic surface to be evaluated, which may be difficult especially posteriorly on the left. Positioning the OR table in reverse Trendelenburg with the right side down is indicated, as is the use of a 30-degree scope for improved inspection. If a nonperipheral injury to the diaphragm is found, a chest tube should be placed not only to prevent a potential tension pneumothorax but also because a lung injury cannot be excluded. The diagnosis may be suspected even prior to scope insertion with insufflation creating a symptomatic pneumothorax or causing a new large air leak in a patient with a previously inserted chest tube. If a lesion is detected, the Ligasure (trademark Covidien) laparoscopic instrument or the Harmonic Scalpel (trademark Ethicon) device may be used for the purposes of ensuring local hemostasis. Nonabsorbable sutures should be placed and tied either intra- or extracorporeally (Fig. 66.2). The specific type of primary repair has not been shown to matter. The Endostitch (trademark Covidien) device may be helpful especially in instances where intracorporeal tying may be a challenge.

An injured hemidiaphragm is usually more obvious following blunt trauma. An experienced laparoscopist may perform the repair and address associated injuries without necessarily converting to an open procedure in a hemodynamically stable patient. If the repair is deemed technically difficult or the exploration deemed suboptimal, converting to laparotomy is indicated. In addition, any instability should prompt consideration for conversion to laparotomy.

Laparotomy

The supine patient is prepped and draped as for any trauma laparotomy. Principles of operative trauma including packing, hemorrhage control, and minimization of contamination are followed. Diaphragmatic evaluation should be thorough, especially for penetrating trauma. On the left, the stomach and the spleen are retracted inferiorly and medially with gentle traction (Fig. 66.3). On the right, the round ligament can be clamped and ligated and the falciform incised so that the liver may be retracted for better visualization. Division of the right triangular and coronary ligaments will allow the surgeon to mobilize the liver inferiorly and medially to expose the undersurface of the right hemidiaphragm (Fig. 66.4). Herniation through an injured diaphragm is usually readily apparent and should be immediately reduced to prevent respiratory insufficiency. Since associated injuries are likely to divert attention from an injured diaphragm intraoperatively, it is important to maintain a high index of suspicion and to thoroughly evaluate the entire undersurface via inspection and/or palpation to prevent a missed lesion.

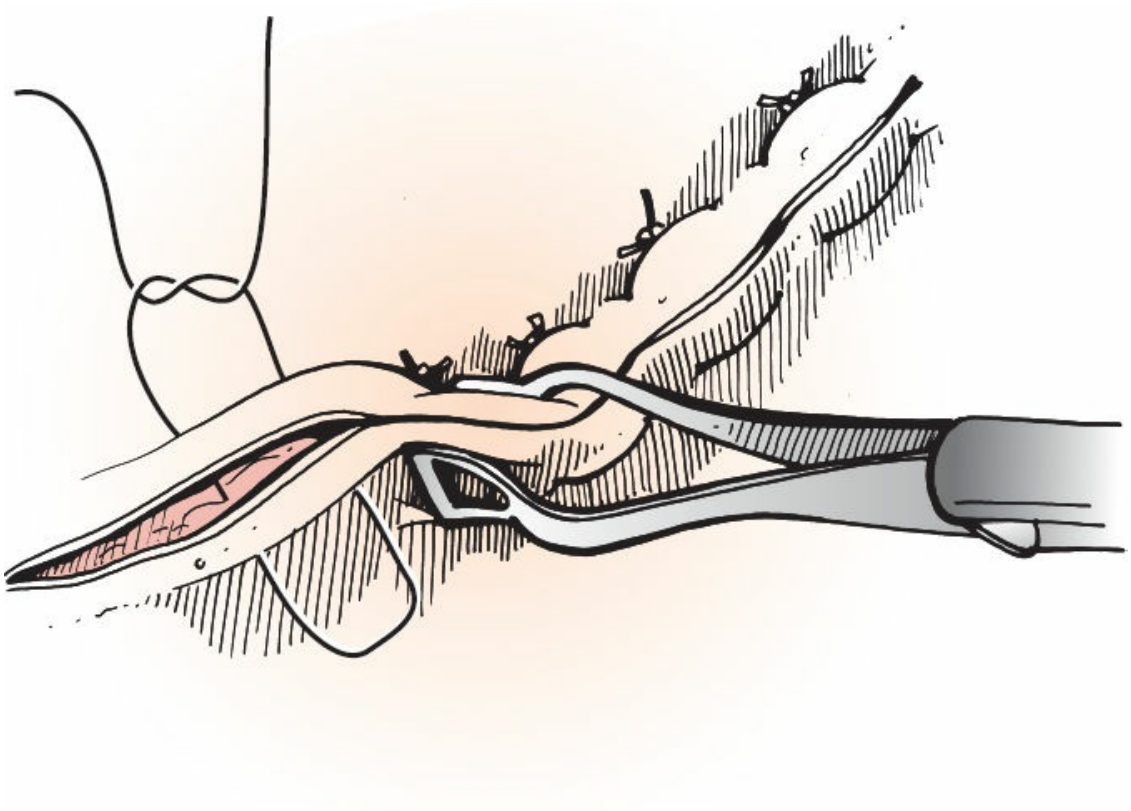

Figure 66.2. Repair of injured diaphragm using interrupted horizontal mattress sutures.

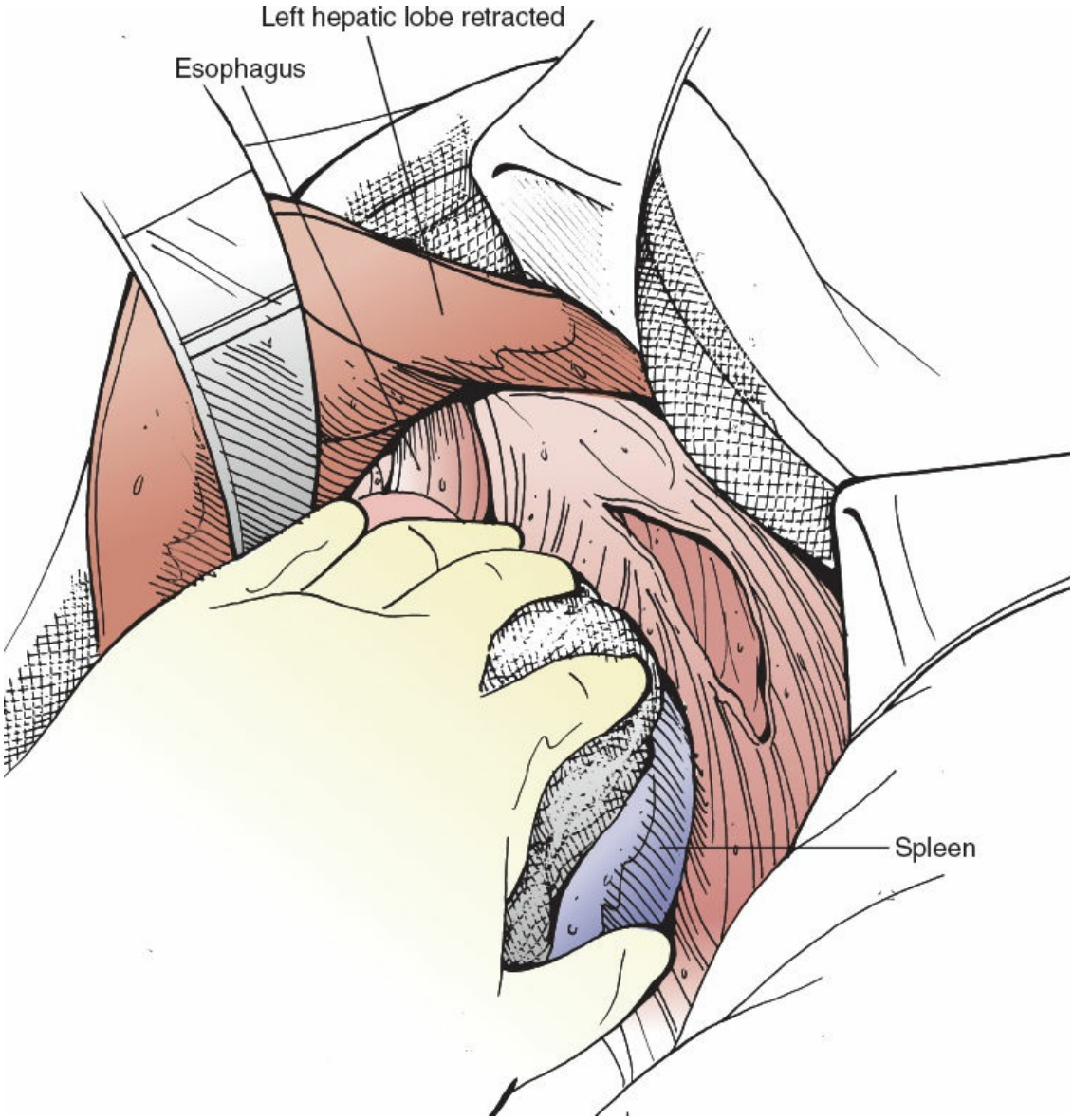

Figure 66.3. To inspect the left hemidiaphragm, the stomach and spleen are retracted inferiorly and medially with gentle traction.

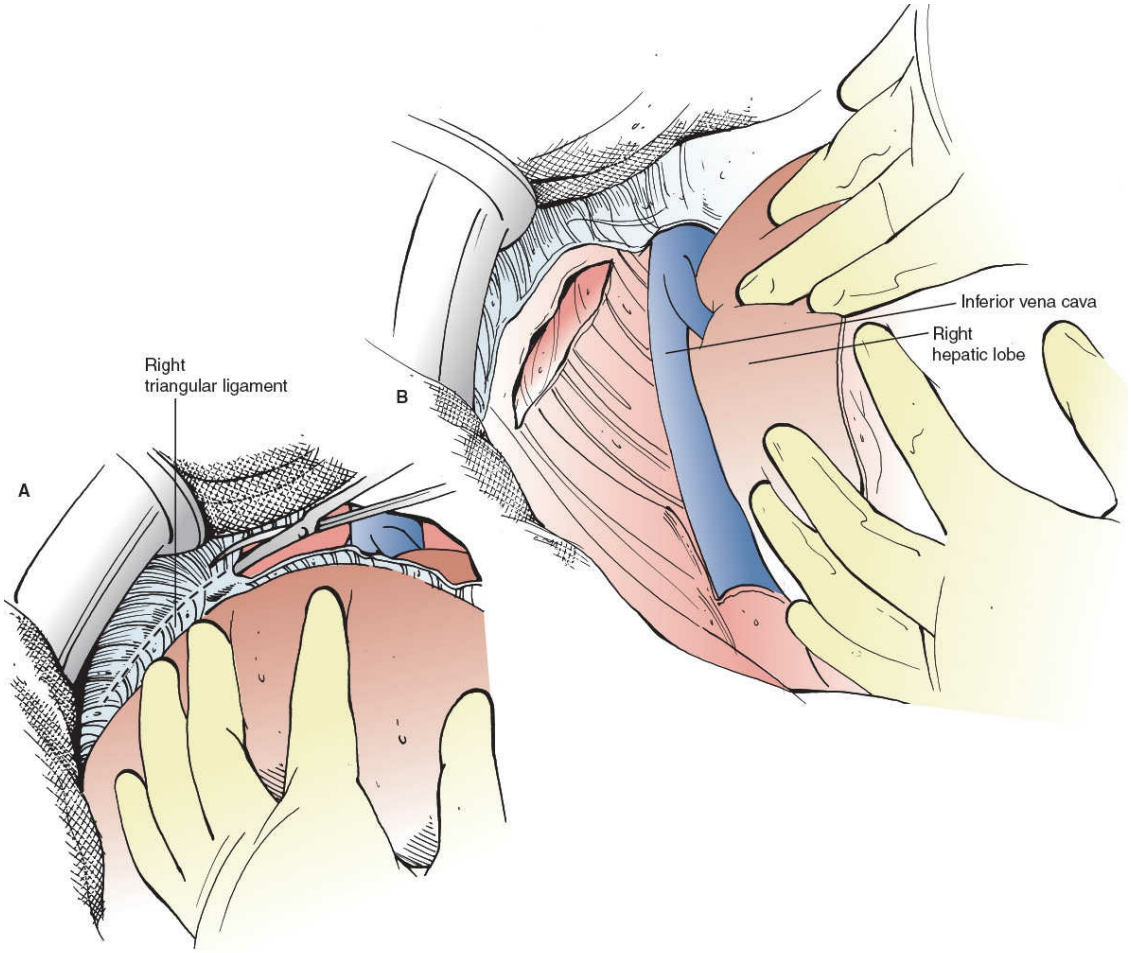

Figure 66.4. To expose the right hemidiaphragm, the right triangular and coronary ligaments are divided and the liver mobilized inferiorly and medially.

In acute trauma to the diaphragm (whether blunt or penetrating) where a lung injury cannot be ruled out, a chest tube should be placed. It may be efficacious to lavage the pleural cavity with saline if there is a concomitant full-thickness bowel injury to reduce the incidence of an empyema. When there is a large diaphragmatic defect, the ipsilateral lower lung lobe may be inspected for injury.

Repair of the injured diaphragm involves debridement of devitalized edges. This is especially important for firearm injuries, where inadequate debridement may play a role in the breakdown of the repair. Hemostasis is assured with bovie electrocautery or suture ligatures. The great majority of acute injuries may be managed with a primary repair. The type of repair—interrupted vs. running, one layer vs. two—has not been shown to matter in terms of recurrence. An interrupted suture repair may include a simple, figure of eight, or horizontal mattress technique (Fig. 66.5). Running

repairs (Fig. 66.6) are often performed in a simple, locked fashion by grasping the lacerated edges with an Allis or Babcock clamp. Zero or no. 1 nonabsorbable suture material (e.g., polypropylene) is preferred. Most surgeons repair the diaphragm in a single layer aiming for an airtight closure.

Prosthetic mesh patches (Goretex, Composix) and biologics (Strattice, Alloderm [registered LifeCell]) are preferred for large defects or for those where primary repair produces too much tension (Fig. 66.7). Interrupted polypropylene sutures should be used to sew in the patch. In the event of an accompanying bowel injury, a nonabsorbable mesh is contraindicated and instead a biologic acellular tissue matrix such as Alloderm or Strattice may be used. In the rare likelihood that the diaphragm has avulsed from the chest wall, it may be reattached in a primary fashion using polypropylene sutures placed circumferentially around the ribs (Fig. 66.8). Alternatively, bone suture anchors appropriately sized for rib thickness can also be used to secure the avulsed diaphragm to the chest wall.

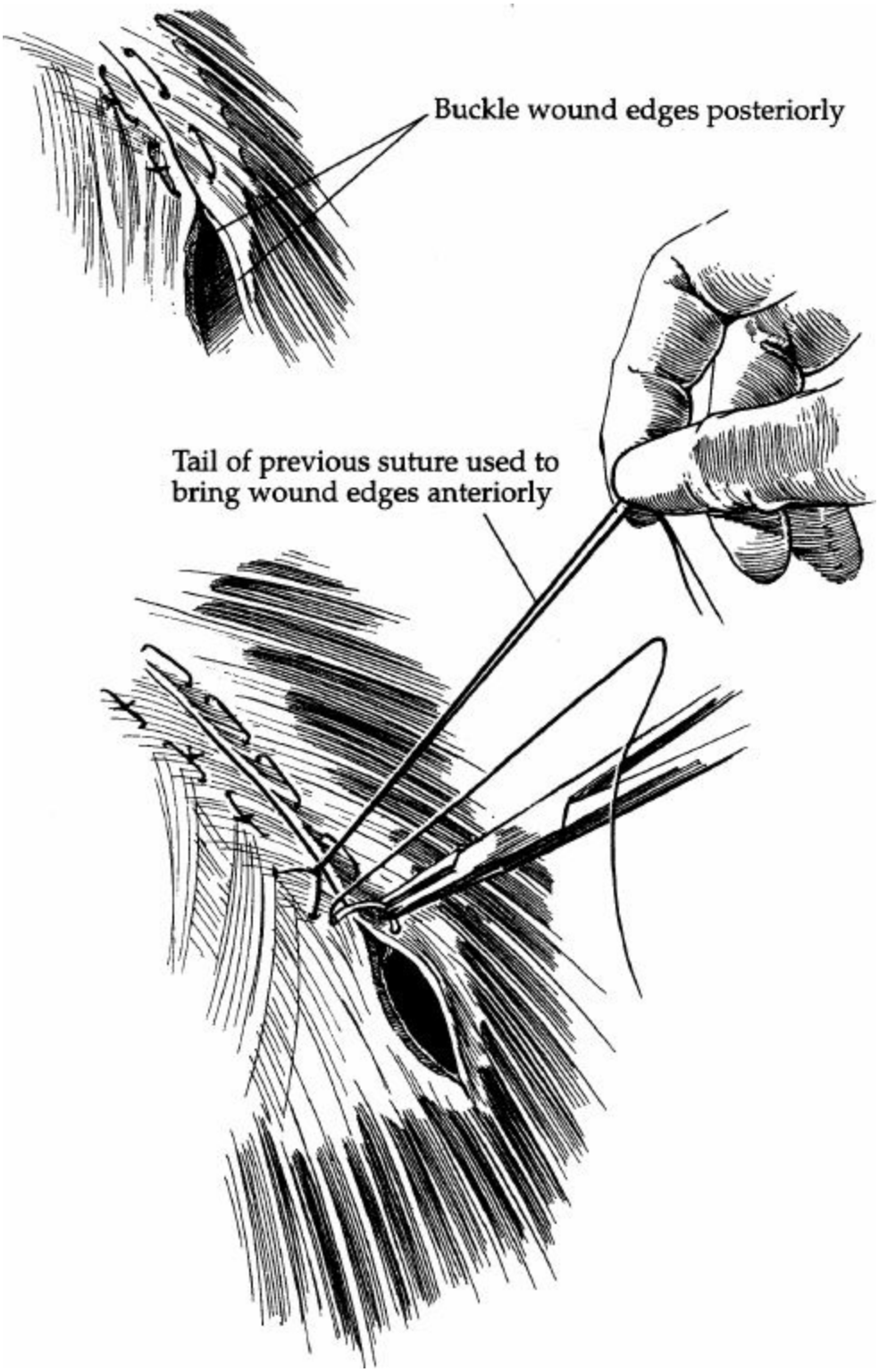

Figure 66.5. Use of the tail of the previously placed suture as a handle to improve exposure for repair of the posterior portion of the defect.

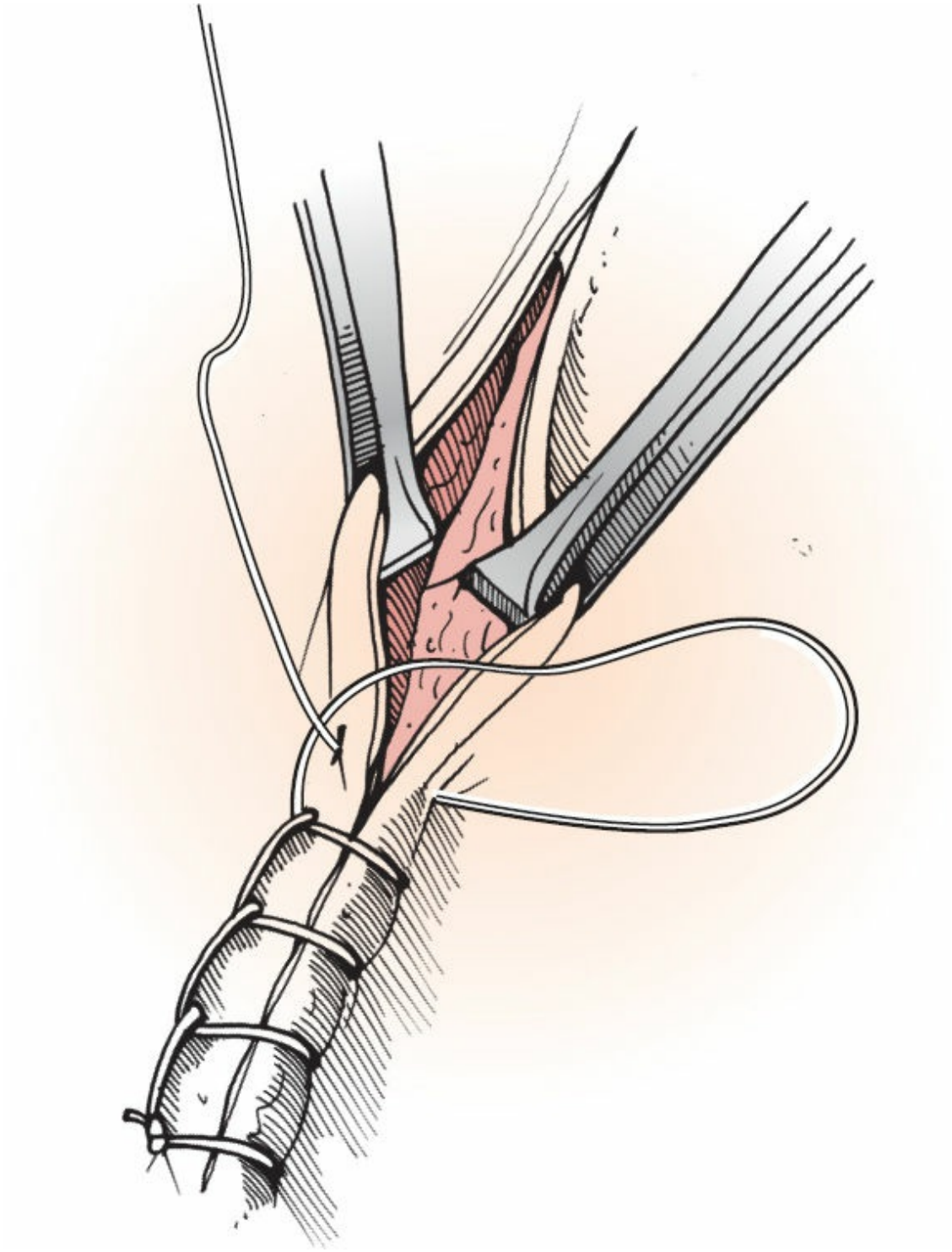

Figure 66.6. Allis clamps may be used to elevate the lacerated edges as a running locked suture is placed. The Allis clamps may be advanced as the edges are brought together.

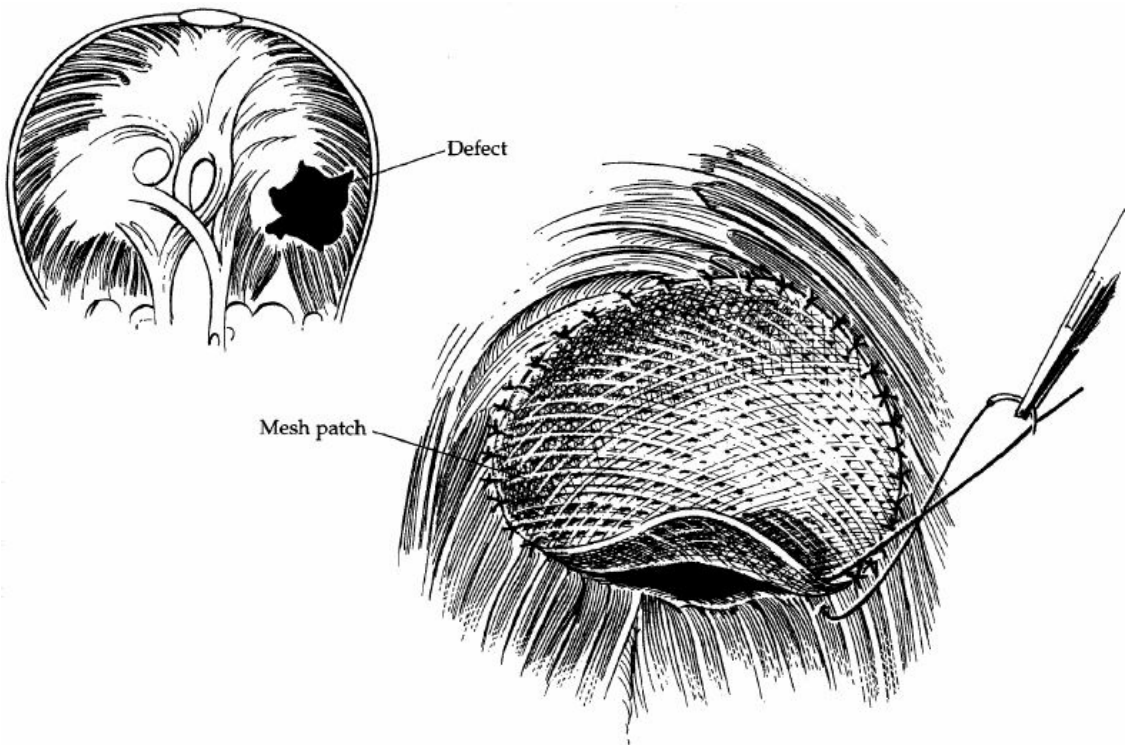

Figure 66.7. Closure of a large defect with polypropylene mesh using interrupted sutures.

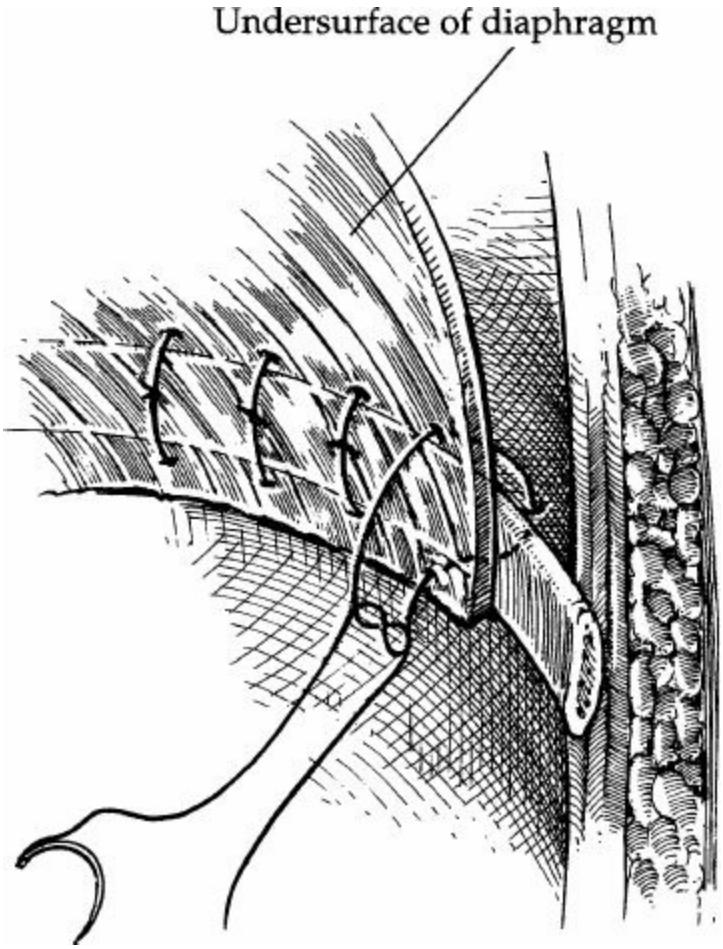

Figure 66.8. Reattachment of diaphragm avulsed from costal origin with interrupted mattress sutures placed around the rib.

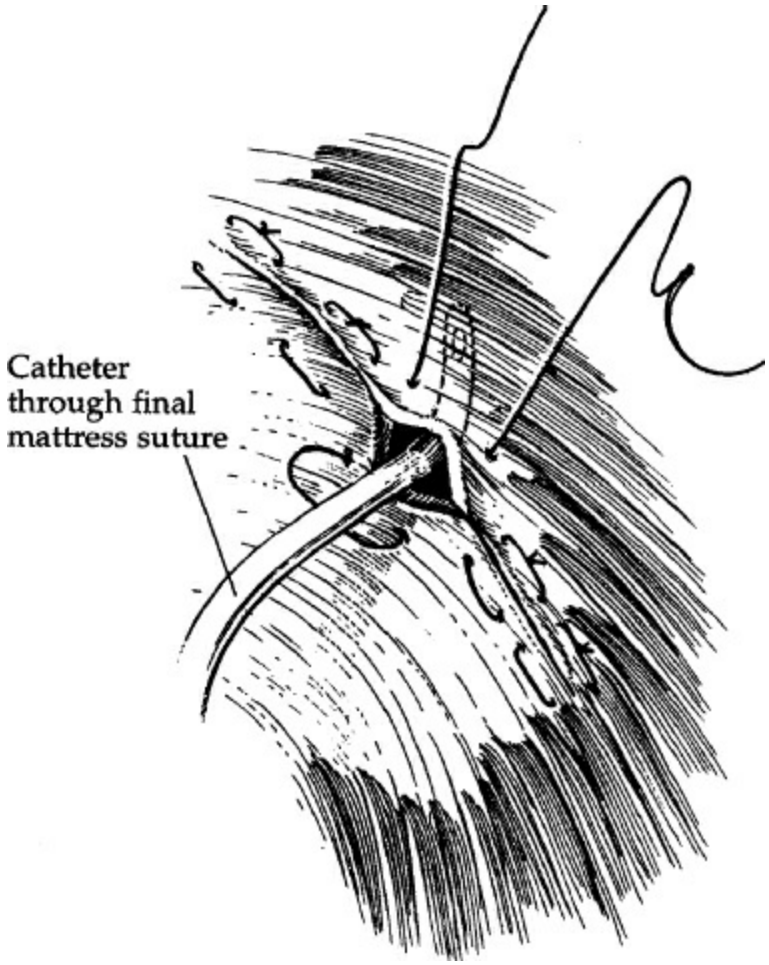

Figure 66.9. Aspiration of residual pneumothorax with a 24-French red rubber catheter. The catheter is extracted as the final suture is tied.

For chronic diaphragmatic herniation, a thoracotomy may provide better visualization for the difficult dissection. The diaphragm repair otherwise follows the same principles as in an acute injury scenario. Practically all of these repairs will require mesh since their long-standing nature has contributed to diaphragmatic scarring, which would make primary reapproximation difficult and create tension. As with any hernia, a tension-free repair is required to minimize recurrence. Following thoracotomy, a chest tube should be employed. If a laparotomy is performed, a red rubber catheter may be used to suction out air from the pleural cavity as the final stitches are tied to negate the need for a thoracostomy tube (Fig. 66.9).

POSTOPERATIVE CARE

Postoperative resuscitation is guided by monitoring vital signs and hourly urine output. Bedside physical examinations and common laboratory tests, including hemoglobin/hematocrit, bicarbonate, pH, base deficit, lactate, and coagulation parameters, can help ensure the adequacy of resuscitation. A postoperative plain radiograph of the chest is relatively routine after any diaphragm repair. The postsurgical management of patients with a diaphragmatic injury is generally influenced more by the accompanying injuries and their related management issues.

COMPLICATIONS AND THEIR MANAGEMENT

The morbidity and mortality of patients with diaphragmatic injuries are directly related to their associated injuries. Patients with diaphragmatic injury from blunt trauma, as opposed to penetrating trauma, have higher mean injury severity scores and an increased mortality rate, primarily as a result of injuries to other organs including the brain and pelvis. In comparison with left-sided injury, right diaphragmatic injury has been shown to be associated with higher rates of death. Overall mortality in patients with diaphragmatic injury approximates one in five.

Complications related to the diaphragm repair include a disruption of the repair, phrenic nerve injury, and peridiaphragmatic infection. Disruption of a repair is more common with large injuries or with those involving avulsion from the chest wall.

Left or right phrenic nerve injuries may be caused by the diaphragmatic rupture at the time of impact or may be iatrogenic as a result of the repair. Peripheral injuries and repairs are much less likely to cause damage to main branches of the phrenic nerves. Diaphragmatic injuries just lateral to the esophageal and caval openings carry a high risk for left and right nerve lesions respectively and must be repaired with the nerve distribution in mind to prevent an iatrogenic injury.

Subdiaphragmatic abscess and empyema are recognized postoperative infections and may be more common with associated hollow visceral injuries. These complications lengthen the duration of intensive care unit and hospital stay and increase morbidity and mortality. Pneumonia is also more common in patients with diaphragmatic rupture.

A missed or incompletely repaired right diaphragm injury when associated with a deep liver injury can lead to a biliopleural fistula. Although papillotomy and biliary stenting are often performed, they are

frequently unsuccessful as negative intrapleural pressures maintain the output of the fistula. These patients often require a thoracotomy for repair of the diaphragm and decortication of the lung.

A missed diaphragm injury with subsequent herniation may lead to severe sequelae. Often in a delayed fashion, these patients may present with symptoms of bowel obstruction, sepsis secondary to strangulation and necrosis, or pulmonary insufficiency. A missed injury may result in septic shock and death.

The repair of a chronic diaphragmatic hernia is more difficult than in the acute setting given the dense intrathoracic adhesions. Since the muscle edges have retracted and fibrosed with time and pressure from the sac contents, these repairs are much more involved, routinely require mesh, and not uncommonly result in complicated hospital courses.

SUMMARY

The diagnosis of traumatic diaphragmatic injury following both penetrating and blunt mechanisms may be difficult. CT with multiplanar reformations represents the screening imaging modality of choice, although diagnostic laparoscopy remains the gold standard for diagnosing an injury. In the hemodynamically stable patient, laparoscopy also allows for peritoneal exploration to assess for associated injuries and for simultaneous therapeutic interventions. Most diaphragm injuries should be repaired, although the aggressiveness with which small injuries, especially on the right, should be sought is controversial. The use of laparoscopy in stable patients is increasing and lowers nontherapeutic laparotomy rates and their associated costs, although laparotomy remains the most common operative approach for repair of diaphragmatic injuries. Acute injuries to the diaphragm should generally be approached through the abdomen, while a thoracic approach offers advantages for chronic injuries with herniation.

Suggested Readings

Berg RJ, Inaba K, Okoye O, et al. The peril of thoracoabdominal firearm trauma: 984 civilian injuries reviewed. *J Trauma Acute Care Surg* 2014;77:684–91.

Friese RS, Coln CE, Gentilello LM. Laparoscopy is sufficient to exclude occult diaphragm injury after penetrating abdominal trauma. *J Trauma* 2005;58:789–92.

Hanna WC, Ferri LE, Fata P, et al. The current status of traumatic diaphragmatic injury: lessons learned from 105 patients over 13 years. *Ann Thorac Surg* 2008;

85:1044–8.

Lewis JD, Starnes SL, Pandalai PK, et al. Traumatic diaphragmatic injury: experience from a level 1 trauma center. *Surgery* 2009;146:578–84.

Lopez PP, Arango J, Gallup TM, et al. Diaphragmatic injuries: what has changed over a 20-year period? *Am Surg* 2010;76:512–6.

O'Malley E, Boyle E, O'Callaghan A, et al. Role of laparoscopy in penetrating abdominal trauma: a systematic review. *World J Surg* 2013;37:113–22.

Powell BS, Magnotti LJ, Schroeppel TJ, et al. Diagnostic laparoscopy for the evaluation of occult diaphragmatic injury following penetrating thoracoabdominal trauma. *Injury* 2008;39:530–4.

Stein DM, York GB, Boswell S, et al. Accuracy of computed tomography (CT) scan in the detection of penetrating diaphragm injury. *J Trauma* 2007;63:538–43.

Ties JS, Peschman JR, Moreno A, et al. Evolution in the management of traumatic diaphragmatic injuries: a multicenter review. *J Trauma Acute Care Surg* 2014;76:1024–8.

Zarour AM, El-Menyar A, Al-Thani H, et al. Presentations and outcomes in patients with traumatic diaphragmatic injury: a 15-year experience. *J Trauma Acute Care Surg* 2013;74:1392–8.

EDITOR'S COMMENT

Dr. Pachter and colleagues present a nice review article on an uncommon but serious complication of both blunt and penetrating trauma of the diaphragm. Traumatic diaphragmatic injury (TDI) is a rarely diagnosed injury in trauma. A recently published study utilizing the American College of Surgeons National Trauma Data Bank examined demographics, diagnoses, mechanism of injury, and outcomes for patients with TDI in 2012. There were a total of 833,309 encounters. A total of 3,873 patients had a TDI (0.46%). Of those, 1,240 (33%) patients had a blunt mechanism and 2,543 (67%) had a penetrating mechanism. Patients with blunt TDI were older (44 ± 19 vs. 31 ± 13 years, $P < 0.001$), had a higher injury severity score (33 ± 14 vs. 24 ± 15, $P < 0.001$), and a higher mortality rate (19.8% vs. 8.8%, $P < 0.001$). Compared with patients with penetrating injuries, those with blunt TDI were more likely to have injuries to the thoracic aorta (2.9% vs. 0.5%, $P < 0.001$), lung (48.7% vs. 28.1%, $P < 0.001$), bladder (5.9% vs. 0.7%, $P < 0.001$), and spleen (44.8% vs. 29.1%, $P < 0.001$). Penetrating TDI was associated with liver and hollow viscus injuries. In another study, a trauma registry from a Primary Adult Resource Center for Trauma was queried for patients admitted with a TDI from January 1995 to December 2009, a 15-year period. Most injuries were penetrating (73%) and left-sided (57%). The overall mortality rate in TDI was 21%.

TDI is more commonly diagnosed on the left. As the authors mention, this is likely related to an increased rate of diagnosis of injuries on the left, and potentially related to a protective effect of the liver on the right side. An interesting study of the natural history of right-sided diaphragm injuries in an animal model suggests that the majority of these injuries heal on their own without herniation. The fact that right-sided injuries may be less aggressively pursued diagnostically given a lower likelihood of untoward sequelae (e.g., hernia) if missed certainly contributes to a diagnostic bias in comparing injury rates. As the authors mention several times in this chapter, a high likelihood of suspicion for diaphragm injuries based on the mechanism of injury is warranted, even despite the fact that these injuries are relatively rare.

Having read this chapter, I am left with a few impressions. First of all, I am impressed that TDI is as rare as it is and by the degree of associated injuries observed, especially for blunt injuries. Second, I am surprised that in this day and age, detecting a traumatic diaphragm injury is so difficult without surgery unless organs wind up in body cavities where they don't belong. The rate of initially missed diagnosis on CT scan ranges from 12% to 63%. A missed diagnosis can later present as intrathoracic visceral herniation and strangulation with a mortality rate of 30% to 60%. While multidetector CT (MDCT) is the most sensitive and specific noninvasive test for TDI (MDCT with variable sensitivity and specificity of 61% to 87% and 72% to 100%, respectively, for the diagnosis of diaphragmatic rupture), it is far from 100% accurate. As CT technology and software advance, it is possible the ability of CT to diagnose these injuries reliably will improve, but for now surgery remains the gold standard.

Finally, I would like to make a comment of repairs that require mesh. The authors discuss the different types of mesh that may be used to reconstruct the diaphragm when a primary repair is not possible secondary to tension associated with muscle loss. Reconstruction of the diaphragm and large defects with mesh is much more commonly performed in elective procedures for repair of congenital defects and repair of large hiatal hernias. When a defect can be repaired primarily, especially in an emergent setting, mesh need not be employed. If a defect cannot be closed primarily and mesh is needed, then by definition the mesh is being used to bridge a defect. The goal in such a repair would be to minimize the risk of recurrence while balancing the risk of mesh infection or severe adhesions to the mesh itself—either on the abdominal side or on the thoracic side of the repair. In settings where there is significant contamination of the abdominal cavity—especially in an unstable patient—a permanent prosthetic is associated with an unacceptable risk of chronic infection and a bioabsorbable prosthetic is the best choice. It is highly likely (if not entirely certain) that in these cases a biologic is used to bridge a defect that the patient will experience a recurrence. Data on the abdominal wall and at the esophageal hiatus of the diaphragm suggest that bridging biologic meshes nearly always fails. For these reasons, in the absence of contamination a

biologic mesh such as Strattice or AlloDerm should never be utilized for reconstruction of a diaphragm defect that cannot be closed but with mesh.

Overall, this is an excellent summary describing the diagnosis and management of a rare but significant injury in both blunt and penetrating trauma. Surgeons who take care of trauma patients should be well-acquainted with the information in this chapter. The chronic traumatic diaphragm injury is a different entity, and requires a slightly different approach. This can be a devastating condition if not recognized, and for this reason all general surgeons should be aware of how these injuries may present in a very delayed manner. General surgeons, trauma surgeons, minimally invasive surgeons, and thoracic surgeons should all be familiar with the different options for reconstruction and repair of these chronic diaphragm injuries.

Jon C. Gould

Suggested Readings

Caiel BA, Scapulatempo N, Souza J, et al. Analysis of natural history of the diaphragmatic injury on the right in mice. *Rev Col Bras Cir* 2015;42(6):386–92.

Candage R, Jones K, Luchette FA, et al. Use of human acellular dermal matrix for hernia repair: friend or foe? *Surgery* 2008;144(4):703–9.

Chen HW, Wong YC, Wang LJ, et al. Computed Tomography in left-sided and right-sided blunt diaphragmatic rupture: experience with 43 patients. *Clin Radiol* 2010;65:206–12.

Fair AK, Gordon NT, Barbosa RR, et al. Traumatic diaphragmatic injury in the American College of Surgeons National Trauma Data Bank: a new examination of a rare diagnosis. *Am J Surg* 2015;209(5):864–8.

Panda A, Kumar A, Gamanagatti S, et al. Traumatic diaphragmatic injury: a review of CT signs and the difference between blunt and penetrating injury. *Diagn Interv Radiol* 2014;20:121–8.

Zarour AM, El-Menyar A, Al-Thani H, et al. Presentations and outcomes in patients with traumatic diaphragmatic injury: a 15-year experience. *J Trauma Acute Care Surg* 2013;74(6):1392–8.

67 Paraesophageal Hernia—Open Repair

W. Scott Melvin and Kyle A. Perry

Paraesophageal hiatal hernia is a relatively rare condition that was first identified on postmortem examination in 1903, and by upper gastrointestinal contrast radiography in 1926. Since that time, the importance of these hernias has been recognized due to their propensity to develop potentially life-threatening complications including gastric volvulus with subsequent strangulation and perforation. Management of paraesophageal hernias (PEHs) has changed considerably during the past 20 years, and several areas of controversy remain as techniques continue to evolve. Although laparoscopic PEH repair has gained increased acceptance, circumstances exist when an open abdominal or thoracic approach is necessary, and surgeons should be familiar with these techniques.

Hiatal hernias occur in approximately 10% of the population, with approximately 10% of these being PEHs. Although congenital PEHs have been reported, the vast majority of these hernias are believed to be acquired. The underlying cause of hiatal enlargement is unknown, but may be related to metabolic defects affecting the extracellular matrix composition with the supporting ligaments of the gastroesophageal junction, increased intra-abdominal pressure, or inherent weakness of the diaphragmatic tissues. PEHs typically present later in life with a two to one female preponderance, and are occasionally seen as a complication of antireflux surgery. There is also a familial occurrence that confers a 20-fold increased risk in younger siblings of children with a hiatal hernia.

Gastric volvulus, first described by Berti in 1896, is defined as the rotation of the stomach greater than 180 degrees around a fixed axis of rotation. Gastric strangulation from acute gastric volvulus is a dreaded complication of PEH and it remains the driving force for recommending elective repair of asymptomatic hernias. Gastric strangulation occurs in up to 28% of cases of acute gastric volvulus, and may progress to gastric necrosis, perforation, and severe sepsis leading to cardiovascular collapse

if it is not diagnosed quickly and aggressively managed. The true incidence of gastric volvulus remains unknown, but it affects males and females equally. Approximately 20% of cases occur in infants and young children, with the remainder occurring in adults older than 50 years of age.

ANATOMY

The esophagus enters the abdomen via the esophageal hiatus of the diaphragm. In most patients the limbs of the right diaphragmatic crus comprise this opening, although varying degrees of contribution from the left crus may be present. Although not anatomically correct, most surgical descriptions of hiatal dissection, including those presented here, refer to these limbs as the right and left diaphragmatic crura. The phrenoesophageal membrane anchors the intra-abdominal esophagus to the diaphragm and tethers the squamocolumnar junction within or just below the diaphragmatic hiatus, preventing displacement of the stomach above the diaphragm. Derangements of this normal esophagogastric anatomy produce herniation of the stomach thorough the esophageal hiatus into the thoracic cavity. Hiatal hernias are classified as types I to IV, with types II to IV representing forms of PEH (Fig. 67.1).

Ninety percent of hiatal hernias are type I (Fig. 67.1A), or sliding, hiatal hernias in which the gastric cardia herniates upward with proximal migration of the lower esophageal sphincter (LES) into the thorax. This produces attenuation of the phrenoesophageal membrane, but it remains intact. The term sliding hiatal hernia applies here because the gastric wall comprises a portion of the hernia sac, analogous to retroperitoneal structures in sliding groin hernias.

Type II, III, and IV hiatal hernias represent forms of paraesophageal herniation. True paraesophageal (type II) hernias are uncommon, constituting about 3% of all hiatal hernias (Fig. 67.1B). In this case, the gastroesophageal junction remains fixed in its normal anatomic location and the gastric fundus herniates through an enlarged hiatus. “Parahiatal” hernias may occur in a position adjacent to, but distinct from, the anatomically intact esophageal hiatus; however, these have been reported to comprise only 0.2% of cases in large series of hiatal hernia repairs. These hernias typically occur on the left side and contain the fundus of the stomach producing a clinical picture and radiographic findings indistinguishable from type II PEHs. Type III hiatal hernias involve elements of both type I and II hernias and represent the majority of PEHs

presenting for surgical repair (Fig. 67.1C). Most often, enlargement of a type I hernia defect allows cephalad migration of the stomach in response to the transdiaphragmatic pressure gradient. A true hernia sac is present with fundic herniation and proximal migration of the gastroesophageal junction into the thorax. This type of hernia is associated with laxity of the elements that retain normal gastric position, and the natural history is to progress to complete gastric herniation with the appearance of an upside-down intrathoracic stomach on contrast radiography (Fig. 67.2). Large hernia defects that contain other viscera or abdominal organs are referred to as type IV hiatal hernias, but these hernias are best thought of as a subgroup of type III.

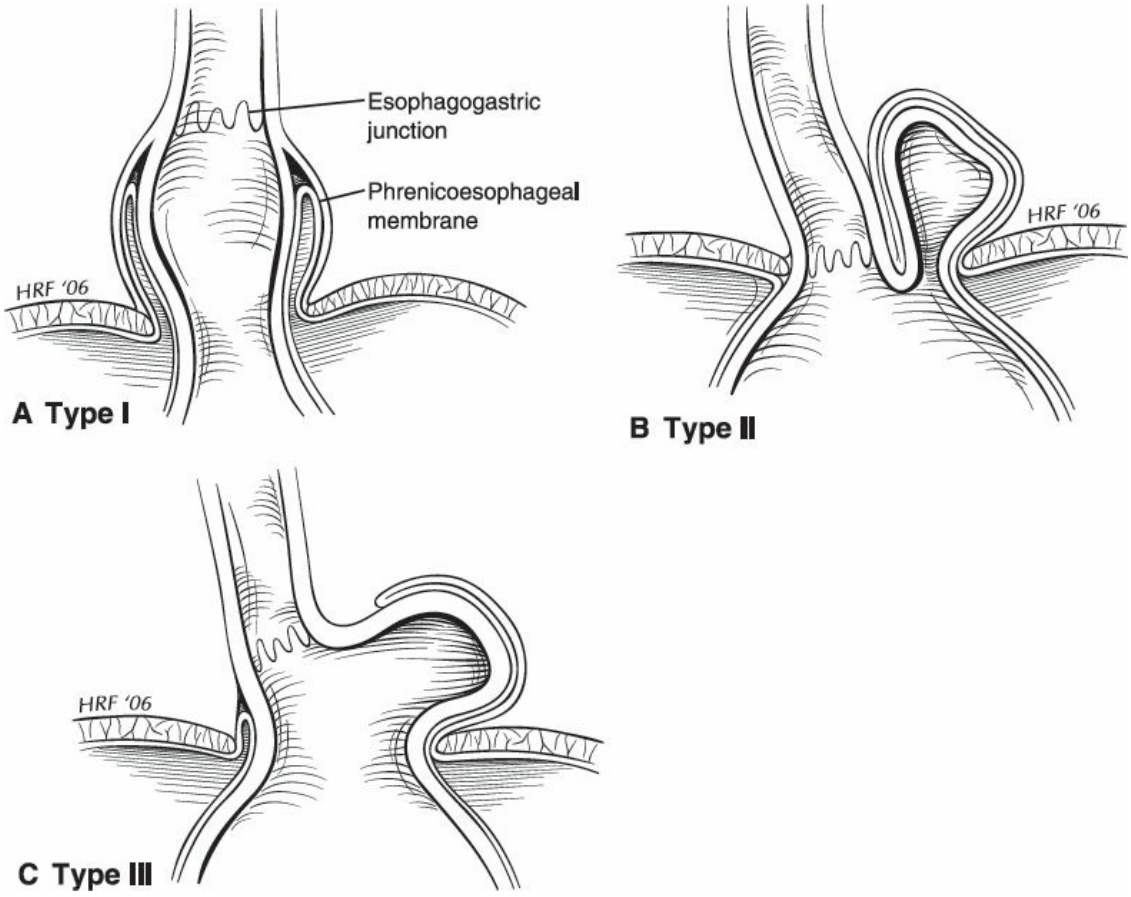

Figure 67.1. Classification of hiatal hernia **A.** Type I, sliding. **B.** Type II, pure paraesophageal. **C.** Type III, mixed hernia.

This classification system can lead to confusion as some hernias may appear to be either a sliding or paraesophageal hiatal hernia depending on patient position. Thus, the term “giant PEH” has been used to describe the large hernias typically classified as type III and IV hiatal hernia. This term refers to hernias in which at least half of the stomach is located within the

thorax on contrast radiography, the hernia measures at least 6 cm in length on preoperative endoscopy, or a distance between the crura of at least 5 cm is noted on intraoperative inspection. Giant hiatal hernias are repaired using the same principles required for all PEHs, but the large hernia sac and propensity for esophageal shortening make these cases especially challenging.

The anatomic classification of gastric volvulus is based on the axis of rotation (Fig. 67.3). Organoaxial volvulus is the most common type, and it accounts for almost all cases of acute gastric volvulus. This involves rotation of the stomach around the anatomic (longitudinal) axis, represented as a line drawn from the cardia to the pylorus, frequently resulting in gastric strangulation. In mesoenteroaxial volvulus, the antrum of the stomach rotates anteriorly and superiorly around a transverse axis that extends from the mid-lesser curvature to the mid-greater curvature. The rotation is typically incomplete and results in intermittent gastric obstruction, rather than acute strangulation.

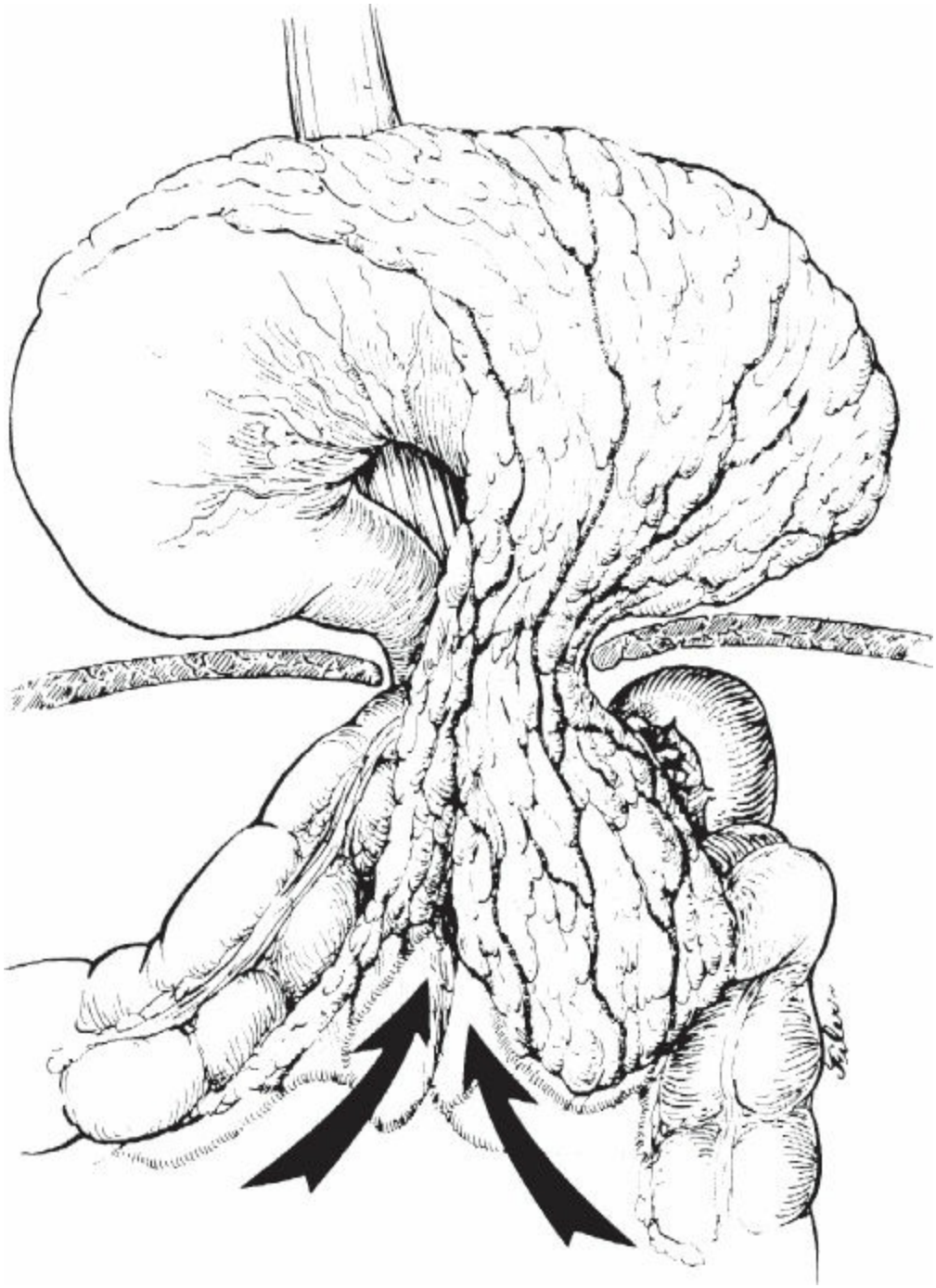

Figure 67.2. Large type III paraesophageal hernia with a large hernia sac and an upside-down intrathoracic stomach.

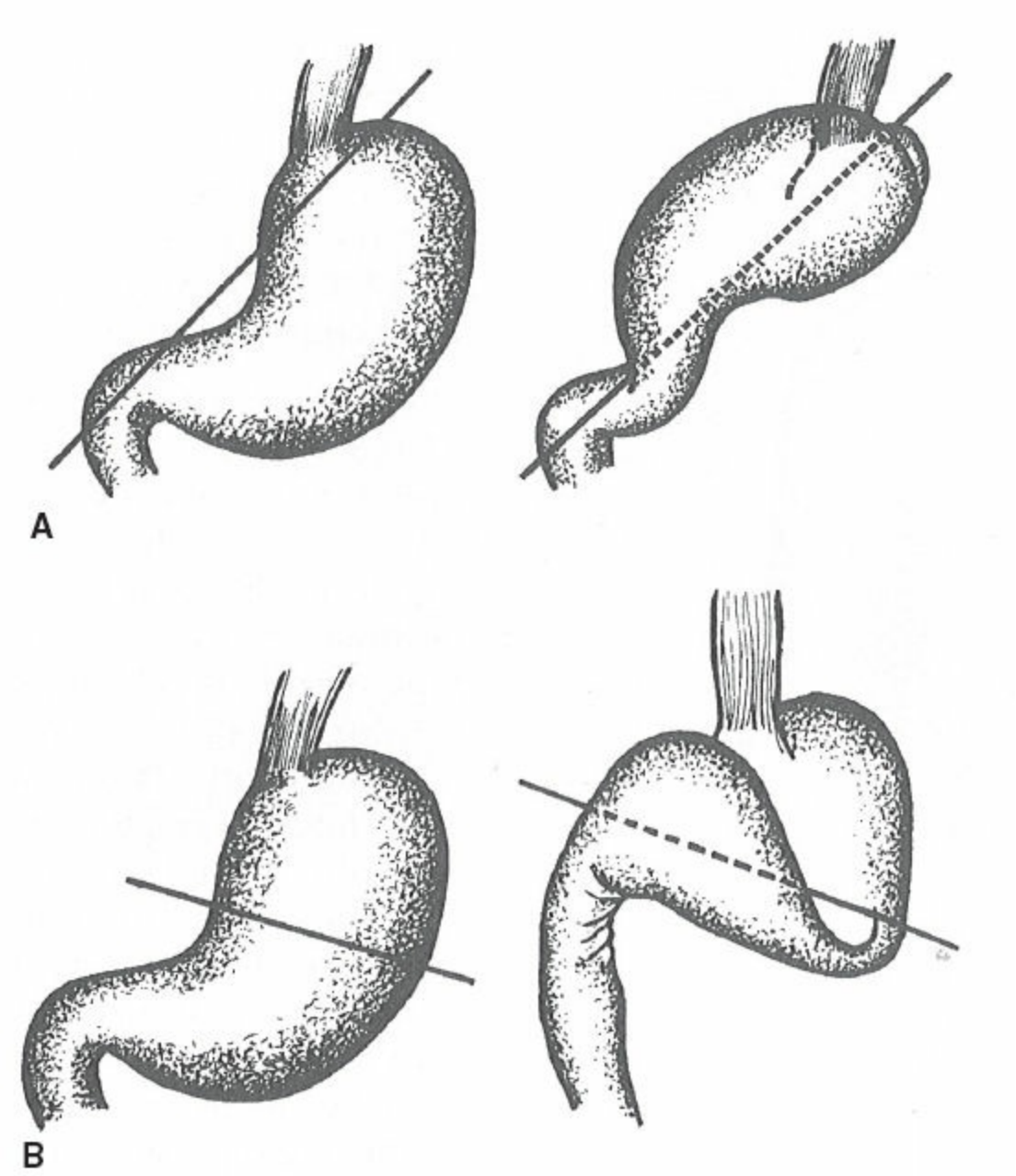

Figure 67.3. Types of gastric volvulus associated with paraesophageal hernia: Organoaxial volvulus (**A**) and Mesentericoaxial volvulus (**B**). *Line* indicates axis of volvulus.

CLINICAL PRESENTATION

Approximately half of all PEHs are clinically silent and become apparent on imaging studies obtained for another reason. Symptoms are caused either by obstruction of the stomach or distal esophagus or by gastroesophageal reflux related to LES incompetence. PEH most commonly present with symptoms of gastric obstruction including epigastric or chest pain, dysphagia, emesis, and postprandial fullness.

Displacement of the LES into the thorax and loss of the angle of His may produce symptoms commonly associated with sliding hiatal hernias such as heartburn, chronic cough, regurgitation, and aspiration. Many of the signs and symptoms of PEH are nonspecific and may mimic those of acute myocardial infarction, gastric ulcer, or pneumonia. One third of patients present with iron deficiency anemia secondary to chronic blood loss from erosions of the gastric mucosa caused by repeated movement across the hiatus, a phenomenon originally described by Collis in 1957, or from an ulcer at the level of the diaphragm described by Cameron.

Acute gastric volvulus typically presents with a history of dysphagia and high gastric obstruction. In 1904, Borchardt described the classic symptom triad of severe epigastric pain, retching and inability to vomit, and inability to pass a nasogastric tube (NGT). Patients may also present with severe chest pain and minimal abdominal findings as the incarcerated segment is often located within the chest. Many patients present with intermittent acute symptoms, and a history of multiple emergency room visits for cardiac events is common. In patients with mesenteroaxial gastric volvulus, diaphragmatic defects are not as common, and ligamentous laxity, aerophagia, or postsurgical changes predominate.

DIAGNOSIS

In the acute setting of foregut obstruction, chest x-ray typically demonstrates a retrocardiac air–fluid level and often a second one below the diaphragm. Pleural effusion, pneumothorax, and pneumoperitoneum are ominous findings that mandate exploration as they are often associated with ischemia and perforation. A barium study will reveal obstruction at the level of the volvulus and can be used as a confirmatory study in this setting if the diagnosis remains uncertain. In the setting of ischemia, the presentation is one of septic shock, with epigastric pain and resultant multiorgan system dysfunction. It should be emphasized that the catastrophic presentations of PEH are quite uncommon.

Several tests may be used to classify the hernia, degree of gastroesophageal reflux, and esophageal motility prior to elective repair. Barium esophagram may suggest the presence of a shortened esophagus and classify the hernia to aid in decision making, especially in frail patients with asymptomatic hernias. In some patients, an upper gastrointestinal series will show complete gastric obstruction due to gastric volvulus, which indicates a need for urgent surgical repair. Upper

endoscopy is required to inspect for gastric ischemia, ulceration, erosion, or cancer. A PEH is identified on retroversion of the scope by noting a separate orifice adjacent to the gastroesophageal junction into which gastric rugal folds ascend. If a gastric ulcer is present, elective surgery should be delayed until after the ulcer is healed, or at least 6 weeks of proton pump inhibitor treatment have been completed. Esophageal manometry can be useful in identifying esophageal motility disorders, which may preclude the use of full fundoplication, but may not be technically possible due to difficulties positioning the catheter beyond the LES. Ambulatory pH testing is rarely useful in evaluation of PEH because the goals of treatment typically involve addressing symptoms related to mechanical obstruction rather than the control of gastroesophageal reflux.

TREATMENT

The repair of PEHs may be approached via thoracotomy, laparotomy, or laparoscopy. The principles of proper surgical repair are the same with each approach:

1. Complete reduction and excision of the hernia sac
2. Reduction of the herniated stomach and 2 to 3 cm of distal esophagus into the abdominal cavity
3. Repair of the diaphragmatic hiatus
4. Fixation of the stomach into the abdomen and/or fundoplication

INDICATIONS

It has been generally accepted that reasonable surgical candidates should undergo repair regardless of symptoms. This recommendation is based on early series that showed an increased mortality after emergency surgery of 30% compared with 1% in elective cases. In 1967, Skinner and Belsey found that 6 of 21 patients with a known diagnosis of PEH died from complications of their hernia when followed conservatively for 5 years.

Other studies have suggested differences in both the natural history of the disease and operative outcomes. Allen et al. followed 23 patients who refused operative repair of PEHs for a median follow-up of 78 months without development of any life-threatening complications. Others have advocated that asymptomatic or minimally symptomatic PEHs may be managed by a strategy of “watchful waiting” with emergency surgery required in only 1.2% of cases with an operative mortality of 5.4% in this

setting. A recent retrospective review of 127 patients undergoing open transabdominal PEH repair in a single institution, however, found emergent surgical repair carried a mortality rate of 22%, compared with 1% for patients undergoing elective repair. In this series, emergent repair was an independent predictor of in-hospital mortality, major complications, readmission to an intensive care unit, and postoperative length of hospital stay.

Our current recommendation is that all type II hernias should be repaired, and consideration should be given to type III hernias regardless of symptoms. However, in the case of an elderly, frail patient with significant comorbidities it may be appropriate to decide on a course of watchful waiting due to increased risks associated with surgical repair in these patients.

Traditionally, transthoracic repair of PEHs has been advocated. Approaching these via thoracotomy provides excellent visualization of the hernia sac from within the mediastinum, allows extensive esophageal mobilization under direct vision, and provides the easiest approach for esophageal lengthening procedures. However, this approach has been associated with longer hospital stay, need for tube thoracostomy, and increased pulmonary complication rates and incisional discomfort. Also, blind reduction of the stomach also leaves the potential for recurrence of organoaxial rotation leading to postoperative intra-abdominal gastric volvulus. Given the high morbidity rates and increased length of hospital stay associated with the transthoracic approach, most PEHs are now repaired using an open or laparoscopic transabdominal approach.

Laparoscopic PEH repair has gained popularity and has been proven feasible, safe, and effective. Laparoscopy provides an attractive option because it combines some of the advantages of both thoracotomy (access to the hiatus, ability to perform extensive mobilization of the esophagus under direct vision) and laparotomy (lower morbidity, no need for single lung ventilation or postoperative chest tube). However, this is a challenging procedure that requires advanced laparoscopic skills and cannot be safely applied in all situations. Current indications for open transabdominal PEH repair include the following:

1. Gastric volvulus with acute peritonitis that cannot be relieved with gastric decompression.
2. Completion of a procedure that has been converted from a laparoscopic approach.

3. Reoperative surgery after a previous laparoscopic or open gastric surgery.
4. Lack of expertise in advanced laparoscopic surgery.

PREOPERATIVE PLANNING

Once the diagnosis of gastric volvulus has been made, intravenous fluid resuscitation should be initiated and an attempt made at gastric decompression with an NGT. If successful, this results in rapid symptom improvement, and allows time for intravenous fluid resuscitation prior to surgical repair. If nasogastric decompression is unsuccessful, the patient must be taken to the operating room immediately for emergent operative repair.

SURGICAL TECHNIQUE

Preparation and Positioning

The patient is placed in the supine position under general anesthesia. A urinary catheter and sequential compression devices are placed, and intravenous antibiotics are administered. Adequate intravenous access is obtained and the arms are carefully padded and tucked at the patient's sides. The surgeon stands to the patient's right with the first assistant on the patient's left.

Incision and Exposure

The abdomen is entered via a midline supraumbilical incision with maximal cephalad extension including dissection of the fascia from the xiphoid process. A table-mounted self-retaining retractor is used to retract the wound edges and costal margin. The triangular ligament of the liver is divided with electrocautery and the left lobe of the liver is retracted to the right with the liver blade of the self-retaining retractor to expose the esophageal hiatus.

Crural Dissection, Reduction of Hernia Sac, and Mobilization of Gastric Fundus

The stomach is gently reduced from the hernia sac and the left diaphragmatic crus is identified. The hernia sac is opened overlying the left crus using electrocautery and the dissection is carried out in the plane between the endothoracic fascia and the hernia sac (Fig. 67.4). After the

anterior phrenoesophageal membrane is divided using electrocautery, the stomach is retracted to the left to expose the right crus. The pars flacida of the lesser omentum is divided and the dissection continues posteriorly along the right crus until the decussation of the crura is visualized. In the case of giant PEHs, care must be taken to identify the left gastric artery and avoid injury to this vessel during dissection. The gastrosplenic omentum is then divided using an ultrasonic dissector, and the short gastric vessels are divided all the way up to the cephalad extent of the stomach as the stomach is completely reduced from the mediastinum. Division of the posterior gastric attachments creates a retroesophageal window through which a Penrose drain is passed around the distal esophagus to facilitate caudad retraction on the esophagus and create exposure for the mediastinal dissection. Dissection proceeds from right to left, and the sac is opened to reveal a plane between the peritoneal sac and the mediastinum. Careful blunt dissection develops this plane, with care taken to identify and preserve the vagal trunks and the scar tissue at the hiatus, which aids in the crural closure. With gentle retraction, the sac can be slowly mobilized out of the mediastinum and reduced into the abdominal cavity. Most individuals excise and remove the hernia sac, but excessive fastidiousness in this exercise risks injury to the vagus nerves as they course in close apposition to the hernia sac in the epiphrenic fat. We usually remove the majority of the sac, including all sac and epiphrenic fat on the left side of the esophagus, well away from the vagal trunks and the end branches of the left gastric artery. In cases of acute gastric volvulus, the viability of the stomach should be assessed at this time, and gastric resection undertaken as necessary. Feeding jejunostomy tube placement should also be considered in these cases.

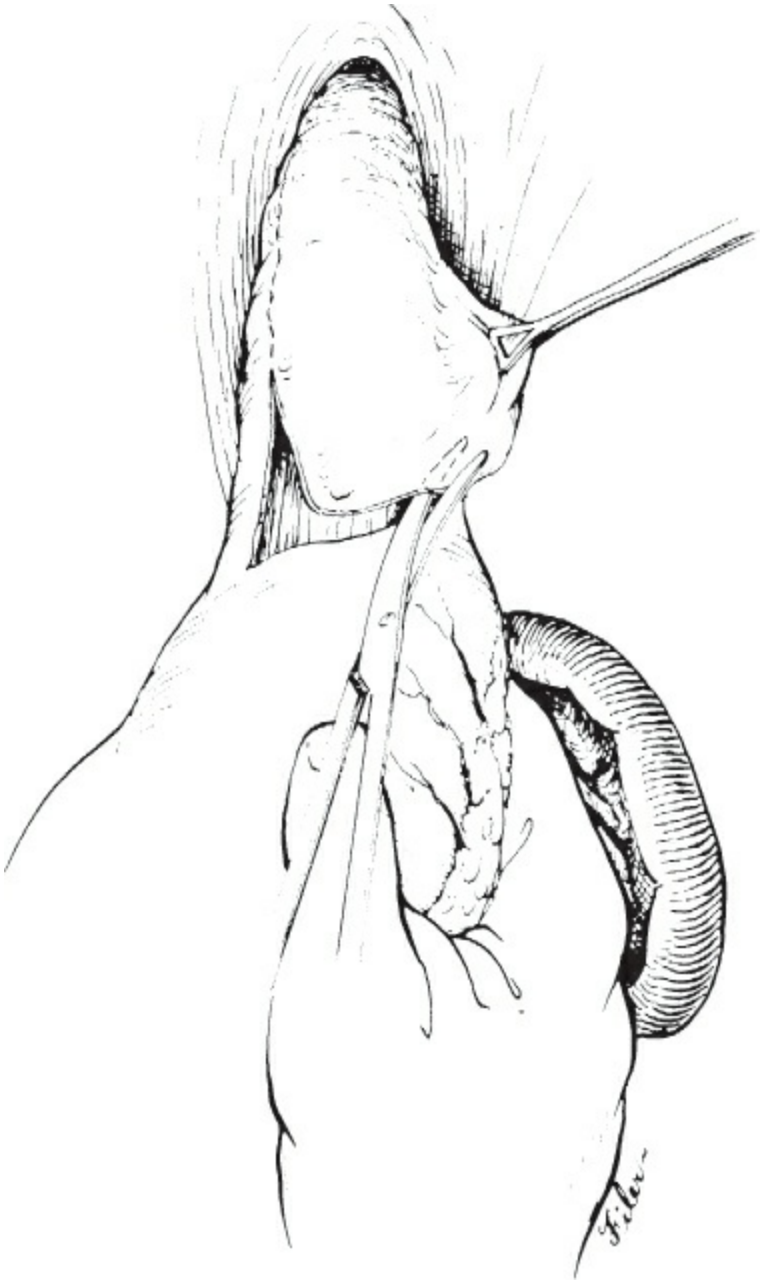

Figure 67.4. Manual reduction of the stomach facilitates identification, dissection, and excision of the anterior hernia sac.

Assessment of Esophageal Length and Esophageal Lengthening

Presbyesophagus has been recognized and studied for several decades, with the Collis gastroplasty described for its treatment in 1957. While some have argued against its existence, most esophageal surgeons today agree that it is a real clinical entity that results from chronic esophageal inflammation in the setting of proximal migration of the gastroesophageal junction. Failure to recognize this condition during PEH repair results in

tension on the hiatal repair, which has been implicated in up to 33% of surgical failures. Although preoperative testing can show the position of the gastroesophageal junction and suggest the presence of shortened esophagus, these tests cannot reliably predict difficulty reducing the stomach to its anatomic position without tension intraoperatively.

When the hernia sac is completely reduced from the mediastinum, it is imperative to have at least 2.5 cm of tension-free intra-abdominal esophageal length. If a shortened esophagus is identified an extensive circumferential mobilization of the intrathoracic esophagus is performed, which usually provides the desired esophageal length. In cases of true shortened esophagus, we perform a wedge gastroplasty over a large bougie. A point is marked 3 cm below the angle of His, and a transverse staple line is created with two or three applications of a linear endo-GIA stapler. When the esophageal dilator is reached, a vertical staple line created along the bougie creates a 3- to 4-cm neoesophagus, and the gastric wedge is removed from the abdomen (Fig. 67.5). Esophageal lengthening procedures should be performed in all cases when adequate tension-free esophageal length cannot be obtained from mediastinal dissection alone.

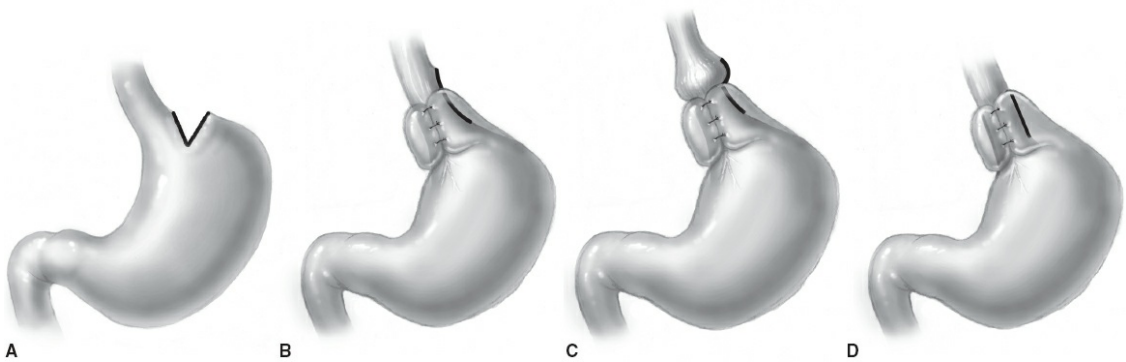

Figure 67.5. Esophageal lengthening via wedge fundectomy. **A.** Appearance of the gastric fundus after creation of transverse and longitudinal staple lines. **B.** Placement of fundoplication too low on the neoesophagus. **C.** Proximal dilation of the neoesophagus creating the appearance of a “slipped” Nissen fundoplication. **D.** Correct position of the fundoplication with complete coverage of the gastric staple lines. (From Van Hove CE, Hunter J, Perry K. Laparoscopic antireflux surgery: esophageal lengthening procedures. In: Soper NJ, Swanström LL, Eubanks WS, eds. Mastery of endoscopic and laparoscopic surgery, 3rd ed. Philadelphia, PA: Lippincott Williams & Wilkins, 2009.)

Repair of the Crura

After complete reduction of the hernia sac and identification of an adequate length of intra-abdominal esophagus, attention is turned to the crural closure. A posterior cruroplasty is performed using an interrupted, braided nonabsorbable suture such as 0-silk (Fig. 67.6). In cases where the crura are attenuated, pledgeted sutures should be used to distribute tension and minimize tearing of the crural fibers. Once complete, the adequacy of crural closure may be tested by the passage of a 56- to 60-French Maloney dilator, which should completely fill the new hiatal aperture. If the diaphragmatic repair appears to be "pinching" the esophagus with dilator in place, a suture is removed. Conversely, if the closure is loose, the dilator is withdrawn into the upper esophagus and another suture is added.

Uncommonly, we find it necessary to use a mesh reinforcement of the crural repair in situations where the crural muscles are quite attenuated or inadequate for repair. The mesh repair is done with an onlay technique posterior to the esophagus and overlying the edges of the crura away from the esophagus. Mesh should rarely if ever be used as a bridge, and instead should be used to reinforce a primary repair of the hiatus under tension. In certain cases, the hiatal opening is extremely dilated, or the muscle too attenuated in order to accomplish a primary crural closure. In these cases, the use of a crural relaxing incision is recommended. A full thickness incision in the right crus of the diaphragm several millimeters medial to the vena cava and from the base of the crus to the anterior crural vein provides several centimeters of medialization of the muscle. The pleura may be opened during creation of the incision, which is rarely an issue with good communication to the anesthesiologist. Relatively little additional medialization is achieved by opening the pleural membrane, so we avoid entering the right chest during this maneuver if possible. A right-sided relaxing incision is usually all that is needed, although left-sided incisions can be added if needed. Once the hiatus is closed with the medialized muscle following a relaxing incision, mesh is used to close the defect in the diaphragm. If a mesh is needed to reinforce a crural repair, options include a biologic mesh or a permanent prosthesis.

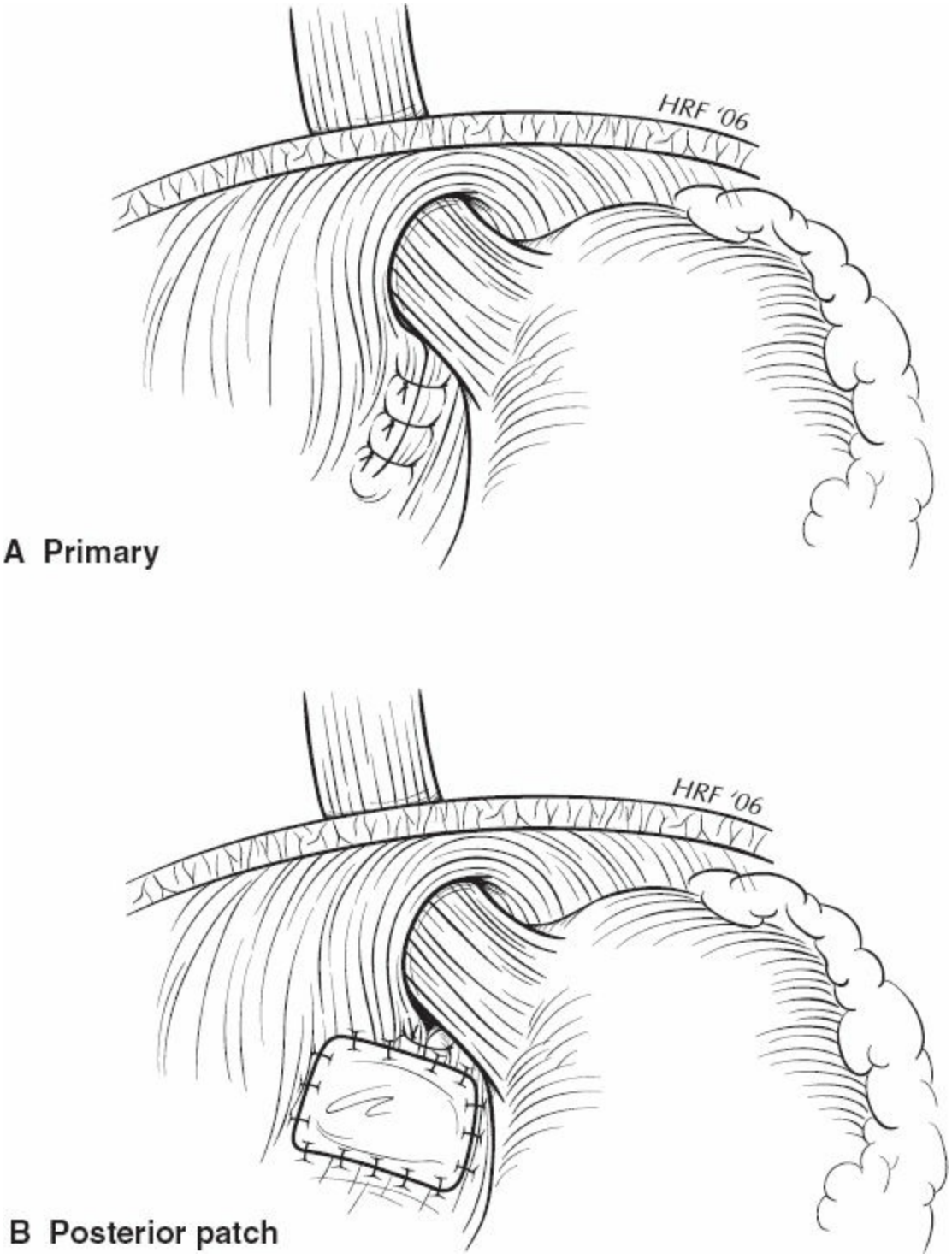

Figure 67.6. Posterior crural closure with and without mesh reinforcement. **A.** Primary. **B.** Posterior patch.

In 2006, a prospective randomized, multicenter trial examined the effect of bioprosthetic mesh on hernia recurrence. This study showed a significant reduction in early recurrences (6-month follow-up) following bioprosthetic mesh repair, without increased dysphagia or impaired quality of life compared with those with primary crural repair. However, 5-year

follow-up was analyzed which demonstrated no significant difference in recurrence rates. This repair appears to have potential, but no direct studies comparing it with synthetic mesh repair have been done, and long-term efficacy and complication rates of each approach need to be determined.

Three prospective studies have shown decreased recurrence rates when prosthetic crural reinforcement is performed compared with primary repair. Two prospective randomized trials have evaluated synthetic mesh reinforcement. One study showed a decreased recurrence rate with polytetrafluoroethylene (PTFE) reinforcement of the crural repair to a median follow-up of 78 months, and another trial showed similar results with Prolene mesh reinforcement of the hiatus. These studies, however, did not carefully assess potential mesh-related complications, and the second series showed an increase in early postoperative dysphagia when mesh was used. Concern also exists about the use of synthetic mesh near the hiatus where movement of the mesh along the esophagus with each respiration can cause complications including mesh erosion, ulceration, stricture, and dysphagia. A decision analysis model of the choice between primary repair and mesh repair of a PEH was constructed in a recent publication. The essential features of the decision were the rate of perioperative complications, PEH recurrence rate, reoperation rate after recurrence, rate of symptomatic recurrence, and type of outcome after reoperation. The literature was reviewed to obtain data for the decision analysis and the average rates used in the baseline analysis. Based on their analysis, the authors of this study concluded that depending on what the decision maker accepts as the recurrence and reoperation rates for PEH repair, either mesh or primary repair may be the treatment of choice; however, the differences between the two are small, and, perhaps, clinically inconsequential.

Fundoplication

After the completion of the crural repair, we routinely perform an antireflux procedure because failure to do so has been associated with a 20% to 40% rate of postoperative reflux and preoperative testing cannot successfully predict postoperative reflux. A Nissen fundoplication is performed unless the patient has a known history of severe esophageal dysmotility, necessitating a partial fundoplication. In this group of patients, a 270-degree posterior (Toupet) fundoplication allows good fixation of the stomach and distal esophagus within the abdomen, and good reflux

control, with a decreased risk of postoperative dysphagia (Fig. 67.7).

A floppy Nissen is performed by passing the fundus of the stomach behind the esophagus (Fig. 67.8). A 56- or 60-French Maloney dilator is advanced into the stomach after the fundus has been successfully passed behind the esophagus in order to reduce the risk of esophageal perforation. When a wedge gastroplasty is performed, the staple line is opposed to the stomach wall, and the most cephalad stitch of the fundoplication is placed on the true esophagus above the neoesophagus, ensuring that no gastric mucosa lies above the fundoplication (Fig. 67.5). The fundoplication is created using three 2-0 silk or braided nylon sutures incorporating the stomach and esophagus with each stitch (Figs. 67.9 and 67.10). An additional suture may be placed from the left posterolateral portion of the wrap to the esophagus.

In select patients, namely, those with severe esophageal dysmotility or gastroparesis, one may consider gastropexy as a preferable means to fix the stomach in its intra-abdominal position. Direct suture fixation of the stomach to the abdominal wall without repair in patients with large hernias was described by Rudolph Nissen. Because of a very high recurrence rate, placement of a gastrostomy tube or full-thickness gastropexy seems more secure in this setting. Percutaneous endoscopic gastrostomy tube placement, usually with several tubes, has been reported with success and may be useful in patients with mesenteroaxial volvulus without a hernia, but should be reserved for use in cases with a hernia in only the most frail of patients.

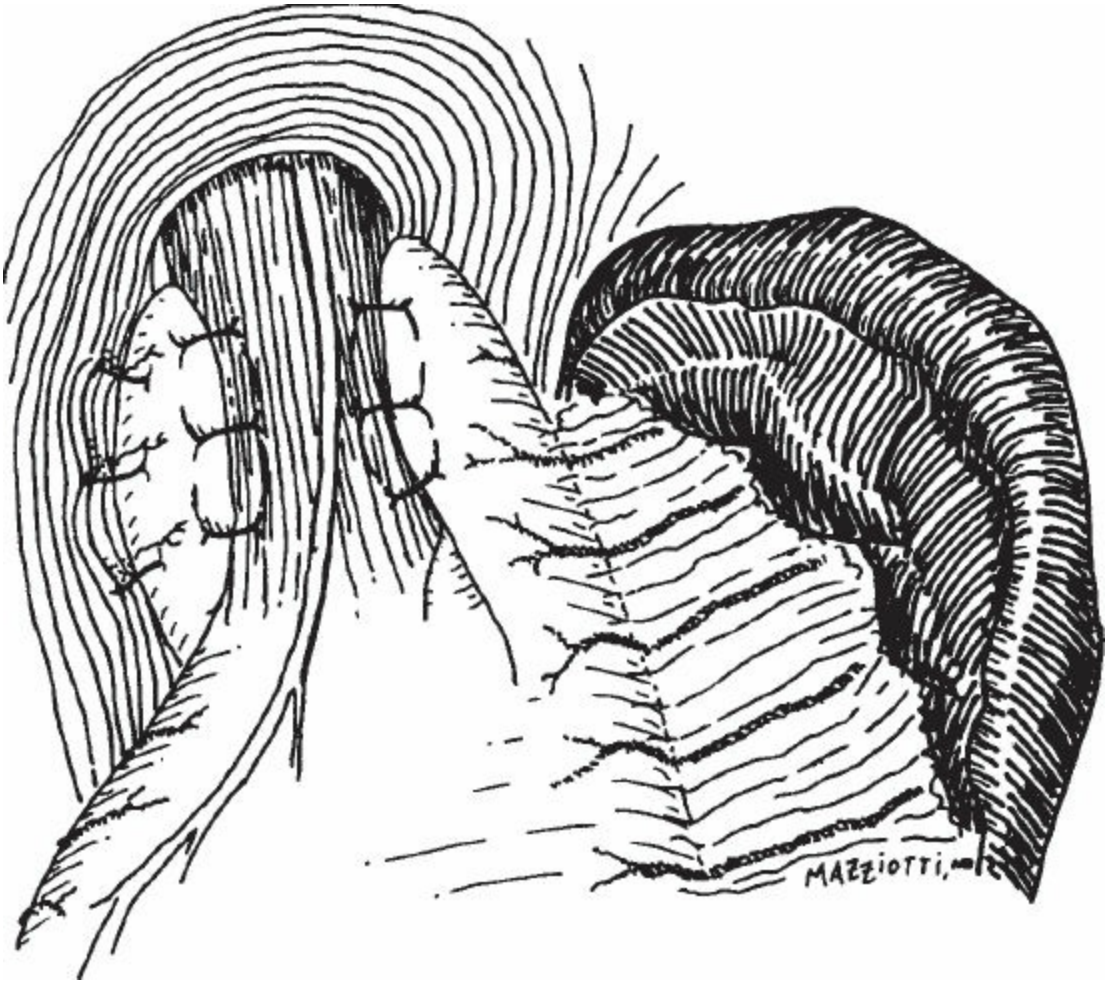

Figure 67.7. Completed Toupet fundoplication.

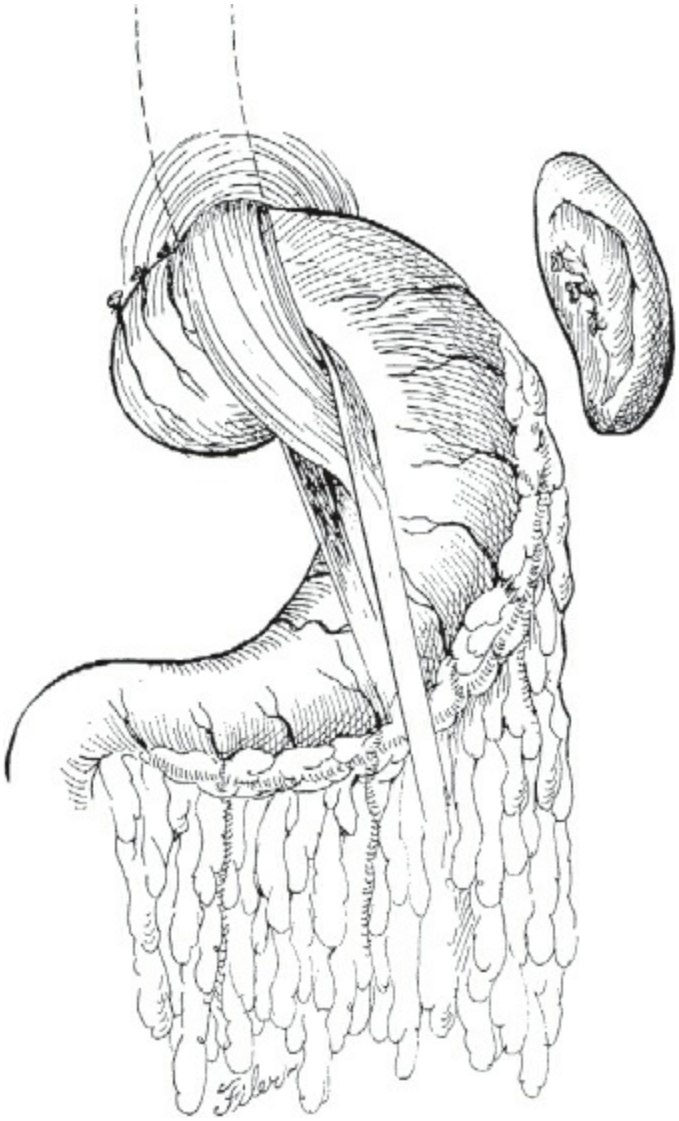

Figure 67.8. The fundus of the stomach is passed through the retroesophageal window and a 56- to 60-Fr bougie is passed into the stomach.

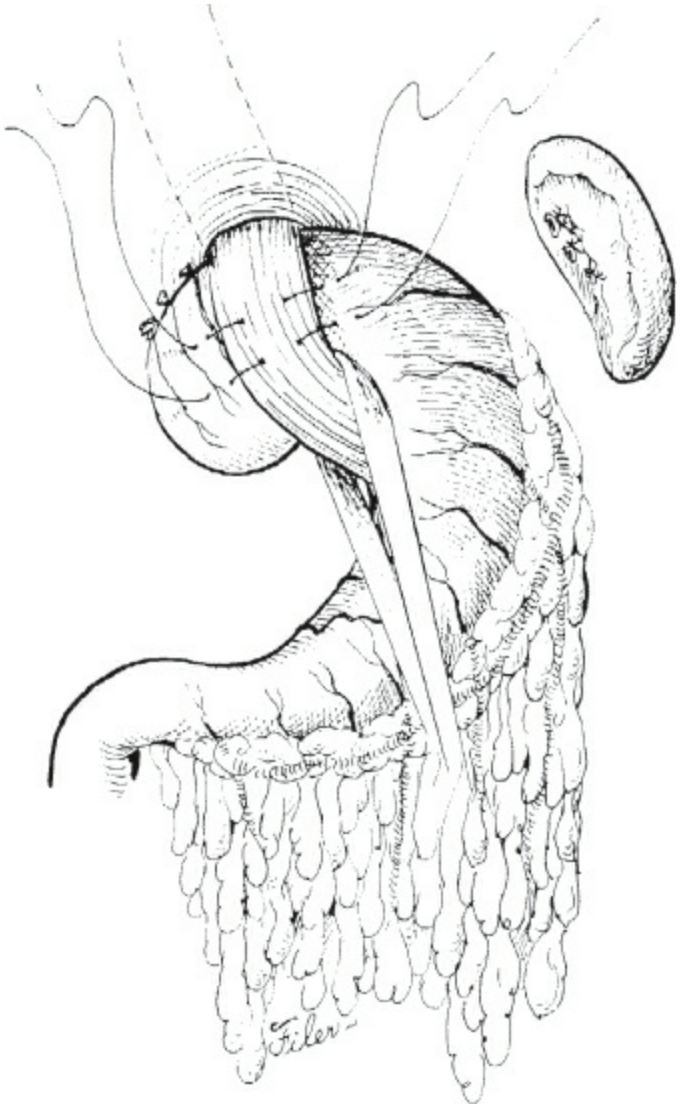

Figure 67.9. Placement of fundoplication sutures with caudal retraction on the gastroesophageal junction.

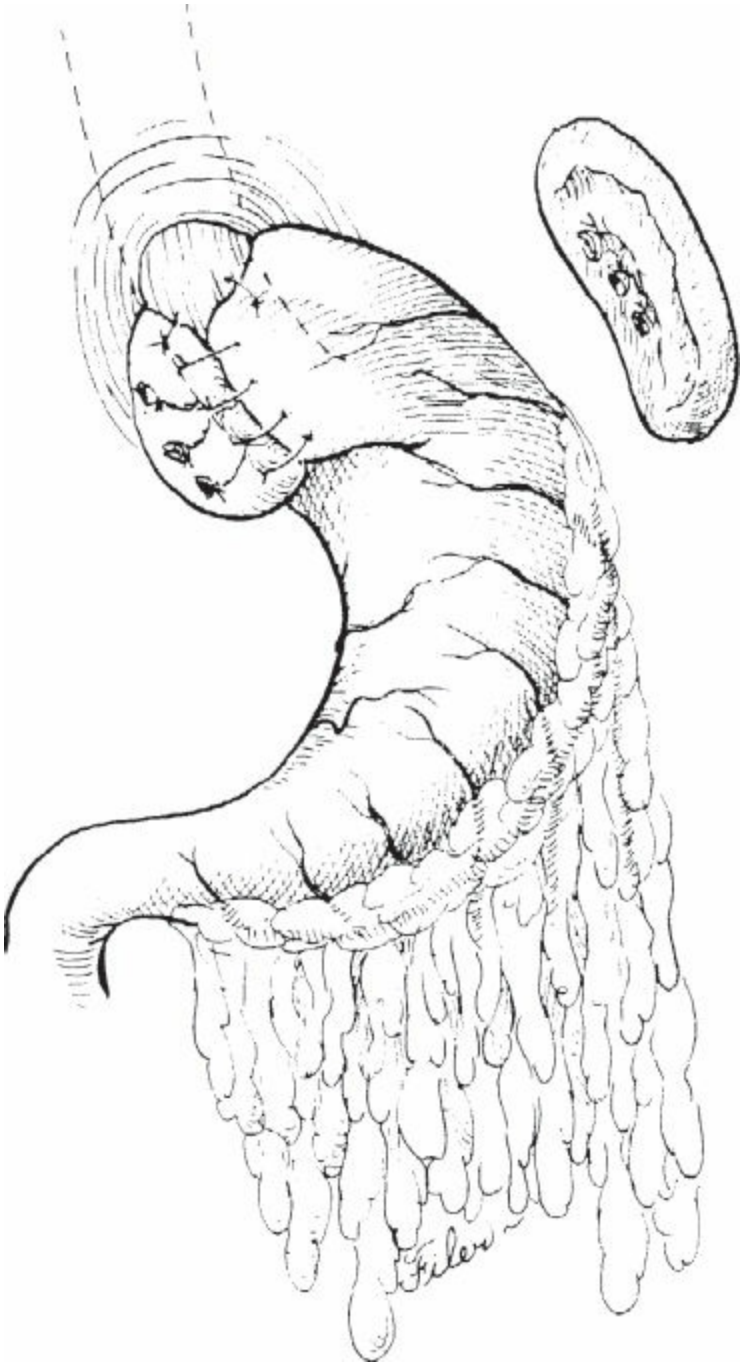

Figure 67.10. Completed floppy Nissen fundoplication.

POSTOPERATIVE MANAGEMENT

Patients are admitted to the hospital, and nausea is aggressively treated with scheduled antiemetics to avoid episodes of retching that can lead to early hernia recurrence or disruption of the fundoplication. An NGT is placed initially and removed after 1 to 2 days. A clear liquid diet is initiated on postoperative day 2, advanced to full liquids on postoperative day 3, and a soft diet on postoperative day 7. The patient is maintained on

a soft food diet for 3 weeks, after which he or she may take a regular diet as tolerated. Patients remain in the hospital until adequate fluid intake and analgesia is obtained, typically 3 to 5 days, and discharged on a full-liquid diet with stool softeners and antiemetic medications as needed.

COMPLICATIONS

Intraoperative complications are rare, but the spleen may be injured during transabdominal fundoplication. Capsular avulsion or small tears causing persistent bleeding occur in approximately 5% of patients, and splenectomy rates of 1% to 3% are reported. Most splenic injuries are minor, and bleeding is easily controlled with tamponade. Another possible complication is injury to the vagus nerves, especially during reoperative cases or in the setting of significant periesophagitis. The sequelae of vagotomy are rarely of long-term clinical relevance, and vagal injury to a single vagal trunk does not necessitate further intervention. Addition of a pyloroplasty should be considered, however, when injury to both vagal trunks is suspected as this may result in gastric atony and severe gastric emptying problems necessitating a late gastric emptying procedure.

The most serious complication, perforation of the esophagus, can cause a great deal of difficulty if it is not recognized. Perforation occurs more frequently in the setting of severe inflammation or revisional surgery. Perforation occurs either during difficult mobilization of the cardia or during the dissection around the back of the esophagus. An unrecognized esophageal perforation is a life-threatening complication, so thorough evaluation of the posterior aspect of the esophagus is mandatory prior to encircling the distal esophagus. If a perforation is identified, it is repaired with interrupted sutures, and the repair is buttressed with the fundoplication. We typically perform an esophagram on postoperative day 1 to ensure that there is no ongoing esophageal leak in this setting.

OUTCOMES

Open transabdominal PEH repair can be performed with low operative mortality of approximately 1% and with lower morbidity than transthoracic PEH repair. A recent population-based study showed a perioperative morbidity rate of 10.6% for open abdominal repair compared with 13.6% for transthoracic repairs. In this report, laparoscopic PEH repair was associated with a perioperative morbidity rate of 7.9%, but concerns remain about the high rate of anatomic hernia recurrence

following laparoscopic PEH repair. In one randomized trial comparing open transabdominal and laparoscopic PEH repair, laparoscopy was associated with a 42% radiographic recurrence rate compared with 15% in the open repair group. These results are comparable with case series reported in the literature; however, most radiographic recurrences in these series are asymptomatic and require no further intervention. Also, in specialized centers, laparoscopic PEH repair has been accomplished with lower rates of radiographic recurrence approaching those associated with open repairs. These results underscore the need for surgeons to assess their own skills and comfort level with these techniques to achieve the best possible outcomes for their patients.

Suggested Readings

Frantzides CT, Madan AK, Carlson MA, et al. A prospective, randomized trial of laparoscopic polytetrafluoroethylene (PTFE) patch repair vs simple cruroplasty for large hiatal hernia. *Arch Surg* 2002;137:649–52.

Hashemi M, Peters JH, DeMeester TR, et al. Laparoscopic repair of large type III hiatal hernia: objective follow-up reveals high recurrence rate. *J Am Coll Surg* 2000;190:553–60.

Kamolz T, Granderath FA, Bammer T, et al. Dysphagia and quality of life after laparoscopic Nissen fundoplication in patients with and without prosthetic reinforcement of the hiatal crura. *Surg Endosc* 2002;16:572–7.

Luketich JD, Nason KS, Christie NA, et al. Outcomes after a decade of laparoscopic giant paraesophageal hernia repair. *J Thorac Cardiovasc Surg* 2010;139:395–404.

Obeid NM, Velanovich V. The choice of primary repair or mesh repair for paraesophageal hernia: a decision analysis based on utility scores. *Ann Surg* 2013;257(4):655–64.

Oelschlager BK, Pellegrini CA, Hunter JG, et al. Biologic prosthesis reduces recurrence after laparoscopic paraesophageal hernia repair: a multicenter, prospective, randomized trial. *Ann Surg* 2006;244:481–90.

Oelschlager BK, Pellegrini CA, Hunter JG, et al. Biologic prosthesis to prevent recurrence after laparoscopic paraesophageal hernia repair: long-term follow-up from a multicenter, prospective, randomized trial. *J Am Coll Surg* 2011;213(4):461–8.

Patel HJ, Tan BB, Yee J, et al. A 25-year experience with open primary transthoracic repair of paraesophageal hiatus hernia. *J Thorac Cardiovasc Surg* 2004;127:843–9.

Stylopoulos N, Gazelle GS, Rattner DW. Paraesophageal hernias: operation or observation? *Ann Surg* 2002;236:492–500.

EDITOR'S COMMENT

In this chapter, Drs. Perry and Melvin have done an excellent job describing the techniques and indications for open PEH repair. While open PEH repair is still performed, the use of this approach has declined dramatically in the past 15 years. A review of the Nationwide Inpatient Sample between 2000 and 2013 revealed that the rate of the laparoscopic approach to PEH repair procedures has increased dramatically from 12.1 per 100 procedures to 91.4 per 100 procedures over this interval. Patients undergoing laparoscopic PEH repair were less likely to experience postoperative infection, bleeding, cardiac failure, renal failure, respiratory failure, shock, and inpatient mortality compared to the open abdominal and thoracic approach. In addition, laparoscopic PEH repair was associated with significantly reduced length of hospital stay and overall cost.

Among the four indications listed in this book chapter for open PEH repair, I definitively agree with one of them: "Open PEH is indicated to complete a procedure that has converted to open from laparoscopic." In the hands of a skilled surgeon with experience in laparoscopic PEH repair, the need to convert to open is an unusual event. These procedures in my opinion actually become more difficult when performed by laparotomy. Visualization high into the mediastinum through an abdominal incision is poor. There is a volume–outcome relationship in these procedures—especially for larger hernias (intrathoracic stomach) and in elderly frail patients. A recently published analysis of the relationship between hospital volume and mortality in laparoscopic diaphragm repair utilized the Nationwide Inpatient Sample for the years 2000–2013. A small but significant inverse relationship between hospital case volume and mortality was observed, with a 10% reduction in adjusted odds of in-hospital mortality for every increase in 10 cases per year. Using 10 cases per year as the volume threshold, low-volume hospitals (≤10 cases/year) had almost a twofold higher mortality compared to high-volume hospitals (0.23 vs. 0.12%, respectively, $p = 0.02$). This likely understates the volume–outcome relationship when taking into account outcomes like long-term recurrence and symptomatic or quality-of-life outcomes, as these are difficult to attain from administrative data. In addition, the size and complexity of a particular PEH and the preoperative indications and urgency (short of emergency surgery) are not easily determined from these datasets. In my opinion, extremely large hernias, hernias where "short esophagus" is a preoperative concern, reoperative procedures, and surgery in frail or medically unfit patients should be referred to laparoscopic surgeons with significant experience and expertise in foregut surgery and in dealing with these kinds of hernias. As discussed in this chapter, esophageal lengthening procedures, diaphragm relaxing incisions, and

gastropexy are tricks that every surgeon performing laparoscopic PEH repair needs to have in his/her toolbox “just in case.” In addition, frail and medically unfit patients are less likely to tolerate a prolonged operative time or a complication.

Emergency repair of an incarcerated or a volvulized PEH is also mentioned as an indication for open PEH repair. On the contrary, when a surgeon with experience in laparoscopic PEH repair is available, the laparoscopic approach to repair remains the preferred approach even in an emergency. We recently reviewed the Nationwide Inpatient Sample to compare the outcomes of emergent versus elective PEH repair. Emergent repair was associated with a higher rate of morbidity (33.4 vs. 16.5%, $p < 0.001$) and mortality (3.2 vs. 0.37%, $p < 0.001$) than elective repair. Emergent repair patients were more likely to be male, were older, and more likely to be minority. Logistic modeling revealed that younger age, elective case status, and a laparoscopic approach were independently associated with a lower probability of complications and mortality.

I have a few comments on the procedure technique and potential pitfalls of surgery. In this chapter the authors describe the use of a Maloney dilator for assessing the adequacy of the crural closure. Most surgeons close the hiatal defect posterior to the esophagus. For very large defects, this technique can result in significant anterior displacement and angulation of the esophagus. When passing the esophageal bougie after posterior crural reapproximation, especially if a member of the anesthesia team is passing the bougie, great care and excellent communication is essential. If any degree of resistance passing the bougie is encountered, the attempt should stop. The heavy bougie may be pushing against the back of the hiatal repair and esophageal perforation is possible. There are several methods for dealing with this issue. If the bougie tip is past the hypopharynx and actually in the esophagus (often not the case when it won’t pass), straightening out the distal esophagus at the hiatus can help it pass. If the esophagus is encircled with a Penrose drain or something similar for retraction, make sure the drain is not angulating the distal esophagus. A smaller bougie can be attempted. Another option is not to use a bougie at all. Some surgeons advocate Nissen fundoplication without an esophageal bougie, although this practice is controversial. An esophageal bougie is rarely used in a Toupet partial fundoplication. I actually favor a Toupet in nearly all of these patients given their median age and the difficulty in attaining adequate and accurate esophageal manometry. Presbyesophagus and nonspecific hypomotility disorders are common in patients who develop symptoms other than gastroesophageal reflux disease (GERD) related to a PEH. A Toupet partial fundoplication works just as well for controlling or preventing GERD following PEH repair. A Toupet is less likely to result in severe bloating or dysphagia that a Nissen fundoplication. It is not clear to me that the rates of recurrent hiatal hernia are any higher in PEH repair with a Nissen versus a Toupet. Dysphagia in a frail and deconditioned patient can be a devastating complication to

overcome, especially if repeat surgery is deemed necessary.

The pendulum has swing with regard to surgical repair of PEHs from repairing all of them whether symptomatic or not, to not repairing a hernia if it is associated with no or minimal symptoms, to something in between in the current era. Patients are living longer and many asymptomatic PEHs identified and not repaired in patients in their seventh or eighth decade of life become symptomatic in these same patients in their ninth or tenth decade. It may make sense to fix these hernias when patients are better able to tolerate the operation. Repair of a PEH in an emergent setting or in an elderly and frail patient is a high-risk intervention associated with substantial potential for morbidity and mortality. Any surgeon who takes general surgery call needs to be familiar with the techniques and concepts outlined in this chapter given the possibility that a patient may present needing urgent surgical repair. This chapter is a very nice account of the natural history, indications for surgery, and surgical techniques needed to properly care for these patients.

Jon C. Gould

Professor Gould has a busy practice of various patients which would be the envy of most of us. At the same time he has developed a heightened sense of what causes disasters and the reflexes as to how to avoid them. His experience is enviable and saves lives.

J.E.F.

Suggested Readings

Andolfi C, Plana A, Furno S, et al. Paraesophageal hernia and reflux prevention: is one fundoplication better than the other? *World J Surg* 2017, May 8. doi: 10.1007/s00268–017–4040–5.

Broeders JA, Mauritz FA, Ahmed Ali U, et al. Systematic review and meta-analysis of laparoscopic Nissen (posterior total) versus Toupet (posterior partial) fundoplication for gastro-oesophageal reflux disease. *Br J Surg* 2010;97:1318–30.

Hassanain J, Seligman JT, Frelich M, et al. A population-based analysis of emergent versus elective paraesophageal hernia repair using the nationwide inpatient sample. *Surg Endosc* 2014;28:3473–78.

Schlottmann F, Strassle PD, Farrell TM, et al. Minimally invasive surgery should be the standard of care for paraesophageal hernia repair. *J Gastrointest Surg* 2017;21(5):778–84.

Whealon MD, Blondet JJ, Gahagan JV, et al. Volume and outcomes relationship in laparoscopic diaphragmatic hernia repair. *Surg Endosc* 2017, doi: 10.1007/s00464–017–5482–4.

68 Gastroesophageal Reflux Disease in Infants and Children

George W. Holcomb III and Brad W. Warner

Gastroesophageal reflux (GER) is a normal physiologic process that involves relaxation of the lower esophageal sphincter (LES) independent of swallowing, and allows gastric contents to pass into the esophagus. GER often occurs several times per day in healthy infants and children, and is not generally accompanied by symptoms. In contrast, gastroesophageal reflux disease (GERD) is globally defined as troublesome symptoms or complications associated with GER. These symptoms can either be esophageal or extraesophageal, and can be further characterized by esophageal mucosal injury.

ETIOLOGY AND PATHOPHYSIOLOGY

Not all infants with GERD require either medical or surgical management. In fact, the majority of these patients do not require therapy. Twenty years ago, Boix-Ochoa showed that there is a maturation process at the LES. In a group of elegant studies in which he evaluated normal infants and children with manometry, he showed that there is a very small length of intra-abdominal esophagus present at birth. However, over the next several months, the length of intra-abdominal esophagus gradually increases. Similarly, he showed that there is a maturation process to the pressure gradient generated by the LES. This maturation of the pressure gradient at the LES corresponds with elongation of the intra-abdominal esophagus. Therefore, infants with marked reflux who do not exhibit any evidence of failure to thrive, apnea/bradycardia, or aspiration can be observed to see if their symptoms resolve in the first 6 to 12 months of life.

Barriers to reflux include an adequate LES length and intra-abdominal location, an adequate LES pressure, lack of inappropriate LES relaxations, an adequate angle of His, normal esophageal motility, and absence of a hiatal hernia. Maturation of the LES leads to the development of a barrier against reflux. Unfortunately, this barrier's function is not always effective

in preventing GERD. In adults, LES pressures greater than 30 mm Hg have been shown to prevent reflux, whereas pressures between 0 and 5 mm Hg have resulted in abnormal pH studies consistent with reflux in 80% of the patients. These adult studies have also found that GERD is more likely to develop when the LES pressure is less than 6 mm Hg at the respiratory inversion point, and the overall LES length is less than 2 cm, of which less than 1 cm is intra-abdominal.

LES relaxation occurs normally with esophageal peristalsis and allows one to swallow without discomfort. Inappropriate LES relaxations have been shown to occur sporadically in nonaffected infants and children. For a number of years, prolonged transient LES relaxations (TLESRs) have been thought to be the primary mechanism for GER in adult patients. Similarly, prolonged or numerous TLESRs have been documented as the likely cause for GER in up to 50% of infants and children.

Although this barrier function at the LES is highly effective, it is imperfect. A short LES length, TLESRs, location of the LES in the chest, or abnormal smooth muscle function can contribute to the failure of the LES, resulting in GER. Moreover, disruption of the LES secondary to a hiatal hernia, abnormal LES function, or previous esophageal surgery can also result in poor function and subsequent reflux.

A second barrier that has been shown to prevent reflux is the intra-abdominal length (IAL) of the lower esophagus. An IAL of greater than 3 cm in adults with normal abdominal pressure has been shown to provide LES competency 100% of the time, whereas an IAL of less than 1 cm results in significant reflux. The importance of the lower esophageal IAL as a barrier to preventing reflux in adults cannot be overemphasized. Whether or not there is a similar minimum IAL in infants and children remains unclear and is discussed later.

Another impediment to reflux is created by the angle of His. Although the precise functional component of the angle of His is not well known, when this angle becomes more obtuse, reflux is more likely to develop. Conversely, accentuation of the angle of His inhibits reflux. In all fundoplication techniques, the angle of His is made more acute. On the other hand, an obtuse angle can develop following the placement of a gastrostomy because the fundus of the stomach is usually relocated more caudad when the body of the stomach is brought up to the anterior abdominal wall.

The final barrier to reflux is often an important factor when considering

operative therapy in adults, but is rarely significant in children. The ability of the esophagus to clear lumenal contents effectively may be diminished with impaired esophageal motility as a result of abnormal smooth muscle function, impaired vagal stimulation, or obstruction from an esophageal stricture. Although an assessment of esophageal motor function is important in adults, it is rarely necessary in children who have no history of a smooth muscle disorder.

CLINICAL PRESENTATION

In infants and young children, symptoms include persistent vomiting (reflux), refusing to eat that leads to failure to thrive and weight loss, choking, gagging/retching, coughing and sometimes aspiration pneumonia, and apnea/bradycardia events (near-SIDS episodes) from laryngospasm. Sandifer syndrome includes facial asymmetry and spasmodic torticollis associated with GER and occurs when the child twists his or her head in an attempt to straighten the esophagus to promote clearance of the acid. In older children, the symptoms are similar to those seen in adults and include persistent heartburn, esophagitis and stricture, and, occasionally, Barrett's esophagus. Hoarseness or a chronic cough may be manifestations of acid-induced laryngeal edema. Many adolescents have been managed medically for several years prior to referral for operative therapy. Neurologic impairment is a significant comorbidity in infants and children. It is difficult to quantify the degree of neurologic impairment with the need for fundoplication. Many neurologic impaired children need a gastrostomy due to swallowing dysfunction. In this situation, a concomitant fundoplication should be considered. This is especially true in neonates and young infants in whom it is not clear if their clinical reflux will resolve spontaneously. In older children with neurologic impairment and no evidence of GERD, a gastrostomy alone is reasonable.

A recent paper looked at the incidence of the need for fundoplication in patients who initially underwent gastrostomy alone. A total of 684 patients from two different centers underwent gastrostomy alone between 2000 and 2008. Of these, 124 of the gastrostomies were performed using the open technique, 282 were performed laparoscopically, and 278 were performed using the percutaneous endoscopic gastrostomy technique. The mean patient age was 2.9 years. Subsequent fundoplication was performed in 62 of these patients (9.1%). Cerebral palsy and anoxic brain injury had the most significant correlation with the need for subsequent fundoplication

and were independent predictors for fundoplication. Interestingly, the laparoscopic gastrostomy approach had a negative correlation with the subsequent need for fundoplication.

Prior to an operation, nonoperative management is usually trialed. In addition to lifestyle changes such as changing the diet and either reducing the volume of feedings or thickening the feedings, positioning infants in a completely upright position, or even placing them prone, has been found to be helpful in some patients. In addition, several medications can also be trialed including antacids, histamine-2 receptor antagonists (H2RAs), and proton-pump inhibitors (PPIs). PPIs have been shown to have superior efficacy compared to H2RAs and antacids. These medications are able to increase the gastric pH greater than 4 for a longer period of time than the H2RAs. Also, the acid suppression ability of PPIs has not been found to diminish with chronic use. Ideally, the PPIs should be administered about 30 minutes after feedings. Prokinetic agents have also been tried, but these medications have been found to have significant side effects and are not used routinely.

INDICATIONS AND CONTRAINDICATIONS

As has been previously mentioned, most infants with GER do not require operative correction. Indications for fundoplication in infants include an apparent life-threatening event (ALTE) episode, weight loss and growth failure, the neurologically impaired infant who requires a gastrostomy, and the infant who develops aspiration pneumonia. In the patients under 6 months of age, in our experience, the two most common indications for fundoplication are the presence of GERD and growth failure, and the neurologically impaired infant who needs a gastrostomy. Another relatively frequent indication is admission to the hospital for an ALTE episode and the presence of GERD. In a report of 81 infants between 2000 and 2005 undergoing laparoscopic fundoplication for ALTE from Children’s Mercy, all but 3 patients had previously been treated with antireflux medication. Moreover, 71 infants (87.7%) were on antireflux medicines at the time of their ALTE. In this study, the median follow-up was 1,738 days. After fundoplication, only three patients (3.7%) experienced another ALTE. Two required a re-do laparoscopic fundoplication for transmigration of the fundoplication wrap, and one underwent pyloromyotomy for pyloric stenosis. None of these three experienced a recurrent ALTE.

For the patients between 2 and 5 years of age, the most common indication is failure to grow appropriately. For those patients older than 5 years of age, the most common reason for operation is failure of medical management. Included in these two older groups are patients with GER and pulmonary symptoms such as refractory airway disease, and recurrent aspiration with a chronic cough. Throughout all these age ranges, however, the neurologically impaired child who requires gastrostomy is often seen. It is the author's opinion that a neurologically impaired child older than 1 or 2 years of age who requires gastrostomy for poor oral intake but does not exhibit symptoms of GER should undergo gastrostomy alone, realizing that a small percentage will subsequently require fundoplication, but the majority will not. The more difficult question is in the neonate or infant in the intensive care unit with neurologic impairment who requires gastrostomy. As alluded to previously, in this particular patient population, fundoplication is usually recommended because of concern about protecting the airway from aspiration due to the reflux.

There really are no contraindications to a fundoplication. However, at some centers, an open fundoplication is preferred to a laparoscopic operation for the baby with significant heart disease and, especially, babies with single ventricle physiology. This is because of the deleterious physiologic effects of a pneumoperitoneum on venous return to the heart and cardiac output. Other centers feel the laparoscopic approach is beneficial in these patients due to a faster recovery from the operation. Also, some surgeons prefer a partial anterior fundoplication (Thal, Boix-Ochoa) to a Nissen fundoplication, especially in infants with esophageal atresia, as these infants have esophageal dysmotility. Other surgeons feel a loose, floppy Nissen can be constructed in these infants.

Finally, in very complicated patients, usually with significant neurologic impairment and three or four failed fundoplications, some surgeons have utilized a technique called esophago-gastric disconnection to control the reflux. The stomach and esophagus are disconnected, and jejunum is anastomosed to the esophagus in a Roux-en-Y fashion. A gastrostomy is placed in the stomach for feeding and decompression.

PREOPERATIVE PLANNING

Prior to referral to a pediatric surgeon, a pH study often has been performed. This study measures acid reflux and has a sensitivity around 90%. Although it has been assumed that the retrograde flow of acid from

the stomach into the esophagus is present in pathologic reflux disease, newer information indicates that alkaline reflux is quite common as well. This information comes from multichannel intraluminal impedance (MMI), which measures the flow of gastric contents into the esophagus by detecting decreases in impedance from high (the esophagus) to low (the stomach) across electrode pairs that are placed throughout the esophagus and stomach. Recent studies using MII suggest that the pH study may not be the best method of evaluating reflux disease as it only measures acid reflux, and many reflux episodes are actually non-acid reflux with a pH above 4. Therefore, MMI is being increasingly used to evaluate reflux disease in infants and children. Other tests that can be used in children include endoscopy with biopsy and bronchoalveolar lavage with evaluation of the lipid-laden macrophage index and the pepsin content.

An upper gastrointestinal (UGI) contrast study is often used to define the anatomy and ensure that there is no evidence of distal obstruction causing the symptoms. In a report from Children's Mercy, malrotation was found unexpectedly in 4% of the patients scheduled for fundoplication. The UGI study should not be used for diagnostic purposes as it has a sensitivity of only 30% to 50%. A gastric emptying study is usually not performed as a routine part of the preoperative evaluation in children. The reason is that fundoplication has been shown in many studies to enhance gastric emptying. Thus, it is difficult to interpret an abnormal gastric emptying study prior to fundoplication. In the author's experience, the gastric emptying study is only used in the rare patient in whom there is a strong suspicion of gastroparesis. However, it is a routine part of the evaluation for either recurrent symptoms or in the patient who needs a second operation. If there is evidence of delayed gastric emptying prior to a second procedure, then pyloroplasty should be considered. Certainly, for a patient undergoing a third operation, pyloroplasty is recommended. As mentioned previously, esophageal motility disorders are rarely seen in pediatric patients. Thus, esophageal manometry is infrequently used prior to fundoplication.

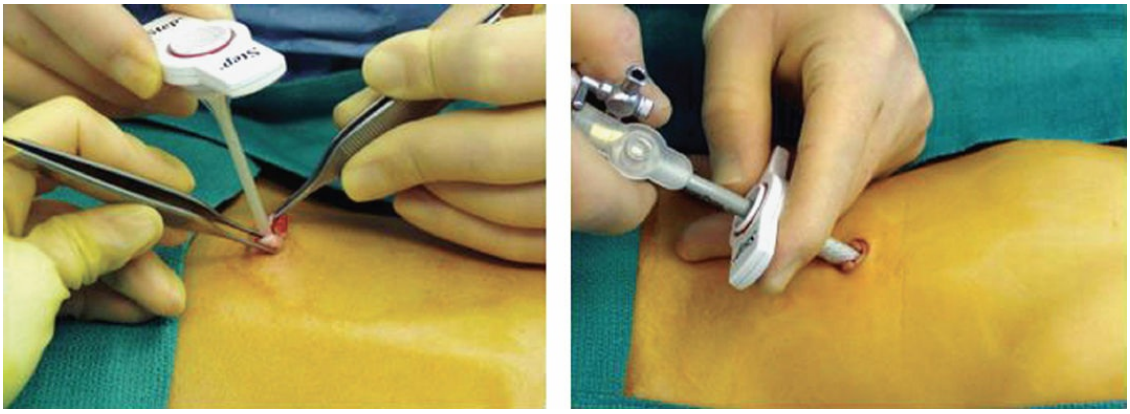

Figure 68.1. A direct cutdown through the center of the umbilical skin and fascia allows the surgeon to introduce an expandable Step sheath (**left**) without using a Veress needle. In this way, injuries from the use of a Veress needle are avoided in infants and small children. Following the introduction of the sheath, a blunt-tipped cannula is introduced through the sheath into the peritoneal cavity (**right**).

A number of operative concerns are peculiar to infants and children. The first concern is safe entry into the abdominal cavity. For this reason, the Veress needle technique is not utilized and the Step system (Covidien, Norwalk, CT) is preferred, especially for infants and young children. When using this system, after incising the center of the umbilical skin and fascia, an expandable sheet without the Veress needle is introduced directly into the peritoneal cavity. A cannula with a blunt tip trocar is then inserted through the sheath (Fig. 68.1).

For many operations, including fundoplication, because of the thin abdominal wall in infants and young children, it is possible to place the working instruments directly through the abdominal wall rather than using accessory cannulas (Fig. 68.2). This is especially advantageous for the instruments that will not be exteriorized and then reintroduced into the abdominal cavity during the operation. In addition to fundoplication, it can also be used for pyloromyotomy, splenectomy, esophagomyotomy, pull-through for Hirschsprung disease, and many other procedures. With this stab incision technique, the number of cannulas needed is reduced, resulting in significant cost savings to the institution and the patient.

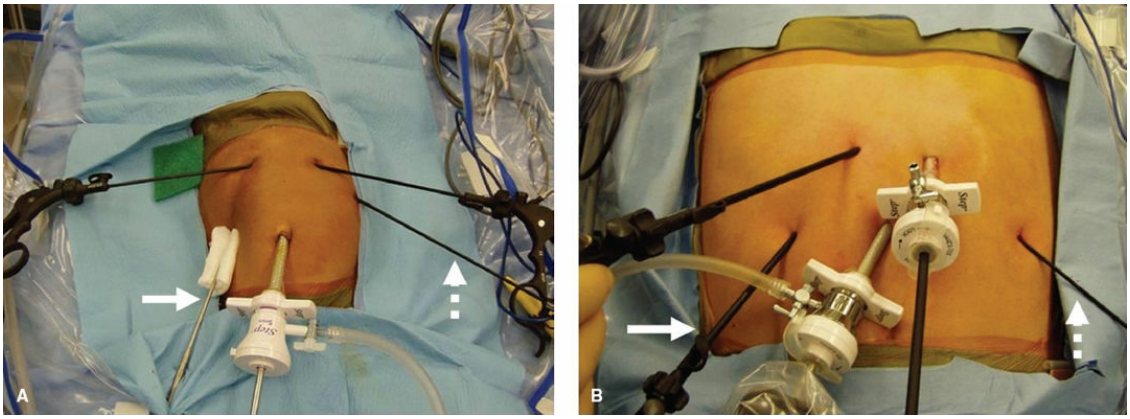

Figure 68.2. There are a number of ways to orient the instruments when performing a laparoscopic fundoplication. With our technique, the 45-degree angled 5-mm telescope is introduced following insertion of the 5-mm umbilical cannula. The liver retractor is introduced in the patient's right subcostal region (*solid arrow*). The two main working ports are in the left and right epigastrium. The main working port for the surgeon is the one in the patient's left epigastric region. It is through this incision that dissecting instruments, needle holder, and suture are introduced. The instrument utilized by the surgical assistant is in the patient's left subcostal region (*dotted arrow*). The stab incision technique can be utilized for both infants (**A**) and adolescents (**B**). (From Holcomb GW III. Laparoscopic Nissen fundoplication. In: Holcomb GW, Georgeson KE, Rothenberg SS, eds. *Atlas of Pediatric Laparoscopy and Thoracoscopy*. Philadelphia, PA: Saunders; 2008, with permission.)

TABLE 68.1 Recommended Bougie Size for Esophageal Calibration According to Patient Weight

2.5–4.0	20–24
4.0–5.5	24–28
5.5–7.0	28–32
7.0–8.5	32–34
8.5–10.0	34–36
10.0–15.0	36–40

Adapted from Ostlie DJ, Miller KA, Holcomb GW III. Effective Nissen fundoplication length and bougie diameter size in young children undergoing laparoscopic Nissen fundoplication. *J Pediatr Surg* 2002;37(12):1664–6. Copyright © 2002, with permission from Elsevier.

An issue peculiar to children is the type of fundoplication that is performed and the use of a bougie to prevent dysphagia when complete fundoplications are performed. Some surgeons prefer the anterior fundoplication in all patients. The use of an anterior fundoplication has already been mentioned in infants with esophageal atresia. In experienced hands, successful repair can be achieved with an anterior fundoplication that is comparable to that achieved with the Nissen wrap. The main advantage of the anterior fundoplication is thought to be the patient's ability to burp or belch and the lack of symptomatic dysphagia. At the same time, in the author's experience, around 50% of the patients can burp/belch with an appropriately performed Nissen fundoplication, and the incidence of dysphagia is less than 1%. An appropriate sized bougie calibrated for the patient's weight can be used to prevent narrowing the lower esophagus with a Nissen fundoplication and helps prevent symptomatic dysphagia (Table 68.1).

SURGICAL TECHNIQUE

Laparoscopic Nissen Fundoplication

The patient is placed supine on the operating table. Infants and young children are placed at the foot of the table in a frog-leg position. The foot of the table is dropped so that the surgeon can stand at the foot of the table adjacent to the patient. The assistant stands to the surgeon's right and the scrub nurse to his or her left. For older patients in whom this technique is not possible, placement in stirrups is preferred, with the surgeon standing

between the patient's legs. A urinary catheter is not routinely introduced, but an orogastric tube is important to decompress the stomach during the operation. If a gastrostomy is also required, the site of the gastrostomy is marked in the left upper abdomen prior to insufflation. This site for the gastrostomy will be used for one of the stab incisions for the laparoscopic fundoplication.

A 5-mm incision is made in the umbilical skin and carried down through the umbilical fascia and peritoneum. Often an umbilical hernia is present in infants, enabling easy access to the peritoneal cavity in these small patients. Using the Step system, an expandable sheath is introduced through the umbilical incision into the peritoneal cavity (see Fig. 68.1). A 5-mm cannula with a blunt trocar is then introduced through the expandable sheath. CO_2 insufflation is initiated at a flow rate between 2 and 5 L/min, depending on the patient's size. A 5-mm, 45-degree angled telescope is inserted and diagnostic laparoscopy is performed. A 70-degree angled telescope is sometimes helpful for improved visualization, especially in small infants.

Four accessory stab incisions are then created (see Fig. 68.2). The first is in the patient's right subcostal region, through which the liver retractor is introduced and secured to the Thompson Rail Clamp (Thompson Surgical Instruments, Traverse City, MI), which is attached to the operating table. The next is in the patient's right epigastric region, through which the instrument used by the surgeon's left hand is inserted. This is usually an atraumatic grasping forceps. In the patient's left epigastrium (at the site of previously marked gastrostomy, if needed), another stab incision is made. A Maryland dissecting instrument connected to cautery is introduced through this site for use by the surgeon's right hand. In the left subcostal region, another stab incision is made through which an atraumatic grasping forceps is placed. This instrument is used by the assistant standing on the left side of the operating table.

The short gastric vessels are ligated and divided with the Maryland dissecting instrument connected to cautery in all patients to create a tension-free fundoplication (Fig. 68.3). The starting point is along the greater curvature of the stomach cephalad to the incisura. In older children, this dissection is performed with the 5-mm ultrasonic scalpel and a second 5-mm cannula is used in the left epigastric region. This dissection along the greater curvature proceeds to the esophageal hiatus. At the level of the esophageal hiatus, the area is carefully inspected. The results of a recently

completed prospective randomized trial have shown that minimal esophageal mobilization and dissection helps prevent the future problem of transmigration of the fundoplication wrap. Therefore, we now perform very little, if any, esophageal mobilization to prevent the postoperative migration of the wrap (Fig. 68.4). Minimal esophageal mobilization has not led to any deleterious effects regarding the efficacy of the wrap in preventing reflux. The retroesophageal space is now identified and entered from the patient's left side, as it is quite easy to visualize this anatomic region with the 45-degree telescope. A retroesophageal window is then created for passage of the fundus behind the esophagus.

An assessment is now made as to whether there is a significant hiatal hernia that needs to be repaired. In many children, there is a small hiatal hernia, which needs closure. Hiatal hernia repair is performed posteriorly with 2-0 silk suture in infants and young children and 0 silk suture in older children (Fig. 68.5). Usually, one suture is sufficient in younger children, but occasionally, two are required to close the crura around the esophagus. This second suture can be placed either anteriorly or posteriorly to the esophagus. However, it is important not to place these sutures too close to the esophagus, especially posteriorly, as they can narrow the esophagus and cause dysphagia. In order to prevent future transmigration of the fundoplication wrap through the esophageal hiatus after the operation and also to secure the lower esophagus in an intra-abdominal position, four 3-0 silk sutures were previously placed between the wall of the esophagus and the crura. These were placed at the 7, 11, 1, and 5 o'clock positions (Fig. 68.6). All sutures were tied intracorporeally. Now, following the results of a recently completed prospective randomized trial (which compared minimal esophageal dissection and mobilization along with the four esophageal crural sutures to minimal dissection/mobilization alone) that showed there was no advantage to these sutures, we no longer place these four esophagocrural sutures. However, we feel it is very important not to mobilize the intra-abdominal esophagus as this dissection disrupts the phrenoesophageal membrane that can lead to an increased incidence of wrap transmigration. The telescope is now rotated to the patient's right side, and the fundus of the stomach (on the patient's left) is visualized through the retroesophageal space. The fundus is then grasped, but is not brought through the retroesophageal space until the bougie has been introduced by the anesthesiologist. In infants and young children, the appropriate sized bougie is determined according to the patient's weight

(see Table 68.1). Care must be taken to watch as the anesthesiologist guides the bougie into the stomach so that perforation of the intra-abdominal esophagus or stomach does not occur. Once the bougie has been advanced into the stomach, the fundus is brought through the retroesophageal space and sewn to itself in a standard Nissen fundoplication fashion. To create the fundoplication, 2-0 silk sutures are used in younger patients and 0 silk sutures are used in older patients. A portion of the anterior esophageal wall is incorporated in the most cephalad suture. The posterior and anterior vagus nerves are both incorporated within the fundoplication wrap (Fig. 68.7). Usually three sutures are adequate, but occasionally four are needed to ensure a fundoplication length of 2 to 2.5 cm. Following creation of the fundoplication, its length is measured and documented. At this point, the bougie is removed.

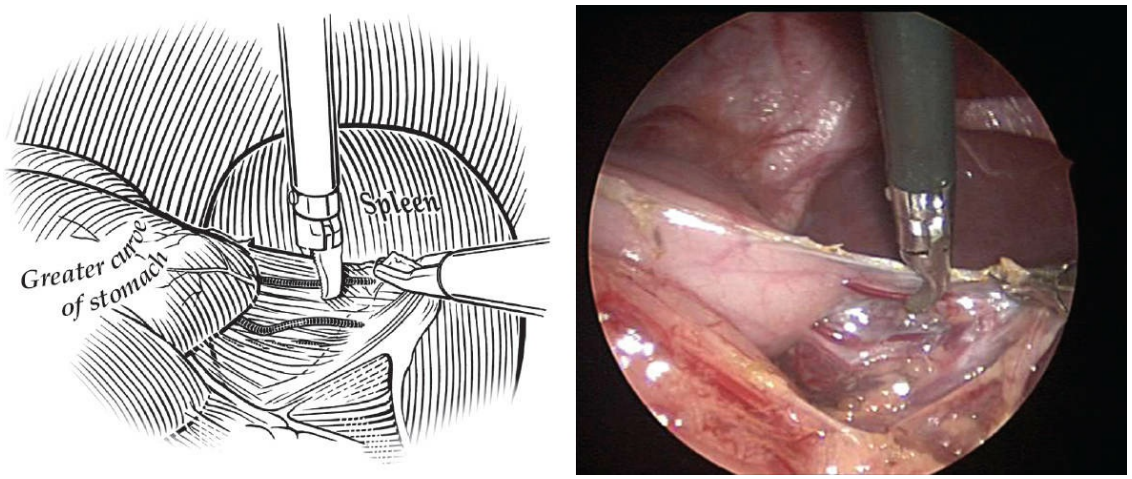

Figure 68.3. The first step in performing a laparoscopic fundoplication in an infant is ligation and division of the short gastric vessels. This is accomplished with cautery connected to a Maryland dissecting instrument. Ligation of these vessels is important in infants in order to create a loose, floppy wrap.

Gastrostomy

If a gastrostomy is also required because of feeding difficulty, the left epigastric incision is enlarged with a hemostat to approximately 5 to 6 mm in diameter. This also allows desufflation of the abdominal cavity so that the stomach can be more easily brought to the anterior abdominal wall. A silicone catheter is placed by the anesthesiologist into the stomach after removal of the bougie, and the stomach is insufflated with 30 to 60 cc of

air. A locking atraumatic grasping forceps is introduced through this left epigastric incision, and a segment of the anterior aspect of the greater curvature of the stomach is grasped and brought to the anterior abdominal wall. Two sutures of 2-0 polydioxanone (PDS, Ethicon Inc., Somerset, NJ) are placed extracorporeally, starting above the epigastric incision, proceeding through the peritoneum and the stomach, and then out through the peritoneum and anterior abdominal wall inferior to the epigastric incision. Each suture is secured with a hemostat. An 18-gauge needle is then introduced through the enlarged epigastric incision into the stomach (Fig. 68.8). Its correct location is confirmed by a rush of air out of the needle. A guidewire is inserted through the needle into the stomach and the needle is removed. A Cook Dilator Set (Cook, Inc., Bloomington, IN) is then used to dilate the tract prior to placing the gastrostomy button. Initially, an 8-French dilator is used to dilate the incision and gastrostomy, followed by 12-, 16-, and then 20-French dilators. Next, the 8-French dilator is introduced through the Mic-Key (Halyard Health, Inc., Alpharetta, GA) gastrostomy button to aid in the placement of the button over the guidewire and into the stomach. Usually, a 12- or 14-French, 0.8-cm button is used in infants, and larger and longer buttons are used in older children. After the gastrostomy button is introduced into the stomach over the guidewire, the balloon is inflated under direct visualization (Fig. 68.9). The dilator and guidewire are then removed from the lumen of the Mic-Key button. Following inflation of the balloon on the button, air is inflated through the button and withdrawn to confirm the button is intragastric. The extracorporeal sutures are then tied over the button to secure the button to the anterior abdominal wall (Fig. 68.10). These sutures are usually cut in 5 days.

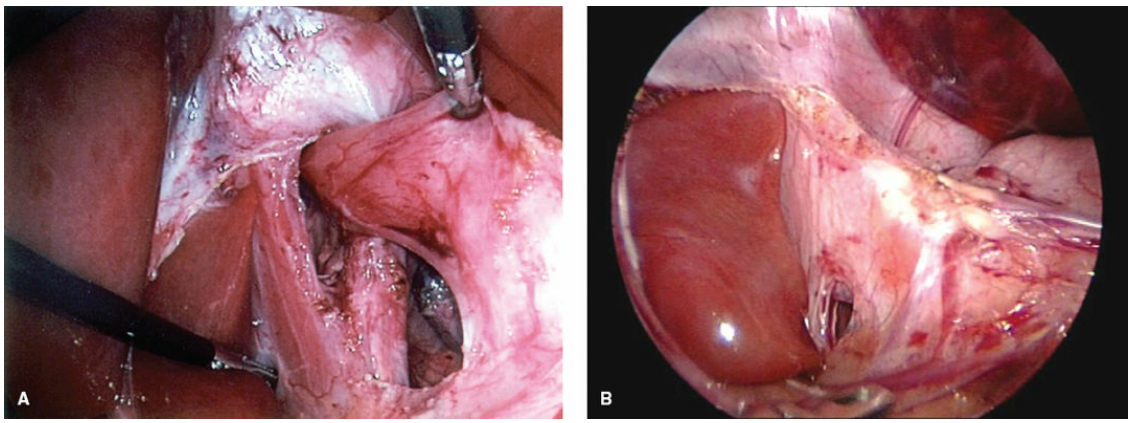

Figure 68.4. There is concern that extensive esophageal dissection and mobilization (**A**) may lead to an increased

incidence of postoperative transmigration of the fundoplication wrap. This concern was initially found in a retrospective review and has been confirmed in a prospective randomized trial. Therefore, our current technique is to perform minimal esophageal dissection and mobilization (**B**) in order to keep the phrenoesophageal membrane intact for the purpose of preventing postoperative wrap transmigration.

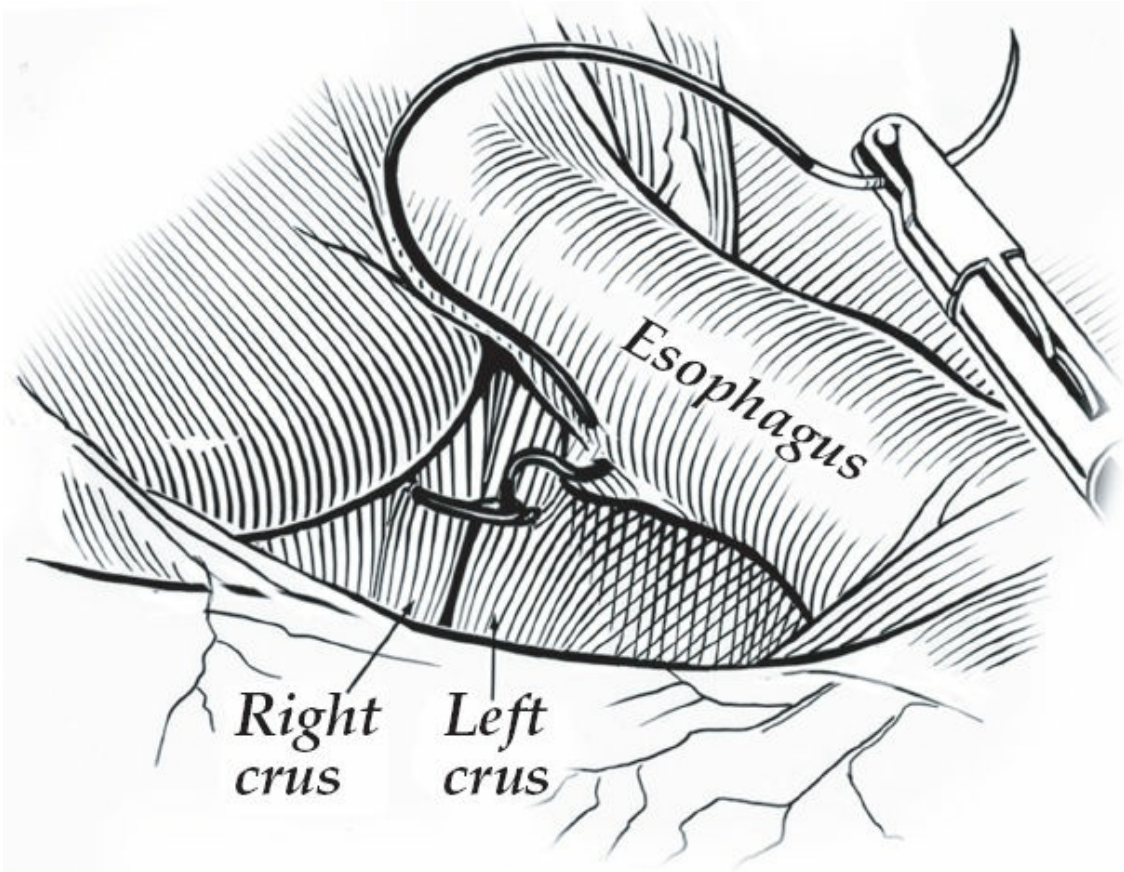

Figure 68.5. Closure of the posterior crura is accomplished with a 2-0 silk suture in infants and 0 silk suture in older children. Also, a portion of the esophagus at ~ 7 o'clock position is often secured with the same stitch in order to help close the hiatal defect posteriorly.

All instruments are then removed and 0.25% bupivacaine is instilled in the incisions for postoperative analgesia. The umbilical fascia is closed with 3-0 absorbable suture in infants and young children, and a larger suture is used in older patients. The umbilical skin is closed with interrupted 5-0 plain catgut sutures in all patients, as these sutures will resorb and will allow drainage if an infection develops. In infants and young children in whom 2.7-mm instruments are used, the skin is

approximated with Steri-strips (3M, St. Paul, MN) as shown in Figure 68.10. If 5-mm instruments were used in older patients, the skin incisions are closed with 5-0 absorbable sutures followed by placement of Steri-strips. A rolled gauze and sterile dressing are placed over the umbilicus. Collodion is used to cover the other incisions.

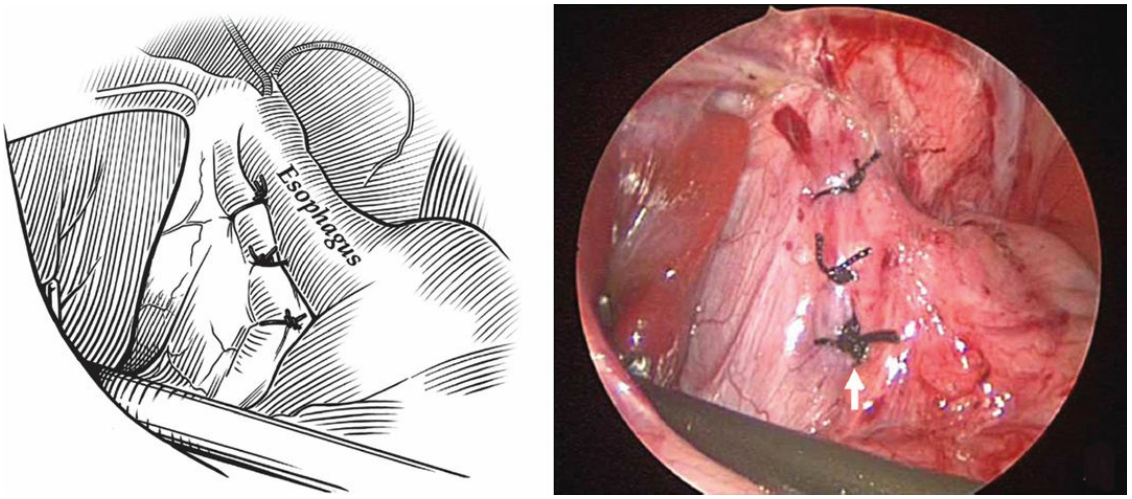

Figure 68.6. The 3-0 silk sutures are used to secure the esophagus to the crura. The photograph depicts these esophagocrural sutures at the 7 and 11 o'clock positions along the right side of the esophagus. Note the suture used to close the crura can also be seen (*arrow*).

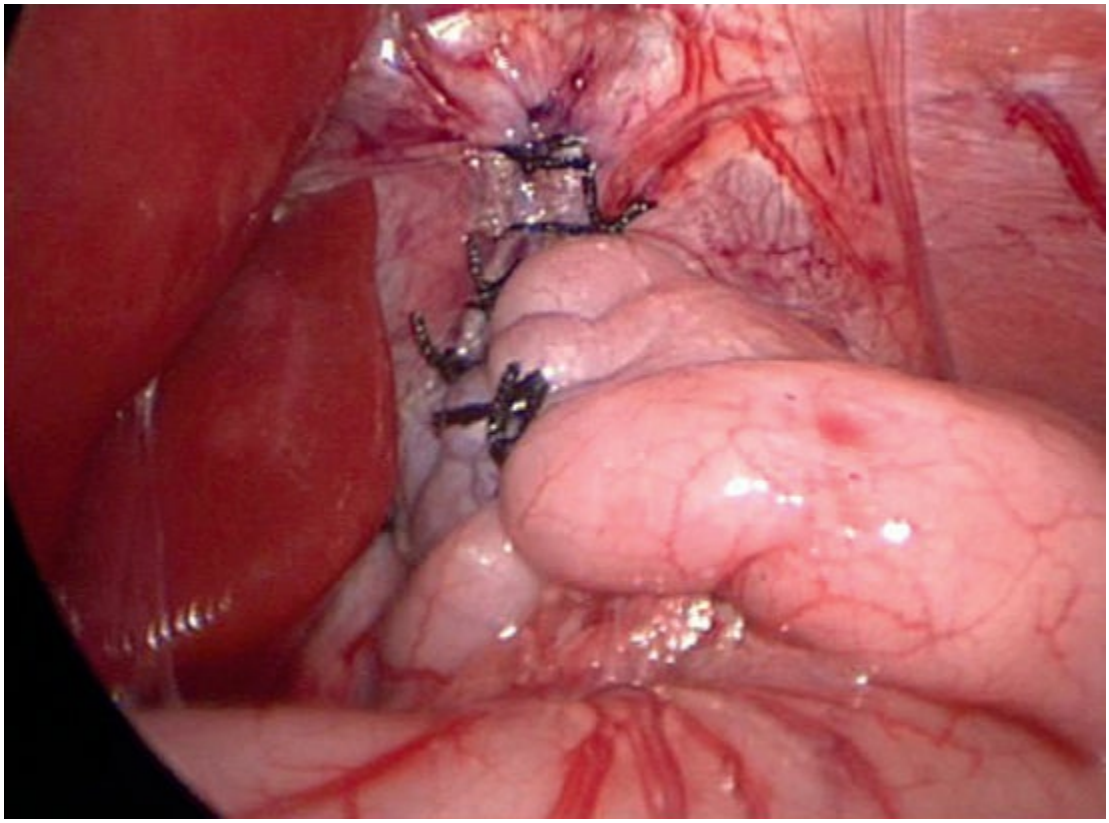

Figure 68.7. Ideally, the suture line for the fundoplication should reside at ~10 or 11 o'clock position as this indicates that the fundoplication is more anteriorly positioned over the esophagus rather than brought through the retroesophageal window posteriorly. The concern with a suture line that is at the 1 or 2 o'clock position is that more of the stomach is brought posteriorly that may cause dysphagia.

Open Fundoplication

The principles of fundoplication performed through the open approach are similar to the laparoscopic operation. Generally, most surgeons prefer an upper midline incision, although some surgeons use a subcostal incision if the child has a broad costal margin. Once the abdominal cavity is entered, the left triangular ligament of the liver is incised that allows the left lobe to be retracted toward the right. A Thompson retractor is helpful for exposure in the open approach. The same operative steps are performed as described for the laparoscopic fundoplication. The short gastrics are divided with cautery or 4-0 silk ties. Minimal dissection of the esophagus is also employed with the open approach as in the laparoscopic operation. The retroesophageal space is opened and sutures are placed in the crura posteriorly if a significant hiatal hernia is present. The bougie is passed

followed by creation of the Nissen fundoplication in a similar manner as described for the laparoscopic operation. The 2-0 and 0 silk sutures are used to create the fundoplication as described previously. The linea alba, subcutaneous tissue, and skin are then closed.

POSTOPERATIVE CARE

Patients are admitted following their operation. If the patient underwent a laparoscopic fundoplication and requires gastrostomy feedings, these are usually initiated 6 to 8 hours following the operation at a low flow and low concentration. The volume and consistency of these feedings can be advanced over a 24-hour period and further advanced when the patient is discharged. If the patient does not require gastrostomy feedings, clear liquids in older patients and formula in infants are initiated the night of the operation. A mechanical soft diet begins the following day in older patients. The mechanical soft diet is usually continued for 3 weeks. In explaining this diet to parents and older children, it is best to describe a soft diet as almost any food but pieces of meat, pizza, or toast. With such a feeding regimen, only one patient among over 900 laparoscopic fundoplications performed by the author has required postoperative dilation for dysphagia.

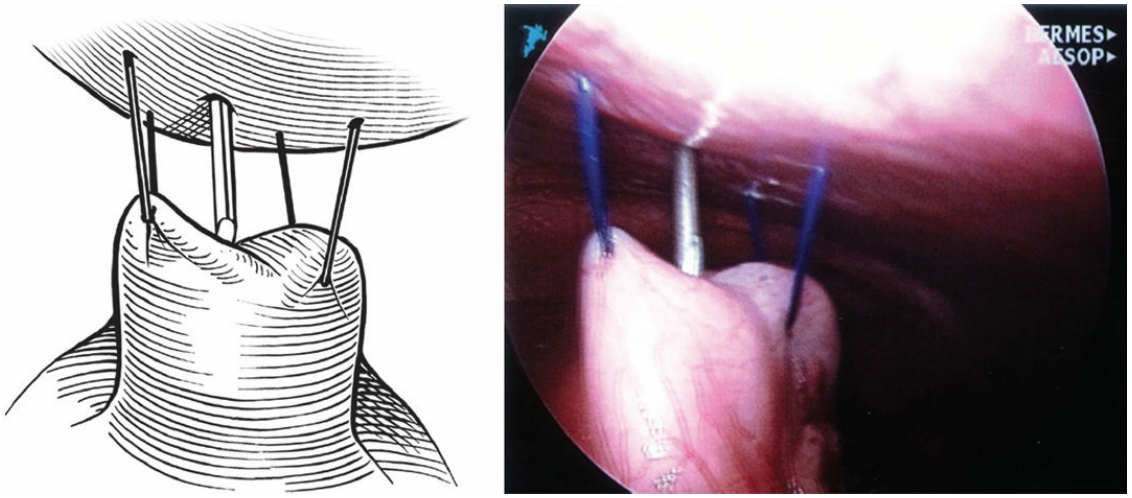

Figure 68.8. Two sutures of 2-0 or 0 PDS (depending on the patient's age) are placed extracorporeally through the abdominal wall, through the stomach, and out through the abdominal wall inferior to the gastrostomy. These sutures are seen on the operative photo and schematic. An 18-gauge needle is then introduced through the left epigastric incision and into the stomach under direct visualization. Following a rush of air

through the needle, a guidewire is placed through the needle and the needle is removed.

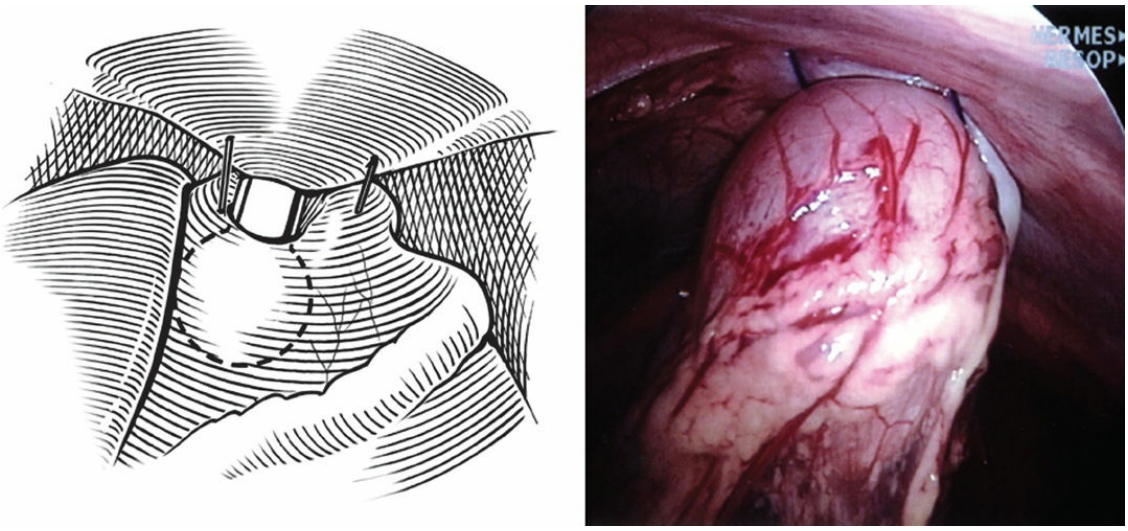

Figure 68.9. After serial dilations of the abdominal wall tract and gastrotomy, the gastrostomy button is introduced over the guidewire and into the stomach. This drawing and operative photograph show the gastrostomy button in the stomach with the balloon inflated.



Figure 68.10. Steri-strips have been used to approximate the remaining three stab incisions. The gastrostomy button has been placed through the left epigastric stab incision. The umbilical fascia has been closed with 3-0 absorbable sutures and the umbilical skin has been closed with 5-0 plain sutures.

With the open operation, an ileus is more likely, so this feeding

schedule is usually started the first postoperative day and similarly advanced. Most patients undergoing the laparoscopic operation are ready for discharge on the first postoperative day. Patients having the open fundoplication are usually more complicated and are in the hospital for 2 to 4 days. All patients are instructed not to allow the incisions to become wet for five days. Older children are asked to restrain their activities for two weeks. At that time, they are seen for a postoperative evaluation, and unrestricted activity is initiated if complications have not developed.

COMPLICATIONS AND THEIR MANAGEMENT

In our experience, as previously discussed, dysphagia is not a common postoperative problem. Wound problems are almost nonexistent with the laparoscopic approach. In several large series of patients undergoing fundoplication (either laparoscopic or open), the need for a second fundoplication varies between 5% and 15%. In many centers with a large experience, the primary reason in infants seems to be transmigration of the fundoplication wrap into the lower chest, thereby limiting the effectiveness of the wrap. As mentioned, one reason may be that the infant's esophagus is short relative to the length of the baby. Therefore, although the fundoplication is intact, it may migrate through the esophageal hiatus due to retraction of the short esophagus.

We performed a recent retrospective review of all patients who underwent laparoscopic Nissen fundoplication at Children's Mercy from 2000 to 2013 and subsequently required a redo operation for recurrence. A total of 796 patients underwent laparoscopic fundoplication during that time. Of these, 82 patients (10.3%) required reoperation during the study period. The mean age at the patient's initial fundoplication was 1.8 ± 3.6 years. Of these 82 patients, 15 (18.3%) required more than one reoperation. Of the 102 reoperations performed, 68 were successfully managed laparoscopically, 31 were performed open from the outset, and 3 started laparoscopically, but required conversion. In those requiring more than one reoperation, there was no difference in age, weight, use of mesh, or time to subsequent reoperation compared with patients who only required one redo procedure.

In analyzing this dataset, 512 patients underwent Nissen fundoplication prior to 2009, of which 70 (13.7%) required reoperation compared with 12 patients of 284 patients (4.2%) who underwent their initial operation after 2009. This was a significant decrease ($p < 0.01$) in the incidence of

reoperation after 2009. Also, there was a significant change in the indication for reoperation after the change in operative technique mentioned previously. Prior to the use of minimal mobilization and the four esophagocrural sutures, wrap transmigration was the primary indication for reoperation (Fig. 68.11). After transitioning to minimal esophageal dissection and mobilization at time of initial operation, wrap disruption became the primary reason for recurrent reflux and the need for reoperation (Table 68.2).

Laparoscopic redo fundoplication following an initial open fundoplication is certainly more difficult, but can be performed. At the time of redo fundoplication, a wide and patulous esophageal hiatus should be anticipated in a patient with transmigration of the wrap. Therefore, an important part of the operation is closure of the enlarged hiatus. Some surgeons close the enlarged hiatus with interrupted silk or other nonabsorbable sutures followed by the fundoplication. Other surgeons believe that reinforcement of this hiatal closure is important to help prevent breakdown of this repair that can occur because of the tension that results from approximating the edges of the hiatus. Therefore, at the time of redo fundoplication for wrap transmigration, whether it is performed open or laparoscopically, a piece of Surgisis can be placed on the abdominal side of the hiatal closure to reinforce the crural closure and help prevent another wrap transmigration (Fig. 68.12).

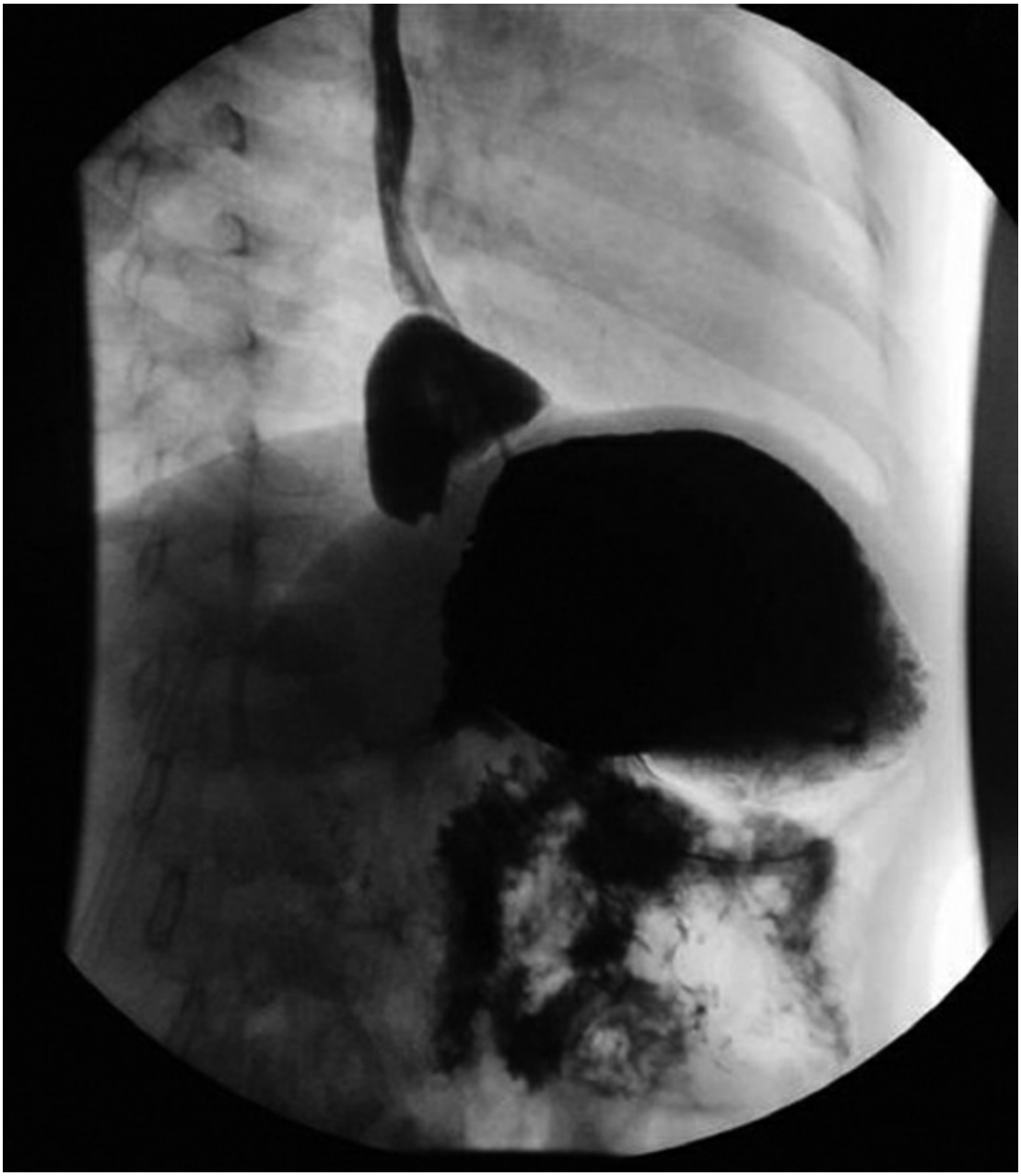

Figure 68.11. At our institution, almost all patients requiring a second fundoplication do so because of transmigration of the fundoplication wrap causing symptomatic gastroesophageal reflux. In our experience, it is unusual for a patient to have breakdown of a wrap that is located intra-abdominally. On this contrast study, the wrap is located in the lower mediastinum.

OUTCOMES

The outcomes following laparoscopic fundoplication are very comparable to the open approach. There are no prospective studies comparing either a partial versus a complete fundoplication or medical management versus surgical therapy for infants and children with GER. Two small prospective

randomized trials have compared open and laparoscopic Nissen fundoplication in children. In one study, 20 children were randomized to open and 19 were randomized to laparoscopic Nissen fundoplication. The mean follow-up in both groups was 4.1 years. Most of the children were neurologically impaired. The incidence of recurrent GER was 12.5% in the open group, and 20% in the laparoscopic group (p = NS). One patient in each group required a redo fundoplication. It was felt that both approaches provided similar control of reflux and a similar quality of life at follow-up. Interestingly, the laparoscopic approach was associated with a reduced incidence of retching at 4-year follow-up. A second study randomized 29 patients between the two approaches. The purpose of this study was to examine inflammatory markers to see if there was a reduction in inflammatory markers in the laparoscopic group. The authors found that there was not a substantially less inflammatory response in the laparoscopic group when compared to the open group in children undergoing Nissen fundoplication. Outside the two prospective trials, most of the known data have been generated from large retrospective studies of both open and, more recently, laparoscopic operations.

TABLE 68.2 Comparison of Patients Prior to and after Change in Surgical Technique

	Initial Surgery		
	Prior to 2009 (n = 512)	After 2009 (n = 284)	P value
Patients requiring reoperation	70 (13.7%)	12 (4.2%)	<.01
Indications for reoperation			
Wrap transmigration	55 (78.5%)	4 (33.3%)	<0.01
Wrap disruption	4 (5.7%)	6 (50%)	<0.01
Recurrent reflux symptoms	1 (1.4%)	2 (16.6%)	0.06
Emergency conditions	4 (5.7%)	0	1.0
Time (years) to first reoperation	2.5 ± 2.6	1.7 ± 1.4	0.3
Patients with >1 reoperation	13	2	1
Mesh at first reoperation	33	4	0.5

From Desai AA, Alemayehu H, Dalton BG, et al. Review of the experience with re-operation after laparoscopic Nissen fundoplication. *J Laparoendosc Adv Surg Tech A* 2016;26(2):140–3.

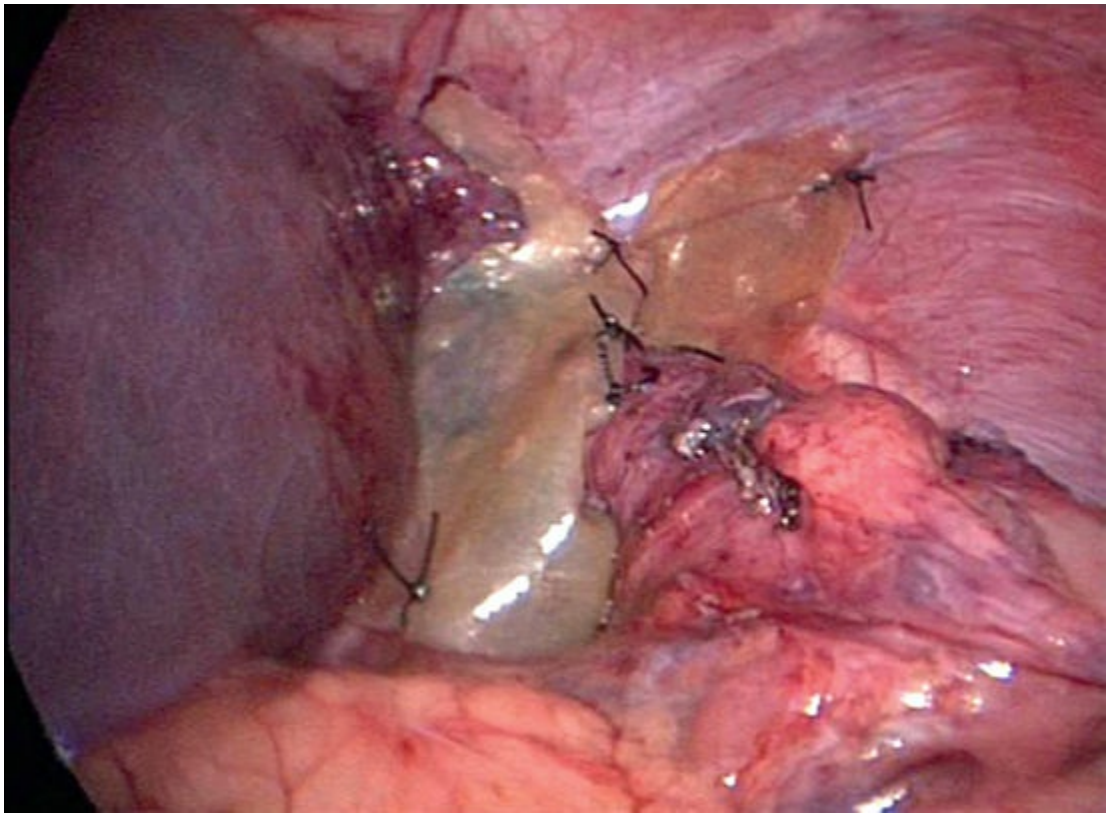

Figure 68.12. This intraoperative photograph shows the Surgisis Gold, which has been wrapped around the esophagus and is sewn to itself anterior to the esophagus. The Surgisis Gold is secured to the esophagus medially and the diaphragm laterally with interrupted 3-0 silk sutures. It is employed to help reinforce the closure of the crura at the time of redo fundoplication. (Reprinted from St. Peter SD, Ostlie DJ, Holcomb, GW III. The use of biosynthetic mesh to enhance hiatal repair at the time of re-do Nissen fundoplication. *J Pediatr Surg* 2007;42(7):1298–301. Copyright © 2007, with permission from Elsevier.)

When looking at the outcomes following fundoplication in infants and children, it is important to understand the patient population. Unfortunately, patients with neurologic impairment are commonly seen by pediatric surgeons for a fundoplication and gastrostomy. The gastrostomy is needed because of the neurologically impaired child's inability to take his or her oral feedings well without oropharyngeal aspiration. The fundoplication is often required because of that child's inability to protect his or her airway from GER and subsequent pulmonary aspiration.

As mentioned, fundoplication seems to be very efficacious in preventing GER based on clinical follow-up. Because of the invasiveness of most tests for reflux, routine pH studies or esophagoscopy and biopsy

are usually not performed in the postoperative period. Therefore, postoperative evaluation is almost entirely clinical. However, because of the nature of this patient population, parents are quite perceptive regarding their child's symptoms and will usually alert their surgeon with any concerns about recurrent reflux. There were several large series in the 1980s describing outcomes for patients undergoing open fundoplication. In general, the need for redo fundoplication was 5% to 15%. Our group at Children's Mercy has been particularly interested in improving outcomes following laparoscopic fundoplication. In a personal series (GWH) between January 2000 and March 2002, 130 patients underwent laparoscopic fundoplication with an incidence of postoperative transmigration of the fundoplication wrap of 12%. At that time, two changes were made in the operative technique. One was to change from fairly extensive esophageal dissection and mobilization to minimal, if any, esophageal dissection and mobilization in order to keep the phrenoesophageal membrane intact and to prevent postoperative wrap transmigration. In addition, the esophagus was secured to the hiatus using 3-0 silk sutures at four sites (8, 11, 1, and 5 o'clock as viewed by the surgeon). This dropped the incidence of transmigration to 5% ($p = 0.072$) in the next 119 patients. In this study, the relative risk of transmigration with extensive esophageal mobilization and without the esophagocrural sutures was 2.29. Based on this retrospective study, our technique changed dramatically to utilizing minimal esophageal dissection and mobilization, and employing the four esophagocrural sutures.

In 2010, our group, along with the pediatric surgical group at the University of Alabama, published a prospective, randomized trial evaluating this concept of minimal esophageal mobilization versus extensive mobilization to validate the previous retrospective findings. In this trial, the primary outcome variable was postoperative wrap transmigration. Based on the previous retrospective review just described, 360 patients were planned to be enrolled in this prospective study with an alpha of 0.05 and a power of 0.8. The large number of patients was needed due to the double randomization sequence (extensive esophageal dissection/mobilization vs. minimal dissection/mobilization and neurologically impaired vs. neurologically normal patients). All patients received four esophagocrural sutures as previously described. Between February 2006 and May 2008, 177 patients were enrolled at the two institutions. There were no differences in demographics or operative time.

One year mortality was 7.8% in the minimal dissection group and 6.9% in the extensive dissection group ($P = 0.99$). There was no mortality related to the operation. In this study, in contrast to previous protocols, a contrast esophagram was performed in all patients at 1-year follow-up to evaluate whether or not transmigration of the wrap had occurred. After approximately half of the patients had been enrolled, an interim analysis was performed. There was a significantly higher transmigration rate of 30% in the patients undergoing extensive esophageal dissection when compared to the transmigration rate in the minimal esophageal mobilization group (7.8%; $P = 0.002$). Also, the need for a redo fundoplication was markedly higher in the patients undergoing the extensive esophageal mobilization (18.4%) when compared with the minimal esophageal dissection group (3.3%; $P = 0.006$). Because the outcomes were significantly different, it was felt unethical to continue the study and the study was closed at the time of the interim analysis when almost half the calculated patients were enrolled. This Level 1 evidence indicates that minimal esophageal mobilization with the use of the four esophagocrural sutures decreases postoperative wrap transmigration and the need for a second fundoplication.

A second prospective randomized trial has recently been completed at Children's Mercy. In this study, 120 patients participated comparing minimal esophageal dissection/mobilization along with the four esophagocrural sutures described previously to minimal esophageal dissection/mobilization without these esophagocrural sutures. Patient demographics were similar between groups. The operative time was significantly longer in the patients with the esophagocrural sutures. No patient in either group developed transmigration of the fundoplication wrap at 2-year follow-up. Thus, it is felt these esophagocrural sutures are not necessary if there is minimal to no esophageal dissection and mobilization.

Suggested Readings

Boix-Ochoa J, Canals J. Maturation of the lower esophagus. *J Pediatr Surg* 1976;11:749–56.

DeMeester TR, Wernly JA, Bryant GH, et al. Clinical and in vitro analysis of determinants of gastroesophageal competence. *A J Surg* 1979;137:39–46.

Desai A, Alemayehu H, Dalton B, et al. Review of the experience with re-operation after laparoscopic Nissen fundoplication. *J Laparoendosc Adv Surg Tech*

2016;26(2):140–3.

Mauritz FA, van Herwaarden-Lindeboom MY, Zwaveling S, et al. Laparoscopic Thal fundoplication in children: a prospective 10- to 15-year follow-up study. *Ann Surg* 2014;259:388–93.

Pacilli M, Eaton S, McHoney M, et al. Four-year follow-up of a randomized controlled trial comparing open and laparoscopic Nissen fundoplication in children. *Arch Dis Child* 2014;99:516–21.

Ponsky TA, Gasior AC, Parry J, et al. Need for subsequent fundoplication after gastrostomy based on patient characteristics. *J Surg Res* 2013; 179:1–4.

St. Peter SD, Barnhart DC, Ostlie DJ, et al. Minimal versus extensive esophageal mobilization during laparoscopic fundoplication: a prospective randomized trial. Accepted for presentation, 2010 meeting of the American Pediatric Surgical Association. *J Pediatr Surg* 2011;46:163–9.

St. Peter SD, Ostlie DJ, Holcomb GW 3rd. The use of biosynthetic mesh to enhance hiatal repair at the time of re-do Nissen fundoplication. *J Pediatr Surg* 2007;42:1298–301.

St. Peter SD, Valusek PA, Calkins CM, et al. Use of esophagocrural sutures and minimal esophageal dissection reduces the incidence of postoperative transmigration of laparoscopic Nissen fundoplication wrap. *J Pediatr Surg* 2007;42:25–30.

Valusek PA, St. Peter SD, Tsao KJ, et al. The use of fundoplication for prevention of apparent life-threatening events. *J Pediatr Surg* 2007;42:1022–5.

EDITOR'S COMMENT

Gastroesophageal reflux (GER) is physiologically normal and occurs in all infants; however, when reflux causes troublesome clinical symptoms (i.e., an aspiration pneumonia, an apparent life-threatening event (ALTE), failure to thrive) or complications (endoscopically documented esophagitis, Barrett esophagus, stricture), GER disease (GERD) is present. Because symptoms vary according to age group and coexisting conditions, pediatric GERD is a complex topic with a spectrum of manifestations. The understanding and management of pediatric GERD continue to evolve integrating both medical and surgical options into treatment algorithms. The authors present an excellent overview of pediatric GERD encompassing pathophysiology, indications for surgical intervention, level I data supporting technical details how best to perform an antireflux procedure, and outcomes. The improvement in technical aspects of the surgical procedure, based off prospective randomized surgical studies conducted in large part by the pediatric surgery clinical research team at Mercy Children's Hospital in Kansas City led by the author GWH, is level I data and

although important illuminates an issue of greater importance—the need for properly designed clinical studies to better determine the optimal management of pediatric GERD. Although an antireflux procedure is one of the most common pediatric surgical procedures performed, analysis of the effectiveness of antireflux procedures performed in children is challenging as reported studies vary by the heterogeneity of patient cohorts (e.g., neurologically impaired, after esophageal atresia, broad age range), the indications for surgery, and the lack of a standardized reporting framework for operative technique. A recent systematic review by the American Pediatric Surgical Association's Outcomes Committee (Jancelewicz T, Lopez ME, Downard CD, et al. Surgical management of gastroesophageal reflux disease [GERD] in children: a systematic review. *J Pediatr Surg* 2016 Oct 14. pii: S0022–3468(16):30460–2.) highlights the many aspects of pediatric GERD in which there is a lack of high-quality evidence supporting the current "standard of care" treatment approaches utilized to treat pediatric GERD. The conclusion of the systematic review recommends a paradigm shift in which the focus is placed on better definitions of the disease process, more clearly defined indications for intervention, interventions in more uniform cohorts, and longer-term follow-up, possibly through registries.

From the perspective of better definitions of the disease process, there is a need for the widespread adoption of standardized diagnostic algorithms based on presenting symptoms to aid in categorizing indications for surgery. The North American Society for Pediatric Gastroenterology, Hepatology, and Nutrition guidelines published in 2009 serves as an excellent template for the standardization (Vandenplas Y, Rudolph CD, Di Lorenzo C, et al. Pediatric gastroesophageal reflux clinical practice guidelines: joint recommendations of the North American Society for Pediatric Gastroenterology, Hepatology, and Nutrition [NASPGHAN] and the European Society for Pediatric Gastroenterology, Hepatology, and Nutrition [ESPGHAN)]. *J Pediatr Gastroenterol Nutr* 2009;49(4):498–547). In the guidelines, treatment algorithms based according to age group (infant vs. older child/adolescent) symptom complex (recurrent emesis, failure to thrive, heartburn, exacerbation of reactive airway disease), complications (esophagitis, Barret's Esophagus), and coexisting conditions (neurologically impaired, esophageal atresia, others) were defined. Within the treatment algorithm were recommendations for when diagnostic interventions such as contrast studies, upper endoscopy and biopsy, pH monitoring, and multiple intraluminal impedance monitoring (MII, which has largely supplanted pH monitoring) should be utilized. By standardizing the diagnostic evaluation, a better understanding of the disease process can be achieved and with it will come more homogeneous cohorts of patients who require treatment for GERD. In so doing, the efficacy of treatment interventions be they medical or surgical can be better assessed. It is uncertain whether those guidelines are being uniformly applied across the pediatric medical community.

In the APSA Outcomes committee systematic review, an analysis on the effectiveness of an antireflux procedure in alleviating symptoms of GERD was

performed and in a consistent fashion, for symptoms ranging from the somewhat subjective—cough, emesis, heartburn to the more clinically significant consequences of an aspiration pneumonia or an ALTE, found a lack of level I or II data supporting efficacy. Nearly all studies were based on institutional experience with varied indications, sample sizes, lack of standardization, and perhaps most concerning, inadequate longitudinal follow-up. When they reviewed the literature for studies focused on efficacy using objective measurements of GERD such as pH monitoring or MMI, there was evidence that antireflux procedures reduced reflux episodes, acid exposure, and impedance values but the studies were underpowered or also had inadequate long-term follow-up. When evaluating efficacy based on age, a population of patients who require particular attention is the neonate/infant group in which an antireflux procedure is performed, the most vulnerable of populations who have longest of long-term consequences. In a review by Pacilli et al. (*Semin Pediatr Surg* 2005;14(1):34–41) focused on this population, multiple studies were combined (with all the attendant limitations of such a combined analysis—single institution retrospective studies subject to selection, attrition, and reporting bias with significant heterogeneity of the indication and patient population) and found that the overall success rate of fundoplication in neonates and infants, defined as a proportion of patients with *subjective* improvement of symptoms, ranged from 67% to 100%, and the incidence of redo fundoplication was 7% to 26%. Clearly, there is a need for better age and efficacy-based studies with more objective assessments in a patient population that has a lifetime ahead of them with such long term consequences.

When one considers the coexisting conditions that may predispose a child to have GERD and how the coexisting condition may impact the efficacy of a fundoplication, more uncertainty is present. As the authors of the chapter mention, the role of an antireflux procedure in the neurologically impaired patient who requires a gastrostomy tube for feeding access has evolved. Abnormal esophageal motility and function of the gastroesophageal sphincter complex with reflux of gastric contents are seen in up to 75% of patients with neurologically impaired. In the past, it was common in a neurologically impaired patient to offer an antireflux procedure while placing a g-tube as the patient “needed” it—resulting in estimates that 40% of the antireflux procedures performed in children were done in this context (Lasser MS, Liao JG, Burd RS. National trends in the use of antireflux procedures for children. *Pediatrics* 2006;118:1828–35). Critical analysis of the literature does not support this approach as an antireflux procedure could engender more complications especially in the neurologically compromised that also have a seizure disorder. The increase abdominal pressure that occurs with seizures can cause the Nissen to “slip” into the chest, which limits the effectiveness of the wrap, may cause dysphagia, and ultimately may require reexploration and revision. A Cochrane review focused in 2013 focused on this population concluded “there remains considerable uncertainty regarding the optimal treatment when faced with the

decision of fundoplication surgery versus antireflux medications for children with GERD and neurologically impaired who are undergoing gastrostomy insertion" (Vernon-Roberts A, Sullivan PB. Fundoplication versus postoperative medication for gastro-oesophageal reflux in children with neurological impairment undergoing gastrostomy. *Cochrane Database Syst Rev* 2013;8:CD006151). As the authors recommend, the routine inclusion of an antireflux procedure when placing a gastrostomy tube can no longer be supported. What is needed is a properly designed prospective trial with adequate longitudinal follow-up in patients with NI comparing fundoplication with gastrostomy versus gastrojejunal tube feeds.

The authors nicely present the details on how they perform an antireflux procedure where they favor a Nissen 360-degree wrap. The level I evidence they generated were important advances and brought to bear clinical research methodology to a surgical procedure; however, as the authors note, there are multiple variants on how best to perform an antireflux procedure including the Nissen 360-degree "complete" wrap, a Thal 180-degree anterior "partial," and the Toupet 180-degree posterior "partial" fundoplication. Interestingly, a group from the United Kingdom has reported level I data comparing outcomes following a complete (Nissen) versus a partial (Thal) in pediatric patients under 21 with a 2.5-year follow-up and found that the complete wrap was more effective but caused more dysphagia and recommended a partial wrap for neurologically intact children with refractory GERD and favor complete fundoplication for NI children (Kubiak R, Andrews J, Grant HW. Long-term outcome of laparoscopic Nissen fundoplication compared with laparoscopic Thal fundoplication in children: a prospective, randomized study. *Ann Surg* 2011;253(1):44–9). More studies like this are needed to document the efficacy of the alternative techniques.

As with many aspects of pediatric general surgery, the utilization of the laparoscopic approach was integrated into antireflux procedures quite quickly and has become the "standard of care." In the APSA outcomes committee review, an analysis of the literature comparing the open versus laparoscopic approach found two underpowered trials, several cohort studies, and multiple retrospective reports. In one of the underpowered trials (poor accrual resulted in the closing of the study prior to reaching an acceptable number of patients) conducted by a team in Norway, 88 children with GERD confirmed by 24-hour pH probe were randomized to undergo laparoscopic or open Nissen fundoplication (Knatten CK, Fyhn TJ, Edwin B. Thirty-day outcome in children randomized to open and laparoscopic Nissen fundoplication. *J Pediatr Surg* 2012;47:1990–6). The primary outcome measure of GERD recurrence was unable to be assessed; however, analysis of secondary outcomes found no difference in early postoperative complications between the two groups indicating laparoscopic Nissen was a viable alternative. Of concern was a follow-up analysis from that study in which the investigators observed a much higher GERD recurrence rate after laparoscopic versus open Nissen (Fyhn TJ,

Knatten CK, Edwin B, et al. Randomized controlled trial of laparoscopic and open Nissen fundoplication in children. *Ann Surg* 2015;261:1061–7). This and other similarly challenged studies led the APSA outcomes committee to reach the conclusion that laparoscopic fundoplication may be comparable to open fundoplication with regard to short-term clinical outcomes; however, long-term effectiveness data remain to be determined.

An important and seemingly obvious consideration is what the long-term complications are after an antireflux procedure performed in a child. Review of the literature indicates that operation to redo or repair the fundoplication after wrap failure is the most often reported adverse event followed by recurrent, new, or persistent symptoms, need for antacid/antireflux medications, abnormal and least commonly mortality. Because of the heterogeneity of the studies, there is no clear consensus as to what defines treatment failure and in that context, difficult to assess long-term complications in a patient population that has a long-term perspective. What is needed is a properly designed longitudinal follow-up study that would allow us to properly inform a family what the long-term challenges are for a patient who undergoes an antireflux procedure in childhood.

Pediatric GERD is a challenging process with long-standing established approaches that are often best practice/institutionally based. The decision when surgical intervention requires multidisciplinary input between the family, surgeon, pediatric gastroenterologist, and the primary pediatric team delivering care. Studies in the future must focus on who best benefits from an antireflux procedure along with longer follow-up to ensure efficacy. As the APSA outcomes committee review concludes, “Until a paradigm shift is realized, management of gastroesophageal reflux in children will remain largely based on anecdotal experience and institutional practice patterns.”

Gregory M. Tiao

SECTION VII

THE GASTROINTESTINAL TRACT

A THE ESOPHAGUS

69 The Anatomy of the Esophagus

Toni Lerut, Willy Coosemans, Herbert Decaluwe, Georges Decker, Paul De Leyn, Lieven De Pypere, Philippe Nafteux, Dirk Van Raemdonck, and Hans Van Veer

The esophagus is not simply a conduit to allow passage of food and drink from the mouth to the stomach. It is an intensely complex part of the gastrointestinal tract. Cranially the esophagus is a continuation of the hypopharynx, and caudally it continues into the cardia of the stomach. As such, a thorough understanding of the anatomy and physiology of the esophagus should be gained before contemplating surgery of it.

EMBRYOLOGY

Description

The esophagus comes from two sources of the primitive gut. The cranial portion is derived from the pharyngeal gut or pharynx and the caudal part from the pregastric segment of the foregut. With the growth of the embryo, the primitive gut lumen becomes almost filled but later, due to a process of epithelial layer vacuolization, hollows out again. At about 4 weeks of embryonic development, the laryngotracheal groove appears, subsequently forming the tracheobronchial diverticulum on the ventral surface of the foregut, at the level of the fourth pharyngeal pouches (Fig. 69.1A,B). The diverticulum is gradually closed by the tracheoesophageal folds (internal ridges of the lateral esophageal groove), caudally first, forming the tracheoesophageal septum (Fig. 69.1). The endoderm forms the mucosal epithelium and associated ducts and glands. The mesoderm forms the lamina propria, muscularis mucosa, and muscular coat, the branchial arches forming the striated muscle and the visceral splanchnic mesoderm the smooth muscle coat. Arterial and venous supply of the esophagus is segmental. The cranial arteries are derived from the branchial arches and

caudal ones from branches of the aorta. With the unfolding and lengthening of the embryo, the esophagus also lengthens. The original cell lining of the esophagus changes from a two- to three-layer pseudostratified columnar epithelium via a stratified columnar stage to a stratified squamous epithelium by 90- to 130-mm embryo length.

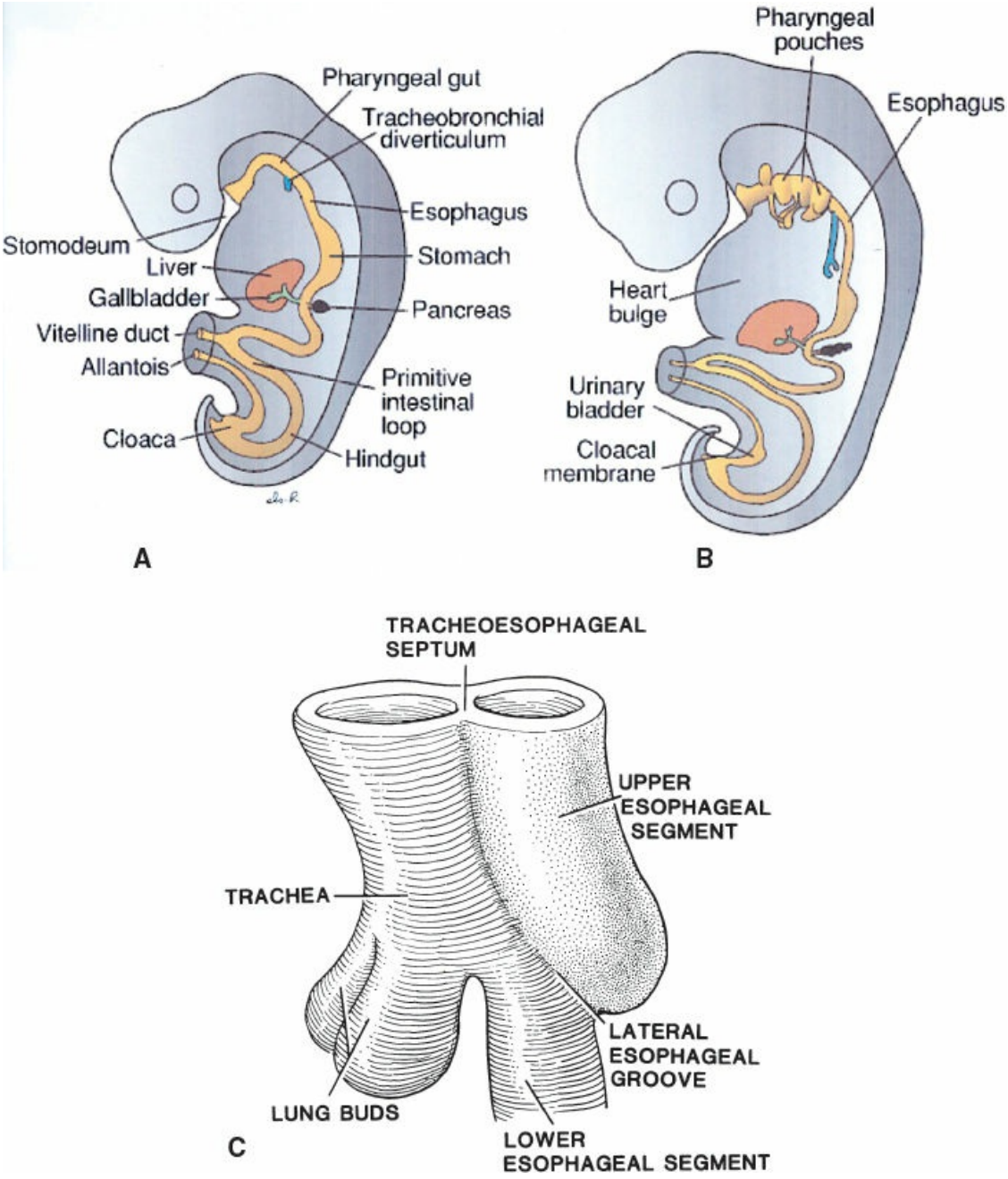

Figure 69.1. **A, B.** Development of tracheobronchial diverticulum from the primitive foregut (4 weeks). (From Sadler TW. *Langman's Medical Embryology.* 10th ed. Philadelphia, PA: Lippincott Williams & Wilkins; 2006.) **C.** Foregut segment in a 4-week-old embryo, showing division into the upper esophageal segment and the primitive lung buds. (From Blevins CE.

Embryology of the esophagus. In: Shields TW, ed. *General Thoracic Surgery*. 6th ed. Philadelphia, PA: Lippincott Williams & Wilkins; 2005:1883.)

Clinical Points of Interest

Overdevelopment of the internal ridges of the tracheoesophageal septum is proposed as the cause of esophageal atresia according to Smith and deviation of the tracheoesophageal septum the cause of tracheoesophageal fistula. Failure of development of the tracheoesophageal septum can cause posterior laryngeal clefts. Defects of vacuolization and/or the persistence of diverticulae during the lengthening of the esophagus may be the cause of embryonic cysts, duplication cysts, webs, rings, and congenital stenosis, the latter including possibly even cartilaginous remnants or rings.

GROSS ANATOMY

Description

The esophagus is about 25 cm long extending from the level of the 6th cervical vertebra down to that of the 11th thoracic vertebra. It is not a fixed structure and moves cranially a few centimeters on swallowing and tilting the head backward. It is anchored superiorly to the cricoid cartilage and pharynx by strips of collagen fibers interspersed with muscle fibers. Similarly, it is tethered along its length to the left and right pleura, the aorta, the left main bronchus, and the fibrous pericardium. These are fine structures macroscopically and consist of a variable amount of collagen, elastic, and muscle fibers. It is normal clinical practice such as in endoscopy to describe the length along the esophagus as being that measured from the incisors teeth, thus including the oropharynx in this measurement. There is a narrowing at 15 to 17 cm (i.e., the upper esophageal sphincter [UES]), another at about 38 to 40 cm (i.e., the lower esophageal sphincter [LES]), and an anterolateral indentation at about 25 cm where the left main bronchus and arch of the aorta cross it anteriorly (Fig. 69.2). The female's esophagus is shorter than the male's by a few centimeters, but in both sexes there is marked variability depending on the height and weight of the individual. The esophagus shows two curves in the anteroposterior plane: although starting in the midline at the junction with the oropharynx, it deviates to the left as it descends to the thoracic inlet then returns to a midline position at about the 5th thoracic vertebra,

before passing once again to the left (Fig. 69.3). The esophagus also follows the contour of the cervical and upper thoracic spine in a lateral plane (Fig. 69.4).

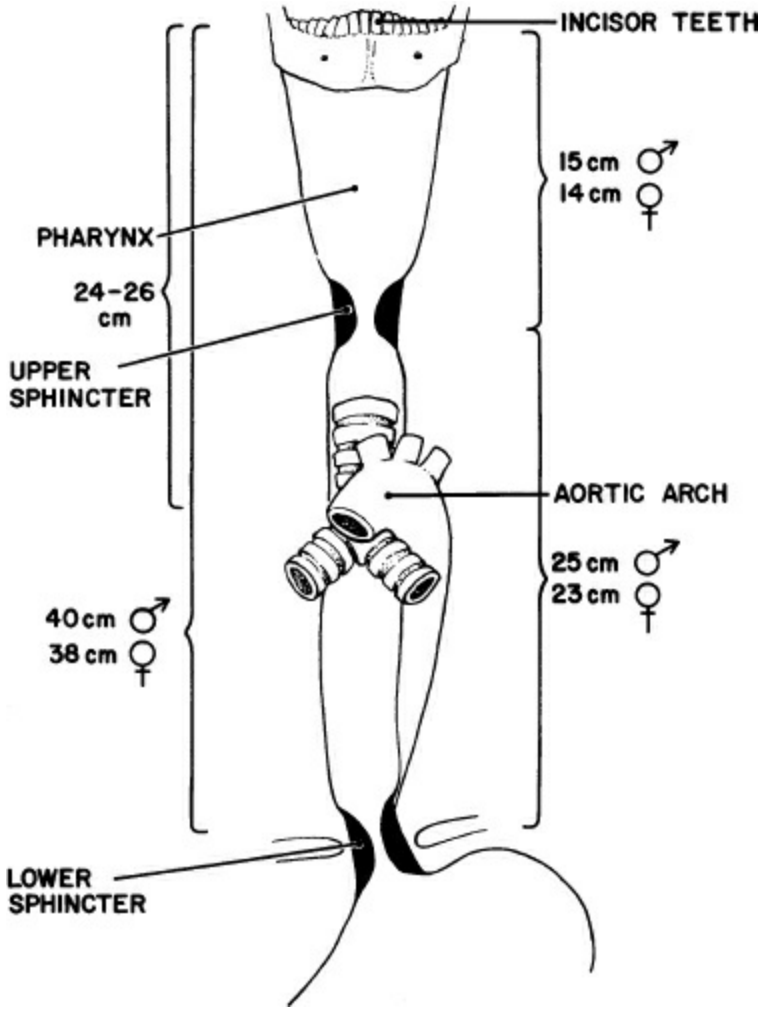

Figure 69.2. Diagram of the indentations of the esophagus with distances from the incisors in males and females. (From Hagen JA, DeMeester TR. Anatomy of the esophagus. In: Shields TW, ed. *General Thoracic Surgery*. 6th ed. Philadelphia, PA: Lippincott Williams & Wilkins; 2005:1887.)

The latest edition of the American Joint Committee on Cancer (AJCC) cancer staging manual divides the esophagus into four parts: cervical, upper thoracic, middle thoracic, and lower thoracic esophagus/esophagogastric junction (EGJ) (Fig. 69.5).

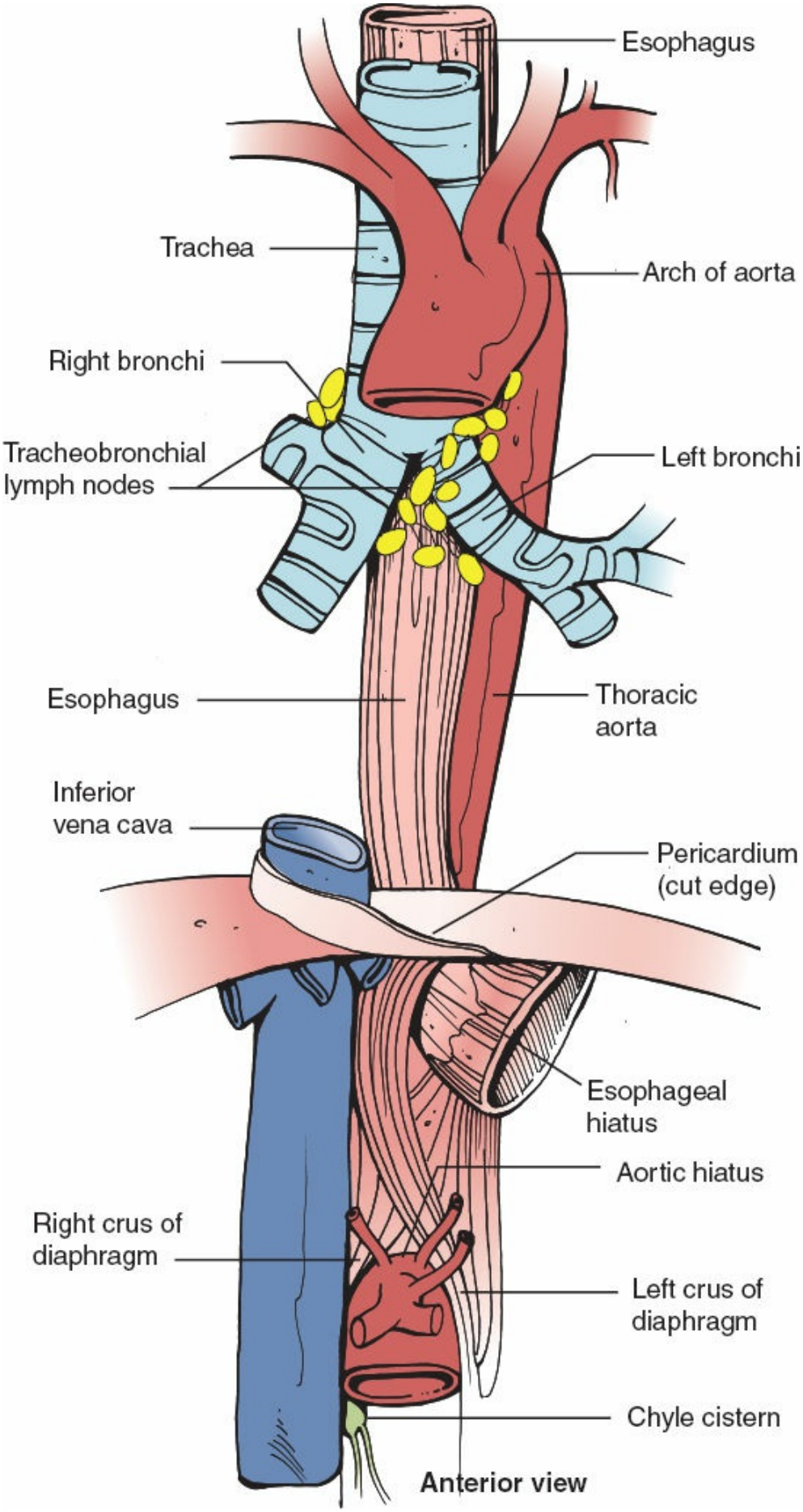
Esophagus
Trachea
Arch of aorta
Right bronchi
Tracheobronchial lymph nodes
Left bronchi
Esophagus
Thoracic aorta
Inferior vena cava
Pericardium (cut edge)
Esophageal hiatus
Aortic hiatus
Right crus of diaphragm
Left crus of diaphragm
Chyle cistern
Anterior view

Figure 69.3. Anteroposterior view of the esophagus.

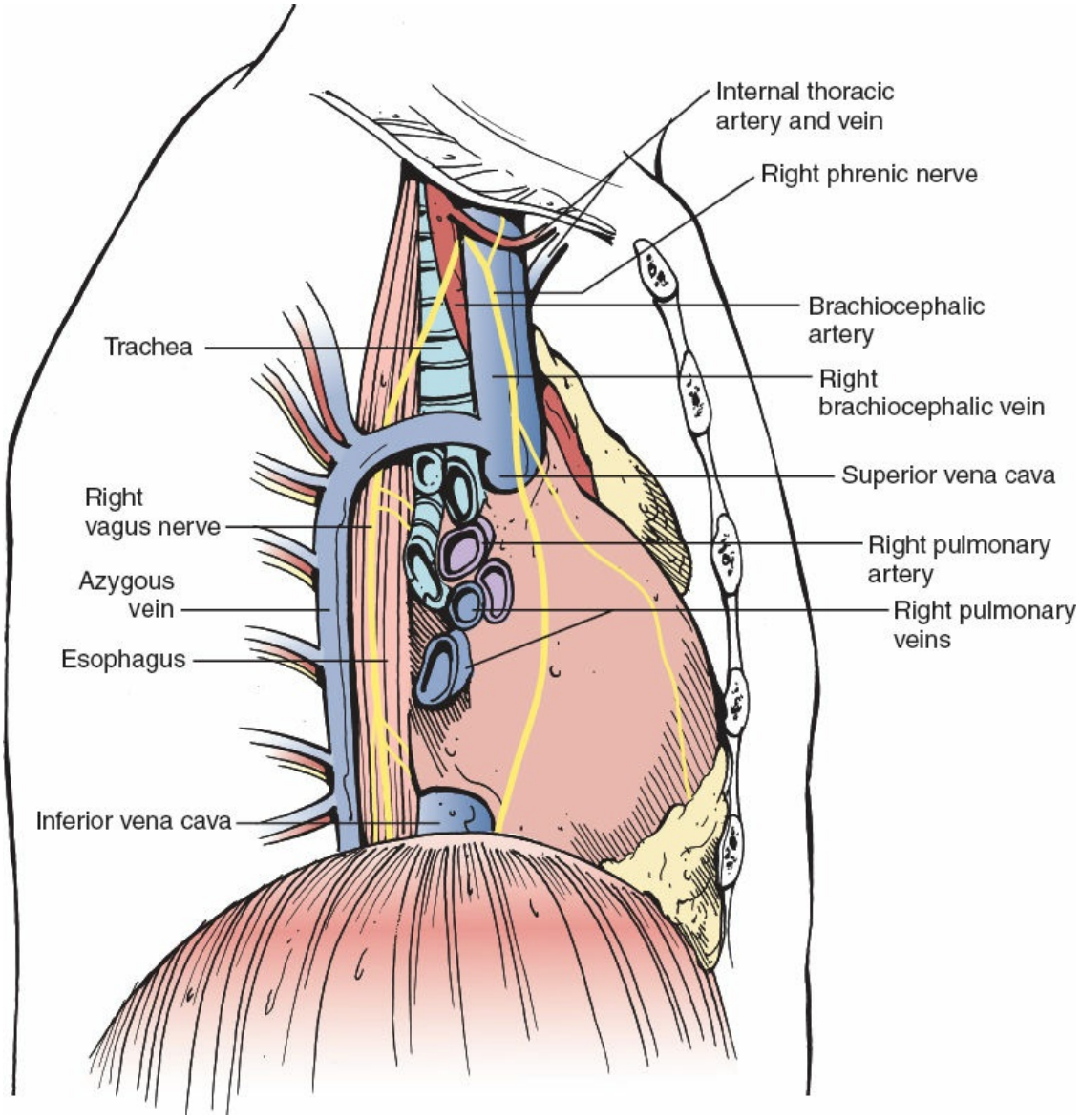

Figure 69.4. Lateral view of the esophagus.

The cervical esophagus lies in the neck, bordered superiorly by the hypopharynx and inferiorly by the thoracic inlet, which lies at the level of the sternal notch. Typical endoscopic measurements for the cervical esophagus measured from the incisors are from 15 to <20 cm.

The upper thoracic esophagus is bordered superiorly by the thoracic inlet and inferiorly by the lower border of the azygos vein. Typical endoscopic measurements from the incisors are from 20 to <25 cm.

The middle thoracic esophagus is bordered superiorly by the lower border of the azygos vein and inferiorly by the inferior pulmonary veins. Typical endoscopic measurements from the incisors are from 25 to <30

cm.

The lower thoracic esophagus is bordered superiorly by the inferior pulmonary veins and inferiorly by the stomach. Because it is the end of the esophagus, it includes the EGJ. Typical endoscopic measurements from the incisors are from 30 to 40 cm.

Clinical and Surgical Points of Interest

Recognition of the different landmark points and the distinct parts of the esophagus is of great help in localizing different lesions and pathologic processes when performing barium swallow contrast radiograms and/or endoscopy. Such reference points are very useful to surgeons to plan access routes to the esophagus, such as a right thoracic approach for supracarinal lesions, and a left thoracic approach for lower third esophageal lesions. The lateral deviation of the esophagus has relevance, for example, in the placement of a cervical esophagostomy, treatment of Zenker diverticula, or fashioning of an esophagogastrostomy, most being performed on the left side of the neck.

The arbitrary 10-cm segment encompassing the distal 5 cm of the esophagus and proximal 5 cm of the stomach, with the EGJ in the middle, is an area of contention. In the eighth edition of the AJCC *Cancer Staging Manual*, cancers whose epicenter is no more than 2 cm into the gastric cardia are stage grouped similar to adenocarcinoma of the esophagus. All other cancers with an epicenter in the stomach >2 cm distal to the EGJ, are stage grouped using the gastric cancer staging system.

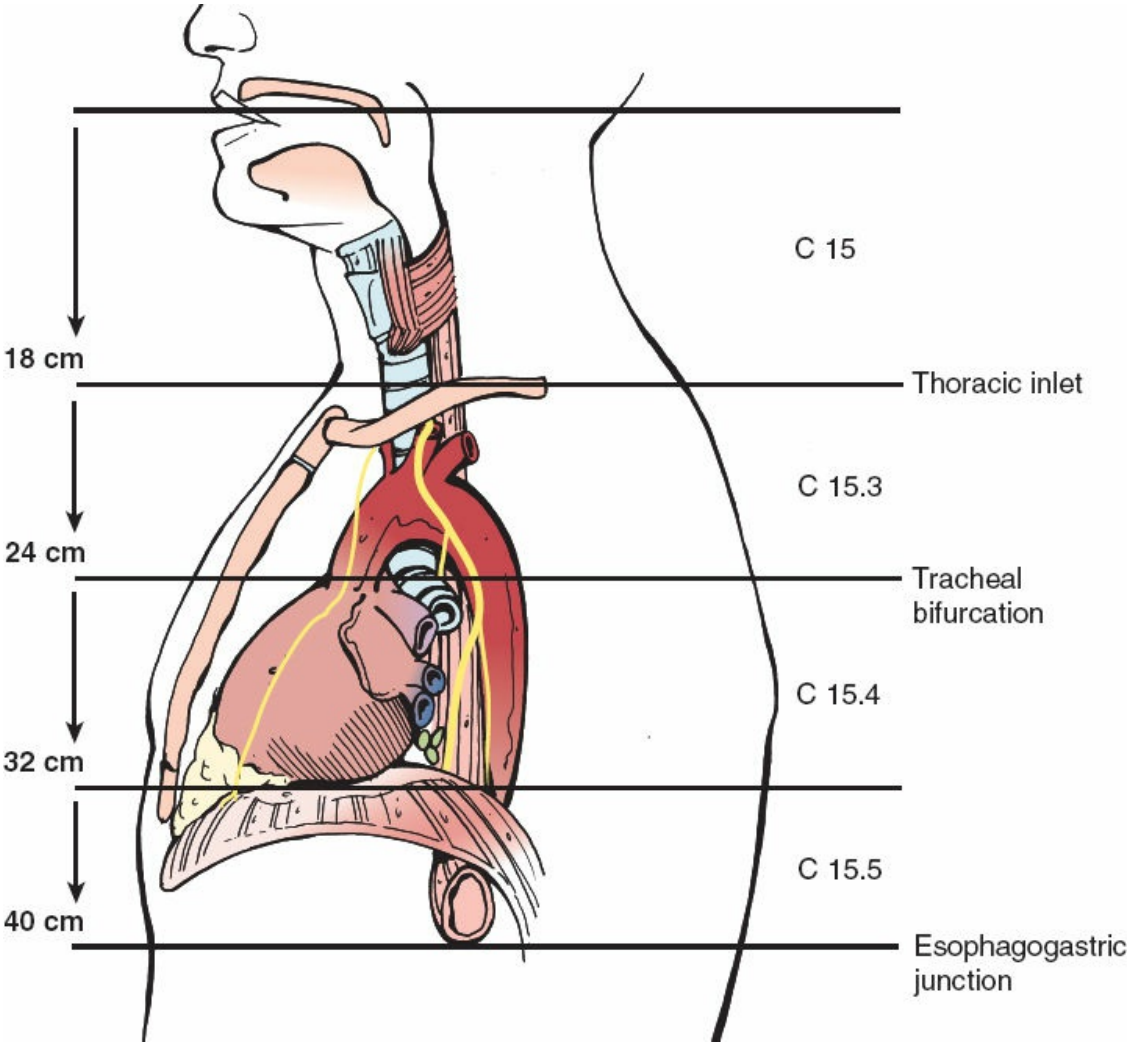

Figure 69.5. The divisions of the esophagus.

THE ESOPHAGEAL SPHINCTERS

Upper Esophageal Sphincter (Fig. 69.6)

The cervical esophagus is ~6 cm long. The UES is a true anatomic sphincter that is composed of the dense cricopharyngeus muscle. When the cricopharyngeus muscle relaxes, the UES opens aided by elevation and forward motion of the larynx. It is attached to the lamina of the cricoid cartilage (Fig. 69.6), and as it passes posteriorly it runs continuously without insertion into the midline raphe of the constrictors, the latter located cranial to it, thereby forming a sling. The cricopharyngeus muscle is considered by Last to be the lower transverse part of the inferior constrictor muscle of the hypopharynx. It blends into the circular fibers of the esophagus below. The longitudinal fibers ascending from the esophagus diverge at this point to form tendons on both sides, the central ones inserting into the posterior lamina of the cricoid cartilage. The

posterior wall of the hypopharynx is relatively weak just above and below the cricopharyngeus. The Killian triangle comprises the area between the thyropharyngeus and cricopharyngeus muscles that comprise the inferior constrictor. Laimer triangle is an area that is formed between the cricopharyngeus muscle above and the divergent longitudinal esophageal muscle fibers below.

Clinical and Surgical Points of Interest

Sometimes and mostly in elderly patients, a pharyngoesophageal pouch develops in Killian triangle, an example of a pulsion diverticulum. However, it is not a true diverticulum as not all layers are involved. The belief is that the pouch forms due to a lack of compliance of the UES and relative weakness of Killian triangle. Although the UES is anatomically short in height, that is, 0.5 cm, manometric measurements show the UES area to be much longer extending into the proximal part of the striated muscle of the cervical esophagus. A myotomy of the UES zone starting distal to the neck of the pouch therefore forms the most significant part of the repair for this condition, rather than excision or diverticulopexy. Importantly, the length of the myotomy should be directed by the manometric not the apparent anatomic, that is, the length of the cricopharyngeal muscle, length. It is important during rigid or flexible esophagoscopy not to enter an esophageal pouch and risk perforation. Indeed, with osteophytes being prevalent at this part of the cervical spine, making esophagoscopy more difficult, this area of weakness is the commonest site of iatrogenic esophageal perforation.

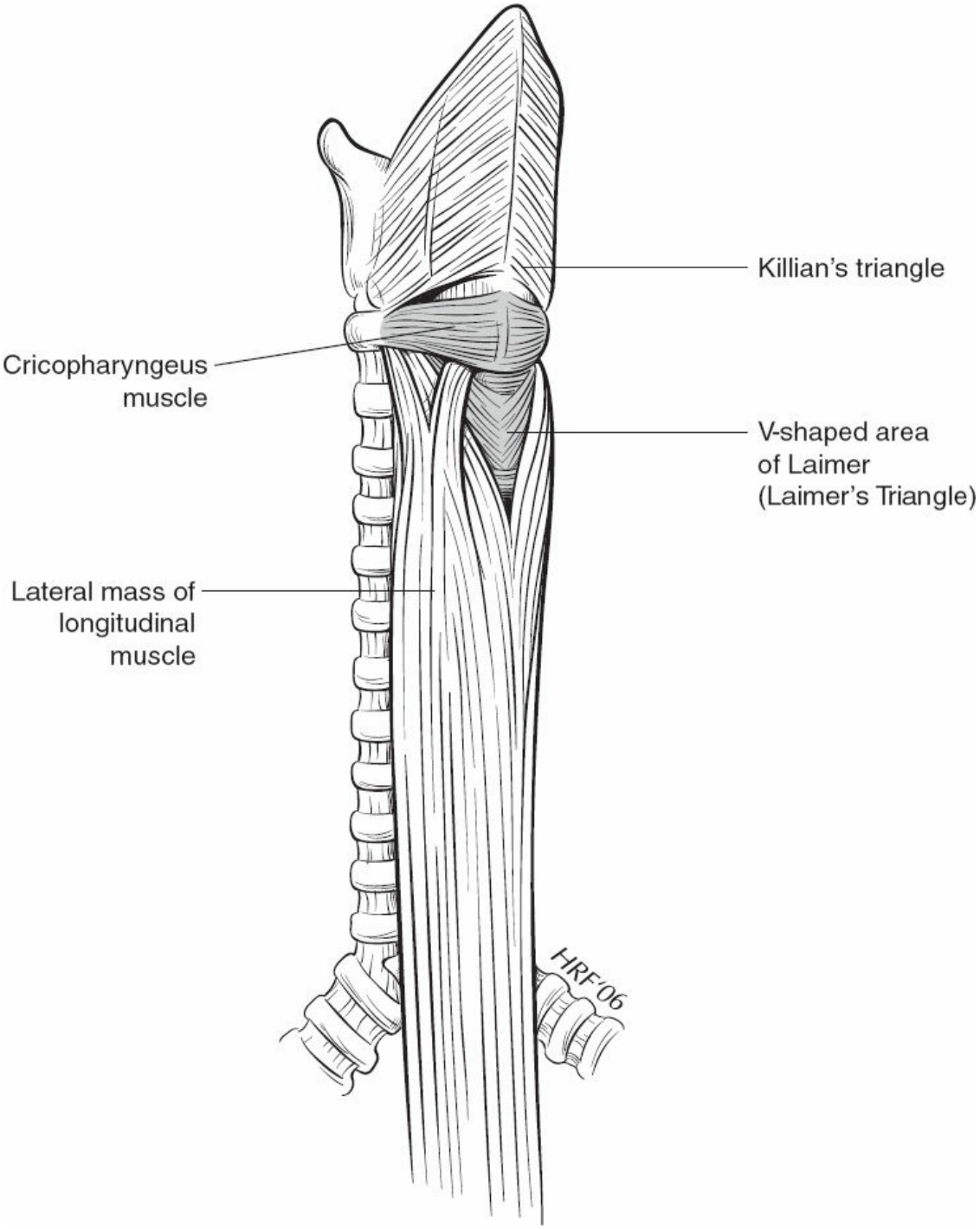

Figure 69.6. Muscle coat arrangement and areas of weakness—Killian and Laimer triangles.

LES and Gastroesophageal Junction (Fig. 69.7)

The LES, however, should be considered more a physiologic sphincter than an anatomic one. It consists of an area of high intraluminal pressure—the high-pressure zone—at the GEJ (gastroesophageal junction), and is influenced by a paracrine hormone effect and the intrinsic nervous system

(see later).

The GEJ has anatomical features that provide a complex antireflux function. The latter includes the length of the intra-abdominal tubular esophagus, the acute angle that the esophagus subtends with the stomach, that is, the angle of His, the gaiter-like effect of the phrenoesophageal ligament, the pinching of the diaphragmatic crura, the sling and clasp fibers of the muscles in the wall (Fig. 69.7), and the rosette of gastric folds of mucosa around the EGJ.

Clinical and Surgical Points of Interest

Endoscopically the LES can be recognized as a relative narrowing just proximal to the GEJ. The GEJ can be endoscopically recognized as the proximal margin of the gastric folds (Fig. 69.8) that in the majority of patients coincides with a pinching at the end of the tubular esophagus and the diaphragmatic indentation. Identifying these endoscopic landmarks allows a precise description of the GEJ, and the confirmation or ruling out of a sliding hiatus hernia. To do so one has to observe the relation between the proximal margin of the gastric folds and the indentation of the diaphragm (Fig. 69.9).

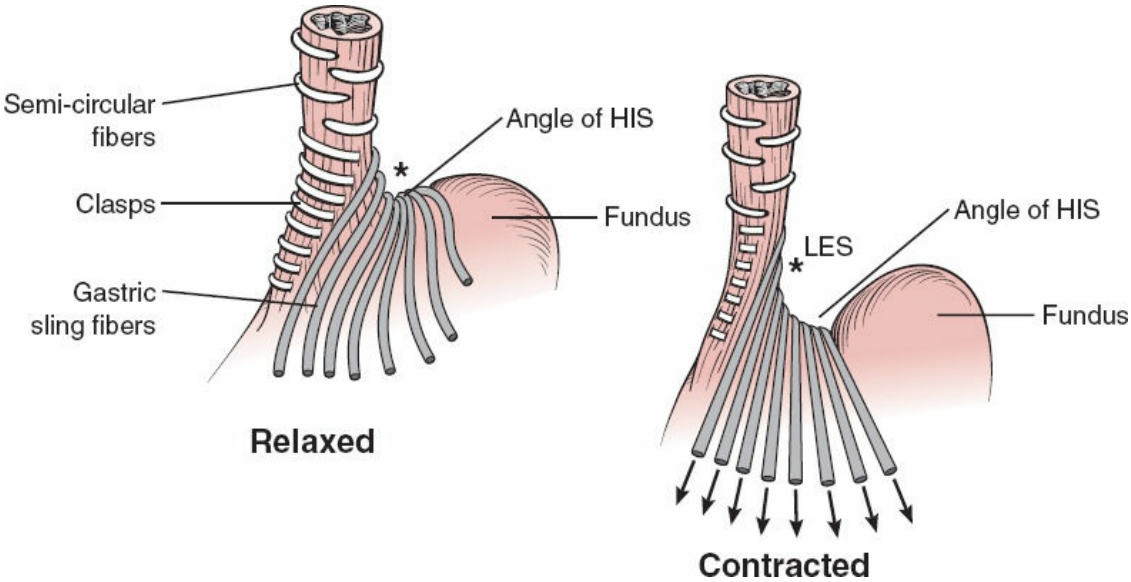

Figure 69.7. Sling and clasp fibers of the LES, in contracted and relaxed states. Sharpening of the angle of His in contracted state. AH, angle of His.

Research has evidenced a key element in preventing reflux is the restoration of 3 to 4 cm of distal esophagus under the diaphragm,

according to Laplace law. This forms the anatomic basis of any type of antireflux surgery. In some patients, the pressure of the LES does not fall to normal resting values on relaxation. This, in conjunction with lack of coordination of the esophageal body, occurs in achalasia (see Nerve Supply Clinical and Surgical Points of Interest). Like the UES, the surgical treatment therefore consists of a myotomy of the last 4 to 6 cm of the esophagus of all layers down to the mucosa, extending 1 to 2 cm onto the stomach. There is discussion as to whether the myotomy should be extended only into the sling fibers or whether it should be performed more to the right and including the clasp fibers. This should be followed by a fundoplication to prevent reflux, classically an anterior (Dor) wrap 4 cm in length.

TISSUE ARCHITECTURE

Description

The esophagus seen in cross-section consists of several layers (Fig. 69.10). The innermost layer is the mucosa, a nonkeratinizing stratified squamous-lined epithelium, except at the GEJ where the mucosa is composed of a columnar epithelium. Cell proliferation takes place in the basal layer lying on a basement membrane; differentiation and maturation occur in the cells progressively, migrating more and more superficially. Next to this is the lamina propria, a layer containing blood vessels, lymphatic capillaries, and nerves. Both the epithelium and the lamina propria contain inflammatory and other cells: melanocytes, neuroendocrine cells, lymphocytes, and Langerhans cells. Adjacent to this layer is the muscularis mucosae that allow crinkling of the mucosa of the esophagus in an undistended state, then the submucosa, loose connective tissue with mucus-secreting glands, and clusters of specialized nerve cells—the Meissner plexus. Outside this is the muscularis propria or muscle coat, composed of two layers—a deep thicker circular and a superficial thinner longitudinal muscle layer with the myenteric or Auerbach plexus found between the two layers. The circular fibers run transversely at the superior and inferior ends of the esophagus but have a helicoidal course between the two. There are more longitudinal fibers laterally in the proximal esophagus, thus making this layer thicker here than the ventral or dorsal sides; however, it becomes more uniform more distally. The longitudinal layer courses in an elongated spiral, turning one quarter around the circumference of the esophagus. There is a loose adventitial covering to the muscular coat, but there is no true serosa and no

mesentery unlike the rest of the distal gastrointestinal tract, except for the rectum. The esophagus can be thought of as consisting of two tubes, one riding almost independently over the other: the inner mucosa and submucosa separated by the muscularis mucosa; the outer muscularis propria.

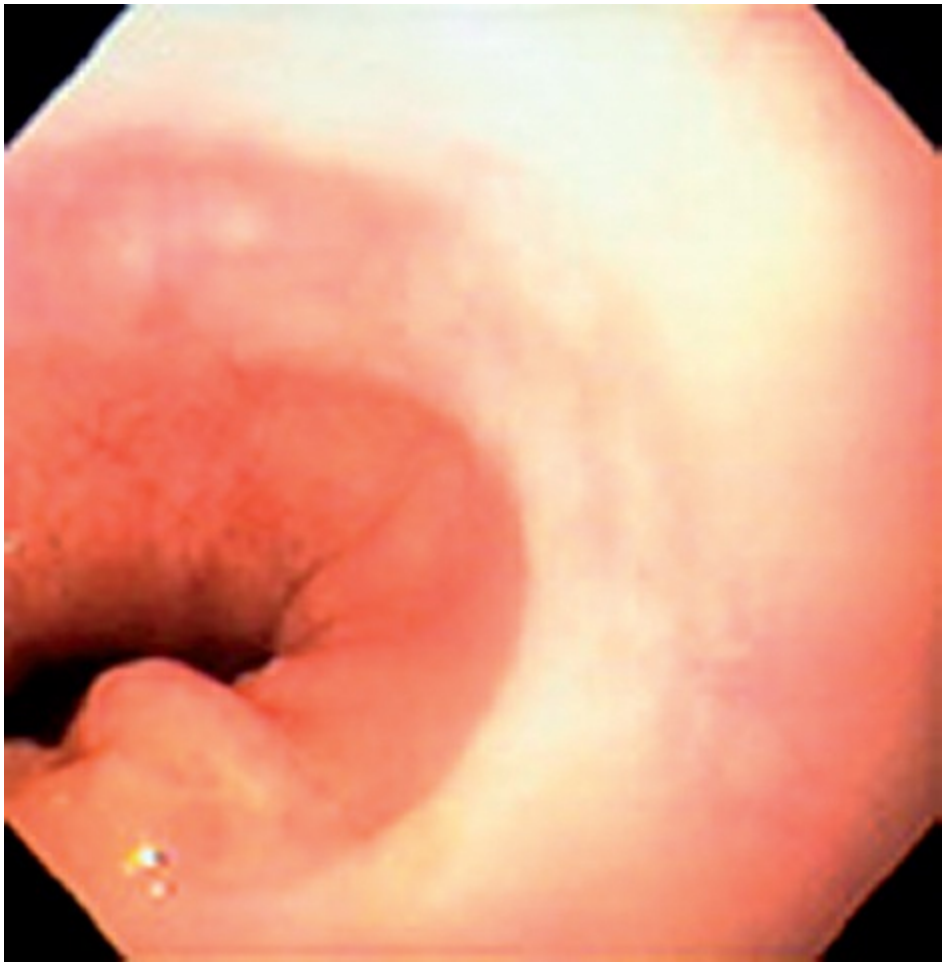

Figure 69.8. Normal endoscopic view of the gastroesophageal junction showing the red velvet appearance of the gastric mucosa and folds and the pale color of the esophagus.



Figure 69.9. Endoscopic view of a hiatus hernia showing the distant pinching of the stomach by the diaphragm and the gastric folds proximal to this.

The esophagus can also be divided into thirds in terms of its muscle type. The proximal third consists purely of striated muscle fibers, the distal third entirely of smooth muscle fibers, and the middle third of a mixture of the two, with a greater proportion of smooth muscle fibers as the esophagus is followed caudally. The circular muscle fibers change from striated to smooth muscle type more proximally than those of the longitudinal muscle layer (Fig. 69.11).

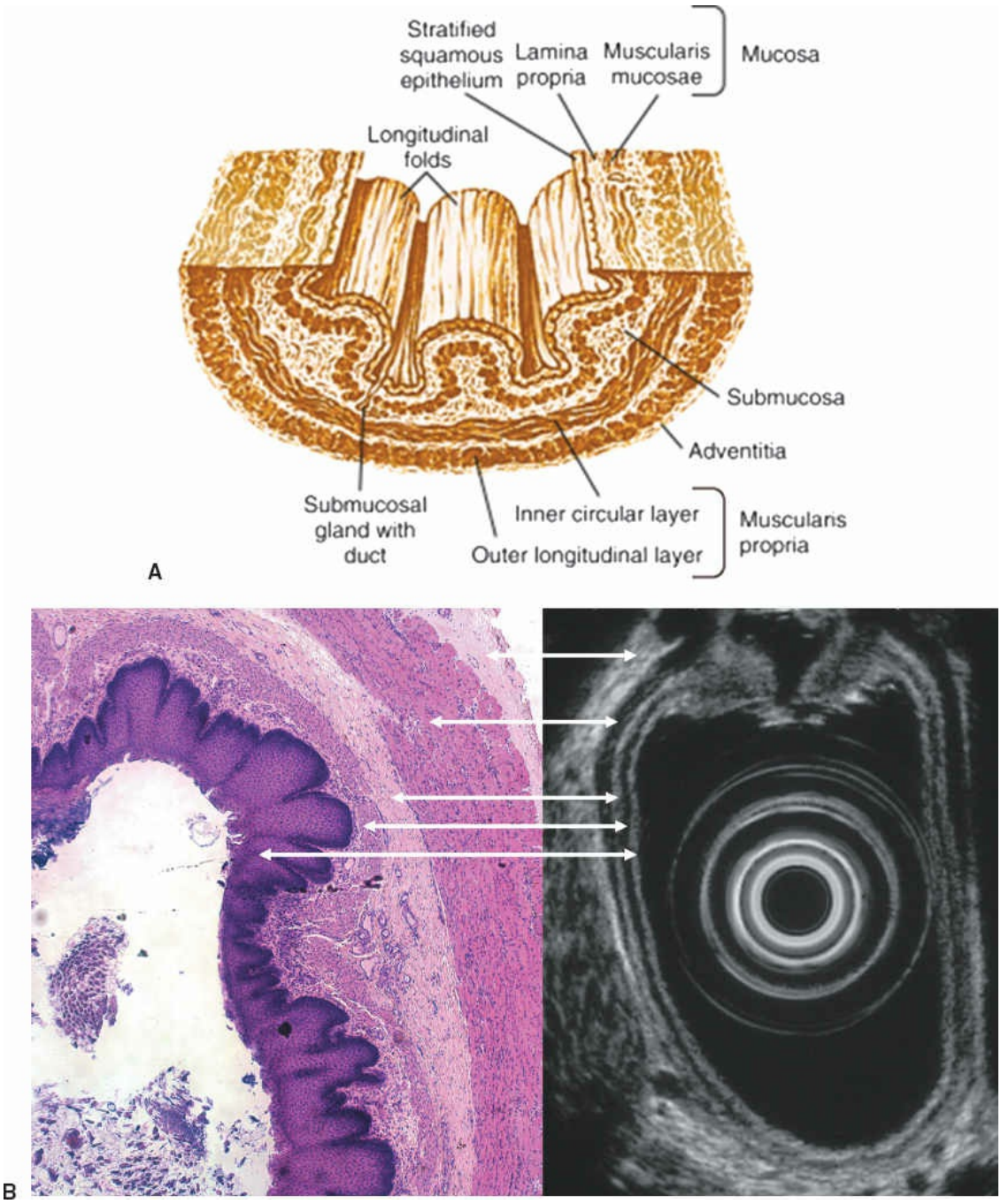

Figure 69.10. A. Histology of the esophagus. (Published in Long J, Orlando R. Anatomy, histology, embryology, and developmental anomalies of the esophagus. In: Feldman MS, ed. *Sleisenger and Fordtran's Gastrointestinal and Liver Disease*. 8th ed. Philadelphia; 2009, with permission. Copyright Elsevier 2009.) **B.** Axial endoscopic ultrasound image (right) and histologic specimen (left) from a normal esophagus. The endoscopic ultrasound layers and histologic layers of the esophagus are correlated. (From Kelsey CR, Chino JP, Christensen JD, Marks LB. Oncologic Imaging/Oncologic Anatomy. In: Halperin EC, Wazer DE, Perez CA, Brady LW, eds.

Perez and Brady's Principles and Practice of Radiation Oncology, 6th ed. Philadelphia; 2013, Lippincott Williams & Wilkins.)

Clinical and Surgical Points of Interest

Endoscopic ultrasound shows a characteristic alternation of hyperechoic and hypoechoic bands representing the different layers of the esophageal wall (Fig. 69.10), and aiding especially in the diagnosis of intramural and extramural masses as well as in distinguishing a T1a (intramucosal) from T1b (submucosal) tumors, standard esophagoscopy not being able to contribute this level of detail.

The helicoidal muscle course aids peristalsis and results in significant elastic recoil, thereby making it challenging to measure distances after resection and difficult, if not impossible, to resect an even short segment of esophagus and fashion an esophagoesophageal anastomosis, for example, in the case of trauma, short stricture, or small tumor. In addition, the mucosa can retract several millimeters inside the muscular coat, when the esophagus is transected, making it important to identify and catch both the mucosal and the muscle layer in each suture when performing an esophageal anastomosis.

It may be difficult to discriminate between true (organic) esophageal shortening caused by fibrosis due to chronic reflux esophagitis and that present in cases of—usually large—mixed hiatus hernia due to changes in elastic recoil caused by helicoidal retraction. The amount of shortening of the tubular esophagus in such hernias can be determined by measuring the distance between the distal border of the upper sphincter and proximal border of the LESs, endoscopically or manometrically determined. Contrast X-ray and endoscopic and manometric information are therefore required before embarking on laparoscopic repair of such a hernia to ensure success. Some authors consider a hiatal hernia of >5 cm as well as a large mixed hernia a contraindication for an abdominal—open or laparoscopic—approach.

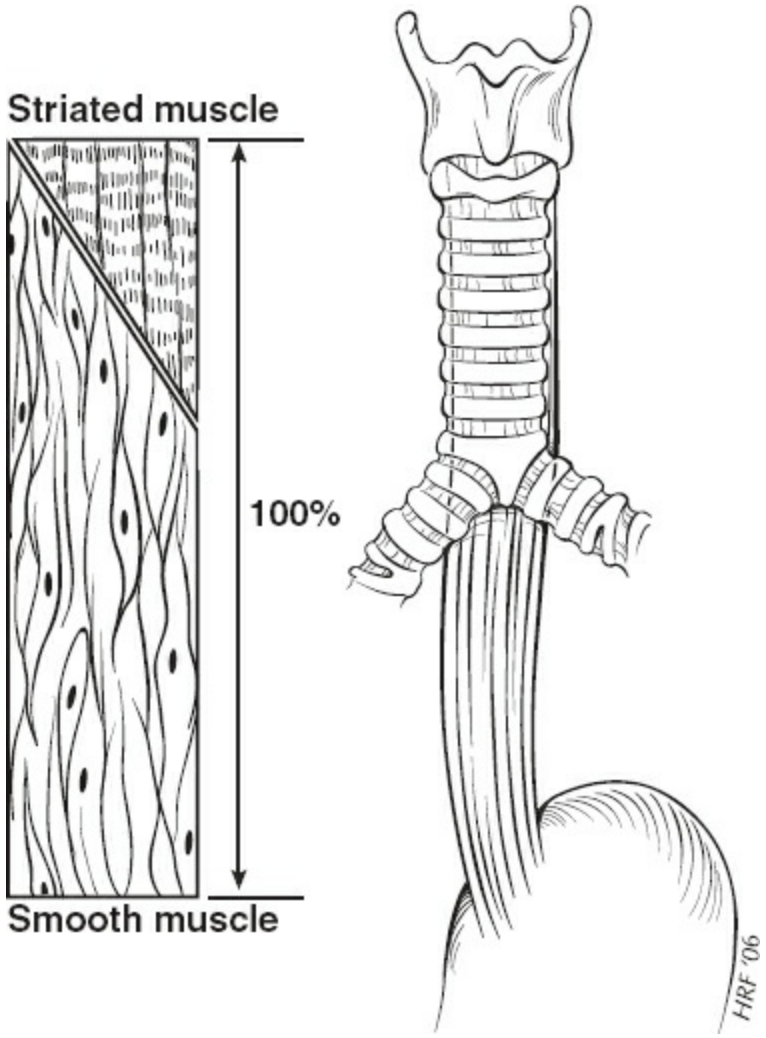

Figure 69.11. Graduation of striated to smooth muscle fibers.

Motility disorders of the esophagus do not involve the proximal esophagus as these are diseases affecting smooth muscle.

Barrett esophagus is a change of the tubular esophageal mucosa from a normal squamous epithelium. Endoscopically it is seen as a velvet red mucosa in the tubular esophagus. Moreover, there is variation in the height of the Z-line—the endoscopically determined transition between the whitish squamous epithelium and the red columnar epithelium, thus making the diagnosis of Barrett esophagus challenging. It is crucial therefore to describe where biopsies are taken from. For this, one must first accurately identify the GEJ (see earlier) and the proximal extent of the squamocolumnar junction, and tongues of Barrett metaplasia if present. According to the American College of Gastroenterology, the contemporary definition of Barrett esophagus requires two major components—a proximally displaced squamocolumnar junction as seen on endoscopy and the identification of acid-mucin–containing goblet cells, that is, specialized

intestinal metaplasia (SIM) in a biopsy from the area of endoscopic abnormality. Based on the length of the columnar segment in the distal esophagus, Barrett esophagus has been arbitrarily divided into short segment (<3 cm) or long segment (≥3 cm). Biopsies in these areas always require the presence of columnar epithelium (columnar epithelium lined lower oesophagus [CELLO]) with presence of intestinal metaplasia. However, biopsies from a macroscopically normal-looking squamocolumnar junction can also contain intestinal metaplasia, considered to be the result of carditis. Studies have shown that progenitor cell populations (stem cells) in the basal layer of the squamous epithelium and in the duct epithelium of the esophageal glands may differentiate into a glandular phenotype, leading to the development of columnar epithelium in the distal esophagus. It is believed that this is the mechanism that results in the development of Barrett esophagus as the result of the healing process in patients suffering from reflux esophagitis, in particular in the presence of mixed acid and biliary reflux.

ARTERIAL SUPPLY

Description

The arterial blood supply to the esophagus tract is segmental (Fig. 69.12). The cervical part of the esophagus is supplied by branches of the inferior thyroid artery from the thyrocervical trunk. Other less consistent arterial blood supply comes from the pharyngeal, subclavian, common carotid, superior thyroid, and vertebral arteries and the costocervical trunk. The upper thoracic esophagus is primarily supplied by branches from the inferior thyroid artery more on the right than the left, and less consistently from an anterior esophagotracheal branch directly from the aorta. The midesophagus, at about the level of the tracheal bifurcation, is supplied by branches of the bronchial arteries or directly from the aorta. The superior bronchial artery originates just below the aortic arch. The vessels are straight and short. The middle and lower thoracic esophagus are supplied by a single short bronchoesophageal branch that arises directly from the ventral surface of the aorta and more variable one or more obliquely coursing unpaired branches arising directly from the aorta. The lowest thoracic and the intra-abdominal segments are supplied by small branches of the left gastric artery and possibly also branches from the left inferior phrenic artery. All branches are small and after supplying the muscularis pass transversely through the outer layers of the esophagus into the

submucosa, where they form rich arterial anastomoses.

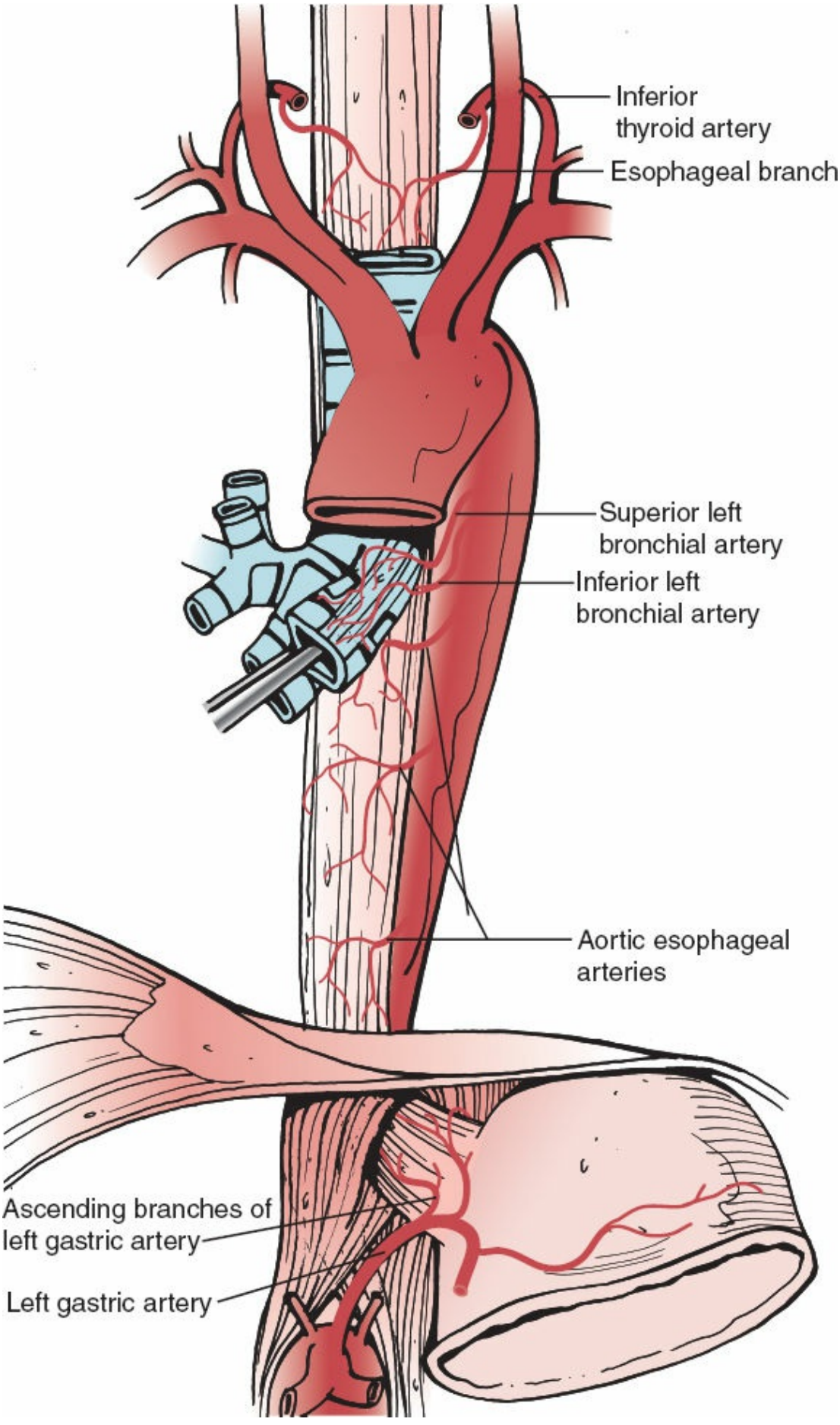
Inferior thyroid artery
Esophageal branch
Superior left bronchial artery
Inferior left bronchial artery
Aortic esophageal arteries
Ascending branches of left gastric artery
Left gastric artery

Figure 69.12. View of posterior mediastinum with lungs and heart removed, and upper abdomen, showing arterial branches supplying the esophagus. Inset is the anatomic variant of the arterial supply to the distal tubular esophagus and the gastroesophageal junction.

Clinical and Surgical Points of Interest

This arrangement of the arteries accommodates a transhiatal approach to the esophagus for resection, as blunt digital dissection peels these branches off resulting in minimal blood loss and vascular compromise. There is debate about the segmental nature of the arterial supply to the esophagus, with some arguing that this leads readily to devascularization and ischemia. Others feel that the esophagus maintains an excellent blood supply over a long distance and seldom can a failed anastomosis be attributable to its esophageal arterial arrangement. In fact, the rich intramural arterial anastomoses allow an extensive mobilization of the esophagus without compromising its viability. However, extensive devascularization of the tubular esophagus may result occasionally in necrosis, for example, after stenting procedures for very large aneurysms of the aorta starting from the aortic root down to a point below the offspring of the mesenteric artery.

VENOUS DRAINAGE

Description

The venous drainage is also segmental (Fig. 69.13). Subepithelial venous plexi in the lamina propria run longitudinally along the whole length of the esophagus, receiving blood from adjacent capillaries, and drain into the submucous plexus (the intrinsic esophageal venous plexus), then into an extrinsic esophageal venous plexus and thereon into nearby larger veins. The upper esophageal veins drain into the inferior thyroid vein, the brachiocephalic vein, and sometimes directly into the internal jugular vein. The upper thoracic esophageal veins drain into the bronchial, posterior intercostal, azygos, hemiazygos, and accessory azygos veins. Studies of the GEJ have shown perforators from the submucous plexus penetrating the muscle coat to become longitudinal veins that then drain into the inferior phrenic and left gastric veins. Again, venous drainage is variable. The venous plexus on the surface of the abdominal esophagus continuous

with the cardia has many interconnecting pathways to the portal venous system.

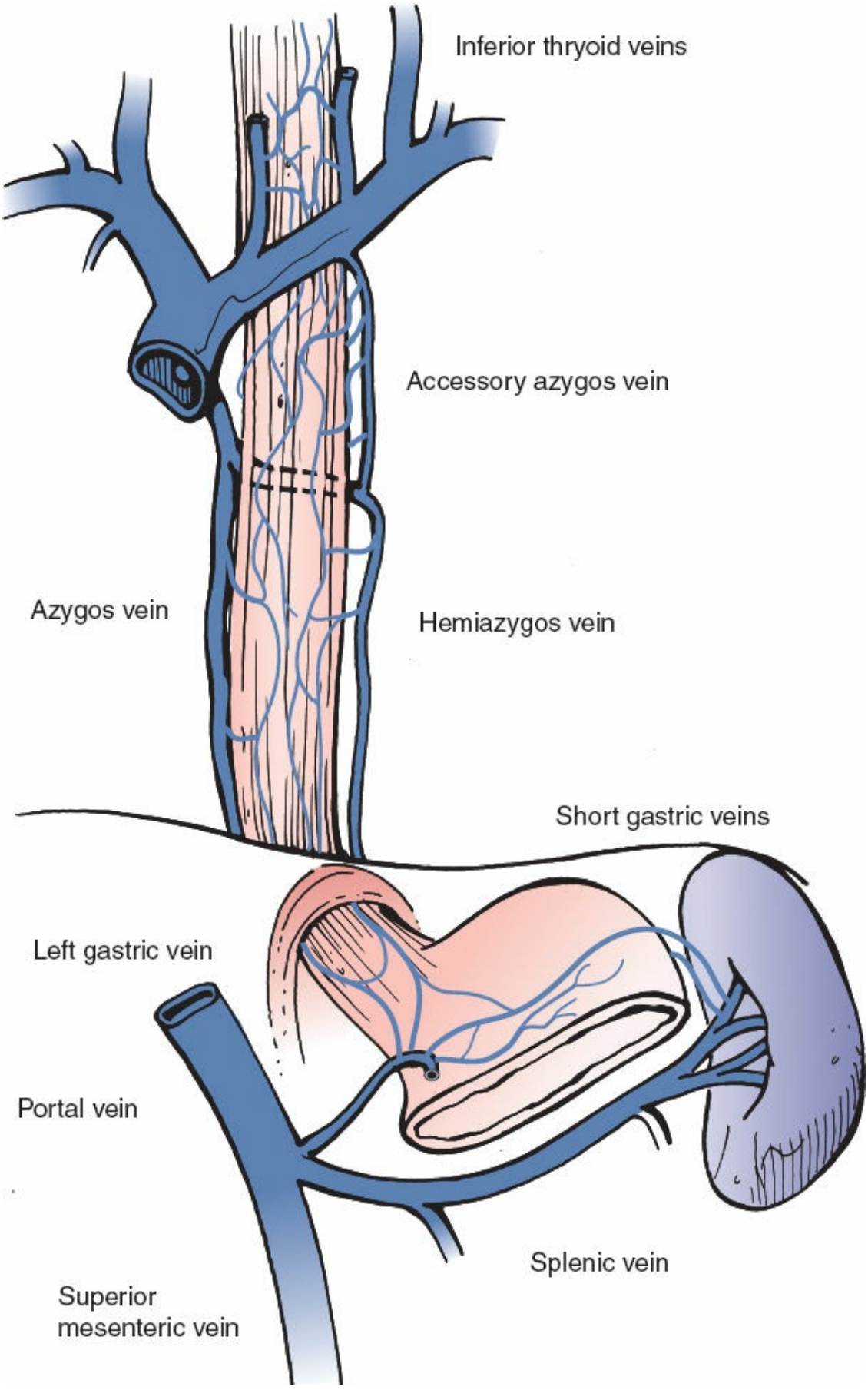

Figure 69.13. View of the posterior mediastinum with lungs and

heart removed, and upper abdomen, showing the venous drainage of the esophagus. Inset is a view of the mucosal veins of the distal esophagus and the gastroesophageal junction.

Clinical and Surgical Points of Interest

The azygos vein can be easily injured in resections of the esophagus particularly in a transhiatal approach, and if tumor is adherent in midthird esophageal cancers. In a right-sided approach to the esophagus for malignancy by thoracotomy or a minimally invasive approach using video-assisted thoracoscopy, the arch of the azygos vein can be divided to allow access to the proximal esophagus and lymph nodes adjacent to the distal trachea, right main bronchus, and recurrent laryngeal nerve.

The rich plexus of interconnecting pathways linking the hepatic portal venous system with the caval veins allows for a diversion of flow in cases of portal venous obstruction leading to dilatation and the formation of varices at the lower end of the esophagus.

LYMPHATIC DRAINAGE

Description

Lymphatic drainage, unlike the arterial blood supply and venous drainage, is not segmental. Moreover, in comparison with other hollow gastrointestinal organs, the esophagus has a unique mucosal lymphatic arrangement. According to electron microscope studies, anastomotic lymphatic capillaries exist in the lower mucosal layers of the esophagus. Mucosal and submucosal lymphatics form a complex interconnecting network that extends the length of the esophagus and exceeds capillaries in number. There are valved lymphatics in the submucosa preferentially coursing longitudinally for large distances, but occasionally perforating the muscle coats interconnecting with subadventitial channels (Fig. 69.14) and then on into outer surface lymphatic trunks. Up to 43% of autopsy studies have shown a direct drainage from the submucosal plexus into the thoracic duct. Studies show that the lymphatics relate to a transverse plane, a divide at the level of the tracheal bifurcation, such that the majority of lymph flow is up to the paratracheal and cervical lymph nodes and down to lower mediastinal and gastric/celiac nodes from this plane (Fig. 69.15). The arrangement of the lymph nodes is in three orders. The most superficial lymph nodes, comprising the first order, are the paraesophageal ones lying

in the periesophageal fatty tissue. The second-order nodes are the mediastinal nodes and those found along the aorta or proximal branches of it; the deep cervical and supraclavicular lymph nodes; and those along the lesser curvature, the left gastric artery, and the coeliac axis. The third-order lymph nodes are more peripheral and consist of the lateral clavicular, pulmonary hilar, splenic hilar/greater curvature, and common hepatic artery lymph nodes. All lymphatics drain into the main thoracic ducts, which have a well-organized system of valves to promote flow against gravity. Classifications (e.g., by the AJCC) have been devised with accompanying lymph node maps to identify regional esophageal and extraregional lymph nodes. Figure 69.16A,B identifies the regional lymph node stations for esophageal cancer including cancer of the EGJ.

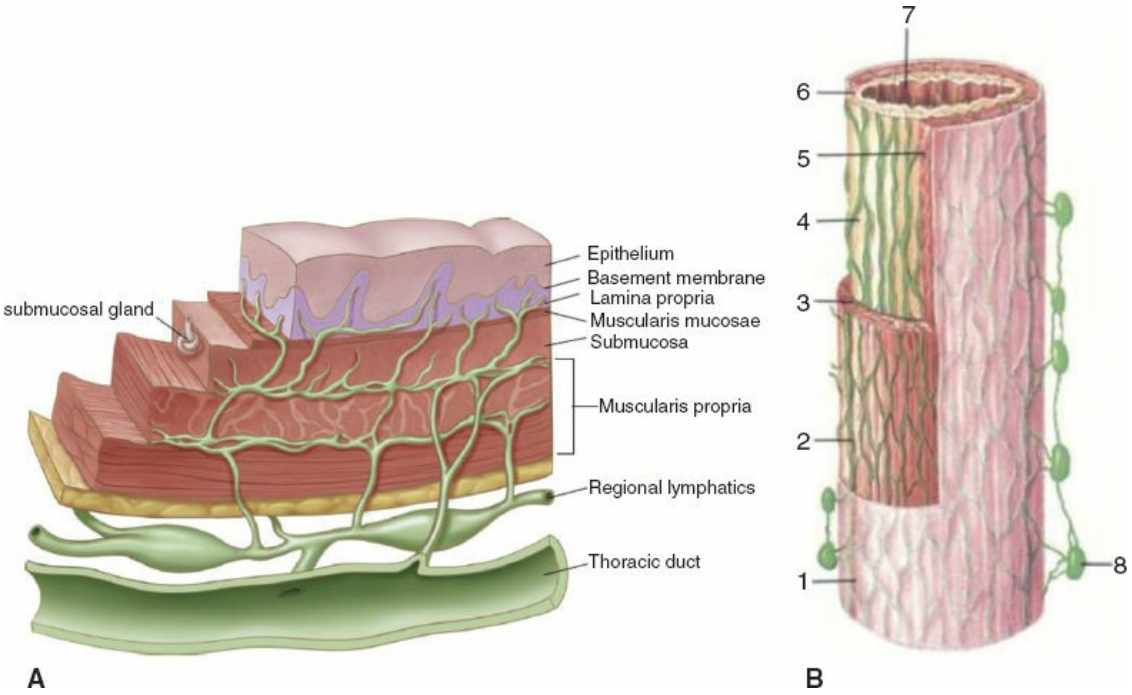

Figure 69.14. A. Schematic showing lymphatics and direction of lymph flow in the mucosa and the submucosa. **B.** Interconnection of mucosal–submucosal network and muscular lymphatic network (with long intramural lymphatics) and paraesophageal lymph nodes. (Reprinted from Rice TW, Bronner MP. The Esophageal Wall. *Thorac Surg Clin* 2011;21(2):299–305. Copyright © 2011, with permission from Elsevier.)

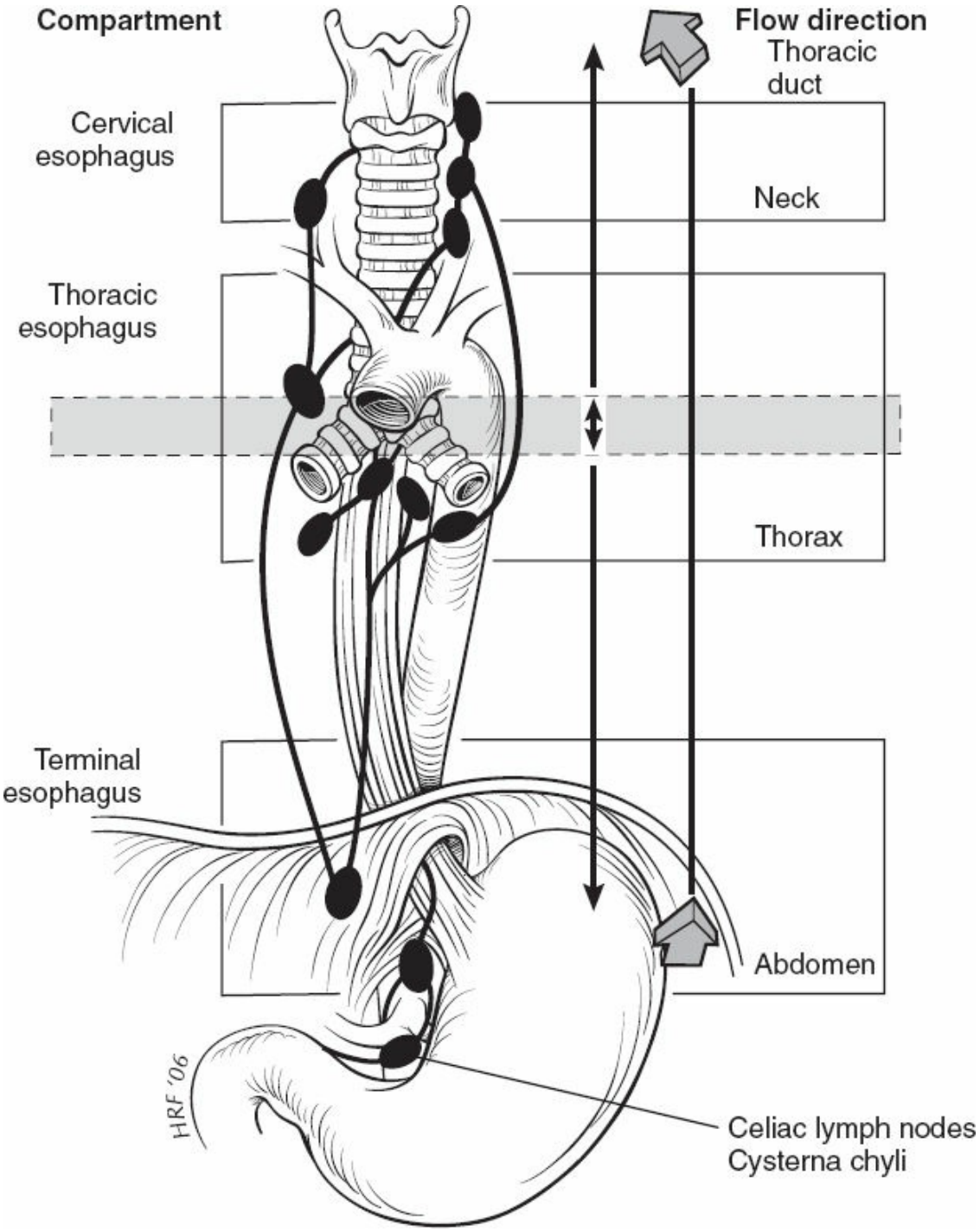

Figure 69.15. Diagram showing lymph flow in relation to the tracheal bifurcation. Lymph above the bifurcation flows cranially to the paratracheal and cervical nodes; below it drains caudally to the lower mediastinal, gastric, and celiac nodes.

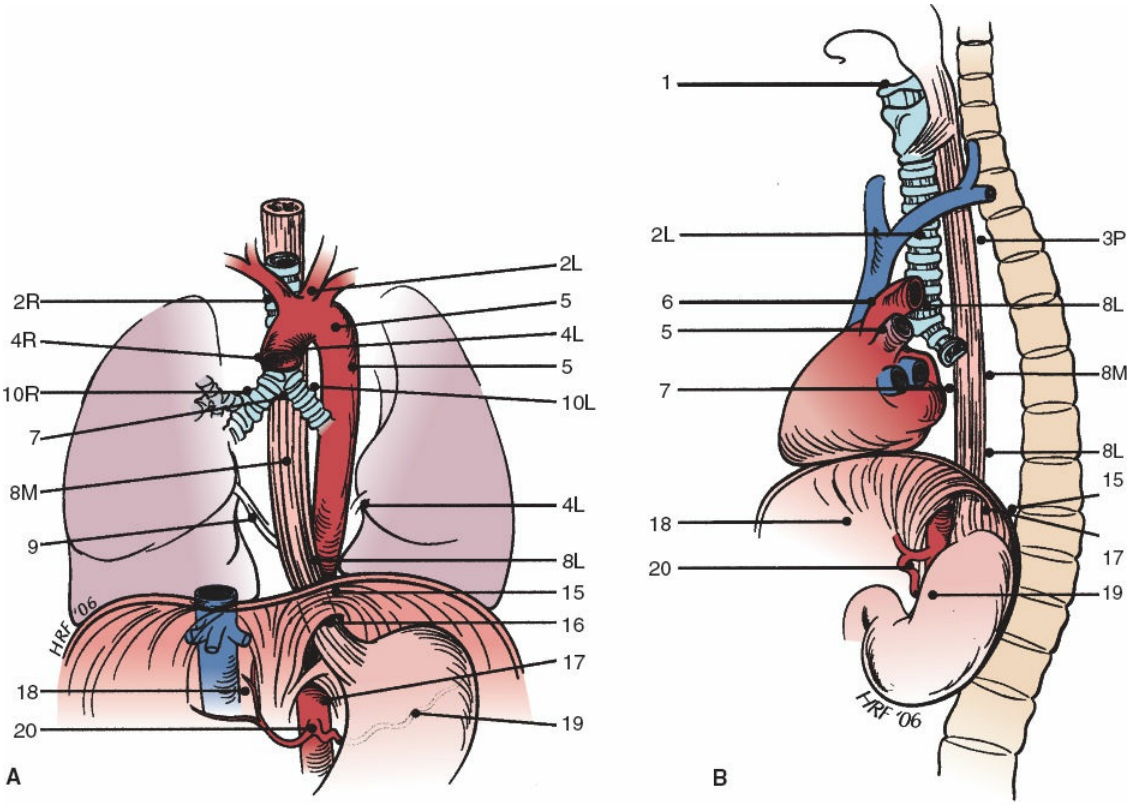

Figure 69.16. A, B. Esophageal lymph node map of the AJCC. (Adapted from Edge SB, American Joint Committee on Cancer: *AJCC Cancer Staging Manual*. 7th ed. New York, NY: Springer 2010;107; permission conveyed through the Copyright Clearance Center, Inc.)

Clinical and Surgical Points of Interest

Cancer cells that invade through the basement membrane of the epithelium may enter the small lymphatics in the lamina propria and then into the submucosal lymphatics that extend the entire length of the esophagus, and the communication of these submucosal lymphatics vessels with the surface lymphatic trunks provides the means for both longitudinal and lateral spread of cancer cells. Because the lymphatic channels are very close to the mucosa, even a stage T1 tumor can have early intramural dissemination and spread some distance along this layer. Because of the preferential longitudinal coursing of lymph, skip lesions can occur. In addition, this lymphatic arrangement explains the high postoperative recurrence rate at the resection margin when a limited resection is performed, and favors a subtotal esophagectomy even in distal third tumors. This also explains why esophageal tumors may extend over a long distance within the esophageal wall before obstructing the esophageal

lumen. Also, a tumor in the upper esophagus could have lymphatic drainage to below the diaphragm, resulting in involvement of the gastric and celiac lymph nodes and even as far as the renal hilum. Similarly, a distal third as well as a gastric cardia tumor may result in positive nodes above the clavicle (Fig. 69.17). Lymph node metastasis in tumors limited to the mucosa (T1a) is a rare event. Therefore in most cases, that is, when the tumor is of limited diameter (<2 cm), endomucosal resection (EMR) eventually combined with radiofrequency ablation in an area of surrounding Barrett metaplasia has become the treatment of choice. In T1b (tumor extending into the submucosa), however, lymph node involvement is frequent with a reported incidence between 30% and 50%. This has been ably demonstrated by various authors. Besides intramural tumoral skip lesions, skip metastases in lymph nodes can occur in such early-stage carcinoma. This early event questions the value of sentinel node detection. The number and level of lymph nodes define the staging and prognosis in the treatment of esophageal carcinoma. Clearance of these nodes determines the residual lymph node disease burden. Approaches that do not allow access to these lymph nodes could be considered inadequate for the purpose of oncologic resection. There is strong evidence that shows that a two- or three-field clearance in appropriate cases gives superior results. In addition, the preferential spread orally of supracarinal tumors and aborally of infracarinal tumors may influence the decision of the route of access. A right thoracic approach may be favored for a supracarinal tumor and a left approach for infracarinal tumors. The thoracic duct is a flimsy structure not easily seen due to its collapsed state, and can be damaged at the time of surgery, resulting in a chylothorax, a potentially life-threatening complication. This can be dealt with by ligating it behind the esophagus in its lowest thoracic level.

The occurrence of lymphatic metastasis in the very early stage of the disease should be kept in mind when using minimally invasive surgery. There is no reason not to perform an adequate lymph node clearance once a tumor penetrates into the submucosa (T1b) given the high incidence of lymph node involvement. Therefore, surgeons using thoracoscopic and laparoscopic approach should familiarize themselves with these lymphadenectomies through the thoracoscope and laparoscope.

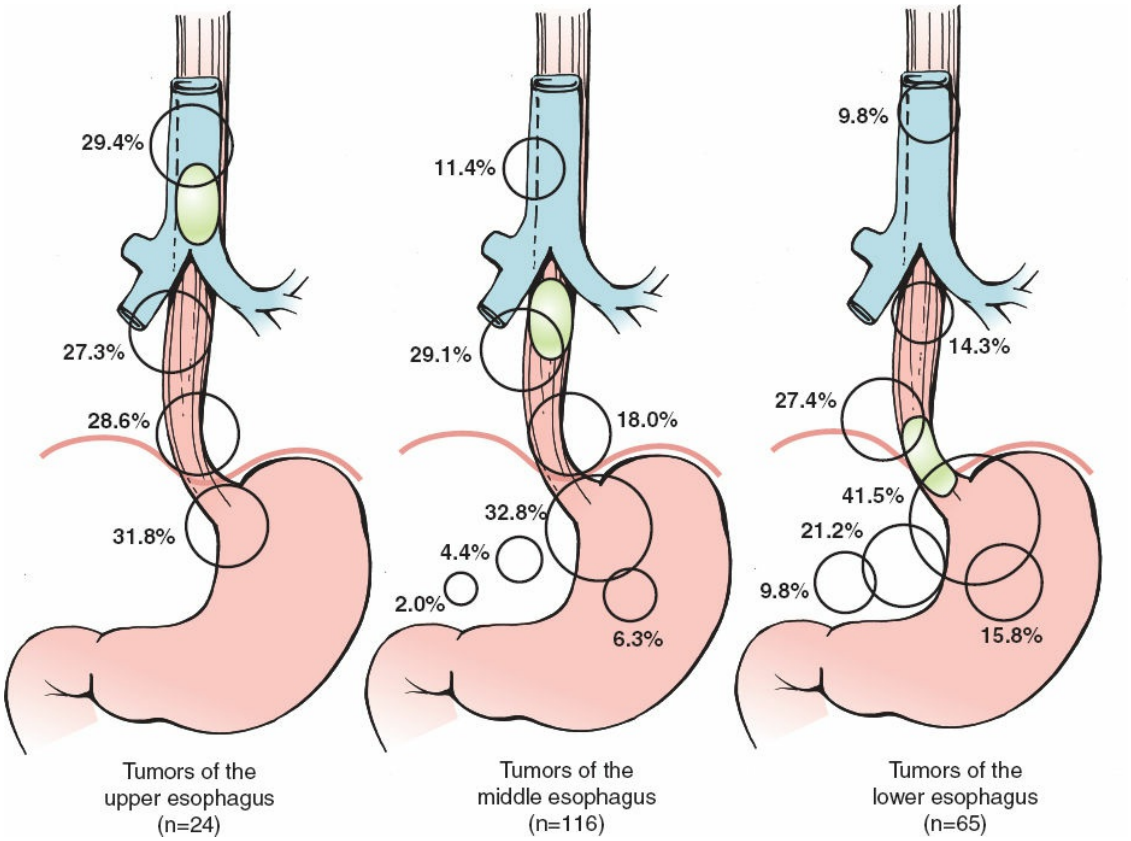

Figure 69.17. Ratio of lymph nodes involved by esophageal tumor to the number of resected cases. (Adapted from Akijama H, Tsurumaru M, Udagawa H, et al. Principles of surgical treatment for carcinoma of the esophagus: analysis of lymph node involvement. *Ann Surg* 1994;220:364.)

Another source of concern when using minimally invasive techniques is the completeness of resection in the more advanced tumor stage (T3). Minimally invasive surgery may require more manipulation as compared with an open approach. Also, the technique of wide peritumoral *en bloc* resection may be more difficult, an incomplete resection with positive lateral margins (R1) being the result, and thus jeopardizing the chance for cure.

NERVE SUPPLY

Description (Fig. 69.18)

The esophagus has a rich nerve supply, both extrinsic and intrinsic (intramural), and controls striated and smooth muscle, glands, and blood vessels. The innervation has parasympathetic and sympathetic components.

The parasympathetic innervation of the esophagus is provided by the vagal nerves. The visceral efferent and efferent cell bodies are located in the dorsal vagal nucleus. The fibers that innervate the striated muscles of the pharynx and the upper segment of the esophagus originate in the nucleus ambiguous. The pharyngoesophageal junction is innervated by the pharyngeal plexus, which is located on the middle constrictor muscle of the pharynx. Smaller branches coming from the 9th and 11th cranial nerve also arrive via the vagal nerves.

By giving off branches to the pharynx, larynx, and trachea, a cervical plexus is formed that also supplies the proximal striated muscles of the esophagus.

The nerve endings of these plexuses make direct synaptic contact through the motor endplates. Both the superior and inferior (recurrent) laryngeal nerves originate from the vagus. The superior laryngeal nerves innervate the intrinsic muscles of the pharynx, hypopharynx, and larynx.

The right recurrent laryngeal nerves originate on the right vagal nerve in front of the subclavian artery, the left one on the left vagal nerve at the lower margin of the aortic arch, lateral to the ligamentum pulmonale. They then swing around these vessels and ascend in the groove between the trachea and the esophagus, giving off a number of branches to both the trachea and proximal intrathoracic and cervical esophagus. Some branches take part in the innervation of the cricopharyngeal muscle. The left recurrent nerve is most pronounced and closest to the esophagus located behind the medial plane of the thyroid entering the larynx just below the cricopharyngeal muscle.

The right recurrent nerve lies somewhat more laterally away from the esophagus when turning around the brachiocephalic trunk. It also divides in several branches before entering into the larynx. The vagal nerves running down pass behind the hilum of the lungs, giving off several small branches to the lungs. The vagal nerves join with fibers of the sympathetic chain to form the esophageal plexus. That is to say that there is intertwining of the left anterior vagus and the right dorsal vagus nerve resulting in a great variation in how both the anterior and posterior vagal nerves split and interconnect. But the result is that both the anterior and posterior vagus trunks contain fibers of the left and right vagus through intertwining when they reorganize at a variable distance from the cardia into two thick trunks running down on the esophageal wall. Together with the esophagus, the vagi pass through the diaphragm to continue their

course along the lesser curvature of the stomach. Finally they divide into several branches on the anterior surface of the stomach—the crow's foot or Latarjet nerve. Branches of the vagus pass laterally to the liver through the gastrohepatic ligament—the hepatic vagal branches—to control gallbladder function. Other branches run along to the hepatic artery, porta hepatis, left gastric artery, and celiac plexus.

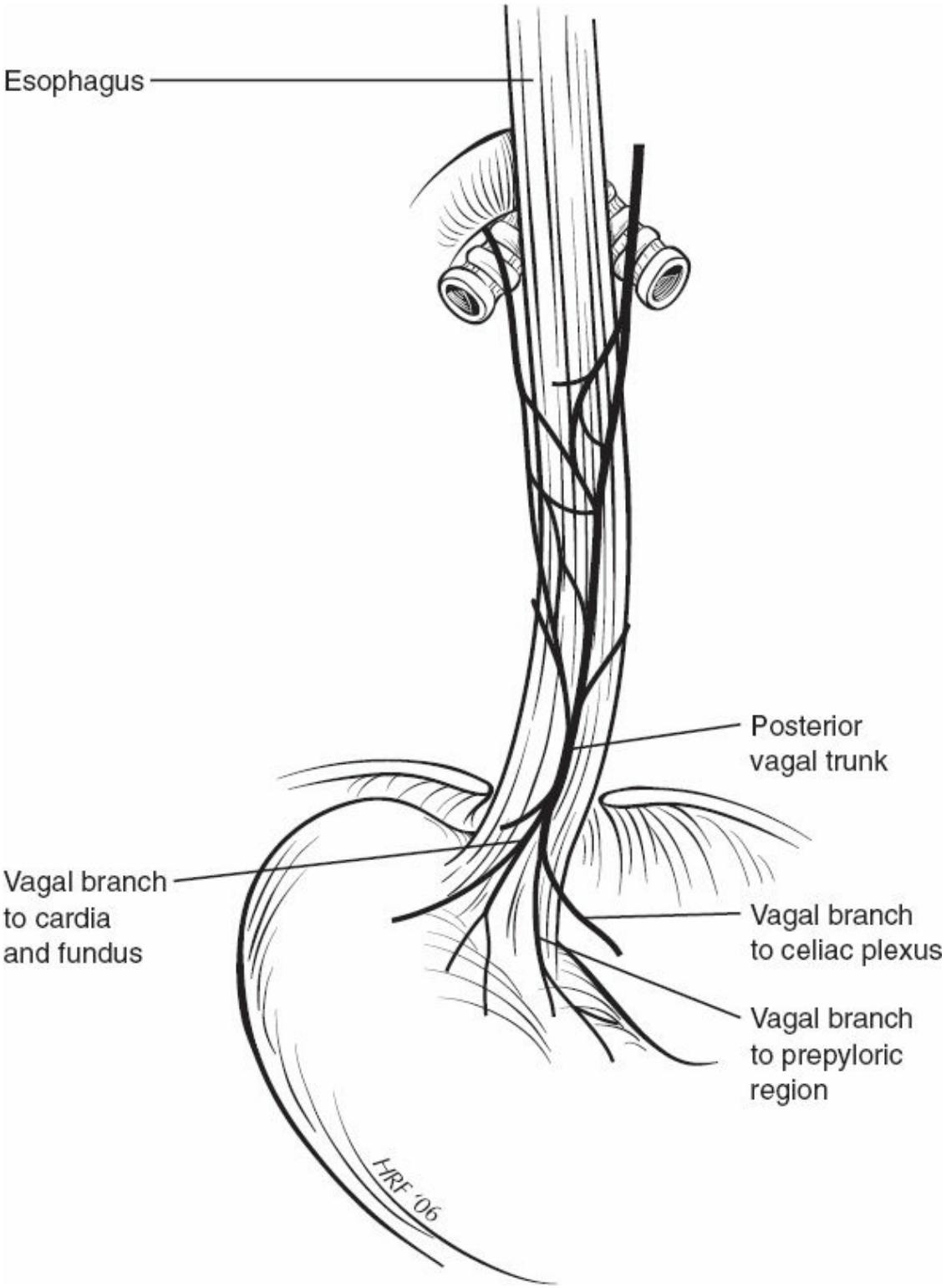

Figure 69.18. Posterior mediastinum with heart and lungs removed; upper abdomen, showing the vagal nerves and nerve plexuses; and sympathetic trunks surrounding and coursing with the esophagus.

The sympathetic nerve supply comes from the cervical and thoracic

sympathetic chain. Sympathetic nerves are involved in motor function of esophageal peristalsis and relaxation, contraction of sphincters, vasoconstriction, and secretory controls of glands. The preganglionary fibers arise from cell bodies in the spinal marrow at the level of T4–T5–T6, leaving the spine via the ventral roots. They make synapse with the corresponding ganglions of the sympathetic chain. The postganglionary fibers reach the esophagus via nerve branches taking off from the sympathetic chain. Some reach the esophageal wall directly, others join the vagal trunk. Thus, the vagal trunks contain postganglionary fibers. The sympathetic fibers form together with the vagal esophageal plexus a dense network between and around the esophagus. The distal esophagus also receives direct sympathetic nerves coming from the celiac ganglion via the periarterial plexus around gastric and phrenic arteries.

The intrinsic nerve supply consists of Meissner plexus in the submucosa and Auerbach (myenteric) plexus in the connective tissue between the longitudinal and circular muscular layers. These contain multipolar ganglion cells and receive afferents from the vagus, sympathetic, and parasympathetic branches via penetrating blood vessels. The fine control of the muscle coat contraction and LES relaxation is by the fibers of the myenteric plexus by nonadrenergic, noncholinergic nitric oxide–mediated inhibition of excitatory neurones, mediated by the interstitial cells of Cajal. Postganglionic fibers of Meissner plexus coordinate peristalsis of the muscularis mucosae and the secretory function of the esophagus. Auerbach plexus regulates the contraction of the muscle coats. All plexuses are interconnected by a network of fibers.

Clinical and Surgical Points of Interest

The recurrent laryngeal nerve is vulnerable in dissections and interventions in the neck, and is not always readily identifiable, in particular on the right side. This is the reason why the left-sided approach is preferred by most surgeons, for example, when performing an anastomosis between the cervical esophagus and gastric tube after esophagectomy. It can also be damaged in the chest at the level of the brachiocephalic trunk on the right, the aortopulmonary window, and more cranially on the left side. Partial and complete paralysis of the vocal cords gives differing symptoms of voice change, difficulties in swallowing, and loss of protection of the airway, leading to aspiration.

It is proposed that the myenteric plexus is involved in diseases of

dysmotility such as achalasia due to decreased numbers of nitric oxide synthetase–producing neurones that cause inhibition of the excitatory intermediate neurones. Recently there has been some evidence produced for viral-induced damage to the myenteric plexus in achalasia. A similar situation exists in Chagas disease where a *Trypanosoma cruzi* infection causes loss of intramuscular ganglion cells. The sharing of visceral afferents allows confusion of symptoms. Thus, esophageal pathology may give symptoms misinterpreted as cardiac pain. Also, in addition to gastroesophageal reflux causing nocturnal aspiration and asthma, there is evidence of acid-mediated reflex bronchoconstriction caused by a vagally mediated reflex, local axonal reflexes, heightened bronchial reactivity, and microaspiration, all resulting in neurogenic inflammation. Damage to the vagal nerves in antireflux surgery will cause dumping, decreased gastric emptying, failure of relaxation of the pyloric outlet, and diarrhea. In particular, the anterior vagal nerve is at risk when performing laparoscopic antireflux surgery as it is barely visible and distinguishable under the phrenoesophageal membrane.

ANATOMICAL RELATIONS

Description

Knowledge of the anatomical topography of the esophagus is imperative before embarking on esophageal surgery. Above the clavicle, the esophagus lies posterior to the trachea, separated by loose areolar tissue from its membranous part (Fig. 69.19). The pretracheal fascia covers the trachea and esophagus and diverges to wrap round the thyroid gland. The buccopharyngeal fascia acts as a sheath that extends caudally from posterior to the pharyngeal muscles to the posterior wall of the esophagus, and laterally to the carotid sheath. Posterior to this is first the alar fascia and then the prevertebral fascia. Thus, a paraesophageal (anterior to the buccopharyngeal fascia) and a retroesophageal space (posterior to the fascia) exist. The recurrent laryngeal nerve lies in the tracheoesophageal groove, the left more closely applied than the right due to the right recurrent nerve wrapping round the brachiocephalic trunk. The inferior lobe of the thyroid gland extends to reach a position anterolateral to the esophagus and the middle thyroid vein and inferior thyroid artery anterolateral to that (Fig. 69.20A). Lateral to the thyroid structures is the carotid sheath with the common carotid artery the most medial. The thoracic duct lies to the left of the esophagus, its highest point being about

4 cm above the clavicle as it drains into the venous confluence.

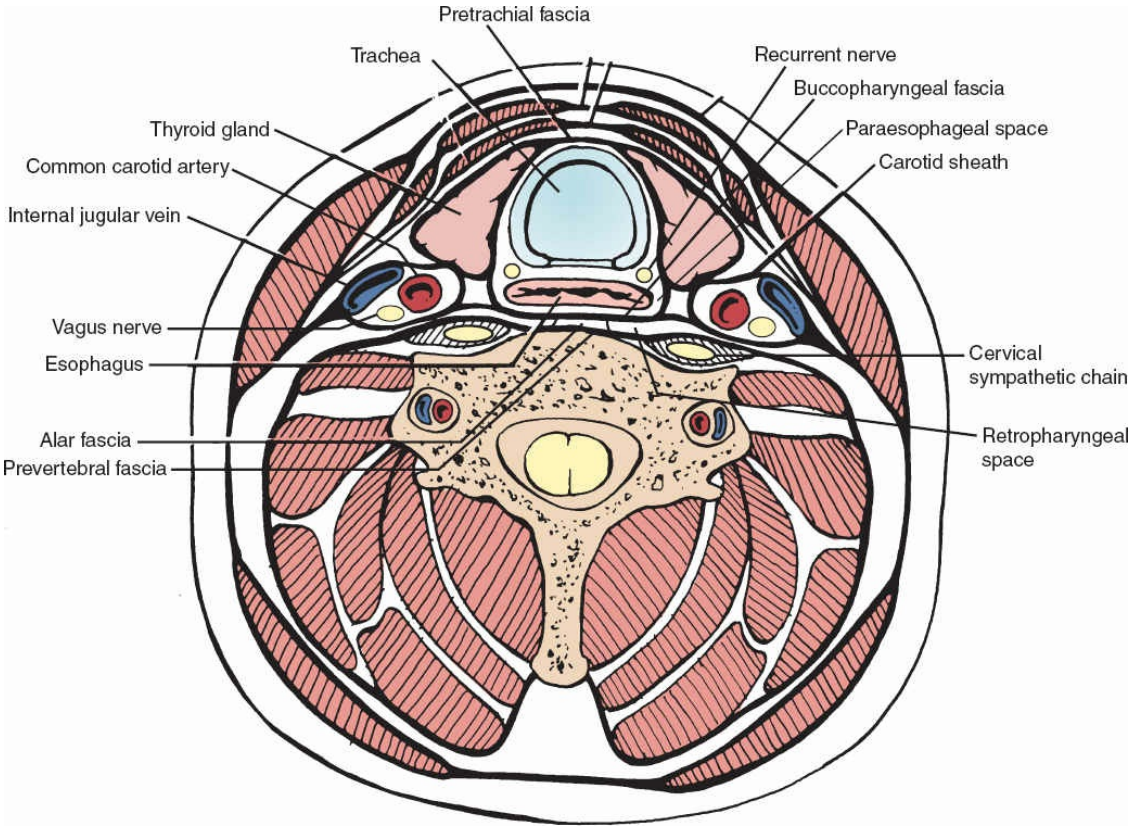

Figure 69.19. Schematic of cross-section of cervical esophagus with anatomically related structures and the paraesophageal and retroesophageal spaces. VII denotes the seventh cervical vertebra. Cross-section of the neck at the level of the thyroid isthmus.

After passing into the thorax, the esophagus gradually inclines to the left, as can be seen on computer tomography reconstruction (Fig. 69.20) and runs posterior and medial to the aortic and azygos arches and the left main bronchus. Its course continues to the right of the descending thoracic aorta. The left and right mediastinal pleura abut it laterally, and the left recurrent laryngeal nerve lies lateral to it (Fig. 69.20). The thoracic duct is in a posterolateral position. At the level of the tracheal bifurcation, the esophagus is in a midline position behind the subcarinal lymph nodes, with the thoracic duct crossing immediately posterior to it.

Below the tracheal bifurcation (Fig. 69.20), the esophagus runs to the right of the descending aorta, posterior to the fibrous pericardium and in between the left and right mediastinal pleura (Fig. 69.20). The anterior and posterior vagal trunks run longitudinally on the esophageal surface, and

the esophagus passes through the diaphragm to the left of the midline into the abdomen (Fig. 69.20). As it does so, there is a fat pad that marks the position of the superior margin of the phrenoesophageal ligament or membrane (Fig. 69.21), a condensation of pleura, endothoracic fascia, transversalis fascia, and the peritoneum, that consists of two sheaths. The upper one is inserted into the lower 1 to 3 cm of the thoracic esophagus. Although the fibers of this sheath are mainly inserted into the outer muscular layer of the esophagus, some penetrate the wall as far as the submucosa. The lower sheath is inserted into the cardia but is separated from the GEJ by a fat pad and loose areolar connective tissue. At the level of the gastric fundus below the cardia, the fibers of this lower sheath disappear into the serosa and the gastrohepatic and gastrosplenic ligament. As a result, the phrenoesophageal membrane is well developed anteriorly but weak posteriorly. Elastic and collagenic fibers are its main elements at histologic examination. They are arranged in bundles forming a meshwork resulting in the necessary strength and plasticity to cope with the continuous respiratory movements of the diaphragm. The phrenoesophageal segment acts as a barrier between the negative intrathoracic pressure and the positive abdominal pressure. It provides at the same time an airtight seal between the thoracic and abdominal cavities. Studies of patients of different ages have suggested that the inferior leaf of the phrenoesophageal ligament is weaker than the superior and with advancing age the ligament ascends into the thorax. The esophagus parts company with the aorta as it descends into the abdomen, moving anteriorly to reach the esophageal hiatus, the aorta passing posteriorly to the median arcuate ligament.

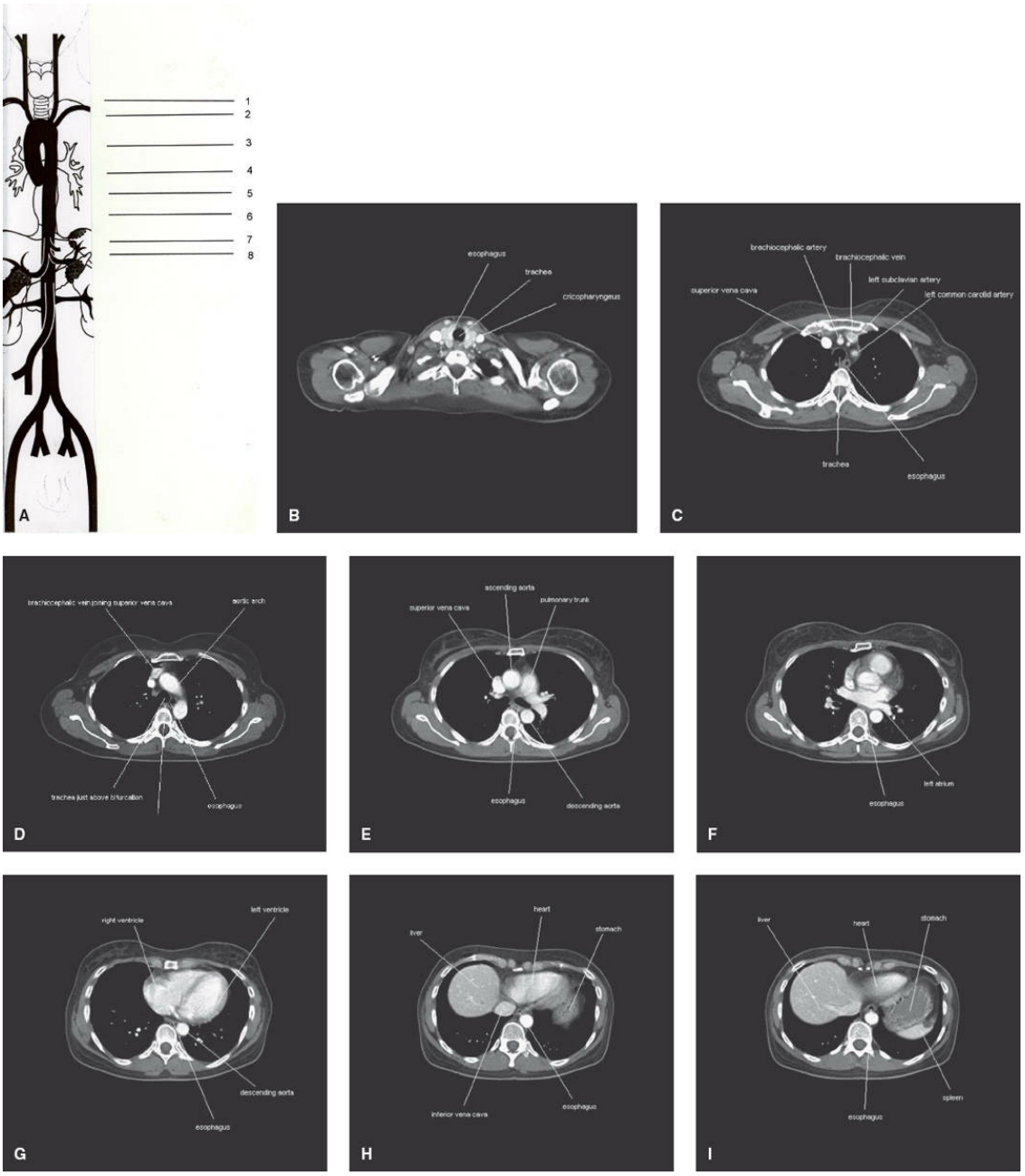

Figure 69.20. A. Diagram showing levels of cross-section and corresponding cross-sectional computed tomography scans (**B**–**I**).

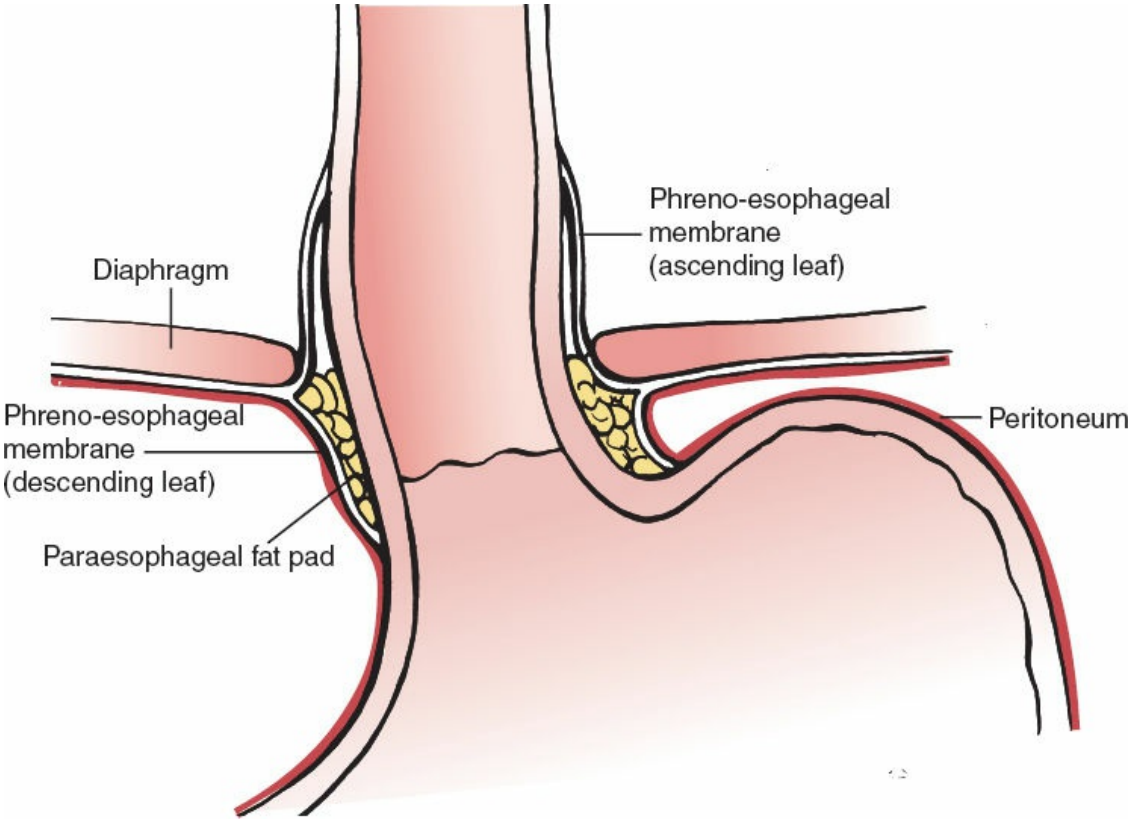

Figure 69.21. Diagram showing the distal esophagus, gastroesophageal junction, and formation of the phrenoesophageal ligament. Attachment and structure of the phrenoesophageal membrane.

The crural arrangement is complex (Fig. 69.22) and variable. The crura have an origin from the first four lumbar vertebrae. The left crus does not divide but the right crus has superficial and deep components, the latter forming a sling around the esophagus. In the most common arrangement, the superficial fibers of the right crus pass anterosuperiorly in a lazy curve to insert into the central tendon of the diaphragm, forming the right pillar; the deeper fibers twist acutely to wrap around the left side of the esophagus, forming the left pillar. The left crus lies to the left of this passing to the left of the aorta and therefore is not an immediate relation to the esophagus. However, in 40% patients the sling does include components of the left crus. Where the right and left crura cross, the median arcuate ligament forms. Posterior to the median arcuate ligament is the descending thoracic aorta as it passes through the diaphragm at the level of the 12th thoracic vertebra. As the esophagus passes the hiatus, a concentric narrowing of the lumen occurs (which, however, is not synonymous with the high-pressure zone although the high-pressure zone

extends into this area). The length of the intra-abdominal segment is said to be from 0.5 to 2.5 cm.

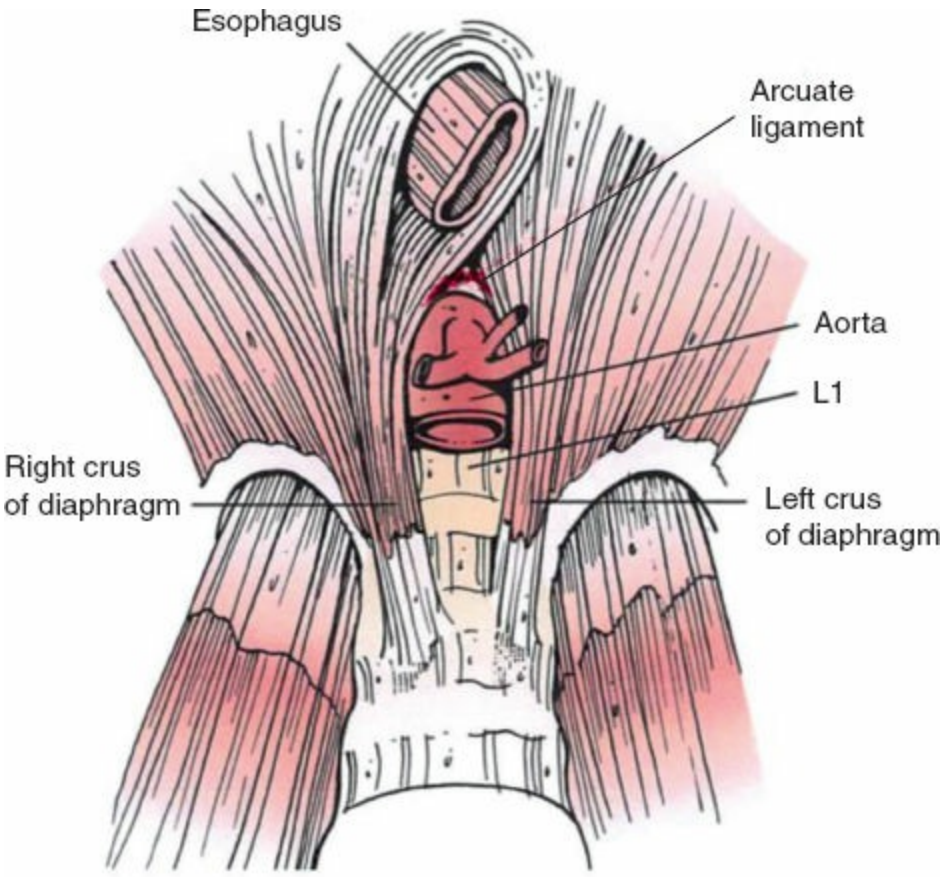

Figure 69.22. Diagram showing the most common variant of anatomic arrangement of the diaphragmatic crura. L1 denotes the first lumbar vertebra.

The angle formed between the left margin of the intra-abdominal segment and the gastric fundus is referred to as the angle of His, based on who first described it in 1903 (see Fig. 69.7).

The intra-abdominal esophagus passes into the cardia of the stomach. At this point, the density of the circular muscle fibers of the esophagus is the greatest (Fig. 69.23A), particularly on the lesser curve side, which combined with the similarly dense oblique muscle fibers of the stomach (Fig. 69.23B) contributes to the antireflux mechanism of the LES, together with the anatomic relation between the esophagus and the area of the hiatus.

The abdominal esophagus is invested in a peritoneal covering consisting of the two layers of the hepatogastric ligament. The hepatogastric ligament extends from the porta hepatis to the lesser

curvature of the stomach and abdominal esophagus. The hepatogastric ligament encloses the abdominal esophagus on the right, and it leaves and comes together on the left side to form the gastrosplenic ligament. The lesser sac lies behind these two ligaments so that there is a bare area in the posterior wall of the stomach.

Clinical and Surgical Points of Interest

The cervical prevertebral fascia is strong enough to take fixing sutures in diverticulopexy operations for a Zenker diverticulum. The retroesophageal space continues inferiorly to the posterior mediastinum, thus permitting the spread of infection from the neck to the mediastinum and causing potentially fatal mediastinitis. Necrotizing mediastinitis resulting from pharyngeal perforation and peritonsillar or dental abscesses may result in rapid and disastrous dissemination of sepsis.

The separation from the aorta in the lower thorax makes the esophagus vulnerable to perforations at this point, especially Boerhaave syndrome. The tear is typically found posterolaterally, thus making a left thoracotomy the ideal approach. Because of the close relation between the cervical esophagus and the pars membranacea of the trachea, great care must be taken at the time of dissection not to cause a tear in the pars membranacea. This is the case in particular when performing blunt transhiatal dissection.

Equally important is to avoid damaging the recurrent laryngeal nerve. These nerves are especially vulnerable just below the point where they pass under the inferior constrictor muscle to become intralaryngeal. When correcting a Zenker diverticulum or when performing a high cervical anastomosis, the surgeon must be aware of these anatomic particularities. Over its course in the mediastinum, the esophagus is surrounded by loose fatty tissue creating a fat plane between the esophagus and descending aorta. Disappearance of this fat plane in a patient presenting with a cancer of the esophagus may indicate irresectability.

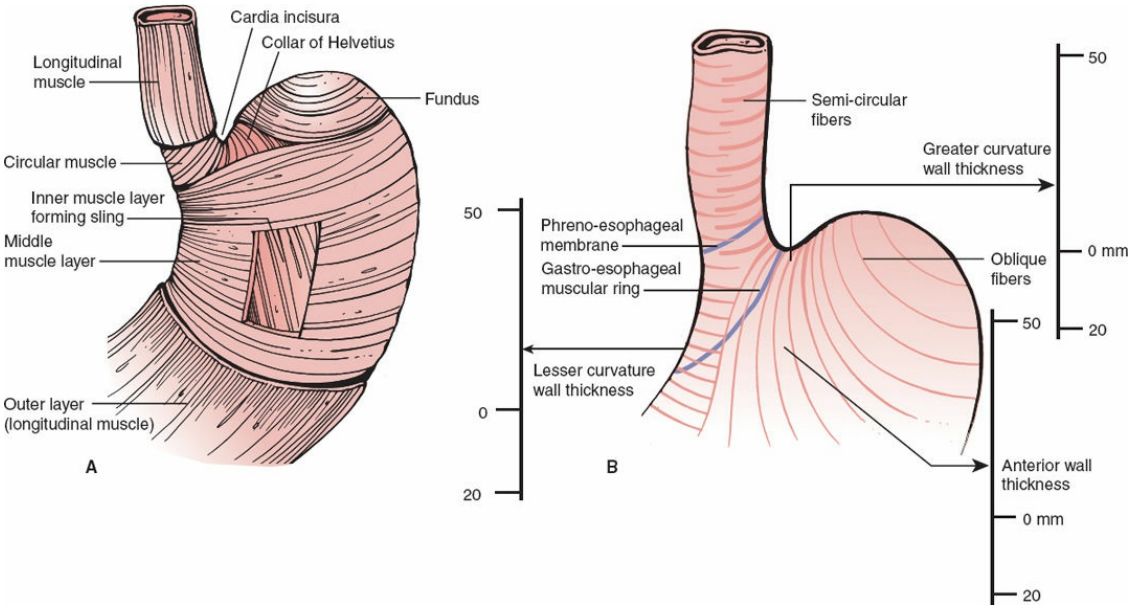

Figure 69.23. **A.** Drawing showing the density of circular muscle fibers at the cardia. **B.** Diagram showing the density of the circular fibers at the gastroesophageal junction and the absolute thickness of the anterior wall and lesser curvature and greater curvature of the stomach.

The upward movement of the phrenoesophageal ligament with age has been proposed as the reason for the increased incidence of hiatus hernia in the elderly. Although most patients with gastroesophageal reflux have a hiatal hernia, many individuals have no reflux. One potential explanation is that the point of attachment of the phrenoesophageal ligament may influence the likelihood of development of reflux. High insertion of the phrenoesophageal ligament onto the thoracic esophagus allows for a still adequate length of the lower esophagus exposed to intra-abdominal pressure transmitted through the hiatal sac.

From an anatomical–surgical point, the antireflux mechanism is based on the following elements:

1. Thickening of the gastric oblique sling fibers and the clasp fibers, which form the lower esophageal sphincter.
2. Intra-abdominal pressure
3. Rosette-like configuration of the top end of the gastric mucosal folds
4. The sharp angle of the fundus (angle of His)
5. The phrenoesophageal membrane and its insertion into the esophagus
6. The pinching of the diaphragmatic crura

Together with the restoration of the 3 to 4 cm of the distal esophagus

under the diaphragm, reconstruction of the angle of His by creating a fundoplication adds to the creation of an antireflux barrier.

Crural sutures to close the hiatus, such as in antireflux surgery, have to be placed with care as the inferior vena cava lies just lateral to the right pillar. Likewise, crural sutures placed too deep and posterior may injure the aorta, causing a false aneurysm.

Since the report of the first laparoscopic antireflux operation by Dallemagne in 1991, further developments and refinements in videoscopic surgery related to esophageal surgery have been spectacular.

Laparoscopic antireflux surgery has become the standard, and gradually more complex operations are becoming manageable using laparoscopic and thoracoscopic approaches. The mediastinal esophagus can be mobilized from the abdomen through the hiatus up to the level of the carina. Lengthening gastroplasty to deal with a shortened esophagus is increasingly used. Giant paraesophageal hernias and motor disorders, for example, achalasia, are successfully treated by laparoscopy, with excellent early results. Reoperations, for example, after failed antireflux surgery, are now mostly performed via a laparoscopic approach as well. Thoracoscopic–laparoscopic esophagectomy for cancer of the esophagus has become the routine in some centers of excellence.

It must be clear, however, that on preoperative evaluation, indications for surgery of esophageal problems are the same as for open surgery. In this respect, familiarity with the anatomic details is equally, if not more, important.

Well-designed prospective studies or trials and long-term follow-up are required to confirm the advantages of videoscopic esophageal surgery over open surgery, in particular when dealing with more complex pathology.

Suggested Readings

Akiyama H, Tsurumaru M, Udagawa H, et al. Radical lymph node dissection for cancer of the thoracic esophagus. *Ann Surg* 1994;220:364–72.

Bonavina L, Evander A, DeMeester TR, et al. Length of the distal esophageal sphincter and competency of the cardia. *Am J Surg* 1986;151(1):25–34.

Cook IJ. Diagnosis and management of cricopharyngeal achalasia and other upper esophageal sphincter opening disorders. *Curr Gastroenterol Rep* 2000;2(3):191–5.

Cunningham ET Jr, Sawchenko PE. Central neural control of esophageal motility: a review. *Dysphagia* 1990;5(1):35–51.

Dallemagne B, Weerts JM, Jehaes C. Laparoscopic Nissen fundoplication:

preliminary report. *Surg Laparosc Endosc* 1991;1(3):138–43.

Diamant NE. Physiology of esophageal motor function. *Gastroenterol Clin N Am* 1989;18:179.

Duranceau A, Liebermann-Meffert D. Embryology, anatomy and physiology of the esophagus. In: Orringer MB, Zuidema GD, eds. *Shackelford's Surgery of the Alimentary Tract: the Esophagus, Vol. 1.* 3rd ed. Philadelphia, PA: WB Saunders; 1991:3.

Eliska O. Phreno-oesophageal membrane and its role in the development of hiatal hernia. *Acta Anat* 1973;86:137.

Goyal RK, Cobb BW. Motility of the pharynx, esophagus and esophageal sphincters. In: Johnson LR, ed. *Physiology of the Gastrointestinal Tract.* New York: Raven Press; 1981:359.

His W. Studien an geharteten leichen über form und lagerung des menschlichen magens. *Archiv für Anatomie und Entwicklungsgeschichte* 1903;4:345.

Hulscher JB, Van Lanschot JJ. Individualised surgical treatment of patients with an adenocarcinoma of the distal esophagus or gastro-esophageal junction. *Dig Surg* 2005;22:130–4.

Jackson RG. Anatomy of the vagus nerves in the region of the lower esophagus and stomach. *Anat Rec* 1949;103:1–18.

Jankowski JA, Harrison RF, Perry I, et al. Barrett's metaplasia. *Lancet* 2000;356(9247):2079–85.

Kumar D, Philips SF. Human myenteric plexus: confirmation of unfamiliar structures in adults and neonates. *Gastroenterology* 1989;96:1021.

Last RJ. Head and neck. In: McMinn RMH, ed. *Last's Anatomy: Regional and Applied.* 8th ed. Edinburgh, UK: Churchill Livingstone; 1990:488.

Lerut T. Zenker's diverticulum: is a myotomy of the cricopharyngeus useful? How long should it be? *Hepatogastroenterology* 1992;39(2):127–31.

Liebermann-Meffert D. The pharyngoesophageal segment: anatomy and innervation. *Dis Esoph* 1995;8:242.

Liebermann-Meffert D, Duranceau A. Anatomy and embryology. In: Orringer MB, Zuidema GD, eds. *Shackelford's Surgery of the Alimentary Tract: the Esophagus, Vol I.* 4th ed. Philadelphia, PA: WB Saunders; 1996:3.

Liebermann-Meffert D, Siewert JR. Arterial anatomy of the esophagus: a review of literature with brief comments on clinical aspects. *Gullet* 1992;2:3.

Luketich JD, Pennathur A, Awais O, et al. Outcomes after minimally invasive esophagectomy: review of over 1000 patients. *Ann Surg* 2012;256(1):95–103.

Matsubara T. Computed tomography evaluation of lymph nodes in cancer of the

thoracic esophagus. *Dis Esoph* 1988;1:109.

Maziak DE, Todd TR, Pearson FG. Massive hiatus hernia: evaluation and surgical management. *J Thorac Cardiovasc Surg* 1998;115:53–60.

Nguyen NQ, Holloway RH. Recent developments in esophageal motor disorders. *Curr Opin Gastroenterol* 2005;21(4):478–84.

Nishimaki T, Suzuki T, Kanda T, et al. Extended radical esophagectomy for superficially invasive carcinoma of the esophagus. *Surgery* 1999;125(2):142–7.

Rice TW, Zuccaro G Jr, Adelstein DJ, et al. Esophageal carcinoma: depth of tumor invasion is predictive of regional lymph node status. *Ann Thorac Surg* 1998;65(3):787–92.

Shapiro AL, Robillard GL. The esophageal arteries: their configurational anatomy and variations in relation to surgery. *Ann Surg* 1950;131:171.

Smith E. The early development of the trachea and esophagus in relation to atresia of the esophagus and tracheoesophageal fistula. *Contrib Embryol Carnegie Inst* 1957;36:41.

Vianna A, Hayes PC, Moscoso G, et al. Normal venous circulation of the gastroesophageal junction. A route to understanding varices. *Gastroenterology* 1987;93:876.

Youmans NB. Innervation of the gastrointestinal tract. In: Code F, ed. *Handbook of Physiology Section 6 Alimentary Canal.* Baltimore, MD: William & Wilkins; 1968:1655–63.

EDITOR'S COMMENT

This is an excellent chapter written by a prominent group of esophageal surgeons. I have really enjoyed writing these commentaries on the anatomy chapters as these represent the perfect opportunity to discuss some of the finer technical points of the surgical procedures commonly performed in these anatomic areas.

The discussion on the LES illustrates well the complexity of the anatomy and physiology of the anatomic reflux barrier. The LES is not an actual sphincter muscle as is found in other areas of the gastrointestinal tract such as the pylorus and the anus. There are three very important characteristics of a competent LES —the failure of any one of which can lead to gastroesophageal reflux disease. These are the overall length, the intra-abdominal length, and the LES pressure. Antireflux surgery with a fundoplication restores the mechanical antireflux barrier by addressing abnormalities of the LES in several ways. It has been demonstrated that a laparoscopic Nissen fundoplication restores the gastroesophageal junction into the abdominal cavity in patients with a hiatal hernia. The crural closure and the fundoplication both contribute to the overall

sphincter length increase that is observed following a fundoplication. The crural closure may contribute more to the increased LES pressure than the fundoplication, but they both play a role.

On the opposite end of the spectrum from GERD is achalasia. In achalasia, the LES does not relax appropriately with swallowing. This is combined with a loss of esophageal peristalsis that usually results in impaired esophageal emptying. In some patients who defer treatment or are inadequately treated, this can lead to significant esophageal dilation. The anatomic defect appears to be a decrease or loss of inhibitory ganglion cells in the esophageal myenteric plexus. Histologic analysis of specimens in patients who ultimately undergo esophageal resection for end-stage achalasia demonstrates myenteric inflammation and progressive depletion of ganglion cells and neural fibrosis. Macroscopically, there may often be thickening of the circular muscular layer of the distal esophagus. Surgical myotomy can be curative. One of the most essential aspects of an adequate myotomy is the distal extent that this travels onto the stomach. These outcomes demonstrate the complex anatomy and associated physiology of the LES, both in health and in disease.

The UES is an important anatomic and functional area that receives less attention than it deserves. In achalasia, it has been demonstrated that in many patients the UES may act as a barrier to prevent supraglottic reflux and aspiration. In patients with GERD and extraesophageal symptoms, the UES is shorter and more hypotonic than in patients without GERD and/or those with GERD without extraesophageal symptoms. Normal UES function and physiology, especially when it comes to the function of the UES in GERD, is poorly characterized.

Knowledge of the vagus nerves and their anatomic locations at the GE junction as well as in the mediastinum is important for surgeons performing foregut surgical procedures. During a primary Nissen fundoplication, the posterior vagus just above the GE junction is fairly easy to identify. The anterior vagus, as mentioned, is more difficult to identify. One trick to finding this nerve is to lift the GE junction fat pad anteriorly. The anterior vagus is usually traveling from the left lateral side of the esophagus and rotating anteriorly to ultimately wind up on the anterior lesser curve of the stomach by traveling just under this fat pad. When suturing a fundoplication to the esophagus, it is important to avoid passing a stitch through this vagus. When performing a Heller myotomy for achalasia, it is helpful to first identify the anterior vagus nerve, so this can be mobilized and protected during the myotomy. As one moves proximally on the esophagus and into the mediastinum for esophageal mobilization in the case of a hiatal or paraesophageal hernia repair, it is imperative to be aware that the anterior vagus will come in lateral to the esophagus on the left and the posterior will come in to the right of the esophagus before moving posteriorly. The true incidence of clinically significant postsurgical gastroparesis following inadvertent (or even intentional) bilateral vagotomy is unknown. In my personal series of more than 100

reoperative fundoplications (data not yet published), 5% of patients with 1 prior attempt, 29% of patients with 2 prior attempts, and 44% of patients with 3 prior attempts at fundoplication suffered from postsurgical gastroparesis. The presumed etiology in these patients is vagal nerve injury. In the reoperative setting, it can be especially difficult to identify the vagus nerves and to differentiate these from scar tissue.

When reading about the surgical repair of large hiatal/paraesophageal hernias, the topic of a "short esophagus" often comes up. A recent review article on the topic states "*If the need for a Collis gastroplasty is used as the most restrictive definition [for short esophagus], then retrospective review of the literature indicates that between 1% and 5% of patients undergoing GERD-related surgery meet criteria.*" In my opinion, true short esophagus is a rare and congenital anomaly present in about 1% of patients in whom this condition is considered prior to surgery. Short esophagus is a diagnosis made intraoperatively and after extensive mediastinal dissection has failed to bring the gastroesophageal junction into the abdominal cavity. Reference is made in the current chapter to the opinion held by some surgeons that hiatal hernias greater than 5 cm should not be repaired by an abdominal approach. This is a minority opinion and the current practice across the country suggests the same. In an analysis of the 2006–2008 Nationwide Inpatient Sample, we determined that paraesophageal hernia repair was performed via a transabdominal laparoscopic approach in 42%, via a thoracic approach in 7%, and via an open abdominal approach in 50%.

Barrett esophagus (BE) is discussed in this chapter. As mentioned, there is variation in the height of the Z-line, which can make the diagnosis of BE challenging. The Prague classification system is a grading system for BE developed by the International Working Group for the Classification of Esophagitis that helps endoscopists to adequately describe the severity of BE using a standard nomenclature. The Prague classification system emphasizes the use of esophageal landmarks to assess the circumference (C) and maximal (M) extent of the endoscopically visualized BE segment. The proximal notch of gastric cardia tissue under moderate insufflation forms the lower measurement boundary. The two upper measurement boundaries are marked by the proximal limit of the circumferential Barrett segment (C) and the longest tongue of Barrett's (M). Accurate documentation in a reliable and reproducible manner that allows endoscopists to communicate to each other about where a specific biopsy is taken as well as the extent of BE observed on endoscopy is important.

Jon C. Gould

This is an erudite commentary which tells us that there is still room for discussion as to what happens to the esophagus in reflux and pain in the upper esophagus. We still have a lot to learn. Dr. Gould as usual writes an erudite commentary which is a pleasure to read.

J.E.F.

Suggested Readings

Goldblum JR, Rice TW, Richter JE. Histopathologic features in esophagomyotomy specimens from patients with achalasia. *Gastronenterol* 1996;111(3):648–54.

Jassim H, Seligman JT, Frelich M, et al. A population-based analysis of emergent versus elective paraesophageal hernia repair using the Nationwide Inpatient Sample. *Surg Endosc* 2014;28(12):3473–8.

Kunio NR, Dolan JP, Hunter JG. Short esophagus. *Surg Clin North Am* 2015;95(3):641–52.

Nadaleto BF, Herbella FA, Pinna BR, et al. Upper esophageal sphincter motility in gastroesophageal reflux disease in the light of the high-resolution manometry. *Dis Esophagus* 2017;30(4):1–5.

Oelschlager BK, Yamamoto K, Woltman T, et al. Vagotomy during hiatal hernia repair: a benign esophageal lengthening procedure. *J Gastrointest Surg* 2008; 12(7):1155–62.

Sharma P, Dent J, Armstrong D, et al. The development and validation of an endoscopic grading system for Barrett's esophagus: the Prague C & M criteria. *Gastroenterology* 2006;131(5):1392–9.

Tsuboi K, Hoshino M, Sundaram A, et al. Role of the lower esophageal sphincter on esophageal acid exposure – a review of over 2000 patients. *Trop Gastroenterol* 2012;33(2):107–11.

70 Transthoracic Antireflux Procedures

Tom R. DeMeester

In 1853 Henry Ingersoll Bowditch published a monograph titled *A Treatise on Diaphragmatic Hernia* in which he commented on the then-current state of knowledge regarding hiatal hernia: “Owing to the ignorance of most of the observers in regard to the true nature of the affection (hiatal hernia), their modes of treatment have been entirely empirical and generally very absurd, and not a few times absolutely harmful to the patient.” Initially, the therapy of hiatal hernia focused only on the surgical correction of the anatomical diaphragmatic defect. The symptoms of hiatal hernia were poorly understood and given no consideration. The possibility that hiatal hernia could encourage the reflux of gastric contents into the esophagus was foreign to the prevailing thought. A typical example of the thinking at the time was one of the publications of Stuart Harrington. He reported on 51 patients with a diaphragmatic hiatal hernia and focused only on describing the anatomical defect and the closure of the hiatus as the surgical treatment. There was no mention of the symptomatology.

It was not until Philip Allison’s publication in 1951 that the symptoms associated with hiatal hernia were linked to the reflux of gastric juice or its contents into the esophagus with the possible development of esophagitis. Allison introduced the term “reflux esophagitis” and emphasized that it was due to a defect in the cardia that allowed acidic gastric juice to reflux into the esophagus. He stated that “it will be noted that it is during inspiration, when the suction pressure in the chest would tend to draw the gastric contents into the esophagus, that the crus of the diaphragm contracts and obstructs this.” Allison theorized, along with others, that “although no internal sphincter can be demonstrated, there is an intrinsic mechanism which contributes to continence.” Allison hypothesized that the latter was due to the anatomical geometry of the gastroesophageal junction since he noted that when the esophagus and stomach were removed from the body, a greater pressure was necessary to drive fluid from the stomach into the esophagus than in the opposite direction. Allison

went on to describe the first rational hiatal hernia repair. The focus was on restoring the normal anatomy of the gastroesophageal junction by reducing the hernia and repositioning the gastroesophageal junction into its normal intra-abdominal location. By doing so he hoped to improve the closing of the gastroesophageal junction by the contracting crus, but added that “if the intrinsic mechanism is ineffective, the diaphragm alone may not be enough to ensure complete continence.” Recognition of a high incidence of symptomatic and anatomic recurrence after the repair led Allison to retract the operation in 1973.

Allison’s contribution altered the surgical approach to hiatal hernia disease. Surgeons started to develop procedures designed to place the gastroesophageal junction in an intra-abdominal position in a more effective manner. A posterior gastropexy was devised by Lucious Hill in 1967, which anchored the gastroesophageal junction and its associated phrenoesophageal membrane to the median arcuate ligament of the aortic hiatus. The Nissen full fundoplication, introduced in 1956, and the Belsey Mark IV partial fundoplication introduced by David Skinner 1967 were designed to establish an intra-abdominal segment of esophagus surrounded by a cuff of stomach in the hope of forming a functional flap valve. The Belsey Mark IV repair was performed through a thoracic incision, the Hill repair through an abdominal incision, and the Nissen repair through an abdominal or thoracic incision.

In 1957 Lee Collis added an important contribution to the repair of hiatal hernia. He introduced a method to manage the shortening of the esophagus that occurred with advanced disease due to reflux-induced intramural fibrosis. He described a technique that adds 3 to 4 cm to the esophageal length by creation of a short proximal gastric tube along the lesser curvature of the stomach. This ingenious technique relieved the tension on a hiatal hernia repair caused by a shortened esophagus and reduced the incidence of reherniation. Later, surgeons added the placement of a partial or full fundoplication around the short gastric tube to improve the competency of the repair.

In 1956 esophageal manometry was introduced by F. Earl Fyke and Charles Cole. This technology led to the discovery of a nonanatomical sphincter at the gastroesophageal junction (Fig. 70.1). This became known as the lower esophageal sphincter and was subsequently shown to be the major barrier against the reflux of gastric contents into the esophagus. In 1979 Dorothy Liebermann-Meffert showed with tedious dissection an

asymmetrical muscle thickening in the wall of the esophagus located below the diaphragm and above the angle of His. A manometrically defined high-pressure zone was located in the area and the length of the high-pressure zone was similar to the length of the thickening. The highest pressure was found in the area of greatest muscle thickening. The ability to measure the height and length of the lower esophageal high-pressure zone allowed assessment of various antireflux procedures in their ability to improve the function of the newly discovered barrier. Of the three procedures, the Nissen full fundoplication was most effective in restoring the competency of the lower esophageal sphincter, followed by the Belsey partial fundoplication and the Hill posterior esophagogastropexy.

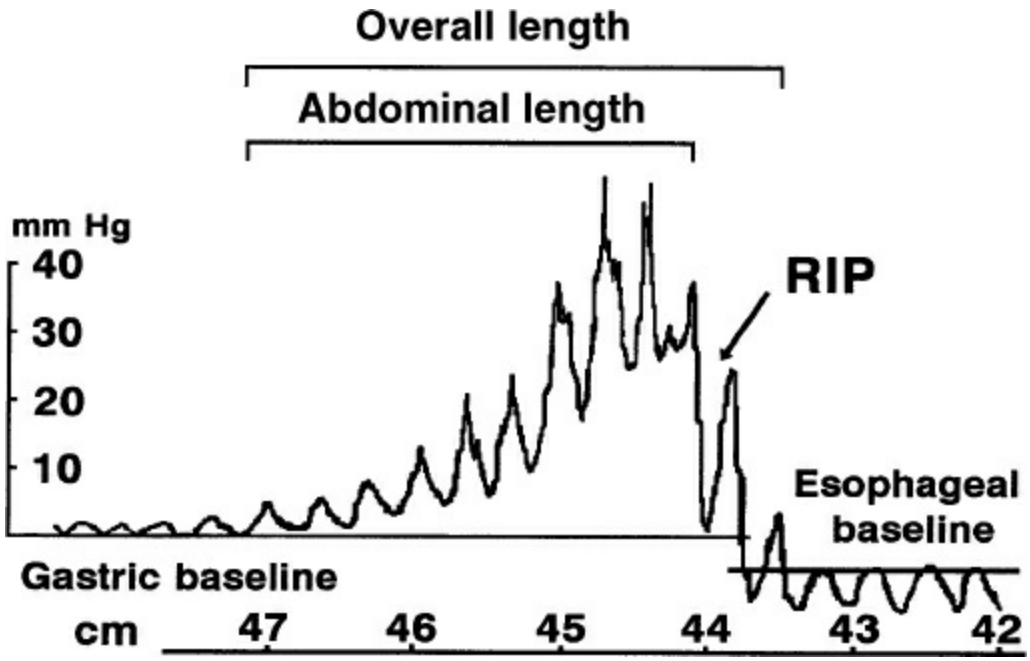

Figure 70.1. Normal manometric tracing of the lower esophageal sphincter obtained by pulling the transducer from the stomach through the gastroesophageal junction and into the esophagus. Note the resting baseline gastric pressure is greater than the resting baseline esophageal pressure. There are positive deflections with inspiration in the gastric or intra-abdominal portion of the record and the negative deflections with inspiration in the intrathoracic or esophageal portion of the record. RIP, respiratory inversion point.

In 1991 Bernard Dallemagne performed the first laparoscopic Nissen fundoplication in a human. He successfully performed laparoscopic ligation of the short gastric vessels, safe posterior dissection of the abdominal portion of the esophagus, and plication of the lower esophagus

between a fold of anterior and posterior fundus. These were significant accomplishments at that time. Today, laparoscopic Nissen fundoplication has become commonplace, and its safe, effective, and patient-friendly reputation has encouraged its use for advanced reflux disease. The major drawbacks of the procedure are the side effects of postprandial bloating, inability to belch or vomit, and a small but significant incidence of persistent dysphagia.

Today, surgeons are comfortable performing laparoscopically a high mediastinal dissection to mobilize the esophagus and a Collis gastroplasty if at least 2 to 3 cm of distal esophagus does not lie comfortably and free of tension in the abdomen after the mobilization. Currently, only the most complex multiple re-do operation requires an open operation, usually done through a transabdominal incision. Rarely is an open transthoracic Nissen performed. I have not performed one in the past 10 years. The only time a thoracic approach is likely to be considered is when a thoracotomy is required for another reason and an antireflux operation also needs to be done. This being said, it is probably wise to describe the technique just in case the need to perform the procedure arises. Indeed, the well-trained esophageal surgeon should have complete mastery of both a partial and full fundoplication whether performed laparoscopically, transabdominally, or transthoracically.

PRINCIPLES OF AN ANTIREFLUX REPAIR

Antireflux surgery is based on the principle that altering the anatomy of an organ can, in some situations, improve the organs function. For a surgeon to do so requires a thorough knowledge of the organs function and an acceptance that the results, because of the various situations encountered, are likely not to be as good as extirpation surgery. The surgeon’s attention to detail and his ability to adapt the procedure to various situations encountered are essential to achieving the best results. In that regard, there are four principles important in restoring the gastroesophageal barrier that should be understood by all surgeons who perform antireflux procedures.

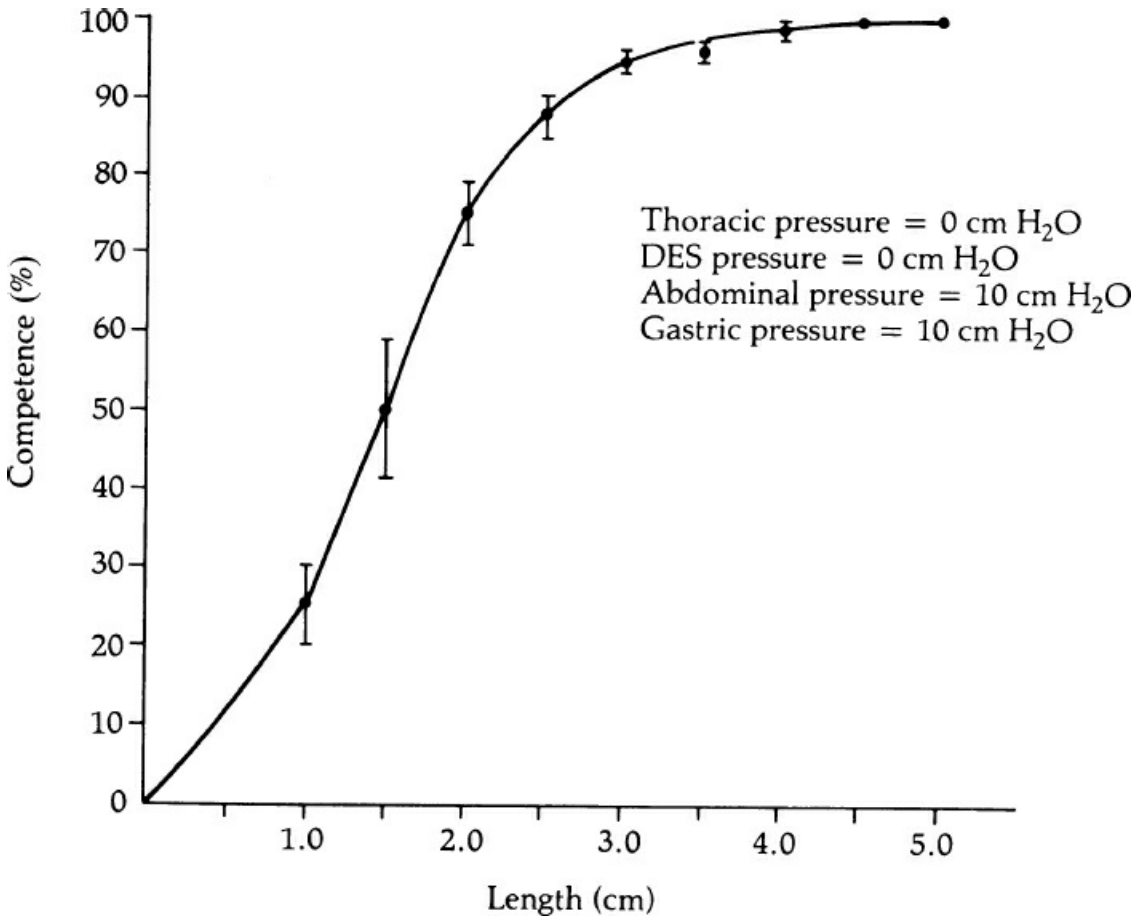

Figure 70.2. The length of abdominal sphincter required for competency in the absence of intrinsic sphincter tone. An abdominal length of 4 cm is required for 100% competence. DES, distal or lower esophageal sphincter.

First, the operation should permanently restore at least 2 cm of abdominal esophagus so that the lower esophageal sphincter can respond to the challenges in intra-abdominal pressure. We showed that the degree of competence provided by the lower esophageal sphincter against resting intra-abdominal pressure is a direct function of its abdominal length independent of its intrinsic muscle tone (Fig. 70.2). This relationship is very efficient in that as intra-abdominal pressure increases, the abdominal length of the lower esophageal sphincter necessary for competence decreases (Fig. 70.3). The intrinsic muscle tone in the lower esophageal sphincter augments this efficiency further. The relationship breaks down when the abdominal length of the sphincter is ≤1 cm (Fig. 70.4). At this length, even high levels of intrinsic muscle tone are unable to restore competency. Consequently, the permanent restoration of 2 cm of the abdominal sphincter length in a patient with normal sphincter tone

maintains the competency of the sphincter over a wide range of intra-abdominal pressures challenges. These observations encourage sufficient mobilization of the distal esophagus so that a ≥2-cm segment rests below the diaphragm without tension. Furthermore, the construction of a conduit to ensure transmission of intra-abdominal pressure challenges around the abdominal esophagus is also an important aspect of restoring competency. A complete or partial fundoplication serves this purpose. In the absence of a conduit, the development of postoperative periesophageal adhesions can prevent the transmission of intra-abdominal pressure challenges to the abdominal portion of the lower esophageal sphincter. This allows the pressure challenges to act unequally on the stomach and the sphincter's abdominal length, resulting in sphincter incompetency and reflux.

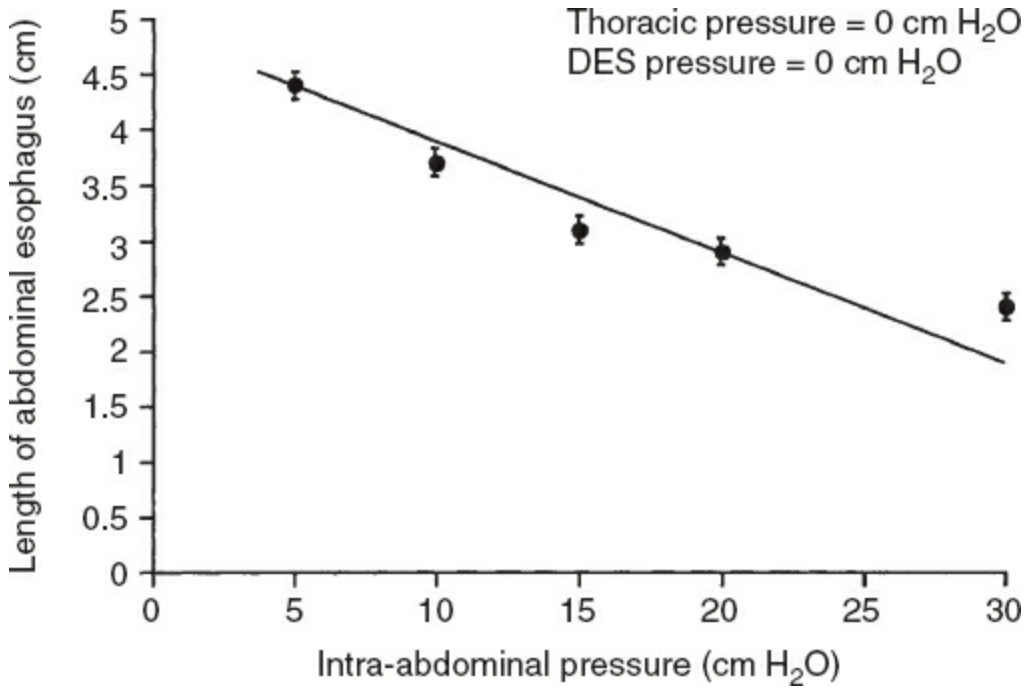

Figure 70.3. The mechanical efficiency of abdominal sphincter length to maintain competency in the absence of intrinsic sphincter tone to challenges of increased intra-abdominal pressure. Increases in intra-abdominal pressure require shorter abdominal sphincter length to maintain competency. DES, distal or lower esophageal sphincter.

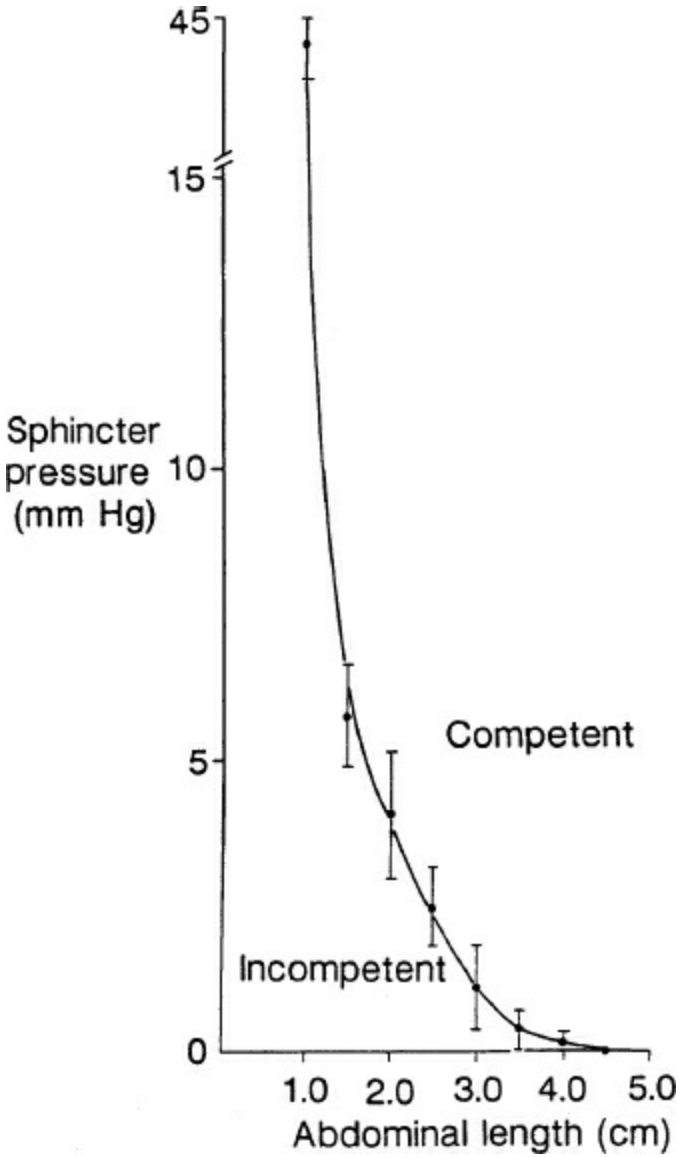

Figure 70.4. The effect of intrinsic sphincter tone on the length of abdominal esophagus required to maintain competency against intra-abdominal pressure challenges. More intrinsic sphincter pressure is required for shorter abdominal sphincter lengths. Physiologic intrinsic sphincter pressure is unable to compensate for abdominal sphincter length ≤1 cm.

The second principle is to use a technique that prevents reflux from episodes of gastric distention and independent increase in gastric pressure over intra-abdominal pressure. This requires augmenting the resting distal esophageal sphincter pressure to a level equal to or greater than three times the resting gastric pressure (~15 mm Hg), and maintaining an overall sphincter length of at least 2 cm. A gastric fundoplication reliably augments the resting lower esophageal sphincter pressures. The level of increase is related to the degree of fundoplication and is likely due to the

addition of gastric muscle tone to the intrinsic muscle tone of the sphincter (Fig. 70.5).

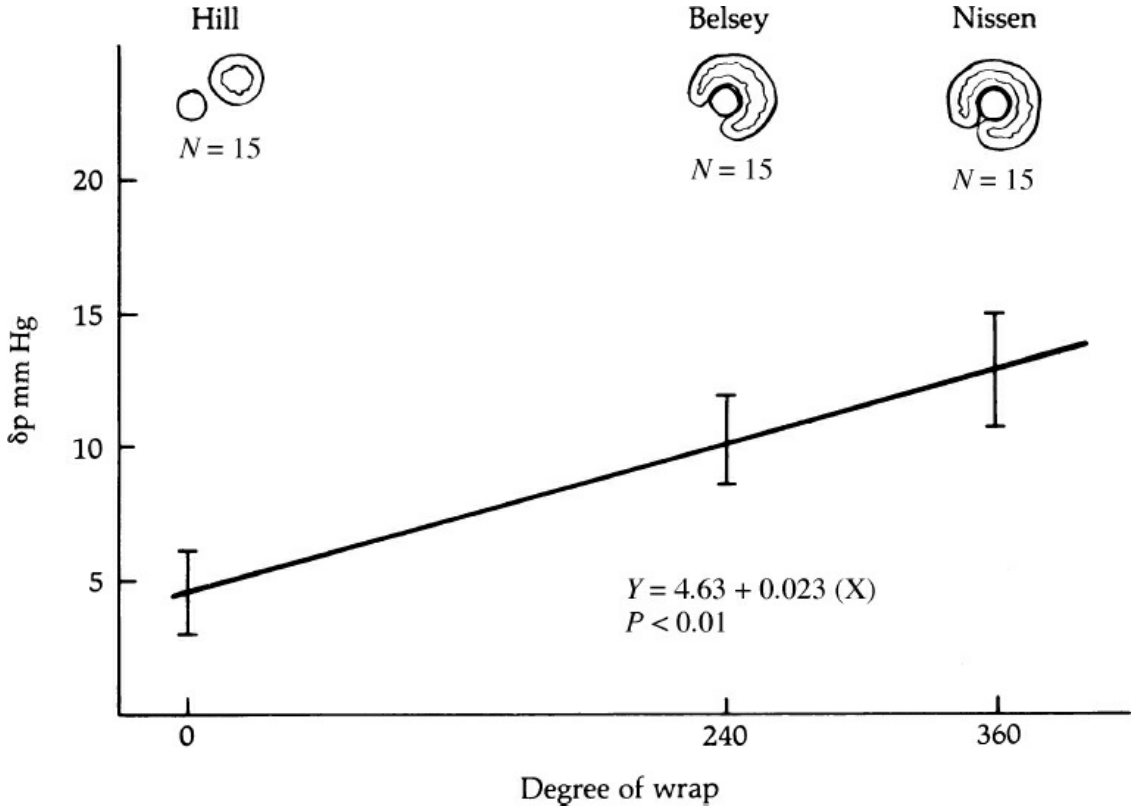

Figure 70.5. The increase in postoperative sphincter pressure over preoperative pressure obtained with various degree of fundoplication.

The transient loss of sphincter length is a recognized cause of reflux in a person with normal sphincter resting pressure and length. Dr. Ayazi has shown that transient losses in abdominal sphincter length are caused by gastric distention. The abdominal sphincter length shortens by effacement into the distended fundus like the neck of a balloon shortens into the distended portion of the balloon with inflation. The shorter the sphincter length becomes, the greater is the intrinsic sphincter pressure required to maintain competence (Fig. 70.6). A fundoplication acts like a collar around the sphincter that effectively prevents the loss of sphincter length in response to gastric distention.

The third principle is to restrict the portion of stomach used to construct the fundoplication to the gastric fundus. To facilitate normal swallowing, the distal esophageal sphincter must relax. On deglutition, a vagal-mediated relaxation of the distal esophageal sphincter and fundus of the stomach occurs. This relaxation lasts for ~10 seconds and is followed by

rapid recovery to its former resting tone. To ensure relaxation of the reconstructed sphincter, only the fundus of the stomach should be used to construct the fundoplication since it is known to relax when the distal esophageal sphincter relaxes.

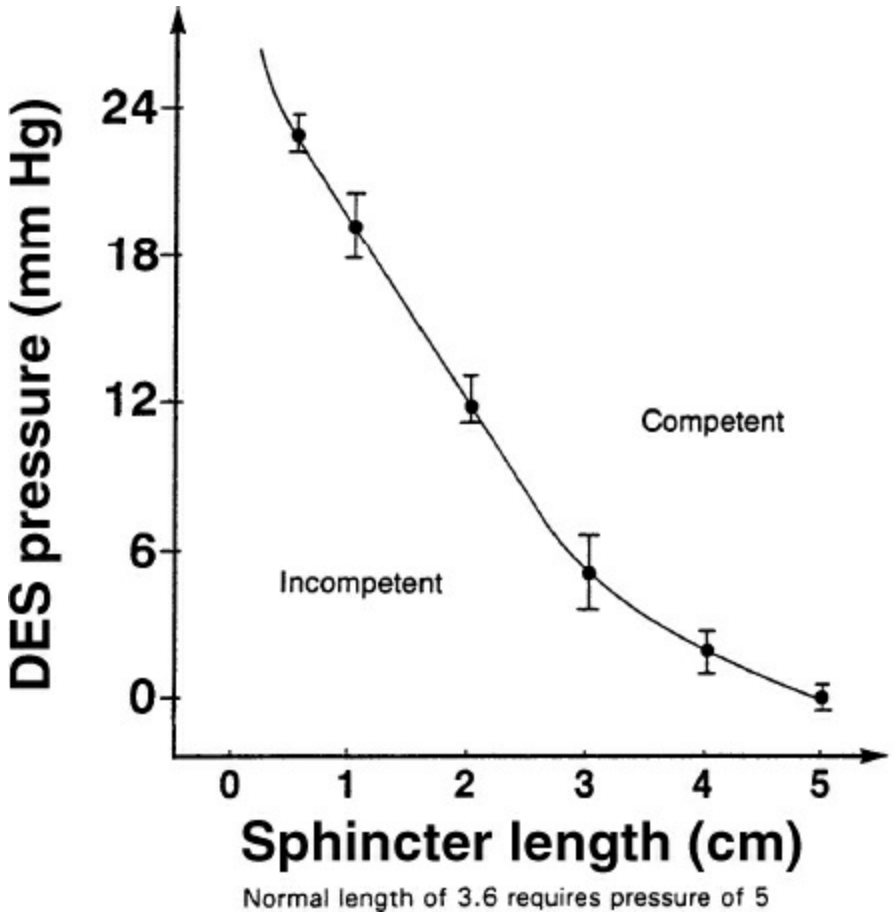

Figure 70.6. The relationship of overall lower esophageal sphincter length and pressure to maintain competency against intragastric pressure challenges. DES, distal or lower esophageal sphincter.

The fourth principle is to use a technique that matches the resistance to flow through the reconstructed sphincter to the propulsive power of the esophageal body. The choice between a 360-degree or partial 240-degree fundoplication is influenced by the strength of the peristaltic contractions. Normal wave progression and strong contractions do well with a complete 360-degree fundoplication. When the prevalence of peristaltic wave progression is reduced to <50%, or esophageal contraction amplitudes in the distal half of the esophagus are ≤20 mm Hg, a partial 270-degree fundoplication is recommended as this degree of fundoplication has no measurable resistance to esophageal emptying (Fig. 70.7). Inappropriate

matching of the body of the esophagus to the resistance of the reconstructed sphincter causes a delay in the passage of food through the sphincter and symptoms of dysphagia. A complete 360-degree fundoplication provides excellent control of reflux but adds considerable resistance to the passage of a bolus through a relaxed sphincter. This resistance is related to the postoperative level of sphincter pressure and the length of the fundoplication. The postoperative sphincter pressure should not be in the hypertensive range and the length of the sphincter should not exceed 1.5 to 2.0 cm (Fig. 70.7).

INDICATIONS FOR THE THORACIC APPROACH

Although the indications for an antireflux repair and the biomechanics of an antireflux repair done by laparoscopic and open approaches are similar, there are specific situations in which an open thoracic approach provides an advantage. These include the following:

1. A patient who has an intrathoracic stomach and a history of multiple previously failed antireflux repairs. A repeat open operation in this situation can be technically easier through the chest.
2. A patient who has extensive shortening of the esophagus. The thoracic approach in this situation allows for maximum mobilization of the esophagus in order to place the repair, without tension, in the abdomen with or without a gastroplasty to lengthen the esophagus.
3. A patient with reflux disease who requires a thoracotomy for another reason. If the pulmonary disease is on the left side, an open transthoracic approach allows both problems to be addressed through one incision.

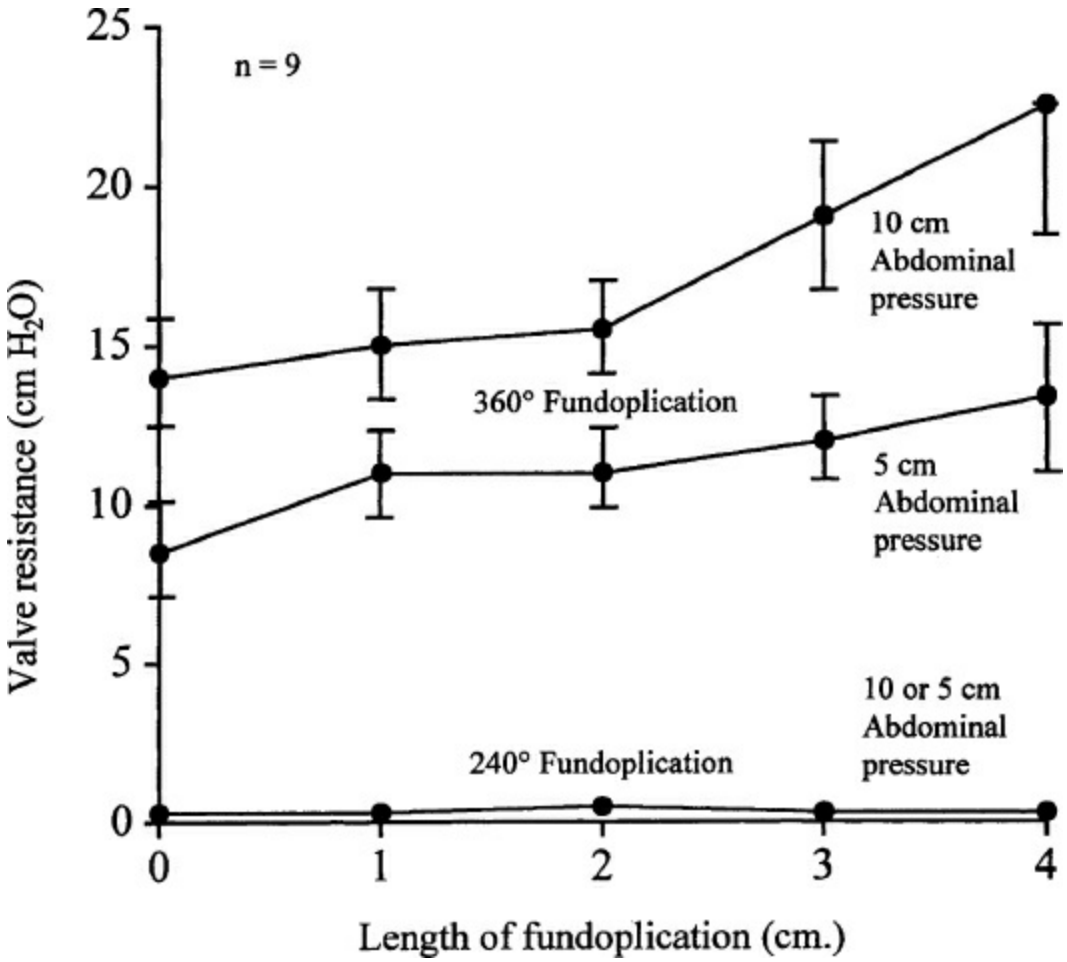

Figure 70.7. The amount of pressure the esophageal body must generate to overcome the resistance of a 360-degree or 240-degree fundoplication of various lengths, in the absence of intrinsic tone, and at different levels of abdominal pressure.

SURGICAL TECHNIQUE

Belsey Mark IV Partial Fundoplication

Professor Ronald Belsey of Great Britain introduced the Belsey partial fundoplication in 1967. The technical details of the Belsey and the transthoracic Nissen operation are similar, differing only in the completeness of the gastric fundoplication and the length of tension-free intra-abdominal esophagus necessary to perform the repair. The former requires a minimum of 4 cm and the latter 2 cm. Consequently, the clinical success of a Belsey repair decreases progressively from 90% in the patients who have no esophageal shortening to 50% in those who have significant shortening.

The diaphragmatic hiatus is approached through a left posterolateral thoracotomy in the sixth intercostal space (i.e., along the upper border of

the seventh rib). For the patients who had a previous failed antireflux repair, we prefer to use the seventh intercostal space. This allows better exposure of the abdomen through a peripheral diaphragmatic incision. The incision is made circumferentially in the anterolateral portion of the diaphragm, 2 to 3 cm from the chest wall, for a distance of 10 to 15 cm. A sufficient fringe of diaphragm must be left along the chest wall to allow for easy closure of the incision. If further abdominal exposure is necessary, the thoracic incision can be extended across the costal margin and diagonally down to the abdominal midline, dividing the fibers of the left rectus muscle. The operation is made easier if a double-lumen endobronchial tube is used for anesthesia and the left lung is selectively deflated.

The esophagus is mobilized from the diaphragm to underneath the aortic arch. Care is taken not to injure the vagal nerves. Branches of the vagal plexus going to the left and right lung must be divided to obtain maximal esophageal length. This allows construction, without tension, of a partial fundoplication over a 4-cm segment of abdominal esophagus. Two vessels arise from the proximal descending thoracic aorta just distal to the arch and pass over the esophagus to the left main stem bronchus. They are the left superior and inferior bronchial arteries. Ligation of these arteries is also necessary to fully mobilize the esophagus. In addition to these arteries, two to three direct esophageal branches come off the distal descending thoracic aorta and pass directly to the esophagus. These are also ligated and divided without concern about ischemic necrosis of the esophagus. There is sufficient blood supply to maintain the integrity of the esophagus through its intrinsic arterial plexus, fed by the inferior thyroid artery in the neck and by the branches from the right bronchial artery in the thorax. This degree of mobilization is necessary to place the repair into the abdomen without undue tension. Failure of adequate mobilization is one of the major causes for subsequent breakdown of a repair and the return of symptoms.

Freeing the gastroesophageal junction and gastric cardia from the diaphragmatic hiatus is the most difficult portion of the procedure, but can usually be completed through the esophageal hiatus. It is unnecessary to make a counterincision through the central tendon of the diaphragm or to enlarge the hiatus by an incision through the crura. The dissection is started by gaining access to the abdominal cavity through the phrenoesophageal membrane. It can be difficult at times to find the correct

tissue plane once the membrane has been divided due to the protrusion of the properitoneal fat. Persistence and dissection underneath the retracted left crus, away from the gastric vessels, eventually yield entry into the free peritoneal space. Entering the abdominal cavity is easier when a hiatal hernia is present.

The proper stance of the surgeon at the operating table aids in freeing the hiatus. With the patient in the left posterior thoracotomy position, the surgeon should stand adjacent to the patient's back, facing the head of the table. The left index and middle fingers are placed through the diaphragmatic hiatus into the abdominal cavity, with the palm facing the patient's feet. The surgeon's line of vision is down and backward under his or her left axilla. With judicious use of the left thumb, index, and middle fingers, the surgeon is able to spread the hiatal tissues and divide them with a scissors controlled by the right hand. In this position, the left hand is also used to retract the esophagus and protect the vagal trunks. Although it sounds somewhat awkward, this stance greatly facilitates the most difficult part of the operation.

All the attachments between the gastric cardia and diaphragmatic hiatus are divided. The short gastric vessels are divided and ligated one by one to allow good mobilization of the fundus. When free, the fundus and part of the body of the stomach are drawn up through the hiatus into the chest (Fig. 70.8). The vascular fat pad, which lies on the anterior and lesser curvature surface of the cardia, is excised. Care must be taken during this dissection to avoid injury to the vagal nerves. The fundus of the stomach must adhere firmly to the lower esophagus, and the fat pad, if not removed, interferes with synechia formation between these two structures.

The completely mobilized esophagus is encircled with a Penrose drain and retracted toward the anterior border of the hiatus to give exposure for the closure of the posterior hiatus. The right and left crura of the diaphragmatic hiatus are identified and approximated with interrupted figure-eight nonabsorbable 0 sutures (Ethibond), taking generous bites of muscle. Usually, there is a decussation of muscle fibers from the right crus that passes anteriorly over the aorta to join muscle fibers from the left crus, but occasionally the aorta lies free within the enlarged hiatus. In either situation, the first crural suture is placed close to the aorta. Traction on this first posterior crural stitch elevates the right crus toward the surgeon and facilitates the placement of subsequent crural sutures. Occasionally, it is necessary to mobilize the pericardium off the diaphragm to give better

exposure of the fascia and muscle making up the right crus. The subsequent crural sutures should incorporate the fascia from the periphery of the central tendon that blends in with the muscle fibers making up the right crus.

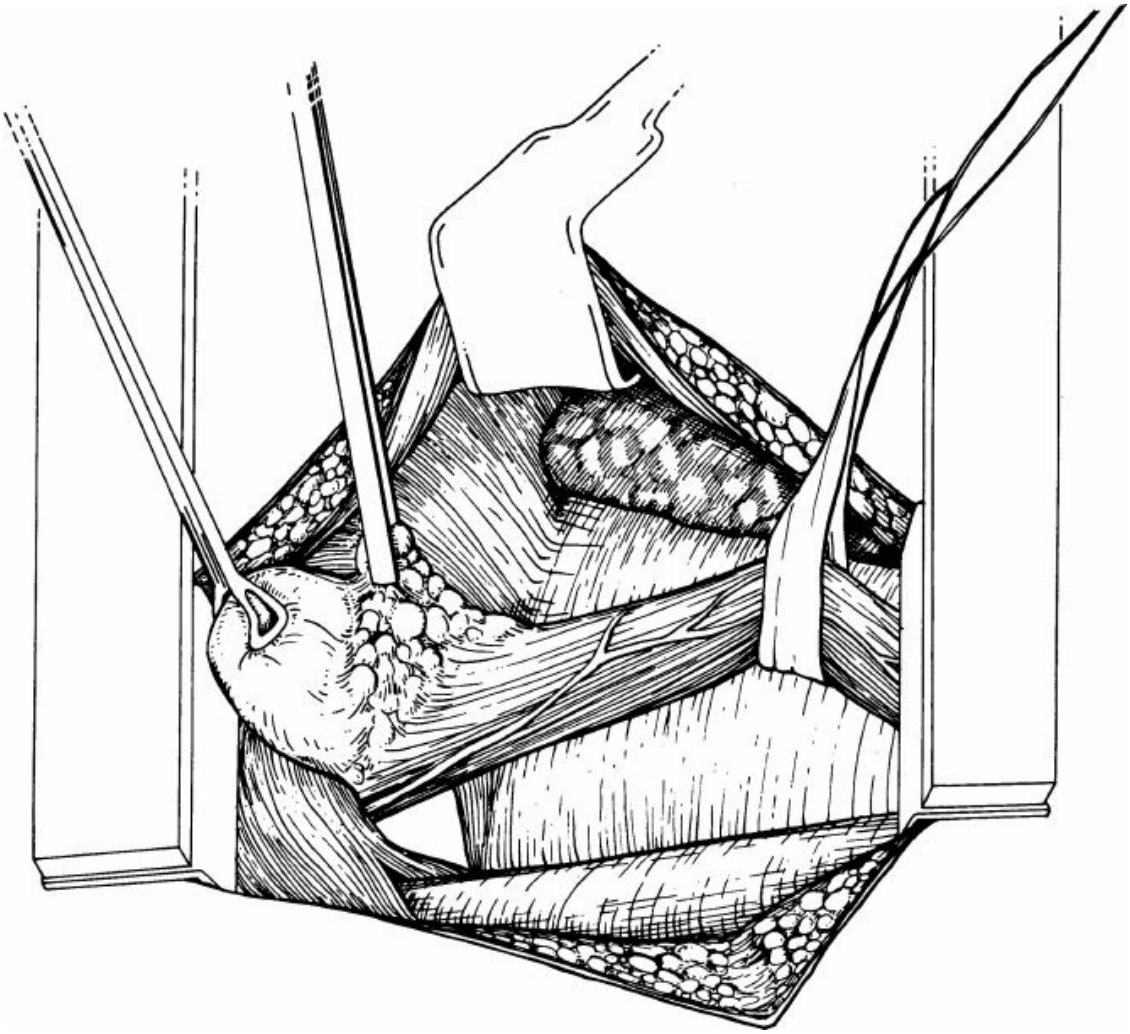

Figure 70.8. Mobilization of the esophagus and stomach through a left posterolateral thoracotomy. The esophagus, gastroesophageal fat pad, stomach, diaphragmatic hiatus, aorta, pericardium, and lung are depicted. The fundus of the stomach is drawn through the hiatus into the chest with a Babcock clamp. The forceps is on the vascular fat pad at the gastroesophageal junction.

On the left side, the sutures are passed through the muscle fibers of the left crus and the firmly adherent overlying pleura. Approximately three to four figure-eight sutures, placed 1 cm apart, are necessary to approximate the crura and to adequately reduce the size of the hiatus. All sutures are

initially placed prior to tying because it is easier to remove those not needed than to add additional sutures after the hiatus has been closed. Tying the crural sutures is the last step in the repair (Fig. 70.9).

The construction of the gastric fundoplication is the keystone of the antireflux repair in that its proper function is responsible for fulfilling the four principles necessary to reestablish the competence of the cardia. In the Belsey Mark IV operation, the fundus of the stomach is plicated around the anterior two thirds of the lower 4 cm of esophagus. The partial fundoplication is held in place by two rows of three horizontal mattress sutures placed equidistantly and in the seromuscular layers of the stomach and the muscular layers of the esophagus. Number 000 silk sutures are used, and each suture obtains a firm grip of the esophageal muscle fibers by passing down to, but not through, the muscularis mucosae. The first row of sutures is placed 1.5 cm above the cardia and is tied only tight enough to obtain tissue apposition without disrupting the muscle fibers of the esophagus. It is important to remember that the hiatus is approached surgically from the left lateral position. To construct the fundoplication over the anterolateral two thirds of the esophagus, it is necessary that the far right suture be placed in the right lateral wall of the esophagus. This is out of the surgeon's view and requires rotation of the esophagus before placement of the suture. A common mistake is placing this suture too far anteriorly, resulting in an anterolateral fundoplication displaced to the left (Fig. 70.10).

A second row of 000 sutures is placed 2 cm above the first row, using the position of the previously placed first row of sutures as a guide (Fig. 70.11). The second row of sutures is tied carefully so as to give tissue apposition without strangulation. The tails of these sutures are not cut, but are separately rethreaded on a large thin Ferguson needle and are passed 0.5 cm apart from each other through the diaphragm from the abdominal to the thoracic surface 1.0 to 1.5 cm from the edge of the hiatus. The diaphragmatic sutures are placed at the 4, 8, and 12 o'clock positions on a clock face, oriented with the 6 o'clock position at the posterior hiatus between the right and left crura just anterior to the aorta (Fig. 70.12). It is important to properly place the right lateral, or 4 o'clock, suture to avoid the common error of putting this suture too far anteriorly, in the 1 or 2 o'clock positions, and constructing an anterolateral fundoplication displaced to the left. These sutures must be carefully placed to avoid injury to the abdominal structures. A spoon retractor has become a popular

instrument to aid in placing these sutures without snagging abdominal mesentery or omentum. The needle is guided along the inner surface of the spoon held firmly against the undersurface of the diaphragm before it is passed through the diaphragm.

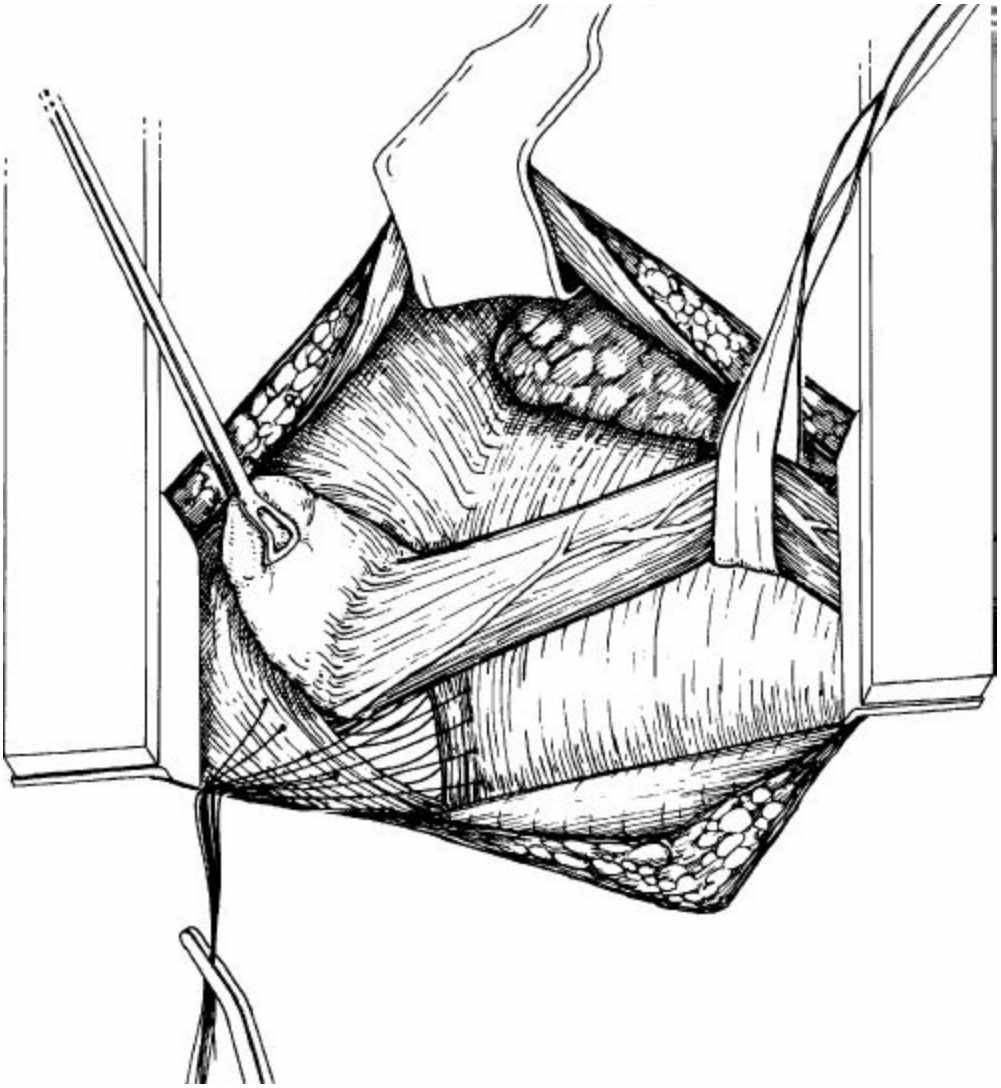

Figure 70.9. A transthoracic exposure showing the vascular fat pad removed and anterior retraction of the esophagus with placement of the crural sutures for closure of the posterior hiatus.

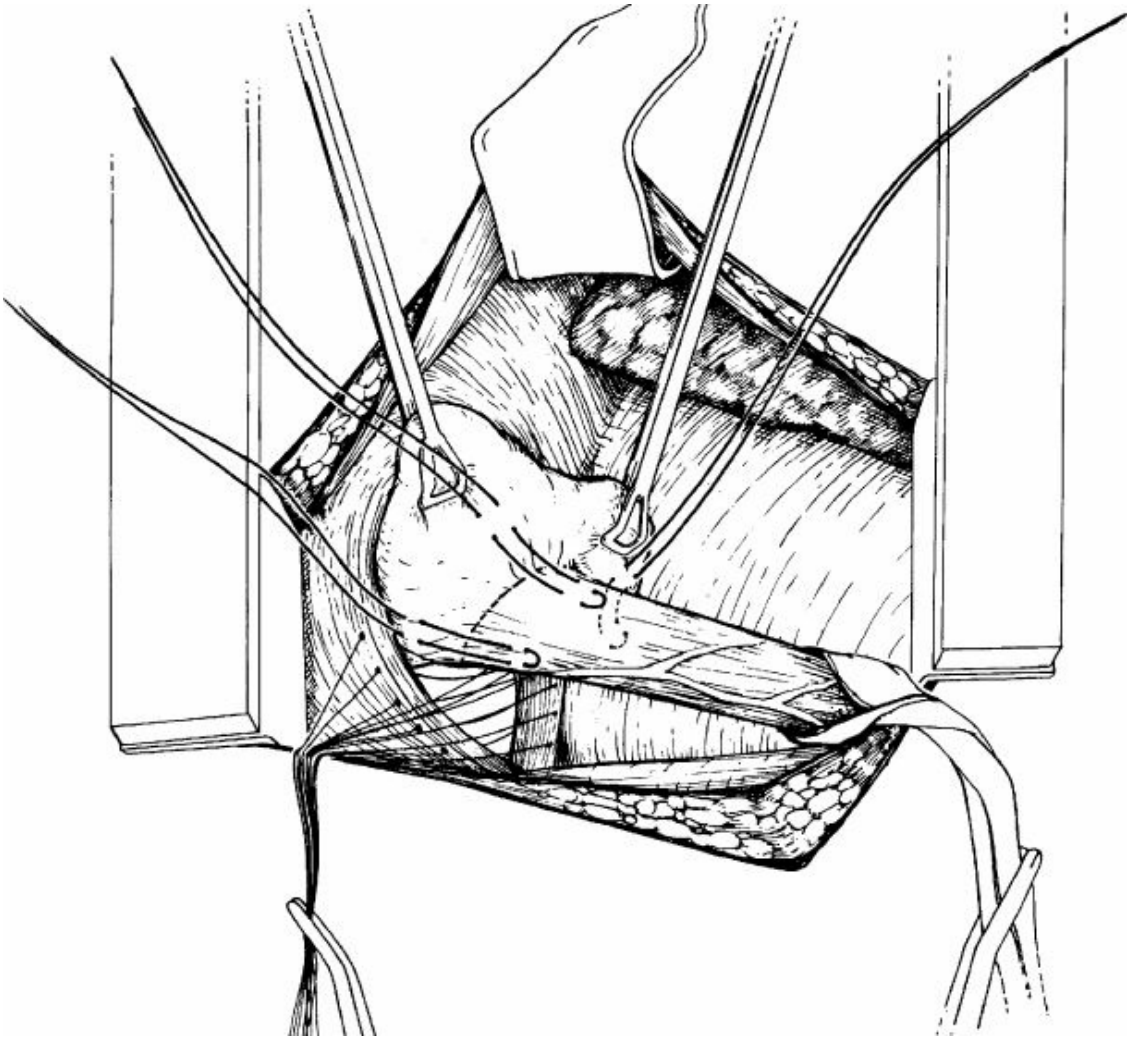

Figure 70.10. Construction of a Belsey 240-degree partial fundoplication showing placement of the first row of sutures 1.5 to 2.0 cm above the gastroesophageal junction. Particular attention must be given to placement of the right lateral suture (see text).

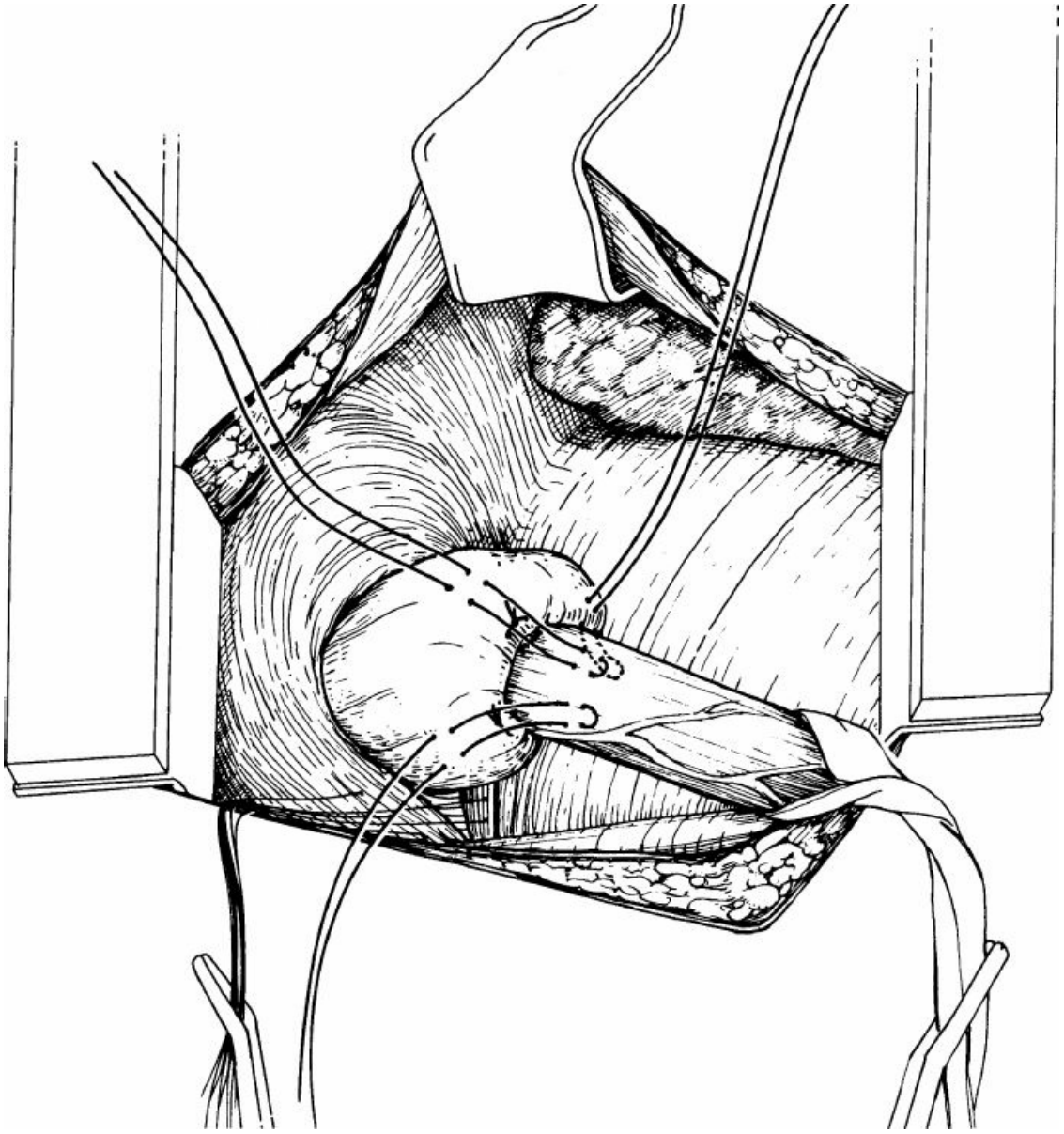

Figure 70.11. Continued construction of the Belsey 240-degree partial fundoplication showing placement of the second row of sutures 2 cm above the row of previously tied sutures.

The partial fundoplication is massaged through the hiatus and into the abdomen. It is not dragged down into the abdomen by pulling on the diaphragmatic sutures, but rather is placed into the abdomen by compressing the fundic ball with the hand and manually maneuvering it through the hiatus. Resistance to placing the repair into the abdomen can result from the shoelace obstruction of the previously placed crural sutures. Opening the crural sutures, as loosening the laces of a shoe, relieves the obstruction and helps in placing the partial fundoplication into the abdomen. Once in the abdomen, the fundoplication should remain

there without tension on the holding sutures. A gentle up-and-down hand motion on the diaphragm should not encourage the fundoplication to pop back through the esophageal hiatus. If the repair remains in the abdomen unaided, the previously placed crural sutures are tied. The holding sutures are then tied, approximating the knot against the previously tied knot so as to avoid any redundancy in the suture between the repair and the diaphragm (Fig. 70.13). An additional safety factor of the double-knot technique is that if one of the tails of the holding sutures breaks while it is being tied, it is not necessary to take the repair down, pull the stomach back up into the chest, and inserting a new suture. Simple anchoring of the single remaining tail to the diaphragm is sufficient to hold the cardia in position. The technique also prevents tying the sutures too tight and causing necrosis of the incorporated esophageal and gastric tissue.

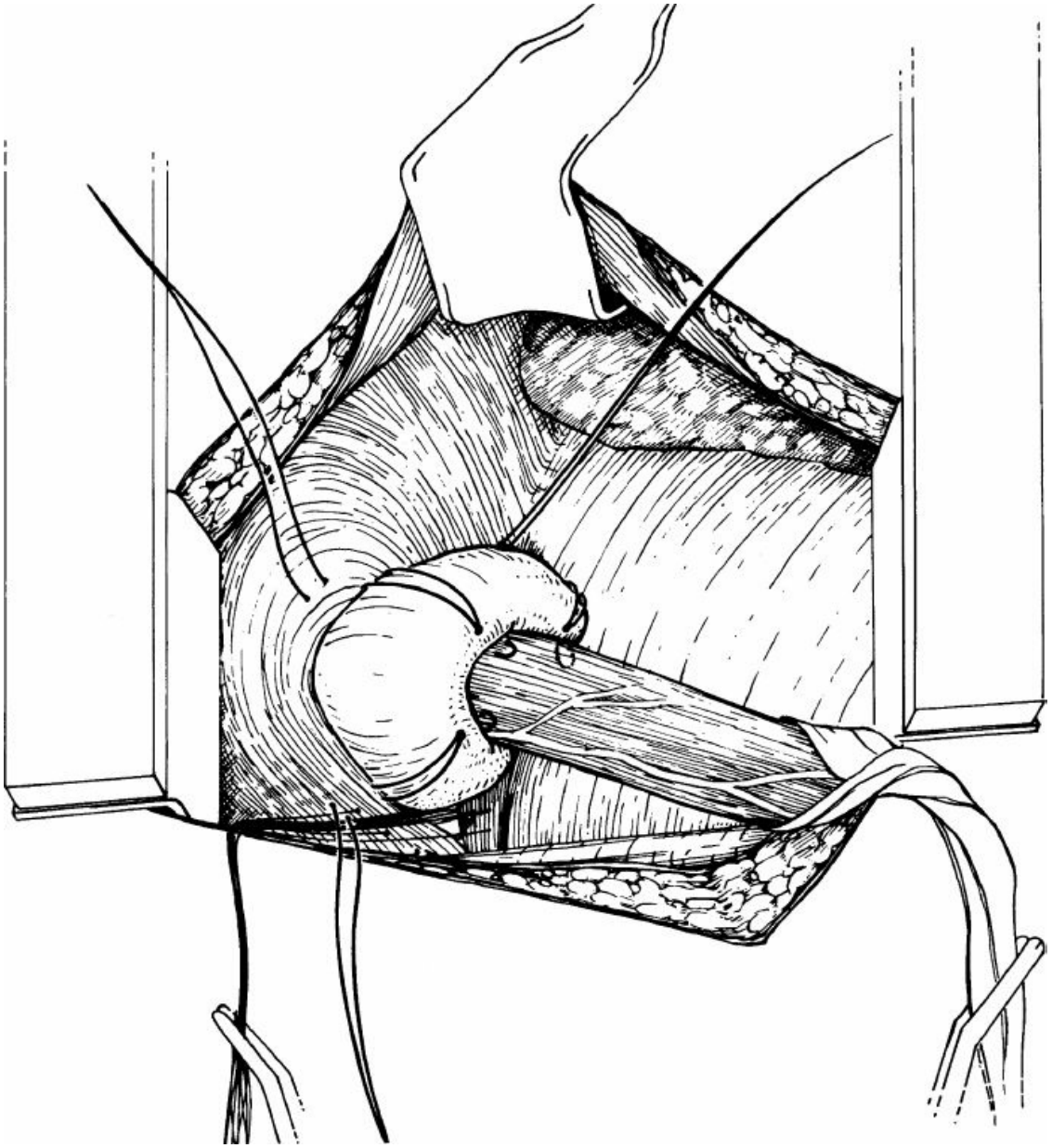

Figure 70.12. Continued construction of a Belsey 240-degree partial fundoplication showing the tails of the previously tied second-row sutures are placed through the diaphragm, 0.5 cm apart and 1.0 to 1.5 cm from the edge of the hiatus. Note the placement of the sutures at the 4, 8, and 12 o'clock positions on an imaginary clock face oriented with the 6 o'clock position posterior in the hiatus between the right and left crura just anterior to the aorta.

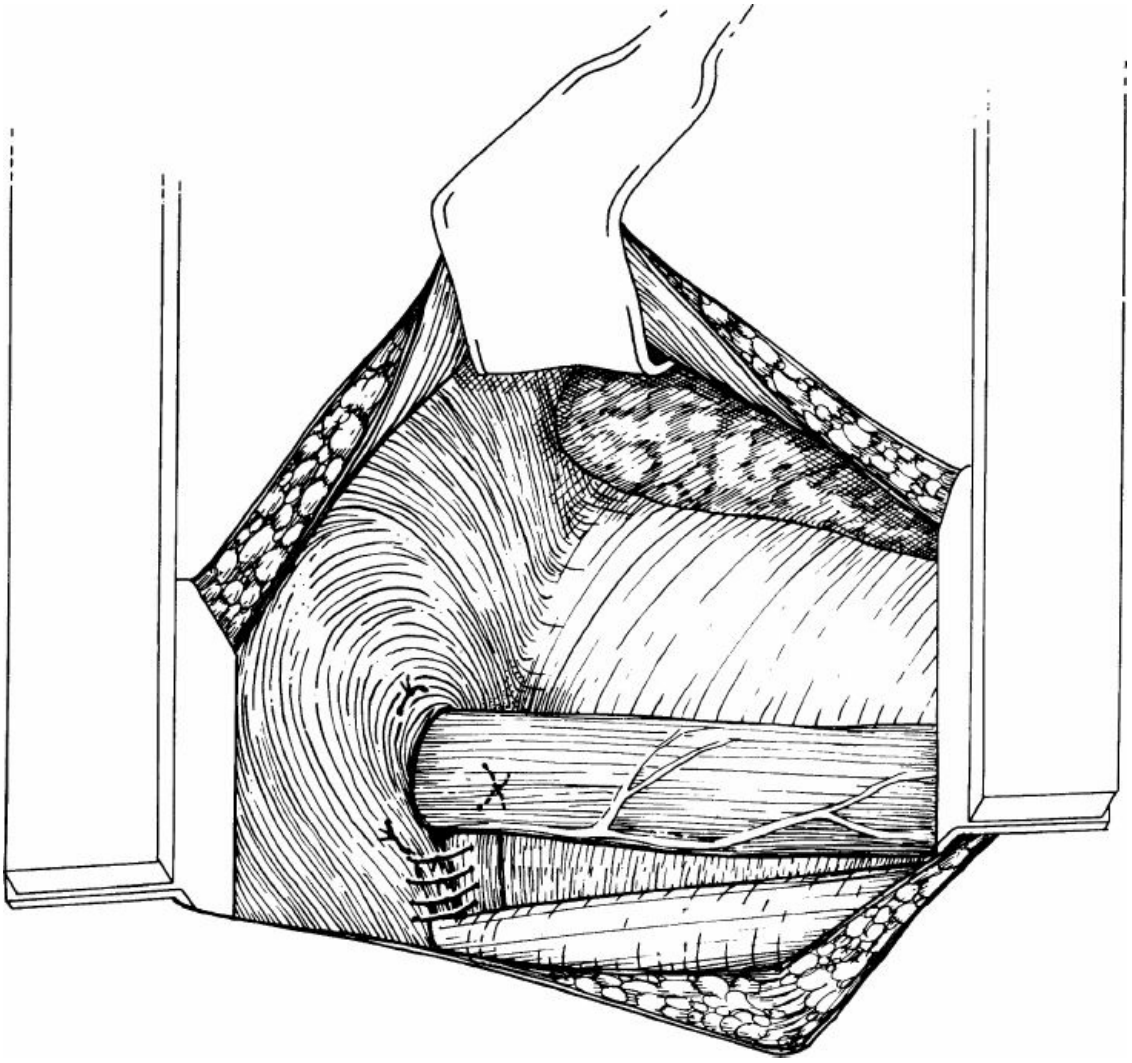

Figure 70.13. A completed Belsey 240-degree partial fundoplication showing the right and left crura approximated after tying the previously placed crural sutures. The positions of the tied holding sutures are also shown.

If the fundoplication tends to ride up through the hiatus, tension on the repair is too great. It is usually caused by inadequate mobilization of the esophagus. If after further attempts at mobilization the tendency remains, a Collis gastroplasty may be necessary.

Transthoracic Collis Gastroplasty

Dr. John Leigh Collis of Great Britain initially introduced the concept of a gastroplasty in 1957 as an antireflux procedure. It was modified in 1987 by Dr. Griffith Pearson to include a Belsey-type partial fundoplication over the gastroplasty tube. The Collis–Belsey procedure, as it was called, is performed in the patients who have gastroesophageal reflux disease

(GERD) complicated by esophageal fibrosis and shortening. As a result of the severe alterations in esophageal body structure and function, many of these patients present with dysphagia in addition to heartburn and regurgitation.

The gastroplasty procedure lengthens the esophagus by constructing a tube along the lesser curve of the stomach to create a "neoesophagus." This allows construction of a tension-free partial Belsey Mark IV or a full Nissen fundoplication over the gastric tube and reduces the risk of subsequent retraction of the fundoplication into the chest. We prefer to combine the full Nissen fundoplication with a gastroplasty because it provides better reflux control. The gastroplasty component of the procedure, in addition to adding esophageal length, provides relatively noninflamed tissue to which the stomach can be sewn in performing the fundoplication. The operation improves the competency of the lower esophageal sphincter sufficiently to heal the reflux-induced esophagitis and ulceration, and soften the fibrotic strictures. With settling of the inflammation, there is some restoration of esophageal compliance and a little improvement in esophageal body contraction amplitude, but commonly the loss is not reversible.

Surgical staplers have made the construction of the gastroplasty tube simple and reliable and prevent spillage of gastric contents into the chest or abdomen. The relative ease with which a gastroplasty and partial fundoplication can be performed has made the procedure particularly suited for the patients who have the sequelae of advanced disease and has reduced the need for esophageal resection and replacement.

To perform the Collis gastroplasty procedure, the esophageal and gastric mobilizations are performed as described for the Belsey Mark IV partial fundoplication. The Collis gastroplasty tube is created along the lesser curvature of the stomach, in continuity with the distal esophagus and for a length of 4 to 5 cm, over a 48-Fr Maloney bougie (Fig. 70.14). The tube can be readily constructed using a single fire of the GIA stapler. To achieve a uniform tube diameter along the lesser curvature, traction is exerted on the greater curvature before the jaws of the stapler are closed (Fig. 70.15). The resultant staple line creates a wedge of fundus that is resected by stapling across the fundus, in a line perpendicular to the staple line on the gastric tube, from the greater curvature to the end of the staple line on the gastric tube (Fig. 70.16). The whole length of the staple line is oversewn with a running absorbable suture (Fig. 70.17). This sutured

reinforcement is essential to prevent subsequent leakage or fistulization from the staple lines. A Belsey partial fundoplication (Figs. 70.18 and 70.19) or preferably a full Nissen fundoplication (Figs. 70.20 and 70.21) is performed over and around the gastroplasty tube. The gastroplasty tube continues to produce acid from its oxyntic mucosa, but rarely is it in sufficient quantities to produce esophagitis or cause heartburn. This is likely due to compression of the gastroplasty tube by the fundoplication. Caution must be exercised in constructing Collis gastroplasty tubes in the patients who have had previous antireflux or gastric surgery. These previous procedures may have interrupted the blood supply to the lesser curvature, resulting in devascularization of the gastroplasty tube and subsequent ischemic necrosis.

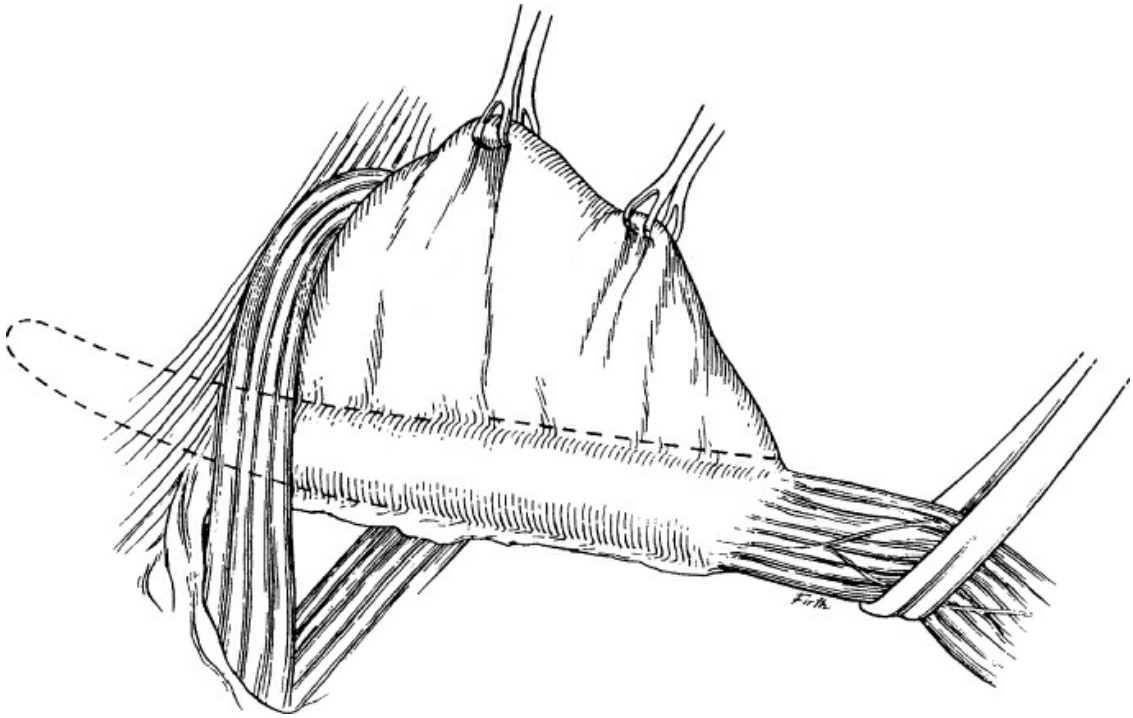

Figure 70.14. Position of the stomach for performing a Collis gastroplasty. A 48-Fr bougie is passed into the stomach. The *dashed line* indicates the proposed site for stapling and cutting the gastric wall to form a gastric tube in continuity with the esophagus.

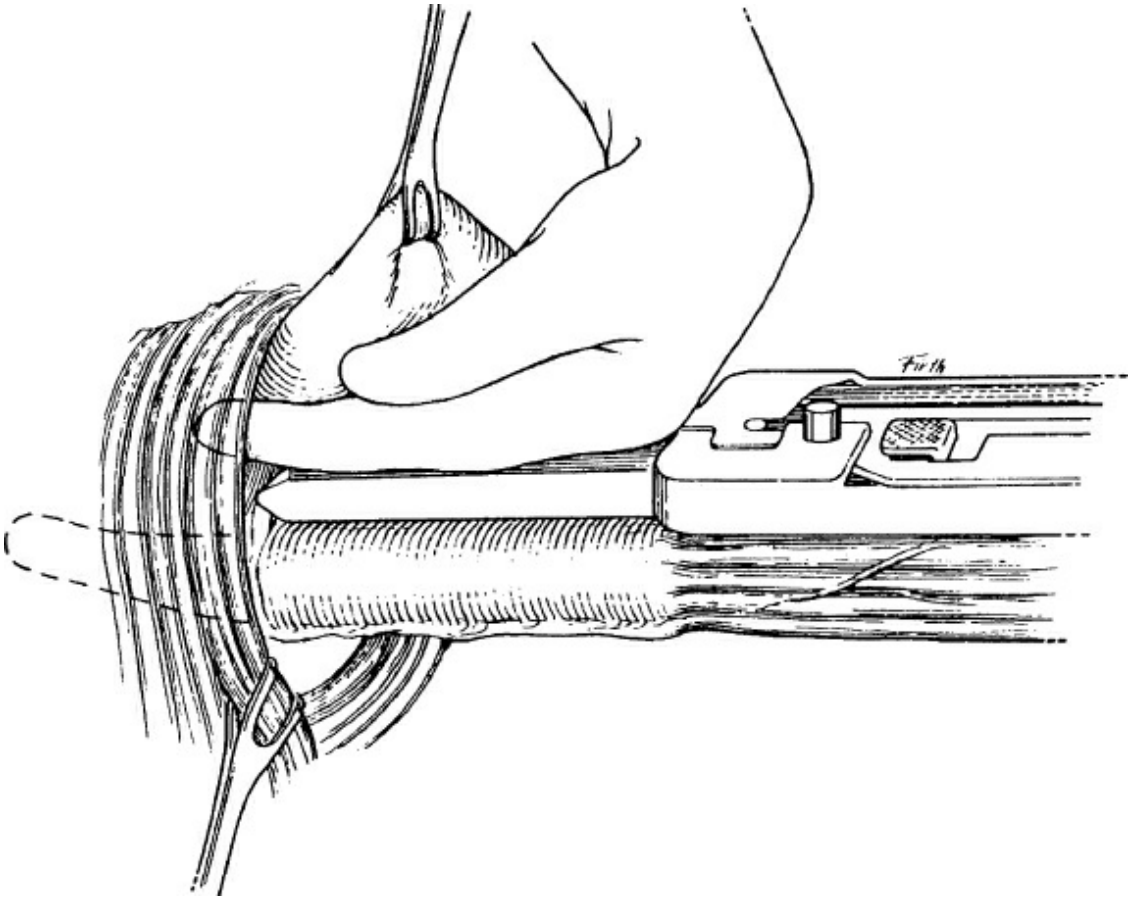

Figure 70.15. Prior to dividing the fundus of the stomach with a GIA stapler, traction is exerted on the greater curvature side of the fundus before closing the jaws of the stapler. This ensures that the gastric tube closely approximates the diameter of the indwelling 48-Fr bougie throughout its length.

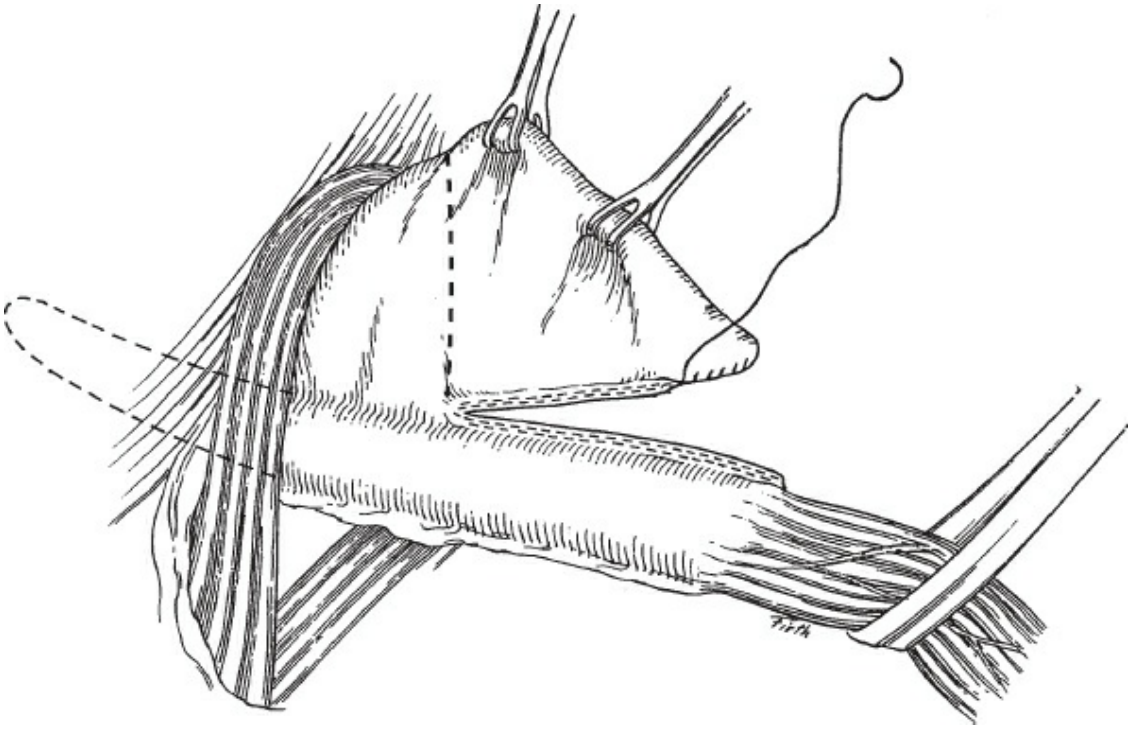

Figure 70.16. The fundus of the stomach is stapled and cut to form a 5-cm gastric tube along the proximal portion of the lesser curvature. This effectively lengthens the esophagus by approximately 4 to 5 cm. The wedge of stomach is removed by stapling vertically from the greater curvature down to the horizontal staple line along the *dotted line*.

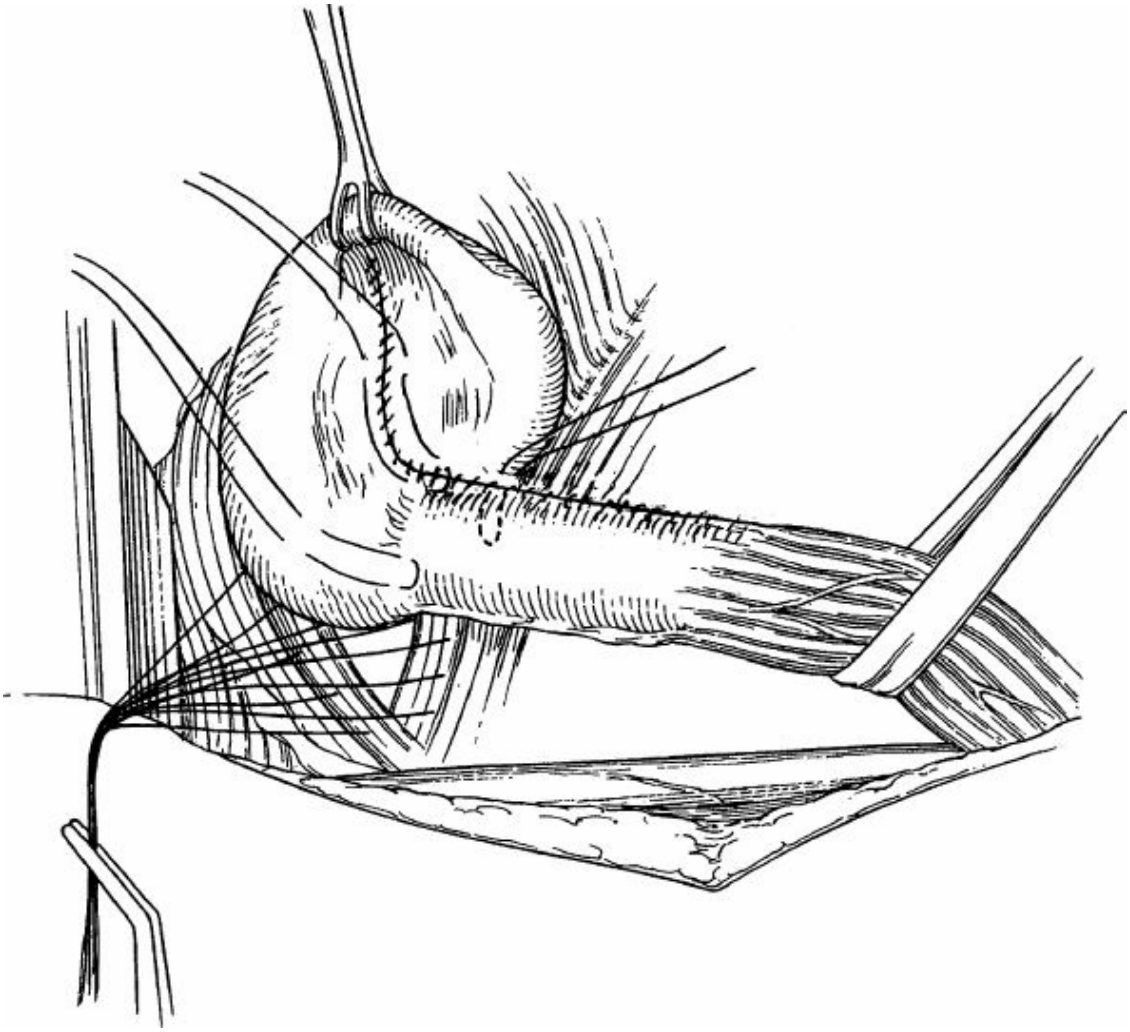

Figure 70.17. The staple line is inverted by a running suture and a Belsey 240-degree partial fundoplication is constructed around the gastroplasty tube. The first row of sutures is placed 1.5 cm above the end of the gastroplasty tube. Particular attention must be given to place the right lateral suture far to the right to avoid constructing a partial fundoplication that covers only the left anterior-lateral portion of the gastroplasty tube.

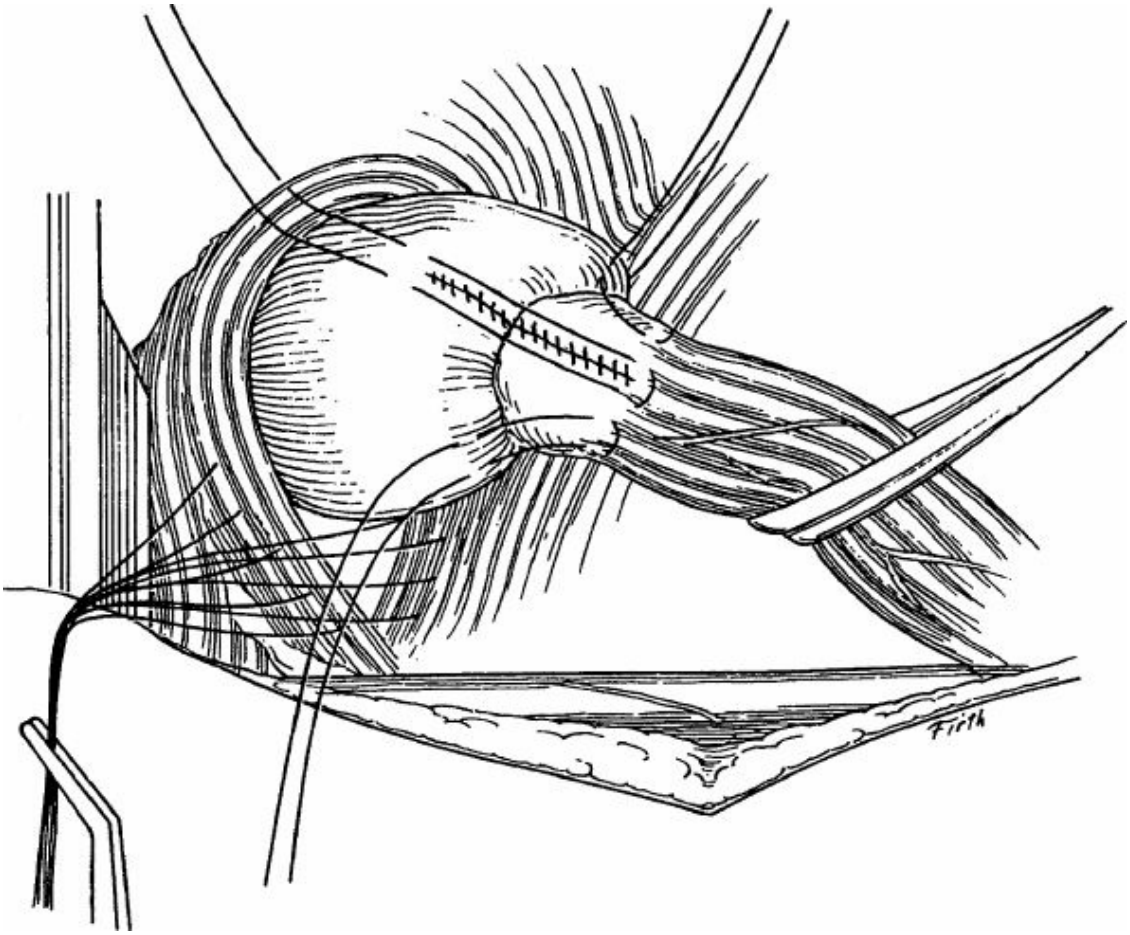

Figure 70.18. Continued construction of the Belsey 240-degree partial fundoplication over the gastroplasty tube by placing a second row of sutures 1.5 cm above the first row of sutures and a third row of sutures 1.0 to 1.5 cm above the previously tied sutures of the second row.

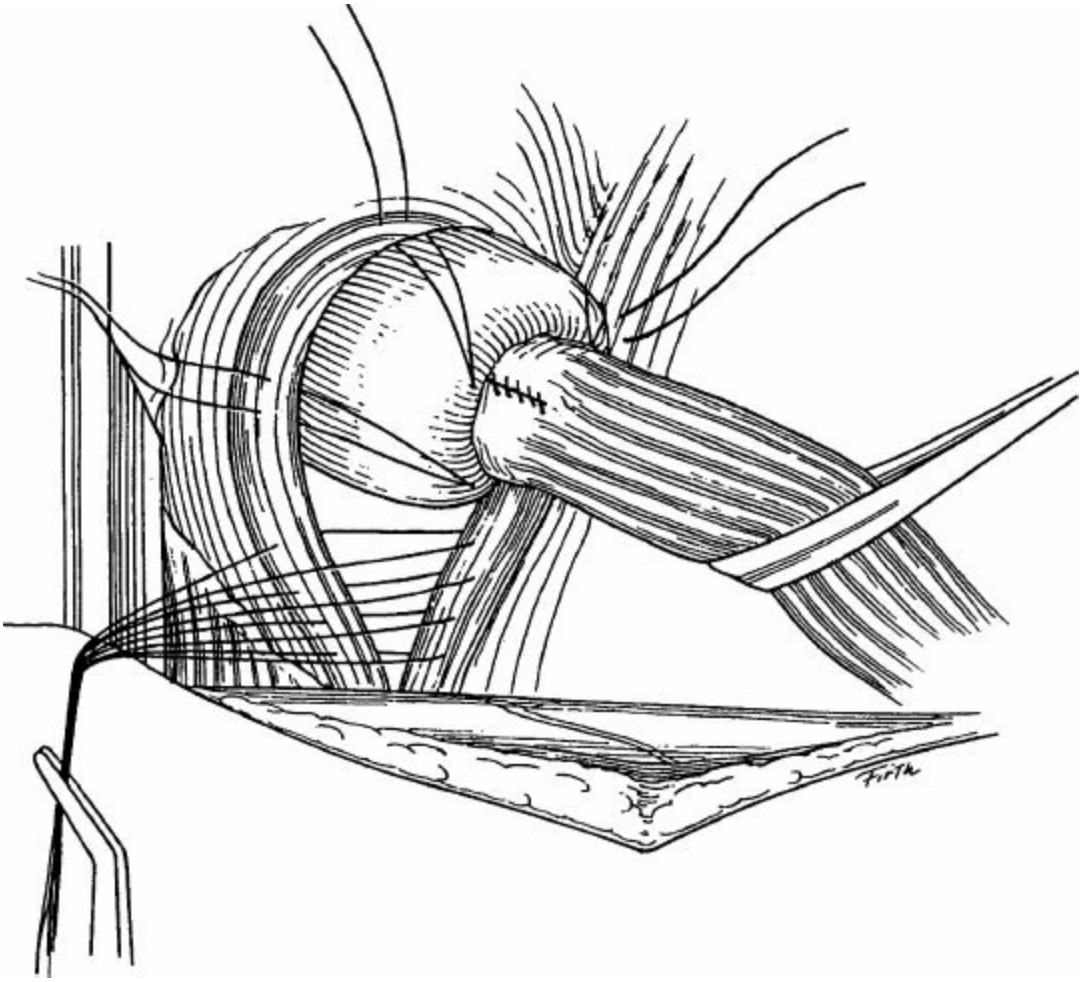

Figure 70.19. Continued construction of the Belsey 240-degree partial fundoplication showing placement of the tails of a third row of sutures through the diaphragm, 0.5 cm apart and 1.0 cm from the edge of the hiatus. Note the placement of the sutures at the 4, 8, and 12 o'clock positions on an imaginary clock face oriented with the 6 o'clock position posterior in the hiatus between the right and left crura just anterior to the aorta.

Transthoracic Nissen Fundoplication

Rudolf Nissen initially described the Nissen fundoplication in German literature in 1956 and subsequently in English literature in 1961. The original procedure was subsequently modified in 1986 to reduce the incidence of side effects. It was found that at reoperation in the patients who complained of recurrent heartburn and regurgitation, traces of a previous fundoplication were completely absent due to disruption of the fundic sutures. This suggested the need for stronger sutures placed in a more durable manner. Other patients complained of dysphagia and inability to belch, even though an endoscope could be passed easily

through the fundoplication and into the stomach. In these patients, the fundoplication was too tight or too long. Observations made from a biomechanic model of the cardia indicated that the fundoplication should be at least 60 Fr in diameter, only 1.5 to 2.0 cm long, and held in place with permanent reinforced sutures. The technique that emerged used one permanent 00 polypropylene suture placed in a U-shaped pattern with two 1.5 × 0.5 cm polytetrafluoroethylene (PTFE) pledgets for reinforcement. The PTFE pledgets are cut to exact size to keep the fundoplication a standard length and give reproducible results. The diameter of the fundoplication was standardized by loosely constructing it over a 60-Fr bougie. When completed, the approximated lips of the fundoplication lie over the anterior right lateral surface of the lower esophagus or gastroplasty tube.

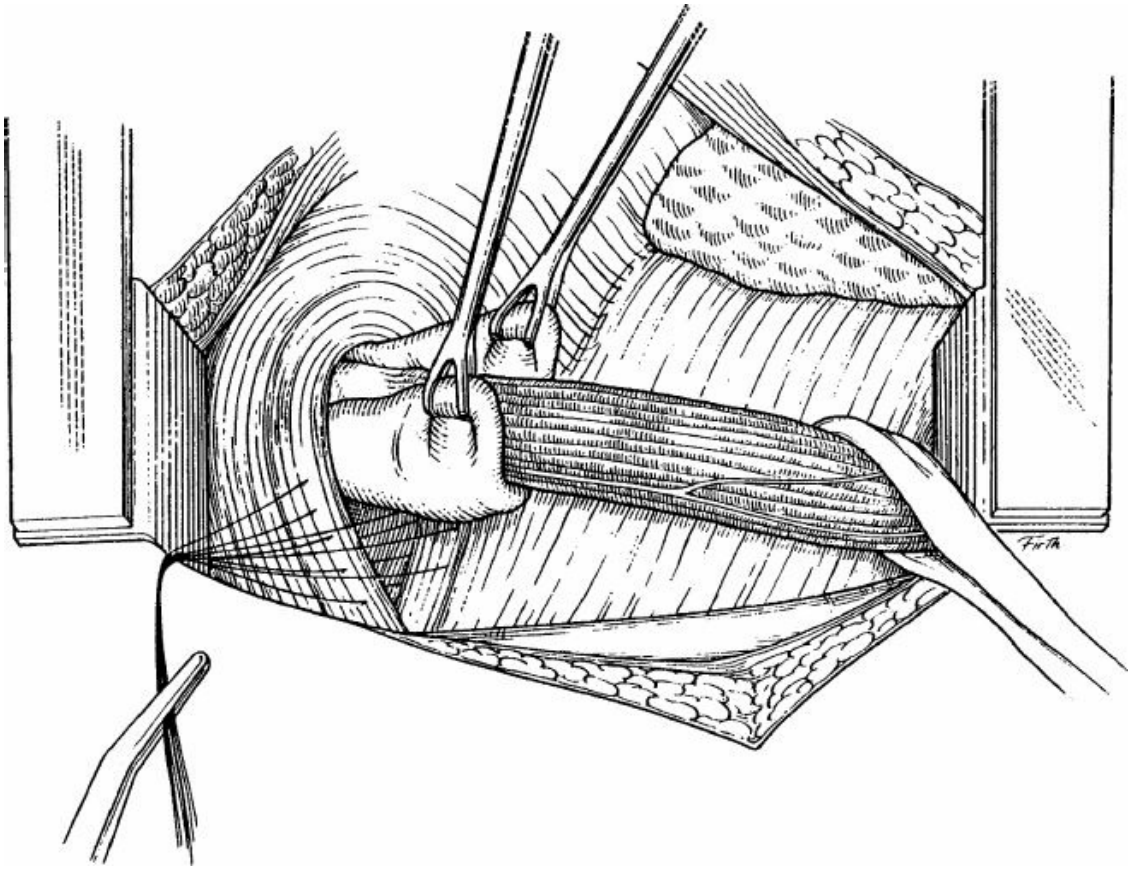

Figure 70.20. Construction of a Nissen 360-degree full fundoplication showing the posterior and anterior fundic wall brought up through the hiatus and plicated around the lower esophagus.

To perform a transthoracic Nissen fundoplication, the esophagus and

cardia are mobilized, and the fundus of the stomach brought up through the hiatus as described for the Belsey operation. When completely mobilized, the fundus of the stomach is placed in its normal left lateral relationship to the esophagus and then plicated around the distal esophagus with the posterior fundic wall posterior and the anterior fundic wall anterior to the esophagus (Fig. 70.20). A 60-Fr bougie is passed by the anesthesiologist into the stomach for accurate sizing of the fundoplication. The lips of the fundoplication are secured in an anterior-right lateral position with a U-stitch, consisting of a double-arm 00 polypropylene suture and a 1.5 × 0.5 cm PTFE pledget on the outside of each fundic lip. A portion of the anterior-right lateral esophageal wall down to, but not through, the muscularis mucosa is incorporated into the stitch. The two limbs of the U-suture are placed through the posterior fundic lip, parallel to each other and separated by 1 cm, and through the esophagus 1 cm above the gastroesophageal junction identified by the site of insertion of the phrenoesophageal membrane. This sandwiches the esophageal wall between the anterior and posterior fundic lips and the two PTFE pledgets (Fig. 70.21).

The polypropylene suture slides through the tissue without sawing and allows a test sizing of the fundoplication without producing damage to the tissue. When the edges of the fundoplication are drawn together, the diameter of the wrap should be large enough to allow the insertion of the surgeon's index fingertip between the stomach and the esophagus containing the 60-Fr dilator (Fig. 70.22). If the surgeon's fingertip cannot fit, the fundoplication is too tight and the U-stitch must be placed more laterally and inferior in the stomach, enlarging the internal diameter of the fundoplication. If the surgeon's fingertip inserts too easily, the fundoplication is too floppy and the U-stitch must be placed more medially and superior on the stomach, reducing the internal diameter of the fundoplication. When the fundoplication is of proper size, the bougie is removed and the limbs of the U-stitch are tied securely. Since only one suture is used to secure the fundoplication, it is important that it is made of permanent material and that PTFE pledgets are used to reinforce its purchase on the tissues.

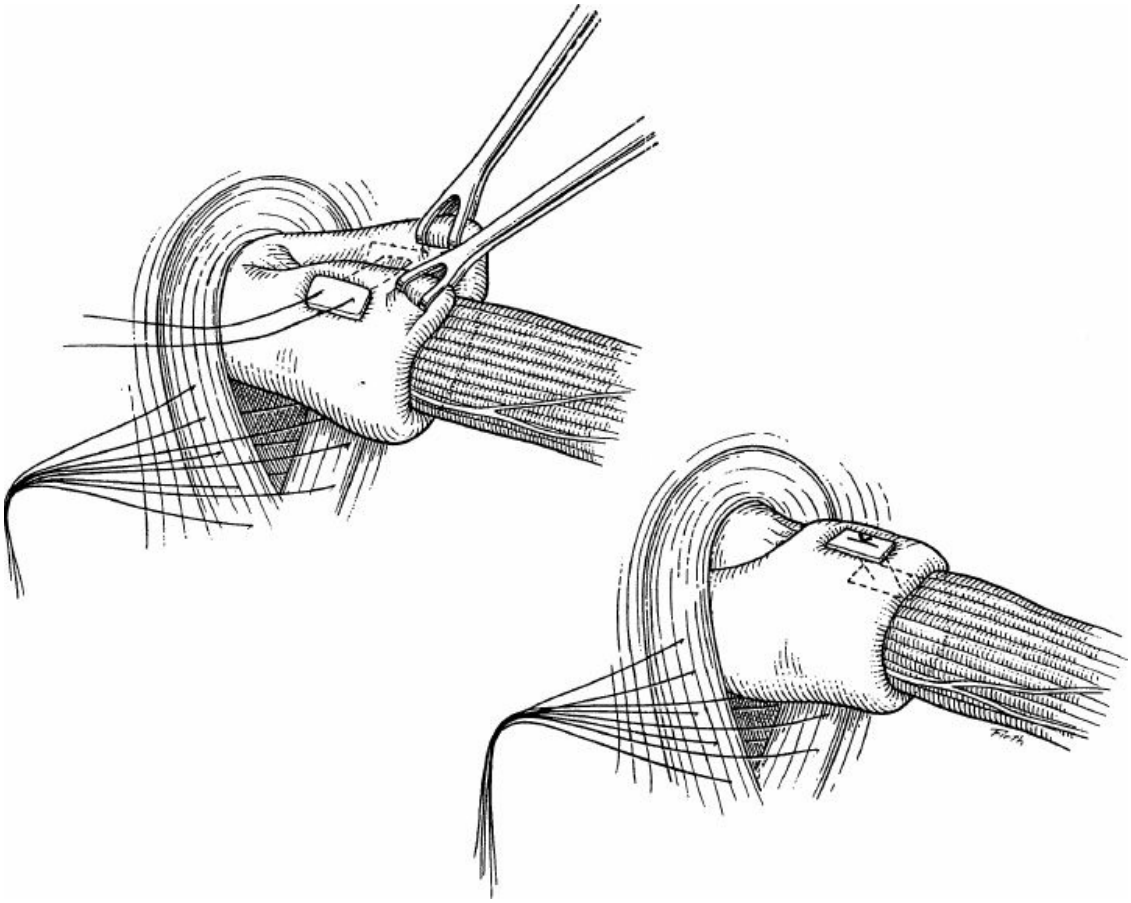

Figure 70.21. Continued construction of a Nissen 360-degree full fundoplication showing the placement of the U-stitch with pledgets. A 60-Fr bougie is passed into the stomach to allow accurate sizing of the fundoplication. The fundoplication is placed 1 cm above the gastroesophageal junction with the anterior and posterior fundic lips approximating on the right anterior-lateral wall of the esophagus.

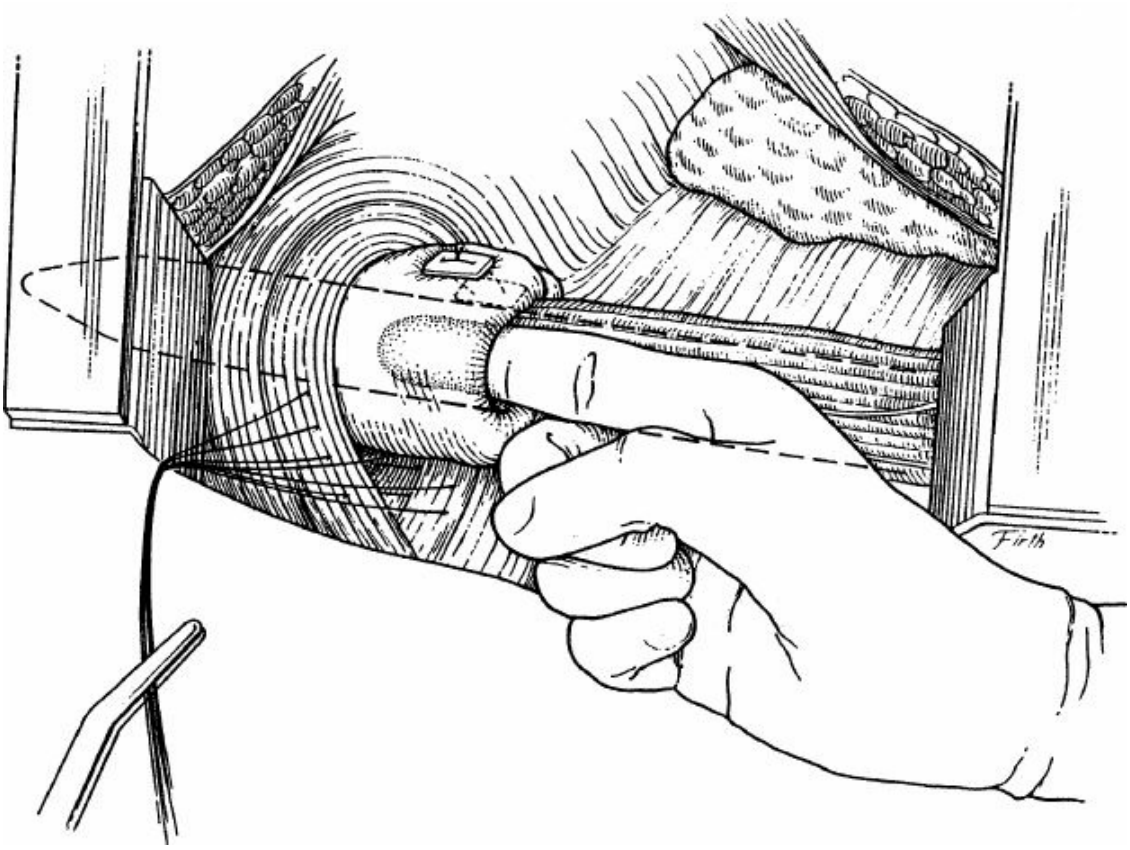

Figure 70.22. Continued construction of a Nissen 360-degree full fundoplication showing the testing of the size of the diameter of the fundoplication by the insertion of the surgeon's index finger between the fundoplication and the esophagus containing the 60-Fr dilator. The stomach and esophagus are in their normal position with the U-stitch located on the right anterior-lateral wall of the esophagus.

When complete, the fundoplication is massaged into the abdomen in a manner similar to that described for the Belsey Mark IV operation. No sutures are used in the Nissen procedure to hold the repair in the abdomen; the fundoplication serves as the anchoring device. Again, as with the Belsey Mark IV operation, the fundoplication should not protrude out of the hiatus when placed in the abdomen. If it does, the repair is under too much tension, and a Collis gastroplasty should be performed. The fundoplication should not be left in the chest as this encourages intrathoracic gastric distension, which cannot be relieved by a belch and can result in gastric ischemia and perforation.

Once the repair is in the abdominal position, the previously placed crural sutures are tied, starting posteriorly at the aortic hiatus and progressing anteriorly until the size of the hiatal opening just allows

insertion of the surgeon’s index finger adjacent to the empty esophagus. Any unused sutures are removed (Fig. 70.23). Leaving the hiatal opening too large encourages reherniation. In the Belsey repair, the closure of the crura provides a posterior buttress against which the intra-abdominal segment of the esophagus is compressed, whereas in the Nissen procedure, the crural closure helps hold the repair in the abdomen. At the completion of the procedure, a nasogastric tube is passed by the anesthesiologist without guidance from the surgeon into the stomach to ensure that there has been no angulation of the fundoplication in relationship to the distal esophagus. A chest tube for drainage of the pleural cavity is placed and the chest incision is closed.

Nasogastric suction is used to avoid overdistention of the stomach in the immediate postoperative period. Gastric distention rarely causes a breakdown of a full Nissen fundoplication if performed as described, but can be detrimental to a Belsey partial fundoplication. A barium swallow is performed on the 6th postoperative day to check the repair and demonstrate free passage of barium into the stomach. Patients often experience slight dysphagia when oral intake is begun, but this usually disappears quickly as the postsurgical edema subsides. Occasionally, dysphagia persists for a longer period. This can be caused by an intramural gastric hematoma at the site of the fundoplication. When present, it will generally absorb within 4 to 6 weeks, and the dysphagia subsides. When the patient recovers from anesthesia, they usually note relief from their heartburn and regurgitation. Before discharge, the patient should be counseled that until the habit of air swallowing is broken, he or she may experience increased abdominal distention and flatus. Early satiety is common until the patient gains confidence in his swallowing ability and takes fewer swallows to ingest their meal, and, as a consequence, ingests in less air with their food.

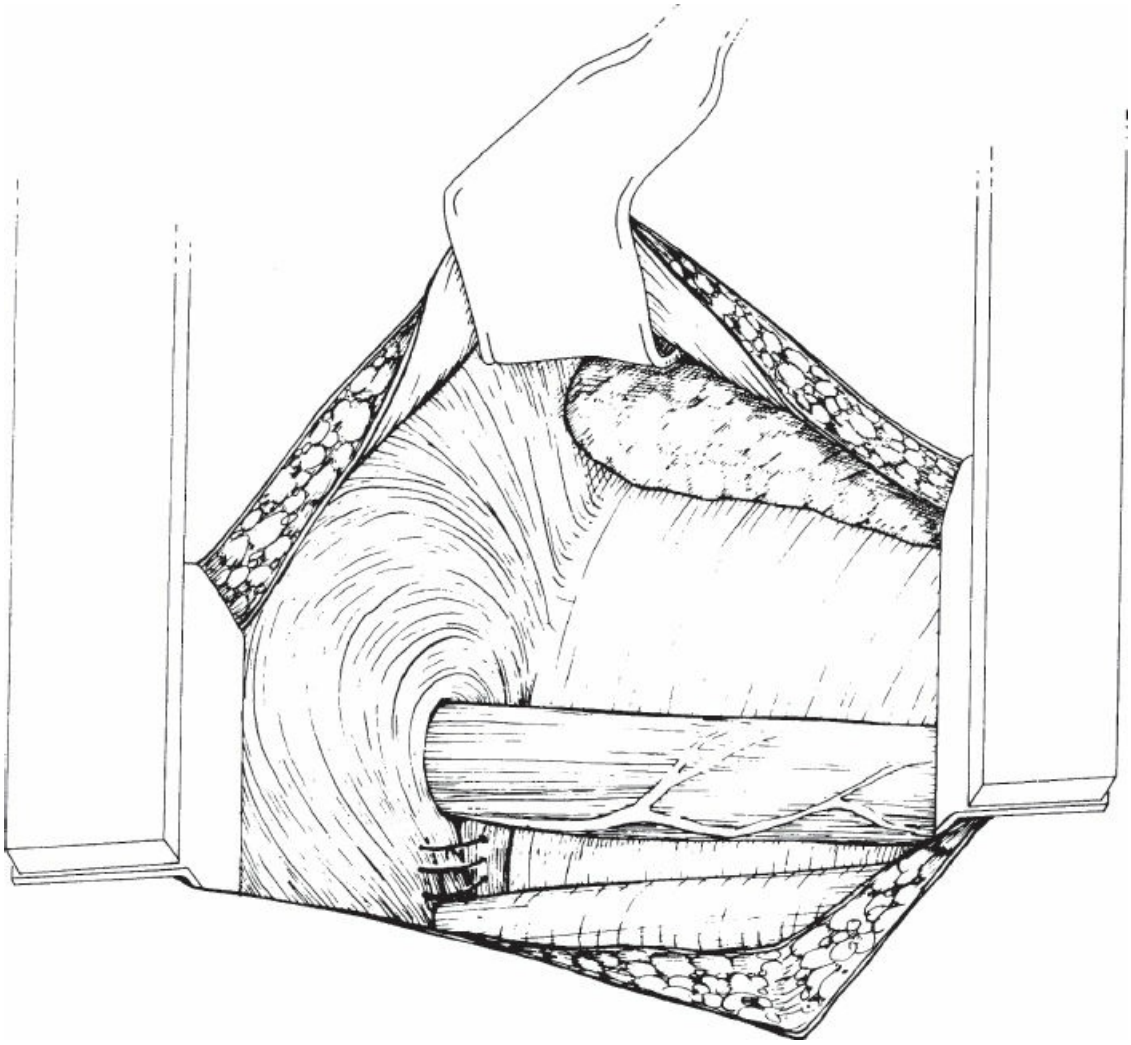

Figure 70.23. A completed Nissen 360-degree full fundoplication with the fundoplication in the abdomen, and the right and left crura approximated by tying the previously placed crural sutures.

We have evaluated our patients after surgery with esophageal manometry, 24-hour esophageal pH monitoring, and a questionnaire about their esophageal symptoms and eating habits. Comparison of the results of these studies with the results of similar studies obtained from healthy volunteers has helped to objectively evaluate what has been accomplished by the surgical repair. Consequently, the described technique represents a refinement of the method initially published by the originators of the operation. The surgeon must keep in mind that the operation is designed to improve the function of the gastroesophageal barrier and offhanded alterations in technique can have a profound effect on postoperative function. No change in technique should be made unless its effects on function are known.

Suggested Readings

Allison PR. Reflux esophagitis, sliding hiatal hernia, and anatomy of repair. *Surg Gynecol Obstet* 1951;92:419.

Allison PR. Hiatus hernia (a 20-year retrospective survey). *Ann Surg* 1967;166:273.

Ayazi S, Tamhankar A, DeMeester SR, et al. The impact of gastric distension on the lower esophageal sphincter and its exposure to acid gastric juice. *Ann Surg* 2010;252:57–62.

Bowditch HI. *A Treatise on Diaphragmatic Hernia.* Buffalo, NY: Jewett, Thomas; 1853.

Campos GMR, Peters JH, DeMeester TR, et al. Multivariate analysis of factors predicting outcome after laparoscopic Nissen fundoplication. *J Gastroint Surg* 1999;3(3):292.

Collis JL. An operation for hiatus hernia with short esophagus. *J Thorac Cardiovasc Surg* 1957;34:768.

Dallemagne B, Weerts JM, Jehaes C, et al. Laparoscopic Nissen fundoplication: preliminary report. *Surg Laparose Endosc* 1991;1:138.

DeMeester TR, Bonavina L, Albertucci M. Nissen fundoplication for gastroesophageal reflux disease: evaluation of primary repair in 100 consecutive patients. *Ann Surg* 1986;204:9.

DeMeester TR, Wernly JA, Bryant GH, et al. Clinical and in vitro determinants of gastroesophageal competence: a study of the principles of antireflux surgery. *Am J Surg* 1979;137:39.

Fyke FE, Code CF, Schlegel JF. The gastroesophageal sphincter in healthy human beings. *Gastroenterologia* 1956;86:135–50.

Gastal OL, Hagen JA, Peters JH, et al. Short esophagus: analysis of predictors and clinical implications. *Arch Surg* 1999;134:633–8.

Gatzinsky P, Bergh NP. Hiatal hernia and shortened oesophagus. *Acta Chir Scand* 1979;145:159–66.

Harrington SW. Diaphragmatic hernia. *Arch Surg* 1928;16:386.

Hill LD. An effective operation for hiatal hernia: an eight-year appraisal. *Ann Sug* 1967;166:681.

Liebermann-Meffert D, Allgower M, Schmid P, et al. Muscular equivalent of the lower esophageal sphincter. *Gastroenterology* 1979;76:31–9.

Nissen R. Eine einfache operation zur beeinflussung der refluxesophagitis. *Schwieze Med Wochenschr* 1956;86:590.

Pearson FG, Cooper JD, Patterson GA, et al. Gastroplasty and fundoplication for complex reflux problems. *Ann Surg* 1987;206:473.

Saloma FD, Lamont G. Long-term results of the Belsey Mark IV antireflux operation in relation to the severity of esophagitis. *J Thorac Cardiovasc Surg* 1990;100:517.

Skinner DB, Betsey RHR. Surgical management of esophageal reflux with hiatus hernia: long-term results with 1,030 cases. *J Thorac Cardiovasc Surg* 1967;53:33.

Zaninotto G, DeMeester TR, Schwizer W, et al. The lower esophageal sphincter in health and disease. *Am J Surg* 1988;155:104.

EDITOR'S COMMENT

Dr. DeMeester is part of the chain of superb surgeons who have brought transthoracic procedures to the United States. A little bit of history outlined in this chapter is worthwhile. I am old enough to remember the repair that Allison proposed in 1951. Allison proposed to cinch up the crura and to use the phrenico-esophageal "ligament" in to reinforce it and to allow the repair to hold, as holding the stomach in the abdomen did not work. First of all, only 50% of the patients have a phrenico-esophageal membrane, as I call it, because it is too flimsy, in my humble opinion, to be called "a ligament." Thus, what one does, if it is absent, is reef up and shut the crura and try and restore the normal anatomic relationships in the abdomen of the stomach and the intra-abdominal esophagus. Second, it did not take long for the repair to tear loose. It was estimated by Allison himself that 80% of the repairs had recurred anatomically. Interestingly enough, only 50% of the patients whose repairs recurred because of splitting of the phrenico-esophageal membrane redeveloped symptoms, suggesting that it was not at all a question of whether or not one could restore the high-pressure zone (as we now know what the mechanism of repair was, and that some patients still had relief). And then, we went into the modern era of basically knowing what we were trying to do, and that is restore a length of intra-abdominal esophagus and thus the high-pressure zone and finding ways of holding it there.

At the Mass General Hospital, there was a rotation in which residents went to the Frenchay Hospital in Bristol, where Mr. Belsey held forth, and I use that term advisedly, to learn about antireflux procedures and the thoracic repair that bears Mr. Belsey's name as the Mark IV. Unfortunately, by the time I reached the level of the residency in which I would have been eligible to go, Mr. Belsey was no longer the chief, and the rotation policy was abolished, which is too bad. David Skinner, who was my predecessor as chief resident on the East Surgical Service in 1963, was among those who were most taken by the aspect of the Belsey repair and also for esophagectomy, and afterward become an acolyte of Mr. Belsey. While Mr. Belsey was an interesting character, there are many

worse people to whom one could be an acolyte. Dr. Skinner was a lifelong student of the esophagus and brought back the discipline of the single-layer running-wire anastomosis of Mr. Belsey and the Belsey Mark IV repair in esophagectomy and esophageal anastomosis. As residents of the Mass General Hospital, we got to do many Belsey Mark IV antireflux procedures, and in my opinion it was an excellent repair. Probably, the best part of it was that one mobilized the "short esophagus" in the chest, and was able to bring it down below the diaphragm by the series of sutures that have been described in this chapter and in previous chapters on the Belsey Mark IV repair, and thus solidify the high-pressure zone within the abdomen and to prevent the repair from slippage. I did quite a number of these, and I thought it was an excellent operation, particularly for patients who were somewhat larger than the standard individual on whom you would do a Nissen fundoplication. One of the advantages of the Belsey Mark IV repair done transthoracically is that you do not have to do a Collis gastroplasty with its attendant requirement of the patient taking proton-pump inhibitors for the rest of his or her life, and also that you could see what you had actually done. It remains a great favorite of mine, and I was disappointed to hear from Dr. DeMeester, when he agreed to do the chapter, that he had not done a Belsey procedure for 10 years. That is unfortunate, because it is, in addition to being a very good procedure, "fun to do." I do believe that, in patients in whom one must do a Collis gastroplasty, given the propensity of patients to stop taking their medication, that one is probably better off mobilizing the stomach through the chest and bringing it down and gaining the length of the esophagus that one needs to avoid a Collis gastroplasty. It seems I am in the minority, but I do not know what happens when patients stop taking their proton-pump inhibitors when they have a Collis gastroplasty—Do they develop an ulcer? Do they get a perforation? Do they get a stricture once again?

Having bid our adieus to the Belsey repair, let me quote a number of papers in which the Belsey repair and the partial posterior fundoplication is followed up by Mardani Jalal et al. (Mardani J, Lundell L, Engström C. Total or posterior partial fundoplication in the treatment of GERD: results of a randomized trial after 2 decades of follow-up. *Ann Surg* 2011;253(5):875–8), in which they followed a group of 137 patients, who had participated in more than 18 years of follow-up at the most, for a randomized trial, which randomized the Toupet posterior partial fundoplication and the Belsey antireflux procedure carried out between 1983 and 1991. Of these 137 patients with gastroesophageal reflux, 26% had died, and 16% could not be traced. The symptom outcomes were assessed by the use of validated self-reporting questionnaires. The authors point out that there are not very many studies in which the symptomatology improvement is actually researched and known.

As far as the outcomes, long-term control of heartburn and acid regurgitation, which the authors interpreted as mild to no symptoms, was present in 80% and 82% after 10 years, and after a total fundoplication in the

80% outcome and 90% after the partial posterior fundoplication. Likewise, dysphagia scores were at 4.6% in group I and 3.3% in group II, and presence of rectal flatulence and gas distension were of similar magnitude in the two groups. Of the patients, 23% with total fundoplication noted some ability to vomit, compared with 31% of the Toupet. In my opinion, I agree with the authors that this is a remarkable record after so many years, and that one can say that the Belsey transthoracic procedure is an excellent procedure with a long-term beneficial outcome.

In another similar follow-up by Ayazi S. and the team headed by the author at the University of Southern California (Ayazi S, Tamhankar A, DeMeester SR, et al. The impact of gastric distension on the lower esophageal sphincter and its exposure to acid gastric juice. *Ann Surg* 2010;252(1):57–62), they attempted to determine what happens to the sphincter when gastric distension of 750 mL occurs and does it really shorten the sphincter and allow increased exposure to the esophagus and acid gastric juice. They studied this mechanism by filling the progressive gastric distension with air and demonstrating progressive shortening of the lower esophageal sphincter ($P < 0.0001$). After infusion of 750 cc of air, there was significant reduction in the median lower-esophageal-sphincter length but not in the thoracic length. As this got to be larger, gastric acid started to slosh back into the esophagus, reducing the pH. At rest, the pH step-up point was 0.5 cm above the lower border of the lower esophageal sphincter, and the distension moved a median of 1.0 cm cephalad within the lower esophageal sphincter. Simultaneously, with the loss of length there was a reduction in lower-esophageal-sphincter pressures of 27.4 mm Hg. They conclude that gastric distension is a real entity, and that the acid does enter into the esophagus when the sphincter is shortened.

Another outcome of 5 years' follow-up is the intra-thoracic stomach and the attempt to follow it objectively in Mittal SK et al. (Mittal SK, Bikhchandani J, Gurney O, et al. Outcomes after repair of the intrathoracic stomach: objective follow-up of up to 5 years. *Surg Endosc* 2011;25(2):556–66). They started with the proposal that they would like to follow the intra-thoracic stomach for 5 years and then they had begun to use mesh for some time to prevent herniation of the stomach, which had been present in 75% of the volume of the stomach on barium swallow. They studied 73 patients with intrathoracic stomach with a mean age of 71 years, and interestingly two thirds were female. There were 7 transthoracic and 66 transabdominal repairs, and there was one intra-operative death due to bleeding. Of the reviewed patients, antireflux procedures were done in 43, of which 20 were Nissens, 18 were Toupet, 4 were Roux-en-Y gastric bypasses, and 1 Dor. Ten patients had Collis gastroplasty for short esophagus. Mesh was used in only 13.7% of the patients and used for crus reinforcement. Follow-up was available for 88% at 1 year, 78% at 3 years, and 92% at 5 years. The authors state that there is no difference in the use of proton-pump inhibitors and that of other antacid medications. Most important, the mean satisfaction scores were 9.1, 9.0, and 9.0 at 1, 3, and 5 years, respectively.

The authors further state that there is a high level of patient satisfaction, and my observation is that if you can do that in this group of patients, that is very good.

Finally, there is a group of really difficult patients, in whom surgical reintervention is necessary for gastroesophageal reflux disease. This is present only in about 3% of the patients, and this kind of treatment has been reported before in several studies. However, there are a minimum of long-term data on patients who underwent subsequent operation because of recurrent reflux symptoms with troublesome dysphagia after primary antireflux surgery.

The symptomatic outcome was determined by questionnaires. Esophageal manometry and 24-hour pH monitoring were performed to assess the objective outcome. There were 144 reinterventions in 130 patients, 94 of whom had recurrent reflux and troublesome dysphagia in 50. Belsey Mark IV fundoplication through a left-sided thoracotomy was performed in 78 and a subsequent Nissen or partial fundoplication during 66 reinterventions. During a follow-up period of 5 years, symptoms were absent but significantly improved in 70%. Of those patients who were tested, esophageal acid exposure was normalized in 70% of the patients after surgery and postoperative complications occurred after 14 subsequent operations. This chapter by Furnée EJB et al. (Furnée EJ, Draaisma WA, Broeders IA, et al. Surgical reintervention after antireflux surgery for gastroesophageal reflux disease: a prospective cohort study in 130 patients. *Arch Surg* 2008;143(3):267–74) indicates that this particular type of reoperation does very well for patients who require this type of reoperation because it is not simple and there can be many pitfalls in which patients' outcomes are not very good, but can be corrected by reoperation.

J.E.F.

71 Laparoscopic Esophagectomy

James D. Luketich and Lara W. Schaheen

INTRODUCTION

Although a complex and technically challenging operation, esophagectomy is often a life-saving and life-enhancing option for patients with early-stage esophageal cancer, perforation or caustic injury, failed antireflux operations, and end-stage functional disorders of the esophagus.

Open approaches to esophageal resection have historically been associated with significant morbidity and mortality and in some cases excluding patients from surgical intervention. A 10-year review of the open esophagectomy experience within the Veterans Affairs system revealed a morbidity of 50% and a mortality of 10%. In an analysis of a national Medicare database, Birkmeyer and associates revealed that the mortality rates from esophagectomy in the United States ranged from 8% in high-volume centers to a staggering 23% in low-volume centers. Although a reduction in complication rates and improved outcomes have been reported by experienced surgeons in high-volume centers, morbidity remains considerable.

In the 1990s, the growing confidence in laparoscopic surgical techniques and instrumentation led to the introduction of various minimally invasive approaches to esophageal resection. Early minimally invasive resection techniques often hybridized more traditional open techniques with newer less invasive approaches. Collard was the first to describe a thoracoscopic technique for esophageal dissection. The first entirely laparoscopic esophagectomy was performed through a transhiatal approach in 1995 by DePaula. In 1996 Luketich and associates at the University of Pittsburgh began performing totally minimally invasive esophagectomy (MIE) via a Mckeown approach and published one of the first large series with a zero percent mortality in their first 77 patients.

Over the past decade, our experience with MIE has evolved considerably. In some of our very first few cases, we utilized the totally laparoscopic transhiatal approach; however, we soon recognized its limited visualization of vital intra-thoracic structures and difficulty performing a

complete mediastinal lymphadenectomy. We quickly transitioned to a minimally invasive modified McKeown approach with thoracoscopic mobilization of the intrathoracic esophagus, laparoscopic gastric tube creation, and creation of a cervical anastomosis. This approach became our procedure of choice for approximately 500 cases and offered reduced perioperative morbidity and mortality in comparison to many open series.

In our experience, we noted as others did that esophageal cancer had transitioned from squamous cell pathology to a lower third adenocarcinoma. Thus, some of the limitations of the McKeown approach, including the need to bring the conduit to the neck, requiring extra length, the need for a cervical dissection, and possibility of associated recurrent laryngeal nerve dysfunction, led us to adopt the Ivor Lewis minimally invasive approach. As described in open series, we noted that the use of a cervical anastomosis led to a significant number of anastomotic leaks and subsequent strictures. We also noted that many of our surgical residents were completing their training with little independent operative experience in the neck area and faced a significant learning curve associated with the cervical dissection that led us to a preference for the minimally invasive Ivor Lewis esophagectomy. This completely laparoscopic-thoracoscopic approach avoids a neck dissection essentially eliminating recurrent laryngeal nerve injury, and allows a more aggressive gastric resection margin, amputation of the most proximal tip of the newly created gastric conduit that is the most susceptible to ischemia and potential leak, and clear visualization during creation of the intrathoracic anastomosis.

Minimally invasive techniques for esophageal resection have evolved significantly from the initial hybrid approaches of laparotomy combined with thoracoscopy to the current definition of MIE, which is performed entirely using laparoscopic and thoracoscopic techniques. Although technically demanding and associated with a significant operator learning curve, when performed at high-volume centers it has been shown to carry similar morbidity, mortality, and oncologic outcomes as open esophagectomy while offering shorter operative times, less blood loss, and shorter hospital stay with no increase in morbidity.

The safety and feasibility of MIE have been demonstrated in several single-institution studies and meta-analyses, yet the results from a large, prospective, multicenter trial investigating MIE have only recently emerged. The eastern oncology cooperative group study (E2202) examined the outcomes of 17 credentialed sites in the United States that

performed MIE on patients with biopsy-proven high-grade dysplasia or esophageal cancer of the mid-esophagus or distal esophagus. Esophagectomy was performed using either a modified McKeown MIE or an Ivor Lewis MIE technique. Protocol surgery was completed in 95 of 104 patients (91.3%). Median ICU stay and hospital stay were 2 and 9 days, respectively. The 30-day mortality for patients who underwent MIE was 2.1%. Adverse events included anastomotic leak (8.6%), acute respiratory distress syndrome (ARDS) (5.7%), and atrial fibrillation (2.9%). At a median follow-up of 35.8 months, the estimated 3-year overall survival was 58.4% (95% CI: 47.7% to 67.6%). Locoregional recurrence occurred in only 7 patients (6.7%). This trial demonstrated that MIE is safe, feasible, with low perioperative morbidity and mortality and good oncologic results, and suggests that MIE can be adopted by other centers with appropriate expertise in open esophagectomy and minimally invasive surgery.

INDICATIONS

Indications for the minimally invasive approach for esophagectomy include Barrett's esophagus with high-grade dysplasia who are not candidates for endoscopic resection techniques, resectable esophageal cancer, end-stage achalasia, intractable esophageal strictures, and reconstructive surgery for patients with a history of failed antireflux operations.

While patients with advanced T4 esophageal cancers are generally not candidates for surgical resection, those with esophageal cancers of all other T stages may be amenable to MIE in experienced hands. As with open operations, a history of prior surgical interventions or preoperative chemo-radiation can add an additional level of complexity. Patients who have a history of previous thoracic or abdominal operations or those who have received neoadjuvant chemo-radiation remain candidates for a minimally invasive esophageal resection in experienced hands. Although no standardized contraindications regarding the use of a minimally invasive approach in esophageal resection exist, patient characteristics and surgeon's experience should be considered carefully when determining the appropriate operative approach.

As there are several minimally invasive techniques available for esophagectomy, the choice between MIE approaches is, to a large degree, based on surgeon preference. However, the operative approach chosen

may be dictated by the anatomic location of tumor and the margins required to achieve an R0 resection. The minimally invasive Ivor Lewis approach can be utilized for distal esophageal cancers, short-to-moderate length Barrett's with high-grade dysplasia, and gastroesophageal junction tumors extending onto the gastric cardia. Total laparoscopic and thoracoscopic Ivor Lewis resections should not be performed for esophageal cancers of the upper third of the esophagus with significant proximal extension due to concern for adequate margins of resection, but rather would benefit from a McKeown approach with the creation of a cervical anastomosis. Some mid-esophageal tumors can be approached with the Ivor Lewis technique, but a very high intrathoracic anastomosis may be needed to gain a negative margin.

SURGICAL TECHNIQUE

Laparoscopy

Before proceeding with the placement of the laparoscopic ports, esophagogastroscopy is performed in all patients to confirm tumor location, evaluate response to neoadjuvant therapy, and access the suitability of the stomach for tubularization and use as an esophageal conduit. Endoscopic insufflation should be minimized in an effort to limit small bowel dilation, which can significantly reduce intra-abdominal visualization. For proximal, mid-esophageal, and squamous tumors, a single lumen endotracheal tube is initially placed to allow for complete bronchoscopic evaluation prior to transitioning to a double lumen endotracheal tube.

The patient is placed supine with arms extended and a padded footboard attached to allow for maximal reverse Trendelenburg positioning. Invasive arterial monitoring and a double-lumen endotracheal tube is placed initially in anticipation of the thoracoscopic phase. The xiphoid process, costal margins, and midline are outlined. The distance between the xiphoid process and umbilicus is measured and divided into thirds. Five ports are utilized for gastric mobilization, conduit creation, and pyloroplasty. Using an open Hassan cut down technique, a 10-mm blunt port is placed two thirds of the distance from the xiphoid process to the umbilicus and 2 cm to the right of midline in the right paramedian area.

Pneumoperitoneum is set to 15 mm Hg, and the patient is placed in steep reverse Trendelenburg position. Under direct laparoscopic

visualization a 10-mm port is placed 2 cm to the left of midline slightly below the level of the original port. The 10-mm 30-degree laparoscopic camera and insufflation are then moved to this left paramedian port. Prior to the placement of additional ports, an intraperitoneal survey should be performed to assess for findings that may preclude successful surgical resection and reconstruction. Additional 5-mm ports are placed at the left subcostal margin and the right subcostal margin with a minimum of a hand's breadth apart from other ports to avoid unwanted contact between ports (Fig. 71.1). A 5-mm port is placed in the right lateral flank location just below the 12th rib to support a liver retractor. A self-retaining retractor is used to elevate the left lobe of the liver and expose the hiatus. The gastrohepatic ligament is divided to expose the right crus. The gastroesophageal junction is freed from the hiatus by dissection up the right crus. The dissection is carried anteriorly and the phrenoesophageal ligament is taken down, to expose the anterior hiatus and left crus. The medial border of the right and left crus is dissected exposing the retroesophageal window and completes the circumferential mobilization of the esophagus.

Once circumferential dissection of the distal esophagus is completed, the stomach is retracted superiorly to expose the celiac vessels and allow for lymph node dissection. A complete lymphadenectomy is performed sweeping all nodal and fatty tissue with the specimen. After complete dissection of the left gastric and celiac nodes, dissection is continued along the superior border to the pancreas and cephalad toward the base of the right and left crus; this dissection plane is then made continuous with the preaortic dissection plane into the distal thoracic cavity. The left gastric artery and vein are then isolated and divided at their base using an Endo-GIA vascular stapler.

The right gastroepiploic arcade is clearly identified, the gastro-colic omentum is divided lateral to this arcade, and a window is created in the greater omentum allowing for entry into the lesser sac. The dissection is then continued along the greater curve of the stomach being certain to leave 2 to 3 cm of omental fat and avoid injury to the stomach while dividing the short gastrics (Fig. 71.2). In patients who have received neoadjuvant chemo-radiation, a pedicled omental flap is created to buttress the intrathoracic esophagogastric anastomosis. As dissection nears the anticipated level of the esophagogastric anastomosis, a segment of healthy omentum supplied by two to three perforating vessels at the level of the

distal gastroepiploic arcade is identified. Omental mobilization is carried laterally such that a 3- to 4-cm wide pedicled omental flap is created near the prospective line of the future esophagogastric anastomosis. As the left gastroepiploic and gastrosplenic vessels are divided during mobilization, the omental flap is supplied by distal branches of the right gastroepiploic artery alone and thus should not be larger than 8 to 10 cm long as to prevent vascular steal from the tubularized conduit. Manipulation of the stomach should be avoided and a “no touch” technique utilized to minimize traumatic injuries to the tissue or vascular supply.

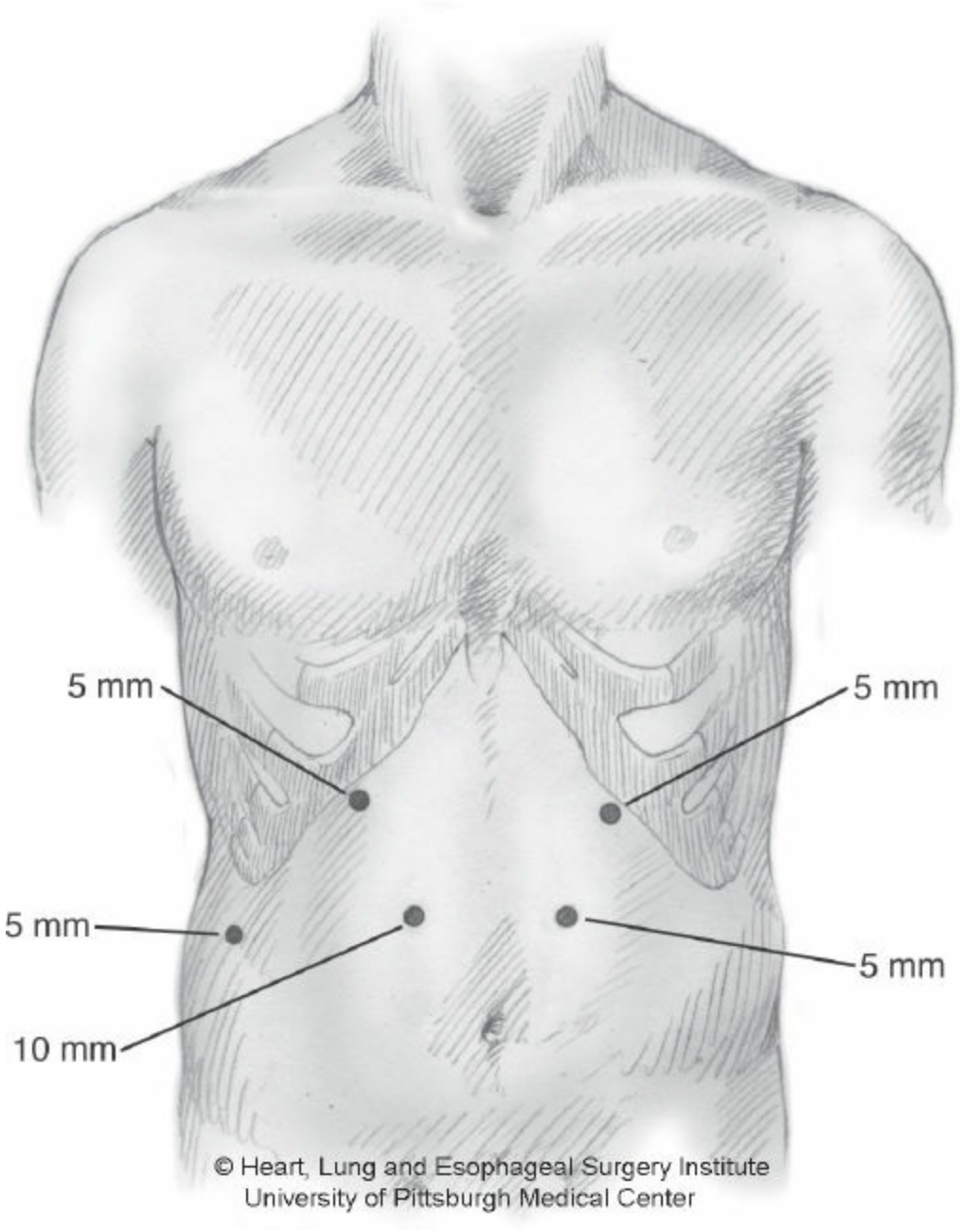

Figure 71.1. Laparoscopic port placement. (Image © Heart,

Lung, and Esophageal Surgery Institute University of Pittsburgh Medical Center.)

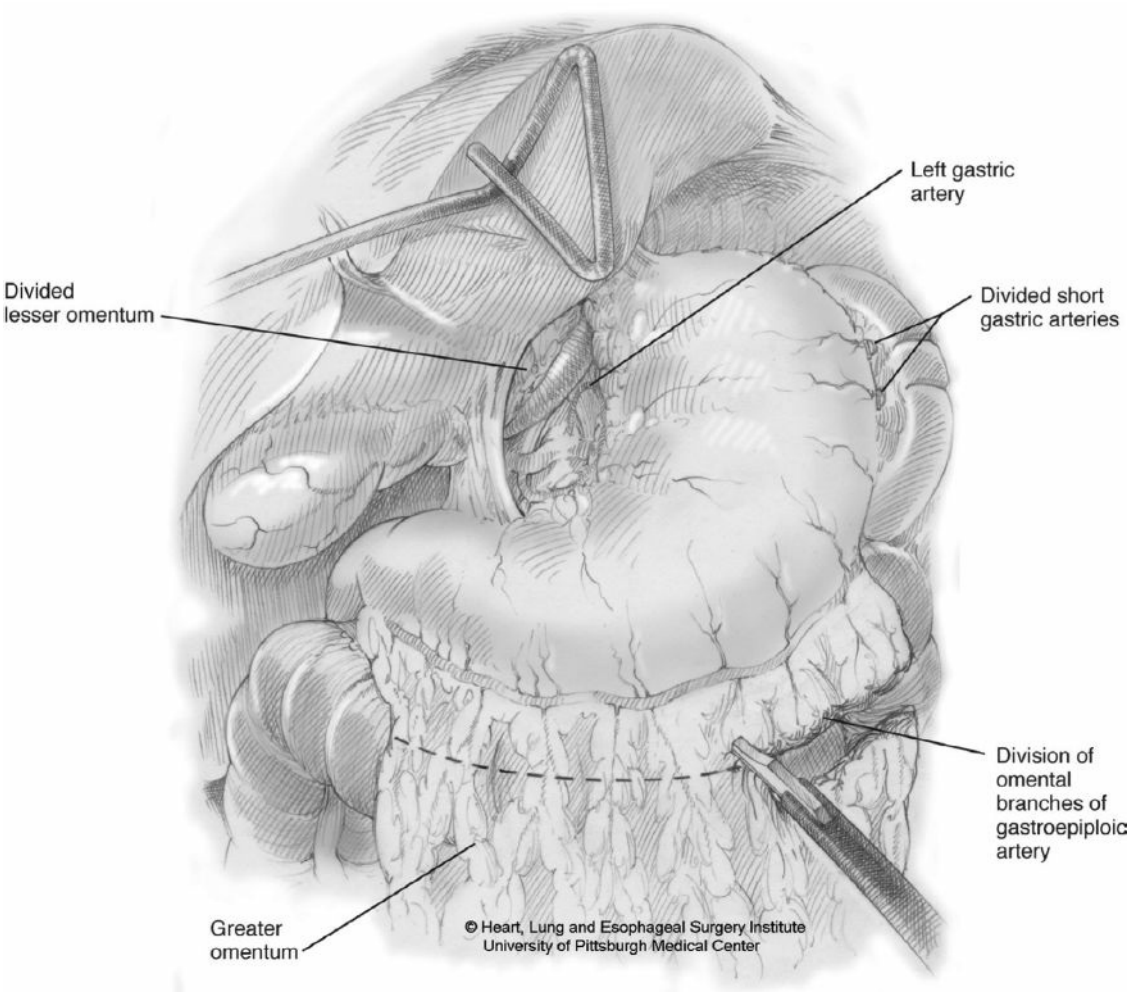

Figure 71.2. Abdominal dissection. (Image © Heart, Lung, and Esophageal Surgery Institute University of Pittsburgh Medical Center.)

Mobilization of the stomach is then carried back toward the pyloroantral region, a Kocher maneuver is performed, and the retrogastric and duodenal attachments are carefully dissected in order to achieve adequate mobilization. The ability of the pylorus to reach the level of the right crus demonstrates adequate mobilization and should be assessed at several time points to determine the degree of dissection required. If there is any difficulty with this maneuver, further pyloroantral mobilization is generally required.

Creation of the gastric conduit can be performed either before or after the completion of the pyloroplasty. Early conduit creation is often performed in patients with significant underlying vascular disease and

often provides additional time to assess the viability of the gastric tube as a conduit. An additional 12-mm port is placed in the distal right paraumbilical area to assist with the creation of the gastric tube and placement of the jejunostomy tube.

The gastric tube is then constructed by first using a vascular load of the Endo-GIA stapler to divide the lesser-curve vessels and fat at an angle toward the incisura while also preserving the right gastric vessels. The first stapler load used is a vascular load, with a staple height of 2.5 mm, to minimize small-vessel oozing along the lesser curve (Fig. 71.3). It is important that no stomach is divided in this initial staple fire. The angle of the first few staple firings will be determined by the desired gastric tube diameter and should be placed accordingly. We prefer to create a gastric tube that is 3 to 4 cm wide. During this stapling, we grasp the tip of the fundus at the line of the short gastrics and apply slight traction toward the spleen. A second grasper is applied through the right paraumbilical port to the antral area with slight downward retraction. This simultaneous traction functions to keep the gastric tube on slight stretch affording a more consistent stapler application. The thick gastric antrum may require the black stapling cartridge with a staple height of 4.5 mm. As the stapling continues toward the fundus, the gastric wall thickness generally diminishes and subsequent stapler loads are transitioned to purple loads with a staple height of 3.5 mm (Endo-GIA Reloads with Tri-staple Technology, Covidien). Subsequent firings of the stapler should be maintained in a line parallel to the greater-curvature arcade and line of the divided short gastrics. It is important to stay parallel to the line of the short gastrics in order to create a consistent tube width and avoid spiraling of the tubularized gastric conduit. The staple line is inspected for hemostasis, and sites of active bleeding are clipped. A single endostitch is placed approximately 4 cm from the pylorus at the transition between the gastric reservoir and the newly tubularized conduit. The stitch is cut long and functions to identify the transition between intra-abdominal and intrathoracic conduit and prevent the common mistake of pulling redundant conduit into the chest. The superior aspect of the gastric tube is then stitched to the specimen (Fig. 71.4). These sutures should be placed from the tip of the fundic portion of the tube to the lesser-curve region of the resected specimen being sure to maintain the appropriate orientation. This also tends to minimize the bulk as the specimen and gastric tube as they are passed through the hiatus. If an omental flap was created, the

distal end of the omental flap should be secured to the tip of the conduit. The specimen and distal aspect of the gastric conduit should be tucked into the hiatus to ensure easy intrathoracic passage.

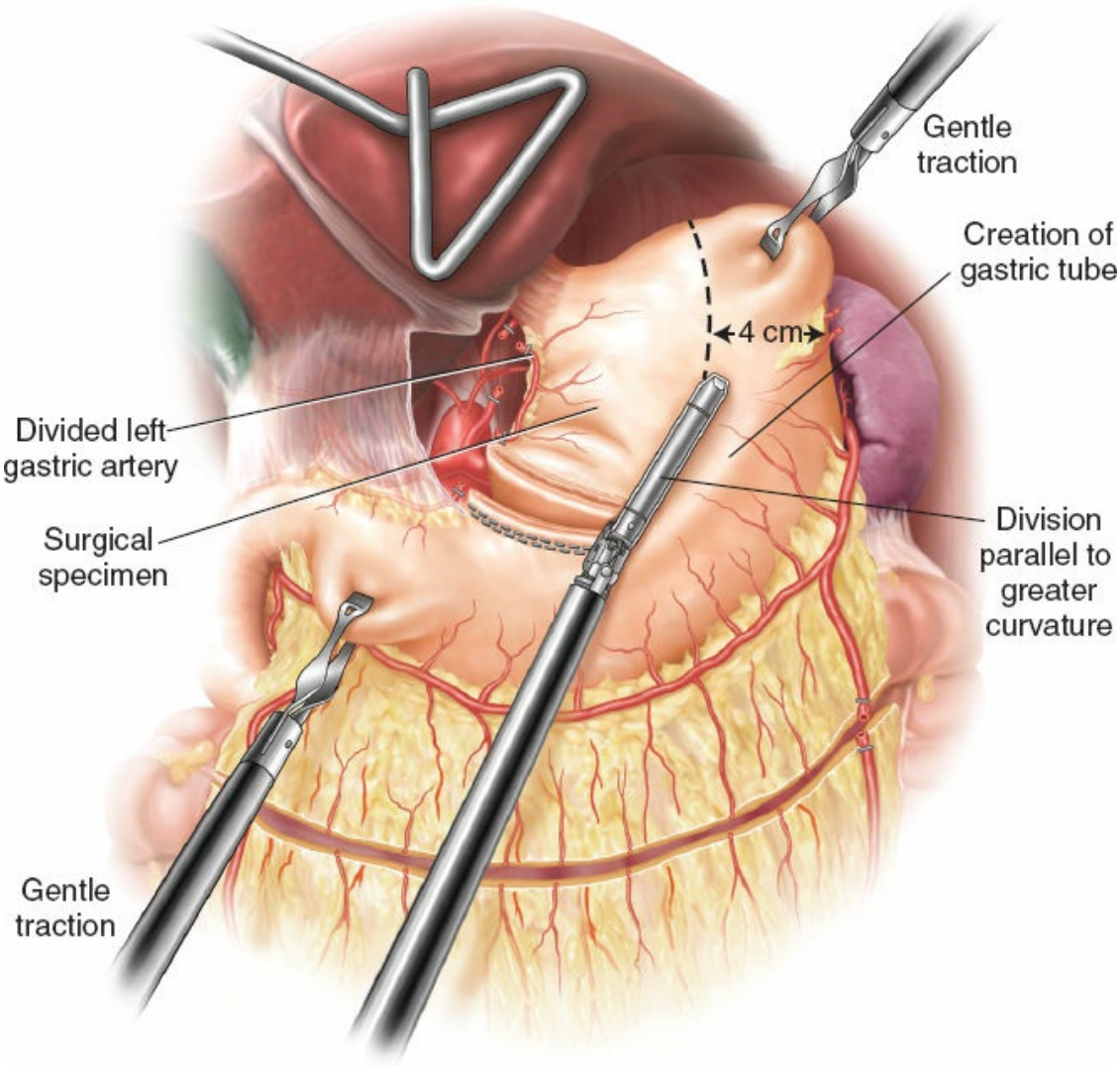

Figure 71.3. Creation of the gastric conduit.

Pyloroplasty

Having previously completely mobilized the stomach, retrogastric, and duodenal attachments, a pyloroplasty is then performed in a Heineke-Mikulicz fashion (Fig. 71.5). Two 2-0 endostitches are placed in the most superior and inferior aspect of the pylorus to provide retraction. These sutures are then used to retract the pylorus anteriorly and away from the posterior wall of the stomach while ultrasonic shears are used to incise the anterior wall of the pylorus. The pyloroplasty is then closed transversely using simple interrupted 2-0 endosutures being sure to include mucosa in

each stitch. After completion of the pyloroplasty, a freely mobile portion of omentum is identified and tacked over the pyloroplasty.

Feeding Jejunostomy

A grasper is applied to the adjacent fatty epiploicae of the transverse colon, and the colon is retracted cephalad identifying the ligament of Treitz. A small needle is placed percutaneously into the peritoneal cavity in the left lower quadrant under direct laparoscopic visualization in order to mark the intended site of jejunostomy creation. A loop of jejunum approximately 40 cm distal to the ligament of Treitz is then attached to the anterior abdominal wall using a single 2-0 endostitch at the site previously marked by the needle. A 12-Fr needle catheter feeding jejunostomy tube is inserted into the jejunum percutaneously using a Seldinger technique (B-Braun, Bethlehem, PA). The percutaneous jejunostomy kit employs a guidewire Seldinger technique, and this guidewire is threaded into the small bowel followed by the dilator, and then the feeding catheter cut to a distance of approximately 25 cm (Fig. 71.6). The feeding tube is then secured with placement of 2 witzel stitches, and further tacked to the anterior abdominal wall using an additional 2-0 endostitch in a purse-string fashion. A single suture is placed approximately 3 cm distal to the entrance site of the feeding tube, to prevent torsion of the distal jejunal limb. The feeding catheter is secured on the skin. If any doubt exists as to true luminal placement, on-the-table intestinal contrast imaging of the J-tube should be performed (such as with diatrizoate meglumine and diatrizoate sodium [gastrograffin]).

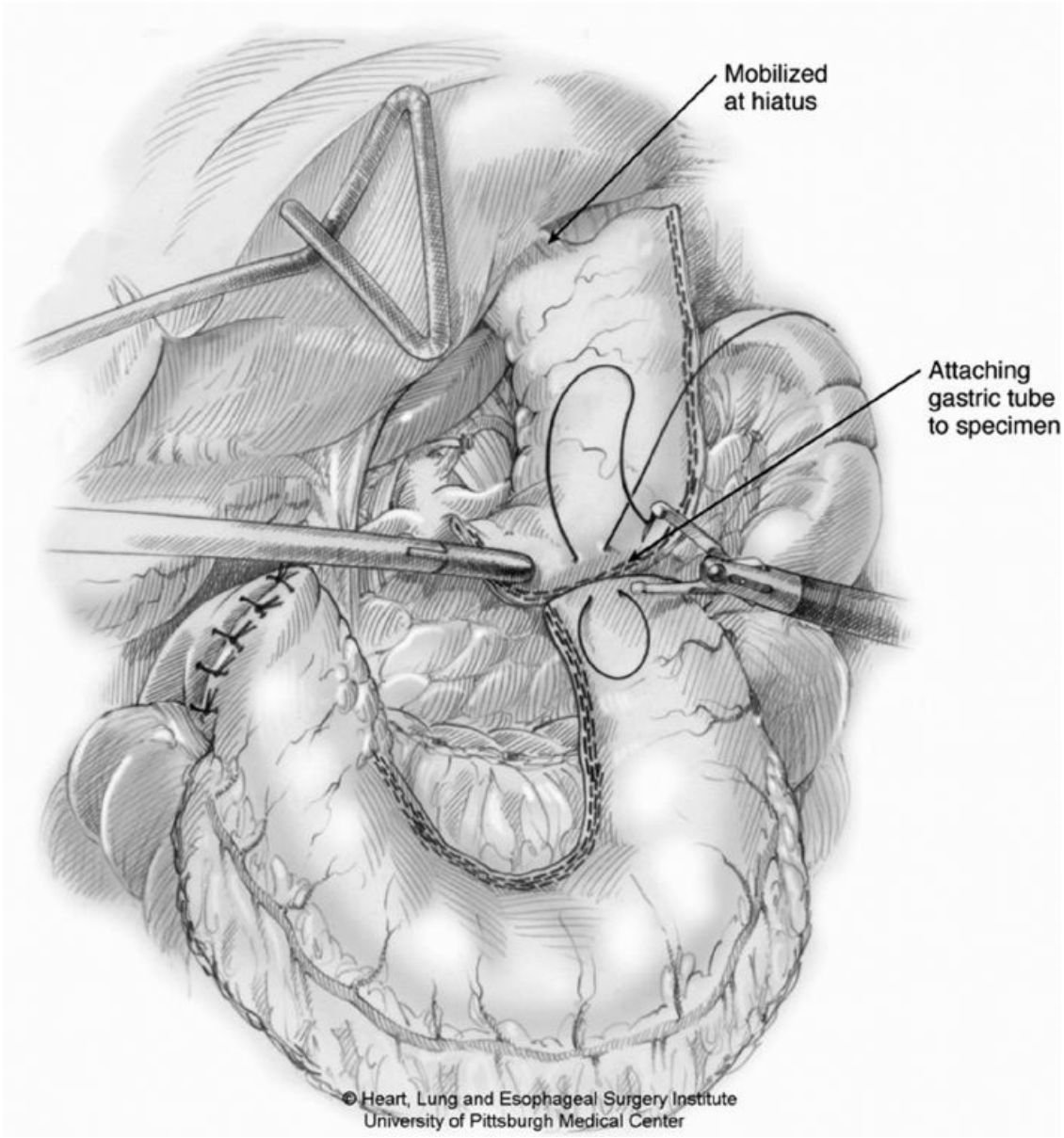

Figure 71.4. Attachment of specimen to gastric conduit. (Image © Heart, Lung, and Esophageal Surgery Institute University of Pittsburgh Medical Center.)

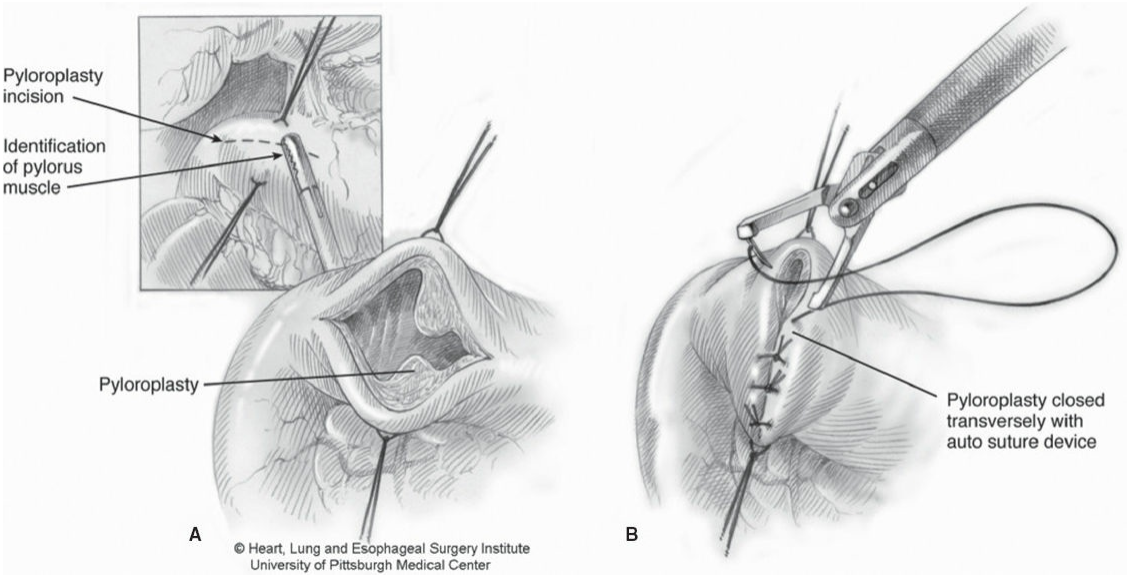

Figure 71.5. Laparoscopic pyloroplasty. (Image © Heart, Lung, and Esophageal Surgery Institute University of Pittsburgh Medical Center.)

Thoracoscopy

The patient is placed in the left lateral decubitus position. Once correct positioning of the double-lumen tube is confirmed, the right lung should be isolated immediately, to provide adequate time for decompression. The operating table is flexed to move the iliac crest away from the costal margin and expand the intercostal spaces and the position of the right scapula is marked.

Five ports are used to complete the intrathoracic dissection. A 10-mm camera port is inserted in the eighth intercostal space just anterior to the mid-axillary line. We prefer this port to be low on the chest and in a more anterior position, so as to enter the chest just above the costophrenic recess. This position affords a nice panoramic view of the chest and also limits any run down of blood onto the thoracoscope. An additional 10-mm port is placed approximately 2 cm posterior to the posterior axillary line in the eighth or ninth interspace. This is the main dissection port for the harmonic ultrasonic scalpel (Ethicon, Cincinnati, OH). A 10-mm port is placed in the fourth interspace along the anterior axillary line in order to allow utilization of a fan retractor to provide retraction of the lung. A 5-mm port is placed inferior to the scapular tip. A final 5-mm port is placed at the sixth intercostal space at the anterior axillary line. A 48-in 0 Endostitch is then placed in the central tendon of the right diaphragm and brought out percutaneously through the low anterior chest wall near the

costophrenic recess using an Endo-Close device (U.S. Surgical). Downward traction on this stitch pulls the diaphragm inferiorly allowing for better visualization of the distal esophagus and hiatus.

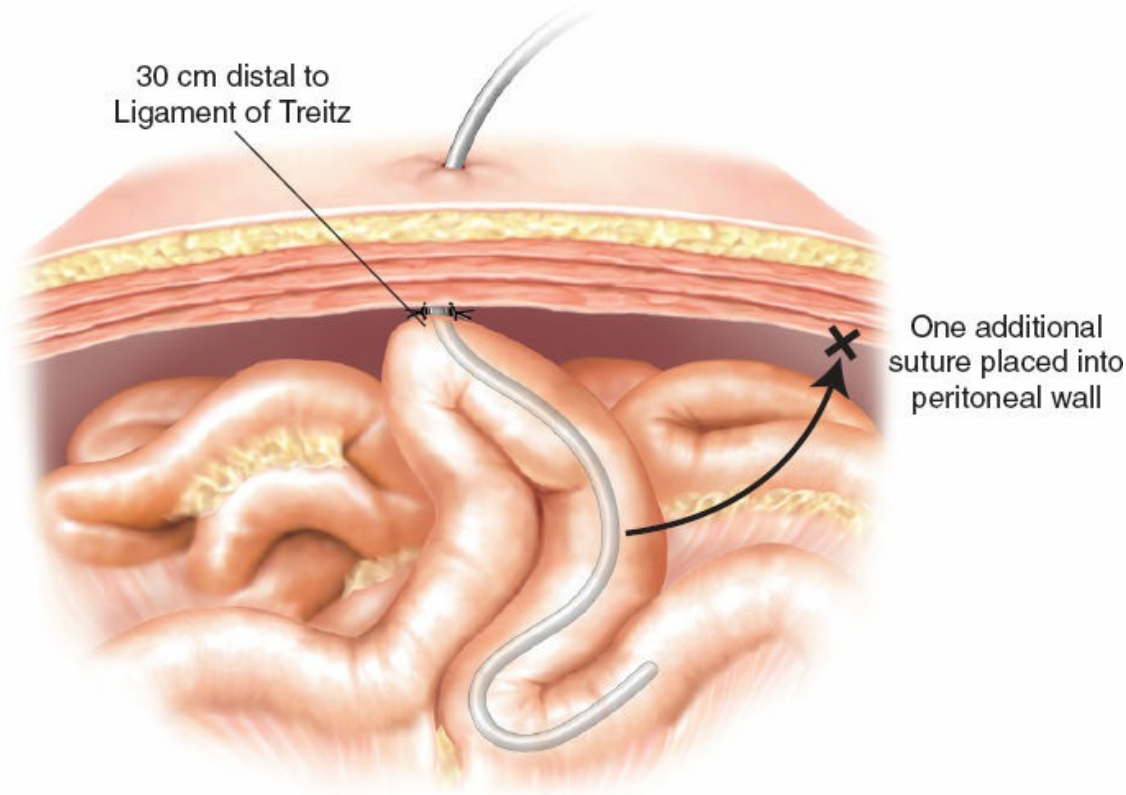

Figure 71.6. Laparoscopic jejunostomy tube.

Dissection begins by taking down the inferior pulmonary ligament up to the level of the inferior pulmonary vein. With the lung retracted anteriorly, the mediastinal pleura is excised along the plane between the edge of the lung and the esophagus and is resected with the specimen up to the azygos vein. The subcarinal lymph nodes are excised en bloc with the esophagus. Care must be taken to avoid injury to the posterior membrane of the right mainstem bronchus, carina, and trachea. The active blade of the dissection device should be oriented away from the posterior membranous airway in order to minimize potential injury. The anesthesiologist can be asked to remove the suction catheter from the endotracheal tube in order to allow for better visualization of the posterior membranous airway. Dissection is carried up to the azygos vein, which is isolated from the mediastinal pleura and divided with an Endo-GIA vascular stapler. Once at the level of the divided azygos vein, the vagus nerve is divided. Above the level of the azygos vein, the dissection plane is transitioned onto the wall of the

esophagus to avoid recurrent laryngeal nerve injury and the surrounding tissue is dissected away from the esophagus.

The mediastinal pleura is then divided superficially near the hiatus and along the posterior groove to the esophagus. Care must be taken in this plane to avoid injury to the thoracic duct and underlying aorta. In cases of difficult dissection, a Penrose drain can be placed around the esophagus and used to provide retraction away from the posterior esophageal attachments and assist with circumferential dissection. Tributaries from the thoracic duct to the esophagus are at risk for subsequent leak, and liberal use of Endo-clips should be used to minimize postoperative chylous leaks. Aortoesophageal vessels are identified, isolated, clipped, and divided to minimize bleeding. All surrounding periesophageal soft tissue and lymph node tissue are taken with the esophagus. The deep margin of the dissection is the contralateral pleura.

Once the esophagus is mobilized fully, the specimen and proximal portion of the gastric conduit are delivered into the chest. The suture attaching the specimen and the conduit is divided. Care must be taken to maintain the proper orientation of the gastric conduit and prevent torsion. Proper orientation requires that the staple line face the lateral right chest wall, and in the left lateral decubitus position the staple line should be facing up toward the operators. The proximal esophagus is divided with thoracoscopic scissors at or above the level of the azygos vein, thus separating the entire specimen. Next, a non–rib-spreading 4- to 5-cm access incision is made between the surgeon’s working port and the tip of the scapula. A wound protector (Applied Medical, Rancho Santa Margarita, CA) is placed to protect the skin and chest wall from trocar implants. The specimen is removed through the access incision and sharply excised and examined on the back table to ensure adequate gastric and esophageal margins prior to being sent for pathologic analysis.

The proximal cut edge of the esophagus is assessed, and the surgeon must make a determination of the appropriate-sized EEA (end-to-end anastomosis) anvil to use. We most commonly use a 28-mm EEA stapler in an effort to minimize the risk of anastomotic stricture. The proximal esophagus can be gently dilated with a large Foley balloon, if needed. The anvil of an EEA stapler is then placed (Fig. 71.7). A total of two purse string sutures are placed using 2-0 endostitch to secure the anvil in the proximal esophagus. Care must be taken to include all layers of the esophagus in the purse-string sutures to ensure creation of a complete

anastomosis with use of the EEA.

The gastric conduit is then delivered entirely into the chest until the distal marking stitch placed during the laparoscopic portion is seen at the hiatus. The proximal end of the gastric conduit is then opened, irrigated, and cleaned of debris. The EEA stapler is delivered into the chest through the access incision (Fig. 71.8). It is gently placed into the open gastric conduit like “a foot in a sock” being certain to maintain appropriate staple line orientation. The spike is then brought out along the line of the greater curve distal to the opening at a point that will allow removal of any potential gastric tip ischemia. This spike is then attached to the anvil, the stapler fired, and the anastomosis is created (Fig. 71.9). The open end of the gastric conduit through which the EEA stapler was introduced is now resected using sequential loads of the Endo-GIA articulating stapler (Fig. 71.10). This partial gastrectomy specimen is then sent to pathology as the final gastric margin. A nasogastric tube is placed and observed to pass through the anastomosis. The surrounding omentum or omental flap is then placed circumferentially around the anastomosis and sutured in place. A 2-0 Endostitch is used to attach the gastric conduit to the right crus and minimize thoracic migration of the gastric conduit. The chest and port sites are irrigated aggressively with antibiotic solution. A 10-mm Jackson-Pratt drain is placed posteriorly with the distal aspect beyond the newly formed esophagogastric anastomosis. Intercostal bupivacaine is injected to provide temporary regional anesthesia. A single 28-Fr straight chest tube is placed through the camera port and directed posteriorly toward the apex (Fig. 71.11). The lung is inflated to check for any injury to the posterior membranes of the trachea or bronchus. The access incision is closed in multiple layers being certain to approximate muscular edges. Once the patient is returned to the supine position, the oropharynx and nasopharynx are suctioned of all secretions and the nasogastric tube secured at a midconduit position of 35 to 40 cm. The double-lumen endotracheal tube is exchanged for a single-lumen tube to allow for complete toilet bronchoscopy and inspection for airway trauma or injury.



© Heart, Lung and Esophageal Surgery Institute
University of Pittsburgh Medical Center

Figure 71.7. Placement of the anvil. (Image © Heart, Lung, and Esophageal Surgery Institute University of Pittsburgh Medical Center.)

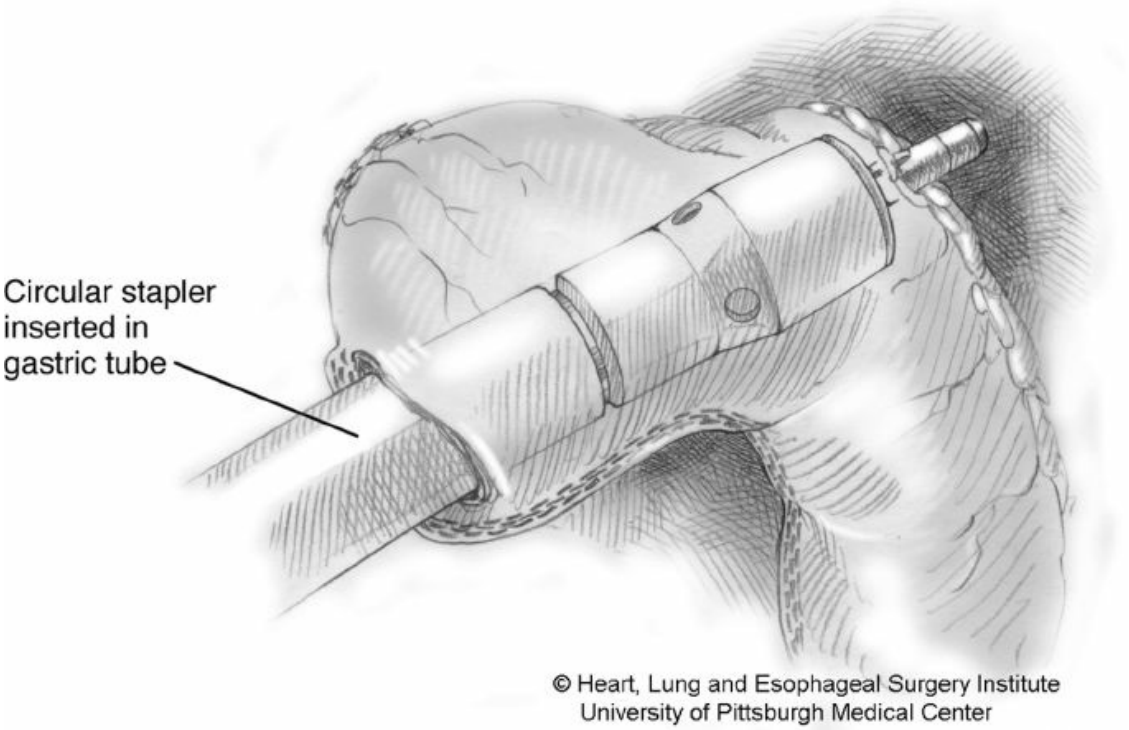

Figure 71.8. Insertion of the EEA handle. (Image © Heart, Lung, and Esophageal Surgery Institute University of Pittsburgh Medical Center.)

RESULTS

Our experience with minimally invasive laparoscopic and thoracoscopic esophagectomy, the largest reported experience to date, highlights some of the potential advantages and pitfalls of this approach. Our initial experience with 222 patients has now grown to more than 2,000 MIEs at the University of Pittsburgh Medical Center. A review of our experience with more than 1,000 patients demonstrated excellent morbidity, mortality, and oncologic outcomes. The modified McKeown MIE was performed electively in 481 patients and the Ivor Lewis MIE in 530. By 2006, the Ivor Lewis had become the preferred approach and thus the majority of patients in the last 5 years of the study period received an Ivor Lewis MIE. The median length of stay (8 days) and ICU stay (2 days) were similar between the two approaches. The median number of lymph nodes resected was 21. The overall operative mortality of both groups was 1.68%. Overall morbidity, mortality, lymph node harvest, and cancer outcomes for the

entire cohort were similar or better than most published series of open esophagectomies. The Ivor Lewis MIE subgroup had a significantly lower incidence of recurrent nerve injury of 1% and significantly lower operative mortality of 0.9% at 30 days.

Nagpal and colleagues performed a meta-analysis of 12 studies with a total of 672 patients who underwent esophagectomy via an open, hybrid or minimally invasive approach. The investigators concluded that MIE was associated with better operative and postoperative outcomes. MIE patients had less blood loss and shorter ICU and hospital stays. In addition, the MIE group had a 50% decrease in morbidity with a significantly lower incidence of respiratory complications in comparison with the open esophagectomy group. No significant differences in anastomotic leak, stricture, gastric conduit ischemia, chylothorax, vocal cord palsy, or 30-day mortality were found. In the subgroup analysis, the investigators found that patients who underwent even one stage of their esophagectomy minimally invasively (e.g., laparotomy with thoracoscopy or laparoscopy with thoracotomy) had significantly less blood loss and fewer respiratory complications compared with patients who underwent open esophagectomy. Oncologic outcomes were comparable in all three groups.

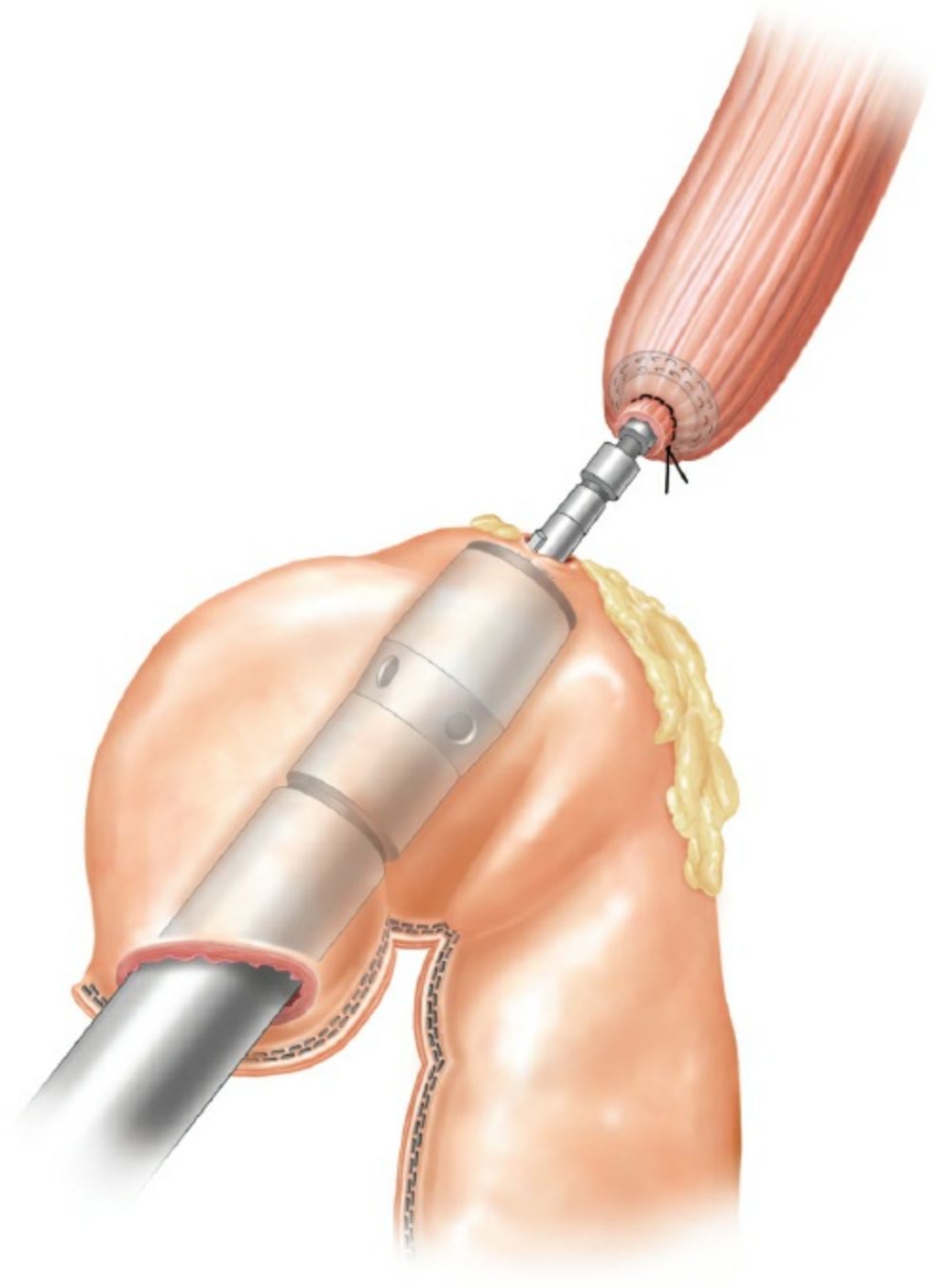

Figure 71.9. Alignment of the EEA stapler.

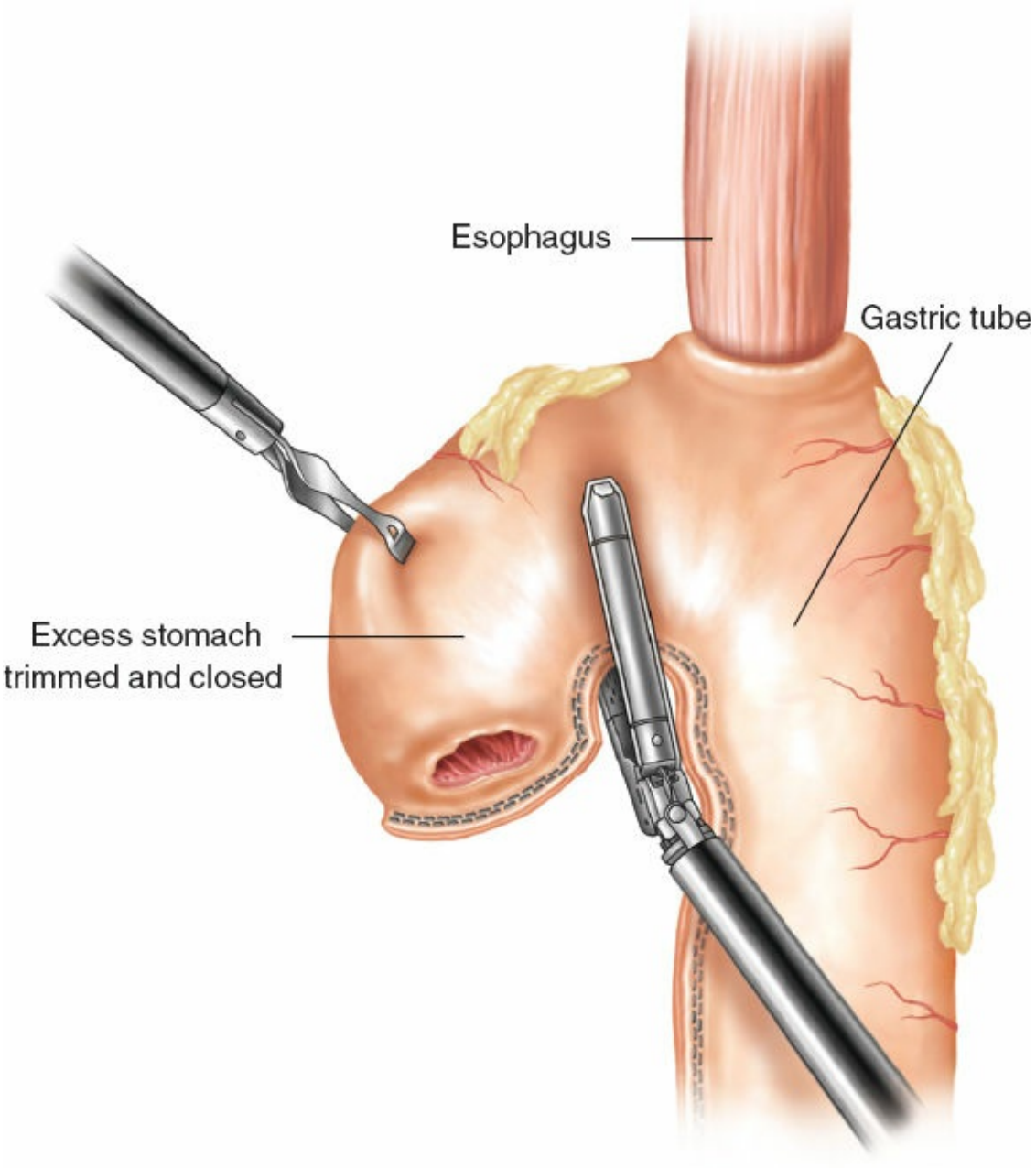

Figure 71.10. Closure of the conduit.

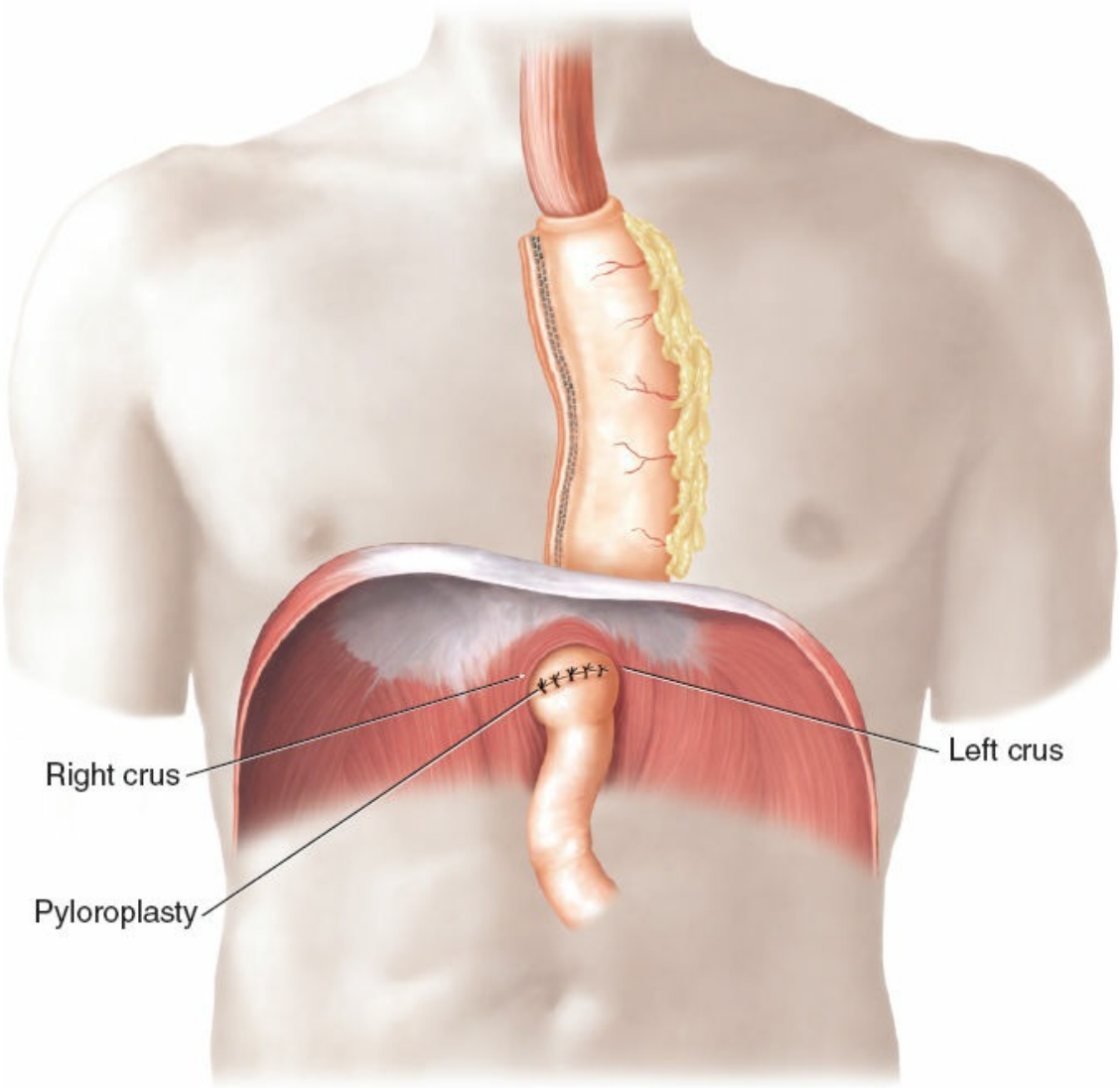

Figure 71.11. Finished reconstruction.

A meta-analysis performed by Dantoc and colleagues examined the oncologic outcomes and 5-year mortality in patients undergoing open esophagectomy versus MIE. This review included 17 case-controlled studies with a total of 1,586 patients. Lymph node yield was significantly higher in the MIE group, median 16 nodes (range 5.7 to 33.9), as compared with the open group, median 10 nodes (range 3.0 to 32.8). The 5-year survival rates were similar in the MIE group (12.5% to 67%) and the open group (16% to 57%). The investigators concluded that MIE provides oncologic outcomes equivalent to those of open esophagectomy.

Biere and colleagues performed the first multicenter randomized controlled trial that compared open transthoracic esophagectomy with minimally invasive transthoracic esophagectomy. They examined outcomes from five centers in three countries from June 2009 until March

2011. They demonstrated a significantly higher rate of pulmonary complications in the open esophagectomy group in comparison to the minimally invasive group. In the open esophagectomy group, 29% of patients had a pulmonary infection within the first 2 weeks and 34% while in hospital. This compared to only 9% and 12% in the minimally invasive group. This trial demonstrated that patients who receive MIE have an improved short-term outcome for pulmonary infections, hospital stay, and quality of life in comparison to those undergoing an open esophagectomy, with no compromise in oncologic principles.

Puntambekar and colleagues demonstrated that thoracolaparoscopic esophagectomy can be accomplished safely in patients over the age of 70 with low morbidity and mortality. In an analysis of 68 elderly patients who received MIE, they reported a mean ICU stay of 3.84 days, mean hospital stay 12.7 days, cardiac complications rate of 10.3%, and a 30-day perioperative mortality of 4.4%. Kilic et al. demonstrated a low mortality of 1.8% in obese patients with a body mass index (BMI) greater than 30. These reports suggest that MIE can be performed in high-risk patients who might not otherwise be considered for surgical resection.

COMPLICATIONS

Morbidity associated with open esophagectomies can be significant, ranging from 35% to 50%. A review of some of the largest series of MIE, transhiatal esophagectomy, and transthoracic esophagectomy compared with a 10-year review of all esophagectomies performed at the Veterans Affairs Medical Centers illustrated favorable outcomes in mortality, length of stay, and several major complication criteria (Table 71.1).

Hulscher published a randomized trial comparing transhiatal and transthoracic open esophagectomies. When compared side by side, the MIE approach seems to impart a lower incidence of anastomotic leaks and vocal cord paralysis (Table 71.2). Sgourakis et al. performed a meta-analysis of more than a 1,000 patients comparing open thoracotomy esophagectomy with both video-assisted thoracoscopic surgery (VATS)/laparoscopic esophagectomy and VATS/laparotomy hybrid esophagectomy. This study demonstrated lower morbidity in patients who had a complete MIE with a VATS/laparoscopic approach.

Thoracic Complications

Bleeding and transfusion requirements were less with the minimally

invasive approach, but it is important to note that even small amounts of bleeding can obscure the operative field, making progress difficult and requiring conversion to an open procedure. Hence, the aortoesophageal vessels must be identified and clipped and bleeding from the azygos vein and peribronchial arteries avoided. Injury to the posterior membranes of the bronchus and trachea must be carefully avoided, especially during mediastinal lymph node dissection. Cautery, auto-sonic, or harmonic scalpel use in close proximity to the posterior membranous airway can lead to tissue damage resulting in an air leak, local ischemia, and subsequent development of a tracheogastric conduit fistula.

TABLE 71.1 Complications

	Luketich et al. (*n* = 1,011) MIE	Orringer et al. (*n* = 2,007) THE	Swanson et al. (*n* = 250) TTE	Bailey et al. (*n* = 1,777) Mixed
Anastomotic leak	5%[a]	12%	8%	N/A
Vocal cord paresis/palsy	4%	4.5%	14%	N/A
Chylothorax	N/A	1%	9%	N/A
Gastric tip necrosis	2%	2%	0.8%	N/A
Myocardial infarction	2%	N/A	N/A	1.2%
Pneumonia/ARDS	7.7%[c]	2%	5%	21.4%
Wound dehiscence	0.0%	3%	N/A	3.7%
Mortality	1.7%	3%	3.6%	9.8%
Length of stay	8 days	8 days[b]	13 days	N/A

[a]Anastomotic leak requiring surgery.
[b]Median length of stay of 944 patients treated from July 1998 to December 2006.
[c]ARDS, acute respiratory distress syndrome.
MIE, minimally invasive esophagectomy; THE, transhiatal esophagectomy; TTE, transthoracic esophagectomy; N/A, result not available.
Data from Luketich JD, Pennathur A, Awais O, et al. Outcomes after minimally invasive esophagectomy: review of over 1000 patients. *Ann Surg* 2012;256(1):95–103; Orringer MB, Marshall B, Chang AC, et al. Two thousand transhiatal esophagectomies: changing trends, lessons learned. *Ann Surg* 2007;246(3):363; discussion 372; Swanson SJ, Batirel HF, Bueno R, et al. Transthoracic esophagectomy with radical mediastinal and abdominal lymph node dissection and cervical esophagogastrostomy for esophageal carcinoma. *Ann Thorac Surg* 2001;72(6):1918; discussion 1924; Bailey SH, Bull DA, Harpole DH, et al. Outcomes after esophagectomy: a ten-year prospective cohort. *Ann Thorac Surg* 2003;75(1):217; discussion 222.

The thoracic duct is at risk for subtle injuries leading to the development of a chylothorax. Early in our experience, in our initial 77 patients undergoing MIE, we noted 3 patients with delayed chylothorax, leading us to become more cautious in this area and transition to the liberal use of metal clips on thoracic duct branches. Vocal cord paralysis from

injury to the recurrent laryngeal nerve is minimized by dividing the vagus nerve just above the azygos vein and dissecting this away from the esophagus. We generally do not perform a lymph node dissection above this level in an effort to avoid injury to the recurrent laryngeal nerves and due to the lack of definitive evidence that lymph node clearance in the upper chest is essential for gastroesophageal junction tumors.

Abdominal Complications

Disruption of the main gastroepiploic arcade can be devastating to the viability of the gastric conduit. Likewise, one must be certain that there is adequate room at the hiatus for the conduit to lie without strangulation. In our series, there was an incidence of gastric tip necrosis of 3.2%. Delayed hiatal herniation of abdominal viscera is also a possibility if the gastric conduit is not properly tacked to the hiatus. Kent et al. reported approximately a 2% incidence of diaphragmatic hernias and a 2% risk of redundant gastric conduit, leading to delayed gastric emptying, reflux, and obstruction. Eighty-five percent of patients with such anatomical complications benefited from reoperative revisional surgery. Orringer's series identified a 2% rate of splenectomy in 2007 open transhiatal esophagectomies.

TABLE 71.2 Comparison of Transthoracic and Transhiatal Esophagectomies

	Luketich et al.		Hulscher et al.	Bousmara et al.	
	(*n* = 1,011) MIE	(*n* = 106) THE	(*n* = 114) TTE	(*n* = 43) THE	(*n* = 47) TTE
Anastomotic leak	5%[a]	14%	16%	21%	11%
Vocal cord palsy	4%	13%	21%	16%	11%
Length of stay	8 days	15 days	19 days	N/A	N/A

[a]Anastomotic leak requiring surgery.
MIE, minimally invasive esophagectomy; THE, transhiatal esophagectomy; TTE, transthoracic esophagectomy; N/A, result not available.
Data from Luketich JD, Pennathur A, Awais O, et al. Outcomes after minimally invasive esophagectomy: review of over 1000 patients. *Ann Surg* 2012;256(1):95–103; Luketich JD, Alvelo-Rivera M, Buenaventura PO, et al. Minimally invasive esophagectomy: outcomes in 222 patients. *Ann Surg* 2003;238:486–94; Hulscher JB, van Sandick JW, de Boer AG, et al. Extended transthoracic resection compared with limited transhiatal resection for adenocarcinoma of the esophagus. *N Engl J Med* 2002;347(21):1662; Bousmara M 2nd, Haasler GB, Parviz M. A decade of experience with transthoracic and transhiatal esophagectomy. *Am J Surg* 2002;183(2):162.

Orringer's open series also noted a 3% incidence of wound infections and dehiscence. The national Veteran's Affairs study revealed a 10.9% rate of wound infections with a 3.7% rate of wound dehiscence. When open transhiatal and transthoracic procedures were prospectively evaluated, the transhiatal approach was associated with a 5% incidence of wound dehiscence and a 2% incidence was associated with the transthoracic approach. Delayed incisional hernias are seldom reported but are estimated to occur in 5% to 10% of long-term survivors. In our initial minimally invasive series of 222 patients, a 0.9% incidence of minor wound infection was seen with only one early incisional port site hernia and no wound dehiscence was observed.

Postoperative Complications

Cardiopulmonary complications, including atrial fibrillation (2.9%), ARDS (5.7%), and pneumonitis (3.8%), were the most frequently encountered complications following MIE in the multi-institution E2202 trial. Our overall anastomotic leak rate requiring surgery with the McKeown approach was 5% and decreased to 4% with the Ivor Lewis approach. The reported leak rate for open procedure is approximately 9.1%. Other MIE series demonstrate similar leak rates. Moderate strictures at the gastroesophageal cervical anastomosis are common and generally can be managed with one or two outpatient dilations. Using the Ivor Lewis approach and a 28-mm EEA stapler, strictures still occur, but generally are less clinically significant and respond favorably to dilations.

ALTERNATIVE APPROACHES

MIE encompasses an array of thoracoscopic and laparoscopic techniques that all seek to reduce the morbidity of an open procedure. Several groups have reported variations in technique that may provide insight in this emerging field. Bonavina described the use of a video mediastinoscope from the cervical incision to assist his mediastinal dissection during a laparoscopic transhiatal esophagectomy. He reported that 10 of 12 operations were successful with a mean operative time of 270 minutes. Mean hospital stay was 10 days with no ICU stays. Palanivelu described a prone approach to thoracic mobilization in an effort to facilitate operative exposure. Low rates of anastomotic leak (3%), low mortality (1.5%), and equivalent stage-specific survival compared with open series have been shown with this thoracoscopic prone approach.

The robotic-assisted esophagectomy is emerging as a potential minimally invasive approach to esophagectomy. Park and colleagues reported their experience with 114 patients who underwent robot-assisted thoracoscopic esophagectomy with extensive mediastinal lymphadenectomy followed by cervical esophagogastrostomy. Their series reported a total operative time of 419 minutes with a mean of 43.5 lymph nodes resected. The most common complication was recurrent laryngeal nerve palsy (26.3%), followed by anastomotic leak (14.9%) and pulmonary complications (9.6%). They reported a median hospital stay of 16 days, and 90-day mortality was observed in 2.5% of patients.

CONCLUSION

MIE is a technically challenging operation with a steep learning curve. However, in a high-volume academic setting, technical proficiency can be achieved over time. Recent reports clearly demonstrate comparable, and possibly improved, mortality and morbidity following MIE in centers with significant experience in open and minimally invasive techniques. When MIE is performed by the most experienced surgeons in our center, the mortality is less than 1%, with a hospital stay of 6 days and, in our experience, patients enjoy a more rapid return to their premorbid lifestyle and quality of life.

Suggested Readings

Altorki NK, Zhou XK, Stiles B, et al. Total number of resected lymph nodes predicts survival in esophageal cancer. *Ann Surg* 2008;248:221–6.

Biere SS, van Berge Henegouwen MI, Maas KW, et al. Minimally invasive versus open oesophagectomy for patients with oesophageal cancer: a multicentre, open-label, randomized controlled trial. *Lancet* 2012;379:1887–92.

Birkmeyer JD, Siewers AE, Finlayson EV, et al. Hospital volume and surgical mortality in the United States. *N Engl J Med* 2002;346:1128–37.

Dantoc M, Cox MR, Eslick GD. Evidence to support the use of minimally invasive esophagectomy for esophageal cancer: a meta-analysis. *Arch Surg* 2012;147:768–76.

Hulscher JB, Tijssen JG, Obertop H, et al. Transthoracic versus transhiatal resection for carcinoma of the esophagus: a meta-analysis. *Ann Thorac Surg* 2001;72:306–13.

Kent MS, Luketich JD, Tsai W, et al. Revisional surgery after esophagectomy: an analysis of 43 patients. *Ann Thorac Surg* 2008;86:975–83.

Luketich JD, Pennathur A, Awais O, et al. Outcomes after minimally invasive esophagectomy: review of over 1000 patients. *Ann Surg* 2012;256(1):95–103.

Luketich JD, Pennathur A, Franchetti Y, et al. Minimally invasive esophagectomy: results of a prospective phase II multicenter trial—the eastern cooperative oncology group (E2202) study. *Ann Surg* 2015;261(4):702–7.

Nagpal K, Ahmed K, Vats A, et al. Is minimally invasive surgery beneficial in the management of esophageal cancer? A meta-analysis. *Surg Endosc* 2010;24:1621–9.

Orringer MB, Marshall B, Chang AC, et al. Two thousand transhiatal esophagectomies: changing trends, lessons learned. *Ann Surg* 2007;246(3):363.

EDITOR'S COMMENT

Since the initial reports of a minimally invasive approach to esophagectomy were published by Cuschieri et al. (Endoscopic oesophagectomy through a right thoracoscopic approach. *J R Coll Surg* 1992;37:7–11) and DePaula et al. (*Surg Laparosc Endosc Percut Tech* 1995;5:1–5), minimally invasive esophagectomy (MIE) has gained substantial popularity as the technique of choice for the surgical treatment of esophageal cancer. Much of this growth in popularity of MIE is due to the outstanding published results (Luketich JD, Pennathur A, Awais O, et al. Outcomes after minimally invasive esophagectomy: review of over 1000 patients. *Ann Surg* 2012;256:95–103) and the leadership of Dr. Luketich and his team at the University of Pittsburgh.

The safety and feasibility of this technically demanding procedure have now been demonstrated not only in single institution studies but also in prospective, multi-institutional studies (Luketich, Pennathur A, Franchetti Y, et al. Minimally invasive esophagectomy: results of a prospective phase II multicenter trial—the eastern cooperative oncology group (E2202) study. *Ann Surg* 2015;261:702–7; Biere, van Berge Henegouwen MI, Maas KW, et al. Minimally invasive versus open oesophagectomy for patients with oesophageal cancer: a multicentre, open-label, randomised controlled trial. *Lancet* 2012;379:1887–92). On balance, when compared to the traditional open, transthoracic esophagectomy, MIE is associated with less postoperative morbidity (primarily fewer pulmonary complications) and shorter lengths of stay in the ICU and in the hospital (Biere, van Berge Henegouwen MI, Maas KW, et al. Minimally invasive versus open oesophagectomy for patients with oesophageal cancer: a multicentre, open-label, randomised controlled trial. *Lancet* 2012;379:1887–92 and Sihag et al. *Eur J Cardiothor Surg* 2012;42:430–7). However, despite the authors' assertions that MIE is also associated with lower mortality rates than the open procedure, the comparison they choose is a published study from the Veterans Affairs, which is hardly representative of the results achieved by the finest, high-volume centers in the United States. Indeed,

Sihag et al. recently published a study (Minimally invasive versus open esophagectomy for esophageal cancer: a comparison of early surgical outcomes from the society of thoracic surgeons national database. *Ann Thor Surg* 2016;101(4):1281–8) comparing the short-term outcomes of open esophagectomy (OE) versus MIE for esophageal cancer in the United States between 2008 and 2011 by querying the Society of Thoracic Surgeons National Database, which includes primarily centers of excellence throughout the United States. These authors found that the overall postoperative morbidity and mortality rates were essentially the same for OE (62.4% and 3.9%, respectively) and MIE (61.5% and 3.3%). Nonetheless, there is widespread agreement that MIE is associated with lower rates of wound infection, ileus, postoperative transfusion, and pulmonary complications than OE; is associated with a better short-term quality of life than OE; and has a shorter median length of hospital stay than OE. In fact, with the use of fast-track protocols in patients undergoing MIE, the length of stay can be safely reduced to 7 days as opposed to 12 days in the conventionally treated group (Pan, Hu X, Yu Z, et al. Use of a fast-track surgery protocol on patients undergoing minimally invasive oesophagectomy: preliminary results. *Interact Cardiovasc Thor Surg* 2014;19:441–7). The fast-track protocol includes a semi-liquid meal administered up to 6 hours prior to surgery as well as 200 mL of a 10% glucose solution 3 hours prior to surgery, no nasogastric tube or abdominal drains, early removal of the chest tube and foley catheter, prevention of hypothermia, early physical therapy, and early enteral nutrition (including oral feeding 48 hours after surgery).

In addition to its proven safety and feasibility as a standard approach to the surgical treatment of esophageal cancer, MIE has also been demonstrated to have equal oncologic efficacy as OE. Tapias et al. (Outcomes with open and minimally invasive ivor Lewis esophagectomy after neoadjuvant therapy. *Ann Thor Surg* 2016;101(3):1097–103) reviewed the outcomes of 130 consecutive patients undergoing MIE (n = 56) or OE (n = 74) for esophageal cancer after neoadjuvant therapy and showed similar nodal yields (median of 20 lymph nodes) and 5-year overall survival rates (OE, 61% vs. MIE, 50%) between the two groups. Moreover, since patients undergoing MIE typically recover more quickly than those undergoing OE, they are more likely to receive any recommended adjuvant therapy in a timely fashion. In fact, Zahoor et al. (A propensity-matched analysis comparing survival after primary minimally invasive esophagectomy followed by adjuvant therapy to neoadjuvant therapy for esophagogastric adenocarcinoma. *J Thor Cardiovasc Surg* 2015;149:538–47) performed a propensity-matched analysis comparing survival after primary MIE followed by adjuvant therapy to neoadjuvant therapy followed by MIE for esophageal cancer and found no difference in survival rates, although only 65% of stage IIb or higher patients undergoing upfront MIE received adjuvant therapy. The authors of this study argued that this approach permits more accurate pathologic stage assignment and could minimize the risk of overtreatment in patients with early-stage disease.

Although the authors do not explicitly state that they routinely perform a D2 lymphadenectomy together with MIE for adenocarcinomas of the gastroesophageal junction (GEJ), they do briefly describe the dissection of the D2 nodes along the left gastric (station 7), celiac (station 9), and proximal splenic (station 11) arteries. However, I think that it is worth emphasizing that for Siewert type II (true cardia) and type III (subcardial) GEJ adenocarcinomas in particular, in which the predominant pattern of lymphatic spread is to the upper abdomen, a D2 lymphadenectomy should be performed together with the esophagogastrectomy (Kakeji Y, Yamamoto M, Ito S, et al. Lymph node metastasis from cancer of the esophagogastric junction, and determination of the appropriate nodal dissection. *Surg Today* 2012;42:351–8). Indeed, whereas Siewert type I tumors frequently metastasize to both mediastinal (~50%) and upper abdominal (~50%) lymph nodes, the lymphatic drainage of type II tumors is primarily directed toward the abdominal nodal basins (~70%), especially the paracardial, lesser curvature, and left gastric nodes, as opposed to the mediastinal nodes (~30%). Type III tumors are similar to type II tumors in almost exclusively metastasizing to intra-abdominal lymph nodes (~90%) and only rarely metastasizing to nodes within the chest (~10%) (Pedrazzani, de Manzoni G, Marrelli D, et al. Lymph node involvement in advanced gastroesophageal junction adenocarcinoma. *J Thorac Cardiovasc Surg* 2007;134:378–85).

In addition to its short-term benefits, MIE is associated with longer term benefits as well, including an improved quality of life (QOL) compared to OE. Maas et al. (Quality of life and late complications after minimally invasive compared to open esophagectomy: results of a randomized trial. *World J Surg* 2015;39:1986–93) conducted a 1-year follow-up analysis of the QOL of patients participating in the first, multicenter, randomized controlled clinical trial comparing OE with MIE (Biere, van Berge Henegouwen MI, Maas KW, et al. Minimally invasive versus open oesophagectomy for patients with oesophageal cancer: a multicentre, open-label, randomised controlled trial. *Lancet* 2012;379:1887–92). They found that patients undergoing MIE had better physical activity, global health, and pain scores than those patients undergoing OE. Interestingly, almost 40% of patients in both groups developed anastomotic strictures, requiring a median of five dilations per patient, although most patients underwent a three-field McKeown-type esophagectomy with a cervical anastomosis.

Of course, in order to achieve expert results similar to those of Dr. Luketich, one must master this technically challenging surgical procedure, and a few groups have examined the learning curve for MIE. Tapias and Morse (Minimally invasive Ivor Lewis esophagectomy: description of a learning curve. *J Am Coll Surg* 2014;218:1130–40) studied the first 80 MIEs performed by a single surgeon with experience in minimally invasive esophageal surgery at a high-volume center and estimated that the learning curve for MIE is approximately 35 to 40 cases. Dhamija et al. (Learning curve to lymph node

resection in minimally invasive esophagectomy for cancer. *Innovations* 2014;9:286–91) estimated that the ability to perform an adequate lymphadenectomy during MIE improves over time and plateaus after the first 25 cases. Lastly, Hernandez et al. (Defining the learning curve for robotic-assisted esophagogastrectomy. *J Gastrointest Surg* 2013;17:1346–51) established that for surgeons proficient in performing MIE, the learning curve for a robotic-assisted procedure appears to begin near proficiency after 20 cases.

Although Dr. Luketich and his team herein describe the laparoscopic approach to MIE, given the advantages of the robotic platform in accelerating the learning curve of MIE with the help of magnified three-dimensional view, improved articulation of instruments, and improved dexterity and ergonomics, it only stands to reason that robotic transthoracic esophagectomy will soon become a standard of care for esophageal cancer. Puntambekar et al. (Robotic transthoracic esophagectomy. *BMC Surgery* 2015;15:47) published the largest series of robotic esophagectomy for esophageal cancer (n = 83) and found that it was not only feasible but allowed precise en bloc dissection with lymphadenectomy in the mediastinum while minimizing operative time, blood loss, and complications. The first randomized, controlled trial (ROBOT trial) comparing robot-assisted esophagectomy with open transthoracic esophagectomy for esophageal cancer was launched in 2012 and is currently accruing patients. Of note, surgeons in this trial will perform the thoracic portion of the Ivor Lewis esophagectomy robotically while performing the abdominal portion laparoscopically (van der Sluis, Ruurda JP, van der Horst S, et al. Robot-assisted minimally invasive thoraco-laparoscopic esophagectomy versus open transthoracic esophagectomy for resectable esophageal cancer, a randomized controlled trial (ROBOT trial). *Trials* 2012;13:230).

In terms of the risk of anastomotic stricture, the authors assert that they try to use a 28-mm EEA stapler to minimize this risk, which in published series is on the order of 30% for the circular stapled technique. Price et al. (A comprehensive review of anastomotic technique in 432 esophagectomies. *Ann Thor Surg* 2013;95:1154–61) at the Mayo Clinic published a comprehensive review of the outcomes with various anastomotic techniques in 432 esophagectomies over a 4-year period. As expected, stricture rates were higher for anastomoses in the neck compared to the chest (26% vs. 15%). For Ivor Lewis esophagectomies, in particular, the 1-year probability of stricture formation was 32% for the circular stapled technique, 27% for the hand-sewn technique, and only 8.6% for the linear-stapled technique. A recent meta-analysis (Zhou et al. Comparison of two different mechanical esophagogastric anastomosis in esophageal cancer patients: a meta-analysis. *J Cardiothor Surg* 2015;10:67) also confirmed the significantly reduced risk of stricture formation with the linear-stapled technique compared to the circular-stapled technique (Risk Ratio 0.26, 95% CI: 0.11–0.60, P = 0.002).

There has been much written about the necessity of performing a pyloroplasty to minimize the risk of gastric outlet obstruction and aspiration

pneumonia. Although the authors describe routinely performing one as part of their MIE, other authors have shown that a pyloroplasty may not be necessary. Lanuti et al. at the Massachusetts General Hospital studied 242 patients (n = 159 had a pyloromyotomy and n = 83 had no pyloric drainage) who underwent OE and found that performance of a pyloromyotomy does not reduce the incidence of symptomatic delayed gastric emptying nor aspiration pneumonia.

The authors also describe placement of a closed suction drain posterior to the esophagogastric anastomosis, presumably to facilitate the detection and (potentially) the drainage of a possible anastomotic leak. Interestingly, there is a recently published study (Perry et al. Serial drain amylase can accurately detect anastomotic leak after esophagectomy and may facilitate early discharge. *Ann Thor Surg* 2015;100:2041–7), which reported that measuring the amylase levels from such drains on a daily basis after esophagectomy may prove more accurate in the detection of an anastomotic leak than a barium esophagram. Specifically, a drain amylase level of 38 IU/L on postoperative day 4 yielded a sensitivity of 100% and a specificity of 52% in detecting a clinically significant leak. Given the relatively low sensitivity of a barium esophagram for the detection of a leak, which in most studies is only on the order of 50%, combined with its potential risks, including aspiration pneumonitis and mediastinitis, perhaps consideration should be given to this simple, low-risk test.

John T. Mullen

72 Nissen–Rossetti Antireflux Fundoplication (Open Procedure)

David I. Watson

The modern era of antireflux surgery began in the 1950s with the description of fundoplication by Nissen. Nissen's original procedure entailed a 360-degree wrap of the fundus of the stomach around the distal esophagus. This was constructed using the anterior and posterior walls of the fundus, without dividing the short gastric blood vessels. Subsequently, a number of modifications have been described, with the aim of either simplifying the performance of the procedure, reducing perioperative morbidity, or preventing side effects. In the mid-1960s, Nissen and Rossetti modified Nissen's original technique so that the anterior wall of the fundus alone was used to construct the 360-degree wrap. Subsequently, DeMeester and Donohue advocated division of the short gastric blood vessels to enable the construction of a "floppy" Nissen fundoplication.

More recently, however, the results from six prospective randomized trials of Nissen fundoplication with and without division of the short gastric vessels have demonstrated that division of the short gastric blood vessels is not necessary. Equivalent reflux control and a similar prevalence of dysphagia at follow-up of up to 10 years are achieved without routinely dividing these vessels. Furthermore, the randomized trials have shown that dividing the vessels actually increases the complexity of the procedure, and produced a poorer outcome in three of the six trials due to an increase in the incidence of bloating symptoms following vessel division.

Until the early 1990s, the Nissen–Rossetti fundoplication was performed using an open abdominal approach, and, less commonly, thoracic access. Following the development of laparoscopic approaches, the vast majority of primary antireflux procedures are now performed laparoscopically, and excellent outcomes have been reported for this approach. This means that the open approach is now used only in a minority of patients undergoing antireflux surgery. Indications for an open surgical approach currently include the following:

1. Lack of expertise in advanced laparoscopic surgery.
2. Patient preference.
3. Completion of a fundoplication that has been converted from a laparoscopic to an open approach (e.g., because of intraoperative difficulties).
4. Concurrent open surgical procedure.
5. Reoperative surgery following a previous laparoscopic or open approach.

The first three indications are now quite rare, as laparoscopic approaches are the standard of care for primary antireflux surgery these days. The main indication for open surgery is now a reoperative procedure. Some reoperative surgeries can be completed using a laparoscopic approach. However, a proportion can be performed only via open surgery, and this is most likely following a previous open operation, or more than two previous laparoscopic antireflux procedures. The transthoracic approach to antireflux surgery has significant morbidity and is now rarely used. It is perhaps best reserved for complex reoperative surgery when at least two previous abdominal operations have been performed—this is rarely undertaken. For this reason, this chapter focuses on the open abdominal approach.

INDICATIONS

1. Symptomatic gastroesophageal reflux in patients in whom medical treatment with acid suppression has not adequately relieved symptoms.
2. Patients with gastroesophageal reflux in whom symptoms are well controlled by medical therapy, but who do not wish to take medication lifelong.
3. Giant mixed or paraesophageal hiatus hernia where some or all of the symptoms are mechanical (e.g., chest pain, intermittent dysphagia)—that is, not due to reflux alone.

The majority of patients fall into the first category.

PREOPERATIVE PLANNING

It is important to take a complete history and to confirm that the symptoms are actually due to gastroesophageal reflux. Typical reflux symptoms include heartburn, water brash (volume regurgitation of acid-tasting liquid), and epigastric pain. Other symptoms that can be caused by reflux

include dysphagia, odynophagia, postprandial fullness, early satiety, upper abdominal bloating, anorexia, nausea, chronic cough, voice change, throat irritation, and wheezing. In general, surgery is very effective for controlling typical symptoms, whereas the response of atypical symptoms to fundoplication is variable.

Preoperative Investigations

Preoperative work entails the following investigations:

1. Endoscopy
2. Barium meal radiology
3. pH monitoring
4. Impedance monitoring
5. Esophageal manometry

Which investigations are included as part of preoperative work-up is tailored to the clinical presentation. Endoscopy should be performed in all patients to determine the presence or absence of ulcerative esophagitis, Barrett esophagus, or hiatal hernia. Up to 50% of patients presenting for surgery have no evidence of esophagitis at endoscopy, often because they are using proton pump inhibitor medication. In these patients 24-hour pH monitoring is required to confirm the diagnosis of reflux. Although many surgeons use pH monitoring routinely, the author's preference is a selective approach in which pH monitoring is used primarily to investigate patients who do not have typical reflux symptoms and evidence of reflux at endoscopy. Impedance monitoring is sometimes added if other tests are negative for reflux, or to clarify the significance of atypical symptoms. However, for the majority of patients impedance monitoring does not change actual clinical decision making.

Esophageal manometry should be performed routinely in all patients undergoing Nissen–Rossetti fundoplication. It identifies the occasional patient with achalasia, and these patients require different treatment. It also identifies a subgroup of patients who have disordered esophageal body motility, and in these patients a partial fundoplication may be better surgical approach.

Barium-meal radiography is not performed routinely in individuals undergoing a primary antireflux operation, but should be considered if a large hiatal hernia is suspected to evaluate and document the anatomy. Barium-meal radiography is also useful to clarify anatomy when

considering revisional surgery. For revisional surgery, the author's preference is to undertake full workup with endoscopy, manometry, pH monitoring (and sometimes impedance monitoring), and barium-meal radiography in all patients, so that any diagnosis of recurrent reflux is confirmed with certainty, and anatomy is well understood before progressing to surgery.

SURGICAL TECHNIQUE

Positioning and Instrumentation

For the open transabdominal approach, the patient is placed on the operating table in the supine position. Good exposure is essential, and this is achieved by using a sternal retractor that lifts the sternum and the costal arch forward. An abdominal wall retractor is also used to separate the abdominal wound edges laterally. The author's preference is to use a sternal retractor that attaches by a chain to a crossbar positioned above the patient's face. An alternative is the Rochard retractor, which uses two blades to lift and retract the costal margin. Exposure can be improved further by bending the operating table forward 20 to 30 degrees to flex the patient at the waist, and then bend the headpiece backward by a similar amount (see Fig. 72.1). This shifts the abdominal wound in a cranial direction, and flattens the diaphragm to improve access to the hiatal region. If this is done, the sternal retractor must be attached to the headpiece of the operating table. A fixed retraction system (e.g., Iron Intern or Omnitract) is used to retract the left lobe of the liver. Extra-long surgical instruments are usually needed for the operative procedure, especially when operating on men and obese patients. A renal vein retractor or 1-inch wide Deaver retractor is also useful for displacing the esophagus when undertaking hiatal repair.

An upper midline abdominal incision is used for access. Proximally, this should extend between the xiphisternum and the left costal margin, and distally it finishes just above or just below the umbilicus. The aim of the procedure is to form an effective antireflux valve by constructing a 360-degree wrap around the distal esophagus, using the anterior gastric wall.

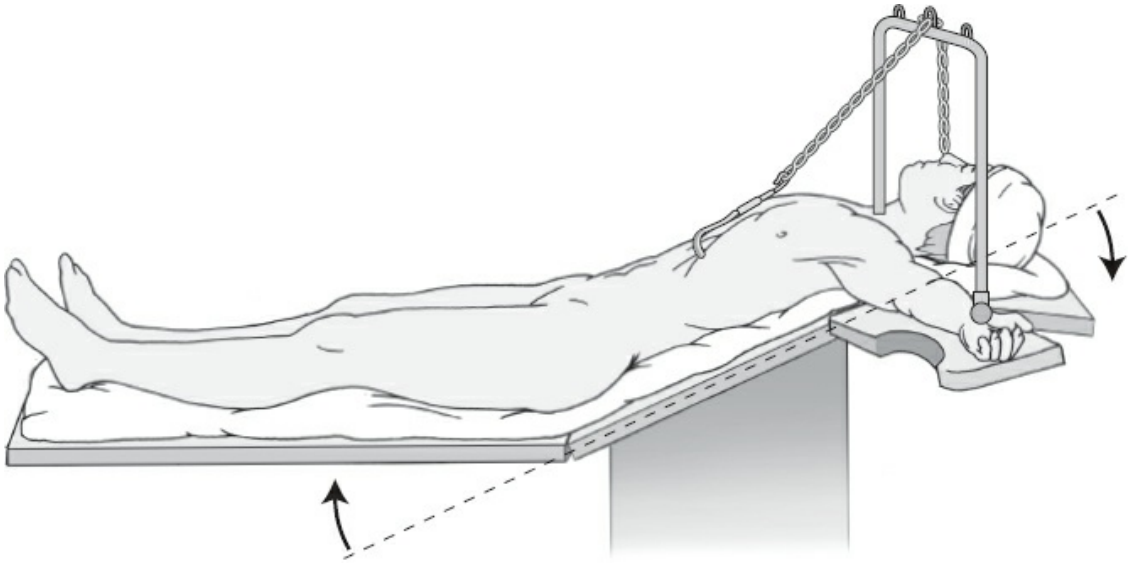

Figure 72.1. Positioning for open Nissen–Rossetti fundoplication: overall head-up tilt, hips flexed, sternal retractor, and neck extended.

Hiatal Dissection

The left lobe of the liver is displaced forward and to the right to expose the upper stomach and the region of the esophageal diaphragmatic hiatus. It is not necessary to divide the triangular ligament of the left lobe of the liver to displace the lobe medially, except on the rare occasion when the liver is excessively enlarged.

The stomach is retracted downward, and the lesser omentum is opened above and below the hepatic branch of the vagus nerve (which is preserved), to display the caudate lobe of the liver and the right hiatal pillar. The phrenoesophageal ligament is divided next (Fig. 72.2). This comprises two layers, a superficial layer of peritoneum and a deeper fibrous tissue layer. Both layers are divided carefully, so that the layer of tissue that covers both sides of the muscle of the right and left hiatal pillars is preserved. The aim of this initial dissection is to display the edges of both hiatal pillars, as far posteriorly as possible, stopping short of the uppermost short gastric blood vessel on the left side. The anterior and lateral aspects of the lower 4 to 6 cm of the esophagus are displayed during this dissection.

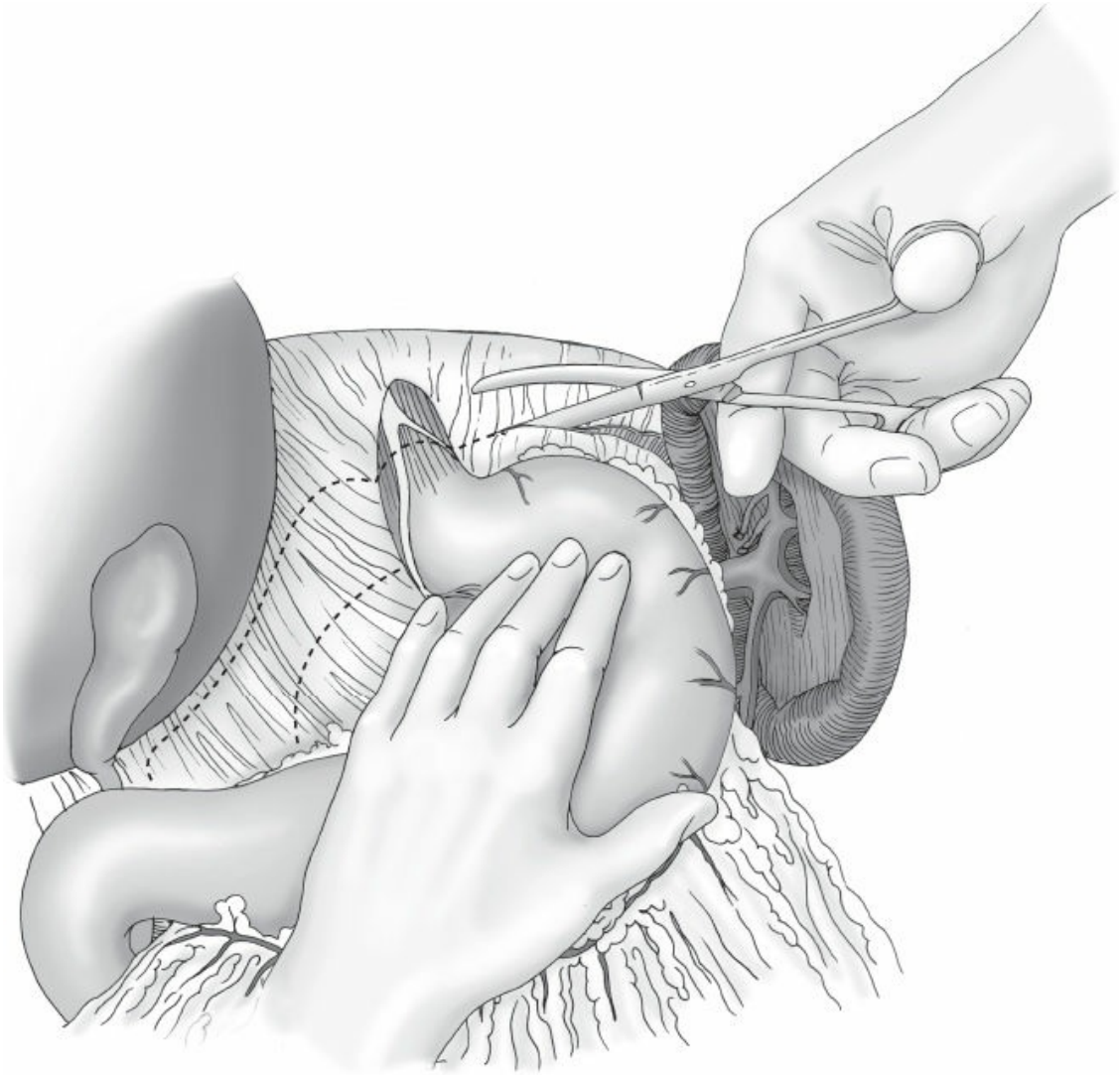

Figure 72.2. Division of the phrenoesophageal ligament and opening the lesser omentum above and below the hepatic branch of the vagus nerve.

Care is taken to preserve both vagus nerves. The anterior vagal branches run along the anterior wall of the esophagus. They are not formally dissected from the esophageal wall, and hence they are routinely included in the fundoplication. The hepatic branch of the anterior vagus nerve is preserved, and the fundoplication is constructed so that it sits above this. The posterior vagus nerve usually sits separately behind the esophagus. It can be readily identified, and it is usually displaced further posteriorly and excluded from the fundoplication. However, if it is attached to the esophagus by a thick layer of connective tissue, it can be included in the fundoplication.

The longitudinal muscle of the distal esophagus is gradually freed from its surroundings by blunt finger dissection, and a space is dissected behind

the esophagus, from left to right, using the index and middle fingers. Once a posterior “window” has been created, a nylon tape or a plastic tube is passed around the distal esophagus. Traction is applied to the tape to lift the esophagus anteriorly, and this exposes the posterior hiatus (Fig. 72.3). The posterior aspect of the distal 6 cm of the esophagus is then fully mobilized. The posterior aspect of the upper part of the stomach can also be separated from the diaphragm at this stage if necessary.

Mobilization of the esophagus is the most dangerous part of the operation, and there is a small risk of esophageal perforation during this step. This risk is greatest if the esophageal wall is inflamed, edematous, or friable, or if previous hiatal surgery has been performed. The consequences of perforation may be greater if it occurs through the posterior wall, as a transmural lesion in the back wall of the esophagus can be overlooked. As long as dissection is in the correct layer, there is little risk of hemorrhage, as the divided structures contain only minute vessels. For this reason, if dissection is performed correctly, it will be relatively bloodless. The surgeon must, however, watch for an accessory left gastric artery running with the hepatic branch of the vagus nerve. If this nerve is preserved, injury to the vessel is unlikely.

Care should also be taken with the left inferior phrenic artery. This runs dorsally to the cardia and fundus, with one or more branches arising directly from the aorta or celiac trunk. It can be, but is not often, damaged during mobilization of the anterior surface of the fundus. In approximately 5% of patients, it arises from the left gastric artery and runs along the edge of the right hiatal pillar. In this situation, it should be ligated and divided to facilitate hiatal dissection. If necessary, the upper short gastric vessels can also be divided, although this is required in less than 5% of Nissen fundoplications.

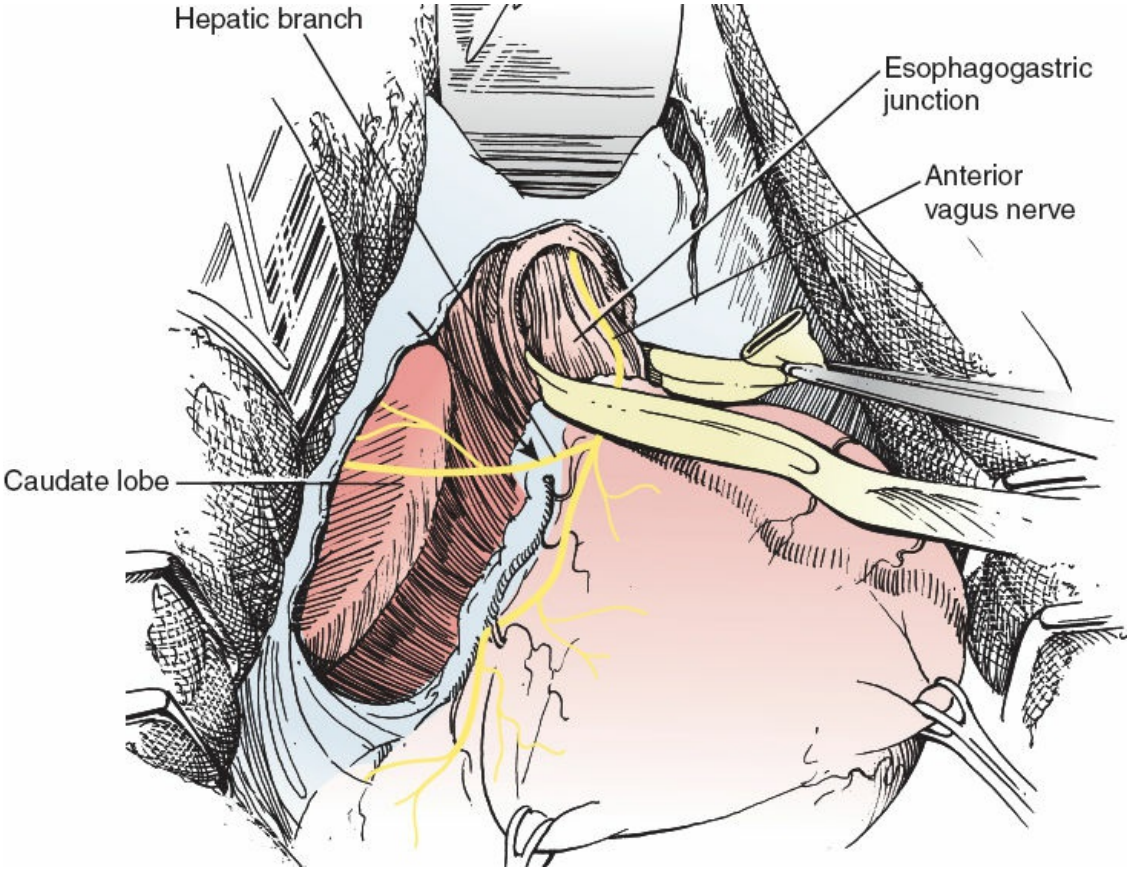

Figure 72.3. Tape passed around the esophagus, lifting the esophagogastric junction forward to display the posterior hiatus.

Hiatal Repair

The hiatus is routinely repaired using posteriorly placed sutures. These should narrow the hiatus to approximately 2.5 cm in diameter (Fig. 72.4). To do this, the reconstructed hiatal rim should sit loosely (not tightly) around the esophagus with a 52-Fr bougie sited across the gastroesophageal junction. In patients without a hernia or with a small hiatal hernia, one or two interrupted 2-0 nonabsorbable sutures should be placed. If a larger hernia is present, more sutures should be placed. When repairing the hiatus, the right and left hiatal pillars are exposed posteriorly by retracting the abdominal esophagus to the left with a renal vein retractor or similar narrow-bladed retractor. The first suture is placed through the pillars from left to right, immediately in front of the posterior junction of the two pillars. Subsequent sutures are placed progressively anteriorly to each previous suture, until the hiatal opening is reduced to the appropriate size. If the hernia defect is very large, the posterior sutures can be supplemented if necessary with anterior hiatal sutures, or a piece of prosthetic material can be used to reinforce the repair. If a bougie is used

to calibrate the hiatal repair, the repair is performed first without the bougie, and the bougie is passed subsequently to assess the hiatal size.

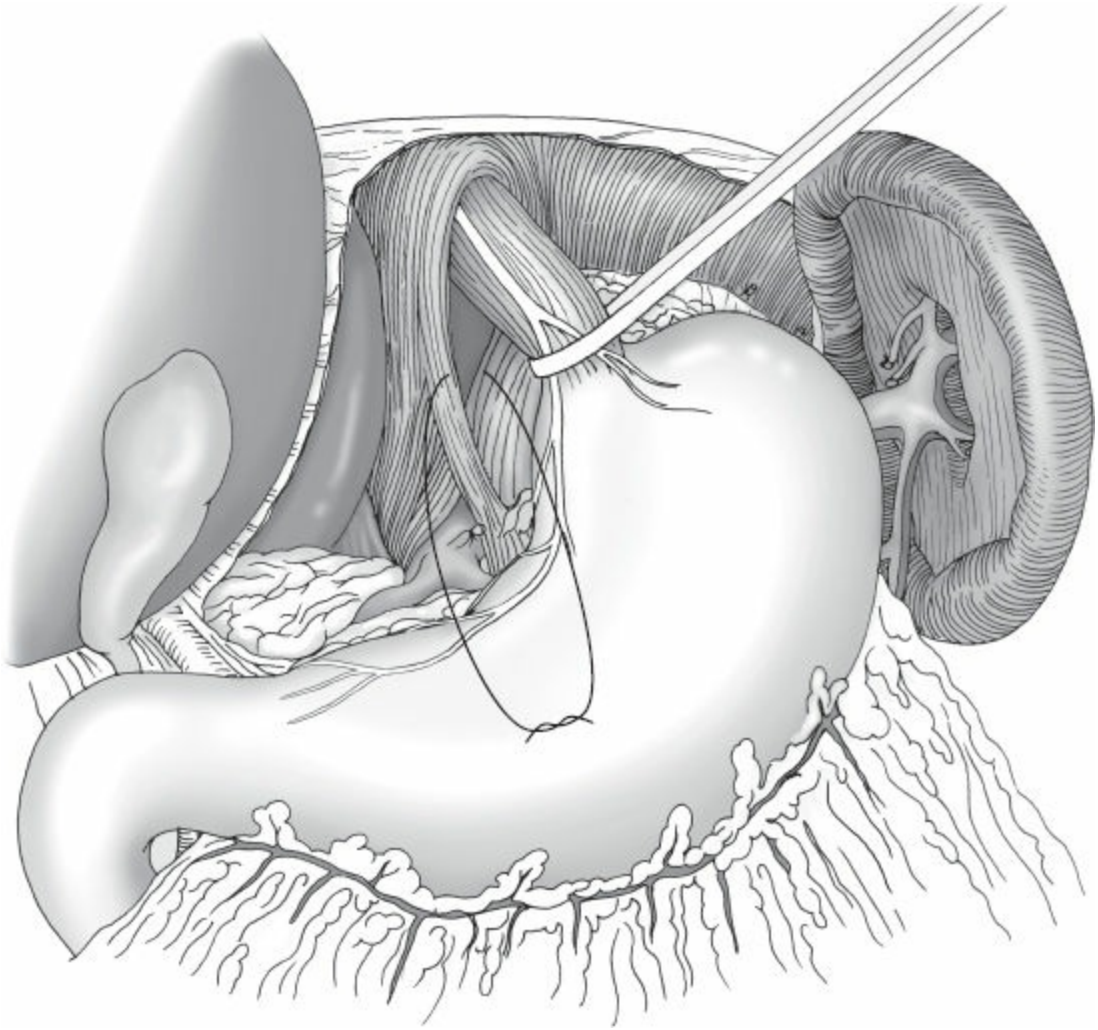

Figure 72.4. Repair of the hiatus by suturing the hiatal pillars behind the esophagus.

Fundoplication

The anterior wall of the fundus, midway between the greater and lesser curvatures of the stomach, at the level of the cardia or just above, is pushed behind the esophagus with the fingers of the right hand until it appears between the left side of the esophagus and the liver. The stomach is then grasped with two pairs of long atraumatic Babcock forceps, and manipulated to ensure that it comes around the back of the esophagus loosely (Fig. 72.5). If the stomach is tight, and does not sit comfortably without undue tension, the Babcock forceps should be progressively adjusted and a looser piece of stomach grasped. This is continued until a

satisfactorily loose piece of stomach is identified. An anterior fold of stomach is then formed from the more distal part of the anterior fundic wall and held with a Babcock forceps so that the two pieces of stomach can be wrapped around the esophagus without pulling or stretching the distal section of the esophagus. This should be done so that there is not excessive tension on the stomach, and the fundus sits comfortably around the lower part of the esophagus. If it is not possible to create a loose enough fundoplication, then it is occasionally necessary to divide the short gastric vessels, or, alternatively, a partial fundoplication can be performed. This scenario is unusual.

Three interrupted 2-0 nonabsorbable monofilament sutures are placed to form the fundoplication. The sutures are not tied at this stage (Fig. 72.6). The sutures are passed deeply through the serosa and muscle of the stomach wall on both sides, and also more superficially through the muscle of the esophageal wall. Some surgeons choose not to include the esophageal wall in these sutures. A Maloney-style mercury-weighted 52-Fr esophageal bougie (or similar) is then passed into the stomach to calibrate the fundoplication. The sutures are tied down after placing the bougie, and the fundoplication should be checked to ensure that it is not too tight. With the bougie still in place, it should be possible for the surgeon to pass a finger between the fundoplication and the left side of the esophagus to ensure that the fundoplication is loose (Fig. 72.7). The completed fundoplication should be between 1 and 2 cm in length (Fig. 72.8). Some surgeons place additional sutures between the fundoplication and the hiatal rim in an attempt to stabilize the fundoplication. However, this step does not prevent the cardia from telescoping within the wrap, and for this reason, the author does not advise this. A wound drain is also unnecessary.

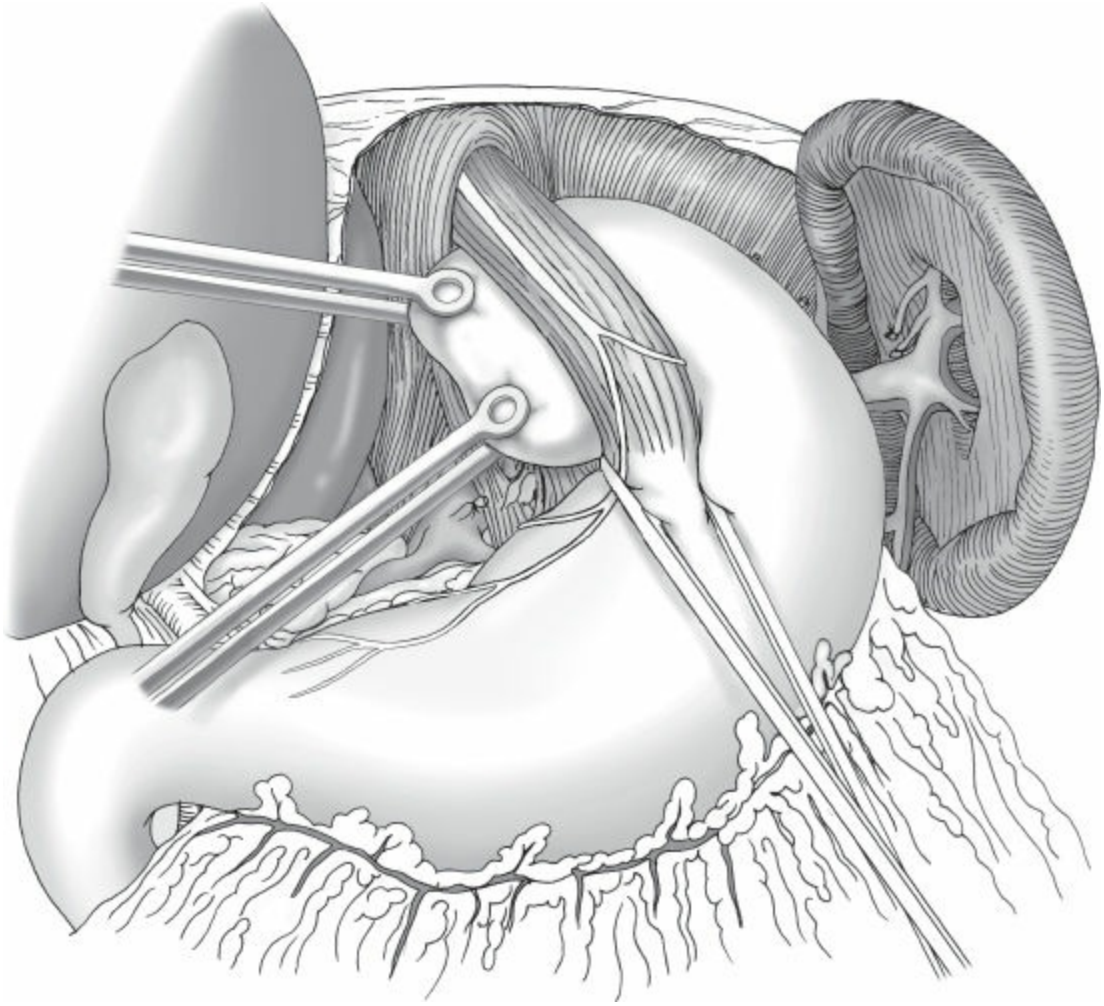

Figure 72.5. The anterior fundus is passed behind the esophagus, and manipulated with Babcock forceps.

POSTOPERATIVE CARE

A nasogastric tube is rarely needed following fundoplication, and its presence can precipitate retching. For this reason, it is best omitted. Intravenous fluids are required for the first 1 to 2 days. Oral fluids are introduced on the first postoperative day, and a vitamised diet is introduced on the second day. The author routinely arranges for a barium-swallow radiograph on the first or second postoperative day to ensure that a satisfactory procedure has been performed. Most patients can leave the hospital between 3 and 5 days after surgery. Diet is restricted to vitamised food for 3 to 4 weeks, and then gradually increased to a normal diet over the next 4 to 8 weeks. At 3 months after surgery, 20% of the patients will still have some dietary restrictions, although after 12 months 95% will be able to eat a full range of food. For the first 3 months, patients should also eat carefully, and chew their food well. Fizzy drinks should be avoided for

at least 3 months.

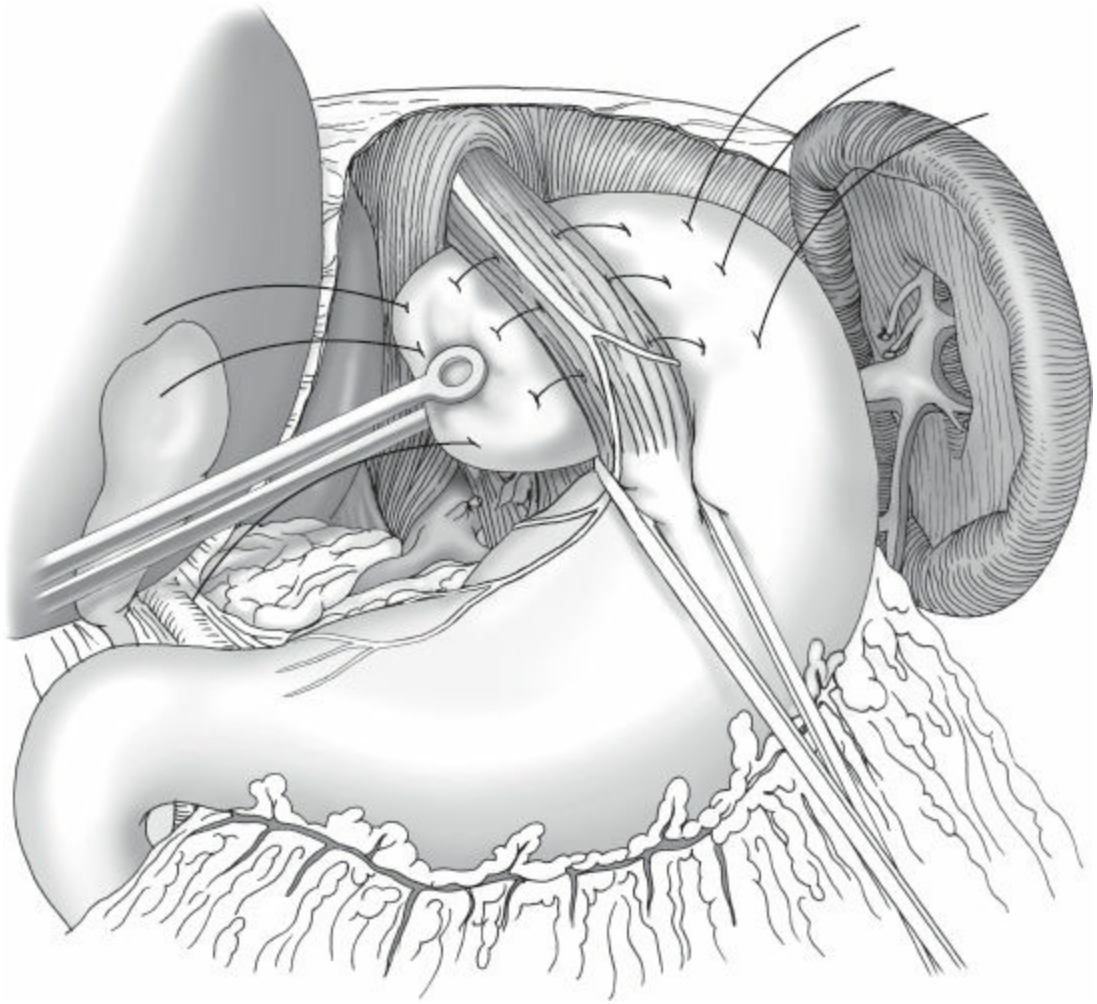

Figure 72.6. Placement of sutures for the fundoplication.

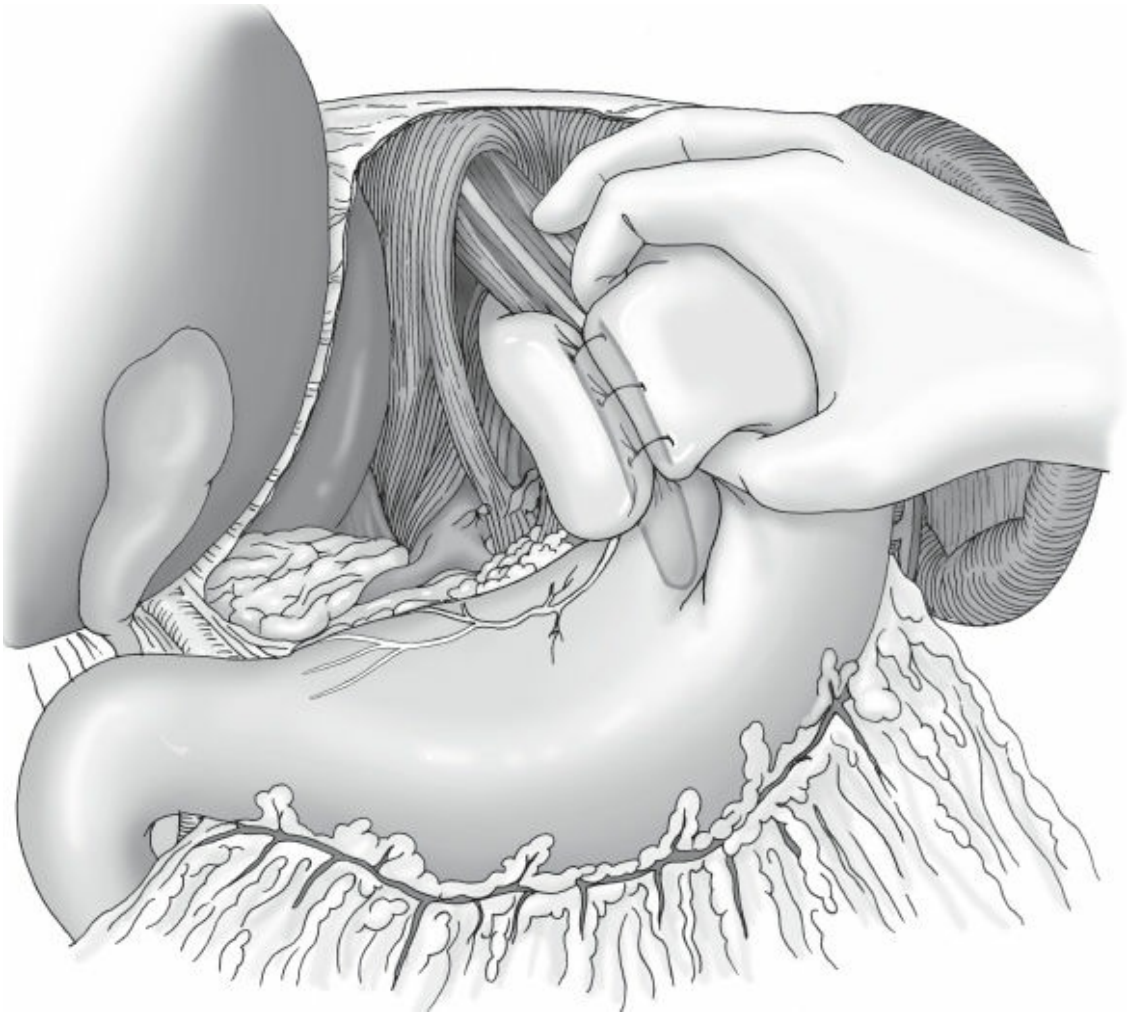

Figure 72.7. The fundoplication is checked by passing a finger between the fundoplication and the esophagus while a bougie is positioned in the lumen of the esophagus.

TECHNIQUE FOR LARGE HIATAL HERNIA

Although most large hiatus hernias can be repaired using laparoscopic techniques, an open technique is occasionally required for the patients who present acutely with an incarcerated stomach, or to complete a procedure that cannot be completed laparoscopically, or to repair a recurrent hernia. The surgical strategy for the open repair of large paraesophageal and mixed hiatal hernias entails the following:

1. Upper midline abdominal incision.
2. Initial decompression of the herniated stomach using a nasogastric tube if the stomach is not empty.
3. Dissection of the hernia sac from the hiatal pillars while preserving the fascial covering over the muscle at the hiatal rim.
4. Complete removal of the sac from the mediastinum. (The stomach

reduces into the abdomen as the sac is progressively dissected from the chest, and the distal esophagus is exposed by this dissection.)

5. Narrowing of the widened hiatus with posteriorly placed nonabsorbable sutures, and reinforcement with mesh if desired.
6. Additional anterior hiatal sutures if necessary to achieve adequate hiatal narrowing.
7. Fundoplication constructed using three nonabsorbable sutures, and calibrated using a 52-Fr bougie.

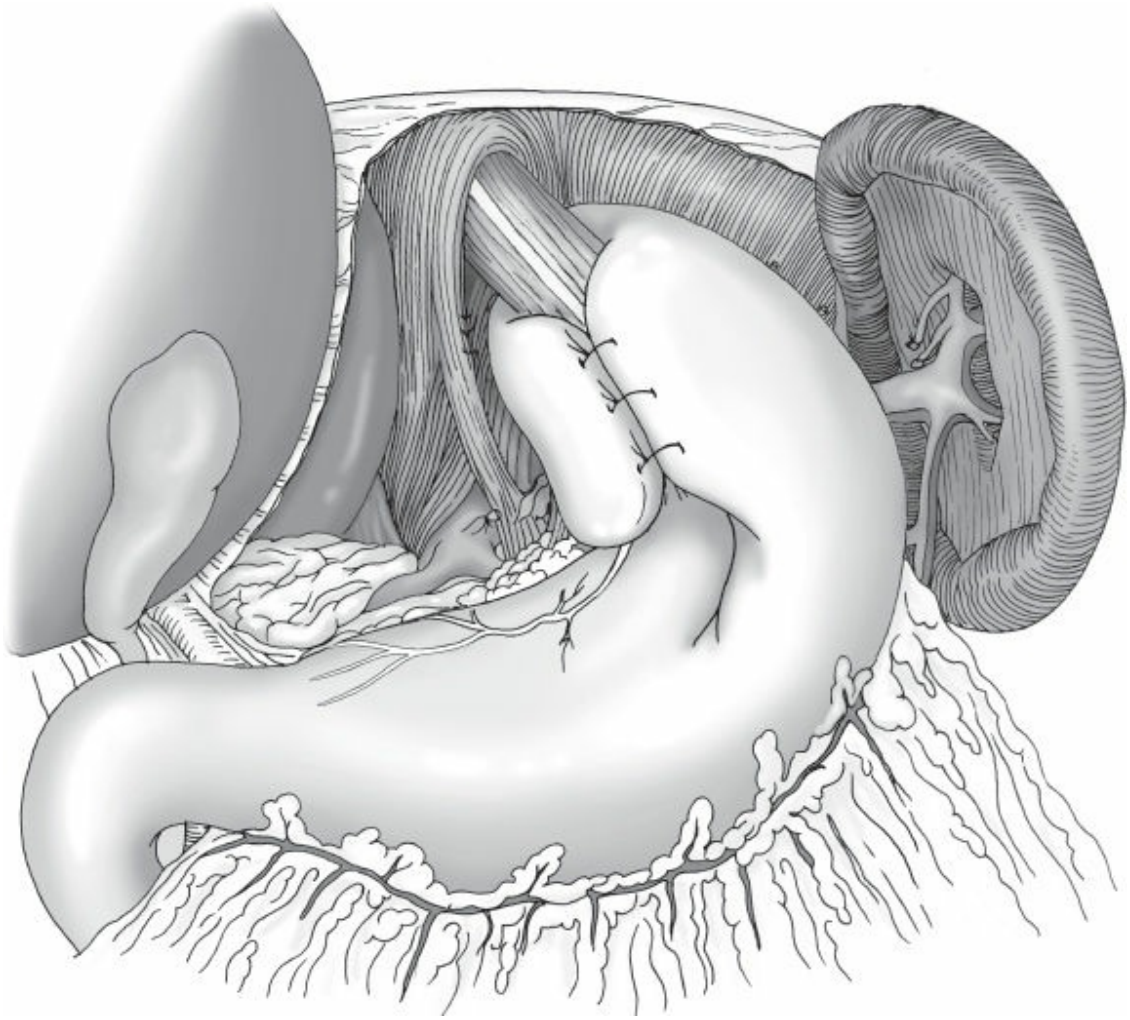

Figure 72.8. The completed Nissen–Rossetti fundoplication.

The fundus of the stomach is quite mobile when a large hiatal hernia is present, and a loose fundoplication can almost always be constructed without dividing the short gastric vessels. The author prefers not to place sutures between the fundoplication and the diaphragm, as this minimizes the risk of the cardia telescoping within the wrap. If the hernia sac has been completely removed from the chest, and the esophagus is well

mobilized, the gastroesophageal junction usually sits below the level of the diaphragm without tension. However, in a small number of patients with a true short esophagus (<2%), an alternative approach, such as a Collis gastroplasty, will need to be undertaken to allow an intra-abdominal fundoplication to be performed. In an attempt to minimize the risk of hernia recurrence, some surgeons reinforce the hiatal repair with a mesh prosthesis. There is evidence from some randomized trials that this reduces the risk of early radiologic recurrence of hiatus hernia, although other trials have shown no advantage for mesh, or no longer-term outcome benefit. Hence, evidence that mesh reinforcement translates to a significant improvement in the clinical outcome is still controversial, and there is a small risk of mesh eroding into the esophageal lumen. The author's preference is to now avoid mesh repair of the hiatus.

ADDITIONAL PROCEDURES

Before the 1990s, some surgeons added a vagotomy and drainage procedure, or a highly selective vagotomy, to an open Nissen fundoplication. The rationale for these additional procedures was gastric acid reduction and a drainage procedure to improve gastric emptying. Delayed gastric emptying is common in patients with reflux, and it will often be found if a gastric emptying study is performed before surgery. Unfortunately, truncal vagotomy can be followed by diarrhea and other postvagotomy problems, and pyloroplasty can add additional morbidity. Both of these can lead to digestive disturbances and should be avoided. Highly selective vagotomy also adds no additional benefit and is unnecessary.

REOPERATIVE SURGERY

Revision antireflux surgery is more difficult than primary surgery for reflux, particularly if the previous procedure was performed using an open technique. Upper abdominal adhesions must be divided to expose the operative field. The left lobe of the liver is usually adherent to the anterior wall of the upper stomach and the previous fundoplication. This must first be separated from the stomach to expose the hiatal region. The tissue planes in the hiatal region are often difficult to find, and the hiatal rim and esophagus must be dissected with caution to avoid perforation of the esophagus or stomach. The vagal nerve trunks are difficult to identify during revision surgery and are often divided. The principles of revision

surgery entail the following:

1. Division of adhesions.
2. Dissection of the hiatal rim and esophagus.
3. Identification of the previous fundoplication.
4. Restoration of normal anatomy by fully reversing the previous fundoplication.
5. Hiatal repair.
6. Formation of a new fundoplication.

COMPLICATIONS

Intraoperative complications are rare. The spleen, however, may be injured during transabdominal fundoplication. Capsular avulsion or small tears causing persistent hilar bleeding occur in approximately 5% of the patients, and splenectomy rates of 1% to 3% have been reported. Splenectomy is less likely during Nissen–Rossetti fundoplication because the short gastric blood vessels are not ligated. Most splenic injuries are minor, and bleeding can easily be controlled with tamponade. Any temptation to use diathermy or to suture the spleen should be resisted, as these maneuvers can make bleeding worse and precipitate splenectomy.

Another possible complication is injury to the vagal trunks, which can occur in the reoperative situation, or occasionally in the presence of marked inflammation of the cardioesophageal junction. The sequelae of vagotomy are rarely of long-term clinical relevance.

The most serious complication, accidental perforation of the esophagus, can cause a great deal of difficulty. Perforation is more likely if the esophagus is severely inflamed (periesophagitis), or if the operation is for revision of a previous fundoplication. Perforation occurs either during difficult mobilization of the cardia or during the attempt to either pass an instrument or dissect around the back of the esophagus. An unrecognized perforation of the esophagus is a life-threatening complication. Thorough evaluation of the situation, particularly of the posterior aspect of the esophagus, before encircling the distal esophagus with any instrument is therefore mandatory. If a perforation is identified, this should be repaired with sutures, and the suture line should then be covered with the fundoplication. This will usually be followed by a successful outcome. However, if the perforation is missed, and repair is delayed, leakage from the suture line is more likely. For this reason, drains should be placed around the hiatal area, and a gastrostomy and feeding jejunostomy

performed if reoperation is required. They are invaluable if an esophageal fistula ensues.

Postfundoplication Side Effects

Following a successful fundoplication, vomiting is not possible, and belching can be more difficult due to the presence of an overcompetent fundoplication valve. In addition, flatulence is common. Belching is always more difficult in the first few months after a total fundoplication, and because many patients become accustomed to swallowing air during the course of their reflux disease, aerophagia is also common in the early postoperative period. Aerophagic patients tend to have more problems postoperatively. However, as follow-up progresses, belching becomes easier in the majority of the patients, and the problem of aerophagia tends to diminish by the end of the first postoperative year in most patients. Upper abdominal bloating symptoms following fundoplication are often blamed on the surgery. However, this symptom is also common in patients who have not undergone surgery. Its overall incidence decreases following fundoplication, although some patients will develop this as a new problem.

Dysphagia occurs in most patients during the first 2 to 3 postoperative weeks, and this is usually due to postoperative edema in the fundoplication or the perihiatal region, as well as transient disturbances of esophageal motor function. It is usually worst in the second and third weeks. It can also occur if the wrap is made too tight. This will manifest as total or near-total esophageal obstruction, which requires early operative reintervention and reconstruction of a looser fundoplication. Less commonly, dysphagia can occur due to excessive scar formation around the distal esophagus at the hiatal rim. Symptoms of this problem usually commence around 7 to 10 days after surgery. Late dysphagia can also follow intrathoracic migration of the collar-like wrap that constricts the fundus and gastroesophageal junction.

Failure

Late failure following fundoplication presents either as recurrent gastroesophageal reflux or hiatus hernia, or both. There are two reasons for the development of recurrent reflux: loosening of the original fundoplication or wrap slippage. The majority of patients with recurrent reflux still have a fundoplication present. However, the fundoplication does not provide an effective barrier to reflux if it comes to lie around the

cardia or upper stomach, rather than around the distal esophagus. Apposition of the fundus to the distal esophagus is critical for the maintenance of an antireflux barrier. Telescoping of the gastroesophageal junction through the 360-degree fundoplication (“slipped Nissen”) during follow-up accounts for most instances of recurrent reflux. Recurrent reflux becomes more common as follow-up progresses, the incidence being approximately 10% at 10 years. The other problem of hiatus herniation can cause mechanical symptoms such as dysphagia and chest pain. This problem usually occurs quite early following the surgery, and the symptoms progress as the hernia progressively enlarges. Both problems can be corrected by revision surgery.

OUTCOMES

A good outcome following Nissen–Rossetti fundoplication is expected in approximately 90% of the patients at 10 years follow-up. The causes of failure are evenly divided between recurrent reflux and persistent troublesome side effects. Six randomized trials of Nissen–Rossetti fundoplication versus Nissen fundoplication with division of the short gastric vessels have shown equivalent outcomes for both reflux control and postfundoplication dysphagia. In three of the trials, the incidence of “wind-related” side effects at late follow-up was less following Nissen–Rossetti fundoplication.

CONCLUSIONS

Open Nissen–Rossetti fundoplication achieves an excellent outcome in the majority of patients who undergo surgery for gastroesophageal reflux, and it is relatively simple to perform. The open approach for primary surgery, however, has now been largely replaced by laparoscopic techniques, and the open approach is now performed only in a subgroup of patients who undergo surgery for reflux. The main role of the open approach is now in the treatment of patients who are undergoing revision surgery, as well as in the small group of patients who require conversion of an attempted laparoscopic approach to an open procedure, or those who are undergoing a concurrent open abdominal procedure. Nevertheless, to successfully deal with the more complex scenarios that can arise during antireflux surgery, surgeons should be able to undertake open antireflux surgery.

Suggested Readings

Principal References

Engström C, Jamieson GG, Devitt PG, et al. Meta-analysis of two randomized controlled trials to identify long-term symptoms after division of short gastric vessels during Nissen fundoplication. *Br J Surg* 2011;98:1063–7.

Rossetti M, Hell K. Fundoplication for the treatment of gastroesophageal reflux in hiatal hernia. *World J Surg* 1977;1:439–43.

Watson DI, Jamieson GG. Antireflux surgery in the laparoscopic era (review). *Br J Surg* 1998;85:1173–84.

Additional References

de Beaux A, Watson DI, O'Boyle C, et al. Role of fundoplication in patient symptomatology after laparoscopic antireflux surgery. *Br J Surg* 2001;88:1117–21.

Engström C, Cai W, Irvine T, et al. Twenty years of experience with laparoscopic antireflux surgery. *Br J Surg* 2012;99:1415–21.

Kelly J, Watson DI, Chin K, et al. Laparoscopic Nissen fundoplication—clinical outcomes at 10 years. *J Am Coll Surg* 2007;205:570–5.

Lamb PJ, Myers JC, Jamieson GG, et al. Long-term outcomes of revisional surgery following laparoscopic fundoplication. *Br J Surg* 2009;96:391–7.

Nissen R. Eine einfache operation zur beeinflussung der refluxoesophagitis. *Schweiz Med Wochenschr* 1956; 86:590–2.

Rieger NA, Jamieson GG, Britten-Jones R, et al. Reoperation after failed antireflux surgery. *Br J Surg* 1994;81:1159–61.



EDITOR'S COMMENT

Open procedures for reflux are rarely performed today. However, Prof. Watson has provided a lovely chapter on the open repair which he probably uses for a number of the redos or corrections, which he and I discussed by e-mail. The chapter begins with a history of the Nissen type of repair and its evolution over the past 60 years. The thrust of the chapter and the manuscripts which will be quoted is that the Nissen–Rossetti-type of repair is the standard repair for reflux. It is also clear that an adequate securing of the hiatus is essential in order for there not to be recurrence, as I will point out in what follows. Not mentioned in the chapter is a new indication in addition to troublesome reflux, esophageal ulceration, and progress toward a stricture, and that is nonseasonal asthma which may in time lead to pulmonary fibrosis. Dr. Thomas DeMeester seems to be convinced that this repair is best in conversations that I have had with him about the chapter I have asked him to write in these volumes. This chapter does not deal with laparoscopic repair. Prof. Watson, however, has been quoted in the literature for his comparative studies between open and laparoscopic

approaches and is obviously comfortable with either.

Over the past 60 years, there has been a great deal of work in the evolution of this technique in which it appears that a number of controversies have been resolved, including disordered motility and its treatment including whether the hiatus is closed or not, division of the short gastrics, and reasons for recurrence. Martin Fein and Florian Seyfried (*J Gastrointest Surg* 2010;14(suppl 1):S67–S74) in an excellent paper given at the DeMeester Festschrift, "Is there a role for anything other than a Nissen's operation?," review the available comparative trials including Nissen versus Toupet (four trials) and Toupet or Nissen versus anterior fundoplication (five trials). A number of comparisons in nonrandomized and, presumably, nonconcurrent studies were also included. First, should antireflux procedures be done at all? The answer appears to be yes, as Lundell et al. (Seven-year follow-up of a randomized clinical trial comparing proton-pump inhibition with surgical therapy for reflux oesophagitis. *Br J Surg* 2007;94:198–203) and Lundell (Comparing laparoscopic antireflux surgery with esomeprazole in the management of patients with chronic gastro-oesophageal reflux disease: a 3-year interim analysis of the LOTUS trial. *Gut* 2008;57:1207–13.) conclude after 3- and 7-year follow-ups that surgical repair is at least as good as prolonged PPI inhibition. Similar results were reached by Catarci et al. (Evidence-based appraisal of antireflux fundoplication. *Ann Surg* 2004;239:325–37) and Lundell again (Therapy of gastroesophageal reflux: evidence-based approach to antireflux surgery. *Dig Dis* 2007;25:188–96). The details of the studies that are properly randomized appear in Table 1 of Fein's paper, but one can see that the numbers are quite small in each group. In comparing partial to anterior wraps, the short gastrics are divided, giving less tension to the repair and enabling a floppier Nissen with bougies as large as 60 Fr.

Booth et al. (Randomized clinical trial of laparoscopic total (Nissen) versus posterior partial (Toupet) fundoplication for gastro-oesophageal reflux disease based on preoperative oesophageal manometry. *Brit J Surg* 2008;95:57–63), Fibbe et al. (Esophageal motility in reflux disease before and after fundoplication: a prospective, randomized, clinical, and manometric study. *Gastroenterology* 2001;121:5–14), Strate et al. (Laparoscopic fundoplication: Nissen versus Toupet two-year outcome of a prospective randomized study of 200 patients regarding preoperative esophageal motility. *Surg Endosc* 2008;22:21–30), and Zornig et al. (Nissen vs Toupet laparoscopic fundoplication. *Surg Endosc* 2002;16:758–66) all compared Nissen repair versus posterior Toupet repairs. The short gastrics were divided. Watson (Prospective randomized double-blind trial between laparoscopic Nissen fundoplication and anterior partial fundoplication. *Brit J Surg* 1999;86:123–30; Multicenter, prospective, double-blind, randomized trial of laparoscopic Nissen vs anterior 90 degrees partial fundoplication. *Arch Surg* 2004;139:1160–7; Five-year follow-up of a randomized clinical trial of laparoscopic total versus anterior 180 degrees fundoplication. *Brit J Surg* 2005;92:240–3) showed that

dysphagia persists in the Nissen repairs, but recurrence is present in the anterior repairs. Similar results were reported by Lundell (Hagedorn C, Jonson C, Lonroth H, et al. Efficacy of an anterior as compared with a posterior laparoscopic partial fundoplication: results of a randomized, controlled clinical trial. *Ann Surg* 2003;238:189–96; Engstrom C, Lonroth H, Mardani J, et al. An anterior or posterior approach to partial fundoplication? Long-term results of a randomized trial. *World J Surg* 2007;31:1221–5). The same pattern of recurrence of symptoms and dysphagia in the Nissen repair and recurrence in the anterior repairs is discussed in Baigrie et al. (Randomized double-blind trial of laparoscopic Nissen fundoplication versus anterior partial fundoplication. *Brit J of Surg* 2005;92:819–23) and Spence et al. (Single center prospective randomized trial of laparoscopic Nissen versus anterior 90 degrees fundoplication. *J Gastroint Surg* 2006;10:698–705). Hagedorn et al. (*op. cit.*), after a 5-year follow-up, report that reflux is higher after anterior fundoplication (60%) versus after Nissen (24%), as measured by pH telemetry. Only a small number of patients required reoperation.

In nonrandomized trials (Table 4: Fein's review), there were higher recurrence rates for the Toupet repair than after a Nissen. But what are we actually talking about? The Nissen repair is not a Nissen repair. It may not be standardized. The hiatal opening may be repaired or it may not, and if it is repaired, how many sutures and how tight is the hiatal repair? Is a bougie used, and if so how large is it and what is the extent of the wrap?

The next controversy is the "tailored approach" which is controversial and in the opinion of many is a failure. Dysphagia, in the opinion of Strate (*op. cit.*), is the result of transhiatal migration. Herniation of the wrap appears to be the reason for a high dysphagia rate in a number of papers. In addition, a number of authors stated that trying to tailor the procedure as to whether or not there is a peristaltic disorder does not work (Fein and Seyfried, *op. cit.*), as a peristaltic disorder is not the reason not to perform a Nissen repair. According to Fibbe et al. (*op. cit.*), the principal cause of reoperation is the failure of hiatal repair.

Tatum et al. (High-resolution manometry in evaluation of factors responsible for fundoplication failure. *J Am Coll Surg* 2010;210:611–19) utilized high-resolution manometry in an effort to determine the etiology of symptoms that between 10% and 25% of patients undergoing antireflux procedures eventually redevelop. This technique allows for sensitive and reliable information about the status of the lower esophageal sphincter. Recurrent hiatal hernia or failure of the hiatal closure results in a dual high-pressure zone (HPZ). Twenty-three patients with recurrent symptoms or abnormal 24-hour pH monitoring and 11 asymptomatic post-Nissen patients were tested with this technique. In the 11 successful patients, only one (9%) had a dual HPZ, while 13 of the 23 unsuccessful patients had a dual HPZ suggesting breakdown of the hiatal repair (56%). The mean LES pressure tended to be higher in the successful group but because of small numbers, just missed the significance. If a dual HPZ equals a breakdown of the hiatal repair, this would suggest what other investigators have

stated, that recurrence of symptoms especially seem to indicate that the hiatal repair has broken down.

There has been some discussion as to whether the long-term outcomes in fundoplication are better in nonerosive esophageal disease. Broeders (Long-term outcome of Nissen fundoplication in non-erosive and erosive gastro-oesophageal reflux disease. *Brit J Surg* 2010;97:845–52) showed a similar fall in PPI use (82% dropping to 21% in the nonerosive group and 81% decreasing to 15% in the erosive group, both $P < 0.0001$). Total 87% of patients with erosive gastrointestinal reflux disease healed their erosions.

Finally, Tsuboi et al. (*Surg Endosc*, published online 2010) attempted to show that good training results in better outcomes even after a short period of experience. However, the follow-up was only for 1 year, thereby invalidating their conclusions as most good papers in this area have evaluated their patients after 5 or, perhaps, as long as 7 years but at least a minimum of 3 years. The conclusions of this paper have not been proved because of the short follow-up.

J.E.F.

73 Modified Hill Repair for Gastroesophageal Reflux

Donald E. Low and Mustapha El-Lakis

Gastroesophageal reflux disease (GERD) is the most common gastrointestinal problem in humans. Currently, 20% of the US population experience heartburn at least once per week. In addition, more money is spent on heartburn medication than any other drug class other than the cholesterol-lowering agents. The goal of antireflux surgery is to control the symptoms and the secondary complications of reflux. Of the four most popular antireflux operations (Nissen fundoplication, Belsey Mark IV, Toupet, and Hill procedures), the Hill procedure is the only operation that originated in the United States. Unlike the more common Nissen fundoplication, the Hill repair has undergone very little modification since its inception at the Virginia Mason Medical Center in Seattle by Dr. Lucius Hill in 1959. The unique feature of the Hill repair is the fact that the operation is based on reestablishing normal anatomy and the normal barriers to gastroesophageal (GE) reflux. These normal anatomic barriers include the presence of a segment of intra-abdominal esophagus, the GE flap valve apparatus, and a competent lower esophageal sphincter.

The least understood of these natural antireflux mechanisms and the one most amenable to surgical restoration is the GE flap valve (Fig. 73.1). All three of the standard operations restore this anatomic structure; however, the Hill operation does so by restoring the normal posterior attachments and tightening the collar-sling musculature, thereby reestablishing the acute angle of His between the esophagus and stomach. Alternatively, the Nissen and Belsey operations restore the valve by horizontal or vertical fundoplications, which rely on more tenuous sutures between the fundus and the esophagus to stabilize the repair (Fig. 73.2).

In our institution, healthy volunteers and those with documented GERD were examined with retroflexed inspection of the GE junction at the time of upper endoscopy. A grading system for the GE valve was established from these findings (see Fig. 73.3). This grading system has been shown to be highly accurate when used in preoperative assessment of the patients

with GERD. It has also led to a greater understanding of esophageal anatomy as reflected by a cited alteration to the description of the GE junction in *Gray's Anatomy* (see Fig. 73.1).

The Hill repair is a transabdominal repair and is the only repair that firmly anchors the GE junction in the abdomen to the strong crural musculature and underlying preaortic fascia. Originally, Dr. Hill recommended the placement of anchoring sutures through the median arcuate ligament. This aspect of the repair, which involves dissection and suture placement to the median arcuate ligament fascia, with its close proximity to the celiac axis, has intimidated surgeons who are not familiar with this anatomy and may explain why this operation has not been as widely accepted as the Nissen fundoplication. The median arcuate ligament is formed by the condensation of the preaortic fascia and is located on the anterior surface of the aorta just superior to the celiac axis. We have advocated an approach using the more easily accessible crural musculature with retrocrural preaortic fascia as the anchor for the repair. This is an important adaptation to the original description of the Hill repair as it simplifies the repair sutures, as many surgeons were not willing to consider the increased difficulty and risk involved with dissecting out the celiac axis and median arcuate ligament.

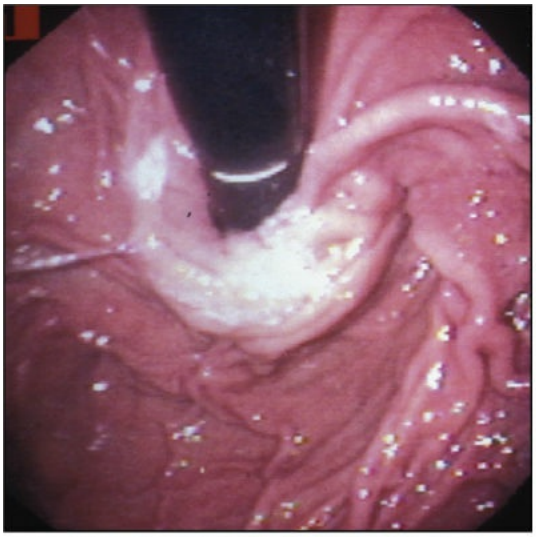

Endoscopic view of the cardiac orifice from below, showing the valve-like fold illustrated.

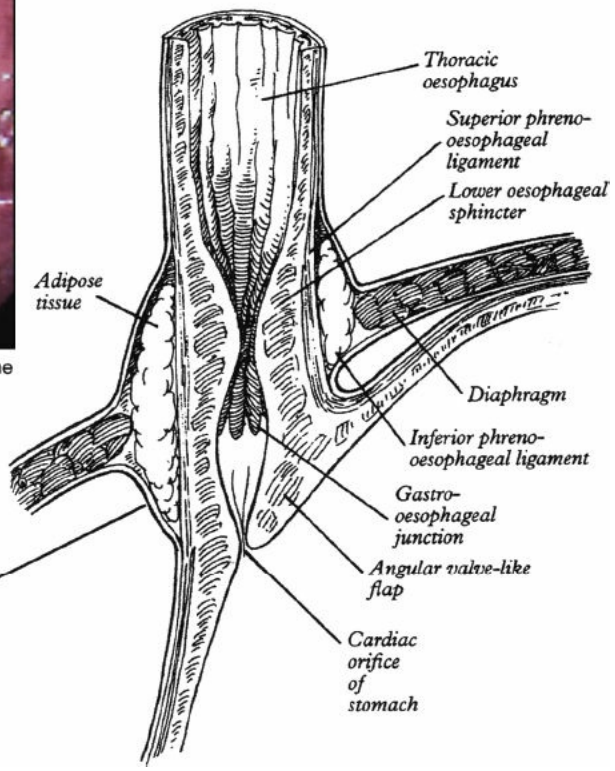

Diagram showing the valve-like structure formed by the cardiac angle wall at the cardiac orifice.

Figure 73.1. The gastroesophageal flap valve is a musculomucosal valve created by the angle of His. The valve is an important adjunct to the sphincter in preventing reflux. The valve closes against the lesser curve with increased intragastric pressure, which produces a functional barrier against reflux. (Published in Bannister LH. Stomach. In: Bannister LH, Berry MM, Collins P, et al., eds. *Gray's Anatomy*, 38th ed. New York: Churchill Livingstone; 1995:1757. Copyright Elsevier.)

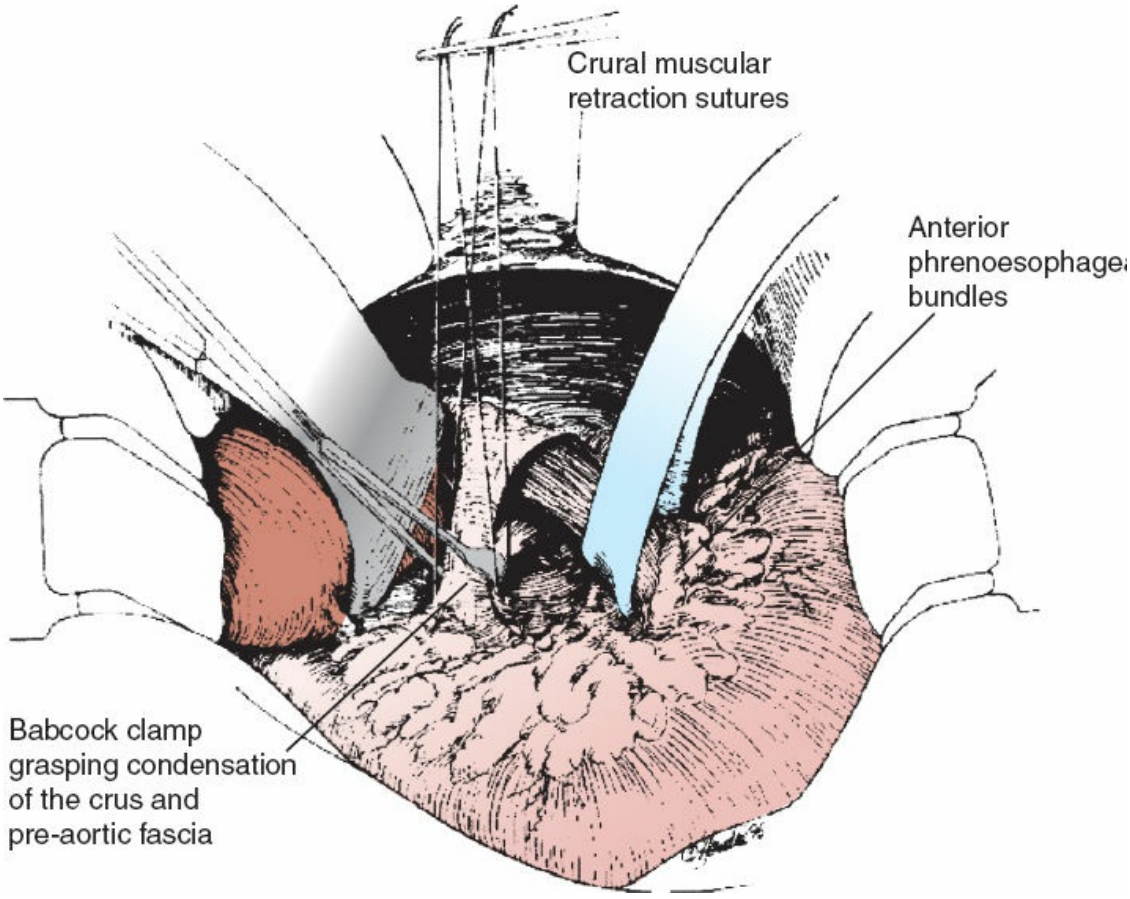

Figure 73.2. BABCOCK clamp shown grasping the right and left crural muscles and the preaortic fascia. Two heavy sutures have been placed above and below the clamp through the crural fibers and preaortic fascia to facilitate retraction away from the aorta to allow the placement of the anchoring sutures.

The Nissen fundoplication was the first antireflux procedure described in 1956. It was then modified by Toupet, Dor, Gaurner, and Rossetti with the premise of reducing various complications such as dysphagia, gas bloat. Previous reports have suggested a higher incidence of dysphagia (26%), gas bloat (25% to 38%), and recurrent GERD after the Nissen repair. These concerns have often been associated with slipped repairs or recurrent hiatal hernia resulting from the lack of a strong posterior fixation of the GE junction. With the Hill procedure, any tendency of the repair to be pulled up into the chest is significantly reduced because of the dependable fixation of the GE junction within the abdominal cavity. This posterior fixation is particularly important in patients with Barrett esophagus, chronic esophagitis, esophageal stricture, and paraesophageal hernia, which has been associated with shortening of the esophagus. Many surgeons advocate the Collis modifications of the standard Belsey and

Nissen operations to avoid recurrent hiatal hernia when esophageal shortening is suspected preoperatively or discovered intraoperatively.

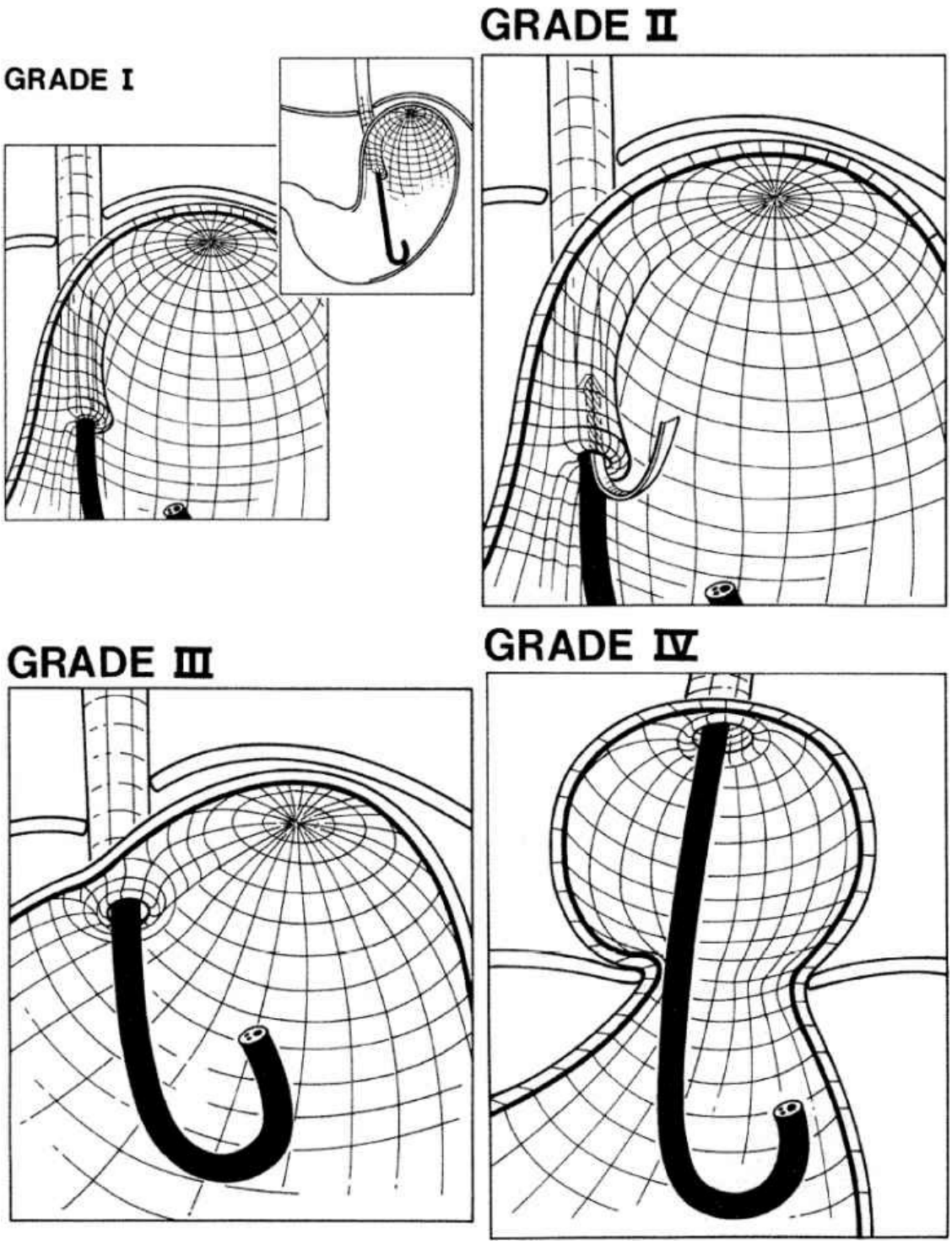

Figure 73.3. The four grades of the gastroesophageal valve. A Grade I valve is a normal musculomucosal valve that stays adherent to the endoscope through all phases of respiration, opens only for swallowing and belching, and closes promptly after opening. A Grade II valve is slightly less defined and shorter than the Grade I, opens with swallowing and belching, closes promptly, and does not allow reflux. The Grade III valve is poorly defined, opens frequently without the stimulus of swallowing or belching, stays open, allows reflux, and is often associated with a

hiatal hernia. The Grade IV valve shows no definition to the musculomucosal fold, stays open constantly, and is associated with a hiatal hernia.

In our experience, adequate length of intra-abdominal esophagus can virtually always be obtained and maintained without the need for any esophageal lengthening techniques by appropriate extensive mobilization of the esophagus from the abdomen (see Fig. 73.5) and use of the firmly anchored Hill operation. This issue strongly suggests that the Hill repair has significant advantages over the other repairs, particularly when dealing with short esophagus and paraesophageal hernias.

We continue to advocate the routine use of intraoperative manometry to control the degree of plication at the level of the GE junction to minimize the incidence of postoperative dysphagia and to eliminate the need for inserting a bougie when constructing the repair. The routine application of intraoperative manometry allows modification of the repair (see Surgical Technique) to obtain lower esophageal sphincter pressures between 25 and 55 mm Hg. These intraoperative pressures have been shown to translate postoperatively to pressures in the normal range, between 15 and 30 mm Hg.

INDICATIONS AND PREOPERATIVE PLANNING

Appropriate patient selection is essential to help ensure good outcomes, including improvement in quality of life. The majority of operative candidates should have typical symptoms that are chronic and refractory to standard medical therapy. With the increasing application of the laparoscopic approach to the treatment of GERD, an ever-increasing temptation is to offer surgical treatment to the patients who are asymptomatic but require regular or high-dose medications. This can be acceptable, especially in young patients who wish to avoid lifetime dependence on medications. If a good outcome is to be achieved in these asymptomatic patients, however, attention to patient selection and operative approach must be particularly meticulous.

All patients being considered for antireflux surgery should undergo preoperative endoscopy and manometry to document the presence of Barrett esophagus, esophageal cancer, or significant motility disorder. Manometry occasionally provides alternative diagnosis, such as scleroderma or achalasia, for which antireflux surgery may be

contraindicated or it may lead to modification of the surgical approach. High-resolution manometry allows the evaluation of esophageal motility by drawing esophageal pressure topography (EPT) to categorize patients according to the Chicago Classification. Impedance combined with manometry or to pH testing can identify whether motility defects and reflux are contributing to patient's symptoms. Abnormal levels of acid reflux documented by standard pH devices especially when correlated with patient symptoms are considered important for predicting operative success. False negative results in standard pH tests can occur in 30% of the cases. Impedance testing can differentiate between acidic and nonacidic reflux that can provide additional data when standard pH studies are normal. Our practice includes routine endoscopy, high-resolution manometry, and 24-hour pH studies in the majority (>90%) of patients to confirm the diagnosis by verifying an abnormal level of GE reflux and, more important, to demonstrate a high level of correlation between symptoms and reflux episodes.

OPEN HILL OPERATION: SURGICAL TECHNIQUE

The operation is performed with the use of both general and epidural anesthesia whenever possible. The epidural is continued postoperatively in a patient-controlled mode, which has greatly facilitated early patient mobilization and discharge. The patient is positioned supine with the right arm tucked and left arm abducted at 90 degrees. A limited upper abdominal midline incision is made from the xiphisternum to 4 to 6 cm above the umbilicus, with the xiphoid process excised if necessary. The "upper hand" retractor system (V. Mueller, Allegiance, and Deerfield, IL) is used throughout the procedure and utilizes two right-angled retractor blades suspended from a transverse bar positioned 3 to 4 cm above the patient's chest. The blades of the retractor are placed under the right and left costal margins, which are retracted superiorly and laterally. This retraction results in a verticalization of the diaphragm, which allows the operating team to work straight down on the GE junction rather than struggling under the diaphragm. The lower aspect of the incision is held open with a Balfour retractor (Fig. 73.4). The left lateral segment of the liver is then mobilized from the diaphragm, with the triangular ligament taken down and the inferior phrenic vein carefully avoided. The gastrohepatic ligament including the hepatic branches of the vagus nerves is incised. This allows retraction of the caudate lobe and the lateral

segment of the left lobe of the liver to the right using a deep Harrington retractor (see Fig. 73.4). The dissection then proceeds over the anterior aspect of the esophageal hiatus. Any hiatal hernia is reduced and the peritoneal reflection is incised to identify the anterior surface of the esophagus. Gentle finger dissection along the right and left crux of the diaphragm facilitates delineation of the esophagus, which is manually encircled; the posterior vagus nerve is kept closely applied to the esophagus. This dissection should be easy to perform in a virtually bloodless plane when done correctly. A 1-in. Penrose drain is then passed around the esophagus and both vagus nerves to facilitate retraction through the remainder of the mobilization of the esophagogastric (EG) junction. Dissection proceeds inferiorly along the medial aspect of the right crus to the point where it converges with the left crus. The esophagus is gently retracted anteriorly and to the patient's left, and the lower aspect of the left crus is mobilized. The peritoneal coverings of the left and right crus should be preserved. The fundus is completely mobilized from the EG junction to the level of the first short gastric vessel. A significant advantage of the Hill operation over the classic Nissen fundoplication is that there is no need to take down the short gastric vessels. If any indication is identified of esophageal shortening at this point, the distal esophagus can be mobilized for a variable distance to facilitate complete reduction of the EG junction into the abdomen. The mobilization can involve up to 10 to 12 cm of distal esophagus and is best accomplished while retracting the crus with BABCOCK clamps to improve visualization (Fig. 73.5).

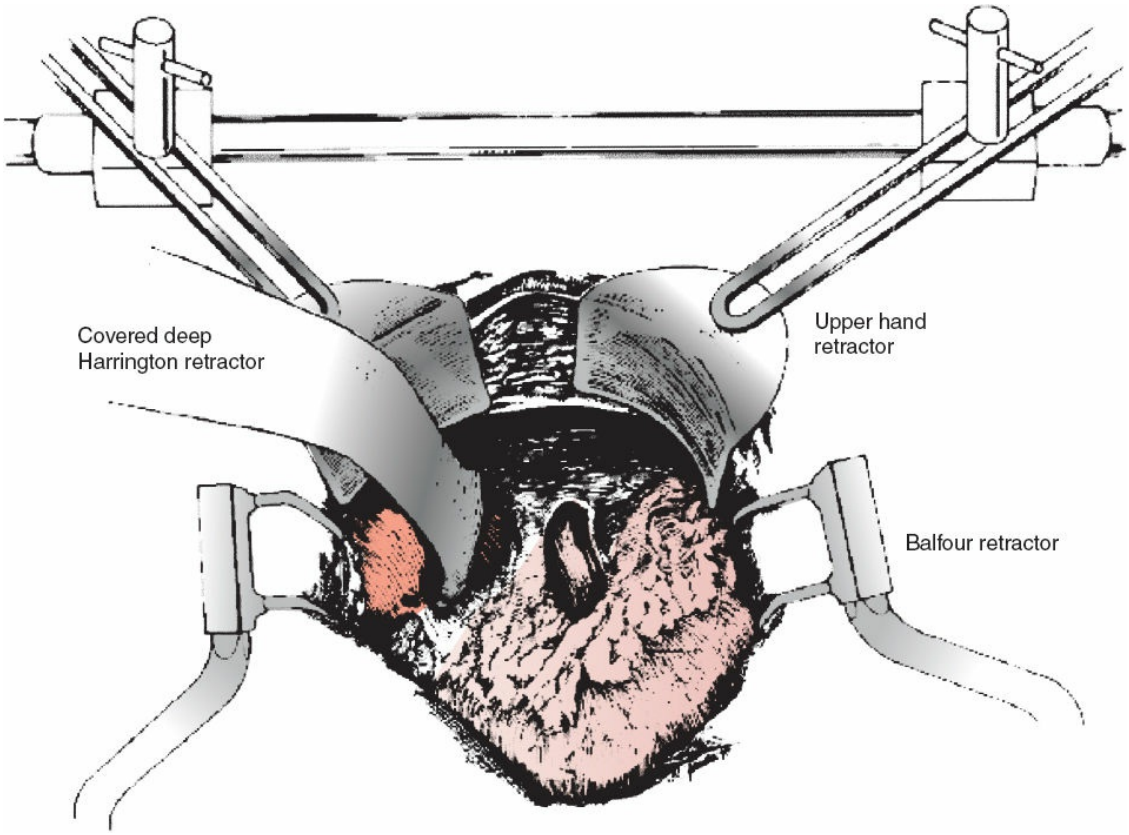

Figure 73.4. The retraction apparatus used to provide exposure of the esophageal hiatus. The setup facilitates the "verticalization" of the diaphragm, so the surgical team can look straight down to the operative field.

If the esophagus is mobilized as described along its normal anatomic planes, both the anterior and posterior phrenoesophageal bundles will be intact and easily visible at the level of the EG junction. The Hill repair uses these strong tissue bundles to recreate the angle of His and reestablish the esophageal flap valve apparatus while anchoring the repair in the abdomen. The phrenoesophageal bundles are composed of fibrofatty tissue and vary significantly in size and bulk according to the patient's body habitus. They form the natural attachments of the EG junction to the diaphragm (see Fig. 73.2).

The upper edge of the preaortic fascia is identified by passing a finger between the right and left crus down to the surface of the aorta. Usually a layer of areolar tissue is present anterior to the aortic fascia; generally, this can be entered bluntly and the surgeon's finger passed underneath the fascia. The preaortic fascia can then be lifted anteriorly along with the junction of the right and left crus of the diaphragm and grasped with a BABCOCK clamp (see Fig. 73.2). In some older individuals or patients

with very large hiatal hernias, the preaortic fascia is not obvious; in these instances, or when the crural musculature is strong and will provide an adequate anchoring point, only the confluence of the right and left crus should be grasped with the BABCOCK. Two No. 1 silk sutures are then placed through the grasped tissue ~1 cm apart at the level of the confluence of the crura to act as stay sutures. These sutures are used to elevate the crural musculature away from the aorta when placing the repair sutures and are used only for retraction purposes (see Fig. 73.2). The esophageal hiatus is then closed, which usually requires one to three figure-of-eight 0 silk sutures with Teflon felt pledgets (Deknatel Division, Fall River, MA). This closure is continued to a point where the tip of a finger can still be easily inserted along the esophagus and through the hiatus. Too tight a closure leads to postoperative dysphagia, which does not respond to dilation (Fig. 73.6). Large hiatal hernias can lead to the esophageal hiatus becoming largely dilated. In these circumstances, utilizing only posterior hiatal closure sutures can distort the path of the esophagus too far anteriorly. Alternatively hiatal closure sutures can also be placed at 10:00 and 2:00 o'clock to decrease the potential for distortion and postoperative dysphagia (Fig. 73.7).

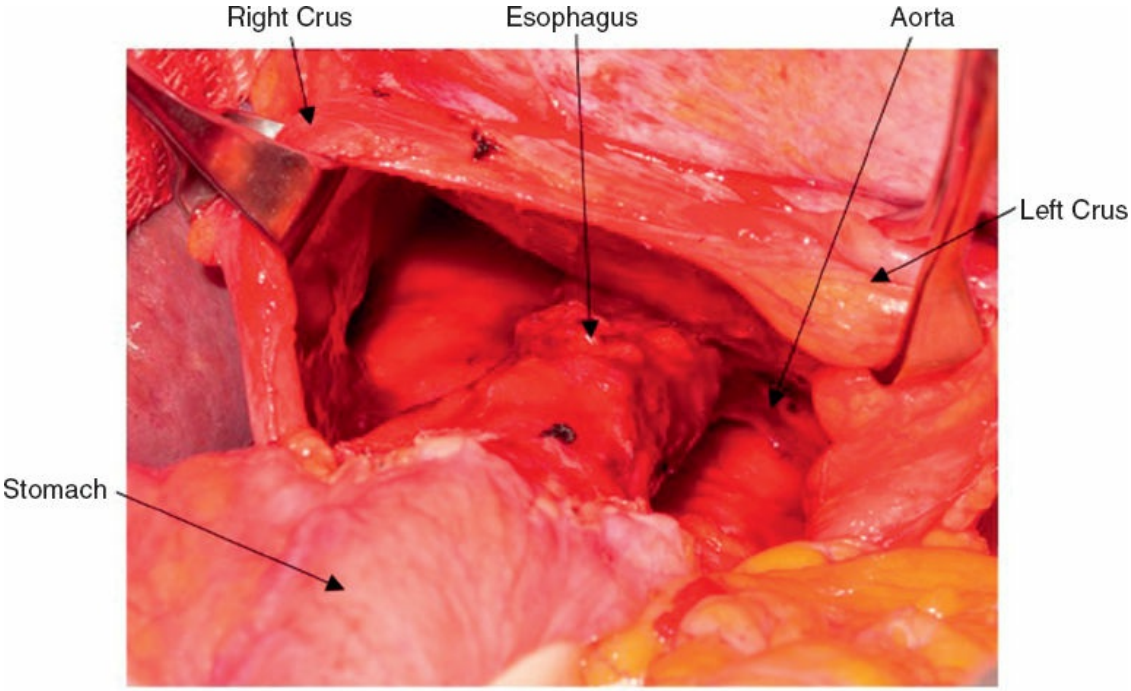

Figure 73.5. The esophagus completely mobilized and dissected circumferentially. The right and left crus are grasped with BABCOCK clamps and retracted, which allows esophageal mobilization high into the mediastinum.

The repair is initiated by grasping the anterior and posterior phrenoesophageal bundles with BABCOCK clamps. The anterior bundle is grasped lateral to the anterior vagus nerve at the base of the angle of His just distal to the esophagofundic junction (Fig. 73.8). The posterior bundle is identified by rotating the posterior fundus to the patient's right behind the EG junction where it can be grasped with a BABCOCK clamp just beside the posterior vagus nerve. The repair is done with five 0 silk sutures. The first is placed laterally on the anterior phrenoesophageal bundle, including a component of the underlying gastric serosa. The same suture is then passed through the superior aspect of the posterior bundle and then down through the crus and preaortic fascia, which is retracted anteriorly using the previously placed stay sutures. The next four sutures are placed in a similar fashion, with each stitch taken more medial on the anterior bundle and more inferior on the posterior bundle and also passed through the crural fibers and preaortic fascia (Fig. 73.9). The position of the anterior and posterior vagus nerves should be noted during the placement of each repair stitch. The first three sutures are placed with Teflon pledgets.

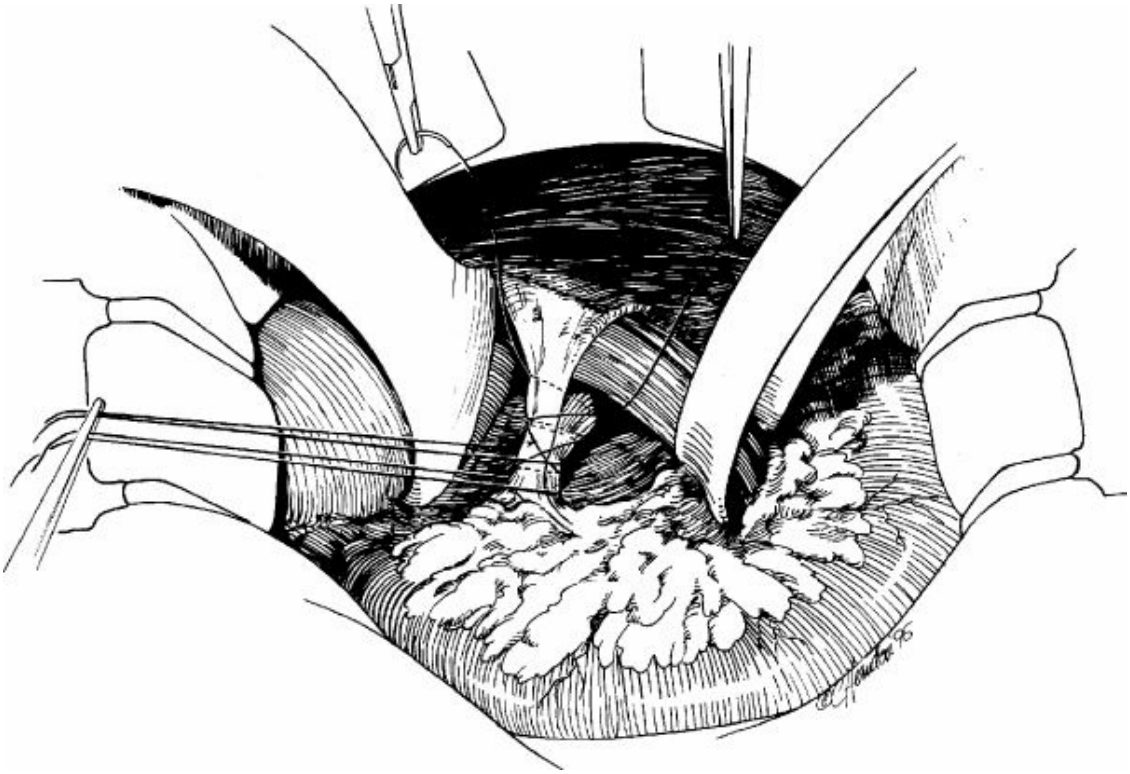

Figure 73.6. Left and right crura are closed with interrupted figure-of-eight silk sutures.

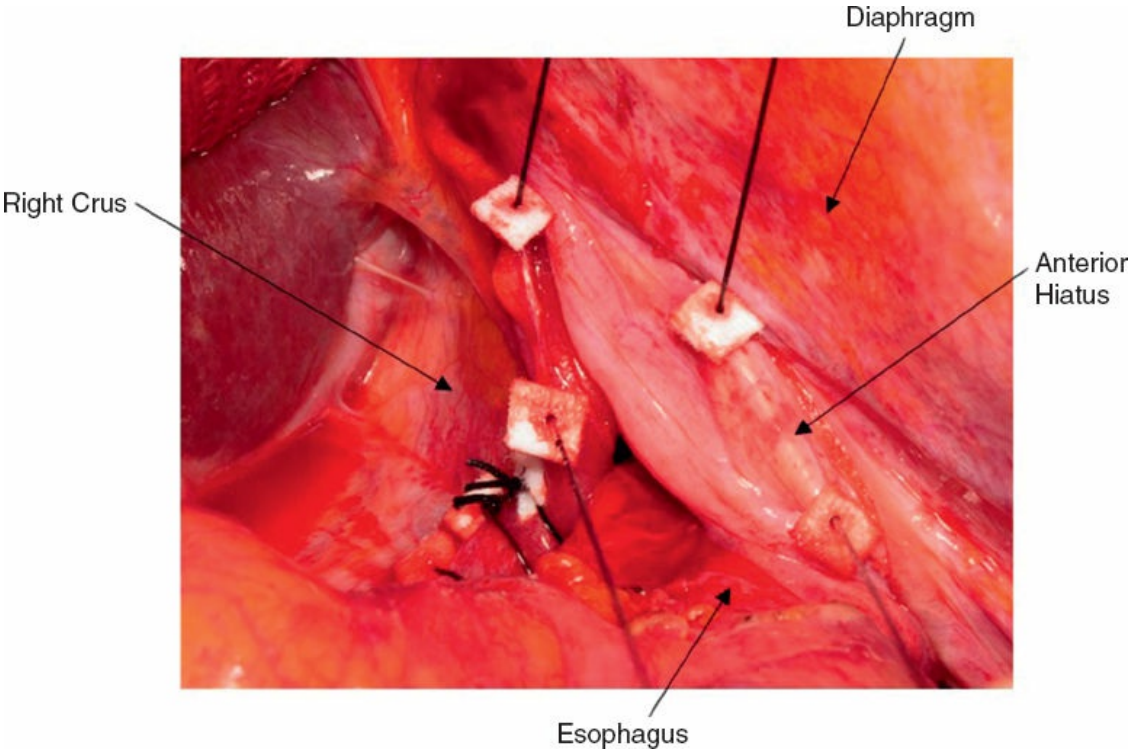

Figure 73.7. 10 o'clock sutures placed in addition to posterior hiatal closure sutures to accomplish hiatal closure around the esophagus and to minimize its anterior displacement.

Once these repair sutures are placed, the first two are tied down to the crural musculature with a single knot and clamped. These two initial sutures are the key aspect of the repair. This deepens the angle of His and produces an easily palpable GE flap valve (Fig. 73.10). The valve is best appreciated by palpation at the level of the EG junction. The valve can be easily assessed at the point where it encircles the nasogastric tube (Fig. 73.11). With the first two sutures tied down and clamped, intraoperative manometric testing is carried out to allow a preliminary assessment of the repair. We use a standard four-channel manometric tube (Medtronic, Skovlunde, Denmark) with manometric side ports located 5 cm apart from the tip of the catheter; this tube can be hooked up to a standard manometric machine or an arterial line transducer. Several sequential manometric pull-throughs of the GE junction are done. Intraoperative pressures ranging between 25 and 55 mm Hg translate into normal postoperative lower esophageal sphincter pressures and reduce the incidence of postoperative dysphagia. The lower esophageal sphincter pressure can be assessed precisely and tension adjusted intraoperatively by tightening or loosening the first two sutures. After the measurements are completed, the first two sutures are tied down permanently and the remaining three sutures are tied.

The two crural retraction sutures are removed. Final manometric pull-through measurements are then obtained. The repair is completed by the placement of the two interrupted 3-0 silk sutures placed on the left lateral and anterior aspects of the EG junction from the fundus to the esophageal muscle and then to the rim of the esophageal hiatus. These sutures help to further close the hiatus and accentuate the GE flap valve apparatus (Figs. 73.10 and 73.12). The nasogastric tube is positioned in the stomach and the abdomen is closed. The EG junction is now fixed posteriorly and can resume normal motility and clearance.

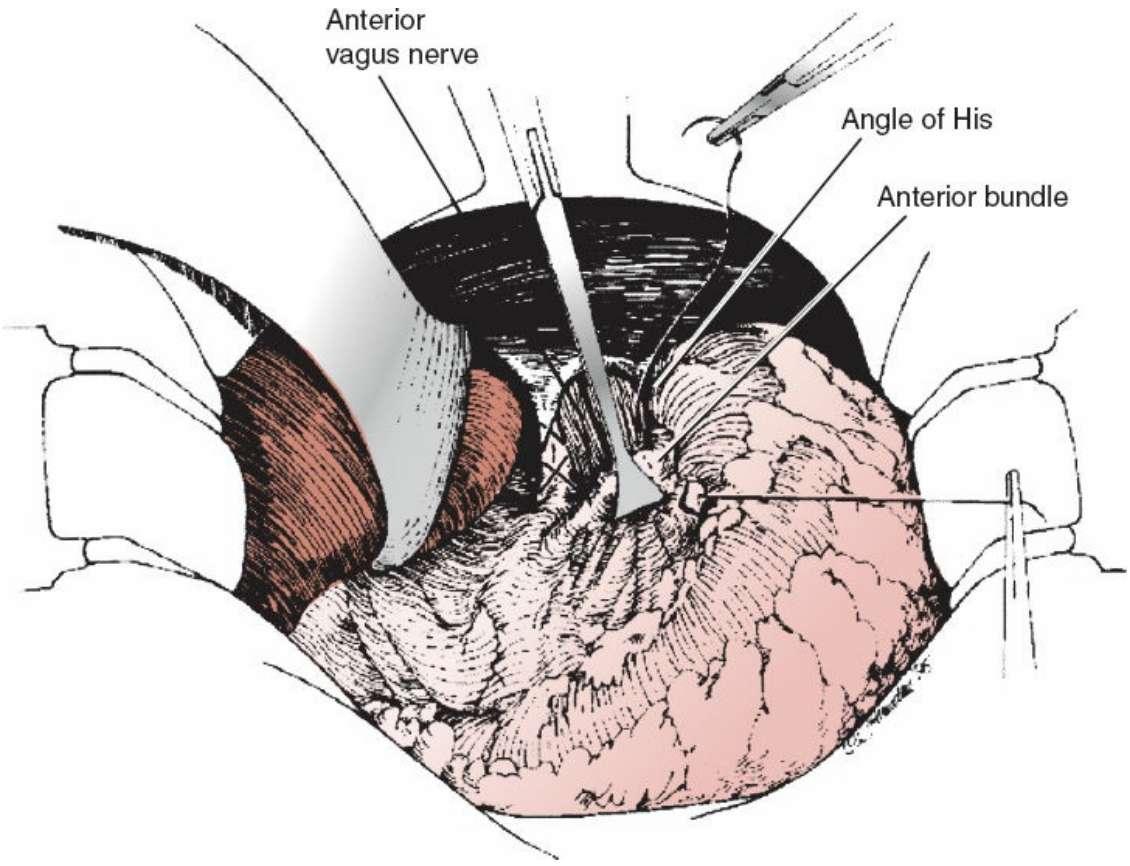

Figure 73.8. BABCOCK clamp shown grasping the anterior phrenoesophageal bundle. The first of five sutures is shown passing through the bundle and its underlying serosa. Notice that this stitch is placed lateral to the anterior vagus nerve, which is visualized as each suture is inserted.

RESULTS

Multiple published reports document the efficacy of the Hill repair for controlling primary reflux, as well as its effectiveness in the patients with reflux-associated esophageal stricture and recurrent reflux and failed

previous repairs and paraesophageal hernias.

The longest follow-up study examining the outcome of antireflux surgery was for the patients undergoing the Hill repair and was published in 1988. This review reported on the long-term results (15 to 29 years) in 167 patients after the Hill repair. The review found that 88% of the patients were still completely satisfied with their results at a mean follow-up of 17.8 years.

More recently, there has been a comprehensive review of the subjective and objective outcomes of the open Hill operation in the patients with giant paraesophageal hernias. This paper involved 72 consecutive patients with a mean age of 69 years, and all of whom presented with paraesophageal hernias involving at least 50% of the stomach. The operative approach was standardized to include sac excision and primary closure of the esophageal hiatus in 97% of the patients. The standard Hill procedure was used in 96%, and no patients underwent a Collis gastroplasty. In spite of being an open operation in elderly patients, the median postoperative hospital stay was 4.5 days and there was no mortality in the series. Follow-up included subjective and objective assessment, which demonstrated statistically significant improvement in both heartburn and dysphagia scores and overall improvement in quality of life. Objective follow-up carried out at a mean of 30 months demonstrated recurrent hernias in 18%, most of which were small, sliding hiatal hernias and none of which required revision on the basis of hernia recurrence or new or recurrent symptoms. This study highlights the efficacy and safety of the Hill repair in a complex operative population and also provides what is often missing from other postoperative assessments, specifically objective assessment of technical as well as symptomatic results.

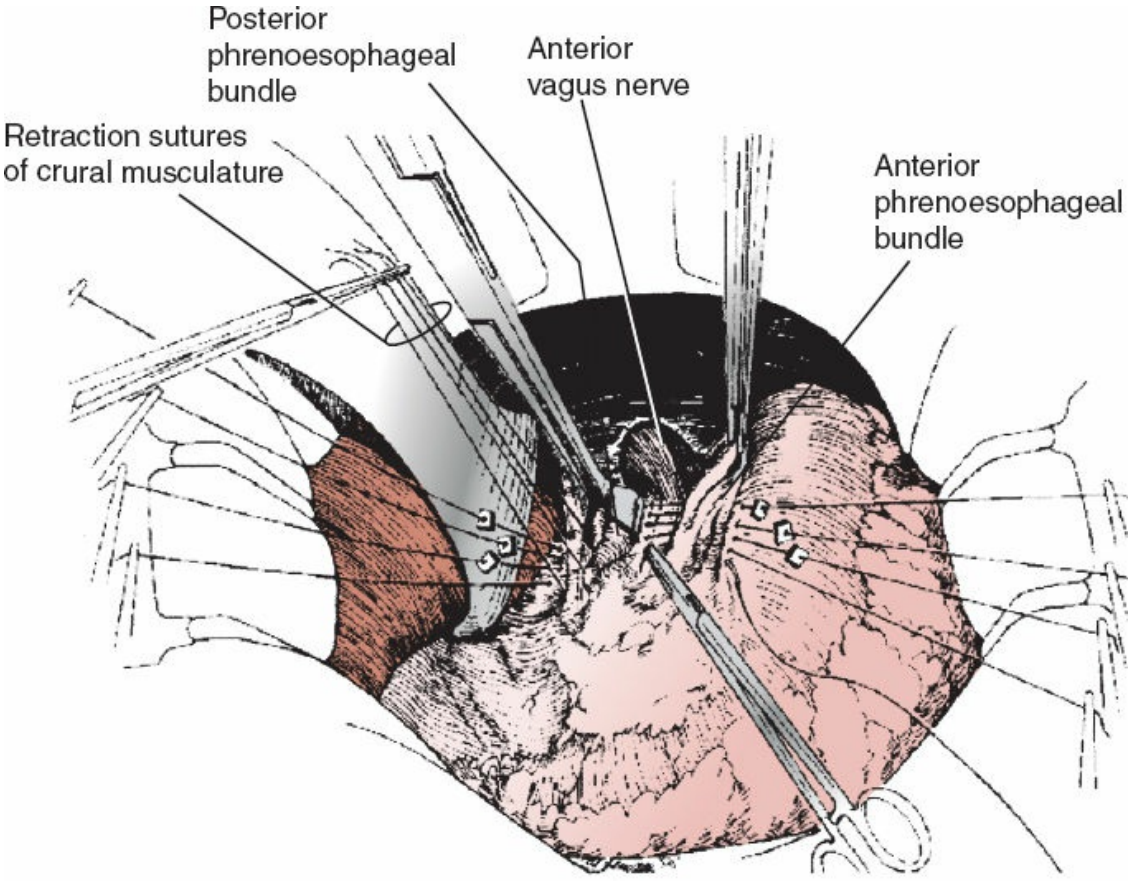

Figure 73.9. The nearly completed repair. All five sutures are demonstrated through the anterior bundle, which is held by the forceps. The posterior bundle is being rotated and held by the BABCOCK. The stitches in the posterior bundle are inserted just posterior to the directly visualized posterior vagus nerve. The sutures are also passed through the crural muscles and preaortic fascia (instead of the median arcuate ligament), which is retracted away from the aorta with the stay sutures (held in the hemostat).

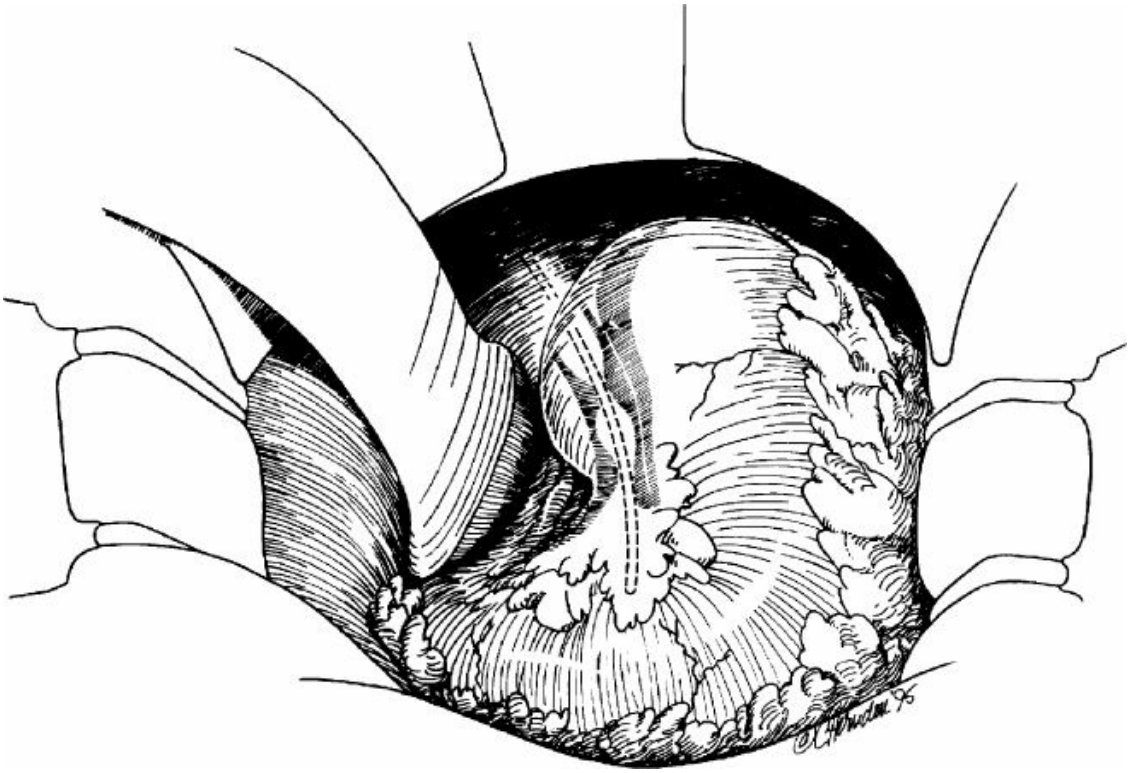

Figure 73.10. Relationship of the completed repair and how it deepens the angle of His and produces a very pronounced flap valve (shown highlighted through the anterior gastric wall), which is the major mechanism for controlling reflux postoperatively.

LAPAROSCOPIC HILL OPERATION: SURGICAL TECHNIQUE

The Hill operation has also seen successful application using the laparoscopic approach. Initially, it was felt that morbid obesity, failed previous antireflux operations, and previous extensive upper abdominal surgery were contraindications; however, additional experience has shown that even these patients can selectively undergo a successful laparoscopic Hill operation.

The tenets of the workup and patient preparation remain the same as the open operation. The repair remains based on secure posterior fixation of the GE junction, tightening of the collar sling musculature, and accentuation of the GE valve. This achieves the combined goals of deepening the angle of His, thereby recreating the GE valve and augmenting the lower esophageal sphincter.

Technical differences include the fact that three tacking sutures are placed between the posterior wall of the gastric fundus and the left side of the crural musculature to align the posterior phrenoesophageal bundle and

facilitate the placement of the actual repair sutures (Fig. 73.13). In addition, the anterior and posterior phrenoesophageal bundles are not grasped with instruments as in the open repair but sewn freehand under direct vision (see Fig. 73.13). Four, rather than five, sutures are utilized and the sutures are inserted bottom to top in the crura and posterior bundle, and right to left in the anterior bundle, which is also different than the open repair. The anchoring sutures are placed in the condensation of the crural musculature and the preaortic fascia, but, without the benefit of the retraction sutures utilized in the open repair, a laparoscopic BABCOCK is often valuable to intermittently grasp the anchoring tissue to avoid injuring the underlying aorta.

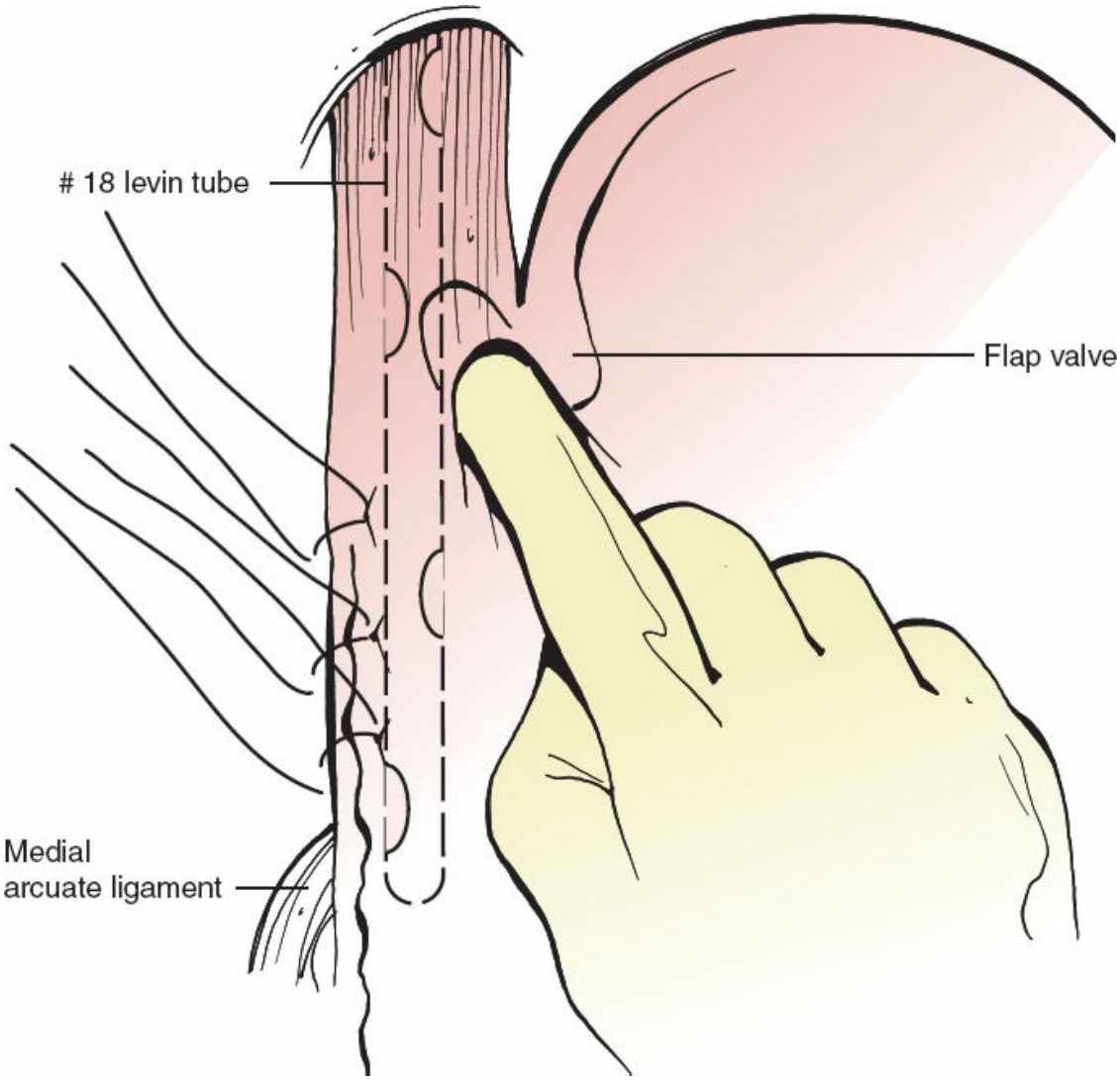

Figure. 73.11. Intraoperative assessment of the flap valve by palpating through the anterior wall of the stomach along the indwelling nasogastric tube.

Because of the fact that the construction of the GE flap valve cannot be manually assessed during its construction as in the open repair (see Fig. 73.11), the laparoscopic operation is typically done under endoscopic guidance that can visually assess the flap valve and facilitate the placement of a wire for the intraoperative insertion of a 42-Fr bougie over which the repair is classically done. Alternatively, a lighted bougie can be used.

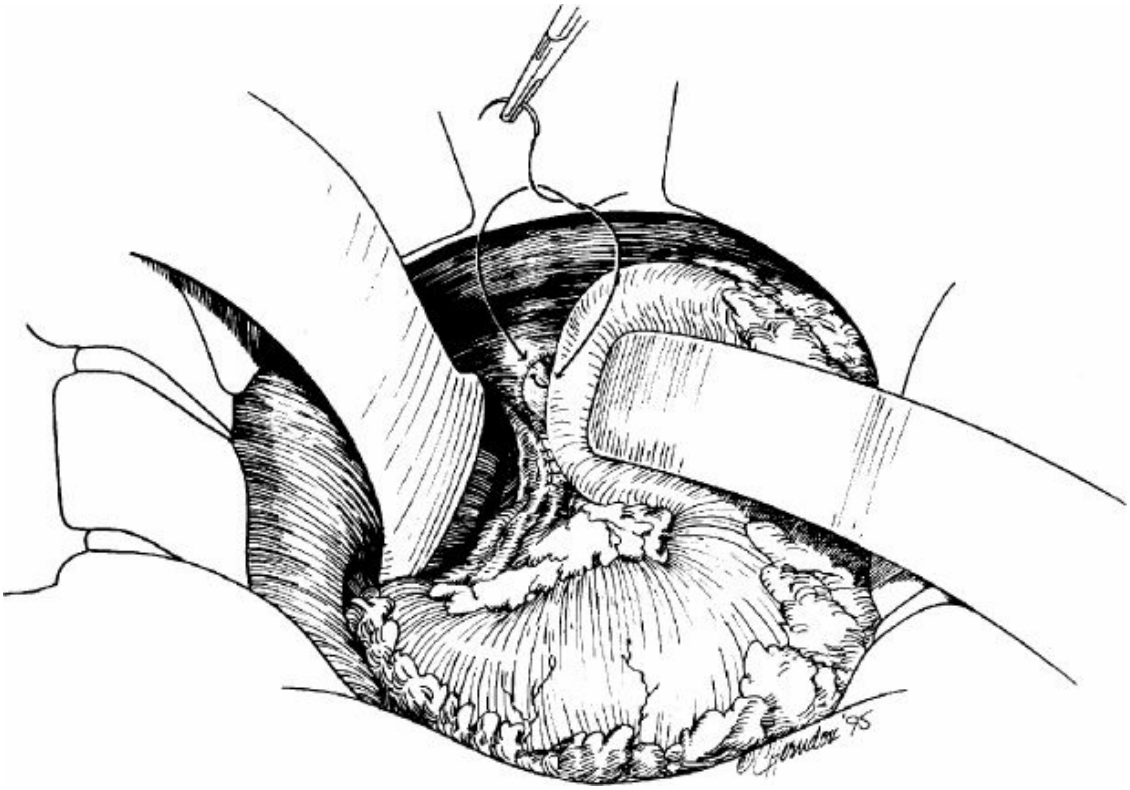

Figure 73.12. View of one of the two sutures that is inserted to seal off the anterior hiatus and maximally accentuate the depth of the angle of His and the flap valve. The suture passes from the anterior aspect of the fundus down to the wall of the esophagus and out through the anterior rim of the hiatus.

The last two sutures are temporarily tied and clamped, standard manometric pressures are taken. The pressures targeted in the laparoscopic repair are different than in the open operation with readings of 20 to 45 mm Hg being preferred. With appropriate measurements being obtained with the initial two sutures, all four repair sutures are permanently tied with final assessments of the valve being done endoscopically and final manometric pressures being obtained.

DISCUSSION

We have found the Hill repair to be a highly efficacious and safe operation. It is an excellent option for operable primary reflux, but it is particularly effective and is likely the best approach to recurrent and complicated reflux problems, especially those involving giant paraesophageal hernias, short esophagus, and in the patients with previous gastric resections. The Hill repair is predicated on restoring the normal anatomy of the GE junction. This is a firmly anchored repair that results in the fixation of the GE junction in its normal intra-abdominal location. By reestablishing the acute angle of His between the esophagus and the stomach, the Hill repair secures the intra-abdominal esophagus and accentuates the flap valve. The grading system for this flap valve has been shown to be highly accurate in assessment of patients with GERD (see Fig. 73.3). The flap valve produced by the Hill repair is the major mechanism of controlling reflux postoperatively and is becoming increasingly well documented and understood, as shown by its current recognition in *Gray's Anatomy*.

We have made minor technical changes from the original description of the Hill repair. The anchoring of the repair to the confluence of the diaphragmatic crus and the preaortic fascia rather than the median arcuate ligament should make the procedure easier to learn and apply in a variety of clinical situations. The results obtained with the Hill repair are durable, with effective long-term symptom control being documented extending over 15 to 20 years following surgery.

A randomized multi-institution comparison of the laparoscopic Nissen fundoplication (LNF) versus laparoscopic Hill repairs (LHR) has been conducted comparing 56 and 46 patients respectively with a 12-month follow-up. Quality-of-life scores improved significantly for both repairs. Dysphagia scores were equivalent postoperatively. Although the mechanism of repair was different, there was no difference in subjective and objective outcomes.

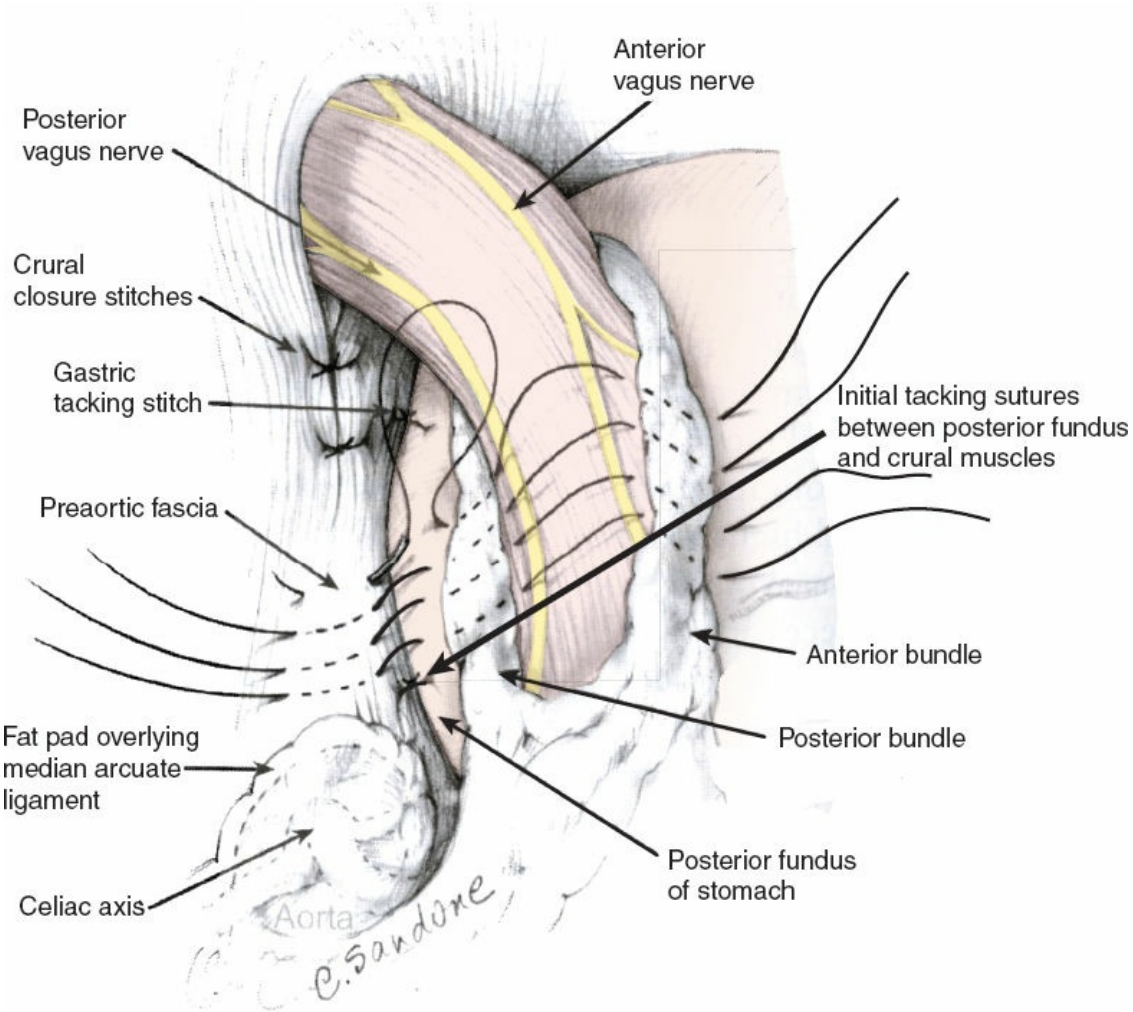

Figure 73.13. Overview of the laparoscopic Hill repair sutures. The critical component of the Hill repair is the recreation of the gastroesophageal valve by fixing the anterior and posterior phrenoesophageal bundles to the preaortic fascia. Crural closure sutures in this illustration have been placed. A tacking suture has also been placed to bring the posterior aspect of the fundus to the left portion of the preaortic fascia, thus aligning the tissues to facilitate the repair. (Adapted from Yang SC, Cameron DE. *Current Therapy in Thoracic and Cardiovascular Surgery*. 1st ed. St. Louis, MO: Mosby; 2004. Copyright © 2004 Elsevier, with permission.)

Based on the fact that LNF and LHR have different mechanisms and in an attempt to mitigate the individual weakness of LNF and LHR, a pilot study was published in 2013 describing a hybrid technique of laparoscopic Nissen-Hill antireflux procedure for patients with paraesophageal hernia and Barrett esophagus. They reestablished the angle of His by two Hill sutures and then constructed the routine Nissen procedure. A total of 24

patients with symptomatic giant paraesophageal hernias and/or GERD with nondysplastic Barrett metaplasia were included with a median follow-up of 13 months. The results showed improvement in DeMeester scores, quality-of-life metrics, and in mean long-term dysphagia severity score index. There was also an increase in the mean lower esophageal sphincter pressures. This study illustrated the feasibility and safety of combining the best qualities of two technically different antireflux procedures.

A prospective trial conducted in 2015 evaluated the safety and clinical efficacy of the hybrid procedure. Fifty patients with symptomatic paraesophageal hernia and/or nondysplastic BE underwent the laparoscopic Nissen-Hill procedure with a follow-up period of 13 months. Mean DeMeester scores improved. Preoperative symptoms were controlled in 90% with only 6% needing resumption of antisecretory medication. All quality-of-life metrics improved significantly. This study established the safety and technical feasibility of the hybrid procedure in groups at higher risk of recurrence.

Suggested Readings

Aye RW, Mazza DE, Hill LD. Laparoscopic Hill repair in patients with abnormal motility. *Am J Surg* 1997; 173:379.

Bannister LH. Stomach. In: Williams P, Bannister LH, Berry MM, et al., eds. *Gray's Anatomy,* 38th ed. New York: Churchill Livingstone; 1995:1757.

Contractor QQ, Akhtar SS, Contractor TQ. Endoscopic esophagitis and gastroesophageal flap valve. *J Clin Gastroenterol* 1999;28:233.

Hill LD, Kozarek RA. The gastroesophageal flap valve. *J Clin Gastroenterol* 1999;28:194.

Hill LD, Kozarek RA, Kraemer SJ, et al. The gastroesophageal flap valve: in vitro and in vivo observations. *Gastrointest Endosc* 1996;44:541.

Low DE. Management of the problem patient after antireflux surgery. *Gastroenterol Clin N Am* 1994; 23:371.

Low DE. Examination of outcome and cost data of open and laparoscopic antireflux operations at Virginia Mason Medical Center in Seattle. *Surg Endosc* 1995;9:1326.

Low DE. Hill antireflux operation. *Chest Surg Clin N Am* 1995;5:411.

Low DE, Anderson RP, Ilves R, et al. Fifteen-to twenty-year results after the hill antireflux operation. *J Thorac Cardiovasc Surg* 1989;98:444.

Low DE, Mercer CD, James EC, et al. Post Nissen syndrome. *Surg Gynecol Obstet*

1988;167:1.

Low DE, Unger T. Open repair of paraesophageal hernia: reassessment of subjective and objective outcomes. *Ann Thorac Surg* 2005;80:287.

Oberg S, Peters JH, DeMeester TR, et al. Endoscopic grading of the gastroesophageal valve in patients with symptoms of gastroesophageal reflux disease (GERD). *Surg Endosc* 1999;13:1184.

Paterson WG. The normal antireflux mechanism. *Chest Surg Clin N Am* 2001;11:473.

Qureshi AP, Aye RW, Buduhan G, et al. The laparoscopic Nissen-Hill hybrid: pilot study of a combined antireflux procedure. *Surg Endosc* 2013;27(6):1945–52.

EDITOR'S COMMENT

I must confess prior to launching this commentary that I like the Hill repair and it is my preferred repair. Realistically, it can only be carried out open, although there are those who perform it laparoscopically; it is not easy, but it does solve the problem which is basic to reflux, in accomplishing the following four goals in antireflux surgery:

1. It mobilizes and secures a length of intra-abdominal esophagus, thereby restoring the high-pressure zone.
2. It results in a satisfactory way of holding the esophagus and the high-pressure zone within the abdomen.
3. It restores the angle of His.
4. As a secondary benefit, because of the fact that the wrap is not total, or 360 degrees, but advertises being 270 degrees and more likely is about 180 degrees in most people's hands, burping or failure to be able to burp is not a problem, and thus patients do not have a problem with inability to burp which some patients undergoing the Nissen procedure do have a significant problem with.

In addition, the Hill repair can be carried out in patients who have a prior gastrectomy. The Nissen fundoplication is very difficult to do in patients who have a significant gastric resection, and while I admit that the number of patients undergoing gastrectomy nowadays have decreased remarkably, if a vagotomy was carried out as part of the gastrectomy despite the attempt to close the hiatus on the part of some surgeons, it does set up a patient for reflux because the closure of the hiatus alone following vagotomy is usually not sufficient to prevent reflux. Thus, in patients with diminished gastric mass, the antireflux procedure can only be carried out simply by Hill repair which must be open. I realize that there are other alternatives, but to me it seems that the Hill repair serves the purpose very nicely.

How good is the Hill repair and how durable? Aye et al. including Dr. Lucius

Hill (The Hill antireflux repair at 5 institutions over 25 years. *Am J Surg* 2011;201:597–602) reviewed five institutions and their Hill repairs over 25 years. In two of the institutions, Lucius Hill–trained surgeons or centers (HTCs) performed the procedures, and three other institutions were either self-taught or developed the skill themselves. Surgeons from the Swedish Medical Center and the Virginia Mason Center in Seattle and a surgeon from Queen's University in Kingston made up the HTCs, while the Massachusetts General Hospital, where I learned how to do the Hill repair; the Norfolk Surgical Group in Norfolk, Virginia; and University Medical Center in Kansas City were the independent performers of the Hill repair. There were a large number of patients—1,381—who were reviewed at the five sites. Follow-up was <2 years in 153 and these were excluded, and 47 were either with incomplete data or deceased, and thus, 1,181 patients were included in the study. Further, HTCs included 843 patients, of which 779 from the Swedish Medical Center and the Virginia Mason Center in Seattle, 64 from Queen's University. Of the independent centers, 57 from Kansas University Medical Center, 247 from the Norfolk Surgical Group, and only 34 at the Massachusetts General Hospital. The preoperative symptoms were relatively common: heartburn, dysphagia, regurgitation, chest pain, cough, and hoarseness. These symptoms were largely present for more than 2 years. All patients underwent flexible upper endoscopy, and the diagnosis of esophagitis was present in most. There were 37 patients who had Barrett metaplasia and esophagitis was present in only 443. Further, 96% of the patients noted improvement in their symptoms, and there was no difference between the independent hospitals, 81.1%, and 79% of the HTCs. It is difficult to understand how 96% noted improvement in their symptoms, although the 79% and 81% were patients with no/mild symptoms. There were no differences between the HTCs and the independent centers, and in most situations, the independent centers did slightly better but it was not statistically significant. The complications to the procedures were 11%, including splenic injury in 9% of the patients, and the usual wound infections, pneumothorax, pleural effusion, pulmonary embolism, and fistula formation, all in <1% of the patients. The resumption of antisecretory medications was low, with only 22% reporting any use at all. Anatomic recurrence was 6.9% and reoperation rate was only 1.9%.

This is in remarkable contrast to Spechler et al. (Long-term outcome of medical and surgical therapies for gastroesophageal reflux disease: follow-up of a randomized controlled trial. *J Am Med Assoc* 2001;285:2331–8) who reported that 62% of the surgical patients were back on regular medication and 16% required reoperation at the 10-year follow-up. In short, the Hill repair produces excellent results that are durable and are not a surprise to me from my own personal experience, although in view of them one wonders who the Nissen is so commonly performed around the country, other than fixing the gastroesophageal junction to either the median arcuate ligament which is present in <50% of the patients and which is close to the celiac axis which frightens many surgeons or the crura alongside the esophagus.

Patients with gastroesophageal reflux disease in severe cases suffer voice loss, chronic cough, globus, and sore throat. While some of these patients will respond to proton pump inhibitor therapy, the results after the Hill repair have not heretofore been reported. Wright and Rhodes (Improvement of laryngopharyngeal reflux symptoms after laparoscopic Hill repair. *Am J Surg* 2003;185:455–61) analyzed symptomatic improvement in 145 patients who underwent laparoscopic Hill hiatal hernia repair. Gastroesophageal reflux was generally improved compared with preoperative symptoms. While the improvement in symptoms such as bloating, dysphagia, regurgitation, etc., were in the 81% to 96%, improvement in the symptoms of laryngopharyngeal reflux were in the 89% to 92% and, of course, the *P* value was <0.001. This is an excellent result, again with the Hill repair in a very troublesome symptom. Unfortunately, asthma which some investigators have associated with gastroesophageal reflux and in which an association probably exists improved only in 25%.

An endoluminal approach to the Hill procedure was reported by Fritscher-Ravens A and Swain P from St. Mary's Hospital in London (Endoluminal fundoplication–the Hill procedure. *Minim Invasive Ther Allied Technol* 2006;15:366–72), in which the antireflux procedure was carried out endoscopically. The purpose of this paper was the feasibility of the crural repair under endoscopic ultrasound to identify the structure in pigs. These were survival experiments in 14 pigs utilizing the linear array of echoendoscopes. Parts of the right crus were identified, and an endoscopic sewing device was used allowing sutures to be placed through a 2.8-mm accessory channel. Knot tying and thread cutting through the 2.8-mm channel required new techniques. Preoperative manometry showed a median lower esophageal pressure of 11 mm Hg; this increased to 22 mm Hg after stitch placement. I agree with the authors that it did appear possible to safely place the sutures into the right crus and thus increase the lower esophageal sphincter pressure. At postmortem examination in a survival experiment, the length of LES increased from 2.8- to 3.5-cm postprocedure which is probably neither statistically significant nor is it physiologically significant. At postmortem, the force to pull the tags out of the median arcuate ligament or what resembled the median arcuate ligament was 2.8 kg. This paper shows that this is possible, but with most endoscopic approaches to antireflux procedures whether they be bulking or some other type of procedure, this unfortunately has not withstood the test of time, but it is good that people are trying to do it.

J.E.F.

74 Laparoscopic Antireflux Surgery

Nathaniel J. Soper and Eric S. Hungness

INTRODUCTION

Laparoscopic antireflux surgery continues to play a major role in the treatment of gastroesophageal reflux disease (GERD). Most operations for GERD involve plicating the gastric fundus 90 to 360 degrees around the distal esophagus. The most commonly performed fundoplication is the Nissen 360-degree fundoplication, which results in >90% long-term control of reflux symptoms. Other fundoplications (e.g., Hill, Belsey, Toupet, Dor, Guarner, Lind) have been developed, applied, and reported, but modifications of the Nissen fundoplication currently are the most widely used operations for GERD.

A randomized trial comparing transabdominal open Nissen fundoplication with medical therapy in patients with complicated GERD proved surgical therapy to be more effective. Despite these findings, many patients and physicians opted instead for lifelong medication and significant lifestyle limitations until 1991, when Dallemagne and Geagea reported the first laparoscopic Nissen fundoplications (LNF). Although LNF follows the same surgical principles as the open operation, randomized trials showed that the laparoscopic approach reduces postoperative pain and shortens both hospitalization and recuperation with outcomes (symptomatic and functional) similar to that of the open operation. Hence, there was a rapid increase in surgical treatment of GERD, with LNF gaining acceptance as an efficacious therapy for GERD.

Over the past decade, however, the number of antireflux operations being performed has diminished. This decrease is likely related to both increased awareness of complications of LNF and “better” medications being developed, resulting in increased resistance from the medical community to refer patients for surgical evaluation. Recent reports and FDA warnings of potential complications with long-term proton pump inhibitor (PPI) use, however, have caused increased discussion in the medical community of the role of surgery in the treatment of GERD.

GASTROESOPHAGEAL REFLUX DISEASE

Demographics and Clinical Presentation

Over 60 million Americans complain of heartburn and indigestion, with approximately 40% of the total US population experiencing reflux on a monthly basis, 20% on a weekly basis, and 7% on a daily basis. Patients with GERD may exhibit typical or atypical symptoms (Table 74.1). GERD often presents as heartburn and regurgitation and can progress to dysphagia, odynophagia, and chest pain. Although typical of GERD, these symptoms may also be caused by other entities that must be included in the differential diagnosis, including cardiopulmonary disease, other foregut problems, gallbladder disease, and functional disturbances.

Anatomy

Barriers to gastroesophageal reflux (GER) include the lower esophageal sphincter (LES), the presence of an intra-abdominal segment of esophagus, the diaphragmatic crura, the phrenoesophageal membrane, the angle of His, and esophageal clearance of acid. The LES and hiatal crura appear to be the major barriers (Fig. 74.1A,B). The LES separates two adjacent lower-pressure zones and normally remains tonically contracted except during swallowing, when it relaxes in advance of the peristaltic wave. LES contraction receives important amplification during inspiration and conditions in which the abdominal pressure is increased by contraction of the crural diaphragm. GER events in healthy individuals normally result from the phenomenon known as *transient relaxation* of the LES complex, in which spontaneous (nonswallow initiated) events permit GER by obliterating the high-pressure zone through a vagally mediated mechanism that is usually stimulated by gastric or pharyngeal stimulation.

TABLE 74.1 Symptoms of Gastroesophageal Reflux Disease

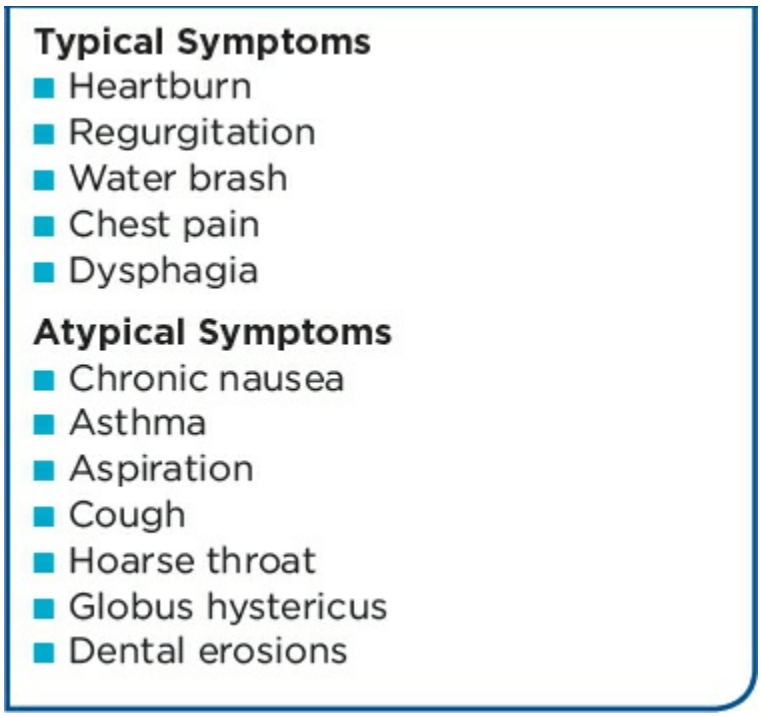

Pathophysiology

GER occurs physiologically in all healthy individuals to a limited degree. Patients with GERD experience reflux more frequently and for longer periods of time than healthy persons. Reflux events may occur by three primary mechanisms: (i) spontaneously, accompanying transient LES relaxations; (ii) stress reflux associated with a weakened LES, the pressure of which does not exceed that of the elevated intra-abdominal pressure; and (iii) in individuals with severe reflux, essentially a nonexistent LES that cannot maintain competency at any point, resulting in spontaneous GER. Many patients with GERD exhibit a hiatal hernia with the proximal stomach residing in the negative pressure environment of the chest, which contributes to GER. Patients with long-standing and/or severe GERD may ultimately develop Barrett esophagus, columns of metaplastic esophageal mucosa associated with an increased risk of adenocarcinoma.

Some authors have proposed that transient LES relaxations initially cause damage to the esophageal mucosa. This is exacerbated by stress reflux usually caused by gastric distention, most commonly from overeating. The progressive mucosal inflammation leads to LES dysfunction, which leads to further reflux. This vicious cycle eventually leads to an incompetent LES. These events may also lead to esophageal dysmotility that may prevent normal esophageal clearance of acid.

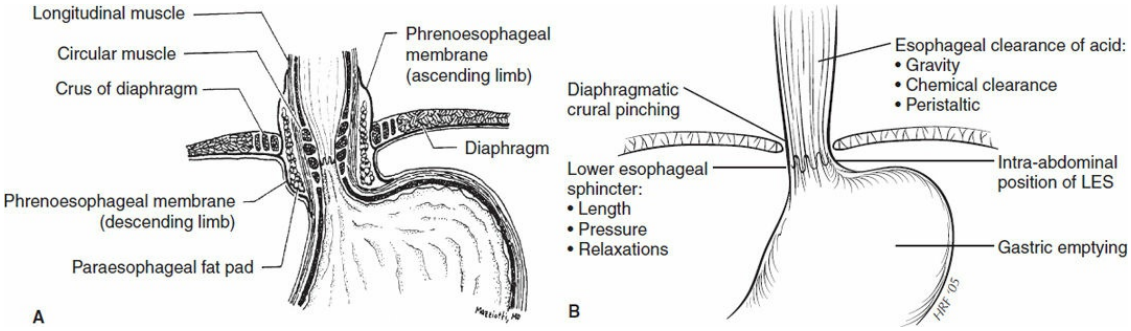

Figure 74.1. A. Anatomy of the gastroesophageal junction (GEJ). Anatomic components of the antireflux barrier include the lower esophageal sphincter (LES), the presence of an intra-abdominal segment of esophagus, the diaphragmatic crura, the phrenoesophageal membrane, and the angle of His. The LES and hiatal crura appear to be the major antireflux barrier components with the LES separating two adjacent lower-pressure zones and normally remaining tonically contracted except during swallowing, when it relaxes in advance of the peristaltic wave. **B.** The physiologic features controlling gastroesophageal reflux disease are multifactorial and include esophageal peristaltic and chemical clearance of acid, mechanical barriers such as the LES and diaphragmatic crura, and gastric emptying.

Savary et al. established a grading system for the endoscopic appearance of reflux-induced damage to the esophageal mucosa as follows: grade I (mild erythema), grade II (isolated ulcerations), grade III (confluent severe ulcerations), and grade IV (secondary complications including Barrett esophagus and stricture). The Los Angeles Classification System, the most commonly used system by gastroenterologists, grades esophagitis according to breaks in the esophageal mucosa: grade A (≤5 mm in length), grade B (>5 mm in length), grade C (continuous between two mucosal folds), and grade D (≥75% of esophageal circumference). However, up to 60% of patients with clinical GERD will have normal-appearing esophageal mucosa at endoscopy. Barrett esophagus is estimated to occur in approximately 10% of patients with GERD. Studies demonstrate that patients with GERD and Barrett esophagus have an estimated 0.4% per patient-year risk of developing adenocarcinoma, compared with a 0.07% per patient-year risk for patients with GERD but without Barrett esophagus.

Diagnosis

Factors other than mechanical barrier deficits at the LES may lead to GERD, and GERD-like symptoms can be reported in the absence of GERD. The esophageal body plays an important role in clearing acid present within its lumen, a function that is aided by the presence of gravity and saliva. Esophageal peristaltic dysfunction is directly related to the degree of mucosal disease, and most patients with Barrett esophagus exhibit abnormalities of esophageal motor function. Abnormalities of the gastric reservoir, including gastric dilatation and delayed gastric emptying, may also predispose to GER. Antireflux operations are designed solely to correct a functionally defective reflux barrier; therefore, tests that measure the function not only of the LES itself but also of the esophagus and stomach may be appropriate in patients with GERD-related symptoms.

Preoperative Testing

Many diagnostic modalities are available for studying patients suspected of having GERD (Table 74.2). A history of recurrent heartburn alone is usually adequate to establish the clinical diagnosis of GERD and initiate empiric medical therapy. However, diagnostic tests should be performed in patients with persistent symptoms, symptoms and signs indicating significant tissue injury (e.g., dysphagia, anemia, or guaiac positive stools), and any patient in whom the diagnosis is uncertain. Individuals who are being considered for antireflux surgery require additional tests of the anatomic and physiologic features of the stomach and esophagus.

TABLE 74.2 Diagnostic Tests for Gastroesophageal Reflux Disease

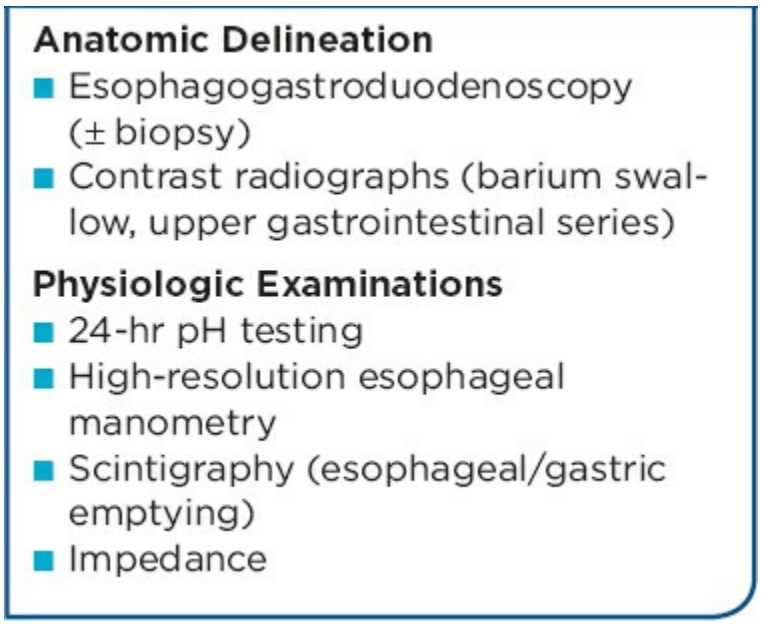

In patients with typical symptoms of GERD, the minimal diagnostic evaluation is esophagogastroduodenoscopy (EGD). High-resolution esophageal manometry should be performed preoperatively to assess the adequacy of esophageal peristalsis. pH testing (24-hour transnasal or 48-hour Bravo) may be helpful, but is not mandatory in patients with typical symptoms if esophagitis is present. However, patients without esophagitis and those who have atypical symptoms of GERD or other functional gut disorders, such as irritable bowel syndrome, and those patients with an atypical response to medical therapy require more detailed preoperative investigation, generally including a pH test to prove the presence of GERD. Some transnasal pH probes also have impedance measurement capability, which is helpful to delineate symptomatic non-acid reflux events.

Anatomic Delineation

EGD is an essential part of the evaluation of patients being considered for antireflux surgery. Barrett esophagus usually appears as salmon-colored mucosal extensions up into the distal esophagus and is confirmed by biopsy that shows intestinal metaplasia. Given the increasing incidence of esophageal adenocarcinoma and the association between long-standing heartburn and adenocarcinoma, the gastroesophageal mucosa should probably be assessed endoscopically at least once in all patients with persistent or severe symptoms of GERD. If Barrett esophagus with dysplasia is discovered on biopsy, the patient should be considered for radiofrequency ablation prior to antireflux surgery.

Contrast radiographs of the upper gastrointestinal tract may be helpful to assess the size of any associated hiatal hernia, to localize precisely the gastroesophageal junction in relation to the esophageal hiatus, and to qualitatively assess the adequacy of esophageal peristalsis and gastric emptying.

Physiologic Examinations

The "gold standard" to confirm the presence of GER is a 24-hour esophageal pH assessment, quantifying the number and duration of episodes of acid reflux into the esophagus. Furthermore, this test correlates subjective symptoms with reflux events and differentiates between upright and supine GER. The sensitivity of prolonged pH monitoring in identifying pathologic GER ranges from 50% to 100% (mean, 85%), and the specificity is somewhat higher. This test requires cessation of H_2-blockers for 3 days and PPIs for 7 days prior to testing. The indwelling wireless esophageal probe has made this outpatient test more tolerable than when nasoesophageal probes were used; and although it is still relatively expensive, it also allows for capture of data up to 72 hours. False-negative tests may result from patients refraining from normal dietary and physical activities during the time the pH probe is in place.

Recently, intraluminal impedance monitoring has been added to the arsenal of diagnostic tests for GERD. Diagnosing GERD by pH monitoring alone depends on acid reflux, and may not detect low-acid or non-acid reflux. The precise role of impedance monitoring in the workup of patients with GERD still needs to be defined, but should be considered especially in patients with atypical and refractory symptoms.

High-resolution esophageal manometry should be performed in all patients before antireflux surgery is considered. With this test, the length, location, and pressure of the LES are assessed along with the ability of the LES to relax during swallowing. In addition, and more importantly, both the amplitude and efficacy of swallowing-induced peristalsis of the esophageal body are measured. Esophageal manometry identifies the rare individual with a primary motility abnormality (such as achalasia or scleroderma) with symptoms of GER. The degree of peristaltic failure caused by the GERD can also be assessed. The surgeon may, thereby, gauge whether a full 360-degree fundoplication will likely result in significant dysphagia, which may result in a tailoring of the antireflux operation. Furthermore, if dysphagia develops postoperatively, a baseline

study is of value in determining subsequent treatment.

In patients whose symptoms include significant nausea and vomiting, and in those patients with severe insulin-dependent diabetes, a scintigraphic gastric emptying test should probably be performed to exclude a significant gastric-emptying abnormality. If a marked delay in gastric emptying is diagnosed, a pyloroplasty or pyloromyotomy should be considered at the time of antireflux surgery. Recent studies have demonstrated significant improvement in both symptoms and gastric emptying scintigraphy for reflux patients with severe gastroparesis ($T_{1/2}$ >150 minutes) undergoing combined LNF and pyloroplasty.

Treatment

Medical

Virtually all patients should receive a short-term (2-month) trial of intensive medical therapy before considering an antireflux operation. Modern medical treatment of reflux disease is aimed at decreasing gastric acidity and reducing esophageal exposure to gastric contents with the goal of healing the injured esophageal mucosa, eliminating symptoms, and preventing or treating the complications of GERD. Most patients with GERD have relatively mild symptoms and may be managed empirically without further testing unless accompanied by signs indicative of significant tissue injury (e.g., dysphagia or gastrointestinal blood loss). The primary tenets of GERD management include lifestyle modifications (Table 74.3) and medical therapy. Unfortunately, recommendations for significant lifestyle modifications are usually ignored. Although most patients with GERD can be managed adequately with PPIs, many eventually require escalating doses over time, relapse quickly when medication is stopped, or desire to be free of medications and their significant expense and potential complications. It is this group of patients who may benefit greatly from LARS.

TABLE 74.3 Lifestyle Modifications for Gastroesophageal Reflux Disease

- Weight loss
- Alteration of diet
  - Avoid chocolate, peppermint, fat, onions, garlic, alcohol, caffeine, and nicotine
  - Nothing by mouth for 2–3 hrs before bedtime
- Elevation of head of bed 6–10 in
- Limit potentially precipitating activities, such as bending over or strenuous exercise

Surgical

Indications for Surgical Therapy

Conditions that require a surgical approach to GERD remain controversial. Foremost, the diagnosis of GERD must be clearly established. For a patient with typical symptoms (heartburn or regurgitation), at least one piece of objective evidence of reflux must be present. For patients with atypical symptoms, two pieces of corroborative evidence of GERD should be demonstrated. In addition to objective evidence of GERD, the most common indications for performing antireflux surgery can be summarized as follows: (a) complications of GERD not responding to medical therapy (e.g., esophagitis, stricture, recurrent aspiration or pneumonia, Barrett esophagus); (b) GERD symptoms interfering with lifestyle, despite medical therapy; (c) GERD associated with paraesophageal hernia; (d) chronic GERD requiring continuous drug therapy in a patient desiring discontinuation of medical therapy (e.g., financial burden, noncompliance, lifestyle choice, young age); and (e) intolerance to PPI therapy (Table 74.4).

Some features of preoperative physiologic testing predict a poor response to long-term acid suppression therapy and should be considered as rationale for referral to surgical therapy earlier in the course. These features include diminished contractility of the esophageal body, large hiatal hernia, markedly hypotensive LES, severe erosive esophagitis that is poorly responsive to antacid therapy, and Barrett esophagus.

TABLE 74.4 Indications for Laparoscopic Antireflux Surgery

- Complications of GERD unresponsive to medical therapy
- Esophagitis
- Stricture
- Recurrent aspiration or pneumonia
- Barrett esophagus
- Continued symptoms despite maximal medical treatment
- Symptomatic paraesophageal hernia
- Patient desire to discontinue PPI therapy
- Financial burden
- Lifestyle choice
- Young age
- Intolerance to PPI therapy

Whether the mere presence of Barrett esophagus should be an indication for antireflux surgery remains controversial. The development of Barrett esophagus generally occurs after long-term, severe GERD, and is therefore a marker for patients unlikely to respond to medical therapy. In addition, recent studies suggest that antireflux surgery results in regression of short-segment intestinal metaplasia in up to 35% of patients and regression of low-grade dysplasia to nondysplastic Barrett esophagus in up to 75%. Likewise, surgery has been shown to reduce progression of intestinal metaplasia to dysplasia compared to medical therapy. However, no prospective randomized trial has answered the question whether medical or surgical therapy prevents the progression of Barrett esophagus to adenocarcinoma. Two recent meta-analyses gave conflicting results on this question. Based on these studies, we believe that patients with Barrett esophagus and severe symptoms of GERD should be offered surgical therapy. More data will be required before definitive recommendations can be made regarding the need for operative therapy in patients who have Barrett esophagus but fewer symptoms.

Radiofrequency ablation has emerged as an effective therapy for the eradication of Barrett esophagus. Short-term results have been promising with up to 100% endoscopic and histologic removal of Barrett esophagus and low-grade dysplasia. The use of this modality in conjunction with Nissen fundoplication (to help prevent recurrence of Barrett esophagus) is

now accepted.

Contraindications to Surgical Therapy

Most, if not all, patients with GERD can be managed effectively for short periods of time with intensive medical therapy. A poor response to aggressive medical therapy may therefore portend a poor prognosis after antireflux surgery. There are fewer absolute contraindications to LARS. These include the inability to tolerate a general anesthetic or laparoscopy and an uncorrectable coagulopathy. Numerous conditions, however, render LARS more difficult and should be considered relative contraindications (Table 74.5). These factors include previous upper abdominal surgery, particularly operations around the diaphragm or esophageal hiatus, and severe obesity. In obese patients, access to the abdominal cavity is not generally a problem, but the omentum and gastrosplenic ligament may be bulky and difficult to retract adequately, and fatty infiltration of the left lateral segment of the liver may make exposure of the esophageal hiatus problematic. These patients should be considered for bariatric surgery, as this usually eliminates GERD in addition to addressing obesity-related comorbidities. Chronic reflux can cause stricture and shortening of the esophagus and prevent the creation of a tension-free intra-abdominal gastric wrap, causing wrap disruption or intra-thoracic displacement. The propulsive force of the esophagus must also be sufficient to propel food across a reconstructed valve. If peristalsis is significantly diminished, a partial wrap may be preferable. Patients having the factors listed in Table 74.5 should probably not be managed by surgeons during their initial learning curve of LARS.

TABLE 74.5 Relative Contraindications for Laparoscopic Antireflux Surgery

- Previous upper abdominal (especially subdiaphragmatic) surgery
- Morbid obesity
- Severe esophagitis ± stricture
- Short esophagus
- Large paraesophageal hiatal hernia

Basic Tenets of Antireflux Surgery

The basic tenets of LARS include restoration of an effective LES and creation of a gastroesophageal valve. These concepts are based on a variety of considerations that have been touted in the literature, such as the role of an intra-abdominal segment of esophagus, the function of the gastric muscularis used to wrap around the esophagus, and the physiologic implications of the law of Laplace. Almost all antireflux operations involve plicating the lower esophagus with gastric smooth muscle, usually the gastric fundus. The notable exception to performing fundoplication is the Hill esophagogastropexy, as described elsewhere in this text.

Fundoplication requires wrapping the *fundus* itself, not the body of the stomach, around the *esophagus*, rather than around the proximal body of the stomach. The fundus, unlike the remainder of the stomach, exhibits a physiologic phenomenon known as receptive relaxation that causes decreased tone of the gastric fundic smooth muscle in association with swallowing-induced relaxation of the LES. If the fundoplication is performed around the stomach rather than the esophagus, periodic contractions of the gastric smooth muscle within the wrap are insufficient to allow free passage of intraluminal contents, and therefore result in dysphagia.

The fundoplication should reside within the abdomen without tension, and the crura should be closed adequately to prevent migration of the stomach or the fundoplication into the chest. If this occurs, an iatrogenic paraesophageal hernia has been created.

In general, complete (360-degree) fundoplications such as the Nissen fundoplication create more resistance to flow (both prograde, which may result in an increased incidence of dysphagia, and retrograde, as desired to lessen the risk of postoperative reflux) and may be more durable over the long term than partial fundoplications. In contrast, partial fundoplications have less resistance to flow, both prograde and retrograde, and are associated with less postoperative dysphagia and postoperative abdominal bloating, but have a greater risk of recurrent reflux or disruption of the wrap.

Choice of Approach

The precise mechanism whereby antireflux surgery exerts its effects remains incompletely understood, and each operation works in a slightly different fashion. Currently, most patients are thought to be best suited to an LNF (Table 74.6). Atypical patients, however, may warrant an

alternative approach. Those patients with a short esophagus will require an esophageal-lengthening procedure, in the form of either a laparoscopic Collis gastroplasty or a transthoracic Collis operation. Effort should be made to avoid a lengthening procedure by maximizing the intra-mediastinal esophageal dissection; however, if obtaining 3 cm of intra-abdominal esophagus is not possible, a Collis procedure is necessary. Because of potential acid secretion in the neo-esophagus and the risk of peptic stricture/esophagitis, these patients should be given postoperative PPI therapy. Patients who have undergone previous subdiaphragmatic foregut surgery or have a hostile abdomen from multiple prior operations may also be best served by a transthoracic approach. Individuals who have previously undergone partial gastrectomy may not have adequate fundus to perform a true fundoplication and may require an alternative operation, such as the Hill esophagogastropexy.

TABLE 74.6 Choice of Operation for Antireflux Surgery

Typical Patient
■ Transabdominal (laparoscopic) fundoplication
Atypical Patient
■ Esophageal-lengthening procedure (Collis)
■ Transthoracic operation (Belsey)
■ Esophagogastropexy (Hill)
■ Esophageal resection

Transthoracic

The primary transthoracic operation used for the control of GER has been the Belsey Mark IV (Chapter 68). In this operation, the distal esophagus is mobilized, and the proximal stomach is delivered through the esophageal hiatus. An anterior 270-degree plication of the fundus is performed up onto the esophagus, buttressed by the diaphragmatic crura. The usual mode of access for the Belsey repair has been a left thoracotomy. McKernan and Champion reported early follow-up on a small series of thoracoscopic-modified Belsey fundoplications with excellent results; however, a recent 5-year follow-up demonstrated high morbidity and recurrence.

Transabdominal

In the total or complete fundoplications, the fundus of the stomach is wrapped circumferentially around the lower esophagus. First described in 1956, the Nissen fundoplication, with various modifications from the original description, has long been the preferred surgical alternative to medical therapy for the treatment of refractory GERD. The fundoplication is accomplished by circumferentially dissecting the distal esophagus, mobilizing the gastric fundus, and plicating the fundus around the lower esophagus, creating a high-pressure zone. This increases the resting tone of the sphincter mechanism, diminishes transient lower esophageal sphincter relaxations, and improves its response to elevated intragastric pressure. Nissen's original description of the operation involved mobilizing the abdominal esophagus and lesser curvature of the proximal stomach and wrapping the posterior wall of the fundus around to join the anterior aspect of the fundus. The newly created fundoplication varied from 3 to 6 cm in length and included the esophageal wall in the fundoplication. Nissen did not describe division of the short gastric vessels using his technique. Two surgeons working with Nissen modified the technique, again without division of the short gastric vessels, to wrap the anterior portion of the fundus around the esophagus such that even less mobilization of the upper stomach was required. This is the Rossetti or Rossetti-Hill modification of the Nissen fundoplication as described elsewhere in the text (Fig. 74.2).

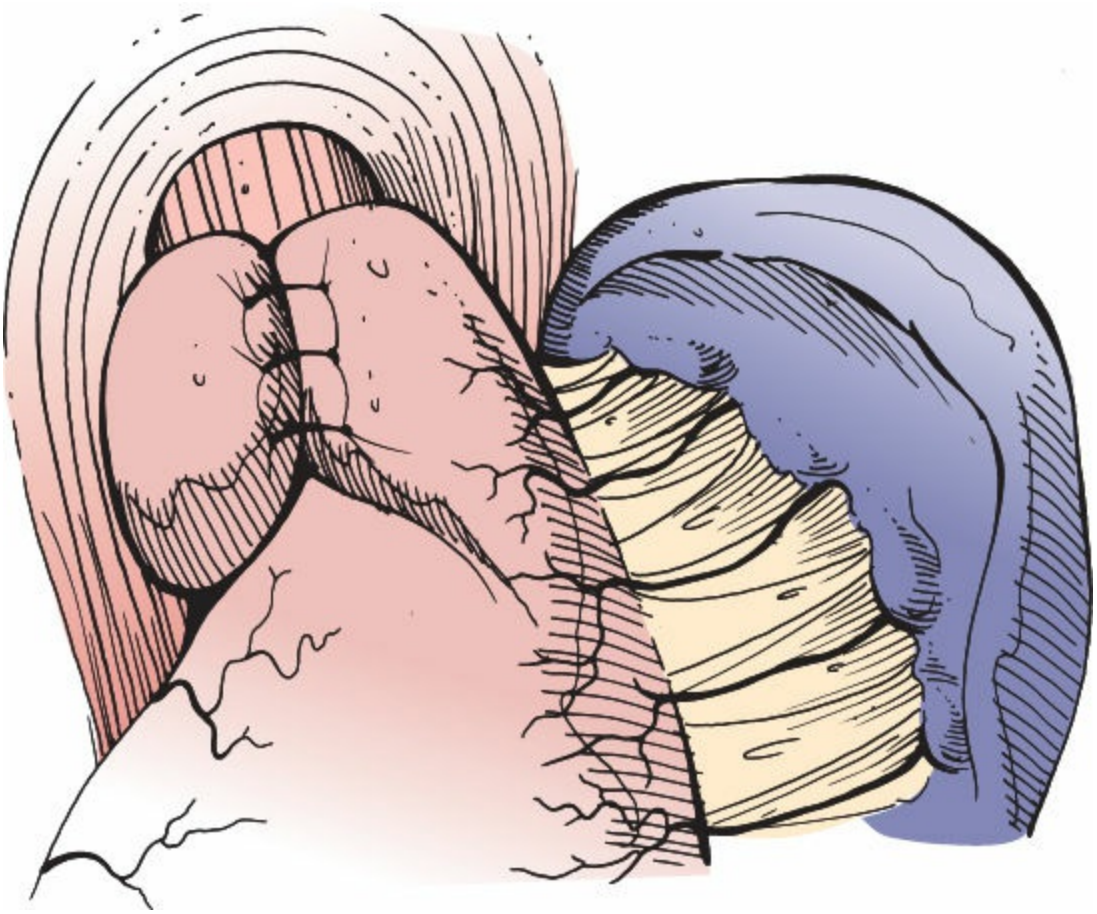

Figure 74.2. Rossetti–Hell modification of the Nissen fundoplication. The Rossetti or Rossetti–Hell modification of the Nissen fundoplication includes wrapping the anterior portion of the fundus around the esophagus without division of the short gastric vessels and with minimal mobilization of the upper stomach, creating a 3- to 6-cm 360-degree fundoplication.

However, most surgeons in the United States today perform a *short, floppy Nissen fundoplication.* In this modification of the Nissen fundoplication, the short gastric vessels are divided with full fundic mobilization. The lateral border of the fundus is wrapped around the esophagus and sutured to the anterior edge of the medial fundus, creating a short (<2.5 cm) fundoplication that is usually fashioned over a No. 50 to 60 French esophageal dilator (Fig. 74.3).

Partial Fundoplications

Partial fundoplications have been used because of concerns that the complete fundoplication may be hypercontinent, leading to some of the well-described postoperative sequelae of the Nissen fundoplication, such as dysphagia, inability to belch, and the gas-bloat syndrome. Partial

fundoplications attempt to provide effective reflux prevention with minimal esophageal outflow resistance. In general terms, partial fundoplications are more difficult to conceptualize and perform for the novice surgeon, limiting their widespread application. There are also concerns that the long-term durability of such repairs will not be as good as that for the Nissen fundoplication. Some surgeons use partial fundoplications for all patients who are undergoing antireflux surgery, whereas other surgeons use partial fundoplications in specific situations. Possible indications for selective use of partial fundoplications are listed in Table 74.7. These include diminished esophageal motility, either primary or secondary, severe aerophagia, reoperative situations, or anatomic conditions that preclude a tension-free complete fundoplication.

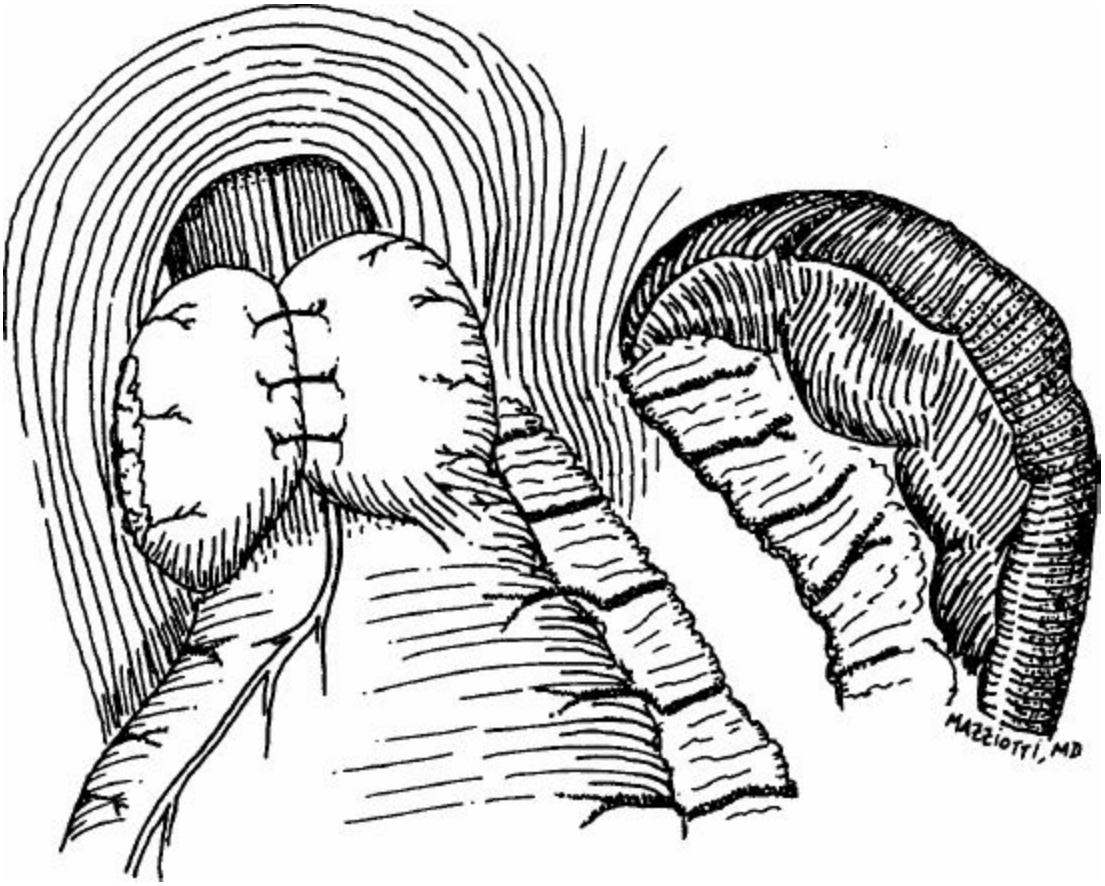

Figure 74.3. "Short and floppy" Nissen fundoplication. *The short, floppy Nissen fundoplication* is a modification of the complete fundoplication in which the short gastric vessels are divided with full fundic mobilization, and the lateral border of the fundus is wrapped around the esophagus and sutured to the anterior edge of the medial fundus. The fundoplication is short (<2.5 cm), is created with three interrupted sutures 5 to 8 mm apart, and is fashioned over a large esophageal dilator. (Reprinted with

permission from Desai KM, Soper NJ. Laparoscopic Nissen fundoplication. In: Soper NJ, Swanström LL, Eubanks WS, eds. *Mastery of Endoscopic and Laparoscopic Surgery*. 2nd ed. Philadelphia, PA: Lippincott Williams & Wilkins; 2005:193.)

TABLE 74.7 Indications for Partial Fundoplication

- Poor esophageal clearance because of esophageal motility abnormality
- Severe aerophagia, particularly in patients with daytime reflux associated with belching
- Insufficient gastric fundus to allow a loose total fundoplication (i.e., tubular stomach, previous gastrectomy)
- Psychological inability to tolerate the side effects of fundoplication
- In association with Heller myotomy for achalasia

A partial listing of the types of partial fundoplications in use is outlined in Table 74.8. These include anterior fundoplications, posterior fundoplications, and the Hill esophagogastropexy. All of these operations have been performed laparoscopically. The Dor fundoplication (Fig. 74.4) is a 180- to 200-degree anterior fundoplication that has been used primarily in association with laparoscopic Heller esophagomyotomy for achalasia. The Watson fundoplication involves fixation of the esophagus in an intra-abdominal location with plication of the fundus along the left anterolateral border of the esophagus and has been championed as a more "physiologic" antireflux procedure. The Hill repair (Fig. 74.5) involves plication of the lesser gastric curvature around the right side of the esophagus with an esophagogastropexy to the median arcuate ligament. Because this operation requires intraoperative manometry for optimal performance, it has not been applied widely.

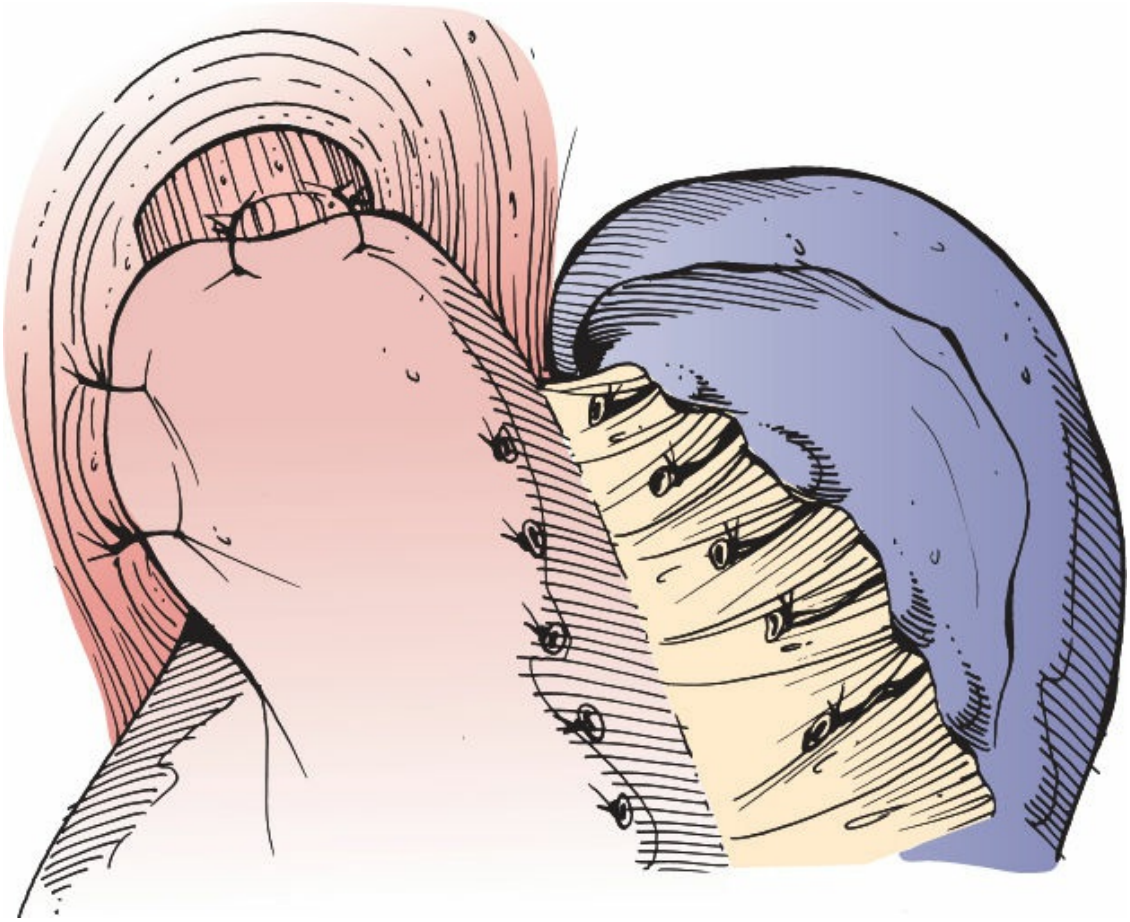

Figure 74.4. Dor fundoplication. The Dor 180- to 200-degree anterior fundoplication is used primarily in association with laparoscopic Heller esophagomyotomy for achalasia.

The Toupet fundoplication and its variations (e.g., Guarner, Lind) have been the most commonly used partial fundoplication since the introduction of laparoscopic fundoplications (Fig. 74.6). With this procedure, the fundus is pulled posterior to the esophagus with suture of the leading edge of the wrapped fundus to the right anterior aspect of the esophagus while the left (medial) side of the fundus is sutured to the left anterolateral aspect of the esophagus. Varying numbers of sutures may be placed between the fundus and the crura for further stabilization.

TABLE 74.8 Alternative Procedures and Their Variations

Procedure	Type of Fundoplication
Partial fundoplications	Belsey Mark IV 270-degree anterior (transthoracic) Dor 180- to 200-degree anterior Thal 90-degree anterior Toupet 270-degree posterior Watson 120-degree anterolateral
Esophagogastropexy	Hill repair 90-degree lesser-curve plication

LAPAROSCOPIC ANTIREFLUX SURGERY

Technical Principles

Laparoscopic antireflux operations are advanced laparoscopic procedures requiring skills that are best developed and practiced in a nonclinical setting to facilitate efficiency and superior technical performance in the human operating room. Technical principles common to all fundoplications include the following:

Dissection should be done away from the esophagus, and the esophagus should never be directly grasped or manipulated with traumatic instruments to avoid esophageal wall injury.
All dissection must be performed under direct vision.
The fundus, rather than any other part of the stomach, must be plicated around the esophagus, rather than around the proximal stomach.
There must not be tension present at the conclusion of the fundoplication, either axially (tending to pull the repair up through the hiatus into the mediastinum) or rotational (pulling the fundus counterclockwise back to the left, creating a twist of the lower esophagus).

Preoperative Planning

During the preoperative office visit, the expectations and risks of LARS are discussed with the patient. Patients are counseled that if at any point a laparoscopic approach cannot be continued safely, the operation will be converted to an open procedure. Gastric or esophageal perforation, injury to the vagus nerves, spleen, or other abdominal viscera, dysphagia, and bloating are all delineated as potential complications and that disruption of the crural repair or wrap as well as migration of the wrap into the mediastinum may require reoperation. Healthy patients are admitted the day of surgery after an overnight fast.

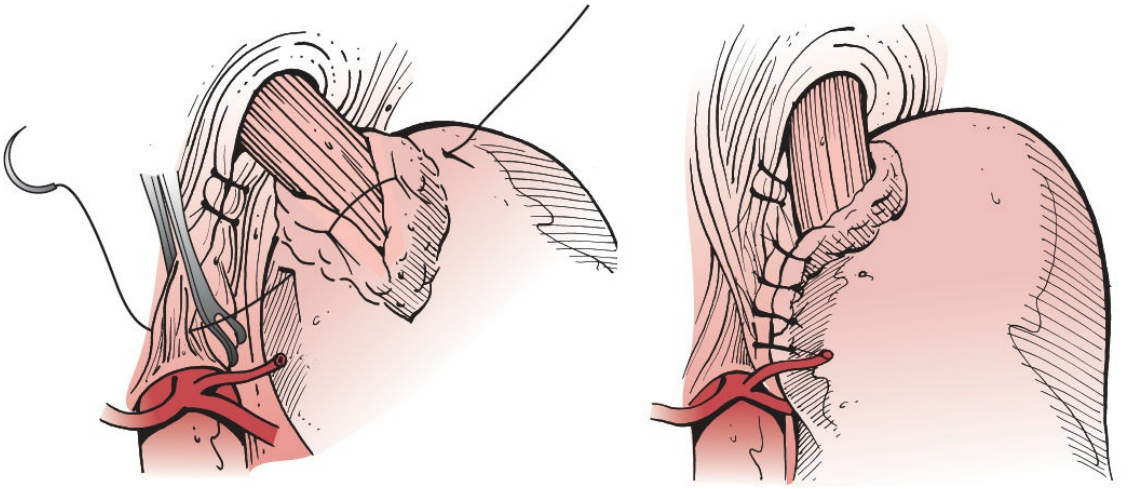

Figure 74.5. Hill esophagogastropexy. The Hill repair involves plication of the lesser gastric curvature around the right side of the esophagus with an esophagogastropexy to the median arcuate ligament, and requires intraoperative manometry for optimal performance.

Patient Positioning and Equipment

The patient must be carefully positioned to protect both the patient and the surgeon from injury and muscular fatigue. Wires, tubes, and other connections to the laparoscopic equipment must be organized to minimize inconvenience and entanglement while maximizing the ergonomics of the operating space. The surgeon stands between the patient's abducted legs facing directly forward during the operation. The legs may be abducted with low lithotomy stirrups or flat, padded boards that allow the knees to be extended and minimize the potential for lower extremity neurovascular traction injury. Video monitors are positioned at the head of the table to allow ergonomically neutral visualization by the surgeon and the assistants. The patient must be firmly affixed to the operating table and padded in the appropriate locations because the table is generally maintained in steep head-up position to allow gravity to displace the abdominal viscera from the subdiaphragmatic region and bring the patient's upper abdomen toward the surgeon. Our practice is to use a vacuum beanbag mattress that supports gently around the patient's sides and perineum to prevent intraoperative movement. The table must be positioned at an appropriate height and angle to permit the surgeon to operate with the hands in a neutral position to prevent shoulder and elbow fatigue.

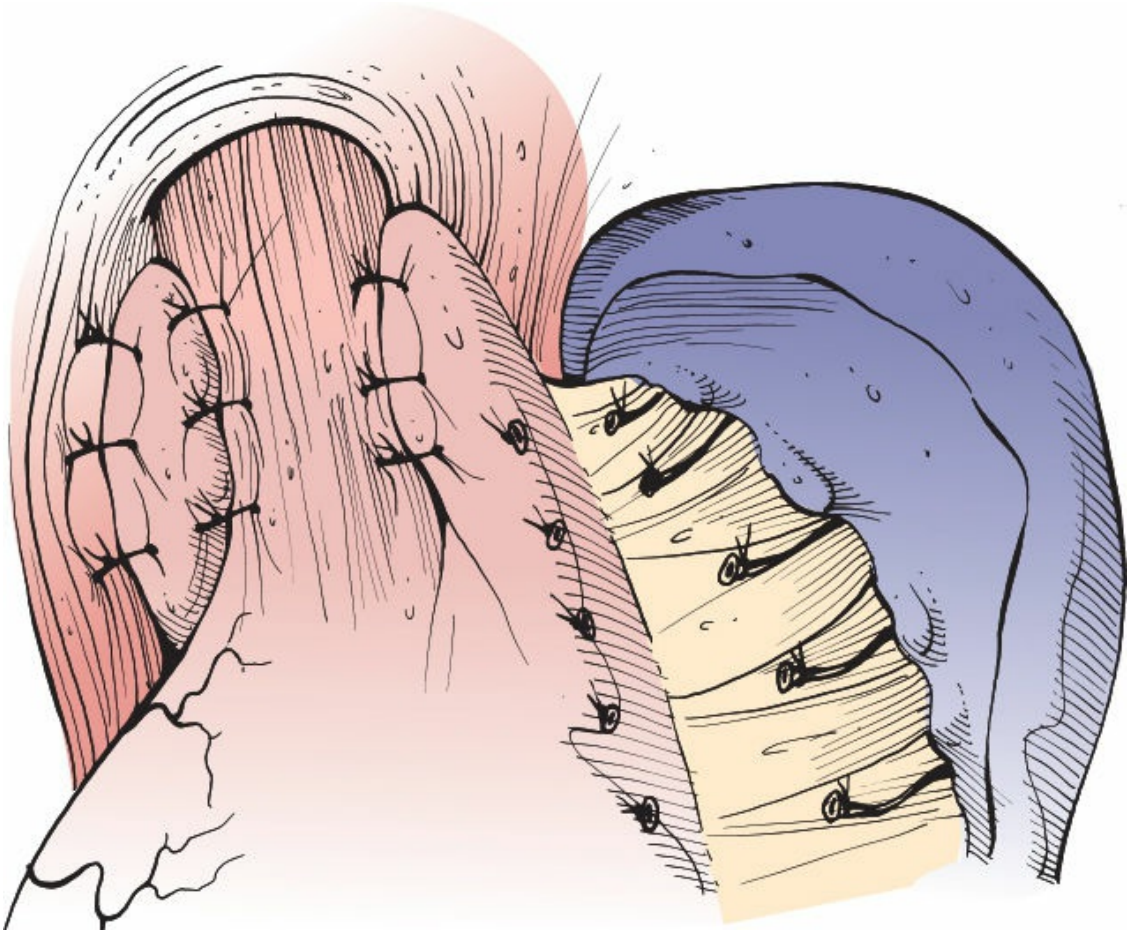

Figure 74.6. Toupet fundoplication. The Toupet fundoplication and its variations have been the most commonly used partial fundoplication since the introduction of laparoscopic fundoplications. The fundus is pulled posterior to the esophagus with suture of the leading edge of the wrapped fundus to the right anterior aspect of the esophagus while the left (medial) side of the fundus is sutured to the left anterolateral aspect of the esophagus. Varying numbers of sutures may be placed between the fundus and the crura for further stabilization.

Several basic varieties of instrumentation are recommended to facilitate the performance of LARS. These include angled laparoscopes (either 30 or 45 degrees), which allow alternative views of the operative field and adequate visualization of the retrofundic and retroesophageal regions. An adequate, atraumatic liver retractor is imperative to allow the left lateral segment of the liver to be elevated for prolonged periods without capsular injury. We use a self-retaining device to hold the liver retractor in an immobile position throughout the operation. This prevents boredom and fatigue by the assistant and decreases the frequency with which the liver retractor is repositioned, and thus the chance of capsular injury.

Atraumatic grasping instruments should be available, including Babcock and DeBakey-type forceps. Appropriate instrumentation for achieving hemostasis and dividing tissues bloodlessly should also be available. These instruments include bipolar and/or monopolar electrosurgical devices, and ultrasonic coagulation and cutting devices. The equipment must be maintained on a regular basis, and back-up instruments should be available in the case of intraoperative failure of any of the devices. Also, a flexible endoscope should be available to allow intraluminal evaluation of the esophagus and stomach, should the need arise.

Abdominal Access and Port Placement

The esophageal hiatus is usually located directly posterior to the xiphoid process. Laparoscopic instruments are generally 30 to 40 cm in length. Ideally, the instrument midpoint should be located at the level of the abdominal wall (fulcrum) during critical portions of advanced laparoscopic procedures to maximize its range of motion during tissue manipulation and establish a 1:1 ratio between external hand movements and internal instrument tip translations. The ports are thus positioned in an arc between 10 and 15 cm inferior to the xiphoid process and costal margin, which are marked prior to pneumoperitoneum.

An open or closed technique may be used to access the peritoneal cavity. With the open technique, a cutdown is performed through a small incision; the fascia is incised under direct vision; sutures are placed at the fascial level; and the peritoneal cavity is entered under direct vision. A Hasson-type trocar and sheath is then placed into the peritoneal cavity, and the abdomen is insufflated with carbon dioxide gas. Alternatively, a Veress needle may be passed directly into the peritoneal cavity. Appropriate maneuvers are performed to document a safe intraperitoneal location of the needle tip, and the peritoneal cavity is insufflated to a pressure of 12 to 15 mm Hg.

Because the esophagus generally enters the abdomen from a slightly right-to-left orientation, and because the falciform ligament and liver limit the right lateral placement of the port for the surgeon’s left hand, we generally place the laparoscope to the left of the midline in a supraumbilical location approximately 12 cm caudal to the midline costal margin (Fig. 74.7). This positioning also prevents the initial port being place within the ligamentum teres. An infraumbilical port site is generally too far inferior on the abdominal wall for operations at or around the

esophageal hiatus.

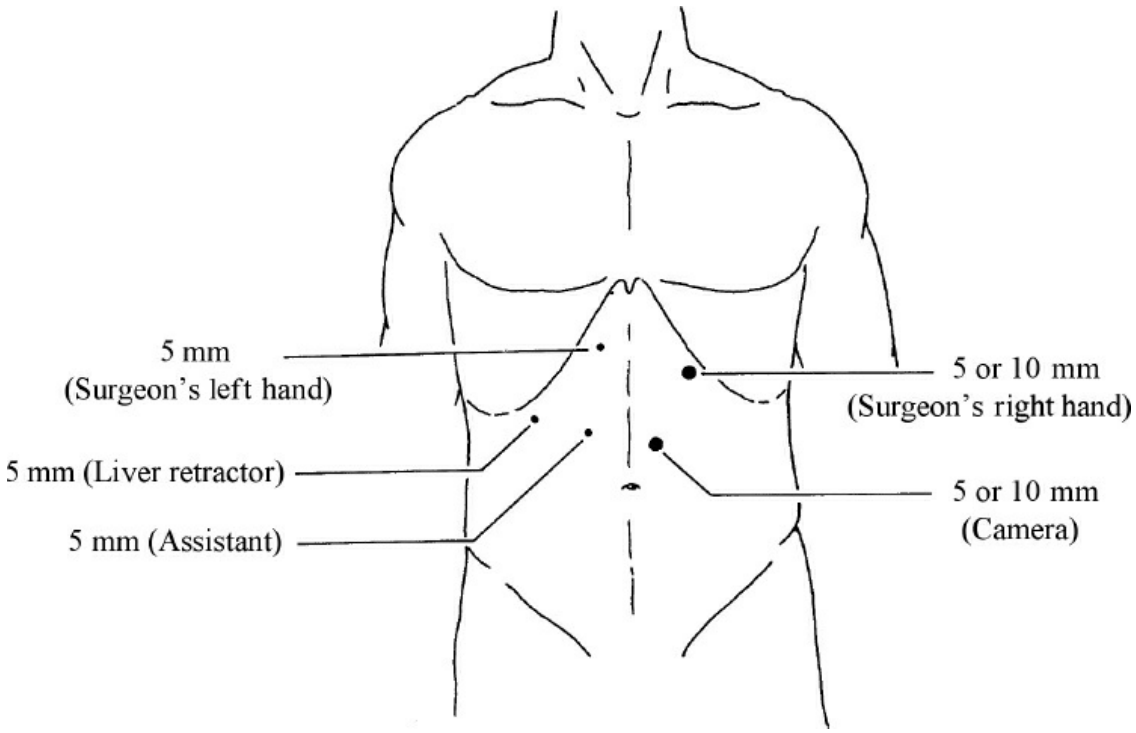

Figure 74.7. Port placement. The costal margin and xiphoid process are marked prior to pneumoperitoneum. The laparoscope is placed to the left of the midline in a supraumbilical location approximately 12 cm caudal to the xiphoid process. With the camera port to the left of midline, the surgeon's right-hand 10-mm port is generally 10 cm from the xiphoid and two fingerbreadths below the left costal margin. A 5-mm right lateral port for the liver retractor is placed at least 15 cm from the xiphoid process two fingerbreadths below the right costal margin. The 5-mm assistant's port is located halfway between the camera and liver retractor. The surgeon's left-hand 5-mm port is inserted after the liver retractor is placed and is generally 5 to 10 cm from the xiphoid process in a right paramedian location.

The skin incision is made in the appropriate location, and a radial dilating sheath and trocar are inserted while the abdominal wall is manually elevated for countertraction. The laparoscope is inserted and a visual exploration is performed of the abdominal cavity, with particular attention paid to the area immediately posterior to the initial trocar insertion site. Currently, we believe that the 10-mm diameter high-definition laparoscopes provide a better video image for advanced procedures because they allow a wider field of view and more brilliant

illumination, even though the use of 2- and 5-mm scopes has been described by other surgeons.

The patient is then rotated into a severe reverse Trendelenburg position, and the accessory ports are placed under direct vision. For optimal visual orientation, the working instruments should be entering the operative field from a 30- to 60-degree angle on either side of the laparoscope. The surgeon's right-hand port is generally placed 10 cm from the xiphoid and two fingerbreadths below the left costal margin. Surgeon preference and instrument use pattern dictate the size of this trocar. We continue to use a 10-mm port because an SH-size needle can be inserted through the valve, whereas if a 5-mm port is used, straight or "ski" needles must be used for suturing. Other "automatic" suturing devices also require a 10-mm port. The 5-mm liver retractor port is then placed at least 15 cm from the xiphoid process two fingerbreadths below the right costal margin. The assistant's 5-mm port is placed halfway between the camera and liver retractor ports. The left lateral segment of the liver is elevated with a self-retaining liver retractor before the surgeon's left-hand 5-mm port is placed. Its precise location depends to an extent on the size and location of the retracted liver and the shape of the liver retractor itself. A Veress needle can be used to "sound out" potential sites on the abdominal wall for this port placement before the incision is made and the final trocar and sheath are inserted.

Other surgeons have described alternative techniques in which the assistant stands to the left of the patient and manipulates tissue through a port placed in the left subcostal region. Others prefer the laparoscopic camera port to be placed in a midline position. Each of these alternatives for port positioning is valid, and surgeons must decide the optimal positioning for the operating team.

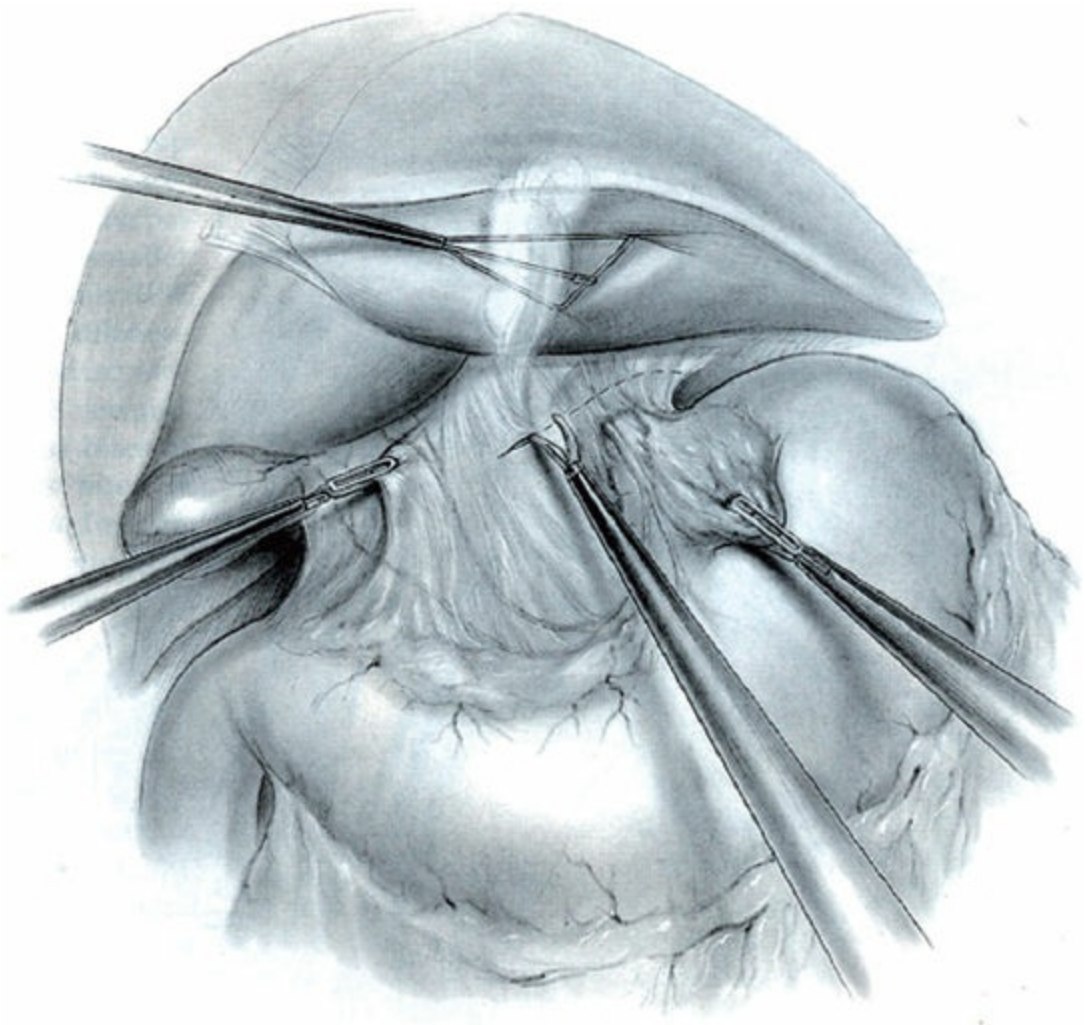

Figure 74.8. Initial dissection: division of gastrohepatic ligament superior to the hepatic branch of the vagus nerve. (Reprinted with permission from Desai KM, Soper NJ. Laparoscopic Nissen fundoplication. In: Soper NJ, Swanström LL, Eubanks WS, eds. *Mastery of Endoscopic and Laparoscopic Surgery*. 2nd ed. Philadelphia, PA: Lippincott Williams & Wilkins; 2005:193.)

Initial Dissection

The anterior gastric wall or the gastroesophageal fat pad is then grasped by the assistant and pulled caudally and to the patient's left, placing traction on the gastrohepatic omentum. The gastrohepatic omentum is divided, beginning just superior to the hepatic branch of the vagus nerve (Fig. 74.8). The surgeon must be wary of the aberrant left hepatic artery of Hyrtl running beside the hepatic branch of the vagus nerve. Although they are encountered in fewer than 5% of patients, they may comprise the majority of arterial inflow to the left lateral segment of the liver. The hepatic branch of the vagus nerve generally does not need to be divided to gain adequate

visualization as long as there is not a large hiatal hernia and one is using an angled laparoscope. The gastrohepatic omentum is divided up to the level of the right crus of the diaphragm and the phrenoesophageal membrane is divided in a transverse direction, with care taken to divide only the most anterior portion to prevent injury to the underlying esophagus and anterior vagus nerve. The gastric fundus is then pulled inferiorly and to the right. The gastrophrenic ligament is divided to mobilize the gastric cardia.

A meticulous dissection is then undertaken around the esophageal hiatus (Fig. 74.9). During the hiatal dissection, the assistant retracts the fat pad inferiorly to place tension on the distal esophagus. Having already divided the phrenoesophageal membrane, it is generally easy to insinuate a blunt-tipped instrument just medial to the right crus of the diaphragm and to establish a plane between the esophagus and the right crus. The surgeon's left-hand instrument grasps or pushes the crus to the patient's right, while the right-hand instrument gradually and gently sweeps the esophagus and paraesophageal tissue to the left to bluntly mobilize the distal esophagus. The posterior vagus nerve is generally clearly seen and is swept along with the esophagus to the left. This mobilization continues in an orad direction as far as possible and then distally to the level of the crus. The tissue attached to the medial border of the base of the right crus is divided until the origin of the right crus from the left crus is visualized from the right side of the esophagus.

Once the right side of the esophagus has been mobilized, the surgeon's right-hand instrument sweeps anterior to the esophagus and elevates the anterior crural arch while gently pushing the esophagus posterior with the blunt side of the left-hand instrument. The posterior-medial aspect of the left crus is visualized, and all of the paraesophageal tissues are swept posteriorly to develop the plane to the left of the esophagus. Generally, the anterior vagus nerve and left pleura are visualized at this time. The initial dissection of the mediastinum is therefore completed, freeing the esophagus from the pleura, the aorta, and the lateral crural attachments. The anterior and posterior vagus nerves are clearly identified to avoid injury. If the pleura are inadvertently lacerated during the dissection, the surgeon must communicate with the anesthetist that this event has occurred. Assuming that the lung parenchyma is not injured, the capnothorax (carbon dioxide) generally poses no serious complications to the patient. The anesthetist can increase the airway pressure while the surgeon slightly decreases the insufflator's pressure limit, and adequate

ventilation and perfusion can usually be maintained. It is almost never necessary to place a chest tube for these pleural tears.

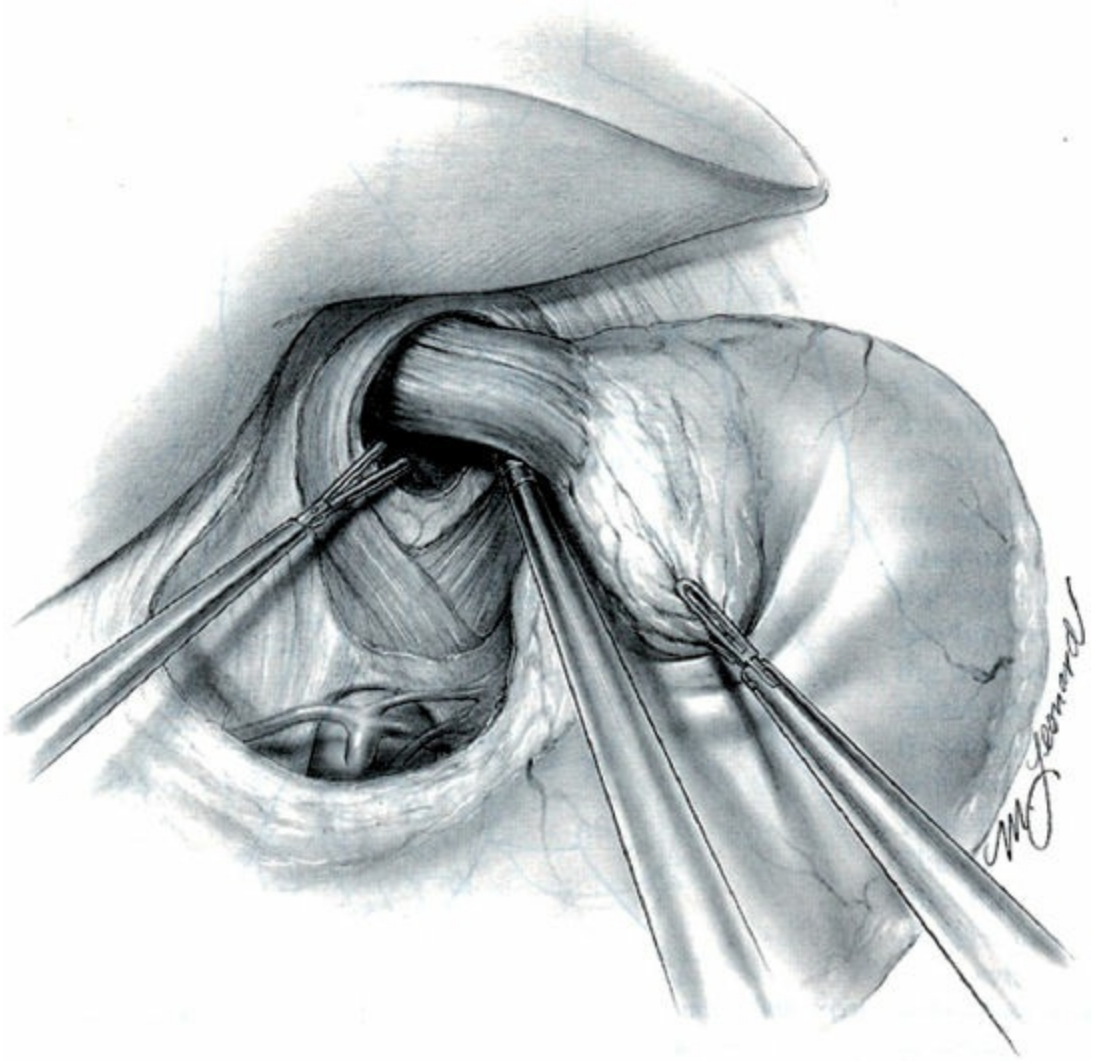

Figure 74.9. Retraction of the fat pad, crural dissection, and identification of vagus nerves. (Reprinted with permission from Desai KM, Soper NJ. Laparoscopic Nissen fundoplication. In: Soper NJ, Swanström LL, Eubanks WS, eds. *Mastery of Endoscopic and Laparoscopic Surgery*. 2nd ed. Philadelphia, PA: Lippincott Williams & Wilkins; 2005:193.)

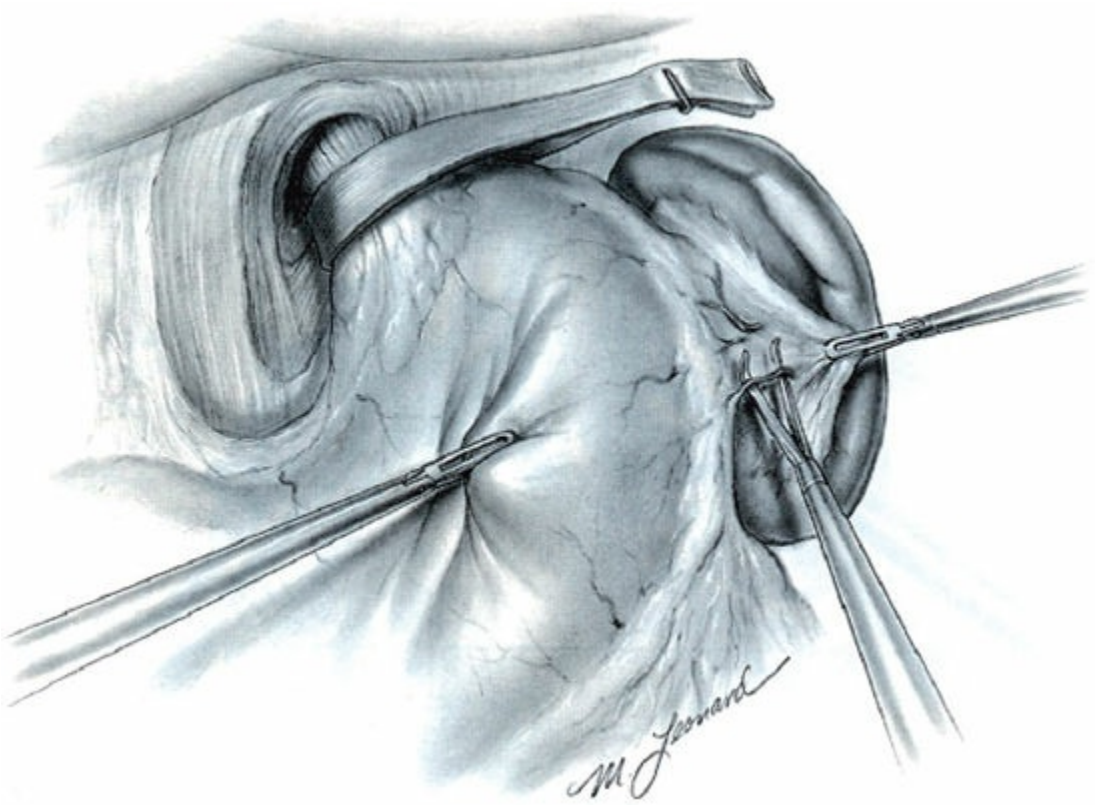

Figure 74.10. Division of the short gastric vessels to the base of the left crus to allow complete fundic mobilization. (Reprinted with permission from Desai KM, Soper NJ. Laparoscopic Nissen fundoplication. In: Soper NJ, Swanström LL, Eubanks WS, eds. *Mastery of Endoscopic and Laparoscopic Surgery*. 2nd ed. Philadelphia, PA: Lippincott Williams & Wilkins; 2005:193.)

The gastric fundus is then mobilized (Fig. 74.10). The left lateral border of the fundus is grasped, elevated, and retracted to the right while the gastrosplenic ligament is grasped, elevated, and retracted to the left. Division of the short gastric vessels is started at a point 10 to 15 cm inferior to the angle of His. The precise location is different with each patient, and it probably makes no difference if excessive fundus is mobilized, but there may be difficulty in creating a tension-free wrap if an inadequate length of fundus is mobilized. We select a point orad to the most proximal gastroepiploic vessels, which are identified by their caudally directed orientation. At this site, a short gastric vessel is identified visually, and a “window” is made between the short gastric vessel and the gastric wall. With the use of a small amount of blunt dissection, entry can usually be made into the free lesser sac, identified by visualizing the space bounded medially by the posterior gastric wall. Once entry into the lesser sac has been gained, traction on the stomach and countertraction on the

gastrosplenic ligament are maintained to align the greater curvature of the stomach with the visual axis of the laparoscope. The short gastric vessels and all other attachments to the fundus are then divided sequentially, proceeding from distal to proximal until the entire fundus has been mobilized.

Division of this tissue may be performed with individually placed clips and sharp division, ultrasonic shears, or bipolar electrosurgery. Prospective randomized trials have shown the ultrasonic shears to perform this task more rapidly and more cheaply than clipping and sharp division. Although we and others have shown an improved outcome with regard to dysphagia and wrap disruption when the fundus is fully mobilized, a prospective randomized trial showed no benefit to short gastric vessel division, although the degree of fundic mobilization in this study was not clear. Division of the short gastric vessels, however, is clearly necessary in certain anatomic situations to allow a tension-free fundoplication. Performing this maneuver routinely develops increased skill and confidence. Dividing the short gastric vessels enhances visualization of the high retrogastric space, which facilitates division of the gastropancreatic ligaments and the posterior gastric vessels. The sites of insertion of the short gastric vessels also clearly identify the lateral border of the fundus, which will later be used for the fundoplication. For all of these reasons, we advocate division of the short gastric vessels and full mobilization of the fundus during all fundoplications.

After complete fundic mobilization, the retroesophageal space is visualized from the left side. The medial border of the left crus of the diaphragm is dissected back to its junction with the right crus, joining the plane previously begun from the right side. A large window is thereby created posterior to the esophagus and the proximal stomach, and anterior to both crura. Once the window is created, many surgeons place a Penrose drain for inferior traction on the gastroesophageal junction (Fig. 74.11). This is a useful maneuver and should be encouraged if traction is difficult to achieve by other means. We generally use the fundus as a retractor, reaching from right to left behind the esophagus to grasp the fundus and retract it back to the right side behind the esophagus. Placing caudal traction on the wrapped fundus, the gastroesophageal junction and distal esophagus can be brought further into the abdominal cavity.

Once the fundus has been pulled to the right behind the esophagus, it is checked for rotational tension and torsion. To assess rotational tension, the

wrapped fundus is released and observed. If it retracts back around the esophagus to the left, there is tension that must be eliminated by dividing more fundal attachments. To check for a twist or entrapment of the wrapped fundus in the posterior window, the “shoeshine” maneuver is performed (Fig. 74.12). The leading edge of the fundus that has been passed behind and to the right of the esophagus is grasped, along with the fundus to the left of the esophagus. The fundus is then retracted back and forth to make sure that it slides easily, the tissues on both sides are in continuity, and the fundus is not twisted.

The distal esophagus is checked to make sure that it has been adequately mobilized to allow at least 3 cm to reside within the abdomen when the traction is released. If this is not possible, further esophageal mobilization must be performed within the mediastinum. If it is not possible to mobilize the esophagus to allow an adequate length of intra-abdominal esophagus, an esophageal lengthening procedure should be performed.

After adequate esophageal mobilization, the crura are re-approximated posterior to the esophagus. Inferior and left lateral traction is maintained on the proximal stomach either by atraumatic graspers placed on the wrapped fundus or with the sling of Penrose drain (Fig. 74.13). One or more sutures are always used to close the crura because even in the absence of a hiatal hernia preoperatively, an iatrogenic one has been created by the paraesophageal dissection. The crura are initially closed posterior to the esophagus, but we usually add one anterior suture to stimulate scarification in this location. We generally use 0 or 2-0 nonabsorbable braided polyester sutures on an SH needle for this purpose. The intra-abdominal crural fascia is incorporated in the sutures rather than the muscle body alone. The crura are closed until they lightly touch the empty esophagus, but it should be possible to pass an instrument between the esophagus and the crura. Esophageal dilators stiffen the esophagus and make it difficult to retract the esophagus anterior for adequate visualization of the posterior crural closure and are, therefore, not used during crural closure.

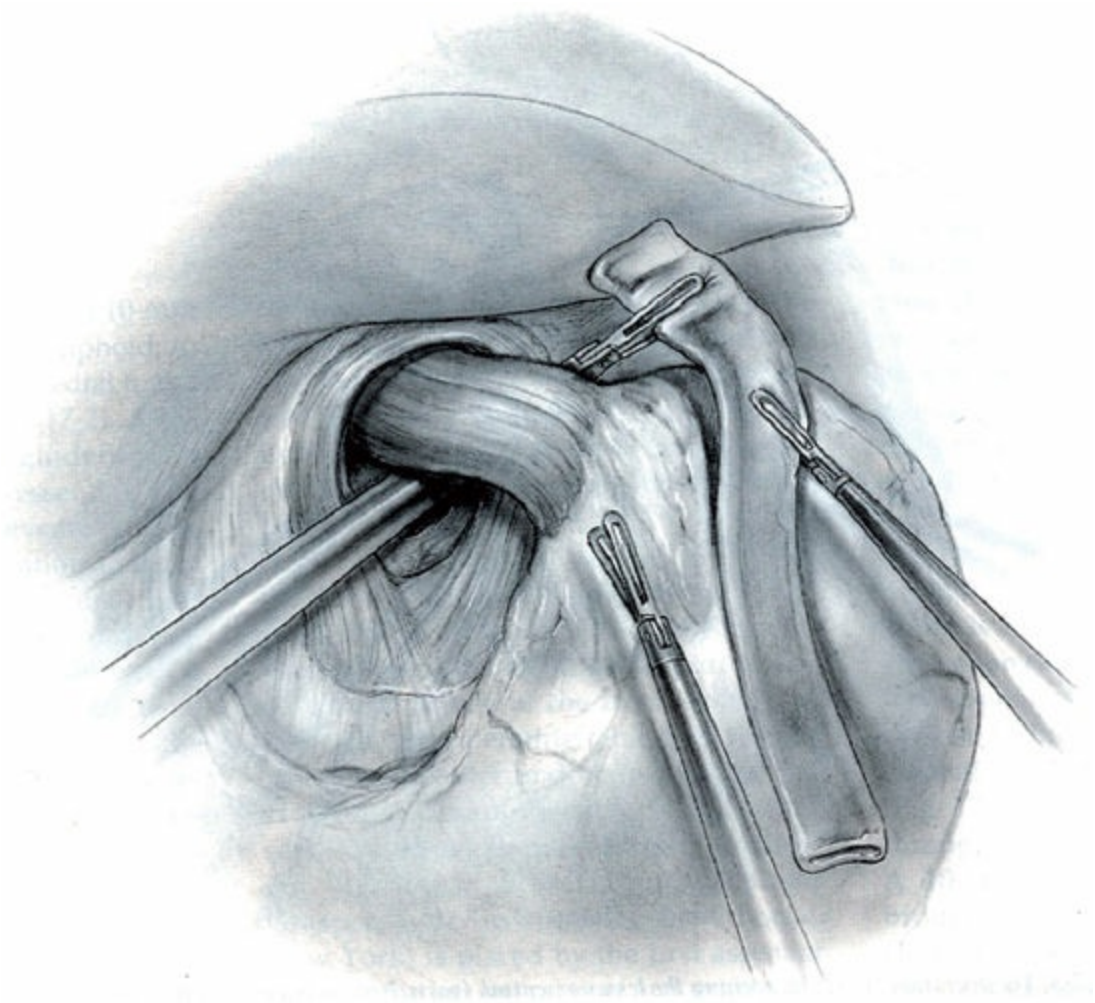

Figure 74.11. A Penrose drain is placed around the esophagus or the gastric fundus is pulled posterior and to the right of the esophagus to provide inferior retraction (optional). (Reprinted with permission from Desai KM, Soper NJ. Laparoscopic Nissen fundoplication. In: Soper NJ, Swanström LL, Eubanks WS, eds. *Mastery of Endoscopic and Laparoscopic Surgery.* 2nd ed. Philadelphia, PA: Lippincott Williams & Wilkins; 2005:193.)

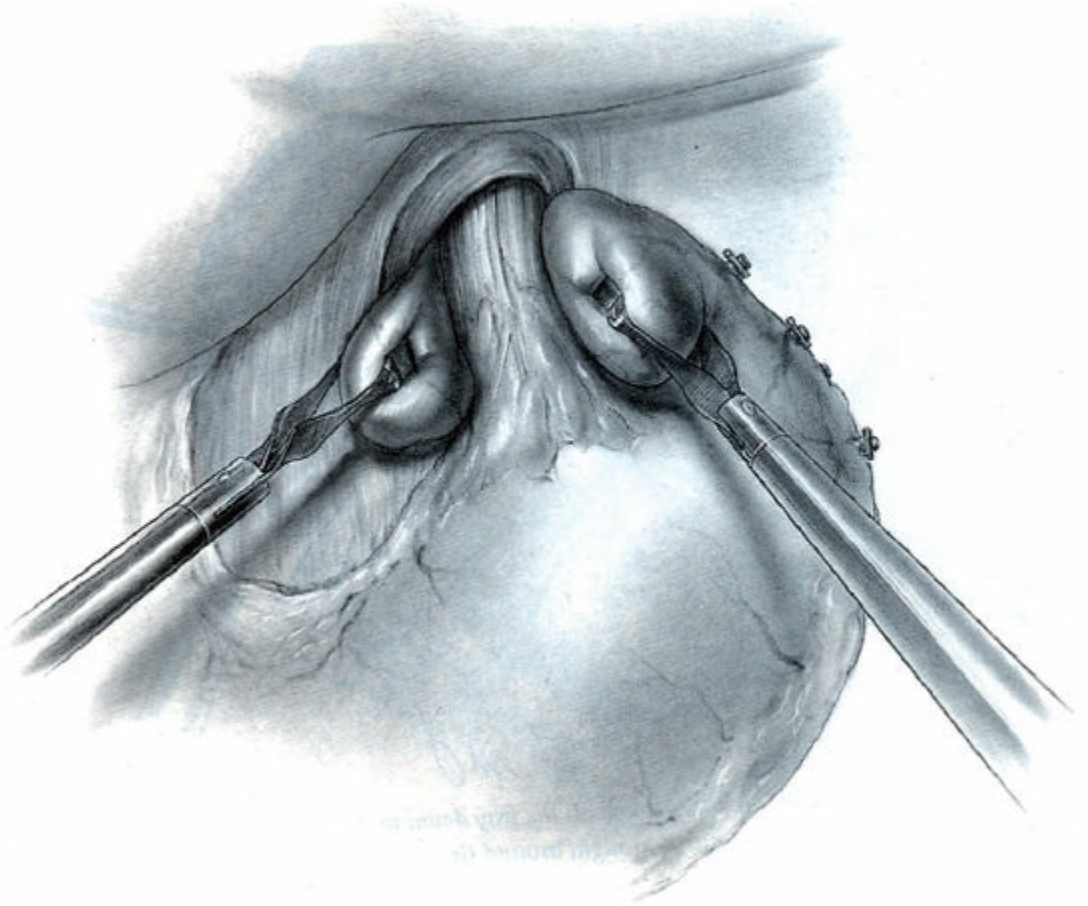

Figure 74.12. The gastric fundus is first pulled posterior and to the right of the esophagus and the “shoeshine” maneuver is performed to ensure that it slides easily and is not twisted. (Reprinted with permission from Desai KM, Soper NJ. Laparoscopic Nissen fundoplication. In: Soper NJ, Swanström LL, Eubanks WS, eds. *Mastery of Endoscopic and Laparoscopic Surgery.* 2nd ed. Philadelphia, PA: Lippincott Williams & Wilkins; 2005:193.)

If closure of the crura appears to be under tension, we now consider performing a right side crural relaxing incision. In the past, we routinely reinforced the crural sutures with bioprosthetic mesh when repairing large hiatal hernias, as promising studies showed reduced rates of reherniation up to 1 year post-op. However, a 5-year follow-up study showed equal rates of re-herniation with or without mesh. We discourage the use of prosthetic material immediately adjacent to the esophagus; it should not be placed circumferentially, and every type of prosthesis has been reported to have the capacity to erode into the esophagus or proximal stomach.

Fundoplication

Most authors advocate the placement of an indwelling bougie dilator during creation of the wrap. We serially pass No. 50 and 60 French Maloney dilators and suture the fundoplication with a dilator in place. Great care must be taken during the passage of the dilators to prevent inadvertent perforation of the esophagus or stomach. The gastroesophageal junction should be maintained in a nonangulated position by the surgeon and the assistant. The dilators are placed under direct vision with clear and constant communication maintained between the individual inserting the dilator and the surgical team. The two sides of fundus are then abutted around the distal esophagus to ascertain whether a tension-free wrap may be achieved.

The medial fundus to the left of the esophagus is then sutured to the leading edge of the wrapped fundus to the right of the esophagus. This may be accomplished with the use of a single-pledgeted horizontal mattress suture of 0 or 00 polypropylene suture or with several interrupted braided polyester sutures. We have used the latter approach. Three heavy-gauge nonabsorbable sutures on SH needles are used, taking deep seromuscular, but non-fullthickness, suture bites in the fundus to the left and right of the esophagus spaced approximately 5 to 8 mm apart (Fig. 74.3). One or two of the three sutures catch the anterior muscularis of the esophagus to the right of the anterior vagus nerve. Great care must be taken during knotting of the sutures to prevent anterior traction, which could cause a tear of the esophageal wall. The dilator is then removed, and the wrap is checked for degree of looseness by passing a 5-mm diameter instrument between the left side of the wrap and the esophagus. The length of the fundoplication should be <2.5 cm, and it must be situated around the esophagus rather than inferiorly on the proximal stomach. The gastroesophageal fat pad is not excised in most patients unless it is so large that it interferes with the ability to perform an adequate fundoplication. The fat pad functions as a handle and is a visual marker of the angle of His. The suggested orientation of the wrap (the point on the esophagus at which the two sides of fundus are joined) varies in different centers. Some surgeons advocate that this junction be placed at the right lateral position of the esophagus, presumably to prevent rotational traction. We tend to place the sutures to the right of the anterior midline of the esophageal wall, with the esophageal sutures placed just to the right of the anterior vagus nerve.

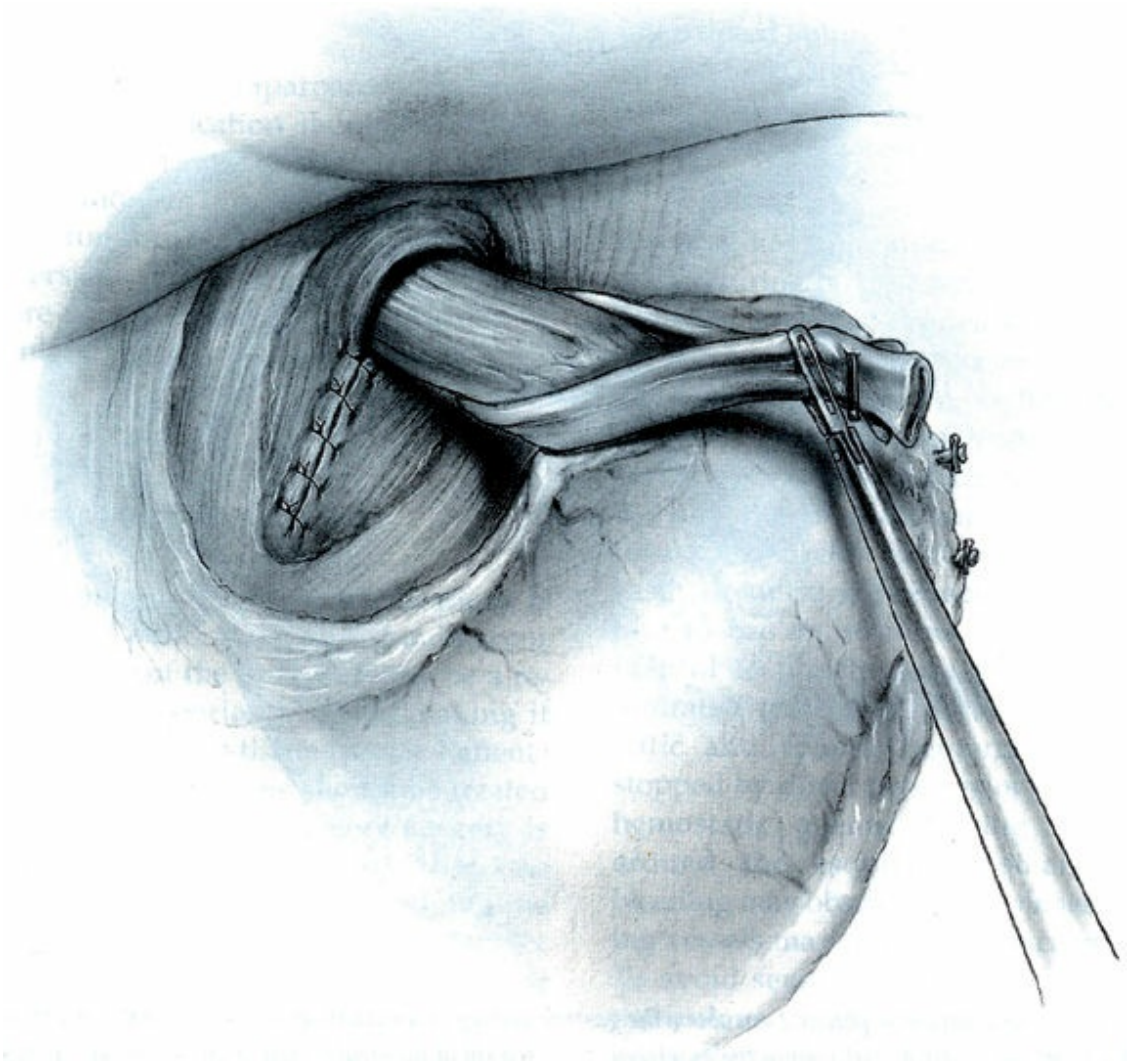

Figure 74.13. Closure of the crural opening posterior to the esophagus with interrupted, nonabsorbable suture. If a Penrose drain is not used, the gastric fundus is used for retraction to expose the crura. (Reprinted with permission from Desai KM, Soper NJ. Laparoscopic Nissen fundoplication. In: Soper NJ, Swanström LL, Eubanks WS, eds. *Mastery of Endoscopic and Laparoscopic Surgery.* 2nd ed. Philadelphia, PA: Lippincott Williams & Wilkins; 2005:193.)

Port Removal and Closure

With the fundoplication completed, the liver retractor is removed, and the undersurface of the liver is examined for capsular tears or bleeding. The upper abdomen is aspirated and checked for hemostasis. The ports are then removed under direct vision. Any port larger than 5 mm in diameter and located below the costal margins on exsufflation of the abdomen should have its fascia closed with heavy-gauge suture, unless radial dilating

trocars are used. If the abdominal wall is thick, we perform this approximation using a fascial closure device under direct vision rather than attempting to suture the deep fascia through the small skin incision after removing the laparoscopic instruments. The abdomen is exsufflated, the ports are removed, and each incision is infiltrated with bupivacaine.

Postoperative Management

Before leaving the operating room, the patient is administered intravenous ketorolac and ondansetron. A nasogastric tube is rarely placed. The patient is given ice chips overnight and allowed clear liquids the morning after the operation. If tolerated, a soft diet is ordered for lunch. We admit patients to the hospital after the operation, but some groups have performed true outpatient LARS. The patient receives scheduled ketorolac and ondansetron intravenously through the first 12 to 18 hours after the operation to minimize the need for narcotics and to diminish the chance of postoperative vomiting and associated disruption of the crural closure and migration of the wrap into the chest. Because of edema narrowing the esophagus in the early postoperative interval, the patient is placed on a soft diet for the first 2 to 4 weeks. Should the patient experience pain out of proportion to what is expected, or if the patient vomits in the early postoperative period, a water-soluble contrast swallow radiograph is obtained to evaluate for disruption or displacement of the wrap or unrecognized perforation. The patients are seen in the outpatient office at 2 to 4 weeks after the operation. Although rapid resumption of full activity is encouraged, activities requiring the Valsalva maneuver are discouraged for at least 6 weeks after the operation.

LAPAROSCOPIC PARTIAL FUNDOPLICATIONS

The general approach and initial dissection for laparoscopic partial fundoplications are identical to those for the Nissen fundoplication. Partial fundoplications are generally reserved for patients with poor esophageal motility associated with GERD, either because of the reflux itself or because of a primary motility disorder associated with reflux. Recent studies, however, suggest that most patients with decreased esophageal motility have better control of reflux after complete fundoplication with equivalent rates of dysphagia. When partial fundoplication is used, the Toupet fundoplication has been the main alternative.

Although it may be possible to construct a partial fundoplication

without fundic mobilization or division of the short gastric vessels, our preference has been to perform complete fundic mobilization routinely, regardless of the type of fundoplication. The precise technical details of the Toupet fundoplication vary considerably among different surgeons. Some authorities describe fixation of the fundoplication to the crura, whereas others have omitted this step. Most individuals use multiple interrupted sutures of heavy-gauge nonabsorbable sutures to fix the fundoplication between 200 and 270 degrees around the posterior circumference of the esophagus.

If the fundus is sutured to the crura, this is performed before a dilator is passed into the esophagus. The wrapped fundus is pulled well to the patient's left to expose the posterior aspect of the wrapped fundus and the crura. Several sutures are placed between both the posterior left aspect of the fundus and the left crus, and between the posterior right aspect of the fundus and the right crus of the diaphragm to stabilize the wrap. A No. 50 French dilator is then inserted, and several interrupted sutures are placed between the anterior esophageal wall and the left and right sides of the gastric fundus. Although the dilator is not absolutely necessary, we feel that it helps by making the esophagus assume a more tubular shape for precise suture placement. The sutures can then be placed with the use of clock-face references. We generally place three sutures between the right anterolateral aspect of the esophagus (at the 11 o'clock position) and the leading edge of the wrapped portion of fundus. Usually, the most cephalad suture is also placed through the crus. The sutures in the esophageal wall should be relatively deep but not full thickness to prevent entry into the lumen with the potential for fistula formation. Several interrupted sutures are placed to create a wrap that is 2 to 3 cm in length along the right lateral aspect of the esophagus. The medial fundus to the left of the esophagus is then grasped with an atraumatic grasping forceps, elevated, and pulled toward the left anterolateral border of the esophagus. Three interrupted sutures of heavy nonabsorbable material are then placed between the fundus to the left of the esophagus and the left anterior lateral wall of the esophagus (at the 1 o'clock position). Care is taken to avoid the anterior vagus nerve while these sutures are being placed. The dilator is then removed, and the area is examined for hemostasis.

It is unclear whether sutures should be placed between the fundoplication and the diaphragm during LARS. Although these sutures may help to buttress the wrap, they may also fix the fundoplication in an

unnatural position in relation to the diaphragm. The axial motion of the esophagus during swallowing and the bellows action of the diaphragm during breathing may pull on these sutures, placing tension on the fundoplication with the potential for its disruption. We recently have begun omitting the sutures between the fundus and the crura of the diaphragm. Instead, multiple interrupted sutures are placed between the fundus and the esophagus in an attempt to fix the wrap permanently in position without the diaphragmatic sutures. Given the impossible task of determining the precise depth of suture "bites" in the esophagus and the understandable anxiety of the surgeon about entering the esophageal lumen or perforating the esophagus, these fundoplication-anchoring sutures may be less deep than ideal, possibly leading to the observed greater incidence of wrap disruption with laparoscopic Toupet fundoplication than with LNF.

Postoperative care of patients who have undergone laparoscopic partial fundoplications is identical to that of patients who have undergone Nissen fundoplication. If the surgeon is concerned about the possibility of esophageal perforation or if the patient retches or vomits in the early postoperative interval, a water-soluble contrast radiograph should be obtained to evaluate for perforation or wrap disruption before any oral intake. If the surgeon suspects an esophageal perforation during the operation, an oral gastric tube should be used to instill methylene blue to assess for perforation while the patient is on the operating table. Alternatively, an endoscope can be passed with performance of a bubble test. Most esophageal and gastric perforations discovered during the operation may be closed laparoscopically with multiple fine sutures, and the adequacy of the repair can be checked by insufflating air or carbon dioxide into the esophagus after flooding the area with saline solution. If possible, the repaired perforation should be buttressed by the fundoplication.

RESULTS OF LAPAROSCOPIC ANTIREFLUX SURGERY

More than 10,000 cases of LARS have been reported in the literature since LNF was first reported in 1991. The results compiled from several large series are summarized in Table 74.9. To keep the outcomes of LARS in perspective, they should be compared with those of open antireflux operations. Splenic injury occurs in up to 8% of open cases, and the mortality rate ranges up to 1.4%. Pulmonary complications occur between

1% and 6.5% of open operations. The length of hospital stay after open fundoplication varies with the institution and the type of health care system. Prospective randomized trials and a recent meta-analysis comparing laparoscopic with open Nissen fundoplication have revealed similar outcomes (symptomatic and physiologic) with reduced hospital stays. Long-term follow-up for the open procedures (>10-year follow-up) demonstrates a success rate >90% for the control of GERD symptoms.

TABLE 74.9 Compiled Results of Laparoscopic Antireflux Surgery

Complication	Incidence
Mortality	0.0–0.5%
Major morbidity	2–10%
Splenectomy	Rare
Converted	1–12%
Early reoperation	0–3%
Early dysphagia	10–90%
Late dysphagia	5–10%
Anatomic failure	5–10%

Early Results

Early postoperative results of LARS demonstrate perioperative rates of mortality and splenic injury both nearly zero. Conversion from a laparoscopic to an open procedure is higher early in a surgeon's experience with the operation, but in most series the conversion rate is <5%. The operative time averages 1 to 3 hours, with a clear learning curve. In series from the United States, the duration of postoperative hospitalization averages <2 days with anecdotal reports of performing outpatient LARS. Respiratory and wound complications are uncommon because of the minimally invasive nature of the access approach with diminished perioperative pain. Perioperative complications requiring reoperation occur in <1% of patients and include perforation of the stomach or esophagus and migration of the fundoplication into the chest as a result of perioperative retching. Early results of Nissen fundoplications, Rossetti-Nissen fundoplications, and partial fundoplications all appear similar, although several reports suggest a higher incidence of dysphagia after the Rossetti-Nissen technique.

Intermediate and Late Results

Postoperative foregut symptoms are relatively common after antireflux surgery, whether performed with open or laparoscopic techniques. Dysphagia is a common problem early after operation, but diminishes over time such that only 5% to 10% of all patients will experience occasional mild dysphagia, and only 1% to 2% of patients will require esophageal dilatation. The so-called gas-bloat syndrome is a relatively uncommon finding, and most patients with postoperative bloating also had significant bloating before the operation. Many patients with GERD develop the habit of swallowing frequently to promote esophageal clearance of acid, leading to aerophagia. With a tight fundoplication, an inability to belch with bloating may occur but often resolves over time. Recurrent reflux symptoms are present in up to 5% of patients, and wrap disruption or migration either into the chest or down onto the stomach occurs in up to 10% of patients over the long term. Most patients are satisfied with the operation, with overall satisfaction rates ranging from 87% to 100%. The quality of life is improved after LARS. Atypical symptoms of GERD, particularly chest pain and pulmonary symptoms, are less reliably resolved after LARS than typical symptoms.

Partial Fundoplications

The long-term outcome after laparoscopic posterior partial fundoplications does not appear to be as good as after complete fundoplications. In their early experience, Patti and colleagues selectively used partial fundoplications for patients with “dysfunction of esophageal peristalsis,” and showed improvement in esophageal peristalsis and postoperative esophageal pH testing. However, they reported their long-term results and concluded that the laparoscopic partial fundoplication was less effective than total fundoplication in resolving GERD with an equivalent incidence of postoperative dysphagia. Other groups have shown similar results, prompting many centers to abandon partial fundoplications except in the setting of severe esophageal motility disorders (i.e., scleroderma, achalasia). Cai et al. however, reported equivalency between laparoscopic Nissen versus Dor partial fundoplication in a recent 10-year follow-up of a prospective randomized clinical trial. We still believe that partial fundoplication is valuable in certain situations and should be part of the surgical armamentarium in treating GERD.

COMPLICATIONS/AVOIDING PITFALLS

The learning curve for LARS requires 30 to 50 operations and is reflected by decreasing operative time and diminishing rates of complications and failed fundoplications. Complications fall into two main categories: anatomic and functional. Anatomic complications usually result in postoperative dysphagia and may be the result of excessively tight closure of the esophageal hiatus, a tight wrap, or tension on the wrap causing twisting of the lower esophagus. Failed fundoplications can take several forms (Fig. 74.14). The most common fundoplication-associated complication after LARS is migration of the wrap through the hiatus into the mediastinum. This is often heralded by new-onset substernal or epigastric pain rather than reflux symptoms. The wrap itself may disrupt or migrate down onto the stomach (the so-called slipped Nissen), but this complication is more frequent after open Nissen fundoplication than after laparoscopic fundoplication. We previously reviewed our experience with anatomic fundoplication failure. Fundoplication disruption and/or migration is associated with surgical inexperience, shortcomings of surgical technique, the presence of a large hiatal hernia, and the occurrence of diaphragmatic stressors, including perioperative vomiting. To prevent fundoplication failure, therefore, the surgeon must carefully select patients, perform the operation with specific attention to full mobilization of the fundus and esophagus, and close the crura around the esophagus adequately.

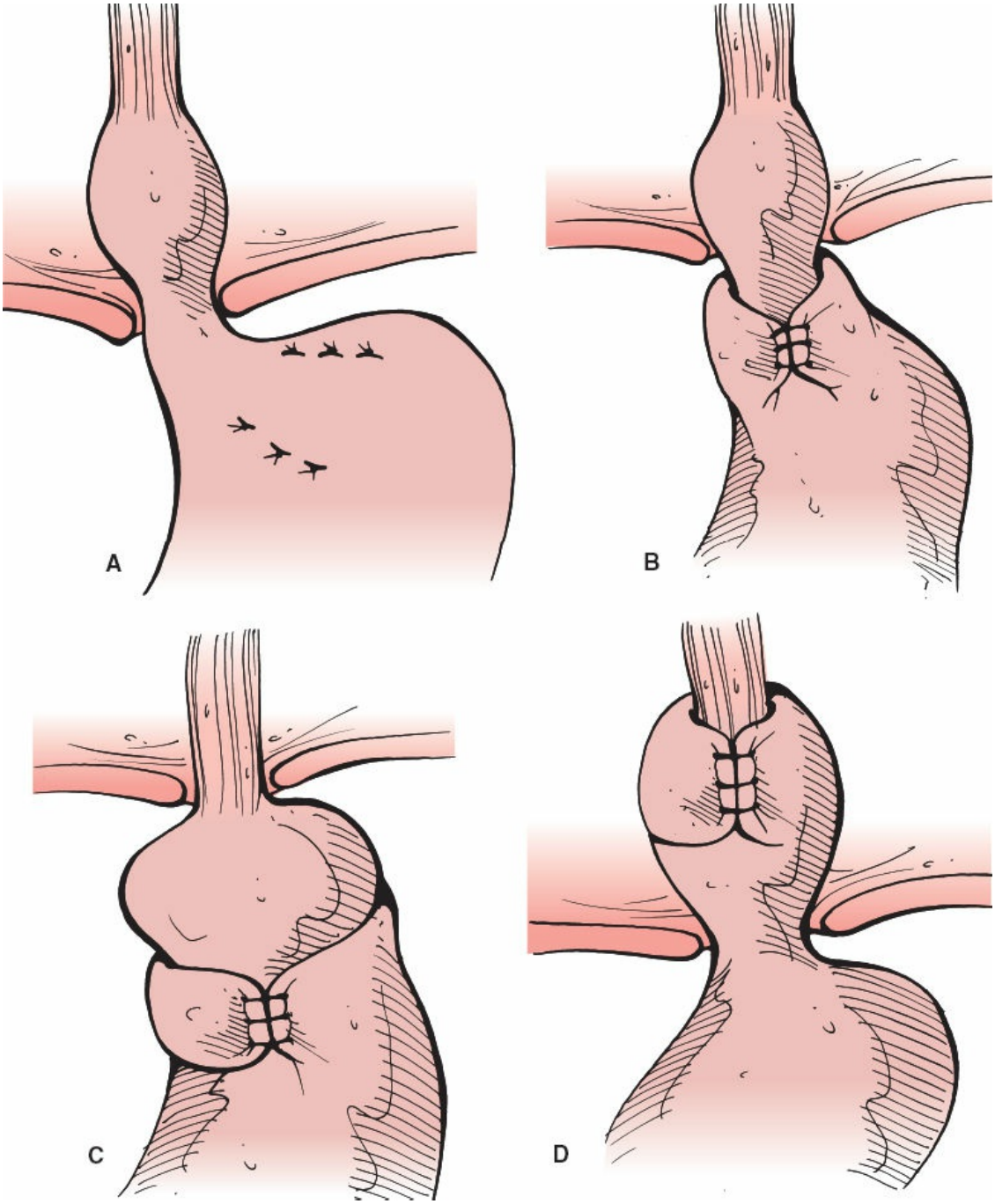

Figure 74.14. Types of fundoplication failures. **A.** Disrupted wrap. **B.** Sliding hiatal hernia with wrap in abdomen. **C.** "Slipped" fundoplication onto proximal stomach. **D:** Intrathoracic migration of the fundoplication. (Reprinted with permission from Desai KM, Soper NJ. Laparoscopic Nissen fundoplication. In: Soper NJ, Swanström LL, Eubanks WS, eds. *Mastery of Endoscopic and Laparoscopic Surgery.* 2nd ed. Philadelphia, PA: Lippincott Williams & Wilkins; 2005:193.)

The management of fundoplication failures after LARS is complex. A barium swallow usually confirms the presence of fundoplication failure,

and this study will also allow an assessment of the location of the gastroesophageal junction in relation to the esophageal hiatus. Before considering reoperative treatment for fundoplication failure, esophageal motility must be assessed to determine the type of fundoplication that can be supported by the amplitude and progression of esophageal peristalsis. If the gastroesophageal junction is located within the abdomen, attempted laparoscopic repair is appropriate. If the gastroesophageal junction is well above the diaphragm, our approach is to perform a thoracotomy with Collis gastroplasty and fundoplication. The patient must be aware that the rates of complication and conversion to open surgery are likely to be much higher in these reoperative situations. After multiple operations or in the presence of severe paraesophageal mediastinal fibrosis, subtotal gastrectomy or esophagectomy may be the best alternative for a patient with failed fundoplication. Finally, some patients have postoperative symptoms and are unhappy with the outcome despite an anatomically and functionally intact fundoplication. These symptoms are usually not related to recurrent GER.

Functional complications usually manifest as bloating, but may also rarely result from dumping syndrome due to the increased gastric emptying seen after fundoplication. Severe bloating symptoms, not attributable to anatomic complication, are usually the result of gastroparesis, either initially undiagnosed or the result of vagus nerve injury. This is one of the reasons why patients who have more atypical symptoms preoperatively should have a gastric emptying scan. Patients with documented severe delayed gastric emptying preoperatively should be offered a concomitant pyloroplasty as several recent reports have demonstrated improvement in bloating symptoms for these patients. This also suggests that patients diagnosed with severe delayed gastric emptying after LARS may also benefit from pyloroplasty if severe bloating systems persist, are not the result of an anatomic failure, and do not respond to pro-kinetic agents. Injury to the vagus nerves at initial operation may result in the bloating described above; however, conflicting data exist as some authors advocate cutting the vagus nerves to avoid a Collis procedure when esophageal shortening is present, and have not demonstrated an increase in postoperative gastroparesis. In addition to pyloroplasty, conversion to Roux-en-Y gastric bypass with resection of the gastric remnant has been described with mixed results.

REOPERATIVE SURGERY

Patients with ongoing, recurrent or new symptoms following transabdominal antireflux surgery may require reoperation. With over 1,000 reoperative cases published in the literature, the most common presenting symptom in this group of complex patients is recurrent GERD, followed by dysphagia, gas bloat, and hiatal hernia. These patients require careful workup before considering an operative approach, as reoperation is technically challenging, and should only be approached by surgeons with extensive LARS experience. Patients in whom several previous antireflux operations have failed and/or who have high-grade dysplasia in the presence of Barrett esophagus may be best managed by esophagectomy.

Patient Selection/Preoperative Workup

Patients being considered for reoperative LARS must undergo a thorough workup beginning with a detailed history of the original and existing symptoms. Whether the patient has recurrent symptoms versus a new symptom can help guide the surgeon in the choice of operation. Additional workup with pH-testing, EGD, UGI, and manometry is essential for the majority of patients, while gastric scintigraphy may help delineate patients with delayed gastric emptying. If available, it is also helpful in reviewing the prior operative note to assist with the operative planning. Table 74.10 details a sample clinical decision algorithm. For example, a patient with recurrent GERD symptoms found to have a disrupted Nissen fundoplication and a positive pH study may best be served with a redo Nissen fundoplication. Alternatively, a patient with new dysphagia and an intact Nissen fundoplication may require conversion to a partial fundoplication. Discussion of these complex patients in a multidisciplinary conference of surgeons and gastroenterologists can aid in the decision making for medical or operative management (see Table 74.10). A recent paper commented that up to one third of patients referred for reoperation were deemed to be better served with medical management.

Laparoscopic Versus Thoracotomy Approach

The majority of reoperative antireflux operations can be successfully approached laparoscopically; however, some debate exists as to the optimal surgical approach for some patients. The primary decision usually rests in the number of prior operations and the presence of esophageal

shortening or a paraesophageal hernia. Again, it is often helpful to have complex cases discussed in a multidisciplinary fashion to determine if a laparoscopic or thoracoscopic approach should be taken. This also allows a thoracic surgeon to know about the patient and be on standby should the laparoscopic surgeon need to convert and not feel comfortable in proceeding with a thoracotomy.

TABLE 74.10 Sample Clinical Decision Algorithm for Reoperative Laparoscopic Antireflux Surgery

Initial Symptom	Initial Operation	Symptom	Findings	Potential Treatment
GERD	Nissen	GERD	+pH	Redo Nissen
GERD	Nissen	Any	Intrathoracic herniation	Redo Nissen or transthoracic Collis/Belsey
GERD	Nissen	Dysphagia	Esophageal dysmotility	Convert to partial
GERD	Nissen	Dysphagia	Twisted or tight fundoplication	Redo Nissen
GERD	Partial	GERD	+pH	Convert to Nissen
GERD	Nissen	Gas bloat	Negative	Convert to partial or medical management
Any	Partial	Dysphagia	Any	Undo fundoplication
Any	Any	GERD, dysphagia, or chest pain	Negative	Medical management
Any	Any	Dysphagia	Slipped fundoplication	Redo fundoplication
Any	Nissen	Dysphagia	Achalasia	Heller, Toupet, or Dor
Any	Any	Gas bloat	Delayed gastric emptying	Pyloromyotomy
Any	Any	GERD	High-grade dysplasia	Esophagectomy or EMR
Any	Multiple prior	Any	Any	Esophagectomy or gastrectomy

EMR, electronic medical record; GERD, gastroesophageal reflux disease.

Dissection Technique

The steps for reoperative LARS are generally the same as that of an initial operation. Consideration of intra-abdominal adhesions, particularly if the initial operation was open, may alter the initial trocar placement position (right upper quadrant vs. midline) and technique (open Hasson vs. Veress needle). Dense adhesions should be expected, especially from the fundoplication to the undersurface of the left lobe of the liver, and are then carefully dissected. Adhesiolysis near the prior fundoplication and esophagus should be performed sharply to avoid thermal damage. The initial fundoplication then needs to be completely undone. During this portion of the dissection, identification and preservation of the vagus nerves can be challenging. Reviewing the previous operative report may be helpful in avoiding injury to these nerves, particularly if the initial surgeon did not incorporate them within the fundoplication. Gastric or esophageal perforation has been reported in approximately 10% to 15% of reoperative cases. These are usually recognized intraoperatively, primarily

repaired, and buttressed with the fundoplication. Hiatal hernia is a contributing factor in up to 50% of recurrent disease. In order to reduce the risk of an additional recurrence, some centers, including ours, routinely use absorbable or biologic mesh to reinforce the crural closure or consider a right-sided crural relaxing incision during these reoperative cases.

Results/Complications

Over the past decade, there have been numerous reports with favorable results for reoperative laparoscopic antireflux operations. A recent meta-analysis demonstrated an 81% success rate, although the definition of "success" varied among the 13 studies that measured this endpoint. An encouraging 73% of patients would have the surgery again, although only 5 studies asked this question. Not surprisingly, operative times and intraoperative complication rates were higher, while conversion rates and hospital length of stay were similar.

LAPAROSCOPIC MAGNETIC SPHINCTER AUGMENTATION

Magnetic sphincter augmentation is emerging as another laparoscopic procedure to help treat patients with GERD. With this procedure, the LINX device (string of magnetic beads) is placed laparoscopically around the gastroesophageal junction. The magnetic force of the beads is strong enough to overcome the intragastric pressure decreasing reflux events. As long as adequate peristalsis exists (preoperative manometry mandatory), a food bolus will overcome the magnetic force of the beads to allow for passage. A minimal dissection technique is used to create a retroesophageal tunnel between the posterior vagus and the esophagus. A sizing device is passed through the window to help choose the appropriate one of five available sized LINX inplants. The beads are passed through the window and closed with a self-containing mechanism. Patients are expected to have transient dysphagia for the first several weeks and are encouraged to "work it out" by maintaining a regular diet. This regimen allows the beads to continue to be able to separate as the body forms a capsule around the device. Multiple recent studies have demonstrated good reflux control with a low complication profile in selected carefully patients with pH study documented GERD with <2 cm hiatal hernia.

CONCLUSIONS

LARS is the gold standard for patients requiring surgical therapy of GERD, due to the minimally invasive nature and the excellent long-term outcomes of these procedures. For optimal results, good patient selection is the key and LARS must be performed by experienced surgeons with technical skill and acumen. Significant postoperative symptoms require full anatomic and functional diagnostic testing prior to considering revisional surgery. “Re-do” esophageal surgery has much higher rates of complications and failure than primary operations, and should be performed only by those with extensive experience in esophageal surgery.

Suggested Readings

Broeders JA, Rijnhart-de Jong HG, Draaisma WA, et al. Ten-year outcome of laparoscopic and conventional Nissen fundoplication: randomized clinical trial. *Ann Surg* 2009;250:698–706.

Cai W, Watson DI, Lally CJ, et al. Ten-year clinical outcome of a prospective randomized clinical trial of laparoscopic Nissen versus anterior 180 (degrees) partial fundoplication. *Br J Surg* 2008;95:1501–5.

DeMeester TR, Peters JH, Bremner CG, et al. Biology of gastroesophageal reflux disease: pathophysiology relating to medical and surgical treatment. *Ann Rev Med* 1999;50:496–506.

Gee DW, Andreoli MT, Rattner DW. Measuring the effectiveness of laparoscopic antireflux surgery: Long-term results. *Arch Surg* 2008;143:482–7.

Lagergren J, Bergstrom R, Lindgren A, et al. Symptomatic gastroesophageal reflux as a risk factor for esophageal adenocarcinoma. *N Engl J Med* 1999;340:825–31.

Lamb PJ, Myers JC, Jamieson CG, et al. Long-term outcomes of revisional surgery following laparoscopic fundoplication. *Br J Surg* 2009;96:391–7.

Patti MG, Robinson T, Galvani C, et al. Total fundoplication is superior to partial fundoplication even when esophageal peristalsis is weak. *J Am Coll Surg* 2004;198:863–9.

Peters MJ, Mukhtar A, Yunus RM, et al. Meta-analysis of randomized clinical trials comparing open and laparoscopic anti-reflux surgery. *Am J Gastroenterology* 2009;104:1548–61.

SAGES Guidelines. Guidelines for surgical treatment of gastroesophageal reflux disease (GERD). *Surg Endosc* 1998;12:186–8.

Soper NJ, Dunnegan DL. Anatomic fundoplication failure after laparoscopic antireflux surgery. *Ann Surg* 1999;229:669.

van Beek DB, Auyang ED, Soper NJ. A comprehensive review of laparoscopic redo fundoplication. *Surg Endosc* 2011;25:706-12.

EDITOR'S COMMENT

The worldwide experience with laparoscopic antireflux surgery has grown exponentially. Various surgical societies have developed and published practice guidelines for the performance of antireflux surgery. As the Society of American Intestinal and Endoscopic Surgeons (SAGES) indicates: "the laparoscopic Nissen fundoplication is a unique operation in the realm of General Surgery, in that the indication for operation is based on the patient's subjective assessment of symptoms, the fundamental aspect of the operation includes an element of surgeon artistry, and the results are largely subjective. Outcomes are therefore highly dependent on patient expectations, and it is difficult to extrapolate the results of a given surgeon's technique to a population served by many surgeons using the same technique." In other words, this is an operation where patient selection and surgeon experience matter as the art of the surgery remains important. Fortunately, with time, the science behind the approaches selected continues to improve with further publication of randomized trials comparing surgery versus medical therapy for gastroesophageal reflux disease (GERD) or comparing different surgical approaches for this condition. As obesity continues to increase in the United States, the epidemic of reflux disease and development of esophageal adenocarcinoma are alarming and a major health concern.

As the authors indicate, laparoscopic antireflux surgery remains an important treatment option for GERD. Dr. Soper and colleagues have done an outstanding job describing in great detail the various steps and pitfalls associated with the workup of possible GERD and performance of partial and complete fundoplications. To complement their previous contributions to *Mastery of Surgery* in this area, per-oral endoscopic myotomy (POEM) for achalasia and endoluminal approaches for GERD have been added in the present edition.

The authors describe the standard workup for patients with GERD, which includes 24-hour pH monitoring, upper endoscopy, upper gastrointestinal barium swallow study, manometry and possibly an evaluation of gastric emptying. There has been little change in the performance of these tests over the last several years except for the continued evolution of high-resolution manometry (HRM). HRM has become increasingly important and is now the new worldwide standard for the clinical evaluation of esophageal motility disorders. The implementation of HRM is a major improvement compared to conventional manometry. As a result, esophageal HRM has replaced conventional manometry in the clinical evaluation of patients with esophageal symptoms, especially dysphagia. HRM is useful to identify the patient with achalasia or scleroderma who has symptoms of GERD. It is also useful in

tailoring the type of antireflux operation (Savarino E, de Bortoli N, Bellini M, et al. Practice guidelines on the use of esophageal manometry—a GISMAD-SIGE-AIGO medical position statement. *Dig Liver Dis* 2016;48(10):1124–35). Postoperative manometry combined with upper endoscopy or barium esophagogram is of value for the assessment of postoperative dysphagia, particularly when it persists for 4 weeks after surgery (Pandolfino JE, Kahrilas PJ. AGA technical review on the clinical use of esophageal manometry. *Gastroenterology* 2005;128(1):209–24). Indeed, they may reveal a migration or disruption of the wrap or abnormalities in terms of peristaltic function, LES pressure, and LES relaxation (i.e., wrap too tight).

The technical steps and maneuvers during laparoscopic antireflux surgery, in the presence and absence of a hiatal hernia, should be carefully understood and committed to memory. This chapter details them very nicely and is based on the author's many years of experience. For instance, tacking the fundus of the stomach to the diaphragm (particularly on the left side) should be done in the absence of a dilator being present in the esophagus. Just try it with a 56 French dilator present and you will understand how difficult this is! In addition, esophageal dilators stiffen the esophagus and inhibit anterior retraction of the esophagus to allow posterior crural closure. Therefore, they are best left out of the esophagus until after crural closure. I have also found that the use of the Enseal to be particularly effective in working around the esophagus as the outer blades do not become that hot and minimize transmission of heat to adjacent critical structures. In addition, use of the Endo Stitch can greatly facilitate suturing.

Controversy continues regarding the effectiveness of Nissen fundoplication versus partial fundoplication in their ability to control symptoms of GER. A recently reported randomized trial compared 5-year results of a Nissen or Toupet utilizing a 1.5- or 3-cm wrap. Nissen or Toupet fundoplication achieved sufficient control of reflux with success rates of 85% at 5-year follow-up. There were no significant differences in the postoperative dysphagia, esophagitis, and bloating rates. However, a significant difference in failure rates was found between 1.5- and 3-cm Toupet groups ($p < 0.05$). A 1.5 cm Toupet fundoplication wrap length was associated with a 32.4% incidence of esophagitis and was concluded to be insufficient (Mickevicius A, Endzinas Z, Kiudelis M, et al. Influence of wrap length on the effectiveness of Nissen and Toupet fundoplications: 5-year results of prospective, randomized study. *Surg Endosc* 2013;27(3):986–91). On the other hand, 12-year follow-up of a randomized trial comparing laparoscopic Nissen versus 180-degree anterior fundoplication was recently reported and had demonstrated subtle improvement in those patients undergoing a Nissen fundoplication. Of the initial 163 patients randomized, only 55% completed 12-year follow-up. There were no differences in heartburn, dysphagia, gas-related symptoms, patient satisfaction, or surgical reintervention rate between the two groups. However, the use of acid suppressing drugs was less common after Nissen than after 180-degree anterior

fundoplication. In addition, the proportion of patients with absent or only mild symptoms was slightly higher after Nissen fundoplication: 45 or 50 (90%) versus 28 of 38 (74%, $p = 0.04$) (Roks DJ, Broeders JA, Baigrie RJ. Long-term symptom control of gastro-oesophageal reflux disease 12 years after laparoscopic Nissen or 180° anterior partial fundoplication in a randomized clinical trial. *Br J Surg* 2017. doi:10.1002/bjs.10473. [Epub ahead of print]).

Perhaps the most exciting new development in the management of achalasia continues to be the evolving technique of per-oral endoscopic myotomy (POEM) for achalasia. Although long-term data are limited with the use of POEM, a recent report combining the experience with 10 tertiary care centers had a minimum of 2 years of follow-up in 205 patients. Clinical success of POEM was achieved in 91% of patients at 2 years. Procedure-related adverse events occurred in 8.2% of patients and 1 patient required surgical intervention. Abnormal esophageal acid exposure and reflux esophagitis were documented in 37% and 18% of patients, respectively (Ngamruengphong S, Inoue H, Chiu PW, et al. Long-term outcomes of per-oral endoscopic myotomy in patients with achalasia with a minimum follow-up of 2 years: an international multicenter study. *Gastrointest Endosc* 2016. pii: S0016–5107(16)30586–7).

Recently, Dr. Madhu Sanaka from the Cleveland Clinic presented 31 POEM patients and 88 laparoscopic Heller myotomy (LHM) patients, testing their levels of pH 2 months post-treatment. While POEM patients showed no statistically significant increase in reflux symptoms, they *did* have higher abnormal pH study findings; 48% of POEM patients had abnormal levels of esophageal acid exposure compared with 14% of LHM patients. Most POEM patients are managed with an anti-reflux medication. This is often unnecessary for LHM patients, because LHM includes a fundoplication.

Many clinicians continue to perform a partial-thickness myotomy—dissecting only the circular muscle layer and preserving the outer longitudinal esophageal muscles. But some centers now perform a modified POEM that duplicates surgical full-thickness myotomy with Dor fundoplication. In this hybrid procedure, the endoscopist extends the procedure as far into the stomach as possible. There is currently debate about how much of the gastric side should be cut. Following the endoscopic portion, the surgeon performs the anti-reflux procedure. Patients benefit from a significant reduction in the risk of reflux—a frequent complication of myotomy resulting from disruption of the LES and phrenoesophageal attachments. This avoids the need to be dependent on proton pump inhibitors long term following POEM. The next several years will further clarify the appropriate use of POEM in the management of achalasia.

Steven N. Hochwald

75 Peroral Endoscopic Myotomy for Achalasia and Endoluminal Approaches for GERD

Edward D. Auyang and Eric S. Hungness

INTRODUCTION

Achalasia is an esophageal motility disorder affecting approximately 1 in 100,000 people per year in which there is primary aperistalsis of the esophagus with nonrelaxation of the lower esophageal sphincter (LES). These anatomy abnormalities result in dysphagia and regurgitation. Ernest Heller performed the first surgical transthoracic esophagomyotomy in 1913. Until the 1990s, open myotomy, either via thoracic or abdominal approach, had been the only surgical treatment option. In 1991, minimally invasive esophagomyotomy was introduced. The first reported laparoscopic myotomy was by Cuschieri in 1991 and the first thoracoscopic myotomy by Pellegrini in 1992. These provided for greater durability of treatment with less postoperative morbidity compared to open myotomy.

Historic treatment of achalasia involved using a sponge-tipped whale bone to push food beyond the LES after each meal. Initial nonsurgical treatment was in the form of pneumatic balloon dilation in the 1970s and 1980s. In the 1990s, botulinum toxin (BTX) injection of the LES was introduced as an additional endoscopic treatment option for achalasia. The long-term durability of dilation and BTX injection has been mixed.

In 2008, Inoue reported the first case series of peroral endoscopic myotomy (POEM) for achalasia. This is an endoscopic approach that allows for dividing the circular fibers of the LES without the need for abdominal or thoracic incisions. Since then, approximately 4,000 POEM cases have been performed worldwide.

Gastroesophageal reflux disease (GERD) is a common problem among the global population in which the LES is incompetent and allows for reflux of gastric contents into the esophagus. This causes symptoms including heartburn, regurgitation, and nocturnal aspiration. Esophagitis is

a result of chronic abnormal reflux and can progress to Barrett metaplasia, dysplasia, and potentially esophageal cancer.

GERD has been treated primarily with medications, ranging from antacids, to H2-blockers, to most recently proton-pump inhibitors (PPI). For most patients, medical treatment is adequate to suppress symptoms. For patients who are refractory, surgical fundoplication has been the treatment of choice. The first gastric fundoplication was performed by Rudolf Nissen in 1955. With the advent of minimally invasive surgery in the 1990s, Dallemagne and Geagea performed the first laparoscopic Nissen fundoplication in 1991. This has been the gold standard for surgical treatment of GERD.

Like for achalasia, endoluminal treatments have been developed as alternative treatments for GERD. These include endoluminal plication and ablative remodeling. The goal of these treatments is to either recreate the gastroesophageal flap valve or remodel the tissue of the LES.

Etiology, pathophysiology, and clinical presentation of achalasia and GERD along with their surgical treatments are covered in other chapters. We will be examining the endoluminal treatments of both of these disease processes.

PERORAL ENDOSCOPIC MYOTOMY

Indications and Contraindications

POEM is performed under general anesthesia (GA) and therefore, contraindication to GA is a contraindication for performing POEM. Relative contraindications include previous achalasia interventions such as BTX, pneumatic dilation, and Heller myotomy or advanced achalasia with sigmoid deformity, particularly early in the surgeon's learning curve. There are reports that previous interventions may result in scarring of the LES making creation of a submucosal plane difficult. Sigmoid deformity of the esophagus poses significant difficulty in creating the submucosal tunnel during POEM. Conversely, there have also been multiple reports of performing POEM after these interventions and even after previous laparoscopic Heller myotomy. Having performed over 175 clinical cases to date, the Northwestern Esophageal center approaches each patient individually but will offer POEM to most, if not all, patients with achalasia.

Preoperative Planning

Patients undergoing POEM should have a complete achalasia workup, including esophagogastroduodenoscopy (EGD), barium swallow esophagram (UGI), and high-resolution esophageal manometry. These tests will confirm the diagnosis of achalasia and rule out the presence of other diseases that may cause pseudoachalasia, such as esophageal cancer.

Patients are instructed to be on a liquid diet for 48 hours prior to the procedure to allow for complete emptying of the esophagus. Patients who have a high risk of retained food in the esophagus undergo EGD 2 days prior to the procedure for clearance. Candida esophagitis has also been reported in patients with achalasia. We recommend nystatin oral suspension (100,000 units/mL) swish and swallow for 7 days or fluconazole (100 mg) PO for 5 days for prophylactic treatment and to reduce the high candida burden known to exist in achalasia patients. The patient is *nil per os* (NPO) at midnight prior to the procedure. Preoperative antibiotics and deep venous thromboembolism (DVT) prophylaxis are administered per guidelines for laparoscopic myotomy. Good intraoperative blood pressure control (SBP <120 mm Hg) helps reduce the risk of submucosal bleeding. The endotracheal tube is taped off the right side of the patient's mouth.

Technique

POEM is performed in the operating room under rapid sequence GA with endotracheal intubation, due to the significant risk of aspiration for achalasia patients. Positive-pressure ventilation also helps any possible untoward effects of CO_2 insufflation within the submucosal tunnel and mediastinum. There is a small risk of esophageal perforation with POEM and therefore, appropriate operating room instruments are on stand-by for laparoscopic or open surgical intervention if needed. Pneumoperitoneum occurs in up to 40% of patients and is easily controlled with the placement of a Veress needle.

The patient is positioned in supine position with the left arm tucked. EGD is performed initially to confirm clearance of the esophagus and absence of candida. Once confirmed, a high-definition (HD) endoscope with CO_2 insufflation and an obliquely cut endoscopic dissecting cap (long bevel positioned posterior) is used for this procedure.

The distance of the gastroesophageal junction (GEJ) from the incisors is first measured to determine the length of myotomy to be created and the start point for the submucosal tunnel. The myotomy is typically made for a

length of 6 cm above the GEJ and 3 cm onto the stomach. The submucosal tunnel is started 4 cm proximal to the proximal portion of the myotomy, thus 12 cm above the GEJ.

The mucosa is lifted with the injection of saline with indigo carmine (or methylene blue) on the anterior esophagus (12 o'clock position) (Fig. 75.1A,B). With the mucosa raised, a triangle tip endoscopic cautery knife is used to create a 2 cm longitudinal incision in the mucosa to allow for entry of the endoscope into the submucosal space (Figs. 75.1C and 75.2A). Coagulating the submucosal tissue and exposing the circular muscle within this initial 2 cm opening greatly facilitates scope entry into the submucosal space. The anterior submucosal tunnel is lengthened using precise endoscopic cautery dissection of the submucosal fibers connecting the circular muscle and mucosa. Additional saline injection can be used to assist in tunnel creation with "hydrodissection." Submucosal vessels are coagulated as they are encountered. In addition, epinephrine can be added to the saline to assist with hemostasis, but is usually reserved for the initial and final injection. The submucosal tunnel is carried at least 3 cm onto the cardia of the stomach (Fig. 75.2B). There are several methods of helping to determine adequate tunnel length: (1) measurement from incisiors; (2) tunnel narrowing at the GEJ that widens onto the cardia; (3) observation of "palisading" blood vessels in cardia; (4) disorganization of circular fibers on cardia; and (5) visualization of blue dye/blanching cardiac mucosa on retroflexion within stomach (Fig. 75.1D). Gastric distention makes distal tunnel creation more difficult, so decompression of the stomach is important when dissecting near the GEJ.

After the tunnel has been created, the endoscope is drawn back to 6 cm above the GEJ as the starting location for the myotomy. This usually leaves 3 to 4 cm of overlap from where the tunnel and the myotomy starts, which theoretically reduces the chance for esophageal leak should the clips become dislodged. The triangle tip cautery knife is then used to divide the circular muscle, proceeding distally onto the gastric cardia (Figs. 75.1E and 75.2C). Care is taken not to divide the longitudinal fibers of the esophagus and perforate into the mediastinum. While this is preferred, splaying of the longitudinal muscle is quite common since it is very thin but is of little consequence as long as mucosal closure is secure (Fig. 75.1F). Of note, the muscle layers of the stomach have obliquely running fibers that will help identify extension of the myotomy onto the gastric cardia. In addition, new techniques using real-time esophageal

distensibility have been utilized to assess for adequate myotomy length during POEM, though application is still in its infancy.

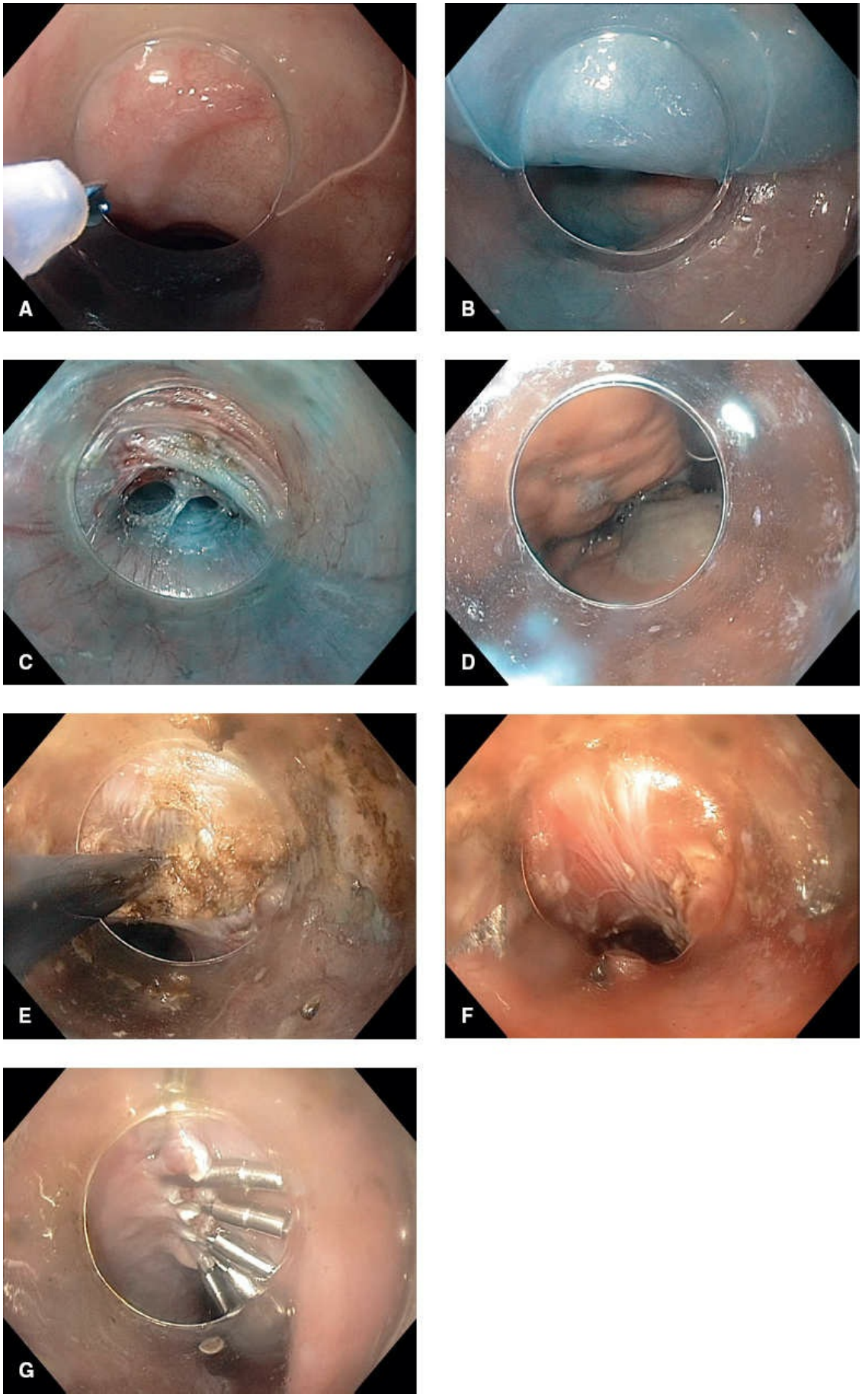
A
B
C
D
E
F
G

Figure 75.1. Steps of POEM procedure: Endoscopic view (Personal images of Dr. Eric S. Hungness). **A.** Injection needle for saline lift. **B.** Mucosa lifted after saline injection. **C.** Submucosal dissection. **D.** Blue dye visualized in gastric cardia with retroflexion. **E.** Circular muscle myotomy. **F.** Myotomy completion with splaying of longitudinal muscle fibers. **G.** Mucosal closure with clips.

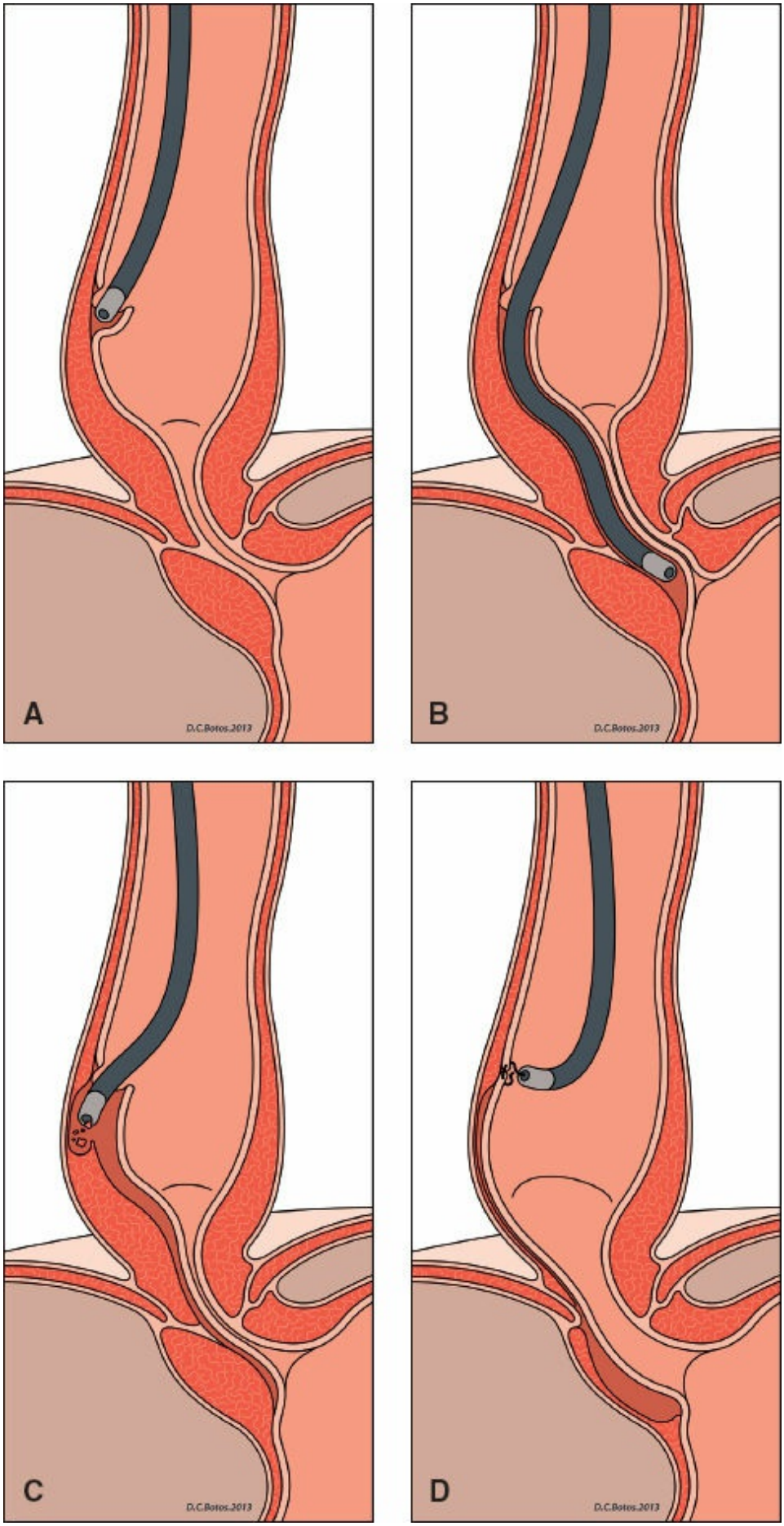
A
D.C.Boros.2013
B
D.C.Boros.2013
C
D.C.Boros.2013
D
D.C.Boros.2013

Figure 75.2. Steps of POEM procedure: Cartoons (Images provided by Dr. Eric S. Hungness). **A.** Mucosal incision. **B.** Submucosal tunnel extension onto gastric cardia. **C.** Myotomy. **D.** Mucosal closure.

Once the myotomy is completed, the scope is withdrawn from the tunnel. Careful inspection is performed to confirm hemostasis and visualize any potential mucosal perforations. If a mucosal injury is found or suspected, clip closure/reinforcement is used. Small bleeding from the cut edge of myotomy are easily controlled with cautery. Bleeding from the mucosa usually stops on its own, but manual pressure from within the true esophageal lumen is sometimes required. Cautery should not be used to control hemostasis on the mucosal side of the tunnel. In addition, good blood pressure control (SBP <120 mm Hg) is key to reduce the risk of submucosal bleeding. The endoscope is removed from the submucosal tunnel and introduced into the stomach. The GEJ should be much more widely open and retroflexion confirms no perforation of the stomach.

The mucosal incision is then closed using endoscopic clips. Clips are placed from distal to proximal to completely reapproximate the mucosa (Figs. 75.1G and 75.2D).

Postoperative Care

The patient is kept strictly NPO overnight. On postoperative day 1, an UGI is should be considered to confirm absence of esophageal perforation/leak prior to starting the patient on a clear liquid diet. We routinely did a POD1 UGI for the first 80 cases, but did not find any clinical utility except when there were worrisome clinical signs such as increased pain, dysphagia, or tachycardia. The patient is discharged on full liquids for 1 week followed by soft foods for 3 additional weeks. After that, the diet is liberalized but patients are advised to chew well, eat smaller more frequent meals. In addition, it is recommended not to consume certain foods such as breads, chunks of meat, and large quantities of raw fiber for this same duration.

Complications and Their Management

Intraoperative complications are associated with two main phases of the procedure, tunnel creation, and myotomy. During tunnel creation, bleeding and perforation can occur. Bleeding is managed with cautery coagulation either with the dissecting knife or endoscopic graspers/biopsy forceps. In

addition, epinephrine in the saline solution will help with hemostasis of smaller vessels. Perforation can occur with the use of cautery during creation of the tunnel or during the myotomy. These can be prevented with more frequent injection to lift the mucosa from the muscle fibers during tunneling. Full perforations are typically small. They may be clipped from using endoclips. In the event of a large perforation, laparoscopic or open surgical closure of the perforation may be necessary.

The most concerning postoperative complication is a perforation and leak. UGI is performed on postoperative day 1 to confirm abscess of a leak. If a leak is found, endoscopic or laparoscopic closure of the perforation is performed immediately. There have been reports of delayed leaks and perforations that have been treated with percutaneous drainage or operative repair.

Mediastinal emphysema may be identified on postoperative imaging, though this is typically without clinical consequence if no leak is identified.

Outcomes

In the largest case series of POEM to date, Inoue reported a significant reduction in symptom score and LES pressure at 2 months and at 3 years. GERD was seen in 16.8% of patients at 2 months and 21.3% of patients at 3 years. The adverse event rate was 3.2% with no mortalities.

Treatment of GERD after POEM is being actively studied. Patients may be placed on PPI's for symptomatic treatment. In addition, there are studies being undertaken to determine if there are technique changes that can be made to decrease post-POEM GERD such as location of myotomy. Patients who have GERD symptoms should be followed with EGD as there have been reports of post-POEM Barrett esophagus and reflux-related strictures.

Conclusion

POEM is a significant minimally invasive advancement with promising results with regard to treatment of achalasia. Long-term outcomes will be determined with additional experience.

ENDOLUMINAL TREATMENTS FOR GERD

Indications and Contraindications

The indications for endoluminal treatments for GERD are similar for surgical treatments—refractory symptoms despite maximized medical management or contraindications to medication therapy. The potential advantage of endoluminal treatments is that some procedures may be performed under conscious sedation without GA, thus allowing a larger population to be treated compared to surgical fundoplication. There are anatomic contraindications for endoluminal fundoplication and radiofrequency ablation (RF) including presence of hiatal hernias longer than 2 cm and wider than 3 cm.

Preoperative Planning

Patients undergoing endoluminal treatments for GERD should have a complete esophageal workup, including EGD, UGI, and esophageal manometry. These tests will evaluate for other disorders of the esophagus that may present as GERD-like symptoms. In addition, the extent of esophagitis and presence of Barrett's must be assessed as other treatments may take priority over simply treating the reflux mechanism. These studies are also necessary to identify anatomic abnormalities that may be contraindications.

There are two primary endoluminal treatments for GERD on the market. EsophyX (Endogastric Solutions, Redwood City, WA) is a device to create incisionless fundoplication that was approved in 2007 by the U. S. Food and Drug Administration (FDA). The Stretta procedure (Mederi Therapeutics Inc, Greenwich, CT) utilizes RF to remodel the LES by contracting collagen and creating a barrier to gastric pressure. In addition, Medigus ultrasonic surgical endostapler (MUSE; Medigus, Omer, Israel), a new endoscopic stapling procedure that creates an anterior partial wrap, has recently entered the market. Each will be discussed individually.

ESOPHYX TRANSORAL INCISIONLESS FUNDOPLICATION

Technique

The EsophyX device is an instrument that is deployed in the stomach with an endoscope that creates a full-thickness plication of the GEJ using H-shaped polypropylene fasteners (Fig. 75.3). The device has gone through several revisions. Transoral incisionless fundoplication (TIF) 1 produced a gastro-gastric wrap at the level of the GEJ. TIF 2 placed the fasteners

above the GEJ to create a gastroesophageal flap valve that replicates a laparoscopic fundoplication. TIF 2.0 is the current technique.



Figure 75.3. EsophyX device.

General endotracheal anesthesia is induced. Endoscopy is performed to confirm no hiatal hernia longer than 2 cm and wider than 3 cm. The device is introduced transorally with CO_2 insufflation. The device is retroflexed and the lesser curve and greater curve landmarks are identified and a helical screw is deployed at the GEJ to retract the tissue. A paddle-shaped tissue mold is then used to deploy polypropylene fasteners to create a "crimp." This technique is performed circumferentially with sequential deploying of fasteners to create a 270-degree fundoplication. After completion, the device is removed and final endoscopy is performed to assess the plication and assess for bleeding or perforation (Fig. 75.4).

Postoperative Care

Patients are kept in the hospital and discharged the following day. They are kept on omeprazole 40 mg for 14 days to promote mucosal healing around fasteners. They are kept on a liquid diet for 2 weeks, then given soft food from weeks 3 to 7. They resume a regular diet after 2 months.

Complications and Their Management

The most commonly reported direct complications of TIF, though few, are bleeding and perforation. Bleeding has been self-limited though patients have required blood transfusion. Perforation is rare and has been treated with laparoscopic transabdominal drainage and partial fundoplication over the damaged esophagus.

Outcomes

Outcomes have varied by study and overall data with regard to randomized controlled studies has been lacking. There are several series that have reported no benefit after TIF. One study reported a 68.4% treatment failure rate. Causes have included technique, missed hernia, or postoperative retching that has disrupted the TIF fundoplication. Patients who have had failure after TIF, however, can be considered for reoperation and surgical fundoplication.

A recent multicenter randomized controlled trial reported the efficacy of TIF versus omeprazole for treatment of symptomatic regurgitation. TIF eliminated symptomatic regurgitation in 67% of patients compared to 45% for PPI. There is little data comparing TIF to laparoscopic fundoplication. The Society for American Gastrointestinal and Endoscopic Surgeons (SAGES) recently reviewed studies related to TIF and confirmed the lack of strong long-term data.

STRETTA

Technique

The Stretta device is an inflatable balloon catheter system with four electrode needle sheaths (Fig. 75.5). Radiofrequency energy is delivered to the electrodes causing the heating of adjacent cells. Power is delivered to achieve a target temperature of 65° to 85°C for 1-minute cycles. The RF induced fibrosis of the LES, thus reducing tissue compliance and transient LES relaxation. These are thought to recreate barrier functions of the LES to reflux.

Patients are placed under deep sedation and initial endoscopy is performed. Patients with hiatal hernias >2 cm in length or having severe esophagitis are excluded. Using a guidewire exchange technique, the Stretta catheter is introduced into the esophagus and placed 2 cm proximal to the Z-line. The balloon is inflated and the electrode needles are

deployed into the esophageal wall. Energy is delivered for a duration of 1 minute. The needles are retracted, the balloon is deflated, and the catheter is rotated 45 degrees. Energy is delivered for another 1-minute cycle. This technique is repeated to cover a length 2 cm above and 1.5 cm below the Z-line. The mucosa is then cooled with water irrigation (Fig. 75.6).

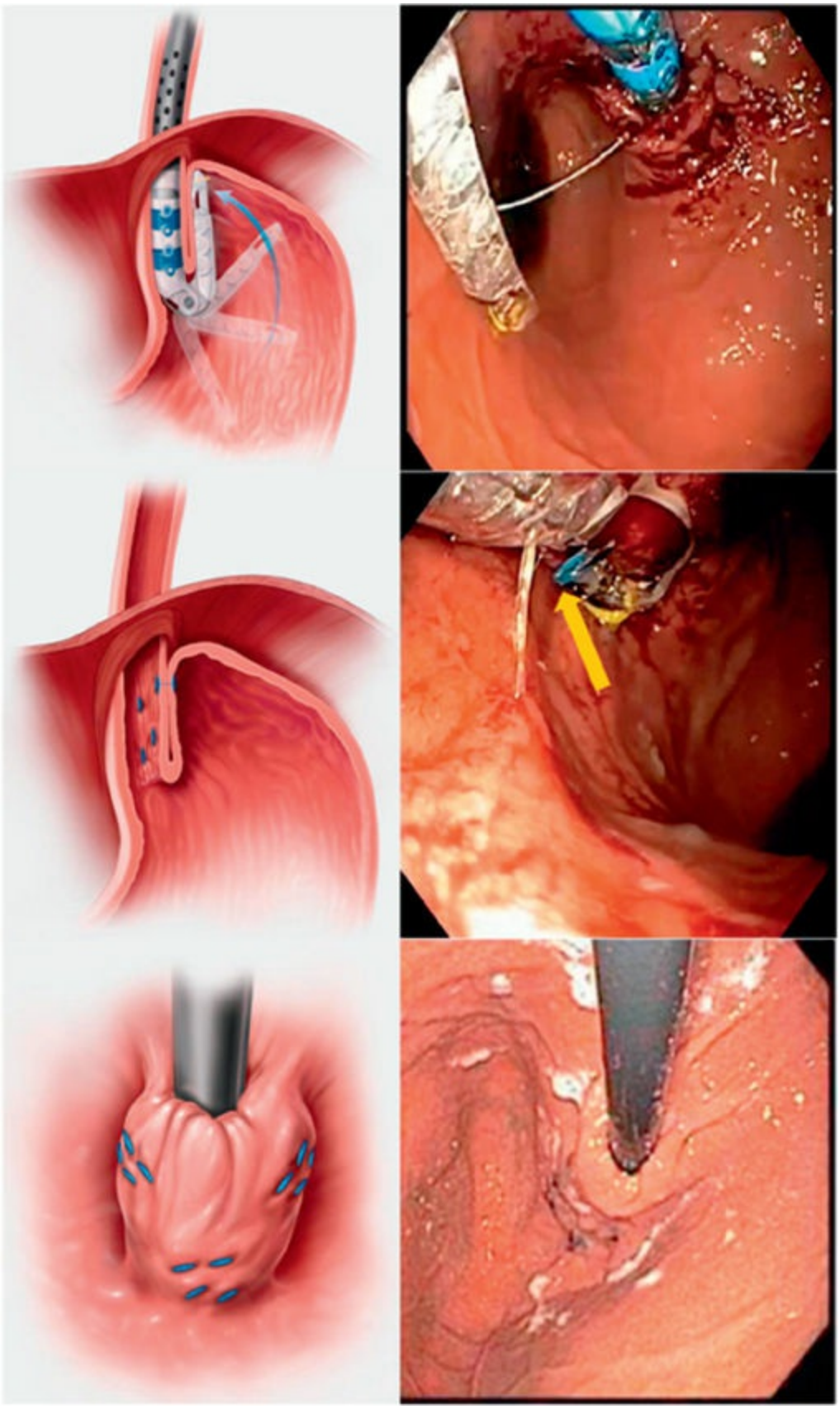

Figure 75.4. TIF Procedure with endoscopic images. (Hunter JG, Kahrilas PJ, Bell Rc, et al. Efficacy of transoral fundoplication vs omeprazole for treatment of regurgitation in a randomized

controlled trial. *Gastroenterology* 2015;148:324–333.e5. doi: 10.1053/j.gastro.2014.10.009. Open Access—No permissions required.)



Figure 75.5. Stretta device. Courtesy of Ray Bengermino and Paul Spier, Mederi Inc. (Images provided by Mederi Therapeutics Inc.)

Postoperative Care

Patients are discharged home on the same day as the procedure. They are instructed to monitor for symptoms of bleeding.

Complications and Their Management

Only mild symptoms have been reported. These include minor bleeding and pain. No perforations have been reported and there have been no reported deaths in the literature.

Outcomes

In a recent meta-analysis, Stretta was shown to significantly improve heartburn scores and improve quality of life. While acid exposure decreased, postprocedural DeMeester score did not normalize. A SAGES review of studies involving Stretta found durable symptomatic treatment and reduction in medication use for symptomatic GERD for 48 months in patients meeting selection criteria.

MEDIGUS ULTRASONIC SURGICAL ENDOSTAPLER

Technique

The device is a stand-alone unit designed to be operated by a single user. It is designed in the shape of an endoscope with a video camera, light source, ultrasonic transducer, and stapling mechanism at the tip (Fig. 75.7). The device is inserted transorally and advanced down the esophagus through an endoscopic overtube with 17 mm internal diameter. It is retroflexed to identify the location for placing staples to create a partial anterior fundoplication. The fundic tissue is compressed against the esophagus and the ultrasonic transducer measures tissue thickness. Once it reaches 1.4 to 1.6 mm, the stapler is fired. This process is repeated several times to mimic a partial anterior fundoplication with a Hill Grade I valve with no visible esophageal mucosa visible on retroflexion. If a small sliding hernia is identified, it is reduced by increasing intrathoracic pressure by increasing ventilator positive end-expiratory pressure (PEEP) to reduce the stomach into the abdomen.

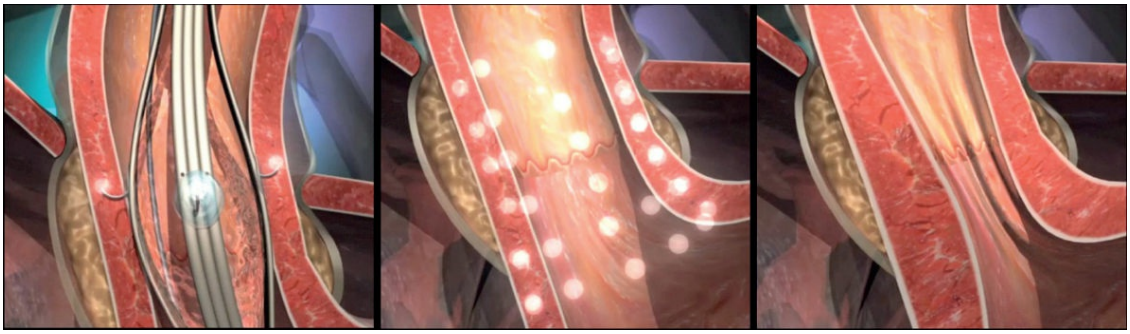

Figure 75.6. Stretta procedure. Courtesy of Ray Bengermino and Paul Spier, Mederi Inc. (Image provided by Mederi Therapeutics Inc.)

Postoperative Care

Patients were observed up to 72 hours postprocedure. UGI was performed

on POD 1 to evaluate for leaks.

Complications and Their Management

So far, less than 100 procedures have been reported worldwide; so complication rates and outcome data are limited. In the initial multi-institutional trial of 64 subjects followed to 6 months, there were two major adverse events. One was an upper GI bleed requiring hospitalization and transfusion. The second was an esophageal perforation resulting in leak and empyema which required drainage. Additional complications have included pneumomediastinum and pneumothorax. Other common complications included chest pain in 16 patients and sore throat in 15 patients.

Outcomes

Improvement in GERD quality of life scores and pH testing have shown improvement in initial studies at 6 months and 4 years. GERD-HRQL scores reduced at 6 months and 4 years, though 12 of 37 patients (32%) were still on PPIs at 6 months. Patients followed to 6 months showed an improvement in DeMeester score from 49.4 ± 47.2 to 29.1 ± 22.0. Normalization of DeMeester score (<14.72) was seen at 6 months in 13 of 35 patients (37.1%).

CONCLUSION

Surgery has been a mainstay for treatment of diseases of the esophagus and GEJ. The advent of minimally invasive surgical options in the early 1990s provided additional benefits of decreased hospitalization time and less postoperative morbidity compared to open operations.

In an effort to decrease morbidity associated with abdominal or thoracic incisions, endoluminal techniques have been developed for treatment of these disease processes. POEM has emerged as potential incisionless treatment for achalasia and early results have shown promise. Stretta and EsophyX have also gained momentum as incisionless endoluminal treatments for GERD with new techniques such as MUSE being currently investigated.

Long-term results of these treatment options are still to be determined, but may offer an even less invasive approach to both common and uncommon disorders of the stomach and esophagus.



Figure 75.7. Medigus stapler. Courtesy of Ray Bengermino and Paul Spier, Mederi Inc. (Image provided by Medigus Ltd.)

Suggested Readings

Acheri J, Roy-Shapira A, Bonavina L, et al. Endoscopic anterior fundoplication with the Medigus Ultrasonic Surgical Endostapler (MUSE) for gastroesophageal reflux disease: 6-month results from a multi-center prospective trial. *Surg Endosc* 2015;29:220–9.

Auyang ED, Carter P, Rauth T, et al. SAGES clinical spotlight review: endoluminal treatments for gastroesophageal reflux disease (GERD). *Surg Endosc* 2013;27:2658–72.

Bell RC, Caidere GB. Transoral rotational esophagogastric fundoplication: technical, anatomical, and safety considerations. *Surg Endosc* 2011;25(7):2387–99.

Hoppo T, Immanuel A, Schuchert M, et al. Transoral incisionless fundoplication 2.0 procedure using EsophyX™ for gastroesophageal reflux disease. *J Gastrointest Surg* 2010;14:1895–1901.

Hungness ES, Teitelbaum EN, Santos BF, et al. Comparison of perioperative outcomes between peroral esophageal myotomy (POEM) and laparoscopic Heller myotomy. *J Gastrointest Surg* 2013;17(2):228–35.

Hunter JG, Kahrilas PJ, Bell RC, et al. Efficacy of transoral fundoplication vs omeprazole for treatment of regurgitation in a randomized controlled trial. *Gastroenterology* 2015;148(2):324–33.

Inoue H, Minami H, Kobayashi Y, et al. Peroral endoscopic myotomy (POEM) for esophageal achalasia. *Endoscopy* 2010;42(4):265–71.

Inoue H, Sato H, Ikeda H, et al. Per-oral endoscopic myotomy: A series of 500 patients. *J Am Coll Surg* 2015;221(2):256–64.

Kim HJ, Kwon C, Kessler WR, et al. Long-term follow-up results of endoscopic treatment of gastroesophageal reflux disease with the MUSE endoscopic stapling device. *Surg Endosc* 2016;30(8):3402–8.

Perry K, Banerjee A, Melvin S. Radiofrequency energy delivery to the lower esophageal sphincter reduces esophageal acid exposure and improves GERD symptoms: a systematic review and meta-analysis. *Surg Laparosc Endosc Percutan Tech* 2012;22(4):283–8.

Stavropoulos SN, Desliets DJ, Fuchs KH, et al. Per-oral endoscopic myotomy white paper summary. *Gastrointest Endosc* 2014;80(1):1–15.

EDITOR'S COMMENT

Perhaps the most exciting new development in the management of achalasia continues to be the evolving technique of POEM for achalasia. Although long-term data is limited with the use of POEM, a recent report combining the experience with 10 tertiary care centers had a minimum of 2 years of follow-up in 205 patients. Clinical success of POEM was achieved in 91% of patients at 2 years. Procedure-related adverse events occurred in 8.2% of patients and 1 patient required surgical intervention. Abnormal esophageal acid exposure and reflux esophagitis were documented in 37% and 18% of patients, respectively (Ngamruengphong S, Inoue H, Chiu PW, et al. Long-term outcomes of per-oral endoscopic myotomy in patients with achalasia with a minimum follow-up of 2 years: an international multicenter study. *Gastrointest Endosc* 2016. pii: S0016–5107(16)30586–7).

Recently, Dr. Madhu Sanaka from the Cleveland Clinic presented 31 POEM patients and 88 laparoscopic Heller myotomy (LHM) patients, testing their levels of pH 2 months posttreatment. While POEM patients showed no statistically significant increase in reflux symptoms, they *did* have higher abnormal PH study findings. Forty-eight percent of POEM patients had abnormal levels of esophageal acid exposure, compared to 14% of LHM patients. Most POEM patients are managed with an antireflux medication. This is often unnecessary for LHM patients, because LHM includes a fundoplication.

Many clinicians continue to perform a partial-thickness myotomy—dissecting only the circular muscle layer and preserving the outer longitudinal esophageal muscles. But some centers now perform a modified POEM that duplicates surgical full-thickness myotomy with Dor fundoplication. This hybrid procedure—the endoscopist extends the procedure as far into the stomach as possible and if it looks satisfactory—there is currently debate about how much of the gastric side should be cut—then the surgeon performs the antireflux procedure. Patients benefit from a significant reduction in the risk of reflux—a frequent complication of myotomy resulting from disruption of the LES and phrenoesophageal attachments. This avoids the need to be dependent

on proton pump inhibitors long term following POEM.

Many experts feel that the absence of an antireflux wrap following POEM leads to an increased risk of reflux with consequent esophagitis in about one third of patients. Therefore, surgical myotomy with an antireflux wrap could be the preferred choice when long-standing gastroesophageal reflux could potentially lead to damage (de Pascale S, Repici A, Puccetti F, et al. Peroral endoscopic myotomy versus surgical myotomy for primary achalasia: single-center, retrospective analysis of 74 patients. *Dis Esophagus* 2017;30(8):1–7). However, others argue that laparoscopic antireflux surgery could be reserved for this subset of patients with esophagitis or symptoms or GERD rather than utilizing a surgical Heller myotomy and DOR or toupet fundoplication on all patients. The increased utilization of transoral incisionless fundoplication may also lead to complete endoscopic management of patients with achalasia by reserving it for symptomatic patients with GERD following POEM. Although randomized trials comparing transoral incisionless fundoplication to surgical fundoplication do not exist, transoral incisionless fundoplication has been shown to improve symptoms of GERD in the short term compared to medical management (Huang X, Chen S, Zhao H, et al. Efficacy of transoral incisionless fundoplication (TIF) for the treatment of GERD: a systematic review with meta-analysis. *Surg Endosc* 2017;31(3):1032–44). The next several years will further clarify the appropriate use of POEM and other advanced endoscopic treatments in the management of achalasia.

Steven N. Hochwald

76 Minimally Invasive Treatment of Achalasia and Other Esophageal Dysmotility

Michael S. Nussbaum, Bestoun H. Ahmed, and Jeffrey L. Ponsky

Most disorders of esophageal motility affect both the esophageal body and the lower esophageal sphincter (LES). The best known and most common of these disorders is achalasia, a primary disorder of the LES with secondary absence of peristalsis in the esophageal body. Achalasia is characterized principally by dysphagia. Diffuse esophageal spasm (DES) and nutcracker esophagus (NE), on the other hand, are primary disorders of esophageal body motility, which are characterized predominantly by substernal chest pain and, to a lesser degree, by dysphagia. Hypertensive LES is the least common of the disorders, characterized by symptoms of dysphagia, chest pain, and, at times, associated gastroesophageal reflux disease (GERD). The distinguishing manometric features of hypertensive LES include elevated LES basal pressure, with normal swallow-induced relaxation and normal esophageal body peristalsis.

ACHALASIA

ANATOMY/PHYSIOLOGY

The LES is a high-pressure segment separating the gastric cavity from the esophageal lumen. The main function of this sphincter is to prevent the reflux of gastric contents into the esophagus, which has a lower intraluminal pressure than the stomach. The LES must relax with swallowing to allow the passage of ingested material from the esophagus into the stomach. Abnormalities of either one of these functions are major causes of esophageal symptoms. Defects in the antireflux barrier function result in GERD and its complications. Defective relaxation of this sphincter results in dysphagia.

The LES is not a static barrier, but responds to a variety of stimuli with changes in the force of its closure. Multiple factors are responsible for the

maintenance of the resting tone of the LES. Neural, humoral, and myogenic factors all contribute to basal sphincter pressure. The specific mechanism responsible for relaxation of LES pressure with swallowing remains to be elucidated. The response appears to be mediated through the vagus nerves. The neurotransmitter for sphincter relaxation is not adrenergic or cholinergic mediated, since adrenergic and cholinergic blockade fails to inhibit relaxation. The general nerve poison tetrodotoxin will abolish neurally mediated responses with little or no effect on smooth muscle. Tetrodotoxin will inhibit vagus-stimulated relaxation of the LES, indicating that this is a neurogenic mechanism. The neurotransmitter responsible for vagus-stimulated LES relaxation by definition is a nonadrenergic, noncholinergic inhibitor. Vasoactive intestinal polypeptide (VIP) is found in rich supply in the nerves in the region of the LES and is the most likely candidate for the specific LES inhibitory stimulus.

Esophageal achalasia is a complex motor abnormality of the esophageal body and LES, characterized by incomplete relaxation of the LES and aperistalsis. The prevalence of achalasia is ~10 cases per 100,000 population, with an estimated incidence of ~1 case per 100,000 people per year and, after GERD, is the second most common functional disorder of the esophagus requiring operation. The etiology is unknown, with data suggesting the possibility of several inciting mechanisms for achalasia, including infection, genetic inheritance, autoimmune disease, and neuronal degeneration as possible causes. Various studies have been performed investigating the possibility of several inciting mechanisms for achalasia. However, the sequence of events leading to this mechanism continues to be poorly understood. Currently, achalasia remains an idiopathic condition that is associated with a patchy inflammatory response consisting of cytotoxic T-lymphocyte, eosinophil, and mast cell infiltration in the esophageal myenteric (Auerbach) plexus with myenteric neural fibrosis, loss of ganglion cells, hypertrophy of the two muscle layers, and hypertrophy of nerve fibers. Preganglionic vagal neurons originating in the dorsal motor nucleus innervate two types of postganglionic nerves in the myenteric plexus of the lower esophagus smooth muscles: (1) the excitatory acetylcholine-secreting neurons and (2) the inhibitory VIP- and nitric oxide (NO)-secreting neurons. It is hypothesized that the aperistalsis of achalasia is secondary to interruption of normal vagal cholinergic motor function, whereas the failure of LES relaxation is due to derangement of the vagal inhibitory (VIP and NO) nerves. Multiple histopathologic studies

have confirmed the loss of inhibitory neurons in the esophageal myenteric plexus as the pathologic hallmark of achalasia. There is a selective loss of postganglionic inhibitory neurons, which contain both NO and VIP, whereas, there is sparing of the postganglionic stimulatory (cholinergic) neurons. This produces a loss of inhibitory input, resulting in a nonrelaxing, hypertensive LES. This is demonstrated by an exaggerated motor response (spasm) to injection of cholinergic agonists, demonstrating a classic supersensitive response of the denervated tissue. Similarly, the LES is also supersensitive to both methacholine and pentagastrin in achalasia. The elevated LES tone may be the consequence of disproportionate loss of inhibitory influence. In addition, NO synthetase levels in the LES muscle are considerably lower in achalasia compared with normals. Depletion of interstitial cells of Cajal (ICC) networks and potential changes in the electrical activity of smooth muscle cells may also play a crucial role. The reduction in CD117-positive ICC and the associated reduced NO synthetase release might underlie the profound ICC impairment and could possibly be responsible for the lack of LES relaxation, because of missing inhibitory neurotransmission. It is unclear, however, whether the ICC loss is largely caused by the accelerated attrition of mature cells or their impaired regeneration. It is further unclear whether the diminished availability of the potent smooth-muscle relaxant, NO, is a primary or a secondary phenomenon. The aperistalsis of the esophageal body is attributed to the loss of the latency gradient along the esophageal body that permits sequential contractions along the esophageal body, a process also thought to be mediated by NO. While several theories have been proposed based on known pathologic disease processes, contemporary thought has suggested that several biologic processes may lead to a common mechanism of neuron loss, which subsequently manifests as achalasia. As more studies have come out, the complexity of possible pathogenic mechanisms has increased.

While the underlying pathogenesis of achalasia is far from being completely defined or understood, the various clinical and histopathologic data have led to a working model for the mechanism of the disease. Specifically, it is a neurodegenerative process that involves genetic susceptibility and an immune-mediated mechanism, involving a combination of genetic factors, including genetic characteristics of the immune system, which establish some potential to develop the disease. Among susceptible individuals, this process may be precipitated by

exposure to infectious agents that stimulate the immune system and provoke a deleterious immune response on the inhibitory myenteric neurons. Achalasia can also be one manifestation of the widespread myenteric plexus destruction in Chagas disease, a consequence of infection with the parasite *Trypanosoma cruzi*. Patients with Chagas disease often have other features of autonomic neural destruction including megacolon, cardiac disease, and neurologic abnormalities. Some data suggest that age- and gender-based differences may exist. However, further study is needed into the genetic, immune, and infectious disease components of the process to provide further insight to and understanding of the mechanism of achalasia.

CLINICAL PRESENTATION

Whatever the etiology, esophageal motor disorders such as achalasia lead to a combination of three esophageal symptom complexes. First and foremost is the insidious development of dysphagia caused by failure of propulsive force, obstruction to flow, and incoordination of contraction and relaxation. The diagnosis of achalasia should be suspected in patients complaining of dysphagia for solids and liquids with regurgitation of bland food and saliva. Frequent associated symptoms may include regurgitation, cough, and aspiration. In addition to dysphagia, some individuals with achalasia describe esophageal pain as well as gastroesophageal reflux symptoms. The cause of these symptoms is speculative, but may be due to an inability to adequately clear the refluxed acid. Conversely, these symptoms may also be related to retention of acid beverages, such as carbonated or fruit drinks and, in some cases, the production of lactic acid from retained food in a markedly dilated esophagus. Respiratory symptoms are also common in patients with achalasia (20% to 40%), like cough, sore throat, and chronic aspiration. Most achalasia patients have some degree of mild to moderate weight loss of 5 to 20 lb at presentation.

DIAGNOSIS

Many patients with achalasia are initially misdiagnosed with GERD. Nearly 40% of achalasia patients will complain of some degree of heartburn due to either poor clearance of refluxed acid or from exogenous ingested acid. Upon further questioning, the most common complaint in achalasia is dysphagia of both solids and liquids with regurgitation of saliva and food. Most will have some degree of weight loss, although not

usually excessive. About 40% of patients with achalasia will complain of substernal chest pain. Other frequent symptoms are respiratory complications (nocturnal cough [30%] and aspiration), mostly observed in patients with significant esophageal stasis.

When achalasia is suspected, the best initial screening study is a barium esophagram, which will show some degree of dilation of the esophagus, loss of primary peristalsis, and a smooth tapering of the lower esophagus. An epiphrenic diverticulum may also be present in this setting. Richter has popularized a modification of the barium esophagram known as the "timed barium swallow," which assesses esophageal emptying of barium in the upright position over 5 minutes. The test can be repeated serially after therapy to evaluate the patient's response to various treatment modalities. Findings at endoscopy include retained saliva, liquid, and food in the esophagus without mechanical obstruction. Esophagogastroduodenoscopy (EGD) should also be carried out to rule out pseudoachalasia due to extrinsic compression or infiltration by a tumor, especially adenocarcinoma of the proximal stomach, at the level of the gastroesophageal (GE) junction. Approximately 2% to 4% of patients suspected of achalasia suffer from pseudoachalasia. Pseudoachalasia should be suspected in elderly patients, when there is a short duration of symptoms, and in the setting of marked weight loss. Endoscopic ultrasound may be a useful adjunct in such patients where there is a high suspicion for pseudoachalasia. Patients with a previous fundoplication or bariatric procedure (lap-band, gastric bypass) may also present with signs and symptoms that mimic achalasia, and it is extremely difficult to make the diagnosis of achalasia in the context of these operations. In these cases, it is important to look for mechanical causes of obstruction, such as anastomotic stricture, tight lap-band, or an obstructed fundoplication.

While EGD and barium esophagram are important screening studies, neither is sensitive enough to make a definitive diagnosis of achalasia. The gold standard test for confirming the diagnosis of achalasia is esophageal manometry, demonstrating esophageal body aperistalsis and incomplete LES relaxation. There are four classic manometric characteristics, which usually include: hypertensive LES, present in ~50% of patients; nonrelaxing LES; esophageal aperistalsis; and elevated lower esophageal baseline pressure. A subset of achalasia patients can have simultaneous contraction waves of variable amplitudes, consistent with preserved muscle function; this is termed *vigorous achalasia.* Esophageal

manometry is required to establish the diagnosis of achalasia and must be done in any patient where invasive treatments, such as pneumatic dilation (PD), endoscopic or surgical myotomy, are planned. Esophageal manometry is typically performed with a water-perfused catheter with five pressure transducers placed 5 cm apart. A typical catheter is 4 to 5 mm in diameter and contains eight channels oriented around the circumference. Water-perfused systems are relatively inexpensive, require little maintenance, and rarely malfunction. However, they are subject to many limitations and inaccuracies. They are uncomfortable for the patient and can induce uncontrollable swallowing. The studies are time-consuming due to the need for evaluating multiple swallows and the use of a pull-through technique to assess the function of the LES. Since the entire esophageal body is usually sampled at only five or fewer points along its length, localized or segmental abnormalities may be missed and the side holes may not be consistently parallel to the bank of pressure transducers, especially in curved locations such as the pharynx or the GE junction. These difficulties are even greater in analysis of the LES because of its short length and its frequent movement with swallowing and respiration. Finally, interpretation of motility tracings is prone to subjectivity and inter-observer variability.

High-resolution manometry (HRM) is faster to perform, more comfortable and acceptable to patients, and appears to provide more accurate and precise evaluation of a wide range of esophageal motility problems. The combination of solid-state miniaturized transducers spaced at very close intervals coupled with the analytical capacity of modern sophisticated software systems has allowed the evolution of this manometric technology. By greatly increasing the number of sensors and reducing the distance between them, it provides a comprehensive representation of the entire pressure profile along the esophagus. The visual display or topographic contour plot makes interpretation more intuitive. In addition to the advantage of the user-friendly visual representation, the software permits the easy calculation of many new parameters. The baseline may be easily adjusted to either gastric pressure or atmospheric pressure depending on the area of interest. In addition, the closely spaced transducers extending from the pharynx to the stomach and straddling the LES allow for simultaneous recording with fewer artifacts than required with the time-consuming traditional water-perfused manometry with pull-through technique. Once it is located in the stomach,

the entire topography of the esophagus and the upper and lower sphincters is identifiable at a glance.

The HRM catheter is heavier and more rigid, making it easier to pass into position without endoscopic guidance. This is particularly important in patients with a dilated esophagus or a large hiatal hernia. This new technology has provided the opportunity to develop novel parameters for classifying functional abnormalities, which is particularly important in achalasia. New studies of achalasia using HRM have revealed three distinct subtypes of this condition (Figs. 76.1 and 76.2): subtype I, classic achalasia with minimal pressurization and impaired LES (esophagogastric junction [EGJ]) relaxation; subtype II, achalasia with impaired EGJ relaxation, absent peristalsis, and pan-esophageal pressurization; and subtype III, achalasia with spasm. These groups have different responses to medical or surgical therapies, with group 2 having the best response and group 3, the worst. Thus, HRM may offer advantages over conventional methods, including improved identification of motility disorders, hiatal hernia, outflow obstruction, and ease of interpretation. HRM studies are shorter than those using conventional methods, interpretation is image based, and correlates with objective endoscopic and physiologic findings. The introduction of HRM in the evaluation of motility disorders appears to provide a significant advance in the outpatient evaluation of esophageal function.

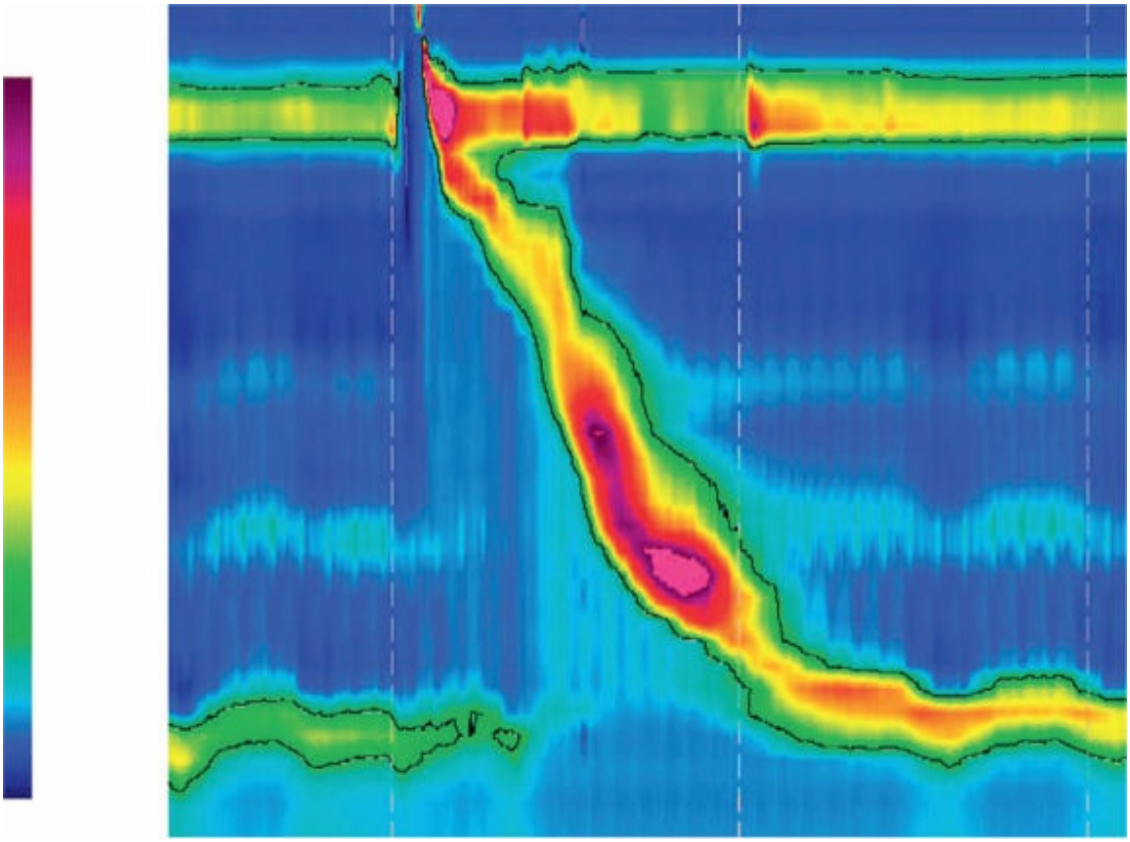

Figure 76.1. High-resolution manometry (HRM) showing normal esophageal peristalsis. (Reproduced with permission from the Nature Publishing Group—Vaezi MF, Pandolfino JE, Vela MF. ACG clinical guideline: diagnosis and management of achalasia. *Am J Gastroenterol* 2013;108:1238–49.)

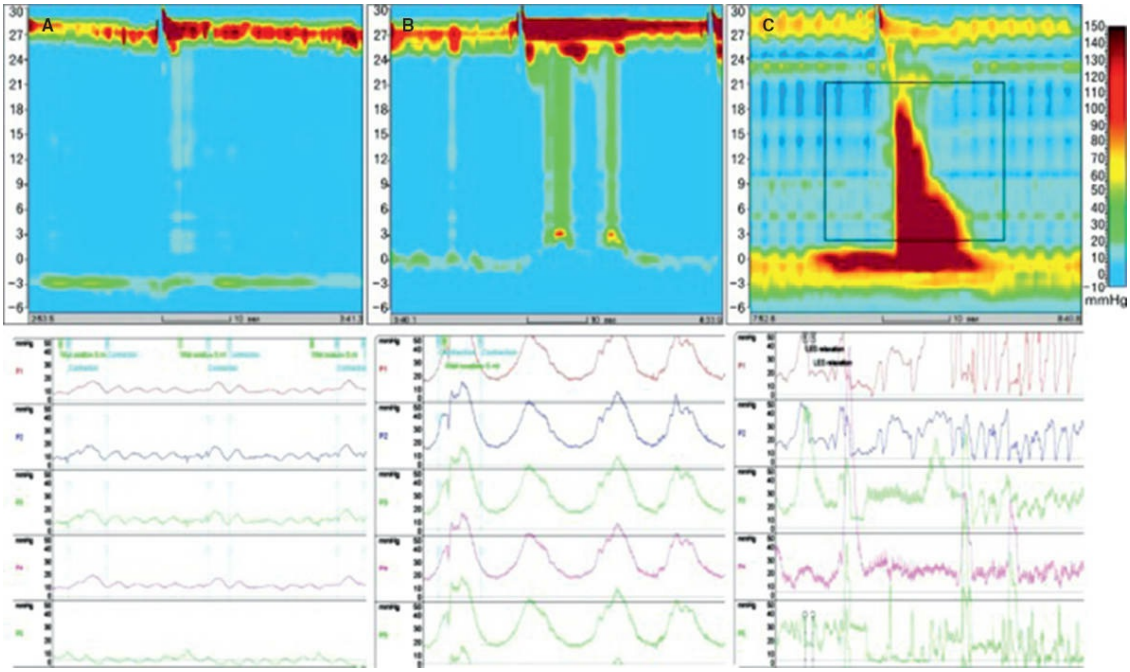

Figure 76.2. The three subtypes of achalasia as seen with HRM

above and the corresponding conventional manometry below demonstrate impaired LES/EGJ relaxation and (**A**) Subtype I with aperistalsis and minimal esophageal pressurization; (**B**) Subtype II with absent peristalsis and pan-esophageal pressurization; (**C**) Subtype III with spastic achalasia. (Reproduced with permission from the *Journal of Neurogastroenterology*—Lee JY, Kim N, Kim SE, et al. Clinical characteristics and treatment outcomes of 3 subtypes of achalasia according to the Chicago classification in a tertiary institute in Korea. *J Neurogastroenterol Motil* 2013;19:485–94. Korean Society of Neurogastroenterology and Motility.)

TREATMENT/INDICATIONS

It is important to acknowledge that achalasia is an incurable disease and treatment should be directed toward the relief of symptoms. The goal of any treatment for achalasia is directed toward reducing the pressure gradient across the LES, in order to eliminate the outflow obstruction and to relieve a patient's symptoms of dysphagia and regurgitation, improve esophageal emptying, and prevent the development of mega esophagus while maintaining a barrier against GERD. Historically, the most popular treatment for achalasia has been by forceful PD. The first case of achalasia was reported over 300 years ago by Thomas Willis and the patient was successfully treated by dilation with a whale bone. PD has become much easier and more standardized with the development of the Rigiflex balloon system (Boston Scientific Corp., MA). The success rate of PD is 55% to 70% with a single dilation but can be increased to nearly 90% with multiple dilations. However, the risk of perforation with each dilation is at least 2% and has been reported as high as 16% in some series. Age (older than 60 years old) is the most important risk factor for esophageal perforation (hazard ratio 3.4 compared with <60). Furthermore, when stratified by age, balloon dilation is <50% effective in patients younger than 40 years; male gender; single dilation with a 3.0 cm balloon; posttreatment LES pressure above 10 mm Hg; and poor esophageal emptying. The only absolute contraindication to PD is poor cardiopulmonary status or other comorbid illnesses preventing surgery should an esophageal perforation occur. In the only prospective, randomized trial performed comparing surgery with balloon dilation using an older single balloon system, surgical myotomy outperformed balloon dilation 95% to 65%. Other more recent studies have failed to show a

difference in outcome between the two procedures, both for short- and long-term follow-up. In a recent large series of 209 patients with achalasia who were treated with PD between 1992 and 2002, initial dilation and then operation for short-term failures yielded good long-term results in >70% and treatment satisfaction in >80% of patients. The postdilation resting LES pressure is a major determinant of long-term success and the postdilation LES pressure can be used as a therapeutic target to determine the number of dilations needed. High long-term success rates can be obtained with repeat dilations for late recurrences and operation for early recurrences. Thus, management with initial dilation followed by a rigorous dilation protocol can provide good or excellent long-term results and high patient satisfaction rates. However, while PD has been found to have a more lasting effect on dysphagia than other nonsurgical treatments, outside of a rigorous dilation protocol, most studies have not demonstrated the long-term outcomes seen after surgical myotomy. Self-expanding stents have been used to treat achalasia. Li et al. reported a 10 years clinical success rate of 83% for the 30-mm stent, while for 20-mm stent and PD was 0%.

Botulinum toxin (BOTOX) is a potent presynaptic inhibitor of acetylcholine release from nerve endings that has proven to be a useful treatment in achalasia. BOTOX causes a short-term paralysis of the muscle by blocking the unopposed cholinergic stimulation of the LES, which is devoid of inhibitory influence in achalasia. The treatment is limited and most treatment effects are associated with approximately a 50% reduction in the basal LES pressure. This reduction may be sufficient to allow esophageal emptying when esophageal pressure rises to a level where it can overwhelm the partially paralyzed LES. BOTOX is easy to perform and has low complication rates. BOTOX injection is less effective than balloon dilation and requires retreatment to maintain an efficacy rate of 65%. The use of BOTOX injection for early recurrences after initial failed dilations is even less successful. Of greater concern is the fact that BOTOX injection leads to scar formation in the submucosal plane, which results in a more difficult myotomy and higher mucosal perforation rate (up to 30%) during dissection. Thus, BOTOX should be reserved for the treatment of patients who are poor candidates for operation and balloon dilation (dilated sigmoid esophagus) or as a bridge to surgery. An additional utility for BOTOX is in aiding in the diagnosis of patients who have equivocal findings on initial evaluation. A good response to BOTOX

is usually an indication that the patient will have long-term relief following successful dilation or surgical myotomy. BOTOX can also be considered as an adjunct treatment in patients with residual spastic contractions above the myotomy site or LES; however, outcome-related data are lacking.

Pharmacologic treatment of achalasia with either long-acting oral nitrates or calcium channel blockers attempts to recreate a balance between the stimulatory and inhibitory influences by inhibiting intramural neurons, and thus decreasing the resting and residual pressure of the LES by smooth muscle relaxation. The phosphodiesterase-5-inhibitor, sildenafil, has also been shown to lower the LES tone and residual pressure in patients with achalasia. Other less commonly used medications include anticholinergics (atropine, dicyclomine, cimetropium bromide), β-adrenergic agonists (terbutaline), and theophylline. The most commonly employed calcium channel blocker is nifedipine, showing time to maximum effect after ingestion of 20 to 45 minutes with duration of effect ranging from 30 to 120 minutes. Thus, it should be used (10 to 30 mg) sublingually 30 to 45 minutes before meals for best response. The clinical response with pharmacologic agents is short acting and the side effects, such as headache, hypotension, and pedal edema, are common limiting factors in their use. Furthermore, they do not provide complete relief of symptoms. The success of such treatment is sporadic at best, is unreliable, and is not recommended for long-term management. These agents are commonly reserved for patients with achalasia who cannot or refuse to undergo more definitive therapies with PD or surgical myotomy and those who have failed BOTOX injections.

Esophagocardiomyotomy was introduced by Ernest Heller in 1914, and remains the most effective long-term treatment for achalasia. When properly performed, a Heller myotomy can be expected to result in permanent relief of dysphagia in 85% to 100% of patients. The operation, as described by Heller, was performed through the abdomen and has remained a popular approach in much of Europe and South America. In 1958, Ellis et al. described the transthoracic approach, which remained the most common approach for performing this procedure in North America, until recently. Despite excellent results with operation and an esophageal perforation incidence of <1%, most patients (75%) opted for balloon dilation as primary therapy because of the significant morbidity associated with a thoracotomy or laparotomy. With advances in videoscopic technology in the early 1990s, this operation was readily transitioned to a

minimally invasive approach. By reducing the pain, the incision size, and the postoperative disability, the surgical therapy has become more attractive to patients.

Initially, minimally invasive videoscopic esophagomyotomy was performed with a thoracoscope. Although effective, the thoracoscopic approach is associated with several difficulties. First, the perpendicular approach to the esophagus is less favorable for attaining and maintaining the submucosal plane than is the horizontal approach afforded by laparoscopic access. It is difficult to judge the appropriate distal end of the myotomy, allowing complete division of the LES without inducing postoperative reflux. Outcomes of thoracoscopic myotomy, as measured by both dysphagia relief and development of postoperative reflux, have been shown to be inferior to the laparoscopic approach in numerous studies. Finally, postoperative pain and length of hospital stay are generally greater following the thoracoscopic approach as compared to the laparoscopic. Today, esophageal myotomy is performed almost invariably through a laparoscopic approach.

Following the rapid acceptance of laparoscopic antireflux procedures, the laparoscopic Heller myotomy (LHM) became a natural extension of this experience and has proven to be more effective than the thoracoscopic procedure with less overall morbidity. The procedure is simpler to learn and to perform, and it allows routine hemifundoplication to prevent postoperative reflux. In selected patients such as a hostile, multiply operated abdomen, following a failed abdominal myotomy, or in diffuse esophageal dysmotility, the thoracic approach may still be preferred. LHM is associated with an 80% long-term success rate. A recent meta-analysis reported success rates of 89% after a mean follow-up of 35 months. Successful LHM may be predicted by high lower esophageal sphincter pressure (LESP), no prior therapy, short symptom duration, or absence of sigmoidal esophagus.

Failure of esophagocardiomyotomy to relieve the dysphagia may be attributable to either incompletely relieving the obstructive achalasia or an obstructing antireflux mechanism distal to the aperistaltic esophagus. In an evaluation of the effect of preoperative PD or BOTOX injection on outcomes after LHM for achalasia in 134 patients, multiple endoscopic treatments were associated with poorer outcomes, and these authors suggest that dilation or BOTOX should be limited to achalasia patients who fail surgical therapy.

Recent data show that both the proximal and distal extents of the myotomy are important. It has been recently recognized that an epiphrenic diverticulum may develop, which is believed to be caused by absence of coverage by the fundoplication over the proximal extent of the myotomy. This increased recognition of the potential for diverticulum formation has led many to limit the proximal extent of the myotomy to that, which can be covered by an anterior fundoplication. It has long been the belief that overzealous extension of the myotomy onto the stomach, in an attempt to avoid incomplete myotomy, is associated with a high incidence of reflux and associated esophagitis. However, recent studies have demonstrated that relief of dysphagia is improved with lengthening of the distal extent of myotomy from 2 to 3 cm onto the cardia of the stomach with disruption of the gastric sling fibers, further decreasing LES pressure. Since an effective myotomy should lower esophageal outflow resistance and improve esophageal emptying, it also increases the propensity for development of GE reflux. There is often a poor correlation between symptoms of reflux and pathologic reflux as demonstrated by pH study. The importance of the addition of a fundoplication to the myotomy has, until recently, been debated.

A prospective, randomized study by the group at Vanderbilt University demonstrated that Heller myotomy plus a Dor anterior fundoplication is superior to Heller myotomy alone in regard to the incidence of postoperative reflux as measured by 24-hour pH testing. Furthermore, there was no increase in dysphagia in the fundoplication group. In this study, abnormal acid exposure on pH monitoring was found in 47% of patients without an antireflux procedure and 9% in patients who had a posterior Dor fundoplication. A subsequent cost–utility analysis based upon the results of this randomized double-blind trial found that myotomy plus Dor fundoplication was more cost-effective than myotomy alone because of the costs of treating GERD. Following successful esophageal myotomy, patients may continue to have minor symptoms of dysphagia, which is attributable to esophageal aperistalsis. The type of fundoplication is important in order to avoid significant obstruction. In general, a 360-degree fundoplication should not be used in patients undergoing a myotomy for achalasia because it will be too obstructive in this setting. The most recent achalasia guidelines from the Society of American Gastrointestinal and Endoscopic Surgeons (SAGES) recommended that patients who undergo myotomy should have a fundoplication to prevent

reflux. Although it has been fairly well established that adding a fundoplication is beneficial for reducing the rate of GERD after myotomy, there is less certainty on the best approach (anterior Dor or posterior Toupet). Both the posterior Toupet and the anterior Dor partial fundoplications have been used effectively, and a recent multicenter trial has suggested no difference between the posterior and anterior fundoplications. Proponents of the Toupet claim the advantage that it holds the edges of the myotomy apart and provides a better antireflux mechanism when the patient is in the supine position. However, in the patient with a markedly dilated esophagus before myotomy, the Toupet may be too obstructing and either an anterior fundoplication or no fundoplication at all is recommended. Proponents of the Dor partial fundoplication prefer the added security of covering the exposed mucosa with the fundus and the avoidance of complete mobilization of the abdominal esophagus, which is required when constructing a Toupet wrap. Dor fundoplication does not require extensive mobilization of the fundus, the short gastric vessels are left intact, and posterior dissection is unnecessary, thus eliminating the disruption of the posterior aspect of the phrenoesophageal ligament. Because of the preservation of these natural posterior attachments and its easier technical construction, most surgeons have migrated toward routine Dor fundoplication. Given the significant chance of reflux after myotomy even with an added partial fundoplication, all patients who complain of heartburn or who have an abnormal postoperative pH study should be treated with long-term proton pump inhibitor (PPI) therapy.

The best surgical treatment (myotomy vs. esophagectomy) for patients with achalasia and a markedly dilated esophagus has been debated; however, several recent studies have reported successful treatment of achalasia with LHM in the setting of a markedly dilated esophagus (>6 cm diameter) and even in patients with extreme mega-esophagus (>10 cm). Occasionally, the degree of esophageal aperistalsis is so advanced that myotomy alone does not relieve the dysphagia and the patient is better served with esophagectomy. Esophagectomy should be considered in a patient with a dilated sigmoid esophagus who remains symptomatic and has had a previous myotomy, with a resting LES pressure of <10 mm Hg.

The utility of intraoperative manometry in laparoscopic myotomy is clear. The technique is safely performed, adds little time to the case, and clearly identifies persistent areas of residual high pressure at the

esophagogastric junction, especially when enhanced with real-time three-dimensional pressure imaging. Intraoperative esophageal manometry can be used during achalasia surgery to verify the myotomy, to provide an objective means of determining the correct length of myotomy, and to better calibrate the reconstructed LES pressure during antireflux procedures. With the recent advent of laparoscopic myotomy, intraoperative manometry has enjoyed a resurgence of popularity as an adjunct to the minimally invasive procedure. If the combination of intraoperative manometry and endoscopy can better guide the extent of the myotomy, then perhaps, one no longer has to choose (or guess) between either incomplete relief of achalasia or incompetence of the cardia. Clearly, intraoperative manometry can improve the adequacy of myotomy. In addition, it may prove a useful tool in decreasing the incidence of significant dysphagia after the antireflux procedure.

Recent developments in gastrointestinal endoscopic methodology, originating from work done in the study of natural orifice surgery (NOTES), have led to the conceptualization and practice of per-oral Endoscopic Myotomy (POEM) an intramural endoscopic approach to the division of the distal esophageal and proximal gastric muscular layer with resultant relaxation of the LES. This procedure was conceptualized and studied in the laboratory by a team led by Pasricha. It was then first performed in humans by a thoracic surgeon, Inoue, in Japan. The method, carried out under general anesthesia, involves creation of an esophageal submucosal tunnel, which is carried onto the proximal stomach (Fig. 76.3). The loose areolar tissue holding the mucosa to the underlying muscle is divided. The muscles of the esophageal and gastric wall are then divided under direct vision. At the conclusion of the procedure, the small entrance to the submucosal tunnel is closed with endoscopic clips. There is no surgical incision on the exterior of the patient's body.

Candidates for POEM include patients with a diagnosis types I, II, or III achalasia, and some patients with NE. Patients who have failed PD and previous Heller myotomy may also be candidates. However, massive esophageal dilatation, severely tortuous esophagus, and large epiphrenic diverticula may be contraindications.

PREOPERATIVE PREPARATION

Prior to operation, the patient should be placed on clear liquids for 48 hours to allow the retained food in the dilated esophagus to pass. The

patient is instructed to shower with chlorhexidine soap the night before the operation and should be NPO after midnight. Bilateral pneumatic compression boots should be placed on the lower extremities prior to induction. A single dose of preoperative antibiotic is given, and a rapid sequence induction anesthesia should be performed in order to minimize the risk of aspiration. Blind placement of a nasogastric tube or esophageal stethoscope should be discouraged in these patients because of the risk of perforation of the esophagus.

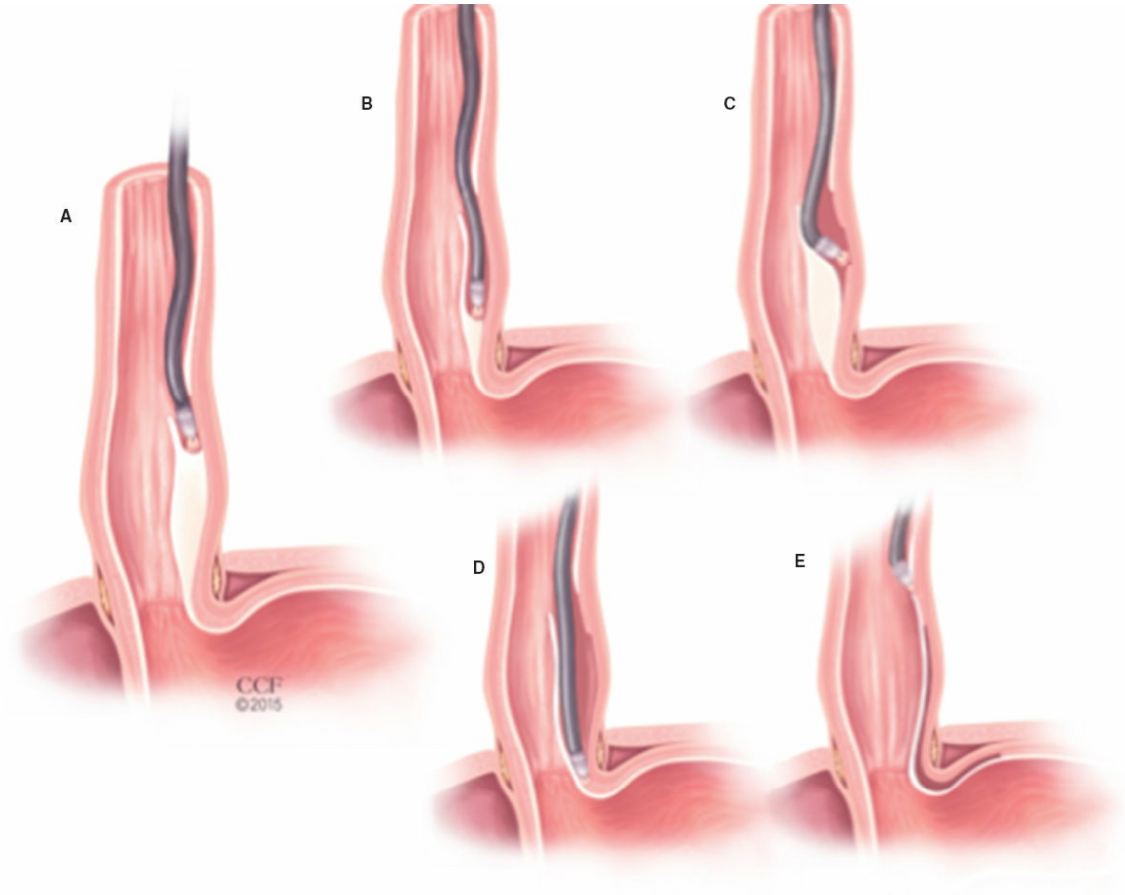

Figure 76.3. Steps in the per-oral endoscopic myotomy.

LAPAROSCOPIC ESOPHAGOCARDIOMYOTOMY

The patient is positioned supine on the operating table with the sequential compression devices placed on the lower extremities. A general endotracheal anesthetic is administered and the patient is positioned with the arms tucked by their sides. The patient's legs are placed in adjustable leg holders in a low lithotomy position or in a split leg position, and a urinary catheter is placed (Fig. 76.4). An endoscope is placed through the patient's mouth, down the esophagus, and into the stomach and left in position for the intraoperative manometry and directed myotomy. The skin of the lower chest and abdomen is cleansed with an antibacterial surgical prep solution. A carbon dioxide pneumoperitoneum is established with a Veress needle puncture via the umbilicus to an intra-abdominal pressure of 15 mm Hg.

All port sites are injected prior to incision with 0.5% bupivacaine. The initial laparoscopic port (either 5 mm or 10 mm depending upon the size of the angled laparoscope) is placed 15 cm below the xiphoid and just to the left of midline. A 30-degree angled laparoscope is placed through this port,

and four additional ports are placed under direct vision. Two 5-mm ports are placed just below both costal margins 15 cm lateral to the xiphoid, and two ports (5 mm on the patient's right and a 10-mm port on the left) are placed 10 cm from the xiphoid and 3 to 4 cm on either side of the midline (Fig. 76.5). The patient is positioned in a reverse Trendelenburg position and a flexible 5-mm liver retractor is placed via the right costal margin port and positioned under the lateral segment of the left lobe of the liver, and elevated to expose the hiatus and the GE junction. At this point, the endoscope is advanced through the pylorus, a guidewire is passed into the duodenum via the endoscope and a manometry catheter is placed over the wire into the body of the stomach, and baseline pressures are measured using a pull-back technique across the LES.

The cardia of the stomach is grasped with an atraumatic grasper from the left lateral port, and the stomach and GE junction are retracted in a leftward and caudad direction. Hiatal exposure is performed using a grasper in the left hand and an ultrasonic shears in the right hand. If a patient is undergoing a myotomy alone or an anterior (Dor) fundoplication, care is taken to only dissect the anterior aspect of the esophagus and to leave as much of the phrenoesophageal ligament intact as possible.

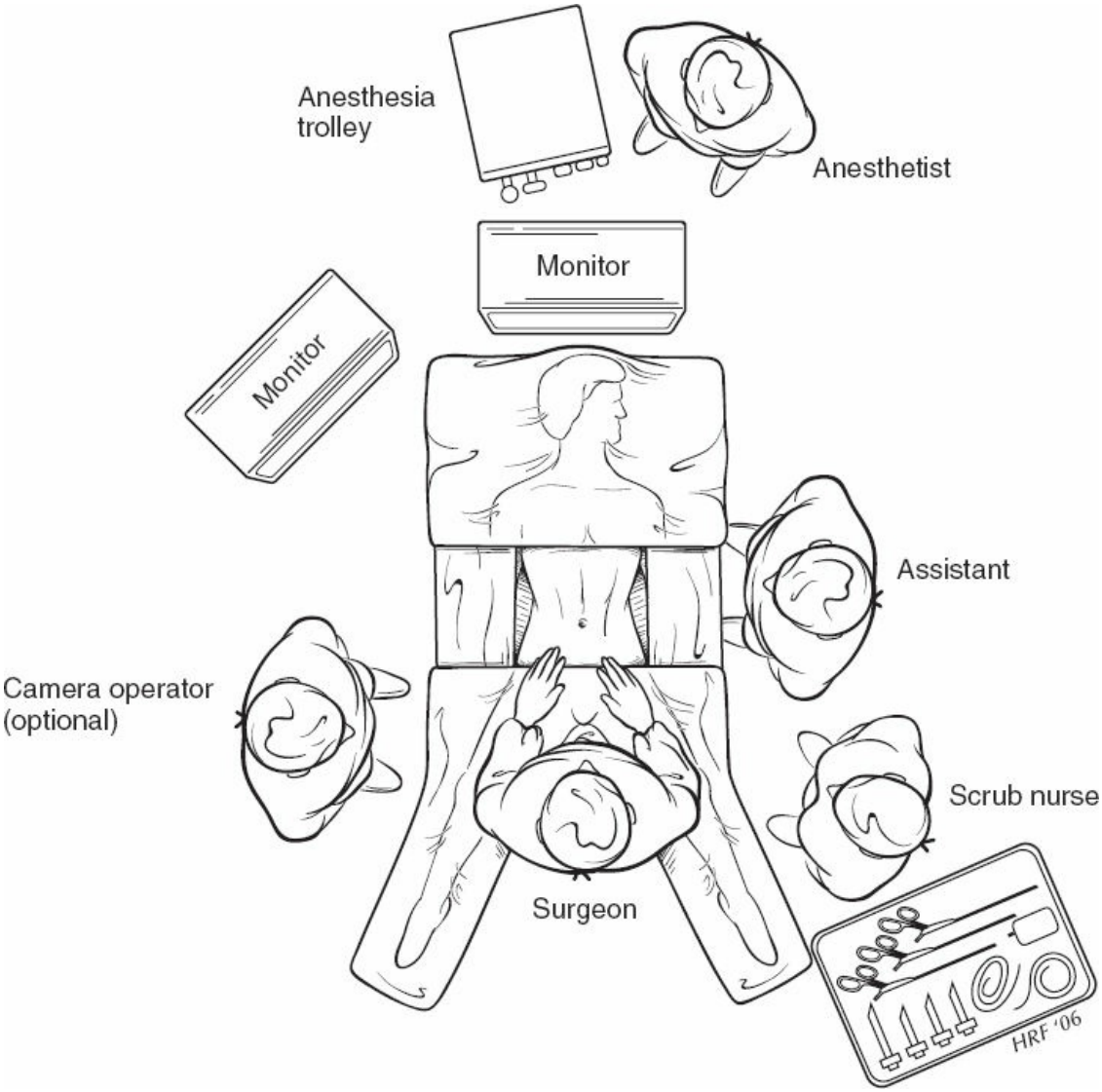

Figure 76.4. Patient position on the operating table for a laparoscopic myotomy. The low lithotomy position with arms tucked allows the surgeon to operate from a midline, coaxial orientation.

If a posterior (Toupet) fundoplication is planned, the esophagus is circumferentially mobilized by clearing the retroesophageal window. The posterior vagus is identified and retracted along with the esophagus, using a Penrose drain placed around the esophagus. The short gastric vessels are divided (only when performing a Toupet fundoplication) using the ultrasonic shears, and the pancreatic and diaphragmatic attachments to the gastric fundus are released (Fig. 76.6).

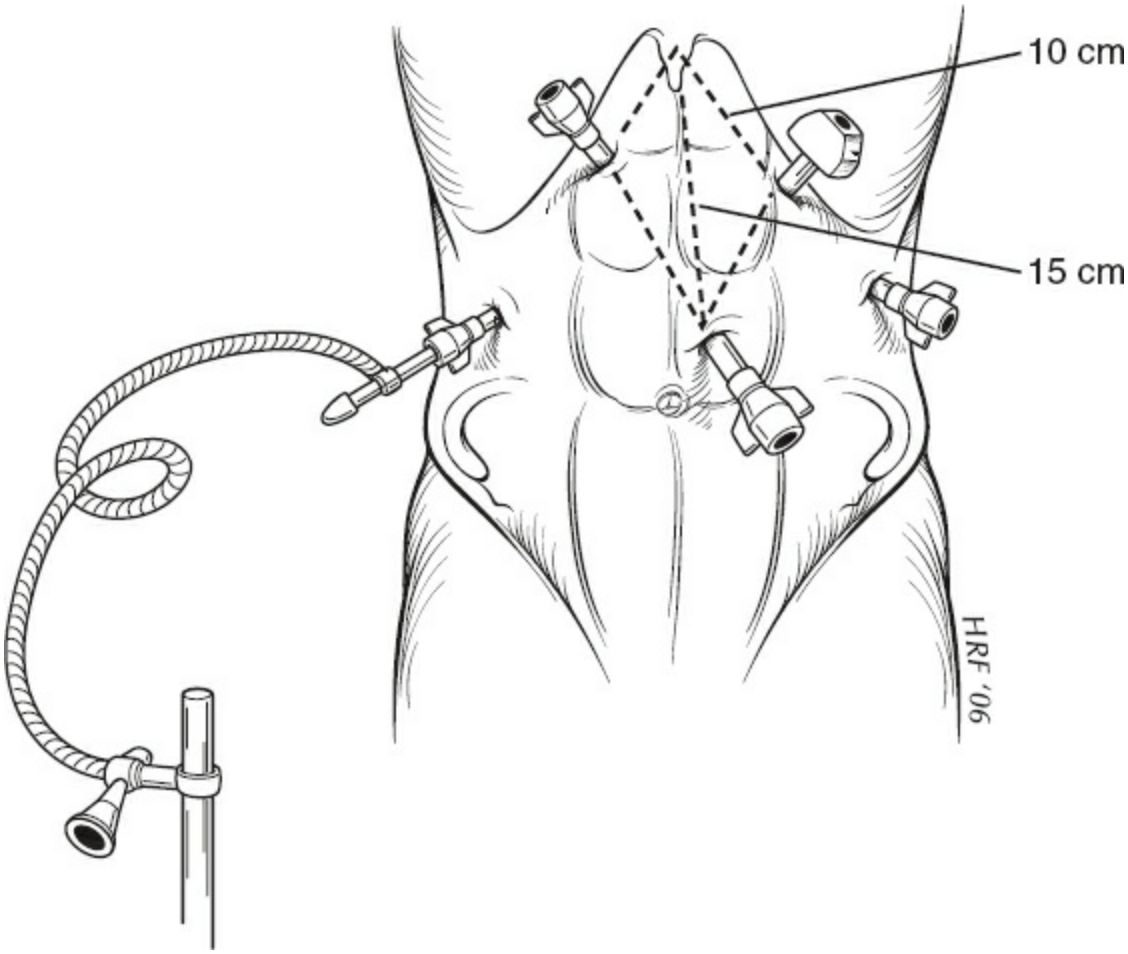

Figure 76.5. Port placement for a laparoscopic myotomy. The surgeon's right hand and left hand form an equilateral triangle with the hiatus and the laparoscope port. The liver retractor and assistant's right hand complete two other equilateral triangles.

After the lower esophagus, anterior vagus nerve, and cardia of the stomach are exposed, the GE fat pad is excised and the anterior esophagus is treated with a concentrated solution of 1:1,000 epinephrine applied by a kittner gauze dissector to aid with hemostasis. The myotomy is then carried out utilizing blunt dissectors, a scissors or hook without electrocautery, and/or an ultrasonic shears (Fig. 76.7). The myotomy is begun on the esophagus and carried proximally a distance of 5 to 6 cm from the GE junction and distally 1.5 to 2 cm onto the cardia. The myotomy is guided by intraoperative endoscopy to ascertain that it is carried at least 1.5 to 2 cm beyond the squamocolumnar junction (Fig. 76.8). Electrocautery and ultrasonic dissection are used sparingly to avoid inadvertent mucosal perforation. Hemostasis is obtained with the use of the epinephrine (1:1,000) soaked kittner and 2 × 2 in gauze sponges. The myotomy should be tested with underwater air insufflation to ensure that

there are no inadvertent mucosal injuries. Mucosal holes are sutured with 4-0 absorbable sutures, and the repair is always tested again with endoscopic insufflation. When the myotomy is felt to be complete, repeat manometry is performed to confirm successful ablation of the pathologic high-pressure zone. If the myotomy is incomplete, then it should be extended until a satisfactory pressure reduction is obtained.

The esophageal hiatus is reapproximated, if necessary, with one to two 0-braided polyester sutures. If an anterior (Dor) fundoplication (Fig. 76.9) is performed, four 2-0 polyester intracorporeal sutures are placed. On the left side, a suture is placed between the fundus, the apex of the left crus, and the superior (cephalad) cut edge of the muscularis to the left of the esophagus. A second suture is placed 2 cm inferior (caudad) to the first suture approximating the left side of the fundus and the left side of the myotomy. The third suture is placed between the fundus and the superior (cephalad) cut edge of the muscularis to the right of the esophagus and the apex of the right crus. Finally, the fourth suture is placed between the right side of the fundus and the inferior (caudad) right side of the myotomy to complete an anterior partial fundoplication. In this way, the entire exposed aspect of the mucosa is covered by fundus to prevent the late development of a distal esophageal diverticulum.

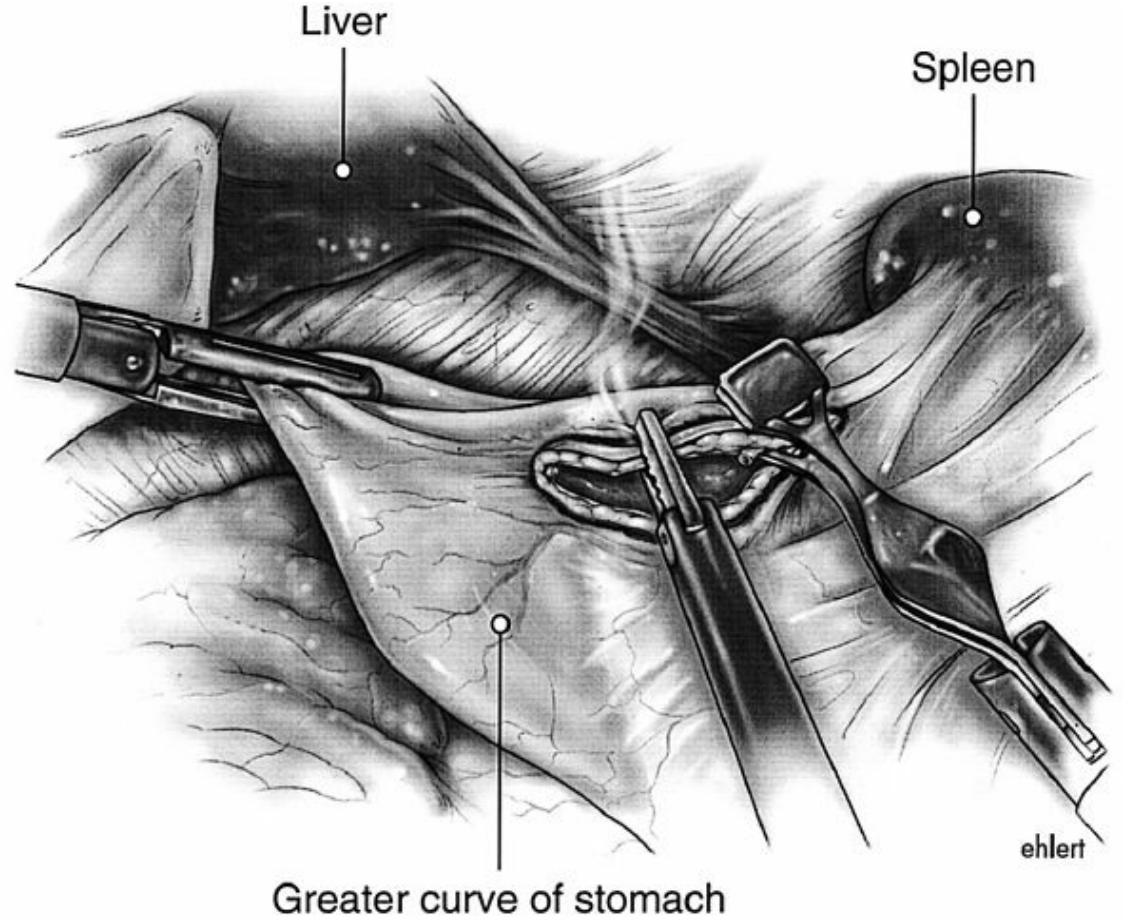

Figure 76.6. Dissection of the short gastric vessels. The assistant retracts the gastrocolic and gastrosplenic ligament anterolaterally toward the spleen, while the surgeon's left hand provides counter traction on the fundus. Ultrasonic shears are used to divide the short gastric vessels.

When a posterior (Toupet) fundoplication is chosen, the fundus is grasped from the right and brought around behind the esophagus through the retroesophageal window, and the posterior fundoplication is fashioned utilizing eight 2-0 braided polyester intracorporeal sutures (Fig. 76.10). On the right side, a suture is placed between the superior (cephalad) extent of the myotomy and the fundus. The outside of the fundus is sutured to the apex of the right crus with a second suture. Finally, two additional sutures are placed further caudad from the first suture, between the cut edge of the muscularis to the right of the esophagus and the fundus, placing each of the three sutures 1 cm apart to create a 2-cm long fundoplication. An identical series of four sutures are placed on the left side of the myotomy and left crus to complete the fundoplication (Fig. 76.11).

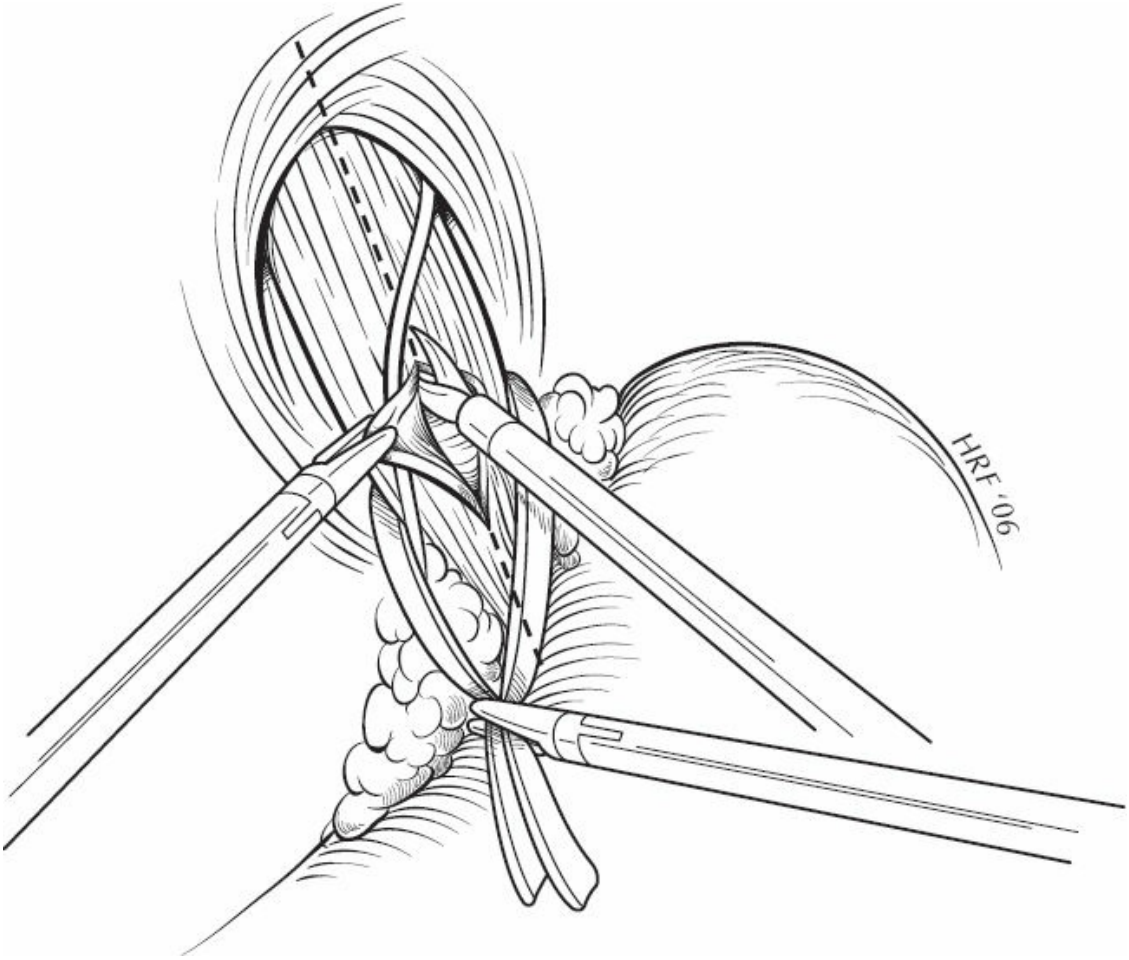

Figure 76.7. Division of the longitudinal muscle fibers of the esophagus is begun 2 to 3 cm above the gastroesophageal junction. Care must be taken to avoid full-thickness injury.

Manometry is repeated at the conclusion of the fundoplication in order to obtain a new baseline and to be certain that the fundoplication does not cause an excessive amount of pressure (the pressure should be no >20 mm Hg). The Penrose drain is removed from around the esophagus, the operative field is irrigated and inspected, the secondary ports are removed under direct vision, and the primary port is used to desufflate the abdomen and then it is removed. The incisions are closed, the urinary catheter is removed, and the patient is transported to the postanesthetic care unit.

ROBOTIC-ASSISTED LAPAROSCOPIC ESOPHAGOMYOTOMY

Recent experience using both the three-arm and four-arm computer-enhanced telesurgery device (*da Vinci* Surgical System, Intuitive Surgical, Sunnyvale, CA, USA) has demonstrated that this is a safe and effective

treatment method for this particular foregut disorder. Computer assistance allows scaling of hand motions, successful dissection of esophageal musculature in a three-dimensional field, and improved ease of suturing. The benefits of magnification and three-dimensional imaging can help prevent esophageal perforation and identify residual circular muscle fibers. Several large studies comparing the robotic with the laparoscopic method have demonstrated equivalent efficacy in relieving the symptoms of achalasia, while the robotic method is safer because it decreases the incidence of esophageal perforation to nearly 0%, even in patients who had previous dilation and BOTOX treatment. Furthermore, patients demonstrated a high level of satisfaction with their health-related quality of life following robotic-assisted LHM and fundoplication, when compared with laparoscopic patients.

The operative technique for the robotic-assisted procedure is essentially the same as described above for the laparoscopic approach. Because of the circumference and increased length of the robotic telescope, the initial access port must be either a 10/12-mm or 8-mm port and should be placed ~2 cm further caudad (17 cm) from the xiphoid. The secondary ports must also be further apart, with a minimum four finger-breadth distance between each port to allow for full range of motion of the robotic arms. The right lateral subcostal port is still used for the static placement of a 5-mm liver retractor; the other three ports are for robotic instruments and can be either 8 mm or 5 mm in size, depending upon the size of the robotic hand instruments available. The myotomy is carried out utilizing a hook dissector, which has a full 7-degree range of articulation and monopolar cautery.

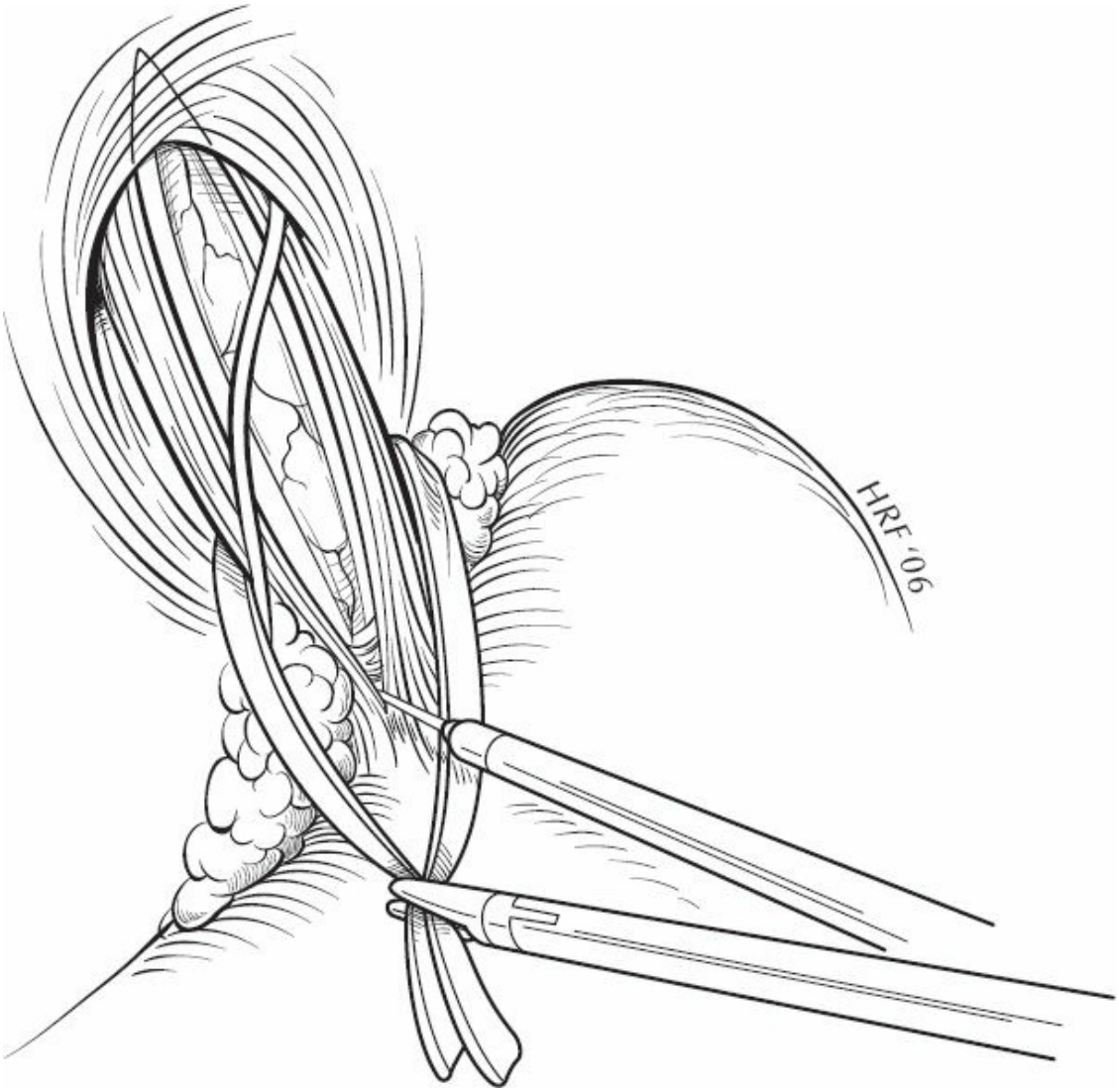

Figure 76.8. The completed myotomy extends onto the cardia of the stomach for 2 cm beyond the squamocolumnar junction as measured using intraluminal endoscopy. The cut edges of the myotomy are separated for at least one third of the circumference of the esophagus.

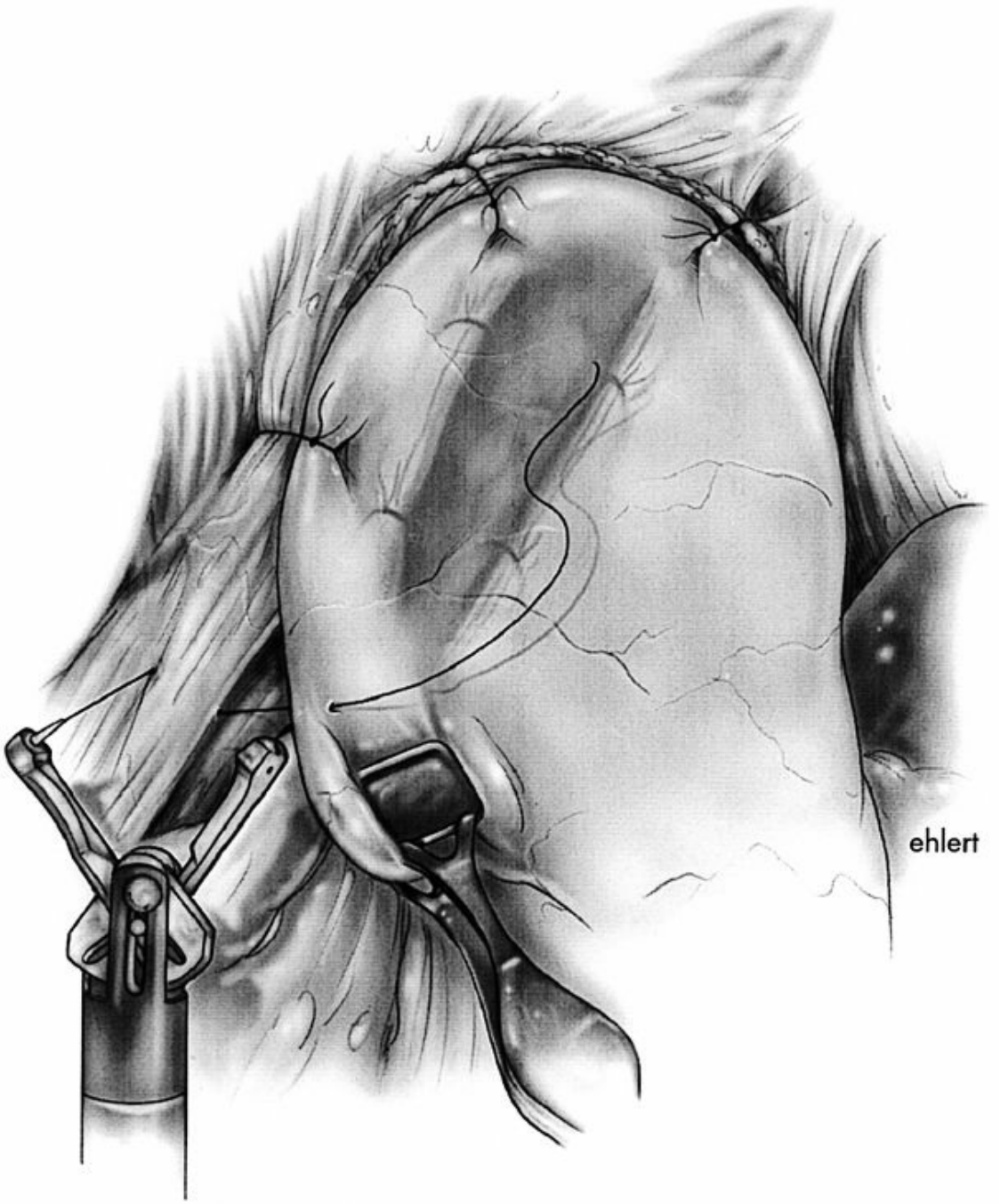

Figure 76.9. Completed anterior partial fundoplication. Several sutures are used to anchor the fundus to the cut edge of the myotomy. The fundus is also anchored to the hiatus. The anterior fundoplication allows the esophageal mucosa to be buttressed by the gastric serosa, and is especially useful if the mucosa was injured during the myotomy.

THORACOSCOPIC ESOPHAGOMYOTOMY

As mentioned earlier, in selected patients such as a hostile, multiply operated abdomen or following a failed abdominal myotomy, the thoracic

approach may still be considered. The thoracic approach is also appropriate in managing patients with proximal esophageal motility abnormalities. Thoracoscopic esophagomyotomy can be performed via either thoracic cavity with the patient in a lateral decubitus position. A double-lumen endotracheal tube is used to allow selective ventilation of the contralateral lung. The surgeon and the assistant stand behind the patient, while the instrument nurse stands facing the patient. The primary videoscope port is placed in the fourth or fifth intercostal space, just inferior and posterior to the tip of the scapula. Two working ports are placed in the second/third and the sixth/seventh intercostal spaces in the mid-axillary line to create an equilateral triangle with the videoscope port. A fourth port or small incision is placed anteriorly to provide retraction of the lung (Fig. 76.12).

The lung is deflated and the esophagus and esophageal hiatus are visualized. As described above, endoscopic and manometric guidance can be used to aid in the identification and dissection of the esophagus, as well as confirming completion of the myotomy. The mediastinal pleura overlying the esophagus is incised and the inferior pulmonary ligament is divided. Dissection is kept to a minimum in order to preserve the normal hiatal structures. Dissection is extended caudad as far as the right hemidiaphragm. If a long myotomy is being performed, dissection is carried proximally beyond the azygous vein on the right and up to the arch of the aorta on the left. The azygous vein can be ligated, clipped, or stapled once it is mobilized off of the esophagus. Myotomy is carried out in a similar fashion to that described in the laparoscopic approach (Fig. 76.13). Because of the perpendicular approach, an L-hook is most useful with careful use of monopolar electrocautery, once the longitudinal and circular fibers are elevated away from the esophagus (Fig. 76.14). The endoscope can facilitate this by applying suction to deflate the mucosa. The myotomy is begun 2 to 3 cm above the GE junction and carried distally beyond the endoscopically identified squamocolumnar junction. The proximal extent of the myotomy depends upon the underlying diagnosis and the intraoperative manometric findings. The integrity of the esophageal mucosa is tested with endoscopic insufflation. Addition of an antireflux procedure is difficult to perform and is usually not employed when using a thoracoscopic approach. A small caliber chest tube is placed, the lung is reexpanded, and the port sites are closed.

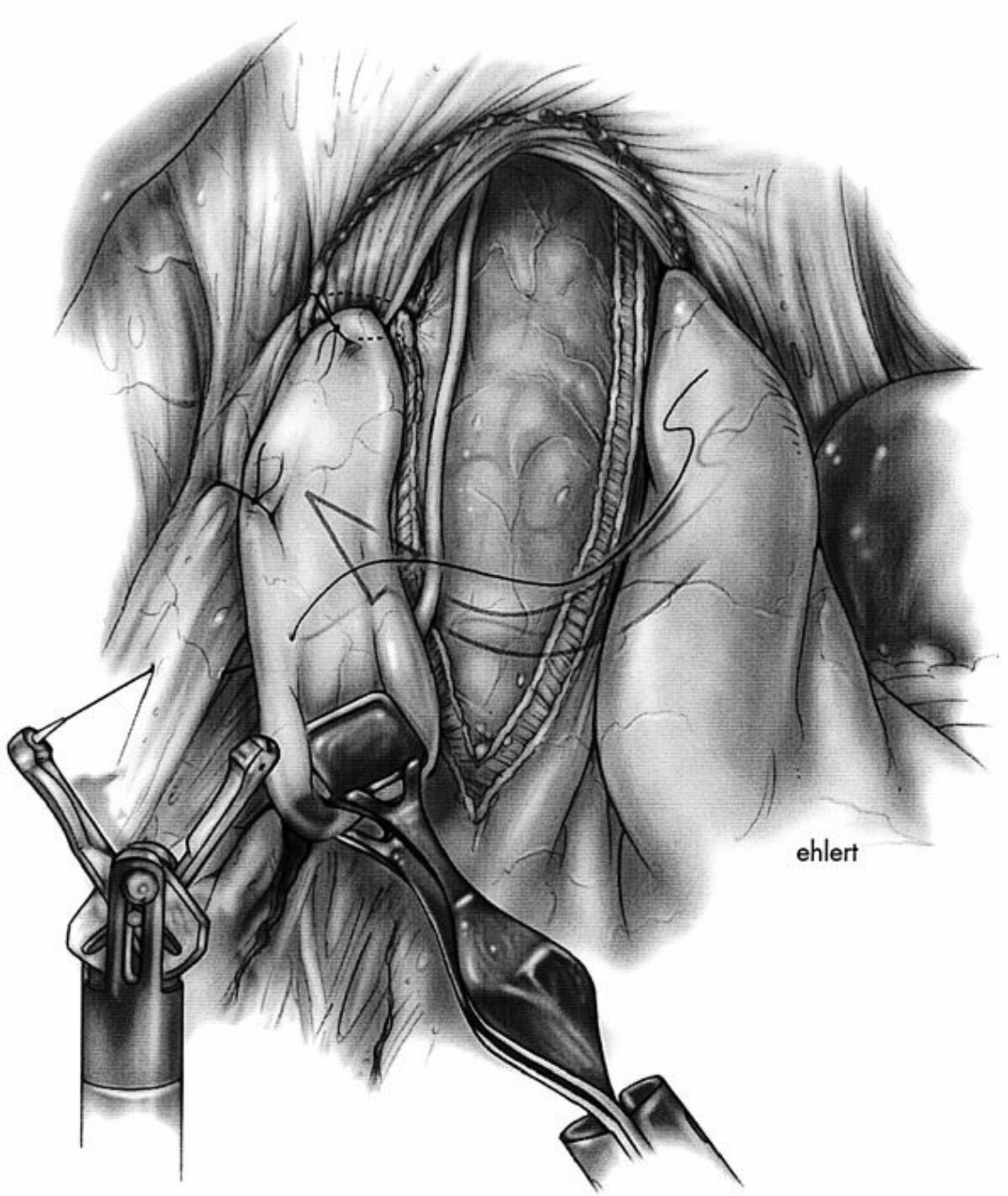

Figure 76.10. The first sutures of a partial posterior fundoplication are used to anchor the fundus to the right crus. This type of antireflux procedure has the advantage of keeping the cut edges of the myotomy separated.

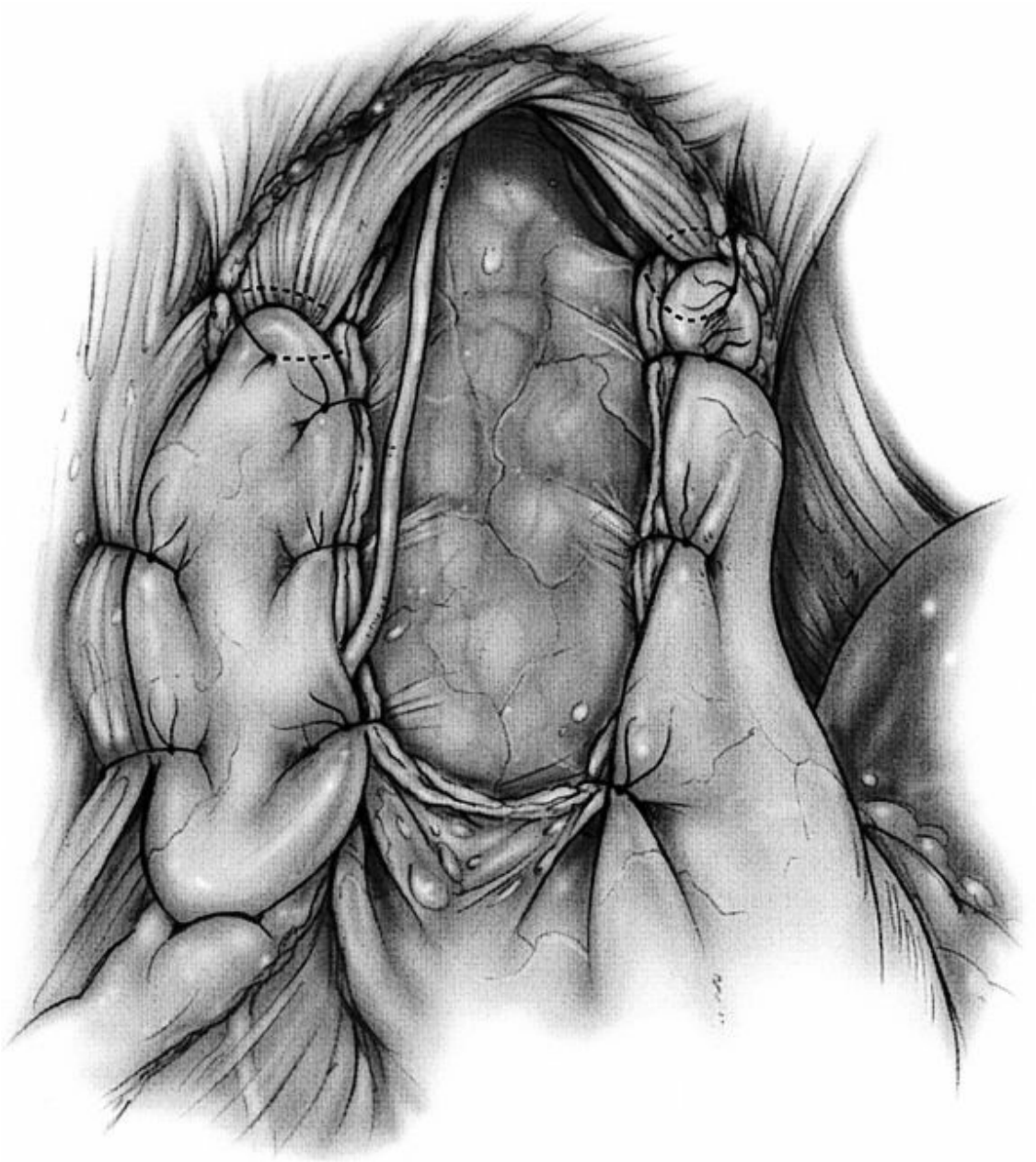

Figure 76.11. Completed posterior partial fundoplication. The fundus is anchored to the crura and the cut edge of the myotomy. The anterior vagus usually passes between the two most distal sutures on the right as it courses toward the lesser omentum.

PER-ORAL ENDOSCOPIC MYOTOMY (POEM)

Patients are evaluated and prepared for POEM in the same way as they would be for a Heller myotomy. Most of these procedures have been performed in the operating theater, although some have been reported to occur in specialized endoscopic suites. All have occurred under general anesthesia with endotracheal intubation. After a careful inspection of the esophagus and stomach, the location of the esophagogastric junction is

noted. In some cases, an endoscopic clip or injection of blue dye may be placed just below the junction for later use in assessing the extent of dissection.

The endoscope is affixed with a plastic cap to assist in dissection and often an overtube is used to facilitate frequent scope removal and reinsertion. An injection of a mixture of saline and indigo carmine or methylene blue is injected into the submucosal space at a point 10 to 15 cm proximal to the esophagogastric junction and a bleb raised. This bleb is then incised with a monopolar cutting current applied with a specialized endoscopic electrode. The injection and incision are most often performed on the anterior esophageal wall, although some have performed the injection and the myotomy posteriorly. After incision of the esophageal mucosa, a submucosal tunnel is created using cautery current to selectively divide the loose areolar tissue that joins the mucosal to the underlying muscle (Fig. 76.15). During this process, the circular muscle fibers of the esophageal wall are clearly visible. Once the tunnel is believed to extend beyond the esophagogastric junction and on to the proximal stomach, the extent of dissection may be verified by returning the scope to the native esophagus and advancing it into the stomach where a retroflex view of the cardia will show blue discoloration if the tunnel is of sufficient extent. If blue dye has been injected into the proximal stomach prior to the tunnel creation, it may be noted during the tunnel dissection when the proximal stomach is reached. If the surgeon has chosen to place an endoscopic clip in the stomach at the beginning of the procedure, fluoroscopic visualization of the scope in the stomach, under the diaphragm, and near the clip may be another useful way to assure that the dissection has gone sufficient distance.

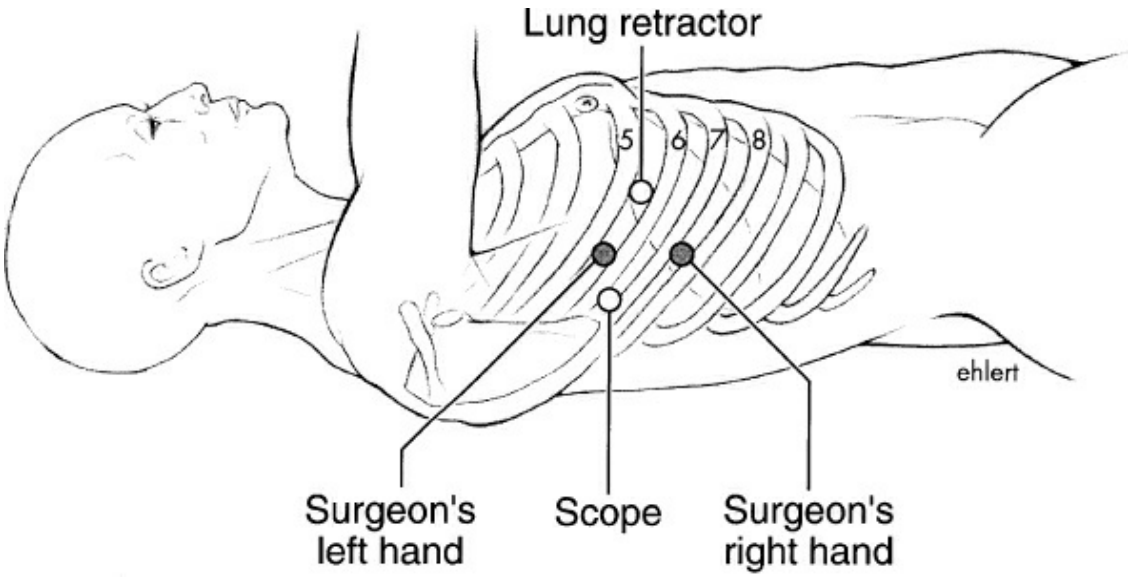

Figure 76.12. Port placement for a right thoracic myotomy. The videoscope is placed in the sixth intercostal space near the tip of the scapula. The surgeon's right hand and left hand are placed in the midaxillary line to create equilateral triangles with the videoscope and the mid-thoracic esophagus. A fourth port is placed more anterior to facilitate retraction of the lung.

After determination that the tunnel is of adequate length, the endoscope is withdrawn to several centimeter beyond the mucosal incision and cautery current is used to divide the esophageal muscle (Fig. 76.16). Most surgeons have chosen to divide only the circular (inner) muscular layer, leaving the longitudinal layer as a barrier between the mucosa and the mediastinum. Others have divided both layers. Comparative studies have shown no clinical difference in outcome between the two methods. In most cases, in spite of sparing the longitudinal fibers, most are torn or splayed out after division of the circular fibers. Following the myotomy, the scope is advanced through the native esophagus and esophagogastric junction to assure that relaxation is sufficient. Following this, the tunnel is sealed by endoscopic clipping of the original mucosotomy (Fig. 76.17).

POSTOPERATIVE CARE

The patient is kept NPO overnight, on intravenous fluids and parenteral analgesics. A gastrografin followed by barium swallow is often performed on the first postoperative day to confirm that there is no extravasation (gastrografin) or obstruction (barium) to flow. If the esophagram is normal, the patient is started on a clear liquid diet and advanced to a post-

fundoplication diet as tolerated. A recent review of 260 patients demonstrated a poor positive predictive value of routine esophagram after LHM, and the authors concluded that esophagography should be used selectively in the immediate postoperative period after an uncomplicated procedure. The patient is discharged once tolerating the post-fundoplication diet, usually on the evening of the first postoperative day. They can be transitioned to a regular diet within 2 weeks following discharge. Postoperative care after POEM is similar to care after LHM. Patients are generally discharged in a day or two following the procedure.

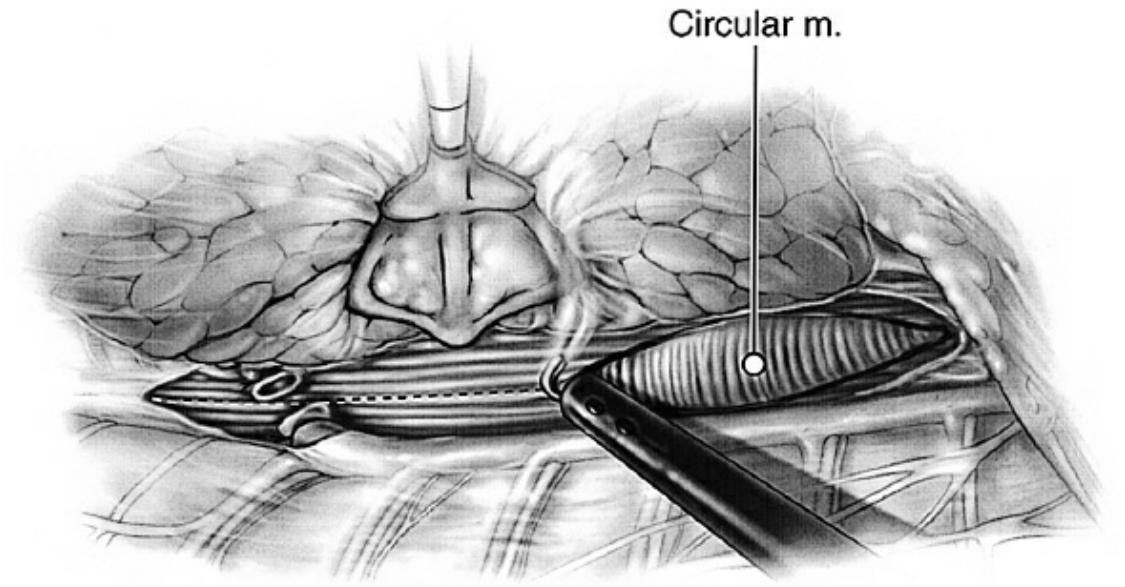

Figure 76.13. Longitudinal muscle fiber division is more difficult with the thoracoscopic approach, as the instruments have a perpendicular orientation to the esophagus.

The longer-term postoperative concerns are directed toward the management of postoperative complications, such as persistence/recurrence of dysphagia, GERD, and the development of esophageal carcinoma. Failures requiring postoperative treatment occur with an incidence of up to 14% in most recent series. The most frequently reported reason for “early” reoperation in achalasia following Heller myotomy is inadequate myotomy. Laparoscopic revision for failed Heller myotomy is feasible with low morbidity and encouraging results. However, the best treatment for failed LHM is the prevention of failures through the routine use of intraoperative endoscopy and intraoperative manometry to ensure that all muscle fibers have been separated properly and by assuring that an adequate length of the myotomy extends at least 2

cm on the gastric cardia. When symptoms—especially dysphagia—do persist or recur after a short interval following Heller myotomy, intensive examinations with barium esophagram, upper gastrointestinal endoscopy, functional testing with esophageal manometry, and—in cases with suspected development of GE reflux—pH monitoring are mandatory to determine the exact cause of failure. Additional findings such as epiphrenic diverticulum or hiatal hernia should be corrected simultaneously. DES associated with achalasia requires extended myotomy, best performed via a transthoracic route.

The risk of postoperative GERD can be minimized by the routine construction of a partial fundoplication in the majority of patients. In that setting ~9% of patients will develop pathologic GERD as defined by an abnormal DeMeester score on pH testing. Since the development of GERD symptoms is not a reliable predictor in this patient population with abnormal innervation of the distal esophagus, all patients should undergo pH testing at 3 to 6 months after LHM. If they have pH study proven GERD, most patients can be successfully treated with lifetime PPI medication. However, close follow-up and long-term routine endoscopic surveillance is required because of the increased incidence of peptic stricture, Barrett esophagus, and esophageal carcinoma in all of these patients. The development of peptic stricture in this setting can present a major therapeutic challenge, and surgical intervention is frequently required. Distal esophageal or GE strictureplasty with antrectomy and Roux-en-Y diversion for peptic stricture and severe postoperative GERD should be considered in extreme cases.

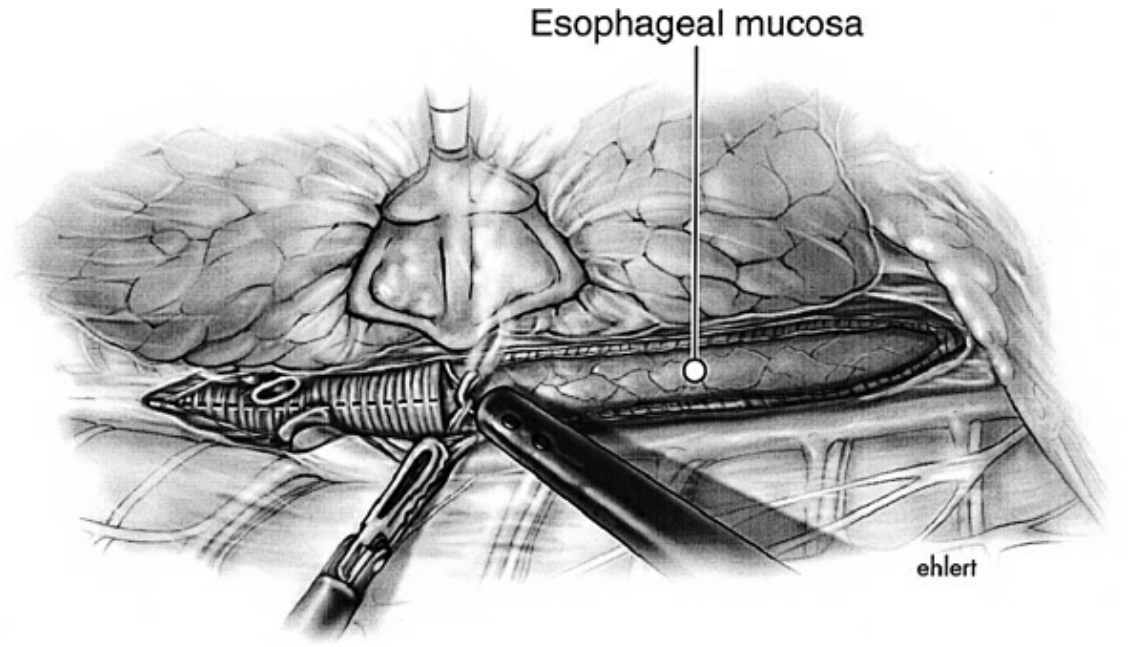

Figure 76.14. The circular muscle fibers are divided by separating and elevating them from the submucosal plane as in the laparoscopic approach.



Figure 76.15. The loose areolar tissue between the mucosa and the esophageal muscle is divided to create a submucosal tunnel.

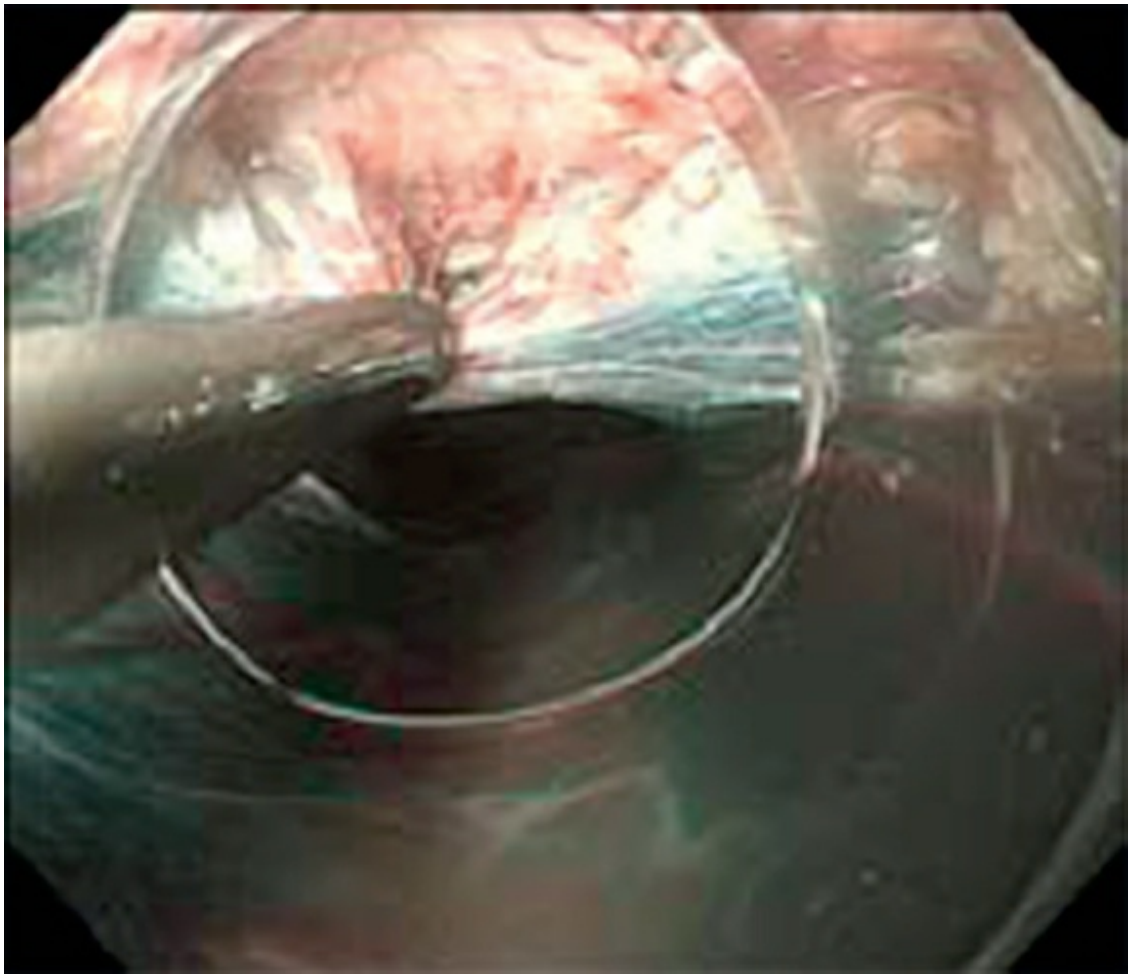

Figure 76.16. The inner circular muscle layer of the esophagus and proximal stomach is divided with cautery.

There have been several thousand POEM procedures performed throughout the world, and objective data collection suggests that results and outcomes are equivalent to those of Heller myotomy. There is, however, a significant incidence of abnormal gastroesophageal reflux following POEM of around 40%. This has been noted in numerous studies. Although most patients are asymptomatic, use of prophylactic acid suppression with long-term PPI therapy has been suggested to protect the distal esophagus from acid injury.

The incidence of developing both esophageal squamous cell carcinoma and adenocarcinoma is significantly higher in achalasia patients than in age- and sex-adjusted controls. The risk of developing esophageal squamous cell carcinoma in patients with long-standing achalasia has been estimated to occur from 1% up to 33% of patients, which is nearly 15 times greater than the general population. Development of adenocarcinoma after myotomy as a complication of Barrett esophagus

might be caused by extending the myotomy too far onto the gastric cardia, failure of the antireflux procedure, or failure of endoscopic surveillance and follow-up in this high-risk population.

Individualized remedial surgery is required to correct many of these problems. Further investigations should focus on comparing the length of the myotomy, the type of added antireflux procedure, and the histopathologic/immunohistochemical findings with regard to scarring in untreated and repeatedly myotomized patients. Reoperation for achalasia may require esophagectomy to relieve symptoms if other measures fail.

OTHER ESOPHAGEAL MOTILITY DISORDERS

PRIMARY ESOPHAGEAL MOTILITY DISORDER (PEMD)

Many esophageal motility abnormalities detected during manometry lack a classification or are categorized as nonspecific motility disorders. With the exception of achalasia, other esophageal motility disorders are poorly understood and studied. Named motility disorders include DES and NE, which are considered primary esophageal motility disorders (PEMD). DES is characterized by simultaneous contractions in >20% and <100% of wet swallows, intermittent peristalsis, and amplitudes >30 mm Hg. In DES, these manometric abnormalities may be found over the total length of the esophagus, but are usually confined to the distal two thirds. NE is a variant of DES, which is characterized by a rapid progression of the esophageal pump with mean distal amplitude waves measuring >180 mm Hg in the presence of normal peristalsis. The LES in patients with PEMD may show normal resting pressure with complete relaxation following deglutition, but may also present with intermittent episodes of incomplete relaxation. The etiology of DES and NE is unknown, and conflicting definitions of the diseases increase the controversies around the topic.



Figure 76.17. The esophageal mucosotomy is closed with clips.

Chest pain is believed to be the most common symptom associated with NE, and NE is the most common manometric finding in patients with noncardiac chest pain. Dysphagia is described as an uncommon finding in NE, while chest pain with dysphagia is the most common presenting symptom of DES. Heartburn symptoms are present in a large number of patients with PEMD. GERD is also commonly associated with secondary esophageal dysmotility, and symptoms such as dysphagia and chest pain may accompany heartburn in these patients. Both DES and NE can only be considered a PEMD in the absence of GERD. If GERD is present, the motility abnormality should be considered secondary and treatment should be directed toward reflux. Symptoms alone are not very useful in the setting of most foregut diseases and correlate poorly with the diagnosis of GERD and PEMD. Thus, pH monitoring is an essential tool in the evaluation of patients with manometric findings suggestive of either DES or NE. Abnormal acid exposure is detected in the majority of patients with manometric findings suggestive of PEMD.

A variety of medications such as nitrates and calcium channel blockers have been used in the treatment of PEMD; however, no single drug has proven to be predictably effective. Most of these drugs act by decreasing

the strength of the peristaltic contractions. In patients with GERD-induced motility disorders, a side effect of these medications may be the relaxation of the LES and consequent worsening of GERD. An acid-reducing medication in patients with GERD and manometric PEMD improves symptoms in >75% of the patients.

The initial treatment of patients with primary PEMD should include medical therapy and life-style adjustments. Indications for operative treatment are not as clear as in achalasia and should only be carried out by surgeons with considerable experience with the technique of long esophagomyotomy. The presence of chest pain alone is not an indication for operative intervention. Long esophageal myotomy is indicated for dysphagia in a patient with documented DES, and whose symptoms are not relieved by medical therapy. The technique of long myotomy is carried out via a thoracoscopic approach as described above, carrying the myotomy over the entire distance of the manometric abnormality. Patients with segmental or DES are at risk for developing an epiphrenic or mid-esophageal diverticulum. The presence of such diverticula complicates the procedure, requiring dissection of the neck of the diverticulum and division via an endoscopic linear stapler. The overlying muscle is reapproximated with permanent sutures, and then the myotomy is performed on the opposite esophageal wall.

HYPERTENSIVE LOWER ESOPHAGEAL SPHINCTER

Hypertensive LES is a primary disorder of esophageal motility characterized by a resting pressure in the LES that exceeds the upper limit of normal, while esophageal body peristalsis is normal. The most common symptoms are dysphagia and chest pain. However, in a certain subset of patients, acid reflux may accompany the hypertensive LES. Thus, as with PEMD the symptoms may be secondary to reflux or alteration of the configuration of the cardia when hypertensive LES is associated with GERD and a type III hiatal hernia. The combination of manometry and pH testing is again essential in defining primary versus secondary hypertensive LES. A laparoscopic myotomy with partial fundoplication is indicated for primary hypertensive LES, while a laparoscopic Nissen fundoplication should be performed in patients with secondary hypertensive LES with associated GERD.

CONCLUSION

After GERD, achalasia is the most common functional disorder of the esophagus, requiring surgical intervention. The most effective long-term treatment for achalasia is surgical esophagocardiomyotomy. The goal of myotomy is the destruction of the nonrelaxing LES. This was achieved in the past via either a laparotomy or thoracotomy. However, with the development of minimal access videoscopic techniques, the laparoscopic (and robotic, where available) approach has become the procedure of choice because of its equal effectiveness and more rapid recovery as compared to the open procedures. When the LES is surgically disrupted, there is an unacceptably high incidence of pathologic GERD. The combination of an incompetent LES and diminished ability to clear the esophageal acid leads to an increased exposure of the esophagus to acid. Thus, it is generally recommended that an antireflux procedure (partial fundoplication) be performed in addition to the myotomy in the majority of patients. The use of intraoperative manometry and intraoperative endoscopy provides useful information in the accurate destruction of the LES and creation of an antireflux mechanism. Thoracoscopic esophagomyotomy is reserved for reoperative cases and patients with disease involving the more proximal esophagus. Esophagectomy is recommended in patients with prior myotomy, low LES pressure, and a dilated sigmoid esophagus. Per-oral endoscopic myotomy has recently been shown to be an effective method for therapy of achalasia and should be used in appropriate candidates to achieve the most optimum outcomes.

Suggested Readings

Ates F, Vaezi M. The pathogenesis and management of achalasia: current status and future directions. *Gut Liver* 2015;9:449–63.

Bhayani N, Kurian A, Dunst C, et al. A comparative study on comprehensive, objective outcomes of laparoscopic Heller myotomy with per-oral endoscopic myotomy (POEM) for achalasia. *Ann Surg* 2014;259:1098–103.

Carlson D, Pandolfino JE. The chicago criteria for esophageal motility disorders: what has changed in the past 5 years? *Curr Opin Gastroenterol* 2012;28:395–402.

Endo S, Nakajima K, Nishikawa K, et al. Laparoscopic heller-dor surgery for esophageal achalasia: impact of intraoperative real-time manometric feedback on postoperative outcomes. *Dig Surg* 2009;26:342–8.

Herbella FA, Raz DJ, Nipomnick I, et al. Primary versus secondary esophageal motility disorders: diagnosis and implications for treatment. *J Laparoendsc Adv Surg Tech* 2009;19:195–8.

Horgan S, Galvani C, Gorodner MV, et al. Robotic-assisted heller myotomy versus laparoscopic heller myotomy for the treatment of esophageal achalasia: multicenter study. *J Gastrointest Surg* 2005;9:1020–30.

Huffman LC, Pandalai PK, Boulton BJ, et al. Robotic heller myotomy: a safe operation with higher post-operative quality of life indices. *Surgery* 2007; 142:613–20.

Inoue H, Minami H, Kobayashi Y, et al. Peroral endoscopic myotomy (POEM) for esophageal achalasia. *Endoscopy* 2010;42:265–71.

Li YD, Cheng YS, Li MH, et al. Temporary self-expanding metallic stents and pneumatic dilation for the treatment of achalasia: a prospective study with a long-term follow-up. *Dis Esophagus* 2010;23:361–7.

Moonen A, Boeckxstaens G. Current diagnosis and management of achalasia. *J Clin Gastroenterol* 2014;48:484–90.

Pasricha PJ, Hawari1 R, Ahmed I, et al. Submucosal endoscopic esophageal myotomy: a novel experimental approach for the treatment of achalasia. *Endoscopy* 2007;39:761–4.

Ramirez M, Patti M. Changes in the diagnosis and treatment of achalasia. *Clin Transl Gastroenterol* 2015;6, e87; doi:10.1038/ctg.2015.8; published online 21 May 2015.

Rawlings A, Soper NJ, Oelschlager B, et al. Laparoscopic dor versus toupet fundoplication following heller myotomy for achalasia: results of a multicenter, prospective, randomized controlled trial. *Surg Endosc* 2012;26:18–26.

Richards WO, Torquati A, Holzman MD, et al. Heller myotomy versus heller myotomy with dor fundoplication for achalasia. *Ann Surg* 2004;240:405.

Snyder CW, Burton RC, Brown LE, et al. Multiple preoperative endoscopic interventions are associated with worse outcomes after laparoscopic heller myotomy for achalasia. *J Gastrointest Surg* 2009;13:2095–103.



EDITOR'S COMMENT

Achalasia is a complex motor abnormality of the esophagus that is considered a neurodegenerative process. As the authors point out achalasia is an idiopathic condition that is associated with a patchy inflammatory response consisting of cytotoxic T-lymphocyte, eosinophil, and mast cell infiltration in the esophageal myenteric (Auerbach) plexus with myenteric neural fibrosis, loss of ganglion cells, hypertrophy of the two muscle layers, and hypertrophy of nerve fibers. The disease itself leads to the failure of peristalsis of the body of the esophagus as well as the inability of the lower esophageal sphincter to relax. Nussbaum and Ponsky point out that the aperistalsis of achalasia is secondary to

interruption of normal vagal cholinergic motor function, whereas the failure of LES relaxation is due to derangement of the vagal inhibitory (VIP and NO) nerves. Multiple histopathologic studies have confirmed the loss of inhibitory neurons in the esophageal myenteric plexus as the pathologic hallmark of achalasia. The incidence is between one and three per 100,000 per year and is most common in the third to fourth decades of life. It is being recognized more frequently in the elderly. Indeed there is a secondary peak in incidence after 60 years of age. Studies have shown that healthy older people, when compared to the young, have: (a) a lower number of ganglion cells in the intramural myenteric plexus; (b) a reduced normal relaxation of the lower esophageal sphincter; and (c) a reduced esophageal peristalsis (Schechter RB, Lemme EM, Novais P, et al. Achalasia in the elderly patient: a comparative study. *Arq Gastroenterol* 2011;48(1):19–23). Thus, as both age and achalasia can produce comparable degenerative changes in the intramural myenteric plexus.

The diagnosis is established by manometry after an esophagram and esophagoscopy to exclude other causes of dysphagia including an esophageal stricture or cancer. High-resolution manometry has replaced conventional manometry. High-resolution manometry offers several advantages: (1) a visual display simplifies placement, (2) the pressure pattern is measured simultaneously avoiding the need to repetitive pull-throughs and catheter repositioning, and (3) a standard display with computer algorithms allow easier more objective interpretation. Using the high-resolution technique has led to a reclassification of the disease into three subtypes as the authors' note.

There are several types of therapies for this disease. Pharmacologic treatment with oral nitrates or calcium channel blockers has sporadic success and is generally unreliable and should be reserved for those who cannot or decline definitive therapies or have failed Botox injections.

Botox injections are effective in about 65% of patients but require repeated treatments. The LES pressure has been reported to decrease as much as 50% a week after treatment. Patients older than 50 years of age have been reported to have nearly double the response rate, compared with younger patients (82% vs. 43%) (Shim CS. Endoscopic botulinum toxin injection: Benefit and limitation. *Gastrointest Interv* 2014:3;19–23). A positive response is predictive of a good response to myotomy. Botox causes scarring the esophageal wall. Due to the initial widespread use of Botox, many patients underwent injection as the first approach in the treatment of achalasia, but some of these patients were later referred for surgery because of the recurrence of symptoms. It has been shown that a previous application of Botox made the myotomy much more difficult, increasing the operative time, and increased the risk of mucosal perforation. In Horgan and Pelligrini's report on their initial experience with 57 patients undergoing surgery, 15 had previous Botox injections; 2 (13.3%) of these patients experienced a mucosal perforation during the myotomy due to the difficulty of separating the mucosa from the muscularis (Horgan S, Hudda K, Eubanks T, et al. Does botulinum toxin injection make esophagomyotomy a

more difficult operation? *Surg Endosc* 1999;13(6):576–9). They reported that none of the patients without Botox had a mucosal perforation. This experience has been repeated over and over again. As such many believe that the application of Botox may not be appropriate as a first line of treatment, due to the short interval of symptom relief, the high relapse rates, the requirement of several applications, and the potential associated risks, especially in those patients who will subsequently undergo surgery. Perhaps the use of Botox should be reserved for elderly patients who tend to have better results or patients with multiple medical problems who are poor candidates for more invasive procedures and for those patients unwilling to undergo either surgery or pneumatic dilatation.

The dilation of the LES is considered the most effective nonsurgical treatment of achalasia. It creates a controlled (or not so controlled) disruption of the LES muscle, resulting in relief of the distal esophageal obstruction with secondary symptomatic improvement. It has been commonly used since the late 1970s as the initial treatment of achalasia. The success rate for pneumatic dilation is between 55% and 70% with symptom improvement in 50% to 89% of patients. Some patients will require a second or third dilatation to achieve up to 90% relief of symptoms. The reported rate esophageal after dilatation is between 2% and 12% of patients with a mortality rate of 1% to 2%. The perforation usually occurs above the cardia on the left side of the esophagus. Postdilation water-soluble contract studies are frequently used to diagnose perforation. In select patients a nontransmural tear may be treated initially with conservative therapy but one must have a high index of suspicion and a low threshold to go to surgery. Pneumomediastinum at initial presentation predicts failure of medical therapy. If there is a transmural perforation, then treatment usually consists of a left thoracotomy, perforation closure, a contralateral myotomy, anterior fundoplication, and pleural drainage.

Heller myotomy is the surgical treatment of choice. It may be performed as an open procedure or with videoscopic techniques transthoracic or transabdominal. Cuschieri first described the laparoscopic approach. Robotic techniques have been developed. According to the SAGES guidelines after laparoscopic esophagomyotomy, symptomatic improvement has been reported in 89% of patients (range 77–100) but that clinical deterioration occurs over long follow-up periods. Csendes et al. demonstrated in a randomized controlled trial that while response rates were 95% at 5 year follow-up, the success rate was reduced to 75% after a mean follow-up of 15.8 years (Csendes A, Braghetto I, Burdiles P, et al. Very late results of esophagomyotomy for patients with achalasia: clinical, endoscopic, histologic, manometric, and acid reflux studies in 67 patients for a mean follow-up of 190 months. *Ann Surg* 2006;243:196–203). SAGES notes that transabdominal is superior to transthoracic esophageal myotomy due to improved postoperative reflux control by the addition of an antireflux procedure, performed only when the myotomy is done transabdominally. Laparoscopic myotomy offers decreased

postoperative pain, length of stay, and morbidity compared to open myotomy. There is no advantage to robotic myotomy except perhaps a reduction in esophageal mucosal perforation. The laparoscopic approach also allows routine incorporation of an antireflux procedure after myotomy. Laparoscopic myotomy is the procedure of choice for the surgical treatment of achalasia in most patients.

There is clear consensus that a partial fundoplication should be performed routinely to reduce the incidence of gastroesophageal reflux. There seems to be equivalent results with an anterior myotomy (180 degrees) (Dor) compared to a posterior (270 degrees) (Toupet).

The per-oral esophageal myotomy (POEM) was described since the sixth edition. A recent meta-analysis involved 7 studies compared POEM with Laparoscopic Heller Myotomy (LHM) in a nonrandomized manner with 486 included patients (196 in POEM group and 290 in LHM group) ranging from 8 to 180 patients per study (Marano L, Pallabazzer G, Solito B, et al. Surgery or Peroral Esophageal Myotomy for Achalasia: A Systematic Review and Meta-Analysis. *Medicine* 2016;95(10):e3001). In this study the efficacy in reduction of Eckardt score was the primary outcome measure of this study. The study showed that POEM resulted in a success rate of 90%, similar to initial treatment success of LHM. In addition there was no significant difference between POEM and LHM as regard the time of interventions, postoperative pain score, and analgesic requirement. Length of hospital stay was significantly less in POEM compared to LHM. Complications of POEM include esophageal perforation in 3% to 16% of cases. Many of these were inherent to the procedure and could be managed conservatively with no perioperative mortality or conversion to another procedure. It is clear that the procedure should be performed at centers and by physicians with significant operative experience. The learning curve is estimated to be 20 cases. Symptomatic gastroesophageal reflux is a common problem after POEM occurring in 16% to 20% of patients. Nearly 65% of patients are reported to have endoscopic findings of reflux after POEM. The incidence of GERD may be the limiting factor in POEM. Time will tell if POEM will make it to the eighth edition.

E. Christopher Ellison

77 Esophagogastrectomy for Carcinoma of the Esophagus

Simon Law

ETIOLOGY AND PATHOPHYSIOLOGY

The etiology factor for the development of esophageal cancer varies between the two major histologic subtypes of squamous cell and adenocarcinoma. Smoking and drinking as independent contributing factors are shown by prospective studies of patients who drink but do not smoke and, conversely, of patients who smoke but do not drink.

Genetic predisposition contributes to the pathogenesis of squamous cell cancer. Genetic polymorphism is important in individuals with chronic alcohol consumption. Approximately 36% of East Asians show a physiologic response to drinking that includes facial flushing, nausea, and tachycardia. This facial flushing response is predominantly related to an inherited deficiency in the enzyme aldehyde dehydrogenase 2 (ALDH2). Alcohol is metabolized to acetaldehyde by alcohol dehydrogenase, and the acetaldehyde is in turn metabolized by ALDH2 to acetate. Two main variants for ALDH2 exist, resulting from the replacement of glutamate with lysine at position 487. Only individuals homozygous with the glutamate allele have normal catalytic activity. Homozygotes with the lysine alleles have no detectable activity, while heterozygotes with Glu/Lys alleles have much reduced ALDH2 activity. The inability to fully metabolize acetaldehyde results in its accumulation in the body leading to the facial flushing and unpleasant side effects. Lys/Lys homozygotes could not tolerate much alcohol because of the intensity of the side effects, and so paradoxically they do not have increased risk because they would refrain from consuming significant amount of alcohol. Individuals who are Glu/Lys heterozygotes may drink, yet have suboptimal catalytic activity and thus the acetaldehyde accumulates. These are the individuals most susceptible to the carcinogenic effects, which is related to acetaldehyde causing DNA damage and other cancer-promoting effects.

Other dietary and environmental factors are important, such as

nitrosamines and their precursors (nitrate, nitrite, and secondary amines). Nutritional depletion of vitamins A, C, E, niacin, riboflavin, molybdenum, manganese, zinc, magnesium selenium, as well as fresh fruits and vegetables, together with an inadequate protein intake, predisposes the esophageal epithelium to neoplastic transformation. Other dietary risk factors include consumption of hot beverages, opium smoking, chewing betel nuts, and mate drinking in South American countries.

The human papillomaviruses and certain fungi belonging to the genera *Fusarium, Alternaria, Geotrichum, Aspergillus, Cladosporium,* and *Penicillium* are infective agents variably found to be associated with esophageal cancer.

Patients with other aerodigestive malignancies have a particularly high risk of developing squamous cell carcinoma of the esophagus, presumably because of exposure to similar environmental carcinogens and "field cancerization." Using esophageal cancer as the index tumor, multiple primary cancers were found in 9.5% of patients, of whom 70% were in the aerodigestive tract. The overall incidence of synchronous or metachronous esophageal cancer in patients with primary head and neck cancer is estimated to be 3%.

Diseases that are known to predispose to esophageal cancer are few. The risk from achalasia is estimated to be 7- to 33-fold, but symptoms of achalasia are present for an average of 15 to 20 years before the emergence of cancer. Other diseases include lye corrosive strictures, Plummer-Vinson syndrome, tylosis, and celiac disease.

For adenocarcinoma, ample evidences have demonstrated that the significant rising incidence can be attributed to the epidemic obesity, gastroesophageal reflux disease, and Barrett esophagus, which are less common in Asian populations. Gastroesophageal reflux disease affects up to 44% of the general population in the United States, and ~5% to 8% will develop Barrett esophagus, with an estimated annual rate of neoplastic transformation of 0.5%. Epidemiologic data suggest a protective role of *Helicobacter pylori* against reflux. The high prevalence of *H. pylori* infection in Eastern populations may guard against reflux and Barrett esophagus, and may account for the difference in cancer cell type. However, this association remains controversial.

CLINICAL PRESENTATION

Most patients present with symptomatic, advanced cancers. The main

symptom is progressive dysphagia or sometimes bleeding, more commonly encountered with adenocarcinoma. Other symptoms include regurgitation, odynophagia, weight loss, and hemoptysis when airway involvement is present. A frank tracheobronchial fistula leads to coughing and choking on drinking and is characteristic. Hoarseness of voice indicates recurrent laryngeal nerve involvement. Bleeding from aortoesophageal fistula is uncommon. Physical examination is usually unremarkable. The most likely site of a positive physical sign is the supraclavicular fossa, where metastatic nodes should be searched for. When diagnosis is made in asymptomatic patients, either incidentally or in screening or surveillance program, the prognosis is generally better.

INDICATIONS AND CONTRAINDICATIONS FOR RESECTION

The primary indication for surgical resection is for potential cure, which can be achieved in patients whose tumors are confined to its wall and only limited local-regional disease is found. One should aim to maximize the chance of an R0 resection (macroscopic and microscopic clearance of proximal, distal, and lateral margins), a parameter that has consistently been shown to result in the best long-term survival. Surgical resection with intentionally palliative intent is rarely performed, although sometimes this is indicated in certain circumstances, such as a bleeding esophageal/gastroesophageal junction tumor requiring frequent blood transfusion (more commonly encountered with adenocarcinoma since squamous cell cancers rarely have significant bleeding), or a cervical esophageal cancer, which has been treated by chemotherapy or radiotherapy, but residual tumor still precludes satisfactory oral alimentation. Situations such as these are difficult to palliate without surgical resection.

Increasingly, neoadjuvant treatments including chemotherapy or chemoradiotherapy are used to treat esophageal cancer. Consistently, these strategies have been shown to result in a higher rate of R0 resection, and a pathologic complete response (in resected surgical specimen) can be achieved in ~10% for chemotherapy alone, and up to 30% for chemoradiotherapy. Practice does vary around the globe. In Japan, two courses of cisplatin and 5-fluorouracil before surgical resection is a standard of care based on a Japan Clinical Oncology Group Trial (JCOG 9907). The Dutch Chemoradiotherapy for Oesophageal Cancer followed

by Surgery Study (CROSS) trial has demonstrated significant survival benefits using neoadjuvant chemoradiotherapy (using Carboplatin and Paclitaxel with 41.1 Gy of external radiotherapy) for both squamous cell and adenocarcinoma and is widely adopted. Yet for gastroesophageal junction adenocarcinomas, many regard them more like gastric cancers and pre- and postoperative chemotherapy (using regimen from that such as the Medical Research Council Adjuvant Gastric Infusional Chemotherapy (MAGIC) Trial) is also utilized. Postoperative chemoradiotherapy also has its advocate. Regardless of regimens, some form of preoperative therapy is very commonly used and this has impact on consideration of surgical resection. When a nonsurgical strategy is planned, often with chemoradiotherapy with a higher radiation dose, surgery for salvage (for incomplete response or recurrence) has significant morbidity and even mortality rates, worse than that in the neoadjuvant setting. Possibility of cure, however, still exists provided only local-regional disease is present. How surgical resection should be integrated into programs of multimodality treatment remains controversial.

PREOPERATIVE PLANNING

Disease Staging

Adequate staging is of paramount importance to ensure a high chance of R0 resection and for planning the surgical approach. Endoscopy and endoscopic ultrasound should be performed, and a positron emission tomography-computed tomography (PET-CT) scan is important to look for nodal and distant spread. A bronchoscopy is also mandatory of tumors that are located near the tracheobronchial tree. Involvement of the airway precludes surgical resection. A percutaneous ultrasound of the neck +/– FNA of cervical nodes is also performed. As alluded to in the section above, preoperative chemo(radiotherapy) is commonly performed, disease staging after such treatments has limited accuracy, and this has to be taken into account when surgery is anticipated.

Patient Selection and Preparation

Other considerations mainly focus on patients' physiologic risks. Factors often cited as being predictive of morbidity and mortality after esophagectomy include advanced age, poor performance status, nutritional depletion and weight loss, more proximally located tumor, poor pulmonary

function, cirrhosis, and abnormal cardiac evaluation. Patients suffering from adenocarcinoma and squamous cell cancers also have different risk profiles. Patients with squamous cell cancers are more likely to be malnourished, have high alcohol intake, are smokers, and have more impairment of pulmonary and hepatic functions. Patients with adenocarcinomas, on the other hand, are more likely to be overweight, and are more at risk from cardiovascular diseases.

Preoperative assessments include a detailed history and clinical physical examination, simple blood profiles, chest radiograph, electrocardiogram, and pulmonary spirometry. More detailed cardiac work-up including echocardiography, myocardial perfusion scans, or angiograms is selectively applied when specific indications exist. Cirrhosis is not a contraindication to esophagectomy, although increased complications may be expected. The presence of esophageal varices usually contraindicates surgery.

In general, limited improvement can be made to a patient's physiologic status, perhaps with the exception of coronary revascularization with angioplasty and coronary stenting in the presence of significant coronary ischemia. Antithrombotic medications such as aspirin and Clopidogrel are often indicated post coronary intervention for a period of time. In such patients, it is prudent to treat them with neoadjuvant therapy, so that time is not lost in waiting for an optimal time for surgery post coronary stenting.

Patients must stop smoking and alcohol intake. Chest physiotherapy is instituted, and incentive spirometry is a good preoperative exercise. Those with chronic obstructive airway disease should have their bronchodilator therapy optimized. Patients with high-grade esophageal tumor stenosis may have lost substantial amount of weight. A fine-bore nasogastric tube can be placed for nutritional support while work-up is performed, and is preferable over parenteral nutrition or gastrostomy or jejunostomy feeding. Diabetic control should be optimized with medication or insulin therapy.

Immediate preoperative preparations include prophylactic antibiotics to be given at anesthesia induction, deep vein thrombosis prophylaxis. Bowel preparation is not necessary, unless a colonic interposition is intended. Further perioperative management is to be discussed in a later section.

SURGICAL TECHNIQUE

Choice of Surgical Approach

The choice of the appropriate technique for esophagogastrectomy depends mainly on (a) the location of the tumor, (b) the intended extent of lymphadenectomy, and (c) reconstructive technique. The surgeon should be versatile and well versed with the many different methods to adapt to different clinical situations.

Tumor Location

Cervical Esophageal Cancer

In 1960, Ong and Lee first described the procedure of pharyngo-laryngo-esophagectomy (PLE) as a one-stage, three-phase operation that involved cervical and abdominal incisions and a thoracotomy. A thoracotomy is first performed for esophageal mobilization; this is followed by cervical incision for pharyngolaryngectomy and cervical esophageal extirpation. A permanent terminal tracheostomy is constructed. A laparotomy is used for delivering the gastric conduit to the neck for pharyngogastric anastomosis. Modern surgical technique has replaced the thoracotomy with transhiatal esophageal mobilization. Thoracoscopic (or laparoscopic) esophageal mobilization is also an alternative and has become our preferred method.

In patients with cervical esophageal cancer that is truly limited to the neck, or that has limited extension below the sternal notch and an adequate distal margin can be obtained, a cervical esophagectomy can be performed without the need for total esophagectomy. A manubrial resection can be added to improve exposure. Surgical field can be reached up to the top of the aortic arch. For reconstruction of the resultant defect, deltopectoral or pectoralis major myocutaneous flaps are options for reconstruction after resection, but perhaps more suitable is the use of free grafts, such as jejunal interposition, anterolateral thigh flap, or posterior tibial flap. Comparing with gastric pull-up, these free grafts are advantageous because the techniques avoid mediastinal dissection, although expertise in performing microvascular anastomosis is essential. The use of free jejunal graft has become the favored method at the author’s institution. The leakage rate is 4% and failure rate 2%. Swallowing problem does exist in some patients, related to the disordered motility of the jejunum.

The need to sacrifice the larynx does make surgical resection an unattractive option, and definitive chemoradiation is often the first choice of treatment, with surgery reserved for salvage only. In case of salvage, surgery is expectedly more difficult especially after heavy irradiation.

Intrathoracic Esophageal Cancer

For tumors in the upper thoracic esophagus, obtaining a sufficient proximal resection margin dictates an anastomosis placed in the neck. For this reason, resection is best carried out by a three-phase esophagectomy or the McKeown approach. In this procedure, a right thoracotomy is first carried out to mobilize the thoracic esophagus together with lymphadenectomy. This is followed by abdominal and neck incisions for the mobilization of the esophageal substitute placing the anastomosis in the neck.

The majority of intrathoracic cancers are squamous esophageal cancers located in the middle and lower esophagus, and Barrett adenocarcinomas in the lower esophagus. A common approach was that described independently by Lewis (1946) and Tanner (1947). The operation begins with an abdominal phase, in which the stomach is prepared; a right thoracotomy and resection of the tumor together with lymphadenectomy follow this. The stomach is then brought up into the chest for anastomosis with the proximal esophagus at the apex of the pleural cavity.

An alternate approach involves a single left thoracotomy incision. Through a left thoracotomy and incision in the diaphragm, both the esophagus and the stomach could be mobilized and resection carried out, and stomach delivered into the chest for anastomosis, either below or above the aortic arch. Proximally, the aortic arch hinders surgical access, making mobilization of the proximal esophagus and subsequent anastomosis difficult. The approach is therefore more suitable for cancer of the cardia or the distal esophagus where an adequate resection margin is obtained below the aortic arch. Distally, however, exposure for the celiac trifurcation lymph node dissection and the pylorus for a drainage procedure are also hampered. Extending the incision across the costal margin to the upper abdomen as a single thoracoabdominal incision gives excellent exposure of the left upper quadrant as well as the mediastinum. But this is a much larger wound.

A transhiatal approach, whereby the thoracic part of the esophagus is mobilized by blunt and often blind dissection through the enlarged esophageal hiatus, and the mobilized stomach is then delivered to the neck and anastomosed to the cervical esophagus. This approach precludes thorough extended mediastinal lymphadenectomy, especially of the mid- and superior mediastinum. Randomized trials have shown lower cardiopulmonary complication rates compared to open thoracotomy; mortality rates are similar. With modern surgical technique and

perioperative care, the benefits of reducing potential morbidity by the transhiatal approach are offset by the inability to perform adequate lymphadenectomy. From a purely safety point of view, transhiatal resection is not suitable for patients with advanced middle- or upper-third tumors, especially patients with tumors closely related to the tracheobronchial tree and after neoadjuvant radiation therapy; tumor infiltration or fibrosis may obliterate tissue planes and make blind dissection unsafe. As such, its application is more suitable for distal esophageal tumors, for which much of the mobilization can be performed under visual control.

Minimally invasive esophagectomy (MIE) has a variety of different techniques; combinations of thoracoscopy, laparoscopy, mediastinoscopy, and open laparotomy and thoracotomy have been advocated. Thoracoscopic esophagectomy enables lesser surgical trauma, and at the same time, mediastinal lymphadenectomy equivalent (if not even better) to that of an open approach. Laparoscopic esophagectomy (without thoracoscopy) can reproduce a transhiatal esophagectomy, and indications are similar. A European multicenter randomized trial (TIME trial) showed that pulmonary complications are significantly less when MIE was compared with open transthoracic approach. Equivalent oncologic clearance (by number of nodes retrieved) is accomplished.

Gastroesophageal Junction Cancer

For cancers that are limited to the abdominal esophagus or gastric cardia, an abdominal-right thoracic approach as in a Lewis–Tanner esophagectomy is one option, with the proximal stomach also resected in order to gain an adequate distal resection margin. A left thoracoabdominal incision through the seventh or eighth rib space also gives excellent exposure of the low mediastinum and upper abdomen. When a thoracotomy is not desired, opening the hiatus widely by splitting the crura laterally and the diaphragm anteriorly can gain access to the low posterior mediastinum, and distal esophagectomy can be performed with the anastomosis performed from the abdomen without the need for a thoracic incision. The anastomosis is made easier with a mechanical stapler. When the proximal stomach is involved by tumor, many prefer a total gastrectomy with Roux-en-Y reconstruction. A Japanese randomized trial comparing a transabdominal versus a left thoracoabdominal approach for adenocarcinomas that have infiltrated 3 cm or less into the esophagus demonstrated no difference in long-term survival between the two and

extended total gastrectomy via the abdominal approach is advocated. A thoracotomy can be avoided, provided frozen sections are carried out to ensure a negative proximal margin. This is sometimes difficult to achieve and ascertain preoperatively. Many would prefer a esophagogastrectomy, preserving the distal stomach for esophagogastrostomy in the chest as in a Lewis–Tanner esophagectomy.

Intended Lymphadenectomy

Knowledge of nodal spread is essential in esophagectomy. Esophageal cancer spreads early, and the lymph nodes can extend from the neck to the celiac axis. The nomenclature and the definition of extent of lymphadenectomy are shown in Figure 77.1. For squamous cell cancers, it is customary to perform a total mediastinal lymphadenectomy. The most difficult areas are those around the right and left recurrent laryngeal nerves, as the nerves are prone to injury. Data from Japan have shown a high incidence of cervical nodal metastases as well, so addition of a neck phase with bilateral cervical nodal dissection is advocated. This constitutes a three-field lymphadenectomy (upper abdomen, mediastinal and neck). For nodes in the neck, the majority of metastases are located below the omohyoid muscle, especially around the paratracheal/paraeophageal area as a continuum of the recurrent laryngeal nerve nodal package from the superior mediastinum. The whole chain of nodes can be regarded as one unit. Performing such extensive nodal dissection imposes more complications (especially those related to nerve injury), so patient selection is important. It should only be performed in patients with sufficient physiologic reserve, with curative intent. When a thorough mediastinal dissection is performed, often most of the paratracheal/paraesophaegal recurrent laryngeal nerve nodes in the neck have been removed from below. Increasingly the indication of a formal neck dissection is being debated and more selectively applied. In patients with lower third tumors for instance, neck dissection may not be necessary. In adenocarcinomas of the lower esophagus or gastroesophageal junction, most surgeons do not perform thorough superior mediastinal or cervical lymphadenectomy as data have suggested nodal spread is predominantly distal in direction, and if metastases are found in the upper mediastinum or neck, prognosis is poor that additional lymphadenectomy may not be beneficial. This remains controversial.

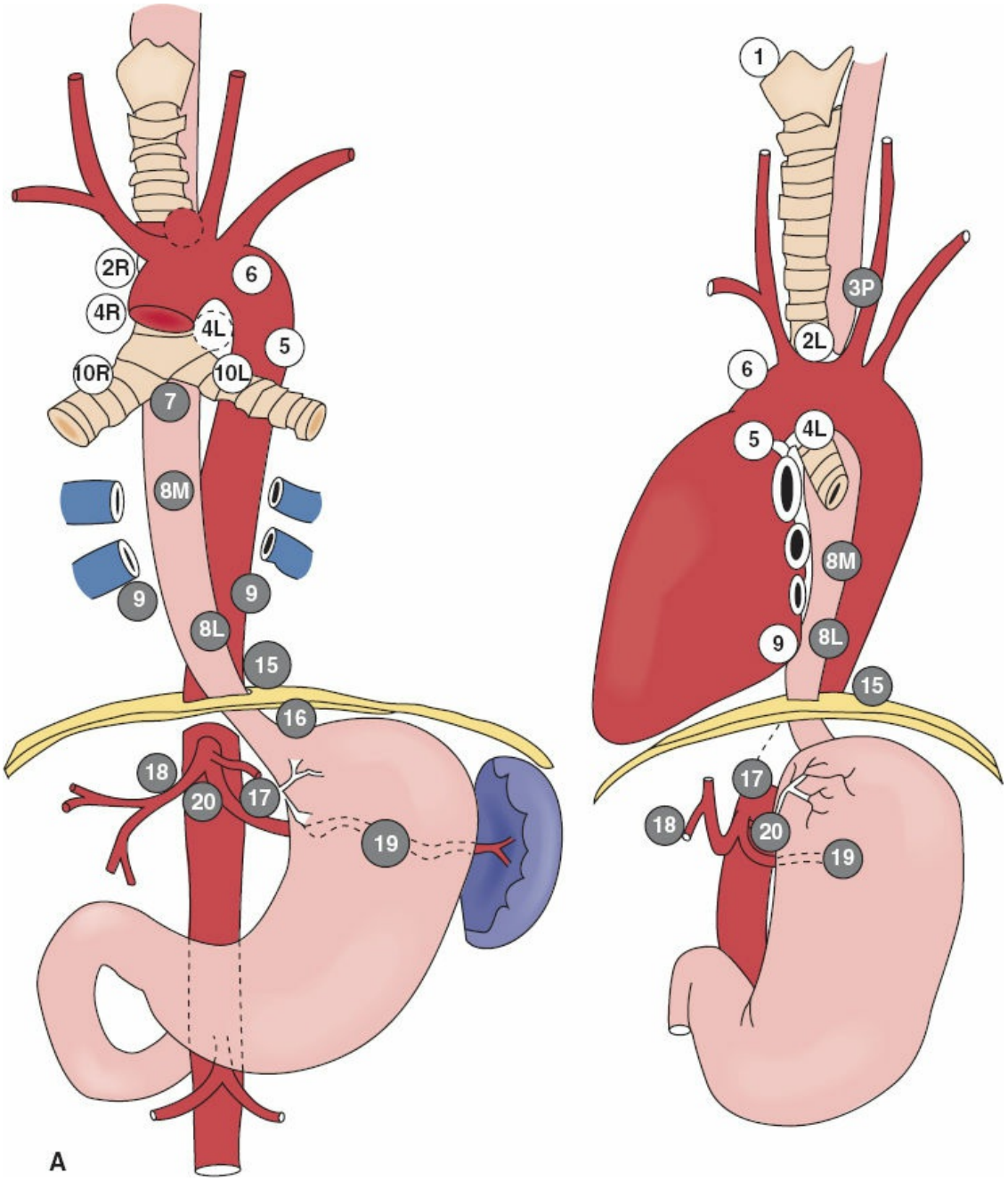
2R
6
4R
4L
5
10R
10L
7
8M
9
9
8L
15
16
18
20
17
19
A
1
3P
2L
6
5
4L
8M
9
8L
15
17
18
20
19

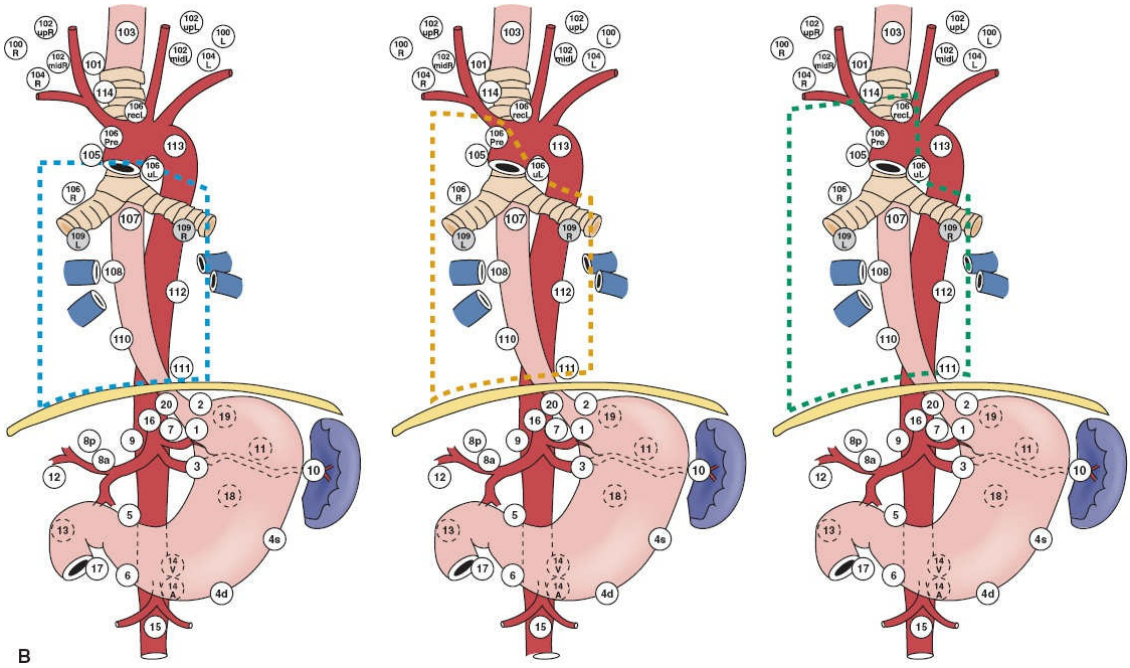

Figure 77.1. Nodal stations according to the American Joint Committee on Cancer (AJCC) manual (**A**) and the Japan Society for Esophageal Diseases (**B**). Regional nodes extend from the cervical region to around the celiac trifurcation. Infracarinal lymphadenectomy is defined as standard mediastinal lymphadenectomy (BI: dotted area defines the area of lymphadenectomy). When superior mediastinal dissection is performed but only including the right recurrent laryngeal nerve and right paratracheal area, it is termed extended mediastinal lymphadenectomy (BII). When the left recurrent laryngeal nerve chain including the subaortic area and left paratracheal area is dissected, it is called complete mediastinal lymphadenectomy (BIII). Upper abdominal lymphadenectomy around the celiac trifurcation with complete mediastinal and bilateral cervical lymphadenectomy is called three-field lymphadenectomy.

The choice of surgical access and intended extent of lymphadenectomy are therefore related; when an extended lymph node dissection is intended in the mediastinum (especially above the tracheal bifurcation), an open transthoracic or thoracoscopic approach is mandatory. When bilateral cervical nodal dissection is planned, a cervical anastomosis makes sense.

Reconstructive Technique

If radiation therapy to the posterior mediastinum after surgical resection is planned, it may be prudent to place the substitute organ in the retrosternal route to avoid radiation injury so a three-phase esophagectomy is

indicated. When a colonic loop is planned for esophageal replacement, sometimes it is advantageous to prepare the colonic conduit before esophageal resection to ensure its viability, especially when the vasculature of the colon has been demonstrated to be suboptimal on preoperative arteriogram. In such cases, the abdominal phase of the operation precedes the thoracic phase, dictating a retrosternal route of conduit placement, unless a second change of body position is undertaken.

Detailed Surgical Techniques

The following sections describe the three phases of an esophagogastrectomy: the abdominal, thoracic, and cervical phases. These three phases can be combined in different surgical approaches, depending on considerations detailed above. For example a Lewis–Tanner esophagectomy will involve the abdominal followed by a right thoracic phase, while a three-phase McKeown esophagectomy will involve the thoracic, followed by an abdominal and cervical phase.

Abdominal Phase

Surgical access can be gained through either an upper midline or an upper rooftop incision. The latter gives improved exposure to the upper abdomen, especially in an obese patient. The stomach used for esophageal replacement is prepared by first taking the gastrocolic omentum off the greater curvature of the stomach but preserving the right gastroepiploic vessels and arcades (Fig. 77.2). Detachment is begun near the pyloric region and continued toward the spleen. Complete omentum resection is not necessary. Division of the gastrocolic omentum can be carried out just outside the right gastroepiploic vessels. It is of paramount importance to preserve these vessels because they form the most important blood supply to the stomach after mobilization. As one approaches the spleen, the division of the short gastric vessels can stay close to the stomach wall. The left crus is exposed when the short gastric vessels are divided and the fundus mobilized medially. The phrenoesophageal membrane is detached and the abdominal esophagus and cardia can be freed on the left side.

The gastrohepatic ligament is then detached from the liver and from the portal structures. In some cases, an aberrant left hepatic artery is seen arising from the left gastric artery. Although its ligation can usually be done with impunity, postoperative deranged liver function and even partial liver necrosis have been reported. When found to be sizable, the artery

should be preserved. This can be accomplished by dissecting upward along the left gastric artery from the celiac axis and ligating vessels going into the lesser curvature of the stomach while preserving this vessel. Dissection from the right side toward the esophageal hiatus frees the right crus, and dissection anterior to the esophagus will meet the already dissected plane from the left. The anterior vagus nerve can be divided at this point. The esophagus is thus freed on both sides as well as anteriorly. A sling placed around the lower esophagus may help later dissection by providing retraction.

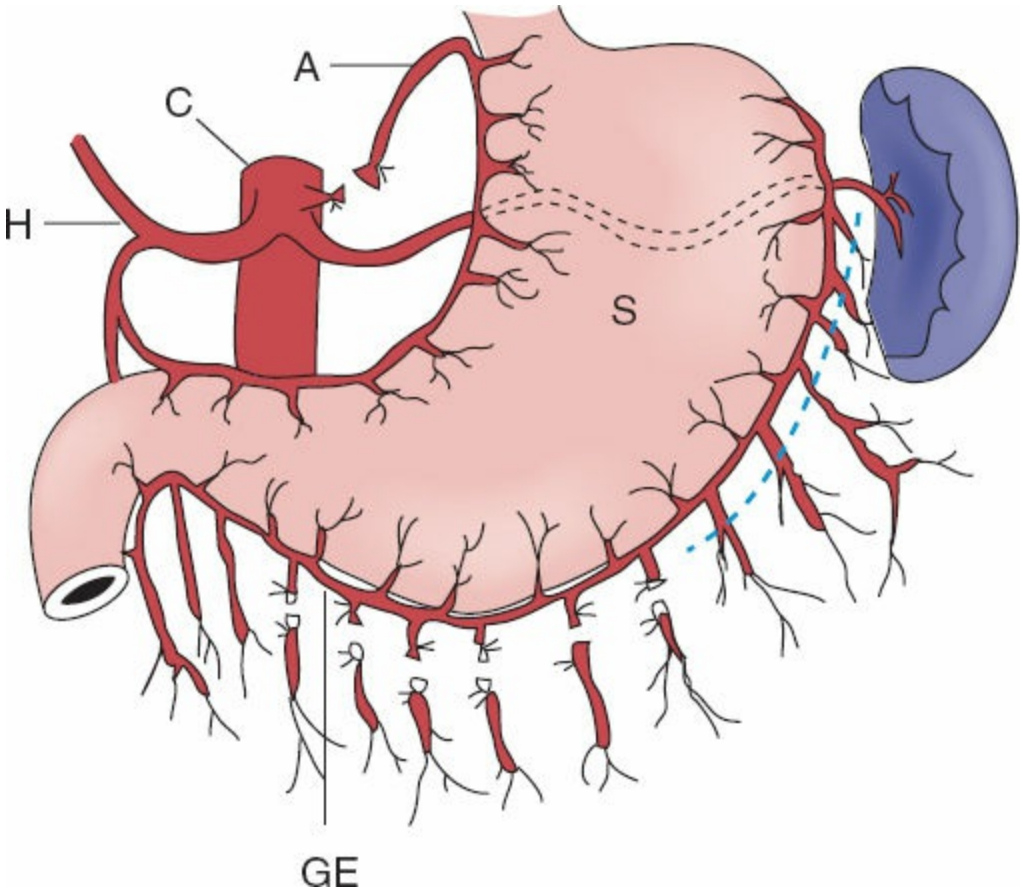

Figure 77.2. The stomach is mobilized by first taking the gastrocolic omentum off the greater curvature of the stomach but preserving the right gastroepiploic arcade. This can be carried out just outside the right gastroepiploic vessels. Short gastric vessel division can be done close to the stomach wall. Dissection of the celiac trifurcation starts on the surface of the hepatic artery toward the left side. Usually, the coronary vein lies anterior to the left gastric artery, and its division precedes the arterial isolation, ligation, and division between ligatures. C, celiac axis; S, splenic artery; H, hepatic artery; A, left gastric artery ligated at its origin; GE, gastroepiploeic artery.

For a tumor of the distal esophagus located at the hiatal opening, especially for a transmural T3/T4 tumor, a cuff of diaphragmatic crura can be removed together with the tumor. Division of the hiatal musculature is begun on the left side. Bleeding from the lateral edge is controlled with suturing or electrocautery. Division is continued along the front and then to the right side until a cuff of muscle is freed. When a cuff of muscle from the esophageal hiatus is removed, both pleural cavities are likely to be entered, but this is of no serious consequence.

The stomach is then reflected upward and dissection is begun at the celiac trifurcation. Using fine electrocautery, dissection is performed along the anterior aspect of the common hepatic artery. This is usually easily performed. Lymphadenectomy can then proceed laterally toward the hepatoduodenal ligament. For a tumor of the intrathoracic esophagus, formal dissection of lymph nodes along the hepatoduodenal ligament (common bile duct and hepatic artery alongside) is not necessary. Medially toward the origin of the left gastric artery at the celiac axis, the left gastric or coronary vein requires ligation. The origin of the left gastric artery is identified separately as it comes off the celiac axis, and it is doubly ligated and cut between ligatures. Further dissection toward the left will clear the lymphatic tissues on the splenic artery. The areolar tissue thus superior to the common hepatic artery and proximal splenic artery is cleared en bloc with the abdominal esophagus toward the hiatus. Continued dissection upward can be carried out through the esophageal hiatus along the front of the aorta. Areolar tissues are freed from the aorta and remain attached to the resected specimen. The cardia and abdominal esophagus are thus freed totally. With fine electrocautery and selective use of metal clips for small vessels, often the celiac trifurcation lymph node dissection can be a bloodless exercise.

On the lesser curvature, the right gastric vessels are divided at a convenient point (Fig. 77.3). This point, however, should be located distal to at least the third branch of the left gastric artery counting from its origin and this ensures adequate lymph node clearance. The preparation of the lesser curvature makes subsequent transection of the stomach easier during the thoracic phase of a Lewis–Tanner operation. When a three-phase esophagectomy is carried out, the stomach can be transected with linear staplers at this stage. The stomach is straightened and the highest point marked. The stomach is transected from the lesser curvature toward this point.

Many factors determine gastric emptying after esophagectomy, including the necessary vagotomy, the size of the gastric tube, and the route of placement of the conduit. Vagotomy in theory will inhibit gastric emptying, a smaller size gastric tube drains better than a whole-stomach conduit, and a stomach brought up to the neck via the posterior mediastinum empties better compared to one in the right thoracic cavity because angulation at the hiatus is avoided. Delayed gastric emptying also rarely occurs with retrosternal route of reconstruction. A Heineke–Mikulicz pyloroplasty or a pyloromyotomy is performed. Some surgeons opine that a pyloric drainage procedure will enhance enterogastric bile reflux. In the author's experience, clinically significant symptomatic biliary gastritis is uncommon. A Kocher maneuver is not mandatory, provided the stomach is of sufficient length. However, this maneuver is easily performed, and does have the advantage of straightening the "axis" of the pyloroduodenal region when the stomach is brought up to the right thoracic cavity.

Right Transthoracic Phase

The patient is placed in a left lateral decubitus position (Fig. 77.4). A double-lumen endotracheal tube provides isolation of the right lung. A single-lumen endotracheal tube with a bronchial blocker is preferred by the author. This is less traumatic, and the tube being less stiff allows better retraction of the trachea and bronchi. This is especially important when nodal dissection above the tracheal bifurcation is intended, and for thoracoscopic resection. A posterolateral thoracotomy through the fifth intercostal space is usually performed. Alternatively, an anterolateral thoracotomy can also be done. The author prefers the latter. When superior mediastinal nodal dissection is planned, a fourth space access provides easier exposure for this part of the dissection. However, exposure for dissection of the lower mediastinum then becomes slightly more difficult. A controlled fracture of the fifth or sixth rib posteriorly eases distraction of the rib space. Patients who have had previous inflammatory pulmonary disease, especially tuberculosis, may have dense pleural adhesions; these can be time consuming to divide. Two rib spreaders placed at right angles to each other are used to open up the rib space.

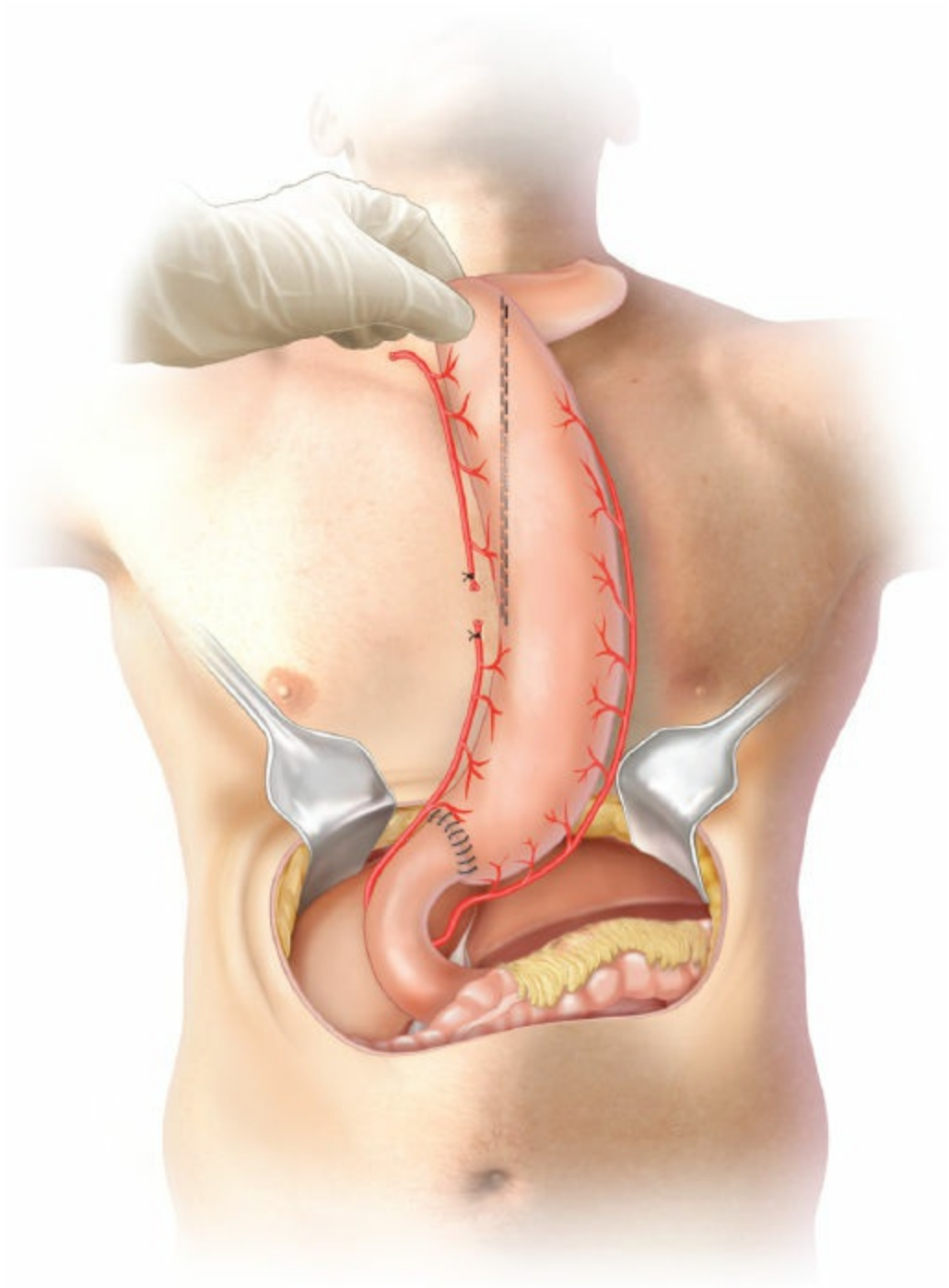

Figure 77.3. The lesser curvature is prepared at a point of transaction at least distal to the third branch from the origin of the left gastric artery. This removes the potential cancer bearing area. The stomach is straightened and its highest point selected. Transection of the stomach can start from the already prepared point at the lesser curvature toward this highest point with linear staplers. The stomach should be stapled just within the branches coming from the lesser curvature so that the conduit is not too narrow. When the width of the gastric tube is narrow more length will be gained but risk impairing the blood supply to the conduit.

When a Lewis–Tanner esophagectomy is planned, the transection line need not be completed, and this will ease delivery of the conduit to the chest. When a three-phase esophagectomy is performed, the transection line can be completed while in the abdomen. A pyloroplasty is performed for drainage.

The arch of the azygos vein as it crosses the esophagus is divided and transfixed; usually, two branches of the vein posteriorly on the spine are divided and resected as well. The right bronchial artery, which can be quite sizable, runs just beneath the vein. It can be preserved if desired.

The superior mediastinal segment of the esophagus can be mobilized first. When a standard mediastinal dissection is performed without a formal superior mediastinal lymphadenectomy, it is sufficient to perform periesophageal dissection of the esophagus at this level. The mediastinal pleura is opened on the back of the trachea. The esophagus is freed from the back of the trachea anteriorly and posteriorly from the spine; it can be slung with a tape to ease later dissection. One should avoid cautery in front of the esophagus, to avoid tracheal injury. Dissection is carried out to the apex. Often, a large branch from the inferior thyroid artery running on the esophagus needs division. The whole length of the upper esophagus is thus freed to the apex.

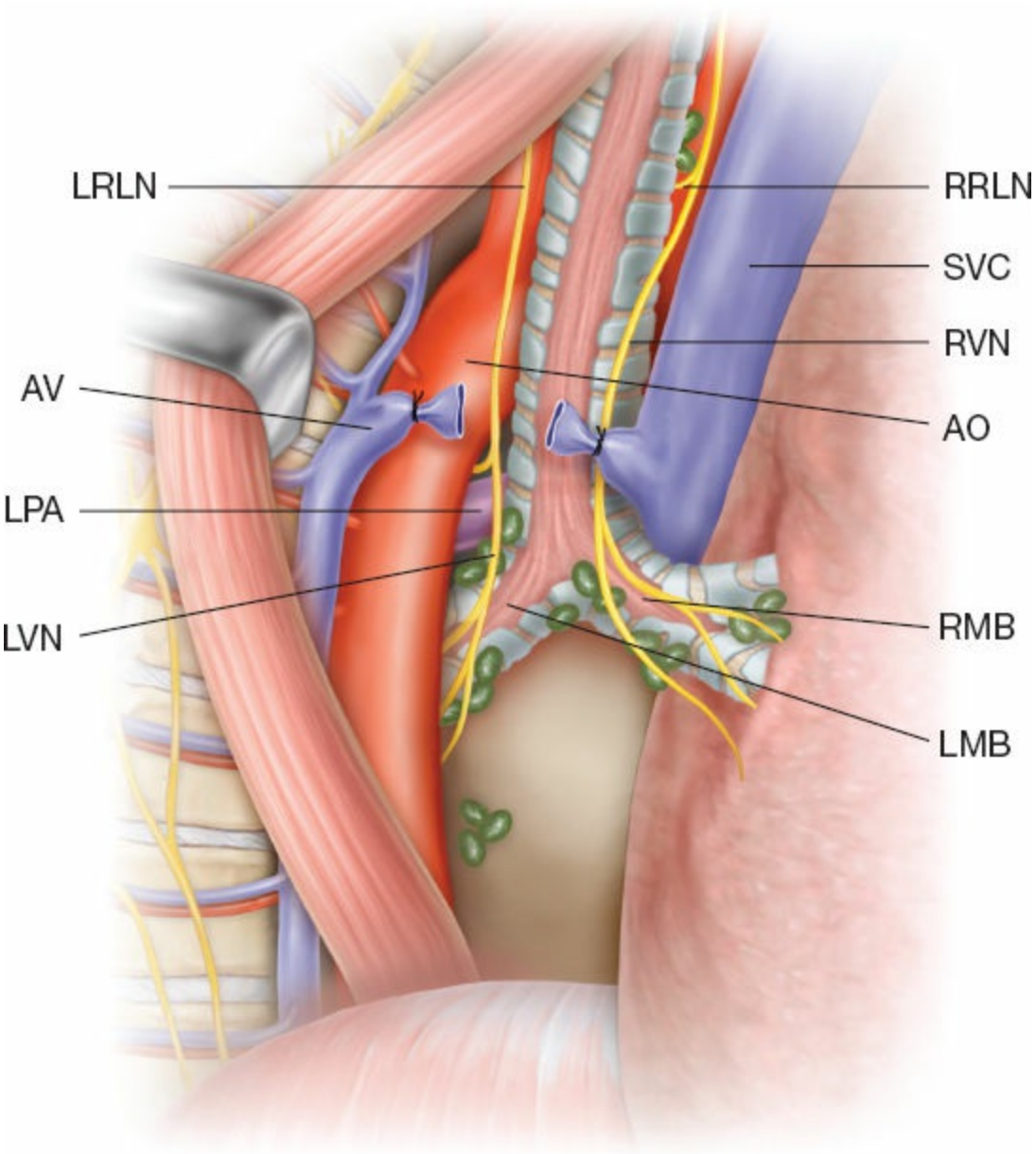

Figure 77.4. Dissection of the mediastinum: The esophagus has been mobilized and retracted to one side. The dissection plane anteriorly is on the pericardium; the right main bronchus, tracheal bifurcation, and left main bronchus have been exposed; and the carinal lymph node cast can be taken en bloc with the esophagus or separately. The mediastinal pleura is opened longitudinally just along the anterior aspect of the azygos vein. The thoracic duct has been ligated and divided near the diaphragmatic hiatus, and resected en bloc with the periaortic connective tissue on the esophagus itself. In the superior mediastinal, the right paratracheal area between the right vagus nerve and the superior vena cava harbors the paratracheal nodal stations. The right recurrent laryngeal nerve nodes surround the area where the nerve hooks around the subclavian artery. The left paratracheal

area contains the left recurrent laryngeal nerve nodes. Retraction of the trachea is necessary to resect nodes along this nerve. The subaortic arch nodes are also taken, preserving the left recurrent laryngeal nerve medially as it runs on the arch. RRLN, right recurrent laryngeal nerve; SVC, superior vena cava; RVN, right vagus nerve; AO, aortic arch; LMB, left main bronchus; P, pericardium; LVN, left vagus nerve; LPA, left pulmonary artery; AV, azygos vein; LRLN, left recurrent laryngeal nerve.

At this point, attention is drawn to the lower mediastinal dissection. The inferior pulmonary ligament is divided with electrocautery to the root of the inferior pulmonary vein. Dissection is then carried on the posterior surface of the pericardium. The right main bronchus is identified, and lymph nodes and connective tissue inferior to it are taken en bloc with the esophagus. Further dissection will lead to the infracarinal lymph node package. This is usually a vascular area. When the lymph nodes are retrieved, small vessels may retract into the precarinal area. Packing with gauze followed by careful hemostasis will control the oozing. The infracarinal dissection is followed toward the left to expose the left main bronchus and the lymph nodes and fatty tissues inferior to its edge. Sharp dissection with careful hemostasis is essential to avoid thermal injury to the membranous parts of the bronchi.

Attention is next turned to the posterior dissection. The mediastinal pleura is incised along the anterior aspect of the length of the azygos vein from above downward. When the point just above the hiatus is reached, the dissection plane deepens onto the surface of the aorta. Anteriorly within the areolar tissue between the azygos vein and the surface of the aorta is the thoracic duct, which is identified, isolated, and ligated. A metal clip marking the site is useful, in case postoperative chylothorax occurs. Routine ligation of the duct lessens the chance of this complication. When the dissection reaches the esophagus anteriorly, the thoracic duct, the areolar, and connective tissue on the aorta are removed en bloc with the esophagus. This resection continues from below upward, until the previous dissection plane from anteriorly on the left main bronchus is met. Vessels that run from the aorta directly to the esophagus should be carefully ligated or cauterized. In cases where a bulky or infiltrative cancer of the mid-esophagus is encountered, the esophagus can be divided first with a stapler near the diaphragmatic hiatus. The stump can then be pulled upward, improving exposure for tumor mobilization. The limits of the lymph node

dissection extend inferiorly to the crura of the diaphragm, anterior on the pericardium, right main bronchus, apically at the tracheal bifurcation, and posteriorly from the left main bronchus along the length of the descending aorta. Further dissection upward should meet the previously slung upper esophagus so that the whole intrathoracic esophagus is freed. The pleura on the left side can be resected en bloc with the esophagus; a cuff of pericardium attached to the primary tumor can also be removed, to improve lateral tumor clearance.

If a three-phase esophagectomy is intended, the chest can now be closed. A 24-Fr chest drainage tube is placed toward the apex. The patient is then turned supine for the abdominal and cervical phases of the operation.

In a Lewis–Tanner esophagectomy, after esophageal mobilization, the gastric tube is delivered up through the diaphragmatic hiatus into the right chest. The division of the stomach is best performed using linear staplers. Gastric transection can be begun at a point located on the greater curvature of the stomach toward the site at the lesser curvature previously prepared during the abdominal phase of the operation. Usually, two to three linear staplers are necessary. A redundant fundus should be resected to avoid postoperative stasis. Inversion of the stapled line ensures hemostasis and would protect against the occasional leak, though this is rare. A Satinsky clamp is then applied across the supra-aortic segment of the esophagus near the apex of the thoracic cavity. A proximal margin of 10 cm from the tumor edge should be aimed at, as this margin almost eliminates the chance of subsequent anastomotic recurrence. The esophagus is divided distal to the clamp. The esophagus with the tumor is thus removed, and the gastric tube is placed in the mediastinum ready for anastomosis.

Superior Mediastinal Lymph Node Dissection

The previous section describes the right transthoracic esophagectomy with a standard infracarinal mediastinal lymphadenectomy. The following describes the procedure of superior mediastinal dissection.

After the arch of the azygos vein is divided, attention is turned to the right paratracheal area. The right vagus nerve is easily identified. The mediastinal pleura over it is opened, and the nerve traced upward to the base of the subclavian artery. The right recurrent laryngeal nerve is found when the fatty tissue inferior to the subclavian artery and posterior to the vagus is dissected. The vagus from the neck and the recurrent nerve together form the two prongs of a “fork” straddling the subclavian artery.

Lymph nodes are removed with the fatty tissue. These nodes connect with the cervical paratracheal and paraesophageal nodes superior to the subclavian artery, which can be removed later in the cervical phase of the operation. This whole chain of lymph node is known as the right recurrent laryngeal nerve lymphatic chain, and it has a high incidence of metastases. One should be cautious in the use of electrocautery to avoid thermal injury to the recurrent nerve. The use of a nerve stimulator as in thyroid surgery can aid identification of the nerve and its preservation.

The right paratracheal area situated between the superior vena cava and the trachea anterior to the vagus nerve contains the right paratracheal nodal basin. These nodes can be removed after the right recurrent laryngeal nerve is identified and protected. Dissection can be carried out from above downward to the tracheobronchial area superior to the right main bronchus. Compared to the right recurrent laryngeal nerve nodes, this right paratracheal area is less frequently involved by lymph node metastases.

The dissection of the left paratracheal area (left recurrent laryngeal nerve chain) is better commenced with the esophagus slung with a tape retracting it posteriorly, but retaining the fibroareolar tissue attachment to the trachea (the mesentery). In this manner, the left recurrent laryngeal nerve is more easily located within this “mesentery.” If the esophagus has been isolated first, then the left recurrent laryngeal nerve tends to remain deeper in the left paratracheal area and therefore more difficult to dissect, especially the nodal tissues anterior to the nerve. A combination of blunt and sharp dissection longitudinally helps locate the left recurrent laryngeal nerve. Once the nerve is identified, lymph node tissue anterior to it in the paratracheal area is removed. This continues toward the apex of the thoracic cavity, reaching an area that can be dissected later from the neck. The thoracic duct that has been isolated from below—its distal portion can be identified running upward—can be resected.

The recurrent nerve is also traced downward on the aortic arch. The infra-aortic arch nodes can be removed by dissecting posteriorly toward the spine. In this area, the left bronchial artery arising from the arch of the aorta can be preserved. It is also very important not to injure the left pulmonary artery in the subaortic area.

Cervical Phase

In a transhiatal or three-phase esophagectomy without cervical lymphadenectomy, a left transverse supraclavicular incision is made extending from just beyond the sternocleidomastoid muscle to the right of

the midline suffices. An incision parallel to the anterior border of the sternocleidomastoid is a satisfactory alternative, the horizontal incision is cosmetically more pleasing, and gives equally good exposure. The left side is chosen because at this level the esophagus is more inclined to the left. Dissection is limited to medial to the carotid sheath. Once the middle thyroid vein is divided and the thyroid retracted to the right, the trachea and esophagus will come into view, especially when this follows the thoracic phase. Dissection of the esophagus should be easy if sufficient dissection has been performed from below. If this cervical phase precedes the thoracic phase or this is part of a transhiatal resection, dissection is first made close to the carotid sheath, and then the posterior wall of the esophagus is separated from the prevertebral fascia behind. Next, attention is turned to isolating the esophagus from the trachea. Dissection should be made as close as possible to the esophageal wall. Traction and compression to the tracheoesophageal groove should be avoided to preserve the recurrent laryngeal nerve (Fig. 77.5). A sling around the esophagus with a tape helps with retraction. If the thoracic phase precedes the cervical phase, a tape around the esophagus in the superior medistinum, with the tails pushed up in the left paraesophageal area, will aid retrieval of the esophagus in the neck as the tape is readily located once the space medial to the carotid sheath is opened.

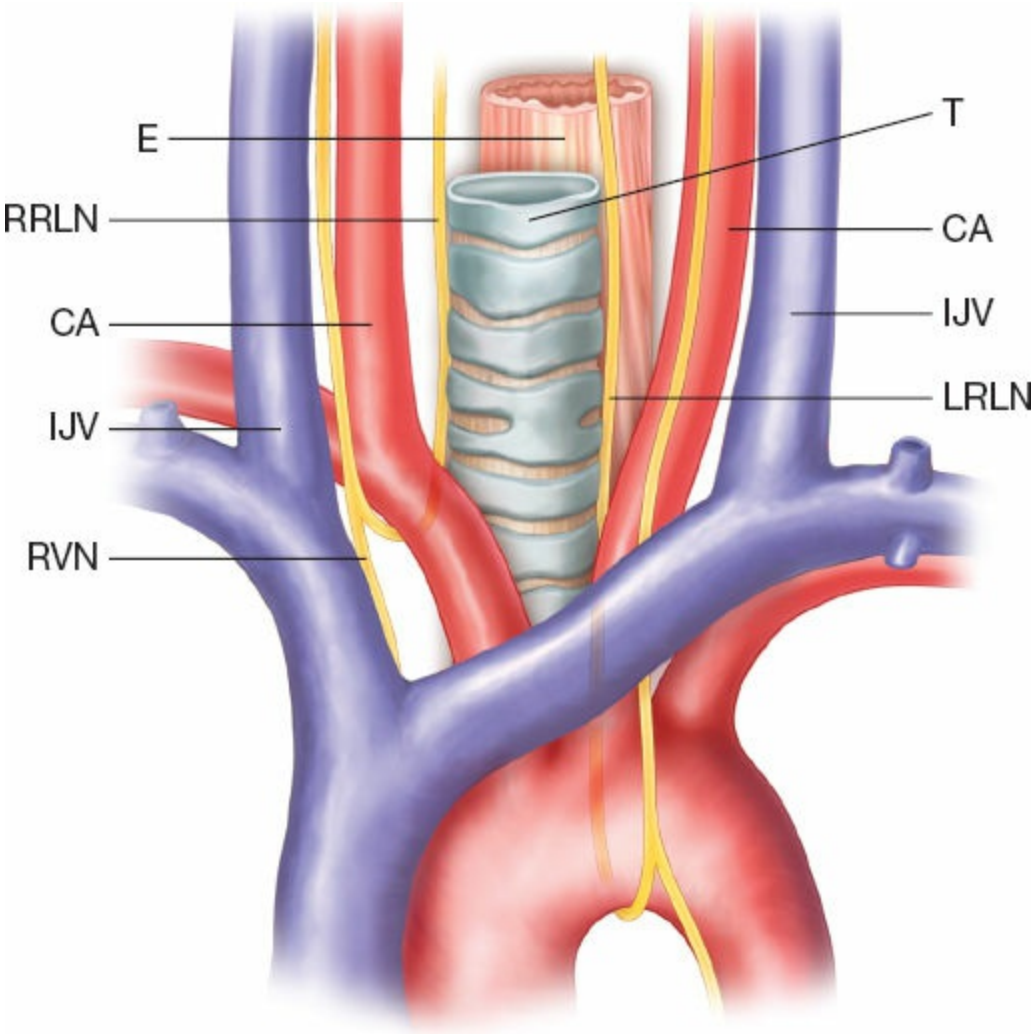

Figure 77.5. Cervical anatomy related to the recurrent laryngeal nerves. On the right side, the right recurrent laryngeal nerve is often situated more laterally as it emerges from the chest. On the left side, the nerve is usually more closely applied in the tracheoesophageal grove. The most important nodes are those along the recurrent nerves extending into the superior mediastinum. E, esophagus; RRLN, right recurrent laryngeal nerve; CA, carotid artery; IJV, internal jugular vein; RVN, right vagus nerve; T, trachea; LRLN, left recurrent laryngeal nerve.

In a transhiatal resection, the residual attachment to the pleura beyond the finger introduced through the neck has to be stripped by the hand inserted through the hiatus from the abdomen. Identifying the correct plane established after cervical mobilization facilitates this step. The whole length of the thoracic esophagus can thus be freed.

Cervical Lymphadenectomy

When three-field lymphadenectomy is performed, a collar incision is made one finger breadth above the clavicle (Fig. 77.6A,B). The anterior jugular vein may require ligation and division. It is not necessary to divide the sternocleidomastoid muscle. The sternohyoid and sternothyroid muscles can be divided to ease exposure. The main focus of nodal dissection is the area below the omohyoid muscles and medially as lymphatic spread above them is uncommon. A dissection plane is easily found above the deep cervical fascia so that the transverse cervical artery and phrenic nerve should stay below the plane of dissection and are preserved. Fatty tissue and lymph nodes are removed toward the carotid sheath, bounded inferiorly by the clavicle. The tissues around the carotid artery and internal jugular vein are removed en bloc. The middle thyroid vein is divided. Dissection medial to the carotid artery leads to the paratracheal nodes anterior to the recurrent laryngeal nerves and the paraesophageal nodes. These are the most critical nodes, as they are the upper limits of the recurrent laryngeal nerve chains from the mediastinum. Involved nodes are most likely found along their paths. Identification of the nerves early is essential to avoid inadvertent injury. On the right side, the recurrent laryngeal nerve lower down toward the clavicle is often at a distance from the tracheoesophageal groove, while on the left side the nerve is much more closely situated in the tracheoesophageal groove. Again a nerve stimulator may be useful. After a thorough mediastinal dissection, the recurrent laryngeal nerves are usually easily found, because dissection from below has partially exposed the nerve. On the left side, the thoracic duct can sometimes be seen. Chylous leak is prevented by ligation of the duct in the thoracic phase of the operation.

Minimally Invasive Esophagectomy

Thoracoscopy

A double-lumen endobronchial tube is introduced for single-lung ventilation, but a single-lumen endotracheal tube with a right bronchial blocker is preferred. The patient is placed in a left lateral decubitus position as for a posterolateral thoracotomy (Fig. 77.7). The right arm is raised to expose the armpit. This will allow more unimpeded use of thoracoscopic instruments. The surgeon stands at the back of the patient, and the first assistant stands on the opposite site. The second assistant using the videoscope stands next to the surgeon on his left side. His position will need to change to his right during the latter part of the

operation when the videoscope changes direction. Two monitors are used: one opposite to the surgeon near the head end of the table and the other opposite to the first assistant.

With the right lung collapsed, a mini-thoracotomy of 5 cm is made in the fourth intercostal space (or fifth space if only an infracarinal dissection is intended) with its posterior limit at the mid-axillary line (MAL). This mini-thoracotomy is useful and permits easier tracheal and lung retraction with a retractor placed through this small wound. A silicone wound retractor (Applied Medical) placed in this wound is sufficient and no forceful retraction with a metal wound distracter is necessary. A 5-mm port is placed in the fifth space at the posterior axillary line (PAL), one 10-mm port is inserted in the seventh space in the mid axillary line, and another 10-mm port placed in the seventh space just posterior to the PAL. The port placements need to be adjusted according to the build of the particular patient. When superior mediastinal nodal dissection is carried out, an additional port at the third space PAL is often added.

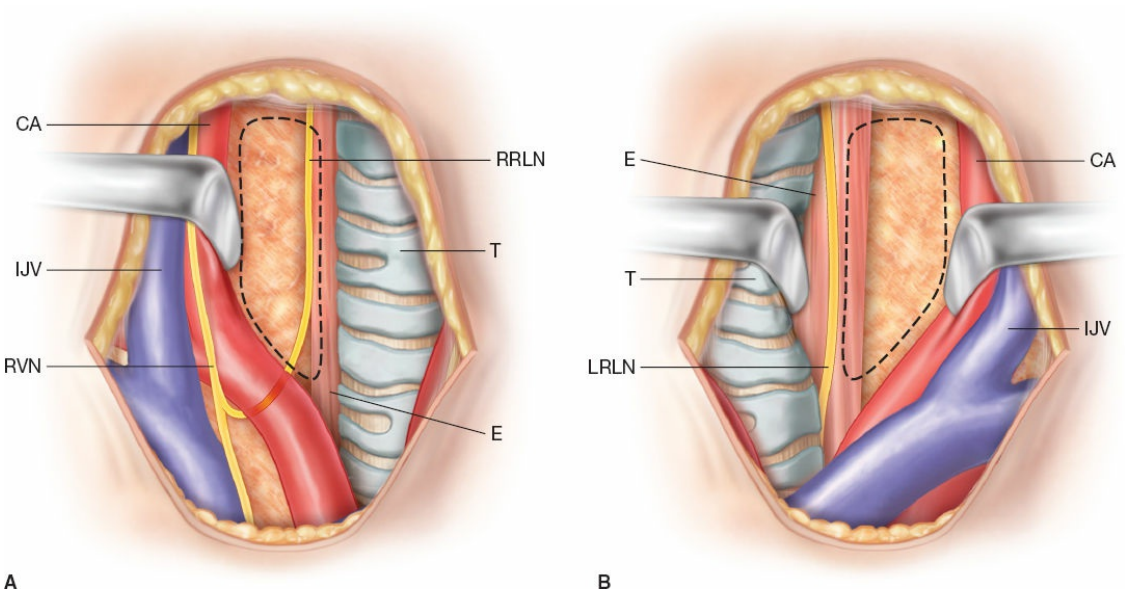

Figure 77.6. **A** and **B:** The area marked by the dotted line indicated the most likely area to harbor metastatic nodes. The chain of recurrent laryngeal nerve nodes extends into the mediastium as a cervicothoracic chain. E, esophagus; T, trachea; LRLN, left recurrent laryngeal nerve; RRLN, right recurrent laryngeal nerve; IJV, internal jugular vein; CA, carotid artery; RVN, right vagus nerve.

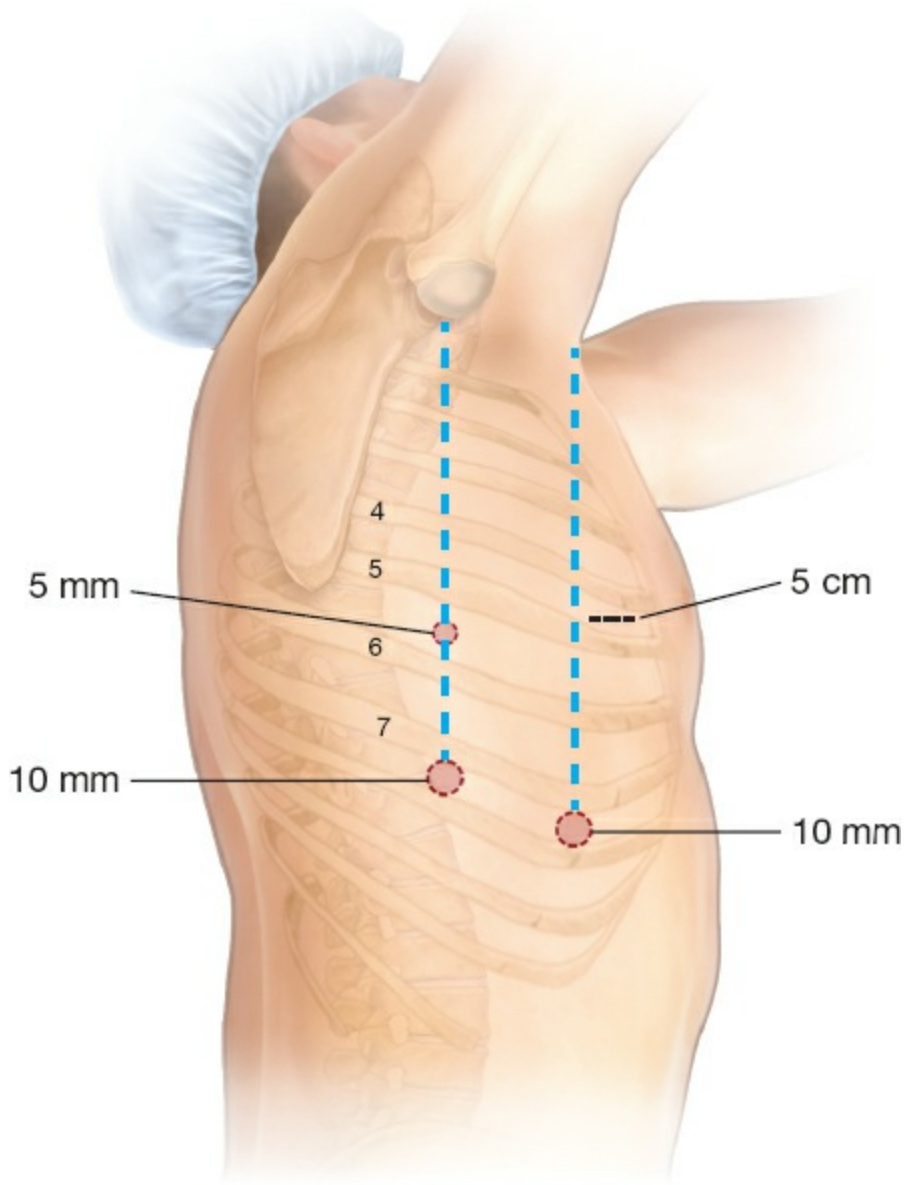

Figure 77.7. Thoracoscopic port sites and positioning: patient in full left lateral position. The surgeon stands at the back of the patient; 5-cm minithoracotomy in the fourth intercostal space with the posterior limit of the incision at the mid-axillary line (MAL). Another 5-mm port placed in the fifth space at the posterior axillary line (PAL). One 10-mm port placed in the seventh space in the PAL, and one 10-mm port in the seventh space MAL. When superior mediastinal lymphadenectomy is carried out, it often helps to add a 5-mm port site at the third intercostal space PAL. During the first phase of the procedure, the videoscope is introduced via the port at the seventh space PAL. When anterior dissection on the pericardium, carina, and left main bronchus is performed, the videoscope is changed to the seventh spaceport at MAL. Similarly, this port is used for superior mediastinal dissection.

The videoscope is introduced in the seventh space posterior port. For this part of the mobilization, the monitor opposite the first assistant can be turned upside down so that his view will be the same as one would see during an open operation. Mobilization of the esophagus is begun by first incising the mediastinal pleura overlying the esophagus below the level of the inferior pulmonary vein. Once a short segment of esophagus is mobilized, a sling (a PDS 1 suture) is placed around the esophagus to ease retraction. Dissection essentially follows the same routine as in open surgery. The division of the azygos vein arch is eased by the use of endovascular stapler. Once the posterior aspect of the esophageal dissection and periaortic tissue including the thoracic duct is dissected, the videoscope can switch to the seventh space port at the MAL. Anterior dissection along the right bronchus, carina, and left bronchus can proceed. During this part of the dissection, the monitor opposite the first assistant can be turned back to its normal position since the direction of view is the same for the surgeon as well as for the assistant. Once infracarinal dissection is finished, the superior mediastinal lymphadenectomy can be performed just as that described in the section on open surgery. Dissection around the recurrent laryngeal nerve has to be particularly meticulous; judicious use of energy source will lessen the chance of nerve injury. After the thoracoscopic phase is completed, the wounds can be closed with a small chest tube placed via the seventh spaceport pointing at the apex. Current practice of the author includes placement of a 19 Fr silicone drain with 4 channels along the sides with a solid core center (Blake drain). It is a closed suction drain connected to a vacuum reservoir, without the need for an underwater seal. Only in cases with extensive pulmonary adhesiolysis or air-leak a conventional chest tube will be placed. This is much more comfortable for the patients. The laparoscopic and cervical phase of the operation can then proceed.

Some surgeons prefer using the prone position for the thoracoscopic phase. The surgeon and the assistant both would stand at the front of the patient. In this position, the lungs, blood, and fluid tend to fall by gravity below the plane of dissection, thus improving exposure of the posterior mediastinum. Reliance on the assistant for retraction is also less. There is some preliminary data showing that oxygenation may be better using the prone compared with the left lateral approach. The potential drawback of the prone position is that dissection of the recurrent laryngeal nerve chains (especially the left) may be more difficult, since the dissection instruments

are coming anteriorly, and thus have to climb over the trachea before the left paratracheal space can be reached. More forceful retraction of the trachea may be required. Other disadvantages include the more difficulty in positioning, and should emergent conversion to open thoracotomy is required, this is more cumbersome.

Laparoscopy and Cervical Phase

The patient is turned to the supine position with the legs apart (Fig. 77.8). The surgeon stands on the right side, the first assistant on the left side, and the second assistant in between the legs holding the videoscope. The first port is placed with a subumbilical cut-down technique. Pneumoperitoneum is established. A 5-mm epigastric port is placed just below the xiphoid and this is converted immediately into a Nathanson liver retractor. One 5-mm port is placed just below the right costal margin slightly medial to the anterior axillary line; another 5-mm port is placed in between this port and the umbilical port about one fist-length away. Two similar ports are placed in the left side. The gastric mobilization and lymphadenectomy are just like the open procedure as described.

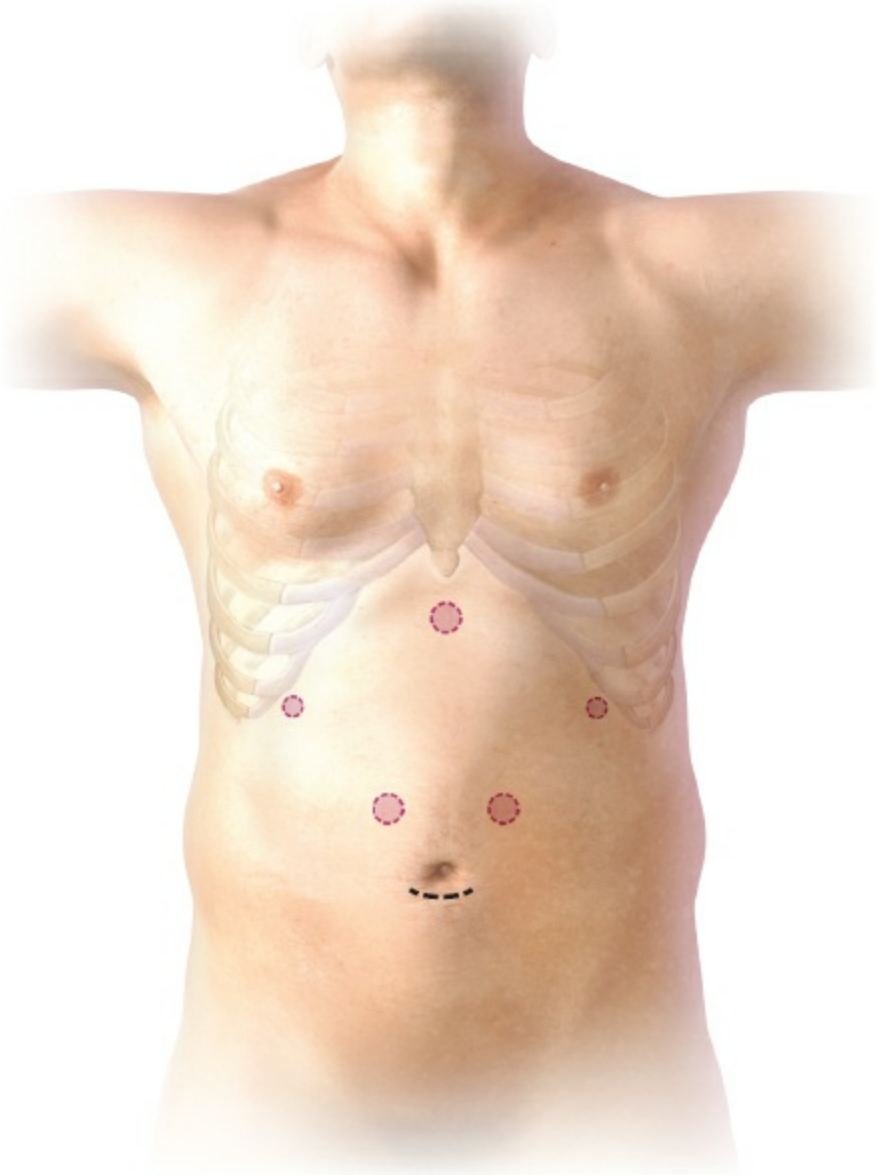

Figure 77.8. Port sites for laparoscopic gastric mobilization. The subumbilical port admits the videoscope, the surgeon stands on the patient's right side, and the assistant surgeon on the left. A Nathanson liver retractor replaces the epigastric port.

The neck is then explored. The esophagus is divided in the neck; the distal stump is closed and tagged to a chest tube or latex drain. Pneumoperitoneum is reestablished. The esophagus with the attached chest tube is grasped and pulled down into the abdomen. The Nathanson retractor is then removed, and this epigastric port is converted to a 5-cm midline mini-laparotomy. A silicone wound retractor is placed. The chest tube with the esophagus and mobilized stomach is pulled outside the abdomen. The lesser curvature of the stomach is prepared just like in open surgery and linear staplers are used to transect the stomach to make it into

a gastric tube. The specimen can then be removed. The apex of the gastric tube is tagged to the chest tube from the neck and replaced back into the abdominal cavity. Through the mini-laparotomy, a pyloroplasty can be performed.

The gastric conduit can be placed inside a plastic bag (such as that used to sheath an intraoperative ultrasound probe), tagged to the chest tube or latex drain, and then delivered to the neck for esophagogastrostomy. The bag protects the stomach (especially the vascular arcades) inside the posterior mediastinum, and also helps slide the conduit upward. The wounds can be closed after the esophagogastrostomy.

Routes of Reconstruction

In a Lewis–Tanner esophagectomy, the conduit is delivered up to the thoracic cavity for anastomosis. When a three-phase or transhiatal procedure is performed, the conduit can be brought up to the neck via the orthotopic (posterior mediastinum), retrosternal, or subcutaneous route.

To make a retrosternal tunnel, the space at the back of the xiphoid is entered. A tunnel is opened up behind the sternum. A flat malleable retractor is introduced to further open the space behind the upper part of the sternum. Little bleeding occurs if dissection is kept in a plane close to the back of the sternum near the midline. The upper part of the tunnel is made from the neck; the right plane can be correctly identified by following the sternal attachments of the strap muscles. Using the index finger, a space is opened by blunt dissection, again keeping close behind the sternum to avoid injury to underlying vascular structures. The narrowest part of the tunnel is usually at the thoracic inlet, and a space of three fingers is generally created to allow for adequate room for the passage of the conduit. Minor bleeding from the tunnel is self-limited and is usually controlled by gauze packing. It is not necessary to resect the manubrium sterni and the clavicular head to provide sufficient space.

The subcutaneous route is rarely used. To make the subcutaneous tunnel, the skin at the upper end of the abdominal incision is lifted up, and, with the use of scissors and electrocautery, the subcutaneous plane is opened up. The tunnel is prepared in a similar manner proximally from the cervical incision. The subcutaneous space in the intervening presternal segment is freed by using a pair of long scissors.

It is important to close the diaphragmatic hiatus after extirpation of the esophagus when the retrosternal or subcutaneous routes are used. Herniation of intestine into the thoracic cavity may occur otherwise.

The Esophageal Anastomosis

The esophageal anastomosis can be performed by a hand-sewn technique, circular stapler, or linear staplers. Whichever technique is used, equally low leakage rate can be achieved. Circular stapler is easier to use in an intrathoracic anastomosis and is less operator dependent, but stricture rate tends to be higher especially when the esophagus is small and a small-sized stapler is used. The hand-sewn anastomosis can be used in any position, and is certainly more economical. When thoracoscopic esophagectomy is performed, it is more difficult to perform the anastomosis in the thoracic cavity and most would prefer a cervical anastomosis.

For the hand-sewn anastomosis, the author uses a single-layer continuous monofilament, absorbable suture of 4/0 Maxon. To ensure success, there must not be tension, and careful apposition of the esophagus and conduit is needed. Tight suturing resulting in strangulation of tissue must be avoided. Other methods using double-layer and/or interrupted suturing, nonabsorbable sutures have their advocates. The method of anastomosis is less important than its proper application.

In the author's institution, all anastomoses in the neck are hand-sewn; similar method is used when open intrathoracic anastomosis is performed. In thoracoscopic intrathoracic anastomosis, a circular stapler is used, and placement of the anvil is eased by using the ORVIL (Medtronic). First the esophagus in the chest is transected with a linear stapler, then the anvil is placed trans-orally (ORVIL). The stapling gun is then introduced by opening up slightly the mini-thoracotomy to put inside the gastric tube to engage the anvil before firing. Another indication of the circular stapler is during trans-abdominal resection of a cancer of the gastroesophageal junction. To ensure a sufficient proximal margin in the lower posterior mediastinum, a hand-sewn anastomosis has poor exposure, and so this double-stapling technique just like the intrathroacic anastomosis can be done.

Preparation of a Colon Conduit for Interposition

The right and transverse colons are based on the middle colic vessels, and the left colon is based on the ascending branch of the left colic vessels (Figs. 77.9 to 77.11). Whichever part of the colon is used, the same meticulous method of preparation is required. When possible, we prepare the conduit in an isoperistaltic manner. A preoperative angiogram can help

in selecting the most appropriate segment, particularly in patients with previous abdominal operations, and preempts anomalous vascular anatomy. In countries where colonic diseases are prevalent, a preoperative colonoscopy may also be useful.

The steps in the mobilization of either right or left colon are similar. On the right side, mobilization of the terminal ileum across the iliac vessels and the ureter enables the terminal ileum, cecum, appendix, and ascending colon to be lifted out of the abdomen. As mobilization proceeds proximally, the duodenum and the head of the pancreas are safe-guarded; in this region, the main right colic vessel may be encountered as it courses over the uncinate process of the pancreas.

Mobilization of the left colon proceeds in a similar manner as before, and the sigmoid colon is freed from the retroperitoneum toward the midline and can also be brought out of the abdominal wound. The splenic flexure is similarly mobilized.

The transverse colon is prepared by detaching the greater omentum from its antimesenteric border. The omentum is first detached left of the midline to enter the lesser sac; further separation can then proceed more readily. Little bleeding should be encountered, and only occasionally does a blood vessel need ligation.

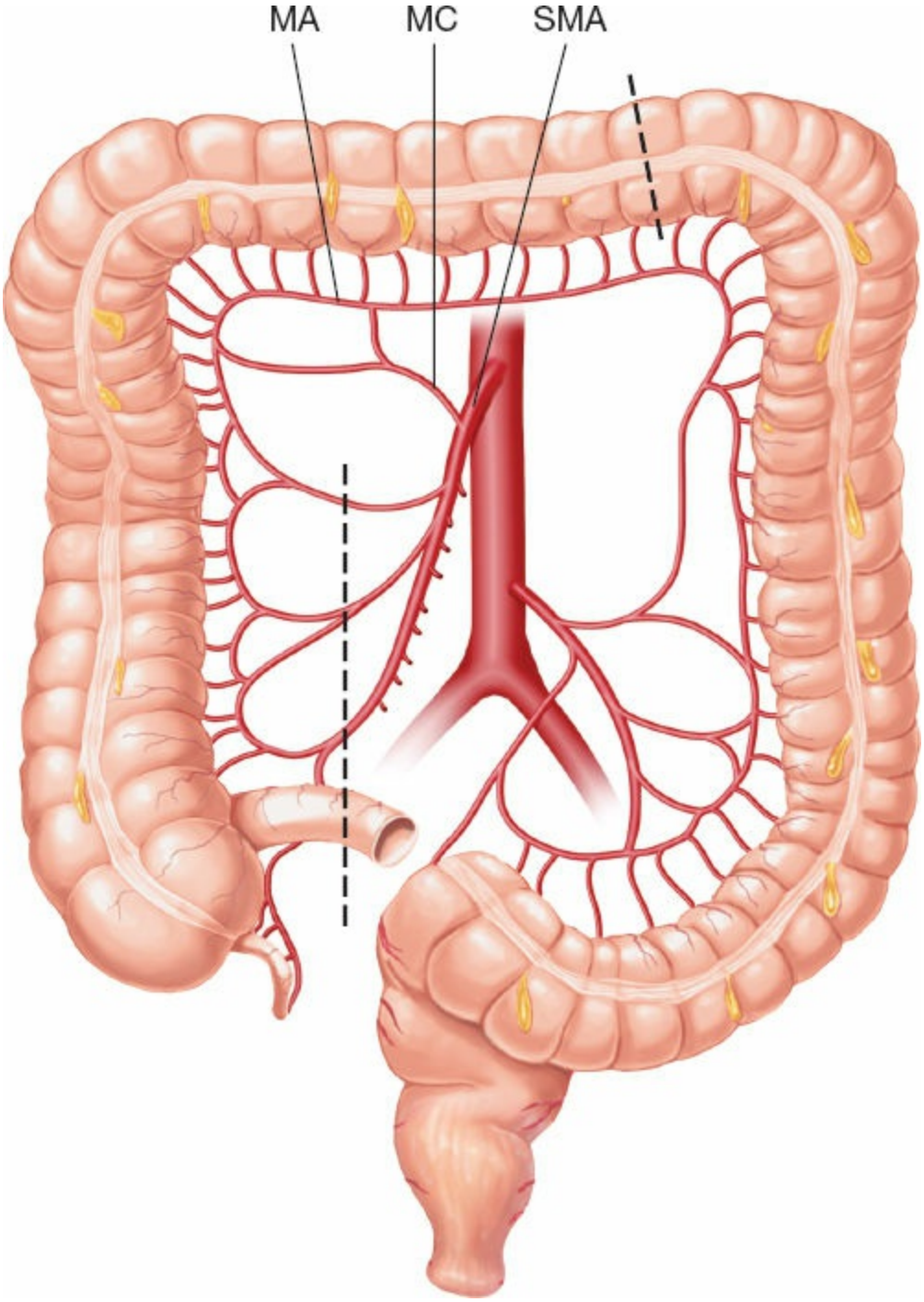

Figure 77.9. The vascular supply of the colonic conduits: right ileocolon loop used. The supply is based on the middle colic vessels with or without preservation of the right colic vessels, most often only the main ileocolic truck needs division for adequate length of the terminal ileum to reach the neck. Careful preservation of the marginal arcade is essential to ensure good vascularization of the colonic loop. *Dashed line* indicates the line of transection of the colon. MC, middle colic vessels; SMA, superior mesenteric artery; MA, marginal arcade.

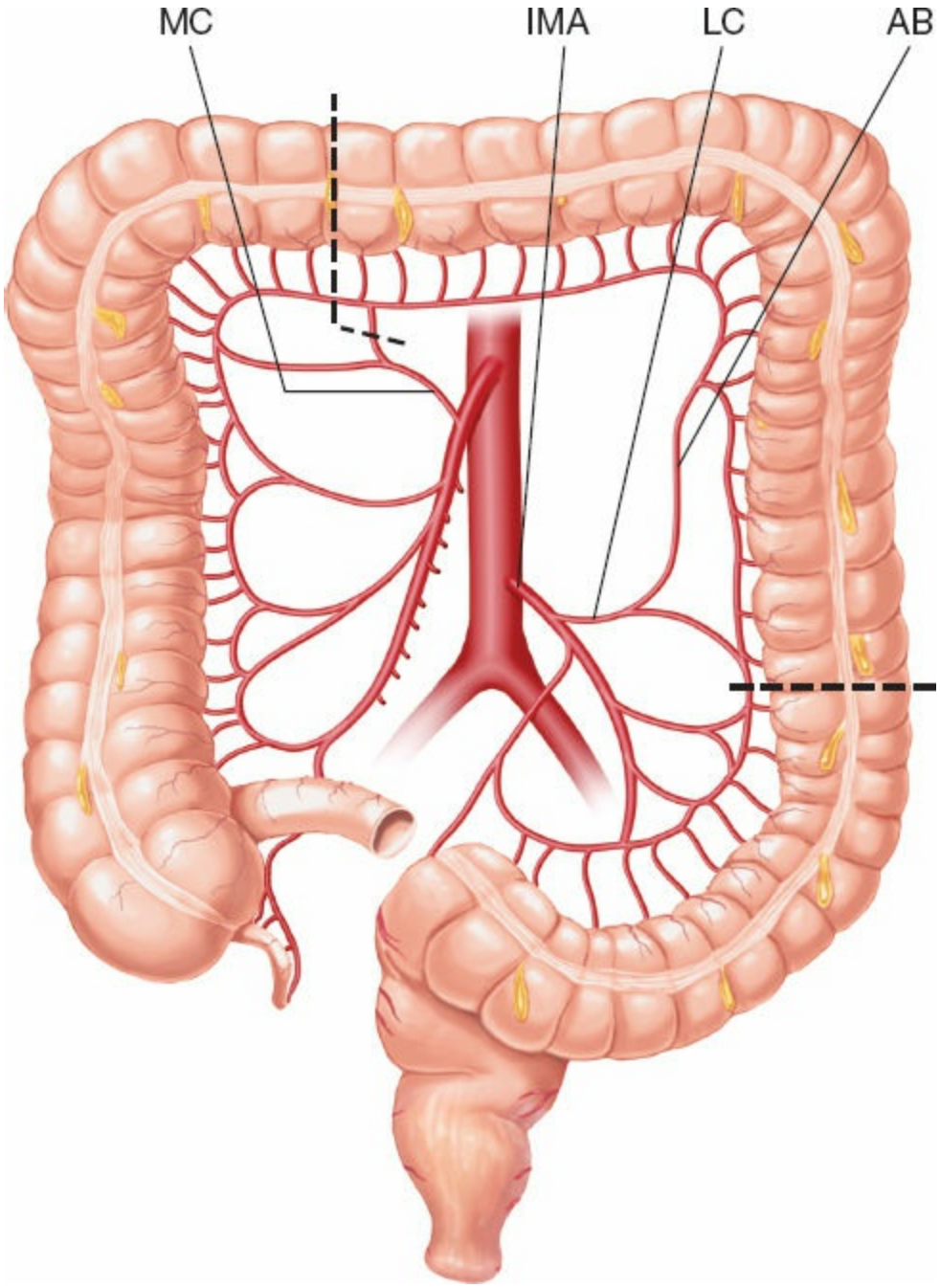

Figure 77.10. Left colon conduit. The vascular supply is based on the ascending branch of the left colic artery. *Dashed line* indicates the lines of transection. IMA, inferior mesenteric artery; MC, middle colic vessel; LC, left colic artery; AB, ascending branch.

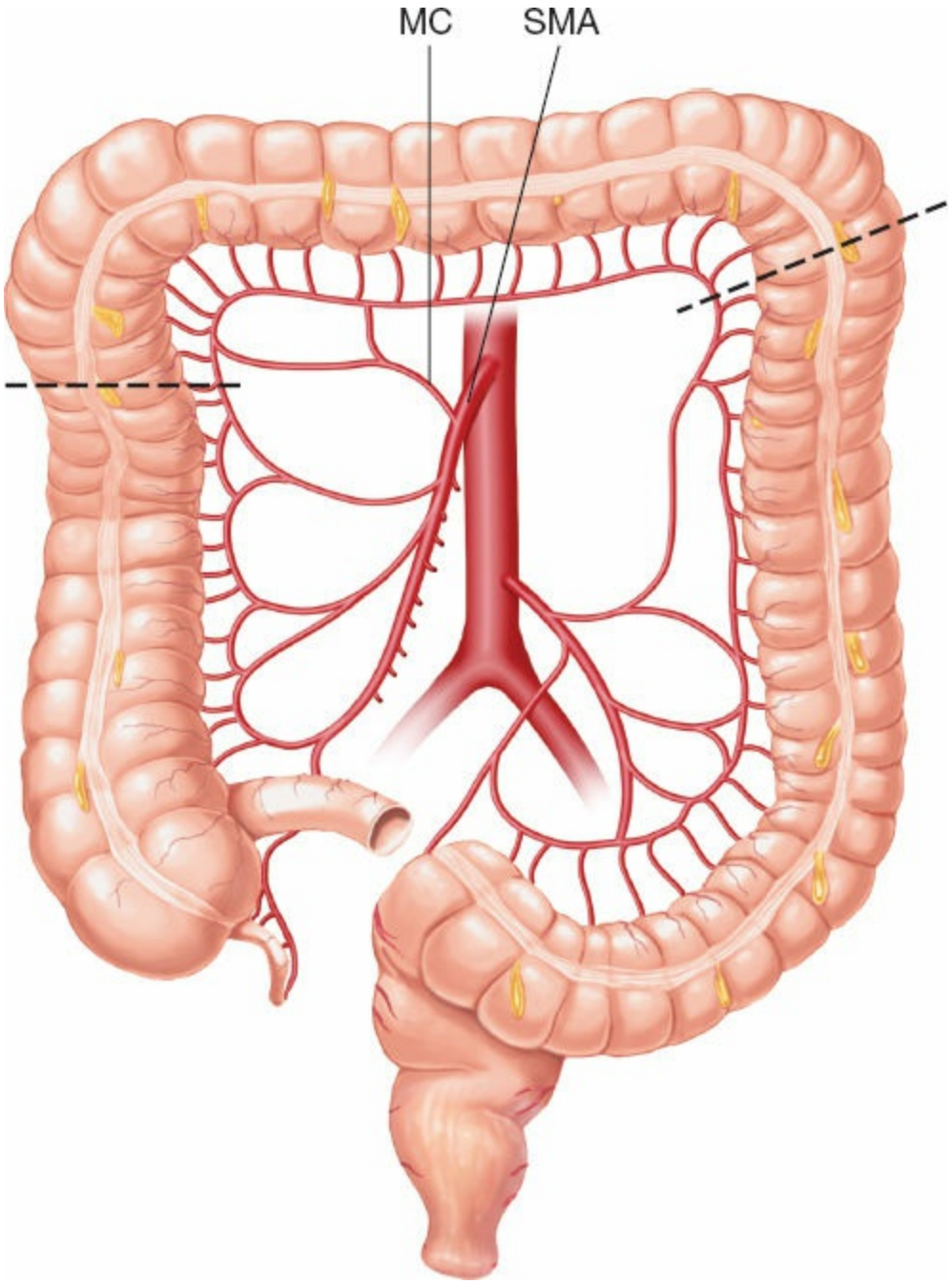

Figure 77.11. Transverse colon conduit. The vascular supply is based on the middle colic vessels. *Dashed line* indicates the lines of transection. SMA, superior mesenteric artery; MC, middle colic artery.

The author prefers using the right ileocolon, using the terminal ileum to anastomose with the esophagus. In the right colonic mesentery, there is usually a large area between the ileocolic and the right colic branches that is devoid of blood vessels. We divide the ileocolic vessels near the origin and then follow this down to the ileum about 15 to 30 cm from the cecum, where the ileum is divided. Usually only the main trunk of the ileocolic

vessels needs division. The marginal arcade connection from the left colic vessels should be preserved. A point on the transverse colon is chosen left of the middle colic vessels. Dissection should be done meticulously between the bowel wall and the marginal arcade (so preserving its connection to the right side) for a short distance to prepare the bowel for transection. Once this part of the transverse colon is divided, the proximal end of the transected bowel is used for the cologastric (if part of the stomach is still preserved) or colojejunal anastomosis. The distal end of the divided colon is anastomosed to the divided ileum to restore intestinal continuity. Often side-to-side anastomses are easier for both. The appendix is removed before bringing the ileocolonic loop up for anastomosis with the esophagus. The loop is usually brought up to the neck via the retrosternal route.

For the left colon, the sustaining arterial supply is the ascending branch of the left colic artery, which originates from the inferior mesenteric artery. When this branch is small and when only the left colon is available, we have used this segment in an antiperistaltic manner, with the blood supply based on the middle colic vessels. Usually, the ascending branch of the left colic artery is robust and the middle colic vessels can be divided. The venous drainage through the inferior mesenteric vein to the splenic vein has to be safeguarded during the preparation of the left colon.

Preparation of the Jejunal Conduit

The duodenojejunal junction is identified, and the proximal jejunum is then examined for completeness of arterial and venous arcades (Fig. 77.12). In patients with a thick mesentery, transillumination by a strong light from behind is helpful.

Dissection is begun in the upper jejunum, at a point approximately halfway between the edge of the intestine and the root of the mesentery, proximal to the branching of the main jejunal arteries. Sometimes the superior mesenteric artery divides into a few main branches with good marginal arcades joining the various main trunks. It is more problematic if the branches are small, and the marginal arcade on the intestine is small or is incomplete. Depending on the vascular supply, a point is first chosen based on a large artery. Usually, three to four sets of jejunal arteries and veins have to be divided for a sufficient length of mesentery and intestine to reach the neck. When a shorter length of jejunum is required, such as for intrathoracic anastomosis, less dissection of the mesentery is required. The proximal end of the intended jejunal conduit is usually 10 to 15 cm from

the duodenojejunal junction. Dissection is started at a safe distance from the marginal arcade. The four sets of jejunal vessels are isolated and then clamped with bulldog clamps to test the adequacy of the marginal arcades. To further ensure that the blood supply is sufficient to support the circulation to the conduit, a soft clamp is applied across the intestine at the upper jejunum to abolish any contribution from the proximal arcade. Often, the conduit of jejunum thus isolated undergoes active peristalsis. After a few minutes, if the color remains pink and the jejunum does not appear congested, and if arterial pulsation can be seen in the arcades, the viability of the jejunal conduit is assured.

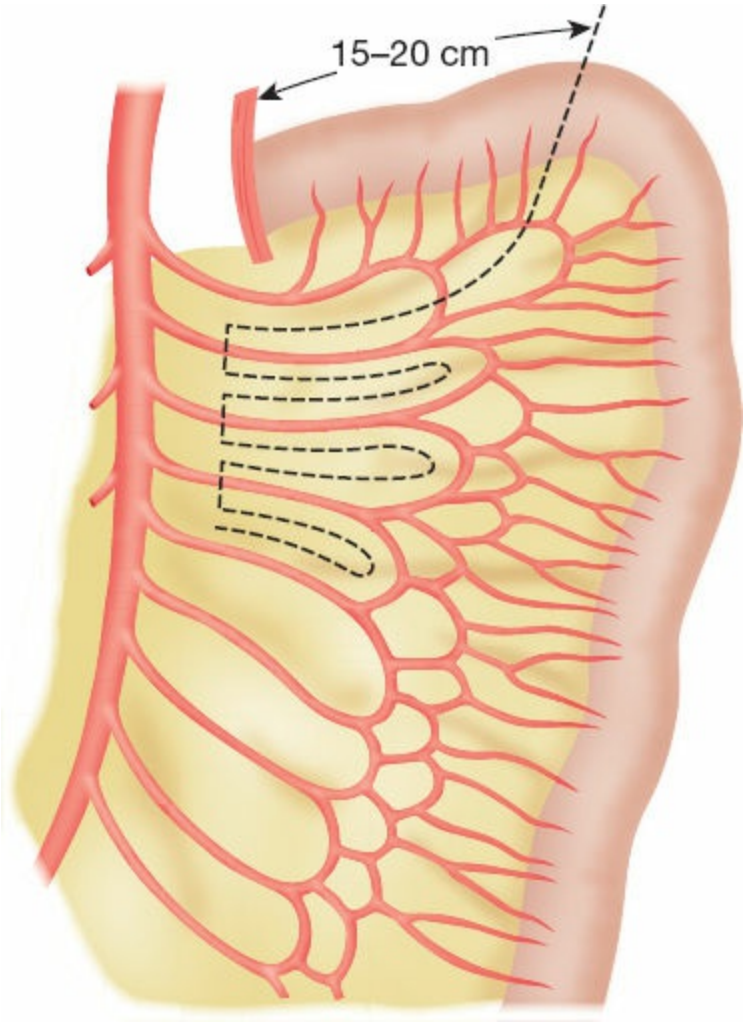

Figure 77.12. The jejunum prepared for esophageal replacement. The upper jejunum is used with division of three to four sets of jejunal arteries. Roux-en-y reconstruction is used.

When there is doubt about the vascular supply of the conduit, evidenced by flaccidity and congestion of the bowel wall and absence of arterial

pulsation, the most proximal bulldog clamp on the jejunal vessel can be released and the viability reassessed. However, if only three branches are divided, the mesentery may reach the neck only with some tension, which should be avoided. Under these circumstances, mobilization of the entire mesentery by dividing the peritoneum at the root as it crosses over the aorta allows the conduit, together with the entire mesentery, to move 4 to 5 cm higher and thus relieve any tension on the anastomosis. It is not the length of the bowel, but that of the mesentery, that limits the length attained.

After the adequacy of the blood supply of the jejunal conduit has been tested, the bulldog clamps and the soft intestinal clamp are removed. The arterial and venous branches are mobilized separately, then divided and ligated with fine ties. The jejunum is then divided proximally. The conduit is then placed in the retrocolic, retrogastric position (when appropriate) before being delivered to the right chest or neck for anastomosis. When a long jejunal loop has to reach the neck however, often the blood supply may not be reliable and augmentation with mirovascular anastomosis may be necessary.

PERIOPERATIVE CARE

Enhanced Recovery After Surgery Program (ERAS) has a definite place in the perioperative management of patients undergoing esophagectomy. However, practice varies and many components of ERAS are not proven. The routine program practiced at the author's institution is shown in Table 77.1.

Pain relief is a major component to postoperative care for esophagectomy, although with the introduction of minimally invasive surgery this may have become less crucial. Epidural analgesia has been our routine method. Overhydration results in more pulmonary morbidities and should be avoided. In general tubes and drains that are used should be of small caliber, as few as possible, and early removal enhances comfort and early mobilization. A nasogastric tube is rarely needed. When a pyloric drainage procedure has been done, especially when a cervical esophagogastrotomy is made, delayed gastric emptying problem is uncommon. Liquid diet can be introduced early, and when tolerated, a soft diet can be started. There is no need for routine contrast study to check the integrity of the anastomosis. Early introduction of diet also would not increase leak rates. The decision to advance oral diet is based on clinical

parameters, and not radiologic appearance. In centers that are experiencing a high leak rate however, this policy may not be appropriate. Other adjuncts like chest physiotherapy, incentive spirometry, mobilization exercise, and preoperative counseling are all contributory to early recovery.

COMPLICATIONS AND THEIR MANAGEMENT

Cardiopulmonary complications are most common; patients are elderly with pre-existing morbidities, surgery is carried out in three body cavities, and extensive mediastinal dissection predisposes to complications. Many patients also have had preoperative radiotherapy to the lungs and heart.

Atelectasis and pneumonia are managed by chest physiotherapy, incentive spirometry, adequate pain relief, avoidance of fluid overload, appropriate antibiotics, and if needed, sputum suction by bronchoscopy.

Atrial fibrillation occurs in around 20% of patients; it is benign in most and is treated by antiarrhythmic medication. In some patients, it is a reflection of underlying serious complication, such as bronchopneumonia or more importantly surgical morbidities such as anastomotic leak or ischemia of the conduit. Its occurrence should prompt appropriate investigations, such as an endoscopy.

Recurrent laryngeal nerve injury is not uncommon when superior mediastinal lymphadenectomy is carried out. Intraoperative nerve monitoring helps lessen this complication. Postoperatively patient will experience hoarseness of voice, coughing becomes less effective, and aspiration may be a problem when diet is introduced. In some patients, hoarseness may not be apparent because of excellent compensation from the contralateral vocal cords. Routine laryngoscopy will document clearly the incidence of nerve paralysis. When nerve palsy is present, more active pulmonary treatment is necessary, and introduction of oral diet should be more cautious. Early injection thyroplasty (within the first 3 to 4 days of diagnosis) is a simple procedure and may expedite recovery.

TABLE 77.1 Routine Perioperative Management at the University of Hong Kong

Preoperative period	Stop smoking and alcohol intake Counseling and education Chest physiotherapy and incentive spirometry
Day of operation	Carbohydrate loading 6 h before surgery Allow fluids 2 h before surgery Prophylactic antibiotics Deep vein thrombosis prophylaxis Epidural analgesia/Patient-controlled analgesia Intraoperative care Fluid management: Goal-directed therapy 19 Fr small vacuum suction drain (Blake drain) No feeding jejunostomy Routine endotracheal tube extubation
Day 1	Bronchoscopy to document state of vocal cords when bilateral recurrent laryngeal nerves dissection has been performed and/or cervical anastomosis Fluid restriction: IV fluid 1–1.5 L/day with additional challenge if necessary Chest physiotherapy Mobilization Sips of water by mouth
Day 2	IV fluid 1–1.5 L/day Chest physiotherapy Remove nasogastric tube Mobilization
Days 3–4	IV fluid 1–1.5 L/day Chest physiotherapy Liquid diet by mouth Remove chest drain if the output is <300 mL in the last 24 h Mobilization Urinary catheter taken off
Days 5–6	IV fluid 1–1.5 L/day (taken off if taking sufficient liquid by mouth) Remove epidural catheter and changing to patient-controlled analgesia or oral analgesics Chest physiotherapy Mobilization Soft diet
Day 7	Discharge if stable and tolerating diet well

Gross ischemia of the conduit usually presents early, within the first 2 to 3 days after operation. Sepsis is obvious. It is important to be proactive and treat this complication expeditiously so that further deterioration does not occur. A high index of suspicion is required. It is the author's practice to have a very low threshold for endoscopy to examine the state of the conduit and anastomosis whenever there are signs of deterioration. Signs leading to endoscopic examination can be unexplained tachycardia, atrial

fibrillation, or poor arterial oxygenation. A normal endoscopy at 3 days after surgery will assure the absence of gross ischemia, and other sources of sepsis (usually pulmonary or urinary) should be looked for. Gross ischemia dictates taking down of the conduit, adequate drainage, and staged reconstruction later once sepsis is under control. In selected cases with ischemia limited to a small portion of the gastric conduit, when the patient is hemodynamically stable with minimal sepsis (importance of early diagnosis before deterioration) and when an adequate length of stomach remains after resection of the ischemic portion, immediate reanastomosis is an option.

Clinically apparent thoracic anastomotic leaks usually occur within the first week. Signs of sepsis, excessive output from the chest drain, which may be turbid in color, may lead to diagnosis. The location and magnitude of the leak can be visualized by a water-soluble contrast study. A carefully performed flexible endoscopic examination is also helpful and will not worsen the leak. For small contained leaks, CT-guided drainage of pockets of collection may suffice. In septic patients with a sizable leak, exploration is warranted. Direct repair is seldom possible or effective, drainage is the key.

For a cervical anastomosis, leakage is suspected when there is inflammation and pain of the neck wound. Turbid infected discharge is found when the skin stitches are removed. Leaks that are truly confined to the neck are simply treated by laying the wound open with daily washing and frequent changes of dressing. The patient is usually not septic. Leaks that communicate with the mediastinum may require formal exploration and placement of mediastinal drains.

In all leaks, treatment with broad-spectrum antibiotics is required and is guided by culture and sensitivity results. Nutritional support is essential. With an intrathoracic stomach, careful endoscopic placement of a fine-bore feeding tube distal to the leak into the duodenum for enteral feeding is useful. A second tube, a nasogastric tube placed in the intrathoracic stomach, will help decompress the stomach and avoid reflux of gastric contents through the anastomosis. Total parenteral nutrition is required if placement of a feeding tube is not successful. Injection of fibrin glue, placement of intraluminal stents, and clip closure of the defect are increasingly used to treat leaks; sealing of the leak allows early control of sepsis and resumption of oral alimentation. The stent can be removed afterward, depending on the severity of the leak in the first place. Usually

4 to 6 weeks will suffice for adequate healing.

Chylous leak is suspected when there is excessive chest drainage. A milk challenge, looking at the color of the effluent before and after taking milk by mouth or via the nasogastric tube, will usually be obvious. This can be aided by biochemical testing of the drain fluid, measuring triglyceride level. In low output fistula of usually <500 mL to 1 liter per day, conservative management for a brief period of time with TPN or a mid-chain triglyceride diet may suffice. Sandostatin has not been shown to be useful. In case of persistence or if output is >1 liter per day, prolonged conservative treatment is not recommended and early reexploration is warranted. A lymphangiogram preoperatively will help locate the site of leakage, and intraoperative milk feed will also serve the same purpose. However, increasingly interventional radiologic method of percutaneous embolization has gained success, and has reduced the need for surgical reexploration.

OUTCOME

The outcome of esophagectomy has improved dramatically over the past three decades. In dedicated centers, mortality from this once feared operation is in the region of 2% to 3%. Morbidities however do remain substantial, especially pulmonary complications. Anastomotic leak rates vary widely, from 1% to 2% to even >20%, and this must be technique dependent. Despite high leak rates in some centers, mortality remains low since supportive treatment has also improved.

Improvement in surgery is evident both in reducing immediate postoperative mortality rates, and also in the extent of lymphadenectomy, which has been shown to be related to long-term prognosis. Multimodality treatment strategies with chemotherapy +/– radiotherapy have also contributed a great deal to survival. Response to neoadjuvant therapy is closely related to prognosis; the best is in patients who have shown substantial or even complete pathologic response to therapy. Overall after treatment in a mutimodality treatment program, a 5-year survival of 40% to 50% is expected. Disease stage remains the most powerful predictor of outcome. Early diagnosis is the best way to treat this deadly disease.

Suggested Readings

Biere S, van Henegouwen MI, Maas KW, et al. Minimally invasive versus open oesophagectomy for patients with oesophageal cancer: a multicentre, open-label,

randomised controlled trial. *Lancet* 2012;379(9829):1887–92.

Findlay JM, Gillies RS, Millo J, et al. Enhanced recovery for esophagectomy: a systematic review and evidence-based guidelines. *Ann Surg* 2014;259(3):413–31.

Law S. Cancer of the esophagus. In: Zinner MJ, Ashley S, eds. *Maingot's Abdominal Operations.* 12th ed. New York: Mc-Graw Hill Medical; 2013:355–88.

Law S. En-bloc esophagectomy. In: Luketich J, Landreaneau RJ, Pennathur A, eds. *Master Techniques in Surgery: Esophageal Surgery.* Philadelphia, PA: Wolters Kluwer; 2014:251–62.

Law S, Suen DT, Wong KH, et al. A single-layer, continuous, hand-sewn method for esophageal anastomosis: prospective evaluation in 218 patients. *Arch Surg* 2005;140(1):33–9.

Tong D, Law S. Extended lymphadenectomy in esophageal cancer is crucial. *World J Surg* 2013;37(8):1751–6.

Tong DK, Law S. Hong Kong experience. In: Ando N, ed. *Esophageal Squamous Cell Carcinoma: Diagnosis and Treatment.* Japan: Springer; 2015:261–78.

Tsang RK, Law S. Adaptation of continuous intraoperative vagus nerve stimulation for monitoring of recurrent laryngeal nerve during minimally invasive esophagectomy. *World J Sur*g 2016;40(1):137–41.

Udagawa H, Ueno M, Shinohara H, et al. The importance of grouping of lymph node stations and rationale of three-field lymphoadenectomy for thoracic esophageal cancer. *J Surg Oncol* 2012;106(6):742–7.

van Hagen P, Hulshof MC, van Lanschot JJ, et al. Preoperative chemoradiotherapy for esophageal or junctional cancer. *N Engl J Med* 2012;366(22):2074–84.

EDITOR'S COMMENT

Although squamous cell carcinoma remains the dominant histologic subtype of esophageal carcinoma throughout the world, there has been a dramatic shift in the epidemiology of esophageal carcinoma in the West, where there has been a marked increase in the incidence of adenocarcinoma (Arnold M, Pandeya N, Byrnes G, et al. Global burden of cancer attributable to high body-mass index in 2012: a population-based study. *Lancet Oncol* 2015;16:36–46). Many studies have implicated obesity, gastroesophageal reflux disease (GERD), and cigarette smoking as the major risk factors for this rising incidence of adenocarcinoma in the West (Thrift AP. The epidemic of oesophageal carcinoma: Where are we now? *Cancer Epidemiol* 2016;41:88–95). Barrett esophagus, a condition in which the normal squamous epithelium is replaced by intestinal-type columnar epithelium due to chronic acid reflux, confers an at least 10-fold increased risk of esophageal adenocarcinoma (Hvid-Jensen F, Pedersen L, Drewes AM, et al.

Incidence of adenocarcinoma among patients with Barrett's esophagus. *N Engl J Med* 2011;365:1375–83), and so these patients are entered into a program of routine endoscopic surveillance. However, it remains unclear whether such surveillance results in a decrease in overall mortality from esophageal adenocarcinoma.

The management of locally advanced esophageal carcinoma has evolved from surgery or radiotherapy as a single modality to trimodal therapy, including neoadjuvant chemoradiotherapy (nCRT) followed by surgery, which has been shown to confer a significant survival advantage over surgery alone (van Hagen P, Hulshof MC, van Lanschot JJ, et al. Preoperative chemoradiotherapy for esophageal or junctional cancer. *N Engl J Med* 2012;366:2074–84). The optimal timing of surgery after nCRT for esophageal carcinoma has not been established in prospective clinical trials. Lin et al. (Increasing the interval between neoadjuvant chemoradiotherapy and surgery in esophageal cancer: a meta-analysis of published studies. *Dis Esophagus* 2016;29(8):1107–14) performed a systematic literature search and meta-analysis of published studies on this topic and found that a longer interval (more than the standard 7 to 8 weeks) from the end of nCRT to surgery did not increase the pathologic complete response rate or have any effect on the anastomotic leak rate or overall postoperative morbidity or mortality rates. In contrast, performing surgery within 7 to 8 weeks after nCRT resulted in better R0 resection and 2-year overall survival rates, leading these authors to conclude that surgery is best performed within 8 weeks after the completion of nCRT.

Definitive chemoradiation therapy (CRT) is a reasonable treatment option for patients with squamous cell carcinoma of the esophagus who are high-risk operative candidates, as even patients with locoregionally advanced tumors enjoy high rates of pathologic complete response (CR). Yet despite the high CR rates, locoregional failure occurs in up to 60% of patients, and salvage esophagectomy is the only real option to achieve long-term survival in this setting. However, salvage esophagectomy after definitive CRT is associated with high rates of postoperative morbidity (~65%) and mortality (~8%) and 5-year survival rates of <30%, and so patient selection is key. Watanabe et al. (Salvage Esophagectomy After Definitive Chemoradiotherapy for Patients with Esophageal Squamous Cell Carcinoma: Who Really Benefits from this High-Risk Surgery? *Ann Surg Oncol* 2015;22:4438–44) examined the outcomes of 63 patients who underwent salvage esophagectomy after definitive CRT for esophageal squamous cell carcinoma at the Cancer Institute Hospital in Tokyo and concluded that the patients who benefit most from this high-risk surgery are those with pretreatment T1 or T2 tumors who relapse after a CR. For patients with relatively shallow, locally recurrent lesions in the esophagus without regional nodal metastasis after definitive CRT, salvage endoscopic therapies such as endoscopic mucosal resection (EMR) and photodynamic therapy (PDT) are highly effective, less invasive treatment options than salvage esophagectomy (Hatogai K, Yano T, Kojima T, et al. Local efficacy and

survival outcome of salvage endoscopic therapy for local recurrent lesions after definitive chemoradiotherapy for esophageal cancer. *Radiation Oncol* 2016;11:31).

Although definitive CRT is an option for patients with adenocarcinoma of the esophagus who are deemed to be poor operative candidates, trimodal therapy (including esophagectomy after CRT) is considered the standard of care, as it is associated with improved survival in retrospective studies (McKenzie S, Mailey B, Artinyan A, et al. Improved outcomes in the management of esophageal cancer with the addition of surgical resection to chemoradiation therapy. *Ann Surg Oncol* 2011;18:551–8; Shridhar R, Freilich J, Hoffe SE, et al. Single-institution retrospective comparison of preoperative versus definitive chemoradiotherapy for adenocarcinoma of the esophagus. *Ann Surg Oncol* 2014;21:3744–50).

Dr. Law asserts that one should aim for a proximal margin of 10 cm from the tumor in order to minimize the risk of a subsequent anastomotic recurrence. Indeed, there has been much written about the optimal gross proximal esophageal margin in patients undergoing esophagogastrectomy or transhiatal total gastrectomy for adenocarcinoma of the GE junction in particular. Minimum gross proximal margins of anywhere from 5 cm to 12 cm have been proposed by many different authors, on the basis that intramural skip lesions should be resected even though they are >5 cm away from the main tumor. However, such tumors with distant intramural skip lesions typically also exhibit extensive lymphovascular invasion and multiple regional nodal metastases and thus have a poor prognosis even if resected completely. Barbour et al. (Adenocarcinoma of the gastroesophageal junction: influence of esophageal resection margin and operative approach on outcome. *Ann Surg* 2007;246:1–8) demonstrated that an in vivo gross proximal esophageal margin length of 5 cm (corresponding to a length of 3.8 cm in the resected specimen due to shrinkage) was an independent prognostic factor for survival in patients with Siewert I, II, or III adenocarcinoma of the GEJ who underwent complete gross resection without neoadjuvant therapy. Mine et al. (Proximal margin length with transhiatal gastrectomy for Siewert type II and III adenocarcinomas of the oesophagogastric junction. *Br J Surg* 2013;100:1050–4), however, found that an in vivo gross proximal margin length of only 28 mm (corresponding to 20 mm in the resected specimen) was adequate for the vast majority of patients with Siewert type II and III GEJ tumors. This study is extraordinarily important, as the choice of operative approach to adenocarcinomas of the GEJ is highly dependent on the location of the tumor and the desired proximal margin. In many cases of adenocarcinoma of the GEJ, a 3-cm proximal margin is achievable via a transhiatal approach, thus sparing the patient the potential morbidity of a thoracotomy.

Another area of controversy in the surgical treatment of esophageal carcinoma is in the need for upper/middle thoracic lymphadenectomy in patients with either adenocarcinoma of the GEJ or squamous cell carcinoma of the lower

esophagus. In a very simple but elegant study, Mine et al. (Thoracic lymph node involvement in adenocarcinoma of the esophagogastric junction and lower esophageal squamous cell carcinoma relative to the location of the proximal end of the tumor. *Ann Surg Oncol* 2014;21:1596–1601) at the Cancer Institute Hospital in Tokyo investigated whether stratification based on the proximal end of the esophageal tumor as assessed by preoperative CT scan images would be useful in predicting upper/middle thoracic lymph node (LN) involvement. These authors used the vena cava foramen (VCF), defined as the level at which the IVC could be clearly separated from the liver parenchyma, as the landmark on the CT scan. For tumors with proximal ends *below* the VCF, the incidence of upper/middle thoracic LN involvement was 0% for adenocarcinomas of the GEJ and 5.9% for squamous cell carcinomas of the lower esophagus, whereas these percentages were over 35% for tumors with their proximal ends *above* the VCF. Thus, this stratification system based on preoperative CT scan images could be used to determine the extent of thoracic lymphadenectomy required for a given patient with a distal esophageal carcinoma.

Minimally invasive esophagectomy (MIE) has gained substantial popularity as the technique of choice for the surgical treatment of esophageal cancer. On balance, when compared to the traditional open, transthoracic esophagectomy (OE), MIE is associated with less postoperative morbidity (primarily fewer pulmonary complications) and shorter lengths of stay in the ICU and in the hospital (Biere SS, van Berge Henegouwen MI, Maas KW, et al. Minimally invasive versus open oesophagectomy for patients with oesophageal cancer: a multicentre, open-label, randomised controlled trial. *Lancet* 2012;379:1887–92; Sihag S, Wright CD, Wain JC, et al. Comparison of perioperative outcomes following open versus minimally invasive Ivor Lewis oesophagectomy at a single, high-volume centre. *Eur J Cardiothor Surg* 2012;42:430–7). In addition to its proven safety and feasibility as a standard approach to the surgical treatment of esophageal cancer, MIE has also been demonstrated to have equal oncologic efficacy and longer-term improvements in quality of life (QOL) compared to OE. Given the advantages of the robotic platform in accelerating the learning curve of MIE with the help of a magnified three-dimensional view, improved articulation of instruments, and improved dexterity and ergonomics, it only stands to reason that robotic transthoracic esophagectomy will soon become a standard of care for esophageal cancer. The first randomized, controlled trial (ROBOT trial) comparing robot-assisted esophagectomy with open transthoracic esophagectomy for esophageal cancer was launched in 2012 and is currently accruing patients.

Dr. Law and his group perform all of their cervical anastomoses in hand-sewn fashion with a single layer of continuous, absorbable suture, and this same method is used for open, intrathoracic anastomoses. For thoracoscopic procedures, Dr. Law prefers the circular stapled technique with the ORVIL. Price et al. (A comprehensive review of anastomotic technique in 432 esophagectomies. *Ann Thor Surg* 2013;95:1154–61) at the Mayo Clinic

published a comprehensive review of the outcomes with various anastomotic techniques in 432 esophagectomies over a 4-year period. As expected, stricture rates were higher for anastomoses in the neck compared to the chest (26% vs. 15%). For Ivor–Lewis esophagectomies in particular, the 1-year probability of stricture formation was 32% for the circular stapled technique, 27% for the hand-sewn technique, and only 8.6% for the linear-stapled technique. A recent meta-analysis by Deng et al. (Hand-sewn vs linearly stapled esophagogastric anastomosis for esophageal cancer: a meta-analysis. *World J Gastroenterol* 2015;21:4757–64) confirmed the significantly reduced risk of both stricture formation (Risk Ratio [RR] 0.56, 95% CI: 0.49–0.64; $P < 0.00001$) and anastomotic leak (RR 0.51, 95% CI: 0.41–0.65; $P < 0.00001$) with the linear-stapled technique compared to the hand-sewn technique.

Although the cause of anastomotic leakage after an esophagogastric anastomosis is thought to be multifactorial, ischemia of the gastric conduit no doubt plays a major role. Ischemic conditioning of the stomach is a method that has been employed to reduce the risk of anastomotic leak by increasing the perfusion of the gastric conduit. This technique consists of partial gastric devascularization through either embolization or laparoscopic ligation of several arteries to the stomach (with the exception of the right gastroepiploic artery) days or weeks before the completion of the esophagogastric anastomosis, with the aim to provide time for the stomach to adapt to the ischemic conditions created by the abrupt disruption of its normal vascular supply. In several studies, this procedure is performed at the same time as a staging laparoscopy with or without feeding jejunostomy tube placement. A thorough review of this technique by Kechagias et al. (*Ann Thor Surg* 2016;Feb 5, Epub ahead of print) shows that the widespread use of ischemic conditioning of the stomach is not justified at this time and that further clinical research with more rigorous methodology is needed in order to identify which patients may truly benefit from this technique.

Dr. Law advocates *not* obtaining a routine contrast study to evaluate for an anastomotic leak, as leaks in the neck or chest are usually quite easily recognized by clinical examination. Indeed, contrast esophagograms are beset by a number of potential problems, including low sensitivity and positive predictive values for detecting a leak as well as the risk of aspiration (and resultant pneumonia) in up to 45% of patients (Jones CM, Heah R, Clarke B, et al. Should routine radiological assessment of anastomotic integrity be performed after oesophagectomy with cervical anastomosis? Best evidence topic (BET). *Int J Surg* 2015;15:90–4). Nonetheless, a contrast esophagogram can be useful in confirming the clinical suspicion of a leak and in documenting its size and location, as this study has specificity rates in the detection of a leak in excess of 90%.

In terms of the treatment of an esophageal anastomotic leak, esophageal stent placement offers the advantages of earlier oral nutrition, reduced hospital stay, reduced morbidity, reduced anastomotic stricture rates, and equal efficacy as

compared to traditional operative repair with primary closure. In order to limit stent-related complications, it is recommended that esophageal stents be removed at 2 weeks when placed for an anastomotic leak and at 4 weeks when placed for an esophageal perforation (Freeman RK, Ascioti AJ, Dake M, Mahidhara RS. An assessment of the optimal time for removal of esophageal stents used in the treatment of an esophageal anastomotic leak or perforation. *Ann Thor Surg* 2015;100:422–8).

John T. Mullen

78 Transhiatal Esophagectomy Without Thoracotomy

Mark B. Orringer

INTRODUCTION

In the mid-1970s, the technique of transhiatal esophagectomy (THE) without thoracotomy and cervical esophagogastric anastomosis (CEGA) was rediscovered, refined, and popularized. Until that time, a transthoracic esophagectomy with an intrathoracic esophagogastric anastomosis was the standard approach to esophageal resection and reconstruction. THE and a CEGA challenged two prevailing surgical tenets: (1) The maximum upward reach of the mobilized North American Caucasian stomach was to the apex of the right chest, and (2) preservation of an intra-abdominal gastric reservoir was important in patients with benign esophageal disease. The purported advantages of the THE were (a) avoidance of a thoracotomy (and therefore less postoperative respiratory distress) and (b) a CEGA (in which an anastomotic leak resulted in a salivary fistula, which was well managed by open drainage and was seldom associated with mediastinitis and its 50% mortality). THE was initially criticized because of concern about inadequate hemostasis in mobilizing the esophagus from the mediastinum "blindly" and failure to permit an en bloc lymph node dissection felt important in other oncologic operations.

Over the past 40 years, the technique of THE has been progressively refined, and the author now regards this approach as the procedure of choice in the majority of patients requiring esophageal resection and reconstruction for both benign and malignant esophageal disease. The technical refinements in mobilizing and handling the stomach, dissecting the esophagus transhiatally, preparing the gastric conduit, positioning the stomach within the posterior mediastinum, and constructing the CEGA are reviewed in this chapter along with management of the most serious complications and results of the operation.

PATHOPHYSIOLOGY

Most often, patients requiring esophageal resection and reconstruction suffer from esophageal obstruction, which not only has nutritional consequences from *impaired caloric intake* but is also associated with *pulmonary sepsis* associated with impaired swallowing. Hypovolemia and *dehydration* are common. Humans produce 1 to 1.5 L of saliva each day, and the patient who is unable to swallow saliva comfortably and is constantly regurgitating and expectorating it may become severely *hypokalemic.*

INDICATIONS AND CONTRAINDICATIONS

THE is indicated in most conditions for which esophageal resection and reconstruction are required. In 2007, the author and his associates reported a series of 2,007 transhiatal esophagectomies, 1,525 of which (76%) had been performed for carcinoma of the intrathoracic esophagus and 482 (24%) for a wide variety of benign conditions (Table 78.1). Although an esophagomyotomy is a highly effective procedure for the treatment of achalasia, this neuromotor esophageal abnormality is not curable, and patients seen after a failed esophagomyotomy, a reflux stricture that has developed after an esophagomyotomy without an antireflux procedure, or those with a megaesophagus of advanced achalasia are candidates for esophagectomy. With the advent of histamine-2 blockers and proton pump inhibitors, the number of esophageal reflux strictures requiring resection has dramatically fallen. On the other hand, the dramatic increase in the number of laparoscopic fundoplications performed for control of gastroesophageal reflux and repair of hiatal hernias and recurrent hiatal hernias has generated an increasing number of failed fundoplications that are becoming a more common indication for esophagectomy. In patients with severe dysphagia or refractory esophagitis after two failed hiatal hernia repairs, the likelihood of achieving lasting reflux control and relief of dysphagia with a third antireflux operation is so low that the author advises an esophagectomy *if* another operation is the only alternative. Clinically significant gastroesophageal reflux following a properly performed CEGA is uncommon, and with no esophagus, the patient is no longer symptomatic from esophagitis. The decision to perform an esophagectomy for recurrent reflux or hiatal hernia, however, is a difficult one, and patients must understand that the outcome may include cervical dysphagia, reflux from the intrathoracic stomach, and dumping symptoms as problematic as their presenting symptoms.

In the author's experience with more than 2,000 transhiatal esophagectomies, this approach has been applicable in 98% of all patients requiring esophageal resection. However, clear contraindications to THE or utilizing the stomach as an esophageal replacement exist. Patients with upper or middle third esophageal carcinoma, who have tracheobronchial invasion documented by bronchoscopy and biopsy, magnetic resonance imaging, computed tomography, or esophageal endoscopic ultrasonography, are not candidates for a THE. Similarly, the author will not proceed with a THE in any patient with documented distant (M1) metastatic esophageal cancer. If the patient has undergone a prior esophageal operation (fundoplication, esophagomyotomy, perforation repair), safe transhiatal mobilization of the esophagus may prove to be impossible, and the surgeon must be prepared to convert to an open thoracotomy and transthoracic esophagectomy. Carcinoma of the esophagogastric junction and cardia with gastric invasion may necessitate resection of a major portion of the stomach to achieve an adequate margin and preclude esophageal replacement with stomach. In patients with such tumors, the suitability of the colon as an esophageal substitute should be determined with a preoperative barium enema examination and a colon bowel prep carried out in the event that a colonic interposition is required to reestablish alimentary continuity after resection of the esophagus and stomach. Without question, the most important contraindication to proceeding with a THE is the surgeon's assessment at the time of transhiatal mediastinal exploration that the esophagus is so adherent to adjacent vital structures that a transthoracic mobilization of the esophagus under direct vision is safer.

TABLE 78.1 Indications for Transhiatal Esophagectomy (2,007 Patients)

	Number (%)		
	Group I—1,063 PTS 1976–1998	Group II—944 PTS 1998–2006	Total—2,007 PTS 1976–2006
Benign conditions	**278 (26%)**	**204 (22%)**	**482 (24%)**
Neuromotor dysfunction	92 (33%)	47 (23%)	139 (29%)
Achalasia	69	44	113
Spasm/dysmotility	21	3	24
Scleroderma	2	0	2
Stricture	74 (27%)	21 (10%)	95 (20%)
Gastroesophageal reflux	40	7	47
Caustic ingestion	18	6	24
Radiation	4	2	6
Other	12	6	18
Barrett mucosa with high grade dysplasia	53 (19%)	90 (44%)	143 (30%)
Recurrent gastro-esophageal reflux	21 (8%)	6 (3%)	27 (6%)
Recurrent hiatus hernia	14 (5%)	14 (7%)	28 (6%)
Acute perforation	15 (5%)	9 (5%)	24 (5%)
Acute caustic injury	5 (2%)	1 (1%)	6 (1%)
Other	4 (1%)	16 (8%)	20 (4%)
Carcinoma of the intrathoracic esophagus	785 (74%)	740 (78%)	1,525 (76%)
Site			
Upper third	35 (4%)	16 (2%)	51 (3%)
Middle third	164 (21%)	63 (9%)	227 (15%)
Lower third and/or cardia[a]	586 (75%)	661 (89%)	1,247 (82%)

PTS, patients.
[a]Includes pathologic gastric carcinomas involving the cardia and the lower esophagus.
Reproduced with permission from Orringer MB, Marshall B, Chang AC, et al. Two thousand transhiatal esophagectomies: changing trends, lessons learned. *Ann Surg* 2007;246:363–74.

PATIENT SELECTION AND PREOPERATIVE PREPARATION

The importance of careful nutritional assessment, medical evaluation, and documentation of adequate pulmonary function and cardiac reserve in insuring a successful outcome after THE cannot be overstated. In contrast

to how major operations were undertaken several decades ago, aggressive preoperative preparation of the patient for THE is now the rule and is consistently rewarded by decreased morbidity and mortality. The author is adamant, even in those with carcinoma, that patients completely abstain from cigarette smoking for a minimum of 3 weeks before operation. An incentive inspirometer is issued to the patient at the time of the first consultation, and regular daily pulmonary physiotherapy is instituted before the patient is admitted for esophagectomy. Patients are instructed to walk 3 miles daily when physically able prior to their scheduled operation, and the importance of early postoperative ambulation is emphasized. If esophageal obstruction is severe, a nasogastric feeding tube is inserted, and administration of supplemental tube feedings at home is initiated. A percutaneous gastrostomy is avoided as it creates the later need to close a hole in the stomach and increases the incidence of postoperative wound infection in the nearby THE upper abdominal incision. Patients are typically admitted for their esophagectomy on the day of the scheduled operation. Preoperative intravenous hyperalimentation is virtually never used, as is the case with hospitalization immediately prior to surgery.

SURGICAL TECHNIQUE

THE is performed in four phases: abdominal, cervical, mediastinal, and the anastomosis. Typically, after induction of general endotracheal anesthesia, flexible esophagoscopy is performed to verify the distance of the esophageal pathology from the upper incisor teeth and to verify that there is a sufficient length of normal proximal esophagus to allow construction of a CEGA. After the esophagoscopy, a nasogastric tube is inserted to decompress the stomach and aid in identifying the esophagus during its mobilization in the neck. The head is turned to the right and supported on a soft head ring, and the neck is extended by placing a small rolled sheet beneath the scapulae. The skin of the anterior neck, chest, and abdomen is prepped and draped from the mandibles to the pubis and anterior to both midaxillary lines. Two large bore peripheral intravenous lines and a radial artery catheter for intraoperative monitoring of blood pressure are placed and carefully padded as the arms are placed at the patient’s sides. The author prefers to avoid “bumping up one side” to allow performance of an anterolateral thoracotomy if needed. If it is necessary to convert to a transthoracic esophagectomy, this is best performed through a true posterolateral thoracotomy, and the author prefers to temporarily close the

abdominal wound, cover it with a plastic surgical drape, and turn the patient to his or her side for performance of the transthoracic mobilization. The chest is then closed, and the patient rolled supine once again for completion of the esophageal reconstruction. A table-mounted self-retaining (upper-hand) retractor optimizes exposure of the upper abdomen for a THE.

Abdominal Phase

The peritoneal cavity is entered through an upper midline supraumbilical incision (Fig. 78.1, inset). The triangular ligament of the liver is divided with electrocautery, and the left lobe of the liver is folded downward and retracted to the right with the liver blade of the upper hand retractor. The left abdominal wall is retracted laterally with the standard abdominal wall retractor blade. A planned esophagectomy for cancer is aborted with the findings of peritoneal implants, hepatic metastases, or bulky unresectable celiac adenopathy. On initial exploration of the abdomen, the stomach is assessed immediately for its suitability as an esophageal substitute. If a prior gastrostomy has been performed, this is taken down from the abdominal wall and the gastrostomy site temporarily closed with a figure-eight chromic suture. The greater omentum along the high greater curvature of the stomach is retracted to the left, and a “clear space” between the stomach wall and the omentum is developed. Once the lesser omental space has been entered behind the greater omentum, fingers inserted into this opening and behind the omentum can be used to define the high short gastric and left gastroepiploic vessels entering the stomach in this region. Several of these vessels are progressively defined, clamped with 13-in long right-angled clamps, divided, and secured with 2-0 silk ties. Care should be taken to divide these vessels well away from the gastric wall to avoid ischemic injury, and traction on the stomach should be minimized to avoid gastric trauma.

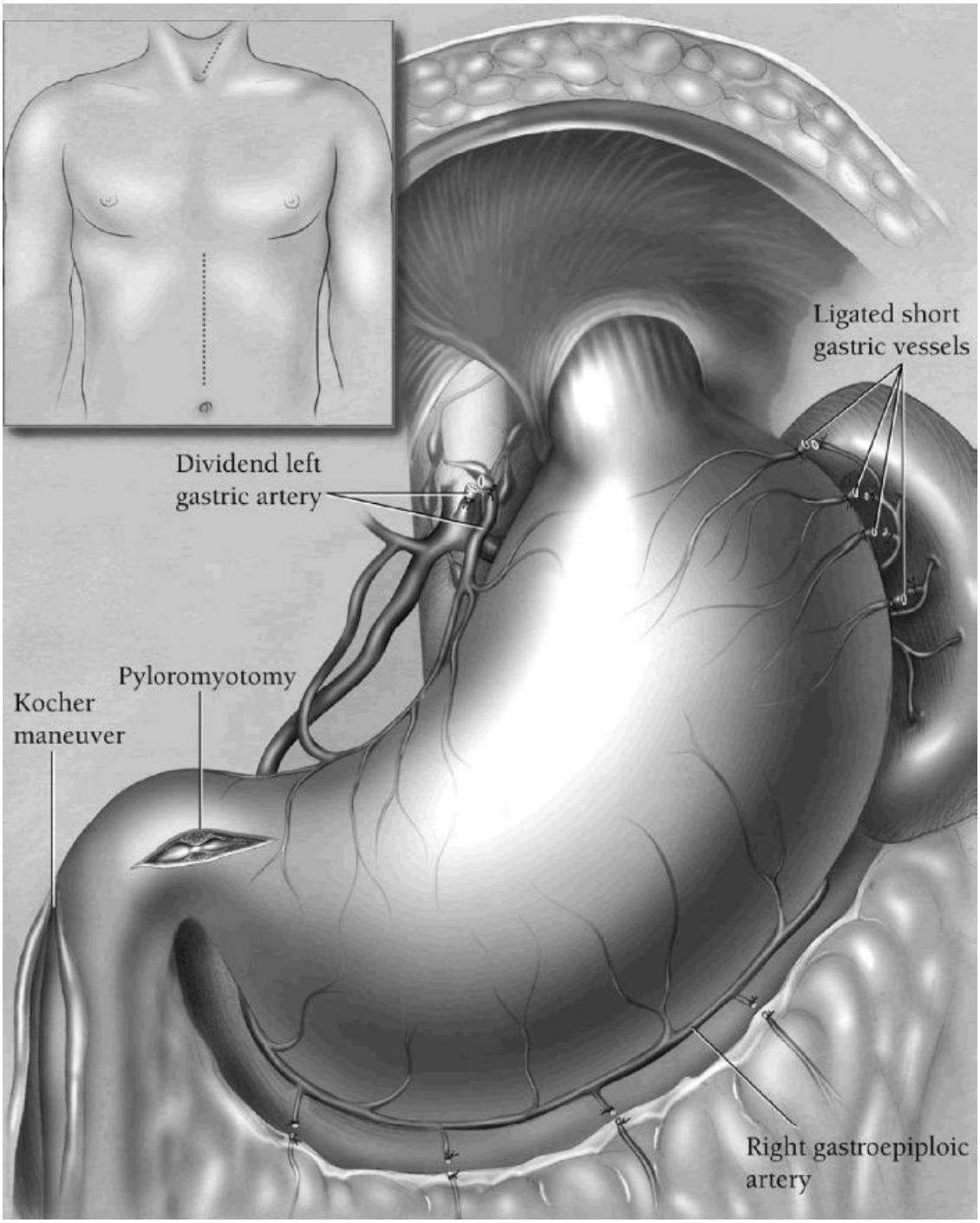

Figure 78.1. Diagram depicting the abdominal and cervical incisions (*inset*) and operative anatomy for the abdominal phase of the procedure. (From Orringer MB. Transhiatal esophagectomy without thoracotomy. *Oper Tech Thorac Cardiovasc Surg* 2005;10:63, with permission.)

Rather than dividing more of the high short gastric vessels at this point, the dissection is carried inferiorly along the greater curvature of the stomach toward the pylorus, dividing each remaining major left

gastroepiploic branch approximately 1.5 to 2 cm away from the greater curvature of the stomach to minimize trauma to the gastric wall. The termination of the right gastroepiploic artery at its communication with the left gastroepiploic artery is identified. From this point inferiorly along the stomach, care is taken to divide the greater omentum 1.5 to 2 cm inferiorly to the right gastroepiploic artery to preserve patency of this vessel, which is the main blood supply of the mobilized stomach when it is used as an esophageal replacement. Once the greater omentum has been separated from the stomach to the level of the pylorus, the remaining attached omentum along the high greater curvature of the stomach is retracted to the left, and the highest short gastric vessels are mobilized, clamped, divided, and ligated. Care is taken to avoid injury to the spleen; gastric necrosis, which results from ligating the gastroepiploic vessels too near the stomach wall; and contusion of the high greater curvature from excessive traction and retraction of the stomach. When the entire greater curvature of the stomach is freed from its adjacent omentum, adhesions between the stomach and the retroperitoneum are carefully divided with electrocautery to ensure complete gastric mobility.

The peritoneum overlying the esophageal hiatus is incised, and the esophagogastric junction is encircled with a 1-in rubber drain. Attention is then turned to the lesser curvature of the stomach. One hand is placed behind the stomach from the greater curvature side until the fingers can be seen through the filmy gastrohepatic omentum along the lesser curvature of the stomach. The gastrohepatic omentum is incised and divided superiorly to the level of the diaphragmatic hiatus with electrocautery. As the gastrohepatic omentum is being divided, it is carefully palpated for an aberrant left hepatic artery arising from the left gastric artery. If the vessel is present, it is preserved. Retraction of the midstomach to the left tenses the soft tissues along the high lesser curvature. The left gastric vein is identified, mobilized, clamped between long right-angled clamps, divided, and ligated with 2-0 silk ties. The adjacent left gastric artery is identified at its origin from the celiac axis. The vessel is doubly ligated toward the celiac artery, clamped, and divided reflecting adjacent lymph nodes to the left with the stomach. The remaining soft tissue adjacent to the lesser curvature of the stomach is progressively divided with electrocautery moving toward the diaphragmatic hiatus so that the soft tissue margin is maximized. With mobilization of the high lesser curvature and entire greater curvature of the stomach now completed, attention is redirected to

the diaphragmatic hiatus.

The phrenoesophageal attachments and adjacent soft tissue are mobilized away from the diaphragmatic hiatus and toward the distal esophagus and esophagogastric junction with electrocautery, and the lower mediastinum is entered. It may be necessary to resect an adjacent rim of the diaphragmatic hiatus if tumor is adherent to the muscle at this point. Insertion of a narrow “heart” Deaver retractor into the hiatus anteriorly and upward traction on it exposes the distal esophagus within the posterior mediastinum and allows mobilization of the soft tissue on either side toward the esophagus. This dissection is typically carried out well into the lower mediastinum using a combination of alternating lateral retraction of the esophagus to tense the contralateral soft tissue, elevation of the tissue with a long right-angled clamp, and division with a long needle-tipped electrocautery. As the esophagus is being progressively mobilized from the low mediastinum, attention should be paid to the pleura on either side, as entry into either pleural cavity warrants later placement of a chest tube. During its mobilization, the esophagus is grasped and “rocked” from side to side to verify that it is not excessively fixed to the adjacent spine, prevertebral fascia, or aorta. In this fashion, mobilization of the distal esophagus and its adjacent periesophageal soft tissue is achieved to the level of the carina. As the dissection is performed, the radial artery blood pressure should be watched carefully to avoid prolonged hypotension resulting from cardiac displacement. Once the distal 10 cm of esophagus has been completely freed from the mediastinum, an abdominal pack is inserted through the diaphragmatic hiatus into the low mediastinum to facilitate hemostasis.

A generous Kocher maneuver is performed until there is sufficient mobilization to allow the pylorus to be elevated from its usual location in the right upper quadrant of the abdomen to a point aligned with the xiphoid process. Two pyloric traction sutures of 3-0 silk are then placed, one on the superior and one on the inferior aspect of the pylorus, and are used to elevate the pylorus into the field in preparation for a pyloromyotomy. Beginning 1.5 to 2 cm on the gastric side of the pylorus, the gastric muscle is elevated from the underlying submucosa with a fine-tipped right-angled clamp and divided with a needle-tipped electrocautery. The muscle incision is carried directly across the pylorus and 0.5 to 1 cm onto the duodenum, exposing the characteristic fine venous plexus that characterizes duodenal submucosa. Inadvertent entry into the

pyloroduodenal mucosa is managed by closing the hole with several interrupted 5-0 polypropylene sutures; the pyloromyotomy is not converted to a pyloroplasty. A pyloromyotomy is preferred over a pyloroplasty because it avoids a suture line at right angles to the vertical axis of the stomach, which will be pulled upward toward the neck. Hemostatic metallic clips are placed on both traction sutures near the pylorus prior to cutting them to allow future identification of the level of the pylorus at subsequent radiographic follow-up.

A 14 French rubber jejunostomy feeding tube is inserted 15 to 20 cm distal to the ligament of Treitz and secured in place with a Weitzel maneuver. The jejunostomy tube is not yet brought through the abdominal wall but rather emerges from the inferior end of the abdominal incision and is clamped with a hemostat and covered with a towel, which is clamped on either side to the drapes to minimize the chance of dislodging the feeding tube during the subsequent dissection. With gastric mobilization, dissection of the distal esophagus from the inferior mediastinum, the Kocher maneuver, pyloromyotomy, and feeding jejunostomy completed (Fig. 78.1), the abdominal phase of the operation ends, and attention is turned to the neck.

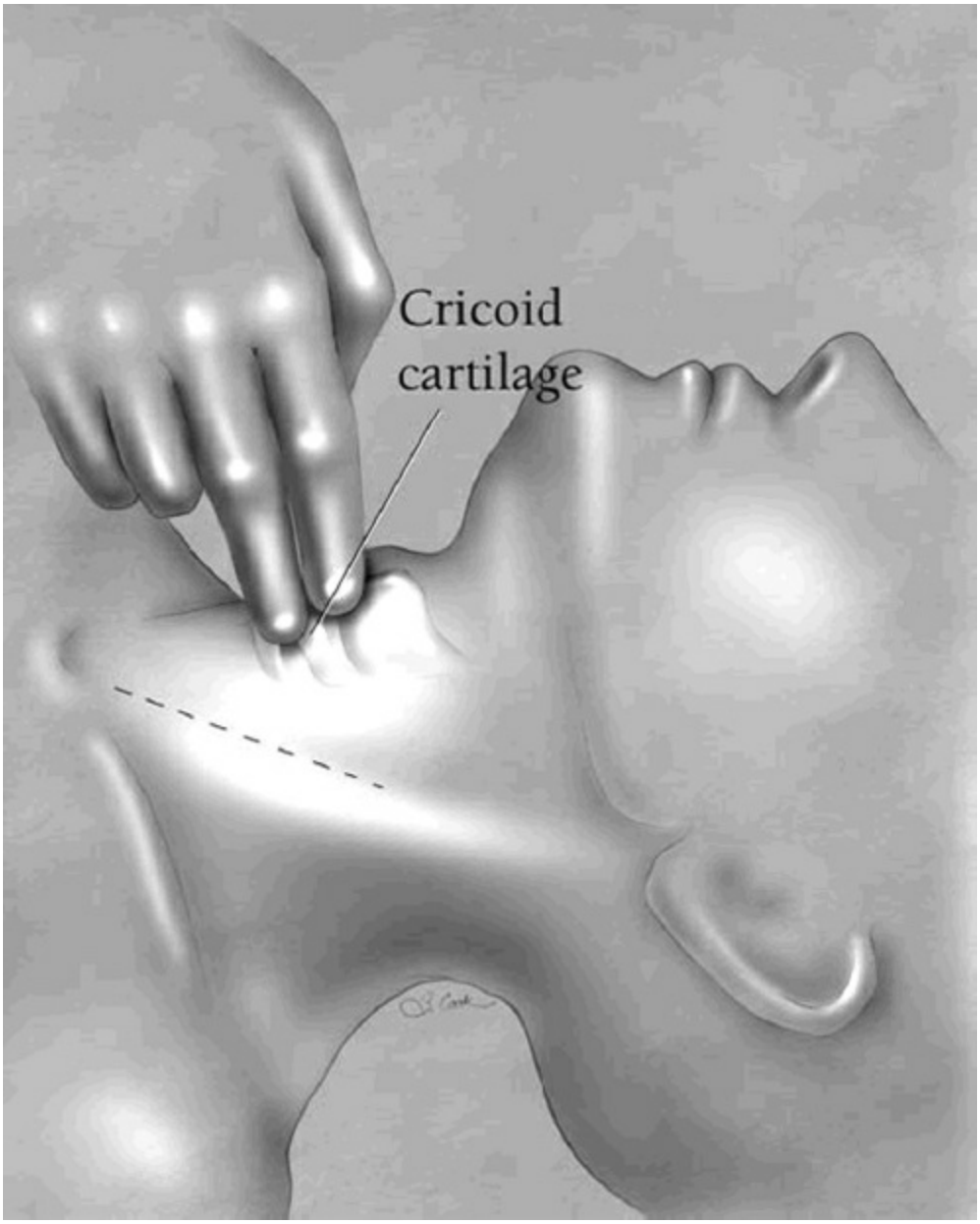

Figure 78.2. A 5- to 7-cm oblique incision paralleling the anterior border of the left sternocleidomastoid muscle is made and extended no >2 to 3 cm superior to the cricoid cartilage. (From Orringer MB. Transhiatal esophagectomy without thoracotomy. *Oper Tech Thorac Cardiovasc Surg* 2005;10:63, with permission.)

Cervical Phase

During the cervical phase of the operation, it is preferable that the surgeon stand on the left side of the operating table. The cricoid cartilage is palpated to identify the level of the cricopharyngeus sphincter. A 5- to 7-cm oblique incision paralleling the anterior border of the left sternocleidomastoid muscle is made and extended no more than 2 to 3 cm

superior to the cricoid cartilage (Fig. 78.2). The incision is carried through the underlying platysma muscle, and the fascia along the anterior edge of the sternocleidomastoid muscle is incised in the direction of the wound. Blunt finger retraction is used to separate the sternocleidomastoid muscle from the underlying cervical fascia medial to it. Retraction of the sternocleidomastoid muscle laterally allows identification of the underlying omohyoid muscle, the central tendon of which is elevated with a right-angled clamp and divided (Fig. 78.3). Elevation of the medial belly of the divided omohyoid muscle tenses the contiguous omohyoid fascia layer, which is incised in the direction of the wound superiorly and inferiorly. The omohyoid fascia layer leads to the carotid sheath and its contents, which are gently retracted laterally. The larynx and the trachea are simultaneously retracted medially by the assistant's index finger (Fig. 78.4). No metal retractor is placed against the tracheoesophageal groove during any portion of the operation to minimize the risk of recurrent laryngeal nerve (RLN) injury. As the interior jugular vein is retracted laterally, the middle thyroid vein is often identified and should be mobilized, clamped at either end with fine right-angled clamps, divided, and ligated. Using the cricoid cartilage as a landmark, the inferior thyroid artery is identified at the same level at the depths of the cervical wound. The artery is clamped with fine right-angled clamps, divided, and ligated. The deep cervical fascia overlying the prevertebral fascia is now incised over the length of the cervical incision. The prevertebral fascia is palpated at the depths of the wound, and the superior mediastinum is entered by blunt finger dissection along the prevertebral fascia. As the trachea is retracted medially, the left anterior cervical strap muscles are tensed, elevated with a right-angled clamp near the left clavicle, and divided with electrocautery, thereby facilitating exposure of the esophagus at the thoracic inlet.

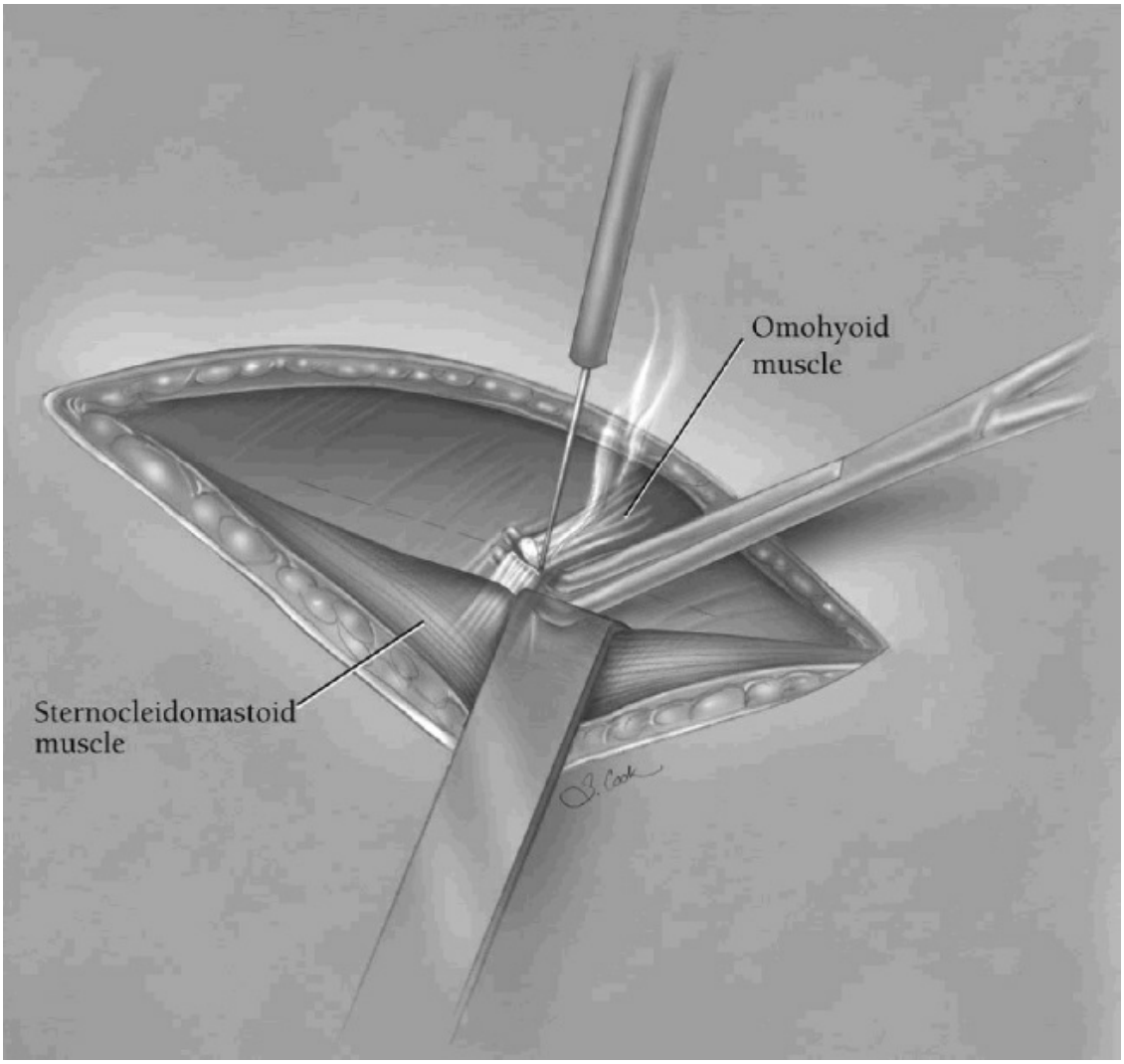

Figure 78.3. Retraction of the sternocleidomastoid muscle laterally allows identification of the underlying omohyoid muscle, the central tendon of which is elevated with a right-angled clamp and divided. (From Orringer MB. Transhiatal esophagectomy without thoracotomy. *Oper Tech Thorac Cardiovasc Surg* 2005;10:63, with permission.)

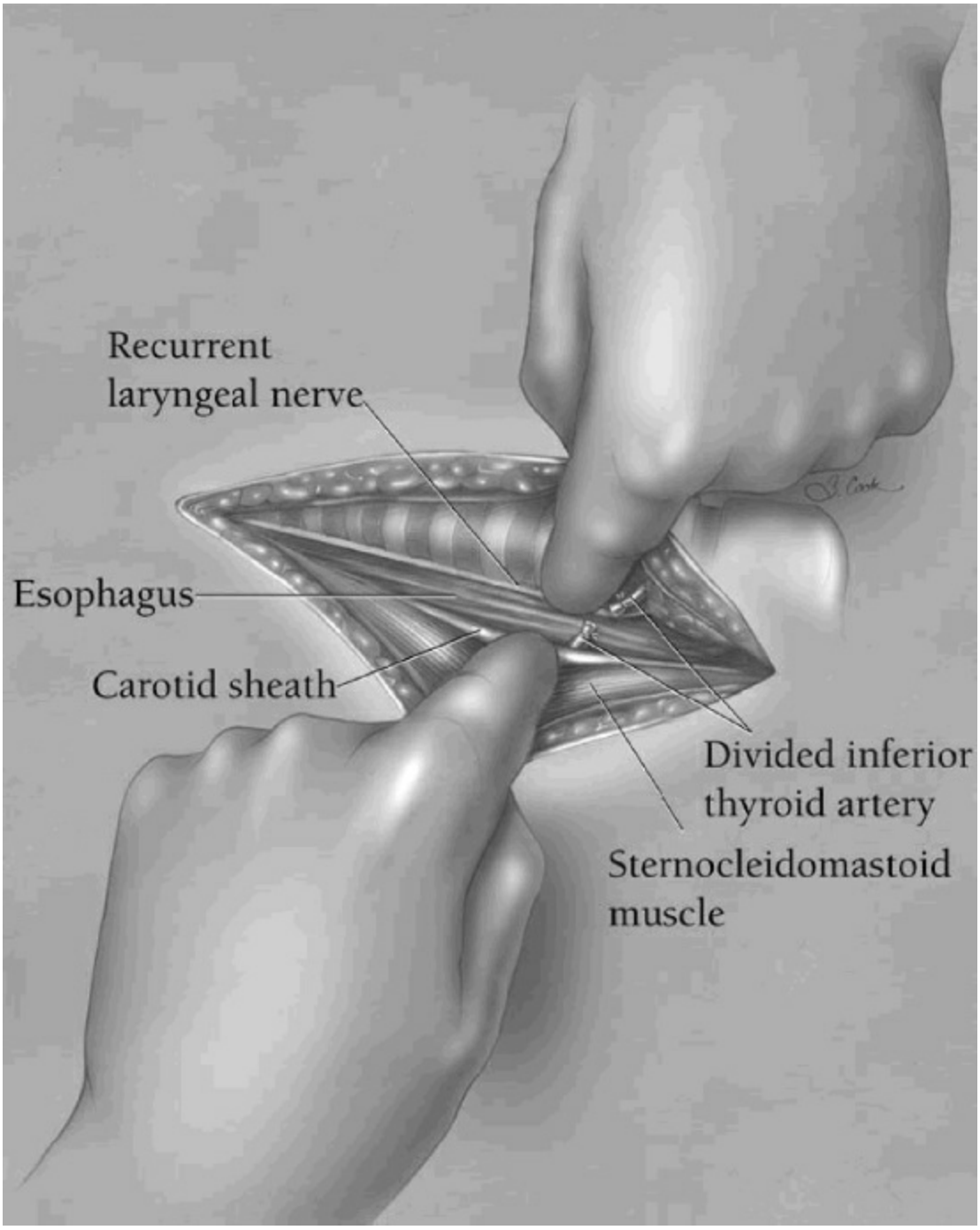

Figure 78.4. The larynx and the trachea are simultaneously retracted medially by the assistant's index finger, and the sternocleidomastoid muscle and carotid sheath laterally. (From Orringer MB. Transhiatal esophagectomy without thoracotomy. *Oper Tech Thorac Cardiovasc Surg* 2005;10:63, with permission.)

The first assistant elevates the esophagus out of the superior mediastinum by applying gentle upward traction on the tracheoesophageal groove at the level of the cricoid cartilage (Fig. 78.5). This maneuver

provides a greater length of cervical esophagus in the wound for subsequent mobilization. The tracheoesophageal groove is developed by sharp dissection posterolateral to the RLN, but no active attempt is made to visualize the nerve. The anterior wall of the esophagus is gently mobilized along the length of the incision. By careful blunt dissection, the surgeon's index finger proceeds medially anterior to the esophagus, which is retracted laterally until the index finger can palpate the medial edge of the esophagus and the prevertebral fascia behind it.

While maintaining upward traction on the tracheoesophageal groove and keeping the left index finger medial to the esophagus and against the prevertebral fascia immediately behind it, a long right-angled clamp is passed posteriorly along the lateral aspect of the esophagus until its tip can be felt by the index finger medially. Once this circumferential mobilization of the esophagus is completed, the esophagus is encircled with a 1-in rubber drain (Fig. 78.6). By retracting the rubber drain superiorly, the cervicothoracic esophagus is elevated to the surface of the wound. As the esophagus is elevated, blunt dissection of the esophagus from the superior mediastinum is carried out while keeping the volar aspects of the fingers closely applied to the esophagus (Fig. 78.7). With the cervical esophagus encircled and several centimeters of the upper thoracic esophagus bluntly mobilized within the superior mediastinum, the cervical dissection is completed.

Mediastinal (Transhiatal) Dissection

With gentle downward traction on the 1-in rubber drain encircling the esophagogastric junction and avoiding trauma to the upper stomach, the opposite hand is passed into the posterior mediastinum along the prevertebral fascia posterior to the esophagus (Fig. 78.7). Resectability of the esophagus and its contained tumor, if present, is continually assessed by "rocking" the esophagus to be certain that it is not fixed to adjacent tissues.

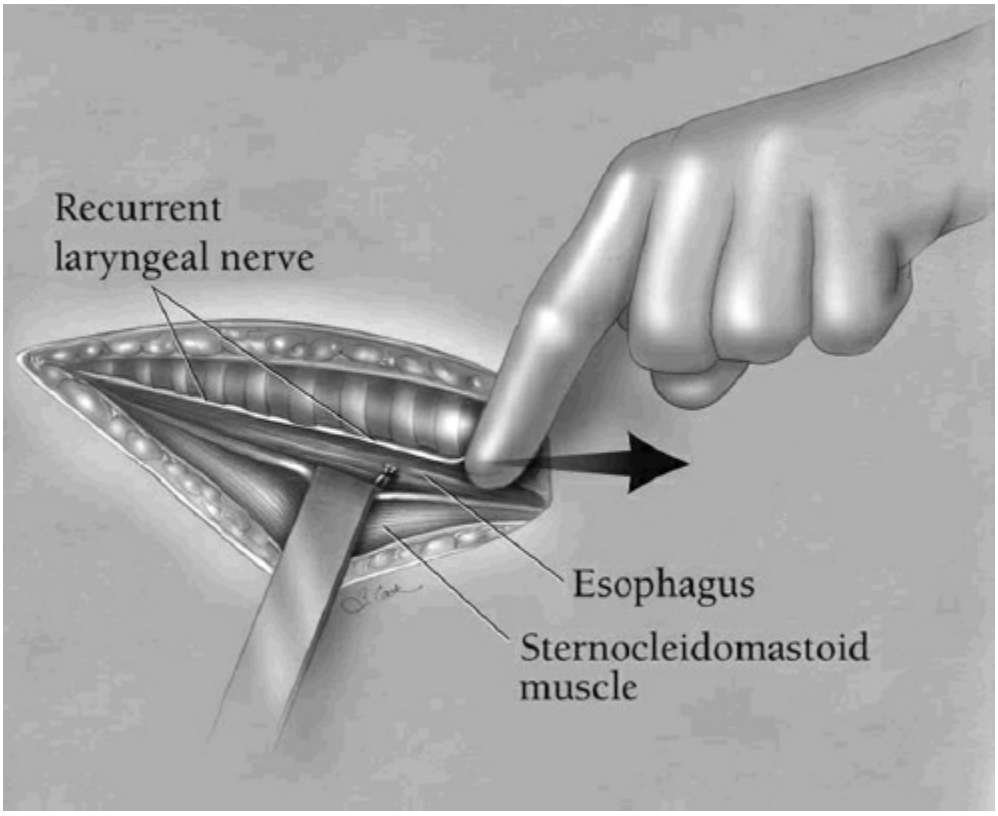

Figure 78.5. Elevation of the esophagus out of the superior mediastinum by applying gentle upward traction on the tracheoesophageal groove at the level of the cricoid cartilage. (From Orringer MB. Transhiatal esophagectomy without thoracotomy. *Oper Tech Thorac Cardiovasc Surg* 2005;10:63, with permission.)

With the rubber drain encircling the cervical esophagus retracted anteriorly and toward the patient's right, a "half-sponge on a stick" is inserted through the cervical incision behind the esophagus and is advanced downward through the superior mediastinum along the prevertebral fascia (Fig. 78.8). Eventually, the sponge can be felt by the fingers inserted through the diaphragmatic hiatus from below. Any remaining posterior esophageal prevertebral soft tissue is disrupted by the sponge-on-a-stick pushed against the fingers inserted from below through the diaphragmatic hiatus. During this portion of the operation and all subsequent phases of the mediastinal dissection, the hand inserted through the diaphragmatic hiatus and into the mediastinum must be constantly kept posteriorly against the prevertebral fascia to avoid creating pressure against the heart anteriorly and resulting hypotension from the cardiac displacement. The radial artery blood pressure is continually monitored during this transhiatal mobilization of the esophagus so that prolonged

hypotension is avoided. Once this posterior mobilization of the esophagus has been completed, a 28 French Argyll Saratoga sump catheter is inserted through the cervical incision and advanced downward into the mediastinum to assist in clearing blood from the posterior mediastinum.

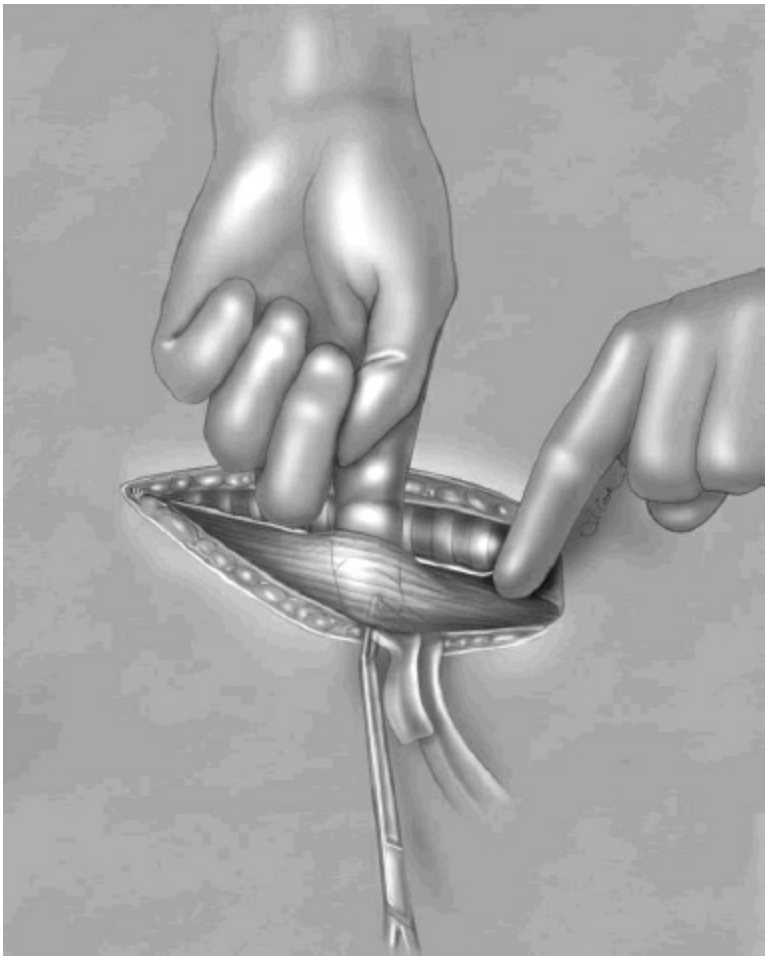

Figure 78.6. A long right-angled clamp is passed posteriorly along the lateral aspect of the esophagus until its tip can be felt by the index finger medially. There is no contact between the clamp and the tracheoesophageal groove to prevent recurrent laryngeal nerve injury. When the circumferential mobilization of the esophagus is complete, the esophagus is encircled with a 1-in rubber drain. (From Orringer MB. Transhiatal esophagectomy without thoracotomy. *Oper Tech Thorac Cardiovasc Surg* 2005;10:63, with permission.)

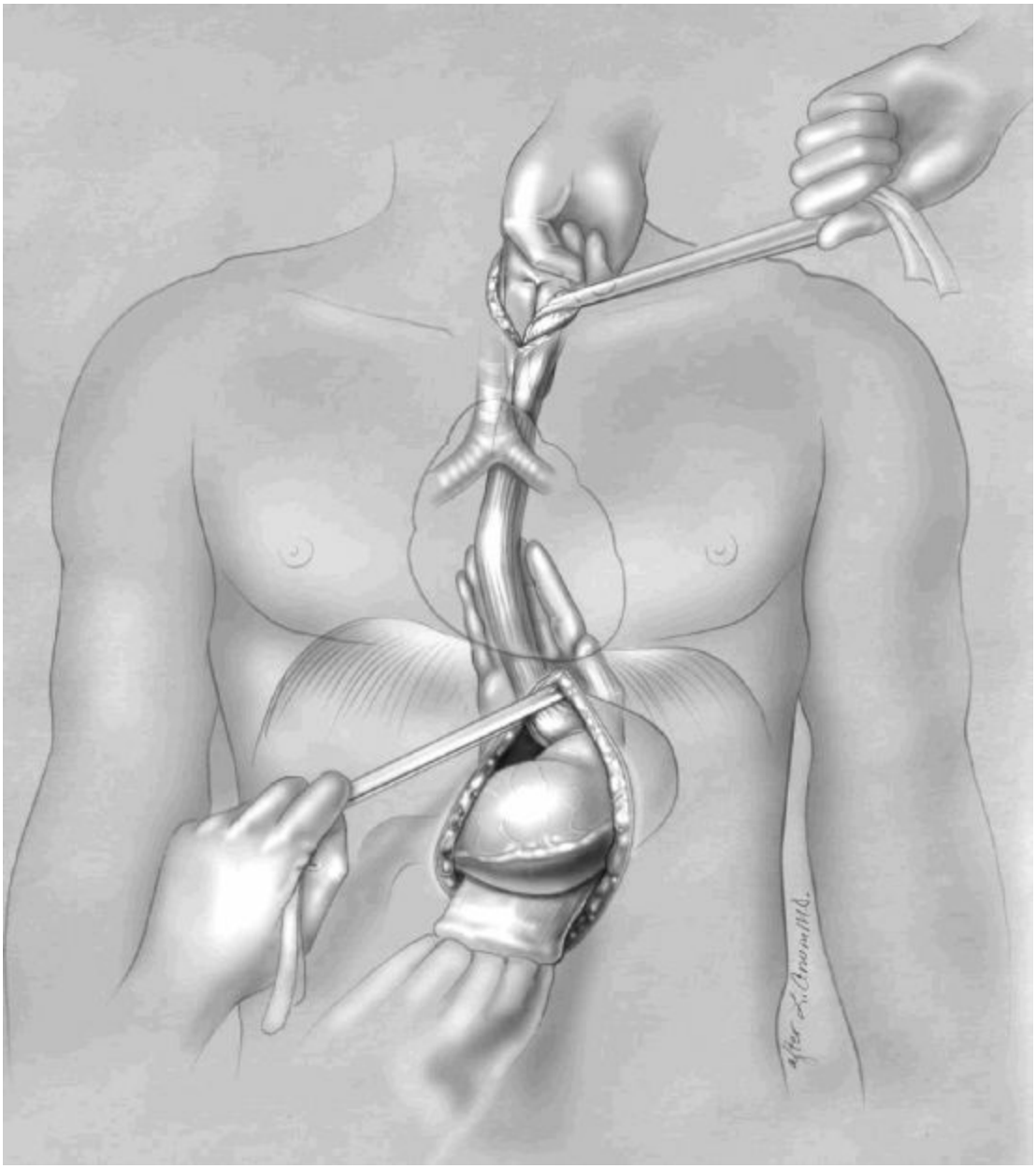

Figure 78.7. As the esophagus is elevated, blunt dissection from the superior mediastinum is carried out while keeping the volar aspects of the fingers closely applied to the esophagus. (From Orringer MB. Transhiatal esophagectomy without thoracotomy. *Oper Tech Thorac Cardiovasc Surg* 2005;10:63, with permission.)

After completion of the posterior dissection of the esophagus, the anterior dissection is begun. As the rubber drain encircling the esophagogastric junction is retracted inferiorly, the surgeon's hand is inserted palm downward against the anterior surface of the esophagus and is slowly advanced upward into the mediastinum (Fig. 78.9). Similarly, the rubber drain encircling the cervical esophagus is retracted superiorly and

toward the patient's left shoulder as two fingers are inserted along the anterior wall of the esophagus and advanced downward into the superior mediastinum toward the fingers being advanced upward from below. Care is needed to avoid injury to the pericardium as the fingers inserted through the hiatus are advanced upward into the posterior mediastinum, or a tear of the posterior membranous trachea as the fingers inserted through the cervical incision sweep the esophagus away from the trachea anterior to it (Fig. 78.10).

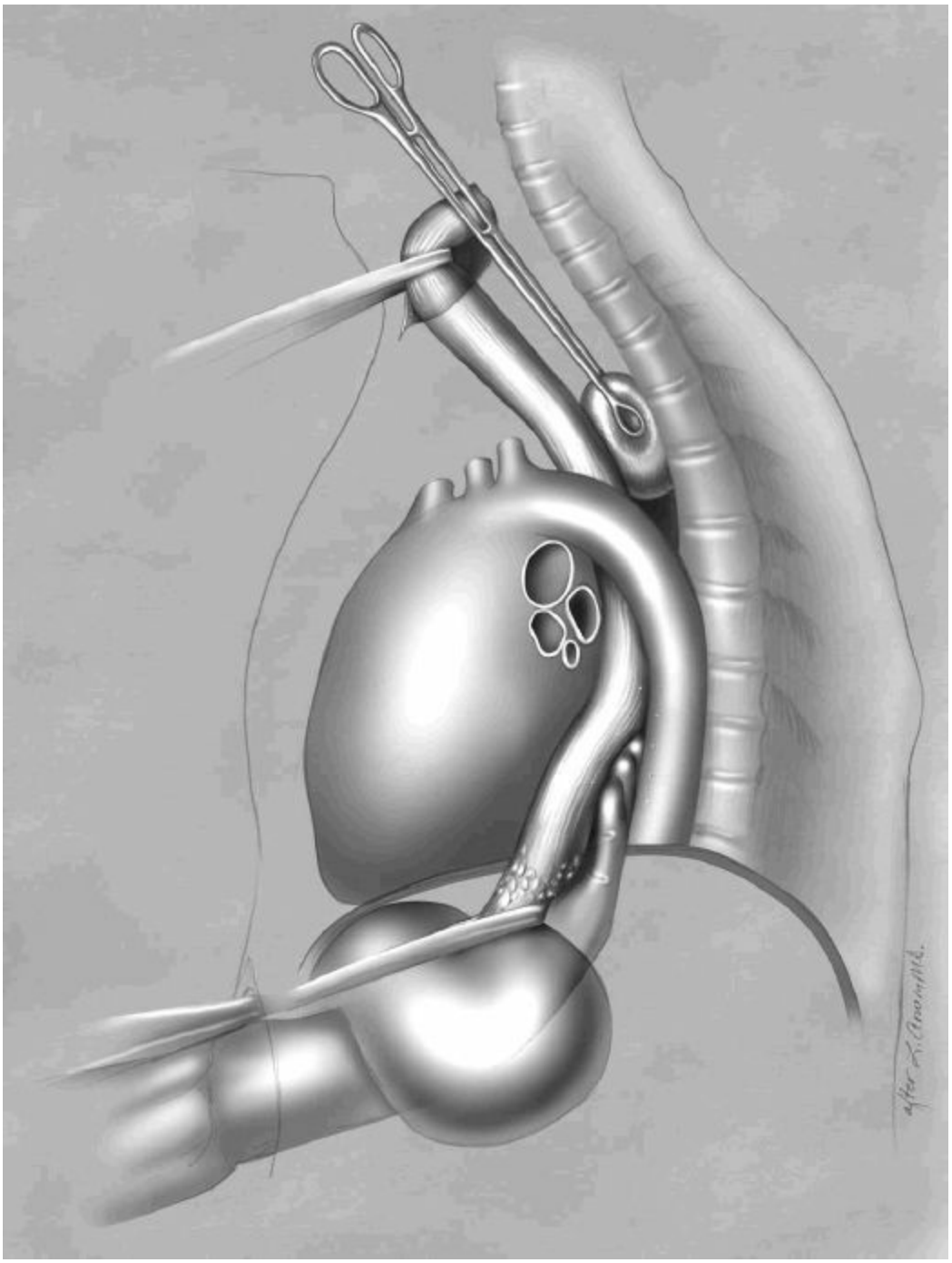

Figure 78.8. A “half-sponge on a stick” is inserted through the cervical incision behind the esophagus and is advanced downward through the superior mediastinum along the prevertebral fascia. (From Orringer MB. Transhiatal esophagectomy without thoracotomy. *Oper Tech Thorac Cardiovasc Surg* 2005;10:63, with permission.)

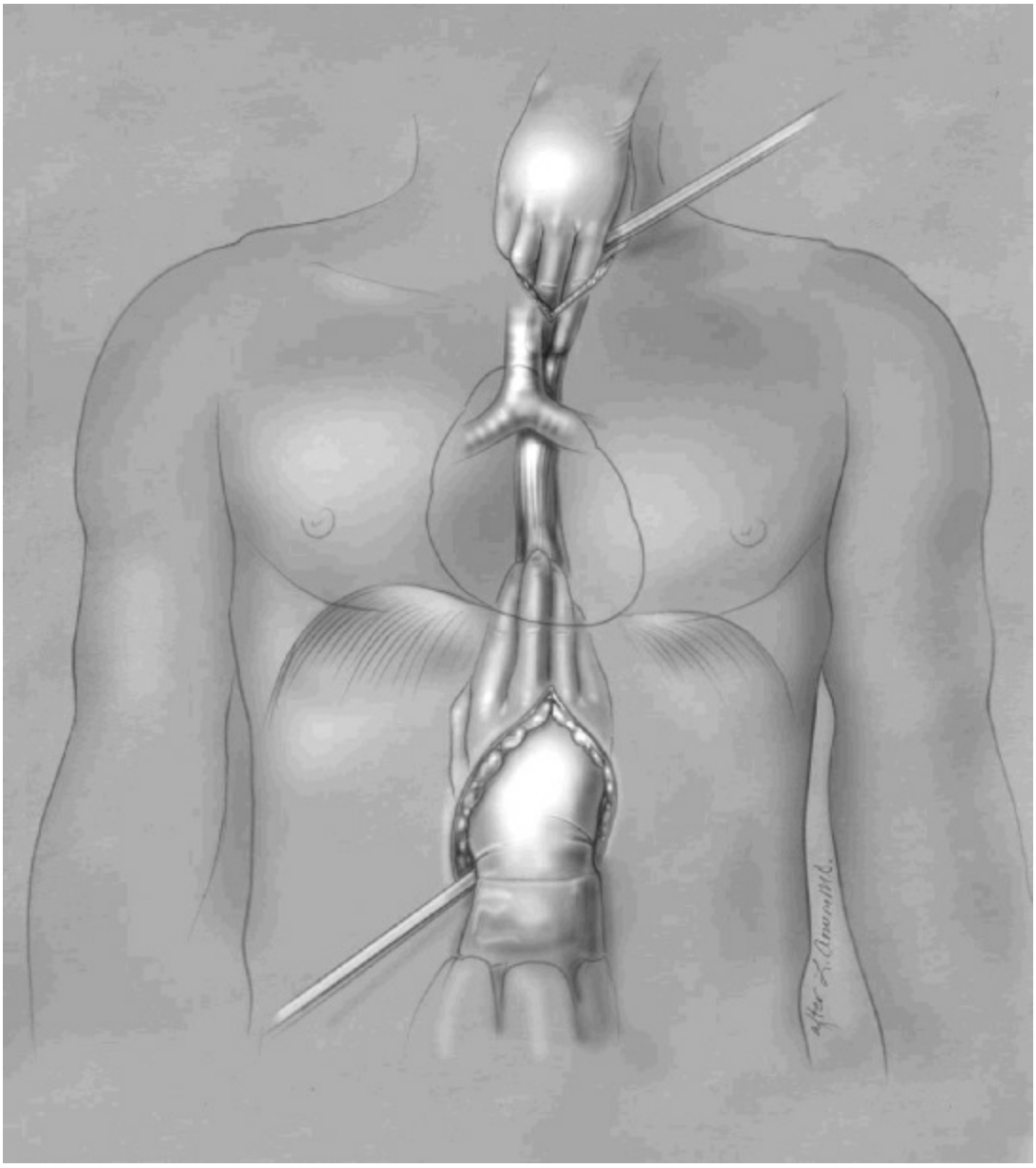

Figure 78.9. As the rubber drain encircling the esophagogastric junction is retracted inferiorly, the surgeon’s hand is inserted palm downward against the anterior surface of the esophagus and is slowly advanced upward into the mediastinum. (From Orringer MB. Transhiatal esophagectomy without thoracotomy. *Oper Tech Thorac Cardiovasc Surg* 2005;10:63, with permission.)

After completion of both the anterior and posterior esophageal dissections, the cervical esophagus is elevated farther out of the superior mediastinum by the surgeon's left index finger "hooked" around it, as lateral esophageal attachments are progressively swept away from the esophagus by the index finger of the right hand, which is progressively advanced downward into the superior mediastinum. This results in complete circumferential mobilization of a 5- to 8-cm length of the upper thoracic esophagus (Fig. 78.11).

One hand is now inserted through the diaphragmatic hiatus and is advanced along the anterior esophageal wall toward the mobilized upper thoracic esophagus (Fig. 78.12). The upper thoracic esophagus is "trapped" against the prevertebral fascia between the index and middle fingers, and with a downward raking motion of the hand, filmy periesophageal attachments and fine vagal branches are avulsed (Fig. 78.13). Larger and more firm vagal nerve branches are encountered below the level of the pulmonary hila, and these are either fractured by firm compression between the thumb and the index finger or delivered downward toward the diaphragmatic hiatus where they can be visualized, elevated with long right-angled clamps, and divided (Fig. 78.13, inset).

After mobilization of the entire intrathoracic esophagus has been completed, 2 to 3 in of the esophagus is elevated out of the mediastinum and into the cervical wound. The previously placed nasogastric tube is pulled back until it is above the level of the upper esophageal sphincter, and using a GIA surgical stapler, the esophagus is divided obliquely from front to back (not transversely), leaving the anterior tip slightly longer than the posterior (Fig. 78.14). Unless the existing esophageal pathology precludes it (e.g., long segment Barrett mucosa with the squamocolumnar junction in the midesophagus, midesophageal carcinoma, etc.), the cervical esophagus divided intentionally 3 to 4 cm longer than is estimated will be required for construction of the anastomosis. If for any reason there is difficulty getting the gastric fundus to reach to the neck, the "extra" esophageal length may prove to be extremely valuable in performing the anastomosis without tension. If the esophagectomy is being performed for benign disease of the distal esophagus, the upper esophagus is divided in the neck at approximately the junction of the upper and middle thirds. If the cephalad reach of the gastric fundus into the neck wound is not adequate, a partial upper sternotomy can be carried out, and the additional length of upper esophagus used for construction of the anastomosis within

the thoracic inlet.

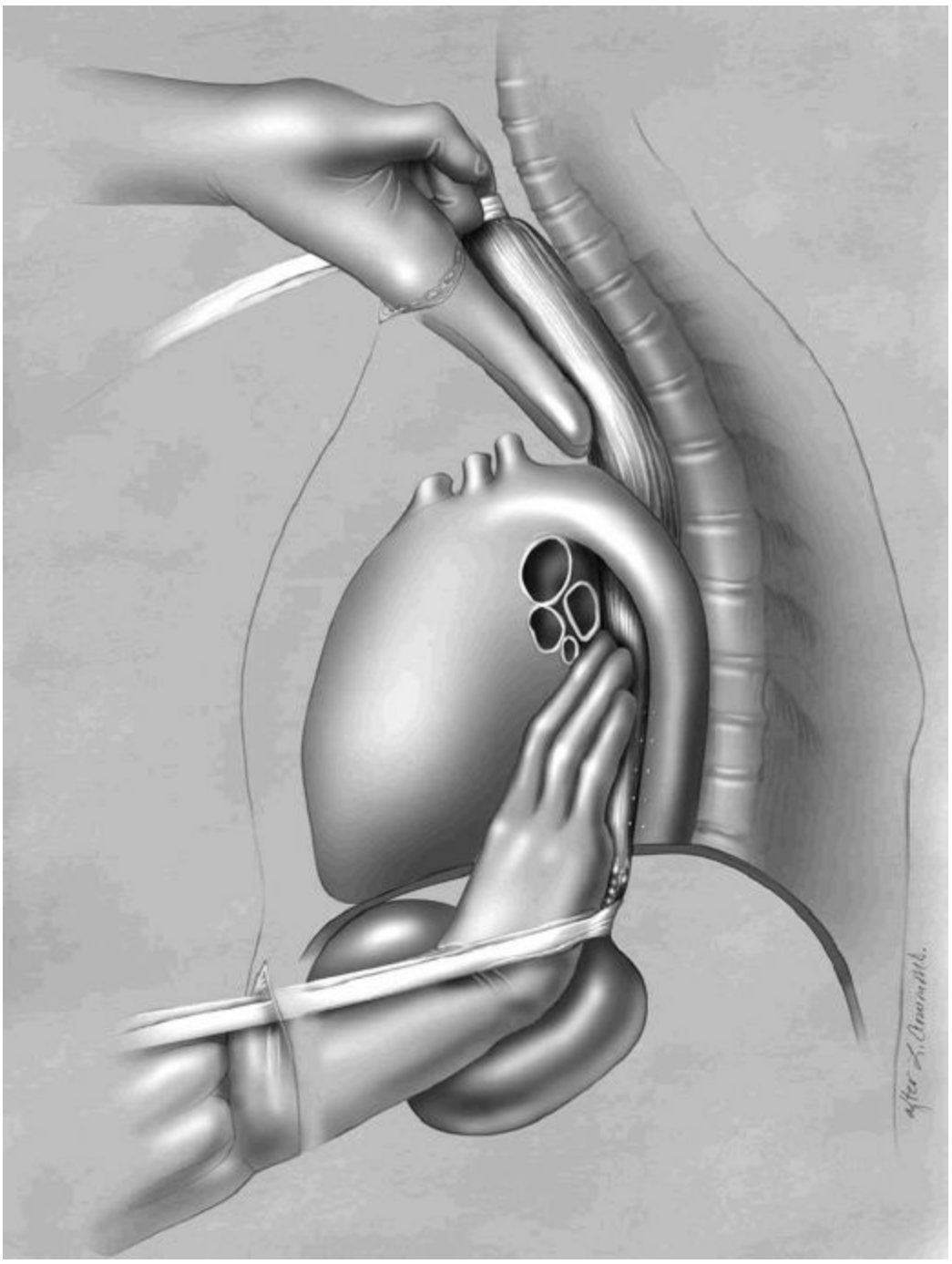

Figure 78.10. The fingers inserted through the hiatus are advanced upward into the posterior mediastinum, and the fingers inserted through the cervical incision sweep the esophagus away from the trachea anterior to it. (From Orringer MB. Transhiatal esophagectomy without thoracotomy. *Oper Tech Thorac Cardiovasc Surg* 2005;10:63, with permission.)

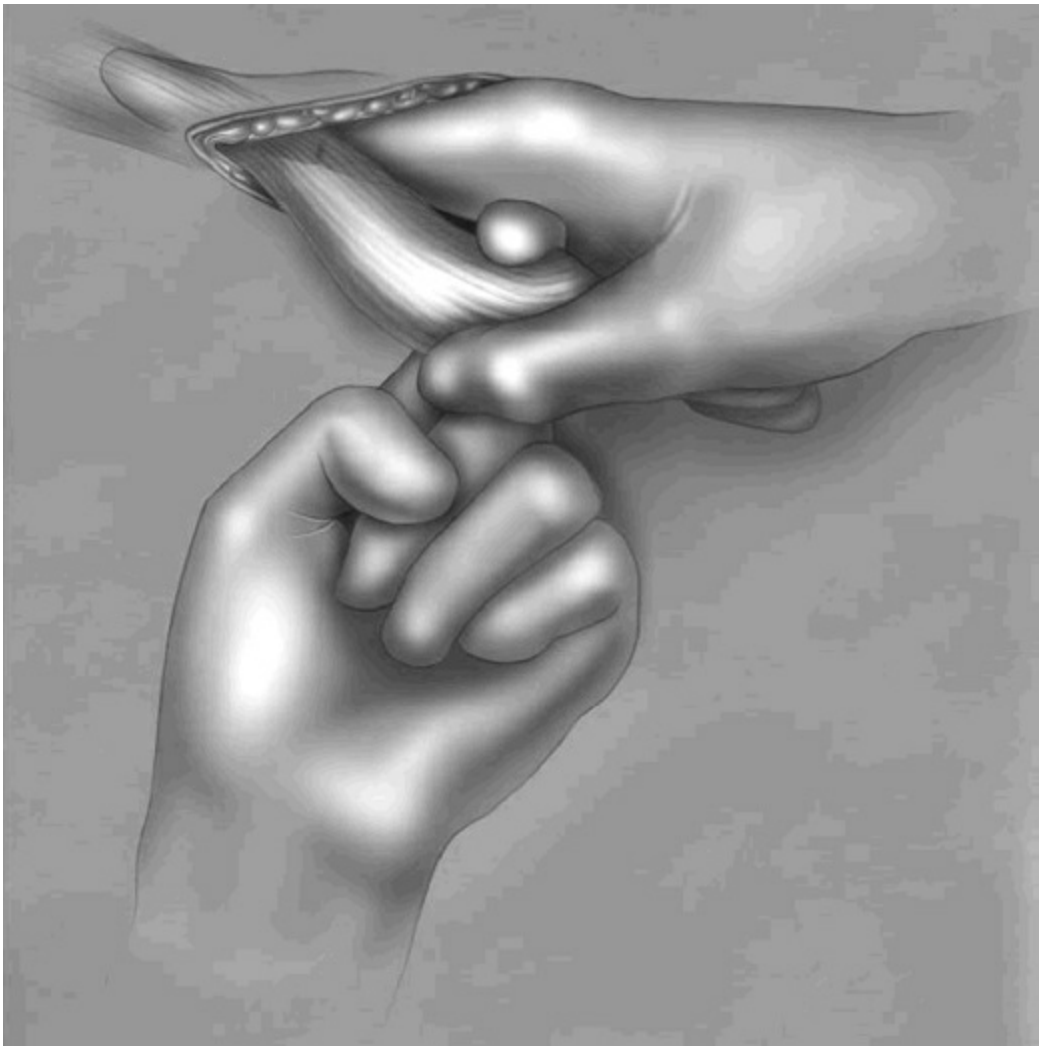

Figure 78.11. The cervical esophagus is elevated farther out of the superior mediastinum by the surgeon's left index finger "hooked" around it, as lateral esophageal attachments are progressively swept away from the esophagus by the index finger of the right hand, which is gradually advanced downward into the superior mediastinum. (From Orringer MB. Transhiatal esophagectomy without thoracotomy. *Oper Tech Thorac Cardiovasc Surg* 2005;10:63, with permission.)

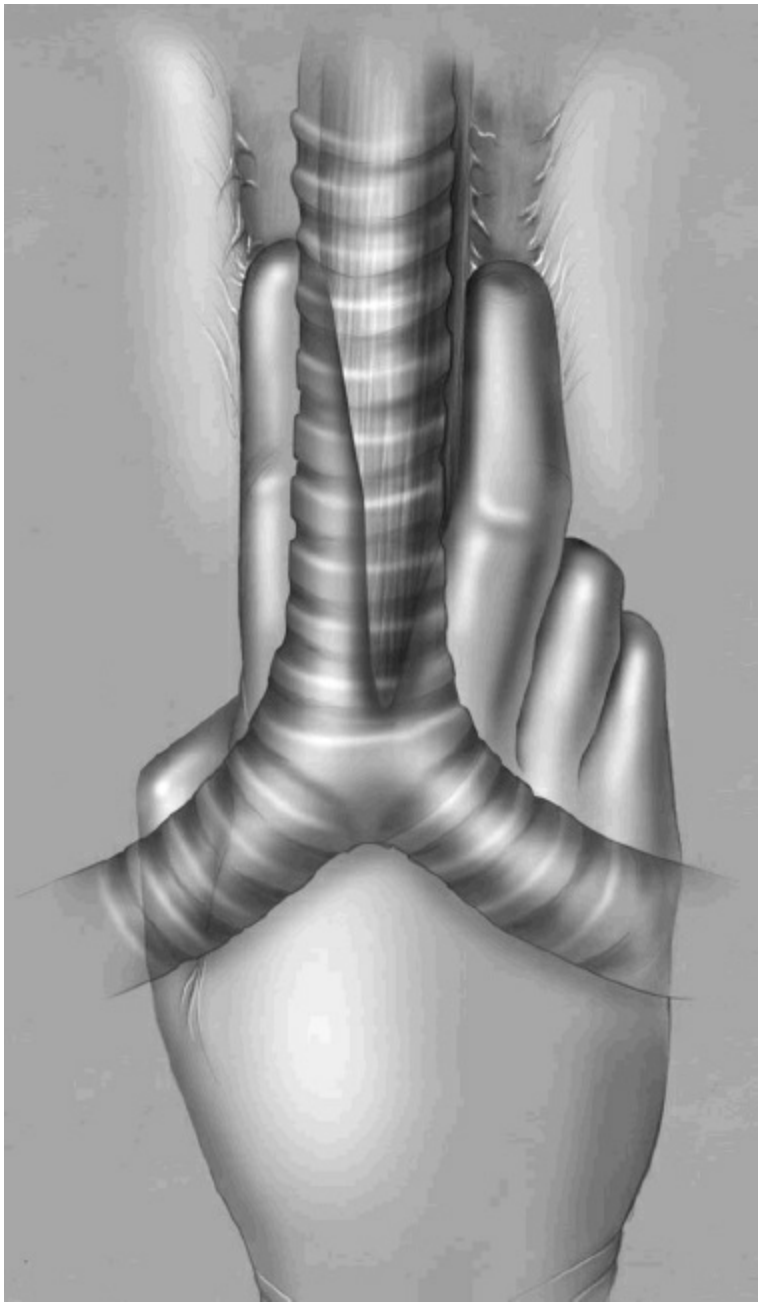

Figure 78.12. One hand is now inserted palm downward through the diaphragmatic hiatus and is advanced along the anterior esophageal wall toward the mobilized upper thoracic esophagus. (From Orringer MB. Transhiatal esophagectomy without thoracotomy. *Oper Tech Thorac Cardiovasc Surg* 2005;10:63, with permission.)

After division of the esophagus in the cervical wound, the stomach is grasped within the abdomen and delivered out of the abdominal wound as the attached thoracic esophagus is brought downward from the posterior mediastinum. With the entire thoracic esophagus now freely in the field, time should not be spent examining the esophageal pathology. Rather, a 28

French Argyll Saratoga sump catheter should be inserted through the cervical incision and into the posterior mediastinum to evacuate blood, as a long narrow Deaver retractor placed into the diaphragmatic hiatus facilitates inspection of the posterior mediastinum for (1) untoward bleeding and (2) entry into either chest as indicated by violation of the mediastinal pleura and visibility of the lung. If either pleural cavity has been entered, a 28 French chest tube is placed below the inframammary crease in the appropriate anterior axillary line, advanced to the apex of the chest, secured to the skin, and connected to underwater seal drainage. When a chest tube is needed, the blades of the upper hand retractor should be temporarily removed during chest tube insertion, as the entry site of the chest tube is distorted by the retraction.

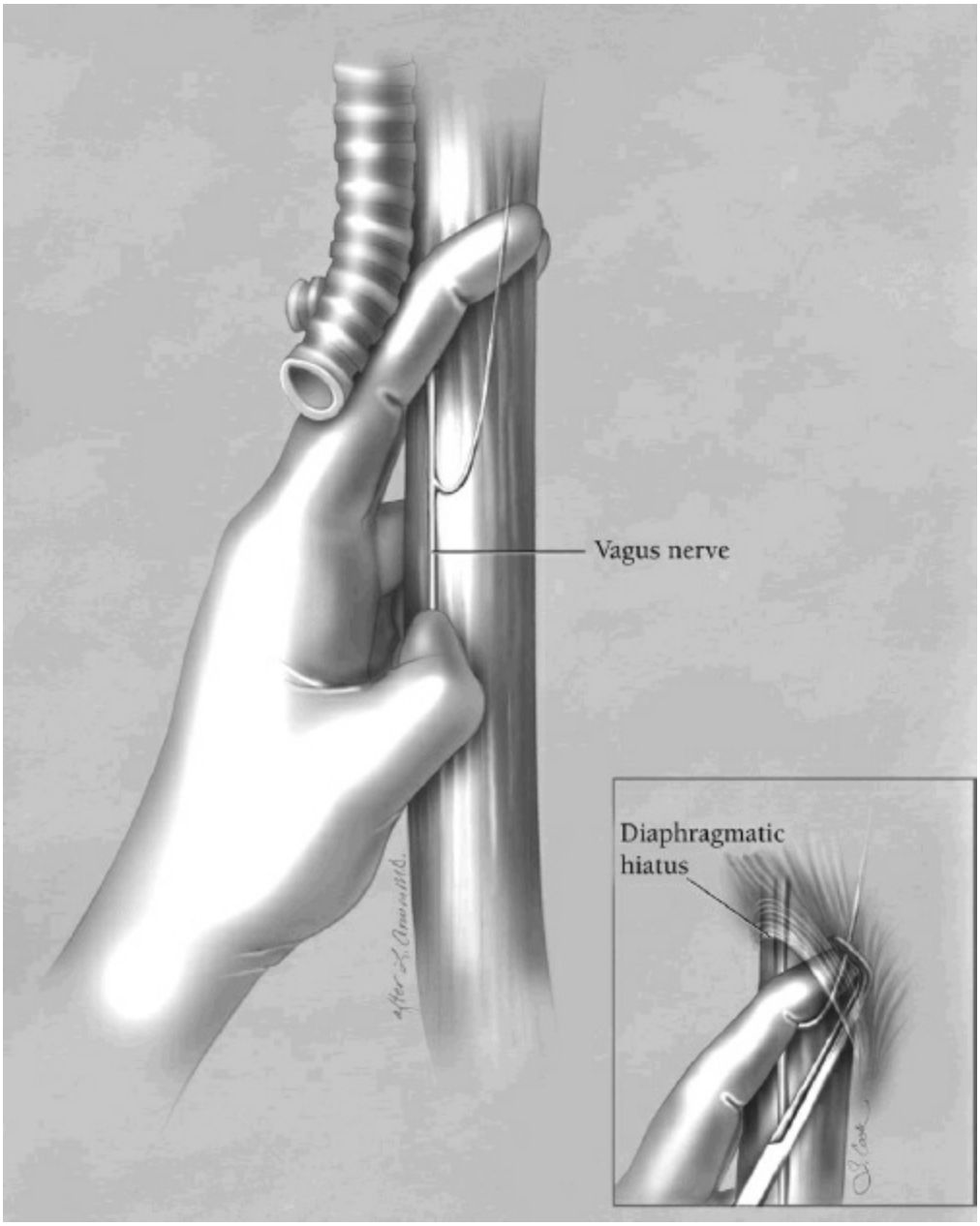

Figure 78.13. The upper thoracic esophagus is “trapped” against the prevertebral fascia between the index and middle fingers, and with a downward raking motion of the hand, filmy periesophageal attachments and fine vagal branches are avulsed. Larger and more firm vagal nerve branches are encountered below the level of the pulmonary hila, and these are either fractured by firm compression between the thumb and the index finger or delivered downward toward the diaphragmatic hiatus where they can be visualized, clamped with long right-angled clamps, and divided (*inset*). (From Orringer MB. Transhiatal esophagectomy without thoracotomy. *Oper Tech Thorac Cardiovasc Surg* 2005;10:63, with permission.)

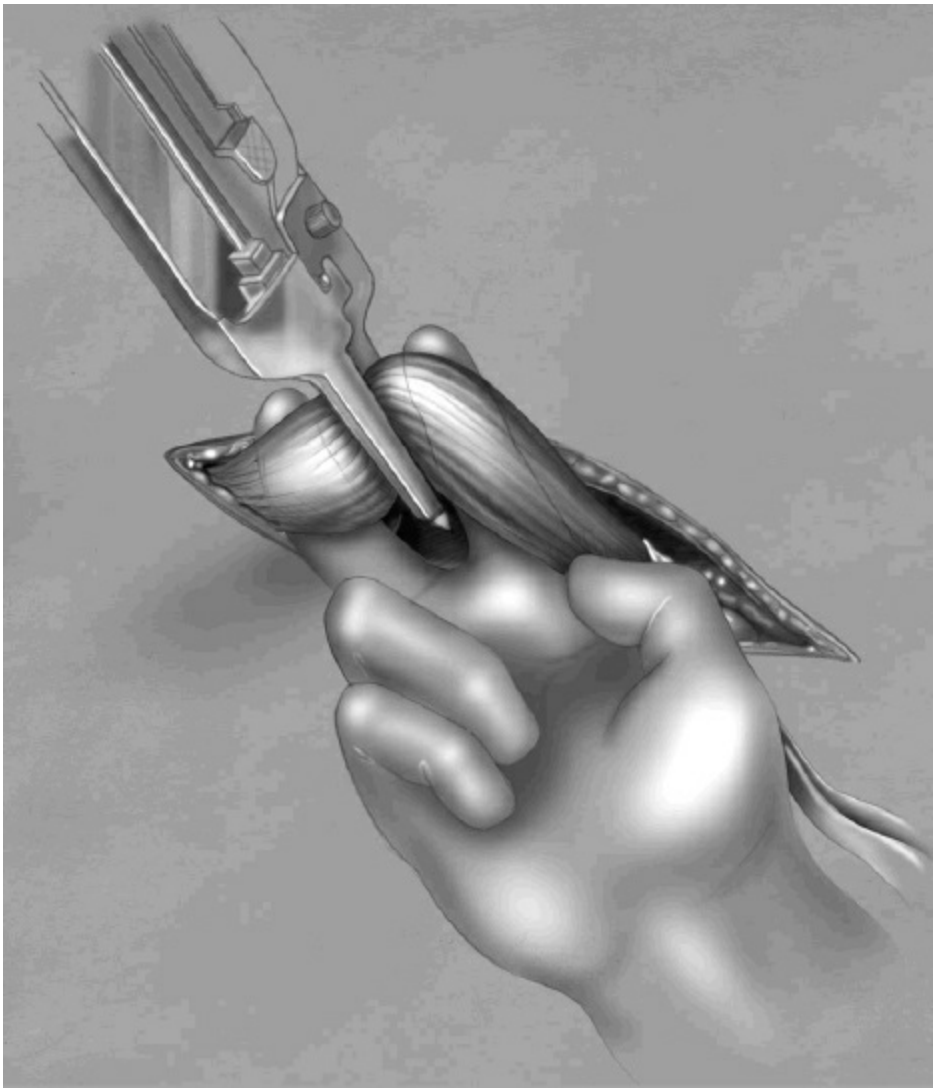

Figure 78.14. The previously placed nasogastric tube is pulled back until it is above the level of the upper esophageal sphincter, and using a GIA surgical stapler, the esophagus is divided obliquely from front to back (not transversely), leaving the anterior tip slightly longer than the posterior. (From Orringer MB. Transhiatal esophagectomy without thoracotomy. *Oper Tech Thorac Cardiovasc Surg* 2005;10:63, with permission.)

After delivering the esophagus out of the posterior mediastinum, the liver blade of the upper hand retractor is removed and replaced with a standard body wall blade, since the liver blade pulls the lesser curvature of the stomach toward the liver and right upper quadrant and impedes maximum upward reach of the stomach through the posterior mediastinum and into the neck. Once it is confirmed that there is no significant mediastinal bleeding and assessing the need for a chest tube(s), the posterior mediastinum is packed with a large abdominal pack inserted

through the diaphragmatic hiatus, and two narrow “thoracic packs” inserted downward into the superior mediastinum through the neck wound. As the superior mediastinum is being packed, one finger is placed against the tracheoesophageal groove to ensure that there is no contact between the packing forceps and the recurrent laryngeal nerve.

After packing the posterior mediastinum to encourage hemostasis, attention is redirected to the stomach and attached esophagus, which are now placed on the anterior chest wall. The highest point along the greater curvature of the stomach that will reach toward the neck is gently grasped with a moist gauze pack by the thumb and index finger and drawn upward toward the neck. A site along the lesser curvature of the stomach at approximately the level of the second vascular arcade (“crow’s foot”) is identified and cleaned of overlying fat and blood vessels between right-angled clamps and ties. The upper stomach is then progressively divided approximately 4 to 6 cm distal to the esophagogastric junction with approximately three applications of the GIA 60–3.5 stapler, starting at the area of the “cleaned” lesser curvature and proceeding toward the greater curvature (Fig. 78.15). With each successive application and firing of the stapler, the stomach is progressively straightened. “Tubularization” of the stomach is minimized as much as possible to ensure preservation of the maximum amount of gastric submucosal collateral circulation. The esophagus and attached portion of proximal stomach are removed from the field and inspected on the back table to ensure adequate proximal and distal margins beyond tumor, Barrett mucosa, or other esophageal pathology.

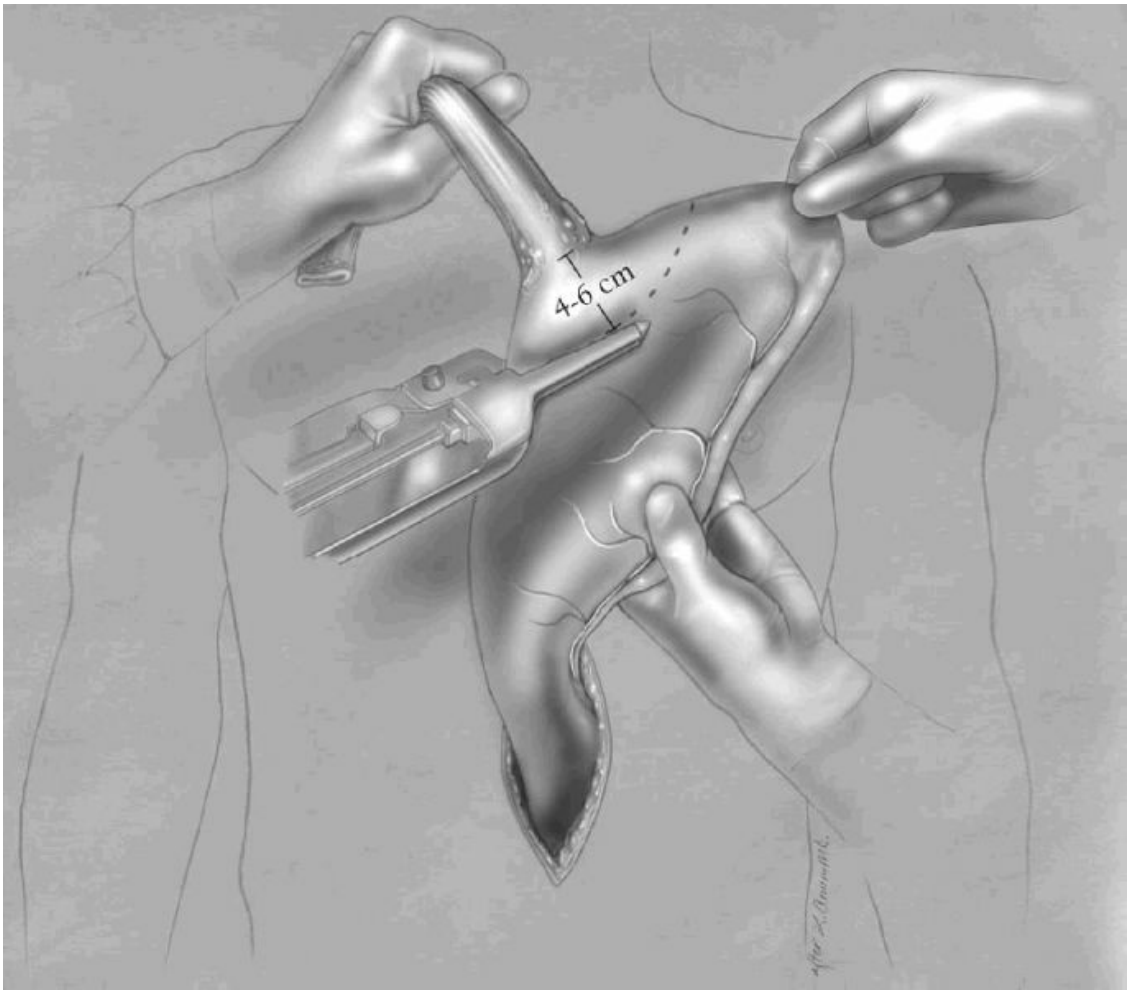

Figure 78.15. The upper stomach is progressively divided approximately 4 to 6 cm distal to the esophagogastric junction with three or four applications of the GIA 60–3.5 stapler applied from the lesser curvature toward the fundus. (From Orringer MB. Transhiatal esophagectomy without thoracotomy. *Oper Tech Thorac Cardiovasc Surg* 2005;10:63, with permission.)

The gastric staple suture line is oversewn with a running 4-0 absorbable polyglycolic acid stitch, which is interrupted at its midpoint to minimize the chance that the stitch will break as the stomach is drawn into the neck. The mobilized stomach placed upon the anterior chest typically reaches above the level of the supersternal notch. The gastric staple line is toward the patient's right side, and the preserved right gastroepiploic vascular arcade is toward the patient's left (Fig. 78.16).

The previously placed abdominal and thoracic gauze packs are removed from the posterior mediastinum, which is again inspected for bleeding. Transposition of the stomach through the posterior mediastinum is now carried out. Over the years, the importance of minimizing trauma to the

stomach prior to transposing it through the posterior mediastinum and into the neck wound has become one of the most important principles of the operation. No traction sutures are placed into the stomach nor suction devices used to pull it upward. With a narrow Deaver retractor placed into the hiatus and elevated, the left upper quadrant abdominal contents are retracted to the left, and the left lobe of the liver retracted to the right. The hand and forearm are inserted upward through the diaphragmatic hiatus along the prevertebral fascia until two or three fingers emerge from the neck incision, thereby ensuring that there is an adequate posterior mediastinal tunnel unimpeded by residual undivided fibrous or vagal bands. The stomach is then gently pushed through the diaphragmatic hiatus along the prevertebral fascia and advanced upward beneath the aortic arch until the tip of the gastric fundus can be palpated through the neck incision. A Babcock clamp inserted downward into the superior mediastinum through the cervical incision is used to gently grasp the stomach (Fig. 78.17). The clamp is not ratcheted closed in order to minimize trauma to the stomach. The hand alongside the stomach within the posterior mediastinum is gradually withdrawn and the stomach gently pushed upward from below as the Babcock clamp is used to guide the gastric tip into the cervical wound. Approximately 4 to 5 cm of gastric length above the level of the clavicles is achieved by pushing the stomach upward through the posterior mediastinum than by pulling it upward through the neck incision (Fig. 78.17, inset).

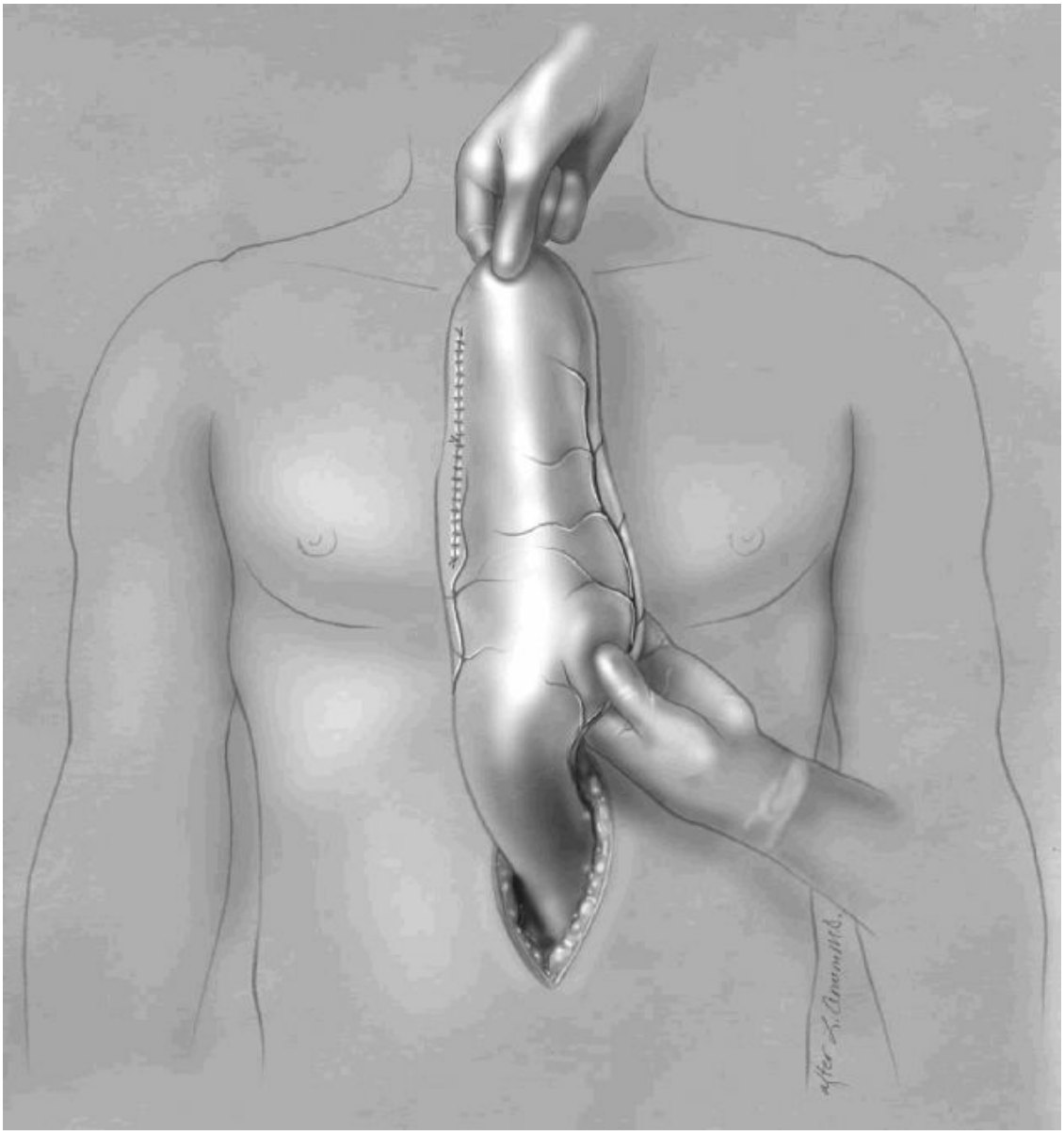

Figure 78.16. The mobilized stomach placed upon the anterior chest typically reaches above the level of the suprasternal notch. The gastric staple suture line is toward the patient's right side. (From Orringer MB. Transhiatal esophagectomy without thoracotomy. *Oper Tech Thorac Cardiovasc Surg* 2005;10:63, with permission.)

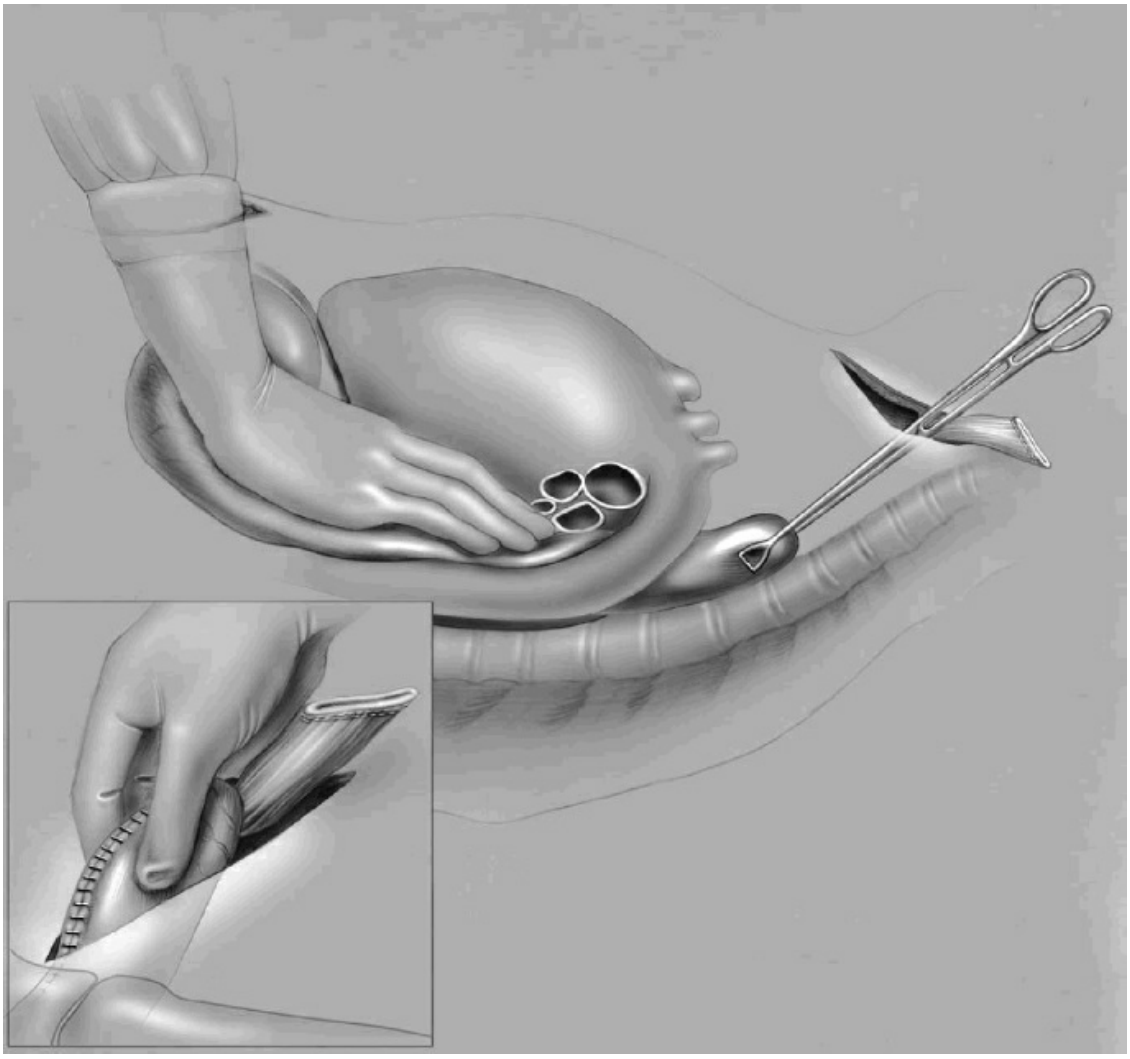

Figure 78.17. A Babcock clamp inserted downward into the superior mediastinum through the cervical incision is used to gently grasp the stomach. An approximately 4 to 5 cm length of stomach above the level of the clavicles is achieved by pushing the stomach upward through the posterior mediastinum rather than by pulling it upward through the neck incision (*inset*). (From Orringer MB. Transhiatal esophagectomy without thoracotomy. *Oper Tech Thorac Cardiovasc Surg* 2005;10:63, with permission.)

Once sufficient stomach has been delivered into the neck incision, it is important to verify that an inadvertent twist of the stomach has not occurred while it was positioned in the chest. While gently holding the tip of the gastric fundus in the cervical wound, the anterior surface of the stomach is simultaneously palpated through the diaphragmatic hiatus and the neck incision to be certain that it is smooth and untwisted and that the gastric staple line is toward the patient's right side. "Suspension sutures"

between the gastric fundus and the prevertebral fascia in the neck are avoided to prevent unnecessary trauma to the vulnerable gastric tip. In addition, suturing the stomach to the prevertebral fascia may at times inoculate the intervertebral disc space, resulting in an epidural abscess. When the stomach has been properly mobilized and positioned in the posterior mediastinum and neck, the tip of the stomach visible in the cervical wound will be pink, healthy, and viable. Retraction of the stomach back downward into the posterior mediastinum seldom occurs unless undue traction is placed on it through the abdominal wound. A hemostat placed on the stump of a ligated high short gastric vessel allows easy assessment during completion of the abdominal portion of the procedure that the tip of the stomach is still situated in the cervical wound, which is covered with a saline-moistened guaze.

It has been the author's practice to isolate the abdominal incision from the cervical wound before opening the esophagus for the anastomosis in order to avoid contamination of the abdominal wound by intraoral contents. Therefore, the abdominal phase of the operation is completed entirely before beginning construction of the anastomosis. Prior to abdominal wound closure, the diaphragmatic hiatus is inspected. Typically, after the hand and forearm have been inserted into the posterior mediastinum during the esophageal mobilization, the hiatus has been stretched and occasionally the left crus partially torn, requiring hemostasis with electrocautery. To prevent subsequent herniation of intestine into the posterior mediastinum alongside the intrathoracic stomach, the hiatus is narrowed with one or two no. 1 silk sutures until it loosely accommodates three fingers placed alongside the stomach. To further discourage late migration of intestine through the hiatus, the edge of the diaphragmatic hiatus is sutured to the anterior gastric wall with one or two interrupted 3-0 silk sutures, the left lobe of the liver is returned to its normal position, and the previously divided triangular ligament of the liver is sutured back to the edge of diaphragmatic hiatus with an interrupted 3-0 silk suture. Typically, after a gastric "pull-up," the pyloromyotomy comes to rest 3 to 4 cm below the level of the diaphragmatic hiatus and beneath the left lobe of the liver. The feeding jejunostomy tube is brought out through a small left upper quadrant abdominal wall stab wound. The jejunostomy tube site is sutured against the anterior abdominal wall with four interrupted 3-0 silk sutures. Each suture is marked with Hemoclip before cutting. The small "diamond" on abdominal imaging formed by the Hemoclips facilitates a

future percutaneous jejunostomy should a feeding tube ultimately be required again. The jejunostomy tube is then sutured to the skin to secure it in place. The color of the gastric tip visible in the cervical wound is periodically inspected to be certain that venous congestion has not occurred as a result of overzealous narrowing of the diaphragmatic hiatus. If necessary, a hiatal suture can be removed before beginning the abdominal wound closure. Once the incision is closed, it is covered with a sterile towel and then with a separate drape to completely isolate it from the cervical field and potential contamination by oral bacteria during subsequent construction of the CEGA.

Cervical Esophagogastric Anastomosis

As indicated previously, the properly mobilized stomach reaches 4 to 5 cm above the level of the clavicles. The lesser curvature gastric staple line is oriented toward the patient's right side (Fig. 78.18A). The anterior surface of the stomach at the level of the suprasternal notch is gently grasped with a Babcock clamp, rotated even more to the right to further displace the gastric staple line away from the subsequent anastomotic site, and elevated superiorly even further into the wound, and a 3-0 silk seromuscular traction suture is placed distal to the clamp (Fig. 78.18B). This suture is used to draw the anterior surface of the stomach to the level of the skin and is then secured to the drapes with a hemostat. During placement of this suture, the stapled divided end of the cervical esophagus is grasped with an Allis clamp, elevated, and retracted to the patient's right to facilitate exposure (Fig. 78.18B).

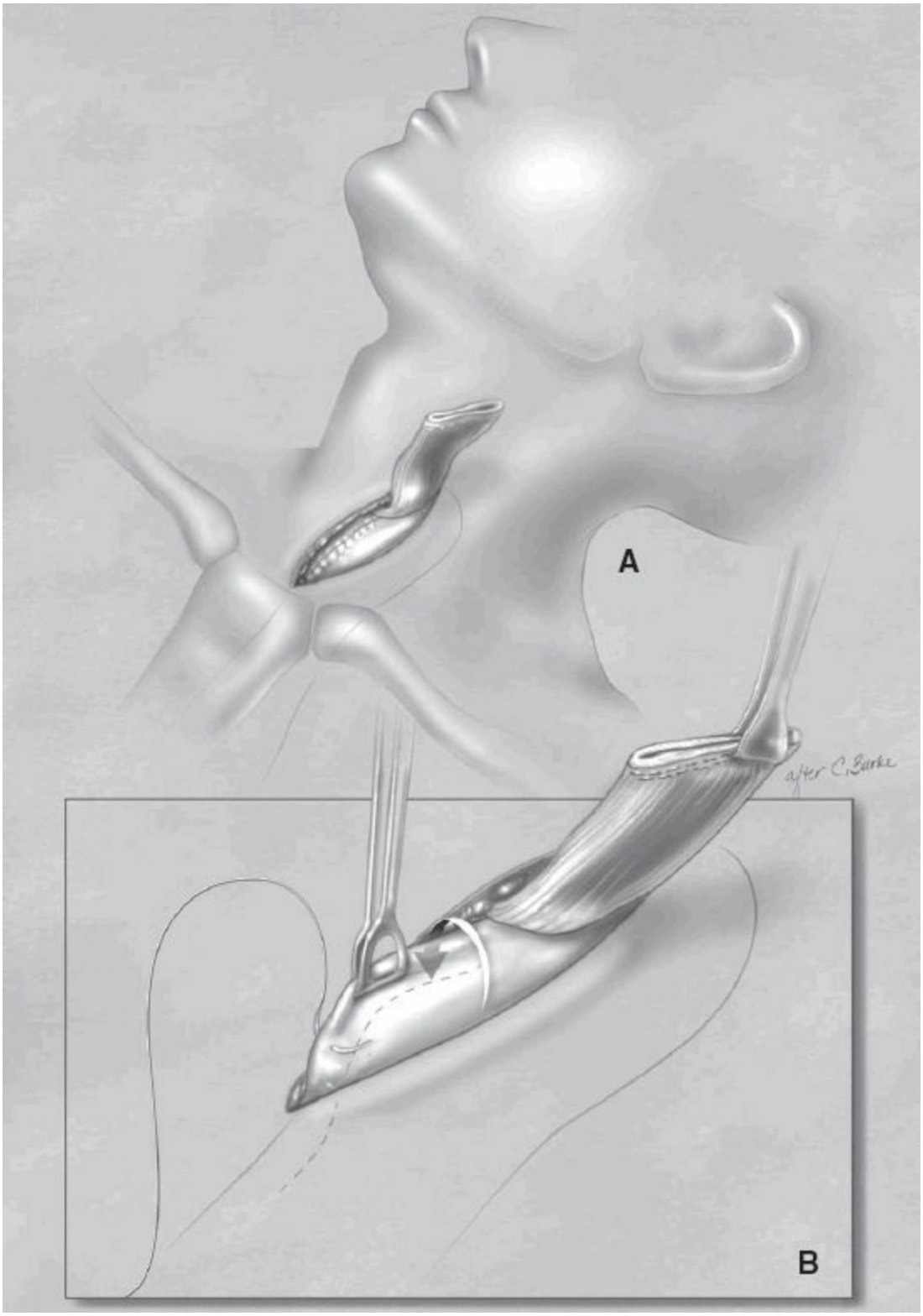

Figure 78.18. **A.** The lesser curvature gastric staple line is oriented toward the patient's right side. **B.** The anterior surface of the stomach at the level of the suprasternal notch is gently grasped with a Babcock clamp, rotated even more to the right to further displace the gastric staple line away from the subsequent anastomotic site, and elevated superiorly even farther into the

wound, and a 3-0 silk seromuscular traction suture is placed distal to the clamp. The anterior gastric wall is elevated by tension on the traction stitch, which is secured to the drapes with a hemostat. (From Orringer MB. Transhiatal esophagectomy without thoracotomy. *Oper Tech Thorac Cardiovasc Surg* 2005;10:63, with permission.)

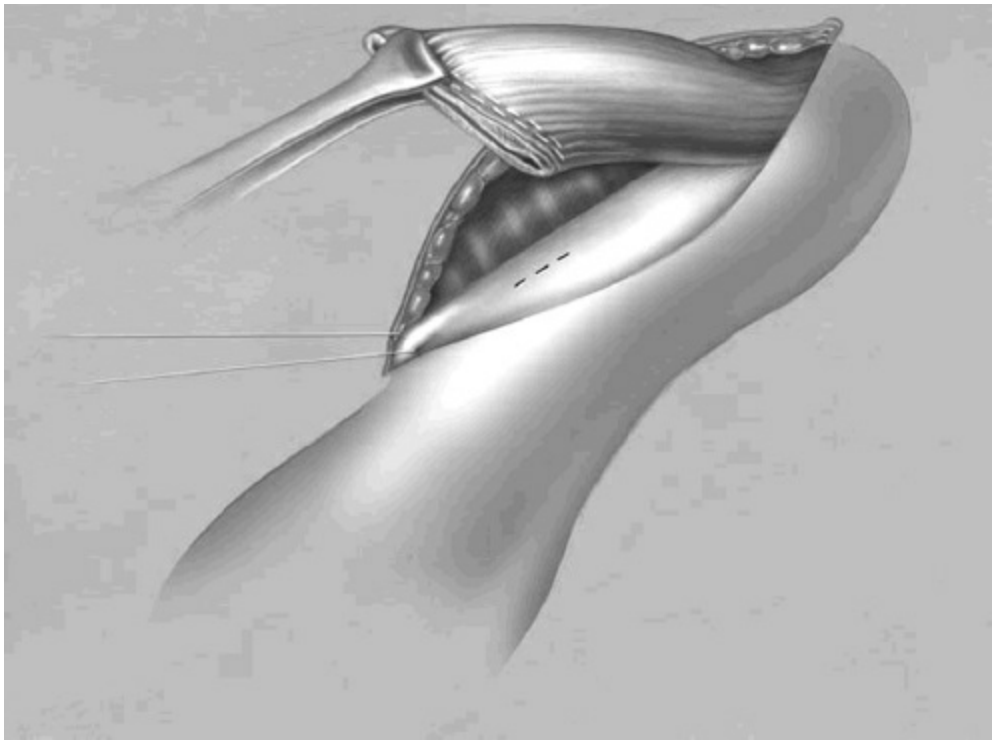

Figure 78.19. The divided end of the esophagus is approximated against the anterior gastric wall, a site for the anastomosis is selected (*dotted line*), and a 1.5- to 2-cm vertical gastrotomy is performed using the cutting current of electrocautery.

The divided end of the esophagus is approximated against the anterior gastric wall, a site for the anastomosis is selected, and a 1.5- to 2-cm vertical gastrotomy is performed using the cutting current of electrocautery (Fig. 78.19). The vertical gastrotomy must be placed low enough from the most superior aspect of the gastric tip to allow subsequent insertion of a 3-cm-long staple cartridge. In addition, there must be sufficient remaining cervical esophageal length so that once the anterior gastric wall traction suture is removed and the stomach drops somewhat downward into the thoracic inlet, there will not be undue tension on the anastomosis. The stapled esophageal suture line is grasped with two Allis clamps, the cervical esophagus held obliquely with a DeBakey forceps, and the staple suture line amputated sharply distal to the forceps, which serves as a guide

for the transection (Fig. 78.20). In patients with carcinoma, the amputated tip of the esophagus is submitted to the pathology department as the "proximal esophageal margin of resection."

Two key stay sutures are now placed to align the esophagus and the stomach. The first suture is a full-thickness 4-0 stitch through the anterior tip of the divided esophagus. The second is a 4-0 stitch that passes into the stomach and emerges approximately 6 to 7 mm from the upper corner of the vertical gastrotomy, then through the posterior corner of the divided cervical esophagus, entering the wall 6 to 7 mm from the end and emerging through the mucosa 2 to 3 mm from its end (Fig. 78.21). Downward traction on these two sutures aligns the back wall of the cervical esophagus with the front wall of the stomach while an Endo-GIA universal articulating 30-3.5 staple cartridge (Covidien) is inserted simultaneously into the esophagus and the stomach. The thinner anvil portion of the cartridge goes into the stomach and the thicker staple-bearing portion of the cartridge goes into the esophagus (Fig. 78.22). The cartridge is gently rotated until its tip is pointed toward the patient's right ear, continually aligning the esophagus with the anterior wall of the stomach (Fig. 78.22A,B), maintaining downward traction on the stay sutures as the staple cartridge is advanced inward, and ensuring that the lesser curvature gastric staple suture line remains well rotated toward the patient's right side so that it does not intersect with the anastomotic staple line.

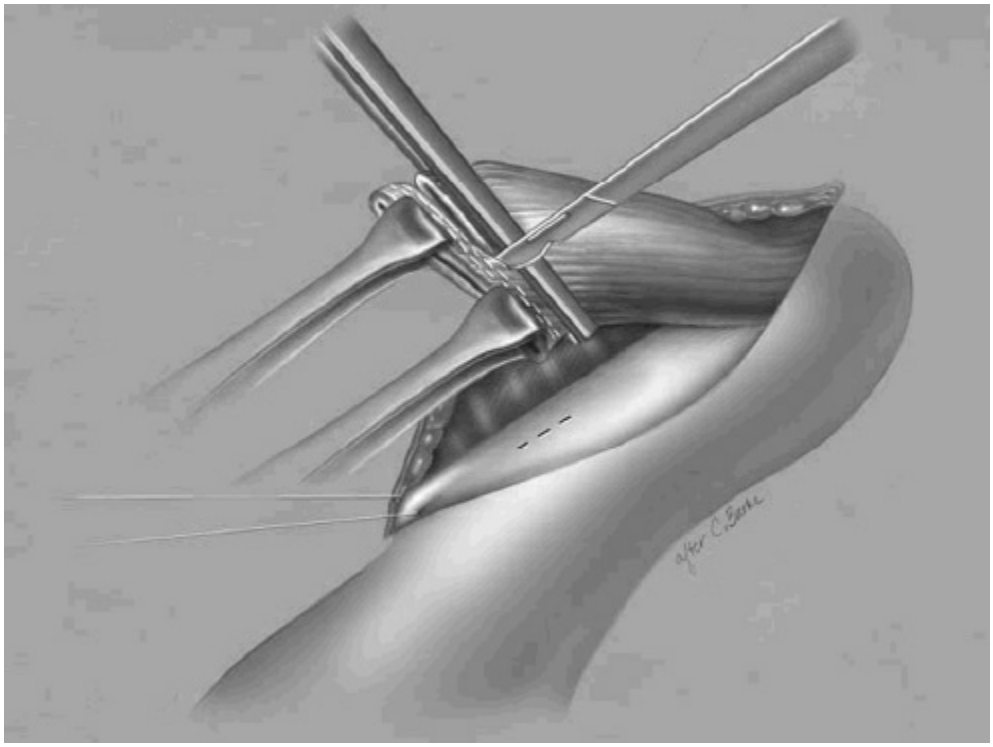

Figure 78.20. The stapled esophageal suture line is grasped with two Allis clamps, the cervical esophagus held obliquely with a DeBakey forceps, and the staple suture line amputated sharply distal to the forceps, which serves as a guide for the transection. (From Orringer MB. Transhiatal esophagectomy without thoracotomy. *Oper Tech Thorac Cardiovasc Surg* 2005;10:63, with permission.)

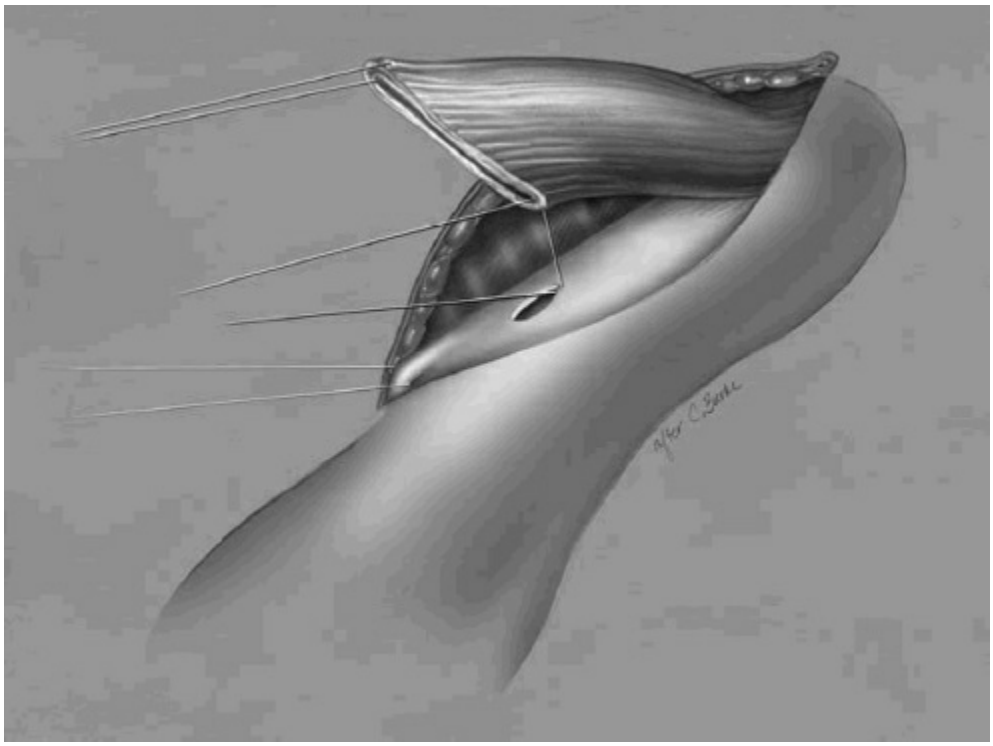

Figure 78.21. Two key stay sutures (4-0 polyglatin-Vicryl-Ethicon) are now placed to align the esophagus and the stomach. The first suture is a full-thickness stitch through the anterior corner of the divided esophagus. The second is a stitch that passes into the stomach and emerges approximately 6 to 7 mm from the upper corner of the vertical gastrotomy, then through the posterior corner of the divided cervical esophagus, entering the muscle 6 to 7 mm from the end and emerging through the mucosa 2 to 3 mm from its end. (From Orringer MB. Transhiatal esophagectomy without thoracotomy. *Oper Tech Thorac Cardiovasc Surg* 2005;10:63, with permission.)

The staple cartridge is closed but not fired at this time. Two interrupted 4-0 absorbable polyglactin (Vicryl) sutures between the anterior gastric wall and adjacent esophagus are placed on either side of the stapler to serve as "suspension" sutures, which take tension off the anastomosis (Fig. 78.23). After placement of the suspension sutures, the stapler is fired, thereby approximating the posterior esophageal wall and the anterior gastric wall and dividing the now common wall between them. The staple cartridge is removed. A 4-0 absorbable polyglactin (Vicryl-Ethicon) traction suture is placed at either corner of the gastrotomy and opened esophagus (Fig. 78.24). A 16 French nasogastric tube is inserted by the anesthesiologist and advanced across the anastomosis and down into the intrathoracic stomach. Anterior closure of the esophagotomy and gastrotomy is achieved with a running, full-thickness 4-0 absorbable monofilament (PDS-Ethicon) suture on the inner layer (Fig. 78.25) followed by a layer of interrupted 4-0 absorbable monofilament (PDS-Ethicon) sutures on the outer layer (Fig. 78.26). A metallic Hemoclip is placed on either of the corner sutures before they are cut to assist with future radiographic localization of the anastomosis. The wound is irrigated with iodine solution. The anterior gastric wall traction suture is removed, and the stomach is gently pushed downward into the thoracic inlet. A ¼-in rubber drain is placed at the depths of the wound near the anastomosis and is secured to the inferior edge of the skin incision with a suture. The cervical wound is then closed with no more than five to six interrupted absorbable sutures in muscle fascia, and the skin edges are approximated with running 4-0 nylon. After dressing all incisions and tube sites and being certain that the nasogastric tube irrigates freely and is functioning properly, a portable chest radiograph is obtained in the operating room to verify that there is no unexpected hemo- or pneumothorax and that all

tubes are properly positioned.

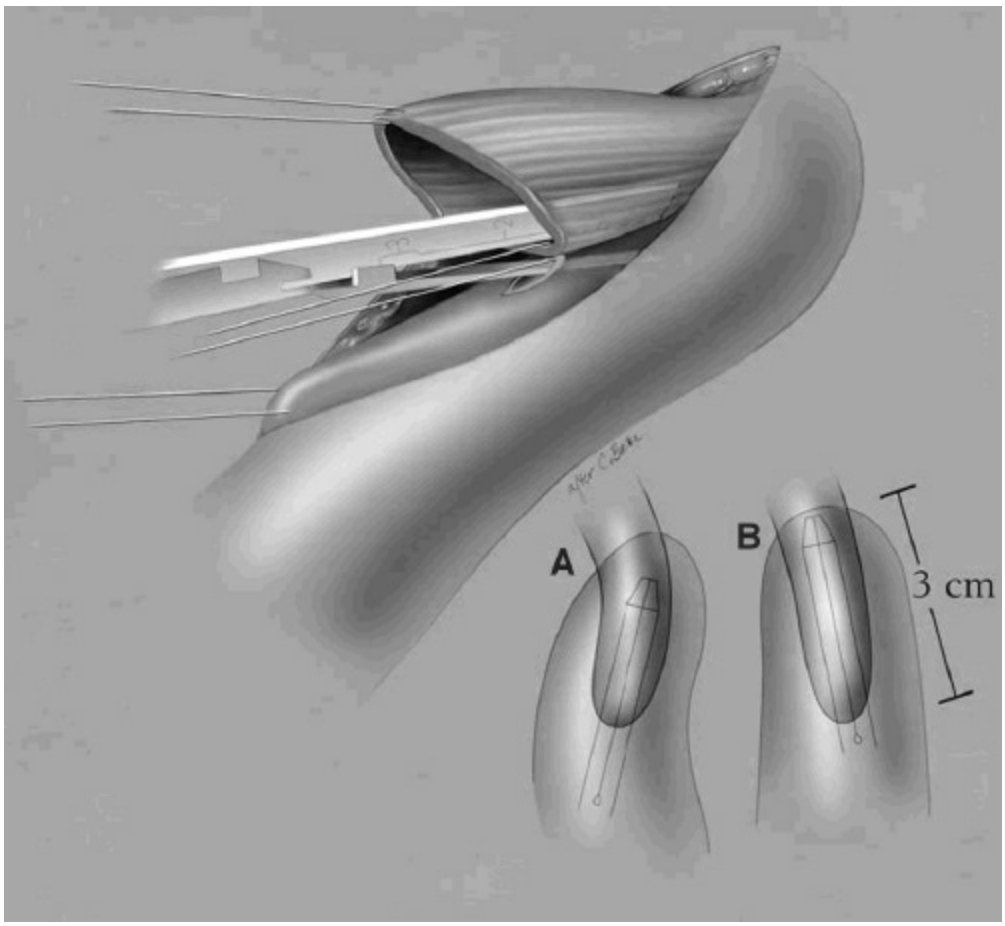

Figure 78.22. While maintaining downward traction on the two stay sutures, an Endo-GIA universal articulating 30-3.5 staple cartridge (Covidien) is inserted simultaneously into the esophagus and the stomach (**A,B**). The cartridge is gently rotated until its tip is pointed toward the patient's right ear, continually aligning the esophagus with the anterior wall of the stomach. (From Orringer MB. Transhiatal esophagectomy without thoracotomy. *Oper Tech Thorac Cardiovasc Surg* 2005;10:63, with permission.)

POSTOPERATIVE CARE

Preoperative conditioning of the patient for a THE with mandatory smoking cessation for a minimum of 3 weeks, walking 3 miles a day, and using an incentive inspirometer issued at the time of the initial consultation is consistently rewarded by a smoother postoperative course. The patient is extubated in the operating room, recovered from anesthesia, and is then moved to a monitored hospital bed and not the intensive care unit. Initial upright posturing with the head elevated at 45 degrees to prevent

gastroesophageal reflux is standard, but fewer patients actually sustain this because postoperative nocturnal regurgitation after a side-to-side stapled CEGA is uncommon. Epidural anesthesia or intravenous patient-controlled anesthesia (PCA) for the first 4 to 5 postoperative days typically provides sufficient analgesia so that the incentive inspirometer can be used the afternoon and evening of the operation, and ambulation (walking in the hallways) can be started the morning of the 1st postoperative day. Hourly use of the incentive inspirometer (five deep breaths at the start of each hour) and walking at least four times a day continue throughout the hospitalization. Chest tubes are discontinued when there is no air leak and drainage is less than 60 cc per 2 consecutive 8-hour nursing shifts. The cervical wound drain is removed on the 3rd postoperative day. Ice chips (<30 cc per hour) for throat comfort are permitted the night of the operation. Suction is applied to the nasogastric tube for 24 hours, then dependent drainage for 24 hours, and if the drainage has been below 200 cc per shift for 2 shifts, the tube is removed. If having no nasogastric tube is well tolerated, a clear liquid diet is begun the next day along with low volume jejunostomy tube feedings. Diet is advanced to full liquids the next day and to a “mechanical soft” (“mushy”) diet the next. The latter is continued for the first several postoperative weeks, after which diet is then gradually liberalized. A postoperative barium swallow is obtained on day 7 prior to discharge to document: (1) no anastomotic leak, (2) satisfactory emptying of the intrathoracic stomach, and (3) unobstructed flow past the jejunostomy tube site. When dumping symptoms (postprandial cramping and diarrhea) occur, they are treated with smaller more frequent feedings and withholding liquids until after meals to minimize gastric distention, avoiding glucose loads, and avoiding milk and dairy products. At times, diphenoxylate may be needed. Patients are typically discharged taking only oral nourishment, and the jejunostomy tube is not routinely used. The tube is removed in follow-up clinic 3 to 4 weeks after discharge unless there is severe dysphagia requiring dilatations and enteral nourishment, or pending adjuvant chemoradiation that may warrant support with jejunostomy tube feedings.

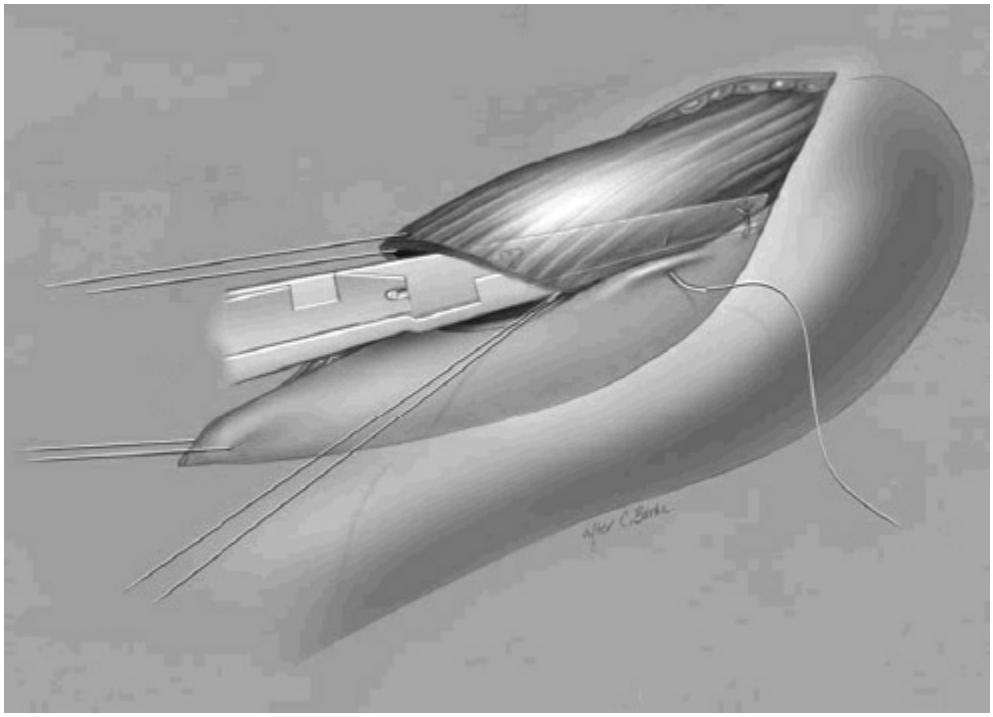

Figure 78.23. Two interrupted 4-0 absorbable polyglactin (Vicryl-Ethicon) sutures between the anterior gastric wall and adjacent esophagus are placed on either side of the stapler to serve as “suspension” sutures, which take tension off the anastomosis. (From Orringer MB. Transhiatal esophagectomy without thoracotomy. *Oper Tech Thorac Cardiovasc Surg* 2005;10:63, with permission.)

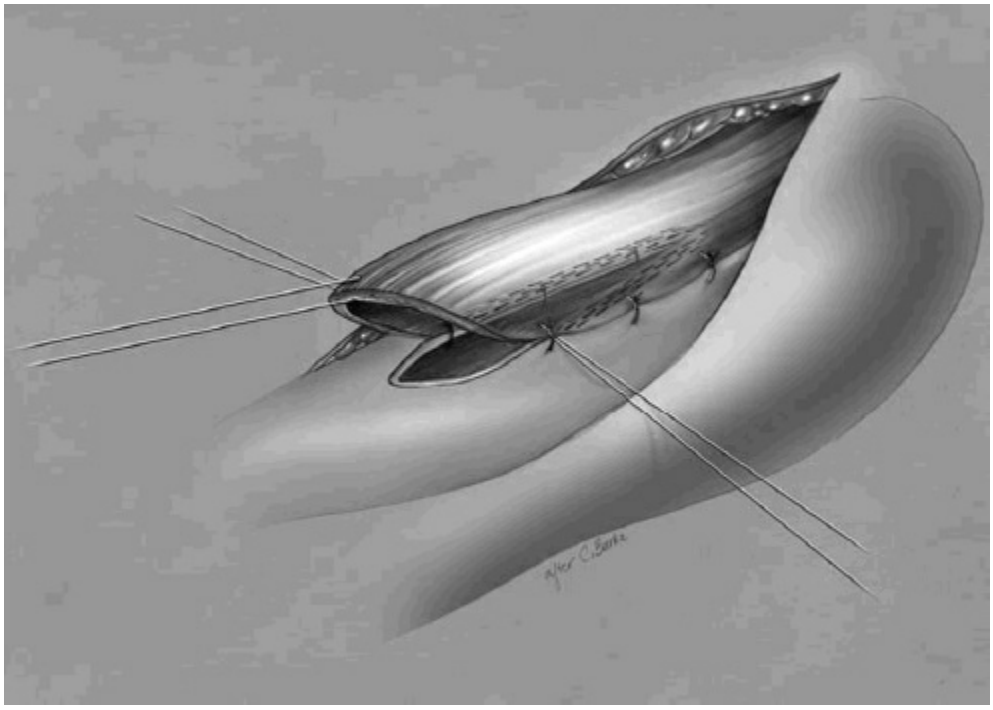

Figure 78.24. A 4-0 absorbable polyglactin (Vicryl-Ethicon)

traction suture is placed at either corner of the gastrotomy and opened esophagus. (From Orringer MB. Transhiatal esophagectomy without thoracotomy. *Oper Tech Thorac Cardiovasc Surg* 2005;10:63, with permission.)

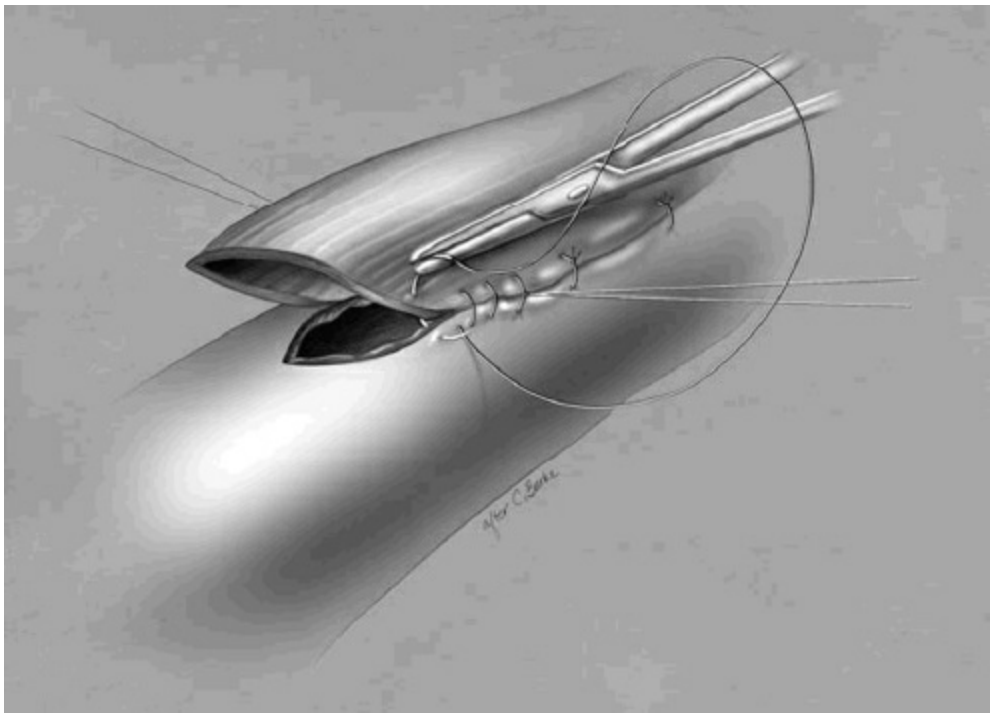

Figure 78.25. After a 16 French nasogastric tube inserted by the anesthesiologist is advanced down into the intrathoracic stomach, anterior closure of the esophagotomy and gastrotomy is achieved with a running, full-thickness 4-0 monofilament absorbable (PDS-Ethicon) suture on the inner layer. (From Orringer MB. Transhiatal esophagectomy without thoracotomy. *Oper Tech Thorac Cardiovasc Surg* 2005;10:63, with permission.)

COMPLICATIONS AND THEIR MANAGEMENT

The complications of THE may be intraoperative, postoperative, or those occurring in long-term follow-up. *Intraoperatively*, entry into one or both pleural cavities in the process of mobilizing the esophagus occurs in nearly 75% of patients, is detected by inspection of both sides of the mediastinal pleura through the diaphragmatic hiatus after removal of the esophagus, and is treated by insertion of chest tubes. Splenic injury can occur in the process of dividing the highest short gastric vessels, usually responds to application of topical thromboplastin, and does not require a splenectomy. Entry into the pyloric or duodenal mucosa while performing the

pyloromyotomy is managed by closing the defect with interrupted 5-0 polypropylene and reinforcing the site with an adjacent omental fat pad flap. Two particular intraoperative disasters associated with THE bear emphasis: massive bleeding and a tracheal tear. Occurring in <1% of THEs, they are rarely discussed in review articles. Consequently, "walking through" the steps of controlling mediastinal hemorrhage or a tracheal tear during a THE—the indications for a thoracotomy and selecting the appropriate side—may be life-saving.

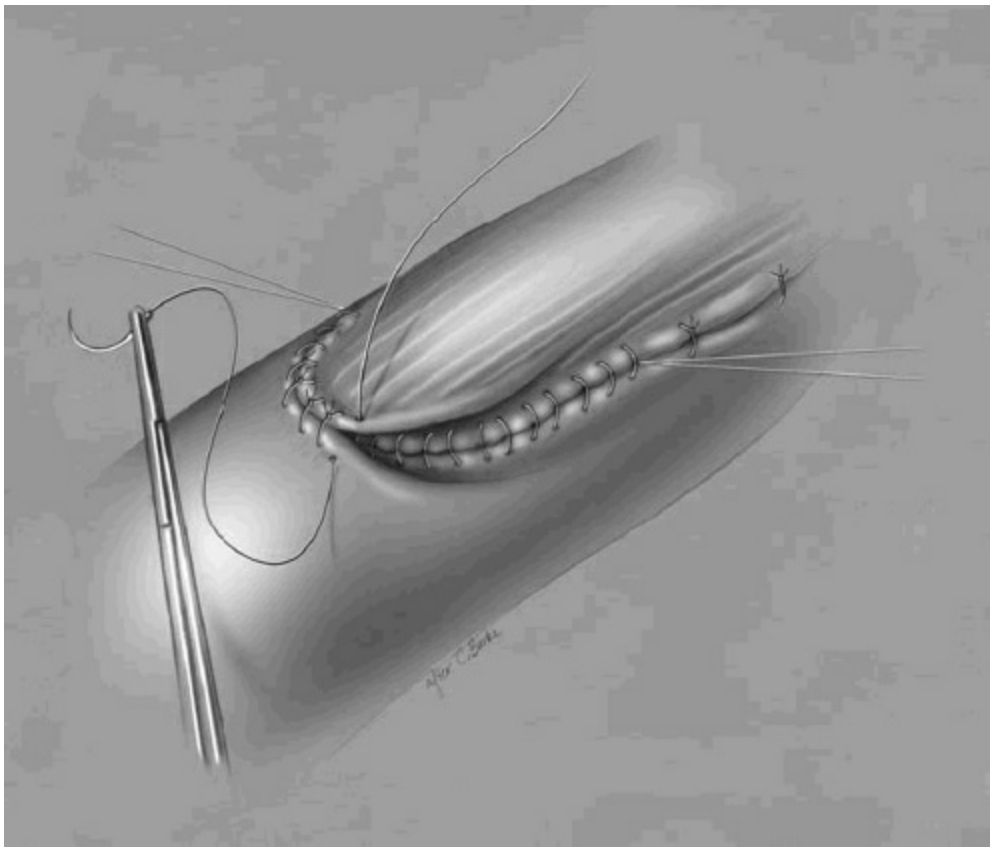

Figure 78.26. Interrupted inverting 4-0 monofilament absorbable (PDS-Ethicon) sutures are used on the outer layer to complete the anastomosis. (From Orringer MB. Transhiatal esophagectomy without thoracotomy. *Oper Tech Thorac Cardiovasc Surg* 2005;10:63, with permission.)

Mediastinal Bleeding

The surgeon should be alerted to the potential for a bleeding complication in a patient a history of bleeding tendencies, a family history of clotting disorders, or the use of anticoagulants or platelet inhibitors. Prior esophageal surgery results in increased periesophageal mediastinal fibrosis, and this is particularly the case after an esophagomyotomy in

which the exposed submucosa has a tendency to adhere to the anterior wall of the adjacent aorta. Mediastinal calcifications due to granulomatous disease seen on preoperative chest radiographs or CT scans often indicate a more difficult subcarinal esophageal dissection.

With unexplained, prolonged severe hypotension during the transhiatal esophageal mobilization, even after the surgeon's hand is removed from the posterior mediastinum, major bleeding should be suspected. If the patient is adequately hydrated and the hypotension has been induced by cardiac displacement, the blood pressure should quickly return to baseline once the hand has been withdrawn from the hiatus. This is not the time for administering pressor agents. If there is no excessive bleeding from either the cervical incision or the hiatus, bilateral 28 French chest tubes should be inserted quickly through low inframammary incisions in the anterior axillary lines, advanced to the apices, secured to the skin, and connected to suction thereby allowing assessment for inapparent intrathoracic bleeding. The two large bore intravenous lines, standard in this operation, allow for volume replacement. Retraction of the hiatus with a narrow Deaver retractors permits direct inspection of the mediastinum. The 28 French Argyle Saratoga sump catheter inserted through the cervical incision helps to evacuate blood from the mediastinal field. If the mediastinal bleeding appears to be "high," draining into the chest through an opening in the pleura, particular from the right side of the high mediastinum, it is likely that the azygos vein has been torn. The posterior mediastinum should be packed quickly through the hiatus with two large laparotomy packs from "below" and two narrow thoracic packs placed behind the esophagus through the cervical wound (Fig. 78.27), protecting the RLN in the tracheoesophageal groove with fingers as the packing is being performed (Fig. 78.27, inset). The abdomen is quickly closed with 4–5 through and through No. 2 monofilament sutures, and the incision covered with an adhesive surgical drape (Fig. 78.28, inset). The cervical wound is similarly closed quickly with running monofilament suture and the incision covered with an adhesive surgical drape. The patient is turned to the left lateral decubitus position and padded for a right posterolateral thoracotomy. A fifth interspace thoracotomy is performed, and the bleeding site (usually a torn azygos vein) identified and controlled. If single lung ventilation is needed for better exposure, the carina is identified and the right mainstem bronchus pinched between the thumb and index finder to occlude it as the anesthesiologist advances the deflated endotracheal tube in the left

mainstem bronchus. If the esophagus has not yet been removed, the esophageal mobilization is completed. The patient is again turned supine, positioned as before, the cervical and abdominal incisions reopened, and the esophageal replacement with the stomach in the posterior mediastinum and a CEGA carried out as originally planned.

In another scenario, at times, once the esophagus has been removed after the transhiatal mobilization, untoward dark venous bleeding from either the cervical incision or the hiatus is managed as above with bilateral chest tubes and mediastinal packing. After waiting 5 minutes, natural hemostatic mechanisms may come into play. If no blood wells up out of the wounds after careful removal of the packs, the posterior mediastinum is inspected through the hiatus. The thrombosed end of the torn azygos vein may be seen and further occluded with a Hemoclip on a long applier or clamped with 14-in extra-long right-angled clamps and ligated. On the other hand, if bleeding resumes after the packs are removed, the mediastinum is repacked, the cervical and abdominal incisions temporarily closed as above, and the patient turned and positioned for a right posterolateral thoracotomy.

Bright red arterial bleeding from the hiatus during the transhiatal esophageal mobilization is quickly assessed by inserting the Argyle Saratoga sump catheter through the cervical wound and “spot sucking” through the hiatus with a Yankauer suction from the lower end of the table. An aortic esophageal arterial bleeder may be identified through the hiatus, clamped with a long right angle clamp, and ligated. Mediastinal packing as described above is again performed and the esophageal bed assessed after 5 minutes. If an ill-advised attempt at blunt dissection of the esophagus from the adherent descending thoracic aorta is undertaken, the resulting hemorrhage from an aortic esophageal wall tear may not be controllable before fatal exsanguination has occurred.

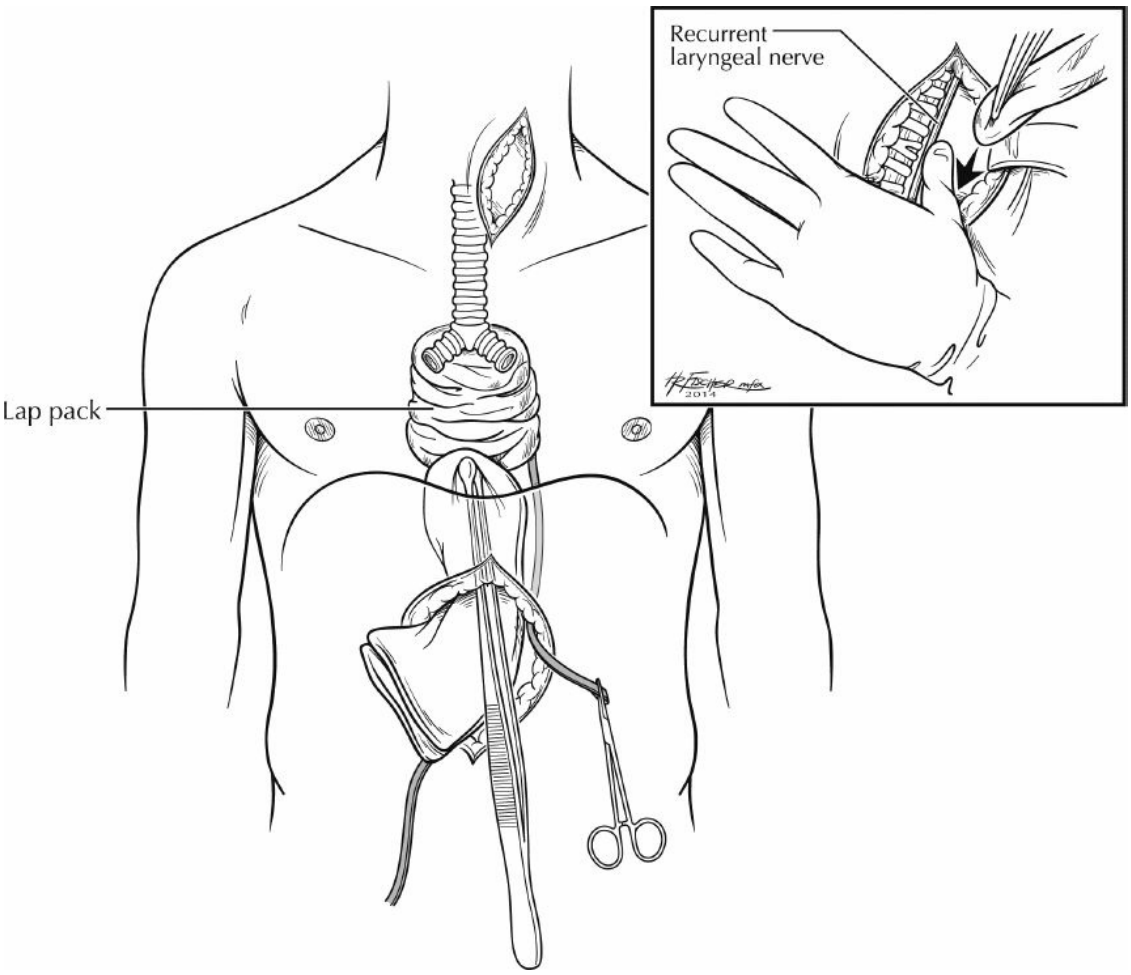

Figure 78.27. To tamponade posterior mediastinal bleeding, two large laparotomy packs are quickly advanced upward into the mediastinum through the retracted hiatus using long Russian forceps, and two narrow “thoracic” packs are advanced into the mediastinum through the cervical incision. The recurrent laryngeal nerve is protected against direct contact with the forceps by a finger held across it (*inset*). (Republished with permission of Springer, from Orringer MB. Transhiatal esophagectomy-intraoperative disasters. In: Pawlik TM, Maithel SK, Merchant NB, eds. *Gastrointestinal Surgery: Management of Complex Perioperative Complications*. New York: Springer; 2015:35–51, permission conveyed through Copyright Clearance Center, Inc.)

Tracheal Tear

As noted above, when mobilizing the esophagus away from the carina during the THE, the fingers must be kept posteriorly as possible to avoid an airway injury. A sudden rush of cool air over the fingers in the posterior mediastinum during the transhiatal dissection, particularly with the

anesthesiologist becoming aware of “losing air” from the anesthetic circuit, is indicative of a posterior membranous tracheal tear. This is not the time for intraoperative bronchoscopy. The anesthesiologist must untape the endotracheal tube so that it is completely mobile. The surgeon’s hand is inserted through the hiatus anterior to the esophagus with the palm and volar aspects of the fingers facing forward. The hand is advanced behind the trachea and the posterior membranous trachea palpated to define the site and extent of the tear and control it with gentle pressure (Fig. 78.29A). The injury is typically distal to the endotracheal tube balloon. The anesthesiologist must deflate the balloon and advance the tube forward (often adding a tube extension) as the surgeon guides the tube into the left mainstem bronchus (Fig. 78.29B). Several passes may be required, but if the right mainstem bronchus is occluded by pinching it as the tube is advanced, a successful left-sided intubation is facilitated. The cuff is inflated after several centimeters of the tube have been advanced into the left mainstem bronchus and single lung ventilation of the left lung instituted. The tube is secured in place by the anesthesiologist and adequate oxygenation is confirmed. While it has been reported that membranous tracheal tears occurring during a THE may seal off against the intrathoracic stomach after extubation of the patient and not require repair, in the absence of reliable indicators of which tears can be managed expectantly in this fashion, the author is not comfortable with this approach. A right posterolateral thoracotomy allows direct reliable suture repair of membranous tears of the lower trachea and carina. Therefore, once adequate oxygenation has been achieved with single left lung ventilation, the abdominal and cervical incisions are temporarily closed as described above for the management of mediastinal bleeding, the patient turned, the thoracotomy and tracheal repair with interrupted 4-0 Vicryl performed, the esophageal mobilization completed, and the patient repositioned supine for the gastric mobilization through the mediastinum and construction of the CEGA. Single left lung ventilation is maintained until the end of the case when the patient is awakened and the tube withdrawn to prevent disruption of the tracheal repair by positive airway pressure. Another alternative approach to repair of the trachea is extension of the cervical incision downward over the upper sternum across the sternomanubrial junction and performance of a partial upper sternal splint (Fig. 78.30). Once the esophagus has been extracted, exposure of the posterior membranous trachea for a direct suture repair is usually feasible.

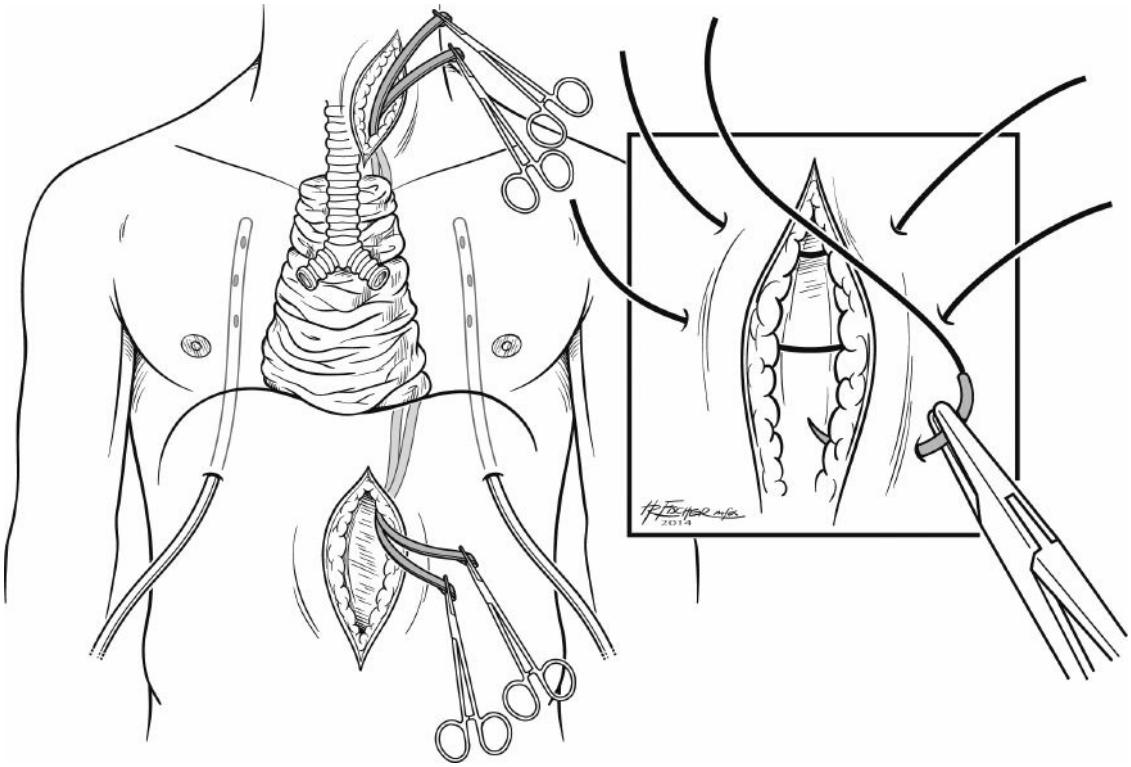

Figure 78.28. With unexplained hypotension and concern for possible intrathoracic bleeding, bilateral chest tubes are quickly placed to allow assessment of blood loss into the chest. Posterior mediastinal bleeding is tamponaded by two large laparotomy packs pushed high into the posterior mediastinum from “below,” and two narrow thoracic packs pushed into the superior mediastinum from “above” through the cervical incision. All packs are “tagged” with hemostats so they are not lost. After 5 to 10 minutes of observation while intravascular volume is replaced and blood pressure restored to a more normal level, if a “second look” into the mediastinum after removing all packs documents persistent bleeding, the mediastinum is repacked. The abdomen is quickly closed with three or four through-and through heavy sutures (*inset*), the cervical wound quickly closed, both incisions covered with adherent plastic surgical drapes, and the patient turned and positioned for a posterolateral thoracotomy. (Republished with permission of Springer, from Orringer MB. Transhiatal esophagectomy-intraoperative disasters. In: Pawlik TM, Maithel SK, Merchant NB, eds. *Gastrointestinal Surgery: Management of Complex Perioperative Complications*.New York: Springer; 2015:35–51, permission conveyed through Copyright Clearance Center, Inc.)

Complications that become manifest *postoperatively* after a THE are RLN injury, CEGA leak, chylothorax, and wound infections. RLN injury

is not simply the “nuisance” of a hoarse voice, as the accompanying cervical dysphagia and aspiration may be life-threatening. Although most patients tolerate the hoarseness and are able to progress their diet as tolerated, a subgroup experience intractable aspiration that is not adequately managed with jejunostomy tube feedings. While the otolaryngologists will typically advise 6 months of waiting to determine if the RLN injury is reversible, or if the patient will learn to adapt to it, in patients with recurrent aspiration aspiration, an early vocal cord medialization procedure with an absorbable material (e.g., Gelfoam) may provide gratifying relief and be life-saving. Chylothorax complicating an esophagectomy is accompanied by loss of protein (albumin) and lymphocytes and is associated with a 50% mortality. Aggressive early surgical intervention (within 1 week of the diagnosis) is advocated if despite a no fat diet, and octreotide injections, the chest tube output persists with a volume of 400 to 600 cc per 8-hour shift or more. A thoracotomy and direct thoracic duct ligation after “priming” the duct with cream administered through the jejunostomy tube for 4 to 6 hours before the operation have been our practice for years. Recently, however, percutaneous thoracic duct embolization of the thoracic duct by the interventional radiologists has been shown to be a very effective means of dealing with this problem and has become the first-line approach. Abdominal wound infections after a THE are very unusual. A cervical wound infection is virtually always indicative of an anastomotic leak. A CEGA leak is managed by opening the cervical wound completely at the bedside, initiating saline gauze wound packing, and maintaining nutrition through the jejunostomy feeding tube placed at the operation. While a CEGA results in a transient salivary fistula rather than mediastinitis associated with an intrathoracic esophageal anastomotic leak, this is far from a benign complication. A CEGA stricture follows 50% of leaks as healing occurs, and dysphagia resulting from an operation intended to restore comfortable swallowing is hardly a successful outcome. Because of the high rate of anastomotic stricture after a leak, we routinely incorporate bedside esophageal dilatations with Maloney bougies (36, 40, and 46 French) within 1 week of opening and packing the cervical wound. Small CEGA leaks do not require that the patient refrain from swallowing any nourishment. With practice, gentle cervical pressure over the wound usually provides sufficient occlusion of the leak that liquids and soft foods can be swallowed while the fistula closes.

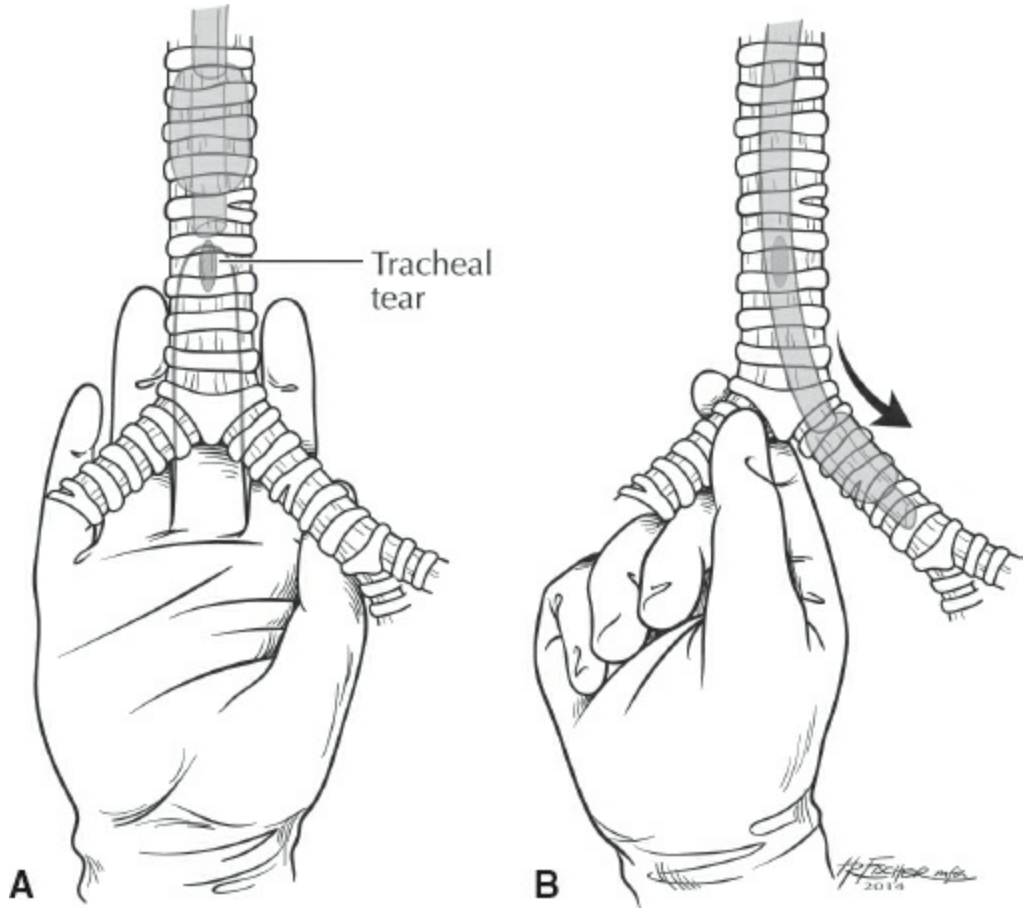

Figure 78.29. A. With a sudden air leak during THE, a posterior membranous tracheal tear is located and gently temporarily controlled with the volar aspect of the middle finger inserted through the diaphragmatic hiatus. **B.** Single lung ventilation of the left lung is achieved by occluding the right mainstem bronchus between the index finger and thumb and having the anesthesiologist advance the tube with the balloon deflated into the left mainstem bronchus beyond the site of the tear. Satisfactory oxygenation with single lung ventilation can be maintained until after the airway is repaired. (From Orringer MB. Transhiatal esophagectomy-intraoperative disasters. In: Pawlik TM, Maithel SK, Merchant NB, eds. *Gastrointestinal Surgery: Management of Complex Perioperative Complications*. New York: Springer; 2015:35–51. Copyright © 2015 Springer, with permission of Springer.)

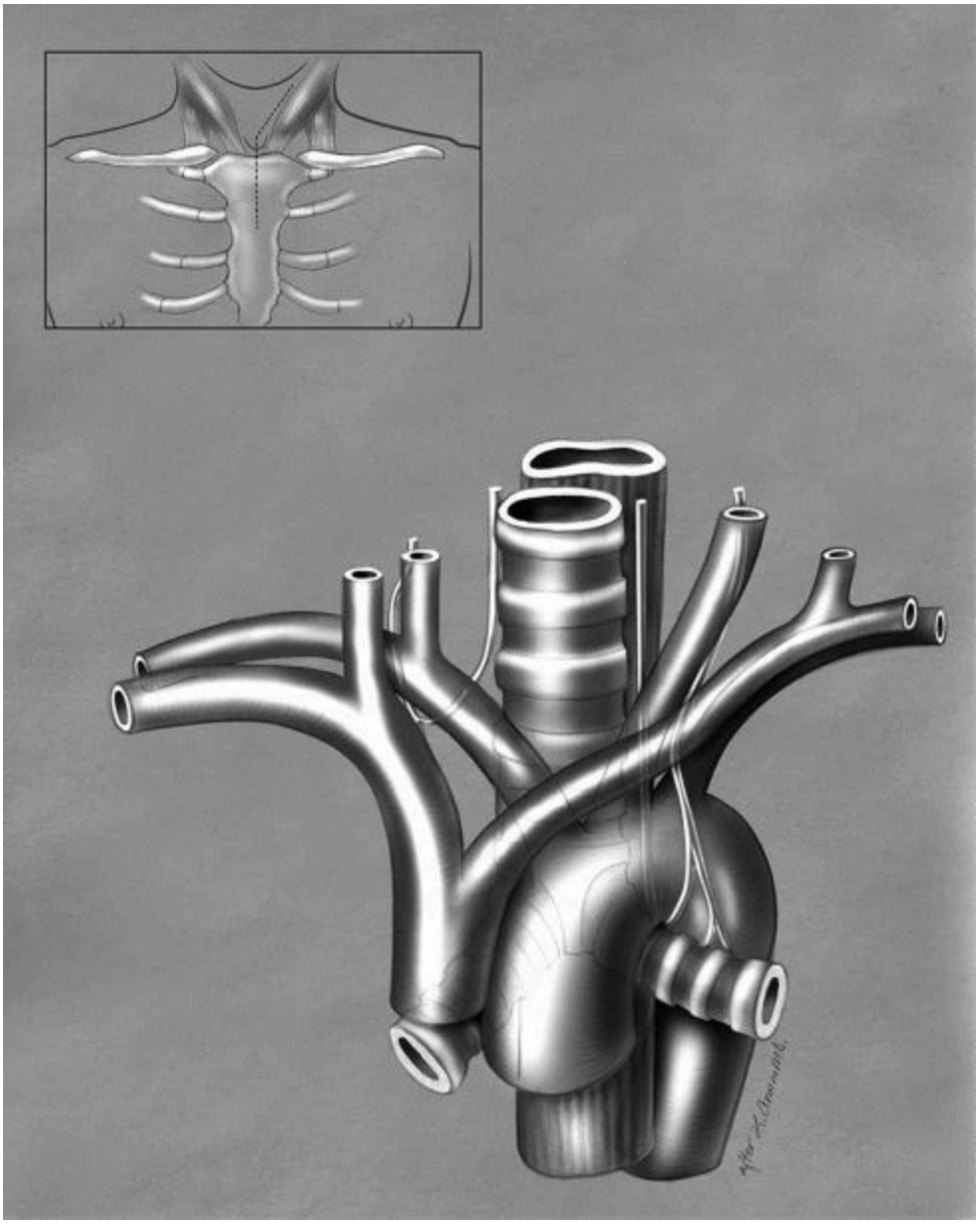

Figure 78.30. If a tear of the posterior membranous trachea is detected after transhiatal mobilization and removal of the esophagus, a partial upper sternal split may provide adequate exposure for direct tracheal repair. The oblique left cervical incision is extended downward in the midline over the manubrium and just across the sternomanubrial junction (*inset*). With a partial sternotomy and a small sternal retractor, access to the superior mediastinum and posterior membranous trachea to the level of the carina as shown is achieved, and suturing of the tracheal tear may be possible without the need for a thoracotomy. (From Orringer MB. Transhiatal esophagectomy without thoracotomy. *Oper Tech Thorac Cardiovasc Surg* 2005;10:63, with permission.)

Long-term complications of THE may include intractable dumping syndrome and a refractory CEGA structure. Dumping symptoms after eating (most often cramping and diarrhea but at times nausea, tachycardia, diaphoresis, and prostration) occur in nearly 25% of patients who undergo a vagotomy. Most often, these symptoms respond to an “anti-dumping” regimen: avoiding over distention of the stomach by eating smaller, more frequent meals, and withholding liquids until after the meal has been eaten; avoiding milk, dairy products, and high carbohydrate loads; addition of fiber to the diet to slow gastrointestinal transit time; and diphenoxylate. Dumping symptoms generally resolve or become manageable after 6 to 9 months. Those with refractory and persistent dumping may require institution of Asian diets—predominately rice, stir-fried vegetables, and fruit. Patients with end-stage achalasia and megaesophagus undergoing a THE appear to have a “parasympathetic dystrophy” that renders them more prone to long-term distressing dumping.

Most patients who experience dysphagia after a THE and CEGA respond to an occasional outpatient passage of tapered Maloney esophageal dilators (36, 40, and 46 French sizes). A 46 French is usually required to ensure comfortable swallowing. For those who develop a recalcitrant CEGA stricture, a standardized therapeutic protocol has been developed and includes instruction in an implementation of self-dilatation with a Maloney dilator. Home use of a Maloney dilator is the simplest, most cost-effective, and efficient means of dealing with this problem. Transferring the care of these patients to a gastroenterologist who typically addresses the problem with multiple time-consuming endoscopic dilatations is expedient but not optimal. Esophageal surgeons should have ready access to a full range of sizes of Maloney esophageal dilators and an established process for issuing them for home use.

OUTCOMES

Since 1976, THE without thoracotomy has been performed by the Thoracic Surgery Service at the University of Michigan Medical Center in more than 3,000 patients. Our experience with the initial 2,000 was reported in 2007. Seventy-six percent of these operations were for carcinoma and 24% for benign disease. Twenty-four percent of the patients were 71 years of age or older and 5% were 80 years of age or older, an increasing number of octogenarians and nonagenarians undergoing THE on our service. Despite initial concerns expressed three

decades ago about the ability of the stomach to reach to the neck in most patients, there is now little question that the properly mobilized otherwise normal stomach will always reach to the neck for construction of a CEGA. Stomach was used as the esophageal substitute in 97% of these operations, only those with a prior gastric resection or those requiring a gastric resection at the time of esophagectomy undergoing a colonic interposition.

Four intraoperative deaths (<1%) occurred as a result of uncontrollable mediastinal bleeding during the THE. Among 3,200 THEs performed at the University of Michigan since 1976, 8 (0.25%) tracheobronchial tears have occurred, 4 repaired through a right posterolateral thoracotomy and 4 through a partial sternal split. All healed without additional postoperative morbidity. Approximately 75% of patients required a chest tube into one or both pleural cavities as a result of violation of the mediastinal pleura during the esophagectomy. Other infrequent intraoperative complications included splenic injury necessitating a splenectomy (3%) and violation of gastric or duodenal mucosa during performance of a pyloromyotomy (<2%), in each case managed successfully by the placement of several 5-0 polypropylene sutures to close the defect and buttressing the closure with adjacent omentum. Postoperative complications included the need to return the patient to the operating room for control of mediastinal bleeding within the first 24 hours in seven patients (<1%) and RLN injury in <5%. If care is taken to avoid placement of any metallic retractors against the tracheoesophageal groove during the cervical portions of the operation, injury to the RLN is rare, in our latest 1,000 patients between 1% and 2%. Less than 2% of our THE patients have experienced pulmonary complications (pneumonia and/or atelectasis) of sufficient severity to prolong their hospital stay. This reflects both the decreased physiologic impact of this type of esophagectomy, which avoids a thoracotomy, and better preoperative preparation by having the patients stop cigarette smoking well in advance of surgery and use an incentive inspirometer. Chylothorax occurred in <1% of our patients and was managed successfully in each case by an aggressive policy of early thoracic duct ligation. More recently, percutaneous thoracic duct embolization by our interventional radiologists has become our initial approach to a post-esophagectomy chylothorax.

Worldwide, the CEGA leak rate averages approximately 14%. It was 13% in our first 1,000 patients to undergo THE and CEGA. However, since adopting the side-to-side stapled CEGA as described in this chapter,

our overall CEGA leak rate is now <3%. Our hospital mortality for THE was 4% in our first 1,000 patients and 1% in our next 1,000 patients. Seventy-one percent of our patients had no postoperative complications. The hospital stay after a THE now averages 7 to 8 days. While an admirable achievement, there is a growing general awareness of the disparity between 30-day and 90-day mortality after esophagectomy, and more data are needed to better define this and improve short-term results.

It must be realized that the functional results of esophageal substitution with stomach are not measured with a satisfactory postoperative barium swallow examination that shows no anastomotic leak and satisfactory emptying of the intrathoracic stomach. Postoperative dysphagia due to anastomotic stricture, posturally related regurgitation, and postvagotomy "dumping" symptoms are all important parameters to be considered. Fortunately, 80% of these patients typically have either an excellent or good result (either no symptoms or occasional cervical dysphagia, regurgitation, or postvagotomy diarrhea requiring no treatment); 17% have a "fair" result (dysphagia requiring an occasional dilation, regurgitation requiring that the patient sleep upright at night, or abdominal cramping or diarrhea after eating requiring medication for control of symptoms); and 3% have a "poor" result (the need for ongoing dilation therapy for a CEGA stricture or aggressive treatment of reflux and intractable dumping symptoms).

The survival of patients undergoing THE for carcinoma has been comparable to that reported for patients undergoing more "radical" esophagectomy and lymph node dissection. The overall actuarial survival rate has been 51% at 2 years and 29% at 5 years, the stage of the resected tumor, as with every patient undergoing an esophagectomy for cancer, being an important determinant of survival after THE. Particularly with the use of neoadjuvant chemoradiation therapy and its potential to eradicate micrometastatic disease, proponents of a direct mediastinal lymph node dissection in patients undergoing esophagectomy have a much weaker argument for a transthoracic approach. Among 583 of our patients who received chemotherapy and radiation therapy before their THE, 125 (21%) were "complete responders" (T0N0 tumor), and their 2-year survival rate was 80% and 5-year survival rate was 58%.

Just as THE generated controversy years ago as a less invasive operation, recent advocates of minimally invasive esophagectomy (MIE) must respond to concerns about this approach. Important operative

principles for a successful THE have clearly been established: preparation of as wide a gastric conduit as possible to preserve submucosal collateral circulation, maximization of the length of the gastric conduit by progressive straightening and cephalad traction with each stapling along the lesser curvatures, a generous Kocher maneuver to facilitate the cephalad reach of the mobilized stomach, a gastric drainage procedure, absolute avoidance of trauma to the tip of the stomach being used for the subsequent esophagogastric anastomosis (no suturing to drains, plastic bags, etc.), direct evaluation and enlargement of the posterior mediastinum by the hand and forearm inserted through the hiatus after extraction of the esophagus to ensure an unimpeded passageway for the gastric conduit, and a CEGA to avoid the risk of mediastinitis associated with an anastomotic leak. With MIE, the stomach is "tubularized" to facilitate mobilization through the hiatus and into the posterior mediastinum that has not been enlarged directly by the hand and forearm and to minimize possible torsion of the intrathoracic stomach that can occur when the right mediastinal pleura has been opened widely; a generous Kocher maneuver is not readily achieved and is often omitted; for the same reason, a gastric drainage procedure may not be done, with predictable increased postoperative problems with gastric emptying; the stomach cannot be "straightened" to the same extent as in the open procedure when it is stapled in situ within the abdominal cavity, thereby increasing tension on the esophagogastric anastomosis and increasing the risk of a leak; and the tip of the mobilized stomach is sutured endoscopically to the divided proximal stomach, traumatizing the area to be used for the anastomosis. As an acknowledgment of the increased anastomotic leak rate due to the above technical issues, proponents of the MIE have gone "full circle" and are advocating an intrathoracic esophagogastric anastomosis, accepting the consequences of mediastinitis from an anastomotic leak in the name of "improved minimally invasive technology." With endoscopic cutting and coagulation for hemostasis, at times too near the trachea or gastric wall, late fistulas between the airway and intrathoracic stomach, seldom seen after a THE, are being reported after MIE. Time will tell whether the added cost and complications associated with MIE warrant general adoption of this technique of esophageal resection.

THE and CEGA are now an established efficient means of treating patients requiring esophagectomy and esophageal reconstruction for both benign and malignant disease. With aggressive preoperative preparation of

the patients and use of epidural anesthesia for postoperative analgesia, our patients are typically extubated in the operating room, are not admitted to the intensive care unit, and are ambulatory the following day. Frequent ambulation and use of the incentive inspirometer are continued postoperatively. The nasogastric tube is removed on the third postoperative day; diet is progressively advanced; and on the seventh postoperative day, a barium swallow examination is obtained to verify that (a) there is no anastomotic leak, (b) the stomach empties adequately through the pyloromyotomy site, and (c) there is no significant obstruction at the site of the feeding jejunostomy tube. Patients are typically discharged after the barium swallow examination on the seventh or eighth postoperative day.

Suggested Readings

Davies AR, Sandhu H, Pillai A, et al. Surgical resection strategy and the influence of radicality on outcomes in oesophageal cancer. *BJS* 2014;101:511–7.

Davis SJ, Zhao L, Chang AC, et al. Refractory cervical esophagogastric anastomotic strictures: management and outcomes. *J Thorac Cardiovasc Surg* 2011;141:444–8.

Devaney EJ, Iannettoni MD, Orringer MB, et al. Esophagectomy for achalasia: patient selection and clinical experience. *Ann Thorac Surg* 2001;72:854–8.

Iannettoni MD, Whyte RI, Orringer MB. Catastrophic complications of the cervical esophagogastric anastomosis. *J Thorac Cardiovasc Surg* 1995;110:1493–501.

Orringer MB. Transhiatal esophagectomy-intraoperative disasters. In: Pawlik TM, Maithel SK, Merchant NB, eds. *Gastrointestinal Surgery: Management of Complex Perioperative Complications.* New York: Springer Publications; 2015:35–51.

Orringer MB, Bluett M, Deeb GM. Aggressive treatment of chylothorax complicating transhiatal esophagectomy without thoracotomy. *Surgery* 1988;104:720–6.

Orringer MB, Marshall B, Chang AC, et al. Two thousand transhiatal esophagectomies—changing trends, lessons learned. *Ann Surg* 2007;246:363–74.

Orringer MB, Marshall B, Iannettoni MD. Eliminating the cervical esophagogastric anastomotic leak with a side-to-side stapled anastomosis. *J Thorac Cardiovasc Surg* 2000;119:277–88.

Orringer MB, Sloan H. Esophagectomy without thoracotomy. *J Thorac Cardiovasc Surg* 1978;76:643–54.

Tsai WS, Levy RM, Luketich JD. Technique of minimally invasive Ivor-Lewis

esophagectomy. *Oper Tech Thorac Cardiovasc Surg* 2009;14(3):176–92.

EDITOR'S COMMENT

Dr. Orringer has written a beautiful and detailed chapter on transhiatal esophagectomy (THE)—an operation that I imagine he has performed literally more often than any other surgeon. This chapter is ripe with very specific technical descriptions and valuable discussions regarding the subtle signs of intraoperative trouble and how to safely and efficiently manage these potential life-threatening complications.

In the current era, the majority of esophagectomies are performed in an open manner and with a thoracotomy and intra-thoracic anastomosis (Ivor Lewis). A recently published review of the Society of Thoracic Surgeons Database reveals that of 3,780 esophageal resections, 62% were either an open transhiatal or Ivor Lewis resection and 22% were performed with a minimally invasive approach (minimally invasive esophagectomy or MIE). Of the open cases, the Ivor Lewis esophagectomy was the most common with 1,291 procedures in the study interval. Open THE was a close second in terms of frequency with 1,065 procedures during the study. From this same manuscript, the morbidity and mortality rates of open and MIE were similar, although MIE was associated with a longer operative time and rate of reoperation. A third type of esophageal resection is known as the McKeown procedure and involves three incisions—an abdominal incision, a right thoracotomy, and a left cervical incision for a cervical anastomosis.

The rationale for a thoracic incision (and accepting the potential morbidity of an intrathoracic anastomotic complication in the case of the Ivor Lewis procedure) is a belief that better visualization of the tumor and a more extensive resection afforded by the thoracic approach including en bloc resection of periesophageal tissue and mediastinal lymph nodes lead to better oncologic outcomes. The transhiatal approach described in this chapter avoids the morbidity associated with a chest incision. This is associated with less pain and fewer pulmonary complications. The cervical anastomosis converts an anastomotic leak from a potentially life-threatening complication with mediastinal sepsis to a non–life-threatening wound complication (and a fistula with increased rate of anastomotic stenosis as also described in this chapter). The fact that there is a roughly equal distribution of transthoracic and transhiatal esophagectomies performed more than 80 years after Turner first described the transhiatal approach is a sign that both techniques are acceptable and there is no current consensus as to the best approach. Decisions regarding surgical technique are frequently based on personal bias, surgeon experience, and comfort with a procedure.

There are a few large meta-analysis published comparing transhiatal to transthoracic esophagectomy in an attempt to determine the most advantageous

approach. Unfortunately, most of the studies included in both meta-analysis are retrospective in nature and were not consistent with regards to technique and therapy in addition to surgery (chemotherapy and radiation before or after surgery). A meta-analysis by Rindani included almost 5,500 patients from 44 series published between 1986 and 1996. Postoperative respiratory and cardiovascular complications were similar with each surgical approach. The transhiatal approach was associated with a higher rate of anastomotic leak and recurrent laryngeal nerve injuries. Thirty-day mortality was 6.3% after transhiatal and 9.5% after transthoracic resection, but survival at 5 years was equivalent. A more recent meta-analysis by Boshier included 5,900 patients in publications up to January 2010. Transthoracic operations took longer and were associated with a significantly longer length of stay. There was no difference in blood loss. The transthoracic group had significantly more respiratory complications, wound infections, and early postoperative mortality, whereas anastomotic leak, anastomotic stricture, and recurrent laryngeal nerve palsy rate was significantly higher in the transhiatal group. Analysis of 5-year survival showed no significant difference between the groups and was subject to significant heterogeneity. A large population-based study has been published, which has evaluated the results of both approaches through the Surveillance, Epidemiology and End Results (SEER)-Medicare linked database from 1992 to 2002. A lower operative mortality was found after THE (6.7% vs. 13.1%). Although observed 5-year survival was higher after THE, after adjusting for stage, patient, and provider factors, no significant 5-year survival difference was found.

The above are important comparisons to bring forward. Dr. Orringer has a massive experience with THE, and the technique he described is developed based on a 40-year experience with the procedure. Even in the past decade since he published the results of 2,000 procedures, he has realized an improvement in morbidity and mortality. Most other surgeons performing esophagectomy will not have the benefit of the experience described here, and no matter how carefully they read Dr. Orringer's chapter would have a hard time replicating his results. There is clearly a volume–outcomes relationship in esophagectomy—a high-risk and complex procedure with a not insignificant rate of morbidity and mortality. I suspect that in esophagectomy, the experience is similar to what we have seen in inguinal hernia surgery—a much more common operation worldwide. While laparoscopic and open mesh-based as well as open tissue-based inguinal hernia repairs are well described with excellent results in terms of morbidity and recurrence rates, no one technique is superior. High-volume, thoughtful, and expert hernia surgeons have excellent results regardless of preferred technique. Like many other things in surgery, do a lot of an operation over a long period and you can get really good results.

I have a few comments on specific topics mentioned in this chapter. First, with regards to smoking cessation prior to surgery, Dr. Orringer describes his strict policy of no cigarette smoking for 3 weeks prior to surgery. There is an

increasing body of literature on this topic when it comes to many different kinds of surgical procedures, and evidence supports this as a sound policy. A recently published collective review revealed that smoking substantially increases the risk of cardiac, respiratory, and septic complications after surgery. Smoking is also linked to inferior long-term surgical outcomes, decreased patient satisfaction, and increased overall costs to the health care system. Importantly, smoking abstinence can avert these negative consequences. This is an important point to which all surgeons should pay attention. Studies show that although up to 75% of smokers who undergo surgery would like to quit, only about half of all surgeons routinely counsel their patients to stop smoking.

As a bariatric and foregut surgeon with a practice full of patients who have failed numerous previous hiatal hernia and antireflux operations, I would suggest that a Roux-en-Y gastric bypass (RYGB) is a better alternative to a THE in patients with two or more failed hiatal hernia repairs. While there is no level-1 evidence to support this suggestion, there is a reasonable body of literature describing RYGB as a salvage operation in failed fundoplication. I agree that these are difficult patients to manage, and surgery of any type should be a last resort.

Overall this is an excellent and very detailed chapter that includes insight and data not available in the published, peer-reviewed literature. Surgeons who perform THE in their practice would be well served to carefully read this chapter, especially the sections where Dr. Orringer describes the intraoperative disasters of massive bleeding and tracheal tear, and his approach to recognizing and managing these issues.

Jon C. Gould

Suggested Readings

Boshier PR, Anderson O, Hanna GB. Transthoracic versus transhiatal esophagectomy for the treatment of esophagogastric cancer: a meta-analysis. *Ann Surg* 2011;254(6):894–906.

Chang AC, Ji H, Birkmeyer NJ, et al. Outcomes after transhiatal and transthoracic esophagectomy for cancer. *Ann Thorac Surg* 2008;85:424–9.

Khullar D, Maa J. The impact of smoking on surgical outcomes. *J Am Coll Surg* 2012;215(3):418–26.

Reames BN, Ghaferi AA, Birkmeyer JD, et al. Hospital volume and operative mortality in the modern era. *Ann Surg* 2014;260(2):244–51.

Rindani R, Martin CJ, Cox MR. Transhiatal versus Ivor-Lewis oesophagectomy: is there a difference? *Aust N Z J Surg* 1999;69:187–94.

Sihag S, Kosinski AS, Gaissert HA, et al. Minimally invasive versus open esophagectomy for esophageal cancer: a comparison of early surgical outcomes

from the society of thoracic surgeons national database. *Ann Thorac Surg* 2016;101(4):1281–8.

Yamamoto SR, Hoshino M, Nandipati KC, et al. Long-term outcomes of reintervention for failed fundoplication: redo fundoplication versus Roux-en-Y reconstruction. *Surg Endosc* 2014;28:42–8.

79 Esophageal Perforation

Eric M. Pauli and Jeffrey M. Marks

INTRODUCTION

Esophageal perforation is a process with numerous etiologies and presentations that carries significant morbidity and mortality if not managed appropriately and aggressively. Novel, less invasive techniques and tools have helped to replace prior more debilitating treatments such as esophageal diversion and/or major thoracic or abdominal surgery. An understanding of the pathophysiology, clinical presentation, available management tools/algorithms, and techniques for treatment are all vital to safely managing these complex patients.

ETIOLOGY

Spontaneous Perforation

Spontaneous esophageal perforations have been well described since the Dutch physician Hermann Boerhaave reported the case of the Grand Admiral of Holland who died as a result of a “spontaneous” rupture of the esophagus in 1724. Spontaneous perforation refers to cases where there is no preceding trauma, intervention, or caustic exposure. Any activity that acutely increases the intraesophageal pressure can lead to perforation. Although the majority of cases are thought to be related to aggressive vomiting, other processes leading to this acute intraesophageal pressure may lead to full-thickness disruption of the esophageal wall. Reported cases have occurred after excessive lifting, laughing, gagging, or seizure activity.

Spontaneous perforations predominantly occur in the distal esophagus, with mid-esophageal and cervical esophageal perforations being quite rare. The anatomy of the esophagus must be understood in that the distal 3 to 4 cm of the esophagus is intra-abdominal and therefore perforations may lead to mediastinal and thoracic soilage but also intra-abdominal contamination based on the site of the perforation (Fig. 79.1).

Unlike iatrogenic perforations, which usually result in tears comparable

to the associated tool/intervention, spontaneous perforations routinely lead to very long, longitudinal defects with irregular edges. This may complicate surgical or endoscopic repair leading to a more challenging and less effective intervention.

Traumatic Perforation

Penetrating trauma and less commonly blunt trauma can result in esophageal perforation, with the site of perforation related to surrounding anatomical structures. Stab and gunshot wounds to the neck, mediastinum, and upper abdomen may all lead esophageal perforation. Due to the unprotected nature of the cervical esophagus, this is the most commonly injured area following penetrating trauma. The intrathoracic esophagus is well protected by the chest wall and other mediastinal structures and is therefore less commonly involved following penetrating trauma. Isolated esophageal injuries are rare, and associated organ injuries to vascular, pulmonary, and mediastinal structures should be anticipated and addressed. Blunt trauma as a source for esophageal perforation is less common and may be difficult to diagnose in patients with multiorgan blunt injury.

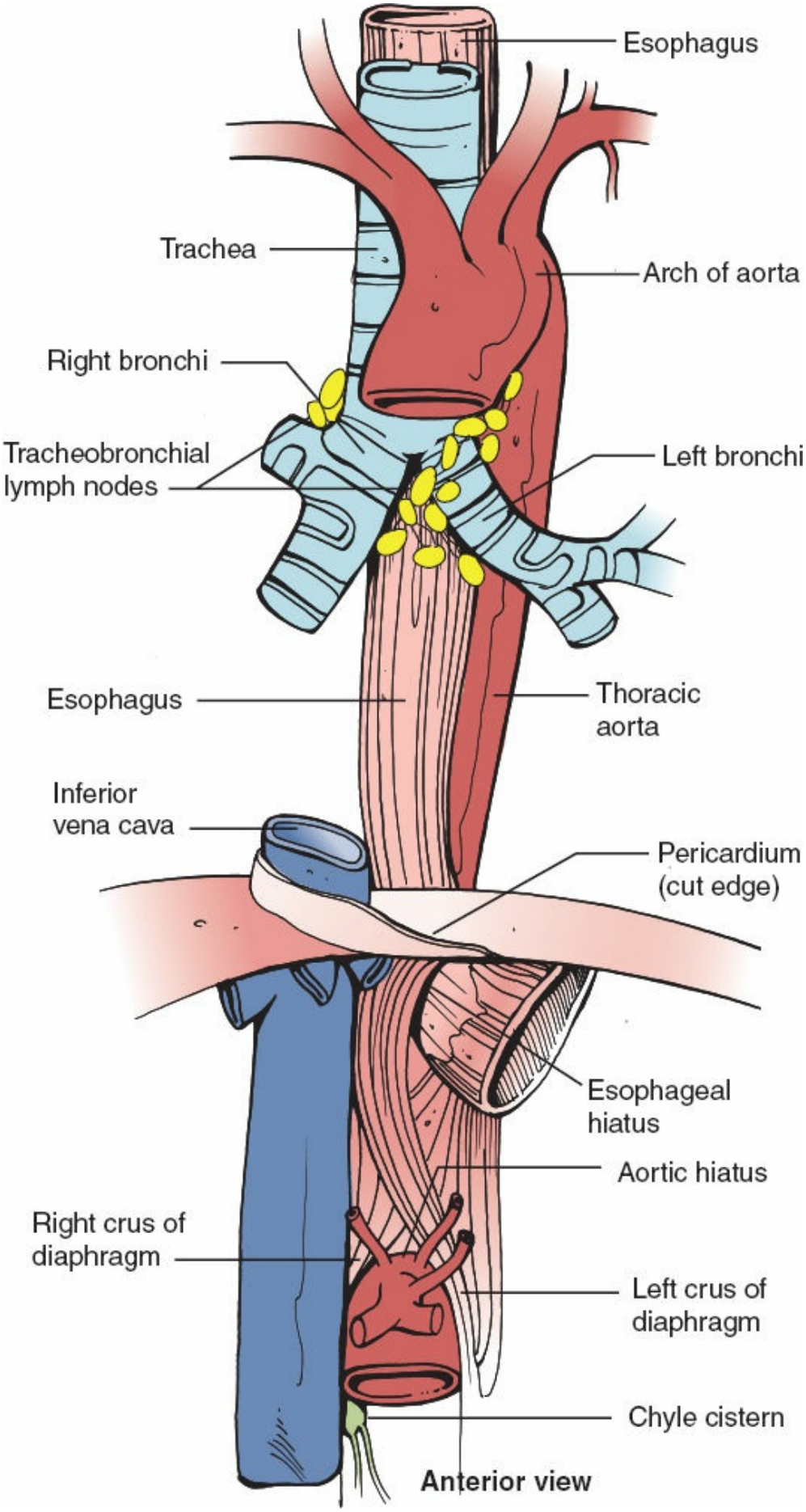
Esophagus
Trachea
Arch of aorta
Right bronchi
Tracheobronchial lymph nodes
Left bronchi
Esophagus
Thoracic aorta
Inferior vena cava
Pericardium (cut edge)
Esophageal hiatus
Aortic hiatus
Right crus of diaphragm
Left crus of diaphragm
Chyle cistern
Anterior view

Figure 79.1. The cervical esophagus lies in the neck, bordered superiorly by the hypopharynx and inferiorly by the thoracic inlet, which lies at the level of the sternal notch. Typical endoscopic measurements for the cervical esophagus measured from the incisors are from 15 to <20 cm. The upper thoracic esophagus is bordered superiorly by the thoracic inlet and inferiorly by the lower border of the azygos vein. Typical endoscopic measurements from the incisors are from 20 to <25 cm.

Iatrogenic Perforation

Iatrogenic perforations represent the most common etiology for esophageal perforation and may occur at the time of an esophageal intervention such as nasogastric tube placement or endoscopic procedures, or doing a nonesophageal procedure such as endotracheal intubation with inadvertent tube placement into the esophagus.

Diagnostic flexible esophagogastroduodenoscopy (EGD) is rarely associated with esophageal perforations, but predominantly will occur in the cervical esophagus and are related to both technical issues and underlying anatomical issues. Forceful advancement of the endoscope may lead to cervical esophageal perforation and is more commonly seen in placement of endoscopic ultrasound scopes, side-viewing duodenoscopes, or transesophageal echocardiogram probes, due to the lack of luminal view with advancement of the scope. Anatomical considerations such as cervical ribs, vertebral osteophytes, Zenker diverticulum, prior radiation, neoplasms, and esophageal strictures may be associated with an increased risk of perforation of the cervical esophagus with endoscopic evaluations. Rigid esophagoscopy, which is not commonly performed, was associated with higher rates of perforation as compared to flexible endoscopy.

Therapeutic endoscopic procedures are more commonly associated with perforations than diagnostic procedures and again are related to both technical and anatomical considerations. Esophageal dilation with both balloons and rigid dilator systems can lead to perforation. Dilation with pneumatic balloons (30 to 40 mm diameter) for achalasia is associated with a rate of perforation of 1% to 5%. Prior dilations and larger balloon size lead to higher risk of perforation. Rigid dilation using wire guided systems (Savory or Maloney dilators) may lead to perforation at the cervical esophagus as well as at the more distal site of stricture being addressed by the dilation. Fluoroscopy will help guide wire placement and position, but does not eliminate the risk of perforation. Anatomical

considerations that increase the risk of perforation are the same as those associated with perforation from diagnostic endoscopic procedures. In addition, dilation of esophageal malignancies, radiation induced strictures, complex strictures, long segment strictures, and those following prior dilation have a greater risk of perforation.

Esophageal stent placement rarely leads to perforation, but predominantly occurs at the site of the stenosis or stricture, and is related to either inappropriate transluminal wire position or forceful advancement of the rigid deployment system without fluoroscopic guidance. Delayed perforations resulting in aortoesophageal fistula, pulmonary fistulae (tracheobronchial), or mediastinitis may occur as a result of radial forces of the esophageal stent at the site of the stenosis/stricture, or at the proximal or distal end of the stent where the metal prongs may erode through the esophageal wall. Lengthy stent placement beyond 8 weeks may increase this complication, as well as placement of too wide of a stent in a very tight malignant or benign stricture.

Endoscopic mucosal ablation or resection may also lead to perforation. Prior ablative therapies such as photodynamic therapy (PDT) were associated with risks of stricture and very low risks of perforation. Radio frequency ablative therapies which have now replaced PDT rarely result in perforation and are mostly related to technical errors in passage of the ablative balloons.

Endoscopic resection of esophageal lesions is divided into mucosal resection (endoscopic mucosal resection—EMR) and submucosal dissection (endoscopic submucosal dissection—ESD). EMR entails removal of smaller lesions either in piece meal fashion or following engagement of the tissue with either placement of a rubber band, or suctioning of tissue into a cap. The captured tissue is then removed via thermal snare resection. Perforation can occur if deeper tissues are captured, leading to a full-thickness resection. Perforation rates are related to clinician experience as well as prior endoscopic therapy at the same site. ESD or en bloc resection similarly is associated with perforation based on the same factors.

Esophageal perforation at the time of surgery can occur during any neck dissection resulting in cervical esophageal injury (e.g., thyroidectomy, cervical spine treatment, carotid endarterectomy, and tracheostomy). Intrathoracic esophageal injury is most commonly related to thoracic aortic surgery and less commonly spinal surgery. Intra-abdominal esophageal

injury is the most common and related to foregut or hiatus surgery (e.g., paraesophageal hernia repair, Nissen fundoplication, Heller myotomy, gastric bypass, and gastrectomy). Intraoperative endoscopy at the time of any foregut surgery will help to quickly identify any breach in esophageal integrity and allow for immediate repair rather than having a delayed presentation with associated increased morbidity.

Iatrogenic drug–induced perforations are not common and are related to both the medication and the presence of any esophageal dysmotility disorders or anatomical abnormalities (e.g., scleroderma, achalasia, Schatzki ring, peptic stricture, and esophageal diverticulum), allowing for increased mucosal exposure to the offending agents. The most likely medications associated with perforation include potassium chloride, NSAIDs, quinidine, and any sustained release formulas in the presence of delayed passage into the gastric lumen.

OTHER NONIATROGENIC PERFORATIONS

Caustic Injury

Caustic injuries to the esophagus leading to perforation are related to both the offending agent and the performance of endoscopic evaluation or nasogastric tube placement, if not done carefully. Therefore, perforations can occur as either an early or delayed process. Liquefactive necrosis of the esophagus following lye ingestion may lead to full-thickness necrosis and resultant perforation, occurring as late as 5 days post insult.

Infectious Injury

Infectious sources for esophageal perforation are quite rare. Esophageal candidiasis, herpetic esophagitis, and cytomegalovirus esophagitis have all been published in case reports as source for esophageal perforation. Immunocompromised patients and those with esophageal dysmotility disorders are at increased risk of these infectious processes.

Foreign Body Injury

Esophageal perforation related to foreign body ingestion can occur immediately or as a delayed presentation. The site of the injury is related to underlying anatomical site of impedance to bolus transit such as the upper esophageal sphincter, lower esophageal sphincter, or strictures/webs. Perforation of sharp foreign bodies may present immediately or within 1 to

2 days, and pressure necrosis and resultant perforation from impacted food or other object can lead to a delayed presentation.

PATHOPHYSIOLOGY

The anatomical position of the esophagus as it traverses through the neck, mediastinum, and peritoneal cavity results in different inflammatory responses to perforation. In addition, the structure of the esophagus (with a lack of serosal surface) allows for unabated periesophageal infection following disruption of the mucosal and muscular tissues. Perforation of the cervical esophagus leads to a localized periesophageal abscess in the neck, most commonly on the left side. As the esophagus enters into the thoracic cavity, it courses along the right side of the mediastinum and mid-esophageal perforation therefore in addition to mediastinitis can result in empyema of the right chest. Finally, as the esophagus traverses the diaphragmatic hiatus, it is on the left side, although it must be understood that proximal to the gastroesophageal junction, there is a component of intraperitoneal esophagus. Distal esophageal perforations therefore may lead to either a left-sided empyema or subdiaphragmatic infection, that is, peritonitis.

The ensuing infectious and inflammatory response is secondary to the vast polymicrobial aerobic and anaerobic pathologic flora that exists in the oropharynx. Contamination of the affected site is related to swallowed saliva and food, as well as from reflux of gastroduodenal contents (i.e., gastric acid, bile, pancreatic secretions). Patients who are immunosuppressed may have bacterial and fungal flora in the mouth and foregut, and those patients on acid suppressive therapy will have greater bacterial counts in the gastric lumen, allowing for more intense infectious processes.

CLINICAL PRESENTATION

Patients with esophageal perforation will have presenting symptoms and signs based on the timing of the injury, the site of the perforation, and underlying comorbid diseases. As stated above, the course of the esophagus from the left cervical region to the right mediastinum and finally back to the left chest prior to entry into the abdomen will help define the diagnosis and site of perforation. As with all patients, a thorough history and physical is required including timing and type of intervention or suspected injury, any anatomical or surgical abnormalities,

and all underlying comorbid diseases and medications.

Cervical Esophageal Perforation

A cervical perforation from either iatrogenic or noniatrogenic causes will lead to a periesophageal inflammatory process in the neck. Pain, chills, drooling, dysphagia, and odynophagia may be common complaints. On physical examination, fever or tachycardia may be present. Subcutaneous cervical emphysema or skin changes, tenderness, fullness, or tracheoesophageal deviation may be signs of cervical esophageal perforation and resultant abscess. Earlier presentation following injury may result in less severe physical findings and more vague clinical complaints.

Mid-Esophageal Perforation

Mid-esophageal perforation and resultant mediastinitis will result in systemic inflammatory response but less succinct physical findings. Patients may complain of centralized chest or back pain, malaise, chills, shortness of breath, pleuritic chest pain, as well as dysphagia and odynophagia. Physical findings of fever, tachycardia, hypotension, auscultatory rales, and muffled heart tones may be present, although complete lack of physical findings may occur. Hamman sign, a crunching sound synchronized with the heartbeat, may be auscultated if there is significant pneumomediastinum associated with the perforation.

Distal Esophageal Perforation

Similar to mid-esophageal perforations, patients may present with complaints of pleuritic chest pain, although now on the left side, chills, malaise, shortness of breath, as well as abdominal pain. Physical findings also may be similar with the addition of signs of peritonitis including guarding and diffuse abdominal tenderness.

DIAGNOSIS

Diagnosis of esophageal perforation requires a high index of suspicion based on history and patients physical presentation. A thorough review of interventions performed or suspected source for injury is helpful in identifying the presence and site of perforation. Although history and physical exam may help predict the presence of a perforation, confirmation

of the diagnosis is routinely based on radiographic imaging or endoscopic findings. Chest x-ray may reveal subcutaneous emphysema in the neck, pneumomediastinum, left or right pleural effusions or pneumothoraces, and pneumoperitoneum. These radiographic findings will help guide the diagnosis of the site of injury based on descriptions above. Plain radiographic studies may confirm suspicion of a perforation but most likely will not lead to a definitive diagnosis. CT scan of the neck, chest, and abdomen may show more succinctly the hallmark signs of esophageal perforation including extraluminal air or fluid in the periesophageal tissues. Extravasation of contrast as well as any identified inflammatory processes with resultant abscess or fluid collections will help guide treatment.

Oral contrast radiographic images, however, are the true definitive diagnostic study. In patients with an aspiration risk (i.e., suspected impacted foreign body), Gastrografin should be avoided due to the resultant severe pulmonary inflammatory and edematous process which can follow aspiration. In these scenarios, dilute barium is preferred. False-negative contrast studies do occur, and if suspicion remains high for perforation in the face of a normal contrast study, patients should continue to be treated as if a perforation is present. Positive studies may reveal free extravasation of contrast into the chest or peritoneal cavity or merely a contained leak (Fig. 79.2). Clinical presentation in conjunction with radiographic findings will guide appropriate therapeutic interventions.

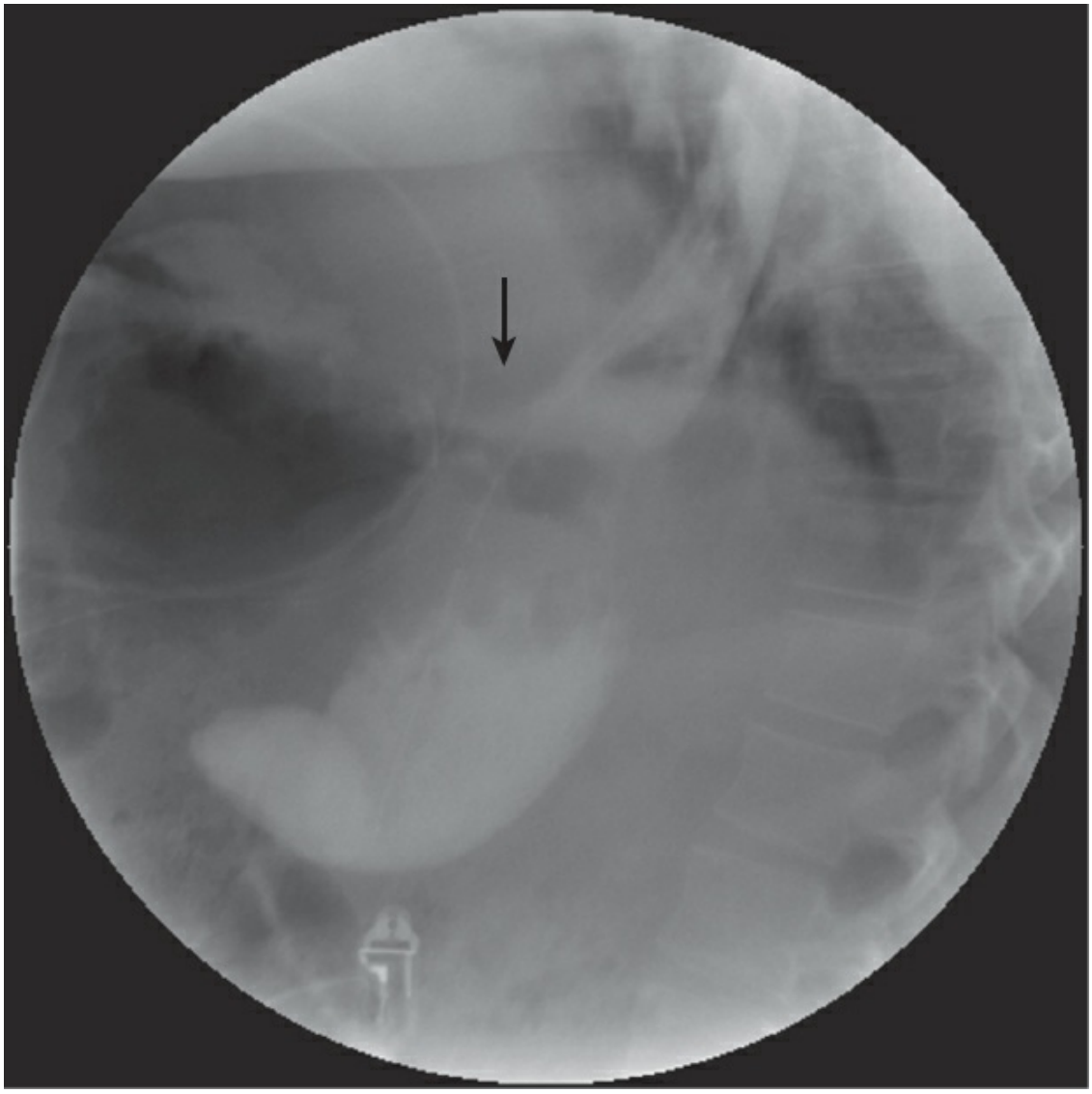

Figure 79.2. Lateral fluoroscope image demonstrating an anterior perforation of the abdominal esophagus with uncontained contrast leak in a patient who had uncontrolled retching while mechanically ventilated following a hernia repair.

Esophageal perforation was previously considered a contraindication to flexible endoscopy. However, with increased clinical experience, as well as development of endoscopic therapies to treat esophageal perforation, endoscopic evaluation is now a vital component of the workup in suspected esophageal perforation. In the presence of equivocal radiographic findings, endoscopy may help confirm or exclude actual presence of this process. In addition, the extent of associated mucosal damage/ischemia can be determined. Injection of contrast via the endoscope at a suspected site of perforation can also increase the potential for confirmation of diagnosis.

Care must be taken of course when performing flexible endoscopy in the face of suspected perforation with careful advancement of the endoscope and utilization of carbon dioxide insufflation rather than room air.

PREOPERATIVE PLANNING

Patients with suspicion for esophageal perforation require expedient confirmation of diagnosis followed by directed therapy to treat systemic responses to the severe inflammatory process, as well precautions to minimize further extraluminal contamination. The degree of systemic response is related to the site of injury, timing of presentation, and underlying pathology and comorbid diseases. For those patients unable to manage their own oral secretions due to associated esophageal obstruction or periesophageal abscess, immediate airway control with endotracheal intubation is imperative.

Localized source control with directed drainage (i.e., thoracentesis, thoracostomy tube, incision, and drainage of neck abscess) may be necessary to confirm diagnosis and alleviate pulmonary and septic consequences. Broad-spectrum antibiotics with coverage of gram-negative and gram-positive aerobes, anaerobes, and fungal organisms are recommended. Those patients who are immunosuppressed may require antiviral medications as well.

Despite the potential devastating complications of esophageal perforations, nonsurgical management of carefully selected patients has been described in multiple reports. Medical therapy with intravenous antibiotics, nasogastric decompression, and parenteral nutrition was first described by Cameron et al. in 1979 and has been studied and modified since that time. Guidelines for such conservative therapy include (1) patients who are clinically stable with minimal signs of sepsis on presentation (and do not develop them during therapy), (2) instrumentation type (generally iatrogenic) perforations in which the patient had been on a regime of nothing-by-mouth (NPO) in the period surrounding the perforation, (3) perforation is detected early (or the patient presents late but has developed “tolerance” to the perforation, and (4) perforation is contained within the neck, mediastinum, or abdomen with no free extravasation of contrast (perforation drains back into the esophagus) and no signs of crepitus, pneumothorax, or pneumoperitoneum.

For patients not meeting these criteria, or who fail conservative

management, surgery is indicated. Regardless of the location of the perforation, the goals of therapeutic intervention are the same; to prevent further contamination through the luminal defect; to restore gastrointestinal (GI) tract continuity (if possible); to manage the sequelae of neck, mediastinal, pleural or peritoneal infection (including the debridement of all necrotic or infected tissues); and to provide a route for enteral (or parenteral) nutrition.

SURGICAL TECHNIQUES

Surgical Approach

The surgical approach to an esophageal perforation depends on the location of the perforation, the patient's clinical condition, the age of the perforation, and the tools/skill set available to the surgeon. Flexible GI endoscopy, minimally invasive (thoracoscopy or laparoscopy), and open surgery (via the neck, chest and/or abdomen) all have a role in the surgical management of esophageal perforation.

Perforation of the cervical esophagus can usually be exposed through an oblique incision in the left neck. The sternocleidomastoid muscle is retracted laterally and the omohyoid muscle and middle thyroid vein divided. By retracting the trachea medially, blunt dissection can be used to free the esophagus into the mediastinum (Fig. 79.3).

Perforation in the upper two thirds of the thoracic esophagus can be approached through a right posterolateral thoracotomy in the fourth, fifth, sixth, or seventh intercostal space (depending on the level of the perforation). The perforation of the lower third of the thoracic esophagus can be approached through a left posterolateral thoracotomy in the sixth, seventh, or eighth intercostal space. Following thoracotomy, the lung is retracted anteriorly and the esophagus identified and encircled with a Penrose drain for retraction.

If the perforation is in the abdominal esophagus, the esophagus can be approached through an upper midline laparotomy. Mobilization and rightward retraction of the left lateral segment of the liver facilitates access to the esophageal hiatus. Division of the short gastric vessels not only facilitates exposure but provides mobilized fundus to utilize as a buttress later in the repair.

Minimally invasive approaches for the management of the esophageal perforation (thoracoscopy or laparoscopy) rely on port placement similar to other minimally invasive esophageal surgeries (such as esophagostomy

or Heller myotomy). Port placement (right chest, left chest or abdominal) depends on knowledge of the location of the perforation as outlined above.

While initially applicable only to early, uncontaminated perforations, advances in minimally invasive technology and techniques now enable surgeons to perform more complex esophageal perforation repairs via thoracoscopy and laparoscopy. Similarly, advances in therapeutic flexible endoscopy over the last decade have permitted endoscopic tools to be applied to an ever widening array of esophageal perforation types.

ENDOSCOPIC MANAGEMENT

At centers with a high level of expertise in therapeutic flexible endoscopy, endoscopic interventions can be used to eliminate, replace, or augment many of the traditional surgical methods. Endoscopic management of esophageal perforation requires coordination with a multidisciplinary team, as the endoscopist may not possess the necessary skill or knowledge to address the surgical aspects of the disease process. All endoscopy performed in the setting of a perforation should be conducted utilizing low pressure carbon dioxide insufflation with the standard high pressure room air endoscope pump maintained off throughout the procedure. Failure to use carbon dioxide can quickly result in high pressure room air entering the mediastinum, pleural cavity, or peritoneum, resulting in rapid cardiopulmonary decline. Such pressure can also disrupt a contained perforation and result in air that can linger clinically and on imaging studies for weeks after the procedure, potentially creating a diagnostic dilemma (i.e., concern for an ongoing leak).

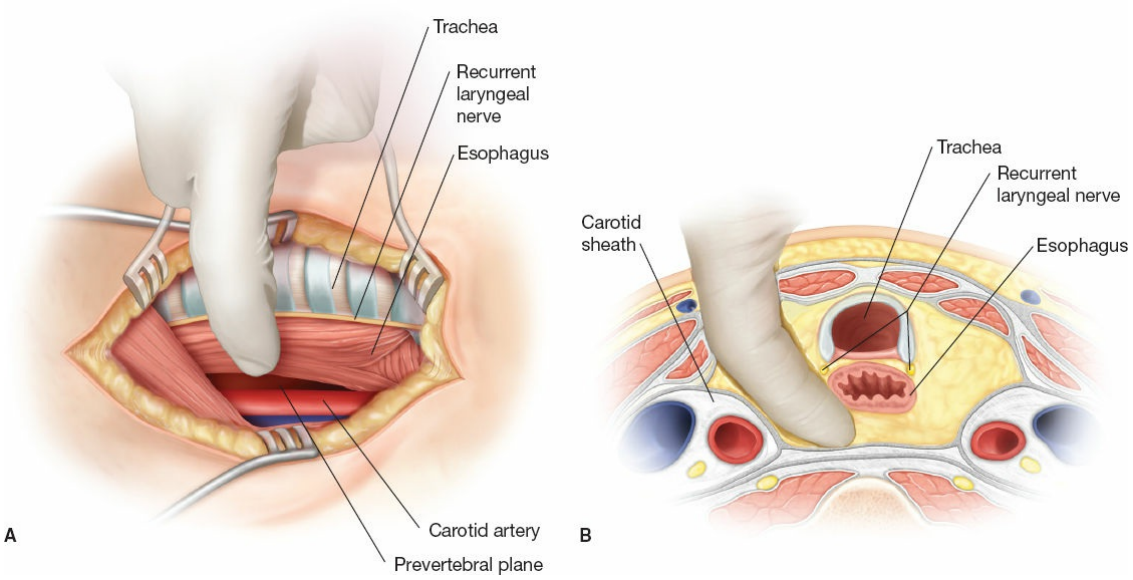

Figure 79.3. A. Transverse section showing the prevertebral space. Dissection is carried out medial to the carotid sheath. The recurrent laryngeal nerve is protected within the tracheoesophageal groove. **B.** Lateral view of the dissected prevertebral space with trachea, esophagus, and recurrent laryngeal nerve retracted anteriorly.

ENDOSCOPIC STENTING

Managing an esophageal perforation with a fully or partially covered endoscopic stent is a commonly employed method for a patient who cannot tolerate a thoracotomy. Stents are deployed under endoscopic and/or fluoroscopic guidance across the area of perforation. The use of stents for this purpose is an off label indication which should be disclosed to the patient. Stents do not result in complete exclusion of the area of perforation; leak around the stent (from both above and below), or through the stent (through imperfections in the polymer coating) are a near universal finding on contrast imaging studies. Patients undergoing stent management of their perforation will still require drainage of any pleural or peritoneal fluid collections and will still need enteral feeding access. Stents placed in the absence of a stricture or tumor have a high rate of migration. Such migration can result in the perforation no longer being covered. Stents cannot be placed across the cervical esophagus (due to pain, sensation of globus, and high migration rates). Stents placed across the gastroesophageal junction result in a high rate of gastric reflux. Patients with distal esophageal perforations being managed with a stent should be fed postpyloric to reduce the risk of tube feed-related reflux and aspiration.

ENDOSCOPIC DEFECT CLOSURE

Endoscopic clips that are passed through the endoscopic working channel and are deployed within the lumen of the GI tract were initially designed for hemostasis and endoluminal marking. They are also referred to as through the scope clips (TTSCs), hemoclips, and endoclips. TTSCs have been shown to be successful in closing iatrogenic defects in the GI tract. Limitations to their success are their small size, small closing force, and mucosa-only tissue apposition; although in the right setting such as small defects that are not gaping, they can be quite effective. Larger defects are more likely to be unsuccessfully managed with TTS clips and therefore

surgeons receive a biased view of the true success rate of the most commonly applied endoscopic therapy.

Over the scope clips (OTSCs, Ovesco Endoscopy, Tubingen, Germany and Padlock, Aponos Medical, Kingston, NH) have gained popularity for the closure of GI tract defects. Their ease of use, large capacity caps, and short learning curve are the factors responsible for their surge in use. Ovesco OTSC are made of elastic, biocompatible nitinol and are capable of full-thickness closure of defects measuring 2 cm in diameter (Fig. 79.4). Because of the larger size of OTSC compared to TTSC, they are able to close larger defects and take full-thickness bites of the tissue. They also provide a larger closure force due to their design. The downside to these OTSC devices is that they have a large outer diameter profile and passage of these may lead to the perforation of the esophagus. Airway protection with endotracheal intubation is routinely required during their placement.

The endoscopic suturing platform (Overstitch, Apollo Endosurgery, Austin, TX) is a disposable device that is attached to the end of a therapeutic double channel endoscope. It allows for the placement of full-thickness absorbable or nonabsorbable sutures. The device can be used multiple times without the need to remove the scope from the patient. The sutures can also be applied in a running or interrupted fashion (including simple and figure-of-eight sutures). Since its introduction, it has been successfully used in the closure of esophageal fistulae, acute perforations, and at sites of full-thickness endoscopic resection.

ENDOSCOPIC ENTERAL ACCESS

Enteral feeding access can be obtained in the majority of situations. Percutaneous endoscopic gastrostomy (PEG) tube placement (via Ponsky pull method) can be safely performed in the setting of many esophageal perforations. If concern exists about passing gastrostomy per os, then an introducer method of gastrostomy insertion utilizing GI T-anchors may be employed. A jejunal extension to the gastrostomy (PEG-J) or a direct percutaneous endoscopic jejunostomy (PEJ) should be considered for postpyloric feeding in patients with known gastroesophageal reflux disease (GERD), hiatal hernia, gastroparesis, or if an endoscopic stent will be placed across the gastroesophageal junction. For patients with a hostile abdomen, who are not suitable candidates for PEG or PEJ, an endoscopically placed nasojejunal feeding tube can be considered.

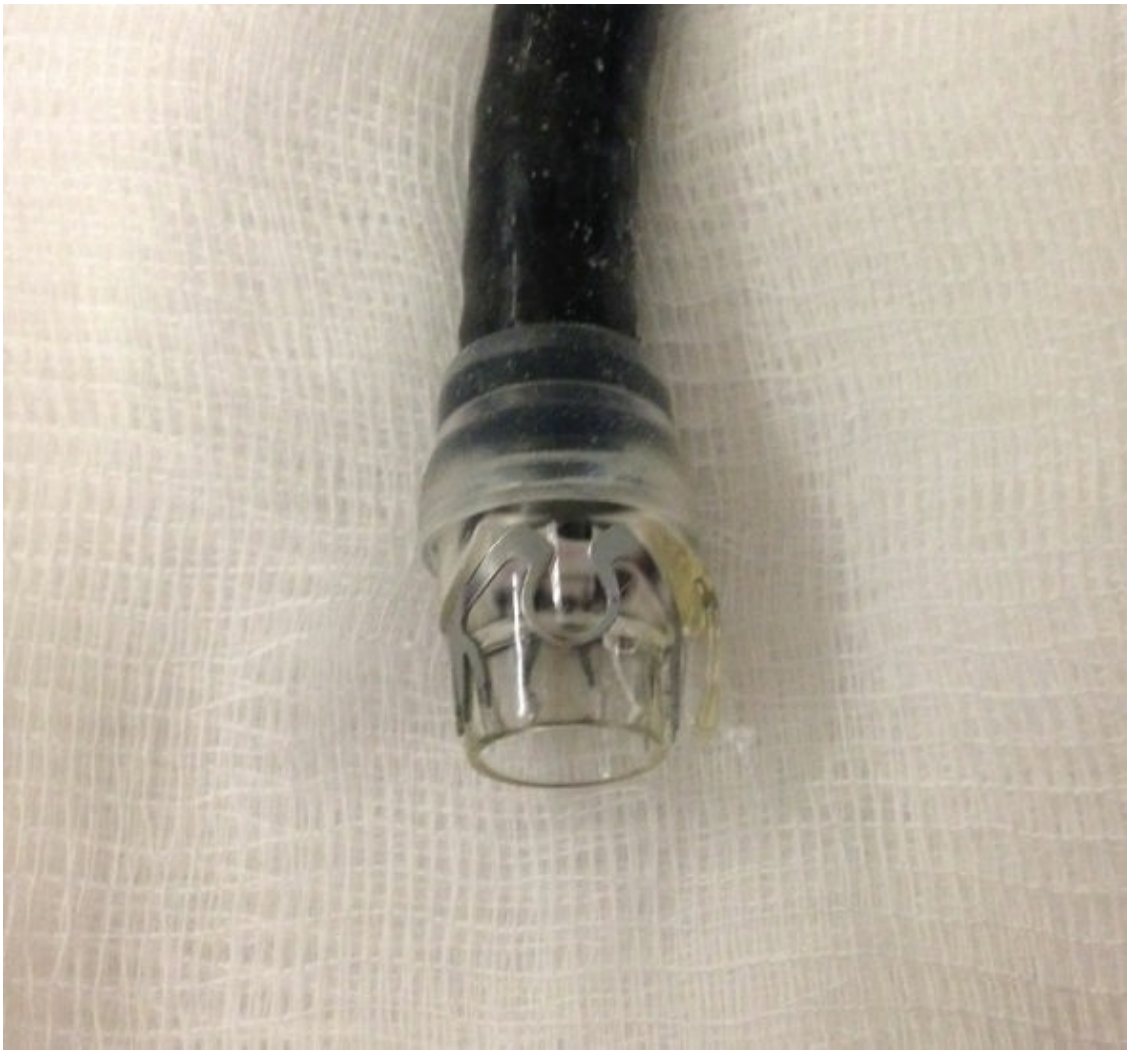

Figure 79.4. Ovesco OTSC mounted on the distal tip of a therapeutic endoscope and ready for deployment at a defect 2 cm or less in size.



Figure 79.5. Vacuum-assisted closure device composed of a porous sponge sutured to a nasogastric decompression tube.

ENDOSCOPIC VACUUM-ASSISTED DEVICES

Vacuum-assisted sponge closure has been used in the setting of chronic esophageal perforations in stable patients. Porous sponge foam is cut to be just smaller than the defect and sutured to the end of a nasogastric decompression tube (Fig. 79.5). This is then grasped with endoscopic graspers and introduced into the defect. The nasogastric tube is then maintained on continuous external suction which minimizes secretions escaping through the defect while increasing blood flow to the area. Furthermore, the sponge induces granulation of the surrounding tissue and promotes healing. Sponges need to be changed every 2 to 3 days. Small defects with adjacent nonseptated fluid collections are more amenable to this therapy.

SURGICAL MANAGEMENT

Primary Closure

Primary closure of the perforation is the most frequently used and most preferable method of surgical treatment. The most important goals of a primary closure are debridement of all nonviable tissue and closure of the

esophageal mucosa and muscle in separate layers. Because the mucosal rent may extend beyond the muscular tear, the muscle layer should be incised to delineate the full length of the mucosal defect to allow complete closure (Fig. 79.6). The mucosal layer is repaired with interrupted absorbable sutures and the muscular layer with interrupted permanent sutures taking care not to narrow the esophageal lumen (Fig. 79.7). A nasogastric tube or endoscope is inserted above the suture line to permit a bubble leak test to be performed with the suture line submerged in saline. Absence of air bubbles indicates an intact suture line. The nasogastric tube is advanced across the repair site and positioned within the stomach.

Depending on the ease of closure and the quality of the esophageal tissue, reinforcement of the closure with healthy tissue flap may be added. If indicated, the lung is decorticated to ensure full reexpansion. A large caliber thoracostomy tube is positioned posterior in the chest cavity near the lateral boarder of the vertebral column to evacuate the pneumothorax, permit full lung expansion, reduce the risk of empyema, and manage any recurrent esophageal leak. For cervical or abdominal perforations, a Jackson-Pratt or Blake drain is positioned near the repair.

Reinforcement of Primary Closure

Reinforcement of the primary closure with well-vascularized tissue is recommended to reduce the risk of postoperative leakage in the cases of late presentation or delayed diagnosis (>24 hours). In cases where the muscle layer cannot be identified or cannot be closed, the mucosa should be securely closed and the reinforcement becomes mandatory.

Native tissues for reinforcement include a pleural flap in the cases with thickened pleura (Fig. 79.8), a pericardial fat pad flap, a diaphragmatic flap (Fig. 79.9), or an omental flap. The gastric fundus can be mobilized and used to cover the distal thoracic and abdominal esophagus (Fig. 79.10). The pectoralis major muscle or the sternocleidomastoid muscle can be used as a cover for the cervical esophagus (Fig. 79.11). Flaps constructed from the serratus, pectoralis major, and latissimus dorsi muscles have been used to close upper thoracic esophageal perforations. By and large, however, an intercostal musculopleural flap is the most commonly used tissue for reinforcement.

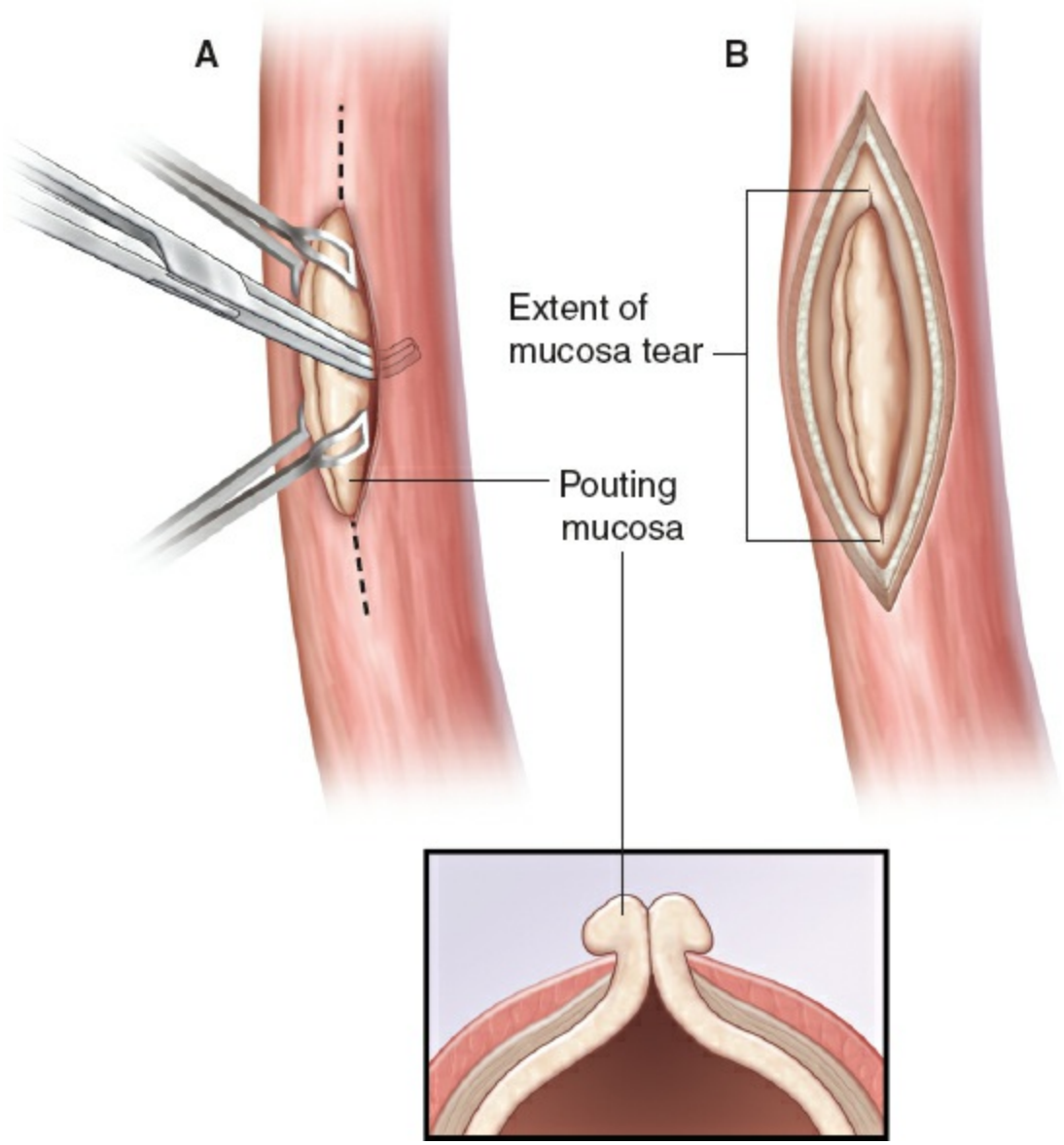

Figure 79.6. **A.** Mucosa pouting through the muscular defects is grasped with clamps. The proximal and distal esophageal myotomy is extended to visualize the full extent of the mucosal perforation. **B.** The entirety of the mucosal and submucosal perforation is visualized in preparation for debridement and closure.

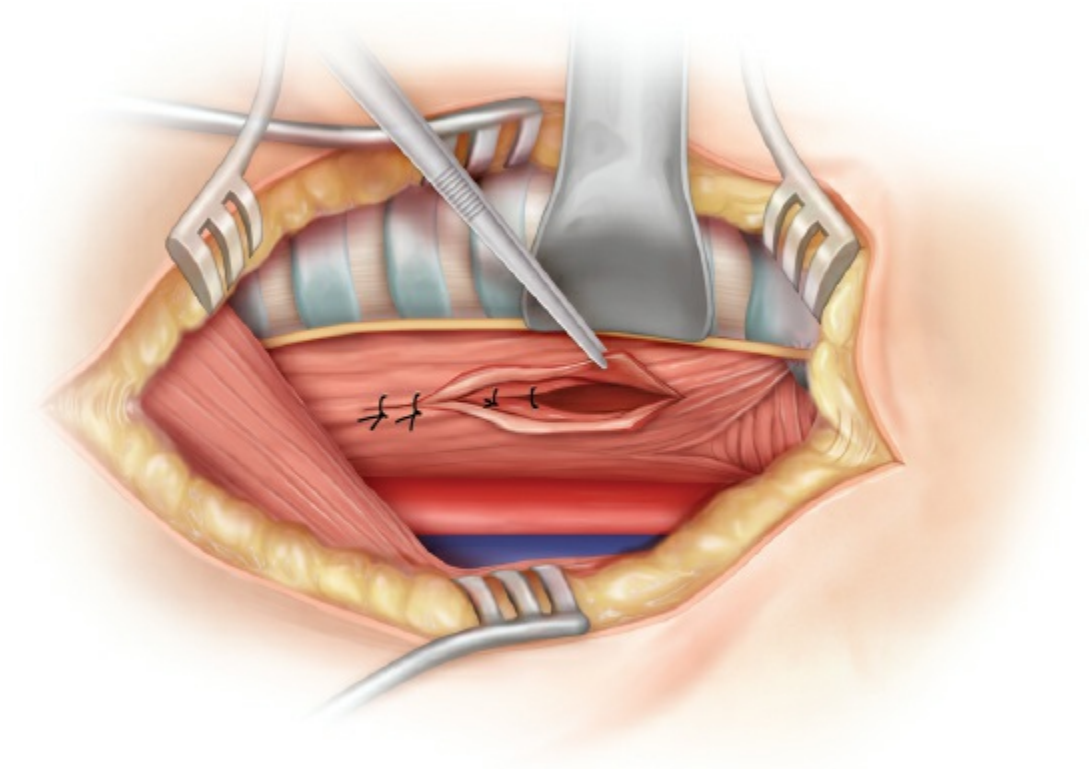

Figure 79.7. Primary repair of esophageal perforation in two layers of simple interrupted sutures. An inner layer of absorbable suture on the mucosa and an outer layer of permanent suture on the muscular layer.

If the procedure is being conducted as an open thoracotomy, the periosteum of the rib below the incision is incised and stripped from its upper border, and the periosteum, pleura, and the intervening intercostal muscle bundle with associated neurovascular bundle are then mobilized for the full extent of the thoracotomy incision (Fig. 79.12). To ensure the flap is of adequate length to reach the esophagus, an umbilical tape can be used to mark the distance needed for adequate length. To create a flap that terminates in a spatulated fashion, a generous width of pleura is resected anteriorly. The spatulated end ensures sufficient tissue coverage of a longer length of repair. The flap is transected anteriorly, is rotated posterior in the thorax, applied to the site of the esophageal repair, and carefully sutured to the muscle closure or muscle remnants (Fig. 79.13). The excess pleura is fixed to whatever mediastinal tissue is available to maintain the flap in position and prevent rotation.

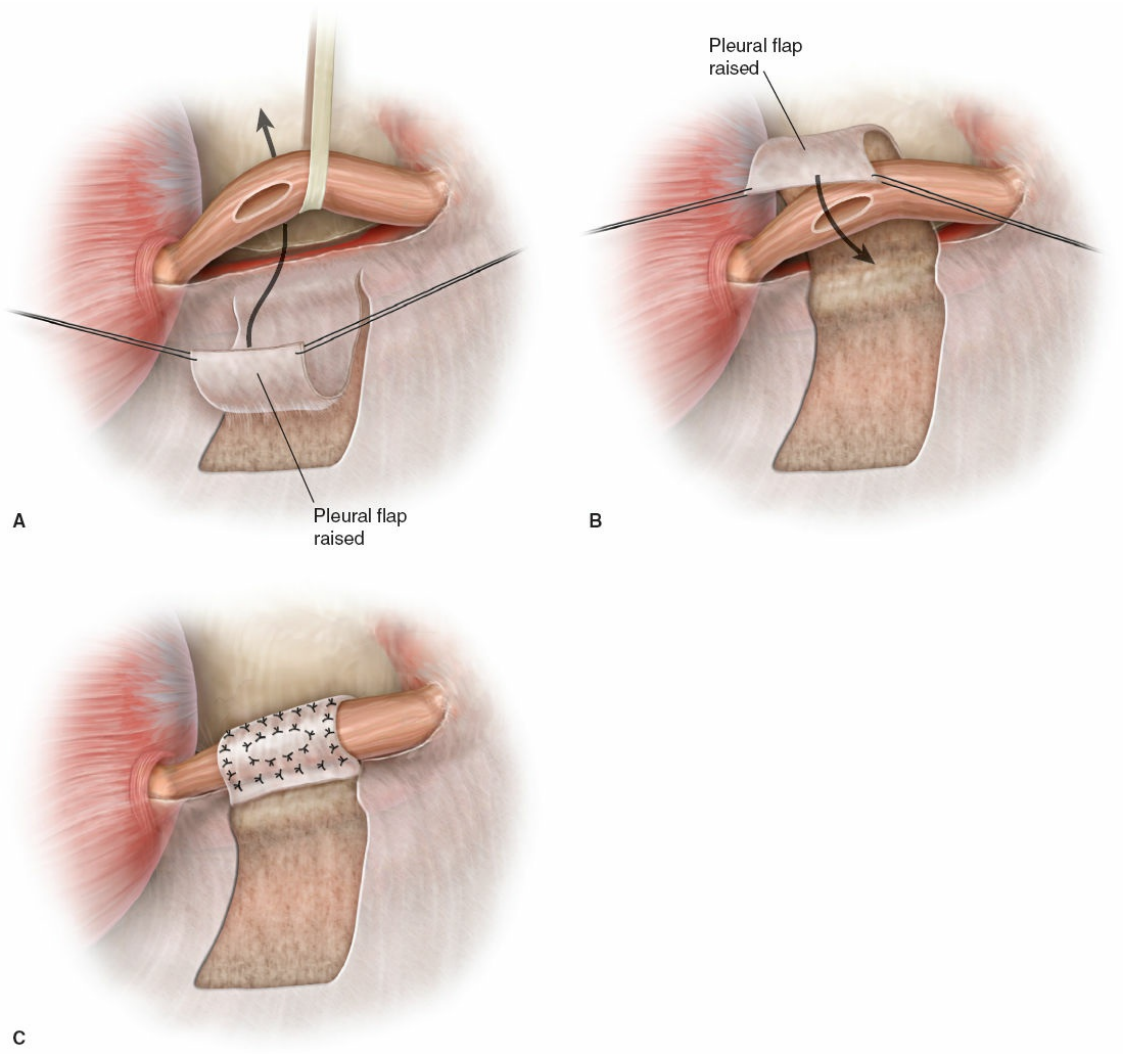

Figure 79.8. **A.** Mobilization of a parietal pleural flap for buttressing of a distal esophageal perforation. **B.** The pleural flap is wrapped around the perforated esophagus **C.** Numerous fine sutures are used to tack the pleural flap to the healthy esophageal muscle, isolating the perforation.

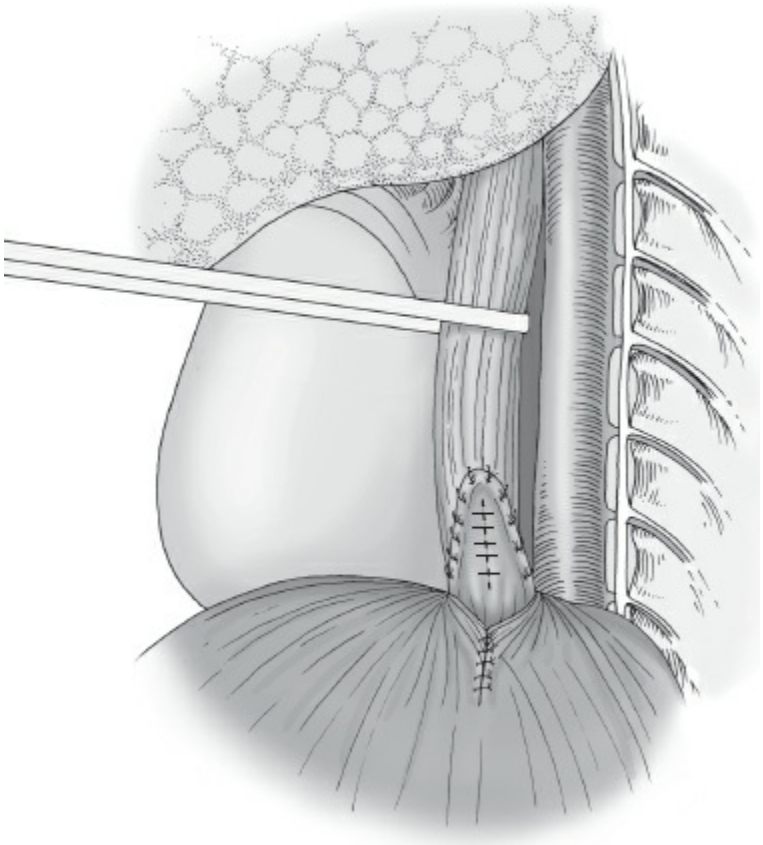

Figure 79.9. A diaphragmatic flap is prepared by cutting the diaphragm in a U-shaped fashion and then rotating the muscular flap to cover the repair site. The diaphragm is then closed linearly.

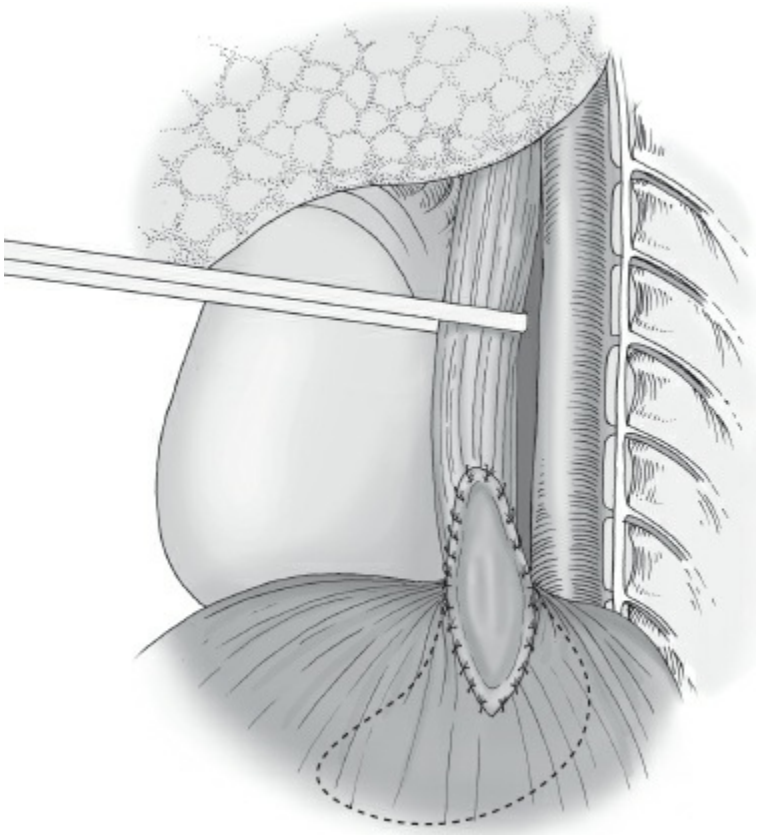

Figure 79.10. A gastric flap is created by ligation of the short gastric vessels and pulling the mobilized fundus through a diaphragm incision. The flap is then sewn to the esophageal repair site as well as the diaphragm itself.

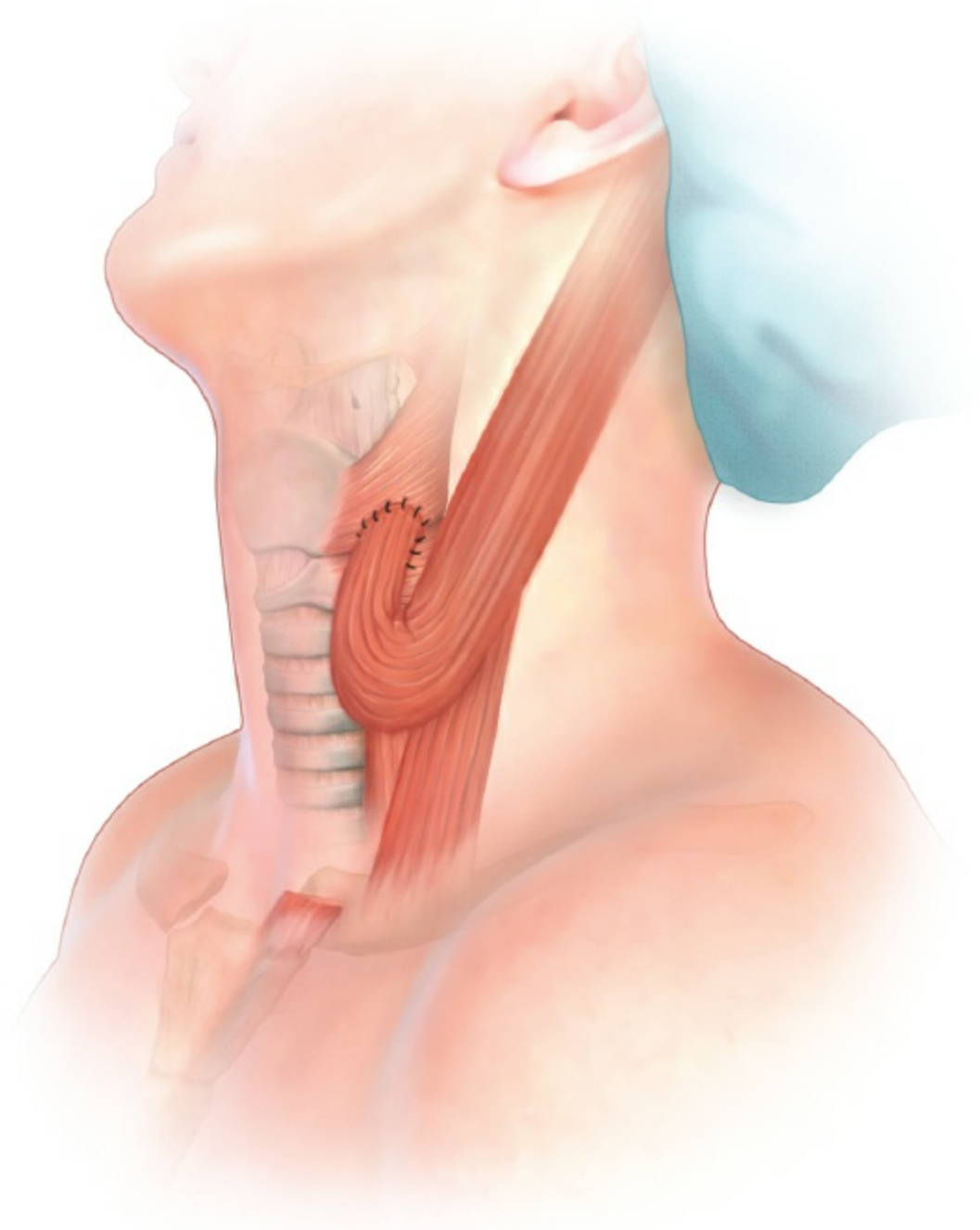

Figure 79.11. A sternocleidomastoid flap is created by detaching the medial head of the muscle from the manubrium, dividing the lower portion of the muscle and securing it to the repair site with suture.

Exceptions to Primary Closure

While primary repair of the perforation is the preferred management strategy, exceptions arise in which such a repair is not technically feasible and an alternative strategy must be employed. Such exceptions include (a) perforations able to be managed with drains alone (such as cervical

esophageal perforations that cannot be accessed surgically), (b) perforations too large to be primarily repaired but amenable to tube based repairs, and (c) perforations warranting an esophageal resection (such as perforated esophageal cancers, perforations in the setting of diffuse esophageal necrosis and/or mediastinal necrosis from alkali ingestion, or perforated end-stage achalasia).

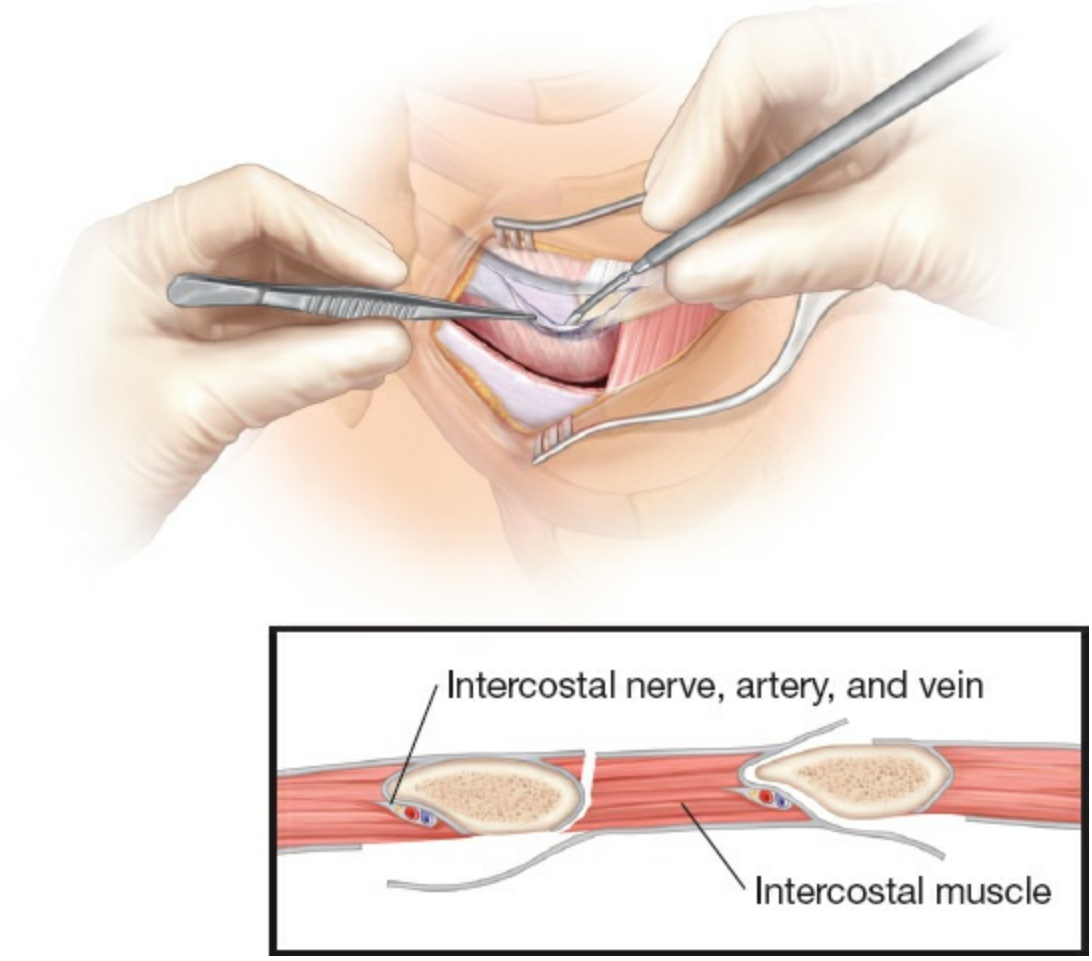

Figure 79.12. Dissection of intercostal flap. The intercostal muscles are dissected form the superior rib by removing the periosteum and following the lower border of the superior rib. Care is taken to preserve the neurovascular bundle with the flap as this is essential to flap viability. The dissection plan is depicted in the inset.

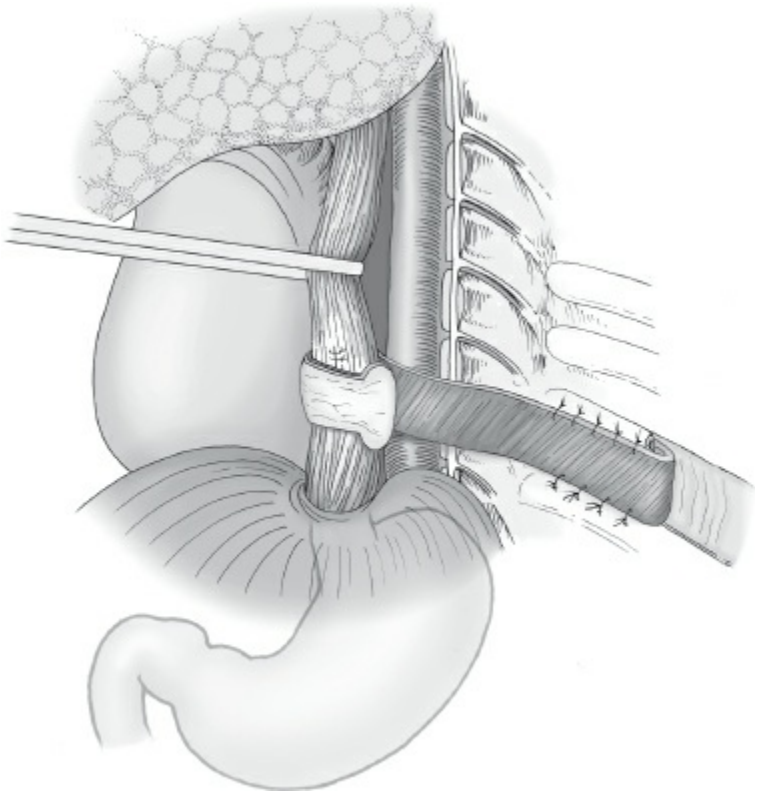

Figure 79.13. Once the intercostal muscle flap has been created, the neurovascular bundle is divided anteriorly and the muscle rotated to the posterior thorax. It is wrapped around the esophagus and secured with sutures to the repair site as well as the posterior pleura to prevent torsion or tension of the flap.

Drainage Alone

For cervical esophageal perforations not able to be completely accessed or visualized, drain placement alone may be sufficient because they can effectively evacuate the neck in a fashion not possible with thoracic or abdominal esophageal perforations (where the mediastinum, pleura or peritoneum are not able to be effectively drained). It is important to evaluate and treat any distal obstruction in such a circumstance.

T-Tube Drainage

In the event that mucosal closure cannot be accomplished in the thoracic esophagus, or if adequate tissue for reinforcement is not available, the perforation can be managed with a T-tube to convert the perforation into a controlled fistula. A large bore silastic tube is inserted into the perforation with short limbs positioned proximal and distal in the esophagus and the long limb traversing the pleural cavity and exiting the chest laterally (Fig.

79.14). A nasogastric tube can be passed through the luminal portion of the tube to aid in gastric decompression and prevent tube migration. The tube should be secured to the diaphragm in a position that keeps it from eroding into the aorta. Mediastinal and pleural drains should also be placed.

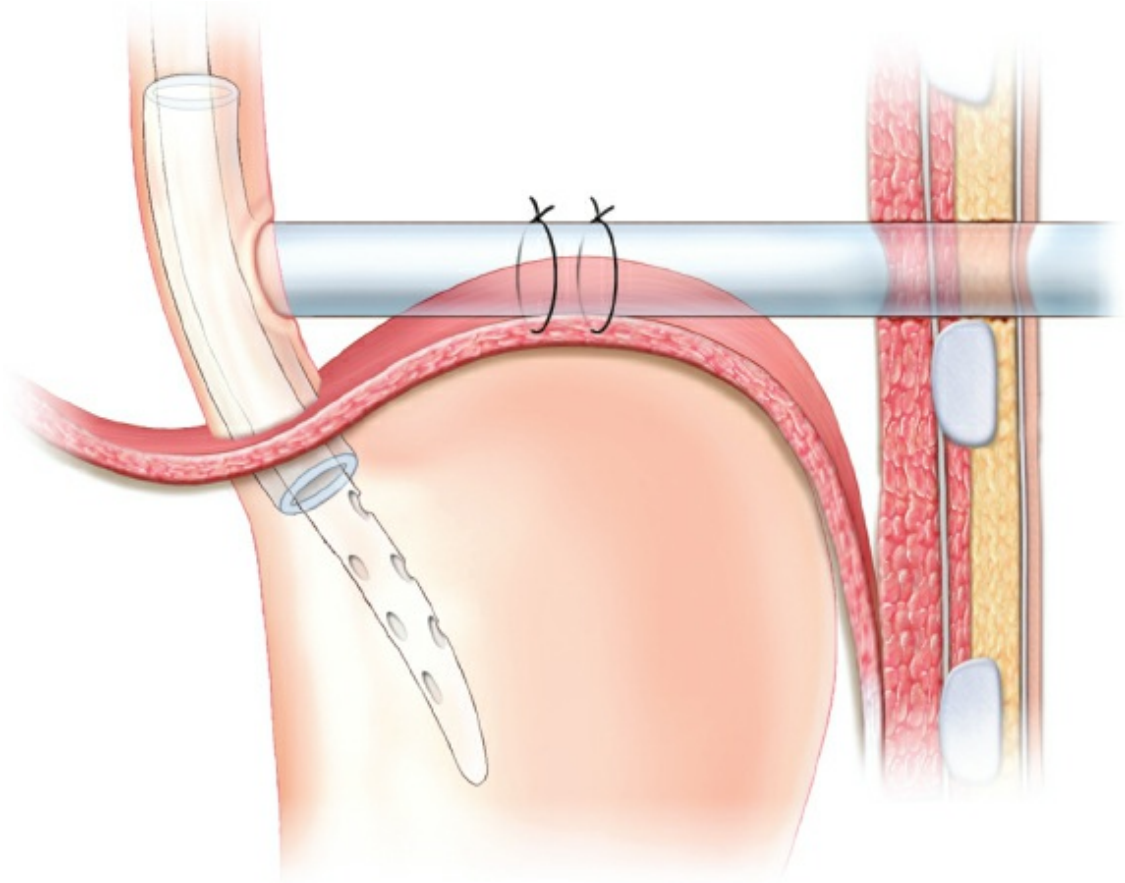

Figure 79.14. T-tube management of a large esophageal perforation. A silastic T-tube is introduced into the perforation with limbs running proximal and distal. The long end of the tube is lateralized through the thorax and secured to the diaphragm to prevent dislodgement and erosion. A nasogastric tube can be passed through the luminal portion of the tube to permit further gastroesophageal decompression.

Exclusion and Diversion

The exclusion and diversion method permits the management of complicated esophageal perforations without the need for esophageal resection. The method includes (1) primary suture of the perforation, (2) wide drainage of contaminated tissue, (3) creation of a loop or end-cervical esophagostomy (and drainage of the distal esophageal remnant), (4) closure of the gastroesophageal junction with temporary suture or staples

(without transection), and (5) creation of a gastrostomy and jejunostomy (Fig. 79.15). The disadvantage of this procedure is that it requires an end-to-end anastomosis of the esophagus in the neck 1 to 2 months after the diversion procedure, putting the patient at risk of a second major surgery. This method is therefore only indicated for the cases in which no other effective method is available and esophageal resection is not desirable. It should be an option of last resort.

Esophageal Resection

Esophageal resection is indicated for perforations associated with carcinoma or extensive necrosis of the esophagus that preclude any other method of management outlined above. A transhiatal or transthoracic approach can be used provided that adequate mediastinal and pleural debridement can be performed through the chosen approach. Reconstruction is performed immediately or, more typically, as a second stage procedure, depending on the patient's condition. The patient is generally left with an end cervical esophagostomy and gastrostomy. Reconstruction with a colon gastric conduit via the substernal or subcutaneous route is often best deferred for several months until mediastinitis has resolved and the patient is in stable, satisfactory condition.

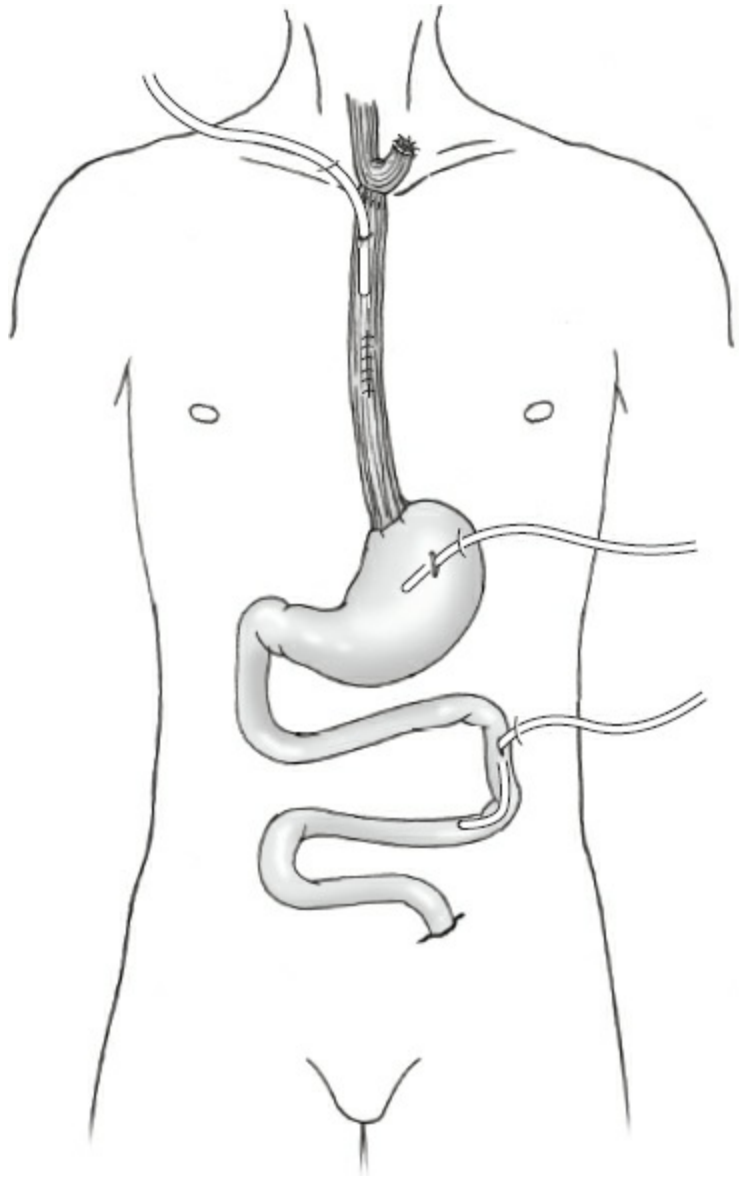

Figure 79.15. Esophageal diversion and exclusion includes (1) primary suture of the perforation, (2) wide drainage of contaminated tissue, (3) creation of a loop or end-cervical esophagostomy (and drainage of the distal esophageal remnant), (4) closure of the gastroesophageal junction with temporary suture or staples (without transection), and (5) creation of a gastrostomy and jejunostomy.

Enteral Feeding Access

After closing the chest or neck, the patient is placed in a supine position, and draining gastrostomy and feeding jejunostomy are performed via an open or laparoscopic approach. Gastrostomy prevents gastroesophageal reflux, and the jejunostomy is essential to maintain nutrition and facilitate healing. A gastrojejunal tube (for both decompression and distal feeding)

is an acceptable alternative.

POSTOPERATIVE CARE

Mechanical Ventilation

Postoperative mechanical ventilation is mandatory for the patients with sepsis who have compromised pulmonary function. Mechanical ventilation ensures that the lung remains fully expanded and adheres to the site of esophageal repair, and it may provide additional support. Elective use of mechanical ventilation and positive end expiratory pressure (PEEP) may be helpful in maintaining lung expansion.

Nutritional Support

Patients are generally kept NPO for a minimum of 5 to 7 days postoperative, and during this time their gastrostomy, jejunostomy, or nasojejunal tube should be used to provide enteral nutrition. If enteral access was obtained, the decision to obtain central IV access and begin parenteral nutrition depends on the surgeons concerns for a postoperative leak (i.e., the difficulty of the repair and the degree of contamination) as well as the patient's baseline level of nutrition before the perforation. In clinically stable patients, oral intake may begin following contrast imaging of the esophagus (typically a Gastrografin swallow study followed by thin barium) that fails to demonstrate leak.

Antibiotic Management

Broad-spectrum IV antibiotics should continue for 7 to 10 days postoperatively, but may continue longer based on the patient's clinical status.

Drain Management

Nasogastric tubes are typically removed following a negative upper GI swallow study. Drains placed around the primary repair site are maintained until the patient is tolerating an oral diet without evidence of leak. Tube thoracostomy is removed when there is no evidence of esophageal leak, empyema, or pneumothorax.

COMPLICATIONS AND THEIR MANAGEMENT

There are no large case series dealing with the overall type and frequency of postoperative complications. Smaller series report the following common complications.

Ongoing Leak

Ongoing (or recurrent) leak from the esophageal repair site is diagnosed clinically as higher than anticipated drain output. Fluid analysis will demonstrate salivary amylase within the drains. Controlled leak (without overt signs of systemic illness) can be managed conservatively with continued distal feeding, NPO status, and drain maintenance. While many leaks will close spontaneously with this regimen, an esophagocutaneous fistula can develop that requires delayed surgical intervention. As a result of this, stable patients with a persistent, controlled leak may undergo an attempt at endoscopic closure, stenting, or vacuum therapy as outlined above. Uncontrolled leak generally presents with signs of systemic infection and warrants ongoing antibiotics and potential urgent reoperative intervention for improved drainage or esophageal diversion/resection.

Stricture

Stricture formation following esophageal repair typically presents later (generally following recovery) with symptoms of dysphagia and can be managed with endoscopic dilation. The endoscopist should be aware of the location and length of the prior repair.

Mortality

The most common cause of death following esophageal perforation (and repair) is multisystem organ failure as a result of ongoing sepsis. Mortality rates are higher for spontaneous perforations than iatrogenic and traumatic (40% vs. 9% to 19%), higher for thoracic and abdominal perforations when compared to cervical perforations (30% vs. 6%), and higher for delayed diagnosis (>24 hours) when compared to early diagnosis (27% vs. 14%).

OUTCOMES

Nonoperative Management

Sarr et al. and Michel et al. used Cameron's criteria to nonoperatively manage perforations and reported mortality rates of 13% and 12.5%,

respectively. Using more highly selective patient criteria and close patient evaluation, some authors have reported a 100% success rate with nonoperative management. Nonsurgical treatment may therefore be indicated in specific situations.

Endoscopic Therapy

Haito-Chavez et al. examined a multicenter experience with OTSCs for full-thickness GI tract defects. Of the 48 patients with acute perforations they examined, 10 were in the esophagus. There were no technical device failures within this group, and they reported a 91.4% success rate of the primary OTSC therapy for all acute perforations (including esophagus, gastric, and colon).

Vacuum-assisted sponge devices have been used successfully in small esophageal defects. In one series of five patients with fluid collections related to a leak at an esophageal anastomosis, all five patients resolved their leak with vacuum-assisted sponge therapy. The median length of therapy was 28 days with nine sponge changes. Two of the patients developed stenosis at the anastomosis and one suffered from a fatal hemorrhage after a dilation procedure revealed an aortoanastomotic fistula.

Surgical Therapy

The largest reported cases series of esophageal perforation from Brinster et al. retrospectively evaluated 726 patients at the University of Pennsylvania from 1990 to 2003. The overall mortality rate of 18% was heavily influenced by the time to diagnosis, the location of the perforation, and the type of repair performed. Primary repair (without or with flap reinforcement) performed within the first 24 hours conferred a 96% survival rate.

Suggested Readings

Boutet N, Liberman M. Treatment of esophageal perforation: cervical, thoracic, and abdominal. In: Hawn M, ed. *Operative Techniques in Thoracic and Esophageal Surgery*. Philadelphia, PA: Wolters Kluwer; 2015:288.

Brinster CJ, Singhal S, Lee L, et al. Evolving options in the management of esophageal perforation. *Ann Thorac Surg* 2004;77(4):1475–83.

Freeman RK, Ascioti AJ, Giannini T, et al. Analysis of unsuccessful esophageal stent placements for esophageal perforation, fistula, or anastomotic leak. *Ann Thorac Surg* 2012;94(3):959–64.

Muir AD, White J, McGuigan JA, et al. Treatment and outcomes of oesophageal perforation in a tertiary referral centre. *Eur J Cardiothorac Surg* 2003;23:799–804.

Peyre CG, Watson TJ. Esophageal perforation. In: Luketich J, ed. *Master Techniques in Surgery: Esophageal Surgery*. Philadelphia, PA: Wolters Kluwer; 2014:456.

Udelnow A, Huber-Lang M, Juchems M, et al. How to treat esophageal perforations when determinants and predictors of mortality are considered. *World J Surg* 2009;33:787–96.

Winder JS, Pauli EM. Comprehensive management of full-thickness luminal defects: the next frontier of gastrointestinal endoscopy. *World J Gastrointest Endosc* 2015;7(8):758–68.

EDITOR'S COMMENT

Pauli and Marks have written a very nice chapter on the modern management of esophageal perforation. One of the most interesting aspects of the current version of this chapter is how much has evolved compared to the previous version of the same chapter. Stents and endoscopic treatments of esophageal perforation have evolved as a viable treatment of many patients. Endoscopic closure of defects and even endoscopic vacuum therapy (EVT) is now described. With the evolution of Natural Orifice Transluminal Endoscopic Surgery (NOTES) techniques and technologies, it is likely that the options for nonsurgical management of upper GI perforations will continue to expand.

Per Oral Endoscopic Myotomy (POEM) for achalasia is an interesting and relatively new procedure where the mucosa of the proximal esophagus is opened, a submucosal tunnel is created, and a circular myotomy is performed. In some cases, either unintentionally or intentionally, a full-thickness transluminal myotomy is created. In these cases, the endoscopist surgeon finds him/herself in the mediastinum. These cases rarely result in significant postoperative morbidity despite the fact that this is essentially an iatrogenic esophageal perforation. It has been shown in previous studies that the interval between the occurrence of perforation and the diagnosis is predictive of morbidity and mortality. As endoscopic and endoluminal surgery becomes more commonplace (endoscopic full-thickness resection of early cancers, endoscopic bariatric and GERD procedures, etc.), we are likely to become more comfortable and experienced managing esophageal perforations without laparotomy or thoracotomy—especially in the iatrogenic cohort.

Attempts have been made to enhance decision making with regard to the optimal management of esophageal perforation by utilizing a perforation severity score (PSS). Schweigert et al. studied the PSS in a review of cases of esophageal perforation from 1990 to 2014. Low-, intermediate-, and high-score groups were identified. Out of 288 patients with esophageal perforation

presenting during the study interval, perforation-related morbidity, length of stay, frequency of operative treatment, and mortality increased with increasing PSS strata. Patients with high PSS were 3.37 times more likely to have operative management compared with low PSS.

A recent analysis of all the published case series reporting the use of metallic and plastic stents in the management of postoperative anastomotic leaks, spontaneous esophageal perforations, and iatrogenic esophageal perforations was conducted by Dasari et al. Primary outcomes assessed were technical success rates and complete healing rates. Secondary outcomes assessed were stent migration rates, stent perforation rates, duration of hospital stay, time to stent removal, and mortality rates. A total of 27 case series with 340 patients were included. Technical and clinical success rates of stenting were 91% and 81%, respectively. Stent migration rates were significantly higher with plastic stents than with metallic stents. Based on their analysis, the authors concluded that endoscopic management of esophageal anastomotic leaks and perforations with the use of esophageal stents is technically feasible, safe, and effective when performed along with mediastinal or pleural drainage.

Lazar et al. reviewed the use of endoscopic clips—through the scope and over the scope in the management of esophageal perforations. Thirty-eight articles including 127 patients were included. Based on their review, the authors felt that clips can be used in the treatment of early (<24 hours), iatrogenic, spontaneous esophageal perforations in the case of limited injury or contamination. “TTS (through the scope) clips are efficacious in the treatment of 10 mm lesions, while bigger (<20 mm) lesions can be treated successfully with OTSC (over the scope clips) clips, whose effectiveness is similar to that of surgical treatment.”

Vacuum sponge therapy is increasingly being recognized as a new promising method for repairing upper GI defects of different etiology. Vacuum-assisted closure (VAC) therapy relies on continuous or intermittent suction and drainage to decrease bacterial contamination, secretions, and local edema. At the same time, perfusion and granulation are promoted. Kuehn et al. reported their single center experience with EVT for substantial wall defects in the upper GI tract. Between 2011 and 2015, 126 polyurethane sponges were placed in the upper GI defects of 21 patients. The most frequent indication for EVT was anastomotic leakage after esophageal or gastric resection (n = 11) and iatrogenic esophageal perforation (n = 8). The median number of sponge insertions was five (range, 1 to 14) with a mean changing interval of 3 days (range, 2 to 4). Median time of therapy was 15 days (range, 3 to 46). EVT in combination with surgery took place in 9 of 21 patients (43%). A successful vacuum therapy for upper intestinal defects with local control of the septic focus was achieved in 19 of 21 patients (90.5%). Based on this experience, the authors concluded that EVT is a promising approach for postoperative, iatrogenic, or spontaneous lesions of the upper GI tract.

Iatrogenic perforations represent the most common etiology for esophageal

perforation and may occur at the time of an esophageal intervention such as nasogastric tube placement or endoscopic procedures. In patients with surgically altered anatomy (Roux-en-Y gastric bypass for example), the risk of esophageal perforation may be especially high. As the authors of this chapter comment, intra-abdominal esophageal injury related to foregut or hiatus surgery such as paraesophageal hernia repair, fundoplication, or Heller myotomy is likely the most common cause of esophageal perforation. Prevention of these injuries requires knowledge of the steps of each procedure most likely to result in an esophageal injury. During fundoplication, the risk of esophageal perforation is highest during passage of the esophageal bougie to calibrate the fundoplication. Careful passage of the bougie, visualization of the distal esophagus, and excellent communication between anesthesia and the surgeon are key factors to minimizing the possibility of esophageal perforation during bougie passage. Some authors even advocate abstaining from the use of a bougie to avoid this possibility entirely, although this practice is somewhat controversial. In a retrospective review of 1,200 foregut surgical procedures from a high volume center, 4.2% of patients experienced either a gastric or an esophageal perforation. The highest rate of perforation was in laparoscopic reoperative hiatal hernia repair (compared to Heller myotomy, primary fundoplication, and paraesophageal hernia repair). The most common mechanisms of perforations were suture placement for primary antireflux surgery, traction for paraesophageal hernia repair, and for Heller myotomy perforations were most likely to occur during the myotomy. Reoperative hiatal hernia repair perforations were most likely to result from dissection/wrap takedown (73%) and traction (14%). Perforations were recognized and repaired intraoperatively in most cases (84%). Perforations discovered postoperatively were more likely to require reoperation, to require more GI and radiologic interventions, and to have higher morbidity than perforations recognized intraoperatively. The authors of this study conclude that if perforations are recognized and repaired intraoperatively, they require minimal postoperative intervention. Unrecognized perforations usually require reoperation and result in significantly greater morbidity. Intraoperative endoscopy and a high index of suspicion for a possible perforation are necessary, especially in reoperative cases.

Esophageal perforation still remains a deadly complication, especially when recognized in a delayed manner. As endoluminal and transluminal foregut surgical technology and capabilities advance, it is likely that the options for managing esophageal perforation in a minimally invasive and effective manner will continue to evolve.

Jon C. Gould

Suggested Readings

Dasari BV, Neely D, Kennedy A, et al. The role of esophageal stents in the

management of esophageal anastomotic leaks and benign esophageal perforations. *Ann Surg* 2014;259(5):852–60.

Kuehn F, Schiffmann L, Janisch F, et al. Surgical Endoscopic Vacuum Therapy for Defects of the Upper Gastrointestinal Tract. *J Gastrointest Surg* 2016;20(2):237–43.

Lázár G, Paszt A, Mán E. Role of endoscopic clipping in the treatment of oesophageal perforations. *World J Gastrointest Endosc* 2016;8(1):13–22.

Lowham AS, Filipi CJ, Hinder RA, et al. Mechanisms and avoidance of esophageal perforation by anesthesia personnel during laparoscopic foregut surgery. *Surg Endosc* 1996;10(10):979–82.

Lv L, Liu J, Tan Y, et al. Peroral endoscopic full-thickness myotomy for the treatment of sigmoid-type achalasia: outcomes with a minimum follow-up of 12 months. *Eur J Gastroenterol Hepatol* 2016;28(1):30–6.

Muir AD, White J, McGuigan JA, et al. Treatment and outcomes of esophageal perforation in a tertiary referral centre. *Eur J Cardiothorac Surg* 2003;23:799–804.

Schweigert M, Santos Sousa H, Solymosi N, et al. Spotlight on esophageal perforation: a multinational study using the Pittsburgh esophageal perforation severity scoring system. *J Thorac Cardiovasc Surg* 2016;151(4):1002–11.

Zhang LP, Chang R, Matthews BD, et al. Incidence, mechanisms, and outcomes of esophageal and gastric perforation during laparoscopic foregut surgery: a retrospective review of 1,223 foregut cases. *Surg Endosc* 2014;28(1):85–90.

80 Repair of Esophageal Atresia and Tracheoesophageal Fistula

George W. Holcomb III

The earliest description of a baby with esophageal atresia (EA) has been attributed to William Durston in 1670. However, it was not until 1939 that a baby survived following operative intervention. On successive days in November 1939, two different babies in two different cities underwent an initial gastrostomy followed, at a later date, by esophageal substitution. The first successful primary repair was performed by Dr. Cameron Haight in Ann Arbor in 1941 through a left thoracotomy. The baby developed an anastomotic leak and stricture, but required only one esophageal dilatation. She stayed in the hospital for many months, but recovered uneventfully and led a normal life. Interestingly, she had a son who was born with EA and a distal fistula.

EA is really a spectrum of anomalies. A number of classification systems (Gross, Vogt, etc.) have been described. However, it seems best to describe the anomaly rather than classify it (Fig. 80.1). EA with an associated tracheoesophageal fistula (TEF) is the most common variant of the EA spectrum of diseases and occurs in about 85% to 88% of all EA cases. Isolated EA (without an associated TEF) occurs in about 7% to 8% of the cases. EA with a proximal fistula is found in 1% to 2% of the cases. The fistula is similar to the H-type TEF and starts proximally on the trachea and ends distally in the dilated proximal esophagus. EA with both a proximal and distal TEF is found in 1% or less of the cases. Although not technically part of the EA classification, an H-type TEF is considered part of the spectrum because these patients also have one or more associated anomalies related to the VACTERL syndrome (**V**ertebral, **A**tresias [GI tract], **C**ardiac, Tracheoesophageal [**TE**], **R**enal, **L**imb). This isolated TEF is usually located in the lower cervical region or upper thoracic cavity, and is almost always amenable to repair through a right cervical approach. The H-type TEF is actually the third most common of these anomalies.

ETIOLOGY

It remains controversial as to the exact etiology for the development of EA/TEF. Around the fourth week of gestation, the foregut begins to differentiate into a dorsal esophageal part and a ventral respiratory segment. Originally, it was felt that the ventral respiratory segment separates from the esophagus by the formation of lateral tracheoesophageal folds which fuse in the midline to create the tracheoesophageal septum. This separation of the trachea and esophagus is usually complete by 6 to 7 weeks of gestation. According to this theory, if there is incomplete fusion of these tracheoesophageal folds, a defective tracheoesophageal septum could develop with an abnormal connection between the trachea and esophagus. However, chick embryo studies have not demonstrated these lateral tracheoesophageal folds. Instead, cranial and caudal folds have been found in the region of the tracheoesophageal separation. According to a second theory, EA/TEF could develop due to an imbalance in the growth of these cranial and caudal folds. A third theory is based on a defect in intracellular signaling due to a deficiency in the sonic hedgehog (Shh) genes. In culture experiments, the fistula tract has been induced to branch by exogenous administration of the Shh signaling molecule and its receptor. These studies support the fistula as arising from the respiratory tract because the normal lung, but not normal esophagus, branches in response to the Shh signaling. Finally, from rat studies, a fourth theory postulates that EA/TEF might result from disturbances in either apoptosis or epithelial proliferation.

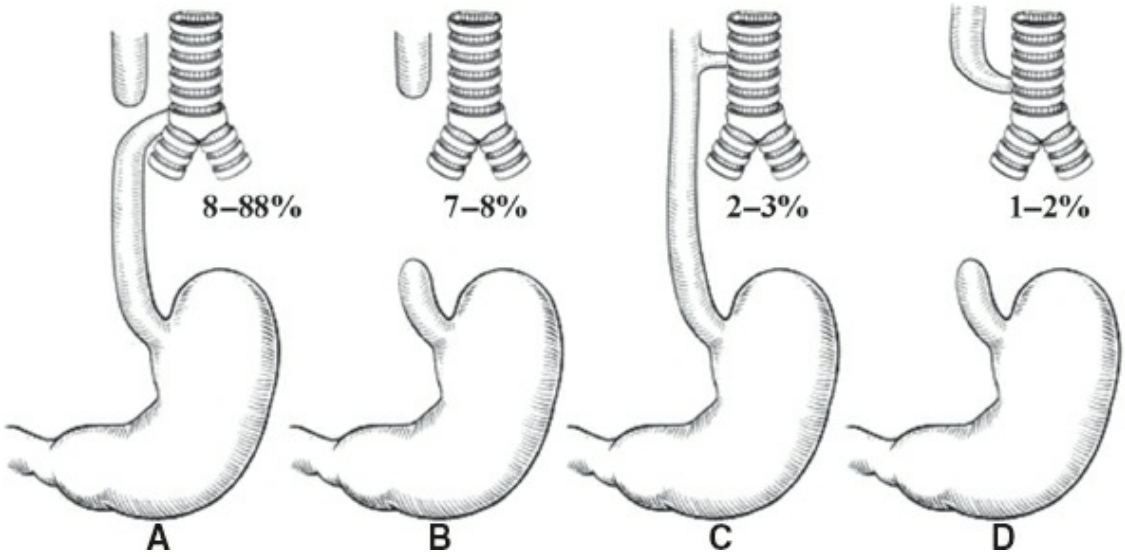

Figure 80.1. This schematic depicts the spectrum of anomalies seen in patients with esophageal atresia (EA) and

tracheoesophageal fistula (TEF). The incidence of each anomaly is also noted. The most common anomaly is EA with a distal TEF (**A**). Next in incidence is EA without a TEF (**B**). Third is an H-type TEF (**C**). EA with a proximal (but not distal) TEF occurs in about 1% of the cases (**D**).

EA is usually a sporadic occurrence. The incidence of EA/TEF is about 1 per 3,500 births. There appears to be a slight male predominance of 1.3. Among parents who have one affected child, the risk of another affected child is between 0.5% and 2%. In addition, the risk of a child with EA/TEF born to a mother or father with EA/TEF is 3% to 5%. A number of etiologic agents have been identified including medications such as progesterone and estrogen, maternal diabetes, thalidomide exposure, the use of methimazole in early pregnancy, and the prolonged use of contraceptive pills, among others. Also, chromosomal anomalies including Trisomy 18 and 21 have been identified in 5% to 10% of the cases. Finally, defects in three different genes have been found to be associated with EA/TEF.

CLINICAL PRESENTATION

On occasion, the diagnosis of EA with or without a fistula can be suspected antenatally. The two findings that can be attributed to EA on prenatal ultrasound (US) are the development of maternal polyhydramnios and an absent or small gastric bubble. However, as polyhydramnios and a small stomach bubble can be found in a number of other fetal anomalies, these findings are not specific for EA. Regardless, their association together does raise the possibility of EA in the fetus. Magnetic resonance imaging (MRI) is a relatively new modality for looking at fetal thoracic conditions. In one study looking at 10 fetuses that were thought to be at risk for EA on the basis of prenatal US findings, the MRI was 100% sensitive for the identification of the five EA/TEF babies.

Postnatally, the diagnosis is usually first suspected when the baby has feeding difficulties and a nasogastric tube cannot be passed into the stomach. In babies with known polyhydramnios or other stigmata of the VACTERL syndrome, a nasogastric tube should be inserted before feeding, thereby excluding the diagnosis of EA. If the nasogastric tube cannot be passed into the stomach, a plain radiograph is obtained. With EA, the tip of the catheter is usually visualized in the superior

mediastinum at the T2 to T4 level (Fig. 80.2). It is important to identify whether air is seen in the gastrointestinal tract, thereby indicating the presence of a distal TEF. A gasless abdomen would be seen in a baby with isolated EA (Fig. 80.3). Interestingly, there have been scattered reports describing a baby with EA and distal TEF with mucous occluding the distal fistula. In such a baby, the abdomen may be gasless on the initial plain radiograph.

As mentioned, the VACTERL syndrome is the strongest syndromic association with the entire EA spectrum of conditions. The frequencies of these associated conditions are as follows: vertebral (6% to 20%), atresias of the intestinal tract (10% to 15%), cardiac (15% to 35%), renal (5% to 15%), and limb (5% to 20%). EA has also been seen occasionally in patients with the CHARGE syndrome (**C**oloboma, **H**eart anomalies, **A**tresia of the choanae, **R**etardation, **G**enital hypoplasia, and **E**ar deformities).

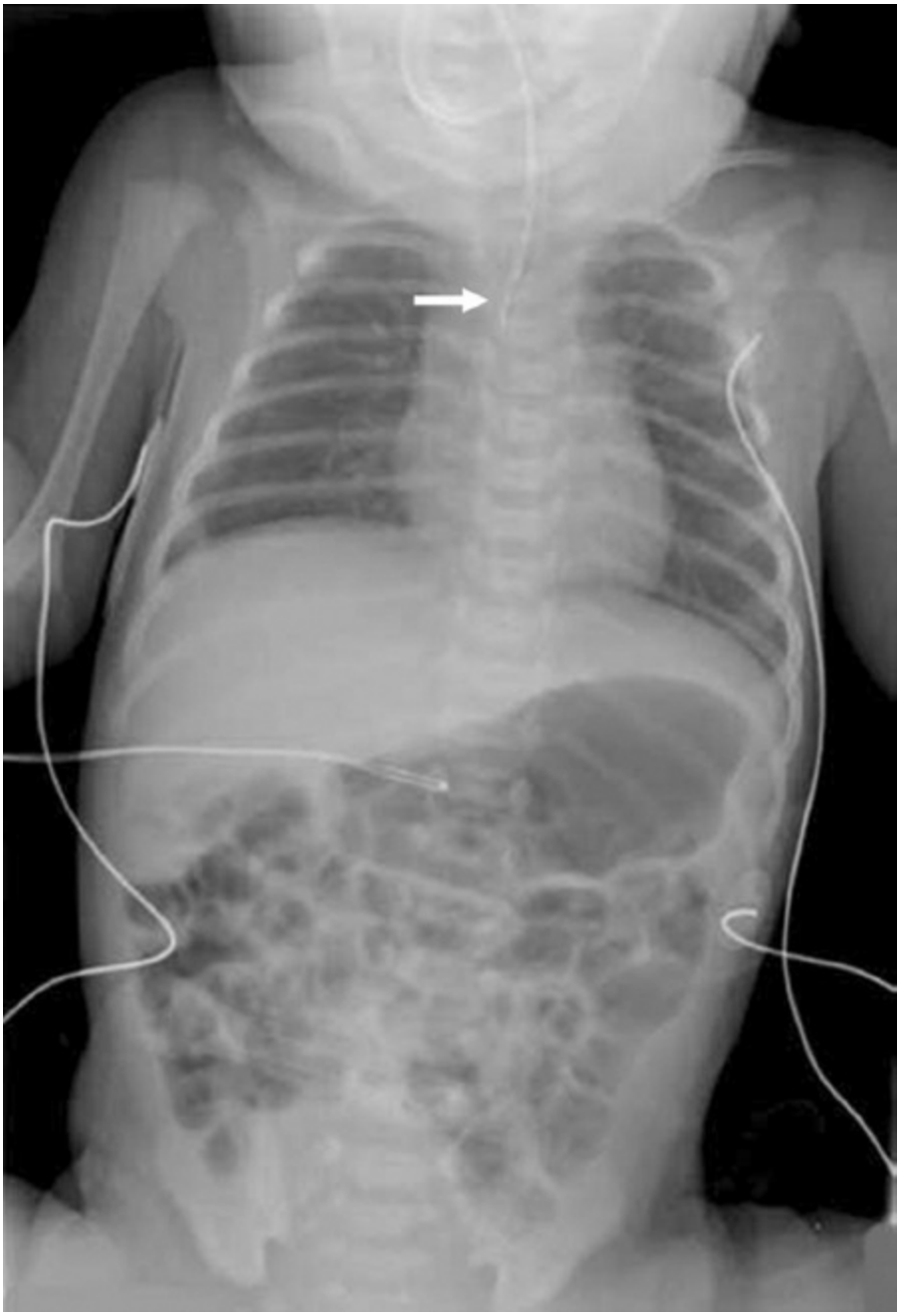

Figure 80.2. This baby developed coughing and feeding intolerance shortly after birth. A nasogastric tube was introduced, but could not be advanced past the upper thoracic esophagus (*arrow*). Air is noted in the stomach, small intestine, and colon. This is a classic radiograph for a baby with EA and a distal TEF.

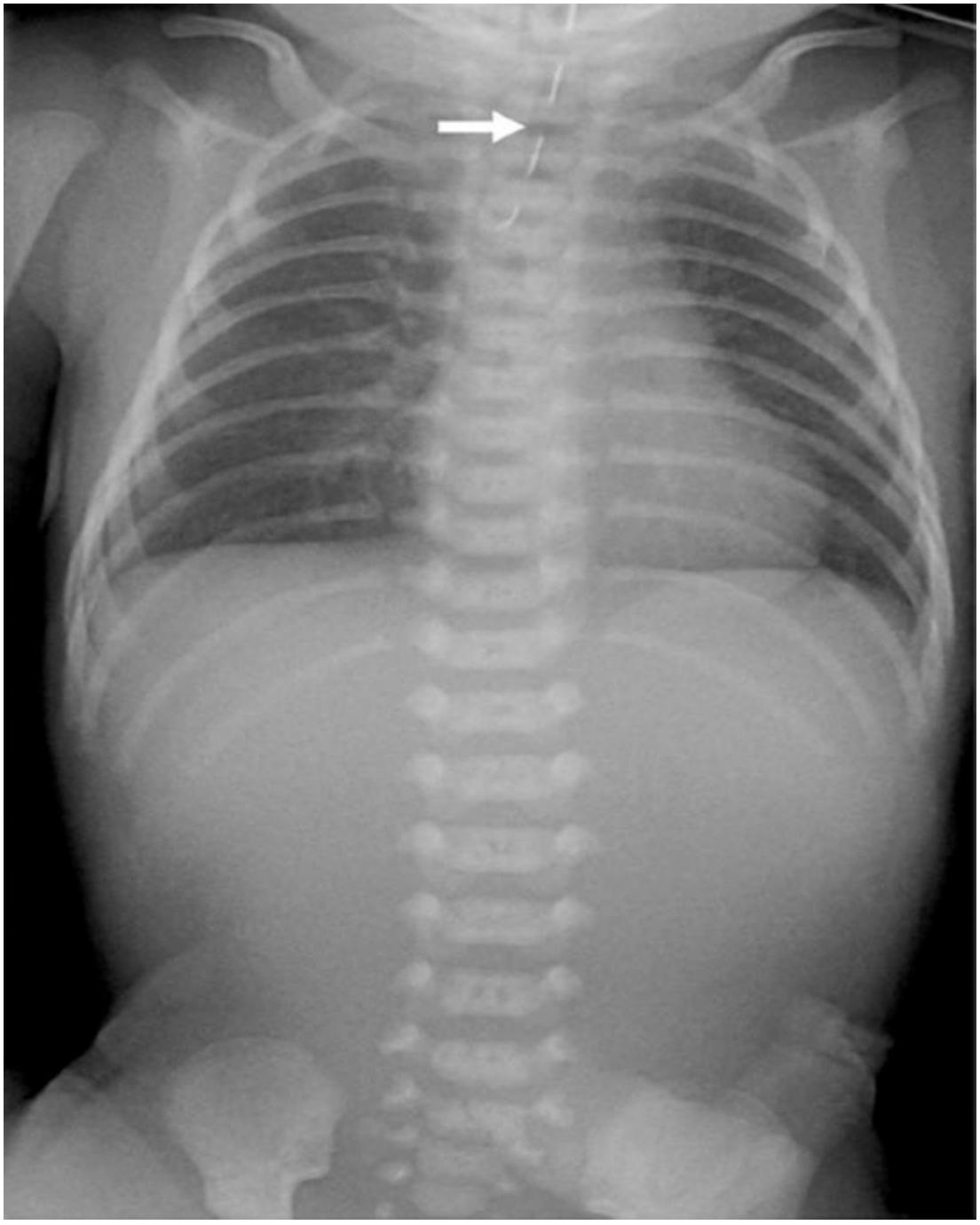

Figure 80.3. This baby has esophageal atresia without a distal fistula. Note the *arrow* is identifying the nasoesophageal tube in the proximal esophageal pouch. There is no air in the stomach or intestinal tract.

In a 2007 paper from our institution, we reviewed the incidence of the VACTERL association in 112 patients with EA anomalies seen between 1985 and 2005. There were 62 males and 50 females. In this review, 24.1% of the babies had vertebral anomalies, 14.3% had intestinal atresias, and 32.1% had cardiac anomalies, which was defined as an intrinsic heart

lesion other than a patent foramen ovale or patent ductus arteriosus. The most common cardiac condition was a ventriculoseptal defect (VSD) found in 22.3% cases. However, a VSD was found as an insolated condition in only 7.1% of the patients. Cyanotic heart disease was found in only 4.5% of the babies and all were tetralogy of Fallot. Of these 112 babies, renal anomalies occurred in 17% and skeletal in 16.1%. A distal TEF was found in 95.5% of these babies.

TABLE 80.1 Waterston Classification

Group	Criteria
A.	Birth weight over 2,500 g and well
B.	Birth weight 1,800–2,500 g and well, or any weight with moderate pneumonia or anomalies
C.	Birth weight <1,800 g, or any weight with severe pneumonia or anomalies

Several clinical classification systems have been developed over the past 65 years. In 1962, David Waterston proposed a classification system based primarily on the baby's birth weight and health status (Table 80.1). This classification is not currently utilized very much, but it was an important classification system during the time that the operative repair of babies with EA was being refined. The Montreal classification system improves upon the Waterston system and accounts for the severity of associated congenital anomalies and any respiratory disease. In this system, birth weight is not a significant factor for mortality, but the need for preoperative ventilation is a factor (Table 80.2). In 1994, Spitz proposed that birth weight and significant congenital heart disease are the major factors associated with mortality (Table 80.3). This classification system may be the most reliable for predicting prognosis for babies with EA and distal fistula. Recently, an updated prognostic classification system from surgeons at Great Ormond Street Hospital for Children makes a prognostic distinction between babies with cardiac disease and low birth weight.

TABLE 80.2 Montreal Classification

Group	Criteria
I.	No ventilator dependence, with minor or major anomalies; or ventilator dependence and minor anomalies
II.	Ventilator dependence, with major anomalies; or life-threatening anomalies regardless of pulmonary status

TABLE 80.3 Spitz Classification

Group	Criteria
I.	Birth weight >1,500 g without major cardiac disease
II.	Birth weight <1,500 g, or major cardiac disease
III.	Birth weight <1,500 g and major cardiac disease

PREOPERATIVE PLANNING

Once the diagnosis is made, further workup for VACTERL associations is important. In addition to the physical examination that may identify anorectal or limb anomalies, renal and spinal US are necessary. Also, a cardiac echo or thoracic US should be performed to try to identify the location of the aortic arch, as the operative approach ideally should be on the side opposite the aortic arch. In approximately 5% of the babies, the aortic arch will descend on the right side, making a right thoracic approach much more difficult. In such a patient, a left thoracic approach should be considered.

In a term baby, EA or EA/TEF is rarely an emergency and there is usually adequate time to complete the preoperative workup and plan the operative approach. However, in the preterm infant with EA and distal TEF and with respiratory distress syndrome requiring mechanical ventilation, the sudden inability to ventilate the baby can be encountered due to the preferential flow of the ventilated gas through the endotracheal tube (ETT), down the trachea, and out through the TEF. This flow pattern

results in poor pulmonary inflation and abdominal distention, both of which inhibit adequate ventilation. Gastric and duodenal perforations have been described. In such cases, a variety of maneuvers have been successful, including immediate gastrostomy with placement of the tube to underwater drainage, immediate thoracotomy with ligation of the fistula, and attempted placement of a Fogarty balloon past the ETT and into the fistula, thereby occluding it. Isolated case reports on the management of babies with this complication can be found in the literature.

While the infant is awaiting operation, it is important to prevent complications resulting from aspiration. The baby should be placed in a head-up position and tilted to one side. Also, it is important that the nasoesophageal catheter is on constant suction. Finally, the baby's mouth and pharynx should be suctioned as necessary, as not all the oral and esophageal secretions will be removed via the nasoesophageal catheter. If the baby requires intubation and ventilation, gentle low pressure ventilation is essential. If the fistula has to be ligated emergently (but is not divided), a delayed primary anastomosis should be performed within 10 to 14 days, as recanalization of the distal fistula is likely to occur.

Preoperative discussion with the anesthesiologist is very important, especially if a thoracoscopic approach is planned. The most important aspect for thoracoscopic repair of EA/TEF is adequate visualization. Impaired visualization often occurs due to the lung being overinflated with traditional ventilation. Also, the anesthesiologist (or anesthesia resident in a teaching hospital) may have limited experience with these cases and fail to understand the importance of low pressure, low volume ventilation to reduce the lung inflation. Moreover, hypercarbia can easily develop. To counteract the problem of lung inflation, CO_2 insufflation has been utilized as a positive pressure maneuver to decompress the lung to allow an optimal view. However, this is not always successful in keeping the lung deflated. Over the past several years, our group has utilized the high-frequency ventilator (HFV) in the operating room for ventilation in the babies undergoing the thoracoscopic approach. With the use of the HFV and proper positioning of the ETT, the lung remains deflated and an adequate operating space is created. Also, the duration of the operation is not as important because the oscillating ventilator is able to remove the CO_2 very efficiently and hypercarbia is not common. Assuming a healthy 3- to 3.5-kg infant, the initial settings are a mean airway pressure of 13 to 15 cm H_2O, a ΔP of 30 to 35, and FiO_2 of 70%. This can usually be

weaned to 40% or so after 10 to 15 minutes. The major problem with using the HFV is with the movement (shaking) of the baby during the ventilation, but this is something that the surgeon becomes accustomed after the first few cases. The Hertz is usually set initially at 11 to 13 but can be decreased to 8 to 9 if the baby is shaking too much (1 Hz is defined as 60 breaths/s). With this background, we rarely perform these operations on the weekend or at night, as our respiratory therapists are routinely involved with management of the HFV in the operating room.

The open operation for EA/TEF was utilized exclusively until 1999 when Lobe and Rothenberg reported their experience in Berlin with thoracoscopic repair in a 3-month-old infant at the time of the annual IPEG meeting. This infant had EA without TEF. At the following year's IPEG meeting, Rothenberg described the thoracoscopic repair of EA/TEF in a newborn. Soon thereafter, other experienced pediatric surgeons began to utilize this approach and retrospective reports followed.

The major advantage of the thoracoscopic approach is the avoidance of musculoskeletal sequelae such as winged scapula, breast deformities in females, spine deformities, and limitation in arm/shoulder abduction. However, this approach can be difficult. It is quite applicable in straightforward cases with a short distance between the two esophageal ends. In my experience, it can safely be utilized in about 75% of newborns with EA/TEF.

SURGICAL TECHNIQUE—THORACOSCOPIC APPROACH FOR EA/TEF

The baby is positioned supine on the operating table and the oropharynx is suctioned. It is my preference to perform a preoperative bronchoscopy for the purpose of identifying the site of the distal fistula. Others may perform a bronchoscopy to exclude a proximal fistula. However, only a very small percentage (1% to 2%) of these babies has a proximal fistula. By knowing the location of the distal TEF, the surgeon has a better understanding of the gap length between the two esophageal segments and where the distal fistula inserts into the trachea. For instance, if the fistula is identified entering the carina (Fig. 80.4), the gap length between the distal and proximal segments could be relatively large (up to 3 to 4 cm). On the other hand, if the fistula is seen to enter the mid-trachea, the gap length will likely be much shorter. The distance between the two esophageal segments will also depend on how caudal the proximal esophageal pouch extends.

This bronchoscopy takes less than 5 minutes and can provide important information to the surgeon performing the repair.

Following bronchoscopy, the baby is intubated and placed in the left lateral decubitus position (assuming the aortic arch is on the left side). The position of the ETT is not as important if HFV is being utilized, although, optimally, the ETT is not in the fistula or right mainstem bronchus. However, if conventional mechanical ventilation is employed, it is best to position the ETT distal to the origin of the fistula (if possible). This is more easily accomplished when the TEF originates in the mid-trachea. However, with the TEF originating at the carina or close to it, the slightest movement of the ETT may cause its tip to enter the distal fistula or one of the mainstem bronchi.

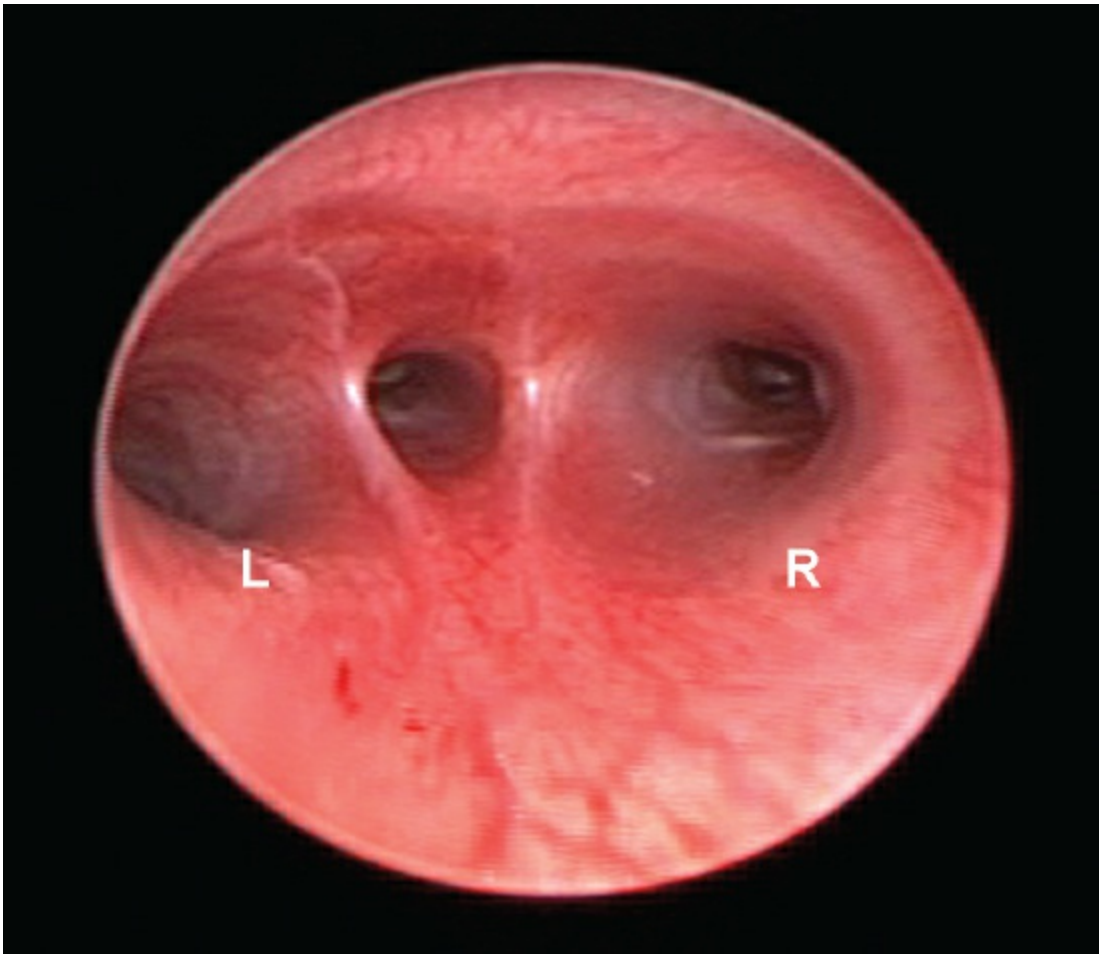

Figure 80.4. Bronchoscopy is often helpful for identifying the location of the distal fistula which allows the surgeon a better understanding of the expected gap length between the two esophageal segments. In this baby, the fistula is seen entering the carina which indicates that there could be a relatively large gap length between the proximal and distal esophageal

segments. R, right mainstem bronchus; L, left mainstem bronchus.

After positioning the baby in the left lateral decubitus and slightly prone position (assuming a left aortic arch) close to the left edge of the operating table, a small roll is placed under the shoulders and left flank to enhance the right intercostal spaces. A 12- to 14-Fr silicone catheter is introduced through the baby's mouth and into the upper esophageal pouch. The table is tilted slightly to the left and in reverse Trendelenburg. The surgeon will stand on the left side of the table with the camera operator to his/her left. The scrub nurse is usually opposite the surgeon at the level of the camera operator. The monitor is situated opposite the surgeon for optimal viewing (Fig. 80.5A). The first cannula is usually introduced at approximately the eighth intercostal space in the posterior axillary line. This 5-mm port is inserted using a cutdown technique, and the cannula with a blunt trocar is gently advanced into the thoracic cavity. This cannula will be used for insertion of the telescope attached to the camera. With the high-frequency oscillator, only a small amount of CO_2 insufflation (1 to 2 L/min at a pressure of 3 to 5 mm Hg) is needed to decompress the lung. A 45-degree or 70-degree, 4-mm telescope is then introduced through this cannula and the thoracic cavity visualized. At this point, the surgeon can decide the optimal location of the two working instruments which he/she will utilize for the operation. Through stab incisions, these 2.7-mm instruments generally are introduced at the fourth and fifth or fourth and sixth intercostal spaces in the mid- to posterior axillary line. If needed, a fourth stab incision is made posteriorly and inferiorly at the 10th or 11th intercostal space through which another instrument can be introduced for additional lung retraction (Fig. 80.5B).

Generally, the azygos vein is well seen as is the proximal esophageal pouch with the silicone catheter in it (Fig. 80.6). If it is difficult to see the pouch, the anesthesiologist is asked to gently manipulate the silicone catheter. This maneuver will usually identify the proximal pouch. Distally, the TEF has been identified preoperatively by bronchoscopy, so the surgeon has a good idea of its site of communication with the trachea. Also, if conventional ventilation is being used, the fistula can often be seen to distend with each ventilating breath. This is not as apparent with the oscillating ventilator. If needed, the azygos vein is ligated and divided with cautery, which aids in identifying the fistula. If ligation/division of the

vein is not needed, it is left intact as it will often lie between the fistula ligation site on the trachea and the subsequent esophageal anastomosis. The pleura overlying the fistula is opened and the fistula is gently identified and mobilized (Fig. 80.7). Care should be taken to protect the vagal nerve fibers which are usually seen coursing along the trachea and fistula.

After definitive identification of the TEF, it is helpful to better identify the proximal esophageal pouch to gain a further understanding of the amount of proximal pouch mobilization that will be required in preparation for the esophageal anastomosis. If the two esophageal segments are in close proximity to each other, very little dissection of the proximal or distal esophageal segment is needed. However, often the two segments are widely separated and the proximal pouch needs to be dissected to the thoracic inlet in order to gain esophageal length. This can be performed in a variety of ways. We prefer the use of cautery to gently mobilize the proximal pouch, taking great care as the proximal esophagus is intimately adherent to the membranous trachea. In one case, dense adherence between the proximal esophageal pouch and trachea was encountered. The reason for this dense connection was unclear at the time. Postoperatively, it was realized that this was the site of a proximal TEF. Therefore, if the dissection between the proximal pouch and trachea is unusually difficult, a proximal fistula may be present and should be evaluated in the postoperative period if respiratory problems develop.

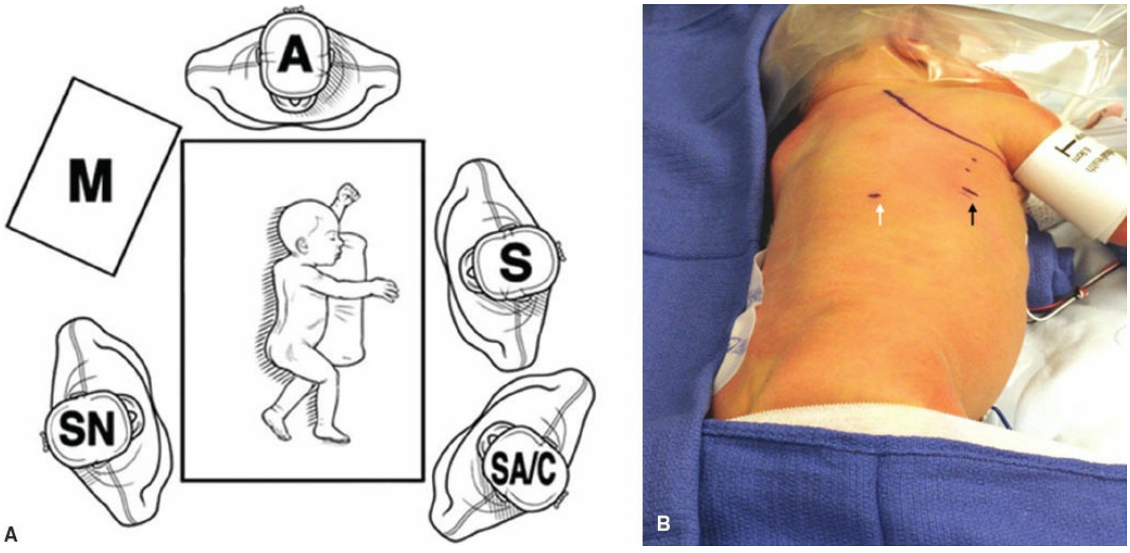

Figure 80.5. A. The location of the operating personnel and monitor is depicted at the left. The surgeon (*S*) stands on the left side of the table with the surgical assistant/camera operator

(*SA*/*C*) to his/her left. The scrub nurse (*SN*) is usually opposite to the surgeon at the level of the camera operator. The monitor (*M*) is situated opposite the surgeon for optimal viewing. *A* is the anesthesiologist. **B.** On the right, the baby has been positioned in a left lateral decubitus and slightly prone position. The location of the ports/instruments is depicted. Also, the inferior border of the scapula has been marked. The initial port (*black arrow*) is introduced using a cutdown technique and a 5-mm cannula with blunt trocar will be gently advanced into the thoracic cavity. This will be the site for insertion of the angled telescope. Above this site are two small marks which represent the stab incisions for the two working instruments for the surgeon. If needed, a retracting instrument can be introduced through a posteriorly and inferiorly created stab incision (*white arrow*).

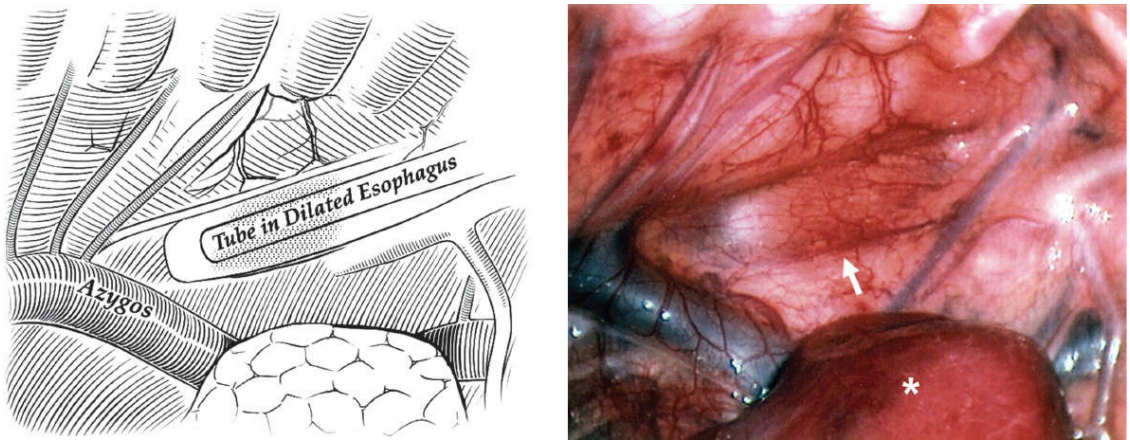

Figure 80.6. The schematic (**left**) and intraoperative photograph depict the creation of adequate intrathoracic working space with lung deflation (*asterisk*), achieving a nice view of the thoracic cavity. A red rubber catheter has been inserted in the proximal pouch (*arrow*) which aids in its identification. Note the azygos vein coursing to the superior vena cava. Just beneath this vein is the typical location for the distal esophagus entering the trachea.

Once the proximal esophagus has been mobilized and is ready for the anastomosis, the distal fistula is ligated and divided. It is not ligated and divided earlier because the distal esophageal segment will often retract into the retropleural tissues during the dissection of the proximal pouch and can, on occasion, be difficult to find. Therefore, we prefer to mobilize the proximal esophageal pouch prior to ligating and dividing the distal fistula in a baby who is stable.

The fistula can be divided in a number of ways. A nonlocking metal

clip (Fig. 80.8) or a locking polymer clip (Hem-O-Lok, Teleflex Medical, Research Triangle Park, NC) can be utilized to ligate the fistula. Also, the fistula can be divided and the trachea closed with one or two silk or Vicryl (Ethicon Inc, Somerville, NJ) sutures. We have utilized all of these techniques. Transmigration of the metal clip may have led to a recurrent fistula in one case, so we prefer either the locking plastic clip or suture closure of the tracheal side of the fistula. Others have used the metal clip without problems.

Once the fistula is divided, the esophagoesophagostomy is performed in a similar fashion to the open operation. Ideally, the posterior row of sutures are placed and tied after all the posterior sutures have been introduced. At times, however, it is easier to tie the sutures individually. We prefer to tie the sutures intracorporeally, whereas others utilize an extracorporeal technique. Also, our preference is to use silk for the anastomosis, but others prefer polydioxanone (PDS; Ethicon Inc, Somerville, NJ) or Vicryl. In another 2007 report from our institution, we found that the suture material does not have an impact on either the development of an anastomotic leak or the need for subsequent esophageal dilation. Once the posterior row of sutures are tied, a 6-Fr tube (Fig. 80.9) is inserted through the infant's nares, across the esophageal anastomosis, and into the stomach. We find this stent useful for a variety of reasons including the ability to feed the baby through it if desired. The anterior portion of the anastomosis is then completed in an interrupted fashion (Fig. 80.10).

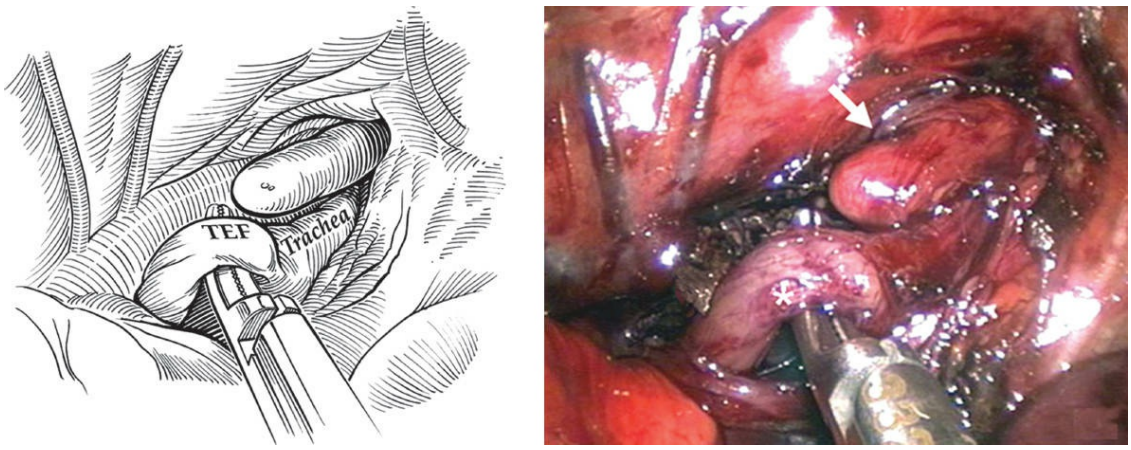

Figure 80.7. In this drawing (**left**) and operative photograph, the distal esophagus (*asterisk*) has been identified and is being encircled just distal to its insertion on the trachea. The *arrow* indicates the proximal esophagus in the photograph. The azygos vein has been divided. (Reprinted with permission from Holcomb

GW III, Georgeson KE, Rothenberg SS, eds. *Atlas of Pediatric Laparoscopy and Thoracoscopy*, 1st ed. Philadelphia, PA: Copyright Elsevier; 2008.)

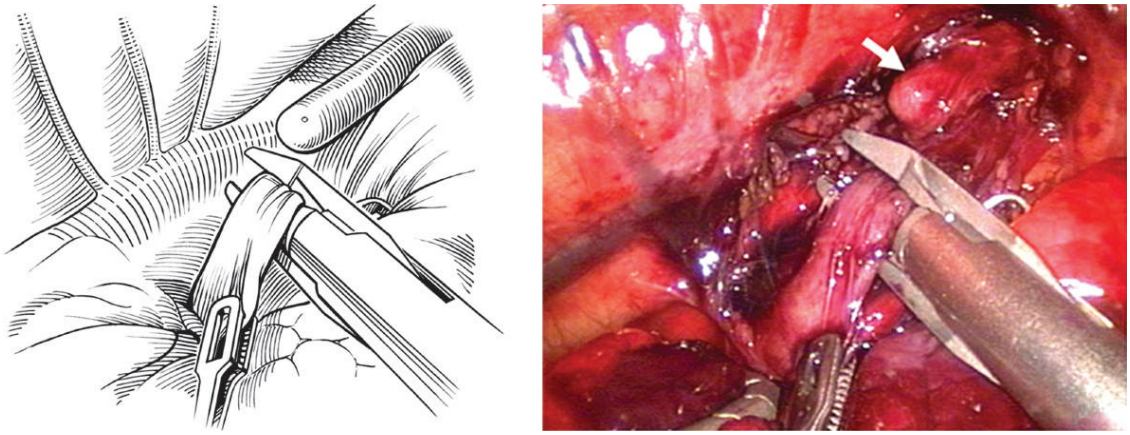

Figure 80.8. In the drawing (**left**) and photograph, an endoscopic clip applier is being positioned across the distal fistula to ligate it. An *arrow* indicates the proximal esophagus in the photograph. (Reprinted with permission from Holcomb GW III, Georgeson KE, Rothenberg SS, eds. *Atlas of Pediatric Laparoscopy and Thoracoscopy*. 1st ed. Philadelphia, PA: Copyright Elsevier; 2008.)

After completing the anastomosis, attention is turned toward trying to separate the esophageal suture line from the fistula closure on the trachea. Usually, these two sites will abut each other. An intact azygos vein often serves this purpose. Also, surgeons have tried interposing pleura or retropleural tissue to separate the two suture lines to prevent a recurrent TEF. However, this is not always easy. On occasion we have interposed a piece of small intestine submucosa (Surgisis, Cook Inc., Bloomington, IN) between the esophageal suture line and fistula to separate them (Fig. 80.11). A small silastic drain is then introduced through one of the stab incisions and positioned near the anastomosis. The 5 mm cannula site is closed with 4-0 and 5-0 absorbable sutures. Steri-Strips (3M Co., St. Paul, MN) are used to close the stab incision(s). Anesthesia is terminated and the baby is transported back to the Neonatal Intensive Care Unit where the baby is gradually weaned from the ventilator over a period of hours to days, depending on the baby's preoperative respiratory status.

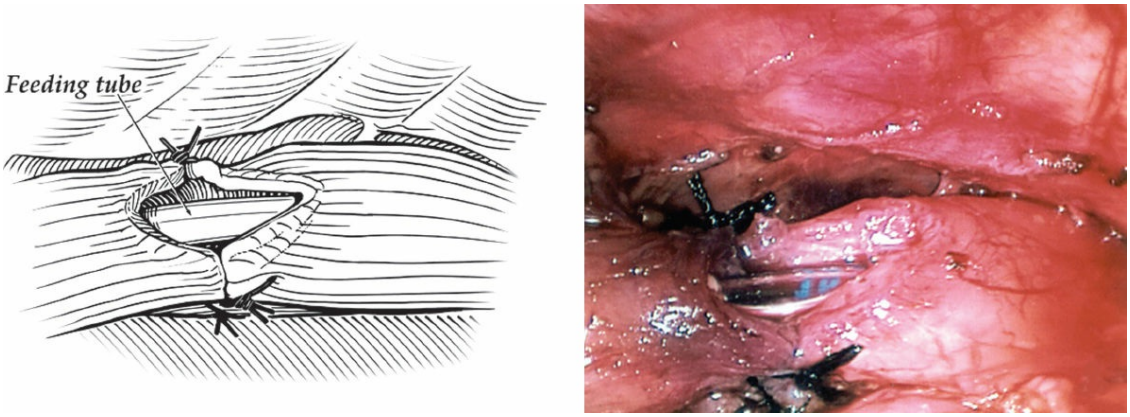

Figure 80.9. In this schematic and operative photograph, after completing the posterior part of the anastomosis, a soft 6-Fr tube has been introduced through the infant's nares, through the esophageal anastomosis, and into the stomach. This is often helpful in the postoperative period for feeding.

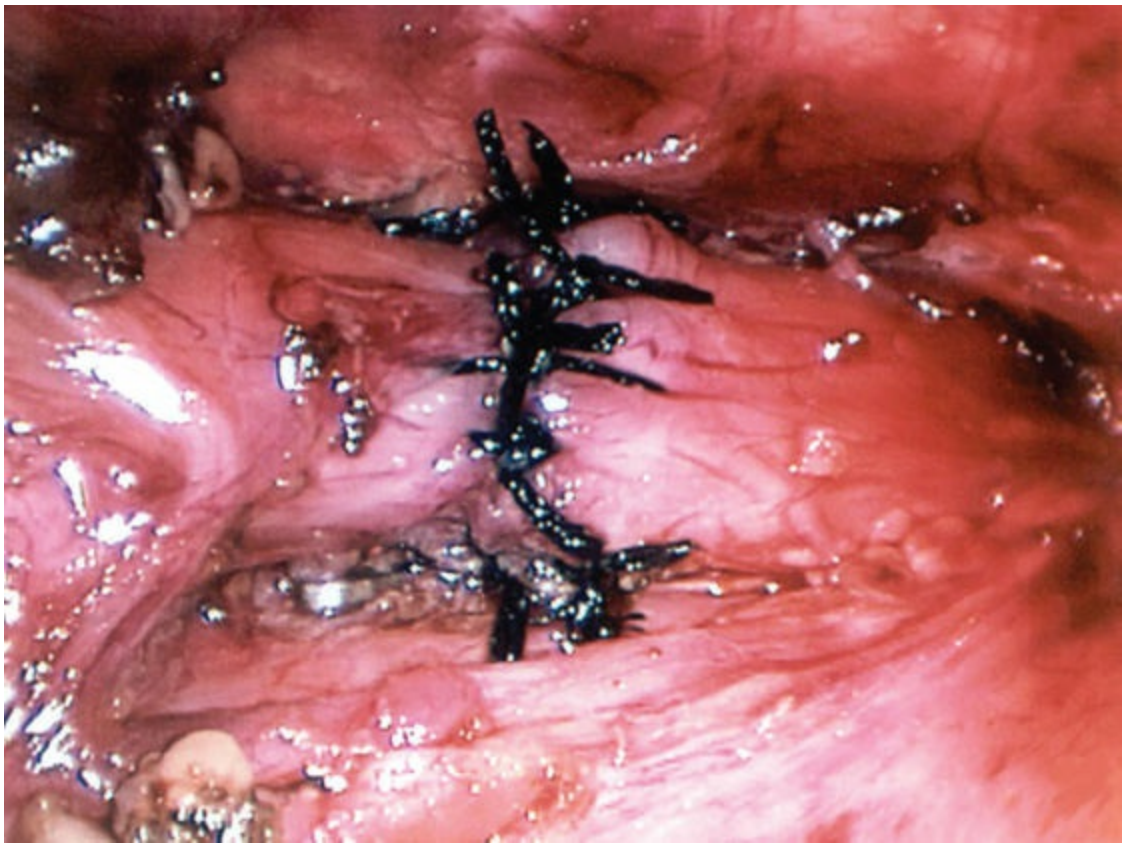

Figure 80.10. The anterior portion of the esophageal anastomosis has been completed with interrupted silk sutures which were tied intracorporeally. (Reprinted with permission from Holcomb GW III, Georgeson KE, Rothenberg SS, eds. *Atlas of Pediatric Laparoscopy and Thoracoscopy*, 1st ed. Philadelphia, PA: Copyright Elsevier; 2008.)

SURGICAL TECHNIQUE—OPEN APPROACH FOR EA/TEF

The principles between the open and thoracoscopic operation for EA/TEF are similar. With the open approach, a short posterolateral incision is made below the level of the tip of the scapula (Fig. 80.12). The latissimus dorsi muscle is retracted posteriorly, the scapula is retracted superiorly, and the serratus anterior muscle is retracted medially. Often, it is not necessary to divide the serratus muscle which avoids the risk of wing scapula. The fourth intercostal space is usually entered, although the third intercostal space can be used if the fistula and/or upper pouch are high in the mediastinum. If possible, an extrapleural dissection is utilized, and an infant rib spreader is inserted for additional exposure. The azygos vein can be left intact, or can be divided, depending on whether or not the operation can be performed without dividing it. At this point, the TEF is identified and encircled with a vessel loop. The upper esophageal pouch is then identified with the oroesophageal tube in it. A traction suture can be placed through both the tip of the pouch and the tube which helps facilitate dissection of the proximal pouch. The pouch is then dissected cephalad as far as needed for mobilization.

Once the proximal pouch has been mobilized sufficiently, the fistula is divided with fine tenotomy scissors and the tracheal side oversewn with 5-0 interrupted or continuous suture (Fig. 80.13). The distal esophageal opening is then gently dilated with a right angle clamp. 4-0 or 5-0 sutures of either absorbable or nonabsorbable material are used to secure the back wall of the esophageal anastomosis. It is important to take a full-thickness bite of both the proximal and distal esophagus with these sutures. Once the back wall of the anastomosis has been completed, a silastic tube is then placed by the anesthesiologist through the nose and into the esophagus, and through the anastomosis and down into the stomach as described previously for the thoracoscopic operation. Closure of the anterior part of the anastomosis is then performed in a similar fashion as the posterior wall, except that the knots are on the outside of the anastomosis on the anterior wall (Fig. 80.14). If the two ends of the esophagus are too far apart for a safe primary anastomosis, a circular myotomy as initially described by Livaditis can be performed to lengthen the proximal pouch. A beaver blade is used to perform the myotomy (Fig. 80.15). Each myotomy generally increases the length of the proximal esophagus by approximately 1 cm. Rarely, a second myotomy may be necessary to relieve tension at the

anastomosis.

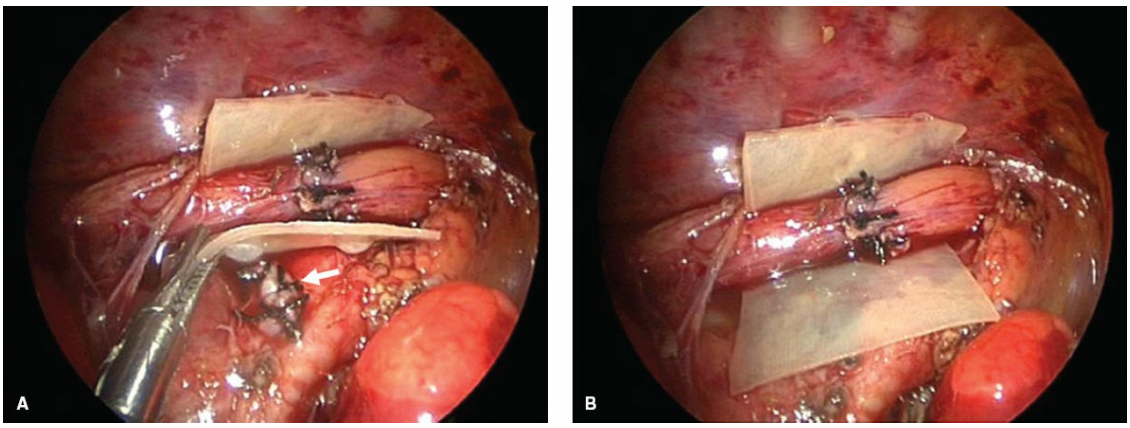

Figure 80.11. After completing the esophageal anastomosis, it is important to try to separate the esophageal suture line from the fistula closure on the trachea, if possible. Often, these two sites will lie next to each other. We now interpose a piece of Surgisis between the two suture lines to separate them (**A** and **B**). On the left (**A**), the *arrow* indicates the fistula closure on the trachea. We have not had a recurrent fistula developed after instituting this maneuver several years ago. (Reprinted with permission from St. Peter SD, Calkins CM, Holcomb GW III, et al. The use of biosynthetic mesh to separate the anastomoses during the thoracoscopic repair of esophageal atresia and tracheoesophageal fistula. *J Laparoendosc Adv Surg Tech* 2007;17:380–2.)

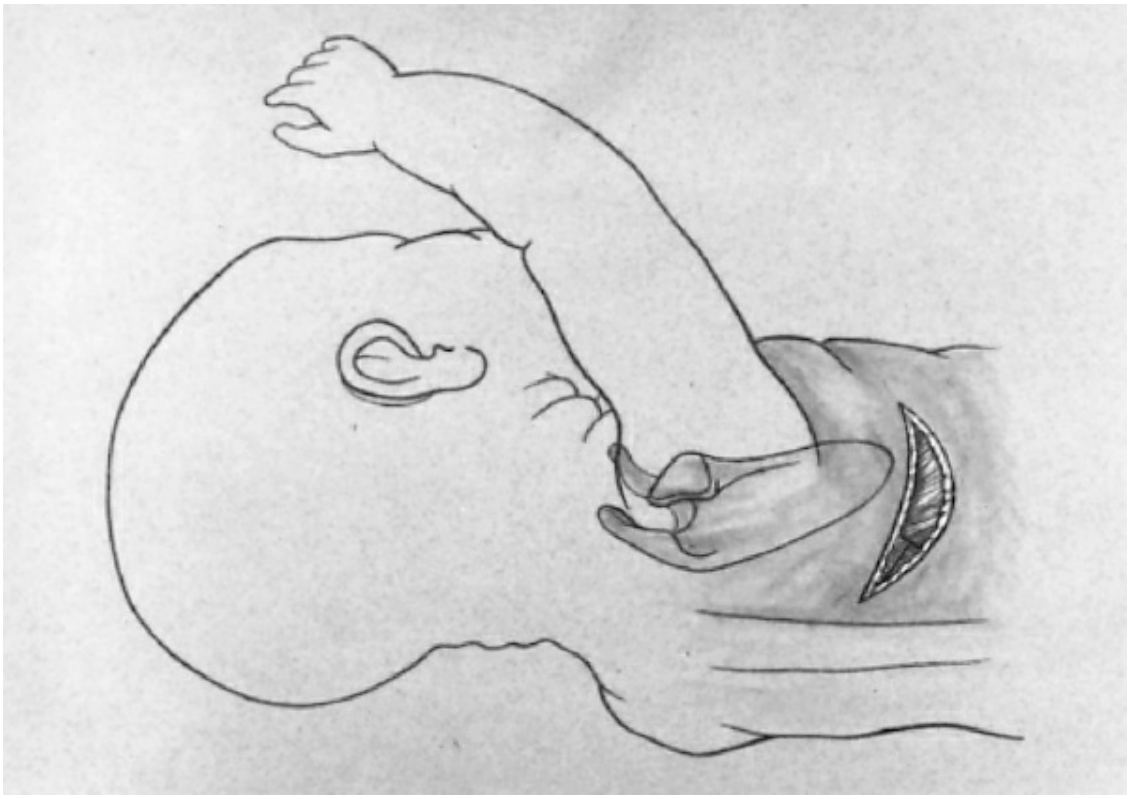

Figure 80.12. A posterolateral incision is made just below the tip of the scapula. The latissimus dorsi muscle is divided while the serratus anterior muscle is retracted anteriorly and medially.

Following completion of the anastomosis, mediastinal pleura, pericardium, or other mediastinal tissue should be interposed between the tracheal closure and the esophageal anastomosis. As mentioned, often the intact azygos vein sits nicely between these two structures and serves the same purpose. A soft silastic chest drain is then placed near the anastomosis and connected to bulb suction. The incision is then closed with absorbable suture.

POSTOPERATIVE CARE

Postoperatively, as mentioned, the ventilator is gradually weaned. We do not routinely utilize a standard number of days of neuromuscular paralysis. However, in general, the babies remain on the ventilator for at least 2 or 3 days and are sedated during that time. The infants are weaned from the ventilator when ready, and are extubated as soon as possible. Between postoperative days 5 and 7, a water-soluble contrast study is performed to evaluate for the presence of an anastomotic leak. If there is no evidence of a leak, oral feeding is initiated as tolerated and the small chest drain is

removed. If the babies do not tolerate oral feedings well, they are supplemented through the nasogastric stent that was placed at the time of the anastomosis. When the oral feedings improve, the stent is removed and the baby is transitioned to full oral feedings. The infants are then discharged when ready for home care.

COMPLICATIONS AND THEIR MANAGEMENT

Anastomotic Leak

A leak rate of between 10% and 21% has been reported in several studies following EA/TEF repair via thoracotomy (Fig. 80.16). However, these studies often include patients with isolated EA as well (in which the leak rate is higher), so the true incidence of leaks following open repair of EA/TEF is unclear. However, most leaks are small and will close spontaneously given enough time. In the largest study (104 patients) describing thoracoscopic repair of EA/TEF, the anastomotic leak rate was 7.6%.

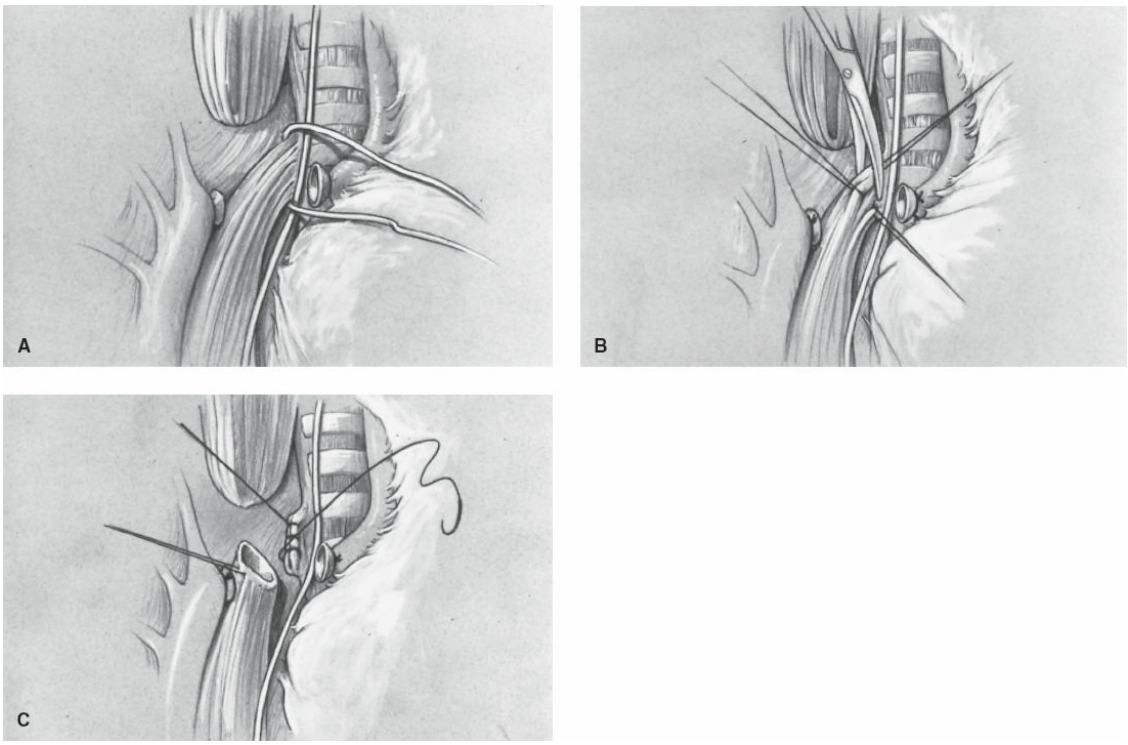

Figure 80.13. A. The tracheoesophageal fistula site is mobilized circumferentially distal to the fistula, and the area is encircled with a vessel loop. **B.** Traction sutures are placed, with great care taken not to encroach on the lumen of the trachea, which can result in narrowing with closure. Division of the fistula is then performed using tenotomy scissors. **C.** The tracheal end is closed

with a 5-0 continuous or interrupted suture. The closure is tested with positive-pressure ventilation to rule out a leak. The tracheal suture line is covered with mediastinal pleura to reduce the risk of recurrent tracheoesophageal fistula should an anastomotic leak occur.

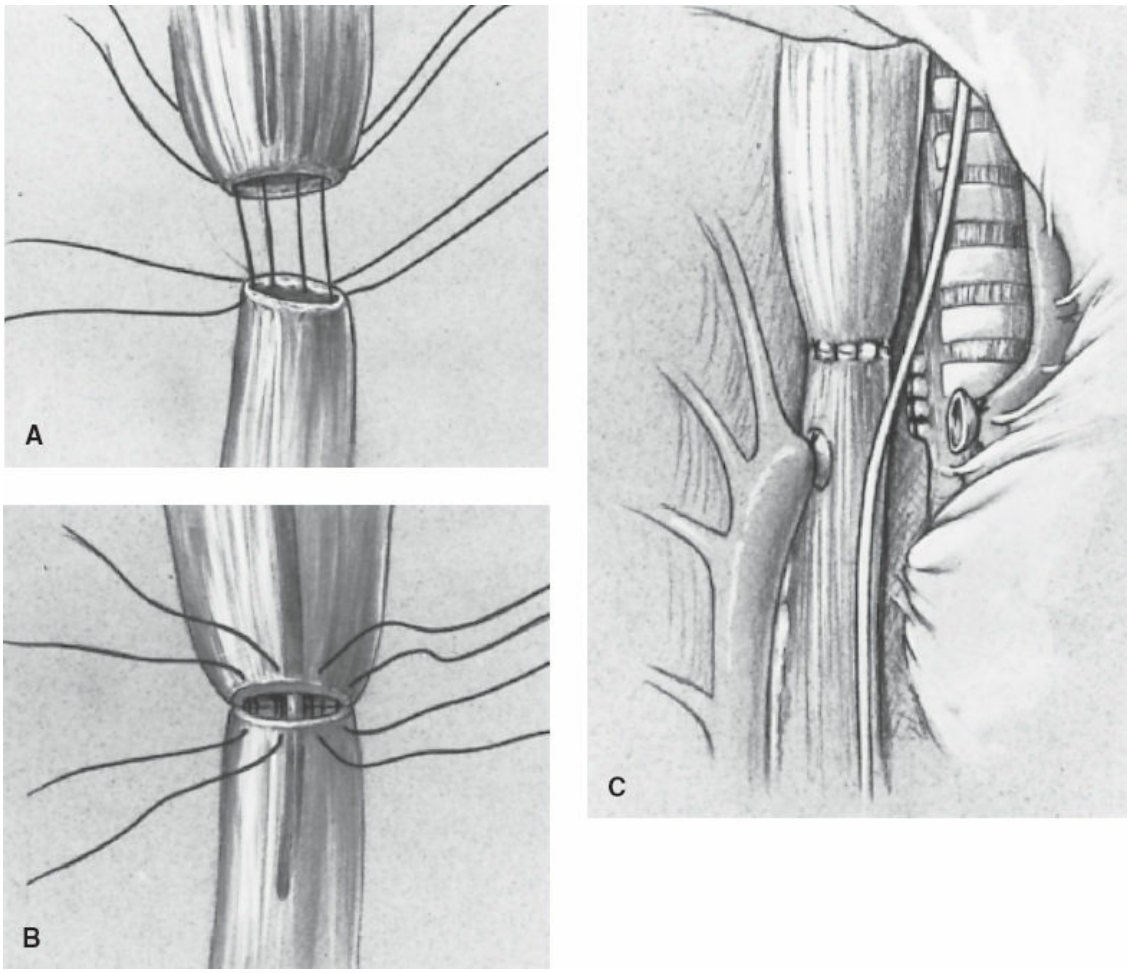

Figure 80.14. **A.** A single-layer anastomosis is performed with full-thickness, interrupted 4-0 sutures, involving mucosa and muscularis. The posterior sutures are placed with the suture knots on the inside. **B.** After the posterior suture line is completed, a feeding tube is advanced into the distal esophagus and stomach. The anterior sutures are inserted to complete the single-layer anastomosis. **C.** The completed anastomosis, sutured tracheal fistula repair, and ligated azygos vein are demonstrated.

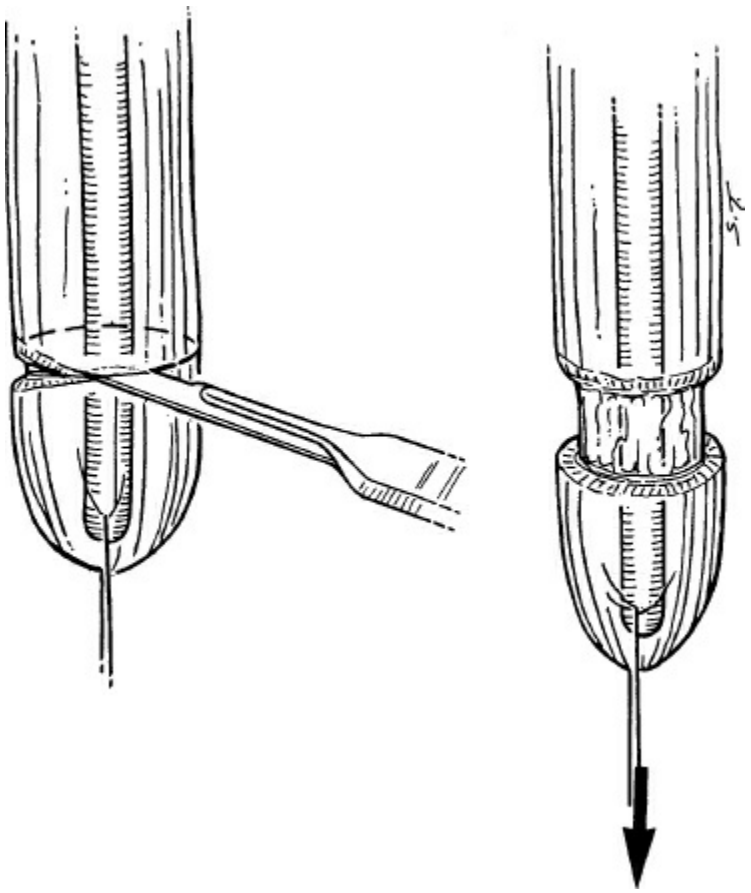

Figure 80.15. Circular myotomy of the proximal esophageal pouch is useful to gain 1 cm of esophageal length for a tension-free anastomosis.

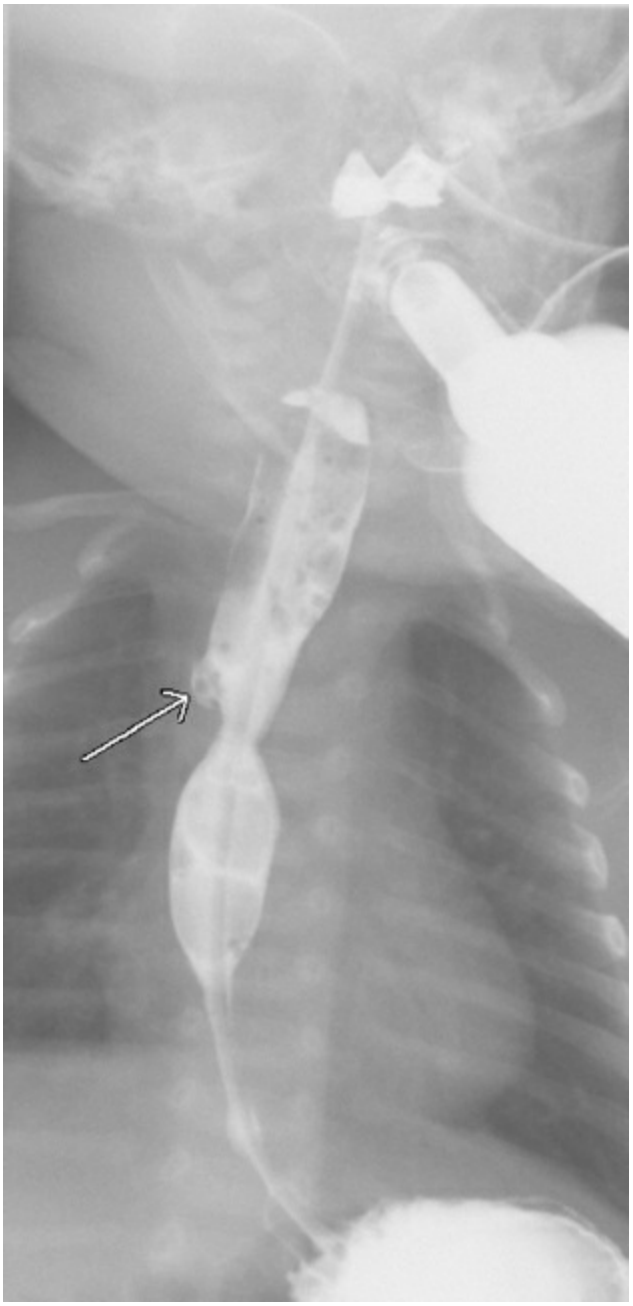

Figure 80.16. Esophogram showing an anastomotic leak at *arrow.*

Anastomotic Stricture

There is no uniform definition for an anastomotic stricture. Some authors define a stricture based on the anastomotic appearance on the initial contrast study, some describe it as a baby needing one esophageal dilation, and others define it as a baby who needs more than one dilation. Therefore, there is a wide range in the reported incidence of an anastomotic stricture following open repair, varying from 4% to 33%. In the study describing 104 patients undergoing thoracoscopic repair, an

anastomotic stricture was defined as a significant narrowing on the initial esophagram. In this series, four babies (3.8%) were found to have a stricture. Also, in this series, 32 babies (31.7%) required one dilation, 12 babies required two dilations (11.5%), and 9 babies (8.6%) required three or more dilations. Strictures usually respond nicely to dilation and anastomotic resection is not usually necessary. Failure of an anastomotic stricture to respond to dilation may be due to gastroesophageal reflux (GER).

Recurrent TEF

The development of a recurrent TEF varies between 2% and 15% depending on the literature report and the decade in which the study was published. Recurrence of the TEF is more likely if an anastomotic leak developed or there was excess tension on the anastomosis. Generally, the higher incidences were reported 30 years ago and the lower incidences are in the most recent time period. In the 104 patients undergoing thoracoscopic repair, two (1.9%) developed a recurrent TEF.

Management of a recurrent fistula can be difficult. Occasionally, a recurrent fistula can be found on a contrast swallowing study. Usually, however, bronchoscopy is needed to either make or confirm the diagnosis. Traditionally, management has required a thoracic approach. However, recently, a number of tracheoscopic treatment techniques have been described, including chemocauterization with 50% trichloroacetic acid, plugging the fistula with Surgisis (Fig. 80.17), or injecting it with Tisseal (Baxter, Deerfield, IL) (or both). Using a laser to abrade the fistula has also been described. Because repair of a recurrent TEF can be difficult, we have tried to prevent it by interposing either native tissue or Surgisis between the trachea and the esophagus at the time of the primary repair.

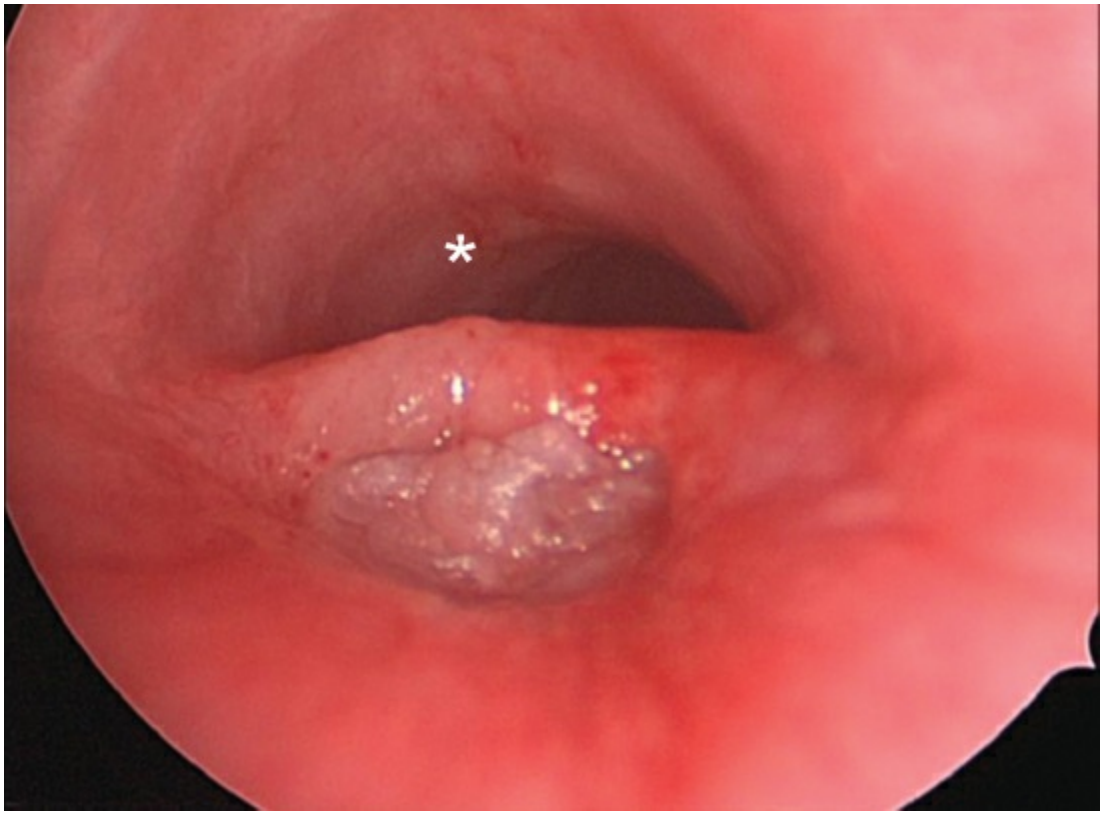

Figure 80.17. Management of a recurrent fistula can be difficult. Recently, we have been asked to treat several patients with recurrent TEF. In a stable patient, our initial approach has been a tracheoscopic approach with plugging the fistula with Surgisis. In this endoscopic view, Surgisis has been introduced into the recurrent tracheoesophageal fistula to occlude it. The tracheal lumen is identified with the *asterisk.*

Tracheomalacia

Tracheomalacia is a well-known problem that is found in almost every baby with EA and TEF. The softening of the tracheal cartilage is thought due to the distension of the adjacent esophagus during gestation. The symptoms are usually mild, but can occasionally be life-threatening. In a severely symptomatic baby, an aortopexy is occasionally required to suspend the aorta and aortic arch against the posterior surface of the sternum. As the anterior wall of the trachea is attached to the aorta, it is suspended as well and the tracheal lumen is thereby enlarged. This operation can be performed through a thoracotomy, mediasternotomy, or thoracoscopically. In the multi-institutional report of 104 babies undergoing thoracoscopic repair of EA/TEF, 7 babies (6.7%) required a thoracoscopic aortopexy.

Gastroesophageal Reflux and Esophageal Dysmotility

Almost all infants with EA with/without TEF will have some degree of GER, and all have esophageal dysmotility. Up to 50% of the babies will have significant GER and many will require a fundoplication. In the 104 babies undergoing thoracoscopic repair, 26 (25%) also required a laparoscopic fundoplication. A recent review on GER and EA described the need for fundoplication in 46% of babies with EA/TEF. Whether or not a complete (Nissen) or partial (Thal) fundoplication should be performed is often argued. Some authors believe that a loose floppy Nissen can be performed in a baby with esophageal dysmotility without causing dysphagia. Others, however, feel that an anterior partial fundoplication is superior to a Nissen as it is less likely to create an obstruction in the presence of disordered esophageal peristalsis.

ESOPHAGEAL ATRESIA WITHOUT A FISTULA

This anomaly is the second most common in the spectrum of EA. Usually, there is a significant gap between the two esophageal ends as the distal esophagus is not connected to the trachea. The gap is usually at least 2 cm and often longer. Gaps of 2 cm or less can usually be repaired primarily, but when the gap is longer, a number of other maneuvers are usually necessary. Ultimately, if the gap cannot be bridged, esophageal replacement with stomach, colon, or small intestine is required. Esophageal replacements are not considered optimal as they are prone to long-term complications as the patient grows. For this reason, most surgeons try to preserve the native esophagus and perform a delayed esophageal repair. Measures utilized to help bridge a significant gap between the two esophageal ends include staged stretching of the proximal esophagus by initially performing an esophagostomy and then periodically advancing it inferiorly onto the chest wall as described by Kimura and Soper. Also, Folker developed a technique that induces tension on the proximal and distal esophagus in an accelerated fashion with the intent to induce esophageal growth. Sutures are placed on each end of the esophagus with pledgets. The sutures are crossed in the thoracic cavity and brought out onto the chest wall above and below the incision and tied over silastic buttons. Tension is placed on the sutures each day in order to induce growth on the two esophageal ends. This technique can be performed thoracoscopically as well (Fig. 80.18). Results have been very good in his series of patients, but not all pediatric surgeons have been able

to achieve similar good results with this technique.

H-TYPE TEF

Isolated TEF (without an associated EA) is the third most common condition found in the spectrum of patients with EA. The diagnosis is often delayed, but persistent coughing or choking during feeding, especially with liquids, is usually found in these babies. Recurrent pneumonia is common as well.

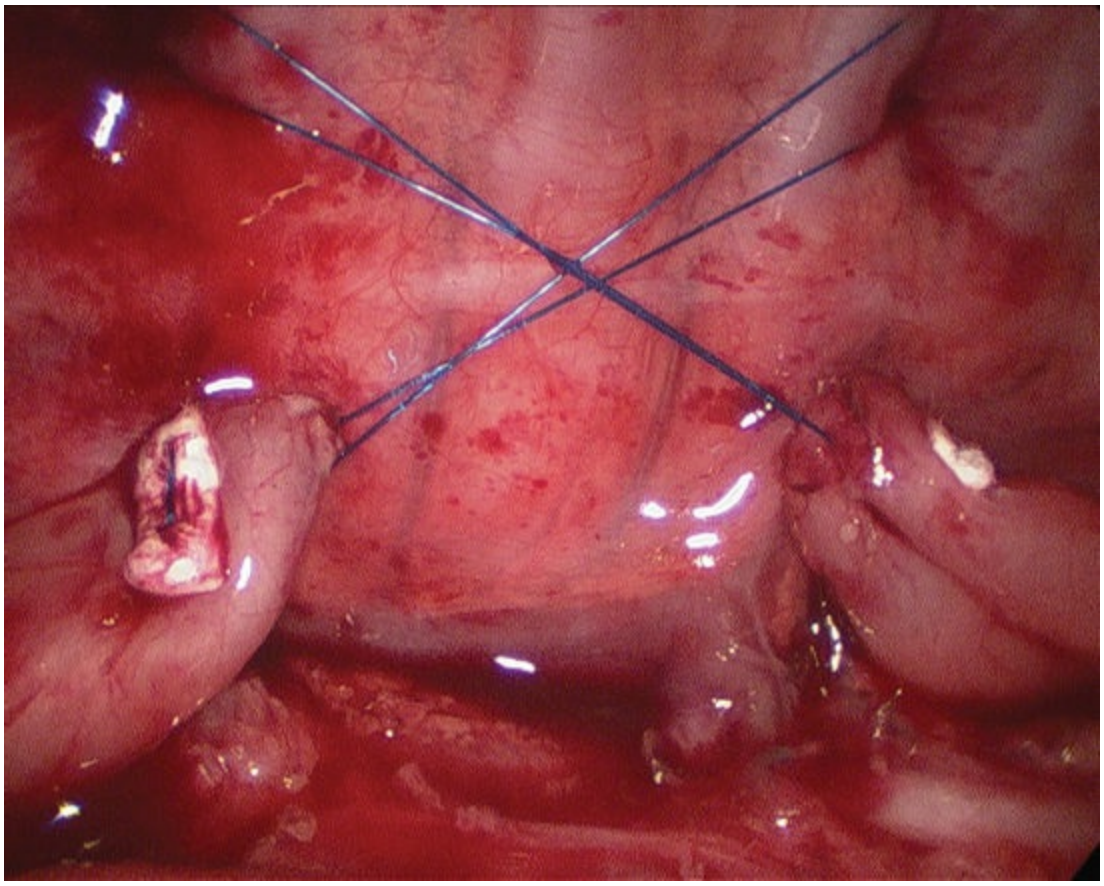

Figure 80.18. Foker technique, thoracoscopic illustration of pledgeted traction sutures.

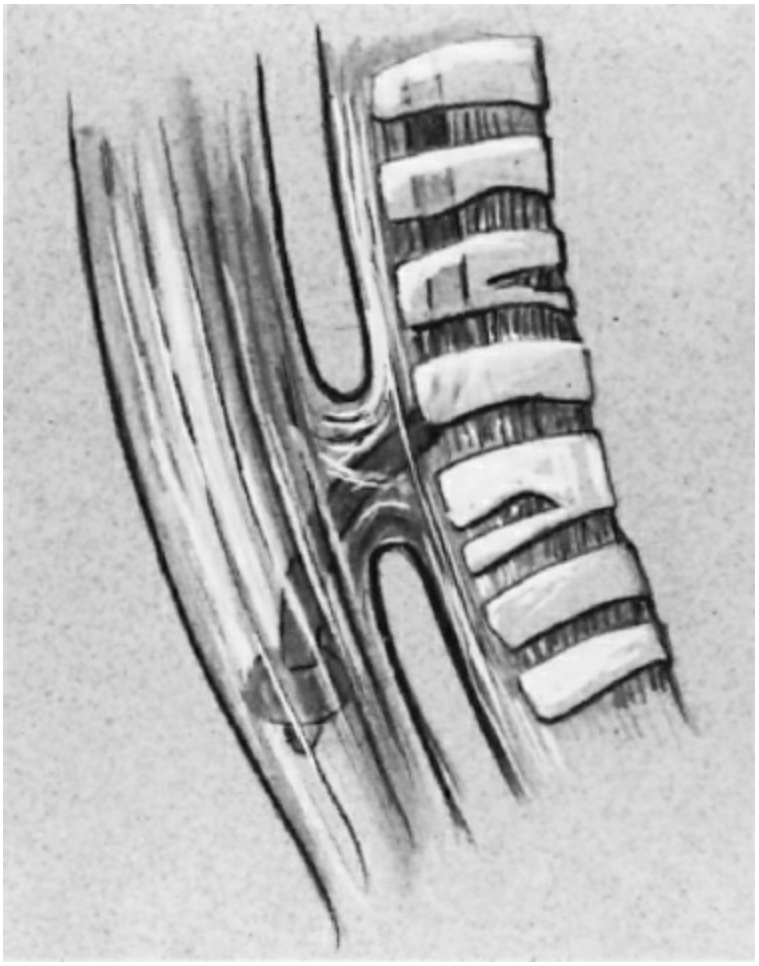

Figure 80.19. Identification of an H-type fistula is aided by placing a Fogarty catheter through the fistula at bronchoscopy.

Most of these isolated TEFs can be approached through a low right cervical incision. Bronchoscopy can be especially helpful to confirm the diagnosis as they are not always evident on esophageal contrast studies. Also, at the time of repair, placement of a fine Fogarty or ureteral catheter through the bronchoscope, through the fistula, and into the esophagus is helpful for identification of the fistula at exploration (Fig. 80.19). At exploration, the esophagus is identified by palpating the nasogastric tube and the fistula is found by palpating the Fogarty catheter. When the fistula is identified, it is divided on the esophageal side to avoid narrowing of the trachea. It is important to identify the vagus nerve and the recurrent laryngeal nerve as they can be injured during the dissection. Both the trachea and esophageal sides are closed with interrupted fine absorbable sutures. A small drain is often placed postoperatively until an esophagram is performed between days 4 and 7.

OUTCOMES

Short-term outcomes following EA/TEF repair have improved significantly over the past 70 years since the first successful repair. A poor outcome is usually associated with other severe congenital anomalies, primarily cardiac in nature, or with a large gap between the esophageal segments. In a recent review looking at outcomes in newborn babies with EA/TEF in the United States, the Kids' Inpatient Database was queried. A total of 4,168 cases were identified with an overall in-hospital mortality of 9%. Multivariate logistic regression analysis identified a birth weight less than 1,500 g, operation within 24 hours, gestational age less than 28 weeks, and the presence of a VSD as independent predictors of in-hospital mortality. A recent review from Great Ormond Street Hospital for Children showed an overall survival rate from 2001 to 2011 of 93% versus 92.6% from 1993 to 2004. However, in the more recent time period, there was significant improved survival in Spitz's group 2 (birth weight less than 1,500 g or major cardiac anomaly) of 82.4%. Also, of the patients in Group 2 who died, 90% had major cardiac anomalies.

Over the long term, dysphagia and food impaction at the site of the esophageal anastomosis are sometimes found in adolescents or young adults who were born with EA/TEF. It is not unusual to perform an esophagoscopy for removal of food impaction in a teenager who has undergone repair of EA/TEF.

A recent report from Helsinki described 588 patients who underwent repair of EA from 1947 to 1985. A total of 235 of these patients were alive with their native esophagus and 169 responded to contact. The information provided by the first 101 patients who replied and agreed to participate made up the clinical study group. Symptomatic GER was found in 34% and dysphagia in 85% of these patients. Vertebral anomalies were found in 45% of the patients with the most common site being in the cervical spine. The risk of significant scoliosis was 13-fold when compared with the healthy control population and thoracotomy-induced rib fusion and other associated anomalies were the strongest predictors for scoliosis. However, in most patients, the clinical course of their scoliosis was mild and did not require bracing or repair. There were no instances of esophageal cancer found in these patients. Interestingly, the authors found that there was no difference in the overall health-related quality of life between patients and controls, indicating that these patients learn to live well with their esophageal dysmotility and scoliosis.

Suggested Readings

Bairdain S, Hamilton TE, Smithers CJ, et al. Foker process for the correction of long gap esophageal atresia: primary treatment versus secondary treatment after prior esophageal surgery. *J Pediatr Surg* 2015;50:933–7.

Borruto FA, Impellizzeri P, Montalto AS, et al. Thoracoscopy versus thoracotomy for esophageal atresia and tracheoesophageal fistula repair: review of the literature and meta-analysis. *Eur J Pediatr Surg* 2012;22:415–9.

Gallo G, Zwaveling S, Groen H, et al. Long-gap esophageal atresia: a meta-analysis of jejunal interposition, colon interposition, and gastric pull-up. *Eur J Pediatr Surg* 2012;22:420–5.

Holcomb GW 3rd, Rothenberg SS, Bax KMA, et al. Thoracoscopic repair of esophageal atresia and tracheoesophageal fistula: a multi-institutional analysis. *Ann Surg* 2005;242:1–9.

Keckler SJ, St Peter SD, Valusek PA, et al. VACTERL anomalies in patients with esophageal atresia: an updated delineation of the spectrum and review of the literature. *Pediatr Surg Int* 2007;23:309–13.

Koivusalo AI, Pakarinen MP, Rintala RJ. Modern outcomes of oesophageal atresia: single centre experience over the last twenty years. *J Pediatr Surg* 2013;48:297–303.

Lelonge Y, Varlet F, Varela P, et al. Chemocauterization with trichloroacetic acid in congenital and recurrent tracheoesophageal fistula: a minimally invasive treatment. *Surg Endosc* 2016;30(4):1662–6.

Malakounides G, Lyon P, Cross K, et al. Esophageal atresia: improved outcome in high-risk groups revisited. *Eur J Pediatr Surg* 2016;26(3):227–31.

St. Peter SD, Calkins CM, Holcomb GW 3rd. The use of biosynthetic mesh to separate the anastomosis during the thoracoscopic repair of esophageal atresia and tracheoesophageal fistula. *J Laparoendosc Adv Surg Tech* 2007;17:380–2.

Sulkowski JP, Cooper JN, Lopez JJ, et al. Morbidity and mortality in patients with esophageal atresia. *Surgery* 2014;156:483–91.

Van Der Zee DC, Bax KN. Thoracoscopic treatment of esophageal atresia with distal fistula and of tracheomalacia. *Semin Pediatr Surg* 2007;16:224–30.

Walker K, Halliday R, Badawi N, et al. Early developmental outcome following surgery for oesophageal atresia. *J Paediatr Child Health* 2013;49:467–70.

EDITOR'S COMMENT

In the field of pediatric surgery, repair of an EA/TEF is one of the most satisfying operative procedures performed converting a life-threatening

congenital anomaly into a surgically reconstructed conduit with life-long benefit. In this chapter, the author presents an excellent overview of the condition. Patients with EA/TEF often have associated congenital anomalies. The VACTERL combination is most well recognized and when the attendant anomalies are present, proper sequencing of the interventions required is critical. If congenital heart disease is present, stabilization of cardiac function takes priority with the type of congenital heart disease dictating the cardiac intervention required. If an additional GI tract anomaly is present, duodenal atresia and imperforate anus being the most common, intervention in the abdomen may be required first. Especially in a patient with duodenal atresia, duodenal reconstruction should occur first as correcting the esophageal atresia with a proximal obstruction could stress the integrity of the esophageal anastomosis. In patients with imperforate anus, there is more latitude to the sequencing of the procedures.

Although EA patients uncommonly require emergent treatment, the premature infant with a TEF can be challenging. Premature infants have immature lungs and often require mechanical ventilatory support and if a large TEF is present, can result in preferential shunting of air into the GI tract resulting in progressive abdominal distention (Templeton JM, Templeton JJ, Schnaufer L, et al., *J Ped Surg* 1985;20(4):394–87). The distention inhibits respiratory mechanics creating a vicious cycle as increased ventilatory support is required. Unimpeded, progressive luminal distention may result in GI perforation exacerbating a tenuous situation. In addition to the strategies described by the author, occluding the distal esophagus at the GE junction with a vessel loop passed twice around the esophagus (similar to a POTTS maneuver around a blood vessel) can be an effective route to temporarily impede air egress through the esophagus allowing stabilization of the neonate's ventilatory requirements. Once stable, division of the TEF through the chest can be performed and the vessel loop removed.

Low–birth-weight infants (<1,500 g) deserve careful consideration. Some of these may be premature and face the challenges described above but others may be small for gestational age and if the TEF is not causing respiratory symptoms are stable. In these patients, the timing of repair is of some debate. Primary repair can be performed safely but studies report increased rates of anastomotic leak and stricture (Petrosyan M, Estrada J, Hunter C, et al. Esophageal atresia/tracheoesophageal fistula in very low-birth-weight neonates: improved outcomes with staged repair. *J Pediatr Surg* 2009;44:2278–81). A staged approach in which the TEF is divided and a G-tube is placed allowing for maturation and growth followed by delayed reconstruction is favored by some and although two procedures are required, may have lower overall morbidity. For the practicing surgeon, primary and staged repair are complimentary alternatives and depending on the specific clinical scenario encountered utilized appropriately.

An ECHO is obtained in all patients with esophageal atresia. It is important

for the surgeon to review the ECHO result establishing on which side of the chest the aortic arch is found. Repairing a TEF with the arch in the field, although successfully performed, can make the procedure more challenging (Parolini F, Armellini A, Boroni G, et al. The management of newborns with esophageal atresia and right aortic arch: a systematic review or still unsolved problem. *J Pediatr Surg* 2016;51(2):304–9). If a right-sided aortic arch is present, one should consider an approach through the left chest to repair the EA. When there is an aberrant arch, a vascular ring is likely present therefore care must be taken to ensure the ring does not cause a distal esophageal obstruction.

As the author notes, the first thoracoscopic repair of an EA/TEF was reported in 1997. Since that time, the thoracoscopic approach has received widespread attention and the author describes in excellent detail, important aspects of the thoracoscopic approach, especially the suggestion to use high-frequency jet ventilation. The benefit of thoracoscopic procedures in pediatric patients remains to be defined. A recent systematic review of pediatric studies evaluating the advantages of video-assisted thoracoscopy revealed that there is no high level of evidence supporting minimally invasive techniques (Dingemann C, Ure B, Dingemann J. Thoracoscopic procedures in pediatric surgery: what is the evidence? *Eur J Pediatr Surg* 2014;24(01):14–9). The evidence in favor of thoracoscopic TEF repair is based on institutional and multi-institutional retrospective case series reviews (Holcomb GW, Rothenberg SS, Bax KM, et al. Thoracoscopic repair of esophageal atresia and tracheoesophageal fistula: a multi-institutional analysis. *Ann Surg* 2005;242(3):422–8). The pediatric surgery community must address whether the benefits of the thoracoscopic approach are greater than the potential risks given the long-term goal of a life time of the esophagus as a conduit. The purported potential benefits of the procedure, decreased rates of a winged scapula and scoliosis are at best poorly documented late complications of the open approach and may not mitigate the risks of a thoracoscopic approach.

Placement of a foreign material between the esophagus and trachea (Surgisis) and the placement of a trans-anastomotic feeding tube as the author recommends has some attendant risks as a recent retrospective multi-institutional study found that they were associated with an increased incidence of either an anastomotic leak or stenosis (Lal et al. *J Ped Surg* 2016;16:305–9). The Midwest Pediatric Surgical Consortium is conducting a prospective observational trial to determine the impact of a bundle of measures including the elimination of the placement of both foreign material and trans-anastomotic tubes assessing its impact on complication rates.

Patients with long-gap EA patients remain the most vexing with a diverse array of alternative strategies utilized to restore GI tract continuity. Consensus has been reached in so far as preservation of the native esophagus is preferred over any other replacement conduit; however, depending on the gap between the two ends of the esophagus can be extremely difficult to achieve. Lengthening of the native esophagus using various techniques in which

continuous application of tension to the two ends of the esophagus have been shown to be effective but comes at the expense of multiple operative explorations (Foker JE, Linden BC, Boyle EM Jr, et al. Development of a true primary repair for the full spectrum of esophageal atresia. *Ann Surg* 1997;226(4):533–41). If the native esophagus cannot be saved, the choice of replacement conduit includes the stomach, colon, and jejunal interposition with a meta-analysis suggesting the gastric pullup associated with a higher respiratory morbidity but fewer gastrointestinal complications (Gallo G, Zwaveling S, Groen H, et al. Long-gap esophageal atresia: a meta-analysis of jejunal interposition, colon interposition, and gastric pull-up. *Eur J Pediatr Surg* 2012;22(6):420–5). Several major children's hospitals have established centers with specialized focus on complex esophageal reconstruction combining multidisciplinary input to optimize treatment strategies and outcome (Lobeck I, Dupree P, Stoops M, et al. Interdisciplinary approach to esophageal replacement and major airway reconstruction. *J Pediatr Surg* 2016;51(7):1106–9; Smithers CJ, Hamilton TE, Manfredi MA, et al. Categorization and repair of recurrent and acquired tracheoesophageal fistulae occurring after esophageal atresia repair. *J Pediatr Surg* 2017;52(3):424–30). The impact of these centers of excellence will become apparent in the coming years.

As the author notes, the challenges following TEF repair can be separated into technical versus physiologic. Technical challenges include anastomotic leak, stenosis and recurrent fistula. The physiologic challenges are tracheomalacia, gastroesophageal reflux, and esophageal dysmotility. An esophageal leak is the most frequent complication following TEF repair. A controlled leak will heal but likely at the expense of a stenosis. Esophageal stenosis will also occur de novo. The pathogenesis of the stenosis may be GER but can be due to other anatomic abnormalities. Pyloric stenosis can occur in any infant and should it arise in a patient with a TEF, will trigger a stenosis. An intrinsic distal esophageal stenosis due to an aberrant cartilaginous ring can also occur albeit with much less frequency (Newman B, Bender TM. Esophageal atresia/tracheoesophageal fistula and associated congenital esophageal stenosis. *Pediatr Radiol* 1997;27(6):530–4). These rings are best addressed with resection as dilatation is associated with higher complications rates.

A recurrent fistula is problematic (Smithers CJ, Hamilton TE, Manfredi MA, et al. Categorization and repair of recurrent and acquired tracheoesophageal fistulae occurring after esophageal atresia repair. *J Pediatr Surg* 2017;52(3):424–30). In the past, the recurrence of a fistula mandated re-exploration but with advances in endoscopic techniques, a recurrent fistula, especially if small may be amenable chemocauterization and fibrin glue–induced closure. If endoscopic approaches fail, exploration is warranted and in these circumstances, placement of an autologous graft between the esophagus and trachea is warranted (Bruch SW, Hirschl RB, Coran AG. The diagnosis and management of recurrent tracheoesophageal fistulas. *J Pediatr* Surg 2010;45(2):337–40). In cases of re-recurrence, slide tracheoplasty has also been

shown to be effective (Provenzano MJ, Rutter MJ, von Allmen D, et al. Slide tracheoplasty for the treatment of tracheoesophogeal fistulas. *J Pediatr Surg* 2014;49(6):910–4).

The physiologic challenges that patients with an EA/TEF encounter are life-long. Tracheomalacia if severely symptomatic can be improved with an aortopexy (Kay-Rivest E, Baird R, Laberge JM, et al. Evaluation of aortopexy in the management of severe tracheomalacia after esophageal atresia repair. *Dis Esophagus* 2015;28(3):234–9). Gastroesophageal reflux disease (GERD) is frequent. Should reflux be severe, an antireflux procedure is warranted. Because of intrinsic dysmotility in the reconstructed esophagus, partial or very "loose" complete wraps are indicated. Long-term follow-up is critical as late effects like the development of Barrett metaplasia is worrisome (Schneider A, Gottrand F, Bellaiche M, et al. Prevalence of Barrett esophagus in adolescents and young adults with esophageal atresia. *Ann Surg* 2016;264(6):1004–8).

Gregory M. Tiao

81 Pathology and Treatment of Zenker Diverticulum

Christopher R. Morse

Zenker diverticula (ZD) are a form of pulsion diverticulum occurring in an area of muscular weakness (Killian triangle) located between the inferior constrictor and cricopharyngeus muscles. The condition was first described by Ludlow in 1764 and subsequently, Zenker published a series of 23 cases in 1877. Symptoms include dysphagia, regurgitation of undigested food, globus sensation, halitosis, and aspiration pneumonia. Surgical intervention has been recognized as the only effective treatment and shown to result in the improvement of symptoms and quality of life with little morbidity.

Initial attempts at repair often failed secondary to leaks and the development of mediastinitis. Early modification of technique involved a diverticulopexy (Schmid). Further evolution of the technique involved pexy of the diverticulum with an interval resection of the diverticulum approximately a week later. It was not until the late 1950s when the concept of a two-stage surgery was challenged with a one-stage approach and a cricopharyngeal myotomy was added.

Repair continued to focus on open resection/pexy and cricopharyngeal myotomy, but recently, the endoscopic repair of ZD has been described and is gaining popularity. This has been an evolution of endoscopic techniques ranging from a sharp division of the diverticular spur with a knife (Mosher) to a needle knife division to bipolar cautery division to laser division, all with varying degrees of success. The most common approach to an endoscopic approach at present is a transoral stapling of the diverticulum with a modified tip to the stapler. As many Zenker patients are elderly with significant comorbid disease, an endoscopic approach avoiding the need for a neck incision may provide several potential advantages.

ETIOLOGY AND PATHOPHYSIOLOGY

The prevailing hypothesis for the development of a ZD is a pulsion diverticulum secondary to a “hypertensive” cricopharyngeal muscle. The decrease in compliance of the cricopharyngeus leads to a “blowout” of the mucosa in a transition zone between and hypopharynx and the esophagus (Killian triangle). The proximal and lateral borders of the triangle are the horizontal cricopharyngeal muscle and the oblique fibers of the constrictor pharyngeus inferior muscle and the area of weakness extends posteriorly. As the pouch dilates and distends, it tends to progress inferiorly, capturing the cricopharyngeus muscle between the diverticulum and the esophagus.

CLINICAL PRESENTATION

Typically a disease of the elderly, symptoms associated with a ZD are variable and correlate with the size of the diverticulum. Early on, with poor compliance of the cricopharyngeus and prior to the development of the diverticular pouch, the primary complaint is primarily choking and dysphagia. With the development of the diverticulum, patients often report dysphagia with the regurgitation of undigested food, halitosis, and aspiration events. Approximately one third of patients with a ZD report losing weight. In the elderly, aspiration can lead to a life-threatening pneumonia (Table 81.1 Previous chapter). There are few findings on physical examination, although can include in rare cases cervical borborygmi and crepitus. The differential diagnosis in these patients includes esophageal cancer with obstructive symptoms, esophageal webs and strictures, Killian–Jamieson diverticuli below the cricopharyngeus, tracheoesophageal fistula, and esophageal foreign body.

TABLE 81.1 Zenker Diverticulum: Clinical Presentation and Symptoms

Clinical Presentation	
Mean age	68 yrs
Symptoms	
Dysphagia	80%
Regurgitation	58%
Choking	20%
Coughing	18%
Globus sensation	21%
Weight loss	23%
Other	14%
Associated Pathology	
Pulmonary infection	37%
Upper GI pathology	60%
Documented reflux	44%
Other	52%

EVALUATION AND PREOPERATIVE PLANNING

A barium swallow and upper gastrointestinal esophagoscopy should be performed in all patients. A barium swallow typically reveals a cervical midline protrusion at the level of the posterior hypopharyngeal wall (Fig. 81.1). Esophageal motility, based on the work of Cook et al., will demonstrate a hypertensive and restrictive pattern of the upper esophageal sphincter. However, motility studies are not necessary in the evaluation of a ZD and it is often difficult to pass the motility catheter. An EGD, performed at the time of the procedure, allows for the evaluation of the diverticulum, removal of any debris from the diverticulum, and an opportunity to examine the esophagus for other pathology. For open, transcervical procedures, there are no size criteria for repair and diverticulum can be repaired at almost any size with symptoms. However, for a transoral stapled approach, the diverticulum should be at least 3 cm in size to allow for entrance of the stapler and a complete cricopharyngeal myotomy. In addition, for a transoral stapled approach, patients should be evaluated for limited mouth opening and inability to adequately extend the neck that can make placement of the Weerda scope laryngoscope difficult.



Figure 81.1. Barium Swallow demonstrating a Zenker diverticulum with the classic posterior midline protrusion.

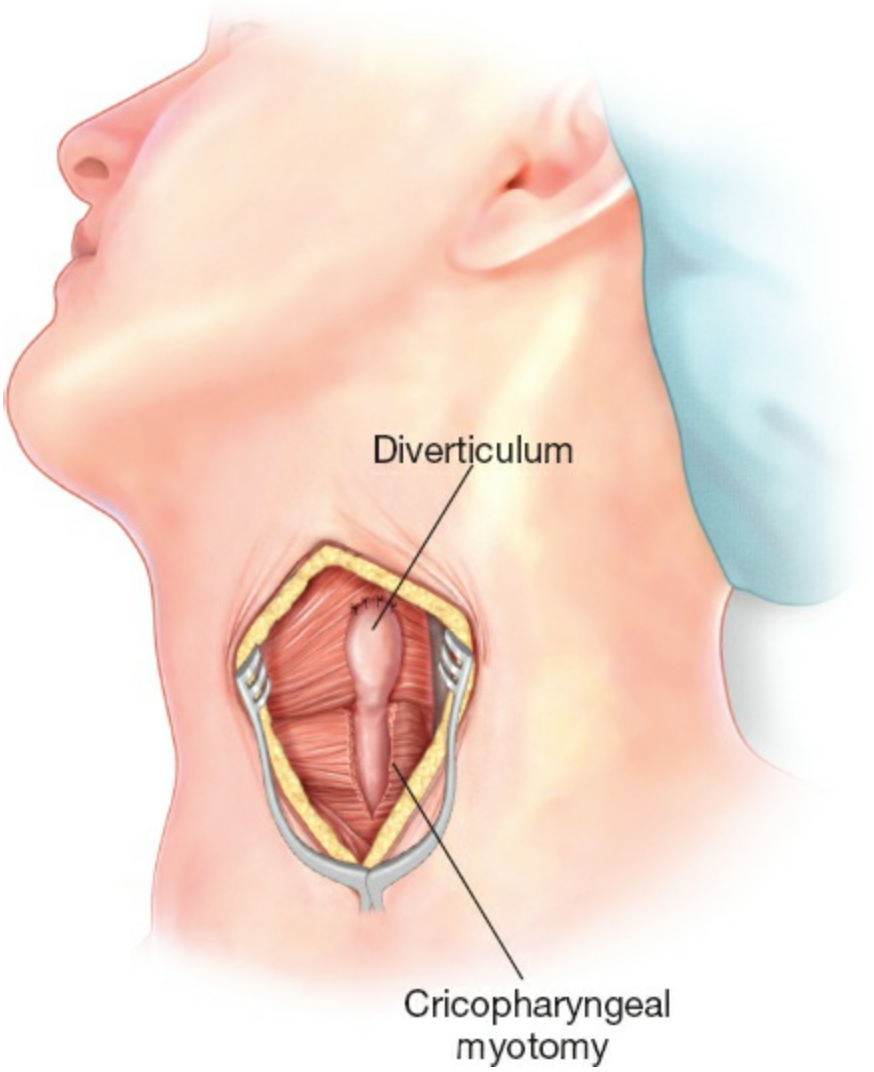

Figure 81.2. Repair of Zenker diverticulum with suspension diverticulopexy and cricopharyngeal myotomy.

SURGERY

There are several open approaches to the repair of a ZD. First is a cricopharyngeal myotomy for small, early diverticulum. Occasionally, in the setting of a small diverticulum, performing an extensive cricopharyngeal myotomy will cause the smallest of pouches (typically <1 cm) to disappear as the mucosa “pouts” with the myotomy. The second approach is a cricopharyngeal myotomy with suspension of the diverticulum (Fig. 81.2). In this situation, the diverticulum is suspended behind the pharynx by suturing it to either the pharyngeal musculature or the prevertebral fascia. An advantage to this approach is the avoidance of opening the diverticulum and preventing the complications of infection and fistula. The third and most commonly described approach is a

diverticulectomy and cricopharyngeal myotomy where the diverticulum is resected and the esophagus closed with a stapler or a hand-sewn technique and an extensive cricopharyngeal myotomy performed (Fig. 81.3). More recently, an endoscopic transoral approach now commonly using a laryngoscope and modified stapler allows for division of the common wall between the esophagus and diverticular pouch. This technique avoids a cervical incision (Fig. 81.4).

There is no special equipment needed for an open transcervical diverticulectomy/diverticulopexy and cricopharyngeal myotomy. With a diverticulectomy, a Maloney bougie is placed prior to stapling and a TA stapler is typically used for the resection of the diverticulum.

Performing a transoral stapled Zenker diverticulectomy requires a Weerda scope laryngoscope (Karl Storz, Tuttlingen, Germany) (Fig. 81.5), a modified stapler with the anvil shortened to allow stapling and cutting to the end of the stapler and 5-mm 30-degree laparoscope to allow for additional visualization.

Positioning

For a transcervical diverticulectomy or diverticulopexy, the patient is placed supine on the operating room table and, after general anesthesia is induced, the head is turned to the right to expose the left neck. Padding is placed beneath the shoulders to extend the neck. For a transoral diverticulectomy, the patient is placed supine on the operating table with the head positioned at the top of the operating table. General anesthesia is established using a small diameter endotracheal tube. Arms are typically tucked at the sides in both procedures.

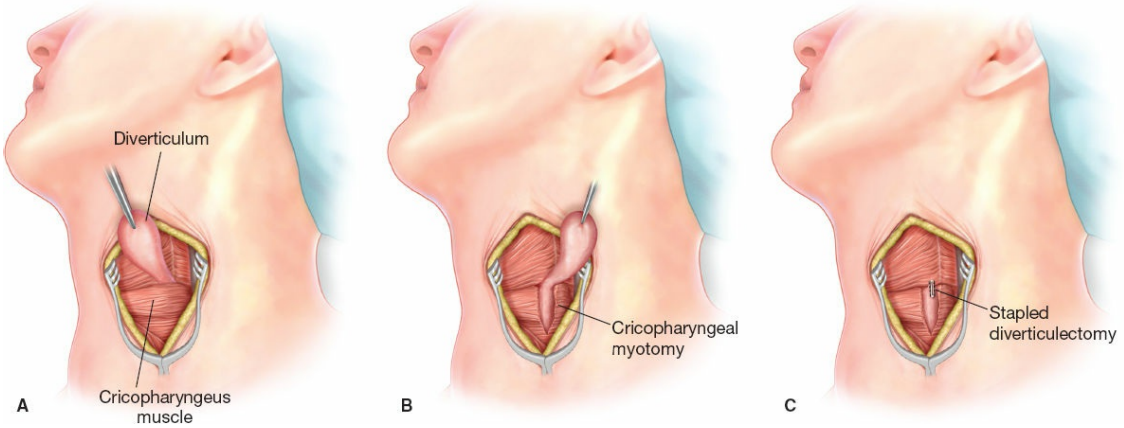

Figure 81.3. Repair of Zenker diverticulum (**A**) with cricopharyngeal myotomy (**B**) and stapled diverticulectomy (**C**).



Figure 81.4. Transoral stapling of Zenker diverticulum using a modified stapler and laryngoscope.

Technique

An open approach for either a diverticulopexy or diverticulectomy both with cricopharyngeal myotomy, an incision is made along the anterior border of the sternocleidomastoid muscle reflecting the carotid sheath laterally. The omohyoid muscle can be divided if necessary for visualization. The prevertebral fascia is identified and moving medially; the esophagus was dissected out with the diverticulum extending posteriorly and inferiorly. After elevation and dissection to the base of the diverticulum, a myotomy is created starting with the division of the cricopharyngeus and extending to the base of the diverticulum. The myotomy should extend 5 to 6 cm distally and completely through the cricopharyngeus. It is then extended 1 to 2 cm onto the hypopharynx proximally. With the myotomy complete, for a diverticulopexy, the dissected diverticulum can be suspended with 4 or 5 silk stitches to the posterior aspect of the pharyngeal esophageal junction. Conversely, the diverticulum can be suspended from the prevertebral fascia in this region.

For a diverticulectomy with the myotomy complete and the diverticulum completely dissected out to its base, a 48 French Maloney bougie is placed within the esophagus and a TA stapler is used to come across the base of the diverticulum. If the diverticulum is to be resected sharply and the suture line closed by hand, this is performed with a two-layer technique with absorbable suture for the inner layer. Some surgeons

advocate for closing muscle over the hand-sewn repair, or buttressing with muscle around the esophagus. If needed, the myotomy can be shifted to be made lateral to the diverticulum, rather than extending from the base of the pouch.

For the transoral stapled approach, the patient is placed in the “sniffing” position and flexible esophagoscopy performed to assess the size of the diverticulum and remove any retained material from the diverticulum. Rigid esophagoscopy is performed using the Weerda laryngoscope (Karl Storz, Tuttlingen, Germany). This scope has two jaws. One jaw is placed in the esophagus and the second is placed in the diverticulum. The jaws are then expanded which allows clear visualization of the diverticulum and the common septum formed by the cricopharyngeus muscle and the esophagus. The addition of a 5-mm 30-degree laparoscope alongside the Weerda laryngoscope can further enable visualization of the diverticulum. A traction suture (US Surgical Endostitch-Norwalk, Connecticut) is placed in the common septum. The traction suture helps to expose the septum and facilitates a complete cricopharyngeal myotomy. Using the suture to provide traction on the common septum, the modified stapler is placed across the septum and fired. The modified anvil is placed within the diverticulum and the disposable cartridge within the esophageal lumen. Further firings of the stapler as needed are performed to ensure the common septum is divided to the base of the diverticulum. Occasionally, the stitch is replaced after a firing of the stapler to further expose the septum. Other options for division of the common septum via a rigid endoscopic approach include the use of a harmonic scalpel and CO_2 laser in combination with the Weerda laryngoscope.



Figure 81.5. Weerda laryngoscope. (From Luketich: With kind permission from: Morse CR, Fernando HC, Ferson PF, et al. Preliminary experience by a thoracic service with endoscopic transoral stapling of cervical (Zenker's) diverticulum, (Figure 1). *J Gastrointest Surg* 2007;11:1901–4. Springer Science+Business Media.)

Finally, there are a number of flexible endoscopic options first reported in 1995. As the procedures are endoscopic, they can be performed with monitored anesthesia and without the need for neck flexion. Techniques used to divide the common septum include electrocautery including needle knife and argon beam coagulation. A transparent hood is attached to the scope to improve visualization and stabilize the instrumentation/scope. Starting at the top of the septum, an incision is made with either the needle knife or argon beam probe and extended inferior. Some operators place clips on either side of the septum to facilitate dissection and advocate for the placement of an nasogastric tube to further facilitate visualization. Without a diverticuloscope, the nasogastric tube has the benefit of serving as an incisional guide when dividing the septum.

POSTOPERATIVE MANAGEMENT

No nasogastric tube is left. With an open approach, a small drain is often

left in place adjacent to the repair. A barium swallow is obtained on the first postoperative day and a liquid diet initiated if satisfactory. The drain is removed after the swallow study and the patient discharged to home on the same day with specific dietary advancement instructions over several weeks. With a transoral/endoscopic approach, a small residual spur is often noted at the inferior aspect of the divided cricopharyngeus on the barium swallow that is thought to be of minimal clinical significance and postoperative manage is similar, except there is no drain placed.

Complications

A leak from the staple line is extremely uncommon and can typically be handled conservatively with antibiotic therapy and nothing by mouth. With an open, left neck approach, a traction injury to the recurrent laryngeal nerve can occur and often resolves with time. Also the formation of a hematoma or wound infection is possible with an open approach. The most commonly reported injury with a transoral stapled approach is a dental injury from the placement of the laryngoscope. Much less frequent, but with significant morbidity, is descending mediastinitis.

RESULTS

There are several large series of open approaches, with most reporting very low complication rates, almost no mortality and excellent symptomatic outcomes (Table 81.2). Lerut report a series of 289 patients with a complication rate of 8.5%, no mortalities and a recurrence rate of 0.03%. Clinical outcomes were outstanding with 94.2% of patients reporting excellent symptom improvement.

The endoscopic options in the treatment of ZD began with Mosher in 1917 with the diverticular spur was divided sharply with a knife/punch biopsy. This was abandoned after seven patients secondary to a patient death. In 1960, Dohlman and Mattson furthered the endoscopic technique using a fixed laryngoscope and a diathermy knife. In their initial 100 cases, they reported no significant complications and 7% of patients with a recurrence of symptoms. In 1982, Van Overbeek reported the endoscopic division of the common diverticular wall with a CO_2 laser. This was done in conjunction with an operating microscope and large diverticuli required several sessions. Collard revolutionized the endoscopic treatment of ZD by the introduction of the endoscopic stapler. They described modifying the tip of the stapler and used video assistance with the procedure. Chang

followed up in this work with a study reporting 150 patients where they reported a 12.5% recurrence rate and 73% of patients with resolution of symptoms. A recent study from Gutschow et al. compared open surgical intervention to endoscopic repair by either endoscopic stapling or endoscopic laser division. In examining 84 patients approached with an open approach and 79 with an endoscopic approach (25 stapled and 54 laser), they note that in larger diverticulum (3 cm or larger), there was difference between the endoscopic and open procedures when examining patients who were either asymptomatic who had mild occasional symptoms at 86% versus 56% with excellent relief of symptoms. However, at less than 3 cm the results dropped off significantly at 85% versus 25% patients reporting results. Further confirming the size criteria of 3 cm for a endoscopic approach is Vinosky, who noted an almost 23% recurrence rate for patients with diverticula less than 3 cm in size.

Finally for a flexible endoscopic approach to ZD, there are a number of studies totally upward for 650 patients. The largest series to date is from Huberty (2013) with 134 patients. The technique employed a needle knife and soft diverticuloscope. Patients on average require 1.2 interventions with a complication rate reported at 2%. There was a 23% recurrence rate. The dysphagia scores were noted to improve from 1.88 to 0.34 (p <0.05).

Today, ZD can be treated safely with low mortality irrespective of the approach. Almost all patients treated for ZD, again irrespective of approach, can be started on oral intake 1 to 2 days following the procedure and can discharged expeditiously. Certainly a transoral stapled endoscopic approach is not appropriate for diverticula less than 3 cm and a review and there are now an increase in reports of endoscopic treatments for ZD. Complicating any interpretation of these results is the lack of any consistent definitions for outcome measures and the unpredictable reporting of complications. However, it does appear that an endoscopic approach results in more frequent reinterventions and a higher incidence of recurrence and/or insufficient control of symptoms. A randomized trial with consistent definitions and end points would certainly help to clarify the landscape, but is unlikely to be performed.

TABLE 81.2 Open Surgical Results

Author	Year of Publication	Time Period	Method	*n*	Complications (%)	Mortality (%)	Results Asymptomatic/ Partial Very Good/ Improvement (%)		Recurrence
Payne	1992	1994–1978	D, DM, M	888	7.9	2	82	11	3.6
Laing GEEMO multi-center	1995	1979–1988	DM	67	16.4	NA	92.5	7.5	3
Rapport	1996	1960–1982	D 184	390	21	1.5		94	4.9
			DM 121		10				4.9
			PM 55		12.7				1.8
			M 26		0				NA
			P 4		0				7.6
Bonafede	1997	1976–1993	M, DM, PM	87	24	3.5	78	13	NA
Zbaren	1999	1987–1997	D, DM	66	15	1.5	77	11	6
Feussner	1999	1982–1998	PM, DM	140	4.2	1	>90		0.8
Leporrier	2001	1988–1998	DM, PM	40	17.5	0	92	8	0
Jougon	2003	1987–2000	DM	73	4	0	99	1	0
Colombo-Benkmann	2003	1985–1995	D, DM	79	15	0	76	19	2.5
Lerut	2004	1975–2003	PM, M, MD	289	8.5	0	94.2	3.8	0.03
Brigand	2007	1975–2005	DM, PM, M	90	27	0			
Lerut	2007	1955–2003	DM, PM, D, M	325	8.5	0	85	94	
Rizzetto	2008	1993–2007	DM, PM	77	13	0		95	
Total				2,322	9.3	0.9			2.9

D, diverticulectomy; P, diverticulopexy; M, myotomy; NA, not announced.

Suggested Readings

Chang C, Payyapilli R, Scher R. Endoscopic staple diverticulostomy for Zenker's diverticulum: review of the literature and experience in 159 consecutive cases. *Laryngoscope* 2003;113:957–65.

Dohlman G, Mattsson O. The endoscopic operation for hypopharyngeal diverticula: a roentgencinematographic study. *AMA Arch Otolaryngol* 1960;71:744–52.

Gutschow CA, Hamoir M, Rombaux P, et al. Management of pharyngoesophageal (Zenker's) diverticulum: which technique? *Ann Thorac Surg* 2002;74(6):1917–22.

Lerut T, van Raemdonck D, Guelinckx P, et al. Zenker's diverticulum: is a myotomy of the cricopharyngeus useful? How long should it be? *Hepatogastroenterology* 1992;39:127–31.

Yuan Y, Zhao YF, Hu Y, et al. Surgical treatment of Zenker's diverticulum. *Dig Surg* 2013;30:214–25.

EDITOR'S COMMENT

The key elements to managing a Zenker diverticulum (ZD) are correction of the hypertensive upper esophageal sphincter (UES), the cricopharyngeal muscle, and reducing the ability of the diverticulum to serve as reservoir for food and other swallowed materials. There are several important points that should be considered: the necessity of a myotomy, the length of the myotomy, and then how to determine what is the best treatment approach for a given patient: an open cervical approach, a transoral stapled technique, or an endoscopic

approach.

Is it necessary to do myotomy to treat ZD? The consensus today is yes. This is based on the rationale of that UES dysfunction could be a cause of the formation of the diverticulum. The literature supports the concept myotomy is crucial to successful treatment. Skinner et al. (Recurrent Zenker's diverticulum: treatment with crycopharyngeal myotomy. *Am Surg* 1998;64:192–5) reported their experience in dealing with recurrent ZD and identified that most patients with an early recurrence had an inadequate cricopharyngeal myotomy. Those who underwent reoperation with a completed myotomy had symptom relief during a 53-month follow-up. Gutschow et al. (Management of pharyngoesophageal (Zenker's) diverticulum: which technique? *Ann Thorac Surg* 2002;74:1677–82) compared open diverticulectomy alone (n = 34) with open cervical approaches along with myotomy (n = 67). The results showed no difference in terms of "good" or "excellent" symptomatic outcomes. However, they noted that diverticulectomy without myotomy predisposed to the development of postoperative fistula and recurrence. Yong Yuan et al. reported a meta-analysis on the treatment of ZD (Yuan Y, Zhao YF, Hu Y, et al. Surgical treatment of Zenker's diverticulum. *Dig Surg* 2013;30:207–18). In 41 studies of open surgeries, only 2 studies did not perform myotomy. They also noted that 2,526 patients out of 2,826 treated with open surgery for ZD received either myotomy alone or along with other approaches, which reflects that most surgeons consider the dysfunction of UES as an etiologic factor for ZD.

How long should the myotomy be? Morse et al. in this chapter state "the myotomy should extend 5 to 6 cm distally and completely through the cricopharyngeus…and…then extended 1 to 2 cm onto the hypopharynx proximally." In order to achieve a complete myotomy, the following muscles should be divided: cricopharyngeus muscle, the inferior pharyngeal constrictor, and the cervical esophageal striated muscle. Yong Yuan et al. note that "there is no general agreement on the exact length of the myotomy, ranging from 2 to 6 cm." Comparing ZD patients with healthy controls, Lerut et al. (Zenker's diverticulum: is a myotomy of the cricopharyngeus useful? How long should it be? *Hepatogastroenterology* 1992;39:127–31) demonstrated that pathologic changes occur in cricopharyngeal muscle as well as the cervical esophageal striated muscle and recommend a long (4 to 5 cm) myotomy for better outcomes. Most employ a linear myotomy as described in this chapter but Duranceau et al. (Physiologic response to cricopharyngeal myotomy and diverticulum suspension. *Surgery* 1983;94:655–62) propose a flap-resected myotomy arguing that this could prevent subsequent healing of the muscle fibers that could lead to a recurrence. It seems that in most cases a long longitudinal myotomy (4 to 6 cm) should be performed but individual variation in cervical muscular anatomy could require a myotomy of lesser extent or perhaps even more.

As described in the current chapter, ZD may be managed by an open cervical technique, a transoral procedure, or endoscopic procedures. The open cervical

approach had been the gold standard until the evolution of transoral and endoscopic techniques. The open cervical approach may consist of cricopharyngeal myotomy with diverticulectomy, myotomy alone for diverticula less than 1 cm, myotomy and inversion of the diverticulum and myotomy and suspension of the diverticulum: diverticulopexy. At our center, we rarely employ the later technique as use of stapling devices to facilitate diverticulectomy has reduced complications. However, there are reports demonstrating the efficacy of diverticulopexy and there may be some merit particularly in the severely debilitated patient. Brigand et al. (Suspension diverticulopexy for Zenker's diverticulum. *J Chir (Paris)* 2008;145:341–5) report diverticulopexy with cricopharyngeal myotomy is an effective, reliable, and reproducible technique for the correction of ZD smaller than 5 cm. In this author's opinion, diverticulectomy should be reserved for larger diverticula. Not many surgeons consider inversion of the diverticulum, but it may be a valuable technique. Mantsopoulos et al. (Evaluation of the different transcervical approaches for Zenker diverticulum. *Otolayngol Head Neck Surg* 2012;146:725–9) reported 54 patients with ZD were treated using a transcervical approach. Three with a small diverticulum underwent a simple myotomy of the cricopharyngeal muscle. Myotomy was combined with a diverticulum inversion in 14 patients and myotomy with diverticulectomy was performed in 37 patients. The surgical procedures were compared with regard to mean anesthesia time, duration of hospitalization, overall complication rate and rate of serious complications, recurrence rate, and follow-up results. They found that hospitalization times were significantly shorter in the inversion group (p = 0.024). No statistically significant differences were observed between the transcervical modalities for any of the other variables investigated. They concluded that inversion is an effective modality and is by definition less traumatic than traditional diverticulectomy. Although the size of the diverticulum appeared to be a helpful criterion, careful intraoperative evaluation is the key element in deciding which transcervical procedure should be used. It is this authors' view that inversion should always "be considered if the individual anatomy of the diverticulum sac (in terms of pharyngeal pouch size and intactness of the mucosa) allows it."

Given that the typical patient is frail and elderly with significant comorbidities, there has been a trend to use transoral or endoscopic techniques more frequently. There is debate about which of the procedures is best and there is no consensus about which approach is superior. To date, there is no strong evidence to conclude whether a procedure is superior over another, and the results vary significantly in different studies because of varied inclusion criteria, sample size, length of follow-up period, and the percentage lost to follow-up. A summary of the comparative studies between 1990 and 2011 by Yong Yuan et al. demonstrated the following:

1. The overall morbidity and mortality rate for the endoscopic approach was

8.7% and 0.2%, respectively, whereas it was 10.5% and 0.6% for open surgery.
2. Application of the endoscopic technique also has reduced the fistula rate from 3.3% in open surgery to 0.6% and eliminated injury to the recurrent laryngeal nerve.
3. The endoscopic approach has increased the risk of esophageal mucosal damage, intraoperative bleeding, and dental injuries, accounting for a higher risk of conversion during the rigid endoscopic procedure.
4. As for the convalescent period, some studies reported that endoscopic approaches needed less anesthetic and operative time, allowed earlier resumption of oral intake, and required a shorter hospital stay.
5. The open cervical approach and transoral endoscopic approach usually require one treatment. The flexible endoscopic procedure is usually performed in stages to reduce the incidence of complications.
6. The recurrence rate for transoral or endoscopic treatment varies from 7% to 40% and that for an open cervical approach varies from 7% to 15%. As many of the studies are uncontrolled and retrospective, it is difficult to arrive at definitive conclusions regarding the overall comparative success rate.

While I believe most authorities would agree that an open surgical approach has a lower recurrence rate than a rigid or flexible endoscopic approach, it may be helpful to look at two recent reports. A study by Shahawy et al. (A comparative study of outcomes for endoscopic diverticulotomy versus external diverticulectomy. *Otolaryngol Head Neck Surg* 2014;151(4):646–51) reported an experience with both endoscopic diverticulectomy and external diverticulectomy using the linear cutting stapler. They conducted a retrospective analysis comparing these two procedures in terms of in-hospital parameters, complications, return to normal diet, and rates of symptom recurrence. The analysis consisted of 67 patients seen at Brigham and Women's Hospital between 1990 and 2012. Although the cervical stapler-assisted procedure for ZD carried a longer intraoperative time and a slightly longer hospital stay than the endoscopic approach, it provided similar days until initiation of an oral diet and a similar incidence of postoperative complications. It was superior to the endoscopic approach when one considers its much lower rate of symptomatic recurrence and need for revision procedures. The rate of recurrent symptoms was significantly higher in the endoscopic group at 39% (13 patients) compared with 0 recurrences in the open cervical group (p = 0.00011). Another recent study by Bonavina et al. is informative as well (Long-term outcome and quality of life after transoral stapling for Zenker diverticulum. *World J Gastroenterol* 2015;21(4):1167–72). They report a prospective experience in 100 patients treated with transoral stapling between 2001 and 2013. The overall success rate was 76% and was improved with a modification of the techniques using a traction suture on the septum. This has been noted by others as well. In this

study, the median age was 75 years. Transoral stapling was performed using a Weerda diverticuloscope under general anesthesia. The technique was modified over time by applying traction sutures to facilitate engagement of the common septum inside the stapler. They reported complications in 4% of the patients but no mortalities. There was improvement in dysphagia and regurgitation scores (p <0.001) during a median follow-up of 63 months. In addition, there was a significant decrease in the median number of pneumonia episodes per year. The overall long-term success rate of the procedure was 76% being greater in patients of 70 years of age or older compared to younger individuals. The application of traction sutures on the septum was associated with an improved success rate compared with the standard procedure. They further noted that all items of the health-related quality of life questionnaire were significantly higher compared to baseline.

From the literature, there is agreement for several considerations. First a transoral or endoscopic approach should be limited to diverticula between 3 cm and 7 cm. The results are superior with open diverticulectomy compared to endoscopic procedures for diverticula less than 3 cm. In addition, transoral or endoscopic treatment of large diverticula >7 cm could lead to a long dynamic segment of the cervical esophagus (Bonavina L, Bona D, Abraham M, et al. Long-term results of endosurgical and open surgical approach for Zenker diverticulum. *World J Gastroenterol* 2007;13:2586–89; Gutschow CA, Hamoir M, Rombaux P, et al. Management of pharyngoesophageal (Zenker's) diverticulum: which technique? *Ann Thorac Surg* 2002;74:1677–82). In addition, there is agreement that the transoral approach and perhaps the endoscopic approach may be more difficult in the following situations: a patient whose diverticular septum cannot be well exposed, such as small pouch, a stiff neck, poor ability to open the mouth widely, prominent maxillary teeth, a short neck, a retrognathic mandible, a large tongue, a rigid cervical kyphosis, and obesity. The flexible endoscopic treatment is promising and may be performed without the need of general anesthesia and hyperextension of the neck and may be preferred in some situations.

Summary

Surgical treatment of ZD has evolved over the previous two decades to a predominantly endoscopic approach but an open cervical approach is still required in a substantial number of cases. It is likely that endoscopic techniques will evolve further with advances in technology. The open cervical approach will serve as a mainstay for small and large diverticula and in those who cannot undergo an endoscopic approach.

E. Christopher Ellison

B THE STOMACH AND DUODENUM

82 Anatomic Considerations in Gastroduodenal Surgery

Petros Mirilas, Marios Loukas, and Lee J. Skandalakis

INTRODUCTION

The purpose of this chapter is to describe the embryology and anatomy of the stomach and duodenum—not in fine detail, but as it is approached in gastroduodenal surgery. An understanding of the anatomy flows from an understanding of the embryology.

The vast majority of gastroduodenal surgeries are still open and traditional. Laparoscopic surgery of the stomach and duodenum continues to evolve. Understanding the anatomic entities will allow the student and the experienced surgeon to transition easily from traditional surgery to a more minimally invasive approach when appropriate, and as supported by advances in device technology.

EMBRYOLOGY OF THE STOMACH, DUODENUM, OMENTA, AND OTHER GASTRIC PERITONEAL LIGAMENTS

Below the tracheal diverticulum, the foregut of the embryo forms the esophagus, which extends until the dilation marking the developing stomach (Fig. 82.1). The gastric dilation is initially (5th week) positioned at the level of C3 to C5 vertebrae (Fig. 82.1A). With the growth of the embryo, the foregut elongates; thus, the length of the esophagus increases and the stomach descends. At the end of 7th week, the stomach is found between T11 and L4 (Fig. 82.1B).

The stomach and duodenum develop between the two folds of the

mesentery. With reference to the intestine, the mesentery is divided into dorsal mesentery, which connects these splanchna to the posterior abdominal wall, and ventral mesentery, connecting them to the anterior abdominal wall (Figs. 82.2 and 82.3).

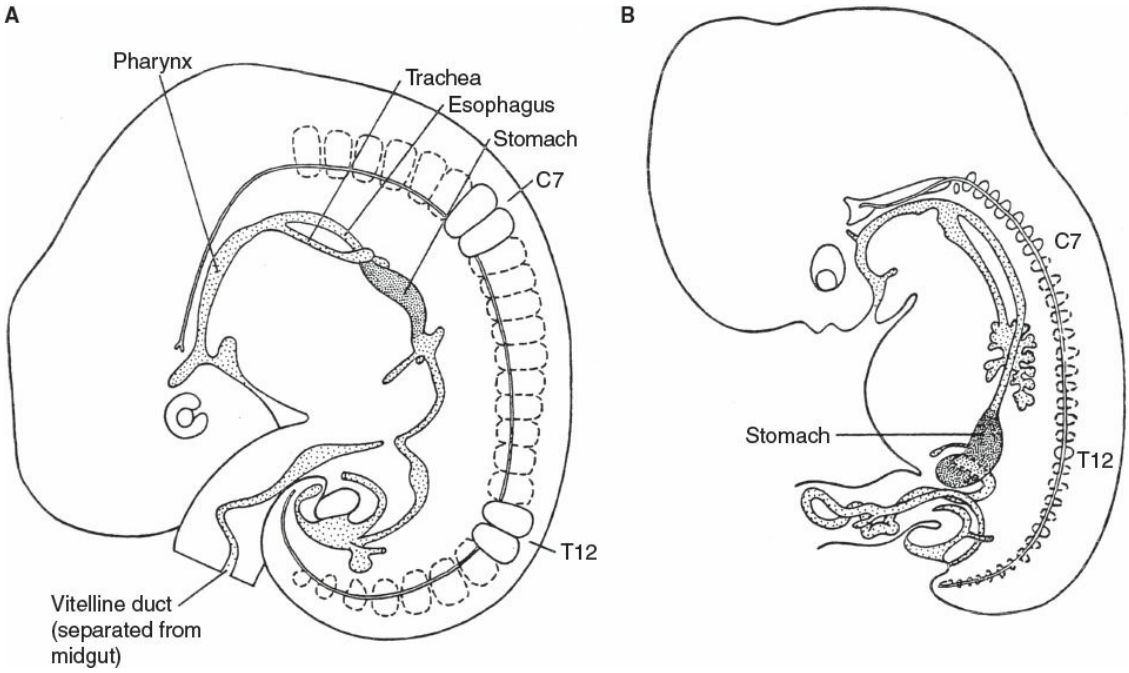

Figure 82.1. The embryonic gut, showing the changes in position of the stomach. **A.** Shape of the stomach at 6.3 mm (6th week). **B.** Rotation and descent of stomach essentially completed at 17.5 mm (end of 2nd month). (From Skandalakis JE, Gray SW, Ricketts R. The stomach. In: Skandalakis JE, Gray SW. *Embryology for Surgeons*. 2nd ed. Baltimore, MD: Williams & Wilkins; 1994:151.)

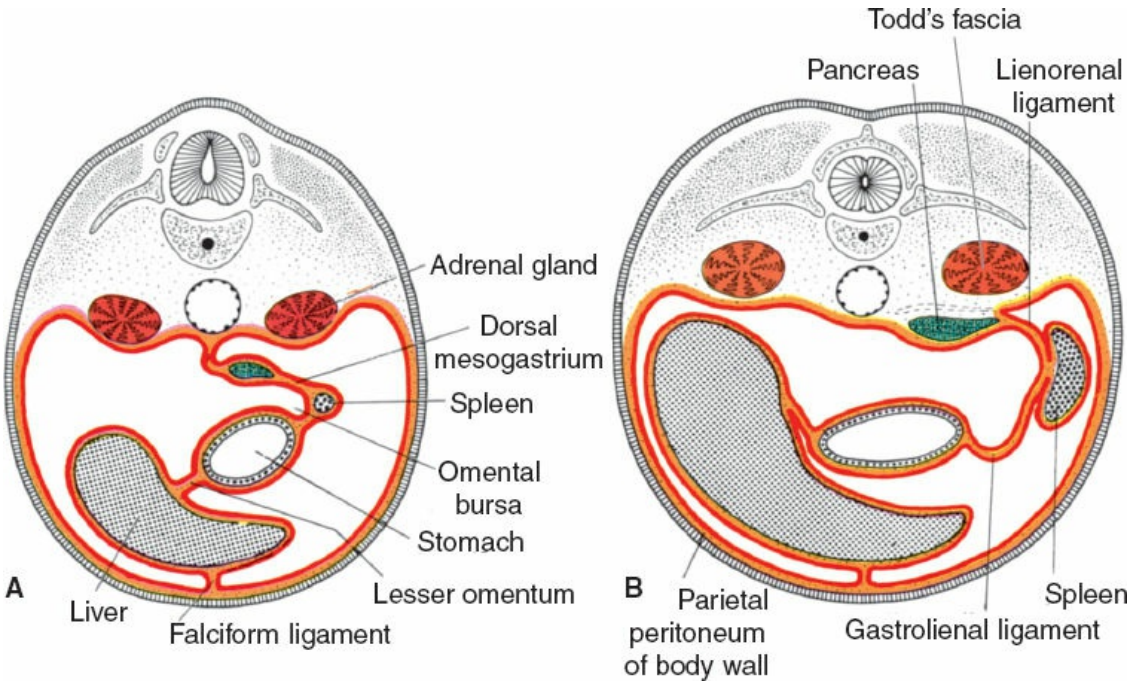

Figure 82.2. A. Transverse sections through the region of the stomach, liver, and spleen, showing formation of the lesser peritoneal sac, rotation of the stomach, and position of the spleen and tail of the pancreas between the two leaves of the dorsal mesogastrium. **B.** With further development, the pancreas assumes a retroperitoneal position. (From Sadler TW. *Langman's Medical Embryology*. 10th ed. Philadelphia, PA: Lippincott Williams & Wilkins; 2006:210.)

Other organs also develop in this configuration: the liver develops in the ventral mesentery and is connected to the anterior abdominal wall by the falciform ligament and to the stomach by the lesser omentum. In the dorsal mesentery, the spleen and pancreas are found; the pancreas is behind the spleen. The peritoneal ligament between stomach and spleen is the gastrosplenic ligament, and then follows the ligament between spleen and pancreas and finally the ligament connecting the pancreas to the posterior wall.

The initial development of these organs in a row (liver-stomach-spleen-pancreas) changes dramatically with the formation of the omental bursa, that is, the cavity behind the stomach. O'Rahilly and Muller point out that the omental bursa develops by the coalescence of small spaces and initially forms the right pneumatoenteric recess, between the lung and stomach. The liver develops below this recess; the recess is associated with the liver and is named the hepatoenteric recess. Finally, the lesser sac develops behind the stomach, extends with a superior recess behind the liver, and

with an inferior recess between the two leaves of the great omentum. From the beginning, the bursa has a communication with the rest of the abdomen, the omental foramen (Winslow's) (Fig. 82.4). Fischer commented that "*the omental bursa, which is the cavity behind the stomach, has a great deal of influence over the anatomical arrangement of the liver—stomach—spleen—pancreas.*"

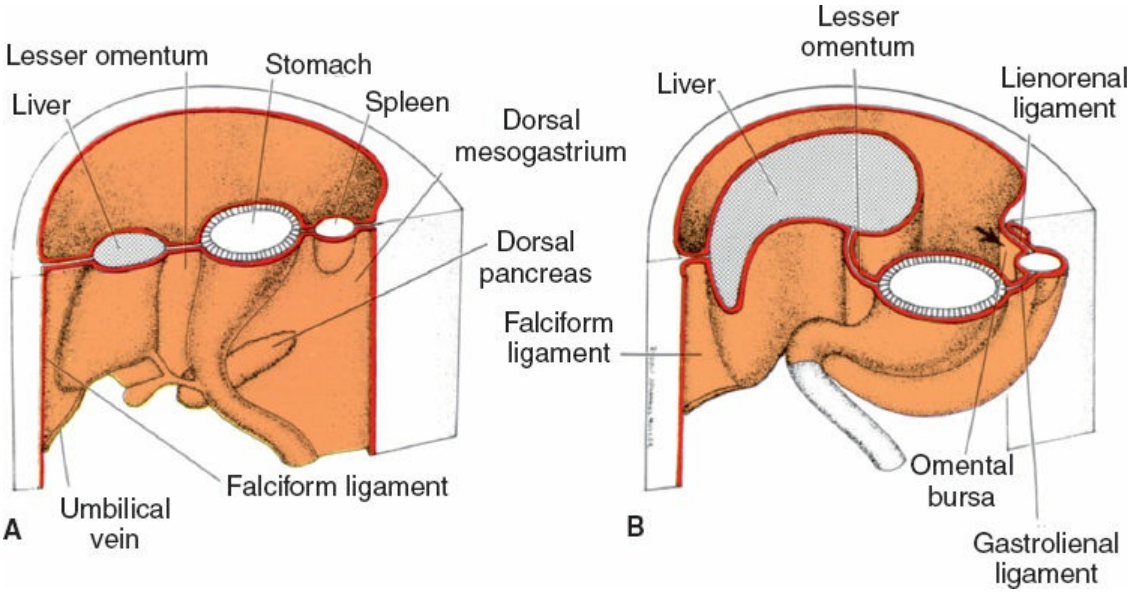

Figure 82.3. A. The position of the spleen, stomach, and pancreas at the end of the 5th week. Note the position of the spleen and pancreas in the dorsal mesogastrium. **B.** Position of spleen and stomach at the 11th week. Note formation of the omental bursa or lesser peritoneal sac. (From Sadler TW. *Langman's Medical Embryology*. 10th ed. Philadelphia, PA: Lippincott Williams & Wilkins; 2006:209.)

The initial theories of embryologists were that a left turn of the stomach takes place and forms the omental bursa. These ideas were useful to understand the alteration of positioning of the vagus nerves: the left vagus on the anterior gastric wall, the right vagus on the posterior abdominal wall. However, such conjectures cannot explain the upper extension of the bursa around the caudate lobe of the liver or the opening of this cavity, the omental foramen (Winslow's).

The truth about the "left turn" of the stomach relies on differential growth of the left wall of the stomach. This results in the formation of a lesser and greater curvature of the stomach, and the repositioning of the ventral and dorsal mesogastria. Thus, the lesser omentum and the gastrosplenic ligament become horizontal (Figs. 82.2 and 82.3). Other

major morphogenetic events are the growth and right-posterior location of the liver and the posterior positioning of the pancreas, which attaches to the posterior abdominal wall and becomes a secondarily retroperitoneal organ. The ligament attaching the pancreas to the posterior abdominal wall disappears, and an avascular plane (Todd's fascia) develops behind the pancreas (Fig. 82.2B). The remaining ligament connecting the spleen to the pancreas now becomes the splenorenal (lienorenal) ligament. The increased growth of the left side of the stomach also affects the respective dorsal mesogastrium, namely the gastrosplenic ligament, which bulges downward and forms the omentum. The posterior double-layered leaf of the omentum attaches on the mesentery or the transverse colon; then, the two leaves of the omentum hanging down from the colon fuse between themselves (Fig. 82.5).

As a general rule, mesenteries connect organs to the abdominal wall and each other and carry all the vascular, neural, and lymph supply for the organs developing within them. Fulfilling this description of a mesentery, the lesser omentum will supply the pathway for the neurovascular supply of the liver, and will be the courier of the hepatic artery, portal vein, ducts, nerves, and lymphatics. The falciform ligament is the mesentery for the umbilical vessels reaching the hilum of the liver. The gastrosplenic ligament contains the short gastric arteries; the splenorenal ligament carries the splenic vessels. The vessels deriving all from the aorta all lie in the retroperitoneum, where they course for a distance and then enter the respective mesenteries to reach the splanchna they supply. For instance, in the adult configuration, the hepatic artery courses retroperitoneally and then enters the lesser omentum, as does the portal vein. The right gastric artery also enters the lesser omentum to reach the lesser curvature.

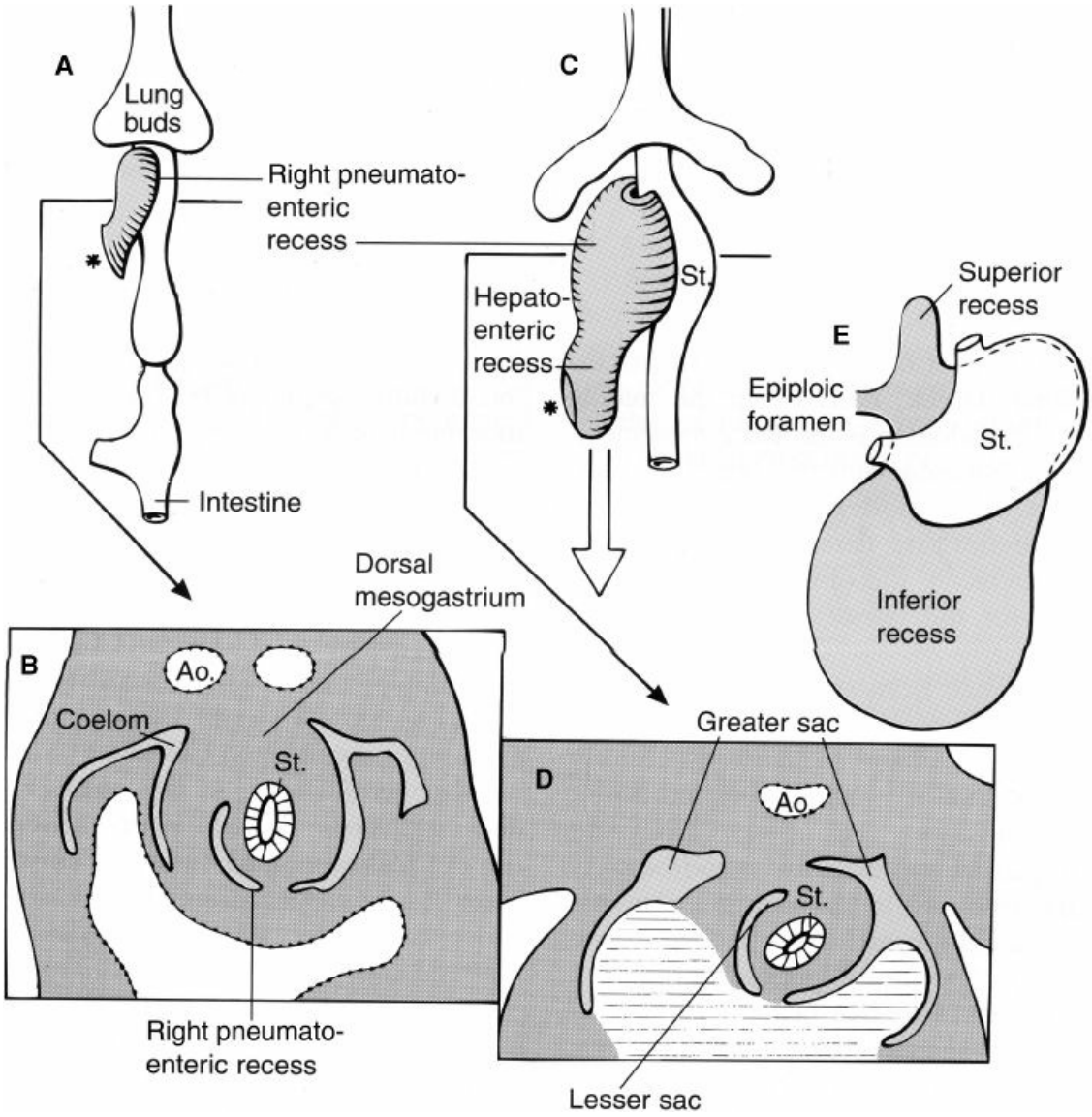

Figure 82.4. Development of the lesser sac of the peritoneal cavity. **A.** Ventral view of the gut at 4½ weeks showing appearance of the right pneumatoenteric recess. The recess communicates with the coelom, and the opening (*asterisk*) may represent the future epiploic foramen. **B.** A day or so later, the recess is becoming wrapped around the right aspect of the stomach (St). **C.** Scheme of the form of the lesser sac in the adult as seen from in front. Superior and inferior recesses are evident, and the lesser and greater sacs communicate by the epiploic foramen. (Modified with permission of John Wiley & Sons, Inc. from O'Rahilly R, Müller F. *Human Embryology and Teratology*. 3rd ed. New York: Wiley-Liss; 2001, permission conveyed through Copyright Clearance Center, Inc.)

The lower esophagus also has a mesentery, the mesoesophagus. After it passes the diaphragm, the lower esophagus lies retroperitoneally; further

caudad it regains its mesentery, which is broad. The result is that the abdominal esophagus is covered by peritoneum anteriorly and on both sides laterally, while its posterior surface toward the diaphragm is still retroperitoneal, giving way to the entrance of the left gastric artery for the lower esophagus and the upper lesser curvature of the stomach.

The adult duodenum corresponds to an area of the embryonic foregut and midgut distal to the stomach. The embryonic midgut undergoes a normal herniation into the umbilical cord during the 5th week of gestation (Fig. 82.6A). This part of the intestine is fed by the superior mesenteric artery (SMA). The herniated intestine undergoes a rotation of 90 degrees around the axis of this artery, bringing the colon over the small intestine. In the 10th week, intestines return in the abdomen. The duodenum comes back first and takes its position under the SMA, while the cecum is still in the umbilical cord (Fig. 82.6B). The distal ileum and the colon are positioned in front of the SMA, and during their return they undergo another 180-degree rotation. Knowledge of these relations is essential for the surgeon in order to understand the normal anatomy, and the cases of anomalies of rotation affecting the duodenum as well as the possible compression of the duodenum under the SMA.

As pointed out previously, abdominal splanchna develop in the mesentery. So does the duodenum, which initially has a mesentery (mesoduodenum). The ventral pancreas also develops dorsally in the mesoduodenum and is met by the ventral pancreas, by way of the “left turn” of the stomach, also affecting this lower area (Fig. 82.7). The duodenum and the pancreas finally locate retroperitoneally (secondarily retroperitoneal organs). The right leaf of the mesentery becomes posterior, meets the parietal peritoneum of the dorsal abdominal wall, and fuses with it, forming an avascular plane. The surgeon who knows this can approach from the left (where no mesentery is found and consequently no vessels exist), dissect and detach the duodenum together with the head of the pancreas, and recreate the original mesentery with all vessels in hand, without risk of bleeding (Kocher’s maneuver).

Another aspect of embryology necessary to understand the anomaly of a preduodenal portal vein is that the vitelline (omphaloenteric) veins, which follow the intestine of the embryo, undergo a major reconstruction of communications between them to form the portal vein (Fig. 82.8). Normally, the anterior communication disappears and the posterior stays; a portal vein thus formed would locate behind the duodenum. In the opposite

case (the anterior, lower communication is kept and the posterior, upper disappears), a preduodenal portal vein is formed.

Another point of embryologic consideration for the surgeon is that the embryogenesis of the lymphatics follows the arteries. This is extremely important to remember and applies everywhere. All lymph nodes are encountered along arteries; nodes and the end of the lymph flow lie at the stem of the arteries. Since the mother artery of the upper abdomen is the celiac trunk, the final destination of lymph flow will be the celiac nodes. The nerves also follow the arteries to reach the respective splanchna. The formation of arteries is a strong morphogenetic event; veins are not the guide for lymphatics and nerves.

Finally, of great importance for the surgeon is to understand that the duodenum is a product of the foregut and midgud. This has tremendous consequences on the blood supply, innervation, and lymphatic drainage:

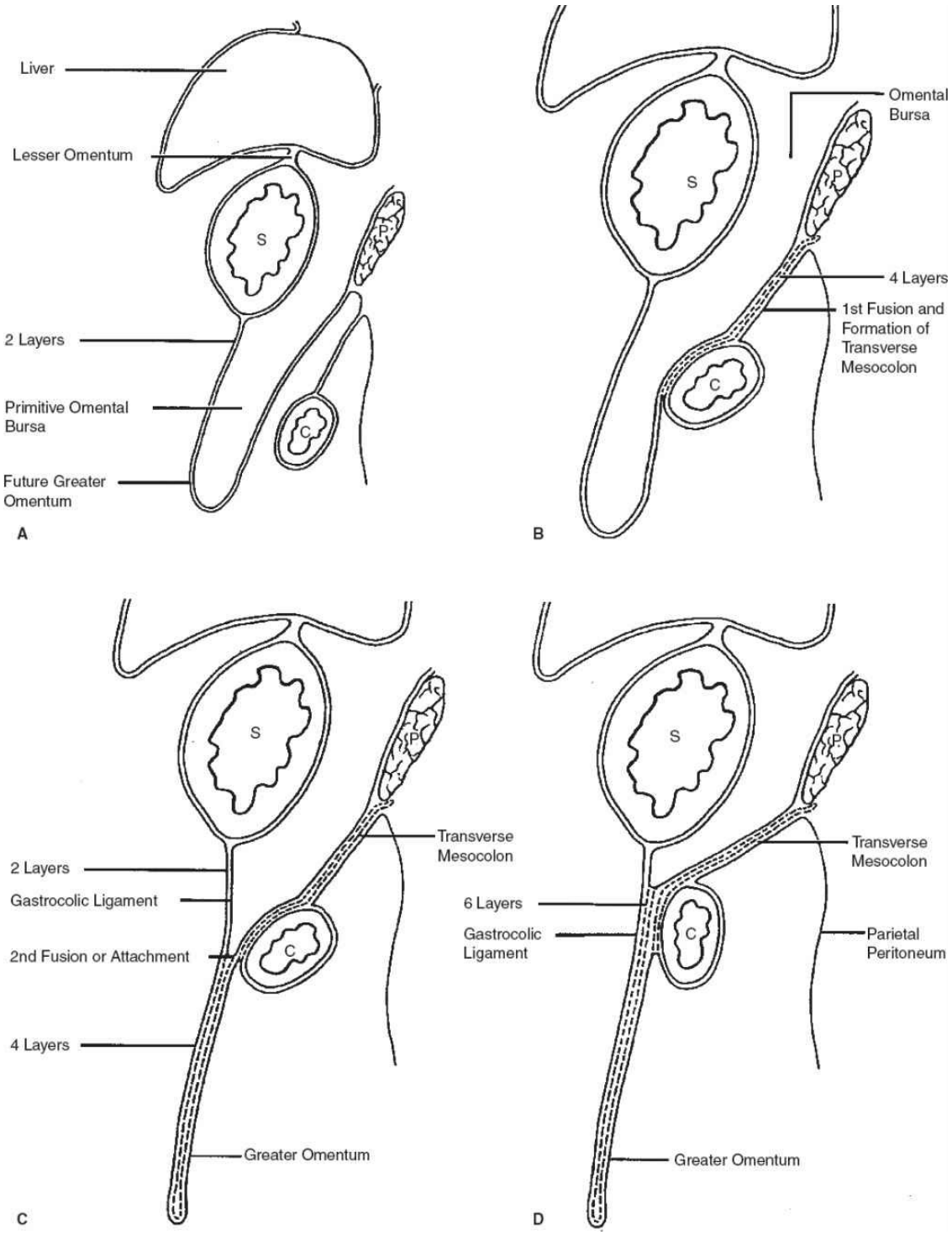

Figure 82.5. Formation of greater omentum. **A.** After rotation of stomach and formation of omental bursa. **B.** First fusion of posterior wall of omental bursa to transverse colon and mesocolon. **C, D.** Second fusion or attachment of anterior and posterior walls of omental bursa to form adult omentum. C, colon; P, pancreas; S, stomach.

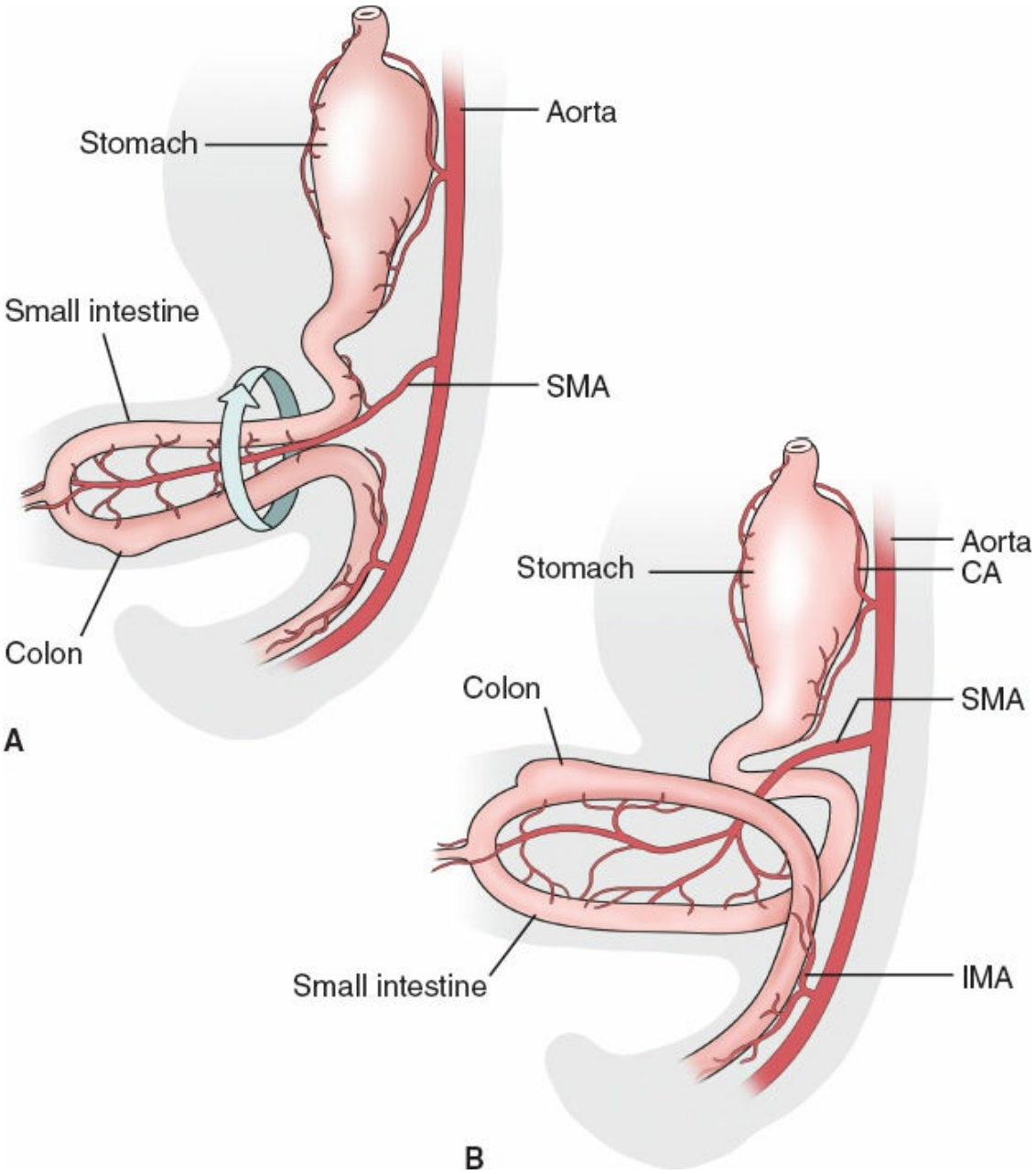

Figure 82.6. **A.** Primary rotation of the herniated embryonic midgut through 90 degrees. The superior mesenteric artery (SMA) lies in the axis of rotation. This artery, the celiac axis (CA), and the interior mesenteric artery (IMA) are the persisting elements of the primitive vitelline arterial system. **B.** The return of the intestines to the abdomen in the 10th week begins with the cranial loop. The future duodenum passes under the SMA. The cecum is still in the umbilical cord. (From Gray SW, Akin JT Jr, Milsap JH Jr, et al. Vascular compression of the duodenum. *Contemp Surg* 1976;9:38–9.)

The first part of the duodenum and the second part up to the entrance of the bile duct are given from the foregut and thus are supplied by branches

of the celiac artery.
The second part of the duodenum beyond the entrance of the bile duct is supplied by branches of the superior mesenteric artery.

CONGENITAL ANOMALIES OF THE STOMACH AND DUODENUM

Stomach

Congenital anomalies of the stomach are presented in Table 82.1.

Duodenum

1. *Malrotation and nonrotation:* The duodenum is not located under the superior mesenteric artery; the duodenojejunal flexure is absent. In incomplete (mixed) rotation, the prearterial segment has failed to rotate; the congenitally high cecum lies in front of the duodenum, where it is fixed to the posterior abdominal wall and may compress the duodenum (Fig. 82.9A). In nonrotation, the postarterial part (distal ileum or colon) of the midgut returns first; the colon is found on the left and the small intestine on the right (Fig 82.9B).

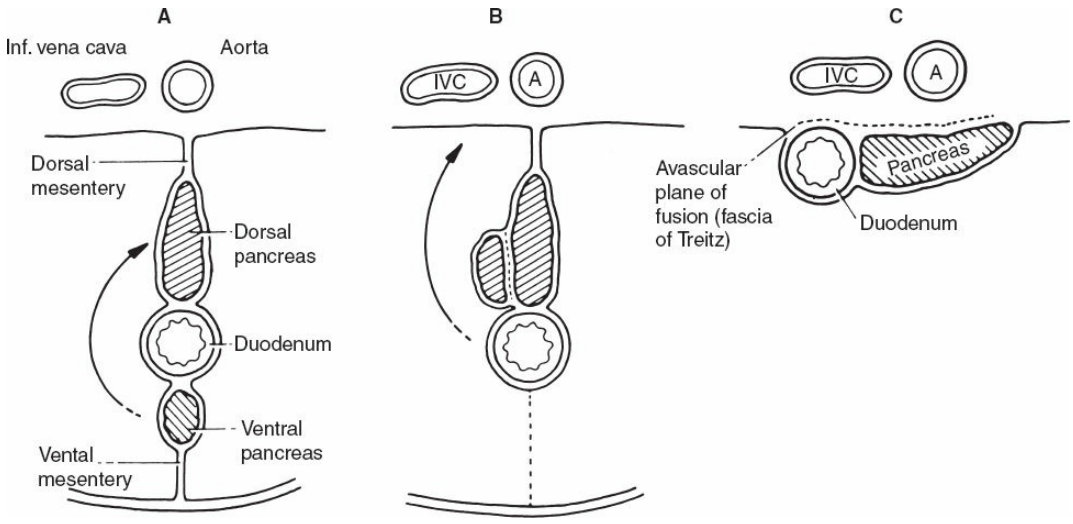

Figure 82.7. Rotation of the pancreas and duodenum. **A.** Primitive relations of dorsal and ventral pancreatic primordia. **B.** Disappearance of ventral mesentery and rotation of ventral pancreas. **C.** Final retroperitoneal position of duodenum and pancreas. The plane of fusion of the mesoduodenum is the avascular fascia of Treitz. (From Skandalakis JE, Gray SW, Rowe JS, et al. Anatomic complications of pancreatic surgery. *Contemp Surg* 1979;15:17–40.)

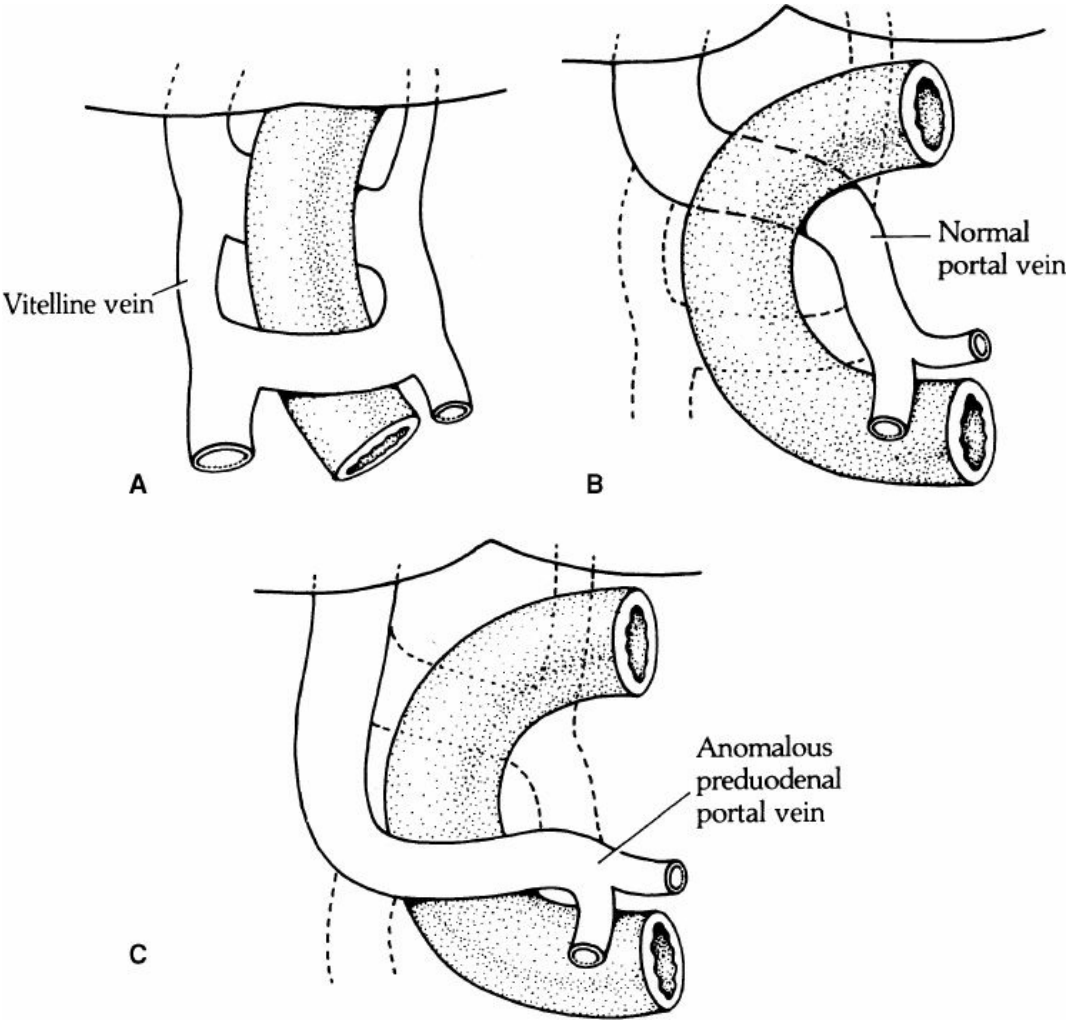

Figure 82.8. Embryonic origin of a preduodenal portal vein. **A.** Embryonic, extrahepatic communications between the vitelline veins. **B.** Normal development. The persisting superior communicating vein forms part of the normal, retroduodenal portal vein. **C.** Anomalous persisting inferior communicating vein forms part of an abnormal preduodenal portal vein. (From Skandalakis JE, Gray SW, Rowe JS Jr, et al. Anatomical complications of pancreatic surgery. *Contemp Surg* 1979;15:17–40.)

2. *Duodenal stenosis and atresia:* anomalies caused by failure of recanalization of the lumen of the duodenum, which is normally occluded between 4th and 7th week by proliferation of the epithelium, followed by recanalization. Stenosis of the duodenum may be associated with annular pancreas or with aberrant pancreatic tissue in the duodenal wall.
3. *Duodenal diverticula:* usually on the concave (i.e., pancreatic) wall of the second and third part of the duodenum. They are usually solitary

and asymptomatic. O'Rahilly suggests that they may be caused by persistence of normally occurring transitory diverticula that are present in the embryo.

4. *Preduodenal portal vein:* caused by abnormal formation of the portal vein as described above (Fig. 82.8). The vein may compress the duodenum to the point of obstruction.
5. *Superior mesenteric artery syndrome:* the result of the compression of the third part of the duodenum between the superior mesenteric artery and the aorta (Fig. 82.10). The condition may be caused by a short mesentery of a congenitally narrow angle between the artery and the aorta.
6. A similar condition is the *nutcracker syndrome*, which refers to compression of the left renal vein between the superior mesenteric artery and the aorta (Fig. 82.10). The result is renal venous hypertension that leads to hematuria due to rupture of thin-walled veins into the collecting system.

Gross Anatomic Parts of the Stomach and Duodenum

The gross anatomic parts of the stomach are: the cardia, the fundus, the body, the antrum (which is the proximal part of the pylorus), and the pyloric canal (Fig. 82.11). There is no external demarcation between the cardia and the fundus of the stomach. The fundus is considered as the part of the stomach located above the entrance of the esophagus. The body of the stomach is the part between the fundus and the pylorus. Again, there is no external demarcation between the body and the fundus. A fairly consistent landmark is an angular notch found two thirds of the way down the lower curvature, which delimits the body from the pyloric portion; a slight constriction at the end of the pyloric portion marks its junction with the duodenum (Fig. 82.12). The junction of the body of the stomach with the antrum can be estimated as in Figure 82.13. While an external examination provides no clue to the line of junction between the stomach and duodenum, some surgeons use the so-called pyloric vein to be as their guide (Fig. 82.12).

The duodenum has an upper, a descending, a horizontal, and an ascending part. The first, or free, part is not attached to the posterior abdominal wall. This part is attached to the hilum of the liver by the hepatoduodenal ligament. It is covered by peritoneum from in front and behind, unlike the rest parts of the duodenum that are retroperitoneal.

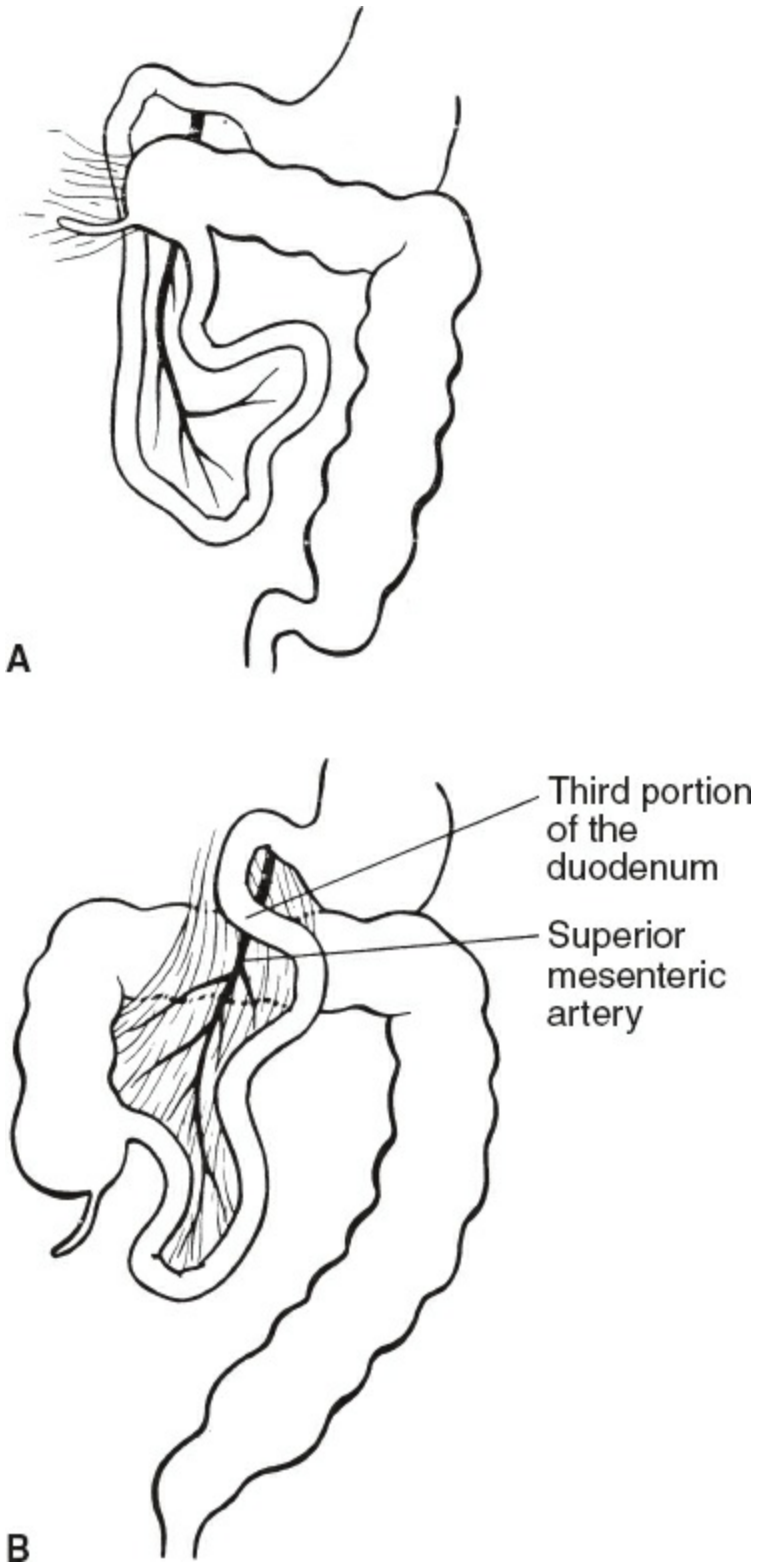

Figure 82.9. **A.** Mixed rotation. **B.** Nonrotation. (From Skandalakis JE, Gray SW, Rowe JS Jr. *Anatomic Complications in General Surgery*. New York: McGraw-Hill; 1983.)

TABLE 82.1 Anomalies of the Stomach

Anomaly	Prenatal Age at Onset	First Appearance	Sex Chiefly Affected	Relative Frequency	Remarks
Agastria and microgastria	Week 4	Infancy	?	Very rare	Many associated gastrointestinal tract and splenic anomalies
Malposition	Week 10	Any age	M	Rare	May be associated with diaphragmatic eventration and hernia
Atresia and stenosis	?	Infancy to adulthood	?	Rare	Maternal hydramnios familial occurrence (?) autosomal recessive associated with epidermolysis bullosa
Membranous partial		Infancy to adulthood			
Membranous entire	?	Infancy to adulthood			
Complete (solid)	Weeks 6–7				
Gastroduodenal discontinuity	?				
Luminal with microscopic canal	?				
Typical stenosis with perforated membrane(s)					
Hourglass stomach	?	Any age	?	Rare	Usually not congenital
Congenital pyloric stenosis	Postnatal week 2	2–4 weeks	M	Very common	Not a true anomaly
Infantile					
Adult					
Congenital muscular defect	Weeks 8–10	Infancy	?	Rare	May not be congenital
Diverticula	?	40–70 years	Equal	Rare	May not be congenital
Duplication, double pylorus	Week 3	Any age	F	Rare	Faulty separation of endoderm and notochordal plate
Mucosal heterotopia	Weeks 4–5				Adhesion or metaplasia
From other organs to stomach					
Pancreas					
Small bowel					
Others					
From stomach to other organs					
Congenital arteriovenous malformations	?	Adult	M	Rare	May not be congenital
Teratoma		Infancy to adulthood	M	Rare	Benign (usually)
Gastroduodenal adhesions	?	?	?	?	?

From Skandalakis JE, Gray SW. *Embryology for Surgeons*. 2nd ed. Baltimore, MD: Williams & Wilkins; 1994, with permission.

From a surgical standpoint, the stomach can be divided into two almost separate organ systems or “gastric units,” each with its own special anatomy, pathology, and surgical significance. The proximal gastric unit consists of the gastroesophageal junction and the proximal stomach (Fig. 82.14). The distal gastric unit includes the gastric antrum, pylorus, and the first part of the duodenum (Fig. 82.15). The border between the proximal and distal stomach is an arbitrary line from the lesser curvature to the greater curvature (Fig. 82.16). This may be thought of as (a) a line starting on the lesser curvature at the third vein down from the gastroesophageal junction to the greater curvature at the point where the left gastro-omental vessels come closest to the gastric wall, or (b) a line starting on the lesser curvature at the first descending branch of the left gastric artery to the greater curvature at the midpoint of the left gastro-omental artery.

Gastric Wall

The wall of the stomach consists of serosa, muscularis, submucosa, and mucosa. The serosa is visceral peritoneum. The muscular layer consists of

three sub-layers: outer longitudinal, middle circular, and inner oblique. From a surgical standpoint, surgeons consider the three sub-layers to be one. One U-shaped band of the inner oblique runs longitudinally and parallel to the lesser curvature on both the anterior and posterior surfaces of the stomach (Fig. 82.17). Contraction of this band is presumably responsible for the "gastric canal." In general, the musculature of the fundus is thin, that of the body is considerably heavier, while in the pylorus the circular ones and certain oblique ones are particularly well developed.

The submucosal layer is the vascular layer of the gastric wall. It is the home of arterial and venous plexuses, characterized by rich anastomoses and excellent collateral circulation. There are distinct differences in the gastric mucosa of the cardia, fundus, body, antrum, and pylorus of the stomach. The distal esophageal mucosa and proximal duodenal mucosa should be added to complete the landscape of "gastric" mucosa from a surgical standpoint.

Surgicoanatomic Units of the Gastroduodenum

Surgically, the gastroesophageal and gastroduodenal junctions are perhaps the most difficult anatomic units in the operating room. The term "junction" attributed to these areas better applies to histology rather than in anatomy, and describes the abrupt changes in mucosal lining.

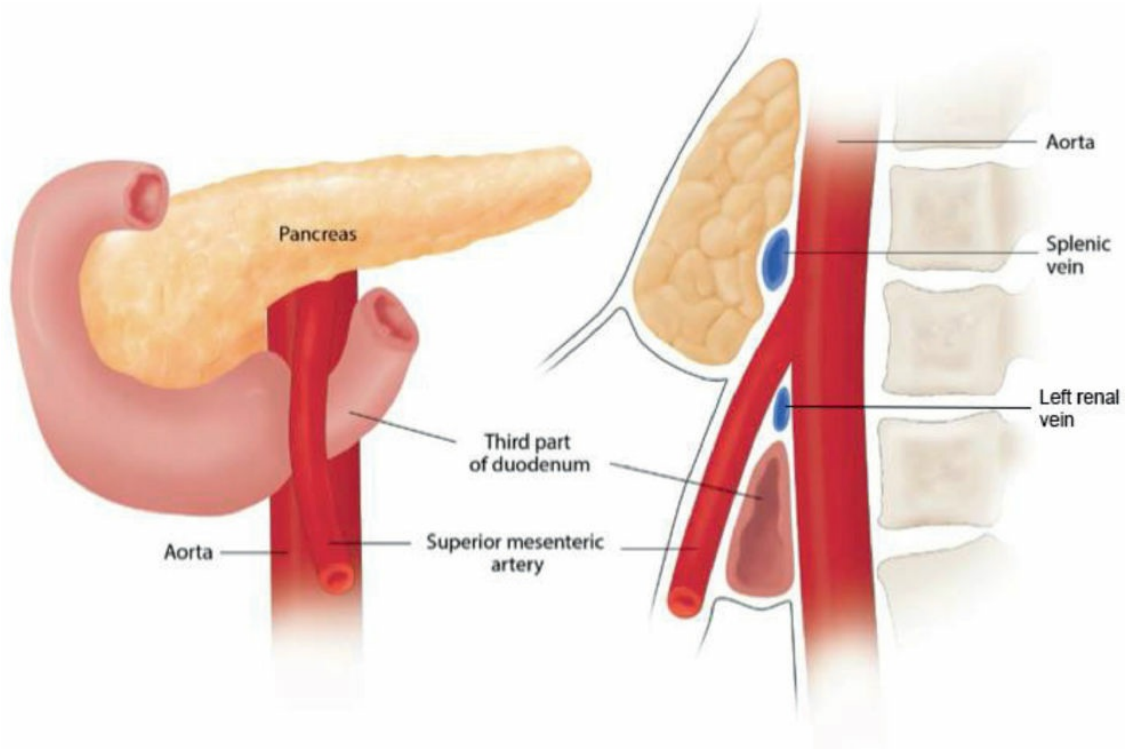

Figure 82.10. Superior mesenteric artery syndrome. The third portion of the duodenum can be compressed between the superior mesenteric artery and the aorta. Similarly, in the nutcracker syndrome, the left renal vein can be compressed in the angle between the two arteries. (Modified from Skandalakis JE, Gray SW, Ricketts R, et al. The small intestines. In: Skandalakis JE, Gray SW. *Embryology for Surgeons*. 2nd ed. Baltimore, MD: Williams & Wilkins; 1994:233.)

Gastroesophageal Junction

The esophagus joins the stomach in the abdomen, just below the diaphragm. The gastroesophageal junction can be anatomically defined as the point where the distal esophagus joins the proximal stomach (cardia).

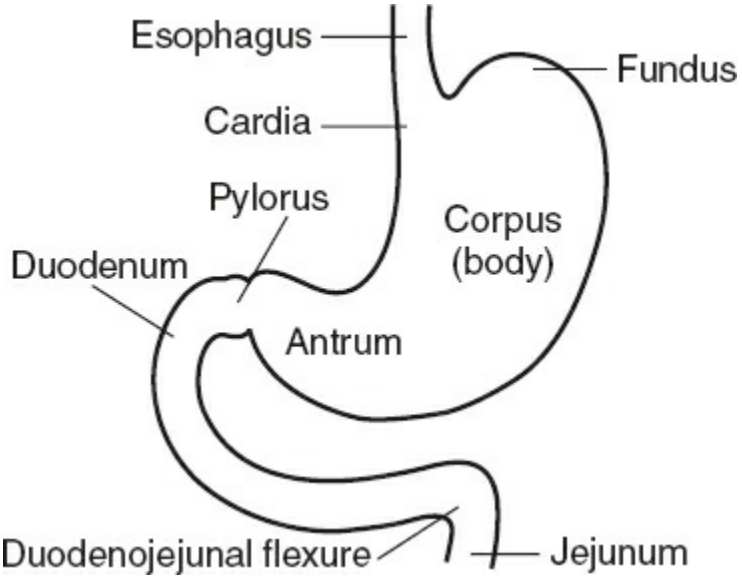

Figure 82.11. Gross anatomic areas of the stomach. (Modified from Griffith CA. Anatomy of the stomach and duodenum. In: Wastell C, Nyhus LM, Donahue PE, eds. *Surgery of the Esophagus, Stomach, and Small Intestine*. 5th ed. Boston, MA: Little, Brown; 1995, permission conveyed through Copyright Clearance Center, Inc.)

The abdominal esophagus lies at the level of the 11th or 12th thoracic vertebrae. It is found lower in tall asthenic individuals and higher in short subjects. In its passage through the esophageal hiatus, the esophagus is bounded by the two diaphragmatic crura and the phrenoesophageal membrane (Fig. 82.18). The length of the abdominal esophagus is from 0.5 to 2.5 cm, but the surgeon has access to an appreciable length of esophagus below the diaphragm.

The abdominal esophagus is related to surrounding structures:

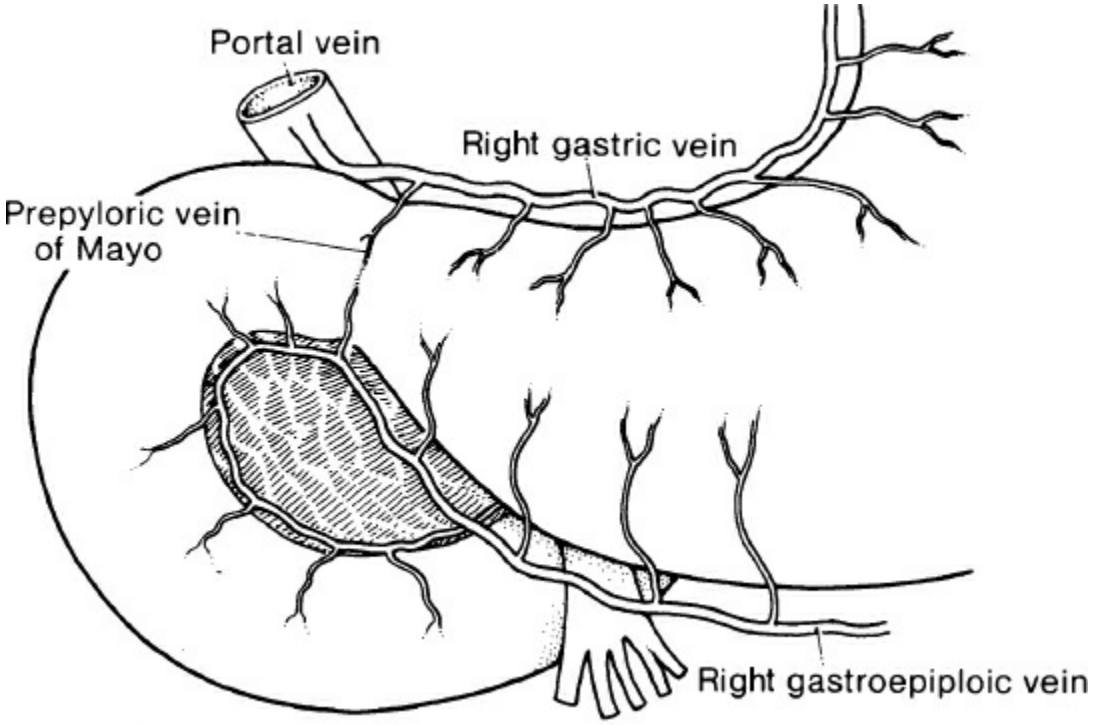

Figure 82.12. The prepyloric vein of Mayo. If present, this indicates the location of the pylorus. (From Skandalakis JE, Gray SW, Rowe JS Jr. *Anatomical Complications in General Surgery.* New York: McGraw-Hill; 1983.)

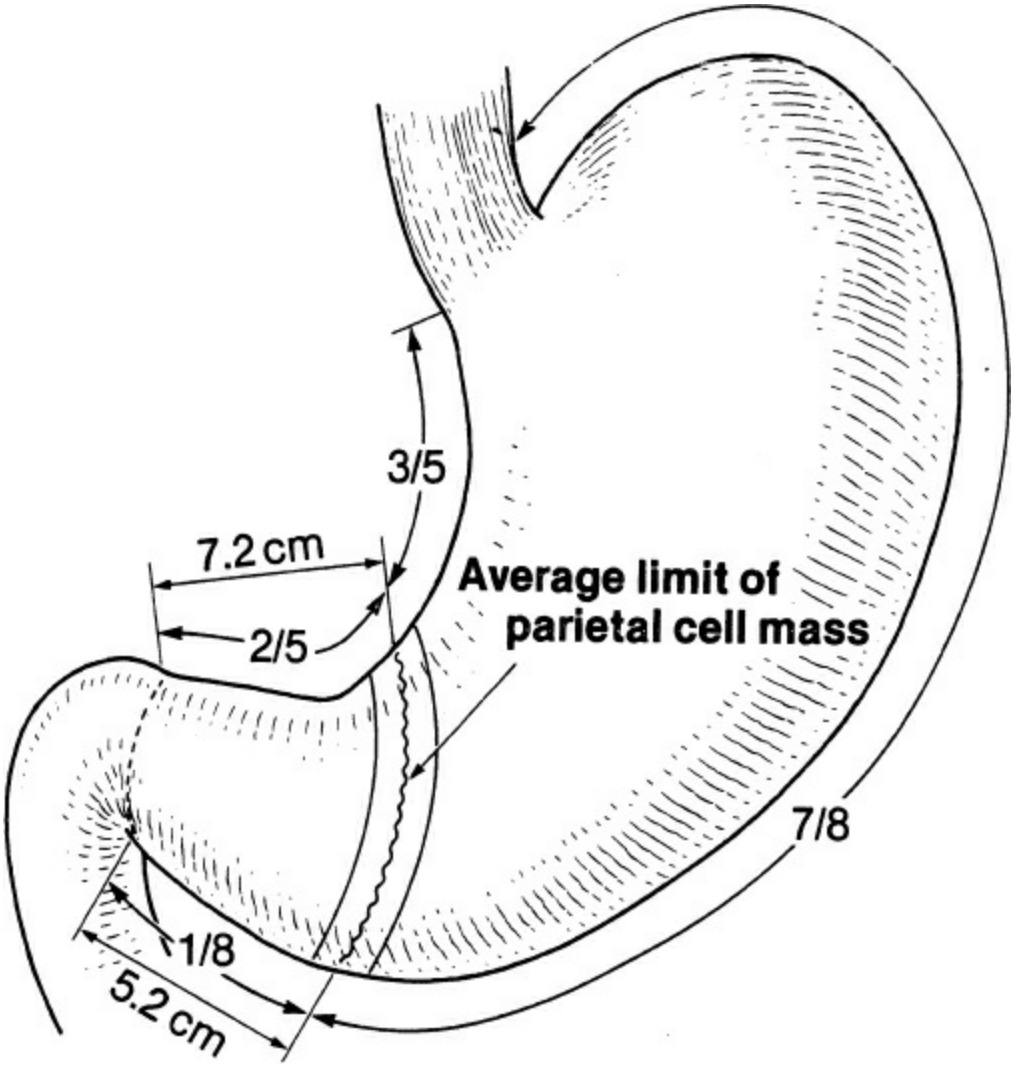

Figure 82.13. The antrum–body junction in the "average stomach" is found at two fifths of the distance from the pylorus to the cardia along the lesser curvature and one eighth of the same distance along the greater curvature. (From Skandalakis JE, Gray SW, Rowe JS Jr. *Anatomical Complications in General Surgery*. New York: McGraw-Hill; 1983.)

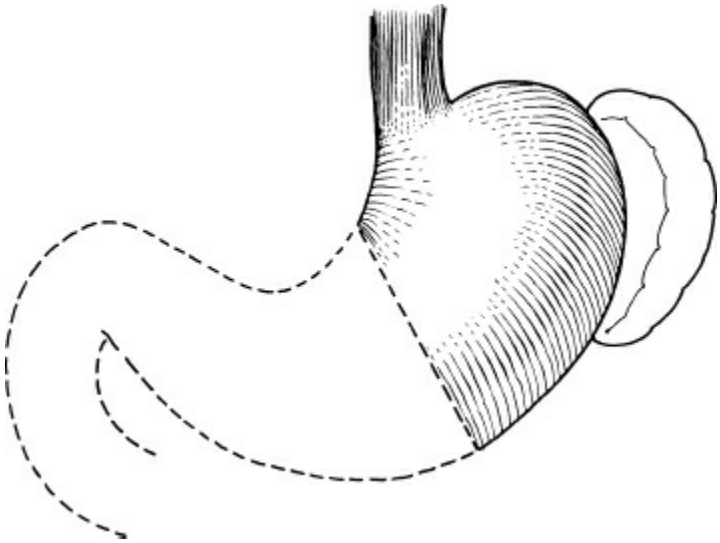

Figure 82.14. The proximal gastric surgical unit. (From Skandalakis JE, Gray SW, Rowe JS Jr. *Anatomical Complications in General Surgery.* New York: McGraw-Hill; 1983.)

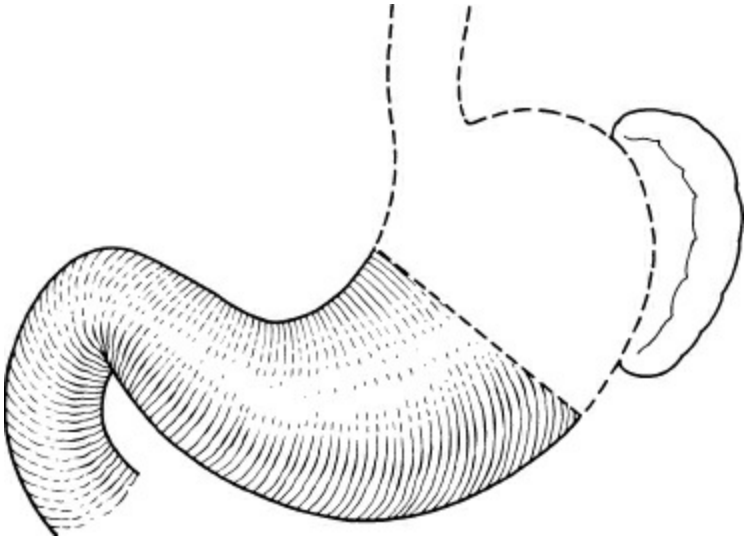

Figure 82.15. The distal gastric surgical unit. (From Skandalakis JE, Gray SW, Rowe JS Jr. *Anatomical Complications in General Surgery.* New York: McGraw-Hill; 1983.)

Anterior: Posterior surface of left lobe of liver
Posterior: Right crus of diaphragm, aorta
Right: Caudate (spigelian) lobe of liver
Left: Fundus of stomach

As noted above, the endoabdominal esophagus is covered anteriorly and laterally by peritoneum at its upper part, and is fully enveloped by peritoneum at its lower part. Under the peritoneum are found the

esophagus, the vagus nerves, anterior and posterior and their branches, and the left gastric vessels (Fig. 82.19). The gastric vessels find their entrance to the lower esophagus at the area where its posterior surface, just below the diaphragm, is still retroperitoneal.

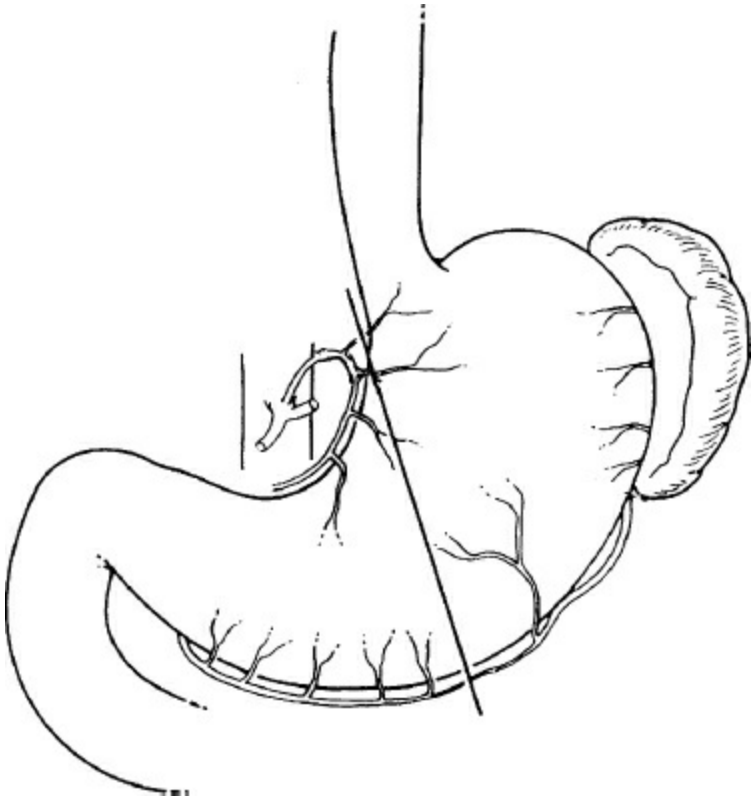

Figure 82.16. Arbitrary landmarks of proximal and distal gastric units.

Because the histologic junction between the esophagus and stomach is not coincident with the external junction, the “gastroesophageal junction” differs with each specialist (e.g., anatomist, surgeon, radiologist, and endoscopist) who speaks of it (Fig. 82.20). For example, a surgeon would point out that, by taking the lowest connective tissue fibers attaching the esophagus to the diaphragm as the inferior limit, there is no “abdominal” esophagus.

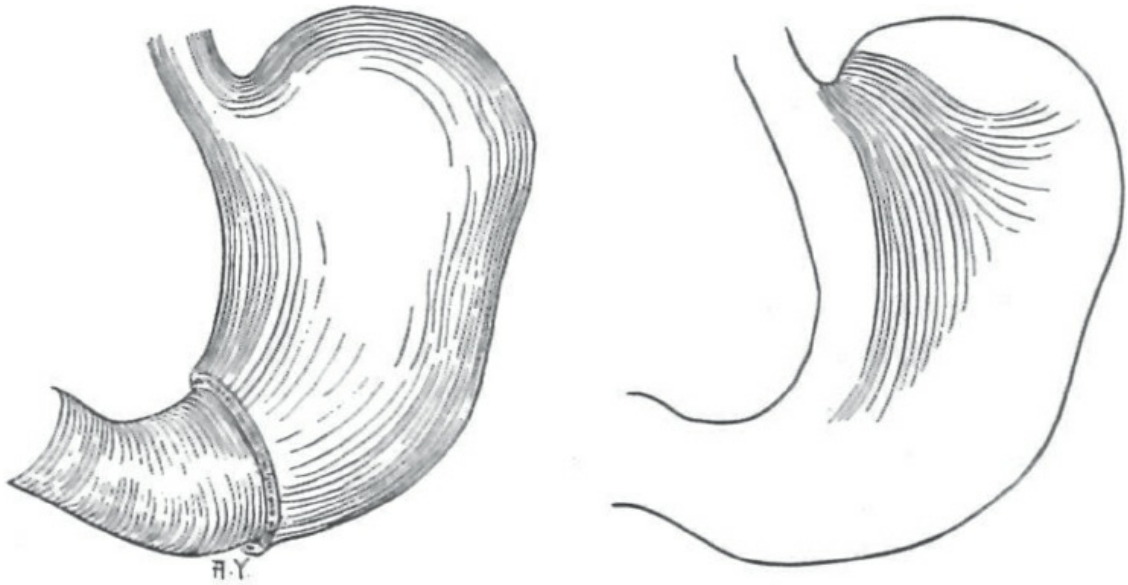

Figure 82.17. Diagrams of the general disposition of the three layers of gastric musculature. In (**A**), the longitudinal fibers have been cut away at the pyloric end of the stomach to show the circular ones; the longitudinal musculature is heavier at the curvatures, and thinner over the anterior and posterior surfaces of the body of the stomach. (**B**) shows the innermost or oblique layer of muscle. (From Hollinshead WH. *Anatomy for Surgeons. Volume 2. The Thorax, Abdomen, and Pelvis*. New York: Hoeber-Harper; 1956:387, Fig. 275.)

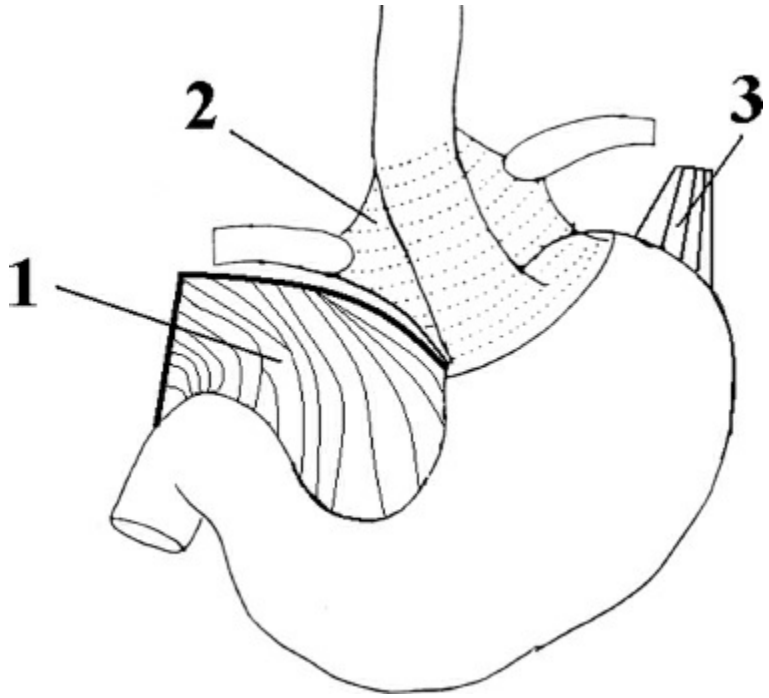

Figure 82.18. Anchoring structures of the endoabdominal esophagus. The diaphragmatic crura are not shown. 1. lesser

omenum (cut), 2. phrenoesophageal membrane, 3. gastrophrenic ligament.

The histologic junction is marked by an irregular boundary between stratified squamous epithelium and columnar epithelium. The loose submucosal connective tissue allows the mucosa to move freely over the muscularis, bulging in folds into the stomach at deglutition. The junctional level may change even at rest, being lower in the full stomach than in the empty one.

The columnar epithelium forms a mucosa unlike that of the body of the stomach. Its glands, lacking chief and parietal cells, secrete mucus. Histologists refer to these as cardiac glands. "Junctional epithelium" has been proposed as a name for this area between typical esophageal and typical gastric mucosae (Fig. 82.21). According to Odze, "*The true gastric cardia is an extremely short segment (less than 0.4 mm) of mucosa that is typically composed of pure mucous glands, or mixed mucous/oxyntic glands that are histologically indistinguishable from metaplastic mucinous columnar epithelium of the distal esophagus. In patients with gastroesophageal reflux disease, whether physiologic or pathologic, the length of cardia-type epithelium increases and extends proximally above the level of the anatomic gastroesophageal junction into the distal esophagus.*"

Most anatomists and surgeons share the idea that there is no true anatomical sphincter to guard the cardiac orifice of the stomach. However, a slight thickening of the circular musculature of the distal esophagus has been described, grossly visible in 64% of specimens. To answer the question whether an anatomical sphincter does exist in the lower esophagus, one of the authors of this chapter (ML) undertook a study in cadavers and found a distinct thickening of the circular muscle layer of the gastro-esophageal region in all specimens. The mean length of this muscular thickening was measured to be 3.1 cm. The thickest part of this segment was at its midsection. This mid-part had a mean thickness of 5.4 mm. The thickness of the esophagus immediately superior to the sphincter had a mean of 2.7 mm. These findings strongly suggest the presence of an internal esophageal sphincter in the distal esophagus.

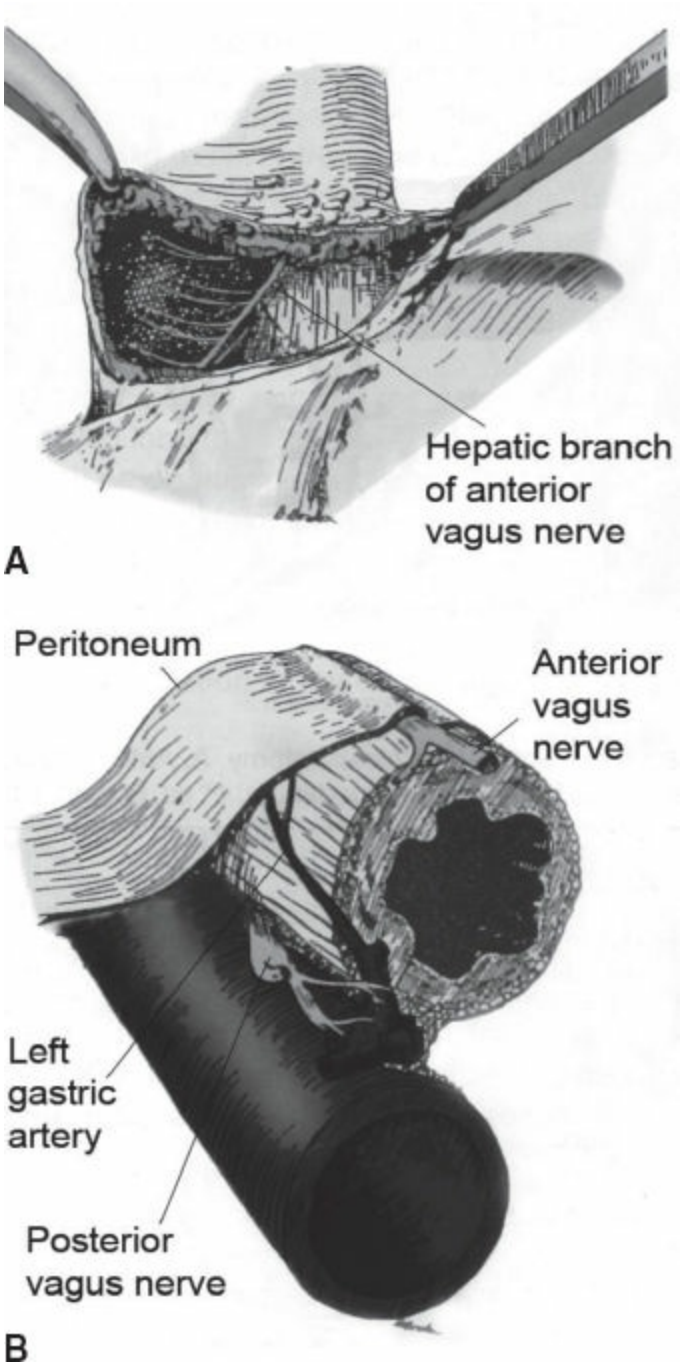

Figure 82.19. Abdominal esophagus and peritoneal reflections. **A.** The two forceps hold the opened peritoneum on the anterior surface of the esophagus. The hepatic branch of the anterior vagus (superficially) and the celiac branch of the posterior vagus can be seen. **B.** The peritoneum covers the esophagus antreriorly and laterally. In this area, the left gastric artery finds its way to the lower esophagus and stomach. The anterior and posterior vagus nerves can also be seen. (Modified from Skandalakis LJ, Colborn GL, Weidman TA, et al. Stomach. In: Skandalakis JE, Colborn GL, Foster RS Jr, et al., eds. *Skandalakis' Surgical Anatomy: The Embryologic and Anatomic*

Basis of Modern Surgery. Athens: Paschalidis Medical Pablications; 2004: Fig. 15-61B and C.)

Various other structures have been held responsible for closing the cardia and preventing reflux from the stomach into the esophagus:

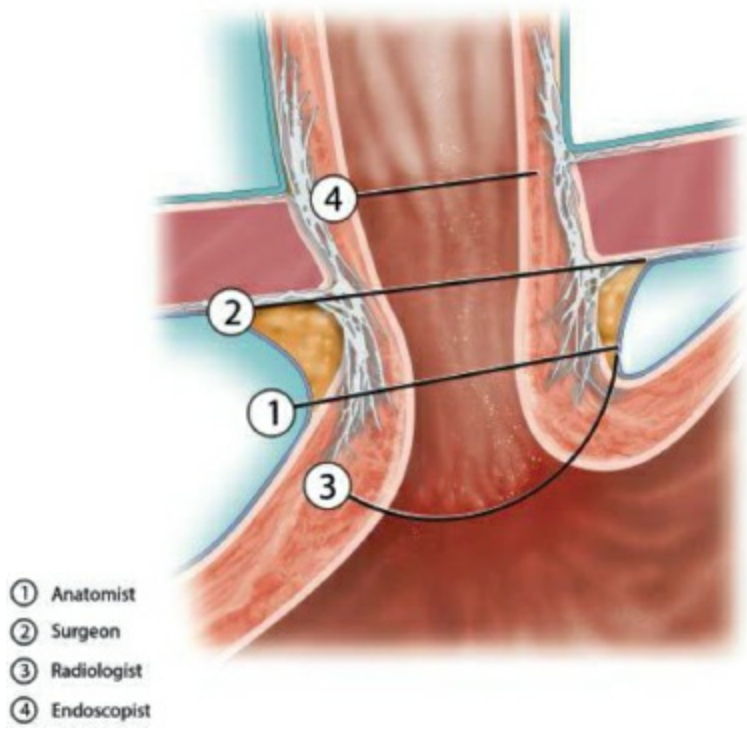

Figure 82.20. Views of the gastroesophageal junction from the point of view of four specialties. Each is "correct." (Modified from Skandalakis JE, Gray SW, Rowe JS Jr. *Anatomical Complications in General Surgery.* New York: McGraw-Hill; 1983.)

The angle of His at which the esophagus enters the stomach
The pinchcock action of the diaphragm
The mucosal rosette, a plug of loose esophageal mucosa
The sling of oblique fibers of the gastric musculature. This component has gained great support for its role in cardiac closure. The arrangement of muscles at the gastresophageal junction led to the term "spiral constrictor" for these muscles.
The phrenoesophageal ligament: the esophagus is attached to the diaphragm at the hiatus with a strong, flexible, airtight seal ligament or (better) membrane. On top of this membrane are the pleura and peritoneum, while connective tissue fibers originating from the endoabdominal fascia (investing fascia of the inferior surface of the

diaphragm, continuation of the transversalis fascia) and from the endothoracic fascia above the diaphragm, insert into the intermuscular connective tissue of the lower esophagus (Fig. 82.21). These fibers allow for a 2-cm vertical movement of the esophagus.

The gastroesophageal junction has been found to be a highly competent barrier to reflux of gastric content into the esophagus. While the lower esophageal sphincter may be the most important component of the barrier, a fold of muscle and mucosa created by the angle of entry of the esophagus into the stomach (the so-called gastroesophageal flap valve) also contributes to the closing mechanism.

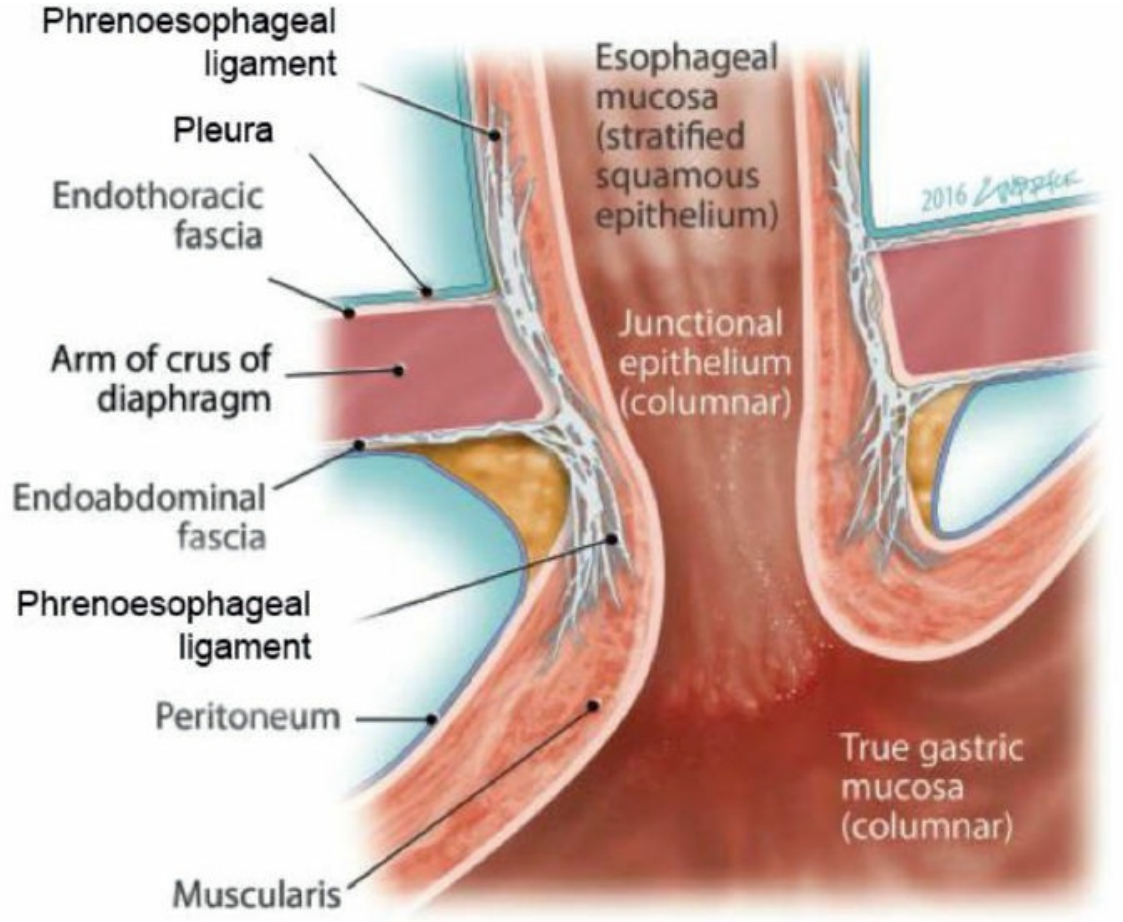

Figure 82.21. Coronal section through gastroesophageal junction and esophageal hiatus of the diaphragm. (Based on Figure 19, in Skandalakis LJ, McClusly AD, Loukas M, et al. Anatomic considerations in gastroduodenal surgery. In: Fisher JE, *Mastery of Surgery*. 6th ed. Philadelphia, PA: Wolters Kluwer/Lippincott Williams & Wilkins; 2012:957–80.)

A major pathophysiologic effect of hiatus hernia is gastroesophageal

reflux, which contributes to esophageal mucosal injury, most notably in patients with severe gastroesophageal reflux disease. Together with the crural diaphragm, the lower esophageal sphincter functions as antireflux barrier, protecting the esophagus from caustic gastric content. Achalasia and gastroesophageal reflux disease are two typical examples of dysfunction of the lower esophageal sphincter. In the presence of normal anatomy of the gastroesophageal junction (i.e., absence of hiatus hernia), the pressure of the gastroesophageal junction is the most important determinant of the strength of the antireflux barrier. The normal pressure of the lower esophageal sphincter ranges from 14.5 mm Hg to 34 mm Hg.

GASTRODUODENAL JUNCTION

The gastroduodenal junction is the boundary between the pylorus of the stomach and the first part of the duodenum. Histologically, there is an abrupt transition in mucosal morphology, and this is the exact site of the "junction". However, surgically, the gastroduodenal junction is conceived as much broader, including the pyloric sphincter and the proximal first part of the duodenum.

In the past, the distal end of the pylorus that extends in the duodenum has been called "pyloric canal" or "pyloric antrum" or even "pyloric ring." This polyphony was to describe the pyloric sphincter, which is the area of the stomach more heavily supplied with circular muscle that is the remainder of the organ. The pylorus is a region rather than a sharply defined structure. Its valve action is to control the flow of partially digested food from the stomach. At its narrowest point, the luminal size never exceeds 19 mm. The size is important in estimating the optimal size of artificial openings, such as in gastrojejunostomies or pyloroplasties.

The pylorus is indistinguishable from the antrum of the stomach. In contrast, there is a sudden transition from the thick wall of the pylorus to the thin wall of the duodenum. The propyloric vein of Mayo can be seen at the area of transition, but the change from a thick to a thin wall can be usually palpated as well.

At the pyloroduodenal junction, the continuity of the circular muscle is interrupted by an annular septum that arises from the connective tissue of submucosa. Proximal to this ring, the circular muscle layer is thickened to form the pyloric sphincter (Fig. 82.22). Distal to the ring, the circular muscle coat of the duodenum is thinner. The sudden decrease of the wall thickness as one passes from the pylorus to the duodenum results in an "os

pylorous” surrounded by a duodenal “fornix.” The existence of this fornix must be kept in mind when performing a pyloromyotomy.

In the initial investigations of the pyloric sphincter, Torgensen (1942) described the septum separating the pyloric sphincter from the duodenum, and stated that this happens only on the side of the greater curvature; on the lesser curvature, the circular fibers are continuous with those of the first part of the duodenum. Moreover, he described that the pyloric sphincter has two portions, a pyloric portion and a duodenal portion, being separated by the septum.

The longitudinal muscle layer of the stomach is also interrupted at the end of the pylorus, except on the side of the lesser curvature, where the most peripheral fibers of the pylorus maintain continuity with those of the duodenum. Most longitudinal fibers turn toward the lumen and terminate in the thick circular muscle (Fig. 82.22). Thus, they form a ring that makes a dilator mechanism within the pylorus. In contradiction to most gut sphincters, the human pylorus maintains a patent lumen most of the time, only intermittently becoming a tightly closed barrier arresting transit to and from the stomach. Contraction of its proximal and distal muscle loops and occlusion of its lumen by mucosal folds mediates pyloric closure.

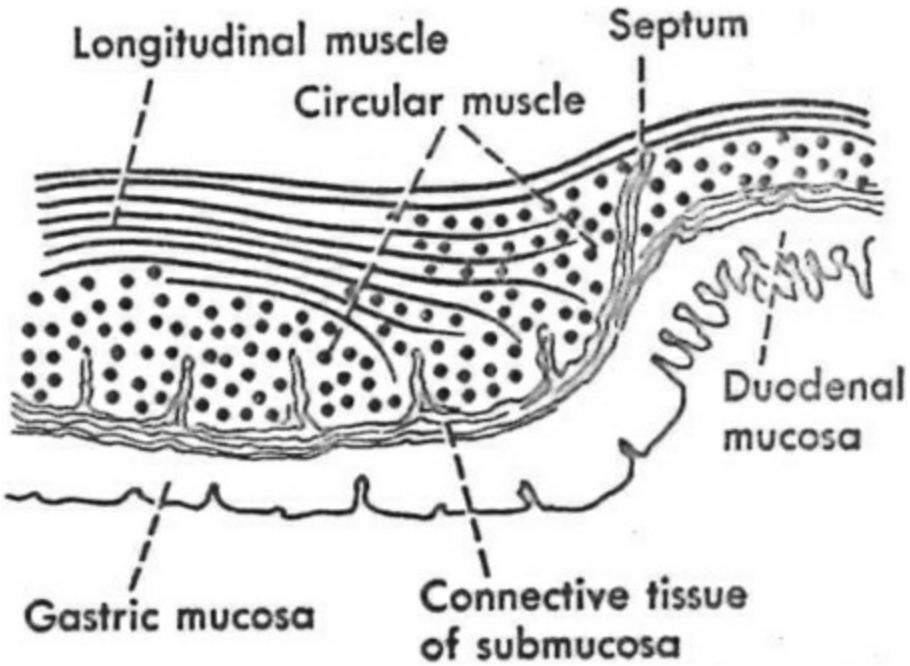

Figure 82.22. Diagram of the arrangement of the muscle fibers in the gastroduodenal junction at longitudinal section through the pyloric sphincter and first part of the duodenum. Note the longitudinal muscle fibers of the stomach that disappear in the thickened circular muscle, and also a few that continue to the

duodenum. Note also that the submucosa sends connective tissue septa into the circular muscle, and that an especially thick one of those separates the circular muscle of the stomach from that of the duodenum. (From Hollinshead WH. *Anatomy for Surgeons. Volume 2. The Thorax, Abdomen, and Pelvis.* New York: Hoeber-Harper; 1956:389, Fig. 276.)

The pyloric sphincteric cylinder and the pyloric mucosal zone are two anatomic and functional units of the pyloric part of the stomach. The cylinder, 3 to 5 cm in length when fully contracted, contains a thickened aboral section, the pyloric ring. The entire cylinder functions as a unit: when the cylinder contracts, the pyloric ring narrows in diameter, as does the pyloric aperture. Keet commented: "On the aboral side, both the cylinder and the mucosal zone end at the ring. The entire cylinder is lined by pyloric mucosa, but the mucosal zone extends orally beyond the confines of the cylinder. In gastric ulcer, it may extend much further up into the stomach. In contrast to the cylinder, the greatest length of the mucosal zone is on the lesser curvature."

From the above descriptions, it is evident that the gastroduodenal junction is the home of the pyloric sphincter and is much wider toward the antrum and duodenum. On this basis, as noted above, it is more important for the surgeon to regard the "distal gastric unit," which includes the antrum, the pylorus, and 1 inch (2.5 cm) of the first part of the duodenum. The latter retains the primitive mesentery and thus is attached to the hepatogastroduodenal ligament (distal part of the lesser omentum) and the distal part of the gastrocolic ligament (greater omenum) (see below). This segment can be mobilized together with the pylorus and antrum of the stomach.

PERITONEAL RELATIONS OF THE STOMACH AND DUODENUM

The stomach is covered anteriorly and posteriorly by peritoneum. This peritoneum is provided by the two leaves of the lesser omentum. The omentum (which has two leaves) extends from the hilum of the liver to the stomach and duodenum, by way of the hepatogastric and the hepatoduodenal ligament respectively (Fig. 82.23). After enveloping the stomach, the two leaves continue as gastrophrenic ligament, from the upper part of the great curvature of the stomach to the diaphragm, and as

gastrosplenic ligament from the upper part of the great curvature of the stomach to the spleen (Fig. 82.23).

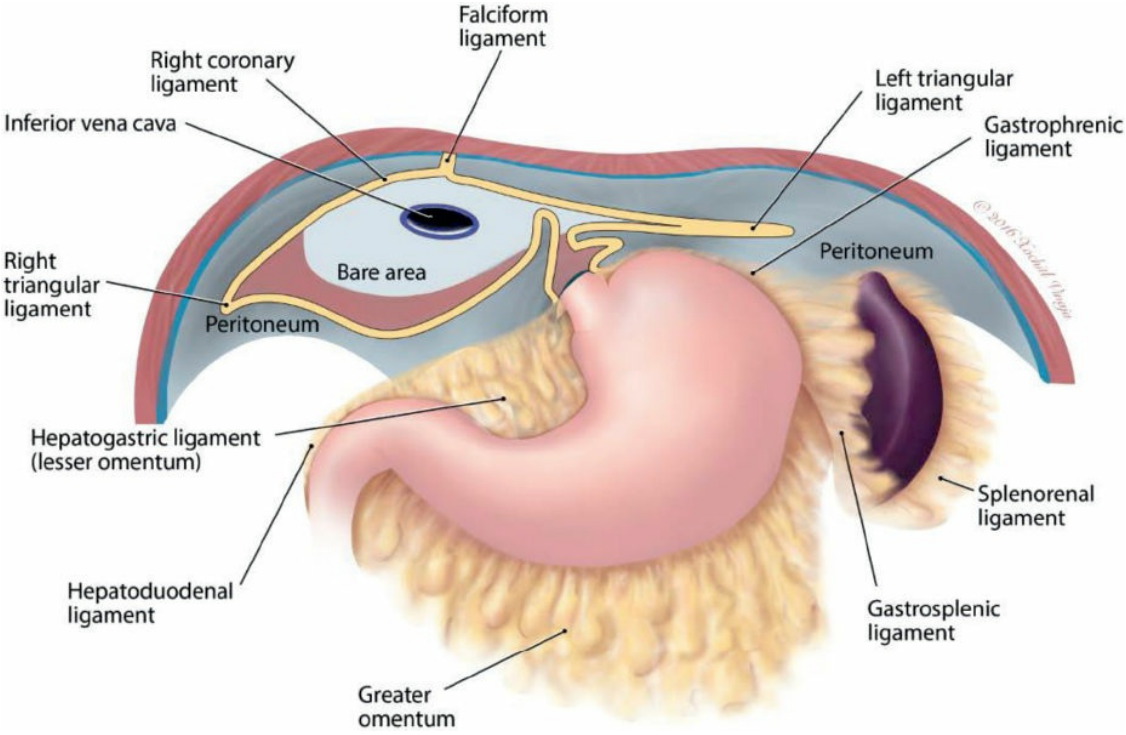

Figure 82.23. Mesenteries of stomach. The yellow line depicts the cut peritoneal reflections around the liver, and esophagus. In the bare area of the liver, the grey color signifies the tendon of the diaphragm and the brownish color shows the muscular part of the diaphragm. (Based on Figure 82.21, in Skandalakis LJ, McClusly AD, Loukas M, et al. Anatomic considerations in gastroduodenal surgery. In: Fisher JE, *Mastery of Surgery*. 6th ed. Philadelphia, PA: Wolters Kluwer/Lippincott Williams & Wilkins; 2012: 957–80.)

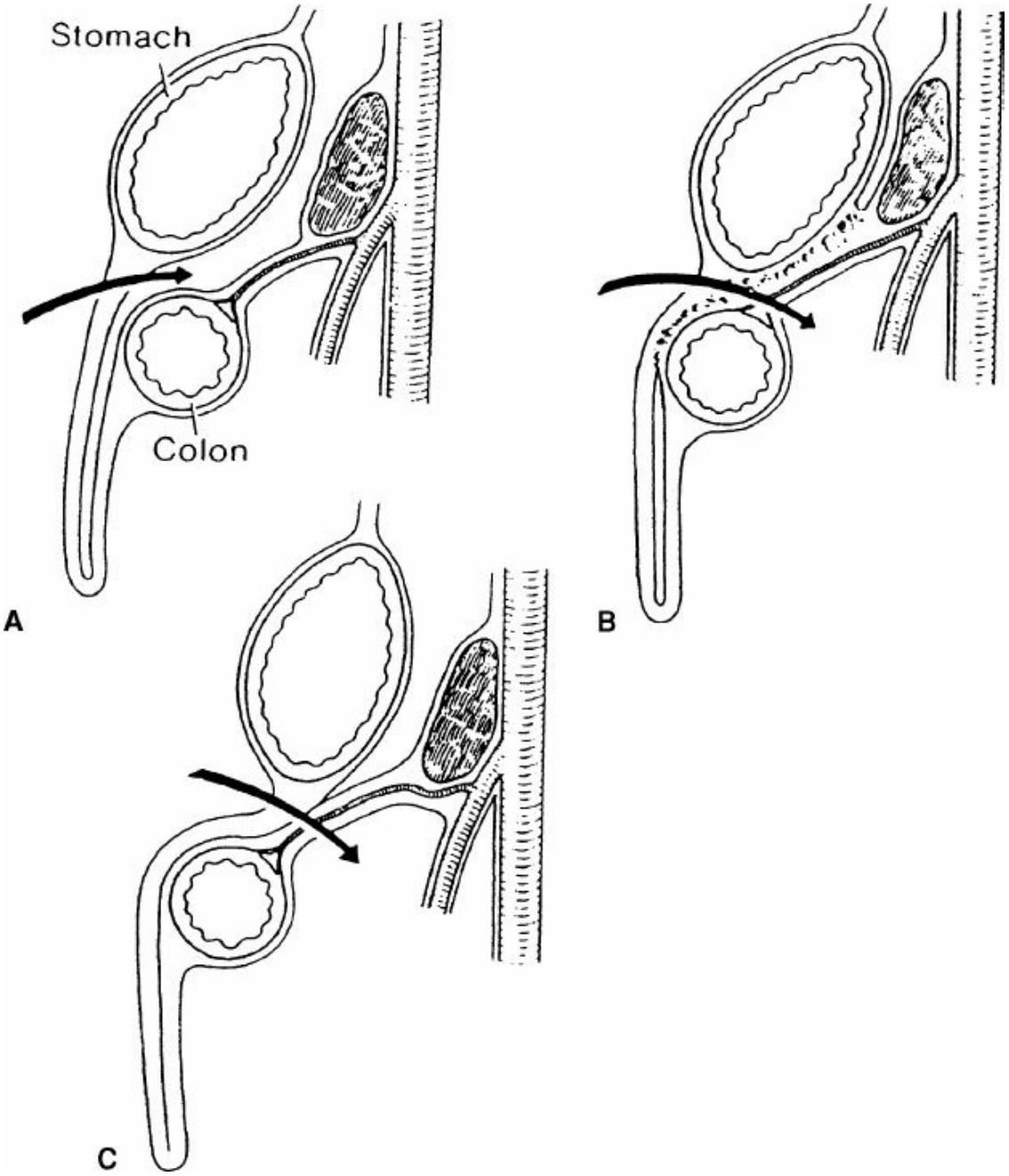

Figure 82.24. Entrance to the lesser sac. **A.** Normal anatomy. *Arrow* indicates entrance through the greater omentum. Middle colic artery in transverse mesocolon in no danger. **B.** Pathologic fixation of the omentum and posterior wall of the stomach with transverse mesocolon. **C.** Normal anatomy, but entrance so far inferior may injure middle colic artery. (From Skandalakis JE, Gray SW, Rowe JS Jr. *Anatomical Complications in General Surgery*. New York: McGraw-Hill; 1983.)

The peritoneum of the anterior surface of the stomach continues upward and covers the anterior and lateral surfaces of the distal abdominal esophagus. The proximal abdominal esophagus, whose posterior surface is

in contact with the diaphragm, is covered only anteriorly by peritoneum.

From the lower part of the great curvature of the stomach, the two leaves of the peritoneum continue as the two leaves of the greater omentum, descending down and then ascending again. They attach to the transverse colon and its mesentery, and continue as such until the pancreas. The fusion of peritoneal layers during this course is shown in Figure 82.5. From there, the two leaves diverge toward the parietal peritoneum of the posterior abdominal wall (lower) or the posterior wall of the omental bursa.

The first part of the duodenum is not attached to the posterior abdominal wall, and therefore free to follow the movements of the pyloric part of the stomach. It is connected with the porta hepatis with the hepatoduodenal ligament, which is the lower part of the lesser omentum. In this ligament are found the portal vein, hepatic artery, and bile duct. The second, third, and fourth part of the duodenum are retroperitoneal.

SURGICAL CONSIDERATIONS OF PERITONEAL REFLECTIONS AROUND THE STOMACH AND DUODENUM

The abdominal esophagus is partially covered by peritoneum. This does not prohibit the existence of the “mesoesophagus,” which contains vessels, nerves, and lymphatics, and must be dissected with attention.

Every ligament or omentum of the stomach is part of the mesentery, and contains vessels, nerves, and lymphatics (except perhaps for the gastrophrenic ligament), and has to be carefully handled and dissected.

Within the lesser omentum, the hepatic triad (hepatic artery, portal vein, bile duct), the right and left gastric arteries, the hepatic branch of the anterior vagus nerve, and lymphatics are contained. A fluid collection within only the lesser sac should be considered postoperative fluid after gastric or hepatobiliary surgery or an inflammatory exudate from pancreatitis, cholecystitis, or gastric perforation. Inflammatory infiltrates in the lesser sac are commonly secondary to acute pancreatitis.

The hepatoduodenal ligament contains the hepatic triad and the left gastric artery.

The hepatogastric ligament carries the anterior branch of the vagus nerve and the left gastric artery.

The whole vascular supply of the duodenum comes from the left side, which permits mobilization from the right side.

Entrance to the lesser sac (Fig. 82.24) normally requires ligation of branches of the gastroepiploic vessels. However, pay extreme attention to the middle colic artery that may be pathologically fixed to the anterior wall and be at risk.

VASCULAR SUPPLY OF THE STOMACH AND OMENTUM

The stomach is among the best vascularized of organs (Fig. 82.25). Not only is it supplied by many arteries, but its wall also contains a rich anastomosing network of vessels extrinsically and intrinsically. General surgeons know that the stomach can survive after ligation of all but one of its primary arteries, and that extragastric ligation does not control bleeding from a gastric ulcer.

ARTERIES

The following is a listing, or summation, of all the arteries that supply the stomach. Each of the principal arteries of supply originates from the celiac trunk. The arteries are:

- left gastric
  - ascending branch: esophageal
  - descending branch: gastric
- hepatic
  - right gastric
  - gastroduodenal
  - anterior superior pancreaticoduodenal
  - retroduodenal
  - posterior superior pancreaticoduodenal
  - supraduodenal
  - right gastroepiploic (major branches)
- splenic
  - posterior gastric
  - short gastrics
  - left gastro-omental (major branches)
  - dorsal pancreatic
  - great pancreatic

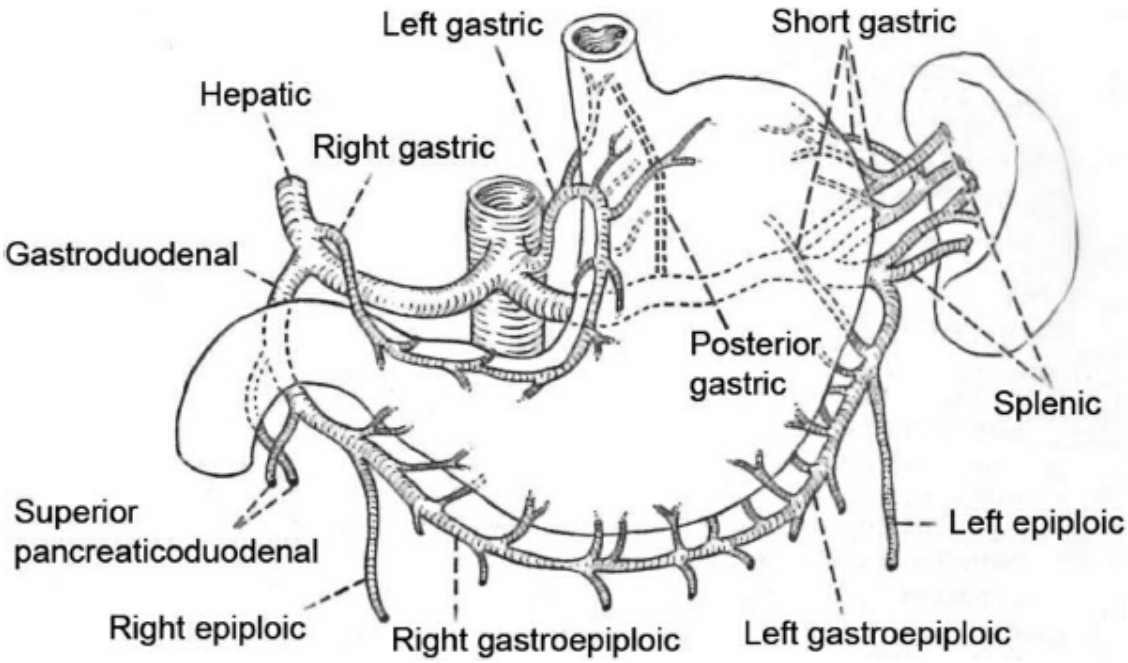

Figure 82.25. Arteries of the stomach. (Modified from Hollinshead WH. *Anatomy for Surgeons. Volume 2. The Thorax, Abdomen, and Pelvis*. New York: Hoeber-Harper; 1956:390, Fig. 277.)

Left Gastric Artery

In approximately 90% of individuals, the left gastric (or coronary) artery is a branch of the celiac axis. However, it may arise from the common hepatic artery, splenic artery, aorta, or SMA (Fig. 82.26). In 4% of individuals, it arises from a gastrosplenic trunk; in 3%, it has a direct aortic origin; and in 2%, the left gastric is a branch of a hepatogastric trunk. A case of left gastric artery originating directly from the aorta has been reported.

The artery travels upward behind the posterior wall of the omental bursa, frequently in a fold of peritoneum (the so-called gastropancreatic fold). It passes across the posteromedial surface of the stomach at about the gastroduodenal junction to reach the lesser curvature of the stomach; here, in approximately 95% of cases, it provides 1 to 3 esophageal branches, which anastomose with the esophageal arteries from the aorta. The esophageal branches have anterior and posterior distributions, and are not associated with the locations of the vagal nerves. The rich anastomoses between thoracic esophageal branches, left inferior phrenic, and left gastric branches can result in troublesome retrograde bleeding from these branches on the posterior side of the stomach. The main part of the artery

continues onto the lesser curvature of the stomach.

The left gastric artery may give origin (in 24% of cases) to an aberrant left hepatic branch. This latter vessel should be sought when the left gastric artery appears uncommonly large.

The left gastric artery commonly divides into an anterior and a posterior branch before attaining the lesser curvature, and, in such cases, the esophageal and cardioesophageal arteries may arise from either of those vessels; more commonly, however, the cardioesophageal artery arises from the anterior gastric branch. The anterior branch runs obliquely across the body of the stomach toward the great curvature. It ends in numerous small ramifications and forms a “crow’s foot” (of Prayne) similar to the anterior nerve of Latarjet. The anterior branch terminates about 4 to 6 cm proximal to the pylorus. The posterior branch follows the lesser curvature until its anastomosis with the right gastric artery.

After its cardioesophageal branch, the left gastric artery usually curves down to the right and thereafter descends along the lesser curvature. As it descends, it bifurcates into an anterior branch that sends branches to the anterior gastric wall and a posterior branch to the posterior gastric wall. The left gastric artery ends by anastomosing with the right gastric artery. Nevertheless, there may be no external anastomoses, but only internal ones.

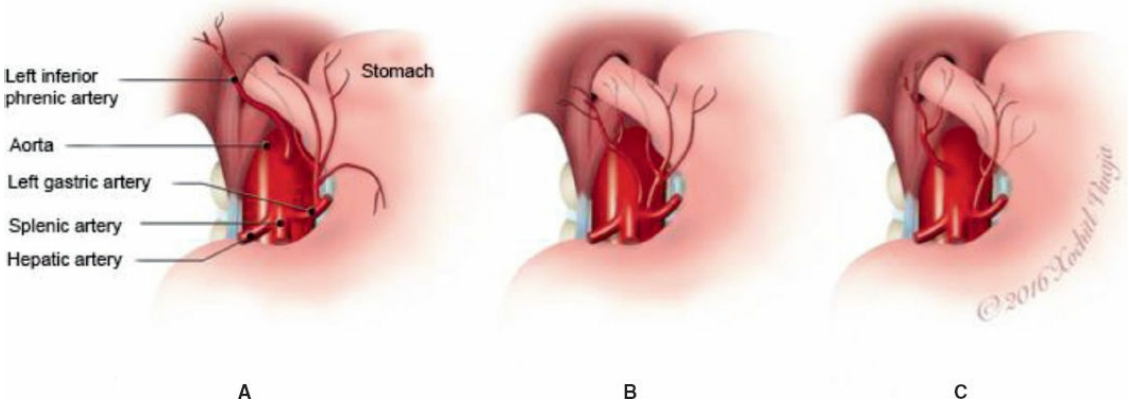

Figure 82.26. Arteries of distal esophagus and proximal stomach. **A.** Inferior phrenic artery supplies margin of hiatus. Esophageal branch of left gastric artery supplies distal esophagus and passes through hiatus to anastomose with thoracic esophageal arteries. **B.** Branches of inferior phrenic and left gastric arteries supply distal esophagus with no thoracic anastomoses. **C.** Branches of inferior phrenic artery supply distal esophagus with thoracic anastomoses (rare). (Based on Figure

24, in Skandalakis LJ, McClusly AD, Loukas M, et al. Anatomic considerations in gastroduodenal surgery. In: Fisher JE, *Mastery of Surgery*. 6th ed. Philadelphia, PA: Wolters Kluwer/Lippincott Williams & Wilkins; 2012: 957–80.)

Hollinshead underlines that because of its direct course to the gastroesophageal junction, the left gastric artery allows little mobility to the upper portion of the stomach. It follows that when this has to be mobilized and raised through the diaphragm, as in excision of the lower part of the esophagus, the left gastric artery has to be sacrificed.

Right Gastric Artery

The right gastric artery is a small branch that arises most commonly from the proper hepatic artery (50% to 68%), left hepatic artery (28.8% to 40.5%), common hepatic (3.2%), or other, less frequent, sources. If it arises from the hepatic artery, this may happen before or after the origin of the gastroduodenal artery.

The right gastric artery normally descends toward the lesser curvature of the stomach and continues along the lesser curvature between the leaves of the lesser omentun to anastomose with the terminal branches of the left gastric artery. The right gastric artery gives origin to one or more suprapyloric branches. Anterior and posterior branches from these anastomose with infrapyloric vessels, and, with the supraduodenal artery, supply the distal gastric unit (e.g., the antrum, pyloric canal, and the first inch of the first part of the duodenum). The right gastric artery passes along the lesser curvature for approximately 4 to 6 cm, approximately 0.5 cm from the lesser curvature, before anastomosing with the left gastric artery. The right gastric artery is the origin of the supraduodenal artery in 13% of studied instances.

Right Gastro-Omental Artery

The right gastro-omental or gastroepiploic artery is a branch of the gastroduodenal artery (or its continuation) in most cases. It occasionally arises from the SMA or from the anterior superior pancreaticoduodenal artery. After giving origin to an infrapyloric branch, the artery passes along the greater curvature of the distal stomach within the great omentum. Sometimes it is very close to the curvature, and sometimes a centimeter or more away from it. It gives 8 to 18 singular or paired anterior and posterior

branches to the gastric wall.

The right gastroepiploic artery also gives descending branches into the great omentum, (anterior epiploic or omental) and finally anastomoses with the left gastroepiploic artery given from the splenic artery. At the right border of the omentum, the right gastroepiploic artery gives its major branch, the right epiploic artery, which is a branch for the posterior layer of the omentum. This anastomoses with a corresponding (posterior) left epiploic artery from the left gastroepiploic artery.

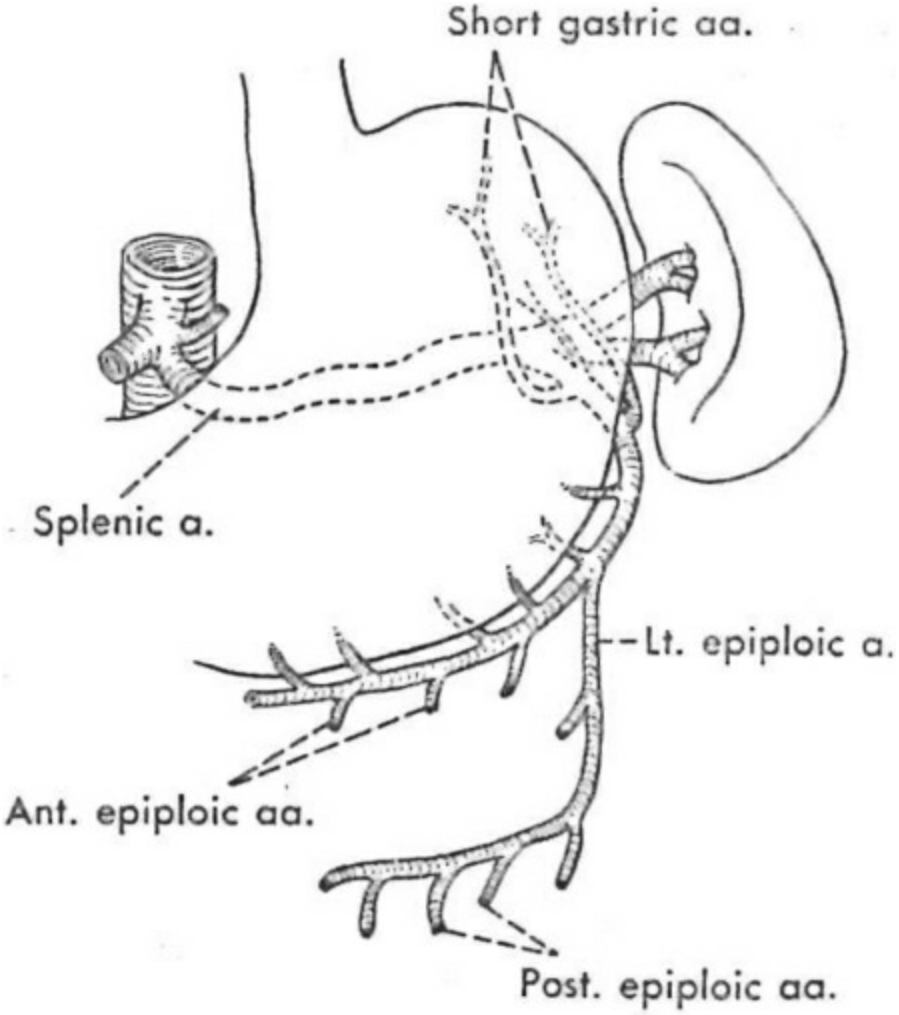

Figure 82.27. Origin, course, and branches of the left gastro-epiploic artery. (From Hollinshead WH. *Anatomy for Surgeons. Volume 2. The Thorax, Abdomen, and Pelvis*. New York: Hoeber-Harper; 1956:393, Fig. 281.)

For omental viability during distal gastrectomy, the right gastro-omental artery should be preserved by one of the following methods: ligating its gastric branches close to the stomach wall, ligating the anterior

omental, or ligating the right gastro-omental distal and close to the origin of the right omental. We prefer to ligate the gastric branches and to imbricate the greater curvature with continuous suture at its “nude,” not resected, part. Some surgeons have not found a need for routine imbrication of the stomach after ligation of the short gastric arteries. Although this is a true and valid opinion, we continue to advise that if there are doubts about the ligation of these vessels, especially the occasional short vessels, the gastric wall should be imbricated.

Left Gastro-Omental Artery

According to Michels, the left gastro-omental artery is a highly variable artery. It arises in most cases (72%) from the distal splenic, inferior splenic terminal, middle part of the splenic trunk, or superior splenic terminal. The observations of Van Damme and Bonte differ rather widely from those of Michels. They state that the left gastro-omental artery arises from the splenic directly in only 26% of individuals. In 66%, it takes origin from the splenic artery by a common stem with the inferior polar splenic branch.

The left gastro-omental artery is the largest branch of the splenic artery (Fig. 82.27). It runs toward the gastrosplenic ligament, to the right and parallel to the great curvature of the stomach. Its course is either along the curvature, or 2 cm or more below it. It may give an inferior polar artery to the spleen and two to four gastric arteries to the stomach. In its course along the great curvature, the left gastro-omental artery gives many ascending anterior and posterior branches to the stomach, branches to the tail of the pancreas, a left epiploic artery, and descending omental arteries (anterior omental). The left epiploic artery runs in the posterior layer of the great omentum below the level of the transverse colon. The left epiploic artery usually anastomoses with the corresponding contralateral branch of the right gastro-omental artery, and also gives some twigs to the transverse colon (posterior epiploic).

In splenectomy, ligation of the splenic artery and vein should be located distal to the origin of the left gastroepiploic vessels. Better still, the surgeon should ligate the splenic vessels very close to their entrance into the spleen. This avoids the postoperative bleeding, which follows ligation proximal to the origin of the left gastroepiploic artery.

Short Gastric Arteries

Approximately five to seven short gastric arteries arise from the terminal

branches of the splenic artery or from the left gastro-omental artery. They may appear to emerge from the substance of the spleen at its hilum, having arisen from terminal splenic branches within the organ. The short gastric vessels provide arterial blood supply of the fundus and upper part of the body of the stomach. Although their branches are distributed to the anterior and posterior surfaces, they appear to supply somewhat more of the posterior surface than the anterior. Outside the gastric wall, the short gastric arteries do not anastomose with each other or with other arteries of the stomach. Therefore, the short gatric arteries alone are inadequate to supply the distal part of the proximal gastric unit.

The first short gastric arteries reach the greater curvature about 2 to 6 cm to the left of the gastroesophahgeal junction. The length of the short gastric arteries varies; some are short, some are long. During splenectomy, specific attention must be paid to the shorter of gastric arteries; these need careful ligation. Imbrication of the greater omentum is a safety measure, not only to avoid bleeding, but also to avoid possible necrosis with perforation.

Posterior Gastric Artery

In approximately 80% of the population, an additional artery may arise variably from the proximal, middle, or distal segment of the splenic artery. It travels up, posterior to the stomach, to vascularize the distal esophagus, cardia, and fundus (Fig. 82.25). This is the posterior (or dorsal) gastric artery. This artery has received great attention, particularly because of its potential clinical significance. Inadvertent ligation or division of the artery can cause focal necroses or postoperative hemorrhage.

The posterior gastric artery is identified as that artery that provides the predominant arterial supply to the posterior wall of the superior portion of the gastric body near the cardiac region and fundus. In a study by Loukas et al. in 120 cadavers, a posterior gastric artery was identified in 81.6% of specimens. The most common origin of the posterior gastric artery was from the left gastric artery (type I), occurring in 41.8% of specimens. In decreasing order of prevalence, were origins from the splenic artery (Type II), occurring in 25.5%; from both the left gastric and splenic arteries as double posterior gastric arteries (Type III) in 22.4%; and from the celiac trunk (Type IV) occurring in 10.2%. The importance of accurate delineation of the posterior gastric artery is crucial for pancreatic transplantation and gastric tumor removal. In addition, knowledge of

variations in this vessel's origin could prove useful in transcatheter arterial embolization for the treatment of chronic bleeding from gastric ulcers. Furthermore, ligation of this vessel during partial gastrectomy, pancreaticoduodenectomy, and parietal cell vagotomy may result in gastric wall necrosis and gastric stump leak.

From our observations, we found that the farther distally along the splenic artery one finds an artery arising that passes vertically toward the fundic region, the more likely it is to provide a superior splenic polar branch. Most distally, at the terminal branching of the splenic artery, a small fundic branch to the stomach may arise from the superior polar branch.

Arterial Circulation of the Gastric Walls

The stomach can survive ischemia after ligation of all but one of its major branches. It is known that the stomach should have adequate circulation after ligation of three major branches (e.g., left gastric, hepatic, and splenic) with preservation of the right gastric or right gastro-omental artery and leaving in situ the other ligated branches. As each of the smaller branches of these arteries penetrates the muscularis of the stomach, it supplies the submucosal plexus. It is this submucosal plexus that interconnects with the extragastric arteries and allows the stomach to tolerate extensive ligation of its extrinsic blood supply. It should be noted that the mucosa of the lesser curvature is supplied by small extrinsic branches of the left and right gastric arteries, rather than by vessels from the submucosal plexus. Despite the richness of the vascular supply of the stomach, necrosis and perforation of the lesser curvature can occur with proximal selective vagotomy in an occasional case. Similarly, necrosis and perforation of the greater curvature after ligation of the short gastric arteries during splenectomy can rarely be encountered, perhaps caused by failure of collateral circulation, as Griffith suggested.

Ischemic necrosis of the gastric remnant after gastrectomy has been reported. The submucosal plexus, which contains many arteriovenous shunts, is the collecting arterial blood reservoir. There is no question that this plexus is the central point of collateral circulation. In fact, dye can reach all intramural branches of all four major arteries after ligating all extramural vessels and injecting any one of the four major arteries.

Because of these findings, Griffith stated the following:

Ligation of most or all extrinsic arteries does not control bleeding from

gastric ulcer.
The stomach remains viable after ligation of all arteries except the right gastro-omental artery and perhaps the right gastric artery.
With subtotal gastrectomy, the gastric remnant remains viable with circulation from the left gastro-omental artery and the short gastric arteries after the left gastric artery is ligated. If present, the posterior gastric artery participates in survival of the remnant.
With 90% to 95% gastrectomy, the remnant stays alive and well because of the descending esophageal arteries. As Griffith stated, however, necrosis rarely can occur.

The blood supply of the proximal gastric pouch depends on three sources: (a) the ascending branch of the left gastric artery, (b) the short gastric arteries, and (c) the posterior gastric artery (if present).

If the spleen is removed, the short gastric arteries must be sacrificed. Every effort should be made to avoid injuring the ascending branches of the left gastric arteries. Adhesions of the posterior gastric wall must not be cut; such adhesions may contain the posterior gastric artery.

The more sparse circulation of gastric vessels is in the pyloric portion of the stomach. The vessels in this region are somehow compressed by the hypertrophic muscle. Compared with the cardia, the pylorus seems to have a less adequate blood supply.

Arterial Supply of the Greater Omentum

The omentum is richly supplied by the right and left gastroepiploic (gastro-omental) arteries (Figs. 82.28 and 82.29). The right gastroepiloic artery is given off from the gastroduodenal artery and the left from the splenic artery. Both gastroepiploic arteries pass tortuously along the greater gastric curvature and decrease in diameter by giving off gastric and epiploic branches at a ratio of 3:1. Finally, having become minute, both gastroepiploics anastomose to the left of the midline of the greater gastric curvature on the exterior or interior of the gastric wall by forming an arcade. The distance of the arcade from the stomach wall varies from 0 to 4 cm.

There are different descriptions of the omental arteries. The classic description, as given by Griffith (Fig. 82.28), defines as anterior omental the branches of the arcade of right and left gastroepiploic arteries that descend in the anterior layer of the omentum. These are said to descend until the edge of the omentum and then ascend in the posterior layer. There

they anastomose between themselves and with the right and left omental arteries; the later are given from the corresponding gastroepiploics and course in the posterior layer of the omentum. The connections of the ascending anterior omental with the right and left form the “arc of Barkow,” located 2 to 4 cm below the transverse colon. A few of the posterior omental arteries from the transverse, dorsal, or great pancreatic arteries enter the arc. Other posterior omental arteries enter the transverse colon directly or anastomose with the vasa recta of the middle colic circulation.

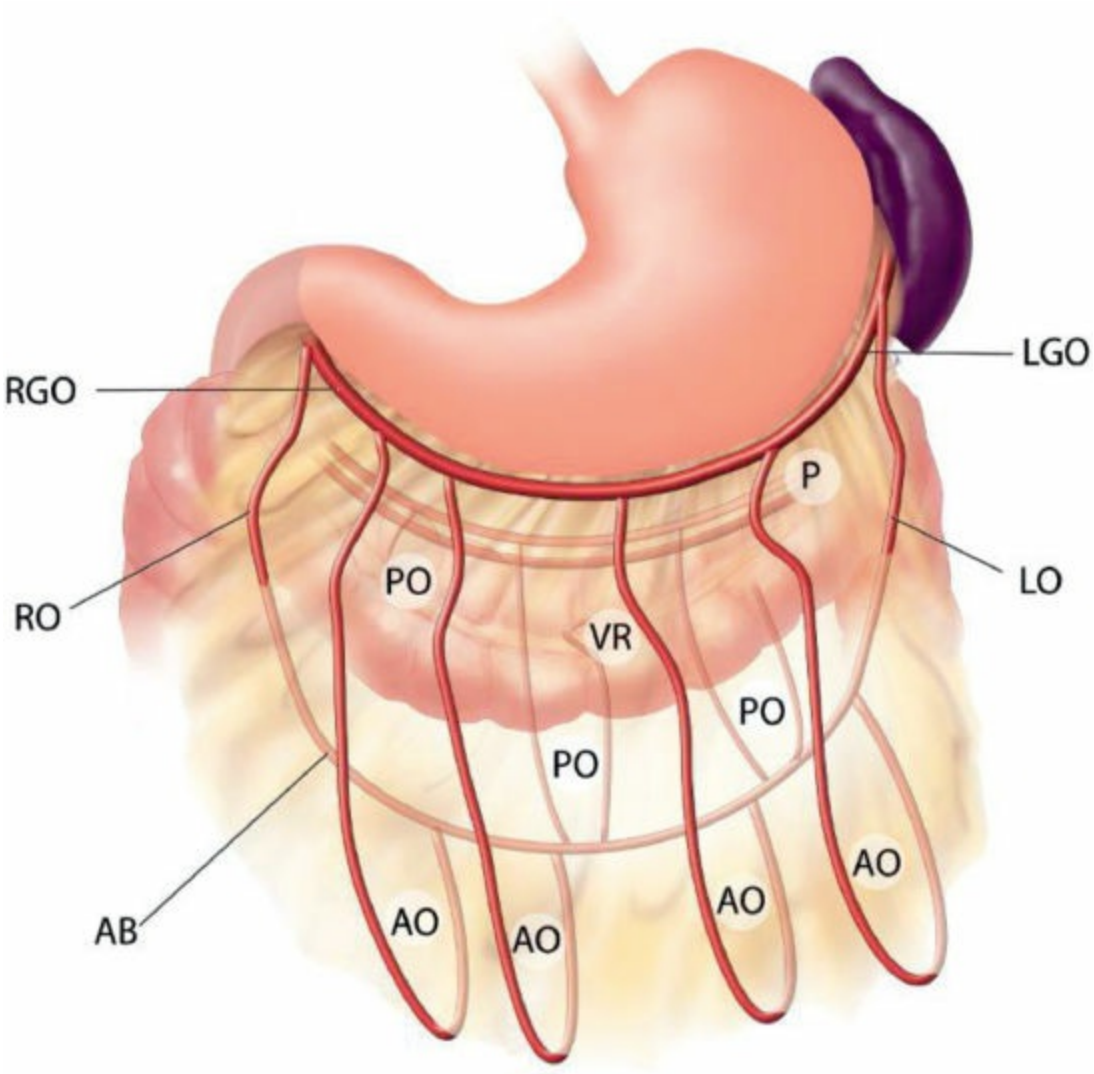

Figure 82.28. Arterial supply to the greater omentum. For description, see text. AB: arc of Barkow, AO: anterior omental, LGO: left gastro-omental, LO: left omental, P: pancreatic, RGO: right gastro-omental, PO: posterior omental, RO: right omental, VR: vasa recta of the middle colic circulation. (Based on Griffith CA. Anatomy. In: Nyhus LM, Wastell C, eds. *Surgery of the Stomach and Duodenum.* 4th ed. Boston, MA: Little, Brown;

1986.)

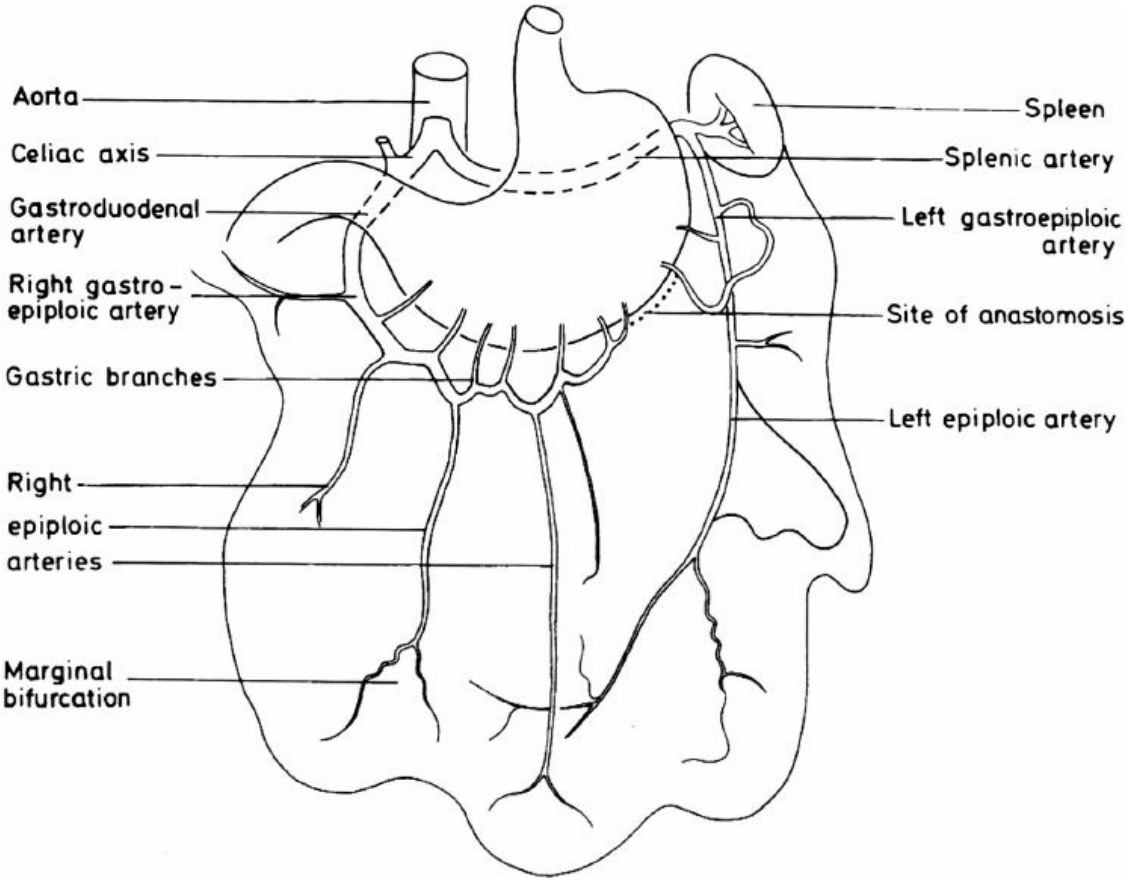

Figure 82.29. Nomenclature, origin, and individual distribution of omental arteries. (Republished with permission of Springer, from Liebermann-Meffert D, White H, eds. *The Greater Omentum: Anatomy, Physiology, Pathology, Surgery, with an Historical Survey.* New York: Springer-Verlag; 1983:37, permission conveyed through Copyright Clearance Center, Inc.)

Dorothea Liebermann-Meffert, a very respected researcher and surgeon of the omentum, claims that in 50% of cases there are no complete gastroepiploic and epiploic arterial arcades (Fig. 82.29). Instead, there is actually no standard pattern. In her investigations, she found 5 to 13 epiploic arteries originating from the right epiploic artery and only one main vessel from the left epiploic artery. They descend in the trabecula mostly at right angles to the greater curvature and bifurcate close to the omental margin, where they eventually anastomose with small branches with adjacent epiploic vessels. In 50% of specimens, the left epiploic coursed downward posteriorly close to the omental margin below the spleen-giving many branches to this area of omentum, thus making it the

best vascularized area; in the rest, it had an oblique course while giving posterior epiploic arteries. The traditional arc was found in just 1 out of 16 specimens, and there was no connection with pancreatic, mesocolon, or transverse colon arteries. Knowledge and preservation of the main vessels are essential to successful lengthening of the omentum in reconstructive surgery.

Ligation of the anterior omental branches or ligation of the right gastroepiploic artery distal to the origin of the right epiploic artery has been advised. It is an open question whether this approach is better than the ligation of the gastric branches that arise from the right and left gastroepiploic arteries to the greater curvature of the stomach. Although the latter may be tedious, it is the opinion of the authors that it is a better choice and is safer.

Remember: The preservation of the blood supply of the omentum in benign gastric disease may be accomplished by careful ligation of the gastroepiploic vessels along the greater curvature of the stomach.

VASCULAR SUPPLY OF THE DUODENUM

In this chapter, we focus on the gastroduodenal anatomy and do not explicitly describe the duodenum beyond the first part, which is supplied mostly by branches of the gastroduodenal artery (see below). The second, third, and fourth part of the duodenum that are bound to the head of the pancreas are supplied by branches of the two pancreaticoduodenal arcades, the anterior and posterior, with superior branches coming from the celiac artery and inferior ones from the SMA (Fig. 82.30). The latter is dictated from the embryologic origin of the pancreas from the foregut (celiac artery) and the midgut (superior mesentery artery). The branches of the pancreaticodudenal arcades are described in detail elsewhere in this book.

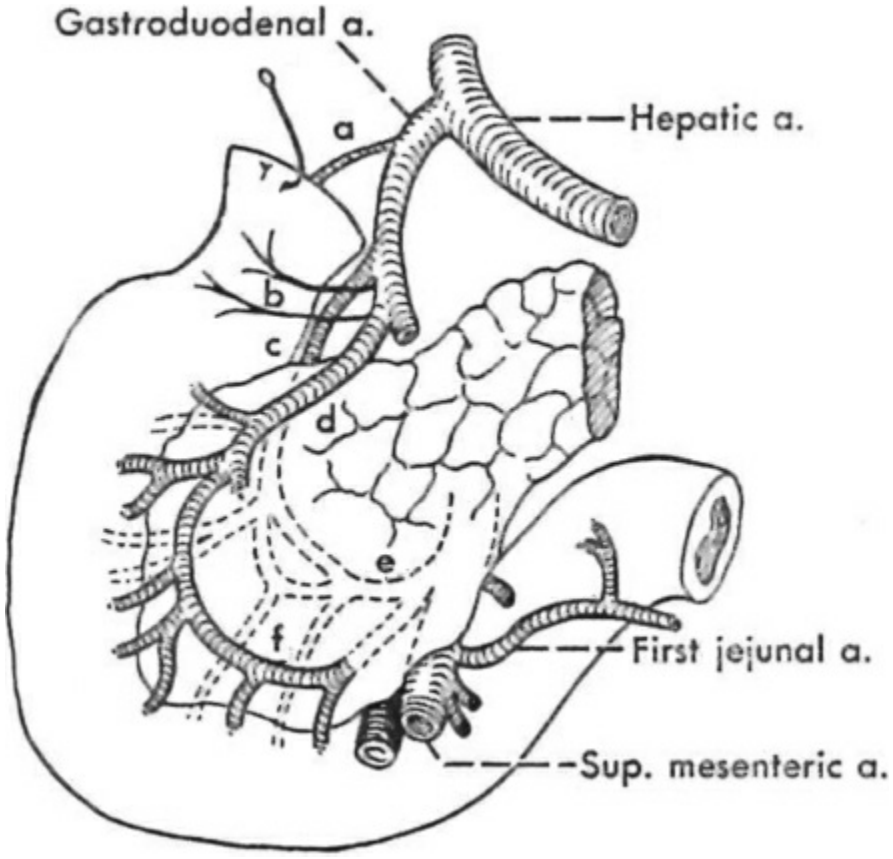

Figure 82.30. Arteries of the duodenum. Those embedded in or running behind the pancreas are shown by *broken lines*. *a,* supradudodenal artery; *b,* retroduodenal and recurrent branches to the first part of the duodenum; *c,* posterior superior pancreaticoduodenal artery; *d,* anterior superior pancreaticoduodenal artery; *e,* posterior inferior pancreaticoduodenal artery; *f,* anterior inferior pancreaticoduodenal artery. (From Hollinshead WH. *Anatomy for Surgeons. Volume 2. The Thorax, Abdomen, and Pelvis.* New York: Hoeber-Harper; 1956:391, Fig. 278.)

Vascular Supply of the First Part of the Duodenum

In contrast to the rich blood supply of the stomach, the arterial supply to the first part of the duodenum is sparse. The arteries of the first part of the duodenum are small: the supraduodenal artery, retroduodenal arteries, and tiny branches from the right gastric or the right gastroepiploic artery (Fig. 82.31).

The gastroduodenal artery is usually the first branch of the (common) hepatic artery. It arises behind, at the upper border or above the first part of the duodenum and then descends behind it. Typically, the gastrodudenal gives off the supradudenal artery; however, there are cases where the latter

arises from the hepatic artery, or the gartoduodenal artery is absent and the right gastric artery takes over to supply the first part of the dudodenum. The supraduodenal artery supplies the upper two thirds of the anterior surface of the first part of the duodenum, and about one third of the posterior surface. The remaining part of the posterior surface is supplied by the retroduodenal artery, which can be single or multiple, in the latter case arising from arteries of the neighborhood such as the anterior superior pancreaticodudenal or the right gastroepiploic arteries (Fig. 82.31).

Regarding the anastomoses between the pylorus and first part of the duodenum, we learn from Hollishead:

"In contrast to the cardiac end of the stomach, where anastomoses between the vessels of the stomach and those of the esophagus are apparently constant and of clinical and surgical importance, it seems to be generally agreed that anastomotic channels between the vessels of the pyloric end of the stomach and the first part of the duodenum are either nonexistent or minimal, and have no practical importance when they do occur."

VEINS

The veins of the stomach correspond to the arteries (Fig. 82.32). They course in parallel to the arteries along the curvatures, and each ends separately in the portal vein. These veins do not have valves, and circulation may shift from one direction to the other when pressure dictates so. For this reason, when portal hypertension is present, the anastomosis of the left gastric vein (portal circulation) with the lower esophageal veins (azygos circulation) leads to esophageal varices.

It is also well known that occlusion of the splenic vein produces obvious extrinsic varicosities of the veins of the proximal gastric unit (short gastrics, left gastro-omental) (Fig. 82.33). Occasional involvement of the right gastro-omental vein and intrinsic gastric and even duodenal varices are also possible. The endoscopist can mistake these varices for hemorrhagic gastritis.

Remember: A great venous arch can develop between the left and right gastro-omental veins during portal hypertension, forming a congested vascular bridge between the splenic and portal veins.

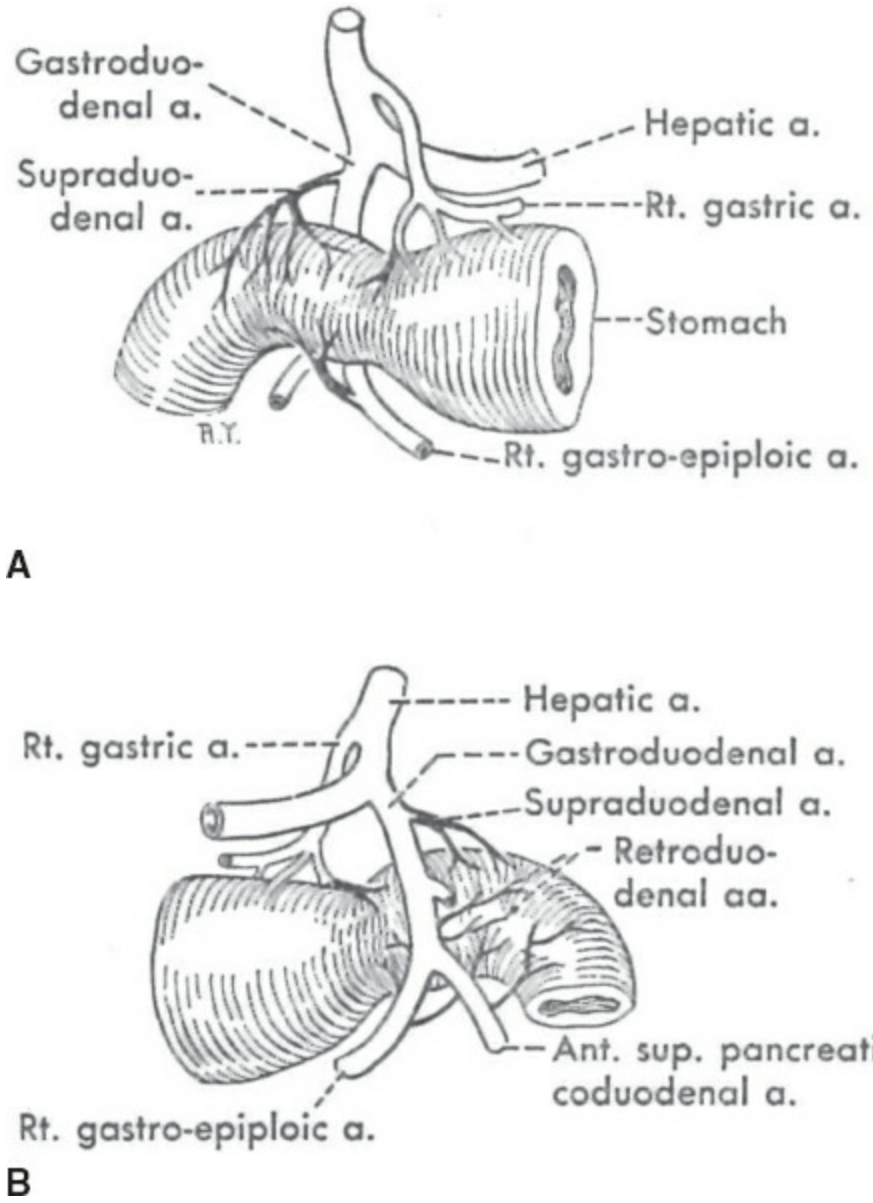

Figure 82.31. Anterior (**A**) and posterior (**B**) views of the blood supply of the first part of the duodenum. (From Hollinshead WH. *Anatomy for Surgeons. Volume 2. The Thorax, Abdomen, and Pelvis.* New York: Hoeber-Harper; 1956:391, Fig. 279.)

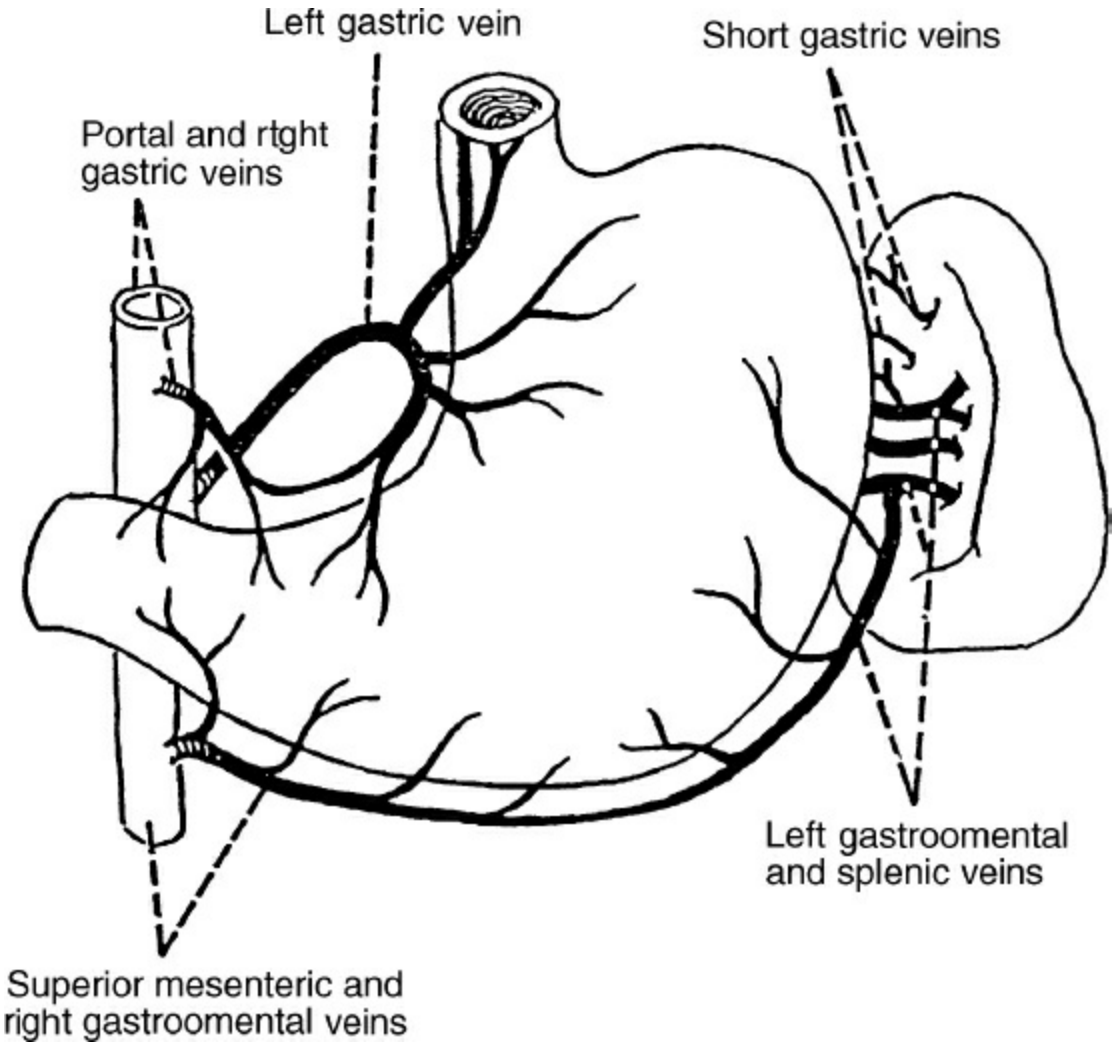

Figure 82.32. General arrangement and drainage of veins of stomach. (Modified from Hollinshead WH. *Anatomy for Surgeons.* New York: Hoeber-Harper; 1956.)

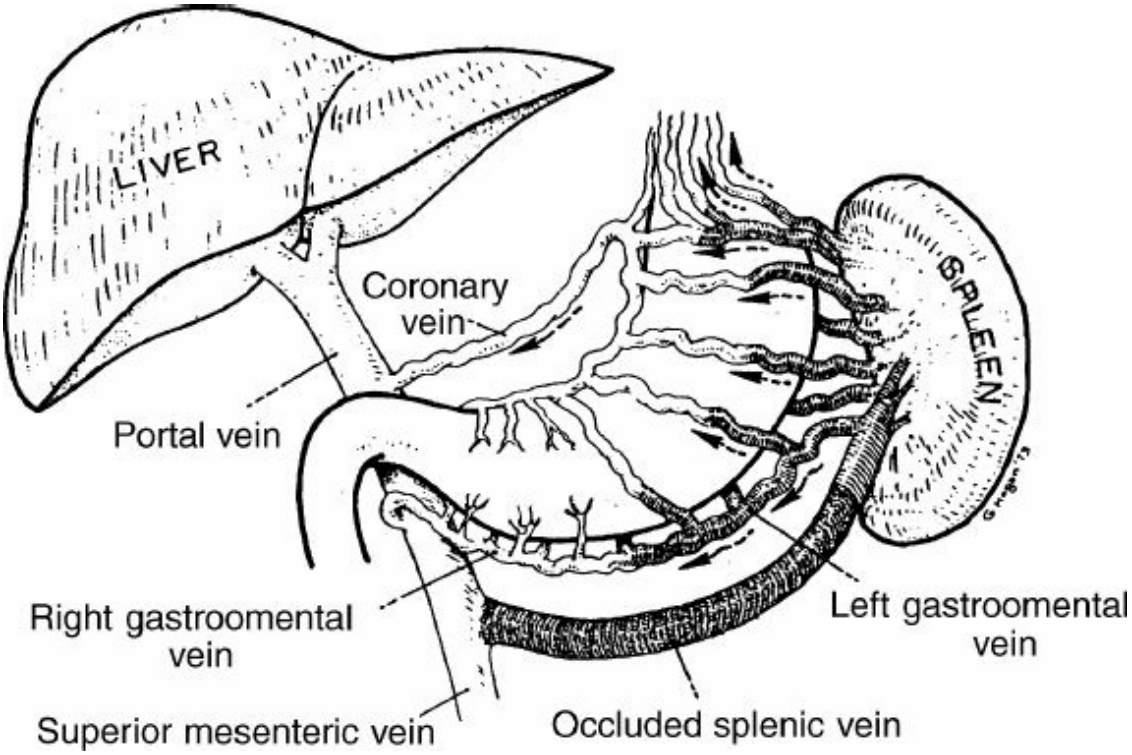

Figure 82.33. Collateral circulation characteristic of isolated occlusion of splenic vein. (Reprinted from Salam AA, Warren WD. Anatomic basis of the surgical treatment of portal hypertension. *Surg Clin North Am* 1974;54(6):1247–57. Copyright © 1974 Elsevier, with permission from Elsevier.)

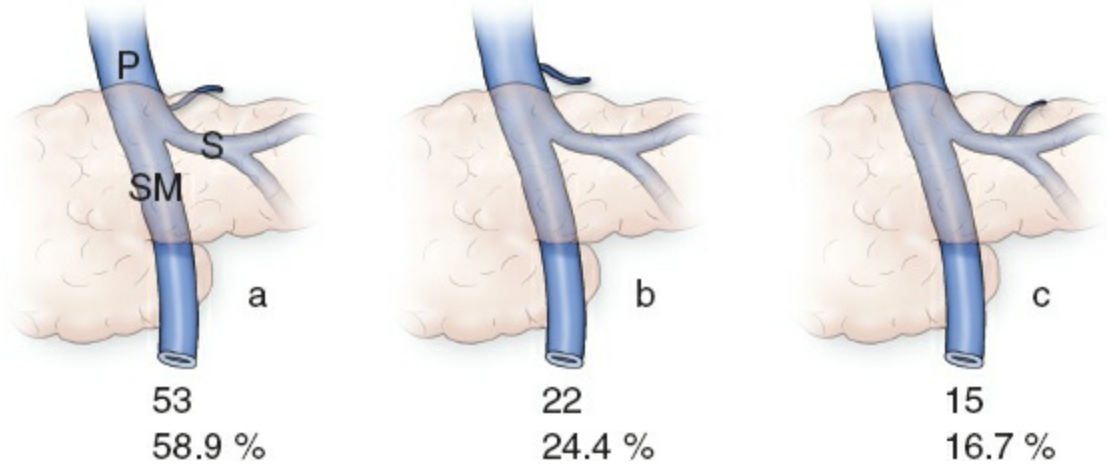

Figure 82.34. Major variations in location of ending of left gastric vein: a, terminates in superior aspect of juncture of splenic (S) and superior mesenteric (SM) veins; b, terminates in portal vein (P); c, terminates in splenic vein distal to juncture with superior mesenteric vein. (From Douglass BE, Baggenstoss AH, Hollinshead WH. The anatomy of the portal vein and its tributaries. *Surg Gynecol Obstet* 1950;91:562. Reprinted with permission from *the Journal of the American College of*

Left Gastric (Coronary) Vein

The left gastric vein is often referred to as the *coronary vein.* One can find the beginning of the left gastric vein at the middle of the lesser curvature, running close to the curvature to a point 2 to 3 cm from the inferior border of the esophageal hiatus where it receives one to three esophageal tributaries. From this point, the left gastric vein turns downward and obliquely to the right to join the portal vein. It accompanies the corresponding artery behind the posterior wall of the omental bursa. The coronary vein may also turn backward to enter the splenic vein. Douglas et al. reported that more commonly it ended in the portal vein just above the level of formation of this (59%), or higher in the portal vein (25%) or in the splenic vein (17%) (Fig. 82.34). An intrahepatic termination of the left gastric vein has been reported.

Right Gastric Vein

The small right gastric vein partially drains the distal gastric unit. It follows the right gastric artery at the distal lesser curvature, passing from left to right and draining into the portal system. The prepyloric vein of Mayo is a tributary of the right gastric vein and is the external landmark of the gastroduodenal junction.

Statistics for the drainage of venous vessels in the area are not in total agreement, but to facilitate memorization, we rounded the relevant percentages (22% to 38%) to the number 30%. Note that this is a memorization aid only, and not completely accurate.

Both right and left gastric veins enter the upper portal in 30%.
Both right and left gastric veins enter the lower portal in 30%.
Both right and left gastric veins enter the junction in 30%.

Right Gastro-Omental Vein

The right gastro-omental vein drains the distal stomach and accompanies the right gastro-omental artery in the great omentum. The right gastro-omental empties into the superior mesenteric vein, usually about 5 cm below the junction of the latter with the splenic vein. In rare cases, it may enter the portal vein itself or the splenic vein (Fig. 82.35).

Frequently, the right gastro-omental vein, near its ending, is joined by a

vein from the mesocolon to form the so-called gastrocolic vein, which is short and located beneath the root of the transverse mesocolon, traveling along the anterior surface of the head of the pancreas.

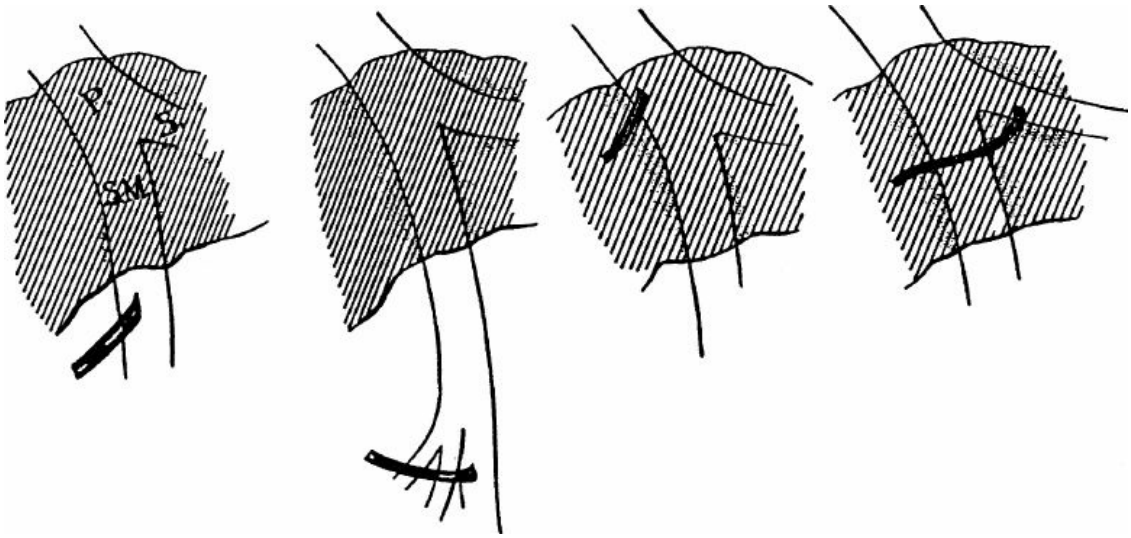

Figure 82.35. Major variations in place of ending of right gastro-omental (gastroepiploic) vein (*shaded*). Diagonally shaded area represents neck of pancreas. Frequency, from view's left to right, is 84%, 12%, 2%, and 2%. P, portal vein; S, splenic vein; SM, superior mesenteric vein. (From Douglass BE, Baggenstoss AH, Hollinshead WH. The anatomy of the portal vein and its tributaries. *Surg Gynecol Obstet* 1950;91:562. Reprinted with permission from *the Journal of the American College of Surgeons*, formerly *Surgery Gynecology & Obstetrics*.)

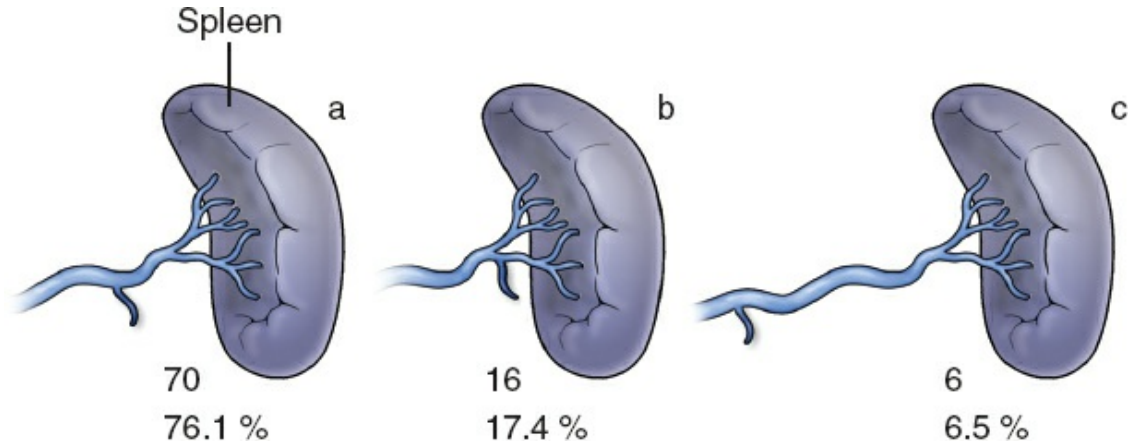

Figure 82.36. Major variations in location of ending of left gastro-omental vein. The ending is represented by the short stump. a, left gastro-omental vein terminates within 2.0 cm of the formation of the splenic vein; b, juncture with a splenic trunk; c, termination more than 3 cm from origin of splenic vein. (From Douglass BE, Baggenstoss AH, Hollinshead WH. The anatomy of the portal

vein and its tributaries. *Surg Gynecol Obstet* 1950;91:562. Reprinted with permission from *the Journal of the American College of Surgeons*, formerly *Surgery Gynecology & Obstetrics*.)

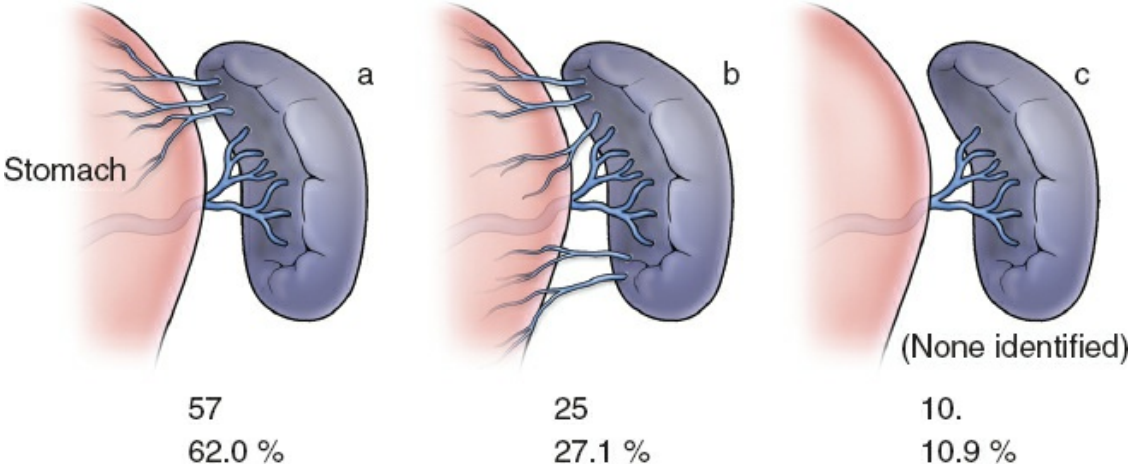

Figure 82.37. Major variations in location of ending of short gastric veins: a, terminate in upper portion or hilus of spleen; b, terminate in lower anterior portion; c, short gastric veins empty directly into spleen. The common ending of one of several short gastrics in a splenic vein (approximately 50% of specimens), and occasional (approximately 2%) ending of one in left gastro-omental not shown. (From Douglass BE, Baggenstoss AH, Hollinshead WH. The anatomy of the portal vein and its tributaries. *Surg Gynecol Obstet* 1950;91:562. Reprinted with permission from *the Journal of the American College of Surgeons*, formerly *Surgery Gynecology & Obstetrics*.)

Left Gastro-Omental Vein

The left gastro-omental vein drains into the splenic vein or into one of the terminal branches of the splenic vein, usually the lower terminal branches (Fig. 82.36). Because the ending of this vein is variable, ligation should be placed as close as possible to the hilum.

Short Gastric Veins

The short gastric veins partially drain the proximal gastric unit. They accompany the corresponding arteries in the gastrosplenic ligament. The great majority of these vessels drain into the splenic vein or one of its contributing veins. According to Douglass et al., in the majority of cases, the short gastric veins enter the upper part of the splenic hilum (Fig. 82.37).

LYMPHATICS

Gastric Lymphatics

The classical view of the gastric lymphatic drainage is shown in Table 82.2 and Figure 82.38. These nodes follow the arteries of the stomach. Some groups, such as the gastroepiploic and the pancreaticosplenic, have been considered of secondary importance since their efferent vessels drain in the celiac nodes, referred by Visalli as "the vortex of the metastatic whorl."

Despite the order of numbering in this classical classification, the largest area of drainage is into the lymphatics of the lesser curvature along the left gastric artery toward the superior gastric nodes (III in Fig. 82.38). These nodes drain almost all the lesser curvature and a large part of the body of the stomach. The next largest area of drainage is the one that drains the pylorus and follows the right gastroepiploic artery toward the inferior gastric nodes (I in Fig. 82.38). These nodes may be found at 3 to 4 cm from the great curvature. The nodes found at the right end of this chain are the subpyloric lymph nodes. The third important area of drainage is from the great curvature, fundus and body along the left gastroepiploic artery and short gastric vessels, which drains into the left gastroepiploic and pancreaticosplenic lymph nodes (III in Fig. 82.38). And the fourth area (IV in Fig. 82.38) is rather small, the distal upper portion of the pylorus. Drainage here is associated with the upper border of the head of the pancreas (right suprapancreatic and lower hepatic nodes).

TABLE 82.2 Lymphatic Drainage of the Stomach

Zone I (inferior gastric)	Nodes around right gastroepiploic and gastroduodenal arteries *to* nodes around hepatic artery *to* celiac nodes
Zone II (splenic)	Nodes around left gastroepiploic and short gastric arteries *to* pancreaticosplenic nodes *to* splenic artery nodes *to* celiac nodes
Zone III (superior gastric)	Nodes around left gastric artery *to* celiac nodes
Zone IV (hepatic)	Nodes around right gastric artery *to* celiac nodes

From Skandalakis JE, Gray SW, Rowe JS Jr. *Anatomic Complications in General Surgery.* New York: McGraw-Hill; 1983:63.

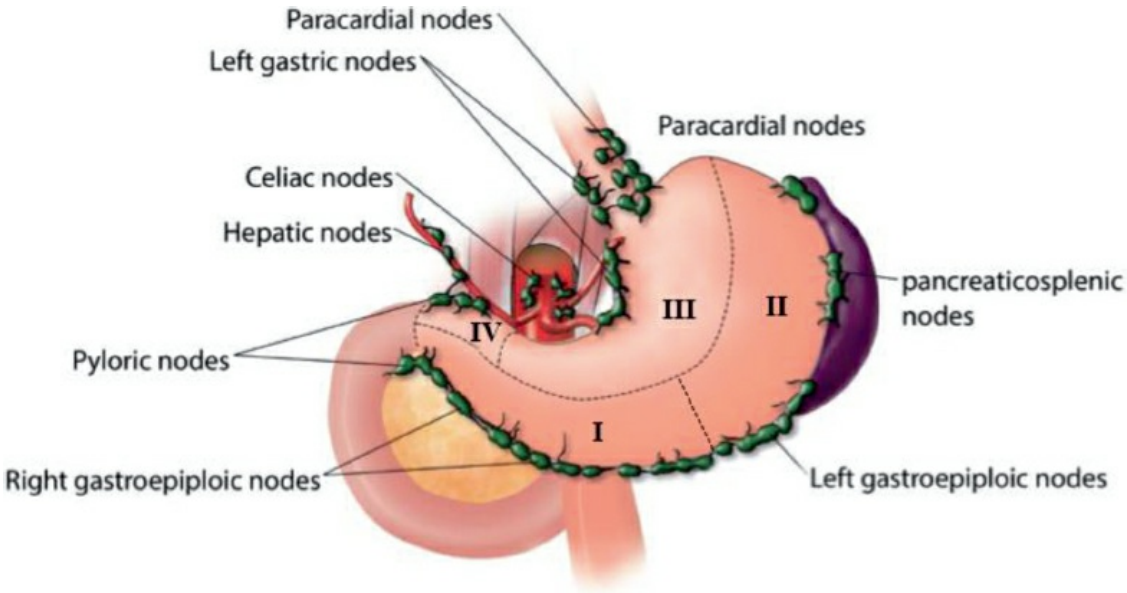

Figure 82.38. Lymphatic drainage of the stomach. Classical view of gastric lymphatic drainage. I, inferior gastric; II splenic; III, superior gastric; IV, hepatic.

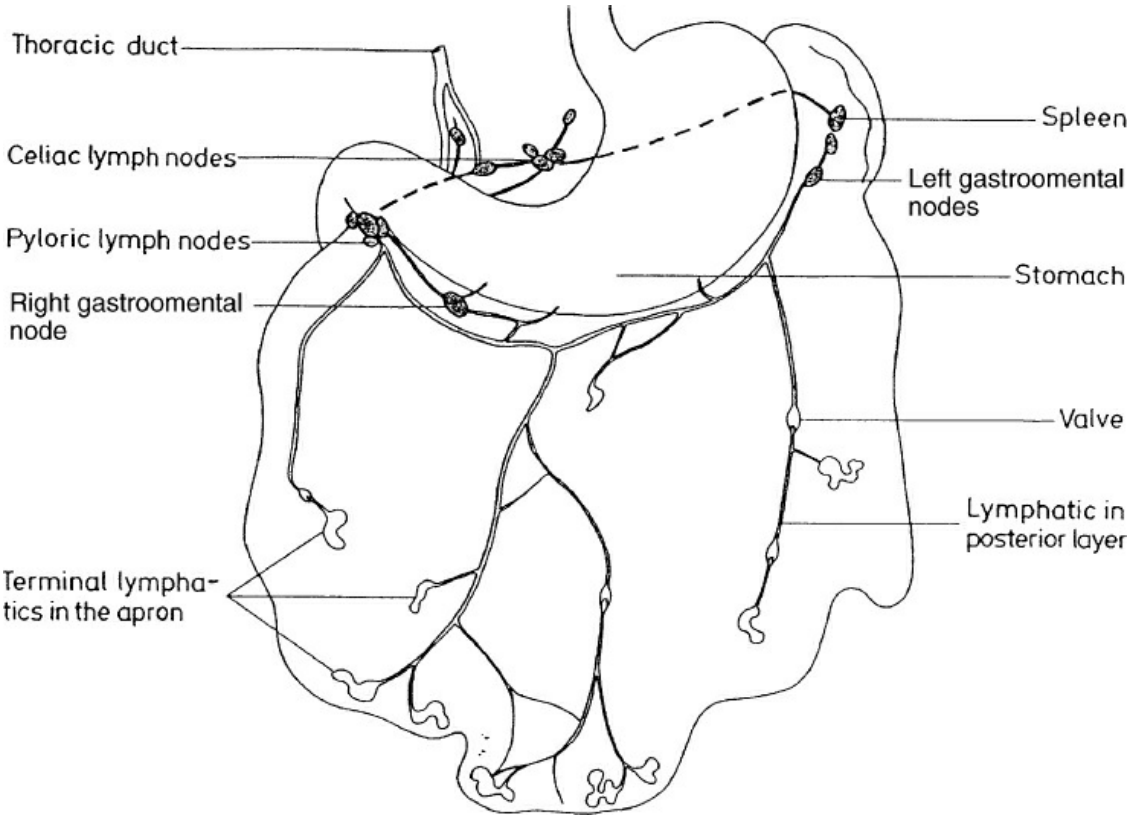

Figure 82.39. Lymphatic drainage of the great omentum. (Modified from Liebermann-Meffert D. Omentum in the adult. In: Liebermann-Meffert D, White H, eds. *The Greater Omentum: Anatomy, Physiology, Pathology, Surgery With a Historical Survey.* New York: Springer-Verlag; 1983, permission conveyed

through Copyright Clearance Center, Inc.)

Gastric lymphatics are continuous with esophageal lymphatics at the cardiac orifice. Lymph from the abdominal esophagus drains in the superior left gastric, paracardial and inferior diaphragmatic nodes.

Lymphatics of the stomach together with veins have a key role in metastasis of gastric cancer. O'Rahilly expresses this colorfully:

"The blood and the lymphatic drainage of the stomach are such that cancer can easily spread: (1) to the liver, by the portal vein or by reversal of flow in lymphatic vessels from the liver; (2) to the pelvis, by retroperitoneal lymphatic vessels; (3) to any other part of the body, both directly by veins and indirectly by way of the thoracic duct. The thoracic duct may be composed of several trunks in the neck, and one or more of these trunks may enter a cervical node."

Lymphatics of the Greater Omentum

The lymphatics of the great omentum are closely associated with the large vessels of the omentum. Thereof the collecting system follows two drainage pathways for the lymphatics of the omentum (Fig. 82.39): one travels to the right toward the subpyloric nodes and the other travels to the left toward the splenic nodes. In the proximal apron of the omentum, there is communication with lymphatics that drain the stomach and pass into the greater gastric curvature.

> Lymph drainage of the peritoneal cavity may largely bypass the lymphatic system of the omentum. The peritoneal cavity is mainly drained through the celiac lymph nodes to the thoracic duct.

Strikingly, we learn from Liebermann et al. that omental lymph nodes seem to be absent or at least very infrequent in the omental apron, in the gastrocolic ligament, and along the great curvature. They found none in the 16 omenta investigated.

When the omentum adheres to a part of the intestine, lymphatic connections rapidly (within a week) develop between the two. The lymph drainage of the omentum is important in metastasis, direct involvement of the omentum by malignant disease, infraction, and torsion.

Lymphatics of the Duodenum

Lymphatics of the duodenum run on its anterior and posterior surface. The

major lymph flow of the duodenum is directed toward the anterior and posterior pancreaticoduodenal nodes, which drain toward the hepatic nodes cranially and to the central superior mesenteric nodes caudally, respectively. In addition, the superior part of the duodenum drains into the pyloric nodes, whose afferents drain up to the hepatic nodes. Respectively, the third part of the duodenum and the gastroduodenal flexure have connections with the inferior pancreatic and central superior mesenteric nodes.

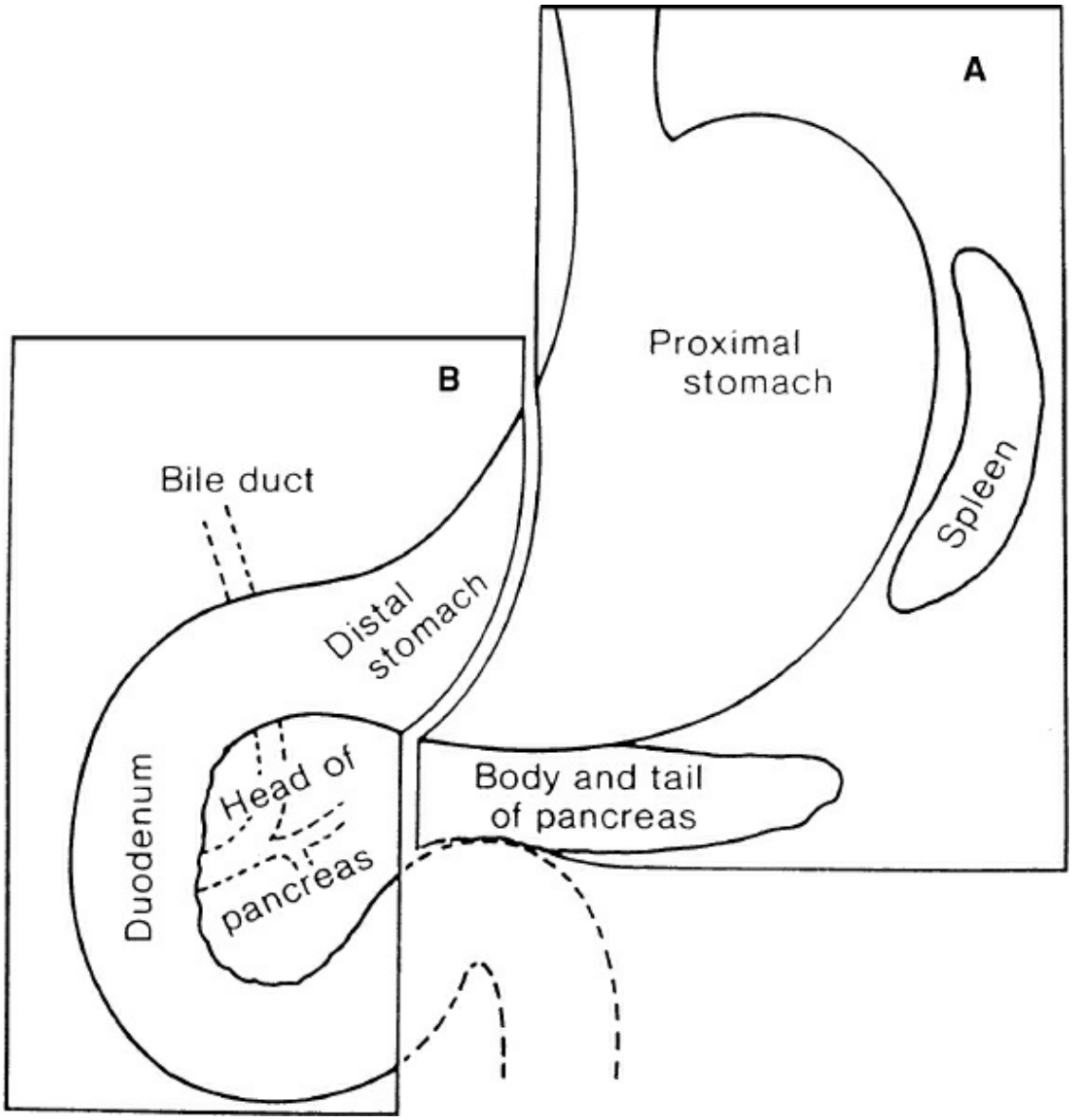

Figure 82.40. Plans for en bloc resections. **A.** Proximal stomach and related organs sharing a common blood supply and lymphatic drainage. **B.** Distal stomach and related organs. (From Skandalakis JE, Gray SW, Rowe JS Jr. *Anatomical Complications in General Surgery.* New York: McGraw-Hill;

1983.)

There is no agreement whether lymphatics of the stomach anastomose with those of the duodenum. However, gastric cancer may involve the duodenum in a percentage (26% to 38%).

Proximal and Distal Gastric Units

After presentation of blood supply and lymphatic drainage of the gastroduodedum, the concept of "proximal and distal gastric unit," introduced earlier in this chapter, is now more clear: the embryology of the stomach and related organs is such that the body and tail of the pancreas (derived from the dorsal pancreatic anlagen) and the spleen lie in the dorsal mesogastrium. They share a common blood supply (splenic artery) and a common lymphatic drainage with the proximal portion of the stomach. The head of the pancreas (derived from the ventral pancreatic anlagen) lies in the mesoduodenum. The pancreatic head shares its blood supply (pancreaticoduodenal and gastroduodenal arteries) and lymphatic drainage with the duodenum, the distal common bile duct, and the distal stomach.

Theoretically, cancer of the proximal stomach can be effectively treated by en bloc resection of the organs supplied by the left gastric and splenic arteries (Fig. 82.40A): distal esophagus, proximal two thirds of the stomach and greater omentum, spleen, and body and tail of the pancreas. Similarly, cancer of the distal stomach can be treated by en bloc resection of the organs supplied by the common hepatic artery, sparing, of course, the artery itself (Fig. 82.40B): head of the pancreas, distal stomach and greater omentum, duodenum, and distal bile duct.

INNERVATION OF THE STOMACH AND DUODENUM

Innervation of the Stomach

The functional components of the innervation of the stomach is shown in Figure 82.41. The stomach is innervated by sympathetic and parasympathetic fibers. The sympathetic innervation is effectuated through branches of the thoracic splanchic nerves that reach the celiac ganglia; from there branches of the celiac plexus travel on a network on the arteries. The sympathetic pathway also conducts afferent impulses that mediate sensations, including pain. The sympathetic nerves are

vasoconstrictor to the gastric vasculature and inhibitory to gastric musculature; to the pylorus, they are motor, and result in constriction.

The parasympathetic innervation to the stomach is given by the branches of the vagus verves; these also transfer afferent sensory fibers. The parasympathetic innervation to the stomach either courses through the celiac ganglia and then on the arteries' plexus together with the sympathetic fibers, or goes directly to the stomach with branches of the vagus verves. Sensory fibers also exit in this parasympathetic network, mostly to mediate reflexes, such as the reflex of activation of gastric secretion.

Parasympathetic Innervation (Vagus Nerves)

The left and right vagus nerves descend parallel to the esophagus and form the esophageal vagal plexus between the level of the tracheal bifurcation and the level of the diaphragm. From this plexus, two vagal trunks, anterior and posterior, form and pass through the esophageal hiatus of the diaphragm. Each trunk subsequently separates into two divisions. The anterior trunk gives a hepatic division and an anterior gastric division; the posterior trunk gives the celiac division and the posterior gastric division (Fig. 82.42).

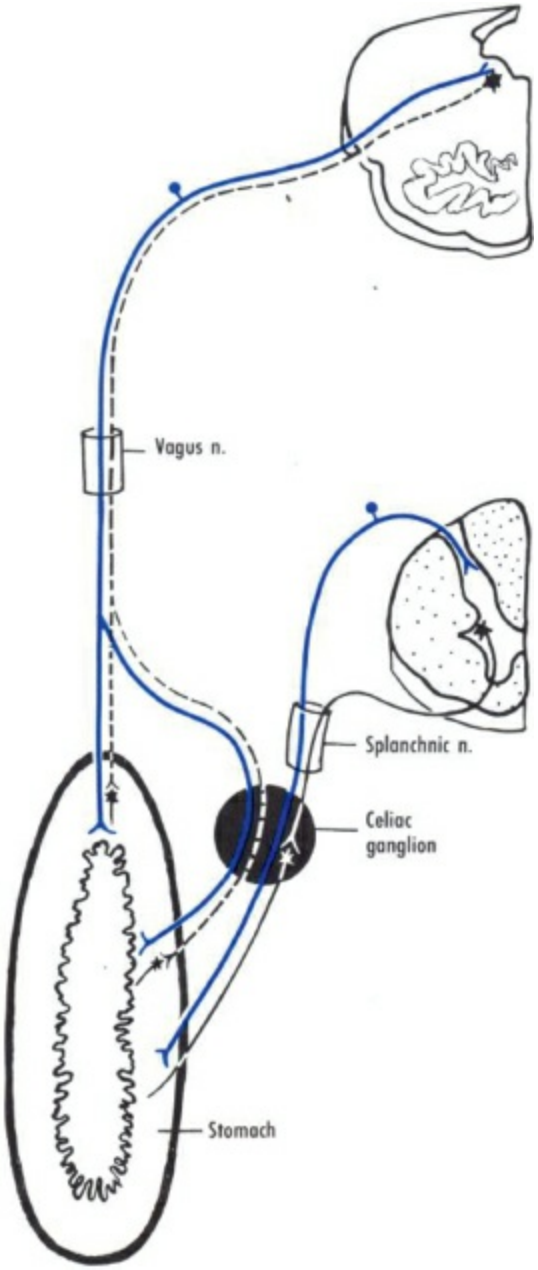

Figure 82.41. Functional components of the innervation of the stomach. Sympathetic fibers are shown as continuous lines, parasympathetic fibers as interrupted lines, and sensory fibers in blue. (Published in O'Rahilly R. *Gardner-Gray-O'Rahilly Anatomy: A Regional Study of the Human Structure.* 5th ed. Philadelphia, PA: W. B. Sunders Co; 1986:390, Fig. 35–7. Copyright Elsevier.)

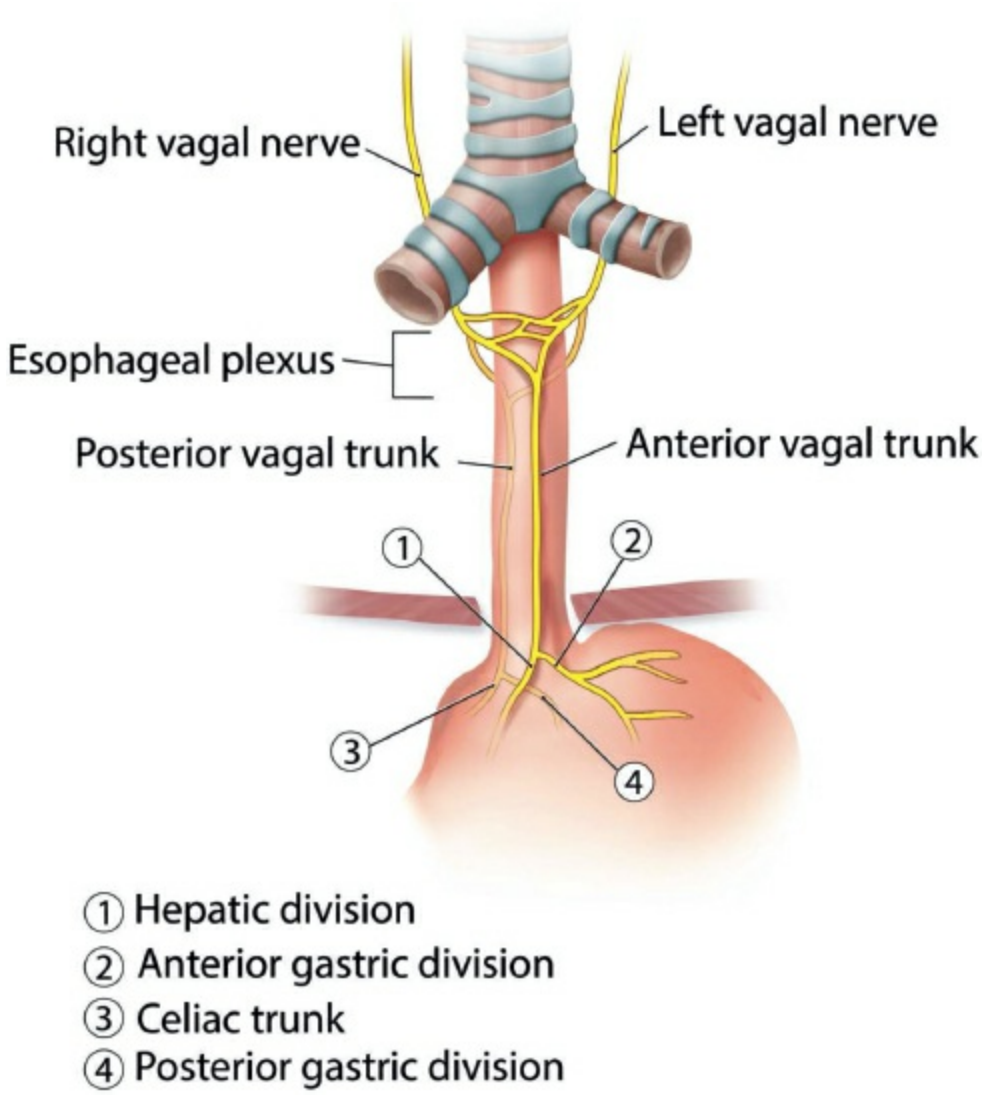

Figure 82.42. Terminology of vagal structures of thorax and abdomen. In this example, two vagal trunks pass through hiatus to enter abdomen. 1, hepatic division; 2, anterior gastric division; 3, celiac division; 4, posterior gastric division. (Modified from Skandalakis JE, Rowe JS Jr, Gray SW, et al. Identification of vagal structures at the esophageal hiatus. *Surgery* 1974;75:233. Copyright Elsevier.)

For the surgeon planning a truncal vagotomy, the pattern of the vagus nerves at the esophageal hiatus is important. The basic configuration and variations are well known. The thoracic pattern, however, is not visible to the abdominal surgeon, who must proceed on the basis of the structures that can be seen.

In our study of vagal structures in 100 cadavers, we found the following:

Two vagal structures only in 88% (Fig. 82.42). These are the anterior and

posterior vagal trunks, which have not yet split to form the four typical divisions. Both trunks are usually to the right of the midline of the esophagus.

Four vagal structures in 7%. These are the four divisions of the vagal trunks. Division has occurred above the diaphragm (Fig. 82.43A).

More than four vagal structures in 5%. These may be divisions and branches of divisions (Fig. 82.43B) (the anterior and posterior trunks lie entirely within the thorax), and elements of the esophageal vagal plexus (Fig. 82.43C) (the anterior and posterior trunks lie entirely within the abdomen).

Anterior Vagal Trunk

The anterior vagal trunk (Fig. 82.44) sends the hepatic division to the liver and pylorus and continues to the lesser curvature of the stomach as anterior division.

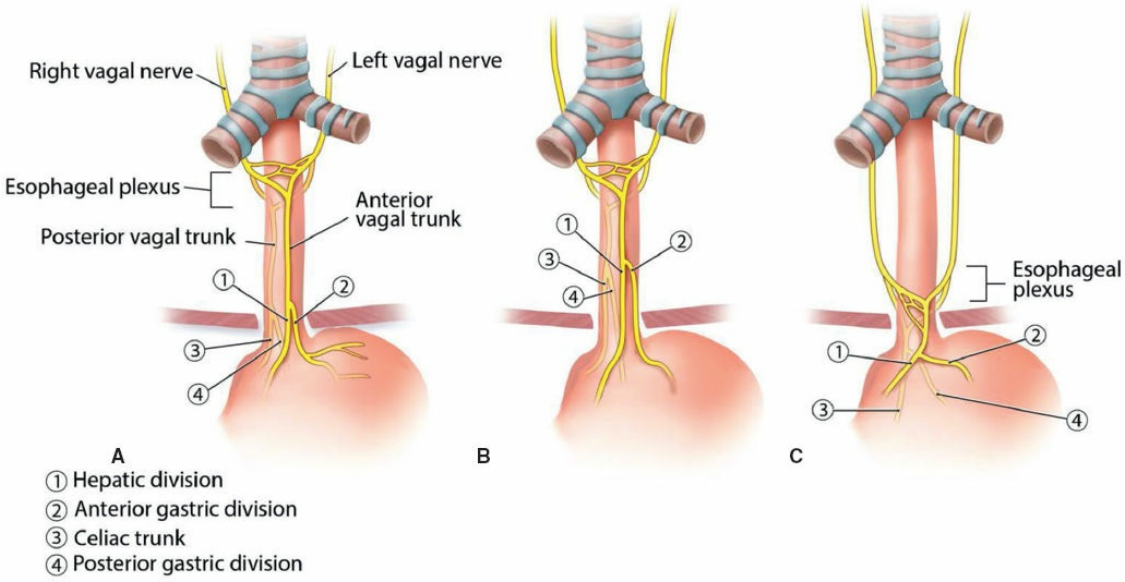

Figure 82.43. Possible configurations of four or more vagal structures emerging through hiatus. **A.** Divisions have separated just above diaphragm. **B.** Divisions and branches arise above diaphragm. **C.** Elements of esophageal plexus extend below diaphragm; vagal trunks entirely within abdomen. 1, hepatic division; 2, anterior gastric division; 3, celiac division; 4, posterior gastric division. (Modified from Skandalakis JE, Rowe JS Jr, Gray SW, et al. Identification of vagal structures at the esophageal hiatus. *Surgery* 1974;75:233. Copyright Elsevier.)

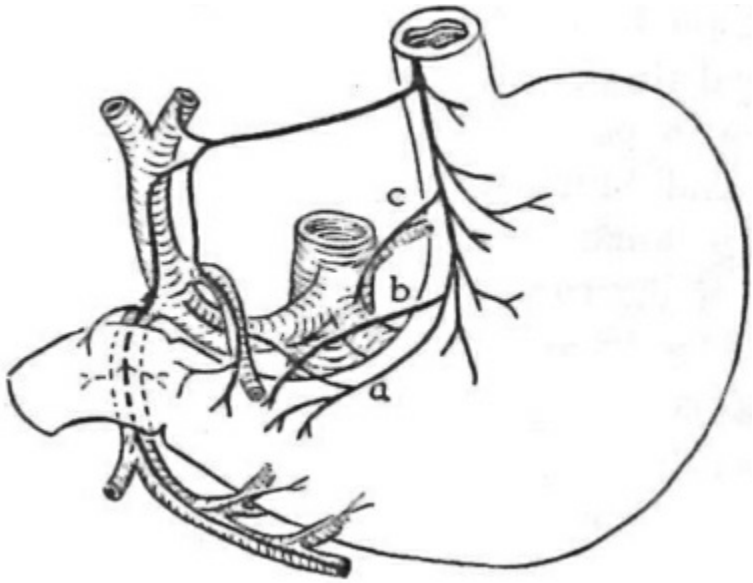

Figure 82.44. Drawing of the distribution of the anterior vagal trunk to the stomach. The hepatic division is unlabeled; it is the first upper branch. *a*, great anterior gastric nerve; *b,* pyloric branch; *c,* branches to the celiac plexus along the left gastric artery. Here fibers are shown to reach the great curvature by way of the right gastroepiploic artery. (From Hollinshead WH. *Anatomy for Surgeons. Volume 2. The Thorax, Abdomen, and Pelvis.* New York: Hoeber-Harper;1956;403, Fig. 291.)

Hepatic Division

The hepatic division of the anterior vagal trunk usually separates from the anterior gastric division at the level of the abdominal esophagus (Fig. 82.44). It courses through the upper, avascular portion of the hepatogastric ligament to reach the porta hepatis. It typically accompanies an aberrant left hepatic branch of the left gastric artery.

At the porta hepatis, some fibers continue into the liver as part of the hepatic plexus on the hepatic arteries. Others descend along the proper hepatic artery and are also part of the hepatic plexus. In dissection, nerve fibers can be traced to the pyloric end of the stomach, including the sphincter, pancreas, and first part of the duodenum. The hepatic division was frequently found in multiple and usually closely parallel branches in our dissections (Fig. 82.45).

Anterior Gastric Division

After giving off the hepatic division, the anterior trunk continues on the lesser curvature of the stomach and gives gastric branches (4 to 10) to the cardia and a major “great anterior gastric nerve” that can be traced until

the pyloric sphincter (but never to the sphincter itself). This nerve parallels the left gastric artery and communicates with a corresponding branch of the posterior vagal trunk. The terminal portion of the pylorus is supplied by the anterior trunk, not by the gastric nerves but through the hepatic branch or other branches of the anterior trunk. The reader is invited to study Figure 82.44.

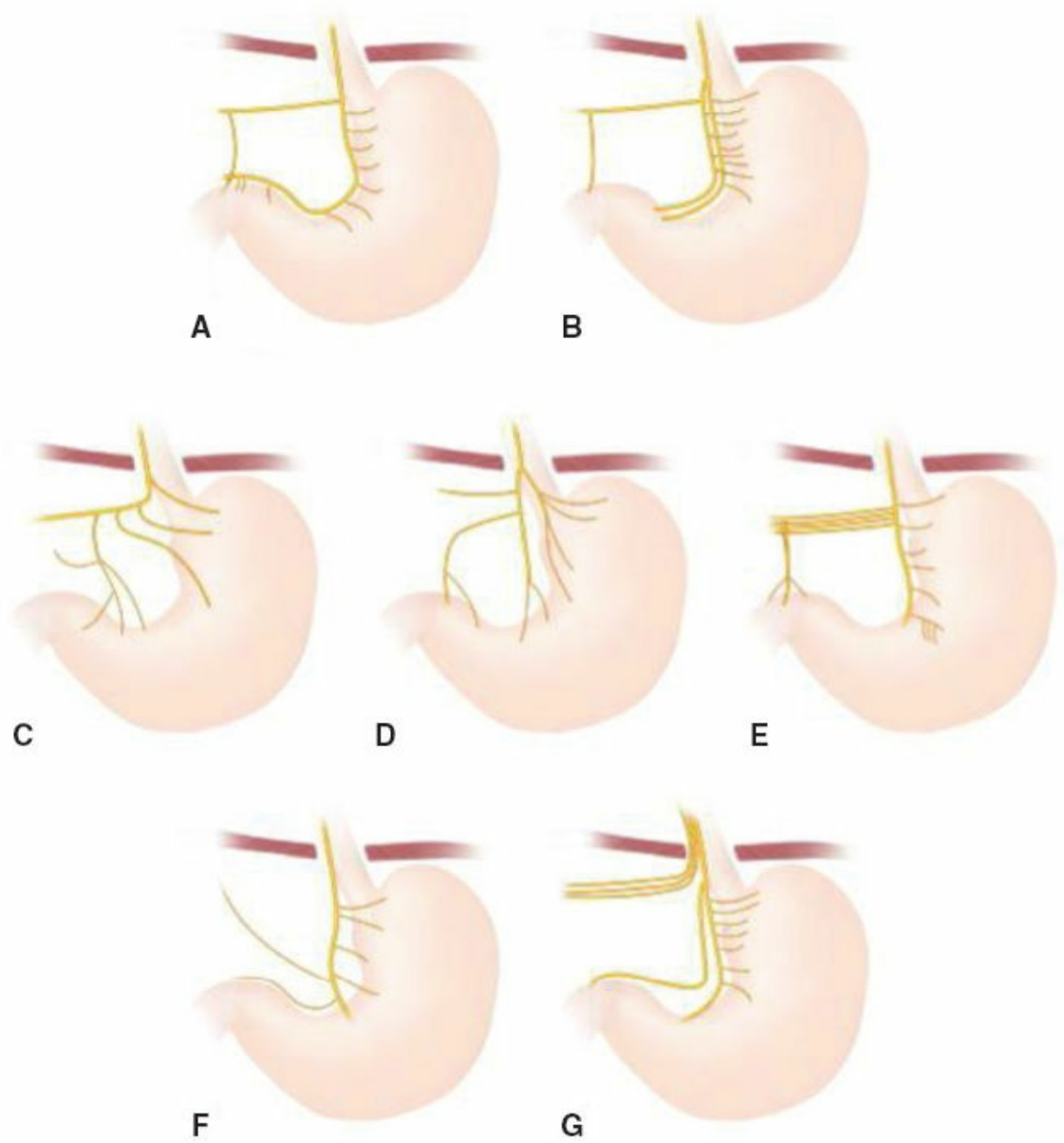

Figure 82.45. Anterior views of several selected specimens. **A.** Innervation of pylorus by anterior gastric division and pyloric branch of hepatic division. **B.** Double nerve of Latarjet. **C.** No typical nerve of Latarjet present. **D.** Gastric branches originate from hepatic division. **E.** Multiple hepatic divisions. **F.** Low origin of hepatic division. **G.** Pyloric branch arises from anterior gastric division. (Modified with permission of Southeastern Surgical

Congress from Skandalakis JE, Gray SW, Soria RE, et al. Distribution of the vagus nerve to the stomach. *Am Surg* 1980;46:130, permission conveyed through Copyright Clearance Center, Inc.)

Hereafter we present our own experience. Among 100 specimens we dissected, the separation of the anterior gastric and hepatic divisions occasionally occurred above the diaphragm, but usually laid on the abdominal esophagus or the cardia. In 96 of our 100 specimens, a major branch of the anterior gastric division formed the principal anterior nerve of the lesser curvature (anterior nerve of Latarjet). It usually laid from 0.5 to 1.0 cm from the lesser curvature. In one of the specimens, it laid beneath the serosa of the gastric wall. This nerve can be traced distally to approximately the level of the incisura in most subjects, but in many it reaches the pylorus, and in a few it is visible as far as the first part of the duodenum (Fig. 82.45). Vagal branches that are subserosal at the surface may penetrate the muscularis and continue down to the antrum in the submucosal (Meissner) plexus.

From 2 to 12 branches pass from the principal nerve to the stomach wall. The average number in our subjects was six. In two of our subjects, the anterior nerve of Latarjet was duplicated; each nerve supplied its own branches to the stomach wall (Fig. 82.45B). The longer of these nerves is called the *antral nerve.* In some subjects, there is no true nerve of Latarjet; a fan of gastric branches arises from the anterior vagal trunk above the origin of the hepatic division, and one or more long branches below this origin descend to supply the antrum (Fig. 82.45). Even where a definite nerve of Latarjet is present, there are usually some, and often many, branches to the gastric cardia and fundus that arise from the anterior trunk proximal to the origin of the hepatic division. Although we have often seen the nerve of Latarjet branch in the “crow’s foot” formation, this pattern is far from constant, being equivocal in some cases and absent in many.

Celiac Branches

Celiac branches are given off the anterior trunk near the cardia and reach the celiac plexus retrogradely, by following the left gastric artery (see Fig. 82.44C). A few others arise from the hepatic division and follow the hepatic artery retrogradely toward the celiac plexus.

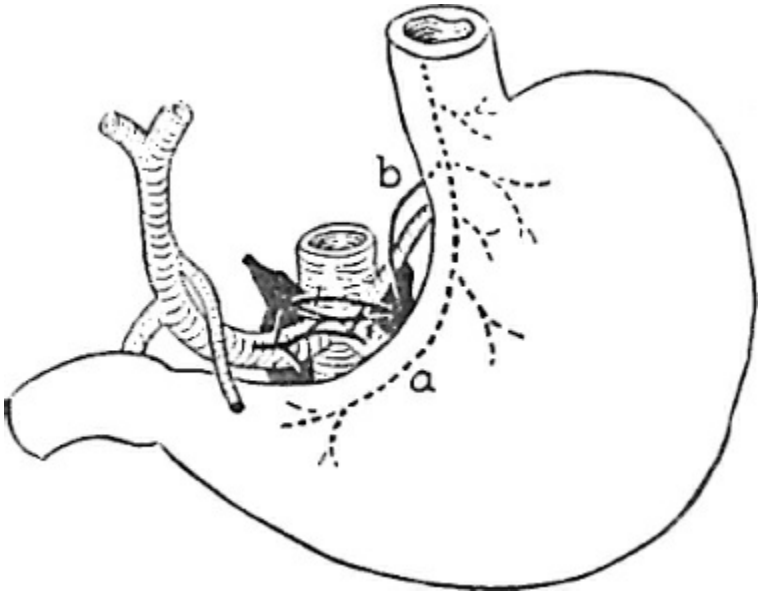

Figure 82.46. Schema of the distribution of the posterior vagal trunk to the stomach. *a,* great posterior gastric nerve, on the lesser curvature; *b,* celiac division. (From Hollinshead WH. *Anatomy for Surgeons. Volume 2. The Thorax, Abdomen, and Pelvis.* New York: Hoeber-Harper; 1956:404, Fig. 292.)

Posterior Vagal Trunk

The pattern of the posterior vagal trunk is quite similar to the anterior trunk, except for the hepatic (and pyloric) branch. The posterior trunk has a posterior gastric division and a celiac division (Fig. 82.46).

Posterior Gastric Division

In most subjects, the posterior gastric division forms the principal posterior nerve of the lesser curvature (posterior nerve of Latarjet). As a rule, the posterior nerve appears to terminate slightly higher on the lesser curvature and possesses fewer gastric branches than does the anterior nerve. In no case has a posterior nerve been observed to reach the duodenum.

The gastric branches arise from the posterior vagal trunk in a variable fashion (Fig. 82.47). In a number of specimens, the gastric branches of the posterior nerve of Latarjet fell into superior and inferior groups. The superior branches arose from the posterior vagal trunk just below, or even above, the diaphragm (Fig. 82.47B). The inferior branches arose from the descending posterior nerve of Latarjet and supplied only the lower body and the antrum. Between these two groups of branches, the lesser curvature had no grossly visible nerve supply. In many of our specimens, the most superior gastric branch, the “criminal nerve” of Grassi, arose at or above the origin of the celiac division. Usually, no single branch seemed

worthy of this dramatic term. In 18 of our 100 specimens, a true posterior nerve of Latarjet was absent; branches arising from the celiac division turned back toward the lesser curvature, and one or more long branches descended to innervate the antrum (Fig. 82.47E).

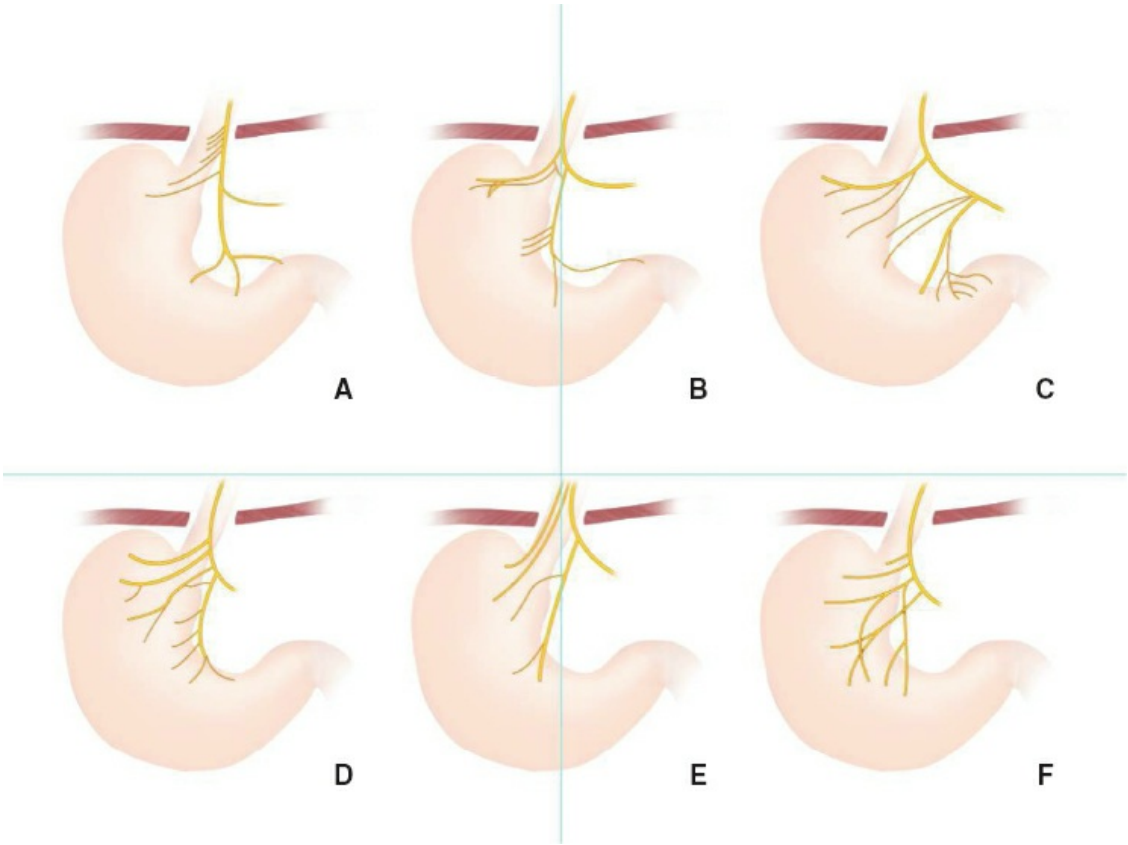

Figure 82.47. Patterns of posterior gastric and celiac divisions of posterior vagal trunks. **A.** Most frequent pattern. **B.** Superior branches arise below the diaphragm. **C.** Posterior nerve reaches pylorus; anterior nerve ends at antrum. **D.** Posterior gastric division forms principal posterior nerve of lesser curvature (posterior nerve of Latarjet). **E.** Superior branches arise above the diaphragm. **F.** True posterior nerves absent; branches to the lesser curvature (and one or more from the antrum) arise from the celiac division. (Modified with permission of Southeastern Surgical Congress from Skandalakis JE, Gray SW, Soria RE, et al. Distribution of the vagus nerve to the stomach. *Am Surg* 1980;46:130, permission conveyed through Copyright Clearance Center, Inc.)

Celiac Division

The celiac division is a large proportion of the posterior trunk and the largest of the four vagal divisions. It leaves the posterior trunk at the point

where the left gastric artery reaches the lesser curvature. It lies in the gastropancreatic peritoneal fold created by the elevation of the peritoneum by the left gastric artery as the nerve follows this artery. In all our cases, it was single and led directly to the celiac plexus. This division may follow the left gastric artery or the right crus of the diaphragm, or it may take an intermediate position in the triangle bounded by the artery, the crus, and the right margin of the stomach. Vagal fibers connect the stomach with the brainstem as they terminate in the gastric mesenteric plexus.

Sympathetic Innervation

The sympathetic chains, the thoracic splanchnic nerves containing afferent and efferent fibers, and the celiac ganglia form the basic elements of the sympathetic innervation of the stomach and duodenum. Branches of the celiac plexus accompany the arteries (Fig. 82.48). In addition, fibers from the hepatic plexus pass to the upper body and fundus of the stomach via the upper limit of the lesser omentum.

Efferent

The thoracic splanchnic nerves are formed mostly by preganglionic fibers from the intermediolateral cell column of the spinal cord at levels T5 to T10. The greater and lesser splanchnic nerves terminate within the celiac ganglia, where preganglionic fibers synapse upon the collateral ganglion cells. Postganglionic fibers from the celiac ganglia reach the stomach and duodenum via their blood supply.

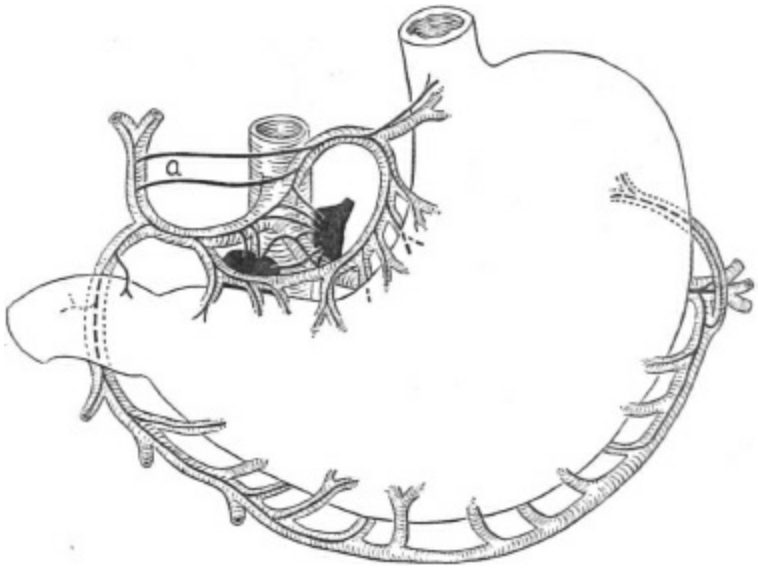

Figure 82.48. Drawing of the sympathetic innervation to the stomach. a. branches from the hepatic plexus that course

through the lesser omentum to reach the stomach through the plexus on the left gastric artery. (From Hollinshead WH. *Anatomy for Surgeons. Volume 2. The Thorax, Abdomen, and Pelvis.* New York: Hoeber-Harper;1956:405, Fig. 294.)

Afferent

Afferent fibers for the sense of pain from the organs supplied by the celiac artery (including the stomach) pass through the celiac plexus and thoracic splanchnic nerves to the sympathetic chains. They reach spinal nerves at thoracic levels T5 to T10. The cell bodies of these fibers are found in dorsal root ganglia at those levels.

Referred Pain

Most sensation of pain from the stomach is poorly localized and is referred to the central epigastium, together with the other structures of the foregut that share blood supply from the celiac axis. Pain from the gastroesophageal junction is referred to the lower retrosternal area. The stimulus of pain ascends with the sensory fibers of the sympathetic innervation. The sympatheric chains communicate with the thoracoabdominal intercostal nerves, and thus the pain is roughly projected on the body wall.

INNERVATION OF THE GREAT OMENTUM

In the omentum, there are nerve fibers for the omental vessels, but not for the omental tissue. This explains the apparent lack of sensory perception.

INNERVATION OF THE DUODENUM

The duodenum apparently shares the pattern of sympathetic and parasympathetic innervation of the stomach in its proximal part, as far as supplied by branches of the celiac artery. The distal part of the duodenum, beyond the entrance of the bile duct, is supplied by branches of the SMA. Thereof, the superior mesenteric ganglia are responsible for giving plexuses on the inferior arteries of the pancreaticoduodenal arcades. Referred pain is the same as in all foregut, and projects in the epigastrium.

ACKNOWLEDGMENTS

The authors wish to thank the medical illustration team at St. George’s

University, Grenada, West Indies: Jessica Holland, MS, CMI; Angélica Ortiz, MScBMC; Charles Wesley Price, MS, CMI; and Xochitl Vinaja, MS, for the creation of color illustrations in this chapter.

Suggested Readings

Apaydin N, Uz A, Elhan A, et al. Does an anatomical sphincter exist in the distal esophagus? *Surg Radiol Anat* 2008;30(1):11.

Bombeck CT, Dilliard DH, Nyhus LM. Muscular anatomy of the gastroesophageal junction and the role of the phrenoesophageal ligament. Autopsy study of sphincter mechanism. *Ann Surg* 1966;164:643.

Griffith CA. Anatomy. In: Nyhous LM, Wastell C, eds. *Surgery of the Stimach and Duodenum.* 4th ed. Boston, MA: Little, Brown and Co; 1986:398–417.

Healy JC. Abdomen and pelvis. Posterior abdominal wall. Vascular supply and lymphatic drainage. In: Standring S, ed. *Gray's Anatomy.* 39th ed. New York: Elsevier, 2005:1122, 1150.

Hollinshead WH. *Anatomy for Surgeons. Volume 2. The Thorax, Abdomen, and Pelvis.* New York: Hoeber-Harper; 1956:386.

Keet AD. *The Pyloric Sphincteric Cylinder in Health and Disease.* New York: Springer; 1993:44.

Liebermann-Meffert D, White H, eds. *The Greater Omentum: Anatomy, Physiology, Pathology, Surgery, With an Historical Survey.* New York: Springer; 1983:1–369.

Loukas M, Wartmann CT, Louis RG Jr, et al. The clinical anatomy of the posterior gastric artery revisited. *Surg Radiol Anat* 2007;29:361.

Mansfield PF. Lymphadenectomy for gastric cancer. *J Clin Oncol* 2004;22:2759.

O'Rahilly R, Müller F. *Human Embryology and Teratology*. 3rd ed. New York: Wiley-Liss; 2001:252.

Skandalakis LJ, Colborn GL, Weidman TA, et al. Stomach. In: Skandalakis JE, Colborn GL, Foster RS Jr, et al., eds. *Skandalakis' Surgical Anatomy: The Embryologic and Anatomic Basis of Modern Surgery.* Athens: Paschalidis Medical Pablications; 2004:690.

Skandalakis LJ, McClusly AD, Loukas M, et al. Anatomic considerations in gastroduodenal surgery. *Mastery of Surgery*. 6th ed. Philadelphia: Wolters Kluwer/Lippincott Williams & Wilkins; 2012:957–80.

Skandalakis JE, Gray SW, Soria RE, et al. Distribution of the vagus nerve to the stomach. *Am Surg* 1980;46:130.

Skandalakis JE, Rowe JS, Gray SW, et al. Identification of vagal structures at the

esophageal hiatus. *Surgery* 1974;75:233.

Yoo E, Kim JH, Kim MJ, et al. Greater and lesser omenta: normal anatomy and pathologic processes. *Radiographics* 2007;27:707.

EDITOR'S COMMENT

Dr. Mirilas and colleagues have written a very nice and detailed chapter on anatomic considerations in gastroduodenal surgery. There are many anatomic considerations and details that have relevance for those of us that perform upper gastrointestinal surgery. The description of the anatomic and functional basis of the lower esophageal sphincter (LES) is very informative. A very interesting description of the evolution of the understanding of the LES and gastroesophageal reflux was published in the *Annals of Surgery* in 2015. The mere existence of a LES was a matter of great debate at first. In 1956, the existence of a manometric high-pressure zone at the distal end of the esophagus was first described. In 1979, investigators at the University of Chicago used 24-hour pH monitoring and manometric measurements of the LES in the same patients to determine which manometric parameters were related to competency of the LES. The analysis of 266 consecutive patients indicated that the competency of the LES depended not only on its overall pressure but also on its abdominal length. Current thinking is that a competent LES is dependent on the triad of adequate pressure, overall length, and intra-abdominal length. If one of more of these characteristics of the LES is deficient, the risk of a patient developing pathologic GERD increases.

As mentioned throughout this chapter, the arterial supply of the stomach is robust and the collateral network is extensive. A 90% to 95% gastrectomy as described is much like the pouch in a gastric bypass. In a gastric bypass, the descending esophageal arteries and the ascending branch of the left gastric artery perfuse the pouch. A gastric bypass can be used as a salvage procedure in the case of multiple failed fundoplication procedures and to control recurrent GERD, to avoid a fundoplication in the setting of severe postsurgical gastroparesis following a failed fundoplication, to treat concurrent obesity in the setting of a prior fundoplication (failed or not), and for other reasons. When the distal esophagus has previously been extensively mobilized, the blood supply from the descending esophageal arteries may be compromised. In these cases, it is important to ensure that the gastric pouch is created distal to the left gastric artery and to take great care in preserving the ascending branches of this artery on the lesser curve. Ischemia and necrosis of the pouch can result in these multiple revision cases if one is not cognizant and careful. An interesting demonstration of the arterial supply of the stomach as described is seen in those rare cases of incarcerated paraesophageal hernia with ischemia/necrosis. While the proximal stomach may be ischemic or necrotic, there is typically a 1 cm or so cuff of cardia and stomach immediately adjacent to the esophagus that

survives. This may allow for a gastrojejunostomy rather than an esophagojejunostomy in cases where resection and anastomosis is appropriate.

The discussion of the arterial supply of the omentum is informative. Omentum has been used in diverse clinical settings to stimulate angiogenesis in ischemic tissues and to promote wound healing. The harvesting of omental tissue has been used for reconstruction and revascularization of extraperitoneal wounds and defects including mediastinitis, perforated viscus, and fistulas. We have even performed laparoscopic mobilization of an omental flap with subcutaneous tunneling to the brain as an indirect bypass in Moyamoya disease (a disease characterized by idiopathic, progressive, and chronic occlusion of major intracranial arteries). The omental pedicle can remain viable and can reach just about anywhere if the pedicle is based on an intact right gastroepiploic artery and vein.

SMA syndrome is discussed in this chapter. This is a rare and somewhat controversial condition caused by compression of the third portion of the duodenum between the aorta and the SMA. This results in chronic, intermittent, or acute complete or partial duodenal obstruction. The symptoms are nonspecific and include bloating, nausea and vomiting, early and prolonged satiety, and weight loss.

Any factor that sharply narrows the angle between the abdominal aorta and the SMA can cause entrapment and compression of the third part of the duodenum. Precipitating conditions include severe and rapid weight loss, prolonged bed rest, and even body casts. The difficult part of making the diagnosis is that many patients with a low BMI have a narrow angle of the SMA and aorta with no symptoms. CT angiogram, MR angiogram, and upper GI series are useful in making the diagnosis. In some patients, supplemental feedings and weight gain can lead to an improvement or resolution of symptoms. Surgical treatment is typically duodenojejunostomy to bypass the compressed portion of the duodenum. Investigators at the Cleveland Clinic recently reported outcomes on a series of 18 patients diagnosed with SMA syndrome to undergo surgery over a 10-year period. Although 14 of 18 patients reported initial symptom improvement, at latest follow-up, only 6 patients reported symptomatic improvement or resolution.

Intestinal malrotation and nonrotation is an interesting phenomenon that illustrates the embryologic development of the midgut. There are a large range of clinical presentations and aberrations in anatomy that can result. Most cases are diagnosed in infancy and childhood and typically before 2 years of age. The classic presentation in an infant is bilious emesis. Upper GI is diagnostic in these children and demonstrates an abnormal duodenal–jejunal junction (usually the duodenum does not cross the midline), and in the case of volvulus an abrupt cutoff of contrast in the proximal small bowel. Less common is a congenital malrotation or nonrotation that presents in an adult. These patients can present with a variety of symptoms including abdominal bloating, pain, nausea, vomiting, weight loss, or other nonspecific complaints. Treatment of a

malrotation at any age is performed surgically and with a Ladd procedure. The steps to a Ladd procedure include reduction of the volvulus if present, complete lysis of adhesive coloduodenal adhesions (so-called Ladd bands), widening of the base of the mesentery, and prophylactic appendectomy. This can be performed laparoscopically, although it requires a lot of skill. I perform about one to two Ladd procedures a year in adults, and I always scrub with a pediatric surgeon who can help keep me oriented.

Paraduodenal hernias are not discussed in this chapter, although these are rare internal hernias related to congenital openings in the mesenteries. Left-sided paraduodenal hernias are more common than right. In a left-sided hernia, the small bowel herniates through the fossa of Landzert, a congenital failure of fusion of the descending colon mesentery to the peritoneum in the left upper quadrant. In a right-sided hernia, the small bowel herniates through the fossa of Waldeyer, a congenital failure of fusion of the ascending colon mesentery to the peritoneum in the right lower quadrant. Right-sided hernias are associated with small bowel malrotation. Patients with paraduodenal hernias can present acutely with a closed loop small bowel obstruction or more commonly with chronic symptoms such as abdominal pain, nausea, or vomiting. In a left paraduodenal hernia, clusters of small bowel loops can be identified in the left anterior pararenal space, behind the inferior mesenteric vein, and behind the left colic artery. In a right paraduodenal hernia, clusters of small bowel loops can be seen inferior to the third portion of the duodenum, behind the superior mesenteric vein and artery, and behind the right colic vein.

A thorough understanding of the embryology and anatomy of the gastroduodenal anatomy is important for surgeons who operate in and around this part of the GI tract. A number of rare congenital conditions can present emergently and in previously undiagnosed patients. The content described in this chapter is important for surgeons to master.

Jon C. Gould

Suggested Readings

Chang J, Boules M, Rodriguez J, et al. Laparoscopic duodenojejunostomy for superior mesenteric artery syndrome: intermediate follow-up results and a review of the literature. *Surg Endosc* 2017;31(3):1180–5.

Fein M, Ritter MP, DeMeester TR, et al. Role of the lower esophageal sphincter and hiatal hernia in the pathogenesis of gastroesophageal reflux disease. *J Gastrointest Surg* 1999;3(4):405–10.

Frasier LL, Leverson G, Gosain A, et al. Laparoscopic versus open Ladd's procedure for intestinal malrotation in adults. *Surg Endosc* 2015;29(6):1598–604.

Greene CL, Worrell SG, Patti MG, et al. The University of Chicago

contribution to the treatment of gastroesophageal reflux disease and its complications: a tribute to David B. Skinner 1935–2003. *Ann Surg* 2015;261(3):445–50.

83 Percutaneous Endoscopic Gastrostomy

Jeffrey L. Ponsky and Benjamin K. Poulose

INTRODUCTION

The endoscopic technique of gastrostomy placement, percutaneous endoscopic gastrostomy (PEG), has permitted long-term gastric access for feeding or decompression without the need for general anesthesia or laparotomy. Reports of comparisons with traditional gastrostomy suggest that the method offers equivalent results with less patient discomfort and at a lower cost. Complications, although consistent with those noted with the open procedure, can be minimized by appropriate patient selection and attention to technical details. Although a number of modifications of the originally described technique have been suggested, the original “pull” method and the closely related “push” approach are the most well-accepted and widely practiced methods.

INDICATIONS AND CONTRAINDICATIONS

The most common and appropriate indication for PEG is the need for long-term alimentation in patients unable to eat but with functional gastrointestinal tracts. Such individuals include those with progressive neurologic diseases, stroke victims, individuals with severe psychomotor handicap, patients with head or facial trauma, and patients with oropharyngeal tumors. The method has also been useful in administering unpalatable medications to children, in the administration of nighttime supplemental feedings to patients with inflammatory bowel disease, as a route for returning external biliary drainage to the gastrointestinal tract, and in providing gastric decompression in those patients with carcinomatosis or radiation enteritis.

Contraindications to PEG are few, but important to consider in minimizing morbidity and mortality of this procedure. The procedure should be avoided in patients with massive ascites, bleeding diatheses, or severe malnutrition as tract formation is impaired and leakage may result.

Multiple system organ failure or systemic sepsis should be corrected prior to the placement of a PEG, as infectious complications are more likely to occur. Feedings may be provided by the nasoenteric route until these problems are resolved. Also, the performance of PEG in patients with very limited life expectancy (i.e., <30 days) is meddlesome and costly, contributing to the high in-hospital mortality reported following the procedure. The underlying disease process gives some estimation of the risk of mortality not related to the placement of the PEG itself. In general, patients undergoing PEG placement for head and neck malignancies, or patients with trauma injuries, nonstroke neurologic disorders, or gastroparesis are considered low risk. Patients with stroke or malignancies other than head and neck cancer have the highest risk. PEG has not proven particularly useful in patients with aspiration secondary to severe gastroesophageal reflux, and in some cases it may exacerbate the problem.

TECHNIQUE

The patient is prepared by fasting overnight or by withholding enteral feedings for 6 to 8 hours prior to the procedure. Preprocedural imaging, if available, is reviewed for anatomic alterations such as a large hiatal hernia. Intravenous access is established for the administration of sedation and wound infection prophylaxis. A preoperative intravenous antibiotic, usually a cephalosporin, is administered to reduce the incidence of wound infection in the abdominal wall surrounding the tube. Swabbing of the oropharynx with an antiseptic solution can help reduce bacterial counts in the mouth and thus may help protect against wound infection. Moderate sedation using an intravenous opioid analgesic and benzodiazepine is usually sufficient for PEG insertion. Alternatively, deep sedation with intravenous propofol can be used in concert with the anesthesia team. Respiration, blood pressure, pulse rate, and oxygen saturation are monitored.

The patient is placed on the endoscopy table in the supine position. Although this position is most appropriate for the performance of PEG, it predisposes to the accumulation of secretions in the patient's oropharynx and may lead to aspiration. Therefore, frequent evacuation of this material by suctioning is imperative. Abdominal hair in the upper abdomen is clipped and the skin cleaned with a preparatory solution, and draped in a sterile manner. The procedure is commenced with the introduction of the gastroscope into the patient's esophagus. This can be somewhat difficult

with the patient in the supine position and may be facilitated by slightly turning the patient to the left for the passage of the instrument. The scope is then advanced into the stomach and the room lights are dimmed. A rapid but thorough inspection of the stomach and duodenum should be performed to rule out pathology or pyloric obstruction. The instrument is then pulled back into the gastric body and turned anteriorly as the assistant inspects the external aspect of the abdominal wall, looking for transillumination. Transillumination of the abdominal wall by the light from the endoscope can help localize the optimal area for gastric lumenal access. Finger palpation of the abdominal wall may reveal a point of light when gentle pressure is applied. Once the point of brightest transillumination is identified, continued finger pressure is applied to this site by the assistant, and this should create a clear and prominent indentation of the gastric wall that is visible to the endoscopist. Multiple sites may be palpated until the best transillumination and gastric indentation are achieved. Alternate palpation of two separate fingers adjacent to each other with visible confirmation of two separate indentations on endoscopic examination can also help identify an area for safe gastric access. Extra time spent at this stage of the procedure is well worth the effort and will help reduce inadvertent puncture of adjacent organs (Fig. 83.1).

The “safe tract” technique, described by Foutch et al., has been developed to help minimize the risk of visceral injury during PEG placement. This approach is especially useful in obese patients where other methods of gastric lumenal access localization are inadequate. In this method, the best site for puncture is initially localized by transillumination and finger pressure, as previously described. Then, using a syringe half-filled with local anesthetic in its barrel, a small-caliber needle is inserted into the skin at the proposed spot and suction is applied to the plunger. The syringe is slowly advanced into the stomach until the needle is seen to enter the gastric lumen endoscopically and air is seen to bubble into the syringe barrel externally. Should air appear in the barrel prior to the appearance of the needle in the gastric lumen, one may assume that there is a loop of bowel interposed between the stomach and the abdominal wall. The needle is removed and an alternative site is selected and tested in the same manner. In this way, the possibility of a fistulous communication is minimized (Fig. 83.2). A few milliliters of local anesthetic are infiltrated into the skin at the selected site, and a 5-mm incision is made through the

skin and into the subcutaneous tissue.

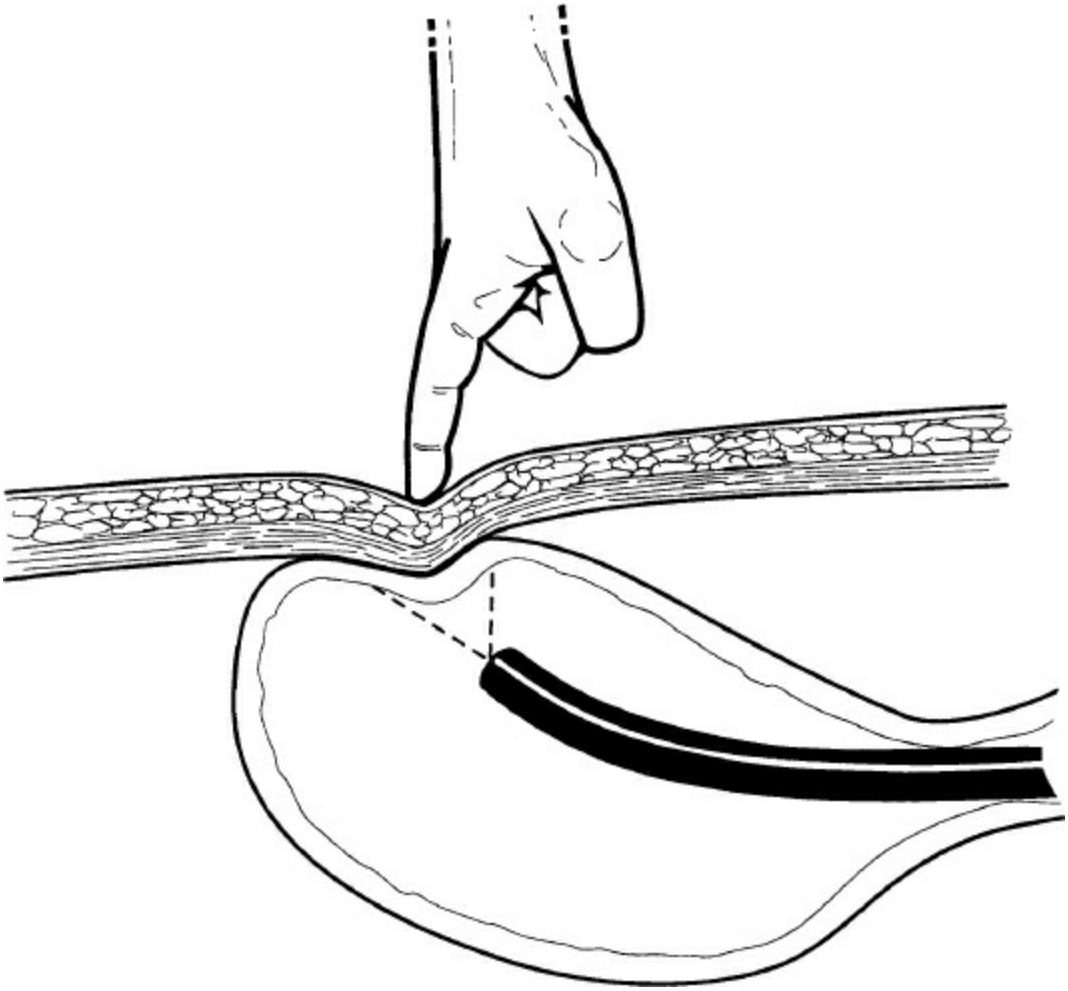

Figure 83.1. The site for gastric lumenal access should be carefully selected, using transillumination of the abdominal wall and gastric indentation with finger pressure as a guide.

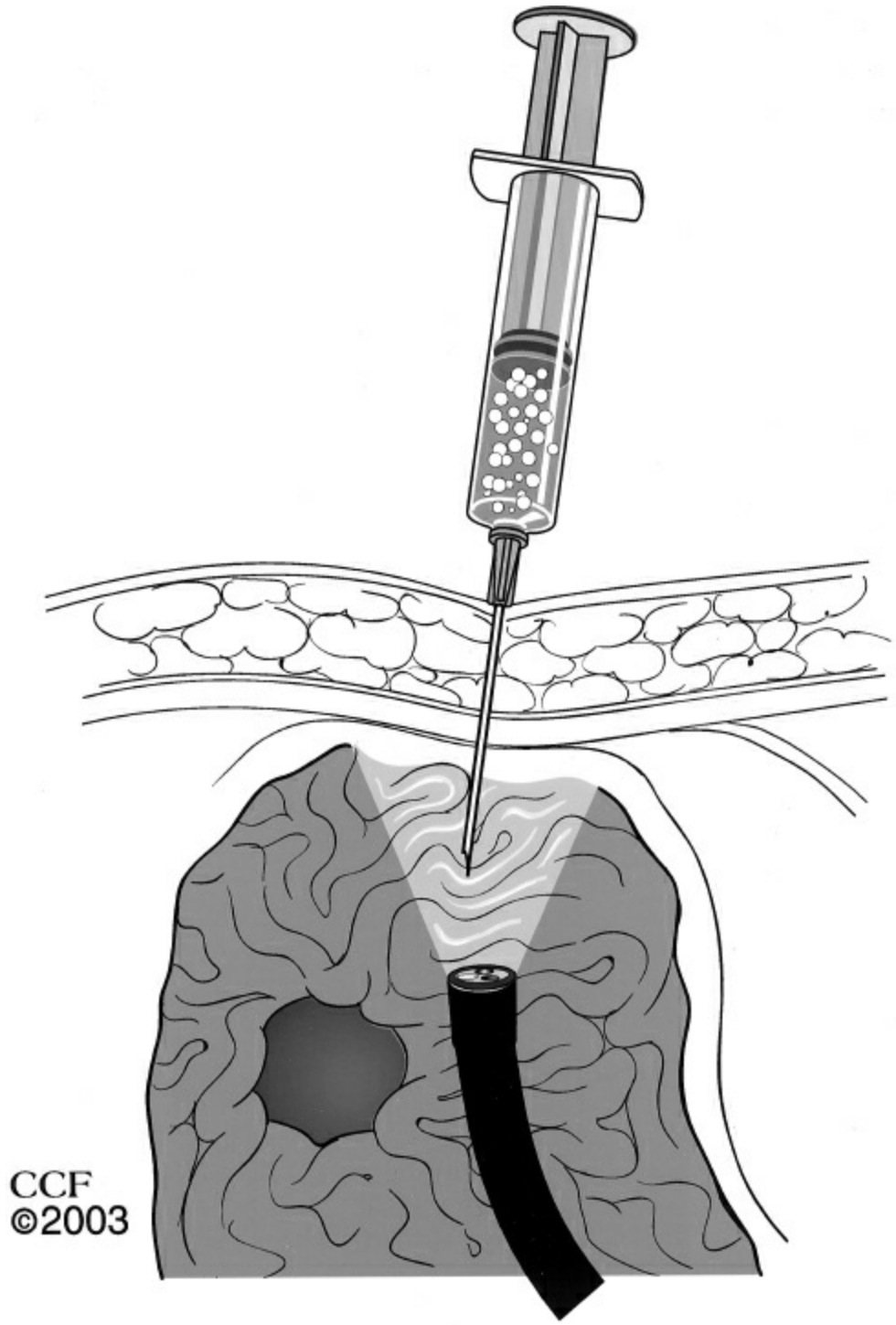

Figure 83.2. The “safe tract” method will help to protect against inadvertent puncture of an adjacent viscus. The syringe is slowly advanced into the stomach until the needle is seen to enter the gastric lumen and air is seen to bubble into the syringe barrel. Should air appear in the barrel prior to the appearance of the needle in the gastric lumen, one may assume that there is a loop of bowel interposed between the stomach and the abdominal wall. (Image © CCF 2003.)

While the assistant anesthetizes the abdominal wall skin, the endoscopist uses a polypectomy snare, passed through the biopsy channel of the endoscope, to surround the area of gastric indentation. When the endoscopist is ready, the assistant passes a needle cannula with an outer plastic sheath through the skin incision and into the stomach. This maneuver is done swiftly to minimize displacement of the gastric wall away from the abdominal wall. The open polypectomy snare in the gastric lumen will surround the cannula and is tightened around it. The inner needle is then removed and a long suture or wire is threaded through the cannula into the stomach. After several centimeters of the suture have entered the stomach, the snare is slightly loosened, the cannula pulled back a bit, and the snare retightened around the suture itself (Fig. 83.3). The gastroscope is then withdrawn from the patient's mouth, pulling the suture along with it.

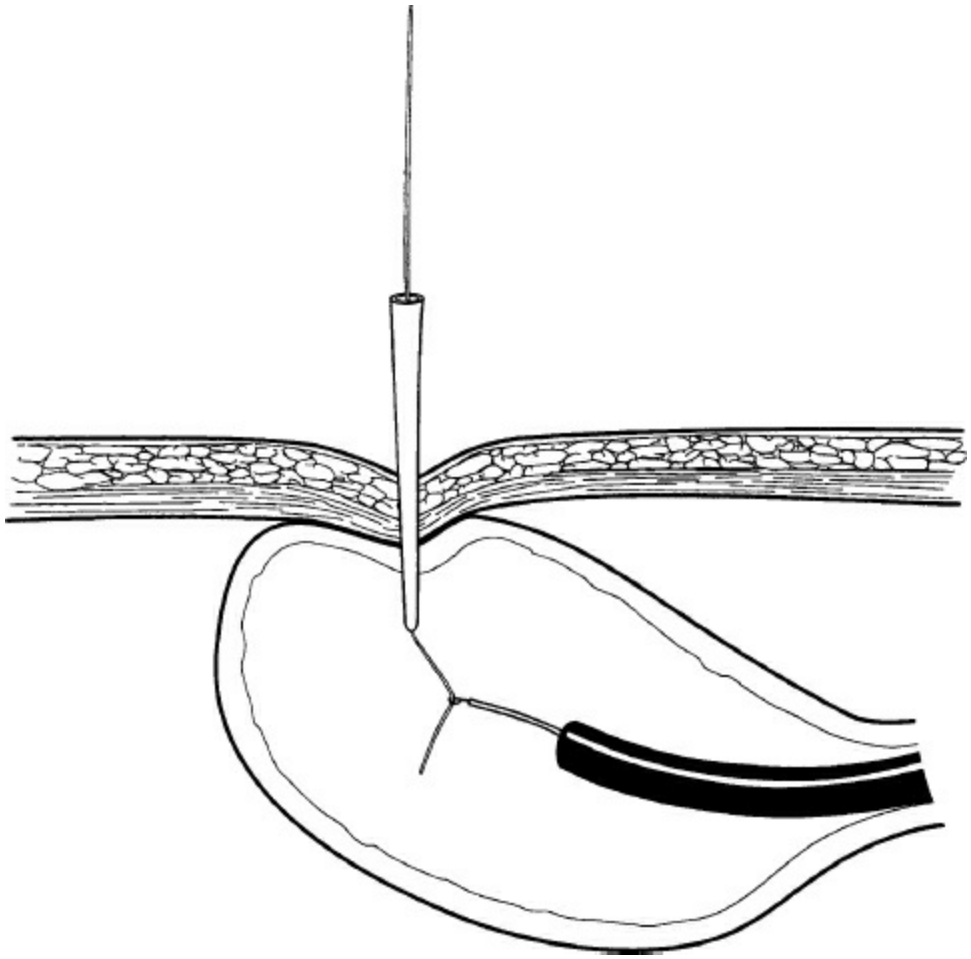

Figure 83.3. Once several centimeters of suture have entered the gastric lumen, the snare is loosened from around the cannula, repositioned on the suture, and once again tightened.

The two most frequently used techniques for PEG are the pull and the push methods. Typically, 20 French PEG tubes are inserted. In the pull method, the gastrostomy tube is affixed to the suture exiting the patient's mouth and pulled down through the esophagus and into the stomach, its end emerging from the abdominal wall (Fig. 83.4). In the push method, a guidewire instead of a suture is used and the tube is threaded over the wire and pushed down the esophagus and into the stomach as tension is applied to both ends of the guidewire (Fig. 83.5). In each method, when the tube emerges from the abdominal wall it is grasped and pulled upward. The gastroscope is reintroduced to monitor the position of the head of the catheter (i.e., the intralumenal bumper) and to ensure that it comes to lie in contact with the gastric mucosa.

The second passage of the instrument can be facilitated by snaring half the head of the gastrostomy catheter and following this down with the endoscope into the esophagus (Fig. 83.6). The head of the catheter should come to lie in loose contact with the gastric mucosa (Fig. 83.7). When the head of the catheter is determined to be in the correct position, pull is discontinued on the tube. An outer bolster is applied to the tube and moved close to the skin (Fig. 83.8). The bolster should not apply pressure to the skin; a distance of 2 or 3 mm from the skin is advisable. Tension is not necessary to hold the stomach in contact with the abdominal wall and, in fact, has been associated with ischemic necrosis of the intervening tissue with subsequent abdominal wall infection, tube extrusion, and, occasionally, separation of the stomach from the abdominal wall. The bolster may be sutured to the abdominal wall, but this is usually not necessary with most traction-removal–type PEG tubes. An occlusive dressing is discouraged because it encourages skin maceration and fungal infection. Preferably, the site should be left open and cleansed with saline or peroxide twice daily. With uncomplicated insertion, feedings, flushes, and medications may be commenced without delay following the procedure.

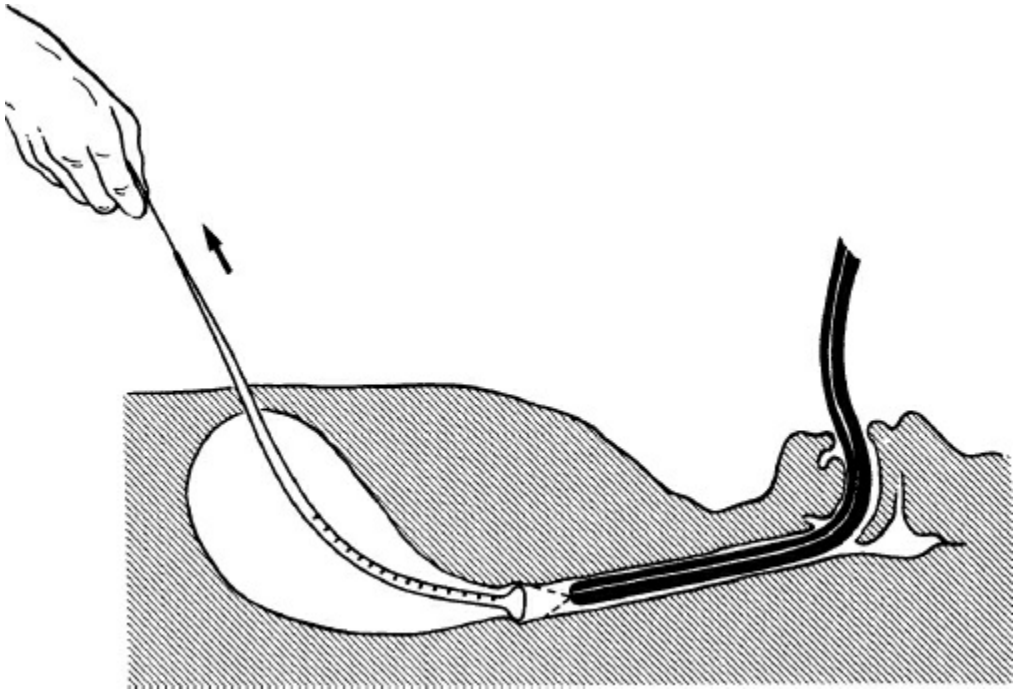

Figure 83.4. The suture is affixed to the end of the gastrostomy catheter, and the catheter is pulled down the esophagus, into the stomach, and out of the abdominal wall. The scope is reintroduced to follow the progress of the tube, and care is taken to avoid undue tension.

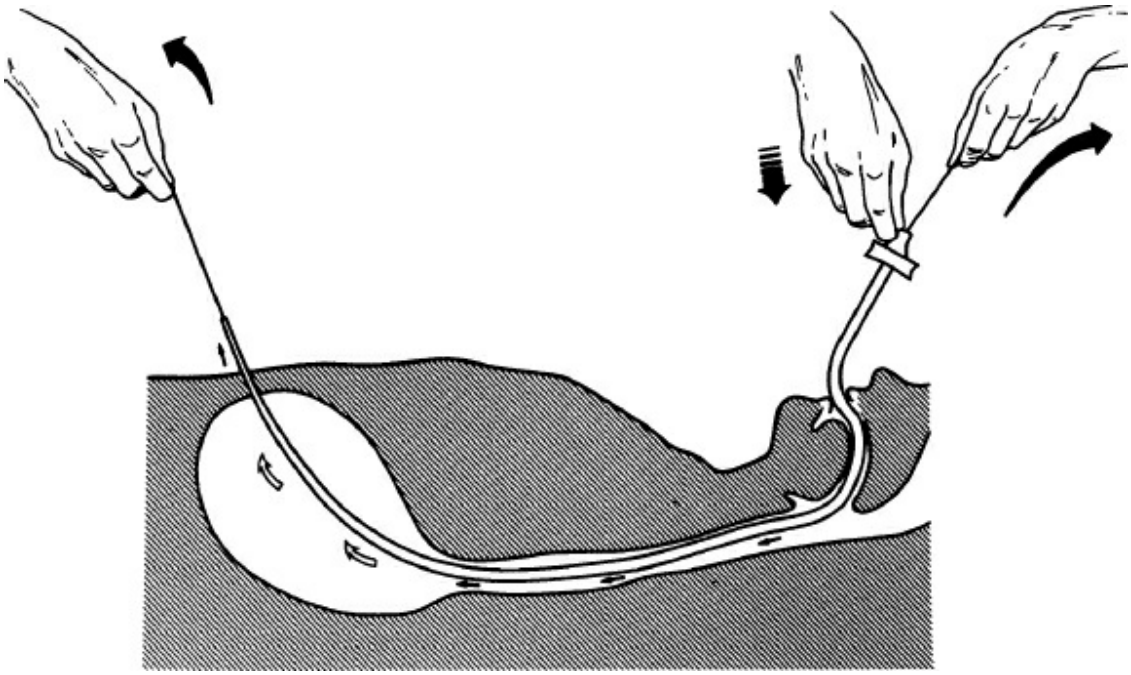

Figure 83.5. In the “push” method, both ends of the guidewire are held taut as the tube is pushed over the wire and out of the abdominal wall.

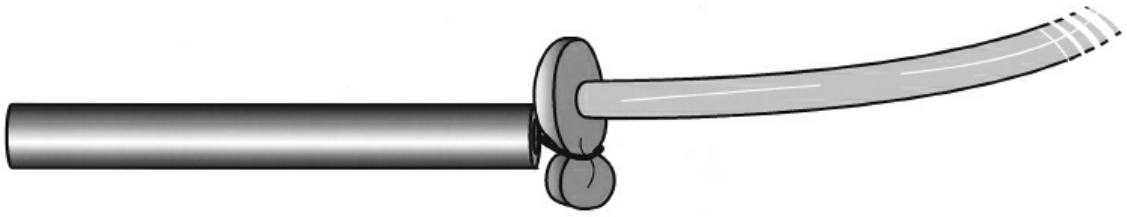

Figure 83.6. The second passage of the instrument can be facilitated by snaring half the head of the gastrostomy catheter and following down with the endoscope into the esophagus. (Image © CCF 2003.)

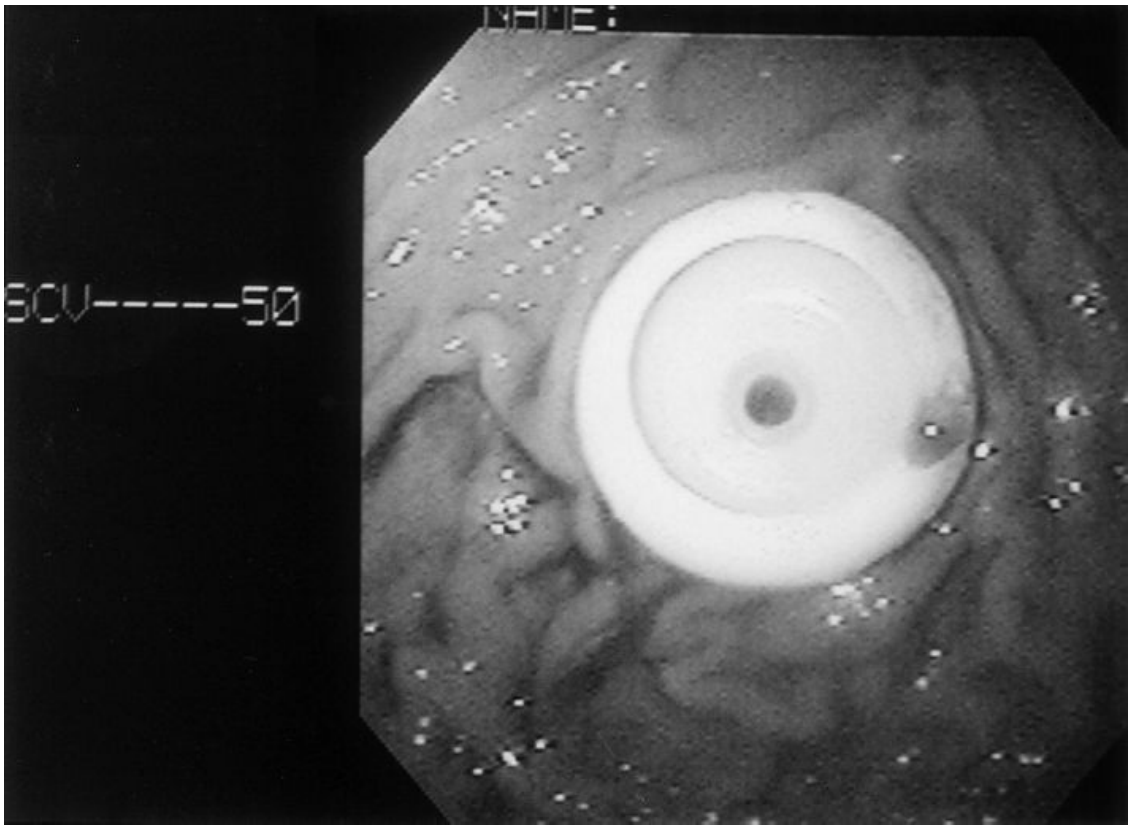

Figure 83.7. The head of the gastrostomy tube should be noted to lie in loose contact with the gastric mucosa.

Alternative methods of PEG placement have been developed for situations where traversal of the oropharyngeal tract by the PEG tube may be inadvisable or impossible. These situations typically include patients with esophageal strictures or oropharyngeal tumors. In general, smaller-caliber (i.e., pediatric) endoscopes are used to traverse the area of difficult

anatomy and the gastric lumen is insufflated and visualized. In the modified Russell technique, T-fasteners are used to appose the gastric wall to the abdominal wall and a peel-away introducer used to introduce the feeding catheter into the stomach. The SLiC method uses a similar principle with a 7- to 8-mm dilating trocar placed directly into the gastric lumen under endoscopic visualization. An obturator is used to place a 20 French Malecot catheter through the sheath of the trocar into the stomach; the sheath is then removed over the catheter.

POTENTIAL COMPLICATIONS

Most of the complications associated with PEG are usually minor, but some may be life-threatening. Immediate postprocedural bleeding can usually be controlled with temporary tube traction placed on the mucosal surface of the stomach. Care must be taken to ensure no undue compression of the gastric and abdominal wall once hemostasis has been achieved. Minor irritation around the tube, wound exudate, and skin irritation can be handled by close attention to cleansing and use of appropriate skin preparations. When fungal infection seems likely, antifungal powders or creams are beneficial. Redness, swelling, tenderness, or fluctuance around the tube should initiate concern regarding the presence of an abdominal wall infection. When this suspicion exists, the area may be aspirated or incised to look for pus. Antibiotics should be administered, and any tension between the outer bolster and the skin should be relieved. When the infection seems to be spreading or the patient deteriorating, one may suspect a necrotizing abdominal wall infection and surgical debridement should be initiated.

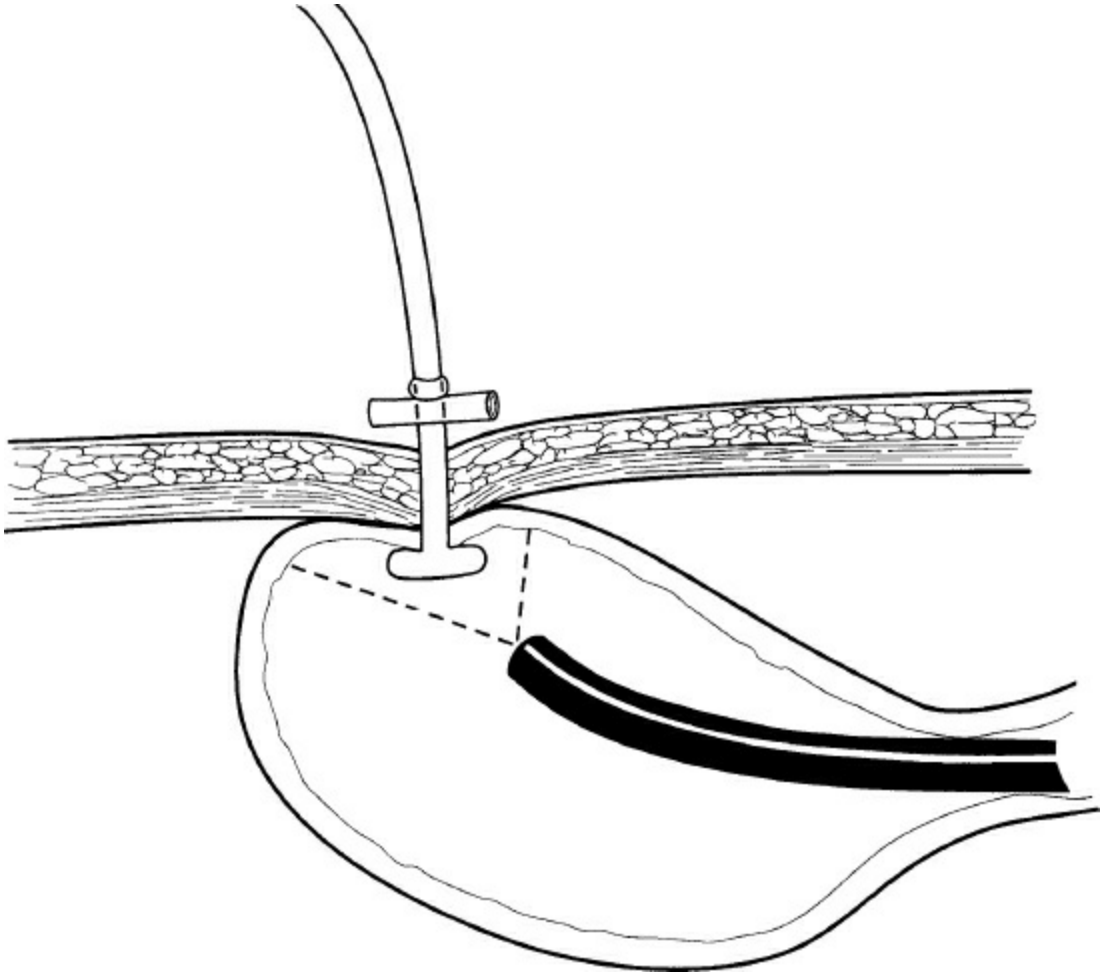

Figure 83.8. An outer bolster is applied to prevent the tube from migrating inward. This should be placed several millimeters from the skin.

Migration of the gastrostomy tube through the abdominal wall has been reported and is almost always secondary to excessive traction with necrosis of the intervening abdominal wall tissue. Again, this can be prevented by avoidance of compression of the abdominal wall and stomach. The type of external bolster is less important than correct placement at the skin level. Our preference is to use a simple linear crossbar-type bolster that affords easy assessment of its position along the tube and distance from the skin. In addition to avoiding unnecessary compression at the time of original insertion, vigilance must be maintained by caregivers in reassessing bolster position on a regular basis to prevent tissue ischemia and resulting necrosis. Conversely, if the outer bolster is placed too far from the skin (i.e., more than several centimeters), the tube may migrate inward, obstructing the pylorus. Should this occur, it is a simple matter to pull the catheter back and place the bolster closer to the

skin.

Gastrocolic fistula has been known to occur following PEG. This can be the result of puncture of the colon at the time of the performance of the procedure or a result of pinching the colon between the stomach and abdominal wall. This problem may appear long after placement of the gastrostomy or at the time of tube replacement. Frequently, the patient will have diarrhea. This should prompt an upper or lower gastrointestinal study using barium. When identified, these fistulae are usually easily managed by simply removing the gastrostomy catheter, with the fistulous tract closing within several days.

Separation of the stomach from the abdominal wall may occur soon after the performance of the PEG. Early after the performance of the procedure, the tube may be inadvertently pulled out by patient or staff. If this is recognized, treatment with nasogastric suction and intravenous antibiotics may be all that is required, with the procedure being repeated in 5 to 7 days. Should the patient show signs of deterioration or sepsis, an immediate laparotomy is indicated. The use of an abdominal binder can help prevent inadvertent early PEG dislodgement. Separation may also be the result of tissue necrosis resulting from excessive tension on the tube. When a patient develops signs of abdominal sepsis following a PEG, it is wise to stop feedings and confirm the intragastric position of the tube with a contrast study. Contrast agent is introduced through the tube and its position in the stomach ensured (Fig. 83.9).



Figure 83.9. Injection of water-soluble contrast following a percutaneous endoscopic gastrostomy tube change demonstrates disruption of the tract and intraperitoneal extravasation.



Figure 83.10. Fluoroscopic observation notes the position of the "enteroscope" deep within the small bowel and helps to localize the site of lumenal access for direct percutaneous endoscopic jejunostomy.

EXPANDED APPLICATIONS OF PEG TECHNIQUE

Since the introduction of PEG two decades ago, it has become apparent that the method provides additional opportunities for gastrointestinal access. These have included establishment of portals for intragastric surgery, creation of a percutaneous cecostomy for colonic decompression, and direct jejunostomy for enteral access in patients who are unable to tolerate gastric feedings. The latter is accomplished by the same method as followed for percutaneous gastrostomy but employs the use of longer "enteroscopes" or small-caliber colonoscopes to permit deep intubation of the small bowel. Smaller-size tubes, 15 or 16 French, are commercially available and are used for this procedure. The "safe tract" technique and

fluoroscopic guidance may facilitate site selection for safe lumenal access (Figs. 83.10 and 83.11).

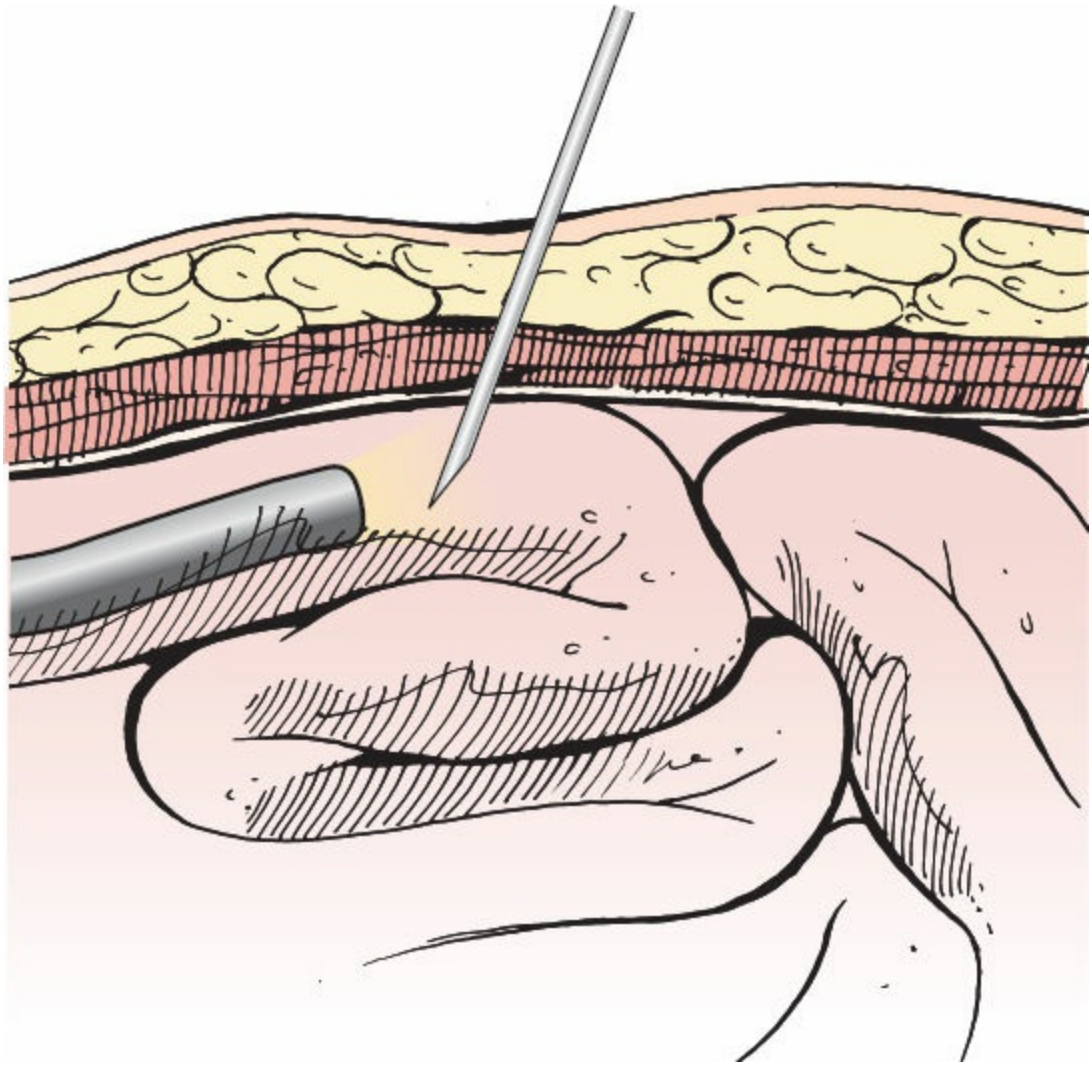

Figure 83.11. The “safe tract” method is also used to help localize the appropriate loop of small intestine for jejunal access.

CONCLUSION

PEG has become the method of choice for the establishment of gastrostomy in appropriately selected patients. Improvements in details of technique, familiarity with the prevention and management of complications, and new developments in tube design have helped improve the safety and expand the applications of the method. Attention to details of the technique and careful patient selection will ensure that the best results are achieved.

Suggested Readings

Foutch GP. Complications of percutaneous endoscopic gastrostomy and jejunostomy, recognition, prevention, and treatment. *Gastrointest Endosc Clin North Am* 1992;2:231.

Foutch GP, Talbert GA, Waring JP, et al. Percutaneous endoscopic gastrostomy in patients with prior abdominal surgery: virtues of the safe tract. *Am J Gastroenterol* 1988;83:147.

Hogan RB, DeMarco DC, Hamilton JK, et al. Percutaneous endoscopic gastrostomy: to push or pull, a prospective randomized trial. *Gastrointest Endosc* 1986;32:253.

Mellinger JD, Ponsky JL. Percutaneous endoscopic gastrostomy: state of the art. *Endoscopy* 1998;30:126.

Ponsky JL. Percutaneous endoscopic gastrostomy, "How I do it." *J Gastrointest Surg* 2004;7(8):903.

Ponsky JL, Gauderer MW. Percutaneous endoscopic gastrostomy: a nonoperative technique for feeding gastrostomy. *Gastrointest Endosc* 1981;27:9.

Poulose BK, Kaiser J, Beck WC, et al. Disease-based mortality after percutaneous endoscopic gastrostomy: utility of the enterprise data warehouse. *Surg Endosc* 2013;27:4119–23.

Russell TR, Brotman M, Forbes N. Percutaneous gastrostomy: a new simplified and cost-effective technique. *Am J Surg* 1984;148:132.

Sabris A, Liu R, Chand B, et al. SLiC technique: a novel approach to percutaneous gastrostomy. *Surg Endosc* 2006;20:256–62.

Sacks BA, Vine HS, Palestrant AM, et al. A non-operative technique for establishment of a gastrostomy in the dog. *Invest Radiol* 1983;18:485.

Shike M, Latkany L. Direct percutaneous endoscopic jejunostomy. *Gastrointest Endosc Clin North Am* 1998;8:569.

Stellato TA, Gauderer MW, Ponsky JL. Percutaneous endoscopic gastrostomy following previous abdominal surgery. *Ann Surg* 1984;200:46.

Wolfsen HC, Kozarek RA. Percutaneous endoscopic gastrostomy: ethical considerations. *Gastrointest Endosc Clin North Am* 1992;2:259.

EDITOR'S COMMENT

Enteral feeding is the preferred method of delivering nutrition to patients with a functioning gastrointestinal tract. For those patients unable to safely feed themselves, the PEG tube has long been considered an optimal technique for restoring enteral nutrition. Dr. Jeffrey Ponsky developed the technique in 1980 and now shares his pearls of wisdom related to this procedure and technique in

this edition of *Mastery of Surgery*. This is an excellent chapter describing different techniques and considerations in the placement of gastrostomy tubes endoscopically.

Since the introduction of the PEG technique in 1980, the utilization of endoscopically placed gastrostomy tubes for enteral feeding has increased dramatically. A recent review of the Nationwide Inpatient Sample (NIS) examining patients in the United States >65 years of age revealed that from 1993 to 2003, placement of PEG tube increased by 38% in elderly patients. In 1993, the rate was 2.71 procedures during hospitalization per 1,000 people. This rate increased to 3.75 procedures during hospitalization per 1,000 people by 2003. Placement of PEG tube in patients with Alzheimer dementia doubled (5% to 10%) over the study period. In Taiwan, 99% of the entire population in covered by the National Health Insurance (NHI) Program. A review of the NHI database revealed that from 1997 to 2010, the incidence of PEG increased from 0.1 to 3.8/105 population and incidence of PEG among aged patients increased from 0.9 to 19.0/105 population. Cerebrovascular events and esophageal cancer were increasingly common indication for PEG placement. Medical costs, Charlson Comorbidity Index (CCI) scores, and post-PEG mortality rates were higher in the 2005 to 2010 period than in the 1997 to 2004 period. It appears from these data that PEG is being utilized at an increasing rate and in sicker and older patients as well.

A recently published systematic review revealed that in more than 1,000 patients to receive a percutaneous gastrostomy tube, that the 30-day mortality following PEG was 5.5%. This likely relates in part to the health status of patients to receive a PEG, but also speaks to potential morbidity and complications that can be observed in this procedure. Almost every year at a surgical morbidity and mortality conference in my home institution, a significant complication from PEG placement is presented. Ponsky and Poulose emphasize that for any patient with sepsis after PEG, feedings should be stopped immediately and contrast study performed to confirm proper tube placement. When position is in doubt and a patient is ill, diagnostic laparoscopy or laparotomy is usually warranted.

In addition to endoscopic guided placement of a gastrostomy tube, fluoroscopic imaging can be used to guide percutaneous access. The benefit of radiographic guidance includes the ability to avoid the sedation required to perform an endoscopy to place the tube. Aspiration is potential risk of PEG. Radiographic guidance is helpful in patients with head and neck cancers for whom upper endoscopy is difficult or contraindicated. Percutaneous image-guided gastrostomy is most commonly performed transabdominally under fluoroscopic guidance. First, a nasogastric tube is placed to insufflate the stomach, followed by gastropexy under fluoroscopic or ultrasound guidance using one to four “T-fasteners” arranged around the planned gastrostomy site to bring the stomach to the abdominal wall (gastropexy). Using the Seldinger technique, a needle is passed into the stomach followed by a guidewire over

which the tract can be dilated and eventually a gastrostomy tube can be passed. The colon can be opacified with contrast to ensure a radiologic window by administering oral contrast the night before the procedure or a contrast enema. A systematic review and meta-analysis of PEG versus radiographically guided gastrostomy revealed that 30-day mortality was significantly lower in PEG (OR, 0.60; 95% CI, 0.38−0.94; P = 0.026). This is partly related to differences in patient populations offered each technique. Another advantage of transoral PEG compared to transabdominal percutaneous image-guided gastrostomy is the more robust and larger tube that is usually placed. In a transabdominal approach, the catheter must be pushed through the gastric wall. Therefore, despite the use of dilators or peel-away sheaths that help facilitate catheter insertion into the stomach, the diameter of the catheters is generally smaller than PEG tubes. The smaller size, combined with the use of a balloon as an internal bumper instead of the mushroom bumper of pull-type transoral tubes, contributes to the relatively higher occlusion rates, more frequent tube displacements, and less reliable internal fixation of the image guided percutaneous tubes. For these reasons, while percutaneous image-guided gastrostomy holds some advantages over PEG, it is generally not employed as a routine first-line alternative to PEG.

When a PEG or percutaneous image-guided gastrostomy is impossible, difficult, or inadvisable for various reasons (obesity, previous gastric bypass, failed attempts to place due to interposed intra-abdominal organs between stomach and abdominal wall), a surgeon is well advised to have a variety of additional options at his/her disposal. For many of these challenging situations, laparoscopic-assisted PEG is an alternative. Laparoscopic-assisted PEG combines the advantages of PEG with direct intraperitoneal visualization, helping ensure a safe tube placement tract free of intervening organs or structures. In uncomplicated cases, laparoscopic-assisted PEG can be performed with two or even one 5-mm trocar and does not require an advanced laparoscopic skill set. In patients undergoing laparoscopic surgery for another indication (laparoscopic paraesophageal hernia repair for example), laparoscopic-assisted PEG is a simple way to achieve enteral access. Some surgeons advocate for the placement of a laparoscopic-assisted PEG at the time of paraesophageal hernia repair in the case of large and complex hernias and in elderly frail patients as a mechanism for reducing the stomach and any associated gastric volvulus or obstruction. Laparoscopic and open gastrostomy tube placement are useful techniques in cases where endoscopic gastrostomy tube placement is impossible or contraindicated (as in the case of a postgastric bypass patient who requires enteral access in the remnant stomach). The laparoscopic gastrostomy tube placement technique does require a more advanced skill set than laparoscopic-assisted PEG as gastropexy is typically needed to fix the stomach to the posterior abdominal wall.

In patients who cannot tolerate gastric feedings or in whom gastric feedings are contraindicated, percutaneous endoscopic gastrostomy with jejunal

extension (PEG-J) is an endoscopic technique that may prove useful. Patients with severe GERD and aspiration, gastroparesis necessitating a venting gastrostomy and access to the jejunum for enteral nutrition and some patients with refractory symptoms due to chronic pancreatitis may benefit from PEG-J. The technique of PEG-J involves an initial placement of a PEG tube using the same techniques described in this chapter. If feasible in PEG-J, a location on the distal gastric body is ideal in PEG-J to minimize the opportunity for the jejunal extension to coil in the stomach. Once the PEG is in place, a guidewire is placed through the gastric tube and grasped endoscopically. The guidewire is then advanced to the jejunum (15 to 20 cm distal to the ligament of Treitz) under endoscopic and fluoroscopic guidance. The guidewire is released and a 12Fr, 60- or 90-cm jejunal tube is then threaded over the guidewire into the jejunum under fluoroscopic guidance. A recently published series of 102 PEG-J tubes demonstrated an overall technical success rate of 97%. During a median follow-up period of 22 months (1 to 46 months, $n = 90$), at least one tube malfunction occurred in 52/90 (58%; 177 episodes) after a median of 53 days (3 to 350 days), requiring a median of two tube replacements. Short-term (<30 days) tube malfunction occurred in 28/90 (31%) and delayed in 24/90 (27%); these included dislodgement (29%), clogging (26%), and kinking (14%). The PEG-J is a useful technique for dual enteral access to the stomach and jejunum, but requires an advanced endoscopic skill set and can be somewhat labor intensive to maintain as described.

General surgeons are often called upon to establish enteral access in patients requiring both temporary and long-term access. Given the aging population and complex postsurgical anatomy that these patients can present with, familiarity with a variety of techniques including and related to the PEG can be extremely useful.

Jon C. Gould

Dr. Gould has discussed an entrance to the GI tract which is somewhat different that the feeding tube that I am accustomed to. A tube may be utilized as the author states but most of the time I use tube feedings rather than TPN when I can. I find myself using percutaneous latex tubes often. I am accustomed to open gastrostomy or jejunostomy. There are many approaches but the key for all is a careful and safe "permanent" access. Secure sutures so tube does not slip or leak.

J.E.F.

Suggested Readings

Chang WK, Lin KT, Tsai CL, et al. Trends regarding percutaneous endoscopic gastrostomy–a nationwide population-based study from 1997 to 2010. *Medicine* 2016;95:24.

Kawai M, Hiramatsu M, Lee SW, et al. Endoscopy-assisted percutaneous anterior gastropexy for gastric volvulus: a minimally invasive technique using a special instrument. *Endoscopy* 2013;45(Suppl 2 UCTN):E151–2.

Lim JH, Choi SH, Lee C, et al. Thirty-day mortality after percutaneous gastrostomy by endoscopic versus radiologic placement: a systematic review and meta-analysis. *Intest Res* 2016;14(4):333–42.

Mendiratta P, Tilford JM, Prodhan P, et al. Trends in Percutaneous Endoscopic Gastrostomy Placement in the Elderly From 1993 to 2003. *J Alzheimers Dis Other Demen* 2012;27(8):609–13.

Ridtitid W, Lehman GA, Watkins JL, et al. Short- and long-term outcomes from percutaneous endoscopic gastrostomy with jejunal extension. *Surg Endosc*, online October 2016, doi 10.1007/s00464-016-5301-3.

Sutcliffe J, Wigham A, McEniff N, et al. CIRSE Standards of Practice Guidelines on Gastrostomy. *Cardiovasc Intervent Radiol* 2016;39(7):973–87.

84 Distal Gastrectomy With Billroth I or Billroth II Reconstruction

Rudolf Bumm and J. Rüdiger Siewert

Partial gastrectomies consist of the removal of the distal portion of the stomach. According to the type of disease (ulcer or carcinoma) and the location of the basic disease (duodenal ulcer, gastric ulcer, high-gastric ulcer), they are performed as antral, two-thirds, four-fifths, or high subtotal gastrectomy. *Distal partial gastrectomy* is named according to the type of anastomosis between the small intestine and the gastric remnant, regardless of the extent of the gastrectomy.

The Billroth I (BI) operation is a gastroduodenostomy that can be performed end-to-end or end-to-side. In the Billroth II (BII) reconstruction the gastrojejunostomy is performed end-to-side. As an alternative, Roux-Y (RY) reconstructions can be done (see Chapter 82). A decisive difference between the BI and BII procedure is that in BI reconstruction the duodenal passage remains intact. Because of anastomotic requirements, the BI operation is, as a rule, performed as an antrectomy. Gastroduodenostomy is difficult or impossible after more extended gastrectomies, because direct anastomoses between gastric fundus and duodenum may not be free of tension and followed by postoperative complications. Therefore, for the more extended partial gastrectomy, a BII or RY reconstruction should be favored. Furthermore, it is an interesting but unexplained clinical impression that mobility of the duodenum seems to be better in women and one can do a BI with greater resections than with males.

HISTORICAL NOTE

Pean and Rydigier attempted partial gastrectomies in 1879 and 1880, respectively, with neither of their patients surviving. Theodor Billroth performed the first successful partial gastrectomy on a patient who had antral carcinoma in 1881. He reconstructed the gastrointestinal passage by a superior end-to-end gastroduodenostomy with the duodenum anastomosed to the lesser curvature side of the stomach (Fig. 84.1A).

Billroth later changed his surgical technique by effecting the anastomosis to the greater curvature (Fig. 84.1B). The reconstruction of the gastroduodenal passage in the BI operation has undergone numerous modifications. The end-to-end anastomosis (EEA) was performed as a posterior or anterior gastroduodenostomy, or the duodenal end was connected to the entire circumference of the cut edge of the stomach (Fig. 84.1C–E). End-to-side gastroduodenostomy was performed by anastomosing the stomach to the side of the duodenum opposite the major duodenal papilla or entirely below the level of the papilla (Fig. 84.1F,G). Further modifications are the tube-shaped resection for ulcers high on the stomach and subsequent reanastomosis of the duodenum to the greater curvature side of the stomach (Fig. 84.1H), and antrectomy performed in combination with gastric vagotomy and followed by an EEA (Fig. 84.2).

The technique most frequently used today is the Schoemaker modification of the BI operation, with partial closure of the stomach remnant along the lesser curvature and an inferior gastroduodenostomy.

ARGUMENTS IN FAVOR OF BI GASTRECTOMY

A leading argument in favor of BI anastomosis as compared with other forms of gastrectomy (e.g., BII) is the preservation of the duodenal passage. The question arises as to whether the important functions of the duodenum are dependent on the presence (or absence) of the food passage.

Acids are neutralized in the duodenum by pancreatic and duodenal bicarbonate through neural and hormonal regulation. After distal stomach resection, this regulation is disturbed regardless of the type of anastomosis. Proportioned, regulated stomach emptying is no longer possible because the antrum and pylorus are gone, and the value of providing a duodenal passage cannot be properly assessed because rapid and uncoordinated emptying of the stomach precludes the function of the digestive process that normally takes place in the duodenum. However, the benefit of the duodenal passage is clearer with regard to the function of the pancreas, the changes in the stomach remnant, and the function of the cardia.

The duodenal brake, a mechanism for shutting off acid, does not operate even if food passes the duodenum because of the denervation of transection. However, release of hormones in the duodenum does not necessarily require innervation. Better absorption of calcium and iron in the duodenum are proven advantages of the BI hookup.

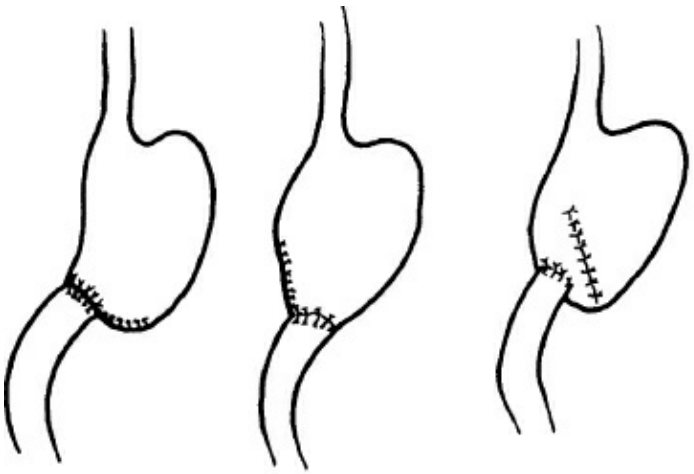

Billroth
1881
A

Billroth
1881
B

Kocher
1890
C

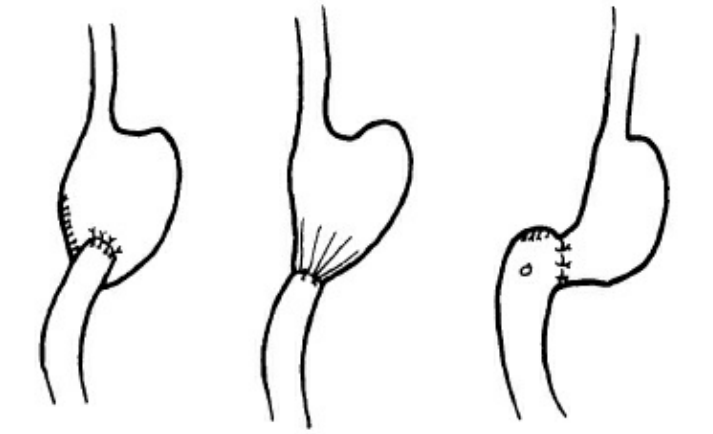

Kutscha-
Lissberg
1925
D

v. Haberer
1920
E

v. Haberer, 1922
Finney, 1923
F

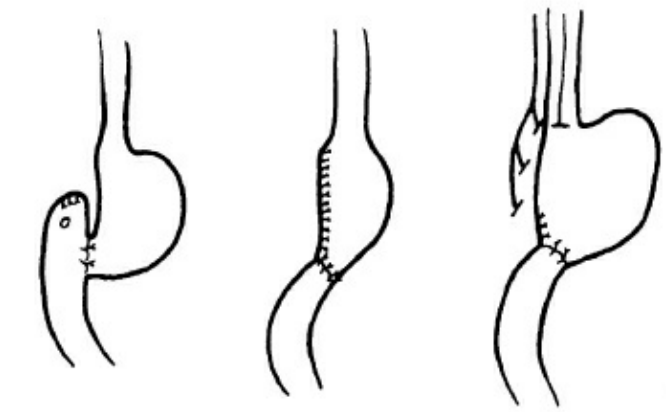

Winkelbauer
1927
G

Schoemaker
1911
H

Harkins, Nyhus
1960
I

Figure 84.1. A–I: Modifications of the BI resection from a historical point of view.

Experimental and clinical investigations indicate undisturbed pancreatic function, even after gastrectomy, but altered pancreatic function is apparent after gastrojejunostomy (BII). Fat loss in the feces is considerably greater after BII resection than after gastroduodenostomy. This loss may indicate insufficient digestion of food by pancreatic enzymes.

In a recent randomized comparison between patients after BI and RY reconstructions, endoscopic examination revealed that the frequency of bile reflux and degree of inflammation in the remnant stomach were less in the RY group than in the BI group, which is most likely due to the absence of pylorus in the RY group. However, RY reconstructions did not prevent esophagitis and were associated with more initial stasis complications.

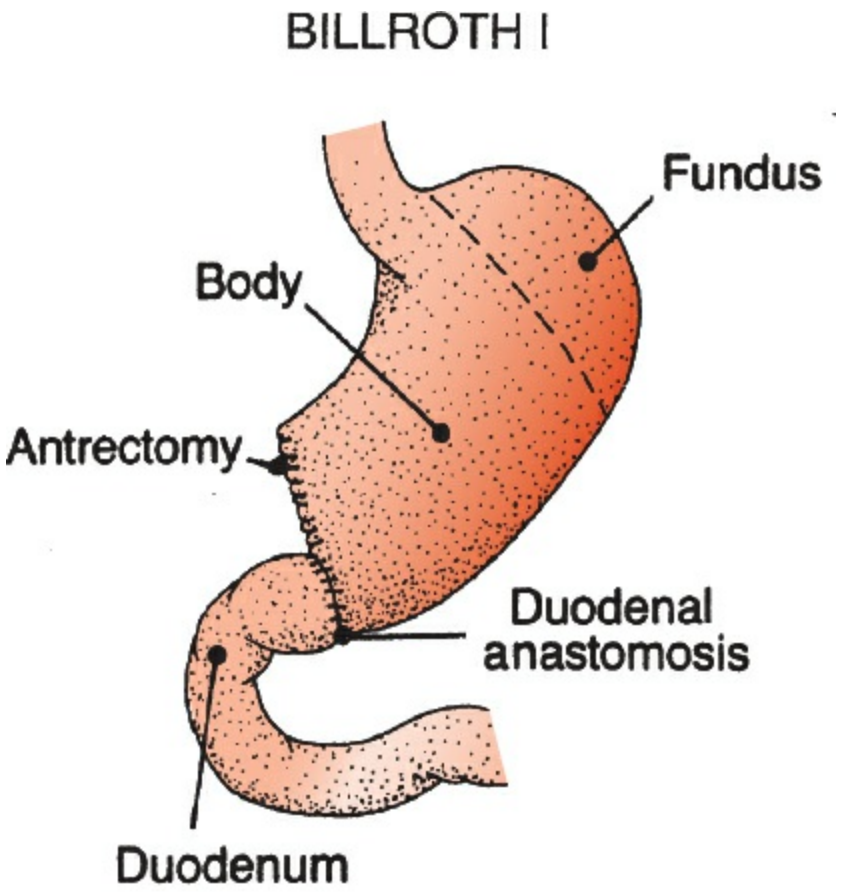

Figure 84.2. Billroth I gastrectomy. (From Diepenbrock NH. Quick Reference to Critical Care, 4th Edition (2012); Wolters Kluwer Health | Lippincott Williams & Wilkins.

Even histologic changes of the stomach mucosa characteristic of chronic atrophic gastritis seem to be present to a lesser degree after a BI resection than after BII. The same is true for the frequency of carcinoma of the stomach remnant.

Cardiac function tests demonstrate similar lower esophageal sphincter pressures in reaction to a test meal before and after gastroduodenostomy. After BII resection, the tonicity of the lower esophageal sphincter decreases, but this functional disturbance of the cardia is rarely of clinical relevance.

ARGUMENTS IN FAVOR OF BII GASTRECTOMY OR RY RECONSTRUCTION

The main argument in favor of BII reconstructions is that a larger portion of the stomach can be resected and lymphadenectomy is easier. In all cases in which a BI reconstruction could only be accomplished with tension, one should choose BII. In some cases a BII reconstruction results in early dumping symptoms (see following discussion). Those patients should undergo, if conservative treatment fails, relaparotomy and reconstruction according to RY. The RY offers a better control to avoid enterogastric reflux into the gastric remnant and is the method of choice when early dumping or reflux problems occur.

INDICATIONS OF PARTIAL GASTRECTOMY

Gastric Ulcer

The main indication for partial gastric resections is gastric ulcer, and this is usually a recurrent ulcer after adequate antisecretory treatment and eradication of *Helicobacter pylori.* Partial gastrectomy is the method of choice because

1. the gastric ulcer is removed in toto during distal resection and can be examined histologically,
2. the point of least resistance on the antrum–corpus border of the lesser curvature is eliminated,
3. the number of chief cells is reduced by removal of a part of the fundus,
4. the antrum as the point for the formation of gastrin is eliminated,
5. the remainder of the stomach is partly vagotomized by dissection of the lesser curvature above the resection border and the standard reconstruction for partial gastrectomy in gastric ulcer patients is BI.

Prepyloric Ulcer

Prepyloric ulcers represent a good indication for partial gastric resections. Because of its secretory behavior, this ulcer type was, as far as the surgical and therapeutic consequences were concerned, previously included with duodenal ulcers and historically represented an indication for vagotomy only. However, results after 5 years of using this procedure showed relatively high recurrence rates; therefore, it can be concluded that prepyloric ulcers would be better regarded as gastric ulcers as far as surgical treatment is concerned. Partial gastric resections for prepyloric ulcers should, in our view, be combined with selective gastric vagotomy.

Complicated Ulcers

Although elective ulcer surgery has strongly decreased in the decade of potent antisecretory drugs, the frequency of operations for complicated ulcers has remained relatively stable.

The classic indications for partial gastric resections in ulcer surgery are perforation, bleeding, obstruction, and intractability. In addition, gastric "ulcers" may mask or be at risk for the development of gastric adenocarcinoma. Therefore, all gastric ulcers must be biopsied and followed until healing. Giant gastric ulcers (>3 cm) have a 30% incidence of harboring a cancer.

Early Carcinoma and Carcinoma of the Antrum

Partial gastric resections cannot be recommended as a standard treatment of locally advanced gastric cancer because a total gastrectomy with adequate lymphadenectomy is the method of choice. As an exception, in our institution patients with well-differentiated and early (T1/T2 N0) gastric adenocarcinomas undergo *subtotal gastric resection*, in which four-fifths of the stomach is resected with a standard D2 lymphadenectomy, and a BII or RY reconstruction is done. In the Far East, mucosal cancers of the antrum are common and more frequently resected by partial gastrectomy and BI reconstruction. Sentinel lymph node dissection after distal gastrectomy for early gastric cancer has been evaluated with conflicting short-term and open long-term results. Therefore, the general use of this technique for discriminating between partial or total gastrectomy for early gastric cancer cannot yet be recommended.

SURGICAL TECHNIQUE: BI GASTRECTOMY

Gastroduodenostomy with Anastomosis to the Side of the Greater Curvature of the Stomach

As a rule, midline epigastric incision is the best approach (Fig. 84.2). Alternatively, a transverse epigastric rectus muscle-cutting incision or an upper vertical muscle-splitting incision to the right can be made.

The dissection of the stomach begins at the middle of the greater curvature by incision of the gastrocolic ligament. Thus, the omental bursa is opened. The dissection for gastric ulcers can be done between the gastroepiploic vessels and the gastric wall. In carcinoma, the greater omentum corresponding to the extent of the resection of the greater curvature must be removed at the same time. When the omental bursa has been opened, the flimsy part of the gastrohepatic omentum may be pierced by the finger, and a soft rubber Penrose drain can be placed around the stomach. The dissection is then continued step-by-step along the greater curvature toward the duodenum. Near the pylorus, the greater curvature of the omentum becomes thick and divides into a front and back layer. The dissection should be continued bluntly in the loose intermediate tissue in the direction of the duodenum; the layers of tissue carrying the vessels should then be ligated individually.

The preparation of the duodenum begins above or just below the second portion of the duodenum from a lateral direction, the so-called Kocher maneuver. The peritoneal reflection is sharply cut along the lateral duodenal wall between the second portion of the duodenum and the beginning of the hepatoduodenal ligament. By putting traction on the second portion of the duodenum medially, the retroperitoneal tissue is loosened (part bluntly, part sharply) until the duodenum is mobilized. In this way, a good general exposure can be achieved; this important maneuver facilitates the subsequent gastroduodenostomy. The preparation of the free first part of the duodenum is then continued.

By stretching the stomach, the dissection proceeds along the greater curvature toward the left medial duodenal wall, then toward the back wall, and finally toward the lateral duodenal wall as far as the beginning of the hepatoduodenal ligament. In this way, 3 to 5 cm of the back wall of the duodenum can be exposed, usually without technical difficulty. The transition from the free first part of the duodenum to the part fixed dorsally on the pancreas can be recognized from the course of the gastroduodenal

artery (Fig. 84.3). At this point, the serosa reaches from the duodenum to the head of the pancreas. The surgeon must be especially careful here because the artery is important for the blood supply to the duodenum and the pancreas.

After mobilization of the duodenum, the dissection is continued along the lesser curvature of the stomach. The right gastric artery is divided between clamps and ligated (Fig. 84.4). Difficulties may arise as a result of penetration of a gastric ulcer. Frequently, a penetrating gastric ulcer can be pinched free of underlying tissue by finger pressure.

We recommend addition of a selective vagotomy of the gastric remnant only for benign ulcer surgery in which gastric hypersecretion is assumed as one of the main pathogenetic factors, that is, in cases with multiple ulcers or prepyloric ulcers. In these rare cases we carefully divide the vagal branches of the anterior and posterior vagus that lead to the gastric remnant and leave the hepatic vagal branches intact.

In every case, the dissection must leave an adequate portion of intact stomach wall for subsequent anastomosis with the duodenum. According to the localization of the ulcer, the dissection of the stomach along the lesser curvature can be continued to the proximal resection line. The layers of the gastrohepatic omentum rest at varying intervals on the front or back wall of the stomach. These layers encompass a tissue rich in fat within which the branches of the left gastric artery and vagal branches are found. The dissection proceeds by bluntly forcing the intermediate tissue apart and individually severing the front and back layer of the gastrohepatic omentum. As long as the ascending trunk of the left gastric artery is not directly involved, it should remain intact during the resection.

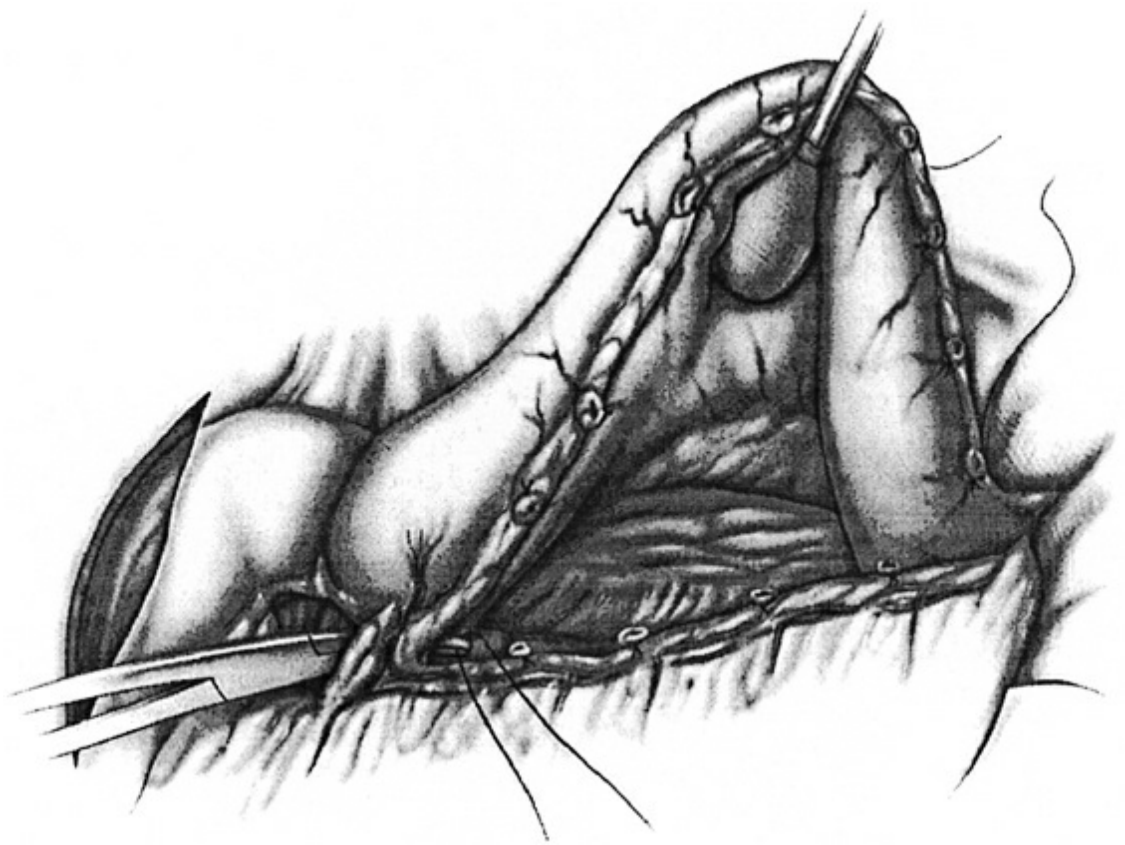

Figure 84.3. Dissection of the greater curvature and ligation of the gastroepiploic artery. (From Siewert JR, Hölscher AH. Billroth I gastrectomy. In: Siewert JR, ed. *Breitner chiururgische operationslehre band IV chirurgie des abdomens II. Ösophagus, magen und duodenum.* 2. Auflage. 1989 © Elsevier GmbH, Urban & Fischer, Munich.)

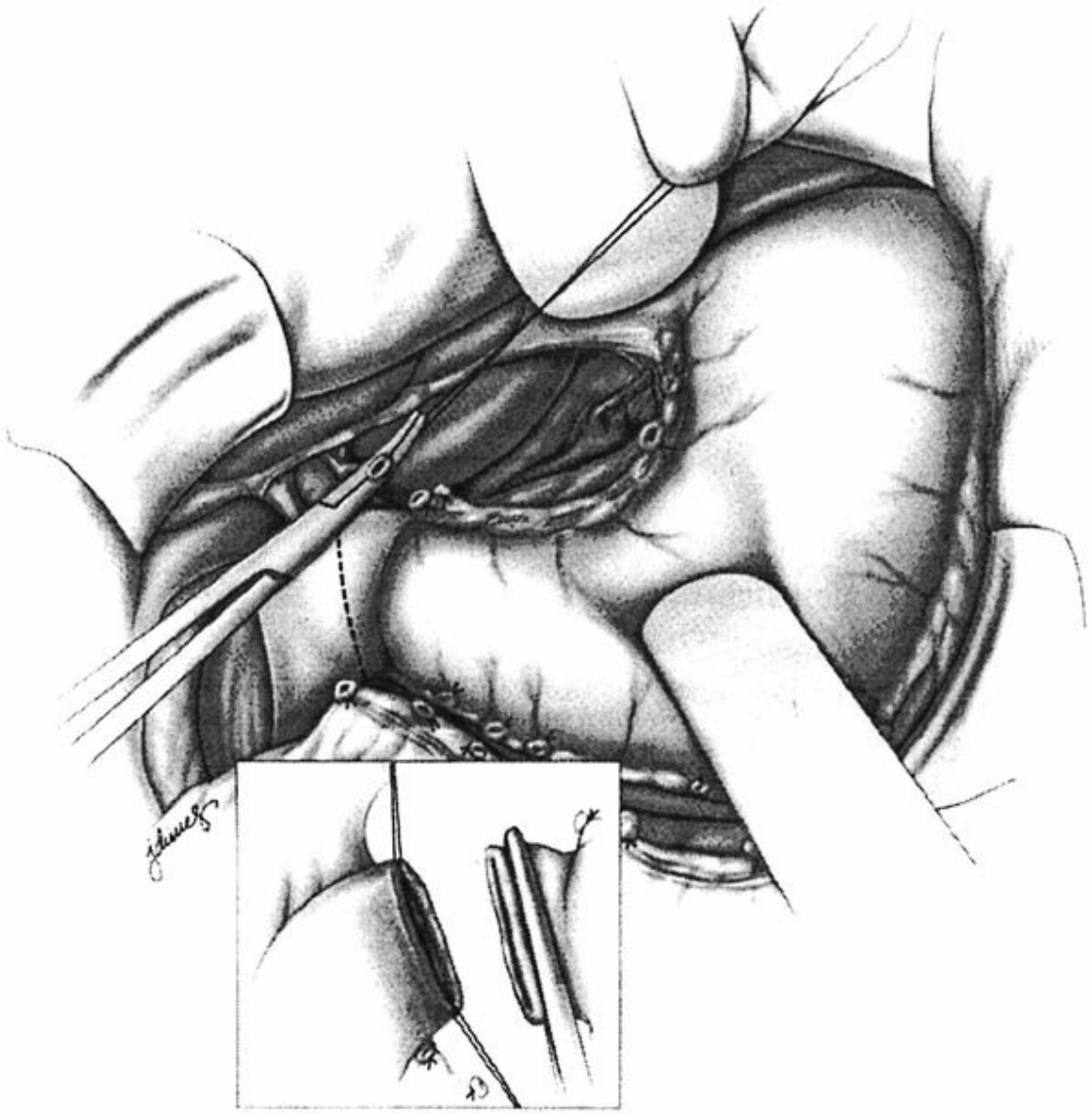

Figure 84.4. Dissection of the lesser curvature and ligation of the right gastric artery. The duodenum is transected below the proximal clamp (*inset*). (From Siewert JR, Hölscher AH. Billroth I gastrectomy. In: Siewert JR, ed. *Breitner chiururgische operationslehre band IV chirurgie des abdomens II. Ösophagus, magen und duodenum.* 2. Auflage. 1989 © Elsevier GmbH, Urban & Fischer, Munich.)

The actual resection starts with the cutting of the duodenum between holding or guy sutures. The duodenum is temporarily closed with a sponge; the resection borders of the stomach are then determined.

A sewing instrument (e.g., stapler, TA-90 (Covidien) or TL90 (Ethicon)) facilitates the final step of stomach removal. The incision follows at an angle of 45 degrees to the lesser curvature (Fig. 84.2). The staple line can, but need not, be oversewn (Fig. 84.5). After removal of the

distal portion of the stomach, a clamp is fitted at right angles to the greater curvature. The clamp is thus pushed far enough orally for the removal level to correspond in size to the duodenal lumen. The remaining aboral end is cut off after stay sutures are placed at each cut edge (Fig. 84.5). It is recommended that the so-called von Haberer submucosal sutures (4-0 polyglycolic acid) be used in the front and back walls to achieve hemostasis. The anastomosis should be performed without clamps.

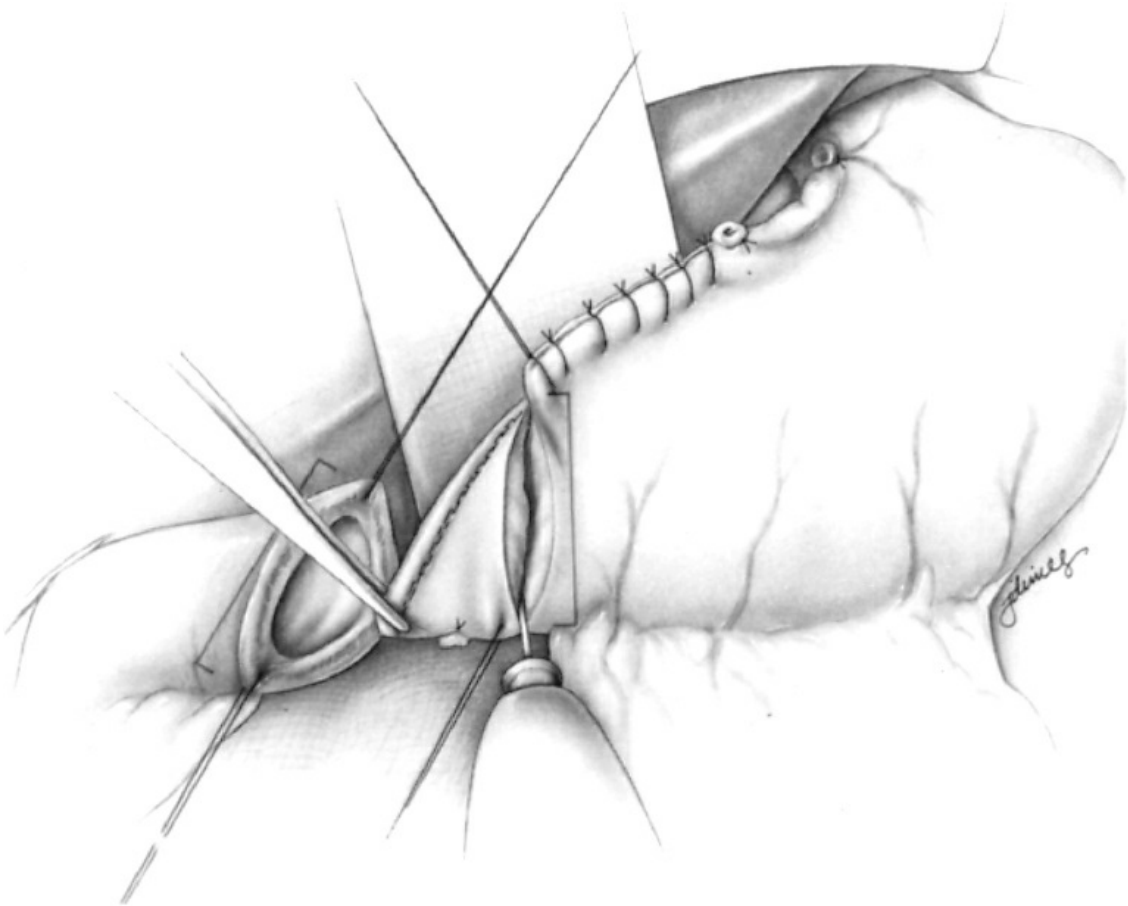

Figure 84.5. Distal gastric resection. After removal of the distal stomach and the distal end of the greater curvature, the two cut surfaces are placed adjacent to each other. (From Siewert JR, Hölscher AH. Billroth I gastrectomy. In: Siewert JR, ed. *Breitner chiururgische operationslehre band IV chirurgie des abdomens II. Ösophagus, magen und duodenum.* 2. Auflage. 1989 © Elsevier GmbH, Urban & Fischer, Munich.)

The end-to-end gastroduodenostomy is accomplished by anastomosing the duodenum to the end of the greater curvature. For this purpose, the two cut surfaces are placed adjacent to each other and two corner stitches are placed, starting at the stomach through the seromuscular layers with

tangential grasping of the mucosa. At the duodenum, this stitch is done from inside to outside. The corner suture at the lesser curvature is tied, whereas the suture on the opposite side is left open (Fig. 84.6). The back wall is reconstructed by interrupted back stitches (3-0 polyglycolic acid). These stitches start through all layers of the back wall at the cut edge of the lesser curvature from inside to outside and go through all layers of the posterior wall of the duodenum from outside to inside. The suture is led back grasping only the mucosa, first of the duodenum and then of the stomach (Fig. 84.7). Knotting these sutures leads to an exact coaptation, especially at the level of the mucosa (Fig. 84.7, inset). The front wall is best closed with one row of interrupted sutures through all layers with tangential stitches of the mucosa with the same technique as the corner stitches (Fig. 84.8). Special attention must be paid to the so-called Jammerecke (angle of sorrow) on the lesser curvature (Fig. 84.9). It is advisable to use the triple seromuscular structure, which includes the duodenal walls as well as the front and back wall of the stomach. Another alternative is shown in Figure 84.10.

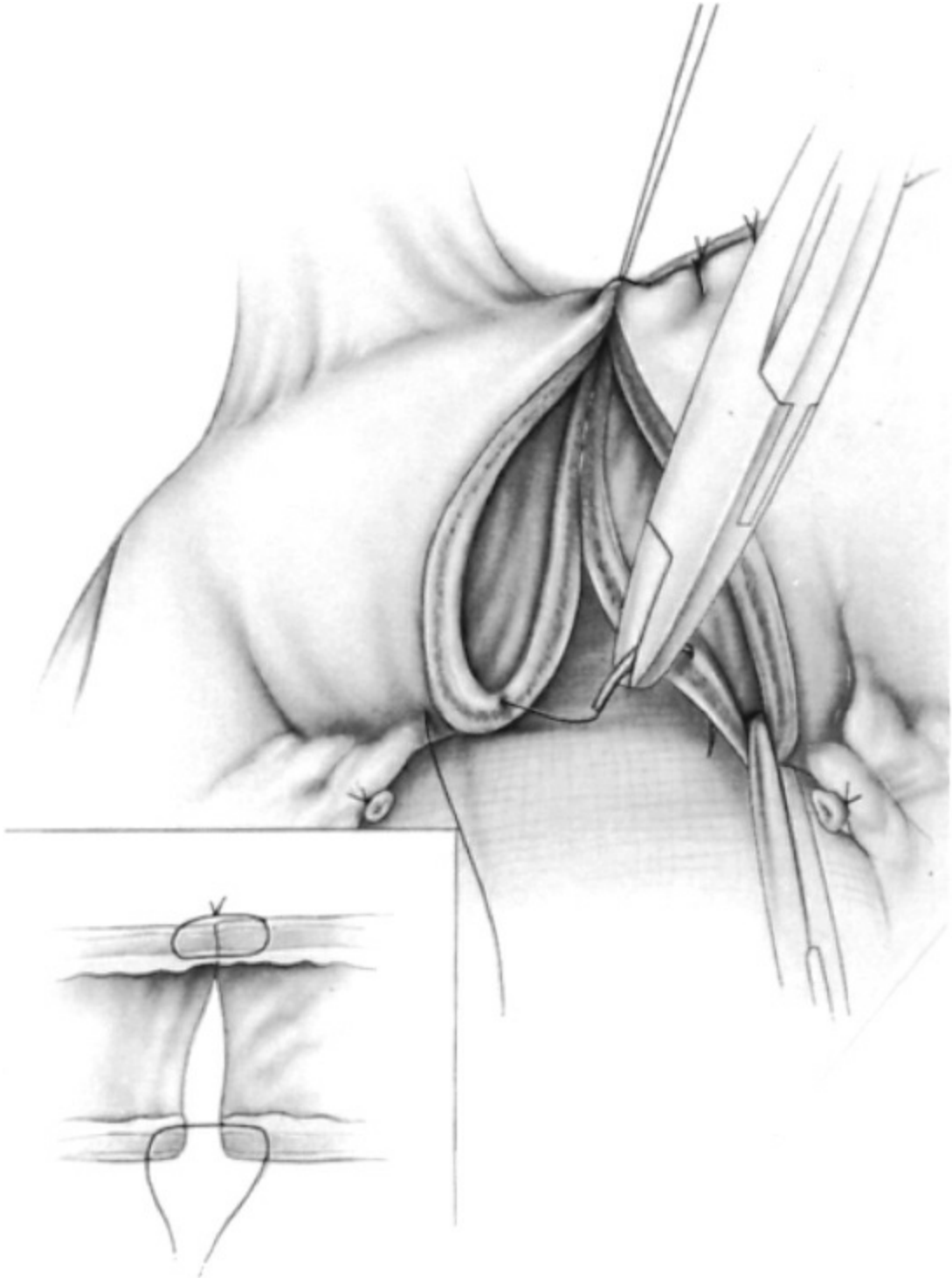

Figure 84.6. Gastroduodenostomy with duodenum connected to the stomach on the side of the greater curvature. Corner sutures are seromuscular stitches that grasp the mucosa tangentially. The suture is tied on the lesser curvature side and left open on the opposite side (*inset*). (From Siewert JR, Hölscher AH. Billroth I gastrectomy. In: Siewert JR, ed. *Breitner chiururgische operationslehre band IV chirurgie des abdomens II. Ösophagus, magen und duodenum.* 2. Auflage. 1989 © Elsevier GmbH, Urban & Fischer, Munich.)

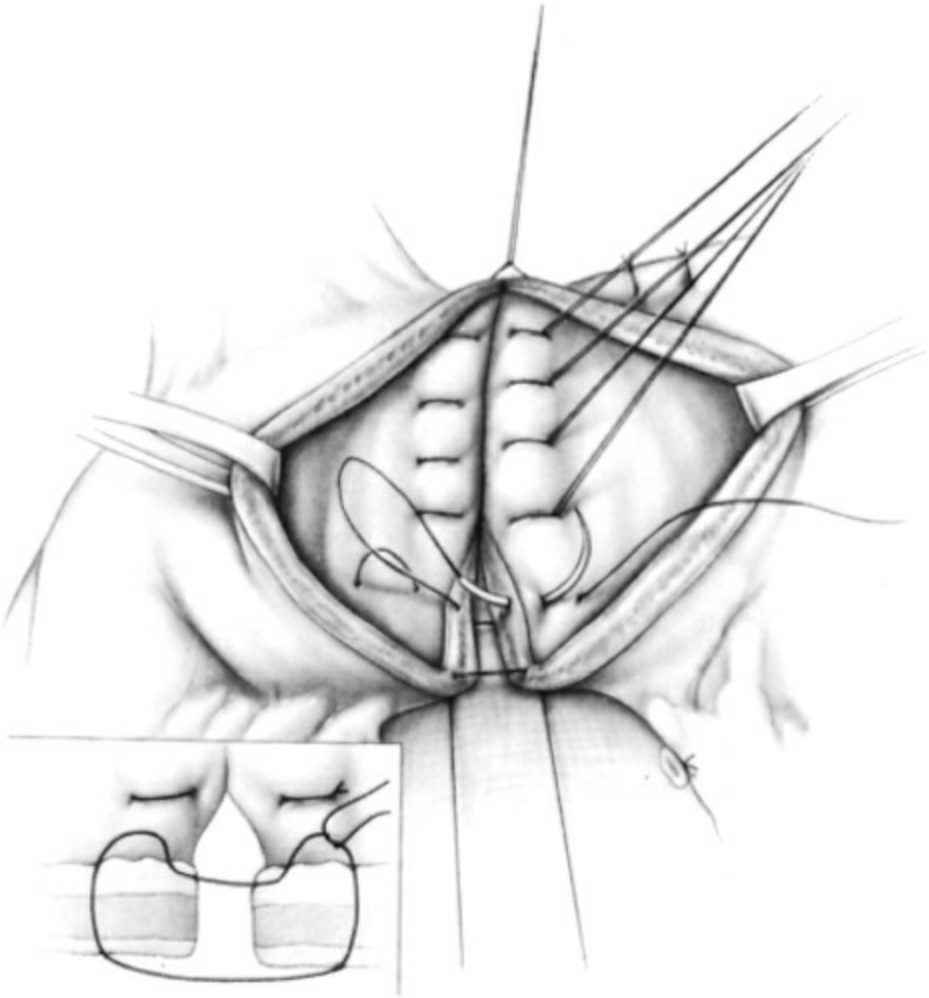

Figure 84.7. Suture technique of the back wall. Interrupted sutures in the so-called back-stitch technique, first through all layers of the stomach, duodenum, and back, grasping only the mucosal edges. (From Siewert JR, Hölscher AH. Billroth I gastrectomy. In: Siewert JR, ed. *Breitner chiururgische operationslehre band IV chirurgie des abdomens II. Ösophagus, magen und duodenum.* 2. Auflage. 1989 © Elsevier GmbH, Urban & Fischer, Munich.)

Finally, the anastomosis is checked for patency with the thumb and index finger. The position of the stomach tube is also checked to ensure it crosses the anastomosis. A double-lumen gastric tube is placed across the anastomosis for 2 to 3 days, allowing early enteral nutrition via the distal lumen. We do not routinely perform intraoperative leakage tests.

Alternative Method: End-to-Side Gastroduodenostomy

In difficult duodenal ulcers, it can be impossible to preserve enough duodenal wall to be able to construct a tension-free anastomosis. In this

situation, it is safer to close the duodenum with a row of TA-55 or TL60 staples. The reconstruction of the intestinal passage can then proceed by end-to-side anastomosis (Fig. 84.11). For this purpose, the stomach is removed as previously described; the dissected stomach lumen is then anastomosed onto the front wall of the duodenum. Usually, an oblique incision should be made on the duodenal front wall so that the incision level starts from oral–medial and goes to aboral–lateral. The suturing technique is the same as for the end-to-side anastomosis. In technically difficult duodenal stump closures, additional coverage of the stump with the back wall of the stomach can be obtained.

Anastomosis Using the Stapler Technique

Performing a stapler anastomosis in BI gastrectomies is usually not necessary in open surgery. This is mainly because of the high cost of the device compared with sutures. Furthermore, there are no differences of anastomotic insufficiency rates between handsewn and stapled BI anastomoses. For completeness, the stapler procedure is described here.

The preparation of the stomach and duodenum proceeds as described previously. After the duodenum is cut, a circular purse-string suture is performed at the edge of the opening. The removable anvil of the EEA (Covidien) or EDH (Ethicon) stapler (size 28 or 31) is introduced in the duodenum, and the purse-string suture is tied around the center rod of the anvil. The circular stapler is then introduced into the stomach and, at the posterior wall of the stomach, the sharp tip of the center rod of the stapler is pushed through the gastric wall. After removal of the tip, the center rod is connected with the anvil and the stapler is closed. After firing of the instrument, the stapler is removed, and the excised circular tissue doughnuts of duodenum and stomach are inspected for completeness. The stomach resection is performed aborally to the anastomosis after closure of the proximal stomach with linear staples. The cut surface of the stomach can be oversewn, but this is not mandatory.

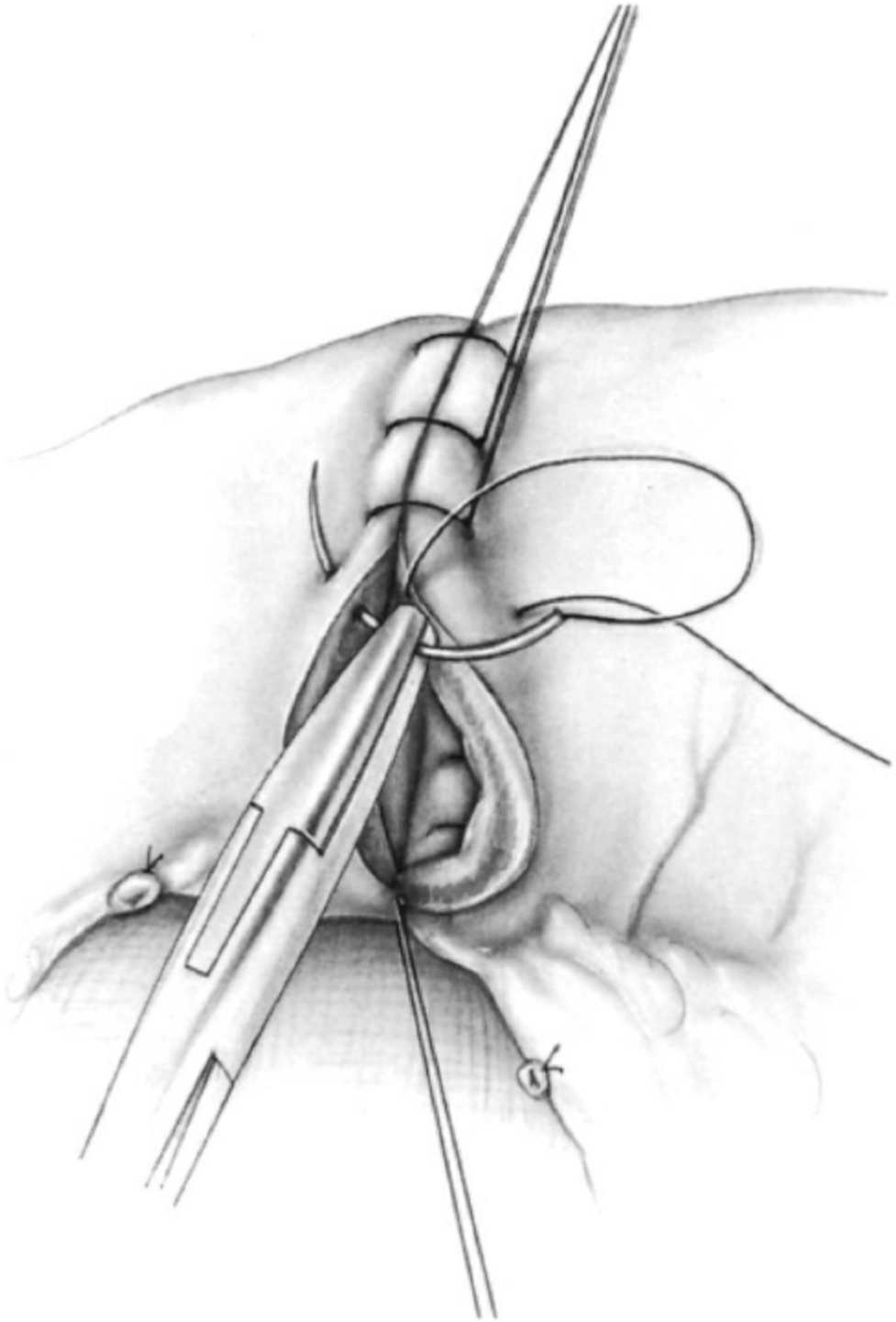

Figure 84.8. The front wall is closed by interrupted sutures with seromuscular stitches that grasp the mucosa tangentially. (From Siewert JR, Hölscher AH. Billroth I gastrectomy. In: Siewert JR, ed. *Breitner chiururgische operationslehre band IV chirurgie des abdomens II. Ösophagus, magen und duodenum.* 2. Auflage. 1989 © Elsevier GmbH, Urban & Fischer, Munich.)

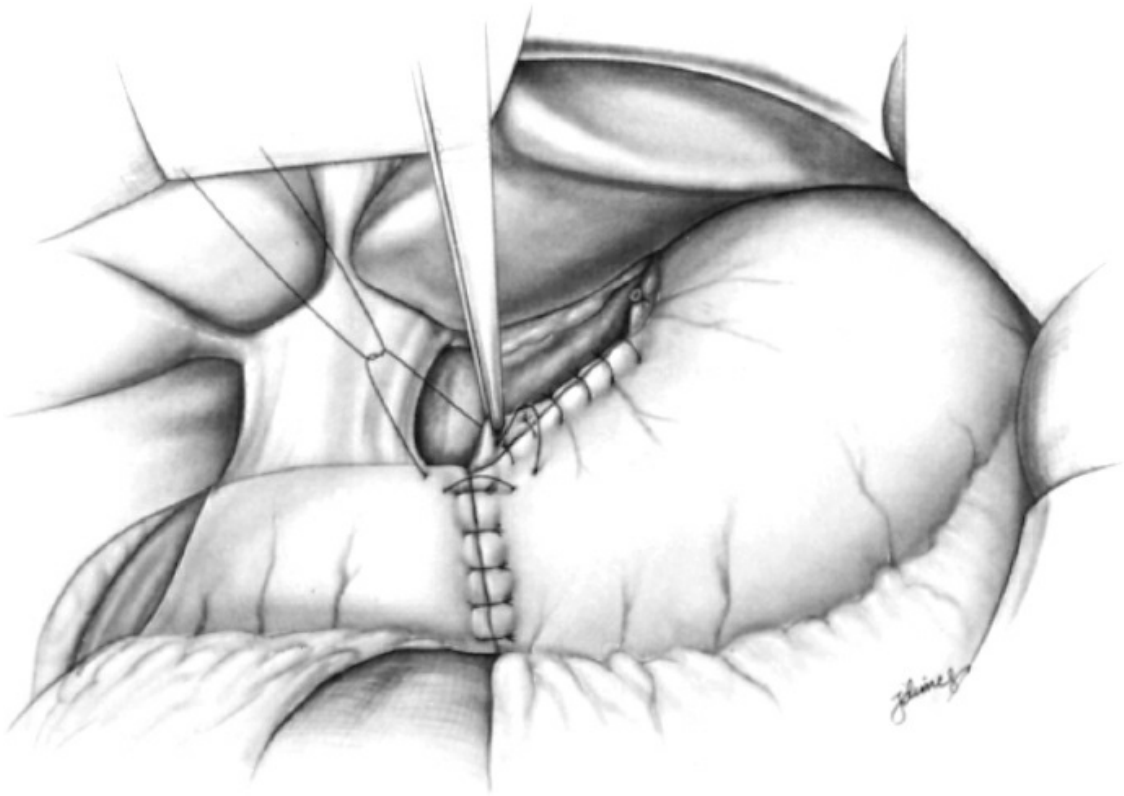

Figure 84.9. The so-called Jammerecke is traditionally covered by a triple seromuscular suture, including the front wall of the stomach, the duodenum, and the back wall of the stomach. (From Siewert JR, Hölscher AH. Billroth I gastrectomy. In: Siewert JR, ed. *Breitner chiururgische operationslehre band IV chirurgie des abdomens II. Ösophagus, magen und duodenum.* 2. Auflage. 1989 © Elsevier GmbH, Urban & Fischer, Munich.)

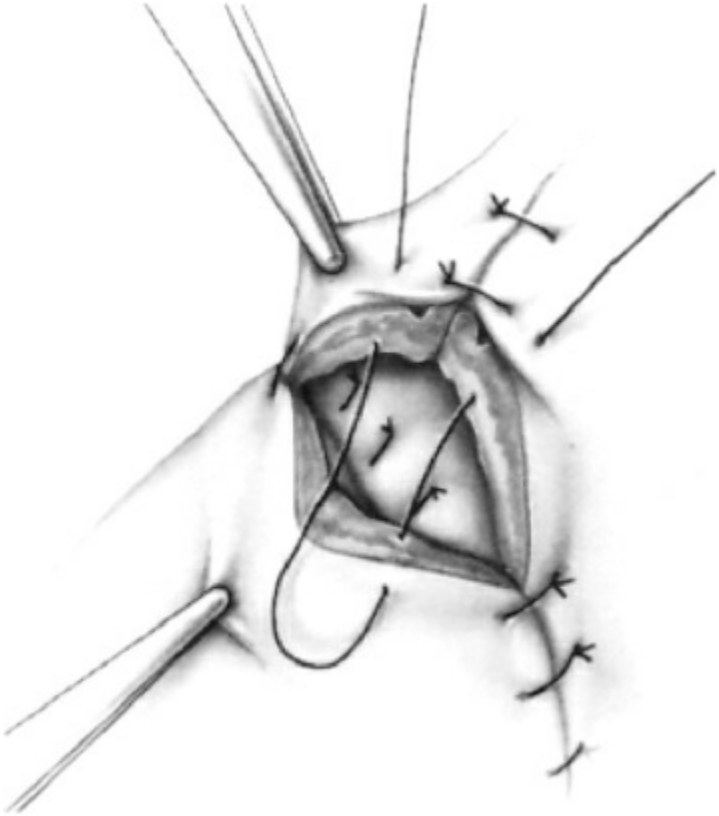

Figure 84.10. Alternative method for closing the Jammerecke with a single-row stitch technique. Seromuscular stitches are taken in the front wall of the stomach from outside to inside, including seromuscular layers of the duodenal walls and the back wall of the stomach in the same manner. This suture does not achieve exact adaptation of all layers but does lead to good closure of the corner by pulling the duodenal wall between the sutures at the lesser curvature. (From Siewert JR, Hölscher AH. Billroth I gastrectomy. In: Siewert JR, ed. *Breitner chiururgische operationslehre band IV chirurgie des abdomens II. Ösophagus, magen und duodenum.* 2. Auflage. 1989 © Elsevier GmbH, Urban & Fischer, Munich.)

Laparoscopic BI Gastrectomy

In Japan, where the rate of early gastric cancer is more than 50% due to early detection, laparoscopic resection and BI is popular due to its minor invasive nature. Several working groups have shown that laparoscopic BI gastrectomy is feasible. They claim that this procedure reduces perioperative pain and hospital stay as a result of limited surgical access. However, operating time is longer, the procedure is technically demanding, and it requires expensive instruments. They accomplish the same steps of dissection as in open surgery through four to five working

trocars and a 30-degree fiberoptic laparoscope. The greater and lesser curvatures are dissected by a harmonic scalpel or the ligasure. The resection of the distal margin is performed with monopolar coagulation, and the proximal resection margin is formed by multiple endolinear staples. After good duodenal mobilisation, the anastomosis is performed extracorporeally with single, extracorporeally knotted stitches, identical to open surgery. In addition, stapler techniques (side-to-side linear or end-to-end circular stapler) have been described. The disadvantages of laparoscopic resections are the lack of tactile feedback when palpation of a tumor or an ulcer is required and a more difficult orientation during the operation. In summary, laparoscopic BI gastrectomy is technically demanding and has, apart from centers in the Far East, not yet been established as a standard in gastric resections.

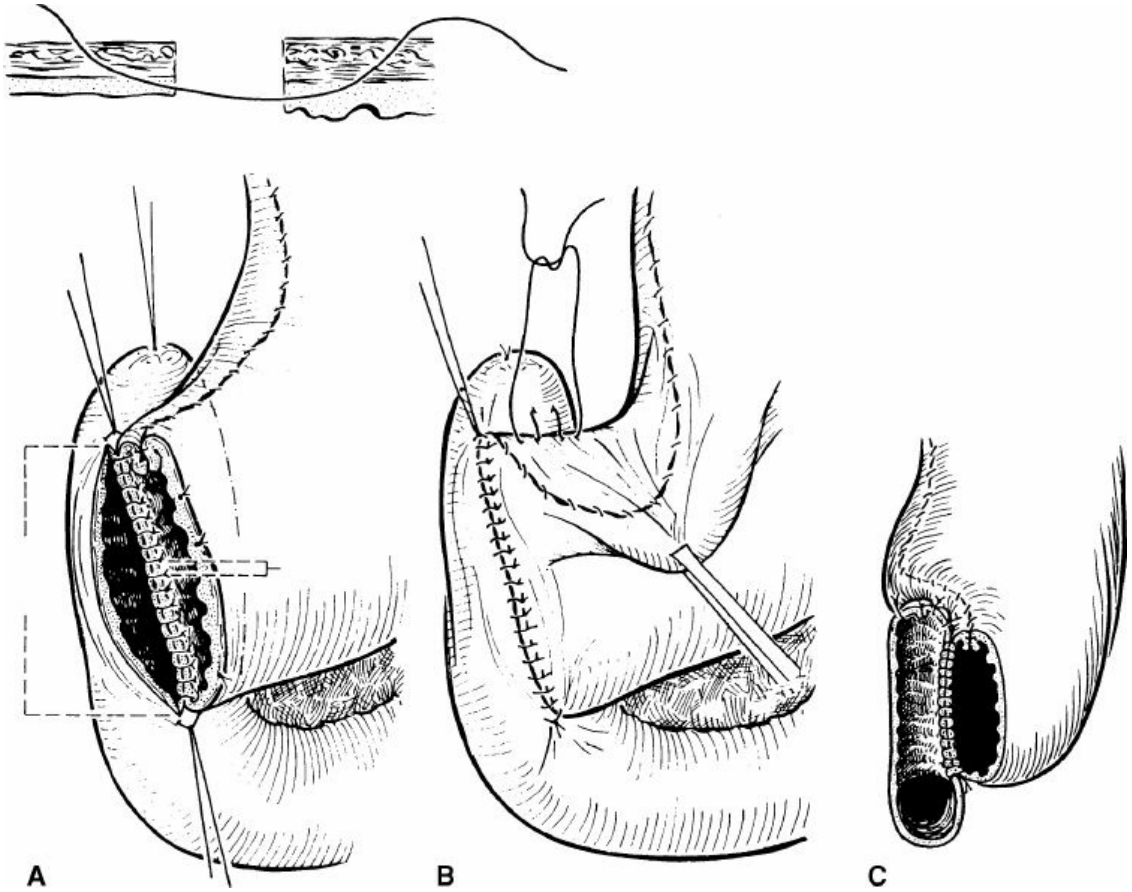

Figure 84.11. End-to-side gastroduodenostomy (**A**). After removal of the distal stomach, the gastric lumen is anastomosed onto the front wall of the duodenum. (The suturing technique is the same as described in Figs. 84.7 through 84.12) (**B**). The duodenal stump is covered with the back of the gastric wall (**C**). (From Siewert JR et al. Chirurgische Leitsymptome. Berlin: Springer, 1990, with permission of Springer.)

Other Modifications of BI Gastrectomy

Again, working groups from Japan and China, where early gastric cancer is more frequent than in the Western hemisphere, have introduced two modifications to the standard BI gastrectomy. These are pylorus-preserving BI gastrectomy and vagus-preserving BI gastrectomy. Early results of the techniques, which can be combined, have demonstrated a better quality of life after resection as compared with the standard technique, but these results still require further confirmation and both modifications are not widely used.

SURGICAL TECHNIQUE: BII GASTRECTOMY

The surgical access to the abdomen (midline epigastric incision) is equal to the one described for the BI operation. After dissection of the greater and lesser curvature (Fig. 84.12A) and partial removal of the omentum the duodenum is mobilized according to Kocher and circumferentially dissected. The right epiploic artery and the corresponding vein as well as the right gastric artery are divided between clamps and ligated (Fig. 84.12C). The duodenum is then divided with the help of a linear stapler (TA-55 (Covidien) or TL60 (Ethicon)) 2 cm aborally to the pylorus (Fig. 84.12B). Oversewing of the staple line of the duodenal stump is still in debate; we recommend it (seromuscular interrupted sutures, resorbable, 3-0) in all cases in which this can be done tension-free and without damage to the seromuscular layer of the duodenal stump. Meanwhile, the distal antrum is temporarily closed with a clamp. Dissection of the greater and lesser curvature is then finalized and the resection can be more extended as compared with the BI operation.

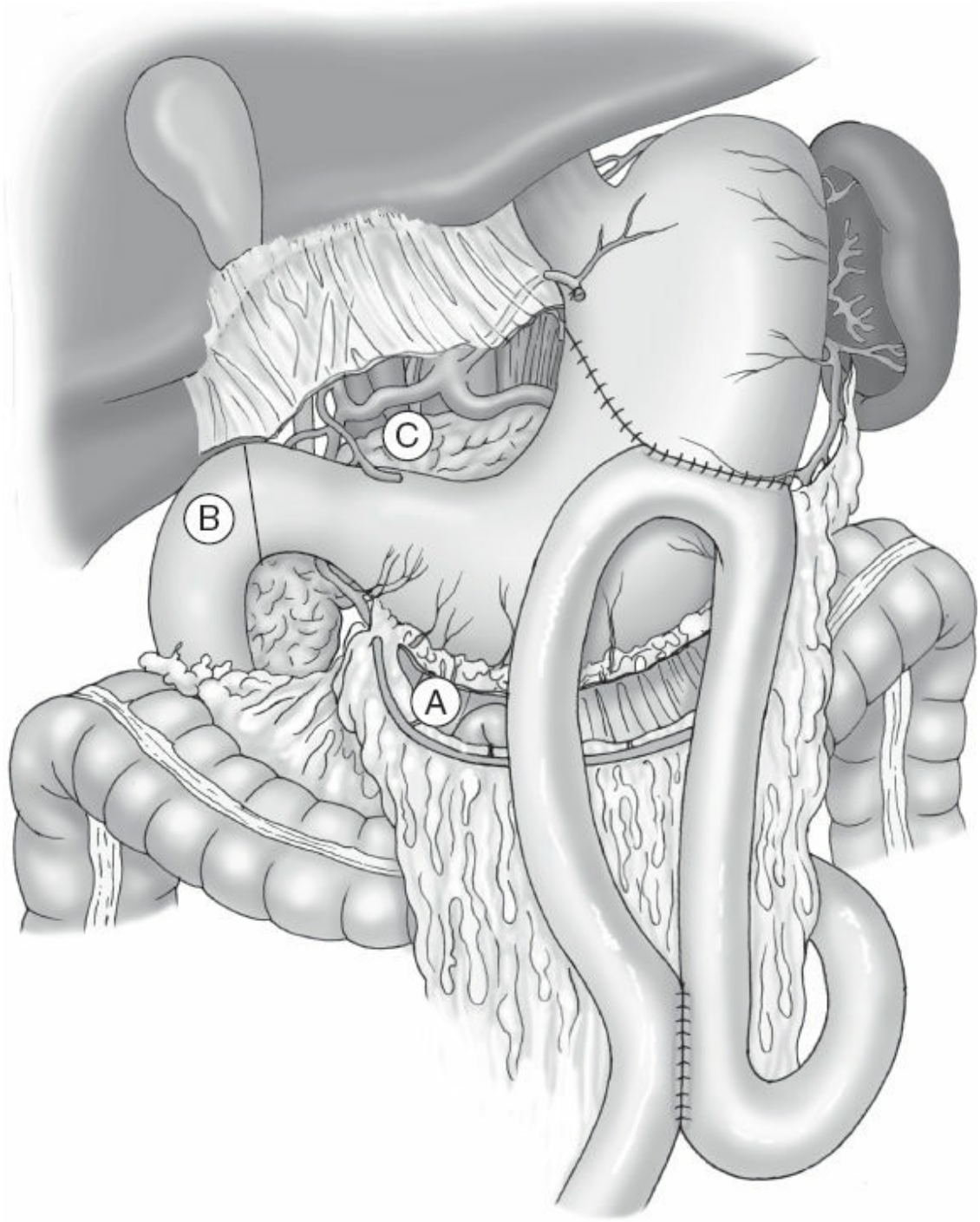

Figure 84.12. The BII reconstruction. The first or second jejunal loop of the jejunum is used, and a jejunojejunostomy (according to Braun) should be accomplished in order to prevent bile reflux. See text for details.

In the standard BII procedure, both the left gastric and left epiploic artery are preserved. At the oral margin of the dissection line, usually covering two-thirds of the stomach, the resection is completed by transverse application of a linear stapler (TA-90) in a way that the

complete stomach is divided between one stapler application. The specimen is removed. Again, we recommend addition of a selective vagotomy of the gastric remnant only for benign ulcer surgery in which gastric hypersecretion is assumed as one of the main pathogenetic factors, that is, in cases with multiple ulcers or prepyloric ulcers. In these rare cases we carefully divide the vagal branches of the anterior and posterior vagus that lead to the gastric remnant and leave the hepatic vagal branches intact.

The staple line can be oversewn, is not a must. In the next step, the first or second loop of the jejunum is mobilized and placed tension-free and in a retrocolonic fashion opposite the greater curvature of the remaining stomach. The loop should be long enough and should have a jejunojejunostomy (Braun) between the ascending and the descending loop.

Retrocolonic BII reconstructions in the Polya–Reichel technique (short ascending loop without enteroanastomosis) are rarely, if ever, performed today. The last 4 to 5 cm of the stapler line toward the greater curvature should be excised with the help of an electrocautery device in order to form a slim opening for the subsequent gastrojejunostomy. Meticulous hemostasis at the front and back wall of the stomach is required. Stay sutures are placed on both sides of the anastomosis. The jejunum is incised with the electrocautery device opposite the mesenterium. The gastrojejunostomy is performed by single interrupted sutures with resorbable suture material (3-0) and, as the anastomosis cannot be turned, the back wall is sutured by interrupted mattress sutures and the front wall by extramucosal interrupted sutures. Alternatively, continuous suturing with a monofilament resorbable thread (3-0) on both sides of the anastomosis is possible.

Before finalization of the front wall, a double-lumen gastric tube is placed distally to the anastomosis, allowing early enteral nutrition. In order to prevent enterogastric (bile) reflux, the formation of a jejunojejunostomosis, the so-called Braun anastomosis, side-to-side and 30 cm aborally of the gastrojejunostomy is mandatory. This anastomosis can be either handsewn (interrupted or continuous technique, resorbable suture material, 3-0) or stapled. Placement of a drainage in the BII procedure is controversial; in most cases we regard a drain as unnecessary. The use of circular staplers for the gastrojejunostomy has been described, but we regard this technique as far too expensive for routine use.

SURGICAL TECHNIQUE: RY GASTROJEJUNOSTOMY

The surgical technique of RY gastrojejunostomy is discussed in detail in Chapter 82.

SURGICAL TECHNIQUE: SUBTOTAL GASTRECTOMY

The subtotal gastrectomy (Fig. 84.13) is an alternative, more extended gastric resection enabling a D2 lymphadenectomy suitable for removal of early (T1, T2), well-differentiated, and distally located gastric cancers. As a general rule, at least four-fifths of the stomach is removed. In contrast to total gastrectomy, the technique preserves an intact lower esophageal sphincter as well as a small remaining gastric reservoir. The standard access is a transverse upper laparotomy, which offers good exposition of the stomach and the celiac axis. In the first step the omentum is dissected from the transverse colon, opening the omental bursa, and left at the specimen for complete removal. The gastrosplenic ligament, including the short gastric vessels, are divided up to the resection line (illustrated in Fig. 84.13) at the greater curvature. However, it is crucial to preserve the main trunk of the left gastroepiploic artery as well as the spleen to ensure good perfusion of the gastric remnant.

Mobilization of the duodenum, division of the right epiploic artery, and transverse stapler duodenotomy are performed as in BII gastrectomy. At the lesser curvature we dissect up to the level outlined in Figure 84.13, preserving the hepatic vagal innervation. As the next step, a complete D2 lymphadenectomy including central division of the right and left gastric artery (see Chapter 93) can be performed. It is advisable to leave all resected lymph nodes and the left gastric artery *en bloc* at the specimen. After this step, the gastric remnant is perfused mainly from the left epiploic artery and orally from branches of esophageal arteries. The proximal division of the stomach with the TA-90 stapler is as described for BII gastrectomy. The specimen is removed, and we reconstruct the gastrointestinal passage as for the RY reconstruction. The most common technical error is that the greater curvature is dissected too far and that blood supply from the left gastroepiploic artery is insufficient for the gastric stump. In these cases, subtotal gastrectomy should be given up and, alternatively, a total gastrectomy should be performed.

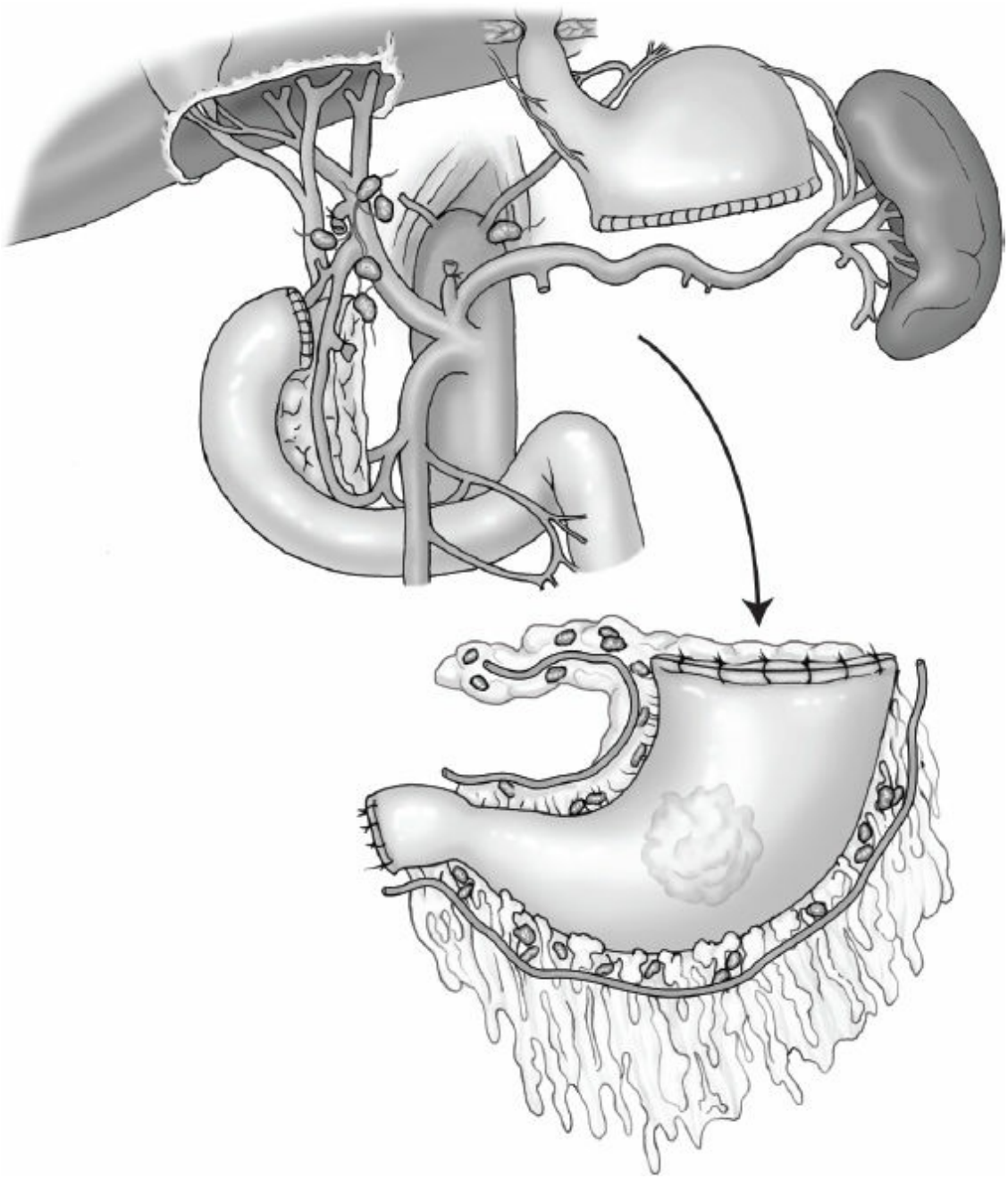

Figure 84.13. Subtotal gastrectomy. The resection involves four-fifths of the stomach, including the omentum, the right and left hepatic arteries, and the lymph nodes at the lesser and greater curvature, as well as the lymph nodes in the gastroduodenal ligament. The left epiploic artery must be preserved. This drawing shows the main portion of the left gastric artery intact. In case a complete DII lymphadenectomy is needed, the artery should be centrally ligated and resected.

POSTOPERATIVE CARE

Abdominal drains after partial gastric resections are usually not required,

except for partial gastric resections for perforation. A gastric tube is useful but can be removed after 1 to 2 days. Oral liquid intake is usually begun on the 2nd postoperative day. Alternatively, early enteral nutrition can be accomplished by an enteral feeding tube with the tip of the tube placed distally of the anastomosis. All patients receive one shot of antibiotic perioperatively.

POSTOPERATIVE COMPLICATIONS

After partial resections of the stomach, the following complications can occur: anastomotic leak in the area of the gastroduodenostomy (1% to 4%), bleeding (2%), passage disorders (2% to 5%), and postoperative pancreatitis (0.9%). Symptoms of an afferent loop syndrome (stasis, fullness, biliary vomiting) have become rare because placement of Braun anastomosis usually prevents this condition. If this occurs, some patients might need reoperation and RY reconstruction.

Suture insufficiency of the gastroduodenostomy or gastrojejunostomy are infrequent and can be managed well with conservative therapy as long as suture dehiscence does not occur in the first 3 or 4 days after the operation. It is imperative that the leak is well drained. With additional drainage by a gastric tube, and high doses of proton pump inhibitors, and parenteral nutrition, it is usually possible for the anastomotic leak to heal.

Problems with gastric emptying rarely occur after gastroduodenostomy. If gastric stasis is a problem, it is usually a consequence of anastomotic edema or a hematoma and resolves after 10 to 14 days with good drainage of the stomach. Revisions are rarely necessary.

Intragastric or intraperitoneal bleeding is infrequent. Management depends on the extent of bleeding. Endoscopic hemostasis by injection therapy should always been attempted. Reoperation should follow if more than four units of blood per 24 hours are needed for replacement of the lost volume and endoscopic intervention is not possible. For intraluminal bleeding from the anastomosis or the stomach remnant, the stomach must be reopened with a horizontal incision approximately 3 to 5 cm above the anastomosis. The anastomosis and the stomach remnant can be surveyed easily from there, and hemostasis can be obtained. Closure of the incision follows in a horizontal direction. Extraluminal bleeding sources are dealt with in a typical way. If the spleen represents the source of bleeding, hemostasis by coagulation, application of polyglactin 910 mesh or, if inevitable, splenectomy may be required.

Postoperative pancreatitis is usually of the edematous variety, and the prognosis is relatively good. If it is hemorrhagic or necrotizing pancreatitis, however, a high mortality must be expected. In postoperative pancreatitis of this kind, mechanical injury of the pancreatic duct should always be suspected.

RESULTS AND POSTOPERATIVE DISEASE

A mortality of 1% to 2% was observed in former studies of partial gastric resections for an uncomplicated gastric ulcer, and the mortality is independent of the mode of reconstruction. Mortality tends to be higher in emergency surgery for complicated ulcers. Ulcers recur in 0% to 4% of patients, and serious postgastrectomy problems are observed in 3% to 5% of patients.

Chronic Gastritis, Gastric Stump Cancer

In 80% to 90% of patients who have undergone partial gastrectomy, chronic gastritis of varying extent occurs in the stomach remnant 15 to 25 years after resection. That atrophic mucosal changes are less pronounced after BI resection than after BII resection has not been sufficiently proven. However, studies support the hypothesis that the risk of gastric stump cancer is higher after BII than after BI gastrectomy. The overall risk of developing cancer after partial gastrectomy is increased up to eightfold over the normal population.

Enterogastric reflux, achlorhydria, bacteria overgrowth, and *H. pylori* appear to be the major factors involved in the pathogenesis of the gastric stump cancer. Treatment consists of resection of the gastric remnant, esophagojejunostomy, and regional lymphadenectomy. Most patients who have undergone gastrectomy and present with atrophic gastritis do not complain of symptoms. Only approximately 10% of patients complain of symptoms and require treatment. The cause of these complaints is apparently not chronic gastritis itself, but enterogastric reflux. Bile acid quantity and concentration progressively decrease from BII to BI. The clinical signs and symptoms are epigastric pain, feeling of fullness, nausea, and bile vomiting. The disappearance of epigastric symptoms after bile vomiting is characteristic, as is its intensification by stimulation of bile or pancreatic secretion. Conservative treatment includes metoclopramide, spasmolytics, and perhaps cholestyramine, antacids, and dietary regulations. An antiperistaltic jejunal interposition is rarely necessary.

Dumping

Dumping problems, in the sense of early dumping, are less frequent after BI resection than after BII resection. The frequency is between 7% and 29% of patients. The most important conservative measure is dietary (no sweet meals, frequent small meals, no liquid intake with food). All attempts with drugs, including serotonin antagonists, have proved disappointing, except for somatostatin, which is available in intravenous or subcutaneous forms but not for oral intake. The most serious dumping forms can be an indication for surgical revision and conversion of a BII into a RY gastrojejunostomy or antiperistaltic jejunal interposition.

Gastroesophageal Reflux

Gastroesophageal reflux does not frequently occur after resection of the distal part of the stomach. The medical history often reveals that gastroesophageal reflux was present before the operation; this frequently occurs in patients who have ulcers. There is no evidence that reflux after BI resection is less frequent than after other forms of stomach resection. However, researchers have described decreased lower esophageal sphincter pressures after partial gastric resections. In case of problems, the diagnostic examination of reflux esophagitis after stomach resection requires endoscopy, 24-hour pH measurement, and an examination of the refluxed material for bile acids. Metoclopramide can be useful, but antacids are also helpful because of their bile acid-absorbing qualities. Serious reflux esophagitis can be an indication for a conversion to a Roux-en-Y gastrojejunostomy with a long efferent loop.

H. pylori infections in the gastric remnant are frequent after partial gastrectomy. Eradication is mandatory after detection. There is, however, no evidence that these infections lead to major clinical consequences or to an increased frequency of ulcer recurrence in these patients.

Suggested Readings

Adachi Y, Shiraishi N, Ikebe K, et al. Evaluation of the cost for laparoscopic-assisted Billroth I gastrectomy. *Surg Endosc* 2001;15:932.

Adachi Y, Shiraishi N, Shiromizu A, et al. Laparoscopy-assisted Billroth I gastrectomy compared with conventional open gastrectomy. *Arch Surg* 2000;135:806.

Avidan B, Sonnenberg A, Schnell TG, et al. Gastric surgery is not a risk for

Barrett's esophagus or esophageal adenocarcinoma. *Gastroenterology* 2001;121:1281.

Chen XZ, Hu JK, Yang K, et al. Short-term evaluation of laparoscopy-assisted distal gastrectomy for predictive early gastric cancer: a meta-analysis of randomized controlled trials. *Surg Laparosc Endosc Percutan Tech* 2009;19(4):277–84.

Csendes A, Burgos AM, Smok G, et al. Latest results (12–21 years) of a prospective randomized study comparing Billroth II and Roux-en-Y anastomosis after a partial gastrectomy plus vagotomy in patients with duodenal ulcers. *Ann Surg* 2009;249(2):189–94.

Fukuhara K, Osugi H, Takada N, et al. Reconstructive procedure after distal gastrectomy for gastric cancer that best prevents duodenogastroesophageal reflux. *World J Surg* 2002;26:1452.

Haglund UH, Jansson RL, Lindhagen JG, et al. Primary Roux-Y gastrojejunostomy versus gastroduodenostomy after antrectomy and selective vagotomy. *Am J Surg* 1990;159:546.

Ishikawa M, Kitayama J, Kaizaki S, et al. Prospective randomized trial comparing Billroth I and Roux-en-Y procedures after distal gastrectomy for gastric carcinoma. *World J Surg* 2005;29(11):1415–20; discussion 1421.

Izbicki JR, Gawad KA, Quirrenbach S, et al. Is the stapled suture in visceral surgery still justified? A prospective controlled, randomized study of cost effectiveness of manual and stapler suture [in German]. *Chirurg* 1998;69:725.

Kim YW, Baik YH, Yun YH, et al. Improved quality of life outcomes after laparoscopy-assisted distal gastrectomy for early gastric cancer: results of a prospective randomized clinical trial. *Ann Surg* 2008; 248(5):721–7.

Kitano S, Shiraishi N, Fujii K, et al. A randomized controlled trial comparing open vs laparoscopy-assisted distal gastrectomy for the treatment of early gastric cancer: an interim report. *Surgery* 2002;131:S306.

Kitano S, Shiraishi N, Uyama I, et al. A multicenter study on oncologic outcome of laparoscopic gastrectomy for early cancer in Japan. *Ann Surg* 2007;245(1):68–72.

Montesani C, D'Amato A, Santella S, et al. Billroth I versus Billroth II versus Roux-en-Y after subtotal gastrectomy. Prospective [correction of prespective] randomized study. *Hepatogastroenterology* 2002;49:1469.

Orsenigo E, Tomajer V, Di Palo S, et al. Sentinel node mapping during laparoscopic distal gastrectomy for gastric cancer. *Surg Endosc* 2008;22(1):118–21. Epub 2007 May 5.

Safatle-Ribeiro AV, Ribeiro U Jr, Reynolds JC. Gastric stump cancer: what is the risk? *Dig Dis* 1998;16:159.

Shibata C, Shiiba KI, Funayama Y, et al. Outcomes after pylorus-preserving gastrectomy for early gastric cancer: a prospective multicenter trial. *World J Surg* 2004;28(9):857–61.

Siewert JR, Bumm R, Holscher AH. Surgical therapy of stomach ulcer [in German]. *Schweiz Med Wochenschr* 1989;119:690.

Stein HJ, Feussner H, Kauer W, et al. Alkaline gastroesophageal reflux: assessment by ambulatory esophageal aspiration and pH monitoring. *Am J Surg* 1994;167:163.

Tanimura S, Higashino M, Fukunaga Y, et al. Laparoscopic distal gastrectomy with regional lymph node dissection for gastric cancer. *Surg Endosc* 2003;17:758.

von Holstein CS. Long-term prognosis after partial gastrectomy for gastroduodenal ulcer. *World J Surg* 2000;24:307.

EDITOR'S COMMENT

We are very pleased to have Professor Bumm and his mentor, Professor J. Rüdiger Siewert, back again as authors in this edition. Once again, I am often asked why we bring up a new edition every 5 years, and the relevant answer in this regard is that there have been significant changes in the whole area of gastrectomy in general and carcinoma of the stomach in particular. First, there has been a general consensus of the superiority of the Roux-en-Y as compared with the Billroth II for a major gastric resection; in other words, a carcinoma of the stomach with extension beyond the halfway point so that to get an adequate margin, one would have to take it fairly high to 75% or 80% gastrectomy point. In that case, the reconstruction certainly cannot be a Billroth I but it is between a Billroth II and a Roux-en-Y. There has been a flight away from the Billroth II as a number of works, particularly from the Tokyo Cancer Hospital, headed by Dr. Katai, which has demonstrated well in a randomized trial that the Roux-en-Y, at least the way they do it, which is not to do the end-to-side gastrojejunostomy less than 55 cm downstream from the ligament of treitz, is a much more satisfactory outcome as far as bile reflux and reflux esophagitis with a Roux-en-Y than with a Billroth II anastomosis is concerned. Indeed, there are several studies from Japan and Korea where many studies have been done comparing these various anastomoses following major and not so major gastrectomies, but the Roux-en-Y is not only better from the standpoint of food intake, residual gastritis, bile reflux, esophagitis, and so on, but also seems to be superior to the Billroth I. This is not to denigrate the work that both of our authors have done, particularly Dr. J. Rüdiger Siewert, who has set a new standard for carcinoma of the stomach and various gastrectomies; we are indeed pleased to have him back as a coauthor. Nonetheless, in the United States, it is almost as if nobody has heard of the Roux-en-Y reconstruction, and indeed at the Beth Israel Deaconess it is rare to see a reconstruction with a Roux-en-Y,

and Billroth Is and Billroth IIs are thought of as perfectly adequate. It seems that there is some problem in getting the message across the medical fraternity.

The second point in which things have changed is the status of the D2 nodal dissection for carcinoma of the stomach. Carcinoma of the stomach is fairly rare in the United States, and therefore the completeness of the dissection, especially in the nodal dissection for carcinoma of the stomach, leaves even surgeons with good experience doing gastrectomies for carcinoma of the stomach at a disadvantage with the nodal dissection. The Japanese results have always been superior, and although Japanese surgeons have been given some credit for their experience, it had been stated that the reason why the Japanese results are so good is that "there are no fat Japanese." Those who have given this statement have not been to Japan lately. It does appear that the Japanese, particularly males, now have their share of obesity, and so one cannot describe the results that the Japanese surgeons get with a completeness of the gastric resection and their long-term survival to "skinny Japanese." Indeed, when the Dutch did one of their famous randomized prospective trials on carcinoma of the stomach, and the results were very much inferior to the Japanese results, with respect to complications, mortality, and in oncological outcome, it was finally suggested that the Dutch surgeons and anybody else who was interested to go to Japan and watch the Japanese surgeons, especially at the Tokyo National Cancer Hospital, do these operations. Interestingly, that suggestion was taken, and after watching the prowess of the Japanese surgeons in doing cancer surgery on the stomach including D2 resections, the European surgeons came back, adopted the techniques, and after a while their results were just as good as what they have observed. Therefore, we now have acceptance of the Roux-en-Y, not necessarily practiced in this country, but a D2 resection, which is deemed an essential part of an operation for gastric carcinoma.

I very much like Professors Bumm and Siewert's article entitled, "Arguments in Favor of Billroth II Gastrectomy or Roux-en-Y Reconstruction." They point out that a Billroth II reconstruction allows a major gastrectomy for carcinoma of the stomach and the lymphadenectomy, particularly the extended lymphadenectomy is easier. I am neither advocating partial pancreatectomy nor am I arguing for splenectomy to get the nodes in this particular case. They point out that in Billroth II, especially with a small pouch, there may be the dumping syndrome, in which case they can be reconstructed with a Roux-en-Y. There are good arguments for the use of partial gastrectomy particularly in the treatment of gastric ulcer because this is theoretically a low-acid ulcer, there may be a malignancy that is lurking in the ulcer, and because one does reduce both the chief cells and the antrum for the formation of gastrin. There are also excellent points concerning early carcinoma and the carcinoma of the antrum, in which they state openly that in locally early carcinoma and carcinoma of the antrum, the standard operation for locally advanced gastric cancer should be a total gastrectomy with adequate lymphadenectomy. However, they also state that a well differentiated early T1/T2 N0 gastrointestinal carcinoma should undergo a

subtotal gastric resection, with a 4/5 gastrectomy and a standard D2 lymphadenectomy. The reconstruction should be a Billroth II or a Roux-en-Y and it is also pointed out that in the Far East, their surveillance is religious, mucosal cancers of the antrum are common, and a lesser gastrectomy is frequently done with a Billroth I reconstruction. Sentinel lymph node dissection has been advocated, but I have yet to see a really convincing argument for a sentinel lymph node, and I suspect why this really does not work is because of many sentinel lymph nodes, and by the time you are finished with these various sentinel lymph nodes, you have essentially done a lymph-node dissection.

The authors also make an excellent technical point of stretching the stomach along the greater curvature in the left duodenal wall and then going around the back and toward the lateral duodenal wall at the point of the hepatic duodenal ligament. In doing so, they manage to free up 3 to 5 cm of the back wall of the duodenum, and the transition from the free first part of the duodenum to the duodenum fixated to the pancreas can be recognized by the gastroduodenal artery. The artery is of course important for the blood supply to the first and second parts of the duodenum and the pancreas. This is a better way of getting around some of the difficult parts of partial gastrectomy, especially if one desires to do a Billroth I type of anastomosis. One of the appropriate technical points is that, in doing a complete D2 lymphadenectomy, all resected lymph nodes in the left gastric artery are attached *en bloc* to the specimen. The gastric remnant at that point is perfused mainly from the left gastric artery and orally from the branches of the esophageal artery and, if present, the posterior gastric artery, which is rare. Clearly, these are two surgeons who are excellent technicians, who have remarkable experience of gastric resection.

Some of the papers that I quote, I admit in this regard, are somewhat disappointing, in which the surgeons, although well known and very highly respected, seem to be in [a] different place and asking different questions than perhaps they should be. A good example of this is the first paper authored by Kojima K et al., “Comparison of Roux-en-Y and Billroth-I reconstruction after laparoscopy-assisted distal gastrectomy” (*Ann Surg* 2008;247:962–7), in which it is almost as if they are testing out whether such procedures can be carried out laparoscopically instead of asking more sophisticated questions, which they are quite capable of. In this study, they have evaluated a total of 133 patients who underwent laparoscopic-assisted distal gastrectomy for gastric carcinoma, and in whom the reconstruction was 65 randomized to Billroth I and 68 randomized to Roux-en-Y. They reported tumor characteristics, operative details, postoperative outcomes, and nutritional status. They also evaluated the endoscopic description of the gastric remnant and the esophagus a year postoperatively. However, there are no differences between the two groups. In the Billroth I group, three patients developed anastomotic leakage and four patients an anastomotic stricture requiring balloon dilation. The so-called functional stasis after Roux-en-Y reconstruction or the Roux syndrome, which is a popular bugaboo in our country, does not seem to occur, possibly because

of where side-to-end anastomosis is done for the Roux-en-Y, it being longer and probably less prone to spasm than a shorter Roux-en-Y, which I believe is the practice in this country. There is a higher incidence of heartburn in the Billroth I group (37%), and only 8% in the Roux-en-Y group (P = 0.0002). A novel aspect of the follow-up was comparing the amount of meal consumed with a preoperative value, which was significantly higher in the Roux-en-Y group, 83.6%, versus 79% (P = 0.047), and then an endoscopic finding showing remnant gastritis was significantly lower in the Roux-en-Y group than in the Billroth I group, B-1, being 34% and Roux-en-Y being 12% (P = 0.002). This has been an almost constant finding in Japanese studies comparing these two drainage procedures.

The next paper is from the Rui Jin Hospital, which is the principal international-class hospital of the Shanghai Medical School in China by Sah BK et al., "Gastric cancer surgery: Billroth I or Billroth II for distal gastrectomy?" (*BMC Cancer* 2009;9:428–54, published online). I personally visited this hospital and spoke at the institution. I found it a world-class institution, which was well-equipped, very interested in learning about simulation and education of residents, and would assume facilities and, it seems, excellent surgeons. They compared the Billroth I and Billroth II types of anastomoses with distal gastrectomies in 809 patients with gastric cancer in 4 years. The study endpoint was limited to an analysis of patients' postoperative complications. They did evaluate the risk-adjusted complication rate by comparing the outcome to physiological and operative severity score for enumeration of morbidity and mortality (POSSUM).

There was no randomization in this study. While Billroth I accounted for 626 of the 809 drainage procedures, Billroth II accounted for 183. They did find, and it is not clear, other than the surgeon's preference, what influenced in deciding whether the patient would require a Billroth I or a Billroth II. The procedures carried out did not include a total gastrectomy. They have another method of accounting for complications in addition to the one that was used in this paper. Interestingly, the summary statement would be that the ratio of observed to estimated complications was 1.03 for the Billroth II group, while it was only 0.74 in the Billroth I group, which freely translated means that there are fewer complications in the Billroth I group as proposed, because of the POSSUM evaluation, than there were in the Billroth II group. Leaks at the anastomosis and other severe complications were considerably greater in the Billroth II group, as was the cost. Anastomotic leak, for example, was 8 in the Billroth I group and only 6 in the Billroth II group, but remember that the difference in the patient population was three to four times in the Billroth I group; nonetheless, this is not statistically significant. In Figure 84.1, the percent complications were given showing an advantage in the Billroth I group of all complications. Not surprisingly, the expenditure in the Billroth II was greater than in the Billroth I.

A similar paper was published by Kang K-C et al. that compared Billroth I

and Billroth II reconstructions after laparoscopy-assisted distal gastrectomy results. In this case, it seems that the authors were still comfortable with the Billroth I and Billroth II done laparoscopically, where, in other papers from Korea, it would seem that they have adopted the point that, after 50 to 75 laparoscopic gastrectomies, one became comfortable with the procedures. There were 875 patients in the Billroth I group, and 384 in the Billroth II group. There was no assessment of nutritional status preoperatively, and there was no Roux-en-Y carried out. It seems to be a constant practice in the Korean papers, and perhaps they either are not performed as readily or are not performed as an initial drainage procedure but only after complications. In the Billroth I group, the overall complication rate was 11.4% and in the Billroth II it was 17% (P = 0.011). However, the differences in the major complication rates depending on the complication were not individually separate. Blowout of the duodenal stump was the most frequent complication following the Billroth I, but the mortality rate did not reach statistical significance. One would point out that this was a good study, because the comorbidities in the Billroth I were approximately 35% and in the Billroth II group 39%, but of course the number of patients is much different.

In continuation of the exploration of technique for performing the Billroth II anastomosis as well as doing a Billroth I, the next paper is by Oh SJ et al. (*J Gastrointest Surg* 2011;15:1244–6), in which it seems that a standard type of Billroth II anastomosis was done, with a slightly different stapling technique, in which an Allen clamp was then placed along the greater curve, and then a biopsy was taken from the proposed site of the anastomosis, and, once the frozen section was negative, they made an opening in the greater curvature for the anastomosis. This is done with a circular stapler. There are photographs, which do not reproduce well, or at least I cannot see well what they are actually doing, although there are drawings that are a little more explicative as far as what is happening, but I am not certain. Suffice it to say that under “Results,” “Since June 2002, we have employed a mechanical stapling technique instead of the traditional hand-sewn anastomosis…following distal gastrectomy.” This has been performed in 520 patients over a period of 8 years. There have been no anastomotic leaks or stenotic complications. There were two episodes of intraluminal bleeding, although clearly this group is delighted with their circular-stapling technique to do a Billroth II anastomosis.

In another paper from Korea, however, An JY et al. (*J Surg Oncol* 2009;100:518–519), at Yonsei University, modified a double-stapling technique to avoid stapling on the suture line. This is a short paper but, except for the last two drawings, I do not understand exactly what they are referring to. This is a double-stapling technique not coming across the suture line of the stapling line, which results in a Billroth I anastomosis, with which they are apparently fairly happy. Here again neither the photographs nor the drawings are particularly understandable, except that it seems that they are happy with it.

In short, it is unfortunate that it seems that people are trying to do in the Far

East, where they have lots of fertile ground for studies, is to see whether or not they can convert from the open technique to the stapling technique, and, if they do have a stapling technique, then they are trying to figure out new ways of doing Billroth Is and Billroth IIs. It is interesting that in all of these papers the Roux-en-Y as a principal means of reconstruction does not make an appearance. With this volume, it would be nice to have some confirmation of what we have observed in other studies, that is, the Roux-en-Y is superior to the Billroth I and Billroth II. It should be possible to put together such a study, which, I am sorry, we have not seen in this group of a large number of patients, which seem to have been concentrated on whether they can do Billroth Is and Billroth IIs. Perhaps, in the next edition we will see this type of study is undertaken.

J.E.F.

85 Selective Vagotomy, Antrectomy, and Gastroduodenostomy for the Treatment of Duodenal Ulcer

Lloyd M. Nyhus

*This Chapter can be accessed in the accompanying eBook edition (see inside front cover for access instructions).*

The surgical treatment of complicated duodenal ulcer has undergone marked change since vagotomy was reintroduced by Dragstedt and Owens in 1943. Subtotal gastrectomy alone had been the mainstay operation for the prior 50 years, followed by various surgical procedures, including truncal vagotomy, gastroenterostomy, pyloroplasty, 70% subtotal gastrectomy, and antrectomy. My experience with the combined operation of truncal vagotomy, antrectomy, and gastroduodenostomy began in the early 1950s. It became apparent that the method of vagotomy could be improved. Therefore, my associates and I modified our technique of vagotomy to the selective method and changed the name of the procedure to the "revised combined operation." Thus, the specific procedure included selective vagotomy, antrectomy (35% distal gastrectomy), and gastroduodenostomy (Billroth I anastomosis). This operation has a good record in terms of ulcer recurrence. The recurrent ulcer rate after this procedure should be no greater than 0.5%.

Because of the interest in proximal gastric vagotomy, we have departed from gastrectomy as a routine operative procedure in our clinic. Yet, because of the occasional need to perform a partial gastrectomy or antrectomy, the technical lessons we learned must not be forgotten. For this reason, I highlight the classic "revised combined operation of Harkins" in this chapter.

SURGICAL TECHNIQUE

Failure to appreciate technical details is reflected not only in resultant

anatomic disturbances such as postoperative suture line leakage, but also in physiologic effects (e.g., recurrent ulcer from incomplete vagotomy). My experience in performing the revised combined operation (i.e., selective vagotomy plus antrectomy plus gastroduodenostomy) has led to the modification of certain steps in the technique.

Surgery is an art, and, like all art, it must be developed, not discovered. The technique described is the one that seems to give the best results at the present time. Much of the following surgical technique is applicable to the Billroth II procedure as well as to the Billroth I operation.

GENERAL PRINCIPLES

Sutures

A variety of sutures are used throughout the operation. Whereas fine silk was used predominantly in the past, new absorbable and nonabsorbable sutures may be used now. Most vessels are simply ligated, but transfixion sutures are occasionally used. An absorbable suture is used essentially as a mucosal stitch with inversion for the inner layer of the anastomosis. Seromuscular sutures continue to be of 4-0 or 3-0 black silk. The abdominal wall closure has changed from silk to stainless-steel wire sutures to the current use of several monofilament synthetic sutures.

OPEN ANASTOMOSIS

I prefer the open to the closed type of anastomosis for several reasons. First, because the open technique provides direct visualization at all times, bleeding from the anastomosis can be entirely prevented. Second, the size of the anastomotic stoma can be ensured, and the surgeon can be certain that the anterior and posterior walls are not included in one or more sutures. Third, through the open duodenal stump, the ampulla of Vater can be palpated and biliary flow can be noted; also, the area can be inspected for postbulbar duodenal ulcer and other duodenal abnormalities. I have seen no difficulty arise from soiling of the surgical field with the use of the open technique. The bacterial flora of the stomach and duodenum are few if there is no distal obstruction, and adequate protection can be achieved by careful placement of laparotomy pads to protect the remainder of the operative field. An inner mucosal or full-thickness layer of continuous absorbable sutures and an outer seromuscular layer of interrupted silk sutures are routine to complete the anastomosis.

DRAINAGE

If it is suspected that the pancreas has been subjected to undue surgical trauma, a Penrose drain or a double-lumen sump-suction catheter can be placed down to the site of suspected injury and brought out laterally through the abdominal wall via a stab wound; it is never brought through the main incision. Rarely, I place a Penrose drain near, but not on, the anastomosis if some aspect of the coaptation causes concern.

ADEQUACY OF RESECTION

I adhere inviolably to the dictum that an adequate resection must be performed on the basis of the presenting disease before any decision is made to use or not to use any particular type of anastomosis. In fact, this decision is not made until the anastomosis is to be done. If there is any tension whatsoever in attempting to perform a gastroduodenal anastomosis, this method is abandoned and a modification of the Billroth II procedure is used. The anastomosis should not be forced. In general, the resection may be only 35% when protected by selective vagotomy.

PROTECTION OF VITAL STRUCTURES

The only way to avoid injury to important structures is to visualize the part of the structure that lies in the field of dissection. The inflammatory reaction and scarring characteristic of many gastroduodenal lesions can cause distortion of the normal anatomy. This distortion, coupled with the extreme variability in “normal” anatomy, makes dissection in this region extremely hazardous unless good visualization or identification of the vital structures to be preserved is constantly sought.

The simple maneuver of opening the common bile duct in certain instances is useful when the porta hepatis is involved in ulcer scar or inflammatory reaction. It is important to recognize the possible distortion of normal anatomic configurations of the common bile duct and the pancreatic ducts. A catheter or Bakes bile duct dilator introduced via choledochotomy is reassuring when dissecting a duodenum that is thickened, distorted, or inflamed. Special care should be taken to avoid injury to the common hepatic artery, which sometimes can be retracted near a posterior penetrating duodenal ulcer crater. On the greater curvature side of the pyloric region, the middle colic artery can be so densely adherent to the ulcer scar that it easily may be mistaken for the right

gastroepiploic artery.

Caution should be used to avoid vigorous palpation or traction in the region of the spleen. The splenic vessels, particularly in older persons, are friable and easily torn. Moderate traction on the greater curvature of the stomach is sufficient to cause tearing of the splenic vessels or of the splenic substance. When such an accident occurs, appropriate splenic repair should be carried out; splenectomy may be necessary if the bleeding cannot be controlled with argon beam coagulation. Splenectomy is not a catastrophe; it can appreciably increase morbidity and even mortality.

The tenets of good modern surgery—the gentle handling of tissues, the avoidance of undue traction, and meticulous identification of adjacent structures to be preserved—are essential to a technically satisfactory operation.

AVOIDANCE OF MASS LIGATURES

In dividing the blood supply to the portion of the stomach and duodenum to be resected, it is important that small bites of tissue be ligated. Especially in patients with a large quantity of omental fat, there is a tendency, if the vessel ligatures are placed around large quantities of this fat, for the vessels to retract proximal to the ligature and cause troublesome hematomas or a dangerous hemorrhage. Particularly in older people, I have been impressed with the increased quantity of fat that surrounds the left gastric vessels high on the lesser curvature. This situation is observed even in thin elderly patients.

REMOVAL OF ULCER

In association with gastric resection, I regularly remove the duodenal ulcer for mechanical rather than physiologic reasons. Only rarely do I leave a duodenal ulcer *in situ*. However, I do not hesitate to leave the depths of an ulcer crater in the tissue into which it may have penetrated.

TECHNICAL PROCEDURE

Only the combined operation of selective vagotomy plus hemigastrectomy (antrectomy) plus gastroduodenal anastomosis is described in this section. The sequence of performance of the various steps applies to most operations. However, certain conditions germane to each situation can make a somewhat altered sequence more desirable. A step-by-step

description of the technique is undertaken merely because it is easier to describe it in this manner. It is the integration of all these steps into a smoothly performed surgical procedure that is productive of technical satisfaction.

TABLE 85.1 Step-by-Step Outline of the Combined Procedure for Selective Vagotomy Plus Antrectomy Plus Gastroduodenal Anastomosis

1. Incision
2. Abdominal exploration
3. Selective vagotomy
4. Freeing of the greater curvature
5. Mobilization of the duodenum
6. Strauss maneuver for division of the duodenum
7. Division of the gastrohepatic omentum and left gastric vessels
8. Resection
9. Closure of the Schoemaker suture line
10. Anastomosis
11. Wound closure

The surgical technique I prefer (Table 85.1) is described in the following 11 steps.

INCISION

An upper midline abdominal incision is used almost exclusively. This incision is begun in the left xiphocostal angle and is extended down the linea alba to the level of the umbilicus or below, if necessary. The incision is usually approximately 15 cm long. In patients for whom the distance between the costal arch and the umbilicus is short, I extend the incision inferiorly to one side of the umbilicus. If more room is needed proximally, I excise the xiphoid process. The peritoneum is cut approximately 2 cm to the left and lateral to the skin and fascial incision, which gives a "staggered" effect so that the underpart of the fascial closure is more or

less protected by the intact peritoneum.

ABDOMINAL EXPLORATION

The surgeon must curtail his or her enthusiasm to attack the gastroduodenal disease for which the operation was performed until there is ample opportunity to explore the entire peritoneal cavity. Unless a general exploration is performed as soon as the peritoneal cavity is entered, this important step is apt to be forgotten. In addition, it is probably a better technique to explore the general peritoneal cavity before the gastrointestinal tract has been entered to avoid the small but ever-present chance of disseminating contaminated debris. Two exceptions to the rule of exploring the general abdominal cavity before beginning the gastric procedure are emergency operations for a bleeding gastroduodenal lesion, when control of the hemorrhage should take priority, and operations for obvious acute perforation of a peptic ulcer.

It is only after adequate inspection of the gastroduodenal disease that the final decision to perform a gastric procedure should be made. This decision should, however, depend on the sum total of information available about the patient and not solely on the findings at the operation. Most often, the presence of an active ulcer, ulcer scar, or carcinoma of the stomach can be detected by external inspection and palpation. Occasionally, a posterior duodenal or a lesser curvature gastric ulcer can be identified by palpating the crater through the anterior wall of the duodenum or stomach. Often, after rapid withdrawal of the palpating finger, the anterior wall of the duodenum or stomach can be observed to remain depressed into the crater by a suction effect.

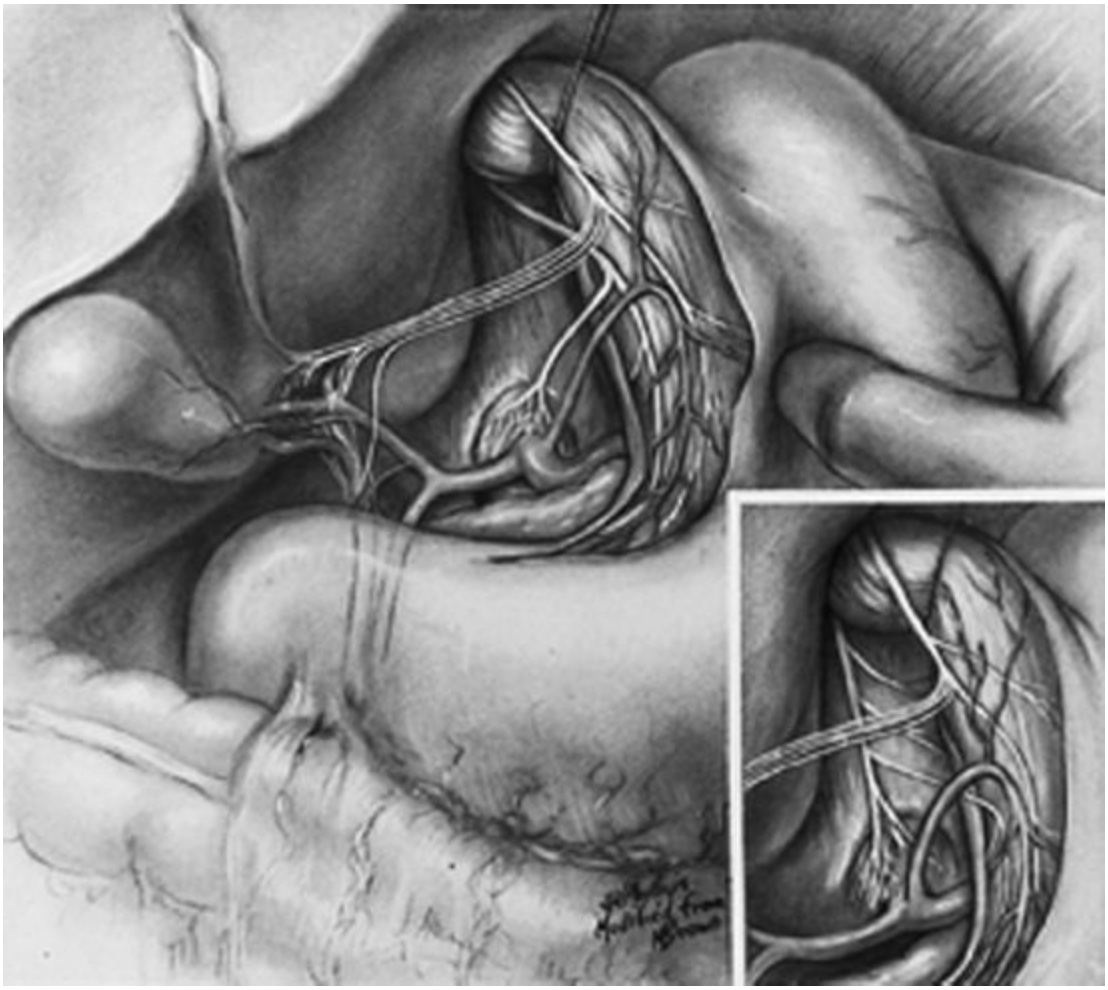

Figure 85.1. The abdominal vagi. All vagal fibers shown in this illustration are readily identified by gross anatomic dissection. The hepatic vagal division (usually consisting of multiple fibers) from the anterior trunk courses within the lesser omentum to the porta hepatis. The celiac vagal division from the posterior trunk goes to the celiac autonomic plexus, usually in close association with the left gastric artery but occasionally with the right diaphragmatic crus (*inset*). The main anterior and posterior trunks run distally within the lesser omentum adjacent to the cardia to the antrum. (From Griffith, 1977, with permission.)

SELECTIVE VAGOTOMY

Henry Harkins and Charles Griffith of Seattle (1957) are credited with modification of the truncal (total) vagotomy method to the selective technique, which preserves all extragastric vagal fibers. The late Professor Griffith fine-tuned these important advances in technique. To commemorate his contribution, I have paraphrased his 1977 and 1986 presentations.

An essential difference between truncal and selective vagotomy concerns the different anatomic levels at which vagotomy is performed. Truncal vagotomy is conventionally performed at or just above or below the diaphragmatic esophageal hiatus. In contrast, selective vagotomy is performed at the lower level of the most distal esophagus and gastric cardia (Fig. 85.1). The lower level is selected because it is the only place where all gastric vagi always gather to innervate the stomach. In taking advantage of this fundamental anatomic fact, all gastric vagi can be encircled and brought into the surgical field with anatomic certainty. This is the first and basic requirement for accomplishing complete gastric vagotomy, and it is in definite contrast with the uncertain encirclement at the hiatus, where incomplete vagotomy can and does occur because the encircling finger may exclude one or more vagal fibers.

SELECTIVE TECHNIQUE

Selective gastric vagotomy entails ligation and transection of all the previously described encircled tissues, except for the esophagus and the hepatic and celiac vagal branches. In addition, the descending branch of the left gastric artery must also be ligated and transected to interrupt posterior gastric vagi that may arise distally from the celiac division of the posterior trunk and may go to the stomach and the left gastric artery. Neither the hiatus nor the vagal trunks are dissected or exposed. Furthermore, the gastric vagi are not purposely exposed or identified. Instead, all tissues known to contain the gastric vagi are clamped, ligated, and transected.

For initial definition of the surgical field, the esophageal hiatus and vagal trunks are not exposed purposely. Instead, the hepatic vagi are identified. These vagi can always be seen in the avascular lesser omentum contrasted against the dark background of the caudate lobe of the liver (Fig. 85.2). The lesser omentum is incised below the hepatic vagi, well to the right of the patient’s gastric cardia. No gastric vagi lie to the right of this incision in the lesser omentum. Next, the peritoneum that overlies the cardioesophageal angle of His is incised, and this opening is enlarged with the finger. No gastric vagi lie to the patient’s left of this opening at the angle of His. Thus, all anterior gastric vagi are included between these two incisions in the lesser omentum and angle of His. None has been excluded.

The method of encircling all posterior gastric vagi cannot be illustrated. It is done by finger dissection. The finger is worked into the angle of His,

not with the aim of encircling the esophagus, but with the aim of palpating the posterior trunk–celiac division posterior to the esophagus. Once the posterior trunk–celiac division has been positively identified by palpating its course to the celiac plexus, the finger is dissected through the areolar tissue behind (i.e., dorsal to) the posterior trunk–celiac division. This technique isolates all posterior gastric vagi because none lies behind the division. At this point, the fingertip may be seen through the incision in the lesser omentum initially made below the hepatic vagal branches (Fig. 85.3). The encirclement of all gastric vagi with the most distal part of the esophagus is thereby accomplished with anatomic certainty. The encircling finger is replaced by a soft rubber urethral catheter to maintain encirclement and exposure.

By finger dissection, the posterior trunk–celiac division is mobilized from its bed and is encircled with another rubber urethral catheter so that it may be gently retracted to the patient's right (Fig. 85.4). The original catheter is then repositioned to encircle all anterior gastric vagi with the most distal part of the abdominal esophagus, which then may be retracted to the patient's left.

Attention is now directed to the loop of the left gastric artery, where it approaches the lesser curvature of the stomach and bifurcates into the descending gastric and ascending esophageal branches. I prefer finger dissection to isolate the descending left gastric artery to facilitate the transection of any posterior gastric vagi that may accompany that vessel to the stomach. Then, as indicated by the dashed line in Figure 85.5, the lesser curvature is freed entirely from the gastric cardia by successive transactions between clamps and ligation up to the encircling catheters to facilitate the transection of any other posterior gastric vagi. Clearly, this dissection is the step that makes selective vagotomy more difficult than total vagotomy. It may be more complicated if an aberrant left hepatic artery from the left gastric artery is encountered (not illustrated, but present in approximately 10% of patients). By transecting all lesser omental attachments to the gastric cardia, thereby totally separating the posterior trunk–celiac division from the distal esophagus and gastric cardia, all posterior gastric vagi are severed (Fig. 85.6).

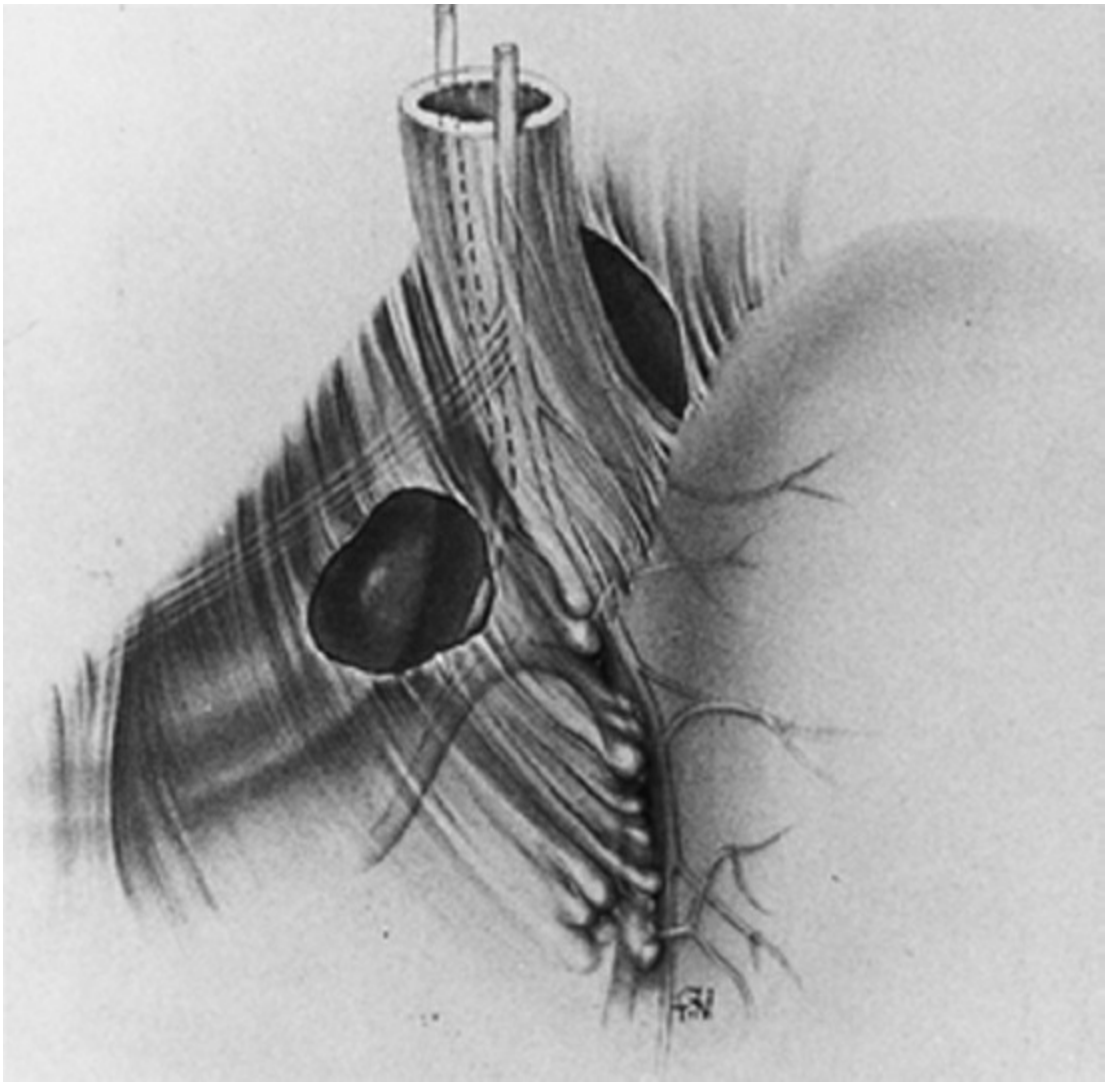

Figure 85.2. Initial definition of the surgical field. (From Griffith, 1986, with permission.)

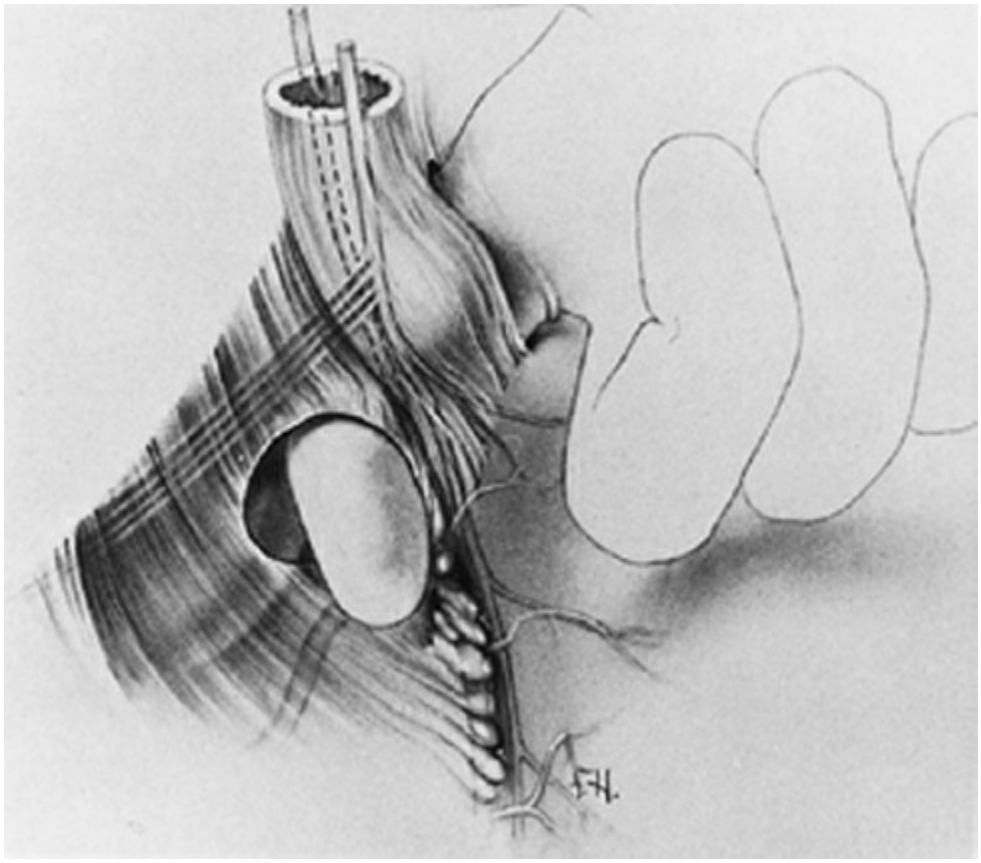

Figure 85.3. Technique for encirclement of the main gastric vagal trunks. (From Griffith, 1986, with permission.)

All remaining tissue anterior to the esophagus (i.e., all tissue between the original incisions in the lesser omentum and angle of His) is dissected from the esophagus with the finger before division between right-angle clamps and ligation. This tissue contains all anterior gastric vagi and some esophageal vessels (Fig. 85.7).

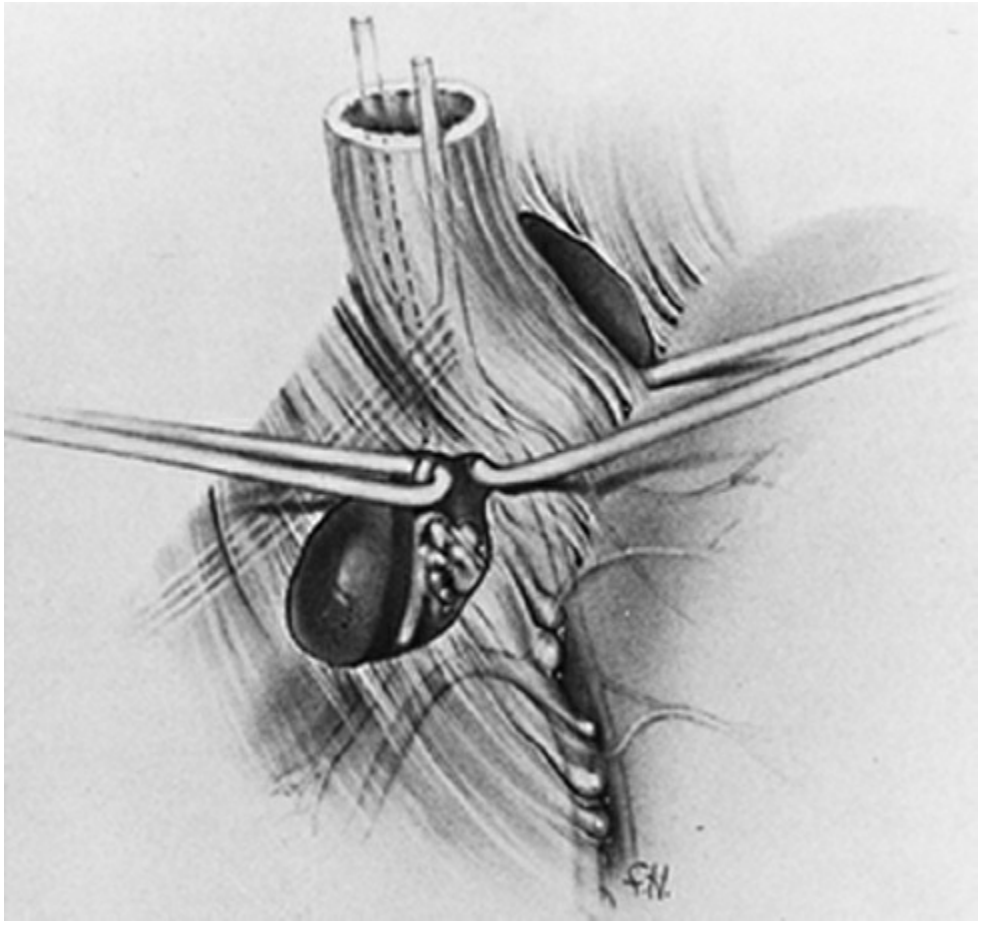

Figure 85.4. Attention to the celiac division of posterior vagal trunks. (From Griffith, 1986, with permission.)

The distal esophagus and gastric cardia are now completely separated from their attachments to all other tissue, including the vagal trunks (Fig. 85.8). The only gastric vagi that can remain are small twigs that may have arisen from the main vagal trunks or esophageal plexus above the surgical field. The usual careful search for the small twigs is, therefore, carefully conducted in and beneath the esophageal fascia propria. The esophageal muscle is thereby bared in its entire circumference. The esophageal muscle is not violated because any nerves found within the muscle innervate the esophagus, not the stomach. Two encircling fingers are used to feel for any intact fibers around the distal esophagus.

FREEING OF THE GREATER CURVATURE

The gastrocolic omentum is perforated in an avascular portion by a curved hemostat, thus permitting the lesser peritoneal sac to be entered. Unless care is taken in the execution of this maneuver, the middle colic vessels can be damaged. To minimize the possibility of such an error, it is

recommended that the anterior wall of the stomach and the transverse colon be elevated and gently pulled apart to tense the gastrocolic omentum. It is easier to find a good cleavage plane by entering the gastrocolic omentum at the level of the junction of the lower and middle third of the greater curvature of the stomach, or even farther to the left; usually, most of the adhesions that tend to obliterate the lesser peritoneal sac are found in the region of the pylorus and lower third of the stomach. At the higher level, it is easy to identify an avascular area between the main trunk of the gastroepiploic vessels and the colon.

After it is certain that the correct plane has been entered, the defect in the gastrocolic omentum is enlarged superiorly and inferiorly, distal to the main gastroepiploic trunk. The avascular portions of the omentum can be divided with scissors or cautery without ligation. When vessels have been identified, the omentum is again perforated on the opposite side of the vessel, and ligatures of 4-0 black silk are passed around the vessel. These ligatures are then tied and the vessels are divided between the ligatures. I have found that there is much less chance of losing a vessel and encountering troublesome bleeding and hematoma formation if the ligatures are tied before the vessels are divided. Often, these vessels are so fragile that the slightest tension on a clamp causes tearing. Superiorly, the greater curvature is freed to a point approximately 14 cm proximal to the pylorus or at a point on the greater curvature perpendicular to the lesser curvature incisura. Transection of the stomach between this point and the middle of the lesser curvature (proximal to the gastric incisura) ensures an antrectomy (approximately a 35% distal gastrectomy) (Fig. 85.9).

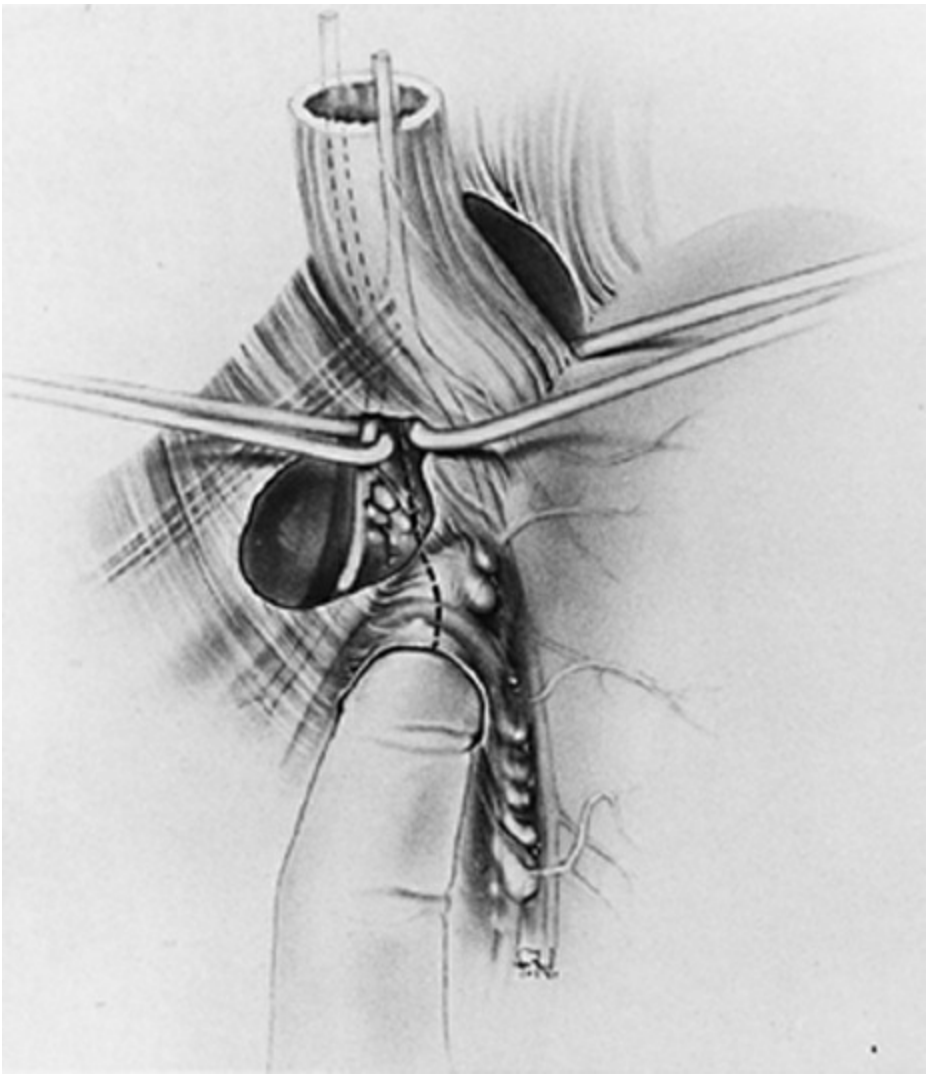

Figure 85.5. Dissection of the gastric lesser curvature, which ensures severance of celiac gastric vagal branches. (From Griffith, 1986, with permission.)

The freeing of the gastrocolic omentum superior to the point of initial breakthrough is carried out distal to the main gastroepiploic trunk. Inferiorly, the omentum is freed–again, distal to the right gastroepiploic trunk–down to a point approximately 5 cm proximal to the pylorus. From this point onward, inferiorly, division of the gastrocolic omentum is carried out between the greater curvature of the stomach and the right gastroepiploic vessel. The main trunk of the right gastroepiploic artery and vein is transected and ligated previously at approximately 5 cm proximal to the pylorus. Special care must be taken from this point on to keep the location of the middle colic vessels constantly in mind.

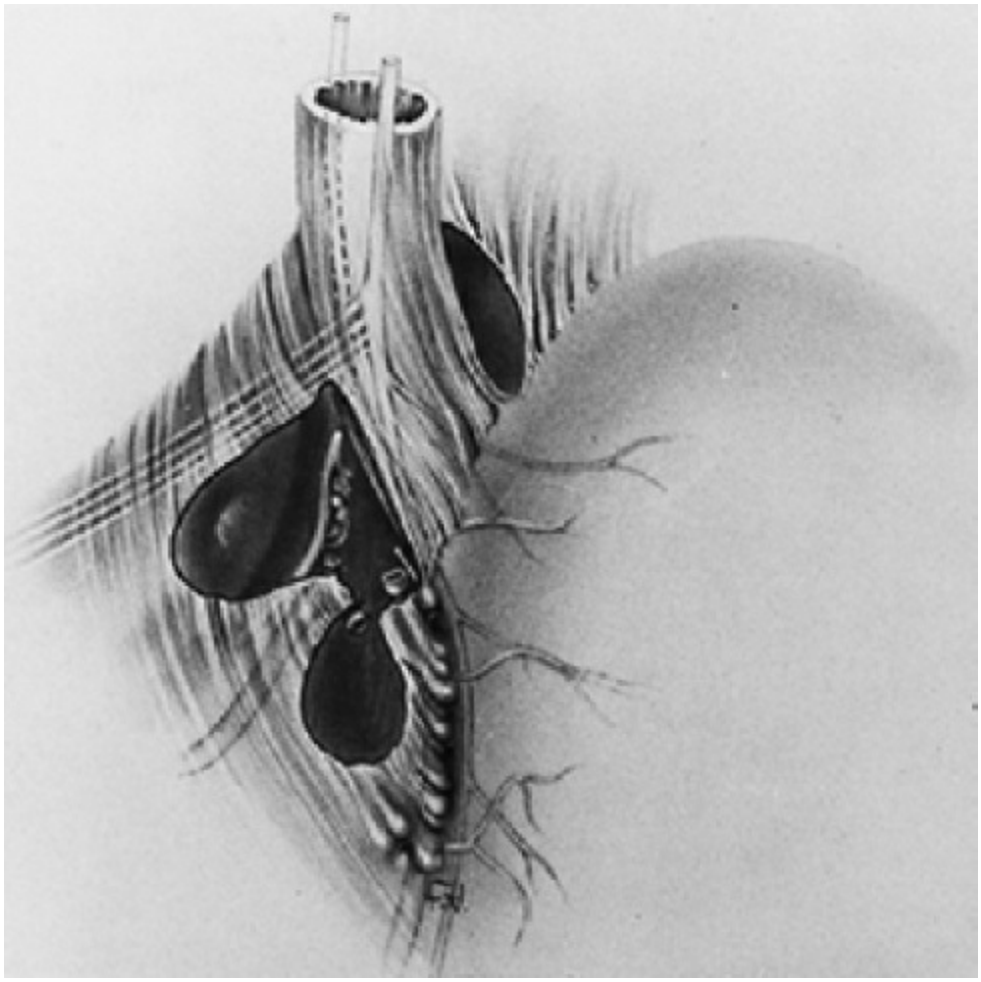

Figure 85.6. Completion of posterior trunk–celiac division (gastric branches) nerve section. (From Griffith, 1986, with permission.)

Approximately at the level of the pylorus, the right gastroepiploic artery at its origin is deep to the line of division of the gastrocolic omentum. Unless the right gastroepiploic vessels are intimately adherent in scar tissue in this region, they can and should be preserved to provide an adequate blood supply to the portion of the gastrocolic omentum that is being left behind. However, when the right gastroepiploic vessels are intimately adherent, and it is impossible to preserve them, they must be sacrificed. Perhaps attempts to protect this vessel represent unnecessary conservatism, but I believe vessels should be preserved if possible. At this point, any readily accessible adhesions to the posterior gastric wall should be divided to allow greater mobility of the stomach.

MOBILIZATION OF THE DUODENUM

One of the most valuable technical contributions to surgery of the stomach

and duodenum is the technique of mobilization of the duodenum originally described by Kocher in 1903. Duodenal mobilization is one of the two phases of the operation best achieved with the surgeon standing on the left side of the operating table. A laparotomy pack is placed on top of the duodenum, and the surgeon pulling the other viscera is positioned to the left side of the patient, which causes the lateral peritoneal reflection of the duodenum to become taut. The peritoneal reflection can then be plainly seen and incised along the lateral margin of the second portion of the duodenum. Then, by gentle, blunt dissection, two fingers can be placed superiorly and inferiorly beneath this layer of the peritoneum. By tenting the peritoneum with the fingers, the peritoneum can be incised with scissors or a scalpel, depending on the preference of the surgeon.

The fascia propria (loose areolar tissue) along the lateral and posterior aspects of the second and third portions of the duodenum is divided by sharp dissection. For the most part, this plane is avascular, although, occasionally, several small bleeding vessels can be encountered. Cautery dissection is often used in this part of the duodenal mobilization.

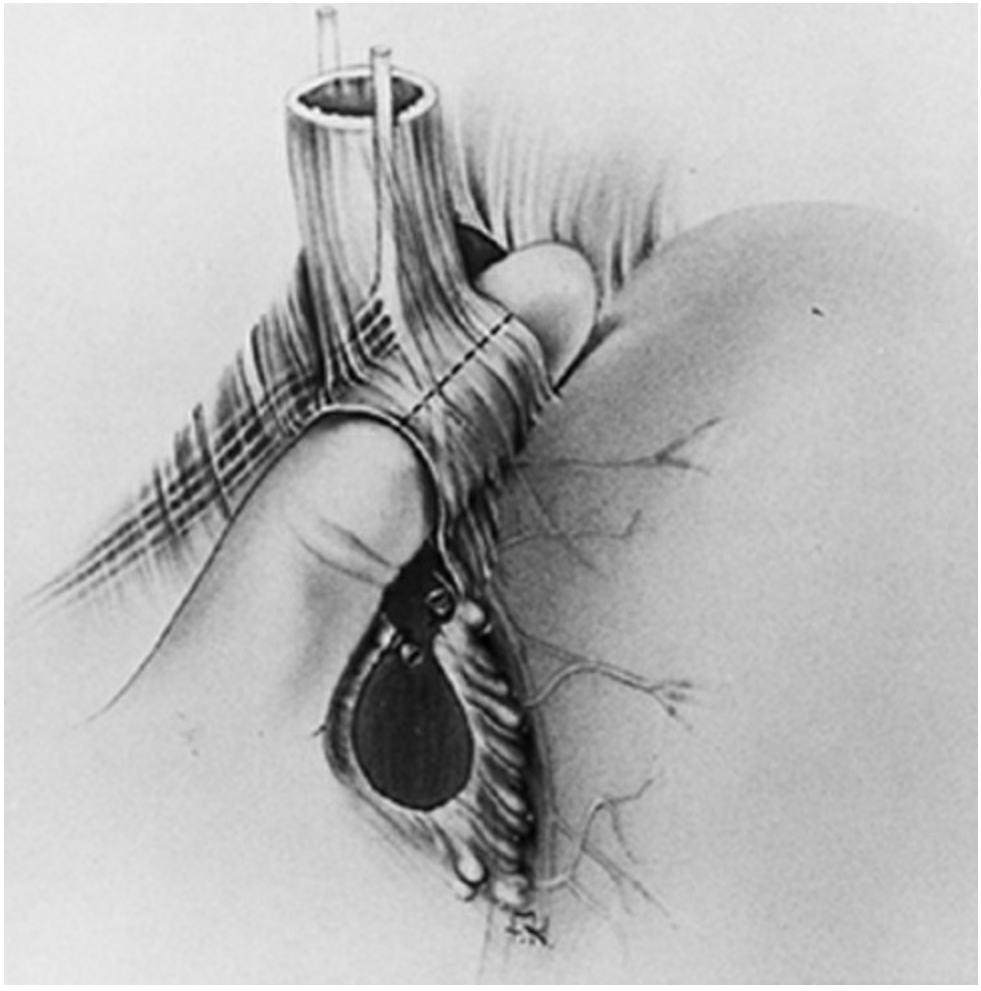

Figure 85.7. Section of all anterior gastric vagal nerves. (From Griffith, 1986, with permission.)

Mobilization is carried out superiorly and proximally to include the superficial avascular portion of the hepatoduodenal ligament. The duodenum is mobilized distally and inferiorly to the point at which the superior mesenteric vessels cross above the third portion of the duodenum. With the duodenum thus mobilized, the second and proximal third portions can be shifted and rotated to the left and superiorly, moving with them the head of the pancreas and the common bile duct. Complete duodenal mobilization should allow visualization of the inferior vena cava. Occasionally, the right margin of the aorta can be seen.

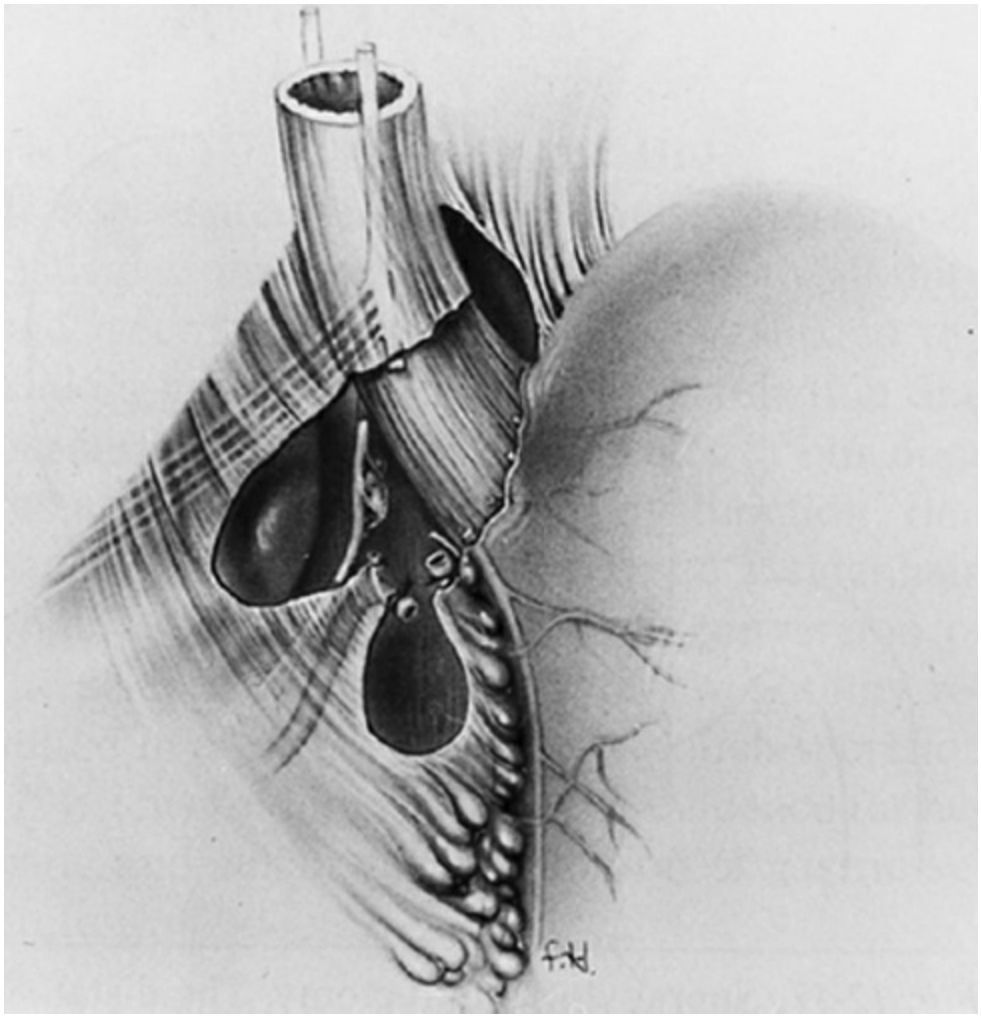

Figure 85.8. Completed dissection of gastric vagal nerves. Hepatic system of anterior vagal branches and posterior celiac vagal nerves preserved; gastric vagal innervation is selectively severed. (From Griffith, 1986, with permission.)

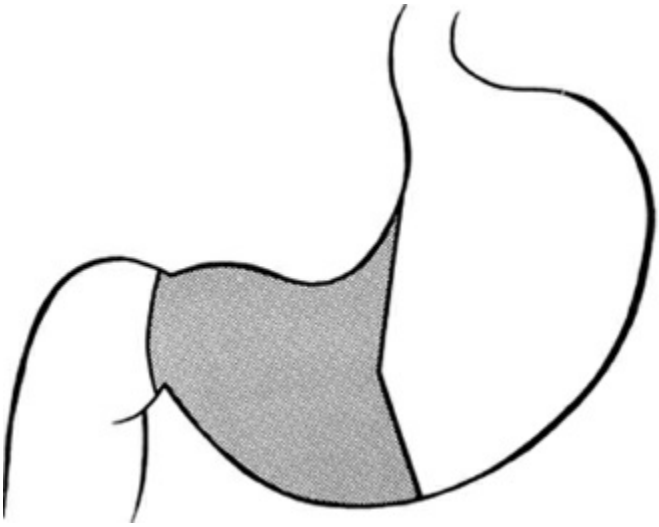

Figure 85.9. Extent of antrectomy (*stippled area*). It should represent a 35% gastrectomy.

The duodenum can usually be mobilized farther than would seem possible. When it appears that the duodenum has been mobilized to its maximal extent, I follow the useful practice of trying again. Usually, some additional degree of mobilization can be gained. After complete mobilization of the duodenum, a moist laparotomy pack should be placed beneath the duodenum to elevate it into the more superficial portion of the surgical field.

Mobilization of the duodenum not only facilitates gastroduodenal anastomosis but also serves two other important functions: (a) it minimizes the chance of injury to the common bile duct by allowing better visualization, and (b) it allows the dissection around the proximal duodenum to be performed in a more superficial part of the surgical field.

After its mobilization, the duodenum is freed, first on its greater curvature (i.e., caudal) side and then on its lesser curvature (i.e., hepatic) side, with division of the right gastric artery and, usually, of the supraduodenal artery of Wilkie.

STRAUSS MANEUVER FOR DIVISION OF THE DUODENUM

The proper and safe division of the duodenum is an important and sometimes difficult maneuver, particularly when one is dealing with posterior penetrating duodenal ulcers. I am indebted to the late Alfred A. Strauss of Chicago for the technique of duodenal division that I use for all duodenal ulcers adherent to the pancreas.

This step is best accomplished when standing at the patient's left side. The maneuver consists of elevating the first portion of the duodenum with a finger placed against the posterior wall of the duodenum, just to the right of the head of the pancreas. To conserve all duodenal length possible, no resection clamps are placed on the duodenum before division. The anterior wall of the duodenum distal to the ulcer scar is incised first with a scalpel as close to the pylorus as the duodenal lesion allows, and the posterior wall is then incised under direct vision from the internal to the external side and at a level just distal to any possible posterior wall ulcer disease. By incising the posterior wall from the inside out, one can minimize the danger of injuring the subjacent structures. If the posterior wall is adherent to the pancreas because of a posterior penetrating ulcer, the duodenal mucosa proximal to the line of division is shaved off the adherent area, leaving the outer portion of the duodenal wall adherent to the ulcer scar. When a posterior penetrating ulcer is situated immediately distal to the pylorus, it is usually possible to obtain a satisfactorily mobilized end of the duodenum distal to the line of transection, and one that is entirely suitable for end-to-end anastomosis. In brief, the Strauss technique involves a separation of the pylorus from in front and to the left rather than from behind and to the right, as is usually done.

However, if the posterior penetrating ulcer lies more distally in the duodenum (beyond approximately 2.5 cm), it is usually necessary to leave the posterior wall of the distal duodenal end attached to the posterior penetrating ulcer and to plan a modified closure of the duodenal stump, as is described later in this chapter. I almost always remove active duodenal ulcers in my resections. However, I occasionally leave active ulcers *in situ* when they are situated in the more distal parts of the duodenum and, so far, I have had no cause to regret doing so.

Under no circumstances should the ulcer crater be excised from the pancreas because this procedure is dangerous and unnecessary.

In performing the Strauss maneuver, the following anatomic facts concerning the duodenum are worthy of attention. In hundreds of gastric resections, after cutting across the duodenum just distal to the ulcer (i.e., approximately 2 cm distal to the pylorus), I have regularly felt for the ampulla of Vater. The index finger of the right hand is used and is inserted with the operator standing on the left side of the table. The distance to the palpated ampulla is then measured; it averages 5.3 cm from the cut end of the duodenum. Thus, the ampulla averages a total of 7.3 cm from the

pylorus. Occasionally, the opening of the duct of Santorini or a pancreatic lobule may be mistaken for the ampulla. Sometimes the ampulla cannot be palpated, but the palpation generally seems accurate.

Having identified the exact point at which the common bile duct enters the duodenum, the surgeon can proceed with more assurance that he or she will not interfere with this important ostium. After complete division of the duodenum, a sponge is placed in the distal end and another sponge is tied loosely about the proximal end to avoid gross spillage of bile and other contents. As stated previously, the final disposition of the duodenal stump is decided *after* an adequate resection has been performed.

With the Strauss maneuver, one can remove the duodenal ulcer in most instances. Its advantages are (a) it stops bleeding if present, (b) it removes enough duodenum to give assurance that the antrum is out, (c) it eliminates the indeterminate period an unremoved ulcer takes to heal, and (d) it provides a clean duodenum for anastomosis or closure.

DIVISION OF THE GASTROHEPATIC OMENTUM AND LEFT GASTRIC VESSELS

The gastrohepatic omentum is usually a thin layer of peritoneum with a minimal amount of fat, although the latter is somewhat variable. At a distance of 1.5 to 2.0 cm from the lesser curvature, no sizable blood vessels are encountered until the level of the left gastric vessels, which are in a separate fold placed more posteriorly. A good portion of the dissection of the gastrohepatic omentum can be carried out without ligatures and, usually, it is necessary to ligate only two or three rather small vessels before the left gastric vessels are reached. This part of the dissection is usually easy, but some difficulty can be encountered when there is thickening, scarring, and inflammatory reaction secondary to a gastric ulcer on the lesser curvature. The hepatic branch of the left vagus nerve lies in this curvature just above the level of the left gastric artery. It should not be cut, although cutting this branch makes no difference if a truncal vagotomy is performed above this level.

The left gastric artery is the largest artery supplying the stomach, and, occasionally, division of this vessel gives rise to difficulty. It is usually surrounded by a moderate amount of fat, which is increased in elderly patients, making it difficult to identify the lesser curvature margin of the stomach. In addition, dissection of this vessel is more hazardous if there is scarring or an inflammatory reaction around it secondary to ulceration on

the lesser curvature of the stomach.

A word of caution should be interjected at this point concerning the occasional origin of an aberrant left hepatic artery from the left gastric artery. Sometimes this vessel constitutes the sole blood supply to the left lobe of the liver, and its sacrifice would almost certainly mean necrosis of the lobe. Therefore, it is worthwhile to examine carefully the configuration of the left gastric artery and its branches and to make certain that the vessel is divided distal to any such possible aberrant hepatic branch. Generally, in patients with benign disease, I ligate the left gastric artery, after it has divided, close to the stomach. This method is easier and avoids unnecessary clamping of the celiac branch of the posterior vagus nerve, although, again, if a truncal vagotomy is to be performed, such clamping makes no difference.

RESECTION

The lines of resection of the stomach should now be decided. For duodenal ulcer, if selective vagotomy has been performed, a distal resection of 30% to 35% is sufficient (Fig. 85.9). The extent of resection and the exact placing of the line of resection are important. The antrum is higher along the lesser curvature than along the greater. Thus, it is important to do a Schoemaker type of tubing of the lesser curvature, removing the stomach at a higher level at the lesser curvature than at the greater curvature.

When the site of transection of the stomach has been selected, an Allis clamp is placed on the greater curvature just distal to the selected site. A small Payr clamp is then applied perpendicular to the greater curvature at the selected level and extended across the width of the stomach for a measured distance of 5 cm (Fig. 85.10). The clamp is closed and a Carmalt clamp is placed just distal to the Payr clamp and parallel to it. The walls of the stomach between the two clamps are incised with a scalpel to a point just distal to the tip of the Payr clamp (Fig. 85.11). The two clamps are separated widely, and a GIA or TAA stapler is then angled up to the lesser curvature side of the stomach, approximately 2 to 3 cm below the esophagogastric junction. A double row of staples is then placed along the line of application of the stapler, and the stapler is removed. The anterior and posterior walls of the stomach are then divided between the double row of staples (Fig. 85.12). Just before the division of the upper portion of the lesser curvature of the stomach is completed, a 4-0 silk suture is placed in the form of Lembert suture just above the most superior staple. Using

this suture for traction to prevent the upper portion of the Schoemaker line from retracting upward, the remaining stomach between the double row of staples is completely incised, and the specimen is removed from the surgical field. Occasionally, a few small vessels bleed between the staples. These bleeding points should be clamped and ligated with 4-0 black silk ligatures to achieve complete hemostasis. Otherwise, troublesome hematomas can form and prevent satisfactory closure of the Schoemaker line.



Figure 85.10. Transection of a stomach. A small Payr or another crushing clamp is placed perpendicular to the greater curvature for a distance of 5 cm across the stomach. To achieve a 30% to 35% distal gastric resection (i.e., antrectomy), this Payr clamp is placed approximately 14 cm proximal to the pylorus. The broken line shows the proposed line of excision of the lesser curvature.

CLOSURE OF THE SCHOEMAKER SUTURE LINE

The stapled closure of the Schoemaker suture line is now oversewn by interrupted 4-0 black silk Lembert sutures placed close enough to obtain

continuous serosa-to-serosa approximation. These reinforcing sutures are placed to a point 1 cm above the tip end of the Payr clamp. This terminal 1 cm is left unsutured until the anastomosis is completed (Fig. 85.13).



Figure 85.11. A Carmalt clamp is placed parallel to Payr clamp. The stomach is divided between the two clamps, and a mechanical stapling device is placed along the proposed line of excision of the lesser curvature.

ANASTOMOSIS

At this point, the type of anastomosis must be chosen. There are few instances in which a gastroduodenal anastomosis cannot be performed and, usually, this anastomosis can be of the end-to-end type. In difficult situations, the scope of the Billroth I anastomosis can be greatly extended by use of the von Haberer–Finney end-to-side anastomosis, particularly when the proximal cut end of the duodenum has to be left attached to the distal margin of a posterior penetrating duodenal ulcer.

The anastomosis should not be forced (i.e., performed under tension). If

the surgeon believes it is technically difficult to use the duodenum in reestablishing gastrointestinal continuity, a gastrojejunal anastomosis should be performed (Billroth II). If the end-to-end type of anastomosis is decided on, the anastomosis is achieved by an outer row of interrupted 4-0 noninverting black silk Lembert sutures. The inner row is closed with a continuous 4-0 absorbable suture that includes only the mucosa and submucosa (Fig. 85.14). During the course of the anastomosis, it may be necessary to ligate several bleeding points in the end of the gastric stump.

When the anastomosis is complete, special care is taken to reinforce the critical angle (i.e., the point of junction between the Schoemaker suture line and the anastomotic line). The reinforcement consists of the placement of a 000 black silk purse-string suture, taking a bite of the anterior wall of the stomach, the posterior wall of the stomach, and the wall of the duodenum at the critical angle. When this suture is tied down, there is good serosal apposition of all three components–namely, the anterior gastric wall, the posterior gastric wall, and the wall of the duodenum (Fig. 85.15). The completed anastomosis should admit one to two fingers.

If the end of the duodenum is unsuitable for end-to-end anastomosis, I prefer to use the terminolateral modification of the Billroth I procedure rather than a Billroth II anastomosis. As stated previously, the main reason for the unsuitability of the end of the duodenum for anastomosis is the presence of a posterior penetrating ulcer. Under these circumstances, a modified type of duodenal stump closure is achieved using the method described by Nissen (Fig. 85.16). This method consists of suturing the free anterior wall of the duodenum to the distal margin of the ulcer crater in the pancreas and then rolling the anterior wall of the duodenum in such a manner that it covers the ulcer crater.

After the closure of the duodenal stump, an end-to-side gastroduodenal anastomosis is performed just distal to the duodenal stump closure. The resultant anastomosis is the same size as, or slightly larger than, the end-to-end anastomosis. When the end-to-side gastroduodenal anastomosis is used, the ampulla of Vater can be opposite the gastroduodenal stoma.

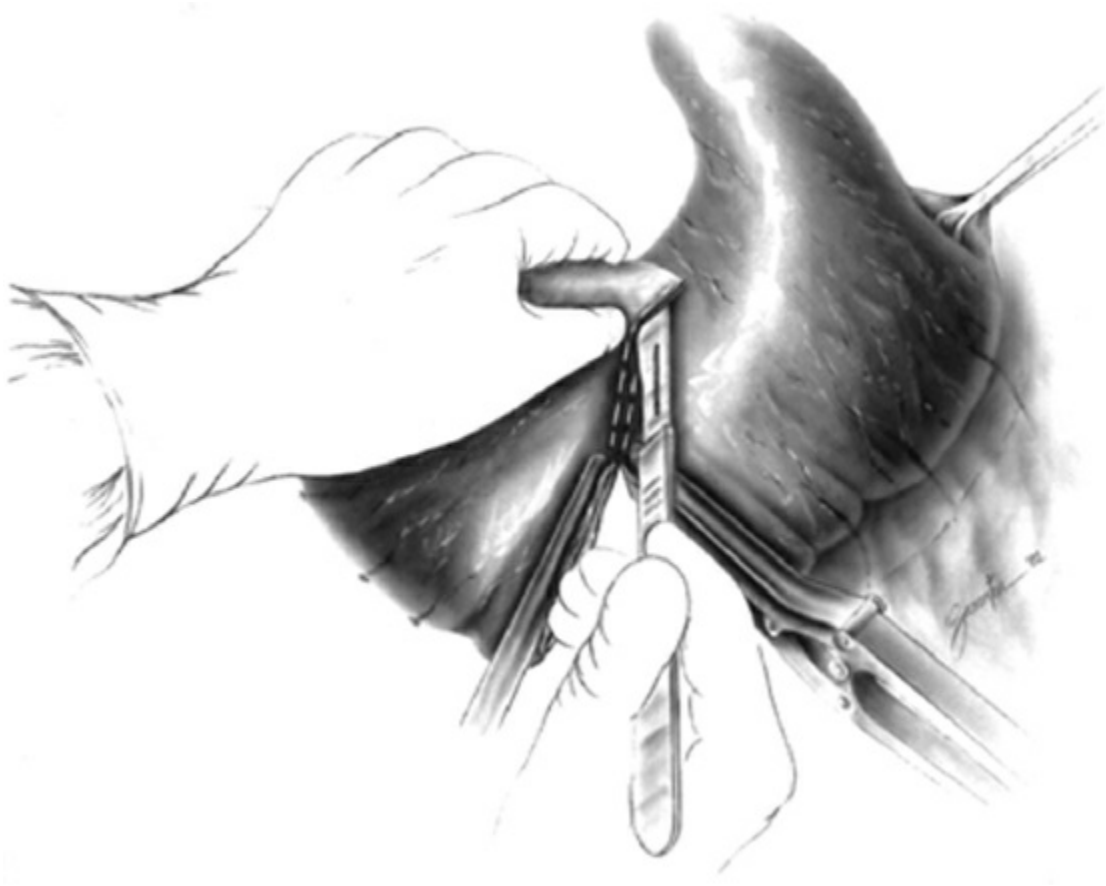

Figure 85.12. A double row of metallic hemostatic clips. The stomach is divided. Any of a number of stapling instruments can be used to close the lesser curvature.

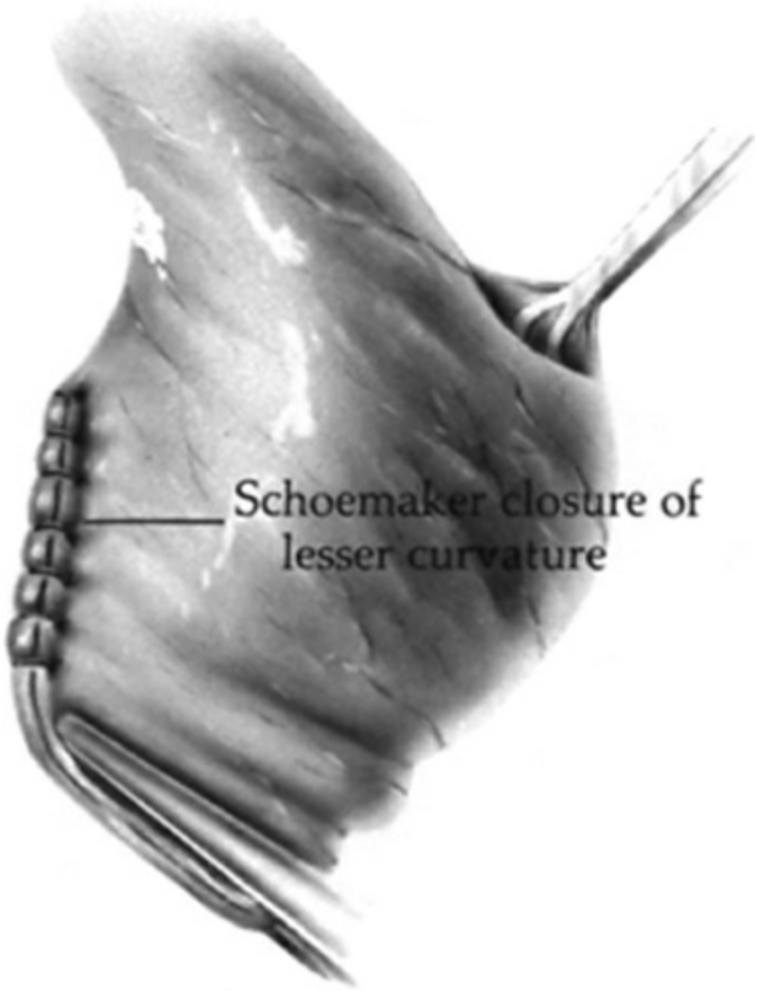

Figure 85.13. The Schoemaker closure of the lesser curvature with interrupted Lembert sutures of 4-0 black silk.



Figure 85.14. The end-to-end anastomosis. The posterior row of interrupted 4-0 black silk seromuscular sutures has been placed. The inner continuous absorbable hemostatic (baseball stitch) suture is seen.

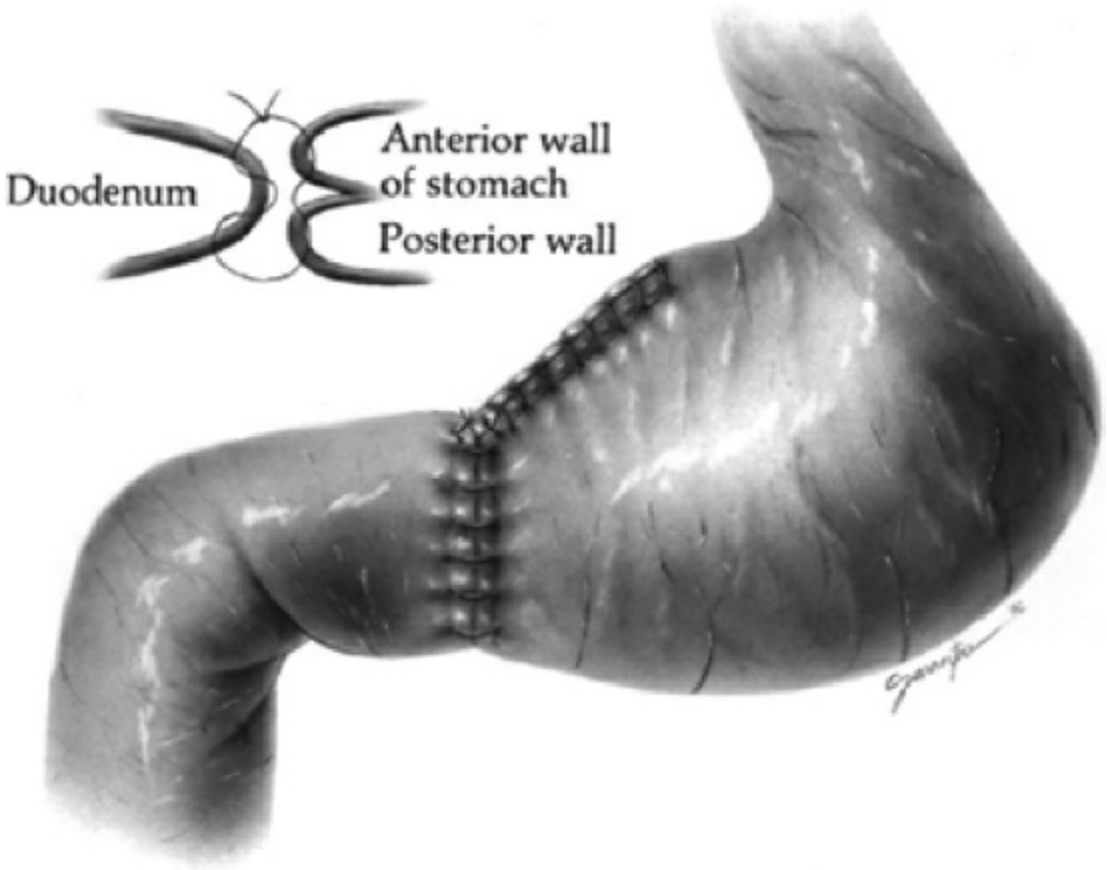

Figure 85.15. Completed operation—selective vagotomy, antrectomy, and gastroduodenostomy. Infolding of the stomach at the corner of the Schoemaker closure of the lesser curvature and the duodenum at the superior portion of the anastomosis (*inset*). This suture, which usually involves two bites to the stomach and one or two to the duodenum, protects against an anastomotic leak at this potentially weak part of the closure. The suture should be a deep Lembert and should not enter the lumen of either viscus.

WOUND CLOSURE

I make no attempt to close the peritoneum and have noted no difficulty or complication arising from this omission. It seems that the ligamentum teres of the liver and the falciform ligament quickly adhere and can form a more anatomic peritoneal closure than would be accomplished by suture. The fascia of the linea alba is closed by interrupted nonabsorbable sutures. No subcutaneous sutures are used, and, after closure of the fascia of the linea alba, the skin edges are approximated.

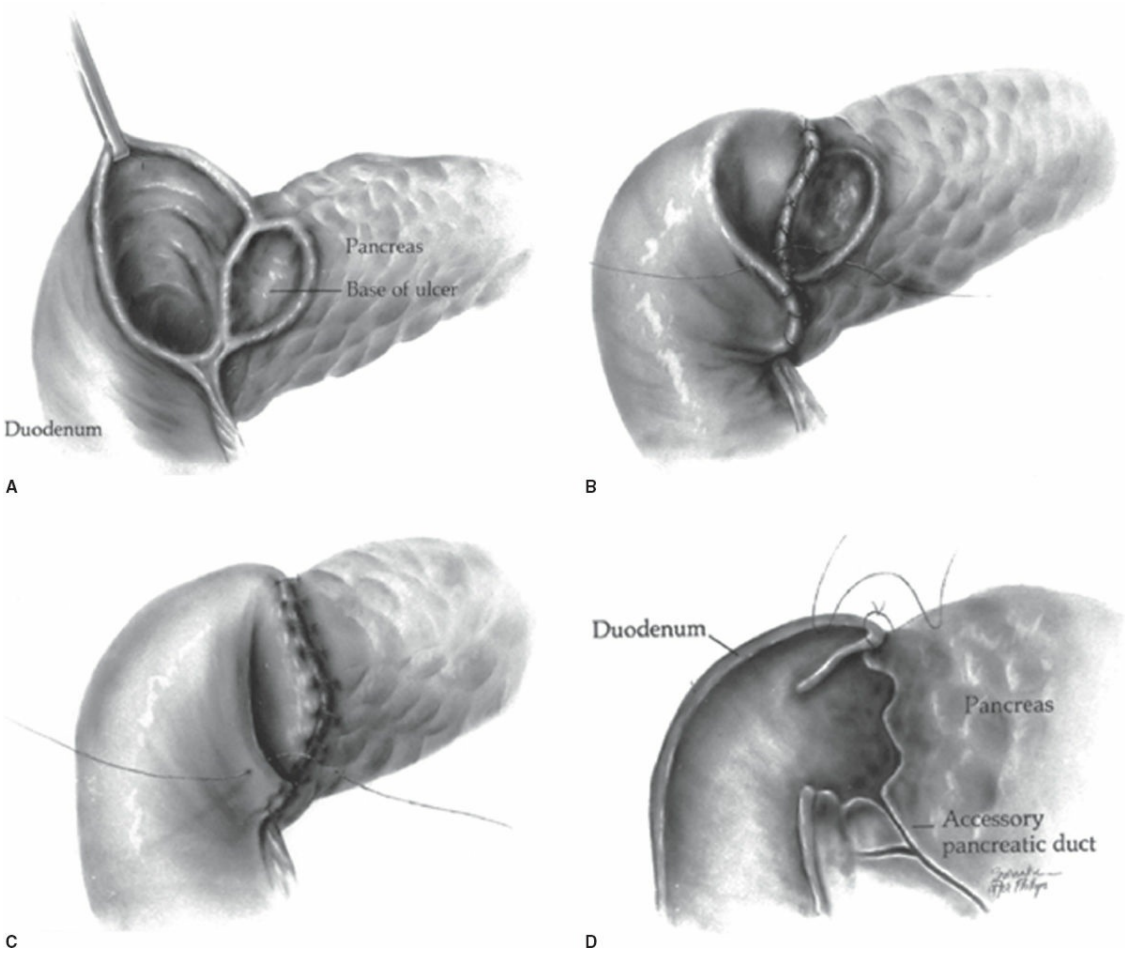

Figure 85.16. Closure of the difficult duodenal stump when a terminolateral anastomosis is contemplated (i.e., closure after the method of Nissen). **A:** The distal duodenum is adherent posteriorly to the distal margin of the ulcer bed. **B:** The anterior duodenal wall is sutured to the distal margin of the ulcer bed, and a second row of sutures is begun, suturing the anterior wall to the proximal ulcer margin. **C:** The second row is completed, and the third and final row is begun, folding the anterior duodenal wall against the capsule of the pancreas proximal to the ulcer. **D:** This cross section shows the omission of the first row of sutures when an accessory pancreatic duct opens into the ulcer bed. This omission allows pancreatic juice to drain into the duodenal lumen.

Suggested Readings

Donahue PE. Extended highly selective vagotomy. In: Wastell C, Nyhus LM, Donahue PE, eds. *Surgery of the Esophagus, Stomach and Small Intestine.* 5th ed. Boston, MA: Little, Brown and Company; 1995.

Donahue PE, Nyhus LM. Exposure of the periesophageal space. *Surg Gynecol Obstet* 1981;152:218.

Donahue PE, Nyhus LM. Surgical excision of gastric ulcers near the gastroesophageal junction. *Surg Gynecol Obstet* 1982;155:85.

Donahue PE, Bombeck CT, Condon RE, et al. Proximal gastric vagotomy versus selective vagotomy with antrectomy: results of a prospective, randomized clinical trial after four to twelve years. *Surgery* 1984;96:585.

Griffith CA. Selective gastric vagotomy. In: Nyhus LM, Wastell C, eds. *Surgery of the Stomach and Duodenum.* 3rd ed. Boston, MA: Little, Brown and Company; 1977.

Griffith CA. Selective vagotomy plus suprapyloric antrectomy. In: Nyhus LM, Wastell C, eds. *Surgery of the Stomach and Duodenum.* 4th ed. Boston, MA: Little, Brown and Company; 1986.

Harkins HN, Nyhus LM. *Surgery of the Stomach and Duodenum.* Boston, MA: Little, Brown and Company; 1962.

Harkins HN, Jesseph JE, Stevenson JK, et al. The "combined" operation for peptic ulcer. *Arch Surg* 1963;80:743.

Harkins HN, Griffith CA, Nyhus LM. The revised combined operation with selective gastric vagotomy. *Am Surg* 1967;33:510.

Kocher T. Mobilisierung des duodenum und gastroduodenostomie. *Zentralbl Chir* 1903;30:33.

Nissen R. Zur resektion des tiefsitzenden duodenalgeschwurs. *Zentralbl Chir* 1933;60:483.

Nyhus LM. The Sun Yat-Sen lecture: the surgical treatment of duodenal ulcer: past, present and future. *J Gastroenterol Hepatol* 1994;9:172.

Nyhus LM, Donahue PE, Krystosek RJ, et al. Complete vagotomy: the evolution of an effective technique. *Arch Surg* 1980;115:264.

Waisbren SJ, Medlin IM. The evolution of therapeutic vagotomy. *Surg Gynecol Obstet* 1990;170:261.

Weil PH, Buchberger R. From Billroth to PCV: a century of gastric surgery. *World J Surg* 1999;23:736.



EDITOR'S COMMENT

This chapter is one of the classic chapters in this book written by an acknowledged master of gastric surgery, Dr. Lloyd Nyhus.

Gastric surgery, of course, has largely disappeared from academic and other medical centers in the country, except for gastrointestinal bleeding from duodenal ulcers that is not amenable to endoscopic intervention. Historically, gastric and duodenal ulcer surgery, as well as gastric cancer, was a major part of

a residency program and of a surgeon's armamentarium. The referral patterns in the United States differ somewhat from those of the United Kingdom, which is what explains the different approaches to duodenal ulcers, even today. In the United Kingdom, the primary care physician cares for the patient; endoscopists see the patient occasionally. Duodenal ulcer is still considered a surgical disease when *Helicobacter pylori* eradication does not work or when *H. pylori* is not present. Thus, patients are referred early. To take someone with relatively moderate or mild-to-moderate symptoms with duodenal ulcer and render them a gastric cripple is considered inappropriate. Thus, early on, the differences in referral patterns in the United Kingdom have rendered the approach to duodenal ulcer quite different than that in the United States, and that is to accept a certain amount of recurrence in exchange for a patient who is functional and not a gastric cripple following operation.

In the United States, referrals are late, often with people who are in the last quintile of their disease and who are extremely disabled with gastric outlet obstruction, crippling pain, anorexia, several bleeds, perforations, and so forth. Here, the emphasis on the lack of recurrence is often compromised as far as the long-term outcome regarding gastric function is concerned.

Historically, the original standard operation for duodenal ulcer was subtotal gastrectomy, and I mean subtotal. The stomach was transected at the first branch of the left gastric artery, cutting across to a short gastric artery in which the second or third short gastric artery had been ligated in continuity. This really was an 80% gastrectomy. Many of the patients were gastric cripples with a small-pouch syndrome, weight loss of 20 and 25 pounds, and an inability to eat a full meal. In retrospect, this approach became even more unacceptable with a recurrence rate of approximately 7%. In the late 1950s and early 1960s, in an effort to get a better functional result, patients started to undergo hemigastrectomy or antrectomy and vagotomy, in which the antrectomy was approximately 35% to 50%, and the recurrence rate should have been less than 1%. The most classic series of antrectomies and vagotomy was that of the 3,000 hemigastrectomies and vagotomies of John Sawyer and Linwood Herrington, which they reported in *Current Problems of Surgery*, with only 12 recurrences; as I recall, three were as incomplete vagotomy and the others were endocrinopathies, including hyperparathyroidism and the Zollinger–Ellison syndrome.

We then progressed in this country to pyloroplasty and vagotomy, which had all the disadvantages of resection, plus a 15% to 20% recurrence rate, and to my way of thinking, unless there was an unapproachable duodenum, offered little. Parietal cell vagotomy does offer a great deal more. It is my standard operation for women who usually do not tolerate any gastric resection without significant symptoms and weight loss.

In this operation, which has University of Washington origins, Dr. Nyhus probably gives too much credit to Drs. Griffith and Harkins and little to himself. All the gastric vagal fibers are severed and the celiac and hepatic branches are

maintained; the celiac is maintained so that postvagotomy diarrhea is not present, and the hepatic nerves remain to minimize the influence of the vagotomy on gallstones later in the course.

The antrectomy is somewhat different than the one I was taught to do, in which I resect the stomach from the second branch of the left gastric to the confluence of the bare area between the left gastroepiploic and the right gastroepiploic. This is more like a 50% gastrectomy but has the advantage that the reconstruction is not as difficult as it is here in the Schoemaker approach, which I was taught as the Kelling Madlinger approach, and which was usually used for a high, lesser gastric ulcer that was benign.

The selective vagotomy never caught on, and truncal vagotomy continues to be the standard of most gastric operations in antrectomy and vagotomy. The anterior portion of the vagotomy emphasizes that ones does not take down the esophageal hiatus and that the branches that one is looking for, which are anterior, are right at the hiatus, perhaps thus sparing an increased incidence of hiatal hernia following truncal vagotomy, which I believe exists. It is the posterior aspect of this dissection, taking the posterior gastric branches and the vagus and sparing the celiac nerve to the celiac axis, that makes this more difficult and why it has never really caught on.

Why not perform a proximal gastric vagotomy or a highly selective vagotomy, or a parietal cell vagotomy, which are synonyms for the same operation? That is an easy answer. The parietal cell vagotomy, and whatever else it is called, is performed because it retains the motility to the lower part of the stomach and the pyloric-emptying mechanism. Here one is resecting that portion of the stomach in which one wants to maintain the emptying capacity, and so one never gets to save the crow’s foot.

In preparing the patient for an operation today, most patients are taking a protein pump inhibitor, which means that they may have all sorts of organisms that make this not a clean case or even a slightly contaminated case, but basically a clean, contaminated case, not unlike colonic resection. In addition, in patients who are partially obstructed, *Clostridium myositis* is considerably more common after gastric resection in which the stomach is obstructed. Mushrooms are a notable source of *Clostridia*, and I have seen a number of cases in which the preparation for the operation did not include antibiotic prophylaxis and clostridial myositis resulted.

Some technical aspects have evolved since this chapter was originally written. The sutures are different. I happen to use two layers of interrupted 4-0 silk, plus a triangle of the sutures as described by Dr. Nyhus at the angle of death, or the confluence of Hoffmeister turn-in, as I call it, and the Schoemaker turn-in, as Dr. Nyhus calls it. The reason that I use two layers of interrupted suture is so as not to render the gastroduodenostomy stenotic, which happens when one is using a running suture. I do not generally drain these except when, in order to close the duodenum, one must take the small branches from the pancreas to the duodenum, several of which encompass and include small

pancreatic ducts. In that case, a closed-suction drain, such as the Blake drain or Jackson Pratt drain, should be left close to, but not immediately adjacent to, the anastomosis.

I differ with Dr. Nyhus with all due respect in certain ways that the technique is described. Dr. Nyhus insists on leaving the transection of the stomach for the last thing. To my way of thinking, this compromises the ease of the operation if the distal stomach is separated first and then one can use this stomach as a handle, especially to get behind the duodenum and get length as one is taking down the duodenum for closure. I do ligate the small branches of the pancreas, including the ducts in continuity using a right angle Jacobson clamp to pass 4-0 silk sutures behind, tying them in continuity and then dividing between them with a Potts biliary scissors.

Dr. Nyhus, for some reason, seems to insist on trying to do a resection of the ulcer even when there is foreshortening of the duodenum and the first portion of the duodenum is nonexistent, with the common bile duct very close to the ulcer. To my way of thinking, this is an excellent indication for a vagotomy and drainage in which a gastrojejunostomy avoids the possibility of injuring the common bile duct. It has a 15% to 20% recurrence rate, not terribly different from what subtotal gastrectomy used to be, and much lower than a proper antrectomy and vagotomy, but it is much better than a severed or damaged common duct.

There are several technical details of the operation that I think are difficult. The first is the separation of the posterior vagus and the celiac nerve so that one can ligate and divide the gastric fibers, which go to the acid-reducing portion of the stomach, while the celiac nerve continues on its way. This is done bluntly and, needless to say, many of our young surgeons have so little experience in gastric surgery and vagotomies that it will be difficult for them to perform this aspect of the operation. I will point out that in this technique the vagus is not encircled, and this may make it more difficult. In addition, in the blunt separation of the esophageal fibers, both vessels and nerves from the body of the vagus nerve may lead to an increased incidence of postvagotomy dysphagia, which I have seen a number of times. If it persists, one usually ends up dilating them with Maloney or other types of dilators and it improves. An occasional patient, however, has continued esophageal spasm and does require something else, such as a Heller myotomy or some other kind of spasm-relieving operation.

In this country, in the absence of much in the way of ulcer surgery in most centers, there is not a great deal of activity. However, one series of hospitals has recorded a fair number of vagotomies for duodenal and gastric ulcers, and especially bleeding ulcerations, and that is the Veterans Administration (VA) system. The VA system, of course, has initiated the National Surgical Quality Improvement Program (NSQIP). This has a wealth of information, which de la Fuente et al. (*J Am Coll Surg* 2006;202(1):78) used to compare vagotomy and resection with vagotomy and pyloroplasty. The results are somewhat surprising,

as they compared outcomes, recurrent ulcers, and 30-day postoperative morbidity and mortality, and rebleeding and the postoperative length of stay. All patients in this 11-year period were included in this review. Patients were compared according to age, ASA class, presence of ascites, coma, diabetes, functional status, hemiplegia, and history of steroid use, among others. All of these were markers or predictors of postoperative death. Having a resective procedure (hemigastrectomy and vagotomy, the ASA classification hemiplegia, history of chronic obstructive pulmonary disease, and requiring a ventilator increased the length of hospital stay. The interesting finding of this study was that in comparing vagotomy and drainage with vagotomy and resection, the incidence of cardiac arrest was 5.8% in the vagotomy and drainage group and 7.5% in the resection group; myocardial infarctions were 2.12% in the vagotomy and drainage group and 0.51% in the vagotomy and resection group, which is somewhat surprising. Vagotomy of the mortality rate was identical, another surprising feature, with an 18%, 30-day mortality rate in vagotomy and drainage (n = 518) and 17.2% mortality rate in vagotomy and resection (n = 389). These findings are quite interesting because they are not what one would expect, although most of the patients who died really had many comorbidities, as one might expect from one's experience in the VA system.

There has been much activity, especially in Japan, in the technique of duodenal anastomoses, which involves stapling. Omori (*Surg Endosc* 2005;19:734) used a duodenotomy just distal to the pylorus, in which he inserted the anvil as well as a side EEA stapler through the distal stomach with good results. Takeuchi et al. (*World J Surg* 2005;29:113) used a similar side-to-end gastrojejunostomy. This was performed in 18 consecutive patients in whom the side-to-end anastomosis was carried out first and then the stomach was resected. Kuwabara et al. (*J Am Coll Surg* 2004;198(4):670) used another technique of EEA stapling for a gastroduodenostomy. Although all of these are interesting, having done much postgastrectomy work, the tendency, certainly in the stomach and perhaps elsewhere, is for gastrojejunostomies as well as gastroduodenostomies that are done with staplers to stricture. That would be my objection to this technique. A two-layer, interrupted suture, end-to-end gastroduodenostomy is probably preferred and gives the best results, in my experience.

J.E.F.

86 Selective and Nonselective Vagotomies

Theodore N. Pappas and Mohan K. Mallipeddi

INTRODUCTION

The understanding and management of peptic ulcer disease (PUD) have drastically changed over the past two centuries. In the 19th century, scientists and clinicians demonstrated that the stomach not only contained but also secreted acid. However, it was not until the early 20th century that clinicians began associating gastrointestinal ulcers with acidity. In 1902 Ivan Pavlov demonstrated that the vagal nerves were responsible for stimulating gastric acid secretion during the cephalic phase of digestion. Shortly thereafter surgeons began experimenting with vagotomy as a means of suppressing gastric acid secretion. Although Andre Latarjet is credited with performing the first truncal vagotomy for the management of peptic ulcers in 1922, it was Lester Dragstedt who popularized the clinical use of vagotomy nearly two decades later. Over the subsequent years, the operation evolved into various forms with associated drainage, resection, and/or reconstruction procedures.

The three main types of vagotomy are truncal, selective, and highly selective (a.k.a. parietal cell or proximal gastric). Truncal vagotomy entails division of both the anterior and posterior vagal trunks at the esophageal hiatus above the origins of the hepatic and celiac branches. Thus, this method results in indiscriminant vagal denervation of abdominal viscera. A drainage or resection/reconstruction procedure is compulsory with such a vagotomy. This operation has the highest mortality and morbidity but lowest rate of recurrence. Selective vagotomy entails division of the vagal trunks distal to the origins of the hepatic and celiac branches. This added complexity does not obviate the need for a drainage procedure and a prospective trial comparing truncal and selective vagotomy did not reveal statistically significant differences in dumping syndrome, diarrhea, or other lifestyle limiting signs and symptoms. Finally, highly selective vagotomy (HSV) entails division of the vagal fibers to the acid producing

parietal cells of the gastric cardia while maintaining those to the antrum and other viscera. This version has the lowest mortality and morbidity but the highest recurrence rate owing to its technical difficulty.

The era of surgical predominance in managing PUD has long since yielded to the current era of medical therapy. This transition was driven by better appreciation and targeted treatment of the major causative factors of PUD—for example, combination therapy for *Helicobacter pylori,* proton pump inhibitors (PPIs) for acid oversecretion, smoking cessation, and more judicious use of nonsteroidal anti-inflammatory drugs. The efficacy of modern medical therapy has rendered surgical management virtually obsolete such that, in those instances when surgery is warranted, there are few surgeons comfortable with all of the classic operations.

INDICATIONS

Surgical management of PUD is warranted for (1) treatment of complications (bleeding, perforation, and gastric outlet obstruction [GOO]), (2) intractability despite maximal pharmacologic therapy, (3) suspicion of malignancy, and (4) select causes beyond the scope of medical management, such as gastrinoma or patient noncompliance. However, surgical management does not always involve vagotomy. We discuss the nuanced role of vagotomy in the case of bleeding or perforation below. Treatment of GOO is included in the discussion of drainage procedures later in the chapter. The management of malignancy is beyond the scope of this chapter. The other indications for surgery do in fact call for vagotomy.

Gastrointestinal hemorrhage in the setting of PUD resolves with medical treatment in ~80% of cases, and thus surgery is reserved for special circumstances. Any patient with clinically significant gastrointestinal hemorrhage should undergo aggressive resuscitation and initial attempts at stabilization via endoscopy or interventional radiology if necessary. Bleeding gastric ulcers warrant biopsy or excision to rule out malignancy but seldom warrant vagotomy because of an infrequent association with hyperacidity. Duodenal ulcers eroding into the gastroduodenal artery may necessitate trans-duodenal three-point ligation (Fig. 86.1); a truncal vagotomy and drainage procedure incorporating the duodenotomy are indicated for patients who have failed or are unable to tolerate medical therapy.

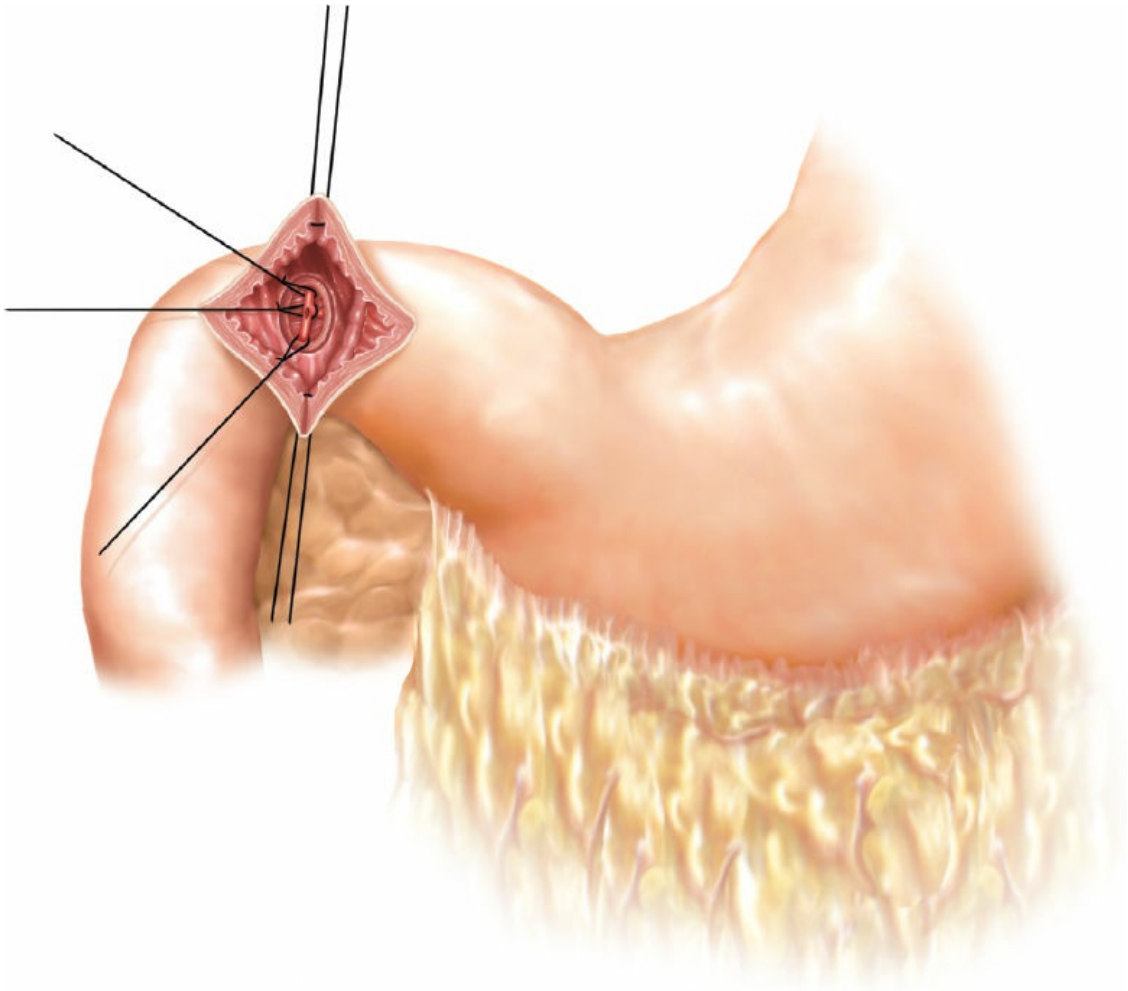

Figure 86.1. Three-point suture ligation of bleeding duodenal ulcer. The culprit is usually the gastroduodenal artery. The ligation can be done with individual stitches or a single “U-stitch” but must be sure to include the side branch.

Perforation in the setting of PUD can be managed nonoperatively in a stable patient when it is contained according to a dynamic contrast study; otherwise, the perforation requires prompt surgical treatment. As noted above, gastric ulcers warrant biopsy or excision to rule out malignancy; whether to append a truncal vagotomy to the excision remains controversial and should be determined based on the patient’s clinical status, underlying cause of PUD, and response to medical treatment. The preferred treatment of duodenal perforation is primary repair with interrupted suture and omental patching. A truncal or selective vagotomy and drainage procedure incorporating the perforation are reasonable in otherwise stable patients who have failed or are unable to tolerate medical therapy. A HSV is inadvisable because the risk of misadventure during the delicate dissection is high in a soiled field.

Medically intractable peptic ulcers persist despite at least 12 weeks of maximal acid suppression therapy, whereas recurrent peptic ulcers recur after complete healing despite maintenance therapy. In either case, an elective acid suppression surgery is warranted. We recommend the option with the greatest likelihood of success in that surgeon's hands. That said, in our experience and interpretation of available evidence, the most appropriate option is truncal vagotomy plus resection as this is the most straightforward, comprehensive, and definitive. Selective and highly selective vagotomies should be utilized by surgeons well-versed in these techniques in patients with unsullied anatomy and uncomplicated, medically recalcitrant disease (usually *H. pylori* negative). The technical complexity and high rates of recurrence associated with selective and highly selective vagotomies limit their use in modern times.

ANATOMY

The two major vagal trunks descend along the esophagus and emerge through the esophageal hiatus of the diaphragm as anterior and posterior branches (Fig. 86.2). The anterior branch originates from the left side and gives off the hepatobiliary and pancreatic branches. This anterior branch continues along the lesser curvature of the stomach in the anterior leaflet of the gastrohepatic omentum as the anterior nerve of Latarjet. The posterior branch originates from the right side and ultimately gives rise to the celiac branch. This celiac branch provides parasympathetic innervation to the pancreas, duodenum, small intestine, and right colon; this posterior branch continues in the posterior leaflet of the gastrohepatic omentum as the posterior nerve of Latarjet. There is a plexus of fibers that connect the right and left vagus nerves. Furthermore, many patients manifest their major trunks of the vagus nerves as multiple branches. This fact alone is likely responsible for the incomplete denervation of the stomach during truncal vagotomy.

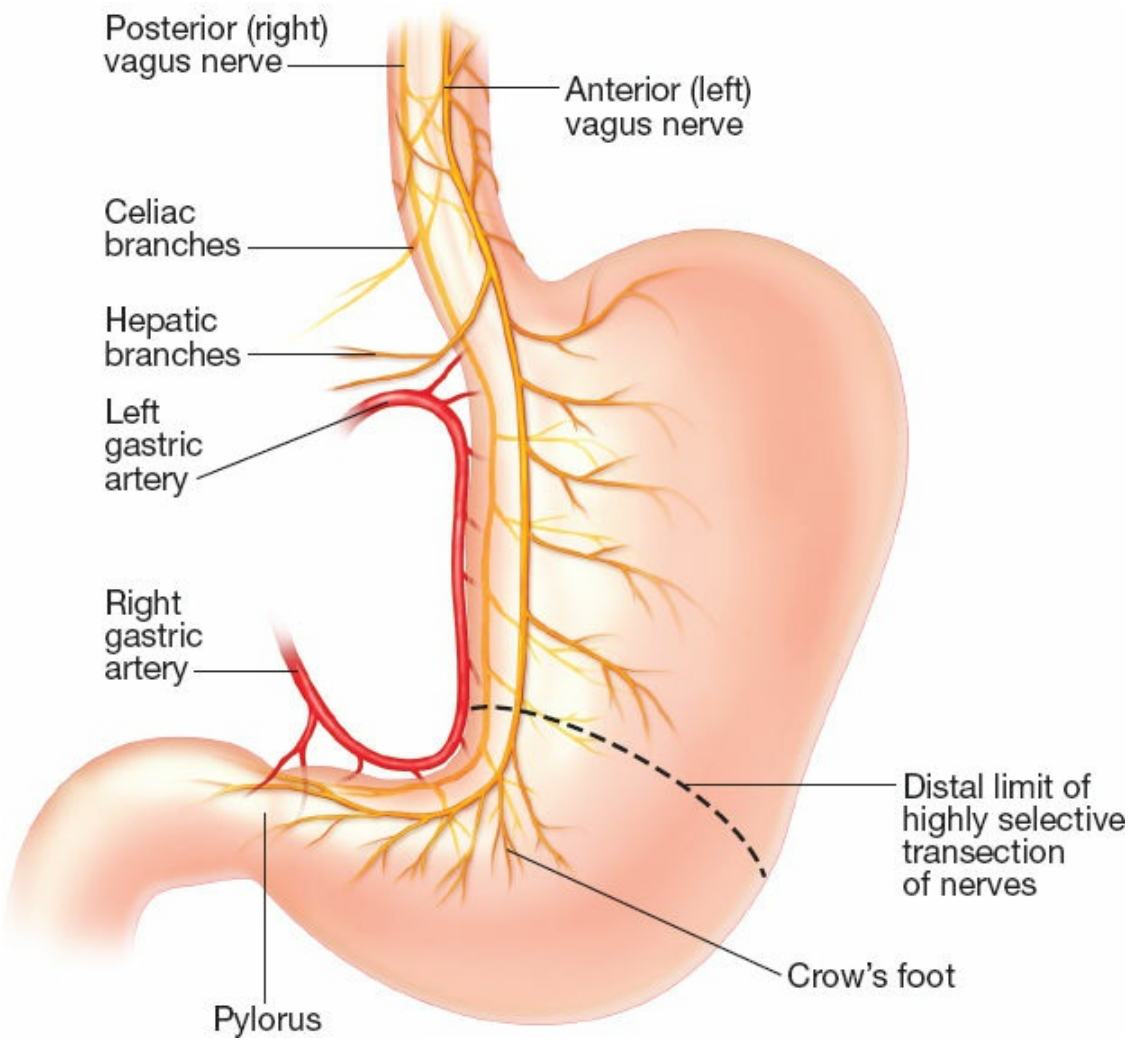

Figure 86.2. Vagal nerve supply to the stomach. Also shown are the various branches relevant to both the selective and highly selective vagotomy.

SURGICAL TECHNIQUE

Preoperative Preparation

The patient should be positioned supine on the operating table with arms abducted 90 degrees. Prior to induction of general anesthesia, sequential compression devices and/or pharmacologic deep venous thrombosis prophylaxis should be administered. After induction of anesthesia, a Foley catheter and temporary orogastric tube should be inserted; however, if the operation is being performed on an obstructed/dilated stomach, a surgical gastrostomy tube is more appropriate since it may take several weeks for emptying to normalize. Prophylactic antibiotics are then administered.

For both open and laparoscopic cases, the anesthesiologist is situated at the head of the operating table, the surgeon stands on the patient's right,

and the first assistant stands on the patient's left (Fig. 86.3). If the case is approached laparoscopically, standing alongside the patient may facilitate dissection around structures more so than operating in-line while standing between the patient's legs. A second assistant can pilot the laparoscope from further along on the patient's left side. A single monitor is placed directly above the patient's head.

Open Truncal Vagotomy

The patient is initially placed in the neutral position. A midline laparotomy incision is made from the xiphoid to just below the umbilicus. A Bookwalter or similar self-retaining retractor is then inserted and used to elevate the costal margin and open the incision. A broad malleable retractor is used to elevate the left lobe of the liver, thus exposing the esophagogastric (GEJ) junction, stomach, and duodenum. Retraction is facilitated by leaving the liver attached to the diaphragm as opposed to taking down the triangular ligament. At this juncture, the patient is placed in slight reverse Trendelenburg position to improve exposure of the operative field.

The peritoneal reflection at the esophageal hiatus of the diaphragm is incised, and the fibrofatty tissue overlying this segment of the esophagus is thinned using blunt dissection along the long axis of the esophagus. Pushing the esophagus toward the spine will expose the anterior vagus as a taut band embedded in the esophageal wall. To avoid incomplete vagotomy, at least 5 cm of the trunk should be isolated above the esophagogastric junction and divided between clips. The specimen must be sent to pathology for immediate confirmation. In the meantime, the esophagus is circumferentially dissected so that a Penrose drain can be passed around it. Ideally, this drain would ensnare both the esophagus and closely associated posterior vagus. Retracting the esophagus toward the patient's left and anteriorly should help reveal the posterior vagus as another taut band on either inspection or palpation; if the trunk is not obvious, the surgeon should explore along or between the crura closer to the aorta. Once identified, a 5-cm segment of the posterior trunk is also divided between clips and sent for frozen pathologic review.

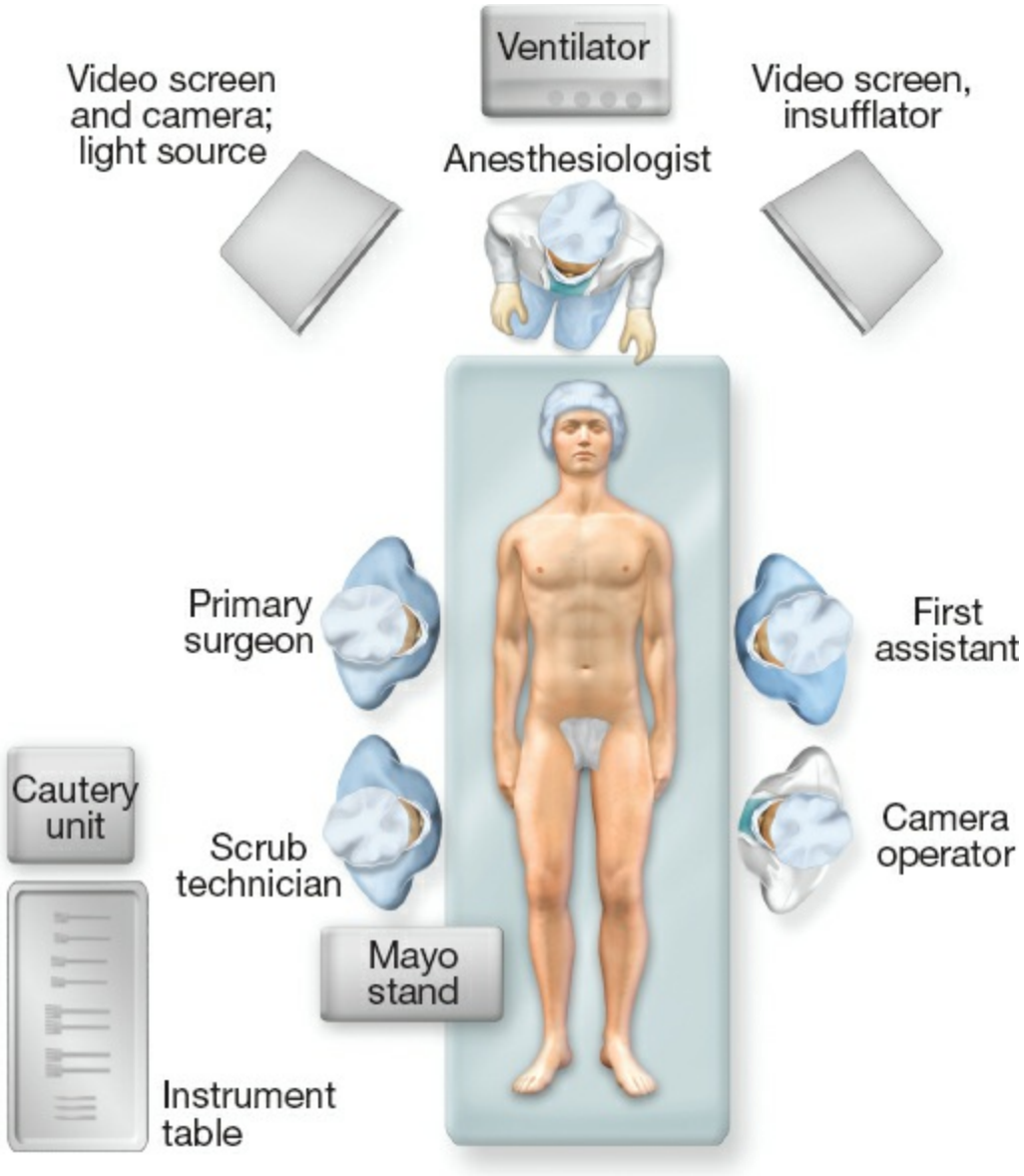

Figure 86.3. Arrangement of operating room and personnel.

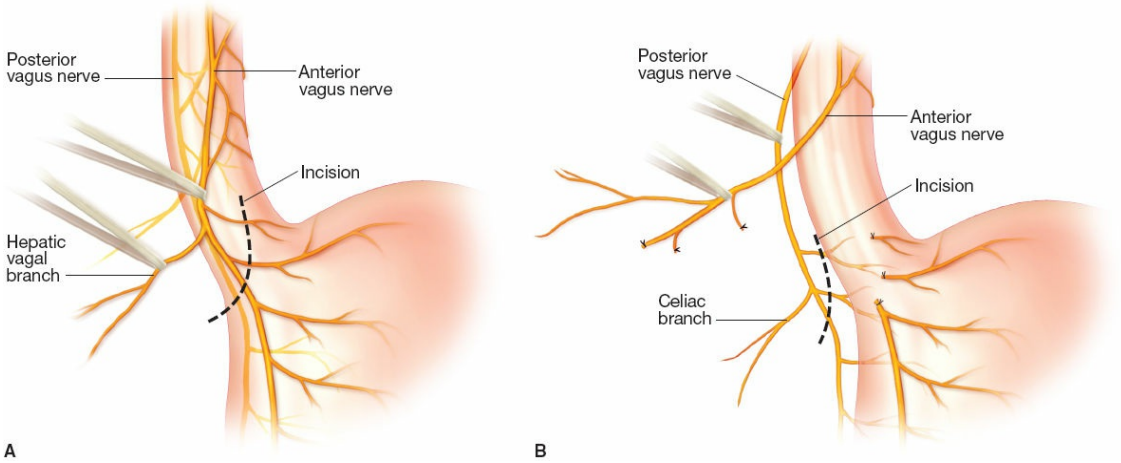

Figure 86.4. Selective Vagotomy. **A.** Isolation and division of the anterior vagal branches distal beyond the hepatic branch. **B.**

Isolation and division of the posterior vagal branches distal beyond the celiac branch.

After denervation of the gastric mass, patients lose their antral pump function and receptive relaxation, resulting in delayed emptying of solids and accelerated emptying of liquids. Some clinicians have promoted the use of pyloric dilation and prokinetic agents as treatment, but the preponderance of evidence suggests gastric stasis is a significant and persistent problem necessitating a drainage or resection/reconstruction procedure. Drainage procedures will be discussed in the next section. The classic resection procedure is an antrectomy followed by a Billroth I, Billroth II, or Roux-en-Y reconstruction.

Open Selective Vagotomy and Pyloroplasty

Entry and initial exposure of the operative field are the same as for the truncal vagotomy. In contrast, the selective vagotomy is centered on the distal esophagus and esophagogastric junction. The fibrofatty tissue overlying the junction should be thinned as described above. The anterior vagal trunk is then identified by inspecting and palpating for a “bow string” along the anterolateral aspect of the esophagus. Once identified, this vagal trunk is encircled with a vessel loop near the GEJ and gently elevated anteriorly off the esophagus. This maneuver should also tent the hepatic vagal branch passing to the right. The hepatic branch is followed proximally to its junction with the anterior vagal trunk. The continuation of the vagal trunk distal to this junction traveling along the lesser curvature (i.e., anterior gastric vagal branches) is divided (Fig. 86.4A). Similarly, the posterior vagal trunk is identified by retracting the stomach to the left and inspecting posteriorly, often along the aorta. Once identified, this vagal trunk is encircled with a vessel loop and gently retracted to the right. This should allow the surgeon to palpate the taut celiac vagal branch passing to the celiac axis. This branch is followed to its junction with the posterior vagal trunk. The continuation of the vagal trunk distal to this junction traveling along the lesser curvature (i.e., posterior gastric vagal branches) is divided (Fig. 86.4B). The nerves can be divided between clips or using an electrosurgical instrument. Regardless, the surgeon must be careful to avoid confusing the hepatic and celiac branches for the continuations of the main vagal trunks. Typically, the hepatic and celiac branches arise several centimeters cephalad to the esophagogastric junction and clearly

travel away from the lesser curvature.

To ensure there are no residual nerves traveling to the stomach, the surgeon should clear a plane between the vagal trunks and the distal 5 cm of the esophagus, being especially certain to divide the posterolateral Criminal Nerve of Grassi on the left (Fig. 86.5). Alternatively, some prefer to make a superficial incision circumferentially around the GEJ extending to the first short gastric vessels (Fig. 86.6).

As noted earlier, the selective vagotomy does not obviate the need for a drainage procedure. The classic drainage procedures are gastrojejunostomy and pyloroplasty, the former of which is not recommended in routine cases because of the propensity for marginal ulceration. While there are multiple types of pyloroplasty, the two most common are the Heineke–Mikulicz and Finney. Even with a drainage procedure, patients undergoing selective vagotomy in the setting of GOO frequently require protracted gastric decompression and should have a gastrostomy tube placed during the index case.

Heineke–Mikulicz Pyloroplasty

This is the most common and straightforward pyloroplasty. A full-thickness 5- to 6-cm longitudinal incision is made through the anterior wall of the pylorus. Silk traction sutures are placed at the midpoint of the incision and retracted perpendicular to the incision to facilitate the transverse closure (Fig. 86.7A,B). As originally described, the Heineke–Mikulicz pyloroplasty is closed in two layers, but the added labor puts the channel at risk of narrowing. The recommended and more common variation calls for a single layer closure using interrupted, full-thickness 3-0 polyglycolic suture. Omentum can be used to buttress the incision by securing it under the tails of several sutures.

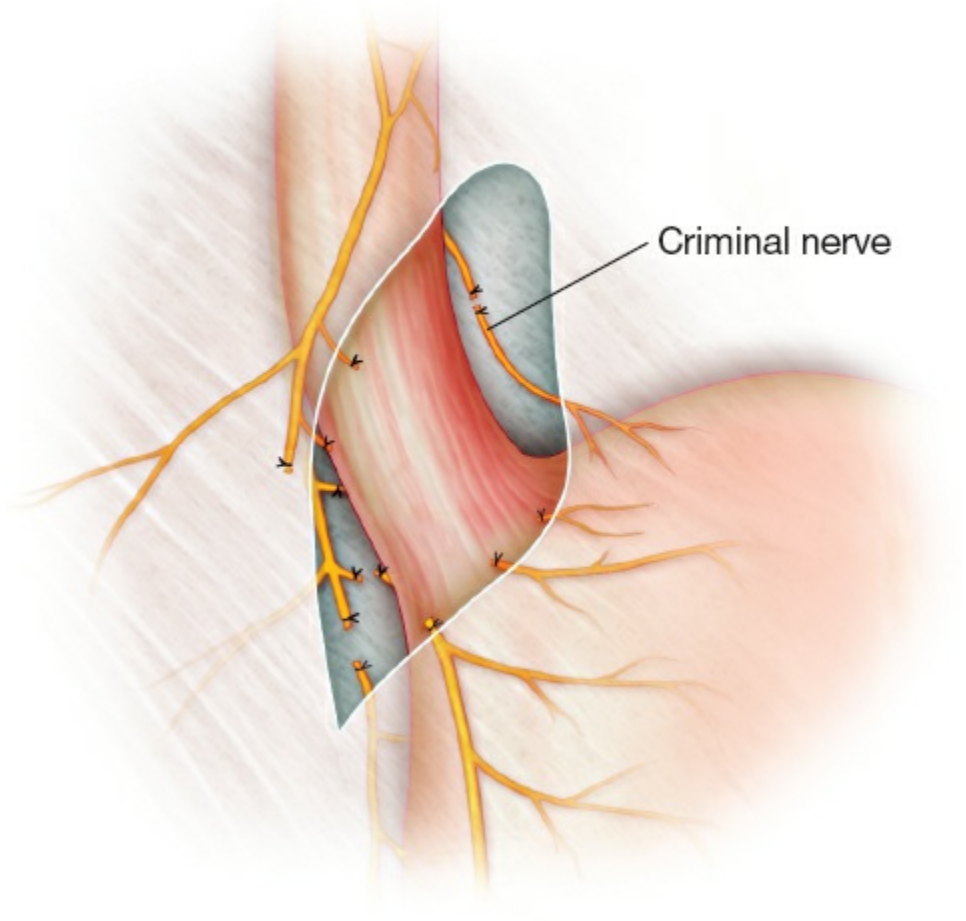

Figure 86.5. Dissection above the esophagogastric junction and division of the Criminal Nerve of Grassi.

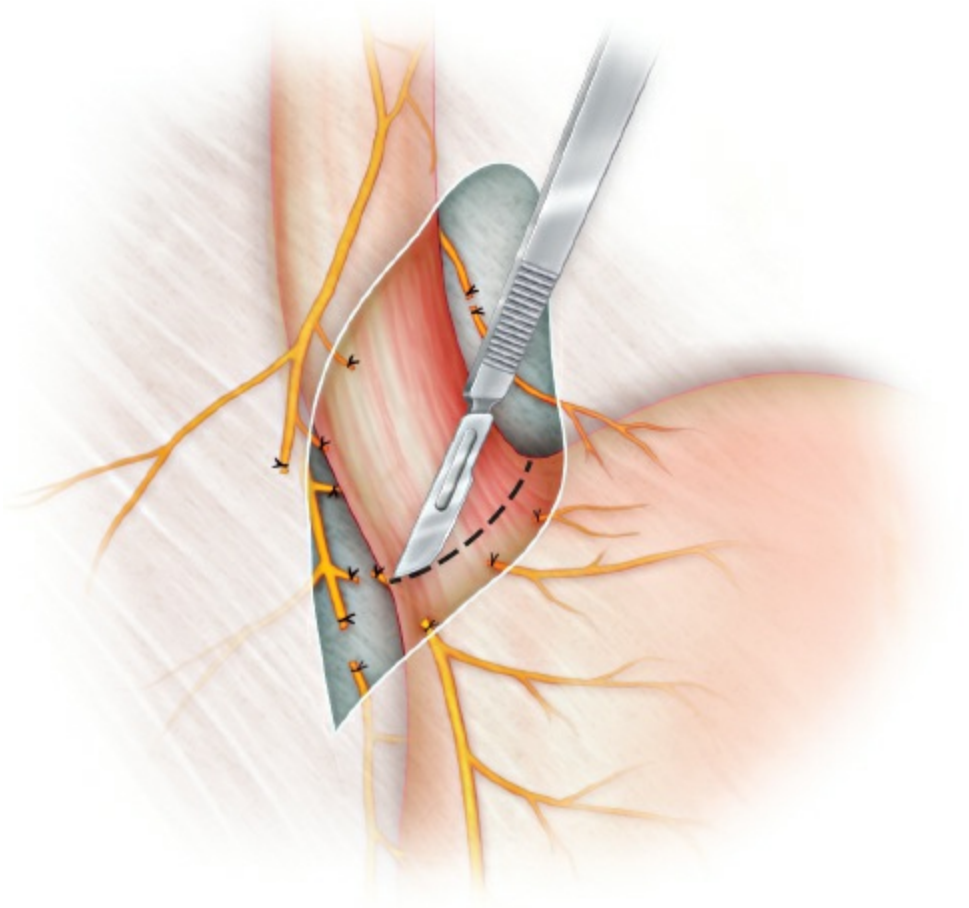

Figure 86.6. Superficial incision along the esophagogastric junction to divide residual longitudinal nerve fibers.

Finney Pyloroplasty

This pyloroplasty requires an extensive Kocher maneuver and essentially creates a gastroduodenostomy. The traditional approach begins by incising the peritoneum along the lateral aspect of the duodenum and mobilizing the duodenum and pancreas off their retroperitoneal attachments. A deep traction stitch is then placed on the superior aspect of the pyloric ring, and another stitch is placed 3 to 4 cm inferiorly between the antrum and duodenum. These sutures are then retracted in opposite directions to approximate the gastric antrum and duodenum. An antral gastrotomy and opposing duodenotomy are created and must be connected through the pylorus—inclusion of the pylorus is the major distinction between this technique and the Jaboulay. The anastomosis is fashioned with a single layer of full-thickness interrupted 3-0 polyglycolic suture along both the posterior and anterior walls (Fig. 86.8).

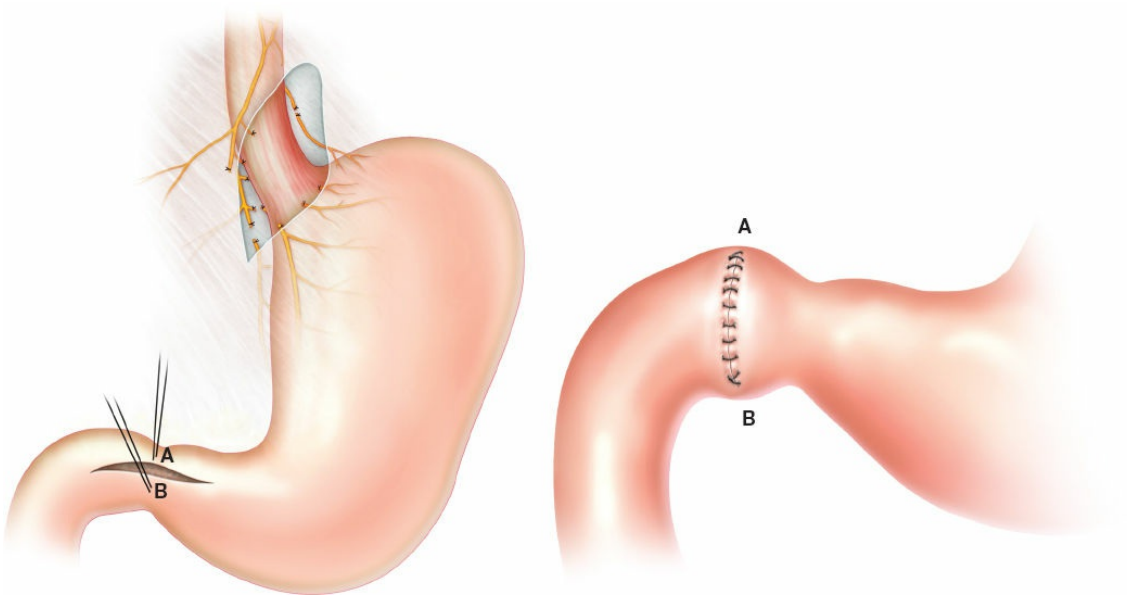

Figure 86.7. A. Longitudinal incision and traction sutures for the Heineke–Mikulicz pyloroplasty. **B.** Completed transverse, full-thickness closure of the Heineke–Mikulicz pyloroplasty.

Highly Selective Vagotomy Open

Entry and exposure of the operative field are the same described as above. The distinguishing feature of this form of vagotomy is dividing the gastric vagal branches only so far as the antrum (Fig. 86.9). This distal limit is found in two ways: by measuring 6 to 7 cm cephalad from the pylorus and/or by finding the Crow's Foot of the vagus along the anterior surface of the stomach. The vagal branches to be divided begin cephalad to the Crow's Foot and are intimately associated with the vascular arcade supplying the stomach. Care must be used to individually divide the neurovascular bundles in both the anterior and posterior leaflets of the gastrohepatic omentum close to the gastric surface—too far and the main vagi are injured, too close and the now marginally vascularized portion of the stomach is injured. Typically, the dissection is carried distal to proximal along the anterior leaflet and then along the posterior leaflet. The bundles can be divided between silk sutures or clips, or by using an electrosurgical device as the assistant provides traction caudally along the greater curvature.

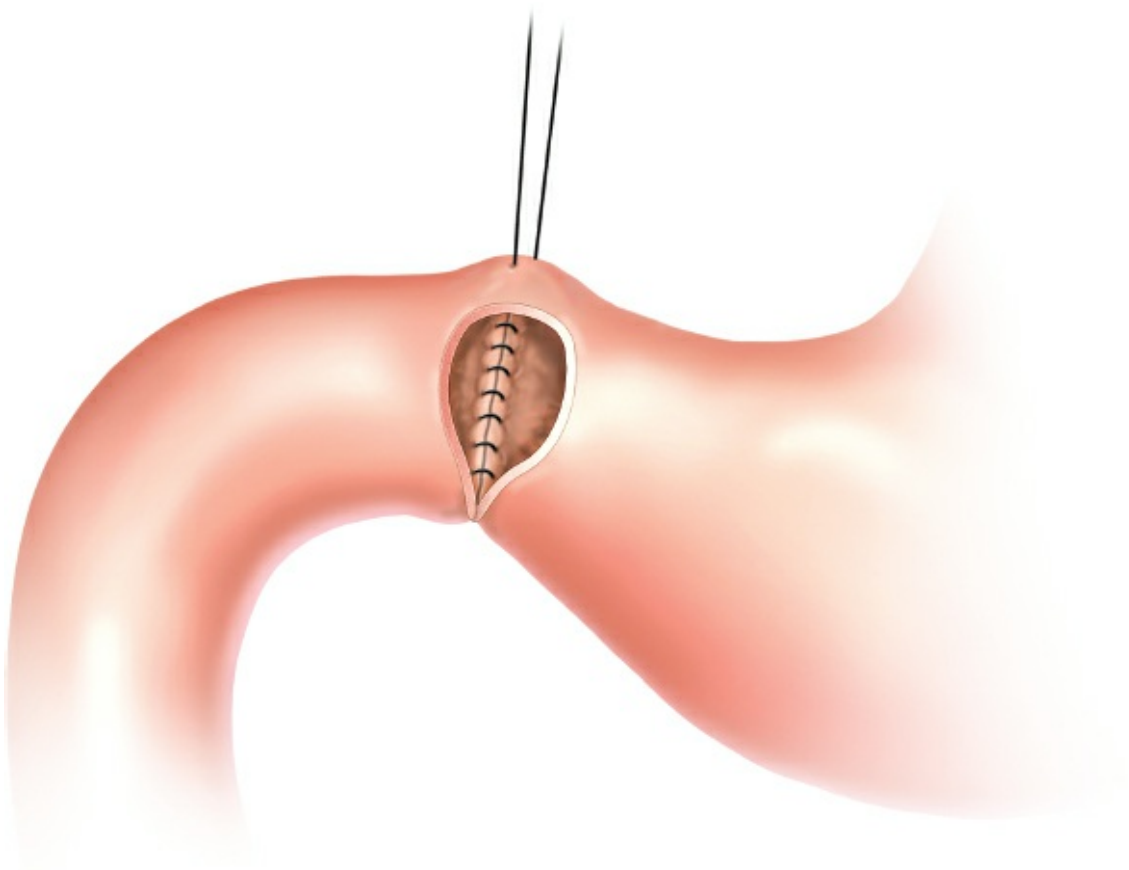

Figure 86.8. Inverted U incision and posterior full-thickness suture line for Finney pyloroplasty.

Once the esophagogastric junction is reached, the surgeon must circumferentially free the junction from any attachments and continue to clear the plane between the vagal trunks and esophagus for approximately 5 cm. This ensures any residual nerve fibers are extinguished, such as the Criminal Nerve of Grassi originating from the posterior trunk sometimes well above the hiatus. Of note, when performing this part of the case it is critically important to appreciate and avoid the vagal trunks which are embedded in the fat pad surrounding the junction. The left/anterior trunk is identified by feeling for a “bow string” along the left lateral aspect of the distal esophagus. The right/posterior trunk is identified by tenting the esophagus to the left and inspecting posteriorly. A window is created between each trunk and the esophageal wall allowing the nerves to be controlled with vessel loops as the dissection is continued. Ultimately, the surgeon should be able to tent the esophagus to the left and move the anterior and posterior trunks freely to the right.

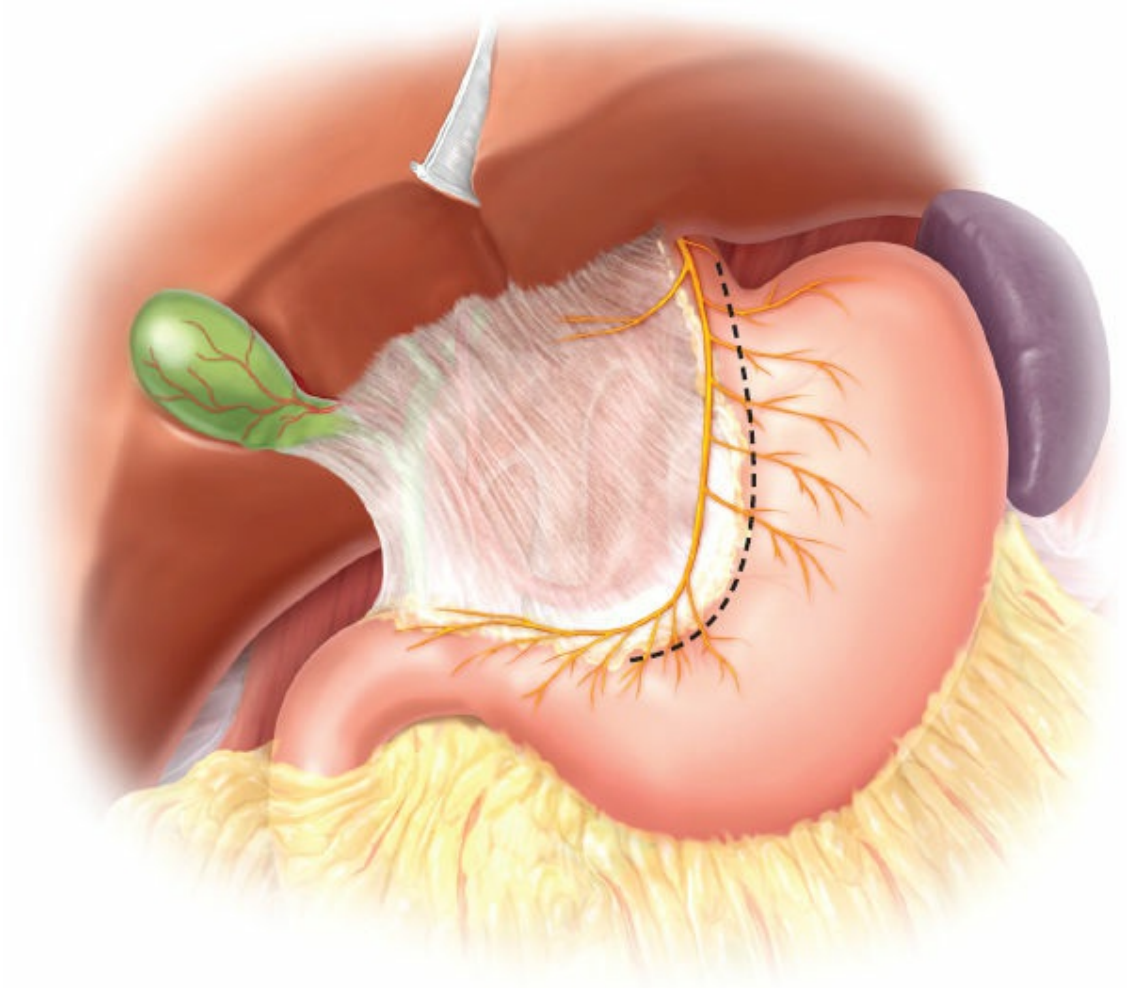

Figure 86.9. Extent and general path of highly selective vagotomy (marked by *dashed line*). The dissection is done in two planes, anterior and posterior, and from distal to proximal. The gastric vagal branches of interest are divided between clips or using an electrosurgical instrument with care not to injury the stomach or Nerve of Latarjet proper.

Finally, the lesser curvature is inspected for signs of ischemia. Barring any concerning findings the bare areas between the ligated neurovascular bundles are covered by imbricating the serosa with running 3-0 polyglycolic suture (Fig. 86.10).

Laparoscopic

The steps of the laparoscopic HSV are similar to the open case, and only important differences or nuances will be covered here. For one, the surgeon will require the following laparoscopic instruments: an angled (30-degree) laparoscope, curved dissector, either a bipolar or ultrasonic electrosurgical device, atraumatic self-retaining liver retractor, atraumatic

bowel graspers, needle driver, and clip applier. Secondly, all ports are placed in the upper hemi-abdomen with at least one hand's breadth of spacing between them. In all, five ports are required: 5- and 10-mm ports in the right upper quadrant for the surgeon, a 10-mm port at the umbilicus for the laparoscope, a 5-mm port in the left upper quadrant for the assistant, and a final 5-mm port just inferior to the xiphoid for liver retraction (Fig. 86.11).

A Veress needle or Hasson trocar is used to enter the peritoneal cavity and insufflate it to 15 mm Hg. If the Veress is preferred, it should be placed in the left midclavicular line two finger breadths below the costal margin; this site can also be used to introduce the assistant's 5-mm port. If the Hasson is preferred, it should be placed either above or below the umbilicus (below for shorter abdomens). Once the peritoneal cavity is entered and insufflated, the laparoscope is introduced and the abdomen inspected for gross pathology. The remaining ports are placed under direct visualization. The surgeon's ports should adhere to the principle of triangulation with the apex at the hiatus, the 10-mm port slightly right of midline, and the 5-mm port more lateral and cephalad. A self-retaining liver retractor should be inserted through the subxiphoid port. Finally, the patient is positioned in slight reverse Trendelenburg to improve exposure of the operative field.

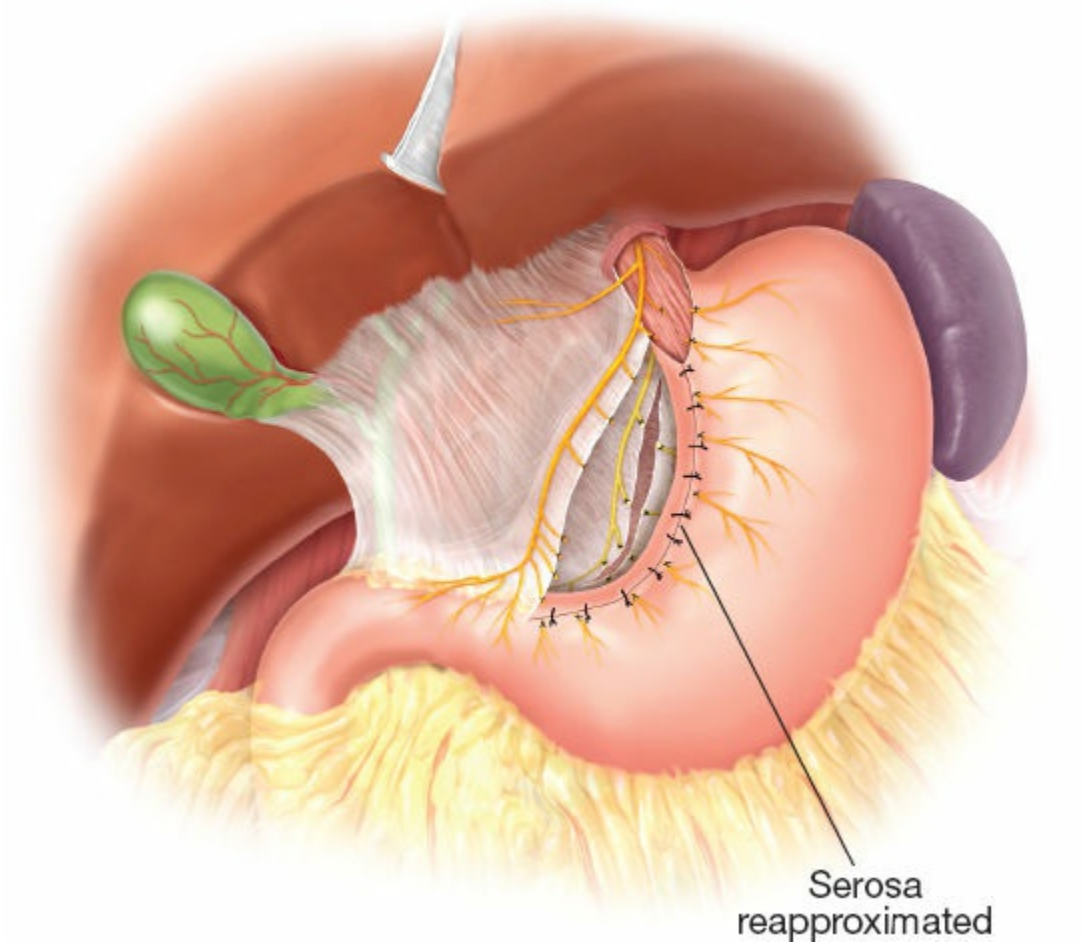

Figure 86.10. Closure of the gastric serosa along the lesser curvature upon completion of the HSV.

There are a few important technical nuances when translating the open HSV into its laparoscopic form. Foremost, we recommend using an electrosurgical instrument with a dissecting tip to improve efficiency. A good assistant can also improve efficiency by providing good retraction and exposure, especially while dissecting the lesser curvature and around the esophagogastric junction. In the former case, the surgeon retracts the gastrohepatic ligament toward the right as the assistant retracts the greater curvature to the left, thereby creating a taut plane in which to dissect and ligate each anterior neurovascular bundle; the assistant then retracts the lesser curvature to improve exposure of the posterior bundles. In the latter case, the surgeon must use the angle of the laparoscope in addition to the assistant to gain adequate visualization and exposure of the vagal trunks since palpation is less reliable. Once the case is completed, the fascia at all of the 10-mm port sites should be approximated to prevent herniation.

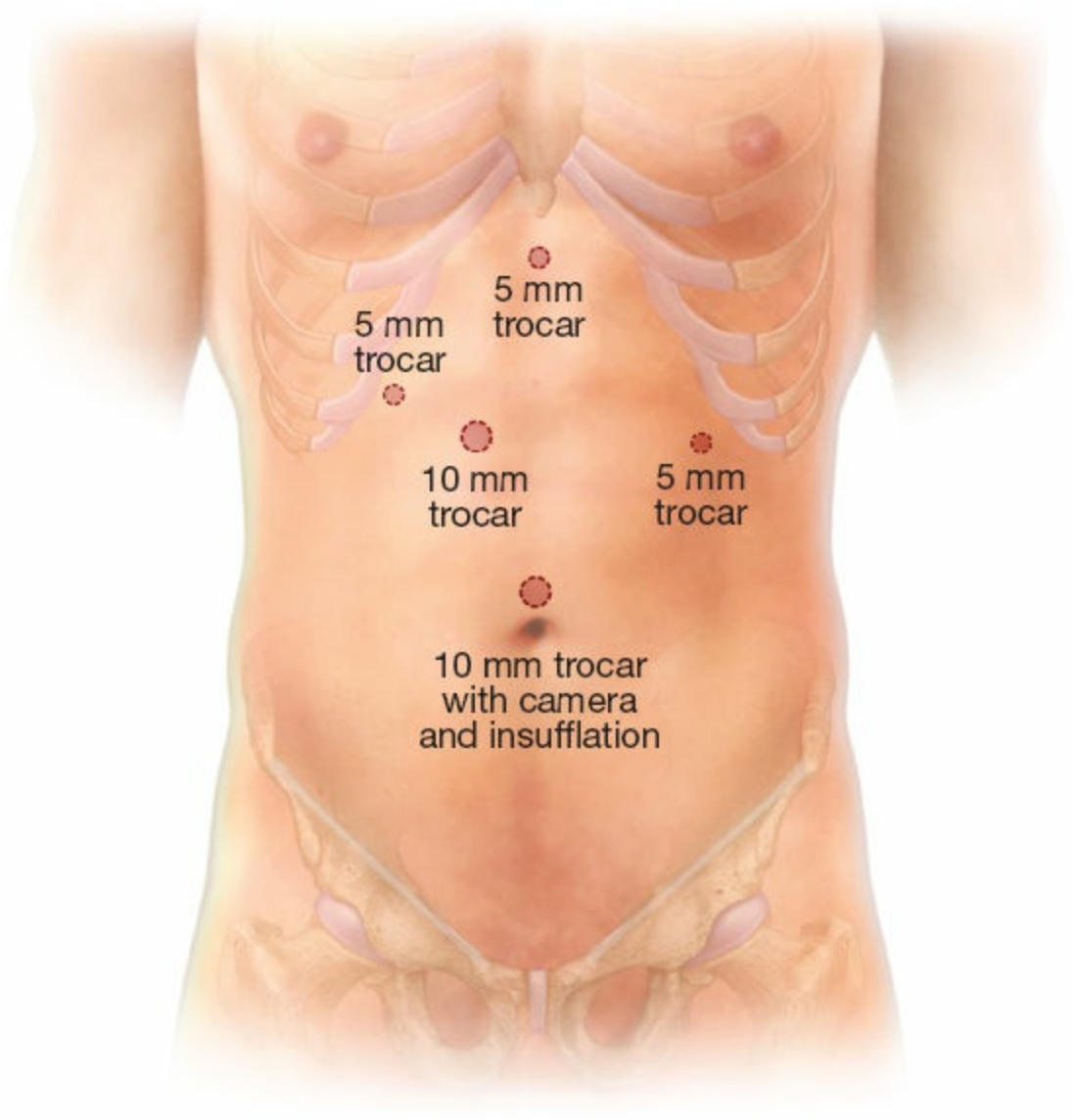

Figure 86.11. Port placement for laparoscopic vagotomies.

POSTOPERATIVE CARE

Patients undergoing selective and HSV are typically discharged once they are able to tolerate a liquid diet. Such a diet can be initiated the evening of surgery for patients undergoing HSV. Patients undergoing selective vagotomy plus a drainage procedure may require protracted gastric decompression via gastrostomy tube, especially in the setting of preoperative obstruction. The diet is advanced to normal on an outpatient basis.

COMPLICATIONS

After truncal or selective vagotomy and drainage, the surgeon should be

mindful of three potentially serious complications. The first is bile reflux gastritis. Ablation of the pylorus induces reflux of bile into the stomach, which often manifests as epigastric pain, nausea, and vomiting. In the minority of patients who experience intractable symptoms or evidence of severe chronic gastritis, the pyloroplasty should be converted to a Roux-en-Y gastrojejunostomy with a 50- to 60-cm limb. The surgeon should be warned that in patients with gastroparesis, conversion to a Roux will mitigate the bile reflux but make gastric emptying worse. The second is dumping syndrome, now an infrequent complication of an infrequent operation. Loss of gastric relaxation during meals causes “dumping” into the duodenum and release of vasoactive hormones, which often manifest as tachycardia, diaphoresis, hypotension, and abdominal pain. Delayed signs and symptoms are predominantly a function of hypoglycemia secondary to a surge in insulin from the food bolus that rapidly enters the duodenum. Patients with disabling dumping syndrome may require conversion to a Roux-en-Y gastrojejunostomy, but most patients can be managed with separation of solids and liquids as well as consumption of small, frequent meals high in protein and fat but low in carbohydrates. Finally, an ill appearing patient or one who fails to convalesce appropriately should raise suspicion for a leak, especially in the setting of fever and tachycardia. The issue can be investigated using computed tomography or upper gastrointestinal fluoroscopy with dilute or water soluble contrast. If a leak is identified, the surgeon must ultimately decide between percutaneous drainage or resection, reconstruction, and wide drainage.

Surgeons should not ignore the possibility of a leak from the devascularized lesser curvature after an HSV. Treatment entails primary repair plus omental patch if the defect is small and the patient is stable, resection if the compromised portion falls within limits of a standard gastric resection, or wide drainage.

OUTCOMES

There are no reliable modern series to assess recurrence rates or side effects between selective and HSV. This prevents assessment of their efficacy in the setting of modern surgical training and referral patterns (i.e., for medically recalcitrant disease). Historically, recurrence rates have ranged from 1% to 2% after truncal vagotomy plus antrectomy to 9% to 14% after selective vagotomy and pyloroplasty to 15% to 26% after HSV.

These statistics likely underestimate modern outcomes. Regardless, since these surgeries are now primarily used for salvage, the surgeon should select the approach most successful in his/her hands.

Suggested Readings

Christiansen J, Jensen HE, Ejby-Poulsen P, et al. Prospective controlled vagotomy trial for duodenal ulcer: primary results, sequelae, acid secretion, and recurrence rates two to five years after operation. *Ann Surg* 1981;193:49–55.

Clarke RJ, McFarland JB, Williams JA. Gastric stasis and gastric ulcer after selective vagotomy without a drainage procedure. *Br Med J* 1972;1:538–9.

de la Fuente SG, Khuri SF, Schifftner T, et al. Comparative analysis of vagotomy and drainage versus vagotomy and resection procedures for bleeding peptic ulcer disease: results of 907 patients from the Department of Veterans Affairs National Surgical Quality Improvement Program database. *J Am Coll Surg* 2006;202(1):78–86.

Donahue PE, Griffith C, Richter HM. A 50-year perspective upon selective gastric vagotomy. *Am J Surg* 1996;172:9.

Emos S, Eriksson B. Twelve-year follow-up of a prospective, randomized trial of selective vagotomy with pyloroplasty and selective proximal vagotomy with and without pyloroplasty for the treatment of duodenal, pyloric, and prepyloric ulcers. *Am J Surg* 1992;164:4.

Gustafson J, Willing D. "No acid, no ulcer"—100 years later: a review of the history of peptic ulcer disease. *JACS* 2010;210(1):110–6.

Hom S, Sarr MG, Kelly KA, et al. Postoperative gastric atony after vagotomy for obstructing peptic ulcer. *Am J Surg* 1989;157:282.

Lagoo J, Pappas TN, Perez A. A relic or still relevant: the narrowing role for vagotomy in the treatment of peptic ulcer disease. *Am J Surg* 2014;207(1):120–6.

Sawyers JL, Scott HW Jr. Selective gastric vagotomy with antrectomy or pyloroplasty. *Ann Surg* 1971;174(4):541–7.

Schroder VT, Pappas TN, Vaslef SN, et al. Vagotomy/drainage is superior to local oversew in patients who require emergency surgery for bleeding peptic ulcers. *Ann Surg* 2014;259(6):1111–8.

EDITOR'S COMMENT

The authors clearly describe the three types of vagotomies (truncal, selective, and highly selective) and a variety of ulcer operations. Today many of these operations are only rarely performed owing to effective pharmacologic acid

inhibition and treatment of *Helicobacter pylori,* the most common cause of ulcer disease. Whereas in the past these operations were performed for refractory ulcer disease, today these are performed for emergencies such as perforation, bleeding, or gastric outlet obstruction. Hence, the practicing surgeon may have little experience to draw upon in these urgent situations. Therefore, it does behoove the surgeon to be familiar with the nuances of the procedures.

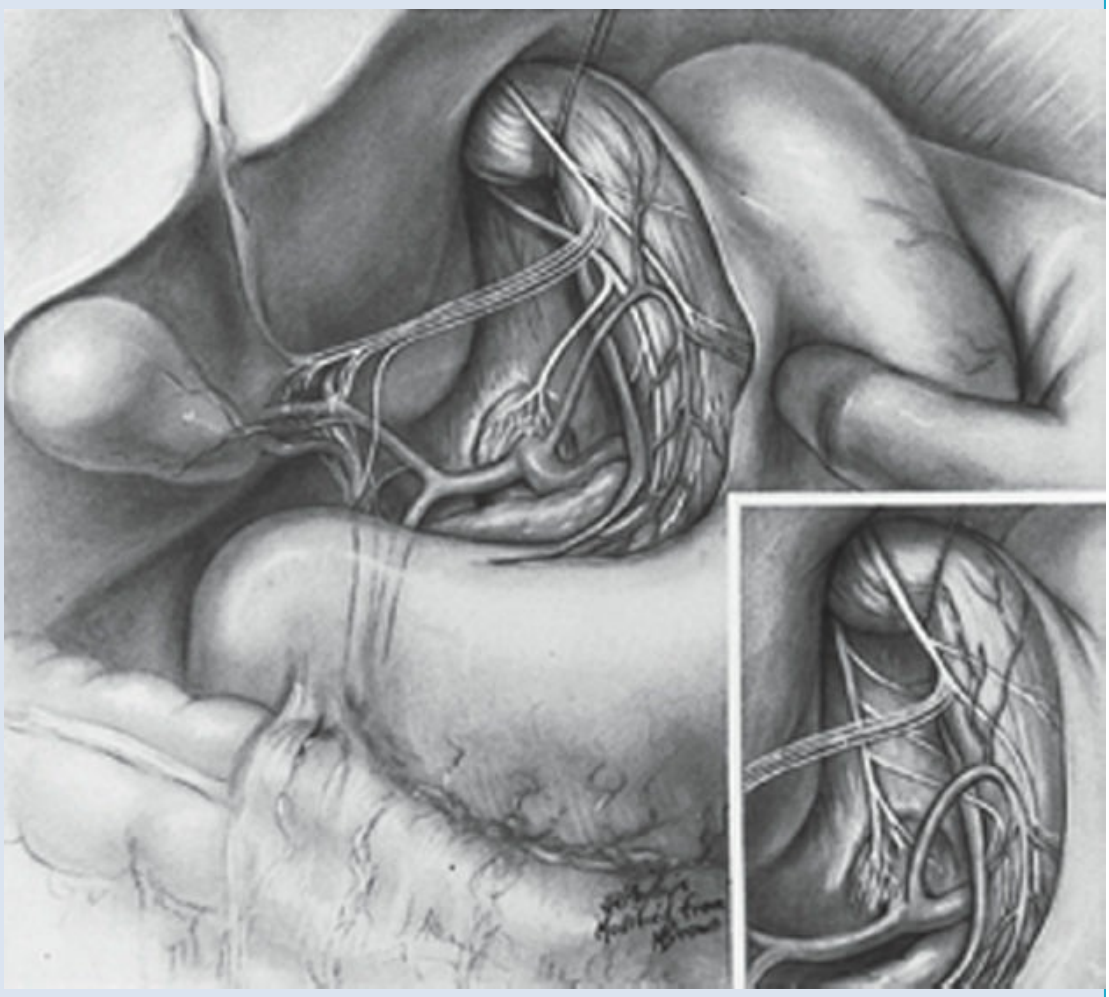

The abdominal vagi. All vagal fibers shown in this illustration are readily identified by gross anatomic dissection. The hepatic vagal division (usually consisting of multiple fibers) from the anterior trunk courses within the lesser omentum to the porta hepatis. The celiac vagal division from the posterior trunk goes to the celiac autonomic plexus, usually in close association with the left gastric artery but occasionally with the right diaphragmatic crus (*inset*). The main anterior and posterior trunks run distally within the lesser omentum adjacent to the cardia to the antrum. (From Griffith CA. Selective gastric vagotomy. In: Nyhus LM, Wastell C, eds. *Surgery of the Stomach and Duodenum*. 3rd ed. Boston, MA: Little, Brown and Company, 1977.)

Vagotomy was reintroduced by Dragstedt and Owens in 1943. Prior to that

time, subtotal gastrectomy had been the mainstay of treatment for refractory ulcer disease and complicated ulcer disease. After the importance of vagotomy in the prevention of recurrence of ulcers following resection was established, various other procedures were employed, including truncal vagotomy with gastroentreostomy or pyloroplasty, 70% subtotal gastrectomy, and antrectomy. In these operations, the key to prevention of recurrence was a complete truncal vagotomy. The anatomy of the vagus nerve is well described by the authors. The figures in the chapter clearly demonstrate the basic anatomic considerations in performing a vagotomy. An illustration taken from the 6th edition (Griffith CA. Selective gastric vagotomy. In: Nyhus LM, Wastell C, eds. *Surgery of the Stomach and Duodenum.* 3rd ed. Boston, MA: Little, Brown and Company, 1977) adds additional visual information.

A common cause of incomplete vagotomy is the anatomic variability between patients. Some patients will have single main trunks of the anterior and posterior vagus, whereas others may have multiple trunks. In order to avoid an incomplete operation, a long segment of the vagal trunk above the esophagogastric junction must be isolated, divided between clips and removed. A segment of the vagus nerve must be removed not only cut! This is more of a *vagectomy* than a vagotomy. In addition, it is important to skeletonize the esophagus circumferentially for 5 cm to divide any accessory branches of other trunks. The authors refer to obtaining immediate pathologic confirmation. This may be difficult in the middle of the night during emergency procedures as a pathologist may not be present. In addition, if you do have two trunks confirmed there is still the possibility of additional trunks. Hence, it is preferable to skeletonize the esophagus so as to eliminate all small fibers.

The identification of the anterior vagus is facilitated by downward traction on the anterior stomach after encircling the esophagus with a Penrose drain and retracting it cephalad. With this tension, the anterior vagus will feel like a banjo string and can easily be identified. It is sometimes buried in the adventitia. In addition, the inexperienced operator may dissect into the esophageal musculature and be fooled that the longitudinal muscles are nerve fibers. Muscle fibers are soft and do not develop tautness when stretched. The posterior vagus may be difficult to identify. The most common reason in my experience is that when the surgeon dissects behind the esophagus, the plane of dissection is anterior to the posterior vagus, which is then left between the diaphragmatic crura rather than being encircled with the esophagus. The surgeon can then mistake small nerve fibers or muscle fibers for the main trunk of the posterior vagus. The posterior vagus is usually a sizable nerve trunk. In these situations, the surgeon should explore between the diaphragmatic crura and palpate along the anterior surface of the aorta to identify the nerve. The same is true of the laparoscopic approach. Careful inspection of the tissue posterior to the esophagus is essential.

There is considerable debate about the role of vagotomy in the management of emergencies related to duodenal ulcer disease. This follows from our

understanding that by the majority if not all ulcers are caused by *H. pylori* infection. Hence the role of vagotomy has been challenged. A 2007 study by Rueben et al. (Trends and predictors for vagotomy when performing oversew of acute bleeding duodenal ulcer in the United States. *J Gastrointest Surg* 2007;11:22–8) using the National Inpatient Sample showed that there had been a significant decrease in the number of bleeding duodenal ulcers from 1999 to 2003 and a significant decrease in the number of vagotomies. There is no indication that trend has reversed itself. However, in a retrospective analysis of data from the ACS NSQIP database for the period 2005–2011 for 3,611 patients who had emergency surgery for bleeding (775) or perforation (2,374), Schroder et al. found that simple repair was the procedure of choice for perforated peptic ulcer as vagotomy and drainage had a significantly greater length of hospitalization. Conversely, for patients requiring emergency surgery for intractable ulcer bleeding, vagotomy and drainage was associated with significantly lower postoperative mortality than local ulcer over sewing alone. In addition, they found that patients undergoing vagotomy and gastric resection were associated with significantly greater postoperative morbidity when performed for perforation or bleeding.

Should resection be necessary most surgeons would agree that if a gastric resection with Roux-en-Y reconstruction is performed for ulcer disease-related complications, then a vagotomy should be performed to reduce the predictable occurrence of a marginal ulcer. There is also general agreement with gastrojenostomy, but less so with antrectomy and either Billroth I or Billroth II reconstruction. In the latter situations, it appears that long-term proton pump inhibitor (PPI) therapy may be equivalent to vagotomy in the prevention of ulcer recurrence, but there are no randomized trials to verify this hypothesis.

The authors discuss the role of selective and highly selective vagotomy. Each of these has a limited role today because of effective medical therapy and hence they are largely of historic significance.

One notable exception to the rule that most gastrointestinal ulcerations are caused by *H. pylori* are the ulcers caused by the excessive acid secretion provoked by secretion of gastrin by neuroendocrine tumors associated with the Zollinger–Ellison syndrome. Even in surgery for the Zollinger–Ellison syndrome, the role of any acid-reducing procedure has been limited. Most surgeons rely on tumor resection and long-term treatment with PPIs and avoid surgical resection and vagotomy. In the case of perforation or bleeding, one could argue that closure of the perforation or three-point ligation of the bleeding ulcer could be combined with vagotomy and pyloroplasty as this may be helpful in achieving better acid control particularly in the patient who had been on PPI at the time of the emergency.

Vagotomy is only part of the treatment for duodenal ulcer complications. I offer the following insights based upon my operative experience concerning duodenotomy and pyloroplasty for management of bleeding duodenal ulcer. Obviously to perform a three-point ligation requires accessing the duodenum.

This can be accomplished by a duodenotomy or pyoloroplasty. If the surgeon decides on local control only and use of PPI postoperatively rather than a vagotomy, then a duodenotomy may be made for exposure of the ulcer. Prior to making a duodenotomy, a kocher maneuver should be performed. The duodenotomy should be made with electrocautery as a longitudinal incision over the second portion of the duodenum. Once the three-point ligation is successfully performed, then closure of the duodenotomy is undertaken. I prefer to close the duodenal incision longitudinally with a single layer of 3-0 silk. The second portion of the duodenum is patulous, and it is very difficult to narrow the lumen. No drain is used. If there is concern about the caliber of the duodenum, the transverse closure may be accomplished. A two-layer closure or use of a Gambee stitch as noted below may be performed. There will be "dog ears" at the lateral and medial margin of the closure. As long as the closure is water tight, these should not leak.

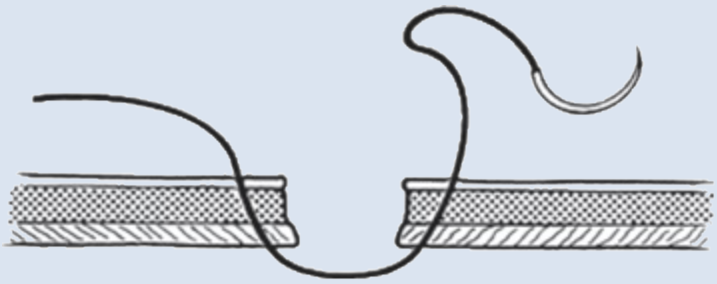

Placement of sutures for Weinberg pyloroplasty.

Various methods of reconstruction of pyloroplasty are described. As with the duodenal exposure noted above, a Kocher maneuver should be performed to free up the duodenum and avoid undo tension on the closure. I prefer a single-layer interrupted closure with 3-0 silk. Reconstruction of a pyloroplasty may be accomplished by the use of a Gambee stitch. This accomplishes in essence a two-layer closure using a single stitch. The above figure shows the use of the Gambee suture technique for the Weinberg modification of the Heinke–Mikulicz pyloroplasty.

E. Christopher Ellison

87 Duodenal Ulcer Disease: Pathogenesis and Management of Complications

James W. Maher, Daniel T. Dempsey, and E. Christopher Ellison

INTRODUCTION

Population studies have shown that peptic ulceration remains a major public health problem worldwide. The lifetime frequency of peptic ulcer disease (PUD) in the United States has been shown to be ~10%. Studies by Logan and associates indicated that, in the United States alone, some 300,000 new cases of peptic ulcer are diagnosed each year. The frequency rates of duodenal ulcers in other countries are variable and have been shown to be primarily associated with *Helicobacter pylori* and use of nonsteroidal anti-inflammatory drugs (NSAIDs). Although, as noted above, the surgical treatment of PUD has been fundamentally transformed, mortality and morbidity resulting from duodenal ulceration with perforation remain substantial. For example, the rate of peptic ulcer complication in patients of all age groups is ~1% to 2%.

Duodenal ulcers are one manifestation of what has been referred to as PUD and account for two thirds of all peptic ulcers. Duodenal ulcers are characterized by the presence of a well-demarcated break in the mucosa that may extend into the muscularis propria of the duodenum. It has been shown that >95% of duodenal ulcers are located within the first portion of the duodenum; most are <1 cm in diameter. Unlike gastric ulcers, which may be malignant in about 5% of cases, duodenal ulcers are benign. Duodenal perforation is the second most common complication of PUD (Schwartz) and occurs in as many as 10% of patients with PUD. Nowadays, perforation is by far the common indication for surgery in duodenal ulcer patients. While bleeding remains the most common complication of duodenal ulcer, this is almost always managed nonoperatively. Obstruction is the third most common complication of duodenal ulcer while today intractability is rare. Most perforations arise from ulcers in the anterior aspect of the duodenal cap. Studies have shown

that 92% of perforated duodenal ulcers perforated through the anterior duodenal wall; 10% of these are also associated with a concurrent, bleeding ulcer along the posterior wall, the so-called kissing ulcer.

ETIOLOGY AND PATHOGENESIS

The pathogenesis of PUD is multifactorial. Nevertheless, there are several environmental and/or host factors, which contribute to duodenal ulcer formation by increasing gastric acid secretion or weakening the mucosal barrier. Full understanding of the pathophysiology and pathogenesis of duodenal ulcers and their perforation complications requires a brief discussion of the two major etiologies: *H. pylori* infection and use of NSAIDs as well as the impact of other environmental factors.

Under normal physiologic conditions, the duodenal mucosa resists damage from the effects of gastric acid and pepsin, with the help of protective factors such as the mucous layer, bicarbonate secretion, and prostaglandins, which exert a protective effect. A duodenal ulcer occurs when an imbalance occurs between the protective factors above and the aggressive factors: acid and pepsin. Any process that increases gastric acidity (e.g., individuals with increased maximal and basal acid output), decreases prostaglandin production (e.g., NSAIDs), or interferes with the mucosa layer (e.g., *H. pylori* infection) can lead to PUD with its attendant increased risk of duodenal perforation.

H. pylori Infection

H. pylori is a gram-negative spiral flagellated bacterium. The organism is uniquely designed for survival in the hostile acidic stomach environment. The urease produced by this organism breaks down urea to alkaline ammonia and CO_2, which protects the bacterium from acid injury. The flagella and spiral structure allow penetration of the mucus and attachment of the bacteria to the gastric epithelial cell.

More than half the world population is infected with *H. pylori.* It appears to spread by fecal-oral transmission, and rates of infection are inversely proportional to socioeconomic status. Gastric inflammation is present in virtually all infected patients. There is no state of colonization without pathology. Infection is enduring and is never cured spontaneously. Eradication with antibiotic therapy results in resolution of gastritis. In the United States, ~80% of duodenal ulcer patients are infected and this contrasts with infection in ~60% of gastric ulcers. Nevertheless, only

20% of infected individuals develop a peptic ulcer; thus, the exact mechanisms producing ulceration are incompletely understood. It is established that in *H. pylori* patients with an ulcer, there is an increase in stimulated and basal acid output that is eliminated by eradication. In addition, *H. pylori* can interfere with mucosal protective mechanisms. *H. pylori* is a double-edged sword: increasing acid and reducing protection. We know that eradication of *H. pylori* infection in ulcer patients reduces the ulcer recurrence rate to well below 10%.

Nonsteroidal Anti-Inflammatory Drugs

In the Western countries, it is estimated that up to 30% of regular NSAIDs users have one or more ulcers. Both NSAIDs and aspirin interfere with the protective mucus layer by inhibiting mucosal cyclooxygenase activity and reducing levels of mucosal prostaglandins. Gastric acid also exacerbates NSAID injury, and conversely, gastric acid suppression has been shown to partially protect against NSAID injury. However, the exact mechanism by which NSAIDs cause duodenal perforation has not been clearly defined.

NSAID use has been reported to increase the risk of ulcer perforation by five to eight times that of nonusers (Svanes), and NSAID use is a factor in between one fifth to one third of perforations, the proportion increasing with increasing age.

Other Environmental Factors

Other environmental factors include cigarette smoking, excessive alcohol intake, and extreme emotional or physical stress. Cigarette smoking is a risk factor for PUD and its complications. Furthermore, cigarette smoking may adversely affect the healing of peptic ulcerations and, in the absence of treatment for *H. pylori*, may predispose to relapses. Cigarette smoking does not appear to influence the relapse rate for peptic ulceration if *H. pylori* in these patients has been eradicated. Nevertheless, at least one study has disputed the association between smoking and PUD. Smoking probably promotes peptic ulceration by increasing gastric acidity and maximal acid output and enhancing *H. pylori* proliferation. Smokers have been found to have decreased prostaglandin concentrations in their gastric and duodenal mucosa, and smoking has been shown to inhibit acid-stimulated duodenal mucosal bicarbonate secretion. It is not clear which, if any, of these proposed mechanisms contributes to peptic ulceration in cigarette smokers.

Alcohol

Alcohol has also been thought to be a strong risk factor for peptic ulcer, although there are little hard data to support this. While the prevalence of ulcers is higher in alcoholic cirrhosis, no association has been demonstrated in drinkers without cirrhosis.

Spicy Foods and Caffeine

Ulcer patients commonly describe dyspepsia with ingestion of certain foods, but there is no evidence that such foods cause ulcers. Coffee (caffeinated and decaffeinated), tea, and colas are all potent acid secretagogues. It was once popular to prescribe a bland diet for ulcer patients; however, they are generally conceded to exert no benefit.

Emotional Stress

Ulcers have long been associated in the public's mind with emotional stress; however, this association has been disparaged since the appreciation of the role of *H. pylori* infection and NSAID use. Emotional stress is probably not sufficient to cause ulcers in most patients since eradication of *H. pylori* and elimination of NSAIDs generally prevent ulcer recurrence despite the patient's emotional state.

Heredity

There are some suggestions that genetic factors may predispose a patient to peptic ulcer. The incidence among identical twins is higher than that for nonidentical twins, and there is an increase in first-degree relatives of ulcer patients. The genes responsible are unknown. Some of this increased susceptibility may be due to a high rate of *H. pylori* infection among family members. It was initially thought that elevated serum levels of serum pepsinogen I might be a genetic marker, but this now appears to be a consequence of *H. pylori* infection, which disappears with eradication. Other proposed markers include O blood group, lack of secretion of blood group antigens in saliva, and the presence of certain HLA subtypes; however, it now appears that these associations relate more to susceptibility to *H. pylori* infection.

COMPLICATIONS OF PEPTIC ULCER DISEASE

Complications of PUD include bleeding, perforation, and gastric outlet

obstruction. The treatment of these has undergone significant evolution. Management now includes the early use of high-dose intravenous (IV) proton pump inhibitors (PPIs), treatment to eradicate *H. pylori*, improved endoscopic and radiologic methods for control of hemorrhage, and changes in surgical indications and procedures. While historic studies suggest that hospitalizations for potentially life-threatening ulcer complications had plateaued or increasing, more contemporary reports indicate a steady decline in rates of hospitalization and in the incidence of bleeding and perforation. For example, Wang and colleagues found an ~30% to 40% fall in hospitalizations for PUD complications. They reported that the national estimate of hospitalizations for PUD decreased significantly from 222,601 in 1993 to 156,108 in 2006 (−29.9%), with a larger reduction in duodenal ulcers (95,552 in 1993 vs. 60,029 in 2006, −37.2%) than gastric ulcers (106,987 in 1993 vs. 86,064 in 2006, −19.6%). In addition, the inpatient mortality rate of PUD decreased from 3.8% to 2.7% during 1993 to 2006 ($P < 0.001$). Hemorrhage remained the most common complication (71.6% in 1993; 73.3% in 2006) but perforation had the highest mortality (15.1% in 1993; 10.6% in 2006). Further comparison to 1993 showed patients hospitalized for PUD in 2006 more frequently had endoscopic treatment to control bleeding (12.9% vs. 22.2%, $P < 0.001$), similar use of surgical over sewing of the ulcer (7.6% vs. 7.4%), less use of gastrectomy (4.4% vs. 2.1%, $P < 0.001$), and less use of vagotomy (5.7% vs. 1.7%, $P < 0.001$). Another study from the United States evaluated the National Inpatient Database and found that the rate of perforation and bleeding has been decreasing in the United States and hypothesized that this could be caused by the decrease prevalence of in *H. pylori.*

Of note the incidence of *H. pylori* rose dramatically prior to 1998, peaking at an estimated 97,823 cases in 1998 (SE = 3,155; 95% CI = 6,184). Since that time it has decreased and then stabilized. Another review estimated that the annual incidence of peptic ulcer hemorrhage is on the order of 19 to 57 cases per 100,000 individuals, and that the annual incidence of ulcer perforation is on the order of 4 to 14 cases per 100,000 individuals.

In the subsequent sections, we will discuss the management of three most common complications of duodenal ulcer disease: bleeding, perforation, and gastric outlet obstruction.

Bleeding Duodenal Ulcer

Hemorrhage is the most common complication of duodenal ulcer accounting for over two thirds of complications. The incidence is estimated to be 103 cases per 100,000 adults. Hematemesis is the most dramatic manifestation of massive upper gastrointestinal (GI) bleeding but may not be the most common. Melena may occur instead, or both may be present. Hemodynamic changes confirm the severity of the bleeding. Duodenal ulcer hemorrhage is usually self- limited, but in up to 25% of patients the bleeding persists or recurs despite medical management with IV PPI. Clinical factors such as hematemesis, shock, and transfusion requirement help to define this high-risk subgroup that requires urgent and aggressive multidisciplinary management; virtually all operations for bleeding, and all deaths, occur in this subgroup. A nasogastric (NG) tube is always indicated in patients with signs of sudden GI blood loss and no hematemesis, to help confirm or deny the presence of blood in the stomach. Significant duodenal bleeding usually has some duodenogastric reflux of blood even if no vomiting occurs. Thus, hematemesis or bloody NG tube suctioning confirms upper GI bleeding.

Knowledge of the patient's medical history is important to focus the next steps on resuscitation and diagnosis prior to therapy. Patients with known cirrhosis and portal hypertension will be much more likely to have hematemesis on the basis of bleeding esophageal varices, for example. For patients without any suggestion of liver disease or chronic alcohol ingestion, bleeding ulcer must be considered as the most likely cause for hemodynamically significant upper GI hemorrhage.

Resuscitation

When a surgical consultant is asked to see a patient with upper GI bleeding, it is essential that the surgeon ensure that there is: (a) a plan for and (b) completion of resuscitation ideally prior to starting definitive diagnostic procedures. The patient with signs or suggestions of a significant upper GI bleed should have the following resuscitative measures performed:

1. Large bore intravenous access, 16 gauge or larger, with two such lines available
2. Central venous access to monitor CVP and intravascular volume status
3. Foley catheter to monitor urine output

4. ICU bed with hemodynamic constant monitoring
5. Consideration of intubation if airway protection is indicated
6. Sufficient blood products available to meet the needs for resuscitation of both red cells and the capacity to clot normally

Diagnosis

Flexible upper endoscopy is the diagnostic procedure of choice. A gastroenterologist skilled in therapeutic endoscopy should be consulted unless the surgeon is an experienced endoscopist with therapeutic credentials. During the upper endoscopy, the following steps are warranted: continued monitoring of the patient's vital signs and volume status is imperative, as is protection of the airway. The most frequent technical challenge to the endoscopist performing a successful diagnostic and potentially therapeutic intervention is the presence of a large amount of blood within the lumen of the stomach. Evacuation of this clot via a very large bore gastric lavage tube (32 French, Ewald tube) is recommended. The tube is passed perorally and is capable of evacuating large clots. Lavage with several liters of water, not saline, may be needed before adequate visualization may occur. The water should not be cold so as to avoid hypothermia from it.

Once the stomach lavage return is clearing, the flexible endoscope is introduced and the esophagus, stomach, and duodenum inspected to the end of the third portion of the duodenum, and depending on the clinical findings the fourth portion of the duodenum may be examined as well if it can be accessed. Virtually, all upper GI bleeding sources are in the proximal duodenum, but may occur more distally. Bleeding lesions other than a duodenal ulcer may include esophagitis, esophageal varices, Mallory Weiss tear, Dieulafoy ulcer, gastritis, gastric varices, gastric ulcers, duodenitis, and tumors or polyps in any of these areas. Aortoenteric fistula should always be considered if there is a history of vascular surgery or (rarely) treatment (e.g., radiation or stenting) for advanced esophageal or gastric cancer. The typical bleeding duodenal ulcer is located within several centimeters of the pylorus on the posterior aspect of the duodenum. Significant hemorrhage arises because the ulcer has eroded into a branch of or the main lumen of the gastroduodenal artery. If the latter has occurred, then the bleeding is brisk and may be associated with projectile hematemesis and shock.

Endoscopic Therapy

The endoscopist has several options for treating the bleeding duodenal ulcer. These include

1. Endoscopic clips placed directly on any visible vessel
2. Injection of the base of the ulcer with dilute epinephrine solution
3. Bicap probe to coapt the vessel lumen
4. Heater probe to coagulate the vessel lumen
5. Argon beam for more diffuse oozing surfaces (less likely for a bleeding vessel)

Skill and experience are needed to perform therapeutic endoscopy to arrest vigorous bleeding from a duodenal ulcer. The main technical problem is the ability to see through the scope despite the ongoing bleeding. The suction capacity of the endoscope is limited, and when used, performs the automatic negative process of removing the insufflated air within the lumen of the duodenum necessary to maintain visualization during the procedure.

If the initial endoscopic treatment fails and recurrent bleeding ensues, it must be noted that not all patients need to proceed to embolization or surgery. A selective approach to treatment may be adopted based on the local characteristics of the ulcer and the pre-existing comorbidities of the patients. Large ulcers (>2 cm) and those with a visible vessel may best be treated by surgery if recurrent bleeding occurs. Patients who are poor surgical candidates might benefit from repeated endoscopic treatment, but in some instances the patient is then best served by moving on to either radiologic or surgical therapy. The decision for which treatment is best should be individualized and requires surgical judgment taking into account the above factors and the hemodynamic stability of the patient.

Radiologic Therapy

Since the last edition of this text, the radiologic approach to upper GI bleeding has become even more popular as the next therapeutic option with failure of interventional endoscopy. Over the past decade, interventional radiologists in many institutions have developed increasing experience in vascular embolization to arrest hemorrhage. The concern for end-organ ischemia that is present when embolization of organs such as the colon or small bowel is considered is not as great a concern with a bleeding duodenal artery, as the collateral circulation provided by the

pancreaticoduodenal artery to the duodenum will usually prevent ischemia should the gastroduodenal be occluded from embolization. The radiologist uses a combination of coils or other intraluminal objects to achieve the desired embolization of the gastroduodenal artery. Success with this approach is good as defined by leaving the hospital without further intervention. However, in some circumstances, the backflow of the vessel or the volume of the bleeding is such that even this approach may fail. At that point, surgical therapy is the indicated course.

Although it is still controversial as to whether radiologic intervention is superior to surgical intervention in terms of overall outcomes for treating bleeding duodenal ulcer, it has now become the next step in many institution's algorithms of treatment of bleeding duodenal ulcer after endoscopy and before surgery. This situation depends on the local expertise available in any institution and the ability to respond as rapidly as surgery. The less invasive nature of the radiologic intervention has appeal in terms of limiting abdominal wall morbidity as well as other potential complications which may arise from abdominal surgery. Radiologic intervention for bleeding duodenal ulcer is also ideal when the patient has failed endoscopic treatment and for a variety of reasons and is a poor surgical candidate. These reasons could include inherent existing diseases of the patient, poor anesthetic risk, or multiple previous abdominal operations making abdominal access difficult, among others.

SURGICAL TREATMENT

The current indication for surgical therapy for treatment of bleeding duodenal ulcer is when

1. Less invasive therapies have failed
2. Less invasive therapies are not available
3. The severity of the bleeding does not allow for the potential for a lesser invasive procedure to be done in terms of the time allowable before the hemorrhage must be controlled (a hemodynamically unstable patient)

Surgical therapy must be exercised whenever the patient shows hemodynamic instability along the above algorithm, indicating that the ability to tolerate ongoing blood loss at that rate is limited in terms of time, and failure of an endoscopic or even radiologic approach could prove life-threatening. This assumes that the patient is a candidate for surgical therapy. Primary emergency surgery is indicated when shock persists

despite aggressive volume resuscitation and when blood loss continues, necessitating transfusion in excess of 6 units of blood over a 24-hour period. Other factors to consider in the decision-making process include patient >70 years (physiologically), the presence of multiple comorbidities, and a previous history of ulcer diathesis. Especially where interventional radiologic alternatives do not exist, the poorer the surgical candidate, often the more rapid and aggressive must be the surgical intervention if the patient is to survive. The timing of primary emergency surgery should be influenced by these factors, given that the morbidity and mortality are greatly increased with delayed intervention.

CHOICE OF OPERATION

In choosing the type of operation for treatment of the actively bleeding duodenal ulcer, factors to be considered are the patient's condition and the technical difficulty and expected duration of the operation. Local factors around the potential operative site including previous surgery and scarring must also be considered. The various operations that have been performed in the past have been well analyzed to allow some judgment as to their efficacy and appropriateness in the setting of treating duodenal ulcer.

While many operative procedures are now routinely done using a laparoscopic approach, the indications for surgical intervention for bleeding duodenal ulcer usually are such that one is performing an emergent operation where speed and simplicity are valuable components of the procedure. Laparoscopic opening of the duodenum and suturing of a bleeding ulcer may be quite within the technical abilities of some surgeons, and this approach, if able to be carried out with good visualization of the ulcer, is not to be ruled out. Nevertheless, the experience of most surgeons in rarely performing surgical therapy for bleeding duodenal ulcer and the technical difficulty of maintaining the pneumoperitoneum in the face of constant suctioning of blood from the bleeding vessel site make the laparoscopic approach limited in its application to a select fewer surgeons.

It is now also quite clear that the decades old recommendation of performing an antrectomy and truncal vagotomy as the most definitive treatment of PUD is also to be avoided in the setting of the emergent operation for bleeding duodenal ulcer. First, the duodenum must be opened to treat the ulcer, making the closure of the duodenum more difficult in the setting of antrectomy. The typical bleeding ulcer is posterior and thus, by

definition, in the pancreas. Resection in this setting is fraught with opportunity for duodenal leak. Multiple options exist for dealing with the "difficult duodenal stump," but the best technique is not to create the duodenal stump in the first place. The additional surgery needed for resection as well as anastomosis is rarely justified in the emergency setting.

The operation of choice for the high-risk, unstable patient continues to be suture ligation of the bleeding vessel. In the stable patient, vagotomy and drainage may be considered. If the duodenotomy is easily incorporated into a Heinike–Mikulicz pyloroplasty, then that is the drainage procedure of choice. If the duodenotomy is too long or too distal, then simple closure with gastrojejunostomy may be preferable if truncal vagotomy is performed. Instead of truncal vagotomy, it may not be unreasonable to rely on long-term PPI therapy. Suture ligation alone is perfectly acceptable followed by PPI treatment. If there is no access to medical therapy, then truncal vagotomy or even highly selective vagotomy may be performed. Certainly, any vagotomy, truncal or highly selective, is the last step of the operation once hemostasis has been achieved and the duodenum is closed. At that point, the condition of the patient as well as other factors that may be relevant should combine to allow the surgeon to make the best decision regarding vagotomy.

CHOICE OF INCISION

An upper midline vertical incision serves most situations for performing upper abdominal surgery. The pylorus and duodenum are sufficiently close to the midline to allow good exposure with such an incision. The incision may need to be carried up to the xiphoid if truncal vagotomy is contemplated, especially if the patient is obese. The lower extent of the incision is usually around or above the umbilicus.

Upon entering the peritoneal cavity, rapid exploration should confirm the presence of a NG tube or Ewald-type tube in the lumen of the stomach (at times from the endoscopy) and gastric decompression. The round and falciform ligaments are divided. Additional exposure of the duodenal area is achieved through the use of mechanical self-retaining retractors. Several brands are available and afford adequate exposure. There should be an appropriate retractor for the liver to both retract it and avoid parenchymal injury. A Kocher maneuver should be done.

If a laparoscopic approach is used in a more elective setting, we use

port placement similar to what we would use in the performance of an antireflux operation, but situating the surgeon's right hand port closer toward the midline and the left port slightly further to the patient's right. This allows the main axis of the camera, located in the umbilical region, to be pointed toward the duodenum. There is no place for single port surgery in this setting. A Nathanson, flexible triangular, or other epigastric to right subcostal located liver retractor is appropriate.

SURGICAL TECHNIQUE

Suture Ligation

The primary objective during surgery to treat a bleeding duodenal ulcer is to control the bleeding vessel. Thus, this step takes precedence and is of paramount importance. When the bleeding vessel has been localized by endoscopy to be in the first portion of the duodenum, a Kocher maneuver is performed for mobilization of the second portion of the duodenum. The pyloric vein is used as a landmark to identify the pylorus, if it is not readily identifiable by visualization and palpation. Traction sutures of 2-0 silk are placed superior and inferior to the pyloric ring. A longitudinal full-thickness incision is made starting on the prepyloric antrum halfway between the greater and lesser curvature (Fig. 87.1). Once the distal stomach is entered, a blunt hemostat can be used to gently traverse the pylorus into the proximal duodenum. This instrument is used to guide the full-thickness cut through the pylorus into the duodenum. We use the cautery. Often a 3-cm longitudinal incision is sufficient. It is important to ensure good hemostasis. Traction on the sutures opens the incision into the form of a diamond, which allows adequate exposure. Intraluminal clot is suctioned away. Occasionally, the incision needs to be extended another 1 to 2 cm further into the duodenum if the ulcer is slightly more distal.

Once the incision is completed, the bleeding source and ulcer are identified. Direct pressure is applied to any ongoing bleeding while preparing to suture ligate the site. It is helpful after Kocherization for surgeon or assistant to elevate duodenum with left hand permitting manual compression of the bleeding ulcer. This pressure can be held as long as necessary to allow anesthesia to catch up with resuscitation. If the ulcer has a clot over it, the clot must be cleared away adequately to define the location of the bleeding vessel. If the bed of the ulcer has stopped actively bleeding, suture ligation is still performed. However, in this setting, a search for other potential bleeding sites should be performed. If it is clear

that there is ongoing hemorrhage from a site more proximal to the pyloromyotomy from the stomach, attempts to intraoperatively visualize it through the incision should be made. Extension of the incision may be needed if the source is identified as close. If the source is unclear, intraoperative gastroscopy by a colleague is indicated to determine the site of the bleeding. Then a second gastrotomy can be made at that site to treat it appropriately.

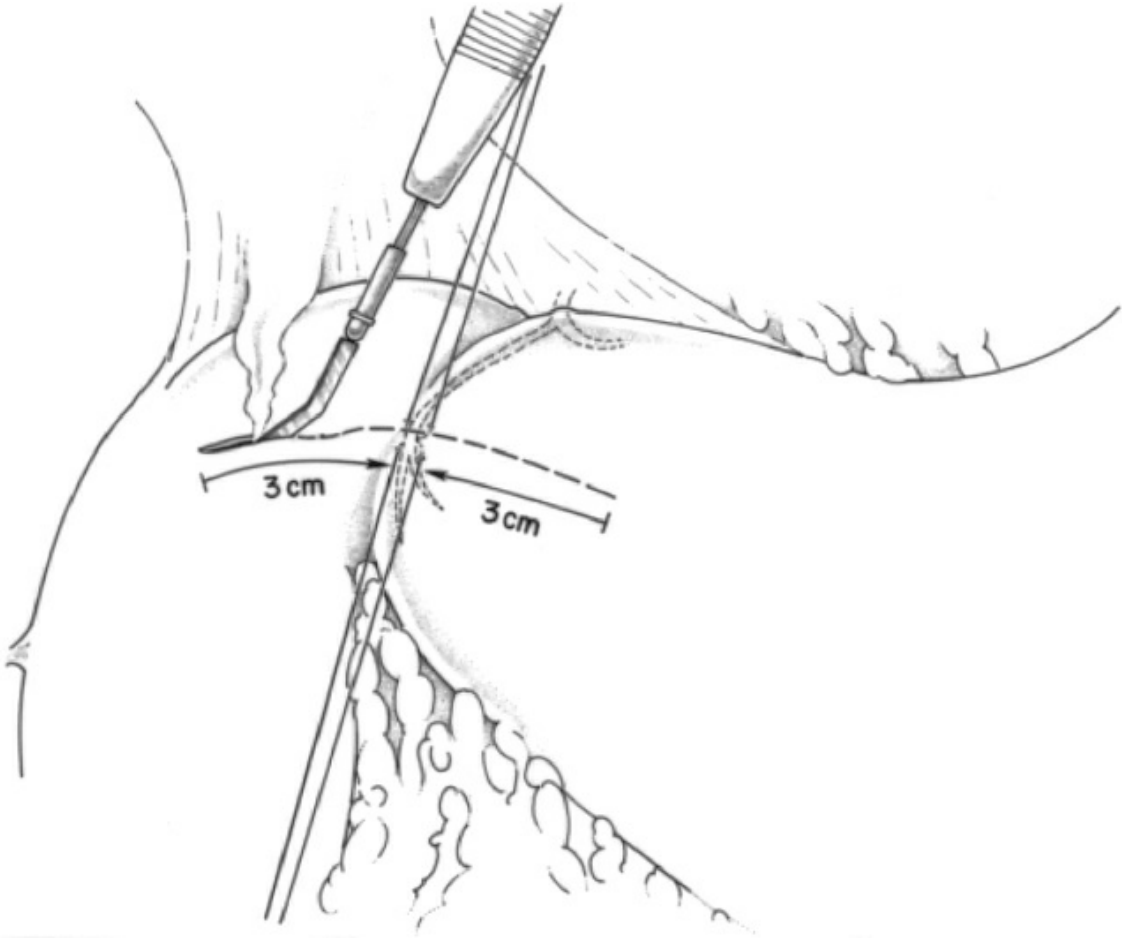

Figure 87.1. A longitudinal incision is made, spanning 3 cm on each side of the pylorus, to give adequate access to the duodenal bulb for suture ligation of the bleeding duodenal ulcer. Traction sutures of 3-0 silk have been placed at the level of the pylorus, identifiable by the vein of Mayo.

When an actively bleeding duodenal ulcer is identified, direct pressure is followed by suture ligation. A thorough understanding of the anatomy of the gastroduodenal complex, described as the T-three vessel junction, is important when performing suture ligation (Fig. 87.2). The gastroduodenal complex should be transfixed at three points, with the gastroduodenal

artery ligated proximal and distal to the site of penetration. The third suture ligature, a U stitch, should transfix the transverse pancreatic branch, which is located medially. Major rebleeding, if it occurs, is most likely due to imprecise placement of these suture ligatures through failure to recognize that the arterial site of bleeding is located at a junction of the gastroduodenal complex. Some prefer to use heavy absorbable synthetic suture (2-0 weight), but the use of silk suture is certainly acceptable and preferred by many. Heavier round surgical needles are indicated if there is excessively thick scarring of the posterior wall of the duodenum from the ulcer, which is usually the case. Care must be taken to adequately incorporate the vessel into the ligature, but to avoid such a depth of penetration so as to avoid injury to any surrounding structures. The bile duct may be close enough to the ulcer that injury may occur with deep sutures or with superficial ulcers in proximity to the ampulla of Vater. If there is concern, then a cholangiogram may be performed. If the ampulla of Vater is involved with the ulcer, it may be necessary to place a biliary fogarty into the common bile duct via the cystic duct and thread this into the duodenum so as to mark the ampulla so that injury may be avoided. All of these maneuvers take time, and if speed is of the essence in an unstable patient the surgeon may need to proceed without these precautions.

Heineke–Mikulicz Pyloroplasty

The simplest closure of the pyloromyotomy is a standard Heineke–Mikulicz pyloroplasty. This involves simply closing the longitudinal opening in a transverse direction using a single layer of sutures. Typically the incision is closed transversely with 3-0 seromuscular silk sutures (Fig. 87.3). In this technique, the sutures are placed first and then all tied seriatim. Classically, care is taken that no mucosa is protruding up through the apposed serosa. Probing between the suture gaps with a fine clamp may identify the need for additional seromuscular sutures that are placed as needed. More technically involved suture techniques such as the Gambee suture are proven traditional methods as well (Fig. 87.3). This suture technique involves a full-thickness penetration of the bowel from serosa to mucosa on one side, then a submucosal bite on that same side intraluminally, followed by a mirror image submucosal bite in the bowel inner surface on the opposite side of the opening, then a full thickness from mucosa out through serosa of the second bowel wall. This is illustrated in Figure 87.3, which shows closing in a Heineke–Mikulicz

fashion.

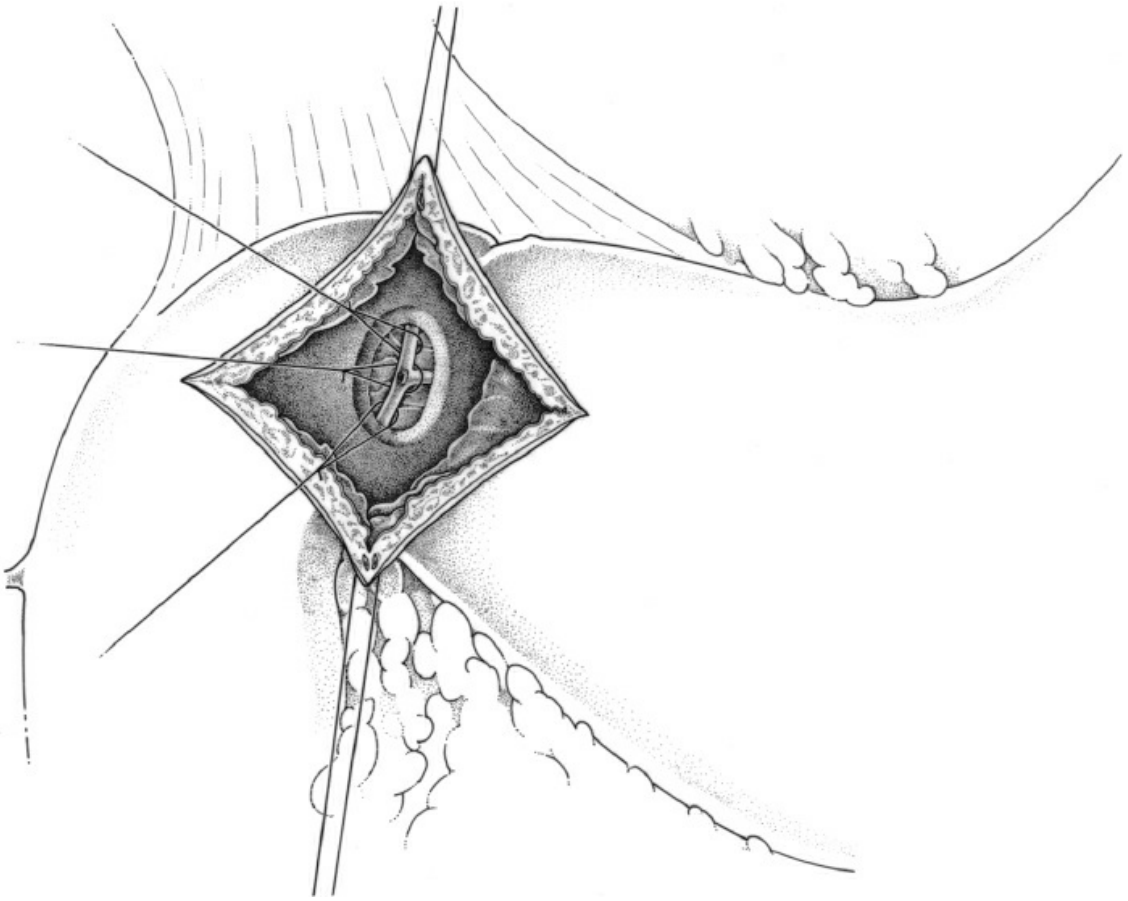

Figure 87.2. Proper suture ligation of a bleeding ulcer arising from the gastroduodenal artery requires a three-suture ligation. The proximal and distal branches of the gastroduodenal artery are transfixed. A third suture, U type in configuration, is necessary to transfix the transverse pancreatic branch of the artery.

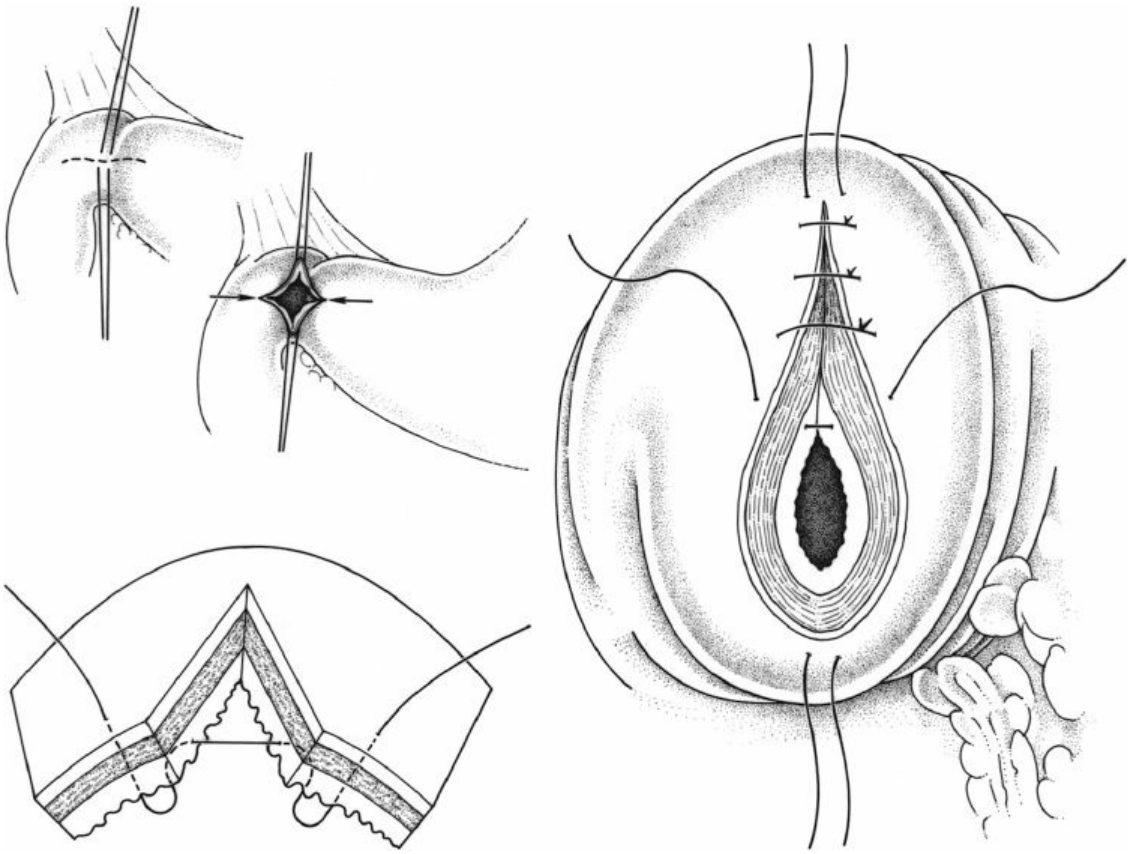

Figure 87.3. A standard Heineke–Mikulicz pyloroplasty performed with a single layer of sutures (Weinberg). The longitudinally oriented incision (**upper left**) is closed transversely (**middle left**), such that the former end points of the longitudinal incision (*arrows*) are apposed; this transverse closure of the incision prevents potential functional gastric outlet obstruction after vagotomy. Sutures are placed as shown in the **lower left,** creating a single inverting layer (**right**).

Finney Pyloroplasty

This operation requires more extensive dissection than Heineke–Mikulicz pyloroplasty, so a larger incision is necessary if done open. This would be needed infrequently to manage a bleeding duodenal ulcer and more common for an obstructing ulcer or penetrating ulcer. A Kocher maneuver is necessary. A 10- to 12-cm longitudinal gastroduodenotomy is made, transecting the pylorus, which should be at the midpoint of this longitudinal incision. This incision is then closed as a side-to-side gastroduodenostomy, with the pylorus at one apex. Ideally, the closure is in two layers. Finney used running silk on the back outer layer, then running absorbable suture on the inner layer, and then interrupted silk on the outer front layer. Again, it seems prudent to test anastomotic integrity

with air insufflation and consider postoperative gastric decompression with an NG tube.

Jaboulay Pyloroplasty

This is essentially a side-to-side anastomosis between the greater curvature side of the distal stomach and the anterior proximal duodenum. Takedown of the hepatic flexure of the colon may facilitate exposure especially in the obese patient. A Kocher maneuver should be performed, and then a standard two-layer longitudinal tension-free hand-sewn anastomosis should be done and tested. An anastomosis 4 to 5 cm in length is adequate. We prefer silk and braided absorbable suture to the stiffer monofilament suture. It is possible to utilize stapling instruments to perform this anastomosis, perhaps a laparoscopic 45-mm linear cutter and TA 30. Staple size should be chosen based upon the thickness of the stomach, and hemostasis of the linear staple line assured. Again, the integrity of the anastomosis is tested with air insufflation. Although it is possible to envision other stapling techniques for pyloroplasty or gastroduodenostomy, we generally do not favor making additional openings in the GI tract to accomplish this.

Truncal Vagotomy

This is an expanded description of open truncal vagotomy, also known as total abdominal vagotomy, described in Chapter 86. This is sometimes performed in the emergent setting in the stable patient after the pyloroplasty has been completed. Retraction of the left lobe of the liver is performed. Division of the left triangular ligament may be performed only if further exposure is needed.

Downward traction is gently applied to the stomach, placing the gastroesophageal junction (GEJ) area under slight traction. The phrenoesophageal ligament and the peritoneum covering the GEJ area are divided transversely (Fig. 87.4). The right hand thumb and index finger of the surgeon are now used to bluntly develop the plane beneath the anterior lip of the esophageal hiatus and to the left of the esophagus (Fig. 87.5). The esophagus is circumferentially bluntly dissected with the right index finger and thumb. The index finger continues along the posterior surface of the esophagus, bluntly dissecting the posterior phrenoesophageal ligament, and the esophagus becomes encircled by the index finger and thumb (Fig. 87.6). The NG tube within the esophagus serves as a guide for confirming

the esophagus as this maneuver is being performed. Once encircled by the surgeon's fingers, a Penrose drain may be placed around the esophagus to facilitate retraction at this point (Fig. 87.7). Retraction must be gentle to avoid tear or injury. Although most surgeons do the dissection in the abdomen, one can develop a plane on the anterior esophagus and dissect the esophagus in the chest (taught to JM by Professor Dragstedt). Dragstedt referred to this as a transabdominal intrathoracic vagotomy.

The vagal trunks are now identified. The anterior one is always buried within the anterior muscle fibers of the distal esophagus, between the 12 and 2 o'clock positions. It is best located 2 to 4 cm above the GEJ in this location (Fig. 87.8). Gentle, sharp, and blunt dissection frees the nerve from the surrounding muscle fibers (Fig. 87.9). Direct palpation of the anterior wall of the esophagus is usually the best way to find this nerve. The posterior trunk, on the other hand, is more often not adjacent to or within the muscle of the esophagus. It is instead usually located within the 6 to 8 o'clock area of the esophageal circumference, laying on the posterior crural intersection. The posterior nerve is always larger than the anterior nerve and palpating along the upper right side of the esophagus, then moving downward to posterior to the esophagus, and palpating in a downward direction on the crural intersection will often reveal the location of the nerve. Failure to properly identify the posterior nerve is the most common error in this operation. Often the inexperienced surgeon will mistake some of the fibrous tissue along the posterior surface of the esophagus as the nerve. Remember, the posterior nerve is larger than the anterior one. If the surgeon is having difficulty finding the nerve using the above technique, then further dissection with the left index finger along the right mediastinum further up along the right side of the esophagus will usually allow its identification. Dissection of esophagus several centimeters above the GEJ allows the posterior nerve to be picked up in the initial encirclement. When dissecting esophagus, surgeon should try to include as much tissue as possible to avoid leaving behind the posterior nerve.



Figure 87.4. Total abdominal vagotomy begins by incision of the phrenoesophageal ligament transversely at the level of the abdominal esophagus.

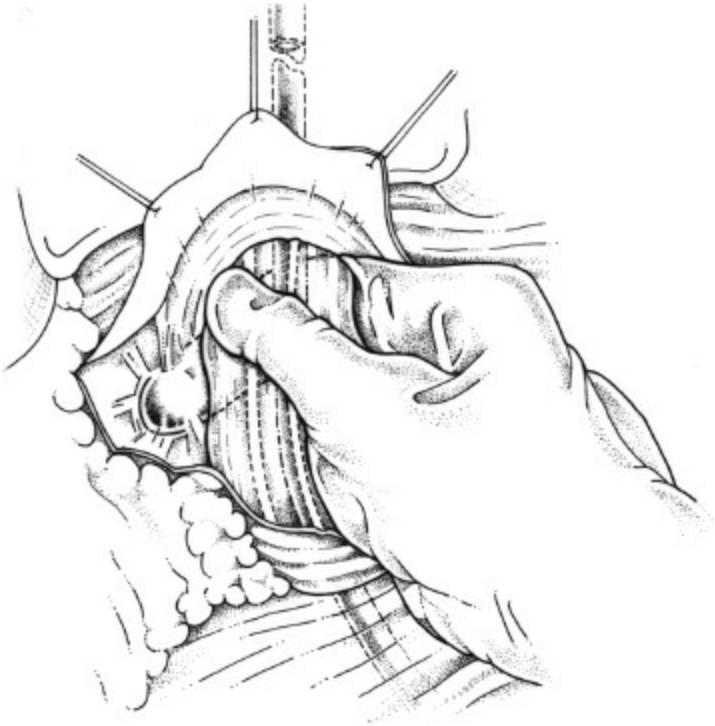

Figure 87.5. The surgeon's right index finger and thumb are used to blunty create a window posterior to the palpable wall of the esophagus, with the loose tissue and peritoneum dissected off

the esophagus. The nasogastric tube is palpated to confirm the location of the esophagus as this dissection begins.

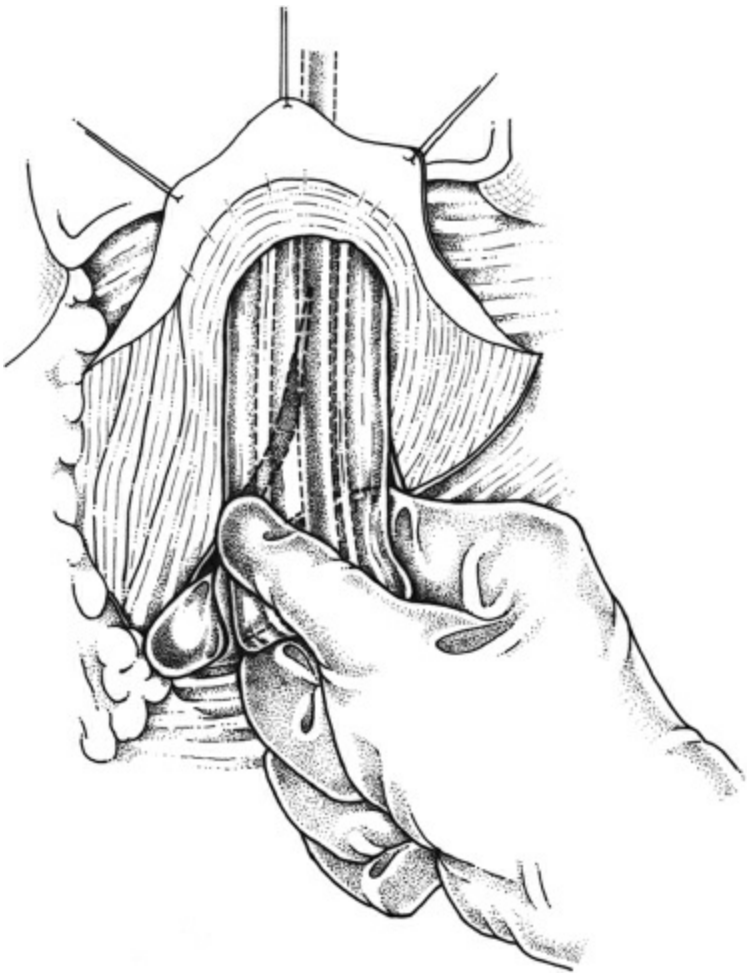

Figure 87.6. The surgeon has now completely encircled the posterior abdominal esophagus with the right index finger.

Once both trunks of the vagus nerve are identified, they are separated from the surrounding tissues with a nerve hook or a right angle clamp (Fig. 87.10). Medium clips are applied to each nerve proximally and distally allowing 2 cm of nerve between the clips, which is then resected and inspected to be certain, by visual inspection, that the tissue is neural tissue (Figs. 87.11 and 87.12). Pathologic confirmation of the neural tissue is also indicated. In the setting of reoperative surgery for incomplete vagotomy, a frozen section of the neural tissue may be necessary to confirm its identity.

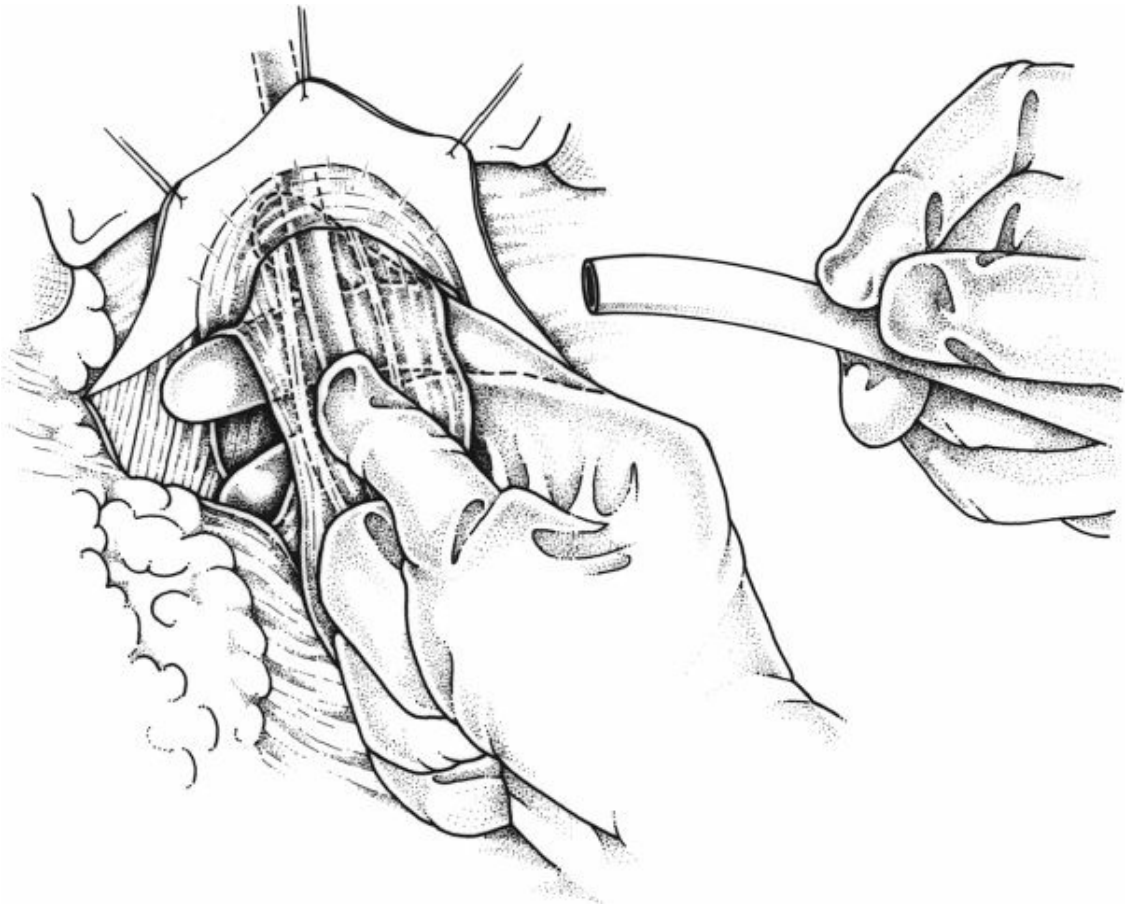

Figure 87.7. The retroesophageal opening is widened bluntly to permit passage of a Penrose drain, which allows more efficient esophageal retraction to facilitate the remaining portion of the vagotomy.

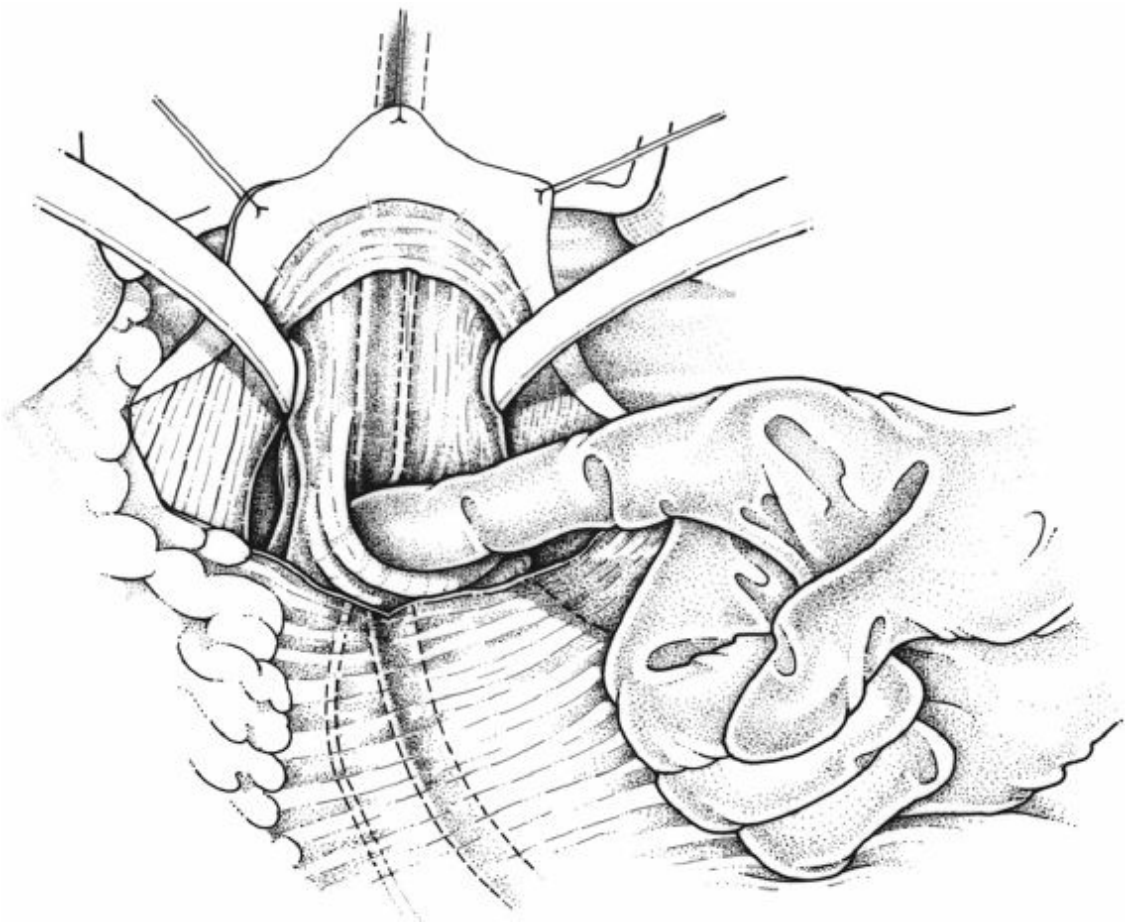

Figure 87.8. Identification of the anterior trunk of the vagus nerve is performed bluntly, by palpating the very firm structure of the nerve in the midportion of the lower abdominal esophagus using gentle downward rolling pressure.

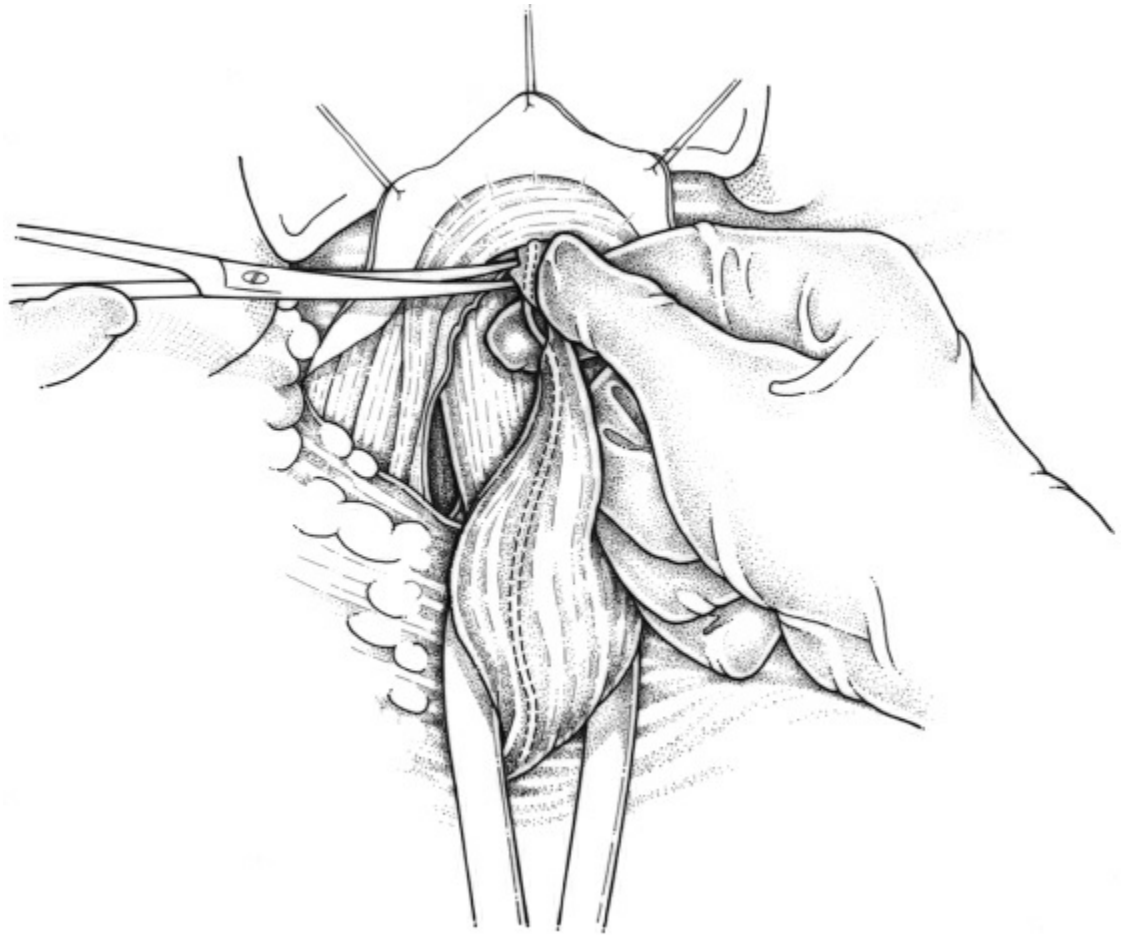

Figure 87.9. The anterior nerve is best found lying on the anterior surface of the esophagus, between 12 o'clock and 2 o'clock, 2 to 4 cm above the gastroesophageal junction. Gentle sharp and blunt dissection frees the nerve trunk from surrounding tissue.

The final step of the vagotomy is the skeletonization of the distal 5 cm of esophagus of all neural fibers. The "criminal nerve" of Grassi is included among these neural fibers. It originates from the posterior vagus and runs toward the left side of the distal esophagus. The operation is completed once skeletonization is complete and hemostasis is present.

In summary, the role of the vagotomy in 2017 is unclear. Our modern understanding of the pathogenesis of peptic ulcer suggests that treatment of *H. pylori* and elimination of NSAID use should result in cure of the underlying risk of ulcer. Furthermore, with the advent of PPIs it is now possible to medically eliminate gastric acid production without the side effects of vagotomy. Although level 1 data exist for perforated duodenal ulcer demonstrating that *H. pylori* treatment eliminates the need for definitive ulcer surgery, there is to date no trial that confirms this finding in the case of bleeding duodenal ulcer. Despite the lack of level 1

evidence, surveys of surgeons in the United Kingdom and national data from the United States suggest that most surgeons no longer perform a vagotomy as a component of operation for bleeding duodenal ulcer.

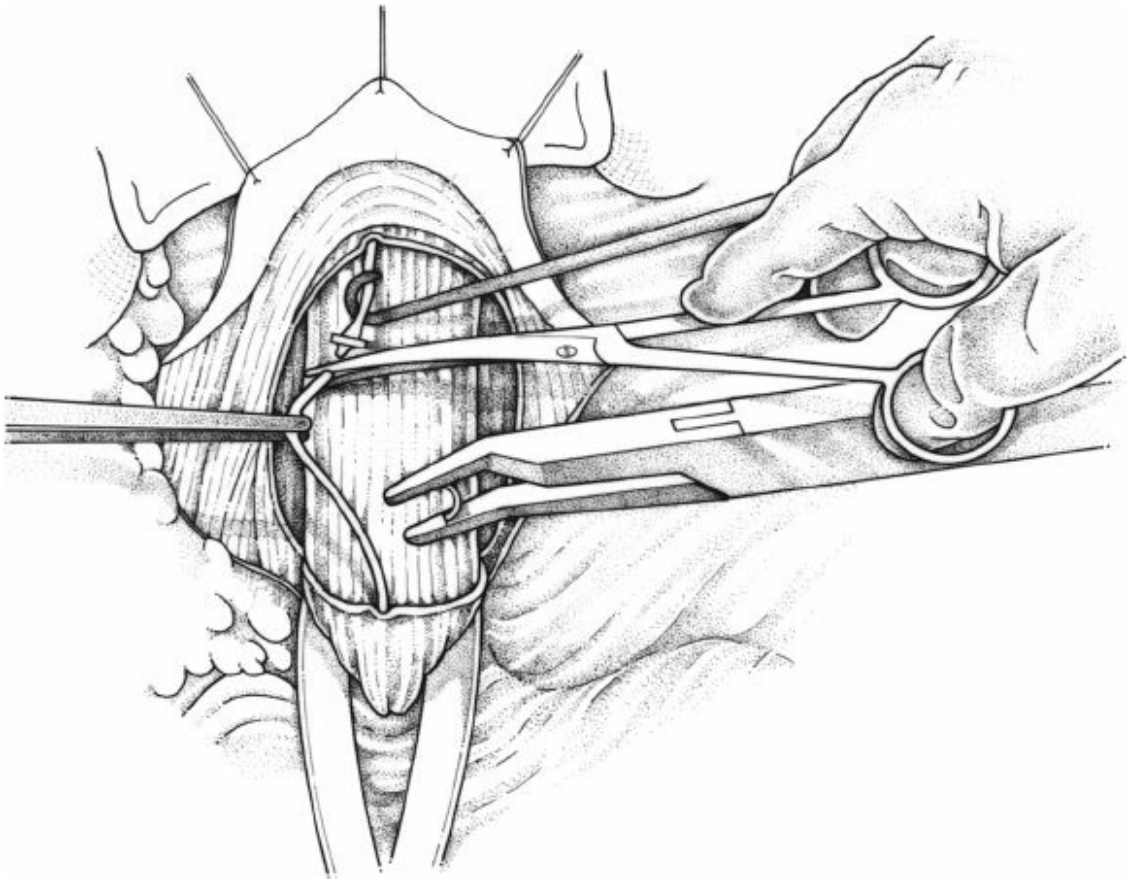

Figure 87.10. A nerve hook facilities lifting the nerve truck away from surrounding tissue, which allows clipping of the nerve proximally and distally. The nerve is then divided to remove a section of it for confirmatory pathologic analysis.

Duodenotomy

In a young, hemodynamically stable individual in whom there is no obesity and the anatomy of the stomach is well visualized, it is acceptable to perform a lateral duodenotomy to approach the ulcer in order to accomplish over sewing of the ulcer and preserve the pylorus. The patient may be treated with PPI and avoid vagotomy, although highly selective vagotomy is an option. The increased operative time for highly selective vagotomy is justified only in a hemodynamically stable patient. The result may be a physiologically better operation with reduced morbidity.

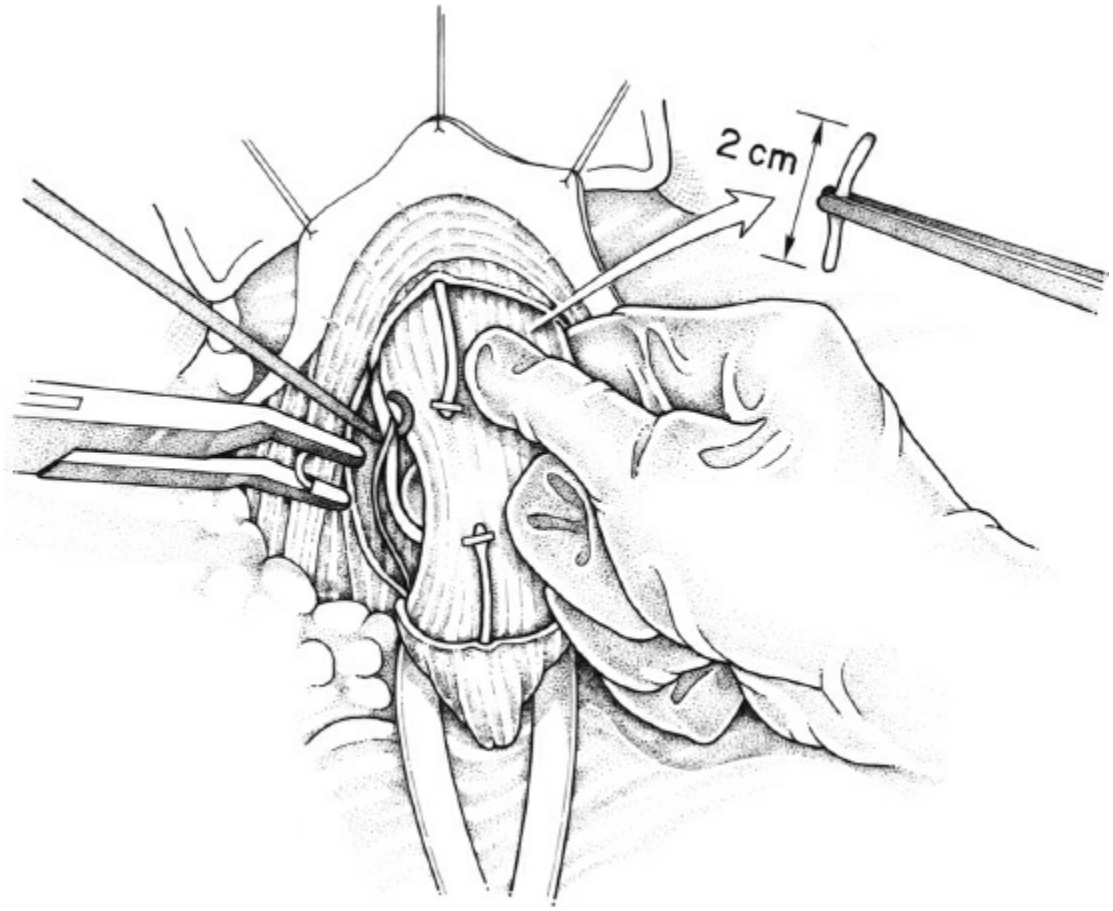

Figure 87.11. A 2-cm section of the anterior nerve has been removed. Attention now focuses on locating and dividing the posterior nerve. The posterior nerve is always larger than the anterior and is usually found lying away from the esophagus in the 6 o'clock to 8 o'clock position. Once located, it is hooked and clipped as was the anterior nerve.

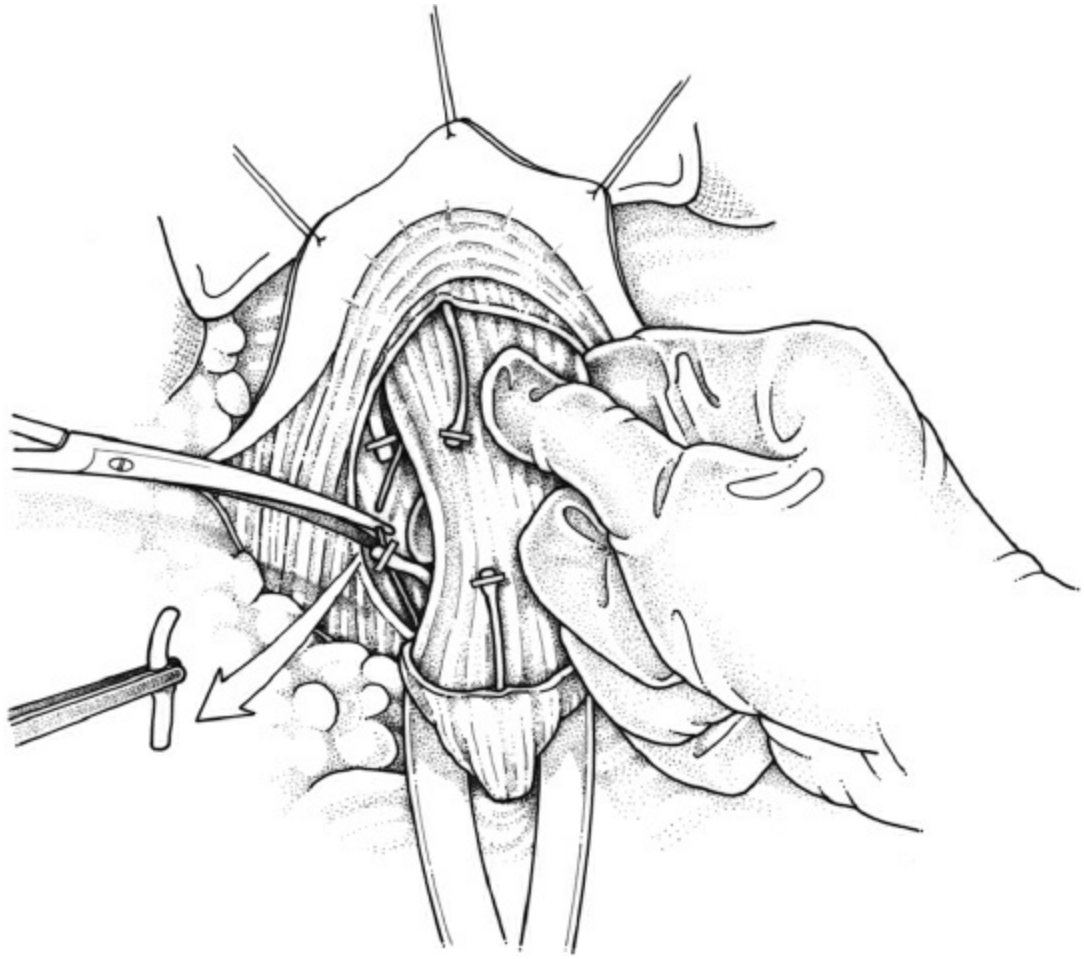

Figure 87.12. A 2-cm section of the posterior nerve has now been removed (*arrow*). The final step in vagotomy is total skeletonization of the distal 5 cm of the abdominal esophagus. Here a small fiber innervating the posterior fundus, often called the “criminal nerve” of Grassi, is divided as part of the skeletonization process.

Highly Selective Vagotomy

After a duodenotomy and ligation of the ulcer are performed, the acid-producing parietal cells may be selectively denervated while smooth muscle innervation to the antrum is preserved. This procedure is facilitated the Harmonic scalpel or other energy sources to coagulate the nerves and the associated vasculature. This approach affords a rapid, efficient means of performing the highly selective vagotomy compared with the tedious conventional approach of individual nerve ligation.

The left lobe of the liver is retracted with a Weinberg retractor. The first landmark one should identify is the terminal branch of the anterior vagal nerve, the nerve of Latarjet, which runs parallel to the lesser curvature of

the stomach. One should accurately identify the first terminal branch of the anterior nerve or the “crow’s foot.” The avascular window in the lesser omentum is incised between the anterior nerve and the lesser curvature. The Harmonic scalpel is introduced into the opening and positioned parallel to the anterior nerve of Latarjet (Fig. 87.13). With the assistant retracting the lesser curvature to the left, the operating surgeon applies traction to the lesser omentum with the left hand and uses the Harmonic scalpel with the right hand. In this manner, the crow’s foot and the anterior nerve of Latarjet are adequately exposed and visualized. The Harmonic scalpel is used ultrasonically to coagulate the neurovascular bundles in the anterior leave of the lesser omentum. The dissection of the anterior leaf proceeds from the proximal branch of the crow’s foot and culminates at the GEJ. The first branch of the crow’s foot has been demonstrated to innervate exclusively parietal cells and should therefore be coagulated.

Several technical points must be emphasized regarding the use of the Harmonic scalpel or Ligasure. The flat blade of the scalpel should be used when medium-sized vessels are divided ultrasonically. The surgeon needs to check both blades before implementation to ensure that they are appropriately coapted. If the blades are not flush on closure, the vessel will not be adequately sealed. One must also past point when dissecting out a neurovascular pedicle to be certain that the entire bundles are in the blade and coapted. It is advisable to put the hot blade up and the cold blade down in an attempt to avoid thermal injury to the stomach that conceivably could result in a delayed perforation. The final point is to let the Harmonic scalpel do the work. Unnecessary tension applied by the surgeon may tear these fragile vessels before adequate coaptation by the Harmonic scalpel.

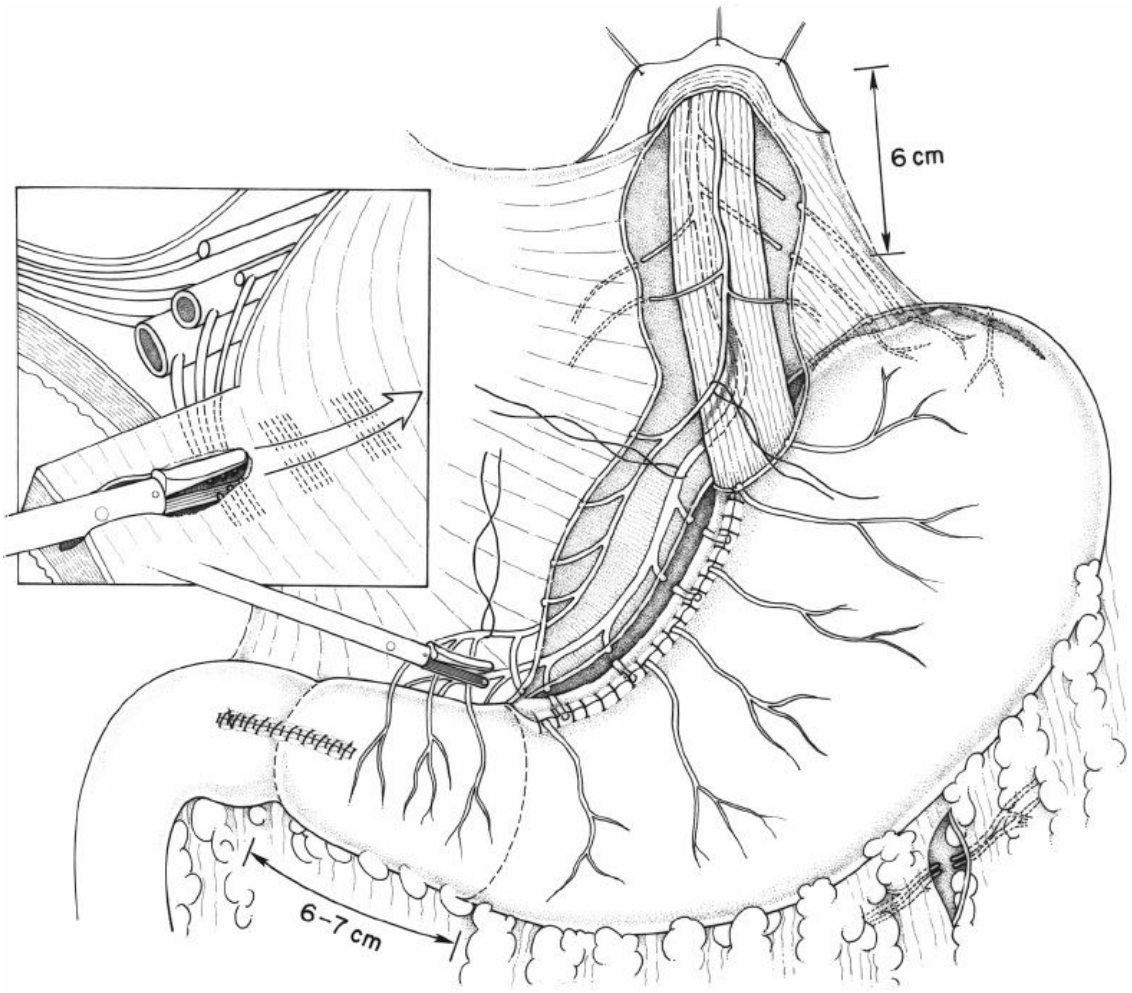

Figure 87.13. Highly selective vagotomy. Beginning 7 cm proximal to the pylorus, the small branches of the vagus running between the posterior and anterior branches of the nerve of Latarjet are divided, which effectively denervates the stomach proximal to the antrum. The “crow’s foot” is the landmark used to start the proximal dissection. The Harmonic scalpel (*inset*) is used to divide the plane of tissue between the wall of stomach along its lesser curvature and the actual trunk of the nerve of Latarjet, which is protected. First the anterior and then the posterior leaflets are divided. Finally, 6 cm of abdominal esophagus are skeletonized, except the main nerve trunks here are kept intact. The final step of the operation is division of the right gastroepiploic pedicle.

The dissection then continues toward the anterior surface of the esophagus with the goal of clearing the esophageal branches of the anterior and posterior vagus. Initially, the left side of the esophagus is dissected to the angle of His, with the fat pad of the cardioesophageal junction coagulated. The anterior and posterior surfaces of the esophagus are then

cleared of vagal fibers for 6 to 7 cm. The posterior fundus of the stomach is also dissected free with the Harmonic scalpel, with the criminal nerves of Grassi sacrificed during this maneuver. Occasionally, the superior short gastric vessels are sacrificed to adequately divide the posterior fundic vagal branches. The Harmonic scalpel is then directed toward the posterior leaf of the lesser omentum, which is approached through the already opened anterior leaf. The scalpel is positioned between the posterior nerve of Latarjet and the lesser curve, once again starting at the proximal branch of the crow's foot and progressing parallel to the nerve. The posterior dissection terminates by division of the vagal fibers in the gastropancreatic fold. During the course of the procedure, the position of the anterior and posterior nerves and main vagal trunks must continually be visualized and preserved. The final area of vagotomy is the right gastroepiploic pedicle, which is located on the anterior greater curvature 10 cm from the pylorus (Fig. 87.13).

Predication of Outcome and Recurrent Bleeding

Advanced age, poor health status or comorbid illness, continued or recurrent bleeding, fresh hematemesis or hematochezia, and the onset of bleeding in hospitalized patients (i.e., those admitted for reasons other than upper GI bleeding) predict a poor prognosis and a higher likelihood of death. Operative mortality for bleeding duodenal ulcer may be as high as 20%. Endoscopic predictors of poor outcome, including active bleeding, major stigmata of recent hemorrhage, a visible vessel, ulcers >2 cm in diameter, and the location of ulcers in proximity to large arteries, were also identified as factors that predict recurrent bleeding.

PERFORATED DUODENAL ULCER

Brief Historical Perspective

Muralto first described duodenal ulcers at autopsy in 1688. Crisp published a landmark paper in which he described symptomatology of perforated peptic ulcers in 1843. Therapy of perforated ulcer has been a hallmark of general surgical practice for well over 100 years. Our understanding of the problem has changed drastically over the last 20 years. The last 10 years of the 20th century witnessed a scientific revolution in our recognition of the role that infection with *H. pylori* plays in producing the gastric acid hypersecretion that characterizes peptic ulcer.

This hypersecretion, and attempts to control it, had in fact been the subject of a previous scientific revolution during the 1950s and 1960s that had shepherded a transition from surgical therapy that focused on resection of acid-secreting mucosa via subtotal gastrectomy to eliminating the hypersecretion by section of the vagus nerves. This revolution was best summarized by the Nobel Prize-nominated vagotomy pioneer, Lester Reynolds Dragstedt, whose philosophy regarding the controversy between the choice of resection versus vagotomy was best summarized in his remark that "the stomach is a mighty handy organ to take to the dinner table." This is a reminder that is even more valid today. This concept of duodenal ulcer as an infectious disease, not to mention the wide "over-the-counter" availability of H2 blockers and PPIs, has led to a marked decrease in the incidence of complications, such as intractability and/or gastric outlet obstruction that formerly might have led to surgery. Unfortunately, our new understanding has not yet led to any detectable changes in incidence of ulcer perforation. Thus, ulcer perforation continues to be an important, even if somewhat diminished, staple of surgical practice. Indeed in most centers, perforation is the most common indication for operation in the patient with duodenal ulcer.

Opportunities for prevention must necessarily focus on the two etiologies most responsible for perforations: treatment of *H. pylori* infection and use of NSAIDs. However, this is a formidable undertaking when one considers that ~50% of the population of the United States harbors *H. pylori* infection and that there is a ubiquitous availability of NSAIDs as over-the-counter remedies. The decrease in the incidence of uncomplicated duodenal ulcers over the past three to four decades has been somewhat attributable to our increased understanding of the multiple etiologies, risk factors, and epidemiology of duodenal ulcer disease; however, honest observers will note that the decrease in duodenal ulcer disease predated our understanding of its infectious nature as well as the remarkable therapeutic medications that are now so widely available.

Lifetime risk of duodenal perforation in patients with duodenal ulceration who do not receive therapy has been reported to be 10%. In patients who require surgical interventions for complications, such as perforation, the mortality rate is significantly higher in the elderly than in other age groups. Recent studies have indicated that the lifetime prevalence of duodenal ulcers to be 11% to 14% for men and ~8% to 11% for women. The epidemiology of perforated duodenal ulceration has

changed significantly. The male to female ratio has decreased from 10:1 to 1.5:1, and the median age has increased to >60. As the proportion of patients with associated disease increases, the mortality and morbidity have remained fairly constant in the last three decades despite improvements in general medical care.

DIAGNOSIS

Clinical Presentation

Perforated PUD typically causes sudden and severe epigastric abdominal pain that may progress to involve the entire abdomen. The pain caused by the spillage of highly caustic gastric secretions into the peritoneum rapidly reaches peak intensity and remains constant. Many patients can state the exact time of onset of their symptoms. Radiation to the right scapula region is common because of right subphrenic collection of gastric contents. Occasionally, pain is sensed in the lower abdomen if gastric contents travel caudally through the paracolic gutter. Peritoneal irritation is usually intense, and most patients avoid movement to minimize discomfort. The degree of peritoneal findings, however, is strongly influenced by a number of factors:

- Size of the perforation
- Amount of bacterial and gastric contents contaminating the abdominal cavity
- Time between perforation and presentation
- Spontaneous sealing of the perforation

Physical examination reveals low-grade fever, diminished bowel sounds, and rigidity of the abdominal wall musculature. The patient can also demonstrate signs and symptoms of:

- Early shock
- Tachycardia
- Hypotension and
- Diminished urine output

Other indicators of toxicity (such as peritoneal irritation, fever, and increased white blood cell count with left shift) may actually be absent in both elderly and immunocompromised patients. Furthermore, other acute conditions such as myocardial infarction, dissecting aortic aneurysm, cholecystitis, pancreatitis, diverticulitis, appendicitis, and renal colic can

mimic the symptomatology of perforated PUD.

Laboratory Studies

It has been argued that, in general, laboratory studies are of little value in evaluating a patient with suspected duodenal ulcer perforation, but such tests as complete blood cell count, amylase and lipase determinations, and liver functions tests may be useful in excluding other causes of upper abdominal pain.

Complete blood cell count (Leukocytosis with left shift is found in many cases.)

Serum gastrin levels: Gastrin levels >1,000 pg/mL are suggestive of gastrinoma; however, use of acid-reducing agents may cause some elevation of gastrin. Gastrin levels in patients who are taking acid-reducing agents are usually not >300 to 450 pg/mL. If there is any question, a secretin stimulation test will make the diagnosis; however, these measurements are not pertinent to the acute presentation.

H. pylori infection testing

Serum *H. pylori* antibody detection: Antibodies (immunoglobulin G, IgG) to *H. pylori* can be measured in serum, plasma, or whole blood; however, they only indicate past infection and do not confirm current infection.

Pathologic identification of *H. pylori* on biopsy is diagnostic as is a positive CLO test on biopsy; this is not helpful in the acute presentation, but may be useful in postoperative therapy.

Urea breath tests: These are used to detect active *H. pylori* infection by testing for the enzymatic conversion of urea to CO_2 and ammonia. Current use of PPI agents may result in false negative tests.

Fecal antigen tests: Fecal antigen testing is used to identify active *H. pylori* infection by revealing the presence of *H. pylori* antigens in stools and will probably become the gold standard for diagnosis.

Imaging Studies

Upright chest radiography or lateral abdominal decubitus radiography reveals evidence of free air (pneumoperitoneum) (60% to 85% of patients). Even though this finding is not specific for perforated peptic ulcer, free air is usually present in much smaller amounts with perforation of abdominal viscera other than the duodenum or stomach.

An upper GI study with water-soluble contrast, such as gastrografin, can

demonstrate extravasations if the ulcer has not spontaneously sealed. The lethal effects of barium when mixed with stool in the setting of colon perforations are well known; the effect of barium in the peritoneal cavity in duodenal perforations is unstudied. Nevertheless, prudence would suggest that barium be avoided when there is a risk of duodenal perforation. A contrast study with gastrografin may show leak from the duodenum or its sealing, and it can be a useful test when one is considering nonoperative treatment or in the situation where the diagnosis is in doubt. Currently, upper endoscopy is not recommended if perforation is definitely present or strongly suspected precisely because it may disrupt spontaneous sealing of the perforation.

Computed tomography (CT) scanning of the abdomen may demonstrate free air in the presence of perforated duodenal ulcer. CT with contrast may also demonstrate extravasation of contrast in the presence of a perforated ulcer. If history and physical examination raise the possibility of perforation, upright chest radiography and an upper GI contrast study with water-soluble contrast are the diagnostic studies of choice. CT scanning is usually not needed in this situation.

RISK STRATIFICATION

Mortality from perforated duodenal ulcer is dependent upon the presence or absence of several risk factors. Individual risk can also be assessed by use of APACHE II. Overall mortality is ~10% in most studies. It has been reported that in the developing world, the high morbidity and mortality experienced by patients with perforated duodenal ulcer are probably due to delayed presentation. Those in whom diagnosis is overlooked almost always die. Risk factors affecting prognosis are:

Delay in treatment (>24 hours)
Preoperative shock (BP <100 mm Hg)
Concurrent serious medical illness

It is reported that when all three are present, the mortality rises to 100% (39).

TREATMENT

Nonoperative Management

Current management of perforated duodenal ulcer in the United States usually includes operative approaches, but nonoperative management may

be appropriate (Fig. 87.14) if the patient is doing well and there is radiologic confirmation that the perforation is sealed.

Traditionally, perforated peptic ulcers were managed by urgent surgical repair, with or without an acid-reducing procedure. However, several studies have indicated that many patients can be successfully managed without an operation. The decision to proceed with surgery or nonoperative treatment is best individualized and made by the surgeon based on his or her assessment of the patient. In 1935, Wangensteen advocated a nonoperative approach in patients with perforation but without pneumoperitoneum. He believed that the absence of pneumoperitoneum indicated that the perforation had already sealed by the time of patient presentation; surgical exploration and repair was recommended for patients with demonstrable free air. More recently, Berne and Donovan have emphasized the use of the water-soluble upper GI study, which demonstrates spontaneous sealing of the perforation. They note that as many as 40% of perforated PUD ulcers have sealed on an upper GI study performed shortly after the patients present. Crofts et al. from Hong Kong, in 1989, showed that selective nonoperative treatment of perforated duodenal ulcer was accompanied by a low mortality rate and was not associated with a large number of complications when the gastroduodenogram demonstrated a sealed perforation. The mortality rate for patients treated operatively in their series was 6.2%, compared with mortality rate of 3% in those patients treated nonoperatively (retrospective review). Patients selected for nonoperative management should be treated as follows:

Nasogastric decompression
Fluid resuscitation with replacement of fluid and electrolytes
PPIs
Broad-spectrum antibiotics
Serial abdominal examinations, preferably by the same examiner with operative therapy for progression or nonresolution of symptoms
Subsequent follow-up endoscopy to monitor ulcer healing
Treatment of *H. pylori*—The U.S. Food and Drug Administration has approved some regimens, which are now accepted internationally, for the treatment of *H. pylori* infection in patients with PUD, both gastric and duodenal. These regimens are also known as triple therapies and have reported cure rates from 85% to 90%. Unfortunately, with the increasing rise in antimicrobial resistance, there has been an associated increase in

the failure rate of standard triple therapy for *H. pylori* infection. These triple therapies should be administered for 10 to 14 days The treatment regimens are omeprazole, amoxicillin, and clarithromycin (OAC) for 10 days; bismuth subsalicylate, metronidazole, and tetracycline (BMT) for 14 days; and lansoprazole, amoxicillin, and clarithromycin (LAC), which has been approved for either 10 days or 14 days of treatment.

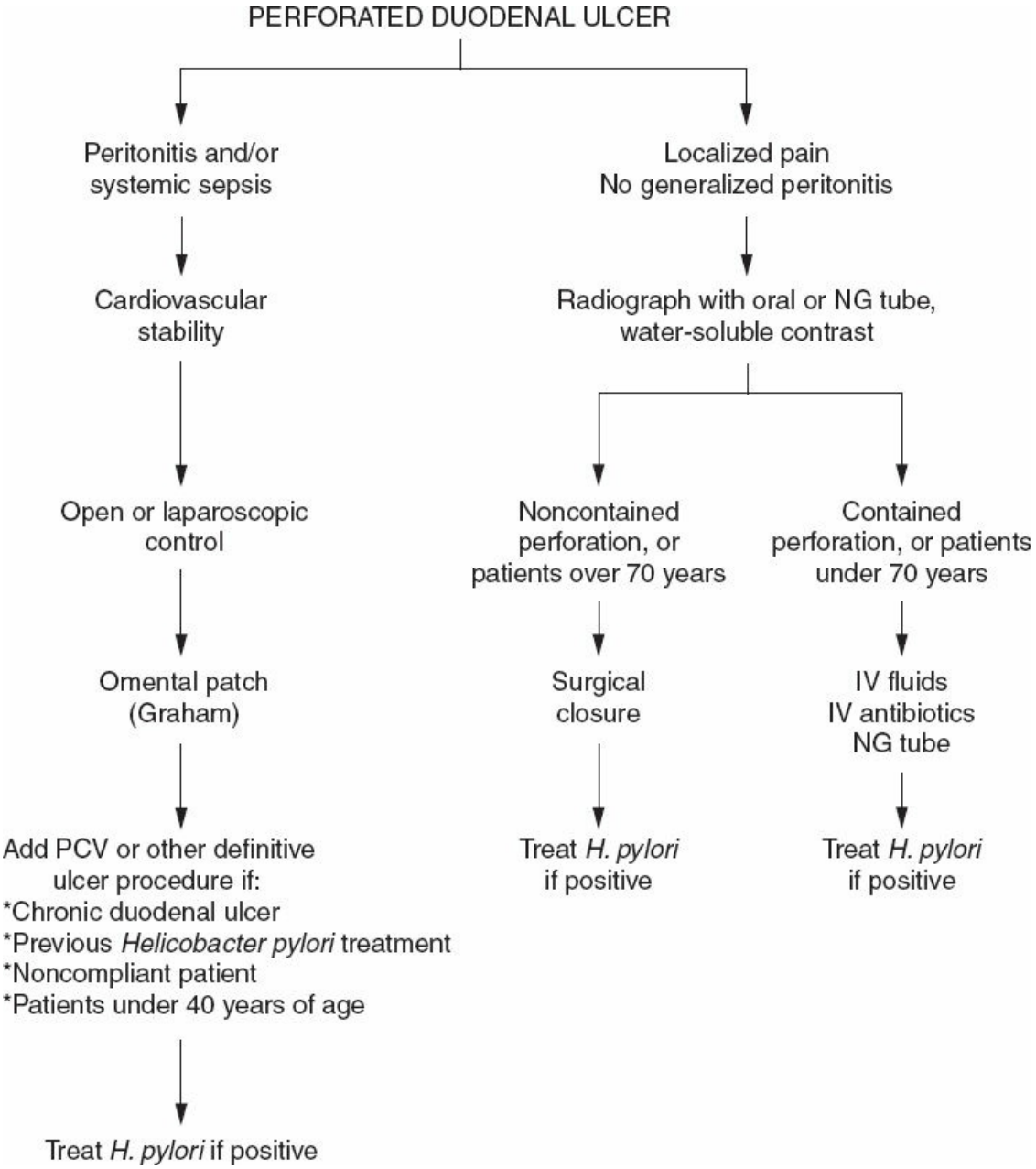

Figure 87.14. The algorithm for management of perforated duodenal ulcer usually includes operative management, but occasionally nonoperative management is indicated. PCV, parietal cell vagotomy; NG, nasogastric.

Despite encouraging reports and a number of other nonrandomized studies, nonoperative treatment of perforated duodenal ulcer has not become popular. Nonoperative management has not been widely adopted probably due to problems with misdiagnosis and the lack of opportunity to perform definitive ulcer surgery. Many reports indicate that nonoperative management has largely been restricted to those who are too unwell to undergo laparotomy. This may also have something to do with the American medical malpractice climate as well as difficulties with continuity of care attendant to comply with work hour restrictions. If nonoperative therapy is chosen, the ideal hand off from the responsible physician to the physician accepting responsibility would be to examine the patient together and agree on the criteria for continuing nonoperative therapy. Indications to abandon nonoperative treatment in favor of surgery include failure of symptoms to improve over 12 to 24 hours, peritoneal signs, and an increase in abdominal tenderness and hemodynamic instability.

Operative Management

Although numerous reports suggest that nonoperative management is an option appropriate for many patients with perforated duodenal ulcer, many surgeons still practice universal operative intervention in these patients. Surgical intervention is recommended in patients who present with the following:

- Hemodynamic instability
- Signs of peritonitis
- Free extravasations of contrast on upper GI contrast studies

The type and timing of operative intervention have been debated for decades. The arguments that revolve around the choice of simple closure versus closure with an acid-reducing procedure remain controversial. In addition, debate exists about the type of ulcer-curative procedure that should be performed. The first description of simple closure for a perforated duodenal ulcer was provided by Graham in 1937. In his report, he described placing three absorbable sutures in an interrupted fashion through the ulcer. A piece of omentum, either free or left as a pedicle, was then placed over the sutures and the sutures tied “just sufficiently tight to hold the omentum graft in situ.”

The traditional management of a perforated duodenal ulcer has been a

Graham Omental Patch and a thorough abdominal lavage. Although this operative procedure continues to be effective at providing adequate closure of the perforation, many authors have noted a high recurrence rate of both ulcer symptomatology and recurrent ulceration. This concept of immediate definitive ulcer surgery has been debated among surgeons since the 1940s. There is good evidence that, in the emergency situation, highly selective vagotomy combined with simple omental closure of the perforation in patients without risk factors is just as effective as that performed in the elective setting. The success of this operation is surgeon-dependent; however, fewer surgeons under the age of 65 today have had any significant experience with it. However, immediate definitive ulcer surgery has not gained widespread popularity because of concerns that it is associated with higher mortality than simple omental patch closure, although studies have shown that in the absence of shock this is not a valid concern.

Older surgeons were trained in the era when ulcer surgery and surgical therapy of its complications as well as the surgical treatment of the complications of surgical therapy (postgastrectomy syndromes, blown-out duodenal stumps, alkaline gastritis, afferent loop syndrome, etc.) were common. This was also an era when there were no medical options that would reduce gastric acid secretion. The underlying rationale for definitive surgery was to permanently reduce acid secretion. We now have available to us “over-the-counter” medications, which, if taken in sufficient doses, result in the medical equivalent of a total gastrectomy. No investigator has suggested that any type of vagotomy, with or without gastric resection, can improve on the initial healing rates achieved with medical therapy.

Given that *H. pylori* is able to be implicated in up to 90% of perforated duodenal ulcers, many surgeons now agree on the use of simple omental patch closure and subsequent antibiotic treatment of the infectious agent, saving definitive surgical ulcer management for those who fail this regimen. Experts opine that the choice of operative procedure for perforated duodenal ulcer depends on variables, such as the presence of shock, life-threatening comorbid conditions, the degree of contamination of the upper abdomen, the amount and duration of perforation, and whether the patient has a history of or currently has intraoperative evidence of chronic peptic ulceration. Our recommendations are:

1. In the presence of life-threatening comorbid condition and severe intra-abdominal contamination, the safest technique for 1 cm or smaller

acute anterior duodenal perforation is a simple Graham patch closure plus abdominal lavage. Several full-thickness simple sutures are placed across the perforation using 2-0 silk sutures. A segment of omentum is placed over the perforation. The silk sutures are secured drawing the omentum into the opening.

2. If contamination of the upper abdomen is minimal and the patient is hemodynamically stable, it is acceptable to choose a definitive ulcer procedure (Table 87.1), especially if there is a question of whether the patient will be compliant with medical therapy. For a perforated duodenal ulcer, this may include a highly selective vagotomy, a truncal vagotomy and pyloroplasty, or vagotomy and antrectomy (V&A) (Table 87.1). Dragstedt's exhortation about the stomach's being a "handy organ to take to the dinner table" weighs heavily. Furthermore, V&A is associated with a higher mortality and more postgastrectomy syndromes. It also forces the issue of the "difficult duodenal stump." Current surgeons, unfamiliar with the use of V&A, may not appreciate the controversy that was formerly associated with closing such a stump. Leakage from the duodenal stump was responsible for most of the mortalities associated with V&A. Many older surgeons were persuaded that the best way to handle a difficult duodenal stump is not to create one. Thus, they avoid gastric resection for duodenal ulcer. There are some who would dispute this but V&A is an aggressive choice for a condition that responds well to medication.

Preoperative Details

Step 1. Preoperative preparation

Nasogastric suction reduces the risk of further spillage of gastroduodenal contents leading to peritoneal contamination

Fluid resuscitation, Foley catheter placement, and insertion of effective venous access

Broad-spectrum IV antibiotics and IV PPI

TABLE 87.1 Perforated Ulcer Patients Who May Require Procedures Other Than Graham Patch Closure

1. Large perforations (>2.0 cm) may require Thal Patch (Fig. 87.8), or rarely vagotomy, antrectomy, Billroth II reconstruction
2. Synchronous bleeding and perforation: may require vagotomy, resection of perforation, pyloroplasty, U-stitch control of posterior bleeding
3. Chronic ulcer symptoms, *H. pylori* negative: patch closure, parietal cell vagotomy, or vagotomy, pyloroplasty with ulcer excision
4. NSAIDs dependence (or noncompliant patient): patch closure, parietal cell vagotomy, or vagotomy, pyloroplasty, ulcer excision
5. Previous *H. pylori* treatment failure or known *H. pylori* negative patients: patch closure, parietal cell vagotomy, or vagotomy, pyloroplasty, ulcer excision
6. Previous ulcer complications: patch closure, parietal cell vagotomy, or vagotomy, pyloroplasty, ulcer excision

Intraoperative Details

Step 1. Patient positioning

Supine with a footboard attached to the table to facilitate reversed Trendelenburg position that exposes the upper abdomen by using gravity for downward traction on the upper abdominal viscera

Step 2. Incision

Supraumbilical midline

Step 3. Exploratory laparotomy and closure of the duodenal perforation

The commonest site of duodenal perforation is the anterior wall of the

first portion of the duodenum. If this area is normal, then the anterior and posterior aspects of the stomach should be inspected; and if no perforation is found, the remainder of the GI tract must be thoroughly assessed including the posterior gastric wall by opening the lesser sac.

A small duodenal perforation is closed by placing interrupted full-thickness 2-0 silk sutures along the margins of the ulcer (Fig. 87.15A–C), leaving the ends sufficiently long, so that a viable omental patch can be securely placed over the perforation (Fig. 87.16). The sutures are tied drawing the patch into the perforation (Fig. 87.17). Some surgeons prefer primary closure with placement of the omentum over the primary closure (Fig. 87.18A,B).

A chronic ulceration containing a large defect with a friable margin can be difficult to close primarily. In this situation, it is recommended to place the 2-0 silk sutures away from the ulcer margins and simply use them to secure the omental patch directly onto the perforation. Omental patch of larger perforations, however, is associated with problems of gastric outlet obstruction and occasional recurrent leakage from the perforation (Fig. 87.19). Good alternatives in this situation include: Thal serosal patch of the large ulcer with a loop of jejunum (Fig. 87.20), Roux-Y drainage of the perforation or patch closure with concomitant gastrostomy, feeding jejunostomy, and retrograde threading of a decompressive Robinson catheter from the proximal jejunum to the duodenum (Fig. 87.8). It is wise to complement closure of this large perforation with drainage of the area with a closed-suction drain.

Thorough irrigation of the peritoneal cavity with 3 L of warm normal saline-containing antibiotics. Drainage is unnecessary and may increase morbidity.

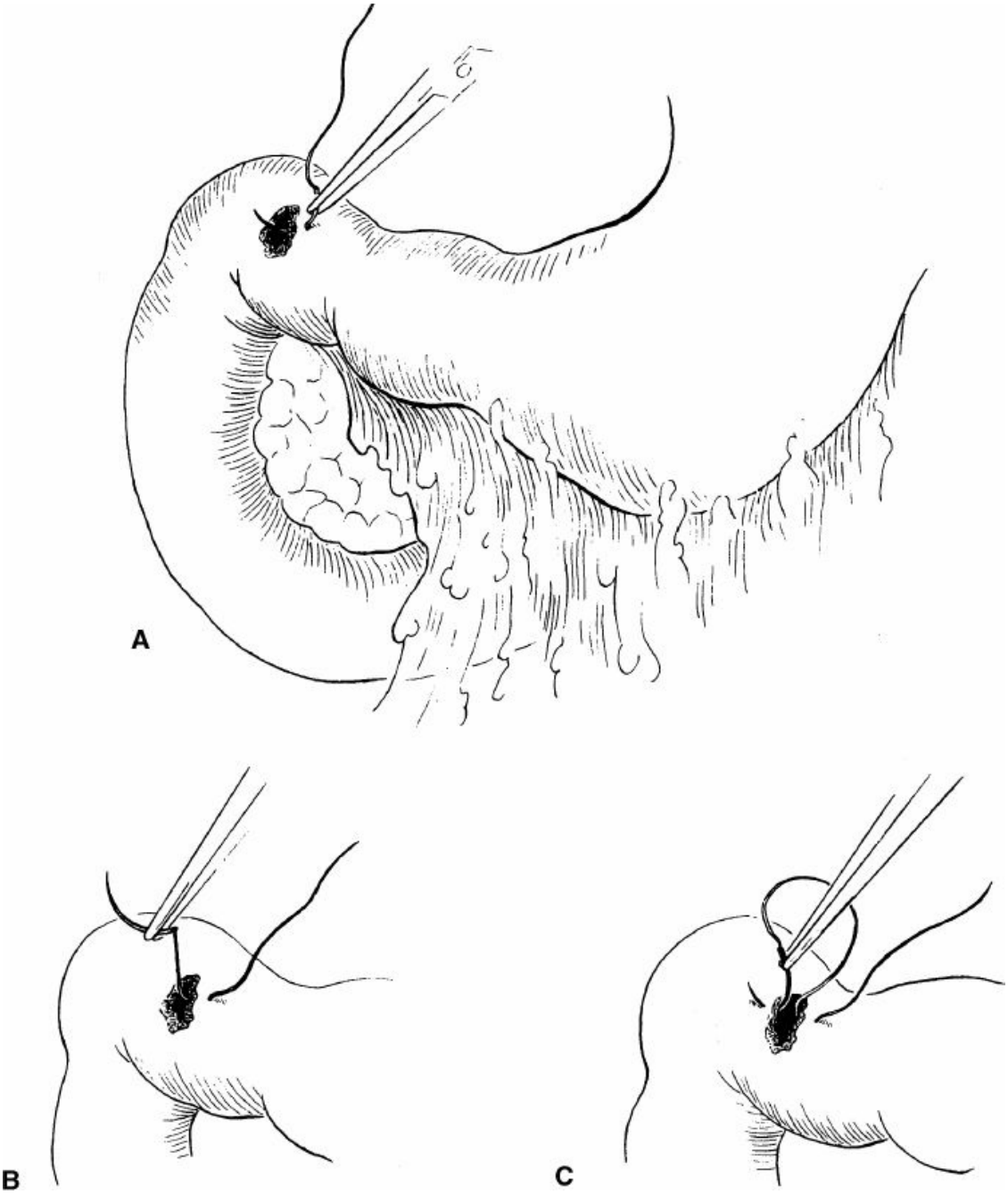

Figure 87.15. A. After appropriate aspiration and irrigation in the periduodenal area, operative closure is undertaken by placing full-thickness sutures through the duodenal wall and into the perforation. **B.** The needle holder regrasps the needle, and the opposite wall of the duodenum is secured by a similar bite, far enough from the ulcer perforation to ensure that the suture will not tear through when tied. **C.** The sutures should be placed so that both the superior and inferior edges of the perforation will have a securing suture to hold the omentum against both the upper and lower ulcer edges.

Step 4. Abdominal wall closure

- Fascial closure with heavy nonabsorbable or monofilament absorbable sutures
- Skin closure with staples or clips

Postoperative Details

- On average, patient is discharged 7 to 10 days if uncomplicated recovery
- It has been shown that >90% have *H. pylori* infection. Discharge with eradication therapy and an 8-week course of PPI to prevent ulcer recurrence
- Recommendations for follow-up endoscopy to check duodenal ulcer healing

OUTCOME AND PROGNOSIS

It has been reported that emergency operations for peptic ulcer perforation carry a mortality risk of 6% to 30%. Factors that affect the prognosis include the following:

- Shock at the time of admission
- Delaying the initiation of surgery >12 hours after presentation. It has been shown that the delay in diagnosis beyond 24 hours is associated with a sevenfold increase in mortality, three-fold risk of morbidity, and double the hospital stay
- Concurrent medical illness (e.g., cardiovascular disease, diabetes mellitus)
- Age >70 years
- Cirrhosis
- Immunocompromised state (e.g., HIV)
- Location of ulcer (mortality associated with perforated gastric ulcer is twice that associated with perforated duodenal ulcer)

LAPAROSCOPIC MANAGEMENT OF PERFORATED DUODENAL ULCER

With experience gained from laparoscopic cholecystectomy, many surgeons now have the skills to repair perforated ulcers laparoscopically. Theoretically, laparoscopic access is associated with less metabolic and physiologic disturbance than open surgery, and this may also benefit the septic patient. Successful treatment of perforated duodenal ulcer with

laparoscopic approach was first reported by Mouret et al. in 1990. Some surgeons have used an omental patch that was held in position with fibrin sealant. Laparoscopic approach has undergone many modifications; however, there seems little reason to depart from a technique that closely mimics Graham's original open procedure.

This technique is performed in reverse Trendelenburg position with patient's legs either spread apart or together. A 10- to 12-mm trocar is placed at the umbilicus, followed by a similar size-trocar in the midline in the epigastrium. This is followed by two 5-mm cannulas in the right, hypochondrium in the midclavicular, and anterior axillary lines. The laparoscope can be inserted through either of the 10- to 12-mm trocars to visualize the perforation and the peritoneal cavity irrigated. A 2-0 silk suture on 30-mm curved needle is introduced into the abdomen via the 10- to 12-mm trocar. Then, a second needle holder is inserted through the medial 5-mm trocar.

A grasper introduced through the lateral 5-mm tracer is used to mobilize a suitable piece of omentum close beside the perforation. The needle is then passed through the normal duodenum a small distance away from the edge of the perforation on either side. The grasper then positions the omental patch over the perforation, and the mounted needle is passed through the omentum. The needle is then withdrawn, and a knot is tied to fix the patch to the perforation. Additional sutures can be placed as required to surround the perforation. The adequacy of the seal may be tested by insufflation of air and/or methylene blue into the NG tube. Various modifications of this procedure have been performed. Laparoscopic omental patching has now widely been reported with comparable results to open surgery. Small series have been reported adding laparoscopic posterior truncal vagotomy, anterior seromyotomy, and highly selective vagotomy. Studies have shown that conversion rate from a laparoscopic approach to an open approach varies from 0% to 25%. Contraindication for laparoscopic repair for perforated duodenal ulcer includes large perforation, a posterior location of the perforation, shock, and a poor general state of health.

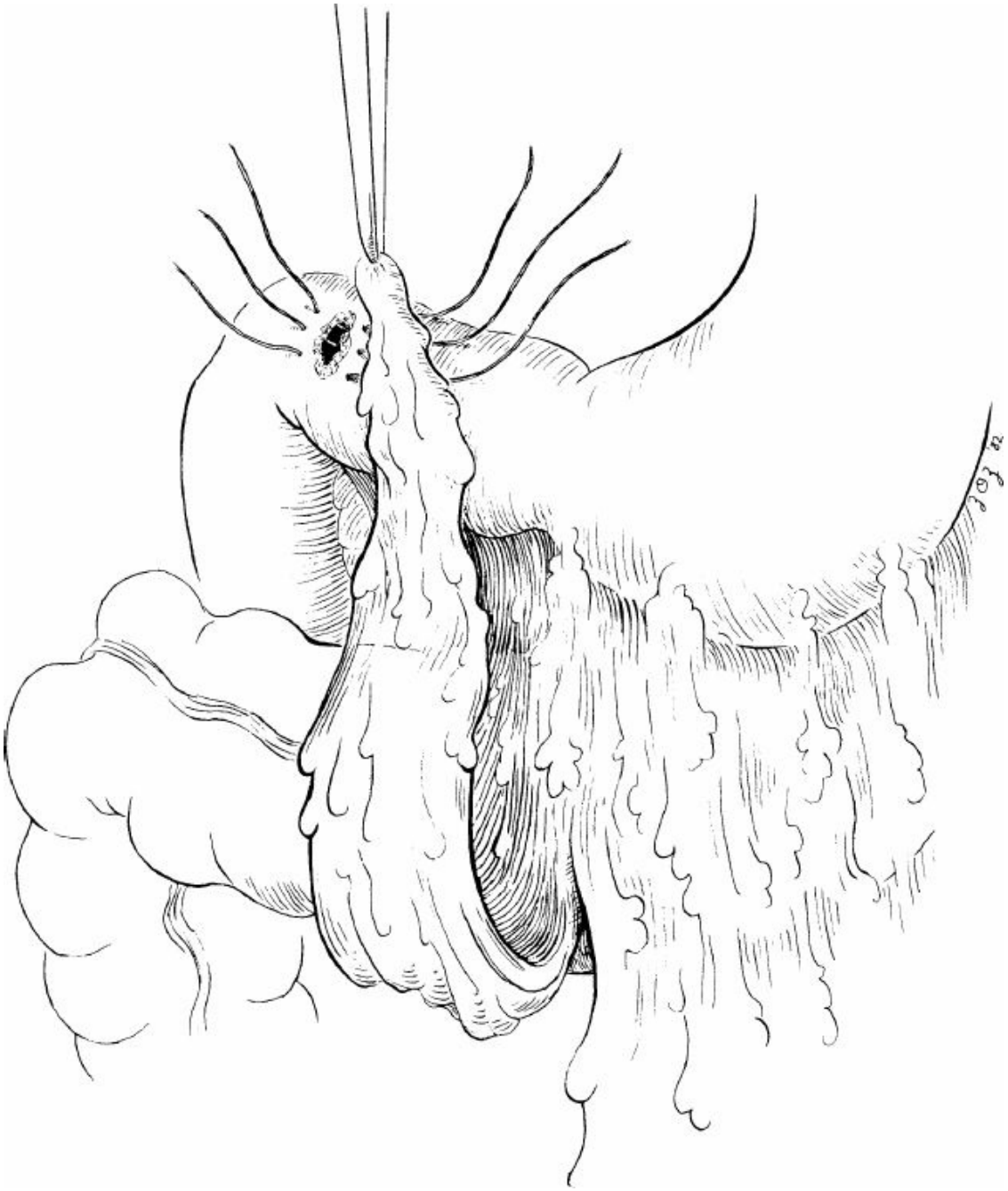

Figure 87.16. After placing three or four sutures, a vascularized tongue of omentum is mobilized and brought superiorly to close the defect. It is not necessary to push the end of the omentum into the defect like an obturator, but rather use the omentum as an external patch.



Figure 87.17. When the sutures are tied loosely enough so that the blood supply to the omentum is not compromised, the seal is complete, even with larger perforations.

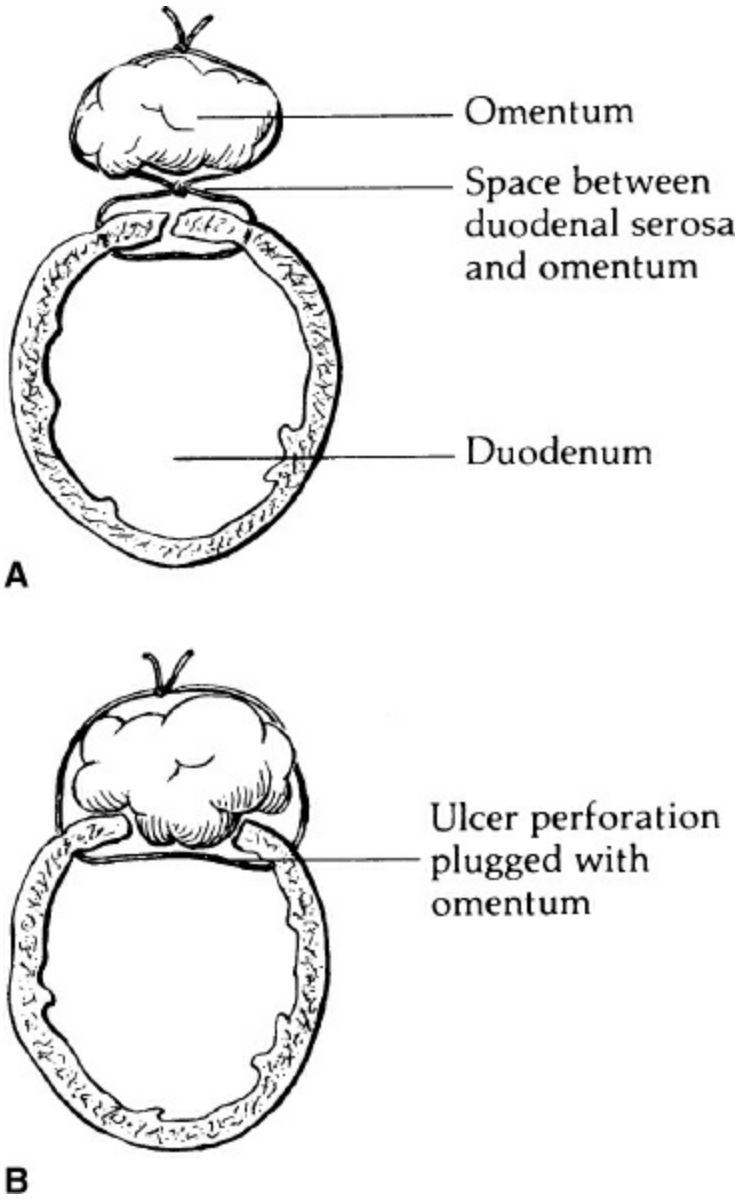

Figure 87.18. A. Although it is sometimes done, tying the sutures to close the perforation prior to placing the omentum at the defect has the disadvantage of preventing broad apposition of the omentum to the duodenal serosa. **B.** Furthermore, there is a potential or actual space between the duodenal serosa and the omentum. If the sutures are tied after the omentum is in place, with no attempt to sew the ulcer perforation closed, the omentum will effectively plug the perforation.

Compared to the open approach, the following results have been observed with laparoscopic method:

1. Increased operative time
2. Reduced requirement for postoperative analgesia
3. Reduced time to return to a normal diet

4. Shorter hospital stay
5. Earlier return to work

No difference was found in blood loss, stress response (as determined by endotoxemia, bacteremia, and inflammatory markers), postoperative gastric emptying, or morbidity or mortality. Most contemporary studies support equivalent outcomes with the open or laparoscopic approach in the stable patient.



Figure 87.19. A suitable alternative to transulcer full-thickness fixation of the omentum is to bring the omentum up and hold it in place with a series of seromuscular Lembert sutures around the circumference of the patch. The first sutures should be placed and tied at the inferior margin of the omental patch before the

other sutures are tied to prevent any leakage from the inferior margin of the defect. (From Jordan PH Jr, Thornby J. Perforated pyloroduodenal ulcers: long-term results with omental patch closure and partial cell vagotomy. *Ann Surg* 1995;221[5]:481.)

GIANT DUODENAL ULCERS

Giant duodenal ulcers (GDUs) are a subset of duodenal ulcers that have historically resulted in greater morbidity than usual duodenal ulcers. A GDU has been defined as a full-thickness peptic ulcer that is 2 cm or larger in diameter and usually involving a large portion of the duodenal bulb (Fig. 87.21). The history of GDUs dates back to 1931 when Britzka first described these exceptionally large ulcers that comprise a large portion of the duodenal bulb. GDUs comprise ~1% to 2% of all duodenal ulcers and 5% of peptic ulcers requiring surgical intervention. The male to female ration in those with GDUs is 3:1.

The etiology of GDUs may differ somewhat from ordinary duodenal ulcers. Recent studies suggest that the percentage of GDUs associated with *H. pylori* is less when compared to standard sized ulcers, and that NSAIDs use may play a more prominent role. For example, in 1999, Fischer et al. reviewed 28 cases of GDU. In their study, only 39% of patients tested were found to have *H. pylori* infection. In addition, Colleen et al. evaluated 184 patients with standard sized ulcers and compared them to those with GDUs. They found that 53% of patients with GDU had used daily NSAIDs in the month before presentation versus only 8% in the standard sized duodenal ulcer group. These data suggest that daily NSAIDs use plays a more prominent role in the formation of GDUs than in standard sized duodenal ulcers. While *H. pylori* infection likely plays a role in the formation of GDUs, it is not as prevalent as it is with the formation of standard size duodenal ulcers. GDUs have high rates of morbidity and mortality. Feared complications associated with these giant ulcers include massive hemorrhage and perforation. Perforation rates between 0% and 7% have been reported by different groups. Unfortunately, little data exist to explain the pathophysiologic differences that lead certain patients to develop these giant variants. Plausible explanations include genetic predisposition, dietary or environmental factors, microbial influences, variations in immunologic response, or any combinations of these factors.

Presenting symptoms include severe abdominal pain, involving the midepigastric region, the right hypochondrium, and/or radiation to the

back. The pain of these giant ulcers is persistent and is not relieved with food of alkali. These giant inflammatory masses can also produce significant constitutional symptoms such as weight loss, cachexia, and malnutrition. This can often mislead clinicians to suggest malignancy as the most likely diagnosis. Radiographic diagnosis with barium has been difficult. The size of these giant ulcers often causes replacement of the duodenal bulb. As a result, the GDUs may be altogether missed or misinterpreted as a deformed bulb, diverticula, or pseudodiverticulum during a barium study. The advent and widespread use endoscopy has markedly improved clinician's ability to detect GDUs with greater accuracy.

Management of GDUs continues to evolve. The advent of new acid suppression medication, the discovery of *H. pylori* and its role in ulcer formation, and the eradication therapy have opened avenues to successful medical management of the GDUs. In 1999, Fischer et al. published a prospective study of 28 patients with GDUs; 27 of these patients were placed on omeprazole therapy. Their results showed that 15 of these patients had complete healing of their GDUs on endoscopy. Despite the marked improvement associated with PPIs, surgical evaluation of a patient with a GDU should remain an integral part of the patient care. Emergent indications for surgical intervention include uncontrolled hemorrhage, perforation, and unresolving obstruction. Perforation of GDUs is considered particularly hazardous because of the extensive duodenal tissue loss and surrounding tissue inflammation, which are said to preclude simple closure with omental patch, often resulting in postoperative leak or gastric outlet obstruction. Several surgical options have been suggested. These have included resection of the perforation bearing duodenum and gastric antrum in the form of a partial gastrectomy, with reconstruction with a Billroth II anastomosis, as a Billroth I reconstruction is difficult in these circumstances. In some cases, an even more morbid procedure of gastric disconnection may be indicated. This includes vagotomy, antrectomy, gastrostomy, lateral duodenostomy, and feeding jejunostomy (see Fig. 87.22) with restoration of intestinal continuity electively after 4 weeks of discharge. However, resection of these large ulcers may increase the likelihood of common bile duct injury, which may be present in the base or adjacent to the ulcer. Others have recommended conversion of the perforation into pyloroplasty, or closure of the perforation using a serosa patch or pedicle graft of the jejunum. Proximal gastrojejunostomy and/or

vagotomy may be electively added to these procedures to provide diversion and a definitive acid-reducing procedure, respectively. However, each of these procedures has its own morbidity that may add up significantly to alter the final outcome of the patient, and more importantly, none of them is immune to the risk of leak in the postoperative period, which has been the main concern against performing the omental patch in large perforations.

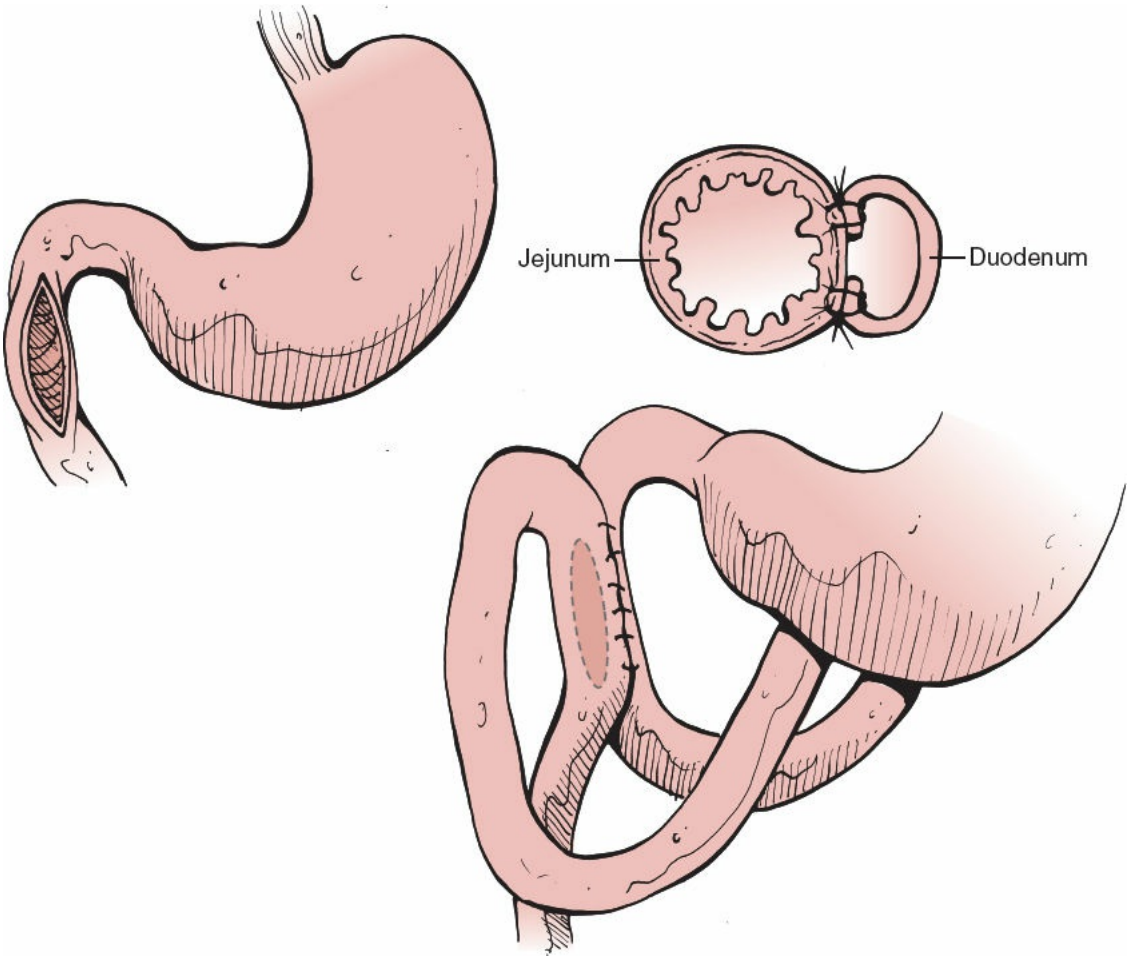

Figure 87.20. Diagrammatic representation of the method adopted for jejunal serosal patch grafting (Thal Patch) of duodenal defect.

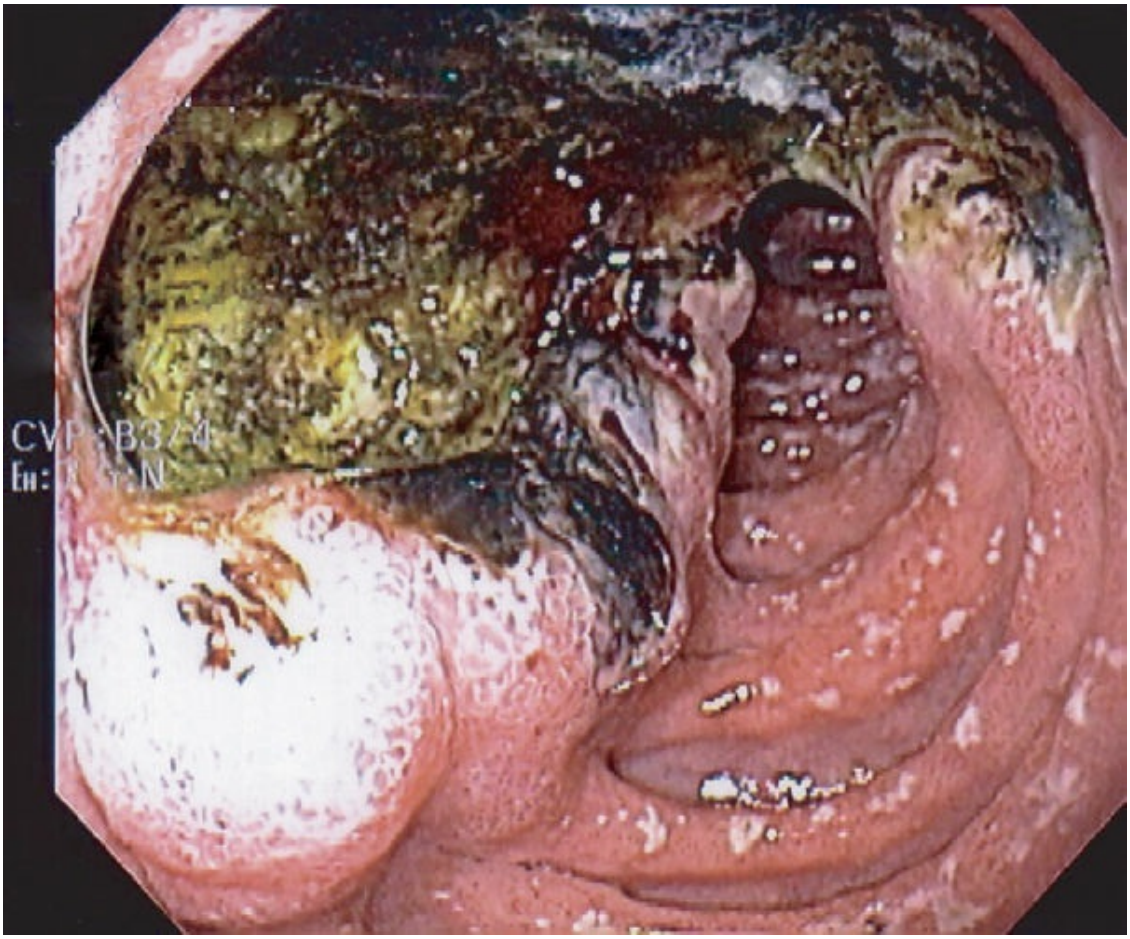

Figure 87.21. Endoscopic photograph of a giant duodenal ulcer in a patient taking NSAIDs. The ulcer involves the proximal second portion of the duodenum. The ulcer seen is >2 cm, and involves over 50% of the mucosal circumference.

GASTRIC OUTLET OBSTRUCTION: PYLOROPLASTY AND GASTROJEJUNOSTOMY

Many of the popular and widely performed early gastric operations were drainage procedures designed to treat PUD or obstructing carcinoma. Wolfler first performed anterior gastrojejunostomy in 1881 for obstructing pyloric cancer, at the suggestion of his assistant Nicoladoni. Posterior gastrojejunostomy was conceived by Courvoisier in 1882 and improved upon by von Hacker in 1885. In 1892 Braun described the anastomosis between the afferent and efferent limbs of the gastrojejunostomy, to divert bile away from the stomach. In 1901 Czerny shortened the afferent loop of the posterior gastrojejunostomy as suggested by Peterson. Roux described the “en Y” gastrojejunostomy in 1897. The eponymous Heineke–Mikulicz pyloroplasty was simultaneously devised and reported in 1886 by Heineke

and in 1887 by Mikulicz. Finney published his more elaborate (and at the time more versatile) operation in 1902, while Jaboulay had already described his side-to-side gastroduodenostomy in 1892.

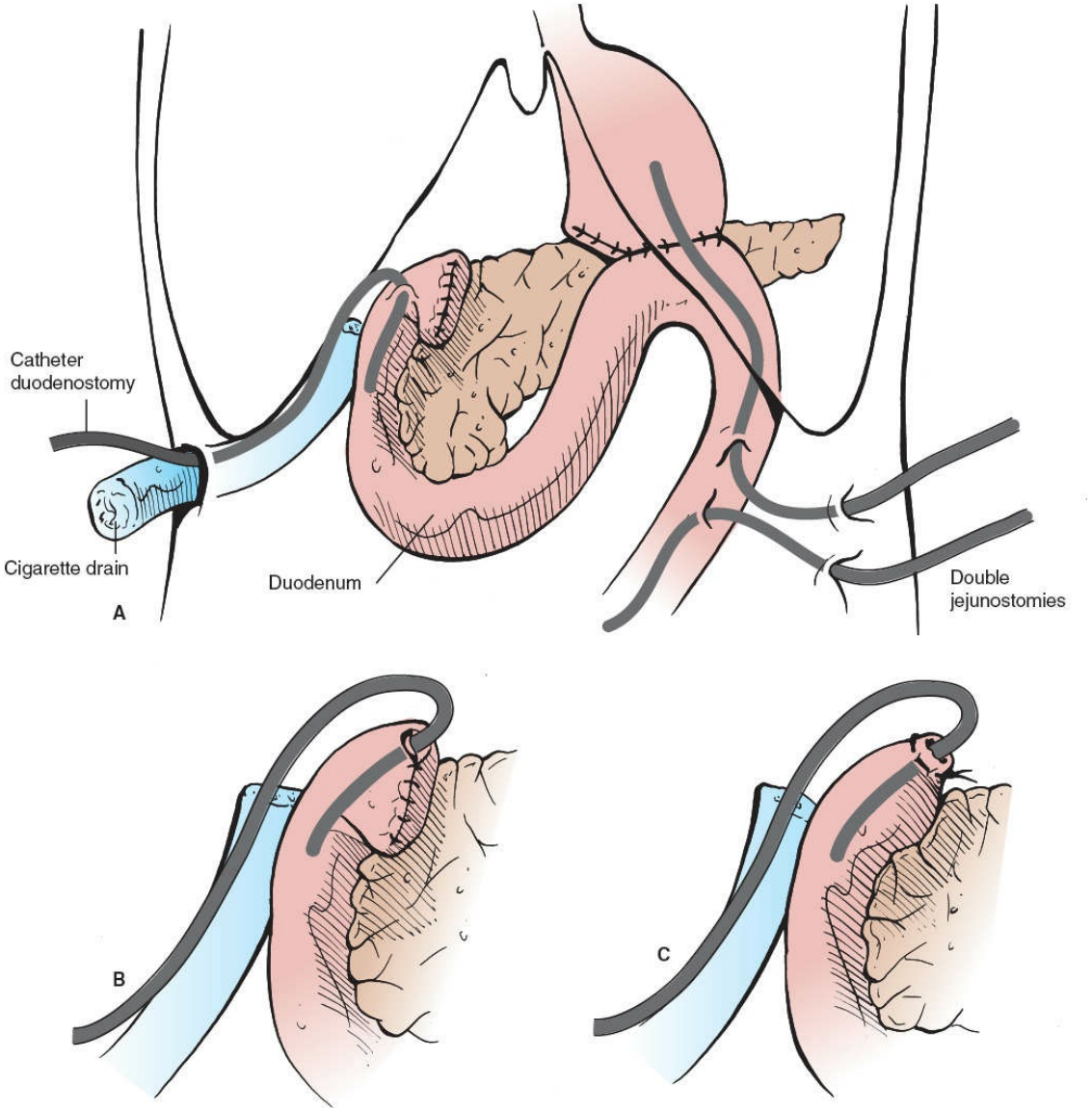

Figure 87.22. Catheter duodenostomy. (**A**) Duodenal decompression can be carried out by inserting a catheter into anterior duodenal wall distal to turnin or (**B, C**) through end of duodenum. In addition, a large cigarette drain should be used. Double jejunostomy may or may not be used.

These operations initially performed with great frequency became less common by the mid-20th century as distal subtotal gastrectomy became the operation of choice for peptic ulcer and gastric cancer. In his effort to find a more physiologic and better tolerated operation for peptic ulcer, Dragstedt suggested transthoracic truncal vagotomy, which was associated with intolerable symptoms of gastric stasis in 20% of patients with another 20% experiencing tolerable symptoms manageable without operation. With the addition of a concomitant pyloroplasty or gastrojejunostomy, the truncal vagotomy became an abdominal procedure and the gastric drainage

operations were resurrected in the 1950s and 1960s. Pyloroplasty and gastrojejunostomy remain an important part of the general surgeon's armamentarium today. This section discusses some of these procedures in the adult patient.

INDICATIONS FOR GASTRIC DRAINAGE PROCEDURES

Mechanical Gastric Outlet Obstruction (Malignant)

Most patients admitted to hospital today with symptomatic gastric outlet obstruction have cancer. A palliative gastric drainage procedure may be indicated if the tumor is unresectable, or if the patient's condition prohibits a more substantial operation. Dependent loop gastrojejunostomy is the surgical procedure of choice, but in certain situations endoscopic stenting may be better (see below). When "double bypass" is done for palliation of pancreatic cancer, the gastric anastomosis is placed distal to the biliary anastomosis. When bypassing malignant gastric outlet obstruction, it is important to choose a site on the stomach that is likely to remain tumor free for at least several months. If this cannot be done without placing the anastomosis high on the stomach, alternative methods of palliation (e.g., gastrostomy and jejunostomy and/or endoscopic stenting) should be considered. Anterior gastrojejunostomy is acceptable if placed in the distal third of the stomach. All patients with palliative gastrojejunostomy should be maintained on acid-suppressive medication unless shown to be achlorhydric since the operation is inherently ulcerogenic. Admittedly, most of these patients will not live long enough to experience the complications of marginal ulcer.

When the obstruction is in the proximal duodenum and/or distal stomach, gastrojejunostomy usually helps the troublesome symptoms of abdominal pain and vomiting. But when the duodenal obstruction is distal to the ampulla of Vater, gastrojejunostomy may not help, since with this procedure the biliary and pancreatic secretions must decompress retrograde through a functional pylorus. In this case, consideration should be given to adding a pyloroplasty or pyloromyotomy to the dependent gastrojejunostomy. An alternative may be to anastomose a Roux limb or jejunal loop first to the proximal duodenum, and then to the dependent portion of the greater gastric curvature. We have used both alternatives with good clinical results.

Meta-analysis suggests that endoscopic stenting compares favorably with surgical bypass in patients with malignant gastric outlet obstruction. Thus, surgical bypass of malignant gastric outlet obstruction should not be performed in patients deemed to have a survival measured in weeks. Palliative endoscopic stenting of malignant gastric outlet obstruction should be considered in these patients. In many patients, this palliates the vomiting and may allow them to take some liquids orally.

Mechanical Gastric Outlet Obstruction (Benign)

The causes of benign gastric outlet obstruction include peptic ulcer (by far the most common), duodenal webs, hypertrophic pyloric stenosis, and Crohn disease. Although distal gastric resection is the preferred operation in the good-risk patient with ulcer-related gastric outlet obstruction, the lesser operation of highly selective vagotomy and pyloroplasty or gastrojejunostomy has been shown in a prospective randomized study to give comparable clinical results. Perhaps lifelong oral PPIs and gastrojejunostomy would be just as good or better. One attraction of gastrojejunostomy is that it can be performed laparoscopically or with a laparoscopic-assisted technique. Furthermore, if this procedure fails to improve the obstruction and/or ulcer symptoms, it does not preclude distal gastrectomy. Finally if gastrojejunostomy were to be associated with intolerable dumping, it is reversible. One disadvantage of gastrojejunostomy to treat obstructing peptic ulcer is that pyloric or duodenal cancer can be missed. In general, pyloroplasty (particularly the Heineke–Mikulicz and Finney type) requires pliability of the pyloric channel, and is therefore not a good option to relieve obstruction from peptic ulcer. Occasionally the chronic cicatrix is disk-like (rather than long and cylindrical) and near the pylorus, and amenable to pyloroplasty. It is worth remembering the Jaboulay pyloroplasty technique (essentially a side-to-side duodenogastrostomy) in the occasional patient in whom gastrojejunostomy is difficult due to adhesions and/or previous operations.

Gastrojejunostomy is a good operation to relieve the obstructive symptoms caused by proximal duodenal webs or Crohn disease. Obstruction distal to the ampulla of Vater is best treated with a proximal side-to-side duodenojejunostomy (Roux or loop). Duodenal webs or peptic strictures are often amenable to stricturoplasty using the Heineke–Mikulicz technique.

Vagotomy

It is generally accepted that a drainage operation should be added to truncal or total gastric (i.e., selective) vagotomy since the antrum and pylorus are denervated with these procedures. Denervation results in a spastic pylorus and a sluggish antrum, the net effect of which is symptomatic gastric stasis in some (but not all) patients. Gastric drainage is unnecessary with highly selective vagotomy, which preserves the vagal innervation of the antrum and pylorus. Some surgeons perform a pyloromyotomy or pyloroplasty as part of a transhiatal or transthoracic esophagogastrectomy unless a vagal sparing approach is used. With laparoscopic transhiatal esophagectomy, this is not necessary. In the unusual circumstance when a transabdominal proximal subtotal gastrectomy is performed, severing the vagal trunks and anastomosing the distal stomach to the distal thoracic esophagus, we do not disrupt the pylorus since we feel that preserving the pylorus may spare the patient (usually a poor-risk patient with a large tumor) the unenviable sequelae of bile esophagitis.

Functional Gastric Stasis

Increasingly, symptomatic patients without previous operation are being identified with quantifiable delayed gastric emptying. Some have other demonstrable abnormalities in GI motility, and/or irritable bowel syndrome, and/or diabetes. These patients are a challenging group and remind us that there is much about GI pathophysiology that is unknown or poorly understood. The managing physician for these complex patients should usually be a gastroenterologist with motility expertise, not the general surgeon. Rarely, carefully selected patients may benefit from a gastric drainage procedure, but this surgical decision should never be made without the participation of the managing gastroenterologist, patient, and family. While the T½ gastric emptying time measured by scintigraphy may be improved by pyloroplasty, this can easily be outweighed by the pain and bilious vomiting associated with the attendant increased duodenogastric reflux sometimes associated with this procedure. Remember, we cannot use the large body of surgical literature on peptic ulcer surgery to predict the functional complications of pyloroplasty in this unusual group with primary gastroparesis. Also, remember that pyloroplasty is not reversible. Prior to considering pyloroplasty to facilitate gastric emptying for gastroparesis, it may be prudent to render the

sphincter temporarily incompetent with balloon dilation and/or botox. A favorable response to these maneuvers may increase the likelihood of a favorable response to pyloroplasty. Alternatively, loop gastrojejunostomy, a reversible operation, may be considered and PPIs prescribed. Finally some of these patients may benefit from gastric pacing.

Not infrequently patients who present with gastroesophageal reflux disease (GERD) symptoms and objective criteria indicating fundoplication are found to have delayed gastric emptying on preoperative scintigraphy. While these patients may have a somewhat higher incidence of gas bloat symptoms post fundoplication, the large majority do well without the addition of pyloroplasty. It has been shown that fundoplication increases gastric emptying in most of these patients, and only rarely will subsequent pyloroplasty be necessary.

CHOICE OF DRAINAGE OPERATION

Pyloromyotomy or Pyloroplasty?

Most surgeons feel that pyloromyotomy and Heineke–Mikulicz pyloroplasty are comparable gastric drainage procedures. This was the conclusion of at least one prospective randomized trial in adults undergoing esophagectomy. The advantage of the pyloromyotomy is presumed to be a lower leakage rate. The disadvantage is there may be a tendency among nonpediatric surgeons to leave undivided pyloric muscle fibers, which could produce a suboptimal clinical result.

Which Type of Pyloroplasty?

By far the easiest and most commonly performed pyloroplasty is the Heineke–Mikulicz type, but general surgeons should be familiar with the other types as well. For instance, if a 10-cm gastroduodenotomy is required to deal with a large posterior bleeding ulcer, closure with an Heineke–Mikulicg pyloroplasty may be difficult or impossible, but closure with the Finney technique may be straightforward. Or if the original plan was gastrojejunostomy but the proximal jejunum is involved with dense adhesions (e.g., s/p left colectomy) or Crohn disease, Jaboulay pyloroplasty would be a straightforward alternative. These operations are described earlier in this chapter under management of bleeding duodenal ulcer.

Pyloroplasty or Gastrojejunostomy?

These procedures are equally effective as gastric drainage operations. The major advantage of the pyloroplasty is that it does not require entry into the inframesocolic abdomen, and perhaps a leak might be more easily managed with drainage and gastric suction, since it is proximal to the entry of bile and pancreatic juice. The major advantage of the gastrojejunostomy is that it is easily reversible (unlike pyloroplasty). Furthermore, if subsequent distal gastrectomy is required, previous gastrojejunostomy rarely presents a technical challenge. But previous pyloroplasty, particularly the Finney or Jaboulay, may make the handling of the duodenal stump quite problematic. The major disadvantage of gastrojejunostomy is that it is ulcerogenic since the jejunal mucosa is less resistant to acid peptic injury than the proximal duodenum with its higher concentration of buffering and cytoprotective factors. Long-term acid suppression may mitigate this disadvantage. Another potential disadvantage of gastrojejunostomy is dysfunction, associated with the "circus movement" of duodenal contents, or proximal small bowel obstruction associated with kinking or adhesions.

Roux or Loop Gastrojejunostomy? Add Braun?

Loop gastrojejunostomy involves one anastomosis, while Roux gastrojejunostomy involves two anastomoses and is more ulcerogenic (due to the complete lack of duodenal contents in the vicinity of the gastrojejunostomy). Therefore, Roux gastrojejunostomy should be used only rarely as a drainage procedure with an intact stomach. On occasion we have used a Roux limb to drain the distal stomach (along with transection of the duodenal bulb and preservation of the right gastroepiploic artery) in patients with a history of severe bile esophagitis following proximal subtotal gastrectomy.

The Braun modification of the loop gastrojejunostomy adds an anastomosis between the afferent and efferent limbs, theoretically to allow bilious duodenal contents to go from the former to the latter without having to enter the stomach. But this adds another anastomosis, and is only partially diverting.

Gastrostomy or Jejunostomy Tube

Some patients who require a gastric drainage operation are significantly

malnourished and/or have long-standing gastric stasis. It may therefore be prudent to add a temporary tube gastrostomy (for drainage) and/or tube jejunostomy (for feeding) to the pyloroplasty or gastrojejunostomy procedure. We have sometimes regretted not placing one or both of these tubes, but have rarely regretted placing them.

TECHNIQUE: LOOP GASTROJEJUNOSTOMY

This operation can be done through a small upper midline incision or with a laparoscopic (total or assisted) technique. The ligament of Treitz is unequivocally identified and the proximal jejunum brought anterior to the transverse colon to lie against the dependent greater gastric curvature without tension. If this cannot be accomplished, an alternative anastomotic technique should be considered. Usually an antecolic anastomosis can be done between the dependent greater gastric curvature and the proximal jejunum without difficulty. The serosa of the greater curvature is exposed by dividing the small branches of the gastroepiploic arcade. If necessary, the gastroepiploic arcade can be divided. The orientation of the small bowel is again checked. We prefer the afferent limb on the left side of the gastrojejunostomy and the efferent limb on the right side, with the afferent limb short (12 to 18 in at the most). This is called an isoperistaltic gastrojejunostomy. If the “lie” seems to be better with the afferent loop on the right side and the efferent loop on the left side, this antiperistaltic orientation can be used, but it may mean that the spot chosen on the greater curvature is too high on the stomach. The function of isoperistaltic and antiperistaltic gastrojejunostomies is probably the same. A 4- to 5-cm longitudinal gastrostomy and a jejunostomy are made and a two-layer hand-sewn side-to-side anastomosis effected. Alternatively, stapling instruments may be used but care should be taken not to use short staple heights with a thick-walled stomach. The anastomosis is tested.

If an antecolic tension-free gastrojejunostomy cannot be done, a retrocolic posterior gastrojejunostomy should be considered. While the stomach can sometimes be accessed from below through an avascular window in the mesocolon (easier in the thin patient with a big stomach and a big tube in the stomach), it is often more straightforward to enter the lesser sac to the left of the midline through the gastrocolic ligament, and then make an opening through the mesocolon into the lesser sac. The posterior gastric wall near the greater curvature can then be delivered to the jejunal side of the mesocolon and the anastomosis performed. The

afferent limb should be short (6 in or less), and the completed anastomosis should lie without kinks or twists. It is prudent to tack the posterior gastric wall to the edges of the mesocolic opening to prevent postoperative herniation of small bowel into the lesser sac.

Although anterior gastrojejunostomy is a mechanically unappealing palliative operation in patients who spend much of their final days supine in bed, it must be recognized that reasonable results have been described with this operation, the original technique described by Wolfler. If this approach must be used, we recommend that the anastomosis be placed in the distal stomach, no higher than the imaginary idealized border between the antrum and the body of the stomach.

TECHNIQUE: ROUX GASTROJEJUNOSTOMY AND BRAUN ENTEROENTEROSTOMY

As mentioned above, draining the intact stomach with a Roux limb should be done only rarely. First, this operation exposes the unbuffered jejunal mucosa to the acid peptic prowess of the complete vagally innervated parietal cell mass. Thus, it is ulcerogenic. Second, the abnormal motility in the Roux limb may lead to functional obstruction of the gastrojejunostomy (Roux syndrome). However, should the reader find a good indication for this procedure, it may be performed open through an upper midline abdominal incision, or laparoscopically. The ligament of Treitz is unequivocally identified and the jejunum is divided 40 to 50 cm distal to this. The distal end is then anastomosed to the dependent part of the gastric greater curvature. The proximal jejunum is then anastomosed to the Roux limb 60 cm distal to the gastrojejunostomy. Either or both of the anastomoses can be stapled or hand-sewn and may be tested with luminal air insufflation. If the surgeon must operate on a patient with intolerable bile (enterogastric) reflux after distal gastrectomy and loop gastrojejunostomy (B-II), the procedure can be converted to a Roux by transecting the afferent loop just proximal to the gastrojejunostomy, and then anastomosing this afferent loop to the efferent limb 60 cm distal to the gastrojejunostomy. Obviously the surgeon must be absolutely certain which limb is which. It is usually prudent to delay reoperation for 6 months after the original distal gastrectomy.

The side-to-side Braun enteroenterostomy (between the afferent and efferent limbs of the loop gastrojejunostomy) diverts some of the bilious duodenal contents away from the stomach. It also should decrease the

incidence of afferent loop syndrome, caused by kinking or partial obstruction of the afferent limb at or near the gastrojejunostomy. If this procedure is contemplated, it may be prudent to make the afferent limb slightly longer than usual. A stapled or hand-sewn Braun enteroenterostomy is typically performed about 30 cm proximal and distal to the gastrojejunostomy. It might be more prudent to make the anastomosis on the efferent limb 50 to 60 cm distal to the gastrojejunostomy in the event that intolerable enterogastric reflux ensues anyway and subsequent conversion to a Roux configuration is necessary. If the Braun anastomosis has been made far enough down the efferent limb, this conversion could be accomplished by simply resecting the segment of afferent limb between the Braun enteroenterostomy and the gastrojejunostomy. If the original Braun anastomosis is too close to the stomach on the efferent limb, this simple conversion cannot be relied upon to keep bile out of the stomach.

POSTOPERATIVE MANAGEMENT AND COMPLICATIONS

Common complications include wound infection, deep venous thrombosis (DVT), pneumonia, leak, abscess, and delayed GI function. Prophylactic antibiotics are started preoperatively and continued for 12 to 24 hours. DVT prophylaxis (pneumatic compression and subcutaneous heparinoid) is started preoperatively and continued until discharge. Preoperative duplex screening for DVT may be wise in patients who have been hospitalized or bedridden preoperatively. Aspiration of gastric contents is a potentially fatal complication in patients requiring gastric drainage procedures, and gastrostomy cannot always be relied upon to keep the stomach decompressed in the early postoperative period. All patients are given PPIs and antiemetics. We maintain a functioning NG tube until there is clinical evidence of gastric emptying. If this is not evident by the third postoperative day, we perform a gastrografin upper GI series to rule out leak and to document gastric emptying. All members of the surgical team should be cognizant of the harm that could be done by the careless manipulation or reinsertion of an NG tube in a patient who has a fresh gastroduodenal or gastrojejunal suture line. Anastomotic leakage should be treated promptly with drainage and antibiotics, and early reexploration considered. Return of GI function and tolerance of oral feeding may occur promptly, but are often delayed. It is important for the surgeon to manage

the patient's expectations, not judging the functional success or failure of the drainage operation too soon. Decompressing gastrostomy and feeding jejunostomy can be helpful in avoiding frustration and time pressure postoperatively.

SUMMARY

Despite improvements in pharmacologic therapies and endoscopic treatment of peptic ulcer disease, complications such as hemorrhage, perforation, and obstruction from duodenal ulcer continue to occur and remain a clinical challenge. Multidiscipline team cooperation and communication between the gastroenterologist, radiologist, and surgeon can optimize the approaches used for the initial treatment of bleeding duodenal ulcer. Endoscopy is used for diagnosis and initial therapy in most cases. Interventional radiology is used when the patient is deemed a poor operative candidate and endoscopy has failed to achieve hemostasis. In the setting of massive or recurrent upper GI bleeding from a diagnosed duodenal ulcer, one must follow strict criteria for operative intervention. If these criteria are met, excessively delayed or repeat endoscopic procedures are not warranted if the patient has recurrent or continued hemorrhage. When emergency surgery is indicated, the primary objective is to stop the bleeding. Precise application of the three-point ligation is emphasized, and if the ligation is adequately performed, it will prevent rebleeding. The secondary objective is to perform an operation that will prevent early rebleeding and recurrent ulceration without increasing morbidity or mortality. The choice of operation is ultimately influenced by the physiologic condition of the patient on entering the operating room. Most patients today are treated with oversewing the ulcer and control of the bleeding without a truncal vagotomy and pyloroplasty. Only in a hemodynamically stable patient with favorable anatomy and in the absence of medication or a noncompliant patient would a vagotomy and pyloroplasty be performed. In these situations, a highly selective vagotomy may be performed, which avoids the adverse sequelae of total abdominal vagotomy. The role of laparoscopy in the management of bleeding duodenal ulcer has been very limited and is reserved only in nonemergent intervention where hemodynamic stability is present and the gastroduodenal anatomy is favorable to a laparoscopic approach.

The current management options of perforated duodenal ulcer remain debatable. The debates of earlier in the century regarding simple patch

closure versus immediate definitive surgery have been complicated by the arguments for and against laparotomy, the introduction of laparoscopy, and the discovery of the role of *H. pylori.* For a patient with perforated duodenal ulcer, the role of nonoperative management should be first considered by the surgeon. Should this option be selected for the patient who requires close vigilance and a readiness to intervene at any moment when the patient shows signs of deterioration or failure to progress satisfactorily. Current evidence supports simple omental patch closure and lavage followed by antibiotics treatment for *H. pylori* in cases in which operative management is indicated. It has been suggested that if the ulcer fails to heal after surgery and *H. pylori* eradication, then a highly selective vagotomy should be performed after exclusion of a pathologic hypersecretion state. In the case of a patient who is negative for *H. pylori*, or who has been treated and then perforated, immediate definitive ulcer surgery should be performed in the absence of preoperative risk factors. Opinions between authors differ greatly, with some advocating an algorithm consisting of nonsurgical and surgical approaches depending on the characteristics of patient presentation. Presently, patients should be managed based on their physical and radiologic findings, risk factors, and *H. pylori* status (Fig. 87.1). The management of this complicated problem will continue to evolve with the improvement of laparoscopic techniques, increased acceptance of nonoperative therapy, and improved recognition of the role of *H. pylori* in perforated duodenal ulcers.

Gastric obstruction may be treated with pyloroplasty, gastrojejunostomy, or gastric resection. Which operation is chosen is made on the basis of the findings at operation.

Suggested Readings

General Considerations

Bashinskaya B, Nahed BV, Redjal N, et al. Trends in peptic ulcer disease and the identification of *Helicobacter pylori* as a causative organism: population-based estimates from the US nationwide inpatient sample. *J Glob Infect Dis* 2011;3(4):366–70.

Lau JY, Sung J, Hill C, et al. Systematic review of the epidemiology of complicated peptic ulcer disease: incidence, recurrence, risk factors and mortality. *Digestion* 2011;84(2):102.

Wang YR, Richter JE, Dempsey DT. Trends and outcomes of hospitalizations for

peptic ulcer disease in the United States, 1993 to 2006. *Ann Surg* 2010; 251(1):51–8.

Bleeding Duodenal Ulcer

Chiu PW, Chan FK, Lau JY. Endoscopic suturing for ulcer exclusion in patients with massively bleeding large gastric ulcer. *Gastroenterology* 2015;149(1):29–30.

El Ouali S, Barkun A, Martel M, et al. Timing of rebleeding in high-risk peptic ulcer bleeding after successful hemostasis: a systematic review. *Can J Gastroenterol Hepatol* 2014;28(10):543–8.

Laine L. Upper gastrointestinal bleeding due to a peptic ulcer. [Review]. *N Engl J Med* 2016;374(24):2367–76.

Schroder VT, Pappas TN, Vaslef SN, et al. Vagotomy/drainage is superior to local oversew in patients who require emergency surgery for bleeding peptic ulcers. *Ann Surg* 2014;259(6):1111–8.

Tjwa ET, Holster IL, Kuipers EJ. Endoscopic management of nonvariceal, nonulcer upper gastrointestinal bleeding.*Gastroenterol Clin North Am* 2014;43(4):707–19.

Venclauskas L, Bratlie S-O, Zachrisson K, et al. Is transcatheter arterial embolization a safer alternative than surgery when endoscopic therapy fails in bleeding duodenal ulcer? *Scand J Gastroenterol* 2010;45:299–304.

Perforated Duodenal Ulcer

Byrge N, Barton RG, Enniss TM, et al. Laparoscopic versus open repair of perforated gastroduodenal ulcer: a national surgical quality improvement program analysis. *Am J Surg* 2013;206(6):957–62; discussion 962–3.

Ge B, Wu M, Chen Q. A prospective randomized controlled trial of laparoscopic repair versus open repair for perforated peptic ulcers. *Surgery* 2016;159(2):451–8.

Soreide K, Thorsen K, Harrison EM, Perforated peptic ulcer. [Review]. *Lancet* 2015;386(10000):1288–98.

Pyloroplasty and Gastrojejunostomy

Danikas D, Geis WP, Ginalis M, et al. Laparoscopic pyloroplasty in idiopathic hypertrophic pyloric stenosis in an adult. *JSLS* 2000;4:173–5.

Law S, Cheung MC, Fok M, et al. Pyloroplasty and pyloromyotomy in gastric replacement of the esophagus after esophagectomy: a randomized controlled trial. *J Am Coll Surg* 1997;184(6):630–6.



Peptic ulcer disease (PUD) has come to represent a unique surgical challenge in the 21st century. As with some other diseases within the purview of the contemporary surgeon, the incidence of PUD has steadily declined over the past 50 years due to many factors, including advances in medical therapy. Unlike most of these other diseases however, these improvements have not resulted in a decreased incidence of emergency complications leaving the need for and number of emergency interventions constant. As the authors of this chapter make clear, the surgical management of PUD is a complex and technically challenging topic both in the operating room (OR) and after. Fortunately, despite the challenges of these emergency operations, the associated morbidity and mortality continue to decrease.

Emergency Surgery for PUD

Medical therapy and the discovery of *H. pylori* have revolutionized the treatment of PUD but have not managed to eliminate or even reduce the number of emergency operations done to treat bleeding and perforation. In addition, it is not expected that further advances in medical therapy will result in an appreciable decrease in emergency operations as the persistence of PUD in 21st century America is likely due to multiple factors occurring in two distinct (but often overlapping) populations of patients. The first group represents patients who cannot be reached with preventative health care, such as the elderly, malnourished, immunosuppressed, and the underserved who may engage in high-risk behaviors for the development of PUD. As the authors indicate, the second group is made up of those on chronic NSAID therapy including long-term aspirin. As many as 30% of these people have ulcers and are already taking proton pump inhibitors with only partial protection. It is hard to imagine either of these clusters of patients ever disappearing from our society and taking the bulk of the remaining PUD with them. This leaves us, surgeons trained in the modern era without extensive experience with peptic ulcer operations, to sort out the safest and most effective ways to manage their complications.

Bleeding

Bleeding remains the most common complication of PUD resulting in hospitalization and intervention in the United States. The two biggest questions we must answer when faced with a patient with a bleeding ulcer are whether or when to operate and what operation to perform. Traditionally the question of operative timing in the setting of gastrointestinal (GI) bleed was distilled down a magic number of units transfused, where surgery was recommended after the sixth unit of blood. This recommendation was a product of a simpler time when the options for intervention were surgery alone and patients either stopped bleeding or needed an operation. While this two-variable decision tree may still be appropriate for those practicing in smaller hospitals with fewer resources, those practicing in large institutions (with 24-hour access to endoscopists,

interventional radiologists, and intensivists) believe a more sophisticated algorithm should be employed.

We prefer a process that utilizes the skill of each of these specialists and saves the operating room for patients who fail to respond to other modalities or are deemed inappropriate for them. Also, patients who fail to respond to resuscitation may be advanced along the algorithm in an accelerated fashion. Like all “conservative” or nonoperative treatment strategies, the surgeon must be intimately involved in every step, guiding every decision, and constantly assessing for success or failure in a cooperative fashion with the other procedural specialists.

The support of the blood bank and possibly a massive transfusion protocol to ensure balanced transfusion and the aggressive correction of medical coagulopathy in a goal directed fashion (such as the use of thromboelastography if available) are also critical. The expectation is not that bleeding will necessarily stop with these measures but rather that less invasive strategies will be more likely to be successful when the clotting milieu is not deranged by factor depletion and dilution from the transfusion of red cells. This is also true for the patient who fails to stop bleeding and requires an operation. Another goal of this labor-intensive resuscitative strategy is preventing the patient from descending into an uncompensated shock state characterized by episodes of profound hypotension and oliguria. Even brief periods of shock result in higher rates of morbidity and mortality after the bleeding stops. Nevertheless, a transfusion requirement does not have to equal shock. In a well-run resuscitation, the patient remains stable, and an absolute number of units transfused become less relevant as a decision point.

We generally recommend two attempts at therapeutic upper endoscopy prior to surgical intervention. In addition, we often recommend an attempt at embolization of the bleeding vessel in interventional radiology prior to proceeding to surgery in selected high-risk patients with multiple comorbid conditions. We agree with the authors that fewer surgeons are facile enough to manage a bleeding ulcer laparoscopically. We value ease and speed when treating a bleeding ulcer and favor open surgery. The currently available data suggest that simple oversew of the bleeding vessel, without vagotomy, is inferior to oversew, vagotomy, and drainage. Our own analysis of the NSQUIP database indicated that the best outcomes with respect to 30-day morbidity and mortality occurred after transduodenal oversew of the bleeding vessel plus vagotomy and drainage (the addition of vagotomy, decreased mortality by 50%).

Therefore, for patients with bleeding duodenal ulcer disease that requires surgery, we recommend opening the duodenum, oversewing the ulcer to achieve hemostasis, closing the duodenum using an appropriate pyloroplasty for the situation, and performing a truncal vagotomy prior to closing the abdomen. We do not recommend vagotomy and antrectomy given the increased difficulty as well as the higher postop complication rate when this procedure is used in the

emergency setting. In addition, we do not recommend other technically challenging operations in the emergency setting such as highly selective vagotomy.

Perforation

As with bleeding, surgeons faced with perforated peptic ulcers must also choose both when and how to operate. The presentation of a perforated ulcer can be nonspecific and subtle especially in the most vulnerable population where it may be easily confused with other acute conditions. We must remain vigilant and keep this life-threatening complication high on our differential diagnosis because while PUD has decreased in incidence, perforation has not. By keeping our index of suspicion high, we avoid both delays in treatment and unnecessary diagnostic tests.

While we agree with the authors that upper gastrointestinal (UGI) contrast studies can help identify perforations that have sealed, we disagree that they are of vital in the diagnosis of perforated peptic ulcer. Even in busy hospitals, UGI is unlikely to be available outside of regular daylight hours and reliance on this test will lead to delays in diagnosis and treatment translating to higher morbidity and mortality. We follow a simplistic diagnostic algorithm that starts with an upright chest x-ray. For 60% of perforated patients who have free air on presentation, we would argue no further testing is necessary. This is especially true if there is massive free air, where the source is usually from the upper gut. For those without free air on this initial imaging, CT scan, ideally with oral and IV contrast, should be the next test. Unlike UGI, CT scan is readily available around the clock in most emergency departments. Upper GI contrast studies, while potentially adding some increased sensitivity due to their dynamic nature, are less practical and significantly less available in all but the elective setting.

The mortality associated with perforation is high, and outcomes are best if patients are treated within 12 hours. We advocate for a low threshold for operating and the liberal use of diagnostic laparoscopy if the diagnosis of perforated PUD is high on the differential. With two or three 5-mm ports, the entire abdomen can be explored. If the diagnosis of PUD is confirmed, we perform patch closure alone. In our review of the NSQUIP database, we examined nearly 2,400 patients with perforated peptic ulcers and found that patients fared best, with lower rates of both 30-day morbidity and mortality, after local patching procedures alone. For perforated duodenal ulcers, vagotomy was of no benefit. Depending on the surgeon’s individual skills, patching a duodenal ulcer can be done either laparoscopically or through an upper midline laparotomy.

Among perforated ulcers, giant ulcers deserve special mention, as they will always prove more difficult to handle. In contrast to the authors of the chapter, we do not recommend the use of highly selective vagotomy for the treatment of giant ulcers. Highly selective vagotomy is a technically challenging operation with a long learning cure that is largely of historical interest and has no practical

use in the emergency setting. If vagotomy is to be used in this setting, it should be a truncal vagotomy. Closure of these ulcers may require extensive duodenal mobilization and may be aided by a jejunal serosal patch.

Elective Surgery for PUD

It is possible to spend an entire career in general surgery and never see a PUD patient with an indication for elective surgery. The two indications for these elective operations are obstruction and intractable pain. In the past, elective peptic ulcer operations were selected to minimize dumping and postvagotomy syndromes. Today, elective operations should be selected for the lowest ulcer recurrence rate. Since these operations are rare, troublesome postvagotomy syndromes are almost never seen. On the other hand, recurrence rates are very high in these extremely selected patients who are often cigarette or aspirin abusers. We recommend vagotomy and antrectomy as the elective operation of choice for complicated PUD. The decision to use a Billroth1 or Billroth2 reconstruction should be made based on the quality of the duodenum. Again, we do not recommend highly selective vagotomy in this environment due to the higher recurrence rate.

Vanessa Schroder and Theodore N Pappas

Suggested Readings

Lagoo J, Perez A, Pappas TN. A relic or still relevant—the narrowing role of vagotomy in the treatment of peptic ulcer disease. *Am J Surg* 2014;207:120–6.

Schroder VT, Pappas TN, Vaslef SN. Vagotomy/Drainage is superior to local oversew in patients who require emergency surgery for bleeding peptic ulcers. *Ann Surg* 2014;259:1111–8.

88 Gastric Cancer

John T. Mullen

Although the incidence of gastric cancer in the United States has dramatically decreased during the past several decades, gastric cancer remains an important cause of cancer-related death, with an estimated 24,600 cases and 10,700 deaths in 2015. Despite significant improvements in staging modalities, surgical therapy, and perioperative care, the prognosis of most patients with gastric cancer remains poor. This is largely a result of the aggressive biology of this cancer as well as the advanced stage of disease at which most patients present to the clinician. Risk factors include *Helicobacter pylori* and Epstein-Barr virus (EBV) infection, pernicious anemia, prior gastric resection, smoking, and high salt intake. Approximately 10% of gastric cancers are due to inherited cancer syndromes, including hereditary diffuse gastric cancer (HDGC), characterized by germline mutations in the E-cadherin (CDH1) gene, and hereditary nonpolyposis colorectal cancer (HNPCC) syndrome, characterized by germline mutations in DNA mismatch repair genes. Recently, a comprehensive molecular evaluation of gastric cancer has led to a classification scheme that defines four major genomic subtypes and their approximate frequencies: EBV-infected tumors (9%), microsatellite unstable (MSI-high) tumors (22%), genomically stable tumors (20%), and chromosomally unstable tumors (50%). This chapter focuses on the preoperative diagnostic and staging evaluation of the patient with gastric cancer as well as the technical maneuvers involved in the performance of a subtotal or total gastrectomy for this disease.

PREOPERATIVE PLANNING

The evaluation of the patient with suspected gastric cancer includes a careful physical examination, laboratory studies, *H. pylori* status, endoscopic ultrasound (EUS), computed tomography (CT) and positron emission tomography (PET) scans, and laparoscopy. My current algorithm for the diagnosis and treatment of patients with gastric cancer is illustrated in Figure 88.1. The diagnosis of gastric cancer is usually readily

established by endoscopy with biopsy. Endoscopy defines the location and extent of the tumor within the stomach and, when combined with EUS, allows for accurate estimation of the depth of tumor invasion (T stage). EUS is the most sensitive modality in establishing the T stage of a gastric cancer, and EUS enables an assessment of the regional lymph nodes and needle biopsy of suspicious nodes to confirm nodal involvement (N stage). A CT scan of the chest, abdomen, and pelvis should be performed to evaluate for distant metastatic spread, such as to the lungs, liver, peritoneum, or lymph nodes outside the field of resection. In addition, a CT scan is sensitive in detecting even small amounts of ascites that may represent peritoneal tumor spread and that can be sampled by image-guided means for cytologic examination. Although PET and PET–CT scans are not routinely recommended in the preoperative staging of gastric cancer, they may certainly provide additional useful information. PET has a low sensitivity in detecting the primary tumor, especially in early and diffuse-type gastric cancers, but PET has a higher specificity than CT (~90% vs. ~60%) in the detection of regional lymph node metastases, and PET has a reasonable sensitivity for the detection of liver, lung, and distant lymph node metastases. In addition, PET can be used to monitor tumor response to neoadjuvant chemotherapy, as it accurately detects responders to therapy at an early stage, thus enabling the clinician to maintain patients on as active a chemotherapy regimen as possible. Nonetheless, PET has shown variable success at best in predicting histopathologic response and long-term survival.

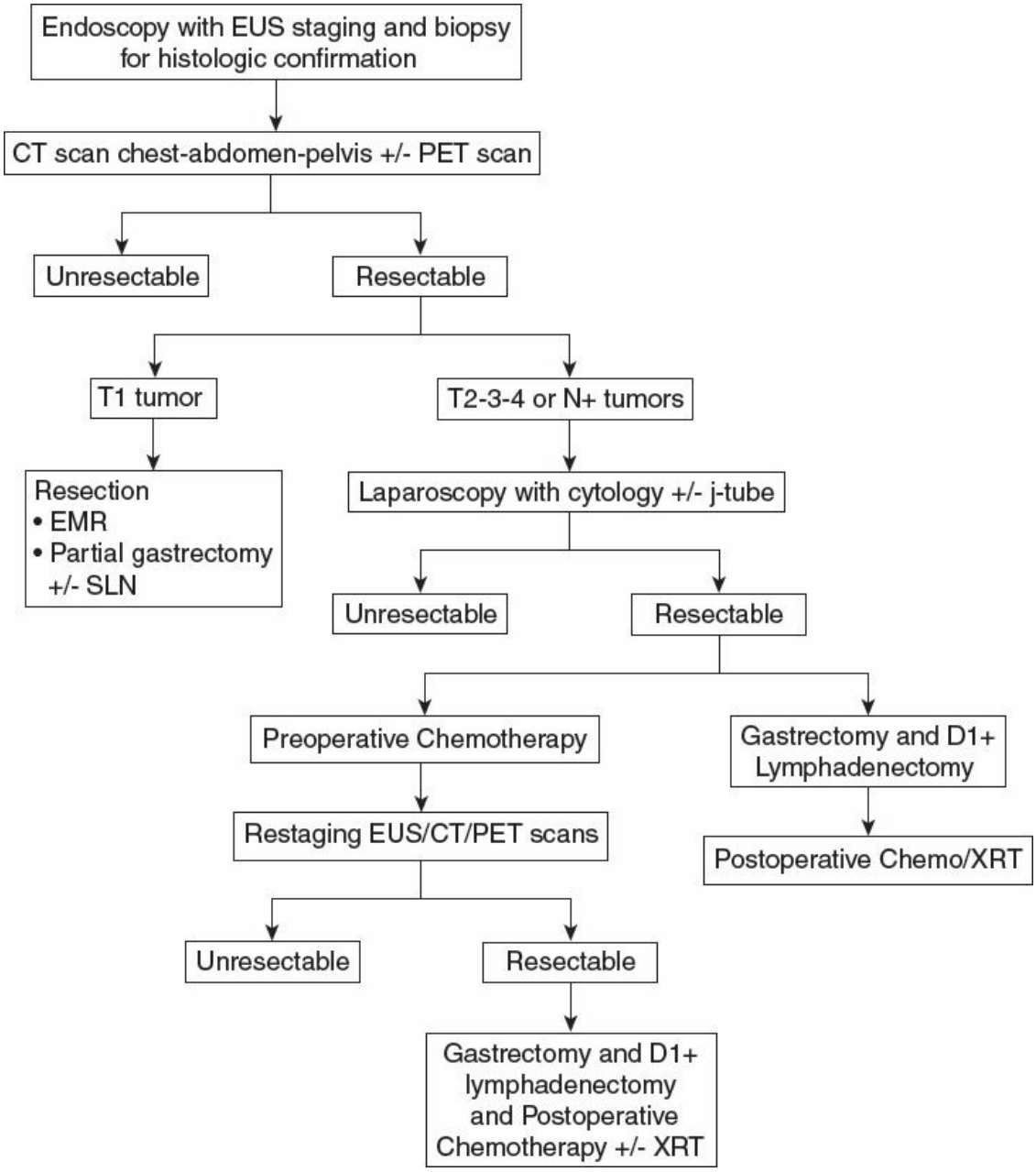

Figure 88.1. Algorithm for the diagnosis, staging, and treatment of gastric cancer. EUS, endoscopic ultrasound; CT, computed tomography; PET, positron emission tomography; SLN, sentinel lymph node biopsy; EMR, endoscopic mucosal resection; chemo/XRT, chemoradiation therapy.

Patients who should be considered for immediate resection include those with early-stage (T1/T2 N0) gastric cancers and those who require immediate palliation of bleeding or high-grade tumor-associated luminal obstruction. However, the perioperative morbidity and mortality rates in this latter population of patients are significant and must be carefully weighed against the likely benefits of resection. Patients with more

invasive lesions revealed on EUS are considered for additional pretreatment staging by laparoscopy. Staging laparoscopy can be done immediately prior to the planned laparotomy or as a pretreatment procedure performed in patients considering preoperative therapy. Staging laparoscopy upstages 20% to 30% of patients through the identification of radiographically occult peritoneal and liver metastases and positive cytology. It is a particularly high-yield procedure for those patients with tumors involving the gastroesophageal junction (GEJ) or whole stomach. For patients considering preoperative chemotherapy or chemoradiation therapy who have lost significant weight and/or are having significant difficulty meeting their nutritional needs by mouth, a feeding jejunostomy tube may be placed at the time of staging laparoscopy.

The most common treatment paradigm for gastric cancer in the United States has historically been upfront surgery, followed by adjuvant chemoradiation therapy (as described in the Intergroup 0116 trial) for those patients with high-risk (T3/4, node positive, poorly cohesive-type) tumors. However, only 64% of the patients in this trial could receive the postoperative chemoradiotherapy as planned, and so I favor perioperative chemotherapy for such patients, as described in the MAGIC trial conducted by the British Medical Research Council. In this trial, patients were randomized to receive either perioperative chemotherapy (three cycles of epirubicin, cisplatin, and 5-fluorouracil [ECF] preoperatively and postoperatively) and surgery or surgery alone. Five-year survival rates were superior in the perioperative chemotherapy group compared with the surgery-alone group (36% vs. 23%). Although only ~40% of patients complete all of the recommended therapy with this treatment approach, >85% of patients receive all three planned cycles of preoperative chemotherapy, and all patients receive at least one cycle of chemotherapy. Administration of at least a few cycles of systemic therapy in advance of surgery for patients with high-risk tumors confers several advantages: (1) It permits early treatment of possible micrometastatic disease; (2) one can monitor the in vivo tumor response to the therapy, such as with PET–CT scan imaging; and (3) one can select for those patients with particularly bad tumor biology who develop early metastatic disease and who would thus derive no survival benefit from gastrectomy.

SURGICAL CONSIDERATIONS

A complete margin-negative (R0) resection remains the only potentially

curative treatment for gastric adenocarcinoma. The choice of operation depends on the location of the tumor as well as the stage of disease. Superficially invasive (T1a) gastric cancers of favorable histologic grade can be treated by endoscopic mucosal resection or wedge excision with or without concomitant sentinel lymph node biopsy with excellent results. Such procedures have been extensively described by our surgical colleagues from Japan, where gastric cancers are frequently diagnosed at an early stage given the prevalence of screening endoscopic examinations in that country. Because the majority of patients in the United States present with symptomatic, locoregionally advanced tumors, the primary surgical question is which procedure offers the greatest chance for cure with acceptable morbidity and mortality. Many patients are not candidates for any surgical procedure either because they are medically unfit or because of the presence of metastatic disease seen on preoperative imaging studies or at the time of laparoscopy. For those patients who are candidates for gastric resection, the options include total, proximal subtotal, and distal subtotal gastrectomy. There is an increasing worldwide experience in performing these procedures laparoscopically, with improved short-term outcomes and nodal yields and survival outcomes that are on par with the traditional open procedures. However, the vast majority of resections for gastric cancer in the United States are still performed via the open approach. The indications for and technique of laparoscopic gastrectomy are discussed elsewhere in this volume. This chapter focuses on the technical issues of an open subtotal or total gastrectomy. First, however, there are three major surgical considerations that merit discussion.

EXTENT OF LUMINAL RESECTION

The extent of gastric resection is determined by the location and extent of the primary tumor. Prospective, randomized trials failed to demonstrate a survival advantage for total gastrectomy over distal, subtotal gastrectomy for patients with tumors of the distal stomach. Therefore, for those patients in whom a 5- to 6-cm margin from the tumor can be obtained, while still maintaining a reasonably sized gastric remnant, a more conservative gastric resection should be performed, as this confers an equivalent survival rate with less morbidity and a better quality of life than does a total gastrectomy. Nonetheless, a total gastrectomy should be performed if necessary to achieve an R0 resection, as positive resection margins (R1 resections) lead to very poor survival. In the Dutch gastric cancer trial,

10% of patients had a positive resection margin and a correspondingly inferior 3-year survival (18% vs. 63%) compared with those who had a negative resection margin. However, microscopically involved margins appear to affect long-term survival only in those patients with five or fewer lymph node metastases. For proximal gastric cancers, many surgeons prefer a total gastrectomy over a proximal gastrectomy owing to the long-term sequelae of symptomatic acid reflux with the latter procedure.

EXTENT OF LYMPH NODE DISSECTION

The extent of lymph node dissection is one of the most controversial issues in the management of gastric cancer. Retrospective studies from Japan suggest that performing an extended lymphadenectomy improves survival and demonstrate that it can be done safely, with a perioperative mortality rate of <1%. The Japanese Research Society for Gastric Cancer categorizes the draining lymph node basins of the stomach into 16 stations, including 6 perigastric stations and 10 regional stations along the major vessels and adjacent to the pancreas (Fig. 88.2A,B). The extent of lymph node dissection is indicated by the designation D: A D1 dissection includes only the perigastric nodes (stations 1 to 6); a D2 dissection includes the lymph nodes along the common hepatic, left gastric, celiac, and splenic arteries (stations 7 to 11); and a D3 dissection includes additional nodes within the porta hepatis and adjacent to the aorta (stations 12 to 16).

Two large, prospective randomized trials comparing the outcomes of D1 dissection with those of D2 dissection have been conducted in Western patients. Fifteen-year follow-up of the larger of these two studies, namely, the Dutch Gastric Cancer Group Trial, demonstrated no long-term overall survival benefit with the D2 lymph node dissection (29% vs. 21%, P = 0.34) but did show a significantly decreased gastric cancer-related death rate (37% vs. 48%, P = 0.01) and a lower locoregional recurrence rate than D1 surgery. However, there were significantly higher rates of postoperative morbidity (43% vs. 25%) and mortality (10% vs. 4%) in those patients undergoing the more extensive D2 lymphadenectomy, in large part resulting from the greater numbers of splenectomy and pancreatectomy performed in this group in order to achieve a complete node dissection. Similarly, the British Cooperative trial conducted by the Medical Research Council reported an increased morbidity, associated with high rates of concomitant splenectomy and pancreatectomy, without a

benefit in overall or recurrence-free survival in those patients randomized to a D2 dissection.

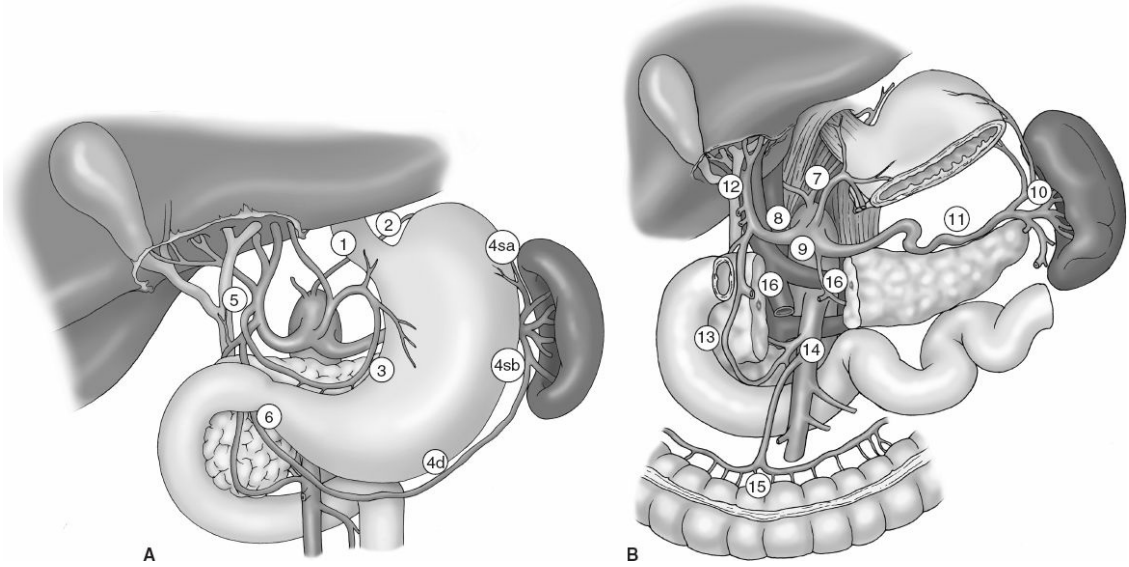

Figure 88.2. Lymph node stations including (**A**) the perigastric, or D1, lymph nodes (stations 1 to 6) and (**B**) the regional, or D2 and D3, lymph nodes (stations 7 to 16).

Despite the findings of these two studies, investigators have argued that if the complication rate after an extended D2 lymph node dissection could be decreased, the survival benefit conferred by a D2 dissection, as reported by experienced centers in Korea and Japan, might be translated to Western patients with gastric cancer. In fact, analysis of the group that did not undergo a pancreatectomy or splenectomy in the Dutch trial showed a significant survival advantage for those patients who underwent a D2 dissection (11-year survival 47% vs. 33%, $P = 0.018$). Thus, the Italian Gastric Cancer Study Group conducted a phase III trial randomizing patients to either a pancreas-preserving D2 lymphadenectomy or a D1 lymphadenectomy at high-volume centers by surgeons who completed rigorous training in the technique through observation of master surgeons in Japan. They reported impressively low morbidity (17.9%) and mortality (3.0%) rates in patients undergoing the D2 dissection, in which a pancreatectomy or splenectomy was performed only for direct tumor invasion. However, they found no difference in 5-year overall survival between the D1 and D2 groups (66.5% vs. 64.2%; $P = 0.695$), although subgroup analyses suggested that a D2 lymphadenectomy may be of benefit to patients with T2–T4 and/or node-positive tumors.

It remains unclear whether a D2 lymph node dissection is simply a

thorough staging procedure or whether there may be a therapeutic benefit for certain subsets of patients (e.g., patients with N2 disease). It should be noted that the accurate staging of patients with gastric cancer, according to the most recent seventh edition of the American Joint Committee on Cancer (AJCC) Staging Manual, demands the evaluation of at least 15 lymph nodes. The nodal staging is then based on the number of positive nodes, with N1 (1 to 2 positive nodes), N2 (3 to 6 positive nodes), N3a (7 to 15 positive nodes), and N3b (16+ positive nodes) categories. Studies have shown a correlation between improved patient survival and larger numbers of lymph nodes examined in the specimen. Of course, this may simply reflect more accurate staging as opposed to a therapeutic benefit from the procedure. However, there is indirect evidence that more extensive lymphadenectomies result in lower rates of locoregional recurrence, and this may translate into a survival benefit. Indeed, a randomized trial conducted at a single center in Taiwan identified an overall 5-year survival advantage for those patients undergoing a D3 dissection (59.5%) compared with those undergoing a D1 dissection (53.6%). However, a recently conducted trial by the Japan Clinical Oncology Group, in which patients undergoing an R0 resection are randomized at the time of surgery either to a D2 lymphadenectomy alone or with a para-aortic (D3) nodal dissection, demonstrated no difference in survival between the groups.

So in light of these conflicting data, what is one to conclude about the appropriate extent of lymph node dissection for gastric cancer in Western patients? I recommend performing either a formal D2 lymphadenectomy or, at a minimum, an “over-D1” (or “D1+”) lymphadenectomy, in which all D1 (perigastric) lymph nodes and as many D2 lymph nodes as are predicted to harbor metastatic disease, and that can be safely removed without the need for splenic or pancreatic resection, are included with the gastrectomy specimen. The Maruyama computer program may prove to be a helpful preoperative tool in this regard, as it accurately predicts the risk of lymph node metastasis in each nodal station based on the input of eight variables, including tumor histology, diameter, depth of invasion, and location. Failure to dissect those regional lymph nodes harboring metastatic disease, as predicted by the Maruyama program, will generate a high Maruyama Index (MI) of unresected nodal disease, which in retrospective analyses has been shown to result in higher rates of regional recurrence and inferior survival. The extent of lymph node dissection

required for a D1 and D2 dissection based on the site of the primary tumor is illustrated in Figure 88.3A–C.

EXTENT OF ADJACENT ORGAN RESECTION

The value of extended organ resection for advanced gastric cancer is another area of great debate, particularly in light of the increased morbidity and mortality accompanying such resections as shown in the Dutch and British trials previously mentioned. However, in order to achieve an R0 resection in patients with T4 lesions, it is often necessary to resect additional organs en bloc with the stomach. With careful patient selection, limiting gastrectomy with additional organ resection to those with clinical T4 tumors without evidence of visceral, peritoneal, or extensive regional nodal disease, long-term survival with acceptable perioperative morbidity and mortality is possible. Additional organ resection is not an adverse predictor of survival in this group of patients; rather, the depth of tumor invasion and nodal stage are the primary determinants of survival.

SURGICAL TECHNIQUE

Subtotal or Total Gastrectomy and D2 Lymphadenectomy

The reader will note that there are very few technical differences in the performance of a subtotal versus a total gastrectomy, and so both procedures will be described together in the text that follows, with important differences highlighted where relevant.

Exploration

The patient is positioned supine on the operating room table, and at the time of induction a single dose of a broad-spectrum antibiotic (e.g., a second-generation cephalosporin) is administered. It is important to note that in this chapter we consider only those gastric cancers confined to the stomach or GEJ, which can be adequately resected via an abdominal approach alone. More proximal GEJ or distal esophageal tumors may require either a left thoracoabdominal incision or a combined abdominal and thoracic approach (e.g., Ivor-Lewis procedure) to enable sufficient exposure of the esophagus to permit a negative-margin resection. These procedures are described elsewhere in this volume.

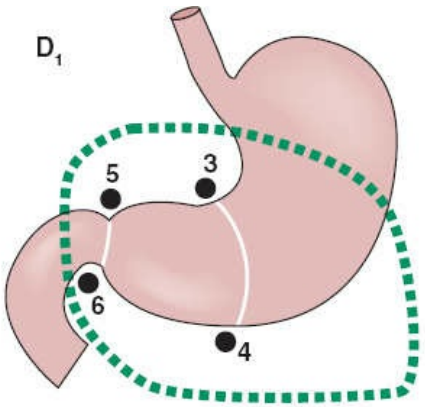

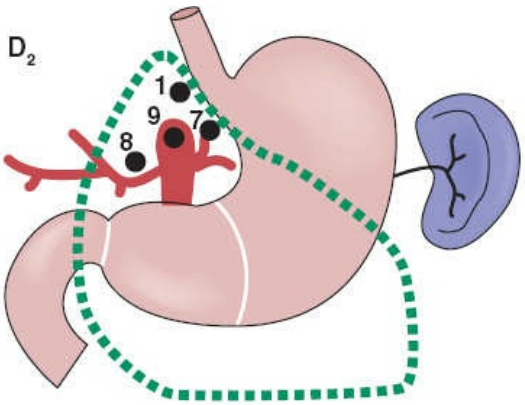

3 Lesser curvature
4 Greater curvature
5 Suprapyloric
6 Infrapyloric

1 Right cardiac
7 Left gastric artery
8 Hepatic
9 Celiac

A

* = Optional

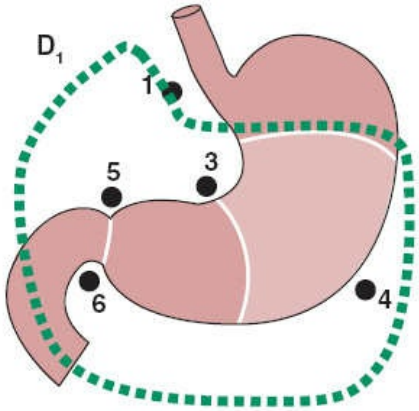

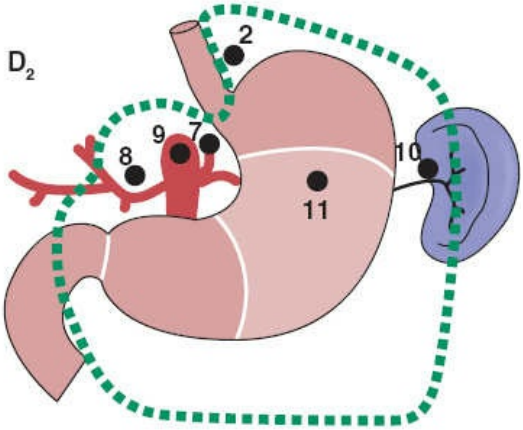

1 Right cardiac
3 Lesser curvature
4 Greater curvature
5 Suprapyloric
6 Infrapyloric

2 Left cardiac*
7 Left gastric artery
8 Hepatic
9 Celiac
10 Splenic hilar*
11 Splenic artery

B

* = Optional

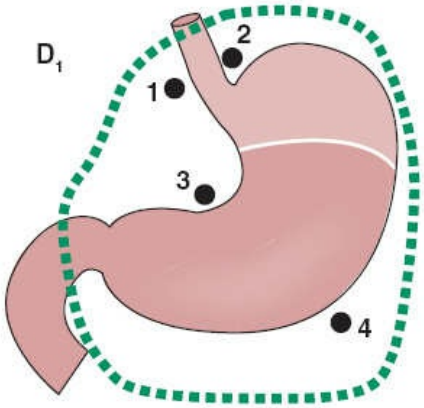

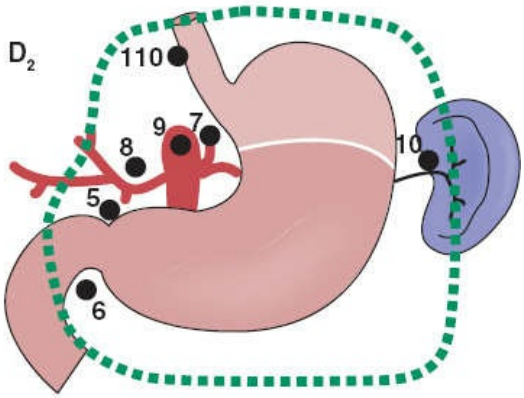

1 Right cardiac
2 Left cardiac
3 Lesser curvature
4 Greater curvature & gastric

5 Suprapyloric*
6 Infrapyloric*
7 Left gastric artery
8 Hepatic artery
9 Celiac
10 Splenic hilar
11 Splenic artery
110 Paraesophageal (cardia lesions)

C

Figure 88.3. **A.** Extent of gastric and lymph node resection for lower one-third lesions. **B.** Extent of gastric and lymph node resection for middle one-third lesions. **C.** Extent of gastric and lymph node resection for upper one-third lesions.

The abdomen is entered via a generous vertical midline incision extending from the xiphoid process to the umbilicus. Although a bilateral subcostal incision affords excellent exposure of the upper abdomen as well, I prefer a midline incision, as this is associated with less postoperative pain. The falciform ligament is divided and retractors are placed on the abdominal wall with the aid of the Thompson, Bookwalter, or Omni retractor system. The abdomen is then carefully explored to evaluate both the extent of locoregional disease and the presence of distant metastases. Special attention should be focused on all peritoneal surfaces as well as the liver.

Sequence of Operative Procedures

The sequence of operative steps of a subtotal (or total) gastrectomy and D2 lymphadenectomy is illustrated in Figure 88.4 and includes the following:

1. Mobilization of the greater curvature with omentectomy and division of the left gastroepiploic and short gastric vessels
2. Infrapyloric mobilization with ligation of the right gastroepiploic vessels
3. Suprapyloric mobilization with ligation of the right gastric vessels
4. Duodenal transection
5. D2 lymphadenectomy, with dissection of the porta hepatis, common hepatic artery, left gastric artery, celiac axis, and splenic artery, and ligation of left gastric vessels
6. Gastric (or esophageal) transection
7. Reconstruction by loop or Roux-en-Y gastrojejunostomy (or Roux-en-Y esophagojejunostomy)

Greater Curvature Mobilization

The greater omentum is dissected off the transverse colon with the aid of electrocautery (Fig. 88.5A). This step should be bloodless if dissection is correctly carried out in the avascular plane between the omentum and appendices epiploicae of the colon. I do not routinely resect the anterior leaf of peritoneum of the transverse mesocolon or the peritoneum

overlying the anterior pancreas unless dictated by local tumor invasion. It is unrealistic to believe that routine resection of these layers comprising the omental bursa (bursectomy) confers a survival advantage by potentially removing microscopic peritoneal metastases. The omentum is resected with the specimen, as it contains numerous perigastric (D1, station 4) lymph nodes and is nonetheless devascularized during the course of the gastrectomy.

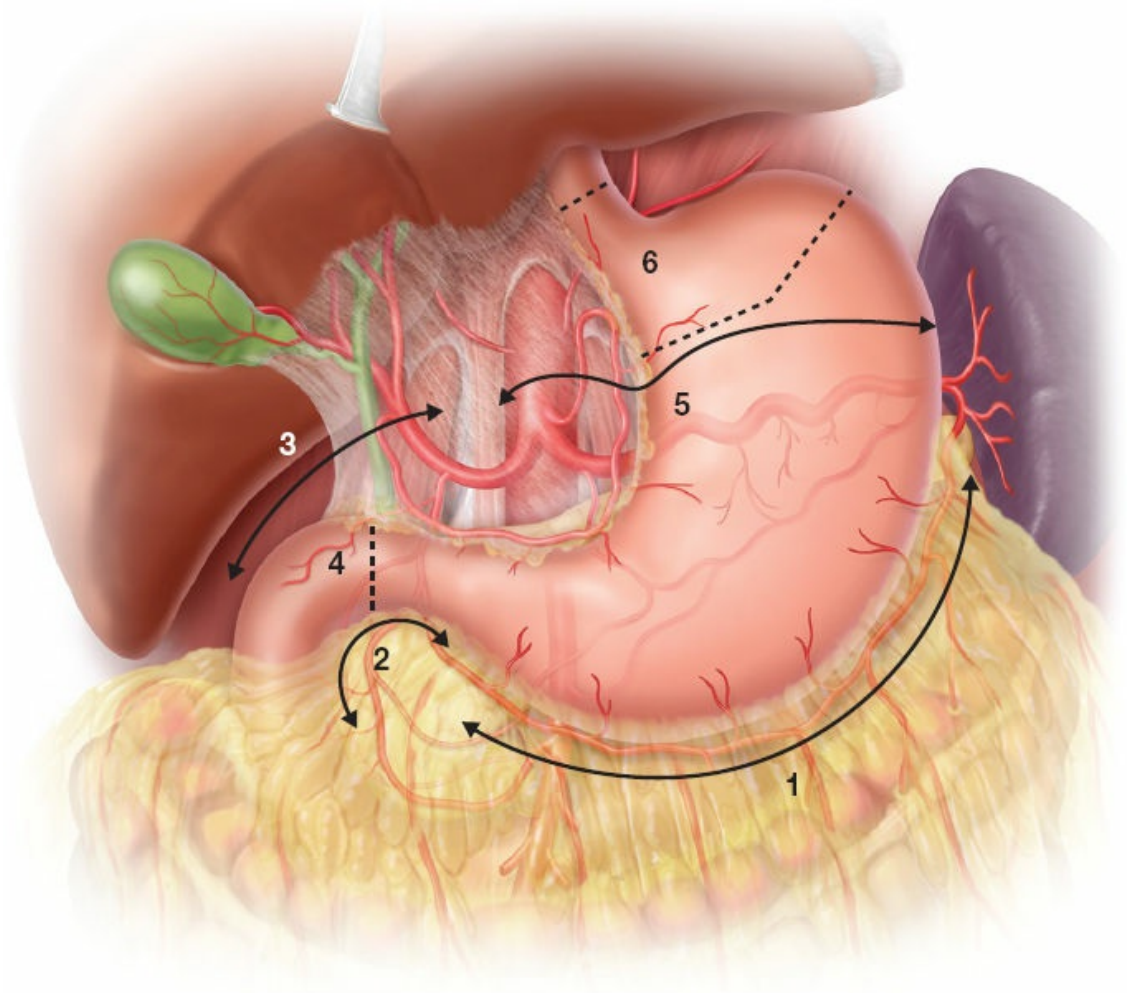

Figure 88.4. Sequence of operative procedures. (See text for details.)

With the greater omentum reflected superiorly, dissection commences on the left side of the abdomen such that the omentum is dissected off of the splenic flexure and the inferior pole of the spleen, exposing the body and tail of the pancreas. The left gastroepiploic vessels are identified and divided near their origin from the splenic vessels (Fig. 88.5B). The spleen is carefully elevated into the operative field with moist packs placed

posterior to it, and omental and colonic attachments to the spleen are lysed with the electrocautery (if needed) to prevent inadvertent capsular tears during the course of the dissection. The short gastric vessels are then divided each in turn close to the spleen, and for a total gastrectomy, all of the short gastrics are divided. However, for a subtotal gastrectomy, preservation of at least a few of the short gastric vessels is critical because this operation entails division of all four main arteries supplying the gastric remnant. In fact, one of the purported reasons for the unacceptably high morbidity and mortality rates reported in the Dutch Trial is that a number of patients who underwent distal gastrectomy also had ligation of the short gastric vessels as part of the mandated splenectomy to achieve a complete node dissection. Ligation of the short gastric vessels devascularizes the gastric remnant with resultant ischemia of the gastrojejunal anastomosis, and this perhaps explains the high anastomotic leak rate reported in this trial. A related point is that if during the course of a distal subtotal gastrectomy a splenic injury occurs, such that a splenectomy is necessary, a total gastrectomy should be performed in order to avoid the risk of necrosis of the gastric remnant.

Infrapyloric Mobilization

Once the left side of the stomach has been fully mobilized, dissection of the omentum continues over to the right side of the abdomen, near the hepatic flexure of the colon where the omentum is divided up to the duodenum. The colic branch of the gastrocolic trunk is identified within the transverse mesocolon, and its course is followed to its confluence with the right gastroepiploic vein to form the short gastrocolic venous trunk, which in turn drains into the superior mesenteric vein. For tumors of the distal stomach, the nodal tissue anterior and medial and lateral to the superior mesenteric vein at the inferior border of the pancreas (station 14v) should be resected as a separate specimen. The right gastroepiploic vein is divided at its juncture with the gastrocolic trunk and the inferior pancreaticoduodenal arcade (Fig. 88.6A). Note that the dissection should proceed carefully here because of the fragility of these venous tributaries. The right gastroepiploic artery is divided as it arises from the gastroduodenal artery, and the station 6 lymph nodes are dissected away from the head of the pancreas and included with the specimen (Fig. 88.6B). A plane is developed just anterior to the head of the pancreas and posterior to the pylorus, sweeping all nodal and soft tissue off of the

pancreas and with the specimen.

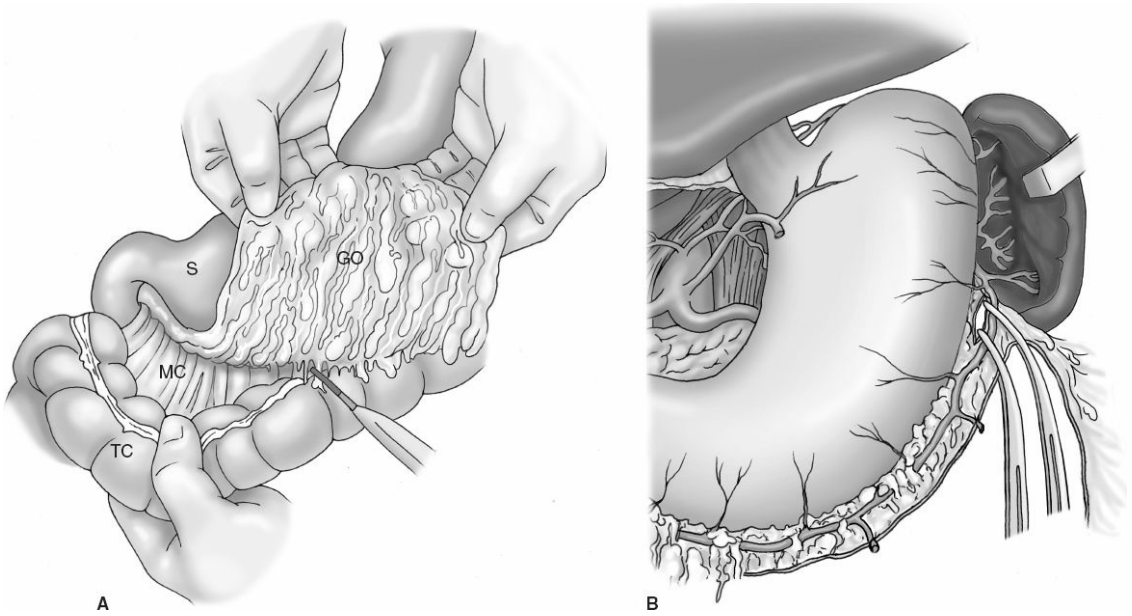

Figure 88.5. Mobilization of the greater curvature of the stomach (S), including (**A**) detachment of the greater omentum (GO) from the transverse colon (TC) and mesocolon (MC) and (**B**) ligation of the left gastroepiploic vessels.

Suprapyloric Mobilization

The gastrohepatic ligament is divided, being cognizant of a possible accessory or replaced left hepatic artery coursing through this ligament. If discovered, a replaced left hepatic artery can almost always be ligated with impunity, but I typically place a bulldog clamp on it for several minutes to ensure that the liver remains well-perfused prior to dividing it. The hepatoduodenal ligament is opened vertically in the direction of the proper hepatic artery, exposing completely the right gastric and gastroduodenal arteries. The right gastric artery is divided at its origin from either the proper hepatic artery or the gastroduodenal artery, the right gastric vein is divided close to its junction with the portal vein, and the station 5 lymph nodes are dissected up with the specimen (Fig. 88.7). Any residual fatty attachments and small vessels are ligated, and the duodenum is then fully mobilized.

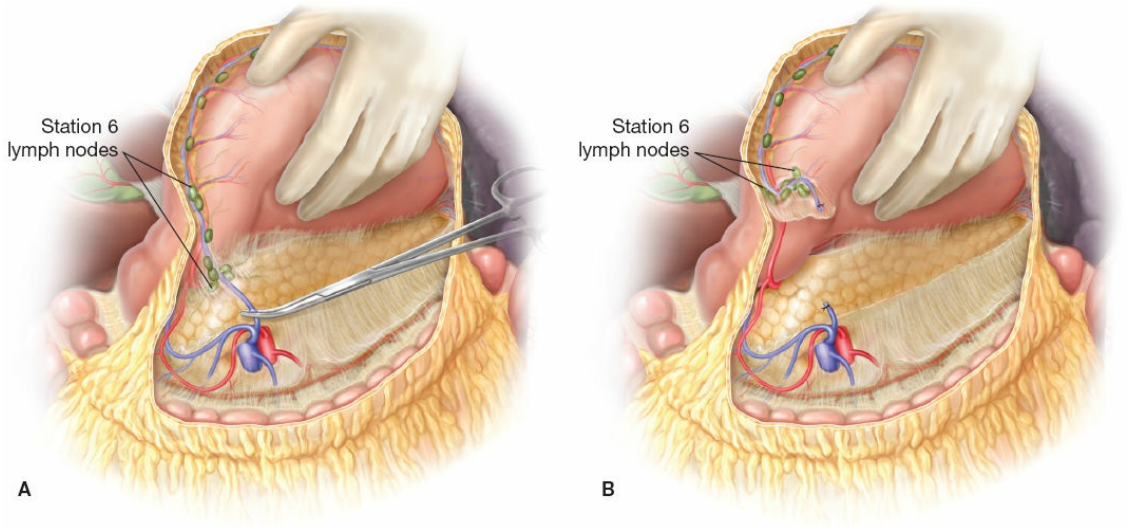

Figure 88.6. Infrapyloric mobilization, with (**A**) ligation of the right gastroepiploic vein at its juncture with the gastrocolic trunk, and (**B**) dissection of the station six lymph nodes up with the specimen.

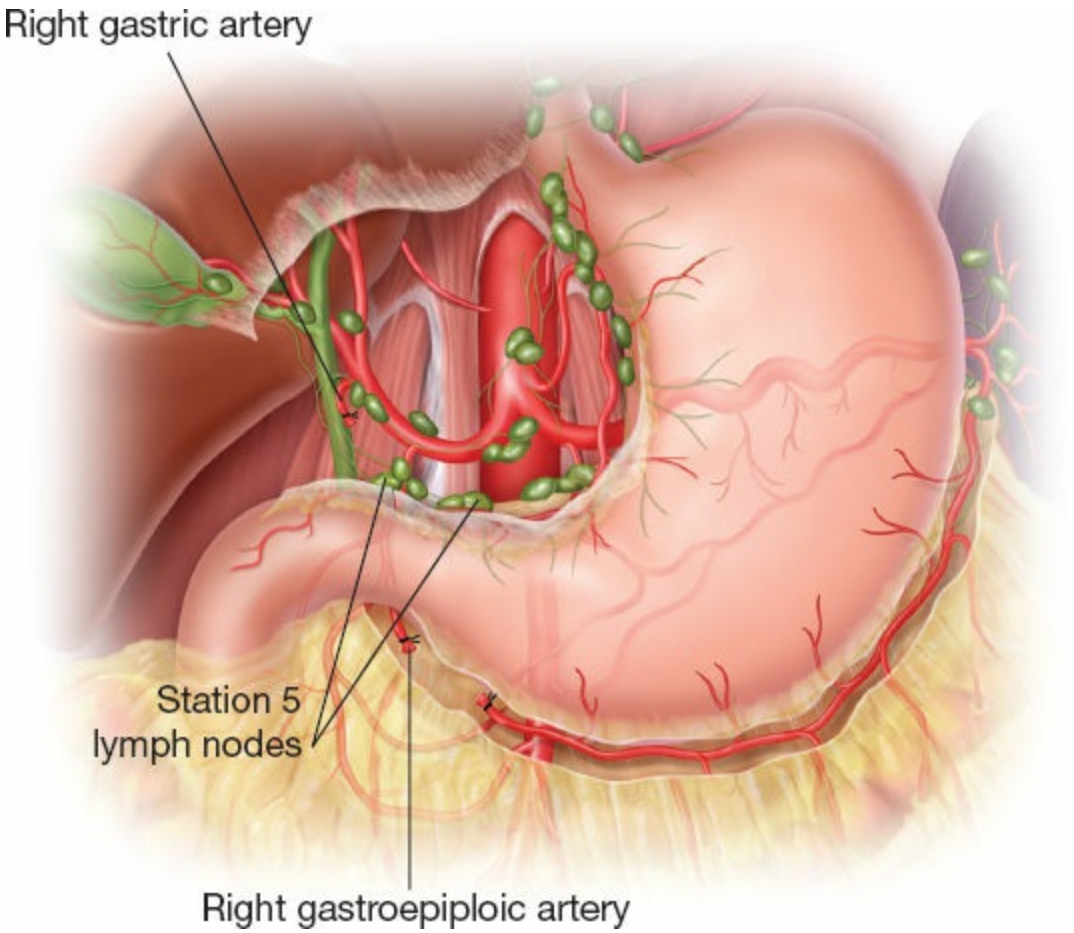

Figure 88.7. Suprapyloric mobilization, with ligation of the right gastric vessels in the porta hepatis and dissection of the station five lymph nodes up with the specimen.

Duodenal Transection

At this point, transection of the duodenum is simple and is typically performed with a GIA stapler (Fig. 88.8). The duodenum should be divided just distal to the pylorus unless invasion of the duodenum by tumor is suspected, in which case the duodenum should be divided more distally to ensure a negative histologic margin. The staple line on the duodenal stump may be inverted with interrupted Lembert sutures, though perhaps the most important factor predicting satisfactory healing of the stump is an adequate blood supply. Transection of the duodenum allows elevation and rotation of the stomach out of the field to permit subsequent dissection of the nodal tissue that comprises the D2 lymph nodes (Fig. 88.9A).

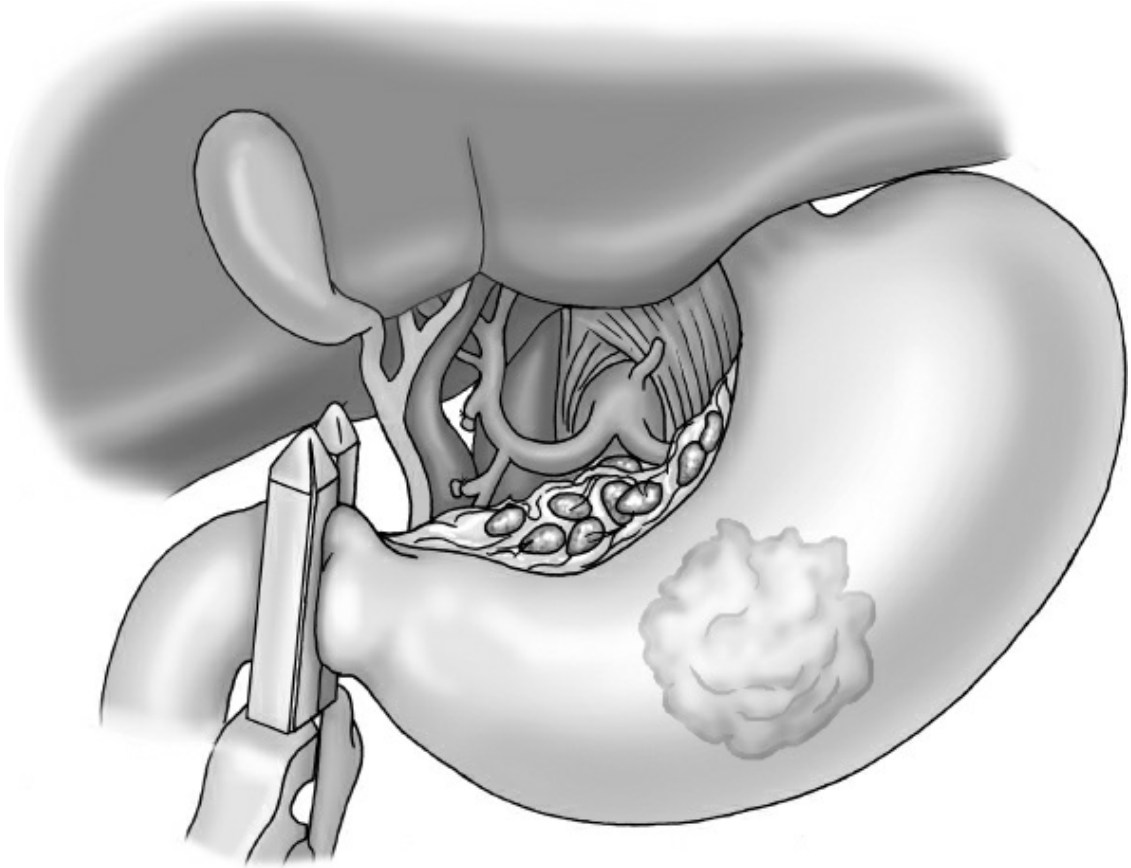

Figure 88.8. Transection of the duodenum with the GIA stapler.

D2 Lymphadenectomy

The dissection commences by dividing the peritoneum and lymphatics in the superior porta hepatis from right to left until the opening in the lesser omentum is reached. The nodal tissue is dissected off of the lateral aspect

of the proper hepatic artery toward the left side of the abdomen. The right gastric artery having been ligated previously, the proper hepatic artery is then gently retracted to the right side of the abdomen, and the nodal tissue along the anterior surface of the portal vein as well as the posterior surface of the proper hepatic artery is dissected free. The station 12 lymph nodes and investing fibrofatty connective tissue are then pulled into the omental bursa to the left of the porta hepatis. The dissection proceeds along the superior border of the pancreas, dividing the tissue between the common hepatic artery and pancreas and including this tissue with the station 8 lymph nodes along the anterior and posterior aspects of the common hepatic artery. This nodal tissue is quite vascular, so a vessel-sealing device such as a harmonic scalpel can be helpful with this dissection. The left gastric, or coronary, vein is identified coursing posteriorly from the lesser curvature; it is ligated and divided at its confluence with the portal or splenic vein. The nodal tissue at the upper border of the pancreas and along the proximal splenic artery (station 11) is dissected free and swept cephalad and to the left, together with the other lymphatic tissue.

The dissection continues medially to the celiac axis, which is invested with a firm plexus of nerves, and is limited to the nodal tissue on the anterior surface of the celiac artery (Fig. 88.9B). The left gastric artery is identified, either stapled or suture-ligated at its origin, and the adjacent nodal tissue is reflected toward the crura of the diaphragm (Fig. 88.10A). The dissection then proceeds proximally along the lesser curvature of the stomach to the right border of the esophagus. The peritoneum overlying the anterior surface of the abdominal esophagus is freed and the lymphoareolar, nodal-bearing tissue along the right cardia (station 1) is dissected off of the GEJ and the anterior wall of the lesser curvature of the stomach. An important anatomic point is that the left gastric artery usually bifurcates high on the lesser curvature (often at the level of the GEJ) into cranial and caudal branches (Fig. 88.10B). Therefore, in order to adequately dissect the lymph nodes along the cephalad branch of the left gastric artery, one must be assiduous in carrying the dissection proximally along the lesser curvature, often including the lower 2 to 3 cm of the intra-abdominal esophagus. This is a particularly important technical point in the performance of a subtotal gastrectomy for distal lesser curvature lesions.

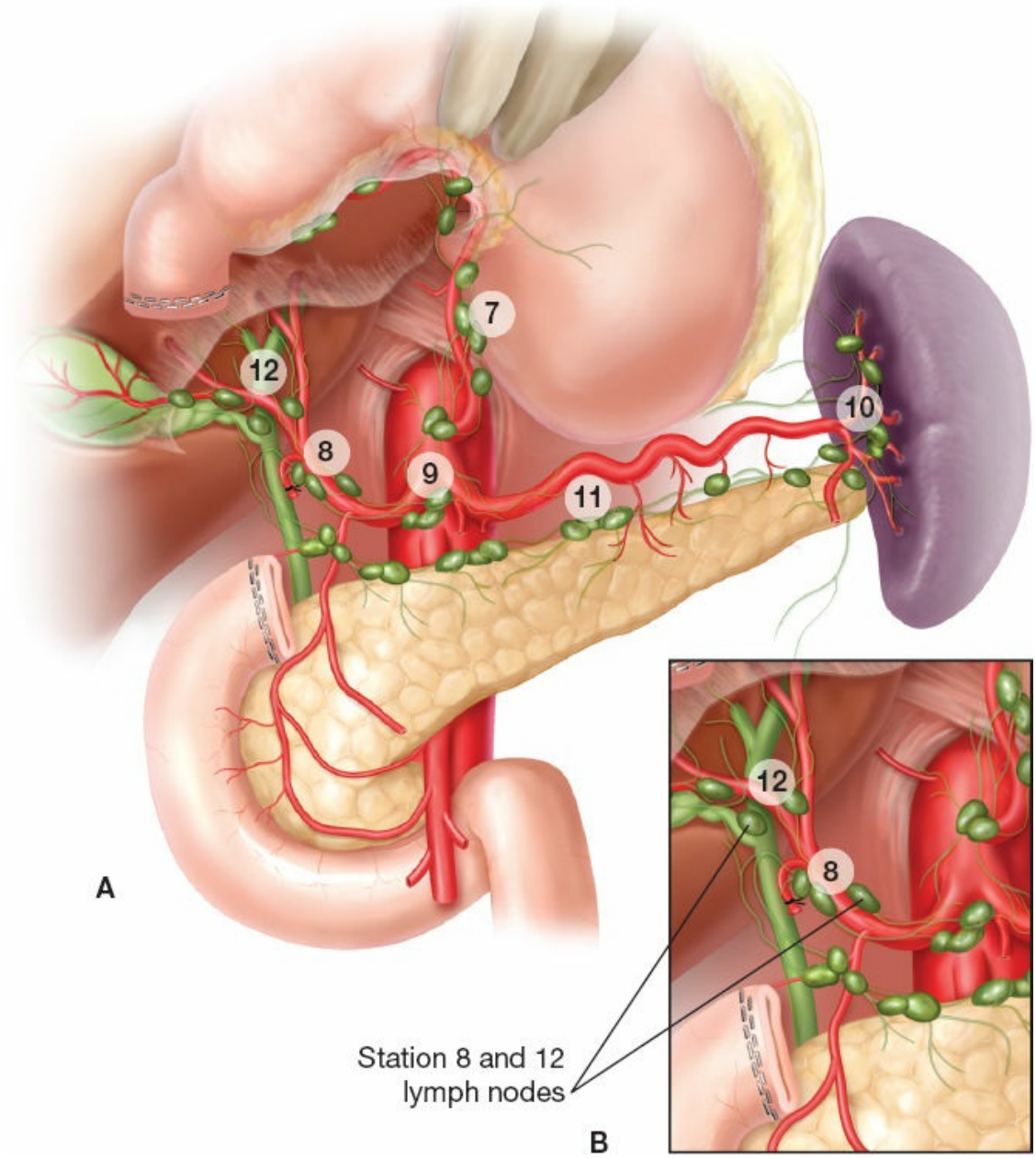

Figure 88.9. A,B. The D2 lymphadenectomy, including the nodes in the porta hepatis (station 12), along the common hepatic artery (station 8), along the left gastric artery (station 7), at the celiac axis (station 9), along the splenic artery (station 11), and within the splenic hilum (station 10).

The nodal dissection then continues along the splenic artery to the posterior gastric artery, which arises from the splenic artery and supplies blood to the posteromedial wall of the stomach. For distal gastric adenocarcinoma, one does not need to routinely dissect the lymph nodes beyond this point into the splenic hilum (station 10) unless these nodes appear to be grossly involved. The spleen is removed only if necessary to

resect locoregional disease. The spleen should not be routinely sacrificed as part of a D2 lymphadenectomy, as this has been shown to increase the morbidity of the procedure without conferring a survival benefit in Western studies. The reader will note, however, that our colleagues in Korea and Japan routinely perform a splenectomy at the time of total gastrectomy with little morbidity.

Gastric or Esophageal Transection

For a subtotal gastrectomy, the line connecting a point ~2 cm distal to the GEJ on the lesser curvature and a point at least 5 cm proximal to the upper border of the tumor on the greater curvature of the stomach is selected. Straight bowel clamps are placed on the greater curvature side of the stomach for a distance of ~6 to 8 cm, and the stomach is divided between these clamps with the knife. This cut surface of stomach will serve as the site of anastomosis in the fashion of Hofmeister. The remaining stomach from the tips of the straight clamps to the chosen point on the lesser curvature is divided with the GIA stapler to create a short Hofmeister shelf (Fig. 88.11A,B). The staple line is then inverted with a running monofilament suture (Fig. 88.11C). Alternatively, the stomach may simply be divided with several firings of the GIA stapler and the greater curvature portion of the staple line excised for the anastomosis.

In the case of a total gastrectomy, the phrenoesophageal ligament is divided with the cautery and the paracardial nodal tissue in stations 1 and 2 reflected off of the right and left crura and toward the specimen. Both vagus nerves are divided and the intra-abdominal esophagus circumferentially dissected free for a distance of at least 5 cm. If a stapled anastomosis is planned, I prefer to place an automatic pursestring device on the esophagus several centimeters above the GEJ and then to divide the esophagus with the curved esophageal scissors. If a hand-sewn anastomosis is planned, I prefer to secure the esophagus with an atraumatic Satinsky clamp on the esophagus prior to its division in order to prevent its retraction up into the mediastinum (Fig. 88.12).

The specimen is passed to a sterile back table in the operating room where it is carefully oriented for the pathologist. I also find it helpful to anatomically dissect the relevant lymph node groups from the specimen and to assign their numerical stations for the pathologist. Although this takes some time, I have found that it dramatically increases the nodal yield and ensures that the final pathology report includes not only the total

number of positive and retrieved lymph nodes but also their location(s). Intraoperative frozen sections of the proximal gastric (or esophageal) and distal duodenal margins are obtained prior to initiating the reconstruction.

RECONSTRUCTION

Although there are several options for reconstruction, including various types of interposition loops and pouches, I will discuss the two most common, feasible types of reconstruction after a subtotal gastrectomy: the Billroth II loop gastrojejunostomy and the Roux-en-Y gastrojejunostomy. Although a Billroth I gastroduodenostomy is an excellent reconstructive option following a distal gastrectomy, it is not a realistic option after a true subtotal gastrectomy in which at least 75% of the stomach is resected, as the duodenum will simply not reach the gastric stump in the majority of cases, even after an extensive Kocher maneuver. A loop gastrojejunostomy may be constructed by bringing the jejunum to the gastric pouch either in front of the transverse colon (an antecolic anastomosis) (Fig. 88.13A) or through a defect in the transverse mesocolon (a retrocolic anastomosis) (Fig. 88.13B). In either case, a proximal loop of jejunum (just distal to the ligament of Treitz) that reaches the stomach without tension or angulation should be chosen. It is particularly important to avoid an excessively lengthy afferent limb draining the biliary and pancreatic secretions, as such a limb is prone to kinking and occlusion, with the resultant afferent loop syndrome.

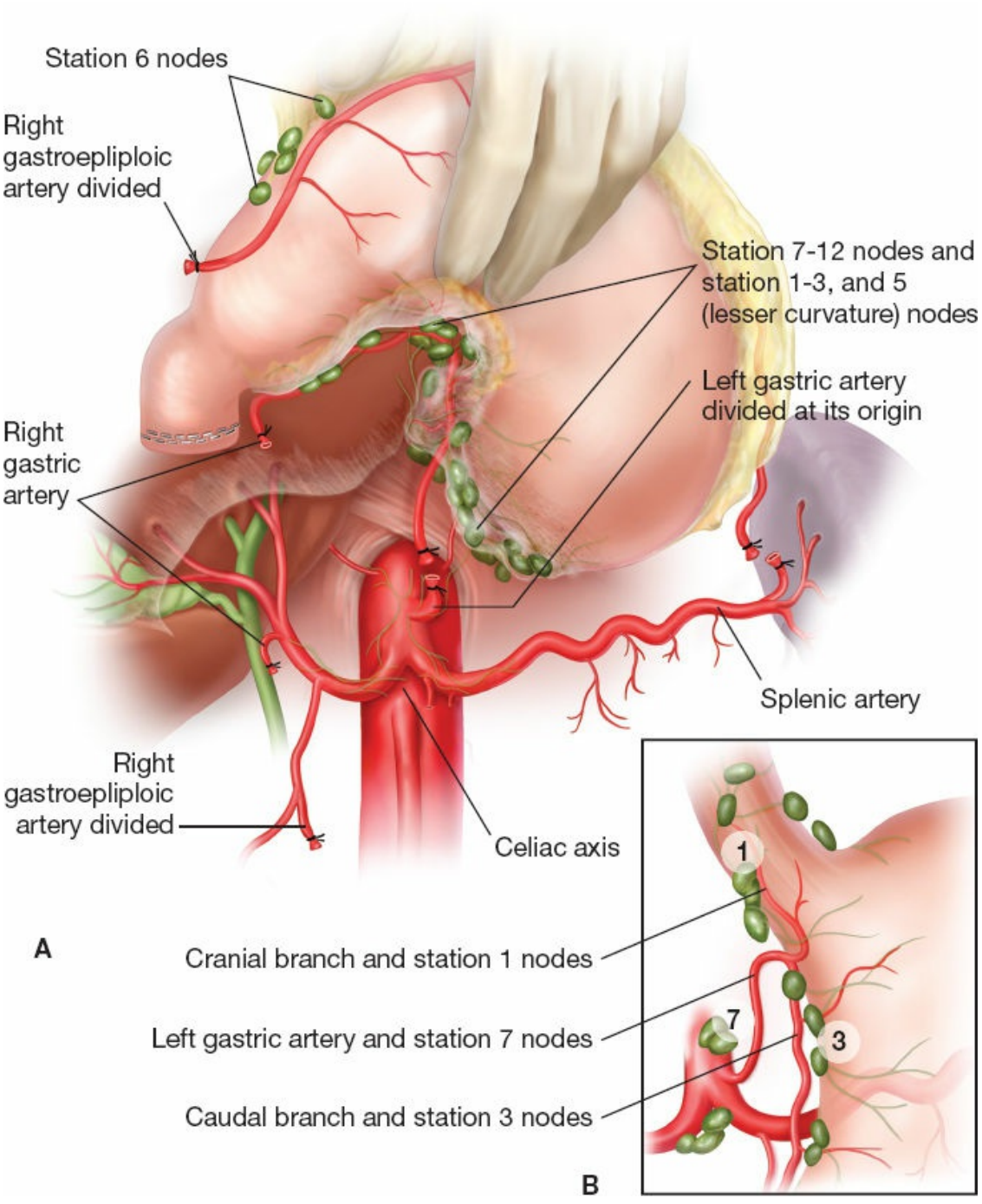

Figure 88.10. **A.** The left gastric artery is identified, suture-ligated at its origin, and the adjacent nodal tissue is reflected toward the crura of the diaphragm. **B.** The left gastric artery bifurcation into cranial and caudad branches occurs at a point high on the lesser curvature of the stomach. An adequate lymphadenectomy to include the nodes along the cranial branch of the left gastric artery requires dissection of all of the lymphoareolar tissue along the proximal lesser curvature of the stomach and the distal esophagus.

The gastrojejunal anastomosis may be performed in either a stapled or a hand-sewn fashion. I prefer the latter and will describe this technique. The jejunal loop is brought up to the gastric pouch in a side-to-side, isoperistaltic fashion with the proximal end of the jejunum apposed to the greater curvature side of the opening in the stomach. An outer, posterior row of interrupted, 3-0 silk seromuscular (Lembert) sutures is placed between the posterior gastric wall and the jejunum (Fig. 88.14A). The straight clamp is removed from the stomach, and an incision is made in the jejunum of slightly shorter length than the gastrotomy with the electrocautery (Fig. 88.14B). The inner, posterior layer of the anastomosis is performed with a running 3-0 PDS suture in simple over-and-over fashion, including the full thickness of both the stomach and jejunal walls (Fig. 88.14C). The inner layer anastomosis is continued anteriorly as a running Connell suture, which inverts the anastomosis. Of note, a nasogastric tube is advanced through the gastric remnant just into the efferent limb of the jejunum prior to completing the anterior layer of the anastomosis. The anterior portion of the gastrojejunostomy is completed with the placement of interrupted, 3-0 silk Lembert sutures (Fig. 88.14D). Special care should be directed to the placement of a three-cornered Lembert suture at the junction of the lesser curvature gastric staple line and the gastrojejunostomy, the so-called “angle of death.”

Frequently, however, I employ a Roux-en-Y reconstruction with a small residual gastric pouch in order to minimize the symptoms of gastroesophageal reflux and the incidence of erosive esophagitis and gastritis due to alkaline bile reflux. I have always been taught to ensure that the residual gastric pouch after subtotal gastrectomy is not too large in order to minimize the risk of delayed emptying due to gastric remnant atony. It can be difficult to distinguish the symptoms of gastroparesis, such as nausea, vomiting, postprandial fullness, and upper abdominal pain, from those of “Roux limb (or stasis) syndrome,” the etiology of which is unclear. The true incidence of Roux limb syndrome is probably much lower than previously considered, at 2% or less, and so I don’t believe this should deter the surgeon from this method of reconstruction. The jejunum is divided ~20 cm distal to the ligament of Treitz and brought up to the stomach through a defect created to the left of the middle colic vessels in the transverse mesocolon (Fig. 88.15A). The gastrojejunal anastomosis is performed as described for the loop anastomosis. Intestinal continuity is restored with a side-to-side jejunojejunostomy at a distance of at least 45

to 50 cm distal to the gastrojejunostomy in order to prevent the reflux of biliary and pancreatic secretions into the gastric remnant (Fig. 88.15B). The jejunojejunostomy may be performed in a stapled or a hand-sewn fashion. For a stapled anastomosis, two small enterotomies are created in the antimesenteric borders of the small intestine. One fork of a GIA stapler is placed in each intestinal lumen and then fired. The common enterotomy is then closed with either a TA stapling device or a full-thickness running monofilament suture after inspection of the staple line for hemostasis.

After a total gastrectomy, the standard reconstruction is a retrocolic, end-to-side Roux-en-Y esophagojejunostomy. As above, a Roux limb is created of a length of at least 45 to 50 cm from the jejunojejunostomy and delivered through a rent in the transverse mesocolon to the left of the middle colic vessels. It is critical not to accidentally twist this limb as it is brought up to the esophagus, and one way to be sure of the proper orientation of this limb is to be certain that the staple line on the cut edge of jejunum is always facing the patient's left side. Several options exist for the anastomosis of the esophagus to the jejunum. I prefer an end-to-end stapling device. The esophagus is atraumatically dilated with a Foley catheter balloon serially inflated up to 6 to 10 cc, depending on the diameter of the esophagus. Four, full-thickness 3-0 silk traction sutures are placed just distal to the pursestring suture in four quadrants, the anvil is placed with the aid of lubricant into the esophagus, and the pursestring suture is tied. Although I prefer to place a 28-mm anvil in the esophagus to allow for a larger diameter anastomosis (and thus hopefully a lower incidence of stricture), in most cases I find that the esophagus will only accept a 25-mm anvil. The staple line on the end of the Roux limb is excised and the EEA stapler introduced and the spike advanced out the anti-mesenteric border of the jejunum. This is then married to the anvil within the esophagus and, being careful to ensure that the Roux limb is not twisted, the stapler closed and fired. The stapler is removed, two complete mucosal donuts are assured, and the open end of the Roux limb is closed with a firing of the GIA stapler (Fig. 88.16A,B). Although I still tend to place a nasojejunal tube after total gastrectomy, there is an abundance of data demonstrating that routine nasojejunal decompression after total gastrectomy is not only unnecessary but in fact may be associated with a higher risk of pulmonary complications in addition to the annoying local discomfort experienced by the patient. The completed reconstruction is shown in Figure 88.17.

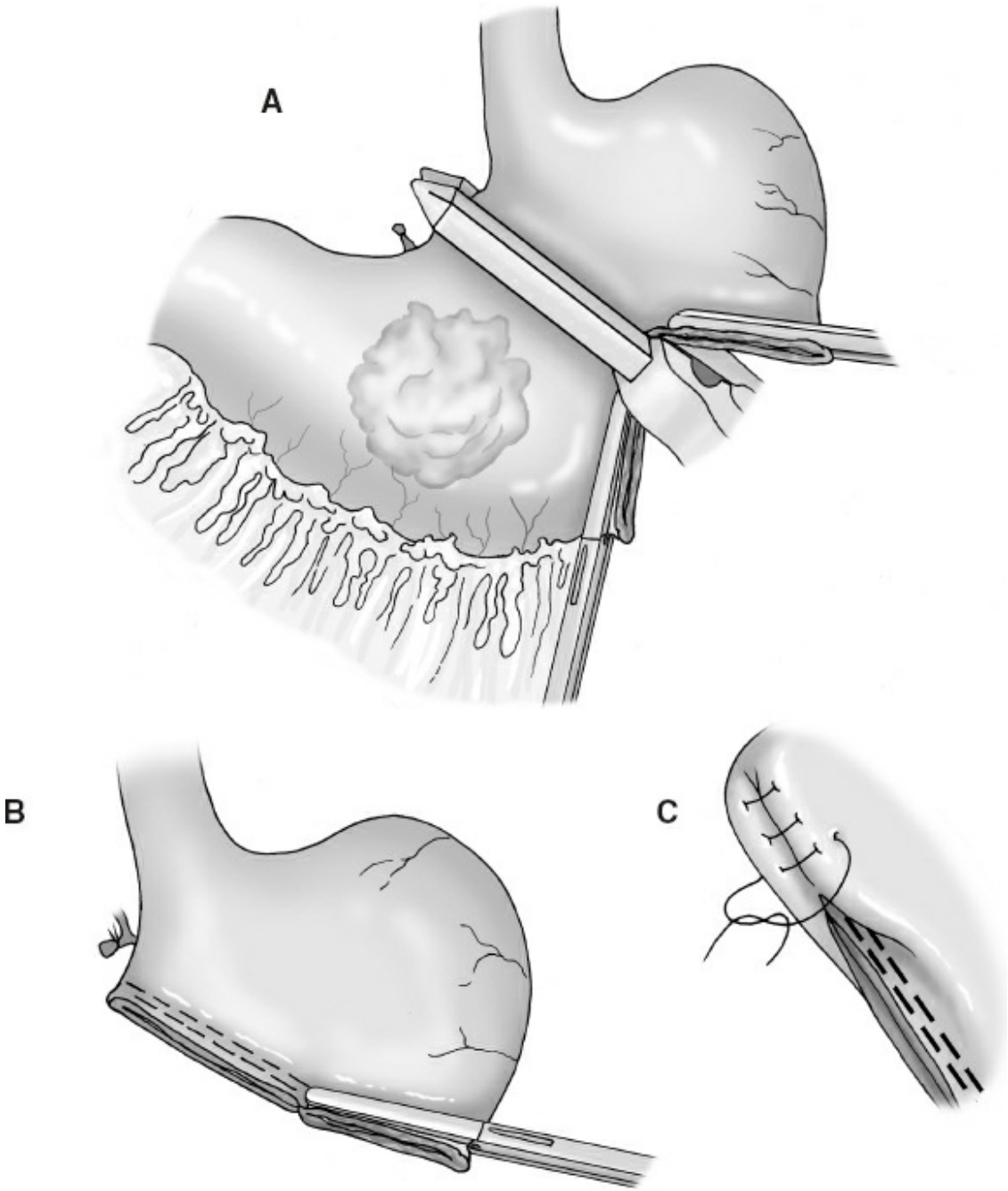

Figure 88.11. **A,B.** The stomach is divided by placing straight bowel clamps on the greater curvature side for a distance of ~6 to 8 cm, cut for this distance with the knife (serving as the site of future anastomosis in the fashion of Hofmeister), and then completely divided with the GIA stapler. **C.** The staple line is then inverted with a running monofilament suture.

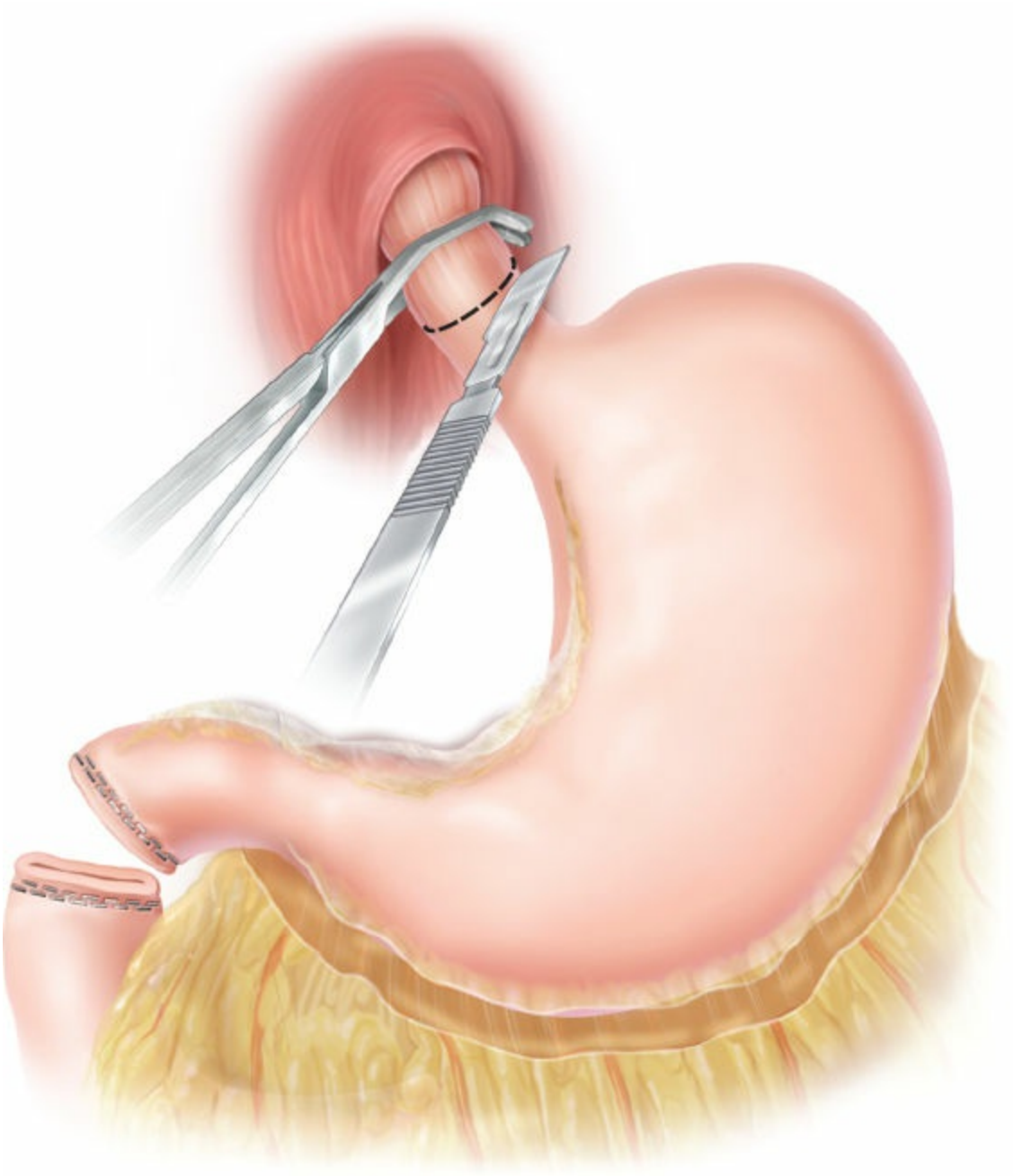

Figure 88.12. The esophagus, stabilized by a Satinsky clamp or the automatic pursestring device, is divided sharply by a knife or curved esophageal scissors.

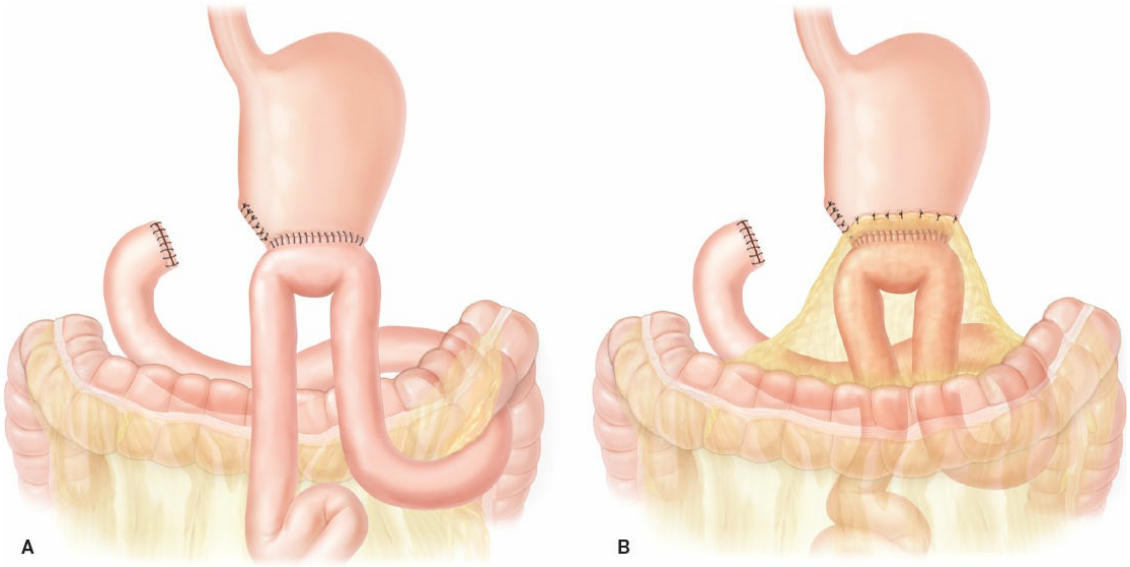

Figure 88.13. Reconstruction can be achieved by a loop gastrojejunostomy (Billroth II anastomosis), constructed by bringing the jejunum up to the gastric pouch either (**A**) in front of the transverse colon (antecolic anastomosis), or (**B**) through a defect in the transverse mesocolon (retrocolic anastomosis).

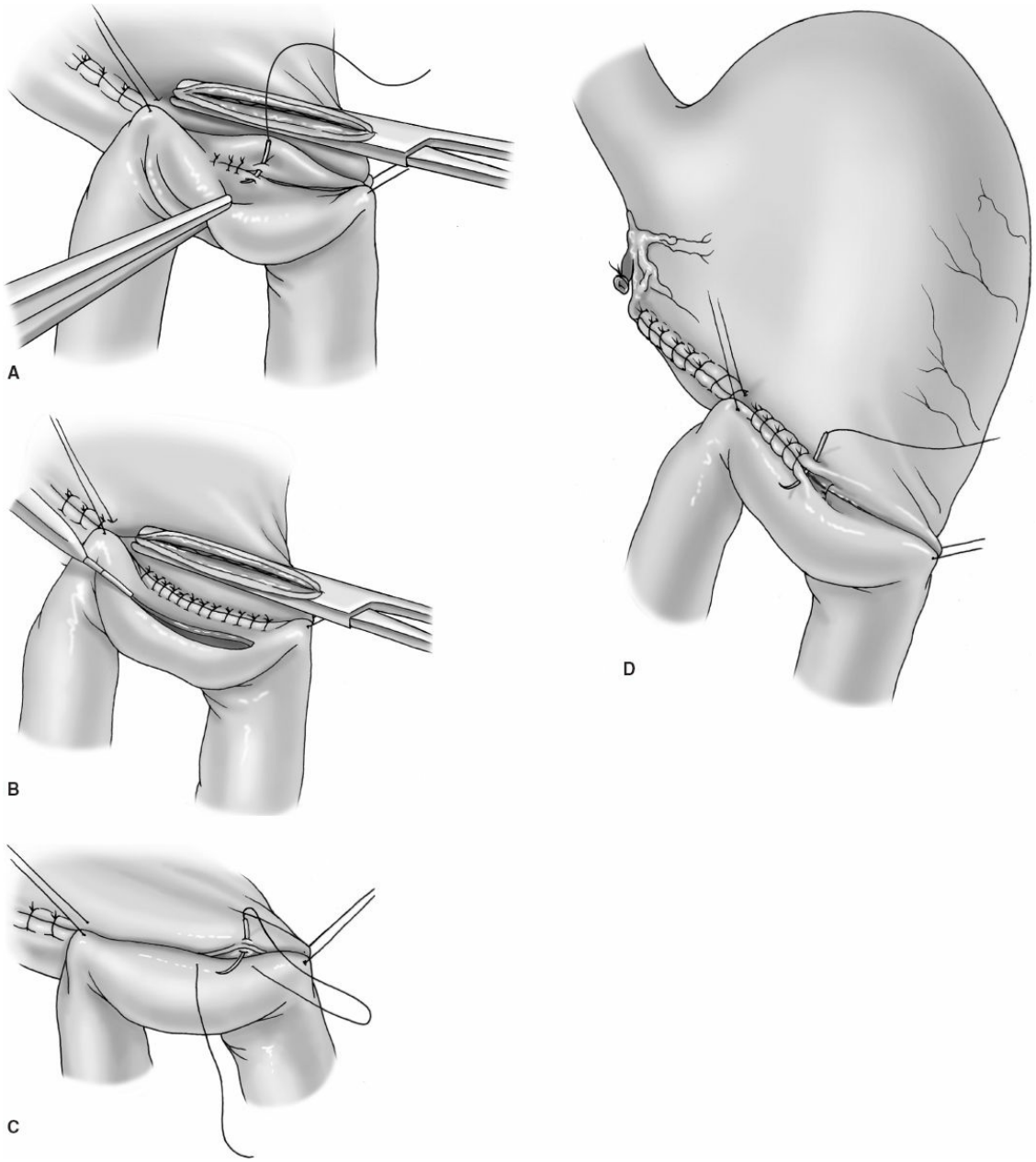

Figure 88.14. Standard technique for a two-layer, hand-sewn gastrojejunal anastomosis. **A.** After the placement of corner sutures, a back row of interrupted 3-0 silk Lembert sutures is placed. **B.** A jejunostomy is made with the cautery. **C.** The inner layer anastomosis is constructed in running, full-thickness fashion with 3-0 PDS. **D.** Several interrupted 3-0 silk Lembert sutures complete the anastomosis anteriorly. (See text for details.)

Although many surgeons routinely place intra-abdominal drains and/or feeding tubes at the time of gastrectomy, I take a much more selective approach in this regard. I would consider the placement of a closed-suction intra-abdominal drain, for instance, in the patient in whom extensive peripancreatic dissection or a partial pancreatectomy is necessary for a

margin-negative resection. Similarly, I rarely place a feeding jejunostomy tube after a subtotal gastrectomy but do so with some regularity after a total gastrectomy, particularly in patients with significant preoperative nutritional compromise.

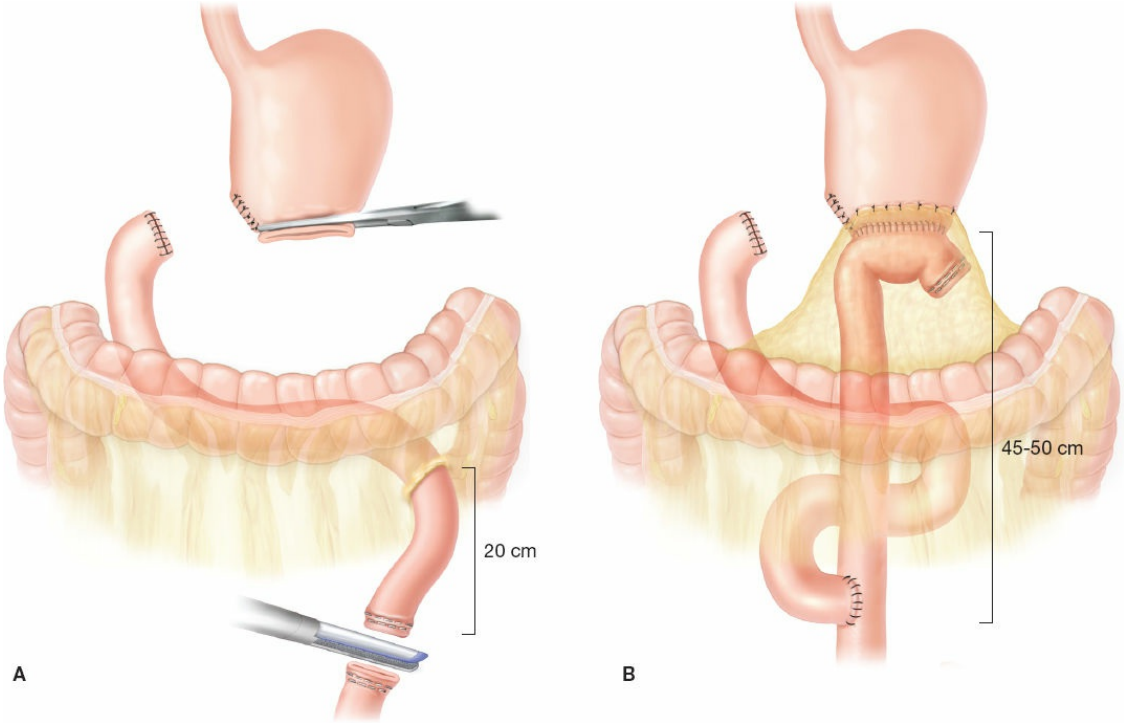

Figure 88.15. Reconstruction by a retrocolic, Roux-en-Y gastrojejunostomy. **A.** The jejunum is divided with the GIA stapler ~20 cm distal to the ligament of Treitz. **B.** A retrocolic, end-to-side Roux-en-Y gastrojejunostomy is created with a Roux limb at least 45 cm in length.

POSTOPERATIVE CARE

Routine postoperative care with early mobilization and pulmonary toilet is initiated. Pain control is achieved with continuous epidural analgesia, typically with a combination of fentanyl and bupivacaine. The epidural catheter remains in place for 3 to 4 days, at which point narcotics are administered enterally via a jejunostomy tube (if present) or orally. Prophylactic antibiotics are typically continued in the postoperative period for <24 hours. Of course, careful fluid and electrolyte balance are maintained, and I prefer early diuresis, as I find that this decreases the incidence of cardiopulmonary complications and may shorten the duration of ileus. My habit is to administer furosemide on the evening of postoperative day 2 to those patients who do not exhibit spontaneous

diuresis, with daily diuresis and electrolyte monitoring thereafter until the postoperative weight returns to within 1 kg of the immediate preoperative weight.

For patients undergoing subtotal gastrectomy, the nasogastric tube is removed when there is audible return of bowel function, or sooner, if daily aspirated volumes are low. This is typically on postoperative day 3. After removal of the nasogastric tube, the patient is started on a clear liquid diet and slowly advanced to a post-gastrectomy diet consisting of six small daily meals. I do not routinely obtain a postoperative contrast study such as a Gastrografin swallow test, as clinically occult, radiographically defined anastomotic leaks are usually of minimal or no clinical significance. However, if the patient exhibits unexplained fever, tachycardia, or prolonged ileus, such a contrast study (along with cross-sectional imaging to identify a possible fluid collection or abscess) is obtained. Clinically significant anastomotic leaks are usually drained, preferably by a percutaneous, image-guided route. For patients undergoing total gastrectomy, I do routinely obtain an upper gastrointestinal (GI) swallow test with water-soluble contrast followed by thin barium on postoperative day 3; and if no anastomotic leak is found, the nasojejunal is removed and a clear liquid diet started. If tolerated, a full liquid diet is started on postoperative day 4 and a soft, post-gastrectomy diet on postoperative day 5 or 6. In this way, most of my total gastrectomy patients can be discharged by postoperative day 6 or 7. If an anastomotic leak is discovered, the nasojejunal tube is left in place and the patient kept NPO; and if the leak is clinically significant, a CT scan is obtained and percutaneous drainage pursued.

For the subset of patients in whom a jejunostomy tube is placed, low-dose elemental enteral feeding is initiated on the morning of postoperative day 2 and then advanced slowly as tolerated to the goal rate of 100% of the patient’s caloric and protein needs. With the return of bowel function and the start of a post-gastrectomy diet, the tube feedings can be cycled nightly and continued in this fashion post-discharge until the patient is capable of meeting his or her nutritional requirements by oral intake alone. Of note, a feeding jejunostomy tube is helpful in maintaining the nutritional status of patients who suffer a postoperative complication, especially an anastomotic leak, which prohibits or limits adequate oral intake.

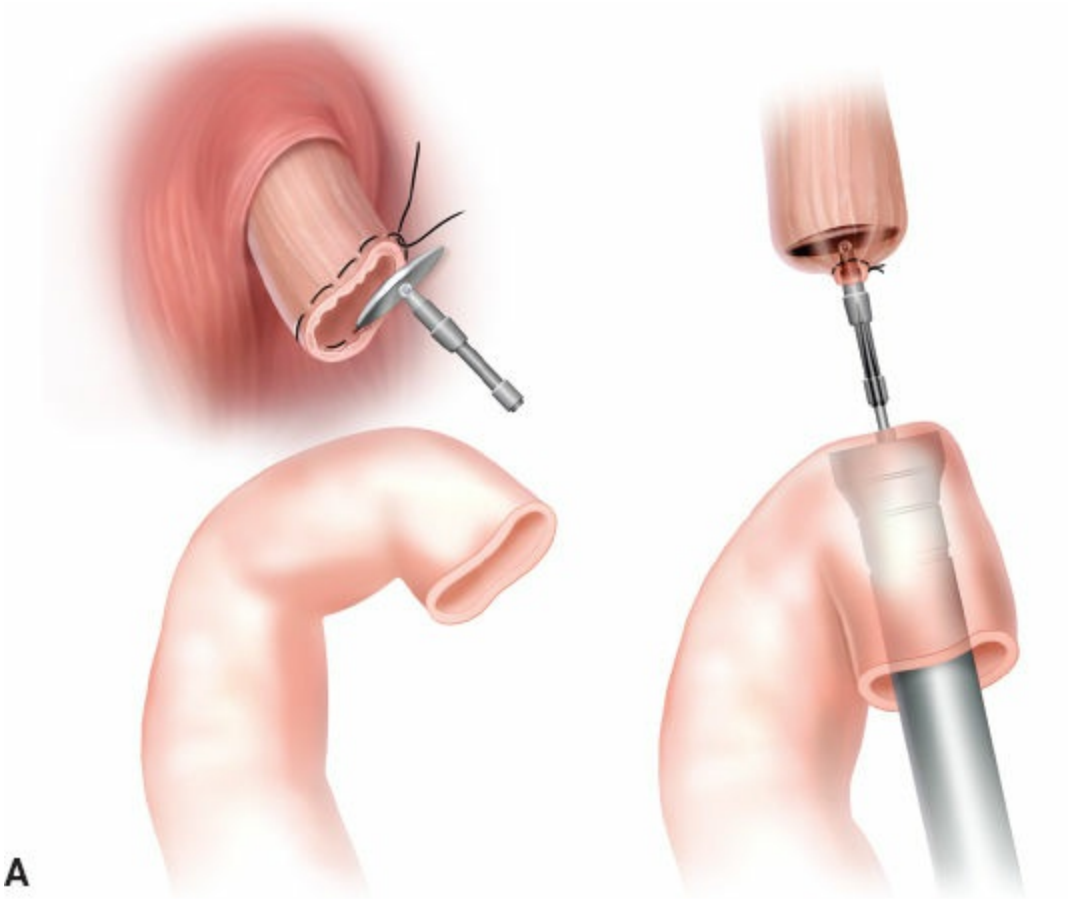
A

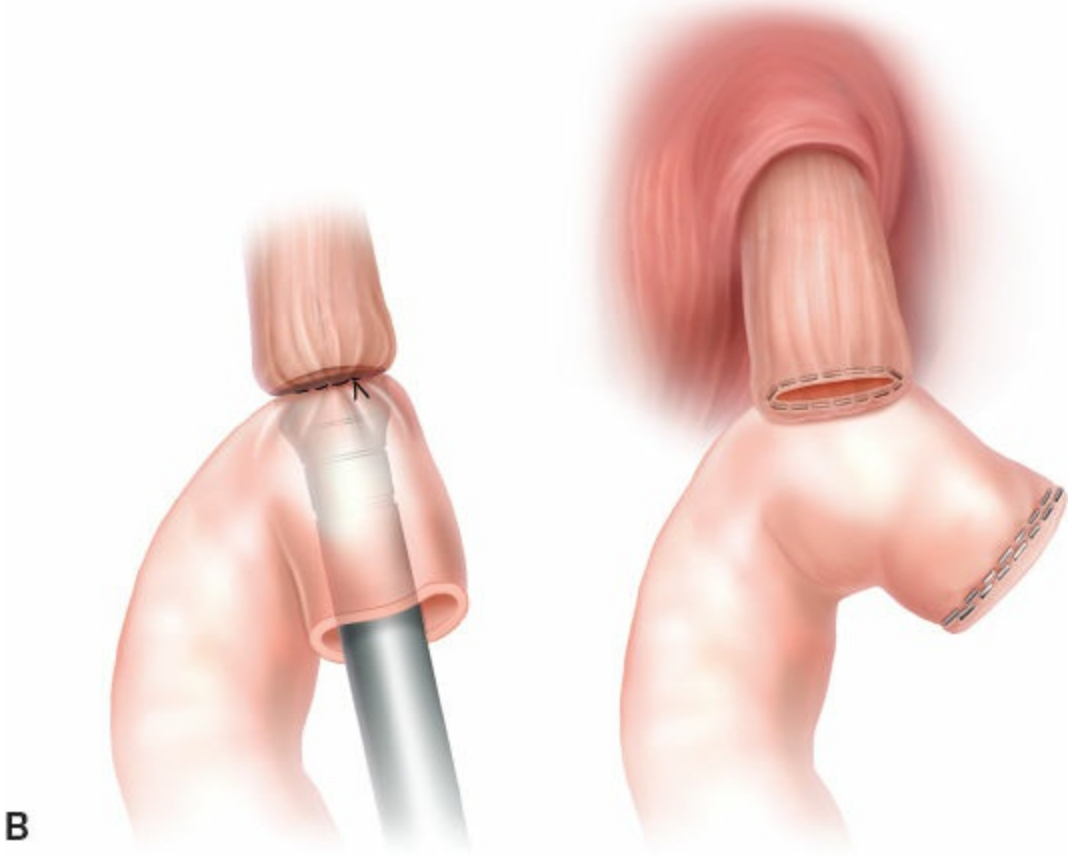
B

Figure 88.16. Reconstruction using the EEA stapler. **A.** Placement of the EEA stapler through the divided Roux limb. **B.** Completion of the stapled anastomosis and closure of the end of the Roux limb with a stapler.

COMPLICATIONS

Although the morbidity and mortality rates and survival results of the UK and Dutch randomized trials did not support the routine performance of a gastrectomy and D2 lymphadenectomy for Western patients with gastric cancer, it is now clear that this procedure can be done safely at specialized centers in the West. For patients treated at Massachusetts General Hospital over the past decade, we have reported morbidity and mortality rates after gastrectomy and D2 lymphadenectomy of 17% and 0%, respectively, and our median lymph node yield with ex vivo dissection of the specimen has increased to 40 nodes. The Memorial Sloan Kettering group recently published detailed 90-day outcomes on >230 patients undergoing curative-intent total gastrectomy. They reported that 62% of patients had at least one postoperative adverse event and that 28% experienced a major adverse event requiring invasive intervention. The most common adverse events were anemia (20%) and wound complications (18%), and the most common major adverse event was esophageal anastomotic leak, which occurred in 15% of patients and required invasive intervention in 10% of patients. Duodenal stump leak occurred in 3.8% of patients, and one third of these leaks were fatal, whereas only 6% of esophageal anastomotic leaks were fatal. The 90-day mortality rate was 2.9%, and the readmission rate was 20%. The median length of stay for subtotal and total gastrectomy in the United States averages 9 to 10 days, although many patients are discharged within 7 days. The long-term complications of subtotal and total gastrectomy include vitamin and mineral deficiencies, particularly of vitamin B_{12}, vitamin D, iron, and calcium, and the classic post-gastrectomy syndromes, such as alkaline reflux gastritis, dumping syndrome, Roux stasis syndrome, and afferent limb syndrome, all of which are described in detail elsewhere in this volume.

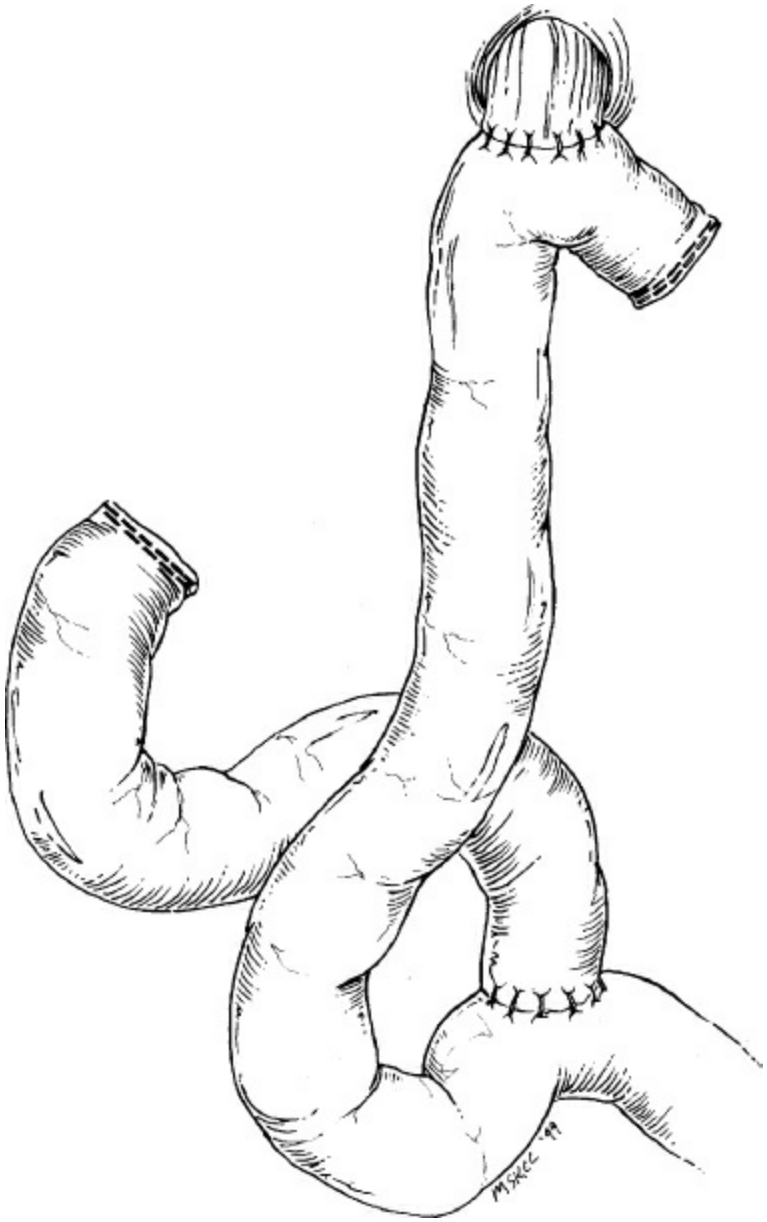

Figure 88.17. The completed Roux-en-Y reconstruction.

OUTCOMES

Surgery is the only potentially curative therapy for localized gastric cancer, yet even for those patients in whom an R0 resection is possible, only 35% to 40% 5-year survival is achieved with either perioperative chemotherapy or postoperative chemoradiotherapy. Preoperative therapy may increase the R0 resection rate and ensure that all patients with advanced tumors, and thus at high risk for distant failure, receive systemic therapy as early as possible. Although extensive gastric resections and D2 lymphadenectomies can now be performed at specialized centers with low operative morbidity and mortality rates and excellent nodal yields, future

progress in the treatment of gastric cancer depends on the development of better systemic therapies as well as techniques for earlier diagnosis.

Suggested Readings

Bonenkamp JJ, Hermans J, Sasako M, et al. Extended lymph-node dissection for gastric cancer. Dutch Gastric Cancer Group. *N Engl J Med* 1999;340:908.

Cunningham D, Allum WH, Stenning SP, et al. Perioperative chemotherapy versus surgery alone for resectable gastroesophageal cancer. *N Engl J Med* 2006;355:11–20.

Cuschieri A, Weeden S, Fielding J, et al. Patient survival after D1 and D2 dissections for gastric cancer: long-term results of the MRC randomized surgical trial. *Br J Cancer* 1999;79:1522.

Degiuli M, Sasako M, Ponti A, et al. Randomized clinical trial comparing survival after D1 or D2 gastrectomy for gastric cancer. *Br J Surg* 2014;101:23–31.

Kampschoer GH, Maruyama K, van de Velde CJ, et al. Computer analysis in making preoperative decisions: a rational approach to lymph node dissection in gastric cancer patients. *Br J Surg* 1989;76:905–8.

Macdonald JS, Smalley SR, Benedetti J, et al. Chemoradiotherapy after surgery compared with surgery alone for adenocarcinoma of the stomach or gastroesophageal junction. *N Engl J Med* 2001;345:725–30.

Schmidt B, Chang KK, Maduekwe UN, et al. D2 lymphadenectomy with surgical ex vivo dissection into node stations for gastric adenocarcinoma can be performed safely in Western patients and ensures optimal staging. *Ann Surg Oncol* 2013;20:2991–9.

Selby LV, Vertosick EA, Sjoberg DD, et al. Morbidity after total gastrectomy: analysis of 238 patients. *J Am Coll Surg* 2015;220:863–71.

Songun I, Putter H, Kranenbarg E, et al. Surgical treatment of gastric cancer: 15-year follow-up results of the randomised nationwide Dutch D1D2 trial. *Lancet Oncol* 2010;11:439–49.

Wu CW, Hsiung CA, Lo SS, et al. Nodal dissection for patients with gastric cancer: a randomized controlled trial. *Lancet Oncol* 2006;7:309–15.

EDITOR'S COMMENT

Despite almost eight decades of evidence, many surgeons continue to debate the rationale of aggressive surgery in the management of gastric cancer. This discussion, I believe, is best viewed through the lens of history. Although the earliest descriptions of gastric cancer date back to the Ebers Papyrus of 1600 BC,

the French surgeon Jules-Émile Péan performed the first gastric resection on April 9, 1879. Unfortunately, this and subsequent attempts at the operative management of gastric cancer were met with failure until Theodor Billroth successfully performed a subtotal gastrectomy with gastroduodenal anastomosis on January 22, 1881. Billroth went on to record a series of 257 subtotal gastrectomies for cancer during his illustrious career. Karl Schlatter, an understudy of Billroth and colleague of Rudolf Ulrich Krönlein, proposed that the poor clinical outcomes associated with this operation, including high rates of mortality and recurrence, could be improved upon by total gastrectomy. He therefore performed the first total gastrectomy and esophagojejunostomy for cancer in 1897 on a 56-year-old woman who survived for more than a year before succumbing to recurrent disease. Little progress in the technical aspects of gastric cancer surgery was made until the concept of extended resections surfaced in the 1930s, when Dr. Owen Wangensteen began to incorporate a more aggressive approach that included both extended lymph node dissections and resections of the pancreas and spleen. Considerable debate continues regarding the best operative technique for the management of gastric cancer. In this chapter on gastric cancer, Mullen presents a concise, evidenced-based approach to this insidious disease. I would submit that there are four important issues facing surgeons who manage gastric cancer: the extent of lymphadenectomy, reconstruction techniques, the emerging role of minimally invasive surgery in this population, and regionalization of care.

The potential benefits of extensive lymphadenectomy include enhanced staging, as well as improved disease-specific and overall survival. As such, the extent of lympadenectomy for gastric cancer has been conveniently divided into three categories. A D1 dissection includes only the perigastric lymph nodes. A D2 dissection also includes the lymph nodes along the hepatic, celiac, left gastric, splenic artery, and hilum as well as the nodes that are >3 cm away from the primary tumor. A D3 dissection includes all of the D2 stations plus nodes in the porta hepatis, retropancreatic, and periaortic areas. Interestingly, a recent review of the Surveillance, Epidemiology and End Results database demonstrated that only 29% of 10,897 patients who underwent resection for gastric cancer in the United States received lymphadenectomies of 15 or more lymph nodes (Reid-Lombardo, 2007). These findings suggest a much-needed improvement in the operative management of gastric cancer in the United States. Mullen’s treatment of lymphadenectomy in the description of both total and subtotal gastrectomies is excellent, but this chapter would benefit from a comprehensive review of more recent literature on this topic.

Given superior survival outcomes for extended lymphadenectomy in Asian studies as well as improved results in patients undergoing D2 resections relative to historical controls, two early prospective randomized trials were conducted by the Medical Research Council in the United Kingdom and the Dutch Gastric Cancer Group. These initial trials seemed to support less extensive lymphadenectomy, as there were not only high morbidity (43% and 46%) and

mortality rates (10% and 13%) relative to historical cohorts in Asian centers, but they also failed to show improvements in overall survival (Bonenkamp, 1999; Bonenkamp, 1995; Cuschieri, 1996; Cuschieri, 1999). Interestingly, a recent follow-up of the Dutch trial demonstrated that D2 resections were associated with lower disease-related death rates relative to the cohort that underwent D1 resections (37% vs. 48%, $p = 0.01$) at a median follow-up of 15 years (Songun, 2010). A subsequent trial from Taiwan demonstrated significantly lower morbidity (17.1%) and mortality (0%) in more extensive D3 resections compared to the D2 resections in the aforementioned studies. Moreover, the Taiwanese trial demonstrated a significant overall survival advantage in the more extensive resections (59.5% vs. 53.6%, $p = 0.041$) (*Br J Surg* 2004;91(3):283–7; *Lancet Oncol* 2006;7(4):309–15).

The Italian Gastric Cancer Study Group addressed the role of technique in outcomes for this patient population by employing extensive surgeon training to reduce morbidity and mortality in their prospective, randomized trial. This resulted in lower morbidity (12%) and mortality (2.2%) for D2 resections. Long-term follow-up from this group showed no difference in the overall 5-year survival rate (66.5% vs. 64.2% for D1 and D2 lymphadenectomy, respectively; $p = 0.695$). However, subgroup analyses showed a trend toward 5-year disease-specific survival benefit for patients with pT2–4 tumors and positive lymph nodes in the D2 group (59% vs. 38% for the D1 group; $p = 0.055$) (*Br J Surg* 2010;97(5):643–9; *Br J Surg* 2014;101(2):23–31). Taken together, these data support the age-old surgical notion that technical skill and patient selection are the greatest determinant of patient outcomes. This seems to be particularly true for patients who present with more advanced tumors and positive lymph nodes.

We would be remiss if we did not consider two large retrospective series from the United States and China that have evaluated the contribution of lymphadenectomy to the survival of patients with gastric cancer. The United States Gastric Cancer Collaborative reported on their series of 742 patients who underwent gastrectomy for gastric adenocarcinoma from 2000 to 2012 at seven academic institutions. The vast majority of these patients (65%) had at least 16 lymph nodes removed. This group reported that disease-specific survival was not significantly longer after removal of ≥16 versus 7 to 15 lymph nodes (10-year survival, 55% vs. 47%, respectively; $p = 0.53$) for the entire cohort, but was significantly improved in the subset of patients with stage IA to IIIA disease (10-year survival, 74% vs. 57%, respectively; $p = 0.018$) or N0–2 disease (72% vs. 55%, respectively; $p = 0.023$). Based upon these data, the authors concluded that the number of lymph nodes removed during gastrectomy appears to have prognostic implications for long-term survival (*J Am Coll Surg* 2015;221(2):291–9). Similarly, a 12-year series of 1,637 patients was recently reported by The Peking University People's Hospital. The median number of lymph nodes retrieved in this study was 19 (range, 2–69) with 81.4% of patients having ≥15 lymph nodes retrieved during curative resection. Furthermore, 86.4% of these patients underwent D2 or greater resections. I found it

particularly interesting that the majority of the clinical outcomes were improved in the 13.7% of patients in whom lymphadenectomy retrieved ≥30 lymph nodes, resections that would be considered radical by Western standards. This study demonstrated an overall survival of 64.4% in patients with >30 lymph nodes retrieved during lymphadenectomy while those with <14 nodes and those with between 15 and 29 nodes had overall survival rates of 53.6% (p = 0.006) and 58.3% (p = 0.024), respectively (*Am J Surg* 2015;210(3):431–40). I would invite readers to review this manuscript as it proposes a unique paradigm for the treatment of these patients that can improve clinical outcomes.

Mullen presents a nice summation of technical considerations, including dissection of the surgical specimen on the back table and reconstruction after resection. Given the importance of lymph node harvest and location, it is essential that the specimen be dissected on a sterile back table with lymph nodes labeled by station for pathology evaluation. This is especially important given recent information on the correlation between positive node location and clinical outcome (*Am J Surg* 2015;210(3):431–40). Likewise, the treatment of reconstruction techniques is critical. Roux-en-Y reconstructions with a small gastric pouch avoid long afferent limbs and the resultant afferent loop syndrome that sometimes occurs in Billroth II gastrojejunostomies. However, recent data from the US Gastric Cancer Consortium suggest that there is no difference in outcomes between Billroth II and Roux-en-Y gastrojejunostomy reconstruction techniques. In this report of 447 patients, 257 underwent Roux-en-Y reconstructions and 190 underwent Billroth II reconstructions. Roux-en-Y operations were slightly longer (244 min vs. 212 min, $p < 0.001$) and associated with somewhat higher blood loss (243 mL vs. 205 mL, p = 0.033) in the seven academic institutions that submitted data for this study. However, there were no significant differences in the length of hospital stay, readmission rate, 90-day mortality, morbidity, dependency on jejunostomy tube feeding at discharge, receipt of adjuvant therapy, or 5-year survival (*Gastric Cancer* 2016;19:994–1001). Based upon these findings, I encourage the reader to strongly consider both options when re-establishing continuity, particularly in subtotal or distal gastrectomies.

As a technical point, I would challenge the author's use of diuretics in the early postoperative period as recent data have drawn a correlation between postoperative diuretics and acute kidney injury (AKI) in patients undergoing surgery for gastric cancer (OR = 2.39, 95% CI = 1.98–2.88, p = 0.001) (*PLoS One* 2013;8(12):e82289). The authors suggest that although it is unclear whether use of diuretics is a cause or a consequence of postoperative AKI, indiscriminate use of diuretics to treat postoperative low urine output should be avoided, especially in patients with hypovolemic status.

Although covered later in this volume, any consideration of operative management of gastric cancer would be incomplete without a discussion of open versus laparoscopic gastrectomy. Several reviews and meta-analyses have shown an advantage in short-term outcomes of laparoscopic gastrectomy

compared to open procedures, with similar oncologic outcomes (*Surg Endosc* 2013;27(5):1509–20; *Ann Surg* 2012;255(3):446–56; *PLoS One* 2014;9(2):e88753; *Ann Surg* 2012;256(1):39–52). As an extension of these findings, a multicenter, prospective, randomized trial, Laparoscopic versus Open Gastrectomy for gastric Cancer (LOGICA-trial), is currently underway in the Netherlands. The primary endpoints of this trial will include R0 resection rates, number of lymph nodes retrieved, and postoperative length of stay. Secondary measures include postoperative morbidity and mortality, readmissions, cost-effectiveness, oncologic outcome, and quality of life (*BMC Cancer* 2015;15(1):556). The results from this study and others will guide future directions in the use of minimally invasive surgical techniques in the management of gastric cancer.

Finally, I believe that it is essential to address the potential for regionalization of surgery for gastric cancer. Reports from as early as the late 1990s demonstrated that patients undergoing surgery operations at high-volume centers have lower perioperative mortality than those at lower-volume centers. Interestingly, Birkmeyer et al. published a study on the relationship between volume and outcomes in high-risk cancer surgery that demonstrated a higher mortality odds ratio for patients who underwent gastric cancer surgery at low-volume centers relative to high-volume centers (OR = 1.51, 95% CI = 1.16–1.97) (*Cancer* 2006;106(11):2476–81). Given the impact of the aforementioned technical considerations on outcome, I would ask: Is it time we act upon the findings?

I would like to commend Mullen on an outstanding review of the management of gastric cancer. It is widely accepted that this disease is best approached with aggressive surgery that leverages extensive lymphadenectomy. Future considerations, including the role of regionalization of care as well as minimally invasive surgical techniques, will define the role of the surgeon as we make continue to make strides in the management of this disease.

John H. Stewart, IV

89 Distal Gastrectomy With Roux-en-Y Reconstruction and Laparoscopic Gastrectomy

Miguel A. Mercado and Gonzalo Torres-Villalobos

HISTORY

In 1881, the same year he performed the first successful gastrectomy, Theodor Billroth performed the first gastroenterostomy. The continuity of the gastrointestinal (GI) tract was achieved by means of a gastroduodenostomy, later known as a Billroth I procedure. Four years later, the Viennese surgeon modified his technique and began using a latero-lateral anastomosis with the jejunum, later known as a Billroth II procedure.

The medical community soon began to report cases of postoperative bilious vomiting as the Billroth II became a more popular procedure. Hence, in 1897, a Swiss surgeon from Lausanne, César Roux, first described a gastrojejunostomy performed from a sectioned and defunctionalized jejunal loop with intestinal continuity established by means of a distal termino-lateral jejuno-jejunal anastomosis, the Roux-en-Y.

More than a century after its original description, the Roux-en-Y has evolved into an easier, safer, and quicker procedure and has become the preferred approach to reestablish continuity of the GI tract after distal gastrectomy (DG) in many centers.

Duodenal participation in the reestablishment of the GI tract is a theoretical advantage of the Billroth I procedure. A more physiologic response to the passage of the bolus as well as a better absorption of calcium and iron are achieved with this operation. Nevertheless, several studies have shown that both short- and long-term results are similar when compared with other techniques. A delay in gastric emptying that is normally observed after bolus enters the duodenum, the so-called duodenal brake, is theoretically absent due to neural disruption as it would be for all other techniques mentioned.

As pyloric function is lost after resection, biliopancreatic reflux may cause severe symptoms due to direct irritation of the mucosa as well as increase the risk of cancer of the gastric remnant.

The anastomosis of the gastric remnant to a defunctionalized jejunal limb in a Roux-en-Y reduces biliopancreatic reflux and abolishes the afferent loop syndrome.

Laparoscopic distal gastrectomy (LDG) for early gastric cancer was developed in Japan and was first reported by Kitano et al. in 1994. Since then, the number of laparoscopic surgeries has rapidly increased and has been extended to include even locally advanced gastric cancer. The use of laparoscopic gastrectomy for treating gastric cancer has come into widespread use mainly in Japan but also throughout Korea and China. According to the eighth nationwide survey conducted by the Japan Society for Endoscopic Surgery, approximately 25% of gastrectomies for gastric cancer were treated laparoscopically in 2009. This important growth in laparoscopic gastrectomy in the Asian region is in part because the incidence of gastric cancer is greater; the incidence of early gastric cancer is higher as it is detected at a higher rate due to screening programs. However, this is contrary to the Western population in which gastric carcinoma is usually diagnosed at an advanced stage and in older patients. Therefore, it is unclear if the results of these Asian studies can be extrapolated to the Western world and the introduction of laparoscopic surgery for gastric cancer in the West has been slower than that in the East.

The feasibility of robotic gastrectomy for gastric cancer has been reported. Robotic surgery may help surgeons overcome technical difficulties but its use is just being explored.

INDICATIONS OF DISTAL GASTRECTOMY

The main indication for DG in the previous century was peptic ulcer disease (prepyloric, pyloric, and postpyloric). Complete removal of the ulcer as well as most acid-producing parietal cells was accomplished with surgery. Today, with potent proton pump inhibitors as first-line therapy, surgery is reserved for complicated ulcers (penetrated and/or perforated, peptic stenosis, or bleeding refractory to both medical and endoscopic therapy).

The amount of stomach resected is an important issue when it comes to choosing the type of reconstruction. When antrectomy is performed a Billroth I can usually be accomplished without tension. Even when an

ample Kocher maneuver has been done, when part of the corpus is removed it may be difficult to perform a Billroth I without tension in the gastroduodenal anastomosis. Recurrence of disease may also be a determinant factor when choosing the type of reconstruction especially when the duodenal stump is affected by disease or if a free margin is not obtained, in which case a Billroth I would not be optimal.

When the procedure of choice is a subtotal gastrectomy, the preferred reconstruction in most cases is a gastrojejunal anastomosis.

DG may also be indicated in early distal gastric cancer but is not recommended as standard treatment in locally advanced gastric cancer. In the latter, a formal gastrectomy with lymphadenectomy is the procedure of choice. Some cases with localized tumors can be treated with a subtotal gastric resection.

Other types of tumors can be adequately treated with a DG. Gastrointestinal stromal tumors (GIST) originating from Cajal cells are a good example of such tumors. Leiomyomas and other rare benign tumors may also be treated with limited resections.

DG with latero-lateral gastrojejunostomy is also an intrinsic part of the classic Whipple procedure. The pylorus-preserving variant (PPPD) can also be done anastomosing the remnant of the first portion of the duodenum to the jejunal limb, distal to the pancreatic and bilioenteric anastomosis. Despite controversy, PPPD probably has a lower incidence of postoperative delayed gastric emptying and prevents biliopancreatic reflux to the stomach. Roux-en-Y reconstruction can safely be performed after pancreatoduodenectomy and is preferred by some groups. Detractors of the Roux often mention the additional entero-enteric anastomosis as a disadvantage.

Several recent trials aimed at determining the best reconstruction after DG, mostly comparing Roux-en-Y to one or both classic Billroth procedures, have been published.

In a recent meta-analysis by Xiong et al., including four randomized controlled trials and nine nonrandomized observational clinical studies, they compare Roux-en-Y versus Billroth I reconstruction after DG for gastric cancer. The Roux-en-Y reconstruction had a lower incidence of bile reflux, remnant gastritis, and reflux esophagitis; however, it was associated with a longer operation time.

One series of 60 patients examined by Chan DC et al., compared Roux-en-Y reconstruction, classical Billroth II, and Billroth II plus distal entero-

enterostomy (Braun). There was significant reduction of enterogastric reflux as well as lower incidence of *Helicobacter pylori* infection in the Roux-en-Y group.

Csendes et al. reported a prospective, randomized study with long-term follow-up comparing Billroth II and Roux-en-Y reconstructions for the treatment of duodenal ulcers. With a follow-up of 12 to 21 years, they showed that Roux-en-Y is significantly better than traditional Billroth II reconstruction.

Another study was published by Kojima et al. except that DG was performed laparoscopically. Besides proving that laparoscopy is a feasible approach to such operations, the data also favored the Roux-en-Y.

Nunobe et al. analyzed the quality of life in the postoperative period in a large series of patients with early gastric cancer treated by subtotal gastrectomy. Subgroups of patients reconstructed by a Billroth I anastomosis and a Roux-en-Y were compared. There were fewer cases with dumping syndrome and endoscopically proven gastritis, yet a higher incidence of cholelithiasis in the Roux-en-Y group. They therefore concluded that a Roux-en-Y was superior to Billroth I reconstruction.

A published review by Hoya et al. mentions possible disadvantages of Roux-en-Y reconstruction, including development of stomal ulcers, increased likelihood of cholelithiasis, difficulty during endoscopic approach to the ampulla and bile duct, and the so-called Roux stasis syndrome due to inadequate peristalsis of the jejunal limb. Detractors of the Roux-en-Y report delayed gastric emptying in the early postoperative period, the so-called Roux stasis syndrome, in 20% to 30% of patients although most patients respond with conservative measures. Modifications in the surgical technique have been advocated by some to reduce this complication.

Both the extent of gastrectomy and the addition of vagotomy (truncal or selective) affect the presence of stomal ulceration. Vagotomy is advisable when antrectomy is performed in order to prevent such ulcers. When the critical mass of parietal cells is greatly diminished, as in subtotal or total gastrectomy, the possibility of ulceration is low and there is no need for vagotomy.

In a meta-analysis by Vinuela et al., the effectiveness of LDG versus open DG in patients with gastric cancer was compared. LDG reduced significantly overall complications, medical complications, and minor surgical complications. Open DG retrieved statistically significant more

lymph nodes compared to laparoscopic methods but this may result in clinically insignificant increase.

Laparoscopic gastrectomy compared with open resection of mostly clinical early gastric cancers has reduced morbidity and mortality in controlled trials but long-term studies are scarce.

PREOPERATIVE PLANNING

The preoperative evaluation of patients with gastric cancer includes establishing the diagnosis, assessing the extent of local disease, ruling out distant metastases, and assessing the patient's medical condition.

In the vast majority of cases, all necessary information to plan surgery is gathered with an upper GI endoscopy in combination with endoscopic ultrasonography and a triphasic computed tomography (CT) scan. Magnifying endoscopy, chromoendoscopy, and virtual chromoendoscopy can increase the detection of gastric lesions. The development of multidetector-row helical CT (MDCT) and three-dimensional (3D) display allows some advantages in preoperative staging.

Dehydration and electrolytic imbalances are common and must be corrected prior to surgery. Most patients should have an empty stomach with a 12-hour fast prior to surgery, yet patients with gastric outlet obstruction or gastroparesis may need considerably longer. Either ultrasound the day prior to surgery or gastric lavage through a nasogastric tube may be needed to confirm an empty stomach.

Prophylactic antibiotics are mandatory because of the high frequency of bacterial overgrowth in the retaining stomach and associated surgical site infections including complicated infections such as clostridial myositis.

SURGICAL TECHNIQUE

Although an upper midline incision is preferred by most, other upper abdominal incisions may also be appropriate.

A routine inspection of the abdominal cavity is done and the procedure chosen depends on the location and extent of disease at laparotomy. Care must be taken to preserve all oncologic principles when the indication of surgery is early gastric cancer.

The greater omentum is included in the specimen when surgery is due to cancer, and it should be dissected close to its insertion in the transverse colon with electrocautery, a diathermy system (LigaSure), or an ultrasonic scalpel (Fig. 89.1). Otherwise, the greater omentum is divided from the

middle of the gastrocolic ligament toward the left just distal to the gastroepiploic vessels. The left gastroepiploic vein is the upper limit when an antrectomy is to be performed. Attention is then directed to the lesser omentum, which is divided from the emergence of the hepatic artery to the right toward the level of the left gastric artery; since it is practically avascular it can be divided with electrocautery.

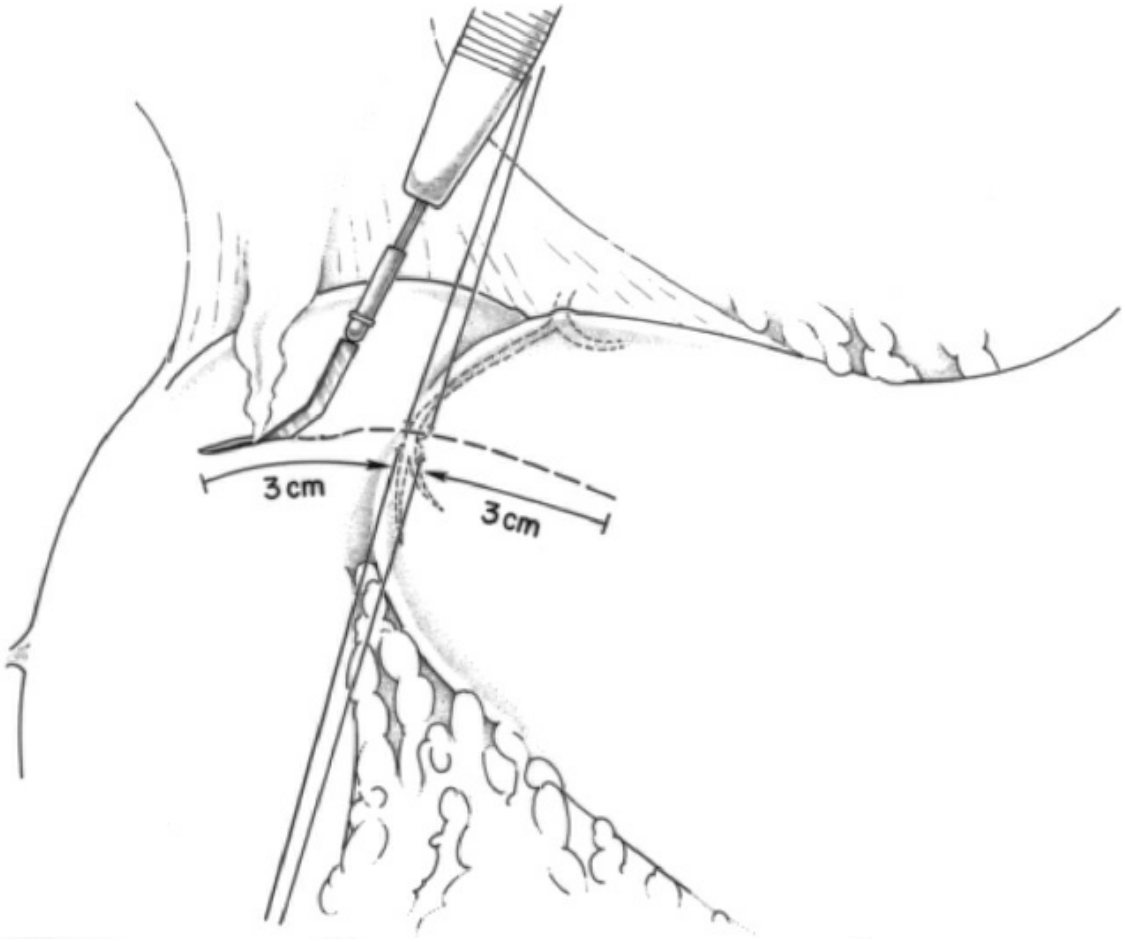

Figure 89.1. View of the posterior aspect of the stomach with greater omentum attached to the specimen as is performed when surgery is due to cancer. (Notice arterial circulation of the lesser curvature.)

The transition between the corpus and antrum may be indirectly identified near the caudal branch of the left gastric artery and vein, where the nerve of Latarjet is identified. The vasculature is carefully removed where transection is planned in order to expose the bare area of the small curvature as well as the greater curvature.

Stapler devices can be used to transect the stomach at the desired level although clamps and running suture can also be used in the absence of

such technology (Fig. 89.2). Care should be taken to pull out the nasogastric tube when present to avoid including it in the staple line. After transection of the stomach, the distal part is pulled out of the incision and with the utilization of ultrasonic scalpel or a diathermy device the dissection is continued toward the first portion of the duodenum (Fig. 89.3). Larger vessels including the right gastroepiploic vessels on the greater curvature, the right gastric artery, and the caudal branch of the left gastric artery on the lesser curvature should be ligated when encountered. The gastroduodenal artery (GDA) should be preserved. The pylorus is then identified and the first portion of the duodenum is skeletonized to the level were the pancreas adheres; small branches of the GDA may need ligature at this point. Transection of the first portion of the duodenum with a linear stapler device should be performed 2 cm distal to the pylorus. A retracted and fibrous duodenum may add considerable difficulty to this transection. In especially difficult cases where dehiscence and fistulization are likely, a duodenostomy (Foley or Pezzer catheter) can be created through the duodenal stump. Difficult duodenal stumps can also be protected with a side duodenostomy tube at the junction of the second and third portion of the duodenum or a retrograde tube placed at the ligament of Treitz.

An ample Kocher maneuver is performed when a Billroth I reconstruction is selected to avoid tension at the anastomosis; such maneuver is not necessary for a Billroth II or a Roux-en-Y.

The specimen is removed, and, although not mandatory, many invaginate the duodenal stump with simple Lembert sutures over the staple line. The same is done at the level of the gastric stump.

At this point the reconstruction begins and the technique now differs depending on the type of reconstruction chosen. The creation of a Roux-en-Y will be described in detail here.

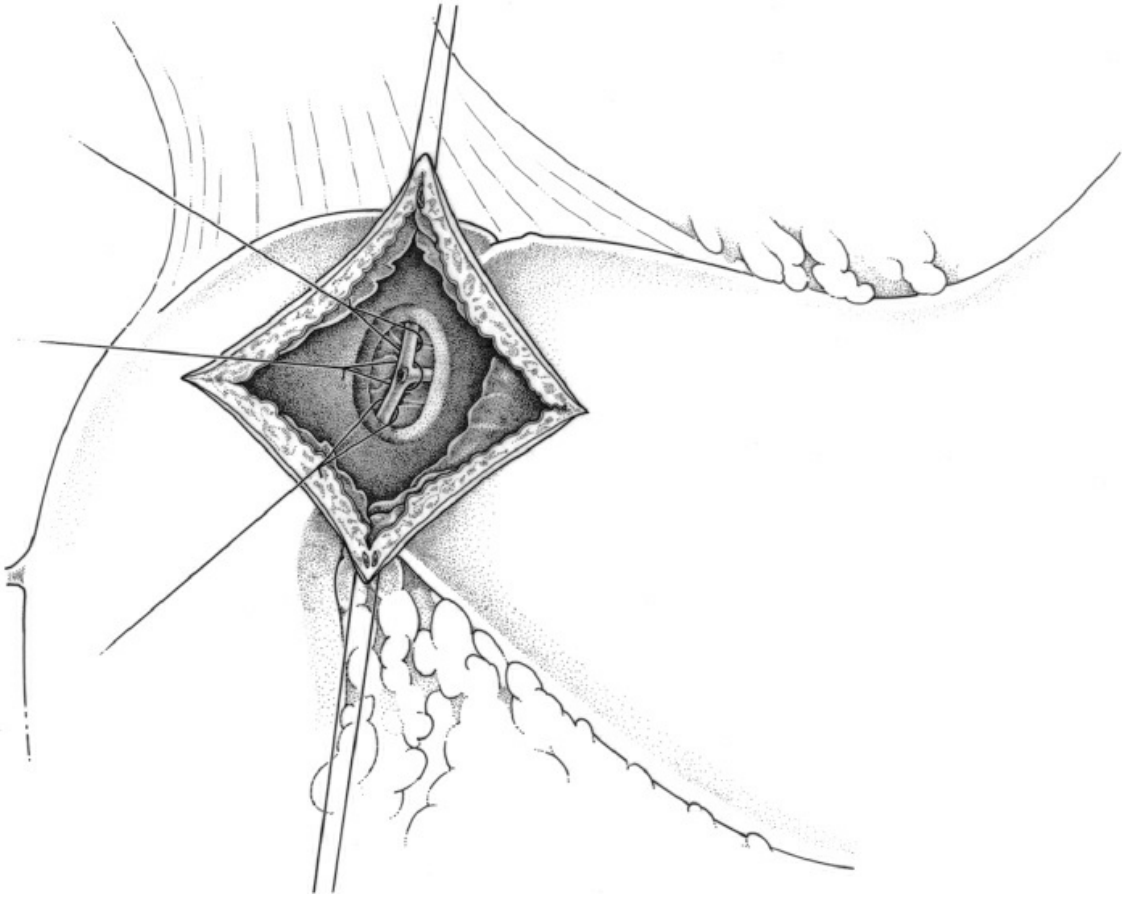

Figure 89.2. Transection of the stomach with a linear stapling device and reinforced with Lembert stitches with 3-0 silk.

The jejunum is identified at the level of the angle of Treitz. The most proximal jejunal loop that reaches the gastric remnant without tension is chosen for the anastomosis. With transillumination, a vascular arch that will allow to comfortably stretch the loop of jejunum toward the gastric remnant is selected and the jejunum is transected at this level between clamps or with a linear stapler.

The end of the proximal jejunum is anastomosed to the side of the distal jejunum at least 40 cm from the staple line. An end-to-side manual two-layer continuous suture in the antimesenteric border is our personal preference. We perform the inner suture with a 4-0 synthetic hydrolyzable monofilament suture and the outer layer is constructed with a 4-0 monofilament synthetic nonabsorbable suture.

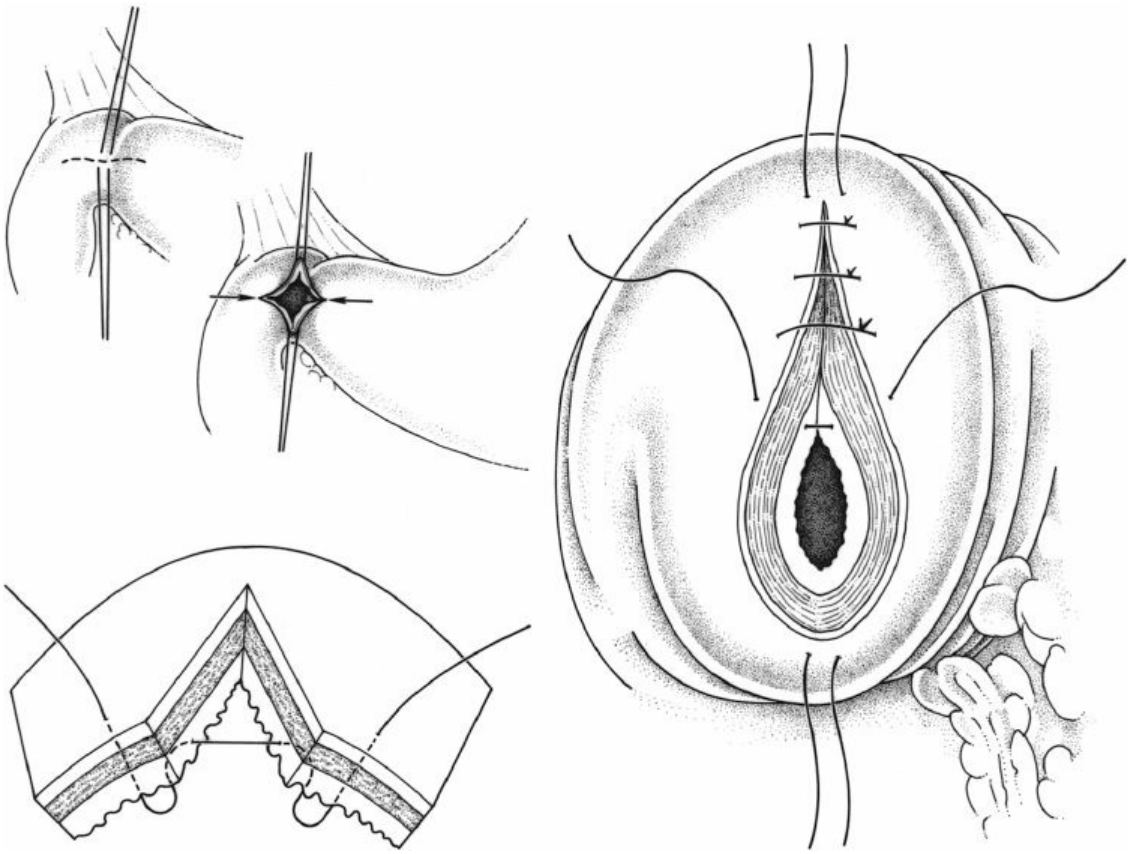

Figure 89.3. After transection of the stomach the distal end is pulled outward and dissection is continued toward the first portion of the duodenum.

A latero-lateral jejuno-jejunostomy with a stapler device could also be performed; yet we do not favor this technique since we have observed that the blind jejunal stump of the afferent limb tends to dilate and may become a source of symptoms and even a cause for reintervention. The mesentery is closed in order to prevent postoperative internal herniation.

The jejunal loop is now brought toward the gastric remnant and anastomosed end to side. For malignant disease, placing the loop in the antecolic position is advisable to prevent obstruction in case of recurrence. If performed retrocolically the mesocolon must be fixed to the loop to avoid herniation.

Several techniques for gastrojejunal anastomosis have been developed in the last decades, commonly identified with eponyms such as Hofmeister and Polya.

Both the greater and lesser curvatures are retracted in Allis clamps in order to stretch the gastric remnant. A small triangle is then removed from the staple line at the greater curvature. A 3- to 4-cm open orifice is now available for the two-layered manual anastomosis. As in the jejuno-

jejunostomy, an inner layer of continuous 3-0 synthetic hydrolyzable suture is constructed followed by an outer layer of nonabsorbable suture (Fig. 89.4). Since the tip of the anastomosis on the lesser curvature side is prone to ischemia, a three-point inverting suture is placed at this particularly vulnerable angle known as the angle of sorrow. The final aspect of a DG with a Roux-en-Y reconstruction is depicted in Figure 89.5.

A stapler device can be used to safely and rapidly perform the gastrojejunal anastomosis in which case the gastric remnant is retracted outside the wound and a small orifice is done in the posterior wall 1 in away from the stapler line. It is important to leave this margin because an incision too close to the stapler line can produce ischemia of the gastric wall. For the same reason, I also recommend that the jejunal limb be directed toward the fundus instead of directing it parallel to the stapler line. After shooting and extracting the stapler device, careful hemostasis of the inner aspect of the staple line is accomplished with cautery or with isolated stitches when necessary. The orifice in the jejunum and stomach, now communicated, is closed with an inner running suture of a 3-0 hydrolyzable monofilament and an outer layer of nonabsorbable suture as in the manually performed anastomosis.



Figure 89.4. A two-layer manual gastrojejunal anastomosis. (Notice only a small portion of the staple line toward the greater curvature is used for the gastrojejunal anastomosis.)

A nasogastric tube can now be placed; the final position of the tip is guided manually by the surgeon with no need to go through the newly created anastomosis. Its purpose is postoperative decompression of the gastric remnant (air extraction more than fluid) and can be a good monitor for intraluminal bleeding in the first hours postoperatively.

Duodenostomy, when performed, should be let out through a separate incision and secured to the skin with suture. Drains are not placed routinely but if uncertainty of the state of the staple line in the duodenal stump exists, closed suction drains should be placed. The abdominal wall is closed in a standard fashion.

LDG is performed using five abdominal ports. All port sites are infiltrated before incision with a mixture of 40 mL of 0.75% ropivacaine, 40 mL of 1% lidocaine with epinephrine, and 40 mL of 0.9% saline. Each port site is infiltrated with 20 mL: 10 mL under the parietal peritoneum and 10 mL in the dermal and subdermal planes. The first incision is a 5-mm cut made at the left anterior axillary line just inferior to the costal margin. A Veress needle is inserted and the abdomen is insufflated with carbon dioxide gas to a pressure of 12 to 18 mm Hg. Once insufflation is obtained, a 5-mm trocar is placed and a 45-degree angled scope is inserted into the abdomen. Exploratory laparoscopy is then performed to rule out metastatic disease. A 12-mm port is placed to the left of the umbilicus and 5-mm and 12-mm ports are placed in the right upper quadrant. If a liver retractor is needed it can be placed through a subxiphoid stab wound for the Nathanson liver retractor (Cook Medical, Bloomington, IN) or in the anterior axillary line depending on the type of retractor used. Reverse Trendelenburg position is employed at intervals during the procedure. As described for the open DG, in case of gastric cancer the resection should include the greater omentum, duodenal bulb, and surrounding nodal tissue. The dissection is carried out as described with the vessel sealing devices. The transection line on the stomach is identified with the left gastroepiploic vein as the upper limit with the caudal branch of the left gastric artery and vein, and the nerve of Latarjet as other anatomical references. The vasculature is carefully removed at the transection plane exposing the area from the small curvature as well as the greater curvature. In case of gastric cancer, before the transection of the stomach an intraoperative gastroscopy is performed to confirm the location of the tumor and marked by suturing in the outer gastric wall. The stomach is

transected using a 60-mm linear stapler with 4.8-mm staple leg lengths. The pyloric and duodenal mobilization is performed keeping the lymph nodes with the specimen. After dividing the right gastric and right gastroepiploic vessels, the duodenum is transected using a 60-mm linear stapler with 2.5-mm staples; the over sewing of the staple line may be used depending on the surgeon's preference. A large plastic bag is used for the removal of the resected specimen at the end of the procedure.

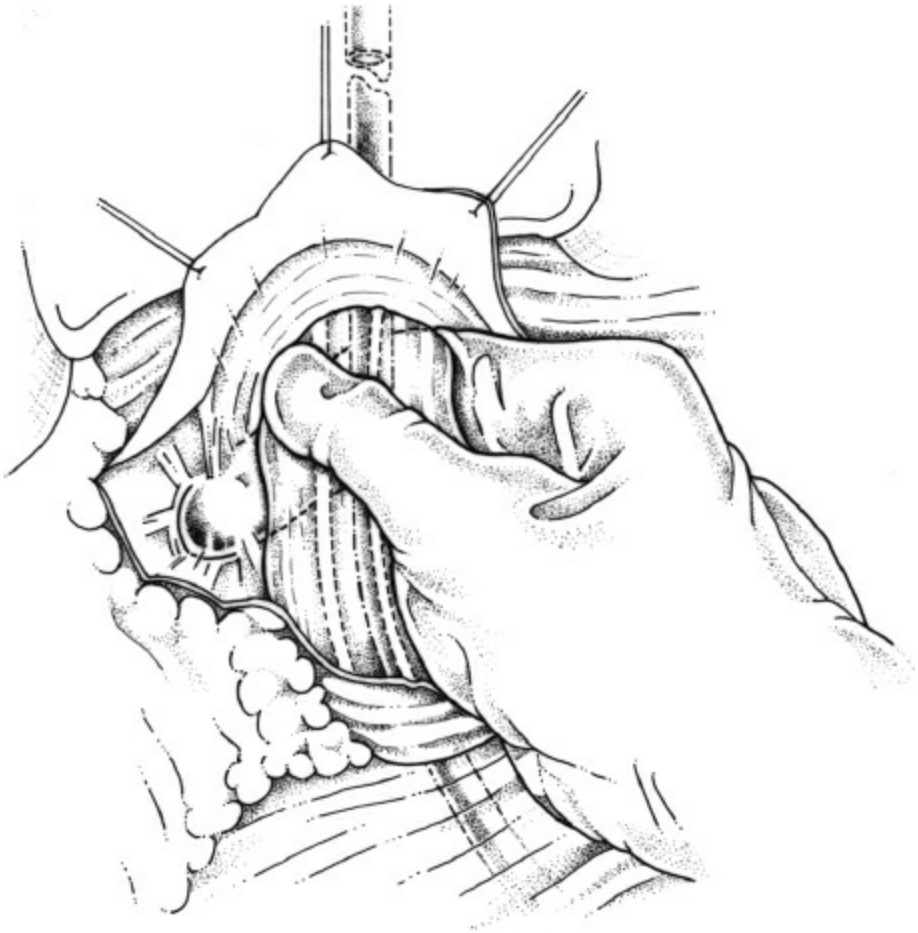

Figure 89.5. Distal gastrectomy with a Roux-en-Y reconstruction.

For the Roux-en-Y reconstruction the omentum is placed cephalad, the transverse colon is elevated, and the ligament of Treitz is identified. At 50 cm a small incision is made in the mesentery close to the jejunum and a ¼″ Penrose drain is passed to manipulate the bowel.

The Roux limb is brought to the stomach in an antecolic fashion. The omentum can be divided using a bipolar sealing device up to the midtransverse colon to facilitate this. To create a two-layer anastomosis between the gastric remnant and the Roux limb, an outer layer on the posterior portion of the gastric remnant is performed with a running 2-0

Surgidac suture using the endoscopic suturing device (Endo Stitch, 10 mm; Covidien, Mansfield, MA). With an ultrasonic dissector, a gastrotomy is made on the posterior portion of the gastric remnant, near the inferior border of the staple line and also an enterotomy is performed. The inner layer is done with a 45-mm long, 3.5-mm thick linear stapler introducing one leg of the stapler in the stomach and the other in the jejunum. The gastro-enterotomy is closed using a running 2-0 Polysorb suture and a second layer of 2-0 Surgidac is then performed over the anastomosis in running fashion. The jejunum is divided using a 60-mm long laparoscopic linear stapler with 2.5-mm staple thickness. A bowel clamp is placed on the Roux limb and an intraoperative endoscopic leak test is performed. At least 40 cm from the staple line a side-to-side functional end-to-side jejunojejunostomy is created. An enterotomy is done in the Roux limb as well as in the distal portion of the biliopancreatic limb using an ultrasonic dissector. The 60-mm long, 2.5-mm staple thick laparoscopic linear stapler is introduced in the corresponding enterotomies and fired. The common enterotomy is then closed transversely with the linear stapler. A stress relief suture is placed at the end of the staple line. The mesenteric and Petersen defects are closed with a running 2-0 Surgidac suture with the endoscopic suturing device.

POSTOPERATIVE CARE

The nasogastric tube is removed 24 to 48 hours after surgery or when there is evidence of peristalsis. Liquid diet is also begun at this time and progressed as tolerated to a normal diet. Giving smaller portions of food five times a day can be a helpful strategy in the early postoperative period.

POSTOPERATIVE COMPLICATIONS

Common complications include leak from the gastrojejunal anastomosis (1% to 4%), bleeding (2%), passage disorders (2% to 5%), and postoperative pancreatitis (0.9%). Leaks can occur at the gastrojejunostomy, jejunojejunostomy, or the gastric staple line. The diagnosis is made by a combination of clinical and radiographical findings; CT is more reliable for leaks than upper GI. Symptoms of a leak include abdominal pain, shoulder pain, and back pain. Signs include tachycardia, fever, tachypnea, oliguria, hypotension, hypoxia, or even shock. Dehiscence of the gastrojejunostomy is infrequent and can be managed conservatively if no systemic response is observed. Anastomotic leaks tend

to heal conservatively with adequate drainage using a gastric tube, close suction drains, and parenteral nutrition are implemented.

Gastroparesis is more common when limited resections are performed. Gastric stasis is usually secondary to edema or a hematoma of the anastomosis, which resolves conservatively in 10 to 14 days with the aid of a gastric suction tube to avoid emesis. Motility disorders of the gastric remnant may also play an important role. When gastric stasis is observed preoperatively it is more likely to be present in the postoperative period.

Intragastric or intraperitoneal bleeding is infrequent. Management depends on the extent of bleeding and the possibility of it subsiding spontaneously. Endoscopic hemostasis by injection or coagulation therapy should always be attempted if upper GI bleeding occurs. Reoperation is considered in these cases when blood transfusions and endoscopic intervention fail to stabilize the patient. During surgery, enterotomy may be used to achieve hemostasis at the anastomosis but we favor redoing the anastomosis manually after hemostasis is achieved; maneuvering, we believe, reduces the possibility of dehiscence.

DUMPING SYNDROME

Dumping is mainly a consequence of vagotomy but can be seen after any gastric surgery. The frequency of clinically significant dumping after DG is around 1% to 2%. It has an early and late form, the latter being much less common. GI symptoms include postprandial fullness, crampy abdominal pain, nausea, and explosive diarrhea. Other symptoms are associated with vasomotor manifestations: diaphoresis, dizziness, flushing, and palpitations. These are more frequent in the early form and appear to be secondary to abnormally rapid gastric emptying. The early syndrome is probably the result of hyperosmolarity of intestinal content although some hormonal mechanisms have also been advocated. The late syndrome is probably related to hyperinsulinism and hypoglycemia secondary to a large amount of carbohydrates in chime and is therefore pancreatic in origin. The actual physiopathology of this syndrome remains elusive. Dietary modifications are the mainstay of treatment in both early and late dumping, yet surgical conversion is sometimes necessary (Billroth II to I, interposition of antiperistaltic loops, and conversion of Billroth II to Roux-en-Y gastrojejunostomy). Careful evaluation, often by a multidisciplinary group, must be done to select appropriate treatment for individual patients. Dumping predisposition can be evaluated preoperatively with the

apomorphine test to determine which patients are more likely to have incapacitating dumping syndrome with obvious practical implications, as described by Fender et al. in the 1960s.

ROUX STASIS SYNDROME

Occurring in about 5% to 30% of patients after DG and a Roux-en-Y reconstruction, this syndrome includes symptoms of fullness, abdominal pain, nausea, and vomiting in the early postoperative period. The interruption of the duodenal pacemaker seems to be involved in such motility problems and it is seen more often with jejunal limbs longer than 40 cm. As in other procedures that present with delayed gastric emptying, most patients respond to conservative measures; yet hospital stay may be prolonged. When complications are mentioned in comparative studies, other forms of reconstruction show similar frequency of passage disorders.

POSTVAGOTOMY DIARRHEA

This condition occurs approximately in 20% of patients with truncal vagotomy and much less in more selective vagotomies. Other etiologies must be ruled out in the postoperative period, and, although the spectrum of disease may vary greatly, postvagotomy diarrhea may be debilitating and cause malnutrition in about 1% of patients. The loss of central nervous system (CNS) modulation of the enteric nervous system might cause increased motility; yet, many other factors including bacterial overgrowth have also been advocated.

Medical treatment and dietary modifications (quality, quantity, and frequency) are offered initially. Refractory cases may need surgical intervention most commonly consisting of interposition of an antiperistaltic jejunal segment.

BILIARY REFLUX AND AFFERENT LOOP SYNDROME

Biliary reflux occurs more commonly after a Billroth II reconstruction but may also occur after a Billroth I reconstruction. The main advantage of the Roux-en-Y operation is that the isolated jejunal limb greatly diminishes clinically significant reflux to the gastric remnant.

Although hard to prove on imaging studies, afferent loop syndrome is thought to occur due to partial obstruction of such a loop and is more common when the gastrojejunostomy is made toward the greater curvature

and the ligament of Treitz is more to the left than usual, predisposing to a kinking of the loop. Afferent loop syndrome by definition occurs after a Billroth II gastrojejunostomy. The Roux-en-Y does not have an afferent limb and therefore such a syndrome is completely abolished.

The important reduction in biliary reflux and bilious vomiting is surely one of the main arguments in favor of the Roux-en-Y and explains why it has become the preferred method of reconstruction after DG by many.

VAGOTOMY

When antrectomy is performed, usually for peptic ulcer disease, a truncal or a highly selective vagotomy is indicated. This maneuver interrupts the central phase of acid secretion, reducing the risk of marginal ulcers. Truncal vagotomy requires the opening of the phreno-esophageal membrane, blunt dissection of the lower third of the esophagus, palpating the anterior and posterior vagus nerves, and subsequently ligating both proximal and distal stumps and sectioning them. In order to confirm vagotomy a small segment of the nerve is removed and sent to pathology.

If a selective vagotomy is done, both the anterior and posterior vagus nerves are retracted and the small anterior branches of the fundus and corpus, including the gastroepiploic and posterior branches, are cut. Since only the left gastric and short gastric vessels are preserved after DG, care must be taken not to compromise arterial flow during vagotomy. The selective vagotomy implies devascularization that can jeopardize the circulatory status of the gastric remnant.

If a subtotal or near total gastrectomy is done, there is no need for vagotomy, because the critical mass of parietal cells is drastically diminished.

Suggested Readings

Chan DC, Fan YM, Lin CK, et al. Roux-en-Y reconstruction after distal gastrectomy to reduce enterogastric reflux and *Helicobacter pylori* infection. *J Gastrointest Surg* 2007;11(12):1732–40.

Csendes A, Burgos AM, Smok G, et al. Latest results (12–21 years) of a prospective randomized study comparing Billroth II and Roux-en-Y anastomosis after a partial gastrectomy plus vagotomy in patients with duodenal ulcers. *Ann Surg* 2009;249(2):189–94.

Griffiths JM. The features and course of bile vomiting following gastric surgery. *Br J Surg* 1974;61(8):617–22.

Haglund UH, Jansson RL, Lindhagen JG, et al. Primary Roux-Y gastrojejunostomy versus gastroduodenostomy after antrectomy and selective vagotomy. *Am J Surg* 1990;159(6):546–9.

Hoya Y, Mitsumori N, Yanaga K. The advantages and disadvantages of a Roux-en-Y reconstruction after a distal gastrectomy for gastric cancer. *Sur Today* 2009;39(8):647–51.

Inokuchi M, Kojima K, Yamada H, et al. Long-term outcomes of Roux-en-Y and Billroth-I reconstruction after laparoscopic distal gastrectomy. *Gastric Cancer* 2013;16(1):67–73.

Kojima K, Yamada H, Inokuchi M, et al. A comparison of Roux-en-Y and Billroth-I reconstruction after laparoscopy-assisted distal gastrectomy. *Ann Surg* 2008;247(6):962–7.

Skellenger ME, Jordan PH Jr. Complications of vagotomy and pyloroplasty. *Surg Clin North Am* 1983;63(6):1167–80.

Viñuela EF, Gonen M, Brennan MF, et al. Laparoscopic versus open distal gastrectomy for gastric cancer: a meta-analysis of randomized controlled trials and high-quality nonrandomized studies. *Ann Surg* 2012;255(3):446–56.

Xiong JJ, Altaf K, Javed MA, et al. Roux-en-Y versus Billroth I reconstruction after distal gastrectomy for gastric cancer: a meta-analysis. *World J Gastroenterol* 2013;19(7):1124–34.

EDITOR'S COMMENT

In this chapter, Drs. Mercado and Torres-Villalobos nicely summarize the literature concerning the optimal method of GI tract reconstruction after distal gastrectomy. Whether performed for an early gastric cancer or for benign ulcer disease, far and away the most common method of reconstruction after distal gastrectomy worldwide is a gastroduodenostomy (Billroth I). This is the only method which preserves the physiologic continuity of the GI tract, it is a relatively straightforward end-to-end anastomosis, and many authors have reported improved nutritional parameters and weight gain with the BI reconstruction compared with other techniques. However, bile reflux gastritis is a significant problem with both the Billroth I and II reconstructions, leading many surgeons to advocate for the Roux-en-Y reconstruction, which virtually eliminates the problem of bile reflux assuming the Roux limb is sufficiently long. Though the authors of this chapter prefer a limb length of at least 40 cm, I generally opt for an even longer Roux limb length of 50 to 60 cm. Detractors of the Roux-en-Y technique point to it as a more complicated method of reconstruction (with two anastomoses instead of one) and to the risk of Roux stasis syndrome, a functional obstruction of the Roux limb which results in delayed gastric emptying. Roux stasis syndrome is hypothesized to be due to the

separation of the Roux limb from the natural small bowel pacemaker, which is located in the proximal duodenum, and it has been said to occur in up to 20% of patients (Ishikawa M, Kitayama J, Kaizaki S, et al. Prospective randomized trial comparing Billroth I and Roux-en-Y procedures after distal gastrectomy for gastric carcinoma. *World J Surg* 2005;29:1415–20), though many other authors have reported a much lower incidence.

Nakamura et al. (Nakamura M, Nakamori M, Ojima T, et al. Randomized clinical trial comparing long-term quality of life for Billroth I versus Roux-en-Y reconstruction after distal gastrectomy for gastric cancer. *Br J Surg* 2016;103:337–47) conducted a randomized clinical trial comparing the long-term quality of life of patients undergoing Billroth I versus Roux-en-Y reconstruction after distal gastrectomy for gastric cancer. A total of 122 patients were randomized—60 to Billroth I and 62 to Roux-en-Y reconstruction—and the primary endpoint was quality of life using the Functional Assessment of Cancer Therapy-Gastric (FACT-Ga) questionnaire 36 months after surgery. Patients randomized to the Billroth I group had significantly less epigastric fullness, diarrhea, and fatigue as well as less weight loss (6.8% vs. 10%) than those in the Roux-en-Y group, but they had more severe bile reflux gastritis in the remnant stomach. Delayed gastric emptying due to Roux stasis syndrome occurred in 7% of the patients who had a Roux-en-Y reconstruction. Despite these differences in individual symptoms and parameters, there were no significant differences between the two groups in terms of overall quality of life as measured by the FACT-Ga total score. Thus, the authors concluded that both the Billroth I and the Roux-en-Y reconstructions are equally acceptable methods of reconstruction after distal gastrectomy.

One technique that may help to prevent the Roux stasis syndrome is the so-called “uncut” Roux-en-Y reconstruction. This technique is a simple modification of the Billroth II with Braun anastomosis in which the jejunogastric pathway is occluded with either sutures or a nonbladed linear stapler. It is known to reduce the incidence of Roux stasis syndrome by maintaining the integrity of the intestinal wall, thereby allowing normal conduction of the myenteric impulses (Miedema BW, Kelly KA. The Roux stasis syndrome: treatment by pacing and prevention by use of an ‘uncut’ Roux limb. *Arch Surg* 1992;127:295–300). The original uncut technique was associated with a high rate of recanalization of the uncut staple line or of the suture closure, but with the use of a 6-row linear stapler, this risk is substantially reduced. Park and Kim retrospectively examined 221 patients who underwent laparoscopic distal gastrectomy between 2005 and 2013 and had one of the following four methods of reconstruction: Billroth I (18.5%), Billroth II (36%), Roux-en-Y (26.1%), and uncut Roux-en-Y (19.4%) (Park JY, Kim YJ. Uncut Roux-en-Y reconstruction after laparoscopic distal gastrectomy can be a favorable method in terms of gastritis, bile reflux, and gastric residue. *J Gastric Cancer* 2014;14:229–37). They found that the Roux-en-Y and uncut Roux-en-Y reconstructions were equally superior to BI and BII with Braun anastomoses in

terms of bile reflux gastritis, and the uncut Roux-en-Y method showed improved stasis compared to the conventional Roux-en-Y gastrojejunostomy. There were no significant differences in body weight change among the four reconstructive procedures 1 year after surgery.

Laparoscopic-assisted distal gastrectomy (LADG) was initially developed and shown to be highly effective for the treatment of early gastric cancer in the East. However, in contrast to early gastric cancer, a D2 lymph node dissection is required for the treatment of advanced gastric cancer, and there has been much concern about the technical feasibility as well as the oncologic safety of laparoscopic gastrectomy with D2 lymphadenectomy for advanced gastric cancer. A recently published randomized, phase II, multicenter clinical trial (COACT 1001) of LADG versus open D2 distal gastrectomy (ODG) for advanced gastric cancer (Park YK et al. *Ann Surg* 2017; Epub ahead of print) goes a long way to diminishing those concerns. These authors randomized 204 patients to either LADG (n = 105) or ODG (n = 99) and found no significant differences in the overall noncompliance rate of lymph node dissection between the two groups. Furthermore, there were no significant differences in postoperative complication rates or the surgical stress response, as measured by blood levels of the following inflammatory markers: C-reactive protein, fibrinogen, total bilirubin, interleukin-6, interleukin-10, and tumor necrosis factor alpha. The authors surmised that perhaps surgical stress was influenced more by the sheer extent of surgery (gastrectomy and D2 lymphadenectomy) than by the open or laparoscopic approach per se. Finally, the 3-year disease-free survival rate was essentially equivalent between the groups (LADG, 80.1% and ODG, 81.9%). This study, taken together with similar results reported by many other authors, including one of the largest reports from the West (Kelly KJ, Selby L, Chou JF, et al. Laparoscopic versus open gastrectomy for gastric adenocarcinoma in the west: a case-control study. *Ann Surg Oncol* 2015;22:3590–6), demonstrates the safety, feasibility, and oncologic efficacy of laparoscopic gastrectomy in the treatment of advanced gastric cancer. I am certain that there will be many more reports espousing the benefits of minimally invasive gastrectomy, including robotic gastrectomy, in the years ahead.

John T. Mullen

90 Postgastrectomy Syndromes in the Current Era

KMarie Reid and Michael G. Sarr

INTRODUCTION

At the turn of the 20th century, the epidemic of *Helicobacter pylori* infestation/infection ushered in a new problem for the surgeon—that of peptic ulcer disease. Secondary to the ulcer diathesis induced by the *H. pylori*, duodenal ulcer and related gastric ulceration (and also gastric adenocarcinoma) became commonplace, affecting as much as 20% of the population at some time in their lives. Duodenal ulceration led to multiple acute complications as well as causing the often intractable symptoms of dyspepsia; remember, there were no histamine 2 (H_2) blockers or proton pump inhibitors (PPIs). Initially, prior to effective, long-lasting pharmacologic acid suppression, operations were designed to treat the complications—pyloric stenosis/stricture, hemorrhage, perforation, and benign gastric ulcers (now uncommon). These operations included gastrojejunostomy initially, but thereafter, hemigastrectomy and subtotal gastrectomy became the procedures of choice.

The pioneering work on vagal control of acid secretion by Lester Dragstedt gave birth to the era of operative vagotomy as a therapeutic intervention for symptomatic duodenal ulcer disease. Soon thereafter in the 1960s, the explosion of the anti-inflammatory medications, like aspirin and later the nonsteroidal anti-inflammatory drugs (NSAIDs) to treat painful arthropathies, also led to gastroduodenal ulceration, once believed also to be related solely to acid production. The 1950s, 60s, and 70s were the decades that completed our understanding of the drivers of acid secretion —neural input (vagus nerves), hormonal effects (gastrin), and intramural paracrine effects (histamine). All these factors stimulated the very prevalent operations on the esophagogastroduodenal axis in attempts to treat the ulcer disease (and gastric cancer) involving various forms of total abdominal or selective gastric vagotomies (to inhibit neutrally mediated acid secretion) often combined with some form of distal gastrectomy (to

abolish gastrin secretion) which led to a relatively high prevalence of the postgastrectomy/postvagotomy syndromes.

The introduction of the first H_2 antagonists and more recently the PPIs has eliminated virtually all elective operations for duodenogastric ulcer disease. Many investigators also believe that a concomitant decrease in the true prevalence and incidence of duodenal ulcer disease was occurring simultaneously in the developed world and actually preceded the introduction of effective acid-suppressive medications—probably somehow related to eradication of *H. pylori* infestation.

Currently, however, with the virtual disappearance of elective ulcer surgery as well as the lack of the use of vagotomy as a therapeutic procedure, the spectrum of postvagotomy disorders has changed, and the postvagotomy syndromes which were so common in the recent past are much less prevalent now (and have become poorly understood or appreciated by a new generation of surgeons unfamiliar with the postvagotomy spectrum).

This chapter will review the classic postgastrectomy/postvagotomy disorders of the era of ulcer surgery seen only rarely today, and building on our understanding of the pathophysiology related to the prior "ulcer operations," this discussion will focus and concentrate on the more common consequences of gastrectomies and esophageal operations seen today. Many of the past operations "designed" to treat some of the postgastrectomy disorders but no longer used today will be mentioned only in passing (e.g., reversed jejunal segment for dumping).

GENERAL REVIEW OF RELEVANT OPERATIONS

Gastric Resections

By virtue of the respective procedure, a gastrectomy obligates several irreversible consequences/side effects. Gastric resection requires restoration of esophagogastrointestinal continuity, whether by gastrojejunostomy to a loop of proximal jejunum (Fig. 90.1A), gastroduodenostomy (Fig. 90.1B), gastrojejunostomy to a defunctionalized Roux-en-Y limb (Fig. 90.1C), or an esophagojejunostomy to a defunctionalized Roux-en-Y limb (Fig. 90.1D).

All these reconstructive procedures are subject to potential *mechanical* problems.

Ulceration/stricture/stenosis of the anastomosis can occur secondary to

poor technique or acid-peptic/NSAID–induced injury. The gastrojejunostomy and the gastroduodenostomy allow free reflux of proximal intestinal content (i.e., bile) into the gastric remnant; whether bile reflux "gastritis" really occurs or not is debatable, but bile reflux esophagitis is a very real possibility in patients with underlying gastroesophageal reflux. The Roux-en-Y procedures obligate another infracolic anastomosis, subject potentially to adhesive obstruction either at the anastomosis or at the defect in the transverse mesocolon if the Roux limb is brought retrocolic; similarly, internal hernias can occur through the anatomic defects created in the reconstructions. Depending on where the actual site of obstruction occurs, either the Roux limb, the pancreatobiliary (afferent) limb, or both can become incarcerated in these mesenteric defects, and the obstruction of each limb has its own symptomatology.

There are several potential *functional* consequences. Resection of the pylorus and bypass of the duodenum (Fig. 90.1A, C, and D) alter the control of gastric emptying. Loss of a functional valve at the gastrojejunal, gastroduodenal, or esophagojejunal anastomosis (Fig. 90.1A, B, C, and D) allows early, rapid gastric emptying (dumping) of liquids into the small intestine and the potential for the dumping syndrome. Similarly, dumping can be exaggerated by the bypass of the duodenum with a gastrojejunostomy or Roux-en-Y reconstruction, which prevents the slowing of gastric emptying. This is mediated by the duodenal receptors for acid, glucose, fat, and osmolarity, which provide feedback to the proximal stomach to slow gastric emptying. Depending on where the gastric resection occurs, and if some form of either a therapeutic vagotomy, obligate vagotomy (e.g., for oncologic clearance), or inadvertent vagotomy (of the gastric, hepatic, or intestinal branches during a periesophageal operation) is performed, resultant motor disorders of the gastric remnant and/or intestine can occur, further exacerbating dumping or leading to the very rare instance of postvagotomy diarrhea. In addition to gastric or vagal effects, transection of the jejunum to create the Roux limb alters intestinal motility, especially in the proximal aspects of the Roux limb, which is now isolated from the duodenal pacemaker which may rarely lead to the Roux stasis syndrome.

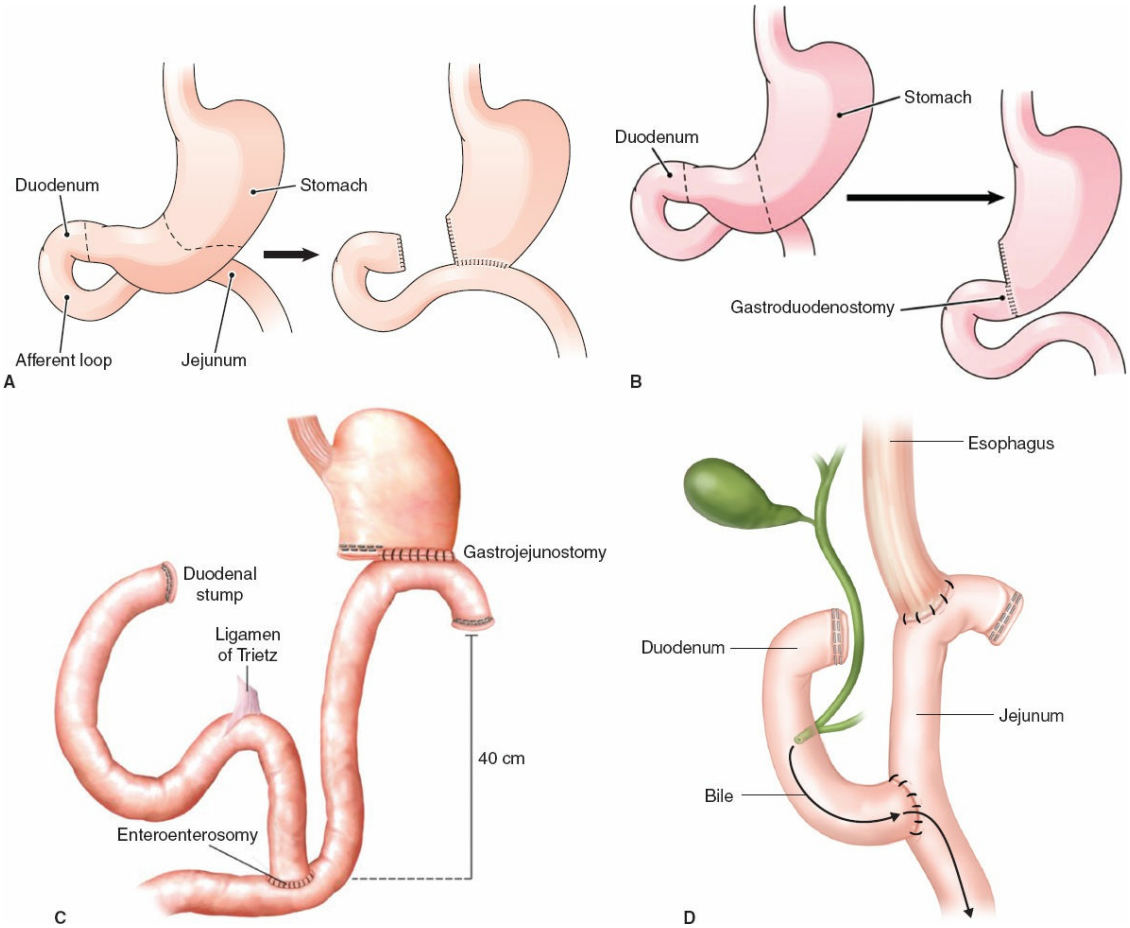

Figure 90.1. Gastric resections. **A.** Antrectomy with loop gastrojejunostomy. (Reproduced from Cohen BJ. *Medical Terminology: An Illustrated Guide.* 4th ed. Lippincott Williams and Wilkins; 2003). **B.** Antrectomy with end-to-end gastroduodenostomy. (Reproduced from Cohen BJ. *Medical Terminology: An Illustrated Guide.* 6th ed. Lippincott Williams and Wilkins; 2010). **C.** Antrectomy or subtotal gastrectomy with Roux-en-Y gastrojejunostomy. (Reproduced from Nussbaum MS. *Master Techniques in Surgery: Gastric Surgery.* LWW; 2012.) **D.** Total gastrectomy with Roux-en-Y esophagojejunostomy.

Metabolic consequences follow gastrectomies as well. Loss of gastric acid affects calcium and iron absorption from the duodenum, especially if the duodenum is bypassed. Incomplete antrectomy with retaining of a segment of isolated distal antrum can lead to the unusual “retained antrum syndrome” and its consequences. Bypass of the duodenum markedly alters the postprandial neurohormonal control of pancreatobiliary secretions and neuroregulatory postprandial hormones, the consequences of which still remain poorly understood (e.g., late dumping also and more appropriately called reactive hypoglycemia).

Therapeutic Vagotomy

Although several types of vagotomy do not involve any gastric resection (vagotomy/pyloroplasty and highly selective vagotomy), these now unusual procedures can lead to disorders that fall under the category of postgastrectomy syndromes (Fig. 90.2). *Mechanical* problems involve primarily the abnormalities discussed above—ulceration/stenosis, obstruction of afferent or efferent limbs of jejunum, and internal hernia. *Functional* problems are secondary to a combination of the loss of the pseudovalvular function of the pylorus after pyloroplasty, antrectomy, or the gastrojejunostomy, and the potential functional effects on gastric and intestinal motility (rapid gastric emptying of liquids-dumping, gastroparesis with delayed gastric emptying of solids, and rarely postvagotomy diarrhea).

Esophagogastrectomy Procedures

These operations involve resections of the esophagus, the esophagogastric junction including the lower esophageal sphincter (LES), and the vagal innervation to the gut (Fig. 90.3). Although the consequences of these resections are not "classic" postgastrectomy disorders, these types of resections are being performed more commonly, and the pathophysiologic consequences are similar to many of the classic postgastrectomy/postvagotomy syndromes. The *mechanical* problems of the esophagogastric resections (Fig. 90.3A and B) relate to anastomotic problems as well as the loss of the LES with consequent free gastroesophageal reflux; reconstruction with a colonic interposition adds all the infracolic *mechanical* problems of creating the colonic segment—adhesive obstruction, anastomotic stricture, etc. but avoids bile or acid reflux. Probably most relevant for this discussion, however, are the potential *functional* consequences of the obligate vagotomy—gastric emptying disorders or the dysmotility of the Roux limb or the colonic conduit. Definite *metabolic* sequelae are rare.

Nonresective Procedures at the Esophagogastric Junction

These operations are primarily the antireflux procedures (Fig. 90.4). *Mechanical* effects involve obstruction at the wrap—either too tight of a wrap or the wrap slips. More relevant to this chapter, however, are sequelae of inadvertent injury to the vagus nerves (especially with redo

antireflux procedures) with the potential *functional* motor disorders of the stomach and/or intestines. Definite *metabolic* sequelae are rare.

Bariatric Procedures

While the potential sequelae of bariatric operations do not fall "classically" under the category of postgastrectomy syndromes, the prevalence of these operations and their side effects on gastric function are very relevant currently and need also to be discussed in this chapter. The *mechanical* problems involve both of the anastomoses of the Roux-en-Y gastric bypass (Fig. 90.5A) and the biliopancreatic diversion/duodenal switch (Fig. 90.5C). The gastric sleeve (Fig. 90.5B) has its own, specific *mechanical* sequelae related primarily to obstruction either at the esophagogastric junction or at the incisura region of the sleeve; the creation of a lesser curvature sleeve of stomach also leads to a segment of proximal stomach that has no phasic contractile motility, which obligates a *functional* component to any relative obstruction at the region of the incisura. After a laparoscopic adjustable gastric band (Fig. 90.5D), the primary disorders involve a potential *mechanical* obstruction at the band (the band can be too tight or the band can slip) or a *functional* type of obstruction leading to a form of pseudoachalasia. Obviously, these bariatric procedures have many *metabolic* sequelae related to the underlying obesity, postoperative weight loss, nutritional challenges, etc., but the "postgastrectomy-like" potential sequelae secondary to the operations and their anatomy are often forgotten or not acknowledged. These involve the duodenal (jejunal) bypass (Fig. 90.5A), described above or the jejunoileal bypass (Fig. 90.5D); in addition, these excluded segments are subject to bacterial overgrowth.

Mechanical Disorders

Afferent Limb Syndrome

Construction of an anastomosis between the stomach and small bowel as a loop gastrojejunostomy (Fig. 90.1A) or in a Roux-en-Y configuration (Fig 90.1C,D) leaves the duodenum and the proximal-most jejunum proximal to the gastroenterostomy or the enteroenterostomy out of the flow of ingested chyme; this segment is called the biliopancreatic limb (or afferent limb). This proximal small bowel is responsible for delivering pancreatic secretions and bile into the more distal segments of intestine, where these digestive juices mix with and allow for digestion of the ingested food delivered via the efferent limb of a gastrojejunostomy or a Roux limb.

Disruption to the flow of the pancreatobiliary secretions past these anastomoses due to a partial or complete mechanical obstruction, such as from an anastomotic stricture, adhesions, an internal hernia, or recurrent cancer as after prior resection for gastric cancer, can lead to the development of afferent limb syndrome. The operative procedures that are at risk for this complication include gastrojejunostomy, subtotal or distal gastrectomy with Billroth II or Roux-en-Y reconstruction, and pancreatoduodenectomy with the typical Roux-en-Y–like reconstruction.

Symptomatology

Patients may present acutely and immediately after surgery with signs of mechanical obstruction, such as nausea, vomiting of liquids but not the ingested food, often vomiting of large amounts of bile (but not the ingested food) late after a meal, and abdominal discomfort, or the patient may present with low-grade, nonemergent, chronic complaints of generalized abdominal discomfort specifically after eating. The latter represents a more chronic and insidious form of afferent limb syndrome that requires operative intervention, the urgency of which is determined by the presentation of the patient. Rarely, the presentation can be either with acute pancreatitis secondary to obstruction of the pancreatic duct or jaundice secondary to obstruction to the flow of bile out of the bile duct secondary to the obstruction of the afferent loop with severe dilation of the pancreatobiliary limb. An acute presentation may warrant urgent or emergent operative intervention as determined by the physical examination, constellation of symptoms, and imaging. Presentation can be as early as the first week postoperatively or up to many years after operation. The average reported presentation is 5.5 years after the primary esophagogastric operation.

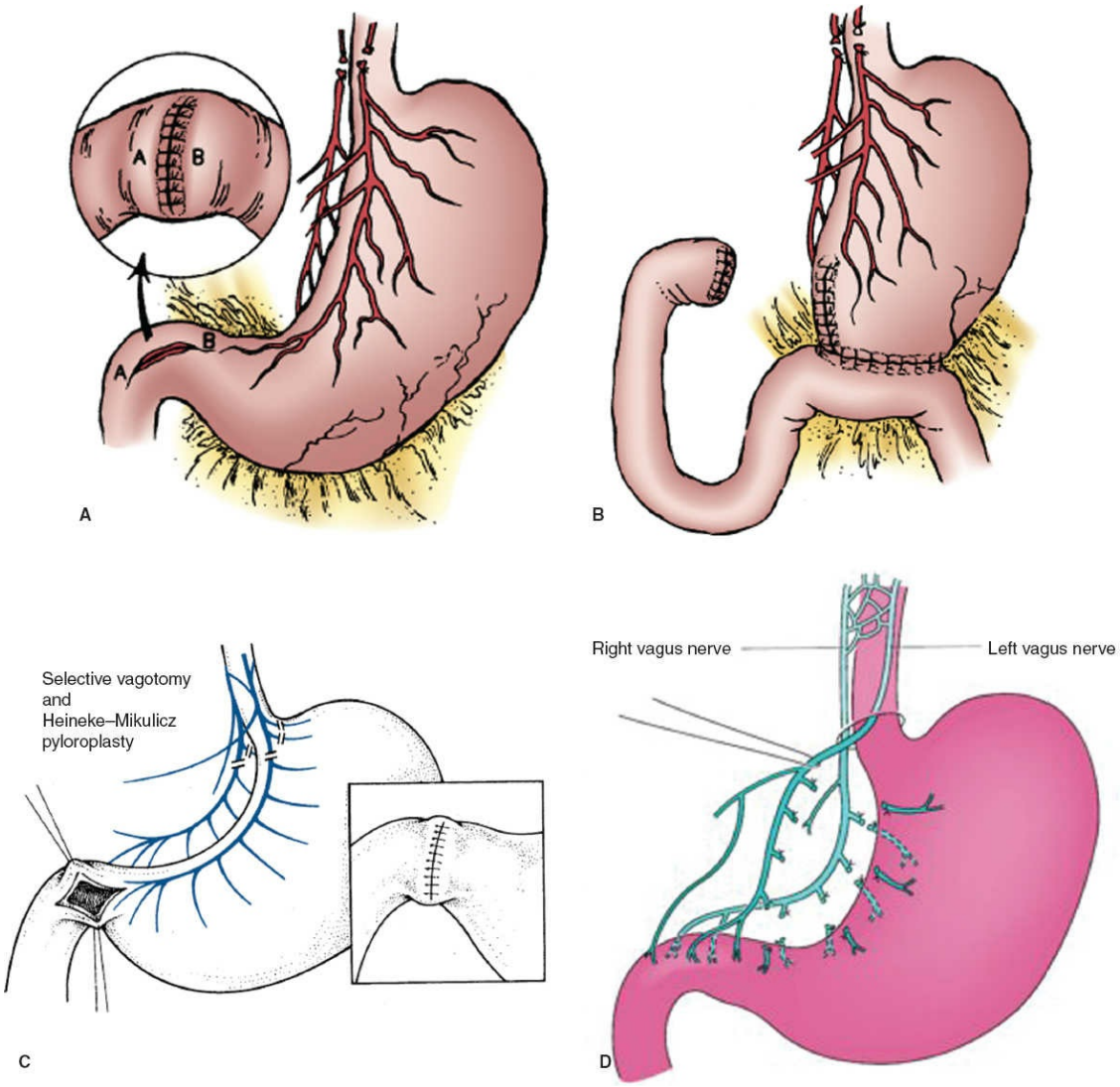

Figure 90.2. Therapeutic vagotomies. **A.** Truncal vagotomy with pyloroplasty. (Modified from Jarrell BE. *NMS Surgery (National Medical Series for Independent Study).* 6th ed. LWW; 2015.) **B.** Truncal vagotomy with loop gastrojejunostomy. (Modified from Jarrell BE. *NMS Surgery (National Medical Series for Independent Study).* 6th ed. LWW; 2015.) **C.** Truncal vagotomy/antrectomy/gastroduodenostomy. (From Lawrence PF, Bilbao M, Bell RM, et al., eds. *Essentials of General Surgery.* Baltimore, MD: Lippincott Williams & Wilkins; 1988:180.) **D.** Highly selective vagotomy (selective transaction of only vagal branches to the acid-producing corpus of the stomach). (Modified from Mulholland MW. *Greenfield's Surgery: Scientific Principles and Practice.* Lippincott Williams & Wilkins; 2017.)

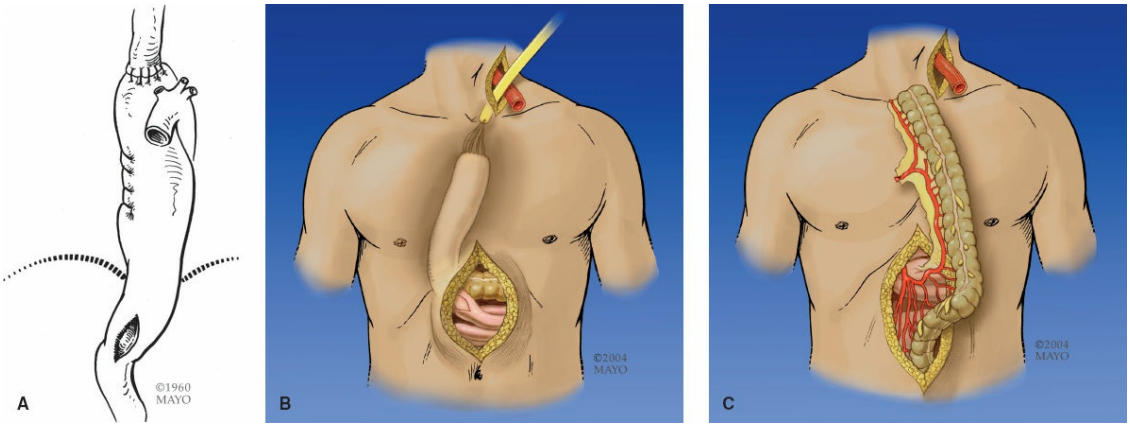

Figure 90.3. Esophagogastric resections (Mayo Clinic). **A.** Esophagogastrectomy with intrathoracic esophagogastrectostomy. **B.** Total esophagogastrectomy with gastric pull-up. **C.** Total/partial esophagectomy with colonic interposition.

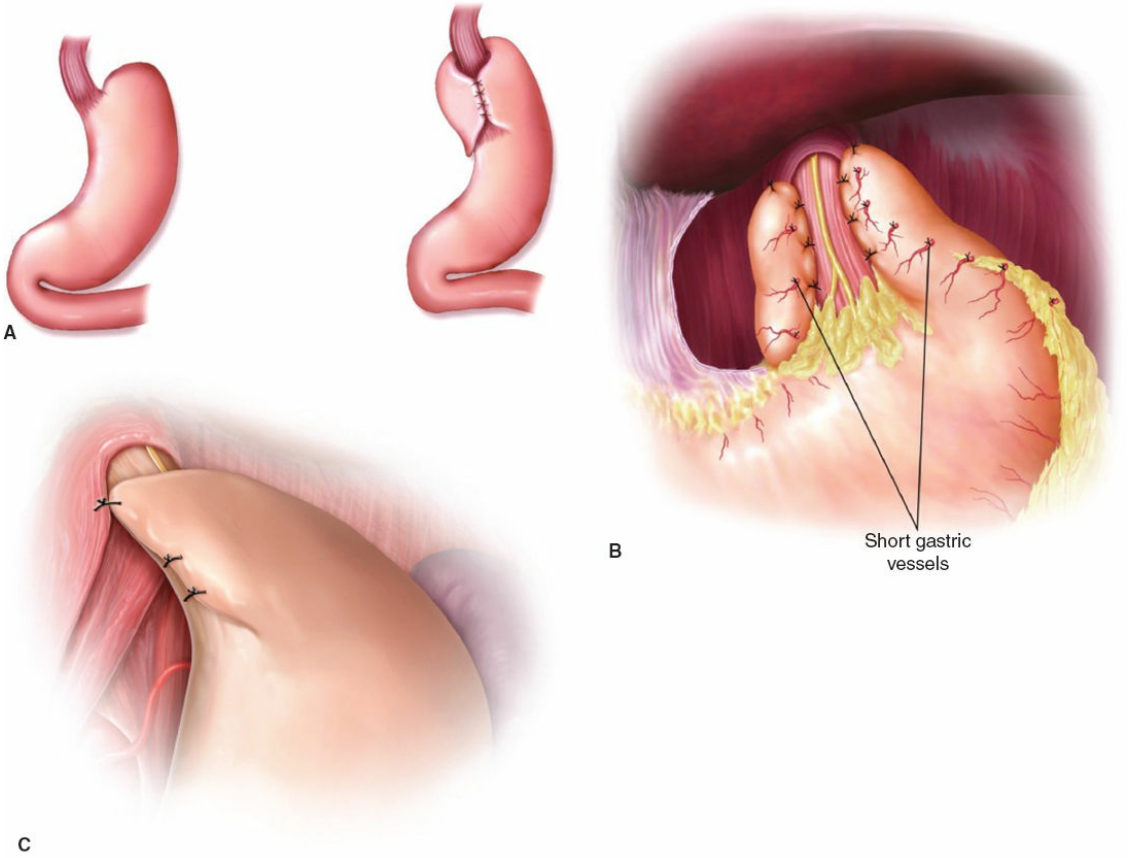

Figure 90.4. Procedures at the esophagogastric junction. **A.** Nissen fundoplication. (Reproduced from Kyle T. *Pediatric Nursing Clinical Guide.* 2nd ed. LWW; 2016.) **B.** Dor fundoplication. (Reproduced from Luketich J. *Master Techniques in Surgery: Esophageal Surgery.* 1st ed. LWW; 2014.) **C.** Toupet fundoplication. (Reproduced from Hawn M. *Operative*

Techniques in Thoracic and Esophageal Surgery. 1st ed. LWW; 2015.)

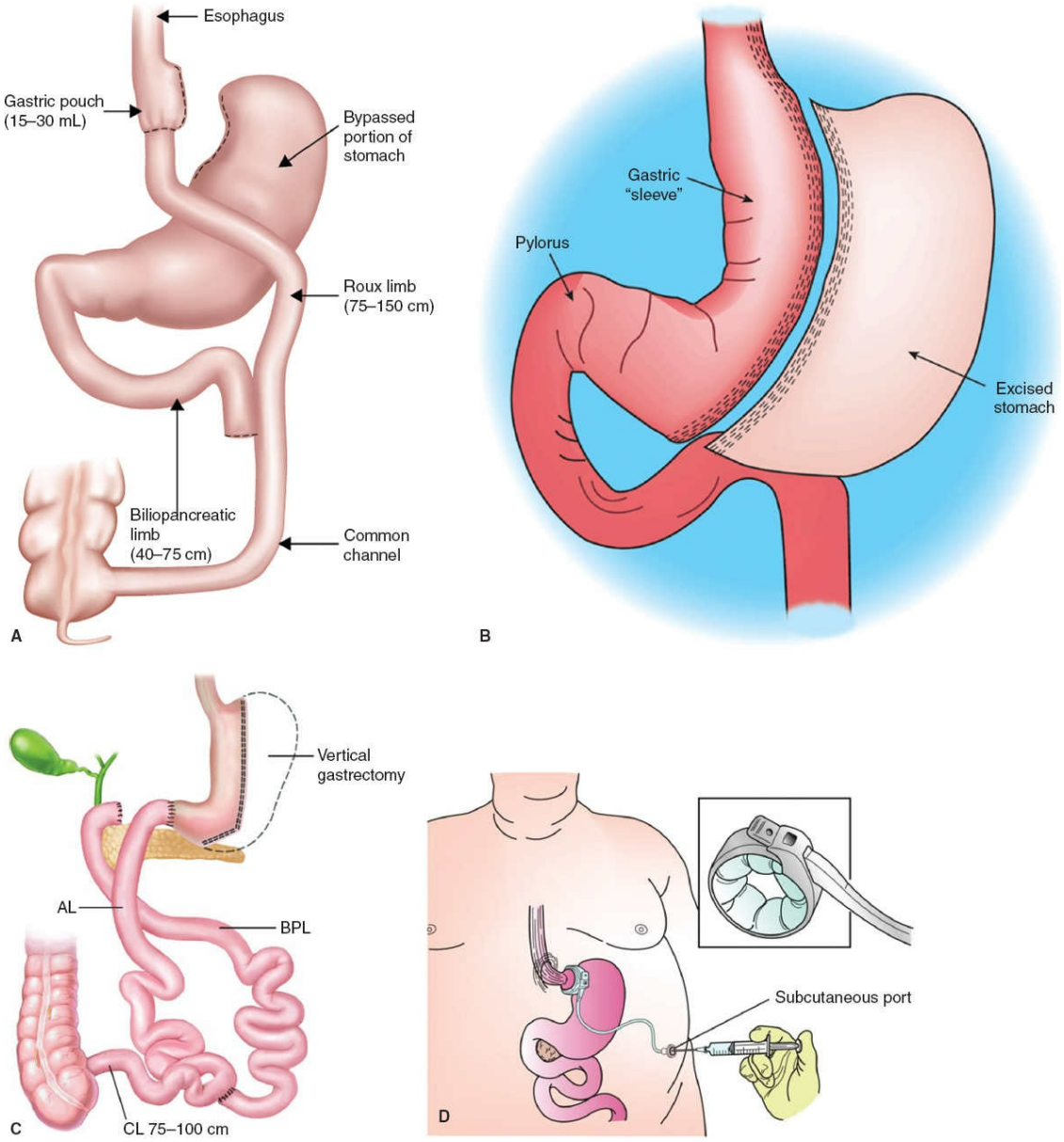

Figure 90.5. Bariatric procedures. **A.** Roux-en-Y gastric bypass. (Reproduced from Jarrell BE. *NMS Surgery (National Medical Series for Independent Study).* 6th ed. LWW; 2015.) **B.** Gastric sleeve. (Reproduced from Nettina SM. *Lippincott Manual of Nursing Practice.* 10th ed. Lippincott Williams & Wilkins; 2013.) **C.** Pancreatobiliary diversion/duodenal switch. (Reproduced from Nussbaum M. *Master Techniques in Surgery: Gastric Surgery.* LWW; 2012.) **D.** Laparoscopic adjustable gastric band. (Reproduced from Mulholland MW. *Greenfield's Surgery Scientific Principles & Practice.* 6th ed. LWW; 2016.)

Etiopathogenesis

A variety of anatomic complications can lead to the manifestations of mechanical obstruction. Postoperative adhesions may compromise the

flow of pancreatobiliary secretions past the anastomosis. In addition, the patient might have an intussusception, anastomotic ulcer from stricture, volvulus, or a bowel obstruction secondary to an internal hernia contributing to the mechanical obstruction. These hernias (often referred to as a Petersen hernia) occur posterior to the mesentery of a loop gastrojejunostomy or between the transected edge of the jejunal mesentery of the Roux limb (if brought retrocolically) and the retroperitoneum infracolically or the transverse colon if the Roux limb is brought antecolically. More rare etiologies include ingestion of nonfood objects, such as foreign objects or hair, causing a gastric bezoar blocking emptying of the stomach. Understanding the etiology is imperative to achieving a good long-term outcome, because the treatment of the underlying cause of the disease will decrease the risk of recurrence. For example, if the patient has a chronic problem with ingesting foreign materials in that clinical scenario, psychologic intervention is warranted. If the patient ingests routinely anti-inflammatory medications excessively, salicylate levels in the urine (not in the blood which has a much shorter half-life) may be performed to document if abuse is suspect and provide counseling as to the ongoing risks of this behavior. If the obstruction is secondary to salicylate or NSAID abuse, this behavior needs to be corrected before any operative intervention or the problem will likely recur.

Diagnosis

The diagnosis of afferent limb syndrome includes obtaining a full history and physical examination paying special attention to the associated pain after eating. Imaging includes an abdominal flat plate, an upper gastrointestinal study with small bowel follow-through performed with barium, or more often computed topography (CT). If the patient has a presentation indicative of chronic insidious symptoms, the diagnosis may be missed, and therefore, a high index of suspicion must be held. CT is the radiographic study of choice. On CT, the findings may be a dilated and fluid-filled duodenum and proximal jejunum (and stomach if still present). Again, a high index of suspicion may be necessary, because this finding may be absent after a prolonged fast. Likewise, an upper GI series may demonstrate the same finding of a markedly dilated pancreatobiliary limb, however, it is not unusual for nonopacification of the afferent loop in a normally functioning gastrojejunostomy or the pancreatobiliary limb after a Roux reconstruction; therefore, nonvisualization of the pancreatobiliary (afferent) limb after oral administration of contrast is suspicious but not

necessarily pathognomonic for the afferent loop syndrome. Abdominal plain radiographs may be helpful in identifying abnormal bowel gas patterns or air/fluid levels in the stomach; however, further confirmatory imaging study such as a CT may be needed. Utilization of endoscopy in the form of upper endoscopy to visualize anastomotic problems directly, such as marginal ulceration or kinking of the limb, can be tried. If there are worrisome submucosal or mucosal changes suggestive for instance of recurrent cancer after a prior resection for a gastric cancer, deep biopsies can then be obtained at that time if the recurrence does not involve the mucosa, however, the biopsies may be negative. Patients may have associated bacterial overgrowth in a chronic situation, and treating empirically for bacterial overgrowth may help to diagnose this pathology in a difficult scenario.

Treatment

Operative intervention is the mainstay of this disease process. The acuity of the presentation will determine the urgency of the operation. As stated above, the patient presenting with an acute obstruction may require an emergency operation. Patients who have a more chronic and insidious onset of symptoms may have the time for a proper evaluation paying attention to their nutritional status. Correction to improve their perioperative nutrition will help ward off postoperative complications such as delayed healing.

Intraoperative takedown of the prior anastomosis may be warranted. If the patient has a gastrojejunostomy, a conversion to a Roux-en-Y anastomosis is often preferred over the option of conversion to a gastroduodenostomy; note, however though, if the ulcer is acid-related, a higher gastrectomy is warranted to decrease acid production. While the gastroduodenostomy replicates the more normal anatomic state, mobilization of the remnant stomach and duodenum may be a challenge. Avoiding tension with a newly created gastroduodenostomy is critical, because the risk for anastomotic leakage increases. With the simple scenario of an adhesive band, perhaps adhesiolysis is all that is required. The quality and character of the small bowel will dictate whether or not a concomitant bowel resection is required. Intervention can be either via an open operation or a minimal access attempt at repair.

Efferent Limb Syndrome

The efferent limb (can be the Roux limb as well) is the segment of bowel

from the gastrojejunostomy that receives ingested food from the stomach to transport distally. In bariatric surgery, the length of this limb will affect weight loss; the longer the limb the more malabsorption that occurs. Efferent limb syndrome is a rare phenomenon that is seen after gastric surgery where there is a mechanical obstruction to the efferent limb. It is seen more commonly in the earlier postoperative period but can be seen years after the original operative procedure. If the original operation was for gastric cancer, one must always worry about recurrent gastric cancer with both the efferent loop syndrome and the afferent loop syndrome.

Symptomatology

The classic symptoms associated with the efferent loop syndrome are nausea and extreme crampy abdominal pain relieved only by vomiting. The vomitus will consist of the ingested food stuffs and may or may not consist of bile depending on the type of prior gastrectomy; bile will be absent if the patient has a Roux-en-Y reconstruction. The patient will also complain of early satiety and upper abdominal distention early after a meal.

Etiopathogenesis

The most likely etiology for the efferent limb syndrome is an ulcer at the gastrojejunal anastomosis or an internal hernia (see Petersen hernia below). Other factors, such as kinking, adhesions, or recurrent cancer can contribute to the clinical finding.

Diagnosis

An upper GI series with small bowel follow-through should show the source of the obstruction. The best diagnostic test after a prior loop gastrojejunostomy would be an upper endoscopy; the endoscopist will either see a stricture at the anastomosis or may not be able to get the endoscope out of the stomach. After a Roux-en-Y drainage, the endoscopist should be alerted to plan for an extended endoscopy down the Roux limb as well.

Treatment

As with afferent loop syndrome, operative intervention is the mainstay for treatment of this syndrome with revision of the gastrojejunostomy and as with the afferent limb syndrome, possible resection of more of the gastric remnant if the obstruction is related to ulceration at the anastomosis.

Endoscopic management is being reported increasingly with the use of endoscopic endoluminal stents to relieve the obstruction.

Petersen Hernia

In the early 1900s, the German surgeon Walther Petersen described this internal hernia after partial gastrectomy and gastrojejunostomy reconstruction. After the creation of a gastrojejunostomy, there is a potential space posterior to the anastomosis. This potential space may or may not be closed at the time of operation at the surgeons' discretion. Herniation of small bowel into this space may result in a bowel obstruction depending on how the loop of jejunum or the Roux limb is delivered to create the gastrojejunostomy. A retrocolic anastomosis brings the Roux limb through the transverse mesocolon, and bowel can become trapped infracolically in the defect posterior to the cut edge of the mesentery to the Roux limb and the retroperitoneum creating a true surgical emergency (as well as in the defect in the mesocolon).

Symptomatology

The symptoms of patients with a Peterson hernia may be vague. It is important that the surgeon and team have a high index of suspicion for this condition in patients presenting with small intestinal obstruction after gastrectomy and especially those bariatric patients with diffuse abdominal pain or unexplained vomiting after a Roux-en-Y gastric bypass. After bariatric surgery, the symptoms may occur related to the massive weight loss (and loss of fat making the defect larger) and typically will present during the 6- to 24-month window after laparoscopic Roux-en-Y bypass.

Etiopathogenesis

The frequency of this internal hernia space increased markedly during the early phase of laparoscopic gastric bypass surgery and was reported to be as great as 10% in some series and much greater than was observed with open surgery. Initially, these potential sites of internal hernias were not closed routinely. Decreased adhesions after laparoscopic surgery allows for the persistence of this defect, which was usually obliterated by the trauma of open surgery. In addition, patients often present after having a large weight loss; this weight loss is presumed to lead to loss of the fat in this region, thereby causing the defect to become bigger. Hernias after a Roux-en-Y gastric bypass can occur in three different locations: at the defect in the transverse mesocolon where a retrocolic Roux limb is

delivered to create the gastrojejunostomy, at the mesenteric defect of the enteroenterostomy, and posterior to the mesentery of the Roux limb in either in a retrocolic or antecolic position (this is the Petersen hernia). Higa et al. evaluated 2,000 patients with an internal hernia; the majority of the hernias, 67% occurred at the mesocolic defect, followed by the mesenteric defect at the enteroenterostomy (21%), and those at Petersen defect (8%), posterior to the mesentery of the jejunal limb. Because this phenomenon is now realized, most surgeons will now close these defects in order to avoid this postoperative complication.

Diagnosis

In addition to symptoms, a CT may show swirling of the mesentery in the left upper quadrant or a picture of a bowel obstruction. Imaging will have a better chance of detecting the hernia when the patient is symptomatic because of the dilation of the obstructed bowel; unfortunately, the CT is diagnostic in only about 65% of patients with an internal hernia. A small bowel follow through (SBFT) may help with the diagnosis. The normal finding should locate the enteroenterostomy in the left upper quadrant and no evidence of dilation. Worrisome findings will include either an obstructed Roux limb or a dilated pancreaticobiliary limb with displacement of the staple line with "clustering" of small bowel in the mid-abdomen or the left upper quadrant.

Treatment

A high index of suspicion is important to enable a successful outcome. Even in the setting of a negative imaging study, the surgeon may have to perform a diagnostic laparoscopy to exclude the possibility of such a devastating complication as strangulation of the Roux limb or the majority of the small bowel. Treatment of a presumed Petersen hernia represents a true surgical emergency that differs from the often-quoted adage used in other types of postoperative small bowel obstruction—"the sun should never rise and set on a small bowel obstruction." Treatment consists of operative exploration, reduction of the herniated contents, resection of compromised small bowel, and closure of the defect.

Stomal Ulcer

Symptomatology

Long-term studies have documented numerous complications that can occur after Roux-en-Y gastric bypass surgery. These bariatric patients

have been found to have inordinate amounts of acid secreted into the gastric pouch and may develop a stomal ulcer or a perforation in the staple line with a gastro–gastro fistula. These patients often present with symptoms of epigastric pain, hemorrhage, or even free perforation. Patients may report that the pain awakens them at night or pain that is relieved by taking antacids or ingesting food. Additional symptoms include nausea, vomiting, or the presence of blood in the vomitus; usually blood in the stool is absent. The presence of persistent epigastric pain despite adequate suppression of acid production may signify a chronic, contained perforation, which can lead to disabling epigastric pain.

Etiopathogenesis

Prior to the Roux-en-Y gastric bypass, stomal ulcers were associated with gastrectomies performed for malignancy or peptic ulcer disease that were reconstructed primarily with a Roux-en-Y configuration; although stomal ulcers can occur after a typical antrectomy and gastrojejunostomy or gastroduodenostomy with or without a truncal vagotomy, the incidence is quite low. In contrast, the incidence of stomal ulcers is as great as 10% after Roux-en-Y gastric bypass. The goal of creating a small pouch for weight loss is to restrict caloric intake and also to allow for decreased acid exposure of the anastomosis to the "unprotected mucosa" of Roux limb. It is often found that patients who develop stomal ulcers have an enlarged pouch that generates too much acid production or that a breakdown in the staple line allows acid formed in the bypassed stomach to reflux into the pouch and thereby damage the Roux limb. Other important proulcerogenic exposures to consider are chronic NSAID or aspirin exposure allegedly and excessive alcohol intake. Technical complications, such as an ischemic staple line, too large a pouch, and incomplete division of the gastric pouches with persistence of a gastro–gastro communication can contribute to the pathogenesis. In addition, several authors have implicated smoking and alcohol abuse in the etiopathogenesis of stomal ulcers after Roux-en-Y gastric bypass, but the senior author of this chapter does not support smoking or alcohol abuse as a cause of stomal ulcers.

Diagnosis

A history and physical examination are often able to distinguish whether the patient's symptoms are attributable to a stomal ulcer. Symptoms of dysphagia, pain that is worsened with eating, and nausea are indicative of the diagnosis. The definitive study of choice is an upper endoscopy paying

close attention to the area of the anastomosis. Additional studies such as a Gastrografin-guided evaluation of the upper GI tract may provide useful information.

Treatment

Treatment for this complication consists of decreasing and discontinuing proulcerogenic factors, such as discontinuing all aspirin and all NSAID use to aid in healing of the ulcer. Operative intervention is reserved for patients with complications related to the ulcer, such as perforation, stenosis, or unresponsiveness to medical management.

Functional Disorders

The majority of functional disorders after esophagogastric surgery are related to disruption of the neurohormonal regulation of motility of the stomach and small intestine secondary to either vagal nerve disruption (planned, obligate, or inadvertent), intestinal transection (creation of a Roux limb), and/or alteration of the normal anatomy of flow of ingested content (e.g., duodenal bypass). Regulation of gastrointestinal motility is a complex interplay of extrinsic neural innervation (primarily vagal innervation—both descending as well as ascending pathways), intrinsic innervation, and the continuity of the small intestine (the myenteric plexus), and postprandial hormonal release in the early phase (upper gut—duodenum, jejunum, and pancreas) and the late phase (distal gut—ileum and proximal colon) after ingestion of a meal.

Dumping Syndrome

Dumping syndrome is related to rapid emptying of ingested content into the small intestine. The spectrum of symptoms affects most all patients to a varying extent who undergo some form of gastric resective operation and/or a vagotomy. The term “dumping” has been used inappropriately in many situations and has become a term used too commonly to explain symptoms that may be related to many other disorders. In this chapter, we will define the appropriate use of this term and the appropriate situations where dumping is related to a postgastrectomy disorder.

Symptomatology

The symptoms of dumping are nausea, a feeling of bloating, and crampy abdominal pain often associated with the cardiovascular (“sympathetic”) symptoms of palpitations, tachycardia, flushing, and diaphoresis with a

feeling of being unwell. These symptoms come on early, within 10 to 20 minutes, after eating a meal. Many patients need to lie down for 30 to 60 minutes until the symptoms resolve. Note, diarrhea is not an obligate symptom of dumping, although diarrhea can occur later (2 or 3 hours postprandial) in some patients. The majority of patients do not have prominent diarrhea. The word “dumping” refers to the rapid, uncontrolled emptying of fluid from the stomach, gastric remnant, or esophagus into the small intestine (i.e., dumping of liquids), and not to having a watery bowel movement or diarrhea as thought of erroneously by many patients and too many physicians.

These symptoms are present to some extent in all patients with loss of pyloric function secondary to resection or pyloroplasty, but prolonged persistence of clinically relevant symptoms for greater than a month or two is quite rare unless there has been a concomitant vagotomy (see Etiopathogenesis below). For instance, after a Roux-en-Y gastric bypass (Fig. 90.5A), prolonged clinically relevant dumping almost never occurs, in contrast to the dumping symptoms after antrectomy and vagotomy (Fig. 90.1A,B) or after vagotomy with pyloroplasty or gastroenterostomy (Fig. 90.2), where clinically relevant dumping symptoms can persist for months or years, albeit still rare (2% of patients).

Etiopathogenesis

The etiology of the dumping syndrome is secondary to rapid, early emptying of liquids into the small intestine. The primary cause of dumping is related to the loss of the regulation of liquid emptying secondary to either resection of the pylorus with some form of gastroenteric or esophagoenteric anastomosis or to disruption of the function of the pylorus (pyloroplasty or pyloromyotomy). Addition of a vagotomy to the operation exacerbates markedly the early gastric emptying, because the vagotomy abolishes receptive relaxation of the proximal stomach. This vagally mediated “receptive relaxation” is very important physiologically, because the proximal stomach (and the intragastric pressure) controls gastric emptying of liquids. Vagotomy prevents the gastric “accommodation” of ingested liquids (i.e., gastric relaxation, which keeps the intragastric pressure low), causing increased intragastric pressure immediately after a meal and thereby accelerating gastric emptying of liquids. While almost everyone who undergoes loss of the pylorus or a pyloroplasty experiences some element (albeit usually transiently) of dumping, severe and prolonged dumping occurs virtually only inpatients with a concomitant

vagotomy. When ingested content “bypasses” the duodenum (Figs. 90.1A,C, 90.2B, and 90.5A,C), the physiologic feedback to slow gastric emptying mediated by the duodenal mucosal receptors for acid, sugar, fat, and osmolality is lost, also exacerbating early phase rapid emptying of liquids.

The pathogenesis of the symptoms is complex and still remains poorly explained. There was a lot written in the past about rapid, voluminous mucosal secretions into the intestinal lumen in attempt to decrease the high intraluminal osmolality secondary to rapid emptying of sugars into the small intestine with subsequent intravascular contraction and hypotension causing a sympathetic response (diaphoresis, nausea, etc.). That theory has been refuted—indeed, ingestion of high sugar content does exacerbate markedly the symptoms, but other meals without such a high content of sugar are also associated with symptoms in many patients. Currently, most investigators believe that the symptoms of dumping are related to a neurohormonal response to the rapid entry of nutrients into the small intestine (jejunum > duodenum) with the release of vasoactive agents that cause the symptoms (see below treatment with octreotide which inhibits much of this neurohormonal response).

Diagnosis

The diagnosis of dumping is a clinical diagnosis based on symptoms. A radionuclide gastric emptying test can be confirmatory but is not always necessary, and one must be certain that the radionuclide marker is a marker of liquid emptying, not a marker of the emptying of solids. Similarly, a glucose challenge of 200 mL of a 50% glucose solution should elicit the spectrum of symptoms but again, is usually unnecessary.

Treatment

In the era of gastric vagotomies for duodenal ulcer disease, dumping was quite common but is much less common now that elective therapeutic vagotomies are no longer performed. Currently, most patients do well with diets avoiding liquids when eating as well as avoiding any high sugar loads. Moreover, symptomatic dumping almost always improves with time postoperatively. For instance, after a Roux-en-Y gastric bypass, mild dumping is quite common early postoperatively (some even maintain that the dumping symptoms are a form of behavior modification—i.e., avoidance of calorically dense foods). After the first month or two, however, this dumping disappears (unfortunately in the mind of a bariatric

surgeon); indeed, prolonged symptoms of “dumping” after a Roux-en-Y gastric bypass should question the diagnosis of dumping. The lack of prolonged symptoms is probably due to the lack of a vagotomy with these bariatric operations.

There is a small subset of patients with persistent dumping—again usually after an obligate vagotomy accompanying a gastric resection. If intensive dietary intervention fails, including a trial of acarbose, an alpha-glucosidase inhibitor to slow the breakdown of complex carbohydrates in the gut (this pharmacologic trial usually fails), then consideration should be given to a trial of octreotide given 30 minutes before each meal; the rare patient will have dramatic benefit, and treatment with a long-acting depot of octreotide is indicated.

Should incapacitating symptoms persist, and again this scenario is quite unusual, some consideration can be given to operative intervention in selected patients. The idea of a reversed 10-cm segment of proximal jejunum is an operation of historic interest only. Most classic GI surgeons (like the authors of this chapter) do not believe this operation provides any benefit, and it does have some risk of a relative obstruction if the reversed segment is too long. In contrast, if the patient has an intact pylorus after a prior vagotomy and gastroenterostomy (Fig. 90.2B), or has had a loop gastrojejunostomy after an antrectomy (Fig. 90.1B), restoration of gastroduodenal flow of ingested content may help the symptoms. If the patient has had a pyloroplasty, reconstruction of the pylorus may help—note that published, evidence-based experience with pyloric reconstruction is scarce and largely anecdotal. Finally, conversion from a loop gastrojejunostomy to Roux-en-Y gastric drainage (Fig. 90.1C) may help, because Roux-en-Y drainage of the stomach often slows gastric emptying. No one has much experience with these operations, and an honest discussion with the patient with no guarantees is suggested when discussing this approach preoperatively in the persistently symptomatic patient.

Gastroparesis

The gastroparesis that complicates many forms of gastric and esophageal resections and also the therapeutic vagotomies of the past are unappreciated, misdiagnosed, and all too often poorly understood. Consideration and diagnosis of this postgastrectomy/postvagotomy disorder requires an understanding of normal gastric motility, while treatment is based on the pathophysiologic consequences of the

combination of both the gastrectomy, but importantly, also the associated vagotomy.

Symptomatology

Postgastrectomy/postvagotomy gastroparesis is primarily a clinical diagnosis based on symptoms. The cardinal symptoms are early satiety and especially vomiting of nondigested food more than 6 hours after eating. Weight loss can be substantial and rarely life-threatening, but in other patients with a more mild form, weight loss may be unimpressive. Nausea, bloating, and/or abdominal pain can be common complaints as well, but the key sign that is virtually pathognomonic is that of vomiting of solids eaten the day before. Interestingly, this symptomatology often takes years to become clinically important after the gastrectomy, on occasion up to 5 years postoperatively and in patients with a prior gastrectomy, only in those who have had a concomitant vagotomy.

Etiopathogenesis

Understanding gastroparesis requires a basic understanding of the regulation of gastric emptying. In summary, the proximal stomach controls the emptying of liquids, while the mid to distal stomach controls the breakdown and emptying of solids. Normally with the ingestion of a meal, the proximal stomach relaxes to accommodate the volume; this is referred to as “receptive relaxation.” The proximal stomach then slowly increases its tone, decreasing its volume by a slow, tonic contraction, and thereby increasing intragastric pressure; when the pressure in the gastric lumen exceeds the intraluminal pressure in the duodenum, liquids empty from the stomach, usually emptying completely within 30 to 40 minutes. The distal stomach plays a minimal role in emptying of liquids.

In contrast, the distal stomach controls emptying of solid foods. Postprandially, the stomach changes its contractile pattern to one of propagated, peristaltic contractions (3 to 5 per minute) designed to break down mechanically the solid ingested particles in the antrum into pieces less than 1 mm, the so-called “trituration”; the pylorus contracts and relaxes in coordination with these antral contractions in a way that only allows small particles (less than or equal to 1 mm) to pass through the pylorus and into the duodenum—this coordination is referred to as the “antropyloric pump.” Particles larger than 1 mm are retropulsed back into the lumen of the body of the stomach, and the trituration process continues until the solids are fully broken down and emptied over the next 1 to 2

hours. Emptying of solids requires phasic, peristaltic contractile activity in the mid to distal stomach. This antropyloric coordination is also mediated in part by the vagal innervation.

Vagotomy has two effects. First, vagotomy prevents proximal gastric relaxation, causing the pressure in the proximal stomach to increase rapidly after a liquid meal, leading to an early, rapid emptying of liquids—one of the aspects of dumping. The second effect of vagotomy is a disruption of the antropyloric coordination, causing a relative obstruction at the pylorus which fails to relax fully with the onset of the antral contractions, often with prevention of gastric emptying of solids. This is the reason that Dragsted recommended pyloroplasty when performing a truncal vagotomy and why after an esophagogastrectomy (which obligates a truncal vagotomy), most surgeons perform either a pyloroplasty or a pyloromyotomy.

Diagnosis

The diagnosis of gastroparesis requires suspicion, and the hallmark is the presence of vomiting of food eaten the day before. Confirmation of the clinical diagnosis requires exclusion of any mechanical obstruction at the gastroenteric anastomosis, at the pylorus if it is still intact, or in the small intestine. The finding of solid food particles in the gastric lumen after an overnight fast and the lack of gastric distention in the absence of any mechanical obstruction virtually clinches the diagnosis of postgastrectomy/postvagotomy gastroparesis. Note, unlike with the mechanical obstruction related to a pyloric stricture, obstruction of an antral neoplasm, or stomal stenosis where the stomach is dilated and the gastric muscular wall is thickened, gastroparesis lacks both gastric distention and gastric wall thickening.

Formal radionuclide tests of gastric emptying can be done and should show retention of a solid marker, with a markedly decreased percentage emptied at 4 hours and with a half-emptying time of greater than 2 hours. Be careful to confirm that the radionuclide marker used actually labels the solids and not the liquids; this assurance is very important, because postvagotomy/postgastrectomy gastroparesis affects solids more than liquids. Upper gastrointestinal radiologic contrast studies and CT will show the presence or absence of gastric dilation; however, the rate of emptying of the contrast agent is unreliable as a test of gastric emptying.

Treatment

The first approach to treatment involves dietary modification in attempt to find foods that are soft and broken down easily but provide enough calories to maintain health and nutrition. Many patients can be managed by dietary change alone. Low-dose erythromycin to treat symptoms (150 mg given 30 minutes before a meal) may help with emptying of gastric contents and relieve symptoms. There are few if any other good or effective prokinetic agents available. Domperidone targets dopaminergic receptors in the antrum and may provide some benefit as may metoclopramide, but usually both of these purported prokinetic agents are ineffective. Note that domperidone will be ineffective after a distal gastrectomy.

When oral intake cannot support nutritional needs, operative treatment needs to be considered. The principles of operative treatment are based on the underlying abnormal motility and not the site of any gastroenteric anastomosis or the diameter of the anastomosis (unless there is an anastomotic obstruction secondary to a stricture or neoplasm). After a vagotomy and either pyloroplasty (Fig. 90.2A) or gastrojejunostomy (Fig. 90.2B), the problem lies in the more proximal stomach; an antrectomy, even with a very wide gastroduodenostomy or gastrojejunostomy, will not solve the problem of the gastroparesis. After a distal gastrectomy with either gastrojejunostomy (Fig. 90.1A) or gastroduodenostomy (Fig. 90.1B), widening of the anastomosis, or converting a loop gastrojejunostomy or a gastroduodenostomy, to a Roux anatomy or vice versa, will also fail, because the problem is a generalized lack of tonic contractions (proximal stomach) or coordinated distal phasic, peristaltic gastric contractile activity. Therefore, the best operative option is to resect greater than 95% of the stomach, leaving only a 1-cm cuff of cardia (a near total or near-total completion gastrectomy) with Roux-en-Y cardiojejunostomy; leaving 1 cm of cardia allows a safer gastrojejunostomy versus an esophagojejunostomy. The key is not to leave a gastric remnant (reservoir) of greater than 20 mL where stasis of solids can occur.

Despite a complete workup and a confident, careful diagnosis of gastroparesis, a near-total gastrectomy with Roux-en-Y cardiojejunostomy provides complete relief in only about 50% of patients; the other 50% require some form of nutritional support, either intravenously as parenteral nutrition or via an enterostomy tube which in the authors' opinion should be placed routinely at the time of the near-total gastrectomy. Patients who

fail near-total gastrectomy probably have a form of intestinal dysmotility induced by the disruption of the vagal innervation to the gut. One preoperative symptom that is worrisome for a poor is the presence of crampy abdominal pain. In these patients before proceeding with near-total gastrectomy, the senior author of this chapter recommends a trial of nasojejunal tube feeding; if the patient cannot tolerate tube feedings at a rate of at least 75 mL/hr of 0.9% sodium chloride, a near-total gastrectomy would not be expected to provide any benefit.

Special situations: Two forms of gastroparesis complicating two types of operations deserve special mention: esophagogastrectomy (Figs. 90.1D and 90.3) and antireflux operations (Fig. 90.4). Similarly, early delayed gastric emptying after a gastrectomy will be discussed to differentiate this reversible, transient delayed emptying from gastroparesis.

Esophagogastrectomy

Complaints of delayed gastric emptying after this operation are very common for several reasons. First, this operation obligates a complete vagotomy of the remnant stomach and small intestine. Second, most surgeons perform a concomitant pyloroplasty or pyloromyotomy, thereby further disrupting pyloric function and allowing free reflux of duodenal content into the gastric remnant. And third, the gastric conduit (Fig. 90.3A) is largely intrathoracic, and thus subject to the negative pressures of inspiration, which exacerbates the reflux. Symptoms involve an element of early satiety, gastroesophageal reflux and orogastric regurgitation, and vomiting in all patients, but these symptoms are especially severe in the subset of patients with moderately severe gastroparesis. Weight loss is common and can be severe enough to threaten maintenance of nutrition and health by oral intake alone. The diagnosis is relatively severe with the presence of solid matter and often bile in the gastric conduit.

Treatment is complicated and involves dietary management, a trial of erythromycin as a prokinetic agent, and supportive care. But there is a subset of patients in whom oral nutrition is unable to support their weight and health, and vomiting and reflux are incapacitating. The usual operative treatment for gastroparesis, that is, near-total gastrectomy to remove any gastric reservoir, is quite a bit more complicated in these patients with their anatomy, because access to allow resection of the gastric conduit through the abdomen is not feasible. For this reason, operative intervention is much less common. Operative treatment would involve resection of the

gastric conduit and reconstruction with an esophageal anastomosis to a defunctionalized intestinal conduit. This operation requires a thoracic as well as abdominal approach with construction of a conduit of preferably a Roux limb of jejunum, provided an adequate, well-vascularized length of jejunum can be created. If a Roux limb of jejunum is not possible, then a colonic conduit can be constructed (Fig. 90.3B); however, the functional results of a colonic conduit, though not well described, would be expected to be less satisfactory than those of a Roux limb. A colonic conduit adds considerably more potential postoperative morbidity. Obviously, such an undertaking is a substantial endeavor, and no one has any sizable experience with this procedure; therefore, no strong recommendations are possible based on evidence-based data. There have been reports of lesser operations such as creation of a Roux limb to be sewn to the gastric conduit to "help" gastric emptying—these operations should be condemned for gastroparesis after an esophagogastrectomy, because they do not treat the pathophysiology.

Antireflux Procedures

Although not a classic postgastrectomy disorder, gastroparesis can occur after these procedures—albeit quite rarely. This form of gastroparesis is also related to a vagal injury that occurs during the antireflux procedure; most cases occur in the setting of a reoperative procedure, where there is difficulty recognizing the vagal trunks and protecting them during the mobilization. Symptoms differ a bit from the more common gastroparesis that complicates esophagogastric resections. Vomiting and gastroesophageal reflux are much less common, because of the antireflux fundoplication (Fig. 90.4). In contrast, early satiety, bloating, and often abdominal pain are more common. Many of the symptoms mimic those that are common early postoperatively after an antireflux procedure, but these early postoperative symptoms usually resolve in 2 to 3 months. In contrast, when these symptoms persist, the diagnosis of postgastrectomy gastroparesis is neither entertained nor understood. The diagnosis relies on endoscopy showing retention of solid material in the stomach indicative of delayed gastric emptying. As with postgastrectomy gastroparesis, the stomach should not be dilated or have a thickened wall. Should the stomach be dilated with a thickened wall, a source of mechanical obstruction should be sought, for example, pyloric stricture or a dysfunctional pylorus secondary to the vagotomy.

Treatment of gastroparesis complicating a presumed vagal injury during

an antireflux procedure is complicated. Because antireflux procedures do not include any operative alteration of the pylorus, and we know that vagal innervation does modulate the antropyloric coordination, a trial of erythromycin, metoclopramide, and/or domperidone as a prokinetic agent is indicated; if no positive results occur, then prior to any operative intervention, a trial of injection of botulinum toxin into the pyloric muscle to cause relaxation should be tried, especially if the stomach is dilated or has a thickened wall. If these pharmacologic approaches provide good relief, a pyloroplasty done laparoscopically should be entertained with the thought that the vagotomy had its effects on the distal and not the proximal stomach.

If neither of these pharmacologic trials have any noticeable defect (which is most common), then the discussion with the patient and the patient's medical physician becomes difficult, because the suggested operative procedure will be to create the anatomy of a near-total gastrectomy by performing a nonbariatric Roux-en-Y gastric bypass or maybe better called a "stomach bypass" (so that it is not confused with a bariatric operation by the patient's insurance carrier). This operation should minimize the volume of the proximal gastric pouch to less than 20 mL; resection of the rest of the stomach is not necessary (Fig. 90.5A), because it will be functionally bypassed, and ingested food will not enter the dysfunctional stomach. Results with this approach, though limited, have been disappointing unfortunately with satisfactory results in only about 20% to 40% of patients; the remainder of patients have required enteral feeding or parenteral feeding if the vagotomy also affects the ability to tolerate enteral feeding.

Early Postoperative Delayed Gastric Emptying

Prolonged delay in gastric emptying in the early postoperative period is a well-known, transient complication of gastrectomy with and without vagotomy, and although the vagotomy (and probably some form of dysmotility) plays a role in this transient dysmotility, most patients recover in 2 to 6 weeks; persistence of this "gastroparesis" is very unusual. Interestingly, the patients who develop later the chronic form of postgastrectomy/postvagotomy gastroparesis described above, do so months to years after the vagotomy and not early postoperatively. Treatment of this form of early postoperative delayed gastric emptying is supportive and expectant, because the delayed gastric emptying is expected to resolve completely. A trial of erythromycin and/or

metoclopramide can be tried, but no operative intervention should be undertaken. A relatively common clinical situation of delayed gastric emptying postoperatively is in patients who have undergone operation for chronic (mechanical) gastric outlet obstruction from stricture or cancer who have a markedly dilated stomach and a thickened wall; when treating these patients with either a pyloroplasty, a gastrojejunostomy, or a distal gastrectomy, some consideration should be given to placing a tube gastrostomy, such that should delayed gastric emptying occur, as it does in 5% to 10% of patients with chronic mechanical obstruction, they will not need a long, indwelling nasogastric tube.

Reactive Hypoglycemia or Noninsulinoma Pancreatogenous Hypoglycemia Syndrome (NIPHS)

Symptomatology

Reactive hypoglycemia, often called inappropriately "late dumping," involves the development of true hypoglycemia (blood glucose concentrations of less than 40 mg/dL) that occurs usually 90 to 150 minutes postprandially. The symptoms are similar to those of dumping but are much more pronounced and are those primarily of hypoglycemia—tachycardia, palpitations, diaphoresis, and in severe cases even seizures, syncope, and seriously altered mentation, even suggestive of a psychiatric condition. These symptoms mimic all those of an insulinoma and can be quite incapacitating by affecting job performance, safe driving, and social interactions. Many patients, just as those with an insulinoma, have learned to reverse the symptoms with an oral load of sugar when they can anticipate the onset of the symptom, but more worrisome are those in whom there are no real premonitory signs or symptoms.

To the generation of classic GI surgeons who experienced the postgastrectomy/postvagotomy disorders of in the era of duodenal ulcer surgery, this disorder of "reactive hypoglycemia" was well known, albeit rare. Currently, this syndrome has resurfaced again with the now very prevalent use of the Roux-en-Y gastric bypass procedure for morbid obesity; the presence of hypoglycemia about 2 to 3 hours after eating has been noticed increasingly in this population and has been termed the noninsulinoma pancreatogenous hypoglycemia syndrome or NIPHS as a "new" entity. Actually, NIPHS and reactive hypoglycemia are the same entity with the same symptoms, both related to early entry of caloric-dense carbohydrates into the proximal small intestine in conjunction with a

concomitant bypass of the duodenum (Fig. 90.5A) (see Etiopathogenesis below).

Etiopathogenesis

Reactive hypoglycemia can occur secondary to the rapid emptying of sugar into the jejunum associated with bypass of ingested content from the duodenum. Entry of sugars into the jejunum leads to rapid absorption of glucose and a very rapid increase in blood glucose concentration usually 30 to 60 minutes postprandially, often although not always associated with symptoms of dumping. This rapid increase in blood glucose concentration leads to a resultant, uncontrolled release of insulin from the pancreas which then leads to a rapid "reactive" decrease in blood glucose concentration to values less than 40 mg/dL (the lower limit of normal in women; the value in men is less than 60 mg/dL). There is one important difference in these patients compared to those with only dumping—that is, the duodenal bypass. Diversion of luminal sugars from the duodenum prevents a poorly understood "brake-like" function on insulin release when ingested foods pass through the duodenum. Whether this inhibition is mediated by the duodenum (the foregut theory) or by the distal small intestine (the hindgut theory) remains highly debated currently. Supporters of the foregut theory suggest that there are receptors that act via pancreatoduodenal neural pathways or hormones released by the duodenal mucosa that suppress any "overshoot" in insulin release secondary to the acute, early, postprandial hyperglycemia; in contrast, supporters of the hindgut theory implicate hormones released from the distal gut that prevent the "brake" on insulin secretion from the pancreas in response to the hyperglycemia. Several groups have studied patients with NIPHS and have suggested the presence of a reactive beta-cell hyperplasia as causative of this condition based on the pathology of the resected pancreas. Definitive pathologic confirmation of this type of a nesidioblastosis, however, is not yet overwhelmingly convincing. The concept of a hyperplasia of beta cells is a very attractive one, because the onset of NIPHS usually occurs months to several years after the Roux-en-Y gastric bypass and not immediately or early postoperatively and resolves with operative intervention (see below) which also takes several months to occur fully; this condition requires chronic duodenal diversion but for unknown reasons does not occur in everyone undergoing a Roux-en-Y gastric bypass, thus suggesting some underlying predisposition. Indeed, local intra-arterial infusions of agents known to stimulate the release of

insulin have suggested an abnormal response with augmented insulin release, suggestive of the loss of the normal “break” on insulin release in response to hyperglycemia.

Diagnosis

The diagnosis of reactive hypoglycemia (or in the bariatric patient with NIPHS) requires first the clinical suspicion in the patient with the appropriate postoperative anatomy (note that the bariatric operations of gastric sleeve [Fig. 90.4B] and laparoscopic adjustable gastric band [Fig. 90.4D] are not associated with NIPHS) and a documented blood glucose concentration of less than 40 mg/dL. The use of the various indirect estimates of blood glucose by, for instance, blood glucose tapes or subcutaneous sensors as used commonly today, lack appropriate sensitivity and specificity; direct measurements of blood glucose concentration by venous blood are necessary. Without documented hypoglycemia, the symptoms of many disorders can be quite similar and nonspecific, because they are quite subjective (palpitations, diaphoresis, changes in cognition) and “supported” by the all-too-common complaint of “hypoglycemia” by many patients; true hypoglycemia is quite uncommon despite the often-voiced concerns by the patient of “hypoglycemia.”

The diagnosis of reactive hypoglycemia requires exclusion of an insulinoma and the other causes of hypoglycemia—medications, surreptitious injection of exogenous insulin, etc. If other causes are excluded, monitoring of blood glucose concentrations and blood insulin levels beginning 30 minutes after the type of meal that stimulates the symptomatology and continuing the blood glucose concentrations at 15-minute intervals for 3 hours can obtain support for the diagnosis. Supportive evidence would include blood glucose concentrations increasing rapidly from 30 to 60 minutes, followed by blood insulin levels increasing rapidly from 60 to 90 minutes, followed by rapidly decreasing blood glucose concentrations, eventually decreasing to less than 40 mg/dL; patient symptoms should parallel these late decreases in blood glucose concentrations.

Treatment

As with dumping, most patients can be controlled with dietary management—avoidance of foods with a high sugar density, limiting liquid ingestion with meals (in an attempt to slow gastric emptying), and a trial of acarbose (an alpha-glucosidase inhibitor) and octreotide, both of

which rarely work successfully. In the rare patient who remains incapacitated, the goal of operative intervention is to restore the flow of ingested content back into the duodenum. This anatomy can be accomplished by taking down the Roux-en-Y gastric bypass and restoring normal gastroduodenal continuity (Fig. 90.4A), by converting the Roux-en-Y anatomy to that of a gastric sleeve (Fig. 90.4B), by placing a gastrostomy into the gastric remnant for delivery of nutrition (not an attractive solution), or by transecting the Roux limb about 60 cm distal to the gastrojejunostomy and diverting the luminal outflow of the Roux limb into the proximal duodenum by a jejunoduodenostomy All these procedures take several months before the full extent of improvement in the hypoglycemia occurs, thus supporting the concept of "reactive nesidioblastosis" and the need for reversion or subsequent reversal of the hyperplasia of the beta cells to a more normal number of insulin-releasing cells. For the more unusual patients who have had a gastrectomy with Roux-en-Y drainage, redirection of the Roux limb into the duodenum is possible and restores the flow of ingested content into the duodenum. The senior author has anecdotal experience with this type of redirection of the drainage of the Roux limb into the proximal duodenum in eight patients recently; the results have been very encouraging with near complete reversal of symptoms in 6 of the 8 patients by 6 to 12 months postoperatively.

Postvagotomy Diarrhea

Postvagotomy diarrhea is extremely uncommon and is largely untreatable. This disorder is solely a diagnosis of exclusion, and when this disorder is present, it proves to be incredibly frustrating to both the patient as well as the treating physician.

Symptomatology

The overwhelming symptom is postprandial watery diarrhea that accompanies each meal and comes on early 15 to 30 minutes after eating. There can be cramping but usually the discomfort is mild. Often, the diarrhea will contain noticeable particulate matter of the food ingested, indicative of very rapid transit. Weight loss can occur but is usually not life-threatening. One of the distinguishing factors is that between meals and during fasting, there is no diarrhea.

Etiopathogenesis

The cause of postvagotomy diarrhea is largely unexplained. The vagus nerves innervate all the organs of the upper gut, including the jejunoileum. Vagal innervation affects gastric motility (see above Postgastrectomy/Postvagotomy Gastroparesis) but also small intestinal motility. Unfortunately, the effects of vagotomy on intestinal motility are not well understood. Hindering our understanding of postvagotomy diarrhea is the fact that vagotomy causes this form of diarrhea in less than 1% of those undergoing total abdominal vagotomy; unlike in gastric motility, there is no good experimental model for the study of small intestinal postvagotomy dysmotility. Vagal innervation, just like sympathetic innervation, also does modulates absorption and secretion from the gut, and postvagotomy diarrhea appears to have an element of both abnormal motility (rapid transit) and abnormal absorption (secretory diarrhea).

Diagnosis

Postvagotomy diarrhea is a true diagnosis of exclusion; there is no pathognomonic sign, symptom, or laboratory test. The diarrhea is neither a pure secretory form, nor steatorrhea, nor a global malabsorption. All other causes of diarrhea need to be excluded: mucosal abnormalities, infection, inflammatory bowel disease, partial small intestinal obstruction, colonic disorders, pharmacologic side effects, etc. A strong suggestion is to get the input of a thoughtful gastroenterologist in the workup. Once all the other potential causes of diarrhea have been excluded, the diagnosis can be entertained in patients with the appropriate clinical scenario who have had an abdominal vagotomy.

Treatment

The real problem is that there is no known effective treatment for this disorder, neither pharmacologic nor operative. In the past, suggestions based solely on anecdotal observations have been made to construct a reversed intestinal segment—no one has had a large enough experience to provide any level of evidence-based support for any operative treatment. Pharmacologic treatments to slow the transit or to decrease “secretion,” even with the use of octreotide, have been unsuccessful. Because this is a type of secretory, rapid transit diarrhea and not a global malabsorption, malnutrition is usually not the problem—rather; volume replacement and social implications of debilitation predominate.

Roux Stasis Syndrome

The term “Roux stasis syndrome” was coined to describe a spectrum of symptoms noted in patients who had undergone some form of gastrectomy with restoration of intestinal continuity via a Roux-en-Y anatomy; the Roux limb was believed initially to be the site of functional obstruction of ingested content. Much of the interest in this “entity” was popularized before our current understanding of the importance and prevalence of postvagotomy/postgastrectomy gastroparesis. Whether the Roux stasis syndrome really exists or is even common remains questionable in the minds of many GI surgeons. If it does exist, the incidence is exceedingly rare, and the majority of patients who are diagnosed with this “syndrome” are much more likely to have gastroparesis.

Symptomatology

Symptoms of the Roux stasis syndrome are vague but dominated by early satiety and vomiting, symptoms that are very similar if not identical to postgastrectomy gastroparesis in patients with a gastric remnant. Support for an etiology that involves abnormal motility in the Roux limb is those patients after a total gastrectomy in whom there is no gastric remnant but who exhibit this clinical scenario. Clinically, the course can be serious with weight loss threatening the ability to maintain adequate nutrition orally. A notable observation is that virtually all, of these patients have had a prior vagotomy as part of their gastrectomy. Interestingly, this syndrome is absent in the hundreds of thousands of patients who have undergone a Roux-en-Y reconstruction (which does not involve a vagotomy) as part of the Roux-en-Y gastric bypass. Challenging the existence of this disorder is the fact that if this syndrome was related solely to the Roux anatomy, we should have seen many patients to date in our bariatric population.

Pathogenesis

The underlying disorder with the Roux stasis syndrome is likely related to a functional obstruction to the flow of ingested food distally through the Roux limb. All studies used to explain the abnormal motility have been done experimentally in the dog model that appears to be a good model of many aspects of intestinal motility in man. Physiologically, small intestinal contractions are oriented aborally (proximal to distal) controlled by the continuity of the myenteric plexus and their rate and direction of propagation are driven by the duodenal “pacemaker” located in the proximal duodenum. When the intestine is transected (as needed for the

creation of a Roux limb), the continuity of the myenteric plexus is disrupted, and multiple sites of new “pacemakers” take over; if the site of this new pacemaker is distal to the site of transection, then this new pacemaker drives the direction of contractions proximally in a pathologic, retrograde direction and distally in a “normal” prograde direction. If this site of the new pacemaker is far enough distally, the retrograde direction of contractions in the proximal Roux limb will “functionally” obstruct the flow of content though this segment of the Roux limb. Most of the time, this new pacemaker is located close to the site of the transection, and flow of intestinal content distally is not disrupted substantially; but if a dominant pacemaker site occurs 15 to 30 cm downstream from the gastro or esophagoenteric anastomosis, a clinically important “functional” obstruction can occur.

Diagnosis

The diagnosis is primarily one of exclusion. Oral radiographic contrast studies and extended upper endoscopy are first used to exclude a mechanical site of obstruction at the gastro or esophagoenteric anastomosis, along the Roux limb itself from adhesions, at the mesocolic defect if the limb was brought retrocolic, or at the site of the enteroenterostomy from adhesions, a mesenteric internal hernia, or a retrograde intussusception. If no mechanical obstruction is found, the differential then becomes one of gastroparesis if there is a sizable gastric remnant (this diagnosis of gastroparesis would be much more likely) or if there is no gastric remnant, then the Roux stasis syndrome would be a possibility. A nuclear medicine radionuclide study using an orally administered radionuclide marker should show the persistent presence of the marker in the Roux limb, suggesting a functional obstruction to distal flow in the Roux limb. Actual documentation of such functional obstruction in a Roux limb, however, is extremely rare and has led many investigators to question the Roux stasis as a distinct entity.

Treatment

Treatment is largely supportive with dietary management aimed at providing oral nutrition in whatever form (liquid, semisolid) that can deliver adequate calories and volume to maintain health, similar to the dietary management of gastroparesis. Supplemental enteric feeding distal to the enteroenterostomy with a tube jejunostomy or via parenteral feeding if enteral feeding is not possible for whatever reason may be necessary.

There is no known effective pharmacologic therapy available, although some investigators have tried erythromycin as a prokinetic agent.

Several surgical options have been discussed, but no one has enough experience with these “theoretic” options, all cases are anecdotal, and there is no evidence-based support for their efficacy. Moreover, gastroparesis must be excluded first, because the treatment is much different—that is, treatment directed at the gastric remnant and not at the Roux limb. If the diagnosis is consistent with the Roux stasis syndrome, then the operative focus is on the Roux limb. If the patient has a large enough gastric remnant (usually greater than 30% of the normal total gastric volume) and no clinically relevant gastroesophageal reflux, the conversion of the Roux anatomy to that of a loop gastrojejunostomy 30 to 40 cm distal to the proximal end of the Roux limb is indicated. If the gastric remnant is small, beware, because conversion of a Roux anatomy to loop drainage of a small gastric remnant may lead to bile reflux esophagitis which itself can be incapacitating, especially if there is an element of gastroparesis. In this situation, a so-called “uncut Roux” anatomy may be entertained, whereby a loop drainage of the remnant is constructed, but the afferent limb of the loop is stapled across but not cut by using two rows of linear staples and supported externally by a small piece of permanent prosthetic material to prevent restitution of luminal continuity (which occurs with time after simple stapling); note that the intestine is not transected (this form of disruption of luminal continuity but without a formal transection of the myenteric plexus does not disrupt of the direction of contractions distal to the site). Distally, a Braun-type of enteroenterostomy, 60 cm distal to the esophago or gastrojejunostomy allows the pancreatobiliary secretions to enter the intestinal lumen distal to the site of gastro or esophagoenterostomy; theoretically this anatomy should maintain the normal direction of contractions in the efferent limb of the loop anastomosis but prevent reflux of bile into the remnant stomach or esophagus. If there is no gastric remnant, then the proximal 20 to 30 cm of the Roux limb can be resected, and the Roux anatomy restored in hopes that the site of the pacemaker will be in the proximal-most aspect of the new Roux limb. Possibly the best theoretic operation involves converting the Roux anatomy into an Omega loop anatomy which should allow both limbs of the Omega anatomy to drain their content into the distal part of the Roux limb. All these operations are theoretically sound, but again, no one has extensive experience with any of them.

Bile Reflux Esophagitis

Much has been written about bile reflux "gastritis" in the past after any operative procedure that destroys the function of the pylorus (pyloroplasty, gastroduodenostomy after antrectomy, loop gastrojejunostomy with or without antrectomy, and esophagogastrectomy with concomitant pyloroplasty or pyloromyotomy). The cardinal symptoms were pain and vomiting of bile with pooling of bile in the stomach on endoscopy. But virtually all these symptomatic patients had undergone a previous vagotomy as part of their primary operative treatment, and the coexistent presence of disturbed gastric emptying, that is, gastroparesis, and the "expected" esophagitis was often not appreciated for its importance. The following discussion includes bile reflux "esophagitis" and not "gastritis" as part of the spectrum of a postgastrectomy/postvagotomy disorder because of the authors belief/bias that the entity of clinically important bile reflux gastritis does not exist.

Symptomatology

The overwhelming symptom of bile esophagitis is the vomiting of bile and usually but not always substernal or epigastric discomfort. The bilious vomiting and substernal discomfort are most prominent between meals when the vomitus can be relatively pure "bile" without food particles. Early satiety and many of the other symptoms of gastroparesis can coexist as well. Symptoms are especially worse when the gastric remnant, if present, is small and if the patient had a history pregastrectomy of symptomatic gastroesophageal reflux. As would be expected, the syndrome of bile reflux esophagitis does not occur in patients in whom gastroenteric drainage was restored with a Roux-en-Y anatomy after the gastrectomy, unless the Roux limb was made too short—less than 50 to 60 cm. (Note the prior classic recommendation of a 40-cm Roux limb length is too short; reflux of biliary markers into the gastric remnant occur in 60% of patients with a 40-cm Roux limb.)

Etiopathogenesis

The etiology of bile reflux esophagitis is a combination of functional disruption of an intact pylorus, an element of gastroparesis secondary to the concomitant planned or inadvertent vagotomy, and gastroesophageal reflux. One exception to the need for vagotomy is that of a loop gastrojejunostomy in patients with pre-existent, severe gastroesophageal reflux or those in whom a loop gastrojejunostomy has been created

inappropriately to a very small volume gastric remnant (subtotal gastrectomy). Disruption of pyloric function leads to free reflux of pancreatobiliary secretions into the stomach or gastric remnant; yes, there is an associated "gastritis" of the gastric mucosa, but this inflammation occurs also in asymptomatic patients secondary to the irritant effect of the bile. The pathogenesis of the symptoms (bilious vomiting, substernal/epigastric discomfort) is the concomitant associated reflux of the bile into the esophagus and the irritant effects of the bile on the esophageal epithelium, not the gastric mucosa. In normal physiology, reflux of some duodenal content into the stomach is normal postprandially, and although this refluxed content does contain some bile as well, normal gastric motility empties this back into the duodenum as with liquid emptying; in between meals, little to no pooling of bile occurs in the gastric lumen. In gastroparesis, however, such refluxate is not emptied rapidly, pools in the stomach, and if there is an incompetent LES, reflux of this pooled biliary content will reach the esophageal epithelium.

Interestingly, not all patients with postgastrectomy/postvagotomy gastroparesis have concomitant bile reflux esophagitis if they have a competent LES. As suggested above, there are several situations where fully symptomatic reflux esophagitis occurs in the absence of any gastroparesis. One such situation occurs in patients with a loop gastrojejunostomy without a concomitant vagotomy in whom free reflux of bile occurs into the stomach, but in whom the LES is incompetent, thereby allowing reflux of the intragastric refluxate (bile) from the jejunum into the esophagus. One of the early bariatric operations called a loop gastric bypass, which has been redesigned a bit recently and dubbed the "mini gastric bypass," involved partitioning the stomach into a very small pouch of proximal stomach that was then drained by a loop gastrojejunostomy.

Diagnosis

Most often, the diagnosis should be immediately obvious by the presence of bilious vomiting in between meals. One key to the diagnosis is the presence of esophagitis on endoscopy and usually with pooling of bile in the gastric lumen or on occasion even in the distal esophagus. If substantial pooling of bile in the stomach or gastric remnant is evident, especially if solid mater is also present, one must also suspect concomitant gastroparesis, because the stomach or a gastric remnant with normal motor function should have minimal volume and certainly no solid matter.

Treatment

The goal of treatment is twofold: first to totally divert bile from reaching the esophageal lumen with a Roux-like limb, and second, if symptomatic gastroparesis coexists, to treat the gastroparesis as well. In the patients without postvagotomy gastroparesis, simple conversion of the loop drainage to a Roux-like drainage should suffice; note, just a simple Braun-like enteroenterostomy between the afferent and the more distal aspect of the efferent limb (60 cm downstream from the gastrojejunostomy) is not reliable enough to divert the bile from the afferent limb across the enteroenterostomy. Care should be taken to insure that there is no gastroparesis; the presence of solid matter in the stomach/gastric remnant should heighten ones concern about gastroparesis.

In patients with a history of vagotomy and suspected gastroparesis, simple conversion to a Roux anatomy will divert the bile and relieve the esophagitis, but as described above, transection of the jejunum to create the Roux limb will disrupt myenteric continuity which may further exacerbate the delayed gastric emptying. Roux-en-Y drainage of the stomach tends to slow gastric emptying to some extent. In these patients with concomitant gastroparesis, consideration needs to be given to markedly decreasing the volume of the gastric remnant, even to that of a completion near-total gastrectomy.

An especially difficult situation involves patients with symptomatic reflux esophagitis after an esophagogastrectomy with an intrathoracic esophagogastrostomy. All these patients have had an obligate vagotomy, have a conduit in a low pressure area (intrathoracic), have had a pyloroplasty or pyloromyotomy, and usually have some element of delayed gastric emptying. If their sole symptoms are those of bile reflux between meals without vomiting and without solid mater in the gastric remnant or conduit, the biliary diversion can be accomplished by a classic “duodenal switch”; this procedure involves transection of the proximal duodenum about 4 cm distal to the pylorus but proximal to the ampulla of Vater and the minor papilla, closure of the distal duodenal stump, and creation of a Roux limb of jejunum that is then sewn to the proximal stump of the duodenum. In contrast, for those with bile reflux and gastroparesis, the problem is much more complicated (see above Postgastrectomy Gastroparesis—Special Situations).

Metabolic

Because bariatric surgery is so common currently, much of this discussion will center on metabolic problems associated with bariatric surgery, but gastrectomies will also be associated with many similar problems. Roux-en-Y gastric bypass intentionally creates a restrictive physiology with a very small volume, gastric reservoir for ingested food and a state of selective malabsorptive by bypassing the proximal small bowel (especially the duodenum). Because of this specific area of the gut bypassed, micronutrient deficiencies and anemia can present in the postoperative period. Iron-deficiency anemia is common along with specific deficiencies involving vitamins B_1, A, K, D, and E and copper.

The stomach serves multiple physiologic functions other than just a reservoir for ingested food. While the acid/peptic environment aids digestion, it also provides an acid environment for oxidation of iron as well as bactericidal barrier to certain organisms, for example, tuberculosis bacillus, and others as well. This section will concentrate on the role of gastric secretions, specifically acid and R-factor/intrinsic factor, in mediating the absorption of Fe^{3+}, Ca^{2+}, and vitamin B_{12} from a metabolic aspect.

In addition, after a gastrectomy with duodenal bypass (gastrojejunostomy, esophagojejunostomy), several aspect of maldigestion can also occur. The complications that arise from the operative re-routing of the flow of ingested foods are important to share with the patient preoperatively so that they not only understand the risks and benefits but also the long-standing sequelae that they will face and need to protect against.

Iron Deficiency Anemia

Symptomatology

Patients will present with symptoms of anemia: fatigue (lack of energy), headaches, shortness of breath, or paleness and coolness to the skin. In severe cases, the patient may complain of dizziness on standing. Interestingly, pica for ice is uncommon in this population. Women in the childbearing age who are still menstruating are much more susceptible to this form of iron-deficiency anemia in the postbariatric surgery state.

Etiopathogenesis

The development of anemia is multifactorial after esophagogastric surgery. After Roux-en-Y gastric bypass, there is malabsorptive state despite usual

supplementation of multivitamins, iron, and micronutrients. Iron absorption in obese patients is impaired in part due to the inflammatory state that exists and contributes to the poor absorption of iron. After Roux-en-Y gastric bypass, this malabsorption is deranged further. With creation of the small gastric pouch, the amount of acid secretion is markedly decreased or is absent. This lack of acid is very important, because iron in the diet is ingested as the ferrous ion (Fe^{2+}) but is oxidized by the acid in the stomach to the ferric ion (Fe^{3+}) which is the preferred ion for absorption primarily in the duodenum. After a Roux-en-Y gastric bypass or after a gastrectomy, the acid in the stomach is decreased, thereby, inhibiting the oxidation of the ferrous ion to the ferric ion and the bypassing of the duodenum, further limits absorption of iron. Even with supplemental oral iron (usually given as the ferrous ion [$FeSO_2$]) the patient may have persistent deficiency or will be unresponsive response to this conventional form of therapy.

Diagnosis

The pan micronutrient deficiency especially of B_{12} and copper levels may also contribute to anemia postoperatively; evaluation should determine whether or not it is driven solely by iron deficiency. Evaluation of iron stores, ferritin levels, and other compounding pathologies should be evaluated. One must always remember that the presence of an iron-deficiency anemia in these patients needs also to be evaluated for blood loss from the gut with a stool examination for blood, and should not be assumed to be just related to iron malabsorption, even in the younger female patients.

Treatment

Treatment is to correct the iron storage. First, the most common source of iron deficiency is blood loss from the gut. A stool sample should be checked for occult blood, and if present, colonoscopy and/or other diagnostic testing are mandatory. If the patient is unresponsive to oral therapy, several factors should be considered. Excluding other hematologic conditions will be necessary. Once you are confident that the iron deficiency is related to iron malabsorption, then oral supplementation is indicated. The usual medication is an iron supplement, but the addition of a relative acid environment may help; some of the oral iron supplements have an acidic pH. In some menstruating patients with heavy menses,

especially the younger women after Roux-en-Y gastric bypass, intravenous iron may be necessary on a 6 monthly or yearly basis until the onset of menopause or until the menorrhagia is controlled.

Vitamin B_{12} Anemia

Vitamin B_{12} (Cyanocobalamin) deficiency is the most common deficiency observed after gastric bypass or after a near-total or total gastrectomy. The formation of red blood cells and especially white blood cells are dependent heavily on B_{12}.

Symptomatology

Symptoms are related to the ensuing anemia that includes fatigue or a feeling of shortness of breath. Patients may complain of GI complains such as constipation. Memory loss or depression and unusual neurologic complaints, such as numbness and tingling or even disordered thinking mimicking psychosis, are late, albeit unusual, complications. The patient's examination may show signs of anemia, such as paleness to the skin and mucosal membranes and a smooth tongue.

Etiopathogenesis

In normal physiology, the absorption of vitamin B_{12} occurs initially via the oral mucosa but only to a minor extent and only as free cyanocobalamin. The majority of the absorption, however, is due ultimately to the binding of B_{12} with intrinsic factor—the combination of which is absorbed eventually in the ileum. Absorption, however, is much more complicated. For normal absorption of orally ingested vitamin B_{12}, an acid environment as well as the presence of R-factor and intrinsic factor produced by the parietal cells of the stomach is necessary.

Orally ingested vitamin B_{12} in foodstuffs occurs in the form of pterylcyanocobalamin; for absorption to occur, the pteryl group first need to be cleaved from the cyanocobalamin; this step requires acid. Then, the free cyanocobalamin binds to R-factor in the stomach after which the complex of R-factor/cyanocobalamin is emptied into the duodenum, where R-factor is cleaved off the cyanocobalamin, and the cyanocobalamin then binds to intrinsic factor. It is then this cyanocobalamin/intrinsic factor complex that is recognized by the ileal mucosa and transported by a specific mucosal transporter. If there is achlorhydria, as occurs with pernicious anemia, but also after Roux-en-Y gastric bypass and high

gastrectomies, this chemical process of cleaving off the pteryl groups does not occur, such that the binding of the pterylcyanocobalamin to intrinsic factor cannot occur. Also, if the stomach is removed, neither R-factor nor intrinsic factor is available to blind with vitamin B_{12} leading to a deficient state. If the duodenum is bypassed, then the cleavage of the R-factor/cyanocobalamin complex is disrupted in part.

Interestingly, without intrinsic factor, the intestine can absorb about 1% of ingested, free vitamin B_{12} (cyanocobalamin), that so with adequate daily supplementation postoperatively, the risk of anemia can be prevented. When the stomach and duodenum have been bypassed, there will be enough intrinsic factor secreted by the stomach into the duodenum that will reach the jejunum and mix with the ingested free cyanocobalamin that relatively normal absorption of the free vitamin B_{12} occurs. This type of physiology can be exploited after Roux-en-Y gastric bypass or the subtotal gastrectomies that bypass the duodenum by supplementing the diet with daily free vitamin B_{12}.

Diagnosis

Vitamin B_{12} levels should be checked periodically, and if symptoms arise, they should be treated. One caveat should be mentioned. Normally the liver has about 1 year's worth of vitamin B_{12} stored; this really is important, because the symptoms of vitamin B_{12} deficiency only occur after one or more years postoperatively, and all too often, the diagnosis is not entertained or is made only late in the course of the anemia.

Treatment

The recommended daily allowance for vitamin B_{12} is 2 μg. Replacement can occur via oral or injectable means. Injectable free vitamin B_{12} is available as a monthly subcutaneous injection of 1,000 μg. This is the preferred method by the authors; oral forms of free vitamin B_{12} or preparations able to be administered nasally are available, but they are much more costly and need to be administered daily. Certain insurance providers reject requests to pay for these oral or nasal preparations. Interestingly, the monthly injections may allow for a greater rate of compliance when compared to the need for daily oral supplementation. Therefore, after a gastric bypass or near-total gastrectomy, routine supplementation with vitamin B_{12} should be encouraged strongly.

Maldigestion

After a total gastrectomy, patients tend to suffer with lack of weight gain and often lose up to 10% to 15% of their normal body weight. Indeed, some patients, especially very thin women, may present with malnutrition and signs and symptoms of maldigestion. Loss of the natural volume reservoir of the stomach leads to inadequate mixing of digestive enzymes and even altered physiologic responses of important digestive enzymes. Bypass of the duodenum, where it is estimated that 80% of the entire absorption of nutrients occurs, combined with the relatively rapid transit through the gastrointestinal system, can lead to mild or severe maldigestion secondary to lack of normal mixing of pancreatobiliary secretions with ingested foods.

Symptomatology

Patients on directed questioning may report having experienced foul smelling, nonformed stools (steatorrhea). These stools are rich in fats and so may float in the toilet. The malabsorption of fat leads to abdominal discomfort, increased gas production with subsequent bloating, and feelings of urgency to stool. As a consequence, the patient will have weight loss and difficulty maintaining a healthy weight.

Etiopathogenesis

The pathogenesis of malabsorption is multifactorial. The resultant discoordination of the mixing of ingested food and digestive enzymes in the stomach and jejunum plays a major role in this maldigestion. In addition, the loss of the reservoir of the stomach leads to rapid emptying of digestive food and juices into the small bowel, where rapid transit may lead to ineffective absorption. Bacterial overgrowth can contribute to maldigestion as bacteria compete with the absorption of fats. Finally, there is a relative pancreatic exocrine insufficiency that occurs that is associated with decreased levels of gastrin and cholecystokinin, combined with a decrease in the later release of other post prandial peptides.

Diagnosis

Numerous studies are available to support the diagnosis of pancreatic insufficiency after a gastrectomy that bypasses the duodenum. We will describe three tests based on samples of stool, duodenal secretions, and a breath test. Using the stool as the specimen, the fecal elastase test can be performed in one of two ways. Sudan staining of the collected stool can be

evaluated for the observed percentage of fat per high-power field, but this test is subjective, not quantitative, and is really just a diagnostic test for gross steatorrhea. A more quantitative study can be performed that measures the amount of the fat collected from the stool when the patient is on a controlled fat diet (usually 100 g a day).

The secretin-cerulein test is an invasive study that requires intubation of the duodenum to collect duodenal contents after hormonal stimulation with secretin and cholecystokinin. The test is the most sensitive and accurate test that measures not only pancreatic function but also gives some insight into biliary function. It has been reported that three months after total gastrectomy, the volume and content of trypsin, chymotrypsin, and amylase in pancreatic secretion were decreased by 76%, 89%, 91%, and 72%, respectively which can be detected by the secretin-cerulein test. Despite being the most accurate, this test is invasive, takes time, and is quite unpleasant for the patient and is rarely if ever performed today except in certain centers. The least invasive test is the ^{13}C-mixed triglyceride breath test, which is able to determine if the bacterial overload is contributing to the maldigestion observed.

Treatment

While there are no randomized controlled trials or consensus on how to treat maldigestion after total gastrectomy, treatment with pancreatic enzymes may resolve or mitigate the symptoms. The effectiveness of treatment with pancreatic replacement can be tracked with resolution of observed symptoms. A titration of pancreatic enzymes may be required. Patients should take enzymes to replicate the normal physiologic response with the dosage split to begin at the start, during, and after a meal. Dosing of the number of tablets taken should reflect the size and fat content of the meal. For example, for small snacks, one to two tablets and for large meals six tablets with two before, two during, and two at the end of the meal is best. Too many times, the amount of replacement enzymes is too small-remember, adults cannot take too many tablets, but they can take too few. Children are different story; the dosage of the time-release tablets in children less than 15 should be controlled carefully, because there is a very small but well-recognized incidence of colonic strictures with too high a dose. Increased federal regulation has moved to restricting unreliable pancreatic replacement products from the market. Currently, only three preparations to replace pancreatic enzymes are available: Creon, Pancreaze, and Zenpep; all are time-release tablets, and many

pancreatologists suggest that the patient empty the granules and take them as the free granules.



EDITOR'S COMMENT

Drs. Reid and Sarr have done an outstanding job discussing postgastrectomy syndromes in the modern era. They breakdown the issues into the older and traditional syndromes that were iatrogenic and associated with gastrectomy for ulcer disease. Today, much of the man-made causes of postgastrectomy syndromes are associated with the rapid rise of obesity in the United States and concomitant increases in the bariatric surgical procedures performed to address this condition.

The authors point out that dumping syndrome is associated with rapid, uncontrolled emptying of fluid from the stomach, gastric remnant or esophagus into the small intestine leading to a neurohormonal response with the release of vasoactive agents that cause symptoms. The symptoms do not have to be diarrhea as the majority of patients do not have significant diarrhea. Not every patient with rapid transit develops symptoms of dumping syndrome and this attests to the adaptability of the enteric nervous system in individual patients. This adaptability may also contribute to the resolution of dumping syndrome symptoms soon after surgery in many patients. In adults today, gastric bypass surgery is the most common cause with the incidence of dumping syndrome as high as 75%. Roux-en-Y gastric bypass with an associated gastrojejunostomy was until recently the most common type of bariatric surgery in the United States and is therefore an important cause of dumping syndrome. Sleeve gastrectomy is now the most commonly performed bariatric surgery in the United States. With the small gastric tube that is created, dumping syndrome is less frequent than following Roux-en-Y gastric bypass and this may be due to the intact pylorus and preservation of nerve innervation along the lesser curvature of the stomach and to the pylorus.

Vagotomy is associated with blunted pyloric relaxation in those patients that have a pylorus and can contribute to dumping syndrome through reduced gastric relaxation in the presence of a meal bolus. Vagotomy also may reduce feedback inhibition pathways that delay gastric emptying once the food bolus reaches the small intestine (Berg P, McCallum R. Dumping syndrome: a review of the current concepts of pathophysiology, diagnosis and treatment. *Dig Dis Sci* 2016;61:11–8). Antrectomy for ulcer disease with vagotomy may induce some symptoms of dumping syndrome in at least one third of patients. However, in only about 10% of patients have the symptoms severe enough to warrant significant lifestyle modifications (Ukleja A. Dumping syndrome: pathophysiology and treatment. *Nutr Clin Pract* 2005;20: 517–25).

Due to the rapid rise of gastroesophageal junction malignancy, esophagogastrectomy is being more frequently performed with the need for

vagotomy for tumor clearance in many patients. Symptoms of gastroparesis are common following this operation. Many surgeons advocate for the performance of a pyloroplasty to assist in emptying of the stomach as absence of pyloric relaxation is problematic following vagotomy in some patients. The benefit of pyloroplasty in this setting remains controversial as it may result in bile reflux with esophagitis due to reflux of duodenal contents. Some patients have significant complaints of repeat episodes of regurgitation or vomiting of bilious fluid following pyloroplasty. Therefore, I have taken the approach of avoiding pyloroplasty in the majority of my patients undergoing esophagastrectomy. Since the vast majority of patients can now undergo a minimally invasive esophagogastrectomy, early ambulation and reduced hospital stay is the norm rather than the exception. With increased mobility, emptying of the gastric conduit improves and pyloroplasty is not necessary. Most patients have only typical and mild symptoms associated with delayed gastric emptying following esophagogastrectomy without pyloroplasty. Studies have shown only a 7% to 10% late onset of symptomatic delayed gastric emptying, and most of such cases can be managed using nonsurgical means. These outcomes compare positively with studies that have evaluated functional results in patients undergoing esophagogastrectomy with pyloroplasty. In the absence of pyloroplasty, botox injection into the pylorus at the time of esophagogastrectomy has been utilized to enhance pyloric relaxation and has been associated with favorable results in retrospective studies. It has the additional benefit of avoiding the potential surgical and physiologic complications of pyloroplasty or pyloromyotomy. It may provide an advantage in the early postoperative period when complications of delayed emptying are most likely to occur (Martin JT, Federico JA, McKelvey AA, et al. Prevention of delayed gastric emptying after esophagectomy: a single center's experience with botulinum toxin. *Ann Thorac Surg* 2009;87(6):1708–13). Similar to others, I have found that late complications of delayed gastric emptying following esophagogastrectomy or proximal gastrectomy occurs in less than 10% of patients and can be managed endoscopically or by minimally invasive pyloroplasty if necessary (Ben-David K, Tuttle R, Kukar M, et al. Minimally invasive esophagectomy utilizing a stapled side-to-side anastomosis is safe in the Western patient population. *Ann Surg Oncol* 2016;23(9):3056–62). In the setting of esophagogastrectomy, prospective randomized trials of pyloroplasty or not, as well as alternative strategies to manage the pylorus, need to be performed to answer the question whether early and late symptoms of gastroparesis are significantly improved with interventions directed at the pylorus.

Following pancreaticoduodenectomy, delayed gastric emptying remains a significant concern resulting in increased hospital time and reduced nutritional status and quality of life. Over 100 years ago, Braun introduced a modified technique of gastrojejunostomy in which an anastomosis between the afferent and efferent limbs of jejunum was performed following gastrectomy. I have

included the use of a Braun jejunojejunostomy in the setting of pancreaticoduodenectomy in over 150 patients. Our initial nonrandomized results in the hands of several surgeons utilizing different treatment algorithms demonstrated a significant reduction in delayed gastric emptying following nonpyloric preserving pancreaticoduodenectomy (Hochwald SN, Grobmyer SR, Hemming AW, et al. Braun enteroenterostomy is associated with reduced delayed gastric emptying and early resumption of oral feeding following pancreaticoduodenectomy. *J Surg Oncol* 2010;101(5):351–5). For the Braun enteroenterostomy to be effective it should be placed approximately 25 cm downstream from the gastrojejunostomy. Since our publication, a single surgeon series of a small number of patients has confirmed the benefit of Braun enteroenterostomy in reducing symptoms of delayed gastric emptying following pancreaticoduodenectomy from 35% to 4.2% (Nikfarjam M, Houli N, Tufail F, et al. Reduction in delayed gastric emptying following non-pylorus preserving pancreaticoduodenectomy by addition of a Braun enteroenterostomy. *JOP* 2012;13(5):488–96). Others have shown Braun enteroenterostomy following laparoscopic gastrectomy with gastrojejunostomy to be associated with similar incidences of gastric residue, remnant gastritis and bile reflux compared to Roux-en-Y reconstruction (Cui LH, Son SY, Shin HJ, et al. Billroth II with braun enteroenterostomy is a good alternative reconstruction to Roux-en-Y gastrojejunostomy in laparoscopic distal gastrectomy. *Gastroenterology Res Pract* 2017;2017:1803851). Furthermore, a meta-analysis of studies which have evaluated Braun enteroenterostomy following pancreaticoduodenectomy has shown in 1,401 patients that the occurrence of delayed gastric emptying was lower in the Braun group and plays an important role in reducing morbidity and length of stay (Huang MQ, Li M, Mao JY, et al. Braun enteroenterostomy reduced delayed gastric emptying: a systematic review and meta-analysis. *Int J Surg* 2015;23:75–81). Future randomized trials will need to clarify the benefit seen in retrospective studies in regard to the use of the Braun enteroenterostomy.

It is clear that the functional and metabolic effects of gastrectomy remain significant on our patients. A careful analysis of patient complaints and appropriate diagnostic tests will help the treating health care worker diagnose and manage this perplexing problem. Unfortunately, available medications to treat gastroparesis and delayed gastric emptying are limited. Metoclopramide is presently the only Food and Drug Administration approved medication for the treatment of gastroparesis. This field is in great need of new treatments such as small molecule drugs that act as motilin receptor or ghrelin agonists or new highly selective histamine receptor agonists that have focused actions on the upper gastrointestinal tract and simultaneously minimal off target side effects.

Steven N. Hochwald

91 Congenital Pyloric Stenosis and Duodenal Obstruction

Hale E. Wills, Alexis D. Smith, and Thomas F. Tracy

Congenital pyloric stenosis and duodenal obstruction are important causes of emesis in infants that can be corrected by surgery. Little has changed in recent years in the surgical principles of management of these conditions. Improved recognition of hypertrophic pyloric stenosis (HPS) by pediatricians and family practitioners along with improved access to ultrasound has led to earlier diagnosis and fewer infants presenting with severe dehydration and metabolic derangements. In fact, it is not uncommon for infants to be referred for ultrasound early in the development of HPS and be found to have borderline measurements of their pylorus and a patent pyloric channel, only to return days to weeks later with complete gastric outlet obstruction. The adoption of a laparoscopic approach has retained the benefits of Ramstedt procedure while offering quicker recovery, reduced pain, improved cosmetic results. Regardless of the surgical approach, this remains one of the most satisfying conditions to treat as a surgeon as it eliminates a potentially life-threatening condition and rapidly returns the child to health and a normal lifespan potential. Congenital duodenal obstruction and malrotation have also seen few changes in evaluation and management recently. The infant with bilious emesis must be evaluated urgently to identify malrotation and volvulus must be treated as a surgical emergency. While the anatomical approaches to malrotation and duodenal obstruction are largely unchanged, the experience with laparoscopic approaches has increased and outcomes have become better defined.

CONGENITAL PYLORIC STENOSIS (HYPERTROPHIC PYLORIC STENOSIS)

Introduction

HPS is the most common surgically correctable cause of nonbilious vomiting in infants. While there have been reports of nonsurgical therapies

in small case series, this condition is most commonly corrected by pyloromyotomy with low morbidity. In the United States, HPS occurs at a rate of 2 to 4 per 1,000 live births, with the highest rates among Whites and Hispanics and significantly lower rates among those of African or Asian ancestry. Infants most often present between 3 and 5 weeks of age, with rare presentations before 2 weeks or after 12 weeks of age. There have been cases reported of fetal diagnosis by ultrasound. Males are affected four to six times as frequently as females. Birth order does not seem to play a strong role as previously thought. An increased incidence has been reported in premature infants born between 28 and 36 weeks gestation, but the onset in these infants seems to correlate with their corrected gestational age so they may present several weeks later after birth compared to term infants. The impact of maternal socioeconomic or health factors is unclear.

The pathophysiology of HPS is hypertrophy of the muscular wall of the pylorus. The resulting thickening and elongation of the muscle with narrowing of the pyloric channel result in gastric outlet obstruction. The natural history is progressive dehydration and weight loss from the inability to absorb fluid and nutrients. There is also a concurrent metabolic derangement from loss of chloride in the emesis leading to alkalosis, early selective renal sodium retention in exchange for potassium loss into the urine in an attempt to retain blood volume, followed by renal potassium retention and proton dumping into the urine to offset critical potassium depletion. The result is hypochloremic, hypokalemic metabolic alkalosis with paradoxical aciduria. Unconjugated hyperbilirubinemia has been reported in 2% to 5% of infants with HPS and is thought to be due to transient dysfunction of bilirubin uridine diphosphate glucuronyl-transferase in the setting of caloric deprivation, dehydration, and decreased hepatic blood flow. Hepatic dysfunction resolves over several weeks after surgical correction of the HPS.

While there is no single unifying etiology for the pyloric hypertrophy, several theories have been proposed. Observation of male preponderance, family clustering, high rates of HPS in children of affected parents, and concordance in monozygotic twins suggest a genetic predisposition. Specific genetic mutations have been described in HPS families that affect nitric oxide synthase, smooth muscle cation channels, or by pathways that are not yet clear. Discordant rates of HPS in dizygotic twins and within affected families suggest the effect of environmental factors. Infant

exposure to erythromycin, hypergastrinemia, sleeping position, type of feed, and maternal smoking have all been implicated. The reported success of atropine, an anticholinergic agent with strong antimuscarinic activity, in treating HPS in small series suggests the role of acetylcholine and muscarinic receptors in the smooth muscle of the pylorus. Whatever the mechanism, it must take into account that HPS usually occurs several weeks after birth and is transient, even without myotomy.

Clinical Presentation

The diagnosis of pyloric stenosis can be made by history and physical examination. The typical presentation is an otherwise healthy infant with nonbilious emesis that has become progressively more frequent and forceful (“projectile”) over several days or weeks. Some have blood tinged emesis from gastritis. Many infants will have been evaluated for intolerance of feeds, food allergy, and gastric reflux and have failed to improve with formula changes or trial of acid suppressing medication. There is often oliguria. In advanced cases, weight loss occurs that may be profound. The physical examination should search for signs of dehydration and palpation of an epigastric mass (the “olive”). If an epigastric mass is palpated, no further imaging is required. Decompression of the stomach with a nasogastric tube may aid the physical examination, but gastric decompression should not be continued preoperatively as that would only worsen fluid and chloride losses. Assessment of serum electrolytes is essential to gauge the degree of alkalosis.

In those patients who do not have a discrete epigastric mass, ultrasound is the first test of choice. While there is some variability in the measurements reported in the literature, a combination of a pyloric wall thickness greater than 3 mm with channel length greater than 15 mm and limited fluid passage through the pyloric channel has a reported sensitivity and specificity of nearly 100%. In the case of an equivocal ultrasound or any concern for bilious emesis, upper gastrointestinal (UGI) series is an appropriate test. The findings of pyloric stenosis on UGI include “shoulders” created by the hypertrophied pyloric muscle bulging into the antrum, a long pyloric channel, and the “string sign” or “double track” sign from contrast in the narrow pyloric channel. There must be some contrast seen in the duodenal bulb for an adequate study to confirm the length of the pylorus. In the event that pyloric stenosis is ruled out, the UGI may show other causes of obstruction like a duodenal web or malrotation.

It must be remembered that surgical correction of pyloric stenosis is not an emergency. It is imperative that the patient's metabolic abnormalities be corrected prior to administering a general anesthetic. The degree of dehydration and metabolic alkalosis should be assessed by clinical and laboratory examination. Fluid and electrolyte repletion should begin a solution of D5/0.45NS without potassium at 150 mL/kg/day until and titrated until the infant is making urine. Once urine output is established, KCl should be added at 20 Eq/L. Two to three normal saline boluses of 20 mL/kg may be given in the severely dehydrated patient. General anesthesia should not be considered until the sodium bicarbonate is less than 30 mEq/L, chloride is over 90 mEq/L, and urine output is 1 mL/kg/hr, which may take several days in some cases. Failure to correct the metabolic alkalosis preoperatively may lead to prolonged apnea after general anesthesia.

OPERATIVE TECHNIQUE

Open

Traditionally, the abdomen is entered through a 2- to 3-cm muscle-splitting right upper quadrant incision midway between the umbilicus and xiphoid. More recently, a supraumbilical skin incision with midline fascial incision has become popular with similar results and potentially better cosmesis. The liver edge is retracted cephalad and the stomach is grasped and the greater curve delivered. With gentle rightward then leftward traction, the pylorus is delivered. The hypertrophied pylorus is easily identified by its firm, rubbery texture compared to the adjacent normal stomach and duodenum. The pylorus is stabilized between the index finger and thumb of the nondominant hand. The serosa is scored in an avascular line beginning distally in line with the pyloric vein and extending onto the stomach beyond the proximal extent of the hypertrophied muscle (Fig. 91.1). The muscle is then split with the back of the scalpel handle down to the level of the submucosa. The myotomy is extended toward the duodenum and stomach with a Benson spreader or a small clamp. Care must be taken to avoid placing traction on the submucosa as this may cause a perforation into the pyloric channel, particularly at the duodenal end. The submucosa should bulge into the incision. When the pyloromyotomy is adequate, the superior and inferior edges of the pyloromyotomy move independently.

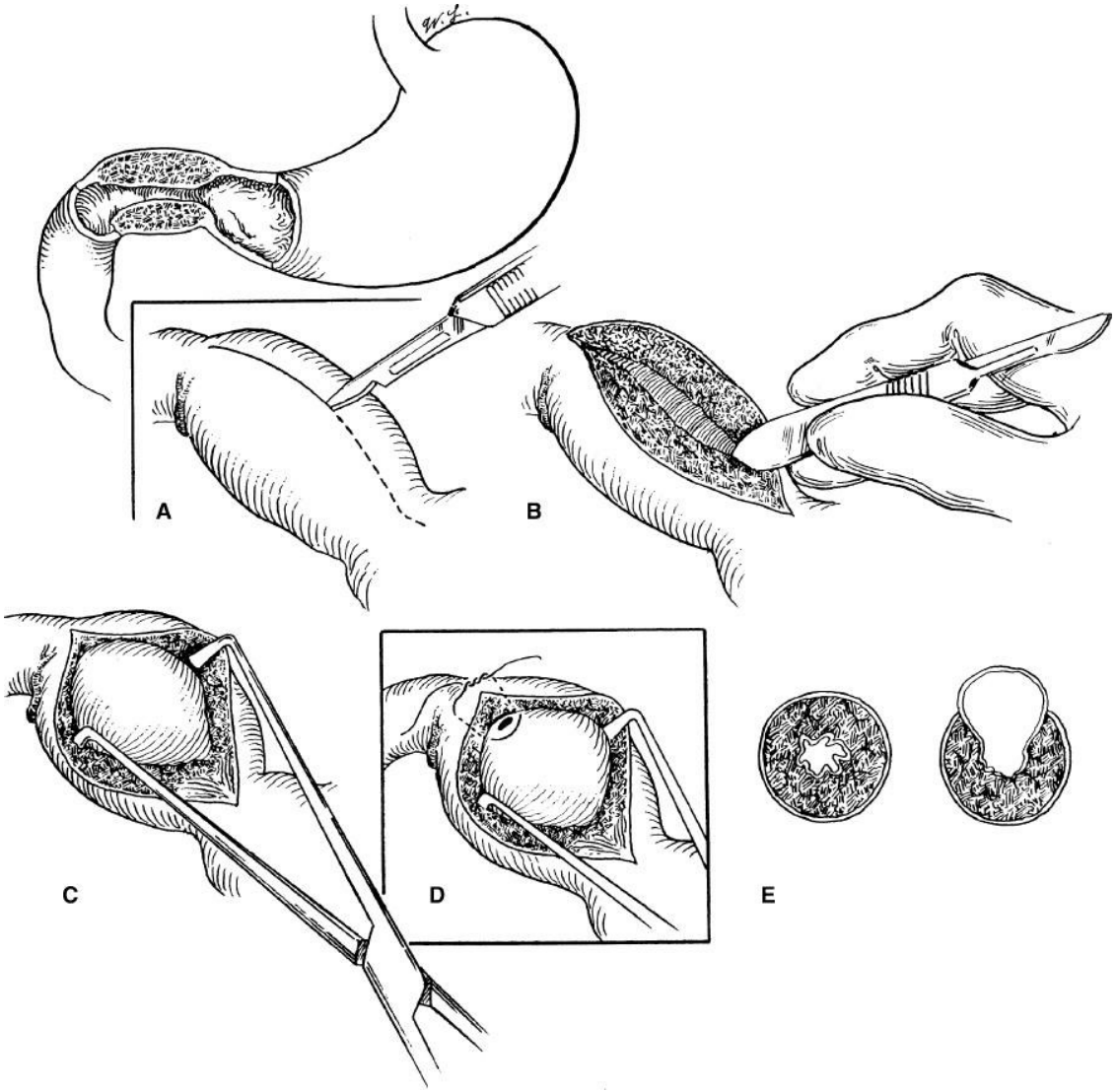

Figure 91.1. Pyloromyotomy. **A.** The superficial serosal incision is begun on the duodenal end of the hypertrophied pylorus and carried onto the stomach. **B.** The scalpel handle divides the fibers. Note asymmetry of upper and lower muscle, indicating a complete myotomy at the duodenal end. **C.** The pyloric spreader further mobilizes the muscle. **D.** A perforation is closed with a horizontal mattress suture. **E.** The completed myotomy shown in cross-section with a “bulging” pyloric mucosa.

A systematic search for mucosal perforation is made by gently milking the duodenum and antrum and looking for air bubbles, bile, or gastric contents. There is usually some bleeding from the cut edge of the serosa and muscle due to venous congestion of the pylorus being delivered through a small incision. This will stop spontaneously once the pylorus is returned to the abdomen. The abdominal incision is closed in layers with absorbable suture.

If a perforation is identified, a single horizontal mattress suture that slides the pyloric mucosa into the duodenum may be sufficient. An omental patch akin to the Graham patch may be added. Alternately, the myotomy can be closed, the pylorus rotated 180 degrees, and a new myotomy performed.

Laparoscopic

After induction of general endotracheal anesthesia, the patient is turned 90 degrees and positioned so the surgeon is standing at the patient's feet (Fig. 91.2). In younger patients, a fine hemostat is used to bluntly enter into the peritoneum through the umbilical stalk, otherwise an infraumbilical incision will suffice. A 3-mm cannula is then placed under direct vision, and pneumoperitoneum of 6 to 8 mm Hg is established. Under camera visualization, a stab incision is made in the right upper quadrant with a No. 11 blade and a 3-mm laparoscopic grasper is passed directly through the abdominal wall without a cannula. In the same fashion, a stab incision is made in the left upper quadrant through which a Bovie electrocautery blade with a protected tip is directly inserted.

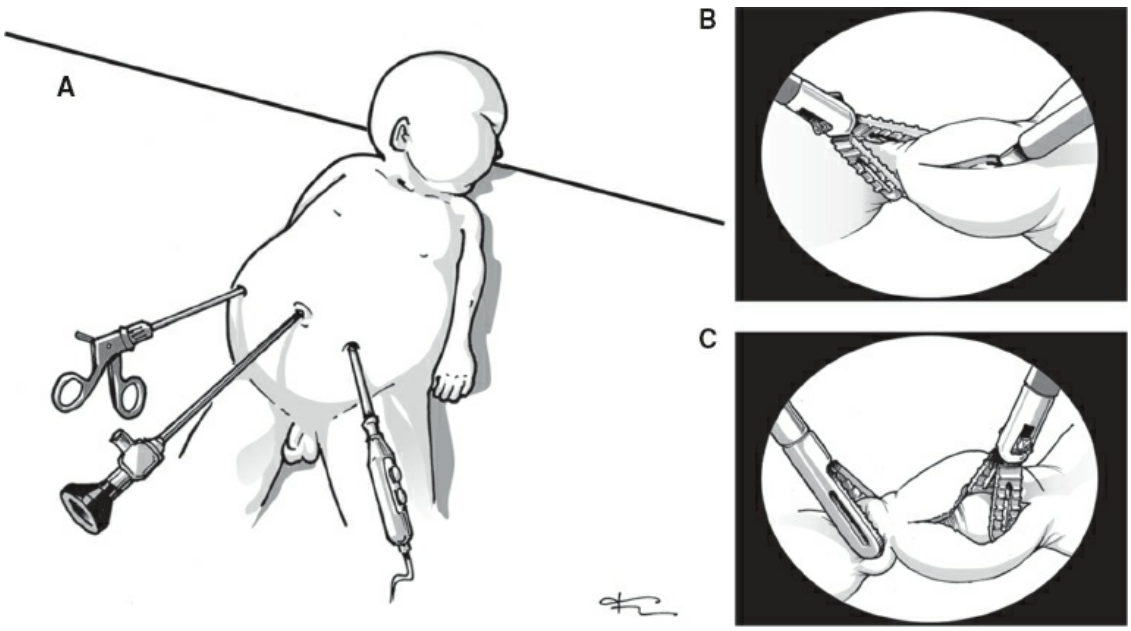

Figure 91.2. A. The patient is placed at right angles to the operating table with the surgeon at the patient's feet. The camera and instruments are placed as shown. **B.** The serosa over the pylorus is divided with Bovie electrocautery, beginning at the pyloric vein and extending just on to the antrum. After the cautery has cooled, the tip is used to crack the hypertrophied muscle at its thickest point by gently inserting the blade into the muscle and

rotating the blade 90 degrees. **C.** Beginning where the muscle was cracked, the muscular layer is spread until the submucosa is visible. We find it easiest to spread toward the stomach first, then toward the duodenum. Care is taken to spread only the muscle and to avoid spreading on the submucosa.

The duodenum is grasped just distal to the pylorus with the left hand and rotated out from under the edge of the liver. The serosa over the pylorus is divided with Bovie electrocautery, beginning at the duodenum and extending just on to the antrum. After the cautery has cooled, the tip is used to crack the hypertrophied muscle at its thickest point by gently inserting the blade into the muscle and rotating the blade 90 degrees. The cautery is removed and a laparoscopic pyloric spreader is introduced through the same incision. Beginning where the muscle was cracked, the muscular layer is spread until the submucosa is visible. We find it easiest to spread toward the stomach first, then toward the duodenum. Care is taken to spread only the muscle and to avoid spreading on the submucosa.

Adequacy of the extent of the pyloromyotomy is assessed by grasping the cut edges of the serosa at the middle of the incision and moving them in opposite directions. The edges should move independently from one another. With the duodenum obstructed distally by the grasper, 30 mL of air is insufflated through an orogastric tube to check for mucosal perforation. The fascia at the umbilical incision is closed with a mid-acting absorbable suture. The stab incisions are closed with skin glue.

If a perforation is identified, it may be repaired in a similar fashion to the open procedure. This may be accomplished laparoscopically or with conversion to an open approach depending on the laparoscopic skills of the surgeon.

OPERATIVE PITFALLS AND COMPLICATIONS

Regardless of the surgical approach, complications after pyloromyotomy should be infrequent. Postoperative vomiting is common and typically thought to be due to discoordinated gastric contractions resulting from the preoperative obstruction or transient gastroparesis. Gastroparesis generally resolves in 12 to 24 hours and most vomiting resolves in 48 to 72 hours. Perforation typically occurs at the duodenal end of the myotomy where the mucosa may be thinned out over the shoulder of the pyloric muscle. Concern for missed perforation should prompt evaluation by contrast study

or operative exploration. Inadequate myotomy may be present in patients with persistent postoperative emesis and usually occurs when the myotomy is not carried sufficiently onto the stomach. A contrast study may show a persistently narrowed pyloric channel, whereas ultrasound will continue to show a hypertrophied muscle for several weeks and may not demonstrate an inadequate myotomy. The preoperative metabolic alkalosis and immature brainstem put HPS patients at risk of apnea and delayed extubation. Other reported complications include wound infection and fascial dehiscence that can be minimized with attention to meticulous technique.

POSTOPERATIVE CARE

Postoperatively, the infant is kept with the head of bed elevated 30 degrees with cardiac and apnea monitoring. We initiate feeds after 6 hours with a half an ounce of balanced electrolyte solution, then convert to full breast milk or formula for subsequent feeds and advance by half an ounce every feed to a goal two ounces. Most infants can be advanced to goal in 24 hours and be ready for discharge when they have completed an adequate period of apnea monitoring. Both retrospective reviews and prospective randomized trials have compared early versus late initiation of feeds, and staged versus *ad libitum* feeding regimens. Late and staged feeding regimens result in fewer patients with emesis and fewer episodes of emesis per patient, whereas early and *ad libitum* feeds decrease the length of hospital stay despite correlation with more emesis. The choice of regimen is based on surgeon's preference and local practice.

DUODENAL OBSTRUCTION

Introduction: Intrinsic Versus Extrinsic Duodenal Obstruction

Congenital duodenal obstruction is a relatively common problem encountered in pediatric surgical practice with an incidence of 1 in 5,000 live births and accounts for approximately half of all neonatal intestinal obstructions. An understanding of the various forms of congenital duodenal obstruction and associated anomalies is essential to successful surgical outcomes. Congenital duodenal obstruction may be intrinsic to the duodenal wall, extrinsic due to compression of an anatomically normal duodenum, or a combination of both; and may be complete (duodenal atresia) or partial (duodenal stenosis). In *intrinsic* obstructions, there is a

developmental abnormality of the duodenal wall with or without mural continuity. Complete duodenal atresia accounts for 50% of all small intestinal atresias. Partial or incomplete intrinsic obstructions always have mural continuity and an intraluminal mucosal diaphragm or web. “Windsock” deformity refers to elongation of the intraluminal diaphragm in which the site of attachment of the web is proximal to the apparent level of obstruction as indicated by bowel caliber change. Congenital *extrinsic* obstruction of the duodenum can occur due to a number of different etiologies, including intestinal malrotation with Ladd bands or volvulus, preduodenal portal vein, annular pancreas, cysts or pseudocysts of the pancreas and biliary tree, or gastroduodenal duplications. Each of these anomalies may occur in combination with an intrinsic duodenal obstruction. Annular pancreas, encircling of the duodenum with pancreatic tissue contiguous with the head of the pancreas, is almost invariably associated with an intrinsic duodenal obstruction.

Diagnosis of congenital duodenal obstruction most often occurs with prenatal imaging and is confirmed clinically early in the neonatal period. Even in the setting of incomplete obstruction, the majority of patients present in the first year of life, while some presenting later in childhood or even adulthood. Improvements in prenatal diagnosis, refined surgical techniques, and advancements in neonatal intensive care have resulted in marked improvement in early perioperative morbidity and mortality. Late complications occur in approximately 10% to 15% of patients and highlight the need for long-term follow-up into adulthood to address these late occurrences. Malrotation of the intestines is another important cause of duodenal obstruction because of its attendant risk of midgut volvulus and intestinal ischemia. Malrotation can present at any age including adulthood, but most commonly presents in the first month of life.

Pathophysiology

The widely accepted embryopathologic event leading to intrinsic duodenal obstruction is failure of recanalization of the developing duodenal lumen early in gestation. The solid core stage of duodenal development is followed by vacuolization in the 8th to 10th week. Failure of coalescence of vacuoles causes failure to recanalize, and a subsequent complete or partial duodenal obstruction results. This is in contrast to atresia of the jejunum and ileum, which occur at later stages of development, are infrequently associated with other anomalies, and are attributed to a

sporadic vascular accident. Reports of familial duodenal atresia in the literature imply that at least some cases are the results of genetic abnormalities.

Congenital duodenal obstruction most commonly occurs at the junction of the first and second portions of the duodenum with 80% occurring distal to the ampulla of Vater (pre-ampullary), and the remaining 20% proximal to the ampulla (post-ampullary). The incidence of an addition distal duodenal atresia is extremely low (1% to 3%). The rare occurrence of double atresias in the duodenum has a distinct familial occurrence and is frequently associated with other pancreaticobiliary anomalies, such as biliary atresia, gallbladder agenesis, and common bile duct stenosis. Depending on the degree of obstruction, the proximal duodenum and stomach are often dilated to several times their normal size with concomitant distal bowel decompression. Duodenal perforation in utero is rare due to the proximal location and natural decompression of the obstruction. Thus, polyhydramnios is a common prenatal finding in approximately 75% of cases and premature delivery occurs in one third of patients.

Associated anomalies occur in up to 50% of all neonates with a congenital duodenal obstruction and account for the majority of the morbidity and mortality in these patients. Structural heart disease (30%) and trisomy 21 (30% to 40%) are the two most frequently associated conditions. Other associated anomalies include intestinal malrotation (20%), esophageal atresia or imperforate anus (10% to 20%), heterotaxia, gallbladder agenesis, and less frequently genitourinary and orthopedic malformations. Therefore, it is imperative that once the diagnosis of duodenal obstruction is established, a thorough evaluation for associated anomalies occurs prior to anesthesia for corrective surgery.

Clinical Presentation

The diagnosis of congenital duodenal obstruction is made by prenatal ultrasound or magnetic resonance imaging (MRI) in up to 50% of cases with greater accuracy in those cases with complete obstruction and resultant maternal polyhydramnios. Postnatal diagnosis is dependent on the degree of obstruction, the presence and size of a duodenal web, and location of the obstruction relative to the ampulla of Vater. The majority of affected infants present clinically in the neonatal period. In classic post-ampullary duodenal atresia, the neonate presents with bilious emesis in the

first 24 hours of life. In cases of pre-ampullary obstruction, emesis is nonbilious and diagnosis may be delayed as this is a common finding in a newborn. Physical examination typically demonstrates a stable infant with upper abdominal distention that resolves with placement of a nasogastric tube. With complete obstruction, placement of a nasogastric tube may result in a scaphoid abdomen due to the absence of distal gas in the gastrointestinal tract. With partial obstruction, symptoms may present later in the first year of life with the introduction of solid foods. In rare cases, diagnosis may even be delayed into later childhood or adulthood usually in association with gastroesophageal reflux, esophagitis, duodenal ulcer, or obstruction of the duodenum proximal to the stenosis by a foreign body or bezoar.

The classic radiographic finding is the “double bubble” seen on abdominal x-ray, which represents air distention of the stomach and duodenal bulb with no distal bowel gas (Fig. 91.3). If a nasogastric tube has been placed prior to the initial film, instillation of 30 to 40 mL of air may help aid in diagnosis. Specific attention should be paid to the presence or absence of air distal to the duodenum. The classic “double bubble” sign in the setting of no distal air is pathognomonic for duodenal atresia, and no further diagnostic investigations are necessary. A rare cause of distal air in duodenal atresia is an anomalous bifid common bile duct that inserts both above and below the obstruction, which allows passage of air into the distal bowel. However, in the majority of cases the presence of air in the intestinal tract distal to the duodenum suggests incomplete duodenal obstruction and mandates an urgent UGI contrast study to evaluate for intestinal malrotation with possible midgut volvulus, which would require an emergent operative intervention.



Figure 91.3. A classic plain film of a newborn with duodenal obstruction demonstrating the “double bubble” sign.

A thorough evaluation for associated congenital anomalies is carried

out. Following a thorough physical examination, plain radiographs, echocardiography to evaluate for congenital heart disease, and chromosomal analysis should be obtained in all patients. The presence of complex congenital cardiac anomalies, esophageal atresia, or imperforate anus may impact the timing of operative intervention and operative approach. Radiographic evidence of a nasogastric tube in the stomach rules out esophageal atresia. Passage of meconium and a normally positioned and patent anus should be documented. Investigation for extrinsic causes of compression may begin with an abdominal ultrasound to search for anomalies of the pancreas or biliary tree or rare findings like preduodenal portal vein or duodenal duplication. Further imaging with abdominal computed tomography (CT) scan, magnetic resonance cholangiopancreatigraphy, and hepatobiliary scintigraphy is obtained selectively as indicated.

Preoperative Management

The etiologies of congenital duodenal obstruction, with the notable exception of malrotation with midgut volvulus, do not require emergency surgical intervention. Preoperative management therefore includes nasogastric decompression and correction of electrolyte and metabolic derangements. Maintenance intravenous fluids are given, with replacement fluid added to account for gastric losses. Prophylactic preoperative antibiotics are administered (ampicillin and gentamicin in neonates). Neonates should receive 1 mg of intramuscular vitamin K. In premature infants with extremely low birth weight (<1,000 g), consideration can be made for delayed operative intervention for several weeks with nasogastric decompression and parenteral nutrition to allow for growth of the infant.

OPERATIVE TECHNIQUE

Open

A generous right upper quadrant transverse incision is made. The patient is eviscerated and the bowel is inspected for intestinal fixation and the positioning of the ligament of Treitz. If present, volvulus is derotated counterclockwise until the mesentery is flat. The bowel is then inspected externally for continuity from the pylorus to the terminal ileum. The duodenum is then widely exposed by mobilization of the hepatic flexure followed by a Kocher maneuver. Complete anteromedial rotation of the

duodenum is necessary to identify the complete nature of the obstruction. The duodenum is inspected for caliber transition from proximally dilated to distally collapsed bowel, mural continuity, annular pancreas, and preduodenal portal vein. The location of the duodenal obstruction may be obvious, as in complete atresia with mural discontinuity or annular pancreas. In patients with mural continuity and without annular pancreas, an orogastric or nasogastric tube is advanced by the anesthesiologist and directed by the surgeon through the duodenum. As the tube abuts the atresia or web, the wall of the duodenum dents in at the attachment point of the obstructing membrane or web, which may be proximal to the external transition from dilated to collapsed bowel. Alternately, a Foley catheter of Fogarty balloon may be passed by mouth or via an anterior gastrostomy through the duodenum, then withdrawn after inflation of the balloon.

The most widely accepted surgical approach to congenital duodenal obstruction is duodenoduodenostomy. An anastomosis is created between the dilated proximal duodenum and the diminutive distal duodenum, bypassing the atresia and any annular pancreas. In patients with annular pancreas, the pancreatic tissue should not be divided as this may lead to pancreatic fistula. The “diamond-shaped” duodenoduodenostomy originally described by Kimura (Fig. 91.4) is now the most commonly employed anastomosis. This technique creates a widely patent anastomosis that leads to a shorter time to full postoperative feeding than the side-to-side duodenoduodenostomy while avoiding the blind loop of a duodenojejunostomy. A transverse incision is made on the anterior wall of the proximal duodenum, and a similar length longitudinal incision is made on the antimesenteric border of the collapsed distal duodenum. The location of the duodenotomies is selected to allow anastomosis without tension or compression of intervening pancreatic tissue or preduodenal portal vein. Following opening of the distal segment, a small red rubber catheter should be passed distally into the jejunum to assess for a rare second duodenal atresia. Saline is then injected to distend the distal bowel to rule out any jejunoileal atresia. The “diamond-shaped” anastomosis is then completed by approximating the ends of one incision to the midpoints of the other incision (Fig. 91.4B) using a single-layered technique with silk or absorbable suture. The use of a transanastomotic feeding tube is left to the surgeon’s preference. Tapering of the proximal dilated duodenum has been advocated by some at the time of the initial duodenoduodenostomy

with the goal of improving apposition of the bowel wall during peristalsis. This may be performed along the antimesenteric wall with a bovie and handsewn closure or with a linear cutting gastrointestinal stapler. We prefer to preserve this maneuver for those patients who exhibit persistent postoperative duodenal stasis and poor duodenal function.

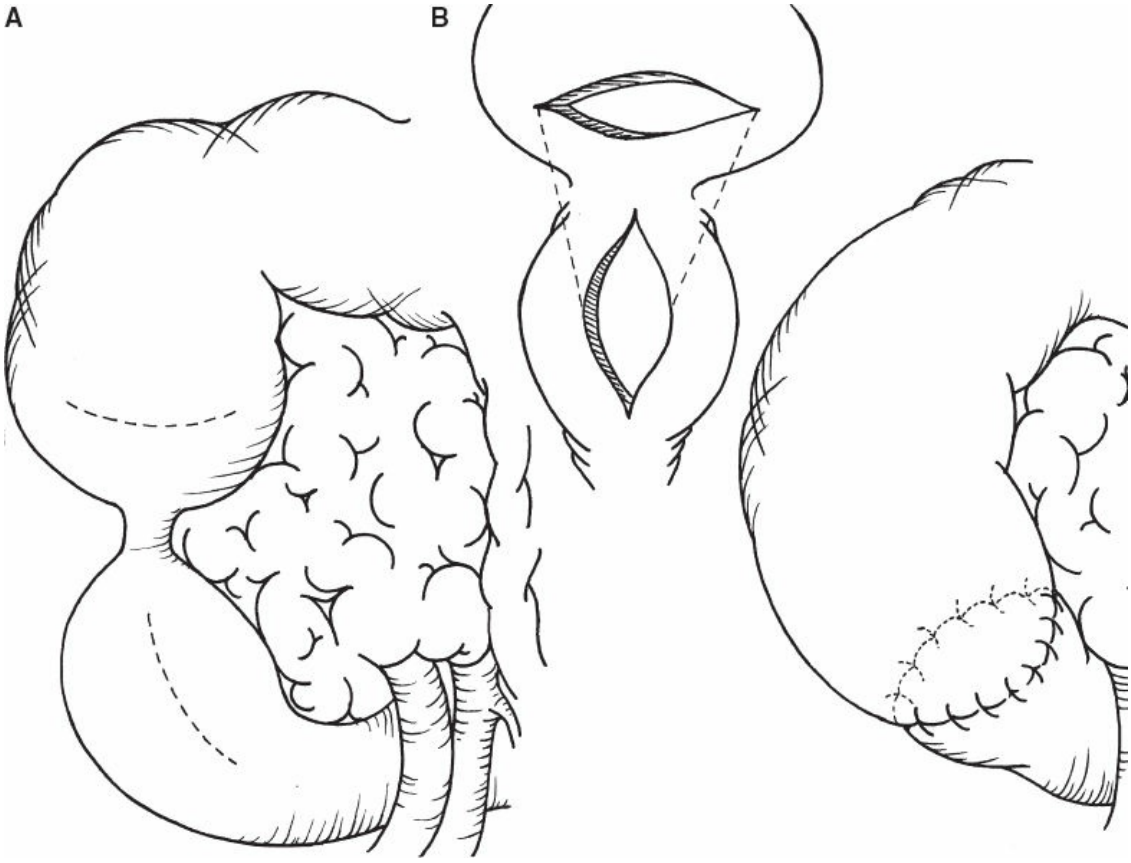

Figure 91.4. **A.** The Kimura diamond-shaped duodenoduodenostomy. The proximal duodenotomy is curvilinear extending cephalad medially. The distance of the proximal duodenotomy to the obstruction is slightly greater than the distance from the obstruction to the distal longitudinal duodenotomy. **B.** The anastomosis is performed with interrupted full-thickness sutures of 5-0 silk or polygalactin.

In certain situations, duodenoduodenostomy is impractical, such as the existence of large gap between the proximal and distal duodenal segments in patients with normal rotation and a normal ligament of Treitz or in infants less than 1,000 g. In this setting, a retrocolic duodenojejunostomy may be employed (Fig. 91.5). A window is made in the mesocolon through which a loop of jejunum is passed. An end-to-side duodenojejunostomy is then fashioned in a single layer with silk or absorbable suture. The

mesocolic defect is closed by suturing the mesocolon to the wall of the duodenum.

Duodenal stenosis typically causes a tapered transition from proximal to distal due to the elongated web ("windsock deformity"), in contrast to the abrupt size discrepancy of duodenal atresia. The perforated web may extend for a variable length distally and may lengthen in the postoperative period if left intact. After identifying the constricting ring from which the web originates by passage of a nasogastric tube, a longitudinal duodenotomy on the antimesenteric wall is made, which centers on the constricting ring. The web is resected laterally, anteriorly, and posteriorly, taking care to avoid and preserve the medial third of the web. This minimizes the risk of injury to the ampulla. A hemostatic, running absorbable suture is placed along the cut edge of the web, and the medial portion is left to hang distally into the lumen. The doudenoplasty is then completed by closing the duodenotomy transversely in a single layer with silk or absorbable suture to further open the constricting ring.

Laparoscopic

In recent years, descriptions of laparoscopic approaches to congenital duodenal obstruction including duodenoduodenostomy, duodenotomy with web resection and duodenoplasty, and correction of malrotation. The laparoscopic approach appears to lead to shorter time to reaching full enteral feeds and an overall shorter postoperative hospitalization. Neonates must be able to tolerate pneumoperitoneum and be of adequate size, which often precludes those with congenital heart anomalies or those under 2 kg. The patient is placed with the feet at the end of the table with the surgeon standing to the left at the patient's feet. Three incisions are used—one at the umbilicus with an appropriately sized cannula, one in the right lower quadrant, and one in the left upper quadrant. Stab incisions may be used in neonates, while cannulae are typically used in older patients. If the liver is obstructing the view, it can be elevated using a suture passed through the abdominal wall, around the falciform ligament then back out the abdominal wall and tied over a sponge. In older patients, a fourth incision in the right upper quadrant may be necessary for a liver retractor. The steps of the operative approach proceed as for the open technique with systematic inspection of the rotation, fixation, patency, annular pancreas, and preduodenal portal vein, as described for the open approach. Likewise, the selection of surgical correction of the duodenal obstruction and steps of

repair are the same. The duodenoduodenostomy may be performed with either intracorporeal or extracorporeal suturing. Some surgeons describe the use of metallic clips to minimize the manipulation and trauma to the bowel.

Postoperative Care

Patients are typically maintained *nil per os* until there is return of bowel function and no evidence of an anastomotic leak with gastric decompression using a nasogastric sump tube. Neonates receive parenteral nutrition, and excessive gastric aspirates are replaced to maintain appropriate urine output. We obtain a UGI contrast study in patients with continued high output of bilious material for more than 7 days, or sooner if there is any clinical concern for a leak. Feeding is initiated when there is evidence of bowel function and anastomotic leak has been ruled out. We caution against relying solely on the return of bilious material to presume postoperative ileus as this may lead to delay in initiating feeds, since the patulous duodenum may pool bilious material and exhibit poor function for some time after the repair. In term infants and older patients, feeds are advanced as tolerated, while premature infants are advanced according to premature feeding protocols at 10 to 20 mL/kg/day.

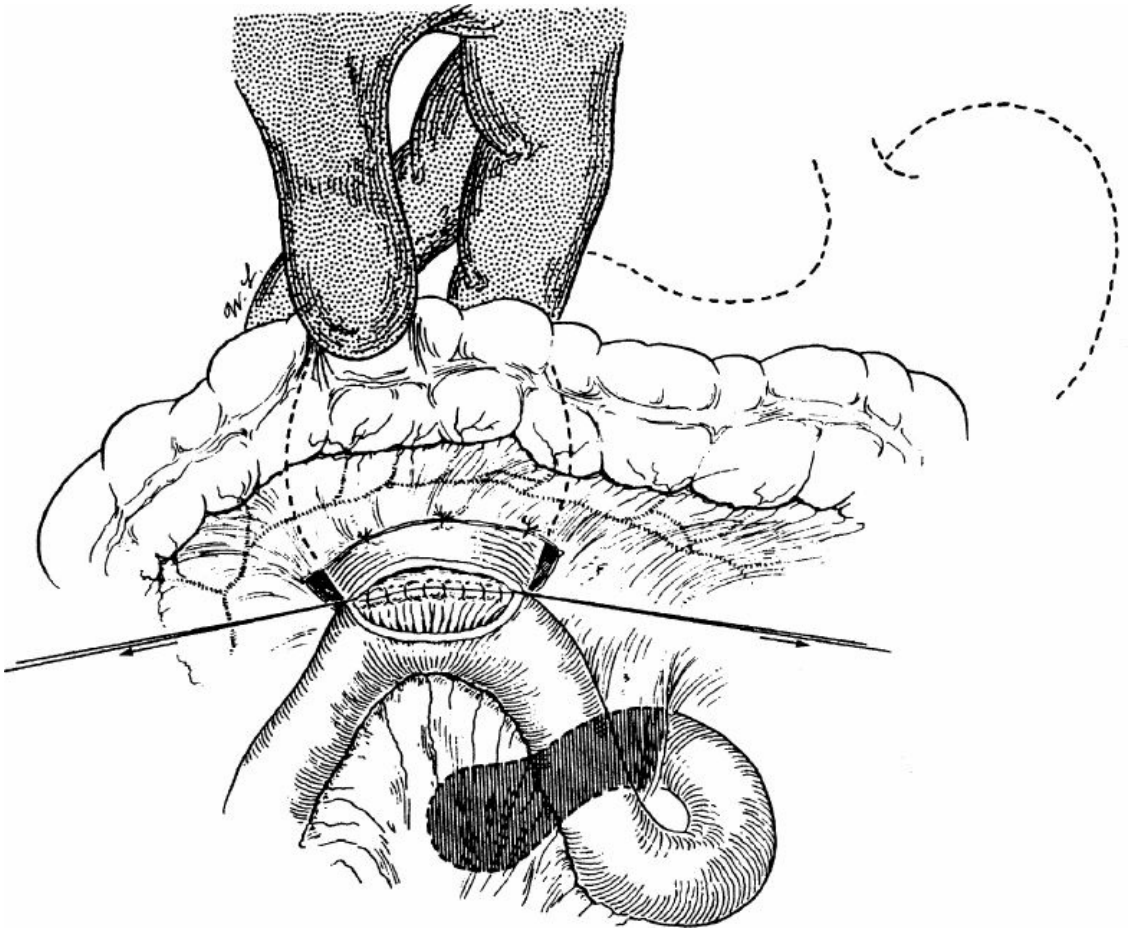

Figure 91.5. Retrocolic duodenojejunostomy. The proximal duodenotomy is performed as in Figure 91.4. Incision in the right transverse mesocolon creates a defect, the edges of which are sutured to the duodenum cephalad to the duodenotomy. A proximal loop of jejunum is then incised on the antimesenteric border for a distance of 3 cm. The anastomosis is performed using full-thickness interrupted 5-0 silk or polygalactin sutures.

Advances in operative technique, anesthesia, and neonatal critical care have led to nearly 95% early survival for correction of congenital duodenal obstruction. The most common short-term complication is feeding intolerance, which is usually the result of delayed gastric emptying and duodenal dysmotility. Other complications include wound complications, anastomotic leak or stricture, duodenogastric or gastroesophageal reflux, gastritis, gastric cancer, duodenal ulcer, megaduodenum, and blind loop syndrome. Most children achieve normal somatic growth. Patients with congenital duodenal obstruction benefit from long-term follow-up with a surgeon to identify and address potential complications.

MALROTATION AND MIDGUT VOLVULUS

Clinical Presentation and Diagnostic Evaluation

Malrotation of the intestine is a common congenital anomaly that may occur in isolation or in association with other congenital anomalies. The clinical presentation depends on the presence or absence of midgut volvulus. The vast majority of patients with midgut volvulus present in infancy, with roughly 50% in the first week, 75% in the first month, and 90% in the first year of life. Those patients without midgut volvulus may present later with chronic, nonspecific gastrointestinal complaints. In some individuals, malrotation is clinically silent and is discovered incidentally during abdominal imaging or at surgery for another indication. Recognition occurs across the age spectrum from birth to adulthood. Clinically apparent malrotation is believed to present in 1 in 6,000 live births. With increasing use of ultrasound for screening for patient with congenital heart disease, heterotaxy syndrome, and other conditions, estimates on the incidence of malrotation range from 3.9 per 10,000 to as high as 1 in 500 live births.

The rotation and fixation of the intestine occur late in the first trimester. Initially, the elongating intestine herniates into the base of the umbilical cord. As the intestine returns to the abdominal cavity, it undergoes a counterclockwise rotation (when viewing the patient anteriorly). The duodenojejunal junction rotates 270 degrees in a course caudad to the superior mesenteric artery (SMA) and superior mesenteric vein (SMV), leftward in front of the spine, and comes to rest at the level of the pylorus to the left of the aorta. The duodenum becomes fixed to the retroperitoneum with the duodenojejunal junction suspended at the ligament of Treitz. The cecum rotates 270 degrees about the axis of the SMA, anterior to the duodenum and comes to rest in the right lower quadrant. The cecum and ascending colon become fixed along the right abdominal gutter and the descending colon along the left abdominal gutter. The mesentery of the small intestine is broadly based across the posterior abdominal cavity from left upper quadrant to the right lower quadrant.

Disorders of rotation and fixation occur on a spectrum with several clinically relevant consequences. The midgut is not fixed to the posterior abdominal wall and the mesentery of the small bowel is narrow. The process of cecal fixation occurs in abnormal locations leading to bands of adhesions (“Ladd bands”) that may obstruct the duodenum or may entrap portions of the bowel. Volvulus of the nonfixed midgut leads to torsion

and compression of the SMV and SMA, which will result in infarction of the midgut if not relieved with urgent intervention.

Patients with congenital diaphragmatic hernia, gastroschisis, and omphalocele almost universally have malrotation due to disruption of the normal return of the intestine to the abdominal cavity. Approximately 10% to 20% of patients with duodenal atresia and one third of those with jejunoileal atresia have malrotation. Among infants with malrotation, duodenal obstruction from a web or stenosis has been reported in 8% to 12%.

The first step to a correct diagnosis is the constant suspicion that any child with bilious emesis has malrotation with volvulus. There is no consistent diagnostic finding of malrotation on plane radiographs that solidifies or rules out the diagnosis. In patients without peritonitis, the diagnostic study of choice is a contrast UGI series to assess the position of the doudenojejunal junction and proximal jejunum. In the anteroposterior projection, the duodenum should descend below the pylorus, cross to the left of the spine, and ascend to the duodenojejunal junction at the level of the pylorus. In the lateral projection, the duodenojejunal junction should be at or posterior to the anterior vertebral bodies. The proximal loops of jejunum should lie in the left upper quadrant. Failure of the duodenum to cross to the left of the spine, failure of the duodenojejunal junction to ascend to the level of the pylorus, and the presence of proximal jejunal loops in the right upper quadrant are evidence of malrotation. There are instances in which the bowel coincidently is lying in the normal position at the time of UGI, though without normal fixation. Other findings that may indicate volvulus are a “bird’s beak” or “corkscrew” configuration of the duodenum or jejunum. Contrast enema may have utility in select situations but must be interpreted with caution. Infants often have a mobile cecum without malrotation, and in 20% of patients with malrotation, the cecum is in the correct position in the right lower quadrant. There has been interest in the use of ultrasound to assess for malrotation to avoid the radiation exposure of contrast radiographs. Ultrasound is being increasingly used as a screening for malrotation in asymptomatic patients by assessing the relationship of the SMA and SMV, and following the course of the duodenum. Because of a reported high false negative rate or identifying malrotation and volvulus, ultrasound must be used with caution in the symptomatic patient and not allowed to delay either UGI or operative intervention. Malrotation is often noted incidentally on CT and MRI.

The traditional approach to the asymptomatic patient has been to electively perform a Ladd procedure since the lifetime risk of volvulus is unpredictable and there is no radiographic test to define the true risk of volvulus. However, in patients with congenital diaphragmatic hernia, omphalocele, or gastroschisis, the combination of an expectation of a broad mesentery and adhesions from the primary corrective surgery has led most pediatric surgeons to observe these patients and to only intervene on symptomatic patients. The routine screening of asymptomatic patients with congenital heart disease or heterotaxy syndromes is controversial. Evidence suggests there is benefit to routine Ladd procedure in asymptomatic patients in the first two decades of life, but there must be a consideration of the risks versus the benefits of Ladd procedure later in life.

Preoperative Preparation

The clinical condition of the patient depends on the degree of intestinal ischemia, the presence of absence of venous return from the ischemic bowel, and the duration and volume of emesis prior to presentation. Patients with prolonged emesis may exhibit hypochloremic, hypokalemic metabolic alkalosis. The ischemic bowel may cause an elevated serum lactate, although a normal lactate is not reassuring as there may be no venous return from the ischemic intestine. In symptomatic patients, assessment, fluid resuscitation, and preoperative preparation should occur simultaneously so that the patient can proceed emergently to surgery if the diagnosis is confirmed. In infants who present with bilious emesis and peritonitis, exploration may need to proceed without contrast examination.

Operative Technique

Since Ladd first described the operative correction for malrotation in 1932, little has changed. Infants with volvulus are approached through a transverse right upper quadrant incision. In older children with an acute abdomen, an upper midline incision may be used. The bowel is completely eviscerated. The volvulus is immediately addressed by rotating the bowel counterclockwise, which may require multiple complete rotations. If the bowel is ischemic, it is packed in warm saline-soaked sponges and reassessed for the impact of reperfusion. If the bowel is frankly necrotic, a decision must be made regarding primary resection with stoma creation or primary anastomosis with an attempt to preserve as much intestinal length

as possible. If the viability of the bowel is uncertain or the patient's physiologic condition is unstable, temporary abdominal coverage and second look operation should be considered. Patients with complete midgut infarction present difficult ethical considerations that should be addressed with the family, including short bowel syndrome, effects of prolonged parenteral nutrition, bowel transplant, and mortality. In this setting, temporary closure and planned second look may give the family time to come to terms with the patient's condition and potential outcomes.

TABLE 91.1 Ladd Procedure

1. Laparotomy with complete evisceration
2. Counterclockwise detorsion of volvulus
3. Division of Ladd bands
4. Broadening of midgut mesentery
5. Incidental appendectomy
6. Replacement of the small bowel along the right abdominal gutter, colon along the left abdominal gutter with cecum in the left upper quadrant

If the gut is viable, a Ladd procedure (Table 91.1) and appendectomy should be completed. Ladd bands extending from the duodenum to the right abdominal wall are sharply divided (Fig. 91.6). The duodenum is then completely mobilized with the goal of achieving a straight course from the right upper to right lower quadrant. The second portion of the duodenum is mobilized from lateral to medial. The third portion of the duodenum may take a variable course, including into the root of the mesentery. Dissection must remain on the anterior surface of the duodenum to avoid the medially located vascular supply. Once the duodenum is completely freed, the lumen should be interrogated for intrinsic obstruction. This may be accomplished with the passage of a large orogastric tube from the mouth to the distal duodenum. Alternatively, a Fogarty balloon or Foley catheter may be passed through the mouth or via a gastrostomy, advanced to the jejunum, and swept retrograde after

inflation of the balloon. Air or saline may be milked distally to assess the patency of the distal bowel.

The base of the mesentery is inspected and broadened. This is accomplished by dividing any additional abnormal adhesive bands down to the SMA and SMV. Small bowel may be found to be entrapped within adhesive bands, so a careful inspection of the full length of bowel from duodenojejunal junction to the ileocecal valve is imperative. Once the mesentery is properly widened, the risk of volvulus of the mesenteric pedicle is low.

The small intestine is placed along the right abdomen from right upper quadrant to right pelvis, and the colon is placed in the left abdomen. The cecum is placed in the left upper quadrant. While pexy of the duodenum and cecum has been advocated by some, this has not proven beneficial. Because of the abnormal position of the cecum and to prevent future diagnostic confusion, an incidental appendectomy is performed. This may be done by inversion technique to prevent entry into the gastrointestinal tract.

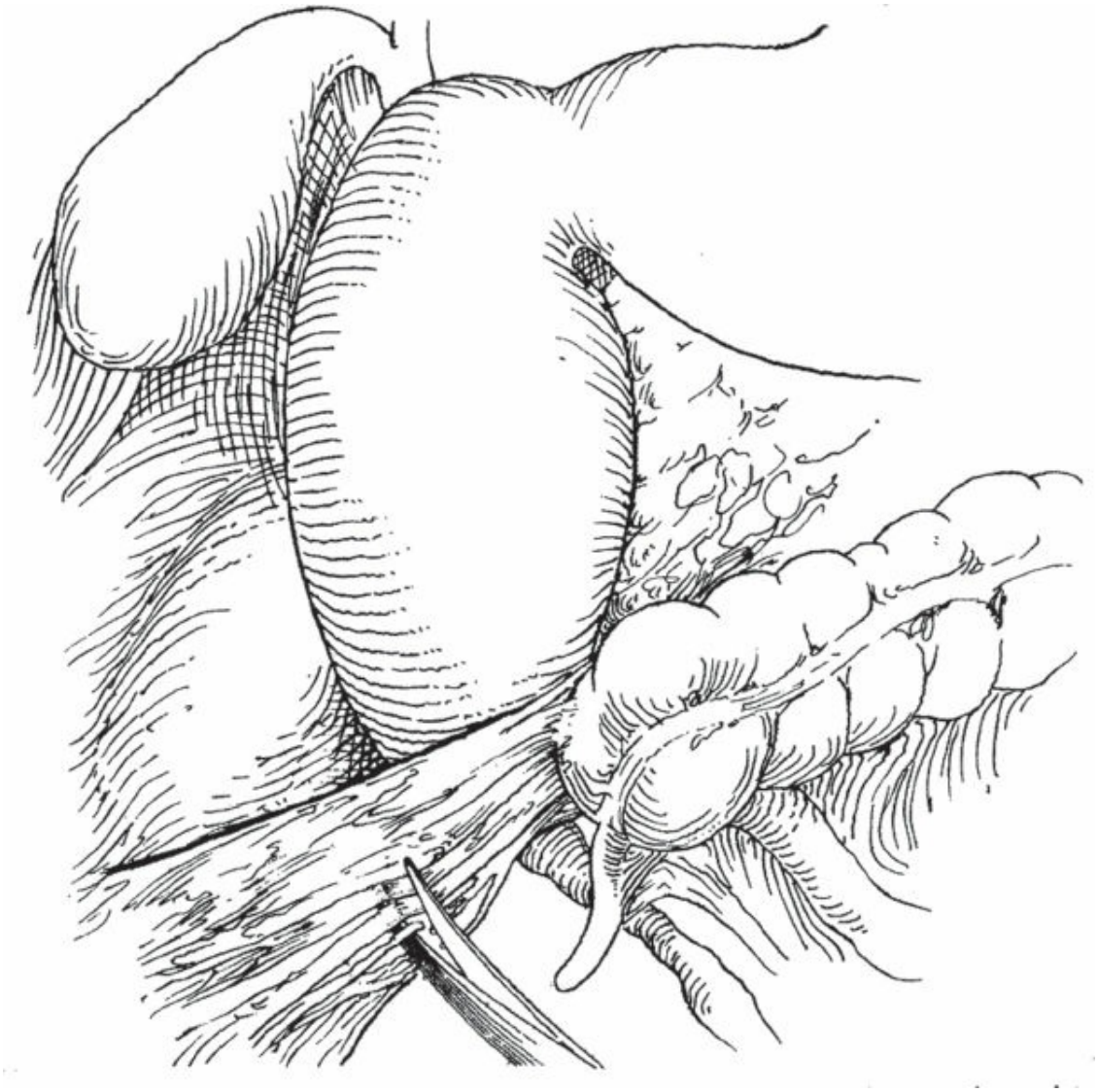

Figure 91.6. Ladd procedure for malrotation. The abnormal peritoneal attachments to the posterior parietes are first divided by cecal mobilization exposing the anterior wall of the second and third portions of the duodenum. Dissection should occur on the anterior wall of the duodenum to avoid vascular or pancreatic injury. (From Michael D. Klein, Diana L. Farmer. Congenital pyloric stenosis and duodenal obstruction. *Mastery of Surgery*. 4th ed. Philadelphia, PA: Wolters Kluwer Health/Lippincott Williams & Wilkins; 2002; Chapter 81.)

In patients without volvulus, the Ladd procedure may be safely performed laparoscopically. This approach is well suited for patients who are minimally symptomatic or asymptomatic. We typically use three laparoscopic cannulae, at the umbilicus, right lower quadrant, and left lower quadrant. If the liver is obstructing the view, it is suspended with a suture passed through the abdominal wall, under the falciform ligament,

back out the abdominal wall, and tied over a sponge. The initial cannula is placed through an infraumbilical incision by open technique. We use 3-mm instruments in infants, and 5-mm instruments in older children and adults. The intestine is systematically inspected for the position of the duodenojejunal junction, the position and attachments of the cecum, and the breadth of the base of the mesentery. Once the diagnosis of malrotation is confirmed, the surgeon may complete a Ladd procedure laparoscopically or convert to open depending on their preference, technical skills, and ability to complete the key components of the procedure, which are the same manner as the open approach. The appendectomy may be completed with standard laparoscopic techniques or externalized at the umbilical incision to allow completion of inversion appendectomy.

Postoperative Considerations

The outcome after the Ladd procedure for volvulus depends on the condition of the bowel and whether the patient retains adequate intestinal length. While the field of intestinal and multivisceral transplant is advancing, the short- and long-term treatment and complications of short bowel syndrome are complex. For those with symptomatic malrotation without intestinal loss, the outcomes are excellent with the expectation of normal growth potential and life expectancy. The results for patients who are minimally symptomatic or asymptomatic are less well defined. The symptoms attributed to abnormal rotation may be multifactorial or the result of chronic partial obstruction. In patients with heterotaxy syndromes or complex congenital heart disease, long-term outcomes are generally related to underlying cardiac function and prognosis. Complications include small bowel intussusception, adhesive obstruction, recurrent volvulus (about 1%), and the usual complications seen after abdominal surgery or bowel anastomosis. Mortality is estimated to be 3% after Ladd procedure and is highest in those with intestinal infarction, prematurity, or other congenital anomalies. Laparoscopic techniques offer shorter hospital length of stay and reduced pain compared to laparotomy. Advances in neonatal critical care, pediatric surgical intensive care, anesthesia, and bowel rehabilitation have contributed to improved outcomes.

Suggested Readings

Graziano K, Islam S, Dasgupta R, et al. Asymptomatic malrotation: diagnosis and surgical management: an American pediatric surgical association outcomes and

evidence based practice committee systematic review. *J Pediatr Surg* 2015;50(10):1783–90.

Ranells JD, Carver JD, Kirby RS. Infantile hypertrophic pyloric stenosis: epidemiology, genetics, and clinical update. *Adv Pediatr* 2011;58(1):195–206.

Spilde TL, St Peter SD, Keckler SJ, et al. Open vs laparoscopic repair of congenital duodenal obstructions: a concurrent series. *J Pediatr Surg* 2008;43(6):1002–5.

Sullivan KJ, Chan E, Vincent J, et al. Feeding post-pyloromyotomy: a meta-analysis. *Pediatrics* 2016;137(1):1–11.

EDITOR'S COMMENT

Foregut obstruction in an infant is common due in large part to the frequency of pyloric stenosis. Less common causes of a proximal bowel obstruction in children include duodenal atresia and malrotation. The authors present an excellent overview of the three topics. As the authors note, pyloric stenosis is the most common surgically correctable cause of nonbilious emesis; however, because nonbilious emesis in an infant is common and typically due to gastroesophageal reflux or formula intolerance/allergy, the diagnosis can be delayed. Often, the primary care physician will have recommended a series of formula changes before considering pyloric stenosis. In the past, pyloric stenosis was a diagnosis established by history and a physical examination in which the hypertrophied pylorus was palpated as an "olive" in the right upper quadrant. In the current era, that skill set has been diminished as ultrasound has been integrated into the diagnostic algorithms such that it is obtained before the pediatric surgical team is consulted. Emergency room teams cite efficiency as the basis for early ultrasound, minimizing the requirements of a careful examination (Gallagher RA, Levy JA. Advances in point-of-care ultrasound in pediatric emergency medicine. *Curr Opin Pediatr* 2014;26(3):265–71). We encourage all trainees to palpate the olive in the operating room to maintain the ability to properly detect an enlarged pylorus.

Because of the relative frequency of pyloric stenosis, it is a cohort that has undergone significant outcome-focused analysis. Multiple prospective randomized and observational cohort studies have been performed providing evidence-based guidelines to optimize care. From a preoperative standpoint, the frequency of laboratory tests which can be anxiety provoking to family and patient can be limited (Dalton BG, Gonzalez KW, Boda SR, et al. Optimizing fluid resuscitation in hypertrophic pyloric stenosis. *J Pediatr Surg* 2016;51(8):1279–82.). Prospective trials have been performed comparing laparoscopic versus open pyloromyotomy (Hall NJ, Pacilli M, Eaton S, et al. Recovery after open versus laparoscopic pyloromyotomy for pyloric stenosis: a double-blind multicentre randomised controlled trial. *Lancet* 2009;373(9661):390–8; St Peter SD, Holcomb GW 3rd, Calkins CM, et al.

Open versus laparoscopic pyloromyotomy for pyloric stenosis: a prospective, randomized trial. *Ann Surg* 2006;244(3):363–70). Although the evidence in support of laparoscopic approach is not overwhelming, the laparoscopic approach has become prevalent and will supplant the open approach as the most common approach utilized (Jia WQ, Tian JH, Yang KH, et al. Open versus laparoscopic pyloromyotomy for pyloric stenosis: a meta-analysis of randomized controlled trials. *Eur J Pediatr Surg* 2011;21(2):77–81). Postoperatively, prospective studies have shown that early initiation of feeds using full-strength formula with a rapid advance is well tolerated and shortens hospitalization such that some patients are discharged within 12 hours after the procedure (Adibe OO, Iqbal CW, Sharp CW, et al. Protocol versus ad libitum feeds after laparoscopic pyloromyotomy: a prospective randomized trial. *J Pediatr Surg* 2014;49(1):129–32; Clayton JT, Reisch JS, Sanchez PJ, et al. Postoperative Regimentation Of Treatment Optimizes Care and Optimizes Length of Stay (PROTOCOL) after pyloromyotomy. *J Pediatr Surg* 2015;50(9):1540–3).

The authors nicely present the details of how they approach pyloromyotomy. The laparoscopic procedure has the advantage of easier access to the enlarged pylorus. Especially when the hypertrophied pylorus is marked, delivering it through an umbilical incision can be frustrating. With the laparoscopic approach, the hypertrophied pylorus is readily visualized. The technical details on how to perform a laparoscopic pyloromyotomy are well depicted, but I would add one detail that facilitates efficiency. After using the Bovie to “crack the olive,” the use of a 3-mm Maryland placed in the site where the Bovie blade has created the separation of the muscularis to further expand the site will aid the insertion of the laparoscopic Benson spreader.

Complications after pyloromyotomy are uncommon, but as the authors note mucosal injury is the most serious and requires early recognition as if missed, the consequences of enteric contamination in the right upper quadrant can be significant. After repair of the mucosal injury, one may consider obtaining a UGI before starting PO feeds and start of feeds should be delayed for at least 24 hours. On occasion, an incomplete pyloromyotomy will be performed such that persistent emesis occurs with feeding. Repeat exploration is an option but atropine to treat pyloric stenosis may be considered. Atropine treatment can be used to treat pyloric stenosis precluding surgery; however, when that approach is utilized, a long course of atropine will be required and weight gain will be a marginal (Kawahara H, Imura K, Nishikawa M, et al. Intravenous atropine treatment in infantile hypertrophic pyloric stenosis. *Arch Dis Child* 2002;87(1):71–4). Should a patient have an incomplete pyloromyotomy and there is hesitation to offer second exploration, a course of atropine may resolve the intolerance of feeds.

The authors provide an excellent review of duodenal atresia along with the important treatment considerations. In patients with duodenal atresia, associated anomalies are frequent. In patients who have a combination of esophageal

atresia and duodenal atresia, duodenal reconstruction should occur first, as a downstream obstruction from an uncorrected duodenal atresia could stress the integrity of esophageal reconstruction. Ideally, trisomy syndromic assessment (clinical assessment, not genetic testing) should be completed prior to repair as should it be present, consideration for gastrostomy tube placement may be warranted.

As with many procedures in pediatric surgery, laparoscopy has been applied to duodenal atresia. A systematic review analyzing the benefits of laparoscopic versus open approach was recently published (Chung PH, Wong CW, Ip DK, et al. Is laparoscopic surgery better than open surgery for the repair of congenital duodenal obstruction? A review of the current evidences. *J Pediatr Surg* 2017;52(3):498–503). The benefits of the laparoscopic approach outside of cosmesis appear limited with the challenge of additional cost (due in large part to prolonged OR time). Long-term follow-up of patients with duodenal atresia is warranted as some will develop dilated proximal duodenum due either to motility abnormalities or stenosis at the anastomosis (Escobar MA, Ladd AP, Grosfeld JL, et al. Duodenal atresia and stenosis: long-term follow-up over 30 years. *J Pediatr Surg* 2004;39(6):867–71). These patients will benefit from exploration and tapering of the dilated duodenum.

Malrotation is a common cause of proximal bowel obstruction and if volvulus is present is a true pediatric surgical emergency. As the authors observe, any child with bilious emesis should be presumed to have malrotation until it has been ruled out by UGI. If malrotation is present with volvulus, then the patient should proceed to the OR emergently. There should be no delay as bowel ischemia with resulting compromise of GI tract length outweighs the need for immediate resuscitation. As the volvulus is decompressed, the anesthesia team can continue to resuscitate the patient reducing ancillary organ injury.

An area of some controversy is the patients with malrotation who have congenital heart disease and situs abnormalities. These patients do not have classic rotational abnormalities, but because they have heterotaxy, the intestines are not properly fixated and may be at risk for volvulus (Papillon S, Goodhue CJ, Zmora O, et al. Congenital heart disease and heterotaxy: upper gastrointestinal fluoroscopy can be misleading and surgery in an asymptomatic patient is not beneficial. *J Pediatr Surg* 2013;48(1):164–9; Yu DC, Thiagarajan RR, Laussen PC, et al. Outcomes after the Ladd procedure in patients with heterotaxy syndrome, congenital heart disease, and intestinal malrotation. *J Pediatr Surg* 2009;44(6):1089–95). What must be assessed (by UGI or cross-sectional imaging) is the width of the base of the mesentery—the distance between the ligament of Treitz and the right colon—which is the critical determinant of the risk of volvulus. If the base of the mesentery appears narrow, then the patient is at risk of volvulus and operative exploration should be considered. If the width is broad, then the risk of volvulus is small and exploring these patients can be confusing as their rotational variations result in

abnormal positioning of the intestine.

As with duodenal atresia and pyloric stenosis, laparoscopic approaches have been applied to malrotation. The benefits of laparoscopy for this diagnosis need to be critically assessed. The generation of adhesions fixing the bowel in the "proper" position after it has been returned to the abdomen—small bowel on the right, colon on the left—is an important unsaid component of the procedure. The challenge with laparoscopy is that the likelihood of forming adhesions, both to the small port incisions and within the abdomen, is reduced.

In the unfortunate circumstance of midgut volvulus, in which the viability of a significant amount of small bowel is compromised, a careful counseling of the family is required. Although a decision to close the patient and institute comfort measures is a choice, advances in intestinal rehabilitation and intestinal transplantation have made long-term survival plausible. Should salvage be attempted, we recommend a series of second-look procedures preserving any intestine possible. Once the amount of viable intestine has become defined, we restore GI tract continuity as quickly as possible as nutritional and fluid management is much easier without significant stoma losses. Families must be taught careful care of central access as recurrent infections will trigger loss of access/thrombosis. Finally, it is important to note that there have been exciting developments in biotechnology where human intestine can be developed from stem cells which in the future may give these children long-term options that just a few years ago would have been unfathomable (Watson CL, Mahe MM, Munera J, et al. An in vivo model of human small intestine using pluripotent stem cells. *Nat Med* 2014;20:1310–4).

Gregory M. Tiao

92 Diabetes and Other Metabolic Diseases

Kevin El-Hayek and R. Matthew Walsh

INTRODUCTION

The average surgical patient has changed significantly over the past 30 years, especially in relation to medical comorbidities such as obesity, diabetes, and other metabolic diseases. The prevalence of metabolic diseases has reached epidemic proportions and their impact spans the globe. Recent reports indicate that the incidence of obesity continues to rise, particularly in younger age groups. The World Health Organization estimates that 39% of the adult population is overweight (body mass index [BMI] >25 kg/m^2) while 13% are obese (BMI >30 kg/m^2). In the United States alone roughly 17% of children aged 2 to 19 years are obese. Likewise, diabetes rates among all age groups globally are projected to rise from 2.8% in 2000 to 4.4% by 2030. The impact of this increasing prevalence will ultimately lead to higher rates of obesity-related complications including disorders of the ophthalmologic, vascular, and renal systems. The financial strain on health care systems will continue to increase to manage these diseases and their subsequent consequences, despite these disorders being classified as preventable. In terms of the surgical role in these disorders, the focus in the past was on management of complications. Currently, the focus has shifted away from management of complications to prevention or amelioration of disease by surgical interventions.

The concept of surgery for prevention of metabolic diseases was introduced by Henry Buchwald and Richard Varco in their 1978 book, *Metabolic Surgery*. They defined metabolic surgery as “the operative manipulation of a normal organ or organ system to achieve a biologic result for potential health gain.” Since that time, many scientists and clinicians have either directly studied the effects of surgery or have serendipitously noticed metabolic changes after various operations. Because of this ongoing work, the understanding of metabolic surgery has

undergone significant evolution in the subsequent decades—an evolution that has been mirrored by a global increase in patients with metabolic diseases. Furthermore, because of the extremely high prevalence, advancements in medical and surgical approaches have expanded at a rapid pace. Remaining current with the most recent standards is challenging, especially in light of the numerous multidisciplinary opinions and data that continue to emerge. There is also a significant variation in the surgical options offered for these diseases depending on the local expertise and bias.

Not surprisingly, many of the metabolic diseases to be discussed have a significant correlation with obesity. Worldwide rates of obesity are also increasing at epidemic proportions, with an alarming increase in childhood and adolescent populations. Many of the therapies directed at obesity control also apply to the predominant metabolic diseases. An important reminder is to consider the whole person when offering therapy, such that clinicians can improve all aspects of the patient's health including obesity, diabetes, and other metabolic diseases. The value of a multidisciplinary team including internal medicine and appropriate subspecialties, clinical dietetics, psychiatry/psychology, and anesthesia cannot be overstated. Finally, the benefit of these therapies must also outweigh the risk so as to adhere to the fundamental medical principle: "First do no harm."

The purpose of this chapter is to discuss the pathophysiology of diabetes and other metabolic disorders, to review the various surgical options for management of these diseases, to report outcomes from the differing approaches, and to highlight novel interventions that are being applied to this broad category of diseases.

DIABETES

Etiology and Pathophysiology

Diabetes mellitus comes from the Greek "to pass through" and "from honey." Early investigators noted the high frequency of urination that had a sweet character, thus leading to the ascribed name.

Currently, diabetes is classified into two types. Type I diabetes, formally known as juvenile diabetes, makes up roughly 5% to 10% of all cases of diabetes. It is typically diagnosed in patients and is mostly related to an autoimmune destruction of pancreatic beta cells. This beta-cell destruction leads to a lack of insulin production in the body, followed by increasing hyperglycemia. The etiology of type I diabetes is multifactorial.

While there are certainly genetic links, many patients may also have sporadic development of type I diabetes. The genetic locations associated with type I diabetes include IDDM1-IDDM18—all of which affect the immune response. First-degree relatives of those with type I diabetes have a roughly 10% chance of developing it, and this scenario is more commonly seen inherited via the paternal route. For sporadic cases, onset may follow a viral illness, which is presumed to cause an autoimmune cascade and subsequent beta-cell destruction. Viruses that have been implicated in the ultimate development of type I diabetes include the Coxsackie family, mumps and rubella, as well as enteric families. Because type I diabetes typically presents in a younger population, it is not necessarily related to increased BMI as seen in type II diabetes. On the other hand, with the increase in overall rates of obesity, type I diabetes is being increasingly seen in overweight or obese individuals, whose sensitivity to insulin may already be impaired.

Type II diabetes, formally known as adult-onset diabetes, is a disease of progressive insulin insensitivity. Type II diabetes makes up 95% of all cases of diabetes. Based on large-scale databases, roughly 14.3% of the entire US population has diabetes, while 38% has a condition known as prediabetes. While there have been genetic patterns recognized, there are a significant number of genes associated and none have emerged as the predominant etiologic factor. Disease etiology has been directly linked to individual behaviors such as a poor diet and sedentary lifestyle. Unlike that of type I diabetes, patients with higher BMI are also at risk for increased insulin resistance. Overall fat mass, in particular intra-abdominal fat, increases the body's resistance to circulating insulin. Furthermore, the diseases within the "metabolic syndrome" such as increased BMI, hypertension, hyperlipidemia, and hypertriglyceridemia are also associated with an increase in overall insulin resistance. Once the insulin resistance progresses to a severe, chronic level, eventually the beta cells' ability to produce insulin decreases. This progressive phase of type II diabetes is further classified as insulin-dependent type II diabetes.

Clinical Presentation

Patients with type I diabetes may present following a viral illness and this is most commonly seen in younger populations. Early practitioners recognized this entity clinically as excessive urination due to spilling of glucose into the urine. This cascade causes an osmotic dieresis that has a

sweet character that attracted ants. The lack of insulin production and failure to identify early symptoms can lead to severe hyperglycemia and ultimately a scenario of diabetic ketoacidosis. The signs and symptoms of diabetic ketoacidosis can occur within 24 hours and include excessive thirst, urination, nausea and vomiting, abdominal pain, weakness, and confusion. It is considered a medical emergency requiring immediate evaluation. The etiology of ketoacidosis revolves around the lack of insulin and an eventual state of severe hyperglycemia. Because the body cannot store the glucose as indicated by the excess levels in the blood, fat is inappropriately broken down into acids known as ketones. As these ketones build up in the blood, a metabolic acidosis ensues. This presentation may be the first indication of a patient's diagnosis of type I diabetes. Diabetic ketoacidosis is rare in patients with type II diabetes.

The clinical presentation of type II diabetes is often more insidious and patients may appear mostly asymptomatic in early phases. Ultimately, frequent urination becomes more obvious and patients may present for evaluation. Other presentations occur in those who have already developed complications such as ophthalmologic diseases and peripheral neuropathy. Due to the excess buildup of glucose in the microvasculature of the eyes, progressive ophthalmologic conditions such as diabetic retinopathy may develop over time in type II diabetics. Diabetic retinopathy is the leading cause of blindness for adults in the United States of America. The same mechanism occurs within the periphery as glycated blood leads to chronic ischemia of the peripheral nerves, leading to diabetic peripheral neuropathy. Occult renal dysfunction may also be recognized on routine laboratory studies, but often the diagnosis is made prior to development of this complication.

Diagnosis

Clinical presentation and laboratory data are the most helpful components to confirm the diagnosis of both type I and type II diabetes. As previously stated, type I diabetes is more rare and often seen in younger individuals, though there are examples of late-onset type I diabetes. Rapid point of care testing of blood glucose is a screening method to assist with diagnosis to direct acute care in severe cases, particularly for type I diabetes. In stable cases, several tests are available to make the diagnosis of diabetes. Hemoglobin A1c, also known as glycated hemoglobin, is a marker of blood glucose levels over 2 to 3 months. With chronic hyperglycemia,

glucose can bind to hemoglobin within the red blood cells. This glucose buildup over time will lead to a percentage of glycated hemoglobin compared with normal hemoglobin within the blood sample. Prediabetes is defined as those patients with levels of glycated hemoglobin of 5.7% to 6.4% while those with >6.5% have diabetes. On the other hand, fasting plasma glucose is a direct measure of blood glucose after 12 to 14 hours of fasting. Glucose measures from 70 to 99 mg/dL are considered normal, 100 to 125 mg/dL are considered prediabetes, and >126 mg/dL are considered diabetes. The final test to measure for diabetes is the oral glucose tolerance test. In this investigation, fasting blood glucose levels are tested before and then 2 hours following a calibrated dose (75 g) of glucose are administered to a patient. Patients with levels less than 140 mg/L are considered normal, those with levels 141 to 200 mg/dL have prediabetes, while those greater than 200 mg/dL have diabetes.

OTHER METABOLIC DISEASES

While diabetes alone can wreak havoc on the human body, other metabolic diseases often present in conjunction with diabetes. The most common associated comorbidities include hyperlipidemia and hypertriglyceridemia, which together with hypertension make up the metabolic syndrome. When considered together, patients with these diseases are at higher risk for coronary artery disease, stroke, and early mortality. The next section will focus on the etiology, pathophysiology, clinical presentation, and diagnosis of hyperlipidemia and hypertriglyceridemia.

Etiology and Pathophysiology

Hyperlipidemia and hypertriglyceridemia are diseases of abnormally high levels of lipids, lipoproteins, and triglycerides within the blood. Hyperlipidemia is classified into primary and secondary subtypes. Primary hyperlipidemia is less common and etiology is linked to genetic abnormalities. Familial hyperlipidemias are classified into five types according to the Frederickson classification. The pathophysiology of these disorders include several mechanisms, such as decreased lipoprotein lipases (LPL), LPL inhibitors, decreased low-density lipoprotein receptors, and defects in degradation enzyme synthesis. Each of these various mechanisms results in an increase in lipids and lipoproteins circulating within the blood, leading to multiple downstream effects.

Secondary or acquired hyperlipidemia makes up the majority of cases

worldwide. The etiology is related to a poor diet, rich in processed, high fat foods, as well as physical inactivity. Other diseases such as diabetes, hypothyroidism, renal failure, alcohol use, and various prescription drugs can also lead to hyperlipidemia. The pathophysiology of these forms is related to the underlying causes, such as excessive lipid intake from diet, degradation enzyme injury from hyperglycemia, and direct drug interactions with low-density lipoprotein receptors.

Clinical Presentation

Patients with either primary or secondary hyperlipidemia/hypertriglyceridemia often have no symptoms directly related to the increased blood levels of lipids or triglycerides. Rarely, with severely high levels and in those with type I or type IV primary hyperlipidemia, the presenting disease may be acute pancreatitis from direct pancreatic injury. In these cases, circulating levels are often extremely high and a familial predilection is seen. For other patients where presentation is more subtle, symptoms from associated diseases such as diabetes, hypothyroidism, and renal failure may prompt physicians to diagnose concomitant hyperlipidemia. As with many metabolic diseases, isolated presentation is unlikely for hyperlipidemia.

Diagnosis

Clinical history is especially important in cases of familial hypertriglyceridemia and hyperlipidemia, while dietary and activity habits remain key components for those with secondary causes. Physical examination is focused mainly on associated findings such as high blood pressure, high BMI, and particularly central obesity. The mainstay for diagnosis is a fasting lipid and triglyceride panel. The most common components of this panel include low-density lipoprotein, high-density lipoprotein, triglycerides, and total cholesterol. These values are then used to calculate very low-density lipoprotein and the cholesterol:HDL ratio. A low-density lipoprotein level greater than 3.3 mmol/L is considered borderline high, while levels greater than 4.9 mmol/L denote very high levels corresponding to increased rates of cardiovascular disease.

INDICATIONS AND CONTRAINDICATIONS FOR SURGERY

Indications

Medical therapies and counseling for lifestyle and dietary modifications remain the foundation for treatment of metabolic diseases. Particularly for familial diseases, all modifiable risk factors such as diet, smoking, and physical activity should be optimized. Likewise, maximal medical therapy should be offered for patients with these disorders. Newer medications are gaining traction within the medical community; however, recidivism, compliance, and poor disease control remain significant issues. The National Institutes of Health convened a consensus conference in 1991 to address the epidemic of obesity and the metabolic syndrome and recommended surgery for selected patients who meet the following criteria: patients with a BMI greater than 40 kg/m^2 and those with a BMI greater than 35 kg/m^2 with associated comorbidities. These recommendations have largely remained unchanged over the past 25 years; however, there is growing interest in offering surgical therapy for patients with lower BMI (e.g., 30 to 35 kg/m^2 with associated comorbidities such as severe diabetes). Important recommendations also include evaluation by a multidisciplinary team prior to surgical therapy as well as providing lifelong follow-up for patients. The different options for surgical therapy will be discussed in the following sections; however, it is important to note that regardless of the operation offered, patients who are followed in a center providing multi-disciplinary, lifelong follow-up fare better than those who opt for a “quick fix” operation with no follow-up. Data have also shown that patients who maintain a high level of motivation starting at the preoperative phase and continuing into the postoperative phase have improved outcomes. Finally, patients with shorter duration of diabetes and other metabolic diseases likely gain a more profound benefit from the operations than those with long-standing diseases.

Contraindications

Most contraindications for metabolic surgery are considered relative, but the following factors must be heavily considered prior to offering surgery for diabetes, obesity, and other metabolic disorders. Patients with severe heart failure, unstable coronary artery disease, active cancer, hepatic cirrhosis, substance abuse, mental retardation or severe intellectual impairment, and end-stage lung disease are generally not considered to be candidates for metabolic surgery. Also, patients with severe inflammatory bowel disease such as Crohn disease may not be well suited for Roux-en-Y

gastric bypass or biliopancreatic diversion with duodenal switch due to their long-term risk of small bowel disease potentially requiring surgical resection. Significant prior abdominal surgery with adhesive disease and ventral hernia also creates more complexity when considering candidates for surgery, especially when a minimally invasive approach is being contemplated. In these challenging cases, surgeons must be prepared to perform the operation in an open fashion as indicated. Currently, patients with a BMI between 30 and 35 kg/m^2 are not candidates based on the 1991 National Institutes of Health criteria, but active research is being performed on these patients and potentially may lead to an extension of the criteria, especially for those patients with severe comorbidities including diabetes. Extremely high BMI (e.g., >60 kg/m^2) was once considered a contraindication for metabolic surgery; however, advances in anesthesia care, critical care, and surgical equipment and techniques have allowed many of these patients to currently undergo surgery in controlled and experienced settings. Patient age is a final consideration, especially as rates of diabetes, obesity, and other metabolic diseases increase both in younger and older individuals. Data are mounting to answer the value of metabolic surgery for patients under 18 and over 60 years of age. Some authors believe performing metabolic surgery on children and adolescents may prevent the development of many diseases including diabetes and metabolic disorders while others question the ethics of this intervention. For those over age 60, surgeons should expect poorer outcomes for weight loss and metabolic effects as well as higher complication rate and length of stay.

Preoperative Planning

The preoperative phase of patients undergoing metabolic surgery provides the foundation for a successful treatment course. Centers of excellence focus on a clearly defined pathway that starts with a preliminary introduction to metabolic surgery, often in a seminar setting. Once patients have made the decision to proceed with a surgical evaluation, they are introduced to a multidisciplinary team including medical weight-loss specialists, medical specialist for underlying comorbidities such as cardiac, pulmonary, or endocrine diseases, clinical dieticians, and psychologists/psychiatrists focused on food management. The pathway often takes a minimum of 3 to 6 months, during which time the patient is able to prepare for a potential change in their gastrointestinal anatomy.

Also, it is during this period when the medical team can supervise behaviors and identify signs that patients may not be well suited for a surgery. Examples of this behavior include not being able to follow diet and lifestyle modification recommendations, noncompliance with medications, and severe binge eating behaviors. An area of special attention is on preoperative glucose control to optimize outcomes in diabetic patients. Perna and colleagues examined the effect of increased preoperative HgbA1c and demonstrated an association between higher HgbA1c and worse outcomes—namely postoperative glucose control, poor diabetic remissions, and increased morbidity. These data parallel those seen in other surgical scenarios and have led to strong recommendations regarding appropriate glucose control in the perioperative period. Once a patient has completed the nonoperative optimization period, a final meeting with the surgeon to review expected course and a more detailed discussion regarding potential complications is paramount. Roughly 2 weeks prior to the operation, a protein-sparing liquid diet is helpful to decrease the size of the patient's liver which improves technical aspects of the operation. Anesthesia evaluation focuses on any underlying airway deficiencies such as clinical or silent obstructive sleep apnea. Prior anesthetic history is helpful in preparing for any potential complications from general anesthesia. Psychological assessment of worrisome behavioral history, diagnosed psychiatric disorders, and coping mechanisms for handling stress is also vital prior to undertaking surgery for these individuals. When the above components of the pathway have been adequately fulfilled, the patient is ready to proceed with metabolic surgery.

COMMON SURGICAL OPERATIONS FOR DIABETES AND METABOLIC DISEASES

Today there are numerous operations and procedures being used as treatment options for diabetes and metabolic diseases. It is valuable to briefly review the chronology of the various options that evolved over time.

The first operation offered for the treatment of obesity and related diseases was the jejunal-ileal bypass, which was first performed in the 1950s by Dr. Richard Varco. The weight-loss results and initial metabolic effect were excellent in these early patients. In particular, even prior to significant weight loss, surgeons began to note improvements in blood

glucose levels as well as lipid metabolism. These improved metabolic parameters continued with ongoing weight loss at rates higher than would be expected with weight loss alone. On the other hand, the operation was associated with a number of serious short-term and long-term side effects. These side effects included malabsorption of vitamins and minerals, electrolyte imbalances, severe diarrhea, calcium oxalate nephrolithiasis, and most significantly steatohepatitis and progressive liver disease. At the time physicians began recognizing major complications associated with the jejunal-ileal bypass, Roux-en-Y gastric bypass was introduced for obesity and related comorbidities in the mid-1960s. Following several modifications to the original operation, the RYGB largely replaced the jejunal-ileal bypass as it was found to have excellent results without the frequency of side effects seen with jejunal-ileal bypass. In particular, many of the same metabolic improvements were immediately seen following Roux-en-Y gastric bypass including improved blood glucose control and lipid metabolism prior to significant weight loss. Vertical banded gastroplasty arose in the 1980s and for a significant portion of the 1980s and 1990s rivaled the Roux-en-Y gastric bypass as a popular option within metabolic surgery. The vertical banded gastroplasty was developed as a technically simpler operation than Roux-en-Y gastric bypass with no anastomosis and initially offered an attractive option to avoid the malabsorptive effects of Roux-en-Y gastric bypass. Despite not having the same metabolic efficacy as its predecessors, the short-term complication profile was attractive to many clinicians. Unfortunately, as failure rates due to weight regain and band-related complications arose in the mid to late 1990s, popularity waned and revisional operations after vertical banded gastroplasty were being offered as salvage therapies. Also, the metabolic effects seen in this operation were directly linked with weight loss, and metabolic disease relapse occurred with subsequent weight regain. In an effort to obtain results similar to the jejunal-ileal bypass without the associated complications, the biliopancreatic diversion with duodenal switch was introduced in the late 1990s. While the metabolic effects were excellent with fewer complications than the jejunal-ileal bypass, this operation is considered complex and nutritional deficiencies remain higher than those seen in Roux-en-Y gastroplasty and the other options available. Therefore, the biliopancreatic diversion with duodenal switch is currently offered as a metabolic operation on rare occasions and only at specialized centers. Introduction of the less invasive, reversible

operation of adjustable gastric banding was popularized in the 1990s and 2000s. This popularity coincided with the expansion of minimally invasive approaches in gastrointestinal surgery, and laparoscopic adjustable gastric banding became a dominant option. Similar to the vertical banded gastroplasty, metabolic effects of adjustable gastric banding were directly linked to weight loss. However, as overall rates of weight regain increased and band-related complications occurred in up to 20% of patients, popularity again waned and this operation is now offered less frequently for metabolic diseases. Thanks to tremendous advancements in both technology and technique, by the mid-2000s, most metabolic operations could be performed safely and effectively using a minimally invasive, laparoscopic approach. The addition of a minimally invasive approach ultimately improved outcomes for all of these operations and led to an overall increase in the number of patients undergoing metabolic surgery. By 2005, the predominant options for metabolic surgery were Roux-en-Y gastric bypass, adjustable gastric banding, and biliopancreatic diversion with duodenal switch. Surgeons at this time found that patients undergoing staged sleeve gastrectomy prior to biliopancreatic diversion with duodenal switch had excellent weight loss and some of these patients did not ultimately undergo the second stage. For this reason, several clinicians began to investigate sleeve gastrectomy as a stand-alone option for metabolic surgery. Today, sleeve gastrectomy is being done at increasing frequency and is the second most common operation performed overall in the United States. Long-term data are still pending regarding durability of weight loss and amelioration of metabolic diseases.

Worldwide, the most popular operation remains Roux-en-Y gastric bypass (Fig. 92.1A), which is being performed 45% of the time. As mentioned, sleeve gastrectomy (Fig. 92.1B) is on the rise and is now performed 37% of the time. The remaining operations include adjustable gastric banding (Fig. 92.1C) at 10%, biliopancreatic diversion with duodenal switch (Fig. 92.2) at 2.5%, and other options in rare cases.

Postoperative Care

Because the gold-standard approach for most metabolic procedures is via minimally invasive approach, rapid recovery is an appropriate expectation. Early ambulation, avoidance, or early removal of urinary catheters and commencement of an oral diet and medications are recommended in noncomplicated cases. Close monitoring of pulmonary and respiratory

status with telemetry and frequent vital signs is recommended, especially in the first 24 hours. The metabolic changes vary depending on the operation performed—generally speaking the more alteration of the gastrointestinal tract, the more attention needs to be paid toward metabolic effects.

Postoperative care should be centered around appropriate glucose control in the diabetic patient. For patients undergoing more involved metabolic operations such as Roux-en-Y gastric bypass or biliopancreatic diversion with duodenal switch, often the glucose levels decrease immediately and patients who are on oral antiglycemic agents can reduce dosing or eliminate altogether. Those patients with insulin dependence will often require less insulin to manage blood glucose levels, and some patients will be discharged without the need for insulin. Consultation with endocrinologists is quite valuable in the perioperative period for these patients.

In general, antihypertensive medications should be on hold during the immediate postoperative period to avoid masking of important vital parameters such as tachycardia and urine output. Specifically, diuretics should be monitored closely even on discharge as one of the major effects of bariatric surgery is dehydration in the early period.

Discharge is predicated on the ability of the patient to tolerate a liquid diet, be at a baseline ambulatory state, and to have appropriate pain control. Patients also need to be counseled on dietary intake since nausea/vomiting is a frequent cause of readmission. Many centers offer outpatient operations, particularly for adjustable gastric banding, while a 2- to 3-day hospitalization can be expected for sleeve gastrectomy, Roux-en-Y gastric bypass, and biliopancreatic diversion with duodenal switch.

Complications and Their Management

Metabolic surgery is associated with predictable early and late complications. Early complications include bleeding, infection, leakage from staple lines or anastomoses, venous thromboembolic disease, and cardiopulmonary diseases. Complication rates vary depending on the complexity of the operation and the fitness of the patient and typically range from 1% to 10%. Late complications include strictures, ulcer disease, internal herniation, and device-related (i.e., gastric band) malfunctions. These rates also vary from 1% to 20%.

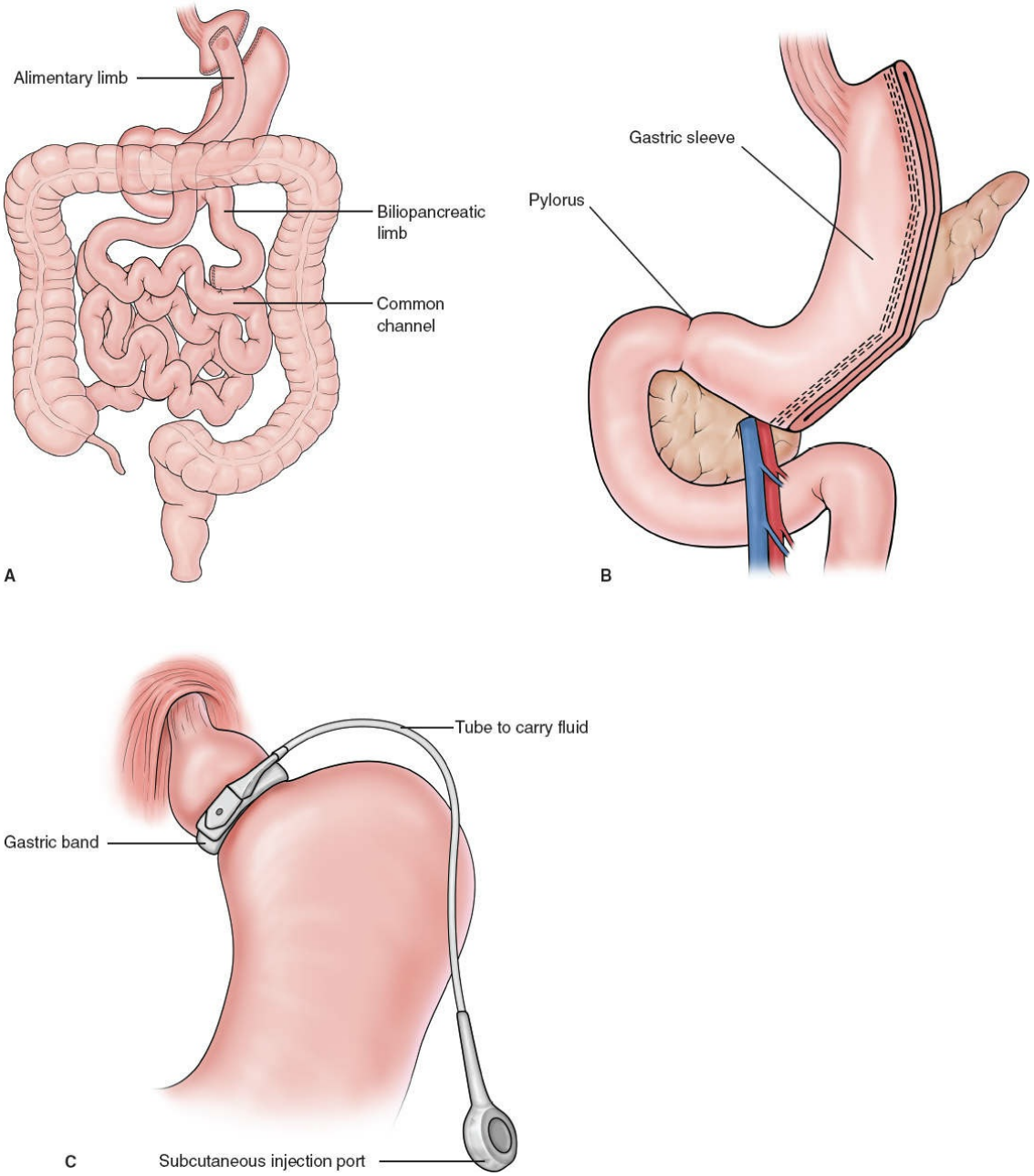

Figure 92.1. Most commonly performed weight-loss surgery procedures. **A.** Roux-en-Y gastric bypass. **B.** Sleeve gastrectomy. **C.** Gastric banding.

Management of complications can vary from medical therapy for infections or venous thromboembolic disease, to endoscopic management of bleeding, strictures, or leaks, and finally to reoperation for failed nonoperative attempts, or immediately for a suspected internal hernia.

Mortality in centers of excellence is extremely low for most operations and is generally quoted at 0.4%.

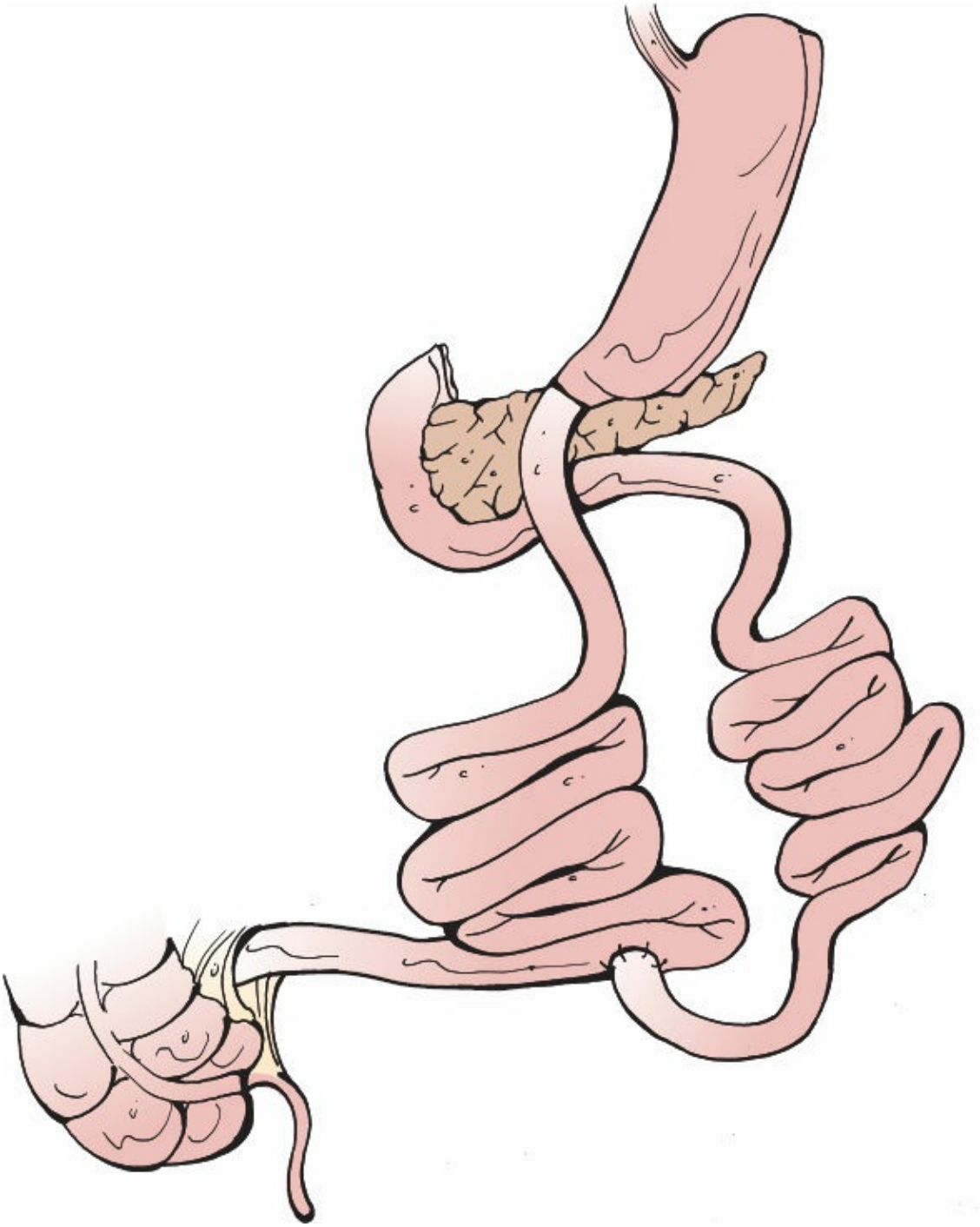

Figure 92.2. Biliopancreatic diversion with duodenal switch.

MECHANISMS OF METABOLIC CHANGE BY SURGERY

Overall outcomes of metabolic surgery in terms of weight loss and metabolic effects vary depending on the operation performed. The next section will highlight the proposed mechanisms of action and outcomes of the dominant bariatric operations in relation to diabetes and other metabolic diseases.

The degree of weight loss is directly associated with improvement or resolution of diabetes and other metabolic diseases. On the other hand, multiple investigators have shown that interruption and reconfiguration of the gastrointestinal tract leads to metabolic changes that occur independently from weight loss. This realization has led to the advancement of several theories regarding various mechanisms for metabolic control.

Hormonal Mechanisms

When food bypasses the proximal gastrointestinal tract and is delivered earlier to the distal bowel, hormonal changes may lead to an enhanced glucose tolerance. This is the so-called “foregut hypothesis” and has been suggested as a mechanism in such operations as the Roux-en-Y gastric bypass and biliopancreatic diversion with duodenal switch. In particular, duodenal exclusion has been implicated as one of the strongest aspects of the foregut hypothesis. In addition to enhanced glucose tolerance, early satiety remains a key aspect of metabolic surgery. Ghrelin is one such hormone whose level correlates with early satiety. In fact, levels of ghrelin are highest immediately prior to a meal and decrease after eating. Most studies have shown ghrelin decreases in operations such as Roux-en-Y gastric bypass, biliopancreatic diversion with duodenal switch, and sleeve gastrectomy. As expected, no change in ghrelin is seen after laparoscopic adjustable gastric banding. In addition to the foregut hypothesis, rapid delivery of nutrients to the distal bowel has also been shown to increase insulin secretion, sensitivity, and satiety. This mechanism is referred to as the “hindgut hypothesis” when used in reference to metabolic surgery. In the hindgut hypothesis, various fat and gut-derived hormonal axes are changed by metabolic surgery to increase weight loss and metabolic changes. Circulating levels of hormones such as glucagon-like peptide 1 (GLP-1) and glucose-dependent insulinotropic peptide were two of the initial hormones discovered in these pathways. These two substances are called incretin hormones and are released by the gut endocrine cells following exposure to food. The incretin effect is the improved insulin secretion in response to glucose. The effects of GLP-1 and glucose-dependent insulinotropic peptide include suppression of glucagon, central mechanisms of weight loss, delayed gastric emptying, and most importantly, improving insulin release following a food bolus. Another effect may be an increase in beta-cell mass of the pancreas. Peptide YY is

another gut-derived hormone that appears to work in concert with GLP-1 to provide an “ileal break,” or delay of gastric emptying and overall bowel transit time. As caloric intake increases, so do secretion of both GLP-1 and peptide YY. In addition, the fat derived peptide hormone leptin has been shown to stimulate GLP-1 secretion, synergistically suppress appetite, and augment energy expenditure. Leptin is the least understood hormone in terms of obesity and metabolic control, but newer data is emerging showing that the leptin feedback loop appears to be altered in obese subjects.

Many studies have examined the changes in these hormonal levels following the dominant bariatric operations. In general, many authors have shown decreases in ghrelin following sleeve gastrectomy, Roux-en-Y gastric bypass, and biliopancreatic diversion with duodenal switch, with no change after adjustable gastric banding. Levels of GLP-1 and peptide YY are also generally increased following sleeve gastrectomy, Roux-en-Y gastric bypass and biliopancreatic diversion with duodenal switch, while no change is seen after adjustable gastric banding. Finally, glucose-dependent insulinotropic peptide has been shown to increase, decrease, and have no change in sleeve gastrectomy, Roux-en-Y gastric bypass, and biliopancreatic diversion with duodenal switch, again with no change after adjustable gastric banding. The variability of glucose-dependent insulinotropic peptide levels after these operations may be secondary to differing surgical techniques, the lengths of the Roux limb and alimentary channel, as well as differing preoperative levels secondary to diabetes and glucose insensitivities. A summary of these changes is highlighted in Table 92.1.

Neural Mechanisms

It is well established that the neural innervation of the gastrointestinal tract is complex and involves both the parasympathetic and sympathetic systems. Parasympathetic vagal nerve function, of which 80% are afferent fibers, accounts for significant signaling pathways to the brain. These afferent pathways are associated predominantly with central cortical centers focusing on hunger, appetite, and satiety. Sympathetic efferent nerve function, of which 15% to 20% is efferent, derives from the celiac axis and is predominantly responsible for much of the glucose production and release as well as gastrointestinal enzyme release. These sympathetic fibers also function to delay intestinal peristalsis. The interplay between

afferent parasympathetic fibers and efferent sympathetic fibers ultimately accounts for the dominant signaling route for gut metabolism. Finally, nervous system innervation occurs within the submucosal layers of the intestinal tract, and likely serves as the initial receptors in response to a food bolus and bowel distension.

TABLE 92.1 Affect of Various Metabolic Operations on Fat- and Gut-Derived Hormones

	Ghrelin	GLP-1	GIP	PYY
AGB	no Δ	no Δ	no Δ	no Δ
RYGB	↓	↑	↑, ↓, no Δ	↑
SG	↓	↑	↑, ↓, no Δ	↑
BPD/DS	↓	↑	↑, ↓, no Δ	↑

GLP-1, glucagon-like peptide 1; GIP, glucose-dependent insulinotropic peptide; PYY, peptide YY.

The various bariatric operations affect these neural pathways in some capacity: via alteration or disruption. In the setting of the adjustable gastric banding, compression of the band on the gastric cardia creates a background of satiety that is augmented when a food bolus passes through the constricted area of the stomach. These effects are likely influenced by the vagal afferent fibers with signaling to the hypothalamic center responsible for hunger, appetite, and satiety. The sleeve gastrectomy involves a large-volume gastric resection, particularly of the fundus and body, where a significant number of intrinsic nerve fibers reside. This loss of the fundic gastric pacemaker ultimately leads to neural signaling promoting the sensation of satiety for patients. When the vagal fibers are disconnected quite proximally by Roux-en-Y gastric bypass and more distally with biliopancreatic diversion with duodenal switch, a sympathetic nervous response is likely induced. Many of these neural effects have been the target of novel interventional therapies which will be discussed later in the chapter.

Bile Acids and the Microbiome

Another exciting area of research in terms of changes following metabolic surgery involves the alteration of gastrointestinal bile acids and the microbiome. Specifically, bile acids secretion has been implicated in glycemic control via a binding mechanism with receptors on multiple cells

within the gut. Hepatic glucose metabolism also appears to be affected by a nuclear receptor pathway called *Farnesoid X Receptor* (FXR). Bile acids may improve glucose control via FXR-induced growth factor pathways within the gastrointestinal tract. Several authors have shown that diversion of bile acids to the distal gut may enhance glucose homeostasis, and it has been shown that after bypass operations such as Roux-en-Y gastric bypass and biliopancreatic diversion with duodenal switch, bile acid concentrations are higher.

In conjunction with bile acid effects, significant changes to the gut microbiome occur with alteration of the anatomy as seen in the bypass type operations. While understanding of the mechanism of the microbiome remains limited, research has shown an impact on glucose and metabolic control, particularly in obesity.

OUTCOMES OF METABOLIC OPERATIONS

Many retrospective, observational reviews have shown substantial reductions in diabetes and other metabolic diseases with the commonly performed metabolic operations, though rates have differed between each operation. In 2004, a meta-analysis by Buchwald and colleagues found an overall diabetes resolution rate of roughly 75% with adjustable gastric banding, Roux-en-Y gastric bypass, and biliopancreatic duodenal switch. Subgroup analysis found that these rates were roughly 50% for adjustable gastric banding, 84% with Roux-en-Y gastric bypass, and 99% with biliopancreatic duodenal switch. These rates were again confirmed when examining results from national databases with the highest reported 12-month diabetes remission rates seen in biliopancreatic diversion with duodenal switch (74%), followed by Roux-en-Y gastric bypass (62%), sleeve gastrectomy (52%), and adjustable gastric banding (28%). Factors shown to predict diabetes remission include shorter duration of diabetes, increased weight loss, and previous treatment with oral antidiabetic agents. Similarly, patients with longer duration of diabetes and those with preoperative insulin had lower rates of remission.

More recently, several investigators have compared the rates of diabetes and metabolic control between surgery and best medical therapy in a randomized-controlled fashion. The “Surgical Treatment and Medications Potentially Eradicate Diabetes Efficiency” (STAMPEDE) trial randomized 150 patients to receive medical therapy, sleeve gastrectomy, or Roux-en-Y gastric bypass and measured patients who achieved diabetes remission as

defined by glycated hemoglobin less than 6.0%. One-year results demonstrated that 42% of patients in the Roux-en-Y gastric bypass arm, 37% in the sleeve gastrectomy arm, and 12% in the medical arm achieved diabetes remission. Three-year outcomes demonstrated remission rates for Roux-en-Y gastric bypass, sleeve gastrectomy, and medical therapy as 38%, 24%, and 5%, respectively. Use of diabetic medications and insulin was also significantly reduced in patients who underwent surgery versus those who underwent medical therapy. These results, mirrored by several other authors, highlight the superiority of metabolic surgery when compared to medical therapy alone in relation to diabetes control in the obese population.

In regard to nonobese patients with type 2 diabetes, a number of clinicians have begun to examine the effects of various metabolic operations on diabetic control. The decision to move forward with surgery in these settings, which would typically not be recommended based on the National Institutes of Health guidelines, was due to the unexpected findings in lower BMI diabetic patients who underwent gastric resections for other reasons (i.e., peptic ulcer disease, cancer). Subsequent data for diabetic patients with a BMI between 30 and 40 kg/m^2 who underwent adjustable gastric banding were found to have diabetic remission rates of 73% at 2 years with weight loss being the predominant factor for success. Diabetic patients with a BMI <35 kg/m^2 who underwent laparoscopic Roux-en-Y gastric bypass also showed significant reductions in fasting blood glucose in the absence of excessive weight loss. The reportedly less morbid loop minigastric bypass was also performed on a group of diabetic patients with a BMI <35 kg/m^2, and again, 77% of this population was found to achieve an HbA1c <7.0% at 1-year postoperatively. Finally, a prospective study examining biliopancreatic diversion in patients with a BMI <35 kg/m^2 found that 83% of this diabetic population was off all antidiabetic medications at 1 year. These results have also been seen in Asian diabetics with a BMI <30 kg/m^2—yet another population with rising rates of diabetes without concomitant morbid obesity. Taken together, this mounting evidence is leading clinicians to discuss metabolic surgery even in the nonobese, though long-term data are still warranted at this time.

TABLE 92.2 Randomized Clinical Trials Comparing Metabolic Surgery to Nonsurgical Therapies

Author	Year	Follow-Up	Metabolic Surgery > Nonsurgical Treatment
Hiendruff	1997	40 wk	WL
Mingrone	2002	1 yr	WL, CL, TGL, GL, GH
O'Brien	2006	2 yr	WL, MSR
Dixon	2008	2 yr	WL, DR, MSR, CL, TGL, GL, GH
O'Brien	2010	2 yr	WL, MSR, TGL, GL
Reis	2010	2 yr	WL
Dixon	2012	2 yr	WL, MSR, CL, TGL, GL
Mingrone	2012	2 yr	WL, DR, CL, TGL, GL
Schauer	2012	1 yr	WL, DR, MSR, CL, TGL, GL, GH
Ikramuddin	2013	1 yr	WL, CL, TGL, GL, GH
Liang	2013	1 yr	DR, CL, TGL, GH

WL, weight loss; DR, diabetes remission; MSR, metabolic syndrome remission; CL, cholesterol level; TGL, triglyceride level; GL, glucose level; GH, glycated hemoglobin.

A number of groups around the world have also looked at the cost benefits of metabolic surgery versus medical therapy for diabetes management. Based on the high remission rates of diabetes after surgery, many patients are able to either decrease or eliminate the need for medical therapy in the short- and mid-term time frames. A predictable number of patients may relapse and develop recurrent diabetes, but even these patients may have lower needs for medication. Various payer systems including those in Australia, United Kingdom, Spain, and Austria have all seen cost-effective improvements with metabolic operations when compared to medical therapy. A robust report of cost-effectiveness in Australia by Keating and colleagues demonstrated a mean health care savings of roughly $1,800 USD and an additional 1.2 quality-adjusted life year for patients who underwent metabolic surgery versus conventional medical therapy. Several authors have criticized some of these findings based on low patient numbers, retention, and length of follow-up. Therefore, long-term results must be gathered, particularly in the nonobese, to make further recommendations regarding metabolic surgery for the nonobese diabetic population.

When reviewing outcomes of metabolic operations on other metabolic diseases such as hyperlipidemia and cardiovascular disease, similar findings have been reproduced. Reductions in hypertension, hypertriglyceridemia, and hyperlipidemia have been shown at rates ranging from 23% to 70%. These improvements have been shown at early (<1 year), mid (1 to 2 years), and late (2 to 4 years) periods of surveillance. Several large, long-term observational studies have demonstrated

improved cardiovascular disease and mortality in obese patients who underwent metabolic surgery when compared to obese patients with only medical therapy. Cardiac function and various cardiomyopathies have also improved following metabolic surgery, again mirroring results seen in the diabetic population.

While the various mechanisms for these changes in diabetic and metabolic control continue to be elucidated, the evidence supporting metabolic surgery as the most effective treatment course continues to mount. A recent review of 11 randomized controlled trials comparing metabolic surgery with nonsurgical treatments showed superiority of metabolic surgery in relation to weight loss, diabetes and metabolic syndrome remission, plasma cholesterol and triglyceride levels, plasma glucose levels, and quality of life, among others (Table 92.2).

NOVEL OPERATIONS FOR DIABETES AND METABOLIC DISORDERS

While results have been for the dominant metabolic operations have been promising, clinicians continue to explore less invasive methods for management of diabetes and metabolic diseases. An area of active innovation is that of gastrointestinal neural modulation through implantation of stimulator devices.

As mentioned previously, afferent vagal pathways contribute a large proportion of the innervation of the gastrointestinal tract. Disruption of these pathways via gastric stimulation is one method that was investigated by Dr. Shikora and colleagues in 2009. In a randomized trial, patients underwent submucosal placement of gastric neurostimulators with one group receiving electrical stimulation and another group receiving no stimulation. The proposed mechanism is via gastric relaxation and delayed gastric emptying, thus leading to a feeling of satiety and decreased appetite. Following 1 year of therapy, both groups loss an equivalent amount of excess body weight (roughly 12%), favoring a placebo effect rather than a true therapeutic result. Extending the concept from this study, direct vagal blockade has been another area of active clinical interest. In this design, the anterior and posterior proximal vagal nerve receives an electrical impulse designed to block the afferent pathway to the brain, thereby inducing satiety and decreased caloric intake. A prospective, randomized trial with this therapy was designed to examine 1-year results of hunger and appetite, eating, and quality of life, with the primary end-

point being excess body weight loss. Similar to the gastric electrical stimulation trials, results at 1 year were not significant between the groups with stimulation and those without, but both groups lost roughly 16% excess body weight. A redesigned trial which delivered a 12-hour impulse to the vagus nerve showed a significant improvement in excess weight loss of the treatment versus control group (24% vs. 16%).

Neural modulation more distal on the gastrointestinal tract, namely the duodenum, is another area currently under investigation. A 12-month follow-up after laparoscopic implantation of the BALANCE duodenal stimulation device showed modest improvements in mean glycated hemoglobin, fasting blood glucose levels, and mean HDL levels with a safe and effective profile. In addition to duodenal stimulation, targeted ablative therapy of the perirenal sympathetic fibers has also emerged in investigations for modulating glucose and metabolic diseases in patients. This therapy is actually delivered via a vascular catheter approach via the renal arteries and has previously shown benefit in refractory hypertensive patients. These same sympathetic fibers also control various aspects of glucose metabolism and insulin resistance, therefore, ablation may improve these parameters. Several small, short-term studies have shown conflicting results in this regard, with some indicating improved metabolic control and others showing no change. No randomized data exist for either of these novel therapies, but their emergence as possible therapies highlights the ongoing search for less invasive methods to control significant medical comorbidities.

The conflicting and emerging results of these novel therapies demonstrate that there may be a therapeutic effect from neural modulation of the vagal afferent and sympathetic efferent pathways, but results remain inferior to surgical therapy and the results for diabetic and metabolic control remain to be seen, especially in the long term.

CONCLUSIONS

Surgery for diabetes and other metabolic diseases has undergone a tremendous evolution since the introduction of this concept many years ago. This evolution has been mirrored by the unfortunate rise in global rates of obesity, diabetes, and metabolic disease. Whereas in the past these diseases were relegated to the medical community alone, it is now clear that surgery plays a major role in the management of these diseases. The burden that these diseases place on resource utilization in healthcare and

the overall wellness of society is arguably one of the greatest challenges facing us today. The complexity of the problem stretches beyond the medical profession and into the realms of the food and advertising industries, addiction services, and politics. While the focus of this chapter was the surgical management of diabetes and other metabolic diseases, it is only with a concerted effort to affect change in all these areas will we starting shifting the needle back toward healthy communities. For now, a multidisciplinary medical, psychological, and surgical approach to these diseases is the most effective means of helping individuals with these diseases. Future research will focus on more detailed understanding of the neurohormonal changes that occur during metabolic surgery, as well as how targeted therapies can improve overall metabolism. While the challenge is great, many clinicians and scientists continue to work toward curing these harmful diseases.

Suggested Readings

Buchwald H. The evolution of metabolic/bariatric surgery. *Obes Surg* 2014;21:1126–35.

Corcelles R, Daigle C, Schauer P. Management of Endocrine Disease: Metabolic effects of bariatric surgery. *Eur J Endocrinol* 2016;174:R19–28.

Gloy V, Briel M, Bhatt D, et al. Bariatric surgery versus non-surgical treatment for obesity: a systematic review and meta-analysis of randomized controlled trials. *Brit Med J* 2013;347:f5934.

Kurian M, Wolfe B, Ikramuddin S, eds. *Metabolic Syndrome and Diabetes.* New York: Springer; 2016.

Menke A, Casagrande S, Geiss L, et al. Prevalence of and trends in diabetes among adults in the United States, 1988–2012. *J Amer Med Assoc* 2015;10:1021–9.

Menzo E, Szmstein S, Rosenthal R. Changing trends in bariatric surgery. *Scand J Surg* 2014;104:18–23.

O'Brien P. Controversies in bariatric surgery. *Brit J Surg* 2015;102:611–8.

Perna M, Romagnuolo J, Morgan K, et al. Preoperative hemoglobin A1c and postoperative glucose control in outcomes after gastric bypass for obesity. *Surg Obes Relat Dis* 2012;6:685–90.

EDITOR'S COMMENT

Obesity is at epidemic proportions in the United States. This may be in part due to the obesogens and endocrine disrupting chemicals introduced into our

environment that further disrupt metabolism and promote the metabolic syndrome. Conditions associated with obesity are more than diabetes, hypertension, and hyperlipidemia including but not limited to coronary artery disease, obstructive sleep apnea, gastroesophageal reflux, nonalcoholic liver disease and liver failure, deep venous thrombosis and pulmonary embolus, osteoarthritis and osteoporosis, infertility, depression, stress urinary incontinence, and cancer. It is clear from the literature reviewed in this chapter as well as recent consensus statements that metabolic surgery offers a sustained albeit partial relief of obesity and its complications. The impact of obesity on general surgical complications is also enormous. Obesity has the same impact on surgical complications as smoking—that is seven fold.

The indications for metabolic surgery are changing as well. The 2009 Asian Consensus Meeting on Metabolic Surgery recommended a lowered indication for surgery as Asians have a higher adiposity for a given level of obesity. The recent International Diabetes Federation guidelines recommend reorienting our focus on metabolic disease not just a BMI $\geq$35 kg/m^2. Significant benefit of surgery is seen in those patients who have metabolic syndrome but don't meet the accepted BMI criteria. Like any operation, metabolic surgery was initially applied to those with the most to gain and the least to risk. The indication for surgery is expanding in the laparoscopic age and with mortality rates reduced to as low as 0.12% in large series. Benefit can be seen in the young and overweight patients with severe metabolic syndrome. Studies in these subgroups are limited.

Not included in the review of procedures in this chapter is that of reversible endoscopically placed synthetic duodenojejunal bypass liners to improve glycemic control, improve insulin resistance induce weight loss, and decrease cardiovascular risk. There are essentially three different types which include the duodenojejunal bypass sleeve that attaches to the duodenum and is a 60-cm GI liner that extends distally to mimic a Roux-en-Y bypass. A modification of this includes a flow restrictor to slow gastric emptying. The other is a gastroduodenojejunal bypass sleeve that is attached more proximally and extends for 120 cm. Multiple prospective randomized sham-controlled trials have shown the efficacy of these studies. The advantages to these devices are the ease of reversal reported at under 5 minutes.

Despite the effectiveness of these operations, an unmotivated patient can "out eat" the benefit and thus only the truly motivated patient should be offered such operations. As has been standard for years a preoperative period of weight loss is the best way to determine not only the motivation but the outcome of these types of operations.

V. Suzanne Klimberg

Suggested Readings

Espinet-Coll E, Nebreda-Duran J, Gomez-Valero JA,. Current endoscopic techniques in the treatment of obesity. *Rev Esp Enferm Dig* 2012;104:72–87.

Heindel JJ, vom Saal FS, Blumberg B, et al. Parma consensus statement on metabolic disruptors. *Environ Health* 2015;14:54.

Jain D, Singhal S. Endoscopic bypass using endobarrier devices: efficacy in treating obesity and metabolic syndrome. *J Clin Gastroenterol* 2015;49(10):799–803.

Lakdawala M, Bhasker A; Asian Consensus Meeting on Metabolic Surgery (ACMOMS). Report: Asian Consensus Meeting on Metabolic Surgery. Recommendations for the use of bariatric and gastrointestinal metabolic surgery for treatment of obesity and type ii diabetes mellitus in the Asian population: August 9th and 10th, 2008, Trivandrum, India. *Obes Surg* 2010;20(7):929–36.

Lubrano C1, Genovesi G, Specchia P, et al. Obesity and metabolic comorbidities: environmental diseases? *Oxid Med Cell Longev* 2013;2013:640673.

Moradi S, Mirzaei K, Abdurahman AA, et al. Adipokines may mediate the relationship between resting metabolic rates and bone mineral densities in obese women. *Osteoporos Int* 2017;28(5):1619–29.

Neff KJ1, le Roux CW. Bariatric surgery: the indications in metabolic disease. *Dig Surg* 2014;31(1):6–12.

93 Vascular Compression of the Duodenum

Stanley W. Ashley and Matthew T. Menard

Compression of the duodenum between the vertebral column and the superior mesenteric artery (SMA) is a relatively rare clinical condition. Known by a wide variety of names since first reported, in recent decades it has been termed “vascular compression of the duodenum,” a designation which most accurately reflects the anatomic basis for the disorder. Associated symptoms are those typical of intestinal obstruction, and the onset is often insidious and marked by the gradual appearance of nausea and vomiting. In the appropriate clinical setting, the diagnosis is made on the basis of characteristic computed tomographic (CT) findings. The syndrome may follow weight loss, prolonged immobilization in bed, and various operative procedures, but has also been reported to occur spontaneously. Treatment most often involves surgical decompression in the form of division of the ligament of Treitz and a duodenojejunostomy, with generally favorable outcomes.

HISTORY

The Austrian anatomist Carl Von Rokitansky, rumored to have performed over 30,000 autopsies over the course of his pioneering career, first described constriction of the third portion of the duodenum by the overlying SMA in 1942. Kundrat subsequently postulated the root of the mesentery to be the anatomic structure responsible for partial obstruction of the duodenum, whereas the German physician Albrecht believed that mesenteric traction was the etiology of the constrictive problem. In the early 20th century, there was recognition of the frequent association with gastric dilatation and suggestion that duodenal stasis and dilation were causative factors in such patients. In 1907, Bloodgood described several cases of gastromesenteric ileus and was the first to propose that surgical decompression in the form of a duodenojejunostomy might be an effective treatment. One year later, Slavely reported the first such procedure.

Since Von Rokitansky's landmark observation, interest in this clinical entity has been variable, and for periods of time, its validity has been questioned by the reigning medical establishment. This lack of full acceptance was in large part due to a poor understanding of the pathophysiology of the condition. Specifically, a distinction between duodenal stasis and mechanical obstruction was often not made, leading to inconsistent treatment results. For example, for a period in the early 1900s, both resection of the colon and plication of the mesentery were tried in an effort to relieve mesenteric compression. Others described a gastropyloroduodenojejunostomy as a means of decompressing persistent gastric distension following duodenojejunostomy.

Reports by Kellogg and Wilkie in the late 1920s helped establish duodenojejunostomy as the surgical treatment of choice. In one of the larger published series, Wilkie described 75 patients with duodenal obstruction treated with a 6% operative mortality rate. He also identified a subset of patients who had a poor response to the procedure in whom it was less clear that a mesenteric source of compression was responsible. In subsequent years, as the indications for operative decompression were liberalized and the treatment was more widely applied, overall outcomes were noted to be less favorable. A resurgence of interest in this problem in the 1960s was attributed to a comprehensive review of the available literature by Barner and Sherman. A number of further publications that helped clarify the anatomic basis and elucidated additional clinical features of the syndrome also served to reinforce its legitimacy. Today, it is perceived by most to be a true clinical entity. The numerous names by which vascular compression of the duodenum has been referred to over the years, some of which continue on occasion to be utilized, are listed in Table 93.1.

ANATOMY

The duodenum, so named as it was considered to be equal in length to the width of 12 fingers, is most susceptible to compression by the overlying SMA within its horizontally oriented third portion. This segment of the duodenum typically crosses the vertebral column at the lower portion of the third lumbar and/or upper portion of the fourth lumbar vertebra. Notably, the fourth vertebra is the most anterior part of the spinal column. The duodenum is fixed at three anatomic points: the pylorus, the peritoneum of the second and third portions of the peritoneum, and the

ligament of Treitz.

The SMA typically arises from the anterior aorta at the level of the lower aspect of the first lumbar vertebra. A significant degree of variation of this takeoff point has been noted, however, with the origin reported to range from the 12th thoracic to the third lumbar vertebra. Though the average angle formed by the SMA and the aorta was found to be 42 degrees in one autopsy series, there is also considerable variability in this measurement; the angle as reported in the literature ranges between 18 and 70 degrees. Inside this angle lies the left renal vein, the uncinate process of the pancreas, the third portion of the duodenum, and a retroperitoneal fat pad that typically encircles the SMA (see Fig. 93.1).

A markedly narrowed aortomesenteric angle is a hallmark diagnostic finding in patients with vascular compression of the duodenum (see Fig. 93.2). Lukes et al. found this angle to be as low as 8 degrees in their review, whereas other authors have reported the aortomesenteric angle to range from 6 to 40 degrees in patients with radiographic evidence of compression. Lukes et al. also reported a significantly reduced distance from the origin of the SMA to the midpoint of the duodenum, known as the aortomesenteric distance, with involved patients having an average distance of only 3.3 mm compared to a distance of 18 mm in control patients. Aberrancies of the normal anatomic pattern of the SMA and its branches in relation to the duodenum (see Fig. 93.3) and the ligament of Treitz (Fig. 93.4) have also been implicated in the described clinical syndrome. In particular, the patients in whom the duodenum crosses the vertebrae at the fourth lumbar vertebrae where the lumbar curvature is at its most pronounced anteriorly are at elevated risk of developing obstructive problems (Fig. 93.2C).

TABLE 93.1 Historical Names for Vascular Compression of the Duodenum

Arteriomesenteric duodenal obstruction
Cast syndrome
Cast syndrome incognito
Chronic duodenal ileus
Chronic duodenal pseudoobstruction
Chronic intermittent arteriomesenteric occlusion of the duodenum
Gastromesenteric ileus
Nutcracker syndrome
Superior mesenteric artery (SMA) syndrome
Vascular compression of the duodenum

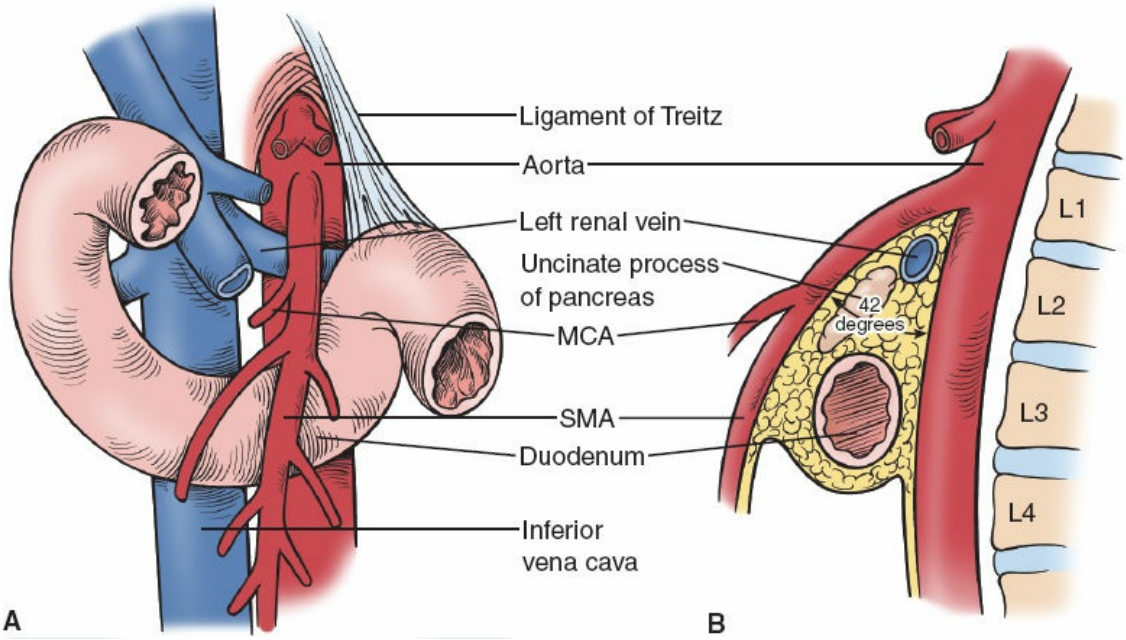

Figure 93.1. **A.** Demonstration of the normal anatomic relationships of the duodenum, ligament of Treitz, aorta, and SMA crossing over the third portion of the duodenum. **B.** The lateral view demonstrates the average normal aortomesenteric angle of 42.4 degrees, the normal relationship of the aorta and SMA to the spine, and the contents of the aortomesenteric angle: the left renal vein, uncinate process of the pancreas, the duodenum, and the retroperitoneal fat pad. MCA, middle colic artery; SMA, superior mesenteric artery.

The long recognized association of rapid weight loss with the syndrome

is believed to be a result of loss of the mesenteric and retroperitoneal fat in this anatomic region that further serves to reduce both the aortomesenteric angle and distance. Additional anatomic aberrancies that have been linked to a smaller angle between the SMA and aorta include an abnormally low origin of the SMA, excessive lumbar lordosis, a foreshortened or hypertrophied ligament of Treitz, and an unusually high fixation point of the ligament of Treitz. Of note, a zone of elevated pressure preceding one of reduced pressure has been noted in the distal duodenum in normal subjects assessed with manometry. This intriguing finding suggests an anatomic and physiologic basis for a possible predisposition to a functional duodenal obstruction that remains to be further elucidated.

CLINICAL PRESENTATION

The predominant clinical symptoms present in patients with vascular compression of the duodenum are that of nausea, vomiting, and postprandial abdominal pain centered at the epigastrium. These symptoms can be episodic or constant, and, if persistent, dehydration and/or weight loss is common. In fact, associated mortality secondary to dehydration, cachexia, and aspiration following emesis have all been described. Patients are typically young, and there is a predominance of female versus male patients. As mentioned, an asthenic body habitus is also frequently present in the patients with vascular compression of the duodenum, and it has long been noted that concomitant weight loss often precedes the onset of other symptoms. The anatomic considerations detailed above provide one rationale for how antecedent rapid weight loss is thought to lead to the development of the syndrome.

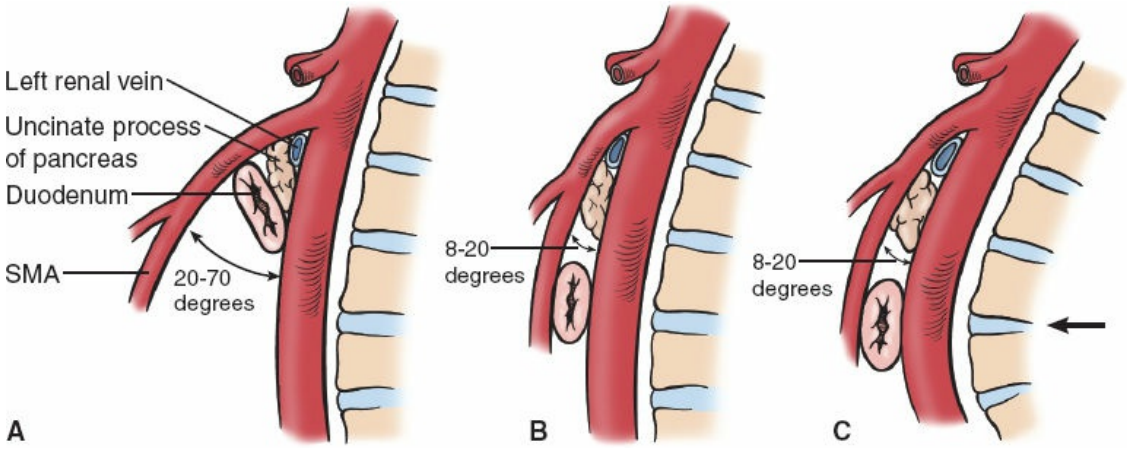

Figure 93.2. **A.** Normal aortomesenteric angle. **B.** Narrowed aortomesenteric angle in a patient with vascular compression of

the duodenum. **C.** Severe lumbar lordosis can exacerbate a narrowed aortomesenteric angle. SMA, superior mesenteric artery.

Though nearly half of the patients with vascular compression of the duodenum have no obvious clinical trigger and therefore would be considered idiopathic, Akin et al. identified supine immobilization, scoliosis, and the placement of a body cast in addition to weight loss as predisposing conditions to syndrome development. The so-called “cast syndrome” was first described in 1950 by Dorph to characterize the patients in whom placement of a whole body cast precipitated the subsequent onset of intractable nausea and vomiting with accompanying gastric and duodenal dilatation. The majority of the reported cases were in young patients, many of whom were being treated for scoliosis. Removal of the cast, rehydration with intravenous fluids, and nasogastric decompression usually led to the resolution of symptoms. Some authors later reported successful management of this problem with the institution of total parenteral nutrition, whereas others noted recovery only with surgical decompression.

Vascular compression of the duodenum has also been reported in other disease states associated with significant weight loss, including anorexia nervosa, severe combat injury leading to a prolonged bedridden status, and major burns. In one report of burn patients, all patients had a >30% total body surface area burn and the syndrome developed soon after the burn injury. Associated symptoms of aspiration, gastroduodenal ulceration, and sepsis were common. Though some patients had symptomatic relief with positional maneuvers, the best results were achieved with operative decompression. Prone positioning was more successful in relieving duodenal compressive symptoms in a number of patients rendered bedridden following severe combat injuries.

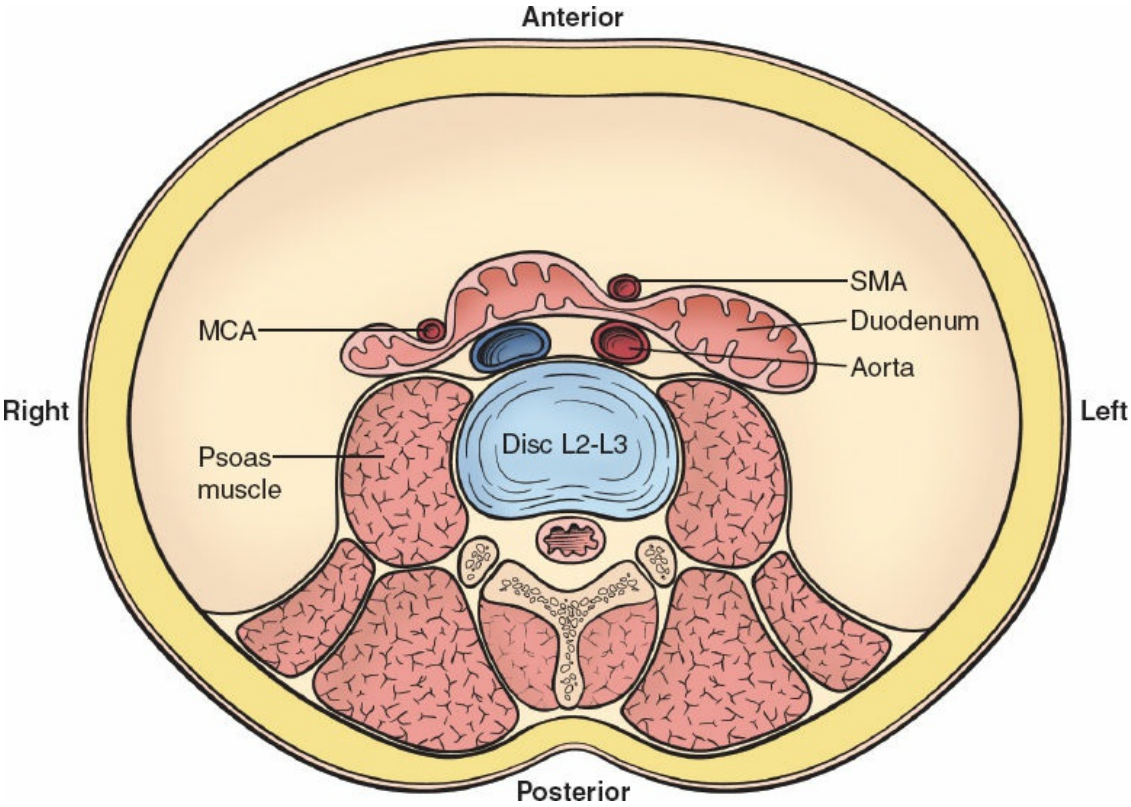

Figure 93.3. Axial view at the level of the second to third lumbar vertebrae shows the potential points of obstruction of the third portion of the duodenum between the SMA and the aorta, or the MCA and right psoas muscle. SMA, superior mesenteric artery; MCA, middle colic artery.

Isolated descriptions of a similar compressive symptom complex that have followed total proctocolectomy and J-pouch anal anastomosis have been attributed to traction on the mesentery by the translocated terminal ileum. Finally, vascular compression of the duodenum has also been described in the pediatric population. Though it has typically been seen in this setting in those having experienced either rapid weight loss or rapid growth, it has also been reported in those with age-appropriate weight and height.

DIAGNOSIS

Diagnosis of vascular compression of the duodenum combines an appropriate degree of clinical suspicion with radiographic confirmation. Traditionally, assessment began with plain abdominal radiographs, which typically delineated a dilated stomach and proximal duodenum. Air fluid levels proximally, absence of air distally, and a clear demarcation line in the duodenum were particularly suggestive of the diagnosis. Given the

poor specificity of plain films and the broad differential diagnosis associated with proximal dilation on plain radiographs, follow-up contrast studies were typically obtained. Both barium and hypotonic contrast have been employed, with the latter considered more sensitive and specific. An upper gastrointestinal tract series (UGIS) utilizing contrast taken orally or via nasogastric tube reveals gastroduodenal dilation and the characteristic linear defect indicative of extrinsic compression in the third portion of the duodenum. Inability of contrast to traverse the point of duodenal obstruction is a reliable diagnostic finding and suggests a severe degree of compression. Fluoroscopy obtained during the swallow study will frequently demonstrate a “to-and-fro” appearance to the peristaltic waves in the proximal duodenum. Subsequent passage of contrast beyond the obstruction and simultaneous relief of attendant symptoms following positional changes during fluoroscopy is also highly suggestive of the correct diagnosis. Positional maneuvers that may produce relief through widening of the aortoduodenal angle include knee-to-chest, prone, or left lateral decubitus positioning.

Combining aortic and selective SMA angiography with contrast imaging of the intestine has been used as a further confirmatory modality and for a period was considered the gold standard diagnostic strategy. Documentation of narrowing of the aortomesenteric angle and colocalization of the duodenal obstruction to the point where the SMA crosses over the duodenum are the hallmark positive findings of these paired investigations. In recent years, the advent of high-quality CT and magnetic resonance imaging (MRI) has supplanted barium swallow and UGI studies. Multislice CT undertaken with intravenous and oral contrast and three-dimensional reconstruction in particular provides a rapid, highly accurate and noninvasive means of visualizing both the relevant vascular and intestinal structures. It has the further advantage of providing detailed information on the remainder of the abdominal organs and, as such, shedding light on additional potential diagnostic entities. Modern-day magnetic resonance angiography (MRA) is also an excellent noninvasive means of delineating the mesenteric vasculature; a study failing to demonstrate either a narrowed aortomesenteric angle or findings suggestive of duodenal obstruction would strongly argue against the diagnosis.

Differential Diagnosis

The differential diagnosis of vascular compression of the duodenum includes multiple other inflammatory and neoplastic entities affecting the duodenum and adjacent anatomic structures. In the era in which peptic ulcer disease was ubiquitous, this disease process was a frequent cause of duodenal and gastric obstruction. Biliary tract pathology, as well as duodenitis and pancreatitis from a number of inciting causes, can result in secondary fibrotic changes that lead to a similar constellation of symptoms. Obstruction from a variety of tumors, including choledochal, pancreatic, duodenal, and jejunal neoplasms, as well as metastatic disease and para-aortic lymphadenopathy, all need to be considered in the patients presenting with proximal intestinal obstruction and weight loss. Cystic pathology of the bile duct and pancreas comprises additional possible sources, as do pancreatic pseudocysts, surgical adhesions, inflammatory bowel disease, and malrotation. Less typical entities included in the differential diagnosis are anorexia, bulimia, porphyria, vitamin D deficiency, visceral neuropathy, and postvagotomy syndrome. Celiac artery compression syndrome as an inciting trigger to rapid weight loss and subsequent vascular compression of the duodenum has been described. Finally, diseases associated with duodenal dysmotility, such as diabetes mellitus, chronic idiopathic intestinal pseudo-obstruction, and collagen vascular diseases such as scleroderma, can on occasion lead to “megaduodenum” and should also be considered.

Although now perhaps more of historic note, there has been a well-documented association between vascular compression of the duodenum and peptic ulcer disease. Indeed, one study describing nearly 300 patients with vascular compression since 1960 indicated that 32% had concomitant peptic ulcer disease. Patients identified as having both pathologies typically had chronic compressive symptoms and were often males of normal body habitus rather than thin and asthenic in appearance. The pathophysiologic process connecting the two disease states is poorly understood, though it has been noted that gastric secretions do not tend to be elevated in these patients. This association is notably less common with the more recent fall in incidence of peptic ulcer disease.

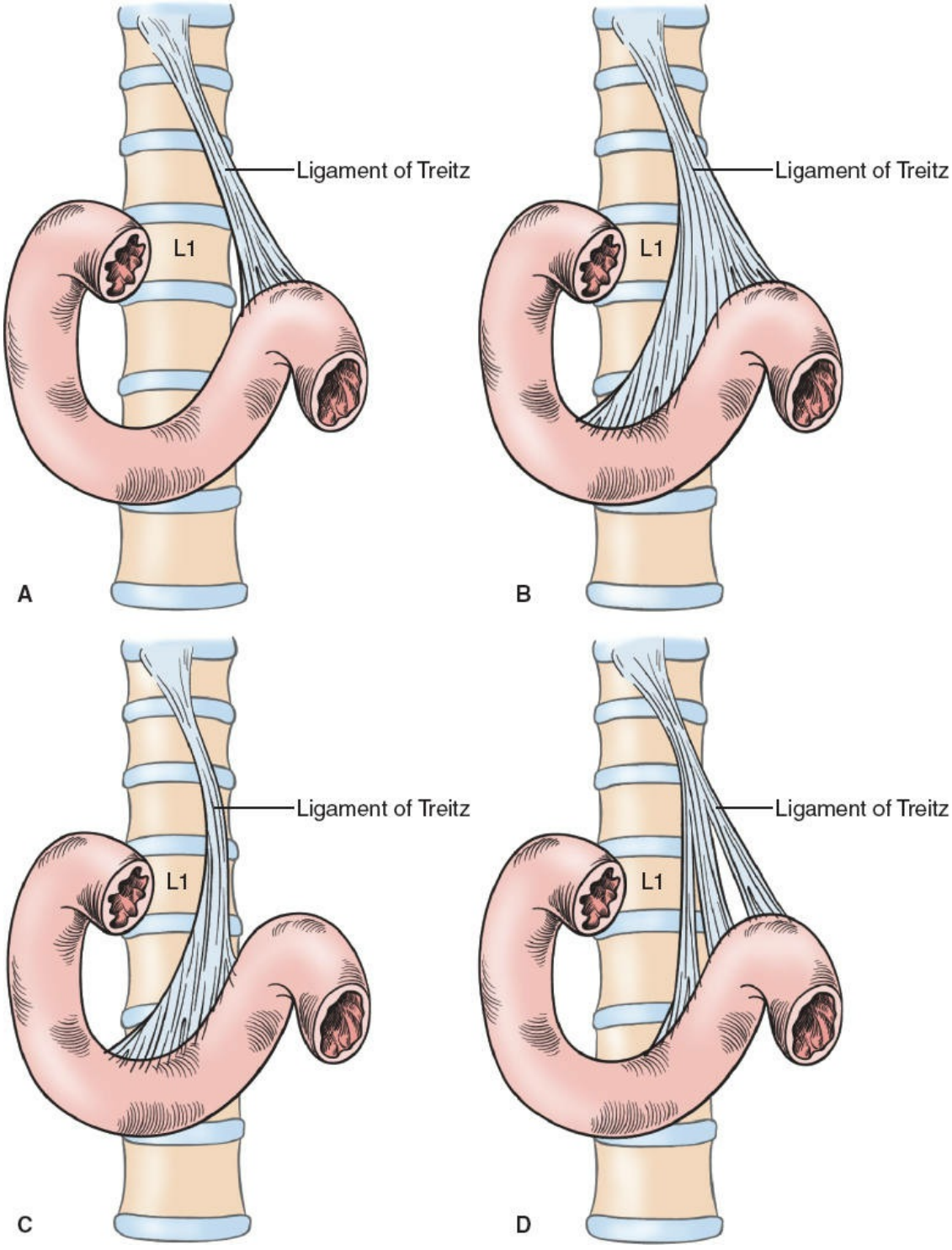

Figure 93.4. Variations in the attachment of the ligament of Treitz. Example B is the most common configuration.

MANAGEMENT

The initial management efforts in patients with vascular compression of the duodenum should be focused on the alleviation of the associated obstructive symptoms and treatment of volume and nutritional depletion.

Identified electrolyte imbalances are managed with intravenous fluid rehydration, and gastroduodenal decompression is typically accomplished by passage of a nasogastric tube. Given the historic association with concurrent peptic ulcer disease and the need to reduce secretions proximal to the obstruction, control of gastric acid secretion with either H_2 receptor blockers or proton pump inhibitors has been an important component of the treatment of patients diagnosed with or suspected of having the syndrome.

The patients in whom the diagnosis is highly suspected or confirmed, every effort should be made to alleviate any aggravating circumstances that may be contributing to disease progression. Although rarely utilized in the current era, patients with a whole body cast for the treatment of scoliosis or trauma or a hip spica cast should have the cast removed as it frequently results in symptomatic improvement and can even lead to the resolution of the syndrome. Efforts at windowing of the cast, on the other hand, have not traditionally been sufficient to achieve definitive relief.

The high prevalence of weight loss and malnutrition mandates that significant attention be given to restoring body weight and nutritional balance. Patients tolerant of oral intake should have a modified diet of small meals administered more frequently. Accompanying postprandial postural changes when practical may serve to reduce the pain associated with ingestion and facilitate the passage of food beyond the point of obstruction; the left lateral decubitus, prone, and knee–chest positions have all been utilized successfully toward this end. If adequate nutrition cannot be attained by oral means, enteral nutrition via a nasojejunal tube advanced endoscopically or radiographically past the point of duodenal obstruction is recommended. For the minority of the patients intolerant of enteral feeding, the use of total parenteral nutrition is an appropriate alternative means of nutritional support. The presumptive aim of such efforts to accomplish weight gain is restoration of the retroperitoneal fat pad and attendant expansion of the aortoduodenal angle.

While a trial of conservative therapy should be instituted in all patients, success with nonoperative measures is variable and is related to the etiology and extent of obstruction at the time of presentation (see Fig. 93.5). Patients with prolonged or severe symptoms initially or those who fail to gain weight with adjunctive nutritional support are more likely to respond poorly to conservative treatment. Given the advanced stage of decline present in many patients at the time the syndrome is correctly

recognized, it is perhaps not surprising that the majority of patients with vascular compression of the duodenum eventually require surgical relief.

SURGICAL TECHNIQUE

When nonoperative therapy proves insufficient, there are two current mainstays of surgical treatment for vascular compression of the duodenum: division of the ligament of Treitz and a duodenojejunostomy bypass around the point of obstruction. Strong et al. in 1958 first advocated that division of the ligament of Treitz and downward mobilization of the duodenum is appropriate and sufficient treatment for the syndrome. In their subsequent report nearly two decades later reviewing the accumulated literature from the previous 30 years, Akin et al. reinforced this position, citing an 83% success rate with the maneuver.

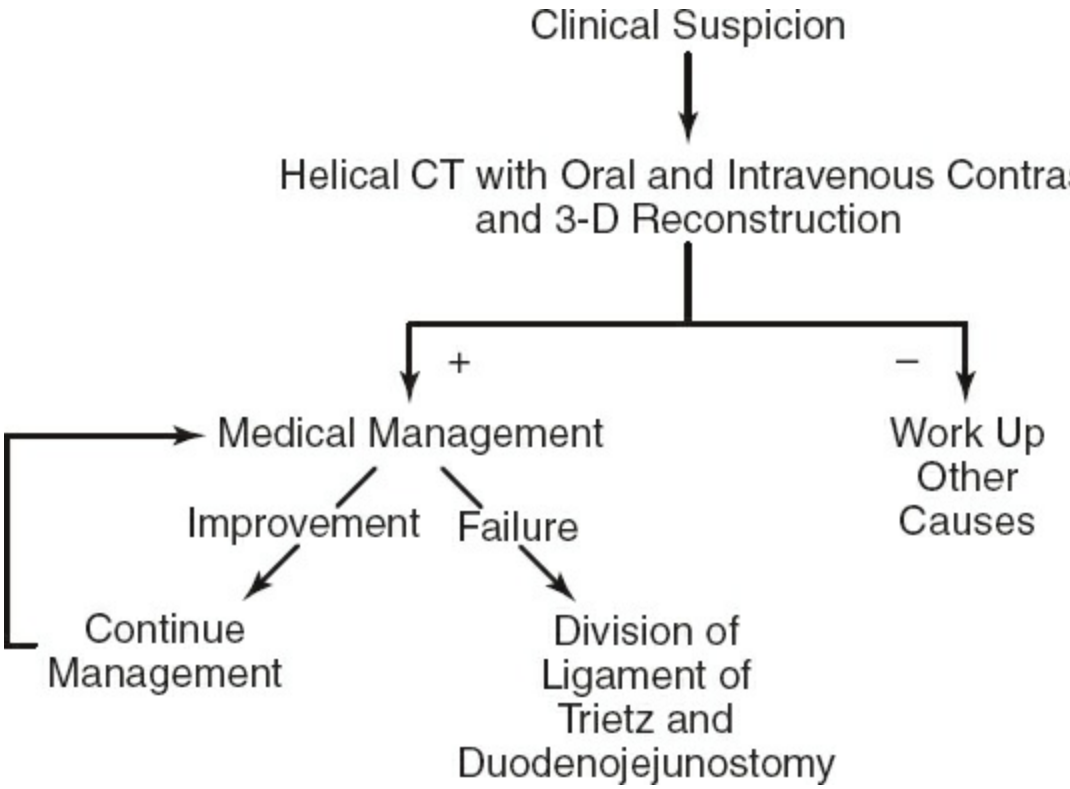

Figure 93.5. Decision-making algorithm for the diagnosis and treatment of vascular compression of the duodenum. CT, computed tomography.

For the patients in this series who experienced a less favorable response with division of the ligament alone, a subsequent duodenojejunostomy resulted in symptomatic relief and a good outcome in most cases. Notably, the patients who underwent a duodenojejunostomy concurrently with

division of the ligament of Treitz had a near universal 99% rate of success. Reported symptomatic relief was prompt and postoperative weight gain was steadily progressive in this review. Multiple additional reports of duodenojejunostomy in the literature have been similarly favorable, with positive outcomes following the procedure seen in 80% to 100% of the cases performed for this indication. Though employed as a successful surgical strategy for correctly diagnosed vascular compression of the duodenum for nearly a century, duodenojejunostomy continues to be the operative treatment of choice of most authorities.

Various other surgical approaches have also been utilized over time for vascular compression of the duodenum. One author reported successful 12-month results in all 10 patients undergoing transposition of the third portion of the duodenum anterior to the SMA. A modification of simple division of the ligament of Treitz has been championed in the pediatric surgical literature and presumably grew out of the experience with lysing of Ladd's bands in patients with congenital malrotation. After full mobilization of both the right colon and the duodenum, the unfolded small bowel is placed in the right colonic gutter and the right colon is transposed to the left. Though several reports have indicated a success rate as high as 90% with this derotation procedure in the pediatric community, it has never gained popularity in the adult population.

Additional strategies for which early enthusiasm has dimmed include colonic resection, colonic plication, mesenteric plication, and gastrojejunostomy. Although multiple authors describing their anecdotal experience with small numbers of patients have reported excellent outcomes with gastrojejunostomy, in larger reviews the documented success rates have been much lower, ranging from 40% to 70%. As indicated in Figure 93.6, the necessity for biliary and pancreatic secretions to drain in a retrograde fashion is a key limitation to this surgical option and a likely contributing factor for the associated reduced success rates. In the recent era, both division of the ligament of Treitz and duodenojejunostomy have been successfully performed laparoscopically. Whereas the reported experience is limited to a small number of case series with few patients, the success rates have mirrored the open surgical experience in that the results of duodenojejunostomy have been more favorable than those involving division of the ligament of Treitz and mobilization of the duodenum alone. Both open and laparoscopic approaches can be undertaken with minimal operative morbidity and

mortality in appropriately resuscitated patients.

Division of the Ligament of Treitz

The abdomen is entered through a midline incision, and a general survey of the peritoneal cavity is carried out. Intraoperative confirmation of the diagnosis of vascular compression of the duodenum can be achieved by insufflation of 150 to 300 mL of air through a nasogastric tube. Historically, expansion of the duodenal diameter by >3 to 4 cm is considered a positive response. The omentum and transverse mesocolon are elevated superiorly to allow exposure of the ligament of Treitz and the duodenojejunal flexure, the latter identified as the jejunum emerges from the base of the posterior aspect of the transverse mesocolon to the left of the spine. With the proximal jejunum under gentle downward stretch, the peritoneum along the left lateral aspect of the jejunum is first incised (Fig. 93.7A). Further mobilization of the duodenojejunal flexure is achieved by dividing the suspensory muscle of the duodenum, or ligament of Treitz, along the anterior and cranial aspect of the third and fourth portions of the duodenum (Fig. 93.7B). This maneuver serves to lower the third and fourth portions of the duodenum from the aortomesenteric angle; once successfully completed, the space between the duodenum and the origin of the SMA should easily allow the passage of two fingers (Fig. 93.7C).

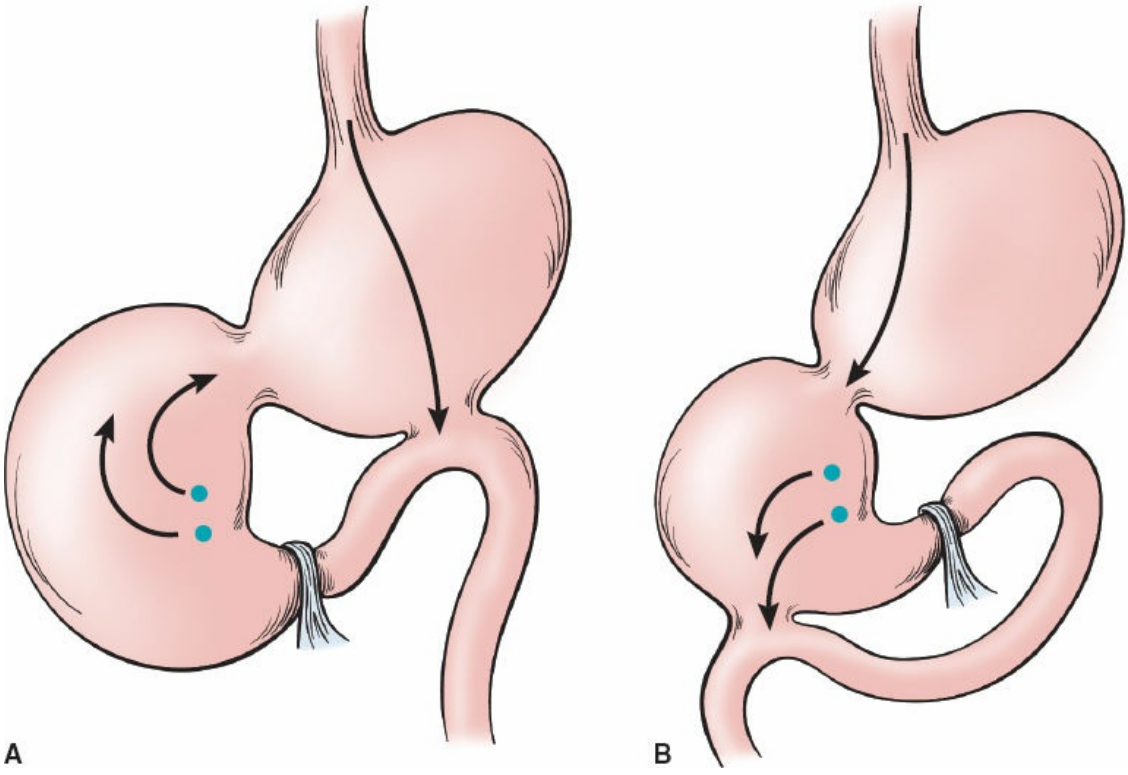

Figure 93.6. A. Gastrojejunostomy necessitates drainage of bile and pancreatic secretions in a retrograde fashion through the stomach. **B.** This potential cause of suboptimal operative outcome is obviated by duodenojejunostomy.

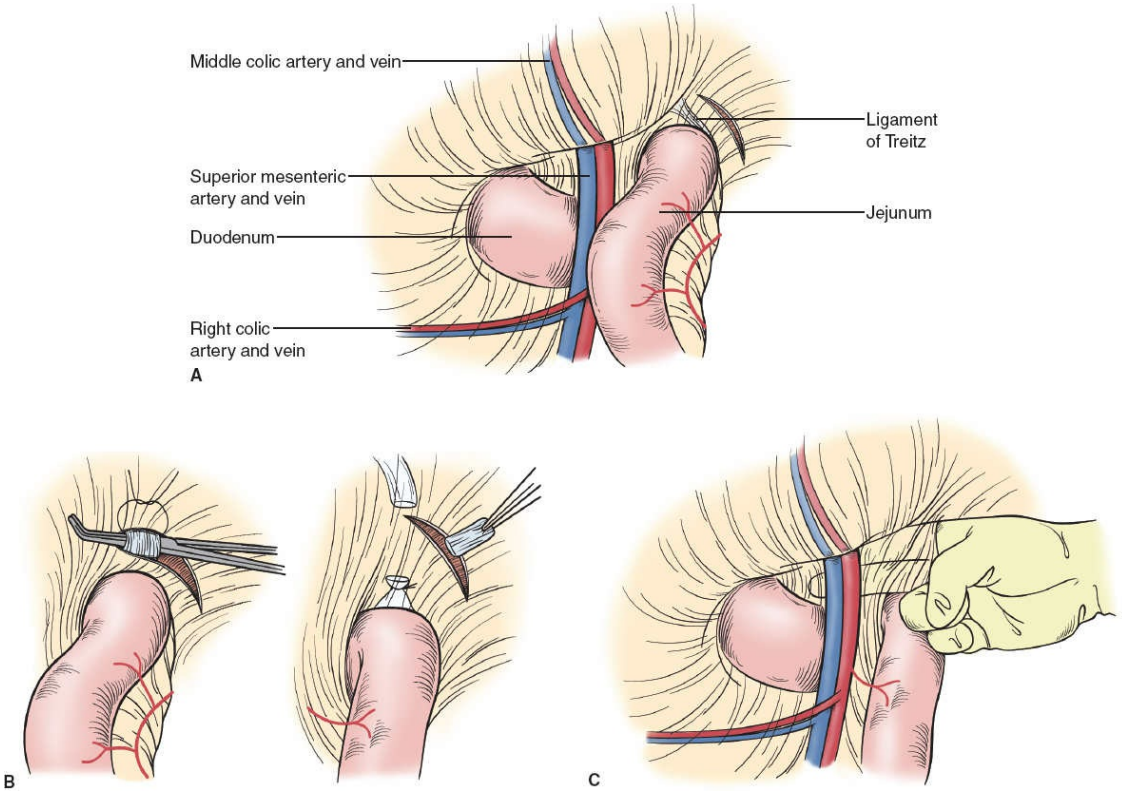

Figure 93.7. Division of the suspensory ligament of the duodenum. **A.** Incision of the peritoneum along the left aspect of the duodenojejunal flexure. **B.** Division of the ligament of Treitz. **C.** Mobilization of the duodenal flexure out of the aortomesenteric angle should allow at least two fingers to pass between the duodenum and the origin of the SMA.

If desired, more complete mobilization of the second and proximal aspect of the third portion of the duodenum can be obtained by undertaking a wide Kocher maneuver. Similarly, more extensive exposure of the distal duodenum can be gained by incising the transverse mesocolon and gastrocolic ligament and extending the dissection to include the retropancreatic space, the superior aspect of the paraduodenal fossa, and the posterior aspect of SMA. Following these steps, subsequent internal herniation can occur if the peritoneal defect along the left aspect of the duodenojejunal flexure is not closed. The described dissection can also be complicated by bleeding from multiple vascular structures. The vessels most prone to injury include the inferior mesenteric vein and the SMA and

superior mesenteric vein and their proximal middle colic and inferior pancreaticoduodenal branches. Both variations in the anatomy of the ligament of Treitz and encountered bleeding difficulties during lysis of the ligament have been implicated as possible explanations for the generally inferior results when treatment is limited to division of this ligament alone.

Duodenojejunostomy

If a duodenojejunostomy is to be performed, it is begun after mobilizing the second and third portions of the duodenum as described above and retracting the duodenum caudally through the peritoneal incision (Fig. 93.8A). A side-to-side duodenojejunostomy is preferred and is created by orienting the proximal 10 to 15 cm of the jejunum to the right of the SMA and superior mesenteric vein (Fig. 93.8B). A posterior row of interrupted 3-0 silk sutures is then placed between the junction of the second and third portions of the duodenum and the jejunum. A longitudinal enterotomy of at least 5 cm is carried out on the antimesenteric border of both the duodenum and jejunum, and an inner layer of 3-0 absorbable suture is run circumferentially. An anterior row of interrupted 3-0 silk seromuscular sutures is placed to reinforce the anastomosis (Fig. 93.8C).

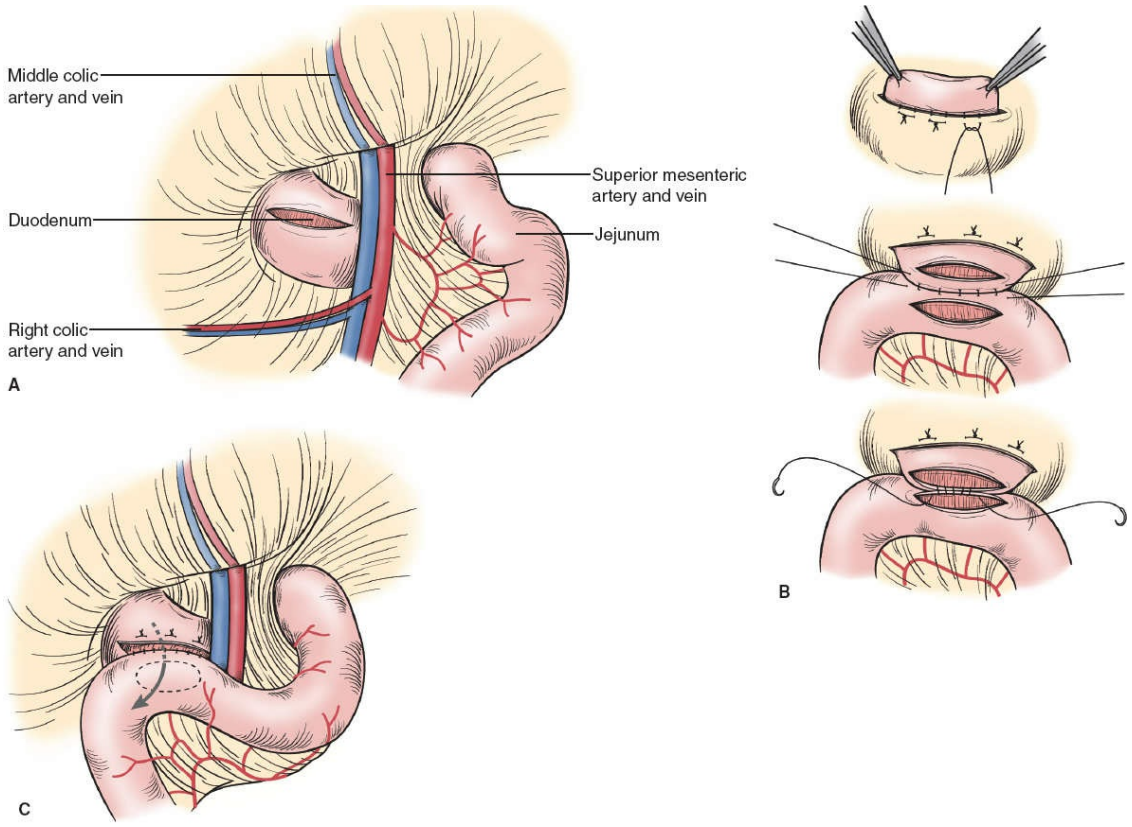

Figure 93.8. Construction of a side-to-side duodenojejunostomy.

A. Incision of the peritoneum and exposure of the junction of the second and third portions of the duodenum. **B.** Posterior row of seromuscular nonabsorbable sutures is placed between the duodenum and jejunum and a longitudinal incision is made on the antimesenteric borders of the bowel. Running absorbable sutures create the inner layer. **C.** An anterior row of interrupted nonabsorbable sutures completes the anastomosis.

An acceptable alternative approach involves creation of a Roux-en-Y duodenojejunostomy (Fig. 93.9). This option is less commonly utilized, given the increased risk associated with the additional anastomosis.

Laparoscopic Approaches

Multiple case reports describe successful laparoscopic, even robotic, performance of these procedures, either alone or in combination. These options clearly depend on the skill and comfort level of the surgeon; to date, benefits have not been demonstrated conclusively. When performed laparoscopically, the duodenojejunostomy is generally undertaken with either 4 or 5 trocars. Two trocars are placed lateral to the left rectus sheath, one below the left costal margin, and one more caudally. A third trocar is placed through the umbilicus and one or two additional trocars are placed lateral to the right rectus sheath. Given the proximal duodenal dilation typically encountered beneath the transverse colon, a retrocolic stapled duodenojejunostomy is often technically easiest to construct.

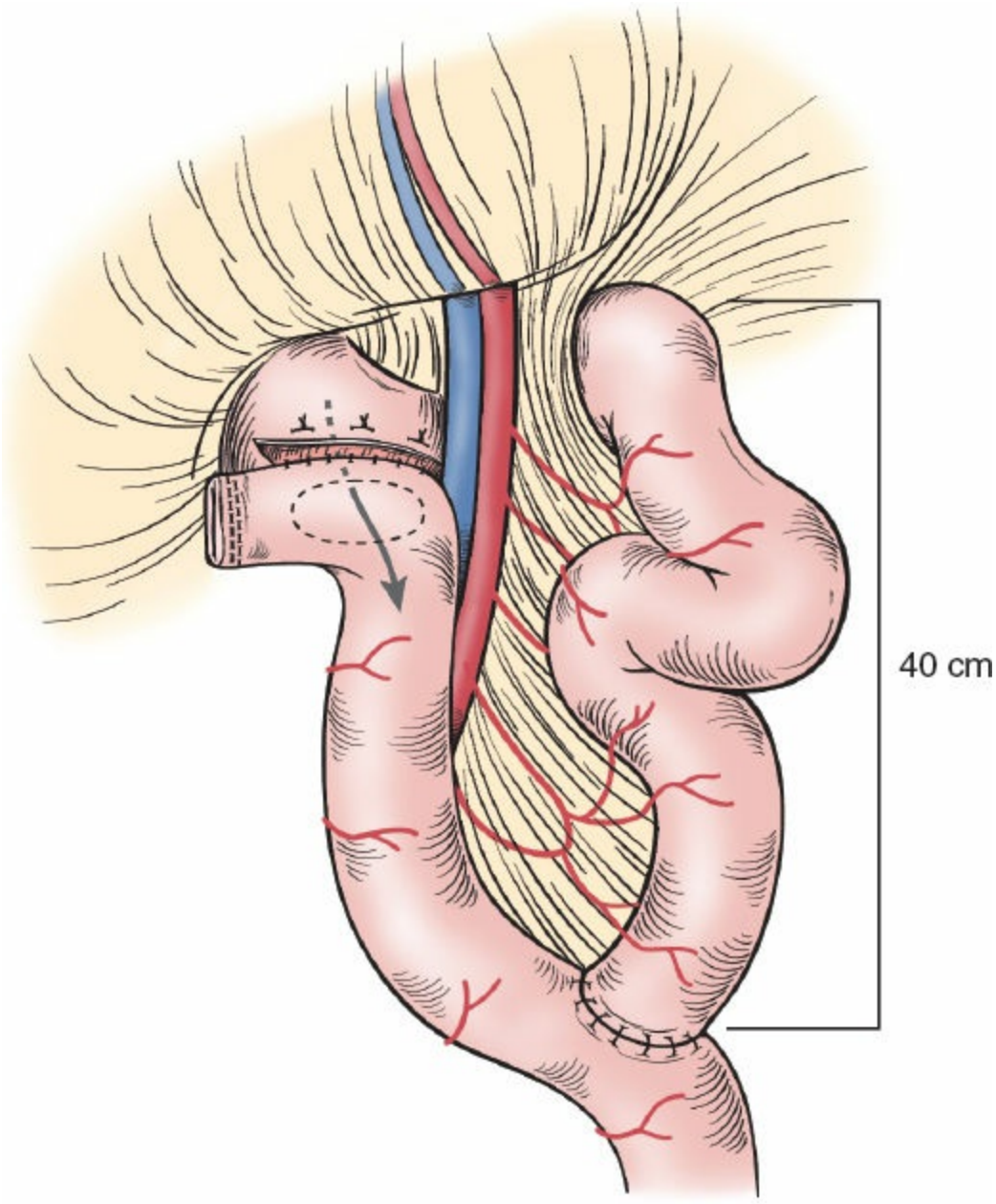

Figure 93.9. Completed Roux-en-Y duodenojejunostomy.

Suggested Readings

Akin JT, Gray SW, Skandalakis JE. Vascular compression of the duodenum: presentation of ten cases and review of the literature. *Surgery* 1976;79:515.

Applegate GR, Cohen AJ. Dynamic CT in superior mesenteric artery syndrome. *J Comput Assist Tomogr* 1988;12:976.

Barner HB, Sherman CD. Vascular compression of the duodenum. *Int Abstracts Surg* 1963;117:103.

Bermas H, Fenoglio ME. Laparoscopic management of superior mesenteric artery syndrome. *JSLS* 2003; 7:151.

Dorph MH. The Cast Syndrome—Review of the Literature and Report of a Case. *N Engl J Med* 1950;243:440.

Duvie SO. Anterior transposition of the third part of the duodenum in the management of chronic duodenal compression by the superior mesenteric artery. *Int Surg* 1988;73:140.

Jones AS, Carter R, Smith LL, et al. Arteriomesenteric duodenal compression. *Am J Surg* 1960;100:262.

Marchant EA, Alvear DT, Fagelman KM. True clinical entity of vascular compression of the duodenum in adolescence. *Surg Gynecol Obstet* 1989;168:381.

Muhammad IA, Jonathan GF. Prolonged gastroparesis after corrective surgery for Wilkie's syndrome: a case report. *J Med Case Reports* 2008;2:109.

Strong EK. Mechanics of arteriomesenteric duodenal obstruction and direct surgical attack upon etiology. *Ann Surg* 1958;148:725.

Tseng CK, Su WB, Lai HC, et al. Superior mesenteric artery syndrome caused by celiac axis compression: a case report and review of the literature. *Eur J Gastroenterol Hepatol* 2008;20(6):578.

Wilkie DPD. Chronic duodenal ileus. *Am J Med Sci* 1927;173:643.

Wilkinson R, Huang CT. Superior mesenteric artery syndrome in traumatic paraplegia: a case report and literature review. *Arch Phys Med Rehabil* 2000;81:991.

EDITOR'S COMMENT

In the majority of cases, vascular compression of the duodenum (Wilkie syndrome) is a secondary event. It may be the result of weight loss, correction of scoliosis, obesity, enforced bed rest in the supine position, and the presence of a body cast which may alter unfavorably the angle of mesenteric traction and increase the possibility of duodenal compression (Akin JT Jr, Skandalakis JE, Gray SW. The anatomic basis of vascular compression of the duodenum. *Surg Clin North Am* 1974;1361–70). Unfortunately, according to another paper from the Skandalakis group rarely underlying anatomical causes may contribute to the syndrome including a congenitally short mesentery, aberrant superior mesenteric artery syndrome, excessive mobility of the right colon, malrotation, and a short suspensory ligament may also be involved (Androulakis J, Colborn GL, Skandalakis PN, et al. Embryologic and anatomic basis of duodenal surgery. *Surg Clin North Am* 2000;80:171–200). Unfortunately, these are absent is many patients.

The obstruction may be diagnosed by an upper GI series, but more commonly by CT of the abdomen with IV and oral contrast. The usual setting of the superior mesenteric artery syndrome is the patient who has undergone a

period of weight loss secondary to prolonged fasting and lack of adequate nutritional intake. Theoretically, at least there is a fat pad which lists the superior mesenteric artery on the third portion of the duodenum and as the fat is reabsorbed for calories the superior mesenteric artery syndrome results. This has been very difficult to prove. Indeed the use of hyperalimentation to restore the fat pad is not particularly successful in every patient. Another cause of superior mesenteric artery syndrome is neoplasm in the area of the midportion of the pancreas as the superior mesenteric artery arises and passes over the duodenum. In addition, primary tumors of the duodenum may cause the obstruction as well as Crohn disease involving the duodenum, duodenal diverticulum or rarely peptic ulcer disease. In these cases, other procedures, such as resection, may be an option rather than duodenojejunostomy. Hence in the evaluation of these patients with CT as indicated above should also include esophagogastroduodenoscopy to exclude primary duodenal pathology. It has been noted that this syndrome may occur after ileoanal anastomosis (Ravindra KV, Rajasekhar P, Rozario AP, et al. Superior mesenteric artery syndrome following ileo-anal pouch procedure. *Indian J Gastroenterol* 1999;18(1):35–6) and after left colectomy (Yerdel MA, Moreira LF, Iwagaki H, et al. Acute superior mesenteric artery syndrome following left hemicolectomy: a case report. *Acta Med Okayama* 1992;46(6):479–82).

Another situation in which there is a significant amount of theoretical causation of superior mesenteric artery syndrome is kyphoscoliosis and its correction. According to this hypothesis, this may also be associated with severe weight loss (Munns SW, Morrissy RT, Golladay ES, et al. Hyperalimentation for superior mesenteric-artery (cast) syndrome following correction of spinal deformity. *J Bone Joint Surg* 1984;66:1175–77; De Giorgi G, Stella G, Becchetti S, et al. Cotrel-Dubousset instrumentation for the treatment of severe scoliosis. *Eur Spine J* 1999;8(1):8–15). Hyperalimentation following the superior mesenteric artery syndrome (cast syndrome) in which this was successful in reversing the superior mesenteric artery syndrome. In Munns publication, which originated from Maryís Hospital for Children in the United Kingdom, there were two cases one of which had a paralytic lumbar scoliosis that gradually became particularly too difficult and was corrected in a cast made an uneventful recovery and was treated conservatively in the usual fashion. The other patient required a duodenojejunostomy because nonoperative therapy failed.

As the authors state mobilizing of the Ligament of Treitz may be sufficient but the repair is usually more successfully treated with a side-to-side duodenojejunostomy. An open, laparoscopic (Sun Z, Rodriguez J, McMichael J, et al. Minimally invasive duodenojejunostomy for superior mesenteric artery syndrome: a case series and review of the literature. *Surg Endosc* 2015;29(5):1137–44) or robotic approach may be employed (Ayloo SM, Masrur MA, Bianco FM, et. al. Robotic Roux-en-Y duodenojejunostomy for superior mesenteric artery syndrome: operative technique. *J Laparoendosc Adv Surg*

Tech A 2011;21(9):841–4).

E. Christopher Ellison

C BARIATRIC AND METABOLIC DISEASES

94 Gastrointestinal Stromal Tumors

G. Travis Clifton and Paul Mansfield

ETIOLOGY AND PATHOPHYSIOLOGY

Gastrointestinal stromal tumors (GISTs) are a relatively rare tumor type although the commonest mesenchymal cancer of the gastrointestinal tract. They are thought to most commonly originate from the myenteric interstitial cells of Cajal, responsible for intestinal neuromediation and myenteric packmaking, or their precursor cells and thus can be found anywhere along the gastrointestinal tract. GISTs are most commonly found in the stomach (50% to 60%) and small intestines (20% to 35%). Less common locations include the colon and rectum (~5%), esophagus (1%) and, rarely, extraintestinal locations such as the omentum or mesentery.

GISTs represent around 1% of primary gastrointestinal cancers and have an incidence of between 3 and 20 cases per million individuals per year. The incidence has increased as improved molecular diagnostics have increased the proportion of gastrointestinal mesenchymal tumors classified as GIST. Even then, the rate of subclinical GISTs may be much higher, particularly for subcentimeter (micro-GISTs), as they have been found in high rates in meticulous evaluation of gastric specimens removed during sleeve gastrectomy and in autopsy studies.

The mutational drivers of GISTs are increasingly well characterized and important for both diagnosis and treatment. In most GISTs, oncogenic mutations are present in KIT (75% to 80%) or platelet-derived growth factor receptor-α (PDGFA, 10%). Both are homologous surface tyrosine kinase receptors that are constitutively activated by a number of well-characterized mutations, which leads to pathologic cell proliferation. Patients with heritable mutations of KIT or PDGFRA are susceptible to developing gastric and small bowel GISTs, often at a young age. However,

these mutations alone may not be sufficient for malignant behavior as they are present in small, incidentally discovered GISTs that appear to have a more indolent natural history.

About 10% to 15% of GISTs, in which no c-KIT or PDGRA mutation is present, are considered “wild type” (WT-GIST). WT-GISTs derive their oncogenic potential from downstream tyrosine kinase mutations such as succinate dehydrogenase (SDH), BRAF, and insulin-like growth factor-1 and are more common among GISTs in children. Several conditions predispose individuals for development of WT-GIST, particularly at a younger age. Carney triad (GIST, paraganglioma, pulmonary chondroma) is a nonheritable syndrome that affects younger women, which may be associated with SDH deficiency. Carney–Stratakis syndrome is due to a heritable mutation in SDH causing a familial predisposition for GIST and paragangliomas. Patients with neurofibromatosis type 1 are also at increased risk for developing GIST.

The clinical behavior and prognosis of GISTs is highly variable and greatly dependent on their size, mitotic rate, and location.

CLINICAL PRESENTATION

GISTs are most common in elderly individuals (median age 55 to 60 years old) but can occur at any age and are occasionally seen in children. They have a roughly equivalent prevalence in males and females.

The most common presenting symptoms are gastrointestinal hemorrhage, anemia, abdominal pain, and abdominal mass. Less commonly, tumors can present with more urgent symptoms of bowel obstruction or tumor rupture with hemoperitoneum. Up to a third of the time GISTs are discovered incidentally on imaging or during surgical or endoscopic procedures. Given that GIST arise in the submucosal and intramuscular layers of the gastrointestinal tract, endoscopically GISTs often appear as a mass with intact overlying mucosa, although ulceration certainly can be present.

GISTs can become quite large before symptoms develop, with most larger than 5 cm at the time of diagnosis. Small bowel GISTs are typically larger and more likely to have metastatic disease at presentation compared to gastric GISTs.

PREOPERATIVE PLANNING

When a suspected GIST is encountered, evaluation with a high-quality

abdominal and pelvic CT scan with IV contrast is necessary to characterize the tumor morphology, the local extent of disease, and evaluate for metastatic disease. Unlike other mesenchymal tumors, metastases to the lungs are exceedingly rare so imaging of the chest is not mandatory in localized disease unless symptoms or physical examination findings dictate otherwise.

Further evaluation with endoscopic ultrasound (EUS) and fine needle aspiration (FNA) can be used to secure the diagnosis and is necessary prior to considering either observation or preoperative systemic therapy. Percutaneous core needle biopsy should generally be avoided in cases of suspected GISTs due to fragility of the tumors and risk of hemorrhage or dissemination. Localized suspected GISTs that are easily resectable, particularly if they are not readily accessible endoscopically, do not necessarily need a tissue diagnosis prior to proceeding with surgical resection.

Observation

Very small, asymptomatic gastric GISTs (<2 to 3 cm) can, at times, be safely observed without surgical resection due to their low malignant potential, particularly in patients who are elderly or poor surgical candidates. Observational studies have shown that gastric GISTs less than 2 cm, regardless of their mitotic rate, have an exceedingly low rate of metastasis (Table 94.1). High-risk endoscopic ultrasonographic features such as an irregular border, cystic spaces, ulceration, echogenic foci, and heterogenicity have been associated with higher rates of malignant behavior and should lead to surgical excision. Should observation be selected, the lesion should be re-evaluated at by EUS to ensure stability.

TABLE 94.1 Rates of Metastases or Tumor-Related Death in GISTs by Tumor Location, Grouped by Tumor Size and Mitotic Rate

Tumor Parameters			Percent of Patients With Progressive Disease During Long-Term Follow-up and Characterization of Risk for Metastasis			
Group	Tumor Size (cm)	Mitotic Rate (HPF)	Gastric GISTs (%)	Jejunal and Ileal GISTs (%)	Duodenal GISTs (%)	Rectal GISTs (%)
1	≤2	≤5/50	0 none	0 none	0 none	0 none
2	>2 ≤5	≤5/50	1.9 very low	4.3 low	8.3 low	8.5 Low
3a	>5 ≤10	≤5/50	3.6 low	24 moderate	34 high[b]	57 high[b]
3b	>10	≤5/50	12 moderate	52 high		
4	≤2	>5/50	0[a]	50[a]	[c]	54 high
5	>2 ≤5	>5/50	16 moderate	73 high	50 high	52 high
6a	>5 ≤10	>5/50	55 high	85 high	86 high	71 high[b]
6b	>10	>5/50	86 high	90 high		

[a]Denotes tumor categories with very small numbers of cases.
[b]Groups 3a and 3b or 6a and 6b are combined in duodenal and rectal GISTs because of small number of cases.
[c]No tumors of such category were included in the study. Note that small intestinal and other intestinal GISTs show a markedly worse prognosis in many mitosis and size categories than gastric GISTs.
Adapted from Miettinen M, Lasota J. Gastrointestinal stromal tumors: pathology and prognosis at different sites. *Semin Diagn Pathol* 2006; 23(2):70–83.

Neoadjuvant Therapy

Neoadjuvant therapy with the tyrosine kinase inhibitor imatinib should be considered in patients with GISTs that are locally advanced and when decreasing the tumor size would potentially decrease the surgical morbidity associated with the resection. This can be particularly beneficial in anatomically difficult locations such as the distal esophagus, duodenum, or distal rectum. In addition, observing the response to neoadjuvant therapy may provide clinically relevant information of the behavior of the tumor. For this reason, some advocate neoadjuvant therapy in patients who clearly have an indication for adjuvant imatinib after resection. While neoadjuvant therapy has not clearly demonstrated a survival benefit, the available data is limited to relatively small trials in which it has been found to be safe and effective at decreasing the tumor size in the majority of patients and rendering unresectable tumors resectable or decreasing the scope of the planned operation. The use of preoperative therapy in patients with metastatic or locally recurrent GISTs has also proven safe although it generally demonstrates lower response rates and is associated with a higher risk of incomplete resection. The use of neoadjuvant therapy is a decision of clinical judgment that should be made in the context of a multidisciplinary care team.

A tissue diagnosis is necessary prior to initiating systemic therapy. Knowing the mutational status of the GIST will help inform the individual

chances of success with therapy. Data extrapolated from response rates in advanced GIST indicate that the patient will have a partial or complete response by RECIST criteria (≥30% decrease in the sum of the longest diameter) in 63%, 37%, and 37% of the time for KIT exon 11 mutant, KIT exon 9 mutant, and WT-GIST, respectively. However, particularly important for patients in whom increased tumor size would preclude resection, progressive disease (≥20% increase in sum of the longest diameter) is seen in 6%, 9%, and 18% of patients with KIT exon 11 mutant, KIT exon 9 mutant, and WT-GISTs, respectively. Some mutations, such as PDGFRA D842V, have proven resistant to imatinib and in patients with GIST driven by these mutations alternative strategies may be necessary.

When using neoadjuvant therapy, early and regular interval assessment for response, typically every 8 to 12 weeks, with CT scans will ensure that preoperative therapy is not continued unnecessarily and that surgery is pursued at the time of maximal response which is determined by no further reduction in size on successive imaging. Typically, maximal response is achieved between 6 and 12 months. In patients in whom any progression would potentially render the tumor unresectable, assessment by PET-CT before and soon after initiation of therapy can be utilized. Multiple studies have demonstrated that a decrease in metabolic activity on PET scan, typically measured 8 to 14 days after initiation of therapy, but even as soon as 24 hours after initiation, is predictive of subsequent reduction of tumor burden or progression-free survival.

Second-line therapy with sunitinib can be used when resistance or intolerance to imatinib is present or develops and further reduction in tumor size is necessary for safe surgical resection.

Recurrent and Metastatic Disease

Up to 50% of patients with GIST will present with metastatic disease and there is an approximately 30% to 50% recurrence rate after resection of primary disease. There is a more limited role for surgery in cases of recurrent disease or when distant metastases are present; however, patients with resectable disease may benefit from resection in selected cases. Preoperative treatment with imatinib or sunitinib can help select patients with more favorable disease biology who will derive greater benefit from surgical resection. In patients with disease that remains stable on imatinib or sunitinib treatment, resection has been associated with prolonged

disease-free intervals and excellent disease-free survival. Likewise, in those with multifocal disease with isolated foci of metastases that become resistant to imatinib or sunitinib, resection of the unresponsive lesion, if it can be resected with limited morbidity, often can provide extended benefit in the form of disease control. In contrast, in patients with multifocal disease resistant to therapy, resection is unlikely to be complete and is associated with a short progression-free interval and few patients surviving more than 12 months. In these cases, the decision to operate should be individualized based on the potential oncologic and symptomatic benefit and the risks of surgery in the context of coordinated multidisciplinary care.

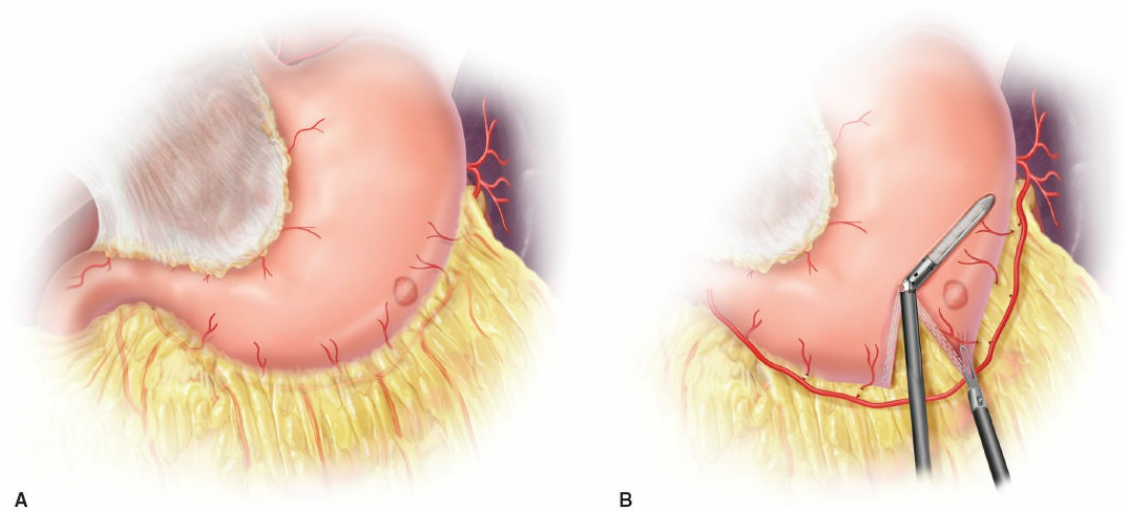

Figure 94.1. Laparoscopic wedge resection of a gastric GIST. Gastrointestinal stromal tumors located away from the gastroesophageal junction or pylorus (**A**) can often be resected laparoscopically with a stapled wedge resection (**B**).

SURGICAL TECHNIQUE

The aim of surgical resection of GIST is to remove the tumor intact while limiting surgical morbidity. Careful handling of the tumor is imperative as GIST tend to be friable and prone to rupture, which is associated with an increased risk of recurrence. In addition, GISTs treated with preoperative imatinib often have a dense surrounding desmoplastic reaction that can make removal from surrounding tissue tedious. While a margin-negative resection should be the surgical goal, microscopically positive margins (R1) have not been shown to increase the risk of recurrence with or without adjuvant imatinib in some series, although the data is mixed.

Minimally Invasive Versus Open Resection

The role of minimally invasive resection of small gastric GIST is well established. Smaller tumors, particularly in favorable locations (along the greater curvature of the stomach, jejunum, or ileum), can be resected laparoscopically with minimal morbidity and oncologic outcomes equivalent to open resection. Laparoscopic resection of larger gastric GIST and GIST in less accessible locations have been reported with favorable outcomes. However, as previously discussed, GISTs are prone to fracture leading peritoneal to dissemination of tumor. The tumor should be removed from the abdomen in an endoscopic retrieval bag to avoid tumor rupture and perionteal seeding. Resection of larger GISTs and those in more difficult anatomic locations should weigh the advantages of a minimally invasive approach with the risk of rupture and should only be attempted by those with sufficient minimally invasive expertise.

Gastric GIST

The stomach is the most common location for GIST tumors. Most gastric GIST can be resected with a wedge resection while achieving a grossly negative margin and maintaining intestinal continuity. Oftentimes, particularly for smaller lesions, this can be performed laparoscopically (Fig. 94.1). Care must be taken to avoid narrowing the stomach too much, particularly at the incisura. This can be prevented by the placement of a bougie or endoscope while using linear cutting staplers to transect the stomach. However, larger lesions and those located close to the pylorus or gastroesophageal junction may require partial or total gastrectomy in order to safely remove the tumor. If decreasing the tumor size would potentially allow a wedge resection, then neoadjuvant therapy should be considered.

Duodenal GIST

GIST in the duodenum, like other small bowel locations, most often present with bleeding or abdominal pain. Given the low likelihood of transmural spread and lymph node involvement, an adequate resection with negative margins can often be obtained for duodenal GIST with a limited resection thus minimizing potential surgical morbidity. If the lesion is small and away from the duodenal mesentery, a partial duodenal wall resection with primary closure or duodenojejunostomy can achieve adequate margins while minimizing potential morbidity (Fig. 94.2). In the

third or fourth portion of the duodenum, a segmental resection with end-to-side or end-to-end duodenojejunostomy may be technically easier and lay better. A more extensive operation for greater lymph node yield is not necessary in the absence of concerning radiographic or intraoperative findings. If a pancreaticoduodenectomy seems likely secondary to proximity to the ampulla of Vater or due to local invasion from the tumor, neoadjuvant treatment should be strongly considered. Even when tumors are quite large, they often remain encapsulated and displace rather than invade surrounding structure. However, in some cases, even after neoadjuvant therapy, a pancreaticoduodenectomy or pancreas-preserving duodenectomy will be necessary for adequate resection. Clinical judgment should be used in selecting appropriate patients for major resections based on the patient's ability to tolerate the operation and risk of local issues or metastases based on the tumor characteristics.

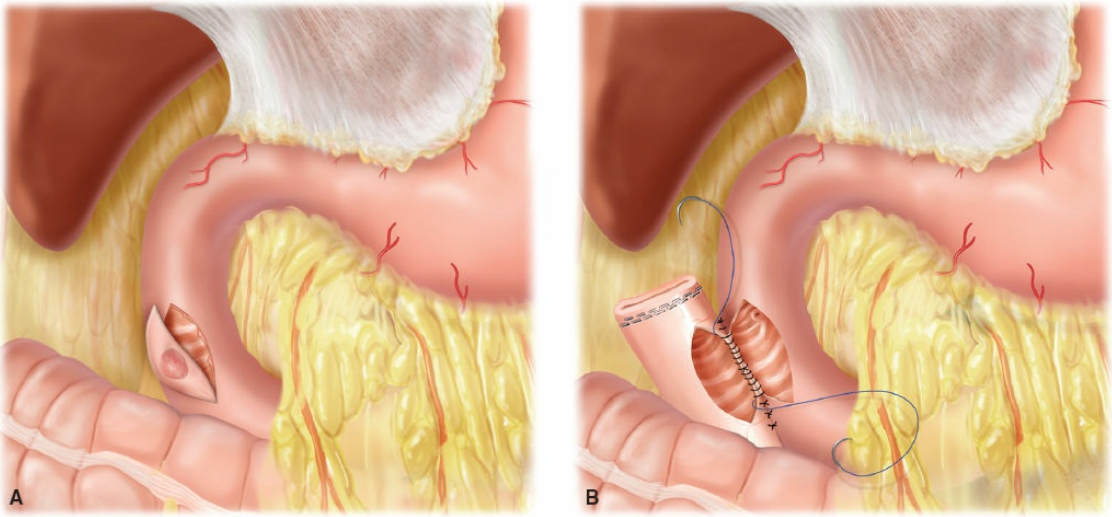

Figure 94.2. Resection of a duodenal GIST with duodenojejunostomy. Gastrointestinal stromal tumors in the second portion of the duodenum that are away from the mesentery and hepatopancreatic ampulla can be often be removed with negative margins by a partial duodenal resection (**A**). The resultant defect can be challenging to close primarily without narrowing the duodenum or leaving significant tension on the closure. A duodenojejunostomy can be used as a repair with favorable results (**B**).

Jejunal and Ileal GIST

In general, small bowel GISTs have a worse prognosis than gastric GIST when matched for size and mitotic rate. GIST of the jejunum and ileum are

typically treated with a segmental bowel resection with primary anastomosis. Many of these lesions may not be easily accessible endoscopically, so a preoperative histologic diagnosis may not be possible. However, if the diagnosis is known, an extensive lymphadenectomy is unnecessary as the rate of lymph node involvement is low. As with other locations, more advanced lesions that will potentially require multivisceral resection should be considered for neoadjuvant therapy first.

Rectal GIST

Rectal GISTs are uncommon and tend to be located in the distal half of the rectum. As in other locations, transmural spread and lymph node involvement are rare and so the optimal procedure for achieving a margin negative resection can be tailored based on the size and location of the tumor as well as the local expertise of the operating team. Transanal excisions are often possible for smaller tumors within 5 cm of the anal verge. Larger and more proximal tumors are likely to require an anterior resection. For larger lesions and those in close proximity to the anal sphincter, neoadjuvant therapy may ease resection and allow sphincter preservation.

Esophageal GIST

Esophageal GISTs commonly present with dysphagia, chest pain, and reflux symptoms. It can be difficult to distinguish esophageal GIST from more common esophageal leiomyoma without an FNA. The extent of resection of esophageal GIST is controversial given the relative infrequency and small reported case series. There have been reports of favorable oncologic outcomes with open or thoracoscopic enucleation of small esophageal GIST, although the series have been small and follow-up limited. If the preoperative diagnosis is secure, a negative margin resection with partial esophageal wall resection and primary closure or esophagectomy should be performed depending on the size and location of the tumor. If the diagnosis is made histologically after an enucleation is performed, the need for reoperation to achieve negative margins is not clear and should be decided based on weighing the risk of recurrence against the risk of further procedures.

POSTOPERATIVE CARE

The immediate postoperative surgical care depends on the type and extent of surgery performed. In patients who undergo a laparoscopic or open wedge resection for gastric GIST, a nasogastric tube may not be necessary as long as there is not concern for edema impeding outflow. The diet can be advanced postoperatively as tolerated and most patients can be discharged on postoperative day 2 or 3. More extensive gastric resections may require more time to achieve adequate oral intake. Similarly, patients who undergo a segmental small bowel resections for small intestinal GIST can generally have their diet advanced as tolerated while watching for signs of an ileus and be discharged after bowel function as returned. The care for patients undergoing resection of rectal GIST should be the same as for similar procedures done for more common rectal polyps or adenocarcinoma.

Adjuvant imatinib should be given to all patients who received and responded to neoadjuvant imatinib for 36 months of therapy total. This can be restarted postoperative as soon as the patient is tolerating a regular diet well.

Patients with a significant risk of recurrence based on tumor size, location, mitotic rate, and rupture/completeness of resection after resection should receive adjuvant imatinib for 36 months. In randomized trials, 36 months of therapy have improved relapsed-free and overall survival compared to 12 months of therapy GIST tumors with a high risk of recurrence (defined as tumor >10 cm, >10 mitoses per 50 high power fields [HPFs], >5 cm and >5 mitoses per HPF, or tumor rupture). The minimum risk of recurrence necessary to benefit from adjuvant imatinib therapy has not been well established and the decision to treat should be based on the individual risk of recurrence and the risk of treatment. A risk calculator based on three retrospective patient cohorts is available online to help determine the individual risk of recurrence after surgery and help inform the decision for adjuvant therapy (https://www.mskcc.org/nomograms/gastrointestinal/stromal-tumor). An additional nomogram from the Armed Forces Institute of Pathology experience can also be used (Table 94.1).

While the value of 36 months of therapy is well established, the value of treatment beyond this point is not clear and currently being evaluated (36 months vs. 60 months) in a randomized phase III trial (NCT02413736).

Patients at significant risk of recurrence should be evaluated with a

history and physical examination and cross-sectional imaging every 3 to 6 months for the first 5 years to evaluate for recurrence. Care should be taken to continue close surveillance after patient completes adjuvant imatinib therapy as a significant portion of patients have recurred within the first 2 years of finishing imatinib in randomized trials.

OUTCOMES

The disease-free and overall survival is highly dependent on the size, mitotic rate, location of the tumor, completeness of resection, underlying patient factors, and presence of tumor rupture. In small (<2 cm) gastric GIST after a complete resection, the risk of recurrence and distant metastases is remote. In contrast, large tumors with high mitotic indices can behave quite aggressively. In high-risk tumors, a significant portion will recur although this rate is improved by adjuvant imatinib. As previously discussed, recurrent or metastatic disease should be treated on an individualized bases with local and systemic therapy options considered based on the disease distribution and behavior.

Suggested Readings

Bednarski BK, Pisters PWT, Hunt KK. The role of surgery in the multidisciplinary management of patients with localized gastrointestinal stromal tumors. *Expert Rev Anticancer Ther* 2012;12(8):1069–78.

DeMatteo RP, Ballman KV, Antonescu CR, et al. Adjuvant imatinib mesylate after resection of localised, primary gastrointestinal stromal tumour: a randomised, double-blind, placebo-controlled trial. *The Lancet* 2009;373(9669):1097–104.

Eisenberg BL, Trent JC. Adjuvant and neoadjuvant imatinib therapy: current role in the management of gastrointestinal stromal tumors. *Int J Cancer* 2011;129(11):2533–42.

Fong Y, Coit DG, Woodruff JM, et al. Lymph node metastasis from soft tissue sarcoma in adults. Analysis of data from a prospective database of 1772 sarcoma patients. *Ann Surg* 1993;217(1):72–7.

Gold JS, Gonen M, Gutiérrez A, et al. Development and validation of a prognostic nomogramfor recurrence-free survival after complete surgical resectionof localised primary gastrointestinal stromal tumour: a retrospective analysis. *Lancet Oncol* 2009;10(11):1045–52.

Heinrich MC, Owzar K, Corless CL, et al. Correlation of kinase genotype and clinical outcome in the North American Intergroup Phase III Trial of imatinib mesylate for treatment of advanced gastrointestinal stromal tumor: CALGB

150105 Study by Cancer and Leukemia Group B and Southwest Oncology Group. *J Clin Oncol* 2008;26(33):5360–7.

Joensuu H, Eriksson M, Sundby Hall K, et al. One vs three years of adjuvant imatinib for operable gastrointestinal stromal tumor: a randomized trial. *JAMA* 2012;307(12):1265–72.

Joensuu H, Hohenberger P, Corless CL. Gastrointestinal stromal tumour. *Lancet* 2013;382(9896):973–83.

McCarter MD, Antonescu CR, Ballman KV, et al. Microscopically positive margins for primary gastrointestinal stromal tumors: analysis of risk factors and tumor recurrence. *J Am Coll Surg* 2012;215(1):53–9; discussion: 59–60.

Miettinen M, Lasota J. Gastrointestinal stromal tumors: pathology and prognosis at different sites. *Semin Diagn Pathol* 2006;23(2):70–83.

Miettinen M, Lasota J. Gastrointestinal stromal tumors. *Gastroenterol Clin North Am* 2013;42(2):399–415.

Miettinen M, Monihan JM, Sarlomo-Rikala M, et al. Gastrointestinal stromal tumors/smooth muscle tumors (GISTs) primary in the omentum and mesentery: clinicopathologic and immunohistochemical study of 26 cases. *Am J Surg Pathol* 1999;23(9):1109–18.

Rubin JL, Sanon M, Taylor DC, et al. Epidemiology, survival, and costs of localized gastrointestinal stromal tumors. *Int J Gen Med* 2011;4:121–30.

EDITOR'S COMMENT

The authors present an excellent overview of gastrointestinal stromal tumors. As pointed, GISTs are relatively rare accounting for about 1% of primary gastrointestinal cancers with an annual incidence of 3 to 20 cases per million populations per year. The stomach is the most common site accounting for 50% to 60% of tumors, followed by the small intestine (20% to 25%), colon and rectum (5%) and the esophagus 1%. They arise from the interstitial cells of Cajal (ICC). ICC are an integral part of the GI neuromuscular apparatus, transduce inputs from enteric motor neurons, generate intrinsic electrical rhythmicity in phasic smooth muscles, and have a mechanical sensation ability. Ultrastructural studies suggest that ICC are either primitive muscle cells or fibroblast-like cells that are electrically rhythmic. ICC were previously characterized by morphologic criteria until the discovery that ICC express the receptor tyrosine kinase, Kit (CD117) and that the majority of the Kit-positive cells in the GI tract are indeed ICCs. Not all ICC do express c-Kit, such as those in the deep muscular plexus in the human small intestine. ICC are located throughout the gastrointestinal tract and are located predominantly between the circular and longitudinal muscle. ICC serve several important functions in the

GI tract including: electrical slow wave generation, coordination of pacemaker activity and active propagation of slow waves, transduction of motor neural inputs from the enteric nervous system, and sensation to stretch of GI muscles. ICC are more densely located in the corpus and antrum than in the fundus of the stomach. This is interesting in that in my experience the majority of GISTs occur in the fundus. ICC are involved with GI motility disorders including achalasia, gastroesophageal reflux disease, gastroparesis, infantile hypertrophic pyloric stenosis, diabetic gastroenteropathy, chronic intestinal pseudo-obstruction, and Hirschsprung disease. In these instances there are sparse of absent ICC cells.

Most GISTs are found when they are less than 4 cm in diameter. As the authors note, bleeding is a frequent early manifestation. Other symptoms are vague and nonspecific abdominal pain or discomfort (most common); early satiety or a sensation of abdominal fullness; palpable abdominal mass (rare); malaise, fatigue, or exertional dyspnea with significant blood loss, and rarely peritonitis if there is perforation or tumor rupture. Obstructive symptoms may also occur. Diagnosis is made by cross-sectional imaging in many cases. CT is important in determining the location size of the lesion as well as staging. On CT GISTs display a homogeneous density if less than 5 cm or a heterogeneous density if greater than 5 cm. CT criteria associated with high-grade histology and increased mortality include a tumor larger than 11.1 cm, irregular surface contours, indistinct margins, adjacent organ invasion, heterogeneous enhancement, and hepatic or peritoneal metastasis. MRI is less well studied for diagnosis of GIST than CT. Of note is that GISTs may appear hypointense on T2–weighted images. EUS is also helpful in obtaining tissue and further characterization of the tumors. This is an important technique if observation of a small GIST is chosen over excision.

As the authors point out, GISTs arising from the stomach may be excised by a wedge excision. The debate about the importance of negative margins was discussed. As indicated the goal should be negative margins and I concur. Larger tumors with unfavorable imaging characteristics may require formal gastric resection. A laparoscopic approach is reasonable in many cases. I concur with the use of a bag to remove the tumor so as to prevent seeding of the peritoneal cavity. Small GISTs may be difficult to find at laparoscopy and we have found that tattooing is helpful. A newer approach is submucosal endoscopic tumor resection (SET). This is based on techniques used in POEM. The pilot series report by Inoue et al. (Submucosal endoscopic tumor resection for subepithelial tumors in the esophagus and cardia. *Endoscopy* 2012;44:225–30) described outcomes in nine patients. Conversion to an operative procedure was necessary in two patients with larger tumors (greatest diameter 7.5 cm and 6 cm), but in seven, the procedure was successful (greatest diameters 1.2 to 3 cm). Additional confirmatory reports and longer follow-up are needed for validation of the safety and efficacy of this technique.

Esophageal lesions are amendable to enucleation; however, esophageal

resection is required for larger tumors. Duodenal GISTs are rare and may be amendable to local excision if small, but may require pancreas preserving duodenal resection or pancreaticoduodenectomy. For GISTs in the small intestine segmental resection is warranted as with colonic GISTs. Rectal GISTs are amendable to local excision depending on size.

The use of imatinib for large or metastatic GIST is a major advance. The cost is not insignificant. A generic imatinib is available in Canada for $8,800/year and Gleevec is available for $38,000/year. In the United States, Gleevec is priced at about $146,000/year and the "generic price" in the United States was in fact not much lower than the branded drug price. (Hagop Kantarjian; The Arrival of Generic Imatinib Into the U.S. Market: An Educational Event, http://www.ascopost.com/issues/may-25-2016/the-arrival-of-generic-imatinib-into-the-us-market-an-educational-event/. Published May 25, 2016.)

In summary, GISTs are rare tumors that arise form ICC and may be approached by a variety of surgical techniques and are sensitive to imatinib.

E. Christopher Ellison

95 The Laparoscopic Gastric Band Technique of Placement

Paul E. O'Brien

INTRODUCTION

Laparoscopic adjustable gastric banding (LAGB) was introduced in 1992 by Favretti and Cadiere as a major innovation in bariatric surgery by adding the laparoscopic approach to the key features of adjustability and ready reversibility of the Kusmak band. The Lap Band has been the most used version of the LAGB. It was developed by the Inamed Corporation (Carpenteria, California) in the early 1990s and was introduced into surgical practice by Mitiku Belachew in Belgium in September, 1993. The device is currently owned by Apollo Endosurgery (Austin, Texas). As the Lap Band is the only LAGB device I have used, all comments provided herewith relate to my experience with this device.

The LAGB rapidly rose to the dominant procedure worldwide in bariatric surgery during the 1990s and, after approval for the use in the United States in 2001, across the USA also. However, many surgeons have become disenchanted with the band because of its particular need for careful follow-up, a perceived lesser weight loss than the gastric stapling procedures, a greater demand for revisional surgery and a concomitant rise in enthusiasm for the sleeve gastrectomy. It now contributes around 15% of bariatric procedures worldwide.

In our clinic in Melbourne, we appear to be out of step with the rest of the world as the LAGB still constitute 85% of our bariatric procedures. We continue to achieve good weight loss outcomes and happy patients. It is a day procedure that is very safe. It remains our preferred bariatric option on the basis of proven benefits and low risk.

There are three factors driving this. First, from our research studies of the mechanisms of effect of the LAGB, we have established a clear set of rules regarding eating after the band and we can provide the LAGB patient with a strong understanding of why the rules are what they are. This enables an effective partnership between our clinic staff and our patients.

And they both get to appreciate the power and the beauty of adjustability. Second, we are able to provide comprehensive and profitable aftercare with sufficient well-trained staff and an excellent data management system. Third, through the extensive clinical experience and deep awareness of the mechanisms of action, we are able to manage more easily those clinical situations that others find challenging and cause them to seek alternative pathways.

The LAGB is characterized by its safety and effectiveness in achieving major and durable weight loss. It reverses the comorbidities of obesity and improves quality of life. Further, it provides a gentle approach to the control of obesity because its placement is truly minimally invasive, its primary mode of action is by inducing satiety, and the degree of effect is controlled postoperatively through its adjustability. It offers the additional attraction of complete reversibility.

There are three essential components to effective use of the LAGB. First, it must be placed correctly. This requires correct operative technique, which will be reviewed in detail in this chapter. Second and equally important to the technical detail of the operation, there must be a permanent process of aftercare, which is based on an understanding of how the band works and includes knowing how to make decisions regarding adjustments of the tightness of the band in association with patient advice and support. It is essential that this be learned and followed if optimal results from the procedure are to be obtained. Finally, there must be and understanding of the symptoms and adverse events that may occur after the band so that simple correction can be applied rather than confusion and then reversal through lack of this understanding.

PERIOPERATIVE MANAGEMENT

The technique of Lap Band placement has evolved significantly over the past 20 years since its introduction. Some elements of the procedure are still subject to variation between surgeons who are achieving apparently equal outcomes, but the key positioning of the band is now essentially identical across all groups. The technique described is the product of 20 years of experience and placement of more than 4,000 Lap Bands. Throughout this time I have sought to identify a technique that is safe, quick, minimally traumatic, less expensive, and able to cope with the challenges of superobesity. The details provided are just one variation on the theme, and alternative approaches appear to be equally effective and

efficient. This description, however, does provide a solid starting point for new Lap Band surgeons, who can then evolve techniques of their own as they build up their experience.

PREOPERATIVE ASSESSMENT

Initial clinical assessment includes full routine history and examination and specific documentation of the problems generated by the obesity, including all the comorbidities and the physical and social limitations present. Laboratory studies include all routine hematology and biochemistry plus specific screening for diabetes and insulin resistance, micronutrient deficiencies including iron studies, vitamin B_{12}, folic acid, and lipid profile. Special investigations such as upper gastrointestinal endoscopy, barium swallow and meal, ultrasound of gallbladder, esophageal manometry and 24-hour pH study, 24-hour blood pressure monitoring, and polysomnography are performed only when a specific indication exists. We do not require routine preoperative psychological and nutritional assessments.

Perioperative Care

All patients are given antimicrobial prophylaxis, administered at the commencement of the procedure. We use a β-lactamase–resistant penicillin (flucloxacillin, 1 g IV stat) to cover skin contaminants and a broad spectrum to cover the enteric flora such as a third-generation cephalosporin (cefotaxime, 1 g IV stat). Prophylaxis against deep venous thrombosis consists of subcutaneous heparin until discharge (sodium heparin, 500 units b.i.d. subcutaneously commencing immediately after completion of the procedure). Pain relief is principally by Fentanyl during anesthesia and Endone 5 mg repeated every 12 hours if needed. Oral soluble paracetamol (acetaminophen) is then used. Opiates are avoided. Ondansetron (× 4 mg IM) is available for nausea but rarely used.

Operative Position and Port Placement

The patient is placed in a reverse Trendelenburg position of a 25-degree slope, legs apart. The surgeon stands between the legs and one assistant stands on the patient's left side. We use five ports: three are 5 mm in diameter and one is 15 mm in diameter (their positions are shown in Fig. 95.1). We use a 10-mm end-viewing telescope for insertion of the initial

optical port and a 10-mm, 30-degree telescope for the rest of the procedure. The video system must be a high-definition system of optimal quality.

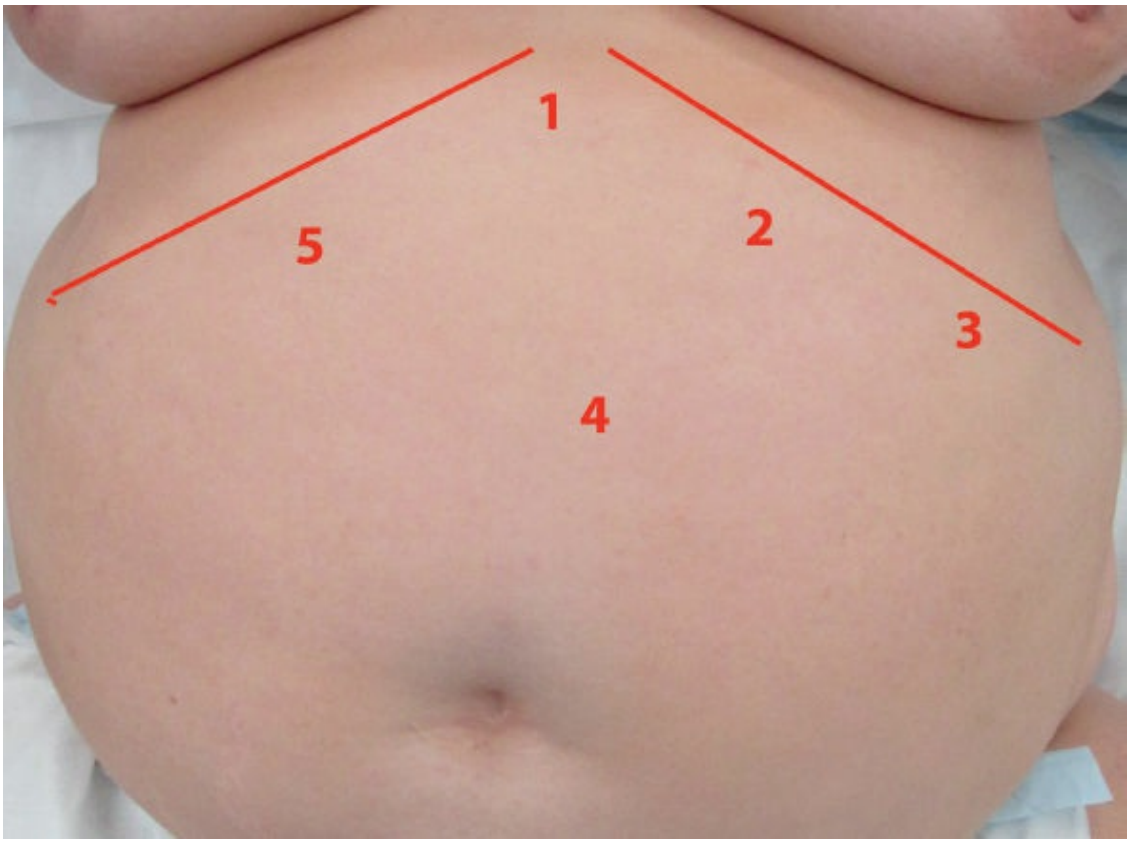

Figure 95.1. Port positions. There is an initial 10-mm optical port, then 3 × 5 mm ports and 1 × 15 mm ports are placed under direct vision. The port at position 1 is removed and a Nathanson liver retractor (5 mm) is placed.

The initial port is a 10-mm optical port (FIOS, Applied Medical, Rancho Santa Margarita, CA) placed at position 2 (Fig. 95.1). The 15 mm port (position 4) and the three 5 mm ports (Applied Medical) are then inserted under vision. The 15 mm port is the path for the hook diathermy and the introduction of the band and of sutures. It becomes the site of the access port at completion. AT port site 1 the port is removed and the Nathanson liver retractor is placed in the midline just below the xiphisternum. The two 5-mm ports at positions 3 and 5 are 15 cm long (Applied Medical). This extra length enables them to be passed through the abdominal wall on an angle such that they are heading toward the upper stomach. As all elements of the procedure occur in a small area, there is minimal lateral pressure on these ports.

SURGICAL TECHNIQUE

Dissection at the Angle of His

The liver is retracted by a Nathanson liver retractor (Automated Medical Products, New Jersey, USA), which is held by an external clamp (Iron Intern, Automated Medical Products). The omentum covering the fundus of the stomach is drawn inferiorly using the graspers at positions 3 and 5. The grasper at position 3 draws the fundus of the stomach downward. The grasper at position 5 then retracts the fat pad over the distal esophagus to the right to open up the area of the angle of His. Using a hook diathermy through the 15-mm port (position 4), the peritoneum over the left crus is divided over approximately a 2-cm length (Fig. 95.2). It is not necessary to fully expose the fibers of the left crus but essential to be at this anatomic site. That completes the dissection at this point and attention moves to the lesser curve.

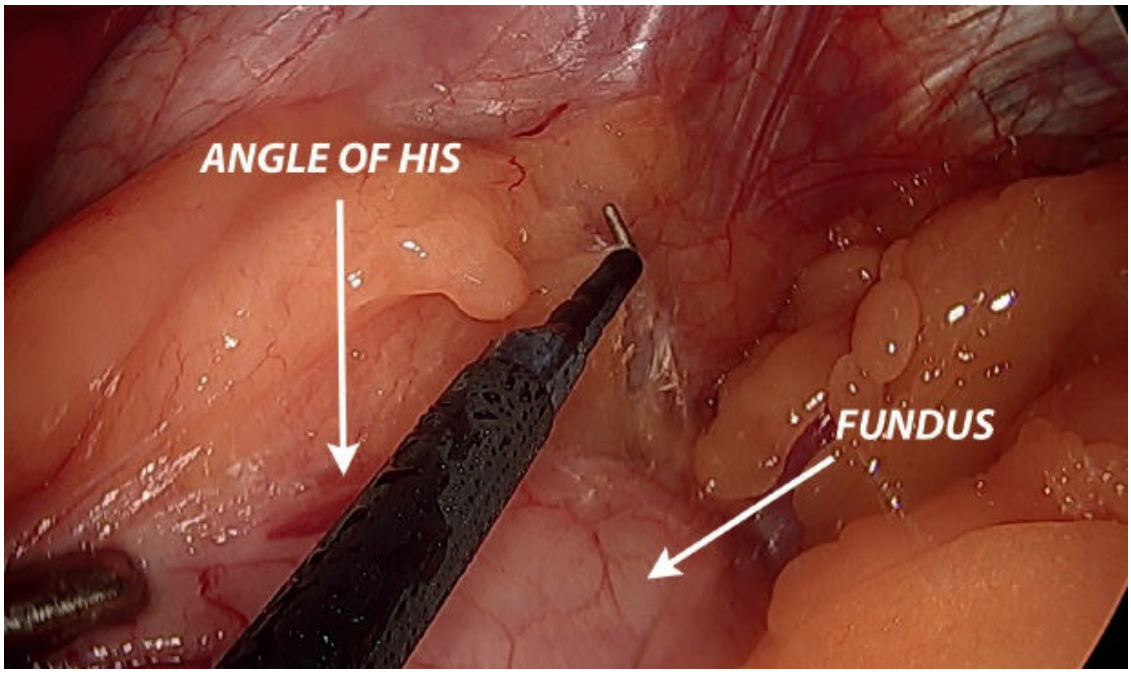

Figure 95.2. Initial dissection at the angle of His. Note that this occurs at the interface with the diaphragm and involves the peritoneum alone.

Dissection of the Anterior Fat Pad

It is essential that the band be placed over the gastric cardia, immediately below the esophagogastric junction. If you are unsure, the position of the esophagogastric junction can checked with the calibration tube that comes

with the Lap Band. This tube is passed by the anesthetist earlier in the procedure to a length of 45 cm. At this stage, 25 mL of air is introduced into the balloon. The tube is withdrawn until the balloon impacts at the esophagogastric junction. In its final position the band should overlie the highest point or equator of the balloon, not positioned below the balloon.

If this line for the band is covered by a significant anterior fat pad, this pad will need to be dissected upward or excised. Our preference is to dissect it upward until we can see gastric wall above where the band is expected to sit (Fig. 95.3). This dissection is necessary in about 90% of patients and is done with the hook diathermy. The band must not be placed on top of a fat pad or the satiety-inducing effect of the band will be reduced.

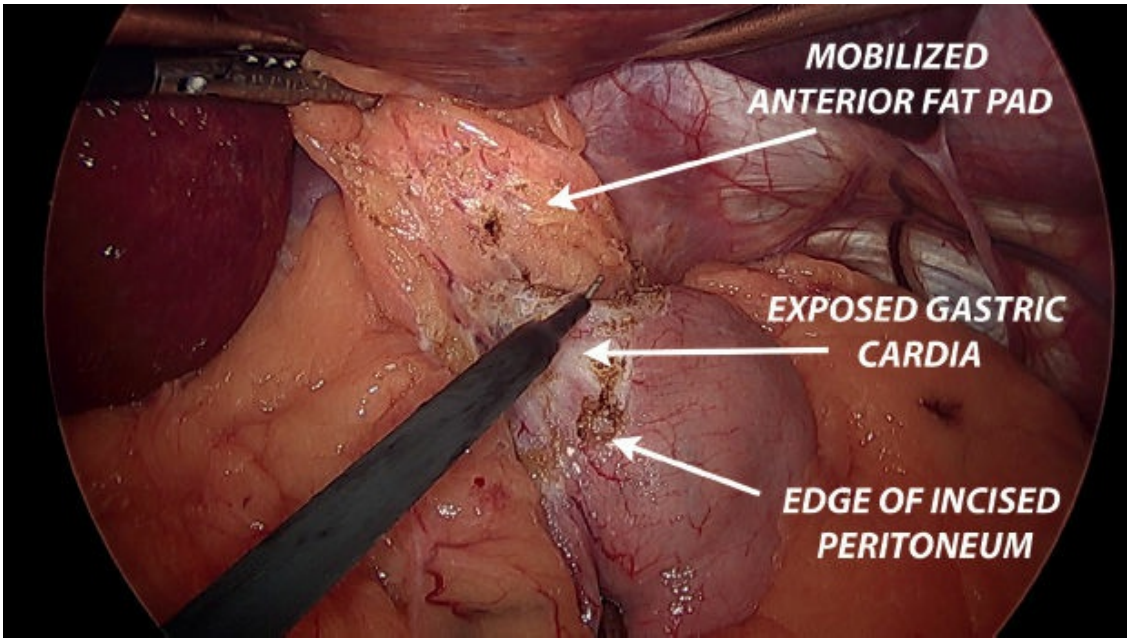

Figure 95.3. The anterior fat has been reflected upwards to ensure the band is closely applied to the surface of the cardia, thus ensuring optimal satiety effect.

Dissection on the Lesser Curve

The grasper at position 3 takes hold of the fat adjacent to the lesser curve of the stomach and draws it to the left. The pars flaccida of the lesser omentum is divided to expose the posterior wall of the lesser sac. The grasper at position 3 then draws the fat on the posterior wall of the lesser sac to the left and the grasper at position 5 retracts the caudate lobe of the liver to expose the lower aspect of the right crus. The peritoneum of the posterior wall is opened over a 5-mm length using the hook diathermy.

The point of this opening is critical. It should be 5 mm in front of the anterior margin of the right crus at its most inferior point (Fig. 95.4).

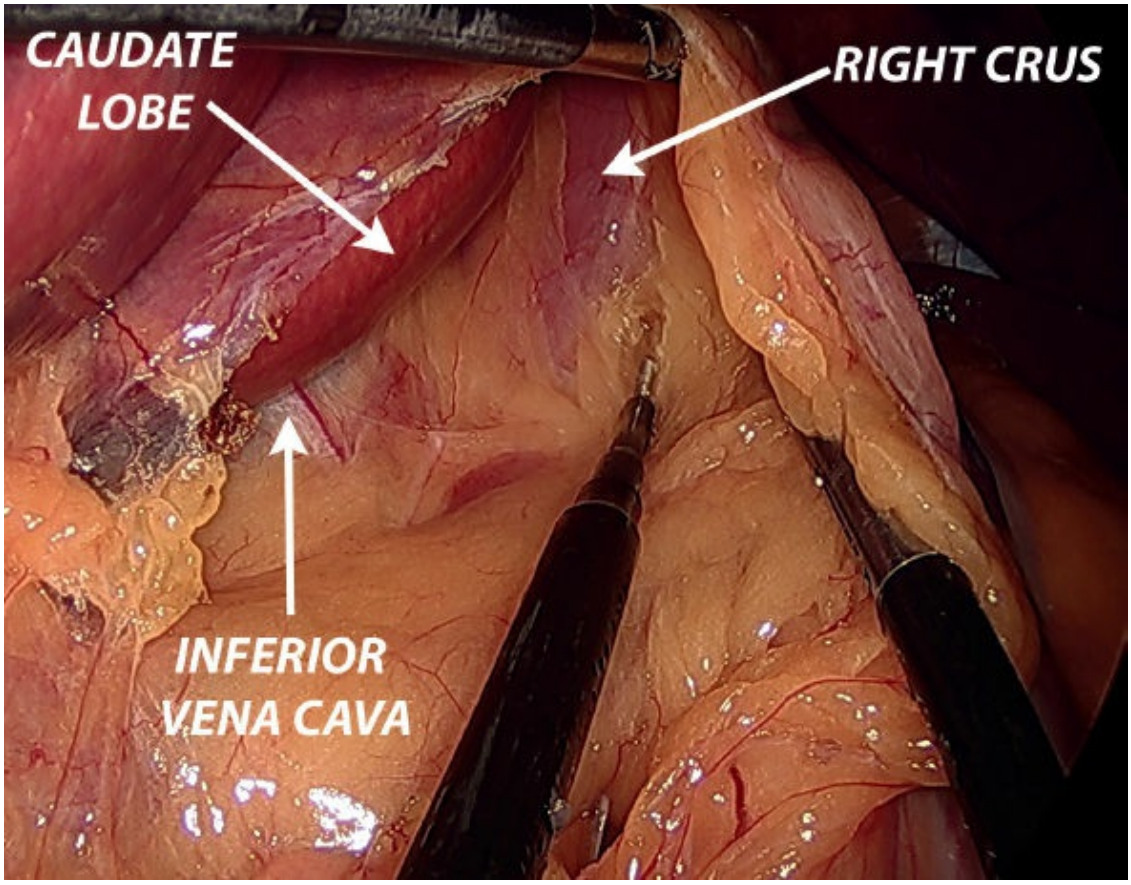

Figure 95.4. The point of dissection is 5 mm in front of the anterior border of the right crus at its lowermost aspect. Note that the caudate lobe of the liver is retracted upward and the inferior vena cava is visible to the left.

Passing the Lap Band Placer

The grasper at position 5 is withdrawn and the Lap Band placer is passed. The Lap Band placer (Automated Medical Products) is 5 mm in diameter and has a flexible and curved distal segment ending with a blunt tip containing a notch to hold the tubing of the Lap Band. The rounded tip of the Lap Band placer is placed into the opening created by the grasper and passed as a spiral pathway rotating the tip anticlockwise across the back of the esophagus to the site of dissection at the left crus (Fig. 95.5). The grasper at position 3 moves back to the angle of His and exposes this area again. Under clear vision, the tip of the Lap Band placer is rotated and gently advanced until it completes passage by passing through the loose connective tissue behind the esophagus. At no time should any significant

force be used with the Lap Band placer. It should be fingertip controlled at all times.

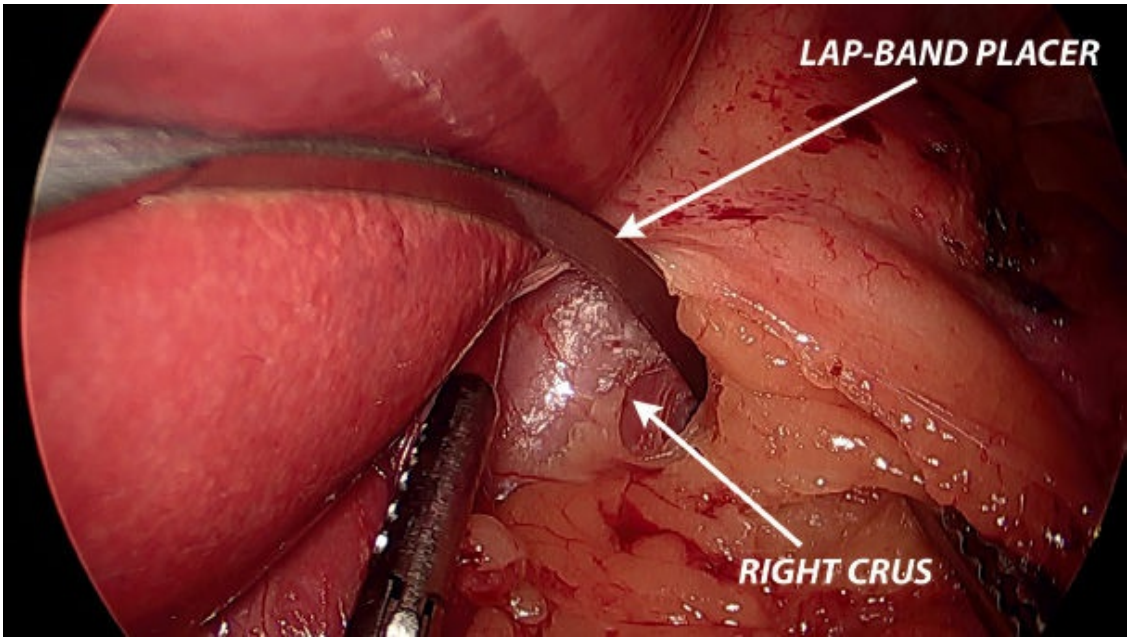

Figure 95.5. The rounded tip of the Lap Band placer commencing the traverse of the posterior aspect of the cardia at the dissected opening of the peritoneum of the lesser sac.

Selection of Lap Band Size

We use the Lap Band placer to determine which band to place. After passing it across the back of the stomach, we place the proximal edge of the flexible flat metal strip so that it is just visible at the edge of the lesser curve fat. We then look at the distal aspect of the placer at the angle of His. If 1 cm or more is visible without retraction of the fat, a Lap Band APS is appropriate (see Fig. 95.6). If <1 cm is visible, we use Lap-Band APL. In practice, I use the Lap Band APS in at least two thirds of patients. The factors that are associated with more frequent use of the APL are male patients, extensive fat padding around upper stomach, central obesity, massive superobesity, and the presence of insulin resistance. Whenever there is doubt, choose the APL.

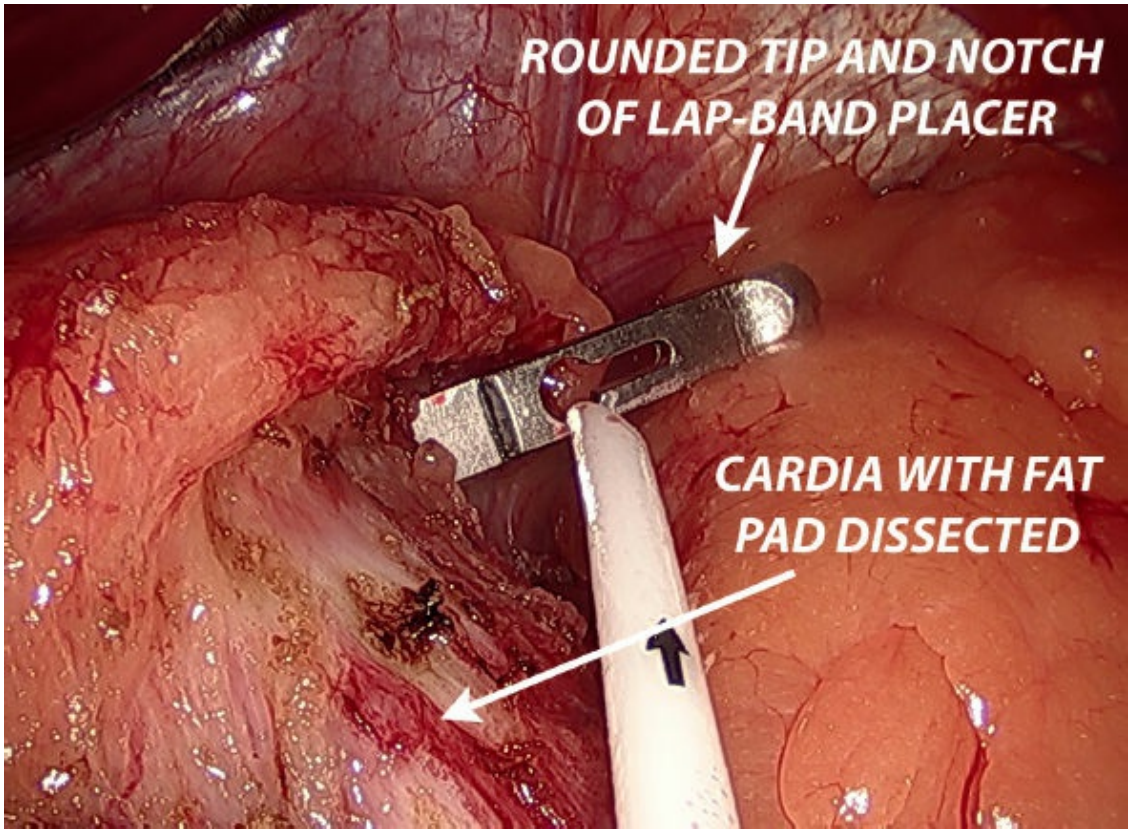

Figure 95.6. The curved Lap Band placer has been passed across, the size of the band to be used has been determined, and the band introduced into the abdomen. About 2 in of tubing is passed through the opening in the Lap Band placer.

Positioning, Calibrating, and Closing the Lap Band

The Lap Band is introduced though the 15-mm port under direct vision using the Lap Band introducer (Automated Medical Products). One or 2 in of the end of the tubing is passed through the slot in the Lap Band placer, which is then withdrawn along the path. The tubing is drawn through until the band is in position.

The band is then positioned and the tubing drawn through the buckle until it is almost closed. At this point, the surgeon checks that the band will not be too tight if closed. This is a subjective estimate. If there is suspicion, proceed with dividing the fat on the lesser curve, with hook diathermy or a Ligasure or harmonic scalpel may be preferred. When it appears that the band will not be too tight, it is closed with the Lap Band closer tool (Automated Medical Products). The buckle is then temporarily rotated to the patient's right to facilitate anterior fixation.

Anterior Fixation

Each suture (2/0 Ethibond cut to a 16-cm length on a 26-mm taper-pointed needle) is introduced through the 15-mm port (position 4). The needle holder is then used through port 3 and a fine grasper for the left hand is in port 5. A standard grasper is passed through port 4. The two graspers are used to draw the greater curve across to carefully select the site of the inferior bite of the first suture. It should be within 1 cm of the greater curve and distal enough to allow drawing of the gastric wall across the band without undue tension but without excessive slackness. The grasper at position 4 holds the gastric wall at this point while the suture is placed. The two graspers are then used above the band to select the site for the second bite. It must be into visible gastric wall, not into the fat pad, so that gastro-gastric approximation is seen (Fig. 95.7). Again the grasper is used to lock onto this site while the suture is placed. The suture is then tied and the grasper released. This process can be repeated for each further suture as needed to achieve clear visualization of the correct point of placement. Most commonly, three sutures are placed with the aim of covering almost all the visible bands up to the buckle but stopping about 1 cm from the buckle. The band is gently rotated to the left so that the buckle is facing anteriorly at the lesser curve but not pushed hard against the wrap of the anterior fixation.

A lesser curve suture is now placed to stabilize the anterior wall of the stomach below the buckle. This consists of three bites from the anterior wall of stomach below the band as shown in Figure 95.8. The tubing is then drawn out through the 15-mm port (position 4) for attachment to the access port at this site. All instruments are removed, insufflation is ceased, and the ports are removed.

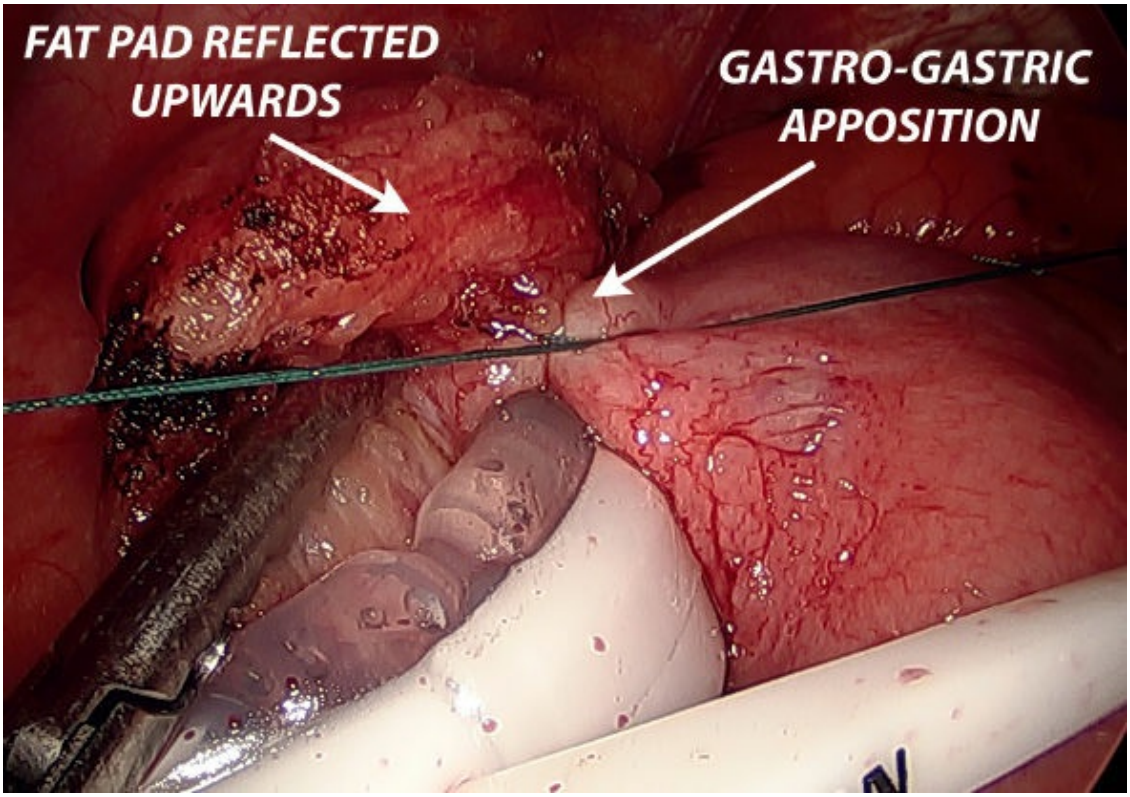

Figure 95.7. The anterior fixation sutures must be between gastric wall below and visible gastric wall above the band.

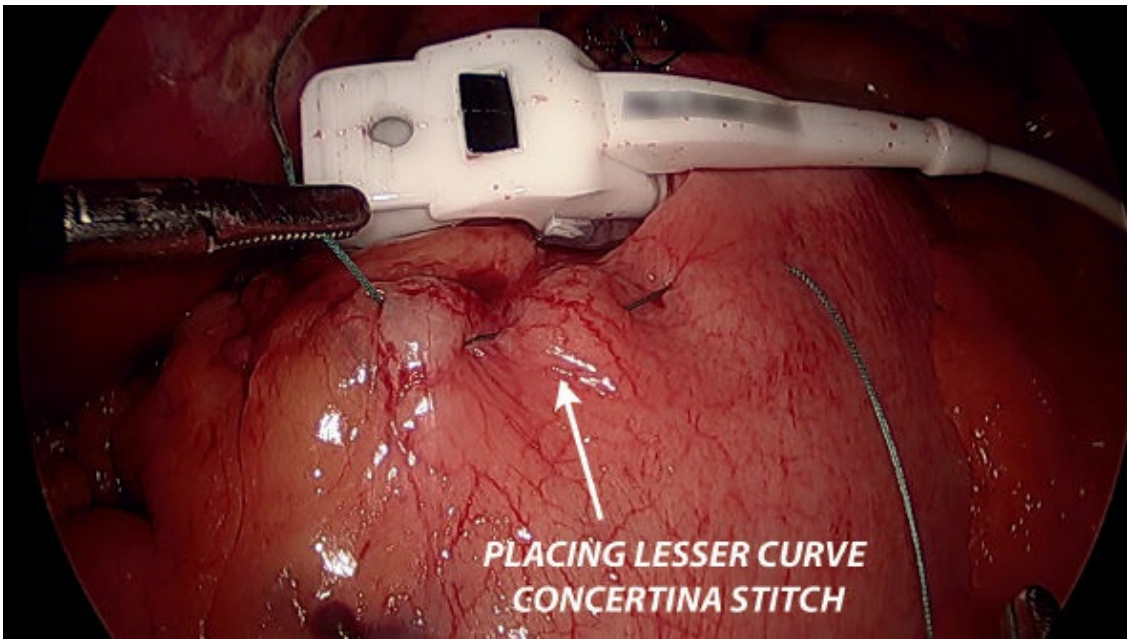

Figure 95.8. A lesser curve suture which concertinas the gastric wall below the buckle completes the anterior fixation.



Figure 95.9. A sheet of mesh is fixed to the deep aspect of the access port and then cut to form a circle.

Mesh Fixation of the Access Port

Three options for port fixation exist. The port can be fixed to the anterior rectus sheath with three sutures of 2/0 Prolene. I had used this approach until about 3 years ago. It can be stapled to the rectus sheath using the RapidPort device. I have rarely used this approach. Or it can be stabilized in the subcutaneous layer using mesh fixation. This is now our preferred approach as it can be done without extending the 15-mm port incision. It is less painful for the patient, faster and easier for the surgeon and much easier for the aftercare providers to access the port for adjustments. It can be done using the standard port or with the RapidPort EZ.

A circle of Prolene mesh is fixed to the base of the port with three sutures of 2/0 Prolene (Fig. 95.9). The right index finger is passed through the 15 mm port site, and pushed downwards for about 8 cm through the

subcutaneous fat at a depth of approximately 2 cm below the skin. Depending on the degree of obesity this path may lie superficial or deep to Scarpa fascia. For the standard port, be careful not to widen the path beyond one finger's width. For the RapidPort EZ, it needs to be widened to two fingers breadth. Connect the port to the tubing, check that it is not rotated and then slide the port and mesh along the track to its deepest point. Check the port remains facing correctly. Return the excess tubing to the abdominal cavity.

Alternative techniques are suture fixation and use of the RapidPort (Apollo). For both methods, the incision at position 4 is extended to 4 cm length and the soft tissues divided to clearly expose the anterior rectus sheath. For suture fixation, four sutures of 2/0 Prolene (Ethicon, Cincinnati, OH) are placed about 1 cm apart to create a square pattern. The access port is connected to the tubing and the sutures are threaded to the port. The tubing is now carefully reintroduced into the abdomen until the port is in position and there is a smooth path of the tubing directly into the abdomen with no kinking or looping. The sutures are tied securely. For the RapidPort, the port is attached to the tubing, the device placed firmly on the anterior rectus sheath and fired. The device holder is then removed and the port checked for fixation. The excess tubing is returned to the abdominal cavity.

Check for complete hemostasis, clean with Betadine and close each port site with 4/0 Caprosyn (Autosuture, Norwalk, CT) as a subcuticular suture.

Suggested Readings

Allen JW, Coleman MG, Fielding GA. Lessons learned from laparoscopic gastric banding for morbid obesity. *Am J Surg* 2001;182(1):10.

O'Brien P. *The Lap Band Solution—A Partnership for Weight Loss.* 2nd ed. Melbourne: Melbourne University Publishing; 2011.

O'Brien PE. Laparoscopic adjustable gastric banding. In: Bray GA, Bouchard C, eds. *Handbook of Obesity: Clinical Applications.* 3rd ed. Informa Healthcare; 2008. Chapter 33: 517–33.

O'Brien PE, McDonald L, Anderson M, et al. Long term outcomes after bariatric surgery: fifteen year follow up after gastric banding and a systemic review of the literature. *Ann Surg* 2013;257:87–94.

Ren CJ, Fielding GA. Laparoscopic adjustable gastric banding: surgical technique. *J Laparoendosc Adv Surg Tech A* 2003;13(4):257.

Watson M, Jones DB. *Lap-Band Companion Handbook.* Woodbury, CT: Cine-

Med; 2007.

EDITOR'S COMMENT

This is a great chapter on the technique of placement of the Lap Band by one of the world's experts on the topic. Dr. O'Brien has performed literally thousands of procedures over nearly two decades in Melbourne, Australia. He is a tireless champion of the device and procedure, having published numerous articles on the topic in prestigious journals. As he correctly points out, his experience is a bit out of step with the rest of the world, especially in the United States.

Obesity is a devastating problem worldwide. According to the World Health Organization, the prevalence of obesity has more than doubled across the globe since 1980. In 2014, more than 1.9 billion adults (39%) were overweight and 600 million (13%) obese. The numbers in the United States are even direr. Obesity causes serious and life-threatening diseases such as diabetes, coronary artery disease, and obstructive sleep apnea. The average life expectancy is less and the average annual health care expenditure is significantly greater in the obese than in the nonobese (Atella V, Kopinska J, Medea G, et al. Excess body weight increases the burden of age-associated chronic diseases and their associated health care expenditures. *Aging (Albany NY)* 2015;7(10):882–92). According to a Cochrane Database Systematic Review published in 2014, bariatric surgery results in greater improvement in weight loss outcomes and weight associated comorbidities compared with nonsurgical interventions, regardless of the type of procedures used (Colquitt JL, Pickett K, Loveman E, et al. Surgery for weight loss in adults. *Cochrane Database Syst Rev* 2014; (8):CD003641). When compared with each other, certain procedures resulted in greater weight loss and improvements in comorbidities than others. Outcomes were similar between Roux-en Y gastric bypass and sleeve gastrectomy, and both of these procedures had better outcomes than adjustable gastric banding. No doubt, short-term complications following laparoscopic adjustable gastric band placement have been demonstrated to be less than following most other bariatric surgical procedures. Long-term rates of reoperation and failure have been demonstrated to be quite high for the adjustable gastric band in the United States (Spivak H, Abdelmelek MF, Beltran OR, et al. Long-term outcomes of laparoscopic adjustable gastric banding and laparoscopic Roux-en-y gastric bypass in the United States. *Surg Endosc* 2012;26:1909–91). According to the American Society for Metabolic and Bariatric Surgery (ASMBS) Patient Information website, the laparoscopic adjustable gastric band is associated with less weight loss, higher failure rates, and more reoperations than other bariatric procedures. This is supported by several published reviews on the topic. According to research conducted by an ASMBS task force, between 2011 and 2014 the adjustable gastric band accounted for 35% of all primary bariatric procedures and the sleeve gastrectomy for 18%. In just 3 years (by 2014), it was

estimated that only 9.5% of all primary bariatric procedures performed were adjustable gastric bands with 52% now sleeve gastrectomy (Ponce J, Nguyen NT, Hutter M, et al. American Society for Metabolic and Bariatric Surgery estimation of bariatric surgery procedures in the United States, 2011–2014. *Surg Obes Relat Dis* 2015;11(6):1199–200). This is in spite of the fact that in 2011, the U.S. Food and Drug Administration (FDA) expanded the indications for the Lap Band to include patients with a body mass index (BMI) as low as 30 kg/m^2. This expanded indication theoretically added over 50 million patients to the potential pool of Lap Band candidates.

Dr. Obrien postulates that there are three primary factors driving the differing experience with adjustable gastric band devices in the Unites States as a whole versus his experience. They can be summarized as a deep understanding of the mechanism of effect and a committed partnership between his clinic and his patients, a comprehensive aftercare program, and an understanding as to how to manage challenging clinical situations that would cause other surgeons to recommend a different bariatric procedure or convert a band to a different procedures such as a sleeve or a gastric bypass. This equals a significant commitment to the adjustable gastric band procedure and to the patients who have one of these devices surgically placed.

My own personal experience with the adjustable gastric band is similar to my American bariatric surgery colleagues on whole. I have largely stopped placing gastric bands. I will allow an occasional patient to talk me into placing a band, but never in a patient with a BMI over 50 kg/m^2. I am a committed bariatric surgeon with a comprehensive program at a major academic medical center. We have been continuously accredited by the ASMBS and now the American College of Surgeons as well for the past 10 years. The band is definitely labor intensive when compared to some of the other bariatric surgical procedures I perform. Sometimes I get frustrated with the effort or compliance of my patients who receive a band and just cannot seem to lose weight. Many of these patients go on to become successful bariatric surgery patients with a gastric bypass or a sleeve gastrectomy. Maybe I could be more committed to the procedure. Maybe my patients are different. Long-term care of bariatric surgery patients in my part of the country (upper Midwest) can be complicated by travel difficulties for part of the year (winter roads) and to insurance obstacles year round. Many bariatric surgery patients switch insurance companies periodically, and the new insurer often declines to provide benefits for ongoing care including gastric band adjustments. It must take an incredible commitment and belief that the band will work in almost anyone to demonstrate the kind of results Dr. O'Brien has described.

Although Dr. O'Brien only describes the placement of one brand of FDA-approved laparoscopic adjustable gastric band, there are few major differences in the Realize adjustable gastric band placement technique and the major tenets remain the same. I am intrigued by his routine placement of a lesser curve suture to stabilize the anterior wall of the stomach below the buckle of the band.

This seems like a harmless addition to the classic description of this procedure, but I wonder if there is evidence to support the necessity of this additional step. The pars flaccida technique is described which has been demonstrated to result in fewer instances of slip or prolapse than the perigastric technique (not described).

The technical, step-by-step description provided in this chapter is concise and fairly easy to replicate for an experienced surgeon. The 60 minutes spent in the operating room placing an adjustable gastric banding device are important, but fairly insignificant compared to all the time leading up to and following that hour of operative time when it comes to defining the outcomes and success (or lack thereof) of the adjustable gastric band.

Jon C. Gould

96 Revision and Conversion of Vertical Banded Gastroplasty

Eric J. DeMaria and Daniel B. Jones

ETIOLOGY AND PATHOPHYSIOLOGY

With the growing popularity of gastric bypass and sleeve gastrectomy, the vertical banded gastroplasty (VBG) has fallen into disfavor and is a rarely performed procedure today in the United States. One of the values of VBG was its ability to induce weight loss without affecting the normal sequence of digestive events or inducing malabsorption. VBG however, like adjustable gastric banding which is similar in many regards, is more dependent on the patient's ability to maintain lifelong behavioral compliance with healthy solid food eating habits. These changes include avoiding high calorie liquids and such calorie-rich foods as cake, cookies, and other junk foods that undergo substantial liquefaction in the mouth and thus arrive in the VBG pouch as a liquid slurry that is not substantially restricted by the outlet. This dependence on patient behavior is the likely source of the higher weight failure rate seen after VBG than after procedures incorporating a degree of malabsorption and which result in dumping in response to sweets eating, such as Roux-en-Y gastric bypass. Revision of VBG in patients who exhibit these maladaptive eating behaviors is not likely to be as effective in promoting long-term weight loss unless the patient can adapt and pursue more healthy eating behaviors (see Preoperative Planning), thus ongoing nutrition counseling is an important component of management.

CLINICAL PRESENTATION

There are also a number of ways in which VBG can fail that are not dependent on patient behavior. Patients may present with loss of satiety, dysphagia, severe gastroesophageal reflux, vomiting, weight gain, or excessive weight loss. The two common complications include staple line breakdown and stoma obstruction (Fig. 96.1). All bariatric surgeons should be prepared to identify these complications, however, the best option for

revision of the failed VBG is referral of the patient to a bariatric surgeon with significant experience with revisional procedures.

Staple Line Dehiscence

Staple line dehiscence has been a major problem after VBG. The initial iteration of the operation involved placing two to three applications of the TA-90 stapler from the window to the angle of His. This technique did not reliably produce healing of the vertical staple line and staple line dehiscence led to a revision rate of 2% per year early on. This problem was largely solved by introduction of the TA-90B stapler which placed four closely spaced staggered rows of staples which healed more solidly. The revision rate following this innovation dropped precipitously but sporadic dehiscences are still occasionally seen, particularly in postpartum patients for reasons that are unknown. Small dehiscences do not always cause problems or impede the restrictive effects of the operation, but larger openings in the staple line (2 cm or greater) often cause both weight gain and/or symptomatic gastroesophageal reflux disease. While it is possible to re-staple a dehisced staple line, reapplying staples to a thickened, scarred stomach wall may be associated with not only another dehiscence but also leaks from the staple lines. The success rate in resuming and maintaining weight loss with reapplication of staples is also generally less satisfactory than substitution of a procedure that induces malabsorption such as gastric bypass or biliopancreatic diversion. Nevertheless, patients who had a good result prior to the staple dehiscence may respond well to reconstruction of the VBG.

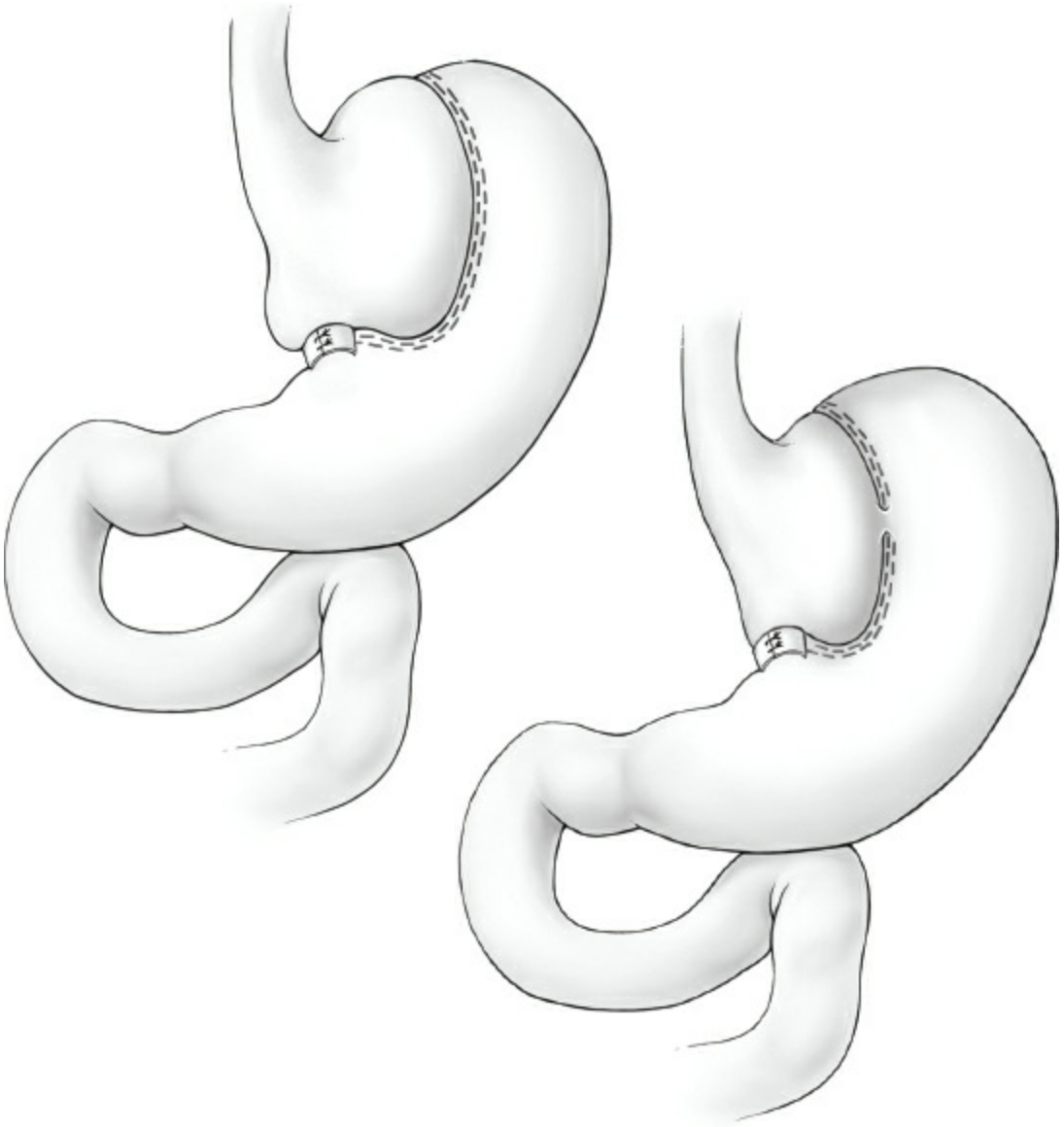

Figure 96.1. Most long-standing VBG procedures demonstrate a dilated proximal gastric pouch. If the gastroscope is not able to pass across the banded segment into the distal stomach that signifies a stricture causing obstruction. One must also assess the patient for band erosion and staple disruptions at the time of endoscopic evaluation of VBG. Even if the gastroscope is able to pass across the banded portion, the patient may still suffer from relative obstruction and exhibit gastroesophageal reflux or episodes of food obstruction of the outlet, particularly when trying to eat solid healthy foods. This is a frequent reason for VBG weight-loss failure in that patients gravitate toward eating soft foods and drinking liquid calories due to inability to eat solid healthy foods. Although often called “maladaptive eating,” in fact it is eating behavior that is adaptive to the anatomic limitations enforced by the relative obstruction of the nonadjustable banded outlet.

Pouch Enlargement

Providers should not automatically blame dietary indiscretion when patients report frequent vomiting after meals. Pouch enlargement may indeed be secondary to long-standing repetitive gorging by the patient to the point of emesis or a mechanical obstruction. A careful dietary history can usually determine whether a behavioral problem is the cause. More commonly, however, pouch enlargement and vomiting is secondary to a stricture of the banded segment. Inclusion of an excessive amount of fundus within the gastric pouch by the surgeon at the initial surgery is yet another known cause of pouch enlargement. The surgeon should remain cognizant that part of the function of the fundus is to dilate to accommodate ingestion of larger meals. At operation for VBG, as is likely true for other restrictive procedures, the vertical staple line should be placed at or close to the angle of His to avoid excessive retained fundus within the gastric pouch.

Pouch enlargement, with or without stricture, may be associated with weight gain, gastroesophageal reflux, nausea, and vomiting. Dietary indiscretion also plays a role in weight gain as most patients gravitate toward a liquid calorie-dense diet or other high calorie junk foods such as cake that undergoes liquefaction in the mouth and arrive in the pouch in the form of a liquid slurry which is more likely to pass through a strictured outlet. As the pouch enlarges, the banded stoma is no longer found in a dependent position and, since this portion of the stomach has no active peristalsis, gastric stasis is promoted. Correction of the reflux and stasis may be accomplished by simply removing a portion of the marlex band and dilating the pouch outlet. This approach however, is almost invariably accompanied by regain of lost weight. Band removal or division may be appropriate in severely debilitated patients where gastric stasis has led to aspiration pneumonia, but in general, patients should have some sort of procedure to maintain or resume their weight loss. Mason has described the so-called “Faberge” technique (referring to the “egg within an egg” works of art of the Romanov dynasty) of constructing a second appropriately sized VBG pouch within the initial enlarged VBG pouch. Such procedure can be constructed by an open surgical procedure using a new circular window and vertical stapled partition. This technique may be quite successful with selected patients; however, many individuals with an enlarged pouch have this problem because of an inability to permanently change their eating habits following the first operation. Further, re-stapling

the previously stapled thickened gastric tissue is also difficult as it is frequently adherent posteriorly to the pancreas and retrogastric structures. In many situations it is likely preferable to substitute a procedure which induces some degree of malabsorption: either a gastric bypass or a biliopancreatic diversion.

Erosion

Erosion of a mesh band into the gastric lumen is sometimes seen in patients following VBG and may be associated with weight regain, reflux, pain, vomiting or microcytic anemia. The etiology is unknown but may be more common in patients ingesting anti-inflammatory medications. Patients who are completely asymptomatic without weight regain may not require any treatment. The eroded band is usually partially intraluminal and partially extraluminal. Sometimes this can be treated by endoscopic excision of the intraluminal portion of the mesh, avoiding the need for reoperation. This technique requires a dual-channel therapeutic gastroscope. One technique is to use a heavy biopsy forceps be threaded through the loop of a colonoscopy snare. The endoscopist grasps the mesh with the forceps and, with traction on the mesh, the snare is snugged down around the base of the mesh. The snare cautery is then activated and the mesh transected. Many times excision of the protruding mesh renders the patient asymptomatic. If this technique is not successful, the patient should have transgastric excision of the mesh through a gastrotomy. This can be combined with conversion to another bariatric procedure, as indicated.

PREOPERATIVE PLANNING

All patients being considered for revision should be thoroughly evaluated by an accredited bariatric program with a multidisciplinary team (bariatrician, nurse educator, dietitian, social worker/therapist). To start, a good dietary history is important and should be reviewed with the dietitian. One technique is to require the patient to maintain a food diary for a several weeks, measuring portions to enable an accurate analysis of dietary habits by the dietician. Nutrition laboratories should be assessed to exclude issues like thiamine deficiency, for example, in the scenario of frequent vomiting. The social worker or therapist should exclude any psychosocial problems that could compromise the patient’s care or ability to comply with treatment recommendations. The bariatrician or medical consultant should review overall health status, especially if comorbid diseases are

present such as coronary artery disease, diabetes, obstructive sleep apnea, or hypertension.

If a revision is planned, candidates for VBG conversion to an alternative procedure will need to understand the risks, benefits and behavioral changes associated with the new procedure. The nutritionist may initiate a solid food low calorie diet avoiding all caloric liquids, as well as cookies, cake, candy, and other high calorie snacks that might undermine a successful revision. Daily exercise is usually encouraged.

INDICATIONS AND CONTRAINDICATIONS

Persistent vomiting and regurgitation should not be ignored and either a revision or reversal is usually necessary. Occasionally, a patient will present with just weight gain will present for evaluation. In the absence of symptoms, patients who are candidates for revision should have significant weight regain and usually a diagnosis of morbid obesity such as a BMI >35 with a comorbid condition or BMI >40 without associated illnesses.

SURGICAL TECHNIQUES

An increasing number of bariatric surgery revisions and conversions are performed laparoscopically today. We will start with a review of open surgical approaches for a complete review of revision/conversion approaches for the sake of completeness, however the laparoscopic revision of VBG to Roux-en-Y gastric bypass is becoming the most frequent reoperative procedure for VBG patients today.

Open Repair of Staple Line Dehiscence

Repair of a staple line dehiscence is simple in concept, may be challenging in its application. As soon as the adhesions to the abdominal wall are separated, a table-mounted retractor should be mounted for stable retraction of the abdominal wall and the patient should be placed in steep reverse Trendelenburg position (a foot board should be placed to avoid slippage of the patient). The next step is to separate the liver from the stomach. This may be relatively easy if the previous surgeon was considerate enough to cover the Marlex band of the VBG with omentum in the recommended fashion. However, all too often this may be somewhat difficult. There is no substitute for careful sharp dissection here. We routinely place the endoscope through the banded outlet of the pouch prior

to initiating dissection. This allows the surgeon to palpate (open) and/or visualize (laparoscopically) the area of the band. This is also a great aid in the dissection of the anterior wall of the stomach. After freeing the anterior wall the liver should be retracted superiorly and, if possible, the pouch window should be opened (this has usually contracted to quite a small opening). The lesser curve access to the lesser sac inferior to the left gastric artery through the gastrohepatic omentum is typically obliterated due to adhesions and scar tissue. It may be advisable to open the gastrocolic omentum outside the gastroepiploic vessels and dissect the posterior wall of the stomach from this aspect. Again, careful dissection is important to avoid injury to the pancreas or posterior gastric wall (Fig. 96.2).

At this point during open surgical revision, with both anterior and posterior gastric walls free, one can try and develop a connection between the two areas at the angle of His. A 19 French red Robinson catheter is then passed so that its tip exits the angle of His and the large end comes through either the previous window, or failing that, next to the lesser curve below the left gastric vessels. A standard TA-90B stapler may be applied if one is able to bring the Robinson catheter through the previous window. The catheter is used as a guide to bring the stapler foot up to the angle of His. The catheter is then removed from the stapler tip and the alignment pin applied. The stapler is then closed. The anesthetist should be asked to move the endoscope in and out to insure that the stapler doesn't impinge on the endoscope. Only then should the stapler be fired. If the previous window cannot be opened sufficiently to accommodate the stapler, a notched TA-90BN stapler may be applied such that the notch accommodates the endoscope while the end of the stapler exits the angle of His. The authors recommend insufflation of air through the scope with occlusion of the pylorus and placement of fluid into the upper abdomen to rule out leaks. The greater omentum should be used to cover the stomach and is sutured to the lesser omentum. The incision is then closed in the usual fashion. Clear liquids are started the next morning at a rate of 30 to 60 cc every 30 minutes and the patient may be discharged when they are tolerating adequate liquids to maintain hydration. Clear liquids should be given for 1 week, followed by several weeks of full liquids with liquid protein before advancing to soft moist foods.

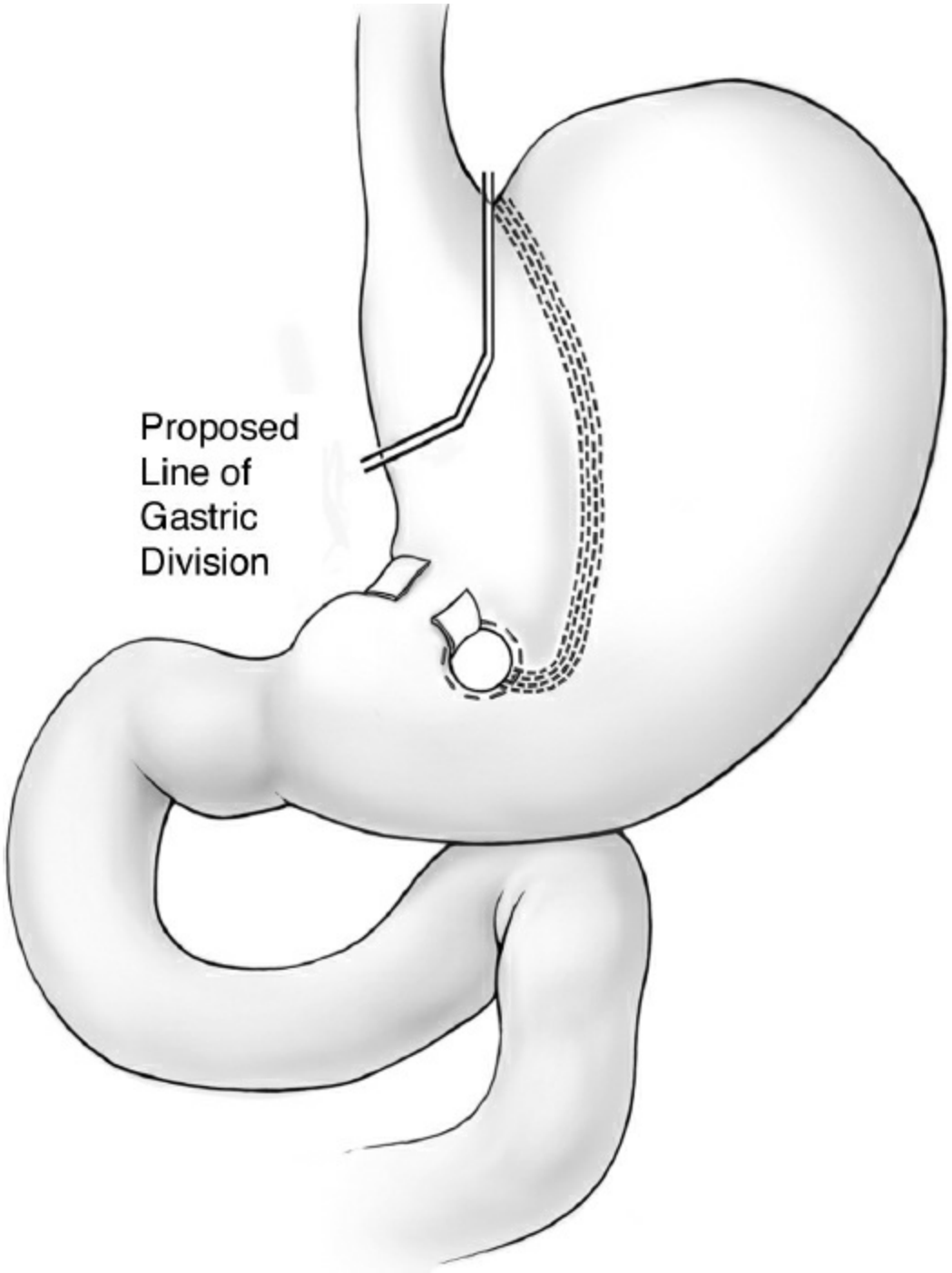

Figure 96.2. Proposed line of gastric division with revision of VBG to Roux-en-Y gastric bypass.

Open Faberge Technique

The initial approach to dissection of the old pouch is similar to the technique described above up to and including freeing the angle of His. At that juncture, dissection next to the lesser curve is performed sufficient to pass a Penrose drain around the gastrohepatic omentum. A second window may be made above the original one with a 28-mm EEA by passing the

anvil retrograde from posterior to anterior stomach approximately 3 to 4 cm to the left of the lesser curve. A Robinson catheter may be brought from the angle of His down through the new window and the TA-90B may then be passed using the Robinson catheter as a guide. The new pouch is then stapled after insuring that the endoscope moves freely. A 7.0 cm × 1.5 cm Marlex band can then be passed through the window and around the pouch outlet adjacent to the lesser curve. It is sutured to itself at a 5.0 cm circumference using interrupted polypropylene sutures in an overlapping fashion. No sutures should attach the mesh to the stomach. A section of the old mesh should be removed to avoid later compromise of the pouch outlet.

If the surgeon wishes to steer clear of the necessity for another window as described above, which may at times be awkward to perform, they can avoid this by passing a notched TA-90BN stapler in the fashion described above to construct the pouch and then use Long's technique of encircling the pouch outlet with three Dacron sutures placed through the staple line and adjacent to the lesser curvature over a 22 mm length. These encircle a dilator and are used to simulate the restriction of a banded outlet.

Open and Laparoscopic Conversion to Gastric Bypass

Surgical conversion to gastric bypass is the preferred surgical procedure when VBG failure occurs today. In part, this results from the adaptation of laparoscopic techniques to perform revisional bariatric surgery in which the endoscopic staplers perform tissue transaction rather than stapling in-continuity. The operative strategy is determined by the status of the previous VBG proximal pouch. If the VBG staple line is intact and the pouch nondilated, then we seek to superimpose our staple firings on the previous staple line after removal of the prosthetic band. In the event that the VBG pouch is dilated or if the staples have dehisced, we often plan our stapling to create a new smaller pouch above the previous staple lines. This is less important if there is no evidence of intact staples on preoperative contrast imaging. The stomach may be transected or stapled in continuity using three precisely superimposed firings of the stapler. Long (e.g., 4.8 mm or greater) staples should be utilized because of the thickness of the previously stapled gastric wall (Fig. 96.3).

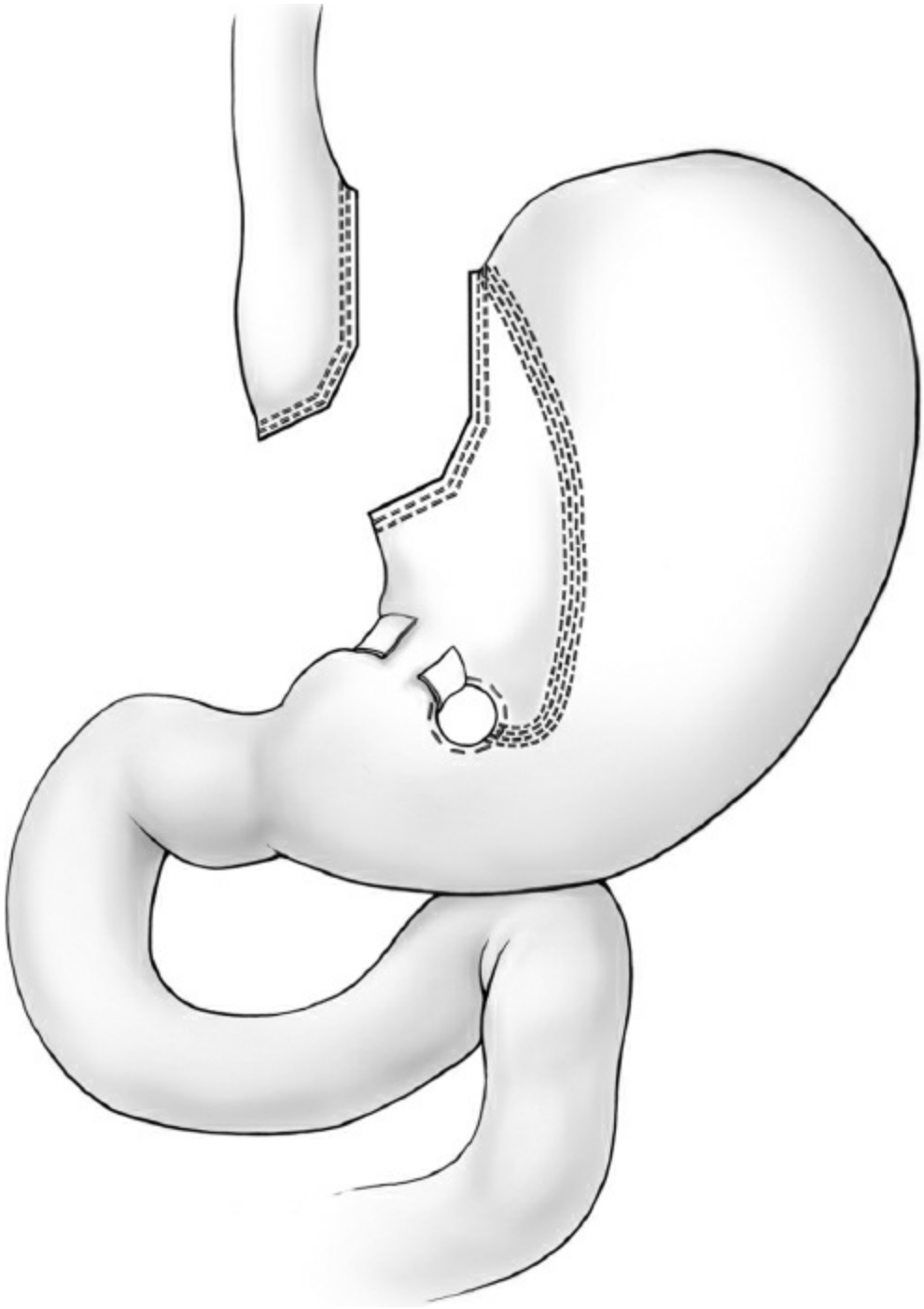

Figure 96.3. Division of the stomach in VBG prior to conversion to gastric bypass. Removal of the band or resection of a section of band is done to avoid the possibility of a closed-loop obstruction within the old dilated pouch. Gastric transection should be carried out with large 4.8-mm or greater staples because of the thickened stomach. The distal stomach staple lines are most commonly resected in current laparoscopic approaches to VBG conversion to gastric bypass. If not resected, it is critical to be certain that the isolated stomach segment between the two staple lines is able to drain without obstruction

to avoid blowout.

Laparoscopic conversion of VBG to Roux-en-Y gastric bypass is typically performed via similar port placements as utilized for primary laparoscopic gastric bypass. Adhesions are often dense, particularly at the location of the banded outlet. Removal of a silastic ring is much easier than removal of a mesh band. Identification of the location of the mesh band is usually indicated when the most dense adhesions are encountered. The band often provides an indication of the location of the previous gastric staple lines which are typically not easily seen as they lie at the base of gastrogastric adhesions. Teasing the fundus of the stomach from the anterior pouch is tedious but necessary to reveal the previous staple sites but also to decrease the gastric tissue overlap as much as possible so that stapling can be accomplished with appropriate tissue thickness and decrease the risk of staple line leak. Buttressing materials are often used for this purpose in revisional surgery, however with no strong clinical evidence that they accomplish this objective. When creating a small new gastric pouch above a previous VBG staple line, many surgeons prefer to resect the superior-most portion of the gastric remnant in order to obtain a more secure closure of the remnant and to avoid the possibility of an isolated segment of stomach sequestered between the old and new staple lines. The previous band is often included in this resection.

The Roux limb is then created by measuring 50 cm distal to the ligament of Trietz as a point to divide the jejunum with the linear cutting stapler. The distal end is marked to avoid confusion. A suitable length of mesentery is divided with either clamps or the 2.0-mm “vascular” linear staple cartridge to permit the distal jejunum to reach the cardia easily. The Roux limb may be brought up antecolic antegastric, retrocolic retrogastric (if the stomach is transected), or retrocolic antegastric (our preferred method when stapling the pouch in continuity rather than transecting it). The jejunojejunostomy is created using standard techniques a variable distance downstream from the transection site (Fig. 96.4). Many surgeons feel this measured length should be increased to 150 cm in superobese patients to enhance weight loss, although this concept has not been proven in the long term. The end of the Roux limb is then brought up in proximity to the newly created proximal gastric pouch where an anastomosis is completed using one of a number of available techniques.

Linear stapling can be utilized and is particularly favorable if the

revision is undertaken using laparoscopic access. Circular stapling is commonly utilized with both open and laparoscopic access techniques. Finally, we prefer a two-layer handsewn anastomosis when performing an open revision to gastric bypass while others prefer a circular stapled anastomosis (e.g., Orvil, Covidien). In general, we believe it to be beneficial to oversew the new staple lines with nonabsorbable suture if the stomach has been transected to create the new proximal pouch. Leak is more common after revision to gastric bypass than after a primary gastric bypass operation and therefore we recommend intraoperative interventions to detect and treat leak should it occur. Intraoperative testing of the anastomosis using intraluminal injection of methylene blue dye or air insufflated via a flexible gastroscope with submersion under saline is helpful to detect intraoperative leaks if the anastomosis is sufficiently distended during the test. Alternatively, a methylene blue saline test can be used. We routinely place a drain near the anastomosis and especially after open approach, we place a gastrostomy tube in the remnant stomach. With extensive adhesiolysis or a difficult dissection of the stomach, the leak rate is severalfold higher and a well-placed rain a G-tube can ease the management of a GJ leak. Finally, all mesenteric defects are closed to prevent an internal hernia. A nasogastric tube is placed to low intermittent wall suction.

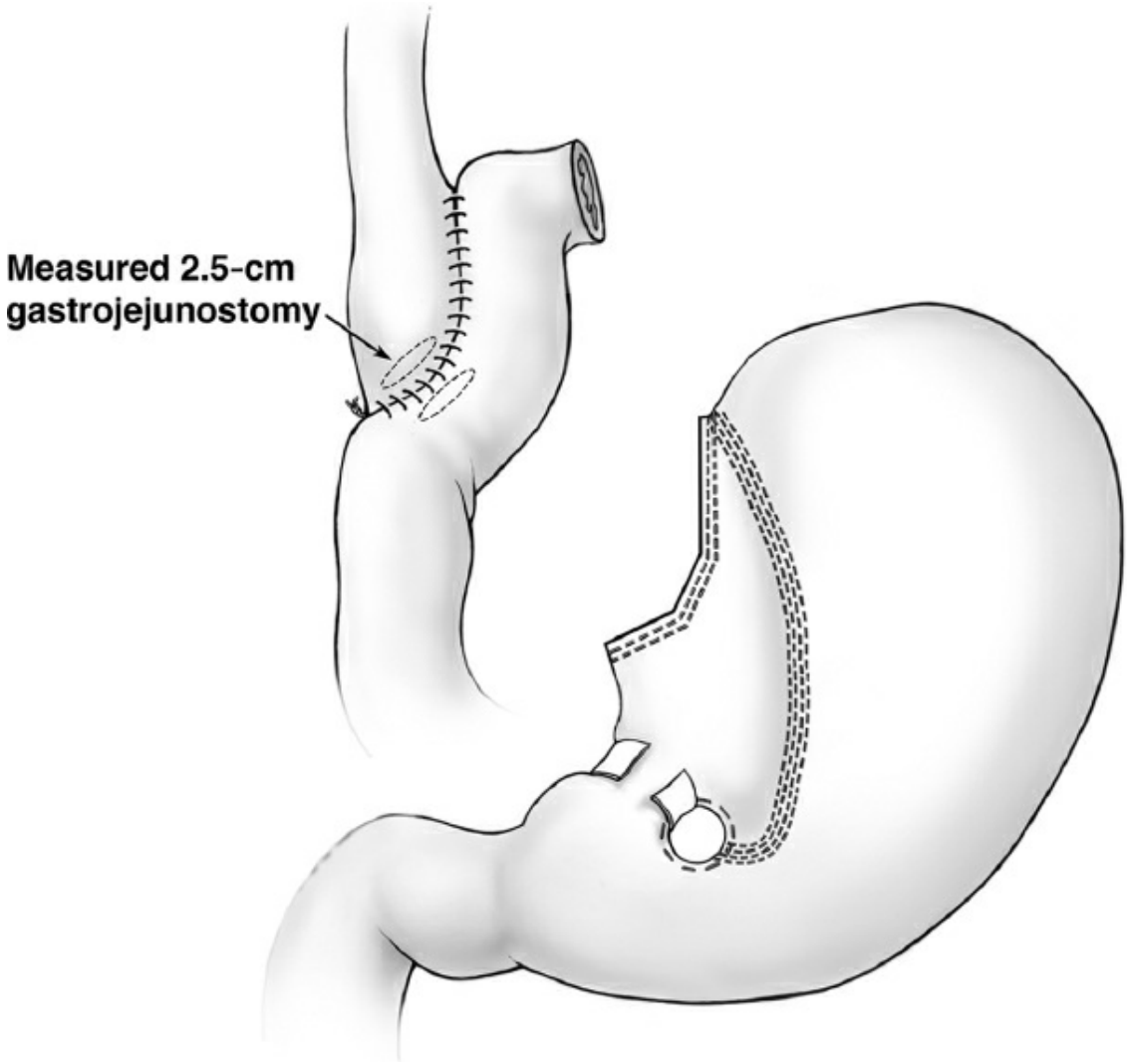

Figure 96.4. Construction of the gastrojejunostomy to the new pouch. Although the remnant may occasionally be left intact with the band either removed completely (easy to do in the case of a silastic ring band but almost impossible with a mesh band due to dense incorporation into the gastric wall), most surgeon would resect the areas of previous staple lines and remove that portion of the stomach entirely.

POSTOPERATIVE CARE

Postoperative the patient is continues on perioperative SQ heparin, SCDs, and 3 doses of antibiotics. POD 1 the nasogastric tube is removed and urinary catheter discontinued. Patients are encourage to use the incentive spirometer and ambulate the hallways. After the swallow study confirms no leak or obstruction, the diet is advanced from water to protein shakes. The dietitian will provide dietary instructions. The patient will be discharged on antacids and multivitamins.

COMPLICATIONS AND THEIR MANAGEMENT

After a revision, leaks are a dreaded complication and require prompt recognition. Ischemia may play a greater role in causing leaks after revision because the gastric blood supply may have been compromised in unpredictable ways at the time of the primary surgery. We routinely perform a postoperative water-soluble contrast study during the postoperative period before resumption of oral diet to assess for this complication in all patients who have undergone revision to gastric bypass. In addition, the study provides documentation of the new anatomy following the revisional procedure. If the patient develops tachycardia, respiratory compromise and later urinary retention or abdominal pain, a leak should be expected even if swallow study and/or CT scan is negative and reoperation should be considered.

This patient population is also at higher risk for venous thromboembolic events including fatal pulmonary embolism. Sequential compression devices and perioperative anticoagulation is routinely given. Longer-term low–molecular-weight heparin or other anticoagulant prophylaxis may be used if the patient has a history of DVT, PE, in patients who are nonambulatory or in those with venous stasis disease or hypercoagulable conditions. Leg pain/swelling should prompt lower extremity Doppler and shortness of breath should be evaluated by CT pulmonary angiogram.

OUTCOMES

Most patients will be discharged home 3 to 5 days after open revision and 1 to 3 days after laparoscopic revision. Modest weight loss is expected. Most patients will have near complete resolution of vomiting and reflux with revision or conversion to gastric bypass.

Suggested Readings

Apers JA, Wens C, van Vlodrop V, et al. Perioperative outcomes of revisional laparoscopic gastric bypass after failed adjustable gastric banding and after vertical banded gastroplasty: experience with 107 cases and subgroup analysis. *Surg Endosc* 2013;27(2):558–64.

Behrns KE, Smith CD, Kelly KA, et al. Reoperative bariatric surgery. Lessons learned to improve patient selection and results. *Ann Surg* 1993;218(5):646–53.

Gagné DJ, Dovec E, Urbandt JE. Laparoscopic revision of vertical banded

gastroplasty to Roux-en-Y gastric bypass: outcomes of 105 patients. *Surg Obes Relat Dis* 2011;7(4):493–9.

Gagner M, Gentileschi P, de Csepel J, et al. Laparoscopic reoperative bariatric surgery: experience from 27 consecutive patients. *Obes Surg* 2002;12(2):254–60.

Martin MJ, Mullenix PS, Steele SR, et al. A case-match analysis of failed prior bariatric procedures converted to resectional gastric bypass. *Am J Surg* 2004;187(5):666–70; discussion 670–1.

Sanchez VM, DeMaria EJ, Provost DA, et al. Reoperative bariatric surgery. In Callery MP, *Handbook of Reoperative General Surgery*. Malden: Blackwell Publishing; 2006:67–82.

Sugerman HJ, Kellum JM, DeMaria EJ, et al. Conversion of failed or complicated vertical banded gastroplasty to gastric bypass in morbid obesity. *Amer J Surg* 1996;171:263–9.

Tevis S, Garren MJ, Gould JC. Revisional surgery for failed vertical-banded gastroplasty. *Obes Surg* 2011;21(8):1220–4.

EDITOR'S COMMENT

The surgical treatment of obesity has undergone tremendous change since its inception in the 1970s. Early procedures such as the jejunoileal (JI) bypass have long since been abandoned with subsequent reversals. Only extremely rarely are patients encountered with the JI bypass and the reversal is straightforward. The vertical banded gastroplasty (VBG) was widely performed in the 1980s and early 1990s, and as a result, there are numerous patients that still have the VBG anatomy despite the fact that long-term failure rates of VBG are high. When significant weight gain happens or complications occur, the options for revisional surgery are multiple and more complicated. Today's bariatric surgeons need to be well versed in how to treat these patients and potentially perform revisional surgery, especially since most will have never seen a VBG actually performed.

Dr. DeMaria and Dr. Jones offer an excellent tutorial on the etiology and pathophysiology of VBG complications, including sections on clinical presentation, staple-line dehiscence, pouch enlargement, and erosion. They then share their vast experience in the preoperative planning, indications and contraindications, and both open and laparoscopic techniques utilized when performing revisional VBG surgery.

As with all patients that present for consideration of revisional surgery following any primary bariatric operation, the authors appropriately emphasize the preoperative workup needed to understand the potential factors involved in weight gain or complications. Weight regain can be the result of lack of dietary compliance, staple-line dehiscence, or pouch dilation. Dietary noncompliance

must be addressed head-on with intensive dietary and behavioral counseling, with a very high bar set prior to considering any revision. These are the patients that I will often mandate 10% to 20% preop EBW loss to ensure dietary and program compliance prior to undertaking a complicated and potentially risky revisional operation.

Staple-line dehiscence is one of the major reasons for VBG failure and complication. A small dehiscence is usually not an indication for revisional surgery, but conversion to a Roux-en-Y gastric bypass (RYGB) is probably the best option to fix a large dehiscence in a compliant patient. The challenge with this revisional operation is that the pouch may not be enlarged, making it difficult to staple medially to the original staple line. This in combination with chronic scarring may necessitate the resection of the pouch and creation of an esophagojejunostomy. Resection of the proximal portion of the remnant stomach is also often needed to reduce the risk of leak from the remnant stomach. Placement of a gastrostomy tube in the remnant stomach is a reasonable option, as this not only allows for remnant decompression but can also be used as an enteral nutrition access site.

Dilation of the pouch is another mechanism of weight regain, and I would agree with the authors that although it's easy to blame the patient, careful evaluation of other potential causes such as a stricture need to be considered. When evaluating a patient with a dilated pouch, a "chicken and the egg" conundrum exists. While the etiology of pouch dilation may be related to how the original operation was performed and making the pouch too large and including too much fundus, it is usually the result of lack of behavioral compliance with chronic overeating or stricture at the band site. When an appropriate revisional surgical patient is chosen, again, I believe that RYGB is the procedure of choice for revision. A recent published report by van Wezenbeek et al. examined the "long-term results after revisions of primary vertical banded gastroplasty" and concurred that RYGB was better than re-VBG or conversion to a sleeve gastrectomy anatomy (van Weezenbeek MR, Smulders FJ, de Zoete JP, et al. Long-term results after revisions of failed primary vertical banded gastroplasty. *World J Gastrointest Surg* 2016;8(3):238–45). Of the 392 patients that underwent primary VBG, 152 (39%) ultimately underwent revision which is consistent with previous reports of high failure rate with the VBG. RYGB resulted in a higher total% EBWL compared with re-VBG and sleeve gastrectomy with lower complications. Unlike with staple-line dehiscence, pouch dilation usually allows for adequate room above the level of and medial to the previous staple line for staplers to be applied. Caution should always be emphasized when stapling across thickened stomach and scar, thus the highest staple height should be chosen to allow for appropriate staple formation. Despite this, I still advocate the placement of two JP drains (anterior and posterior to the gastrojejunostomy) to help control any leak that may occur during the initial postop period. Likewise, all of my patients undergoing revision to a gastric bypass will get a routine gastrografin study to evaluate for

leak prior to initiation of PO intake.

If stricture at the level of the band or mesh is the cause of pouch enlargement, a novel endoscopic technique that was originally described by Wilson et al. and more recently reported by the Minnesota group specifically for VBG could be considered (Wilson TD, Miller N, Brown N, et al. Stent induced gastric wall erosion and endoscopic retrieval of nonadjustable gastric band: a new technique. *Surg Endosc* 2013;27(5):1617–21; Lim CH, Amateau SK, Ikramuddin S, et al. Endoscopic management of vertical banded gastroplasty stricture: feasibility, safety, and efficacy. *Obes Surg* 2016;26(11):2802–8). A self-expanding metal stent is placed endoscopically across the level of the stricture. Pressure on the strictured mucosa between the stent and gastric band causes pressure necrosis of the gastric wall over a period of several weeks. The stent and silastic ring or mesh is then able to be retrieved endoscopically.

Band erosion is the final reason for revisional surgery for VBG patients. The authors appropriately caution that an asymptomatic erosion does not automatically require any intervention. If symptoms such as pain, PO intolerance, reflux, or bleeding necessitate revision, newer endoscopic techniques now exist and can often avoid a major surgical revision. The endoscopic technique described by the authors is effective and skilled endoscopists can help avoid revisional surgery.

Attentive postoperative management is required for these complex surgical revisions, and as the authors state, these patients are at higher risk of all complications, especially that of leak and venous thrombotic events. I feel that these types of operations should only be performed by experienced surgeons such as Dr. DeMaria and Dr. Jones at a center of excellence and part of the Metabolic and Bariatric Surgery Accreditation and Quality Improvement Program (MBSAQIP).

Eric Hungness

97 Laparoscopic Gastric Bypass

Alan C. Wittgrove

INTRODUCTION

As the disease is morbid obesity and the metabolic syndrome has developed into epidemic proportions, worldwide, the field of bariatric and metabolic surgery has likewise grown. From our development of the laparoscopic technique for the gastric bypass in 1993, now, nearly all primary bariatric operations are performed laparoscopically. This evolution has allowed for safer procedures with excellent outcomes while shortening the hospital length of stay allowing the patient to enjoy an active life earlier.

Over the last several years we have seen trends change in bariatric surgery. Laparoscopic adjustable gastric banding, for example, has all but ceased to exist as a primary bariatric operation. Many bands have been removed. The laparoscopic sleeve gastrectomy is now the most commonly performed bariatric/metabolic operation, worldwide. The gastric bypass continues to be performed, both as a primary operation and as a revision or conversion option, as it has a very consistent and reliable postoperative course and outcome pattern.

Also over the past 10 years, we have seen the number of fellowship training programs expand in laparoscopic and bariatric surgery. With this expansion has come a better understanding of the etiology of the disease and the mechanisms of action for the various operations. As more information is gleaned, hopefully we will be able to better fit a specific operation to a specific patient.

HISTORY

As has been cited many times, Dr. Mason and Dr. Ito are recognized as performing the first gastric bypass, for weight loss, in 1967. Their operation was performed after they had made the clinical observation that partial gastrectomy patients had difficulty with gaining weight. By today's standards their operation was quite different; using a loop configuration

and a gastric pouch of about 150 cc. Over the years the pouch size has been shown to be important in consistency and longevity of response so the operation has been modified to have a much smaller pouch; based on the lesser curvature (to avoid the distensibility of the greater curvature). The loop configuration was changed to a Roux-en-Y to counteract the postoperative bile reflux. More recently, surgeons have once again investigated the loop intestinal configuration; this time with a more elongated gastric pouch and a more distally placed anastomosis. This "loop gastric bypass" will not be discussed in this chapter.

The laparoscopic approach to the gastric bypass was first performed by my group in 1993. Our main drive to this approach was to avoid our biggest complication at the time, incisional hernias. We had performed thousands of open gastric bypass operations and biliopancreatic diversions by that time and we were performing more upper abdominal laparoscopic operations (Nissen fundoplication) as well. As instrument companies developed more suitable laparoscopic choices and we worked in the laboratory to refine techniques, we were finally able to perform the first laparoscopic gastric bypass. Our studies showed consistent weight loss and comorbid resolution with the laparoscopic technique and improvements in instrumentation and training, the techniques have been expanded.

The concept of the multisystem effects of the gastric bypass were being understood as Dr. Buchwald coined the term "Metabolic Surgery." In the mid-1990s, Dr. Pories asked the provocative question "Who would have thought diabetes is a surgical disease?" As gut hormones (Incretins), adiponectin and other active substances have been identified and analyzed, our understanding that the gastric bypass is much more than a "restrictive" procedure has come to light.

CANDIDATES FOR LAPAROSCOPIC GASTRIC BYPASS AND PATIENT SELECTION

The guidelines to determine candidacy for bariatric surgery were established in 1991 by the National Institutes of Health (NIH) Consensus Conference on Gastric Surgery for Severe Obesity. These were reestablished by the ASMBS in 2004. They determined candidates should have a body mass index (BMI) $\geq$40 kg/m^2 or a BMI $\geq$35 kg/m^2 with certain obesity-related comorbidity. These criteria were established as arbitrary guidelines for the evaluation of the patient who suffers from the disease of morbid obesity but it is up to the surgeon (or bariatric team) to

determine who is a good candidate for bariatric surgery. As we have learned more regarding metabolic disease and genetics, the BMI guideline has come down for some individuals with an elevated “metabolic burden.” Since these surgeries are life-changing and many patients with this disease are, in some way, compromised, bariatric surgery patients should undergo an extensive and individualized, preoperative evaluation. The work-up should try to optimize the patient with regard to their known comorbidities and should evaluate the patient for potential comorbidities such as coronary artery disease, sleep apnea, metabolic syndrome, and obesity hypoventilation syndrome. A multidisciplinary approach is required to evaluate bariatric surgery candidates. The team should include nursing, nutritionists, behavioral health specialists, and medical subspecialists as well as the bariatric surgeon. Family and social support, as well as organized support groups offered by the program, are important for the overall success of the patient. Potential patients with ongoing substance abuse or uncontrolled psychiatric disorders are not candidates for bariatric surgery though patients who are well controlled on psychiatric medications can be considered as surgical candidates.

The informed consent process is very important in the field of bariatric surgery and the patients who being worked up for surgery must be fully informed about the risks and possible benefits for all the available surgical (and nonsurgical) options. Though some programs have developed pathways, there is no “evidence-based” algorithm that can predict the best outcome for a specific patient. Currently, the patient’s preference tends to be the main driver in determining the specific operation chosen. This, of course, should not be done in a vacuum and the patient’s medical history and the surgeon’s experience should round out the process. The patient and bariatric team must take into account the follow-up requirements and programmatic guidelines (e.g., exercise and supplementation requirements) as they try to anticipate degrees of success.

Risk stratification is important and the surgical literature has identified several factors that increase the risk for complications. These factors are male gender, age over 55, BMI >45, hypertension, and high risk of pulmonary embolism (PE, previous thrombosis, pulmonary embolus, inferior vena cava filter, right heart failure, and obesity hypoventilation). Both the bariatric team and the patient should be aware of the conditions and their theoretic added risk.

MECHANISM OF ACTION

It is true that the gastric bypass Roux-en-Y is a restrictive procedure: but it is much more. The small gastric pouch (15 to 45 cc) with a limited outlet, through the gastrojejunostomy sized to 10 to 12 mm, at least early on causes a restriction to the volume of food that can be consumed. The basic effect is so much more than restriction. We know we can limit one's intake by diet or other means and still not achieve the effects of the gastric bypass. The key to the bypass is the changes in hormones that occur which allow the patient to feel comfortable eating less by achieving a sense of "satiety." With these hormonal (Incretin) effects come the "metabolic" effects which aid in resolving type 2 diabetes (within days of the operations!), decrease lipid levels, decrease in blood pressure and change in sleeping patterns; even before weight loss. By placing nutrients and other substances directly into the small intestine and allowing for rapid transfer to the more distal GI tract, incretin patterns change in a beneficial way, following the gastric bypass.

The Roux limb is 75 to 150 cm in length and the biliopancreatic limb can measure from 15 to 50 cm from the ligament of Treitz. These lengths do not typically cause malabsorption of macronutrients since the common channel is several meters in length. The duodenum, however, is the most efficient area to absorb di- and tri-valent cations, metals such as iron and calcium. Lifelong supplementation of multivitamins, iron (in menstruating females), calcium, and vitamin B_{12} is recommended following the gastric bypass to avoid micronutrient deficiencies.

TECHNIQUE

Access and Exposure

The patient is placed in the supine position with arms extended on arm boards (for access if needed). The standard precautions are used for leg strap and warming. We do not use a foot board though some facilities do use that as the patient will be placed in a reverse Trendelenburg position.

The operating surgeon stands on the patient's right side and the assistant on the left. We establish pneumoperitoneum with a Veress needle inserted just below the rib margin in the left upper quadrant incision, near the anterior axillary line. The first port is placed with visual assistance using an optical trochar (Endopath Xcel, Ethicon Endosurgery, Cincinnati, OH). This first port is generally at the umbilicus though it may be inserted

off the midline if the patient had prior surgery and adhesions are anticipated. The remaining ports are placed under direct vision after skin and subcutaneous infiltration with a long-acting local anesthetic. Figure 97.1 shows our usual port placement. Since we perform a stapled anastomosis, both at the gastrojejunostomy and the enteroenterostomy, the ports are placed to facilitate those actions. The port placement may be altered if the anastomosis is created via the hand-sewn technique, to better allow for triangulation of instrumentation. A total of six ports are used but if significant adhesion formation is encountered, additional 5-mm ports are often used to facilitate additional dissection. A 5-mm port is placed in the subxiphoid space and is used for liver retraction. We use a simple toothed grasper to the diaphragm, just anterior to the hiatus, but some surgeons prefer other retraction systems such as the Nathanson liver retractor. No matter what system is used, adequate exposure of the gastroesophageal junction is mandatory.

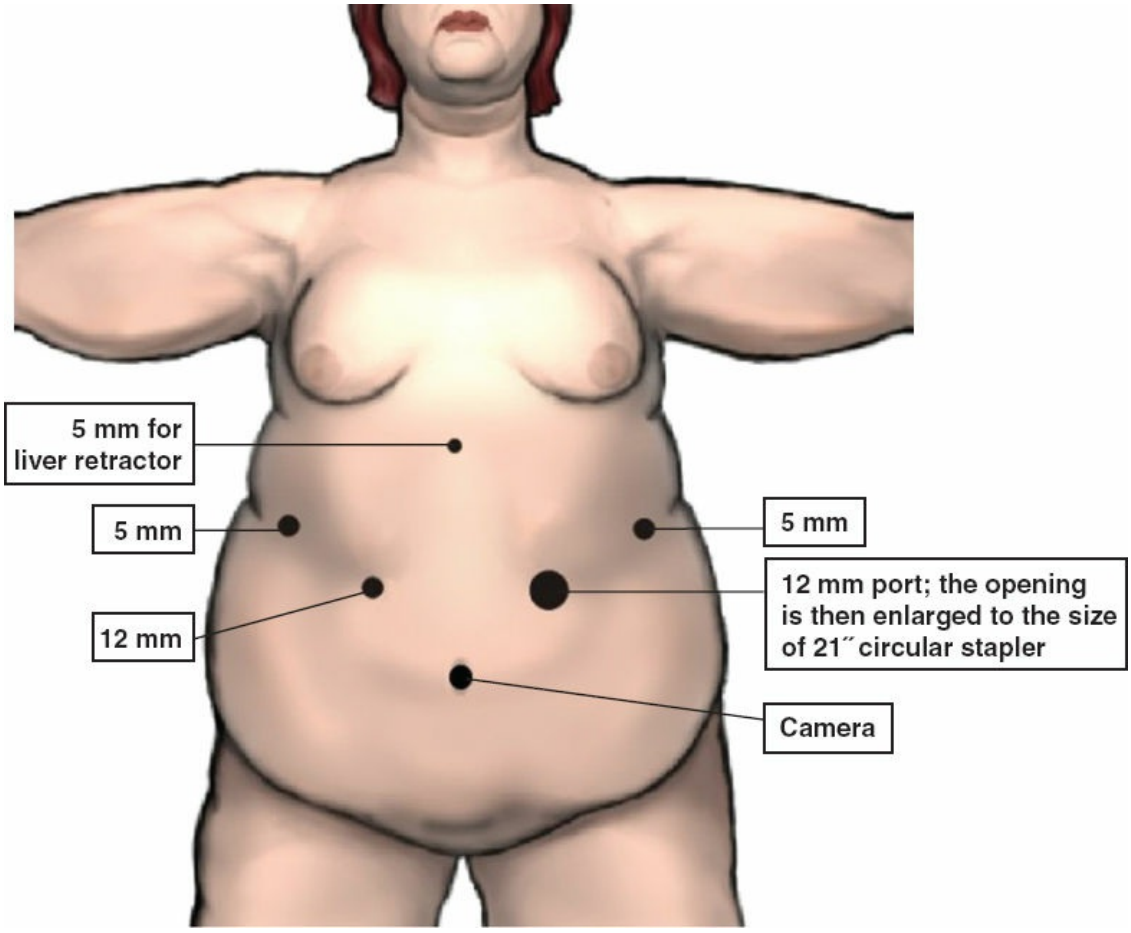

Figure 97.1. Laparoscopic port placement for gastric bypass. (Courtesy Ethicon, US, LLC.)

Gastric Pouch

The patient is placed in reverse Trendelenburg position (and we add a degree of sitting position to shorten the distance between the umbilicus and the hiatus) (Figs. 97.2 and 97.4). The assistant retracts the lateral fundus and the surgeon takes down the adhesions at the angel of His. This maneuver will allow more complete exclusion of the greater curvature during the final steps of the gastric transection. A sizing balloon is placed and filled to 15 cc with air. The anesthesiologist then gently snugs the balloon into the esophagogastric junction. The assistant has one grasper along the lesser curvature, near the incisura and the other on the gastric wall just below the balloon. We dissect in a paragastric fashion (some surgeons more fully transect the hepatogastric ligament) to create a tunnel behind the stomach to facilitate stapler placement. Once the tunnel is created, the balloon is removed (as well as any other device placed in the esophagus, to avoid stapler mishaps) and the small gastric pouch is created (Fig. 97.3). After the first firing of the linear stapler, the assistant retracts the lateral fundus. This lessens the amount of redundant stomach found posteriorly and aids in the creation of a very small and consistent pouch size. The first firing of the stapler is generally horizontal while the second and possible third firings are angled cephalad toward the angel of His. Care is taken for the assistant not to retract too aggressively as this may cause encroachment into the esophagus during the final firing. Blue staple loads are used in primary cases but green loads maybe need if the gastric wall is thickened of in revision cases. Buttress material is not used by our team.

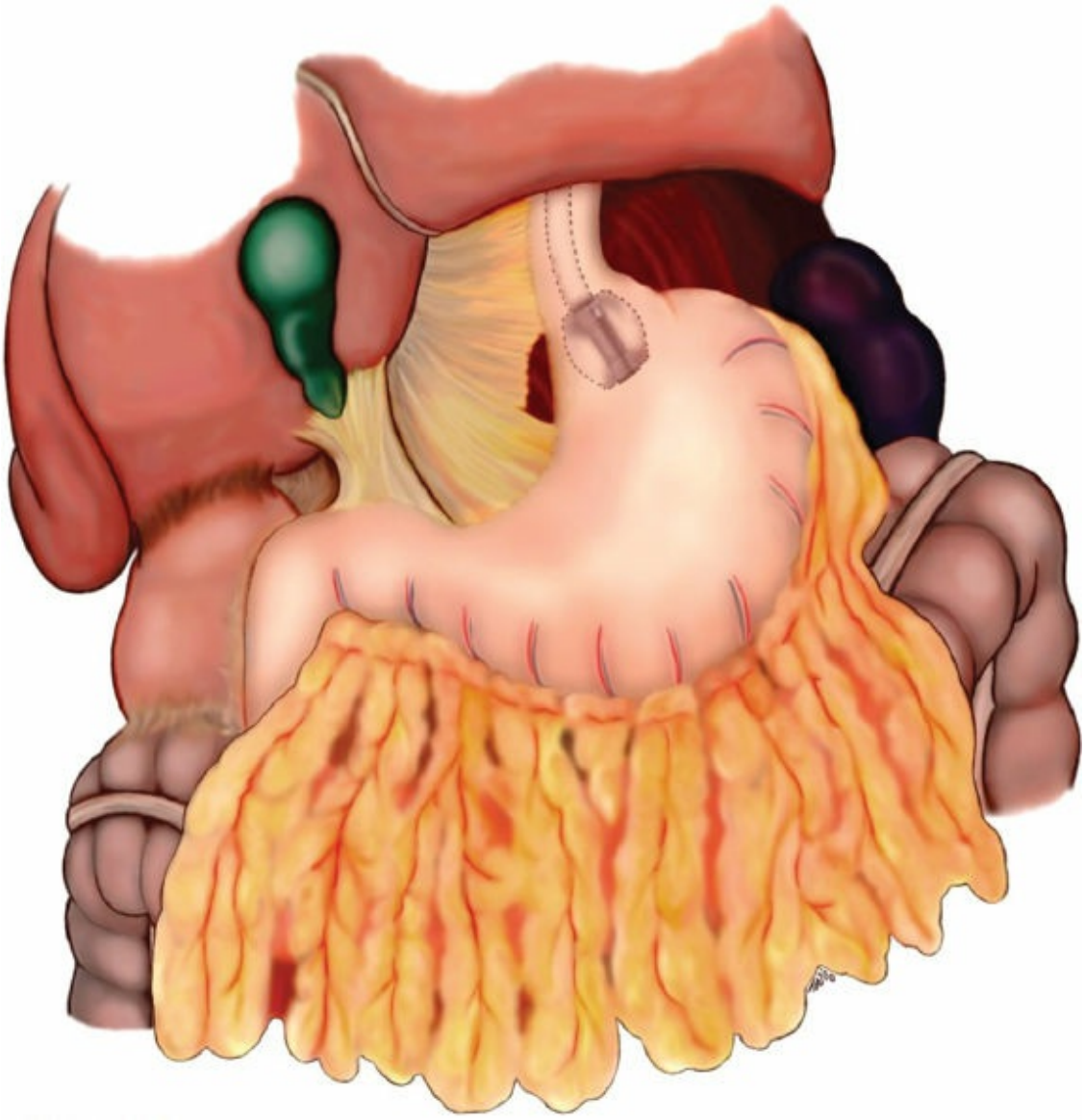

Figure 97.2. The liver is retracted and a balloon is used to size the gastric pouch. (Courtesy Ethicon, US, LLC [modified].)

Jejunojejunostomy and Roux Limb

The omentum and transverse colon are reflected superiorly and cephalad into the upper abdomen and the ligament of Treitz is identified (Figs. 97.5 and 97.6). The assistant retracts the mesocolon anteriorly to visualize the ligament and facilitate opening the base of the transverse mesentery, into the lesser sac. Since we use a retrocolic/retrogastric placement of the Roux limb, it is important to identify this space and even place a Penrose drain, into this space, to aid in bringing the small bowel into the upper abdomen.



Figure 97.3. A linear stapler is used to divide the stomach. (Courtesy Ethicon, US, LLC.)

The jejunum is then divided 15 to 50 cm distal to the ligament of Treitz using a blue stapler load of the linear stapling device. I will note here that we use a short biliopancreatic limb (BP) (15 cm) and have done so thousands of times. Some surgeons create a longer BP limb. A shorter BP limb tends to have less tendency to “kink” or twist and some feel as if the longer BP limb adds beneficial metabolic effects. The mesentery of the jejunum is not further divided with our technique as the retrocolic/retrogastric passage is very short and there is minimal tension on the gastric anastomosis. In addition, if the small bowel mesentery is not transected, there is more consistent blood supply to the Roux limb and there is essentially no Petersen space. The proximal stapled end of the Roux limb is sutured to a Penrose drain to facilitate transit behind the colon and stomach.

The Roux limb is measured distally for 75 to 150 cm. This

measurement is based on Dr. Roux' work to prevent reflux of bilious material, back up the limb. More recently some programs have lengthened the limb to 150 cm in hopes of aiding weight loss. We have always used 75 cm for the Roux limb. This measurement is made with the bowel straightened but not on stretch and using some reproducible process to create a uniform operation, patient to patient. Remember some medications given by anesthesia can alter this measurement (anticholinergics such as Atropine and Robinal). Once the appropriate Roux limb length is measured, a side-to-side (functional end to side) enteroenterostomy is created between the Roux and BP limbs. We use a linear stapler technique with white loads to perform this anastomosis but it can be hand sewn as well. Stay sutures can be used to stabilize the bowel for this anastomosis but we use graspers to align the bowel and create traction/countertraction so the stapler can be inserted through the lower port of the primary surgeon. The opening for the introduction of the linear stapler is then closed with another staple firing. Care needs to be taken not to narrow or kink the anastomosis. We then close the small bowel mesentery with running permanent suture. One single suture is then placed to align the Roux limb, just proximal to the anastomosis, to the stapled end of the BP limb. This "Brolin stitch" also helps to avoid kinking.



Figure 97.4. The gastric division is complete with the final stapler firing going to the angle of His. (Courtesy Ethicon, US, LLC.)

Once the mesentery is closed, the stapled end of the Roux is brought into the upper abdomen with the Penrose drain, through the lesser sac. An alternative method is to bring the Roux limb antecolic/antegastric. Division of the omentum can shorten this distance and facilitate this maneuver with less tension. If the bowel is brought up “ante,” there is clearly a longer Petersen space to consider.



Figure 97.5. The small bowel is divided distal to the ligament of Treitz. (Courtesy Ethicon, US, LLC.)

Circular Stapled Gastrojejunostomy, Transoral Method

This is our primary technique for creating the gastrojejunostomy (Fig. 97.7). When we developed the laparoscopic technique in 1993 the laparoscopic instruments were inferior to those being used today. They were short, often too traumatic or with poor holding ability. Delivering to anvil into the gastric pouch in much the same way we were able to perform a PEG afforded us the opportunity to complete the operation even with

limited instrumentation.

We continue to perform an endoscopy after the gastric pouch is created. A snare is placed through the endoscope, through the gastric wall near the staple line. A percutaneous pull wire is introduced into the peritoneal cavity and grasp with the snare. The endoscope is removed and the pull wire now protrudes out the patient's mouth. The anvil is fastened to the pull wire and by pulling back on the wire, the anvil travels down into the stomach. An alternative method is now available to surgeons without the use of the endoscope. Utilizing a system in which a 21-mm anvil is already attached to the end of an orogastric tube, the tube is placed down the esophagus and into the gastric pouch. The tip of the tube is placed just posterior to the horizontal staple line of the gastric pouch and, using cautery, the tube is advanced into the abdomen and out one of the ports. With either technique, as the anvil is placed in the posterior pharynx, the jaw should be retracted anteriorly allowing gentile passage of the anvil into the pouch. Once the stem of the anvil protrudes through the gastric wall, the tube is secured and the pull wire or tube is cut free and removed.

The Roux limb is brought into the upper abdomen and the lower port site on the left is enlarged just enough to allow passage of the circular stapling device. We open the antimesenteric boarder of the Roux about 6 to 10 cm from the stapled end and introduce the circular stapler through this opening. The stapler is advanced to the stapled end, connected to the anvil, closed and fired. Prior to removing the circular stapler from the abdomen, it should be covered to avoid wound contamination and infection. This can be accomplished with EITHER a plastic wound protector or, with the Ethicon product, by using the plastic cover already on the device. If proper covering is done, wound infections are rare. The stapler is removed from the abdomen and the antimesenteric opening is closed with a linear stapler. Using this technique, we are able to avoid any afferent limb issues later in the patient's course and the final linear staple line helps stabilize the small bowel at the transverse mesentery, avoiding an internal hernia potential at that space. An alternative method would be to introduce the circular stapler through the stapled end and creating the anastomosis along the antimesenteric boarder of the Roux. The remaining "afferent limb" is the transected and removed. We do not prefer this method for reasons outlined above, but it does have popularity. Interrupted sutures can then be placed to buttress the anastomosis or involute staple lines.

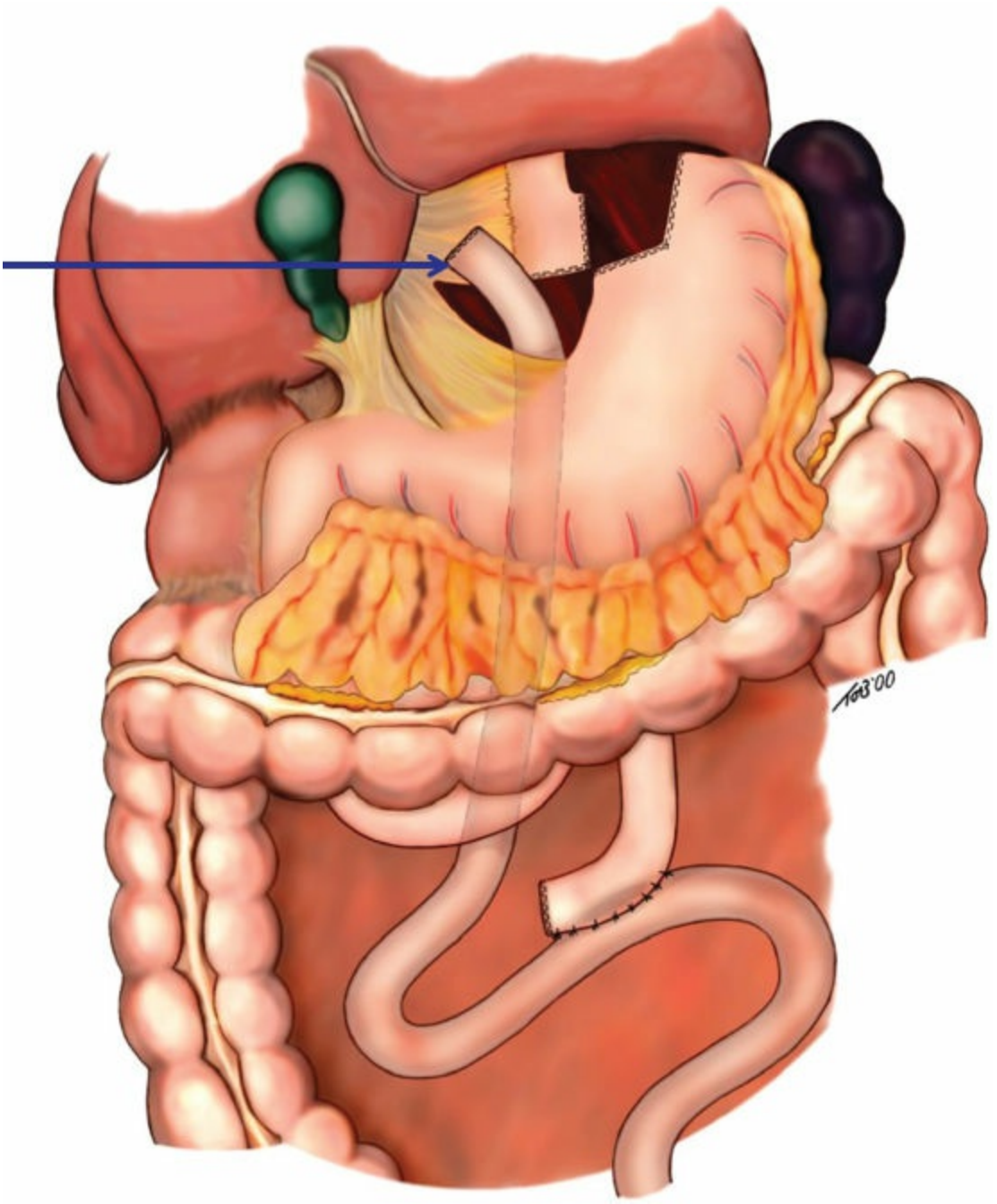

Figure 97.6. An enteroenterostomy is performed and the Roux limb is brought up to the gastric pouch. A Penrose drain is attached to the stapled end of the Roux limb (*arrow*) to facilitate transit to the upper abdomen. (Courtesy Ethicon, US, LLC [modified].)

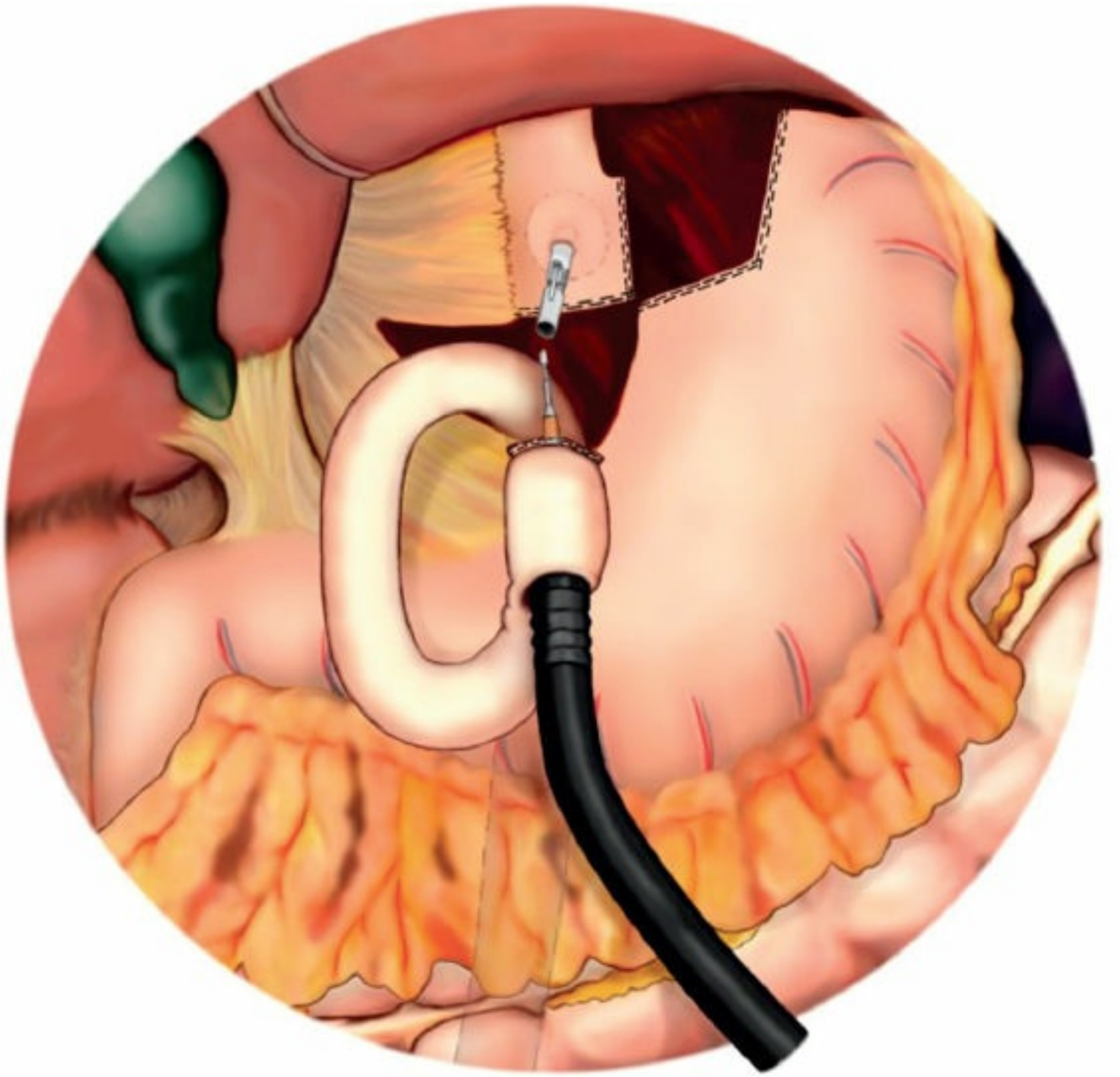

Figure 97.7. The anvil is placed in the gastric pouch and the circular stapler is introduced into the small bowel to complete the gastroenterostomy. (Courtesy Ethicon, US, LLC.)

Leak testing and drain placement are discussed in the “final steps” section.

Circular Stapled Gastrojejunostomy, Transgastric Method

The transgastric approach entails introducing the anvil of the circular stapler directly into the stomach rather than introducing it through the mouth and down the esophagus. There are several ways of accomplishing this task but in general the anvil is introduced through a gastrotomy, usually with a suture attached. A long, curved grasping device is then used to bring the suture and therefore the stem of the anvil out near the esophagogastric junction. The gastric pouch is then fashioned below the

anvil. The circular stapler is then delivered into the abdomen as discussed above. The gastrotomy in the body of the stomach is closed with a linear stapler. This technique originally had less wound complications than the transoral anvil placement since there is no oral bacteria "contaminating" the anvil. With the wound covering techniques discussed earlier with the oral anvil placement wound infections are now rare with either method. Larger anvil size is possible with this technique and there is obviously no chance of getting the anvil stuck at the cricopharyngeus as rarely can happen with the transoral technique.

Hand-Sewn Gastrojejunostomy

As the laparoscopic instrumentation has improved and the use of robotic surgery has been developed in the bariatric arena, the hand-sewn gastrojejunostomy has become more popular.

Drs. Higa and Boone were first to describe and popularized this laparoscopic technique. This technique essentially mimics the technique used for years in open surgery. There are advantages in that less expensive staplers are used and less specialized equipment is needed. The skill set needed to create a two-layer gastrojejunostomy, sized to 12 mm, is significant.

Gastrojejunostomy, Linear Stapled Technique

With this technique, the Roux limb is generally brought toward the gastric pouch in an antecolic/antegastric manner. It is important to ensure that there is no twisting of the mesentery of the small bowel as the stapled end of the Roux is secured to the pouch with absorbable suture. Some surgeons will run an entire back row of suture while others will interrupt sutures to hold both the Roux and gastric pouch in apposition. The anastomosis is generally created with a blue load of a linear stapler, using only about 15 to 20 mm of the firing to assist in sizing the anastomosis. The closure of the common opening is done with a running, absorbable suture, over a sizing tube. If an endoscope is used to size the anastomosis to 30 French, it can also be used to perform a leak test as previously described with the circular stapler. In general, this technique requires a larger gastric pouch and care is needed to insure the pouch is long and narrow rather than over all larger. A generally larger pouch (depending obviously on the degree) may not have the same longevity of success for the patient. Because this technique generally employs an antecolic/antegastric orientation for the

Roux limb, the Petersen space needs to be addressed. Some surgeons do not close any of the potential internal hernia spaces. Though there is no mandate to close these defects, most surgeons do close them with nonabsorbable suture. With this technique, the long Petersen space potential is closed with running 2-0 nonabsorbable suture securing the mesentery of the Roux limb to the transverse colon, omentum, and defunctional stomach.

Final Steps and Discussions

Since the inception of the laparoscopic technique for the gastric bypass, we have performed a leak test at the end of the case. We cross clamp the Roux just distal to the gastroenterostomy and perform a second endoscopy. Air is insufflated into the pouch with the anastomosis submerged in saline. If no air bubbles are noted, we pull the redundant Roux limb down below the transverse mesentery and secure it with a single suture. Since we insert the circular stapler through an opening in the antimesenteric boarder of the small bowel and close that with a linear stapler, that final staple line ends up at the transverse mesentery and assists in closing this space. This technique tends to avoid internal hernias at the transverse mesentery space. A Blake drain is placed in the subdiaphragmatic area on the left and close the fascia where the circular stapler was introduced. The skin is closed with staples or other preferable means. If air bubbles are noted, sutures are placed to over sew the area prior to drain placement and closure. Alternative methods can be used to check the anastomosis using methylene blue instilled into the gastric pouch and the anastomosis and pouch staple line inspected for any leakage of dye. Some surgeons do not use drains.

In my opinion, cholecystectomy should not be prophylactically performed during a laparoscopic gastric bypass. Some studies have shown a higher complication rate of the gall bladder operation if it is performed at the same time as a bariatric procedure. If the patient is symptomatic for gall bladder disease, the cholecystectomy should be performed first and the gastric bypass only done if the gall bladder is removed without complication.

Liver biopsy, core or wedge, can be performed as indicated but care should be used to avoid areas that have been retracted or compressed as that may introduce artifact.

Gastrostomy tube placement is not routine but can be efficiently performed, in the defunctional stomach, if needed. We place gastrostomy

tubes in patients: who have severe sleep apnea on CPAP or BiPAP; who are stable on medications they will need to take postoperatively but may not tolerate them orally (i.e., psychotropic medications); who are undergoing revision cases; where there are significant questions about the operative course and complications are more likely to occur postoperatively.

Staple line buttress materials have been used to try to mitigate bleeding and their use has been shown to improve burst strength. The use of buttress materials has never been well adopted by gastric bypass surgeons because of the expense and the fact that its use has not been shown to have "clinical" relevance. As staple technology continues to improve and the skill set of the surgeon advances, complication rates have reflexly decreased. It has been shown that, on the small bowel, isolated staple line bleeding can be controlled with cautery. The gastric bypass is a low-pressure system and improved burst pressure is not generally an issue. And finally, there is some reservation about introducing a foreign body into that small gastric pouch.

POSTOPERATIVE MANAGEMENT

Since 2004 when the concept of "centers of excellence" in bariatric surgery was introduced, postoperative patients have had more consistent and well-trained nursing care, in most facilities. Since patients who suffer with morbid obesity often don't show the same signs and symptoms of a complication and their general health can be compromised, early recognition of complications is important. Hospitals should be encouraged to have Certified Bariatric Nurses (CBN) on staff to care for postoperative patients.

Since many of our patients suffer with some degree of sleep apnea, managing postoperative pain without aggravation of sleep apnea is important. Newer modalities like long-acting local anesthetics injected in the wound, intravenous acetaminophen and anti-inflammatory medications are now used to give pain reduction without the risk of respiratory depression. It is also important to set the patient's expectations correctly and have them understand "there will be discomfort to pain after any big operation."

Antiemetic therapy is started in the operating room or recovery room and continued as needed on the surgical floor. Some medications given preoperatively may need to be continued intravenously until the patient is

started on liquids but this is rare. Once the patient starts tolerating liquids, most medications are tolerated in their original form. Patients ambulate with assistance within hours of their surgery. Coughing, deep breathing, and the use of incentive spirometry are strongly encouraged. Patients are kept "*npo*" the night of surgery and allowed to have water, broth, and sugar-free Jell-O the next morning if their course appears routine on morning rounds. Although it is not done in all programs, we perform an upper gastrointestinal (GI) study in the morning of the second postoperative day. We continue this practice because we have a number of patients coming from outside our geographic area and we like to document no leak or obstruction before the patient returns home. If the swallow study is negative for leaks or obstruction, the patient is generally discharged to home or to the local area if they live more the 45 minutes away. The drain is removed prior to discharge if there is no abnormal drainage.

The three most significant complications following gastric bypass surgery are leak, PE, and bleeding. Thankfully, since 2004 the number and percent of complications have fallen significantly. This reduction of complications has come from several factors. First, we have a much better understanding of how to optimize patients before surgery. Second, the concept of centers of excellence established certain benchmarks that centers needed to subscribe to gain certification. And, education through the ASMBS, and other societies and institutions, gave a better understanding of "Bariatric Life Support" and "Certified Bariatric Nursing." Major complications often present with subtle findings in these patients and confirmatory physical examination findings (peritoneal irritation) are often the exception rather than the rule; even when an abdominal catastrophe is developing. Leak and PE can give very similar clinical presentations. These two complications are the most common cause of death following bariatric surgery so clinicians need to have a heightened sense of vigilance, knowing bariatric patients don't always show the "usual" signs or symptoms. Sustained tachycardia in the postoperative bariatric surgery patient (pulse >120) should cause concern. This concern should be felt even if the patient looks and feels well. Studies have shown that sustained (4 to 6 hours) tachycardia is often the only sign of an anastomotic leak. Tachypnea or decreasing oxygen saturations can signal early sepsis from a leak or a PE. Early recognition of complications is important since delay in treatment can be deadly in bariatric surgery

patients. The diagnosis of a leak from the gastric remnant staple line or jejunojejunostomy is often delayed since a normal upper GI contrast study offers false reassurance. Bariatric surgeons, or general surgeons caring for bariatric patients, should aggressively evaluate any postoperative fever, tachycardia, or tachypnea and return to the operating room early, even if diagnostic tests are inconclusive or negative but clinical suspicion for a leak is high.

The majority of life-threatening complications occur within the first week following a gastric bypass. Our group has always tried to mitigate delay in care by insisting that patients who live out of our demographic area must stay locally for at least a week following surgery. Our practice is to see the patient in the office at 1 week and they attend a postoperative class which includes diet advancement, behavioral changes recommended, complication awareness, medication review and follow-up scheduling. An examination is also performed and if they are experiencing a “normal” recovery, they are allowed to return home.

The most common complication we have occur following the laparoscopic gastric bypass using a 21-mm, transoral anvil placement of a circular stapling device is stricture formation at the gastrojejunostomy. As we have studied and reported on the complication over the years it has remained stable at about 4%. This occurs most frequently at 30 days postoperative (due to the phases of wound healing) and is generally treated with balloon dilation to 12 mm.

Earlier it was noted that a very small gastric pouch is created. With such a small pouch, there are very few if any parietal cells and therefore minimal to no gastric acid. Marginal ulcerations are rare in nonsmoking patient using this very small pouch technique. In addition, a small pouch tends to stay small and therefore may have more prolonged benefits to the patient. This seems to be as much physics and physiology: using Laplace law where the tension on the wall of a sphere is the product of the pressure times the radius, a small pouch will tend to stay smaller longer and hopefully more therapeutic over time.

WEIGHT LOSS AND RESOLUTION OF COMORBIDITIES

Morbid obesity is truly a systemic disease affecting every system of the body. The resultant weight loss and metabolic effects of the gastric bypass improve or resolve those systemic effects. I understand that is a strong statement but over the years, studies have shown, this has validated.

Weight loss is one of the most obvious effect since it can be measured easily but also seen. Gastric bypass, though not all performed in a standard fashion, have amazing near standard effects on comorbidity resolution. The typical weight loss at 1 year is 60% to 75% excess weight loss (EWL). There is a normal weight regain pattern such that after 5 to 10 years this falls to 50% to 60% EWL. It has been shown that to maintain the best results programmatic influence (education, follow-up, support group attendance) is important.

The beneficial effects of the gastric bypass certainly don't end with weight loss. Type 2 diabetes resolves in over 80% of patients. This effect is related to severity of disease and duration but is so profound and consistent that finally the ADA has recommended bariatric surgery. Since Dr. Pories, our group and others have noted the duration of diabetic disease versus, response to diabetic resolution following the gastric bypass, bariatric surgeons would much prefer to operate on diabetic patients before 8 years of duration. Since the gastric bypass is a low-pressure system and the small pouch has little or no acid, GERD resolves in nearly 100%. Hypertension, dyslipidemia, obstructive sleep apnea, arthritis, stress incontinence, headaches, congestive heart failure, and depression improve or resolve in the majority of postgastric bypass patients. Even more conclusive data have shown over the past several years that the all-cause mortality drops by over 30% after gastric bypass (vs. matched cohort of patients) as the incidence of heart disease, diabetes, and some cancers are decreased following the operation.

SUMMARY

It has never been more true that diabetes and the underlying cause of obesity are a major threat to the world's population. This threat is not only to the health and well-being of the people but, from a population health standpoint, to financial stability as these conditions are remarkably expensive to treat. The gastric bypass, through its restriction and hormonal effects, is an effective and consistant treatment for the disease of morbid obesity and the metabolic syndrome. Over the past 15 years training has expanded and bench mark certification has become the norm. Morbidity and mortality have been reduced. Mechanisms of action of these operations have become better understood. With all of this, the laparoscopic gastric bypass is a safe and effective treatment for this patient population.

Suggested Readings

Albaugh VL, Banan B, Ajouz H. Bile acids and bariatric surgery. *Mol Aspects Med* 2017;S0098–2997(16)30118–2.

Batterham RL, Cummings DE. Mechanisms of diabetes improvement following bariatric/metabolic surgery. *Diabetes Care* 2016;39(6):893–901.

Dixon JB, Zimmet P, Alberti KG. Bariatric surgery for diabetes: the international diabetes federation takes a position. *J Diabetes* 2011;3(4):261–4.

Kohli R, Myronovych A, Tan BK. Bile acid signaling: mechanism for bariatric surgery, cure for NASH? *Dig Dis* 2015;33(3):440–6.

Pories WJ, Swanson MS, MacDonald KG. Who would have thought it? An operation proves to be the most effective therapy for adult-onset diabetes mellitus. *Ann Surg* 1995;222(3):339–50; discussion 350–2.

Purnell JQ, Selzer F, Wahed AS, et al. Type 2 diabetes remission rates after laparoscopic gastric bypass and gastric banding: results of the longitudinal assessment of bariatric surgery study. *Diabetes Care* 2016;39(7):1101–7.

Rondan A, Nijhawan S, Majid S, et al. Low anastomotic stricture rate after Roux-en-Y gastric bypass using a 21-mm circular stapling device. *Obes Surg* 2012;22(9):1491–5.

Schauer PR, Bhatt DL, Kirwan JP. Bariatric surgery versus intensive medical therapy for diabetes - 5-year outcomes. *N Engl J Med* 2017;376(7):641–51.

Schwoerer A, Kasten K, Celio A, et al. The effect of close postoperative follow-up on co-morbidity improvement after bariatric surgery. *Surg Obes Relat Dis* 2017; S1550–7289(17)30159–4.

Spaniolas K, Pories WJ. Surgery for type 2 diabetes: the case for Roux-en-Y gastric bypass. *Surg Obes Relat Dis* 2016;12(6):1220–4.

Wittgrove AC, Clark GW. Laparoscopic gastric bypass, Roux-en-Y- 500 patients: technique and results, with 3–60 month follow-up. *Obes Surg* 2000;10(3):233–9.

Wittgrove AC, Clark GW, Tremblay LJ. Laparoscopic gastric bypass, Roux-en-Y: preliminary report of five cases. *Obes Surg* 1994;4(4):353–7.

https://asmbs.org/integrated-health/cbn-certification

EDITOR'S COMMENT

Dr. Wittgrove presents an excellent overview on laparoscopic Roux-en-Y gastric bypass. As pointed out the development and evolution of procedures in the area of bariatric surgery is a rich history. From gastric stapling to gastric banding and then gastric bypass, it was the Roux-en-Y gastric bypass that has withstood the test of time. Clearly bariatric surgery has evolved to much more

than weight reduction surgery. It is indeed a metabolic surgery.

Before considering a gastric bypass or for that matter any bariatric procedure, a multidisciplinary evaluation is necessary. This includes a medical, endocrinology, psychiatric, and dietary consultation. These evaluations are best delivered as part of a weight management center. Educational sessions and support groups both play an important role in preparing the patient for surgery and in ongoing management after the procedure.

Gastric bypass not only results in consistent and reproducible weight loss, but it also has a profound impact on the resolution of type 2 diabetes. This seems unrelated to the weight loss. Indeed gastric sleeve which is the most common bariatric procedure performed today results in equivalent weight loss but not the same impact on glucose control. I recall a patient with insulin-dependent type 2 diabetes that I did an open Roux-en-Y gastric bypass upon who presented to our clinic 2 weeks post op with signs and symptoms of hypoglycemia. We stopped his insulin with resolution of his hypoglycemia and return of normal glucose homeostasis. He had lost about 15 lb. The rapid return of normal glucose control was clearly unrelated to the weight loss.

The improved glycemic control after gastric banding or gastric sleeve depends on weight loss, but after gastric bypass surgery this improvement occurs before weight loss. Two physiologic mechanisms are thought to be responsible for the normalization of glucose control after gastric bypass. The first hypothesis is that exclusion of the duodenum and proximal jejunum may reduce insulin resistance. The second hypothesis proposes an exaggerated response from the distal small bowel to nutrients. This theoretically causes an augmented release of gastrointestinal peptides produced in the distal small bowel such as glucagon-like peptide 1 (GLP-1) which may act as incretins. Incretins act on the pancreatic beta cells to restore normal first phase insulin responses. In addition, there seems to be an increased beta cell mass in some patients following gastric bypass. In rare cases, nesidioblastosis may develop and this can lead to severe hypoglycemia. This rarely warrants pancreatic resection. Most authorities agree that the return of normal glycemic control after gastric bypass is related to changes in the secretion of gastrointestinal peptides which promote insulin secretion.

A clinical bundle for provision of care after surgery includes DVT prophylaxis, glucose monitoring, respiratory therapy, physical therapy and introduction of a step up gastric bypass diet. Early in the postoperative period the surgeon must be attentive to the possibility of a leak from the gastrojejunostomy or the enteroenterostomy. The patient may have no increase in abdominal pain. There may be neither abdominal tenderness nor peritoneal signs. The signs may be tachycardia, tachypnea, with or without fever. An upper gastrointestinal study with water-soluble contrast or CT with IV and oral contrast may establish the diagnosis. Leaks from the enteroenterostomy may be difficult to diagnose by imaging and reoperation may be warranted for the above signs in the absence of abnormal imaging.

The most common late complications include stenosis of the gastrojejunostomy, marginal ulcer, and internal hernia. Stenosis of the gastrojejunostomy occurs in approximately 3% to 27% of patients after gastric bypass, and must be suspected when the patient experiences inability to take solids or liquids, nausea and vomitingenosis is manifest as inability to eat. It is diagnosed with upper endoscopy and treated by sequential balloon dilation. The etiology of the stricture may involve a stomal ulcer, reflux, ischemia, scar retraction, or a technical complication. Technical considerations include the size of circular staple anastomoses. It also seems that circular staples are more commonly implicated than either linear staples or a hand-sewn anastomosis. There is no increase in this complication whether there is retrocolic or antecolic positioning of the Roux limb. It does seem that circular staples are more implicated than either linear staples or a hand-sewn anastomosis. Nguyen showed that this complication is more common after laparoscopic RYGBP than after open RYGBP (Nguyen NT, Stevens CM, Wolfe BM. Incidence and outcome of anastomotic stricture after laparoscopic gastric bypass. *J Gastrointest Surg* 2003;7(8):997–1003). The reasons that best explain the formation of stricture after laparoscopic RYGBP are the unpredictable blood supply to the pouch or the development of a subclinical leak at the level of the gastrojejunostomy.

Marginal ulcer formation is one of the most common complications after Roux-en-Y gastric bypass. The rate varies from 1% to 16% of RYGB patients. The etiology is unclear. Patients are often prescribed proton pump inhibitors for 90 days or longer postoperatively in an effort to prevent early marginal ulcers. In the study by Moon et al., 59 marginal ulcers occurred in 2,535 patients from 1 to 64 months after surgery (mean 15.2 months) (Moon RC, Teixeira AF, Goldbach M, et al. Management and treatment outcomes of marginal ulcers after Roux-en-Y gastric bypass at a single high volume bariatric center. *Surg Obes Relat Dis* 2014;229–34). Interestingly 44% of those with marginal ulcer required reoperations including 12 (20.3%) with perforated ulcers. Urgent operation was required in 14 (23.7%) patients due to perforation or active bleeding, and elective operation was performed in 10 (16.9%) patients for chronic and refractory ulcer or gastrogastric fistula.

After laparoscopic Roux-en-Y gastric the estimated incidence of an internal hernia is between 0.9% and 4.5% (Madan AK, Lo Menzo E, Dhawan N, et al. Internal hernias and nonclosure of mesenteric defects during laparoscopic Roux-en-Y gastric bypass. *Obes Surg* 2009;19(5):549–52). It can lead to an acute strangulation of the intestine with possible fatal consequences. With retrocolic Roux-en-Y gastric bypass two possible internal hernia sites arise: the opening in the mesentery of the enteroenterostomy and the opening between the mesentery of the alimentary loop and the mesentery of the transverse colon. A hernia through the latter is called a Petersen hernia, named for the space it occurs in. In patients with a Roux-en-Y gastric bypass with an antecolic Roux limb is associated with a lower incidence compared to a retrocolic alimentary

loop, 0.4% versus 4.5%, respectively (Champion JK, Williams M. Small bowel obstruction and internal hernias after laparoscopic Roux-en-Y gastric bypass. *Obes Surg* 2003;13(4):596–600). It has been demonstrated that closure of these spaces during gastric bypass can reduce the incidence of these hernias. However with weight loss and a decrease of mesenteric fat the spaces may reopen.

Roux-en-Y gastric bypass is a tried and true procedure for weight management and also has a normalizing effect on the loss of glycemic control in type 2 diabetes.

E. Christopher Ellison

98 Laparoscopic Gastric Sleeve

Emanuele Lo Menzo, Samuel Szomstein, and Raul J. Rosenthal

INTRODUCTION

The statistics of worldwide obesity continue to illustrate upward trends. In fact, based on the *2013 Guidelines for the Management of Overweight and Obesity in Adults* released by the American College of Cardiology, the American Heart Association, and the Obesity Society, 64.5% of American adults are recommended for weight loss treatment. This translates into 140.2 million adults, which is a 20.9% increment compared to 1998. Of this astonishing number, up to 53.4% (116.1 million) of adults could be considered for pharmacologic therapy in addition to lifestyle therapy, and up to 14.7% (32.0 million) could be considered for bariatric surgery. However, the estimates regarding bariatric surgery needs are based on the current criteria set by the 1991 National Institutes of Health (NIH) Consensus Conference.

As expected, the prevalence of obesity-related comorbidities is also expected to exponentially increase with time. According to the World Health Statistics of 2012 from the WHO, diabetes currently affects 1 in 10 adults. The International Diabetes Federation has calculated that the number of patients with diabetes will increase from 366 million in 2011 to 552 million by 2030.

Bariatric surgery has been long recognized as the most effective remedy for morbid obesity and its associated comorbidities. It is not surprising then that the total number of bariatric operations worldwide has dramatically increased and will likely continue to do so. According to the estimates of the American Society of Metabolic and Bariatric Surgery, 193,000 bariatric procedures were performed in the United States during 2014. If the total number of procedures should not pose any surprise, the breakdown of the types might. In fact, according to the same source, the percentages of the different bariatric operations were as follows: sleeve gastrectomy 51.7%, Roux-en-Y gastric bypass (RYGB) 26.8%, revisional procedures 11.5%, laparoscopic adjustable gastric bands (LAGBs) 9.5%, and biliopancreatic diversions (BPDs) with or without duodenal switch

(DS) 0.4%.

We will be describing in this chapter the characteristics of the most popular of the bariatric operations, the laparoscopic gastric sleeve or sleeve gastrectomy (LSG) from its historic perspectives to the current technique, as well as its complications and results.

HISTORY OF LSG

The idea of a vertically shaped gastroplasty to modify the flow of nutrients dates back to the late 1990s. The authors then introduced the concept of the Magenstrasse, or “street of the stomach,” which conveys food from the esophagus to the antral Mill. After that original description, no bariatric application of the concept was described until Hess in 1988 initially and Marceau later in 1993 combined the BPD by Scopinaro with the DS described by DeMeester for reflux gastritis. In fact, the major flaws of the Scopinaro BPD were marginal ulceration and bile reflux gastritis. Also Lawrence L. Tretbar reported weight loss after anti-reflux surgery, so he begun extending the fundoplication in order to create a tubular stomach.

In order to keep the pylorus intact, the shape of the gastrectomy had to be modified in the modern lesser curvature-based sleeve. At this stage, however, the majority of the metabolic and weight loss successes of the BPD-DS were mostly attributed to the malabsorptive component of the operation, and only in small percentage to the restrictive nature of the sleeve itself.

The next stage of the evolution of the modern LSG is marked by the description of a totally laparoscopic BPD-DS. Although very effective for weight loss, the laparoscopic BPD-DS carried significant short-term morbidity. For this reason, the isolated LSG was introduced as a first-stage operation for high-risk superobese patients, with the intent of performing the completion BPD-DS with malabsorptive intestinal resections and reanastomosis 6 months after the initial weight loss. However, during the close follow-up after the LSG stage, it was noticed that 94% of patients continued to experience significant weight loss and comorbidity resolution and never required progression to the full BPD-DS. Since then, the LSG experienced a substantial increase in popularity among bariatric surgeons to the point of reaching the leadership in terms of number of procedures performed annually for weight loss.

INDICATIONS AND CONTRAINDICATIONS

In general, the indications for LSG remain the same as per any bariatric operations. The criteria are still the ones established by the 1991 NIH consensus conference and include severe obesity of body mass index (BMI) between 35 and 40 kg/m^2 with related comorbidities such as hypertension, diabetes, coronary artery disease, obstructive sleep apnea, or morbid obesity of BMI of 40 kg/m^2 or greater even in the absence of related comorbid conditions. Obviously, the recommendations were made based on the clinical evidence and procedures available at the time, namely RYGB, BPD, and vertical banded gastroplasty (VBG).

Significant evolutions of techniques and research have occurred since then, including the introduction of laparoscopic techniques in 1994. Currently the majority of the bariatric operations are performed laparoscopically, with significantly lower morbidity and mortalities lower than laparoscopic cholecystectomies. The VBG, in spite of its respectable mid-term results, demonstrated high rates of weight regain and complications that led to its disappearance from clinical practice. Also, the introduction of alternative operations such as the LAGB and LSG with better safety records was not taken into consideration to establish the criteria for surgery. Finally, those recommendations were made with only little evidence of the positive metabolic effects of these procedures, in particular on diabetes mellitus. Now level 1 evidence exists on the benefit of most of the bariatric operations on type 2 diabetes with mechanisms beyond weight reduction and decrease in calorie intake.

Because of its relative simplicity in technique, LSG has also been utilized with good success and safety in obese pre-kidney and transplant candidates in order to improve future graft function and preservation.

It is paramount to select motivated patients who are willing to commit to the lifelong changes these procedures require and with good understanding of the potential risks and complications.

Among the contraindications are prohibitive anesthesia risks, advanced malignancy, and severe uncontrolled psychiatric illnesses, including certain eating disorders (malignant hyperphagia). More specifically to LSG, the presence of uncontrolled gastric reflux, especially in the presence of histologic changes at the esophagogastric junction (Barrett esophagus), is considered a relative contraindication. Also a history of severe gastroesophageal reflux disease (GERD) is considered by most experts an absolute contraindications, although this remains a controversial topic.

PREOPERATIVE PLANNING

Preoperative planning for LSG is similar to the other bariatric operations. The patient should be appropriately counseled about the risks, benefits, implications, and necessary dietary and lifestyle modifications. Often this process is conducted during multidisciplinary intake seminars. After this initial introduction to bariatric surgery, a one-to-one consultation with the surgeon addresses the details of the patients' medical conditions, risk assessments, and formulation of goals and expectations. Fundamental to the success of any bariatric operation is dietary counseling, in which perioperative and postoperative modifications are carefully explained. The next step is to obtain both appropriate medical and psychological clearances. We routinely obtain either an upper intestinal contrast evaluation or upper endoscopy. This is especially important for patients with history of gastroesophageal reflux or Barrett esophagus. What is unclear is the role of preoperative pH/impedance.

SURGICAL TECHNIQUE

The LSG consists of a partial gastrectomy of the greater curvature along the vertical axis of the stomach. As such, the remaining stomach is constituted primarily by the lesser curvature. Furthermore, a functional pylorus and a variable portion of the antrum are left in place (Fig. 98.1).

The abdominal cavity is accessed in the supraumbilical region and just to the left of the midline using an optical trocar. After exploration of the abdominal cavity, two auxiliary 5-mm trocars are inserted in the sub-xyphoid position for the liver retractor and along the anterior axillary line just below the 12th rib for the assistant. Once the liver is reflected cephalad using a "fan-type" retractor, four additional 12-mm trocars are inserted in the right upper quadrant, epigastrium, left upper quadrant, and right paramedian regions (Fig. 98.2).

The pylorus is then identified by both "palpation" with laparoscopic grasper and visualization of the prepyloric vein of Mayo. At a distance of approximately 2 to 6 cm from the pylorus, the short gastric vessels are divided using ultrasonic energy. This step allows access to the lesser sac (Fig. 98.3). Occasionally in the presence of thicker omentum, it is recommended to gain access to the lesser sac more superiorly along the greater curvature of the stomach by starting the division of the short gastric vessels more proximally. In this latter scenario, the more distal short gastric vessels can be divided directing the dissection toward the pylorus.

The rest of the short gastric vessels are then divided sequentially by marching along the greater curvature of the stomach. At the level of the proximal body of the stomach, the gastrosplenic ligament is constituted by two separate leaflets of peritoneum, one more anterior and one more posterior. Whenever the thickness is significant, the two leaflets can be divided separately. Often the splenic artery is readily visible at this point. Since the fundus of the stomach is variably in contact with the spleen capsule, gentle traction has to be used. Then the assistant retracts the upper body of the stomach medially and inferiorly in order to expose the first short gastric vessels and the left crus of the diaphragm (Fig. 98.4). If a known or visible hiatal hernia is identified, a formal hiatal dissection and posterior hernia repair are performed. However, it is our practice to postpone the hiatal closure to the end of the procedure after the sleeve has been completed. Additional posterior gastric adhesions are removed in order to assure proper visualization of the lesser curvature of the stomach.

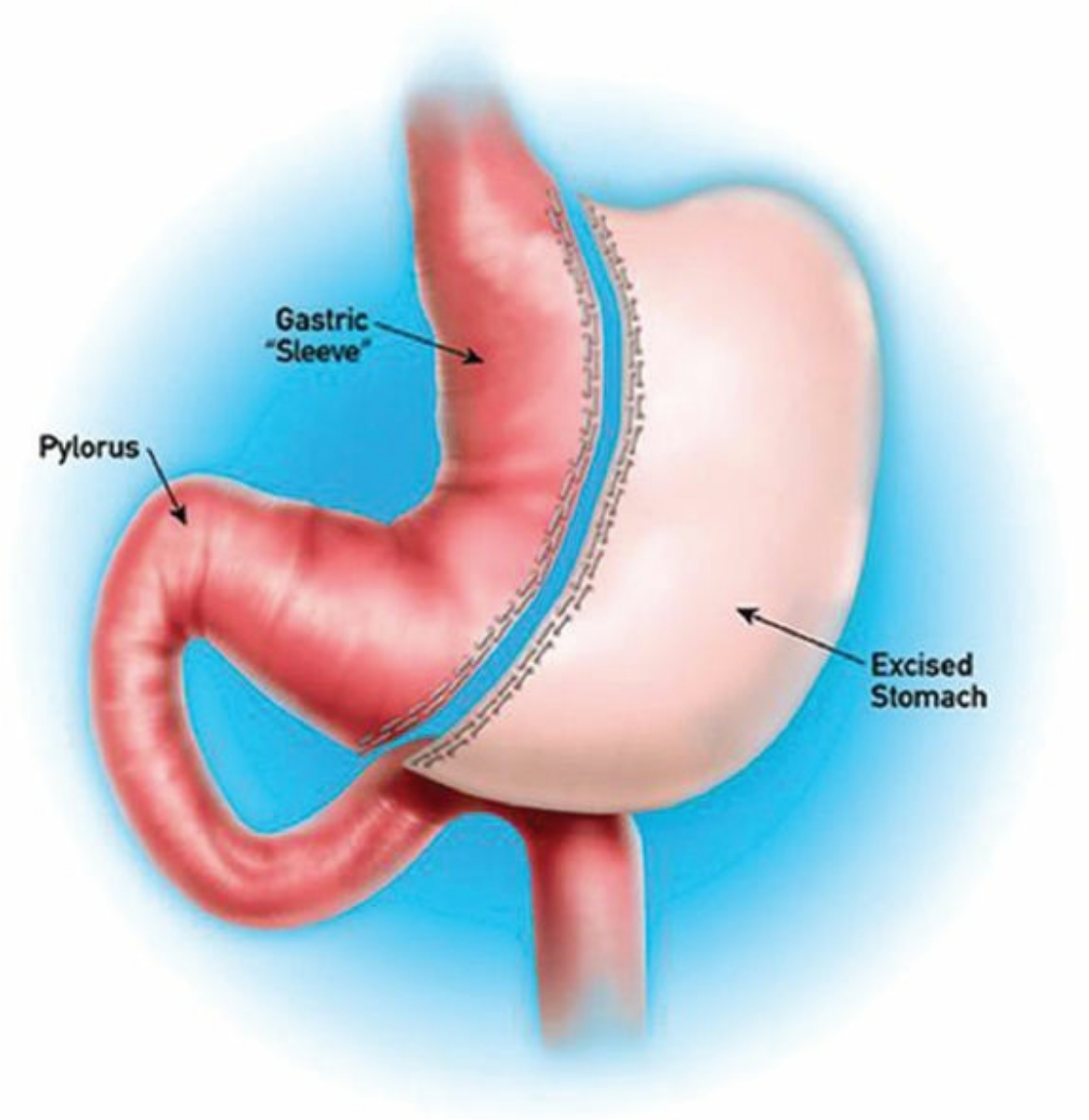

Figure 98.1. Diagram illustrating the final anatomy of the sleeve gastrectomy. Only the greater curvature side of the stomach is removed. The pylorus is preserved. (*Source:* http://www.chicoweightloss.com/bariatric-surgery/vertical-sleeve-gastrectomy/)

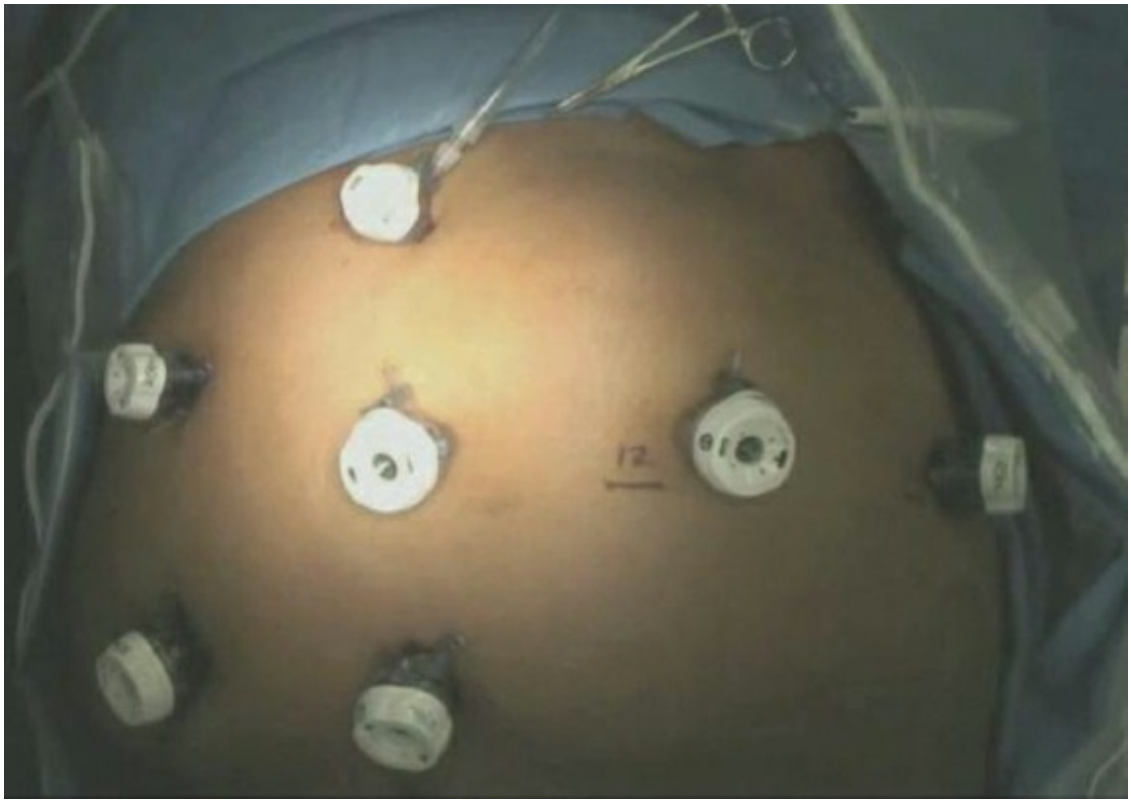

Figure 98.2. Trocar placement for laparoscopic sleeve gastrectomy.



Figure 98.3. The ultrasonic dissector is used to divide the vessels on the greater curvature of the stomach.

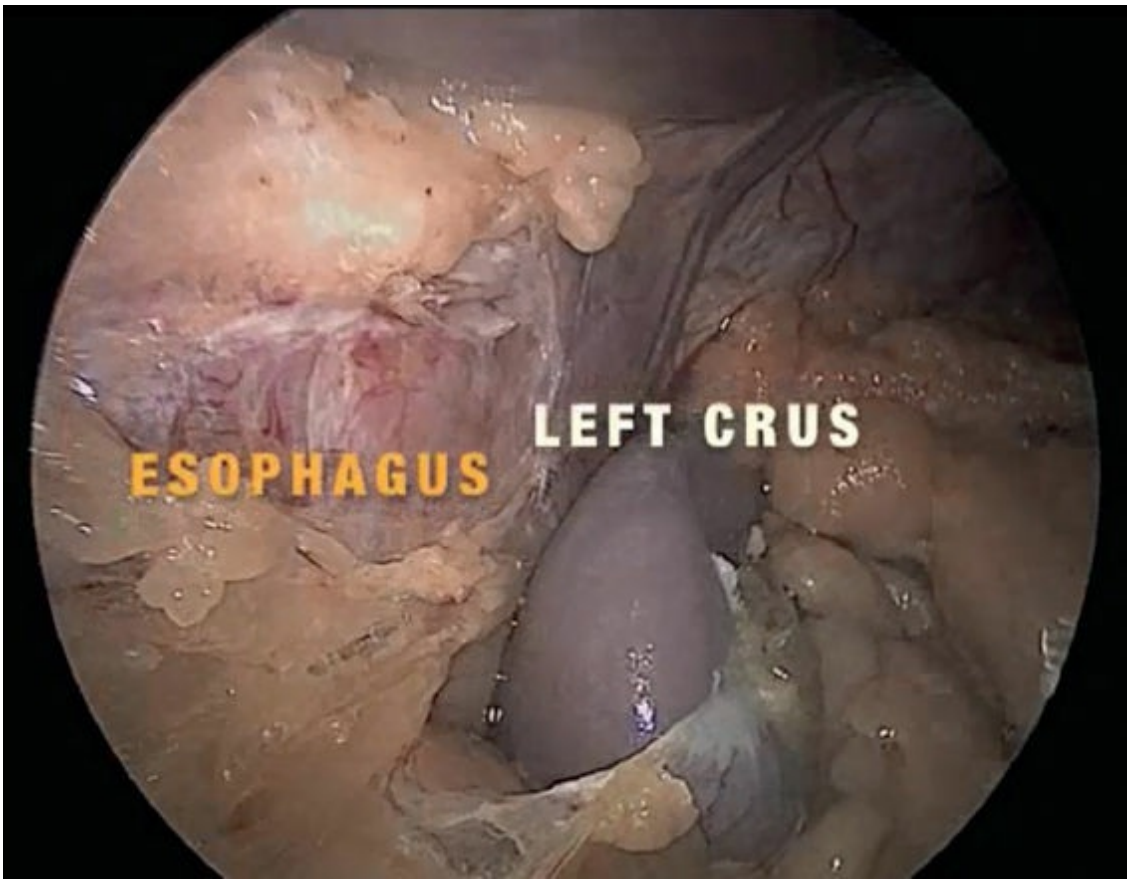

Figure 98.4. The vessel dissection is carried out to expose the left crus of the diaphragm.

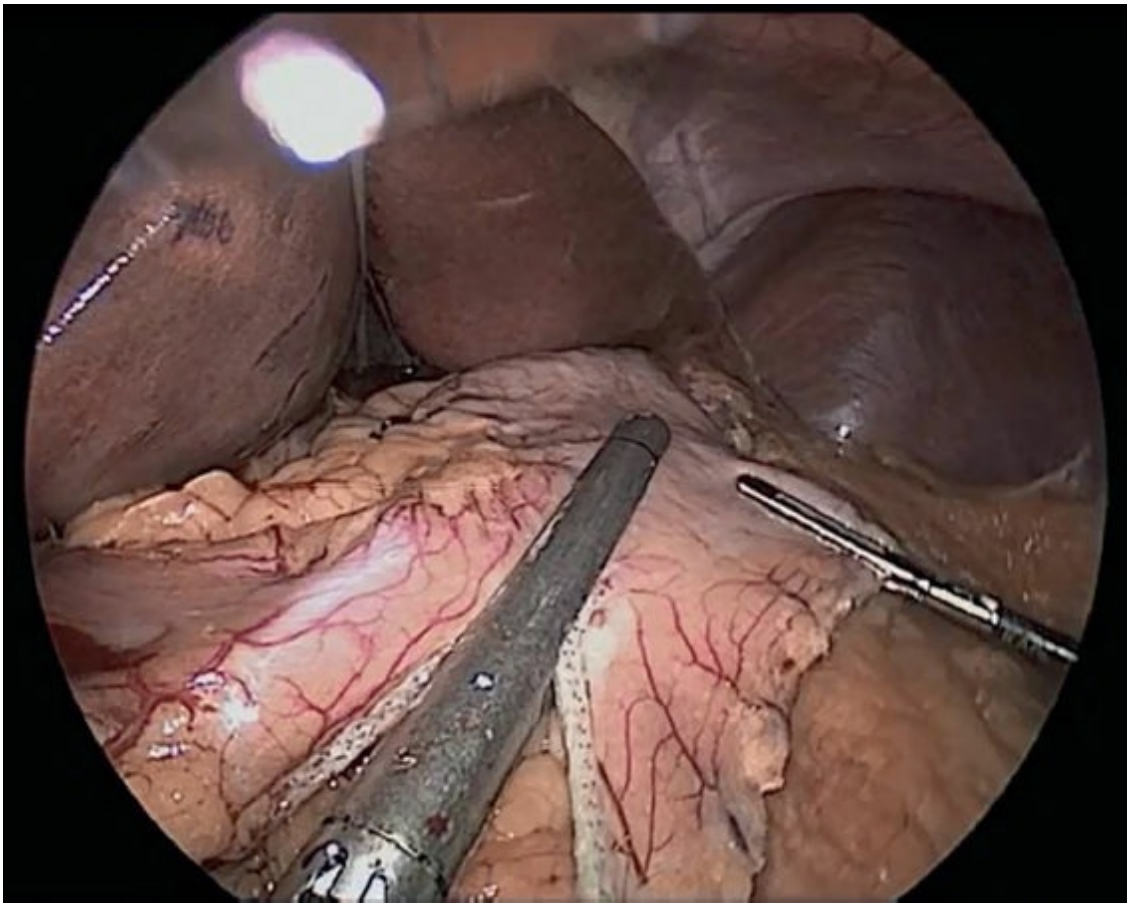

Figure 98.5. The stapling of the stomach is done while symmetric traction is applied by the assistant.

At this point, an orogastric calibrating tube is introduced by the anesthesiologist and carefully advanced to the antrum under direct visual guidance. It is important to remember that the esophagogastric junction is located posteriorly, so cephalad and medial retraction of the gastric fundus is necessary to visualize the orogastric tube once it reaches the proximal stomach. Variable types and sizes of calibrating tubes have been described in the literature, and significant variation remains in practice. However, based on the International Sleeve Gastrectomy Expert Panel Consensus Statement, the optimal sizes are between 32 and 36 Fr. In our practice, we use a 38-Fr mercury-weighed Hurst bougie. The tapered tip Maloney type can be used as it negotiates the curve of the antrum better, but care must be taken not to include its fine tip into the stapler.

The 60-mm linear stapler is then utilized to sequentially divide the stomach. The first fire starts 2 to 6 cm from the pylorus, and it is oriented rather horizontally toward the patient’s left shoulder. The articulation of the stapler head and the utilization of different trocars aid in obtaining the

optimal angle of staple firing. It is imperative to pay attention at the level of the incisura angularis in order to avoid excessive narrowing of the sleeve. Additional important technical aspects are the symmetrical lateral retraction of the greater curvature by the assistant and the visualization of both the anterior and posterior aspect of the sleeve prior to each cartridge firing. Pitfalls of this key aspect of the procedure include excessive narrowing of the sleeve from firing too close to the bougie and spiral twisting of the sleeve from asymmetrical lateral traction of either the posterior or anterior wall of the stomach (Fig. 98.5).

The next key stapling area is by the esophagogastric junction. In general, our preference is to avoid abutting the stapler to the bougie at this level and preserving the esophagogastric fat pad. In our opinion, this maneuver will decrease the chance of potential ischemia of the superior corner of the sleeve. However, different schools of thought exist and proponents of closer stapling to the esophagogastric junction believe that redundancy of gastric tissue at this level might contribute to the development of postoperative gastroesophageal reflux.

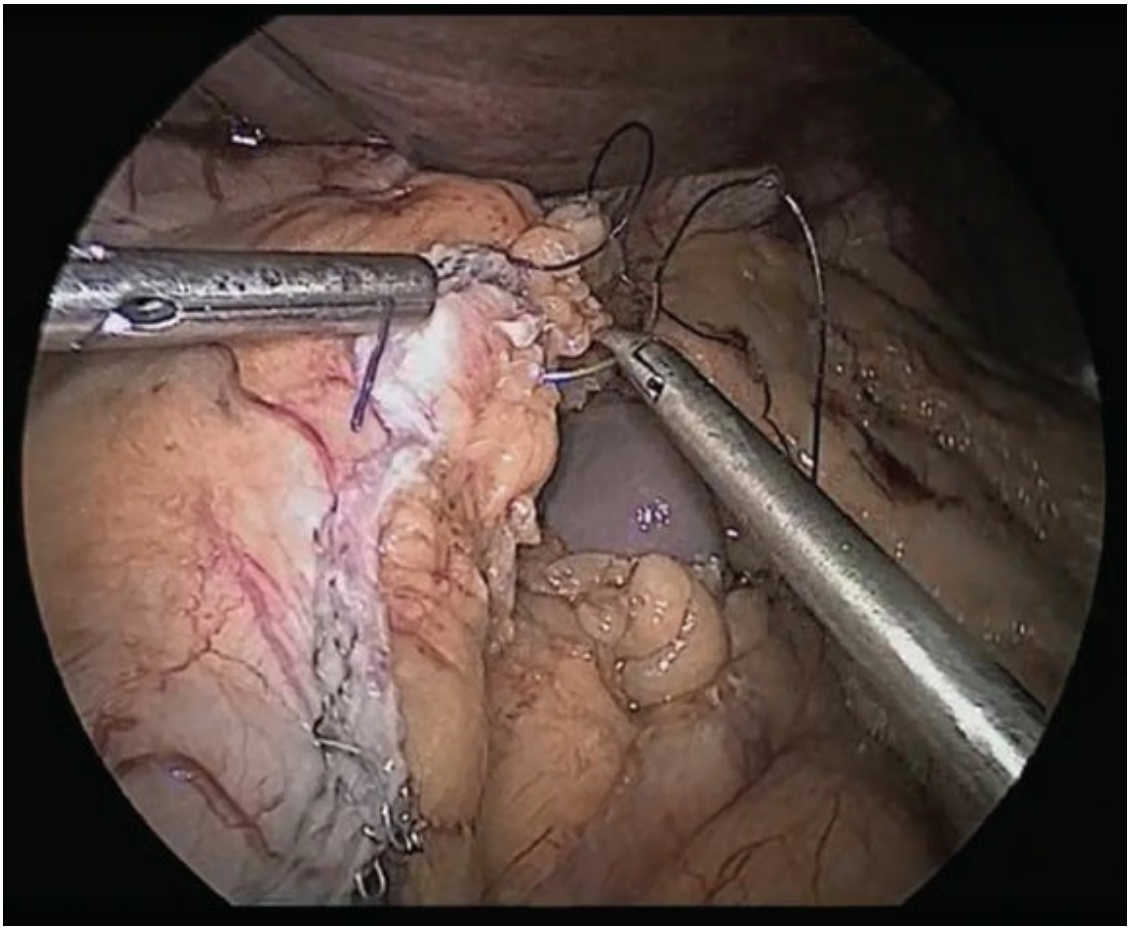

Figure 98.6. The staple line is oversewn with imbricating suture

while the bougie is in place.

Although not uniformly accepted, the general consensus calls for reinforcement of the long staple line resulting from the gastric resection. This reinforcement can be obtained either by using absorbable synthetic or biologic staple line reinforcement strips or by oversewing the staple line in its entirety or in parts. Our preference is to imbricate the entire staple line using absorbable sutures (Fig. 98.6). It is paramount to maintain the bougie in place during this step, as generous imbrication can lead to sleeve stenosis.

The procedure terminates with the specimen extraction and port sites closure.

POSTOPERATIVE CARE

The patient is transferred to a monitor setting, especially if previous history of obstructive sleep apnea exists. Postoperative nausea is a common finding, and it can be controlled with intravenous ondansetron, with the addition of prochlorperazine and/or scopolamine patch as needed.

Standard deep vein thrombosis prophylaxis with fractionated or unfractionated heparin is carried out as per protocol. Early ambulation is also paramount to decrease the incidence of deep vein thrombosis. The day after the procedure, the patient is started on a clear liquid diet and, if tolerated, can be discharged home.

Postoperative upper gastrointestinal (UGI) contrast studies are used selectively in cases of oral intolerance or clinical derangements for the normal postoperative course. Pain control can be achieved with either intravenous narcotics or, when available, intravenous acetaminophen. Liquid or crushed oral narcotics are prescribed upon discharge.

COMPLICATIONS AND THEIR MANAGEMENT

LSG is, in appearance, a technically easy operation, especially for the bariatric surgeon. However, several pitfalls of this procedure exist. Postoperative complications related to the actual technical aspect of the sleeve include bleeding, leak, and stenosis. The other postoperative complications such as cardiovascular, thromboembolic, and pulmonary will not be discussed in this chapter.

Bleeding

Postoperative bleeding should be suspected in the case of tachycardia, especially if this is cyclical. Hypotension, low urine output, and shock are more advanced signs of persistent hemorrhage. Postoperative bleeding after LSG can be encountered intra-abdominally, intraluminally, or at the port sites. Overall bleeding after LSG has been described in up to 15% of the cases. The most likely sources of intra-abdominal bleeding are at the level of the devascularization of the greater curvature of the stomach, in particular the short gastric vessels and spleen itself. Under normal conditions, ultrasonic energy is very safe and effective in the devascularization of the stomach. However, whenever the instrument is not entirely across the vessel or in the presence of thick surrounding fat, the vessel sealing could be incomplete. Furthermore, the fundus of the stomach is at a variable distance to the spleen itself. It is not uncommon to then determine either traction or burn injuries to the splenic capsule itself. Small tears can be managed with pressure and topical hemostatic agents, whereas larger tears and significant bleeding from the organ might even require splenectomy in rare cases. In order to avoid this complication, it is important to obtain clear exposure to the left upper quadrant. The divided omentum needs to be retracted laterally and the gastric fundus and body medially. The first short gastric vessels are posterior and, once transected, can retract into the adipose tissue, obscuring the presence of continuous hemorrhage.

The long staple line can be the source of both intraluminal and intra-abdominal bleeding. The intra-abdominal component can be easily visualized and treated with clips, sutures, and fibrin glue. Evidence exists on the efficacy of staple line reinforcement in the prevention of staple line bleeding. More difficult to diagnose is intraluminal bleeding. In fact, the long staple line in such a well-vascularized organ is the perfect setup for the complication. Furthermore, a bleeding staple line might indicate a weaker area susceptible to leak. The presence of hematemesis or melena in the setting of a dropping hematocrit leads to an easy diagnosis of intraluminal bleeding. Slower bleeding might require endoscopy to be recognized. Most often, the intraluminal bleeding is self-limited, but it can require endoscopic or surgical intervention.

Port site hemorrhage is rare; however, it can be significant and insidious. Direct observation of the port site after removal of the port itself helps with early recognition and treatment of this complication. But this is not foolproof and bleeding can start later after the pneumoperitoneum is

evacuated and the systemic blood pressure increases.

Staple Line Leak

Although LSG does not involve any anastomosis, the long staple line, the increased intraluminal pressure for the narrower diameter of the organ, and the presence of an intact pylorus and, often, lower esophageal sphincter (LES) explain the higher incidence of leaks as compared to the RYGB (0.7% to 2.4% in large retrospective studies). For all these reasons, the leaks are also less likely to close spontaneously as compared to RYGB.

As in other staple line leaks, the etiology includes ischemia, staple line hematomas, staple malfunction, and the already mentioned increased intraluminal pressure proper of the LSG. Staple misfiring is not such an uncommon event. Besides the rare manufacturing issues, the rest of the misfires are due to improper choice of staple height, or use of the stapler itself. In choosing staple heights, consideration should be given to the progressive decrease in thickness of the gastric wall from the antrum to the fundus. Also, in order to avoid potential misfires, care must be taken not to include excessive tissue at the site of staple closure and removing loose staples from the trajectory of the knife of the device. Staple line leaks can result from staple firings too close to the bougie as well, especially in case of smaller bougie size.

Based on the timing of onset, leaks can be identified as acute (within 7 days), early (within 1 to 6 weeks), late (after 6 weeks), and chronic (after 12 weeks). The timing of the leak is strictly related to its etiology. Technical staple line problems tend to manifest early on. Ischemic leaks, on the other hand, become clinically apparent around 5 to 7 days postoperatively. Finally, the leaks secondary to stricture or torsion of the gastric body can manifest even later.

As far as location goes, most commonly the leak occurs in the proximal aspect of the LSG at the esophagogastric junction. This is in fact the most vulnerable area in the presence of distal stenosis. Distal leaks are less common and more likely result from technical staple line failure.

The diagnosis of leak is clinical first of all, and sustained tachycardia is the most consistent sign. Also fever, abdominal pain, tachypnea, and increased white blood cell count (WBC) and C-reactive protein are commonly found, but are not obligatory signs. Abdominal pain can be localized at the epigastrium, left shoulder, back, or diffusely in the abdomen. Among the imaging studies, computed tomography (CT) scan is

the most sensitive to diagnose staple line leaks. In fact, in addition to potentially showing the leak itself, it can identify secondary changes related to it, such as extraluminal collections, fat stranding, pleural effusion, and free air. Contrast UGI series have lower sensitivity, and it can be deceiving if obtained immediately after surgery when most of the leaks have yet to occur. Finally the combination of the two modalities increases further the accuracy of the diagnosis in up to 84% of cases.

The treatment of the leak is guided by the following main factors, the overall clinical condition of the patient, the timing, and location of it. The goals of treatment are control of the local and systemic sepsis with wide drainage and broad-spectrum antibiotics and antifungals, control of the secretions with nil by os, and early nutrition either enteral via jejunostomy tube or parenterally. As for any other bariatric procedures, in the presence of hemodynamical instability and uncontrolled sepsis, emergent reexploration is mandatory. Under these circumstances, primary repair of the leak is seldom possible or effective. In cases of hemodynamically stable patients nonoperative options can be used. Imaging-guided percutaneous drainage, endoscopic procedures such as stents and clipping, and distal dilatations have all been described with mixed results.

Undoubtedly these endoscopic options find their best application in acute and early leaks, as they are usually futile once the leak has become chronic. Distal leaks can be converted to controlled fistula by inserting a T-tube directly in the fistulous tract. In the absence of distal obstruction, the t-tube can be clamped and removed after 4 to 6 weeks. More challenging are the proximal leaks that become chronic. These leaks can also fistulize into adjacent viscera and anatomic space, including the pleural space. As previously mentioned, less invasive endoscopic approaches are rarely effective in these cases, and more radical surgical is necessary. It is important to optimize patients' nutrition, to control local and systemic sepsis, and to temporize until 12 weeks prior to operation in order to find a less hostile surgical field. The described surgical options are based on small cohort studies. One option involves suturing a Roux limb directly to the fistulous tract, as proposed by van de Vrande et al. In their report, the success rate was 100%, with 54% achieving immediate resolution. The other alternative has been described by our group and consists of a laparoscopic proximal gastrectomy including the fistulous tract with a Roux-en-Y esophagojejunostomy. In our initial experience, we reported a releak rate of 6.6%, requiring only 4 weeks of nil by mouth and

total parenteral nutrition, but no other significant morbidity or mortality.

Stenosis

Stenosis is another worrisome complication of LSG, and it can be the cause of a proximal leak from increased intraluminal pressure. The incidence of stenosis is between 0.26% and 4%. The etiology of the stricture is usually mechanical, and derives from the use of small bougies, stapling too close to it, especially at the incisura angularis, twisting of the staple line creating a “spiral” sleeve, or aggressive imbrication of the staple line itself. Functional stenoses are typically transient and derived from edema or hematomas of the staple line. The latter type of stenosis presents immediately after the LSG and resolves spontaneously with expectant treatment.

Based on the timing of onset, the stricture can be manifest acutely or early after sleeve or more chronically. The location is mostly at the level of the incisura angularis, but they can occur anywhere along the long staple line.

The diagnosis is usually clinical. The typical findings are regurgitation, vomiting, poor oral tolerance, frothing and sialorrhea, or gastroesophageal reflux. As previously mentioned, the distal stenosis can be the cause of a proximal leak, so the symptoms could be as previously described. UGI is usually the first diagnostic test. This is usually performed with water-soluble contrast, especially if a leak needs to be ruled out. However, the risk of aspiration has to be taken into account. The UGI can give important information regarding the presence of kinking, degree of obstruction, and location of the stenosis. EGD is a complementary test, and it should be reserved for stenoses that do not quickly resolve. The EGD can confirm the presence of internal kinking and narrowing, but also diagnose spiraling along the vertical axis of the sleeve itself. In milder cases, the gentle dilatation of the endoscope can be therapeutic. Some authors have used technetium-99m scintigraphy as a diagnostic modality, as well.

The treatment modality depends on the time of onset, the degree of obstruction, and the possible etiology. As previously mentioned, stenoses that occur immediately after surgery can be usually treated with observation nil per os, protein pump inhibitors, and antiemetics. If the stenosis is functional in origin, it will likely resolve in a few days. Occasional careful passage of nasogastric tubes, preferably under fluoroscopy, is necessary to control the secretions.

If nonoperative management fails, invasive intervention is necessary. The role of endoscopy in these cases is limited to dilatation with or without stenting. The success rate depends on the etiology and degree of stenosis, but can be as high as 88%.

When reoperation is necessary, several options are available. In the acute phase, the simple removal of the imbricating suture could be therapeutic. Another option is to perform a gastric seromyotomy of the stenosed segment. This technique was described by Dapri et al., and according to their series of 14 patients they reported a significant leak rate (35.7%) and need for reoperation (35.7%). The same authors also reported fewer cases of segmental gastrectomy of the stenosed segment and gastro-gastrostomy. However, long-term studies are needed to assess the outcome of this technique.

Finally, the conversion to RYGB is probably the most utilized option. This can be accomplished laparoscopically with minimal morbidity.

OUTCOMES

Over the last several years, LSG has been performed with increased frequency, to the point that it is now the most common primary bariatric operation. Part of its increased popularity is certainly due to the relative technical simplicity of the operation. But also, the overall very positive results have contributed to it. Based on large database reviews, LSG compares very favorably with the LAGB and RYGB. In fact, in terms of postoperative complications, readmissions, and reintervention, LSG (5.6%, 5.4%, 2.97%, respectively) offers better results than laparoscopic Roux-en-Y gastric bypass (LRYGB) (5.9%, 6.4%, 5%, respectively) but worse than the LAGB (1.4%, 1.7%, 0.9%, respectively). However, when weight loss and comorbidity resolution results are analyzed, the LSG is far superior than the LAGB and slightly inferior to the RYGB. Based on our series of 1,020 patients, we reported a mean percentage of excess weight loss (%EWL) at 1, 3, 5, and 8 years of 86%, 63%, 61%, and 52%, respectively. This translates to an overall success rate (%EWL > 50%) of 92% after 1 year, 89% after 3 years, 75% after 5 years, and 73% after 8 years. Early postoperative complications included leak in 0.1%, stricture in 0.1%, and bleeding not requiring reintervention in 3%. Long-term complications included stricture in 0.49% and gastroesophageal reflux disease (GERD) in 6%. As far as remission of comorbidities, diabetes improved or resolved in 57% of the patients, hypertension in 91%, obstructive sleep apnea in 99%,

and hyperlipidemia in 79%. There was no mortality in this series.

These results are comparable to the long-term result of LRYGB based on the Swedish Obese Subject Study. When LSG and LRYGB are directly compared in randomized controlled trials, there is no significant difference between the two procedures as far as levels of glycosylated hemoglobin, fasting plasma glucose, number of subjects using oral antihyperglycemic medications and insulin, body weight, BMI, or waist circumference. The only significant difference found between the two procedures is the cardiovascular risk, which is decreased significantly more in the RYGB group. Five year results of randomized trial continue to show comparable metabolic improvements of LSG as compared to LRYGB.

CONCLUSIONS

LSG is currently the most commonly bariatric operation performed. Its popularity is mostly due to the technical simplicity, the overall paucity of short and long-term complications, and the effectiveness for both weight loss and comorbidity resolution. However, several critical aspects of its technique should be kept in mind in order to avoid severe morbidity. In general, LSG is more comparable to LAGB in terms of complication and to LRYGB in terms of results. Furthermore, when compared to other procedures LSG is not only simple as a primary procedure, but it also offers more and safer reoperative alternatives in case of weight regain.

Suggested Readings

Alvarenga ES, Lo Menzo E, Szomstein S, Rosenthal RJ. Safety and efficacy of 1020 consecutive laparoscopic sleeve gastrectomies performed as a primary treatment modality for morbid obesity. A single-center experience from the metabolic and bariatric surgical accreditation quality and improvement program. *Surg Endosc* 2016;30(7):2673–8.

Aurora AR, Khaitan L, Saber AA. Sleeve gastrectomy and the risk of leak: a systematic analysis of 4,888 patients. *Surg Endosc* 2012;26(6):1509–15.

Dapri G, Cadière GB, Himpens J. Laparoscopic seromyotomy for long stenosis after sleeve gastrectomy with or without duodenal switch. *Obes Surg* 2009;19(4):495–9.

Fridman A, Moon R, Cozacov Y, Ampudia C, Lo Menzo E, Szomstein S, Rosenthal RJ. Procedure-related morbidity in bariatric surgery: a retrospective short- and mid-term follow-up of a single institution of the American College of Surgeons Bariatric Surgery Centers of Excellence. *J Am Coll Surg*

2013;217(4):614–20.

Regan JP, Inabnet WB, Gagner M, et al. Early experience with two-stage laparoscopic Roux-en-Y gastric bypass as an alternative in the super-super obese patient. *Obes Surg* 2003;13:861–4.

Rosenthal RJ; International Sleeve Gastrectomy Expert Panel. International Sleeve Gastrectomy Expert Panel Consensus Statement: best practice guidelines based on experience of >12,000 cases. *Surg Obes Relat Dis* 2012;8(1):8–19.

Sasson M, Ahmad H, Dip F, et al. Comparison between major and minor surgical procedures for the treatment of chronic staple line disruption after laparoscopic sleeve gastrectomy. *Surg Obes Relat Dis* 2016;12(5):969–75.

Schauer PR, Bhatt DL, Kirwan JP, et al.; STAMPEDE Investigators. Bariatric surgery versus intensive medical therapy for diabetes—5-year outcomes. *N Engl J Med* 2017;376(7):641–51.

Thompson CE 3rd, Ahmad H, Lo Menzo E, et al. Outcomes of laparoscopic proximal gastrectomy with esophagojejunal reconstruction for chronic staple line disruption after laparoscopic sleeve gastrectomy. *Surg Obes Relat Dis* 2014;10(3):455–9.

van de Vrande S, Himpens J, El Mourad H, et al. Management of chronic proximal fistulas after sleeve gastrectomy by laparoscopic Roux-limb placement. *Surg Obes Relat Dis* 2013;9(6):856–61.

Vilallonga R, Himpens J, van de Vrande S. Laparoscopic management of persistent strictures after laparoscopic sleeve gastrectomy. *Obes Surg* 2013;23(10):1655–61.

Wang MC, Guo XH, Zhang YW, et al. Laparoscopic Roux-en-Y gastric bypass versus sleeve gastrectomy for obese patients with type 2 diabetes: a meta-analysis of randomized controlled trials. *Am Surg* 2015;81(2):164–9.

EDITOR'S COMMENT

Drs. Lo Menzo, Szomstein, and Rosenthal have together written an exceptional chapter on laparoscopic sleeve gastrectomy. I find the story of the evolution of the sleeve gastrectomy from an almost accidentally created operation to the most commonly performed bariatric surgical procedure in the United States to be fascinating. The sleeve gastrectomy has enjoyed a rapid surge in popularity over a very brief period of time. According to the American Society for Metabolic and Bariatric Surgery, in 2011 the sleeve gastrectomy accounted for 17.8% of all bariatric procedures. By 2015, this had increased to 53.8% of all procedures.

There are several advantages to the sleeve gastrectomy when compared to other commonly performed bariatric surgical procedures. From a technical perspective, the sleeve gastrectomy is easier to perform (especially in patients

who suffer from super morbid obesity) than the laparoscopic Roux-en-Y gastric bypass. In patients with a significant history of prior intra-abdominal surgical procedures (perforated diverticulitis, laparotomy for bowel obstruction for example), sleeve gastrectomy may be more feasible than a gastric bypass. A sleeve gastrectomy is a simpler operation with fewer steps and requires less intra-abdominal laparoscopic working space (hard to come by during laparoscopy in the super obese) than the gastric bypass. These features of the sleeve gastrectomy can facilitate the minimally invasive approach to bariatric surgery in extremely obese patients. In fact, the sleeve gastrectomy evolved as a stand-alone bariatric operation in part related to these facts.

I performed a quick review of the Metabolic and Bariatric Surgery Accreditation and Quality Improvement Program (MBSAQIP) database for 2016 and determined that at accredited centers, there were significant differences in patients who underwent sleeve gastrectomy compared to gastric bypass. Patients undergoing gastric bypass (n = 45,370 gastric bypasses and n = 115,627 sleeve gastrectomies) were more likely to suffer from obstructive sleep apnea (42.5% vs. 32.5%, $p < 0.001$), GERD (39.6% vs. 28.6%, $p < 0.001$), to have a previous history of a deep vein thrombosis (DVT) (2.0% vs. 1.5%, $p < 0.001$), or to suffer from diabetes (33.9% vs. 22.7%, $p < 0.001$). A published and peer-reviewed analysis of National Surgical Quality Improvement Program (NSQIP) data reveals a trend in favor of females, lower body mass index (BMI), and fewer patients with diabetes and hypertension in sleeve gastrectomy. There is significant local and regional variation in practice related to who is counseled to undergo a sleeve gastrectomy across the country. In fact, many bariatric centers only offer sleeve gastrectomy.

A prospective, randomized controlled trial comparing sleeve gastrectomy to gastric bypass conducted in Switzerland compared outcomes at 3 years postop for 217 patients to undergo either a laparoscopic sleeve gastrectomy or a laparoscopic Roux-en-Y gastric bypass. Excess BMI loss was equivalent in each study group at 3 years. Comorbidities were significantly reduced and comparable after both procedures with the exception of GERD and dyslipidemia, which were both more successfully treated with a gastric bypass. Complication rates were similar in each study arm. A recently published meta-analysis of six randomized controlled trials including 695 patients and comparing complication rates after sleeve gastrectomy and gastric bypass determined that the sleeve gastrectomy was associated with significantly fewer major complications within 30 days of surgery. Neither procedure was found to have a higher readmission rate, reoperation rate, or 30-day mortality.

A couple of specific complications discussed in this chapter warrant additional discussion. Leak following sleeve gastrectomy is fortunately a rare event. I'll add to the discussion on treatment options for chronic leaks after sleeve gastrectomy the option of negative pressure vacuum-assisted closure (VAC) treatment. While this is a new and evolving concept, one recently published series of nine patients with leak after sleeve gastrectomy (including

five patients in whom a stent failed) reported 100% resolution of leak (after an average of 10 sponge changes per patient and 50 days therapy). To be sure, when these leaks become chronic, they can be difficult problems to overcome. Portomesenteric venous thrombosis is being increasingly recognized as a potential complication following sleeve gastrectomy. Presentation may be variable ranging from asymptomatic and incidentally discovered to bowel infarction and necrosis. Theories attempting to explain this complication have been proposed, such as venous stasis from increased intra-abdominal pressure, intraoperative manipulation of splanchnic vasculature, and systemic hypercoagulable states. The rate is higher for sleeve compared to Roux-en Y gastric bypass and is likely around 1%. A high index of suspicion and preventative measures in those at highest risk (extended chemoprophylaxis in those with hypercoagulable disorder) is needed to minimize the chance of a catastrophic outcome.

The impact of a sleeve on GERD is controversial. A review article on the relationship between sleeve gastrectomy and GERD evaluated 13 studies including 5,953 patients in whom sleeve gastrectomy had a negative impact on GERD. In this same review, 12 studies including 1,863 patients demonstrated a positive impact of sleeve gastrectomy on GERD. A systematic review and meta-analysis examining the relationship between sleeve gastrectomy and GERD included 33 studies. The authors of this study concluded “because of high heterogeneity among available studies and paradoxical outcomes of objective esophageal function tests, the exact effect of laparoscopic sleeve gastrectomy on the prevalence of GERD remains unanswered.” Part of the controversy surrounding the true impact of sleeve gastrectomy on GERD relates to the impact that technical factors may play on the GERD-related outcomes. Leaving an excessively large or dilated sleeve may contribute to the possibility of GERD. There is also a growing body of literature that suggests hiatal hernias can be difficult to recognize at the time of sleeve gastrectomy. Several studies suggest that routine hiatal hernia repair and crural repair can decrease the incidence of GERD in sleeve gastrectomy patients. A recently published review of nearly 3,000 patients in the state of Michigan who underwent laparoscopic sleeve gastrectomy over a more than 7-year period revealed widely varied rates of new acid reduction medication use 1 year following surgery. This suggests that differences in surgical technique may contribute to disparate GERD outcomes following sleeve gastrectomy. A systematic review and meta-analysis comparing GERD-related outcomes for Roux-en-Y gastric bypass to sleeve gastrectomy was recently published. A total of 32 studies and 6,526 patients were included in the final analysis. Gastric bypass had a significantly higher incidence of resolving GERD. Although the GERD-related outcomes following sleeve gastrectomy continue to be a matter of controversy, I personally feel strongly that patients with GERD symptoms and/or signs (erosive esophagitis or Barrett esophagus) that persist despite acid reduction medical therapy should be advised to undergo gastric bypass rather than a sleeve.

A couple of technical factors described in the current chapter warrant additional commentary. Dr. Rosenthal and his colleagues describe the importance of removing posterior gastric adhesions in order to ensure proper visualization of the lesser curve. This is an important step to avoid leaving an excessively large proximal gastric pouch and to minimize the chance of creating a "twisted sleeve" where the staple line is much closer to the lesser curve on the anterior stomach than on the posterior stomach. They also describe performing a formal hiatal dissection in the case of a hiatal hernia but deferring formal repair until after the sleeve is created. In my opinion, this is very important as passing a bougie after the crus have been reapproximated posteriorly in a hiatal hernia repair places the patient at unnecessary increased risk for esophageal trauma and even perforation from the bougie as it is passed. A minor semantic point—when dividing the arteries 2 to 6 cm from the pylorus, you are actually dividing branches of the right gastroepiploic artery and not the short gastric vessels.

This is an exceptional chapter written by one of the world's foremost experts on sleeve gastrectomy. The authors have a wealth of experience with this procedure and long-term lessons learned to share. Even for those who don't perform bariatric surgery as a part of their practice, this is essential reading.

Jon C. Gould

I agree that this is an excellent commentary both as to technique but also a resolution for bariatric surgeons. Weight reduction has become a major part of our society and the procedures must be performed well.

J.E.F.

Suggested Readings

Daes J, Jimenez ME, Said N, et al. Laparoscopic sleeve gastrectomy: symptoms of gastroesophageal reflux can be reduced by changes in surgical technique. *Obes Surg* 2012;22(12):1874–9.

Khorgami Z, Shoar S, Andalib A, et al. Trends in utilization of bariatric surgery, 2010–2014: sleeve gastrectomy dominates. *Surg Obes Relat Dis* 2017. doi:10.1016/j.soard.2017.01.031. [Epub ahead of print]

Leeds SG, Burdick JS. Management of gastric leaks after sleeve gastrectomy with endoluminal vacuum (E-Vac) therapy. *Surg Obes Relat Dis* 2016;12(7):1278–85.

Li JF, Lai DD, Lin ZH, et al. Comparison of the long-term results of Roux-en-Y gastric bypass and sleeve gastrectomy for morbid obesity: a systematic review and meta-analysis of randomized and nonrandomized trials. *Surg Laparosc Endosc Percutan Tech* 2014;24(1):1–11.

Oor JE, Roks DJ, Ünlü Ç, et al. Laparoscopic sleeve gastrectomy and

gastroesophageal reflux disease: a systematic review and meta-analysis. *Am J Surg* 2016;211(1):250–67.

Osland E, Yunus RM, Khan S, et al. Postoperative early major and minor complications in laparoscopic vertical sleeve gastrectomy (LVSG) versus laparoscopic Roux-en-Y gastric bypass (LRYGB) procedures: a meta-analysis and systematic review. *Obes Surg* 2016;26:2273–84.

Peterli R, Wölnerhanssen BK, Vetter D, et al. Laparoscopic sleeve gastrectomy versus Roux-Y-gastric bypass for morbid obesity-3-year outcomes of the prospective randomized Swiss Multicenter Bypass Or Sleeve Study (SM-BOSS). *Ann Surg* 2017;265(3):466–73.

Varaban OA, Hawasli AA, Carlin Am, et al. Variation in utilization of acid reducing medication at 1 year following bariatric surgery: results from the Michigan Bariatric Surgery Collaborative. *Surg Obes Relat Dis* 2015;11(1):222–8.

99 Laparoscopic Biliopancreatic Diversion With Duodenal Switch

Gregory Dakin and Alfons Pomp

INTRODUCTION

Medical treatment of morbid obesity is generally ineffective, making bariatric surgery the only option for this growing population of patients. Commonly performed operations such as gastric bypass (GB), adjustable gastric banding, or sleeve gastrectomy utilize caloric restriction as the primary means to achieve weight loss. However, long-term data has shown that for many patients, particularly those that start with a body mass index (BMI) greater than 50 kg/m^2, such restrictive operations have a high rate of failure, with regard to both % excess weight loss (%EWL) achieved and to subsequent weight recidivism. The biliopancreatic diversion with duodenal switch (BPD-DS) is an operation that combines a restrictive component (sleeve gastrectomy) with a significant malabsorptive intestinal rearrangement. Literature demonstrates that the BPD-DS (or its predecessor BPD) is the most effective weight loss operation, inducing the greatest weight loss and resolution of comorbidities such as diabetes, maintained up to 15 years after surgery.

Though highly successful, the BPD-DS constitutes only 2% of procedures performed (see Table 99.1). This is likely due to several reasons, including the perceived high rate of metabolic complications such as protein-calorie malnutrition, vitamin and mineral deficiencies, and the technical difficulty of the procedure when compared to other more common operations. While there is no doubt it is one of the more technically demanding bariatric procedures, with proper patient selection and careful follow-up, the BPD-DS can be performed safely with an acceptable long-term complication profile. It is a particularly good option for the super-obese patient and for those patients who have failed other operations and should be a weapon in every bariatric surgeon's armamentarium. With the increasing popularity of sleeve gastrectomy as an initial choice, the BPD-DS may well increase in popularity as the most

appropriate “second-stage” surgery for many patients.

TABLE 99.1 Bariatric Procedures Performed Worldwide

Procedure	Rate Performed
Roux-en-Y gastric bypass	47%
Sleeve gastrectomy	28%
Laparoscopic gastric banding	18%
Biliopancreatic diversion-duodenal switch	2%
Other	5%

HISTORY OF THE PROCEDURE

The first reports of jejunal-ileal bypass (JIB) were published in the 1950s, commonly credited as the first malabsorptive operation for morbid obesity. The most widely accepted version of the operation used a 35-cm segment of proximal jejunum anastomosed to the distal 10 cm of terminal ileum (see Fig. 99.1). While this operation was successful in inducing weight loss, there were high rates of significant long-term complications, including bacterial overgrowth, vitamin deficiency, renal failure, and ultimately hepatic failure. These problems led to the development of other bariatric procedures, notably the GB by Edward Mason, in the 1960s, and the JIB was largely abandoned.

Italian surgeon Nicola Scopinaro first described the biliopancreatic diversion (BPD) for morbid obesity when he published his first human series of 18 patients followed for a year. He developed the procedure to maintain the malabsorptive component of the JIB while eliminating the long blind limb thought to be responsible for many of the long-term problems. He performed a distal gastrectomy and anastomosed a 250-cm distal Roux limb to the proximal stomach, with the long biliopancreatic limb anastomosed to this limb 50 cm from the ileocecal valve to create a short common channel. He has published excellent weight loss sustained up to 15-year follow-up in his patients.

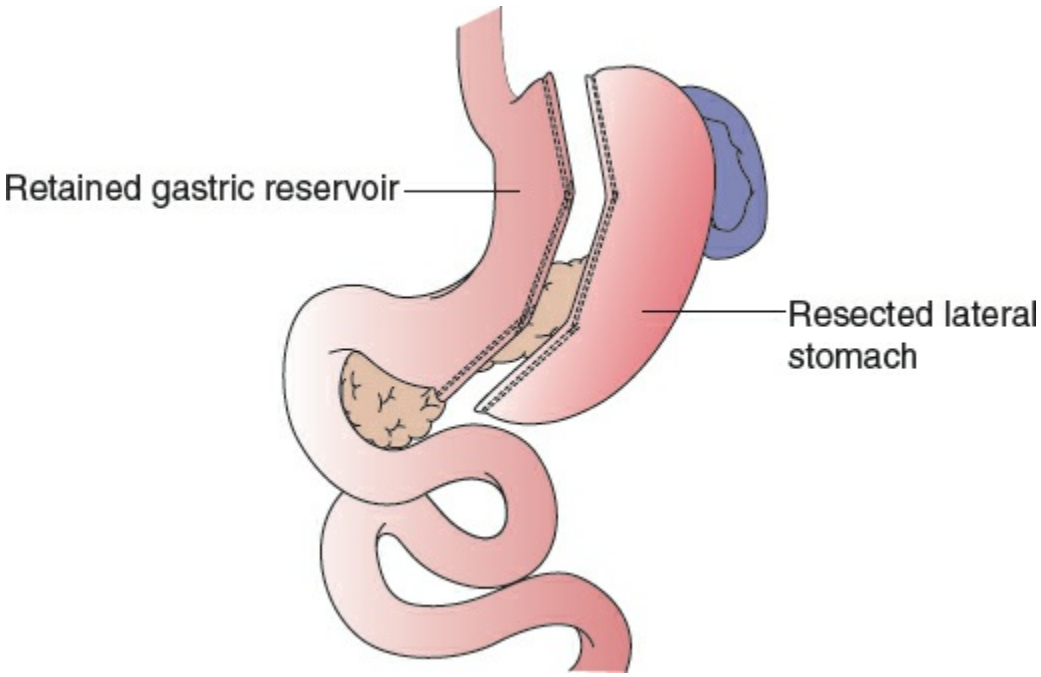

Figure 99.1. Jejunal–ileal bypass. From O'Rourke RW. Management of Obesity. In: Mulholland MW, Lillemoe KD, Doherty GM, et al., eds. Greenfield's Surgery: Scientific Principles and Practice, 6th ed. Philadelphia: Wolters Kluwer, 2017, with permission.

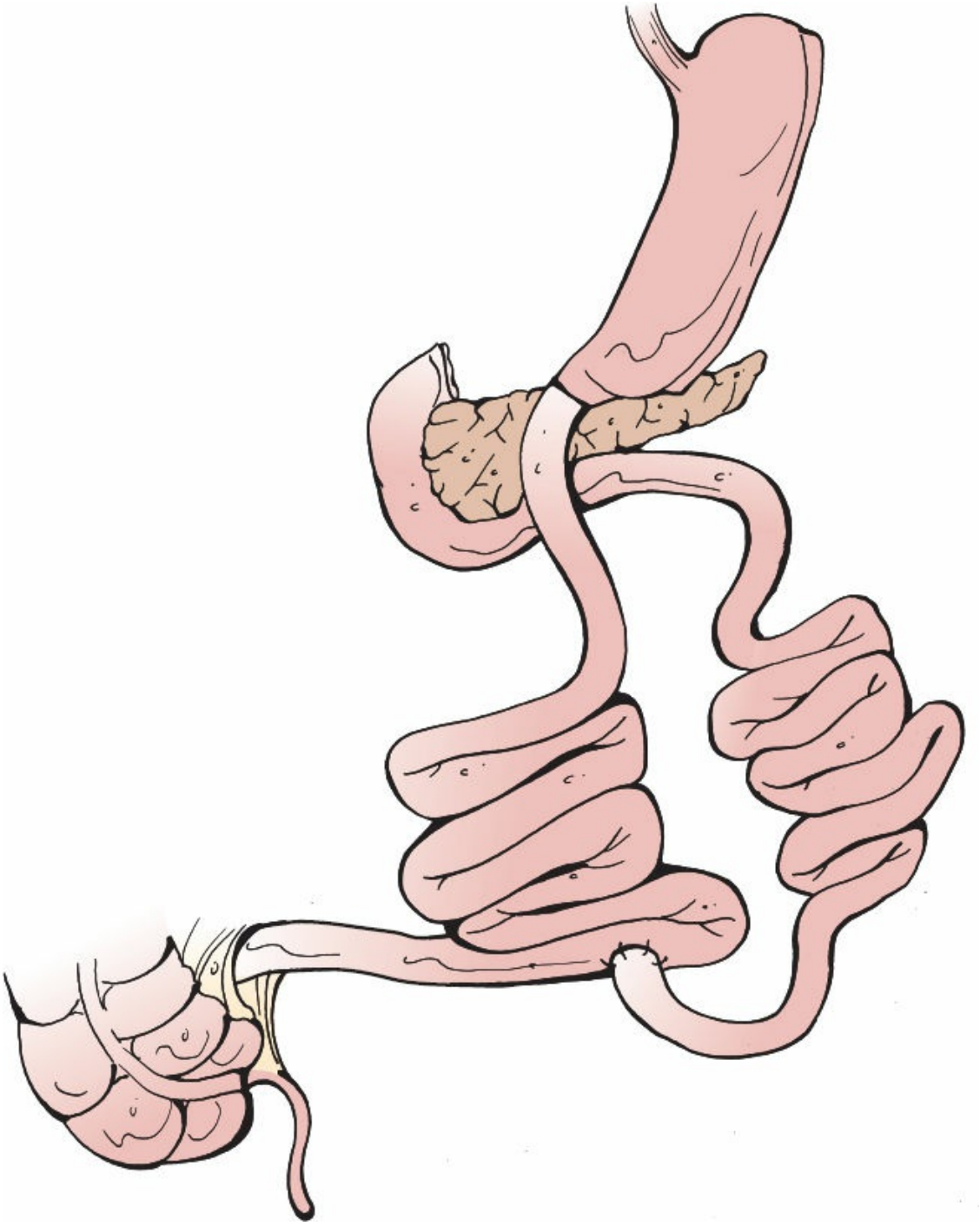

Figure 99.2. Biliopancreatic diversion with duodenal switch (BPD-DS).

The first duodenal switch operation for morbid obesity was described by Marceau in 1993. The original BPD was modified by creating a vertical (or sleeve) gastrectomy rather than a distal gastrectomy and then anastomosed the Roux limb to the stapled (nondivided) proximal duodenum. While this minimized problems with dumping and marginal ulcers seen with the BPD, staple-line breakdown in the duodenum led to

later weight regain. Hess and Hess further modified the Marceau duodenal switch in 1998 with the division of the duodenum, leading to the modern-day BPD-DS.

Today, the standard BPD-DS consists of a sleeve gastrectomy with an alimentary limb of approximately 150 to 200 cm anastomosed to the proximal duodenum, and a 50- to 100-cm common channel (see Fig. 99.2). Gagner described the first laparoscopic BPD-DS in 2000. An interesting variant involving a single anastomosis of an ileal loop to the proximal duodenum is also currently being popularized as a technically simpler version with potentially fewer long-term complications.

INDICATIONS AND CONTRAINDICATIONS

The standard indications for bariatric surgery apply, namely meeting the NIH consensus conference criteria of BMI >40 kg/m^2, or >35 kg/m^2 with significant medical comorbidities such as hypertension, diabetes, or sleep apnea. Patients outside of these general entry guidelines are only carefully considered for surgery with an Institutional Review Board-approved study.

Patient selection for the BPD-DS is of the utmost importance, more so than other bariatric operations that do not include the significant malabsorptive component. If patients are not meticulous in their dietary behavior and postoperative follow-up, the BPD-DS can result in significant malnutrition. We often invoke a rule of thumb that a patient should be at “the head of their class” for the consideration of BPD-DS. We favor the BPD-DS in patients with a BMI >50 kg/m^2, provided the patient can demonstrate appropriate understanding of the nutritional demands of the operation as well as ability to follow up appropriately. For those patients with a BMI >60 kg/m^2, we use a staged approach in which the patient first undergoes laparoscopic sleeve gastrectomy, followed by a second-stage duodenal switch after a 12- to 18-month period of significant weight loss.

Many potential contraindications to surgery exist but generally include pre-existing severe gastrointestinal (GI) disorders (inflammatory bowel disease, cirrhosis, portal hypertension, esophageal varices, chronic pancreatitis) or medical disability (severe congestive heart failure, pulmonary hypertension, extreme immobility). It is rare that any condition is considered an “absolute contraindication”; rather, each patient is evaluated as a whole to determine operative suitability.

PREOPERATIVE PLANNING

A thorough multidisciplinary evaluation is performed in all patients. The initial office visit includes a detailed history and physical exam, with particular attention to previous dietary efforts, medical comorbidities, surgical history, and previous thromboembolic event. Patients considered at high risk of deep vein thrombosis (DVT) or pulmonary embolism, such as those with a prior event or extreme BMI, are no longer referred for preoperative vena caval filter placement, but are made aware of the need for postoperative anticoagulation that should be administered for approximately 1 month. While there are several predictors of poor outcomes from bariatric surgery, we generally do not offer surgery to nonambulatory patients. Additional components of the standard evaluation include psychology/psychiatry to ensure understanding of the procedure, appropriate rational for undergoing surgery, and absence of any untreated eating disorder. We perform routine upper endoscopies with biopsy for *Helicobacter pylori* which is eradicated if present. Specific medical evaluations (cardiac, pulmonary, endocrine) are obtained as necessary.

One of the most critical keys to success is intensive nutritional counseling with specialized bariatric nutritionists experienced in managing patients after BPD-DS. It is essential that the nutritionists be closely involved with the bariatric practice to facilitate communication between surgeon and nutritionist. Because of the long-term nutritional risks, all patients demonstrate knowledge of the procedure by completing a questionnaire detailing the inherent risks and benefits of the operation. As with all bariatric procedures, patients are extensively counseled that the BPD-DS is best thought of as a tool to assist in behavior modification and is by no means a “short-cut” to achieve weight loss goals.

LAPAROSCOPIC BPD-DS OPERATIVE TECHNIQUE

Having a dedicated operating room team that is adept with advanced laparoscopic bariatric procedures and the BPD-DS in particular is imperative. The operation is complex and the value of a team of anesthesiologists and nurses familiar with the setup and instrumentation cannot be stressed enough.

General anesthesia is induced. Urinary catheterization is performed for all patients due to the lengthy (3 to 4 hours) operative time. DVT prophylaxis is given (compression stockings and subcutaneous heparin injection) and appropriate broad-spectrum antibiotic coverage

administered. We position patients in the supine, split-leg position for all bariatric operations. For the duodenal switch, however, we tuck the left arm using an arm board as an extension if necessary. The enables surgeon and assistant to stand on the left comfortably while working on the distal small bowel. We use a standard open entry technique into the abdomen at the umbilicus to establish pneumoperitoneum. Trocars are placed as shown (see Fig. 99.3). In general, all stapling can be done via the umbilical site thereby allowing the remaining trocars to be 5 mm which minimize abdominal wall trauma and to not require fascial closure. However, if stapling the distal bowel proves difficult, we advise replacing the left upper midaxillary with a 12-mm trocar. A quick visual inspection is performed and any adhesiolysis undertaken.

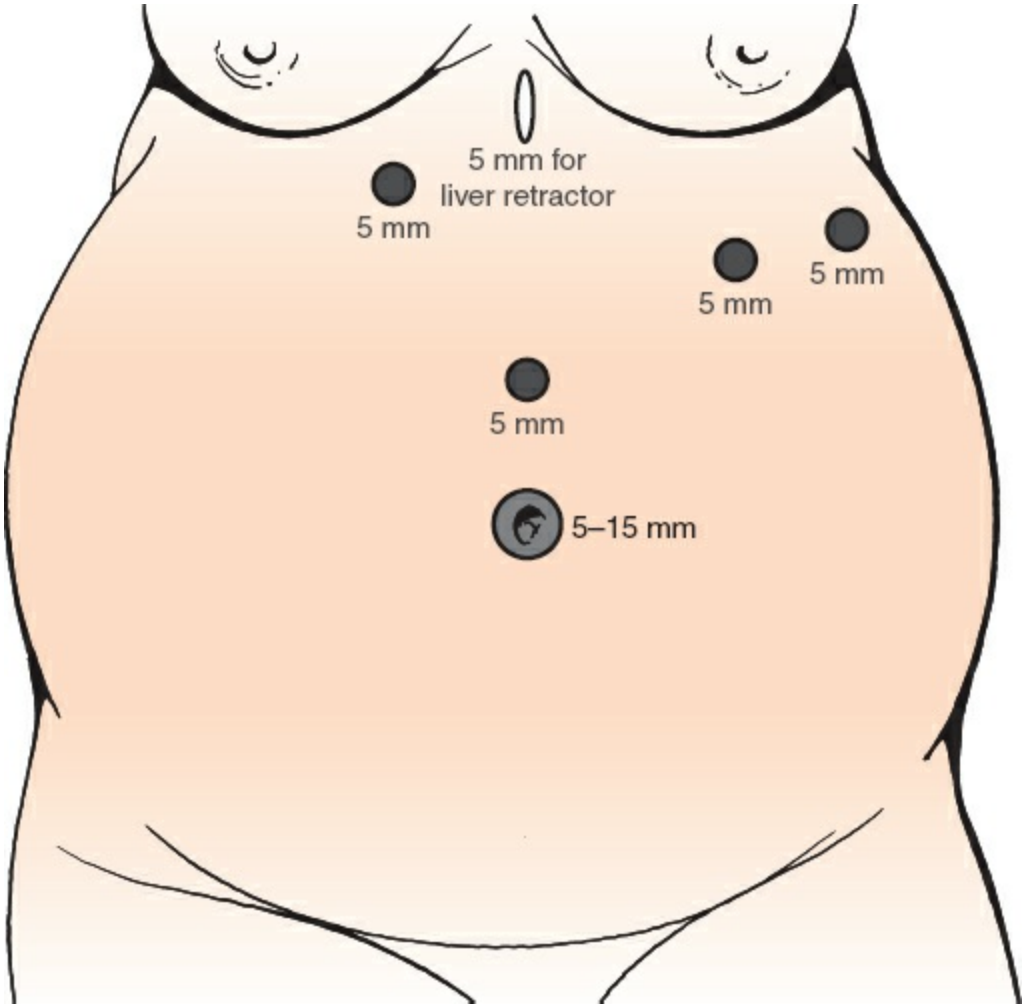

Figure 99.3. Trocar arrangement.

We begin with the sleeve gastrectomy which at this point is a standard operation for most bariatric surgeons. Unlike the standard sleeve

gastrectomy, however, the greater curvature dissection must be carried onto the proximal 2 cm of duodenum. Once fully mobilized, the stomach transection begins on the greater curvature at the level of the crow's foot just distal to an imaginary vertical line created from the incisura (Fig. 99.4). We utilize 60-mm length staplers for the entire resection. The staple-firings for the thick antral tissue should be 4.5 to 5.0 mm in height (usually the first 2 to 3 firings) and thereafter can change to 3.5-mm height. We typically use one of several commercially available reinforcing strips to buttress the staple line and reduce bleeding (we omit this buttress on the first firing as that portion of the antrum is typically too thick to allow for proper staple closure with the addition of the buttress). After the first two firings, a 40F bougie or similar device is placed and guided towards the pylorus to aid in the resection. The bougie should be held in place the entire time by the anesthesiologist to avoid accidental movement and/or transection of the bougie. All stapling is performed via the umbilical trocar. The staple line is inspected for hemostasis and proper staple closure. Any bleeding points are oversewn with 2-0 Vicryl suture. The stomach specimen is removed using via the umbilical port. (Note: if an Endobag is used, place the stomach in the bag such that the corner of the first staple line is left outside, that corner can be easily grasped once the bag is delivered through the wound. This will orient the stomach longitudinally and it can then be extracted with only minimal dilation of the trocar site.)

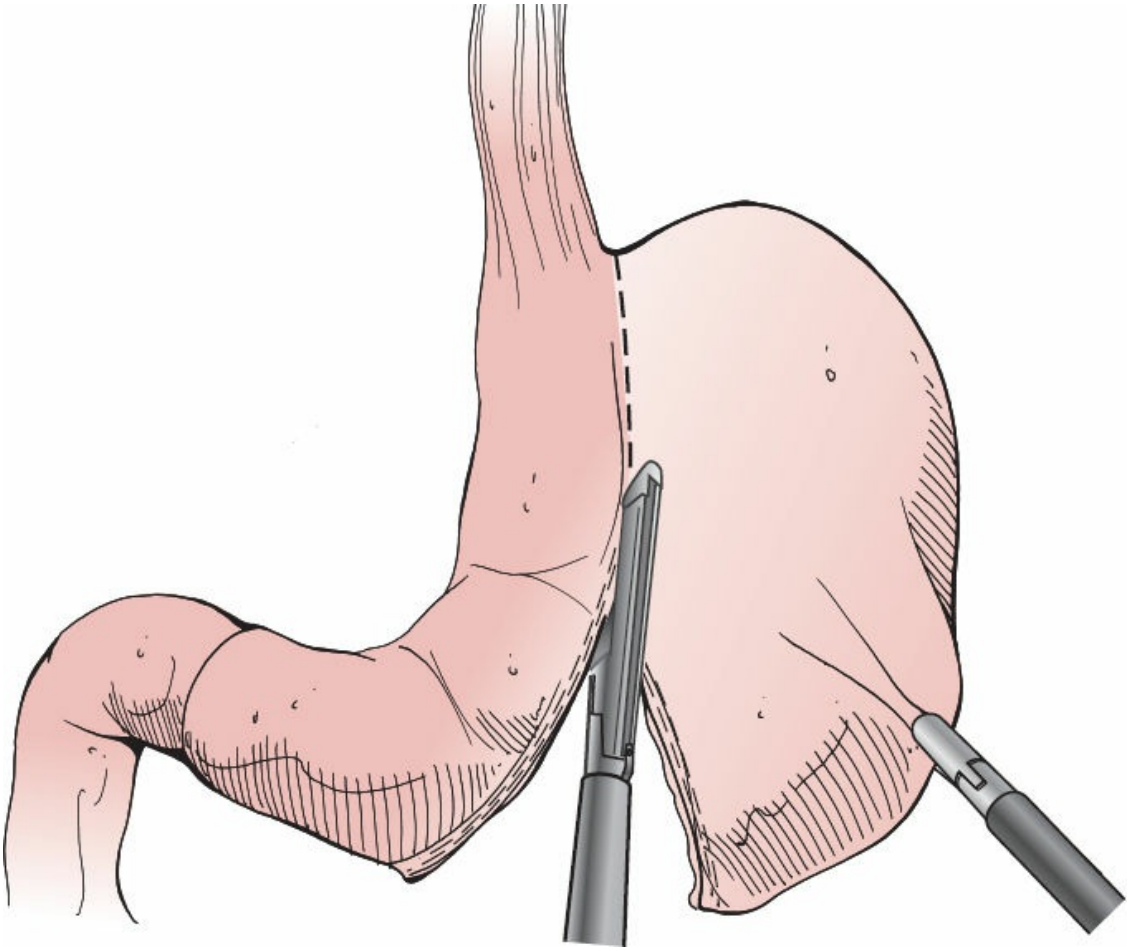

Figure 99.4. Sleeve gastrectomy.

Once the sleeve gastrectomy is completed we move to the periduodenal dissection, which is carefully undertaken to preserve small vessels supplying the distal duodenal stump. A window is dissected on the lesser curvature side of the duodenum just proximal to the hepatoduodenal ligament (this should be well proximal to the common bile duct), avoiding the hepatic artery. A right-angled instrument can be passed beneath the duodenum and placed through the window. The duodenum is transected via the umbilical trocar with a nonbuttressed 60- to 2.5-mm Endo-GIA stapler (Fig. 99.5). We routinely oversew the duodenal stump.

To work on the distal small bowel, the surgeon and assistant move to the patient's left side. If creating an antecolic Roux limb, the greater omentum is divided off the transverse colon from the hepatic flexure medially to a point past the proximal duodenum. We do not feel the antecolic route creates any problems with tension and allows us to avoid creating an additional transmesocolic mesenteric defect. However, if the colonic mesentery is bulky or the small bowel mesentery foreshortened,

consideration can be given to performing a retrocolic roux limb. Next, using the high-epigastric and umbilical ports as working ports with the camera in the epigastric port, the distal bowel is measured proximally with a precut umbilical tape a distance of 100 cm and this site of the common channel marked with hemoclips (note: the length of the common channel is increased to 125 cm in patients with BMI 35 to 45 kg/m^2). The bowel is measured further proximally 150 cm to complete the alimentary limb. The bowel is divided at this point (instruments are exchanged to permit stapler placement via the umbilical trocar) with the nonbuttressed 2.5-mm Endo-GIA. Once divided, the bowel is again run using a counterclockwise rotation moving distally to proximally to ensure proper orientation of the bowel and its mesentery.

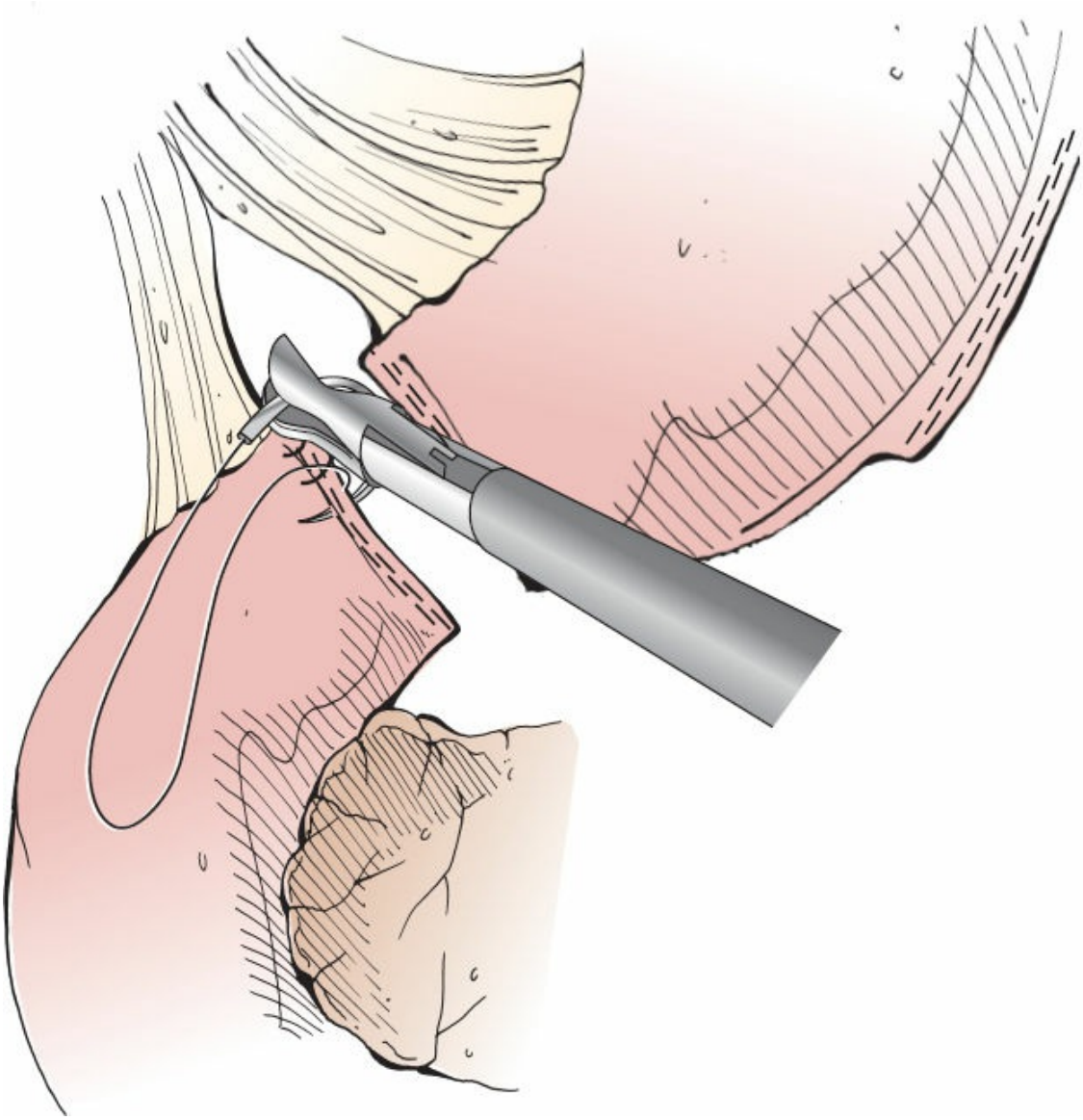

Figure 99.5. Duodenal transection.

The duodenoileostomy is performed in standard hand-sewn fashion which we have found to be technically simpler than performing a circular stapled anastomosis. With the surgeon back between the patient's legs, the staple line of the distal ileum is sewn to the staple line of the proximal duodenum with 2-0 silk as a posterior layer. Enterotomies are made in the proximal duodenum approximately 1 cm in width and anastomosed in running fashion with 3-0 monofilament absorbable suture to complete the inner layer (Fig. 99.6). An orogastric tube is inserted at this point and a Methylene blue leak test is performed, inspecting the duodenoileostomy as well as the gastric sleeve staple line. Once satisfactory, the anterior second layer of the anastomosis is completed with 2-0 silk suture.

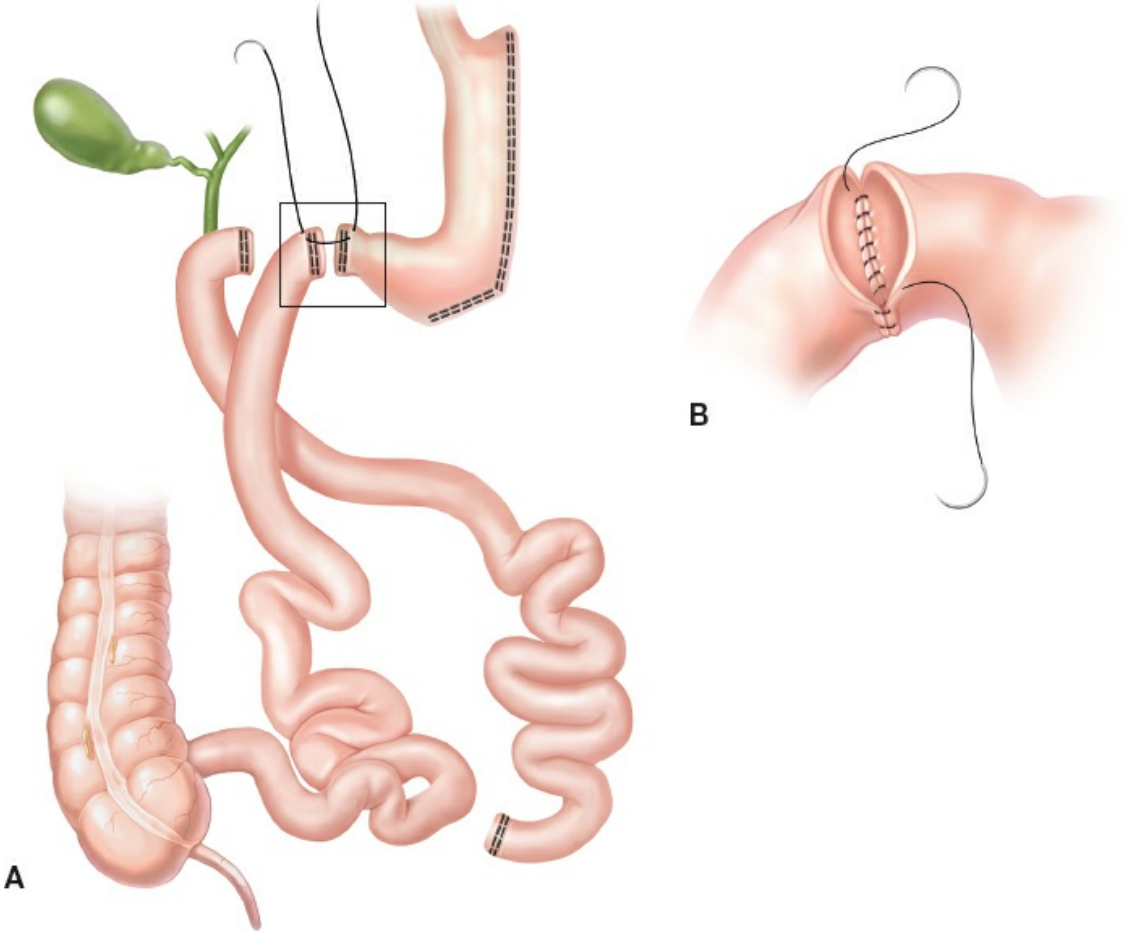

Figure 99.6. Hand-sewn duodenoileostomy.

Intestinal continuity is restored with the distal anastomosis by attaching the biliopancreatic limb to the alimentary limb at the previously marked site of the common channel with the Endo-GIA 60- to 2.5-mm stapler. The open enterotomy can be closed in layers with standard intracorporeal sutures. An alternate technique is to triple-staple the anastomosis (the "M"

technique). With this technique, the biliopancreatic limb and alimentary limb are connected with one firing; the alimentary limb is connected to itself with another firing; and finally the open enterotomy is closed with a third firing (Fig. 99.7). This technique allows for a totally stapled anastomosis with minimal risk of luminal narrowing. The enteroenterostomy defect and Peterson's defect are both closed with running nonabsorbable suture.

We do not routinely place drains. The abdomen is inspected and hemostasis verified. Any trocar sites >5 mm are closed with 0-Vicryl suture and trocars are removed under direct vision. The skin incisions are closed with absorbable subcuticular stitch or skin glue.

Single-anastomosis variant: In the single-anastomosis duodenal switch, the operation proceeds as above to the division of the duodenum. The distal small bowel is then measured proximally a distance of 200 to 250 cm and then brought to the proximal duodenum as a loop. The bowel is anastomosed in standard hand-sewn end-to-side fashion in two layers and leak tested appropriately (Fig. 99.8). The mesenteric defect is not closed.

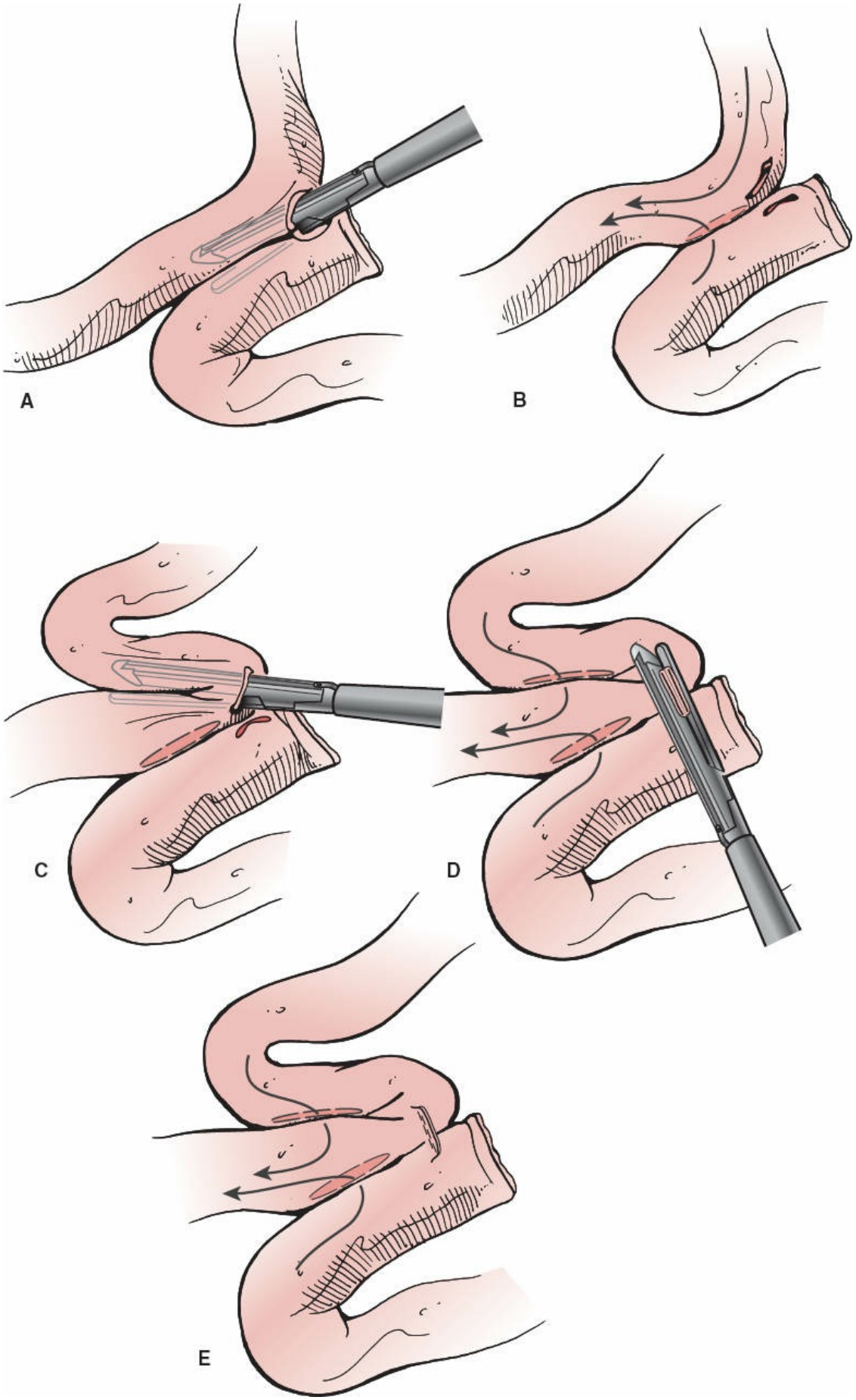
A
B
C
D
E

Figure 99.7. Creation of enteroenterostomy using the "M" technique. The linear stapler is fired between the alimentary and biliopancreatic limb (**A, B**). Then the stapler reinserted and the adjacent alimentary limb is joined to itself (**C**) to form the "M." Finally the open enterotomy is closed again with the linear stapler (**D, E**).

POSTOPERATIVE CARE

From the operating room patients are transferred to the recovery room until cleared by anesthesia before transfer to a regular floor. In patients with significant cardiovascular risks factors (severe sleep apnea, CAD, CPOD), consideration is given to moving them to a more monitored setting ("step-down," or even ICU if drip medications are planned). Maintenance fluids are given to maintain urine output of at least 1 mL/kg/hr. DVT prophylaxis (early ambulation, compression stockings, and unfractionated subcutaneous heparin are continued). For patient with sleep apnea, CPAP is instituted right in the recovery room.

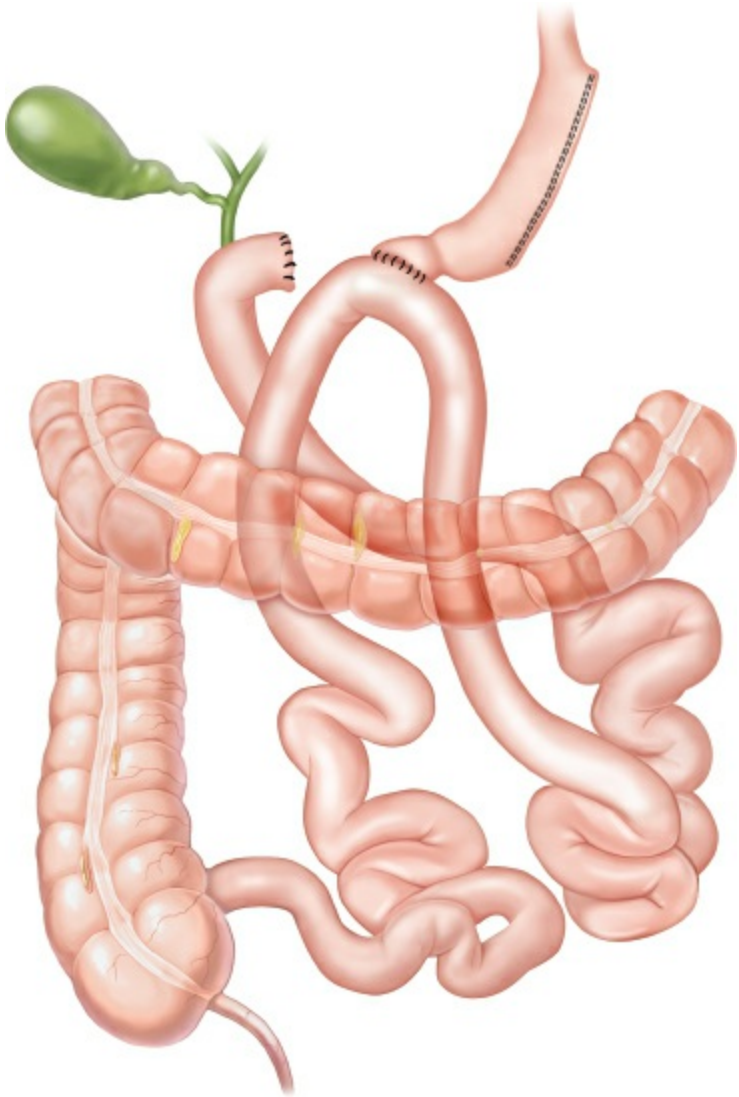

Figure 99.8. Single-anastomosis duodenal switch.

The dietary progression has evolved in recent years. We no longer perform routine upper gastrointestinal (UGI) studies on the first postoperative day. If there were no concerns about the operative procedure, patients are allowed clear liquids right away (postoperative day zero). If, however, the patient has any signs of instability (fever, HR >105, low urine output), consideration is given to obtaining an UGI contrast study to evaluate the sleeve gastrectomy and proximal anastomosis, or CT scan to exclude pulmonary embolism.

Provided the patient is doing well clinically, the urinary catheter is removed on postoperative day 1 and the patient-controlled analgesia is changed for oral pain medicine. Patients are advanced to full-liquid diet on the second postoperative day. Most patients are discharged on the second or third postoperative day and continue full-liquid diet until their first

postoperative visit at 3 weeks. Patients take calcium carbonate and multivitamins daily.

We see patients routinely at 3 weeks, 3 months, 6 months, 12 months, and then 6 months to yearly thereafter. On the first postoperative visit, patients are seen by our dedicated nutritionists and counseled on the transition from full-liquid diet to solid foods. They are started on oral iron supplementation, vitamins A and D, and calcium citrate. Vitamin D is dosed based on current serum levels and degree of secondary hyperparathyroidism. Ursodiol 250 mg b.i.d. for 6 months is prescribed to prevent gallstone formation. It is essential that patients see the dedicated bariatric nutritionist at each postoperative visit to adjust vitamin supplementation as necessary and to reinforce the dietary guidelines critical to success. Nutritional lab values are checked at least every 6 months and can be more frequent if a deficiency state exists. We advise patients to attend monthly support-group meetings.

COMPLICATIONS AND THEIR MANAGEMENT

The early complications of BPD/DS are similar to those of other stapled bariatric procedures including GB and sleeve gastrectomy. The morality rate (0.5%) is generally considered to be marginally higher than other procedures due to the technical complexity of the operation and the fact that it is generally offered to higher BMI patients who are at greater risk. Support for this comes in part from Buchwald's 2004 meta-analysis, where operative mortality for BPD-DS was reported at 1.1%, or twice that of GB. As well, the Anthone series in 2003 had an operative mortality of 1.4%. However, many series show mortality results not significantly greater than that for GB. Scopinaro's reported mortality is < 0.5%. In Hess' large series mortality was 0.57%. One experienced center reported a decrease in operative mortality from 1.3% to 0.2% during a 20-year study period.

Pulmonary embolism is a devastating complication of any bariatric surgery. The reported incidence is low (0.1% a recent study) but logic would dictate the incidence to be higher than for other procedures simply due to the prolonged operating time. Management of pulmonary embolism is supportive and outcome is tied to early recognition. Leak rates range from 0% to 2% but again are generally considered to be marginally higher than other procedures. Management will depend on the site of the leak (stomach vs. duodenoileostomy vs. ileoileostomy), the time of presentation (early vs. delayed), and the clinical status of the patient (stable vs. septic).

The most critical aspect is early recognition and consequent action. In labile patients, a return to the operating room is necessary to control sepsis, attempt repair, and place enteral feeding access which is essential to support the patient while the leak is healing. In stable patients, other options such as interventional drainage or endoscopic stents or suturing can be considered. Bleeding as an early complication can be expected in a small (1%) number of patients.

TABLE 99.2 Morbidity After BPD-DS

Acute	
Death	0.5–1.1
Leak	2–3
DVT/PE	1–2
Bleeding	1–2
Wound infection	2–3
Chronic	
Anatomic	
Dumping	0
Stricture	<1
Ulcer	3–5
Internal hernia	3–5
Incisional hernia	2–4
Systemic	
Protein malnutrition	2–20
Hepatic failure	<1
Weight gain	<5
Steatorrhea	5–10
Cholestasis	<5

The late complications of BPD/DS include bowel obstruction, incisional hernia, internal (mesenteric hernia), and biliary symptoms. Management of these is generally per standard bariatric care; however, a low threshold for operative intervention of bowel obstruction should be held due to the possibility of closed-loop obstruction present after such a significant intestinal bypass procedure. Revisional operations will be necessary in a percentage of patients (0.7% to 2.9%) and patients should be counseled accordingly. Nutritional deficiencies are discussed below.

We feel it important to inform patients that while perioperative morbidity and mortality for BPD-DS may be slightly higher than that for RYGB, when performed by experienced groups, the incidence of major adverse events is quite acceptable (Table 99.2).

RESULTS

Several large series with long-term follow-up are available describing weight loss with BPD. The largest series was reported by Scopinaro detailing 2,241 patients undergoing the original BPD followed for 21 years. These patients had 77% EWL at 10 years. Hess and Hess reported on a cohort of 182 patients who were >10 years out from BPD-DS surgery. With 92% follow-up, their patients exhibited 75% EWL. Rabkin reported in 2003 on a series of 345 laparoscopic BPD-DS procedures. Mean %EWL at 2 years was 91%. Anthone and colleagues reported 71% EWL at 3 years in a group of 701 BPD-DS patients. In a small series of our own laparoscopic BPD-DS patients, we reported 84% EWL at 27 months. Marceau reported on 2,615 patients followed over 20 years with 71% EWL.

Super-obese patients (BMI >50 kg/m^2) are unlikely to achieve satisfactory weight loss after GB (BMI <30 kg/m^2 or %EWL ≥50%), with fewer than 60% reaching resulting in long-term success. Thus, the BPD-DS may be most appropriate for this group of patients. In a recent series of super-obese patients, Prachand compared 198 BPD-DS patients to 152 GB patients. Weight loss was greater in the BPD-DS group at all follow-up intervals. At 36 months, %EWL was 68.9% versus 54.9%, p <0.05. In a randomized, controlled trial, SÖvik et al. studied 60 super-obese patients randomized to either laparoscopic GB or BPD-DS. At 1 year, the mean % of BMI lost was significantly greater in the BPD-DS group (74.8% vs. 54.4%). This cohort was reported on by Risstad in 2015 with 5-year follow-up showing greater weight loss in the BPD-DS group and greater improvements in certain comorbidities. Given the high failure rate of GB in the super-obese, we feel that any patient in this category should be considered for BPD-DS if they meet the relatively rigid screening criteria.

For super-obese patients who have previously undergone GB and have failed, either due to weight regain or inadequate weight loss, conversion to BPD-DS is a reasonable consideration. However, be advised that the laparoscopic procedure is challenging, involving first reversal of the GB followed by a sleeve gastrectomy and duodenal switch. Due to the

technical complexity and length of the procedure, in most cases it may be advisable to accomplish the operation in two separate stages. Our initial experience and the technical details of the procedure have been previously reported (Parikh, 2011) with 63% EWL in a small series of patients.

Long-term nutritional deficiencies after BPD-DS are oft-cited as reasons to avoid the procedure. Any operation that bypasses the duodenum will lead to a certain percentage of iron and calcium deficiency, as the duodenum and proximal jejunum is the primary site of absorption for those nutrients. However, deficiency rates in demonstrate a range in the literature. Iron deficiency anemia can develop in up to 50% of patients after duodenal switch (comparable to that after long-limb GB) and if not responsive to oral supplementation, can be treated with parenteral iron. Vitamin B12 deficiency is more uncommon owing to the preservation of more gastric mucosa in the duodenal switch procedure than with GB. Many obese patients have secondary hyperparathyroidism and vitamin D deficiency preoperatively. The distal bypass and short common channel of the BPD-DS negatively impact vitamin D absorption, thus careful monitoring and supplementation are necessary. One recent study indicates that chronic secondary hyperparathyroidism in BPD-DS patients leads to a high rate of bone turnover and decreasing bone mineral density, further underscoring the need for close monitoring of this nutritional axis. With proper follow-up and supplementation, most if not all vitamin deficiencies are avoidable.

Perhaps the most significant long-term nutritional sequela is protein malnutrition. While the degree of hypoalbuminemia after BPD-DS is not as severe as that found after long-limb GB, owing to the lesser degree of restriction with the sleeve gastrectomy of the DS, the incidence can vary widely from 7% to 20%. Even with careful monitoring and supplementation, a patient may still develop protein malnutrition due to the limited absorptive capacity of the common channel. Therefore, there will be an incidence of patients requiring revisional limb-lengthening surgery. This incidence is low (3.7% in the Hess series, 10% in the Risstad series of super-obese) but can increase in poorly compliant patients.

Single-Anastomosis Duodenal Switch

The newest variant of the BPD-DS goes by many names, including single-anastomosis duodenal switch, loop duodenal switch, single anastomosis duodenoileal bypass with sleeve gastrectomy (SADI-S), or the stomach

intestinal pylorus-sparing (SIPS) procedure. It is a potentially attractive version, in that it is technically simpler to accomplish than the standard BPD-DS. There may be a reduction in GI side effects such as diarrhea, flatulence, and malodorous stools, as well as a reduced incidence of vitamin or protein deficiency. Weight loss may not reach the levels seen in standard BPD-DS. However, the weight loss may be greater than that achieved by GB or sleeve gastrectomy alone.

Torres' group from Spain has published the longest follow-up after the SADI-S procedure. They reported on their first 50 patients with a starting BMI of 44 kg/m^2 and followed them out to 3 years. Percent EWL was 94.7% sustained at 3 years with remarkable follow-up. While the incidence of hypoalbuminemia was 8% after 1 year, all patients recovered to normal levels by the third year. A total of 27 diabetic patients were included and all had normalized HbA1c levels after 6 months off all antidiabetic medications. They had two leaks from the gastric suture line which they attribute to technical error early in their learning curve.

Another group performed a matched cohort analysis of 54 patients undergoing loop duodenal switch to GB. Weight loss was comparable between groups followed out to 18 months (40% weight loss). However, the loop duodenal switch group had fewer immediate complications and less postoperative nausea. The loop duodenal switch group also had significantly fewer postoperative upper endoscopies (3 vs. 21), fewer ulcers (0 vs. 6), and fewer reoperations (2 vs. 10). Long-term data, both with regard to weight loss and complications, is necessary to determine what role the single anastomosis variant will play.

CONCLUSION

Throughout the world's literature, the BPD-DS has been shown to induce the most weight loss of any bariatric procedure with the greatest degree of long-term success. Though it requires advanced technical skill, in experienced centers it can be performed with a safety profile nearly equivalent to that of the more common GB. Owing to its malabsorptive nature, more rigorous screening of patients should be performed to ensure proper understanding of the operation, its long-term risks, and avoidance of negative nutritional sequela. The BPD-DS is an important option for any bariatric surgeon to offer, especially for the super-obese patient that is likely to fail with other operations. The bariatric surgeon must assemble a comprehensive team (both operative and nutritional) to provide proper

long-term follow-up of all patients.

Suggested Readings

Aasheim ET, Björkman S, Søvik TT, et al. Vitamin status after bariatric surgery: a randomized study of gastric bypass and duodenal switch. *Am J Clin Nutr* 2009;90:15.

Anthone GJ, Lord R, DeMeester TR, et al. The duodenal switch operation for the treatment of morbid obesity. *Ann Surg* 2003;238:618.

Cottam A, Cottam D, Medlin W, et al. A matched cohort analysis of single anastomosis loop duodenal switch versus Roux-en-Y gastric bypass with 18-month follow-up. *Surg Endosc* 2016;30(9):3958–64.

Hess DS, Hess DW, Oakely RS. The biliopancreatic diversion with duodenal switch: results beyond 10 years. *Obes Surg* 2005;15:408.

Marceau P, Biron S, Marceau S, et al. Long-term metabolic outcomes 5 to 20 years after biliopancreatic diversion. *Obes Surg* 2015;25:1584.

Parikh M, Pomp A, Gagner M. Laparoscopic conversion of failed gastric bypass to duodenal switch: technical considerations and preliminary outcomes. *Surg Obes Relat Dis* 2007;3:611.

Prachand VN, DaVee RT, Alverdy JC. Duodenal switch provides superior weight loss in the super-obese (BMI ≥ 50 kg/m^2) compared with gastric bypass. *Ann Surg* 2006;244:611.

Rabkin RA, Rabkin JM, Metcalf B, et al. Laparoscopic technique for performing duodenal switch with gastric reduction. *Obes Surg* 2003;13:263.

Ren CJ, Patterson E, Gagner M. Early results of laparoscopic biliopancreatic diversion with duodenal switch: a case series of 40 consecutive patients. *Obes Surg* 2000;10:514.

Risstad H, Sovik TT, Engstrom M, et al. Five-year outcomes after laparoscopic gastric bypass and laparoscopic duodenal switch in patients with body mass index of 50–60 a randomized clinical trial. *JAMA Surg* 2015;150:352.

Sanchez-Pernaute A, Herrera M, Perez-Aguirre ME, et al. Single anastomosis duodeno-ileal bypass with sleeve gastrectomy (SADI-S). One to three-year follow-up. *Obes Surg* 2010;20:1720.

Scopinaro N, Adami GF, Marinari GM, et al. Biliopancreatic diversion. *World J Surg* 1998;22:936.

Strain GW, Gagner M, Pomp A, et al. Comparison of weight loss and body composition changes with four surgical procedures. *Surg Obes Relat Dis* 2009;5:582.

Søvik TT, Taha O, Aasheim ET, et al. Randomized clinical trial of laparoscopic gastric bypass versus laparoscopic duodenal switch for super obesity. *Br J Surg* 2010; 97:160.

EDITOR'S COMMENT

This excellent technical treatise provided by Professors Dakin and Pomp reiterates the exclusive medical value of bariatric surgery and the only objective therapeutic option for the growing population of the morbidly obese. The American Heart Association (AHA) predicts that by 2030 total medical costs for chronic diseases initiated by obesity will reach $860–957 billion. Moreover, contemporary studies suggest that steeper growth of some chronic diseases is more evident in the obese than in the general population growth. Thus, the annual medical costs associated with obesity in 2016 for the United States will range from $147 billion to approximately $210 billion; this epidemiologic factor further notes that each obese worker enhances employer costs by approximately $500 per year, thus shifting manufacturing, labor and disability costs to the consumer. The AHA further regards obesity as a global epidemic that initiates hypertension, cardiovascular disease, type II diabetes, hypercholesterolemia, stroke and cardiac failure. The global impact of obesity is profound and is etiological of additional chronic illnesses including joint disease, depression, cancer, gall bladder disorders, breathing/respiratory insufficiency and infection, and also premature cardiovascular disease. The Trust for America's Health, reported that in 1980, no state had an obesity rate at or above 15%; in 1991, none of the 50 US states had a rate of obesity that exceeded 20%.

Morbid obesity has demographic profiling in the United States with the largest populations in the South, Southeast, and Southwest areas which often relates to poor socioeconomic status, education, and income. The Trust for America's Health and the Robert Wood Johnson Foundation released data in 2015 with rates of obesity exceeding 35% in three states (Arkansas, West Virginia and Mississippi). Additionally, 22 states have rates above 30%, 45% are above 25%, and every state is >21%. Arkansas has the highest adult obesity rate (35.9%); Colorado is considered the state with having the lowest rate (21.3%). Trends in America suggest that greater than a third of all adults (34.9%) are obese, more than two thirds were in both overweight and obese ranges (68.6%). This demographic notation further delineates the escalating frequency of obesity in children and teenagers (2 to 19) of nearly 17%. And greater than 8% of children ages 2 to 5 are obese (State of Obesity: Better Policies for a Healthier America: 2015). This data accounts for the type II diabetic and hypertension rate increases in many states of the South and Southwestern United States.

Professors Dakin and Pomp have emphasized that despite the success of the laparoscopic biliary pancreatic diversion with duodenal switch (LBPD-DS), the

procedure currently represents only 2% of all bariatric surgery procedures (Table 99.1). LBPD-DS is the most highly successful of weight reduction bariatric procedures and the Gagner group document that it produces the most significant weight loss, and further, provides amelioration of many obesity-related comorbidities relative to those of its bariatric weight reduction counterparts (Anderson B, Gill RS, deGara CJ, et al. Biliopancreatic diversion: the effectiveness of duodenal switch and its limitations. *Gastro Res Pract* 2013;2013:974762). In contrast to the open or laparoscopic gastric bypass (GB), adjustable gastric binding or sleeve gastrectomy, the LBPD-DS is clearly the more technically demanding of the category of bariatric surgery. Superior outcomes, as noted by numerous surgeons, require the requisite patient selection with detailed analytical follow-up; this process allowed LBPD-DS to be completed in a safe and acceptable manner with excellent long-term comorbidity and complication profiles.

As discussed by the authors, the most significant long-term morbidity is inclusive of the nutritional sequela of protein, electrolyte and mineral depletion, and subsequent malnutrition. Long-limb gastric bypass initiates a more profound degree of nutritional protein-malnutrition than that of the LBPD-DS, which results from its lesser degree of restrictive capacity with the sleeve gastrectomy of the DS. The authors detail that this variance is 7% to 20% for nutritional protein depletion. Therefore, careful monitoring and protein serum content must be assessed to identify protein malnutrition second to the absorptive and limited capacity of the protein molecule transfer across the common channel. Protein malnutrition can be remedied completely or in part by revision and limb-lengthening surgery as discussed in the series by Hess et al. (Hess DS, Hess DW, Oakely RS. The biliopancreatic diversion with duodenal switch: results beyond 10 years. *Obes Surg* 2005;15:408) the frequency was 3.7%; in the Risstad (Risstad H, Sovik TT, Engstrom M, et al. Five-year outcomes after laparoscopic gastric bypass and laparoscopic duodenal switch in patients with body mass index of 50–60 a randomized clinical trial. *JAMA Surg* 2015;150:352) series this frequency was 10% in the super-obese. Identification of the poorly compliant patient is paramount to avoid advanced protein nutritional depletion with other comorbidities that result in potential inanition and death as a complication.

The above observations of protein malnutrition are partially explained by Kodama and associates (Kodama Y, Johannessen H, Furnes MW, et al. Mechanistic Comparison between Gastric Bypass vs. Duodenal Switch with Sleeve Gastrectomy in Rat Models. *PLoS OnE* 2013;8(9):e72896). These authors note that the initiation of rapid energy expenditure of less available food substrate is the principal mechanistic explanation for the success of the gastric bypass outcomes; whereas duodenal switch with sleeve gastrectomy induces greater body weight loss by both the reduction in food intake together with increase in energy expenditure and malabsorption in rat models. These differences are highly statistically significant in the rat model with comparison

of the GB versus the BPD-DS. Again, Kodama et al. indicate further that both procedures initiate restriction in food intake and absorption with the decrease in gastric volume and the additional effect of bypass of segments of the small intestine. The DS procedure is superior to GB in body weight loss, as well as providing reduction in the proportions of major comorbidities inherent with the GB: inclusive of diabetes, hypertension, and dyslipidemia. As Drs. Dakin and Pomp note, the most profound nutritional deprivation is the malnutrition resulting from protein repletion and its ultimate consequences. The LBPD-DS remains less severe for morbidity with less hypoalbuminemia with less frequency than that of the long-limb GB; however, LBPD-DS initiates more infrequently vitamin B-12, calcium, vitamin A and D, and multivitamin deficiency, but more commonly iron deficiency. Ferrous iron absorption deficits with lack of transfer across the duodenum can be noted in as great as 50% of LBPD-BS patients. With exclusion of duodenum continuity, the LBPD-DS is more frequently observed to have iron deficiency when compared to long-limb GB. This deficit is successfully treated with oral iron replacement or parenteral-route iron repletion.

The Torres team from Madrid created the newest variant of the BPD-DS procedures and is inclusive of the single-anastomosis duodenoileal bypass, with sleeve gastrectomy (SADI-SG). This procedure was remarkably effective as noted by the authors with percent EWL of 94.7% and only an 8% hypoalbuminemia rate at 1 year in which all patients had recovered by year 3 (Sánchez-Pernaute A, Rubio MA, Conde M, et al. Single-anastomosis duodenoileal bypass as a second step after sleeve gastrectomy. *Surg Obes Relat Dis* 2015;11:351–5). In the diabetic population (n = 27), the normalization of the Hgb A1c at 6 months and removal from antidiabetic medications is a remarkable achievement. The Torres group's most recent analysis (2015) suggests the SADI procedure can be performed with few postoperative complications that are ultimately corrected; mean excess weight loss was 72% at 2 years, with complete remission rates of 89% for diabetes, 60% for hypertension, and 40% for dyslipidemia. The evidence of clinical hypoalbuminemia is essentially resolved with this mature, but technically more demanding technique for bariatric surgical weight loss.

In summary, the Figure depictions provided by Professors Dakin and Pomp in this chapter of The Mastery of Surgery emphasize a fundamental advancement in technical approach for the super-obese and additional steps for the consideration of revision of gastric bypass to biliopancreatic diversion with duodenal switch. Experimentally and clinically, and in experienced hands, the LBPD-DS is objectively the most secure and tested technique for weight loss of all bariatric procedures. Further, LBPD-DS provides the clinician and their patients the greatest long-term success probability for the reduction in comorbidities. Despite these accolades of safety in the right hands, the authors acknowledge that more technical expertise is required to achieve this outcome. Both North American and European clinics have achieved unprecedented safety

of the LBPD-DS technique with highly acceptable outcomes that are comparable to the more commonly performed (and less complex) gastric bypass procedures. The technical difficulty of the LBPD-DS is less problematic in high-volume related practices as in the Torres Clinic. This team noted similar morbidity from bariatric GB. Staging of the procedure as recommended by DeMaria and Associates (DeMaria EJ, Murr M, Byrne TK, et al. Validation of the obesity surgery mortality risk score in a multicenter study proves it stratifies mortality risk in patients undergoing gastric bypass for morbid obesity. *Ann Surg* 2007;246:578–82), and Regan and Gagner (Regan JP, Inabnet WB, Gagner M, et al. Early experience with two-stage laparoscopic Roux-en-Y gastric bypass as an alternative in the super-super obese patient. *Obes Surg* 2003;13:861–4) have resulted in excellent postoperative outcomes. We agree that the BPD-DS represents a superior consideration to the bariatric surgeon that is tantamount to any of his/her repertoire of operations. This procedure provides the morbidly obese and super-obese patients referred to their clinics superior outcomes in weight loss and comorbidities. As suggested in this text, and by other bariatric care systems (Brethauer SA, Chand B, Schauer PR. Risks and benefits of bariatric surgery: current evidence. *Cleve Clin J Med* 2006;73(11):993–1007), a comprehensive learned team of clinicians, nurses, surgeons, social and psychiatric professionals is required to complete this advanced management team in bariatric surgery to ensure health to these disadvantaged individuals throughout the world.

Kirby I Bland

Suggested Reading

Center for Disease Control and Prevention U.S. Obesity Trends, 1985–2008. www.cdc.gov/obesity/data/trends.html/

100 EndoBarrier for the Treatment of Morbid Obesity and Type II Diabetes

Keith S. Gersin

INTRODUCTION

Obesity grades 2 and 3 (body mass index [BMI] 35 to <40 kg/m^2 and BMI ≥40 kg/m^2) and type 2 diabetes mellitus (T2DM) affect 15.4% (2011–2012 data) and 8.4% of the United States population, respectively. Furthermore, because the prevalence of T2DM increases with increasing BMI, there is some overlap between these two populations. In a recent survey involving individuals who had not previously been diagnosed with diabetes, 16% of patients with BMI 40 to 49.9 kg/m^2 and 21% of those with BMI ≥50 kg/m^2 had T2DM.

Body weight reduction has been shown to reduce overall mortality, increase diabetes recovery rate, and improve cardiovascular risk factors in patients who are obese. Decreases in body weight also reduce glycated hemoglobin, improve cardiovascular risk factors, reduce comorbidities, and improve quality of life in overweight or obese patients with T2DM. Weight reduction is thus of paramount importance for improved health in patients with obesity, T2DM, or both.

Management of obesity through lifestyle intervention and use of drugs is associated with mean reductions in body weight of 3% to 9%. However, up to 60% of patients may not achieve clinically meaningful (≥5%) weight loss with pharmacologic intervention, and bariatric surgery may be an option for this subset of patients. For those with morbid obesity (typically defined as BMI ≥40 kg/m^2 or ≥35 kg/m^2 with comorbidities), bariatric surgery is associated with substantial weight loss, improvements in weight-associated comorbidities, and reductions in mortality. However, surgical intervention is not indicated or not ideal for all patients with obesity and/or T2DM. For example, bariatric procedures are generally not indicated in patients with BMI <35 kg/m^2, and there may be potential for complications during and after bariatric surgery, including perioperative

mortality. Moreover, some bariatric procedures are not reversible, and many patients have serious concerns about undergoing weight loss surgery. There is therefore a role for a reversible, endoscopic procedure that promotes weight loss and improves glycemic control, and that may be more effective than medications and less invasive than surgery.

DUODENAL–JEJUNAL BYPASS LINER

The duodenal–jejunal bypass liner (EndoBarrier Gastrointestinal Liner System) is an impermeable, fluoropolymer intestinal liner with an integral anchor system, proximal radiopaque marker, and retrieval drawstrings (Fig. 100.1) that is delivered and removed endoscopically. The proximal end of this 61-cm long, open-ended liner is anchored in the duodenal bulb via a self-expanding nitinol stent containing bidirectional barbs that affix the device to the duodenal wall. These barbs help prevent distal and proximal migration of the anchor and liner.

The EndoBarrier is available as a sterile, one-time use, prepackaged capsule/delivery system. Prior to implantation, the liner and anchor are collapsed and contained within a protective capsule (Fig. 100.2) that is affixed to a flexible custom-delivery catheter (Fig. 100.3). The capsule is delivered endoscopically to the duodenum just distal to the pylorus, and the device is delivered from the capsule during implantation. A ball on the distal end of the catheter facilitates atraumatic tracking of the liner through the duodenum and proximal jejunum, with the assistance of continuous dynamic fluoroscopy. Once the liner has been completely delivered, aided by visualization of the proximal radiopaque marker exiting the delivery capsule, the self-expanding nitinol anchor is released within the duodenal bulb, 1 to 2 cm distal to the pylorus.

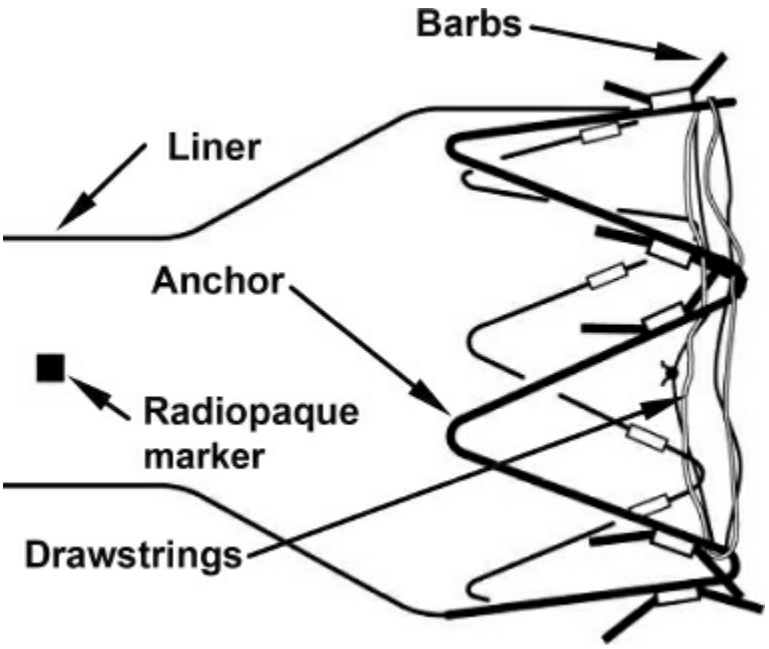

Figure 100.1. Proximal end of duodenal–jejunal bypass liner showing anchor, bidirectional barbs, and drawstrings. (From The EndoBarrier Gastrointestinal Liner with Delivery System: Instructions For Use (50–10–00552 Rev N IFU EB GI Liner with Delivery System.pdf). Lexington, MA: GI Dynamics Inc.)

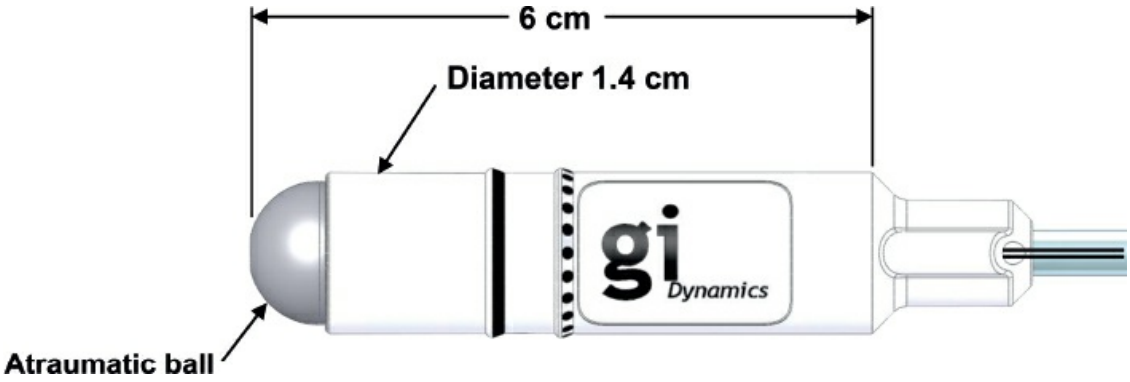

Figure 100.2. Capsule containing the duodenal–jejunal bypass liner. (From The EndoBarrier Gastrointestinal Liner with Delivery System: Instructions For Use (50–10–00552 Rev N IFU EB GI Liner with Delivery System.pdf). Lexington, MA: GI Dynamics Inc.)

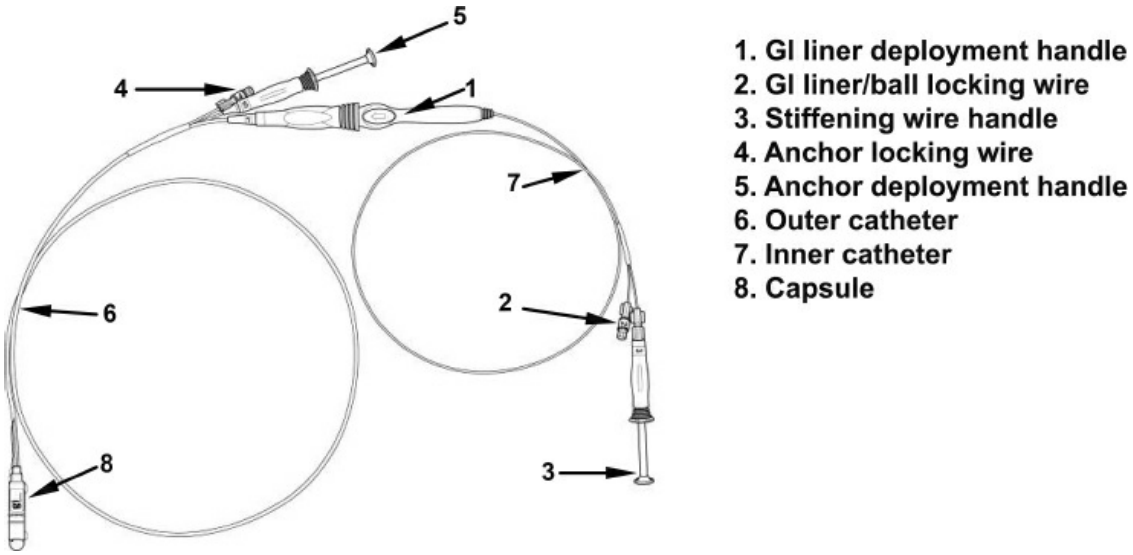

Figure 100.3. Delivery system for the duodenal–jejunal bypass liner. (From The EndoBarrier Gastrointestinal Liner with Delivery System: Instructions For Use (50–10–00552 Rev N IFU EB GI Liner with Delivery System.pdf). Lexington, MA: GI Dynamics Inc.)

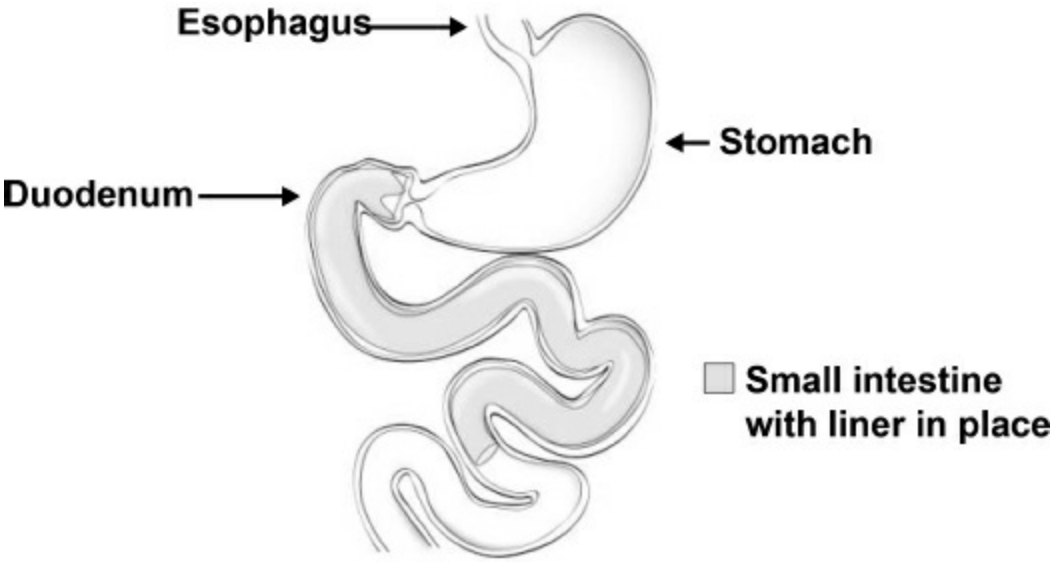

Figure 100.4. Position of the duodenal–jejunal bypass liner in the small intestine. (From The EndoBarrier Gastrointestinal Liner with Delivery System: Instructions For Use (50–10–00552 Rev N IFU EB GI Liner with Delivery System.pdf). Lexington, MA: GI Dynamics Inc.)

In this manner, the liner creates a duodenal–jejunal bypass (Fig. 100.4). Biliary and pancreatic secretions pass around the outside of the impermeable liner and mix with chyme as it exits the distal end of the liner in the jejunum. The liner excludes the duodenum and proximal jejunum

and thus mimics the anatomical effects of Roux-en-Y gastric bypass. The liner has been shown to induce weight loss and improve cardiovascular risk factors in obese patients with or without concomitant T2DM, and to improve glycemic control in obese patients with T2DM.

The liner is removed using a custom retrieval system and hood (Figs. 100.5 and 100.6) after a maximum implantation period of 12 months. It is recommended that both implantation and explantation be performed by physicians who are skilled in therapeutic endoscopy, to minimize tissue damage that can occur. Such damage can include laceration, perforation, and bleeding. Initial training and proctoring of the endoscopic team is therefore extremely important to help ensure the success of procedures performed by early adopters.

INDICATIONS

Implantation of a duodenal–jejunal bypass liner can be considered for adult patients 18 to 70 years of age who have T2DM and a BMI ≥35 kg/m^2 or a BMI ≥30 kg/m^2 plus ≥1 other comorbidity (e.g., dyslipidemia, hypertension, BMI ≥35 kg/m^2). Implantation of the bypass liner may be particularly appropriate in patients with T2DM who are poorly controlled despite lifestyle changes and escalating diabetes medications, and in obese patients for whom bariatric surgery is contraindicated or is considered a therapy of last resort. Although the EndoBarrier is currently indicated for a maximum implantation period of 12 months only, preliminary data suggest that serial implantation is safe, and associated with further weight loss.

PATIENT SELECTION

Patients should be participating in a multidisciplinary weight management program that includes endoscopists and endocrinologists. Selection of appropriate candidates is important for success, and screening of all prospective implant recipients by both a dietitian and a mental health provider is recommended. Female patients should be postmenopausal, surgically sterile, or receiving contraception.

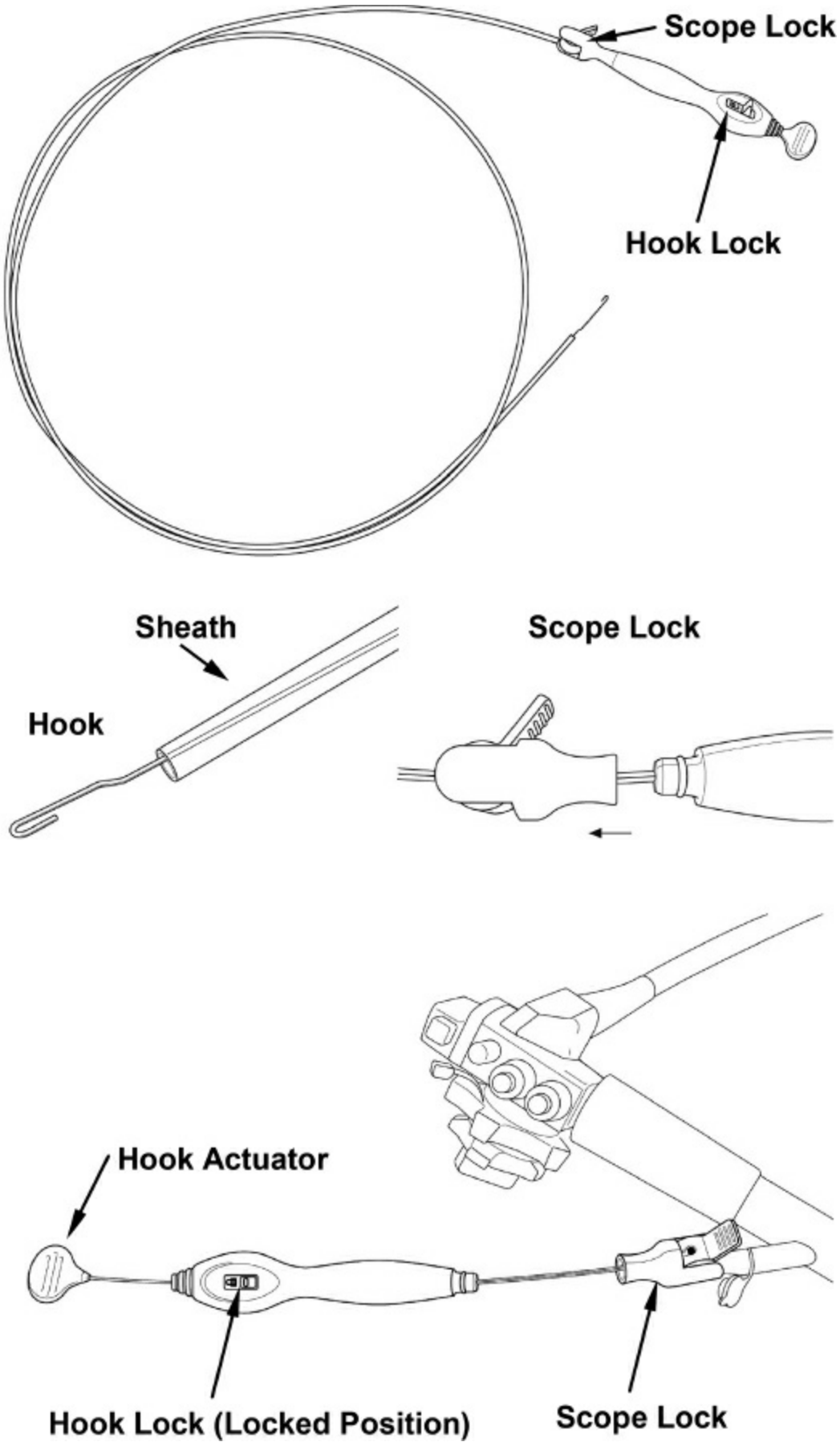

Figure 100.5. Retrieval system for the duodenal–jejunal bypass

liner. (From The EndoBarrier Gastrointestinal Liner Retrieval System: Instructions For Use (50–30–00637 Rev N IFU EndoBarrier GI Liner Retrieval System with Certified Translations.pdf). Lexington, MA: GI Dynamics Inc.)

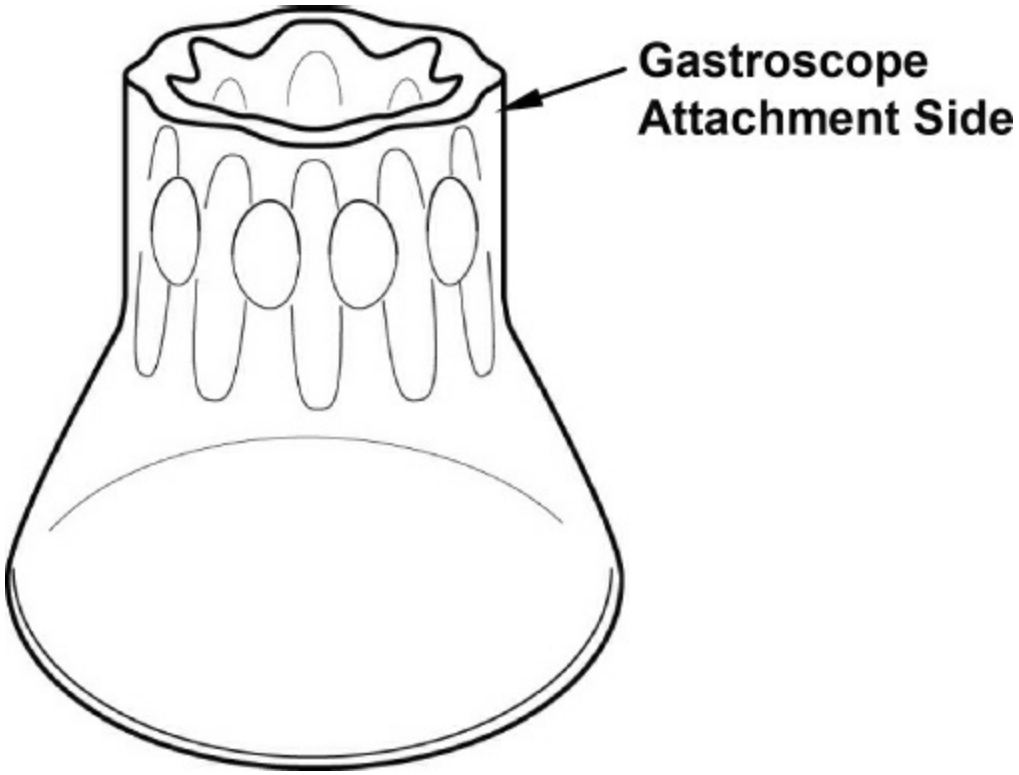

Figure 100.6. Endoscope hood (available in two attachment diameters: 8 to 10.5 and 10.6 to 13.2 mm). (From The EndoBarrier Gastrointestinal Liner Retrieval System: Instructions For Use (50–30–00637 Rev N IFU EndoBarrier GI Liner Retrieval System with Certified Translations.pdf). Lexington, MA: GI Dynamics Inc.)

Table 100.1 describes contraindications to duodenal–jejunal bypass liner implantation. It should be noted that, even with careful patient selection, implantation may prove unsuccessful in a small proportion of patients; this is usually related to unfavorable patient anatomy that prevents delivery of the liner and anchor.

TABLE 100.1 Contraindications to Implantation of the Duodenal–Jejunal Bypass Liner

Pregnancy

Medication Use

Nonsteroidal anti-inflammatory drugs
Anticoagulation therapy
Weight loss medication
Appetite suppressants

Gastrointestinal Conditions

Active *Helicobacter pylori* infection
Inflammatory bowel disease
Severe gastroesophageal reflux disease
Gastrointestinal tract abnormalities (e.g., atresia, stenosis)
Ulcers
Crohn disease
Previous surgery of the gastrointestinal tract that could make the implantation difficult

Family or Patient History of:

Systemic lupus erythematosus
Scleroderma
Any autoimmune connective tissue disorder

Conditions Predisposing to Blood Loss/Anemia

Iron deficiency
Iron deficiency anemia
Bleeding diathesis
Congenital or acquired intestinal telangiectasia
Coagulopathy
Upper gastrointestinal bleeding conditions (e.g., esophageal or gastric varices)

Diseases of Other Organ Systems

Pancreatitis
Symptomatic kidney stones
Symptomatic gallstones
Symptomatic coronary artery disease
Symptomatic pulmonary dysfunction
Any severe systemic or end-organ disease

Bacterial Infection in Any Site

Unresolved Substance Abuse

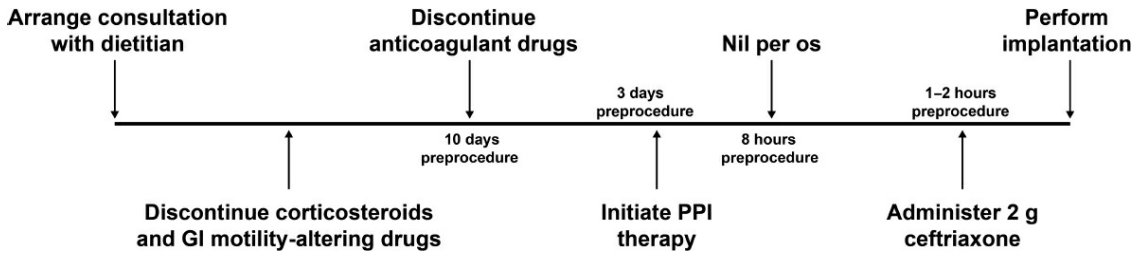

Figure 100.7. Preprocedural preparation for implantation of duodenal–jejunal bypass liner. GI, gastrointestinal; PPI, proton pump inhibitor.

PREIMPLANTATION PREPARATION

Appropriate patient selection, expertise in device placement and removal, and the presence of an experienced multidisciplinary team are of vital importance for safe and effective use of the duodenal–jejunal bypass liner. This includes on-demand availability of a surgical team and an interventional radiologist in case a severe adverse event occurs in

association with implantation or explantation, or during the period that the liner is in place.

Patients should have a consultation with a dietitian prior to liner placement to discuss dietary changes that will be necessary after implantation (Fig. 100.7). The preimplantation pharmacologic regimen must also be considered. Patients should discontinue taking corticosteroids and any drugs that affect gastrointestinal motility prior to liner placement. Antispasmodic agents may be used at the time of implant delivery and for a short time after implantation if the patient experiences discomfort. Patients should not take any anticoagulant medications (e.g., aspirin, heparin, or nonsteroidal anti-inflammatory drugs [NSAIDs]) for 10 days prior to liner placement and for the duration of treatment. Clinically significant bleeding has occurred in patients who have taken inhibitors of platelet aggregation and/or heparin after liner placement and, on occasion, in those who have not. Patients must take a proton pump inhibitor (PPI) (40 mg omeprazole twice/day, or equivalent) for 3 days prior to the procedure and should continue this medication throughout the period of liner implantation, and for 2 weeks after explantation.

Patients must not eat or drink for 8 hours prior to the implantation procedure. A single 2-g dose of ceftriaxone (or equivalent) should be administered intravenously 1 to 2 hours prior to liner placement to reduce the potential for infection. Because it is important that the patient remains still throughout the procedure, the patient should be anesthetized or sedated, as appropriate.

IMPLANTATION TECHNIQUE

The liner is placed endoscopically under fluoroscopic guidance. The equipment needed is described in Table 100.2. With the patient lying on his/her left side, the gastroscope is advanced into the duodenum and a thorough examination of the stomach, pylorus, and duodenum is performed. This is done to ensure that the patient's alimentary canal is free of abnormalities that could interfere with the delivery, function, and removal of the liner. As part of this examination, the papilla and other accessory ducts should be observed to ensure that they are not located in the bulbous duodenum. If this is the case, the patient is not a suitable candidate for liner placement due to concerns of biliopancreatic duct obstruction.

The guidewire is advanced into the duodenum through the gastroscope

and its tip is advanced and looped in the duodenum/proximal jejunum. The gastroscope is then removed over the wire while maintaining the wire's position in the small intestine. After fluoroscopic verification of the position of the guidewire loop, the capsule of the catheter is lubricated and advanced over the guidewire and into the duodenum. The guidewire is then removed. The inner catheter (Fig. 100.3) is advanced slowly under fluoroscopic guidance, pushing the liner and atraumatic ball through the proximal small intestine until it has been fully delivered. Slow delivery of the catheter is important; it may prolapse if advanced too quickly. The atraumatic ball is then released from the distal end of the catheter. Release of the ball, which passes through the gastrointestinal tract by peristalsis and is passed in the stool, is confirmed by fluoroscopy.

The gastroscope is reintroduced into the stomach during delivery of the liner and anchor to ensure that the delivery capsule is fully within the bulb of the duodenum and that the anchor crowns are not visible across the pylorus after the anchor is extruded from the capsule. Under endoscopic visualization, the anchor is deployed so that the barbs on the circumference of the anchor engage the muscularis of the bulbous duodenum, proximal to the ampulla of Vater. Gastrografin contrast (diluted to 20%), followed by air and saline, are injected through the inner catheter to ensure patency of the liner. The inner catheter is then removed from the outer catheter and fluoroscopy is used to confirm that the implant has not bunched during inner catheter withdrawal.

TABLE 100.2 Equipment Needed for Liner Implantation and Explantation

Implantation	Explantation
Liner delivery and retrieval systems	Liner retrieval system
Fluoroscopy unit	Fluoroscopy unit
Video gastrointestinal endoscopy system, including gastroscope with 2.8 mm working channel and outer diameter of 8.6–9.8 mm	Video gastrointestinal endoscopy system, including gastroscope with 2.8 mm working channel and outer diameter of 8–10.5 mm, or colonoscope with outer diameter of 10.6–13.2 mm
Gastrografin, Renografin, or equivalent water-soluble contrast media (not barium)	Esophageal overtube 50 cm in length that will fit an 8.6–10.5-mm endoscope
0.035 in super-stiff nitinol guidewire	
Esophageal overtube 50 cm in length that will fit an 8.6–10-mm endoscope	

After removal of the gastroscope and delivery device, the gastroscope is reintroduced to examine the liner in the duodenal bulb. The delivery capsule must remain distal to the gastroscope during withdrawal to help prevent esophageal perforation by the capsule. Additional introduction of 20% Gastrografin solution into the liner is used to confirm patency and to stretch out the liner section. Removal of the gastroscope completes the procedure. In one study, the total procedure time ranged from 12 to 111 minutes, including 2 to 27 minutes of fluoroscopy time.

POTENTIAL COMPLICATIONS DURING IMPLANTATION

A number of technical errors may occur during liner implantation. These include incorrect positioning of the anchor, incomplete liner delivery, and liner obstruction. In these situations, the liner should be removed from the patient using the custom retrieval system. Upon removal, another attempt at liner delivery may be performed. Another potential problem is crossover of the anchor crowns, which prevents full expansion of the anchor. In this situation, the crossed crown should be lifted and separated from the others using biopsy forceps.

POSTIMPLANTATION MANAGEMENT

Patients are typically discharged from the hospital on the day of the procedure. Because it is currently unknown whether certain foods (e.g., grains, nuts) could interfere with correct functioning of the liner, patients

should follow a diet similar to that recommended for individuals who have undergone Roux-en-Y gastric bypass. A consultation with a dietitian before and after implantation is recommended. If a medical condition that necessitates use of anticoagulants develops during the period of implantation, the device should be removed prior to initiation of the anticoagulant.

EXPLANTATION TECHNIQUE

Removal typically takes less time than delivery but can be more challenging due to anchor migration, tilting, or tissue ingrowth. The liner retrieval system (EndoBarrier Gastrointestinal Liner Retrieval System) (Fig. 100.5) consists of a grasper (a hook within a protective sheath) and custom hood (Fig. 100.6), both of which are compatible with standard gastroscopes. The equipment needed for explantation is described in Table 100.2. The procedure is performed endoscopically under fluoroscopic guidance, with the patient under general anesthesia or sedation.

With the patient lying on his/her left side, a gastroscope is passed into the duodenum, a surveillance examination is performed, and the retrieval drawstrings are identified. The endoscope is removed from the patient and the retrieval hood is attached to its tip. The endoscope is reinserted into the duodenum, the anchor and one of the retrieval drawstrings are visualized, and the grasper hook is used to pull the drawstring inside the protective sheath. As the hook and drawstrings are retracted, the anchor collapses. The endoscope and hood are then advanced so that the proximal anchor barbs are contained within the hood. Collapse of the anchor and capture of all the proximal barbs within the hood are monitored fluoroscopically. The grasper and endoscope are then locked together and retracted as one until the hood and its collapsed anchor are contained in the stomach, where there is more space to reposition the anchor within the hood (if needed), as well as to ensure that the barbs are fully covered by the hood before removal via the esophagus. Use of fluoroscopy and endoscopy within the stomach helps to ensure this. The endoscope, grasper, and implant are then removed together under fluoroscopic visualization. The explant site is reinspected for signs of bleeding. In one study, the time taken for explantation ranged from 3 to 182 minutes, including 1 to 24 minutes of fluoroscopy time.

There are a number of technical considerations during explantation. For example, if both drawstrings have failed or broken, explantation requires

the use of an overtube. In this situation, the endoscope is passed through the overtube, the liner and anchor are everted (using rat-tooth graspers and a polypectomy snare so that the anchor barbs are within the anchor), and the implant is withdrawn inside the overtube under fluoroscopic visualization. If the liner is being removed because of distal food impaction, the anchor is collapsed within the hood and withdrawn into the stomach as in a normal explantation. The drawstrings are then released and, using endoscopic scissors, the liner is cut distal to the anchor. The anchor is then collapsed and retrieved inside the hood as normal, and the sleeve portion of the liner is left inside the patient to be passed naturally.

EFFICACY

The duodenal–jejunal bypass liner has been associated with substantial weight loss and improved cardiovascular risk factors in obese patients with or without concomitant T2DM, as well as clinically relevant improvements in glycemic control in obese patients with T2DM. Improvements in plasma parameters of nonalcoholic fatty liver disease have also been demonstrated. Other potential but as yet unstudied mechanisms of action may include changes in vagus nerve activity, the presence of undiluted bile in the proximal small intestine, increased levels of oxyntomodulin, and altered GI microbiota. It should be noted that a number of published studies evaluated an earlier version of the device that differed from the commercialized version in some technical features (in particular, the bidirectional barbs were shorter) and had a shorter implant duration (3 months vs. 12 months).

Weight Loss

Weight loss in association with liner placement has been demonstrated in patients with morbid obesity and in overweight and obese patients with T2DM. Although the majority of clinical studies involving implantation of the liner were uncontrolled, the effect on body weight has been compared with that of a sham implantation procedure and with dietary intervention alone. The results of these studies demonstrate that, in general, liner implantation is significantly more effective in inducing weight loss than either placebo intervention (sham implantation) or dietary intervention alone (Table 100.3). Uncontrolled studies in morbidly obese patients have documented mean percent excess weight losses of up to 47%, mean total body weight decreases of up to 20% (Fig. 100.8), and mean BMI

reductions of 9 kg/m^2 after implantation periods of up to 1 year.

The mechanisms by which the liner induces weight loss have not been fully established. However, early ideas that the device may cause weight loss solely via malabsorption are not supported by more recent work. In particular, there is evidence that the weight loss associated with liner implantation may be mediated in part by changes in the levels of hormones that affect satiety, including peptide YY (PYY) and glucagon-like peptide-1 (GLP-1). In this manner, the mechanism may be similar to that of bariatric procedures that exclude the proximal small intestine. However, in contrast to the reduction in ghrelin levels that typically occurs after Roux-en-Y gastric bypass, patients who have undergone liner implantation show increased levels of this hormone. Liner implantation has also been associated with reduced food intake, increased satiety, and delayed gastric emptying.

TABLE 100.3 Effects of Duodenal–Jejunal Bypass Liner Implantation on Body Weight in Controlled Studies

Study	Duration of Implantation	*n*	Effect on Body Weight			
			Excess Weight Loss (%)		Change in Body Weight (kg)	
			Liner	Control	Liner	Control
Gersin et al., 2010[b]	12 weeks	Liner: 13 Control: 24	11.9 ± 1.4[a]	2.7 ± 2.0	–8.2 ± 1.3[a]	–2.1 ± 1.1
Rodriguez et al., 2009[b]	20 weeks[c]	Liner: 12 Control: 6	NA	NA	–10.2 ± 1.3	–7.1 ± 4.3
Schouten et al., 2010[d]	12 weeks	Liner: 24 Control: 11	19.0 ± 10.9[a]	6.9 ± 6.1	NA	NA
Tarnoff et al., 2009[d]	12 weeks	Liner: 25 Control: 14	22.1 ± 8[a]	5.3 ± 6.6	10.3 ± 3.2	2.6 ± 3.5

[a]P <0.05 vs. control arm.
[b]Control arm = sham procedure; data shown as mean ± standard error of the mean.
[c]Planned study duration = 24 weeks but *n* = 3 in sham procedure arm at 24 weeks, hence 20 week data shown.
[d]Control arm = dietary intervention; data shown as mean ± standard deviation.
NA, data not available.
From Gersin KS, Rothstein RI, Rosenthal RJ, et al. Open-label, sham-controlled trial of an endoscopic duodenojejunal bypass liner for preoperative weight loss in bariatric surgery candidates. *Gastrointest Endosc* 2010;71:976–82; Rodriguez L, Reyes E, Fagalde P, et al. Pilot clinical study of an endoscopic, removable duodenal-jejunal bypass liner for the treatment of type 2 diabetes. *Diabetes Technol Ther* 2009;11:725–32; Schouten R, Rijs CS, Bouvy ND, et al. A multicenter, randomized efficacy study of the EndoBarrier Gastrointestinal Liner for presurgical weight loss prior to bariatric surgery. *Ann Surg* 2010;251:236–43; Tarnoff M, Rodriguez L, Escalona A, et al. Open label, prospective, randomized controlled trial of an endoscopic duodenal-jejunal bypass sleeve versus low calorie diet for pre-operative weight loss in bariatric surgery. *Surg Endosc* 2009;23:650–6.

Glycemic Control

In patients with T2DM, improvements in glycemic control are associated with significant reductions in the risks of macrovascular and microvascular events. Moreover, posttrial monitoring of patients enrolled in the United Kingdom Prospective Diabetes Study (UKPDS) showed that the beneficial effects of intensive glucose control continue well beyond the period of control.

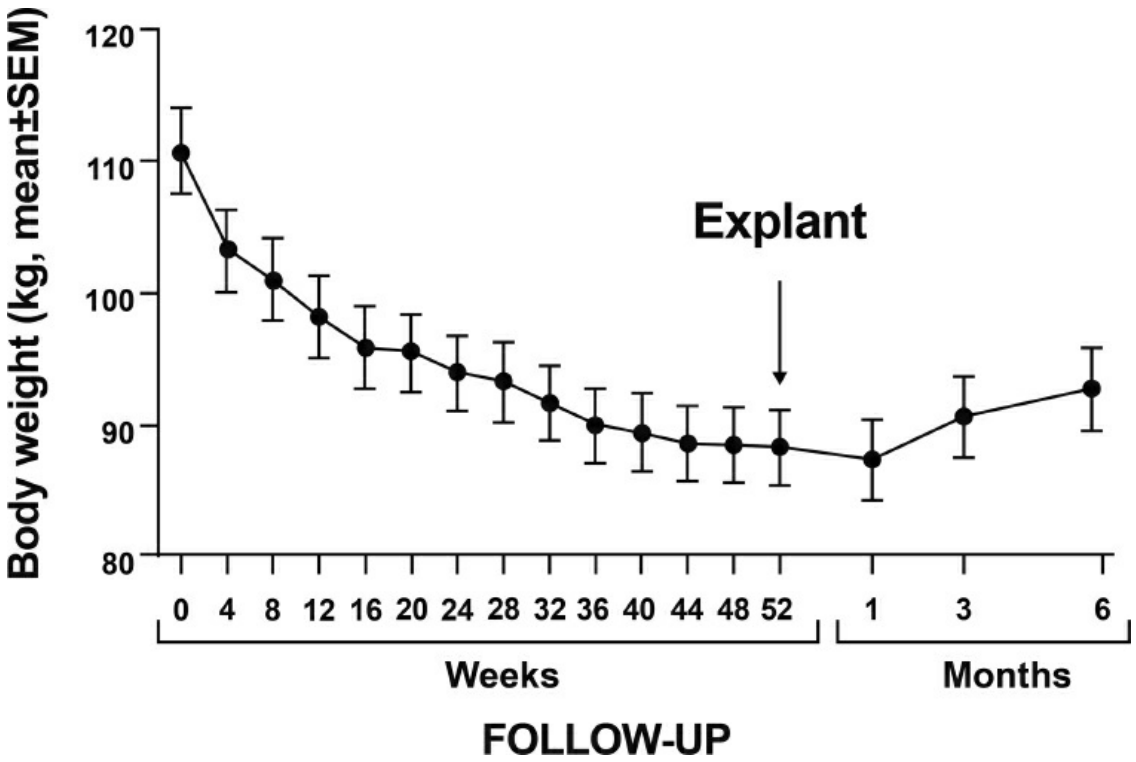

Figure 100.8. Mean change in body weight (±SEM) over the 52-week implantation period and for 6 months after explantation (n = 24). SEM, standard error of the mean. (From Escalona A, Pimentel F, Sharp A, et al. Weight loss and metabolic improvement in morbidly obese subjects implanted for 1 year with an endoscopic duodenal-jejunal bypass liner. *Ann Surg* 2012;255(6):1080–5.)

To date, no clinical trial has investigated the effects of the duodenal–jejunal bypass liner on the incidence of macrovascular and microvascular events. However, improvements in glycemic control have been demonstrated consistently in studies involving patients with T2DM, including those who undergo early explantation. The improvements in glycemic control are rapid in onset and of a magnitude that is clinically significant. In studies involving patients with T2DM, liner implantation has been associated with significant reductions from baseline in fasting glucose, insulin levels, insulin resistance, and HbA1c. In one such study, the percentage of subjects with HbA1c <7% increased from 4.5% at baseline to 73.0% at the final assessment. Figure 100.9 shows the gradual improvement in HbA1c during the period of liner placement. The mean reduction in HbA1c in this study was 2.1%, from a mean value at baseline of 8.9%. Importantly, improvements in glycemic control appear to be independent of HbA1c at the time of implantation.

Postprandial glucose excursions are also more likely to decrease in liner-implanted patients than in controls, and use of diabetes medication has been shown to decrease by up to 42%. Moreover, results from a small number of patients suggest that the improvements in glycemic control may be maintained for up to 6 months after device removal. The rapidity of the improvement in glycemic control suggests that this beneficial effect may be at least partially independent of weight loss. Increases in GLP-1, accompanied by reductions in hepatic glucose production and increases in insulin sensitivity, are believed to underlie this effect.

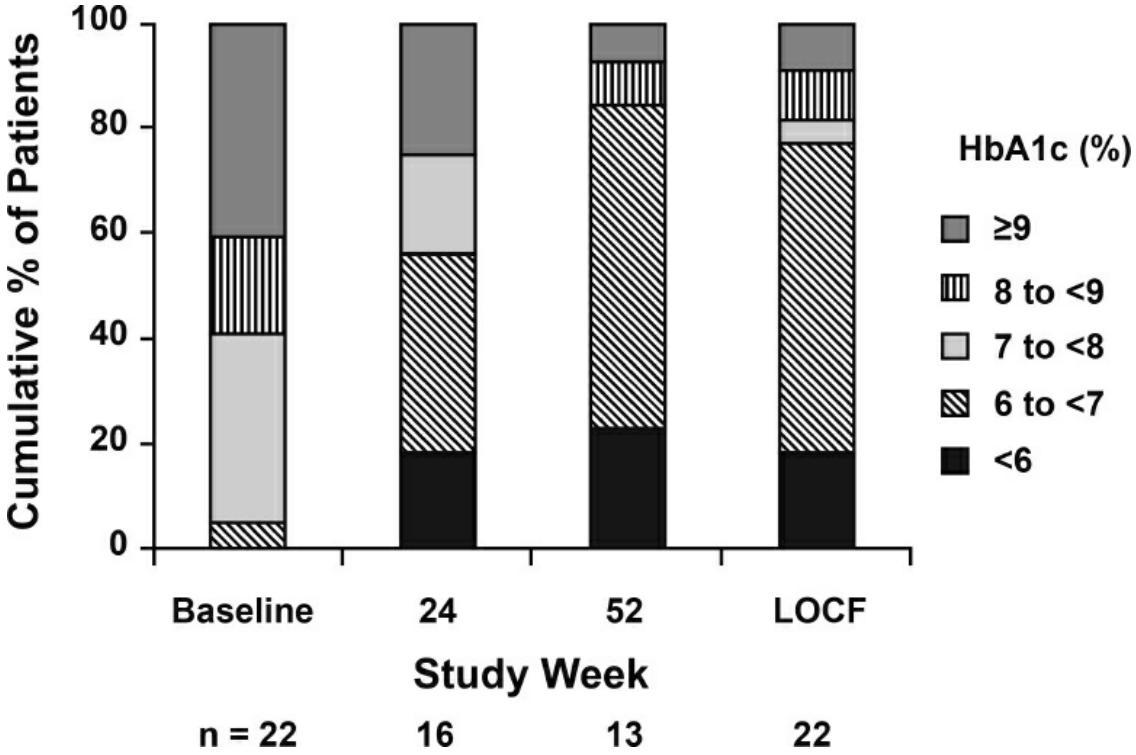

Figure 100.9. Distribution of HbA1c levels during a 1-year study involving obese patients with type 2 diabetes. LOCF, last observation carried forward. (From de Moura EGH, Martins BC, Lopes GS, et al. Metabolic improvements in obese type 2 diabetes subjects implanted for 1 year with an endoscopically deployed duodenal-jejunal bypass liner. *Diabetes Technol Ther* 2012;14(2):183–9.)

Cardiovascular Risk Factors

The bypass liner has shown beneficial effects on a range of cardiovascular risk factors. These include: levels of total cholesterol, low-density lipoprotein cholesterol, and triglycerides; systolic and diastolic blood pressure; and waist circumference. In one study, these improvements led to

a decrease in the prevalence of metabolic syndrome from 83% at baseline to 42% at 52 weeks after liner implantation, and in a separate study, to a reduction in patients' 10-year cardiovascular risk of between 19% and 33%, depending on the search engine used.

ADVERSE EVENTS

The adverse event profile of the duodenal–jejunal bypass liner does not appear to differ between studies that primarily enrolled patients with obesity and those that primarily enrolled patients with T2DM. No deaths have been reported in association with liner placement.

In some case series, early explanation related to adverse events occurred in up to 40% of patients for whom a 12-month implantation period was planned. With increased experience of the endoscopy team with the device, early explantation rates as low as 8% have been achieved.

Approximately 50% of patients report symptoms of abdominal pain, nausea, and vomiting in the first 2 weeks after liner placement. These symptoms have been successfully managed with a standard regimen of tramadol, butylscopolamine, and metoclopramide. However, if abdominal symptoms persist despite lifestyle changes and medication, early explantation may be necessary. Acid reflux and constipation may also occur in the period immediately after liner placement. A low residue, semi-liquid diet for 2 weeks after implantation is usually helpful to control these symptoms, and high-dose PPI therapy (40 mg omeprazole twice/day, or equivalent), with or without addition of sucralfate, can aid in management of acid reflux. A fluid intake of at least 2 L/day may help to combat constipation, although enemas and laxatives may also be necessary.

Although these safety data are reassuring, serious adverse events can occur. Suboptimal technique, faulty equipment, and anatomical abnormalities may lead to tissue damage during implantation or, more commonly, during explantation. The esophagus is the most likely site of trauma; mucosal damage and rupture of the esophagus have both been reported. For this reason, the presence of or access to a multidisciplinary team (including an interventional radiologist) during implantation and explantation procedures is mandatory.

Other serious adverse events include invagination of the liner, implant obstruction, pancreatitis, development of hepatic abscesses, duodenal penetration/fistula formation (with or without secondary gall bladder

impaction and cholecystitis), and gastrointestinal bleeding. The majority of these adverse events require device removal in addition to surgical and/or medical management, as appropriate. Table 100.4 shows the incidence of adverse events that resulted in device removal after implantation in more than 3,000 patients. To date, all reported serious adverse events associated with liner implantation/explantation have been successfully managed.

TABLE 100.4 Serious Adverse Events/Complications Resulting in Device Removal: Postmarket Surveillance Data, November 2008 to June 2015

	Incidence During Postmarketing Surveillance	
Adverse Event	*n*	% of Total Population Implanted (*N* = 3,150)
Hepatic abscess	26	0.8
Intolerance	50	1.6
Liner obstruction	24	0.8
Gastrointestinal bleeding	48	1.5
Migration	50	1.6
Pancreatitis	12	0.4
Perforation	10[a]	0.3
Surgical removal	10	0.3
Total	230	7.3

[a]Four subjects experienced a perforation during either the implantation or explantation procedure.

SUMMARY

The duodenal–jejunal bypass liner represents an effective, endoscopic treatment for both obesity and T2DM. Weight loss and improvements in glycemic control are substantial and are typically accompanied by improvements in cardiovascular risk. Implantation and explantation are uneventful in the majority of patients, and the adverse event profile is manageable. Availability of a surgical team and an interventional radiologist is imperative in the event of a serious adverse event for optimal management. Because the device is temporary and the changes it induces are fully reversible, the implant can be removed in the face of adverse events, which typically leads to resolution of the problem.

A full understanding of the duodenal–jejunal bypass liner's role in the management of obesity and T2DM requires further research. This will require controlled studies involving implantation of the commercialized

version of the liner in large numbers of obese patients both with and without T2DM, follow-up for an extended period after explantation, and incorporation of microvascular events, macrovascular events, and all-cause mortality as endpoints.

Suggested Readings

Betzel B, Koehestanie P, Aarts EO, et al. Safety experience with the duodenal-jejunal bypass liner: an endoscopic treatment for diabetes and obesity. *Gastrointest Endosc* 2015;82:845–52.

de Moura EG, Martins BC, Lopes GS, et al. Metabolic improvements in obese type 2 diabetes subjects implanted for 1 year with an endoscopically deployed duodenal-jejunal bypass liner. *Diabetes Technol Ther* 2012;14:183–9.

Escalona A, Pimentel F, Sharp A, et al. Weight loss and metabolic improvement in morbidly obese subjects implanted for 1 year with an endoscopic duodenal-jejunal bypass liner. *Ann Surg* 2012;255:1080–5.

Gersin KS, Rothstein RI, Rosenthal RJ, et al. Open-label, sham-controlled trial of an endoscopic duodenojejunal bypass liner for preoperative weight loss in bariatric surgery candidates. *Gastrointest Endosc* 2010;71:976–82.

Koehestanie P, de Jonge C, Berends FJ, et al. The effect of the endoscopic duodenal-jejunal bypass liner on obesity and type 2 diabetes mellitus, a multicenter randomized controlled trial. *Ann Surg* 2014;260:984–92.

Muñoz R, Escalona A. Duodenal-jejunal bypass liner to treat type 2 diabetes mellitus in morbidly obese patients. *Curr Cardiol Rep* 2014;16:454.

Rodriguez L, Reyes E, Fagalde P, et al. Pilot clinical study of an endoscopic, removable duodenal-jejunal bypass liner for the treatment of type 2 diabetes. *Diabetes Technol Ther* 2009;11:725–32.

Schouten R, Rijs CS, Bouvy ND, et al. A multicenter, randomized efficacy study of the EndoBarrier gastrointestinal liner for presurgical weight loss prior to bariatric surgery. *Ann Surg* 2010;251:236–43.

Tarnoff M, Rodriguez L, Escalona A. Open label, prospective, randomized controlled trial of an endoscopic duodenal-jejunal bypass sleeve versus low calorie diet for pre-operative weight loss in bariatric surgery. *Surg Endosc* 2009;23:650–6.

Zechmeister-Koss I, Huić M, Fischer S; European Network for Health Technology Assessment (EUnetHTA). The duodenal-jejunal bypass liner for the treatment of type 2 diabetes mellitus and/or obesity: a systematic review. *Obes Surg* 2014;24:310–23.

EDITOR'S COMMENT

Obesity is the leading epidemic in the Unites States with over one third of Americans overweight or obese. Billions of dollars are spent trying to lose weight and on the health care consequences of obesity such as type 2 diabetes, hyperlipidemia, hypertension, back pain, knee pain, and obstructive sleep apnea. While it is clear that diets and medical therapy are for the most part useless among patients with severe obesity, operations such as the laparoscopic adjustable band, gastric sleeve, Rou-en-Y gastric bypass, and duodenal switch can achieve superior and more durable weight loss in the morbidly obese patient than might be expected from a 12-month duodenal–jejunal liner.

It is estimated that only about 1 in every 400 patients who meet medical necessity for weight loss surgery actually undergo an operation. Therefore, most patients who need treatment are not getting it, in part because surgery is seen to be too drastic and fraught with complications and even weight regain. Therefore, there is a need for an effective and less invasive option to help with weight loss.

The appeal of the EndoBarrier sleeve is that it is a device that is conceptually simple. It is a 61 cm duodenal–jejunal liner anchored to the duodenal bulb that prevents the normal mix and absorption in the proximal small bowel. The device claims in "uncontrolled studies" to promote weight loss (47% excess weight loss; 9 kg/m^2 BMI decrease), improve glycemic control, and reduce cardiac risk factors. If true, one needs to ask, "why has the EndoBarrier sleeve not taken off?"

Dr Gersin claims that the EndoBarrier sleeve is more effective than diets and less invasive than commonly performed weight loss operations. The claim to be better than placebo and diets is a minimal claim since diets fail 95% of the time. To date there is no data to suggest the duodenal–jejunal sleeve has any superiority to lap band, gastric sleeve, gastric bypass, or duodenal switch operations for weight loss and resolution of comorbid conditions. And while there is no skin incision on the abdominal wall, the EndoBarrier should not be considered risk free. The procedure is known to cause gastrointestinal laceration, perforation, and bleeding. The patient requires an anesthetic and sedation which poses its own airway risk among patients with obstructive sleep apnea. The procedure requires significant fluoroscopic time and exposes both the patient and the provider to radiation. Half of the patients report pain, nausea, and reflux. Others require enemas and laxatives to address constipation. Serious complications such as esophageal rupture have also been reported. Dr. Gersin emphasizes that the procedure requires a trained endoscopist with surgeons and interventional radiologists on backup call for the rare but potentially serious complications during EndoBarrier sleeve placement.

Like other weight loss operations, the science is lacking to fully understand the mechanism of action of the EndoBarrier. Dr Gersin notes that satiety after

the EndoBarrier may occur by changes in PYY and GLP-1 hormones. However, increasing the ghrelin hormone after EndoBarrier should stimulate hunger. Other mechanisms of action are proposed such as changes in vagal activity, bile composition, and gut microbiota. Further research excluding parts of the GI tract as achieved by the EndoBarrier device will be important to advance our understanding of the physiologic and hormonal effects leading to weight gain and regulating weight loss.

Randomized studies comparing EndoBarrier with lap band and the intragastric balloon are needed to compare the relative risk and benefits of other "less invasive" MIS weight loss options in the diabetic patient with a BMI >30. Meanwhile, all patients undergoing EndoBarrier sleeve should be entered in the ACS ASMBS MBSAQIP data registry and these results should be made publically available so that outcomes and resolution of diabetes can be assessed with this technique.

Daniel B. Jones

101 Revisional Bariatric Surgery

John Rodriguez and Matthew Kroh

INTRODUCTION

Bariatric surgery has proven to be efficacious and safe for treatment of morbid obesity and weight-related comorbid conditions. Accruing data demonstrate its successful impact on metabolic disease. Laparoscopic surgery has helped improve perioperative outcomes making bariatric surgery an increasingly common procedure. It is estimated that more than 190,000 bariatric operations were performed in the United States and more than 450,000 worldwide in 2013. The overall safety and quality of these operations have improved with metrics including reporting of data and centers of excellence, but even as such, the sheer number of procedures performed dictates that there will be a number of patients who ultimately encounter complications requiring revisional surgery, or have failure of weight loss. Morbid obesity is a chronic disease requiring lifelong therapy, and bariatric surgery is an important component of these therapies.

As such, an additional consideration for revisional surgery is weight loss failure, measured both by percent excess weight loss (%EWL) and by persistence of comorbid disease. Although definitions vary based on author and operations, <50% EWL is often considered failure after gastric bypass. Weight loss failure is further categorized by time frame, either at the time of the nascent procedure or by means of recidivism. When these outcomes occur, bariatric procedures may then ultimately require revision. Revisional procedures that result in a different operation from the index procedure are known as conversion. Revisional procedures that address complications or problems with the index procedure, but don't change the type of procedure performed, are referred to as corrective. Procedures that restore, as best possible, original anatomy, are referred to as reversal.

Revisional bariatric surgery includes technically challenging operations in previously operated patients who often also have significant comorbid disease. When performed by experienced surgeons in comprehensive bariatric care centers, revisional procedures can impart significant improvement in weight-related disease and overall quality of life for

patients, with acceptable risk and complication rates. This chapter focuses on the management of patients being considered for revisional bariatric surgery, both for complications from previous bariatric surgery and also from initial weight loss failure and weight recidivism.

Preoperative Evaluation

Ultimately, the decision to perform revisional or corrective operations should be based on careful evaluation of each individual patient's specific risk-benefit profiles, in the context of a multi-disciplinary team approach. Reoperations either for revision or for conversion after bariatric surgery require careful preoperative planning, accurate understanding of the target anatomy, and anticipation of potential pitfalls. In the setting of revision for complications, a detailed history focusing on the predominant symptoms often will give direction to the necessary work-up prior to reintervention. Dysphagia is a common complaint for patients presenting with obstructive complications, such as strictures, adhesions, or internal hernia. Gastrointestinal bleeding, either acute or chronic, may indicate the presence of marginal ulceration at an anastomosis, or foreign body erosion into the gastric lumen. For patients with weight recidivism, a thorough evaluation of their postoperative course, including weight nadir and time frame to regain, is important. Patients with failure of weight loss after an initial operation versus those who lost and subsequently regained weight will have different evaluations to review prior to consideration of revision.

Surgical complications often result in nutritional derangements. This may be a result of poor oral intake, or maladaptive eating behaviors, or secondary to sepsis or chronic illness. Any surgeon performing revisional bariatric procedures should be prepared to identify signs of malnutrition that can be detected during a clinical visit. In addition to physical exam findings of pallor, temporal wasting, dermal anomalies, or Kwashiorkor, we routinely obtain nutritional parameters when ordering laboratory studies as part of preoperative workup. Commonly deficiencies of iron, calcium, vitamin D, vitamin B_{12}, and fat soluble vitamins are identified, in addition to protein-calorie malnourishment. Obtaining objective data to quantify the degree of malnutrition is helpful, especially when setting goals prior to surgery. Nutritional optimization prior to any surgical intervention will result in improved outcomes, especially during reoperative procedures with higher complication rates. This may be achievable with nutritional counseling and oral supplements in some

patients, but other patients will require placement of temporary enteral access, most commonly a nasojejunal feeding tube, but also potentially a staged surgical procedure before definitive revision.

Existing clinical documentation is important to successful preoperative planning. Initial operative reports, prior imaging studies, and endoscopy reports are helpful both to guide the ultimate surgical procedure and to plan what additional examinations should be performed before surgical intervention. Understanding the existing surgical anatomy is important to successful bariatric revisional surgery, as there is wide variation in technique of the current types of bariatric procedures performed among different surgeons, as well as a spectrum of different historical bariatric procedures that are no longer commonly performed. Esophagogastroduodenoscopy (EGD) is a valuable tool that provides a breadth of information. We strongly believe that bariatric surgeons should perform diagnostic and therapeutic endoscopy, especially in this patient population. EGD will help obtain measurements of pouch and stoma sizes, evaluate for strictures and angulations, diagnose foreign body erosions, and provide a platform for therapeutic intervention for most of these conditions.

Radiologic studies are a useful complement. Upper gastrointestinal (UGI) contrast x-rays provide additional information regarding anatomy, and may show functional abnormalities beyond EGD. UGI series are effective to evaluate stenosis, leaks, and gastrogastric fistulas. We routinely recommend obtaining an UGI series prior to revisional surgery. In selected cases, a computed tomography (CT) exam with oral and intravenous contrast may be helpful, especially when looking for foreign bodies that may have been implanted, and to evaluate the extra-luminal environment, including abscesses, and the relationship of adjacent organs, for example, whether a Roux limb is retro- or antecolic.

Laboratory studies should focus on detecting any abnormality that needs to be corrected prior to surgery. We routinely obtain a complete blood count and metabolic panel. We also favor a complete nutritional screen, including prealbumin, transferrin, vitamin B_{12}, vitamin D, and iron. Patients may have significant metabolic derangements that need to be addressed by either oral supplementation or a temporary enteral feeding tube.

Postoperative Care

We elect to place closed-suction drains after revisional bariatric operations, especially those involving an anastomosis or long suture line. In the absence of a complication, we remove drains prior to discharge from the hospital. In most instances, a single drain is all that is needed. Although rarely required, thoracostomy tubes may need to be placed when there is significant dissection into the mediastinum with violation of the pleura.

It is well understood that leak rates are higher in revisional surgery, ranging from 2% to 22%. Although routine UGI studies have poor sensitivity to detect leaks after primary bariatric procedures, the increased perioperative complication rates, including increased leak rates, have prompted our group to perform UGI study routinely postoperatively. The timing varies according to the post-surgical anatomy. For gastrojejunal anastomosis, we obtain the study on postoperative day 1. For esophagojejunal anastomosis, we typically obtain the study on postoperative day 3. Despite this practice, clinical suspicion of a leak should prompt the surgeon to act accordingly regardless of radiologic findings.

Oral intake is started after the UGI study confirms appropriate transit of contrast with no evidence of leak. After normal UGI study, patients start on a phase 1 diet that consists of small volume clear liquids. Patients should drink slowly and sip 2 to 3 ounces at a time. Patients slowly increase the total volume while in the hospital. Prior to discharge, this is advanced to full liquids ad lib.

Establishing enteral access tubes at the time of revisional surgery is determined by several factors, including overall nutritional status, and the type and complexity of the revisional case performed. Patients who are malnourished and required enteral access prior to surgery often also require extended nutritional augmentation afterward. Those who are at risk for complications based on surgical reconstruction also benefit from enteral access. We favor placing feeding tubes in the gastric remnant when feasible. If a gastrectomy is done, or no remnant is available, a feeding jejunostomy in the proximal common channel or Roux limb is performed. If a feeding tube is present, tube feeds are started early in the postoperative course—typically at a low rate, and slowly advance to goal. Many patients will require tube feeds after discharge from the hospital, and proper arrangements need to be made to provide education and make pertinent discharge plans. In many instances, the tube serves as a backup plan in

case patients encounter complications or they have difficulty achieving adequate oral intake. Unused feeding tubes are removed at 4 to 6 weeks postoperatively.

REVISIONS AND CONVERSIONS FOR COMPLICATIONS

Despite an overall excellent safety profile, major complications occur at a rate of 3.4% to 12%, and vary widely between procedures. Complications range in severity as well, and major complications requiring surgical revision vary tremendously depending on the original procedure. Overall serious complication rates for all procedures range from 2% to 4%. Commonly, revisions performed for treatment of complications include indications such as leak, recalcitrant ulcer with bleeding and/or stricture, stenosis, fistula, obstruction, severe malnutrition, persistent gastroesophageal reflux disease (GERD), and dumping syndrome. Complications unique to laparoscopic adjustable gastric banding (LAGB) include esophageal dilation, prolapse and pouch dilation, intolerance, and erosion.

For nearly all revisions, we favor a laparoscopic approach, even in cases that have been done through a laparotomy previously. Entry into the peritoneal cavity is achieved with an optical trocar, away from the previous surgical access site. Once entry is achieved, the remaining trocars are placed depending on visualization. In cases where significant adhesions are found, we place additional 5-mm trocars as needed to lyse adhesions and identify the existing anatomy. Once adhesions are taken down, we favor a 5-mm port upper abdominal trocar placement in a gentle "U" fashion, with the surgeon at the right side of the table. In most instances, the left lobe of the liver is adhered to surrounding structures, which needs to be addressed prior to insertion of the liver retractor. We use the Nathanson liver retractor, which is inserted through an incision in the epigastrium, away from our working trocars. The surgeon utilizes a 5-mm trocar for his left hand, and a 12-mm trocar for his right, which allows transmission of both linear staplers and curved needles for free-hand suturing. The camera port is usually a 12-mm trocar that accommodates a 45-degree angled scope. The assistant uses two trocars that vary in diameter depending on the case. The assistant's left hand can be upsized to a 12-mm trocar in cases where challenging stapling angles are needed. The assistant's right hand can be upsized to a 15-mm trocar to allow space for

insertion of the EEA stapler and/or specimen extraction.

We routinely use endoscopy in the operating room throughout the procedure, especially during revisional surgery. Upper endoscopy is used to identify the anatomy and define landmarks, such as previous staple lines, eroded foreign body, chronic fistulas, or strictures. We also inspect our suture lines and anastomosis for intraluminal bleeding and leak after reconstruction is complete.

Complications of Roux-en-Y Gastric Bypass

Revisions of Roux-en-Y gastric bypass (RYGB) are typically secondary to gastrojejunal anastomotic complications, including leak, stricture and ulcer, or fistula formation most commonly to the gastric remnant. The key features to understand prior to surgery are pouch size, roux limb length, anatomic location of the limb (antecolic or retrocolic), and the abnormal pathology to be addressed.

Gastrojejunostomy Revision

Revision of the gastrojejunostomy is indicated for recalcitrant, nonhealing ulcers or chronic strictures that fail endoscopic therapy. Laparoscopic revision, even after previous open surgery, is usually possible, when performed by an experienced surgeon. After entry into the peritoneal cavity and port placement, we focus on identifying the gastric pouch. There are typically adhesions to the left lateral segment of the liver that need to be addressed early in the case. We use a combination of sharp dissection and electrocautery using an L hook to elevate the left lobe of the liver from the gastric pouch and allow placement of the Nathanson liver retractor. The goal of the operation is to resect the gastrojejunal complex (Fig. 101.1) and identify well-vascularized tissue that can be reanastomosed without tension. One of the pitfalls to avoid is injury to the left gastric pedicle, which would result in devascularization of the gastric pouch. Early division of the proximal roux limb will allow entry into the retrogastric space (Fig. 101.2). Marginal ulcers often cause intense inflammatory reactions, and this may be manifest both anteriorly and posteriorly. In this instance, releasing the pouch from retroperitoneal structures, including the pancreas, may be required. The surgeon should take special care to identify vascular structures, and in particular, the splenic artery can be easily injured during this portion of the dissection. After the left gastric pedicle is identified and preserved, the pouch can be

divided safely. We recommend adjusting staple height to the thickness of the tissue, taking into account that taller staple heights may be required to accommodate abnormal, reoperative gastric tissue. We selectively oversew staple-lines based on tissue character.

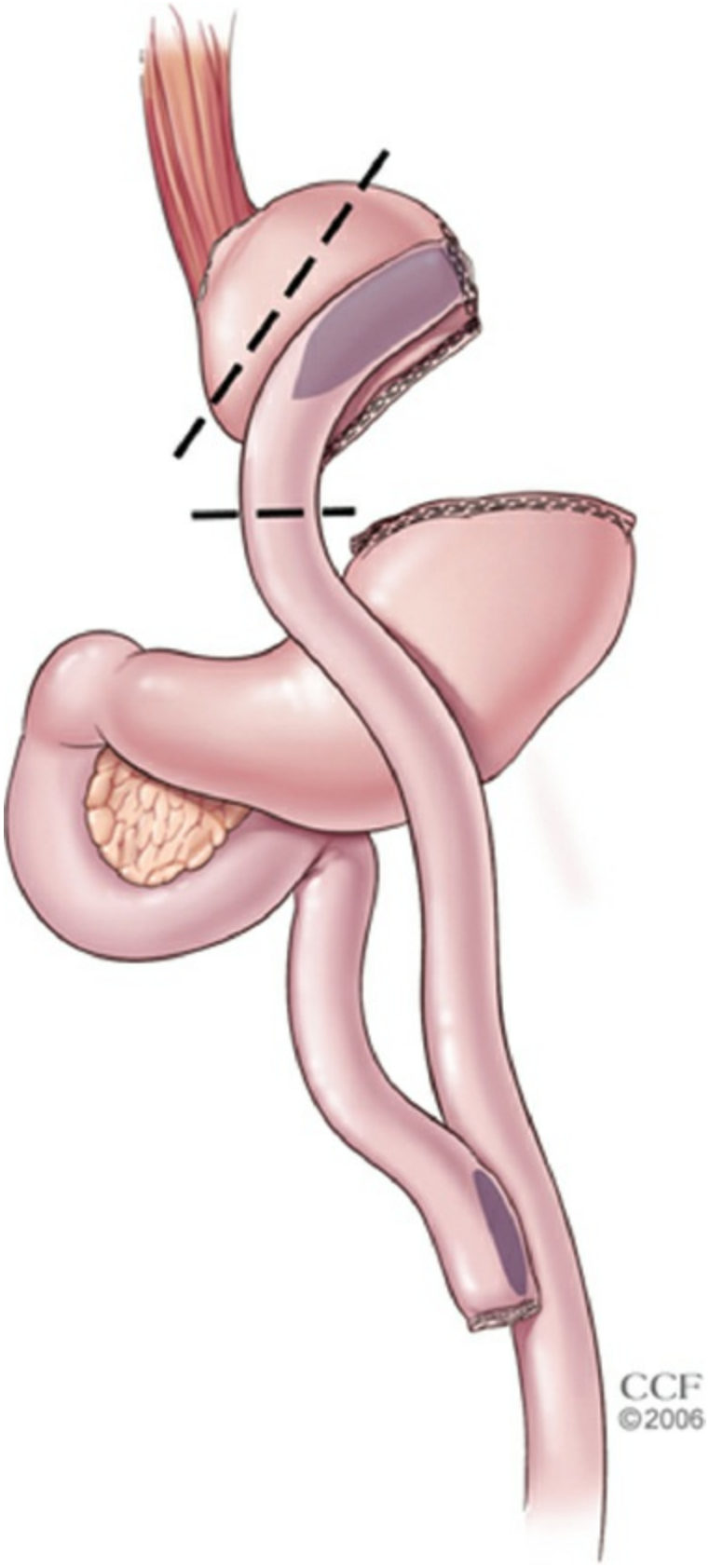

Figure 101.1. Resection of the gastrojejunal anastomosis for revision of gastrojejunostomy.

After the gastrojejunal anastomosis is resected, the specimen is retrieved, or placed over the right lobe of the liver for later extraction. The next step focuses on the Roux limb. Length of the Roux limb and tension are paramount to constructing a tension-free anastomosis. The mesentery of the antecolic Roux limb should be mobilized off of the transverse colon and mesocolon. The total length of the Roux limb should be measured to ensure appropriate distance to minimize bile reflux. Retrocolic Roux limbs may require additional dissection to avoid potential tension on the anastomosis. The Roux limb should be lysed free from the mesocolic defect to allow it to be transmitted freely to the newly formed pouch. After construction of the gastrojejunostomy, the mesocolic defect should be closed with permanent sutures to prevent internal herniation.

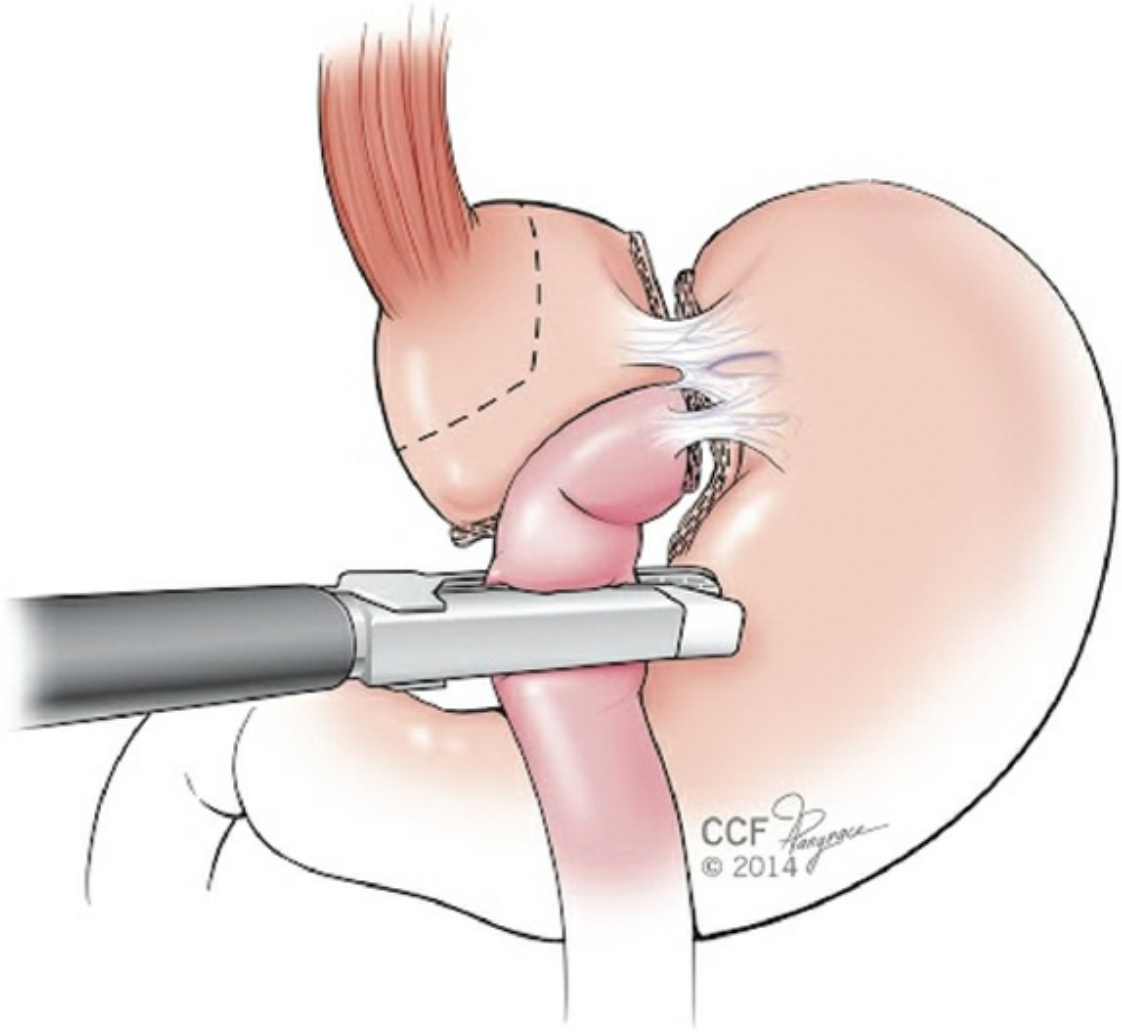

Figure 101.2. Early division of Roux limb to enter retrogastric space.

Once the Roux limb is successfully advanced, the gastrojejunostomy is created. We mostly use a 25-mm EEA stapler to create an end-to-side gastrojejunostomy. We use a free-hand suturing technique in cases of revisions without known underlying etiology or suspected inflammatory response to foreign body, including staples. The patient is placed back in steep reverse Trendelenburg position and the pouch inspected. An endoscopic leak test is often done to the pouch alone, prior to anastomosis, as well as after creation of the gastrojejunostomy. A commercial device with an orogastric tube mated to the stapler end is inserted through the mouth and advanced. The tip of the orogastric tube is guided to the end of the pouch and a gastrotomy is made. The orogastric tube is then pulled until the anvil of the stapler comes into view and the anchoring stitch can be cut. The left upper quadrant port site is converted to an access site to allow insertion of the EEA stapler. The surgeon then opens the tip of the roux limb and the EEA stapler is inserted, after assurance that there is no twist or tension on the Roux limb (Fig. 101.3). After mating the anvil, the anastomosis is then created. The candy-cane end of the Roux limb is closed using linear stapler. We routinely reinforce the gastrojejunostomy by placing absorbable, interrupted Lembert stitches. The Roux limb is occluded and after submersion of the anastomosis in saline, an endoscopic leak test is performed. The staple lines are also inspected for bleeding. If a feeding tube is indicated, a remnant gastrostomy can be placed at this time (Fig. 101.4). A closed suction drain is then inserted and positioned along the anastomosis and left subphrenic space.

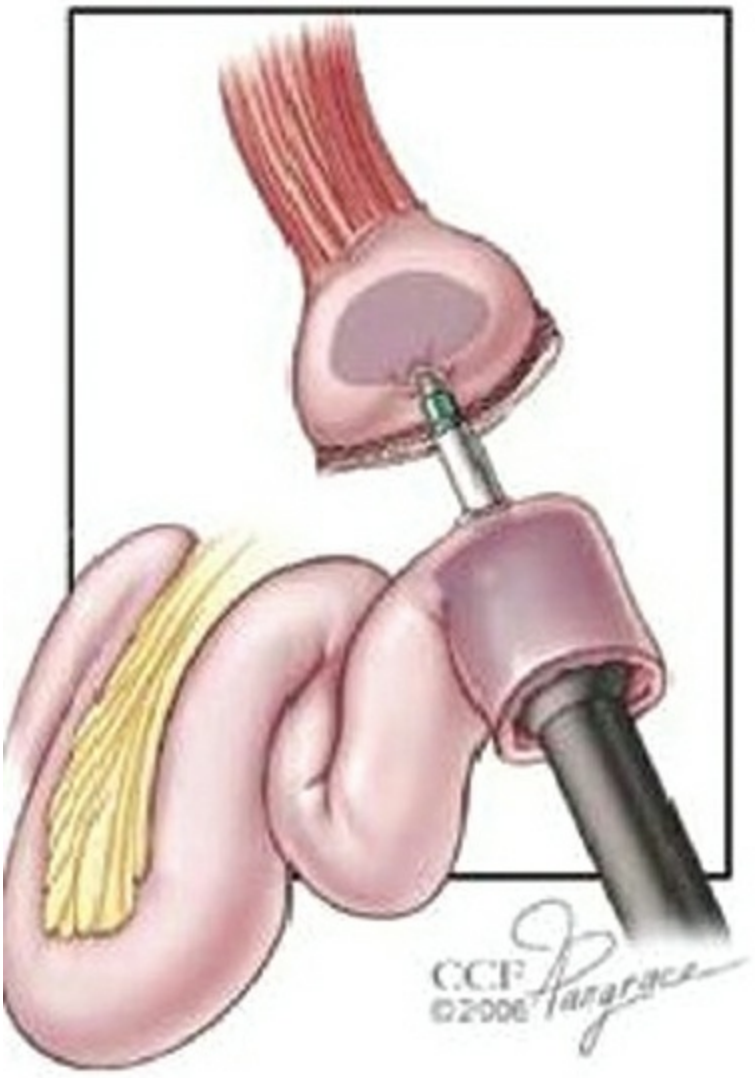

Figure 101.3. Insertion of EEA stapler into tip of Roux limb and coupling.

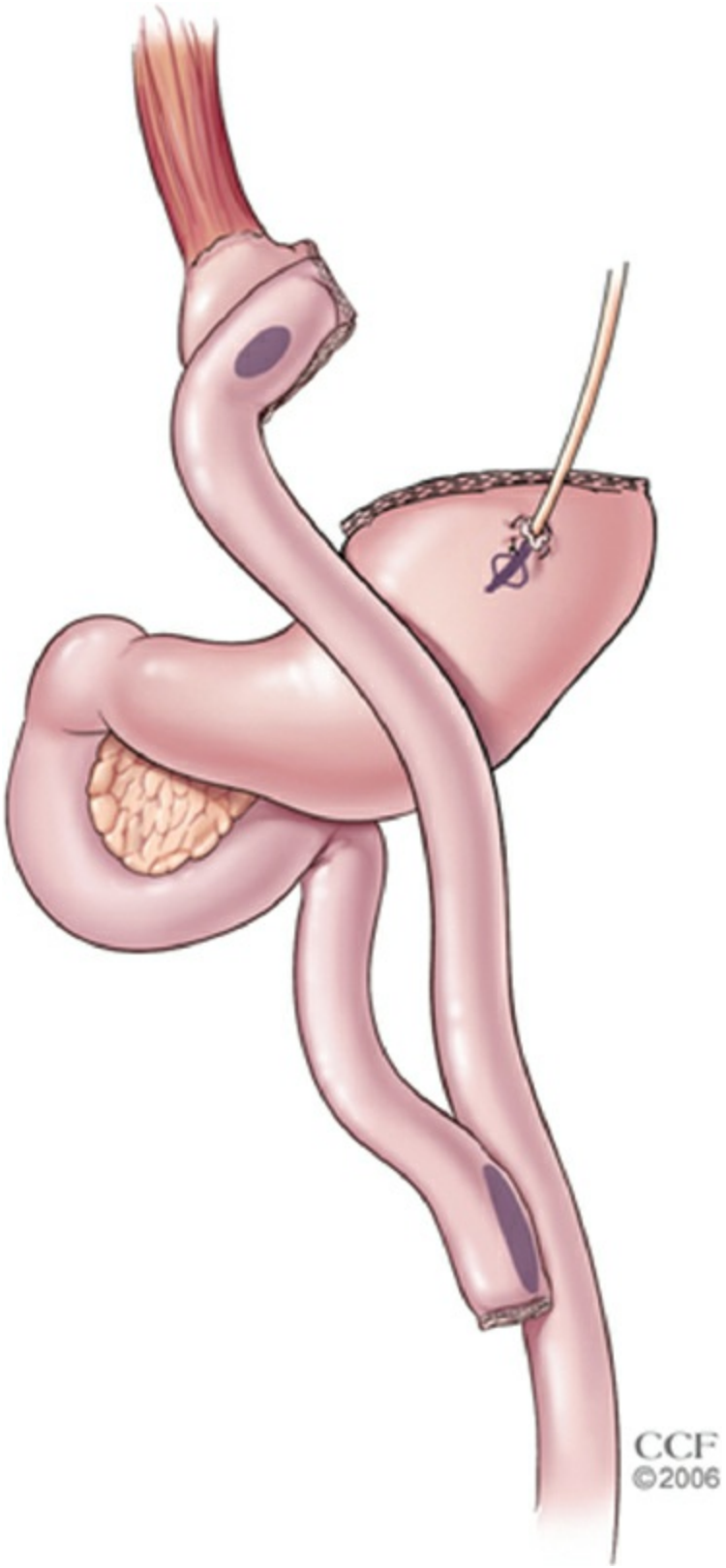

Figure 101.4. Completion of revision gastrojejunostomy, including placement of remnant gastrostomy tube.

Revision for Gastrogastric Fistula

Gastrogastric fistulas may occur after both divided and undivided gastric bypass. Management usually requires some degree of remnant gastrectomy with or without revision of the gastrojejunostomy. The etiology and preoperative identification of the fistula site guides the operation. Important considerations include the location to the gastrojejunostomy relative to the esophagus, presence of foreign body, and the general fibrosis and abnormality of the gastric tissue. Fistulas resulting from chronic marginal ulcers and anastomotic complications such as leaks will typically require revision of the gastrojejunostomy as well as remnant gastrectomy. Fistulas that develop along the vertical staple line after a divided bypass may be managed by pouch and/or remnant gastrectomy alone.

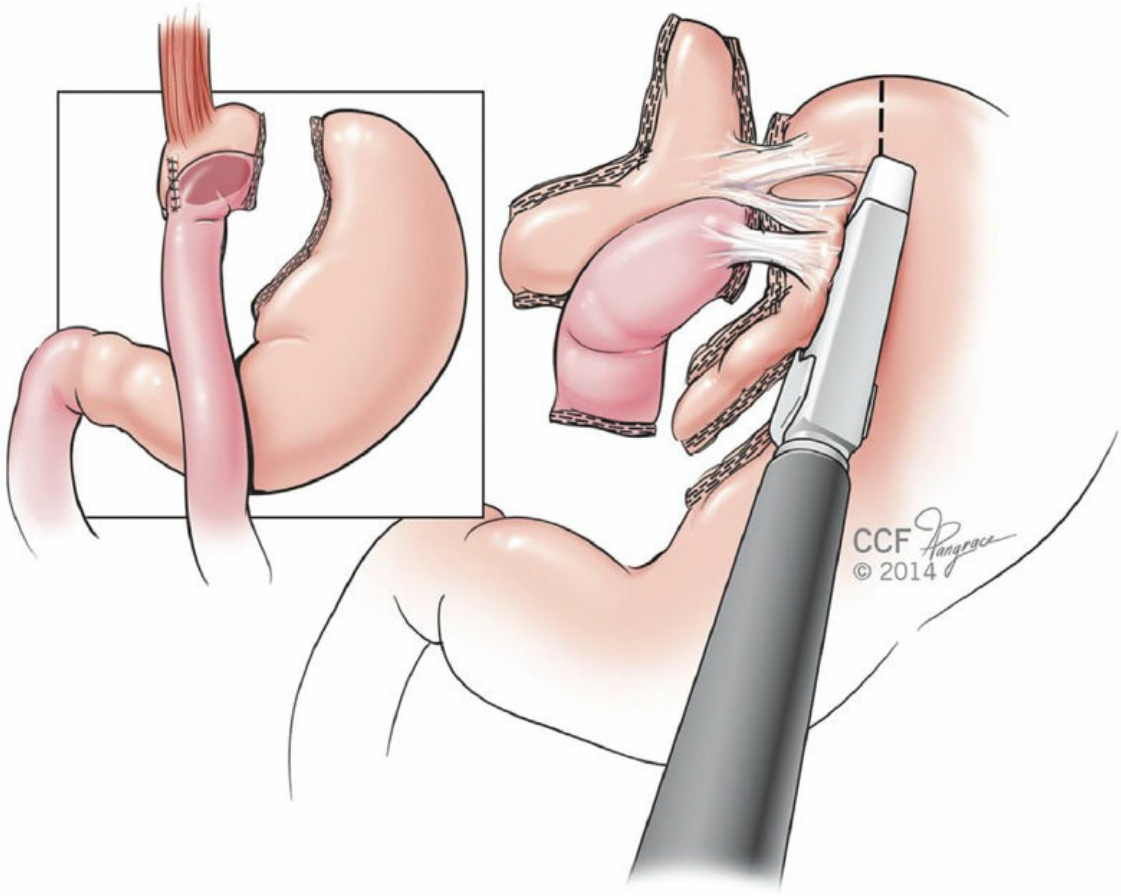

Figure 101.5. Transection of remnant, including fistulous connection to pouch and prior gastrojejunostomy.

After placement of trocars and identification of the relevant anatomy, attention is directed to the gastric remnant. Early division of the gastrocolic ligament and entry into the retrogastric space can help identify

the anatomy and avoid an inadvertent injury to the pouch or gastrojejunal complex. After the greater curvature is mobilized and the short gastric vessels divided, the gastrohepatic ligament is opened. Division of the stomach distally is performed with sequential deployment of a linear stapler.

Once the distal stomach is divided, the vertical staple line and fistula can be identified and retracted laterally. In some cases, a neo-pouch can be created by extending the vertical staple line medially without revising the gastrojejunostomy. During this step, it is crucial to identify the angle of His to avoid encroaching on the esophagus with the proximal staple line. If the gastrojejunostomy is involved as part of the fistula, or in cases of undivided gastric bypass, revision of the gastrojejunostomy will need to be performed as previously described, in addition to remnant gastrectomy (Fig. 101.5).

Complications of Sleeve Gastrectomy

Complications of sleeve gastrectomy (SG) typically result from leak, twisting of the tubularized stomach, or angulation or stenosis causing persistent dysphagia and failure to thrive. In severe cases, nonhealing gastric fistulas to the skin or chest may result as a consequence of a distal stricture. These tend to form in the most proximal aspect of the staple line near the esophagogastric junction and may be challenging to manage. Revisions require accurate identification of the anatomy.

Long segment strictures that fail endoscopic therapy may be managed by a longitudinal seromyotomy or transverse gastroplasty (Fig. 101.6). Clinical experience with this procedure is limited, but short-term results have demonstrated some success. In most instances, a stenosed or angulated sleeve will require revision to RYGB. Chronic proximal fistulas require resection of the involved stomach and reconstruction by means of esophagojejunostomy or gastrojejunostomy when a small proximal pouch can be salvaged. Some centers have also demonstrated success with fistula control by anastomosis to a Roux limb after proper debridement.

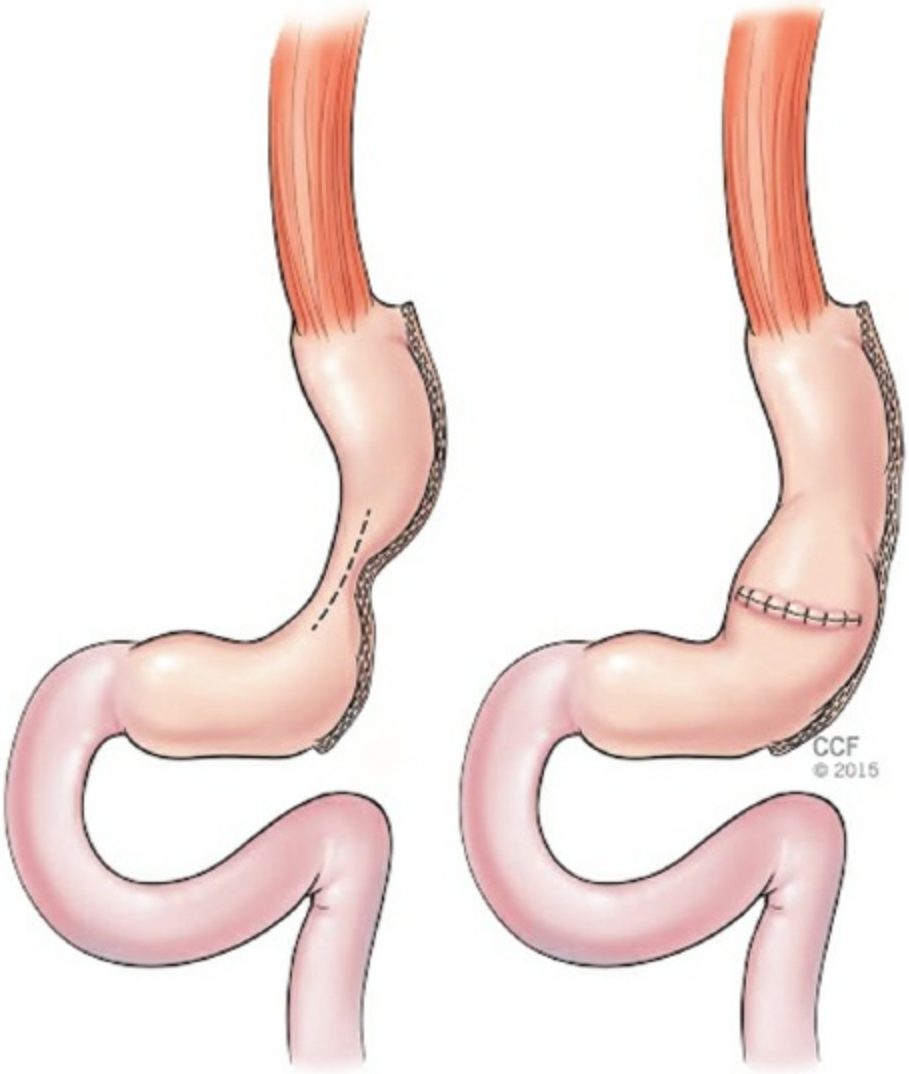

Figure 101.6. Laparoscopic gastroplasty for management of sleeve stenosis.

Revision for Sleeve Stenosis

After initial entry and trocar placement, the tubularized sleeve is identified. The left lateral segment of the liver is dissected away from the anterior stomach and the Nathanson liver retractor is positioned. Omental adhesions that may have formed are addressed. Some surgeons routinely sew the omentum to the neo-greater curvature, requiring additional dissection to properly identify the anatomy. In cases of a leak, adhesions may be more severe and sometimes involve other organs like the pancreas and colon.

Once the entire sleeve is visualized, the stenotic segment is identified. Endoscopy is a useful adjunct to identify the anatomy, as this may not be easily recognized by laparoscopy alone. The goal is to create a gastric

pouch by dividing the sleeve proximal to the stenosis. As with other revisional bariatric procedures, we emphasize early identification of the left gastric pedicle to avoid injury. The stomach is then divided distal to the main trunk of the left gastric artery but proximal to the stenosis. Transection distal to the stenosed area will complete the gastrectomy (Fig. 101.7). Staple height is adjusted accordingly, usually using higher staple heights with thickened tissue. Proximally, it is important to recognize abnormalities such as hiatal hernia or the presence of retained fundus. If identified, hiatal hernias should be repaired concomitantly, and redundant fundus may be resected as deemed necessary during construction of the pouch.

A Roux limb is created with our standard technique, and the gastrojejunostomy fashioned with the EEA stapler as described above. The distal gastric remnant may be used for gastrostomy tube placement if there is enough stomach remaining to reach to the anterior abdominal wall, and if indicated.

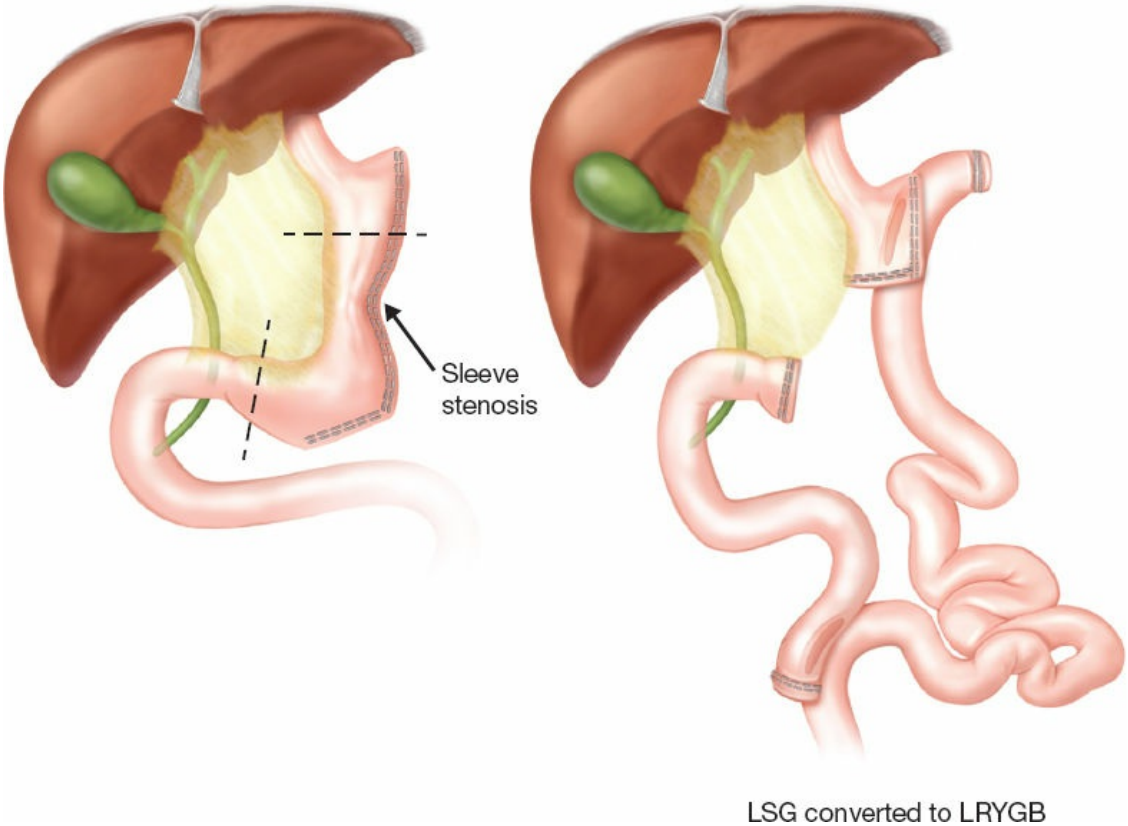

Figure 101.7. Typical appearance of sleeve stenosis at incisura and after resection of stenosis, and conversion to RYGB.

Revision for Chronic Gastric or Esophageal Fistula

Revision of SG for chronic fistula is one of the most challenging bariatric complications to manage. Patients typically require nutritional support, and they have often failed multiple attempts at management, including nonoperative, endoscopic, and surgical techniques.

The main objective of this operation is to remove the affected segment of the stomach or esophagus and reconstruct to proximal healthy tissue. Because of fistulas secondary to staple line dehiscence at the esophagogastric junction, dissection often needs to be extended into the mediastinum. This allows for adequate mobilization of the esophagus to clear any abscess cavity or necrotic tissue and then construct an anastomosis to viable tissue. Careful review of preoperative studies such as EGD and UGI identifies the location and post-surgical anatomy. In addition, abdominal and chest CT scan are helpful, as they can identify any undrained collection, or extension into the proximal mediastinum or lung spaces.

The most challenging aspect of this operation involves dissection of the proximal stomach and distal esophagus. Chronic leaks tend to cause severe inflammation and distortion of the anatomy. It is not uncommon to encounter an abscess cavity around the involved segment of the sleeve. Intraoperative endoscopy is a necessary tool during these difficult dissections. After the liver is mobilized and retracted, dissection of the proximal stomach is performed. If adhesions are severe, early transection of the distal stomach can help find a less distorted plane, usually in the retrogastric space. We make an effort to identify the left and right crus before entering the chest. It is not uncommon to find adhesions between the vena cava and the right crus, and caution is warranted here. The left crus is often involved in the more severe inflammatory process. Dissection is continued proximally, taking special care to avoid an esophageal injury. Placement of a Penrose drain around the gastroesophageal junction allows for less traumatic retraction of the esophagus. If esophagojejunostomy is planned due to the proximal fistula site, the left gastric pedicle is divided with the use of clips or a linear stapler using a vascular height staple load. Mediastinal dissection is typically performed with a combination of sharp and blunt instruments. We minimize the use of energy sources in an attempt to decrease the risk of a delayed thermal injury. Once the area of the fistula is identified and debrided, esophageal transection is performed with a linear stapler proximal to the site, ensuring that healthy tissue is present at the staple line. The specimen consisting of the proximal stomach

and distal esophagus should then be completely free and ready for extraction.

A Roux limb is then constructed as previously described. Roux limb length can be adjusted depending on the patient's body mass index (BMI) and the presence of comorbidities, typically between 80 cm and 150 cm. The anastomosis is then constructed with the use of an EEA 25-mm stapler using the per-oral technique as previously described. An alternative technique is to handsew the anastomosis using a single interrupted layer of absorbable suture. After completion, the Roux limb is occluded and a leak test is performed with the aid of the endoscope. The anastomosis is also inspected endoscopically for any bleeding. A closed suction drain is then placed in proximity to the anastomosis extending into the mediastinum.

We have a low threshold for enteral tube placement in these cases, especially in patients who required aggressive nutritional support prior to surgery. The gastric remnant is a good option if it can be approximated to the anterior abdominal wall without tension. If reach is limited without tension, a jejunostomy tube is placed in the Roux limb.

REVISIONS FOR WEIGHT RECIDIVISM AND WEIGHT-RELATED COMORBID DISEASE

A majority of patients undergoing primary bariatric surgery have successful outcomes in terms of weight loss and resolution or improvement of weight-related comorbid disease. However, there are subsets of patients who either fail to achieve appropriate initial weight loss or have weight regain at some time after the operation. Comorbid disease severity is often correlated to these failures. The likelihood of these scenarios occurring varies among the various type of operations performed. Careful evaluation of the first operation, including historical operations no longer commonly performed, is important to successful planning for surgical revision in the setting of recidivism. Even more so than in the setting of complications, reoperation for recidivism requires a multidisciplinary approach. In a comprehensive bariatric surgery program, this should include psychological evaluation to identify modifiable behavioral health problems contributing to weight regain, a complete nutritional evaluation to carefully evaluate eating propensities and caloric intakes, medical evaluation by a physician with expertise in bariatric medicine to identify contributing medical illnesses and to plan for reoperative intervention, as well as the bariatric surgeon for operative

planning and examination of the previously performed operation. The decision to proceed with operative intervention for weight recidivism should be discussed in the context of all contributing providers to determine the risk-benefit ratio for that particular reoperative intervention.

Revision of Roux-en-Y Gastric Bypass for Weight Regain

RYGB, both open and laparoscopic, has been the most commonly performed bariatric operation in the United States until recently, when it was supplanted by laparoscopic SG. Having been performed commonly for a long period of time, there are increasing numbers of patients who have weight recidivism, or failure of initial weight loss after RYGB. Prior to reintervention, it is important to evaluate the current state of a patient's comorbid disease as well. Operations for revision of RYGB are better categorized as corrective, and not conversion, as most revisions target a particular component of the gastric bypass anatomy. The most common targets for surgical revision are the gastric pouch, gastrojejunal anastomosis, and small intestinal limb lengths.

Resection and Revision of Pouch and Gastrojejunostomy for Weight Regain

Surgical revision of the gastric pouch may be indicated for a large pouch as determined by both endoscopy and upper gastrointestinal radiography. Pouch size may determine satiety and fullness, and data have linked decreased pouch size with better weight loss. Simultaneously, the aperture of the gastrojejunal anastomosis can be evaluated. Gastrojejunal anastomosis dilation, typically beyond 2 cm, has also been shown to contribute to weight regain after RYGB. Resection and revision of a large gastric pouch and/or dilated gastrojejunostomy may improve feelings of satiety, increasing restriction, with a resultant improvement in weight loss. Most revisional procedures for RYGB are approached laparoscopically, even in the setting of previous open RYGB, with successful outcomes and reasonable complication rates. However, conversion rates to open procedures are higher than primary bariatric procedures. Conversion to open procedures is appropriate in situations of unclear anatomy, excessive adhesions, and at the discretion of the operating surgeon based on experience.

A successful operative approach to the gastric pouch and gastrojejunostomy after previous RYGB is dependent on correct

intraoperative identification of important landmarks. Typically adhesions from the left lobe of the liver will overly the pouch and gastrojejunostomy, and these can be quite severe in previously open RYGB procedures. Early identification of the Roux limb as ante- or retrocolic will facilitate the dissection approach. Most commonly, laparoscopic RYGB are constructed with antecolic Roux limbs, and often, open RYGB are created with retrocolic Roux limbs. Mobilization of the retrocolic Roux limb involves working under the mesocolon, and opening of the mesocolic defect through which the Roux limb is transmitted.

Once the Roux limb is identified, the location of the left gastric vasculature is identified and preserved, as this will be the blood supply to the remaining pouch after resection. The actual anastomosis is often adhered posteriorly to the retroperitoneum and the pancreas. These adhesions can be severe especially in situations of a previous leak, or concomitant gastrogastric fistula. When the left gastric vasculature has been identified and preserved, the gastrojejunostomy mobilized posteriorly, a more accurate evaluation of the gastric pouch is possible. Size of the pouch and location of the gastrojejunostomy can be aided by intraoperative endoscopy. This also allows for detection of sometimes previously unrecognized gastrogastric fistula as well as hiatal hernia, and therefore would alter the operative approach. Presence of a gastrogastric fistula usually requires simultaneous remnant gastrectomy for definitive therapy.

Once the pouch and anastomotic anatomy has been clearly identified, pouch resection is performed with linear-cutting staplers. The reoperative nature of these procedures usually requires higher staple height use for the thickened tissue, and this is an intraoperative decision. The Roux limb is also disconnected immediately distal to the gastrojejunostomy on normal appearing jejunum. After resection of the pouch and anastomosis, leak test is performed on the pouch prior to reconstruction, usually with air insufflation and submersion in saline. This allows for easier identification and repair of potential staple line dehiscence. Reconstruction of the gastrojejunostomy is as per the surgeon’s discretion, and equally good results are reported using linear- and circular-stapled, as well as hand-sewn techniques. Once completed, repeat leak test should be performed. Intraoperative endoscopy to perform the leak test gives additional information that is helpful including the patency of the anastomosis, and identification of any staple line bleeding that can be treated immediately.

Additional considerations include examination of the Roux limb length prior to construction to ensure appropriate length and diminish potential bile reflux into the pouch. Closure of any mesenteric defects is also important to prevent internal herniation.

Endoscopic revision of both the gastric pouch, by means of sutured plication to reduce the volume, and gastrojejunostomy by placing additional sutures to decrease the aperture has been reported. Both interventions have limited applications currently as studies are small, retrospective, and highly selected. Anastomotic outlet reduction by means of endoscopic suturing appears to be a more durable and efficacious intervention than pouch reduction in these series.

Placement of Fixed or Adjustable Band Over Existing Pouch for Weight Regain

In some cases, placement of an adjustable or fixed gastric band over an existing gastric pouch after RYGB has been reported. In such cases, patients with weight recidivism and comorbid disease accruement are selected for such a procedure if there is a large gastric pouch, a dilated gastrojejunostomy, or in the setting of relatively normal post-RYGB anatomy, but with a patient perceived sense of diminished restriction. An adjustable gastric band in this position may give a desirable option of increased restriction in time with fluid insertion via the port. Complications unique to band placement, including erosion, tubing disconnections, and port complications, seem to occur with a frequency at least as the same as primary procedures, and likely more common in the revisional setting. Most reported series are quite small, with modest additional weight loss.

The technical approach for placement of an adjustable gastric band begins similarly as with pouch or anastomotic revision. Important landmarks to identify again include the left gastric vasculature and the position of the Roux limb relative to the mesocolon. Once verified, insertion is similar to primary adjustable gastric banding techniques, including the pars-flaccida approach through the gastrohepatic ligament, development of a retrogastric tunnel, insertion of the band, and positioning of the band on the gastric pouch, above the gastrojejunostomy (Fig. 101.8). Gastrogastric plication may be performed from the adjacent remnant to the pouch to potentially decrease migration rates, if the proximity of the remnant allows for such. Some authors have performed the procedure without plication. Port and tubing setup are the same as in a primary

banding procedure. Adjustment protocol varies per surgeon and center preference. Placement of fixed bands has also been reported, with similar techniques as above.

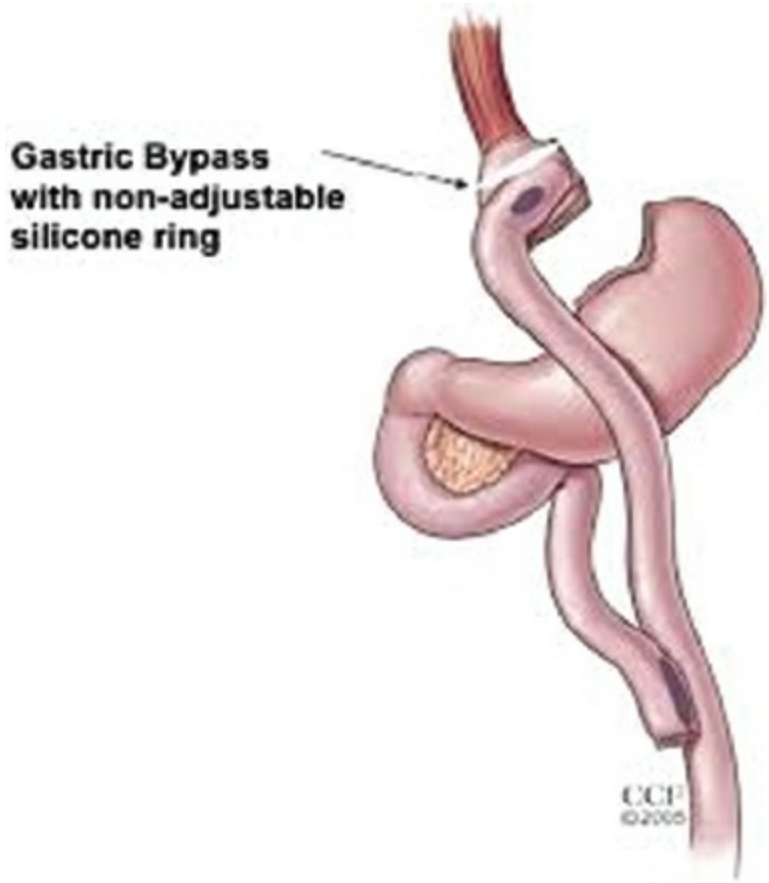

Figure 101.8. Placement of nonadjustable silicone ring over gastric pouch.

Limb-Lengthening: Resection and Revision of Jejunojejunostomy for Weight Regain

Limb-lengthening procedures target intestinal exclusion or malabsorption as targets after failed RYGB, different than the pouch and gastrojejunal anastomotic alterations described above. The amount of small intestine in continuity with both biliopancreatic secretions and food constitutes the common channel. Roux limb lengthening (increasing the length of the Roux to common channel) and distal (decreasing the common channel length) gastric bypass are two strategies to impart additional weight loss. The technical conduct of each requires disconnecting the biliopancreatic limb from the Roux and common channel, or resecting the jejunojejunostomy entirely and reconstruction. Lengths of each vary based on surgeon and center experience. Published series report weight loss after

these procedures, but the overall quality of the evidence is limited. Specifically, patients who undergo limb-lengthening procedures may be at risk for increased macro- and micronutrient deficiencies, particularly with distal gastric bypass. The performance of such procedures should likely be limited to comprehensive bariatric surgery centers with a multidisciplinary approach to patient section and evaluation, and the technical conduct should be limited to experienced bariatric surgeons.

Revision of Laparoscopic Adjustable Gastric Band for Weight Regain

LAGB is a less technically demanding operation with low perioperative complications, and as such, was quite popular. Its main weight loss effects are likely mediated through a restrictive component. Weight loss and resolution of weight-related comorbid disease have consistently been reported as less than RYGB. Revision of LAGB typically implies repositioning the band secondary to slip, or replacing secondary to device failure of some sort, in a patient who has done well initially in terms of weight loss. Weight loss and comorbidity improvements for failed band conversions to either RYGB or SG appear to be similar to outcomes for primary RYGB or SG. This section will focus on conversions to other procedures, typically RYGB or SG, which are the most commonly performed procedures for failed weight loss or recidivism after banding.

Conversion of LAGB to RYGB for Weight Regain

Typically, a laparoscopic approach is used for conversion of LAGB to RYGB. Conversion includes removal of the band, tubing, and port. After initial laparoscopic access is obtained, the tubing is identified and any adhesions to this are lysed. The tubing is transected and incision is made in the skin overlying the port for removal. We use this incision as another trocar access site. At initial placement, the port is either sewn to the fascia or metal tines in the port itself are used for attachment (Realize-type band, Ethicon Endo-Surgery, Cincinnati, Ohio, USA) and requires a removal device or directed dissection to the area of attachment. It is important to remove all of the tubing and eliminate any remaining foreign body.

Once the full complement of trocars has been placed, including liver retractor, adhesions to the left lobe are lysed and the band is visible. Identification of the buckle allows for the safest and most efficient approach for removal. A fibrous capsule usually envelops the band, and

this is removed with sharp dissection and judicious energy use. Once identified and mobilized, dissection proceeds along the band, laterally toward where the gastrogastric plication sutures are placed. These sutures are placed at the initial operation to minimize prolapse, and form a tunnel from the greater curvature of the stomach to the proximal pouch above the band. There are typically from 2 to 4 sutures here. These are taken down completely until the fundus and the left crus are identified and clear. The band can be cut, either with scissors or energy, and removed. Once removed, the stomach should be evaluated for injury and, if there is any, appropriately repaired. With significant injury or in the acute setting of a prolapse with ischemia, conversion should be deferred. In most elective situations, however, conversion can be accomplished in a single operation. Removal of all capsular remnant is important prior to pouch construction, as this may result in faulty staple line formation, leading to bleeding or leak. Pouch construction may be somewhat altered to avoid areas of the stomach that were incorporated into the band capsule. As with standard RYGB, blood supply to the pouch is based on the left gastric vasculature, so care must be taken to avoid injury here. Gastrojejunostomy and jejunojejunostomy are performed as per the surgeon's discretion in the usual fashion. Leak test should be performed for all revisional procedures.

Conversion of LAGB to Sleeve Gastrectomy for Weight Regain

For conversion of LAGB to SG, the initial approach for tubing and port removal is the same as for RYGB. Band removal is also performed similarly. For conversion to SG, it is important to fully mobilize the fibrous capsular attachments to the stomach and left crus of the diaphragm. This is especially important to allow for accurate identification of any previously undiagnosed hiatal hernia, which should undergo concomitant repair. In addition, the long staple line created in SG will likely traverse at least part of the fundus involved in the gastrogastric plication from the band. Because of this, staple line construction will likely be within gastric tissue with the abnormal thickening and devascularized tissue of the capsule. Once the band is removed and the capsule lysed, SG is performed in a typical manner. General principles include starting the sleeve around 4 cm from the pylorus; using a sizing device and higher staple height in the antrum than the fundus, with a diameter of 36 French or greater; avoiding encroachment on the lesser curvature at the incisura; identifying any posterior fundus to include in the specimen ultimately removed; and either oversewing (our preferred technique) or using staple line reinforcement

material. Especially in the reoperative setting, intraoperative endoscopy allows for immediate identification of leaks or stenosis, and if found, they can be repaired at the time. Acceptable morbidity and leak rates have been reported for conversion of LAGB to SG, but the leak rate is higher in the revisional setting. This is likely secondary to scarring at the Angle of His, and resultant poor staple line construction. Band removal and conversion to SG have been reported as both two-stage and single operation procedures, and the decision as to which to perform is made by the surgeon intraoperatively, largely based on the degree of scarring and complexity of removal.

Revision of Sleeve Gastrectomy for Weight Regain

Laparoscopic sleeve gastrectomy was initially described as the first step in a planned two-stage procedure, with the goal of performing biliopancreatic diversion with duodenal switch (BPD-DS), in the setting of high BMI and high-risk patients. The durable success of this as a stand-alone procedure has been demonstrated, in terms of both weight loss and resolution of weight-related comorbid disease. Weight recidivism and regain of weight-related disease are seen in a subset of patients after primary SG.

Prior to performing a conversion operation, evaluation of the existing gastric anatomy is critical. There are several technical aspects of the initial construction that can relate ultimate failure. The diameter of the sleeve, including uniform, proximal, or distal dilation, may be related to poor sensation of satiety and subsequent weight regain. Retained fundus, especially posteriorly, or significant antrum may lead to increased volume capacity. An unrecognized hiatal hernia during the first operation may lead to significant retained fundus in the chest, and may result in outflow obstruction at the hiatus and dilation long term, leading to an increased reservoir. In some of these circumstances, resleeving the patient may be an option, although most published reports are small series in select patients. This section will focus on the more commonly performed conversions to other bariatric procedures, most commonly to BPD-DS and RYGB.

Conversion of SG to BPD-DS

Performance of SG is typically among the first steps in creating a primary BPD-DS. In primary BPD-DS, a larger sizing device (60 French) is used to calibrate than that which is used for a primary SG (36 to 40 French). In the second stage of a planned conversion from SG to BPD-DS, the sleeve will

likely then be of larger diameter, than for conversion secondary to weight loss failure from primary SG. In most instances, except with anatomic abnormalities of the sleeve such as retained fundus, hiatal hernia, or severe caliber abnormalities, the sleeve is kept as is. Conversion to BPD-DS starts then with mobilization of the duodenum, and transection with a linear stapler 2 cm distal to the pylorus. After measuring small intestinal limbs, a duodenoileostomy is then constructed and forms the alimentary limb, typically at a distance of 250 cm. This anastomosis can be performed hand-sewn, or circular- or linear-stapled. The biliopancreatic limb is anastomosed as an ileoenteric anastomosis, creating a 100-cm common channel, with a linear stapler and hand-sewn enterotomy closure. Weight loss and resolution of weight-related comorbid disease are more robust than that seen with conversion to RYGB, although nutritional deficiencies occur more commonly with this malabsorptive procedure.

Conversion of SG to RYGB

Most commonly, conversion of SG is performed for complications of SG, including stenosis at the incisura and resultant outflow obstruction, as well as GERD. Conversion of SG to RYGB is an option for weight loss failures as well. Technical conduct requires identification of any abnormalities of the sleeve. This is usually completed preoperatively with UGI radiography and upper endoscopy, but careful inspection of the sleeve conduit should be performed in the operating room as well. Once completed, the left gastric vascular bundle is identified and preserved. The short-gastric vessels will have been divided, and as such, adhesions laterally to the omentum and posteriorly to the pancreas should be freed. Once the tubularized stomach has been mobilized, the descending branch of the left gastric vessels is controlled, with either an advanced energy source or stapler. The gastric pouch is then created by transecting the sleeve horizontally. The may require one or two 60-mm stapler applications. A Roux limb is then created in the usual manner and brought up to create the gastrojejunostomy in a typical manner, after creation of the jejunojejunostomy. The anastomosis can be created by means of a hand-sewn, circular- or linear-stapled technique. Intraoperative leak test should be performed, as with all revisional procedures. Using intraoperative endoscopy allows not only identification of a potential leak, but all gives important information on the size of the pouch, both prior to and after gastrojejunostomy creation, and it allows for therapeutic applications, such as for treatment of endoluminal bleeding.

SUMMARY

Bariatric surgery is a proven durable therapy providing weight loss, and improvement and resolution of weight-related comorbid diseases. The safety and efficacy of these procedures have improved secondary to quality improvement efforts, data reporting, and laparoscopic techniques. Even so, a subset of patients will present with complications from their initial operation, failure of weight loss, and weight recidivism. Revisional bariatric surgery can result in correction of complications, better weight loss, and improvement in weight-related disease. Most commonly these procedures can be completed successfully laparoscopically, in the setting of a multidisciplinary, comprehensive bariatric care program, with dedicated experienced surgeons.

Suggested Readings

Brethauer SA, Kothari S, Sudan R, et al. Systematic review on reoperative bariatric surgery: American Society for Metabolic and Bariatric Surgery Revision Task Force. *Surg Obes & Relat Dis* 2014;10:952–72.

Courcoulas AP, Christian NJ, Belle SH, et al. Longitudinal Assessment of Bariatric Surgery (LABS) Consortium: weight change and health outcomes at 3 years after bariatric surgery among individuals with severe obesity. *JAMA* 2013;310:2416–25.

Himpens J, Dobbeleir J, Peeters G. Long-term results of laparoscopic sleeve gastrectomy for obesity. *Ann Surg* 2010;252:319–24.

Morales MP, Wheeler AA, Ramaswammy A, et al. Laparoscopic revisional surgery after Roux en-Y gastric bypass and sleeve gastrectomy. *Surg Obes Relat Dis* 2010;6:485–90.

Shimizu H, Annaberdeyev S, Motamarry I, et al. Revisional bariatric surgery for unsuccessful weight loss and complications. *Obes Surg* 2012;22:330–4.

EDITOR'S COMMENT

This chapter on revisional bariatric surgery is new in the 7th edition of the *Mastery of Surgery* textbook. The history of bariatric surgery dates more than 50 years to right after World War II. A variety of different procedures have been designed over these years to address severe obesity with varying degrees of success and some outright failures. Technological innovation coupled with the rising prevalence of obesity has helped to shape the current landscape of bariatric surgery. In 1954, Kremen and associates published the first peer-reviewed research article on bariatric surgery. In this paper, they describe the results of a jejunoileal bypass (JIB) performed on an obese patient. Kremen and

several other surgeons at the time had observed that patients who had developed the ‘‘shortgut’’ syndrome (usually observed after substantial small bowel resections as a consequence of mesenteric vascular thrombosis leading to necrosis) lost a considerable quantity of weight. The JIB was the first ‘‘malabsorptive’’ bariatric procedure, designed to induce weight loss through inefficient and incomplete absorption of ingested nutrients. In the more than 60 years that have elapsed since this first publication, a variety of procedures have come and gone (the JIB, vertical banded gastroplasty [VBG], horizontal gastroplasty for example). Many were abandoned because of severe potential complications (JIB). Others have been abandoned for a lack of efficacy (horizontal gastroplasty) or a better alternative (VBG for laparoscopic adjustable gastric band). Rodriguez and Kroh discuss in depth revisional procedures for bariatric procedures performed commonly in the current era. It is relatively rare to encounter a surviving JIB patient in need of a revision. We still meet people who had a VBG in the 80s or 90s who present with band erosion, pouch outlet obstruction, recurrent obesity, or severe GERD. While the options for revisional surgery for VBG patients are not described in the current chapter, the basic principles are similar to what is discussed. We have some experience with VBG reversal via gastrogastrostomy, but discourage this approach due to an extremely high incidence of recurrent obesity and relatively few great options in a patient who has undergone a VBG and a VBG reversal who now needs a repeat weight loss operation. In most patients with either complications or recurrent obesity following a VBG, a conversion to a gastric bypass is recommended. As for many revisional procedures, the tissue of the gastric pouch becomes quite thickened and a longer staple height is necessary when creating the gastric pouch. A well-vascularized pouch is critical. The vertical staple line can be difficult to find, and it is important to avoid leaving a portion of stomach that does not communicate with either the pouch or the remnant stomach between a new staple line and an old staple line. For this reason, I usually create a pouch out of stomach clearly inside of the original staple line and resect the proximal portion of the remnant.

Considering the fact that obesity is so prevalent, and that bariatric surgery has become so common in the past 20 years, it is actually amazing that revisional bariatric surgery is still an evolving field. It is estimated that in 2014, there were 193,000 bariatric procedures performed in the United States. This is a sharp increase from 2011 when it is estimated that there were 158,000 procedures performed. During this 3-year interval, the proportion of revisional bariatric procedures performed rose from 6% (2011) to 11.5% (2014). The authors correctly point out that the data supporting many revisional procedures, especially when it comes to revisions for weight regain, are weak.

The options and approach vary based on the original procedure and the presence of issues such as a gastrogastric fistula or a massively enlarge pouch or sleeve. What is troublesome and difficult to sort out from the published literature on revisional surgery for weight recidivism is that many successful

patients have pouch size and gastrojejunostomy calibers that are identical to other patients who have failed to gain weight or have regained lost weight. Many patients have maladaptive eating behaviors, noncompliance, or fail to exercise sufficiently to maintain lost weight. Without addressing these behaviors, a second surgery is likely subjecting patients to risk with little hope of long-term benefit. Screening prior to a primary bariatric surgery procedure to identify patients who should not be offered surgery or who would benefit from additional support, education, or counseling prior to surgical intervention is an inexact science and varies from program to program. When a patient presents with a desire for a second bariatric surgical procedure due to persistent or recurrent obesity, the proper screening process is even less certain. One thing is for sure in my opinion, these patients need careful monitoring and support following surgery to make sure old habits that led to a failed primary attempt at surgically induced weight loss do not recur.

When it comes to complications of primary bariatric procedures requiring revision, the decision to proceed with surgery and the options available are a bit less controversial. Revisional bariatric surgery is a complex intervention with a high degree of technical difficulty. Surgeons who endeavor to perform revisional bariatric surgery should be highly experienced in primary bariatric surgery. In revisions of gastric bypass procedures for recalcitrant marginal ulcers, in conversions of failed Nissen fundoplications to gastric bypass, and in conversion of sleeve gastrectomy to gastric bypass—especially in cases with a chronic fistula related to a proximal sleeve leak, the surgeon should be prepared to perform an esophagojejunostomy. This is a high-risk anastomosis with significant potential for morbidity. Setting adequate patient expectations ahead of time is important. A feeding tube is almost always necessary. It may be 3 months or more until patients are able to maintain their nutrition adequately without enteral tube feeding support. Complications such as esophagojejunostomy stenosis or leak can significantly prolong this feeding tube dependent interval. In our experience with esophagojejunostomy, there is a relatively high incidence of anastomotic stenosis requiring sometimes-repeated dilation. In several patients who have required esophagojejunostomy for numerous failed fundoplications, anastomotic stenosis has been resistant to repeated dilations and stenting has been required.

Although conversion of a failed fundoplication to a gastric bypass is not technically a revision of a previous bariatric operation, I think a word here about these procedures would be of benefit and related to the content of this chapter. Obesity is a risk factor for GERD. Obesity is also a risk factor for fundoplication failure. When obese patients present with symptoms secondary to failure of a previous fundoplication, most often due to herniation of the fundoplication with hiatal hernia, takedown of the fundoplication, repair of the hiatal hernia, and conversion to Roux-en-Y gastric bypass are the best option. In certain patients with multiple failed fundoplication attempts and in those with post-surgical gastroparesis, conversion to Roux-en-Y gastric bypass is the best

option regardless of body mass index. Like all of the revisional procedures described in this chapter, these are complicated and technically complex procedures best reserved for highly experienced surgeons. A common obstacle for all of the procedures discussed in this chapter is a reluctance of insurance companies to pay for revisional or even primary bariatric procedures. Surgeons who perform these procedures should be prepared to spend extra time and effort advocating for their patients by requesting and participating in peer-to-peer discussions whenever possible. Writing letters to the medical director of an insurance company or to an independent external reviewer of an appeal outlining the medical rationale for the requested procedure with supporting peer-reviewed published literature is often necessary.

This is a great chapter on an important topic. I suspect that the next version of this chapter will describe new procedures not yet developed and better data supporting the long-term benefit and efficacy of these revisional procedures. It will be important for bariatric surgeons to follow these patients who undergo revisional procedures for 5 years and beyond. Patient selection for revisional surgery due to weight recidivism will continue to be a controversial topic requiring additional investigation.

Jon C. Gould

Suggested Readings

Gould JC, Garren MJ, Gutowski KA. Bariatric surgery. *Clin Obstet Gynecol* 2006;49(2):375–88. Review.

Ponce J, Nguyen NT, Hutter M, et al. American Society for Metabolic and Bariatric Surgery estimation of bariatric surgery procedures in the United States, 2011–2014. *Surg Obes Relat Dis* 2015;11(6):1199–200.

Tevis S, Garren MJ, Gould JC. Revisional surgery for failed vertical-banded gastroplasty. *Obes Surg* 2011; 21(8):1220–4.

Yamamoto SR, Hoshino M, Nandipati KC, et al. Long-term outcomes of reintervention for failed fundoplication: redo fundoplication versus Roux-en-Y reconstruction. *Surg Endosc* 2014;28(1):42–8.

102 Management of Complications of Gastric Bypass and Repair

Ronald H. Clements and Matthew D. Spann

INTRODUCTION

The pandemic of morbid obesity continues to expand across the globe in both developing and developed nations. The disease plagues both individuals and populational health with comorbidities having immeasurable impact on quality of life and the global economy. Perhaps the biggest challenge to controlling the pandemic remains managing the misconception that the disease is purely a lifestyle choice and not a chronic illness. In 2013, the American Medical Association officially classified obesity as a disease and has brought a new sense of awareness to the problem. Many different strategies exist for the treatment of this disease. The starting point for many patients begins in the 40 billion dollar a year diet industry. However, the literature continues to expand showing bariatric surgery to be superior, and arguably the gold standard of treatment, compared with diet and exercise, at managing the disease of morbid obesity and the associated comorbid conditions.

Nearly 200,000 bariatric procedures were performed in the United States in 2014. The Roux-en-Y gastric bypass (RYGB) accounts for more than 30% of bariatric procedures and arguably the procedure of choice for those patients suffering from both morbid obesity and type 2 diabetes mellitus. Although the majority of the procedures are performed via laparoscopic approach today, the principles behind the RYGB for morbid obesity have not changed significantly from the operation originally described by Drs. Mason and Ito in the 1960s. Historically, the operation is thought to produce weight loss through a restrictive component by creating a 30-mL pouch out of the cardia of the stomach and a malabsorptive component by bypassing 75 to 150 cm of jejunum. Through recent research, other factors such as changes in gastrointestinal hormones, hepatic glucose metabolism, and the microbiota of the gastrointestinal tract are also implicated in metabolic improvements.

Patients and providers should not view bariatric surgery as the cure for morbid obesity, but rather a tool that will help a patient achieve remission of a lifelong condition. As with any tool, a certain degree of maintenance is required. The RYGB allows patients to achieve more weight loss, resolve more obesity related health conditions, and has less weight recidivism than other popular weight loss procedures. These benefits come with a slightly higher risk of postoperative complications and require experienced follow-up care. Preoperative education for the patient and associated providers is critical for appropriate care of the patient with RYGB.

Complications from RYGB are classified into short term, within 30 days of an operation, and long-term complications, those occurring after 30 days. The incidence of complications can vary by number of operations performed by the surgeon as well as differences in technique in preforming the operation. We will examine how to identify the most common complications, their etiologies, and strategies to prevent and treat the complications. As a greater percentage of the population seeks bariatric surgery, careful attention is required of surgeons, primary medical providers, and emergency medical providers in recognizing and treating potential complications. Education of emergency room physicians and on-call surgeons is paramount as a delay of care can quickly lead to a failure to rescue event in this patient population.

EARLY COMPLICATIONS

Anastomotic Leak

Elective division of the gastrointestinal tract and the associated risk of this maneuver must be approached cautiously in any circumstance. For RYGB, anastomotic leak is one of the most feared complications associated with the procedure. Fortunately, the occurrence of anastomotic leak after RYGB for morbid obesity is low, but the clinical consequences of such an event are devastating and therefore demand a high index of suspicion in the postoperative period. Anastomotic leak is often the beginning of a series of other complications that prolong a patient’s hospitalization and increase mortality after RYGB.

The best strategy to treat anastomotic leak is prevention. Leaks at the gastrojejunostomy occur more frequently than at the jejunojejunostomy and warrant early evaluation with any clinical evidence of impaired recovery. As with any operation, a well-vascularized, tension-free

anastomosis is paramount to avoid postoperative complications. While the procedural principles are the same, there is no one standard technique for creating a gastrojejunostomy. The two most described techniques for performing the RYGB is an antecolic or retrocolic (and either antegastric or retrogastric) gastrojejunostomy. The anastomosis can be created with a circular stapler or linear stapler with sutured enterotomy. The authors preform a linear stapled antecolic, antegastric gastrojejunostomy with sutured gastroenterotomy. No technique has consistently been shown to decrease the leak rate associated with the gastrojejunostomy and thus both techniques are popular among surgeons. Perhaps the most important factor is the frequency the surgeon preforms RYGB. In addition to sound surgical principles, some authors advocate the use of anastomotic reinforcement with fibrin sealants. Widespread adoption of such reinforcement has been limited, attributed to high cost and lack of data due to relatively low rates of anastomotic leaks.

The jejunojejunostomy has been described as entirely sutured, entirely stapled, or a combination of the two techniques. The authors preform a side-to-side linear stapled jejunojejunostomy with sutured common enterotomy. When preforming the anastomosis, the key details are an antimesenteric position of the anastomosis and avoiding ischemia at the stapled end of the biliopancreatic limb. With each technique, care must be taken to adequately close the enterotomy while not narrowing the anastomosis.

Early recognition of anastomotic leak is critical to rescue a patient from further complication. Advocates of intraoperative leak test of the gastrojejunostomy cite recognition of technical error at the index operation that may prevent early complication. Many techniques have been described including both pneumatic and endoscopic intraluminal insufflation to assess for air leaks, as well as dye leak test using methylene blue. The authors use intraoperative endoscopy with insufflation to assess the integrity of the gastrojejunostomy and intraluminal hemostasis prior to completion of the RYGB. Surgical drains and routine fluoroscopic contrast evaluations are controversial but should be strongly considered for the revisional foregut or bariatric operation.

The above studies are useful for adding objective data to identify early technical complications; however, a high index of suspicion by an experienced clinician may be the most sensitive test available to the bariatric patient. Unexplained tachycardia, worsening abdominal pain, and

dyspnea are the earliest clinical signs of anastomotic leak and require prompt investigation. While radiographic tests may be useful, the most appropriate study for some patients will be operative exploration.

Management of anastomotic leak will be based on patient stability. Early leaks will often require urgent surgical intervention with surgical drainage around the anastomosis and feeding access in the bypassed stomach. Revision of the gastrojejunostomy in the early postoperative period is rarely required. Endoscopic means have been described and can be considered in the stable patient, especially those patients presenting with a delayed leak.

Bleeding

One of the most common complications after RYGB is postoperative hemorrhage. Hemorrhage is first on the list of differential diagnoses with any patient experiencing hypotension, tachycardia, dizziness, syncope, or objective evidence of acute blood loss anemia. Postoperative hemorrhage after RYGB can be categorized as extraluminal or intraluminal. Extraluminal hemorrhage most often occurs from staple lines, but may also be from splenic or mesenteric injury, hepatic laceration, or port site hemorrhage. Extraluminal hemorrhage usually presents in the acute operative period. Patients may exhibit increasing abdominal pain, abdominal distension, or can be asymptomatic.

Intraluminal hemorrhage is frequently more difficult to diagnose as there are six areas of concern related to the operation alone: gastric pouch staple line, gastrojejunostomy, proximal Roux limb staple line, jejunojejunostomy, distal biliopancreatic limb staple line, and staple line of the excluded stomach. Sites not related to RYGB such as duodenal ulcer, diverticular bleed, and mucosal arteriovenous abnormalities are also possible. Symptoms are typical of other gastrointestinal bleeds including hematemesis, hematochezia, and melena. Sometimes the presenting symptoms will delay the sentinel event by a few days.

As with other postoperative hemorrhage, management will depend on patient stability, time of presentation, and symptoms. The first step with any patient is to ensure adequate intravenous access, active blood type and antibody screen, and blood availability in the institution. Hemodynamically stable patients with minimal symptoms may be candidates for close observation in a monitored setting. Unstable patients require transfusion and likely early operative intervention. Laparoscopic

management can be successful, but some patients will require laparotomy for definitive management of extraluminal, and rarely, intraluminal bleeding.

Early use of gastrointestinal endoscopy should be considered with patients exhibiting the symptoms of intraluminal bleeding described above. Transoral endoscopy can be both diagnostic and therapeutic for the most common sites of bleeding: the gastric pouch and gastrojejunostomy. If intraluminal bleeding is not seen on transoral endoscopy, intraoperative transgastric endoscopy via the remnant stomach is useful at examining the duodenum as well as staple lines within the bypassed stomach and jejunojejunostomy. If endoscopic interventions are unsuccessful at control of hemorrhage from a staple line, a running suture along the staple line or ligating a feeding vessel may be required through a laparoscopic or open approach.

Thromboembolic Complications

Another feared but not uncommon complication after any bariatric surgery is formation of deep vein thrombosis (DVT) and pulmonary embolus. Reported incidence ranges from 0.3% to 6% and 0.2% to 5%, respectively, and account for nearly half of mortalities after gastric bypass. Although there is no standardized method of DVT prophylaxis, establishment of an aggressive prophylactic thromboembolic protocol, with frequent review, is critical to avoid this potentially fatal complication. Elements of the thromboembolic protocol include use of sequential compression prior to procedure start and, perhaps most important, an emphasis on early and often ambulation. The routine use of pharmacologic thromboembolic prophylaxis is debated but should be considered with longer operative times, reoperative surgery, and high-risk patients. The presenting symptoms of patients with thromboembolic disease vary widely requiring high index of suspicion by the clinician to initiate early investigation for DVT in hopes to prevent the morbidity from progressing to mortality.

Early Bowel Obstruction

Small bowel obstruction (SBO) after RYGB can occur at any point after the operation. Patients often present with the typical symptoms of nausea and vomiting or retching with or without abdominal pain. In addition to adhesive disease common with other operations, patients with RYGB can also have obstruction due to blockage at either anastomosis, or mesenteric

volvulus. Workup of the etiology of SBO should proceed with focused examination of the abdomen, radiographs of the abdomen and pelvis, as well as computed tomography (CT) scan if the patient's clinical picture allows.

The management of bowel obstructions after RYGB is quite different than managing adhesive bowel obstructions associated with many other operations. Practitioners should avoid the temptation of nasogastric tubes as this will provide little benefit due to the small size of the gastric pouch and is associated with quite significant morbidity such as aspiration pneumonitis and risk of perforation of the gastrojejunostomy. Any patient with a history of RYGP presenting with nausea, vomiting, and abdominal pain must be ruled out for mesenteric volvulus related to internal hernia as failure to diagnose and operatively manage such patients can result in intestinal ischemia, short bowel syndrome, and death. Internal hernia is uncommon in the early postoperative period and will be discussed later in this chapter.

Within the first 30 days after RYGB, anastomotic obstruction is most common due to edema, ulceration, or stricture at the gastrojejunostomy or jejunojejunostomy. SBOs due to narrowing at the anastomoses are not uncommon when advancing to a new stage of the bariatric diet. Clinically stable patients presenting the symptoms of early SBO related to anastomotic complications can frequently be managed conservatively with frequent physical exams, bowel rest, and IV hydration.

Cardiopulmonary Complications

The second leading cause of death within 30 days after operation is cardiovascular events, responsible for up to one third of mortalities post RYGB. Many patients undergoing RYGB suffer from metabolic syndrome and have baseline cardiovascular risk higher than healthy individuals undergoing other forms of noncardiac surgery. The challenge is ensuring that such patients are medically optimized for surgery. Surgeons should work closely with a patient's cardiologist and/or primary care physician to ensure cardiovascular risk is minimized. For those patients who do not have a family or personal history of cardiovascular disease, obtaining routine preoperative cardiovascular tests are based on the patient's functional status. Patients with a functional status of less than four metabolic equivalents (METs) require thorough cardiac evaluation prior to surgery.

Many patients who experience cardiovascular events after RYGB will have no prior history or no elevated cardiovascular risk. Early recognition and management of cardiovascular events are essential for patient safety. Since the symptoms of cardiac events widely very, investigation is warranted in any patient not experiencing the routine postoperative recovery. Early escalation of care and expert consultation may prevent failure to rescue in this high-risk patient population.

LATE COMPLICATIONS

Marginal Ulcer

One of the most common complications of RYGB after the immediate postoperative period remains gastrojejunal, marginal, or ulceration. Stomal ulceration was recognized by Dr. Mason early in the history of RYGB. Although its incidence has decreased some, it is a reported complication in 1% to 9% of patients after surgery, with the highest risk of development within the first 3 months. Prevention of ulceration begins with preoperative management. Selective, and arguably routine, endoscopic screening in patients interested in RYGB will help identify patients with peptic ulcer disease, the largest risk factor for the development of marginal ulcers. Smoking cessation is also critical in the preoperative period. We advocate screening and eradication of *Helicobacter pylori* prior to surgery with any patient experiencing dyspepsia or with an established diagnosis of gastroesophageal reflux disease. During the operation, a small vertically oriented gastric pouch with volume of approximately 30 mL has been associated with lower ulcer rates. The pouch shape and size are critical to minimize the amount of parietal cells above the gastrojejunostomy. A tension-free anastomosis and preservation of blood flow to the gastric pouch and proximal Roux limb are perhaps the most important technical aspects to avoid marginal ulcers. If suture is required during creation of the gastrojejunostomy, we advocate absorbable suture as permanent suture material is frequently seen near gastrojejunal ulcers on endoscopic evaluation. Postoperatively, use of proton pump inhibitors (PPIs) has been associated with decreased ulcer rates, although the duration of therapy is debated.

Marginal ulceration is suspected in patients presenting with nausea and emesis with or without epigastric pain following gastric bypass. Early initiation of treatment with anyone suspected of marginal ulceration consists of high-dose PPI and sucralfate and often alleviates symptoms

after a few doses. Workup proceeds with upper endoscopy, which will allow diagnosis of the ulcer as well as therapeutic dilation if stricture is identified. Initiation of pharmacologic treatment should not be delayed for endoscopic conformation of marginal ulcer. Lifelong avoidance of nicotine products and nonsteroidal anti-inflammatory medications are essential to decrease development of late ulcers.

Complications of marginal ulcers include bleeding and perforation, which will be the presenting symptoms for some patients. Bleeding ulcers are often successfully treated with endoscopic therapies. Perforation should be managed urgently and will often respond to omental patch, wide drainage, and consideration of feeding access via gastrostomy tube in the remnant stomach. Revision of the gastrojejunostomy will occasionally be required for recalcitrant ulcers. Truncal vagotomy via thoracoscopic approach has also shown promise in marginal ulcers that fail medical management and may carry less morbidity that a revisional gastrojejunostomy.

Anastomotic Stenosis

Gastrojejunal stenosis will occur in up to 10% of RYGB and is similar in incidence for circular stapled, linear stapled, and completely sutured techniques. Anastomotic stenosis can occur in any period after the operation. Patients typically present with difficulty tolerating solids or liquids. Frequently, stenosis at the gastrojejunostomy is associated with ulceration and may be the presenting symptom of a marginal ulcer. Other etiologies include technical complications at the anastomosis. Risk factors for anastomotic stenosis include those associated with marginal ulcers as well as technical error. Stenosis may also be related to banding material used during certain techniques of creating the gastrojejunostomy. Treatment of anastomotic stenosis is aimed at prevention as described above. Early use of endoscopy is useful for diagnostic and therapeutic advantages. Most cases of stenosis will respond to endoscopic interventions, reserving revisional operations for advanced stenosis or cases that have failed to respond to multiple endoscopic dilations.

Stenosis at the jejunojejunostomy is quite rare and is often related to technical error, adhesive disease, or dietary noncompliance. Symptoms of jejunal stenosis include symptoms of bloating, early satiety, unexpected weight loss, and abdominal pain. CT and gastrointestinal contrast studies are useful to confirm the diagnosis showing dilation of the Roux limb or

biliopancreatic limb and remnant stomach. When available, endoscopic evaluation by an experienced endoscopist with or without use of balloon enteroscopy may allow visualization of the jejunal anastomosis. Treatment should be based on the patient's symptoms and revision of the anastomosis is indicated in patients who are unable to tolerate oral intake.

Gastrogastric Fistula

Gastrogastric fistula has been a known complication throughout the history of RYGB. One of the major factors initially was stapler technology that did not allow for division of the stomach when creating the gastric pouch. With advancement in staple technology allowing for complete division, gastrogastric fistulae have reduced but remain a culprit for patients experiencing weight regain or marginal ulceration after surgery. Gastrogastric fistulae are often identified when oral contrast is seen in the bypassed stomach on either CT or gastrointestinal radiographs. Workup for gastrogastric fistula should include endoscopy and potentially video esophagram. Management of fistulae will depend on symptoms. In the asymptomatic patient, gastrogastric fistula may be observed and treated medically with PPIs. Most gastrogastric fistula will be symptomatic and require operative management. Recent technology has provided numerous endoscopic therapies aimed at addressing gastrogastric fistulae. Although some endoscopic methods will be successful, many patients with symptomatic gastrogastric fistula will need revisional operations aimed at dividing the gastrogastric fistula or resection of the pouch and revision of the gastrojejunostomy.

Bowel Obstruction

While bowel obstruction can present both early and late in the postoperative period, most early obstructions are due to technical error, bowel edema, or dietary noncompliance. Bowel obstructions presenting later in the postoperative course often require intervention. Any patient with a history of RYGB presenting with nausea and emesis with or without abdominal pain should be considered to have mesenteric volvulus from an internal hernia until proven otherwise. Internal hernias are potential spaces created in the mesentery by the Roux-en-Y anatomy and will vary slightly depending on the method used to create the gastrojejunostomy. A potential space always exists at the jejunojejunostomy regardless of method of creation (Fig. 102.1). With antecolic gastrojejunostomy, a potential space

exists between the mesentery of the Roux limb and the transverse mesocolon. With creation of a retrocolic gastrojejunostomy, potential spaces are created at both the interface of Roux limb mesentery and transverse mesocolon, as well as a space created when the Roux limb passes through the transverse mesocolon (Fig. 102.2).

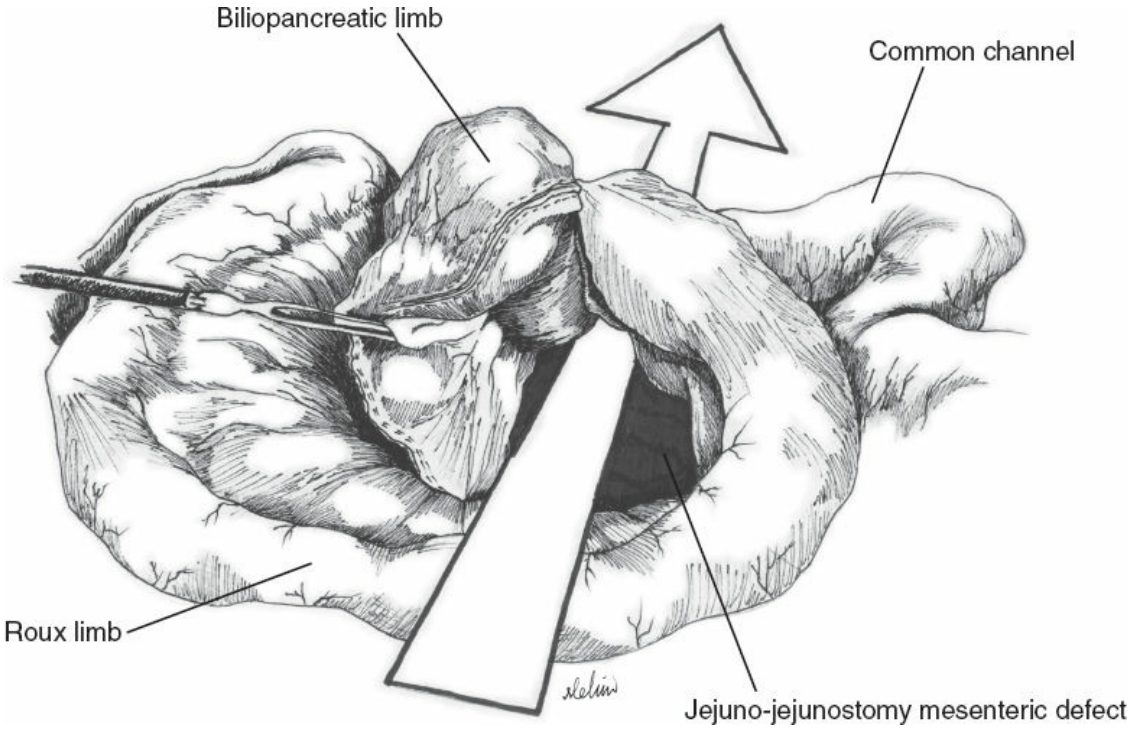

Figure 102.1. Mesenteric defect at jejunojejunostomy.

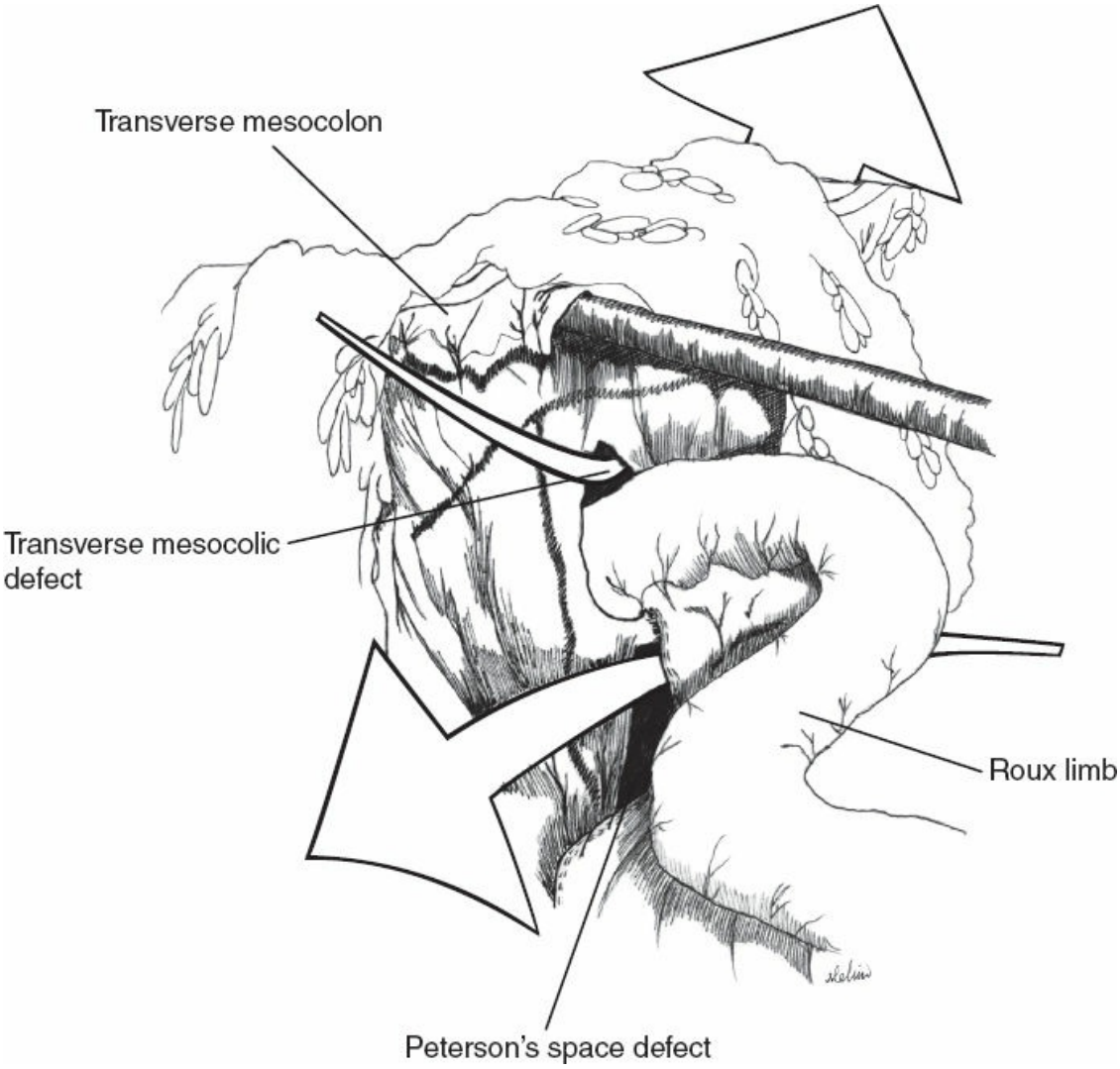

Figure 102.2. Mesenteric defects in patients with retrocolic gastrojejunostomy.

CT is the best initial test during workup of a patient experiencing symptoms of internal hernia. Image analysis is most useful if preformed by a radiologist experienced in analyzing Roux-en-Y anatomy, as well as an experienced bariatric surgeon. Characteristic CT signs of internal hernia include changes within the mesentery, most notably swirling of the mesenteric vessels. The mesenteric "swirl" sign is often recognized with internal hernia at the mesocolic defect created by the mesenteric vessels passing behind the superior mesenteric artery as depicted in Figure 102.3. Other CT findings include evidence of a SBO, jejunum passing behind the superior mesenteric artery, the jejunojejunostomy located in the patient's right hemiabdomen, and clustering of small bowel within one quadrant. As with any disease process, the surgeon must treat the patient and not available radiographic information. A patient with abdominal pain out of

proportion to exam requires exploration to rule out presence of internal hernia even in the setting of normal imaging studies.

Operative exploration is performed via the approach most comfortable to the surgeon. The first aim of the operation is not identification of the potential spaces and/or hernia. Instead, the authors recommend identifying the terminal ilium and performing a retrograde exploration of the small bowel back to both the ligament of Treitz and gastrojejunostomy. By preforming the distal to proximal examination, the surgeon will reduce the internal herniation and may notice a visible difference in the appearance in bowel color and caliber during the exploration. When the entire small bowel has been examined, the potential mesenteric defects need to be inspected. To assess for a defect at the jejunojejunostomy, the Roux limb is swept to the right side of the abdomen. Once the jejunojejunostomy is identified, the mesenteric defect is observed by tracing the cut end of the biliopancreatic limb down to its mesentery. A thin film of adhesions should be present between the mesenteric interface of the biliopancreatic limb and Roux limb down to the root of the mesentery (Fig. 102.4). The mesenteric interface between the Roux limb and transverse mesocolon is assessed by sweeping the Roux limb to the left side of the abdomen and retracting the transverse colon cephalad. A thin layer of adhesions should be present between the transverse mesocolon and the Roux limb mesentery to the root of the mesentery. If the mesenteric defect is open, the proximal jejunum at the ligament of Treitz can be seen through the defect (Fig. 102.5). No small bowel should transverse the defect if the internal hernia is adequately reduced. For patients with a retrocolic gastrojejunostomy, only one limb of intestine should be present going through the transverse mesocolon. The size should be adequate to allow only the Roux limb and its mesentery and, frequently, sutures are placed between the Roux limb and mesocolon to keep the defect closed during massive weight loss.

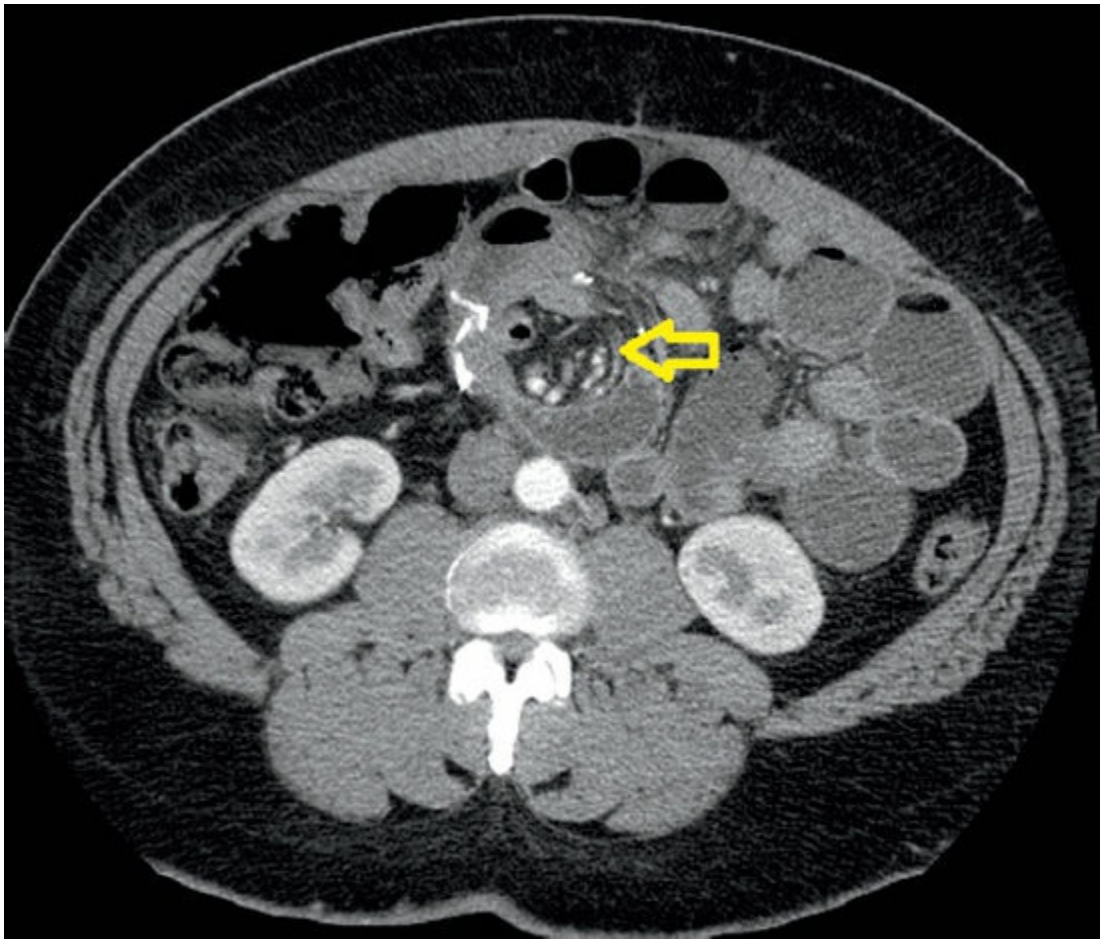

Figure 102.3. Computed tomography (CT) image depicting mesenteric swirl related to internal hernia at Peterson space.

Once internal hernia is excluded, adhesive bowel obstruction must also be considered. Adhesive bowel obstructions are more common in patients with history of open RYGB, but can present in laparoscopic cases as well. Adhesive disease from other operations is possible. Management of adhesive disease should be followed with bowel rest, close observation, and low threshold for surgical intervention. Nasogastric decompression is controversial after RYGB as its benefits are minimal due to the altered anatomy as decompression of the Roux limb or gastric pouch has limited benefit to the management of adhesive bowel obstructions. If nasogastric decompression is desired, use of fluoroscopy may decrease the risk of iatrogenic gastrojejunal perforation.

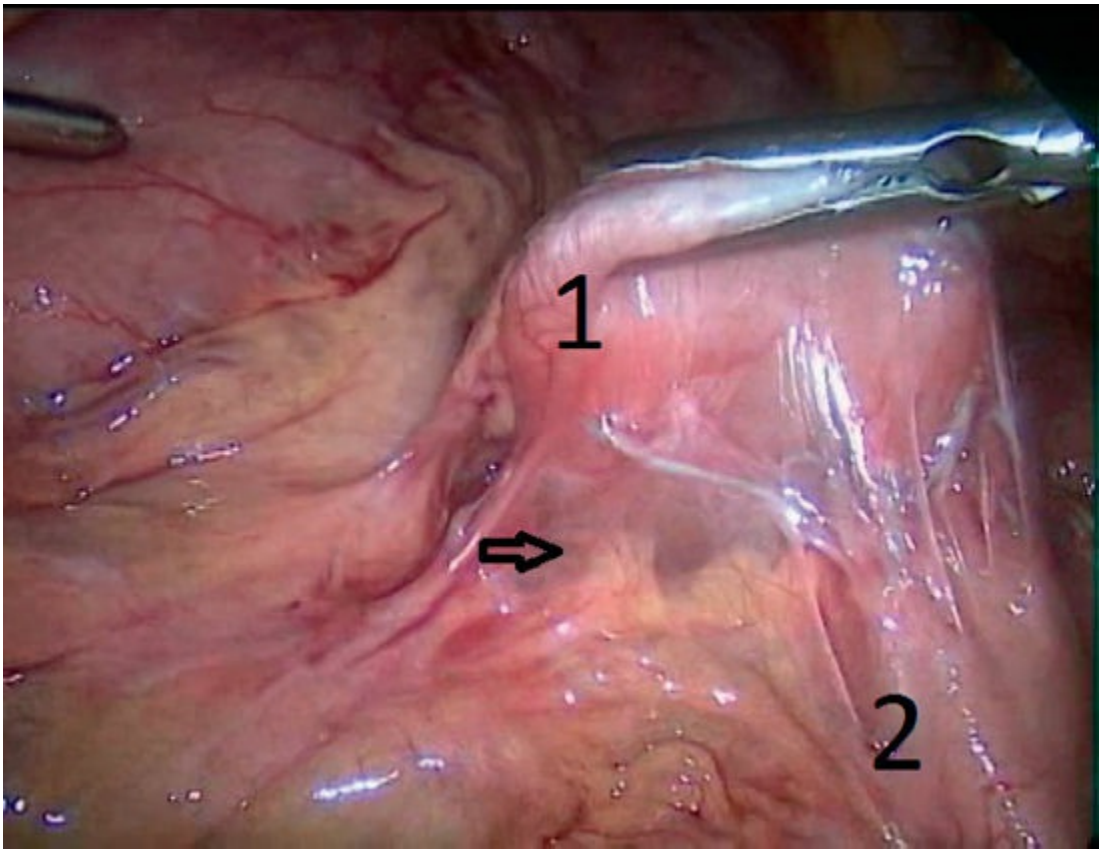

Figure 102.4. Closed mesenteric defect in at jejunojejunostomy (*arrow*). The cut end of the biliopancreatic limb is cephalad (*1*) with Roux limb just below (*2*).

Another rare but well-described cause of bowel obstruction after RYGB includes jejunal intussusception. In addition to symptoms of bowel obstruction, patients experiencing intussusception may have history of hematochezia or melena leading to the event. Jejunal intussusception after RYGB is a retrograde intussusception of the common channel into the Roux limb or biliopancreatic limb. The etiology of intussusception after RYGB is not fully understood, but altered peristalsis with artificial “lead point” at the jejunojejunostomy is suspected. Asymptomatic patients often resolve without intervention. Treatment of symptomatic cases will be based on the patient’s clinical presentation. Many patients will require operative intervention. Controversy exists regarding the best strategy between reduction in the intussusception alone, reduction and enteropexy, or revision of the jejunojejunostomy. Recurrence is possible with each strategy and patients should be counseled accordingly.

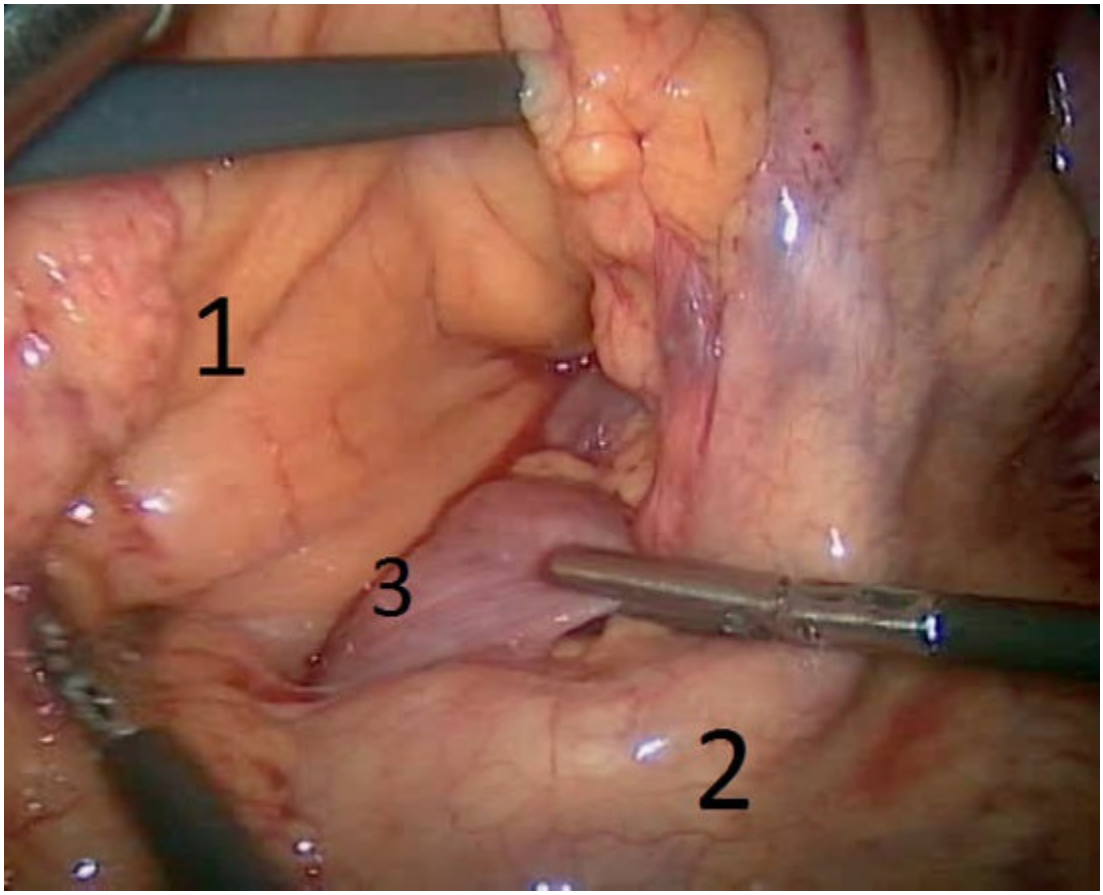

Figure 102.5. Open mesenteric defect between transverse mesocolon (*1*) and Roux limb mesentery (*2*). The proximal jejunum and ligament of Treitz are seen through the defect (*3*).

Nutritional Deficiencies

Nutritional deficiencies have long been recognized as a risk of any weight loss procedure. For patients after RYGB, several factors must be considered. A low-volume gastric pouch alters secretion of gastric acid and intrinsic factor inhibiting the absorption of vitamin B_{12} and other protein-bound micronutrients. The bypassed duodenum and proximal jejunum are the primary sites of absorption of the water-soluble vitamins and necessary cations including calcium, iron, and copper. A side effect of decreased fat absorption leads to malabsorption of the fat-soluble vitamins.

To avoid vitamin malnutrition, pharmacologic supplementation of vitamins and calcium is routine for most patients after RYGB. Careful monitoring of recommended nutritional laboratory parameters is found in Table 102.1. Monitoring is frequent in the immediate post-op period and annually after stability is reached. Clinicians must keep in mind that patients after RYGB and other bariatric operations will become deficient

in vitamins very quickly if oral intake is altered at any point in their postoperative period. Permanent impairment related to deficiency can be avoided with timely intravenous repletion of folate, thiamine, and generic multivitamin in patients with a history of bariatric surgery suffering from decreased oral intake or noncompliant with recommended vitamin regimen.

Weight Recidivism

One of the main factors inhibiting patients and primary care providers from considering bariatric surgery as a tool to treat morbid obesity is fear of weight regain. While some weight gain is expected after the patient's nadir from RYGB, the number of patients who gain more than 10% of their lowest body weight is relatively low. Although long-term results after RYGB are limited due to patients lost to follow-up, the available 10-year follow-up data indicates approximately 10% to 30% of patients will gain more than 10% of their lowest weight.

Recidivism after RYGB is unquestionably multifactorial. Dietary and psychological evaluation and support are crucial in managing a patient suffering from recidivism. Therapy begins by identifying modifiable risk factors, including anatomic and pharmacologic etiologies. Exploration into the anatomy should be considered early in the course of evaluation including gastrointestinal radiographs to define the size and shape of the gastric pouch, examine for gastro-gastric fistulae, and attempt to define the length of the Roux limb if operative reports are unavailable. Upper gastrointestinal endoscopy is also useful at examining for abnormalities in the pouch as well as diameter of the gastrojejunostomy. Examination by an experienced endoscopist may also allow for the visualization of the jejunojejunostomy and potentially the remnant stomach. Weight regain in patients with gastrogastric fistulae or enlarged gastric pouch may benefit from revisional surgery after proper evaluation. Endoscopic therapies to address gastrogastric fistulae and enlargement of the gastrojejunostomy are evolving. Our understanding of gastrointestinal hormone changes after RYGB is limited and may one day help understand recidivism leading to new strategies for prevention and treatment.

TABLE 102.1 Recommended Laboratory Test After Roux-en-Y Gastric Bypass

Test	Rational
Complete blood count	Monitor for anemia, leukocytosis
Basic metabolic profile	Monitor renal function and glucose
Hepatic function panel	Consider in patients with steatosis
Calcium, parathyroid hormone, alkaline phosphatase	Decreased absorption due to bypass of duodenum. Suspect deficiency in patients with low normal calcium, high parathyroid hormone, and elevated alkaline phosphatase. Prolonged calcium deficiency will lead to osteopenia or osteoporosis
Iron, ferritin, total iron binding capacity	Decreased absorption due to bypass of duodenum. Moderate to severe deficiency needed to produce anemia
Folate	Decreased absorption due to bypass of duodenum. Deficiency can lead to anemia
A (Retinol)	Decreased absorption due to lipid solubility. Deficiency linked to ophthalmic symptoms
B_1 (Thiamine)	Decreased absorption due to bypass of duodenum. Stores depleted rapidly with poor oral intake and can lead to encephalopathy
B_2	Decreased absorption due to bypass of duodenum
B_6 (Pyridoxine)	Decreased absorption due to bypass of duodenum
B_{12} (cobalamin)	Decreased binding with intrinsic factor. Deficiency can lead to anemia and neurologic sequelae
D (25-OH D)	Decreased absorption due to lipid solubility. Deficiency can lead to hypocalcemia
E, K, and zinc	Not routinely monitored. Vitamins E and K are lipid soluble. Zinc is bound to albumin and can be low in cases of protein malnutrition
Hemoglobin A1C	Monitored in the initial postoperative period in patients with history of diabetes mellitus. No routine monitoring in patients who have achieved remission of type 2 diabetes mellitus

Psychiatric Considerations

The psychiatric care of the bariatric patient requires careful attention throughout the preoperative and postoperative periods. Psychological screening by an experienced provider before undergoing this truly life-altering procedure can be helpful in preparing every patient as well as identifying patients at-risk of postoperative psychological comorbidities. During this evaluation, many postoperative hurdles can be recognized and treated prior to the operation. Patients should be aware that depression and other psychiatric illnesses may worsen after RYGB. The patient's psychiatric provider can help prepare and careful monitor symptoms during the perioperative period as the absorption of some psychiatric medications is altered after RYGB. Close partnership with the patient's psychiatric provider and weight loss center will provide the patient with

the best chance for long-term success.

CONCLUSION

RYGB has been established as the gold standard for the surgical treatment of obesity for many years. Through the tireless work of pioneers in bariatric surgery, the safety profile has improved significantly over the last two decades. Programs developed through the American College of Surgeons and American Society of Metabolic and Bariatric Surgery have led to a partnership focused on continued quality improvement. The Metabolic and Bariatric Surgery Quality Improvement Project provides a framework for the optimal care of the bariatric patient. Unlike many other procedures, the pathology of morbid obesity is a chronic condition and surgery will not change that fact. As surgeons, we must continue to educate ourselves and communicate with our patient's health care team as we are the experts in the altered physiology.

The causes of obesity are multifactorial and therefore require a multidisciplinary approach. The next frontier of obesity treatment may lie in understanding past and present operations. Although we know the mechanics of the Roux-en-Y gastric bypass well, we are only beginning to unlock perhaps the true reasons the operation works so well by identifying changes in gastrointestinal hormones, the intestinal microbiota, and glucose metabolism. A more complete understanding of these changes will hopefully lead to the best treatment of obesity: prevention.

Suggested Readings

Aminian A, Brethauer SA, Kirwan JP, et al. How safe is metabolic/diabetes surgery? *Diabetes Obes Metab* 2015;17:198–201.

Lockhart ME, Tessler FN, Canon CL, et al. Internal hernia after gastric bypass: sensitivity and specificity of seven CT signs with surgical correlation and controls. *Am J Roentgenol* 2007;188:745–50.

Morton JM, Garg T, Nguyen N. Does hospital accreditation impact bariatric surgery safety? *Ann Surg* 2014; 3:504–9.

Printen KJ, Scott D, Mason EE. Stomal ulcers after gastric bypass. *Arch Surg* 1980;115:525–7.

Sawaya RA, Jaffe J, Friedenberg L, et al. Vitamin, mineral, and drug absorption following bariatric surgery. *Curr Drug Metab* 2012;13:1345–55.

Sjostrom DC, Lissner L, Wedel H, et al. Reduction in incidence of diabetes,

hypertension, and lipid disturbances after intentional weight loss induced by bariatric surgery: the SOS Intervention Study. *Obes Res* 1999;5:477–84.

Sverden E, Mattsson F, Sonden A, et al. Risk factors for marginal ulcer after gastric bypass surgery for obesity. *Ann Surg* 2016;263(4):733–7.

Tao W, Plecka-Osthund M, Lu Y, et al. Causes and risk factors for mortality within 1 year after obesity surgery in a population-based cohort study. *Surg Obes Relat Dis* 2015;11:399–405.

EDITOR'S COMMENT

Dr.'s Spann and Clements have done an excellent job describing the various complications that can be seen following laparoscopic gastric bypass surgery in this chapter. Gastric bypass has been the most commonly performed bariatric surgical procedure since the discipline of obesity surgery was conceived more than 60 years ago. According to the American Society for Bariatric Surgery, the number of procedures increased from about 16,000 in the early 1990s to more than 103,000 in 2003. The ASMBS estimates that 220,000 people in the United States had bariatric surgery in 2008. Given these numbers, there are millions of patients who have had a gastric bypass who might develop some of the late complications that are described in this chapter.

It is remarkable how safe bariatric surgery, and gastric bypass in particular, has become when compared to the first 10 years of the laparoscopic experience in the United States as a whole. A study published in 2009 using the Longitudinal Assessment of Bariatric Surgery consortium data revealed that the overall risk of adverse outcomes of bariatric surgical procedures was low and contingent on patient characteristics. In fact, the investigators found an overall mortality rate of 0.3% and a major complication rate of 4.1%, both of which were comparable to the rates observed in similar patients undergoing other major abdominal surgical procedures. Over the 6-year period of 2004 to 2009, Dimick et al. demonstrated that the rate of serious complications in Medicare beneficiaries undergoing bariatric surgery decreased from over 8% to less than 4%.

I appreciate the way this chapter is constructed—with an emphasis on prevention, recognition, and management of complications. As mentioned, among the most feared and potentially deadly complications is a gastrointestinal leak, most commonly observed at the gastrojejunostomy. The March 2016 Semi-Annual Risk Adjusted Report for the Metabolic and Bariatric Surgery Quality Improvement Program included 41,393 laparoscopic gastric bypass procedures from 629 sites across the country. The overall incidence of leak was 0.36%. When I first started performing bariatric surgery in 2000, we quoted a roughly 1% to 2% rate of leak—our best understanding of the national average of this complication at the time. The decease in the rate of leak following gastric

bypass is likely multifactorial. Factors potentially contributing to the decreased incidence include more experience (both at hospitals and with individual surgeons), better stapling technology, better patient selection, and an understanding of the technical risk factors associated with this complication.

There are actually three techniques commonly employed to create the gastrojejunostomy in gastric bypass. In addition to the linear and circular stapled methods mentioned in the current chapter, totally hand-sewn techniques are also commonly employed. The introduction of the surgical robot has led to increased utilization of a totally sutured gastrojejunostomy. A 2008 study revealed that 21% of bariatric surgeons prefer a hand-sewn technique for the gastrojejunostomy, 43% prefer the circular-stapled technique, and 41% a linear stapled technique. Lois et al. reported that the incidence of specific complications varies by gastrojejunostomy construction technique including a variation in the incidence of stenosis (likely lowest with completely sutured anastomosis), wound infection (likely highest with circular stapled anastomosis), and bleeding (likely highest in circular stapled anastomosis). Weight loss outcomes appear to be similar with the different gastrojejunostomy construction techniques.

Leak rates by surgeon may relate in part to experience and volume. Numerous studies have demonstrated a volume outcome relationship in gastric bypass surgery, with high volume surgeons and hospitals having lower leak rates and overall rates of morbidity than very low volume surgeons and hospitals as a whole. Our group published a study in 2011 that revealed there is a fairly linear relationship between volume and mortality as well as serious morbidity. We did identify numerous low volume centers with extremely low complication rates and high-volume centers with elevated rates of complications. This suggests that hospital and surgeon volume is not the primary factor associated with complications. An interesting study recently used blinded peer review of videos of individual surgeons performing laparoscopic gastric bypass and determined that the technical skill of practicing bariatric surgeons varied widely, and greater skill was associated with fewer postoperative complications and lower rates of reoperation, readmission, and visits to the emergency department.

Patient selection may play a role in decreasing the rate of serious complication including leak following gastric bypass. Men with central obesity and a very high body mass index have been demonstrated to have a higher leak rate after gastric bypass. Many of these men in the current era are instead offered a laparoscopic sleeve gastrectomy.

The Metabolic and Bariatric Surgery Accreditation and Quality Improvement Program (MBSAQIP) has been releasing semiannual risk-adjusted outcome reports for participating hospitals since 2014. This allows bariatric surgery programs to understand where the true opportunities for quality and process improvement lie, and to design protocols and adopt best practices with the goal of improving outcomes in focused areas. As surgeons and bariatric surgery

programs continue to learn from each other and benchmark their performances against their peers, I believe we will see continued improvements in outcomes through better processes of care that will lead to fewer readmissions, reoperations, and complications overall.

Preventing SBOs and internal hernias is another topic of interest. While the current chapter contains a nice description of the diagnosis and management of these complications, a word about prevention is also warranted. The mesenteric defect at the jejunostomy should be closed. Some surgeons opt not to close this defect. The defect at Peterson space behind the Roux-limb mesentery is closed less consistently and is a bit more controversial. An interesting and recently published multicenter, randomized trial examined this issue in a large cohort of gastric bypass patients. At 12 bariatric surgery centers in Sweden, more than 2,500 patients were randomized at the time of surgery to closure of both the jejunojejunostomy defect and Peterson space or no mesenteric closure. At 3 years after surgery, the cumulative incidence of reoperation because of SBO was significantly reduced in the closure group (cumulative probability 0.055 for closure vs. 0.102 for non-closure, hazard ratio 0.56, 95% CI 0.41–0.76, p = 0.0002). Closure of mesenteric defects increased the risk of severe postoperative complications (54 [4.3%] for closure vs. 35 [2.8%] for non-closure, odds ratio 1.55, 95% CI 1.01–2.39, p = 0.044), mainly because of kinking of the jejunojejunostomy. The authors conclude that the results of their study support the routine closure of the mesenteric defects in laparoscopic gastric bypass surgery, but that closure of the mesenteric defects might be associated with increased risk of early SBO caused by kinking of the jejunojejunostomy.

Another issue is the patient with a ventral incisional or umbilical hernia present at the time of gastric bypass. Given the clean contaminated nature of a gastric bypass, there are obvious concerns about the use of mesh concurrently. The options facing the surgeon include deferring repair until another time (preferably after significant weight loss), primary repair (accepting a high recurrence rate), or repair with mesh (most likely a biologic given the potential for bacterial contamination/seeding of permanent synthetic mesh). Eid et al. demonstrated that when the above 3 approaches were employed and retrospectively reviewed, that deferred repair was associated with a high rate of bowel obstruction (5/14; 38% presented with incarcerated hernia and bowel obstruction within 5 months), primary repair had a high recurrence rate (22%), and repair with a biologic mesh had no recurrences or episodes of incarceration on limited follow-up. My own anecdotal experience is that an umbilical hernia if not repaired at the time of surgery is in a location relative to an antecolic Roux limb where an acute incarceration in the first week following surgery can occur (has happened to me 3 times in a lifetime experience of about 2,000 cases so far). I repair every umbilical hernia I encounter at the time of gastric bypass —usually primarily with suture only.

Early recognition and appropriate management of complications after gastric bypass is also critical. This is something that comes with experience—both

programmatically and on an individual surgeon level. There is sometimes a fine line between recognizing a complication early, and pulling the trigger on an invasive intervention on a patient that does not have a complication necessitating surgery. In the current era where the quality of care physicians and bariatric programs provide is assessed based on metrics such as readmission and reoperation rates, there may be a tendency to not readmit a patient who really needs to be readmitted or to defer a reoperation on a patient who would have benefitted from a procedure at an earlier interval. Surgeons need to understand the appropriate evaluation of a postoperative patient having trouble, and when it is best just to go to the operating room rather than spend time on diagnostic tests. The sensitivity and negative predictive value of tests like upper GI esophagrams to evaluate for a leak and a CT to assess the possibility of an internal hernia need to be understood. Unexplained tachycardia or a fluid deficit that does not respond to appropriate resuscitation in an early postoperative patient are both ominous and sensitive, but not specific early indicators of a leak. My personal threshold to operate on an extraluminal, intra-abdominal bleed in a gastric bypass patient is a little lower than in a sleeve gastrectomy patient due to a personal concern that a hematoma could become infected with organisms from the gastrointestinal tract provided access to the peritoneal cavity and clot by the very nature of the procedure. An infected hematoma is difficult to effectively drain percutaneously with CT guidance.

Bariatric surgery has evolved from a fringe discipline with little science or consistency, to a mainstream and evidence-based specialty where best practices are shared for the benefit of the discipline and our patients. This is an excellent chapter covering an important topic that every general surgeon that takes emergency call should understand. For those that choose to make bariatric surgery a part of their practice, there are many nuances and important points made in this chapter that are critical for ensuring good outcomes.

Jon C. Gould

Suggested Readings

Birkmeyer JD, Finks JF, O'Reilly A, et al. Surgical skill and complication rates after bariatricsurgery. *N Engl J Med* 2013;369(15):1434–42.

Dimick JB, Nicholas LH, Ryan AM, et al. Bariatric surgery complications before vs after implementation of a national policy restricting coverage to centers of excellence. *JAMA* 2013;309(8):792–9.

Eid GM, Mattar SG, Hamad G, et al. Repair of ventral hernias in morbidly obese patients undergoing laparoscopic gastric bypass should not be deferred. *Surg Endosc* 2004;18(2):207–10.

Gould JC, Kent KC, Wan Y, et al. Perioperative safety and volume: outcomes relationships in bariatric surgery: a study of 32,000 patients. *J Am Coll Surg*

2011;213(6):771–7.

Lois AW, Frelich MJ, Goldblatt MI, et al. Gastrojejunostomy technique and anastomotic complications in laparoscopic gastric bypass. *Surg Obes Relat Dis* 2015;11(4):808–13.

Longitudinal Assessment of Bariatric Surgery (LABS) Consortium, Flum DR, Belle SH, et al. Perioperative safety in the longitudinal assessment of bariatric surgery. *N Engl J Med* 2009;361(5):445–54.

Stenberg E, Szabo E, Ågren G, et al. Closure of mesenteric defects in laparoscopic gastric bypass: a multicentre, randomised, parallel, open-label trial. *Lancet* 2016; 387(10026):1397–404.

D THE LIVER AND BILIARY TRACT

103 Surgical Anatomy of the Liver and Bile Ducts

Chung Mau Lo and Kelvin K. Ng

INTRODUCTION

The liver is the largest internal organ in the body and accounts for about 2% of the body weight of an adult. It has a unique dual blood supply and an intimate relationship with the bile ducts. These, together with the frequent occurrence of anatomic variants and the discordance between its external morphology and internal segmentation have made understanding the surgical anatomy of the liver and bile ducts challenging. The surgical anatomy of the liver and bile ducts is based on a clear comprehension of the liver's embryology, natural segmentation, and various congenital variants. A better understanding of the surgical anatomy has contributed to the rapid advancement in hepatobiliary surgery and *vice versa*. The advent of living donor liver transplantation in the last two decades, for example, has brought about a more detailed understanding of the anatomical and functional aspects of the hepatic vasculature and bile ducts and has reset the standard for the safety of liver surgery.

Despite the progress made in our knowledge in surgical anatomy of the liver and bile ducts, the terminology in many textbooks remains confusing and is a major source of challenge in surgical training. In this chapter, we try to avoid excessive review of the development of the terms used in the literature and minimize the description of classic but confusing definitions and nomenclatures. Instead, we focus on the modern concept of the surgical anatomy with a set of widely adopted standard terminology. In each section, following a description of the anatomy, the surgical relevance in the operating room will be highlighted and discussed.

SURFACE ANATOMY OF THE LIVER

The segmental anatomy of the liver and bile duct is more pertinent in liver surgery but an understanding of the surface anatomy and the relationship between the external landmarks and the internal structures remains essential. The surface of the liver is covered by a thin fibrous capsule (Glisson's capsule), which is an extension of the visceral peritoneum. It covers the entire organ except the bare area at the back where the organ lies in contact with the inferior vena cava (IVC) and the right hemidiaphragm, and the gallbladder fossa with the liver hilum (porta hepatis) below where the capsule extends to envelope the hepatic artery, portal vein, and bile duct as these structures enter the liver. The shape of the liver is molded by the adjacent organs. When seen at laparotomy, it has three surfaces. The anterosuperior surface is smooth and covered by the peritoneum up to the attachment of the triangular ligaments and the anterior layer of the coronary ligament. It is related to the inferior surface of the diaphragmatic dome. The posterior surface, which includes the bare area, is largely retroperitoneal. It is related to the vertical part of the diaphragm, the retrohepatic part of the IVC, the right adrenal gland, and the upper pole of the right kidney. The caudate lobe projects from this surface as an appendage sitting on the surface of the IVC. The inferior or visceral surface has an irregular contour as it lies in contact with a number of organs, including the right anterior aspect of the stomach, superior part of the duodenum, head of pancreas, gallbladder, common bile duct, hepatic flexure of the colon, right kidney, and right adrenal gland.

The liver is suspended from the anterior abdominal wall and the diaphragm by four peritoneal attachments, which are commonly referred to as ligaments. The falciform ligament is a crescent-shaped fold, which runs between the anterior abdominal wall above the umbilicus and the anterior surface of the liver. It serves as the surface landmark for the border between the left medial and left lateral sections. The anterior and posterior layers of the coronary ligament mark the limit of the bare area as the peritoneum passes from the body wall to the liver surface. The right and left triangular ligaments are formed by the lateral unification of the layers of the coronary ligament on both sides. At where the bare area of the liver lies in contact with the diaphragm and the IVC, the liver is suspended by loose connective tissue and by the three hepatic veins. There are other ligamentous structures, which are attached to the liver. The round ligament (ligamentum teres) contains the obliterated left umbilical vein and runs in

the free edge of the falciform ligament from the umbilicus to the termination of the left portal vein. The hepatoduodenal ligament contains the hepatic artery, portal vein, and bile duct as these structures run from the upper border of the first part of the duodenum to enter the liver hilum. The ligamentum venosum contains the obliterated ductus venosum that connects the left portal vein to the junction of the left hepatic vein and the IVC in the fetus. It lies on a groove that separates the caudate lobe of liver underneath from the left liver in front. The hepatogastric omentum (lesser omentum) comprises two layers of peritoneal reflection that connect this groove to the lesser curve of the stomach.

The term “hepatic fissures” is confusing as these fissures are based largely on their anatomical relation to the three hepatic veins, not on their external appearance. The umbilical fissure is the only fissure that can be seen on the surface. It forms a deep groove on the inferior surface between the left medial and the left lateral sections that contains the umbilical portion of the left portal vein as it runs an unusually long extrahepatic course, giving off branches to both sides and terminating blindly in the round ligament. The umbilical fissure is marked superficially by the attachment of the falciform and round ligaments at its inferior border.

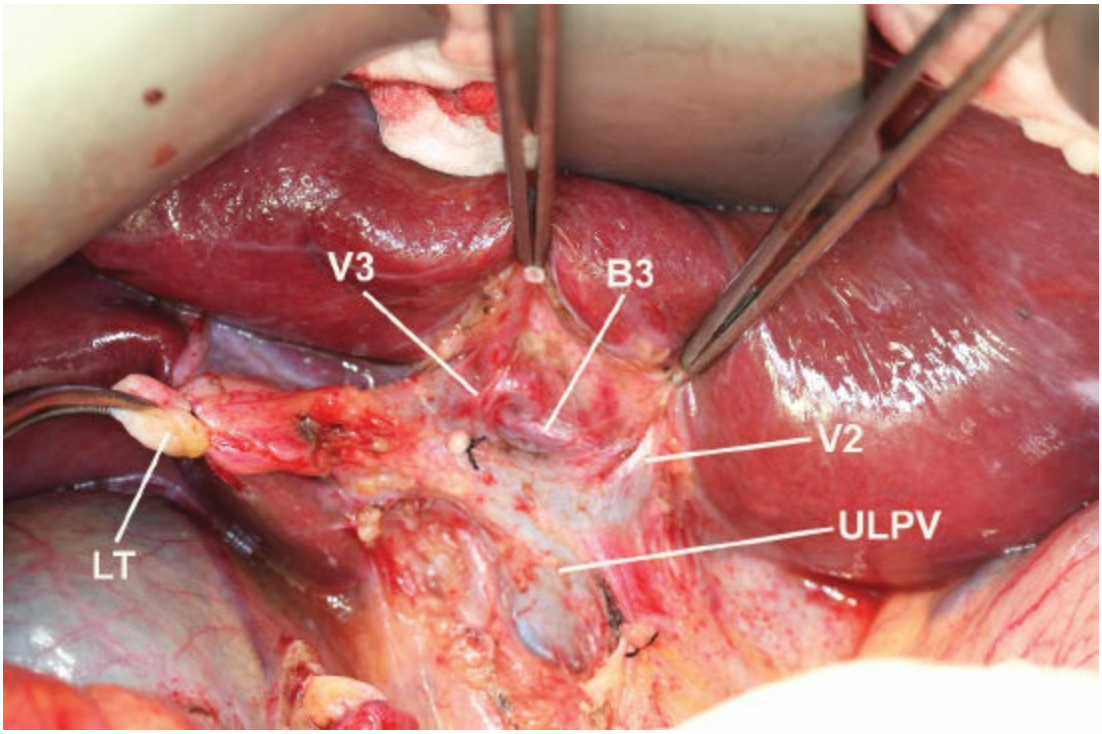

Figure 103.1. Round ligament approach to the segment-3 bile duct. LT, ligamentum teres; ULPV, umbilical portion of left portal vein; V2, branch to segment 2; V3, branch to segment 3; B3,

segment 3 bile duct.

Traditionally, based on the external appearance and the attachment of ligaments, the liver is divided into four anatomical lobes: right, left, quadrate, and caudate. With better understanding of the segmental anatomy of the liver, however, it becomes clear that these terms have very little clinical relevance and are used in different ways by various anatomists and surgeons. Hence, further description and use of these terms except in reference to the caudate lobe should be avoided.

In the Operating Room

Knowledge of the surface anatomy is essential not only for hepatobiliary surgery, but also for any operation around the liver. Mobilization of either side of the liver requires division of various peritoneal attachments such as the falciform ligament, triangular ligaments, and coronary ligament, which are generally avascular. Such division can be done with diathermy except for the round ligament. In patients with portal hypertension, however, venous collaterals may form particularly at the tip of the triangular ligaments and these will have to be ligated before division. Two ligamentous structures provide landmarks for identification of vital structures in hepatobiliary surgery. The round ligament approach allows rapid access to the left portal vein and the left duct, which is a prime location for high bilioenteric anastomosis (Fig. 103.1). The ligamentum venosum marks the left hepatic vein and is important when extrahepatic isolation of the left hepatic vein is required when performing left hepatectomy. Identification and division of the ligamentum venosum at where it attaches to the left hepatic vein will expose the junction of the left hepatic vein with the IVC at the upper border of the caudate lobe (Fig. 103.2).

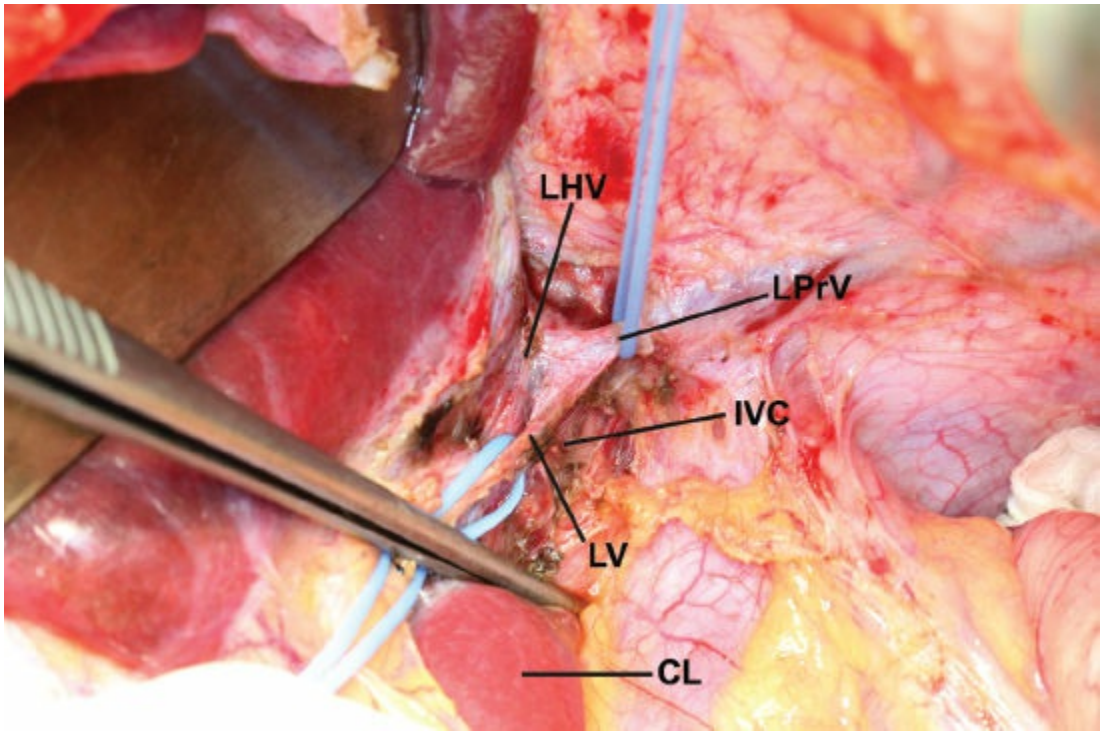

Figure 103.2. Isolation of ligamentum venosum (LV) at its junction with the left hepatic vein (LHV). LPrV, left phrenic vein; IVC, inferior vena cava; CL, caudate lobe.

SEGMENTAL ANATOMY OF THE LIVER

The division of the liver into functional units or segments according to arterial, portal venous blood supply, biliary drainage, and hepatic venous drainage forms the anatomical basis for modern hepatic surgery. Although the concepts of hepatic segmentation as described by Couinaud, Healey and Schroy, and Bismuth, respectively, are close and widely adopted, the terminology is confusing. The Brisbane 2000 Terminology of Hepatic Anatomy and Resections of the International Hepatobiliary Pancreatic Association provides a standard and has been adopted by most textbooks and journal articles.

The Brisbane 2000 Terminology is based on the anatomy of the hepatic artery and bile duct, which has a regular branching pattern, providing arterial blood to and draining the bile from eight functional zones or segments of the liver. As seen from an anterior view, the eight segments are numbered in a clockwise direction as described by Couinaud (Fig. 103.3).

Starting with the proper hepatic artery, the first division is the right and left hepatic arteries supplying the right and left hemilivers or livers, respectively, and there is very little overlap. The plane between the two

distinct zones of blood supply extends from the gallbladder bed anteroinferiorly to the right side of the IVC posterosuperiorly and is called the mid-plane of the liver or Cantlie's line. The middle hepatic vein lies exactly along this plane. On average, the right liver is about two-thirds of the total liver mass while the left liver comprises the other one-third. However, the ratio of the left liver volume to the total liver volume varies significantly and may range from <20% to nearly 50%.

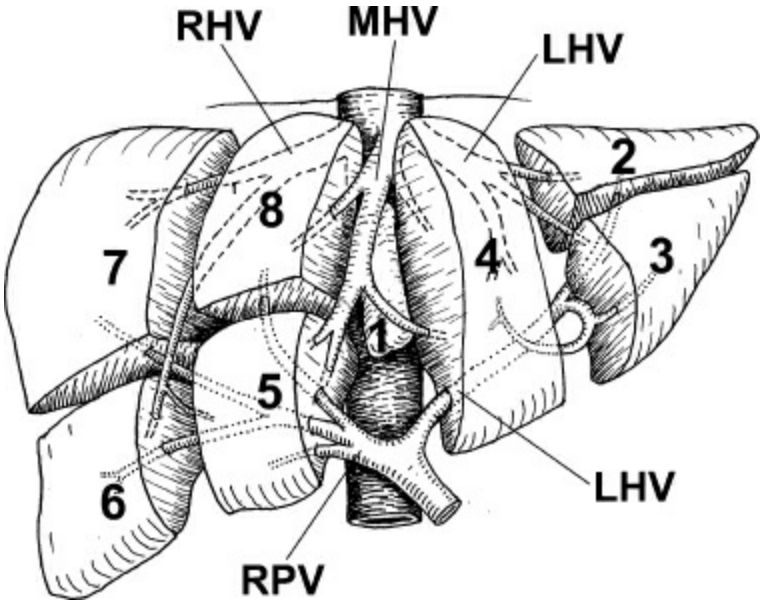

Figure 103.3. Couinaud's anatomic segments of liver (segments 1 to 8). MHV, middle hepatic vein; RHV, right hepatic vein; LHV, left hepatic vein; LPV, left portal vein; RPV, right portal vein.

The right and left hepatic arteries then divide into four second-order sectional arteries each supplying a section of the liver. On the right side, the two sectional arteries supply the right anterior section and the right posterior section, and the plane between these sections is the right intersectional plane. There is no marking on the liver surface for this plane but the right hepatic vein serves as its internal landmark. On the left, the two sectional arteries supply the left medial section and left lateral section. The plane between these sections is the left intersectional plane and is marked by the round ligament at the umbilical fissure and the line of attachment of the falciform ligament to the anterior surface of the liver.

The four sectional arteries divide further to supply seven segments of the liver. The left lateral section consists of segments 2 and 3. The left medial section is a standalone segment 4. The right anterior section is divided into segments 5 and 8 and the right posterior section into segments

6 and 7.

The portal vein branching pattern in the right liver follows the same pattern as that of the hepatic artery and bile duct. The right portal vein divides into a right anterior section branch and a right posterior section branch, which further divide into four segmental branches. The left portal vein, however, has a different branching pattern from that of the left hepatic artery and bile duct. The left portal vein is much longer than the right portal vein and has a transverse portion of 2 to 3 cm located under segment 4 within the hilar plate that sends off only a few branches to segment 4. At the site of attachment of the ligamentum venosum, the left portal vein curves anteriorly and to the left to continue as the umbilical portion in the umbilical fissure (Fig. 103.1). Large branches come off both sides of the umbilical portion of the left portal vein, with multiple branches going from the right side to segment 4 and usually one large one going from the left side to segment 2 and one large one to segment 3. It then terminates as a blind end joining the round ligament anteriorly. Hence, unlike the right portal vein, the left portal vein has a very long extrahepatic course and never enters the liver substance.

Segment 1 or the caudate lobe is a distinct part of the liver functionally independent of the right and left hemilivers. It is bounded posteriorly by the retrohepatic IVC, and superiorly by the left and middle hepatic veins at their origin. Its anterior border is formed by the left portal vein, the liver hilum, and the base of segment 4. The ligamentum venosum also courses along the anterior aspect of the caudate lobe from the left portal vein to the left hepatic vein. The caudate lobe is composed of three parts (Fig. 103.4). The caudate lobe proper (segment 1-l), or Spigelian lobe, sits on the left of the IVC and is separated from the left lateral section by the lesser omentum. The paracaval portion of the caudate lobe lies anterior to the IVC. The caudate process (segment 1-r) fuses indistinctly with segments 6 and 7 of the right liver. Since the venous drainage, arterial and portal venous blood supply, and the biliary drainage of the caudate lobe are completely different from those of the right and left livers, the anatomy of the caudate lobe will be described in a separate section at the end of this chapter.

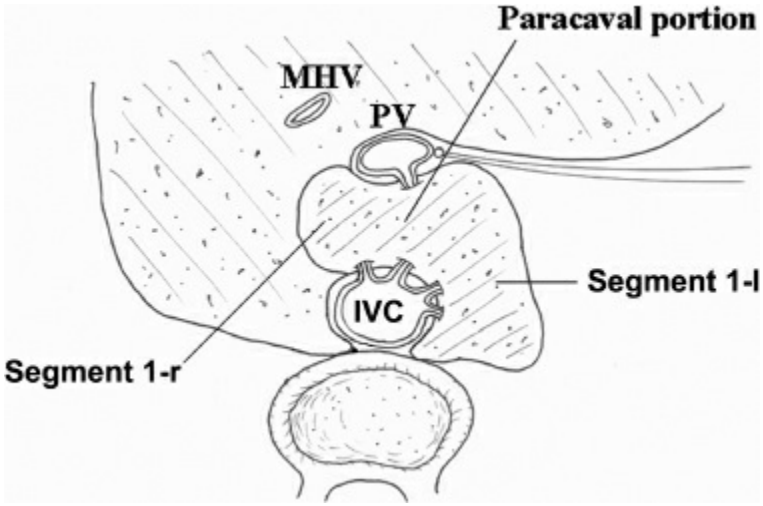

Figure 103.4. Anatomy of caudate lobe. Segment 1-l, caudate lobe proper; Segment 1-r, caudate process; MHV, middle hepatic vein; PV, portal vein; IVC, inferior vena cava.

In the Operating Room

Liver resection can be classified as "anatomical" and "nonanatomical." Anatomical resection refers to removal of functional segments of the liver parenchyma with defined boundaries based on blood supply and biliary drainage. Resections that do not take into account the segmental anatomy of the liver are nonanatomical. Anatomical resections are generally more desirable as the parenchymal transection plane follows the relatively avascular watershed plane between segments and the vascular supply and biliary drainage of the liver remnant are less likely to be compromised. There may be a wider surgical margin with improved oncologic outcome.

The Brisbane 2000 Terminology of Hepatic Resection is based on the segmental anatomy of the liver. Resection of one side, a section or a segment of the liver is referred to as hepatectomy or hemihepatectomy, sectionectomy or segmentectomy, respectively. Hence, there are right and left hepatectomies or hemihepatectomies, and the sectionectomies are left lateral sectionectomy, left medial sectionectomy, right anterior sectionectomy, and right posterior sectionectomy. Resection of three contiguous sections is called trisectionectomy. A right trisectionectomy involves resection of the right liver together with the left medial section, and a left trisectionectomy involves resection of the left liver together with the right anterior section. The term "extended hemihepatectomy" has been used as a synonym for trisectionectomy but may be used for a hemihepatectomy that extends across the mid-plane. Hence, an extended right hemihepatectomy includes the middle hepatic vein with part of

segment 4, and an extended left hemihepatectomy includes the middle hepatic vein with part of segments 5 and 8. A hemihepatectomy or trisectionectomy can be combined with resection of segment 1. While resection of a single segment is referred to as a numbered segmentectomy, more extensive resections can also be named in a similar way. A right hemihepatectomy, for example, is equivalent to resection of segments 5, 6, 7, and 8.

The total liver volume has a relatively constant relationship to the body weight. It is directly proportional to the body surface area and the ideal or standard liver volume of an individual can be estimated using published formulae such as the Urata formula. The ratio of the right or left liver to total liver volume, however, varies considerably between individuals. Hence, in major liver resections or in segmental liver transplantation such as split liver or living donor liver transplantation, preoperative estimation of segmental liver volume using computed tomography or magnetic resonance imaging volumetry is essential. When a right hepatectomy or trisectionectomy is necessary for tumor clearance in a non-cirrhotic liver and the left liver remnant is too small (<25%) on preoperative imaging, a preoperative right portal vein embolization may induce hypertrophy of the future remnant liver and improves the safety of the operation. In segmental liver transplantation, liver volumetry is important for the safety of both the donor and the recipient. In general, the type of liver graft should be chosen to ensure that ratio of the liver graft or remnant volume to the standard liver volume is >35% for the recipient and 30% for the donor. The difference in the recommended acceptable ratio in setting of living donor liver transplantation is attributed to the expected higher standard of safety in the living donor and the presence of ischemic-reperfusion injury, rejection, and presence of portal hypertension in the recipient.

ANATOMY OF HEPATIC VEINS

The anatomy of the hepatic veins of the liver is closely related to its segmental anatomy as the three major hepatic veins run in the intersectional planes between the four different sections and serve as important landmarks within the liver parenchyma for defining the boundaries between different segments. The venous blood from both the right and the left lobes of liver is collected by the branches of the three main hepatic veins (right, left, and middle), which drain into the suprahepatic part of the IVC below the diaphragm (Fig. 103.5). The

middle hepatic vein joins the left hepatic vein to form a common trunk of about 1 cm long in 85% of cases before draining into the suprahepatic IVC. Occasionally, the two veins drain separately into the IVC. The right hepatic vein joins the right side of the IVC at a level slightly below that of the common trunk of the middle and left hepatic veins. There are multiple phrenic veins from both sides of the diaphragm, which drain into the lateral edge of the IVC close to or *via* the right and left hepatic veins. The suprahepatic IVC with the roots of the three main hepatic veins and its junctions with the phrenic veins are enclosed in a thick fibrous sheath, which is a direct extension of the diaphragm. On the posterior aspect of the retrohepatic IVC at the level of the junction with the right hepatic vein, a fibrous band called the IVC ligament (Makuuchi ligament) courses between the dorsal edge of the left side of the caudate lobe and the right liver. This ligament sometimes contains a bridge of thick liver tissue in which case the retrohepatic IVC will appear to pass through a tunnel in the liver.

The right hepatic vein courses in the right intersectional plane between the right anterior and posterior sections. It is the longest vein in the liver and is single in >90% of cases. The main trunk of the right hepatic vein is formed by the convergence of an anterior trunk, which mainly drains segments 5 and 6, and a posterior trunk that chiefly drains segment 7. Over 60% of individuals have one or more right inferior hepatic veins present, which separately drain segment 6 or 7, or even the whole right posterior section directly into the IVC (Fig. 103.6). Under such circumstances, the right hepatic vein itself may be rather small.

The middle hepatic vein lies in the midplane between the right and left livers and provides venous drainage for both the right anterior section (segments 5 and 8) and the left medial section (segment 4). The main stem of the middle hepatic vein originates in three different ways: from the confluence of two equally sized branches from segments 5 and 4, as a main stem receiving multiple small branches from the same segments, and as a main stem from segments 5 and 6. The main stem invariably receives multiple branches from segments 8 and 4 as well. About 60% of the venous branches that drain segment 8 terminate in the middle hepatic vein. The middle hepatic vein provides venous drainage for ～30%, or as high as 50%, of the right liver.

The left hepatic vein arises from a transverse branch, which drains segment 2, and a sagittal branch draining segment 3. In about 10% of

cases, the segment-3 vein drains directly into the IVC; occasionally, it drains into the middle hepatic vein. The left hepatic vein runs in the plane between segments 2 and 3 and enters the left intersectional plane about 1 cm from its termination in the IVC where it may receive a venous branch from segment 4. This segment-4 hepatic vein is frequently named “umbilical vein” (simply because of its close location to the umbilical fissure), which is a misnomer easily confused with the umbilical vein in the fetus (remnant in the round ligament) or the umbilical portion of the portal vein and should be avoided. Venous branches from segment 4 may also drain predominantly into the middle hepatic vein or there may be a mixed pattern.

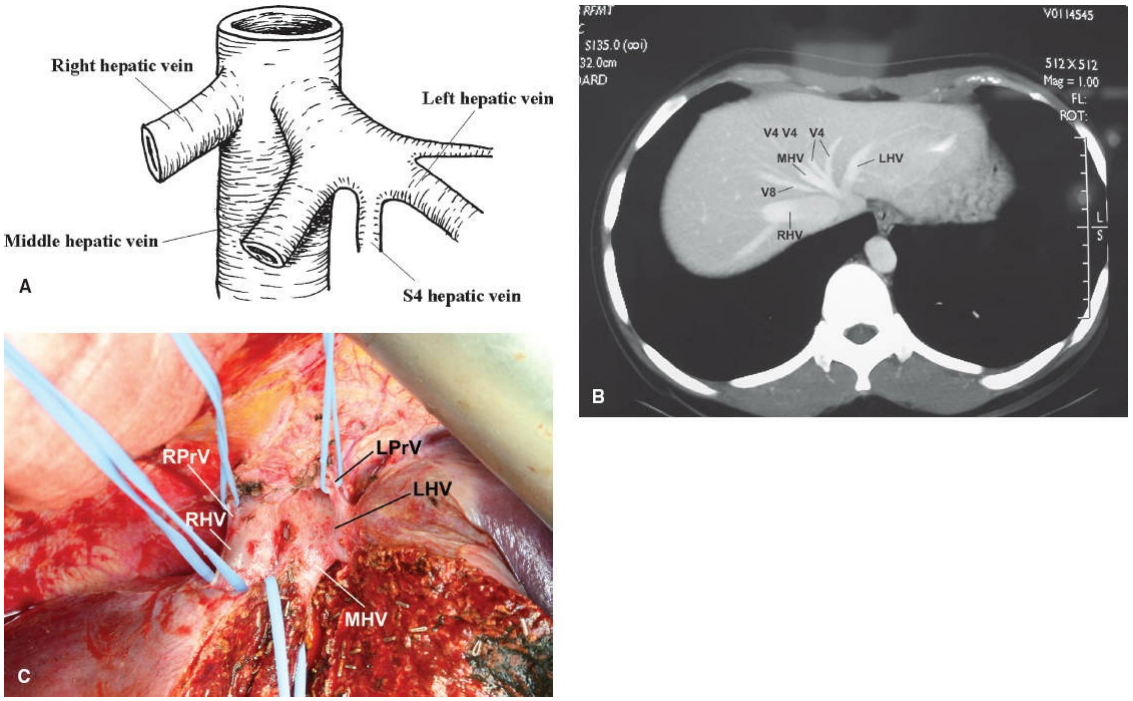

Figure 103.5. **A:** Schematic drawing of the anatomy of the three major hepatic veins. **B:** Contrast CT scan showing the anatomy of the three hepatic veins. **C:** Operative photo during an extended right hepatectomy showing the junction of the three major hepatic veins with the inferior vena cava. RHV, right hepatic vein; MHV, middle hepatic vein; LHV, left hepatic vein; V4, segment 4 vein; V8, segment 8 vein; RPrV, right phrenic vein; LPrV, left phrenic vein.

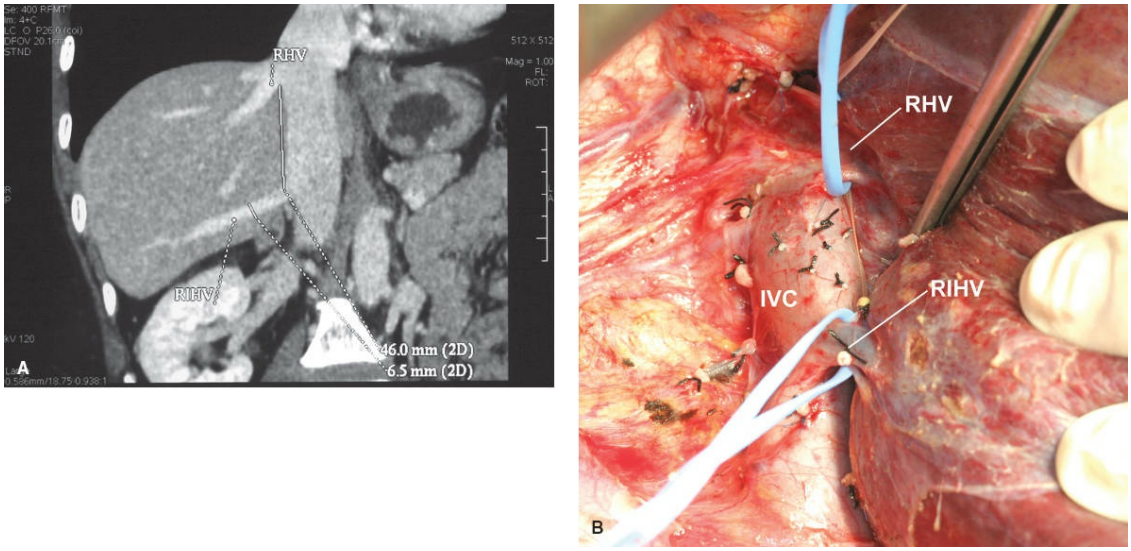

Figure 103.6. **A:** Three-dimensional reconstruction of CT scan showing a large right inferior hepatic vein (RIHV). **B:** Operative photo in a right hepatectomy demonstrating isolation of the right hepatic vein (RHV) and RIHV. IVC, inferior vena cava.

In the Operating Room

Unlike portal vein branches, which are covered by an extension of the Glissonian sheath, hepatic veins have a thin wall with no capsular covering and are hence a common source of major bleeding during liver surgery. Bleeding from hepatic veins is largely related to the central venous pressure and cannot be effectively controlled by inflow occlusion. Many surgeons regard hepatic veins as a source of trouble and try to deviate away from it during liver transection. Without any anatomical landmark, these surgeons can frequently get lost within the core of the liver parenchyma with the possibility of encountering multiple vascular and biliary branches. In practice, hepatic veins serve as landmarks for intersectional planes within the liver parenchyma to guide true anatomical resections. By identifying and following the course of the main stem of the middle hepatic vein in right hepatectomy (Fig. 103.7), for example, the surgeon would have a guide to a precise and relatively avascular transection plane for bisecting the liver. By taking the segment-5 and segment-8 hepatic vein branches at their junction with the main stem of the middle hepatic vein, the number of venous branches encountered and the amount of bleeding can be minimized. It is important to note that the right liver is, in fact, anatomically right posterior and the left liver left anterior, and the mid-plane is slanting in a right anterior to left posterior direction.

Identification of anatomical variations in the hepatic venous drainage is

crucial in the planning of modern liver surgery. The presence of a large right inferior hepatic vein, for example, allows segmental resection of segments 7 and 8 with resection of the right hepatic vein and preservation of the venous drainage for segments 5 and 6. With the advent of right-lobe living donor liver transplantation, the middle hepatic vein controversy has emerged and has led to a better understanding of the branches of this vein and its relative role in the venous drainage for segments 4, 5, and 8. If the right liver has large venous branches from segments 5 and 8 that drain into the middle hepatic vein and the right liver graft without the middle hepatic vein is used, the venous tributaries of segments 5 and 8 will have to be preserved and reconstructed in order to avoid venous congestion in the liver graft. Similarly, when the middle hepatic vein is taken with a right liver graft, branches that drain segment 4 into the root of the middle hepatic vein will need to be preserved for the donor's safety. A segment-3 hepatic vein that drains directly into the middle hepatic vein poses a special risk as its injury will result in severe congestion in the donor's liver remnant.

The fibrous extension from the crus of diaphragm encloses the suprahepatic IVC with the roots of the three main hepatic veins. Thorough division and clearance of this sheath allows these veins to be exposed. Dissection and division of the phrenic veins on either side would enhance the mobilization further and allow an extra length of hepatic vein to be isolated. The extrahepatic portion of the right hepatic vein is anatomically separate from the middle and left hepatic veins and can be easily isolated. In a classic right hepatectomy this is usually done after mobilization of the right liver with division of venous branches between the caudate lobe and IVC and the IVC ligament. On the left side, approach to the root of the left hepatic vein is facilitated by division of the ligamentum venosum as it attaches to the junction between the left hepatic vein and the IVC. However, since the middle and left hepatic veins form a common trunk before drainage into the IVC, extrahepatic isolation of the left or middle hepatic vein individually may not be possible (Fig. 103.8). Hence, isolation and division of the left or middle hepatic vein in a left lateral sectionectomy and extended right hepatectomy, respectively, will have to be done intrahepatically at the end the liver parenchymal dissection.

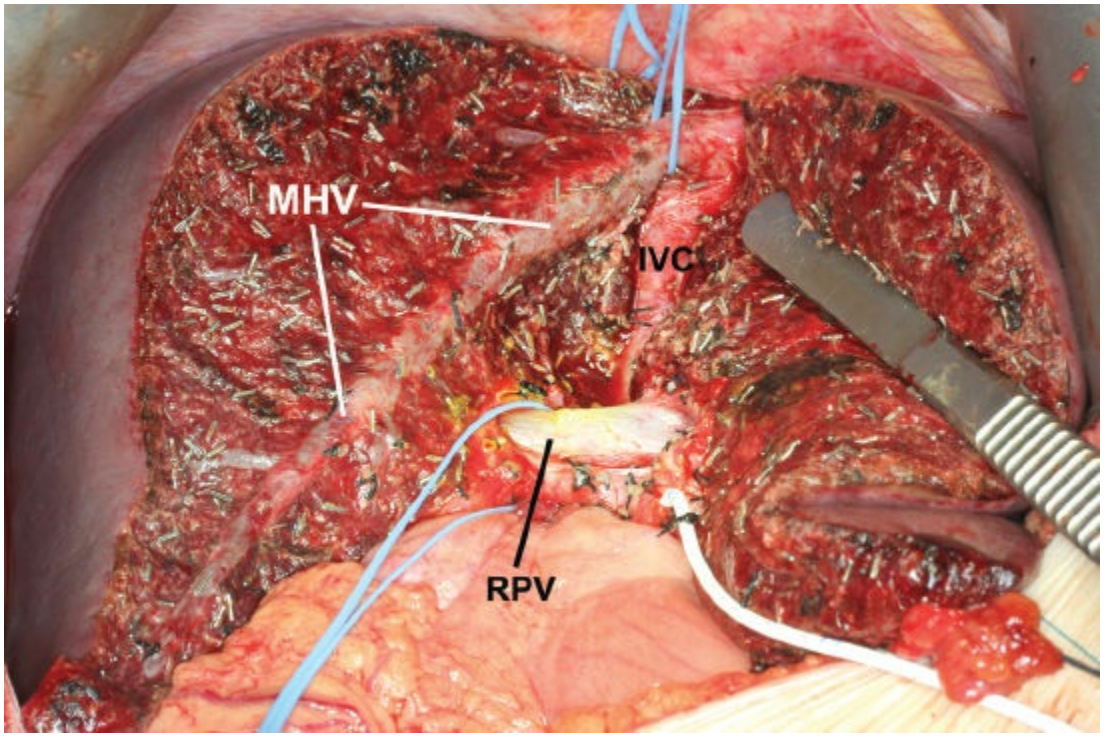

Figure 103.7. Operative photo in a living donor right hepatectomy including the middle hepatic vein showing the mid-plane of the liver following the full course of the middle hepatic vein (MHV). Note the slanting plane of parenchymal transaction. IVC, inferior vena cava; RPV, right portal vein.

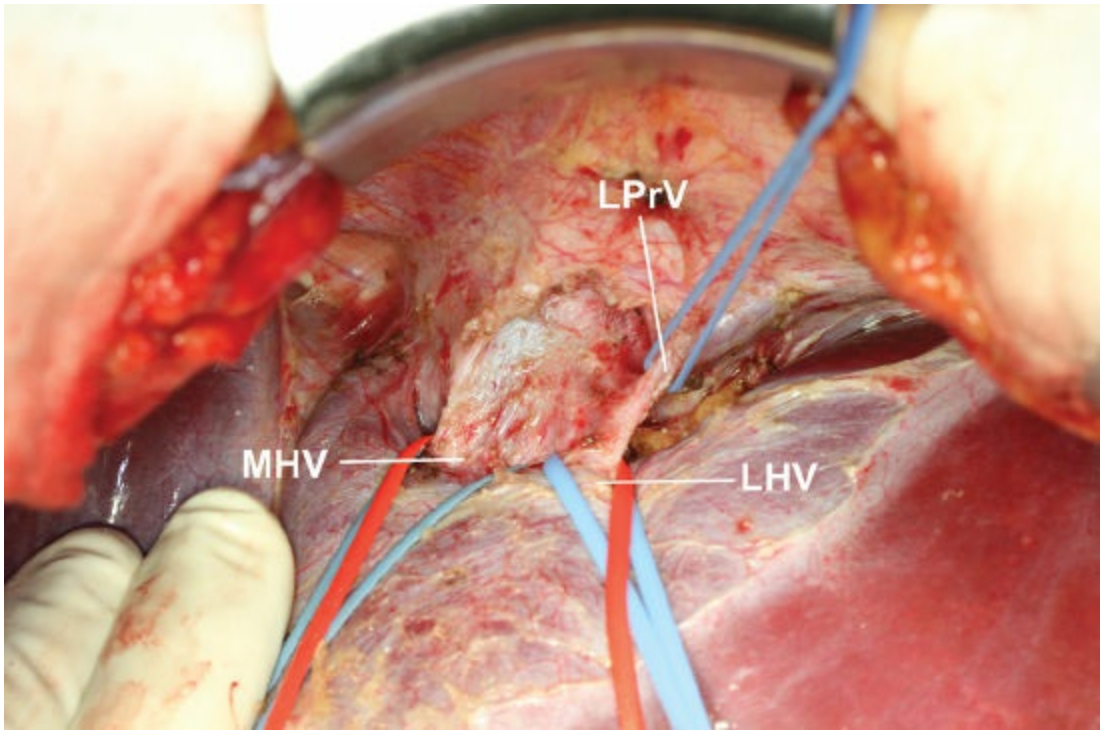

Figure 103.8. Operative photo showing extrahepatic isolation of the left and middle hepatic veins together with their common

trunk. Division of the left phrenic vein allows an extra length of the left hepatic vein to be isolated. MHV, middle hepatic vein; LHV, left hepatic vein; LPrV, left phrenic vein.

ANATOMY OF THE HEPATIC HILUM

The Plate System

The plate system consists of a fibrous sheath that is continuous with Glisson's capsule and extends intrahepatically into the liver and extrahepatically into the hepatoduodenal ligament to surround the branches of the hepatic artery, portal vein, and bile ducts. The combined structure consisting of a fibrous sheath surrounding a hepatic artery, a portal vein, and a bile duct is called a portal pedicle. Within the sheath, there are also lymphatics, nerves, and a small vascular network. The bile duct and hepatic artery are bound together closely while the portal vein is covered with a separate sheath of loose connective tissue. This segmental arrangement of bile duct, hepatic artery, and portal vein in a pedicle is very consistent within the liver, and most of the anatomical variations of the inflow blood vessels and bile ducts occur in the hepatic hilar plate system. There are three plate systems at the liver hilum: the hilar plate, the cystic plate, and the umbilical plate (Fig. 103.9).

The hilar plate is bounded superiorly by segment 4, on the right by the cystic plate, and is continuous with the umbilical plate on its left. The cystic plate is located within the gallbladder fossa and is continuous with Glisson's capsule of the segments 4 and 5. The cystic plate marks the mid-plane of the liver (the Cantle line) in the hilar area and its posterior edge is located on the right side of a right portal vein branch. The umbilical plate is located along the ventral surface of the umbilical fissure. It contains the bile ducts and blood vessels of the left liver and is continuous with the round ligament inferiorly. The upper margin of the umbilical plate is bounded by the superior border of the round ligament.

The lymphatics of Glisson's sheath course through the whole plate system of the hilar area. There is a particularly thick layer of connective tissue between the capsule of segment 4 and the portal vein, containing numerous lymph vessels. The bile duct confluence is located on the hilar plate. It is therefore common that hilar bile duct carcinoma spreads to the plate tissue. On the right side of the hilar plate, the right hepatic artery courses between the cystic plate and hilar plate, while branches of the right portal vein travel posteriorly to the artery before entering Glisson's sheath.

On the left side of the hilar plate, the middle hepatic artery and left hepatic artery course through the umbilical plate, and the left portal vein lies posterior to the artery.

In the Operating Room

The consistent arrangement of bile duct, hepatic artery, and portal vein in a portal pedicle makes it ideal to perform pedicle isolation rather than isolation of individual vessels and bile duct for true anatomical sectional or segmental resection. This is possible on the right side as the right portal pedicle divides into a right anterior portal pedicle and a right posterior portal pedicle supplying the respective sections and then into segmental pedicles supplying the four segments. Hence, in performing right hepatectomy, isolation and division of the right portal pedicle can be performed by lowering the hilar plate and going around the pedicle on its surface. Portal isolation and division can also be performed for right anterior or posterior sectionectomy. The cystic plate narrows at its junction with the hilar plate where it is attached to the sheath of the right portal pedicle. This forms an anatomical landmark for surgical exposure of the right anterior pedicle. On the left side, however, pedicle isolation is not feasible for left hepatectomy or anatomical sectional resection because there is no sheathed portal pedicle for the left liver or its medial and lateral sections.

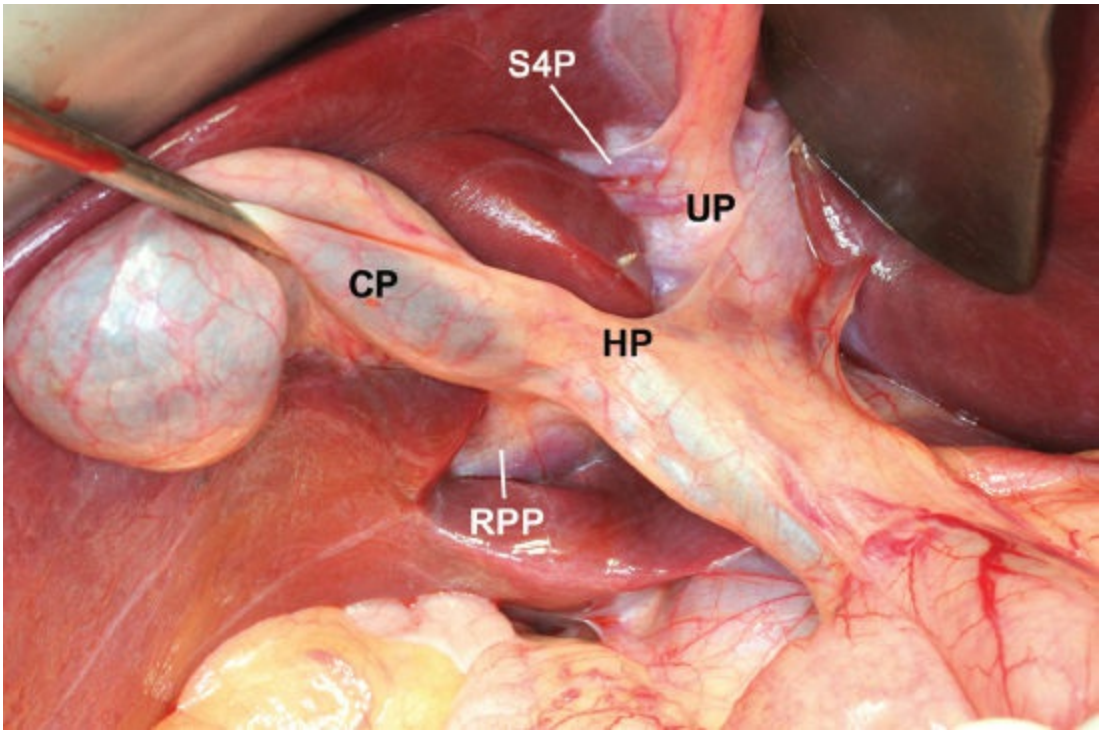

Figure 103.9. Surface anatomy of the plate system showing the cystic plate (CP) covered by the gallbladder, the hilar plate (HP), and the umbilical plate (UP). S4P, segment 4 pedicle; RPP, right posterior pedicle.

The connective tissue of Glisson's sheath at the hilar plate closely encloses the bile ducts while the arterial and portal branches are more loosely bound. Hence, separation of the bile duct from the hilar plate is difficult and will inevitably damage the duct itself or jeopardize its blood supply. In biliary surgery such as living donor hepatectomy where bile duct reconstruction is necessary, the hepatic duct should be isolated together with the surrounding Glissonian sheath and divided sharply with scissors in order to preserve its blood supply.

The cystic plate separates the gallbladder from the liver. However, the origin of the middle hepatic vein lies deep in the plate and there is occasionally a large branch of bile duct at this site. Hence, during cholecystectomy, dissection into the wrong plane and perforation of the plate may result in torrential bleeding and bile leakage.

Portal Vein

The main portal vein divides at the liver hilum into the right and left portal veins, supplying the right and left livers, respectively. The right portal vein lies anterior to the caudate process and enters the right liver through the hilar plate, dividing into anterior and posterior branches. The right anterior portal vein runs forward in a vertical plane, and it divides into descending and ascending branches for segments 5 and 8, respectively. The right posterior portal vein curves posterolaterally in a horizontal plane, and divides to supply segments 6 and 7. The left portal vein has a much longer extrahepatic course. It has a transverse portion of 2 to 3 cm within the hilar plate, and it curves anteriorly and to the left as the umbilical portion towards the base of the umbilical fissure where it joins the round ligament anteriorly. Large branches come off both sides of the umbilical portion of the left portal vein, with multiple branches going from the right side to segment 4 and usually one large one going from the left side to segment 2 and one large one to segment 3. It then terminates as a blind end joining the round ligament anteriorly. The caudate lobe commonly derives blood supply from both the left and right portal veins.

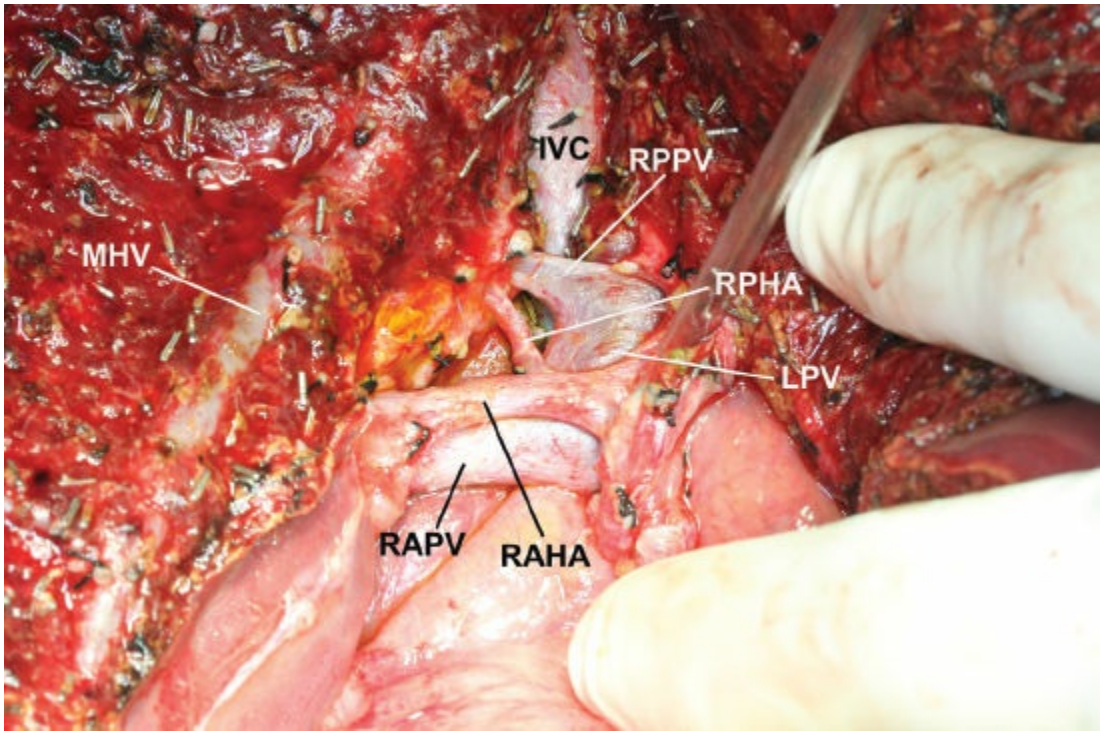

Figure 103.10. Operative photo showing separate right anterior section and right anterior section portal veins. MHV, middle hepatic vein; LPV, left hepatic vein; IVC, inferior vena cava; RAPV, right anterior portal vein; RPPV, right posterior portal vein; RAHA, right anterior hepatic artery; RPHA, right posterior hepatic artery.

The anatomy of the left portal vein is remarkably constant, whereas the right portal vein has more anatomical variations. Normal right portal vein anatomy where a right portal vein bifurcates into a right anterior vein and a right posterior vein occurs in 75% of cases. In 10% of cases, a trifurcation of the main portal vein occurs, where the right portal vein immediately divides into two sectional branches. In about 12% of cases, a right portal vein does not exist and a right posterior sectional branch coming from the left portal vein at a short distance after the main portal vein gives off a right anterior portal vein branch (Fig. 103.10). In these variants of portal vein, the transverse portion of the left portal vein is much shorter than normal. Very rarely, the left portal vein is absent and the main portal trunk is undivided as it enters the liver hilum, giving off the right sectional branches, and then turns left, crossing the umbilical fissure intrahepatically as the left portal vein. Anatomical variants of the portal vein are closely associated with those of the biliary tract in >80% of cases.

In the Operating Room

Failure to recognize portal vein anatomical variants may unintentionally create confusion or jeopardize the portal flow to a section of the liver during hilar dissection in liver surgery. In the event of a portal vein trifurcation or the right posterior portal vein branch arising from the left portal vein, an unsuspecting surgeon conducting right hepatectomy may mistake the lower sectional branch for the right portal vein, only to find the second sectional vein during parenchymal transection. For left hepatectomy, the shortness of the transverse portion of the left portal vein under such circumstances may create difficulty in its safe isolation and division. Isolation and division of branches to the caudate lobe (segment 1) is the key to allow adequate length for the procedure. When the extrahepatic left portal vein is absent, a catastrophic complication may happen during right hepatectomy as the main portal vein may be mistaken for the right portal vein as it enters the liver in a position similar to the right portal vein. The need to preserve blood supply to both sides of the liver in living donor hepatectomy has driven the refinement of preoperative radiological imaging with CT or MR angiogram and 3-D reconstruction, and anatomical vascular variants should now be clearly defined by preoperative imaging and the operation planned accordingly.

The entirely extrahepatic course of the left portal vein in the umbilical fissure and the long left hepatic duct provide an excellent option for liver surgeon contemplating resection of a centrally located liver tumor or bile duct cancer with a right trisectionectomy. The portal vein and hepatic artery branches to segment 4 can be isolated in the umbilical fissure outside the liver capsule on the right of the umbilical portion of the portal vein, thus, providing adequate tumor-free margin even for tumors that appear to compress on the left portal vein on imaging. The left hepatic duct can be divided as much towards the left side as possible even before the junction of the ducts from segments 2 and 3. As a result of the oblique course of the main trunk of the left hepatic vein running between segments 2 and 3 as described in the previous section, the resection can even be extended into the left lateral section on the left side of the falciform ligament cranial to the umbilical fissure.

Hepatic Artery

In normal anatomy, the common hepatic artery, a branch of the celiac trunk, supplies the right and left livers through its right and left hepatic branches, respectively. The common hepatic artery runs on the left side of

the main portal vein in the hepatoduodenal ligament and may divide into right and left branches anywhere between its origin and the hilum of the liver. The division usually takes place to the left of the hilum, resulting in a longer right hepatic artery. The left hepatic artery courses along the left side of the hilar plate with the left hepatic duct and the left portal vein for a varying distance before entering the liver at the level of the umbilical fissure. The right hepatic artery courses laterally to the right, posterior to the common hepatic duct and right hepatic duct but anterior to the portal vein. It gives off the cystic artery and eventually divides into the anterior and posterior sectional arteries before entering the liver parenchyma. The cystic artery crosses the common hepatic duct posteriorly or anteriorly. As it runs towards the gallbladder, it courses through the hepatocystic triangle (Calot's triangle), which is bounded by the common hepatic duct on the left, the cystic duct on the right, and the inferior surface of segment 4 above. The cystic artery runs to the upper border of the gallbladder superior to the site of the cystic duct and divides into an anterior and a posterior branch that ramify on the gallbladder surface.

Anatomical variants of the extrahepatic artery are common and only ~55% of population has a normal anatomy. A variant can be a replaced artery that serves as the only arterial blood supply for a particular part of the liver while the artery in normal location does not exist, or an accessory one that provides dual supply for a volume in conjunction with the normal artery. It may supply a segment, section, hemiliver, or even the whole liver. The commonest arterial variant is a replaced left hepatic artery that arises from the left gastric artery and courses in the lesser omentum to enter the liver at the umbilical fissure. It is found in 25% of cases. A replaced right hepatic artery originates from the superior mesenteric artery and runs behind the portal vein and the lower end of the common bile duct to continue on the right border. It is present in about 17% of cases. More rarely, the common hepatic artery arises wholly from the superior mesenteric artery in 2.5% of cases, and occasionally it arises from the left gastric artery or the aorta. In about 75% of population, there is a normal anatomical relationship between the right hepatic artery and the common hepatic duct, that is, the hepatic artery courses posterior to the bile duct. However, the right hepatic artery may run an aberrant course anterior to the bile duct or even posterior to the portal vein. The cystic artery may arise from the right hepatic artery on the left side of the common hepatic duct and may run anterior to it. It may also arise from an aberrant right

hepatic artery.

The middle hepatic artery is defined as an extrahepatic arterial branch that originates from the liver hilum and enters the umbilical fissure to supply segment 4 and occasionally part of segment 2 or 3 (Fig. 103.11). It exists in about 70% of population, and in the remaining 30%, this hilar vessel does not exist and the arterial supply for segment 4 comes from the left hepatic artery within the umbilical fissure. The middle hepatic artery originates from the right hepatic artery (44%) or, less commonly, the left hepatic artery (26%) when the hepatic arterial anatomy is normal. In the presence of a replaced right or left hepatic artery, the middle hepatic artery always originates from the contralateral hepatic artery in normal anatomic position, which also gives off the gastroduodenal artery. The anatomic variations in the extrahepatic arteries can be explained by their embryology. Embryologically, the liver is supplied by three hepatic arteries: the embryonic left hepatic artery from the left gastric artery, the embryonic middle hepatic from the common hepatic artery, and the embryonic right hepatic artery from the superior mesenteric artery. The replaced left hepatic and right hepatic arteries are the descendant of the embryonic left hepatic artery and right hepatic artery, respectively. The middle hepatic artery is derived from the embryonic middle hepatic artery.

In the Operating Room

Surgeons must be aware of the various anatomical variants of the hepatic artery. Although an artery located on the right side of the bile duct always supplies the right liver, arteries found on the left side may supply either side of the liver. Hence, it is safer not to make assumption on any artery based on its size, position, or direction. Adequate exposure and, if necessary, trial occlusion with confirmation by radiological means (intraoperative Doppler ultrasound) are necessary before any artery at the liver hilum is ligated and divided.

Replaced arteries may confer an advantage or disadvantage during surgery. In the presence of a replaced left hepatic artery that supplies the left liver, right hepatectomy for hilar cholangiocarcinoma can be performed with radical resection of the hepatoduodenal ligament by resecting the entire proper hepatic artery with only the portal vein preserved. The artery of a left lateral section liver graft from a living donor can also be taken to include the left gastric artery at its junction with the celiac axis in order to facilitate arterial reconstruction in the recipient. On the other hand, such a replaced left hepatic artery may be at risk when the

lesser omentum is divided as in a gastric operation. Similarly, a replaced right hepatic artery coursing along the right side of the common bile duct may also be damaged as the bile duct is isolated and divided in operation such as hepaticojejunostomy or Whipple operation.

When more than one artery is encountered in a partial liver graft from a living donor, the arterial reconstruction presents a technical challenge. In general, most of these are end arteries and have to be reconstructed. However, some of these are accessory and may communicate with the main artery through collaterals that may not be visible on preoperative angiography. To determine whether a smaller arterial branch to a partial graft needs reconstruction, the degree of back-bleeding from the stump of the branch can be examined at the completion of a donor hepatectomy or after reconstructing the larger arterial branch in the recipient.

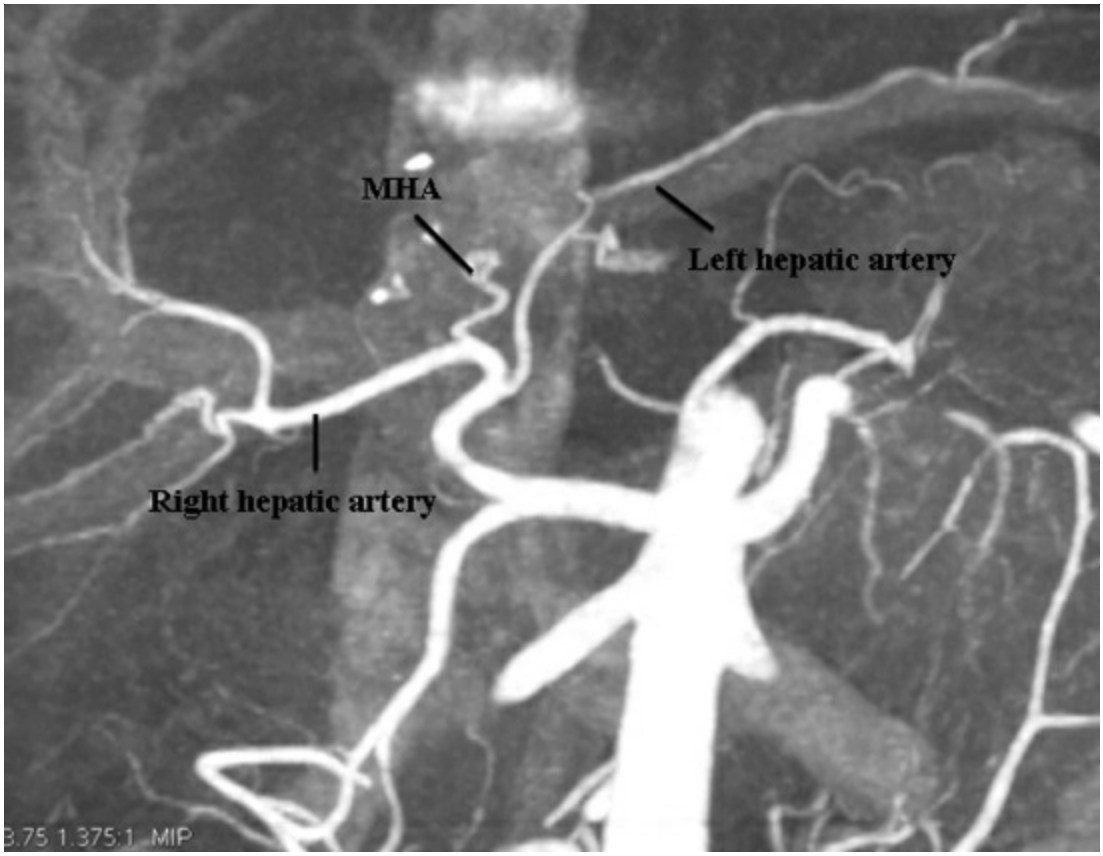

Figure 103.11. CT angiogram showing the middle hepatic artery (MHA) arising from the right hepatic artery.

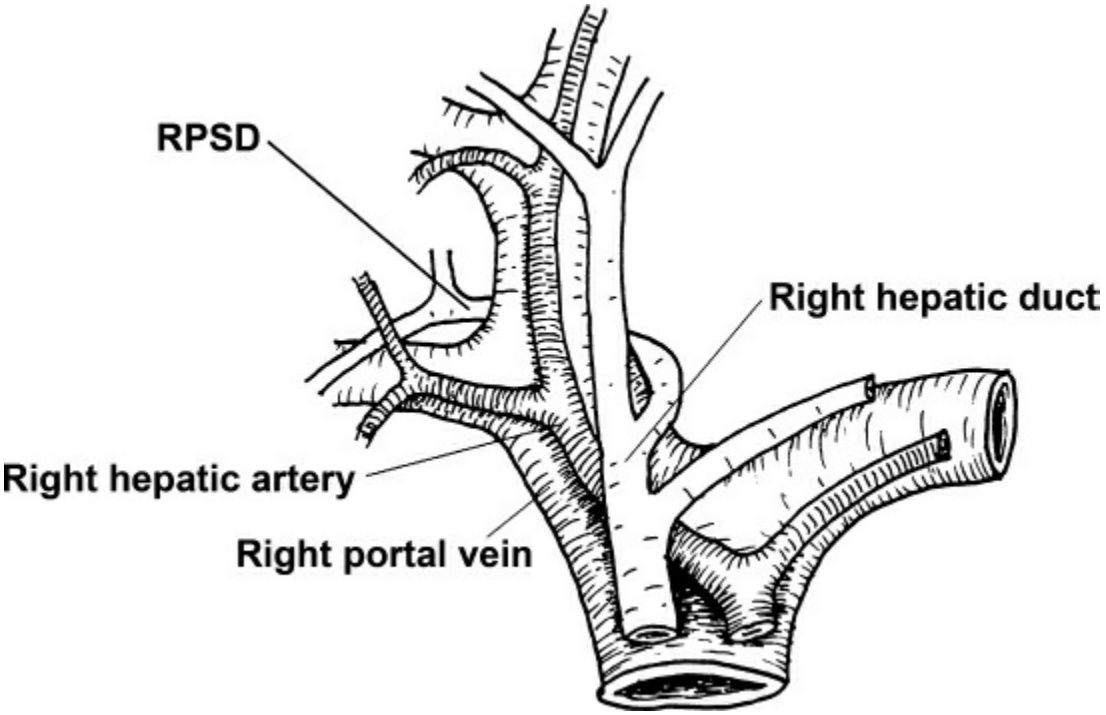

Figure 103.12. Schematic diagram showing the right posterior sectional duct (RPSD) that run superior to the right anterior portal vein (epiportal) to join the right hepatic duct.

During cholecystectomy, the cystic artery is usually identified as it runs in the Calot's triangle towards the gallbladder. Elevation of the undersurface of the liver together with lateral retraction of the neck of the gallbladder allows better exposure for clearance of this triangle and safe identification of cystic structures. Depending on the site of branching of the cystic artery and the point of dissection, a single cystic artery or its anterior and posterior branches may be encountered and divided separately. Occasionally, the right hepatic artery runs an unusually tortuous course low in the Calot's triangle and the cystic artery is very short. Inadvertent injury of the right hepatic artery may occur unless the dissection is kept close to the surface of the gallbladder.

Bile Ducts and Gallbladder

The normal biliary anatomy exits in only about 50% of population. The right hepatic duct, which has a short extrahepatic course of only about 1 cm, is formed by the confluence of the right anterior and right posterior sectional ducts at a variable point in its intrahepatic course. The right anterior sectional duct drains segments 5 and 8. It lies vertically and is located to the left of the right anterior portal vein. The right posterior

sectional duct drains segments 6 and 7. It courses horizontally and usually runs superior to the right anterior portal vein (epiportal) to join the right anterior duct, forming the right hepatic duct above the right portal vein (Fig. 103.12). In about 20% of cases, the right hepatic duct runs inferior (hypoportal) to the right anterior portal vein. In rare situations, there is a combined pattern in which some branches of the right posterior sectional duct enter the distal bile duct supraportally and the remaining branches infraportally. In the left liver, segment-2 and -3 segmental ducts fuse to form the left lateral section duct, which then unites with one or more branches from segment 4 to form the left duct. The left duct runs horizontally from left to right for a distance of 2 to 3 cm along the base of segment 4, first above and then behind the left portal vein, until it joins the right duct to form the common hepatic duct.

The right hepatic duct is frequently absent and a common biliary anatomical variant in the right liver involves a sectional or segmental bile duct joining the left hepatic duct to form a triple confluence (Fig. 103.13). On the other hand, a sectional or segmental duct (Fig. 103.14) may join the common hepatic duct well below the normal confluence. The cystic duct may drain into such an aberrant right duct before draining into the common hepatic duct. The left hepatic duct has a more consistent anatomy, and its major variation involves the site of insertion of the segment-4 duct into the left lateral section duct forming the left hepatic duct, which may vary from its origin at the umbilical fissure to its termination at the confluence with the right hepatic duct. Occasionally, there are multiple ducts draining segment 4 into the left duct, or the segment-4 duct may join the segment-3 duct before uniting with the segment-2 duct.

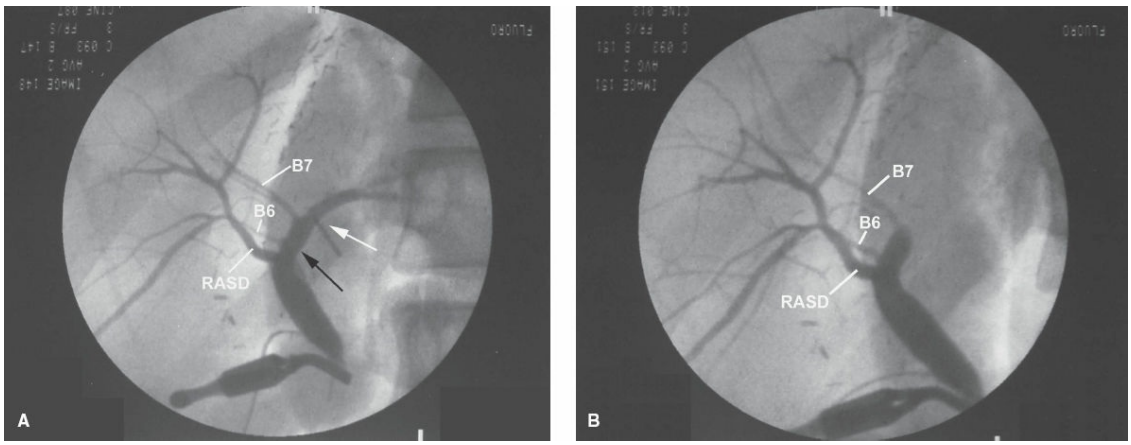

Figure 103.13. A: Operative cholangiogram during a left

hepatectomy showing a separate segment 6 duct (B6) and segment 7 duct (B7) draining into the left hepatic duct. A radiopaque marker showed the correct site of left duct transaction (*white arrow*). Transection too close to the biliary confluence (*black arrow*) would have damaged these right posterior sectional ducts. **B:** Postresection cholangiogram. RASD, right anterior section duct.

The gallbladder sits on the cystic plate on the inferior surface of the liver at its midplane. Its relation to the liver ranges from hanging from a loose peritoneal reflection to being deeply embedded within the liver parenchyma. Large gallstones impacting within the neck of the gallbladder may create a Hartmann's pouch before it narrows towards the cystic duct, which is normally about 1 to 2 cm long and contains the spiral valves. The cystic duct joins the common hepatic duct to form the common bile duct at a variable site ranging from the right hepatic duct to the ampullary region. The configuration of the cystic duct with the common hepatic duct follows three patterns. In the majority, the cystic duct joins the common hepatic duct at an acute angle (75%). In others, the cystic duct runs parallel to the right side of the common hepatic duct for a distance (20%) or spirals posterior to the common hepatic duct before entering on its left side (5%). The common bile duct runs downwards at the right lateral edge of the hepatoduodenal ligament, with the common hepatic artery on its left and the main portal vein at its back. It passes posterior to the first part of the duodenum and crosses behind the pyloric vessels and the pancreaticoduodenal arteries. Then it continues behind or in the posterior part of the head of pancreas, forming its retropancreatic portion before passing through the Sphincter of Oddi to enter the second part of the duodenum at the major papilla. The major papilla protrudes into the duodenal lumen at ~8 cm from the pylorus. The pancreatic duct forms a common channel with the common bile duct in 85% of cases, but occasionally the two ducts enter the duodenum separately.

The intrahepatic bile ducts receive blood supply only from the hepatic artery. The right and left ducts and their confluence have a rich arterial plexus on the liver hilum surface (hilar plexus) with a communicating arcade between the right and the left arterial systems located within the hilar plate. This epicholedochal plexus extends inferiorly to cover the entire common bile duct with two main longitudinal branches running at the 3 o'clock and 9 o'clock positions to anastomose with the arteries

coming from below. The supraduodenal bile duct receives an average of eight small arterial branches from the retroduodenal artery, gastroduodenal artery, and right hepatic artery. The veins draining the bile duct are parallel to the corresponding arteries on the surface of the bile duct.

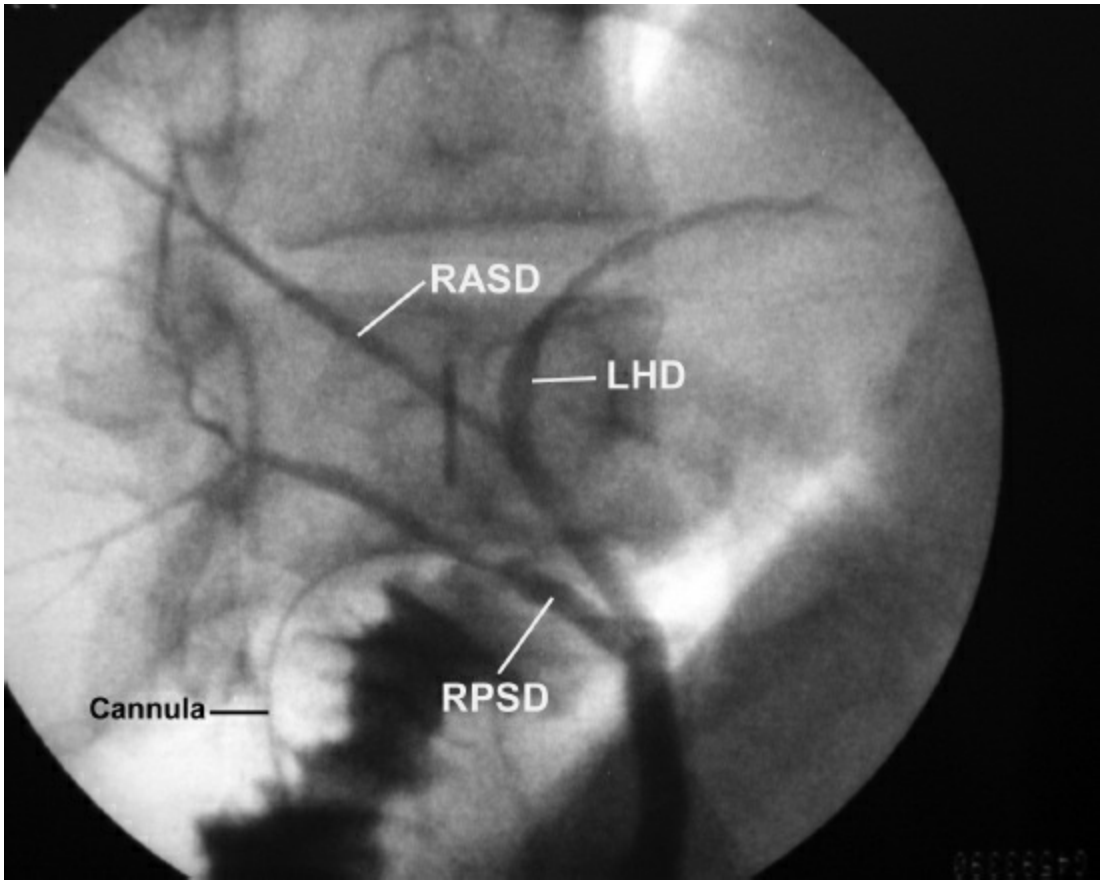

Figure 103.14. Operative cholangiogram showing a right posterior sectional duct (RPSD) draining directly into the common hepatic duct at a low level. The cystic duct drains into this aberrant duct. RASD, right anterior sectional duct; LHD, left hepatic duct.

The lymphatic drainage of bile ducts diverges into two pathways. The superior pathway involves lymph nodes along the cystic duct, hepatic artery, and celiac plexus, whereas the inferior pathway involves the nodes along the cystic duct, the anterolateral aspect of the portal vein, the posterior pancreas, and the aortocaval region.

In the Operating Room

During cholecystectomy, several anatomical variants may predispose to biliary complications. The parallel configuration of the confluence of the cystic duct and the common hepatic duct may predispose the common

hepatic duct to injury at the side, particularly if dissection is performed with diathermy. Tiny bile ducts (ducts of Luschka) may enter the gallbladder through the cystic plate and may be divided. A right hepatic sectional duct, which joins the common hepatic duct at a low level may be mistaken for the cystic duct and be injured. The risk is even higher if the cystic duct actually drains into this aberrant duct (Fig. 103.14). To avoid this complication, it is important to avoid excessive use of powerful hemostatic devices to dissect the gallbladder and the bile duct. Before a tubular structure thought to be the cystic duct is divided, its anatomy should be carefully delineated by dissection towards the infundibulum so as to ensure that the structure does end in the gallbladder.

Biliary complication is a common and serious morbidity after liver surgery and liver transplantation. Knowledge of the biliary anatomy can be obtained by preoperative magnetic resonance cholangiography, but an intraoperative cholangiogram preferably with radiopaque markers provides more detailed information and better localization. Since the right liver is anatomically right posterior and the left liver left anterior, the mid-plane is slanting from right anterior to left posterior and the best direction for a cholangiogram is a right anterior oblique view (Fig. 103.15). Intraoperative cholangiography should therefore be performed under fluoroscopy. When the anteroposterior view is rotated to a right anterior oblique view, the branches of the right anterior section duct will move medially while those of the right posterior section duct will move laterally, and the true length of the right and left hepatic ducts will be more clearly delineated. When an anatomical variant of a right sectional duct draining independently into the left hepatic duct is found during left hepatectomy (Fig. 103.13), the left hepatic duct will have to be divided closer to the umbilical fissure to avoid damage to this right sectional duct. In living donor hepatectomy operation, a highly precise transection point of the hepatic duct indicated with the help of a radiopaque marker is critical for safeguarding the donor’s remnant biliary tree and avoiding biliary complication in the recipient.

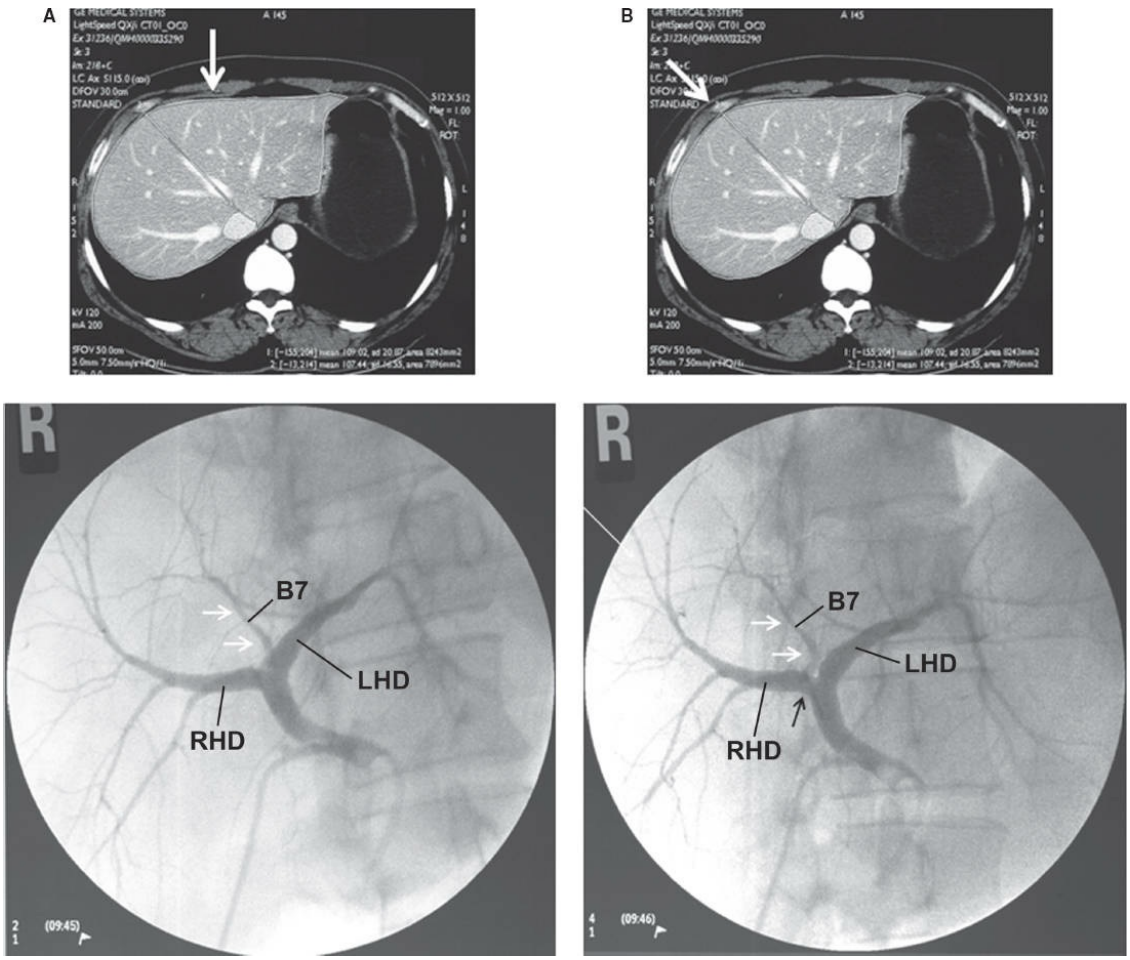

Figure 103.15. A: Operative cholangiogram in an anteroposterior view showing a segment 7 duct (B7, *white arrows*) apparently draining into the left hepatic duct (LHD) in a right liver donor. **B:** The right anterior oblique view showed that B7 actually joins the right hepatic duct (RHD). Transection of the RHD should be made precisely at the site of the *black arrow.*

The axial pattern of the arterial blood supply from both ends of the extrahepatic bile duct implies that there is an arterial watershed and transection of the duct at a different level may result in ischemia of either side of the cut ends. To ensure a healthy bile duct stump, in operations involving the upper end (as in hepaticojejunostomy or a whole liver graft), the bile duct should be divided above the cystic duct junction close to the confluence of the right and left ducts. In operations related to the distal end (as in liver transplant recipients), the level of division should not be extended too much to the hilum and care should be taken to preserve the soft tissue covering the epicholedochal plexus around the duct. As a result of the presence of the hilar plexus around the confluence of the right and left ducts, occlusion of either the right or left hepatic artery will not affect

the blood supply of the bile duct.

ANATOMY OF CAUDATE LOBE

As described previously, the caudate lobe or segment 1 is anatomically and functionally distinct from the right and left hemilivers. It is located behind the liver hilum and in front of the retrohepatic IVC. While the caudate lobe proper, or Spigelian lobe, protrudes visibly from the left side of the IVC, its anterior border fuses indistinctly with segment 4 and its right border with segments 6 and 7. The caudate lobe is the only hepatic segment that does not drain into one of the main hepatic veins. There are one or two large short hepatic veins and numerous small ones that drain directly into the retrohepatic IVC, usually at its left anterior side. An average of three short portal branches from the right, left, or main portal vein close to the bifurcation supply the caudate lobe (Fig. 103.16). There are a similar number of arterial branches directly coming from the right and left hepatic arteries along their courses. Bile drains through a variable number of ducts into the left hepatic duct, right hepatic duct, or both. The segment-1 ducts run above the portal branch and join the corresponding bile duct on its posterior aspect close to the biliary confluence.

In the Operating Room

In difficult right hepatectomy, mobilization of the right lobe of the liver and isolation of the caudate and right hepatic veins may be performed after liver transection is completed (the anterior approach). In order to facilitate and guide the transection, a clamp may be passed to draw a tape along the anterior surface of the IVC between the right and the middle hepatic veins to suspend the posterior surface of the caudate. In making this hanging maneuver, it is important to avoid the large caudate veins, which are usually on the left lateral side of the IVC. In pathological conditions such as Budd–Chiari syndrome, the independent venous drainage of the caudate lobe allows its continued decompression and the increased perfusion results in compensatory hypertrophy. Since the caudate bile ducts join the right or left duct close to the hilar confluence, curative resection of hilar bile duct carcinoma should always involve resection of the caudate lobe.

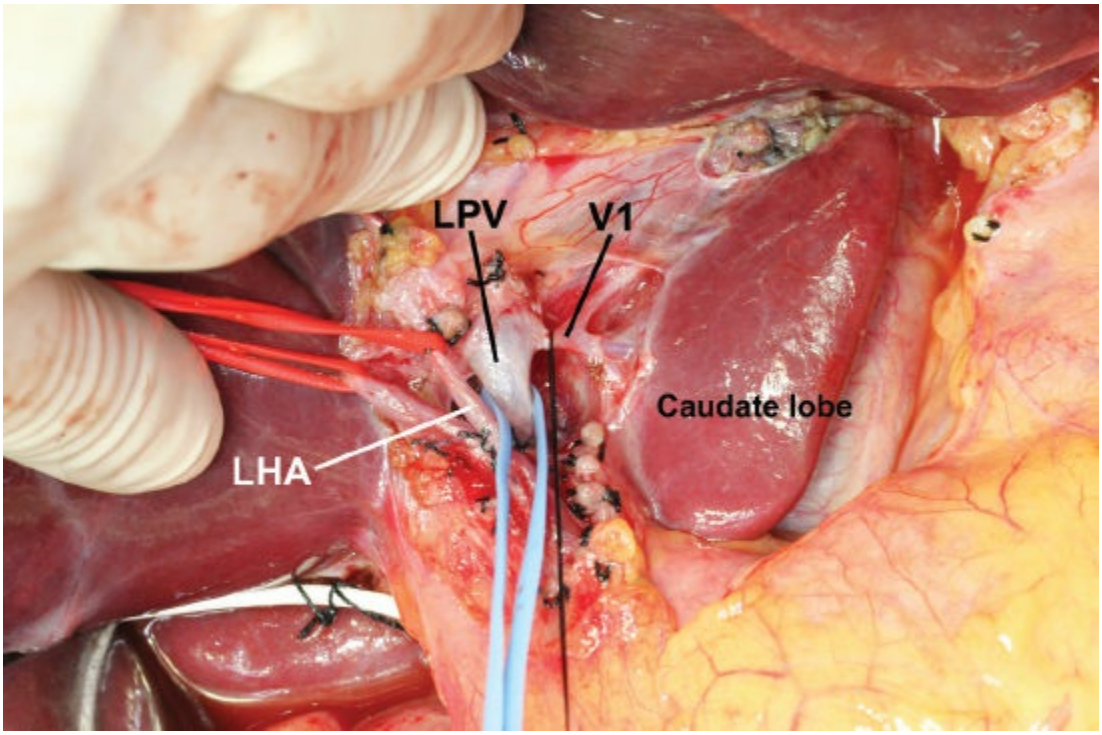

Figure 103.16. Operative photo showing a branch (V1) from the left portal vein (LPV) supplying the caudate lobe. LHA, left hepatic artery.

Suggested Readings

Castaing D. Surgical anatomy of the biliary tract. *HPB* 2008;10:72–76.

Chan SC, Lo CM, Liu CL, et al. Tailoring donor hepatectomy per segment 4 venous drainage in right lobe live donor liver transplantation. *Liver Transpl* 2004;10:755–62.

Ikegami T, Soejima Y, Taketomi A, et al. Hilar anatomical variations in living-donor liver transplantation using right-lobe grafts. *Dig Surg* 2008;25:117.

Imamura H, Makuuchi M, Sakamoto Y, et al. Anatomical keys and pitfalls in living donor liver transplantation. *J Hepatobiliary Pancreat Surg* 2000;7:380.

Kawarada Y, Das BC, Taoka H. Anatomy of the hepatic hilar area: the plate system. *J Hepatobiliary Pancreat Surg* 2000;7:580–6.

Nakamura S, Tsuzuki T. Surgical anatomy of the hepatic veins and the inferior vena cava. *Surg Gyneco Obstet* 1981;152:43–50.

Ohkubo M, Nagino M, Kamiya J, et al. Surgical anatomy of the bile ducts at the hepatic hilum as applied to living donor liver transplantation. *Ann Surg* 2004;239:82–6.

Skandalakis JE, Skandalakis LJ, Skandalakis PN, et al. Hepatic surgical anatomy. *Surg Clin North Am* 2004;84:413–35.

Strasberg SM. Terminology of liver anatomy and liver resections: coming to grips with hepatic Babel. *J Am Coll Surg* 1997;184:413–34.

Strasberg SM, Belghiti J, Clavien PA, et al. Terminology Committee of the International Hepato-Pancreato-Biliary Association: Chairman. The Brisbane 2000 terminology of liver anatomy and resections. *HPB* 2000;2:333–9.

EDITOR'S COMMENT

One of the real pleasures of editing the 6th edition of *Mastery of Surgery* is to come across chapters written by surgeons who have obviously "been there." This is one of them, and this and several other chapters have inspired me to undertake a book on anatomy specifically related to surgeons. In other words, while anatomy can be cut and dried, certain types of anatomy such as this chapter and a number of others clearly indicate that it is not the dry anatomy of the dissecting room (which unfortunately no longer exists in most "improved" U.S. medical schools) but are of great help in the operating room. I do not recall a valid book of anatomy as a help for surgeons that has been published since 1933 in Germany. That 2-volume set was the property of my late father-in-law, Dr. Howard Down, a 1932 product of the Mayo Clinic program and a very busy clinical surgeon who served as a governor of the college and the president of the Iowa Surgical Society.

This chapter is very helpful for the surgeon undertaking a liver resection and probably is even of value to a very experienced surgeon in liver resection. I will try and do the "pearls" justice as I review the chapter and my own views on the points that Professor Lo raises.

Earlier in this chapter Professor Lo takes the course of describing the external anatomical aspects of the liver and relating them to some of the internal anatomical aspects, which will be specifically helpful to the surgeon. In describing the various ligaments to the liver, the ligamentum teres figures prominently as separating the lateral and the medial lobes of the left hepatic lobe. As he points out, there is also the obliterated left portal vein. This actually can be cannulated with Bakes dilators, which I have done on occasion to open up the left portal vein. I have done this while performing an end-to-side emergency portacaval shunt measuring pressures but was misled by the pressures of a swollen, fatty infiltrated liver. It is possible to turn an end-to-side portacaval shunt into a side-to-side shunt, thus decompressing the liver and ridding the patient of intractable ascites. One does this by getting control of the ligamentum teres, finding the obliterated umbilical vein, and with Bakes dilators or probably now with suitable balloon-tip dilators, dilate up the area where the portal vein can be entered and the fibrous band be split. At that point one can take the periumbilical area of the obliterated left portal vein and anastomose it to both long saphenous veins, which have been dissected out and turned up subcutaneously to receive the outflow of the congested liver. The patient will

diurese and properly cared for will survive.

Subsequently, in the latter part of the chapter the author tries to give hints as to how one can avoid massive bleeding by utilizing the middle hepatic vein to minimize bleeding. “By taking the segment-5 and segment-8 hepatic vein branches at their junction with the main stem of the middle hepatic vein, the number of venous branches encountered and the amount of bleeding can be minimized.” Most of us as neophyte liver resectionists viewed the hepatic vein as a nuisance and something that we get into and cause bleeding. Having said so, the junction between the middle and the left hepatic veins must be done intrahepatically; there is no way to do this external to the liver. “Since the middle and left hepatic veins form a common trunk before drainage into the superior vena cava, extrahepatic isolation of the left or middle hepatic vein individually may not be possible. Hence, isolation and division of the left or middle hepatic vein in a left lateral sectionectomy and extended right hepatectomy, respectively, will have to be done intrahepatically at the end of the liver parenchymal dissection.” In talking about the isolation of the hepatic veins, the author states, “Bleeding from hepatic veins is largely related to the central venous pressure and cannot be effectively controlled by inflow occlusion.” Since there are no valves in the connection between the hepatic veins and the vena cava, utilizing a very low venous pressure while the resection is going on can minimize bleeding. Also steep Trendelenburg may help.

Many surgeons regard hepatic veins as a source of trouble and try to deviate away from them during dissection. Here the author gives us some tips as to how to use them to our advantage. In the right hepatectomy, controlling and dividing the right portal pedicles is of great importance. As the author states, one can isolate the right portal pedicle with its division to the right anterior and right posterior portal pedicle, and then the segmental pedicles supplying the 4 segments. Probably an easier way to approach this and the isolation and division of the right portal pedicle can be performed by lowering the hilar plate and going around the pedicle on its surface. In speaking about the hilar plate, the author comments that biliary carcinoma tends to spread within the hilar plate and therefore as complete a resection of the hilar plate as can be achieved is important. Likewise, later in this chapter the author states that the taking of the caudate lobe with the right hepatectomy is absolutely essential since the hilar plate will proceed downward towards the caudate lobe and with a hanging maneuver it can be resected. Also the portal pedicles can be ligated on the way in to the plate on the right side, thus minimizing bleeding.

For left hepatectomy, Professor Lo states that freeing up and ligating the branches to the caudate lobe, that is segment 1, makes the left hepatectomy and isolation of the left portal vein much easier.

A cottage industry, which has sprung up in the United States, is the plaintiffs’ bar and its huge business of suing every surgeon who has performed a laparoscopic cholecystectomy in which a bile duct injury has occurred.

Inevitably, there is a surgeon, usually older and retired, who has not done a laparoscopic cholecystectomy for some time stating as by rote that one must clean out Calot's triangle before clipping anything. While it is true that one should have a pretty good idea by the infundibular approach of identifying the cystic artery and the cystic duct, and then dissecting free to get the critical look, the total clean out of Calot's triangle is only mentioned to be condemned. The reason for this is that the right hepatic artery, especially with covariant may reside low in Calot's triangle and if one gets in a misadventure with the right hepatic artery (massive bleeding), it does not infrequently results in a misadventure with the right hepatic duct. This has been referred to by Strassburg as a vasobiliary injury and is a disaster, and requires rapid conversion to an open procedure.

As to right hepatectomy, any vessel, as the author states, on the right side of the bile duct inevitably supplies the right liver. This is important to remember because in a right hepatectomy there may be a replaced left hepatic artery and this may occur on the right side of the bile duct. Those vessels from the left hepatic artery, which are on the right side of the bile duct inevitably perfuse some aspect of the right liver and thus can be ligated in a right hepatectomy.

Hepatic anatomy, with respect to both the hepatic artery and portal vein, is normal in only 55% of patients. The biliary anatomy occurs in only 50% of patients. This is an anatomical fact, which needs to be more completely stated because it explains why any surgeon independent of how experienced they are and how many laparoscopic cholecystectomies they have done, can fall prey to a deviation in the various biliary and arterial anatomies.

There are enormous numbers of cystic duct variations and this is well illustrated on page 1439 of the 7th edition of Schwartz's textbook in a chapter written by Dr. Seymour Schwartz. There are enormous variations in both the gallbladder as pictured on that page and in the cystic duct. What continues to amaze me as someone who believes that since the percentage of damage to the common duct, 0.5% to 0.7%, has remained stable for the past 15 years around the world, damage to the common duct cannot be practice below the standard. A good pathologic examination of what appears to be the cystic duct, namely the spiral valves of Heister, is essential. I have actually never seen in my review of cases a pathologist review whether or not there are spiral valves in the structure that appears to be the cystic duct. It would be helpful because there are an enormous number of cystic duct variations.

Now for the external portion and the anatomy of the area surrounding the liver. A good rule of thumb is that the major papilla is ~8 cm from the pylorus. After one Kocherizes the duodenum, one can usually feel the major papilla without difficulty. In doing an open (S. Austin Jones-type) sphincteroplasty, I never have to cannulate the cystic duct because I can always feel the major papilla. It also enables one to do a transverse incision and be certain that one is going to have excellent exposure of the papilla. It is worthwhile for individuals who are planning to do that kind of surgery when doing open cholecystectomies

or pancreatectomies to mobilize and Kocherize the duodenum and then see if they can feel the major papilla.

The author makes the point many times that the plane or Cantlie's line, which bisects the liver goes from the right anterior to the left posterior. Thus, if one is going to do cholangiography the right anterior oblique view is most promising. Most cholangiograms cannot be done in this fashion because of the equipment, but if one has the equipment that can do this it is well to remember this.

Finally, in the resection of the caudate lobe Professor Lo outlines the hanging maneuver. The caudate veins drain into the IVC and it is difficult without bringing the caudate lobe up and hanging it to cleanly clamp the caudate hepatic veins. The recently described hanging maneuver is of great help and a contribution into the resection of the caudate lobe, which as stated earlier should do in situation where the hilar plate has been invaded by cholangiocarcinoma or adenocarcinoma because the tumor spreads within the hilar plate and enters the caudate lobe. Not to resect the caudate lobe is to do an incomplete resection.

There is much to learn from an experienced hepatic surgeon like Professor Lo and it is beautifully described and illustrated. It is a pleasure to have this superb chapter in this edition.

J.E.F.

104 Diagnostic Considerations in Biliary and Liver Disease

Kelly M. Collins and William C. Chapman

Biliary tract and liver disease present some of the commonest surgical complaints prompting consultation to the general surgeon. The pathologies range from basic to complex as do the treatment algorithms and approaches, especially with the continual advances in biliary endoscopy and interventional radiology.

The approach to the complex hepatobiliary patient should utilize a multidisciplinary approach at centers with expertise in the following: cross-sectional imaging, endoscopy, interventional radiology, surgery, radiation, and medical oncology.

The general surgeon must have a thorough understanding of best diagnostic modalities in both benign and malignant diseases of the liver and biliary tract to aid in efficient decision making related to diagnosis, surveillance, intervention, or transfer to a center where hepatobiliary surgery expertise is available.

CLINICAL PRESENTATION

Biliary and liver disease is often asymptomatic; however, if a patient presents with symptoms, it is usually with right upper quadrant (RUQ) pain, jaundice, or both.

RUQ pain is nonspecific and will in most cases require further workup with laboratory studies and imaging. A broad differential must be considered, including: acute cholecystitis, biliary colic, cholangitis, hepatitis, pancreatitis, peptic ulcer disease (PUD), cardiac disease (angina or myocardial infarction), lung disease (pneumonia or pulmonary embolism) appendicitis, abscess, and diverticulitis. The basic PQRST (provoking/palliating, quality, radiation, severity, timing) qualifications may be helpful in narrowing a diagnosis: provoking/palliating factors, quality, radiation, severity, and timing. Special attention must be paid in patients who are obese, diabetic and/or pregnant, as their complaints and

physical examination may fit classic patterns.

In patients who present with RUQ pain and hemodynamic abnormalities, the differential should include trauma, ruptured tumor/lesion, and sepsis related to cholangitis or other infection. It requires urgent resuscitation, workup, and, in some cases, transfer to a center with hepatobiliary expertise.

BILIARY DISEASE

Gallbladder Pathologies

We will first consider benign biliary disease, of which the most commonly occurring is cholelithiasis.

The third National Health and Nutrition Examination Survey estimated that 6.3 million men and 14.2 million women aged 20 to 74 in the United States had gallbladder disease. Risk factors include the five F's: female, forty, fat, fertile, and family history; along with rapid weight loss, certain diseases (cirrhosis, Crohn disease), and gallbladder stasis (i.e., long-term total parenteral nutrition [TPN] use). Cholethiasis may be discovered incidentally on imaging for other reasons. Approximately 20% of patients will develop symptoms when followed for 15 years. Asymptomatic patients require no treatment because the risk of complications in these patients is extremely low.

Patients with symptomatic cholelithiasis present with post-prandial (in particular following a fatty meal) pain in the RUQ and epigastric region. It may radiate to the shoulder, subscapular region, and the back. It is typically is transient (<3 hours in duration), with fewer palliating factors. If pain is constant or sustained longer than this, acute cholecystitis or an alternative diagnosis should be entertained. Symptoms may or may not be reproducible on physical examination. It can be difficult to differentiate from PUD. Risk factors should be taken into account for PUD; and if there is a high level of suspicion of this, endoscopic examination of the stomach should precede elective cholecystectomy.

In patients where symptoms are classic, routine blood work should be obtained to ensure that liver function tests (LFTs) are normal.

Rarely, gallstones may be identified on plain abdominal radiographs with approximately 10% of gallstones being detected by this modality. Ultrasound findings of gallstones include an echogenic focus within the gallbladder lumen with posterior acoustic shadowing. There may be gravity-dependent movement of the gallstones with change of patient

position.

Approximately 1% to 2% of patients with asymptomatic gallstones will ultimately become symptomatic. Once symptomatic, patients are at increased risk of developing complications and cholecystectomy should be performed.

Acute Calculous Cholecystitis

Acute calculous cholecystitis occurs in approximately 10% of patients with symptomatic gallstones. It is a clinical diagnosis based on history, physical examination, and laboratory tests. In contrast to biliary colic, which usually subsides after several hours, patients complain of RUQ pain that persists outside of this timeframe and is constant and clenching. There are fewer palliating factors, and the patient may or may not have a history of biliary colic. Nausea and vomiting may be present, but typically follow and rarely precede the pain. Fever may be present. In cases of advanced pathology, the patient may have complaints related to peritonitis.

On examination, the classic clinical sign in acute cholecystitis is Murphy sign, the cessation of inspiration on palpation of the inflamed gallbladder. This may be elicited during the ultrasound examination as well. The absence of this does not rule out the presence of gallbladder inflammation, especially in diabetic and obese patients. In advanced disease, the patient may exhibit peritonitis; this should raise concern for gangrenous cholecystitis or perforation.

Lab values may or may not be affected. The white blood cell (WBC) count may be elevated, with or without a left shift. Liver functions may be normal to slightly elevated. It is unusual for the bilirubin to be elevated >3 mg/dL in isolated cholecystitis. The presence of jaundice, hyperbilirubinemia, or elevations of alkaline phosphatase should alert the clinician to potential of common bile duct obstruction from either choledocholithiasis or Mirizzi-type phenomenon, where a stone impacted in the neck of the gallbladder causes compression of the bile duct.

Because of its high sensitivity and specificity (88% and 80%, respectively), availability, and lack of ionizing radiation, imaging should begin with ultrasound when available. Findings of acute cholecystitis include: enlarged, incompressible gallbladder, sonographic Murphy sign, thickening of the gallbladder wall >4 mm, and the presence of gallstones. There may be pericholecystic fluid.

In patients where computed tomography (CT) scan has been performed

as the initial diagnostic test, ultrasound may add little by way of sensitivity or specificity.

Radionucleotide cholescintigraphy is sensitive and specific for cholecystitis. In a study comparing ultrasound and cholescintigraphy in the diagnosis of histology confirmed acute cholecystitis, in a review of 1,217 cases, hepatobiliary iminodiacetic acid (HIDA) scan was found to be 89.3% sensitive in comparison with ultrasound, which was only 71.1% sensitive. In this same study, ultrasound was more specific (88.1% vs. 66.8%).

Ultimately, acute cholecystitis, much like appendicitis, is a clinical diagnosis; and even if imaging is equivocal and the patient history and examination otherwise raise concern for cholecystitis, the patient may be placed on antibiotics and observed. A missed diagnosis can have a high morbidity, in particular in elderly people. The gallbladder may become walled off by omentum and create a localized abscess that does not produce enough surrounding inflammation to cause peritonitis until it has progressed extensively or ruptured.

The most common complication of acute cholecystitis is emphysematous cholecystitis and with gangrene and perforation of the gallbladder wall. Emphysematous cholecystitis is characterized by secondary infection of the gallbladder wall with a gas-producing bacterium (*Clostridium, Escherichia coli, Pseudomonas,* or *Klebsiella*). It is rare and associated with significant morbidity and mortality due to the sepsis that may ensue with subsequent perforation. It typically occurs in elderly men and diabetic patients. Emphysematous cholecystitis can be radiographically elusive as well until it reaches advanced stages evidenced by pneumobilia (in the absence of previous instrumentation). Sensitivity of ultrasound is diminished as the gas can obscure visualization of the gallbladder; however, findings of air within the gallbladder wall or lumen or nonshadowing echogenic foci in the anti-dependent portion of the gallbladder are specific. CT findings may include air within the gallbladder wall or lumen, and irregular or absent gallbladder wall, irregular enhancement, or pericholecystic abscess. Gangrenous cholecystitis on ultrasound may have intraluminal membranes and marked asymmetry of the gallbladder wall (secondary to intramural microabscesses, intramural hemorrhage, and pericholecystic fluid collections containing debris). On CT scan, there may be gallbladder distention, irregular wall, wall striations, decreased wall enhancement,

intraluminal membranes, pericholecystic fluid or abscess or gas in the gallbladder wall. HIDA scan is not helpful in differentiating between variants of cholecystitis.

The treatment of choice for acute calculous cholecystitis is antibiotics (to cover *E. coli, Klebsiella, Enterobacter, and Enterococcus)* and cholecystectomy.

Early surgery (<72 hours from the onset of symptoms) is optimal. The once argued approach of "cooling off a hot gallbladder" is no longer supported in most cases; however, if symptoms have been present for >72 hours and the patient has clinical improvement with antibiotics, deferring cholecystectomy for 6 weeks is recommended to allow inflammation to subside. If there is clinical suspicion of gangrenous cholecystitis, this should be considered a surgical emergency as the risk for peritonitis, sepsis, and death is up to 15%. A laparoscopic approach is the standard of care; however, conversion to open should not be considered a failure or complication. In patients who are too sick to undergo an operation or who refuse operative intervention, percutaneous biliary drainage is an acceptable option, and should be paired with broad-spectrum antibiotics (even in cases of gangrenous or emphysematous cholecystitis).

If the bilirubin is elevated to level >3 mg/dL or there is biliary dilation on imaging, concomitant choledocholithiasis may be present (see below).

Acalculous Cholecystitis

Certain populations are at risk for acalculous cholecystitis. Situations that create a combination of ischemia and stasis are thought to contribute to its development. It is frequently seen in critical ill patients. Other at risk groups are patients with type II diabetes, congestive heart failure (CHF), leukemia, AIDS, and end-stage renal disease (ERSD). It more commonly occurs in men, in contrast to calculous cholecystitis. In children, it is the cause of cholecystitis in approximately 50% to 70% of cases—with dehydration, infection, and lymphadenopathy as potential contributing factors.

If the patient is conscious, he or she may complain of RUQ pain. Clinical signs of fever and leukocytosis may be present or absent depending on the clinical setting. Often times patients in this population are too immunosuppressed to mount a typical leukocyte expansion response. LFTs are nonspecific and often times normal. The diagnosis should be considered in any critically ill patient with sepsis in which

etiology has not been identified.

The diagnosis relies largely on imaging. Ultrasound is sensitive and specific using the finding of gallbladder wall thickening (>3 or >3.5 mm). Other findings include pericholecystic fluid, intraluminal gas, or intramural edema represented by a sonolucent “halo.” The following algorithm has been suggested for radiographic evaluation: If suspicion of biliary etiology is high, radionucleotide imaging should be the initial test, with CT scan to evaluate the remainder of the abdomen if the testing is normal. However, if suspicion of biliary source is low, CT should be performed first, and cholescintigraphy used to confirm if CT is suspicious but not diagnostic. Morphine can be administered to increase the sensitivity of scintigraphy by causing constriction of the sphincter of Oddi allowing for gallbladder filling.

The treatment of acalculous cholecystitis is determined by the medical condition of the patient. In many cases, the patient is either too ill or too immunosuppressed to tolerate surgery. Initial treatment should be with broad spectrum antibiotics to cover biliary organisms. If the patient fails to improve and is not a surgical candidate, a cholecystostomy tube may be used for decompression. If the patient improves after cholecystostomy, he does not need an interval cholecystectomy as there are, by definition, no gallstones to cause recurrence. The cholecystostomy tube can be removed once a tract has been established, and cholangiography via the cholecystostomy tube demonstrates a patent cystic duct. This might warrant a longer period than usual if the patient is immunosuppressed.

Other Gallbladder Pathologies

Porcelain Gallbladder

Porcelain gallbladder is the result of deposition of calcium carbonate in the gallbladder wall. It has a classic appearance on imaging, and has been reported to be at increased risk of gallbladder carcinoma. Once thought to be highly associated with cancer, several large volume studies have found the incidence of cancer in patients with calcification to be approximately 0% to 5%. On plain abdominal film, the calcifications with the wall may be apparent. On ultrasound, the wall calcification can appear as: (1) hyperechoic semilunar structure with dense posterior acoustic shadowing, (2) a biconvex curvilinear echogenic structure with acoustic shadowing, and (3) irregular clumps of echoes with posterior acoustic shadowing. It may be difficult to discern from cholelithiasis if stones are densely packed

and the gallbladder is contracted; however, if the posterior wall of the gallbladder can be visualized on grayscale, then gallbladder with stones can be excluded. Because of the ring-down artifact produced by wall and gas on ultrasound, it may also be difficult to discern from emphysematous cholecystitis, in which case CT can be utilized to differentiate these two entities. Patients are symptomatic in approximately 70% to 80% of cases, and prophylactic cholecystectomy is recommended due to the increased risk of cancer. The surgeon should be prepared to perform intraoperative ultrasound, liver resection (4b/5), and lymph node dissection at the time of surgery if the intraoperative findings are suggestive of invasive cancer or if cancer is discovered on frozen section.

Adenomyomatosis of the Gallbladder

Adenomyomatosis is a benign finding on imaging or pathology. It is characterized by hyperplasia of the gallbladder mucosa and muscularis propria with out-pouching of the mucosa into or through the muscularis forming diverticula called Rokitansky–Aschoff sinuses. It is usually an asymptomatic, incidental finding. It is not believed to have malignant potential. On CT, it is said to have a "rosary sign," with discrete hypoattenuating intramural lesions with enhancing epithelium within. On magnetic resonance imaging (MRI), "pearl necklace sign" is a result of the multiple ovoid diverticula seen on T2-weighted imaging. It may be generalized, localized, or segmental. If it is found in the setting of acalculous biliary colic, cholecystectomy can be performed.

Gallbladder Polyps

Gallbladder polyps occur in approximately 5% of the population. They are often incidentally found in workup of abdominal pain; however, in rare cases they may be the cause of obstruction of the cystic duct. Cholecystectomy is recommended in patients where the polyp exceeds 1 cm or has a vascular pedicle due to the risk of malignancy. Surveillance is recommended for patients with polyps between 5 and 10 mm (Fig. 104.1).

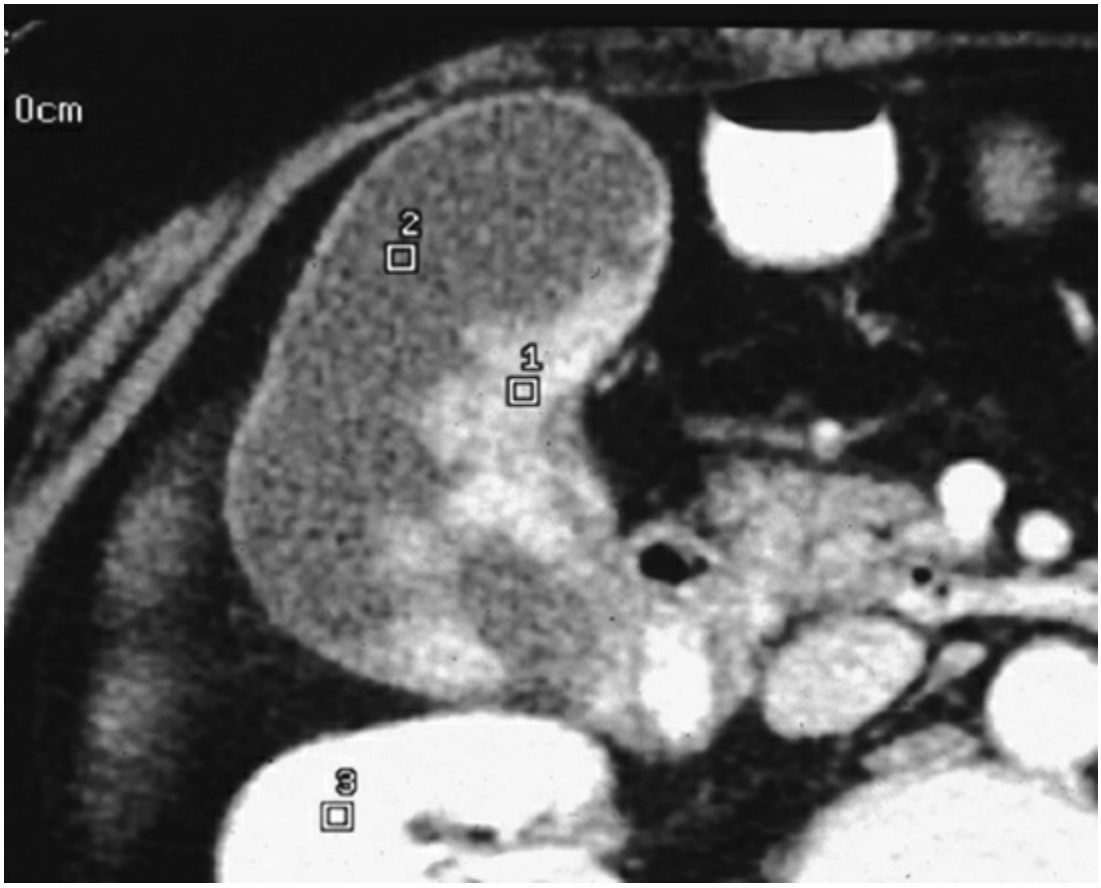

Figure 104.1. Sessile gallbladder polyp seen as incidental finding on computed tomographic scan. Also worrisome is the mass that is brightly enhanced on this scan after contrast injection. 1, sessile polyp; 2, gallbladder; 3, duodenum.

BILIARY OBSTRUCTION

Surgical evaluation may be warranted in evaluation of biliary obstruction in several situations, with the two most common etiologies being obstruction due to choledocholithiasis or obstruction due to mass. As the two etiologies have different algorithms, each will be considered separately in the following sections.

Choledocholithiasis with Obstruction

Choledocholithiasis

Choledocholithiasis is present in 10% to 20% of patients with gallstones. Diagnosis may occur incidentally or in the evaluation of jaundice. In the setting of obstruction, patients may complain of RUQ pain, clay/gray colored stools, cola/brown colored urine or pruritus. On ultrasound, choledocholithiasis should be suspected if the common bile duct is outside

of the normal range for the patient's age (approximately >6 mm), there are stones visualized in the duct, or if there is hyperbilirubinemia >3 mg/dL in the setting of biliary colic or acute cholecystitis. If ultrasound is equivocal, magnetic resonance cholangiopancreatography (MRCP) can be employed with high (90% to 95%) concordance with endoscopic retrograde cholangiopancreatogram (ERCP) for stones >4 mm; however, it is solely diagnostic, and not therapeutic. Endoscopic ultrasound (EUS) and intraoperative ultrasound have also been utilized with good success for detection of choledocholithiasis; however, not all centers have this capability. It is particularly useful in populations where there is reason to avoid ERCP (pregnancy, resolving pancreatitis).

In cases where choledocholithiasis is present in the setting of cholecystitis, the surgeon must make the decision of whether or not to proceed with preoperative ERCP versus intraoperative assessment. If ERCP is deferred, the surgeon must be prepared to perform operative common bile duct exploration or postoperative ERCP. The timing of ERCP is widely debated; however, there is no consensus regarding this and it is largely surgeon-dependent.

Proponents of preoperative ERCP suggest that if the ERCP is unsuccessful, intraoperative exploration will be required and can be performed at the time of cholecystectomy. On the other hand, ERCP does place the patient at risk for bleed or pancreatitis, and it is thought that a trial of intraoperative maneuvers (cholangiogram, flushing the duct, transcystic use of 3F Fogarty to clear the duct) is reasonable to attempt to clear the duct before committing to ERCP. If these initial maneuvers are unsuccessful, the decision must be made whether to proceed with laparoscopic common bile duct exploration, or termination of the operation with plan for postoperative ERCP.

If intraoperative maneuvers are unsuccessful and postoperative ERCP is planned, the surgeon should leave a drain to assess for bile leak as the cystic duct clips may become dislodged at the time of ERCP.

Cholangitis

Ascending cholangitis is a condition that requires urgent intervention. The clinical signs of fever, RUQ pain, and jaundice (Charcot triad) signify cholangitis, which may rapidly evolve into sepsis with the bacterial ascension in the obstructed biliary system. When associated with mental status change and hypotension representing the progression of sepsis, this is referred to as Reynolds' pentad.

Cholangitis may occur in a variety of settings, benign or malignant. In patients who have not had previous biliary surgery or intervention, the most common cause is gallstones. Other etiologies include: Mirizzi syndrome, primary sclerosing cholangitis (PSC) with structuring, infected choledochal cysts, or hemobilia. External compression of the duct may occur in the setting of a mass, most commonly cholangiocarcinoma. Patients who have had previous biliary surgery (bile duct exploration or creation of choledochojejunostomy) are at risk for cholangitis as a result of structuring of the duct. In the setting of an indwelling biliary catheter, cholangitis should prompt externalization of the system to a drainage bag if it is capped and urgent exchange of the catheter as it is likely clogged.

White blood cell count, bilirubin, and alkaline phosphatase are typically elevated. Ultrasound will typically show dilated hepatic ducts beyond the level of the obstruction; however, in some cases this finding may be absent or modest. While MRCP and EUS have acceptable accuracy in diagnosing choledocholithiasis, if suspicion of obstruction is high, ERCP is the test of choice for diagnosis and therapeutic intervention.

Broad spectrum antibiotics (to cover *E. coli*, *Klebsiella*, *Enterobacter*, *and Enterococcus*) should be started immediately along with resuscitation using intravenous fluids. Broad spectrum antibiotics usually result in stabilization of the patient; however, if this does not result in prompt improvement, the biliary system should be decompressed emergently. This can usually be achieved with ERCP; however, if that fails or is not available, either a percutaneously transhepatic biliary drain or operative exploration is considered. If emergency surgery is required, the preferred procedure is simple decompression of the system with the largest T tube that the duct will easily accommodate with plan for definitive surgery when sepsis is controlled. If gallstones are identified as the etiology of the obstruction, stone extraction and sphincterotomy are usually curative. If there is extrinsic mass or compression, brushings should be obtained and a stent placed to decompress the system while further workup is performed.

Biliary Obstruction Without Gallstones

Asymptomatic or “painless” jaundice should raise suspicion of external compression of the duct. Compression of the intrahepatic ducts is most frequently caused by hepatocellular carcinoma (HCC) by external compression or extension into the duct. Other etiologies include intrahepatic or hilar cholangiocarcinoma, metastasis from a nonhepatic

primary, PSC with stricture, and compression from hepatic abscess or cyst. Extrahepatic obstruction is most commonly seen in patients with distal cholangiocarcinoma, pancreatic head adenocarcinoma or neuroendocrine tumors, or ampullary tumors.

Tumor markers can be obtained (CEA, AFP, CA 19–9) if there is a suspicion for malignancy; however, CA19–9 should be interpreted with caution as it may be falsely elevated in the setting of biliary obstruction.

Contrast-enhanced ultrasound (not available in the United States), CT, and MRI have high specificities (82% to 89%) in the diagnosis of focal liver lesions. However, given the addition of MRCP, MRI with contrast and MRCP is the initial test of choice in evaluation of intrahepatic biliary obstruction. It can provide valuable information about the relationship of the tumor to the bile duct and vasculature. It can also be used to obtain liver volumes to aid in the planning of surgical resection. CT scan of the chest should be obtained to complete evaluation for metastatic disease.

In the absence of cholangitis, the decision of whether or not to preoperatively drain patients with obstructing biliary tumors is debated. If the patient is symptomatic from the hyperbilirubinemia or will have a significant interval prior to surgery for neoadjuvant treatment or portal vein embolization, then drainage with an endoscopically or percuntaneously placed catheter is reasonable. If the plan is to go directly to surgical resection, then biliary drainage may not be necessary, and some authors argue that instrumentation in this setting increases complications. If a catheter is placed, brushings should be obtained and be submitted for cytologic analysis.

If the patient is not a candidate for surgical resection, biliary decompression may be used in the palliative setting.

If surgical resection is planned, biopsy for definitive diagnosis is generally not needed prior to resection. If tissue diagnosis would change the management of the patient, this can often be achieved by percutaneous or endoscopic means.

LIVER MASS

A commonly encountered clinical scenario for the surgeon is the incidental finding of a liver mass. The key questions to be answered by the surgeon are: (1) Is the mass benign, malignant, or benign, but with malignant potential? (2) Is intervention necessary? (3) Is surveillance necessary?

Workup of any mass begins with a thorough history and physical

examination. Table 104.1 summarizes liver lesions. Most liver masses are asymptomatic. If symptoms are present, they most commonly occur secondary to mass effect resulting in compression of surrounding structures, or in cases of massive lesions, a sense of abdominal fullness. Peritonitis may be present if a mass is inflamed, or if it has bled or ruptured. Medical risk factors for underlying liver disease should be elucidated: history of hepatitis, alcohol abuse, fatty liver disease, autoimmune diseases, or diseases associated with PSC. Attention should be given to any history that suggests underlying liver disease or portal hypertension, gastrointestinal bleeding, encephalopathy, or ascites. Ascites may be present in cases where there is underlying liver disease or carcinomatosis. If the differential diagnosis of the mass includes abscess, history of travel and abdominal infections should be obtained. The patient's cancer history and cancer screening history (colonoscopy and mammography) should be obtained. The use of estrogen- or androgen-containing medications should be noted.

A thorough understanding of the history of the lesion—how it was discovered, when it was discovered, and what prompted referral to the surgeon—can be helpful in guiding decision making regarding many lesions. Often times this requires the review of past imaging. No decisions should be made based on imaging reports exclusively; all films should be reviewed directly by a team familiar with hepatobiliary lesions.

Lab work should include LFTs, and if there is any concern for underlying liver disease, a hepatitis panel should be obtained. If there is concern for malignancy, tumor markers—carcinoembryonic antigen (CEA), non-maternal alfa feto protein (AFP), and carbohydrate antigen (CA) 19–9—should be obtained.

Lesions can be broadly divided into hemangioma, cystic, or solid. The imaging modality of choice for each of these is variable and at times may vary within an institution's expertise or availability. Many lesions can be diagnosed with the use of history and appropriate imaging alone. In some cases, tissue may need to be obtained for definitive diagnosis.

Hemangioma

Hemangioma is the most common benign liver lesion in adults, with an estimated prevalence of 5% to 20%. It is a vascular liver lesion thought to arise from congenital hamartoma. The majority are <5 cm; however, if the size is >10 cm, they are classified as "giant hemangiomas." Hemangiomas

are often incidental findings, and diagnosis is often made by imaging alone. Outside of cases of strategically located giant hemangiomas, caution should be exercised when attributing symptoms to hemangioma. Ultrasound findings include a hyperechoic, rounded lesion with a well-defined rim and few intranodular vessels, which demonstrates posterior acoustic enhancement. They often lack color flow on Doppler. They are often peripheral and in the posterior segments of the right hepatic lobe. The typical enhancement pattern on CT or MRI is discontinuous peripheral nodular enhancement with progressive centripetal filling, and is considered diagnostic. With MRI, the classic appearance is hyperintensity on T2 imaging (Fig. 104.2). Using extracellular contrast–enhanced MRI, three distinct patterns have been described. First, smaller lesions (<1.5 cm) may have uniform arterial enhancement (referred to as flash filling). Alternatively, larger lesions show either nodular peripheral interrupted enhancement coalescing centripetally to uniform enhancement or nodular peripheral interrupted enhancement that coalesces centripetally but with persistent central hypointensity. Finally, giant hemangiomas may have regions of fibrosis or and/or thrombosis, resulting in central scar with strands of T2 hypointensity. Caution must be used in interpretation of imaging. Some malignant lesions may also be T2 hyperintense, including: neuroendocrine tumors, breast metastasis, cystic subtype HCC, and metastasis from mucinous subtypes of colon and ovarian cancer, as well as primary or metastatic sarcoma.

TABLE 104.1 Summary of Liver Lesions

	Benign	Malignant	Nontumor
Common	Simple hepatic cyst Hamartoma FNH	Metastasis Hepatocellular carcinoma	Focal fat/fat sparing Perfusion abnormality Abscess
Uncommon	Hepatocellular adenoma Biliary cystadenoma	Cholangiocarcinoma Biliary cystadenocarcinoma Sarcoma Lymphoma Hemangioendothelioma	Hematoma Peliosis Pseudotumor

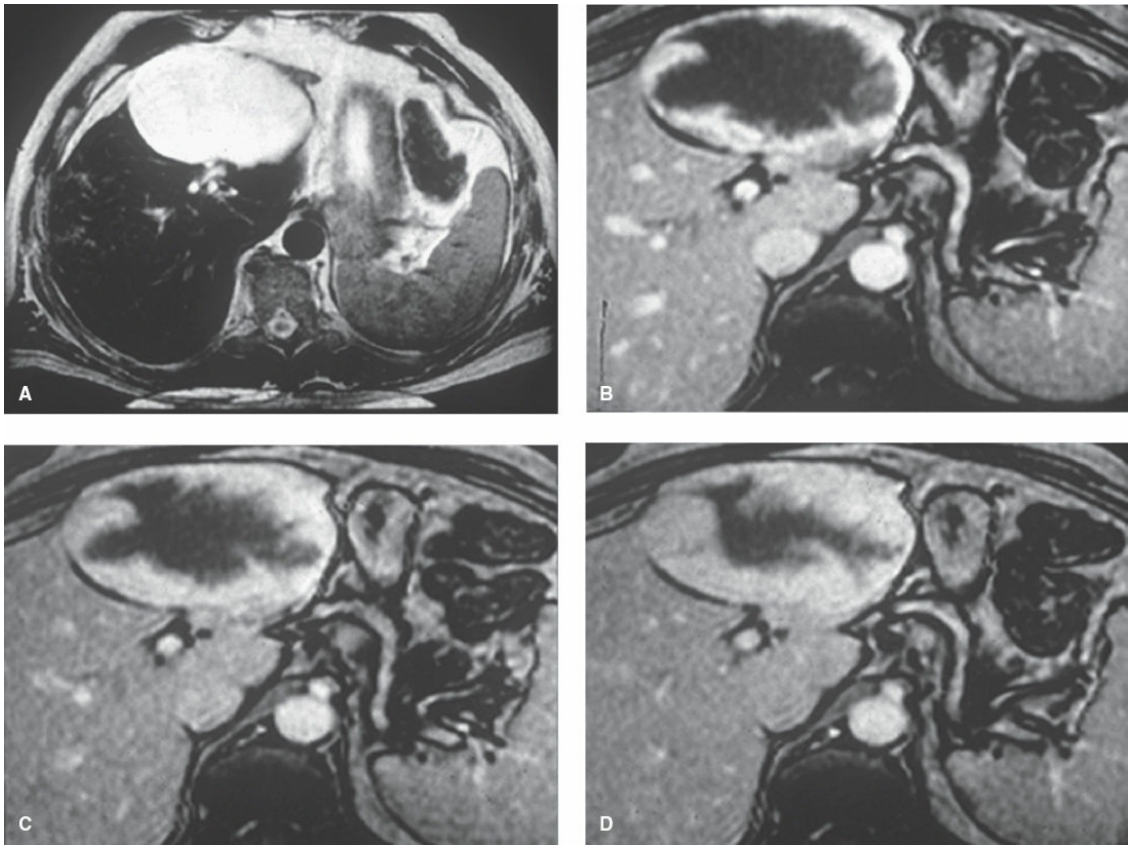

Figure 104.2. Classic appearance of hemangioma on MRI. Lesion is very bright on T2 (**A**) and shows nodular enhancement that fills in from the periphery with increasing time after gadolinium injection (**B–D**).

For asymptomatic hemangiomas, no intervention is necessary. In lesions that are symptomatic, surgical resection or enucleation can be employed. Surveillance imaging in not required for classic hemangioma.

A rare complication of hemangioma is Kasabach–Merritt syndrome. Most commonly occurring after trauma or other violation of the lesion, this consists of coagulopathy with intravascular coagulation, clotting, and fibrinolysis within the hemangioma; however, it may progress to systemic fibrinolysis and thrombocytopenia.

Cystic Liver Lesions

With a prevalence of about 5% to 10% of the population, cystic liver lesions are another common incidental finding that prompts referral to a surgeon. Again, these lesions are usually asymptomatic. Symptoms may occur in the case of extremely large cysts leading to compressive symptoms, rapid enlargement, cyst infection, or hemorrhage. Incidental cystic lesions most commonly represent simple hepatic cysts. Other, less

common possibilities include biliary cystadenomas (BCAs) or cystadenocarcinomas, polycystic liver disease (PCLD), hydatid cysts, cystic metastasis, of necrosis of tumors.

Simple Hepatic Cysts

Simple hepatic cysts are benign and without malignant potential. They vary in size, number, and location. They are thought to be a congenital malformation and consist of a fibrous rim and are lined with columnar epithelium. Ultrasound shows an anechoic, homogeneous mass, with smooth margins. Ultrasound is the best modality to demonstrate septations. CT shows a well-demarcated, water density (Hounsfield units 0–10), which does not enhance with contrast. MRI shows T1 hypointensity and T2 hyperintensity. Lack of homogeneity with septations, fenestrations, calcifications, irregular walls, or daughter cysts should expand the differential to include the more complex, aforementioned lesions. There is no intervention required for a simple, asymptomatic cyst. If cyst becomes symptomatic due to size or infection, cyst aspiration and sclerotherapy or surgical unroofing is reasonable. In patients where it is unclear if the cyst is the cause of the presenting symptoms, cyst aspiration with resultant palliation of symptoms can confirm the association. However, aspiration alone is usually associated with rapid recurrence of the cyst (within days). No surveillance imaging is required for simple hepatic cysts.

Cystic Hepatobiliary Neoplastic (Cystadenoma, Biliary IPMN, Cystadenocarcinoma)

These lesions are believed to arise from an aberrant bile duct remnant. Like the other cysts, they are usually an incidental finding.

BCAs make up <5% of all cystic lesions and have the following three distinct pathologic features originally described by Wheeler and Edmondson: (1) multilocular, (2) lined by a columnar epithelium, and (3) accompanied by a densely cellular ovarian-like stroma. While BCA is predominantly found in females, biliary cystadenocarcinoma (BCAC) is more evenly distributed. The more newly recognized entity, intraductal papillary neoplasm of the bile duct (IPNB), was adopted by WHO in 2010 and is defined as a biliary epithelial tumor, often with mucin production, with exophytic nature exhibiting papillary mass within the bile duct lumen and with prominent intraductal growth pattern. Its epithelial cells have a range of atypia from none to marked, and it is therefore considered a

premalignant lesion to cholangiocarcinoma. Pathologically, it differs from BCA in that it lacks ovarian stroma. On imaging, the two can be distinguished by the fact that BCAs typically have a smooth tumor wall with internal septation, resulting in a "cysts-in-cyst" appearance and papillary projections are frequently seen in IPNB and rarely in BCA.

Distinguishing simple hepatic cysts from hepatobiliary neoplasia is the key as the latter is considered to have malignant potential with a risk of transformation of up to 20%, and therefore requires formal resection. Several points may aid in clarification of the differential. Hepatobiliary neoplasia are commonly single lesions, whereas simple cysts are frequently multiple. On ultrasound, BCA will have a complex appearance, with septations or nodules. These findings should prompt further examination with CT or MRI. CT is able to detect abnormality of the cyst wall and aid in surgical planning. On MRI, BCA will have complex appearance with thickened wall, internal septations, mural nodules, and internal debris. An elevated alkaline phosphatase has been associated with cystadenoma over simple cyst (Fig. 104.3).

BCAC is a rare biliary cancer that is thought to originate either de novo from a formed biliary duct that sustains an insult (ischemia or carcinogens) or from malignant transformation. Because of their rarity, criteria to definitively distinguish BCA from BCAC are limited. In a series of 39 patients with biliary cystic tumors, the imaging findings of polypoid mural nodules, intracystic debris, and bile duct dilation were seen more commonly in BCACs than in BCAs. All BCAs should be completely excised due to the risk of malignant transformation. Because of their risk of malignant transformation and the high risk of recurrence, it is critical that the cyst wall is removed in its entirety and submitted for pathologic examination. This can be performed with surgical resection or enucleation. In cases where there is a high suspicion of BCA, unroofing the cyst is inadequate.

Polycystic Liver Disease

PCLD is thought to be a part of a group of diseases that arises from mutations of the cholangiocyte cilia. It can be distinguished from simple hepatic cysts by the presence of numerous cysts (>20), although the histology of the lesions is similar. The lesions are asymptomatic until they reach a critical mass at which point the patient may present with complaints of abdominal fullness, bloating, or shortness of breath.

Compression of surrounding structures including the IVC and biliary tree may occur. Rare patients may develop portal hypertension with preserved synthetic function. US, CT, and MRI can be utilized in diagnosing PCLD.

The goal in treatment of PCLD is generally palliation of symptoms, with either unroofing of cysts, resection, or, in some highly suspected cases, liver transplantation.

Hydatid Cysts

Echinococcal cysts are a rare occurrence in the United States, but the parasite is endemic in many other areas of the world—the Mediterranean, Africa, the Middle East, South America, Asia, and parts of Europe and in areas where sheep farming is prevalent. In patients where hydatid cyst is suspected, a thorough travel and exposure history should be obtained. Depending on the location of the cyst, LFTs may or may not be affected. Eosinophilia is often present but not specific. The classic findings for hydatid cysts are thick walls, unilocular or multilocular, often with calcifications, and daughter cysts, with the distinguishing features of the cyst being calcifications and daughter cysts. Communication with the bile duct can occur in up to 25% of cases. Most cysts are asymptomatic, however, complications such as cholangitis, anaphylaxis from cyst rupture, and pulmonary infection can occur. Safeguards must be taken to prevent exposure of the patient to the scolices within the cyst—this is done through the use of medical treatment and scolicidal agents. Surgery remains the mainstay in treatment.

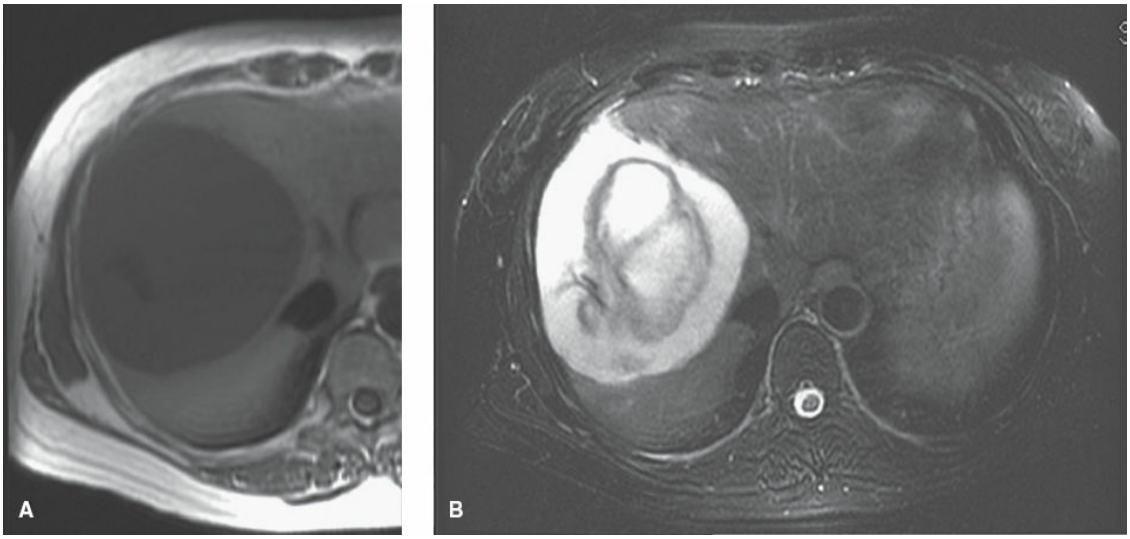

Figure 104.3. Complex cystic mass seen in magnetic resonance image as low-attenuation lesion on T1 (**A**) and as bright lesion

with internal mass on T2 (**B**).

Liver Abscess

The most common etiology of liver abscess is secondary to another intra-abdominal infection (diverticulitis or appendicitis); however, in many cases there is no apparent source and spontaneous abscess formation is the only finding.

Ultrasound typically reveals a hypoechoic lesion with a smooth wall. Gas within an abscess is hyperechoic and casts shadows. CT is both sensitive and specific while offering the benefits of evaluating the remainder of the abdomen for pathology and allowing for interventional planning. The lesion may appear as a single or multiloculated mass with a central hypodense region and peripheral contrast enhancement during the portal phase of examination.

Treatment consists of antibiotics (targeted toward primary etiology or cultures) and drainage. In smaller lesions (<2 cm), antibiotic treatment alone may be sufficient.

In patients with a travel history to endemic areas or history of diarrheal illness, the diagnosis of amoebic abscess should be considered; however, most amoebic cysts are found in asymptomatic carriers. The lesions are more commonly found in the right liver. The diagnosis is confirmed with enzyme-linked immunosorbent assay (ELISA) testing that detects antibodies to the amoeba, *Entamoeba histolytica*. Usually medical treatment with metronidazole is sufficient, along with a luminal agent such as paromomycin to eradicate the intestinal colonization. If the patient fails to improve with medical therapy, cyst aspiration and drainage are indicated.

SOLID LIVER LESIONS

Benign Solid Lesions

Focal Nodular Hyperplasia

Focal nodular hyperplasia (FNH) is the second most commonly occurring benign solid liver lesion, behind hemangioma, with a prevalence of 0.3% to 3%. It is thought to possibly be the result of an ischemic insult to the portal tract that results in hyperplasia of hepatocytes surrounding a central scar. It is most often seen in young or middle-aged women and is frequently an isolated lesion. It is often asymptomatic; however, it is

frequently found incidentally in the workup of abdominal pain, and in case of larger lesions, it can be difficult to determine whether or not the FNH is the cause of the symptoms. Symptoms attributable to FNH are usually the result of compression of surrounding structures, for example, early satiety in the case of a large left-sided lesion.

Because of its composition of hepatocytes, it can be a stealthy lesion, barely discernable on some imaging modalities. Often times, because of its availability and lack of radiation exposure, ultrasound will be the first modality used in evaluation symptoms. On US, FNH will appear as slightly hypoechoic, isoechoic, or slightly hyperechoic relative to the remainder of the liver. On noncontrasted CT, the lesion may blend in with the surrounding parenchyma. With contrast, the lesion enhances rapidly in the arterial phase with a subsequent decrease in the portal venous phase.

Historically, sulfur colloid scanning was used to aid in the differentiation between FHN and other lesions; however, with the advent of hepatocyte-specific contrasted MRI, this has fallen out of favor. Extracellular contrast–enhanced MRI appearance is early nodular arterial enhancement, which becomes isointense with the background liver during the portal venous phase. Hepatocyte-specific contrast is the study of choice. On hepatobiliary phase images, the lesion is iso- or hyperintense with the background liver, reflecting the uptake of contrast by the hepatocytes within the lesion (Fig. 104.4).

FNH is a benign lesion with no malignant potential; therefore, in classic cases, no follow-up surveillance is needed. If surgical resection is required based on the presence of symptoms, nonanatomic wedge resection is sufficient, and no margin is required. For patients to whom resection is not an option because of anatomic or clinical factors, trans-arterial embolization can be effective in achieving tumor shrinkage and symptom relief.

Hepatic Adenoma

Hepatocellular adenoma (HA) is a rare tumor, most frequently seen in young woman, and associated with estrogen-containing medication use (most commonly oral contraceptive pills). They are caused by a benign proliferation of hepatocytes with high glycogen and fat content but lack normal hepatic architecture. There are three subtypes—hepatocyte nuclear factor-1 alpha (HNF-1-α) mutated, beta-catenin, and inflammatory—with the remainder falling into a fourth or unclassified subtype. The details of each subtype are beyond the scope of this chapter. Additional risk factors

include anabolic steroid use and metabolic disease (type 1 glycogen storage disease). Certainty in diagnosis between adenoma and other benign lesions is critical due to the risk of hemorrhage in larger lesions and the risk of transformation to malignancy. Lesions are often solitary; however, in rare cases lesions can be numerous, and if exceed 10 in number, the classification is termed *hepatic adenomyosis.* Smaller lesions are of little consequence; however, when lesions reach 5 cm or greater, there is a risk of spontaneous hemorrhage, occurring in up to 20% to 40% of patients. The inflammatory subtype is at greatest risk for bleeding. Malignant transformation is uncommon and some authors have reported that malignant transformation is a function of size. However, in a review of existing literature, conclusions cannot be made that there is a size below which one can definitively say that malignant transformation does not occur, as there are three reported cases of HCC in lesions <5 cm. Risk factors for malignant transformation include androgen or anabolic steroid intake, male sex, glycogen storage disease, and β catenin subtype. The HNF-1-α subtype is least at risk for complications. Imaging may slightly differ based on subtypes of HA.

Ultrasound of the HNF-1-α subtype reveals a hyperechoic lesion. Contrasted CT shows minimal enhancement with rapid washout. The inflammatory subtype will be hyperechoic, but may be heterogeneous with Doppler signal on US and on CT has strong arterial enhancement that persists in the delayed phase.

The majority of HAs are of the HNF-1-α subtype and the inflammatory type. Inflammatory HA has been described as T2 hyperintense with arterial enhancement that persists on portal venous phase. HNF-1-α lesions have a high lipid content, and their imaging is reflective of this. They may have nonpersistent arterial enhancement and intralesional lipid. MRI can aid in distinguishing HA from FNH, whereas HA rarely retains contrast on hepatobiliary phase images.

In asymptomatic patients, surgical resection is warranted in lesions >5 cm due to risk of spontaneous hemorrhage. In patients who are on estrogen-containing medications, it is reasonable to trial a period without the estrogen stimulus and re-image. While malignant transformation occurs at a mean size of 10.5 cm, because of its rarity, firm recommendations regarding malignancy are difficult to propose and it can be argued that patients with risk factors for malignant transformation should have hepatic adenoma resected at any size. However, the general

guideline remains that for female patients, resection should be performed for lesions >5 cm, while male patients should have adenoma resected at any size due to the increased risk of malignancy in this patient group. Transarterial embolization may be used to treat acute hemorrhage or in select cases where the patient is not an operative candidate and tumor shrinkage is desired. Similarly percutaneous ablation techniques may be employed in poor operative candidates with small lesions (Fig. 104.5).

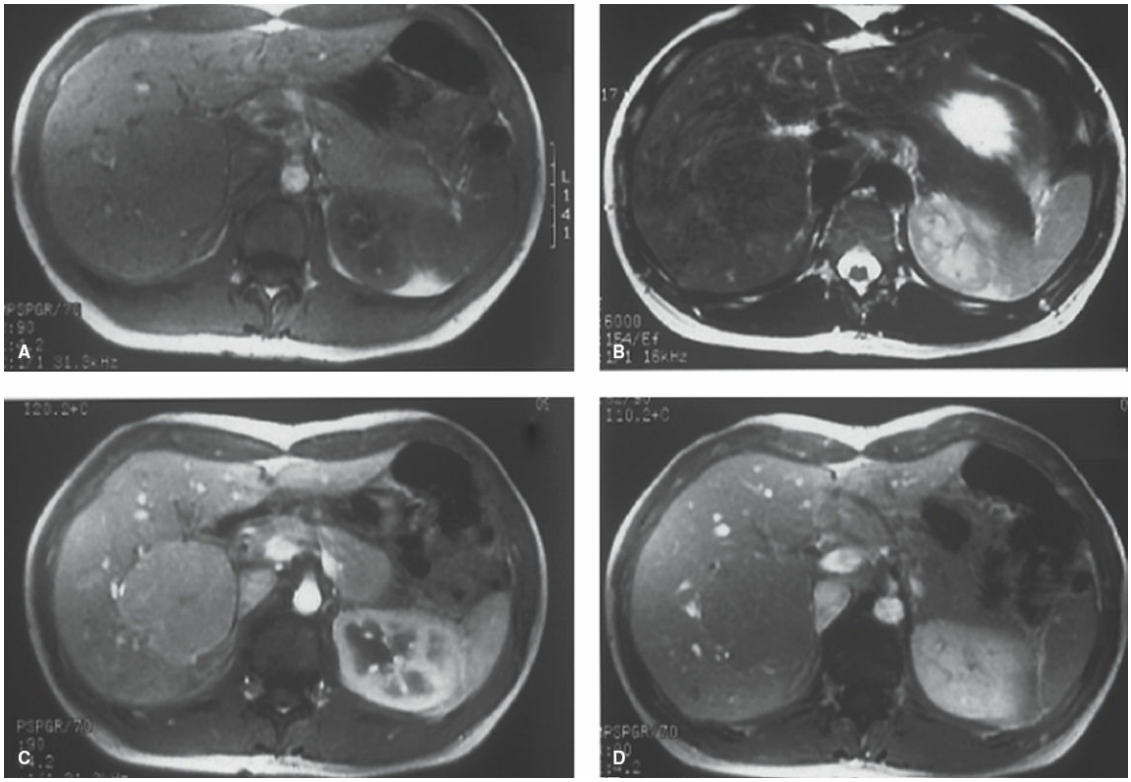

Figure 104.4. MRI appearance of an FNH lesion in the right liver, seen on T1-weighted (**A**) and T2-weighted (**B**) images. The lesion is very homogeneous. After contrast injection (**C, D**), the tumor is initially bright (**C**) but then becomes almost isodense with surrounding parenchyma (**D**). The lesion has a central scar and may be confused with a fibrolamellar HCC.

HA and pregnancy should be discussed on a case-by-case basis; however, generally speaking, pregnancy in patients with HA <5 cm should not be discouraged if they can be compliant with regular ultrasound surveillance (every 3 months) during pregnancy and in the postpartum period. If the lesion changes significantly during the pregnancy, surgical resection should be performed after the patient has entered the second trimester whenever possible.

MALIGNANT TUMORS

The three most commonly occurring solid malignancies in the liver are HCC, cholangiocarcinoma, and metastasis of a nonhepatic primary. As stated previously, the patient's history as it relates to liver disease and malignancies is the key component in the evaluation of any liver lesion.

Primary Liver Cancers

Liver cancer is the fifth most common cancer worldwide in men, and seventh in women.

Hepatocellular Cancer

HCC is diagnosed in approximately 30,000 patients annually in the United States. It rarely occurs before age 40 years and its peak incidence is at age 70 years. Populations who are at the greatest risk are those with liver disease and cirrhosis, with the annual incidence of HCC varying slightly by etiology. Hepatitis B carriers have an estimated risk of HCC of 0.5% to 1%, while those with cirrhosis have an estimated incidence of 2.5% per year. In patients with hepatitis C and cirrhosis, the incidence is 2% to 8% per year. Because of the high risk of HCC in patients with known liver disease and cirrhosis, the American Association for the Study of Liver Diseases (AASLD) has practice guidelines for surveillance in patients with increased risk of HCC (Fig. 104.6). While the guidelines do not recommended AFP, may practitioners obtain surveillance AFP in addition to surveillance imaging.

In patients who present with new liver mass and no history of liver disease, there should be a low threshold to check hepatitis serologies and AFP. Attention should be given to any additional clinical or imaging clues of stigmata of liver disease or portal hypertension. De novo HCC with normal background liver and negative serologies account for only 10% to 20% of all cases.

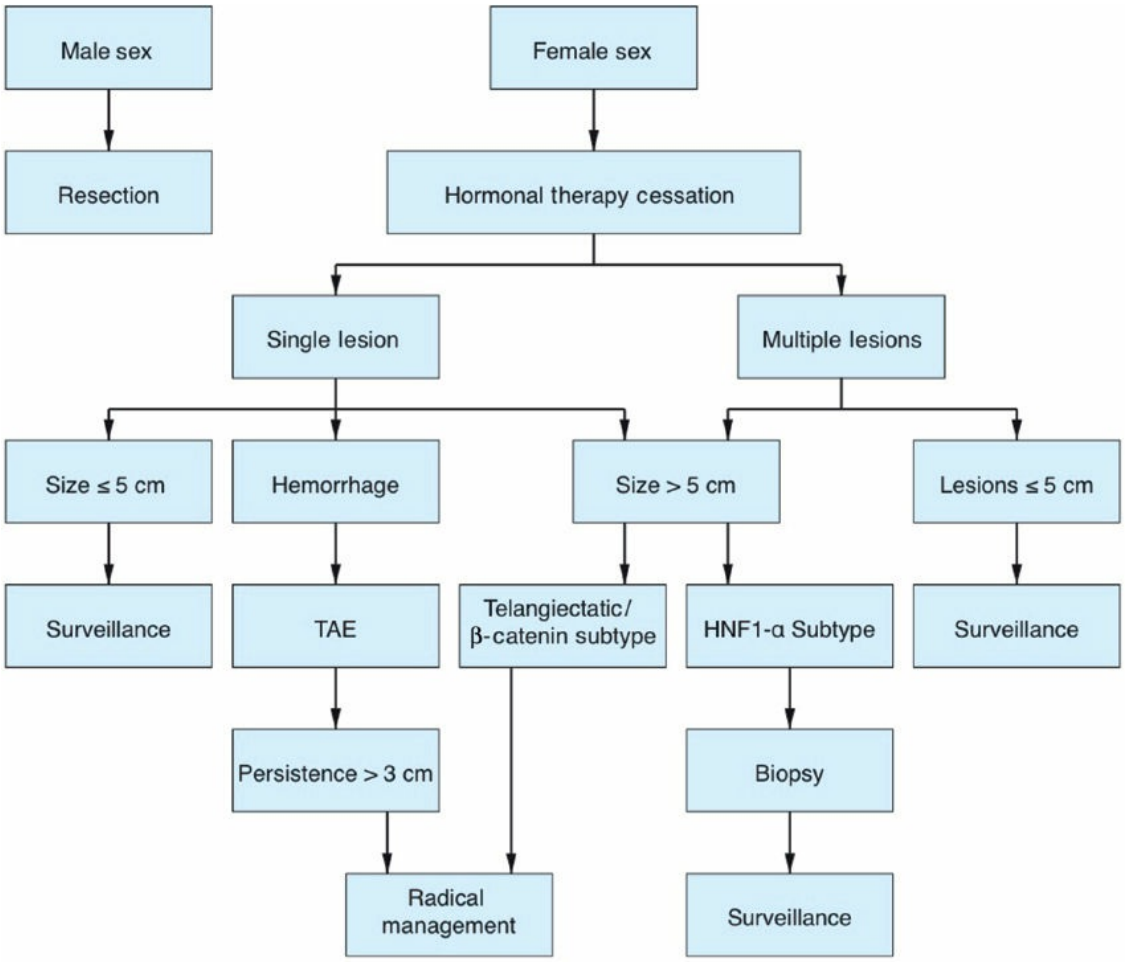

Figure 104.5. Diagnostic/treatment algorithm hepatocellular adenoma. (Reprinted from Agrawal S, Agarwal S, Arnason T, et al. Management of hepatocellular adenoma. *Clin Gastroenterol Hepatol* 2015;13(7):1221–30. Copyright © 2015, with permission from Elsevier.)

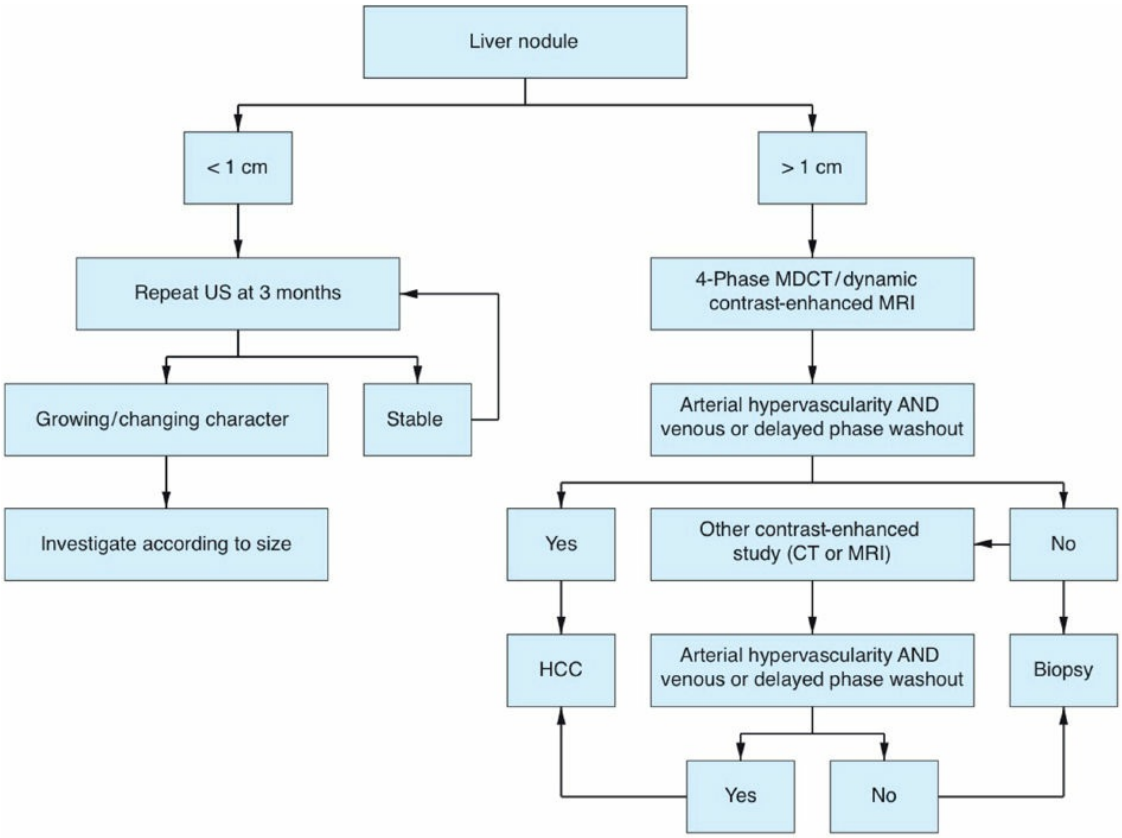

Figure 104.6. AASLD HCC screening guidelines. (From Bruix J, Sherman M, American Association for the Study of Liver. Management of hepatocellular adenoma: An update. *Hepatology* 2011;53(3):1020–2. Copyright © 2011, with permission of John Wiley & Sons.)

Appropriate imaging is often sufficient to make the diagnosis of HCC without the need for a biopsy. On ultrasound, severe fatty liver may be detected as an enlarged liver with diffuse increased echogenicity. The findings of cirrhosis include change in the shape of the liver, parenchymal inhomogeneity, and nodularity. Caudate hypertrophy may be noted. HCC lesions that are multifocal may be difficult to distinguish from the nodular cirrhotic background. Distinct lesions may be hypoechoic. Invasion of vasculature suggests HCC. An equivocal lesion in the setting of an elevated AFP should prompt additional imaging.

Although still debated and at times center specific, there are data to suggest that MRI has improved accuracy over CT for HCC diagnosis. There are two main systems of classification of liver masses with suspicion for HCC. The Liver Imaging Reporting and Data System (LI-RADS) provides a risk stratification based on the level of suspicion for HCC and non-HCC lesions (Table 104.2). The second system, OPTN5,

was created by the United Network for Organ Sharing (UNOS) and Organ Procurement and Transplantation Network (OPTN), to serve as more binary approach to classify lesions as HCC or not, as the presence of HCC is an important criterion used in the allocation of livers for transplantation in the United States.

The findings of HCC using MRI (extracellular contrast–enhanced) or contrasted CT are arterial enhancement, washout, and pseudocapsule. The use of hepatobiliary contrast can aid in the diagnosis of equivocal cases, as the majority of HCCs lack transporters for gadoxetic acid and therefore are hypointense during hepatobiliary phase imaging. CT of the chest and bone scan are recommended to complete staging as 10% to 20% of patients present with extrahepatic metastasis (lung, bone, adrenal, peritoneum).

The treatment of HCC depends largely on the following: (1) the presence or absence of underlying liver disease, (2) the suitability of the patient to undergo resection, (3) the candidacy of the patient for liver transplant (Fig. 104.7).

In patients with well-compensated (Child's class A, MELD <12) cirrhosis and no evidence of portal hypertension, surgical resection remains an option, although with high rate of recurrence (60% to 80% at 10-year follow-up). If resection is entertained, a thoughtful approach to evaluate and optimize the future liver remnant (FLR) is needed. If the estimated FLR is <40% to 50% of nontumorous liver, portal vein embolization of the side to be resected may be employed as a measurement of the patient's ability to hypertrophy postop as well as to optimize the patient for resection.

In patients with more advanced cirrhosis, who meet the Milan criteria (three lesions <3 cm or one lesion <5 cm), do not have vascular invasion, and are candidates for transplant, liver transplantation provides the best long-term survival with the lowest risk of recurrence. In patients who exceed the Milan criteria, many transplant centers have had satisfactory results using a down-staging protocol that incorporates either transarterial chemoembolization (TACE) or transarterial radioembolization (TARE) using Yitrium-90 (Y-90) microspheres in order to bring the patient to within Milan criteria at which point they may be listed for transplant.

In patients who are not candidates for resection or transplant, TACE or percutaneous ablation (of smaller tumors) may provide modest increase in survival.

Cholangiocarcinoma

Cholangiocarcinoma has been used to refer to all primary tumors arising from the malignant proliferation of the epithelial cells lining the biliary tract, including both intrahepatic and extrahepatic ducts. Globally, cholangiocarcinoma accounts for approximately 3% of all gastrointestinal malignancies with an annual incidence rate of 1 to 2 cases per 100,000 population in the United States (approximate incidence of 3,000 cases annually in the United States). Cholangiocarcinoma is the most common primary biliary tract malignancy and second most common primary hepatic tumor (after HCC). The most common type of cholangiocarcinoma is perihilar cholangiocarcinoma (50% to 60%), followed by distal and intrahepatic types constituting 30% to 40% and 5% to 10% of all cholangiocarcinomas, respectively. Most patients with cholangiocarcinoma are in their seventh decade of life at the time of diagnosis with a slightly increased prevalence in males. In general, there is a direct correlation between the age of the patient and the incidence of cholangiocarcinoma; however, in patients with underlying PSC or congenital biliary tract disease (e.g., choledochal cysts), cholangiocarcinoma tends to present earlier, around 30 to 50 years of age.

The clinical features of the perihilar cholangiocarcinoma depend on the stage and location of the tumor. In the majority of patients (>90%), the disease remains clinically silent until it presents at advanced stages with obstructive jaundice (secondary to obstruction of the biliary drainage system by the tumor). Symptoms of progressive cholestasis such as pruritus, dark urine, and clay-colored stools typically accompany the appearance of the jaundice. However, in patients with incomplete biliary obstruction of the right or left hepatic duct or segmental ducts, jaundice might not be the presenting feature. Systemic symptoms of malignancy such as fatigue, malaise, weight loss, fever, and anorexia are observed in up to one-third of the patients at the time of presentation.

TABLE 104.2 LI-RADS for Non-HCC Lesions

LI-RADS Category	Comment	Potential Management
LR-1 (definitely benign)	Imaging features diagnostic of a benign entity Hemangiomas, cysts, fibrosis	Continue routine surveillance
LR-2 (probably benign)	Imaging features suggestive of a benign entity Focal fat, hypertrophic pseudomasses, focal scars	Continue routine surveillance
LR-3 (intermediate probability HCC)	Imaging features that are neither definite nor probably benign Nodular arterial portal shunting, some cirrhotic nodules	Variable follow-up depending on clinical considerations
LR-4 (high probability HCC)	Imaging features suggestive of HCC but that do not meet criteria	Close follow-up imaging, consideration for biopsy or treatment
LR-M (probably malignant but not specific for HCC)	Imaging features may suggest a non-HCC malignancy Cholangiocarcinoma, biphenotypic tumor	Discussion at multidisciplinary meeting, correlation with serum tumor markers, consideration for biopsy

Adapted from Fowler KJ, Saad NE, Linehan D. Imaging approach to hepatocellular carcinoma, cholangiocarcinoma, and metastatic colorectal cancer. *Surg Oncol Clin N Am* 2015;24(1):19–40. Copyright © 2015, with permission from Elsevier.

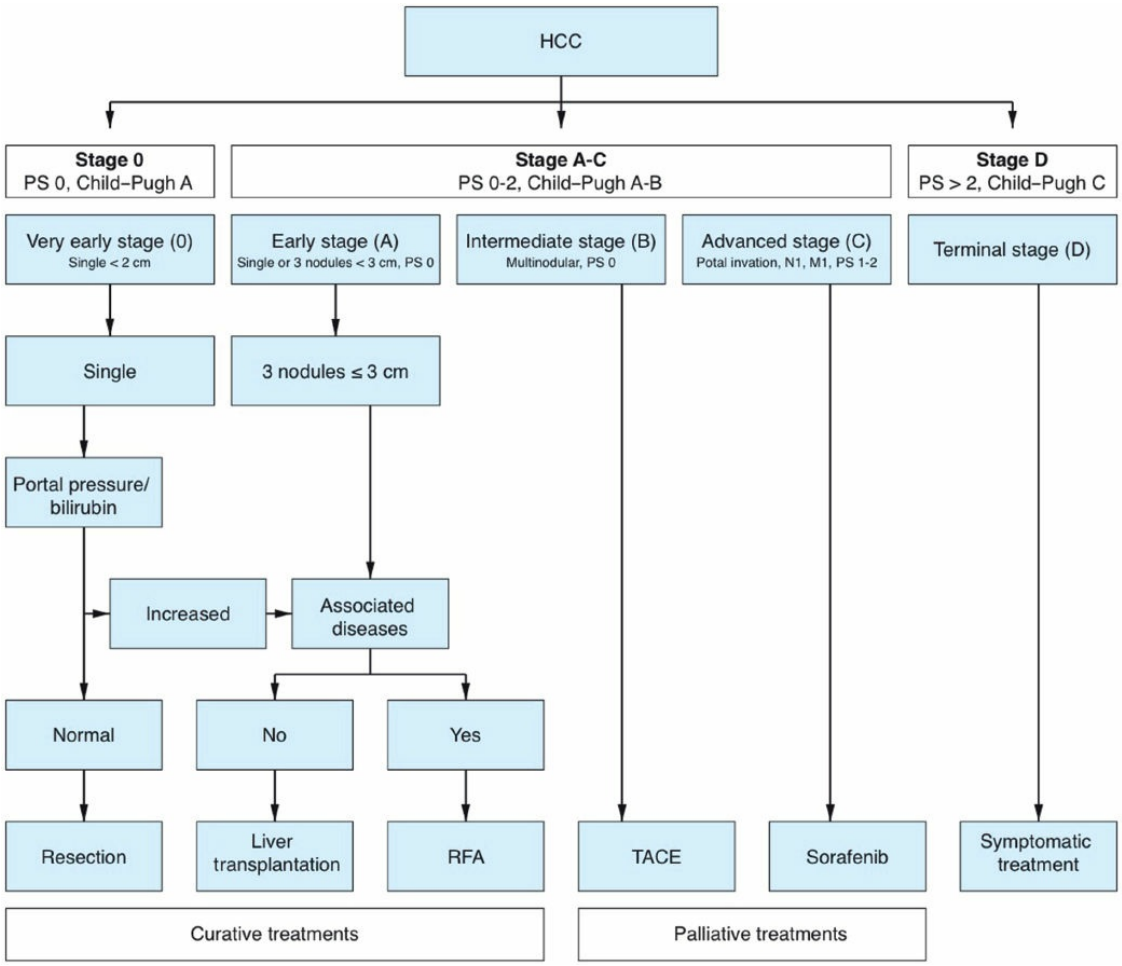

Figure 104.7. Treatment algorithm for HCC. M, metastasis classification; N, node classification; PS, performance status; RFA, radiofrequency ablation; TACE, transarterial chemoembolization. (From Bruix J, Sherman M, American Association for the Study of Liver. Management of hepatocellular adenoma: An update. *Hepatology* 2011;53(3):1020–2. Copyright © 2011, with permission of John Wiley & Sons.)

Rarely, the evaluation of vague abdominal pain or abnormal liver tests

leads to the diagnosis of cholangiocarcinoma in early stages of the disease. Abdominal pain related to the tumor is generally described as a constant dull ache located in the RUQ without radiation. Cholangitis is an unusual presentation (in up to 10% of patients) in the absence of previous biliary instrumentation.

The diagnosis of perihilar cholangiocarcinoma is notoriously difficult and in a patient presenting with obstructive jaundice requires high index of suspicion combined with multiple complementary diagnostic studies. Carbohydrate antigen 19–9 (CA 19–9) and carcinoembryonic antigen (CEA) are two markers being used broadly in diagnosis and surveillance of several intra-abdominal malignancies and its specificity in the diagnosis of cholangiocarcinoma is limited. US findings are largely operator-dependent and play a minimal role in the definitive diagnosis of cholangiocarcinoma. US can be used to exclude underlying benign pathologies (like cholelithiasis, cholecystitis) as the cause of presenting symptoms. In addition, US is sensitive in detecting biliary tract dilation that can be seen in cholangiocarcinoma and in localizing the level and assessing the severity of the obstruction. Ductal dilation >6 mm in the absence of bile duct stones is suggestive of an obstructing bile duct lesion.

MRI/MRCP with contrast is the imaging technique of choice, while MDCT is an alternative in patients who cannot undergo MRI/MRCP. Direct cholangiography techniques (like ERCP or PTC) are considered if there is indication for preoperative biliary decompression or tissue sampling.

If there is high clinical suspicion based on laboratory and imaging findings, surgical therapy may be offered without confirmation by tissue diagnosis or in setting of equivocal tissue sampling. However, tissue sampling via EUS-guided FNA, ERCP, or PTC with brush cytology or in the cases of visible perihilar mass lesion CT-guided/MRI-guided can be considered. Intraductal ultrasound and cholangioscopy are additional adjuncts that might be useful in obtaining tissue.

It should be emphasized that operative exploration remains the definitive technique to rule out cholangiocarcinoma. Relying on the cytology results of the specimens obtained via either of the above-mentioned techniques, considering their low negative predictive value is dangerous and might result in missing the opportunity of resecting an early-stage cancer.

PSC is a well-known risk factor for cholangiocarcinoma with a lifetime

risk of 5% to 15% for malignancy development; therefore, screening of these patients is paramount. With its high incidence (relative risk >1,500), some experts consider PSC a premalignant condition that progresses in the stepwise sequence transforming cholangiocytes to the malignant cells; however, the definitive molecular pathogenesis of this transformation is not as well understood as are other gastrointestinal malignancies, like colon cancer. Moreover, many of these patients present at later stages due to the difficulty in differentiating between benign dominant biliary stricture and malignant stricture. Although there are no definitive guidelines for screening patients with PSC for the development of cholangiocarcinoma, frequent (annual or on an every 6-month basis) surveillance programs consisting of serum tumor markers (i.e., CA 19–9) along with imaging studies (ultrasound or MRI/MRCP) may be beneficial. Patients with persistently elevated CA 19–9 and highly suspicious lesions visualized by noninvasive imaging techniques (i.e., MRCP) should undergo attempts to obtain tissue or cytology using ERCP or EUS. Cholangiocarcinoma in these patients carries a very dismal prognosis.

Surgical resection or transplant (in highly selected cases) remains the best chance for cure for hilar cholangiocarcinoma. The goals of surgical resection are to provide a chance for cure through (1) complete oncologic resection (RO), (2) preservation of sufficient liver remnant, and (3) palliation of biliary obstruction. While transplantation for cholangiocarcinoma is only performed in select centers, if a patient is deemed borderline or not resectable, consideration should be made to evaluation for candidacy for liver transplantation and the patient should be made aware of this option. Transplantation is generally only considered for unresectable hilar tumors <3 cm in size with negative sampled regional nodes and treated with neoadjuvant chemoradiation protocol. Transperitoneal biopsy (percutaneous or EUS-guided) has been associated with an increased recurrence risk after transplant, so it is important to avoid such biopsies in potential transplant candidates, until this option has been ruled out.

LIVER METASTASIS FROM PRIMARY OF ANOTHER ORIGIN

Liver lesion(s) in the setting of previous malignancy should raise suspicion of metastasis secondary to their original cancer. Appropriate surveillance of the primary with imaging and tumor markers should be utilized to

assess for recurrence. Metastasis will have varying appearance on imaging, with metastasis from adenocarcinoma often having a hypoechoic appearance. Tri-phasic (unenhanced, arterial, and portal venous phase) CT of the liver will reveal low attenuating lesions in the case of colorectal, gastric, pancreatic metastasis, while hypervascular lesions are seen in the setting of neuroendocrine, renal cell, breast, thyroid, melanoma, and sarcoma. Tumor-specific imaging may be appropriate, for example, octreotide scan in a patient with a history of neuroendocrine tumor. PET scan should be used liberally to ensure that there is no additional site of metastatic disease or recurrence, especially in cases where the level of tumor marker elevation is incongruent with the demonstrated burden of disease. Biopsy may be necessary to confirm a suspected tissue type in cases where it will effect the treatment plan. Ascites and unilateral pleural effusion without other explanation should raise suspicion for carcinomatosis or malignant effusion. These collections should be sampled and cytology examined.

Colorectal Metastasis

While metastatic disease was once considered a contraindication to aggressive surgical resection, the pendulum has swung and metastasectomy of liver lesions is now well accepted in appropriately selected patients.

Adenocarcinoma of the colon is a significant public health issue, with colon cancer accounting for approximately 10% of all cancer-related deaths.

Because of well-described physiologic and cadaver studies, we know that the liver is the most common site of metastasis for this disease. Twenty-five percent of patients will have liver disease at the time of the diagnosis of their primary cancer, with up to 50% either synchronous disease or metachronous lesions discovered later in the disease course.

The natural history has also been well studied, and the extent of liver disease is one of the principle determinants of survival in these patients.

Multiphasic contrast CT and MRI both have high sensitivity and specificity for the detection of colorectal metastasis (sensitivity 73% and 82% and specificity 97% and 93%, respectively). Lesions are typically hypoenhancing and outside of a history of colorectal cancer, and may be difficult to discern from tumor of other origin. MRI with hepatobiliary-specific contrast enhancement is considered superior in the setting of

background steatosis, which is not uncommon in patients undergoing chemotherapy. The role of PET/CT is unclear and is largely used to detect extrahepatic metastasis that would preclude resection.

While metastatic disease was once considered a contraindication for surgical intervention, resection is now accepted as the gold standard for the treatment of surgically resectable hepatic metastasis. Survival without surgical resection is low with a median of 5 to 10 months; however, excellent results have been consistently achieved using surgical resection. Special attention to a parenchymal sparing approach with a goal of tumor-free margin should be given in colorectal metastatic disease, as a high percentage of these patients will develop recurrence. There is no added survival benefit from a wider margin. The primary tumor should be resected in either a synchronous or staged setting. Most chemotherapy regimens should be stopped 2 to 3 weeks prior to resection, with the exception of Avastin, which should be stopped 6 to 8 weeks prior to surgery due to the increased risk for bleeding and impaired wound healing.

For smaller tumors (<3 cm), promising results have been achieved with percutaneous and operative ablative techniques; however, there are limited data at this time to support this approach over resection except in highly selected patients.

Appropriate treatment for “disappearing metastasis” on imaging in response to chemotherapy remains controversial due to the unclear concordance with complete pathologic response and the evolution of imaging techniques. In general, such sites should be resected or ablated at the time of operative intervention, if they can be identified.

Neuroendocrine Tumors

Patients with gastrointestinal neuroendocrine tumors will have liver metastasis in approximately 10% to 20% of cases. In addition to multiphasic CT or MRI, octreotide scan may be helpful in determining the extent or multifocality of disease. In patients who have been on somatostatin, the timing of their injections must be coordinated with the administration of the examination to prevent a falsely negative study. Resection or locoregional therapy of the lesions is targeted at palliating symptoms (in symptomatic cases) and increasing survival. The goal of resection is cytoreduction of at least 90% of disease, with no significant difference seen in survival between patients who achieved R0, R1, or R2 status. Transarterial therapies have been shown effective in treatment of

these tumors. For patients with unresectable, stable isolated liver disease, transplantation of the liver may be considered, but only in highly selected cases.

HEPATOBILIARY DISEASE IN THE PREGNANT PATIENT

Several hepatobiliary processes are more prevalent during pregnancy. There are several pathologies that are rare during pregnancy, but can be devastating. Several are diseases that are specific to pregnancy, while others are diseases that are not specific to, but exacerbated by the pregnant state.

It should be noted that while special attention should be given to the limiting the exposure of the fetus to ionizing radiation, however, in the emergent evaluation of the pregnant patient, the best and quickest modality should be utilized in order to appropriately diagnose and treat the mother. For this reason, whenever possible, ultrasound modalities are the examination of choice, followed by MRI and lastly CT.

Cholelithiasis is exacerbated by the excess of estrogens during pregnancy. This leads to supersaturated bile and large gallbladder volumes, which results in gallbladder stasis, increased biliary sludge, and gallstones. Ultrasound and MRI/MRCP can aid the diagnosis. MRCP can be particularly helpful in distinguishing choledocholithiasis from cholestasis of pregnancy. EUS is a good alternative to ERCP and fluoroscopy in this setting as well, and has a high sensitivity and specificity. If possible, general anesthesia and surgery should be delayed until the second trimester; however, sepsis has a high risk of fetal loss, so this should be balanced with the risk of surgery at earlier stages of gestation.

Hereditary hemorrhagic telangiectasia (HHT) is an uncommon autosomal-dominant disorder characterized by the development of vascular malformations in multiple organs including the liver. In the liver, arteriovenous and portovenous malformations develop. During pregnancy, likely because of the increase in cardiac output and expansion of blood volume, increased flow through hepatic shunts may result in reversible heart failure. Imaging findings include demonstration of innumerable arteriovenous fistulas, telangiectasias, and focal confluent hepatic masses that become isoenhancing during the portal phase. The hepatic artery is typically enlarged.

Budd–Chiari syndrome is used to define a situation of hepatic venous outflow obstruction. In the noniatrogenic setting, it is usually seen in hypercoagulable states, including pregnancy. It presents with abdominal pain, ascites, and hepatomegaly. It can be diagnosed using duplex ultrasound, which will show an abnormal flow pattern through the portal and hepatic veins. Depending on the chronicity of disease, the liver may have a nodular pattern and collaterals may be present.

As discussed previously, HA and pregnancy should be discussed on a case-by-case basis; however, generally speaking, pregnancy in patients with HA <5 cm should not be discouraged if they can be compliant with regular ultrasound surveillance (every 3 months) during pregnancy and in the postpartum period. The lesion may experience growth during pregnancy in response to the hyperestrogenic state. If the lesion changes significantly during the pregnancy, surgical resection should be performed after the patient has entered the second trimester whenever possible.

Suggested Readings

Aliyev S, Agcaoglu O, Aksoy E, et al. Efficacy of laparoscopic radiofrequency ablation for the treatment of patients with small solitary colorectal liver metastasis. *Surgery* 2013;154(3):556–62.

Burke EC, Jarnagin WR, Hochwald SN, et al. Hilar cholangiocarcinoma: patterns of spread, the importance of hepatic resection for curative operation, and a presurgical clinical staging system. *Ann Surg* 1998;228(3):385–94.

Chapman WC, Klintmalm G, Hemming A, et al. Surgical treatment of hepatocellular carcinoma in North America: can hepatic resection still be justified? *J Am Coll Surg* 2015;220(4):628–37.

Chapman WC, Majella Doyle MB, Stuart JE, et al. Outcomes of neoadjuvant transarterial chemoembolization to downstage hepatocellular carcinoma before liver transplantation. *Ann Surg* 2008;248(4):617–25.

Fowler KJ, Saad NE, Linehan D. Imaging approach to hepatocellular carcinoma, cholangiocarcinoma, and metastatic colorectal cancer. *Surg Oncol Clin N Am* 2015;24(1):19–40.

Gurusamy KS, Nagendran M, Davidson BR. Early versus delayed laparoscopic cholecystectomy for acute gallstone pancreatitis. *Cochrane Database Syst Rev* 2013;9:CD010326.

Heller MT, Tublin ME, Hosseinzadeh K, et al. Imaging of hepatobiliary disorders complicating pregnancy. *AJR Am J Roentgenol* 2011;197(3):W528–36.

Jarnagin WR, Fong Y, DeMatteo RP, et al. Staging, resectability, and outcome in

225 patients with hilar cholangiocarcinoma. *Ann Surg* 2001;234(4):507–17; discussion 517–509.

Marrero JA, Ahn J, Rajender Reddy K, et al. ACG clinical guideline: the diagnosis and management of focal liver lesions. *Am J Gastroenterol* 2014;109(9):1328–47; quiz 1348.

Stoot JH, Coelen RJ, De Jong MC, et al. Malignant transformation of hepatocellular adenomas into hepatocellular carcinomas: a systematic review including more than 1600 adenoma cases. *HPB (Oxford)* 2010;12(8):509–22.

EDITOR'S COMMENT

The surgeon will frequently be asked to consult patients with a variety of biliary and liver problems. Collins and Chapman provide an excellent review of imaging modalities for the gallbladder, biliary tree, and liver. Not uncommonly, the surgeon must complete the evaluation of the patient and order appropriate imaging to sort out various abnormal findings.

Ultrasonography (US) is the procedure of choice for identifying gallstones. Current high-resolution, real-time US can identify gallstones as small as 2 mm, with a sensitivity >95%. Today a variety of providers may perform US and issue reports on the presence or absence of gallstones. In my opinion, the surgeon should rely on the reading by a radiologist. The use of bedside ultrasound by emergency room physicians and other providers is increasing. This is helpful in some emergent situations but is not a replacement for a diagnostic ultrasound performed under the supervision of a radiologist and interpreted by a radiologist. Scruggs et al. (Scruggs W, Fox JC, Potts B, et al. Accuracy of ED bedside ultrasound for identification of gallstones: retrospective analysis of 575 studies. *West J Emerg Med* 2008;9(1):1–5) reviewed the sensitivity and specificity of ultrasound done by emergency medicine physicians compared to radiologists. They found in 575 patients who received both bedside and radiology ultrasounds, radiology diagnosed gallstones in 344 of 575 (60%). ED ultrasound was positive for gallstones in 332 (57.7%) patients. ED bedside interpretation was 88% sensitive (95% CI, 84% to 91%) and 87% specific (82% to 91%), and the positive predictive value (PPV) was 91% (88% to 94%) and negative predictive value (NPV) was 83% (78% to 87%). The accuracy of the ED ultrasound was 87.2%. Importantly, they found that 6% of images obtained by bed side ultrasound were inadequate possibly because of the limited duration of the examination, variable experience, patient positioning, and use of other adjuncts. The radiology literature demonstrates a sensitivity of 81% to 99% for radiology ultrasound for the diagnosis of cholelithiasis, although the majority of the studies demonstrating sensitivities at the lower end of the range were performed in the early years of ultrasound. A rigorous meta-analysis of the radiology literature by

Shea et al. (Shea JA, Berlin JA, Escarce JJ, et al. Revised estimates of diagnostic test sensitivity and specificity in suspected biliary tract disease. *Arch Intern Med* 1994;154:2573–81) for the diagnosis of cholelithiasis found a sensitivity of 97% and specificity of 95% (unadjusted for verification bias). If one is making a decision to perform an operation on a patient, then he or she must have highly accurate imaging.

In addition to identifying gallstones, ultrasound may be helpful in diagnosing acute cholecystitis. The most sensitive US finding in acute cholecystitis is the presence of cholelithiasis in combination with the sonographic Murphy sign. As many as 70% of patients with acute cholecystitis may display this sign. Its absence does not exclude acute cholecystitis. Both gallbladder wall thickening (>3 mm) and pericholecystic fluid are secondary findings. Other less specific findings include gallbladder distension and sludge. The findings should be correlated with clinical findings in the patient to establish the diagnosis.

It is not unusual for the ultrasound to be interpreted as showing gallbladder polyps. Are gallbladder polyps detected incidentally on a diagnostic ultrasound of clinical significance? It is estimated that 4% to 7% of patients who undergo ultrasound of the gallbladder are diagnosed with gallbladder polyps. The question that arises are these truly neoplastic polyps that should be followed. Corwin et al. (Corwin MT, Siewert B, Sheiman RG, et al. Incidentally detected gallbladder polyps: is follow-up necessary? Long-term clinical and US analysis of 346 patients. *Radiology* 2011;258:277–82) reported an extensive study in patients with incidentally found gall bladder polyps. A total of 517 patients with gall bladder polyps were identified. Of these, 171 were excluded because of insufficient follow-up. Of the remaining 346 patients, single polyps were seen in 216 patients, and multiple polyps were seen in 130 patients. Polyps ranged in size from 1 to 18 mm with a mean size of 5 mm. Of the 346 patients, 42 underwent cholecystectomy. Of these, 13(31%) had polyps on pathologic examination, including 1 who also contained a stone and 6 cases of cholesterolosis. Twenty-four (57%) demonstrated stones and no polyps and 5 (12%) showed no stones or polyps on pathologic examination. Of the 346 patients, 149 (43%) had US follow-up and the size of the polyp at the latest follow-up US was stable in 90 (60%), decreased in 8 (5%), and increased in 1 (1%), and the polyp had resolved in 50 (34%) patients. In one patient with a polyp that increased in size, it went from 3 to 5 mm over 4 years. Of the 155 patients who had clinical follow-up from 5 to 10 years after the index ultrasound, none had any evidence of gallbladder-related disease and there were no cases on gallbladder cancer.

Based on this study and many others, it seems that many so-called polyps are in fact gallstone, up to 57%. In addition to gallstones, some of the so-called polyps are adherent cholesterol sludge or cholesterol polyps and not neoplastic polyps. If a patient is having symptoms consistent with gallbladder disease and an US shows a “polyp”, it would seem that cholecystectomy is warranted.

Similarly it would seem that long-term follow-up did not demonstrate any

progression in most patients and no cases in gallbladder cancer during the follow-up period. In addition, the authors reported that no neoplastic polyps <7 mm were seen. Hence, they proposed that incidentally detected polyps less than or equal to 6 mm require no additional imaging for follow-up. In our practice, we order imaging in such cases if the patients have symptoms or if they have anxiety about the diagnosis.

Is the adenoma–carcinoma sequence at play in gallbladder cancer? Kozuka et al. (Kozuka S, Tsubone M, Yasui A, et al. Relation of adenoma to carcinoma in the gallbladder. *Cancer* 1982;50:2226–34) suggested that it does after examining 1,605 cholecystectomy specimens finding 7 adenomas with malignant change and 15 carcinomas with adenomatous changes. All of the adenomas with malignant changes were >12 mm. Other authors favor a dysplasia–cancer pathway.

Combining this information with other literature, we recommend the following regarding the management of gallbladder polyps: Symptomatic patients should be considered for cholecystectomy, patients with a polyp 10 mm or greater or with findings suspicious for malignancy (a vascular pedicle) should have elective cholecystectomy, those with a polyp between 6 and 10 mm should have follow-up ultrasound, and those with polyps 6 mm or less should have clinical follow-up.

Biliary dyskinesia is a gallbladder dysfunction where the gallbladder fails to contract properly and/or a reduction in the speed of emptying of the biliary tree occurs. Patients present with biliary type pain. A busy general surgeon may see a case or two per week. Biliary dyskinesia is defined as a gallbladder ejection fraction <35% and cholecystectomy can be considered. There is a subset of symptomatic patients, however, who have an abnormally high ejection fraction, defined as >65%. The approach to the treatment of these patients with biliary hyperkinesia is still undetermined, as there is little in the literature regarding this entity. Biliary dyskinesia is diagnosed by CCK cholescintigraphy. The technique is described as follows. After an overnight fast, 99mTc-diisopropyl-iminodiacetic acid (DISIDA) or 99mTc-hepatic iminodiacetic acid (HIDA) is given as an intravenous bolus. When the radioactivity is maximal from the gallbladder and is minimal from the liver, an infusion of CCK is started to stimulate gallbladder contraction. This results in gallbladder contraction and emptying of the radiolabeled tracer. A variety of methods of CCK administration are reported. Some prefer a slow infusion of CCK (sincalide 0.02 mcg/kg given over 30 to 60 minutes) (Dibaise JK, Richmond BK, Ziessman HA, et al. Cholecystokinin-cholescintigraphy in adults: consensus recommendations of an interdisciplinary panel. *Clin Nuc Med* 2012;37:3). Rapid administration of CCK over 2 to 3 minutes of CCK is preferred by others. This can be associated with cramping, patient discomfort, and highly variable results. Slower infusion rates (over 30 to 60 minutes) seem to lead to less inter- and intrasubject variability and an overall increase in mean gallbladder ejection fraction compared with rapid infusion. Variability in CCK administration

techniques may account for some of the differences seen in studies examining the ability of the ejection fraction to predict a response to cholecystectomy. Normokinetic biliary dyskinesia (DuCoin C, Faber R, Ilagan M, et al. Normokinetic biliary dyskinesia: a novel diagnosis. *Surg Endosc* 2012;26:3088–93) and hyperkinetic biliary dyskinesia (Lindholm EB, Alberty JB, Hansbourgh F, et al. Hyperkinetic gallbladder: an indication for cholecystectomy? *Am Surg* 2013;79:882–4) have been described. Some patients with the latter findings do improve after cholecystectomy. Frankly, I do not recommend surgery for either of the latter two groups of patients. I have found it helpful to consult with a gastroenterologist. Not uncommonly these patients are diagnosed with irritable bowel syndrome and respond to management for this condition.

The authors discuss imaging for suspected biliary obstruction. Initially an ultrasound should be performed to determine if there is extrahepatic biliary dilation. If present, then additional imaging is based on clinical presentation, labs, and the findings on US. MRI is extremely helpful as it can identify the site of the obstruction and the possible cause, that is, stone, stricture, or tumor. If there is a stone, ERCP is the next step as the stone can be removed. If there is a common duct stone, the patients will need a cholecystectomy. In our experience, there are better outcomes if an ERCP and stone removal proceed cholecystectomy. This may vary on the availability of ERCP at an institution. If there is a tumor or stricture, then endoscopic ultrasound is extremely helpful and will potentially allow a tissue diagnosis.

Dasari et al. reported a systematic review that attempted to answer the question of the safest and most effective method to remove common duct stones and the timing with cholecystectomy (Dasari BV, Tan CJ, Gurusamy KS, et al. Surgical versus endoscopic treatment of bile duct stones. *Cochrane Database Syst Rev* 2013;12:Art. No.:CD003327. doi:10.1002/14651858.CD003327.pub4). The bottom line is that there is no significant difference in the mortality, morbidity, retained stones, and failure rates between the single-stage laparoscopic bile duct clearance and two-stage endoscopic management. They concluded that additional randomized clinical trials without risks of selection bias and random errors are necessary to confirm these findings. There have been numerous studies with the same conclusion. The best advice is to do what you are most comfortable with and the available expertise at your hospital.

The information of imaging of hepatic lesions is particularly well done and inclusion of the LI-RADS nomenclature for outlining treatment steps for HCC workup is extremely helpful. General surgeons are frequently asked to evaluate liver lesions that have been found incidentally—hepatic incidentalomas. The exponential growth in the use of advanced imaging has led to the more frequent detection of incidental hepatic masses in both the oncology and nononcology patient population. This has created a management dilemma that is particularly pertinent to oncology patients, in whom any hepatic mass warrants attention. Hepatic incidentalomas are found in 10% to 33% of imaging studies. At

autopsy, as many as 52% of noncancer patients have benign hepatic lesions, and liver metastases are found in as many as 36% of patients dying with cancer. Whether for cancer or noncancer patient, the key questions are: (1) Is the hepatic incidentaloma associated with a potential adverse outcome? (2) What is the most reliable way to determine which lesions are significant? (3) What is the best management of these incidentalomas? I think that no one has the answers to all these questions. However, Berland et al. prepared a white paper of the American College of Radiology Incidental Findings Committee (Berland LL, Silverman SG, Gore RM, et al. Managing incidental findings on abdominal CT: white paper of the ACR incidental findings committee. *JACR* 2010;7:754–73), which has recommended appropriate terminology to be used by the radiologist in her or his dictation. This can minimize potentially unnecessary tests by establishing common terminology. The key is to strike a balance between overtesting and establishing an accurate diagnosis.

Hepatic incidentalomas challenge physicians and confuse patients with how to manage them. Although it is known that the majority are likely benign and often have little or no clinical significance, the inclination to evaluate them is often driven by physician and patient unwillingness to accept uncertainty and defensive medicine. Nearly 40% of patients with a hepatic incidentaloma have additional imaging. Newer MR modalities have proven useful and are relevant. The recently introduced Gd-EOB-DTPA is a biphasic hepatobiliary MR contrast agent. Chung et al. (Chung YE, Kim MJ, Kim YE, et al. Characterization of incidental liver lesions: comparison of multidetector CT versus Gd-EOB-DTPA–enhanced MR imaging. *Plos One* 2013;8(6):e66141) report a comparison of contrast-enhanced multidetector CT (MDCT) and Gd-EOB-DTPA–enhanced MRI for characterization of incidental liver masses. The results demonstrate that Gd-EOB-DTPA–enhanced MR provides better diagnostic accuracy for the differentiation of benign and malignant lesions and for the specific diagnosis of FNH and focal eosinophilic infiltration. Both dynamic contrast–enhanced CT and Gd-EOB-DTPA–enhanced MR had similarly high diagnostic accuracy for hemangioma and HCC. This may prove the one step test for the final resolution of the hepatic incidentaloma.

E. Christopher Ellison

105 Approaches to Drainage of Hepatic, Perihepatic, and Subhepatic Abscesses

Timothy L. Pruett and Daniel Borja-Cacho

PYOGENIC LIVER ABSCESS

Epidemiology

The incidence of pyogenic liver abscesses in the United States is 3.6 per 100,000 population. This frequency is on par with other Western countries such as Canada and Denmark in which the published incidence was 1 and 2.3 per 100,000, respectively. In contrast, the disease is more common in Asian countries such as Taiwan (17.6 per 100,000 population).

The risk of developing liver abscesses increases with advanced age. Patients older than 65 are more likely to develop this disease as compared with younger patients. Men are affected more frequently. Approximately 60% to 70% of the cases occur in males. The risk of developing pyogenic liver abscesses increases with certain comorbidities. Diabetes mellitus (DM) has been recognized as the most prevalent comorbidity in patients with liver abscesses. It is present in up to 48% of the patients at the time of diagnosis. Diabetic patients develop abnormalities in both cell-mediated and humoral immune responses, resulting in increased susceptibility to infections. Hepatobiliary neoplasms, pancreas and colorectal cancer (CRC), ethanol abuse, chronic immunosuppression, chronic kidney disease, previous liver transplantation, and benign biliary disease are also associated with increased risk of developing liver abscesses.

Pathophysiology

The most frequent mechanisms that lead to bacterial infection of the liver parenchyma include:

1. Ascending cholangitis/biliary infection. It is the most common source of infection. Ascending cholangitis is usually associated with biliary obstruction that predisposes to bile stasis, bacterial proliferation, and

cholangitis with secondary infection of the liver. Not infrequently, patients with obstructive jaundice require repeated instrumentation of the biliary tract and are colonized by resistant bacteria and/or fungi. Common causes of biliary obstruction include choledocholithiasis, periampullary tumors, and extrahepatic cholangiocarcinoma. It can also be due to diseases that are more difficult to treat such as hepatic artery thrombosis in liver transplant recipients. This posttransplant complication leads to biliary ischemia, diffuse biliary strictures, and liver parenchyma necrosis. Additional examples include simultaneous bile duct and hepatic artery injury during laparoscopic cholecystectomies or ischemic cholangiopathy in donor after cardiac death (DCD) recipients.

2. Hematogenous venous dissemination. The first cases of pyogenic liver abscesses were frequently associated with complicated intra-abdominal infections. However, early diagnosis of appendicitis, diverticulitis, and other intra-abdominal infections as well as better antibiotic therapy has decreased its incidence. Nevertheless, any disease that alters the integrity of the gastrointestinal (GI) mucosa can produce bacterial translocation and portal vein dissemination. For example, the chronic inflammation of the intestinal mucosa that occurs in patients with inflammatory bowel disease (IBD) results in a friable mucosa and loss of the normal architecture. Bacteria invade the damaged mucosa and reach the portal circulation. Patients with IBD are at increased risk of developing pyogenic liver abscesses. The relative risk is slightly higher in patients with ulcerative colitis as compared with Crohn disease. Additional examples include bowel ischemia and CRC. Interestingly, in some patients, the diagnosis of liver abscess can precede the diagnosis of non-metastatic colorectal neoplasms more than 2 years. Since the source of bacteria is always the GI tract, the most common pathogens isolated from these abscesses include gram-negative rods and *Streptococcus* species. In the absence of an obvious source of infection, isolation of *Streptococcus* spp. should always increase the concern of a colonic pathology.
3. Hematogenous arterial infection. Infective endocarditis, osteomyelitis, untreated oral infections, and illicit intravenous (IV) drug use can be associated with pyogenic liver abscesses. In these conditions, septic emboli reach the liver through the hepatic artery. It accounts for less than 10% of the cases. Cultures usually show monomicrobial growth of gram-positive cocci such as *Staphylococcus aureus.* Not infrequently, patients have multiple bilateral small abscesses.

4. Direct trauma. Radiofrequency ablation (RFA), cryotherapy, and any other form of liver intervention can be complicated by direct inoculation of bacteria into the liver parenchyma. The incidence of liver abscesses after RFA is 0.4%. Its frequency increases in patients with prior bilioenteric anastomoses. Pyogenic hepatic abscesses may complicate penetrating and non-penetrating liver trauma. Liver abscesses occur in 0.7% to 1.5% of patients undergoing non-operative treatment of liver trauma. Risk factors include coexistence of small bowel injuries, persistent bleeding, massive blood transfusions, and extensive tissue damage.
5. Extension from a contiguous septic process. Although very rare, complicated acute cholecystitis may result in the formation of intrahepatic abscesses. Benign or malignant perforations of the stomach, duodenum, or colon can be associated with the formation of an abscess that directly extends into the liver parenchyma.

In 20% to 27% of the cases, no underlying source of infection can be identified. These abscesses are described as cryptogenic. The frequency of cryptogenic abscesses depends on the type of population studied. Cancer centers have a lower incidence of cryptogenic abscesses because most infections are secondary to malignant biliary obstructions or CRC. On the other hand, cryptogenic abscesses and benign biliary disease are the most common etiology in large community hospitals.

Clinical Manifestations

Constitutional symptoms such as fever, chills, and malaise are very common manifestations of this disease. They frequently precede other symptoms and are present in 80% to 88% of the patients. Right upper quadrant (RUQ) pain is seen in 33% to 70% of the patients. Its frequency is influenced by the size and location of the abscess and the presence of biliary obstruction. RUQ pain is more common in lesions larger than 5 cm and abscesses located close to the diaphragm. Jaundice is present in only 8% to 21% of the cases. Patients with liver abscesses that arise in segments VII and VIII of the liver may develop pleuritic-type pain or cough. No correlation between symptoms and the underlying disease exists.

Fever and hepatomegaly are physical examination signs present in 60% and 40%, respectively. Additional manifestations include RUQ tenderness, jaundice, decreased breath sounds, and crackles in the right hemithorax.

Diagnosis

Leukocytosis is a common finding present in 65% to 77% of the patients. Liver function tests are frequently abnormal, but no specific pattern suggestive of pyogenic liver abscesses exists. Abnormal elevation in alkaline phosphatase, aminotransferases, and total bilirubin occurs in 50% to 70%, 40% to 50%, and 20% to 30% of the patients, respectively. Hypoalbuminemia, hyponatremia, bandemia, and elevated C-reactive protein are very common. However, these are nonspecific findings present in many inflammatory and infectious processes.

The initial assessment includes a chest x-ray to evaluate the fever, cough, and pleuritic pain. Common radiographic findings include elevated right hemidiaphragm and/or right pleural effusion. However, these findings are seen in other pathologies. Pathognomic signs such as the presence of intrahepatic gas or air-fluid levels and portal vein gas are rare.

Liver ultrasound is commonly used as a first step of evaluation. Its sensitivity is 83% to 95% and is influenced by the size, location, and pathologic state of the abscess. During the early phase of infection, before necrosis has occurred, liver abscesses appear solid, hyperechoic, and are difficult to distinguish from normal parenchyma. As liquefaction and necrosis ensue, abscesses appear as complex cystic masses with internal echoes and distal acoustic enhancement (Fig. 105.1). Liver abscesses are not vascularized. Therefore, blood flow is only observed in the periphery. Bile duct structures running through them are not seen.

Contrast-enhanced computed tomography (CT) of the abdomen has a sensitivity of 95%. As Figure 105.2 shows, liver abscesses usually appear as well-defined hypoattenuating lesions. Large abscesses may be unilocular with smooth margins or complex with internal septa and internal contour. Mature abscesses usually do not have internal enhancement. Rim enhancement and the presence of gas are very uncommon (5% to 20% of the patients). Thrombosis of the hepatic veins or portal associated with these infections is a very rare finding that is probably more common in patients with *Klebsiella pneumoniae* infection.

In magnetic resonance imaging (MRI), pyogenic abscesses typically appear as hypointense lesions on T1-weighted images and hyperintense on T2-weighted images (Fig. 105.3A). The abscess wall is always visible without contrast if it is thicker than 5 mm. Rapid and almost universal wall enhancement occurs after IV gadolinium administration. This is independent of the thickness of the wall, and it is secondary to increased

capillary permeability. Internal septa can be present. Mature collections do not exhibit internal enhancement. Liver abscesses show restricted diffusion on diffusion-weighted imaging. As previously described, vein thrombosis is a rare finding. Finally, the biliary reconstruction performed during magnetic resonance cholangiopancreatography (MRCP) is a useful tool that can identify communication between liver abscesses and the biliary tract (Fig. 105.3B).

A solitary and dominant lesion is identified in 60% to 70% of the patients. Abscesses are more common in the right lobe (70%). Bilobar disease is present in 15% of the patients. Solitary abscesses are more likely to be polymicrobial as compared to multiple abscesses.

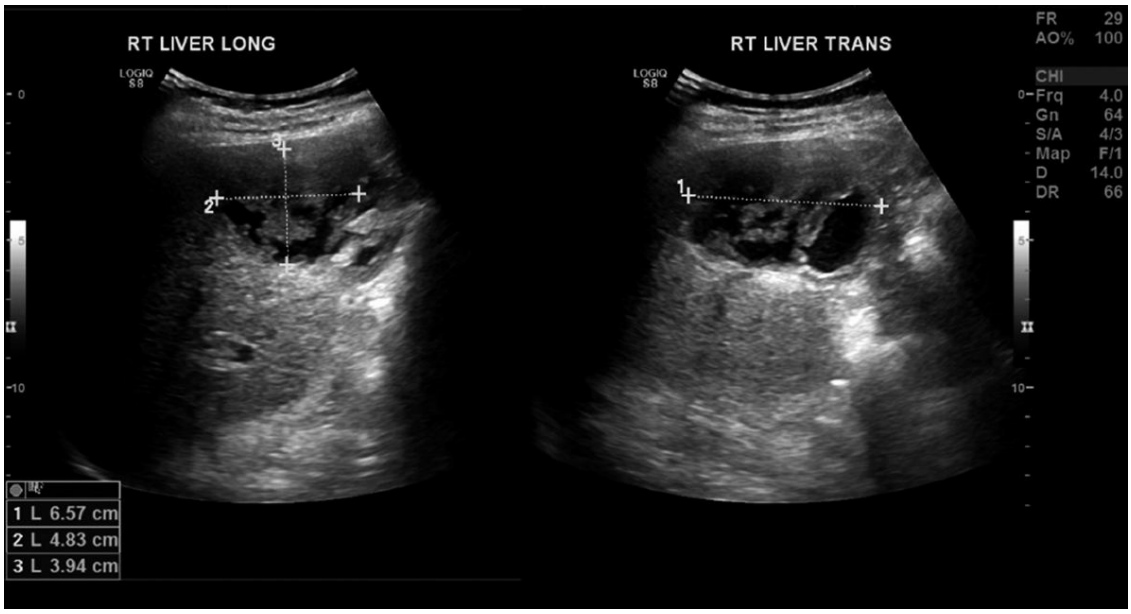

Figure 105.1. Liver ultrasound of a 62-year-old male with history of a liver transplant and late hepatic artery thrombosis. The abscess is located in the right lobe and appears as a complex cystic mass with internal echoes. No evidence of blood flow inside the lesion was seen in the Doppler.

Microbiology

Microorganism identification is critical. It can be done through blood cultures or percutaneous aspirates. The sensitivity of percutaneous aspirates is superior to blood cultures, but blood cultures are very easy to obtain and almost universally available. Ideally, two or more blood cultures should be requested. Systemic antibiotic therapy decreases the yield of bacterial isolation, but such cultures should never delay the treatment. Gram stain and cultures from percutaneous aspirates should be

ordered as soon as the diagnosis has been confirmed.

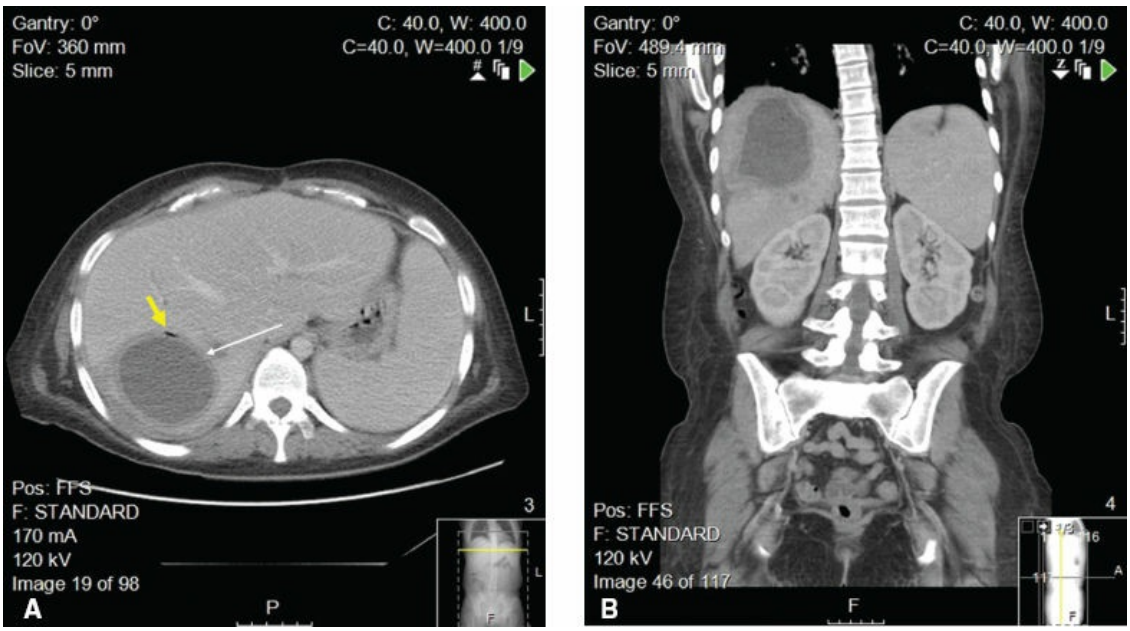

Figure 105.2. Contrast-enhanced CT of a 32-year-old female with a pyogenic liver abscess secondary to simultaneous injury to the right hepatic duct and right hepatic artery. The patient developed recurrence of the abscess three times and required a right hepatectomy for permanent treatment. As illustrated in (**A**), the abscess appears unilocular and hypodense with smooth margins. The abscess has gas (*small yellow arrow*) and contrast enhancement (*large white arrow*). **B.** Coronal view.

The isolated pathogen is influenced by the mechanism of disease and the geographic region. In the largest population-based study performed in the United States, *Streptococcus* species and *Escherichia coli* were the two most common bacteria isolated (29.5% and 18% of the patients, respectively). This finding has been reproduced in several single-institution studies performed in United States, Canada, and other Western countries. Polymicrobial infections are not uncommon, especially in patients with biliary obstruction. The growth of anaerobes such as *Bacteroides fragilis*, *Peptostreptococcus*, and *Fusobacterium nucleatum* occurs in less than 5% to 10% of the patients.

In Southeast Asia, the leading microorganism is *Klebsiella pneumoniae*, but not all *K. pneumoniae* strains are associated with the development of liver abscesses. The presence of capsular serotypes K1 or K2, mucoviscosity-associated gene A (*magA*), regulator of mucoid phenotype A gene (*rmpA*), and aerobactin increases the virulence of this pathogen.

Mutant strains without K1 or K2 antigens, decreased expression of *magA*, or ablation of *rmpA* exhibit increased susceptibility to phagocytosis. Epidemiologic studies have shown that the prevalence of *K. pneumoniae* in healthy Asian adults is 75% with a prevalence of serotype K1 or K2 of 23%. In European studies, this prevalence decreases to 10% to 19%. This difference in prevalence might explain the difference in microbiology among Western and European reports. Interestingly, reports from the United States showed that isolation of *K. pneumoniae* is more common among Asian patients as compared with Caucasian or African-American patients.

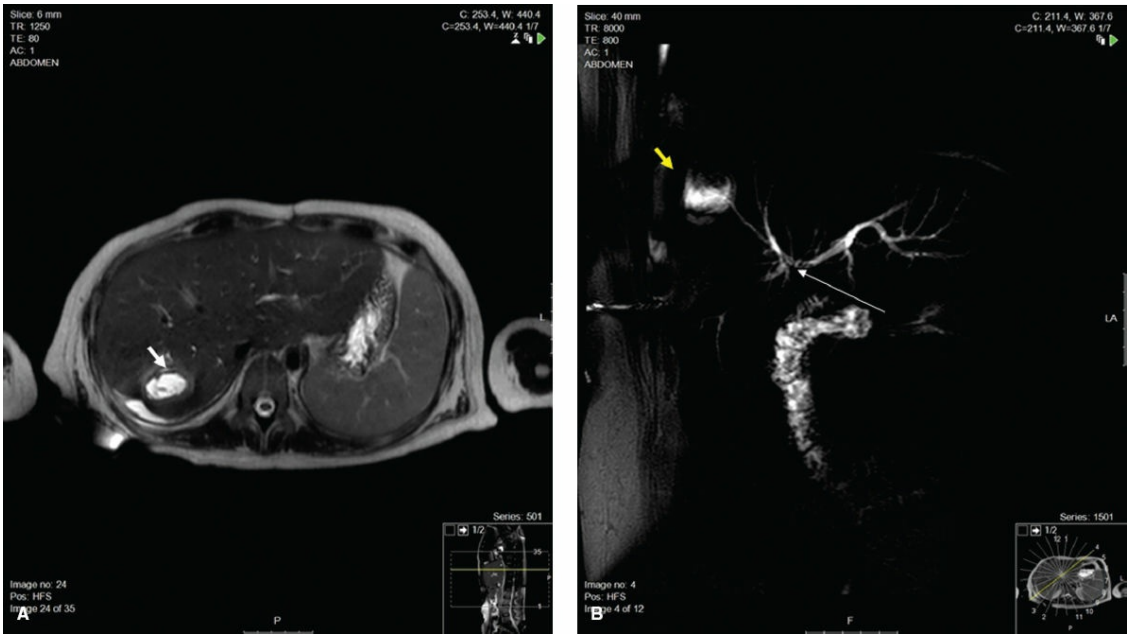

Figure 105.3. Magnetic resonance of liver in a patient with an abscess in the right hepatic lobe. The T2-weighted image (**A**) of a 60-year-old female patient with an abscess in the right hepatic lobe. The abscess appears hyperintense and has contrast reinforcement (*small white arrow*). The MRCP (**B**) demonstrates that the abscess is communicated with the right hepatic duct (*small yellow arrow*) and is secondary to and obstruction at the level of the confluence of the right and left hepatic ducts (*large white arrow*).

Repeated biliary tract manipulation, prolonged intensive care unit stay, recent exposure to broad spectrum antibiotics, and history of liver transplantation increase the risk of colonization and infection by more resistant microorganisms such as extended spectrum beta-lactamase (ESBL)-producing Enterobacteriaceae, vancomycin-resistant *Enterococcus*

faecium (VRE), methicillin-resistant *Staphylococcus aureus* (MRSA), and *Candida* spp.

Treatment

Patients with pyogenic abscesses frequently develop a systemic inflammatory response. Therefore, the initial goals of therapy are similar to any other septic patient and include an aggressive fluid resuscitation, early (within 1 hour) administration of IV antibiotics, and control of the source. Strict glycemic control is very important, especially if *K. pneumoniae* has been isolated.

The initial empirical therapy is influenced by the suspected etiology, recent exposure to antibiotics, history of immunosuppression or chemotherapy administration, repeated biliary tract instrumentation, documented history of colonization by multi-drug resistant bacteria and/or fungi, and the prevalence of drug-resistant organisms in each hospital. Initial broad-spectrum antibiotics against gram-negative rods and gram-positive cocci are recommended. Community-acquired infections can be treated with ampicillin/sulbactam, ticarcillin/clavulanate, piperacillin/tazobactam, a third- or fourth-generation cephalosporin, or a fluoroquinolone with or without metronidazole. Patients with hospital-acquired infections, repeated biliary tract instrumentation, or history of transplantation require ESBL-producing Enterobacteriaceae, VRE, MRSA, and yeast coverage. Early administration of fluconazole or an echinocandin is recommended in patients with suspected *Candida* species infection. Empirical use of micafungin is preferred in patients with severe illness or if *Candida glabrata* is suspected. Carbapenems are the drug of choice for ESBL-producing Enterobacteriaceae. Daptomycin and linezolid are recommended for patients with VRE infection. Deescalation to the most appropriate single-agent therapy should be done as soon as the culture and susceptibility results are obtained. The total duration of antibiotics should be tailored to the clinical and radiographic response.

Source Control/Surgical Treatment

The mainstay of therapy is systemic administration of broad spectrum antibiotics, but source control of the infection should be performed as soon as the initial resuscitation has been completed. In the absence of percutaneous or surgical treatment, the historical mortality rate of liver abscesses was close to 100%. Routine exploratory celiotomy and abscess

drainage decreased the mortality rate, but it was associated with prolonged length of stay and perioperative complications such as bleeding, need for transfusion, surgical site infection, and wound dehiscence. Placement of percutaneous drainage catheters by interventional radiology has slowly replaced surgery because it is less invasive and has a lower incidence of such complications. The success rate of percutaneous drainage depends on the etiology. Factors associated with failure of percutaneous drainage include *Candida* infection, presence of multiloculated abscesses, intra-abscess debris, immunosuppression secondary to chemotherapy or immunosuppressive regimens in transplant patients, and inappropriate placement or early removal of the drain. In the absence of biliary obstruction or neoplasm, the success rate in solitary abscess drainage is 70% to 90%.

Liver abscesses secondary to ascending cholangitis and biliary obstruction require routine percutaneous or endoscopic resolution of the obstruction to avoid treatment failure.

The role of surgical treatment is now limited to patients who fail percutaneous drainage or who require surgery to treat the underlying cause of the disease such as bile duct injury after cholecystectomy, localized neoplasm, need for liver retransplantation, appendicitis, or uncontrolled biliary fistulas.

Operative Approach

With the patient in supine position, an abscess can be approached through a supra-umbilical midline incision or right subcostal incision (Fig. 105.4). In general, the access to isolated liver diseases is achieved better through subcostal incisions. Midline incisions are preferred in patients with additional extrahepatic pathologies. Once the abdomen has been examined, intraoperative ultrasound is recommended to locate the lesion. In experienced hands, it allows visualization of major blood vessels and allows needle aspiration guidance to confirm the presence of purulent fluid. Fluid and tissue specimens should be immediately sent for gram staining, culture, and cytology to rule out malignancy. After the initial aspiration, a small hepatotomy using electrocautery allows irrigation and drainage of the cavity. The next step is placement of a closed suction drain that is exteriorized through a separate incision in the abdominal wall. Closure of the abdomen is performed in the standard fashion.

In selected cases of patients with isolated infected neoplasms or small

abscesses, liver resection can be attempted. However, liver resections in the presence of infection are discouraged due to increased complication rate.

Complications

Rare but potentially serious complications comprise spontaneous rupture to the peritoneal cavity or pleural space. Spontaneous rupture into the pleural space leads to severe pulmonary complications, including empyema (Fig. 105.5), enlarged right pleural effusions, pneumonia, and more rarely bronchobiliary fistula. Right empyema can be the result of percutaneous drainage of livers abscesses through the right diaphragm.

Patients with abscesses secondary to *K. pneumoniae* are more likely to develop metastatic spread of the infection into the lungs, central nervous system, and eyes. Therefore, pneumonia, meningitis, and endophthalmitis are reported more frequently in Asian cohorts.

As Table 105.1 shows, the mortality rate of patients with pyogenic liver abscesses ranges between 2.5% and 32%. Most patients die as a result of uncontrolled sepsis that progresses to severe sepsis, septic shock, and multi-organ failure. The mortality rate is higher in patients with pyogenic liver abscesses arising in the setting of malignancies. Adjuvant therapy is frequently delayed in cancer patients with uncontrolled sepsis. Therefore, patients with liver abscesses arising in the setting of neoplasms die as a result of septic complications and/or malignancy progression. Additional factors associated with poor outcomes include multiloculated abscesses, unresolved bile duct obstruction, multiple abscesses, impaired renal function, and yeast infection. Progression to sepsis and septic shock are independent risk factors for mortality. Although DM is very common in these patients, its presence is not associated with worse outcomes.

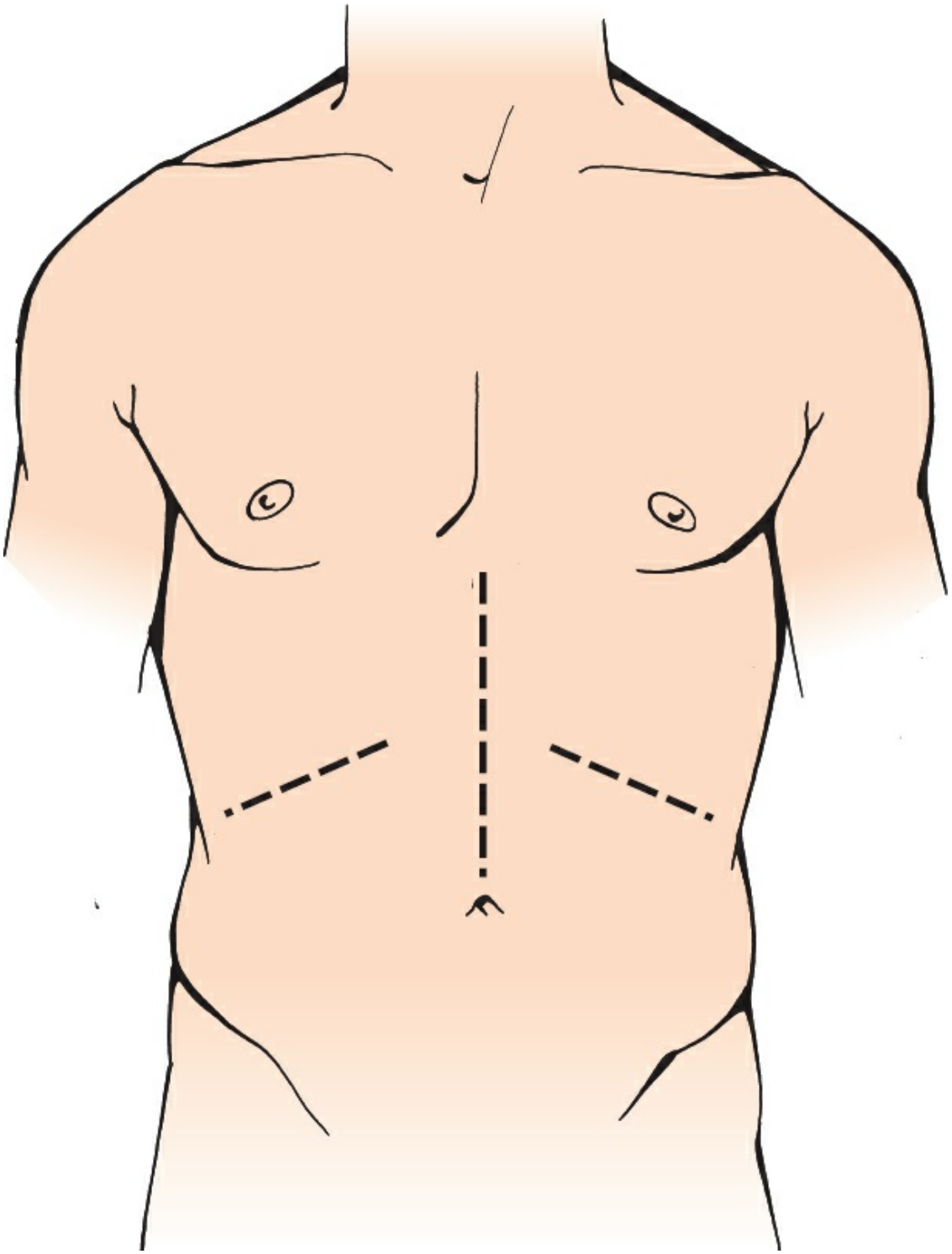

Figure 105.4. The sites for subcostal and midline incisions are shown here. For simple drainage, subcostal sites are preferable, but a midline approach is usually necessary when additional procedures need to be done.

AMEBIC LIVER ABSCESS

Epidemiology

Amebic liver abscesses are rare in the United States, but very prevalent in Mexico, Central and South America, India, Southeast Asia, and Africa. The intestinal infection by this protozoan equally affects both genders, but amebic liver abscesses are more common in males (male/female ratio 10 to 1). In contrast to bacterial abscesses, this disease affects young patients between ages 18 and 50. Factors associated with increased risk of infection include traveling to an endemic country, cell mediated immunosuppression secondary to HIV or steroid use, malignancy, male-homosexuality, and malnutrition.

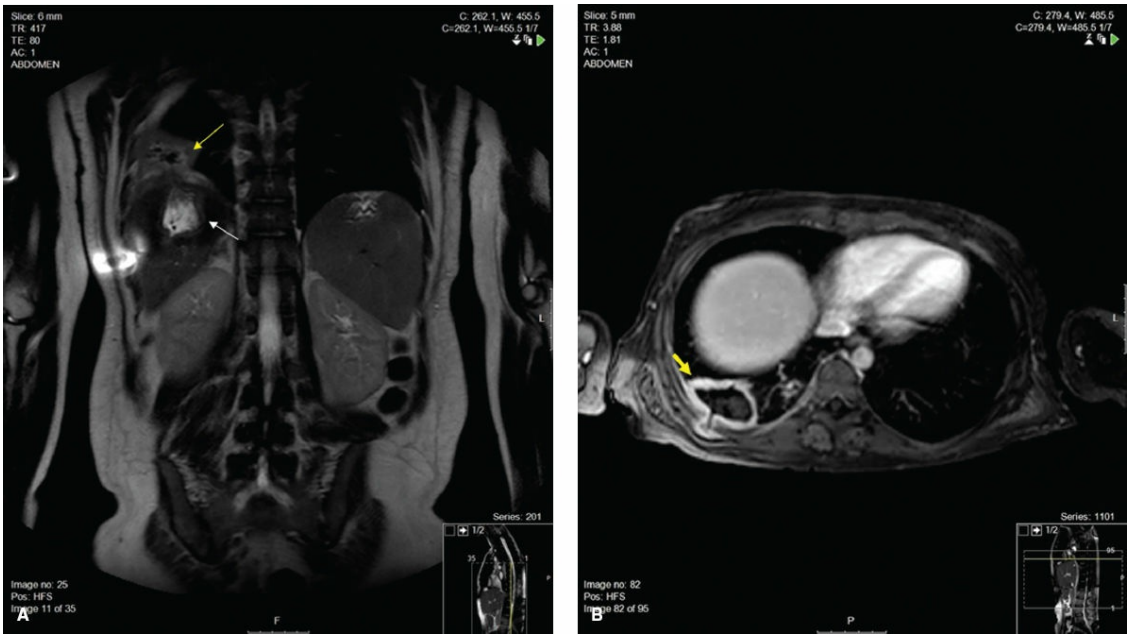

Figure 105.5. MRI demonstrating spontaneous rupture of an abscess in the right hepatic lobe (*thin white arrow*) into the right pleural space (*thin yellow arrow*) (**A**). As demonstrated in (**B**), the empyema appears hypointense with contrast-enhancement in the periphery of the abscess (*small yellow arrow*) in T1-weighted images.

TABLE 105-1 Collected Series of Pyogenic Liver Abscess

Author (ref)	Year	Country	No. of Patients	Age (Years)	Microorganism	Diabetes Mellitus (%)	Malignancy (%)	Mortality Rate (%)
Alvarez	2001	Spain	133	59.9	*Escherichia coli*	13.0	22.0	13.9
Branum	1990	USA	73	55.0	*E. coli* and *Klebsiella pneumoniae*	10.9	17.8	19.0
Foo	2010	Taiwan	377	63 and 58[a]	*K. pneumoniae*	48.3	10.3	6.1
Kaplan	2004	Canada	71	62.4	*Streptococcus milleri* 44%	28.1	19.7	10.0
Lai	2013	Taiwan	44	68.0	*E. coli* 71%	32.0	100.0	32.0
Lo	2015	Singapore	741	62.0	*K. pneumoniae*	36.0	7.0	13.0
Meddings	2010	USA	17,787[b]	Not specified[c]	*Streptococcus* spp. 29.5%	20.0	16.0	5.6
Mezhir	2010	USA	58	Not specified[d]	*Streptococcus* spp.	14.0	88.0	26.0
Njoku	2014	USA	22	62.4	*Enterococcus* 23% *E. coli* 23%	22.7	81.8	14.0
Rahimian	2004	USA	79	56.4	*K. pneumoniae* 41%	15.2	12.7	2.5
Ruiz-Hernandez	2007	Spain	65	64.4	*Streptococcus* spp. 40.5	26.2	14.3	19.0
Shelat	2015	Singapore	288	Not specified[e]	*K. pneumoniae*	38.5	NS	10.7
Tan	2005	Singapore	80	60.0	*K. pneumoniae* 63.8%	45.0	7.5	3.8
Tsai	2008	Taiwan	29,703	61.0	*K. pneumoniae* 80%	33.3	13.9	10.9
Zibari	2000	USA	20	52.0	Gram-negative rods	NS	NS	0.0

[a]Mean age was 63 years in diabetic patients versus 58 in non-diabetic patients.
[b]Patient discharges.
[c]Mean age not specified but 42.9% of the discharges between 65 and 85, 30.1% between 50 and 64 years, 18.5% between 35 and 49 years, and 8.5% between 18 and 34 years.
[d]52% of the patients were older than 60 years.
[e]Mean age in patients with *Escherichia coli* abscess was 68, mean age in *Klebsiella pneumoniae* was 62 years.

Pathogenesis

The route of transmission is fecal-oral. In areas with poor sanitation and hygiene, the infective cysts are ingested with contaminated food. Cysts are very resistant to gastric secretions. Excystation occurs in the small bowel where eight trophozoites are released from each cyst. Trophozoites infest the colon. In most patients, the trophozoites aggregate in the intestinal mucin layer and form new cysts and pass through the feces. Trophozoites are not very resistant and die soon outside of the body. However, amebic cysts are very resistant and survive several weeks. In some patients, the trophozoites invade the colonic mucosa and travel through the bloodstream to the liver, brain, and lungs with resultant extraintestinal infection (Fig. 105.6). Amebic abscesses are composed of a core of dead hepatocytes and cellular debris with a surrounding rim of connective tissue, trophozoites, and inflammatory cells.

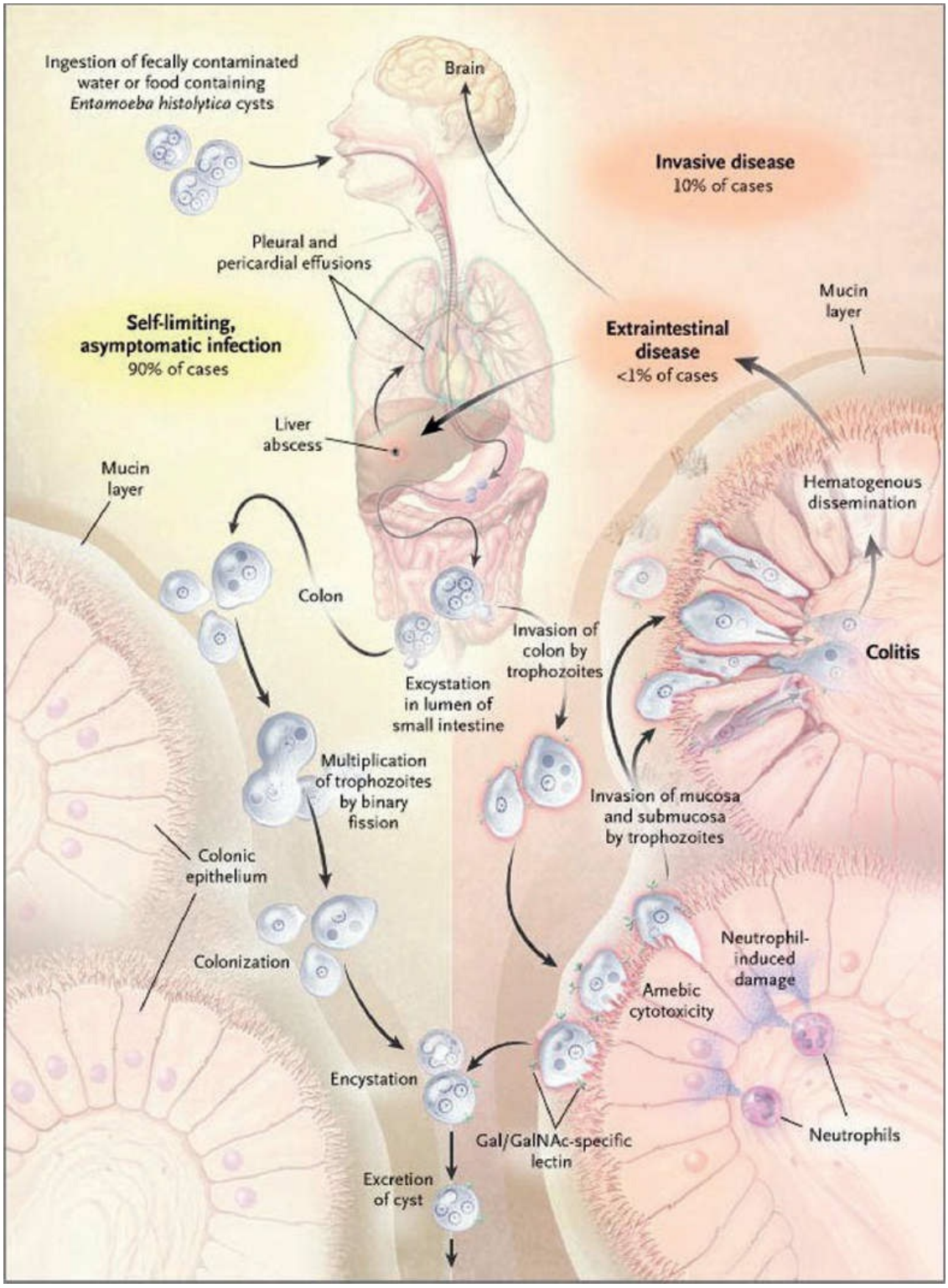

Figure 105.6. Amebic cycle. (From Haque R, Huston CD, Hughes M, Houpt E, Petri WAJ. Amebiasis. *NEJM.* 2003;348(16):1565–73.)

Clinical Manifestations

The most common manifestation of *Entamoeba histolytica* infection is

intestinal amebiasis. Amebic liver abscesses occur in less than 1% of all patients, but it is the most common extraintestinal manifestation of the disease. Most patients present after several days of RUQ pain and fever. The median duration of symptoms is 2 weeks. Abscesses in close proximity to the diaphragm are associated with scapular and/or right shoulder pain. Diarrhea or dysentery is present in less than 40% of the patients. The most common physical findings are RUQ tenderness and hepatomegaly. Jaundice is infrequent.

Diagnosis

Patients with amebic liver abscesses typically have leukocytosis, anemia, hypoalbuminemia, elevated alkaline phosphatase, and hyperbilirubinemia. None of these findings are specific. Once the diagnosis is suspected, the initial approach usually includes a liver ultrasound. Similar to pyogenic abscesses, imaging findings also depend on the pathologic state. During the early phase of infection, abscesses are hyperechoic ill-defined lesions. As necrosis ensues, they appear well defined and hypoechoic. In CT scans, abscesses appear as well-defined avascular hypodense lesions with a hyperdense halo after contrast administration. MRI findings are very similar to pyogenic liver abscesses; mature abscesses appear hypointense on T1-weighted images and hyperintense on T2-weighted images. The most frequent location is the right lobe; less than 15% of the patients have multiple abscesses.

The diagnosis is established by detecting serum antibodies against *E. histolytica.* Several techniques are available, but enzyme-linked immunosorbent assay (ELISA) is the most frequently employed. Its sensitivity is almost 100% after 7 days of infection. In addition, trophozoites can be isolated from percutaneous aspirates. Such aspirates can be tested for amebic antigens. Parasite isolation in stools has been reported in only 24% of the patients.

Treatment

Tissue-amebicide drugs are very effective to eliminate extraintestinal infections, but they fail to eliminate intracolonic cysts in 40% to 60% of the patients. Therefore, the treatment comprises two phases: an initial 7- to 10-day course of treatment with a tissue amebicide (such as metronidazole), followed by 7 days of therapy with an intraluminal amebicide drug such as iodoquinolol or paromomycin to eliminate the

carrier state.

There is no advantage of routine percutaneous drainage of uncomplicated amebic abscesses. Up to 90% of the patients with uncomplicated amebic liver abscesses improve after 72 to 96 hours of treatment. Indications for percutaneous drainage include lack of improvement after 48 to 72 hours of therapy, abscesses located in the left lobe or larger than 10 cm, and impending rupture.

Complications

Similar to pyogenic liver abscesses, complications of this disease include spontaneous rupture of the abscess into the pleura, peritoneum, or pericardium. Large abscesses may produce bile duct compression, inferior vena cava obstruction, or hepatic outflow obstruction. The disease can disseminate to the brain and lungs. The mortality rate in developed countries is less than 1%.

SUBPHRENIC AND SUBHEPATIC ABSCESSES

In most patients, subphrenic and subhepatic abscesses are secondary to other intra-abdominal processes or infections. Examples include cystic stump leaks after cholecystectomies, bile leak after liver resections, perforated peptic ulcer disease, diverticulitis, and appendicitis. In addition, subphrenic and subhepatic fluid collections can be secondary to infected hematomas after trauma, major hepatectomies, or liver transplants. Abscesses are frequently polymicrobial. There is predominance of gram-negative rods, anaerobes, and streptococcus in most patients. Prolonged length of stay, repeated biliary instrumentation, history of liver transplantation, and previous intra-abdominal surgeries are associated with colonization by VRE, MRSA, *Candida* spp., and ESBL-producing Enterobacteriaceae.

In patients with persistent abdominal pain, fever, or leukocytosis, CT scan of the abdomen appears as well-defined hypodense lesions ± gas. Rim enhancement is very common after IV contrast administration (Fig. 105.7).

Treatment

The goals of treatment are the same for pyogenic liver abscess and include early administration of broad spectrum antibiotics, an aggressive fluid resuscitation, and source control. In patients without an intra-abdominal

pathology that requires primary repair, a percutaneous approach is preferred. This is less invasive, allows faster recovery, and decreases risk of contamination to other intraperitoneal areas. If the primary cause of the disease is controlled, the success rate of percutaneous approach is 85% to 90%. The success decreases if the primary pathology has not been treated. In select cases, percutaneous drainage may be used as a bridge to surgery. Once the patient is stabilized, a more permanent surgical treatment should be performed.

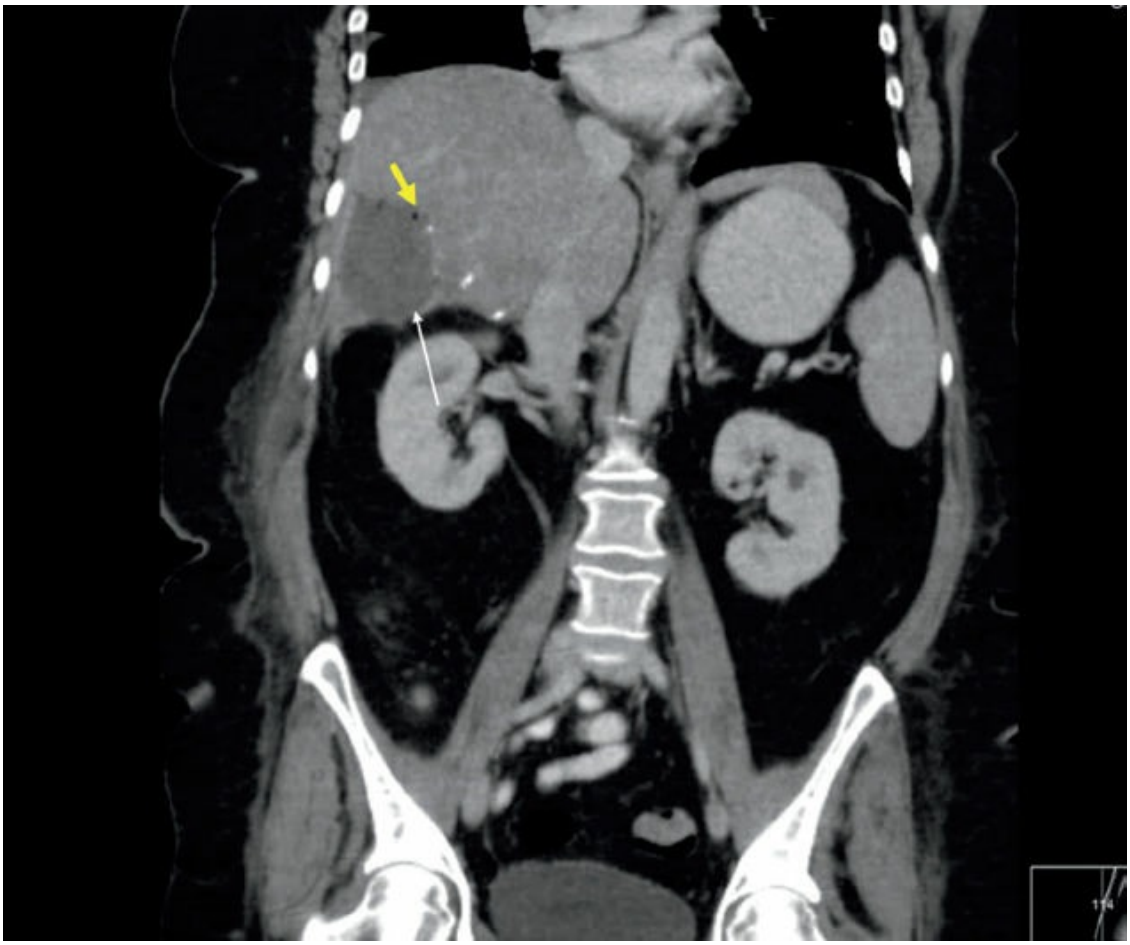

Figure 105.7. Contrast-enhanced CT of a 56-year-old female with a subhepatic abscess after a right hepatectomy. The patient presented with fever and malaise. The CT scan demonstrates a hypodense lesion with gas (*yellow arrow*). There is a rim of enhancement in the periphery of the lesion. Both findings suggest an infected subhepatic fluid collection.

In patients with abscesses secondary to intra-abdominal pathologies such as perforated ulcer disease, complicated gallbladder disease, and appendicitis, an operative approach is recommended to decrease the risk of

uncontrolled sepsis. The most common operative approach is through a midline incision to allow access to any intra-abdominal organ.

Suggested Readings

Cerwenka H. Pyogenic liver abscess: differences in etiology and treatment in Southeast Asia and Central Europe. *World J Gastroenterol* 2010;16:2458–62.

Foo NP, Chen KT, Lin HJ, et al. Characteristics of pyogenic liver abscess patients with and without diabetes mellitus. *Am J Gastroenterol* 2010;105:328–35.

Haque R, Huston CD, Hughes M, et al. Amebiasis. *New Engl J Med* 2003;348:1565–73.

Kaplan GG, Gregson DB, Laupland KB. Population-based study of the epidemiology of and the risk factors for pyogenic liver abscess. *Clin Gastroentrol Hepatol* 2004;2:1032–8.

Lo JZ, Leow JJ, Ng PL, et al. Predictors of therapy failure in a series of 741 adult pyogenic liver abscesses. *J HepatobPancreat Sci* 2015;22:156–65.

Meddings L, Myers RP, Hubbard J, et al. A population-based study of pyogenic liver abscesses in the United States: incidence, mortality, and temporal trends. *Am J Gastroenterol* 2010;105:117–24.

Mezhir JJ, Fong Y, Jacks LM, et al. Current management of pyogenic liver abscess: surgery is now second-line treatment. *J Am Coll Surg* 2010;210:975–83.

Njoku VC, Howard TJ, Shen C, et al. Pyogenic liver abscess following pancreaticoduodenectomy: risk factors, treatment, and long-term outcome. *J Gastrointest Surg* 2014;18:922–8.

Siu LK, Yeh KM, Lin JC, et al. Klebsiella pneumoniae liver abscess: a new invasive syndrome. *Lancet Infect Dis* 2012;12:881–7.

Tan YM, Chung AY, Chow PK, et al. An appraisal of surgical and percutaneous drainage for pyogenic liver abscesses larger than 5 cm. *Ann Surg* 2005;241:485–90.

EDITOR'S COMMENT

Although pyogenic liver abscess was first described by Hippocrates around 400 BC, the seminal review was published by Ochsner and colleagues in 1938. Forty-seven cases were described, largely occurring in patients with appendicitis. The study reported significant reductions in mortality seen with surgical treatment (Ochsner A, DeBakey M, Murray S. Pyogenic Abscess of the Liver. *Am J Surg* 1938;40:292). The current concepts of liver abscess are well described by the authors. The surgeon should know of the changing incidence

and causes relative to what part of the world they live and work and the important role of percutaneous drainage and antibiotic therapy as well as the differential diagnosis and treatment of amebic liver abscess, and the varieties of more rare infectious etiologies.

The two most common varieties are pyogenic and amebic liver abscess. The annual incidence is commonly estimated at 2.3 cases per 100,000. The incidence varies throughout the world. For example, in Taiwan the incidence is as high as 17.6 per 100,000. However, a recent population-based study in the United States by Meddings (Meddings L, Myers RP, Hubbard J, et al. A population based study of pyogenic liver abscesses in the United States: incidence, mortality, and temporal trends. *Am J Gastroentero* 2010;105:117–24) studied pyogenic liver abscess incidence and mortality in the United States in >17,000 patients in the Healthcare Cost and Utilization Project Nationwide Inpatient Sample from 1994 through 2005. During the study period, they reported that incidence increased significantly from 2.7 to 4.1 per 100,000 (overall incidence, 3.6 per 100,000). In addition, they found that in-hospital mortality remained the same (5.6%) and was associated with older age, comorbidities (including cancer, renal failure, and cirrhosis). They reported that those who underwent percutaneous liver aspirations or had positive culture aspirates had diminished mortality risk. Neither endoscopic retrograde cholangiopancreatography nor surgical drainage altered mortality. However, they found increased mortality in those with sepsis and bacteremia.

The epidemiology varies between countries. In the United States, pyogenic liver abscess is usually encountered as a complication of biliary tract disease and cancer, and less commonly intra-abdominal infection such as appendicitis or diverticulitis with seeding through the portal vein. Of the latter type, there is a predominance of right-sided abscesses as the predominant floe of the portal system is to the right lobe of the liver. More common today are cases attributable to chemoembolization. Interestingly, 15% of cases are associated with an intra-abdominal malignancy. A study by Ghosh et al. (Ghosh S, Sharma S, Gadpayle AK, et al. Clinical, laboratory, and management profile in patients of liver abscess from northern India. *J Trop Med* 2014;2014:142382) reported on 200 consecutive cases at Post Graduate Institute of Medical Education and Research (PGIMER) Hospital, New Delhi. The mean age of patients was 41.13 years. Majority of them were from lower socioeconomic class (67.5%) and alcoholic (72%). The abscesses were predominantly in right lobe (71%) and solitary (65%). Etiology of abscess was amoebic (69%), pyogenic (18%), tubercular (7.5%), mixed (4%), and fungal (1.5%). Percutaneous needle aspiration was done in 79%, pigtail drainage in 17%, and surgical intervention for rupture in 4% patients. Mortality was 2.5%, all reported in surgical group. Solitary abscesses were amoebic and tubercular, whereas multiple abscesses were pyogenic. The right lobe was predominantly involved in amoebic and pyogenic abscesses, while in tubercular abscesses left lobe involvement was predominant. The report by Malik et al. (Malik AA, Bari SU, Rouf KA, et al.

Pyogenic liver abscess: Changing patterns in approach. *World J Gastrointest Surg* 2010;2:395–401) confirmed the decreasing incidence of portal pyemia and the rising incidence of abscesses related to biliary disease generally reported elsewhere (31% to 45%). In this series, biliary ascariasis accounted for 17% of cases because of the high incidence of ascaris lumbricoides infestation in the region.

As pointed by the authors, the management of pyogenic liver abscess has evolved over the past three decades due to advances in diagnostic and interventional radiology. Percutaneous drainage, targeted antimicrobial therapy, and source control are the keys to successful treatment. Percutaneous drainage in indicated for abscesses size >5 cm, ongoing pyrexia despite 48 to 72 hours of appropriate medical therapy, and clinical or imaging features concerning for impending perforation. Percutaneous drainage with placement of a drainage catheter is highly successful; however, it will fail in 8% to 36% of patients (Alvarez Perez JA, Gonzalez JJ, Baldonedo RF, et al. Clinical course, treatment, and multivariate analysis of risk factors for pyogenic liver abscess. *Am J Surg* 2001;181:177–86; Chen SC, Tsai SJ, Lee YT, et al. Predictors of mortality in patients with pyogenic liver abscess. *Neth J Med* 2008;66:196–203). Some general indications for surgical drainage include abscess rupture, inadequate source control, incomplete drainage, failure of clinical response, infection with *Candida,* and mutiloculated abscesses. There is some debate about the duration of antibiotic therapy. Current recommendations include parenteral therapy for 2 to 3 weeks or until there is a favorable clinical response, followed by an oral regimen for 2 to 6 weeks or until such time as clinical, laboratory, and radiographic studies demonstrate abscess resolution.

If surgery is required, the use of intraoperative ultrasound may help to identify the abscess, which can be difficult to identify by palpation alone. It is important to break up the loculations in the abscess and debride any necrotic liver parenchyma. There are an increasing number of reports concerning laparoscopy as an adjunct to drain liver abscesses. Ultrasound was found to be helpful. Port placement is similar to laparoscopic cholecystectomy. The overall success rate ranges from 85% to 100% (mean 90.5%). In the laparoscopic approach, the harmonic scalpel has been reported as useful to facilitate hemostasis during unroofing.

The management of amebic liver abscess is not controversial. Medical therapy without percutaneous or surgical drainage is highly effective. Intraluminal cyst control optimizes the outcome.

Sub-hepatic abscess can usually be drained by percutaneous techniques. Approaching a deep abscess that cannot be drained percutaneously through the bed of the 12th rib may be helpful. The patient is placed in the left lateral decubitus position. An incision is made over the 12th rib. The rib is removed and the surgeon’s finger placed into the abscess avowing the pleural space. This approach avoids contamination of the peritoneal cavity and effective drainage.

E. Christopher Ellison

106 Echinococcal Cyst—Open and Laparoscopic Approach

Miroslav N. Milicevic

THE LIVER ECHINOCOCCAL CYST

Definition, Short History, Epidemiology, Significance, and the Surgical Problem

Echinococcosis (echinococcal cyst [EC], hydatidosis, hydatid disease) is a cyclozoonosis caused by the larval (metacestode) stages of cestodes (flat worms) belonging to the genus *Echinococcus* and the family Taeniidae. The biologic characteristics of the parasite enable its survival in nature. The disease exists in two forms: the larval stage (metacestode) and the adult stage (tenia). The parasites are perpetuated in life cycles with carnivores (dogs and wild canine) as definitive hosts. Humans are the accidental intermediate host (dead end), and animals (herbivores and omnivores) are both intermediate and definitive hosts.

The disease has been known since earliest times. It was known to Hippocrates, who speaks of "livers full of water." The word *echinococcus* is of Greek origin and means "hedgehog berry." Hydatid is also of Greek origin (*hudatid, hudatis*) and means a "watery vesicle." The word *hydatid* also originates from the modern Latin word *hydatis* meaning a "drop of water." Therefore, hydatid and cyst have the same meaning and the expression "hydatid cyst" (HC) is a pleonasm. The use of the term *hydatid cyst* in contemporary medicine is widespread and acceptable. The first North American case was observed in 1808 and published in 1822. The true nature of the disease was not known until the second half of the 19th century.

Echinococcosis is widespread and occurs in all continents, including circumpolar, temperate, subtropical, and tropical zones. It is not confined to sheep-raising communities. The varying prevalence and distribution are influenced by agricultural, educational, economical, medical, and cultural factors. In endemic areas, the annual incidence of cystic echinococcosis ranges from <1 to 200 per 100,000 inhabitants. Human cystic

echinococcosis remains highly endemic in pastoral communities, particularly in regions of South America (Argentina, Uruguay, Chile), the Mediterranean littoral (Spain, France, Italy), Eastern Europe, the Near and Middle East (Turkey), East Africa (Maghreb countries), Central Asia, China, and Russia. Increasing migration, growing incidence of world trade and travel, high mobility of troops, and an increasing number of refugees make hydatidosis a global problem. In endemic areas, hydatidosis remains a major health and socioeconomic problem. The estimated minimum global human burden of cystic echinococcosis averages 285,000 disability-adjusted life years (DALYs) or an annual loss of U.S. $194,000,000. The mortality rate from cystic echinococcosis is about 2% to 4%, but it may increase considerably if medical treatment and care are inadequate. Only infection with the metacestode is of clinical relevance.

Although echinococcosis is uncommon in the resident population of industrially developed countries, it is prevalent enough to be seen by most general surgeons in its simple or its complicated form. Because it is a surprise finding, even in tertiary centers, it is overtreated more often than not.

The treatment of hydatid disease has been the responsibility of surgeons for many years, and research into its treatment also seems to be the responsibility of surgeons. There is no other parasitic disease for which the primary treatment is surgical. Because there is no effective treatment of hydatid disease today, either surgical or medical, the best surgical technique is not known. Surgeons will be happy when a proper medical treatment is found and they are needed only for the complications.

A surgeon managing a patient with a HC should understand both the parasitology and pathology of the parasite and be fully aware of treatment limitations and possible complications. The dilemma of whether to perform tissue-sparing, conservative, or radical resectional surgery for hydatid disease is an artificial issue. The operative procedure should be tailored to every individual patient, taking into consideration many factors including the local expertise and facilities, prevalence of the disease, socioeconomic factors, and the age and condition of the patient.

This chapter presents the basics of this disease, and it is intended to help the surgeon manage patients with HCs.

Current Concepts in the Diagnosis and Management of EC

The previous recommendations of the World Health Organization Informal

Working Group on Echinococcosis (WHO-IWGE) for the treatment of human echinococcosis were published in 2001. These recommendations have significantly influenced the way cystic echinococcosis was managed in all continents. Ten years later, after several expert meetings of the WHO-IWGE, a consensus was reached in 2009 about the management of cystic echinococcosis. The consensus has been reached on an image-based, stage-specific approach, which helps in choosing one of the following treatment options: (a) surgery, (b) percutaneous treatment (PT), (c) chemotherapy, and (d) watchful waiting. An image-based classification system differentiating the cyst stage has been reinforced to help in clinical decision making. Unfortunately, the panel of experts also concluded that the majority of published papers about the management of cystic echinococcosis were not consistent and well structured, so the quality of evidence and strength of recommendation are low. Since cystic echinococcosis is mostly treated in developing countries with limited resources, choosing the best treatment option must take into consideration the socioeconomic conditions, the available facilities, and the expertise of the attending surgeon. Nevertheless, surgery remains the most effective treatment. It is frequently technically demanding and risky and postoperative complications can be life-threatening.

This chapter is based on these new concepts.

THE LIVER HYDATID CYST

Parasitology

The genetic and phenotypic variations of *E. granulosus* have been extensively studied. The dog is the most common definitive host and the majority of cases in humans are caused by the sheep strain. The adult tenia lives adhered to the small intestine of the dog (definitive host). It measures from 3 to 6 mm in length, and has three or four proglottids, of which the last one is larger and gravid. The gravid proglottid containing between 200 and 800 ova is shed approximately every 15 days and the ova are expelled in the feces. When the microscopic eggs are ingested by an intermediate host, the life cycle is perpetuated. The intermediate hosts are Bovidae.

There are three known forms of echinococcosis in humans: (a) cystic echinococcosis (hydatid disease) caused by *E. granulosus,* (b) alveolar echinococcosis (alveolar hydatid disease) caused by *E. multilocularis,* and (c) polycystic echinococcosis caused by *E. vogeli* or *E. oligarthus*. Although *E. granulosus* and *E. multilocularis* occur simultaneously in

large endemic areas, mixed infections of cystic echinococcosis are extremely rare. This chapter deals with cystic echinococcosis (hydatid disease) caused by *E. granulosus* only.

Humans are an accidental, intermediate host and become infected when they accidentally ingest eggs of the tapeworm. This can happen directly, by contact with dogs, or indirectly by food, water, and contaminated objects. Direct contact during childhood is an important route. The eggs hatch in the duodenum, and the released oncosphere penetrates the mucosa and reaches a blood vessel. The bloodstream can carry the oncosphere to any part of the body, but it most frequently settles in the liver and lungs. Once settled, the parasite develops its larval stage, the HC, the clinical presentation of *E. granulosus.* The cyst is a chronic, well-localized, and adapted space-occupying affliction that is not affected by the functional status of the host. The protoscolex can multiply asexually *ad infinitum* in the intermediate host as long as the host is alive. Because the parasite is always confined within the HC, a vital HC has the tendency to slowly enlarge and interact with the host. Following a symptom-free period of varying length, depending on the site and number of cysts, life-threatening complications arise. The disease, benign in nature, can cause devastating damage to the liver and death to the patient.

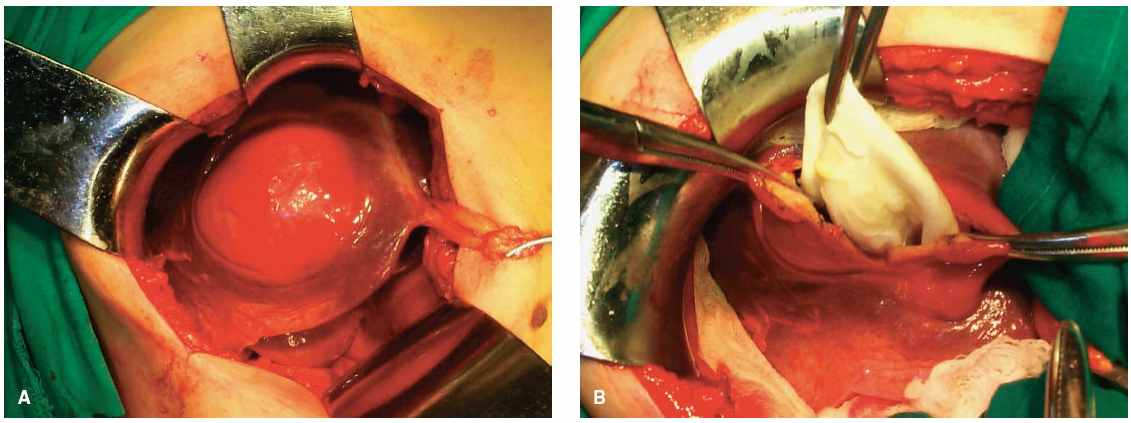

Figure 106.1. A. The protruding part of a liver hydatid cyst on the surface of the liver. **B.** The pericyst is incised and the cut edges are retracted by hemostats. The cyst is univesicular. The white structure in the tissue-grabbing forceps is the parasite (the laminated membrane).

This cycle with two hosts, one definitive and the other intermediate, is the sexual cycle and the resulting disease in humans or animals is “primary echinococcosis.” There is an asexual, “minor” cycle in which the new HCs

develop from any vital element of the larval stage (e.g., protoscoleces, daughter cysts) of the parasite in the same intermediate host. This can occur subsequent to invasive and operative procedures, or following spontaneous or trauma-induced cyst rupture. This disease in humans is "secondary echinococcosis."

Pathology

The cellular response of host tissue to the presence of the larva is an attempt to encase the parasite in fibrous tissue. The parasite reacts by forming around itself a spherical enclosure of inert protective chitinous material. If the parasite survives host defense mechanisms, in approximately 5 to 7 days after infestation, the larva (metacestode) develops into a 6- to 7-mm vesicula. This is the endocyst and it is made up of two distinct layers: (a) the inner germinative layer (live parasite, germinal membrane, proligerous layer) and (b) a protective outer laminated acellular layer (cuticle or laminated layer). The laminated membrane never grows thicker than 2 to 5 mm, regardless of cyst size. After 21 days, the cyst is visible to the naked eye. In 3 months, it can measure 3 to 5 cm in diameter. Compression and interaction of the endocyst with the adjacent host's tissue produce a fibrous layer called the ectocyst or pericyst. By 5 months, the pericyst is formed and a typical mature HC is present.

The pericyst is an integral part of both the liver and the parasite, and it is difficult to remove it from the liver. The parasite (endocyst) is separated from the pericyst (ectocyst) by a small capillary space, and it can easily be detached from it (Figs. 106.1 and 106.2). The pericyst is largely avascular, but there are spaces within it that enclose blood vessels and small bile ducts. The structure of the pericyst seems to be more complex than previously described. According to Chinese authors, it is the result of two different formative processes and it consists of two different layers. The inner layer of the pericyst (the frank "exocyst") is the result of an inflammatory and an unusual granulomatous reaction aimed at walling of the parasite and resorbing the released antigen. The granulomatous layer increases in size with growth of the parasite; it frequently contains osteopontin (regulates macrophage accumulation and calcium deposition) and resembles the granulomatous reaction to other infective agents (e.g., TBC). The outer layer of the pericyst is called the "adventitial" layer, and it is composed of compressed Glissonian biliovascular elements and

tributaries of the hepatic veins. Separating the “ectocyst” from the “adventitial” layer is the basis of “subadventitial cystectomy” pioneered by Chinese authors. There is no cleavage plane between the liver parenchyma and the “adventitia,” and it cannot be readily separated. The pericyst can be 1 to 1.3 cm thick, and it is not present in pulmonary and brain ECs. Vessels and ducts in the “adventitia” remain patent for a long time even in large cysts (hypervascular rim on computerized tomography [CT] scan). Calcification impedes the passage of nutrients and oxygen into the cyst.

A liver HC is typically unilocular. A developing cyst usually survives, with a steady increase in size of about 1 to 1.5 mm in diameter per month, depending on the site and adjacent structures. The hydatid fluid in a vital cyst is under pressure (30 to 70 cm H_2O), and the volume of a human HC can be many liters.

The germinal membrane is of microscopic dimensions and is responsible for the production of the crystal-clear hydatid fluid, the ectocyst, brood capsules, scoleces, and the daughter cysts. The host and parasite in a HC are never physically connected. This means that a HC always separates from, or can be readily lifted out from within, a surgically exposed pericystic cavity (Fig. 106.3). When managing HCs, it must be assumed that any amount of hydatid fluid, no matter how clear, contains potentially infective protoscoleces.

Daughter cyst formation is considered a defense reaction, and it is known as the process of endogenic vesiculation. Daughter cysts are true replicas of the mother cyst but without a pericyst. Daughter cysts produce multivesicular cysts that are more frequent in adults. The presence of daughter cysts is a problem for chemotherapy, protoscolicide activity, and the standard PAIR procedure (puncture–aspiration–injection–reaspiration). Ectogenic vesiculation of *E. granulosus* is infrequent. It occurs when there is a small rupture or defect in the laminated membrane and the germinal layer passes through and creates a “satellite” HC.

Hydatid fluid is antigenic. This antigenicity is rarely of great clinical significance, and the real incidence of allergic reactions in hydatidosis is not known. The incidence appears to be lower than previously described in literature. Allergic reactions range from skin rash to a frank anaphylactic reaction, usually following sudden rupture of the cyst. The antigenicity of hydatid fluid is the basis of serodiagnostics.

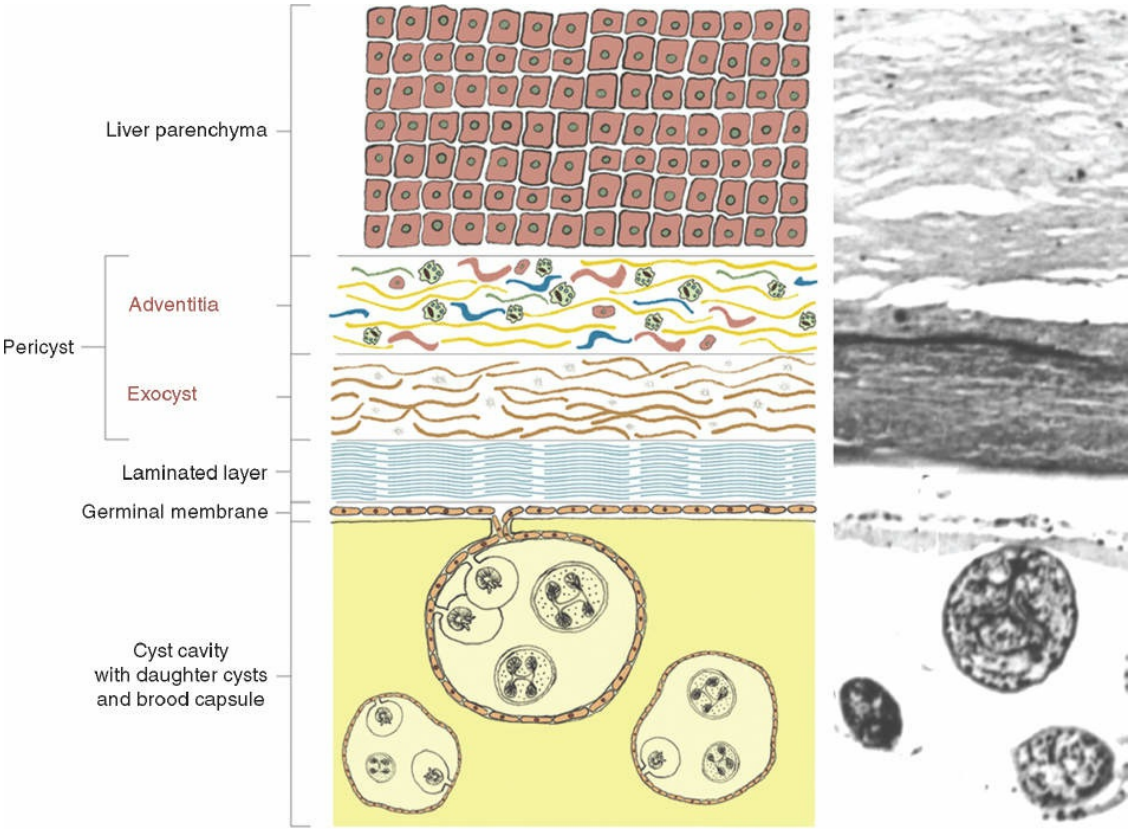

Figure 106.2. Histology of liver hydatid cyst. The "adventitia" layer of the pericyst contains the blood vessels. White circular structures in the exocyst are osteopontin + calcium. Green large cells in the adventitia are macrophages secreting osteopontin and probably regulating calcium deposition. The laminated membrane (visible to the naked eye) protects the vital germinal membrane (not visible to the naked eye) responsible for the production of brood capsules, daughter cysts, and cyst fluid.

HCs in humans are generally long-standing and large, although not all grow to enormous proportions. Host defense mechanisms, injury, and the functional status of the pericyst are factors that determine cyst vitality, growth, and development. When a HC dies, its wall can become calcified. Cyst vitality should not be estimated according to the calcification pattern. Dead cysts are generally no longer a threat to their host, but the issue of how to manage patients should take into consideration many factors.

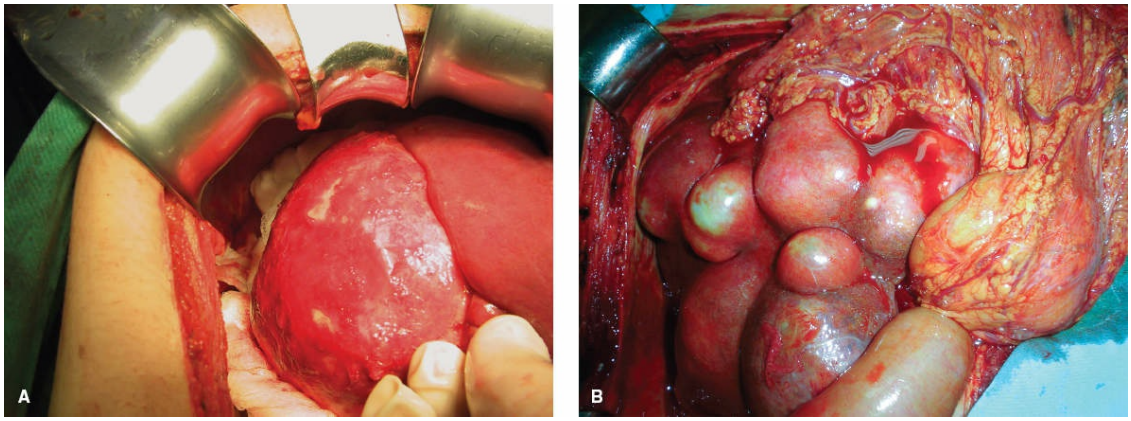

Figure 106.3. A. A large hydatid cyst is shown displacing most of the right lobe of the liver. **B.** Multiple hydatid cysts of the liver and omentum.

CLINICAL PRESENTATION

The Uncomplicated Liver Hydatid Cyst

The clinical features of liver hydatid disease depend on the site, size, number, vitality, and stage of development of the cyst. Simple, uncomplicated liver HCs are usually asymptomatic or present with nonspecific symptoms. Complicated liver HCs cause specific symptoms. If a patient has multiple HCs in the liver, the cysts are different in size, and any one of them can be the cause of symptoms. Most frequently, it is the complicated cyst that causes the symptoms and signs of the disease.

I base my experience of this topic on 1,333 consecutive patients operated for liver hydatidosis at the First Surgical Clinic, University of Belgrade School of Medicine, during January 1963 to December 2014. Dominant symptoms and signs of the patients are presented in Tables 106.1 and 106.2. Only one in three symptomatic patients had moderate to severe pain. The majority of the patients (79.60%) had uncomplicated cysts.

Symptomless, unsuspected HCs can be detected during routine examination or at autopsy. Clinical latency, judging by the size of the HCs at operation, is an outstanding feature of the disease. Adults contracting the disease can rapidly develop severe clinical manifestations. Children in endemic areas with large cysts can progress to “hydatid cachexia” (Tables 106.1 and 106.2).

The Complicated Liver Hydatid Cyst

Suppuration and Secondary Bacterial Infection

Cyst leakage is a prerequisite for bacterial contamination, and the most frequent cause of infection is a cystobiliary communication (CBC). The clinical presentation is as a liver pyogenic abscess. An infected HC undergoes structural changes. The parasite dies.

TABLE 106.1 Dominant Symptoms of Liver Hydatidosis

	Patients	
Symptom	Number	Percent
Right upper quadrant discomfort/pain	1,033	77.49
Dyspepsia	506	37.90
Vomiting	294	22.05
Nonspecific fatigue	246	18.45
Asymptomatic	238	17.85
Weight loss	151	11.32
History of jaundice	94	7.05
History of fever	87	6.52
Allergy	11	0.82

TABLE 106.2 Dominant Signs of Liver Hydatidosis

Sign	Patients	
	Number	Percent
Palpable right upper quadrant mass	541	40.58
Fever	97	7.27
Jaundice	59	4.42
Malnutrition	33	2.47
Pleural effusion	36	2.57
Cholangitis	15	1.12
Splenomegaly	14	1.05
Skin rash	11	0.82
Dyspnea, asthma	33	2.47
Ascites	11	0.82
Edema of extremities	6	0.45
Pancreatitis	1	0.07

Occasionally, the entire cyst content undergoes aseptic necrosis, the parasite dies, and the cyst is filled with amorphous, yellow debris that must be distinguished from the pus of secondary infection (e.g., positive Gram stain). Essentially, this is the gross appearance of a multivesicular cyst and not a suppurated cyst. The real incidence of bacterial infection is unknown because different diagnostic criteria are applied. The incidence in the literature ranges from 11.0% to 27.1%. It is 14.42% (149 patients) in my series.

Pressure Effects, Rupture, and Bile Duct Communications

A viable liver HC has the tendency to grow in the direction of least resistance. This accounts for its frequently irregular shape. In confined areas, such as the central nervous system, small cysts cause serious symptoms. In less restricted areas, the latency period is longer and the symptoms depend on the site and size of the cyst. Pressure effects appear sooner or later, and symptoms result from direct pressure or distortion of neighboring structures or viscera.

An enlarging cyst causes compressive atrophy of surrounding

hepatocytes and fibrosis, which can lead to compensatory hypertrophy of the remaining liver parenchyma. Large cysts can replace an entire liver lobe. Portal hypertension and a Budd–Chiari-like syndrome have been described. Another serious consequence of cyst enlargement is that it can rupture. Three types of cyst rupture have been addressed: (a) obscure, (b) free, and (c) communicant rupture.

Obscure (Internal) Rupture

Injury or penetration of bile into the space between the pericyst and the endocyst can cause rupture of the laminated membrane. The liberated protoscoleces occupy the available space and develop into hundreds of daughter cysts within the pericyst cavity. A typical univesicular cyst becomes multivesicular. When such a cyst is surgically entered, there is no laminated membrane and hundreds of daughter cysts, floating in a yellowish fluid and gelatin-like amorphous mass, crowd the interior of the pericyst. Not all multivesicular cysts have bile-stained fluid, and not all cysts with bile-stained fluid have active communications with the bile ducts. A multivesicular cyst with viable daughter cysts retains its high intracystic pressure, continues to enlarge, and can damage the host.

The clinical significance of multivesicular cysts is that (a) the host is exposed to hydatid antigens in the hydatid fluid, (b) the cyst is bacteriologically sterile, (c) the cyst contents cannot be easily aspirated and need to be scooped out, (d) the cyst must be treated as viable and infective, and (e) bile-stained cyst contents mandate a meticulous search for CBC.

Free Rupture

In free rupture, the hydatid contents disseminate throughout the peritoneal or pleural cavity.

Intraperitoneal Rupture. A vital HC grows in the direction of least resistance, usually reaching the surface of the liver before it reaches enormous proportions. The superficial portion of the pericyst is stretched, thinned out, and the cyst becomes visible as an irregularly shaped, fibrous, whitish structure protruding from normal liver parenchyma. Cysts reaching the anterior and inferior part of the liver continue to grow, protruding into the abdominal cavity. Because of high intracystic pressure, both univesicular and multivesicular cysts can rupture.

There are several clinical presentations of intraperitoneal rupture: (a) In

acute symptomatic rupture, peritoneal irritation and acute abdominal symptoms occur. This is an uncommon event. The incidence is about 1% to 4%. (b) In anaphylactic shock, rupture of the hepatic HC precipitates severe circulatory collapse, which may be fatal, and tends to mask the abdominal manifestations. (c) In silent rupture, the patient presents with disseminated abdominal hydatidosis, unaware when the rupture occurred. (d) Herniation of the laminated membrane ("dumbbell hepatoperitoneal cyst") occurs through the pericyst. The herniating membrane does not actually burst and therefore no spillage of hydatid debris occurs. The initial liver cyst remains small although the herniated, extrahepatic portion of the cyst can attain a volume of several liters. This condition mimics ascites, and attempts at percutaneous aspiration can lead to allergic manifestations. It is an infrequent condition.

Intraperitoneal rupture is a life-threatening complication that results in "secondary echinococcosis." Multiple cysts develop throughout the peritoneal cavity, causing intestinal obstruction, gross abdominal distention, ascites, and cachexia several years after the rupture. This is the secondary, smaller life cycle for the parasite, occurring only in the intermediate host. In endemic areas, the sudden onset of bile-colored ascites in an otherwise healthy person, regardless of the fact that no hepatic cyst is visible, raises suspicion of intraperitoneal rupture.

Intrathoracic Rupture. An elevated hemidiaphragm and a sterile sympathetic pleural effusion can be the first signs of liver hydatid disease. Upward extension of a subdiaphragmatic cyst is usually asymptomatic, although it can cause dry cough, dyspnea, chest pain, and toxemia. The pleura and adherent basal lung segments often become inflamed and indurated. Frank intrapleural rupture with empyema (hydatopiothorax) is rare. A combination of infection and pressure can cause destruction of lung parenchyma, resulting in pneumonitis or lung abscess. A HC may erode into a bronchiole and the contents can be evacuated. Rupture into the lumen of a bronchiole may lead to the appearance of daughter cysts in the sputum. If the cyst is already communicating with the bile ducts, a bronchobiliary fistula will arise. Expectoration of bile-tinged sputum is a sign of bronchobiliary fistula. The incidence of diaphragmatic or transdiaphragmatic thoracic involvement by HCs in the dome of the liver ranges from 0.6% to 16%.

Communicant Rupture

HCs can rupture into physiologic channels (e.g., biliary, blood vessels) or adjacent organs (e.g., digestive tract) (Fig. 106.4).

Intrabiliary Rupture. Compression and displacement of biliary ducts is frequent. Enlargement of the HC stretches and compresses the bile duct, causing bile stasis. At the point of intimate contact, the cyst wall and bile duct gradually weaken. The increase of intraductal pressure facilitates occurrence of horizontal or longitudinal fissures in the duct wall. Bile escapes through this breach of the bile duct wall, decompressing the bile duct and accumulating at the external side of the laminated membrane (internal rupture). This “leak” causes changes in osmotic pressure and a further increase in intracystic pressure that facilitates rupture into the bile duct (external rupture). Because the pressure in the cyst greatly exceeds that in the bile duct, a cystobiliary fistula is frequent. The communication with the bile duct can be terminal or tangential. Peripheral cysts disrupt small-caliber ducts (usually end to side) and central cysts communicate with a major segmental or sectoral duct (usually side to side). A single cyst can have several CBCs to the same or to different bile ducts.

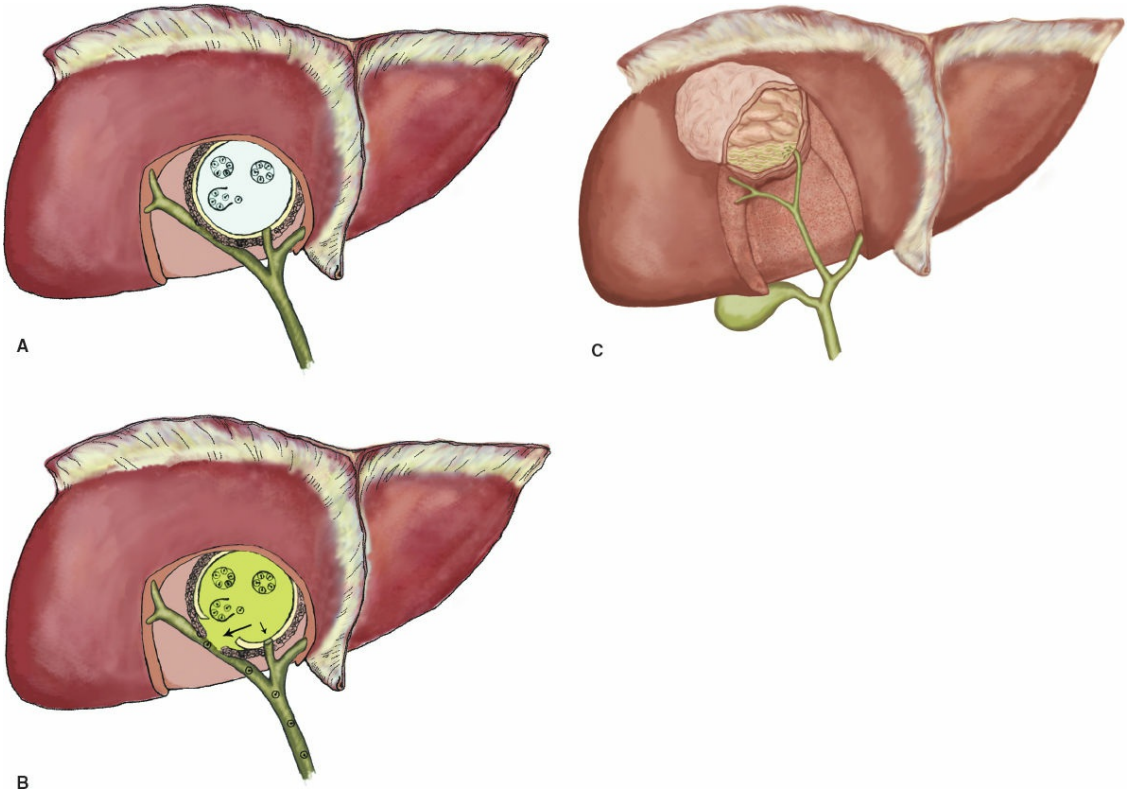

Figure 106.4. Communicant rupture into the bile duct. **A.** Hydatid cyst enlarges and compresses the bile duct, causing bile stasis. If the major duct is compressed and occluded, blood chemistry is

altered and jaundice may occur. **B.** Hydatid cyst ruptures into the bile duct. The laminated membrane is destroyed and the cyst contents discharge into the bile duct. The cyst becomes multivesicular and is bile-stained. **C.** Hydatid cyst in contact with the bile duct and has a terminal communication with the bile duct and bile inside the cyst.

In silent rupture, bile leaks from eroded small ducts into the cyst, causing endogenic vesiculation, suppuration, and eventually death of the parasite. Such cysts are filled with bile-stained detritus, although no visible bile duct communications can be seen. Probably 80% to 90% of HC bile duct ruptures are of the silent type. This type of asymptomatic, silent rupture is known as a "minor communication" but, nevertheless, it can sometimes cause unexpected postoperative bile leakage.

A triad of symptoms characterizes "symptomatic" rupture into the bile ducts: (a) biliary colic, (b) partial intermittent or complete ductal obstruction with cholangitis and jaundice, and (c) germinative membranes in the feces. Rupture into a large bile duct may allow more or less complete emptying of the fluid and detritus and lead to spontaneous cure or cholestatic jaundice with recurrent cholangitis. Incomplete emptying and a persisting communication usually result in secondary infection. In endemic areas, probably 3% to 10% of cases of obstructive jaundice are caused by intrabiliary rupture of hepatic HCs. This type of rupture is also called a "major communication," has a fistula orifice diameter of >5 mm, and communicates with a larger bile duct. This type of rupture is infrequent and has an incidence of 3% to 10%.

The rapid discharge of the cyst contents into a major bile duct or body cavity can lead to the sudden absorption of the hydatid antigen in a sensitized patient, resulting in anaphylaxis. More frequently, pruritus or urticarial rash is the major external manifestation. Episodes of asthma have been reported.

The incidence of rupture of the HC into the bile ducts is difficult to establish. The reported incidence ranges from 2.6% to 30.0%. This complication accounts for 60% of all the complications of hydatid disease and 20% of the postoperative morbidity. In my series, the incidence was 20.40%.

Rupture Into Adjacent Organs. A HC can rupture into the digestive tract, causing *hydatidemesis* or *hydatidenteria*. Rupture into the urinary tract

causes *hydatiduria*. Rupture of HC into the aorta, the inferior vena cava (VCI), the pericystic blood vessels, and the heart with embolism has been described.

Spontaneous Abortion

The parasite survives because of a complex interaction with the host through the pericyst. It is not known why some cysts occasionally stop developing and growing. Involution and death of the parasite are probably the result of malfunction of the pericyst or some other unknown noxious factor. Involution of the parasite is protracted, can probably last for years, and is accompanied with gross structural changes. The final phase is partial or total calcification of the pericyst.

DIAGNOSIS OF LIVER HYDATIDOSIS

Organ Imaging in Diagnosis and Treatment of Hydatid Disease

Roentgenographic Examination

The value of radiography in the diagnosis of uncomplicated liver HCs is very limited because the radiodensity of a noncalcified HC is the same as that of surrounding liver parenchyma. In endemic areas, elevation of the right hemidiaphragm in an otherwise healthy, asymptomatic patient is highly indicative of liver hydatidosis. Sometimes a standard radiographic examination of the abdomen reveals streak-like or round calcification of a senile HC. Cysts in the lung and bone are more readily demonstrated. Angiography and scintigraphy are of historic significance only.

Ultrasound Imaging

Ultrasonography

Ultrasound imaging (US) has revolutionized the diagnosis and investigation of liver hydatid disease. US examination of the liver is readily available and easy to master; it is comparatively cheap and noninvasive, enables interventional procedures, and does not expose the patient to radiation. In areas with endemic hydatidosis, it is the most important single diagnostic tool. On US, HCs are well-defined, circumscribed, cystic lesions with a clear membrane and do not infiltrate surrounding liver tissue. Cysts on examination can be solitary or multiple and univesicular or multivesicular. Pathognomonic US diagnostic features are (a) unmistakable daughter cysts (“rosettes”) within the main cyst

cavity, (b) detachment of the membrane of the cyst ("double-contoured membrane"), (c) agglomeration of daughter cysts in the dependent portion of a HC, and (d) calcification of the cyst wall. Because the US pattern reflects the natural history of the HC (evolution vs. involution), accurate interpretation, standardization, and classification of the ultrasound finding can be used for several purposes: (a) screening in endemic areas and family members in infested families, (b) staging and treatment planning, (c) first-line diagnostics, (d) interventional, nonoperative treatment procedures, (e) intraoperative US (IOUS) during surgery, (f) treatment monitoring and postoperative follow-up, and (g) in the workup of patients presenting with jaundice, as it is possible to differentiate daughter cysts from gallstones in the common bile duct (CBD) in most of these patients.

US is superior to CT in the investigation of the cyst wall, hydatid sand, daughter cysts, and the relationship of the cyst to the diaphragm. Without a clear knowledge and understanding of the disease, accurate interpretation of US findings can be difficult or even impossible. Only "simple HCs" have a uniform, easy-to-interpret US appearance. HCs that have undergone one or more morphologic changes can be a diagnostic problem because of nonspecific US patterns.

Based on US signs, Hassen Gharbi in 1981 classified liver HCs into five types. This classification is still widely used. The cyst types are Type I, pure fluid collection, Type II, fluid collection with a split wall, Type III, fluid collection with septa, Type IV, heterogeneous appearance, and Type V, reflecting thick walls. Gharbi cyst types II and III as well as type V calcified cysts are characteristic for liver cystic hydatid disease. In endemic areas, cyst types I and V suggest cystic liver hydatid disease, and cyst type IV can be a diagnostic problem. Different cyst types can coexist in the same patient, reflecting different developmental stages.

The need to more accurately evaluate the functional state of the parasite, especially in field studies, has resulted in a new, modified ultrasound classification of liver HCs. Based on cyst characteristics described in the Gharbi classification, the WHO-IWGE proposed a new classification reflecting the functional state of the parasite that facilitates selection of treatment modalities, as shown in Table 106.3 and Figure 106.5.

Based on the WHO classification, certain management guidelines have been suggested. In patients with active cysts (type CL, CE1, CE2), about one third of the cysts will be sterile. In these patients, there are three

management options: (a) wait and see, (b) further differential diagnosis, and (c) chemotherapy. The remaining two thirds of the patients will have fertile cysts and half of them will have secondary cysts. In this group, management modalities are surgery, PAIR, and chemotherapy. Active cysts are the most frequent presentation of liver HCs in the clinical setting. In patients with degenerating (transitional state) cysts (type CE3), living protoscoleces can exist and all treatment options should be considered. In patients with inactive cysts (type CE4 and CE5), further differential diagnosis is frequently necessary. As a rule, there are no living protoscoleces in these cysts and, if no complications related to the cyst are present, no treatment is necessary.

TABLE 106.3 The WHO-IWGE Classification of HC

Type of Cyst	Status	Ultrasonographic Features	Remarks
CL	Active	Signs not pathognomonic, unilocular, no cyst wall	Usually early stage, not fertile; differential diagnosis necessary
CE1	Active	Cyst wall, hydatid sand	Usually fertile
CE2	Active	Multivesicular, cyst wall, rosettelike	Usually fertile
CE3	Transitional	Detachment of laminated membrane, water lily sign, less round—decreased intracystic pressure	Starting to degenerate; may produce daughter cysts
CE4	Inactive	Heterogeneous hypo- or hyperechogenic degenerative contents; no daughter cysts	Usually no living protoscoleces; differential diagnosis necessary
CE5	Inactive	Thick calcified wall; calcification partial to complete; not pathognomonic but highly suggestive diagnosis	Usually no living protoscoleces

CE, cystic echinococcosis; CL, cystic lesion.

Intraoperative US

In my experience, IOUS can affect the operative strategy. IOUS can be used (a) for "mapping" of the HC (determining its exact position, shape, and its relationship to neighboring structures, e.g., as partially calcified cysts close to hepatic veins and VCI; central cysts close to the hilum), (b) when managing patients with multiple cysts, (c) when the atrophy/hypertrophy complex distorts the anatomy, (d) in reoperations for

hydatid disease, (e) in the localization and management of small, nonpalpable cysts deep in liver parenchyma, (f) in the examination of the extrahepatic biliary tree, (g) in detection of CBC, which, however, is not always accurate even in experienced hands, and (h) in the search for exogenous vesiculation, especially if nonresectional surgery is performed. An important special technique is that, after partial pericystectomy, the probe should be introduced into the sterilized cyst cavity and the entire inner wall scanned for exogenous vesiculation. An exogenous cyst can be approached and managed directly through the pericyst with minimal risk.

A CBC should be expected when IOUS detects (a) a dead cyst (heterogeneous US pattern of the cyst), (b) hydatid material in the biliary tree, (c) the sign of “lost continuity” of the bile duct adjacent to the cyst wall, and (d) gas in the cyst.

Ultrasonography in Patient Follow-Up

Ultrasonography after operation for liver hydatidosis is complex, and correct interpretation of results demands an understanding of the operative procedure. Symptomatic patients need prompt US exploration. US reveals a variable pattern, and interpretation depends on time of the prior operation, the type, localization, and size of the cyst or cysts, and the type of operation. I classify postoperative ultrasound patterns into two groups: (a) early postoperative appearance and (b) late postoperative appearance.

US examination in the early postoperative period demonstrates one of the following images: (a) empty (transonic) remaining cavity persisting for months; (b) fluid collection, hematoma, or biloma; (c) a partial cavity with solid mass with/without fluid; (d) a hyperechogenic circular pattern after omentoplasty (should not be mistaken for a recurrent cyst); (e) missed cysts; and (f) distortion of the liver contour.

CL
CE 1
CE 2
CE 3
CE 4
CE 5

Figure 106.5. Types of hydatid liver cysts found on ultrasonographic examination of the liver and the classification proposed by the World Health Organization Informal Working Group on Echinococcosis. CL, cystic lesion; CE, cystic echinococcosis.

US examination in the late postoperative period demonstrates one of the following images: (a) compensatory hypertrophy of the liver after operation for a large cyst, (b) hyperechogenic appearance and no cavity at operative site, (c) frank recurrence of a developing cyst (increasing volume of persistent fluid collection at the site of operation), (d) new cysts at a different site (not a recurrence), and (e) calcifications at the operative site.

Computerized Tomography

CT yields the most accurate information regarding the number, position, and cyst characteristics (volume and density) as well as the extent of intra-abdominal disease. Discontinuity of the cyst wall in the vicinity of bile ducts is highly suggestive of CBC. A CT scan can readily demonstrate exogenous vesiculation, which is an important cause of recurrence in conservative surgery for liver hydatidosis. I believe that all patients need a CT scan preoperatively. CT is less operator dependent than US and can give the surgeon an accurate roadmap for operation. For patient follow-up, a CT scan should be obtained only when indicated by US findings.

Magnetic Resonance Imaging and Cholangiopancreatography

Magnetic resonance imaging (MRI) provides high-quality images of liver and abdominal hydatidosis. MRI is irreplaceable in monitoring skeletal and vertebral disease and in cardiac cysts. MR angiography is helpful only when cysts are large and in close proximity to major vessels or when the patient has been previously operated several times for hydatid disease and has distorted liver anatomy. MRI and magnetic resonance cholangiopancreatography (MRCP) is suggested in (a) subdiaphragmatic site of HC, (b) disseminated disease, (c) extra-abdominal location, (d) complicated, symptomatic, cysts, and (e) pre-surgical evaluation and planning (liquid areas and structure of the HC). MRCP is an excellent noninvasive tool for investigating jaundiced patients with liver hydatidosis.

Endoscopic Retrograde Cholangiopancreatography

Since MRCP was introduced, the indications for endoscopic retrograde cholangiopancreatography (ERCP) have been redefined. ERCP has little value in asymptomatic patients and should be avoided. Unavailability of MRCP or the intent to treat (interventional procedures) is the only indication for ERCP. Indications for endoscopic papillotomy in the preoperative period are (a) when US, CT, MRCP, or ERCP detect hydatid material in the CBD and (b) when cholangitis has been a feature of the clinical presentation, regardless of whether a CBC is detected. Because some asymptomatic patients have hydatid debris in the CBD and the CBD can be cleared during the operation without papillotomy, the first indication is not so clear-cut. Preoperative endoscopic papillotomy facilitates flushing of the bile ducts but renders intraoperative cholangiography even less informative. In my practice, indications for endoscopic papillotomy in the postoperative period are (a) hydatid material in the CBD, (b) a biliary fistula lasting longer than 3 weeks, (c) a high-output biliary fistula (>1,000 mL per 24 hours), (d) jaundice, and (e) short stricture obstructing the papilla. Critical use of ERCP and papillotomy in patients with CBCs has reduced mortality and in-hospital stay.

Immunodiagnosis in Individual Patients

The detection of circulating *E. granulosus* antigens is less sensitive than the detection of antibodies. Most serologic tests are based on the reaction and precipitation between the test antigen and the circulating antibodies in the host. The quality of the test antigen determines the sensitivity and specificity of the test.

The initial intradermal Casoni test, the human basophile degradation test, and the complement-fixation test have only historical relevance. The primary tests for antibody detection are (a) the enzyme-linked immunosorbent assay (ELISA), (b) the indirect hemagglutination antibody test, (c) the latex agglutination test, (d) the immunofluorescence antibody test, and (e) immunoelectrophoresis. The secondary tests, usually done in specialized laboratories, are (a) detection of precipitation line (arc 5), (b) identification of immunoglobulin G subclasses, (c) immunoblotting, and (d) polymerase chain reaction (PCR).

Serologic tests must be used and interpreted in correlation with epidemiologic data, clinical presentation, and especially imaging

investigations. Primary tests have a sensitivity of 80% to 95% in patients with liver hydatidosis and 65% in patients with pulmonary hydatidosis. Confirmation should be obtained with secondary tests, which are more specific. Secondary tests should always be used for extrahepatic localizations or calcified cysts. Postoperative seronegativity is usually reached after 3 to 7 years. Persistence of high-specific antibodies or a positive secondary test indicates relapse.

A simple algorithm for serologic testing is (a) imaging negative—no further investigation; (b) primary test negative, asymptomatic patient, lesions resembling cystic echinococcosis—advanced imaging procedures, "wait and observe" approach, repeat serologic tests; (c) symptomatic patient, imaging suggestive of cystic echinococcosis—needs to be managed without further tests; and (d) primary test positive, with/without lesions suggestive of cystic echinococcosis with/without symptoms—needs secondary tests. Differential diagnosis for alveolar echinococcosis and for cysticercosis in patients coming from endemic areas is indicated. Specificity of tests is limited by cross-reaction with some other helminthic disease, some malignancies, liver cirrhosis, and the presence of anti-P1 antibodies. Detection of parasite-specific IgE and IgG4 has no clinical diagnostic advantage.

Establishing the Diagnosis

The diagnosis of hydatid disease follows a certain algorithm. Suspicion of liver hydatid disease is based on the epidemiologic background of the patient, clinical grounds, or noninvasive screening procedures. Available imaging modalities should identify cyst characteristics, and the diagnosis is confirmed by detecting specific antibodies with immunodiagnostic tests. In a very small number of patients, in whom diagnosis cannot be confirmed but suspicion exists (e.g., recurrence), diagnostic puncture can be considered if it is not contraindicated. Microscopic examination following vital staining of fluid aspirated from a HC gives evidence of the parasitic nature and vitality of a cyst. Routine blood and liver function tests are of no value in patients with simple HCs.

According to WHO-IWGE, the clinical criteria for the diagnosis are (a) slowly growing or static cystic mass or masses diagnosed by imaging techniques, (b) anaphylactic reaction due to leaking or ruptured cyst, and (c) incidental finding of a cyst in asymptomatic carriers or detected by screening techniques. The diagnostic criteria are (a) typical organ lesion(s) detected by imaging techniques, (b) specific serum antibodies assessed by

high-sensitivity serologic tests, confirmed by a separate high-specificity serologic test, (c) histopathology or parasitology typical for ECs (e.g., protoscoleces or hooklets in cystic fluid), and (d) pathognomonic macroscopic morphology of EC in surgical specimens. A possible case is any patient with a clinical or epidemiologic history, and imaging findings or serology positive for cystic echinococcosis. A probable case is any patient with the combination of clinical history, epidemiologic history, imaging findings, and serology positive for cystic echinococcosis on two tests. A confirmed case is any patient that has been considered a probable case plus (a) positive microscopic analyses of cyst fluid, or (b) changes of US appearance of liver cyst (e.g., stage CE1 moving toward CE3a) after the administration of albendazole (ABZ) or spontaneous.

MANAGEMENT OF ECHINOCOCCAL CYSTS

Nonoperative therapy can fail due to several factors: (a) the bioavailability of chemotherapeutic drugs is limited and uncertain due to cyst characteristics, (b) cysts are frequently multivesicular and protoscolicidal agents do not penetrate into vesicles and daughter cysts, (c) cysts can have large volumes and dilute the injected protoscolicidal agents, (d) the infective content of vital cysts is under increased pressure and puncture may lead to spillage (percutaneous puncture only for cysts in certain positions), (e) aspirators are frequently obstructed by cyst content/hydatid debris and it is impossible to aspirate paste-like content, (f) CBCs need to be evaluated and managed, and (g) there may be vital parasites in the remaining structures (pericyst wall, exogenous vesiculation) that will cause recurrence of the disease.

Chemotherapy

Thirty years after the first attempts to establish effective medical treatment with benzimidazole carbamates, surgery is still the golden standard for achieving complete cure. At present, of the benzimidazoles, only mebendazole (MBZ) and ABZ are still used. ABZ is the only drug that is ovicidal, larvicidal, and vermicidal and is the drug of choice. Praziquantel, a synthetic isoquinoline pyrazine derivative, has been used in combination with ABZ to increase the protoscolicidal effect of ABZ. Although 45% to 60% of patients experience one or more side effects, drug therapy is discontinued in only 2% to 4% of patients.

Chemotherapy with benzimidazole compounds is currently indicated in

(a) inoperable patients with primary liver and lung cystic echinococcosis, (b) patients with multiple cysts in two or more organs, (c) multiple small (<5 cm, CE1 and CE3) liver cysts, (d) cysts deep in liver parenchyma, (e) prevention and management of secondary hydatidosis, (f) management of recurrent hydatidosis, (g) unilocular cysts in unfit elderly patients, (h) in combination with surgery and interventional procedures, (i) pulmonary echinococcosis, and (j) long-term administration for cysts at specific sites (such as bone, brain, eye).

Benzimidazole chemotherapy is contraindicated for (a) large cysts (>10 cm), (b) cysts with multiple septa divisions (honeycomblike cysts), (c) cysts that are prone to rupture (superficial), (d) infected cysts, (e) inactive cysts, (f) asymptomatic calcified cysts, (g) severe chronic hepatic disease, (h) bone marrow depression, and (i) early pregnancy (animal experiments). Diabetes is a relative contraindication. Chemotherapy for bone cysts is a relative contraindication. Published data are controversial since there is a significantly reduced response.

The expected results of adequate chemotherapy are (a) 10% to 30% cyst disappearance (cure), (b) 30% to 70% degeneration or significant size reduction (improvement), and (c) 20% to 30% no morphologic changes (treatment failures). Younger patients had a better response rate. The rate of relapse after chemotherapy is high (3% to 30%), but, fortunately, relapses are sensitive to retreatment in up to 90% of patients. Most relapses occur within 2 years after therapy. However, interpretation of published reports is difficult because of the lack of standardization and interference with the natural history of the disease.

The effectiveness of preoperative chemotherapy in preventing secondary echinococcosis and recurrence needs further investigation. Chemotherapy is routinely administered prior to interventional procedures and preoperatively in some centers. It is still unclear whether preoperative chemotherapy is beneficial; I do not use it routinely.

According to the WHO-IWGE guidelines, preinterventional administration of ABZ or MBZ should begin 4 days before intervention and continue 1 month for ABZ and 3 months for MBZ thereafter. Based on animal data, 1- to 2-week postspillage therapy may be useful. All the available data suggest that medical management of hydatid disease yields poor results, and in the majority of patients the therapy fails or the disease relapses.

ABZ is given orally at a dose of 10 to 15 mg/kg/day, in two divided

doses, with a fat-rich meal without monthly treatment interruptions. Optimal dosage and treatment duration have not been accurately defined. The optimal treatment period ranges from 3 to 6 months. It seems that prolonging the treatment period does not further increase the incidence of adverse effects. There are emerging data that continuous treatment as opposed to pauses after treatment for 1 to 3 months is safe and more effective and well tolerated. There MBZ is given at a dosage of 40 to 50 mg/kg/day in three divided doses with a fat-rich meal if ABZ is not tolerated. The duration of therapy is also 3 to 6 months.

Limited data are available for the use of praziquantel. The dosage is 40 mg/kg/wk. It has been used for the management of intraperitoneal spillage during operative and interventional procedures.

Monitoring for adverse effects of chemotherapy is mandatory. Many authors suggest a CBC count and liver enzyme determination every 3 weeks for the first 3 months, followed by repeated determinations once a month if the therapy is prolonged.

Minimally Invasive Techniques

Percutaneous Drainage of Hydatid Cysts—PAIR

Percutaneous puncture of HCs was dogmatically contraindicated for fear of spillage, dissemination, and life-threatening anaphylactic reaction. The first successful percutaneous drainage of a HC was reported in the late 1980s. A new interventional treatment modality—the PAIR procedure—emerged in the 1990s. The classical PAIR procedure includes the following steps: (a) percutaneous puncture of the cyst, (b) aspiration of cyst fluid, (c) injection of a protoscolicidal agent, and (d) reaspiration of the cyst content after 15 to 20 minutes.

Indications for PAIR are (a) inoperable patients; (b) patients who refuse surgery; (c) cysts types CL, CE1, CE3, and some CE2 (Gharbi types I and II, and some patients with types III and IV); (d) relapse after surgery; (e) infected cysts; (f) failure of chemotherapy; (g) multiple cysts of more than 5-cm diameter in different liver segments; (h) possibly pregnant women (chemotherapy contraindicated); and (i) possibly children less than 3 years old.

Contraindications for PAIR are (a) inaccessible cysts, (b) superficially located cysts, (c) cysts with multiple septa divisions (honeycomb like cysts CE2, CE3b), (d) cysts with hyperechogenic solid patterns (CE4), (e) cysts communicating with bile ducts, (f) partially or totally calcified cysts

(CE5), (g) most cysts in the lung, and (h) early pregnancy.

PAIR is usually performed under US or CT guidance for cysts larger than 5 cm in diameter. The patient is prepared according to preoperative guidelines. Local anesthesia is administered. The cyst is punctured through the thickest possible transhepatic route using a cholangiography needle (18 to 22 gauge) or transhepatic catheter needle (No. 5 French). The cyst is entered through the nondependent wall to avoid the sediment rich in protoscoleces. About 30% to 50% of the cyst volume is aspirated. If necessary, immediate cytologic and bacteriologic examination of the fluid and sediment can confirm the diagnosis. Radio-opaque contrast is injected into the cyst cavity in order to opacify the cyst and to detect CBC. All daughter cysts need to be punctured in a multivesicular cyst. The initial protoscolicidal agent (usually hypertonic NaCl, 15% to 20%) is not injected if CBC is demonstrated. The cyst is completely reaspirated after 15 to 20 minutes. A sclerosant (usually alcohol) is then injected. If the cyst diameter is more than 6 cm prior to injection of the sclerosant, a drainage catheter is inserted and free drainage is enabled for 24 hours. After 24 hours, a cystogram is performed through the catheter and a sclerosant is injected. Complicated cysts, cysts with many daughter cysts, or large-volume cysts are indications for PAIR modifications: (a) the PAIR-catheterization technique, (b) the D-PAI (double-puncture, aspiration, and injection) technique, (c) the percutaneous evacuation of cyst content (PEVAC) technique, and (d) the modified catheter aspiration technique (MoCAT).

Following successful PAIR, a heterogeneous US pattern is detected, usually within 2 to 4 months, a pseudotumor appears in 4 to 8 months, and cyst obliteration occurs in 9 to 12 months. Not all cysts reach the stage of a pseudotumor or undetectable lesion. The PAIR procedure can be safely repeated.

The overall complication rate in PAIR is 10% to 40% and the overall mortality rate is 0.9% to 2.5%. Mortality is associated with periprocedural complications, advanced age, and infection of the remaining cyst cavity. Fever without an identifiable source occurs in 6% to 35% of patients and, with symptomatic therapy, disappears within 72 hours after intervention. Minor allergic reactions occur in 0% to 12% of patients. The incidence of anaphylaxis is the same as for open surgery (probable range, 0.1% to 0.2%). Infection of the cyst cavity occurs in 2% to 10% of patients, usually within 10 days after the procedure. The local recurrence rate is 0% to 4%.

The incidence of biliary fistulas, rupture, and obstruction is 3% to 6%. There are no reports of caustic sclerosing cholangitis or secondary peritoneal dissemination. Favorable results have been reported following PAIR interventions worldwide with follow-up periods exceeding 5 years. Pretreatment and posttreatment chemotherapy is mandatory.

The PAIR procedure has gained wide acceptance because it is safe, minimally invasive, and easy to perform; has a low morbidity and mortality, a short hospital stay; and is cheaper than surgery. Pulmonary HCs are generally considered a contraindication for PAIR, although good results without mortality have been reported. Percutaneous drug injection (ivermectin, ABZ sulfoxide) without aspiration is still in the experimental phase.

In some countries, mobile specialized teams with specially adapted busses and trucks are sent into rural endemic areas to treat patients, since this is an effective, relatively safe procedure that yields good results.

Open Surgery

The rationale for surgical management of liver ECs is that (a) surgery is the most effective treatment applicable to all cysts, (b) it removes the parasite, (c) it manages the CBC, (d) it manages the cystic cavity (conservative surgery), (e) it has an acceptable morbidity and mortality rate, and (f) it has a low recurrence rate.

There is no prospective randomized study to compare radical surgery with conservative surgery. Surgeons trained in hepato-bilio-pancreatic (HPB) surgery prefer radical procedures, while the majority of general surgeons in endemic areas, the ones who do not talk at meetings and conferences, perform conservative surgery in most cases.

Closed or open total cystopericystectomy (cystectomy) and liver resection have strict, defined indications. The rationale for performing liver resection for a benign disease that can be successfully managed by less extensive liver surgery with acceptable results needs to be evaluated in every patient. The majority of operations for liver hydatid disease are performed at general surgical departments in developing countries in which extensive expertise and facilities for major liver surgery are unavailable. Under such circumstances, a high postoperative morbidity and mortality rate can be expected, especially as liver atrophy is frequently present because of the large size of the neglected cysts. These patients, following liver resection, return to endemic areas in which reinfestation is

possible.

Radical Procedures

The rationale for radical procedures is that (a) total removal of the cyst and exocysts is associated with the lowest recurrence rate, (b) chemotherapy after radical removal of the intact cyst is unnecessary, (c) the use of intraoperative protoscolicidal agents is unnecessary if the cyst is not entered, (d) the chance for a biliary fistula and cavity-related complications is low, (e) calcified cysts can be removed, and (f) in expert hands the mortality and morbidity rates are low.

Radical procedures are (a) closed cystectomy, (b) open cystectomy, (c) near-total open cystectomy, (d) subadventitial cystectomy, (e) nonanatomic liver resection, (f) anatomic liver resection, (g) completion cystectopericystectomy in residual cavities, and (h) total cystopericystectomy in hepatopulmonary transit. The term *closed pericystectomy* is a misnomer and the correct term is *cystectomy*, since the pericyst is part of the EC. It is also known as *radical cystectomy*, *ideal cystectomy*, *capsulectomy*, *total pericystectomy*, and *cystopericystectomy*.

Conservative Procedures

The rationale for conservative surgery is that (a) all cysts can be treated in this manner; (b) it can be performed safely by general surgeons; (c) the liver parenchyma is not entered and there is no threat to the hepatic vasculature and bile ducts; (d) a specialized team for HPB surgery is not necessary; (e) no special equipment is necessary; (f) it is applicable to multiple bilateral cysts; (g) if performed correctly the morbidity, mortality, and recurrence rates are acceptable; (h) it is cost-effective in developing countries; and (i) it is tissue sparing, which is important in endemic areas.

INDICATIONS AND CONTRAINDICATIONS FOR OPEN SURGERY

Surgery is still the “gold standard” in the management of liver hydatid disease. Indications for open surgery are (a) large cysts with multiple daughter cysts type CE2 to CE3b; (b) single liver cysts situated superficially that may rupture; (c) infected cysts; (d) cysts with CBC; (e) cysts exerting pressure on adjacent organs; and (f) cysts in the lung, brain, bones, kidneys, and other organs. Contraindications for surgery are (a) patients refusing surgery, (b) extreme age, (c) pregnant women, (d)

concomitant severe diseases, (e) numerous cysts, (f) cysts difficult to access, (g) dead cysts, (h) cysts partially or totally calcified, and (i) very small cysts (<5 cm, wait and see policy).

PREOPERATIVE PLANNING

The classic open surgical procedures can be subdivided into two groups: (a) conservative, tissue-sparing procedures that are limited to removing the parasite, with part or most of the pericyst left *in situ* and (b) radical, resectional procedures that remove the entire pericyst, with or without entering the cyst itself. The choice of the surgical techniques depends on: (a) the type and size of the cyst, (b) the site, (c) the presence of complications, and (d) the expertise of the surgeon.

Antibiotic prophylaxis is administered. Preoperative chemotherapy and steroids are not routinely given. The operating room must have radiography facilities and possibly IOUS. The anesthetist should have steroids and adrenalin at hand. Operating room personnel should be informed about the nature of the disease.

I present experience with 1,168 operated patients.

OPEN SURGICAL TECHNIQUES IN CYSTIC ECHINOCOCCOSIS

Approach and Exposure

The incision depends on (a) the site of the cyst, (b) its size, (c) the presence of extrahepatic cysts, and (d) the presence of complications. The incision can usually be confined to the abdomen. I prefer a long, right subcostal incision with an upward extension in the midline, if necessary. A right thoracoabdominal incision was used infrequently in my series, in only 2.1% of the patients, and thoracotomy was added to a right subcostal incision in only 0.45% of the patients. The reported high incidence of thoracotomy probably reflects the inability to accurately assess the extent of diaphragmatic involvement. A gigantic posterior cyst with marked elevation of the diaphragm or a preoperatively established bronchobiliary fistula may be an indication for thoracotomy. It is always better to perform a thoracotomy than to extend an abdominal incision into the chest. A midline laparotomy is preferred in patients with (a) cysts in the left lobe of the liver, (b) perforated abdominal HCs, and (c) secondary abdominal echinococcosis.

Before approaching the cyst(s), the entire liver is “walled off” from the rest of the abdomen with packs soaked in hypertonic saline. Careful and completely mobilization of the liver is mandatory. Inflammatory, dense adhesions overlying the most superficial part of the cyst are frequent. Most such adhesions are not the result of rupture, and a thick cyst wall usually exists. The diaphragm should be dissected away from the cyst and its full mobility restored. It is unwise to handle a large posterior cyst in a liver that has not been mobilized, and it is also difficult to manage the residual cyst cavity. If the diaphragm is adherent, postoperative chest complications are more frequent. Inspection, bimanual palpation, and IOUS of both lobes are mandatory. Because large and multiple cysts frequently distort liver anatomy, it is important to assess the relationship of the cyst to the VCI and the hepatic veins. All cysts seen on preoperative imaging must be identified. IOUS examination of the CBD is mandatory. Some authors prefer not to mobilize the liver, but rather isolate the cyst with gauze packs soaked in a protoscolicidal agent prior to decompression. This is feasible for small anterior cysts. It is not an efficient and safe procedure for posterior cysts.

In my series, the cyst was in the right lobe of the liver in two thirds of the patients, in the left lobe in one fifth, and in both lobes in less thyan 20% of the patients. The most frequently involved segments were VII (one third of the patients) and V (one fifth of the patients).

Conservative Surgical Procedures

All of these procedures have some common goals: (a) safe and complete exposure of the cyst, (b) safe decompression of the cyst, (c) safe evacuation of the cyst contents, (d) sterilization of the cyst, (e) management of CBC, when present, and (f) management of the remaining cyst cavity.

Safe Decompression of the Cyst

All cysts should be treated as if they are vital and infectious. The entire area around the mobilized liver is packed with blue or green packs and drapes are soaked in 15% to 20% saline. Colored packs and drapes ensure better visibility of whitish cyst elements. The point where the cyst is to be punctured is determined and a working area, as small as possible, is delineated by additional packing. This is important because the high intracystic pressure makes it difficult to avoid some leakage of cyst

contents. Special devices have been designed for safe decompression of HCs. The use of “cones” (adhere to liver surface by freezing or vacuum) has been described. These devices intended for decompression of a HC in a sealed-off, controlled environment are bulky, impractical, and impossible to attach to posterosuperior cysts. There are no data supporting their routine use. I do not use special devices for cyst puncture and do not inject protoscolicides into an unopened cyst. Two large-bore suction tips connected with transparent tubing to large capacity reservoirs are necessary. The cyst is penetrated by a short, large-gauge needle connected to one of the suction tips in the delineated working area while the other suction tip is held next to the needle at the puncture site. The color of the aspirated hydatid fluid is observed. Usually, 50 to 100 mL can be evacuated before the needle becomes occluded. Once the intracystic pressure is lowered, it is possible to place three stay sutures adjacent to the needle. Upward traction on the stay sutures makes it possible to retract the needle safely. The cyst is incised between the sutures by electrocautery. The rims of the incision are grasped with tissue-grasping forceps and the stay sutures are removed. The incision is enlarged to about 3 to 5 cm so that direct vision of the cyst cavity and its contents is achieved. A large-gauge sump suction is inserted and freely moved around the cyst cavity in order to evacuate all the fluid. Warm saline solution is intermittently injected into the cyst cavity to keep the suction functioning and to evacuate the debris and hydatid sand. It is important to have a small opening at the uppermost part of the cyst and to exert constant upward traction on the edges of the incision so that overflow is avoided. The use of laparoscopic trocars for cyst penetration and evacuation enabling simultaneous irrigation (gas valve) and evacuation (large-bore aspirator open at the tip) has been described.

Once the fluid has been aspirated, the laminated membrane collapses and all the remaining cyst contents can be removed. A small metal dish is brought next to the incision, which is enlarged by electrocautery to facilitate removal of its contents. In a univesicular cyst, the laminated membrane can be extracted with ring forceps and placed into the metal dish. In a multivesicular cyst, the daughter cysts and the debris are best managed by high-power, wide-bore suction. Sometimes, it is necessary to use a “spoon” to evacuate the cyst contents. The presence of a toothpastelike, semisolid material rapidly blocks the suction, and evacuation is continued with the “spoon.” The real benefit of grinder–

aspirator devices for the evacuation of dense cyst contents in open surgery needs further evaluation.

Sterilization of the Cyst and Search for Bile Duct Communications

The redundant portion of the cyst roof is excised by electrocautery, the cyst volume is reduced, and excellent exposure is obtained. The cut edges are oversewn with running resorbable mattress sutures. This is important because the edges can contain small blood vessels and bile ducts. I use the Harmonic scalpel (Ethicon) or LigaSure (Tyco) for this purpose in laparoscopic HC surgery, and these devices can be used in open surgery as well. Sterilization of the cyst cavity is achieved by mechanical cleansing and local application of protoscolicidal agents. The interior is carefully cleansed. I carefully "scrape" the interior of the cyst with sponges soaked in 10% saline, with frequent rinsing and aspiration, in an attempt to remove what is left of the endocyst. Daughter cysts may be tucked away in recesses of the main cavity and overlooked. Curettage with sharp instruments is not safe because hepatic veins frequently run adjacent to the cyst. Any "bulging" of the cyst wall is treated with caution. After removing all the debris, the cyst cavity is flushed several times with saline, inspected for bile leaks, and loosely packed with dry, white-colored packs soaked in 15% to 20% saline. The packs are left in place for 5 to 10 minutes, removed, and inspected for bile stains. Bile stains are indicative of CBC and warrant their identification and management. If no bile stains are visible, definitive sterilization of the cyst is performed.

I do not inject protoscolicidal agents into an intact or partially decompressed HC for sterilization. The efficacy of protoscolicidal agents after mixing with cyst content is uncertain and even HCs with clear contents can sometimes demonstrate CBC after decompression.

Protoscolicidal agents have been used for cyst sterilization since the beginning of the past century. Many surgeons question their merit and efficacy. Minimally invasive techniques have re-established the need for their evaluation. For a good protoscolicidal effect, the choice of protoscolicidal agents and exposure time is crucial. I have studied the efficacy of protoscolicidal agents (exposure time necessary for a 100% protoscolicidal effect, all protoscoleces dead) using standardized human protoscoleces-rich sediment. For 5% saline, the exposure time was 180 minutes; for 10%, it was 30 minutes; and for 15%, 20%, and 30%, it was only 10 minutes. For alcohol (96%, 70%, 48%, and 35%), 10% povidone iodine, 10% formalin, and 5% chlorhexidine gluconate, the exposure time

was 10 minutes. The shortest exposure time was for commercial products Cetavlon (AstraZeneca, Sodertalje, Sweden) and Savlex (Drogsan Pharmaceuticals, Ankara, Turkey), at only 5 minutes. For silver nitrate, the time was 5 minutes, and for 3% hydrogen peroxide, it was 15 minutes. Protoscolicidal agents can cause serious life-threatening complications: (a) acute toxic reaction; (b) anaphylaxis; (c) hypernatremia; (d) air embolism; (e) metabolic acidosis; (f) consciousness disorders, coma, and death; (g) peritoneal adhesions; (h) methemoglobinemia; and (i) caustic sclerosing cholangitis. Caustic sclerosing cholangitis is a new clinical entity described in the late 1980s. It is the result of protoscolicidal agents entering bile ducts and damaging the mucosa. The progression of caustic sclerosing cholangitis is rapid, resulting in segmental bile duct obstruction and deteriorating liver function. Protoscolicidal agents, even in low concentrations, should not be instilled if a CBC is present or suspected.

Management of Cystobiliary Communication

Management of CBC is the crucial issue in conservative surgery for liver hydatidosis. CBC is an independent variable that significantly increases the incidence of postoperative morbidity and mortality. Inadequate management can cause serious, life-threatening complications. The orifice of the CBC is sometimes very easy to identify. A single cyst can have several orifices, and in a patient with multiple cysts, several cysts can have CBC. Successful and safe closure of the CBC is possible in the majority of patients. Unfortunately, not all patients have a CBC that is easy to manage, especially when a major bile duct is involved. In some patients, the cyst can destroy one hepatic duct or the confluens of the hepatic ducts. Such patients need to be identified and certain technical rules need to be observed.

Most CBCs cannot be preoperatively predicted. In my series, specific symptoms (cholangitis, obstructive jaundice, biliary colic, and allergy) were present in only 31.6% of these patients, and specific signs (dilated bile duct with/without debris, altered blood chemistry) in 23.8%. Large cysts (>10 cm) occupying several liver segments and episodes of cholangitis are highly suggestive of HC–bile duct communications.

Management of CBC depends on several factors including, among many other factors (a) their number, (b) type, (c) site, (d) size of the orifice, (e) the involved bile duct, (f) patient status, (g) condition of the liver, and (h) the expertise of the surgeon.

Bile-stained cyst contents are highly suggestive of an existing CBC.

The majority of patients with this condition will not have a visible orifice at operation, suggesting that most of the CBCs were minute, fissure-like communications at some point in the cyst development. In such cysts, search for the orifice should be meticulous as the interior surface of the cyst is corrugated. Sometimes after rapid decompression of a cyst, with only slightly bile-tinted contents, an orifice secreting bile appears. This may be caused by a valve-like mechanism or rupture of an atrophied point of contact once the intrabiliary pressure exceeds the pressure in the cyst. In PAIR procedures, this may be one of the explanations for bile fistulas.

The intraoperative detection and assessment of the CBC is essential for adequate management. Sometimes it is impossible to identify the site of an obvious leak. The routine procedure was to do intraoperative (cystic duct) cholangiography. I disagree with this routine. Intraoperative cholangiography, which theoretically has the advantage that it can demonstrate daughter cysts in the CBD as well, is not routinely necessary for three reasons: (a) only a small proportion of patients have hydatid debris in the bile duct, and they can be identified with IOUS, (b) the majority of these patients have had a preoperative ERCP because they presented with cholangitis, and (c) apart from demonstrating the existence of a leak, it does not necessarily help identify the site of the leak. The dye spills into the cystic cavity and repeated films are even less informative. An alternative would be to fill the cyst with saline and inject air and watch for bubbles instead of injecting additional quantities of dye. Both procedures usually require cholecystectomy, which is not really necessary in most patients. The gallbladder very infrequently has hydatid debris. Methylene blue can be injected into the gallbladder or CBD, but I do not find it particularly helpful. If the site is not identified at the time of injection, the interior of the cyst is colored blue and subsequent identification is even more difficult. It is my practice to pack the cyst with white gauze packs soaked in hypertonic saline and wait for several minutes to see if and where bile stains appear. If bile appears, a meticulous search for the orifice is conducted, aided by gentle squeezing of the gallbladder, if necessary. This will almost certainly demonstrate the orifice.

It is of paramount importance that the orifice is visualized and the CBC assessed. Large, central cysts can grossly distort liver anatomy and make it difficult to identify the bile duct involved. It is important to determine the direction of both ends of the bile duct, if a side-to-side communication is present, by gentle exploration with a thin, curved probe in order to place

the sutures correctly. Terminal branches can be sutured with or without T-tube drainage. CBC with segmental or hepatic ducts needs to be accurately visualized (preferably through the communication) and assessed.

It is my practice to gently clear the ectocyst and the fibrous layer overlying the bile duct in order to perform a secure tension-free suture of the orifice. The opening of the bile duct is cannulated with a transparent soft plastic cannula of similar size. Reflux of bile verifies the position of the cannula. Radio-opaque, diluted dye is injected and a fluorocholangiography is performed. The proximal and distal biliary tree is visualized. The point of entry of the cannula is visible during filling of the bile ducts, and it is possible to see the entire biliary tree. Presence of daughter cysts and debris in the CBD can be demonstrated. The filling of the duodenum is observed as well.

Management is based on the complete assessment of the CBC and should be as simple as possible. The large number of procedures described is confusing. All procedures can be classified, for didactic reasons, into five groups: (a) suture of the communication (e.g., simple suture, suture with T-tube CBD drainage, intralameral pericystectomy, and capitonnage), (b) internal drainage procedures (e.g., biliodigestive bypass, transduodenal sphincterotomy, internal transfistular drainage with or without transduodenal sphincteroplasty), (c) external drainage procedures (e.g., bipolar drainage, cystobiliary disconnection), (d) reconstructive procedures (e.g., pericystojejunostomy, intracavitary biliodigestive bypass, or bile duct repair), and (e) liver resection.

In my series, 272 of 1,333 patients (20.40%) had CBC. All procedures performed for the management of CBC are presented in Table 106.4. Simple procedures are adequate, and there is no need to invent new procedures or to improvise. In some patients with apparently bile-stained hydatid debris, after a meticulous search no CBC was detected and no additional procedure on the bile ducts was necessary. One possible explanation is that penetration of bile into the cyst caused death of the parasite and the small communicating bile duct was obliterated. It is also possible that the communicating bile duct was transected with the redundant portion of the pericyst and that suturing of the rim of the cyst obliterated it (Table 106.4).

In the majority of patients, the CBC is with a peripheral or small duct, and simple suture of the communication is sufficient. I use interrupted 3-0 or 4-0 resorbable sutures Vicryl, PDS (Ethicon, Ltd., Edinburgh, United

Kingdom), Dexon, Maxon, and Biosyn (Tyco HealthCare, Norwalk, USA). A cyst can have more than one communication.

The T-tube drainage of the CBD is infrequently added to the suture of the CBC, only in order to (a) secure and decompress a risky suture of a larger bile duct in a rigid pericyst or (b) to close the choledochotomy done for removing the hydatid debris in the CBD. If hydatid debris is detected in the CBD and a choledochotomy performed, the CBD has to be thoroughly cleansed and, if necessary, a choledochoscopy done before placement of the T-tube. After placing the T-tube and suturing the CBD, perioperative fluorocholangiography is performed.

TABLE 106.4 Procedures Performed in the Management of Bile Duct Communications

Procedure	Number of Patients	Percentage of 272 Patients
Suture	184	67.65
Nothing was done	29	10.67
Suture + T-tube	32	11.76
T-tube	18	6.62
Roux-en-Y cystojejunostomy	5	1.84
Roux-en-Y hepaticojejunostomy	2	0.73
Intracavitary reconstruction	2	0.73
Total	272	100

Infrequently, the orifice of the CBC and the communicating bile duct are not suitable for suturing. Combined drainage procedures that avoid any intervention on the orifice itself enable the fistula to seal spontaneously. This is achieved by placing local drains into the pericyst cavity and decompressing the biliary tree by either external or internal surgical procedures. In bipolar drainage, drains are placed into the pericyst cavity and the CBD is decompressed by a T-tube. In cystobiliary disconnection (Perdomo procedure), an anatomic disjunction between the residual cavity and the biliary fistula is achieved. A transparenchymal, multiperforated drain is passed through the CBC orifice to drain the fistula, while another multiperforated drain is placed into the cystic cavity to drain the cavity. The CBD is drained by a T-tube.

In internal drainage procedures, biliary decompression is achieved by (a) endoscopic papillotomy, (b) transduodenal sphincteroplasty, or (c) biliodigestive anastomosis.

A hilar cyst can have a CBC to a major duct that cannot be sutured

without compromising biliary drainage. In patients with this condition, depending on the size of the cyst and orifice, several options exist: (a) a Roux-en-Y cystojejunostomy, (b) a Roux-en-Y intracystic hepaticojejunostomy, (c) a Roux-en-Y hepaticojejunostomy, (d) intracystic bile duct repair, and (e) liver resection.

Indications for cystojejunostomy are extremely rare. In my experience, it was done only when a 3-cm cyst at the confluens transected the hepatic duct (a proximal and a distal orifice), and in order to avoid resection in a teenager from an endemic area. A Roux-en-Y intracystic hepaticojejunostomy is performed only when a voluminous, centrally located cyst communicating with the hepatic or segmental duct of the orifice is too large to suture. A transintestinal temporary drainage catheter is used when possible. A Roux-en-Y hepaticojejunostomy is indicated only when it is the only means to secure bile drainage. Intracystic bile duct repair is rarely feasible, and it is not a routine procedure. Meddlesome bile duct reconstruction fails, serious complications arise, and reoperation is frequently necessary. When adequate drainage of bile cannot be achieved, it is best to resect.

Biliodigestive bypass procedures are not frequently performed these days. The only indications are (a) massive penetration of hydatid debris and daughter cysts into the bile ducts, (b) a very distended and flaccid CBD, and (c) acute cholangitis. Choledochoduodenostomy was performed in the past when the bile ducts could not be completely cleared. I prefer Roux-en-Y hepaticojejunostomy when bypass is indicated. Indications for sphincteroplasty are very infrequent: (a) obstruction of the papilla with calcified hydatid debris and (b) short stricture at the papilla. Endoscopic papillotomy is the preferred option in most cases. Endoscopic management of CBCs needs further investigation.

Management of the Residual Cystic Cavity

In partial cystopericystectomy, the redundant portion of the pericyst is resected and, depending on cyst geometry, a residual cavity is left behind. It is easy to perform in uncomplicated cysts of all sizes located in accessible regions of the liver. Subtotal pericystectomy (fere totalis) is an alternative to partial cystopericystectomy when most of the pericyst is resected. Small calcified or adherent segments of the pericyst, adjacent to vascular and biliary structures, are left in place.

The residual cavity can be a source of postoperative complications in inexperienced hands. The residual cavity may be (a) superficial and

saucerlike, (b) anterior or inferior, (c) posterior and superior, or have (d) a large opening and large volume, (e) a small opening and a large volume, or may extend (f) through the full thickness of the liver parenchyma.

Because partial cystopericystectomy is the most frequently employed conservative procedure, several techniques for the safe obliteration of the residual pericyst cavity have been developed. The method of managing or obliterating the residual cavity should be selected carefully. The available options are (a) leaving the cyst open, (b) simple cyst closure, (c) marsupialization, (d) external tube drainage, (e) introflexion, (f) capitonnage, (g) omentoplasty, (h) partial capitonnage plus omentoplasty, and (i) Roux-en-Y cystojejunostomy (Figs. 106.6 and 106.7).

Leaving the Cyst Open

Large, shallow cavities that cannot be obliterated may be left open or covered with an omental flap sutured to the rim.

Simple Cyst Closure

The sterilized cyst cavity is filled with saline solution and closed by approximating the edges with running absorbable sutures. This procedure has very few indications, and it is applicable to small, noncalcified, and noninfected cysts only. Such cysts are usually managed by more efficient procedures. Deep residual cyst cavities, especially in the posterior aspect of the liver, should be obliterated because postoperative accumulation of fluid can cause serious complications.

Marsupialization

External cyst drainage by suturing the opening on the pericyst to the abdominal wall has been abandoned. Management of patients in this manner was cumbersome, prolonged, and not well tolerated. Suppuration and bleeding from the cyst was frequent. Morbidity was high.

External Tube Drainage

Operative external tube drainage was frequently used in the past for the management of simple or infected suppurated cysts. After evacuation and sterilization of the cyst cavity, one or more drains were left in place. Today, infected cysts, especially in septic patients, are managed by percutaneous drainage and simple cysts by the PAIR procedure.

Introflexion

Introflexion consists of folding in and approximating opposite edges of the pericyst and suturing them in place. Depending on the size of the cyst, it is sometimes necessary to fold into the cyst a part of the cyst wall including liver tissue covering the pericyst and suture them in place.

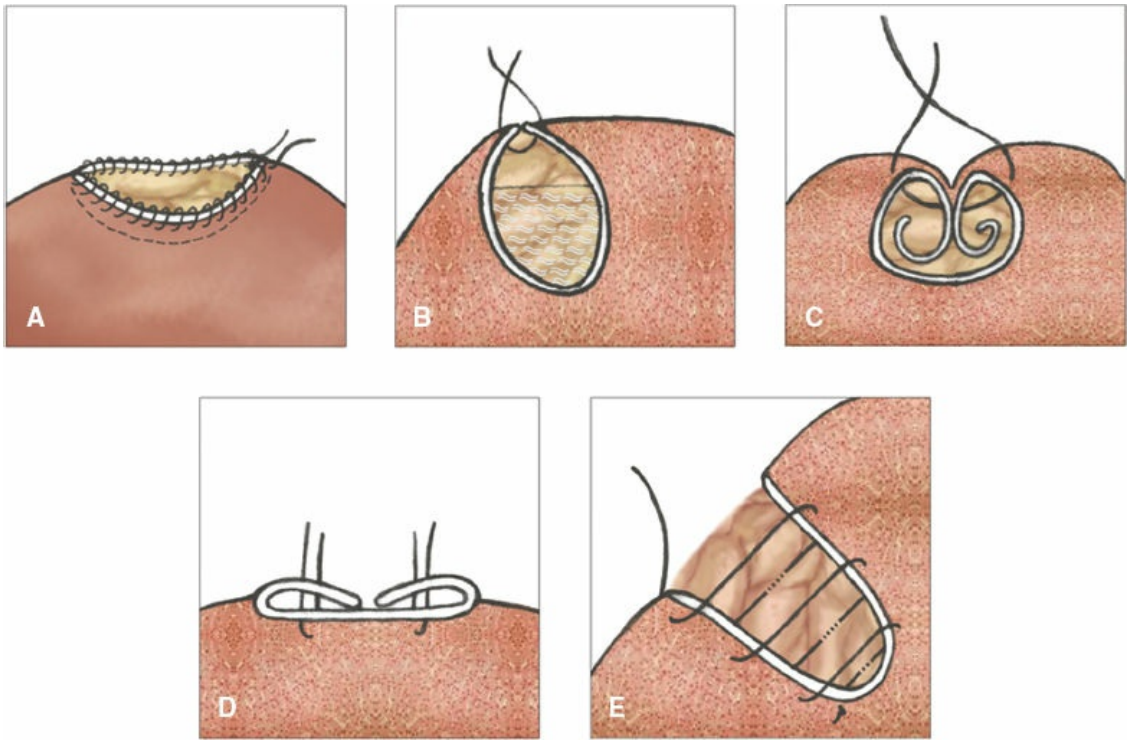

Figure 106.6. Management of the residual cavity. **A.** The pericyst cavity left open after oversewing the rim. This is applicable to small and shallow cavities. **B.** Simple closure of the cyst cavity filled with saline. **C.** Introflexion (infolding) of the rim of the pericyst cavity. Suture does not engage the bottom of the cavity. **D.** Flattening the rim of the pericyst in shallow cysts. **E.** Capitonnage. There is spiral suturing from the bottom of the cavity upward.

Capitonnage

Capitonnage involves infolding the redundant pericyst wall into the depths of the pericyst with successive layers of sutures. An alternate technique is circular suturing from the depth of the pericyst toward the surface. Capitonnage is not possible when the volume of the pericyst is large and when the walls are rigid or calcified. Care should be taken not to place sutures deep into the wall because hepatic veins can be injured. Uncontrolled tension on the sutures, in an attempt to completely obliterate the cavity, can tear liver parenchyma and result in troublesome bleeding.

Omentoplasty

The most frequently used procedure since the beginning of the 1970s is omentoplasty (Fig. 106.8). A vital omental flap is developed and placed into the remaining cyst cavity. The omentum is sutured in place with several absorbable sutures. If the cavity is deep and has a large volume, a closed-system drain is placed alongside the omentum. The drain has to be fixed onto the rim of the cyst opening with rapidly resorbable sutures (e.g., catgut) so that its tip remains in the most dependable portion of the pericyst. Some authors suggest that the liberal use of drains accounts for a high infection rate. The rationale for placing a drain is that there is always accumulation of some fluid in the cavity during the first several postoperative days. The drain is removed as soon as secretion stops. In my series, the pericyst cavity was drained in one third of the patients, the subhepatic space in two thirds, and the subphrenic space in one third. No increased incidence of infection was observed. The omentum does not prevent bile leaks and cannot handle excessive fluid collections. In large cysts that have a posteriorly placed opening that the omentum cannot reach, the omentum is introduced into the cyst from beneath the liver parenchyma.

Partial Capitonnage Plus Omentoplasty

Frequently, some degree of introflexion or partial capitonnage is done when performing omentoplasty. Whether this is beneficial is unclear, but unnecessary distortion of liver anatomy by tight sutures is not advocated.

Roux-en-Y Cystojejunostomy

Indications for this procedure are extremely rare because there are better options for all cyst types.

Myoplasty

Rectus abdominis and diaphragm muscle flaps have been used for obliterating the cyst cavity in complex situations.

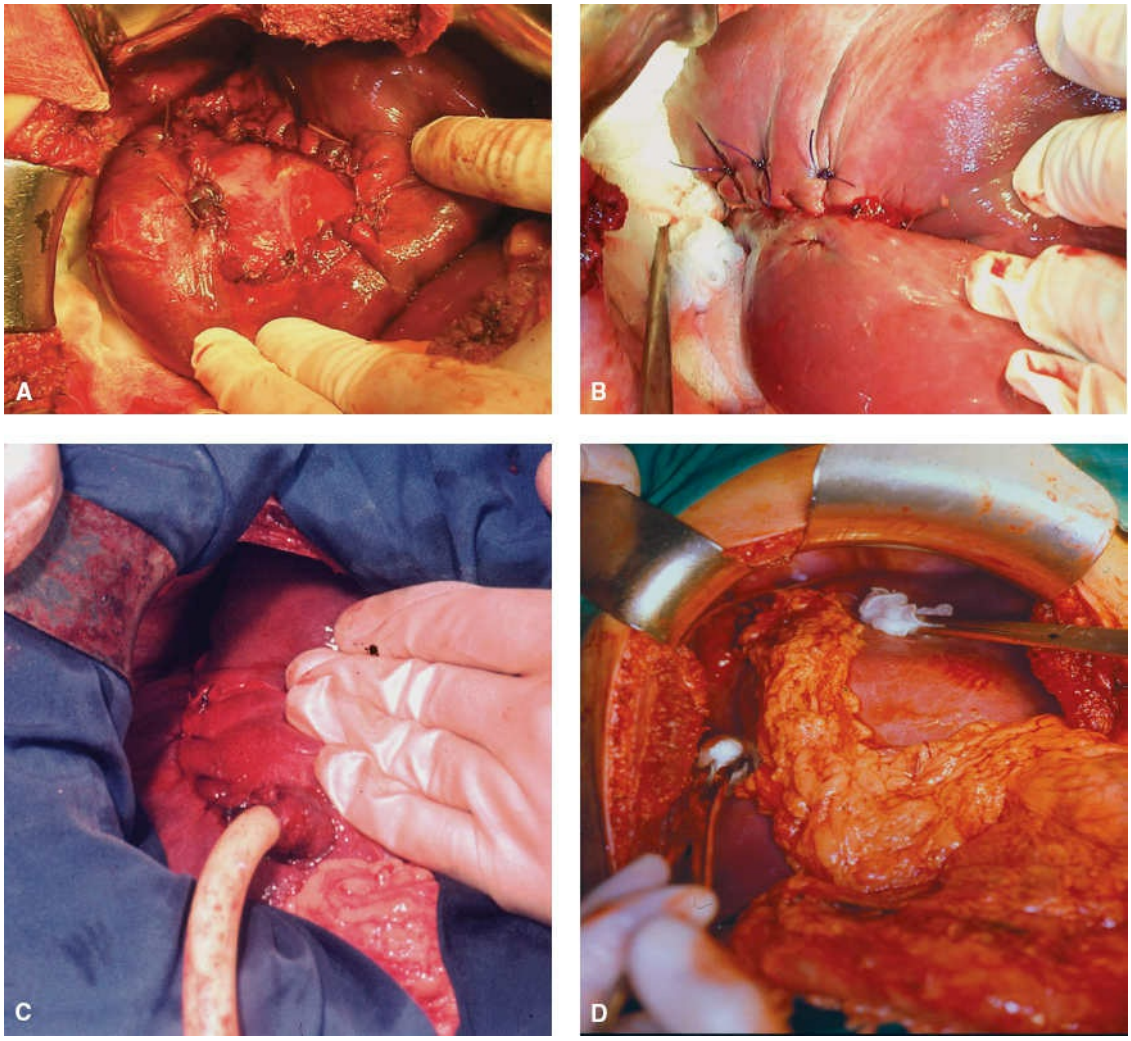

Figure 106.7. Techniques for the management of the residual cavity. **A.** Cyst with oversewn rim left open. **B.** Introflexion. **C.** Capitonnage with drainage. **D.** Omentoplasty.

In a single patient with multiple cysts, different procedures for managing the cavity can be used. The term *dominant cyst* denotes the one cyst in patients with multiple cysts that was either the largest, in the most difficult position, communicating, or complicated and causing the symptoms. Therefore, in the same patient, the other cysts, if simple, small, and in a peripheral position, were frequently managed by closed cystopericystectomy, which is not noted in the statistics. In my large series, 85.20% of dominant cysts in the liver were managed by conservative procedures (Table 106.5).

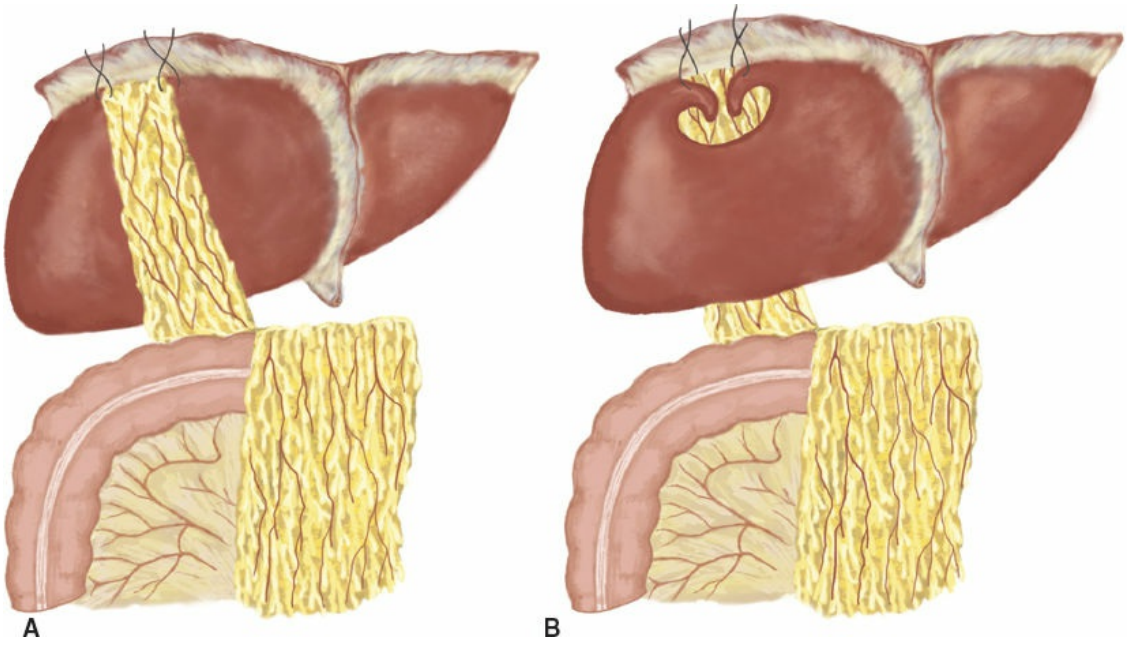

Figure 106.8. Omentoplasty. **A.** Anterior position of omentum. **B.** Posterior position of omentum.

TABLE 106.5 Procedures Performed on the Dominant Cyst

Operative Procedure	Number of Patients	Percentage of 1,333 Patients
Partial pericystectomy or introflexion + omentoplasty	796	59.71
Partial pericystectomy + capitonnage	245	18.39
Total cystopericystectomy	139	10.43
External drainage	6	0.45
Partial pericystectomy w/o external drainage	88	6.61
Left atypical liver resection	19	1.42
Left hepatectomy	18	1.35
Right atypical hepatectomy	19	1.42
Right hepatectomy	3	0.22
Total	1,333	100

Radical Surgical Procedures

Closed or open total cystopericystectomy (cystectomy) and liver resection have strict, defined indications. The rationale for performing liver resection for a benign disease that can be successfully managed by less extensive liver surgery with acceptable results needs to be evaluated in every patient. The majority of operations for liver hydatid disease are performed at general surgical departments in developing countries in which extensive expertise and facilities for major liver surgery are unavailable. Under such circumstances, a high postoperative morbidity and

mortality rate can be expected, especially as liver atrophy is frequently present because of the large size of the neglected cysts. These patients, following liver resection, return to an endemic area in which reinfestation is possible. Liver resection for hydatid disease is indicated in dedicated centers when (a) successful conservative surgery is not possible, (b) conservative tissue-sparing procedures failed to eliminate the disease, (c) the affected lobe or segment is irreversibly destroyed, and (d) efficient reconstruction of biliary drainage cannot be achieved. I performed radiofrequency-assisted Cool-tip (ValleyLab, Boulder, CO, USA) liver resection as well as total cystopericystectomy (cystectomy) in patients with hydatid disease when indicated. The radiofrequency probe, causing desiccation of a narrow, adjacent layer of liver parenchyma, secured excellent hemostasis and biliostasis.

Closed Cystectomy

Closed cystectomy is a complete removal of the cyst without opening it by creating a surgical plane just outside the pericyst layer. It is the ideal procedure to prevent contamination, manage CBC within the liver, reduce complications and morbidity, and shorten the hospital stay. It can be technically demanding, requiring meticulous dissection and hemostasis, and the use of powered instruments can be of some assistance, although it is not mandatory. When dealing with large and complex cysts, it is not a procedure to be suggested to surgeons with little experience in hepatic surgery.

An enlarging HC exerts pressure on surrounding liver parenchyma, causing an inflammatory reaction and progressive fibrosis encompassing and obstructing venous and biliary structures. Arteries, because of their thick and rigid wall, remain patent longer. The HC usually has a more or less irregular shape and the points where it establishes contact with the vasculobiliary structures appear “welded” to the cyst.

The liver should be mobilized and the operating field walled off. Closed cystectomy for cysts that reach the surface of the liver starts by developing a cleavage plane between the visible, smooth, fibrous cyst and the liver parenchyma where it “submerges.” The cyst can be separated from the liver tissue by blunt dissection following this plane (tip of curved dissecting scissors, curved thin hemostat). The dissection should be meticulous and always under visual control, advancing gently, pushing the liver parenchyma away from the cyst, in order to avoid severing biliovascular structures. Excessive, blind, forceful dissection can disrupt

biliovascular structures at the point where they adhere to the cyst surface and cause troublesome bleeding and bilirrhagia. Ligating these structures at a distance from the cyst can compromise blood drainage or cause ischemic areas of the liver. The cyst surface generally does not bleed and small bleeding points can be controlled by hot gauze packs or an argon beam (only superficial electrocautery is allowed). Standard diathermy and sutures should not be used. As the dissection advances, especially in large cysts, it is unavoidable to encounter more or less fibrotic biliovascular elements in a tangential relationship with the cyst. These should be gently dissected off the cyst surface if possible. If this is not possible, they need to be ligated by passing a ligature around them in close proximity with the cyst surface. If these biliovascular elements are torn, both ends need to be ligated. If a CBC is suspected, liver parenchyma around it should be teased away and the communication ligated first at the cyst side and then on the duct side and then cut between the ligatures in order to avoid cyst decompression. The mobilized cyst should be gently retracted in different directions to get a better view of the dissecting plane and dissection can be done from different directions if necessary. It is crucial to avoid injuring branches of the hepatic veins. Hepatic veins have thin walls and side branches and bleed intensely. It is important to preserve the veins whenever possible. Bleeding should be controlled by suturing the tear superficially with 5-0 or 6-0 vascular monofilament sutures. Dissection in closed cystectomy can be done with the aid of the harmonic scalpel, water jet, or RF ablation electrode. The raw surface of the liver is controlled for bleeding and bile fistulas. Argon beam coagulation or tissue glue can be applied. It is my practice to drain this area.

Open Cystectomy

Open cystectomy can be done as an elective procedure (cyst too big to be manipulated) or because the cyst has ruptured and the contents have spilled. The operative technique is essentially the same.

Near-Total Cystectomy

Near-total cystectomy can be done when part of the cyst is in close contact with the retrohepatic vena cava or major branches of the hepatic and portal veins. These vessels are more frequently in close contact to the cyst with a subsequent fibrotic reaction rather than the cyst infiltrating them. Although it is possible to separate these vessels, it is a better idea to leave a small sterilized portion of the cyst overlying them than to forcefully separate

them.

Subadvential Cystectomy

Subadvential cystectomy is a new operation proposed by Chinese authors. They theorize that the pericyst consists of two layers with distinct different formative mechanisms. The outer layer is the “adventitial” layer, and it is the result of compressive and fibrotic mechanisms and includes Glissonian biliovascular elements and branches of the hepatic veins. The inner layer is the avascular “exocyst” layer, and it is the result of a granulomatous reaction. Since these layers can be detached from each other, this procedure does not enter liver parenchyma and cause bleeding or biliorraghia. More experience is needed to establish the feasibility and efficacy of this procedure.

Nonanatomic Liver Resection

The majority of liver resections for cystic echinococcosis are nonanatomic wedge resections. A nonanatomic resection is sometimes safer than cystectomy because control of the biliovascular structures is facilitated. Some authors regard cystectomy as a nonanatomic liver resection because frequently an excised cyst has some liver parenchyma attached to it.

Anatomic Liver Resection

Anatomical liver resection is rarely indicated in cystic echinococcosis. It is indicated when it is impossible to salvage the affected liver lobe due to irreparable destruction caused by the parasite(s). Because of the distorted anatomy and extensive fibrosis, careful liver transaction is mandatory in order not to damage the remnant liver.

Completion Cystectopericystectomy in Residual Cavities With Complications

Conservative procedures for cystic echinococcosis leave residual cavities or parts of the pericyst in the liver, which can infrequently be the source of complications: (a) infection and inflammatory reaction, (b) intrahepatic and perihepatic abscesses, (c) permanent biliary fistulas in calcified pericysts, (d) cholangitis, and (e) recurrent cystic echinococcosis due to exogenous vesiculation. In these patients, completion cystectopericystectomy is frequently indicated. This is frequently a demanding operation due to dense adhesions, distorted anatomy, abscesses, and the adherence of the liver to adjacent organs. Frequently it

is the only way to resolve these complications, and if it is not possible liver resection should be performed.

Cystectomy for Cysts Engaging the Diaphragm

Total cystectomy for cysts at the dome of the liver engaging the diaphragm demands meticulous dissection. Frequently the cyst can be detached without resecting the diaphragm and total cystectomy performed in the usual manner. Sometimes it is necessary to excise the lower surface or full thickness of the diaphragm. If a bronchobiliary fistula exists, it is necessary to excise the diaphragm around the fistula, disconnect the fistula from the lung, and do a closed cystectomy. Management of the lung depends on the present pathology.

The Laparoscopic Approach

The first minimal access, laparoscopic, procedure for cystic liver echinococcosis was described in 1992. A PubMed English literature search in 2013 revealed only 57 relevant published articles including 914 operated patients with 1,116 HCs. Of these patients, 89.17% of patients were operated totally laparoscopically and only 5.58% by the gasless technique. Both radical and conservative procedures were done and the conversion rate to an open procedure was 4.92%. Clinical outcomes were comparable to open surgery, although in a group of selected patients. Some of the reported complications were related to the laparoscopic route.

The identified reasons for conversion were: (a) anatomical location, (b) inaccessible cyst, (c) bleeding, (d) adhesions, (e) inappropriate cyst stage, (f) impossible cyst identification, (g) inadequate evacuation of cyst content, (h) cyst close to major vessels, (i) risk of rupture, (j) iatrogenic liver injury, and (k) hematoma.

The procedures performed on the cyst and the liver during laparoscopic surgery mimic the procedures in open surgery. Length of hospital stay for laparoscopic cyst management was similar to the length of stay after PAIR. Nevertheless, in some developing countries PAIR is done on an outpatient bases. The hospital stay for open surgery is longer. Hospitalization probably depends on the type of cyst and surgery, concomitant diseases, drainage and other complications.

It is probable that the proportion of HCs operated by the laparoscopic route, in both nonendemic and endemic regions, will increase in the future. Indications for the laparoscopic management of liver HCs should not be

broadened just because the facilities are available. The procedures should be done by surgeons experienced in open hydatid surgery. It should be noted that PAIR is less invasive and provides good results. Chemotherapy should be considered in some patients.

Indications for the laparoscopic management of HCs should be strictly defined taking into account preoperative imaging and mapping of the cysts, extrahepatic disease, condition of the patient, availability of less invasive procedures, surgeon experience, and available equipment. Cyst stage and size are not necessarily limiting factors if surgery is warranted, but early-stage cysts are the preferred choice. Preoperative ABZ is advised.

Contraindications are: (a) intraparenchymal deep cysts, (b) inaccessible cysts, (c) recurrent cysts, (d) posterior cysts close to major vessels, (e) cysts with thick calcified wall, and (f) infected cysts (septic patients).

The advantages of laparoscopic surgery that are stressed by many authors are: (a) less pain, (b) better cosmetic results, (c) less blood transfusion, (d) shorter hospital stay, and (e) less adhesions. Potential disadvantages and limitations are: (a) fear of intraoperative spillage of cyst content, (b) uncontrollable bleeding, (c) unavailable adequate instruments, (d) incomplete exposure, (e) long learning curve, (f) difficult cavity obliteration, (g) inadequate postoperative drainage, (h) limited area of manipulation to posterior liver segments, and (i) inability to completely evacuate paste-like degenerated cystic contents. It has not been demonstrated that increased intra-abdominal pressure facilitates spillage of cyst contents.

The patient is in a supine position. The position of the surgeon and assistants and the placement of the trocars depend on the site of the cyst or cysts and personal preferences. There is no standard trocar placement recommended. The 30-degree telescope is introduced through a 10-mm umbilical port, and a 12-mm port is placed in the subxyphoid position for a large bore suction cannula. Two 5-mm trocars are placed on the left side in the standard cholecystectomy position and a fifth is placed on the left side above the level of the umbilicus. If available, laparoscopic ultrasound should be used for accurate orientation.

The critical moment is puncture of a vital cyst with the cyst contents under pressure. The puncture site of the cyst is encircled with long pieces of gauze soaked into a rapid-acting protoscolicidal agent. It is wise to have at least one additional suction cannula next to the puncture site. A large

gauge puncture needle is used to enter the cyst by the shortest route. Several techniques and special instruments have been described for safe cyst puncture and evacuation. After initial puncture of the cyst, a PAIR-like sequence is performed: puncture, aspiration, irrigation, filling with a noncaustic protoscolicidal agent, and reaspiration (decompression). The puncture site is enlarged by scissors or powered instruments, and the large bore suction cannula is introduced into the cyst. The irrigation and reaspiration sequence can be repeated several times until the cyst is completely evacuated. If the laminated membrane and detritus cannot be completely removed by aspiration, a grasper and a specimen retrieval bag are used. The laparoscope is introduced through the cyst orifice, and a thorough magnified view inspection of the cavity is done. If remaining daughter cysts or disrupted parts of the laminated membrane are detected, they are aspirated and removed. Special care should be taken to detect bile duct orifices secreting bile. An orifice secreting bile is cannulated and a cholangiogram performed. In the majority of patients, simple suture is sufficient. If the cyst contents were heavily stained with bile and a meticulous visual search for the orifices failed, a gauze strip is positioned into the cyst cavity and withdrawn after 10 minutes to see if it has bile staining. If still in doubt, a cholecystectomy and cholangiography are performed to verify whether a communication is present and there is hydatid debris in the CBD. The CBD can be cleared through a choledochotomy and closed over a “T” tube. The cyst cavity is exposed to a rapid-acting protoscolicide and flushed. The redundant portion of the cyst is excised, and the cavity managed in the same way as in open surgery. Omentoplasty is the easiest and most frequently applied procedure. Drainage of the cavity is optional.

Several technical innovations have been reported for save evacuation of the cyst contents under pressure, but none of them are in routine use. It is much more difficult to evacuate a cyst with dense, paste, or jelly-like contents, because one cannot be sure that the cyst is not vital. Special aspirator-grinders, powered by electro motors or compressed air turbines, have been developed, but these instruments are not in routine use.

The procedure of flushing the abdominal cavity with a protoscolicide solution or creating perihepatic lakes adjacent to the operation site cannot be recommended. The peritoneum readily absorbs the protoscolicide, especially since the procedure on the cyst can last quite long (eg. several bile duct orifices). Even the indiscriminate use of hypertonic saline can

cause hypernatremia.

The laparoscopic management of liver echinococcosis goes by the same principles as in open surgery only using a minimal access approach with limited maneuverability. Conservative procedures for cysts located in the posterior segments of the liver and radical procedures on the cyst should be reserved for centers with experience in both laparoscopic liver surgery and HC surgery. The procedure looks simple but the complications are severe.

COMPLICATIONS AND RESULTS

Immediate Postoperative Management

All patients should be entered into follow-up protocols. Repeat US examinations and chest radiographs during the immediate postoperative period after operation for large cysts, especially if the cysts were adherent to the diaphragm, are necessary. It is important to detect subdiaphragmatic and subhepatic fluid collection and diaphragmatic pleurisy at an early stage. The interpretation of US images of residual cavities persisting after operation is difficult. In children, within 6 months of operation, most of the cavities have disappeared, become calcified, or are substituted by fibrous scar tissue. Practically all residual cavities disappear by 18 months after operation. Cavities persisting after this period need diagnostic workup: (a) US monitoring, (b) CT or MRI, (c) serology, and (d) diagnostic puncture. The value of chemotherapy in these patients is uncertain. Reoperation is the ultimate option.

There are little relevant data about US patterns during and after medical treatment for liver hydatidosis. Patterns seen during successful medical treatment resemble the patterns seen in cases of spontaneous involution of the parasite. Repeated serologic tests during treatment are of no help in detecting the viability of the cyst.

Postoperative Complications

The incidence and significance of postoperative morbidity after conservative procedures have been exaggerated in many reports. The most frequent postoperative complications are (a) wound infection, (b) chest problems, (c) subphrenic abscess, (d) biliary leaks, and (e) liver abscess. Postoperative morbidity reflects the expertise of the surgeon and the structure of the patient population as well as the incidence of complicated

cysts. In my series, the postoperative morbidity rate was 17.1% for all types of conservative procedures and 15.2% for radical procedures. More than two thirds of all complications were wound infections and some chest problems. The chest complications are easy to manage. Subphrenic abscesses and liver abscesses were probably a result of inadequate surgery and early removal of drains. Today, both complications are managed by antibiotics and interventional radiologists.

Biliary leaks are managed nonoperatively. Bile leakage is drainage of bile through abdominal drains, regardless of quantity, no longer than 10 postoperative days. Persistent, stable external drainage of bile for more than 10 days is a biliary fistula. A biliary fistula is heralded by early postoperative external drainage of large quantities of bile. The most frequent causes are (a) an overlooked CBC, (b) injury to a bile duct, (c) inadequately managed CBC, (d) calcified pericyst, or (e) hydatid debris obstructing the CBD. Early management should be conservative. If an external biliary fistula persists, ERCP is performed, the CBC is verified, and papillotomy is done. Stents are usually not necessary. The optimal timing for ERCP is unknown. Reoperation and attempts at resuturing the fistula orifice are to be avoided. The one exception is when the orifice is in a calcified portion of the pericyst when it will not close spontaneously and more extensive surgery is needed. Endoscopic papillotomy has significantly reduced mortality and in-hospital stay. The success rate of endoscopic management is >85%, but the fistula closure time can last from a few days to a few weeks.

Biliary stricture after surgery for HCs is rare. Passage of even minor quantities of a potent protoscolicidal agent into the CBD can cause caustic cholangitis and subsequent biliary stricture. Attempts at repairing CBCs close to the BD confluence can result in stricture formation, which is hard to manage operatively. Stenting is an option.

In my series, the postoperative mortality was 2.10%. Factors influencing mortality were (a) complicated cysts, (b) communicating cysts, (c) reoperations, (d) concomitant disease, and (e) old age. In published large series, the reported mortality rate ranges from 2% to 4.5%, and in some series with recurrent disease and frequent reoperations the mortality rate was in excess of 10.0%.

Long-Term Postoperative Follow-Up and Recurrence

A postoperative long-term follow-up regimen is essential. Early

postoperative imaging provides a baseline for later comparison. Repeated US examination every 6 months is essential. If recurrence is suspected, a CT or MRI needs to be obtained. Serologic tests are difficult to interpret the first 24 months after operation. Blood titers may decrease very slowly (several months to several years) even after the complete removal of the cyst. It seems that it is the steady rise in the titer of serologic tests rather than the elevated postoperative titer that is indicative of the recurrence. Serologic tests used for the detection of recurrence are (a) complement fixation, (b) immunoelectrophoresis, (c) ELISA, (d) counterimmunoelectrophoresis, and (e) blotting.

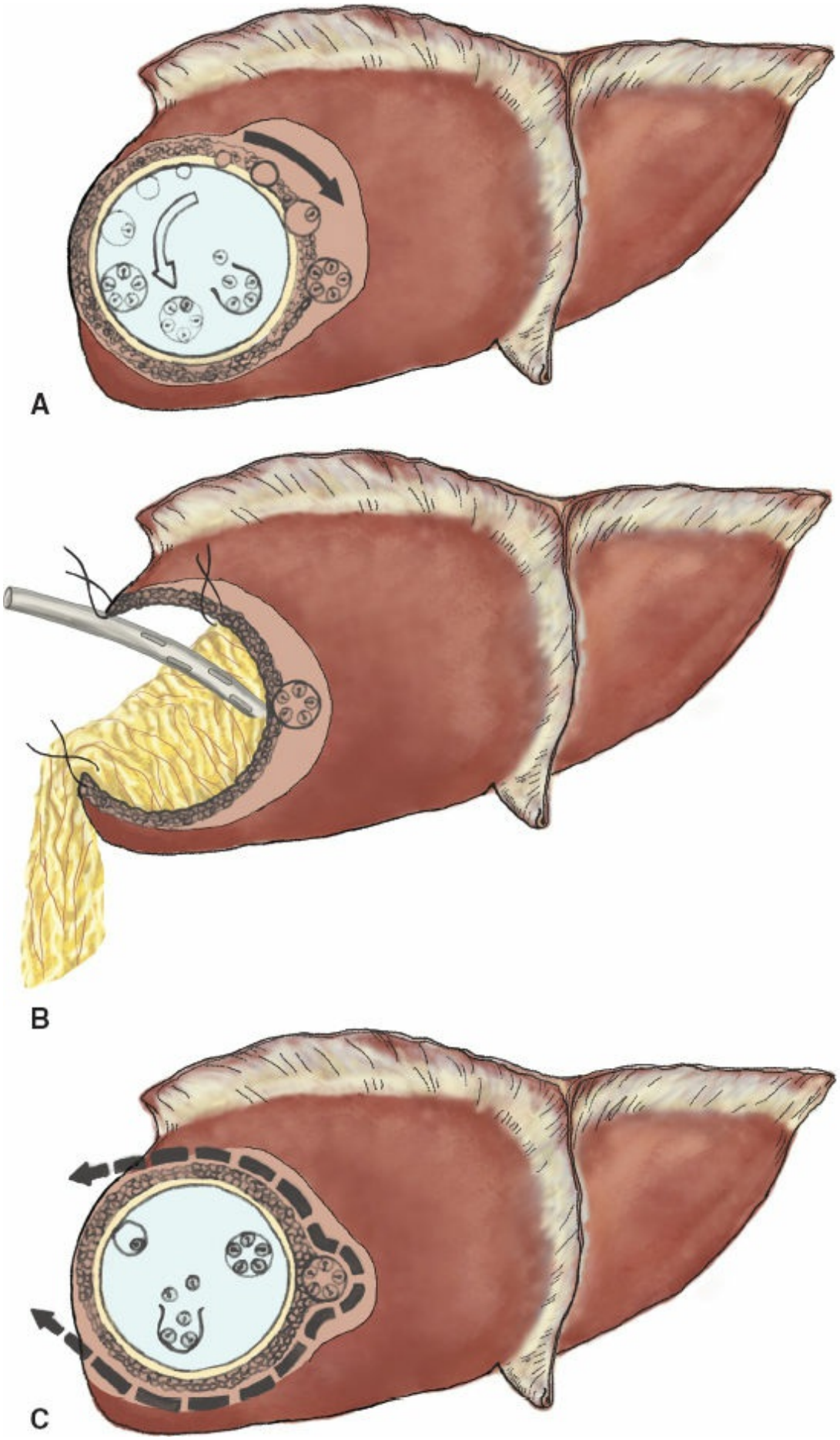
A
B
C

Figure 106.9. Exogenous vesiculation as the cause of recurrence in conservative surgery. **A.** *White arrow* demonstrates development of daughter cysts (endogenous vesiculation) and *black arrow* demonstrates exogenous vesiculation where a daughter cyst passes through the wall of the cyst and develops into a new cyst outside of the original cavity. **B.** Conservative surgery fails to remove this vital cyst and recurrence occurs. **C.** Radical surgery (pericystectomy resection along the dotted line) removes the original cyst and the exogenous cyst as well.

In operated patients, US detection of a new cyst can be from (a) a cyst missed at operation, (b) local recurrence at the operative site, or "frank recurrence," (c) secondary intra-abdominal echinococcosis, (d) progression of disease after operation for secondary echinococcosis, (e) occurrence of cysts in other organs, and (f) reinfestation.

Recurrence refers to a cyst increasing in size between US examinations at the original operative site. This is the result of (a) overlooked exogenous vesiculation, (b) retained vital protoscoleces, or (c) parts of the germinative membrane left behind. A new cyst at a different site, a cyst overlooked at operation, and a cyst developing in another organ is not a recurrence. A new cyst developing in the peritoneal cavity after operation for secondary echinococcosis is progression of the disease. The longest interval after initial operation when a recurrence can start developing is not known (Fig. 106.9).

Recurrence can be asymptomatic. Symptoms of recurrence usually appear 3 to 5 years after recurrence. It is difficult to evaluate the merits of conservative surgery for liver hydatidosis with respect to recurrence because (a) recurrence in reported data is not accurately defined, (b) the series of operated patients have a different proportion of vital, multiple, multivesicular, and ruptured cysts, (c) operative techniques differ, and (d) patients are frequently lost to follow-up.

Published recurrence rates range from 0.9% to almost 30%. In my series, 4.50% of patients were treated for recurrence. In series with very high recurrence rates, there are a large proportion of patients who have had spontaneous or iatrogenic rupture (extrahepatic recurrence) of liver HCs. Some of the recurrences were obviously overlooked cysts. In my opinion, the tolerable recurrence rate should be under 5%. The effect of pre- and postoperative chemotherapy on recurrence needs further investigation.

Once recurrence is detected, options for treatment are (a) wait and see

(unclear diagnosis), (b) chemotherapy, (c) PAIR, and (d) reoperation followed by chemotherapy. I believe that it is how the operative procedure is performed and not only the radicality of the procedure that influences the recurrence rate.

Suggested Readings

Brunetti E, Kern P, Vuitton DA. Expert consensus for the diagnosis and treatment of cystic and alveolar echinococcosis in humans. *Acta Trop* 2010;114(1):1–16.

Eckert J, Gemmell MA, Meslin FX, et al. *WHO/OIE Manual on Echinococcosis in Humans and Animals: A Public Health Problem of Global Concern.* Paris: OIE (World Organisation for Animal Health); 2001.

Kilani T, El Hammammi S, Horchani H, et al. Hydatid disease of the liver with thoracic involvement. *World J Surg* 2001;25:40–5.

Manzano-Roman R, Sanchez-Ovejero C, Hernandez-Gonzales A, et al. Review article: Serological diagnosis and follow-up of human custic echinococcosis: a new hope for the future? *BioMed Research International* 2015;428205:9: http://dx.doi.org/10.1155/2015/428205

Mokham D, Belkhir L, Wallon M, et al. Surgical management of liver hydatid disease: subadventitial cystectomy versus resection of the protruding dome. *World J Surg* 2014;38(8):2113–21.

Nayman A, Guler I, Keskin S, et al. A novel modified PAI technique using a troacar catheter for percutaneous treatmenmt of liver hydatid cysts: a six year experience. *Diagn Interv Radiol.* doi: 10.5152/dir.2015.15011 (preprint)

Saidi F. *Surgery of Hydatid Disease.* Philadelphia, PA: WB Saunders; 1976.

Skroubis G, Vagianos C, Polydorou A, et al. Significance of bile leaks complicating conservative surgery for liver hydatidosis. *World J Surg* 2002;26:704–8.

Thompson RCA, Lymbery AJ, eds. *Echinococcus and Hydatid Disease.* Wallingford, UK: CAB International; 1995.

Utkan NZ, Canturk NZ, Gonullu N, et al. Surgical experience of hydatid disease of the liver: omentoplasty or capitonnage versus tube drainage. *Hepatogastroenterology* 2001;48:203–7.

EDITOR'S COMMENT

Although Echinococcus is fairly uncommon in North America, it is endemic in South America, the Mediterranean, the Middle East, and Asia. Given current travel and immigration patterns, infestation with this flatworm has global

implications. Dr. Milicevic has done an outstanding job in his description of the pathology and treatment of echinococcal disease, and I would like to take this opportunity to expound on the therapeutic approach to this entity.

The clinical management of liver hydatid cyst disease has evolved over the last three decades. In centers with special interest and resource-rich environments, patients benefit from an exceptional concentration of clinical experience and high technologic diagnostic and treatment facilities. On the other hand, endemic regions of the developing world with constrained resources have a limited choice of treatment modalities. Hence studies carried out in either of the two fundamentally different environments lack external validity. Most would agree that the therapeutic approach to patients with hepatic disease should be based upon the World Health Organization classification outlined in Table 106.3. Of note, each classification can be subdivided by size as small “s” (<5.0 cm), medium “m” (5 to 10 cm), and large “l” (>10 cm).

Chemotherapy with benzimidazole compounds is the medical treatment of choice. Only 30% of patients with CL, CE1, and CE3 cysts treated with chemotherapy alone experience a complete clinical or radiographic resolution. Percutaneous aspiration, injection, and re-aspiration (PAIR) is used frequently in patients who do not experience clinical resolution. Furthermore, CE2 cysts are typically managed with PAIR or surgery because they are frequently unresponsive to chemotherapy. The decision of whether to employ operative therapy or PAIR in patients with CE2 disease depends on the number of daughter cysts and the drainability of the cyst contents. Patients undergoing PAIR treatment typically undergo periprocedure chemotherapy with benzimidazole compounds, although the author does not think that adjuvant chemotherapy is necessary. I believe that additional discussion around the omission of chemotherapy agents in this patient population would greatly enhance this chapter.

Surgery is clearly the gold standard for the treatment of echinococcal disease and all patients with CE4 or CE5 cysts should undergo operative management. Basic principles of surgery include the removal of the cyst itself or evacuation of the cyst contents without spilling it in the peritoneal cavity, cyst neutralization with scolicidal agent, and obliteration of the residual cavity. Various procedures have been developed, including liver resections, total or partial pericystectomies, and unroofing the cyst with omentoplasty. While procedures such as marsupialization or simple drainage have been largely abandoned, radical procedures such as total pericystectomy or liver resection provide the best results concerning the recurrence of the disease, but they carry a certain operative and postoperative risk for complications that limit its applicability in resource-challenged environments. Laparoscopic surgery has been introduced lately as a minimally invasive approach to hydatid cystic disease of the liver.

Perhaps the greatest challenge in the management of hydatid cyst disease of the liver is communication with the biliary tract. The progressive enlargement

of the cyst causes pressure atrophy of the surrounding biliary canaliculi, leading to cystobiliary communication. These allow passage of the antigenic fluid and scolices down the biliary tract and the opposite flow of bile and infection into the cyst. If not adequately addressed, the communication results in bile leaks and subsequent choleperitoneum, biliary peritonitis, bile-stained pleural effusion, and biliary fistulae. The intraoperative detection and assessment of the cystobiliary communication is essential for adequate management; therefore, many experts perform an intraoperative cholangiography via the cystic duct. Dr. Milicevic proposes the use of saline and air bubbles to identify cystobiliary communications. He does a very nice job of describing his algorithm for inspecting the cystic duct and subsequent management of communications via suture of the communication, internal or external drainage procedures, reconstructive procedures, and liver resection. The author presents corrective procedures performed on his series of 272 cases in Table 105.4. I believe that this chapter would be enhanced greatly by a discussion of the long-term outcomes in this group of patients.

John Stewart

107 Hepatic Resection for Primary and Metastatic Tumors

Richard Schulick and Ana Luiza Mandelli Gleisner

INTRODUCTION

Major hepatic resection are defined as the resection of three or more liver segments based on Couinaud classification (Fig. 107.1). Major hepatic resections include the resection of the right or left hemilivers (right and left hepatectomies), the right liver along with segment IV (extended right hepatectomy or right trisectionectomy), and the resection of the left liver along with segments V and VIII (extended left hepatectomy or left trisectionectomy). Any of these resections may also involve removal of segment I, which is also referred to as the caudate lobe (Fig. 107.2).

The aforementioned nomenclature was introduced by the International Hepato-Pancreato-Biliary Association in the Brisbane 2000 Nomenclature of Hepatic Anatomy and Resections in an effort to accurately describe the hepatic anatomy and standardize the terminology in the field. This nomenclature also rendered use of the term *liver lobe* obsolete, as this implies the presence of a visible anatomic demarcation (i.e., the umbilical fissure). The current terminology recognizes the anatomic division of the liver based on the vascular watershed—the plane intersecting the gallbladder fossa and the inferior vena cava (IVC), that cannot be seen from the surface of the liver, as described by Cantlie in 1897.

INDICATIONS AND CONTRAINDICATIONS

Major liver resections (LRs) are indicated for the management of a number of primary and metastatic liver tumors (Table 107.1). Initially, the patient's overall health status should be evaluated to determine whether the risks of a major surgical procedure are justifiable and whether there are ways to optimize the patient's medical comorbidities and functional status. The next step is to determine if the resection is oncologically appropriate. For example, major LR is rarely justified in the presence of disease in both the right and left hemilivers (bilobar disease) or extrahepatic disease in

patients with hepatocellular carcinoma (HCC) or cholangiocarcinoma. In contrast, hepatic resection is often considered for patients with colorectal cancer, so long as the extrahepatic disease is limited and resectable. Finally, preoperative imaging is evaluated to determine the resectability of the disease. The goal of the resection is to obtain negative margins, while leaving adequate functional liver parenchyma, intact hepatic arterial and portal venous inflow, venous outflow, and biliary drainage in continuity with the small bowel. While large lesions may involve several segments of the liver, centrally located lesions, even if small, often cannot be removed without compromising biliary drainage, vascular inflow, or the venous outflow of several liver segments. Consequently, removal of these small, central lesions may require resection of a large amount of functional liver parenchyma, thereby increasing the risk of postoperative liver failure. The risk for postoperative liver failure and death is most pronounced in patients with chronic liver dysfunction, especially when there is evidence of cirrhosis. Therefore, these procedures should be limited to cirrhotic patients with Child–Turcotte–Pugh (CTP) class A and no evidence of significant portal hypertension (i.e., thrombocytopenia and history of variceal bleed).

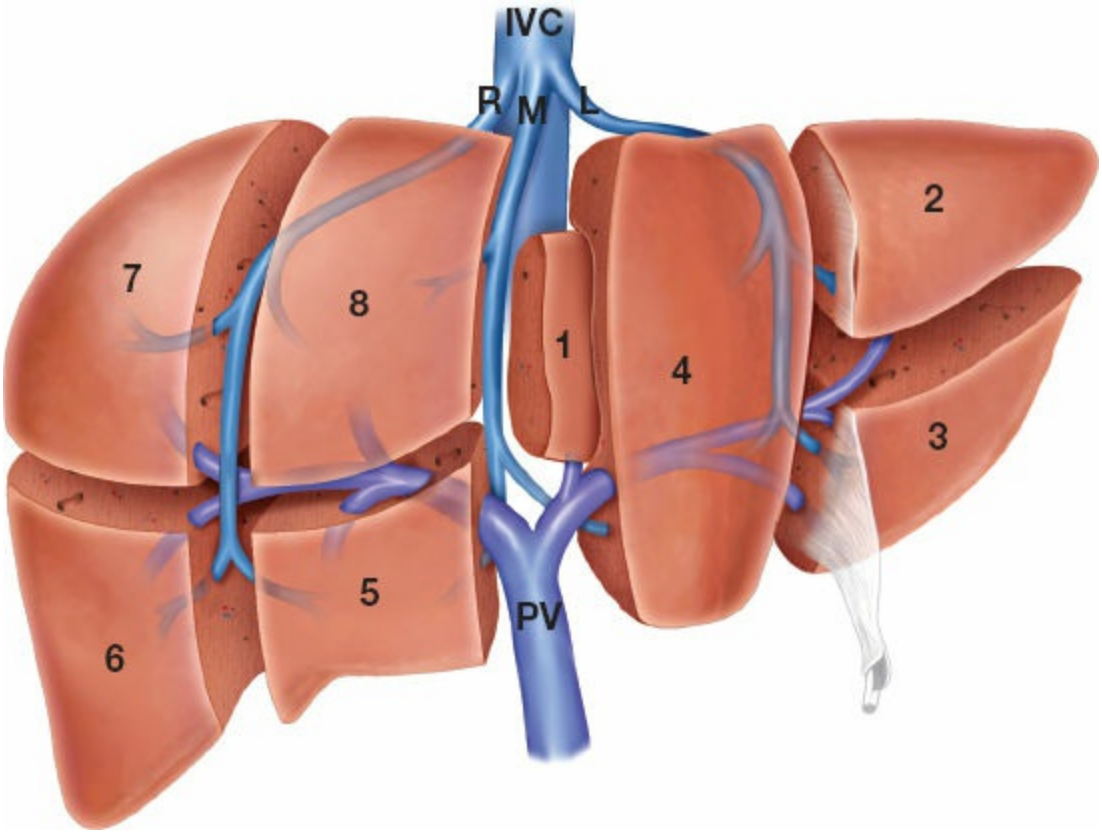

Figure 107.1. Schematic diagram showing the liver segments

assigned by Couinaud. (Reproduced from Hughes SJ. *Operative Techniques in Hepato-Pancreato-Biliary Surgery*. LWW, 2015.)

TABLE 107.1 Primary and Metastatic Tumors That May Require a Major Hepatic Resection

Primary liver tumors
Hepatocellular carcinoma
Cholangiocarcinoma
Hilar cholangiocarcinoma
Gallbladder cancer
Metastatic liver disease
Colorectal cancer
Neuroendocrine tumors
Noncolorectal nonneuroendocrine tumors

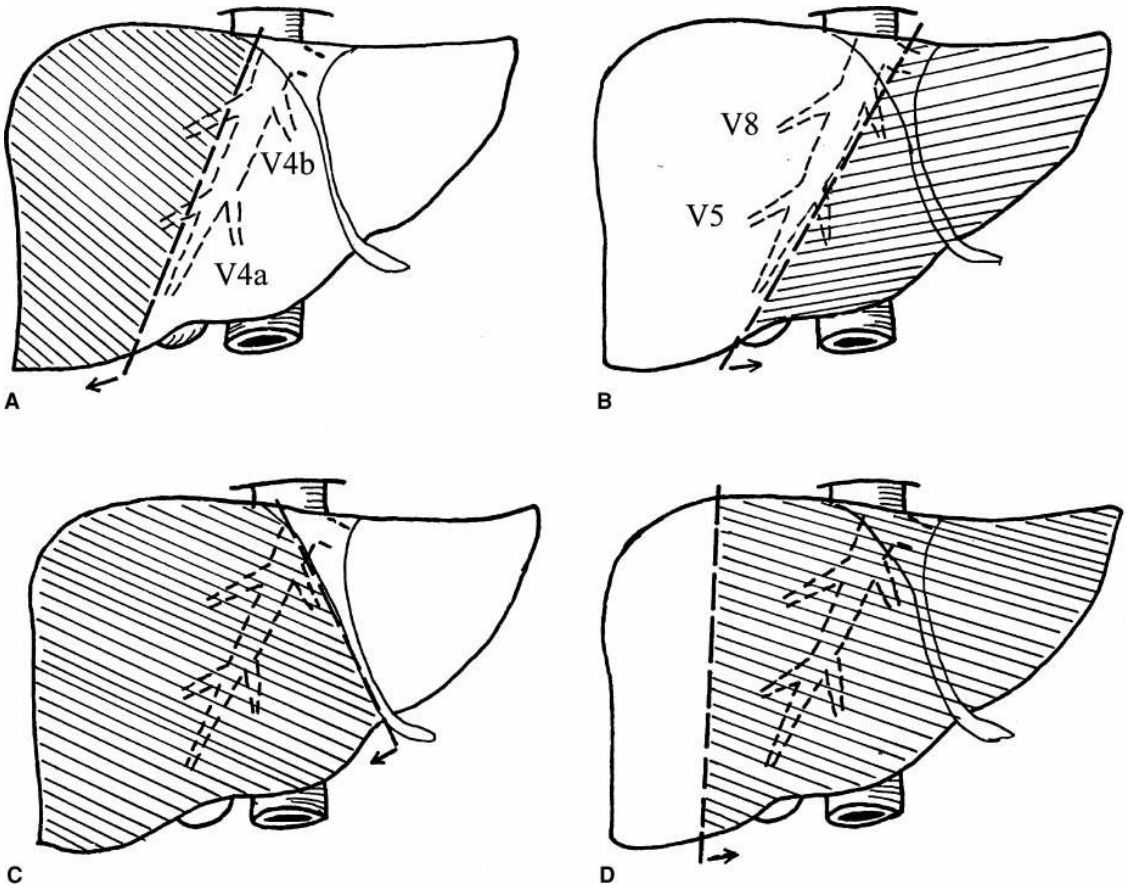

Figure 107.2. Major liver resections: right hepatectomy (**A**), left hepatectomy (**B**), extended right hepatectomy or right trisectionectomy (**C**), and extended left hepatectomy or left

trisectionectomy (**D**). The plane intersecting the gallbladder fossa and the IVC, described by Cantlie in 1897 separates the right and left livers.

For bilobar colorectal metastases, major resection can be combined with wedge resection or ablation of the lesions on the contralateral side. These procedures may be performed at the same time if the anticipated volume of future liver remnant (FLR) is sufficient for adequate hepatic function—otherwise, separate, staged operations should be considered. Superficial hepatic lesions resulting from colorectal metastasis should be treated according to a parenchyma-sparing strategy, with nonanatomic (wedge) resections preferred over anatomic resections if negative margins can be obtained. In patients with colorectal cancer and synchronous hepatic metastasis, the primary tumor and the liver disease can be resected at the same time or separately. Concomitant liver and colorectal resection should be strongly considered when only a minor LR is required or when the colon surgery is straightforward. Major LRs should, however, be avoided when complex colorectal procedures are performed, such as those requiring extensive pelvic dissection or a low rectal anastomosis. In these situations, the hepatic metastases can be addressed first or after resection of the primary. Because the liver is usually the determinant factor for complete disease resection, the “liver first” approach is an attractive option since resectability of the liver metastases will influence the need or extent of the resection of the primary tumor. Occasionally, however, the primary tumor is symptomatic and needs to be addressed first. Typically, preoperative chemotherapy is given to assess tumor response. However, prolonged modern chemotherapy for colorectal cancer can be associated with significant injury to the liver, with increased risk of postoperative complications following LR. Specifically, irinotecan-based treatment is associated with steatohepatitis while Oxaliplatin-based chemotherapy is associated with sinusoidal congestion. The surgeon and the medical oncologist need to work closely to determine optimal duration of preoperative chemotherapy and timing for the surgical procedures.

Alternatives to LR include various ablative techniques. Thermal ablation using heat (radiofrequency and microwave ablation) is currently the most widely used modality, whereas the use of cryoablation has decreased significantly. Irreversible electroporation, a newer technology based on short-duration, high-voltage pulses that result in defects in the lipid bilayer—and, ultimately, cell necrosis—is emerging as an attractive

substitute to thermal ablation. One primary advantage of irreversible electroporation is its ability to target tumors near vascular structures without creating the heat-sink effect that is associated with use of thermal ablation (deflection in the ablation zone due to heat-loss to adjacent vascular structures). Ablation techniques have been shown to be safe and to have low risk of local recurrence (～5%), especially when applied to smaller tumors (<3 cm). These techniques should be considered in small lesions that would otherwise require a large amount of liver parenchyma to be resected, especially in patients with liver dysfunction. Yet, some observational studies have suggested that long-term results with resection are superior to those with ablation, even when only smaller and solitary lesions are considered. Although patient selection likely plays a role in these findings, in the absence of a randomized trial, ablation should not be recommended over resection for patients with resectable lesions and acceptable performance status.

PREOPERATIVE PLANNING

The location of the hepatic lesions and their relationship to the main branches of the portal vein and the hepatic artery, the hepatic veins and the biliary tree should be determined with high-quality imaging (Fig. 107.3). Computed tomography (CT) scan is usually the method of choice but magnetic resonance imaging (MRI) is emerging as a very useful imaging adjunct, especially in patients with steatosis or lesions that cannot be visualized after preoperative chemotherapy. Positron emission tomography (PET) should be used selectively in patients at high risk for extrahepatic metastasis, as higher rates of false negative findings limit its use in patients undergoing chemotherapy or with lesions smaller than 1 cm.

Once the lesions are identified and the planned procedure confirmed, the volume of the FLR is estimated. The volume of the FLR needed to minimize the chances of postoperative liver insufficiency varies according to the quality of the liver remnant. HCC and cholangiocarcinoma are often associated with chronic liver disease (CLD) and preoperative chemotherapy can induce significant liver damage as discussed above. For patients with a healthy liver, the FLR should be at least 20% of the total liver volume. Patients with abnormal background liver (i.e., following preoperative chemotherapy) should have an FLR of at least 30% the total liver volume while those with cirrhosis should have an FLR of at least 40%. When questionable, formal volumetry of the FLR should be

performed. The volume of the expected remnant liver and the total liver volume are measured using either CT scan or MRI. The volume of the nonfunctional liver (parenchyma that is either nonperfused or replaced by tumor) is subtracted from the total liver volume, which is especially important for patients with large lesions. Alternatively, the total liver volume can be estimated with different formulas based on the patient's weight or body surface area. Portal vein embolization (PVE) should be considered for patients with insufficient FLR. PVE involves selective occlusion of the branches of the portal vein feeding the segments planned for resection, inducing contralateral hypertrophy. Volumetry is repeated 4 weeks after the procedure and again in a few more weeks if the minimal recommended FLR has not been achieved (Fig. 107.4). The degree of hypertrophy of the remnant (at least 5% increase in volume or a rate of at least 2% increase per week) has been shown to be correlated with decreased rates of postoperative liver insufficiency.

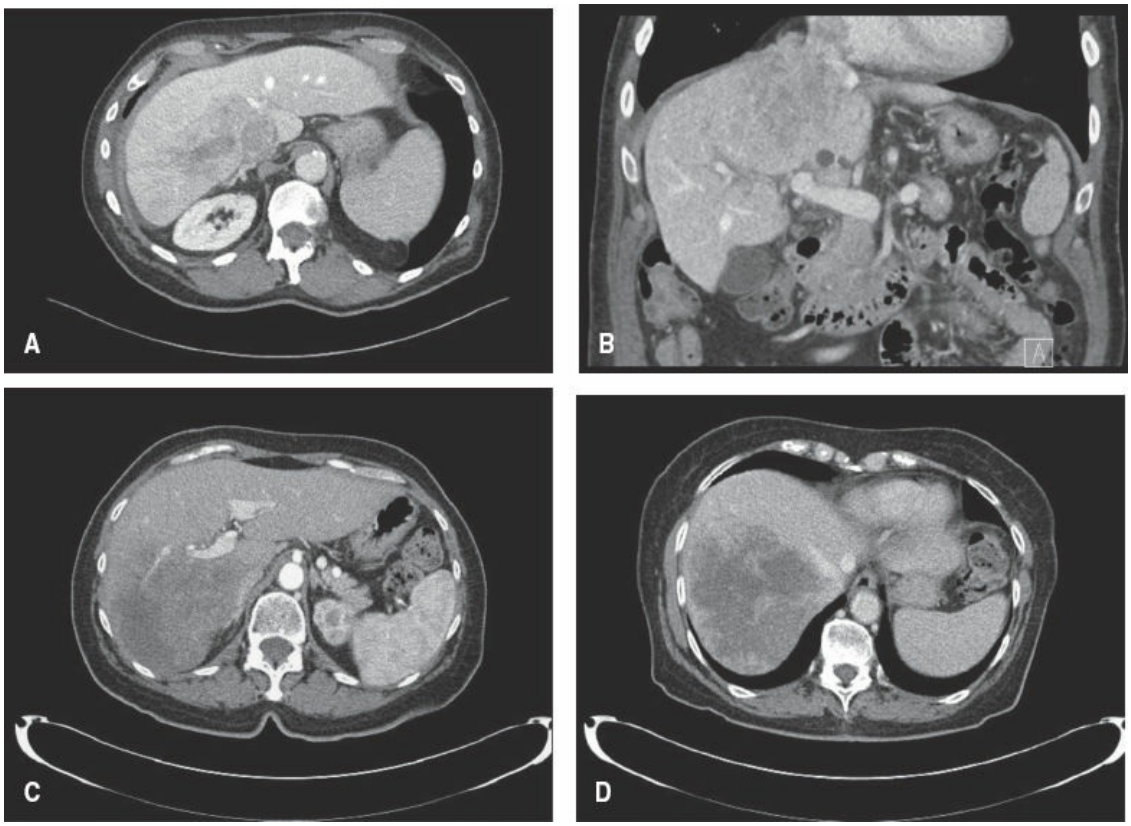

Figure 107.3. Imaging showing hepatic lesions and the relationship with hepatic vessels. **A.** A lesion on the right liver encases the right hepatic vein and abuts the middle hepatic vein. **B.** Coronal reconstruction shows invasion of the tumor into the IVC, extending to the right atrium. A lesion on the right liver encases the right portal vein (**C**) and the right hepatic vein (**D**).

(Courtesy of Ana Gleisner.)

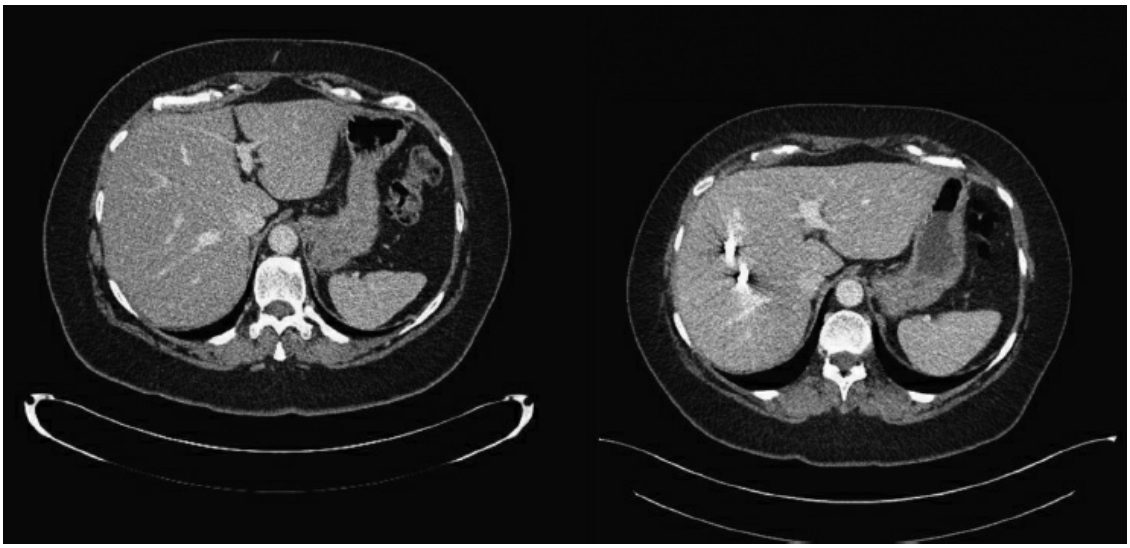

Figure 107.4. Future liver remnant (FLR) before and after portal vein embolization. The volume of the FLR increased by 30% 4 weeks after portal vein embolization. It went from 18% of the estimated total liver to 25%. (Courtesy of Ana Gleisner.)

Anesthetic Considerations

The surgical and anesthesia teams should confer preoperatively to discuss the relative difficulty of the resection and ensure availability of blood products. Hemodynamic goals and blood transfusion threshold should also be established. Adequate venous access for rapid transfusion should be available in the event of major intraoperative bleeding. Central venous cannulation is not mandatory but should be considered in patients with extensive comorbidities, insufficient peripheral access or when the LR is expected to be more challenging. Arterial blood pressure monitoring is strongly encouraged. An orogastric tube should be placed after induction of anesthesia and removed at the end of the case. Intravenous fluids should be restricted until transection of the parenchyma is completed in order to decrease bleeding from hepatic veins, maintaining a central venous pressure less than 5 cm H_2O if a central line is utilized. Once the parenchymal transection has been completed, intravascular volume should be restored to achieve isovolemia. Prophylactic antibiotics are given prior to skin incision. Body temperature should be monitored and normothermia should be maintained.

SURGICAL TECHNIQUE

Patient Positioning, Incision, and Exposure

Patients are positioned supine with both arms extended at 60 degrees to avoid injury to the brachial plexus. Exposure should include the lower chest, up to the nipple line, and the entire abdomen, including both midaxillary lines. Prior to transection of the hepatic parenchyma, the patient should be positioned in Trendelenburg to decrease the risk of air embolism.

A right subcostal incision with an upper midline extension is performed (Fig. 107.5). This incision can be extended to the left subcostal margin if needed. Resection of the xiphoid is performed for better visualization of the suprahepatic IVC. Exposure is obtained with a fixed table retractor, such as the Thompson, Bookwalter, or Omni retractors. For bulky tumors in the right liver that are located near or involve the diaphragm, a J-shaped incision—with a curved thoracoabdominal extension from the midline along the eighth, ninth, or tenth intercostal space—can be performed to allow exposure of the IVC without excessive traction to the liver.

The abdominal cavity is first explored to rule out undiagnosed extrahepatic disease. Once the decision has been made to proceed with the hepatic resection, the round ligament and the falciform ligament are located and dissected up to the anterior surface of the hepatic veins. The gastrohepatic ligament is then opened to expose the caudate lobe. The presence of an accessory or replaced left hepatic artery should be determined. Intraoperative ultrasound is used to evaluate known lesions, survey for new lesions, and determine the relationship of each lesion with nearby vascular and biliary structures. Ultrasound is also used to evaluate the position of the main hepatic vessels relative to the transection plane. Once the planned surgical procedure is confirmed, cholecystectomy is performed, leaving the gallbladder attached to the cystic duct to be used for retraction. The hilar plate is lowered in preparation for inflow control.

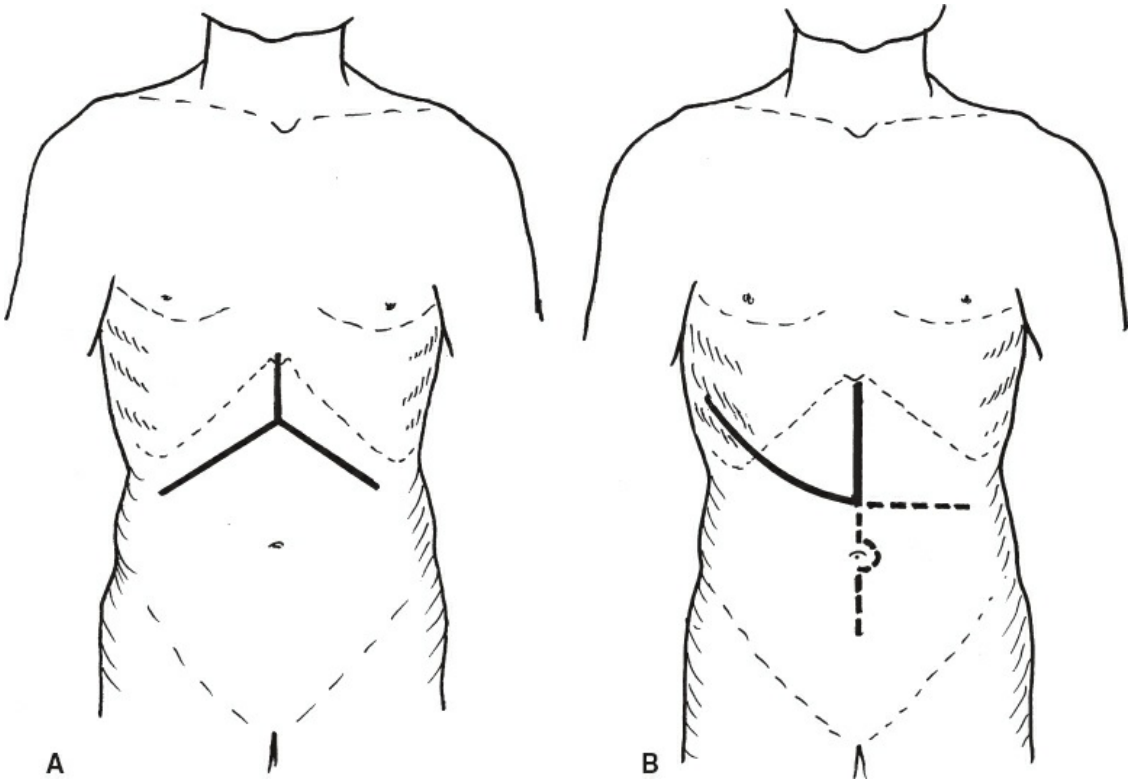

Figure 107.5. A. Bilateral subcostal incision. The midline incision should include excision of the xiphoid process. **B.** A J-shaped incision (popularized by M. Makuuchi) facilitates exposure of segments VII, VIII, or the bulky tumor involving the right diaphragm. If needed, the incision can be extended to the left or lower abdomen.

Parenchymal Transection

Transection of the liver parenchyma can be performed with multiple techniques, most often a combination of techniques, according to the surgeon's experience and preference. More important than the chosen method is the surgeon's utilization of preoperative imaging and intraoperative ultrasound to appreciate the relationship between the transection plane and the intrahepatic vessels. Inflow control prior to the transection will result in a vascular demarcation line that will guide the correct transection plane.

The capsule of the liver is initially incised with electrocautery. Transection of the parenchyma is then performed with or without the use of one of the several energy devices available, including water jet-based devices, bipolar, ultrasound, radiofrequency and microwave energy devices. Parenchymal transection can be performed with finger fracture (digitoclasy) or clamp crushing, which consists of gentle fracture of the

parenchyma while preserving vessels and bile ducts crossing the transection plane. These structures are then controlled with ties, clips, energy devices, or stapler for larger structures. Two devices also work by disrupting the parenchyma while preserving the vessels and bile ducts: the Hydrojet, which uses a water jet and the Cavitron Ultrasonic Surgical Aspirator (CUSA), which uses ultrasound energy. The potential advantage of these devices is greater accuracy, with CUSA providing the additional benefit of some degree of hemostasis. While these techniques are associated with limited devascularization of the liver along the transection line, bleeding from small vessels can be considerable. Bipolar (i.e., LigaSure) and ultrasonic (Harmonic Scalpel) vessel-sealing devices can be used for control of vessels up to 7 to 8 mm—decreasing the need for ties and clips and, thereby, resulting in faster transection. Hemostatic devices such as the argon beam coagulator and the radiofrequency sealer devices (i.e., TissueLink and Aquamantys) are very useful to control bleeding from the cut edge of the liver. Radiofrequency (i.e., Habib 4X) and microwave ablation devices can also be used to precoagulate the transection plane followed by sharp transection, although larger vessels still need to be controlled. Finally, staple devices can be employed for the division of large vessels or, alternatively, for the transection of most of the parenchyma with the serial application of staples in a track created by the gentle application of a large clamp.

After the transection of the parenchyma is completed, the cut edge of the liver is inspected and bleeding and/or bile are controlled with figure-of-eight sutures, argon beam coagulator, or radiofrequency sealer devices as needed. If applied, the Pringle maneuver is then released while continuing to assess hemostasis. Large sutures should be avoided in order to prevent the inclusion of the hepatic veins. Coagulation devices should be used with caution to avoid heat-induced destruction of hemostatic sutures. Hemostatic agents (i.e., Surgicel) can be applied to the cut edge of the liver for further hemostasis. Injection of normal saline through a catheter in the cystic duct is useful to detect extravasation from bile ducts at the cut surface. Bile leakage at the hilar plate should be controlled with 6-0 PDS sutures.

Pringle Maneuver

Occlusion of the portal triad (Pringle maneuver) can be performed prior to the transection of the parenchyma to decrease blood loss. The liver can

tolerate up to 1 hour of ischemia but intermittent vascular occlusion with cycles of 15 to 20 minutes on and 5 minutes off will decrease the ischemia/reperfusion injury which is especially important in cirrhotic livers. Total ischemic time should not exceed 120 minutes.

Right Hepatectomy

Further dissection of the anterior surface of the hepatic veins is carried out to expose the right hepatic vein. The right coronary and triangular ligaments are then divided, exposing the bare area of the liver as the right liver is mobilized and rotated to the left. The right phrenic vein is identified as it drains into the right hepatic vein. Short hepatic veins draining directly to the IVC are ligated with silk ties and/or surgical clips starting distally and proceeding cephalad. Larger veins such as an inferior right hepatic vein may require ligation with a vascular stapler. Smaller vessels can be divided with energy devices such as the Harmonic scalpel or the LigaSure. Large branches from the caudate lobe should be preserved on the medial aspect of the IVC. The retrocaval ligament (Makuuchi ligament) is identified as dissection continues cranially (Fig. 107.6). This ligament is variable in thickness and occasionally contains liver parenchyma or a vein. Consequently, the retrocaval ligament is most safely transected with a vascular stapler. Further dissection between the liver and the IVC will expose the right hepatic vein. The fibrous tissue medial to the vein, between the liver and the IVC, is dissected superiorly. A clamp is passed from below, anterior to the IVC, to emerge between the middle and the right hepatic vein, which is encircled. Attention is turned to the hilum which is dissected for inflow control. The right hepatic artery—traversing between the hepatic duct and the portal vein in 80% of the patients—should be dissected lateral to the hepatic duct to avoid injury to the arterial branch to segment IV, which occasionally arises from this artery. After arterial flow to the left liver is confirmed either by palpation or Doppler ultrasonography, the right hepatic artery is doubly ligated and divided. The common bile duct is retracted medially with a vein retractor exposing the portal bifurcation. The right portal vein is then dissected and divided with a vascular stapler. A branch to the caudate process should be identified and ligated just distal to the portal vein bifurcation to allow enough mobilization of the right portal vein. If a vascular stapler cannot be applied, the vein can be divided between vascular clamps and doubly ligated with a silk suture on the liver side and a running 6-0 prolene suture

on the hilum. In some cases, the main portal vein trifurcates in left, right anterior, and right posterior branches. In this situation, each of the two branches to the right hemiliver are addressed separately. A clear line of vascular demarcation can then be identified between the right and left hemilivers. At this point, the right hepatic duct can be dissected and ligated at the hilum. However, unless necessary for oncologic purposes, the right hepatic duct should be ligated intrahepatically in order to avoid injury to the left hepatic duct. The right hepatic duct will be identified as the transection of the parenchyma approaches the left base of the gallbladder fossa (Fig. 107.7). In about 30% of the patients, the right anterior and the right posterior sectoral ducts drain into the hepatic duct separately and in 6% of the patients, the right anterior or the right posterior sectoral branches drain to the left hepatic duct. The right hepatic duct or sectoral ducts are divided with a vascular stapler or between two vascular clamps and oversewn with 5-0 PDS.

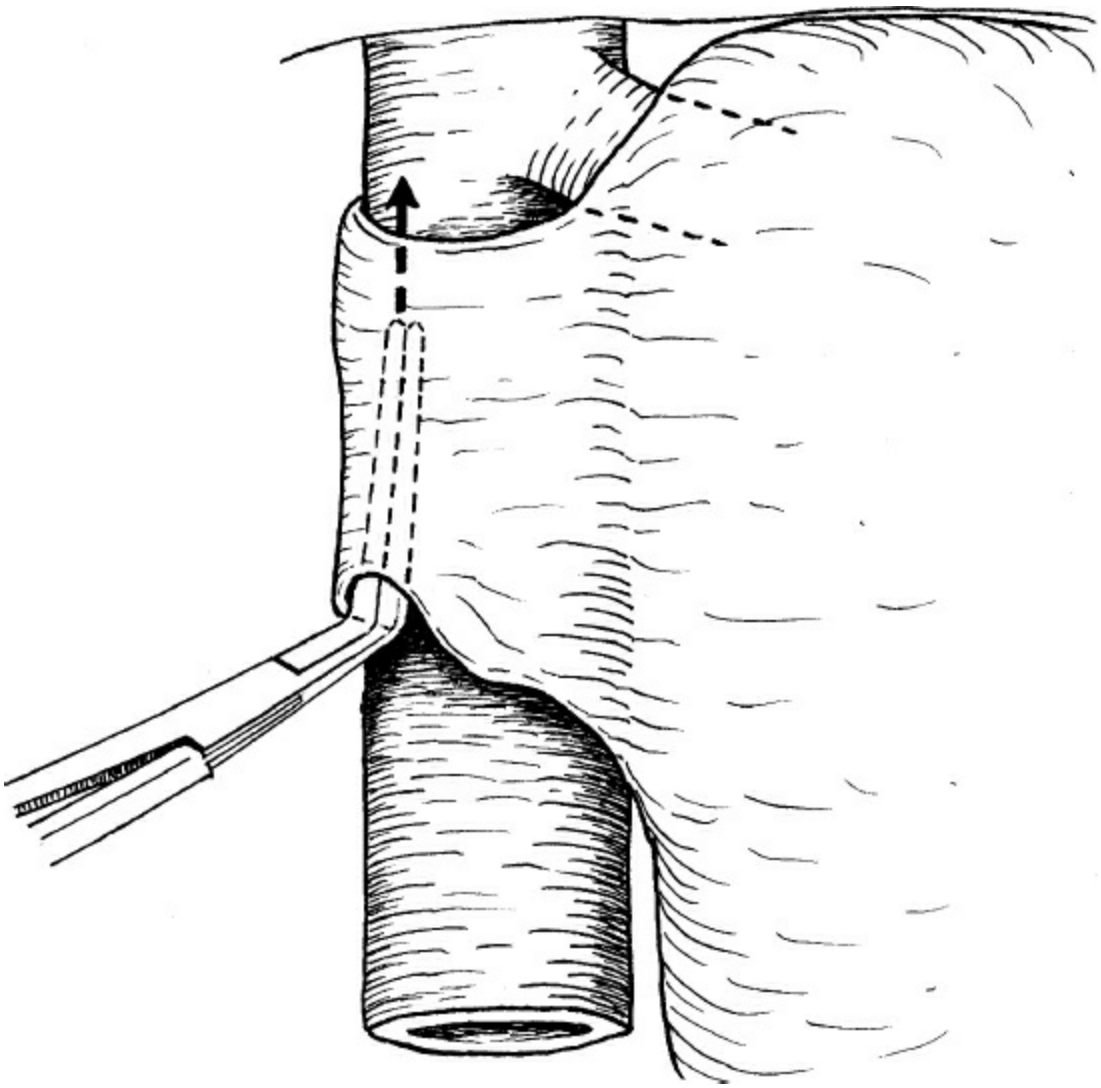

Figure 107.6. The retrocaval ligament (Makuuchi's ligament) is identified as the liver is rotated to the left, exposing the inferior vena cava. This ligament may contain liver parenchyma and/or a vein and is most safely transected with a stapler. Transection will allow exposure and control of the right hepatic vein.

An alternative technique for inflow control includes ligation of the right portal pedicle intrahepatically, either prior to or after transection of the parenchyma. In the Glissonian technique, initially described by Takasaki, the pedicle to the right liver is controlled prior to the transection of the parenchyma with two incisions: one incision is made at the left base of the gallbladder fossa just above the hilum and another is made at the junction of segment VII and the caudate process (Fig. 107.8). This second incision is perpendicular to the hilum. A large curved clamp is passed above and behind the right hilar pedicle to emerge in front of the IVC. An umbilical tape encircling the pedicle is drawn to the left and the pedicle is transected with a vascular stapler. Alternatively, each blade of a vascular clamp can be introduced into the two incisions. The clamp is closed occluding the main right pedicular sheath and vascular demarcation is noticed. The clamp is replaced by a vascular stapler, which is ultimately fired.

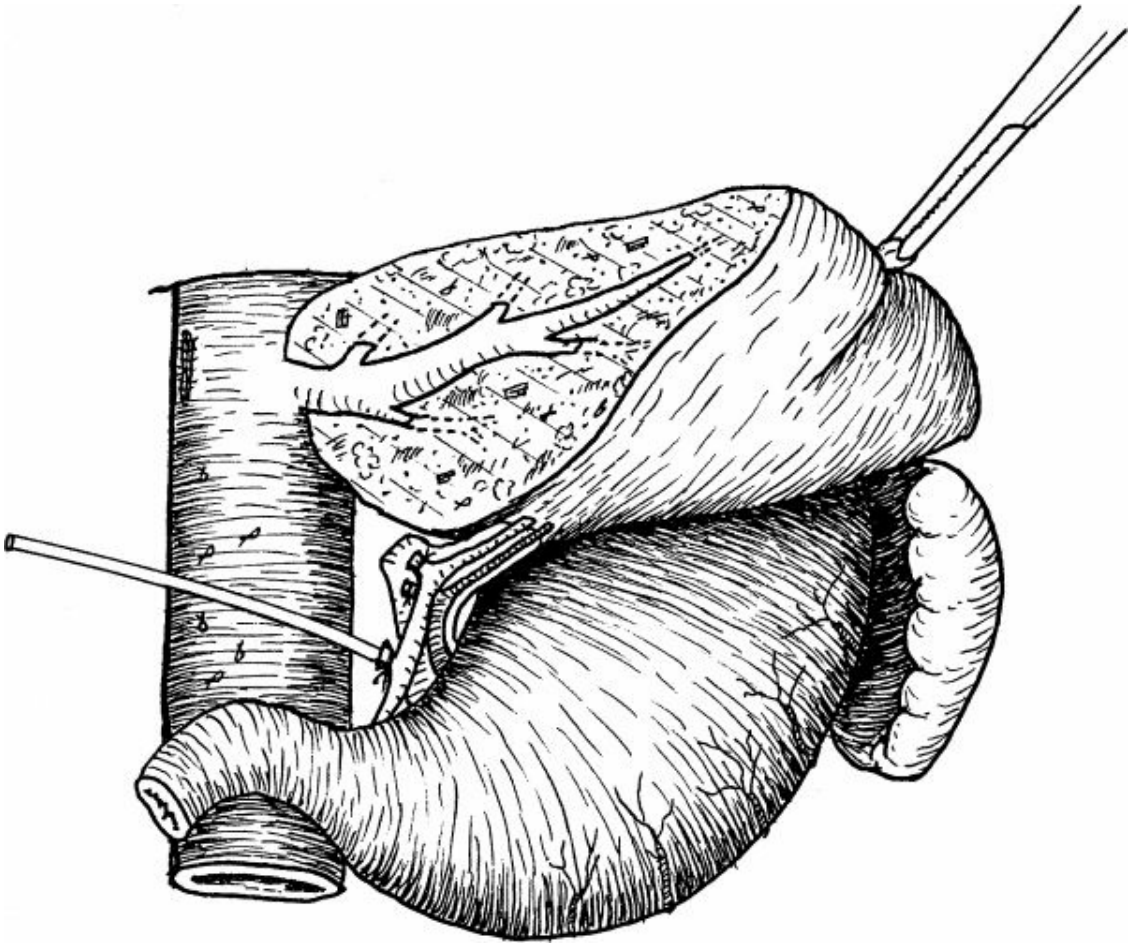

Figure 107.7. For a right hepatectomy, the right hepatic artery is ligated lateral to the bile duct. The bile duct is retracted medially and the right portal vein is ligated. The transection plane follows the area of vascular demarcation along the right side of the middle hepatic vein, from the left side of the gallbladder fossa to the IVC. The right hepatic duct is identified and transected as the transection plane approaches the left base of the gallbladder fossa.

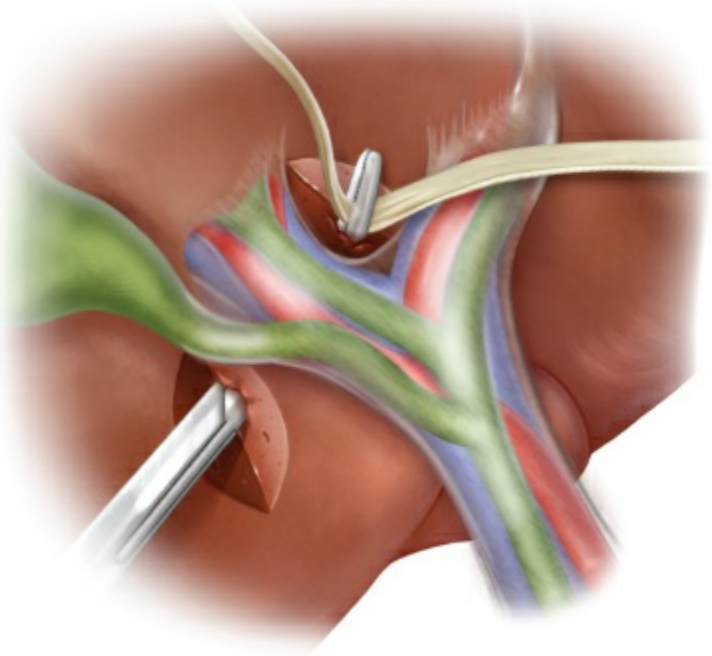

Figure 107.8. Glissonian approach for inflow control of the right hilar pedicle. A hepatotomy is made at the left base of the gallbladder fossa above the hilum. A second hepatotomy is made at the junction of segment VII and the caudate process.

Next, the right hepatic vein is divided with a vascular stapler for outflow control. Alternatively, the vein can be divided between vascular clamps. Two clamps should be placed on the IVC side and, after the vein is transected with a scalpel, one clamp is removed and the stump is closed with a 3-0 polypropylene suture. The proximal stump is also secured with a 3-0 polypropylene suture. The location of the middle hepatic vein is confirmed with the ultrasound and the parenchyma is transected at the area of vascular demarcation, with or without occlusion of the hilum (Pringle maneuver). The transection plane is shifted to the left of the gallbladder fossa at the inferior aspect of the liver to avoid longitudinal transection of the middle hepatic vein. As the transection moves cranially, the terminal branch of the middle hepatic vein is identified and ligated and the dissection continues on the right side of the vein. The parenchymal transection plane is oblique in relation to the IVC, toward the site of division of the right hepatic duct.

If the caudate lobe is to be removed along with the right hemiliver, it should be lifted and dissected from the IVC, with serial ligation of the direct short hepatic veins from the right of the IVC to the left, as an extension of the retrohepatic dissection. Inflow control to segment I is

obtained at the base of the umbilical fissure, as the caudate branches from the left hepatic artery and left portal vein are identified, ligated, and divided. The left lateral segment of the liver is mobilized and rotated to the right and the fibrous tissue connecting the caudate lobe to the IVC is transected. Ligation of remaining retrohepatic veins is then performed. Liver transection continues from the site of transection of the right hepatic duct horizontally, underneath the middle hepatic vein and the left hilar plate, toward the ligamentum venosum (Fig. 107.9).

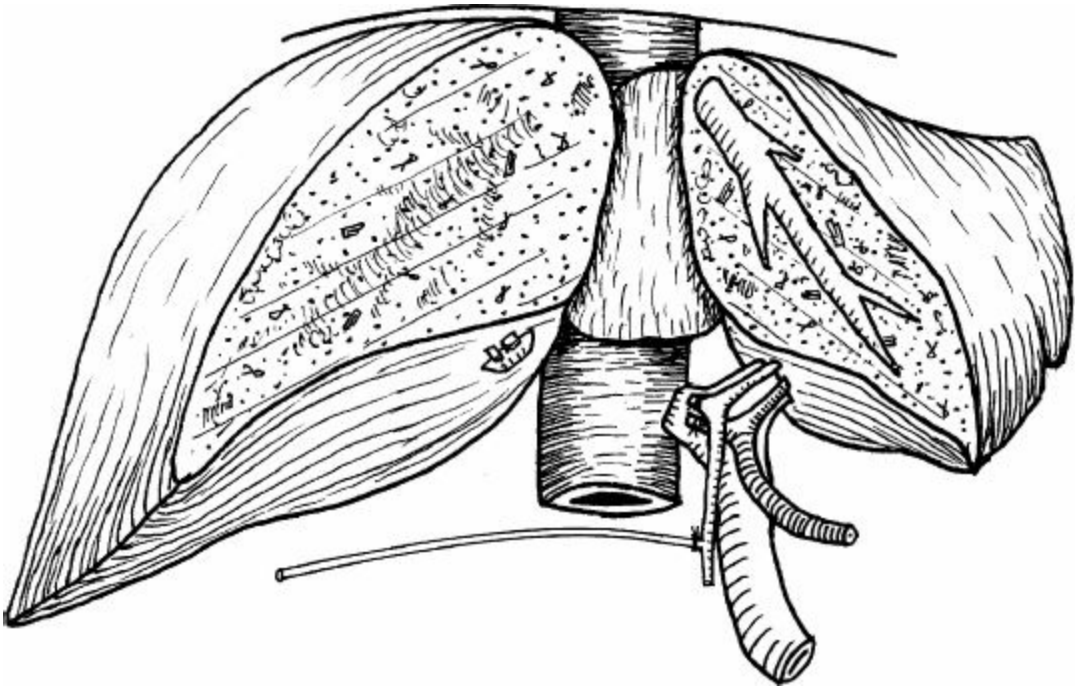

Figure 107.9. Right hepatectomy with resection of the caudate lobe. The transection plane continues from the site of transection of the right hepatic duct horizontally, underneath the middle hepatic vein and the left hilar plate, toward the ligamentum venosum.

Hemostasis and bile stasis is obtained. A cholangiogram may be performed at this time to confirm the patency of the left and common hepatic ducts (Fig. 107.10). The gallbladder is then removed and the cystic duct is ligated. The falciform ligament is reapproximated to prevent torsion of the liver and vascular compromise.

Anterior Approach

Large tumors in the right hemiliver may be adhered to the diaphragm and the retroperitoneum. In this situation, the parenchyma can be divided prior

to the mobilization of the right liver. Inflow control is initially performed as previously described and the parenchyma is transected through the demarcated area (Fig. 107.11). The anterior surface of the IVC is exposed and the right hepatic vein and short hepatic veins are identified and ligated. The hepatocaval ligament is then transected and the right liver is detached from the retroperitoneum as the right coronary and the right triangular ligaments are also transected. The “hanging maneuver,” elevation of the liver by an umbilical tape passed between the anterior surface of the IVC and the liver in the space of Couinaud, as described by Belghiti, can facilitate this approach, serving as a guide to the correct transection plane (Fig. 107.12). The space of Couinaud is a longitudinal avascular plane at the 10 to 11 o’clock position along the anterior wall of the retrohepatic IVC. To access this avascular tunnel, the hepatoduodenal ligament is initially retracted medially to expose the anterior surface of the IVC. Short hepatic veins originating from the caudate lobe are ligated. Superiorly, the space between the right hepatic vein and the middle hepatic vein is dissected, if not already done, for 3 to 4 cm downward. A long clamp is gently passed 4 to 6 cm caudally from the anterior surface of the IVC to emerge between the right hepatic vein and the middle hepatic vein. An umbilical tape is pulled behind the liver, both ends of the tape are elevated and transection of the liver proceeds as guided by the tape.

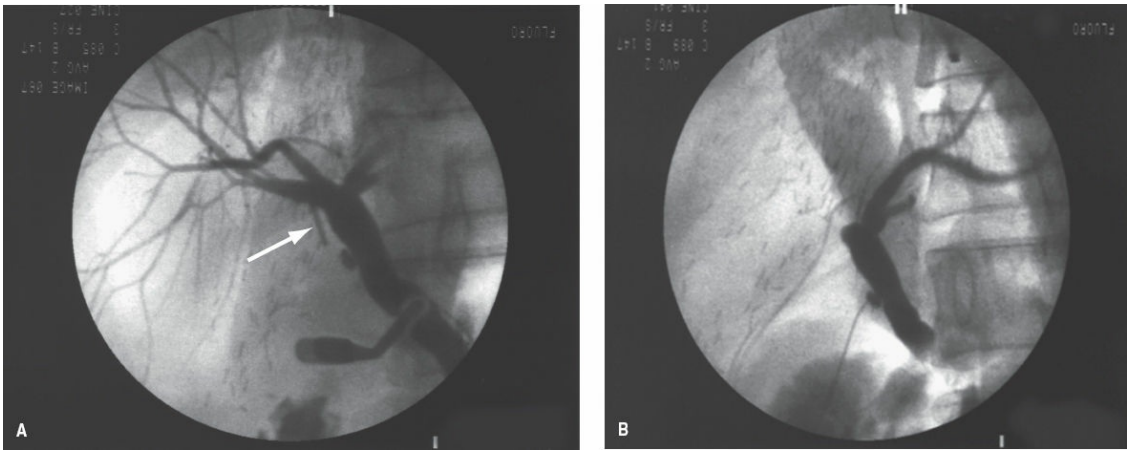

Figure 107.10. Intraoperative cholangiogram. Temporary occlusion of the distal common bile duct helps the delineation of the intrahepatic ducts. **A.** A large clip (*arrow*) marks the site of division of the right hepatic duct. **B.** A cholangiogram performed after division of the right hepatic duct confirms patency of the left and common hepatic ducts.

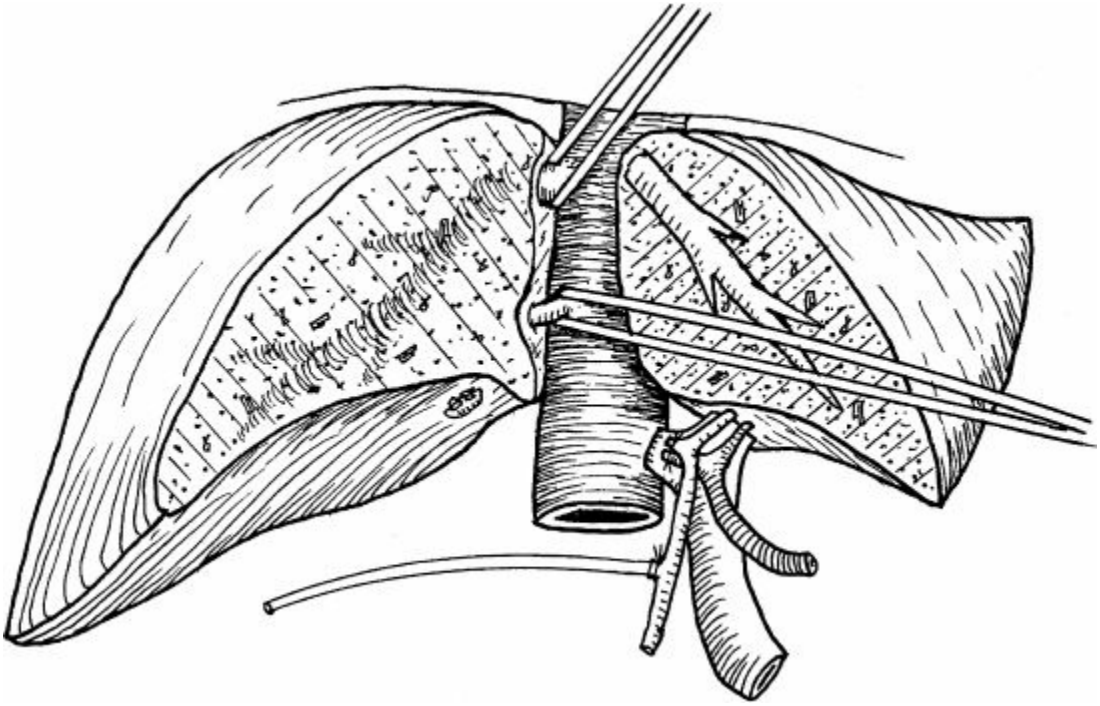

Figure 107.11. Anterior approach to a right hepatectomy. Inflow control is initially performed. The parenchyma is transected following the area of vascular demarcation prior to mobilization of the right liver. The anterior surface of the IVC is exposed and the right hepatic vein and remaining retrohepatic veins are identified and ligated before the right liver is detached from the retroperitoneum.

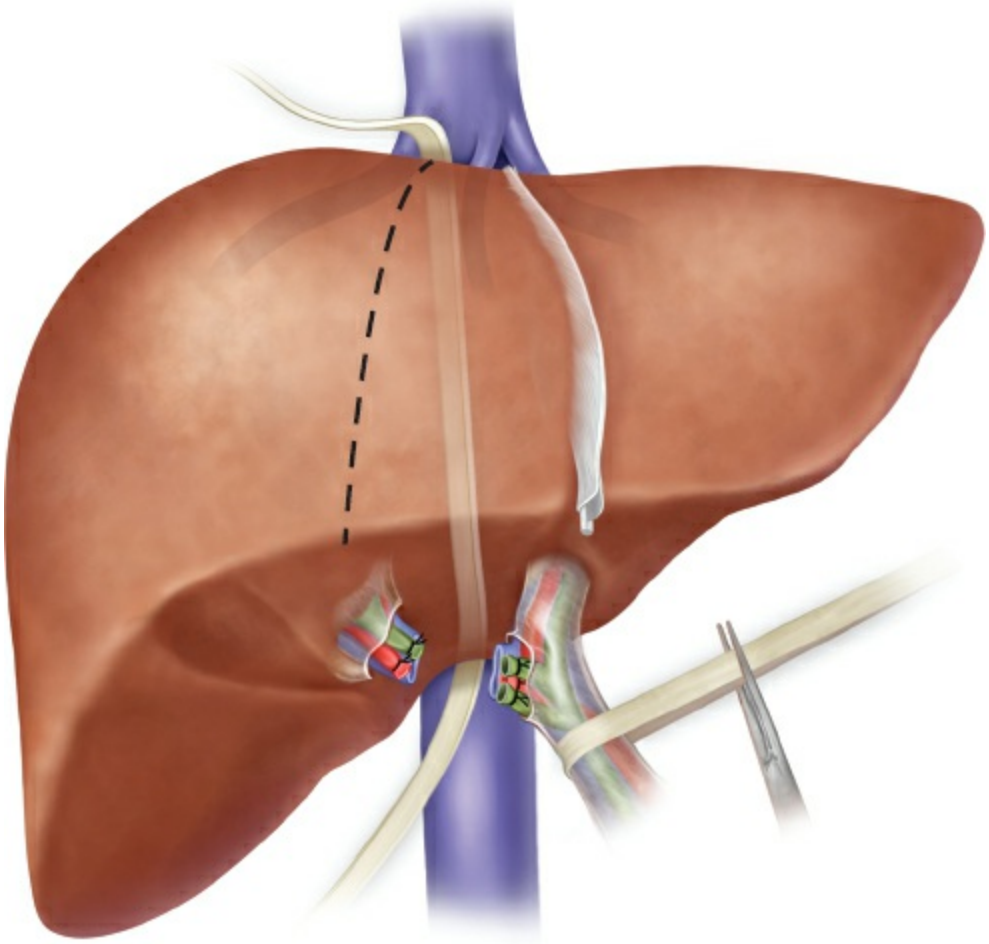

Figure 107.12. The “hanging maneuver” can facilitate the anterior approach to liver resection. An umbilical tape is blindly passed through an avascular plane along the anterior wall of the retrohepatic IVC, from its caudal portion to the space between the middle and right hepatic veins. Both ends of the umbilical tape are elevated, guiding the transection.

Extended Right Hepatectomy

When indicated, segment IV can be resected along with the right liver (Fig. 107.13). The initial steps are the same as previously described for a right hepatectomy. After inflow control to the right liver, the round ligament is elevated and the parenchymal bridge between segments III and IVB is divided exposing the base of the umbilical fissure. The hilar plate is lowered underneath segment IV to protect the left hepatic duct. The middle hepatic artery—which can often be identified to the right of and originating from the left hepatic artery—should be ligated and divided. Additional inflow to segment IV is controlled during the transection of the liver parenchyma, unless the tumor is adjacent to the umbilical fissure, in

which case inflow should be controlled within the fissure (Fig. 107.14). The transection plane is along the right side of the falciform ligament, from the groove separating the middle and left hepatic veins cranially to the right side of the umbilical fissure caudally, directed toward the medial aspect of the right hilar plate and avoiding the confluence of the left and right hepatic ducts. If the confluence needs to be resected for adequate oncologic margins, biliary drainage is restored with a Roux-en-Y hepaticojejunostomy. Finally, as the transection continues cranially, the middle hepatic vein is identified and divided with a vascular stapler.

Left Hepatectomy

A laparotomy pad is placed under the left triangular ligament to protect the spleen and the stomach and the triangular ligament is divided, exposing the IVC and the left hepatic vein. The round ligament is elevated and the parenchymal bridge between segments III and IVB is divided exposing the left hilum at the base of the umbilical fissure. The hilar plate is lowered, separating the left hepatic duct and segment IV. The peritoneum covering the left hilum is opened and the left hepatic artery is identified and ligated after flow to the right liver is confirmed. The left portal vein is dissected and divided with a vascular stapler as it enters the umbilical fissure, distal to the caudate lobe branches. The ligamentum venosum is divided at the junction with the left portal vein. A clear line of vascular demarcation can be identified between the right and left hemilivers. The left hepatic duct is dissected and ligated at the base of the umbilical fissure. Ligation of the left hepatic duct closer to the bifurcation should be avoided, as it could result in injury to aberrant right posterior or anterior ducts (Fig. 107.15).

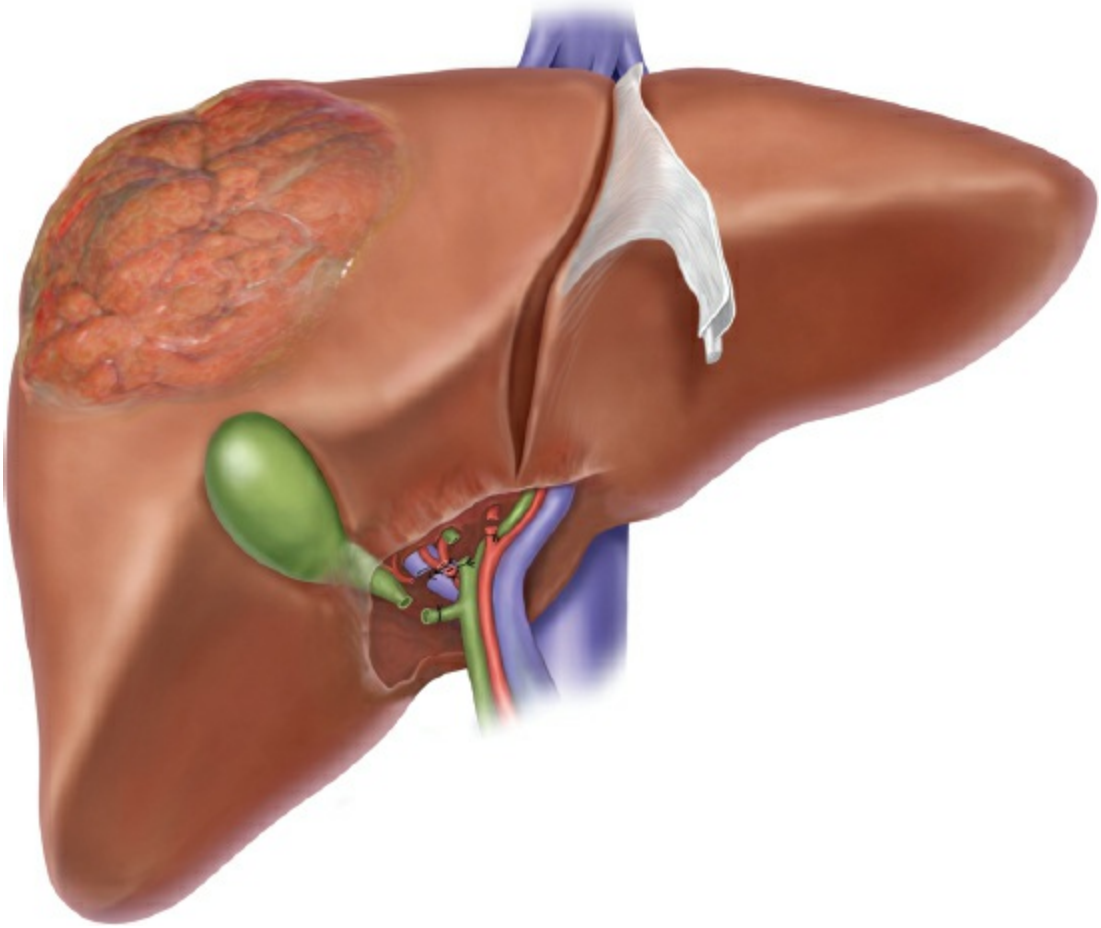

Figure 107.13. For an extended right hepatectomy, inflow to the right liver is controlled as described for a right hepatectomy. Inflow to segment IV is controlled during transection of the liver parenchyma. The transection plane is along the right side of the falciform ligament from the umbilical fissure to the confluence of the left and middle hepatic veins.

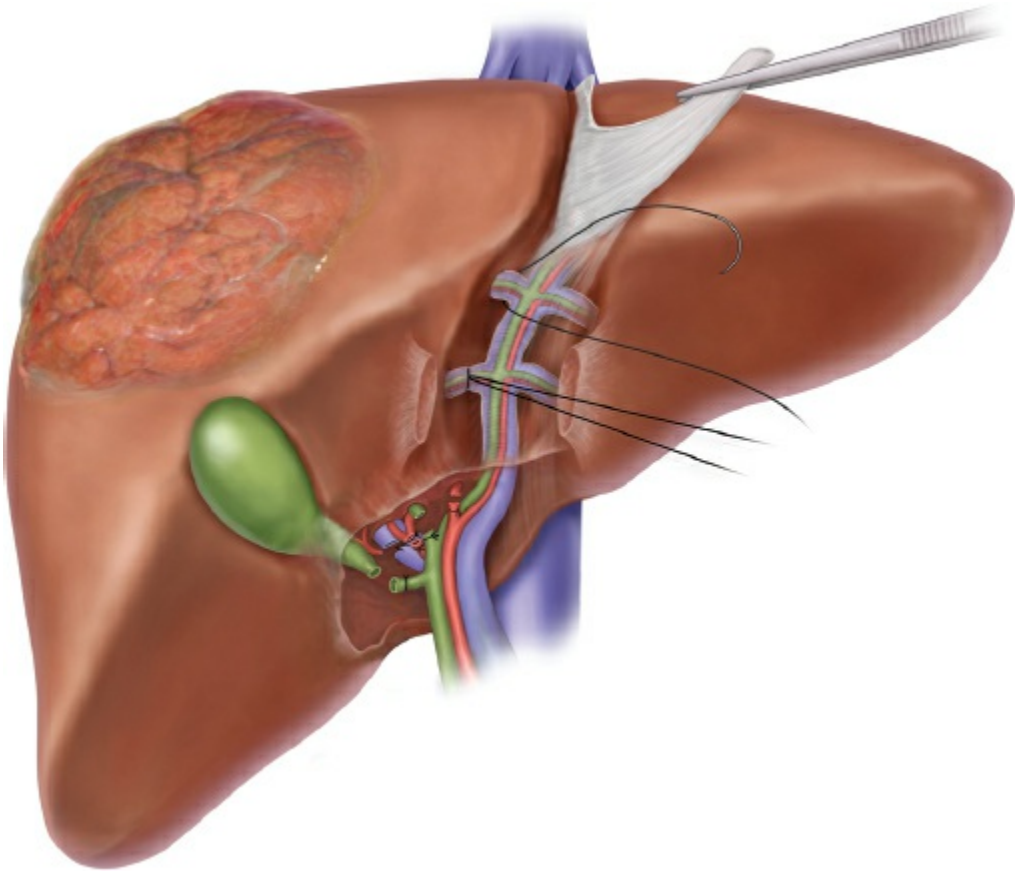

Figure 107.14. Inflow control to segment IV within the umbilical fissure.

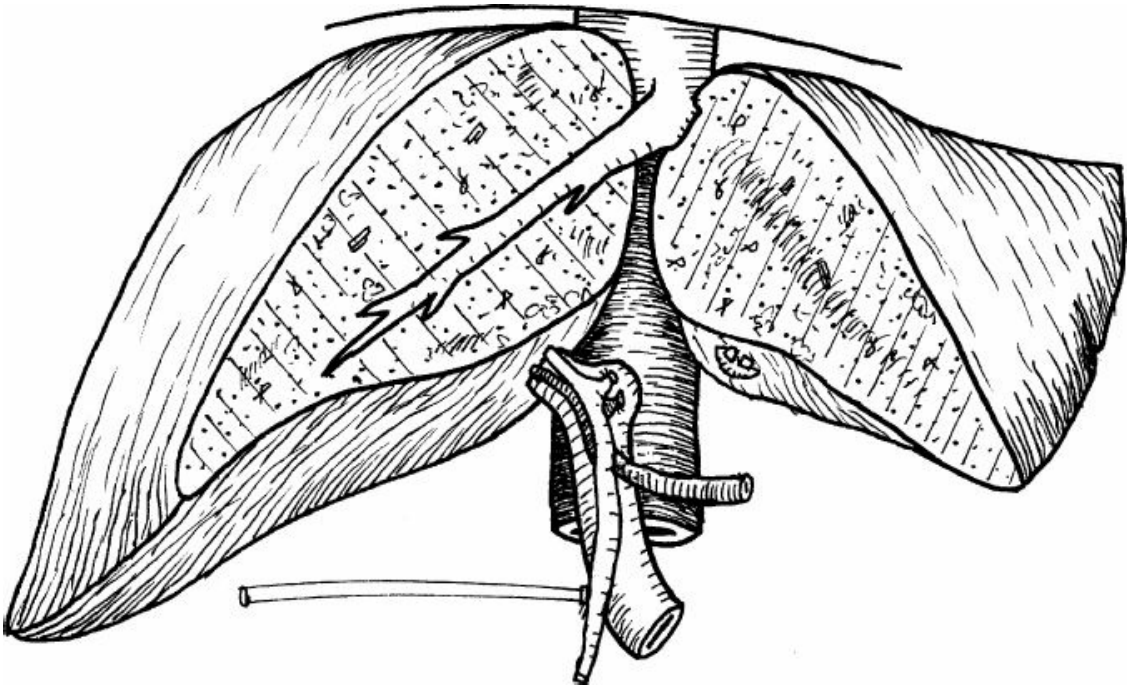

Figure 107.15. For a left hepatectomy, the left hepatic artery, the left portal vein, and the left hepatic duct are ligated at the base of the umbilical fissure. The transection plane runs along either side

of the middle hepatic vein. If oncologic feasible, this plane should run horizontally, 1 cm above the hilum, from the base of the umbilical fissure to the left side of the gallbladder fossa, to avoid injury to aberrant right anterior or posterior sectoral branches.

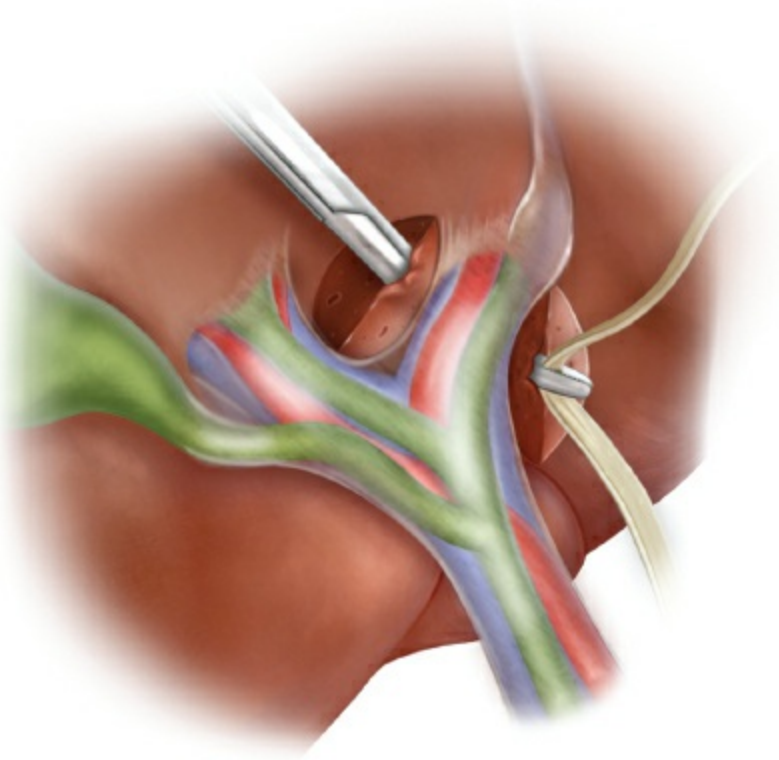

Figure 107.16. Glissonian approach for inflow control of the left hilar pedicle. One hepatotomy is made 1 cm above the left hilum and another is made just above the caudal stump of the ligamentum venosum.

In the Glissonian approach, the left hilum is ligated intrahepatically prior to the transection of the parenchyma. Two small hepatotomies are initially made: one is 1 cm above the hilum in segment IVB and the other is just above the caudal stump of the ligamentum venosum, anterior to the caudate lobe (Fig. 107.16). A clamp is introduced behind the left hilar plate toward the left lower quadrant, exiting anterior to the caudate lobe. An umbilical tape encircling the left pedicle is drawn to the left and the pedicle is transected with a vascular stapler. Alternatively, as described for the right hepatectomy, each blade of a vascular clamp is introduced into the hepatotomies, the clamp is closed, and the area of demarcation is noticed. The clamp is replaced by a vascular stapler, which is fired.

The left lateral segment is rotated to the right and the gastrohepatic ligament is further divided close to its insertion up to the base of the left

hepatic vein. The accessory left hepatic artery, if present, is ligated. The ligamentum venosum (Arantius ligament) is now divided at its insertion in the left hepatic vein. The stump is elevated to expose the window between the left hepatic vein and the IVC. The common trunk of the middle and the left hepatic veins, present in 90% of the population, is encircled as a clamp is passed between the left hepatic vein and the IVC, emerging between the right and middle hepatic veins. If the middle hepatic vein is to be divided due to tumor location, the common trunk is ligated with a vascular stapler. If the middle hepatic vein is to be preserved, the parenchyma between the left and the middle hepatic veins is transected and the left hepatic vein can be isolated. Alternatively, the left hepatic vein can be ligated intrahepatically when encountered during parenchymal transection. The location of the middle hepatic vein is confirmed with ultrasound and the parenchyma is transected close to the demarcated line, on either side of the middle hepatic vein, with or without occlusion of the hilum (Pringle maneuver). The middle hepatic vein branches extending to segment IV—or, if the vein is resected, to segments V and VIII—are identified and ligated. The transection line should run horizontally, approximately 1 cm above the hilum if oncologically feasible, from the area of transection of the left hilar plate to the left side of the gallbladder fossa—thus, avoiding transection of an aberrant right anterior or posterior duct—and then turning vertical, parallel to Cantlie line.

If the caudate lobe is to be removed along with the left hemiliver, inflow control to the left hilum is obtained more proximally, prior to the take-off of the branches of the left hepatic artery and left portal vein that extend to segment I, just before these structures enter the umbilical fissure. The left lateral segment of the liver is mobilized and rotated to the right and the fibrous tissue connecting the caudate lobe to the IVC is transected. Ligation of the retrohepatic veins is performed from the left of the IVC to the right, preserving the inferior hepatic vein, if present. If this dissection cannot be performed safely, the right liver is mobilized and the retrohepatic veins are ligated from caudal to cranial and right to left of the IVC, as described for a right hepatectomy. Liver transection then proceeds horizontally underneath the hilar plate toward the ligamentum venosum,

At completion of the transection, hemostasis and bile stasis is obtained. A cholangiogram may be performed at this time to confirm the patency of the left and common hepatic ducts. The gallbladder is then removed and the cystic duct is ligated. The falciform ligament is reapproximated to

prevent torsion of the liver and vascular compromise.

Extended Left Hepatectomy

When indicated, the right anterior section (segments V and VIII) can be resected along with the left hemiliver. The initial steps are the same as those for a left hepatectomy. After inflow control to the left hemiliver, the right anterior portal vein and artery are dissected in the right hilum. After flow to the right posterior section is confirmed, these vessels are ligated, resulting in a demarcation line between the two sections of the right hemiliver. The common trunk of the middle and the left hepatic veins is isolated, as described above, and the common trunk is ligated with a stapler. The transection plane is horizontal, along the ligamentum venosum, from the base of segment IV extending to the right of the gallbladder fossa and anterior to the right hepatic vein (Fig. 107.17). If the tumor is close to the main right hilum, it may be impossible to establish inflow control to right sectoral pedicle. In this situation, the pedicle to the right anterior sector will be identified and ligated as transection of the parenchyma approaches the hilum.

Laparoscopic Liver Resection

The use of laparoscopy for LR is increasing significantly. The Second International Consensus Conference on Laparoscopic LRs, held in Morioka, Japan in 2014, evaluated the available literature in the field and issued recommendations for the future implementation of this technique. Observational data suggests that laparoscopic resection is associated with decreased wound complications, postoperative pain, and length of stay. Moreover, laparoscopic resection is not associated with increased mortality or increased rate of positive margins. Long-term outcomes have also been shown to be similar between laparoscopic and open LR in patients with colorectal metastases or HCC. However, these results are mostly based on cohort studies with limited sample size. No randomized trials comparing laparoscopic versus open LR have been completed at this time, although there are two ongoing studies. The panel concluded that while minor laparoscopic LRs are standard practice in surgery, although still in an assessment phase, major laparoscopic LRs should be considered an innovative procedure, in an exploration or learning phase with incompletely defined risk. Major laparoscopic LRs should, therefore, be introduced cautiously.



Figure 107.17. For an extended left hepatectomy, the transection plane is horizontal, anterior to the right hepatic vein and the posterior sectoral pedicle, directed to the right side of the gallbladder fossa, continuing through the base of segment IV toward the ligamentum venosum.

Laparoscopic Parenchymal Transection

As with open LR, transection of the parenchyma can be performed by different techniques and with different energy devices, dependent on the surgeon's experience and preference. Intraoperative ultrasound is key to identifying the relationship between major vessels and the transection line. The argon beam coagulator should be used with caution due to the risk of gas embolism.

Laparoscopic Right Hepatectomy

Patient is positioned supine or in low lithotomy position with arms at 60 degrees. Padding is applied underneath the right flank to elevate the right side of the patient. Monitors are placed at the head of the table. The

surgeon and camera operator stand on the left of the patient and the first assistant stands on the right. Alternatively, the surgeon may stand between the patient's lower extremities.

A 12-mm port is initially placed about 2 cm above the umbilicus and CO_2 insufflation is obtained. The 30-degree laparoscope is introduced in the abdomen and the abdominal cavity is inspected for presence of extrahepatic disease. A 12-mm port is inserted at the right midclavicular line. This port will be used for the energy devices and the stapler. Two additional 5-mm ports are placed laterally, along the right subcostal margin, for retraction and suction/irrigation. Finally, an additional 5-mm port is placed in the subxiphoid region for better visualization of the dome. For hand-assist access, the supraumbilical port can be extended (Fig. 107.18). The location of the port sites varies according to the patient's anatomy.

The falciform ligament is transected from the abdominal wall with an energy device through the right midclavicular port. Adhesions to the inferior surface of the liver are lysed with countertraction applied through the lateral ports. The right triangular and coronary ligaments are taken down and the liver is freed from its retroperitoneal attachments. The laparoscopic ultrasound is introduced and the location of the lesions and their relationship with the hepatic vessels is noted, permitting the extent of the resection to be confirmed. The right hemiliver is elevated with a liver retractor, the IVC is exposed, and the retrohepatic vessels are ligated with surgical clips proceeding cranially to the location of the right hepatic vein.

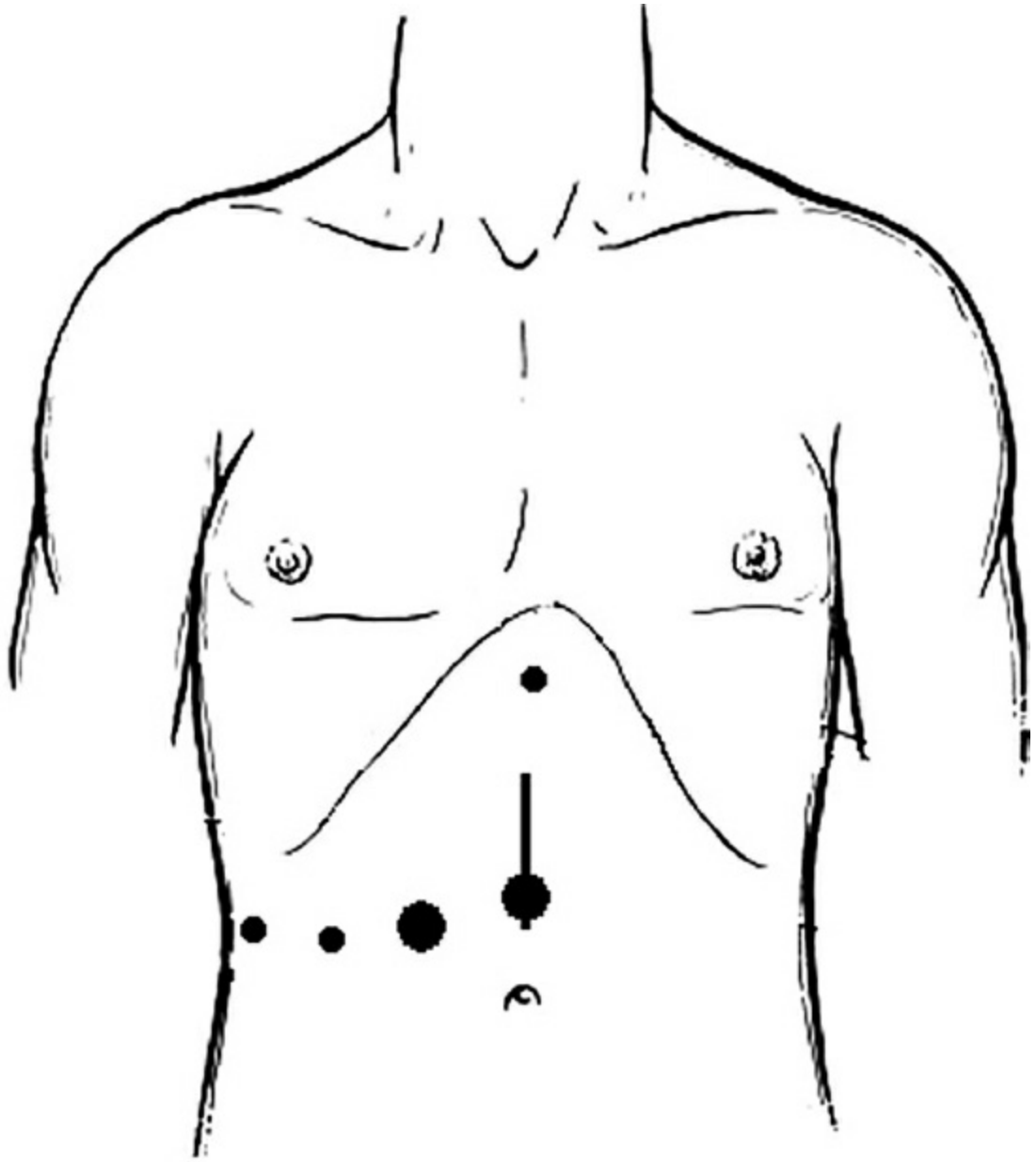

Figure 107.18. Port placement for laparoscopic right hepatectomy: a 10-mm port is initially placed about 2 cm above the umbilicus; a 12-mm port is inserted at the right midclavicular line and two additional 5-mm ports are placed laterally, along the right subcostal margin; an additional 5-mm port is placed in the subxiphoid region. For hand-assist access, the supraumbilical port can be extended.

Using a Carter–Thompson needle suture passer, an endoloop is placed around the round ligament, retracting the liver superiorly to expose the hilum. Cholecystectomy is performed from the fundus to the neck of the gallbladder. The gallbladder is left attached to the cystic duct to be used as a handle. The right hepatic artery is dissected and transected with a stapler.

The right hepatic vein is also isolated and ligated with a stapler.

A vascular loop or umbilical tape should be loosely applied around the portal triad to allow for the Pringle maneuver. The vascular loop is tightened with a bulldog clamp and released in cycles as described for the open procedure.

The parenchyma is transected in the demarcated line as previously described, using energy devices for transection of smaller vessels and an endovascular vascular stapler for transection of the branches of the middle hepatic vein, the right hepatic vein, and the right biliary duct. The cut edge of the liver is inspected and bleeding is controlled with the argon beam coagulator or radiofrequency sealer. If the argon beam coagulator is used, a port should be vented as the intra-abdominal pressure rapidly increases. The argon beam should not be used near large hepatic veins due to the risk of gas embolism.

The specimen is placed in an extraction bag and is removed through an extension of the supraumbilical port. The falciform ligament is reattached to the abdominal wall with the help of an endoscopic suture device.

Laparoscopic Left Hepatectomy

Patient is positioned supine or in low lithotomy position with arms at 60 degrees. The surgeon stands on the patient's left side or between the lower extremities. A 12-mm port is placed about 2 cm above the umbilicus and CO_2 insufflation is obtained. The 30-degree laparoscope is introduced in the abdomen and the abdominal cavity is inspected for presence of extrahepatic disease. A 12-mm port is placed at the left midclavicular line and two additional ports are placed laterally, below the left subcostal margin. An additional 12-mm port is placed at the right midclavicular line. For hand-assist access, the supraumbilical port can be extended (Fig. 107.19).

The left hepatic artery and portal vein are identified and ligated at the base of the umbilical fissure.

The parenchyma is transected as described above for laparoscopic right hepatectomy, with the branches of the middle hepatic vein, the left hepatic vein, and the left hepatic duct transected with a vascular stapler as they are encountered during the transection. The specimen is removed through an extension of the supraumbilical port and the falciform ligament is reattached to the abdominal wall.

Drainage

Drains are not routinely placed after a major hepatectomy, as they have not been shown to decrease the need for postoperative drainage. However, drains adjacent to the cut edge of the liver should be considered selectively for patients at higher risk of infection, such as those with biliary obstruction and those undergoing simultaneous liver and colorectal resections. Drains should be placed when biliary reconstruction is performed. After 24 to 48 hours, a bile bag with gravity drainage can replace the suction bulb to avoid negative pressure.

POSTOPERATIVE CARE

Patients without major comorbidities that undergo an uneventful procedure may be extubated and admitted to the floor. Fluids should be administered carefully to avoid overload and elevated central venous pressure, with resulting congestion of the remnant. Colloid fluid replacement is preferable for cirrhotic patients. Narcotic pain medication should be used judiciously. Ambulation is encouraged within the first 24 hours of the procedure. Patients are typically advanced to clear liquid diet on the first postoperative day and subsequently advanced as tolerated. Liver function tests are ordered daily for the first 2 days and selectively thereafter. Phosphate levels are monitored closely as hypophosphatemia is common with liver regeneration.

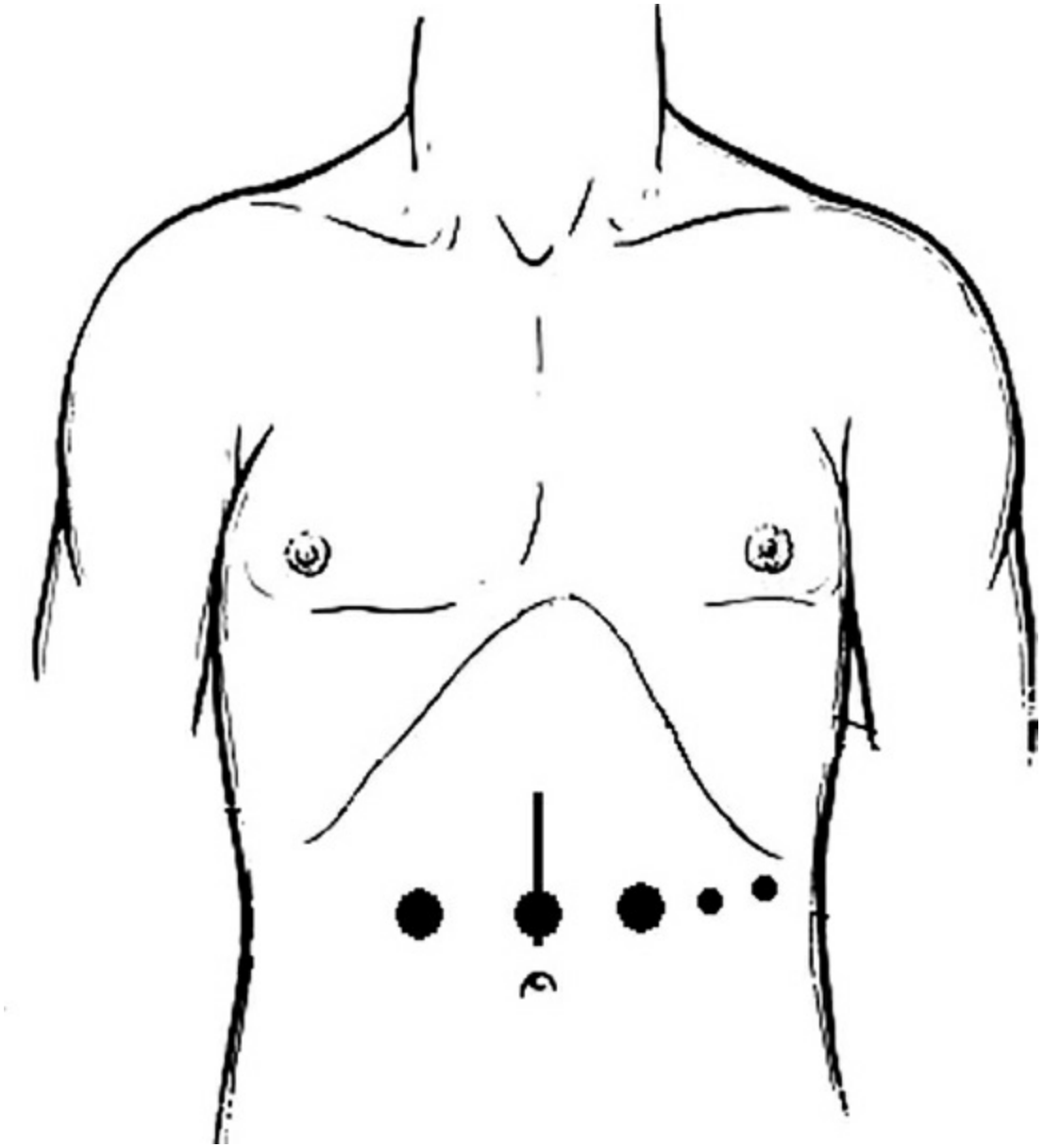

Figure 107.19. Port placement for laparoscopic left hepatectomy: a 10-mm port is placed about 2 cm above the umbilicus; a 12-mm port is place at the left midclavicular line and two additional ports are placed laterally, below the left subcostal margin; an additional 12-mm port is placed at the right midclavicular line. For hand-assist access, the supraumbilical port can be extended.

COMPLICATIONS AND THEIR MANAGEMENT

Intra-abdominal collections at the transected edge of the liver are common after major LRs. These collections should be percutaneously drained if the patient becomes symptomatic or there are clinical signs of infection. Factors associated with infection of these fluid collections include biliary obstruction, presence of cirrhosis, and combined LRs with colorectal

resections. If persistent bilious drainage exists, ERCP with sphincterotomy can be performed to diagnose the site of the biliary leakage and decrease the output.

Liver insufficiency may present in the early postoperative period with hypotension refractory to vasopressors, respiratory failure, acute renal insufficiency, hypoglycemia, and coagulopathy. Other patients may develop a more protracted course with progressive hyperbilirubinemia, encephalopathy, massive ascites, anasarca, and renal insufficiency. Ascites can result in the disruption of the incision and major fluid and electrolyte losses. While some of these patients will never recover their liver function and eventually succumb to infection, others will regenerate to sufficient size with appropriate support. Factors associated with increased risk of postoperative liver failure include the size and function of the liver remnant, especially in cirrhotic patients, intraoperative blood loss and postoperative complications, most commonly infectious. Patients with cirrhosis are also at higher risk of significant portal hypertension after resection, which may result in variceal bleeding.

Complications of Laparoscopic Liver Resection

Gas (CO_2 and argon) embolisms are unique complications of the laparoscopic approach. While CO_2 embolism is less dangerous than air embolism given CO_2's higher solubility in blood, argon embolization is more worrisome as this gas is 17 times less soluble that CO_2. CO_2 embolism should be suspected if there is an abrupt decrease in the end-tidal CO_2 associated with hypotension. Diagnosis can be confirmed with a transesophageal echocardiogram. The patient should be placed in Trendelenburg and left lateral decubitus and the central line should be aspirated to remove the gas that may collect in the right atrium.

Major intraoperative hemorrhage, usually from the hepatic veins, often requires conversion to open procedure for adequate control. It is best avoided with the use of intraoperative ultrasound to correctly identify the location of the middle hepatic vein as the transection plane is determined.

OUTCOMES

Long-term outcomes following major LR is determined by the primary tumor and the extension of the disease. For instance, 5-year overall and disease-free survival in patients with colorectal liver metastasis are 30% to

60% and 20% to 40%, respectively. Factors associated with long-term survival include the number of lesions, longer disease-free interval between the diagnosis of the primary tumor and the metastatic disease, size of the largest hepatic tumor, presence of extrahepatic disease, and nodal status of the primary tumor. In patients with HCC, with Child's A cirrhosis and no portal hypertension or with no cirrhosis, 5-year overall and disease-free survival are 40% to 75% and 20% to 40%, respectively. While tumor size alone has small effect on long-term survival, presence of multiple lesions HCC (multifocal HCC) and major vascular invasion are associated with high recurrence rates and poor overall survival.

Suggested Readings

Dixon E, Abdalla E, Schwarz RE, et al. AHPBA/SSO/SSAT sponsored consensus conference on multidisciplinary treatment of hepatocellular carcinoma. *HPB (Oxford)* 2010;12(5):287–8.

Liddo G, Buc E, Nagarajan G, et al. The liver hanging manoeuvre. *HPB (Oxford)* 2009;11(4):296–305.

Pulitano C, Bodingbauer M, Aldrighetti L, et al. Colorectal liver metastasis in the setting of lymph node metastasis: defining the benefit of surgical resection. *Ann Surg Oncol* 2012;19(2):435–42.

Rahbari NN, Garden OJ, Padbury R, et al. Posthepatectomy liver failure: a definition and grading by the International Study Group of Liver Surgery (ISGLS). *Surgery* 2011;149(5):713–24.

Ribero D, Abdalla EK, Madoff DC, et al. Portal vein embolization before major hepatectomy and its effects on regeneration, resectability and outcome. *Br J Surg* 2007;94(11):1386–94.

Schwarz RE, Abdalla EK, Aloia TA, et al. AHPBA/SSO/SSAT sponsored consensus conference on the multidisciplinary treatment of colorectal cancer metastases. *HPB (Oxford)* 2013;15(2):89–90.

Strasberg SM. Nomenclature of hepatic anatomy and resections: a review of the Brisbane 2000 system. *J Hepatobiliary Pancreat Surg* 2005;12(5):351–5.

Wakabayashi G, Cherqui D, Geller DA, et al. Recommendations for laparoscopic liver resection: a report from the second international consensus conference held in Morioka. *Ann Surg* 2015;261(4):619–29.

Weng M, Zhang Y, Zhou D, et al. Radiofrequency ablation versus resection for colorectal cancer liver metastases: a meta-analysis. *PloS One* 2012;7(9):e45493.

EDITOR'S COMMENT

There have been substantial advances in hepatic resection for primary and metastatic cancer to the liver. To that end the authors review the technical aspects of the various operations and include important advances including the hanging technique and laparoscopic approaches. In this commentary I will explore the outcomes and some of the controversies related to hepatic resection.

Hepatocellular carcinoma (HCC) is the most common primary malignancy of the liver and the sixth most common cancer. The well-established association of HCC with chronic liver disease (CLD), due to viral infection, alcohol consumption, metabolic syndrome, and so forth, adds complexity and challenges to the surgical treatment of this disease. This is the result of underlying histologic changes in the liver parenchyma which may include steatosis, inflammation, fibrosis, and cirrhosis. These changes affect liver function and resilience as well as predispose the liver to multicentric carcinogenesis that may limit the possibility of curative treatments. Various surgical treatments of HCC include local ablation of small tumors, liver resection (LR) both anatomic and nonanatomic, and liver transplantation (LT).

LR is one of the recommended potential treatments for HCC patients. Recent articles on this topic (Rahbari NN, Mehrabi A, Mollberg NM, et al. Hepatocellular carcinoma: current management and perspectives for the future. *Ann Surg* 2011;253:453–69; Morise Z, Kawabe N, Tomishige H, et al. Recent advances in liver resection for hepatocellular carcinoma. *Front Surg* 2014;1:21) report that the role of LR in HCC has been expanded with better outcomes as a result of advances in screening, improved treatment of the underlying liver disease, earlier radiologic diagnosis, better methods of determining liver function, a clearer understanding of segmental anatomy, as well as evolving of surgical techniques. Currently the expected 5-year survival is 38% to 61% depending on the stage of the disease. However, less than one third of patients with HCC are eligible for surgery. The Liver Cancer Study Group in Japan is the largest single report in the literature with 6,785 patients treated between 1988 and 1999 (Ikai I, Itai Y, Okita K, et al. Report of the 15th follow-up survey of primary liver cancer. *Hepatol Res* 2004;28:21–9). The authors observed the following survival rates: 1 year (85%), 3 years (64%), 5 years (45%), and 10 years (21%). Survival rates as high as 60% at 5 years in patients with good liver function and small localized tumors have been reported by other groups worldwide without differences between Western and Eastern countries.

The alternative to LR for HCC is LT. LT achieves excellent results in patients with limited tumors. An article by Belghiti J and Fuks D (Liver resection and transplantation in hepatocellular carcinoma. *Liver Cancer* 2012;1:71–82) provides an excellent update of the role of liver transplantation in HCC. In this study the authors note that "patients with HCC within the Milan criteria (MC; solitary HCC of <5 cm or with up to three nodules of <3 cm) have

a 5-year survival of 70% after LT with recurrence in less than 10%." This survival is equivalent to liver transplant survival in most other indications. An important observation is that the diameter of the largest nodule or total diameter of nodules is the best predictor of the outcome. It is known that increased waiting time for a donor liver is associated with tumor progression and vascular invasion. Of approximately 7,000 new patients with HCC put on the waiting list every year in the United States each year 10% to 15% die during the waiting period, while in Europe, the dropout rate at various centers ranges between 15% and 35%. Hence it is important to consider the options for tumor management while awaiting transplantation. These include ablation techniques, TACE, and hepatic resection. Interestingly, prior surgical resection does not preclude transplantation as it does not increase the surgical risk nor reduce survival (Belghti J, Cortes A, Abdalla EK, et al. Resection prior to liver transplantation for hepatocellular carcinoma. *Ann Surg* 2003;238:885–92). As Belghiti points out: "resection could be used as a bridge to transplantation, especially for tumors located in the upper part of the right liver, which can be easily and completely removed through a transthoracic incision" (Belghiti J, Fuks D. Liver resection and transplantation in hepatocellular carcinoma. *Liver Cancer* 2012;1:71–82).

Approximately 20% to 30% of patients with metastatic colorectal cancer have a disease that is confined to the liver which is potentially resectable. The traditional "rules" guiding hepatic resection consisted of limiting resection to patients with a maximum of three lesions in the same lobe in which it was possible to achieve 1 cm surgical margins and those without portal lymph node metastases. These have been challenged by advancements in both surgical technique and systemic therapy. The notable improvements in the outcomes of patients with metastatic CRC have been attributed to increased use of hepatic resection in selected patients and more effective chemotherapy. Several recent large series on resection for colorectal liver metastases have reported a 5-year survival ranging from 25% to 44%, with operative mortality of 0% to 6.6%. Let us look at the report by Kanas GP et al. (Survival after liver resection in metastatic colorectal cancer: review and meta-analysis of prognostic factors. *Clin Epidemiol* 2012;4:283–301) who performed a meta-analysis on the topic. They reported an overall median survival of 3.6 years and 5- and 10-year survival ranged from 16% to 74% (median 38%) and 9% to 69% (median 26%). Factors associated with poorer survival included: node positive primary, 1.6 (1.5 to 1.7); carcinoembryonic antigen level, 1.9 (1.1 to 3.2); extrahepatic disease, 1.9 (1.5 to 2.4); poor tumor grade, 1.9 (1.3 to 2.7); positive margin, 2.0 (1.7 to 2.5); >1 liver metastasis, 1.6 (1.4 to 1.8); and >3 cm tumor diameter, 1.5 (1.3 to 1.8). Interestingly, approximately one third of 5-year survivors suffer a cancer-related death, while those who survive 10 years appear to be cured. Because of its clear survival impact, surgical resection is the treatment of choice when feasible. The percentage of patients with isolated hepatic metastases who are amenable to potentially curative resection is a bit of a moving target since

surgeons may have different interpretations of “resectable.” It is safe to say that a majority of patients, with metastatic disease are not curative surgical candidates because of tumor size, location, multifocality, or inadequate hepatic reserve. One consensus statement defined absolute unresectability as nontreatable extrahepatic disease, unfitness for surgery, or involvement of more than 70% of the liver or six segments (Poston GJ, Adam R, Alberts S, et al. OncoSurge: a strategy for improving resectability with curative intent in metastatic colorectal cancer. *J. Clin Oncol* 2005;23:7125–34). Today even patients with bilobar disease may be candidates for resection (Malik HZ, Hamady ZZ, Adair R, et al. Prognostic influence of multiple hepatic metastases from colorectal cancer. *Eur J Surg Oncol* 2007;33:468–73). In this report 484 patients with multiple liver metastases from CRC had 5- and 10-year survival if 47% and 29%.

There continues to be debate about the management of synchronous liver metastases. From the patient’s perspective, simultaneous resection of the primary and metastatic disease is clearly preferable. However, concern has been raised about the safety of LR at the time of resection of the primary colon lesion. To date, comparative studies have indicated that concurrent and staged resection of hepatic metastases are equivalent in terms of operative time, blood loss, transfusion, perioperative morbidity, operative mortality, and overall survival form the date of keratectomy. Overall duration of hospitalization was noted to be longer (up to two times longer) for concurrent resection. The exception is patients that require extensive resection for multiple metastases (>4 tumors), with greater than three segments, or require extended hepatectomy may be better served with delayed hepatic resection. Several surgical case series and meta-analyses have failed to confirm inferior survival or greater morbidity for patients who undergo a one-stage procedure as compared with delayed (staged) hepatic resection, unless major hepatic resection (three or more segments) is needed. One-stage surgery is probably a reasonable option for patients who present with low-volume (four or fewer, less than three segments involved, or all in the same lobe) potentially resectable hepatic metastases.

There is controversy around the role of chemotherapy prior to LR. Initially this was thought to be a good idea, but however this has been challenged by reports of chemotherapy-associated steatosis (CASH), vascular injury, and noncirrhotic portal hypertension in patients receiving receiving regimens containing irinotecan or oxaliplatin. These changes can impact survival after LR. In one study patients with steatohepatitis had a 90-day mortality of 15% compared to 2% in those without CASH. This has influenced thinking regarding management of metachronous liver metastases. The overall benefit of upfront chemotherapy prior to surgery in patients with metachronous liver metastases is uncertain. In the chemotherapy groups, postoperative complications seem higher and there is no overall survival benefit. Many surgeons prefer surgery as the first-line therapy in these cases.

What is the role of chemotherapy on converting unresectable to resectable

disease? The results are mixed. High rates of successful resection for patients with initially unresectable liver metastases have been reported for the FOLFOXIRI regimen with or without bevacizumab in some trials but not on others. The TRIBE trial which compared bevacizumab plus either FOLFOXIRI or FOLFIRI did not result in a significant increase in complete resection (15% vs. 12%) (Loupakis F, Cremolini C, Masi G, et al. Initial therapy with FOLFOXIRI and bevacizumab for metastatic colorectal cancer. *N Engl J Med* 2014;37:1609–18). Toxicity was greater with FOLFOXIRI. There is continued work in this area with various combinations of cytotoxic chemotherapy with or without biologic agents. The best option in these cases is to enroll your patient in a clinical trial if available and if not work with the medical oncologist at your organization on each case individually. Most important in these circumstances is to set realistic patient expectations.

There are several special considerations in performing LR. The first is predicted residual liver volume and its impact on outcome. Three-dimensional hepatic volumetry and virtual resection identified that the incidence of severe hepatic dysfunction and postoperative infection was increased significantly in patients with a functional liver remnant of 26.6% or less and was significantly worsened by high BMI (Schindl MJ, Redhead DN, Fearon KC, et al. The value of residual liver volume as a predictor of hepatic dysfunction and infection after major liver resection. *Gut* 2005;54:289–96). Preoperative portal vein embolization (PVE) is defined as the elective obliteration of portal blood flow to a selected portion of the liver a few weeks prior to planned major LR I order to increase the volume and potentially the function of the FLR to a safe threshold, and minimize the risk of posthepatectomy liver failure and related complications. Usually a right PVE is performed in preparation of or a patient with normal liver function for an extended right hepatectomy or a right hepatectomy in a patient with cirrhosis.

The increase in liver volume is due to hyperplasia and not hypertrophy (an increase in size of existing hepatocytes). Preoperative PVE causes an immediate increase of portal blood flow to the nonembolized liver segments. The increased flow stimulates a regenerative response. The arterial flow to the nonembolized segments is not significantly altered. Interestingly the time course for the expected increase in FLR has been fairly well documented. At 4 to 6 weeks after PVE, the expected increase of standardized FLR ranges from 8% to 13%, although some studies have reported higher rates (Leung U, Simpson AL, Araujo RL, et al. Remnant growth rate after portal vein embolization is a good early predictor of post-hepatectomy liver failure. *J Am Coll Surg* 2014;620–30). This translates to a 40% to 62% increase in FLR expressed as percentage increase from baseline FLR. I have used this technique and it is helpful, or least I think it is in some settings. Surprisingly PVE is tolerated very well by the patient.

The second consideration is hepatic steatosis. Fatty infiltration of the liver resulting in steatosis may impact outcomes of partial hepatic resection as it is

thought to interfere with hepatic regeneration. Kooby et al. (Impact of steatosis on perioperative outcome following hepatic resection. *J Gastrointest Surg* 2003;7:1034–44) showed that marked steatosis is an independent predictor of complications following hepatic resection but does not have a significant impact on 60-day mortality. They concluded that "steatosis alone should not preclude aggressive hepatic resection for neoplasms when indicated; however, patients with marked steatosis undergoing large resections should still be approached with due caution." A case matched study by McCormac et al. (Hepatic steatosis is a risk factor for postoperative complications after major hepatectomy: a matched case-control study. *Ann Surg* 2007;245:923–30) reported that "liver steatosis, regardless of the presence of is the most significant preoperative risk factor for postoperative complications after major liver resection."… and…"concomitant cholestasis in patients with underlying liver steatosis should alert surgeons for the high risk of postoperative mortality."

The final consideration is the role of laparoscopy in resection of primary and metastatic liver tumors. A Medline search done 3–28–17 returned over 2,900 citations (1,376 in the last 5 years and 2,994 in the last 10 years) on this topic. A complete discussion is beyond the scope of this commentary. However, I think it is safe to state the techniques have evolved substantially over past decade and the approach has been met with stepwise improvement and success. Certainly better understandings of liver segmental anatomy as well as technologic advances have contributed to the successful implementation of this modality. In initially recommended for solitary tumors <5 cm, preferably located in the left lateral segments 2 to 3 or in the anterior right-lobe liver segments 5 to 6. More recently the results of an international, multicenter expanded the application to laparoscopic major hepatectomy. Dagher I et al. (Laparoscopic major hepatectomy: an evolution in standard of care. *Ann Surg* 2009;250:856–60) reported results in 210 patients from six centers (three in Europe, two in the United States, one in Australia). There were 136 right and 74 left laparoscopic hepatectomies, with 54% of cases for malignancy. The results were comparable to open resection. Obviously special training in necessary to gain the experience needed to perform these advanced cases safely. Clearly this approach will gain more momentum in the next 5 years.

E. Christopher Ellison

108 Treatment of Major Hepatic Trauma

Donald D. Trunkey

Prior to 1965, the morality from liver injuries that were diagnosed and operated on was very high (Table 108.1). When the operation was done, treatment consisted of sutures and packs, and some surgeons advocated routine drainage. The cautery was very controversial and continued to be controversial until World War II. Based on the work by Madding and Kennedy, treatment changed during World War II, and resection became part of the surgeon's armamentarium. This led to a remarkable reduction in overall mortality. After shifting to this management, 829 wounds to the liver were seen in an 18-month period, and of these patients, 53 died.

The year 1965 was pivotal with the introduction of diagnostic peritoneal lavage. Previously undiagnosed liver injuries were now possible to diagnose. The great majority of these were grade I to III liver injuries, and, thus, it can be appreciated that surgeons had been doing nonoperative management of liver injuries for years; they just didn't know it. evidence for this is present in at least three papers. in a study from canada, 35% of patients lacked any clinical signs of blunt abdominal trauma with injuries to the spleen or liver. similarly, a study from Michigan showed that out of 87 patients subsequently diagnosed by autopsy, 45% had undiagnosed liver injuries. This was affirmed by a study published in the *Surgical Clinics of North America* in 1972.

TABLE 108.1 Mortality in Rupture of Liver, 1872 to 1961

Author	Year	No. of Cases	Mortality (%)
Mayer	1872	135	88
Tilton	1904	25	44
Pringle	1908	2	100
Riebel	1910	44	44
Thöle	1912	260	64
Andersson	1926	24	76
Krieg	1936	60	74
Lamb	1939	60	44
Castren	1946	245	56
Papen	1950	40	64
Wright	1947	32	61
Melnikov	1956	51	24
Hellström	1961	300	37

One of the problems with diagnostic peritoneal lavage and better diagnosis of liver injuries is that in 30% of patients this leads to a nontherapeutic celiotomy. The year 1981 turned out to be another pivotal year with the introduction of computed tomography (CT) scanning to make the diagnosis of intra-abdominal solid organ injury. With this diagnostic modality, it was now possible for the surgeon not only to make the diagnosis, but also to make a rational decision as to whether the patient needed operation based on the degree of injury and hemodynamic stability. More recent studies now show that most patients with grade I and II injuries can be managed nonoperatively, and patients with grade III, IV, and V injuries will require operation in 50% to 75% of the cases (Algorithms 108.1 and 108.2; Figs. 108.1 and 108.2).

Since World War II, there have been two significant events that have changed the approach to major hepatic trauma: pioneering work in the anatomy of the liver and new operative techniques for elective hepatic resection. We now have a better understanding of segmental anatomy, which has allowed segmental resection, and this has led to a marked increase in elective resection of tumors and obstruction of the porta hepatis. The second factor influencing liver surgery has been liver transplant operations, which has furthered our understanding of the anatomy and has particularly influenced surgeons in their ability to perform hepatic isolation procedures.

ANATOMY

Repair and resection for treatment of hepatic trauma demand a working knowledge of the anatomy of the liver. The segmental approach to liver anatomy that is presented here is valuable for the surgeon for prediction of the locations of vascular structures within the liver substance. Whereas small segmental resections are feasible in elective surgery, liver resection for trauma is almost exclusively restricted to nonanatomic debridement of nonviable liver tissue, left lateral segmentectomy, and formal right or left hepatic lobectomy.

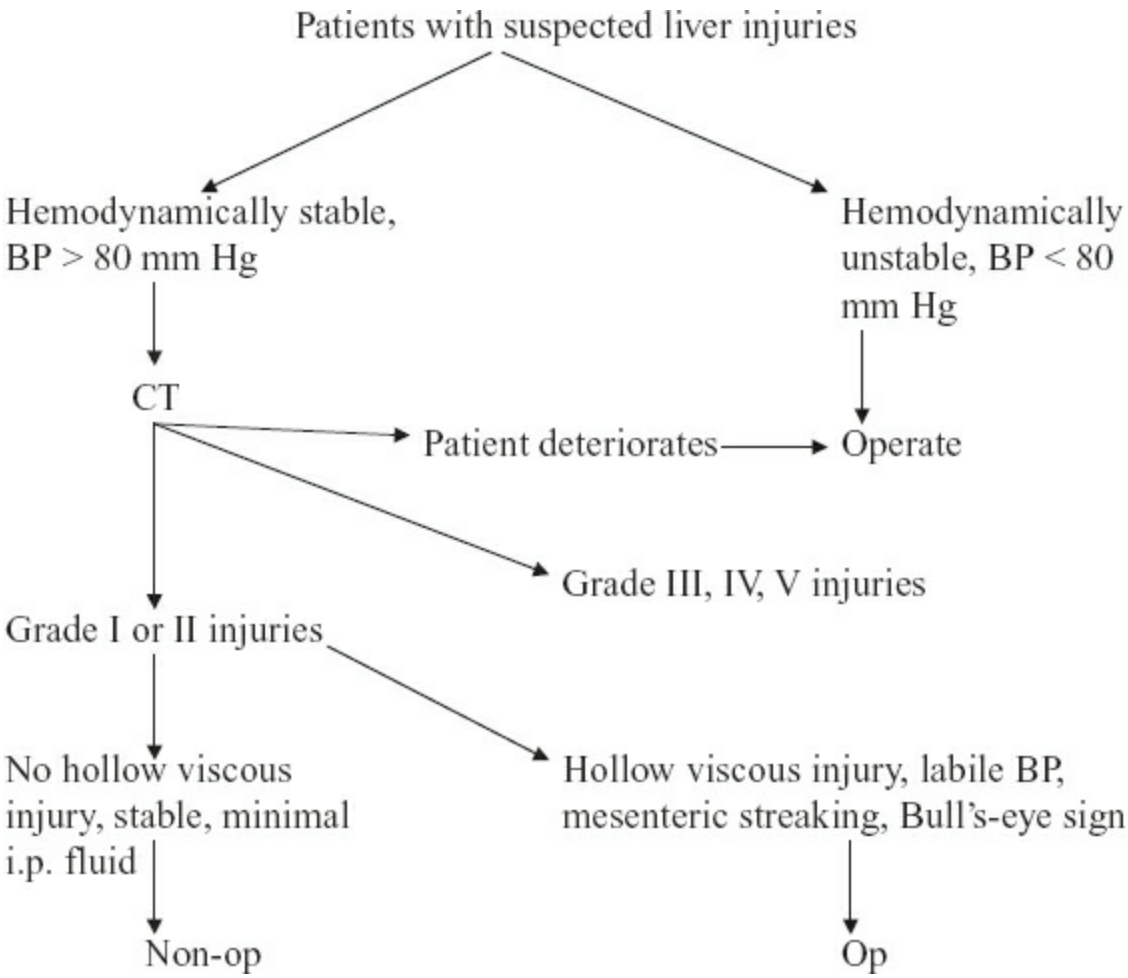

Algorithm 108.1. Algorithm for evaluating patients with suspected liver injuries. BP, blood pressure; CT, computed tomography.

The liver has three major surfaces: superior, inferior, and posterior. The superior and posterior surfaces rest against the diaphragm; however, the inferior surface is more complex, containing the gallbladder, hepatic ducts, hepatic arteries, and portal veins (Fig. 108.3). The liver is attached to

surrounding structures by ligaments, the reflection of the parietal peritoneum (Fig. 108.4). The coronary ligament is formed along the superior surface of the right lobe and secures the liver to the diaphragm posteriorly and superiorly. The two leaves of the coronary ligament join at the extreme left to form the triangular ligament. The falciform ligament and ligamentum teres (obliterated umbilical vein) provide anterior attachment of the midportion of the liver to the anterior abdominal wall.

Morphologically, the liver is described as two main (right and left) and two accessory (quadrate and caudate) lobes. The right and left lobes are divided by the major fissure, with the right being larger. The quadrate lobe is the portion of the right lobe that lies anterior to the transverse hilar fissure, medial to the gallbladder fossa, and lateral to the umbilical fissure. The caudate lobe lies posterior to the transverse liver fissure.

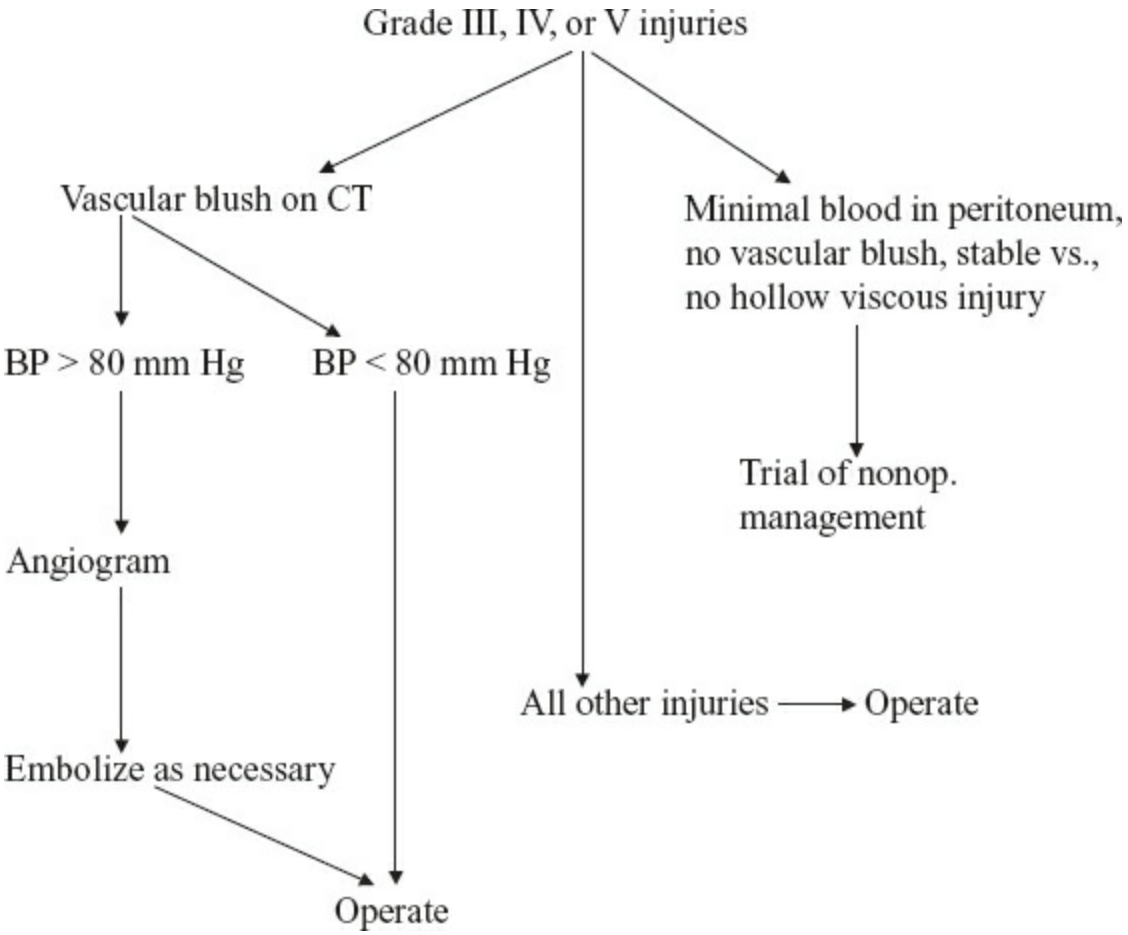

Algorithm 108.2. Algorithm for evaluating patients with grade III, IV, or V injuries. BP, blood pressure; CT, computed tomography.

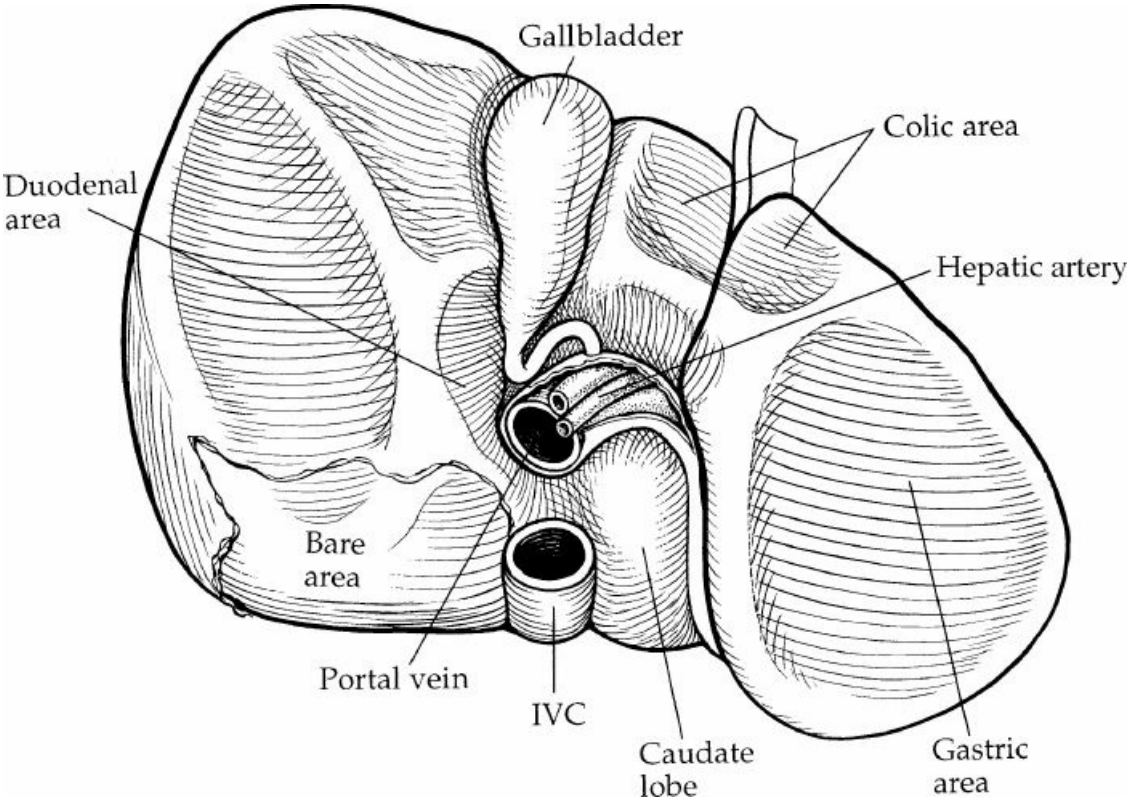

Figure 108.1. Anatomy of the inferior surface of the liver. IVC, inferior vena cava.

Surgical treatment of traumatic injuries relies on a functional anatomic description of the liver. Segmental and anatomic resection has been well documented by Bismuth using an anatomic description from Couinaud. Hepatic segmentation based on the distribution of the portal pedicle and location of hepatic veins defines the functional anatomy (Figs. 108.3 and 108.4). The three main hepatic veins (i.e., the right, left, and middle) divide the liver into four sections: right posterior lateral, right anterior medial, left anterior, and posterior. Each of these sectors receives a portal pedicle. Sectors of the right liver are further divided into two segments each, the anterior medial sector (segment IV anteriorly and segment VIII posteriorly) and the posterior lateral sector (segment VI anteriorly and segment VII posteriorly). The left anterior sector is divided by the umbilical fissure into segment IV (the anterior portion of the quadrate lobe) and segment III (the anterior portion of the left lobe of the liver). The posterior sector is composed of only one segment (II) and lies in the posterior portion of the left lobe. The caudate lobe is considered independently as segment I.

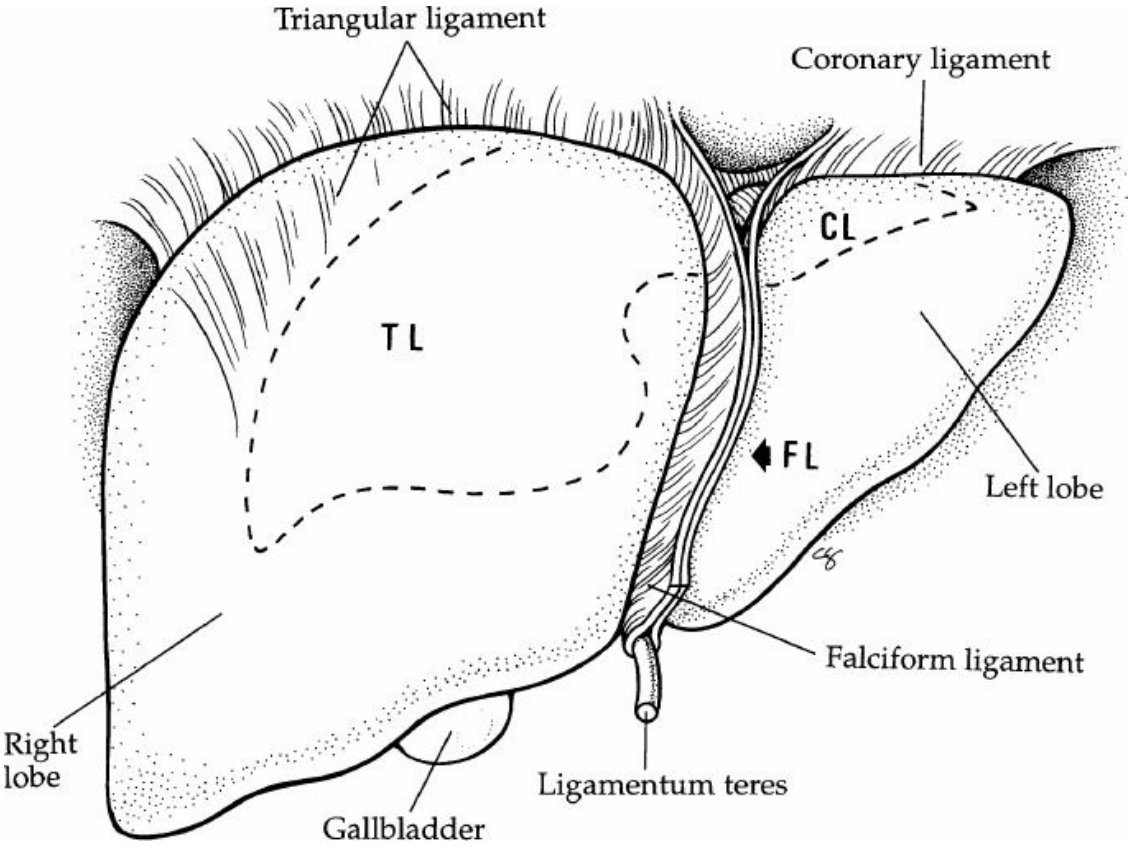

Figure 108.2. Superficial anatomy of the liver showing the ligaments. CL, coronary ligament; FL, falciform ligament; TL, triangular ligament.

The hepatic artery supplies 25% of the blood flow to the liver and 50% of the oxygen. In 55% of cases, the hepatic artery supply is exclusive from the celiac trunk (Fig. 108.5). The common hepatic artery is the contribution of the celiac trunk after the left gastric and splenic arterial branches. The common hepatic artery traverses along the upper border of the head of the pancreas, and then it turns to ascend in the lesser omentum. It lies to the left of the common bile duct and anterior to the portal vein. The gastroduodenal artery arises from the distal horizontal position of the common hepatic artery. The right gastric artery arises from the proper hepatic (40% of cases) or left hepatic artery (40% of cases).

The hepatic artery bifurcates in the porta hepatis to give rise to the right and left hepatic arteries. The right hepatic artery courses to the right behind the common bile duct. The anterior and posterior segmental arteries of the right lobe take separate origin from the right hepatic artery. The anterior segmental branch courses along the gallbladder fossa in close proximity to the cystic duct. The left hepatic artery runs upward obliquely to the left and divides into its two terminal branches—the medial and

lateral segmental arteries. The medial segmental artery descends into the quadrate lobe (segment IV). The lateral segmental artery travels obliquely toward the upper, outer aspect of the lateral segment, where it divides into the superior and inferior branches. The blood supply to the caudate lobe (segment I) is variable. In approximately 35% of cases, the entire blood supply of the caudate lobe comes from the right hepatic artery, and in 12%, it comes entirely from the left hepatic artery. In the majority, however, the blood supply is from both. Aberrant hepatic arteries occur frequently in 40% to 50% of cases. The most frequent anomaly is the left hepatic artery, which arises from the gastric artery (25% to 30%) (fig. 108.6A,B). This includes a 10% incidence of a totally replaced left hepatic artery and a 15% incidence of an accessory left hepatic artery. The right hepatic artery originates from the superior mesenteric artery in 17% of cases: 10% total replacement and 7% accessory (fig. 108.6C,D). The middle hepatic artery arises from the left or right hepatic artery with equal frequency. The cystic artery is usually a branch of the right hepatic artery. It reaches the gallbladder behind the common hepatic duct after traversing the hepatic triangle to the right of the common hepatic duct. In 85% to 90% of cases, there is a single cystic artery.

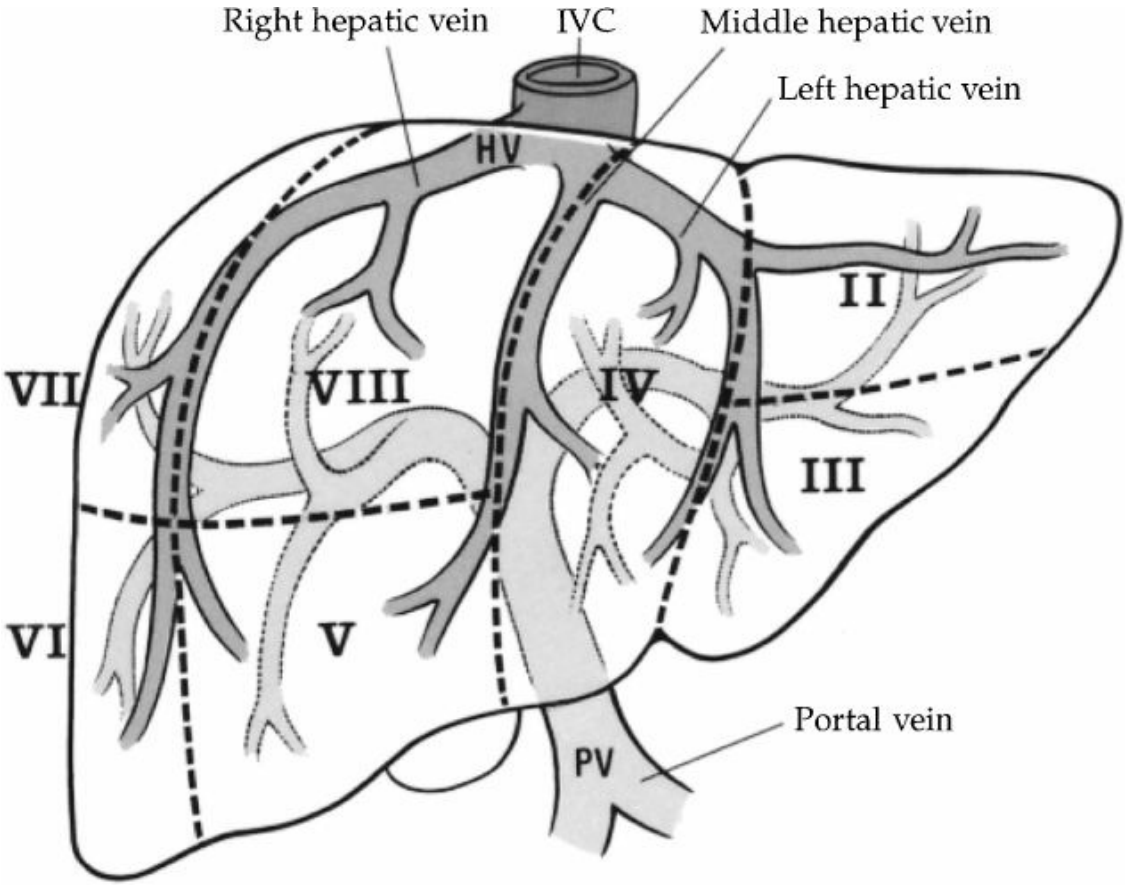

Figure 108.3. An anterior view of segmental anatomy. HV, hepatic vein; IVC, inferior vena cava; PV, portal vein.

The portal vein carries 75% of the blood flow to the liver and 50% of the oxygen. The portal vein is formed by the confluence of the superior mesenteric vein and the splenic vein behind the neck of the pancreas. Approaching the liver within the porta hepatis, the portal vein lies anterior to the inferior vena cava and to the left of the common bile duct and the hepatic artery. The portal vein is 7 to 10 cm in length and bifurcates into the left and right portal veins. The portal lobar veins lie posterior to the hepatic veins and bile ducts. The right portal vein is short and divides into anterior and posterior segmental vessels. Each of these segmental vessels further divides into inferior and superior subsegmental branches. The right portal vein sends a branch to the right side of the caudate lobe (segment I).

The left portal vein is longer than the right and courses to the left in the hilar plate from the bifurcation. It then turns inferiorly in the liver at the umbilical fossa. The superior and inferior subsegmental veins of the lateral segment (segments II and III) arise from the left side of the umbilical portion of the left portal vein. The medial segmental veins rise from the right side of the umbilical portion of the left portal vein. This fact is of importance when performing a left lateral segmentectomy (segments II and III), as the umbilical portion of the left portal vein should be left intact.

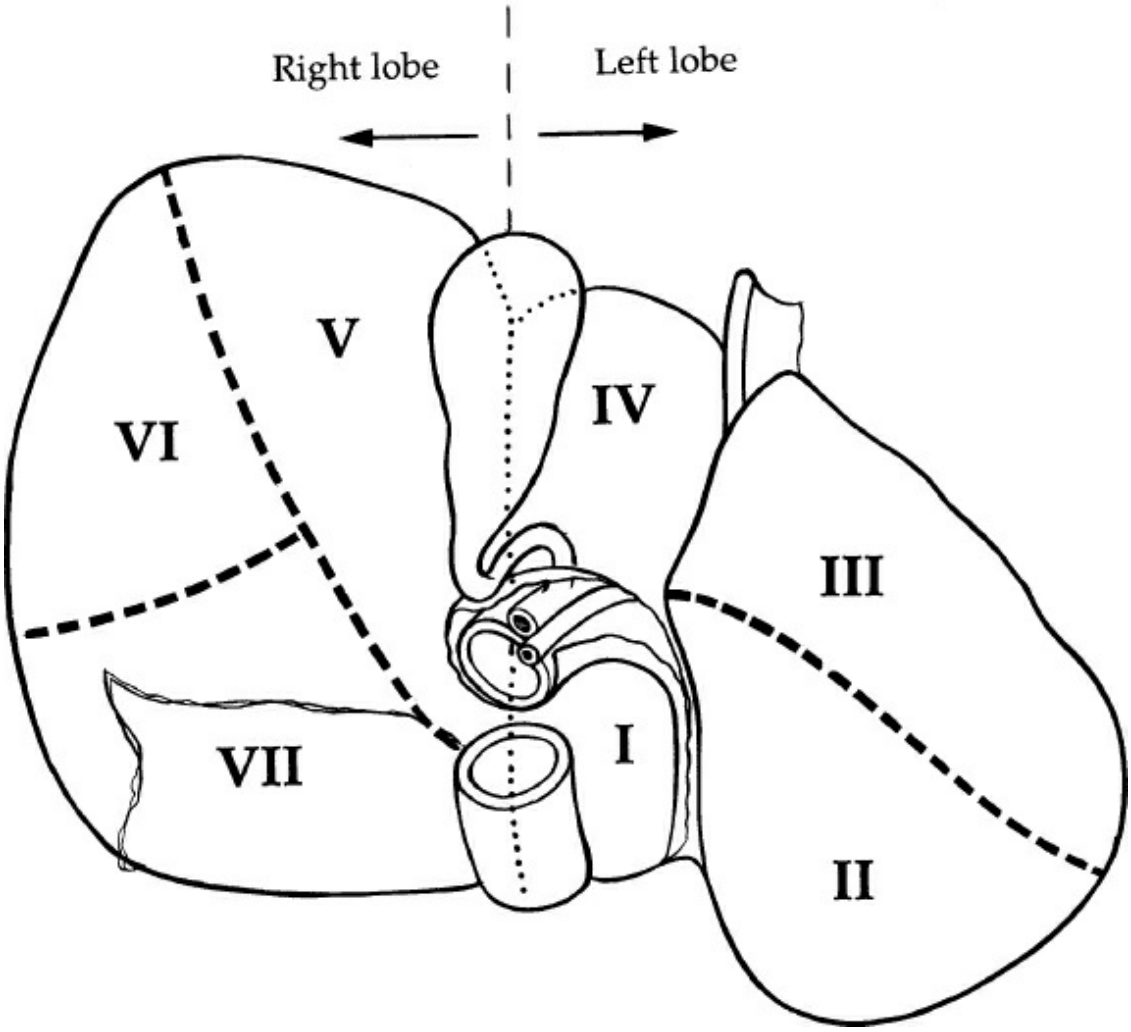

Figure 108.4. Segmental anatomy viewed from the inferior surface.

Venous drainage of the liver is quite simple. The hepatic veins lie in the planes dividing the segments of the liver. There are three major veins: right, middle, and left. The right hepatic vein is the largest and drains the anterior and posterior portions of the right lobe of the liver (segments VI, VII, and VIII). The middle and left hepatic veins frequently enter the inferior vena cava as a single trunk. The middle hepatic vein drains the superior aspect of the anterior segment of the right lobe (segment V). The left hepatic vein drains the superior aspect of the medial and lateral segments of the left lobe (segments II, III, and IV). The caudate lobe (segment I) usually drains directly into the inferior vena cava via multiple small branches.

The biliary drainage of the liver follows a segmental and lobar pattern and shares a common pathway with the blood supply (portal triad). The right hepatic duct is formed by the joining of the anterior and posterior

segmental ducts of the porta hepatis. In 30% of cases, one of the two ducts, usually the posterior, crosses the segmental fissure to drain in the left hepatic duct. The left hepatic duct is formed by the confluence of the medial and lateral segmental ducts. This duct is in the left segmental fissure in 50% of cases and to the right of the fissure in 42%. In the caudate lobe (segment I), drainage is variable and may flow into either the left or right duct. The common hepatic duct is formed by the confluence of the right and left hepatic ducts in the transverse fissure of the liver. Its distal end is defined by the junction of the cystic duct and may range from 1.0 to 7.5 cm in length. The normal diameter is 4 mm. The common bile duct is a continuation of the common hepatic duct, distal to the cystic duct. It ranges in length from 2 to 7 cm. It has a consistent course and is divided into four portions: supraduodenal, retroduodenal, pancreatic, and intramural. The supraduodenal lies between layers of the hepatic duodenal ligament, anterior to the foramen of Winslow. The retroduodenal portion is between the superior margin of the first portion of the duodenum and the superior edge of the pancreas. The gastroduodenal artery lies to the left, and the posterosuperior pancreatic duodenal artery lies anterior to the bile duct. The pancreatic portion of the common bile duct passes from the upper margin of the head of the pancreas obliquely to the right posterior portion of the pancreas to its entrance into the duodenum. The intramural portion of the common bile duct travels an oblique path approximately 1.5 cm long through the duodenal wall. It joins with the main pancreatic duct inferiorly.

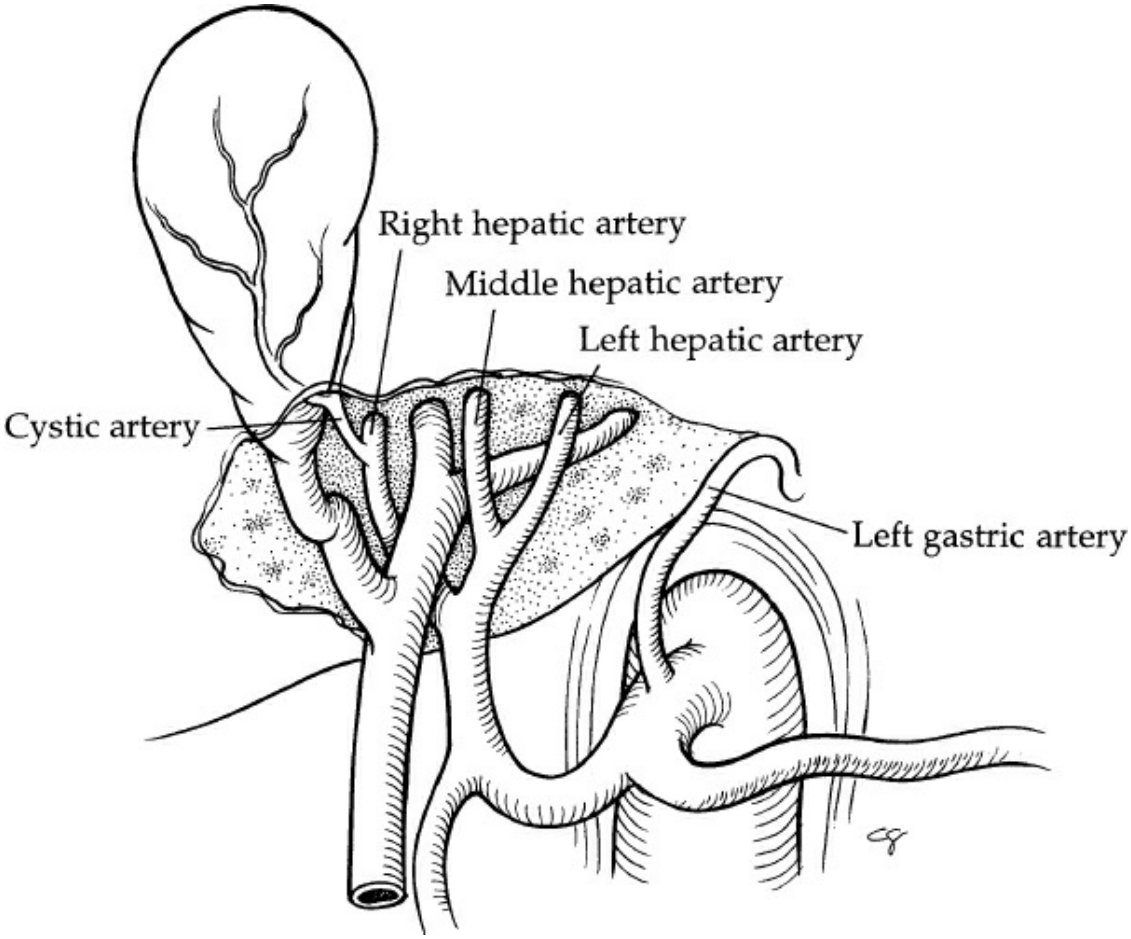

Figure 108.5. The most common hepatic artery configuration.

The dissection of the hilar plate from the liver parenchyma was first described by Couinaud in 1957. Cholecystectomy before the incision of the peritoneal reflection and Glisson capsule aids the surgeon in entering the transverse fissure or porta hepatis. After the cholecystectomy, an incision is made at the junction of the peritoneal reflection of the porta hepatis to the Glisson capsule anteriorly in a U-shaped fashion directed toward the bifurcation of the left and right portal system and then moving toward the falciform ligament. By gently retracting the porta hepatis medially and lifting upward, a second incision in the peritoneal reflection is carried across from the gallbladder fossa over the superior margin of the caudate process. Using blunt dissection, the right porta hepatis can be encircled. After division of the gastrohepatic ligament in the bare area, the left porta hepatis can be encircled. Access to the retrohepatic cava requires lifting the right lobe anteriorly and medially after all of the ligamentous attachments have been taken down from the diaphragm. As the posterior peritoneum reflects up on to the cava, it is incised sharply with the scissors or electrocautery unit and carried cephalad toward the right hepatic vein,

and the surgeon should take care not to injure the cava or the venous branches from the caudate lobe.

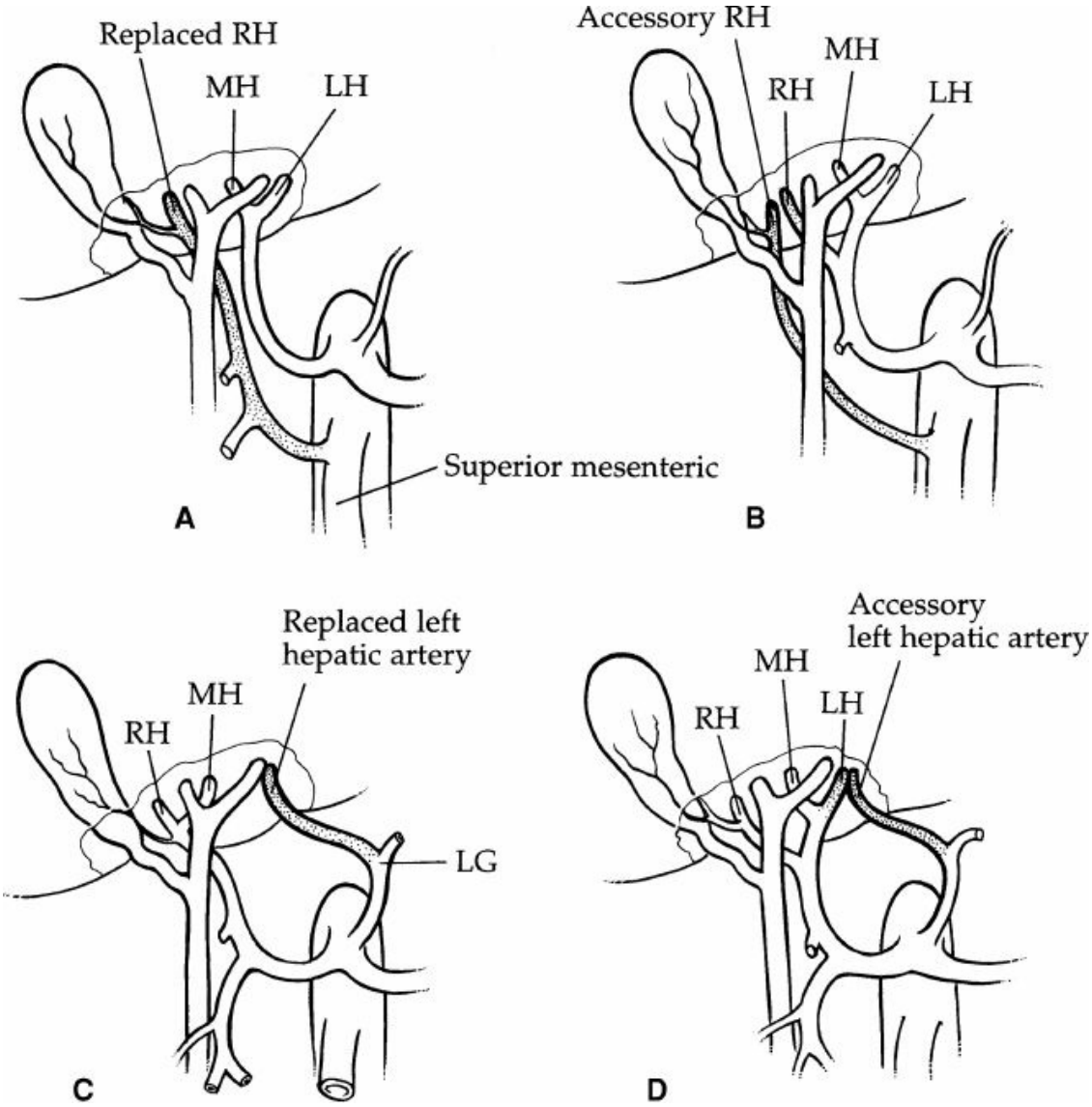

Figure 108.6. Various anomalies of the hepatic artery circulation. **A.** Replaced right hepatic (RH) artery off superior mesenteric artery. **B.** Accessory RH artery. **C.** Replaced left hepatic (LH) artery. **D.** Accessory LH artery. LG, left gastric; MH, middle hepatic.

PATHOPHYSIOLOGY

In general, the amount of damage caused by penetrating missiles to the liver is determined by the kinetic energy. This kinetic energy is a reflection of the mass of the missile, the differential of the velocity of the missile as it enters the tissue, and the velocity of the missile as it exits the tissue. In the 1990s, trauma centers saw an increasing number of medium-velocity

injuries. Typically, these are caused by large-caliber semiautomatic and automatic weapons. More extensive injuries are seen after a shotgun blast and occasional assault rifle injuries.

Blunt trauma typically results from direct compressive forces or shear forces. The elastic tissues within arterial blood vessels make them less susceptible to tearing than any other structure within the liver. Venous and biliary ductal tissue is moderately resistant to shear forces; the liver parenchyma is the least resistant of all. Thus, fractures within the liver parenchyma tend to occur along segmental fissures or directly into the parenchyma, causing shearing of lateral branches of the major hepatic vein and portal veins. With severe deceleration injury, the origins of the hepatic veins may be ripped from the cava, causing devastating hemorrhage. Similarly, the small branches from the caudate lobe entering directly into the cava are at high risk for shear, and thus a linear tear appears on the anterior caval surface. Direct compressive forces usually cause tearing between segmental fissures in an anteroposterior sagittal orientation. Horizontal fracture lines into the parenchyma give the characteristic burst pattern to such liver injuries. These usually underlie the ribs and costal cartilage. Fracture lines that are parallel have been dubbed *bear claw–type* injuries. Occasionally, there will be a single fracture line across the horizontal plane of the liver, usually between the anterior and posterior segments. Because this fracture line involves both lobes of the liver, it can cause significant hemorrhage if there is direct extension or continuity with the peritoneal cavity.

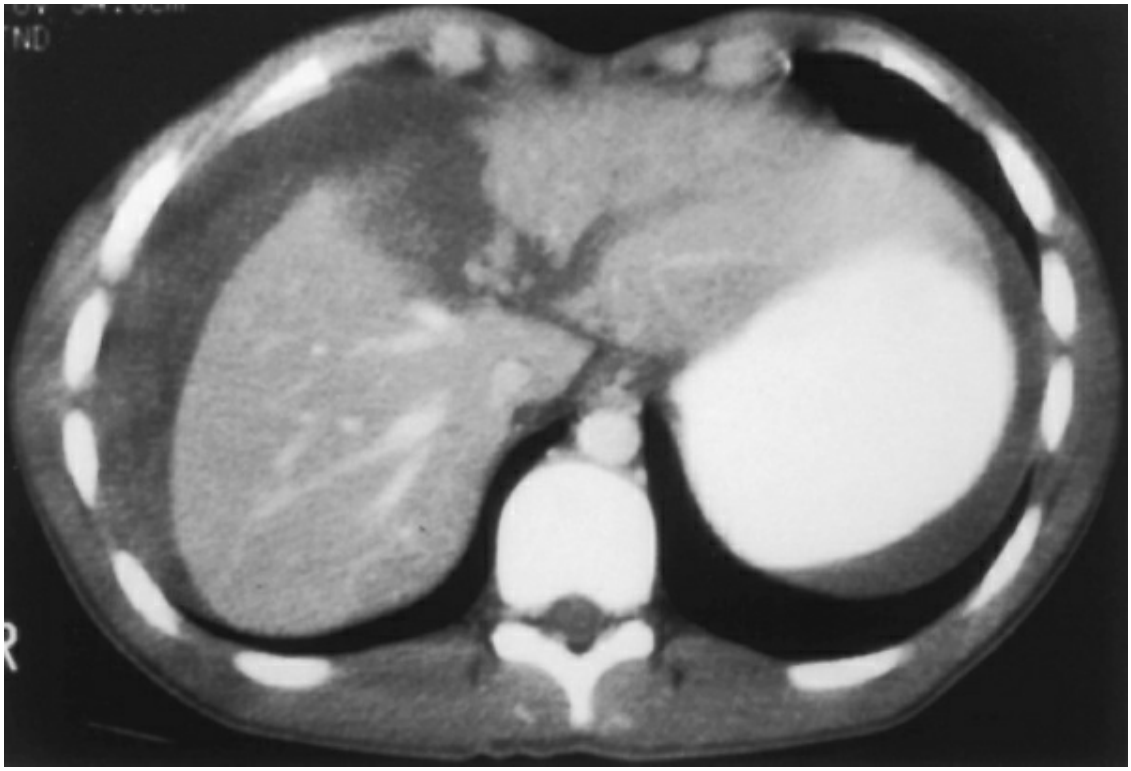

Figure 108.7. This 19-year-old patient was wearing three-point restraints when involved in a high-speed motor vehicle accident. The chest portion of the restraint has caused almost complete transection of the liver in its anatomic plane. A left hepatic lobectomy was performed.

Knowing the mechanism of injury articulated by the paramedics allows the surgeon to anticipate certain patterns of injury. Compressive forces caused by the steering wheel or the shoulder belt of a three-point restraint system can result in extensive bear claw–type injuries to the liver and even transections of the liver (Fig. 108.7). Another example is the so-called T-bone auto crash, which is a crash of two vehicles in a perpendicular fashion. Extensive injury can occur to the liver, usually when the T-bone is into the passenger side, which causes extensive right lateral rib fractures and compression of the right lobe of the liver. An extreme form of this lateral compressive injury is a transverse fracture through both lobes of the liver (Fig. 108.8). Shear injuries are usually associated with deceleration from falls (from a distance greater than two floors) or unrestrained occupants in high-speed motor vehicle accidents. The abrupt deceleration tends to tear the “relatively” heavy liver from its attachments, such as hepatic veins, veins from the caudate lobe, and lacerations into parenchyma at the ligamentum teres, which are often associated with exsanguinating hemorrhage.

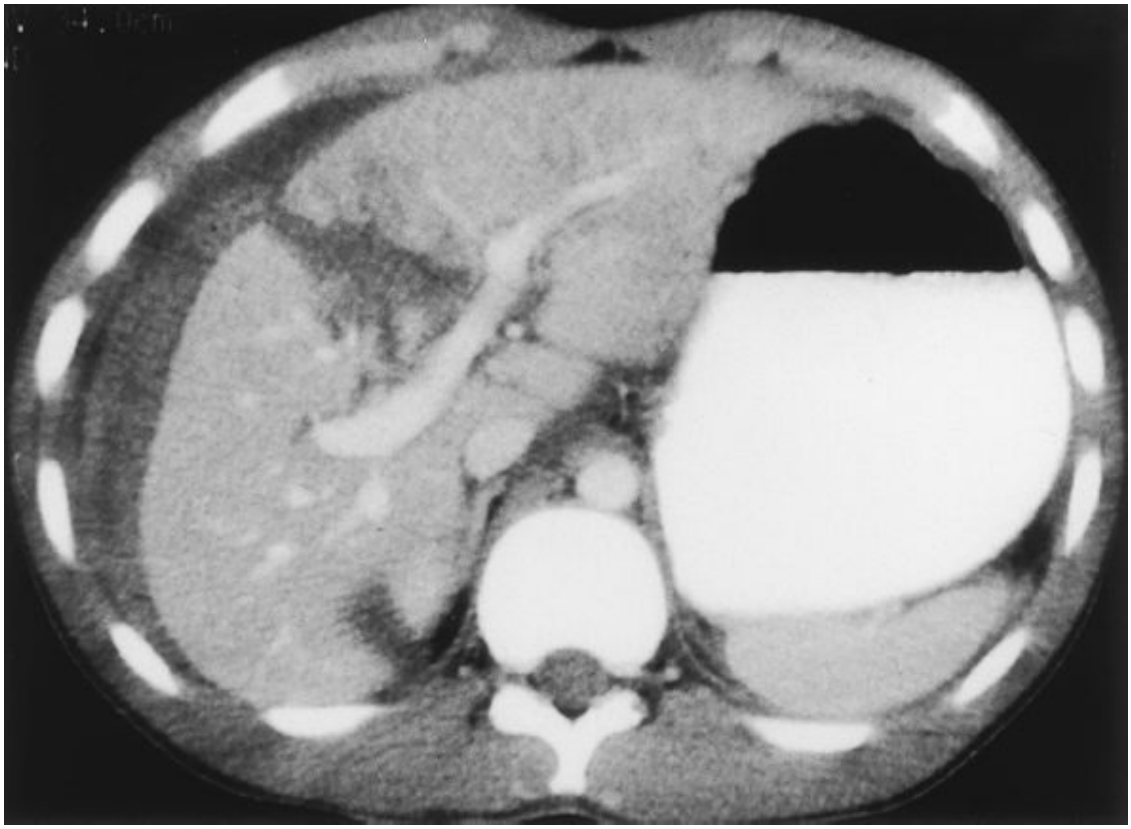

Figure 108.8. This 25-year-old patient was involved in a “T-bone” motor vehicle accident. He has extensive transverse lacerations across both lobes of the liver. The patient was managed nonoperatively.

DIAGNOSIS

The liver is at a high risk for injury from penetrating wounds, because it is the largest parenchymatous organ and its anatomic location is at the junction of the upper one third and middle one third of the torso. Major hepatic trauma is usually associated with medium- and high-velocity wounds. Occasionally, major vessel injury (usually involving the hepatic vein) can be caused by stab wounds, and I have seen several made with large knives, such as bayonets or bowie-type weapons. If a patient with a penetrating wound to the torso, particularly the midportion, is in a hemodynamically unstable condition, he or she requires no diagnostic studies except a chest radiograph, which may help the surgeon decide which torso cavity to open first. If one of the hemithoraces is full of blood, as determined by chest radiograph, it may be prudent to open that cavity first. The pitfall is that a hole in the diaphragm with injury to the left or right lobe of the liver can be the source of exsanguination. This possibility makes the point that the trauma patient should never be in any other

position than the supine one. The surgeon must be prepared to deal with exsanguination on both sides of the diaphragm. Rarely, a patient with major hepatic trauma can present in a hemodynamically stable condition from penetrating wounds. If there is a high index of suspicion of penetration into the abdominal cavity or if peritoneal signs are present, exploratory celiotomy is indicated. If in doubt, the surgeon can use diagnostic peritoneal lavage or ultrasound as a diagnostic adjunct to confirm that intraperitoneal blood is present. It must be emphasized that in the hemodynamically unstable patient with penetrating wounds to the torso there is no diagnostic challenge. The patient requires immediate surgery.

From a diagnostic standpoint, major hepatic injury from blunt trauma can be more vexing than trauma from penetrating wounds, particularly in the young healthy adult who can compensate for significant blood loss. Physical examination, even in an alert patient, is accurate in only one half of cases and carries a 56% false-positive rate and a 34% to 46% false-negative rate. The introduction of diagnostic peritoneal lavage in 1965 dramatically improved the surgeon's ability to diagnose intra-abdominal injury. It is rapidly performed and highly sensitive. More recently, the CT scan has been shown to be an even more valuable diagnostic tool, because it allows the surgeon to make judgments as to whether the patient requires operative intervention. The CT scan is valuable for even extensive liver lacerations. If these lacerations are contained and there is minimal blood into the peritoneal cavity, it may be more prudent to treat the patient nonoperatively.

Ultrasound has also been advocated as a diagnostic adjunct. It has an 85% to 90% sensitivity in picking up intraperitoneal blood, but it does not meet the high-resolution standards of CT. Because of its relative simplicity and low cost, it has been advocated as a useful technique. Intraoperative ultrasound has been found to be useful in elective surgery for patients who require resection for hepatic tumors. The ultrasound can identify metastatic lesions, and it has been useful in mapping out the venous anatomy for living-related hepatic transplant donors. I have not found it that useful during surgery for liver trauma.

The American Association for the Surgery of Trauma has developed a grading of organ injuries, including the liver. This classification is depicted in Table 108.2. Studies have confirmed the utility of this classification, and it has a good correlation with operative management. It must be emphasized that anatomic grading does not necessarily correlate with the

physiology of the patient and, in particular, hemodynamic stability.

TABLE 108.2 Grading of Liver Injuries

Grade	Injury Description
I	
Hematoma	Subcapsular, nonexpanding, <10% surface area
Laceration	Capsular tear, nonbleeding, <1 cm deep parenchymal disruption
II	
Hematoma	Subcapsular, nonexpanding, hematoma 10–50%; intraparenchymal, nonexpanding, <2 cm in diameter
Laceration	<3 cm parenchymal depth, <10 cm in length
III	
Hematoma	Subcapsular, >50% of surface area or expanding; ruptured subcapsular hematoma with active bleeding; intraparenchymal hematoma >2 cm
Laceration	>3 cm parenchymal depth
IV	
Hematoma	Ruptured central hematoma
Laceration	Parenchymal destruction involving 25–75% of hepatic lobe
V	
Laceration	Parenchymal destruction of >75% of hepatic lobe
Vascular	Juxtahepatic venous injuries (retrohepatic cava/major hepatic veins)
VI	
Vascular	Hepatic avulsion

From Moore EE, Shackford SR, Pachter HL, et al. Organ injury scaling: spleen, liver, and kidney. *J Trauma* 1989;29:1664, with permission.

NONOPERATIVE MANAGEMENT

In the past 10 to 15 years, there has been a surge of papers advocating nonoperative management of liver injuries. As noted in the introduction, this was practiced for several years prior to 1965, primarily because we did not make the diagnosis. Since the introduction of CT, we now recognize that a great majority of these previously undiagnosed liver injuries are grades I and II and approximately 50% of the grade III injuries. Concomitant with this interest in nonoperative management is the use of packs as definitive treatment of severe liver injuries. This is not a new concept and was used relatively extensively prior to World War II. Madding and Kennedy's experience with packing early in World War II had similar results with a relatively high complication rate and mortality. They changed to a more aggressive operative approach to liver injuries,

with better results and reduction in both mortality and morbidity. Recent studies also show an increase in liver-related morbidity after packing, and patients who fail this management may succumb to hemorrhage or sepsis. In one multi-institutional study of six institutions over a 5-year period, there were 1,335 patients with liver injuries, of which 210 were grade III, IV, and V injuries. There were 20 of 34 patients treated with packing alone who survived. The overall mortality rates for grade III, IV, and V injuries were 25%, 46%, and 80%, respectively. In another large study by a single institution, 181 patients were identified with grade III, IV, and V injuries, of which 18 were either dead on arrival or died in the emergency department. Of the remaining 163 patients, 47 were treated nonoperatively (28%). Mortality in the 116 patients who had an operation was 32.7%. In another very large series from China, there were 348 patients with grade III, IV, and V injuries, and 74% underwent surgery. The overall operative mortality was 12%. It is apparent that a small number of patients with grade III, IV, or V injuries can be managed nonoperatively or managed definitively with packs. The great majority will require resectional debridement, sutures, hemostatic agents, or lobectomy to control hemorrhage.

INITIAL OPERATIVE APPROACH

The trauma patient who requires celiotomy should be prepared and draped from the midneck to the midthighs anteriorly and from tabletop to tabletop laterally. In a patient in unstable condition, the preparation and draping optimally should be done before the induction of anesthesia, because the administration of a muscle relaxant can lead to a significant drop in blood pressure. The surgeon should be prepared to open the abdomen as soon as possible after the induction of anesthesia.

A generous midline incision is made from the xiphoid to below the umbilicus (Fig. 108.9). Once the abdomen is open and it has been determined that there is a large amount of blood within the peritoneal cavity, this incision should be carried down to the suprapubic area. My initial approach is to evacuate immediately as much clot as possible and then to pack all quadrants of the abdomen. These steps usually temporarily control hemorrhage and allow the anesthesiologist to replace needed volume. The surgeon should make some critical decisions at this juncture. Every effort to keep the patient warm must be made, including turning the thermostat in the operating room up to 85°F. There should be an adequate

blood-warming device, and the humidifier on the ventilator should be turned up to 105°F. It should also be determined at this time whether more access lines to the circulation are needed. If the hospital has a massive transfusion protocol, it should be initiated.

The surgeon should then remove the packs from the lower abdominal quadrants, checking for associated injuries, particularly those that can cause fecal contamination. If no fecal soilage is present, the surgeon can then use autotransfusion devices. The packs in the left upper quadrant are removed, and, if there is associated injury to the spleen, it should be promptly removed to reduce associated hemorrhage while the liver injury is being addressed. Finally, the packs in the right upper quadrant are removed (Fig. 108.10). At this juncture, I usually do a diagnostic maneuver by gently retracting the dome of the liver rostrally. A gush of blood emanating from the central area leads to a presumptive diagnosis of hepatic vein injury. Packs are replaced, and the surgeon must decide what isolation technique should be used. If there are obvious parenchymatous deep lacerations into the liver substance and blood is coming from the depths, another diagnostic maneuver is to apply a vascular clamp across the porta hepatis. If this controls the hemorrhage, it eliminates the portal veins as a source of the major bleeding, and one should presume that it is either hepatic arterial or portal venous bleeding. This presumption may lead to further dissection within the distal porta hepatis to isolate the left and right portal vein and the left and right hepatic artery to selectively control them and to determine which is the source of bleeding.

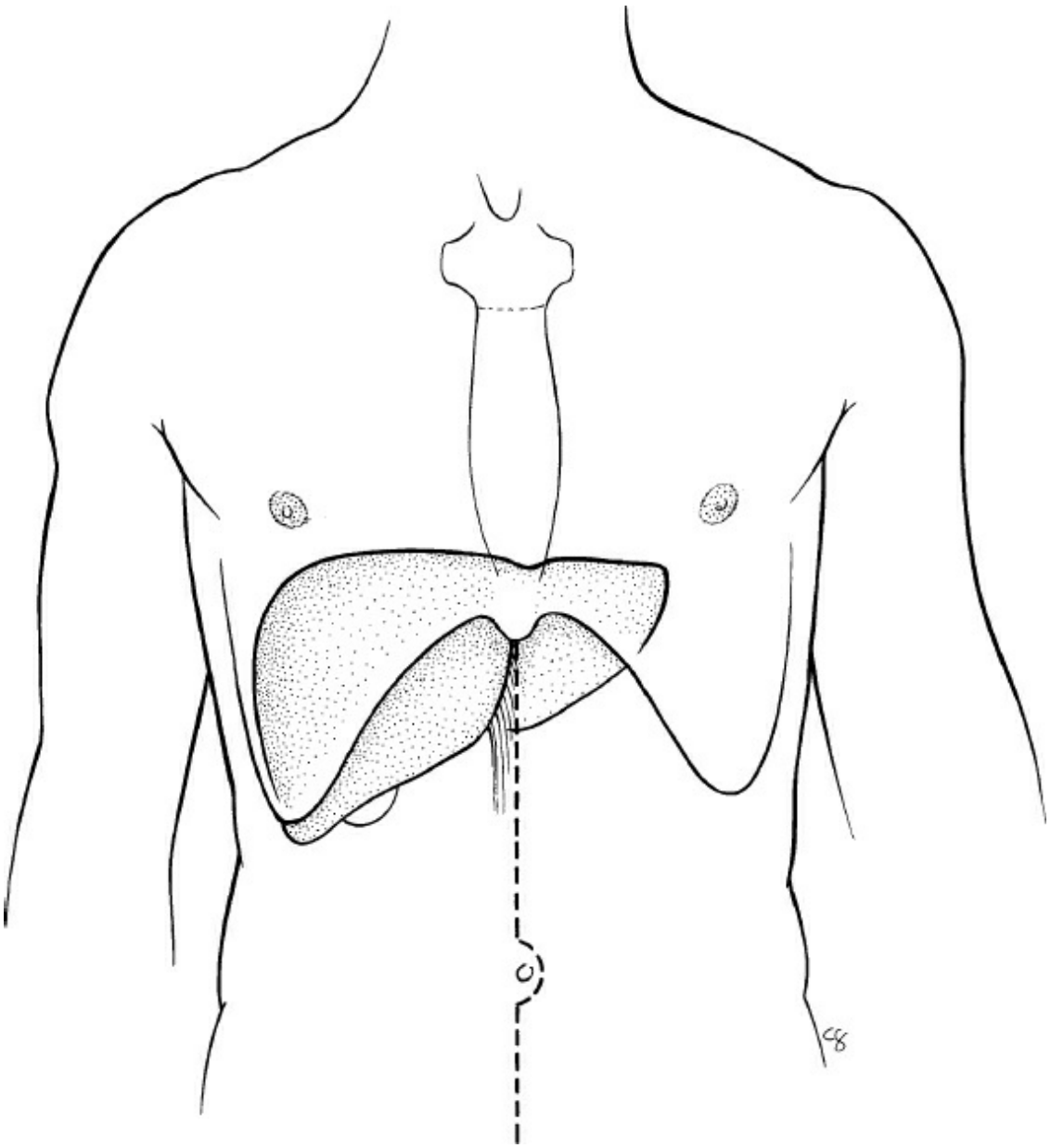

Figure 108.9. An extensive midline incision (*dashed line*) is preferred for all major hepatic injuries, with an option of extending the incision up the sternum.

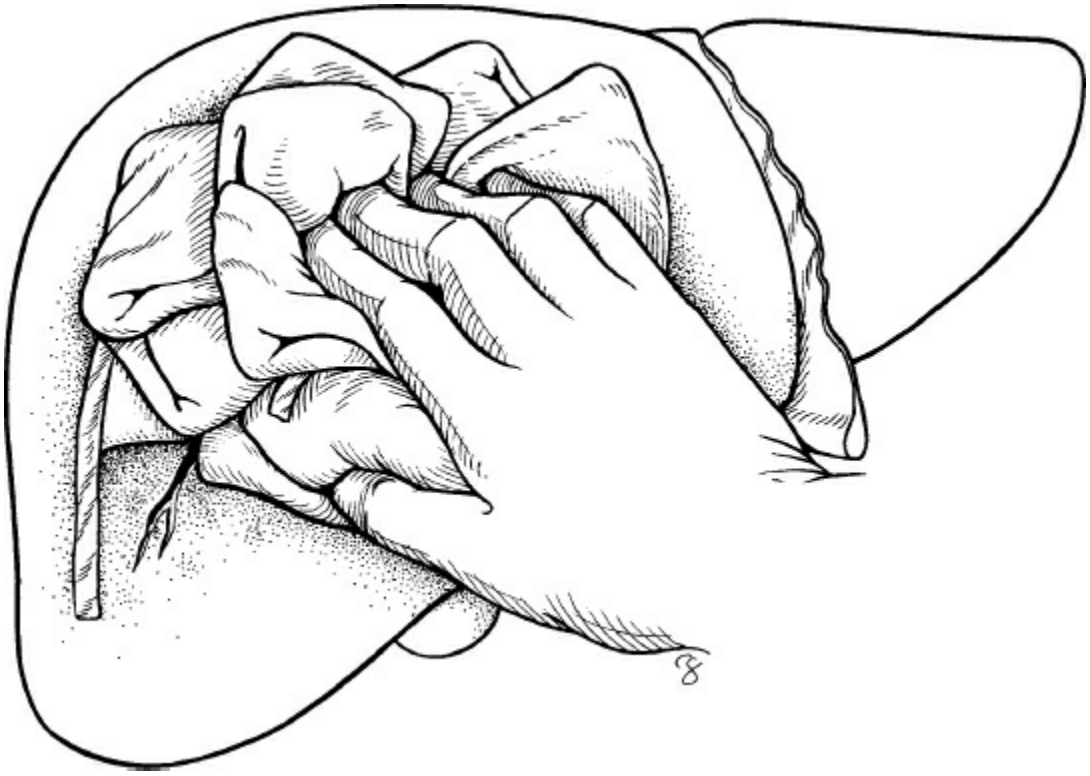

Figure 108.10. Hemostasis of liver fracture. Direct pressure with packs is usually sufficient to control the majority of liver parenchymal bleeding.

Although it has been advocated that a left anterior thoracotomy be done and the descending thoracic aorta clamped, this has not been useful in my experience, and, in fact, it can be harmful. The single exception is the patient with a penetrating gunshot wound to the midline in whom an associated abdominal aortic injury in the lesser sac is suspected. Clamping the descending thoracic aorta to control liver bleeding does not work and simply aggravates the metabolic acidosis and reperfusion injury that ensue when the clamp is removed.

SURGICAL TECHNIQUE

After temporary control of hemorrhage has been achieved by packs or compression, the first priority is to mobilize the liver. This includes sharply dividing the falciform ligament, taking down both leaves of the coronary ligament, and dividing the triangular ligament on the left lobe. If not already performed, the lesser sac should be entered by dividing the avascular area or the gastrohepatic ligament (Fig. 108.11). With these ligamentous attachments divided, the surgeon can mobilize the individual lobes to compress and gain access to the injuries (Table 108.3).

The most common major hepatic injuries that surgeons are called on to treat are deep lacerations into the parenchyma, usually involving the right hepatic lobe or segment IV (quadrate lobe) proximate to the falciform ligament (Fig. 108.12). Controlling the bleeding is best achieved by the assistant who stands on the left side of the patient. He or she can extend the left hand underneath the right lobe and compress the dome or the uninjured part with the right hand. This allows the surgeon to deepen the laceration, using a finger fracture technique and clamping the bleeding vessels and bile ducts. This step is followed by suture ligation of the vessel with 3-0 or 4-0 silk. Although clips have been recommended, I prefer suture ligation because these sutures are less likely to fall off with ventilatory movement of the liver. Deep liver sutures or mattress sutures are rarely indicated for control of hemorrhage, as they can lead to hematobilia, hepatic necrosis, abscess, and hematoma formation within the liver parenchyma. Once hemorrhage has been controlled with suture ligation of the individual vessels, the margins are checked for viability. The use of a viable pedicle of omentum is a useful technique to help with hemostasis and to close the dead space. The omentum also aids wound healing and reduces sepsis. If compression by the assistant is inadequate to control bleeding from the laceration, a vascular clamp can be placed across the porta hepatis (Pringle maneuver) (Fig. 108.13). Once hemostasis is achieved, this clamp should be removed as soon as possible. Although the Pringle maneuver has been used for up to 1 hour in elective hepatic surgery, the safe limit in the hypovolemic trauma patient has not been established. In general, I prefer to limit warm ischemia to 15 minutes but would accept up to 30 minutes.



Figure 108.11. Access to the porta hepatis is achieved by inserting the index finger into the foramen of Winslow and the thumb through the avascular portion of the gastrohepatic ligament.

Resectional debridement is the next most common procedure performed in major hepatic injuries. Resection is not determined by segmental anatomy but by the extent of injury and liver viability. Most often, these injuries are caused by shotgun blasts or large lacerations from blunt trauma that have lateral extensions. The general principles are straightforward. All nonviable liver tissue is resected using a finger fracture technique or the back of the scalpel handle. When resistance is encountered with either technique, this usually indicates the elastic tissue of vessels or biliary ducts. These are doubly clamped, divided, and suture ligated. Nonpulsatile oozing from the parenchyma can be controlled with the electrocautery unit or the argon beam coagulator. Fibrin glue, thrombin-soaked gelfoam, and infrared diathermy are all techniques that have been described to control oozing (Table 108.4). I prefer the electrocautery unit because it is

invariably available.

TABLE 108.3 Contemporary Operative Management

Temporary compression
Tractotomy/suture ligation
Gelfoam, surgicel, thrombin, fibroseal
Omentum
Resectional debridement
Lobectomy
Temporary packs
Embolization

TABLE 108.4 Hemostatic Agents

Dry fibrin sealant
Quickclot
TraumaDex
Chitosan
Rapid deployment hemostat
Surgicel
Gelfoam (thrombin)
Tisseel
TachoComb
Bolheal

If there is any question about the viability of the margins of the tissue after resectional debridement, a second-look operation should be scheduled in 24 to 36 hours. In my opinion, removal of necrotic tissue is mandatory and reduces the incidence of systemic inflammatory response syndrome.

In a few cases (less than 1%), bleeding will continue to vex the surgeon during hepatorrhaphy or resectional debridement. In these instances, it is worthwhile to dissect out the right and left hepatic arteries and portal vein in the porta hepatis.

If application of a vascular clamp to one of these four vessels stops the hemorrhage, it is worthwhile to consider ligating one vessel and one vessel only. Ligating both the portal vein and hepatic artery to one lobe ensures

nonviability. Ligation of the common hepatic artery has been described with maintenance of liver function, because there is adequate collateral through the gastroduodenal artery. Ligation of the proper hepatic artery is contraindicated.

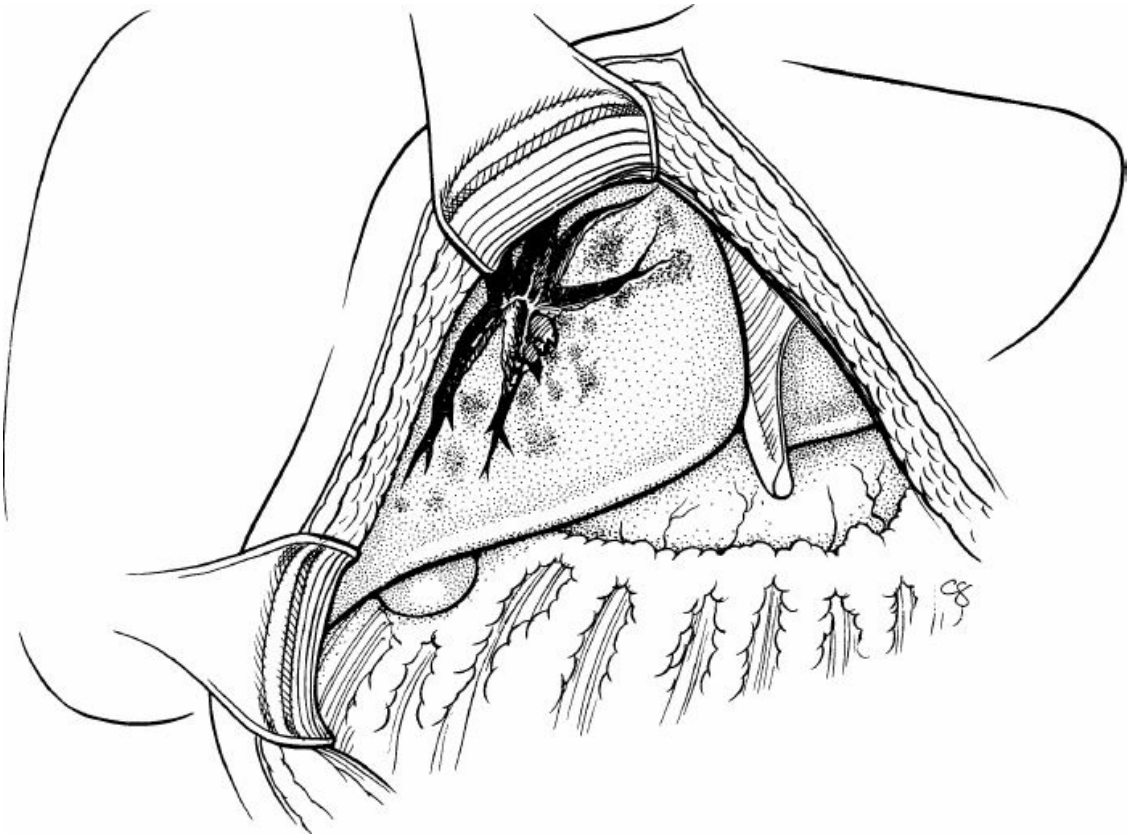

Figure 108.12. An approach to liver fracture. A typical stellate laceration of the right lobe of the liver extending into segment IV is shown. The falciform and triangular ligaments must be incised to mobilize the liver into the midline to control and treat the hemorrhage.

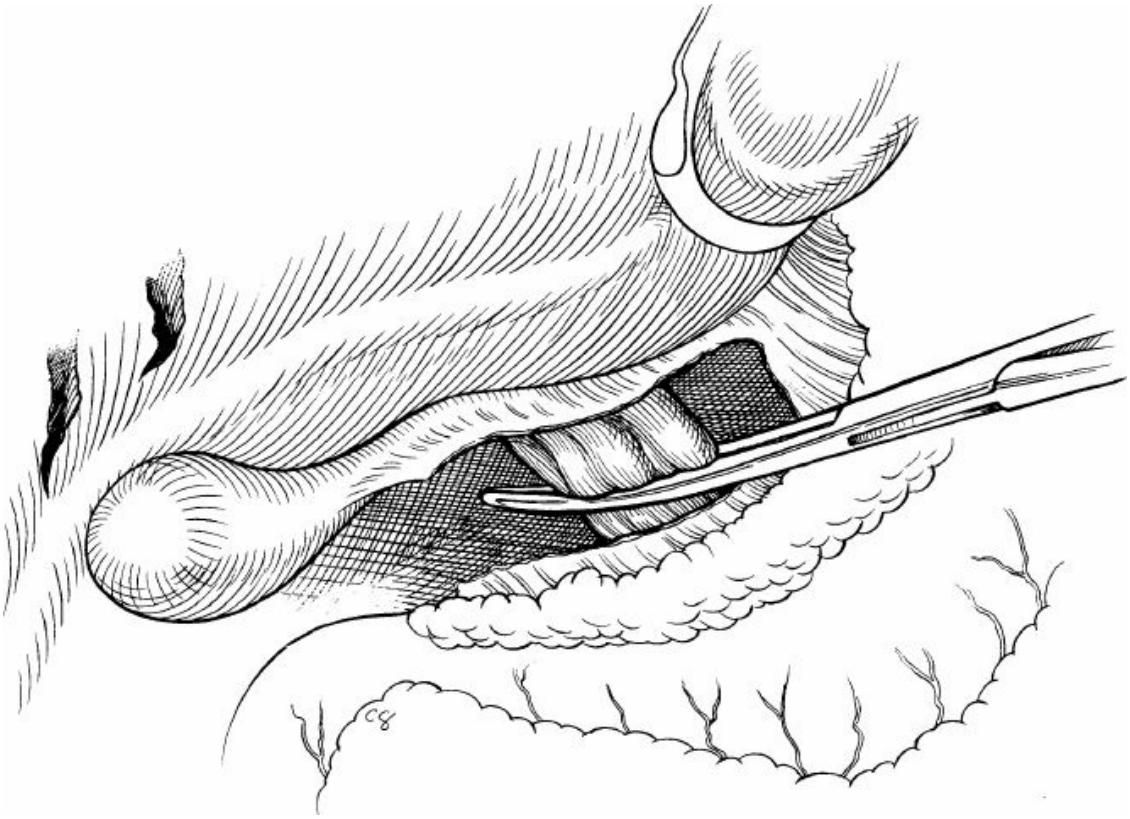

Figure 108.13. The Pringle maneuver.

Hepatic lobectomy is indicated in 2% to 4% of all patients with liver trauma; in major liver trauma, however, it is indicated in approximately 20% of cases. Usually, the extent of injury has made it obvious to the surgeon that a formal lobectomy is necessary to control the hemorrhage. I start the lobectomy by incising the liver capsule with a scalpel or the electrocautery unit in the anatomic plane (Fig. 108.14). The blood loss is minimized by compression of the liver between the assistant's hands. As described previously in this section, the liver parenchyma is divided by the finger fracture technique or the blunt end of a scalpel handle. As vessels and bile ducts are encountered, they are individually ligated with 3-0 or 4-0 silk. For a left lateral segmentectomy (segments II and III), resection is carried down to the left of the falciform ligament (Fig. 108.15). Care must be taken not to divide vessels that may be supplying segment IV. Care must also be exercised when one reaches the proximal part of the left hepatic vein to make sure that the middle hepatic vein is not divided. The left hepatic vein stump is oversewn with a 4-0 vascular silk suture. The arterial supply to segments II and III is ligated to the left of the falciform ligament with 2-0 silk, and the branch of the portal vein to segment II is also ligated with 2-0 silk.

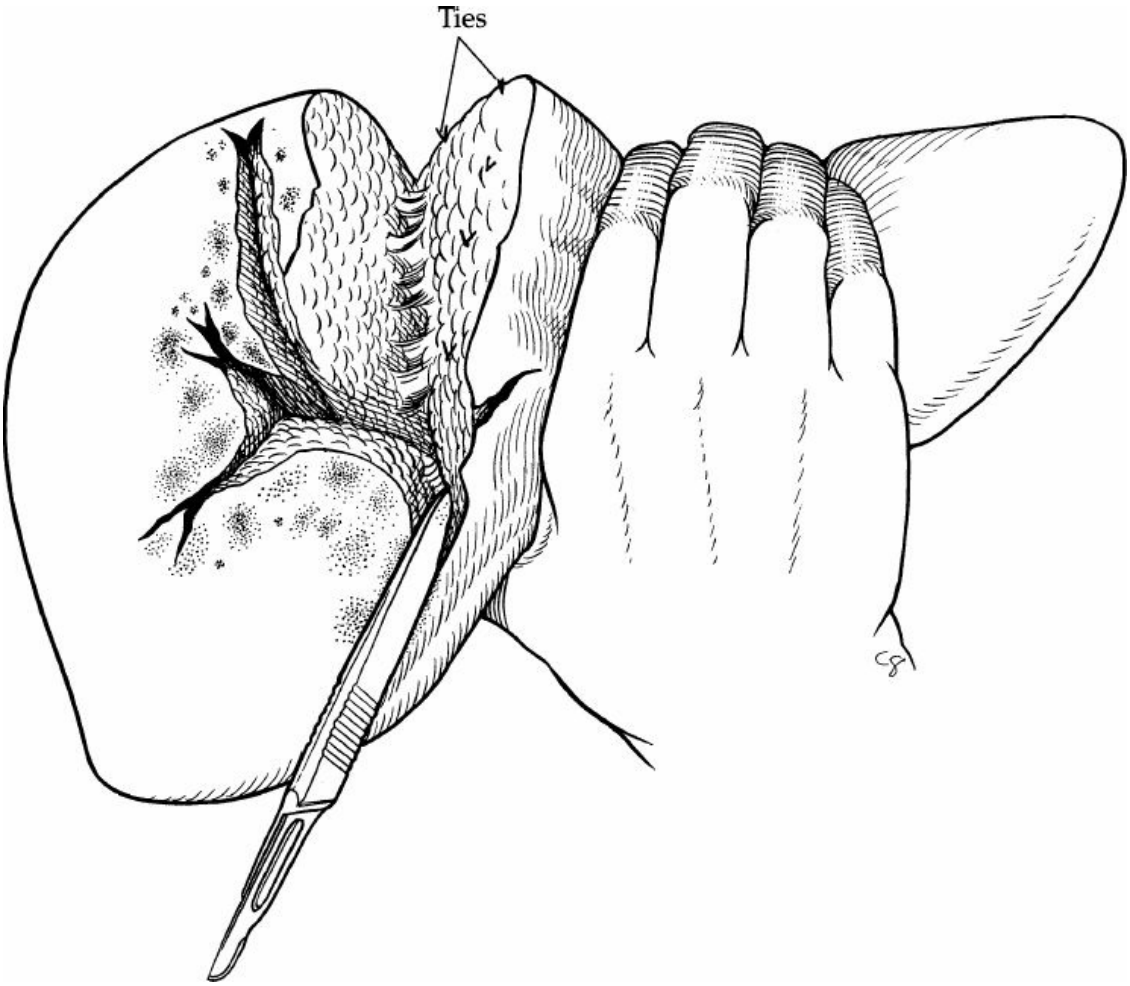

Figure 108.14. Scalpel handle resection. After incision of the liver capsule with the electrocautery unit, the finger fracture technique or the scalpel handle can be used to dissect through the parenchyma to expose the hepatic vessels and biliary radicals, which are individually suture ligated with 2-0 or 4-0 silk.

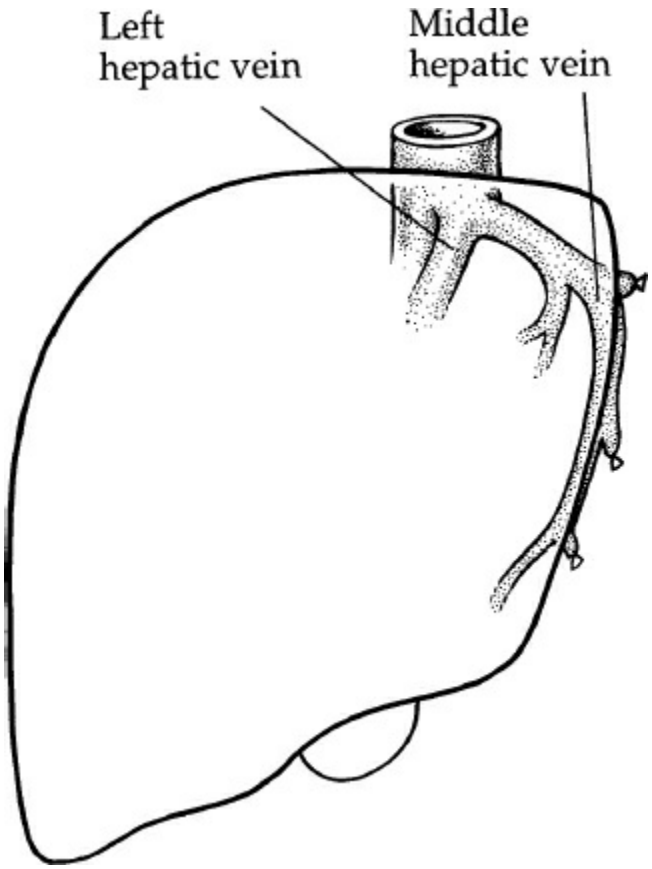

Figure 108.15. Left lateral segmentectomy (segments II and III).

The line of resection for a left lobectomy should be carried out to the left of the gallbladder fossa (Fig. 108.16). It is important to identify the middle hepatic vein during resection, because it drains the superior segment of the right lobe and commonly drains into the left hepatic vein. The left hepatic vein should be ligated and divided distal to the junction with the middle hepatic vein. The left portal vein should not be ligated until it is well exposed in the hilum, because it might give off a branch to the anterior segment of the right lobe. Care should also be taken when dividing the left hepatic duct, because a segmental hepatic duct from the right frequently crosses the segmental fissure to drain into the left hepatic duct. The left hepatic artery supplies only the left side and can be readily ligated.

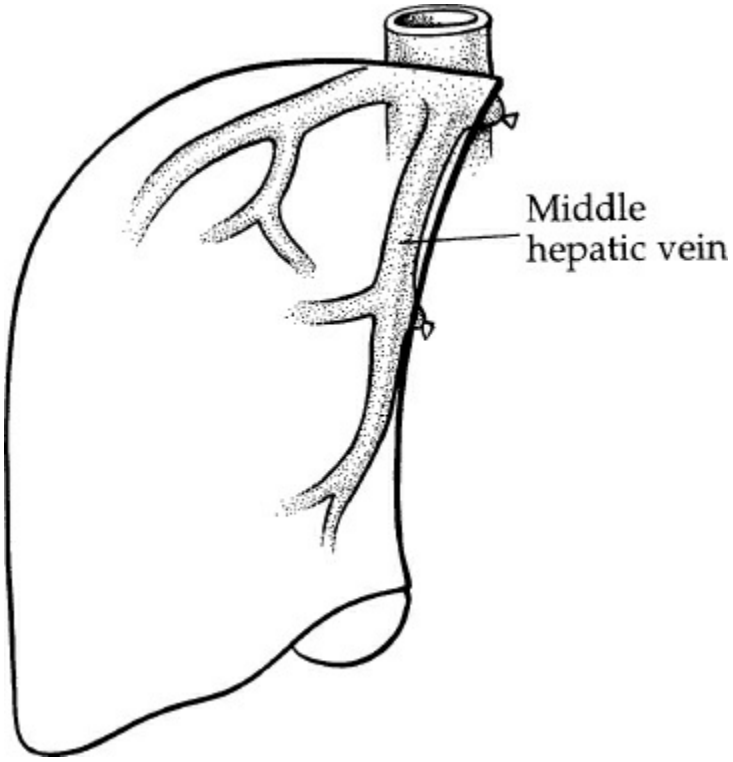

Figure 108.16. Left hepatic lobectomy.

In performing a right hepatic lobectomy, the line of resection should be carried to the right of the gallbladder fossa (Fig. 108.17). The middle hepatic vein should be divided early and proximately to avoid injury to the left hepatic vein. The dissection should then be carried cephalad and posteriorly toward the vena cava to the right of the middle hepatic vein. The right hepatic artery and portal vein can be dissected early in the dissection and ligated to decrease blood loss. Care should be taken to avoid damage to the occasional branch of the right hepatic artery that may supply the medial segment of the left lobe. After either right or left hepatic lobectomy, there is a large raw surface over which I prefer to place omentum that is sutured to the capsule at the cut margins.

A useful adjunct in a small number of patients who require lobectomy, resectional debridement, or hepatorrhaphy is vascular isolation. At least three methods are currently in use: the Heaney maneuver, atriocaval shunting, and venovenous bypass. Of these three techniques, I prefer the Heaney maneuver and would only rarely use venovenous bypass (Fig. 108.18). Atriocaval shunting has been abandoned by most surgeons.

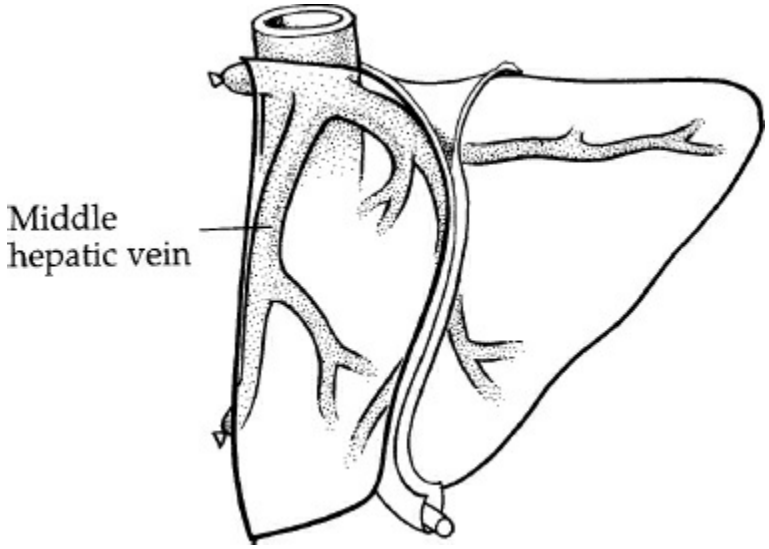

Figure 108.17. Right hepatic lobectomy.

The Heaney maneuver is performed by clamping both the suprahepatic and infrahepatic inferior vena cava while simultaneously applying the Pringle maneuver. During the Heaney maneuver, it is crucial that central pressures are monitored and that fluid replacement is adequate when the inferior vena cava is clamped.

The second most common method of hepatic vascular isolation is venovenous bypass using a centrifugal pump that was initially described by Starzl. The modification of this technique is simply to cannulate the femoral vein in the groin and the axillary vein in the upper arm (Fig. 108.19). Heparin-coated tubing connects the two cannulas. The centrifugal pump is used to assist flow. Complete hepatic vascular inflow can then be accomplished by clamping the suprahepatic vena cava at the diaphragm, suprarenal vena cava, and porta hepatis. It is not necessary to place a portal vein catheter as originally described by Starzl.

One of the papers that advocated the use of nonoperative management of liver injuries suggested that up to 80% to 90% of all liver injuries could be managed in such a manner. In this study, however, 2 patients had bilomas, and 14 patients had major complications from hemorrhage, of which 2 patients died. A more rational approach was presented at the American Surgical Association by Richardson et al., who studied 1,842 consecutive liver injuries from 1975 to 1999. His group looked at 5-year intervals and did a comparative analysis of operative treatment and some of the demographics. Over this period, the number of liver injuries increased, but the severity of liver injuries remained fairly constant. It may also reflect the positive effect of three-point restraints, airbags, and the

triage of patients to trauma centers. This fact might be due to our ability to diagnose liver injuries better with CT. One of the interesting features of this paper, however, is that the mechanism of injury has changed fairly dramatically. Between 1975 and 1979, the blunt-to-penetrating ratio was 48% to 52%, whereas in 1995 to 1999, it was 74% to 26%. Equally dramatic is the nonoperative management in this series, which is 65% compared with the 80% to 90% noted previously. Sixty-five percent may be a more realistic number, but it does not take into account associated injuries.

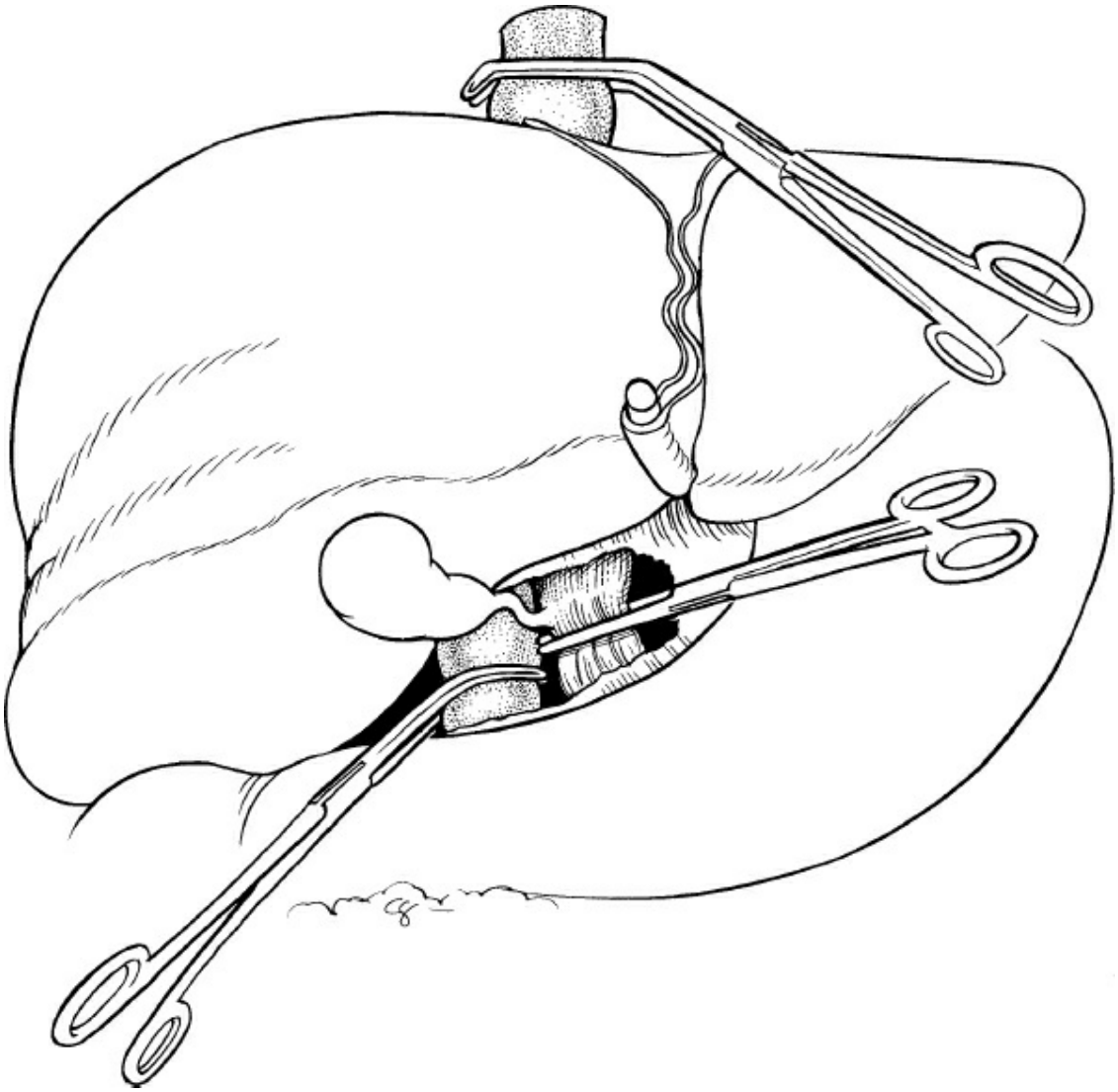

Figure 108.18. The Heaney maneuver for vascular isolation of the liver.

Another approach is one that was advocated by Strong over a 13-year period that 187 patients were admitted to his hospital with liver injuries.

Of these, 37 underwent anatomic resection with an overall operative mortality of 11.1% and a hepatic complication rate of 16%. Strong concluded that the role of resection should be reevaluated and that the wide condemnation of anatomic resection for severe liver injury is inappropriate. Finally, he suggested that general surgeons lack experience to do these resections, and patients should be referred to centers that do extensive hepatobiliary surgery. This was confirmed by a study by Duane et al., who treated 80 grade IV and V injuries. Of 44 patients who had operations, there was 78% mortality. They concluded, “In three years, only 44 patients underwent operations, approximately 15 per year. One must consider whether the relative paucity of need for operation in complex liver injury results in degradation of operation decision-making and skill.” They further stated, “This issue certainly requires some consideration in the future to ensure surgeons will receive adequate training for complicated trauma cases such as these.” Unfortunately, the American Board of Surgery only requires four operative liver cases to sit for the primary certificate.

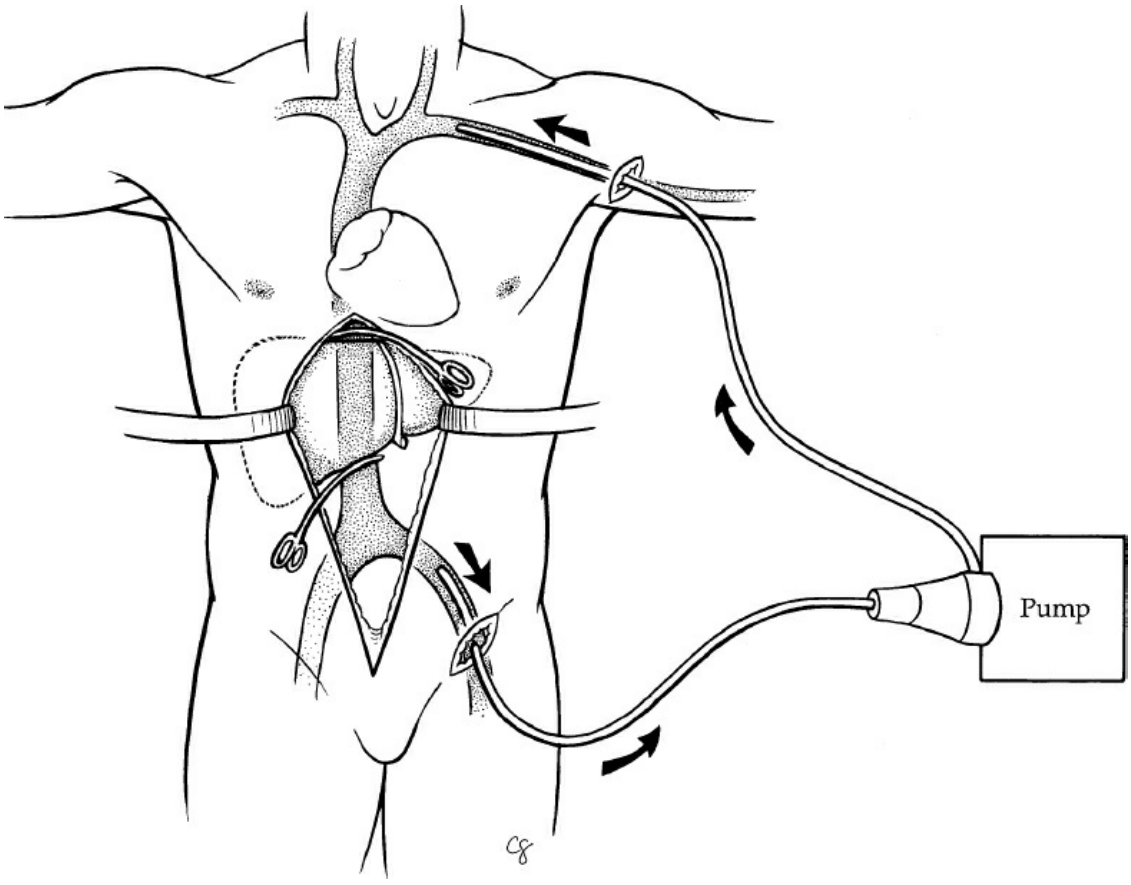

Figure 108.19. Venovenous bypass. Note the placement of the suprahepatic inferior vena cava clamp and the intrahepatic

suprarenal venous clamp.

My own personal experience over an 11-year period (1988 to 1998) involved 74 patients who were admitted for liver injuries. Based on CT scan and physiologic data, I elected not to operate on 24 patients (32.4%). There were 6 deaths in this group, all from closed head injury. The remaining 50 patients (67.6%) required operative management, of which the primary indication in 25 patients was for injuries other than the liver injury. Six of these operations turned out to be nontherapeutic celiotomies. Of the 19 remaining cases, however, 6 required splenectomy, 1 required pancreatectomy, 1 required repair of the bladder, and 2 patients required control of bleeding from the kidney. One patient had a small-bowel injury, 2 patients had duodenal injuries, and 2 patients had colon injuries. The majority of the liver injuries were treated by simple suture techniques or debridement. Twenty-five patients, slightly more than one third of the total number of patients, were operated on primarily for their liver injuries. Six required lobectomies, 1 patient had a resection of segments II and III, 4 patients underwent major resectional debridement, and there were two injuries to the retrohepatic cava. Of these 13 patients, there was 1 death—a patient who bled to death from his retrohepatic caval injury (8% mortality). In addition, 7 patients required suture control of liver hemorrhage; 4 patients were packed, which became definitive treatment; and 1 patient was operated on for compartment syndrome of the liver.

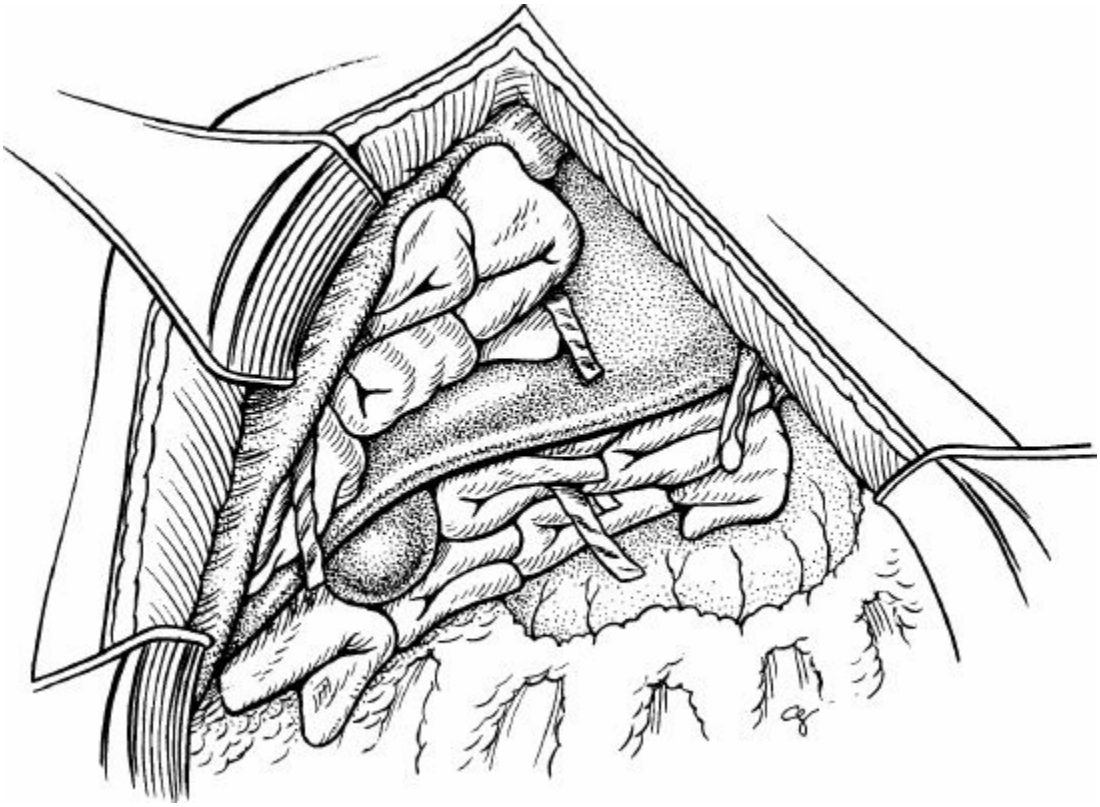

Figure 108.20. Circumferential packs of the liver. Care must be exercised not to impede venous return from the inferior vena cava or to push the diaphragm cephalad, which would compromise ventilation.

As was mentioned earlier, packing was popular before World War II, but the results were poor. More recently, it has been recognized that packing of liver injuries not only buys time to mobilize resources but can be definitive treatment in certain injuries. Such injuries are usually crush injuries to the liver that involve both lobes. It is particularly useful for injuries in which the bleeding is primarily venous. In my experience, it is not successful when ongoing surgical bleeding from arteries is present. Packing is probably the only way of salvaging a patient who is coagulopathic or hypothermic, or both, during operation. The intent here is to pack temporarily, resuscitate and rewarm the patient in the intensive care unit (ICU), and return to the operating room as soon as possible. When packing is being used as definitive treatment with a transverse fracture through both lobes, it often requires repacking at 12 to 24 hours after the initial packing and even repacking a third time 24 hours later.

The technique does not involve simply stuffing laparotomy sponges around the liver. Some surgeons have advocated placement of plastic between the gauze and the liver, but, in my experience, plain gauze is

equally effective. The goal is to pack the perihepatic area so that closure of the injury is accomplished (Fig. 108.20). The rib cage provides a rigid strut so that circumferential compression of the liver is accomplished. The intent is to place the packs so that the diaphragm is not unduly elevated, and the inferior vena cava is not compromised. The latter can be assessed by having the anesthesiologist give the central venous pressure values and blood pressure during the packing. If either of these values falls, compromise of the inferior vena cava is usually indicated. Once the circumferential packs are placed, packs are gently placed against the base of the liver, and closure of the abdomen is accomplished. During the time that the patient is being resuscitated in the ICU, preparation for the next operation is carried out. This preparation includes using venovenous bypass to facilitate hepatic vascular isolation and to mobilize the massive transfusion protocol. After packing, it is also possible to transport the patient to a different center that has more resources.

Drainage of the liver is controversial after repair of injury. In general, I prefer to drain only for biliary leak; thus, the most severe injuries are the ones that will require drainage. I prefer closed drainage systems and drain not only in proximity to the injury but also posterior to provide dependent drainage of fluid collections.

A final therapeutic modality that has to be considered in the context of modern surgery is hepatic transplantation. There have been several successful reported cases after major hepatic trauma. The indication for hepatic transplantation secondary to trauma is a severe nonreconstructible injury to the porta hepatis or bilobar nonreconstructible injuries. Other intra-abdominal injuries and head injuries are relative contraindications. The availability of an appropriate donor is unpredictable, and every effort should be made to consult a liver transplant center as soon as possible so that the anhepatic period is minimized.

Repair of Injuries to the Porta Hepatis

Most of the injuries to the porta hepatis are from penetrating causes. Control of hemorrhage is the first priority. I prefer to perform an extended Kocher maneuver, taking down the entire right colon and mobilizing it toward the midline along with the duodenum. This procedure exposes the portal vein and a significant portion of the inferior vena cava and infrarenal aorta, which may also be injured. In a few instances, it may be necessary to divide the neck of the pancreas to visualize the proximal

portion of the portal vein at the junction of the splenic vein and the superior mesenteric vein. Although successful ligation of the portal vein has been reported, I would make an extra effort to repair it or to do an interposition graft using harvested internal jugular vein from one side of the patient's neck. If the spleen has been injured, it may also be possible to use a portion of the splenic vein as an interposition graft. Injuries to the hepatic artery are problematic. As was noted previously, ligation of the proper hepatic artery is not recommended. Every effort should be made to repair this or replace it with an interposition saphenous vein graft. I prefer to repair most with lateral sutures of 5-0 or 6-0 Prolene.

Injuries to the extrahepatic biliary tree are also usually associated with penetrating trauma; however, blunt trauma can cause stretch or avulsion injuries. When the injury is to the common duct, repair must be meticulous. The normal common duct is approximately 4 mm in diameter. Lateral repair is possible, provided that there is no segmental loss. If segmental loss is present and involves the proximal common bile duct, biliary drainage can be accomplished using a Roux-en-Y procedure to either the common hepatic duct or the gallbladder. This Roux-en-Y can be difficult to perform with a normal-sized common bile duct. To make this anastomosis technically easier, I use a modification of the vascular Carrel patch (Fig. 108.21). A 1-cm length of cystic duct is preserved after cholecystectomy, and the side wall is opened into the common bile duct remnant. This patch of bile duct is then used to anastomose in an end-to-side fashion to the Roux limb. In the unstable patient, temporary biliary drainage can be accomplished by placing catheters into the right and left hepatic ducts or the common duct, which are then brought out of the abdomen laterally. Delayed reconstruction of the biliary systems can be accomplished after the patient recovers from other injuries.

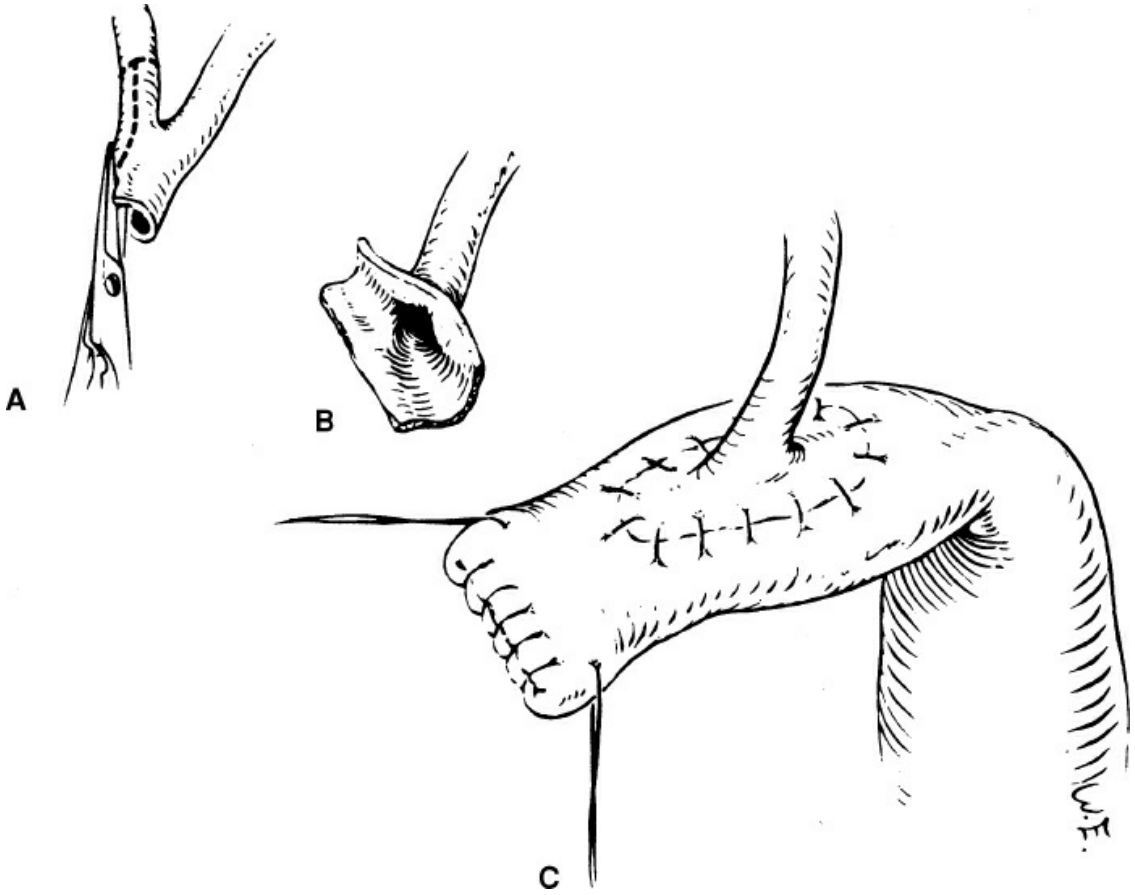

Figure 108.21. Modification of the Carrel patch for choledochojejunostomy in patients with normal-sized common ducts. **A.** The common duct is transected distal to the junction of the cystic duct; the gallbladder is removed, retaining 1 cm of cystic duct. The Y portion is opened as shown. **B.** A carrel patch has been formed. **C.** A choledochojejunostomy is performed end to side as shown.

POSTOPERATIVE MANAGEMENT AND COMPLICATIONS

Massive blood loss, transfusion, tissue trauma, shock, hypothermia, and liver dysfunction contribute to coagulopathy intraoperatively and postoperatively. Treatment of the coagulopathy requires rewarming of the patient as well as replenishment of clotting factors using transfusion of fresh whole blood, packed red blood cells, or fresh frozen plasma in conjunction with platelets in a ratio of 1:1:1. Hematocrit, platelet count, and prothrombin time should be measured frequently as a guide to therapy for coagulopathy. If the coagulopathy has been corrected and the patient continues to hemorrhage, reexploration is indicated. For complex liver injuries (classes IV and V), I would advocate a second-look reoperation at

24 to 48 hours.

Postoperative pulmonary failure is frequent after major trauma. Tissue trauma, large-volume fluid resuscitation, and associated injuries (e.g., rib fracture) contribute to pulmonary failure. The patient should be managed with endotracheal intubation and positive-pressure ventilation until hemodynamically stable. The patient should be extubated as soon as possible, but with the knowledge that reintubation may be necessary.

Jaundice occurs frequently after liver trauma. This may be a sign of severe hepatic dysfunction but is usually related to resorption of hematomas, breakdown of transfused red cells, and mild hepatic dysfunction from central lobular necrosis secondary to shock. Hepatic function returns to normal promptly, although elevated bilirubin levels in the serum may persist for days.

Bile leaks and fistulae can usually be detected when the perihepatic area has been drained. Unless these leaks are from a major bile duct, they generally close spontaneously.

Hematobilia is an uncommon complication, occurring in fewer than 1% of complex injuries. The typical presentation is days to weeks after the injury and can be manifest by melena, upper gastrointestinal bleeding, hypotension, or biliary colic. The diagnosis is confirmed by visualizing blood coming from the ampulla during upper gastrointestinal endoscopy. Treatment is preferentially by percutaneous transvascular selective embolization of the involved artery.

Sepsis after hepatic trauma occurs in 7% to 12% of patients and is related to intra-abdominal abscess, pneumonia, acalculous cholecystitis, and ischemic bowel. Risk factors associated with intra-abdominal abscess postoperatively include associated splenectomy, liver packing to control hemorrhage, class IV or V injury, large transfusion requirement, and colon injury. Subphrenic and subhepatic abscesses are usually marked by fever 4 to 7 days after operation. Pleural effusion may be noted on chest radiography. Diagnosis can be made by ultrasound or CT scan. Treatment includes percutaneous or surgical drainage and intravenous antibiotics. Prophylactic antibiotics are not recommended postoperatively unless there is an associated bowel injury.

Suggested Readings

Bismuth H. Surgical anatomy and anatomical surgery of the liver. *World J Surg* 1982;6:3.

Cogbill TH, Moore EE, Jurkovich GJ, et al. Severe hepatic trauma: a multicenter experience with 1,335 liver injuries. *J Trauma* 1988;28:1433.

Duane TM, Como JJ, Bochicchio GV, et al. Re-evaluating the management and outcomes of severe blunt injury. *J Trauma* 2004;57:494.

Engrav LH, Benjamin CI, Strate RG, et al. Diagnostic peritoneal lavage in blunt abdominal trauma. *J Trauma* 1975;15:854.

Gao JM, Du DY, Zhao XI, et al. Liver trauma: experience in 348 cases. *World J Surg* 2003;27:703.

Heaney J, Scanton W, Halbert D, et al. An improved technique for vascular isolation of the liver: experimental study and case reports. *Ann Surg* 1966;163:237.

Hellström G. Closed injury of the liver: analysis of a series of 300 cases. *Acta Surg Chir Scand* 1961;122:490.

Mavroudis C, Trunkey DD. Choledochoplasty for choledochojejunostomy: variations on a theme by Carrel. *Am J Surg* 1987;142:305.

Moore EE. Critical decisions in the management of hepatic trauma. *Am J Surg* 1984;148:712.

Pacey J, Forward AD, Preto AF. Peritoneal tap and lavage in patients with blunt abdominal trauma: their contribution to surgical decisions. *J Can Med Assoc* 1971;105:365.

Pachter HL, Knudson MM, Esrig B, et al. Status of nonoperative management of blunt hepatic injuries in 1995: a multi-center experience with 404 patients. *J Trauma* 1996;40:31.

Polanco P, Leon S, Pineda J, et al. Hepatic resection in the management of complex liver injury to the liver. *J Trauma* 2008;65:1264.

Pringle JH. Notes on the arrest of hepatic hemorrhage due to trauma. *Ann Surg* 1908;48:541.

Richardson DJ, Franklin GA, Lukan JK, et al. Evolution in the management of hepatic trauma: a 25-year perspective. *Ann Surg* 2000;232:324.

EDITORS' COMMENT

Dr. Donald Trunkey's contributions to trauma care are legendary and indisputable. The principles that he presents in this chapter on the care of hepatic trauma remain as true today as when he originally wrote them. Effective management requires intimate knowledge of hepatic anatomy and physiology and technical skill when surgical treatment is required. He discusses the importance of addressing coagulation abnormalities, management that is based on hemodynamic instability rather than CT findings alone, and the trend toward

nonoperative management, while at the same time being more aggressive when the patient is hemodynamically unstable despite resuscitation attempts. His detailed descriptions of operative management based on the anatomy of the injury and dictated by the patient's clinical condition are timeless.

Dr. Trunkey begins his chapter on management of major hepatic trauma by tracing its evolution over the past century, guided by refined surgical techniques for elective liver resection. Surgeons treating patients with liver injuries will always need a confident command of hepatic anatomy and its variations, as described in this chapter.

Major hepatic trauma, as defined by Dr. Trunkey using the anatomical definitions presented in his Table 108.2, are patients with grade III, IV, and V liver injuries, and in his experience the majority of these patients will need a laparotomy. Although most surgeons agree that the majority of patients with penetrating injury to the liver require prompt surgery, the management of blunt liver injury is a topic of debate and has evolved recently to favor less aggressive management. Studies published in the past decade suggest that a majority of patients with blunt trauma can be managed without an immediate laparotomy. A major factor influencing treatment of these patients is their hemodynamic status. Patients with major liver injury following blunt torso trauma can, in addition to anatomical characteristics, be separated into three categories based upon their clinical course in the first minutes after their presentation to the emergency department: patients who present with a stable "normal" systolic blood pressure over 120 mm Hg are considered hemodynamically stable; patients are categorized as stable-after-resuscitation if they present initially with a transient systolic blood pressure under 100 mm Hg, but sustain their systolic blood pressure in the normal range following intravenous infusions of 1 L of isotonic fluid or one unit of whole blood. Patients in these two groups can safely be transported to the CT scanner for imaging of the chest, abdomen, and pelvis, with subsequent management guided by the severity of liver injury seen on the CT and their clinical course. A third category of patients, based upon clinical course on presentation, is unstable; they have a systolic blood pressure below 80 mm Hg and do not have a favorable blood pressure response to resuscitation. These unstable patients are at risk of immediate death from exsanguination, and most trauma surgeons advocate prompt laparotomy with minimal additional diagnostic testing. However, surgeons currently choose nonoperative management in a substantial majority of patients with liver injury but with no other identified injuries requiring laparotomy even in patients with grade III, IV, and V injuries. Recent studies suggest that the majority of patients can have successful nonoperative management. Melloul and colleagues evaluated management of major blunt hepatic injuries (grades III to V) in a systematic review of the literature, selecting 12 articles of high quality. They found that 66% were managed nonoperatively with a success rate of 94%; arterial embolization (AE) to manage contrast extravasation on CT was employed in only 3% and was 93% successful (Melloul E, Denys A, Demartines N.

Management of severe blunt hepatic injury in the era of computed tomography and transarterial embolization: a systematic review and critical appraisal of the literature. *J Trauma Acute Care Surg* 2015;79:468–74). Boese and colleagues published a summary of eight high-quality manuscripts on blunt liver trauma in 2015 and reported that the failure rate of nonoperative management—meaning the patient had delayed laparotomy after an initial decision to observe the patient—ranged from 0% to 24%, with mean of 10% (Boese CK, Hackl M, Muller LP, et al. Nonoperative management of blunt hepatic trauma: a systematic review. *J Trauma Acute Care Surg* 2015;79:654–60). The average time interval between injury and operation was 12 hours. In this group of severely injured patients, the death rate was 2.4%. Predictor variables that were associated with failure of nonoperative management were: hypotension, need for ongoing fluid resuscitation including blood transfusions, peritoneal signs, higher Injury Severity Score (but not AAST Liver Injury Grade per se), and CT findings suggesting additional intra-abdominal injuries.

Surgical Techniques

When the patient with severe liver injury does require operative management, the pattern of findings on the abdominal CT may permit surgeons to interpret the pattern of liver injury, particularly the precise location of the injury in relationship to major vascular structures, to suggest what surgical techniques may be required at laparotomy. For example, a deep laceration in close proximity to hepatic veins, as demonstrated in Figure 108.7, indicates that traction on the right lobe of the liver causing an inferior displacement may result in a rush of blood. Dissection into the deep laceration in the portal hiatus in Figure 108.8 led to bright red arterial bleeding. Dr. Trunkey advocates a long midline incision to provide optimal exposure, but for some surgeons the bilateral subcostal incision, with superior extension through the linea alba to the sternum, may provide optimal access to the liver. In rare cases of injuries to the junction of the hepatic veins and the inferior vena cava, particularly in large patients with an unfavorable body habitus, prompt extension of the midline incision into a sternotomy can provide improved access to hemorrhage in this location. Having an abdominal wall retraction device that is attached to the operating table readily available may improve operative exposure to the dreaded injury to the retrohepatic veins.

Surgeons performing an urgent laparotomy in a patient with major hepatic injury and bleeding may find several maneuvers useful in the first moments after the incision has decompressed a hemoperitoneum typically in excess of 1 L of blood. The surgeon can advance both hands into the right upper quadrant, grasping the lateral sides of the right and left lobe of the liver and thereby compressing the liver, closing and compacting the bleeding liver laceration (Pachter HL. Prometheus bound: evolution in the management of hepatic trauma—from myth to reality. *J Trauma* 2012;72:321–9). At the same time, the surgical assistant can reach in under the left lobe of the liver, identify by

palpation the junction of the esophagus and stomach, and compress the supraceliac aorta against the spine, thus achieving a prompt increase in perfusion pressure to the brain and heart while the anesthesiologist infuses blood products to restore the depleted blood volume. Dr. Trunkey also provides the prudent admonition that the surgical team must avoid the pitfall of being so distracted by a major liver injury that they overlook other sources of hemorrhage into the abdomen, retroperitoneum, or pelvis. The Pringle maneuver can also help control hemorrhage and also help identify whether the bleeding is superior or inferior to the porta hepatis. However, surgeons should anticipate complications associated with having a vascular clamp across the porta hepatis for more than 20 to 30 minutes, including massive bowel edema or delayed gallbladder infarction, and should have a low threshold following a prolonged Pringle maneuver to perform a routine second look procedure. Hypocalcemia can also occur in a patient who receives a rapid infusion of blood products that contain citrate, a molecule normally cleared by the liver.

Dr. Trunkey highlights that in situations where the initial packing of a liver laceration has controlled bleeding in a patient who is cold, acidotic, and has needed a massive transfusion, the surgeon may prudently select damage control methods, to leave the packs in place and not attempt definitive control of liver hemorrhage at the first procedure. One caveat is that abdomens partially closed with vacuum suction devices may aspirate clots and thereby impair tamponade, resulting in additional bleeding (Cue JI, Cryer HG, Miller FB, et al. Packing and planned reexploration for hepatic and retroperitoneal hemorrhage: critical refinements of a useful technique. *J Trauma* 1990;30:1007–14).

Penetrating Liver Injury

Most patients with a penetrating liver injury need a laparotomy. The surgical techniques described by Dr. Trunkey are used to manage penetrating injury to the liver. One specific problem is a penetrating injury that has an entrance and an exit wound and the tract passes through the central parenchyma of the liver. This latter injury may be best managed by the improvised balloon tamponade method described by Moore et al. (Poggetti RS, Moore EE, Moore FA, et al. Balloon tamponade for bilobar transfixing hepatic gunshot wounds. *J Trauma* 1992;33:694–7).

A few surgeons have questioned the need to operate on all patients with penetrating injury to the liver. Demetriades and colleagues reported that they had modest success nonoperatively managing 30% of isolated low-grade injuries to the liver in a strictly defined subset of patients with penetrating injury in the right upper abdomen and lower chest. The patients were hemodynamically stable, had no peritoneal signs, and no signs of “heavy bleeding” (Demetriades D, Gomez H, Chahwan S, et al. Gunshot injuries to the liver: the role of selective nonoperative management. *J Am Coll Surg* 1999;188:343–8). This and other reports suggest that selected patients with low-velocity penetrating injuries below the right nipple and superior to the right

costal margin can be managed by first a diagnostic CT scan, and if no indication for immediate surgery is seen, delayed laparoscopy to evaluate for penetrating diaphragm injuries or bile leak. Surgeons should be wary that insufflation in a patient with a small diaphragm perforation may lead to a tension pneumothorax.

Angioembolization

Dr. Trunkey advocates in Algorithm 108.2 for selective reliance on angiography and embolization (AE) of bleeding hepatic arterial injuries. Most authors now agree that AE is indicated in patients who have contrast extravasation observed on CT scan. Another group who benefit from AE are those patients transported from the emergency department to the operating room for an immediate laparotomy to control their bleeding liver (Letoublon C, Morra I, Chen Y, Hepatic arterial embolization in the management of blunt hepatic trauma: indications and complications. *J Trauma* 2011;70:1032–7). In a minority of patients in whom peri-hepatic packing fails to stop all bleeding, particularly bright red hemorrhage from deep in a hepatic laceration, surgeons may decide to quickly accomplish a temporary closure of the abdomen and transfer the patient immediately to the interventional radiology suite (Green CS, Bulger EM, Kwan SW. Outcomes and complications of angioembolization for hepatic trauma: a systematic review of the literature. *J Trauma Acute Care Surg* 2016;80:529–37). Over 80% of patients with a CT scan showing contrast extravasation will have a bleeding artery identified on angiogram, and embolization of this intrahepatic vessel stops bleeding in over 90% of patients. The success of AE in stopping hemorrhage from an injured liver highlights that optimal contemporary management of a severely injured patients depends upon a smoothly coordinated team of multiple providers. Hybrid operating rooms provide all the equipment needed for an interventional radiologist and trauma team to perform simultaneous procedures and more efficiently and quickly manage these complex patients.

The most common complications of AE are hepatic necrosis (15%), abscess formation (8%), and biloma or prolonged bile leak (5% or less). The optimal management of hepatic necrosis is excision of the dead liver, often best accomplished at the second or even third abdominal exploration (Dabbs DN, Stein DM, Scalea TM. Major hepatic necrosis: a common complication after angioembolization for treatment of high-grade liver injuries. *J Trauma* 2009;66:621–7).

Because alcohol consumption is a factor that contributes to trauma risk, it is not surprising that CT scans may also inform the surgeon of the presence of cirrhosis, which will affect the patient's clinical course and predict a higher in-hospital mortality (Talving P, Lustenberger T, Okoye OT, et al. The impact of liver cirrhosis on outcomes in trauma patients: a prospective study *J Trauma Acute Care Surg* 2013;75:699–703). Alcohol abuse in itself without cirrhosis increases organ failure rates, but does not predict a higher mortality (Nau C, Wutzler S, Doerr H, et al. Injury. *Int J Care Injured* 2013;44:661–6).

Patients with severe liver injuries often need a massive transfusion that should comply with recent guidelines of 1:1:1 (plasma, platelets, and red blood cells) developed from the PROPPR study. Most Level 1 trauma centers have designed protocols so that a “box of blood” is immediately available when such an unstable patient arrives, but institution of the massive transfusion protocol cannot be forgotten if optimal outcome is to be achieved (Holcomb JB, Tilley BC, Baraniuk S, et al. Transfusion of plasma, platelets, and red blood cells in a 1:1:1 vs a 1:1:2 ratio and mortality in patients with severe trauma: the PROPPR randomized clinical trial. *JAMA* 2015;313:471–82). Converting the first surgical procedure into a damage control procedure, closing the abdomen with retained laparotomy pads compressing the liver to achieved closure of the liver wound, is a judgment based upon multiple factors, including the availability of resources at that moment.

A major concern currently is the lack of experience of trainees with operative management of major hepatic injuries, since the incidence of high-grade injuries is decreasing and fewer injuries require operation. Between 2000 and 2004, the National Trauma Data Bank documented only 1,939 operations nationally for liver injuries (Tinkoff G, Esposito TJ, Reed J, et al. American Association for the Surgery of Trauma Organ Injury Scale I: spleen, liver, and kidney, validation based on the National Trauma Data Bank. *J Am Coll Surg* 2008;207:646–55), and the average graduating surgical resident in 2008 performed only 1.2 operations to stop bleeding (Lucas CE, Ledgerwood AM. The academic challenge of teaching psychomotor skills for hemostasis of solid organ injury. *J Trauma* 2009;66:636–40). Leon Pachter recommends that surgical residents spend a minimum of 3 to 4 months on a hepatobiliary/transplant service to learn hepatic anatomy and operative techniques (Pachter L. Prometheus bound: evolution in the management of hepatic trauma—from myth to reality. *J Trauma* 2012;72:321–9). It is otherwise likely that mortality in the most seriously injured patients will increase in the future or that such patients will require “damage control” surgery with stabilization and transfer to a Level 1 trauma center for definitive management.

Karen Deveney and Richard Mullins

109 Cholecystostomy, Cholecystectomy, and Intraoperative Evaluation of the Biliary Tree

O. James Garden

INTRODUCTION

Although laparoscopic cholecystectomy has become well established in the surgical treatment of gallstone disease in the last 25 years, it is evident from large population studies that open cholecystectomy continues to be performed by some surgeons preferentially or when the minimal access approach fails. This is particularly evident in low-volume hospitals in some countries and may also be impacted by service provision in the emergency setting. There remains a requirement, therefore, for the surgeon to understand the fundamentals of the open approach. Open cholecystectomy may be necessary as an incidental undemanding procedure during more complex surgery of the liver, bile duct, or pancreas. However, a more challenging procedure may result in patients undergoing conversion following failed laparoscopic dissection due to difficult anatomy or more severe gallbladder disease. Some surgeons may opt for an open approach if difficulties with laparoscopic access and dissection are anticipated. The modern surgeon may have acquired greater expertise in the minimally invasive procedure and have little experience of open cholecystectomy. However, there is a need to apply the same safe principles in circumstances that may be more challenging.

SURGICAL ANATOMY

Calot's (hepatocystic) triangle is bounded by the gallbladder, the right side of the common hepatic duct, and the liver. Elevation of the base of the gallbladder from the lower portion of the cystic plate and clearance of this triangle allow clear identification of the cystic structures during cholecystectomy. The cystic duct is approximately 2 cm in length and 3

mm in diameter, joining the common hepatic duct at an acute angle to form the common bile duct (CBD). Given that this junction may occur at any level down to the ampulla, the length of the cystic duct is variable. The cystic artery normally arises from the right hepatic artery in the hepatocystic triangle and runs for 1 to 2 cm to the upper border of the gallbladder, superior to the insertion of the cystic duct. Anterior and posterior branches may be evident at the point of contact with the gallbladder. Where the cystic artery arises from an aberrant or replaced right hepatic artery via the superior mesenteric vessel, the cystic artery, and not the cystic duct, usually lies in the free edge of the hepatoduodenal ligament.

The gallbladder lies on a fibrous area referred to as the *cystic plate*, which is part of the perihilar system of fibrous tissue. The cystic plate attaches directly onto the anterior surface of the right portal pedicle. The hepatic parenchyma lies deep to the cystic plate, through which small bile ducts may penetrate to enter the gallbladder. These ducts of Luschka consist of accessory ducts less than 1 mm in diameter. In approximately 10% of patients, there is a large peripheral bile duct immediately deep to the plate, dissection of which may cause bile leakage that may be mistaken by some surgeons as arising from a duct of Luschka. The origin of the middle hepatic vein also lies at a variable depth beneath the cystic plate and may be entered inadvertently.

Between the gallbladder muscularis and the cystic plate, a thin layer of areolar tissue thickens progressively from the top of the gallbladder downward. The posterior surface of the cystic artery and bile duct will be reached when the areolar tissue is left on the cystic plate during dissection of the gallbladder from the liver. Should dissection be undertaken deep into the cystic plate, as often arises in complicated gallbladder disease, the right portal pedicle may be breached and may result in injury to its structures including the right hepatic duct and artery.

The common hepatic duct is formed by the union of the left and right ducts and runs from the base of segment IV in the right edge of the hepatoduodenal ligament for 2 to 3 cm before joining the cystic duct to join the CBD. The CBD courses above the duodenum for 3 to 4 cm before it passes behind the first part of the duodenum, within or behind the pancreas to enter the second part of the duodenum. The CBD external diameter varies from 3 to 13 mm when distended to physiologic pressures. Low insertions of the right hepatic ducts are the most common anomaly,

and in 2% of patients, the right hepatic sectional (sectoral) ducts join the common hepatic duct close to the cystic duct entry.

The right hepatic artery passes behind the bile duct in 80% of cases and, where there is severe inflammation, fibrosis can cause the artery to become adherent to the gallbladder to form an inverse U-loop. This tethering of the anatomy may place the right hepatic artery at risk if it is mistaken for the cystic artery during cholecystectomy. The CBD derives its arterial blood supply from a plexus of vessels arising from two marginal arteries running at the 3 and 9 o'clock positions. These vessels derive their principal blood supply inferiorly.

CLINICAL PRESENTATION

From autopsy studies, it has been established that 12% of men and 24% of women of all ages have gallstones present and 10% to 30% of gallstones become symptomatic. Patients may present with an acute episode of pain from biliary colic, an ill-defined collection of symptoms often referred to as flatulent dyspepsia, chronic recurrent abdominal discomfort from repeated episodes of biliary colic, or acute cholecystitis. Pain may commence in the epigastrium but will localize to the right upper quadrant if there is local inflammation of the gallbladder. There may be systemic illness if the gallbladder contents become infected. Without intervention, toxemia may result if the gallbladder becomes the seat of an empyema or possibly develops gangrene and perforation. An empyema would normally produce pain, right upper quadrant tenderness, and swinging pyrexia, although in the elderly patient these symptoms may not always be obvious until the patient presents with an acute abdomen and collapse. CBD stones may present with features of obstructive jaundice with the passage of pale stool and dark urine, but these may also be occult and present in up to 10% of patients presenting acutely. Accompanying biliary sepsis represents a significant risk to the patient and presents with pain, fever, and frequently rigors. The development of associated medical signs such as atrial fibrillation in the elderly patient may signal the need for urgent intervention. Jaundice may occasionally result from external compression of the CBD from an inflamed and edematous gallbladder or impacted or eroding stone in Hartmann Pouch or the cystic duct (Mirizzi syndrome).

DIAGNOSIS AND TREATMENT

The diagnosis of gallstone disease is often suspected on clinical grounds

but is confirmed by appropriate laboratory and radiologic investigation. Liver function tests should be performed routinely since they may be abnormal in the presence of CBD stones. Although not always specific for choledocholithiasis, serum levels of bilirubin, alkaline phosphatase, and gamma-glutamyl transpeptidase are the most sensitive tests used routinely. An elevated white blood cell count may indicate sepsis. Ultrasonography (US) is most widely used to confirm the diagnosis of cholelithiasis. Other imaging modalities are used rarely, although cholecystokinin-stimulated hydroxy iminodiacetic acid scanning may be useful in the diagnosis of atypical biliary pain such as in biliary dyskinesia. US may detect evidence of chronic disease, and the presence of a thickened wall and contracted gallbladder may signify that open cholecystectomy may be more likely to succeed than a laparoscopic approach. Edema may be evident in acute cholecystitis, and dilation of the CBD may signify the presence of ductal calculi. These are more likely to be detected by magnetic resonance cholangiography, which may be used to plan the approach to managing choledocholithiasis. Endoscopic retrograde cholangiography allows detection and removal of ductal calculi following sphincterotomy and may be required to decompress the biliary tree preoperatively in Mirizzi syndrome or for the patient who presents with acute cholangitis from obstructing ductal stones.

Symptomatic gallbladder disease would normally be managed definitively by cholecystectomy in the fit patient. For the patient presenting acutely, appropriate analgesia is required and resuscitation with intravenous fluids and antibiotics may be required if there is evidence of sepsis. In general, endoscopic retrograde cholangiography with sphincterotomy, removal of stones, and stent placement would be indicated in the patient with cholangitis since morbidity and mortality are lower than with urgent operative decompression of the bile duct but the surgeon may be prepared to undertake open CBD exploration if operative cholangiography detects ductal stones.

For procedures that may involve associated or coincidental cholecystectomy, investigation will be driven by the underlying disease process. For example, computerized tomography or positron emission tomography may be required to image liver tumor and stage the patient before cholecystectomy and liver resection are performed, whereas magnetic resonance cholangiopancreatography may be required to evaluate pathology such as a choledochal cyst prior to its removal with the

gallbladder.

INDICATIONS

Gallstones may cause multiple biliary tract problems, requiring surgery; the most common indication for cholecystectomy is biliary colic caused by chronic cholecystitis and cholelithiasis. Acute cholecystitis, secondary to obstruction of the cystic duct by a gallstone, is the second most common reason for the removal of the gallbladder. Empyema and perforation are sinister complications of gallstone disease that may necessitate open surgery. Pancreatitis and cholangitis caused by obstruction of the pancreatic duct and/or distal CBD by a stone are generally the third most common indication for cholecystectomy. Incidental open cholecystectomy may be required during liver resection, pancreaticoduodenectomy, open surgery for associated benign pancreatic pathology, such as a pseudocyst or chronic pancreatitis, or for primary biliary pathology, such as choledochal cyst.

Despite the high incidence of gallstone disease in many countries, approximately 75% of patients with gallstones are asymptomatic. Although there are conflicting data, it would appear that less than 20% of patients with “silent gallstones” develop complications within a 10-year period. In the United Kingdom, more than 70,000 cholecystectomies are performed each year, whereas in the United States as many as 900,000 are performed annually. The need for conversion from laparoscopic to open cholecystectomy may be anticipated in patients over the age of 65 years, in male patients, those experiencing multiple previous attacks of biliary colic or during acute admission with acute cholecystitis. Primary open cholecystectomy may be considered in as many as 5% of patients requiring removal of the gallbladder and would include patients such as those undergoing laparotomy for peritonitis or other intra-abdominal pathology when gallbladder disease has not been suspected preoperatively. Other possible indications for open cholecystectomy are listed (Table 109.1), although it is accepted that the threshold for an open rather than a laparoscopic approach will vary with the experience and expertise of the surgeon.

TABLE 109.1 Preoperative Indications for Primary Open Cholecystectomy

- Previous upper abdominal surgery
- General peritonitis
- Incidental during open nonhepatobiliary and pancreatic surgery
- Significant portal hypertension
- Penetrating trauma
- Planned open CBD exploration
- Suspected gallbladder carcinoma
- Gallbladder empyema
- Fistulous disease involving gallbladder
- Incidental during other open hepatobiliary and pancreatic surgery

Cholecystostomy

With improvements in anesthesia and surgery, cholecystostomy is undertaken infrequently and is performed generally by radiologic techniques under local, regional, or general anesthesia. It is a procedure that should be considered when cholecystectomy is deemed unsafe in patients at high risk related to multisystem organ failure; severe pulmonary, renal, or cardiac disease; and recent myocardial infarction. Safe cholecystectomy may be precluded by a local condition such as cirrhosis with portal hypertension; acalculous cholecystitis after severe trauma, burns, or surgery; and where there is empyema or gangrene of the gallbladder.

Open or percutaneous cholecystostomy under local anesthesia should not be considered a minor procedure in the sick patient, and a skilled anesthetist should be present since the patient should be well sedated and oxygenated. Preoperative or operative localization of the gallbladder using US is invaluable in selecting the most appropriate incision site. Ample local anesthetic with 0.5% lidocaine is used to infiltrate the skin muscle and peritoneum. A transverse muscle-splitting incision is preferred for the open procedure and, if the incision site has been well chosen, the gallbladder will be seen immediately on entering the peritoneum.

A purse-string 3-0 polydioxanone suture is placed in the fundus of the gallbladder. Having placed packs or swabs around the isolated gallbladder, a trocar is used to decompress the gallbladder. A disposable 5-mm laparoscopic port is ideal as the sharp trocar avoids unnecessary trauma to the operating field. The contents of the gallbladder are aspirated, and a

sample of bile is obtained for culture. In the absence of empyema or gangrene, an attempt should be made to remove the stones with forceps or a scoop. A stone impacted in the neck of the gallbladder or cystic duct can be dislodged usually by external digital manipulation, stone forceps, or a balloon catheter. Removal of the obstructing stone is important to prevent a subsequent mucous fistula.

On removal of the stones, a No. 20 to 24 French gauge Foley or similar catheter is placed through a separate stab incision in the abdominal wall and is secured within the fundus of the gallbladder, using the purse-string suture (Fig. 109.1). Injudicious attempts at securing the gallbladder to the abdominal wall should be avoided, although this may be achieved frequently by inflating the catheter balloon, which allows the fundus of the gallbladder to be opposed against the parietal peritoneum. The incision is closed using 0 polydioxanone to peritoneum and sheath. If there has been considerable contamination of the wound, it may be elected not to close the skin edges.

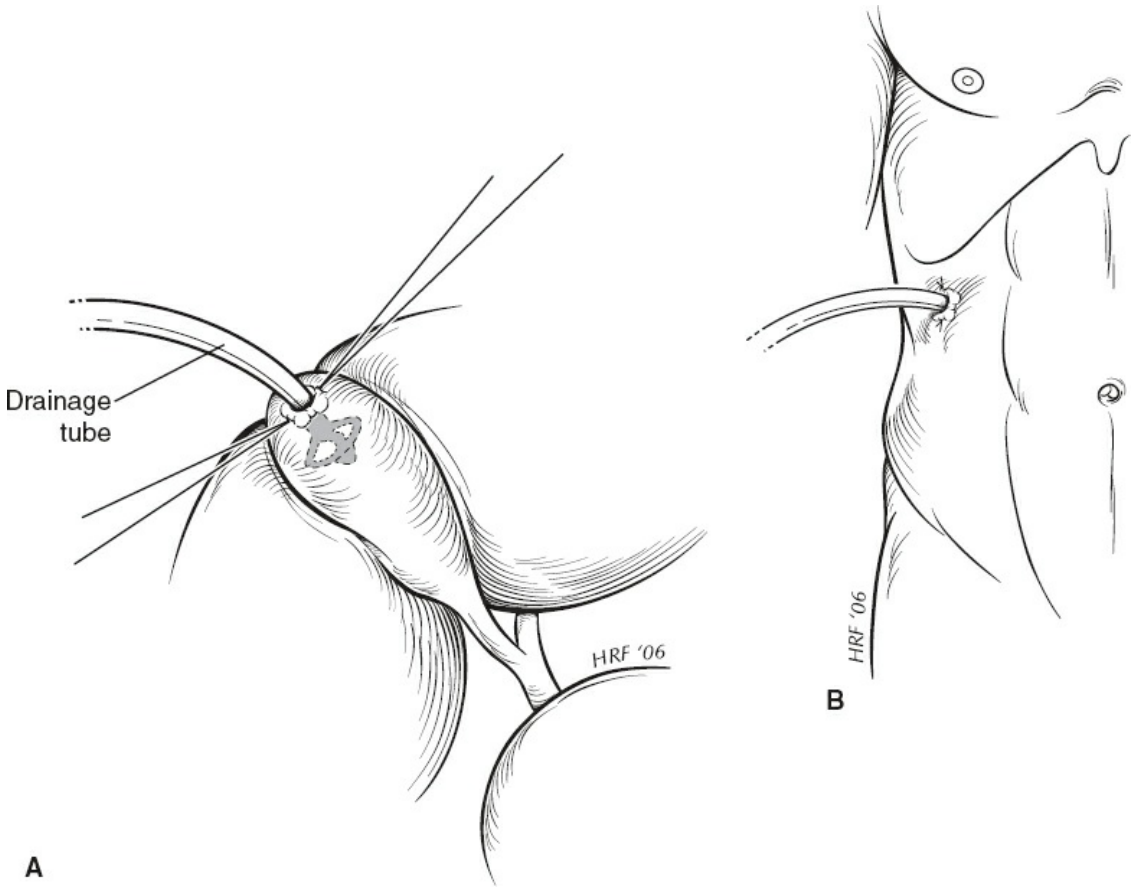

Figure 109.1. Method for securing drainage tube during cholecystostomy. The drainage tube is secured to the gallbladder wall by a purse string suture (**A**) and to the abdominal wall by a

skin suture (**B**).

Given the circumstances under which cholecystostomy is performed, it is not surprising that the procedure carries a higher morbidity and mortality than cholecystectomy. In those patients who recover from the procedure, the cholecystostomy tube can be removed at 6 to 8 weeks if patency of the biliary tract can be demonstrated. Residual stones in the gallbladder may be removed through the tract by percutaneous maneuvers using image intensification or 5-mm flexible choledochoscope. Dissolution techniques are not well tolerated and, in those patients who make a satisfactory recovery, cholecystectomy should be considered. In the elderly, infirm patient or those with comorbid disease, it may be wise to defer cholecystectomy indefinitely.

Open Cholecystectomy

Preoperative preparation requires appropriate thromboembolic prophylaxis according to individual patient risk and administration of a suitable prophylactic antibiotic that would cover common biliary commensal organisms such as cefuroxime or amoxicillin and clavulanic acid. The first dose should be administered before the procedure and preferably within 30 minutes before skin incision. In those patients who have undergone conversion from laparoscopic cholecystectomy, the antibiotic should be administered as soon as is practicable.

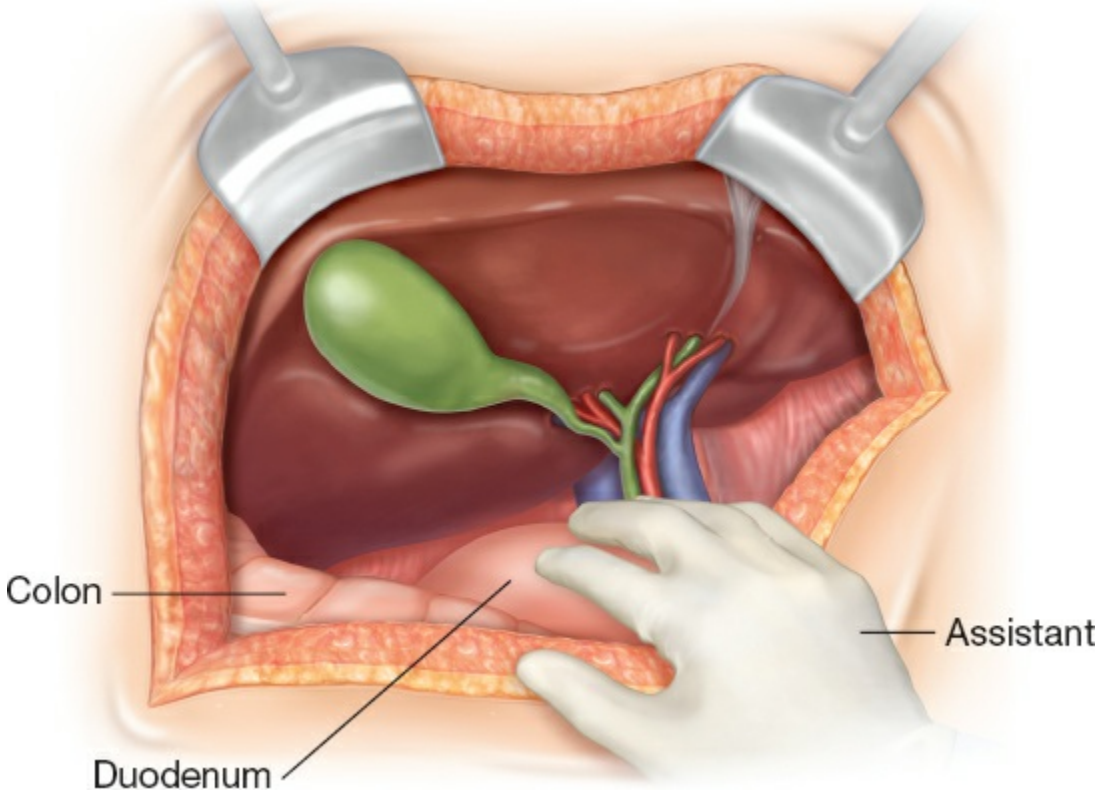

Figure 109.2. Exposure of the gallbladder during open cholecystectomy.

Of the frequently employed incisions for cholecystectomy, a right-sided subcostal (Kocher) or transverse incision provides the optimum exposure. The incision should normally be of sufficient size to provide adequate exposure and to admit the examining hand. In the era of laparoscopic cholecystectomy, there appears little rationale for the so-called minicholecystectomy approach in the patient for whom adequate access will be required to deal with a difficult situation.

The abdomen is explored to exclude other intra-abdominal pathology, and a hand is passed over the right lobe of the liver to allow air to enter the subphrenic space. The costal margin is retracted, and the use of a fixed mechanical retractor is helpful in providing exposure and in freeing the assistant's hands during the operative procedure. Placement of a pack or small swab above the liver may increase exposure of the subhepatic region in some patients. Moist gauze swabs are placed to the right and inferiorly to displace the hepatic flexure of the colon and to the left to displace the stomach away from the operating field. A further pack is used under the assistant's hand to allow traction caudally (Fig. 109.2).

Adhesions between the gallbladder and gastrocolic omentum or transverse colon may be divided using bipolar diathermy scissors.

Placement of a small, moist swab into the subhepatic space to the right and behind the gallbladder will prevent inadvertent spillage of infected bile or stones, which may not otherwise be retrieved easily on completion of the operation. Preliminary decompression of the gallbladder avoids uncontrolled spillage of infected bile during dissection if the gallbladder is tense and acutely inflamed. A trocar can be inserted through the center of a 3-0 polydioxanone purse-string suture placed at the fundus of the gallbladder in an easily accessible location. The gallbladder contents are aspirated before withdrawal of the trocar and closure of the resulting defect by tying the purse-string suture.

With the assistant providing exposure and traction caudally and to the left, a Kelly or similar clamp is placed on the fundus of the gallbladder, which is retracted out of the wound and displaced caudally. A second clamp is applied further down the gallbladder on Hartmann pouch but away from the cystic duct (Fig. 109.3). The peritoneum overlying Calot's triangle is incised and the dissection is continued close to the gallbladder, displacing the cystic node and the fatty, areolar tissues to expose the cystic duct and artery. As for laparoscopic cholecystectomy, the incision to the peritoneum can be continued posteriorly as the Kelly clamp on the infundibulum is displaced upward and medially. This allows clear identification of the cystic duct and artery using a right-angled Lahey or Kittner dissector. The cystic artery is identified and traced onto the gallbladder far enough to ensure that it is not the right hepatic artery. Two braided 2-0 ties are passed around the artery, which is divided between these (Fig. 109.3). The cystic duct is identified by blunt dissection with the right-angled clamp and circled with a ligature, which can be double-looped around the duct to provide temporary atraumatic occlusion of the duct. This maneuver helps prevent small stones or debris being forced down into the CBD during dissection and facilitates performance of a cholangiogram through the cystic duct (see below). If a cholangiogram is not undertaken, the duct can be divided between two ties.

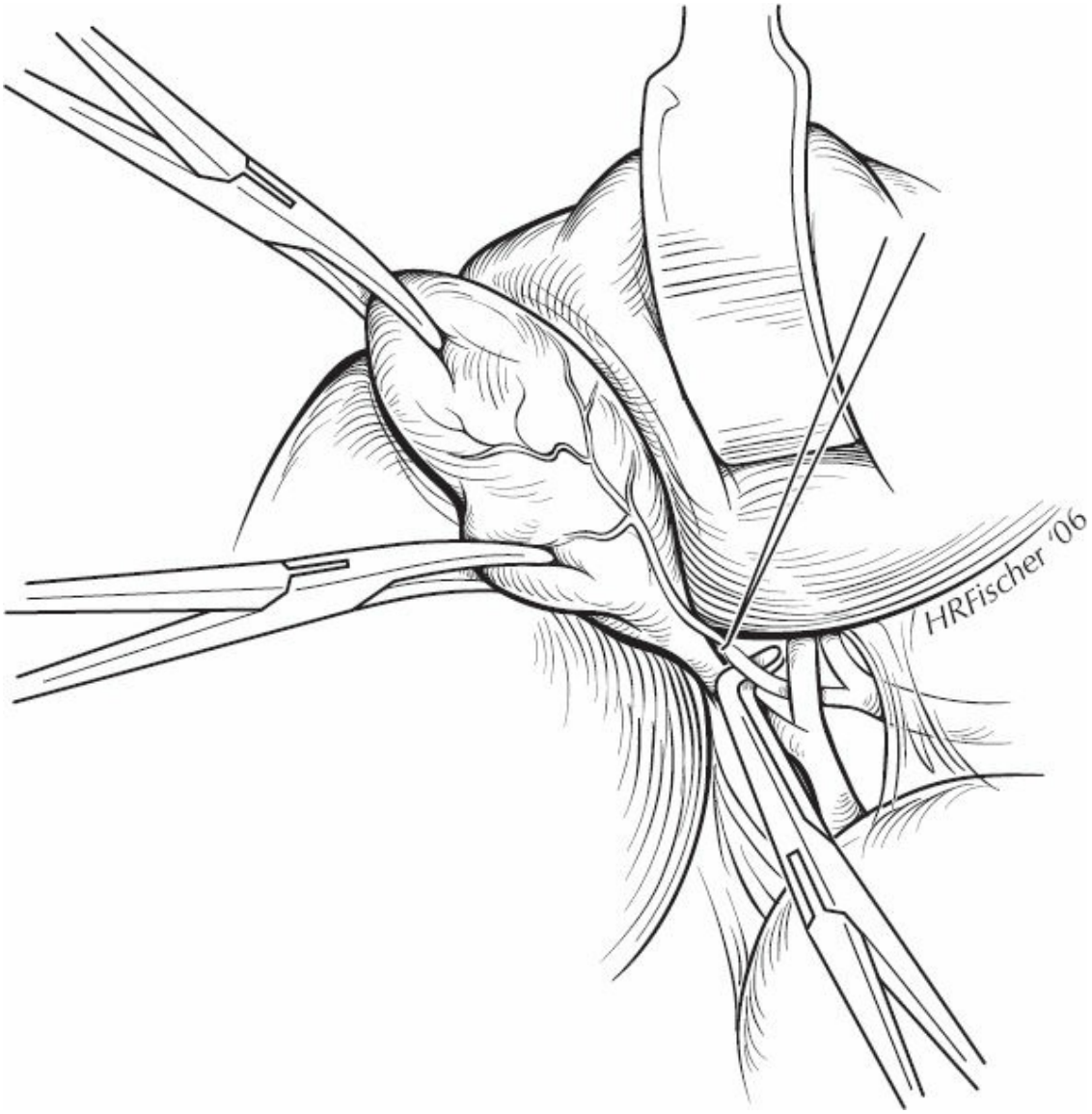

Figure 109.3. Placement of clamps on the gallbladder and dissection of cystic artery during cholecystectomy.

It is inappropriate to dissect the cystic duct to its confluence with the common hepatic duct, but it is important to establish that the cystic duct is free of stones at the end of cholecystectomy. It does not need to be ligated flush with the bile duct because there is no evidence that ligation of the cystic duct at its union with the gallbladder results in residual symptoms. The cystic duct can be short, and dissection may be difficult in the presence of a large, impacted stone, and the presence of acute or chronic inflammation may result in adhesions between the gallbladder and the common hepatic or bile duct, thereby concealing the cystic duct and contributing to the possibility of biliary injury.

Dissection of the gallbladder from the liver proceeds from the fundus

down. In the relatively nondiseased gallbladder, it should be possible to enter the plane between gallbladder and cystic plate, which is superficial to a network of small vessels. Dissection in this plane avoids injury to the liver and any superficial branches of the middle hepatic vein or intrahepatic ductules. Dissection within the correct plane can be facilitated by incising the peritoneum between gallbladder fundus and liver over a right-angled clamp using electrocautery. By displacing the gallbladder from side to side, the attachments between the gallbladder and liver can be exposed and incised (Fig. 109.4). The dissection is continued downward until the peritoneal incision over the gallbladder is continuous with that made previously over Calot's triangle. In a diseased, thick-walled, or fibrotic gallbladder, care should be taken not to enter the cystic plate as dissection deep to this structure risks injury to the right portal pedicle and the right hepatic duct and artery, in particular. If a satisfactory plane cannot be identified as the dissection approaches the hilar structures, consideration should be given to limiting the procedure to a subtotal cholecystectomy.

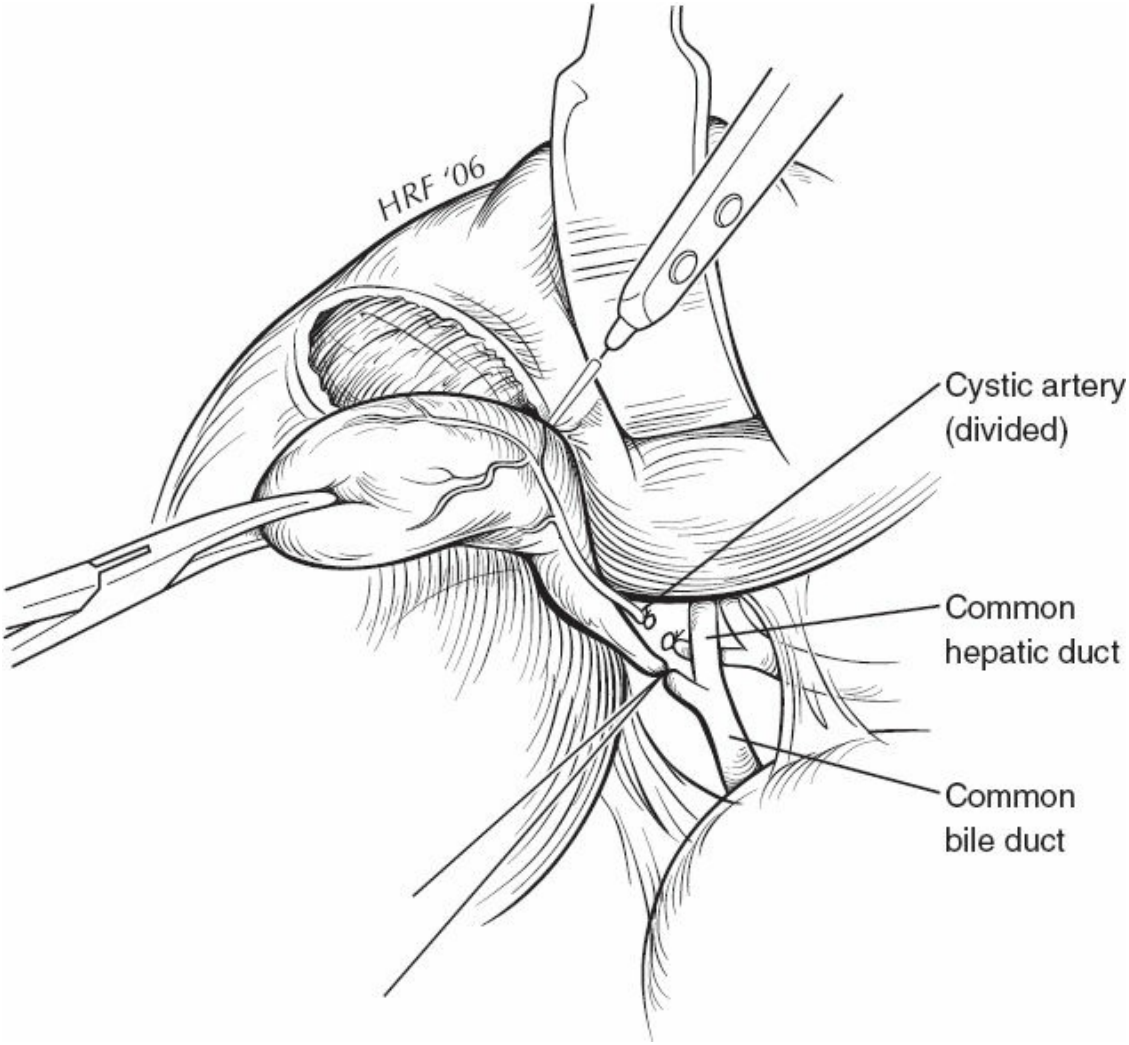

Figure 109.4. Division of peritoneal attachments between the gallbladder and liver using diathermy.

As for laparoscopic cholecystectomy, the mobility gained by clearing the peritoneum posterior to the cystic duct behind Calot's triangle will greatly facilitate the remaining phase of dissection. Having confirmed the continuity between the gallbladder and cystic duct, the dissection should be continued to allow adequate visualization of the common duct–cystic duct junction. Bleeding in the gallbladder bed in the liver is managed by electrocautery as any small vessels are encountered and once the gallbladder has been fully mobilized. Persistent hemorrhage may require the application of a hemostatic agent such as oxidized regenerated cellulose (SURGICEL SNoW or FIBRILLAR©, Ethicon) or for severe problematic bleeding a patch of oxidized regenerated cellulose and VICRYL© containing a dry layer of the human coagulation factors fibrinogen and thrombin (EVARREST©, Ethicon). Care should be taken

to avoid excessive use of unipolar diathermy close to the common hepatic duct as diathermy current may be conducted through the remaining attachments of the gallbladder to the main extrahepatic bile duct. The use of a right-angled clamp for dissection in this area is appropriate until the anatomy is clearly defined.

Operative Cholangiogram

Once the junction of the cystic and common ducts is identified, the bipolar scissors are used to make a small incision in the cystic duct approximately 1 to 2 cm from the common duct. A hemostatic clip or a tie, as outlined previously, should be used on the gallbladder side to prevent spillage of bile when the cystic duct is opened. A soft silastic cholangiogram catheter (measuring No. 5 to 8 French gauge) is used (Fig. 109.5). The catheter and connecting tubes are flushed with sterile saline to remove any bubbles and the catheter is inserted gently into the cystic duct with slight traction being maintained on the gallbladder. As the cannulation is performed, saline solution is injected continuously to avoid air bubbles. A tie or a large or medium-sized hemoclip is employed to secure the cannula, confirming that bile can be aspirated and that saline can be injected easily without extravasation.

Avoiding introduction of air, the syringe of saline is exchanged for one containing dilute or soluble contrast medium. At this point, all packs are removed from the abdomen and any retractors are removed from the operating field. A sterile towel is placed over the wound. The use of operative fluoroscopy and image intensification allows controlled instillation of contrast under gentle pressure to enable full opacification of the extrahepatic biliary tree, confirming free flow of contrast into the duodenum and filling of the right and left hepatic ducts to exclude the presence of any ductal calculi. Should a normal cholangiogram be obtained but contrast fails to enter the duodenum, administration of cholecystokinin (20 mg/kg) or administration of glucagon (1 mg intravenously) should relax the sphincter of Oddi sufficiently to allow the flow of contrast into the duodenum.

Operative Ultrasonography

A 7.5-MHz operative US transducer can be employed to visualize the biliary tree. Imaging is best undertaken before any dissection of the porta hepatis as introduction of air into the adventitial tissues will distort and

compromise the quality of the images obtained. Installation of sterile saline into the right subhepatic space may improve contact as the extrahepatic biliary tree is examined and traced down behind the duodenum into the head of the pancreas and to the ampulla of Vater (Fig. 109.6).

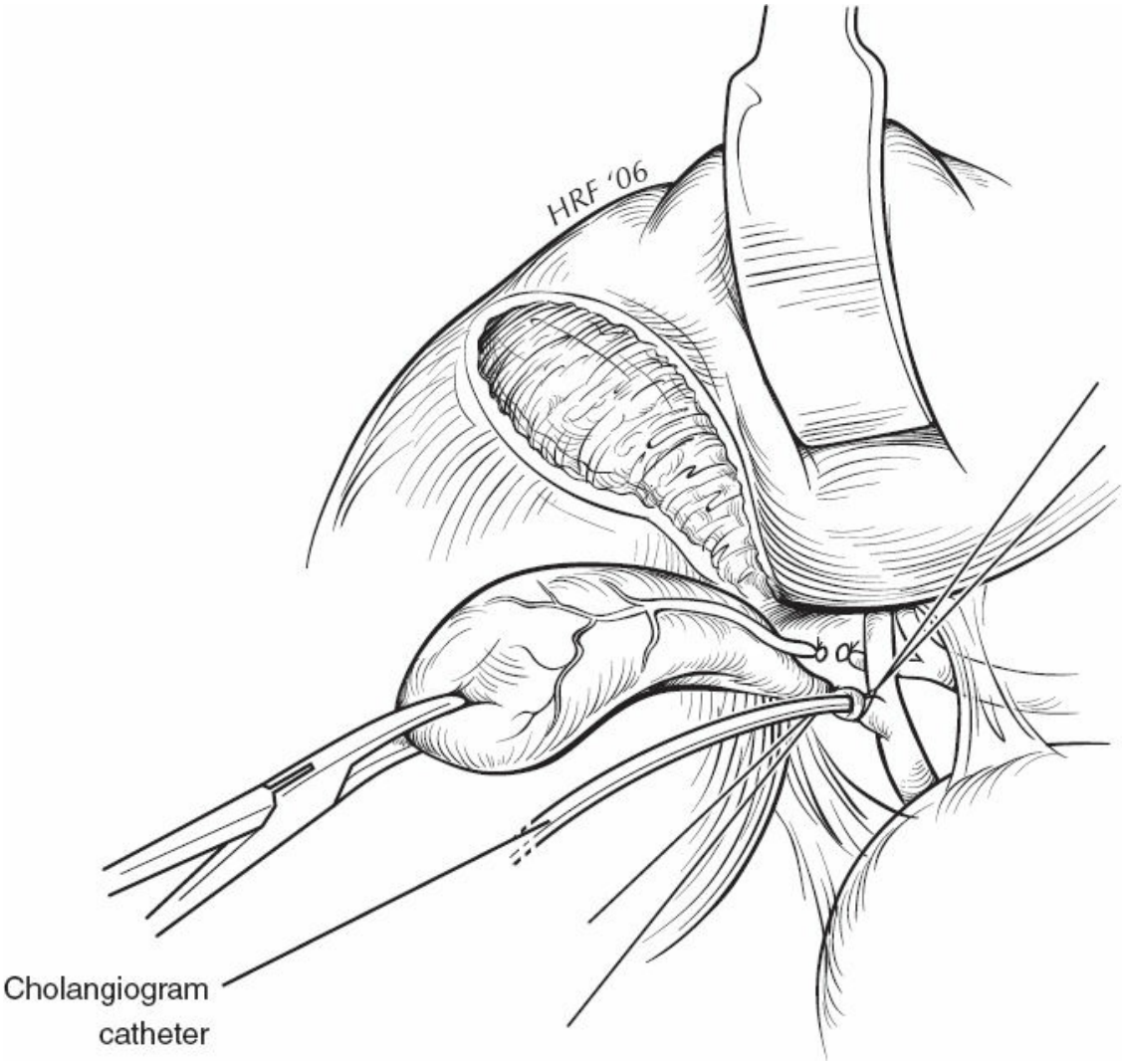

Figure 109.5. A cholangiogram catheter secured in the cystic duct by a ligature.

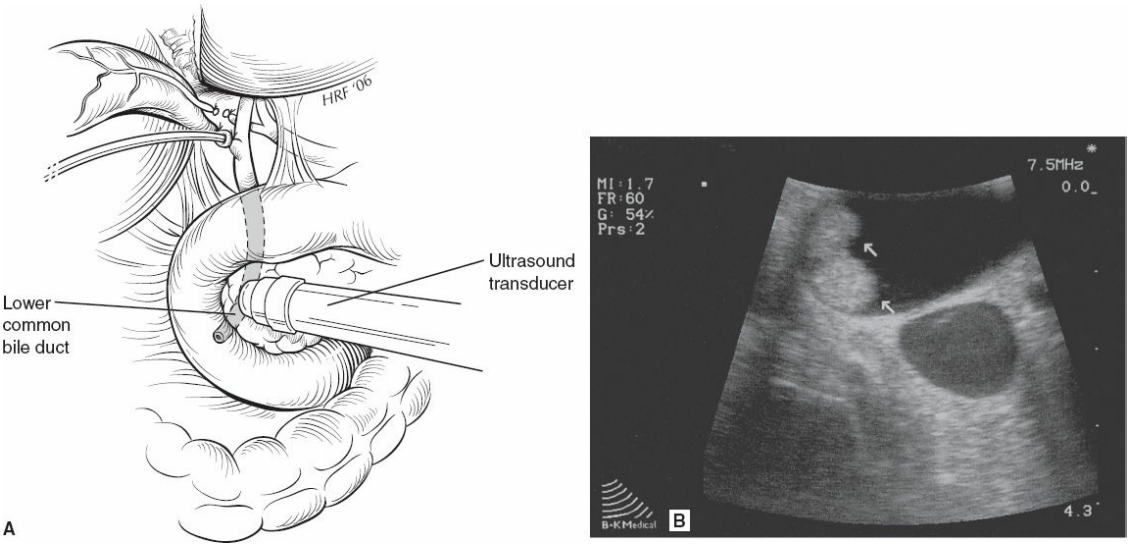

Figure 109.6. A. Ultrasound transducer placed over lower common bile duct (CBD). **B.** Ultrasound image showing multiple small stones (*arrows*) within the lower CBD.

Subtotal Cholecystectomy

Partial or incomplete excision of the gallbladder is a technique that is indicated rarely but may be employed wisely in specific instances when severe inflammation renders identification of the anatomy impossible, such as in some cases of gangrenous cholecystitis, when a scarred partially intrahepatic gallbladder is present, and in some patients with severe cirrhosis and portal hypertension. In such situations, partial cholecystectomy will avoid unnecessary bleeding from the liver bed and eliminate the risk of inadvertent injury to the right portal pedicle.

When total cholecystectomy has to be abandoned, the operating field is protected with packs to avoid contamination of the peritoneal cavity as the gallbladder is opened at its fundus using diathermy. The gallbladder contents are aspirated and any stones are removed. The gallbladder that is not in contact with the liver is excised down to the gallbladder neck but not at its posterior extent at a level that ensures that the common duct is not damaged (Fig. 109.7). If the lumen of the cystic duct cannot be identified, no attempt should be made to transect this structure as disruption of the fibrous tissue in Calot's triangle may again risk damage to the right portal pedicle. A cholangiogram may be obtained by passing a catheter through the lumen of the cystic duct. On completion of this investigation, the cystic duct orifice should be suture-ligated from within with a 3-0 polydioxanone suture. The residual mucosa on the posterior gallbladder wall can be obliterated by diathermy, which should not be directed close to Hartmann

pouch or the cystic duct. With subtotal cholecystectomy, it is essential that the subhepatic space is drained with a closed drainage system.

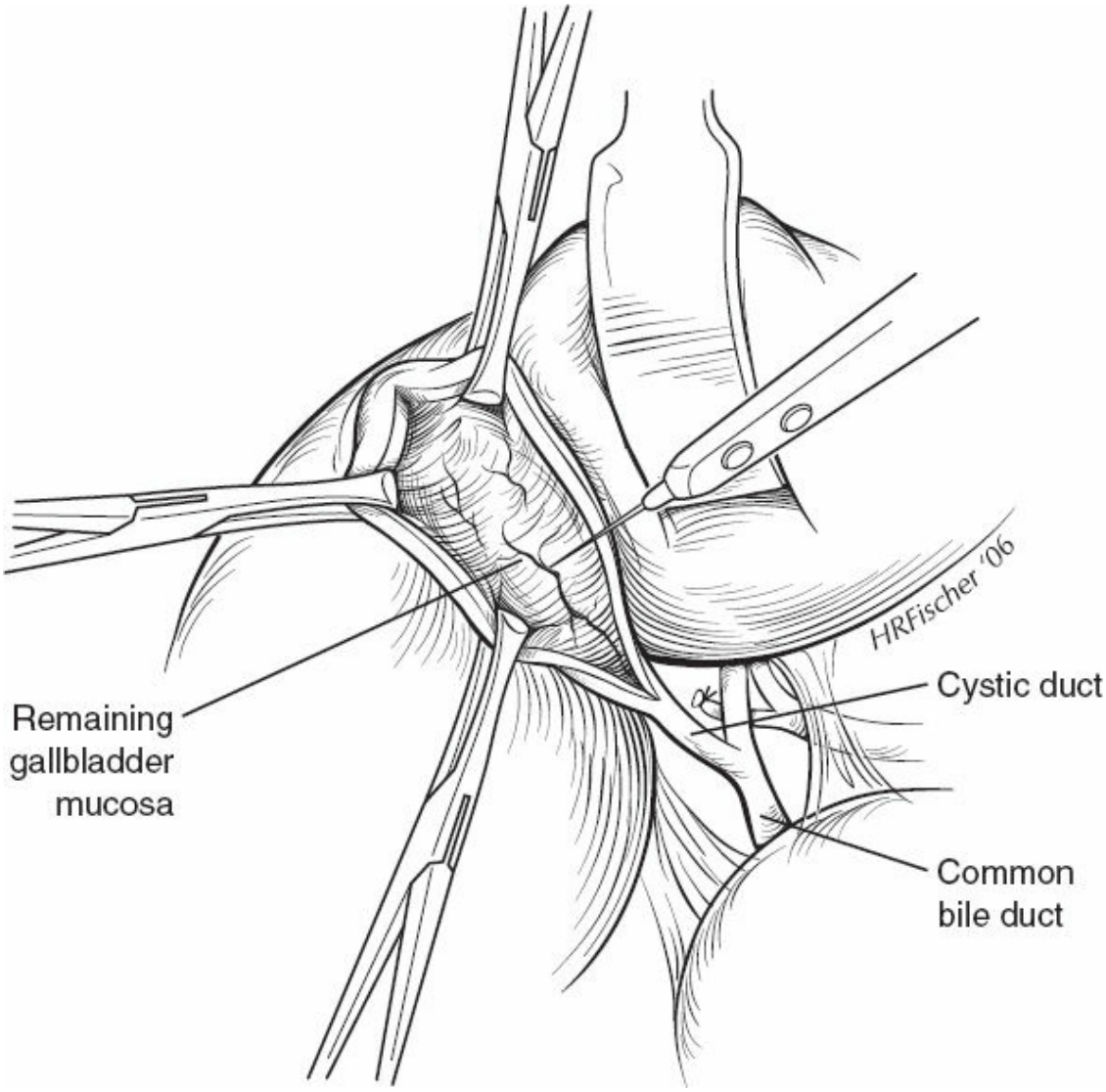

Figure 109.7. Diathermy coagulation being applied to the gallbladder mucosa following subtotal cholecystectomy.

Common Bile Duct Exploration

Operative cholangiography aids the planned exploration of the ductal system by showing the regional anatomy and the approximate number and location of stones. Even if a recent preoperative cholangiogram has been obtained, consideration should be given to undertaking further imaging as the number and location of the stones may have changed.

The ligamentum teres is divided by doubly clamping and ligating the obliterated umbilical vessel in its free edge. Electrocautery is used to divide the remaining ligament. The hepatic flexure of the colon is

mobilized to expose the duodenum. The peritoneum lateral to the duodenum is incised with bipolar diathermy scissors (Fig. 109.8). The second part of the duodenum and head of the pancreas can be displaced anteriorly and medially by passing the index finger of the nondominant hand into the retroperitoneum. The retaining peritoneum is divided with electrocautery, along with any filmy adhesions or vessels. Mobilization should be continued until the nondominant hand can be placed easily behind the head of the pancreas to feel the terminal CBD and ampulla. The hepatoduodenal ligament and lower CBD are palpated for stones and masses. A laparotomy pack is placed behind the duodenum.

Although it may be possible to pass a fine flexible choledochoscope or wire basket through the cystic duct stump to retrieve ductal stones, it is likely that a formal choledochotomy will be required. A short longitudinal incision is made with a No. 11 blade, usually following placement of 4-0 polydioxanone retaining sutures (Fig. 109.9). The previously placed sutures should be elevated to avoid penetration of the back wall with the blade. The choledochotomy should be extended with the blade or sharp scissors to approximately 1 cm in length. Rigid instruments such as Bakes dilators, stone forceps, or scoops have been generally abandoned because of the risk of CBD injury. Stones may be retrieved by gentle irrigation of the duct with saline through a soft rubber catheter. A Fogarty balloon-tipped catheter can be passed both proximally and distally, inflating the balloon before the catheter is gently withdrawn and until all the stones and debris are cleared. Passage of a 3- or 5-mm flexible choledochoscope allows direct visualization and manipulation under direct vision. A Fogarty catheter or wire basket can be passed easily down the channel of a 5-mm choledochoscope to retrieve stones and fragments. Choledochoscopy should always be undertaken to ensure clearance of the ductal system. Saline should be run freely into the duct through the choledochoscope as distention of the duct will allow the lumen to become visible. The scope should not be forced beyond the central lumen of the ampulla, which is generally well visualized. The right and left hepatic duct should be explored superiorly and any stones retrieved.

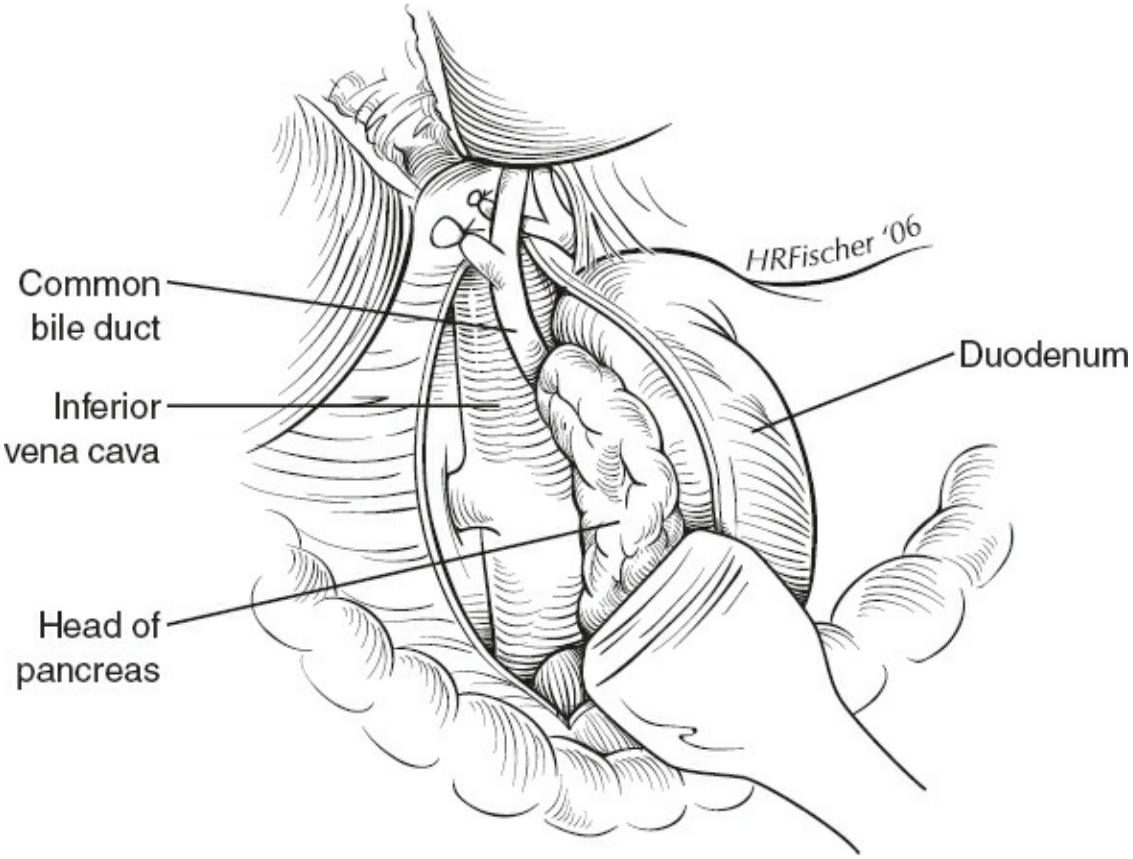

Figure 109.8. Kocherization of the duodenum.

Primary closure of the choledochotomy can be undertaken on completion of duct exploration or a T-tube can be placed to decompress the duct and facilitate the removal of any retained stones in the postoperative period. The tube should be at least a No. 14 French gauge to facilitate percutaneous extraction techniques. Before placement of the T-tube, the back wall of the vertical stem should be excised and a V-shaped wedge fashioned at the junction of the limbs to facilitate subsequent removal of the tube without disruption of the choledochotomy closure (Fig. 109.10). The T-tube should exit the abdomen in a direct fashion, but some slack should be allowed for postoperative abdominal distention. The limb is brought out normally through the anterior abdominal wall laterally so that subsequent radiologic manipulation is possible. It should be established that the vertical limb of the T-tube can slide freely within the CBD. The T-limb is displaced to the upper limit of the choledochotomy so that closure can proceed from below using interrupted 4-0 polydioxanone sutures, ensuring that full-thickness bites of the duct are taken but avoiding narrowing of the lumen. Care should be taken to ensure that the tube itself is not caught by the suture. Saline can be injected into the tube to check for

leaks. It would not normally be necessary to perform a completion cholangiogram if adequate examination of the ducts has been undertaken with choledochoscopy. Stones may be suspected falsely because of previous introduction of air bubbles, and failure of contrast to enter the duodenum may result from sphincter spasm.

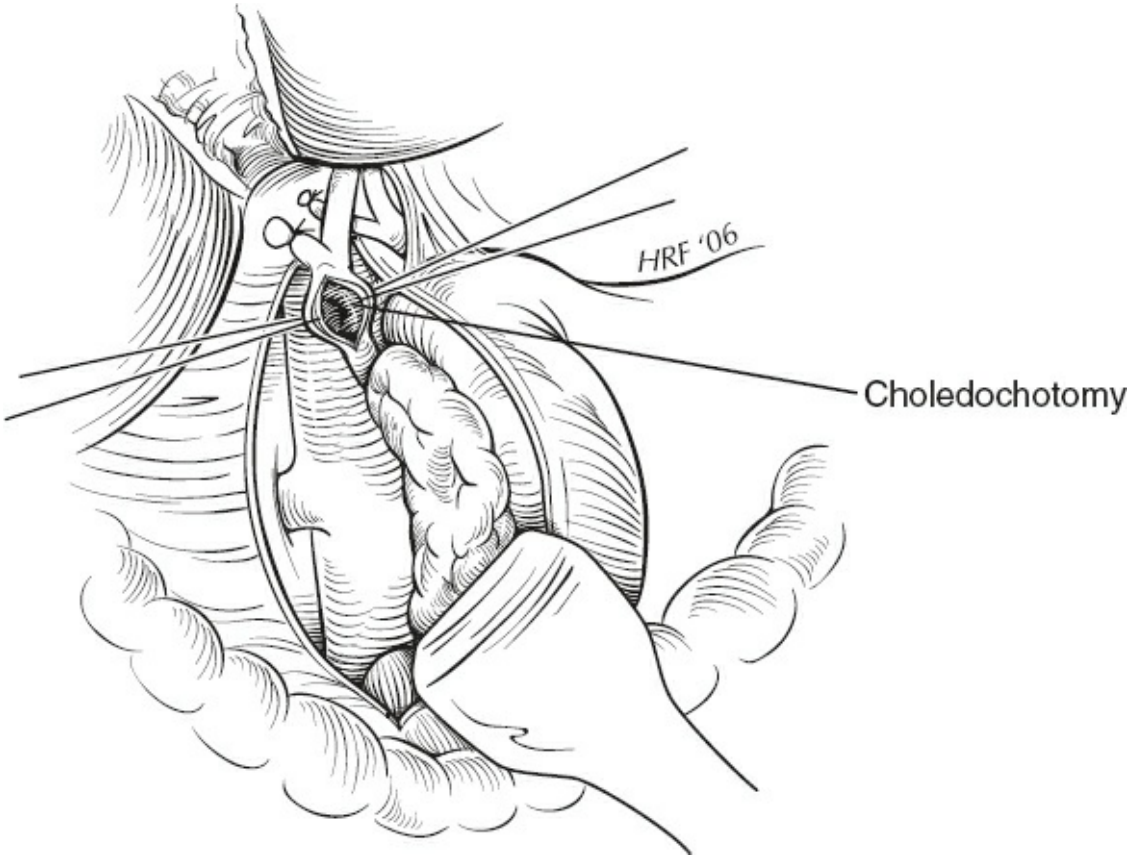

Figure 109.9. Choledochotomy held open by retaining sutures.

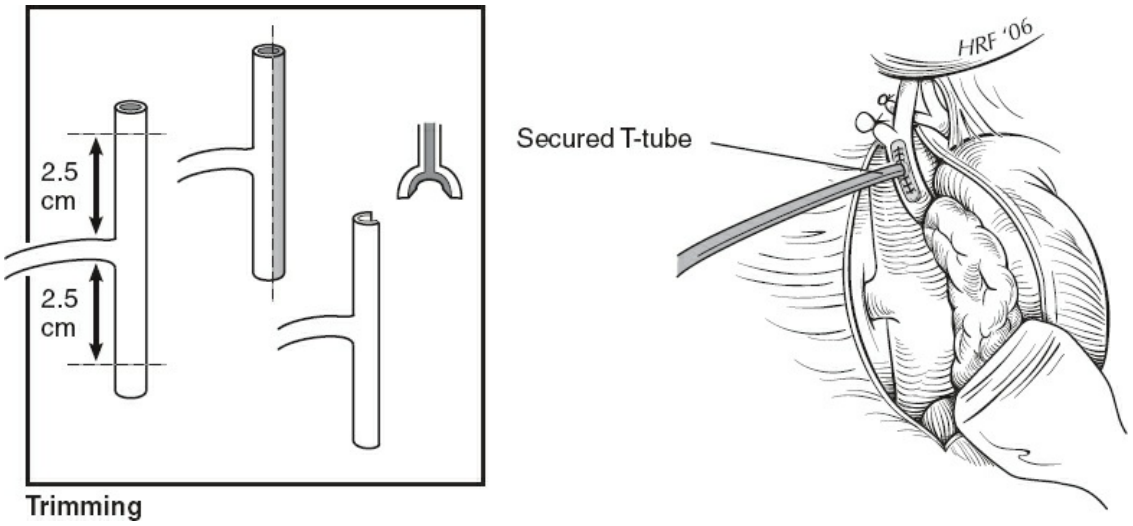

Figure 109.10. The T-tube is trimmed and secured in the choledochotomy by placement of interrupted 4-0 polydioxanone

sutures.

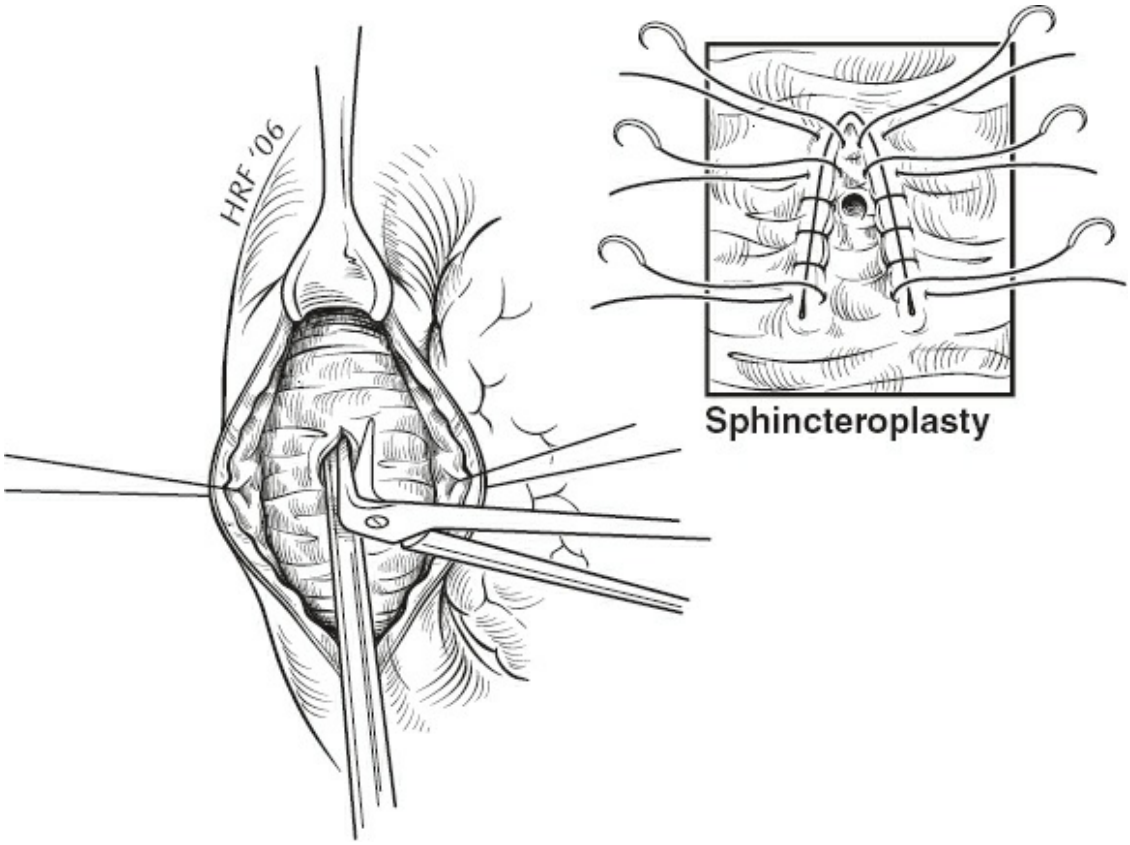

Figure 109.11. Sphincterotomy and fashioning of sphincteroplasty using interrupted 4-0 polydioxanone sutures.

Other Maneuvers

Transduodenal sphincterotomy or sphincteroplasty, along with choledochoduodenostomy and choledochojejunostomy Roux-en-Y, is required uncommonly. With modern techniques for duct exploration, a transduodenal sphincteroplasty is rarely necessary to remove a stone impacted in the distal CBD. A longitudinal duodenotomy approximately 5 cm long is fashioned. A Fogarty biliary balloon catheter can be passed through the ampulla or from above from the choledochotomy as a guide for location of the ampulla. Then, 4-0 polydioxanone stay sutures are placed on either side of the ampulla and are lifted to improve exposure. An incision is made at approximately 11 o'clock to avoid the pancreatic duct orifice, which is usually at about 4 o'clock. Interrupted absorbable sutures (4-0 polydioxanone) are placed along the incision as this is extended superiorly until the opening of the sphincteroplasty is large enough to admit a large Bakes dilator. Any impacted stones can be removed. A

horizontal suture is placed at the apex of the sphincteroplasty to ensure hemostasis and to guard against a posterior perforation of the duodenal wall (Fig. 109.11). The duodenotomy is closed with interrupted 3-0 polydioxanone sutures.

Whereas choledochoduodenostomy can be considered in patients with multiple CBD stones or a distal inflammatory stricture, there is a risk of reflux and "sump syndrome" (Fig. 109.12). Biliary sepsis may result from reflux of food, which may obstruct the anastomosis, and therefore many surgeons prefer drainage into the jejunum. To avoid the risk of sump syndrome and pancreatitis, end-to-side anastomosis following division of the bile duct and oversewing of the distal duct is preferred (Fig. 109.13). A 70-cm Roux-en-Y limb of jejunum is fashioned, restoring intestinal continuity in the infracolic compartment with a single-layer end-to-side anastomosis employing interrupted or continuous 3-0 polydioxanone. The proximal Roux limb is delivered through a defect in the transverse mesocolon, to which it is secured with several interrupted 3-0 polydioxanone sutures. The divided common hepatic duct is anastomosed to the blind end of the Roux limb by constructing a single-layer end-to-side anastomosis with interrupted 4-0 polydioxanone sutures. The anterior wall of the CBD is normally held in place by first securing this using multiple interrupted sutures. The posterior wall anastomosis is constructed again using interrupted sutures, knotting these on the mucosal side. The front wall anastomosis is completed using the previously inserted interrupted sutures attached to the anterior wall of the bile duct and tying these sutures down on the serosal side.

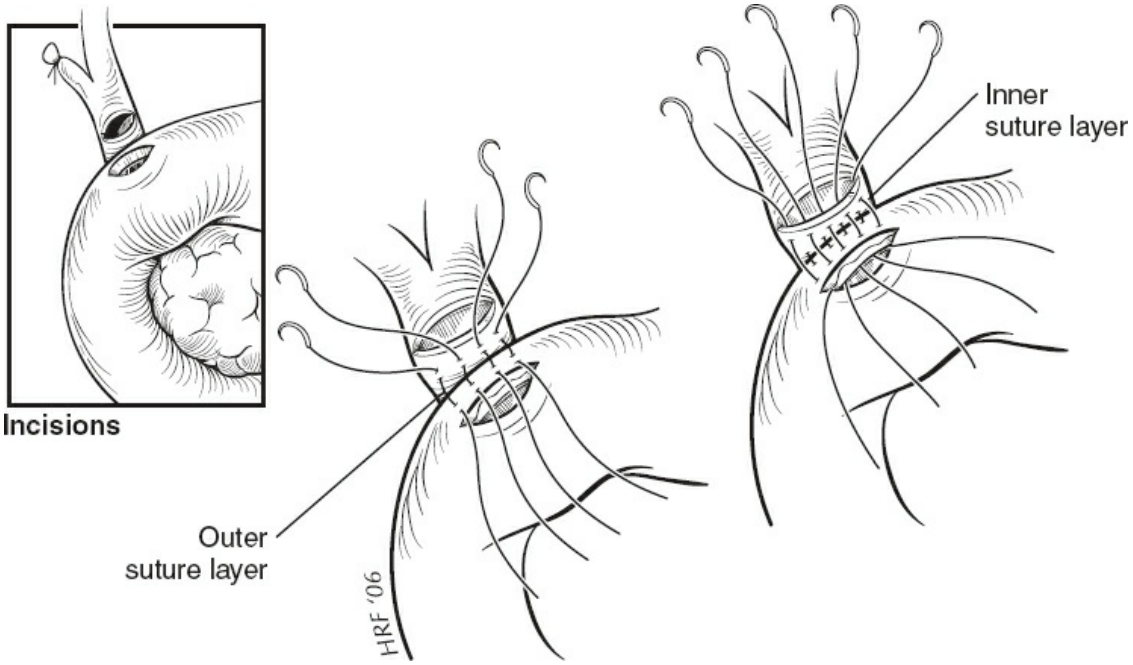

Figure 109.12. A side-to-side choledochoduodenostomy.

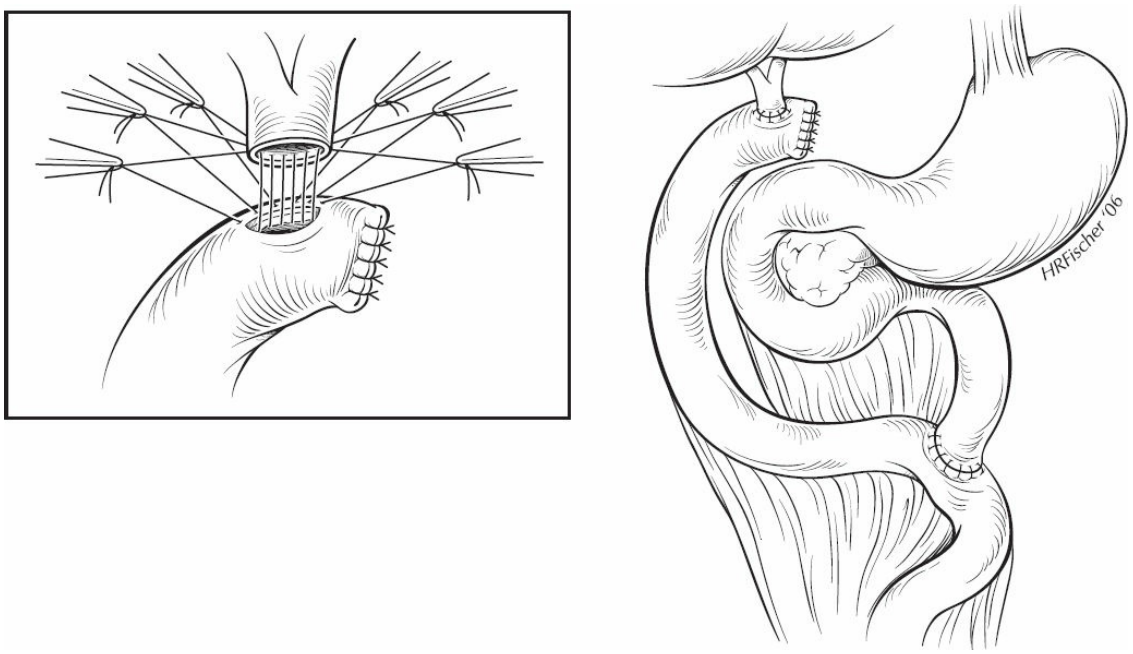

Figure 109.13. Hepaticojejunostomy Roux-en-Y. The anterior wall of the common hepatic duct is secured by retaining polydioxanone sutures.

A Roux-en-Y hepaticojejunal anastomosis is the procedure of choice for those patients with recurrent bile duct stones, biliary stricture related to an intraductal stone, the Mirizzi syndrome, and multiple intrahepatic stones. There is no need to place a stent or tube through the biliary anastomosis.

POSTOPERATIVE MANAGEMENT

Advances in anesthetic and postoperative analgesic care are characterized by enhanced recovery programs that result in early mobilization and discharge. General anesthesia is normally combined with epidural or other regional anesthesia to minimize postoperative pain. In routine cholecystectomy, no drain or nasogastric tube is required. The patient can resume fluid intake and diet when tolerated. Randomized studies have shown no advantage to the routine use of abdominal drains but, in those circumstances where the cholecystectomy or subtotal cholecystectomy has been undertaken for difficult pathology, there may be merit in leaving a closed drainage system to detect any early postoperative bleeding or bile leakage. Closed abdominal drains should be employed in those patients in whom there are concerns for the development of a postoperative collection or when the CBD has been opened. These drains can be removed within 24 to 48 hours when the volume is less than 100 mL per day and there is no bile or fresh blood evident.

In those patients in whom a T-tube has been placed, a cholangiogram is obtained on the 5th to 7th postoperative day. If normal, the tube can be clamped and removed at outpatient review 2 to 3 weeks later. Should a retained stone be identified, the tube is left in place for a further 6 weeks before removal by a radiologist to extract the retained stones percutaneously through the residual tract.

Mild derangement of liver function tests may arise after uneventful cholecystectomy, but any sustained elevation of bilirubin or alkaline phosphatase should prompt reevaluation of the patient's condition and imaging of the abdomen to exclude a postoperative bile leak collection or other complication. The development of a significant collection and/or jaundice mandates early abdominal imaging by computed tomography or postoperative cholangiography by magnetic resonance imaging or endoscopic means to exclude a retained stone or bile duct injury.

Suggested Readings

Bates T, Ebbs R, Harrison M, et al. Influence of cholecystectomy on symptoms. *Br J Surg* 1991;78:964–7.

Bornman PC, Terblanche J. Subtotal cholecystectomy: for the difficult gallbladder in portal hypertension and cholecystitis. *Surgery* 1985;98:1–6.

Harrison EM, O'Neill S, Meurs TS, et al. Hospital volume and patient outcomes after cholecystectomy in Scotland: retrospective, national population based study.

BMJ 2012;344:e3330.

Jenkins PJ, Paterson HM, Parks RW, et al. Open cholecystectomy in the laparoscopic era. *Br J Surg* 2007;94:1382–5.

Keus F, Gooszen HG, van Laarhoven CJ. Open, small-incision, or laparoscopic cholecystectomy for patients with symptomatic cholecystolithiasis. An overview of Cochrane Hepato-Biliary Group reviews. *Cochrane Database Syst Rev* 2010; (1):CD008318. PMID: 20091665.

Sand J, Pakkala S, Nordback I. Twenty to thirty year follow-up after cholecystectomy. *Hepatogastroenterology* 1996;43:534–7.

Strasberg SM, Hertl M, Soper NJ. An analysis of the problem of biliary injury during laparoscopic cholecystectomy. *J Am Coll Surg* 1995;180:101–25.

Vander Velpen GC, Shimi SM, Cuschieri A. Outcome after cholecystectomy for symptomatic gall stone disease and effect of surgical access: laparoscopic v open approach. *Gut* 1993;34:1448–51.

Visser BC, Parks RW, Garden OJ. Open cholecystectomy in the laparoendoscopic era. *Am J Surg* 2008;195:108–14.

Yang TF, Guo L, Wang Q. Evaluation of preoperative risk factor for converting laparoscopic to open cholecystectomy: a meta-analysis. *Hepatogastroenterology* 2014;61:958–65.

EDITOR'S COMMENT

Cholecystectomy is one of the most commonly performed operations. Professor Garden describes the relevant anatomy and indications and contraindications for the procedure. Most elective procedures are performed by the laparoscopic approach. Since the introduction of laparoscopic cholecystectomy (LC), there has been continued evolution in technique, instrumentation, and postoperative management. With increased experience, LC has migrated to the outpatient setting. It is important to note that all cholecystectomies cannot be performed by the laparoscopic technique and the incidence of conversion to an open procedure has been relatively constant at 2.5% to 5%. Hence, it behooves the surgeon to be familiar with open techniques and damage control procedures such as surgical and percutaneous cholecystostomy.

It is interesting to assess cholecystectomy over time in order to determine changes in indications and practice. Talamini and colleagues (Alli W, Yang J, Xu J, et al. *Surg Endos* 2016 September 7 [Epub ahead of print]) used the New York State Planning and Research Cooperative System longitudinal administrative database to assess the indications and incidence of cholecystectomy over time. They found that the incidence of cholecystectomy had not changed but the indications had. In this report from 1995 to 2013, there

were 711,406 cholecystectomies performed in New York State: 637,308 (89.58%) laparoscopic. The overall frequency of cholecystectomy did not increase (1.23% increase with a commensurate population increase of 6.32%). They found that the incidence of calculous cholecystitis declined (–20.09%, $p < 0.0001$) between 1995 and 2013; meanwhile, other diagnoses increased in incidence: biliary colic (+54.96%, $p = 0.0013$), acalculous cholecystitis (+94.24%, $p < 0.0001$), gallstone pancreatitis (+107.48%, $p < 0.0001$), and biliary dyskinesia (+331.74%, $p < 0.0001$). In addition, there was a transition to outpatient LC incidence with 48.59% being done as an outpatient in 2013, from 0.15% in 1995, increasing >320-fold.

Although most cholecystectomies are performed as laparoscopic procedures, there is a conversion rate of 2.5% to 5%. Multiple factors increase the risk of open conversion. Most surgeons have a good feel of the risk for conversion in individual patients with consideration given to the indication for the procedure, gender, previous upper abdominal surgery, etc. Indeed the risk of conversion of an LC to an open cholecystectomy has been widely studied. Information from meta-analyses indicates that age >65 years, male gender, acute cholecystitis, thickened gallbladder wall, diabetes mellitus, and previous upper abdominal surgery were significantly associated with increased risk of conversion. Evaluating these factors may be useful for surgeons in counseling the patient and in planning (Rothman P, Burcharth J, Pommergaard HC, et al. Preoperative risk factors for conversion of laparoscopic cholecystectomy to open surgery—a systematic review and meta-analysis of observational studies. *Dig Surg* 2016;33(5):414–23; Yang TF, Guo L, Wang Q. Evaluation of preoperative risk factor for converting laparoscopic to open cholecystectomy: a meta-analysis. *Hepatogastroenterology* 2014;61(132):958–65). An interesting recent study indicated that an elevated C-reactive protein, as a marker of the degree of inflammation, is an excellent independent predictor of the need to convert to open procedure (Jessica Mok KW, Goh YL, Howell LE, et al. Is C-reactive protein the single most useful predictor of difficult laparoscopic cholecystectomy or its conversion? A pilot study. *J Minim Access Surg* 2016;12(1):26–32). You may want to assess this in your practice.

If there was a validated preoperative stratification, then it could theoretically be used to improve the consent, scheduling (time and ambulatory surgery site or hospital) and identify appropriate training cases. Indeed, a validated risk score for conversion for use in clinical practice has been developed and seems to allow for preoperative identification of patients with a six-fold increased risk of conversion to open cholecystectomy. The risk score was derived from six significant predictors: age ($p = 0.005$), male gender ($p < 0.001$), indication for surgery ($p < 0.001$), ASA Classification ($p < 0.001$), thick-walled gallbladder ($p = 0.040$), and CBD diameter ($p = 0.004$). A score >6 identified patients at high risk of conversion (7.1% vs. 1.2%) (Sutcliffe RP, Hollyman M, Hodson J, et al. Preoperative risk factors for conversion from laparoscopic to open cholecystectomy: a validated risk score derived from a prospective U.K.

database of 8820 patients. *HPB (Oxford)* 2016;18(11):922–8).

The management of the surgically or percutaneously placed cholecystostomy tube is similar. It is best to adopt a standard protocol for your institution or practice. First, the surgeon must wait an appropriate period of time for healing to occur. Premature removal can be associated with intraperitoneal leakage from the cholecystostomy. Second, the gallbladder must be cleared of stones and the patency of the biliary trees established prior to removal of the tube. It is advisable to perform a cholecystogram with water soluble contrast to determine whether there are residual stones in the gallbladder. If the cystic duct is patent, then the common bile duct will also be visualized. Our protocol is to do imaging at 6 weeks post cholecystostomy and proceed with stone clearance or definitive treatment. The management of percutaneously placed tubes has been studied as well. These tubes are considered for removal once the patient has recovered from critical illness, and they show patent cystic and common bile ducts on imaging. Premature removal of the tubes leads to major bile leaks in 3% of patients and an equal frequency of minor leaks. Professor Garden describes the techniques to accomplish stone removal from the gallbladder. If stones are present in the common bile duct, then an endoscopic sphincterotomy should be considered. If the patient has improved and concurrent medical conditions resolved, then the patient may be best served by an open or LC.

A retrospective series of adult patients (n = 185) admitted with a primary diagnosis of acute cholecystitis and who received a cholecystostomy tube from 2002 to 2010 reported that most patients whether they had a percutaneous or surgical cholecystostomy had a successful LC (Cherng N, Witokski ET, Sneider EB, et al. Use of cholecystostomy tubes in the management of patients with primary diagnosis of acute cholecystitis. *J Am Coll Surg* 2012;214:196–201). In this study, the mean patient age was 71 years and 80% had ≥1 comorbidity (mean 2.6). Seventy-eight percent of the tubes were percutaneous and 22% were surgical. The majority (57%) of patients underwent cholecystectomy performed a median of 63 days post-tube placement (range 3 to 1,055 days); of these, 86% underwent LC and 13% underwent open conversion or open cholecystectomy. The authors noted that whether surgical or percutaneous tube placement, the same proportion of patients (85% to 86%) underwent LC as definitive treatment. The disposition of those not having surgery is unknown.

An additional study focusing on percutaneous drains found that only 32% of patients eventually had cholecystectomy. The patients having cholecystectomy were younger and had a lower Charlson comorbidity index (Boules M, Haskins IN, Farias-Kovac M, et al. What is the fate of the cholecystostomy tube following percutaneous cholecystostomy? *Surg Endo* 2017;31(4):1707–12). It is prudent to avoid cholecystectomy in elderly patients who are frail and have multiple comorbid conditions. In addition, the tubes can be safely removed with long-term survival and no recurrent cholecystitis (Cha BH, Song HH, Kim YN, et al. Percutaneous cholecystostomy is appropriate as definitive treatment for acute cholecystitis in critically ill patients: a single center, cross-sectional study.

Korean J Gastroenterol 2014;63(1):32–8).

From these two studies, it is clear that a substantial number of patients having surgical or percutaneous cholecystostomy tube placement do not undergo cholecystectomy. A decision to proceed with definitive surgery should be based on the assessment of the individual patient.

There are two conditions that I think deserve special discussion in the discussion of open cholecystectomy. If either of these is diagnosed preoperatively, then in my opinion an open cholecystectomy should be strongly considered. The first is Mirizzi syndrome and the second is gall bladder perforation.

The authors do comment on Mirizzi syndrome, and it is important to emphasize that if the diagnosis is established preoperatively then the surgeon should plan on an open procedure in the majority of patients. This syndrome develops when multiple and large gallstones become impacted in Hartmann pouch of the gallbladder leading to chronic inflammation and hence compressions of the common bile duct and eventually fistula formation into the adjacent common hepatic duct or common bile duct. As a result, the common bile duct or common hepatic duct becomes obstructed. There are four types: type I A—presence of cystic duct; type I B—obliteration of the cystic duct; and types II–IV—fistula present and classified on the basis of the size of the defect relative to the lumen of the common hepatic duct II <33%, III 33% to 66%, and IV >66%. It is essential to differentiate the conditions from malignancy.

In a recent review, Mirizzi syndrome was identified in 60 of 4,939 patients (1.21%) who underwent cholecystectomy (Kulkarni SS, Hotta M, Sher L, et al. Complicated gallstone disease: diagnosis and management of Mirizzi syndrome. *Surg Endos* 2016 September 1 [Epub ahead of print]). Three had coexistent gall balder cancer. The mean age at presentation was 47 years, and 35 patients were females. The most common symptom at presentation was abdominal pain (100%) followed by nausea/vomiting (87%) and jaundice (43%). Type I was diagnosed in 16 patients and 44 had type II. Preoperative diagnosis was achieved in 43 patients (71%) primarily by magnetic resonance cholangiopancreatography. LC was successful in only 4 out of 16 patients with type I. The presence of the syndrome makes open cholecystectomy likely. Those with type II–IV require open cholecystectomy and not in frequently Roux-en-Y reconstruction of the biliary tree. In situations in which there is severe inflammation, the fistula can be sutured to the roux limb creating a side-to-side choledochjejunostomy.

Acute perforated cholecystitis is probably the most severe complication of acute cholecystitis. This is a rare complication. In assessing this condition and planning for operative intervention, the surgeon must consider the high conversion rate and complications. A recent study looked at the outcome of acute perforated cholecystitis in a register study of more than 5,000 cases in Germany (Jansen S, Doerner J, Macher-Heidrich S, et al. Outcome of acute perforated cholecystitis: a register study of over 5000 cases from a quality

control database in Germany. *Surg Endosc* 2016 August 23 [Epub ahead of print]). In this study, a total of 5,704 patients with acute gallbladder perforation were included compared with 39,661 patients without perforation. Risk factors for perforation were: the male gender, advanced age (>65 years), ASA score >2, elevated white blood count (WBC), positive findings on abdominal ultrasound sonography and fever. Preoperative computed tomography (CT) was ordered significantly more often in the perforated group compared to those without perforation (2.3 vs. 1.0%, $p = 0.001$). Surgery lasted significantly longer in the patients with perforation. For the perforated group, the rates of conversion to an open procedure were likewise greater (18.9 vs. 6.8%), as was bile duct injury (1.4 vs. 0.5%), re-intervention (6.9 vs. 2.9%), mortality (4.3 vs. 1.3%), and the length of stay (13.4 ± 11.4 days vs. 9.0 ± 8.3, $p < 0.001$).

Professor Garden describes an excellent technique for common bile duct exploration (CBDE). It is very similar to the one I employ. One difference is that I have found that the procedure is easier if performed from the left side of the patient. This allows the surgeon to place his left hand behind the routinely Kocherized duodenum to palpate the intrapancreatic portion of the bile duct as part of the procedure while using the right hand for the common duct exploration or choledochoscopy.

A recent study highlighted the marked decline in the use of both open and laparoscopic CBDE in the United States as well as any advantage to the length of stay laparoscopic common duct exploration over ERCP and LC (Wandling MW, Hungness ES, Pavey ES, et al. Nationwide assessment of trends in choledocholithiasis management in the United States from 1998 to 2013. *JAMA Surg* 2016;151(12):1125–30). The authors suggest that common duct exploration may be at risk of disappearing. The study used the National Inpatient Sample data from 1998 to 2013. In total, 37,207 patients were included in the analysis, 36,048 (96.9%) were treated with ERCP and LC, and 1,159 (3.1%) were treated with laparoscopic CBDE and LC. The overall use of CBDE for patients with choledocholithiasis decreased from 39.8% of admissions in 1998 to 8.5% in 2013 ($P < 0.001$). A decrease was also seen for open CBDE (30.6% vs. 5.5%; $P < 0.001$) and laparoscopic CBDE (9.2% vs. 3.0%; $P < 0.001$) independently.

In summary, the prepared surgeon should understand conditions in which open cholecystectomy might be likely. In these circumstances, assessment of the biliary tree with cholangiography is important as is the understanding of appropriate methods of damage control in the critically ill patient. Certain conditions may warrant open cholecystectomy. Familiarity with open common duct exploration is decreasing, and it behooves each surgeon to develop a strategy for dealing with common duct stones that may not be amendable to percutaneous or endoscopic treatment.

E. Christopher Ellison

110 Laparoscopic Cholecystectomy, Intraoperative Cholangiography, and Common Bile Duct Exploration

John G. Hunter and Laura E. Fischer

INTRODUCTION

In 1882, the first open cholecystectomy was performed in Berlin by Carl Langenbuch to treat a 42-year-old man with long-standing biliary colic; however, cholecystectomy was not commonly accepted as a treatment for gallstone disease until the turn of the century. The first two laparoscopic cholecystectomies (LC) in the world were performed by Eric Muhe in Boblingen, Germany, in 1985 and Philippe Mouret in Lyon, France, in 1987. Working independently, two groups of American surgeons performed the first LC in the United States in 1988.

In 1990, 10% of cholecystectomies were being performed laparoscopically in the United States. This figure has risen dramatically over the past two decades and stands at 90.5% in 2010. Never before had a surgical revolution occurred so quickly. The major advantage of the laparoscopic approach was improved recovery, which allowed patients to have better quality of life in the immediate postoperative period. Although prospective randomized trials came late, they showed the clear advantages of LC over open cholecystectomies: less pain with faster recovery. However, this cataclysmic change took its toll. Training of surgeons to perform the highly technical procedure was frequently inadequate, and early complications gave birth to the phrase *learning curve.* It is the purpose of this chapter to review the lessons of the last 30 years and to detail current techniques for LC, intraoperative cholangiography (IOC), laparoscopic ultrasonography, and common bile duct (CBD) exploration.

ETIOLOGY AND PATHOPHYSIOLOGY

Gallstone disease refers to symptoms related to the presence of gallstones

in the gallbladder or the CBD. There are two main types of gallstones—cholesterol and pigmented. There are multiple risk factors related to the formation of cholesterol gallstones, including age >40, female gender, pregnancy, estrogen replacement therapy, family history, obesity, rapid weight loss, diabetes mellitus, and cirrhosis. Gallbladder stasis due to total parenteral nutrition, prolonged fasting, or excess somatostatin can also contribute to the formation of stones. Certain drugs can also promote the formation of gallstones, most importantly ceftriaxone, which is partially excreted through the biliary system. Disorders associated with hemolysis, such as hemolytic anemia, are associated with the formation of pigmented gallstones.

Statins and other dietary factors, including vitamin C, coffee, vegetable protein, nuts, and poly- and monounsaturated fats, have all been associated with a reduced risk of gallstone disease.

It has been estimated that approximately 10% to 15% or over 20 million adults in the United States have gallstone disease. In addition, 1 million new diagnoses are made each year. The prevalence is higher in those of Caucasian, Hispanic, and Native American descent, and lowest in the African American and Japanese populations.

CLINICAL PRESENTATION, INDICATIONS AND CONTRAINDICATIONS

Symptomatic Cholelithiasis

The major indication for elective LC is symptomatic cholelithiasis, also known as “biliary colic.” Classic symptoms present in the majority of patients include stabbing (colicky) pain in the right upper quadrant radiating to the back and to the shoulder. Although it is often taught that this pain occurs 30 to 60 minutes after the patient eats a fatty meal, the pain pattern is not always so predictable. Frequently, the pain occurs in the middle of the night, usually between the hours of midnight and 3 AM. After waking the patient, the pain generally lasts from a few minutes to a few hours. Usually, the pain passes within an hour, and the patient returns to sleep. Frequently, the pain is associated with nausea and vomiting but is rarely accompanied by jaundice, fevers, or chills, unless acute cholecystitis or cholangitis is present. When the pain is most severe and unrelenting, an emergency room visit is prompted. Myocardial infarction is often suspected, but it is “ruled out” with a normal electrocardiogram and

cardiac isoenzymes. An ultrasound of the right upper quadrant should be performed, and if it demonstrates cholelithiasis in this setting, elective LC is indicated. Occasionally, the presentation is less characteristic of biliary colic. The patient may only complain of a nagging, dull pain in the right side, epigastrium, or back without the severity of colic. In this setting, the association of gallstones and right upper quadrant pain that cannot be attributed to another cause merits consideration of LC.

Biliary Dyskinesia

The sphincter of Oddi is a muscular segment of the intraduodenal bile duct and ampulla of Vater. This 6- to 10-mm complex of circular muscle fibers maintains resistance to bile flow and permits filling of the gallbladder in between meals. If this muscle does not adequately relax, the gallblaadder cannot empty and patients can feel pain in the right upper quadrant, similar to biliary colic, but without evidence of cholelithiasis on ultrasonography. This dysfunction can also be associated with recurrent pancreatitis. Functional gallbladder disorders have also been described in which there is a primary absence of gallbladder motility, in the absence of gallstones or sludge. These disorders typically are not associated with elevated liver function tests, bilirubin, amylase, or lipase serum values.

Similar to biliary colic, the pain lasts for a few minutes to a few hours, is located in the epigastrium or right upper quadrant, can awaken the patient in the middle of the night, and is associated with nausea and vomiting. These patients often have an extensive work-up with negative ultrasound and esophagogastroduodenoscopy. It is often a diagnosis of exclusion; however, a CCK-stimulated cholescintigraphy can be used to estimate the gallbladder ejection fraction (GBEF). This study is performed by injecting ^{99m}Tc-hepatic iminodiacetic acid (HIDA) as an intravenous bolus and then measuring the activity of the radiotracer over time. Patients with a GBEF of less than 35% to 40% are considered to have abnormal gallbladder motility and may have symptomatic relief from an elective LC.

Acute Cholecystitis

Complicated gallstone disease is usually managed laparoscopically in the same manner as it was managed during the era of open cholecystectomy. Acute cholecystitis, which is characterized by fever, leukocytosis, right upper quadrant tenderness, and gallstones, demands more immediate attention than biliary colic. LC in patients with acute cholecystitis may be

significantly more difficult and is associated with conversion rates of 5% to 10% (depending on surgeon experience), but it is nonetheless worth pursuing in patients without severe concomitant risk factors. Multiple trials have shown that early treatment of acute cholecystitis has been shown to have a reduced length of hospital stay and does not increase complications. In fact, early surgery has been associated with reduced risk of mortality, fewer bile duct injuries, and less conversion to open when compared to delayed cholecystectomy. Surgery should be performed as soon as possible after the onset of symtpoms, and preferably within 72 hours. Nonoperative management with a plan for delayed cholecystectomy fails in approximately 15% of patients due to recurrent cholecystitis, pancreatitis, or cholangitis. In extremely high-risk patients, the placement of a percutaneous cholecystostomy tube can be an alternative to surgical intervention. However, the procedure is associated with a high morbidity and mortality, so it should be reserved for those patients who are clearly unfit for emergency surgery.

Gallstone Pancreatitis

During initial hospitalization, mild biliary pancreatitis is approached by allowing the patient's abdominal pain to resolve and document that the serum lipase level is trending toward a normal level before performing LC. In this setting, some surgeons choose to perform a preoperative endoscopic retrograde cholangiopancreatography (ERCP) and endoscopic sphincterotomy (ES) (if a stone is detected on ERCP) before LC. Bile duct stones will be found in only 10% to 15% of these patients, subjecting the remaining 85% to an unnecessary procedure and the risk of recurrent pancreatitis. Therefore, it is our practice to perform an intraoperative cholangiogram at the time of LC and perform CBD exploration through the cystic duct or through a choledochotomy if stones are present. For a surgeon inexperienced in laparoscopic bile duct exploration, we advocate completion of the LC with postoperative ERCP and ES. Unless the stones are very large (>1 cm), ERCP with ES has very high success rates and avoids the morbidity of an open cholecystectomy and bile duct exploration. However, conversion to open cholecystectomy with CBD exploration is a reasonable option, and should be chosen when the bile duct stones are large (>1 cm), when the CBD is extremely dilated (>12 mm), or the stone burden is formidable. Anatomic concerns, such as previous gastric bypass operation, will make ERCP a difficult option,

favoring a direct approach to the CBD.

Cholangitis

Cholangitis is characterized by jaundice, shaking chills, and right upper quadrant pain and tenderness. This is a medical emergency that should be treated with urgent preoperative ERCP, ES, and stone extraction unless the infection is quickly and easily controlled with intravenous antibiotic therapy. ERCP and ES are successful at removing all CBD stones in more than 90% of patients with cholangitis. Laparoscopic bile duct exploration and stone extraction in this setting may be difficult because the stone is often impacted and the bile duct is inflamed and friable. If the cholangitis resolves with antibiotics and the patient's symptoms resolve, it may be appropriate to perform elective LC, intraoperative cholangiography, and laparoscopic bile duct exploration if a stone is detected. Alternatively, LC can be performed shortly after the CBD has been cleared through ERCP and ES. The appropriate management of CBD stones in the era of LC remains fertile soil for good clinical studies.

Contraindications

Absolute contraindications to LC are few. Certainly, a patient who is unable to tolerate general anesthesia, a patient with gallbladder cancer (suspected or confirmed), and a patient with a "frozen upper abdomen" due to previous surgery or peritonitis should not undergo LC. In addition, relative contraindications include any previous right upper quadrant surgery, portal hypertension, coagulopathy, and cholecystoenteric fistula. Although successful management of gallstone disease has been achieved in all of these patient groups, these procedures should be left for the surgeon who makes laparoscopy the majority of his or her practice and is technically skilled in these areas.

Pregnancy is not a contraindication to LC and can be performed safely with a few modifications such as the Hasson technique for abdominal access, a left-sided bed tilt, and appropriate placement of trocars to accommodate the size of the gravid uterus. LC is considered the preferred technique for the pregnant patient as it offers a faster postoperative recovery, reduced opioid usage, and fewer wound complications.

PREOPERATIVE PLANNING

Preoperative Testing

In addition to a careful history and physical examination, preoperative testing for 90% of patients with gallstone disease is minimal. An ultrasound of the right upper quadrant usually confirms the diagnosis, and the hepatic biochemical profile (alkaline phosphatase, serum glutamic–oxaloacetic transaminase, bilirubin, and lactic acid dehydrogenase) usually determines the likelihood that CBD stones are present. Striking abnormalities in the hepatic profile or an ultrasonographically dilated CBD may warrant a preoperative ERCP or magnetic resonance cholangiography (MRCP), or both, to search for the cause (e.g., neoplasm or stricture) of the bile duct obstruction.

The diagnosis of acute cholecystitis, when the history and physical examination are less than definitive, can be made with a HIDA scan as described above. As described previously, an ejection fraction of less than 35% at 30 minutes suggests poor contractile function and incomplete emptying of the gallbladder. Nonfilling of the gallbladder in 1 hour, especially after administration of intravenous morphine, which contracts the Oddi sphincter, is a highly accurate predictor of acute cholecystitis. When the ultrasound demonstrates nonuniform thickening of the gallbladder wall or pancreatic head, a computed tomographic scan should be performed to assess the likelihood of the presence of gallbladder cancer.

Operative Equipment

The first step in successful LC is the recruitment of a good operating team. This includes a well-trained laparoscopic surgeon, a first assistant with equivalent skills, and a camera operator who is familiar with the anatomy and technique of LC. With a well-choreographed operation, the first assistant can also be the camera operator. The elimination of a dedicated “camera operator” can only be achieved if the surgeon uses a two-handed operating technique. Ideally, the patient is placed on a fluoroscopic table with the table turned backwards for easy access to the upper abdomen by the fluoroscopic C-arm. Two monitors are placed at the 10 o’clock and 2 o’clock position with respect to the patient’s head (Fig. 110.1). Generally, the surgeon stands to the patient’s left, and the first assistant stands to the patient’s right. If a dedicated camera operator is used, that person stands behind the surgeon on the left side.

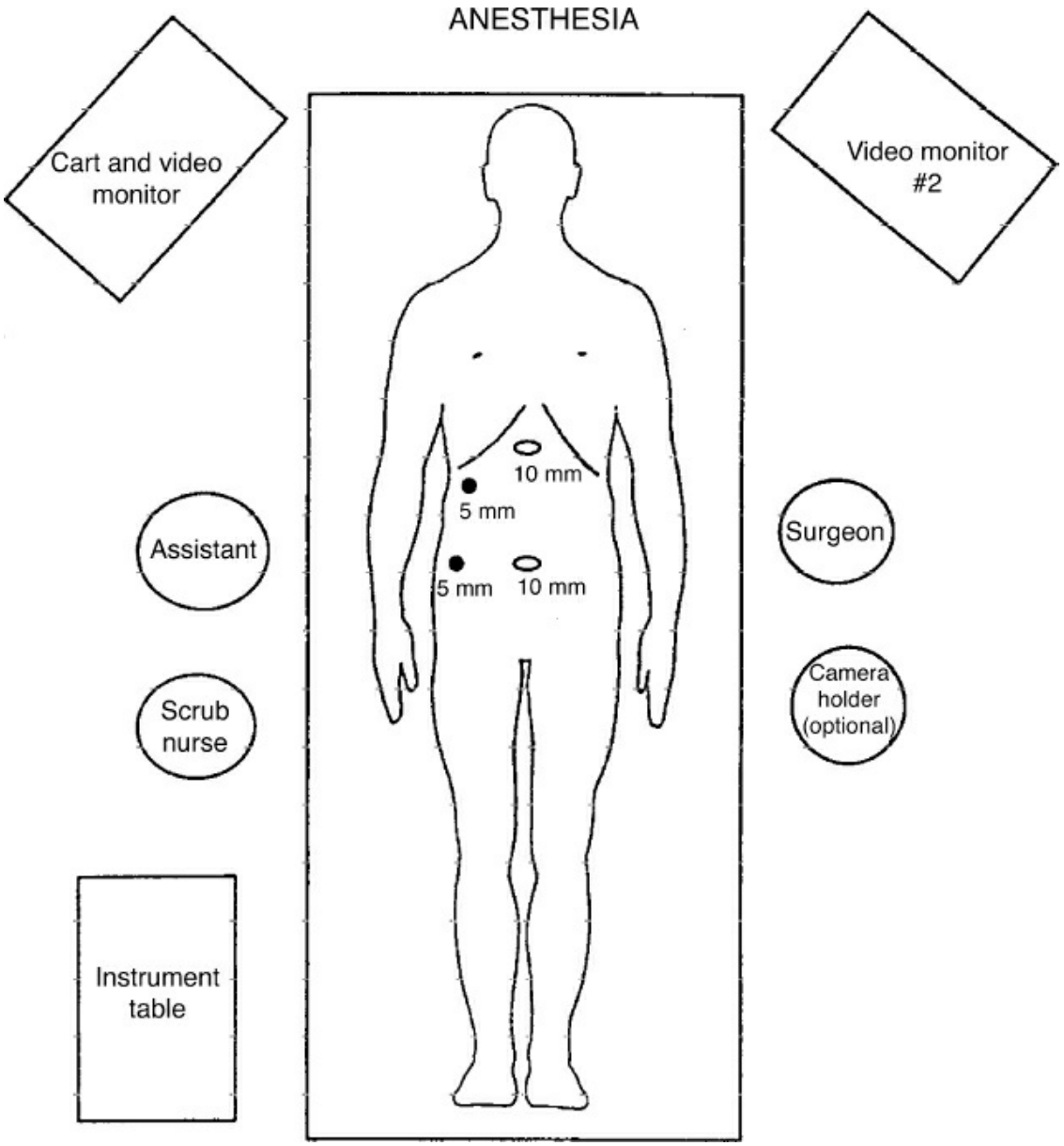

Figure 110.1. Room setup for laparoscopic cholecystectomy.

The equipment for LC is quite simple. The only rigid requirements are that a high-quality videolaparoscope with a 300-W light source be coupled to two high-resolution monitors. A high-flow carbon dioxide insufflator, four trocars (one or two 10- or 12-mm trocars and two or three 5-mm trocars), and approximately 10 specialized laparoscopic hand instruments are required. We frequently use a monopolar electrode L-hook, a fine-tipped Maryland dissector, two gallbladder graspers, a pair of scissors, a medium to large hemoclip applier, and a sterile plastic bag for specimen retrieval. A 10-mm stone retrieval grasper is helpful to remove spilled gallstones. If a cholangiogram is to be performed, some surgeons prefer to use a small “microscissors,” a specialized cholangiogram clamp, and a 4 or

5 French tapered catheter. Techniques of cholangiography are discussed in a later section.

ANESTHESIA

Anesthetic techniques for laparoscopy are quite different than those used for open surgery. Generally, nitrous oxide is avoided to minimize the likelihood of bowel distention. Because insensible fluid losses through the closed abdomen are minimal, intravenous fluids should be run more judiciously than during open surgery. In addition, the pneumoperitoneum is a strong stimulus to antidiuretic hormone release, decreasing intraoperative urine output. If the anesthesiologist responds to oliguria with fluid boluses in the absence of fluid losses, pulmonary edema may result. Last, the anesthesiologist must be acutely attuned to ventilatory function, as the carbon dioxide pneumoperitoneum occasionally leads to hypercarbia and acidosis if close attention is not paid to the carbon dioxide concentration of expired gas (end-tidal PCO_2). In addition, we ask our anesthesiologists to minimize the use of narcotics and administer a powerful antiemetic to lessen postoperative nausea. For elective LC where the gallbladder is not acutely inflamed, preoperative antibiotics have not been shown to be of benefit. All patients should have venous thromboembolic prophylaxis in the form of sequential compression devices prior to induction of anesthesia. Once the patient is anesthetized and intubated, a Foley catheter and an orogastric tube are generally placed. Decompression of the stomach and bladder minimizes the chance of injury during establishment of intra-abdominal access.

SURGICAL TECHNIQUE

Pneumoperitoneum

LC is generally performed with a carbon dioxide pneumoperitoneum at 15 mm Hg pressure. There is no evidence that lower pressures confer a significant safety advantage. Generally, the pneumoperitoneum is obtained by sliding a specialized needle (a Veress needle) through the umbilicus, confirming its position by allowing saline to run through the needle from a plungerless syringe, and then attaching the needle to tubing from the carbon dioxide insufflator. Initially, the flow rate of carbon dioxide is set at 2 to 3 L/min to ensure that proper placement has occurred before a large volume of gas is insufflated. Confirmation of the intra-abdominal position

of the needle can be obtained by observing for uniform abdominal distention, tympani, and the ability to vary the intra-abdominal pressure by raising and lowering the abdominal wall. Initial pressures greater than 10 mm Hg can suggest preperitoneal placement of the needle, although high opening pressures can be difficult to interpret in the morbidly obese patient. Once the surgeon is comfortable that the needle is in the abdomen, the flow rate can be increased until an intra-abdominal pressure of 15 mm Hg is achieved.

An alternate method for establishing pneumoperitoneum is the open Hasson cutdown technique, whereby the abdominal cavity is entered under direct vision. A scalpel, S-retractors, a clamp, and scissors are required for this technique. Once the peritoneal cavity is entered, the initial trocar is inserted and its position is secured with two stay sutures. The abdomen can then be insufflated rapidly with carbon dioxide. Other techniques used to obtain pneumoperitoneum include the opti-view port system in which the laparoscope is directly inserted through the layers of the abdominal wall using a specialized, transparent port.

Any of these pneumoperitoneum techniques are acceptable, but there appear to be fewer major injuries when a novice or occasional laparoscopic surgeon uses an open access technique. Nevertheless, no technique is completely safe. Bowel and vascular injuries have been reported with all these techniques. Ultimately, the safest technique is the one that the surgeon is most comfortable performing.

Trocar Placement

Once the pneumoperitoneum has been established, the first trocar is placed just superior to the umbilicus. Trocars should be placed with a controlled, twisting, not a plunging, motion. It is generally a good idea to apply a second hand to the barrel of the trocar to prevent an inadvertent plunge that could lead to intestinal or vascular injury. If needed, the assistant can provide counter-traction on the abdominal wall during placement of the first trocar. If the patient is morbidly obese, a primary trocar position several centimeters superior to the umbilicus allows better access to the right upper quadrant. If a previous abdominal surgery has been performed through a vertical midline incision, an alternate site for primary puncture is chosen. In this situation, we insufflate through a site adjacent to the umbilicus or in the left upper quadrant using a Veress needle technique, then place the primary trocar—a 5-mm trocar—in the right upper quadrant

and pass a 5-mm telescope. The umbilical trocar is then placed to the right of midline under direct vision, avoiding the adhesions from the previous operation. Many surgeons prefer to use the Hasson technique when previous abdominal surgery precludes primary puncture through the umbilicus. However, if the bowel is adherent to the undersurface of a previous midline incision, this abdominal access method carries a high risk of intestinal injury.

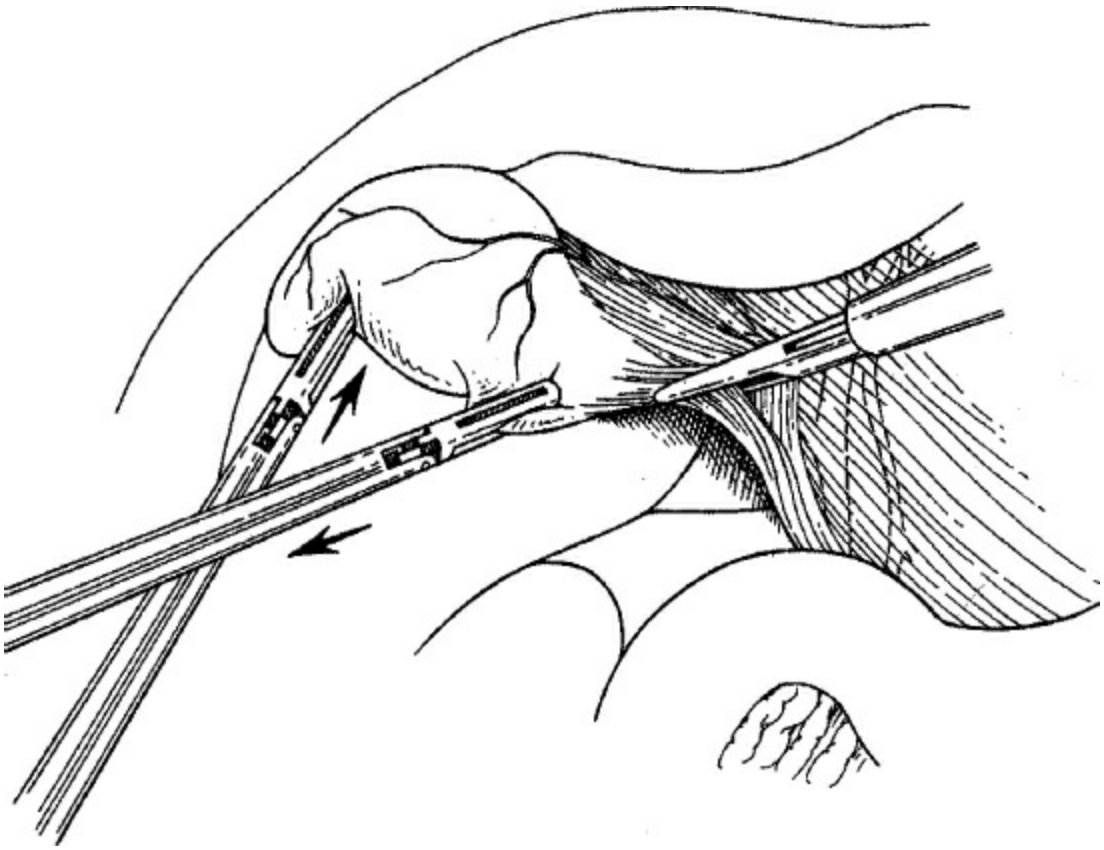

Figure 110.2. Elevation of the gallbladder infundibulum and exposure of porta hepatis.

Once the umbilical trocar is established, a 5- or 10-mm telescope is passed through the primary trocar. An angled (30-degree) telescope allows a better view of the CBD, the posterior wall of the gallbladder, and the triangle of Calot than does a straight (0-degree) telescope. Next, a 10-mm trocar is placed in the epigastrium, starting from the midline and angling toward the gallbladder. This trocar should enter at the level of the inferior liver edge just to the right of the falciform ligament. If this trocar is too low, the surgeon will be working parallel with his or her operating telescope. If this trocar is placed too high, segment IV of the liver will impede the surgeon’s ability to get to the gallbladder fossa. The third

trocar is a 5-mm trocar, which is generally placed 2 to 3 cm below the costal margin in the midclavicular line. The fourth trocar is located in a variable position, generally in the anterior axillary line, several centimeters below the fundus of the gallbladder. If this port is placed too low, it will be impossible to lift the gallbladder up to expose the porta hepatis sufficiently (Fig. 110.2).

Exposure of the Porta Hepatis

Exposure of the porta hepatis requires maximal elevation of the gallbladder fundus and liver edge. This elevation is usually achieved by the placement of a ratcheted, aggressive clamp on the fundus of the gallbladder from the most lateral trocar, and cephalad displacement is initiated until the infundibulum of the gallbladder, the duodenum, and the porta hepatis are well exposed (Fig. 110.2). If exposure of the porta hepatis is inadequate, the patient can be placed in a more severe reverse Trendelenburg position, the fundic grasper can be moved farther down the gallbladder to better elevate the gallbladder, or a fifth trocar can be introduced from the patient's left side to push down on the duodenum. This last technique is rarely necessary.

Stripping the Peritoneum

Using a two-handed technique, the surgeon grasps the gallbladder infundibulum with an instrument in his or her left hand and retracts it laterally. With a fine dissector, the peritoneum is torn at the interface between the gallbladder and periportal fat. The peritoneum is teased toward the common duct until the cystic duct, cystic artery, or lymph node of Calot is identifiable. Complete stripping of the posterior cystic duct is facilitated if the surgeon pushes the infundibulum medially to strip the peritoneum off the posterior aspect of the gallbladder and cystic duct. The 30-degree angled telescope is critical to obtaining this exposure. This lateral and medial retraction of the infundibulum is key for the safe circumferential visualization and dissection of the gallbladder infundibulum (Fig. 110.3).

Pedunculation of the Gallbladder

Stripping of the peritoneum over the gallbladder should reveal the presumed insertion of the cystic duct into the gallbladder. Continued

dissection at this interface, first with a fine dissector and then with a monopolar L-hook between the cystic artery and cystic duct, provides the anatomic definition of important cystic duct anatomy. Complete dissection in this region allows the gallbladder to appear like a polyp on a stalk (the cystic duct). Careful dissection and division of the lymphatics that cross Calot triangle may facilitate the exposure of the cystic duct. The cystic artery that crosses Calot triangle may impede this pedunculation effort and may be divided between clips near the gallbladder, if necessary. Pedunculation of the gallbladder may be assisted by dividing the medial and lateral peritoneal attachments of the gallbladder to the liver along the body of the gallbladder. It is unnecessary to continue the dissection any farther down the cystic duct than is needed to place two clips on the structure. The CBD is usually seen with the angled scope, and it is almost never necessary to dissect the cystic duct down to its junction with the CBD. To do so is to risk injury to this structure (Fig. 110.4).

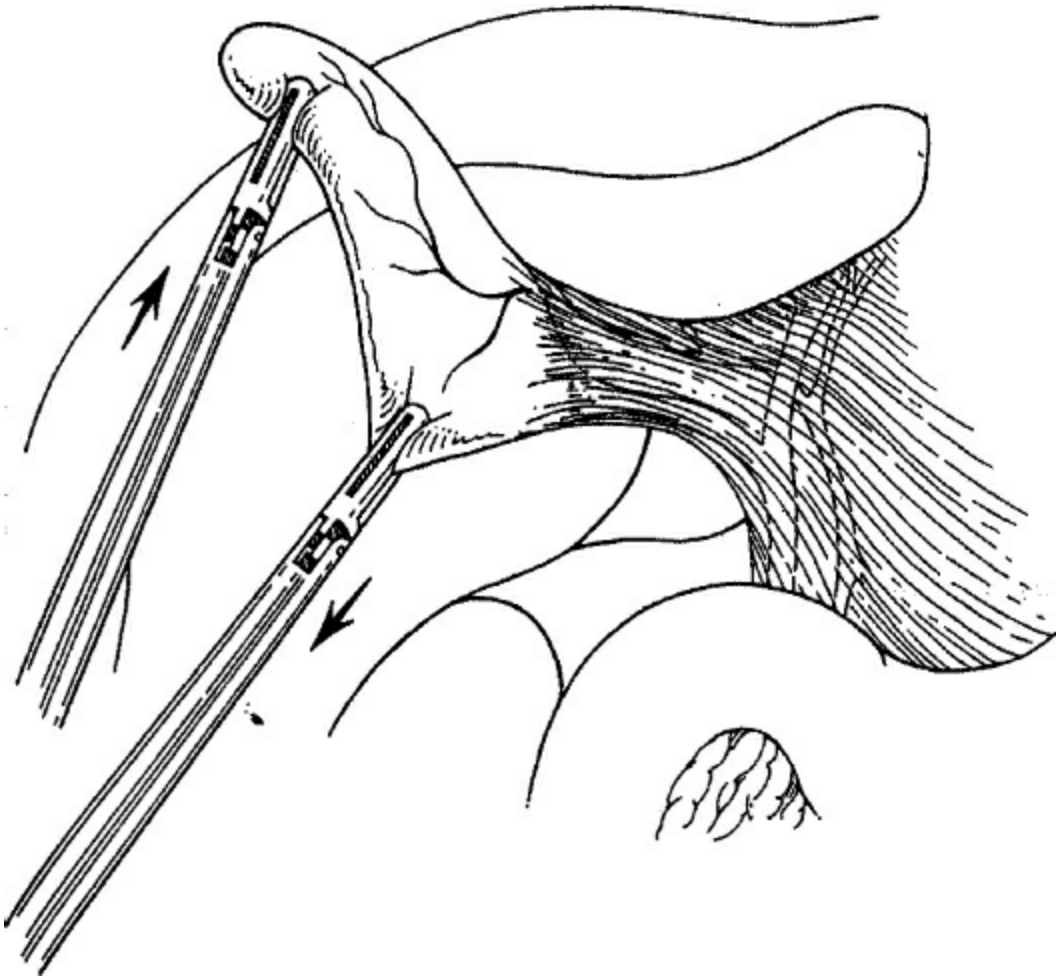

Figure 110.3. The cystic duct is visualized by retracting the gallbladder infundibulum laterally and then stripping the

peritoneum off the gallbladder.

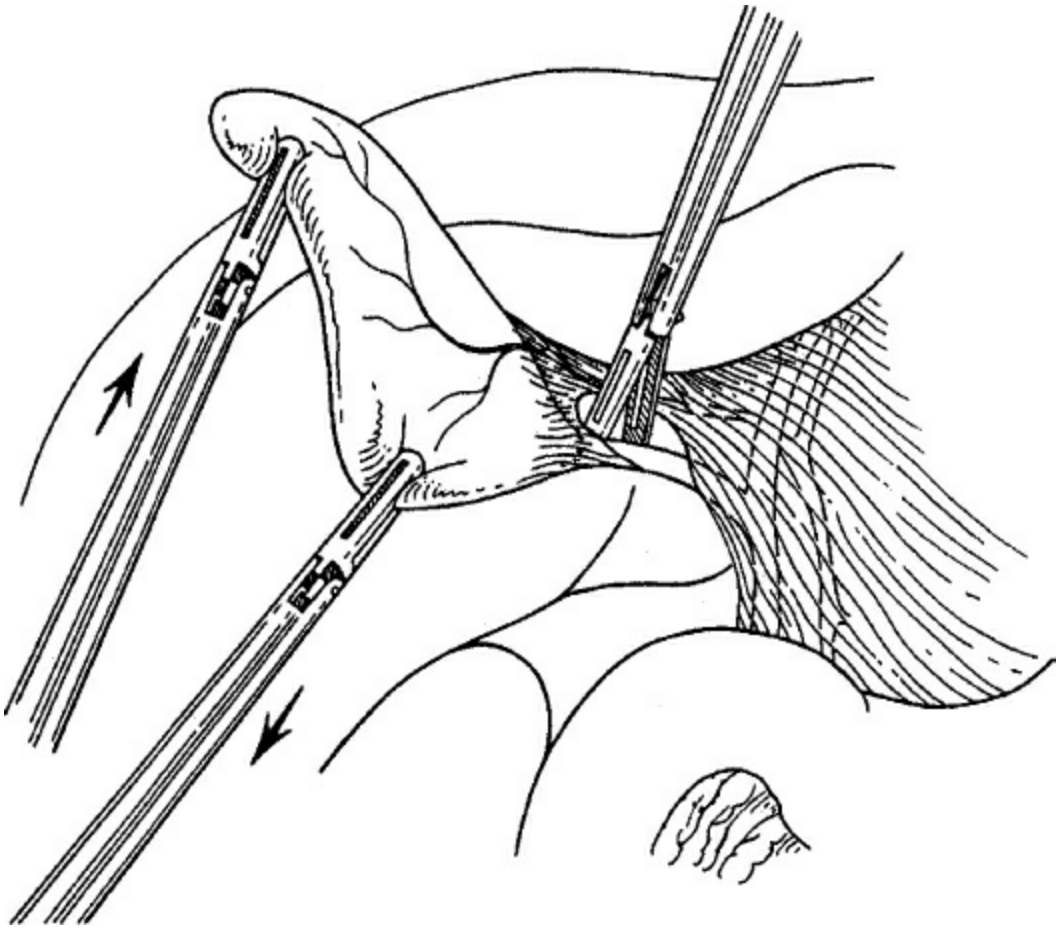

Figure 110.4. Pedunculation of the gallbladder.

Control of the Cystic Duct and Cystic Artery

Generally, the cystic duct is narrow enough that an 8-mm (medium to large-sized) hemoclip can be passed around it and slid up to the infundibulum of the gallbladder, where it is closed. If cholangiography is to be performed (see Intraoperative Cholangiography), it is done now. If a cholangiogram is not to be performed, two clips are placed on the cystic duct immediately below its junction with the gallbladder, and the cystic duct is divided. A long cystic duct remnant is not a concern as long as no stones are retained in this remnant. Two hemoclips are placed on the cystic artery as it crosses onto the gallbladder, if it has not been previously clipped, and the cystic artery is divided (Fig. 110.5).

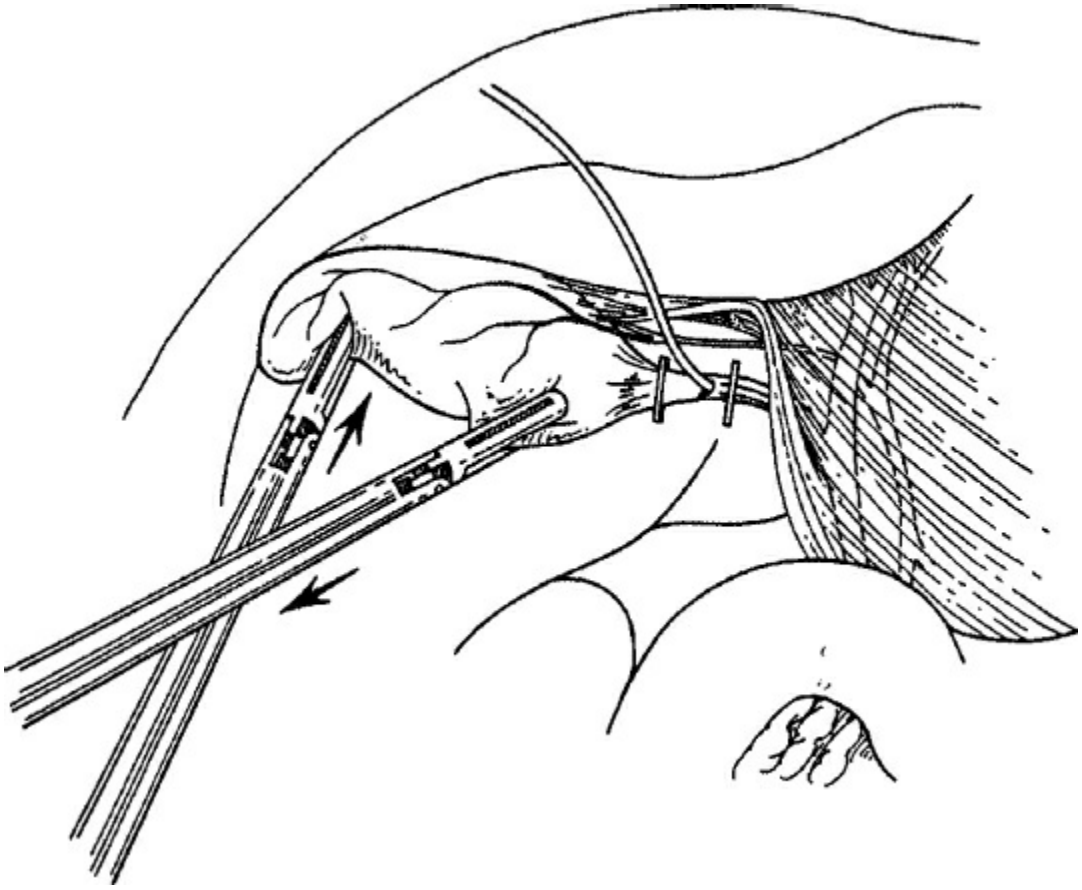

Figure 110.5. The first clip is placed on the gallbladder infundibulum to ensure that proper anatomic identification has occurred, and a cholangiocatheter is inserted and held in place by a partially occluding clip. The *arrows* indicate the direction of retraction of the gallbladder for optimal exposure.

Resection of the Gallbladder

If adequate pedunculation has been performed before cystic duct division, the gallbladder should already be dissected off the liver a quarter of the way to the fundus. Gallbladder resection is facilitated by strong use of the retracting (left) hand to pull the gallbladder away from the liver. As the gallbladder is pulled away from the liver, the monopolar electrode is used to coagulate the small bridging veins and areolar tissue connecting the gallbladder to the liver (Fig. 110.6). If hemorrhage occurs during this dissection, it usually means that the surgeon is not in the right tissue plane, most frequently in the hepatic parenchyma. Holes in the gallbladder occur frequently during this dissection. They can usually be controlled with a pretied chromic ligature, an interrupted figure-eight suture, or carefully placed hemoclips. When the fundus of the gallbladder is reached, the majority of the gallbladder is flipped over onto the anterior surface of the

liver and used as a handle to retract the gallbladder fossa, and hemostasis of the gallbladder fossa is checked (Fig. 110.7). The remaining peritoneum connecting the gallbladder and liver is then divided with electrocautery to disconnect the gallbladder from the liver.

Removal of the Gallbladder

At this point, the sterile retrieval bag is introduced through either the umbilical or the epigastric port, whichever is at least 10 mm in size. The bag is opened under direct visualization, and the gallbladder is placed within the bag, which is then sealed. The bag, which typically has a retrieval string, is then removed via the port site by removing the trocar. If the umbilical port site is used for retrieval, the telescope can be moved to the epigastric trocar to facilitate the maneuver. If the gallbladder does not come out easily, the bile is generally removed from the gallbladder with a small suction device passed into the gallbladder below the level of the fascia. When large stones are present, it may be necessary to dilate the fascial opening with a Kelly clamp or to enlarge the fascial incision with a pair of curved Mayo scissors to facilitate gallbladder removal (Fig. 110.8). Alternatively, if the gallbladder is intact, it can be removed directly from the abdomen without a retrieval bag using a 10-mm gallbladder grasper. The fascia is then closed with an interrupted or figure-eight suture and the abdomen is reinflated. The right upper quadrant is thoroughly irrigated, and all fluid is removed from the subphrenic space. Then the remaining trocars are removed under direct vision, the skin is closed with a subcuticular suture, and Steri-Strips or a sterile glue can be used as a dressing.

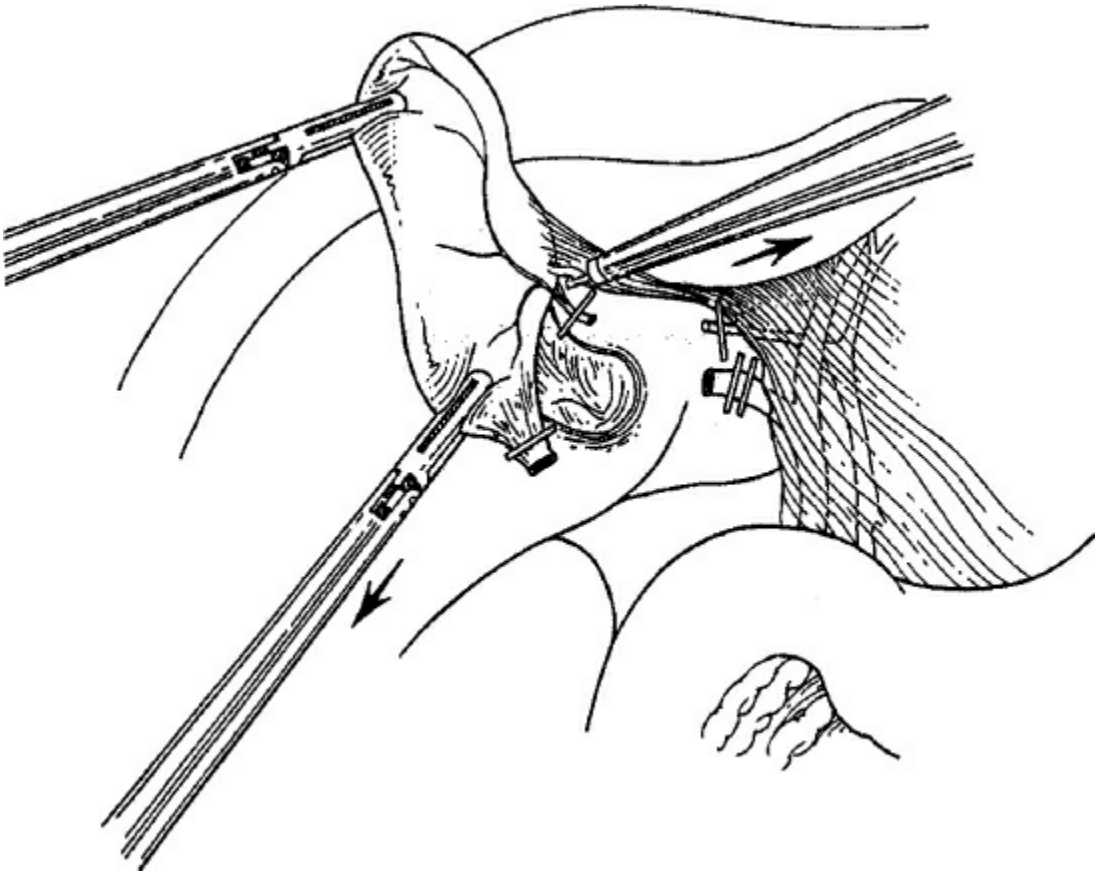

Figure 110.6. The gallbladder infundibulum is retracted from the liver and the cholecystohepatic attachments are divided with a monopolar hook. The *arrows* indicate the direction of retraction of the gallbladder for optimal exposure.

ADDITIONAL OPERATIVE MANEUVERS

Intraoperative Cholangiography

Whether IOC should be performed routinely or selectively is still a matter of great debate. Nonetheless, several convincing population-based studies demonstrate that bile duct injury occurs less frequently when cholangiography is performed by practitioners who are familiar with the technique and proficient at interpreting cholangiograms. IOC has a sensitivity of 79% and a specificity of 100% for CBD injuries. In one large, retrospective study, the CBD stone rate was 10% and of the patients with stones, 30% were unsuspected. The benefits of IOC include improved intraoperative diagnosis of injury, avoidance of diagnosis delay and the subsequent sequelae, and lower cost of early treatment compared with delayed intervention. The downside to IOC is that it requires the surgeon to have expertise in performing and interpreting the study, it lengthens the operative by an average of 6 minutes, and it is associated with higher

operative cost.

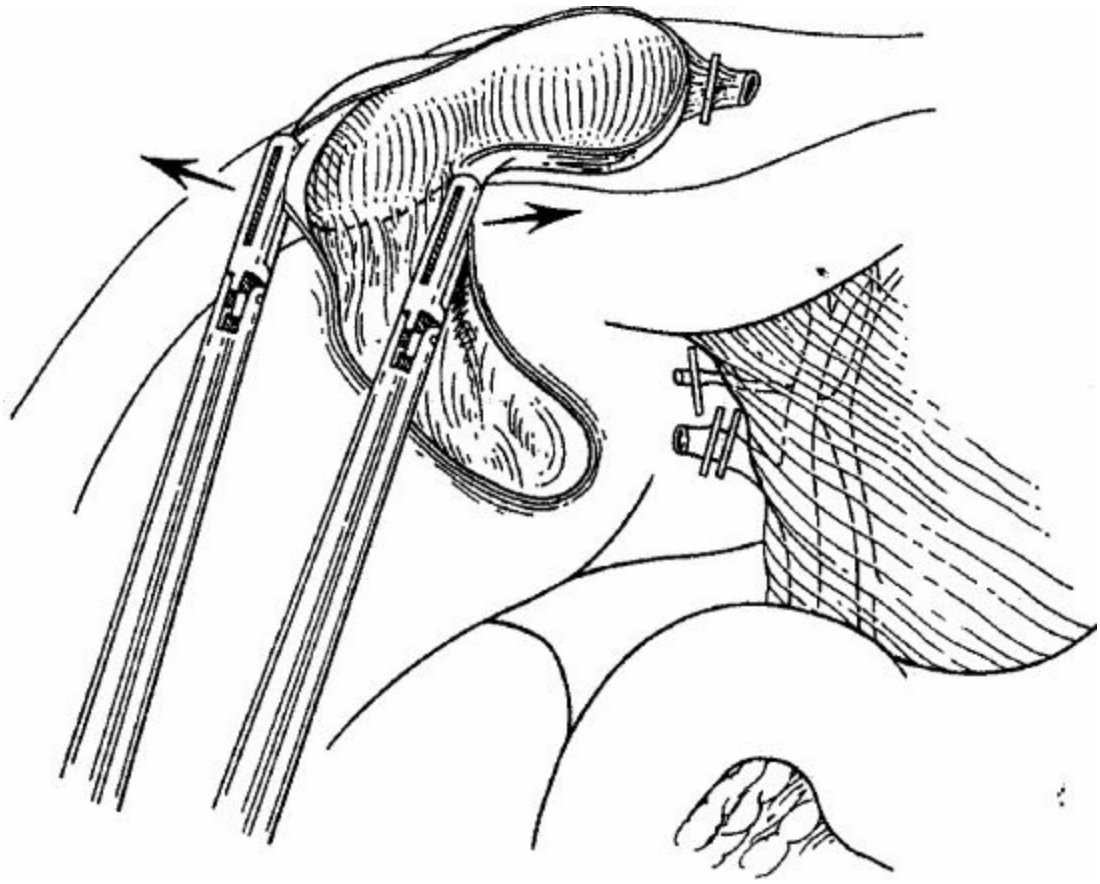

Figure 110.7. Excellent exposure of the gallbladder bed and remaining peritoneum is gained by “flipping” the gallbladder over the liver edge and stretching apart the last bit of peritoneum with two graspers. The *arrows* indicate the direction of retraction of the gallbladder for optimal exposure.

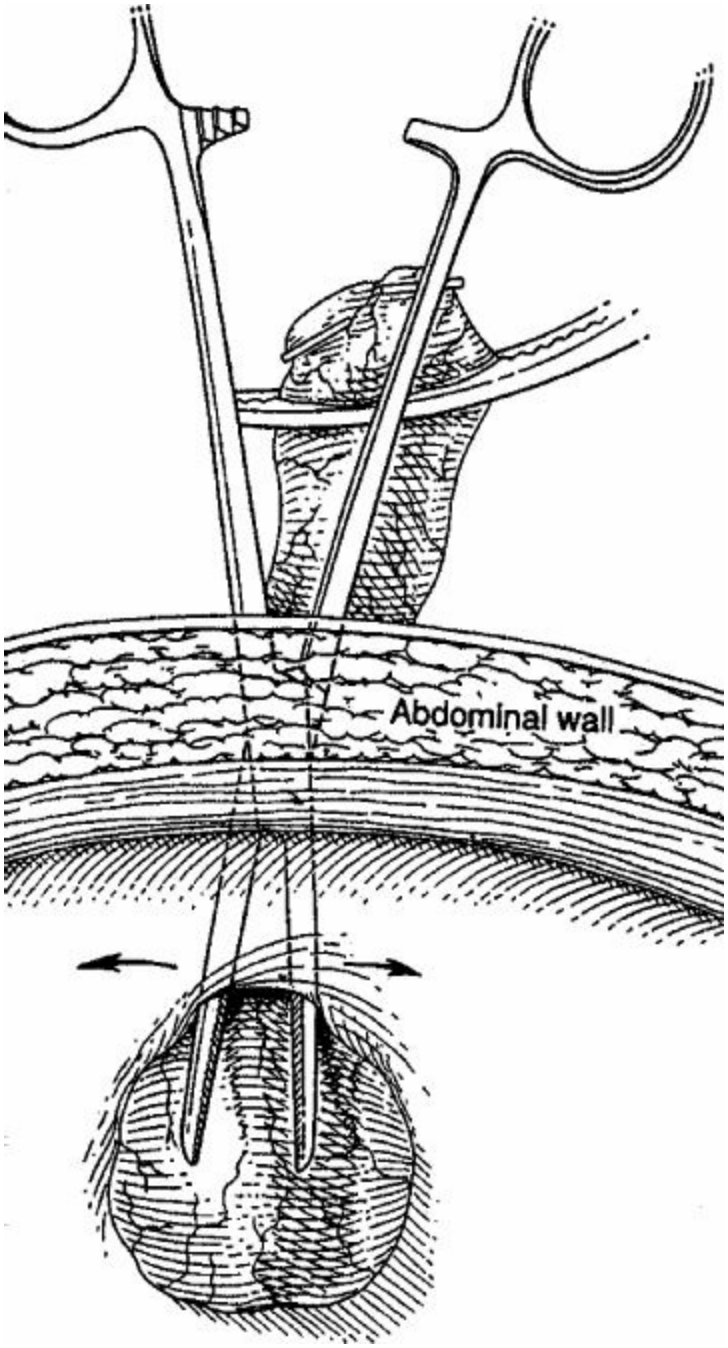

Figure 110.8. Removal of the gallbladder with a large stone burden. The *arrows* indicate the direction of spreading by the Kelly clamp to facilitate gallbladder extraction.

We perform cholangiography routinely to ensure that all surgical residents are familiar with this technique. Two methods are available for performance of cholangiography. In the first method, a specialized cholangiogram clamp—the Olsen cholangiogram clamp—is passed through the subcostal trocar, and a saline-flushed, 60-cm, tapered 5 French catheter is advanced directly into the cystic duct. Surgeons find this

technique difficult if they have not placed the middle trocar immediately beneath the ribs and close to the anterior axillary line. Introduction of the catheter occasionally requires a hydrophilic guidewire to get through the Heister valves. Once the catheter is in the cystic duct, the jaws of the Olsen clamp are closed around the cystic duct.

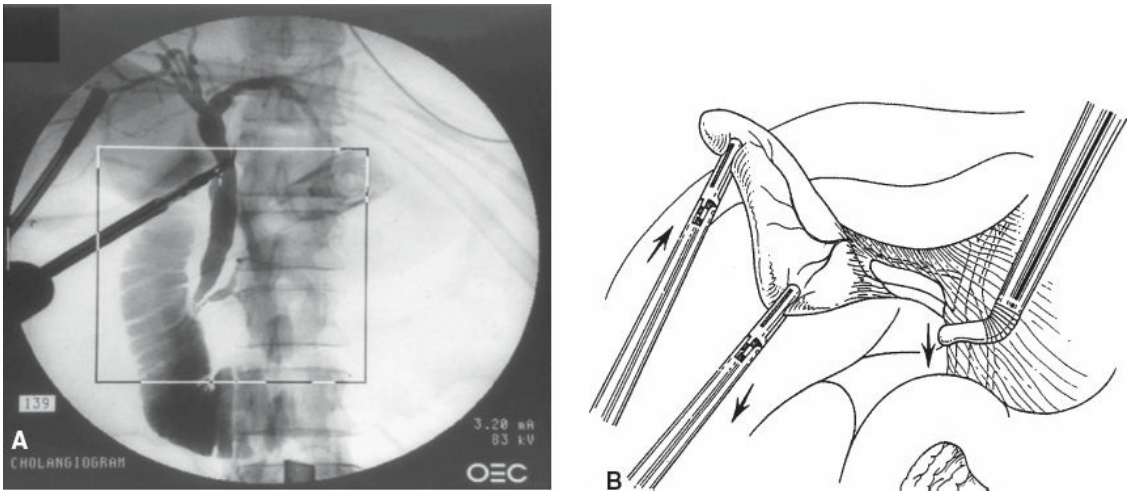

Figure 110.9. A. Operative cholangiography demonstrating good flow of contrast into the duodenum. No filling defects are present. There is opacification of both right and left hepatic ducts. **B.** Ultrasonography is an acceptable substitute for operative cholangiography. The *arrows* indicate the direction of retraction to facilitate intraoperative ultrasound examination of the common bile duct.

The second method for performing cholangiography, a percutaneous cystic duct access technique, appears equally efficacious. With this method, a separate small puncture is made in the abdominal wall, over the cystic duct, with a 2-in, 14-gauge intravenous catheter. A 5 French cholangiocatheter is then slid directly through the intravenous catheter into the cystic duct by the surgeon with a grasper in his or her right hand. Once the catheter is in the cystic duct, it is held in place with a hemoclip.

Before cholangiography is performed, all instruments are removed, and the trocars are positioned so as not to obscure the cholangiogram. A small lead screen with a sterile table cover over it is then rolled up to the left side of the patient, and the surgeon stands behind this screen. The C-arm is introduced and positioned over the right upper abdomen. It is important that all tubing and syringes used for the cholangiogram are preflushed to remove any air bubbles as they may have appearance similar to stones and lead to false-positive cholangiograms. A slow injection of 60% diatrizoate

meglumine (Gastrografin) under fluoroscopic control ensures an initial dilute injection to look for small stones in the CBD. After complete imaging of the distal bile duct, Oddi sphincter, and duodenum has been attained, a second injection, usually under pressure, delineates the proximal biliary radicals. A complete study includes flow of contrast into the duodenum as well as opacification of both right and left hepatic ducts (Fig. 110.9A). The surgeon must identify the two major ductal systems in the right lobe of the liver because low inserting ducts from hepatic segments VII and VIII are frequently injured during LC. Selected images are saved from the C-arm and sent to the hospital imaging storage system. If bile duct stones are seen on the cholangiogram, they can be addressed with transcystic extraction techniques (see later).

Biliary Ultrasonography

Although cholangiography remains the "gold standard," many surgeons find that laparoscopic ultrasonography of the intra- and extrahepatic biliary system can be performed quickly and provides sensitivity and specificity at least equivalent to cholangiography when performed by experienced users (Fig. 110.9B). The lack of radiation makes this technique particularly appealing for biliary imaging in the pregnant patient.

Hydrops of the Gallbladder

If the gallbladder is so tense that it cannot be grasped, it is decompressed using a laparoscopic needle on a 50-mL syringe. After the bile has been aspirated, the grasper used to elevate the gallbladder fundus can be positioned over the needle hole to prevent bile spillage. Alternatively, a cholecystotomy is performed with electrosurgery or a sharp 5-mm trocar and the bile is removed with a suction irrigator. This hole can then be controlled with an Endoloop, hemoclips, or with a clawed grasper.

Wide-Mouthed Cystic Duct

One of the more difficult challenges in LC is the short, wide cystic duct. Clips usually do not reach across this duct and, even if they do, they may risk narrowing the CBD (Fig. 110.10A). Under these circumstances, there are four acceptable techniques for closing the cystic duct. If the duct is long and wide, it can be transected and a pretied ligature (an ENDOLOOP Ligature) can be applied to the cystic duct stump. Alternatively, two ties

can be passed around the cystic duct in continuity and secured with extracorporeal knotting techniques. Occasionally, there is concern that this technique might narrow the CBD. Under these circumstances, the cystic duct is transected with an endoscopic stapling device, or it is simply divided and oversewn with an intracorporeal suturing technique (Fig. 110.10B,C). All of these methods have been applied successfully. A critical factor in avoiding bile duct injury in these circumstances is a clear understanding of the anatomy. Although a cholangiogram may be difficult to obtain in these circumstances, it is just these situations that demand the accurate anatomic detail provided by cholangiography.

Drainage of the Hepatic Bed

If there has been spillage of infected bile, it is prudent to place a closed-suction drain. This placement is simple to perform by bringing a 5-mm grasper in the most lateral trocar and out the 10-mm trocar in the epigastrium. A 19 French BLAKE or a 10-mm Jackson-Pratt flat drain is pulled in through the 10-mm trocar. The external part of the drain is pulled out from the right flank by removing the grasping clamp and the 5-mm trocar. The internal portion of the drain is placed in the gallbladder bed, and external portion of the drain secured to the skin with a permanent suture.

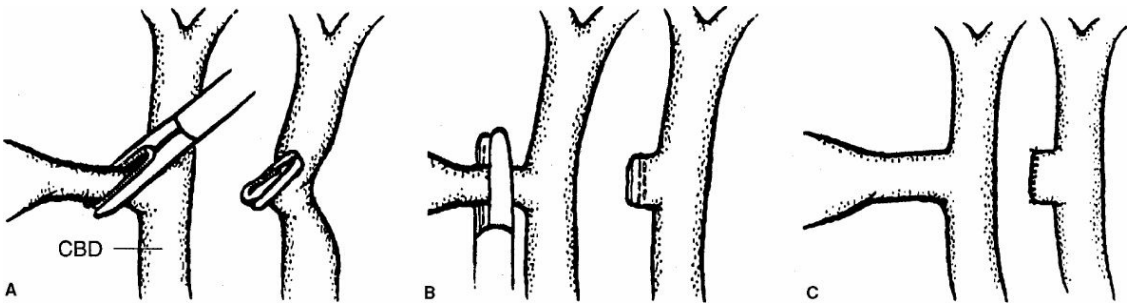

Figure 110.10. Techniques for managing the short, wide cystic duct. When clips are too short or risk common bile duct (CBD) narrowing (**A**), the cystic duct is controlled with an endoscopic stapler (**B**) or sutured closed (**C**).

Single Incision LC

The introduction of minimally invasive surgery has caused many to push the boundaries of surgery toward less and less invasiveness. Single incision surgery has been safely applied to cholecystectomy by experienced laparoscopic surgeons. However, it currently does not have

any advantages over the traditional LC other than cosmesis. Single incision cholecystectomy requires more laparoscopic expertise and specialized instruments, since it is performed through an umbilical incision using angled or flexible tip laparoscope and instruments with reticulating tips. The gallbladder is dissected and removed with close adherence to the principles described for LC to ensure patient safety. An additional 5-mm trocar placed in the anterior axillary line below the costal margin may be used to retract the gallbladder if visualization is inadequate. If any aspect of this operation is not preceding well, then placement of additional trocars and/or conversion to the traditional LC is warranted. It is important to remember that patient safety is paramount and that single incision cholecystectomy has no advantage over LC except cosmetic benefit, and this is only a short-term benefit, as laparoscopic scars are difficult to find on an abdominal wall in most patients after 3 to 6 months.

Conversion to Open Cholecystectomy

The decision to convert to open cholecystectomy should ideally be made before a complication occurs. Currently, the three most frequent indications for conversion are dense upper abdominal adhesions, a necrotic gallbladder wall that precludes grasping and elevation with a grasper, or lack of adequate exposure. If exposure and retraction are accomplished, yet the dissection in the region of the gallbladder neck is tedious and bloody, consideration should be given to conversion. A top-down dissection where the gallbladder is dissected from the fundus down toward the infundibulum can be attempted if a well-trained laparoscopic surgeon is available. This may allow clear identification of the cystic duct and spare the patient an open operation. In general, if the anatomy of the triangle of Calot is not clear, then it is reasonable to convert. Otherwise, this tedious dissection can “go on all day” and may require conversion for bleeding or complication. A conversion rate of less than 5% can be expected in the hands of a well-trained laparoscopic surgeon. Risk factors for conversion include male gender, obesity, cholecystitis (especially after 48 to 72 hours after the onset of symptoms), and choledocholithiasis.

POSTOPERATIVE CARE

After routine uncomplicated LC, postoperative care is simple. We usually start these patients on a clear liquid diet as soon as they awaken. If there is no nausea or vomiting, we proceed immediately to a regular diet. No

postoperative blood tests are required. The patient can usually be discharged several hours after the operation. For successful performance of outpatient cholecystectomy, patients must be aware of potential postoperative complications, including bile leak, bleeding, pancreatitis, intestinal perforation, wound infection, and ileus. Family members must be able to recognize these complications immediately, before life-threatening consequences occur. Hospitalization is required for the elderly; the infirm; and those with acute cholecystitis, pancreatitis, or cholangitis.

COMPLICATIONS AND THEIR MANAGEMENT

Serious complications of LC occur in fewer than 2% of all cases (Table 110.1). Intestinal injury may occur during establishment of abdominal access, adhesiolysis, or dissection of the gallbladder away from the duodenum or colon. An accidental enterotomy made during access with open laparoscopy (Hasson technique) can usually be repaired through the fascial incision. If an accidental intestinal injury is made with a Veress needle, no treatment is generally necessary. An electrosurgical injury to the colon or duodenum should be repaired with careful one- or two-layer suture closure. The incidence of injury to viscera or vessel from a trocar or Veress needle is well documented at 0.2%.

Hemmorhage

Large-vessel vascular injury usually occurs at the time of initial abdominal access and is a result of inadequate anterior abdominal wall distraction or excessive thrusting of the trocar by the surgeon. These may be lethal complications. An unexplained retroperitoneal hematoma or hypotension should be treated immediately by conversion to laparotomy.

Excessive bleeding in the region of the porta hepatis should not be treated laparoscopically. Attempts at clipping or cauterizing significant bleeding usually lead to worsening hemorrhage and/or hepatic artery injury. Minor bleeding can be controlled with clips or electrocautery if the bleeding vessel can be visualized by irrigation. However, once the bleeding is controlled, it is prudent to confirm that vital structures such as the hepatic arteries or CBD were not injured. Major bleeding often necessitates conversion to open cholecystectomy to ensure adequate control without injury to CBD or hepatic arteries. Bleeding in the gallbladder bed can usually be controlled by fulguration of the bleeding site. If a larger intrahepatic sinus has been entered, hemostatic agents (e.g.,

microfibrillar collagen) can be placed laparoscopically in the liver bed, and pressure can be maintained with a clamp.

TABLE 110.1 Complications of LC

Trocar/Veress needle injury
Hemorrhage
Wound infection and/or abscess
Ileus
Bile leak
Gallstone spillage
Deep vein thrombosis
Retained common bile duct (CBD) stone
CBD injury ± stricture
Pancreatitis
Conversion to open procedure

Stone or Biliary Contamination

Stone spillage during gallbladder dissection should be avoided by closing gallbladder perforations when they occur. If a few small stones are spilled from an uninfected gallbladder, no further attention is needed. Attempts to remove large stones with collecting bags are appropriate. The only circumstance in which conversion to an open procedure should be considered is when stones are spilled in the presence of infected bile. Under these circumstances, occult abscesses have been reported to occur in many locations around the abdomen, presenting between 12 days and 12 months after operation.

CBD Injury

Incidence

In the infancy of LC, CBD injury occurred more frequently during LC than during open cholecystectomy. Reasons for the increase in injury during LC included loss of haptic information, incorrect traction forces to the gallbladder leading to misidentification of anatomy, and injudicious use of cautery inside of the triangle of Calot. Although the incidence of CBD injury during LC is no longer as high as it was initially, it still

exceeds that of open cholecystectomy (0.1% to 0.5% in LC vs. 0.2% in open cholecystectomy).

Prevention

CBD injury occurs due to either a technical error or misidentification of the duct. Risk factors that increase the risk of CBD injury include acute cholecystitis, surgeon inexperience, and aberrant anatomy. The most common anatomic variant is an aberrant right hepatic duct. Inadequate video-optics and improper dissection techniques render the CBD susceptible to injury. If the surgeon follows the dissection techniques outlined above, injury to the CBD should be avoided. The essential steps are summarized in Table 110.2. We emphasize that the surgeon should strive to make the gallbladder look like a polyp on a stalk (aka the "critical view of safety") (Fig. 110.11) prior to clipping the cystic duct. If clips are applied before such a view is obtained, the CBD may be mistaken for the cystic duct and accidentally clipped and cut (Fig. 110.12A). If the critical view cannot be obtained due to inflammation or hostile anatomy, it is the authors' opinion that an IOC should be performed prior to dividing the cystic duct. A recent study using an American Medicare database found a reduction in CBD injuries with routine use of IOC (from 0.58% to 0.39%). In 2014, the Society of American Gastrointestinal and Endoscopic Surgeons (SAGES) launched a program to create a culture of safety in order to prevent CBD injuries. The SAGES Safe Cholecystectomy Program offers guidance and training opportunities for surgeons at all levels of training (http://www.sages.org/safe-cholecystectomy-program/).

TABLE 110.2 Steps to Avoid Common Bile Duct Injury During Laparoscopic Cholecystectomy

1. Use a 30-degree laparoscope and high-quality imaging equipment.
2. Apply firm cephalic traction on the fundus and lateral traction on the infundibulum so that the cystic duct is perpendicular to the CBD.
3. Dissect the cystic duct where it joins the gallbladder.
4. Expose the "critical view of safety" prior to dividing the cystic duct.
5. Convert to open procedure if the infundibulum cannot be mobilized or if bleeding or inflammation obscures the triangle of Calot.
6. Perform routine intraoperative cholangiography.

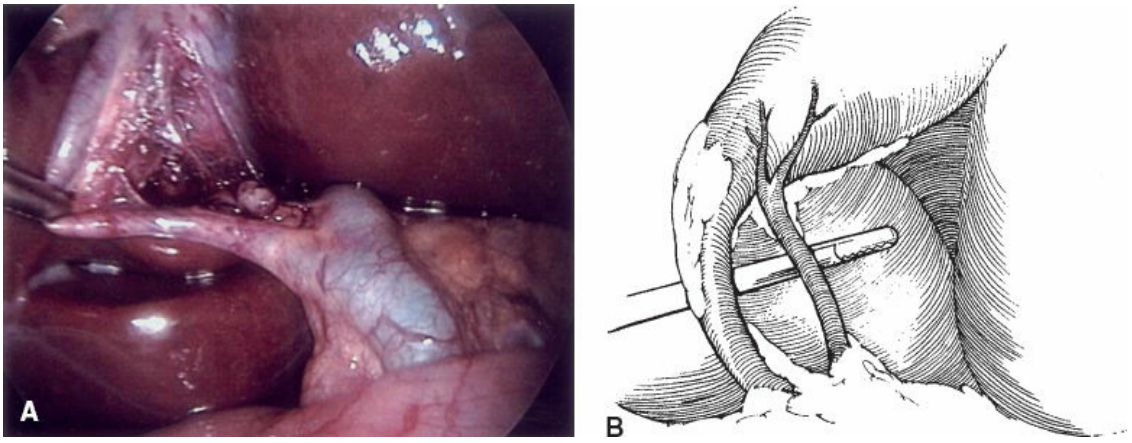

Figure 110.11. A. Intraoperative photograph of the "critical view of safety." The cystic artery has been divided, and the gallbladder appears like a polyp on a stalk. The base of the liver bed is exposed, and the surgeon can be confident that he or she is not mistaking a short common bile duct (CBD) for the cystic duct. **B.** The "critical view of safety." The triangle of Calot is dissected free of all tissue except for the cystic duct and artery, and the base of the liver bed is exposed. When this view is achieved, the two structures entering the gallbladder can only be the cystic duct and artery. It is not necessary to see the CBD. (**B.** This figure was published in Strasberg SM, Hertl M, Soper NJ. An analysis of the problem of biliary injury during laparoscopic cholecystectomy. *J Am Coll Surg* 1995;180:101, with permission from the American College of Surgeons. Copyright Elsevier.)

Classification of CBD Injury

Many different classification systems for CBD injuries exist. The Stewart–Way classification is simple and concise, and was derived from analysis of a series of LC-associated CBD injuries (Fig. 110.13). The most common type of injury (Stewart–Way class III) was found to account for 60% of CBD injuries in this series (Fig. 110.12B). Table 110.3 describes the mechanism of CBD injury.

Management

Early recognition of a CBD injury is of paramount importance. Figure 110.14 outlines our algorithm for a suspected bile leak. We divide CBD injuries into two main categories: (a) immediate intraoperative diagnosis and (b) delayed postoperative diagnosis.

1. *Intraoperative diagnosis:* If an injury occurs to the lateral CBD (class I or II injury), primary repair with or without T-tube drainage through a separate choledochotomy is acceptable. Complete division and/or

resection of a bile duct or aberrant bile duct (class III or IV injury) should be managed by (a) hepaticojejunostomy by a hepatobiliary surgeon or (b) control of the divided CBD with a clip (if possible), drainage, IV antibiotics, and immediate transfer to an institution that specializes in care of these injuries. Repair by surgeons inexperienced in these techniques only complicates subsequent repair, and may increase the rate of postoperative stricture to as high as 25%.

2. *Postoperative diagnosis:* Minor leaks can be treated with drainage alone, usually through a percutaneously placed catheter (if no drain was left in place intraoperatively). Low-output drainage (<300 mL/day) can be observed and should resolve within 5 to 7 days. If the catheter drainage fails to resolve or if the patient has high-output drainage (>300 mL/day), an ERCP should be performed. Three possibilities exist: (a) duct of Luschka leak (injury to a supravesicular duct in the gallbladder bed) that can be treated by sphincterotomy, (b) cystic duct stump leak that can be treated with a transpapillary stent with or without sphincterotomy, or (c) suspected CBD injury. In the latter case, a percutaneous transhepatic cholangiogram (PTC) should be performed to further delineate the anatomy of the proximal biliary tree and to plan subsequent repair. Bile drainage should be controlled, and repair should be undertaken by an experienced hepatobiliary surgeon as this has been shown to optimize long-term outcomes after repair. Principles of repair are to reestablish bile flow into the gastrointestinal tract with a tension-free mucosa-to-mucosa biliary enteric anastomosis, and to prevent cholangitis and/or stricture formation.

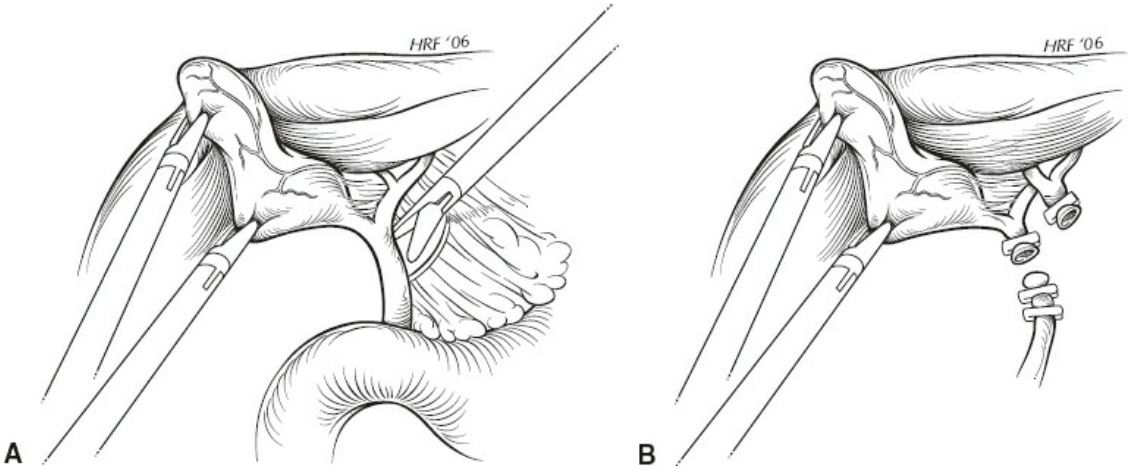

Figure 110.12. Common bile duct injury when the surgeon skeletonizes (**A**), clips, and divides (**B**) the common duct instead of the short cystic duct. This injury would not have occurred if the

surgeon had completely exposed the hepatocystic triangle prior to dividing the “cystic duct.”

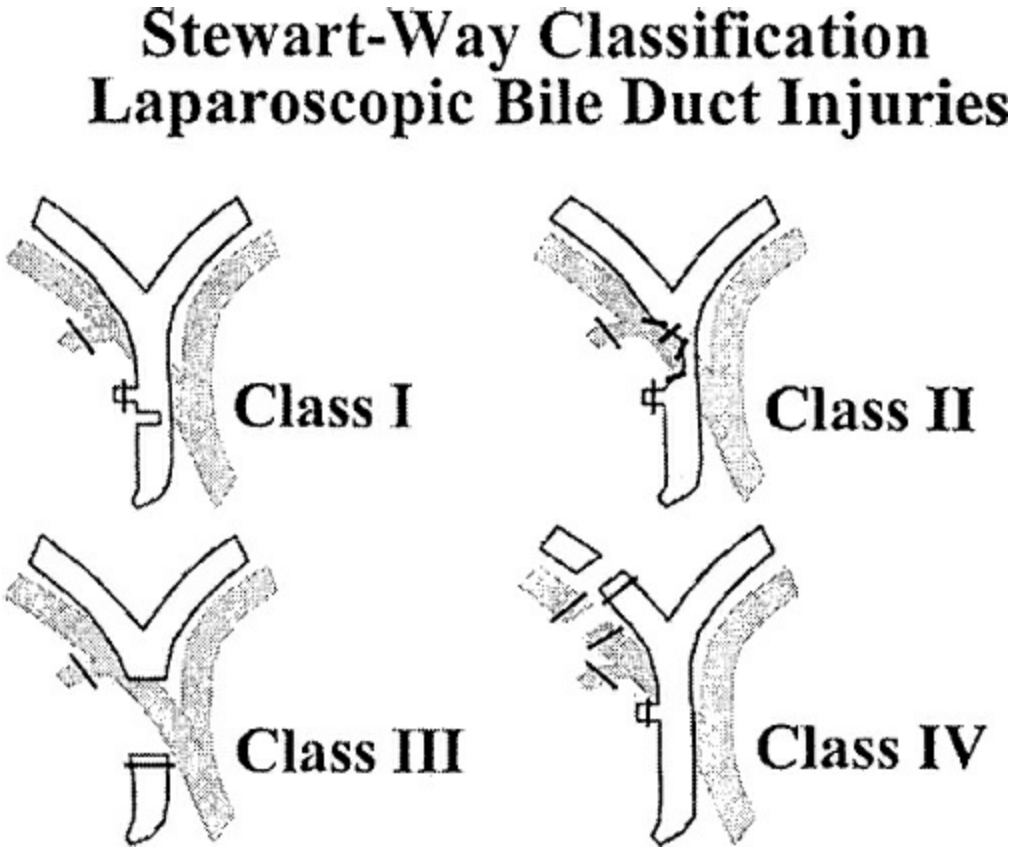

Figure 110.13. Stewart–Way classification of laparoscopic bile duct injuries. The mechanism of injury is in Table 110.3. (Reprinted from Way LW, Stewart L, Gantert W, et al. Causes and prevention of laparoscopic bile duct injuries: Analysis of 252 Cases From a Human Factors and Cognitive Psychology Perspective. *Ann Surg* 2003;237(4):460, with permission of Wolters Kluwer Health, Inc.)

Retained CBD Stones

Laparoscopic CBD Exploration

In 1890, Ludwig Courvoisier was the first to perform a choledochotomy and remove a CBD stone. One hundred years later, LC was in its infancy. The incidence of choledocholithiasis during LC based on IOC was 7.8% in a recent analysis of more than 114,000 patients. This high incidence has led many surgeons to develop techniques for removing these stones at the time of LC. Initially, these techniques were borrowed from ERCP and involved the use of baskets passed into the CBD under fluoroscopic guidance. A technique from endourology that has been valuable is the use

of small-caliber flexible endoscopes to retrieve stones. Other borrowed techniques from retrograde biliary endoscopy include the use of balloon dilators and intraoperative sphincterotomy. Laparoscopic choledochotomy is sometimes necessary for the removal of large stones and for a large number of stones from a markedly dilated CBD. An algorithm for addressing choledocholithiasis begins with IOC or ultrasonography (Fig. 110.15). The variables that determine the best approach to choledocholithiasis are the size of the stone, the number of stones, and the size of the cystic duct, whether the stone is impacted or freely floating, and whether the stone is in the common hepatic duct or the CBD.

Transcystic Versus Transductal Approach

The transcystic (via the cystic duct) approach is successful in over 90% of cases for small stones less than 8 mm in size, and for stones located below the cystic duct entrance. Factors that hinder this approach include acute angulation of the cystic duct–CBD junction, numerous valves of Heister within the cystic duct, a tortuous cystic duct, or placement of the cystic ductotomy more than 15 mm from its junction with the CBD. The transductal approach (via the CBD) is indicated for stones greater than 8 mm in size, and for stones proximal to the insertion of the cystic duct. The transductal technique should not be performed in a CBD less than 10 mm in diameter, as this may lead to postoperative stricture. Transcystic CBD exploration is generally preferred over a transductal CBD exploration as it has lower morbidity and shorter length of stay.

Normal CBD (Smaller Than 6 mm), Small Stone (Smaller Than 4 mm)

Stones that are smaller than 2 mm in diameter will usually pass spontaneously. The best treatment strategies for these small stones are either merely to observe or to dilate the Oddi sphincter with 1 mg of intravenous glucagon and flush the bile duct vigorously with normal saline. We prefer to clear the CBD before leaving the operating room, because even these small stones may cause severe colic or pancreatitis when they pass through the papilla. A stone that does not pass with flushing (e.g., a stone >2 to 4 mm) can usually be basketed with a six-wire helical stone basket (with filiform tip), which is either passed alongside the cholangiocatheter or passed through a 6 French introducer that has replaced the cholangiocatheter after CBD stone detection (Fig. 110.16). All catheter exchanges are performed over a hydrophilic guidewire. The basket is opened in the ampulla of Vater and is trolled backward,

entrapping the small stone. One must be careful not to open the basket in the duodenum, or papillary elements will be ensnared and the basket will become entrapped.

TABLE 110.3 Mechanism of Common Bile Duct Injury (Stewart–Way Classification)

Class I	CBD mistaken for cystic duct, but recognized Cholangiogram incision in cystic duct extended into CBD
Class II	Lateral damage to the CHD from cautery or clips placed on duct Associated bleeding, poor visibility
Class III	CBD mistaken for cystic duct, not recognized CBD, CHD, R, L hepatic ducts transected and/or resected
Class IV	RHD mistaken for cystic duct, RHA mistaken for cystic artery, RHD and RHA transected Lateral damage to the RHD from cautery or clips placed on duct

CBD, common bile duct; CHD, common hepatic duct; L, left; R, right; RHA, right hepatic artery; RHD, right hepatic duct.
Reprinted from Way LW, Stewart L, Gantert W, et al. Causes and prevention of laparoscopic bile duct injuries; Analysis of 252 Cases From a Human Factors and Cognitive Psychology Perspective. *Ann Surg* 2003;237(4):460, with permission of Wolters Kluwer Health, Inc.

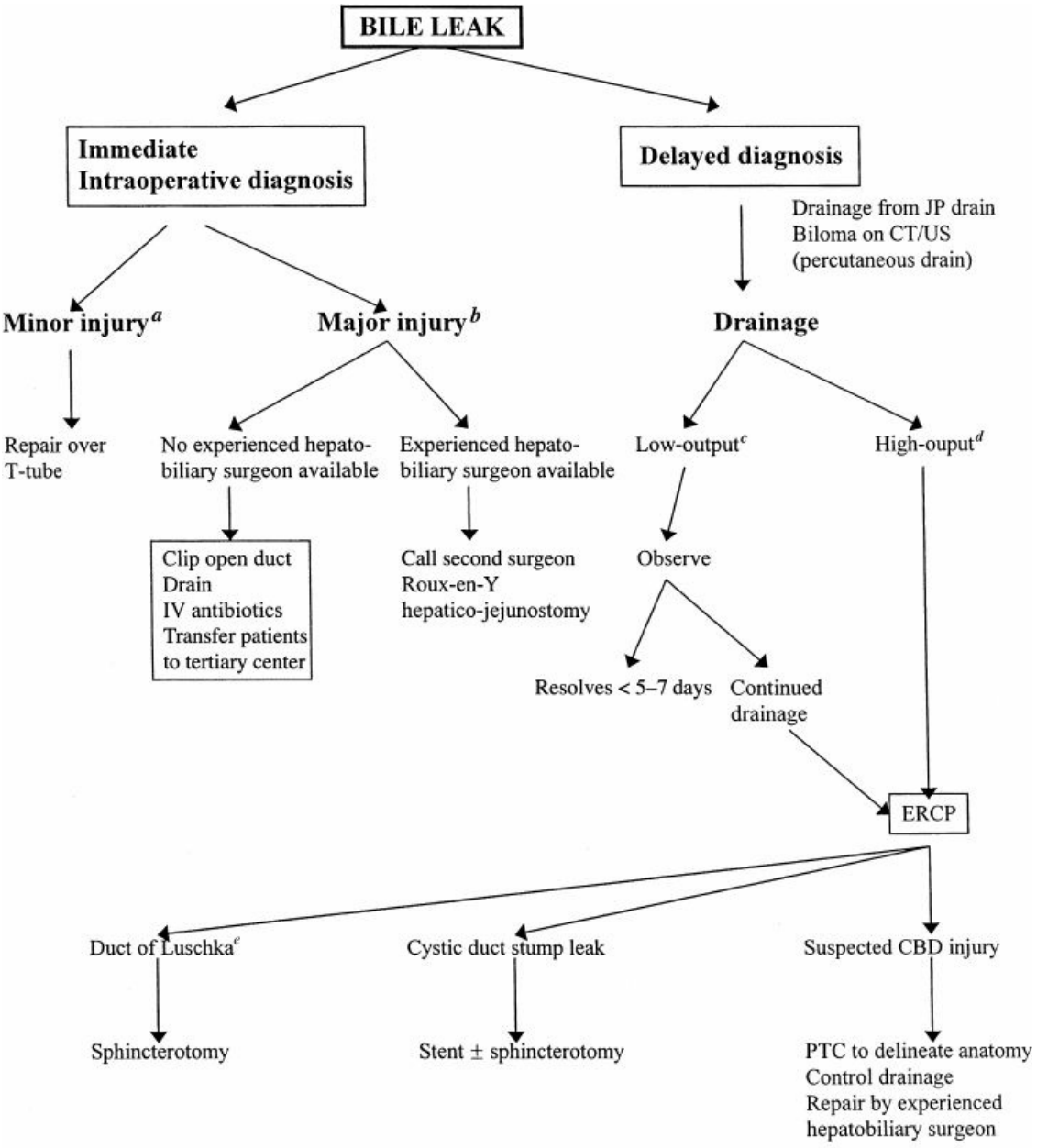

[a] Minor CBD injury: injury less than 50% duct circumference (intact ductal anatomy)
[b] Majory CBD injury: injury over 50% duct circumference (includes ligation, transection, avulsion)
[c] Low-output drainage: less than 300 cc/day
[d] High-output drainage: over 300 cc/day
[e] Bile duct of Luschka: supravesicular duct in the gallbladder bed (no drainage of liver parenchyma)

Figure 110.14. Evaluation and management of a bile leak after laparoscopic cholecystectomy. CBD, common bile duct; CT, computed tomography; ERCP, endoscopic retrograde cholangiopancreatography; JP, Jackson–Pratt; PTC, percutaneous transhepatic cholangiogram; US, ultrasound.

Dilated CBD (Larger Than 6 mm), Medium Stone (4 to 8 mm)

A case involving a CBD dilated larger than 6 mm and a medium-sized stone between 4 and 8 mm is the most common situation. Such stones are

rarely amenable to flushing techniques or fluoroscopic basketing. The basket is usually too narrow to entrap these larger stones. Under these circumstances, a direct-vision basketing approach is preferred. We use a 2- to 5-mm flexible choledochoscope (Karl Storz, Inc., Tuttlingen, Germany) and a second video cart, including a light source, a video monitor, and a video camera. In the majority of circumstances, it is necessary to dilate the cystic duct to a minimum size of 5 mm to introduce the choledochoscope. If the bile duct stone is substantially larger than 5 mm, we dilate the cystic duct to 8 mm using a balloon dilator. The choledochoscope is introduced through a specialized plastic introducer system (Bercí CBD Introducer, Cook Surgical, Bloomington, IN). A rubber-shod Maryland grasper is then used to guide the scope into the cystic ductotomy through the valves of Heister into the CBD. Rubber-shod graspers for endoscope manipulation are important to avoid tearing the outer sheath of the scope. Frequently, we make a second cystic ductotomy close to the CBD to bypass most of the Heister valves. Once the CBD is reached, the choledochoscope almost always drops into the distal duct, where the majority of bile duct stones will be located. A 2.4 French flat-wire Segura basket is then advanced through the operating channel of the choledochoscope, with saline running at low pressure around the basket. The basket is opened, the stone is entrapped, and the apparatus is pulled out. If multiple stones are present, the procedure is repeated. A completion cholangiogram is then performed. This procedure generally works for stones up to 8 mm in diameter.

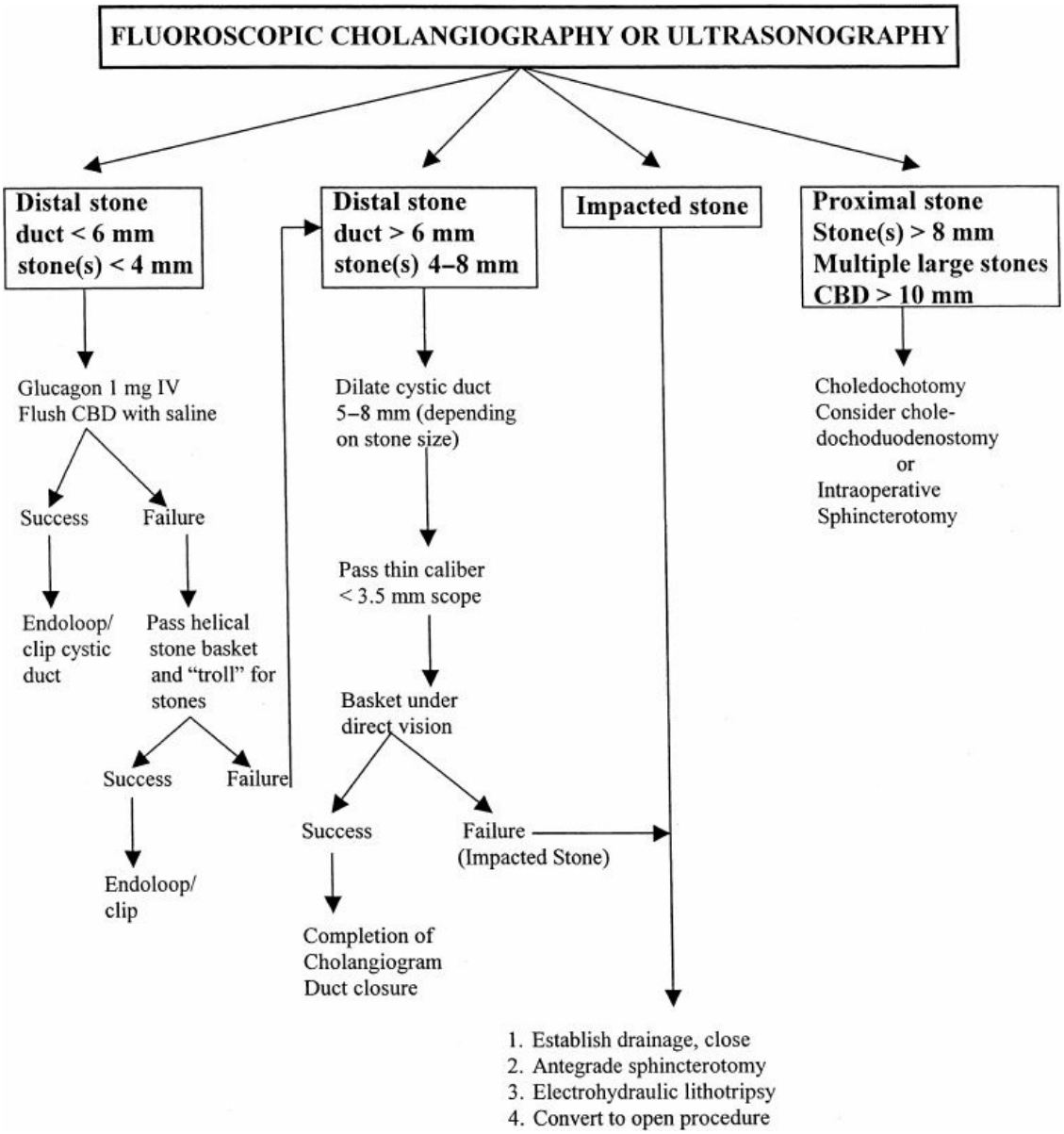

Figure 110.15. Management of common bile duct (CBD) stones with laparoscopic cholecystectomy.

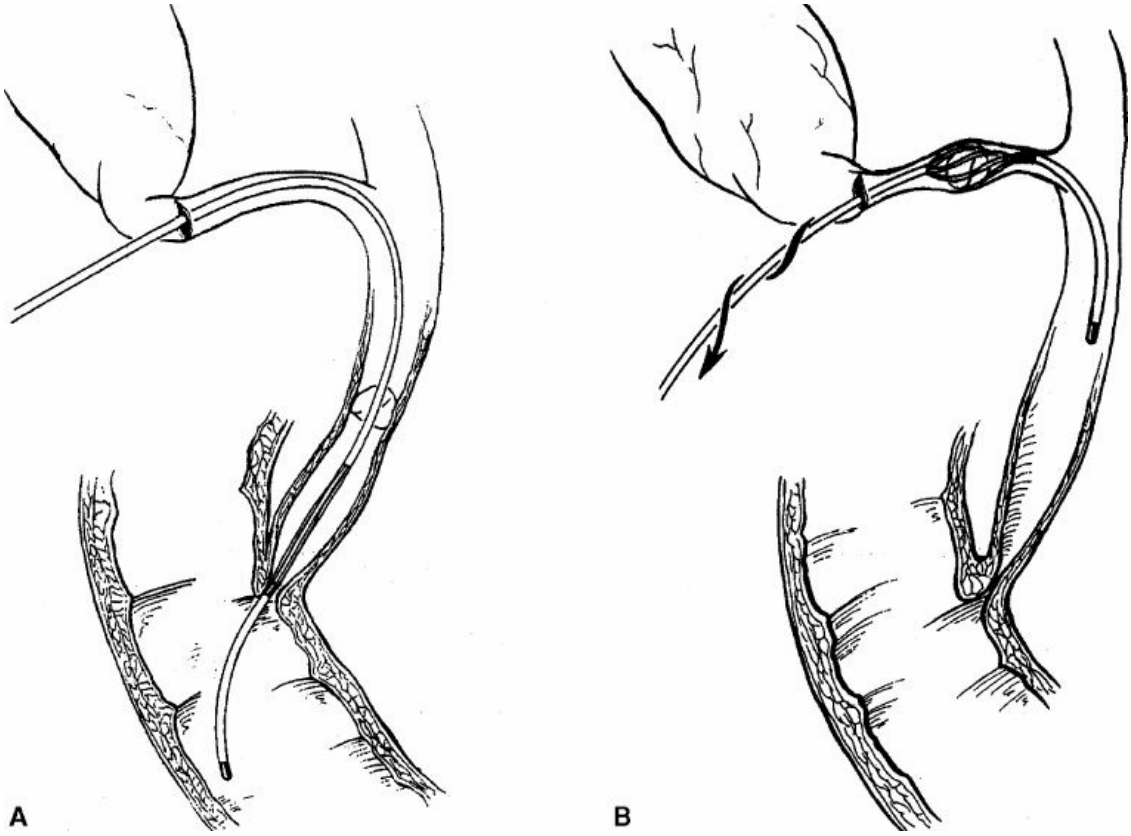

Figure 110.16. Fluoroscopic bile duct exploration using a C-arm and helical stone basket. **A.** Positioned with a closed basket in the distal common bile duct. **B.** Removing entrapped stone with clockwise rotation.

Dilated CBD (Larger Than 10 mm), Large Stone (>8 mm)

Large stones and those above the cystic duct entrance are not amenable to any of these previous techniques. To adequately remove these stones, a choledochotomy must be made, the stone must be fragmented, or a sphincterotomy must be made. If the surgeon is extremely skilled in laparoscopic techniques, curved microscissors can be used to make a small anterior choledochotomy 1 to 2 cm in length. Again, a choledochoscope (generally a standard choledochoscope) is advanced through the choledochotomy, and the stones are entrapped with a Segura basket and pulled out the choledochotomy. Irrigation and Fogarty catheters can also be used. If the bile duct is larger than 2 cm in diameter, or if there are more than five stones, the patient will be at high risk for recurrent primary bile duct stones. Under these circumstances, the surgeon should consider more permanent biliary drainage with a choledochoduodenostomy or ES.

Impacted Stones

When stones are impacted in the ampulla of Vater, they cannot be removed with any of the techniques mentioned previously because it is impossible to get a basket beyond these stones, and even an inflated Fogarty balloon rarely dislodges them. Under these circumstances, there are four acceptable options.

1. The first option is to do nothing further. A drain—either a straight tube or a T-tube—is placed through the cystic duct into the CBD, and then the operation is completed. The drain is secured in the cystic duct stump with a pretied loop (Endoloop). At a later date, a guidewire is passed through the drain into the duodenum, and a retrograde sphincterotomy is performed over the guidewire. Alternatively, using this technique, some surgeons prefer to perform an endoscopic retrograde sphincterotomy on the operating table, which requires exquisite communication and a large degree of expertise on the part of the biliary endoscopist.
2. The second option is a similar technique that is easier for the biliary endoscopist—anterograde sphincterotomy. A guidewire is passed beyond the stone into the duodenum, and a wire-guided endoscopic sphincterotome is passed over the guidewire across the Oddi sphincter. To make sure that the sphincterotome is well-oriented, a duodenoscope is passed through the mouth into the duodenum. The sphincterotomy is then performed at the 11 to 12 o'clock position of the papilla. The bile duct stone is pushed into the duodenum with a choledochoscope or an inflated balloon extractor (Fig. 110.17).
3. The third option is electrohydraulic lithotripsy. Through the choledochoscope, a fine lithotripsy probe—1.8 to 2.8 French—is passed through the operating channel. Under direct vision, the bile duct stone is fragmented into pieces. The fragments are extracted with baskets or pushed into the duodenum. This technique seems to work best with the smaller impacted stones because large stones make large fragments that are difficult to remove through the cystic duct and are similarly difficult to push through the ampulla of Vater without a sphincterotomy.
4. The final option is to convert to an open procedure.

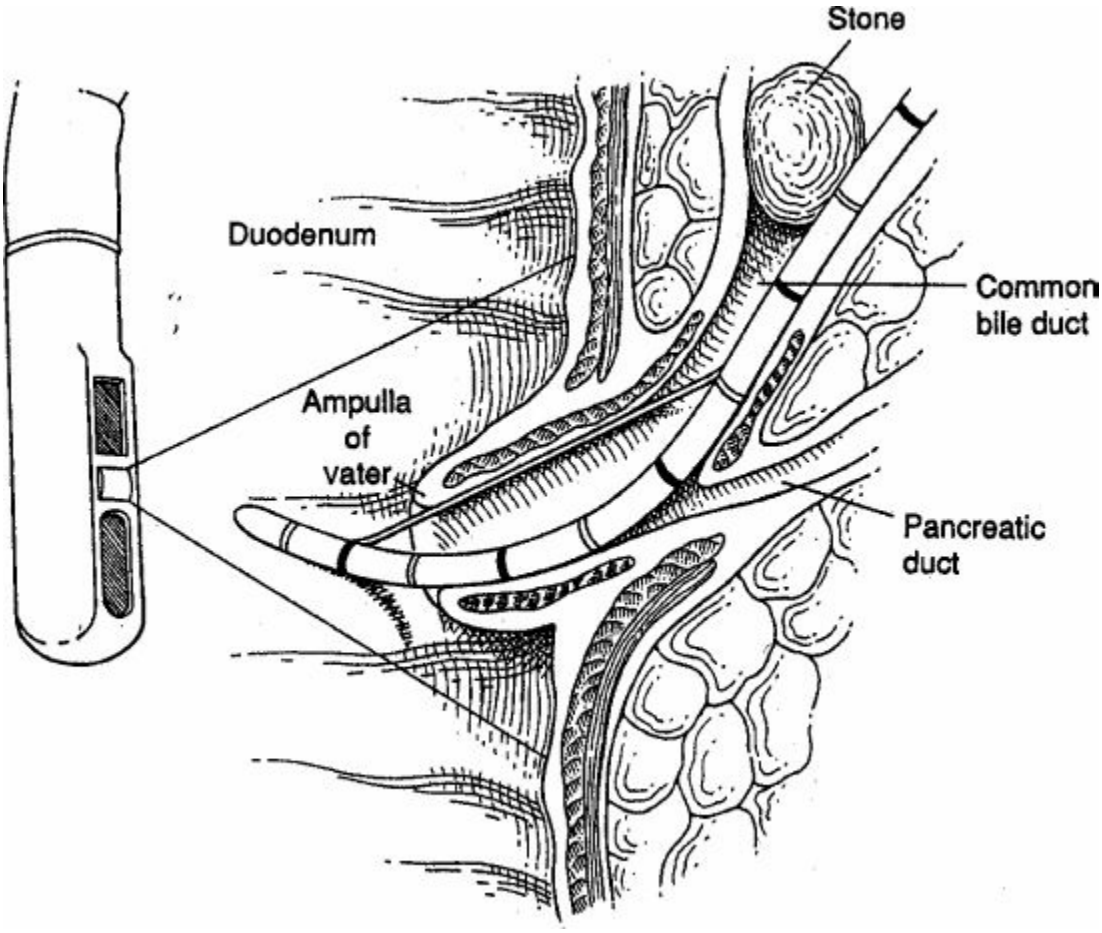

Figure 110.17. Anterograde sphincterotomy performed with the guidance of a side-viewing duodenoscope.

CBD Closure

If the CBD has been explored through the cystic duct, and if the completion cholangiogram demonstrates duodenal filling, the cystic duct can usually be closed with a single Endoloop or two clips. Drainage of the Morrison pouch is unnecessary under this circumstance. If spasm, edema, or obstruction of the Oddi sphincter is present, a straight latex drain is passed into the CBD and secured in place with an Endoloop.

If a choledochotomy was necessary, a small—12 to 14 French—T-tube is passed through a 10-mm trocar and placed in the CBD. The CBD can be closed with two or three interrupted 4-0 monofilament absorbable sutures. Recent studies suggest a higher complication rate (16% vs. 9%) with insertion of a T-tube, so, in the absence of fibrosis or inflammation, the surgeon may choose to perform primary closure of the choledochotomy without placement of a T-tube. A Jackson–Pratt drain is placed in the abdomen near the repair and brought out through one of the lateral trocar holes.

Post-Cholecystectomy Syndrome

Post-cholecystectomy syndrome is a constellation of heterogeneous symptoms occurring after the removal of the gallbladder. It can occur early in the postoperative period or months to years after surgery. It is characterized by a variety of symptoms, including right upper quadrant abdominal pain, nausea, emesis, bloating, or diarrhea. At least half of patients with this constellation of findings will have a gastrointestinal cause such as an undiagnosed bile duct injury, leading to stricture, retained stone, or a primary biliary dysmotility disorder. Other GI causes include irritable bowel syndrome, peptic ulcer disease, pancreatitis, and diverticulitis. The remaining patients will have nongastrointestinal causes, including psychosomatic disorders, coronary artery disease, neuromas, or neuritis. Work-up should include ultrasound and/or CT to evaluate for gastrointestinal causes followed by an MRCP to thoroughly evaluate the biliary tract.

Hernia

Hernia after LC is rare, but typically occurs at the umbilical port site, especially if a larger 10 to 12 mm port is used. One adverse aspect of the single incision laparoscopic and robotic cholecystectomties is the high incidence of incisional hernia: approxiamtely 8%. This rate is higher in the subgroup of older patients (age >50) with a rate of 15% and those with a BMI >30 with a rate of 33%. There is a lack of literature regarding hernia incidence after single-incision robotic cholecystectomy; however, it seems reasonable to assume that it would be similar to single incision LC rates.

SUMMARY

LC has largely replaced open cholecystectomy for the treatment of symptomatic cholelithiasis. The advantages of rapid recovery are clear. With careful, meticulous technique, the complications of this procedure should be fewer than with open cholecystectomy. Appropriate treatment of the CBD stone is the next frontier. At this time, the best management depends on local expertise, but it behooves the next generation of surgeons to achieve the expertise with transcystic bile duct exploration, which will allow the surgeon to remain the primary physician caring for diseases of the biliary tract.

Suggested Readings

Alvarez FA, de Santibanes M, Palavecino M, et al. Impact of routine intraoperative cholangiography during laparoscopic cholecystectomy on bile duct injury. *BJS* 2014;101:677–84.

Campanile FC, Pisano M, Coccolini F, et al. Acute cholecystitis: WSES position statement. *World J Emerg Surg* 2014;9(1):58.

Cao AM, Eslick GD, Cox MR. Early laparoscopic cholecystectomy is superior to delayed acute cholecystitis: a meta-analysis of case-control studies. *Surg Endosc* 2016;30(3):1172–82.

Ford JA, Soop M, Du J, et al. Systematic review of intraoperative cholangiography in cholecystectomy. *Br J Surg* 2012;99(2):160–7.

Hunter JG. Avoidance of bile duct injury during LC. *Am J Surg* 1991;162:71.

Hunter JG. Laparoscopic transcystic common bile duct exploration. *Am J Surg* 1992;163:53.

Marks JM, Phillips MS, Tacchino R, et al. Single-incision laparoscopic cholecystectomy is associated with improved cosmesis scoring at the cost of significantly higher hernia rates: 1-year results of a prospective randomized, multicenter, single-blinded trial of traditional multiport laparoscopic cholecystectomy vs. single-incision laparoscopic cholecystectomy. *J Am Coll Surg* 2013;216(6):1037–47.

Petelin JB. Laparoscopic common bile duct exploration: lessons learned from >12 years' experience. *Surg Endosc* 2003;17:1705.

Rogers SJ, Cello JP, Horn JK, et al. Prospective randomized trial of LC+LCBDE vs. ERCP/S+LC for common bile duct stone disease. *Arch Surg* 2010;145:28–33.

Way LW, Stewart L, Gantert W, et al. Causes and prevention of laparoscopic bile duct injuries: analysis of 252 cases from a human factors and cognitive psychology perspective. *Ann Surg* 2003;4:460.

EDITOR'S COMMENT

The authors present an excellent overview of one of the most common operations performed by the general surgeon. Most cholecystectomies are performed by laparoscopy. I will comment on the timing of cholecystectomy in acute cholecystitis and pancreatitis, the continued problem of bile duct injury, and the use of nontraditional techniques such as single port laparoscopic cholecystectomy and robotic assisted cholecystectomy.

Most laparoscopic cholecystectomies are performed in an elective setting. In two conditions, there is some debate about the timing of surgery. Acute cholecystitis may occur in up to 20% of patients with symptomatic gallstones. The concern is that waiting may lead to complications or more difficult surgery.

Gurasamy and colleagues (Gurusamy KS, Davidson C, Gluud C, et al. Early versus delayed laparoscopic cholecystectomy for people with acute cholecystitis. *Cochrane Database Syst Rev* 2013;6:CD005440) searched the Cochrane Hepato-biliary Group Controlled Trials Register to compare early (<72 hours) and late cholecystectomy (4 to 8 weeks) and found no significant difference between early and late laparoscopic cholecystectomy in mortality, bile duct injury, serious complications, and operating time. The early group had a shorter hospital stay. In the late group, about 18% of patients failed to improve while waiting and had urgent cholecystectomy and the conversion to open cholecystectomy was 45%. Certainly high-risk patients may be treated initially with a percutaneous cholecystostomy tube and later cholecystectomy as described by Professor Garden in Chapter 109. Roulin and colleagues (Roulin D, Saadi A, Di Mare L, et al. Early versus delayed cholecystectomy for acute cholecystitis. Are the 72 hours still the rule?: A randomized trial. *Ann Surg* 2016;264:717–22) have recently completed a randomized prospective trial of early versus delayed cholecystectomy. They reported that the overall morbidity was lower in early group (6 [14%] vs. 17 [39%] patients, $P = 0.015$). Median total length of stay (4 vs. 7 days, $P < 0.001$) and duration of antibiotic therapy (2 vs. 10 days, $P < 0.001$) were shorter in the early group. Total hospital costs were lower in early group as well ($11,873 vs. $15,698, $P = 0.018$). Operative time and postoperative complications were similar (91 vs. 88 min; $P = 0.910$) and (15% vs. 17%; $P = 1.000$), respectively. They concluded early surgery for acute cholecystitis even beyond 72 hours of symptoms is safe and associated with less overall morbidity, shorter total hospital stay, and duration of antibiotic therapy, as well as reduced cost compared with delayed cholecystectomy.

The timing of laparoscopic cholecystectomy after an attack of acute biliary pancreatitis is controversial. It is argued that early surgery would potentially avoid recurrent gallstone pancreatitis. Indeed about 20% of patients will have recurrent pancreatitis or biliary complications if surgery is delayed. But is early surgery safe? What is the timing of cholecystectomy in severe pancreatitis with fluid collections or necrosis? Gurusamy and colleagues using the Cochrane Database compared the benefits and risks of early versus delayed laparoscopic cholecystectomy in people with acute biliary pancreatitis. For mild acute pancreatitis, they defined “early” laparoscopic cholecystectomy as performed within 3 days of the onset of symptoms and considered all those performed beyond 3 days of the onset of symptoms as “delayed.” For severe acute pancreatitis, they defined “early” laparoscopic cholecystectomy as being performed within the index admission and considered all performed in a later admission as “delayed.” They identified no evidence of increased risk of complications after early laparoscopic cholecystectomy. Early laparoscopic cholecystectomy may even shorten the total hospital stay in patients with mild acute pancreatitis. If appropriate facilities and expertise are available, early laparoscopic cholecystectomy appears preferable to delayed laparoscopic cholecystectomy in those with mild acute pancreatitis. In addition, they reported

that there is currently no evidence to support or refute early laparoscopic cholecystectomy for people with severe acute pancreatitis.

Wilson and de Moya performed a literature search (Wilson CT, de Moya MA. Cholecystectomy for acute gallstone pancreatitis: early vs delayed approach. *Scandinavian J Surg* 2010;99:81–5) and identified 59 articles discussing cholecystectomy in the context of gallstone pancreatitis. Most were retrospective studies or reviews, but there were nine prospective observational studies and two randomized control trials. They found that for mild gallstone pancreatitis, laparoscopic cholecystectomy within 48 hours of presentation (without normalization of pancreatic enzymes or absence of abdominal pain) shortened hospital stay without increased morbidity or mortality and that routine preoperative ERCP is unnecessary for patients with mild disease. In general, I agree with these observations. In the typical case, the offending gallstone has passed, the enzymes return to normal, and ERCP is unnecessary. However, I usually recommend waiting until enzymes are normalizing or abdominal pain is in resolution as failure to improve may indicate a persistent common duct stone and progression of the pancreatitis to a more severe condition. For more severe disease, timing of cholecystectomy is governed by clinical status. Interval cholecystectomy (>2 weeks after index admission) can be safely done with low risk of recurrence if the patient has had ERCP and sphincterotomy at index admission. They also recommend sphinctertomy if cholecystectomy is going to be delayed. This recommendation is controversial at best. They conclude that patients with mild gallstone pancreatitis should have cholecystectomy during index admission within 48 hours of arrival, but patients with more severe disease will require cholecystectomy at a later time, depending on the clinical circumstances.

What should the surgeon do in severe acute pancreatitis? Probably wait until fluid collections resolve or can be treated by enteric drainage. The study by Nealon and colleagues (Nealon WH, Bawdumial K, Wasler EM. Appropriate timing of cholecystectomy in patients who present with moderate to severe gallstone-associated acute pancreatitis with peripancreatic fluid collections. *Ann Surg* 2004;239:741–51), although dated, makes a cogent argument for caution in these patients. This group retrospectively studied 187 patients with moderate to severe gallstone-associated acute pancreatitis and associated fluid collections between 1987 and 2003. Moderate to severe acute pancreatitis was defined as >5 Ranson prognostic indicators. In this report, fluid collections were established by computed tomography.

Of 187 patients with moderate to severe gallstone-associated acute pancreatitis who survived their acute stage, 151 had peripancreatic fluid collections. The authors reported that 78 of the 187 had early cholecystectomy, 62 of whom had fluid collections; 109 were monitored before cholecystectomy of which 89 had fluid collections. Fluid collections resolved without intervention in 36 (40%) of the monitored group and in 13 (21%) of 62 in the early cholecystectomy group. Importantly, sepsis was reported in 6 (7%) of 89

in the monitored group and 29 (47%) of 62 in the early cholecystectomy group. This was an almost sixfold increase in sepsis in the early surgery group. In addition, complications of cholecystectomy were reported in 6 (5.5%) of 109 of the monitored patients and in 34 (44%) of 78 in the early cholecystectomy group. Fifty-three patients in the monitored group and 49 patients in the early cholecystectomy group required operative pseudocyst-enterostomy. This procedure was combined with cholecystectomy in the monitored patients. Mean hospitalization was noted to be longer in the early operation group. Nealon concluded that cholecystectomy should be delayed in patients who survive an episode of moderate to severe acute biliary pancreatitis and demonstrate peripancreatic fluid collections or pseudocysts until the pseudocysts either resolve or persist beyond 6 weeks, at which time pseudocyst drainage can safely be combined with cholecystectomy.

The authors clearly describe the technique of laparoscopic cholecystectomy. They note a continuing problem with bile duct injury, which I would like to expand upon. After the introduction of laparoscopic cholecystectomy, there was an initial increase the incidence of bile duct injury. This has decreased but remains a problem that still challenges the surgeon. Bile duct injury occurs in about 3/1,000 cholecystectomies. Much has been learned about preventing this complication. I think the best technique for preservation is establishing the critical view of safety and not dividing any tubular structures until that view is obtained. Three criteria are required to achieve the critical view of safety (Strasberg SM, Brunt LM. Rationale and use of the critical view of safety in laparoscopic cholecystectomy. *J Am Coll Surg* 2010;211:132–8). First the hepatocystic triangle (Calot triangle) is cleared of fat and fibrous tissue. The hepatocystic triangle is defined as the triangle formed by the cystic duct, the common hepatic duct, and inferior edge of the liver. The common bile duct and common hepatic duct do not have to be exposed. Next the lower one third of the gallbladder is separated from the liver to expose the cystic plate. The cystic plate is also known as the liver bed of the gallbladder and lies in the gallbladder fossa. Finally one should see the liver on the through the cleared hepatocystic triangle posterior to the ampulla of the gallbladder and cystic duct and artery. There should be only two structures seen entering the gallbladder: the cystic duct and artery. Some recommend obtaining the Doublet View, which has two components—the anterior and posterior laparoscopic views will demonstrate the critical components of the view of safety. It has further been recommended by SAGES Safe Cholecystectomy Program to adopt a culture of safety to include the above but also considering an intraoperative time-out during laparoscopic cholecystectomy prior to clipping, cutting, or transecting any ductal structures; having a full understanding of potential aberrant anatomy; making liberal use of cholangiography or other methods to image the biliary tree intraoperatively; and recognizing when the dissection is approaching a zone of significant risk and halt the dissection before entering the zone. Finish the operation by a safer method other than cholecystectomy including partial cholecystectomy, and

finally getting help from another surgeon in difficult circumstances. Several studies have found that cholangiography reduces the incidence and extent of bile duct injury but controversy remains on this subject. Logically it may not reduce the incidence of injury but may allow earlier recognition and even reduce the degree of injury to a type I or II according to the Stewart–Way classification that can be repaired over a T-tube or primarily. As a hypothetical example, during the cholangiogram process the surgeon makes a small incision in the presumed cystic duct without transection and performs the cholangiogram only to find that the there is no visualization of the proximal biliary tree. Upon conversion to open the injury may be fully appreciated by dissection and repaired. In experimental animal studies, it has been found that the clips that were used to partially occlude the duct and hold the catheter used to perform the cholangiogram in place may be removed without injury to the integrity of the common duct if done so within 30 minutes. Beyond that time, ischemic strictures may develop. Hence, it is recommended that if you find yourself in this situation to convert to open and remove the clips within that period of time. In actuality the incidence may be reduced when cholangiography is performed not as a result of the cholangiogram but rather because the surgeon obtains the critical view in preparation for the cholangiogram.

In addition to the Stewart–Way classification included in the preceding text, there are four other classifications for bile duct injury that may be helpful to the reader. Most surgeons use the Stewart–Way, Bismuth, or Strasberg classifications.

Bismuth Classification

The first classification of bile duct injury was proposed by H. Bismuth in 1982 in reference to biliary strictures and then adapted to bile duct injury (Bismuth H, Majno PE. Biliary strictures: classification based on the principles of surgical treatment. *World J Surg* 2001;25(10):1241–4). The Bismuth classification is a simple classification based on the location of the injury in the biliary tract. This classification includes five types of bile duct injuries according to the distance from the hilar structures and bile duct bifurcation, the level of injury, the involvement of bile duct bifurcation, and individual right sectoral duct. Type I involves the common bile duct and low common hepatic duct (CHD) >2 cm from the hepatic duct confluence. Type II involves the proximal CHD <2 cm from the confluence. Type III is hilar injury with an intact ceiling of the confluence of the right and left hepatic ducts. Type IV is injury of the confluence resulting in separation of the right and left hepatic ducts. Type V involves the aberrant right sectoral hepatic duct alone or with concomitant injury of CHD.

Strasberg Classification

The Strasberg classification is a modification of the Bismuth classification, but

allows differentiation between small (bile leakage from the cystic duct or aberrant right sectoral branch) and serious injuries performed during laparoscopic cholecystectomy (Strasberg SM, Hertl M, Soper NJ. An analysis of the problem of biliary injury during laparoscopic cholecystectomy. *J Am Coll Surg* 1995;180[1]:101–25). The Strasberg classification A-E includes: (A) bile leak from cystic duct stump or minor biliary radical in gallbladder fossa, (B) occluded right posterior sectoral duct, (C) bile leak from divided right posterior sectoral duct, (D) lateral common bile duct injury, and (E) 1–5 subclassified as in the Bismuth Classification. The potential disadvantage of the Strasberg classification is that it does not describe additional vascular involvement.

McMahon Classification

McMahon et al. proposed another classification of bile duct injuries after laparoscopic cholecystectomy (McMahon AJ, Fullarton G, Baxter JN, et al. Bile duct injury and bile leakage in laparoscopic cholecystectomy. *Br J Surg* 1995;82(3):307–13). They classified the injury by the width of bile duct injury. Based on the McMahon classification, lacerations under 25% of the common bile duct (CBD) diameter or cystic-CBD junction were classified as a minor injury, whereas transection or laceration over 25% of CBD diameter and postoperative bile duct stricture were classified as major injury.

Hannover Classification

Bektas et al. proposed a new classification system named Hannover classification after comparing the classification of bile duct injury for consecutive 72 iatrogenic bile injuries after laparoscopic cholecystectomy (Bektas H, Schrem H, Winny M, et al. Surgical treatment and outcome of iatrogenic bile duct lesions after cholecystectomy and the impact of different clinical classification systems. *Br J Surg* 2007;94(9):1119–27). In the Hannover, bile duct injuries were divided into five types from A to E. Type A is peripheral bile leakage. Type B is stricture of CHD or CBD without injury. Type C is lateral CHD or CBD injury. Type D is total transection of CHD. Type E is bile duct stricture of the main bile duct without bile leakage at postoperative state. Vascular injuries are included in Type C and Type D. The Hannover classification distinguished a total of 21 injury patterns in a small group of patients. The reported advantage of the Hannover classification is that it has a high level of statistical significance to demonstrate the association between the discrimination of classifiable injury patterns and the surgical treatments chosen.

My final comments will be on the role of single port and robotic-assisted cholecystectomy. I have been open-minded about these innovations and curious to see which direction they would go. It is now abundantly clear that there is questionable value of these techniques. The most recent studies show that nontraditional, minimally invasive gallbladder removal by single port access or

using robotic assistance while safe offers significantly less surgical value for elective, outpatient gallbladder removal (Newman RM, Umer A, Bozzuto BJ, et al. *Surg Endosc* 2016 September 1 [Epub ahead of print]; Newman RM, Umer A, Bozzuto BJ, et al. Surgical value of elective minimally invasive gallbladder removal: a cost analysis of traditional 4-port vs single-incision and robotically assisted cholecystectomy. *J Am Coll Surg* 2016;222(3):303–8). Our own experience has been similar. Strosberg and colleagues reported a retrospective study comparing outcomes in 237 patients who underwent robotic (RC) (140) or laparoscopic cholecystectomy (LC) (97). There were no bile duct injuries in either group, no difference in bile leak rates ($p = 0.65$), or need for reoperation ($p = 1.000$). Cost analysis of outpatient-only procedures, excluding cases with conversion to open or use of intraoperative cholangiography, demonstrated higher total charges ($p < 0.01$) and cost ($p < 0.01$) for RC compared to LC (Strosberg DS, Nguyen MC, Musacarella P, et al. A retrospective comparison of robotic cholecystectomy versus laparoscopic cholecystectomy: operative outcomes and cost analysis. *Surg Endosc* 2017;31(3):1436–41).

E. Christopher Ellison

111 Reconstruction of the Bile Duct: Anatomic Principles and Surgical Techniques

Toms Augustin and R. Matthew Walsh

Reconstruction of the bile duct is one of the more technically challenging and potentially morbid procedures performed by general surgeons today. Bile duct reconstructions (BDR) are done for malignant and benign biliary obstructions, and approximately 10% for bile duct injuries. The majority of reconstructions are done at teaching hospitals with only 25% performed at centers with more than 35 cases per year. Overall, BDR are associated with an inpatient mortality rate of 4.2% and a morbidity of about 32%, including postoperative wound complications, acute renal failure, and gastrointestinal bleeding. An understanding of biliary anatomy and proper techniques of BDR are of core importance to any practicing general surgeon. Key principles include precise duct-to-mucosa anastomoses that drain all parts of the liver, are well vascularized, and tension-free.

HISTORY

Prominent international surgeons have advanced the care of patients requiring biliary reconstructions. In 1894, Swain described cholecystojejunostomy as a treatment for choledochal cyst. The first radiologic visualization of the biliary tree was done in 1918 by Reich when he injected petrolatum and bismuth into an external biliary fistula. Bakes in 1923 first reported intraoperative endoscopic visualization of the bile ducts using the Bakes dilators. These metal dilators are not in common use today due to the risk of perforation. In 1928 Ladd described the first successful repair of biliary atresia. In 1944 Allen described a procedure in which a Roux-en-Y segment of jejunum was brought up to the hepatic hilum and sutured to the capsule of the liver around the open proximal hepatic duct. A duct-to-mucosa anastomosis was not performed. Claude Couinaud described the segmental liver anatomy in 1957 that paved the way for anatomical liver resection. Klatskin in 1965 first described

adenocarcinoma at hepatic duct bifurcation. Mouret is credited with the first human laparoscopic cholecystectomy in 1987.

INDICATIONS FOR BILE DUCT RECONSTRUCTION

There are multiple indications to perform a BDR. Recent data from the US Nationwide Inpatient Sample studied 67,160 patients undergoing BDR from 2004 to 2011, approximately 8,400 patients per year. The most common causes were for nonmalignant disease in 48%, malignant diseases in 37%, iatrogenic bile duct injury (IBDI) in 10%, congenital biliary anomaly in 2.5%, and benign neoplasms in 2.3%. Among the patients requiring BDR for malignant causes, pancreatic malignancy was the most common followed by hepatic malignancy, intrahepatic biliary malignancy, and gallbladder malignancy. Within the group of patients with nonmalignant disease, 62% of patients had a concomitant diagnosis of cholelithiasis, cholecystitis, or cholangitis. Thus, the burden of gallstone disease as well as complications related to cholecystectomy requiring BDR may in fact be higher than the 10% quoted for biliary injury.

One of the common indications for resection of bile ducts is cholangiocarcinoma. Other rare indications include gallbladder cancer, pseudotumors, carcinoid tumors, and primary sclerosing cholangitis (PSC). BDR is also an integral step in pancreaticoduodenectomy and in this case the common hepatic duct (CHD) is divided just above the usual level of insertion of the cystic duct where the right hepatic artery normally passes behind the CHD.

HEPATIC HILAR AREA; THE PLATE SYSTEM

The liver plate system consists of the sheath around the bile ducts and blood vessels that is continuous with the Glisson capsule intrahepatically and the hepatodudenal ligament extrahepatically. The three plate systems that exist in the liver are the cystic, hilar, and umbilical plate (Fig. 111.1A). The cystic plate is the bed of the gallbladder and does not have importance in biliary reconstruction. The hilar plate is located at the hilum of the liver that is located at the porta hepatis, a deep fissure on the inferior surface of the liver, and contains the portal vein, the hepatic artery, the right and left hepatic duct system, and nervous and lymphatic plexus (Fig. 111.1B). Division of the hilar plate is essential for surgical access to the left hepatic duct (LHD) (Fig. 111.1C). The arrangement of the structures at the hilum is the hepatic ducts being anterior to the portal vein and the

artery running between the two. The umbilical plate is located at the inferior edge of the umbilical fissure. The segmental branches of the left lobe divide or fuse within the umbilical plate.

BILIARY ANATOMY AND ANOMALIES OF IMPORTANCE IN BILE DUCT RECONSTRUCTION

The “prevailing pattern” is the common anatomical arrangement of bile ducts (Fig. 111.2). In some cases, this is present less than 50% of the time. In contrast, an “anomaly” is a deviation from the prevailing pattern. Both aberrant ducts and accessory ducts are anomalous bile ducts. Aberrant ducts are located outside the prevailing anatomical location. A right posterior sectoral duct draining into the extrahepatic bile duct including the cystic duct or the gallbladder would be considered an aberrant duct. Occlusion of aberrant ducts will obstruct bile flow. Accessory bile ducts on the other hand are supernumerary bile ducts. They drain portions of the liver also drained by other bile ducts. As such occlusion of any accessory duct does not obstruct bile drainage. Accessory bile ducts are not uncommon.

The usual extrahepatic biliary anatomy consists of the right and the left hepatic ducts, which join at the hilar plate to form the CHD. This union is usually in front of the right branch of the portal vein. The CHD varies in length from 1 cm to 7.5 cm and has an average diameter of 4.0 mm. The cystic duct unites with the right border of the CHD to form the common bile duct (CBD) The CBD is 6.0 to 8.0 cm long and drains into the duodenum.

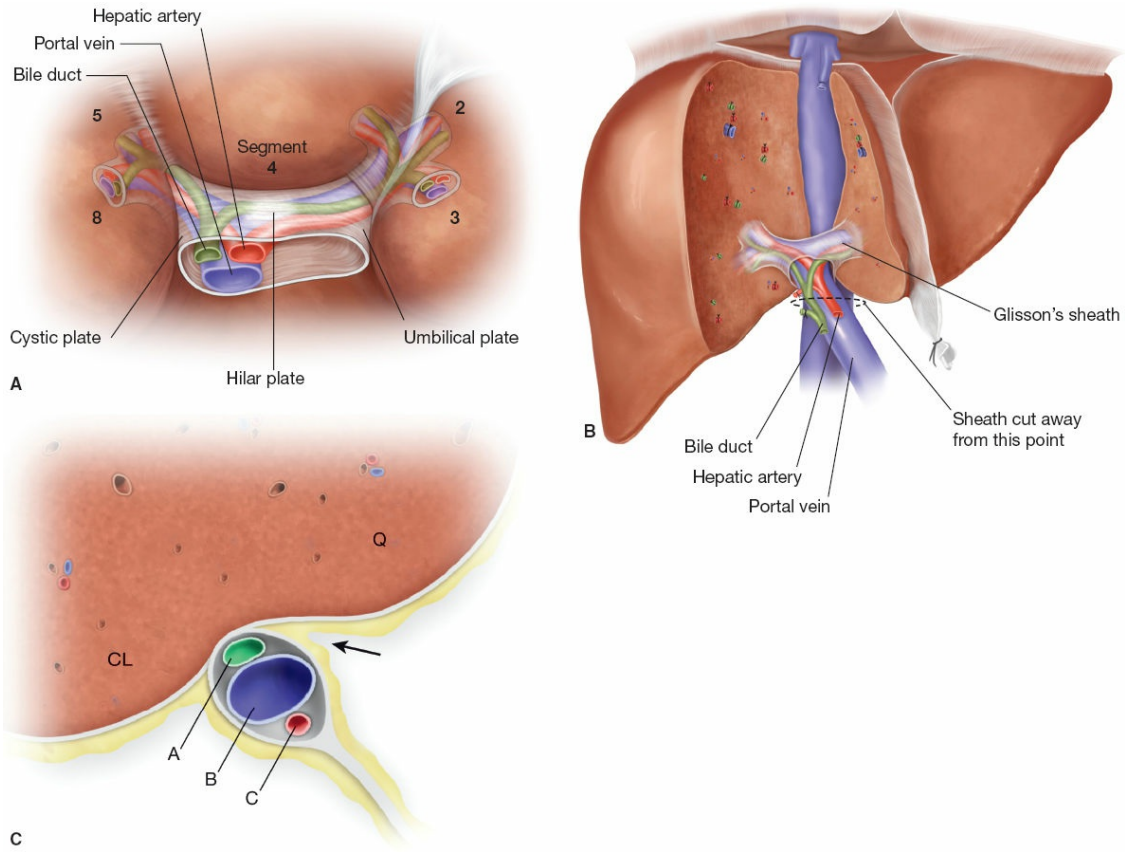

Figure 111.1. **A.** Anatomy of the hepatic plate system. Incising the hilar plate at the inferior most edge of segment IV lowers the biliary system and allows visualization of the hepatic duct system for reconstruction. The umbilical plate is noted to be between segment IV and left lateral segment. **B.** The left and the right portal pedicle are seen at the hilus. The interrupted line is where the hilar plate is incised to lower the plate. **C.** Another representation of lowering of the hilar plate. The Glisson's capsule is incised at the base of segment IV and this dissection is carried toward the left and up the umbilical fissure to expose the left hepatic duct. This dissection may be carried over to the right to expose the right hepatic duct and the confluence. Left hepatic duct (A), left portal vein (B), and hepatic artery. (C. Source: Jarnagin, WR. Blumgart's Surgery of the Liver, Biliary Tract and Pancreas: 2-Volume Set, Expert Consult - Online and Print, 5e. (Saunders: 2012).)

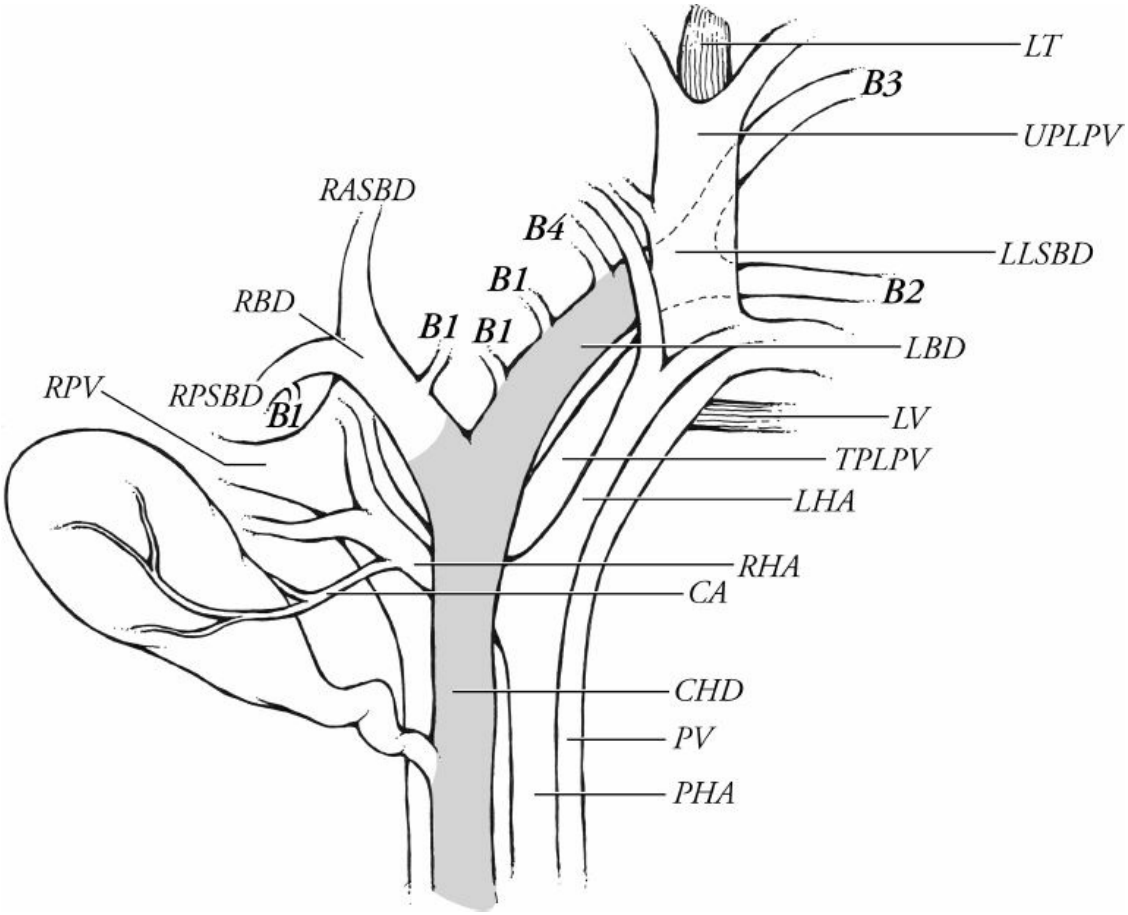

Figure 111.2. Overview of anatomical structures at the porta hepatis. The *hatched area* of the biliary tree is extrahepatic. Note the long extrahepatic length of the left bile duct (LBD) compared with the right bile duct (RBD). Other structures are the common hepatic duct (CHD); sectional bile ducts to the right anterior section (RASBD), right posterior section (RPSBD), and left lateral section (LLSBD); segmental bile ducts to segments I to IV (B1 to B4); arteries (proper hepatic artery [PHA], right hepatic artery [RHA], left hepatic artery [LHA], cystic artery [CA]); veins (portal vein [PV], right portal vein [RPV], transverse portion of the left portal vein [TPLPV], umbilical portion of the left portal vein [UPLPV]), ligaments (ligamentum terres [LT], ligamentum venosum [LV]). B5 and 8 branches of RASBD and B6 and 7 branches of RPSBD not shown.

Prevailing Patterns and Important Variations of the Cystic Duct

A majority of the patients will have a single cystic duct joining the CHD to form the CBD. This is noted in approximately 60% of the patients. There are also important variations in the length of the cystic duct, where it joins the CHD and the angle at which it joins the CHD. A variation of the cystic

duct where it circles anterior or posterior to the CHD prior to its union occurs in 5% of patients. An important variation with respect to IBDI is when the cystic duct drains into the right posterior hepatic duct that is noted in approximately 0.6% to 2.3% of patients. Failure to identify this anatomic variant can lead to a unique form of IBDI where a portion of the right hepatic system is disconnected from the biliary system and presents as a bile leak. Drainage of a normally located gallbladder into an LHD is extremely rare. The ducts of Luschka that occur in 1% to 30% of patients, are 1- to 2-mm ducts draining isolated segments of the right hepatic lobe directly into the gallbladder. These may leak following cholecystectomy if not properly secured.

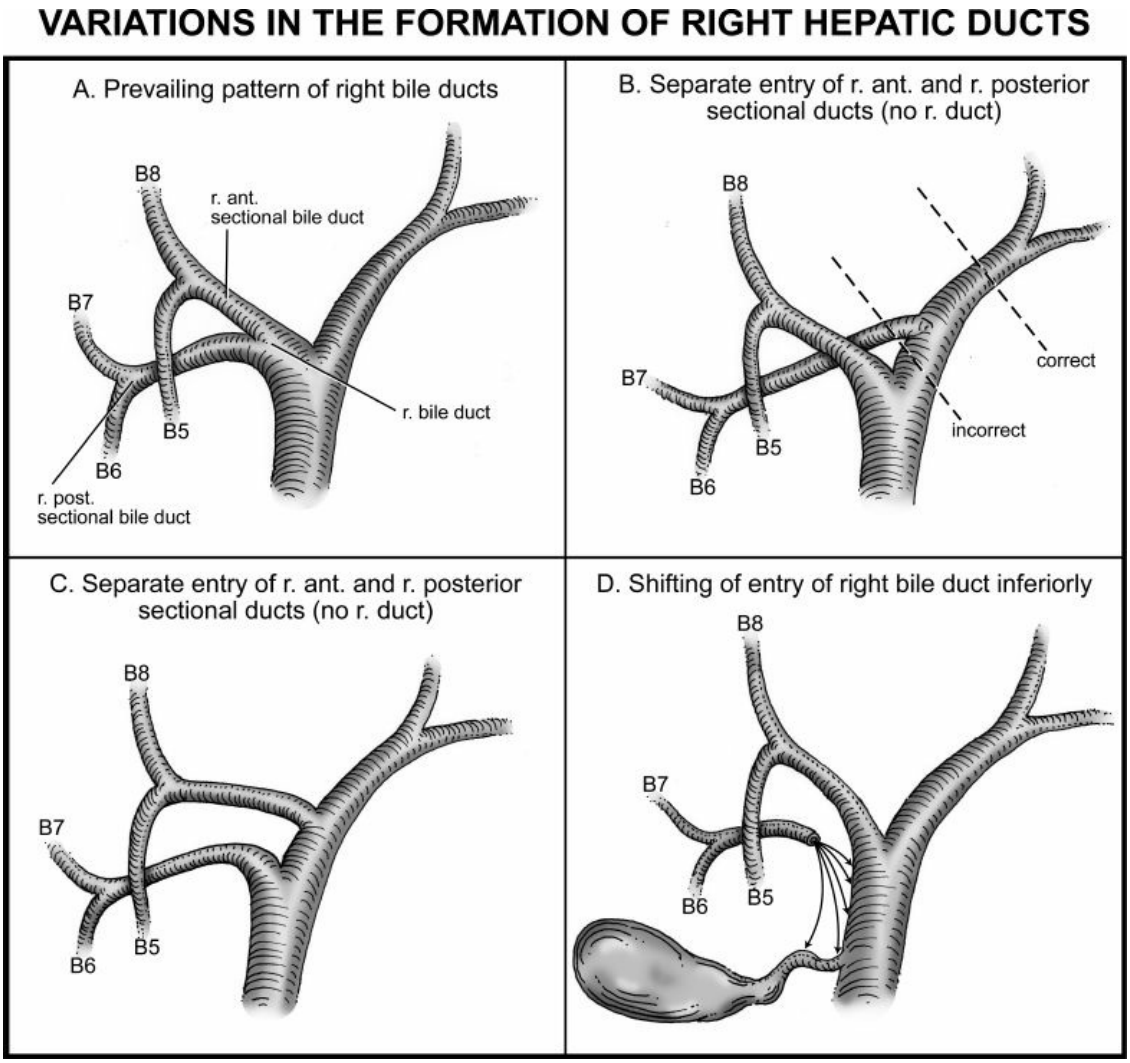

Figure 111.3. (**A–D**) Prevailing pattern and important variations of bile ducts draining the right hemiliver.

Prevailing Pattern and Important Variations of Bile Ducts

Draining the Right Hemiliver

The right hepatic duct (RHD) is approximately 0.9 cm in length and 2.6 mm (±1.2 mm) in diameter (Fig. 111.3). It is usually formed by the union of the right anterior sectional duct that drains segments V and VIII and right posterior sectional duct that drains segments VI and VII. The right posterior sectional duct is more horizontal and usually curves around the anterior sectional portal vein to join the RHD (Hjortsjo hook; Fig. 111.4). This pattern is observed in 57% of the population. Variations from this include the drainage of right posterior sectoral duct (RPSD) into the LHD that is relatively common and occurs in about 20% of the population, drainage of the right anterior sectoral duct (RASD) into the LHD (6% of the population) and as well low insertion of a sectoral duct or the main RHD into the CHD or the cystic duct.

Implications of Anatomical Variations of the RHD; Practical Points

Injury to the RPSD may result if the RASD is ligated very close to its origin. Injury to the RPSD may occur during left hepatectomy in variation B (Fig. 111.3B). In this case the LHD should be ligated in the umbilical ligament to prevent injury to the right sectoral duct. Anomalies with low insertion of the RHD into the CHD or the cystic duct increase the risk of injury during laparoscopic cholecystectomy. This variation should also be kept in mind while dividing the CHD during a pancreaticoduodenectomy at which time reconstruction of the both the ducts may be needed in case of injury.

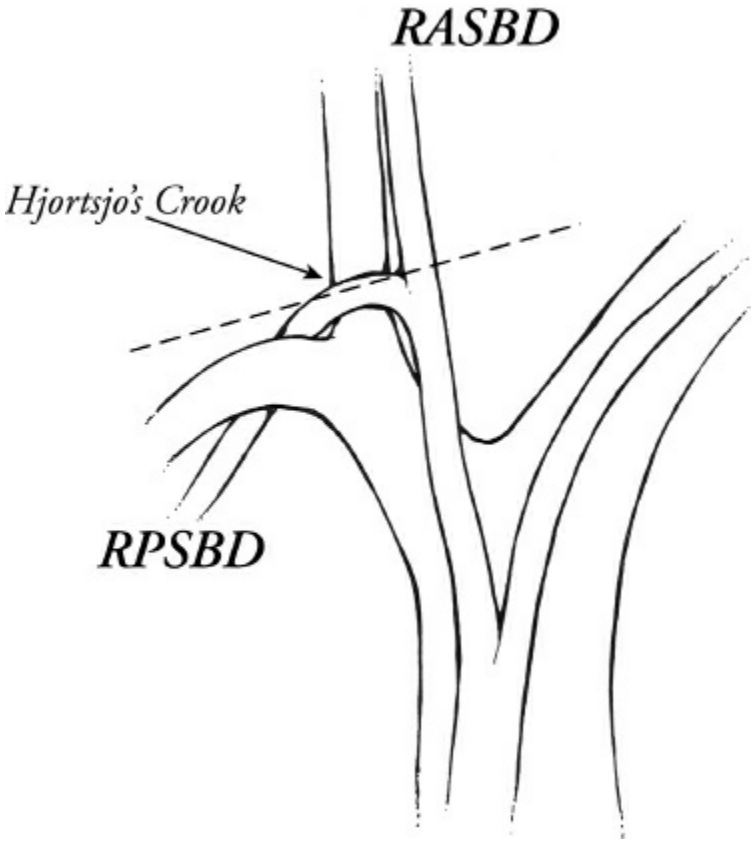

Figure 111.4. Hjortsjo's crook. Note that the right posterior sectional bile duct (RPSBD) crosses the origin of the right anterior sectional portal vein. RASBD, right anterior sectional bile duct. *Dashed line* indicates how RPSBD can be injured if right anterior portal pedicle is divided close to its origin.

Prevailing Pattern and Important Variations of Bile Ducts Draining the Left Hemiliver

The average extra hepatic length of the LHD at 1.7 cm is significantly longer than the RHD. The average diameter is 3 mm (±1.08). Similar to the RHD, the LHD has a left lateral branch that drains segment II superiorly and segment III inferiorly. The union of segment II and segment III (left lateral sectoral duct) passes behind the left portal vein in the umbilical fissure to be joined by the segment IV duct (left medial sectoral duct) to form the main left hepatic duct. This pattern is noted in 67% of the population (Fig. 111.5A). Variation of this anatomy includes the insertion of segment IV duct to the right or left of the LHD (Fig. 111.5B), multiple segment IV ducts draining the LHD (Fig. 111.5C), as well as separate insertion of segment II duct into the LHD (Fig. 111.5D).

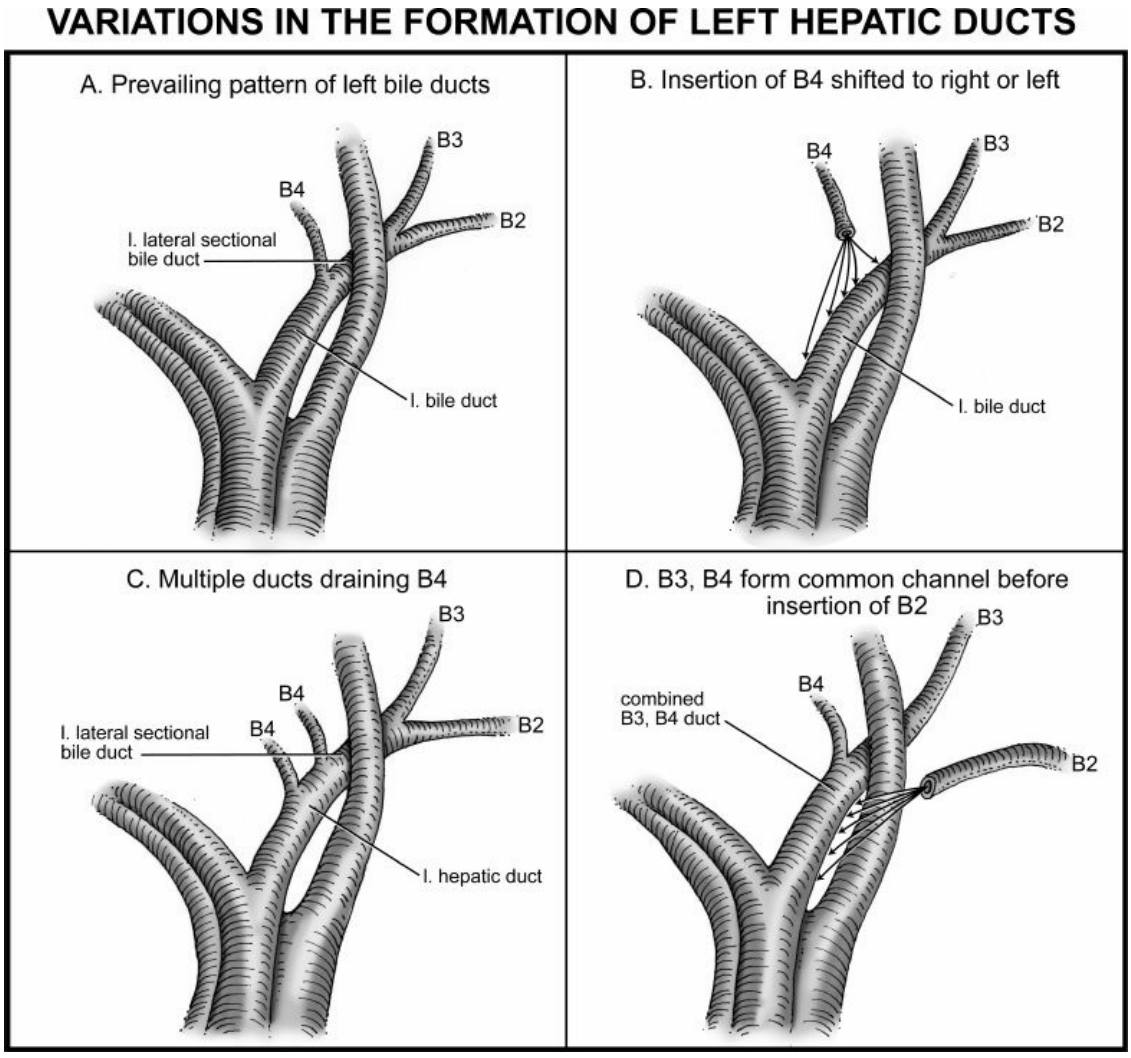

Figure 111.5. (**A–D**) Prevailing pattern and important variations of bile ducts draining the left hemiliver.

Implications of Anatomical Variations of the LHD; Practical Points

The LHD is an excellent conduit for high biliary enteric anastomosis due to length and course of the extrahepatic component that extends from the biliary confluence along the base of segment IV to two thirds of the way toward the umbilical fissure. Cholangiography helps delineate the horizontal course of the duct versus the sharp upward angle in others, which may help prepare the surgeon for the increased difficulty of dissection in these patients. The union of the left sectoral ducts is variable and has important implications during extended bile duct resections like right trisectionectomy. It might be necessary to resect the confluence of B2 and B3 requiring separate duct anastomoses. Additionally in IBDI where resection of the confluence of B4 and the left lateral sectoral duct has occurred, multiple orifices may need to be anastomosed to restore

continuity.

Prevailing Pattern of Bile Ducts Draining the Caudate Lobe (Segment I)

The anatomy of the caudate lobe is important in resection of cholangiocarcinoma as well as in repair of high biliary injuries. About two to four ducts drain the caudate lobe. About half of these ducts merge with RPSD and the other half with the LHD. The orifices are usually located posteriorly and thus less prone to injury even in high biliary injuries. In patients with hilar cholangiocarcinoma, resection of the caudate lobe is usually required.

Blood Supply to the Bile Ducts

The blood supply to the biliary ducts is derived from the celiac axis in patients with the prevailing hepatic arterial anatomy. The supraduodenal CBD has the poorest arterial supply and thus is most prone to an ischemic stricture. The arterial supply to the extrahepatic bile duct including both the CBD and the CHD is provided by two small arteries that travel along the lateral borders of the duct at the 3 o'clock and 9 o'clock positions (Fig. 111.6). The ascending vessels that supply two third of the blood supply to the distal duct are derived from the posterior superior pancreaticoduodenal, supraduodenal artery, gastroduodenal artery, and the retroportal artery. The descending arterial input is derived from the right hepatic artery, and the cystic artery. The 3 o'clock and the 9 o'clock arteries unite to form the epicholedochal plexus, a fine arterial network on the surface of the bile duct. The blood supply of the hilar hepatic ducts comes from the cystic artery and the right and left hepatic arteries. Common arterial variants include a right hepatic artery or the proper hepatic artery originating from the superior mesenteric artery or the left hepatic artery from the left gastric artery. One of the essential components for ensuring a successful outcome of BDR is maintaining adequate blood supply to the bile duct being reconstructed. Arterial perfusion can be quite tenuous from these end arterioles and extra care needs to be taken to minimize their disruption, and may require trimming the bile duct to ensure adequate perfusion.

Implications of the Blood Supply of the Bile Ducts; Practical Points

Unlike the liver parenchmya, which derives its blood supply from both the portal venous system and the hepatic arterial system, the blood supply to the intrahepatic and extrahepatic bile duct is predominantly derived from the hepatic arterial circulation. This has important implications for repair of IBDI with concomitant vascular injury; vasculobiliary injuries. These represent 12% to 61% of patients with IBDI, with this wide range partly based on how thoroughly a vascular injury is investigated. Injury to the right hepatic artery is by far the most common, followed by injury to the common hepatic artery and the portal vein. Isolated injury to the right hepatic artery without a concomitant biliary injury is usually uncomplicated in otherwise healthy patients. However, a vasculobiliary injury may portend a significantly worse outcome after BDR, sometimes requiring liver resection and revisional hepaticojejunostomy for ischemic stricture. Conceptually this should lead to avoiding biliary reconstruction for IBDI recognized in the early postoperative period. This delay allows for demarcation of the ischemic proximal duct so that at the time of BDR the truly viable duct can be identified and used for the anastomosis. IBDI with arterial injuries other than right hepatic artery usually involve the proper hepatic artery or the right or main portal vein, and tend to have severe implications. Injury to the proper hepatic artery or the main portal vein would result in necrosis of the intrahepatic biliary tree and infarction of the liver requiring hepatectomy and/or liver transplantation. In patients with these extreme injuries, the mortality may be as high as 50%. The combination of biliary and vascular injuries and the poor outcome of ischemic biliary anastomosis make it critical to identify any concomitant injuries using either thin slice computed tomography (CT) scan or magnetic resonance imaging (MRI) with contrast prior to BDR.

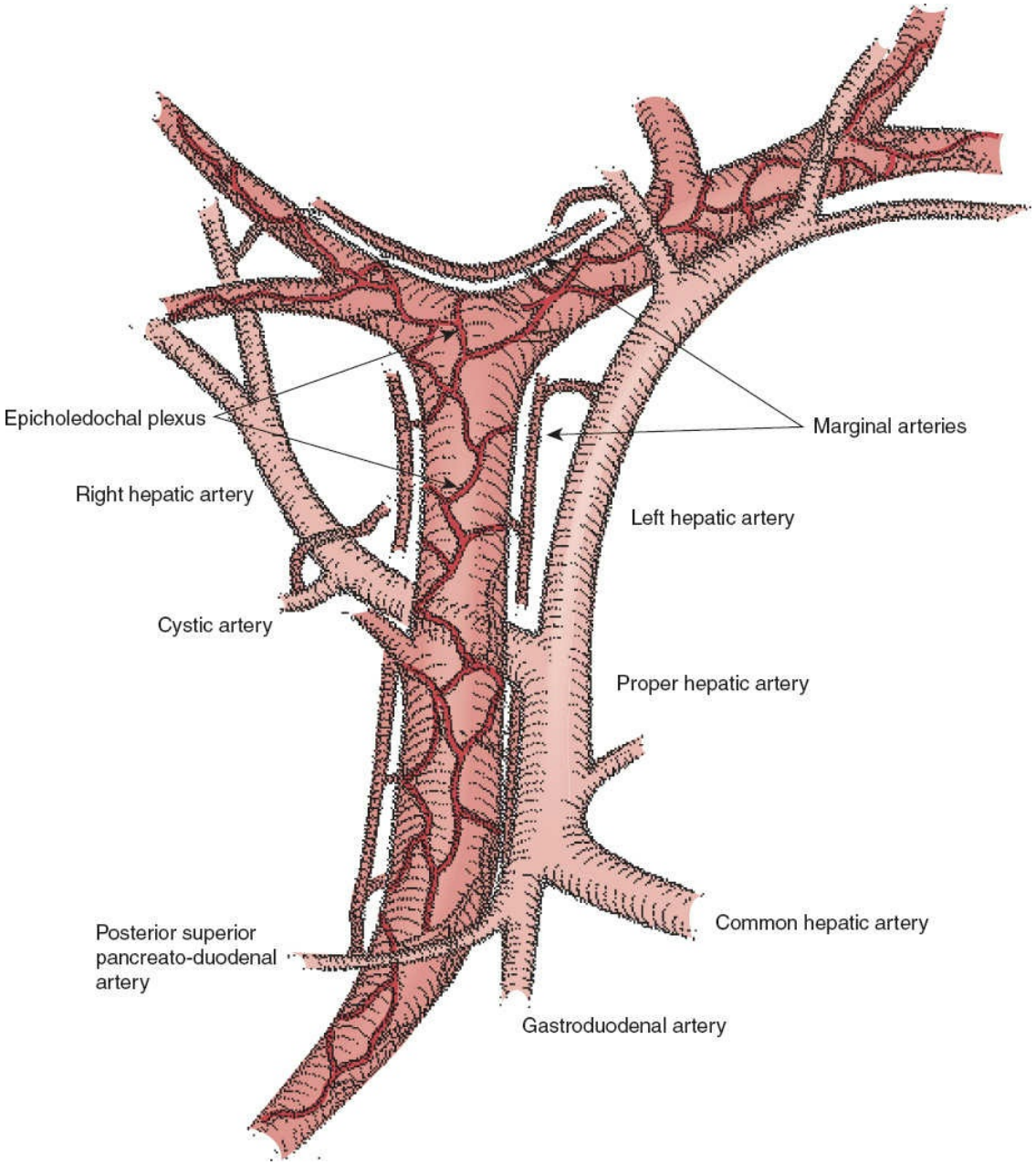

Figure 111.6. Blood supply to bile ducts. The three elements—afferent arteries, marginal arteries, and the epicholedochal plexus—are shown.

Imaging of the Biliary System

The proceeding anatomic descriptions of the biliary system, both prevailing and anomalous, highlight the importance of adequate imaging. This is equally true in both the preoperative and intraoperative settings.

Cross-Sectional Imaging

CT scan is important in patients with biliary obstruction regardless of

etiology. After IBDI is suspected, CT scans can reveal bilomas and allow placement of percutaneous drains to control sepsis and bile leak. In addition, dilated intrahepatic bile ducts suggesting ligation of a bile duct as well hypo-enhancement of the liver parenchyma suggesting a concomitant vascular injury can be easily diagnosed on a contrast-enhanced CT. In patients with hilar or other extrahepatic tumors, apart from intrahepatic bile duct dilation, CT with contrast might reveal the extent of the tumor, arterial and venous involvement, and thus resectability of the tumor (Fig. 111.7).

MRI is uniquely suited to study biliary anatomy in planning for resection of cholangiocarcinomas, to assess biliary anatomy after IBDI, as well as to study strictures after BDR. One distinct advantage of MRI over CT apart is the absence of streak artifacts from clips, which may make CT difficult to interpret in the post-operative patient (Fig. 111.8A). Additionally, the level of biliary obstruction and isolated biliary segments are well visualized with MRI without the need for contrast (Fig. 111.8B). Contrast-enhanced MRI will reveal concomitant vascular injury. MRI has a sensitivity of nearly 100% for detection of bile leaks and 85% accuracy for location.

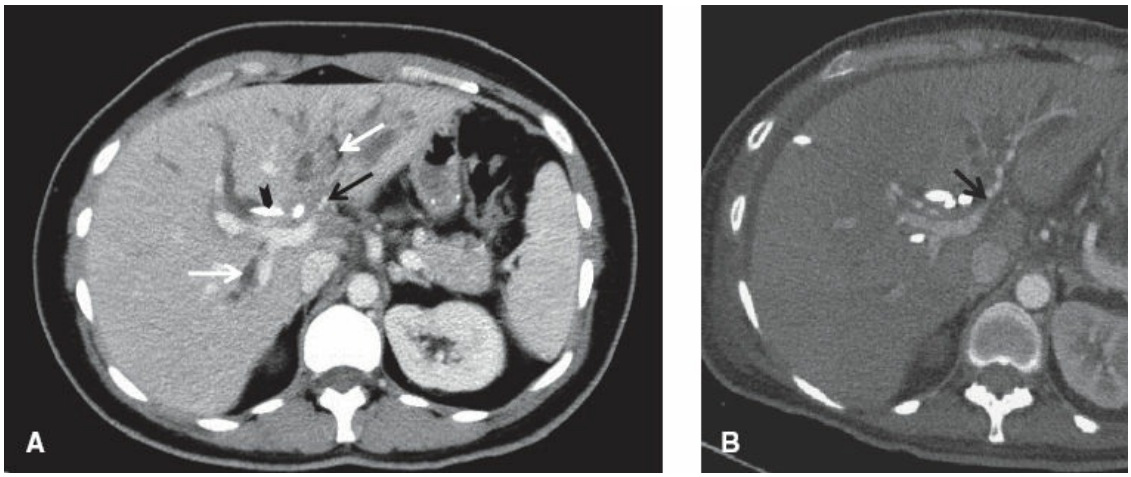

Figure 111.7. **A.** Hilar cholangiocarcinoma. Axial contrast-enhanced CT reveals an infiltrative low-attenuation tumor (*solid black arrow*) sorrounding an internal biliar stent (*black arrowhead*) resulting in bilobar biliary dilation (*solid white arrows*). **B.** Hilar cholangiocarcinoma. The tumor infiltrates the left portal vein causing narrowing (*solid black arrow*).

Endoscopic Retrograde Cholangio Pancreaticography and Percutaneous Transhepatic Cholangiogram

Endoscopic retrograde cholangiopancreaticography (ERCP) allows for placement of an endobiliary stent in incomplete transections and cystic duct stump leaks in IBDI. It however does not permit visualization of proximal duct if complete transection or resection of the bile duct has occurred. On the other hand, percutaneous transhepatic cholangiography (PTHC) allows for visualization of proximal bile duct injuries in patients with complete transection (Fig. 111.9A). It also allows for placement of percutaneous transhepatic biliary drain (PTBD) into the right or the left ductal system, as well as diagnosis of aberrant RHD injury (Fig. 111.9B,C). A limitation of PTHC, apart from being an invasive procedure with a 2% risk of complications, is that it usually requires a dilated duct system to gain access. It is however critically important to define the biliary anatomy prior to an attempted repair of IBDI, even when the system is decompressed by an associated bile duct leak. PTBD placed during PTHC may significantly assist during reconstruction especially in the presence of aberrant ducts or multiple ducts that require enteric anastomosis.

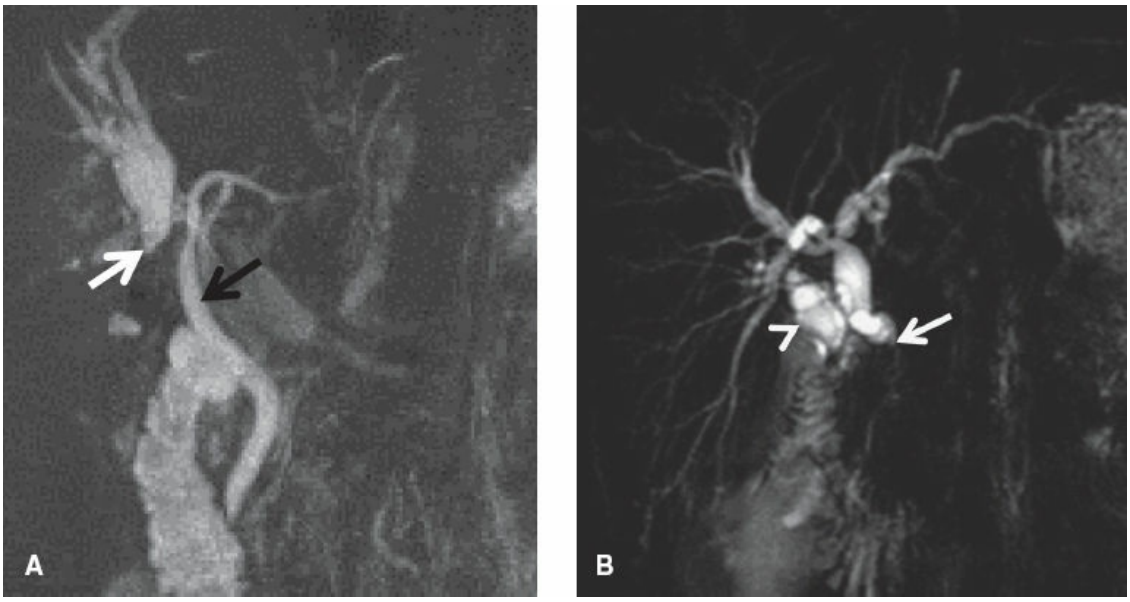

Figure 111.8. **A.** MRI in a patient with iatrogenic right hepatic duct injury. The *white arrow* marks where the right hepatic duct injury is where a stapler was used to transect the gall bladder. The *black arrow* marks a normal common bile duct draining into the duodenum. Note the clear anatomical delineation without artifacts. The patient had an anomalous biliary anatomy with right hepatic duct draining into the gall bladder. **B.** MRI in a patient with bile duct stricture after blunt abdominal trauma. Note the dilated CBD (*white arrow*) tapering to the duodenum. The

gallbladder is marked by *white arrowhead*. Patient underwent a hepaticoduodenostomy.

Approach to Bile Duct Reconstruction

The approach to BDR varies based on whether the reconstruction is related to resection of a malignant tumor, complications of biliary stone disease, or an IBDI that may present challenges in ascertaining the injured anatomy preoperatively. Unique considerations in resection and reconstruction of presumed malignant disease include certainty of diagnosis, and extent of disease that may require an en-block liver or vascular resection. Biliary reconstruction that may be needed in benign conditions such as stone disease and chronic pancreatitis is notable for careful preoperative planning. It may not be in every patient's best interest to undergo laparoscopic cholecystectomy and trans-cystic common duct stone extraction for primary CBD stones. Similarly, ongoing biliary stenting for a fixed common duct stricture in the setting of painful chronic pancreatitis is not optimal management; for both scenarios, biliary bypass may be the best option. It is paramount to be deliberate and thoughtful when presented with patients with complex biliary disease who often benefit from multidisciplinary discussions between surgeons, gatroenterologists, and radiologists. IBDI complicating cholecystectomies are a unique type of complex biliary injury, which are important to consider as they can occur in a commonly performed operation. Thorough review of the index operation with the original surgeon, intraoperative cholangiograms, as well as results of postoperative imaging cannot be overemphasized.

IATROGENIC BILE DUCT INJURIES

Injuries that occur during cholecystectomy are particularly devastating for the surgeon and patient alike as they are an unintended consequence of a presumably "minor" operation. Major bile duct injuries have been a recognized risk of cholecystectomy nearly since its inception. The incidence of injuries has increased since the advent of laparoscopic cholecystectomy from 0.2% to 0.6%. The heightened awareness of IBDI with laparoscopic cholecystectomy has not altered the proliferation of the procedure, nor driven the incidence of IBDI down to the rate during the open era. It is likely that the increased rate is inherent to the procedure. However, every attempt should be made by the operating surgeon to minimize the risk of an injury since the most common reason for an injury

is the misidentification of anatomy. It is incumbent on the operating surgeon to clearly identify the cystic duct–gallbladder junction with adequate lateral traction in a clear operative field, and recognize any biliary/vascular anomalies. In addition to standard laparoscopic techniques, this may require intraoperative cholangiography, ultrasound, or conversion to laparotomy for exposure of the anatomy. Should an injury occur, it is important to be able to identify it at the time of the injury to achieve the best results.

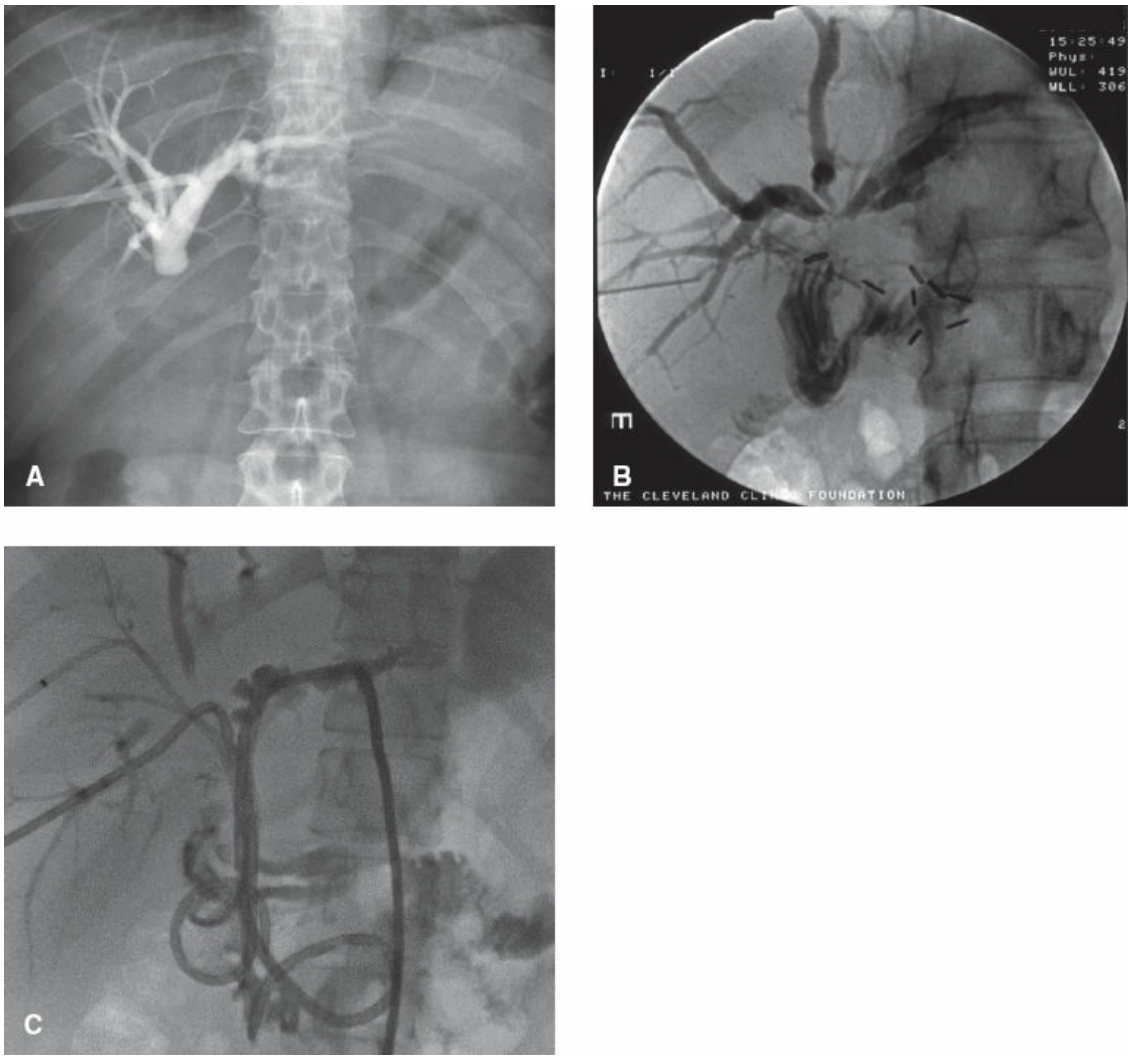

Figure 111.9. **A.** Percutaneous transhepatic cholangiograms in patients with IBDI and cholangiocarcinoma. E2 injury. The left ducts have been injected and the entire intrahepatic biliary tree fills as the confluence is intact. **B.** Percutaneous transhepatic cholangiograms in patients with IBDI. In this case, the biliary confluence is absent. The left bile duct and the right sectoral ducts have been separately cannulated to show the entire biliary tree. **C.** Percutaneous transhepatic cholangiograms in patients

with hilar cholangiocarcinoma. Percutaneous transhepatic cholangiogram reveals complete separation of the intrahepatic biliary tree from the extrahepatic biliary system. PTBD catheters in both the right and the left hepatic system are noted.

Classification of Biliary Injuries

The current classification system for IBDI incorporates both the Strasberg classification from A to E and the Bismuth classification from E1 to E5 (Fig. 111.10). Type A injuries involve a cystic duct stump leak or a duct of Luschka leak. While these are nearly always avoidable, these do not require reconstruction and will not be discussed further in this chapter. Type B injuries are similar to E5 and involve transection of an aberrant right duct without bile leak. These ducts may drain anywhere from a segment to the entire right lobe and can remain asymptomatic. When there is leak of bile from a transected aberrant right duct, it is a type C injury. These usually require reconstruction due to a persistent biliary fistula. If the volume of the liver affected is small, the involved duct may sometimes spontaneously scar down and thus no intervention may be needed. Type D injuries are partial transection of the CHD with bile leak. When the transection is complete these are considered type E injuries. Depending upon the transection being less than or greater than 2 cm away from the confluence, it is referred to as E1 or E2. An E3 injury extends up to the confluence that is intact. In E4 injuries, the confluence is resected and separated right and left ductal systems are noted. An E5 injury involves a clipped and transected aberrant right duct as well as injury to the CHD. When operating on patients with type E injuries, note should be made of the length of missing bile duct. Regardless of the type of IBDI, specific documentation should be made of the presence or lack of vascular injury.

Immediate Repair Versus Delayed Repair in Biliary Tract Injuries

After IBDI is diagnosed, it is best managed at a specialty center by hepatopancreatobiliary (HPB) surgeons. While the timing of repair of injuries diagnosed after IBDI remains controversial, for injuries diagnosed at the time of the index operation, immediate repair by a specialist is the best strategy (Fig. 111.11). The majority of the patients with IBDI however are not recognized intraoperatively and typically present within a week with jaundice, cholangitis, bile leak, or intra-abdominal sepsis. In these patients, control of sepsis prior to any surgical intervention is of

paramount importance. Repair in the face of sepsis portends a poor outcome—both short-term and long-term. In general, repair in the early postoperative period is discouraged due to the degree of inflammation and concern for biliary ischemia, with or without a major vascular injury. Multiple techniques for control of sepsis in these patients can be utilized including placement of bilateral PTBD, intra-abdominal drains, and reoperation. Complete source control of a bile leak is always more important than endobilliary stenting (Fig. 111.12). In patients who undergo early versus delayed repair, outcomes in terms of post-operative complications as well as long-term outcomes can be similar when performed by surgical specialist.

Preoperative Planning for BDR

Complete anatomic detail of an injury is imperative prior to repair. Multiple imaging modalities can be utilized for preoperative planning including ultrasound (US), CT, magnetic resonance cholangiopancreatography (MRCP), ERCP, and PTHC. Of these ERCP and PTHC can be both diagnostic and therapeutic. The added ability of PTHC to precisely define the proximal extent of injury and also leave catheters to guide intraoperative identification of ducts makes it the most useful test in preoperative planning for major injuries. Another imaging modality in patients with surgically or a percutaneously placed drain is fluoroscopy with injection of the drain. The wide modality of testing available mandates individualization for each patient.

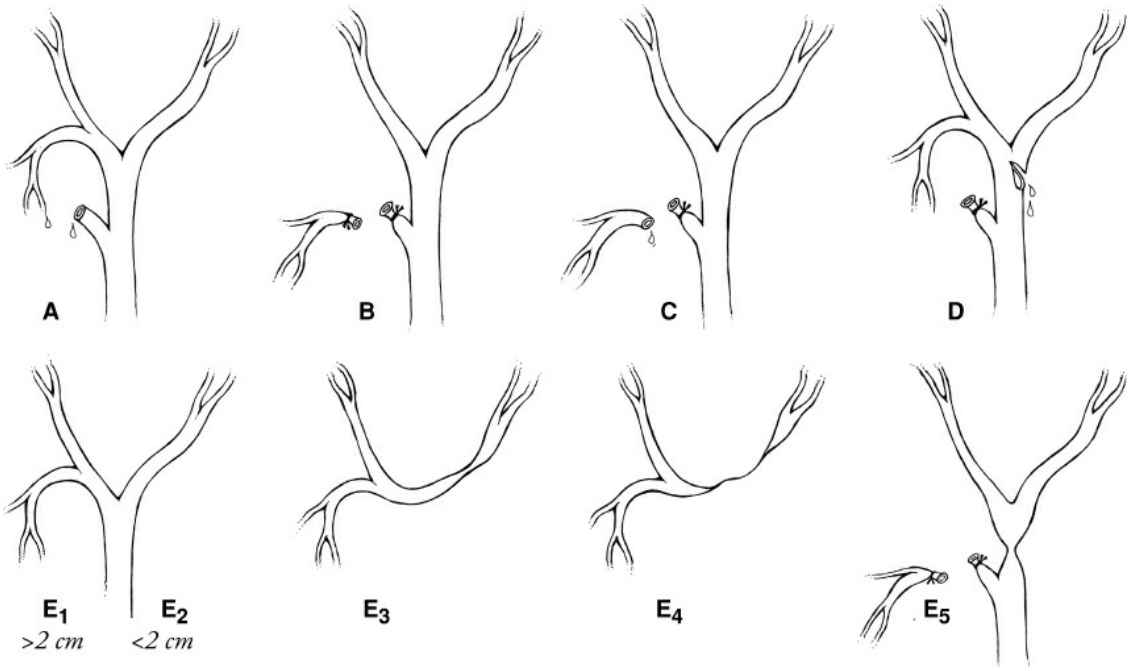

Figure 111.10. Classification of biliary injuries.

Preoperative Patient Preparation

Preoperative planning varies based on the level of injury, presence of bile leak and sepsis, presence of vascular injury, and the timing of diagnosis (Fig. 111.12). For patients who present with sepsis, hemodynamic support and source control is the first priority. Most of these patients have either bilomas or biliary ascites that will need to be drained. ERCP with an endobiliary stent is used when there is a bile leak in the absence of complete transection of the bile ducts. PTHC with PTBD is used in patients with complete transection or resection of the bile duct. Every effort should be made to have PTBD in all disrupted ducts (e.g., the RPSD), to facilitate intraoperative identification and reconstruction of all disrupted ducts. The aim is to control bile drainage until surgery can be accomplished. Other things to consider are electrolyte repletion usually with commercially available drinks like Gatorade, and correction of coagulopathy with intravenous vitamin K. In patients with associated major vascular injury, a planned liver resection may be definitive and expeditious.

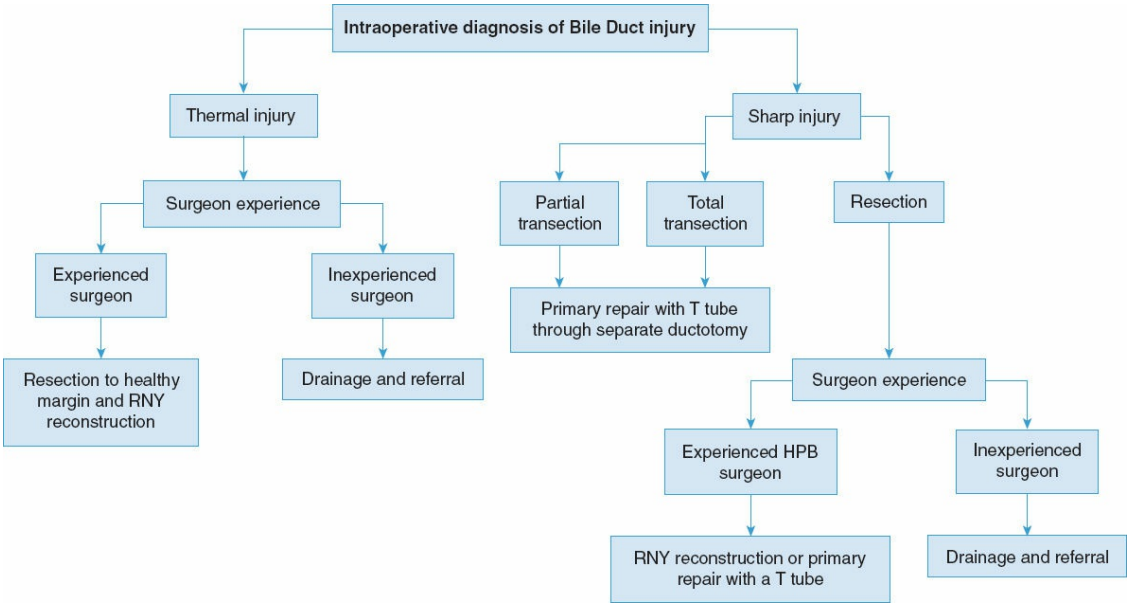

Figure 111.11. Proposed algorithm for management of patients with bile duct injury that are diagnosed intraoperatively.

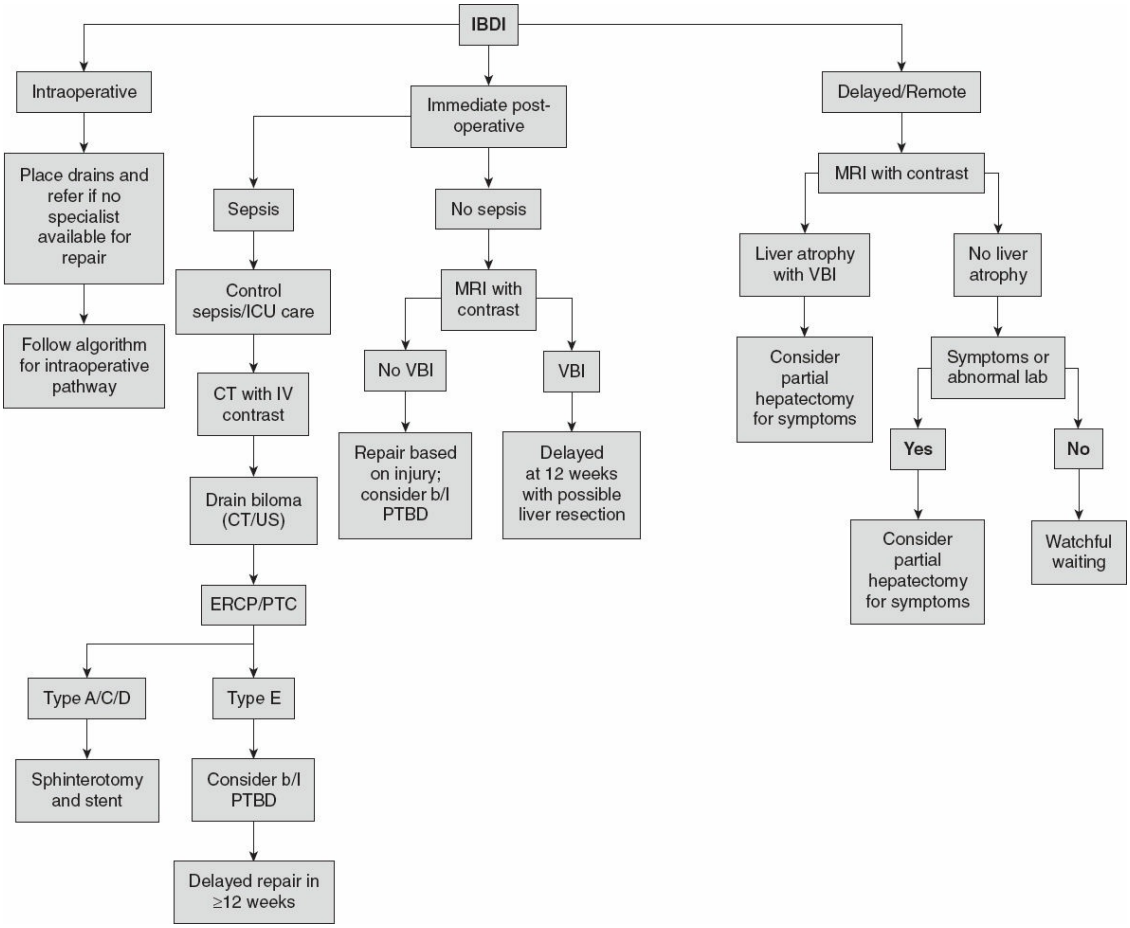

Figure 111.12. A proposed algorithm for management of IBDI.

SURGICAL TECHNIQUES

Options for BDR include end-to-end anastomosis, hepaticojejunostomy (HJ), choledochoduodenostomy, and cholecystojejunostomy. End-to-end duct anastomosis and Roux-en-Y hepaticojejunostomy continue to be the two most common techniques for BDR. While end-to-end anastomosis is more commonly utilized after liver transplantation, HJ is favored for most BDR to reduce the likelihood of an ischemic anastomotic stricture. Choledochoduodenostomy and cholecystojejunostomy have specific indications in the current literature.

General Principles

These general principles apply to all biliary reconstructions: well-vascularized, tension-free, duct-to-mucosa anastomosis. Ischemia or fibrosis at the edges of a biliary anastomosis should be avoided where possible. Resection to refresh the edges of the bile ducts is of utmost importance. Dissection should be meticulous and kept to a minimum

around the duct to avoid injury to the axial arteries within the wall of the bile ducts.

The following section details the reconstructive part of the surgery for BDR. For patients undergoing a concomitant solid organ resection, the detail on how to reconstruct the bile ducts is the same as it is after an IBDI. However, bile duct margins need to be sent for frozen section as appropriate prior to any reconstruction.

Incision and Access

The incision used should allow wide exposure to the right upper quadrant. We commonly use a subcostal or hockey stick incision placed approximately 3 fingerbreadths below the right costal margin or midway between the anterior superior iliac spine and the right costal margin, and extended horizontally to the midline and a vertical midline portion extended to the xiphoid (Fig. 111.13). This can be extended to the left upper quadrant in patients with difficult exposure. If the patient already has a previous Kocher incision, it should be extended to the midline and vertically to the xiphoid process to allow adequate access. Retractor devices that are fixed to the operating table are a critical component for a successful outcome. The retractor systems are generally placed after the Falciform ligament is divided to prevent liver lacerations from retraction of the abdominal wall. Operating loupes with 2–1/2 times to 3–1/2 times greatly facilitate anastomotic precision. Be sure to have adequate illumination, which may require a headlight.

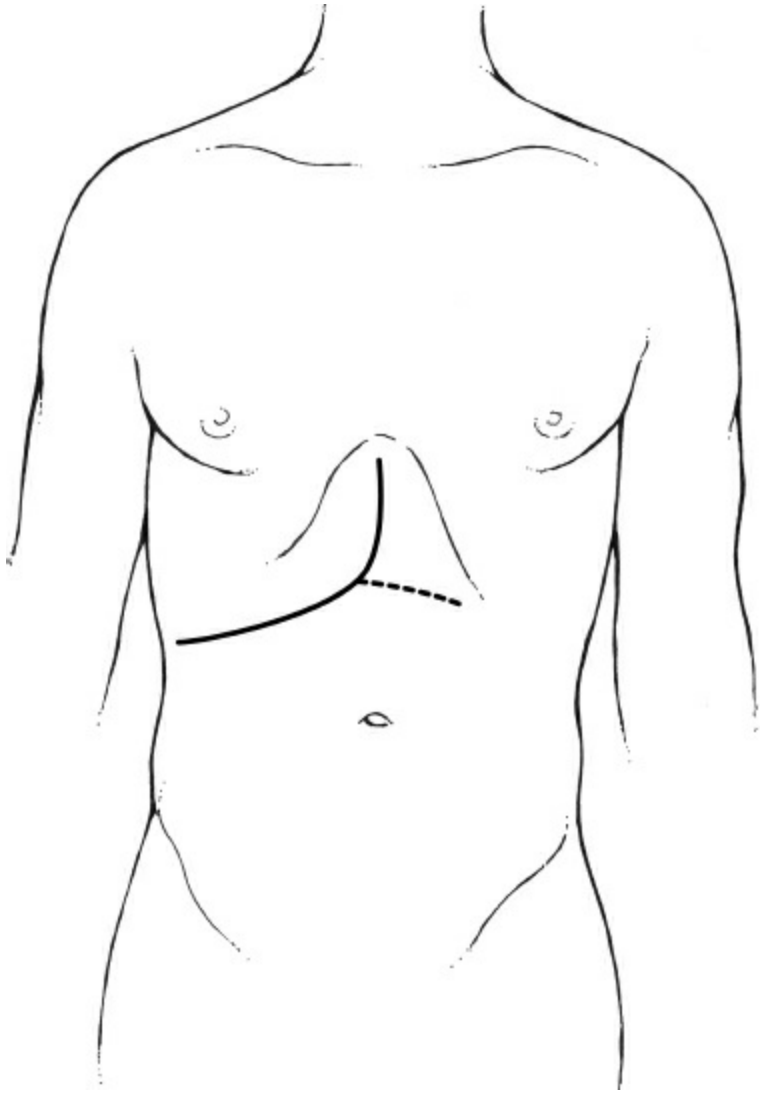

Figure 111.13. Incisions for access to right upper quadrant for bile duct reconstruction as well as major liver resection site. *Dashed line* shows possible extension.

After gaining access to the abdomen and placing a retractor system, any adhesions are lysed to gain access to the right upper quadrant. Wide exposure to the inferior surface of segment IVbis the goal. Significant adhesions off the transected proximal bile duct stump may exist to segment IVb (quadrate lobe). These need to be carefully divided to free up all adhesions, completely freeing up the quadrate lobe prior to incising the hilar plate. A cholecystectomy is completed if was not done previously. Next the area of injury is identified, and all the clips from the bile ducts are removed. A cholangiogram is next performed with the goal to account for every segment of the liver and prevent missing an aberrant right duct. A Kocher maneuver is performed that facilitates identification of the bile duct stump. The distal CBD if it has been clipped off is closed using a

continuous running permanent suture. The cystic artery if it has been clipped is tied. If PTBDs have been placed, these should be carefully protected in order to remove inadvertent removal. Most biliary reconstructions close to or involving the confluence start with lowering the left hepatic duct.

Exposure and Preparation of the Left Hepatic Duct

The LHD is an attractive option for a HJ for multiple reasons, the prime reason being that it is unlikely to be injured at the time of cholecystectomy given its location. Additionally, it usually runs horizontally between the caudate lobe and segment IVb prior to joining the confluence. In this extrahepatic location, it is usually covered by the extension of Glisson capsule onto the bile duct called the hilar plate. There are usually no blood vessels anterior to the bile duct. Incising the hilar plate lowers the LHD and sometimes the confluence. Minor venous oozing from the liver edge at the time of lowering the LHD can easily be controlled with electrocautery or hemostatic agent. The incision on the LHD may be extended to the RHD in E3 injuries. The anastomosis of the LHD to the jejunum in this way was first described in English by Hepp in 1985 based on French description by Hepp Couinaud in 1956 (Fig. 111.14). There are two other useful maneuvers during BDR. The first is to divide the bridge of liver tissue between segment IVB and segment III with care not to injure the left hepatic artery or the left hepatic duct. The other maneuver is to open a sealed off the gallbladder fossa. In some E4 and E5 injuries, either a side-to-side or end-to-side HJ may be needed. A stent in the LHD helps with identification of the right duct especially in cases of re-repair of previous biliary reconstructions.

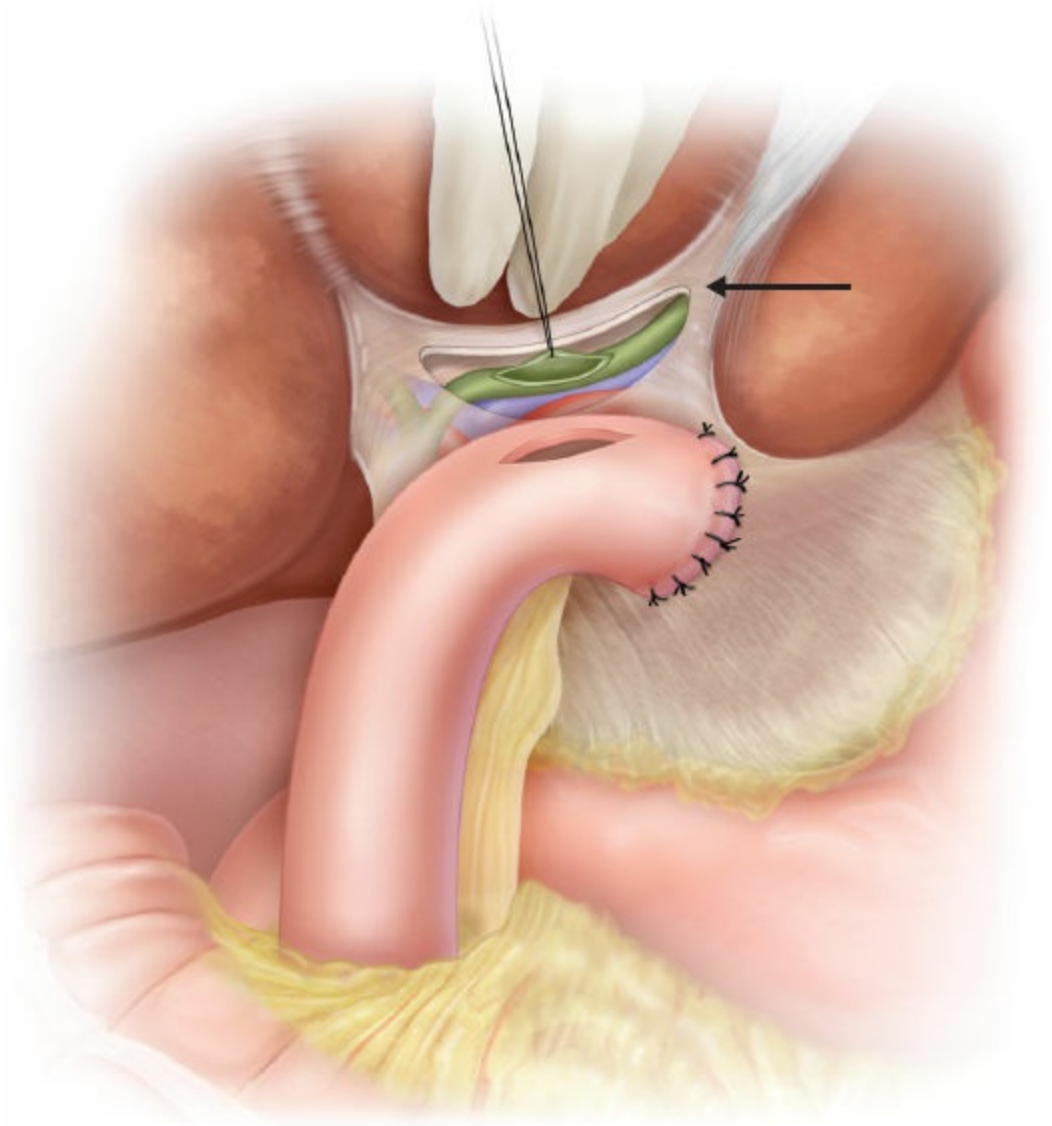

Figure 111.14. The original Hepp–Couinaud technique for exposing the left hepatic duct prior to a HJ. The left HD is subsequently incised horizontally and a side-to-side HJ is performed. The *arrow* indicates the area of the fibrous liver plate, which is divided to lower the left duct. Segment IV is elevated by the surgeon's hand. The duct is opened and prepared for a side-to-side anastomosis.

Exposure and Preparation of the Right Hepatic Duct

The RHD lies along the same coronal plane as the left hepatic duct. To gain exposure to the RHD directly, Glisson capsule at the base of segment IVb is opened. This will allow exposure of the confluence of the right and the left hepatic duct. If the LHD has already been identified and dissected, then this dissection can be carried on toward the right side till the RHD is identified. Sometimes, the base of segment V may need to be opened to

gain exposure to the RHD. Care should be taken not to injure the right hepatic artery that might lie anterior to the duct in this location. As the dissection is carried more to the right side, the cystic plate will need to be incised. Preoperative placement of a stent in the biliary system helps in identification of the right ductal anatomy. Further dissection to segment V will identify the anterior and the posterior sectoral ducts.

Roux-en-Y Hepaticojejunostomy

After the bile ducts have been adequately prepared, an anastomosis is performed. Most commonly, this utilizes a Roux-en-Y hepatojejunostomy. There are various techniques of a HJ. An end (of duct)-to-side (of jejunum) anastomosis is most commonly utilized. However, side-to-side anastomosis may be appropriate in certain cases. In comparison to a direct duct-to-duct anastomosis, a HJ can be used in most patients who require BDR, even those with concerns of bile duct ischemia, significant missing length of duct, or where there are two or more separate ducts that require re-anastomosis. Additionally, a HJ has a significantly lower long-term stricture rate compared to end-to-end anastomosis that can have a long-term stricture rate of up to 80%.

End-to-Side Anastomosis

An end-to-side anastomosis can be used to the CHD after an E1, E2, or E3 injury, separately to the right and left bile duct, or after being joined into a single duct after an E4 or E5 injury. Other reconstructions that utilize a HJ include after a pancreaticoduodenectomy, secondary BDR to repair strictures after liver transplantation and uncommonly after limited resection for bile duct tumors causing obstruction. We commonly perform an end-to-side anastomosis of the biliary duct to Roux limb of jejunum using interrupted monofilament absorbable sutures. This technique is described below (Fig. 111.15).

The jejunum is divided using a stapler at approximately 30 cm distal to the ligament of Treitz and the mesentery is divided to avoid tension. We commonly use a retrocolic window to the right of the middle colic and bring the Roux limb to the end of the bile duct. An enterotomy on the antimesenteric side of the Roux limb with removal of excess mucosa is created with cautery and sized to the caliber of the bile duct. Corner sutures are placed on the right and the left side of the bile duct incorporating at least 3 mm of the bile duct wall and minimal mucosa on

the jejunal side. A posterior row of interrupted sutures is evenly spaced and tied when the row is complete. The anterior row of interrupted sutures is placed with knots fashioned on the outside. Finally, all the anterior row including the corner sutures is tied. A Ray-Tec is left in the operative bed to check for any bile leak. Next a handsewn single-layer jejunojejunostomy is created. All mesenteric defects are closed using interrupted nonabsorbable sutures.

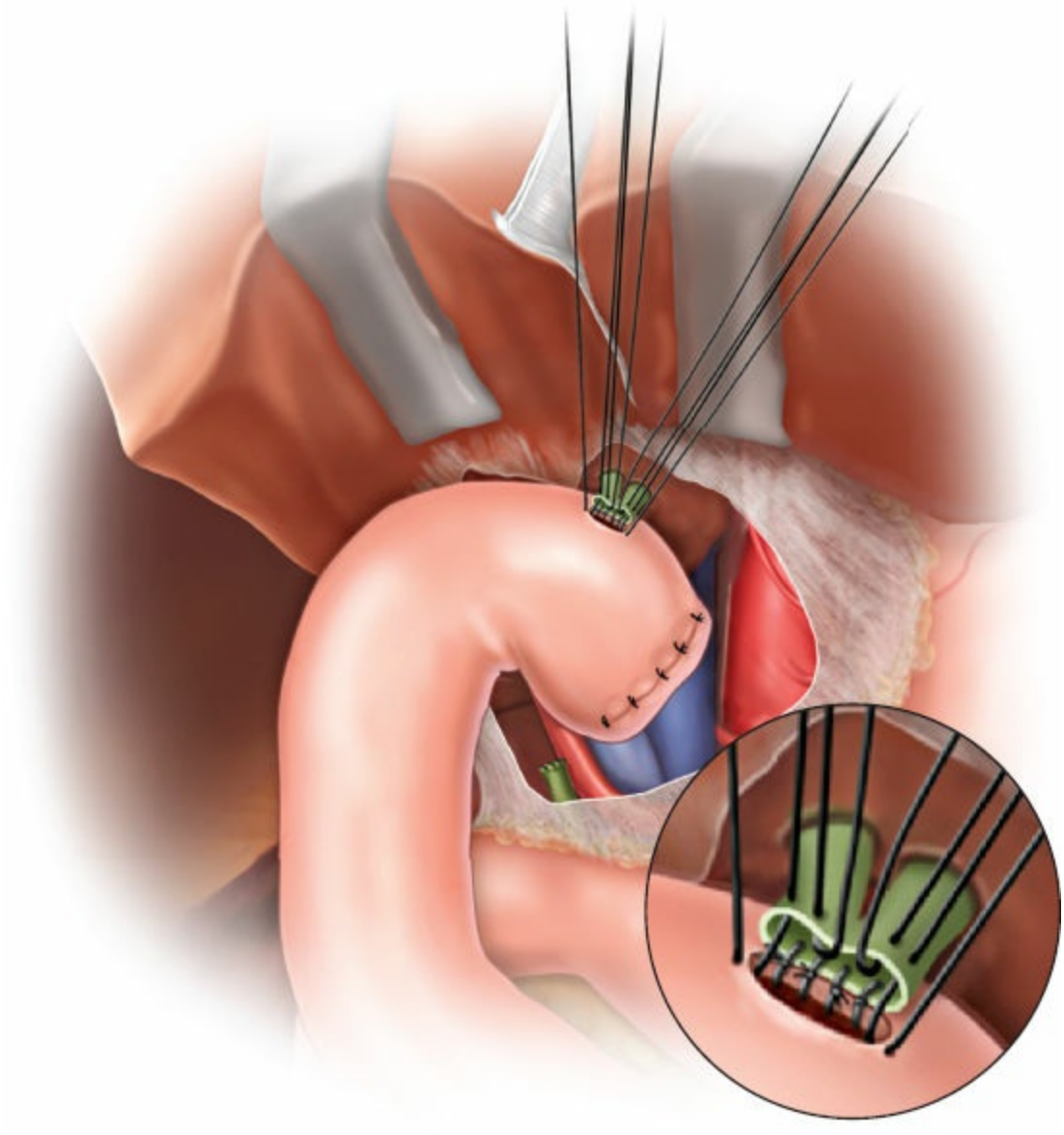

Figure 111.15. End-to-side technique of hepaticojejunostomy. (From Hughes, SJ, ed. *Operative Techniques in Hepato-Pancreato-Biliary Surgery*. Philadelphia, PA: Wolters Kluwer; 2015.)

Side-to-Side Anastomosis

Strasberg et al. have advocated routine use of side-to-side HJ for all injuries, including E1 and E2 injuries. The technique of side-to-side HJ is shown in Figure 111.16. A side-to-side repair in theory limits the amount of dissection around the bile duct causing less devascularization. Additionally, the ductotomy can be fashioned along the long axis of the duct enabling a wider anastomosis. The disadvantage of a side-to-side anastomosis is that it cannot be applied uniformly. For example, when multiple ducts have been transected, then end-to-side anastomosis is more appropriate. Additionally, if the RHD has been transected a very short distance distal to where it is formed from its tributaries, then an anterior slit may not be possible. In cases where a side-to-side anastomosis is possible, a ductotomy is made approximately 1 cm in length. The end of the duct is closed using a 5-0 or 6-0 Prolene. Then a side-to-side HJ is performed as outlined above in an interrupted or running fashion (Fig. 111.16).

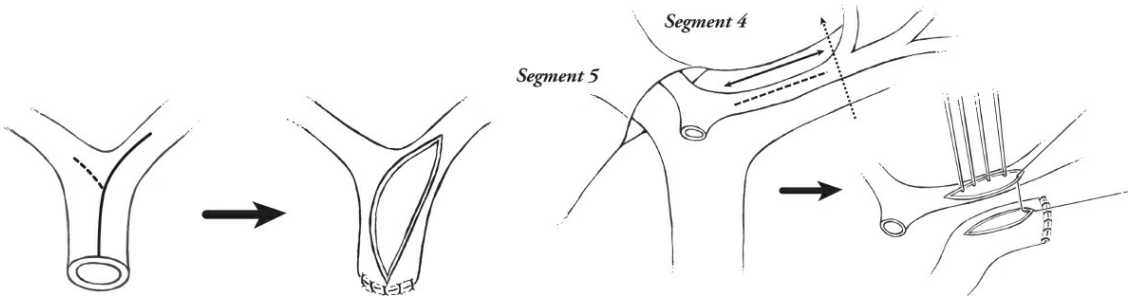

Figure 111.16. Strasberg variation of the HJ. Immediate repair of E1 to E3 biliary injuries. **Left:** The duct is incised on its anterior surface onto the left hepatic duct if necessary to obtain length. The right duct may also be incised if the injury is close to the confluence (*dashed line*). **Right:** The end of the duct is closed and the anastomosis is done side to side to a Roux loop.

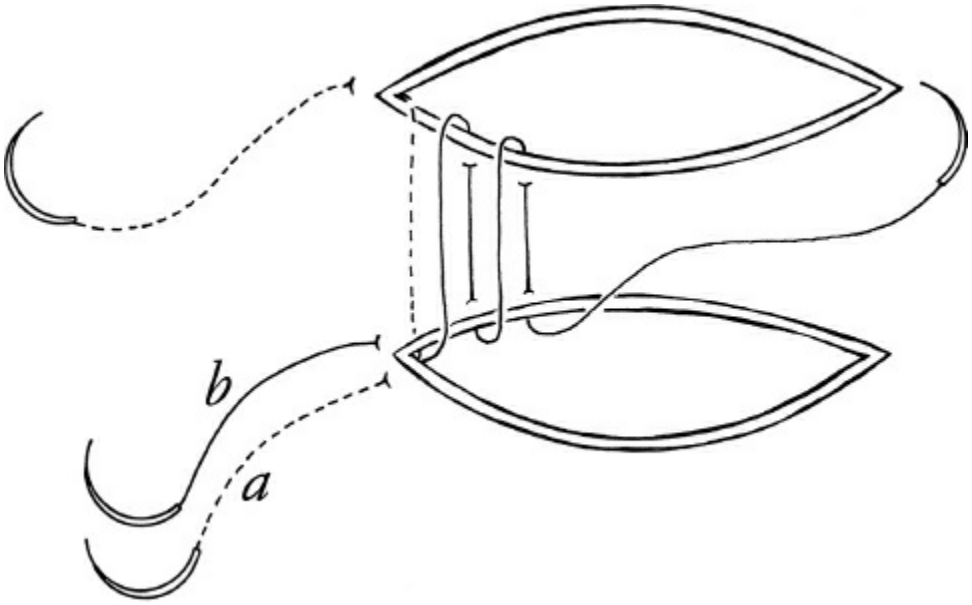

Figure 111.17. Running suture technique for hepaticojejunostomy (posterior row).

Other Variations of the Hepaticojejunostomy

There are multiple variations in approach to the reconstruction of the HJ. One technique involves dividing the HJ into right and left sides by placing the two initial stay sutures anteriorly and posteriorly in the middle. This divides the anastomosis into a right and left side, which is subsequently closed in a similar fashion as above. Some surgeons fashion stitches to place all knots on the outside.

A continuous running technique for creation of a hepaticojejunostomy can also be used especially in larger ducts greater than 1 cm in size and for palliative biliary bypasses in patients with unresectable pancreas cancer (Fig. 111.17). Transplant surgeons also use this technique in live donor liver transplantation (LDLT). A continuous running technique uses a double-armed 4-0 absorbable monofilament suture. A corner suture is first placed and left untied fashioning the future knot on the outside. Next a single-armed suture is started just adjacent to the corner suture and a posterior row is placed in a continuous running fashion keeping the bowel and bile duct still apart. After several sutures have been placed, the bowel is parachuted down onto the bile duct and the corner sutures tied. The free end of the running suture is then tied to the corner suture. The running suture is run through to the opposite corner. An additional suture is placed at the corner in a similar technique, and it is tied to itself and to the running suture completing the posterior row. The corner sutures are run

toward the middle and then tied in the middle thus completing the anterior row.

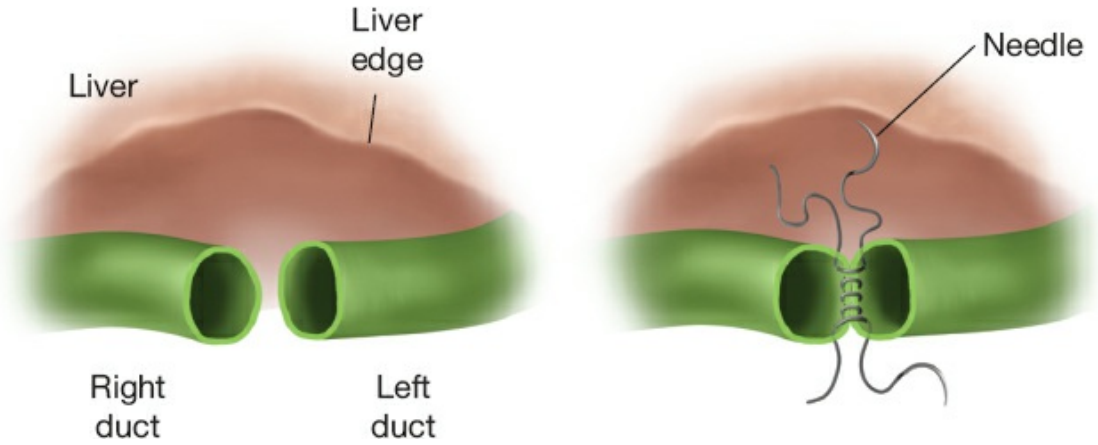

Figure 111.18. Approximation of two adjacent ducts. A double-armed, 6-0 suture is used. Note that the technique buries the knots. (From Hughes, SJ, ed. *Operative Techniques in Hepato-Pancreato-Biliary Surgery*. Philadelphia, PA: Wolters Kluwer; 2015.)

Direct End-to-End Duct Reconstruction

The majority of patients who require BDR after IBDI would need a HJ; certain patients might be candidates for end-to-end anastomosis. These include patients where the injury is diagnosed at the time of the original operation and is a sharp injury, involves less than a third of the circumference of the duct, and is not more than 2 cm away from the confluence without extensive tissue loss or concomitant vascular injury. It may also be advisable by surgeons without access to a HPB specialist and inexperienced in biliary repair. It can and should be accomplished with minimal radial dissection of the bile duct.

Multiple Anastamoses

Situations may call for anastomosing two or three separate ducts to bowel. The technique for reconstruction then depends on their proximity. Commonly when the right and left hepatic ducts are noted to be separate but within 1 cm of each other, they can be sutured to each other using a fine nonabsorbable monofilament suture to create “one” double barrel duct (Fig. 111.18). This is done by placing one or more sutures in the fibrous tissue between the ducts. Then anterior row and posterior row sutures are placed in technique previously described. When the ducts are separated

such that approximation will create tension, two separate intestinal openings are made. In E5 injuries, an aberrant right sectoral duct separated from the main right and left duct may be anastomosed separate from the right and left ducts. Sometimes, one duct lies posterior to the other rather than side-by-side. In this case, the anterior duct is treated as the anterior row and the posterior duct as the posterior row (Fig. 111.19).

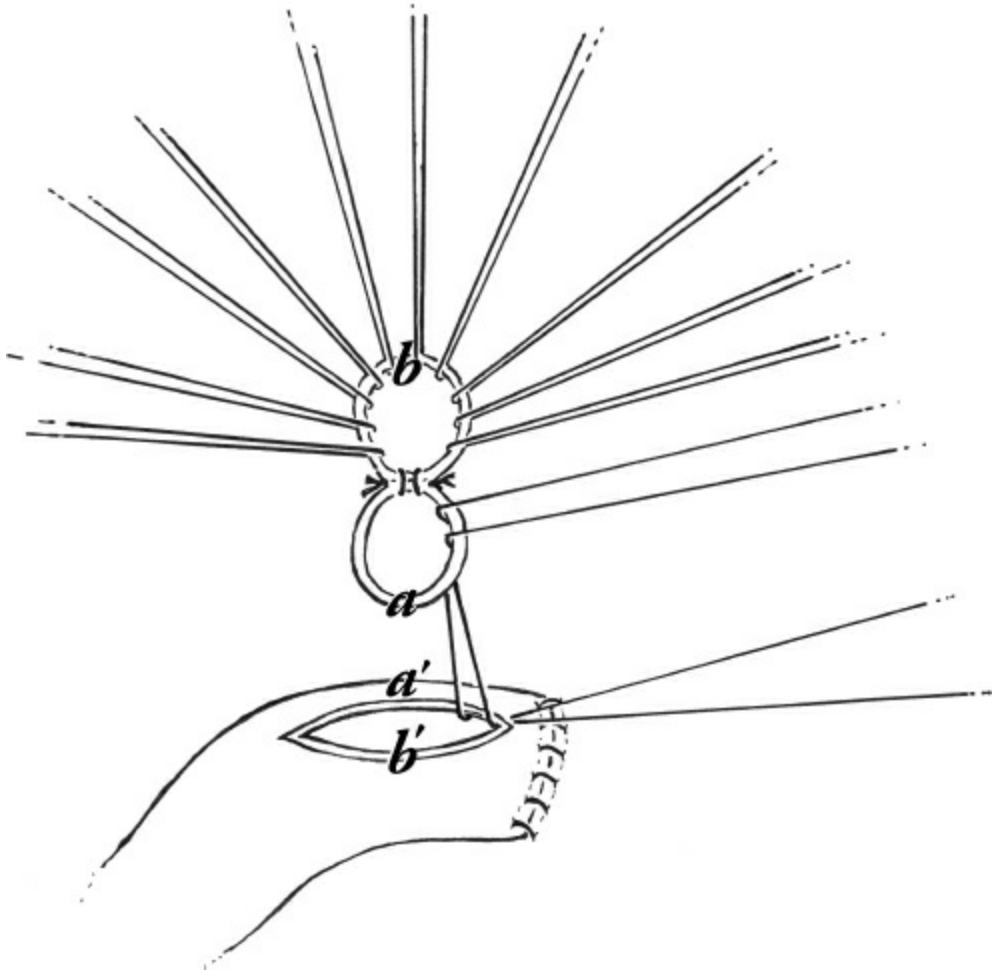

Figure 111.19. Technique for vertically disposed ducts. The anterior duct is treated as the anterior row. Note that “a” comes to “a′” and “b” to “b′.”

Operative Strategy for Reconstruction of Bile Ducts After Elective Resection

The extent of resection for malignant and benign tumors of the liver and bile duct is determined by the extent of the disease process and in the case of cancers the need to obtain negative margins (R0 resection). Bile ducts are usually sharply divided, and the cut surface is well vascularized and visible. Consequently, such ducts are anastomosed end of duct-to-side of

jejunum. The reconstruction follows the technique previously outlined.

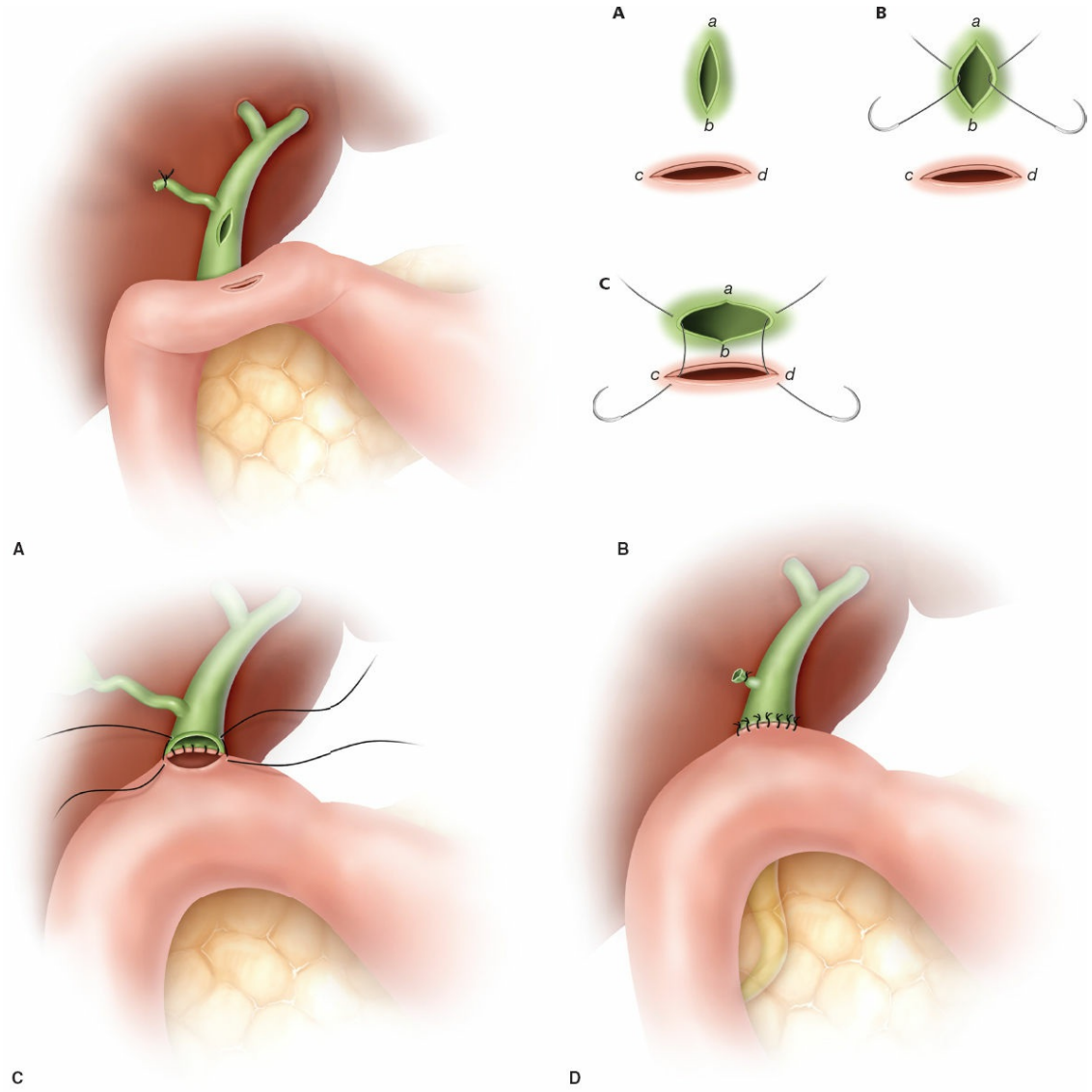

Figure 111.20. **A.** An incision along the axis of the bile duct and duodenum is made after kocherization. **B.** Sutures are placed through the midpoint of the bile duct to the corner of the duodenotomy and another suture to bisect the back row. **C.** Multiple interrupted sutures are placed to complete the back row. **D.** Completed Hepaticoduodenostomy. (From Hughes, SJ, ed. *Operative Techniques in Hepato-Pancreato-Biliary Surgery*. Philadelphia, PA: Wolters Kluwer; 2015.)

Technique for End-to-Side Anastomosis of Very Small Ducts

When very small ducts less than 3 mm in size are encountered, the anastomosis is performed using loupes and 5-0 monofilament absorbable suture. The anterior row of bile duct sutures is placed. A very small opening is made in the antimesenteric border of jejunum using just the tip of the electrocautery. The mucosa of the jejunum is fixed in all four

quadrants using 6-0 Prolene sutures. The posterior row of sutures is then placed with knots on the outside. The anterior row is next completed over an exteriorized 3.5-Fr infant feeding tube to allow for drainage and post-operative cholangiogram. The anastomosis is drained using a closed suction drain.

Choledochoduodenostomy

Choledochoduodenostomy may be considered if it can be performed without anastomotic tension. It can therefore be utilized in select E1 injuries, primary common duct stones, palliation of periampullary carcinomas, or biliary stricture from chronic pancreatitis. Generally patients with biliary injuries or obstructions other than at the lower third of the bile duct are not ideal candidates.

Surgical Technique

Abdominal incision is the same as previously discussed for hepaticojejunostomy. The duodenum is then widely Kocherized allowing significant mobility of the duodenum toward the CBD. The suprodudenal CBD is then identified and a vertical incision is made, which allows for exploration of the duct and removing any stones or debris. The duodenum is incised along its long axis so that a “fish-mouth” can be created with the reconstruction. The choldochoduodenostomy is then created in an interrupted fashion such that the corners of the anastomoses are the end of the enterotomy yet at the midpoint of the bile ductotomy. Similar technique is used for the posterior row first and then the anterior row (Fig. 111.20A–D).

Cholecystojejunostomy

Cholecystojejunostomy should rarely be used as a palliative procedure for malignant obstructions of the distal CBD. It is imperative to confirm that the cystic duct drains into the CBD well proximal to the obstruction prior to creating this type of anastomosis. Additionally, it should only be used when access to the porta hepatitis is not available since high rates of recurrent jaundice have been observed.

Surgical Technique

A wide Kocher incision allows access to the right upper quadrant. The gallbladder is almost always distended. A loop of jejunum is brought to the

right upper quadrant. A posterior row of sutures is placed at the gallbladder fundus. The gallbladder is opened and all the stones are removed. The cystic duct anatomy and absence of obstruction of the cystic duct are confirmed. Additionally, cystic duct insertion into an area of unobstructed CBD is confirmed. Decompression of the CHD is confirmed. Next a jejunotomy is fashioned and an anterior row of sutures is placed to complete the anastomosis.

Minimally Invasive Biliary Reconstruction

Laparoscopic and robotic reconstruction of the bile duct is now being increasingly used for benign and malignant biliary disease. These approaches are aimed at obtaining the advantages of all minimally invasive procedures, but they should not compromise the curative goals of a similar open surgery. The techniques of minimally invasive resection and reconstruction are identical to open procedures, although markedly enhanced by improved optics, magnification, and dexterity in the use of robotics.

Suggested Readings

Abdalla S, Pierre S, Ellis H. Calot's triangle. *Clin Anat* 2013;26:493–501.

Alves A, Farges O, Nicolet J, et al. Incidence and consequence of an hepatic artery injury in patients with postcholecystectomy bile duct strictures. *Ann Surg* 2003;238:93–6.

Bismuth H. Surgical anatomy and anatomical surgery of liver. *World J Surg* 1982;6:3–9.

Couinaud C. Intrahepatic bile ducts. In: Couinaud C, ed. *Surgical Anatomy of the Liver Revisited.* Paris: L'Imprimerie Maugein & Cie; 1989:61.

Eskander MF, Bliss LA, Yousafzai OK, et al. A nationwide assessment of outcomes after bile duct reconstruction. *HPB (Oxford)* 2015;17(9):753–62.

Frilling A, Li J, Weber F, et al. Major bile duct injuries after laparoscopic cholecystectomy: a tertiary center experience. *J Gastrointest Surg* 2004;8:679–85.

Hepp J. Hepaticojejunostomy using the left biliary trunk for iatrogenic biliary lesions: the French connection. *World J Surg* 1985;9:507.

IHPBA Terminology Committee. Terminology of liver anatomy and resections. *HPB Surg* 2000;2:333.

Mercado MA, Orozco H, de la Garza L, et al. Biliary duct injury: partial segment IV resection for intrahepatic reconstruction of biliary lesions. *Arch Surg*

1999;134:1008.

Strasberg SM, Helton WS. An analytical review of vasculobiliary injury in laparoscopic and open cholecystectomy. *HPB* 2011;13:1–14.

Walsh RM, Henderson JM, Vogt DP, et al. Long-term outcome of biliary reconstruction for bile duct injuries from laparoscopic cholecystectomies. *Surgery* 2007;142(4):450–6; discussion 456–7.

Walsh RM, Vogt DP, Ponsky JL, et al. Management of failed biliary repairs for major bile duct injuries after laparoscopic cholecystectomy. *J Am Coll Surg* 2004;199(2):192–7.

Winslow ER, Fialkowski EA, Linehan DC, et al. "Sideways": results of repair of biliary injuries using a policy of side-to-side hepatico-jejunostomy. *Ann Surg* 2009;249:426–34.

EDITOR'S COMMENT

The authors present an excellent chapter on reconstruction of the biliary tree. The section on anatomic variations is outstanding, and the reader is encouraged to study the text and illustrations as these variations come into play in avoiding bile duct injury whether major or minor during the cholecystectomy as well as liver resection.

Variations of the biliary system anatomy increase the risk of trauma to the biliary system and of bile leak after cholecystectomy. Such variations can be unknowingly injured and unnoticed by the surgeon until secondary bile fistula and biliary peritonitis occur. Two important variations that are important to further emphasize are the ducts of Luschka and variations in the anatomy of the right hepatic duct.

The ducts of Luschka present an interesting and important variant. Luschka described aberrant biliary ductules in the gallbladder fossa in 1863. This variant has been variously described in 1% to 30% of patients (Champetier J, Davin JL, Letoublon C, et al. Aberrant biliary ducts (vasa aberrantia): surgical implications. *Anat Clin* 1982;4:137–45; Couinaud C. *Surgical Anatomy of the Liver Revisited.* Paris: Couinaud; 1989; 60–74). I am not certain as to the reasons for the wide variance in the reported incidence. These are usually very small, most often less than 1 mm diameter, bile ducts running along the gallbladder fossa between the gallbladder and the liver parenchyma. They also have been described as "subvesicular" or "supravesicular ducts." It is important to understand that the ducts of Luschka *do not open* into the gallbladder as do the so-called "cystohepaticducts."

Duct of Luschka leaks occur after cholecystectomy regardless of gallbladder pathology or urgency of operation. This has been well analyzed by Mcquillan (Mcquillan T, Manolas SG, Hayman JA, et al. Surgical significance of the bile duct of Luschka. *Br J Surg* 1989;76:696–8) who reported a 9% incidence of bile

leak after open cholecystectomy and four cases of injury to the duct of Luschka during open cholecystectomy. In all four cases, the duct of Luschka was identified and ligated without any further problem.

Interestingly, duct of Lushka leaks have been encountered more frequently in the era of laparoscopic cholecystectomy with an incidence of 0.2% to 2%, according to Jamshidi and colleagues (Jamshidi M, Obermeyer R, Garcia G, et al. Post-laparoscopic cholecystectomy bile leak secondary to an accessory duct of Luschka. *Int Surg* 1999;84:86–8). It is not known why the incidence is greater in laparoscopic cholecystectomy. The visualization of the gallbladder fossa is much better with laparoscopy compared to open cholecystectomy so that poor exposure and visualization are unlikely reasons for the increased incidence. There is use of electrocautery in open as well as laparoscopic cholecystectomy so that is not likely to be the reason for the increased incidence. Certainly during laparoscopic cholecystectomy, there is the need to put outward traction on the gallbladder to facilitate the dissection from the gallbladder fossa. This could contribute, but in open cholecystectomy by the dome down approach there is counter traction used as well. In addition, the ducts of Luschka run parallel to the gallbladder wall and not perpendicular to it and they do not connect to the gallbladder. Hence outward traction forces applied during gallbladder dissection likely play little if any role in the development of such leaks. Hence, there is no clear explanation for the increased frequency of duct of Luschka leaks after laparoscopic cholecystectomy.

Detection of the ducts of Luschka during surgery is very difficult. Intraoperative cholangiography will not detect all such leaks. The only known method of avoiding such leaks is for the surgeon to stay close to the gallbladder wall during its removal from the gallbladder fossa and even then leaks may occur. In the text, the authors refer to ligating these small ductules, if they are seen. The problem is that they are not seen very often if ever during the dissection. It is safe to say that leaks may occur from such ducts and the detection requires a high index of suspicion after laparoscopic cholecystectomy. They can usually be diagnosed and managed by drainage and ERCP and papillotomy with or without stenting.

The authors also note the occurrence of anatomic variants of the right hepatic bile ducts. The surgeon should be familiar with these variations. The aberrant right hepatic duct may occur with a frequency of 4.6% to 8.4% (Puente SG, Bannura GC. Radiological anatomy of the biliary tract: variations and congenital abnormalities. *World J Surg* 1983;7:271–6; Kullman E, Borch K, Lindstrom E, et al. Value of routine intraoperative cholangiography in detecting aberrant bile ducts and bile duct injuries during laparoscopic cholecystectomy. *Br J Surg* 1996;83:171–5). It is well established that the isolated segmental, sectoral, and right hepatic bile duct may be injured during laparoscopic cholecystectomy. This can pass by unnoticed and without serious symptoms; however, it may also lead to serious complications such as cholangitis and liver

abscesses or biliary fistula and peritonitis. The treatment of isolated segmental, sectoral, and right hepatic bile duct injuries is controversial, and the different approaches often depend on the timing of the diagnosis and the attendant complications as discussed in the chapter.

Prevention of injury in these types of anatomic variations is difficult. The critical view of safety may be helpful as it shows the surgeon the safe zone, but establishing this view has not specifically been shown to allow clear visualization of the abnormal variations of right hepatic duct anatomy. My experience has been that there may be subtle clues to right hepatic duct abnormalities including associated anomalies of the right hepatic artery such as an artery that courses up the gallbladder fossa or variations in the cystic duct or artery with very long or short structures. The critical view of safety is essential to the performance of safe laparoscopic cholecystectomy and particularly so in these cases. I think that the use of intraoperative cholangiography for detection of variations in hepatic duct anatomy has not been particularly helpful unless the critical view cannot be obtained in which case it may contribute additional information.

I had commented on the classification of bile duct injuries in the preceding chapter and refer the reader to that commentary. The authors make excellent points concerning reconstruction of iatrogenic bile duct injuries. It is worth emphasizing that there is much controversy concerning the timing of the repair of bile duct injuries. Some authors have recommended early and others late repair; 6 or more weeks after surgery. The report by Stewart and Way is very insightful, and I recommend this to the reader (Stewart L, Way LW. Laparoscopic bile duct injuries: timing of surgical repair does not influence success rate. A multivariate analysis of factors influencing surgical outcomes. *HPB* 2009;11:516–22). They reported a total of 137 injuries that underwent initial repair by a biliary surgeon and 163 injuries that were initially repaired by the primary surgeon. Seven were managed by nonsurgical methods. Of note the repairs by primary surgeons were performed earlier than those by biliary surgeons (11 vs. 59 days; $P < 0.0001$). Interestingly, the analysis of the entire cohort suggested that later repairs might have been more successful than earlier ones (17 vs. 50 days; $P = 0.003$). However, multivariate analysis showed that the timing of the repair was not a significant predictor of outcome ($P = 0.572$). Instead the authors point out that “success correlated with: eradication of intraabdominal infection ($P = 0.0001$); complete preoperative cholangiography ($P = 0.002$); use of correct surgical technique ($P = 0.0001$), and repair by a biliary surgeon ($P = 0.0001$).” Our experience has been similar in that patients without sepsis with an early diagnosis and repair by a hepatobiliary surgeon had better outcomes and better quality-of-life scores than those having delayed repair. Separate multivariate analyses of outcomes for primary and biliary surgeons revealed that timing was unrelated to success in either case. Stewart and Way conclude, “The success of biliary reconstruction for iatrogenic bile duct injuries depended on complete eradication of abdominal infection,

complete cholangiography, use of correct surgical technique, and repair by an experienced biliary surgeon. If these objectives were achieved, the repair could be performed at any point with the expectation of an excellent outcome. We see no reason to delay the repair for some arbitrary period."

Another confounding variable in the assessment of outcomes is the type repair that is performed. Not infrequently the primary surgeon will perform a primary repair for a complete common bile duct transection or a choledochoduodenostomy. Given the blood supply of the bile duct and the variations of site of injury, we usually perform a Roux-en-Y hepaticojejunostomy. As the injured edges will need debridement before an anastomosis, there are few cases where there will be sufficient healthy duct tissue to allow end-to-end anastomosis or choledochoduodenostomy. Both primary repair and choledochoduodenostomy are associated with anastomotic tension and high rates of post-operative stricture secondary to this or a compromised blood supply to the injured bile duct. Accordingly, the long-term success rate for these techniques is poor. In the majority of cases, a hepaticojejunostomy represents the best choice for repair. This allows a tension-free anastomosis and allows the surgeon to expose and preserve a bile duct with a viable arterial supply.

Finally a comment on the need for stenting is relevant to this discussion. There are valid arguments on both sides of the debate of whether to stent or not. It is a decision that should be left to the surgeon as he or she will have the best understanding of their own results given the individual patient and the specific circumstances of the injury. It is our practice that if the patient has transhepatic stents placed prior to the procedure, which is advisable in the situations in which surgery needs to be delayed, then these should be advanced through the anastomosis into the jejunal limb. If the injury is recognized early or during the primary operation, then we do not routinely use stents.

In summary, this is an excellent chapter. I have tried to highlight some of the important considerations. Looking to the future one can imagine novel imaging techniques to visualized the biliary system real-time and also robotic biliary reconstruction.

E. Christopher Ellison

112 Current Application of Endoscopic Sphincterotomy, Lateral Choledochoduodenostomy, and Transduodenal Sphincteroplasty

E. Christopher Ellison, Jeffrey W. Hazey, W. Scott Melvin, and Stephen G. Moon

INTRODUCTION

Endoscopic sphincterotomy, transduodenal sphincteroplasty, and lateral choledochoduodenostomy are complementary procedures used when dealing with distal common bile duct obstruction due to stones, strictures, or, in some cases, motor dysfunction of the Oddi sphincter. Surgical drainage procedures have, in many instances, been replaced by endoscopic retrograde and antegrade papillotomy or sphincterotomy. However, there remain situations in which surgical therapy is required. Each of the procedures has specific indications, contraindications, advantages, and disadvantages. This chapter considers each procedure and discusses applications so that the surgeon can make a rational choice concerning which technique is appropriate to a given clinical circumstance. Before proceeding with discussion of the endoscopic and surgical techniques, the anatomy and physiology of the distal common bile duct and pancreatic duct are addressed.

ANATOMY OF THE DISTAL COMMON BILE DUCT AND PANCREATIC DUCT

The common bile duct and main pancreatic duct run in parallel as they enter the duodenum (Fig. 112.1). It is important to recognize the anatomic relationship between the common bile duct and the insertion of the main pancreatic duct to avoid damage to the latter structure during sphincteroplasty. As the common bile duct courses through the muscle layers of the duodenum, its caliber tapers markedly, producing the characteristic narrowing seen during cholangiography. This tapering is the

result of a complex sphincteric mechanism surrounding the distal common bile duct. The main pancreatic duct opens into the bile duct at a variable distance from the major duodenal papilla. A common channel is present in ~85% of cases. In these situations, dissections have demonstrated that the pancreatic duct is usually located on the medial aspect of the common duct, entering 2 to 3 mm proximal to the papilla of Vater. In ~6% of patients, the ducts open close to one another but separately on the papilla of Vater. The pancreatic and bile ducts open into the duodenum at separate points in 9% of cases.

Control of the flow of bile and pancreatic juice is regulated by a complex sphincteric mechanism that consists of four sphincters of smooth muscle surrounding the intramural portion of the common bile duct, main pancreatic duct, and ampulla (Fig. 112.1B–D). This collection of musculature was first noted by Oddi in 1888 and was expanded upon by Boyden's anatomic descriptions in 1936. This complex is functionally separate from the duodenal musculature. The bile duct sphincter itself consists of three interconnected sphincters: (a) the superior sphincter surrounding the bile duct for 0.5 cm just proximal to its passage through the duodenal wall, (b) a submucosal portion surrounding the intramural duct, and (c) the inferior portion, or the sphincter of the hepatopancreatic ampulla located within the ampulla itself. A pancreatic sphincter is described surrounding the intramural portion of the pancreatic duct as well. Depending on the angle at which the biliary and pancreatic ducts pass through the duodenal wall, the total sphincteric complex may be as short as 6 mm or as long as 30 mm.

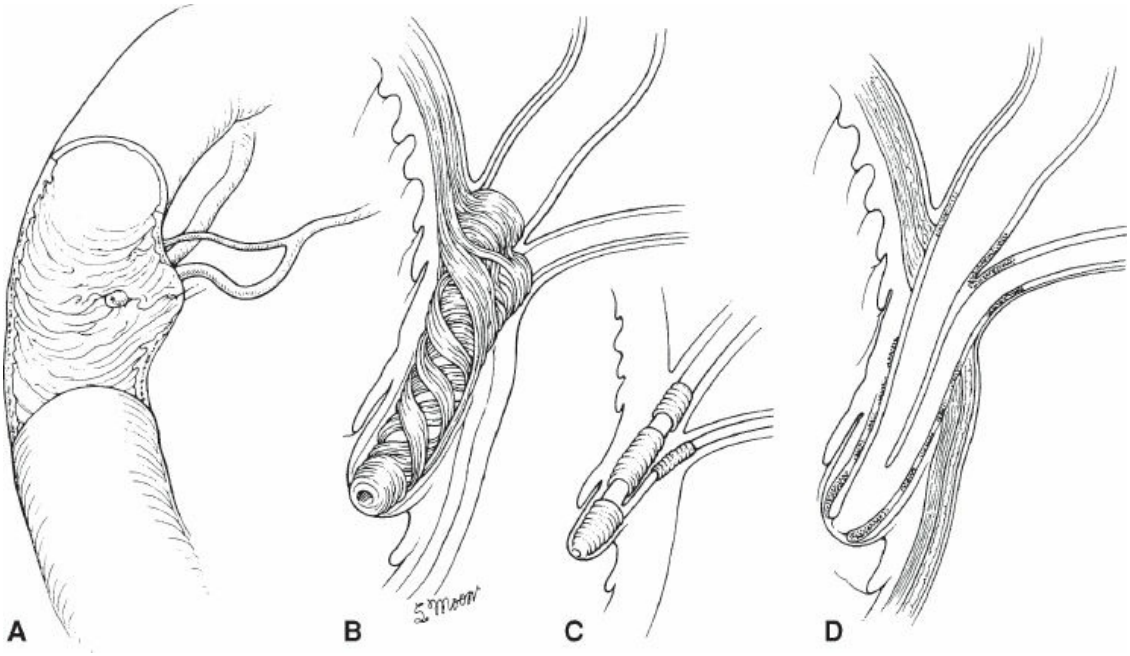

Figure 112.1. Anatomy of the distal common bile duct and pancreatic duct. **A.** The parallel relationship between the bile duct and the pancreatic duct as they enter the duodenum. **B.** The sphincteric mechanism. **C.** The four components of the sphincteric mechanism. **D.** A cross-sectional view of the Oddi sphincter.

PHYSIOLOGY OF THE ODDI SPHINCTER

Physiologic studies have demonstrated that the Oddi sphincter generates a resistance of ~5 mm Hg at the opening of the bile duct and pancreatic duct. The basal pressure measured manometrically is usually 5 to 15 mm Hg greater than the common bile duct pressure and 15 to 30 mm Hg greater than the duodenal pressure. Superimposed on this tonal pressure are prominent phasic contractions (100 to 150 mm Hg), which occur at a frequency of 2 to 6 per minute and are propagated in an anterograde direction (from bile duct to duodenum). Bile flows mainly between these phasic contractions through a relaxed musculature. However, the contractions do propel a small bolus of fluid, allowing clearance of the ductal opening, but the major portion of bile flow occurs by passive means.

The frequency of contractions of the Oddi sphincter varies between the fed and fasted state. During fasting, contractions of the sphincter increase just before phase III duodenal activity. After feeding, the amplitude of contractions decreases, and the tone is reduced. This facilitates passive bile flow. Neuronal and hormonal mechanisms are involved with the fine-

tuning of sphincteric contractions, yet many of the precise details of this interplay have not been fully elucidated.

PATHOPHYSIOLOGY

Successful miniaturization of manometry catheters, so that they can be used through side-viewing endoscopes, has permitted measurement of Oddi sphincter pressures. This has not only enhanced our understanding of normal physiology, but has also allowed accurate manometric definition of disorders of the sphincter complex. These triple-lumen catheters are made of either polyethylene or teflon, with an outer diameter of 1.5 to 1.7 mm. Side holes are oriented so that the lumens record across a length of 5 mm. The catheters are placed with a side-viewing scope before other instrumentation of the papilla. A patient undergoing endoscopic Oddi sphincter manometry is prepared somewhat differently than for standard endoscopic retrograde cholangiopancreatography (ERCP). After topical anesthesia of the oropharynx, mild sedation is achieved with intravenous diazepam or midazolam. It is important to avoid anticholinergics, such as atropine, or opiate analgesics, such as morphine, as they reproducibly alter Oddi sphincter pressures. Figure 112.2A shows a normal motility of the sphincter. Four manometric abnormalities have been categorized. The first abnormality is increased basal pressure in the Oddi sphincter (basal pressure >40 mm Hg). This abnormality has been further subdivided into two entities: (a) papillary stenosis, which occurs if the increased basal pressure does not relax after the administration of smooth-muscle relaxants such as nitrates, and (b) dyskinesia, when the basal pressure does respond to smooth-muscle relaxants. The second condition is *tachyoddia* and is evidenced manometrically by an increased number of phasic contractions (>38 per minute). The third abnormality is an increased number of retrograde waves (from duodenum to bile duct), with a corresponding decrease in the number of anterograde waves. The fourth abnormality is a paradoxic response to cholecystokinin (CCK)-octapeptide. Ordinarily, CCK-octapeptide, when given intravenously, should cause a decrease in Oddi sphincter basal pressure and phasic wave pressures. The paradoxic response occurs when CCK causes an increase in basal and phasic wave pressures.

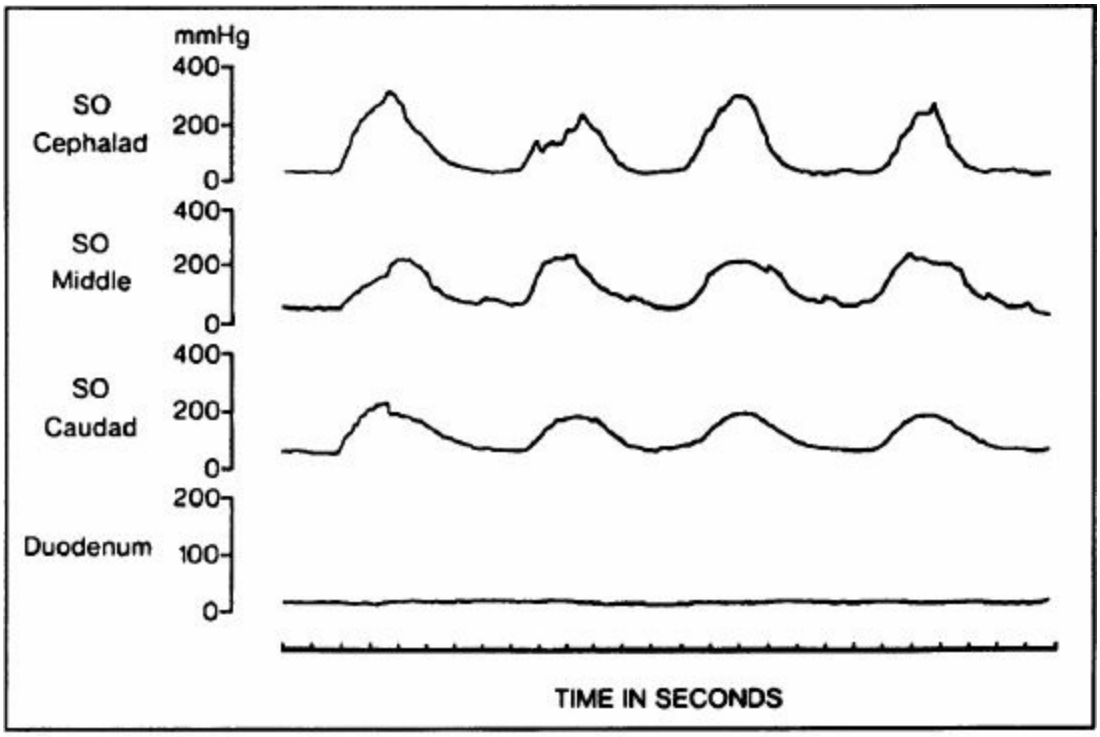
mmHg
400
SO
Cephalad
200
0
400
SO
Middle
200
0
400
SO
Caudad
200
0
200
Duodenum
100
0
TIME IN SECONDS

A

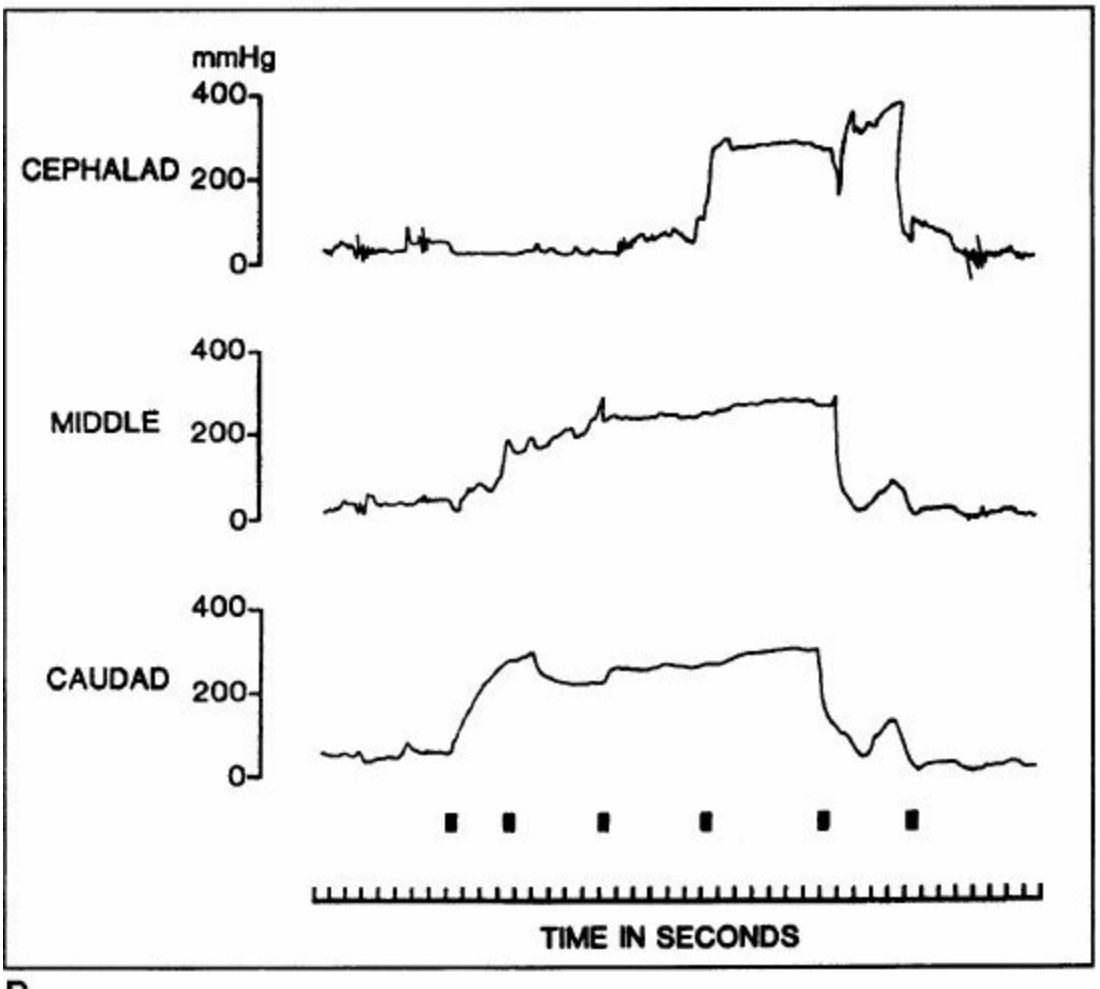
mmHg
400
CEPHALAD
200
0
400
MIDDLE
200
0
400
CAUDAD
200
0
TIME IN SECONDS

B

Figure 112.2. Manometric recording of sphincter of Oddi (SO). **A.** Normal manometry with phasic contractions superimposed on low basal pressure. **B.** Manometry in sphincter of Oddi stenosis characterized by high basal pressure.

These classifications of motility disorders correlate with a spectrum of clinical syndromes. It is postulated that disordered motility causes poor emptying of the biliary tree, ductal dilation, and pain. Most patients have had cholecystectomy, and the symptoms are nearly identical to those produced by cholelithiasis and dyskinesia of the gallbladder. Abdominal pain can be constant or intermittent and may not be temporally associated with dietary intake. Elevation of liver function tests is often seen in these disorders, but the abnormalities may be mild and, in some patients, transient, correlating with their episodes of pain.

Sphincter of Oddi Dysfunction and Endoscopic Sphincterotomy

A number of patients have sphincter of Oddi dysfunction (SOD). These patients present with intermittent biliary- or pancreatic-type pain after cholecystectomy or in the absence of gallstones and without significant "dyskinesia" determined by CCK-HIDA scan. Similarly, idiopathic bouts of acute pancreatitis or pancreatic-type pain in the absence of alcohol ingestion, gallstones, or other risk factors remain an enigma to the clinician. Transient elevations of biliary or pancreatic enzymes may occur in the presence or absence of pain. This may be best assessed with biliary manometry performed utilizing a side-viewing duodenoscope and inserting a manometric catheter through the ampulla selectively into the bile or pancreatic duct. Sphincter of Oddi manometry is quickly becoming the "gold standard" to assess Oddi function. Sphincters with an elevated basal pressure or inappropriately contracting may correlate with the patient's pain and respond to sphincterotomy. New evidence indicates that patients with normal manometric findings and persistent symptoms may benefit from repeat manometry as some patients may have periodic abnormalities in biliary manometry. Endoscopic sphincterotomy is quickly replacing surgical sphincteroplasty as the treatment of choice for SOD.

As indicated above, patients with SOD or sphincter of Oddi stenosis may present postcholecystectomy or after an exhaustive workup for recurrent idiopathic pancreatitis or biliary-type pain in the context of a normal right upper quadrant ultrasound and a normal CCK-HIDA scan.

Patients may have no biliary dilation or increased enzymes that correlate with episodes of pain. Sphincter of Oddi manometry is helpful in such cases. As previously indicated, the sphincter of Oddi is a complex smooth-muscle mechanism with sphincteric musculature involving both the bile and the pancreatic duct (Fig. 112.3A). Manometry can measure the transsphincteric basal and contractile pressures across both systems. Basal pressures >40 mm Hg, ductal pressures >13 mm Hg, and phasic contractions >220 mm Hg for >8 seconds at a frequency of >10 per minute suggest abnormal manometry of either the biliary or the pancreatic sphincter mechanism. The most frequent complication seen with sphincter of Oddi manometry, pancreatitis, is decreasing in frequency with the introduction of nonperfused pressure catheters. Endoscopic sphincterotomy of the biliary, pancreatic, or both sphincteric mechanisms may be necessary to render the sphincter incompetent and alleviate a patient's pain (Fig. 112.3B,C). The Geenen–Hogan sphincter of Oddi classification system has been applied to SOD as a predictor of which patients will respond to sphincterotomy (Table 112.1). Type I SOD comprises patients with biliary-type pain, abnormal serum glutamic-oxaloacetic transaminase (SGOT) or alkaline phosphatase more than two times the normal on two or more occasions, common bile duct diameter >12 mm, and delayed drainage of contrast from the biliary tree after ERCP of >45 minutes. Patients who fulfill these criteria frequently have abnormal manometry (75% to 95%) and have a 90% to 95% symptomatic response to sphincterotomy, making manometry unnecessary in this group of patients. Type II SOD comprises patients who exhibit biliary-type pain and present with one or two of the previous criteria. Abnormal manometry is found in 55% to 65% of these patients. Sphincter of Oddi manometry is generally recommended in this population, and symptomatic relief can be expected in up to 85% in the presence of abnormal manometry. In the face of normal manometry, only 35% of patients can be expected to have relief. Type III SOD patients have biliary-type pain but no other abnormalities. Sphincter of Oddi manometry is abnormal in only 25% to 60% of these patients. Similarly, symptomatic relief can be expected in 55% to 65% of patients with abnormal manometry, but <10% of these patients with normal manometry will respond. To date, this is the only predictive model for patients with SOD as it applies to symptomatic responses given in subjective clinical data and manometric values. Endoscopic sphincterotomy may be applied selectively to either the biliary or

pancreatic duct sphincteric mechanism, depending on manometric findings. The ability to perform selective or dual sphincterotomy has increased success rates and symptomatic response in patients with SOD and recurrent idiopathic pancreatitis (Table 112.1).

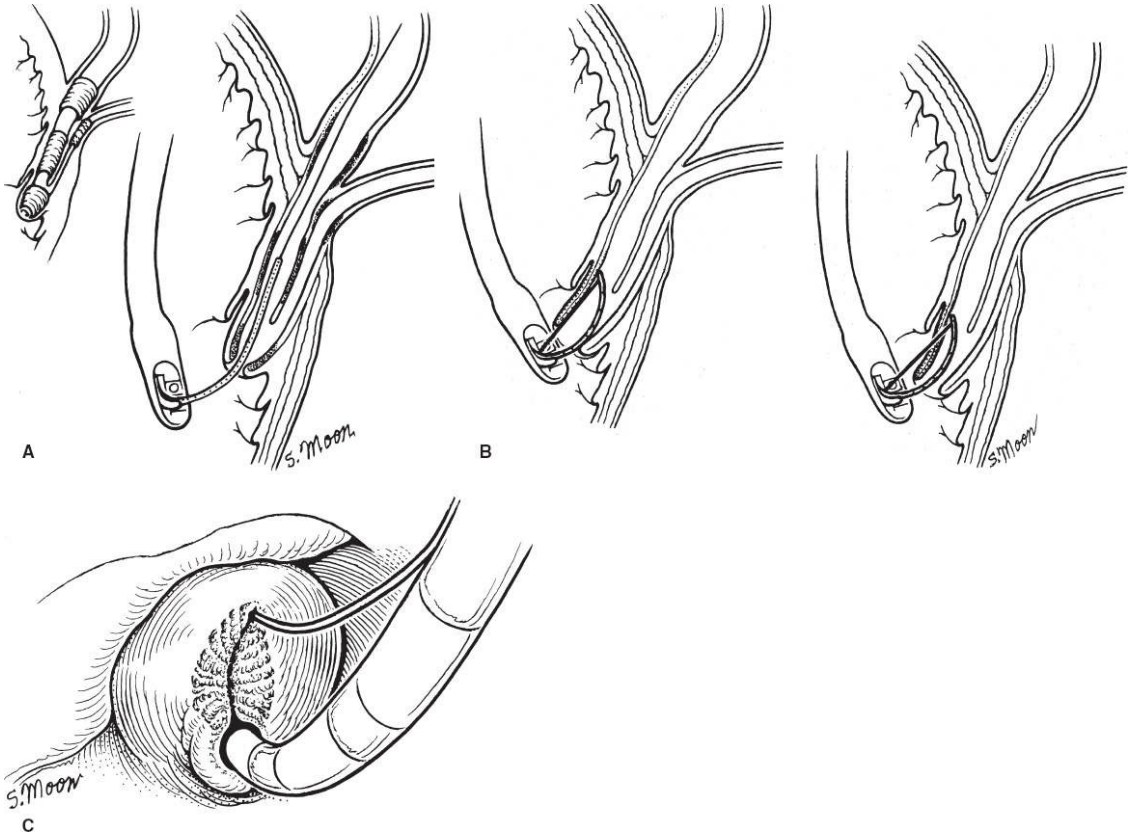

Figure 112.3. **A.** Sphincter of Oddi musculature and biliary cannulation. **B.** Deployment of wire in preparation for sphincterotomy. **C.** Endoscopic view of completed sphincterotomy.

TABLE 112.1 Modified Milwaukee Classification System for Sphincter of Oddi Dysfunction (Assuming All Patients Have Biliary Type Pain)

	Clinical Criteria	Approx. Frequency (%)	Probability of Pain Relief If Biliary Manometry is...	
			Abnormal (%)	Normal (%)
SOD Type I	2 Clinical criteria	65–85	90–95	90–95
SOD Type II	1 Clinical criteria	65	85	35
SOD Type III	No clinical criteria	59	55–60	40

Clinical Criteria: ALT/AST/ALP 2x nl.
Bile duct >12 mm.
From Geenen JE, Hogan WJ, Dodds WJ, et al. The efficacy of endoscopic sphincterotomy after cholecystectomy in patients with sphincter of Oddi dysfunction. *N Engl J Med* 1989;320(2): 82–7. Copyright © 1989 Massachusetts Medical Society. Reprinted with permission from Massachusetts Medical Society.

Patients undergoing endoscopic sphincterotomy for SOD have been found to have increased complication rates when compared with those undergoing sphincterotomy for common bile duct stones. Trials of biliary and pancreatic duct stenting to aid in the diagnosis are generally not recommended with complication rates as high as 38%. The most common complication, pancreatitis, can be expected in up to 7% of all patients undergoing ERCP. Multiple risk factors have been outlined that increase the risk of developing post-ERCP pancreatitis. These include a prior history of ERCP-induced pancreatitis, balloon dilation of the sphincter, difficult cannulation, sphincterotomy, pancreatic duct injection, especially with acinarization, SOD, female gender, and younger age. The decision to alternatively offer these patients endoscopic ultrasound (EUS) or magnetic resonance cholangiopancreatography (MRCP) may be influenced by these risk factors.

Recently, a novel technique to perform an antegrade sphincterotomy in patients who have an ampulla that is inaccessible by traditional endoscopic means (e.g., patients who have undergone a Roux-en-Y gastric bypass procedure) has been described. This may be accomplished by accessing the biliary tree via a percutaneous transhepatic biliary catheter using a small caliber cholangioscope passed through the sheath. An endoscopic sphincterotome can be passed beside the scope under direct visualization and with fluoroscopic assistance. With the cholangioscope retroflexed in the duodenum, the sphincterotome is passed beyond the ampulla and into the duodenum. The ampullary sphincteric complex can then be “cut” using endoscopic energy (as in traditional ERCP) to achieve a sphincterotomy for treatment of ampullary stenosis or common bile duct stones. In a similar fashion, EUS-guided needle and antegrade wire access to the

biliary tree has been described in patients with peroral inaccessible ampullas. These techniques are limited to select centers with limited experience.

Complications of ERCP, Endoscopic Sphincterotomy, and Treatment

The surgeon may be consulted for a patient who develops bleeding, perforation, or stricture after ERCP with sphincterotomy. Bleeding occurs in 2% to 12% of patients who undergo sphincterotomy. This may be minor and self-limited or major, requiring laparotomy and oversewing of bleeding vessels. The majority of cases can be treated utilizing endoscopic modalities, including injection of 1:10,000 epinephrine, thermal therapies, or endoscopic hemoclips.

Perforation rates of 0.3% to 1.0% have been reported. Perforations may occur as a result of endoscopic manipulation independent of ERCP or as a result of sphincterotomy or passage of a guidewire. Treatment of perforations as a result of sphincterotomy depends on location and has been categorized as type I through type IV by Stapfer et al. (Fig. 112.4). Type I perforations involve the lateral or medial wall of the duodenum and are caused by the endoscope. There is often free intraperitoneal extravasation of contrast from the duodenum, and these perforations require laparotomy and repair. Duodenal diversion may be necessary depending on the extent of the injury. Type II perforations, or peri-Vaterian injuries, may be diagnosed during the procedure or with a computed tomography scan with oral contrast. These perforations vary in severity, tend to be small, and are less likely to require surgery. When surgical repair is indicated, stone/foreign body removal, drainage of the periduodenum, and, rarely, duodenal diversion may be necessary. Type III perforations involve only the bile duct and tend to be small. Although these perforations may be diagnosed during the procedure, it is not uncommon for them to be diagnosed after ERCP. The bile duct may be perforated as a result of sphincterotomy, passage of a guidewire, or bile duct manipulation. Conservative treatment with bowel rest, intravenous antibiotics, and either endoscopic stenting or nasobiliary drainage are often successful. In those patients who develop a biloma or an intraperitoneal collection of bile, external percutaneous biliary drainage in combination with internal stenting is generally successful. Free intraperitoneal bile leaks that are not amenable to percutaneous drainage may require

laparotomy, washout, and placement of drains. The need for primary operative repair of biliary injuries/leaks in this setting is unusual. Type IV perforations are associated with retroperitoneal air and no free extravasation of contrast. These are usually limited to the retroperitoneal duodenum. Series report successful treatment in up to 86% of these patients with bowel rest, nasogastric decompression, and broad-spectrum antibiotics. Complex injuries involving both the duodenum and the biliary tree may necessitate more complex treatment algorithms. Using a combination of the above described techniques, surgical intervention may be unnecessary. Postsphincterotomy strictures do occur and may be amenable to repeat sphincterotomy or balloon dilation. In rare circumstances, recurrent stricturing of the ampulla may require operative transduodenal sphincteroplasty.

Infectious complications of ERCP include cholangitis (1% or less) and cholecystitis (0.2% to 0.5%). The placement of stents, presence of strictures, jaundice, and incomplete biliary drainage increase the risk of cholangitis. Drainage of the biliary tree by stenting or sphincterotomy with antibiotics is the treatment of choice. The presence of gallstones is believed to be the causal factor in post-ERCP cholecystitis and can be treated with cholecystectomy.



Figure 112.4. **A.** Type I perforation involving the wall of the duodenum typically as a result of the duodenoscope. **B.** Type II perforation involving the peri-ampullary complex into the peritoneum. **C.** Type III perforations of the bile duct by wire or instrumentation. **D.** Type IV perforation limited to the retroperitoneum.

Lateral Choledochoduodenostomy

Lateral choledochoduodenostomy can be performed as a primary procedure at the time of cholecystectomy or for recurrent common bile duct stones occurring remotely after cholecystectomy that cannot be treated by endoscopic papillotomy. In the past, the frequency of the necessity of this drainage procedure has been ~1% of all biliary operations, 38% of patients having a primary operation and 60% having a secondary procedure. It is more often necessary in the elderly patients; the mean age of patients reported in the literature is 61 years.

INDICATIONS

The surgeon should consider performing a lateral choledochoduodenostomy in patients with a dilated common bile duct secondary to distal obstruction from a benign process. This group frequently has failed previous attempts at endoscopic sphincterotomy. A large duct, measuring >2 cm, is an indication of prolonged obstruction or loss of tone leading to biliary stasis. Biliary stasis results in a potential for primary stones within the duct and, therefore, size alone is a relative indication for this operative procedure. The presence of primary common bile duct stones, numerous bile duct stones (>15), or intrahepatic duct stones, especially in any patient who has undergone a previous choledochotomy, usually requires a choledochoduodenostomy. Distal obstruction from strictures secondary to a primary benign process, such as chronic pancreatitis, is also treated appropriately with choledochoduodenostomy. Lateral choledochoduodenostomy is contraindicated in patients with a common bile duct smaller than 15 mm or a stone impacted in the ampulla.

OUTCOME

A minimum stoma size of 2.5 cm should be achieved in all cases. If a large stoma is created, the results are usually satisfactory, and late stenosis or

cholangitis is rare. If the stoma is small, stenosis or the “sump” syndrome may occur. The “sump” syndrome is the collection of vegetable debris in the distal segment of the bile duct below the anastomosis (Fig. 112.5). This can eventually produce obstruction with cholangitis, jaundice, or even pancreatitis. Overall, the incidence of this complication is below 1%. The advantages of lateral choledochoduodenostomy over sphincteroplasty to drain the biliary system are speed, the ease of performance, and decreased incidence of perioperative morbidity. It is particularly applicable in the poor-risk patient or in the patient with a long stricture who cannot undergo a sphincteroplasty. The main disadvantage of a lateral choledochoduodenostomy is the potential development of the “sump” syndrome. Recent studies have shown good long-term outcomes with very low or absent rates of development of “sump” syndrome. Similarly, endoscopic techniques with clearance of the affected distal common bile duct remnant can be applied to treat this potential complication. In addition, there is decreased visualization of the papilla to exclude malignancy, although it can be excluded through choledochoscopy or direct visualization through the duodenotomy.

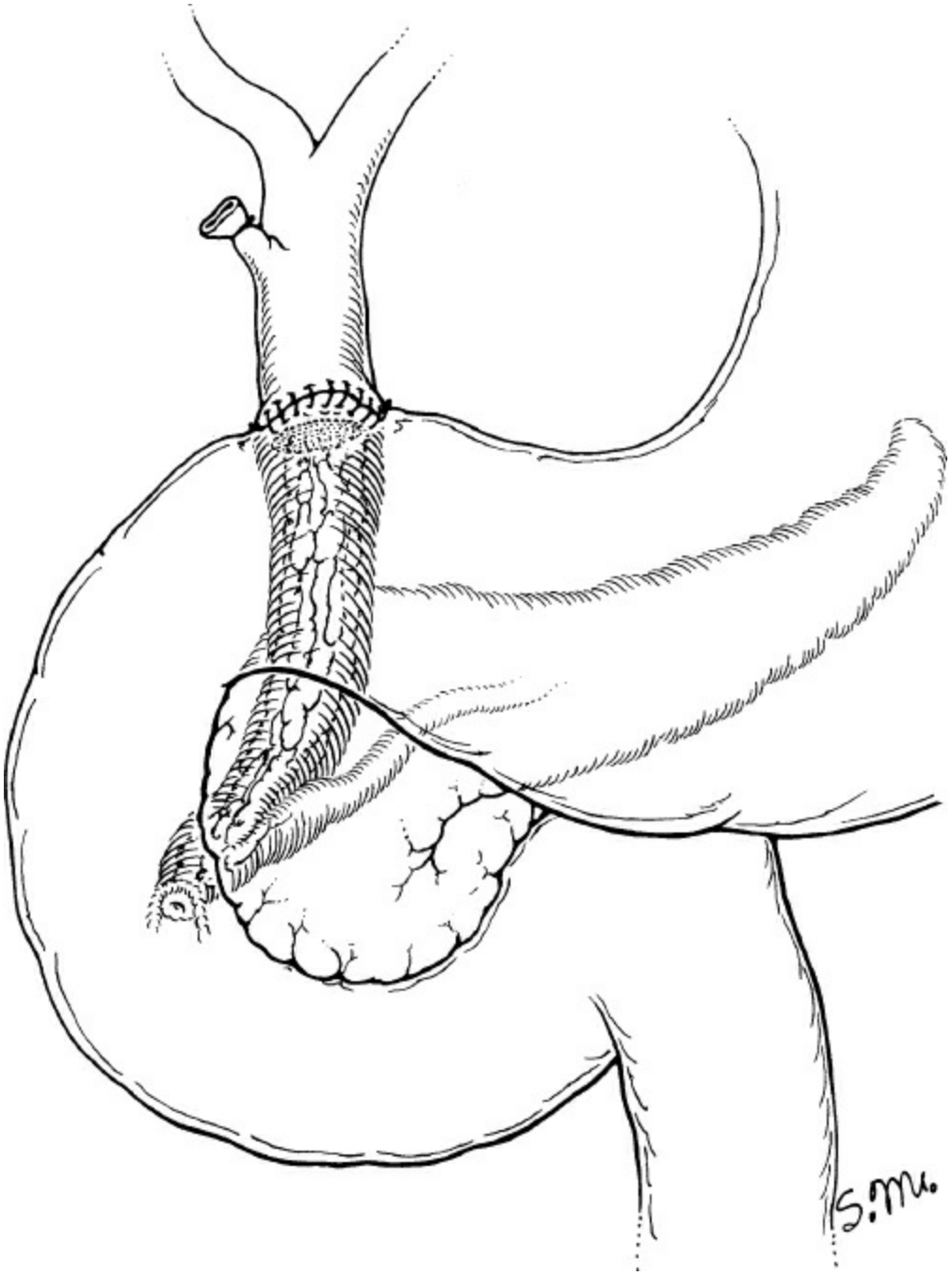

Figure 112.5. Example of the “sump syndrome,” with debris filling the distal bile duct.

SURGICAL TECHNIQUE

After the gallbladder is removed, the common bile duct is exposed by incising the overlying peritoneum. The common bile duct is opened in a longitudinal fashion in the supraduodenal location. An extended Kocher maneuver is routinely performed to enhance exploration of the common bile duct and performance of the choledochoduodenostomy (Fig. 112.6). If findings are compatible with the indications for choledochoduodenostomy,

the incision in the common bile duct is extended to 2.0 to 2.5 cm in the longitudinal axis (Fig. 112.7A). This incision usually will extend up to the common hepatic duct. After the common-duct exploration has been completed and proper mobilization and exposure have been obtained, a longitudinal incision is made in the postbulbar duodenum (Fig. 112.7A). It is wise to make this incision somewhat smaller than the expected stomal caliber, because the elasticity of the duodenal incision can result in excessive stretching and technical difficulty. Stay sutures are placed at the corners of the planned choledochoduodenal anastomosis. These sutures pass from the end of the duodenal incision (Fig. 112.6). The duodenal incision is bisected with a suture placed at the lower aspect of the choledochotomy in the midpoint of the adjacent duodenum (Fig. 112.7B). The posterior row of sutures is then placed with a 4-0 absorbable material, preferably polyglycolic acid, so that knots are placed on the internal aspect of the anastomosis. The anterior row of sutures is then placed without tying (Fig. 112.7C). Traction is used to hold the sutures until all are placed; this prevents inadvertent closure of the posterior wall. Then they are tied, beginning at the medial side of the anastomosis (Fig. 112.7D). It is unnecessary to use a double-layer closure, because a second layer would only cause narrowing of the anastomotic orifice. We routinely place a closed suction-type drain posterior to the choledochoduodenostomy.

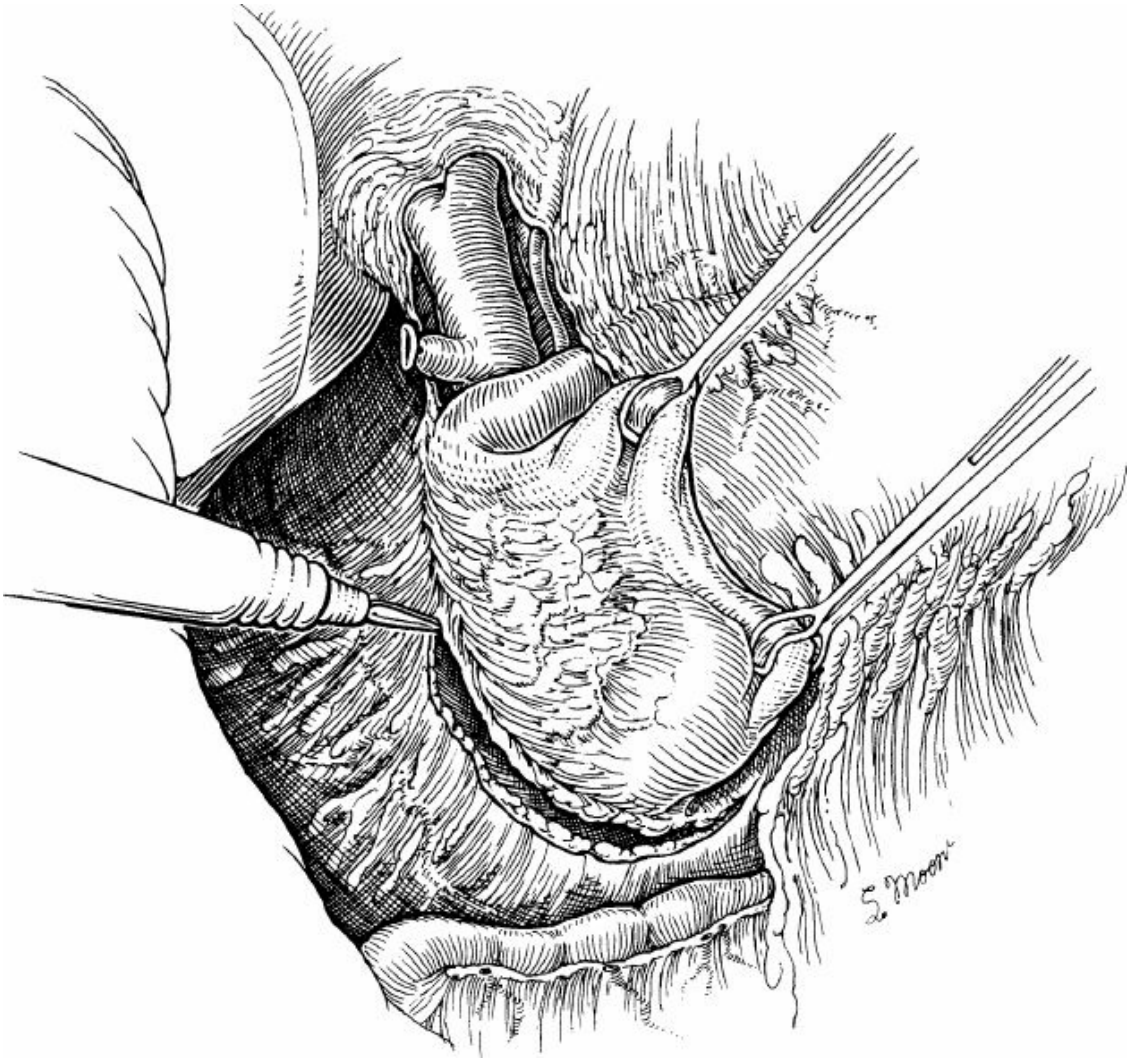

Figure 112.6. A wide Kocher maneuver is necessary for common-duct exploration, choledochoduodenostomy, and sphincteroplasty.

Transduodenal Sphincteroplasty

The usual indications for surgical decompression of the bile duct are anatomic causes of obstruction. It is important, however, to be aware of the various treatments used for Oddi sphincter dysfunction. The classification proposed by Geenan et al., which separates patients with unexplained biliary pain into subgroups based on the number of clinical laboratory and radiologic parameters, is used to guide diagnosis and therapy (Tables 112.1 and 112.2). Type I patients usually have ampullary stenosis. Routine need for Oddi sphincter manometry is not necessary in this group. If an endoscopic papillotomy cannot be performed, then surgical sphincteroplasty is necessary. Type II and III patients often need motility studies to clarify further the pathophysiology. Oddi sphincter

basal pressure is >40 mm Hg in 16% to 68% of type II patients and in 0% to 55% of type III patients, with tachyoddia being present in ~1% of each group (Fig. 112.2B). The wide variety of findings among the reports reflects variations of patient selection.

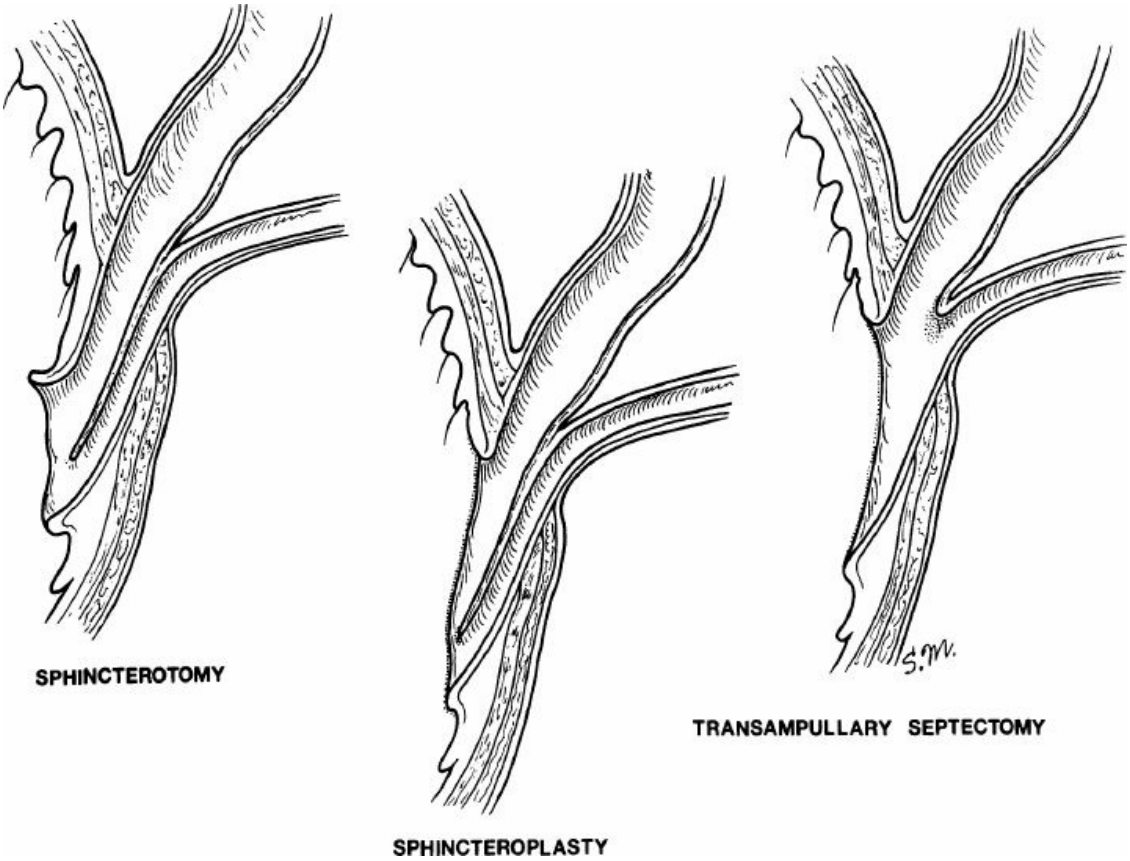

Figure 112.7. Various operations on the sphincter of Oddi.

The initial treatment of type II and III Oddi sphincter dysfunction is the oral administration of smooth-muscle relaxants, such as dicyclomine hydrochloride, cycline trinitrate-sorbide nitrate, and nifedipine. The most effective definitive therapy, however, is endoscopic papillotomy or surgical sphincteroplasty. It should be emphasized that patients in whom recurrent pancreatitis has developed as a result of Oddi sphincter dysfunction require division of the choledochal and pancreatic duct components of the Oddi sphincter. This should be performed by transduodenal sphincteroplasty and septectomy. Most of the patients, however, do not have pancreatitis and can be treated with endoscopic papillotomy.

TABLE 112.2 Absolute and Relative Contraindications for Open Biliary

Preoperative

Contraindication to general anesthesia
Cirrhosis complicated by portal hypertension
Late pregnancy
Suspected gallbladder cancer

Inoperative

Inability to identify anatomy
Multiple omental adhesions secondary to previous surgery
Biliary ductal abnormality on cholangiogram
Intraoperative metabolic acidosis

Type II patients with elevated basal sphincter pressure have a good response to papillotomy in 80% to 90% of reported cases, compared with 50% to 60% in those without a hypertensive sphincter. In a few studies, no correlation was seen between the clinical response to papillotomy and Oddi sphincter motility abnormalities. Type III patients have approximately a 50% response rate when they have manometric evidence of dysfunction.

The indications that will commonly be encountered for performing a transduodenal sphincteroplasty are stones impacted in the ampulla of Vater, papillary stenosis, and recurrent pancreatitis with multiple common bile duct stones. In general, surgical sphincteroplasty can be applied for treatment of Oddi sphincter dysfunction; however, it is usually recommended that this can be treated by endoscopic papillotomy unless specific contraindications to its performance exist or previous endoscopic treatment has failed. Transduodenal sphincteroplasty is contraindicated in patients with a common bile duct with a diameter >2 cm, a long distal common bile duct stricture, a peri-Vaterian duodenal diverticulum, or *severe* inflammatory changes involving the duodenal wall or the head of the pancreas. This procedure is more often performed in younger patients than is choledochoduodenostomy. Major morbidity has been reported in 20% of patients, compared with 11% for choledochoduodenostomy.

SURGICAL TECHNIQUE

Precise terminology should be used in describing the various operations on the Oddi sphincter. A sphincterotomy is essentially a cut made into the sphincter with no suturing of bile duct mucosa to the duodenal mucosa. A sphincteroplasty is the incision of the common portion of the Oddi sphincter with suturing of the mucosa of the common bile duct to the duodenum. The patient with recurrent pancreatitis may need to undergo further septectomy and septoplasty of the septum between the pancreatic duct and common bile duct. These variations are illustrated in Figure 112.8.

The patient is operated on in the supine position. Use of the radiolucent table facilitates fluoroscopic cholangiography or pancreatography if needed. The incision can be either midline or subcostal, although we prefer a subcostal incision. After removal of the gallbladder, an extended Kocher maneuver is performed. The assistant retracts the second portion of the duodenum medially and inferiorly. The peritoneum is incised along the lateral edge of the duodenum. Blunt dissection is used to develop a plane posterior to the head of the pancreas with countertraction provided by the assistant. This is an avascular space between the posterior pancreatic head, the perinephric fat, and the inferior vena cava. It is important to mobilize the third portion of the duodenum sufficiently to allow surgical access to the papilla and for closure of the duodenotomy without tension.

The papilla is normally located at the junction of the lower one third and upper two thirds of the second portion of the duodenum. Identification of its precise location is assisted by passing a balloon-tipped 4 or 6 French biliary Fogarty catheter through the cystic duct stump into the common duct and into the duodenum. By inflating the balloon with a small amount of saline, the surgeon can palpate the exact location of the sphincter mechanism. This allows for accurate placement of the duodenotomy and diminishes the length of the incision that is required. We perform a longitudinal duodenotomy, which permits extension of the incision in the cephalad or caudad direction, if necessary. In addition, when retractors are introduced or stay sutures are placed on the cut edge of the duodenum, any inadvertent increase in the size of the incision would be in a longitudinal dimension rather than medially into the pancreas. Once the duodenotomy is made, the balloon-tipped Fogarty catheter is seen coming out of the papilla (Fig. 112.9A). If the balloon-tipped Fogarty cannot be placed, the papilla can be identified by palpation or by manual inspection of the

duodenal mucosa. The minor papillary orifice is located cephalad ～2 cm.

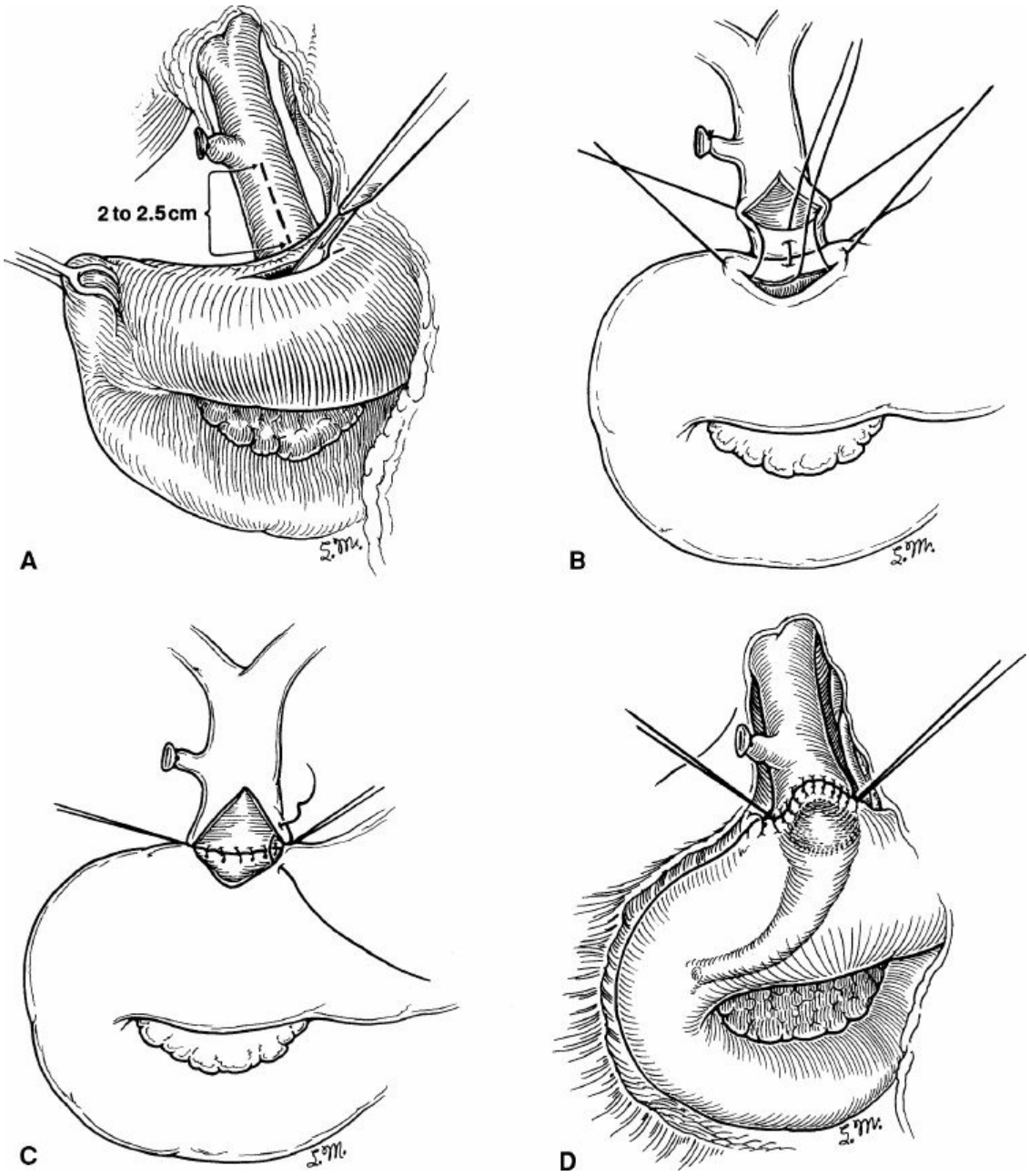

Figure 112.8. **A.** Proper incision of the bile duct for creation of choledochoduodenostomy. **B.** Initial sutures for choledochoduodenostomy. **C.** Posterior row of choledochoduodenostomy is completed. Anterior row is placed, but not tied, until all sutures are completed. **D.** Completed choledochoduodenostomy.

When the Oddi sphincter is identified, traction sutures are placed into the duodenal wall adjacent to, but not into, the ampullary complex to elevate and expose the ampulla. Care must be taken to avoid injury to the

duct of Wirsung, which enters on the medial aspect of the ampulla. We prefer to perform all of the subsequent steps with loupe magnification. The goal is to incise the intraduodenal portion of the distal bile duct completely and approximate the mucosa to the duodenal mucosa. The ampulla should be viewed longitudinally, with the cephalad end at the top—at 12 o'clock—and the caudad end at 6 o'clock. At approximately 11 o'clock, a needle-tipped electrocautery is used to make an initial incision in the sphincter over the Fogarty catheter (Fig. 112.9B). Absorbable sutures, 5-0 or 4-0, are then placed on each side of this incision and are held with fine hemostats and not tied. The incision is continued for ~5 mm, with placement of sutures approximately every 1.5 mm, being held with slight traction to open the bile duct (Fig. 112.10A). At this point, the balloon on the biliary Fogarty is deflated and the catheter is pulled back proximally, and a grooved director is passed into the sphincteric opening. The incision in the sphincter is then continued for the length of the intramural common bile duct, which may vary from as short as 6 mm to as long as 3 cm. The incision is stopped proximally, at the point that the common bile duct leaves the wall of the duodenum. Sutures are continued up to the apex stitch. The apex stitch is important, because it closes the opening on the most outside wall of the duodenum where the bile duct becomes extramural. Failure to place this stitch accurately can result in leakage of the sphincteroplasty. The grooved director is removed, and the opening of the pancreatic duct is identified between 4 and 6 o'clock on the medial aspect of the opening; only after the duct is visualized are the medial sutures placed above the pancreatic ductal opening, so as not to occlude it. The pancreatic duct orifice usually appears as a slit-like aperture. Frequently, it is necessary to cannulate the pancreatic duct opening with a lacrimal duct probe for precise localization (Fig. 112.10B). If the pancreatic duct cannot be identified, it may be necessary to give secretin (75 U/kg IV) to induce pancreatic secretion so that the orifice can be found. Precise localization is mandatory, as inadvertent closure of the main pancreatic duct orifice results in serious postoperative pancreatitis. If the pancreatic duct cannot be precisely identified, medial sutures are avoided between 3 and 6 o'clock.

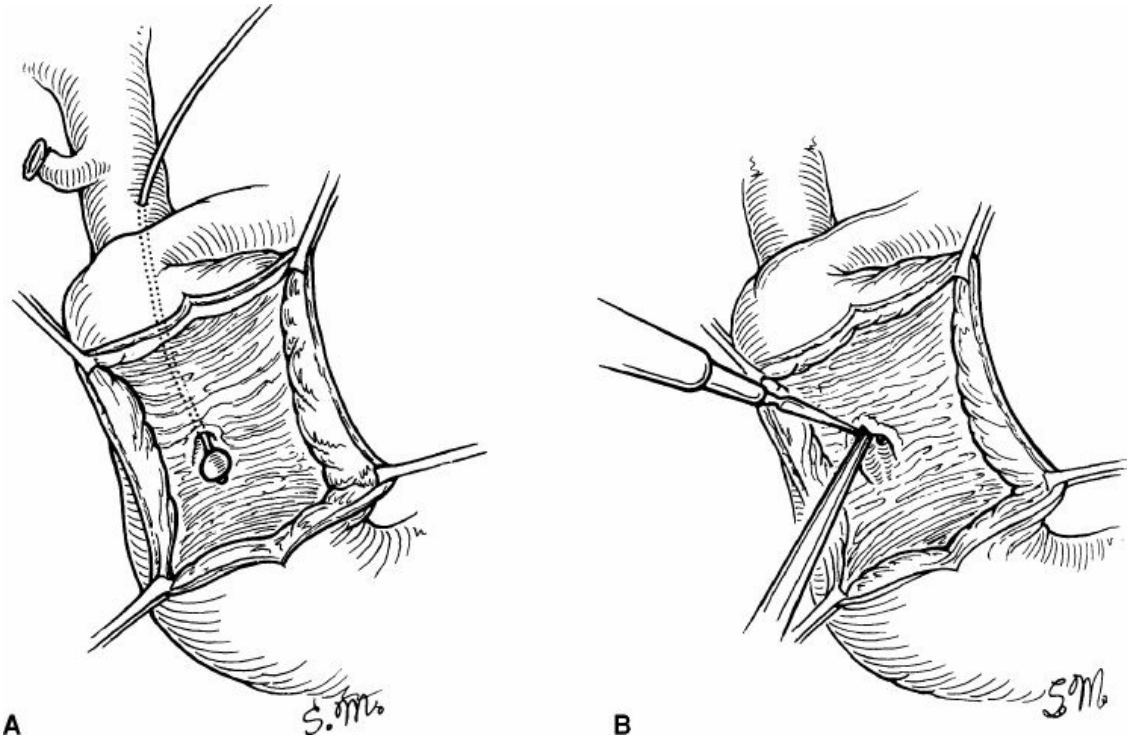

Figure 112.9. **A.** Identification of the ampulla of Vater with a biliary Fogarty catheter passed through either the cystic duct or the common duct. **B.** The initial incision is in the ampulla at 11 o'clock.

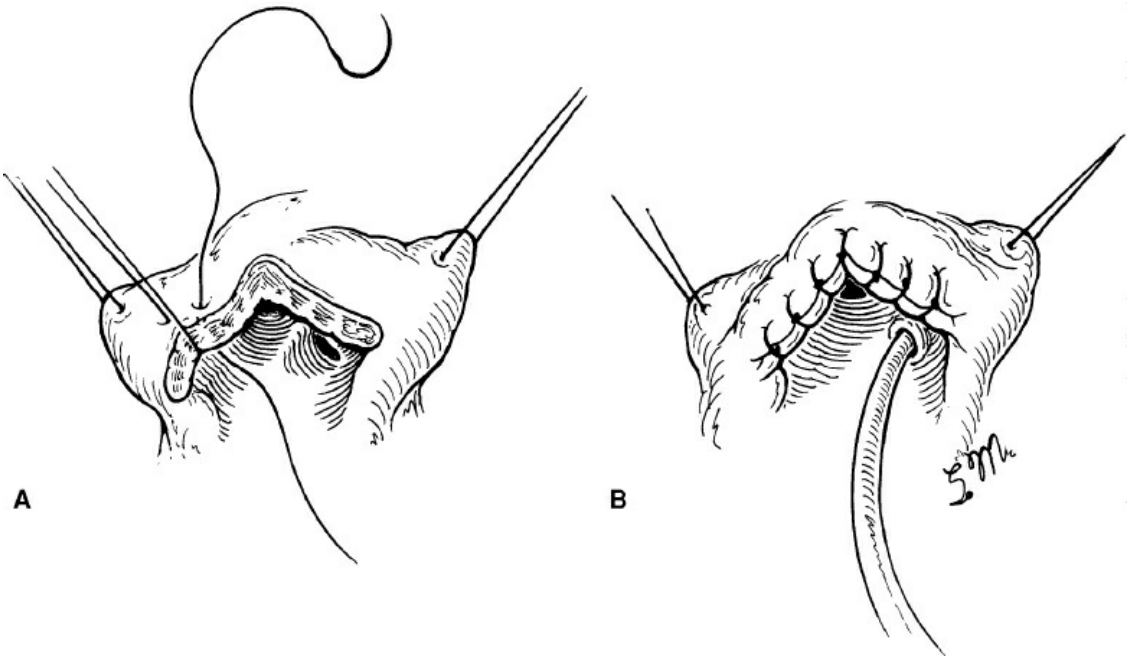

Figure 112.10. **A.** Initial sutures for the sphincteroplasty are placed 1.5 mm apart. **B.** Precise localization of the pancreatic duct.

If the patient has had recurrent pancreatitis and stricturing of the orifice

of the pancreatic duct, or if sphincter dysfunction is thought to exist, a septectomy is performed (Fig. 112.11). Although usually not necessary, pancreatography can be performed to exclude other pancreatic duct abnormalities, if not accomplished preoperatively. This is performed by back loading a 22-gauge angiocatheter onto a lacrimal duct probe. After the tip of the probe is inserted in the duct, the angiocatheter can be placed easily into the duct using the stiffer probe as a guide. Pancreatography is then performed, preferably under fluoroscopic guidance, by a gentle infusion of contrast, introduced by gravity with an elevation of the syringe to no more than 25 cm. The ductal septectomy is performed by inserting the lacrimal duct probe into the pancreatic duct and making an incision over this, removing the septum between the common bile duct and the pancreatic duct. Sutures are placed between the cut edge and the duodenal mucosa. Some surgeons do not use sutures unless bleeding is present. We prefer to complete a septoplasty with sutures. Care must be taken not to expand the incision in the septum into the pancreas to avoid focal postoperative pancreatitis. If this does occur, the defect can be repaired by reapproximating the edges of the duct and the duodenum.

Once the sphincteroplasty is completed, the common bile duct can be explored in a retrograde fashion if it has not already been explored. Choledochoscopy can also be performed through the sphincteroplasty. Placement of a T-tube is not usually necessary, even if a supraduodenal choledochotomy has been made, although it may be advantageous if a stone was impacted in the ampulla, resulting in edema and swelling.

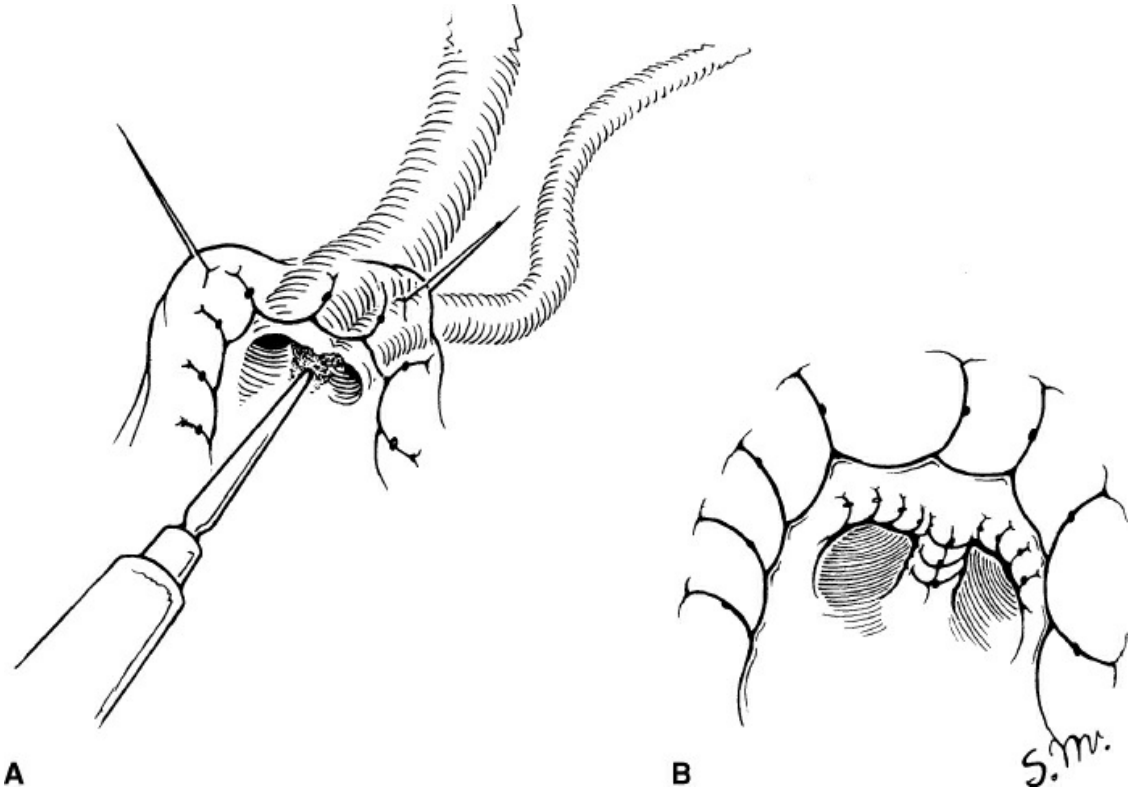

Figure 112.11. A. Septectomy. **B.** Sutures after the septectomy.

Duodenal closure is accomplished in a longitudinal fashion with a single layer of 3-0 silk Lembert sutures in normal cases (Fig. 112.12). A closed suction drain is placed posterior to the duodenum and pancreas. Transverse closure is not necessary, and, in our experience, it has been associated with more complications, particularly anastomotic leakage, duodenal fistula, and possible duodenal stenosis, as transverse closure may require a two-layer anastomotic technique.

Early complications of sphincteroplasty include acute pancreatitis (0.6%), bleeding of the incised papilla (0.3%), and leakage of the duodenal suture line (0.6%). Other major morbidity, however, is reported in ~20% of patients. Late sequelae include routine asymptomatic pneumobilia. Importantly, air in the biliary tree indicates a patent sphincteroplasty. Duodenal biliary reflex may occur and require antibiotics for cholangitis but usually does not cause symptoms or problems. Recurrent papillary stenosis may occur but is rare; if it is suspected, the patient should initially have an upper gastrointestinal barium study to look for barium reflux into the biliary system. If none is detected, stenosis of the sphincteroplasty is suggested, and ERCP is warranted.

Historically, the application of sphincteroplasty became more common after original observations of sphincterotomy performed surgically showed

poor results. The introduction of endoscopic papillotomy has allowed a larger study of simple sphincterotomy. The overall stenosis rate in these cases is ~2%. Surgical sphincterotomy is not the same as endoscopic sphincterotomy. The length of endoscopic sphincterotomy is shorter, and, theoretically, there is more edema that could result in early stenosis or occlusion, accounting for the historically less satisfactory results. Therefore, when indicated, surgical sphincteroplasty is still preferred over surgical sphincterotomy, and it may be appropriate in some patients rather than endoscopic sphincterotomy.

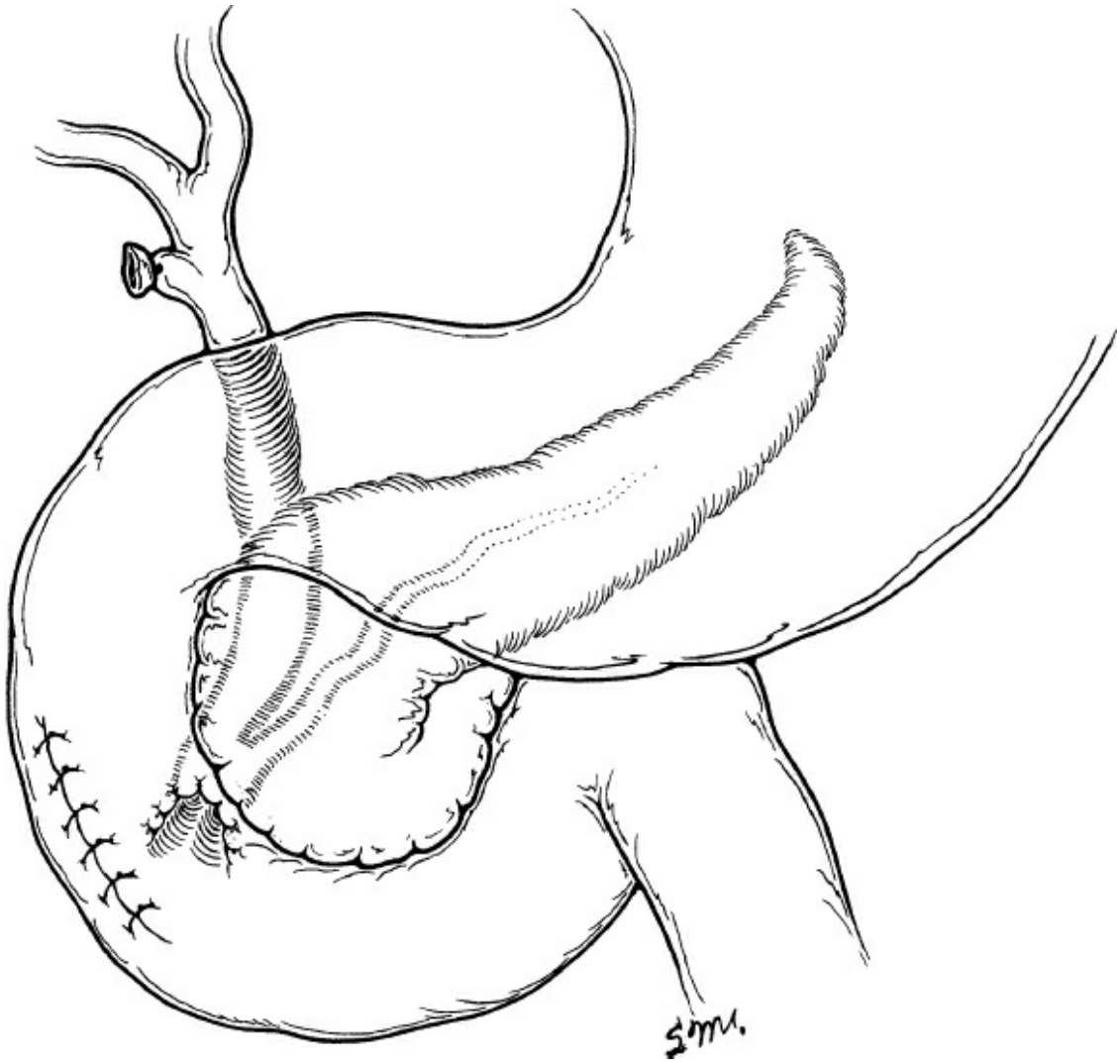

Figure 112.12. Completed sphincteroplasty with longitudinal closure of the duodenum.

POSTOPERATIVE MANAGEMENT

The patient normally has a nasogastric tube in place for ~3 days. It is removed on the 3rd or 4th postoperative day, depending on the output. A

diet is then initiated, first with liquids, with advancement to solid foods as tolerated. The drain is checked for bile and amylase content 24 hours after initiation of oral intake. It is removed if the amylase is normal and without bile. For patients who have had a sphincteroplasty, we check the amylase on the 1st and 3rd postoperative days. If pancreatitis occurs, postoperative care is altered accordingly, and bowel rest is prolonged. The normal hospital stay is ~6 days, although in the elderly patients with concurrent conditions, the length of stay may be as long as 7 to 10 days.

Pancreas Divisum

Pancreas divisum is the most common congenital abnormality of the pancreas. It is found in 5% to 10% of patients. It is caused by failure of fusion of the dorsal and ventral portions of the developing pancreas. In the majority of patients, this anomaly is of no clinical importance. In a certain subset of patients, however, estimated to be ~5% to 20%, pancreas divisum is a clinically important cause of abdominal pain, acute recurrent pancreatitis, or chronic pancreatitis. The frequency of pancreas divisum in patients with pancreatitis in recent studies is ~10%.

The cause of pancreatitis in this common anomaly is hypothesized to be caused by minor papillary insufficiency caused by papillary fibrosis and subsequent stenosis. This is supported by several lines of evidence, including pancreatitis changes being restricted to the dorsal pancreas in the upstream location, prolonged dilation of the dorsal duct in response to secretin, increased pressures at the minor ampulla, and the finding of fibrosis and scarring at the minor papilla in patients undergoing minor duct sphincteroplasty. It is unlikely that the presence of pancreas divisum alone is sufficient to place the patient at risk with pancreatitis. The once-thought putative relationship between divisum and pancreatitis or pancreatic pain does not exist.

The diagnosis is established by ERCP. MRCP is a noninvasive and accurate method of establishing the diagnosis. However, a negative MRCP does not exclude the diagnosis of divisum as the concordance with ERCP ranges from 50% to >70%. The accuracy of the MRCP may be improved by administration of secretin.

Not all patients with pancreas divisum benefit from surgical or endoscopic treatment. In patients with minimal symptoms, treatment with pancreatic enzymes may reduce pancreatic secretion and, hence, pain. Pain management referral may be necessary. Patients with acute pancreatitis are

estimated to benefit from either surgical minor sphincteroplasty or endoscopic minor papillotomy in 75% to 90% of the cases, compared to success rates of 40% to 60% in patients with chronic pancreatitis and 20% to 40% in patients with pancreatic pain alone with no biochemical or structural evidence of pancreatitis. Secretin-simulated ultrasonography may positively predict the outcome of minor papilla therapy, if there is significant dilation of the duct, defined as an increase in ductal diameter of 2 mm or more after the administration of this secretagogue.

There are two treatment options available for patients who are thought to have minor papillary stenosis: surgical sphincteroplasty or endoscopic therapy. The ability to measure minor papillary pressures via endoscopic techniques has improved the success rate of minor duct papillotomy in properly selected patients. Bradley and Stephan compared the results of surgical minor duct sphincteroplasty and endoscopic minor papillotomy. The results of the two techniques are comparable in patients with recurrent pancreatitis, with minor papillary sphincteroplasty successfully eliminating recurrent attacks in 92 of 109 patients (84%) and endoscopic papillotomy of the minor duct in 23 of 31 (74%). Patients with pancreatic pain alone do not do as well, with success in 62% after surgical treatment and 38% after endoscopic papillotomy. The restenosis rate is higher after endoscopic sphincterotomy (26.5%) than after surgical minor duct sphincteroplasty (6.7%), as is the rate of complications (14.6% and 4.2%, respectively).

Investigators have reported the success of endoscopic dilation and stenting of the minor papilla. It has been suggested that a good response to stenting might predict a good outcome of sphincteroplasty, particularly in patients with chronic “pancreatic” pain. Stenting can damage the pancreatic duct, and the long-term consequences of this treatment are not known. There is a significant increase in the rates of pancreatitis with minor duct stenting, and studies suggest that pancreatic duct stenting should be for no more than 4 to 5 days to minimize potential complications. Therefore, routine preoperative stenting, although scientifically appealing, has not been widely applied.

The technique of minor papillary sphincteroplasty is similar to that of sphincteroplasty of the ampulla of Vater. A midline or subcostal incision is used. A cholecystectomy is performed. A Kocher maneuver is completed. If the ampulla of Vater is easily palpated transduodenally, a longitudinal duodenotomy is made over this point. If the major papilla cannot be felt, then the passage of a biliary Fogarty into the cystic duct and hence into the

duodenum helps to identify the location of the major papilla and guide proper placement of the longitudinal duodenotomy. Once the duodenum is opened, the ampulla of Vater is identified. The minor papilla is usually 1.0 to 1.5 cm cephalad. Loop magnification helps, as the orifice is small. Occasionally, intraoperative injection of secretin is necessary to help the identification of the accessory pancreatic ductal opening. Once found, a stay suture is placed in either side of the duct. Using small lacrimal duct probes, the orifice is cannulated. The opening may be smaller than a 000 lacrimal duct probe (0.508 mm). The duct will run perpendicular to the wall of the duodenum. The needle-tip electrocautery on low settings is used to open the duct. An anastomosis is made between the accessory pancreatic duct mucosa and the duodenal mucosa using 5-0 or 6-0 absorbable suture. A stent is not routinely necessary, but may be helpful in situations in which one is concerned about excessive anastomotic swelling or early postoperative stenosis, or both. The duodenotomy is closed in a longitudinal fashion using interrupted 3-0 silk Lembert sutures. A closed suction drain is placed posterior to the duodenotomy.

Postoperative nasogastric suction is continued for 48 to 72 hours. Serum amylase should be checked on the 1st postoperative day and repeated if elevated. Oral feedings are begun on the 4th postoperative day if the amylase is normal and the patient has tolerated having the nasogastric tube out. Postoperative pancreatitis is not uncommon and usually resolves by the 5th postoperative day. If it does not, one may need to consider alternative forms of nutrition or perhaps perform a computed tomography scan to exclude a peripancreatic fluid collection or pancreatic phlegmon.

SUMMARY

The availability of ERCP and hence endoscopic papillotomy has limited the necessity for lateral choledochoduodenostomy or transduodenal sphincteroplasty. Specific instances occur, however, when the surgeon needs to perform these operations. The operations should be considered complementary. The lateral choledochoduodenostomy is preferred for larger bile ducts (>2 cm) or if there is a peri-Vaterian duodenal diverticulum of considerable size that would make performance of the transduodenal sphincteroplasty difficult. The exact choice of one of these operations depends on specific clinical situations.

Suggested Readings

Borak GD, Romagnuolo J, Alsolaiman M, et al. Long-term clinical outcomes after endoscopic minor papilla therapy in symptomatic patients with pancreas divisum. *Pancreas* 2009;38:903–6.

Caroli-Bosc FX, Demarquay JF, Peten EP, et al. Endoscopic management of sump syndrome after choledochoduodenostomy: retrospective analysis of 30 cases. *Gastrointest Endosc* 2000;51(2):180–3.

Eversman D, Fogel EL, Rusche M, et al. Frequency of abnormal pancreatic and biliary sphincter manometry compared with clinical suspicion of sphincter of Oddi dysfunction. *Gastrointest Endosc* 1999;50:637–41.

Geenan JE, Hogan WJ, Dodds WJ, et al. The efficacy of endoscopic sphincterotomy after cholecystectomy in patients with sphincter of Oddi dysfunction. *N Engl J Med* 1989;320:82–7.

Hogan WJ, Sherman S, Pasricha P, et al. Sphincter of Oddi manometry. *Gastrointest Endosc* 1997;45(3):342.

Itoi T, Shinohara Y, Takeda K, et al. A novel technique for endoscopic sphincterotomy when using a percutaneous transhepatic cholangioscope in patients with an endoscopically inaccessible papilla. *Gastrointest Endosc* 2004;59(6):708–11.

Menees S, Elta GH. Sphincter of Oddi dysfunction. *Curr Treat Options Gastroenterol* 2005;8:109–15.

Nussbaum MS, Warner BW, Sax HC, et al. Transduodenal sphincteroplasty and transampullary septotomy for primary sphincter of Oddi dysfunction. *Am J Surg* 1989;157(1):38–43.

Preetha M, Chung YA, Chan W, et al. Surgical management of endoscopic retrograde cholangiopancreatography-related perforations. *ANZ J Surg* 2003;73:1011.

Sherman S, Lehman GA. Sphincter of Oddi dysfunction: diagnosis and treatment. *JOP* 2001;2:382.

Stapfer M, Selby RR, Stain SC, et al. Management of duodenal perforations after endoscopic retrograde cholangiopancreatography and sphincterotomy. *Ann Surg* 2000;232:191.

EDITOR'S COMMENT

Ellison and colleagues have done an outstanding job summarizing the technical nuances and indications for endoscopic sphincterotomy, lateral choledochduodenostomy, and transduodenal sphincteroplasty. These are

complex procedures however, and rarely performed by the typical general surgeon who is most likely to perform a cholecystectomy. The old teaching from 20 years ago to “never leave the operating room following a cholecystectomy without a clear cholangiogram” is no longer an absolute. ERCP is now very common and readily available, even in many rural areas. The incidence of technical failure of ERCP is remarkably low in the modern era. Laparoscopic common bile duct exploration is a complex procedure requiring a skill set many general surgeons who perform laparoscopic cholecystectomy do not possess. The discussion in the current era has evolved to who should have a diagnostic and potentially therapeutic ERCP for suspected choledocholithiasis prior to cholecystectomy and who should instead have an intraoperative cholangiogram with intraoperative or postoperative ERCP if indicated.

A study examining the Nationwide Inpatient Sample between the years 1998 and 2008 identified 166,000 admissions for biliary disease. Mortality from biliary diseases that require ERCP decreased from 1.1% to 0.6% over the study interval. Open cholecystectomy decreased from 12.4% to 5.8%, and unsuccessful ERCPs decreased from 6.3% to 3.2%. It is interesting that endoscopic and surgical treatment of the sphincter of Oddi is now presented in a single chapter. The techniques described fall into a continuum of care and are complementary. The surgeon who can perform ERCP is in a great position to be able to offer the patient any of the techniques described in this chapter depending on what is best for the patient and their disease process.

Dysfunction of the biliary sphincter is often considered in patients with biliary-type pains after cholecystectomy when stones and other pathology are excluded. These patients are more likely to have had elective rather than emergency surgery, to have undergone cholecystectomy for symptoms in the absence of stones, and to have suffered from atypical biliary symptoms. In clinical practice, many patients undergo cholecystectomy for biliary symptoms even in the absence of stones before a diagnosis of sphincter of Oddi dysfunction (SOD) is considered. Functional gallbladder disorder (FGBD) and biliary dyskinesia are rarely diagnosed in countries other than the United States. A review of the Nationwide Inpatient Sample between the years 1991 and 2011 revealed that the incidence of cholecystectomy for biliary dyskinesia per 1,000,000 population per year in the United States increased from 43 to 89 ($p < 0.01$). Using registries from four developed countries in a similar time interval, the incidence of cholecystectomy was less than 25 per 1,000,000 population per year ($p < 0.01$). It has been suggested that the classification of SOD into three types is outdated and should be abandoned. Cotton et al. suggest that most patients with type I SOD suffer from organic stenosis rather than functional pathology and benefit from sphincterotomy for this reason. The EPISOD (Evaluating Predictors and Interventions in Sphincter of Oddi Dysfunction) trial was a multicenter, sham-controlled, randomized trial involving 214 patients with pain after cholecystectomy without significant abnormalities on imaging or laboratory studies, and no prior sphincter treatment or pancreatitis (type III

SOD). These patients were randomly assigned to undergo sphincterotomy or sham therapy at seven referral medical centers. One-year follow-up was blinded. In patients with abdominal pain after cholecystectomy undergoing ERCP with manometry, sphincterotomy versus sham did not reduce disability due to pain. The authors concluded that these findings do not support ERCP and sphincterotomy for patients considered to have type III SOD. Some authors advocate using the term "suspected functional biliary disorder" (suspected FBSD) for patients with post-cholecystectomy pain and some objective findings such as laboratory abnormalities (currently SOD type II).

Like SOD, pancreas divisum is a controversial clinical entity. Pancreas divisum is the most common congenital abnormality of the pancreas. This congenital anomaly is present in 2% to 10% of the population in autopsy studies. In most patients, pancreas divisum is asymptomatic. However, in a minority of patients, abdominal pain, acute pancreatitis, and recurrent acute pancreatitis can occur. A systematic review on endotherapy for pancreas divisum identified 22 studies including 838 patients. Patients with acute relapsing pancreatitis had the best outcomes with a median response rate of 76%. In patients with chronic pancreatitis, median response rates were lower at 42%. Patients with pancreas divisum and chronic abdominal pain without biochemical abnormalities had the lowest response rates at a median of 33%. Given the poor response rates to both endoscopic sphincterotomy and surgical minor duct sphincteroplasty, routine endotherapy in patients with chronic pancreatitis and/or chronic abdominal pain in the presence of pancreas divisum is not recommended, and needs to be individualized on a case-by-case basis.

The availability and success rate of ERCP has limited the necessity for surgical sphincteroplasty and lateral choledochoduodenostomy. There are still circumstances where one of these surgical procedures may be necessary, however. This is an excellent chapter that presents a thorough description of the anatomy, surgical technique, and current indication for these rarely performed but still important surgical procedures.

Jon C. Gould

Suggested Readings

Berger MY, Olde Hartman TC, Bohnen AM. Abdominal symptoms: do they disappear after cholecystectomy? *Surg Endosc* 2003;17:1723–8.

Cotton PB, Durkalski V, Romagnuolo J, et al. Effect of endoscopic sphincterotomy for suspected sphincter of Oddi dysfunction on pain-related disability following cholecystectomy: the EPISOD randomized clinical trial. *JAMA* 2014;311:2101–9.

James PD, Kaplan GG, Myers RP, et al. Decreasing mortality from acute biliary diseases that require endoscopic retrograde cholangiopancreatography: a

nationwide cohort study. *Gastroenterol Hepatol* 2014;12(7):1151–9.

Kanth R, Samji NS, Inaganti A, et al. Endotherapy in symptomatic pancreas divisum: a systematic review. *Pancreatology* 2014;14(4):244–50.

Lu Y, Xu B, Chen L, et al. Endoscopic intervention through endoscopic retrograde cholangiopancreatography in the management of symptomatic pancreas divisum: a long-term follow-up study. *Gut Liver* 2016;10(3):476–82.

Preston JF, Diggs BS, Dolan JP, et al. Biliary dyskinesia: a surgical disease rarely found outside the United States. *Am J Surg* 2015;209:799–803.

Wang B, Guo Z, Liu Z, et al. Preoperative versus intraoperative endoscopic sphincterotomy in patients with gallbladder and suspected common bile duct stones. *Surg Endosc* 2013;27(7):2454–65.

113 Primary Sclerosing Cholangitis

Nicholas J. Zyromski and Henry A. Pitt

INTRODUCTION

Primary sclerosing cholangitis (PSC) is a complex and heterogeneous disease defined by inflammatory strictures of the intra- and extrahepatic biliary tree. This cholestatic disease follows a generally progressive clinical course that ultimately leads to fibrosis and hepatic cirrhosis. Biliary malignancy develops in 10% to 15% of PSC patients, and is often difficult to diagnose. Inflammatory bowel disease (IBD), as well as several other systemic inflammatory diseases are associated with PSC. The pathophysiology of PSC is incompletely understood; this fact is underscored by the lack of effective medical therapy. A wide variety of percutaneous, endoscopic, and surgical approaches are applied to PSC patients based on their anatomic and physiologic presentation. The principal goal of these interventions is to treat dominant strictures and delay disease progression. Liver transplantation is clearly the treatment of choice once hepatic cirrhosis develops. Current investigation is directed toward better understanding the molecular and genetic underpinnings of this challenging disease.

EPIDEMIOLOGY AND ASSOCIATED CONDITIONS

The incidence of PSC in the United States and Europe is approximately 1 to 6 per 100,000, and some current evidence suggests that this incidence may be on the rise. The disease incidence varies worldwide; PSC is much less common in southern climates and Asia. Approximately two thirds of PSC patients are male, with an average age in the 40s at the time of presentation. Many patients are asymptomatic at the time of diagnosis; however, large population series have shown that the median survival from time of PSC diagnosis to death or liver transplantation ranges from 12 to 18 years—substantially shorter than age-matched subjects in the general population. Strictures affect both intra- and extrahepatic bile ducts in 75% of PSC patients (Fig. 113.1); 15% have only intrahepatic and 10% have

only extrahepatic bile duct involvement.

Sixty to 80% of PSC patients are also afflicted by IBD, most commonly ulcerative colitis. PSC patients manifest Crohn disease to a lesser extent. In fact, the diagnosis of PSC is becoming more common in asymptomatic IBD patients. While IBD is quite common in conjunction with PSC, the converse is not true: only 10% of IBD patients will be diagnosed with PSC. Colon cancer is significantly more common in IBD patients with PSC; therefore, an aggressive screening colonoscopy schedule is warranted in this population. Interestingly, the risk of colon cancer in the PSC population persists, and may even increase, after liver transplant.

Several other autoimmune diseases are associated with PSC (Table 113.1). These diseases include type I diabetes mellitus, thyroiditis, ankylosing spondylitis, autoimmune hepatitis (AIH), and celiac disease. PSC has been associated with a moderately increased risk for developing acute pancreatitis and pancreatic adenocarcinoma.



Figure 113.1. Endoscopic retrograde cholangiopancreatography

image demonstrating classic PSC strictures, intra and extrahepatic.

TABLE 113.1 Diseases Associated With PSC

Ulcerative colitis[a]
Crohn disease
Colorectal adenocarcinoma[b]
Type I diabetes mellitus
Thyroiditis
Autoimmune hepatitis
Ankylosing spondylitis
Celiac disease
Acute pancreatitis
Pancreatic adenocarcinoma
Cholangiocarcinoma
Hepatocellular carcinoma
Gallstones
Gallbladder polyps
Gallbladder carcinoma

[a]60–80% of PSC patients will have associated inflammatory bowel disease, most commonly ulcerative colitis.
[b]Colon adenocarcinoma is significantly more common in PSC patients than in the general population; this risk persists (and possibly increases) after liver transplant.

Gallbladder disease is common in PSC patients; the incidence of gallstones (>25%) and gallbladder polyps (5%) in PSC patients is substantially higher than that seen in the general public. Adenocarcinoma is detected in nearly half of the gallbladder polyps arising in the setting of PSC; this fact has led to the recommendation that cholecystectomy should be performed in any PSC patient diagnosed with gallbladder polyps. Some authorities recommend annual screening with gallbladder ultrasound. Hepatocellular carcinoma (HCC) may also develop in PSC patients with end-stage liver disease. Radiologically occult HCC is detected in 2% to 4% of explanted livers from PSC patients undergoing liver transplant. Cholangiocarcinoma (CCA) develops in as many as 15% of PSC patients.

Screening for and diagnosis of CCA are discussed in more detail below.

ETIOLOGY/PATHOPHYSIOLOGY

PSC etiology is incompletely understood, but almost certainly represents a multifactorial process, with genetic, immune, bacterial, and other factors all playing part in disease development.

Genetic

A hereditary component to PSC clearly exists, as first-degree relatives of PSC patients have nearly a fourfold increased incidence of PSC diagnosis compared to the general population. Current work has identified a genetic pattern in PSC that is complex and polymorphic. The major histocompatability complex (MHC) found on the short arm of chromosome 6 encodes many of the aberrant gene loci identified in PSC patients. In addition, other non-MHC genes such as tumor necrosis factor alpha (TNF-α) have also been implicated in the disease etiology. Specific gene mutations are associated with discrete biologic features such as early age of onset or rapid disease progression.

Immune

The common association of IBD and other autoimmune diseases in PSC patients has led many to consider autoimmunity as an etiology. Evidence supports the concept of the biliary epithelial cell both as a target of attack, as well as an active participant in the immunologic cascade. Commonly found autoantibodies in PSC patients include atypical antineutrophil antibody—p-ANCA (found in 88%), antineutrophil antibody, and anticolon antibody.

Bacterial

The coexistence of PSC and IBD also supports the hypothesis of a bacterial etiology. According to this theory, bacterial translocation through intestinal epithelial permeability may lead to Kuppfer cell activation, which in turn leads to production of proinflammatory mediators such as TNF-α. As the subsequent biliary inflammation resolves, variable fibrosis of the biliary tree ensues. Contemporary interest in the gut microbiota has suggested a putative link between the microbiota, enteroportal circulation, and PSC development, particularly in the setting of IBD. Finally, a few

studies have documented the fact that antibiotic treatment is associated with decreased circulating alkaline phosphatase (ALP) and Mayo risk score. While the long-term effects of this antibiotic treatment strategy remain to be seen, these data lend some credence to the concept of bacteria as an etiologic factor.

Pathophysiology

Histologic analysis of PSC documents periductal fibrosis that apparently accumulates in a progressive fashion. This fibrosis affects most commonly medium and large bile ducts, and results in the typical radiographic picture of alternating stricture and dilation. The histologic appearance of mixed inflammatory cell infiltrate (lymphocytes, plasma cells, and neutrophils) around disorganized portal duct proliferation is recognized as "onion-skinning" (Fig. 113.2).

Small Duct PSC

An increasingly recognized sub-type of PSC involves isolated inflammatory strictures of the small ducts alone. In fact, as many as 6% of patients with chronic cholestasis and normal cholangiogram images may have small duct PSC. In these patients, liver biopsy is recommended to secure the diagnosis. Small duct PSC patients have a better prognosis in general, with longer survival and lower risk of CCA development. Over time, though, up to 20% of small duct PSC patients may progress to large duct involvement.

CLINICAL PRESENTATION

The clinical presentation of PSC patients is widely variable, consistent with the broad disease heterogeneity. Many PSC patients present first with typical biliary symptoms of right upper quadrant pain, pruritus, and fatigue. A smaller percentage of patients with intrahepatic bile duct involvement initially present with signs and symptoms of end-stage liver disease and hepatic failure. Patients with isolated extrahepatic biliary strictures may have jaundice as the first clinical sign. A small percentage of PSC patients with strictures and jaundice may present with cholangitis, and the clinical symptoms of fever, chills, and night sweats. As many as 40% of PSC patients are asymptomatic and come to PSC diagnosis from workup of abnormal liver function tests. The IBD patient screened for liver

disease falls into this latter category.

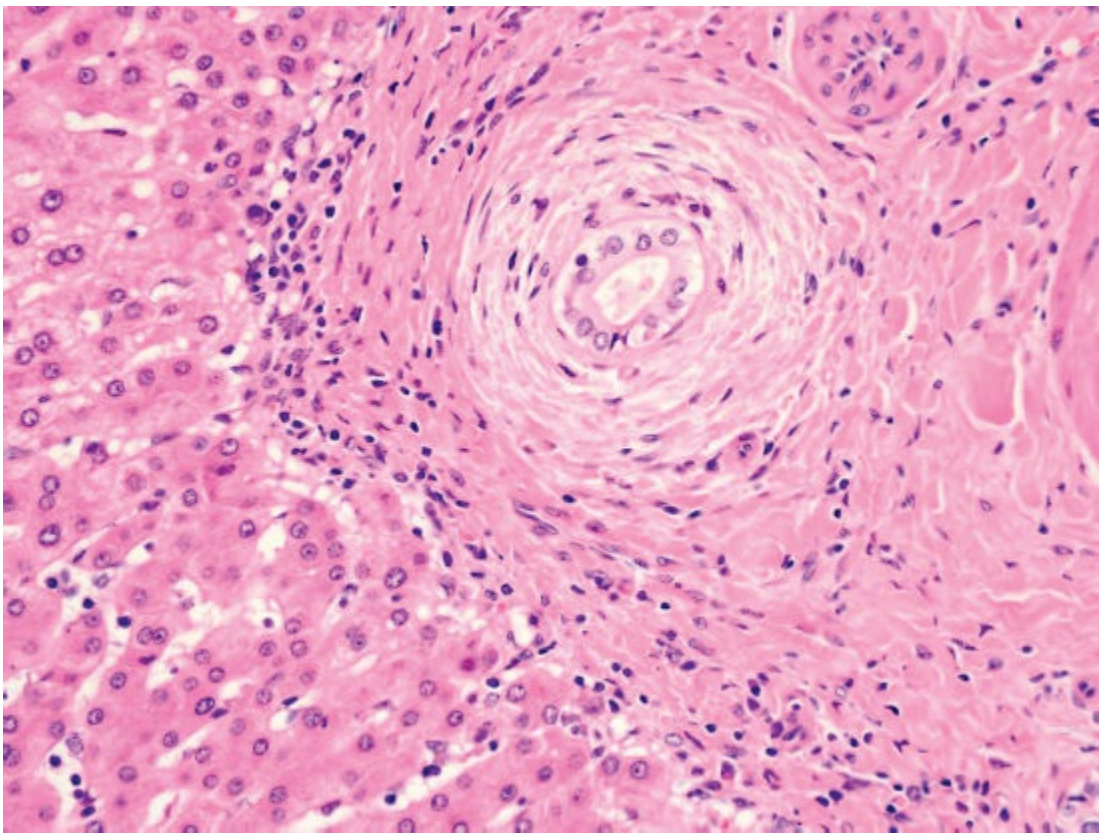

Figure 113.2. Micrograph of resected PSC specimen demonstrating “onion skin” concentric fibrosis surrounding bile duct. (Courtesy of Dr. O. Cummings, Indiana University Department of Pathology.)

Differential Diagnosis

The differential diagnosis of patients with biliary stricture includes numerous etiologies such as infectious, mechanical, toxic, inflammatory, immune, neoplastic, and ischemic. Table 113.2 outlines the differential diagnosis of PSC.

Laboratory Evaluation

Elevation of liver chemistry tests is common; the most frequently aberrant serum chemistry is ALP. In patients with intrahepatic duct involvement, ALP may be the only abnormal laboratory test. Values of ALP vary over the disease course; importantly, normal ALP does not exclude a diagnosis of PSC. Total bilirubin concentration is usually normal, unless the patient has significant biliary obstruction. Transaminase concentration is also commonly within normal limits, although some patients may demonstrate

two- to threefold elevation of circulating transaminases. Transaminase elevation may be associated with concomitant acute biliary obstruction, or may indicate overlap with AIH. Serum autoantibody production is nonspecific in PSC; but, may be useful in diagnosing AIH or immunoglobulin G4 (IgG4)–associated cholangitis.

Radiologic Evaluation

Cholangiography is the cornerstone in diagnosis of PSC. Classic cholangiographic features include multifocal strictures of intra- and extrahepatic bile ducts with alternating normal and dilated segments. Currently, magnetic resonance cholangiopancreatography (MRCP) is the gold standard for radiologic diagnosis. Advantages of MRCP include avoidance of radiation exposure, visualization of intrahepatic bile ducts proximal to high-grade strictures, and morphologic assessment of the liver. In addition, MRCP permits imaging assessment of other abdominal structures. On the other hand, MRCP is quite expensive, may be of variable quality at different centers, is challenging for some patients to tolerate, and is a purely diagnostic test (Fig. 113.3).

Endoscopic retrograde cholangiopancreatography (ERCP) has classically been used to define PSC bile duct anatomy. ERCP accurately demonstrates the intra- and extrahepatic biliary tree over 95% of the time. In addition, ERCP also permits intervention such as stenting, brushing, and biopsy. Currently, ERCP use has been focused toward patients who require these interventions, as the test has a small, but real, potential for complications. Complications of ERCP include cholangitis, visceral perforation, pancreatitis, and hemorrhage (Fig. 113.4).

Percutaneous transhepatic cholangiography (PTC) is used less frequently in current practice. The anatomic changes of PSC render PTC technically challenging even for an experienced interventional radiologist. In selected cases, PTC may be complementary to ERCP, especially in the PSC patient who requires biopsy and/or stenting.

Liver biopsy is performed liberally in PSC patients. As mentioned, liver biopsy may help secure the diagnosis of small duct PSC. Furthermore, in patients with established PSC, liver biopsy is essential to document the degree of hepatic fibrosis. The possibility of lobar atrophy/hypertrophy should be considered when performing a liver biopsy.

TABLE 113.2 Differential Diagnosis of Bile Duct Stricture

Infections:
Cholangitis/chronic bile duct infection
AIDS (CMV/cryptosporidium)

Mechanical:
Choledocholithiasis
Trauma
Bile duct injury
Stenting
Primary biliary cirrhosis

Toxic:
Biliary toxin exposure

Inflammatory/Immune:
Autoimmune hepatitis
IgG4 associated cholangitis
Graft-versus-host disease
Chronic pancreatitis

Neoplastic:
Cholangiocarcinoma
Papillary tumor
Choledochal cyst

Ischemic:
Ischemia biliopathy
Portal vein thrombosis

BILIARY MALIGNANCY IN PSC

Without doubt, the substantially increased risk and difficulty diagnosing CCA represent the most challenging aspects of PSC management. CCA is diagnosed in 1% to 2% of PSC patients annually, with a lifetime risk of 10% to 15%. About half of patients developing CCA will be diagnosed within 1 year of presentation with PSC; many of these patients are diagnosed concurrently. Despite aggressive preoperative screening protocols, unsuspected CCA is identified in 3% to 9% of explanted livers at the time of transplantation for PSC. This CCA incidence represents an increased risk of up to 160 times that of the general population; however, no accurate criteria exist with which to identify a high-risk group amenable for screening. CCA is observed more frequently in females with

PSC, and in those with concomitant IBD. After the first 12 to 18 months, no correlation exists between CCA diagnosis and duration of PSC or the presence of hepatic cirrhosis.

The diagnosis of CCA is challenging in the setting of multiple intra- and extrahepatic bile duct strictures, and outcomes after CCA diagnosis are uniformly poor. In light of the fact that no high-risk group within the PSC population has been identified, rational screening protocols have been advanced. For example, Mayo Clinic authorities recommend annual screening with MRCP or ultrasound, and measurement of serum carbohydrate antigen 19-9 (CA 19-9). In the absence of jaundice or cholangitis, CA 19-9 concentration greater than 130 U/mL has approximately an 80% sensitivity and 98% specificity to detect CCA. Endoscopic evaluation may be applied selectively to patients with increasing CA 19-9 or those in whom jaundice or dominant strictures develop or progress.

Autoimmune	IgG4-related sclerosing cholangitis Autoimmune sclerosing cholangitis Systemic vasculitis
Benign	Intrahepatic stone disease
Malignant	Cholangiocarcinoma
Infection	Cholangiopathy related to AIDS Recurrent pyogenic cholangitis
Injury	Post cholecystectomy Abdominal trauma
Vascular	Hepatic artery thrombosis Portal hypertension Chemoembolization Sickle cell disease
Other	TPN Cholangiopathy of critical illness Histiocytosis X

Figure 113.3. Magnetic resonance cholangiopancreatography of patient with bilobar intra- and extrahepatic biliary strictures.

While tissue histology is the gold standard for making the diagnosis of CCA, the sensitivity of biliary brushings and biopsy obtained at the time of ERCP is less than 40%, (though specificity is almost 100%). Recently, techniques such as fluorescence in situ hybridization (FISH) and digital subtraction analysis (DSA) have been applied more liberally. These tests rely on the fact that chromosomal abnormalities are present in approximately 80% of biliary malignancies. Analysis of aneuploidy by FISH has been subdivided into trisomy (3 copies of chromosomes 7 or 3), tetrasomy (4 copies of all probes), and polysomy (gain of 2 or more chromosomes visualized in 5 or more cells). Each of these strata are

associated with increased risk of CCA, and patients with a dominant biliary stricture and polysomy were found to have an 88% incidence of CCA. A number of evolving technologies hold promise for evaluation of the biliary tree. Some of these include cholangioscopy, endoscopic and intraductal ultrasound, and confocal laser endomicroscopy. Proteomic and metabolomic analysis of serum, bile, and urine may aid CCA diagnosis in the future. The role of positron emission tomography (PET) in diagnosis of biliary malignancy has recently been evaluated; unfortunately, sensitivity and specificity of this test are poor.

Complete surgical resection offers the best prognosis for those patients developing CCA in the face of PSC. Clinicians should therefore have a low threshold for operative exploration in patients with recurrent dominant strictures, those with cellular atypia or dysplasia on cytologic brushing, and those with polysomy on FISH analysis.

PSC patients have a significantly increased risk of developing gallbladder neoplasia, though the precise incidence of this problem is difficult to quantitate. Annual gallbladder ultrasound is recommended by some experts as part of a screening protocol. Cholecystectomy is indicated for ANY size lesion identified, as gallbladder cancers have been identified even in small (<1 cm) polyps in PSC patients. The risk of cholecystectomy must be considered in the context of the generally increased perioperative risks attendant to end-stage liver disease.

MANAGEMENT

Medical Therapy

A variety of agents have been tested with the goal of attenuating the pathologic course of PSC. Some of these compounds include the hydrophilic bile acid ursodeoxycholic acid (UDCA); corticosteroids; immunosuppressive agents such as tacrolimus, cyclosporine, and methotrexate; antifibrotic agents such as pentoxifylline and pirfenidone; and TNF-α inhibitors. To date, none of these medical therapeutics have effectively slowed PSC progression, prolonged survival, or decreased the incidence of CCA.

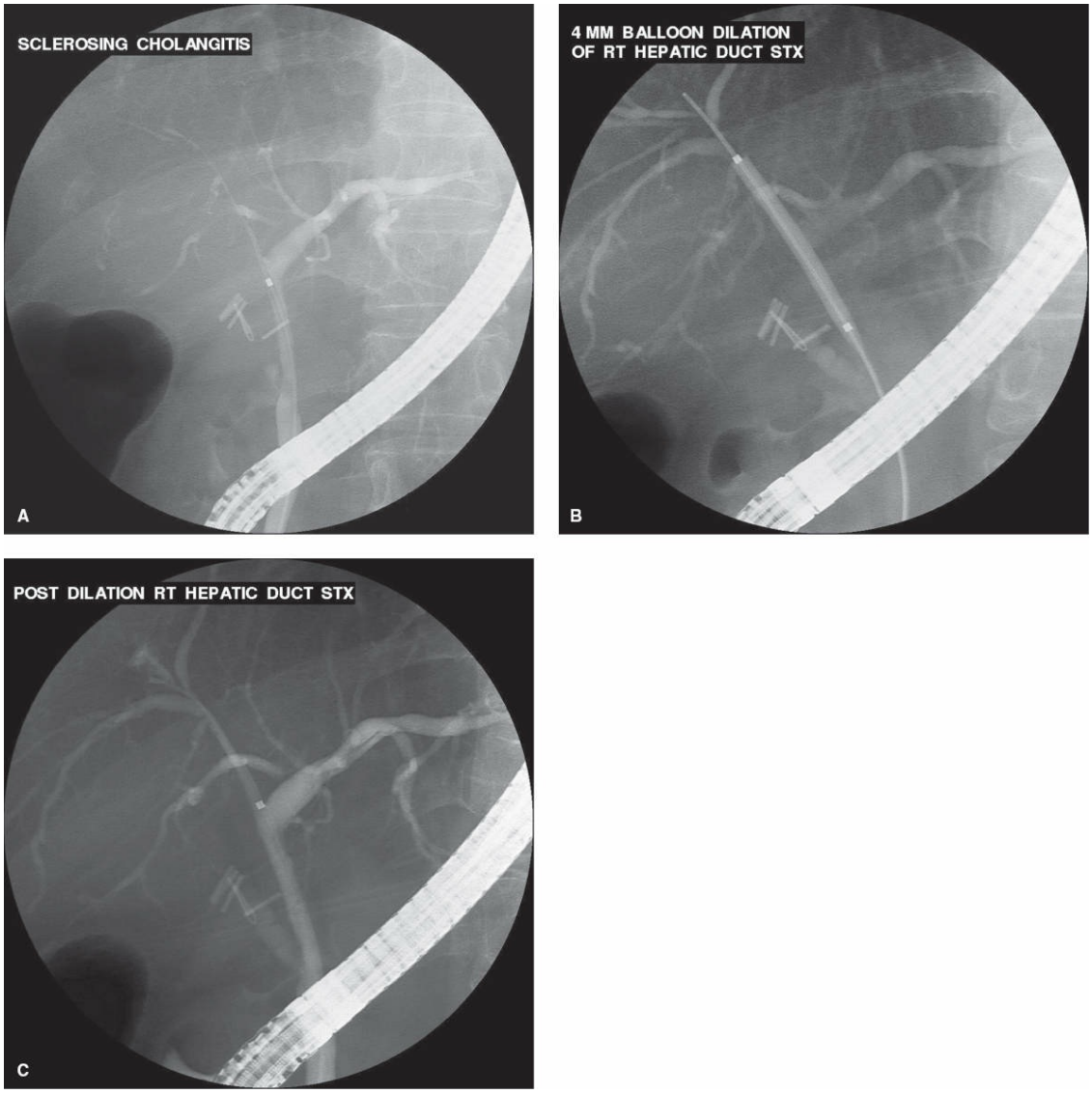

Figure 113.4. Endoscopic retrograde cholangiopancreatography of patient with dominant right hepatic duct stricture. **A.** Preintervention. **B.** During endobiliary balloon dilatation. **C.** Postdilatation documenting widely patent right hepatic duct. (Images courtesy of Dr. Stuart Sherman, Indiana University Division of Gastroenterology.)

The most widely studied agent in PSC is UDCA. An early, large, prospective randomized trial demonstrated improvements in serum liver chemistry values but failed to show improvement in liver histology or transplant-free survival with low-dose (12 to 15 mg/kg daily) UDCA. Four subsequent prospective studies have been performed using increased doses of UDCA; none has shown definite benefit, and one was halted prematurely due to increased risk of disease progression. Collective analysis of these studies by meta-analysis showed no beneficial effect on

symptoms, serum liver chemistry values, quality of life, or transplant-free survival. Currently, the American Association for the Safety of Liver Disease recommends against the use of UDCA in PSC patients; the European Association for the Study of Liver Disease does not recommend for or against UDCA prescription.

Targeted therapy with antifibrotic agents, TNF-α inhibitors, T-cell modulators, and inhibitors of "toxic bile" formation (Farnesoid X agonists) all are in conceptual or early investigative phases.

Endoscopic and Percutaneous Therapy

Dominant strictures are defined as narrowing ≤1.5 mm in the common bile duct or ≤1 mm in the common hepatic duct. Both percutaneous transhepatic stenting and endoscopic dilatation with or without stenting have been used to treat dominant strictures in PSC. Endoscopic techniques have advanced to the point that currently, the majority of tertiary centers treating PSC patients favor the endoscopic approach. No randomized studies have compared results of balloon dilatation alone versus dilatation and stenting. Clinical response can be demonstrated in up to 80% of patients after endoscopic balloon dilatation. This fact, in conjunction with the increased risk of complication associated with stenting, has limited placement of endobiliary stents to patients in whom balloon dilation fails to maintain luminal patency. Periprocedural antibiotic administration is important, and stenting duration of 6 to 8 weeks is probably optimal to avoid cholangitis. Some patients require extended periods of stenting (up to 12 months) before stricture resolution has been achieved. Complications of endoscopic therapy arise in approximately 10% of patients and include bleeding, perforation, pancreatitis, and cholangitis. The majority of these complications may be treated medically. Advanced endoscopic techniques such as cholangioscopy and intraductal ultrasound are practiced more routinely at high-volume biliary centers, and may be helpful particularly in diagnosing CCA.

Percutaneous interventional radiology approaches are used less frequently but they remain important therapeutic adjuncts in selected patient groups including those who have had previous biliary bypass or surgical bariatric procedure (Roux-en-Y gastric bypass or duodenal switch).

Surgical Resection

Surgical resection is applied to select PSC patients. Those PSC patients with CCA localized to the extrahepatic bile ducts may benefit from resection of the extrahepatic biliary tree. Those with Bismuth IIIa or IIIb level CCA may be candidates for resection of the extrahepatic biliary tree with hepatectomy. Figure 113.5 illustrates the Bismuth classification of CCA. Finally, highly selected PSC patients with dominant extrahepatic strictures and no hepatic cirrhosis may benefit from resection of the extrahepatic biliary tree. In these patients, surgical resection provides durable relief of jaundice and definitively confirms or excludes the diagnosis of cholangiocarcinoma. Furthermore, resection of a dominant extrahepatic bile duct stricture may delay the progression of hepatic cirrhosis and need for liver transplantation.

Ahrendt and colleagues performed an early, classic study in which they evaluated 146 PSC patients managed by surgical resection, percutaneous or endoscopic treatment, medical therapy alone, and transplantation. In noncirrhotic patients, the overall 5-year survival (85% vs. 59%) and transplant-free survival (82% vs. 46%) were significantly longer in the resection group compared to those managed endoscopically (Fig. 113.6A and B). No surgically treated patient developed cholangiocarcinoma with follow-up more than 5 years. In this series, patients with hepatic cirrhosis survived longer after transplantation than after resection or endoscopic management. In a follow-up analysis by Pawlik et al., 77 patients had outcomes comparable to hepatic transplantation, and none developed cholangiocarcinoma. In addition, only 10% even required a liver transplant.

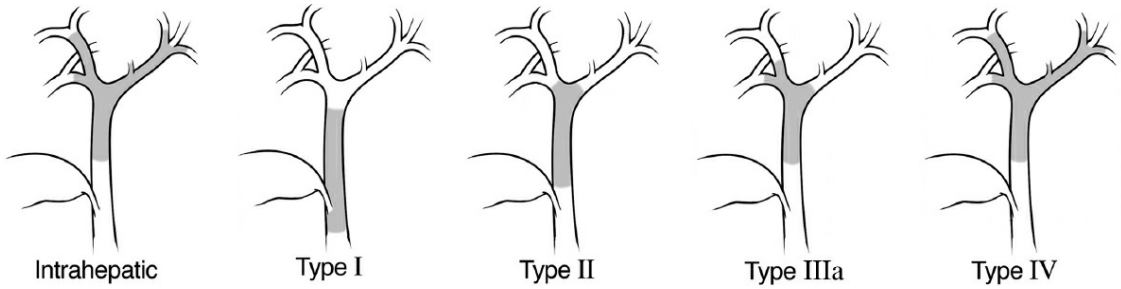

Figure 113.5. Bismuth classification of cholangiocarcinoma.

Surgical Technique

Preoperative preparation for resection of the extrahepatic biliary tree includes appropriate imaging, biliary drainage, nutritional consideration, and antibiotic prophylaxis. High-quality cross-sectional imaging

(computed tomography or magnetic resonance imaging) with intravascular contrast documents hepatic vascular anatomy as well as the presence of liver atrophy/hypertrophy. Most (approximately 80%) patients with dominant strictures manifest hepatic duct bifurcation involvement; therefore, percutaneous stents are placed preoperatively into both the right and left hepatic ducts. This maneuver greatly facilitates dissection of the hepatic bifurcation and provides a stenting tract for the reconstructive hepaticojejunostomy. Bile cultures permit tailoring of perioperative antibiotic therapy to specific bacteria cultured from the bile. Attention should be given to identification and proper treatment of resistant organisms, which are more prevalent in patients who have required multiple instrumentation. Antibiotics should be continued postoperatively to treat the mild cholangitis that occurs with intraoperative stent manipulation and cholangiography. Antibiotics may be discontinued when the patient has been afebrile for 24 hours.

The general approach to extrahepatic biliary tree resection with Roux-en-Y hepaticojejunostomy over transhepatic stents is illustrated in Figure 113.7. An upper midline incision provides excellent exposure of the liver provides flexibility for positioning of the transhepatic stents on the abdominal wall. Careful abdominal exploration includes intraoperative ultrasound, which may be particularly helpful in the case of nonstandard hepatic vascular anatomy. Any suspicious lymph nodes are biopsied for frozen-section analysis; evaluation of celiac, portal, and retropancreatic lymph nodes is an important part of thorough abdominal exploration. The hepatic flexure of the colon is mobilized from the pancreatic head, which exposes the right transverse mesocolon for later delivery of the Roux limb. A wide Kocher maneuver provides critical exposure of the porta hepatis.

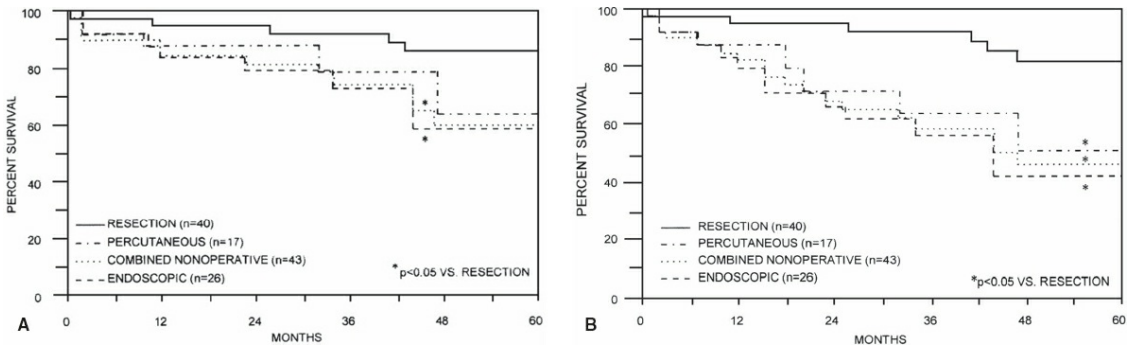

Figure 113.6. Kaplan–Meyer curves documenting overall (**A**) and transplant-free (**B**) survival curves for noncirrhotic patients undergoing resection, percutaneous, and endoscopic treatment of dominant extrahepatic biliary strictures in PSC. (From Ahrendt

SA, Pitt HA, Kalloo AN, et al. Primary sclerosing cholangitis: resect, dilate, or transplant? *Ann Surg* 1998;227(3):412–23; with permission from Wolters Kluwer Health, Inc.)

Cholecystectomy is performed if the gallbladder is in situ, and the common bile duct is divided at the cranial portion of the pancreatic head. After oversewing the distal common bile duct at the pancreas, dissection is carried proximally by lifting the bile duct off of the portal vein. It is important to anticipate the right hepatic artery at this point of the dissection, as its usual course is posterior to the common hepatic duct. Inflammation inherent to PSC may be compounded by instrumentation from multiple endoscopic procedures. This challenging portion of the dissection should be performed sharply. Should the right hepatic artery be involved to the degree requiring resection, the inferior mesenteric vein is an excellent reconstruction conduit that is readily available in the exposed operative field. The right and left main hepatic ducts are then divided proximal to the bifurcation. Frozen-section analysis of the proximal and distal bile duct margins rules out malignant transformation. The preoperatively placed transhepatic stents are exchanged retrograde for large (14–20 French, depending on the size of the bile ducts), soft Silastic catheters. Exchanging these stents over a guidewire ensures safe maintenance of the tract.

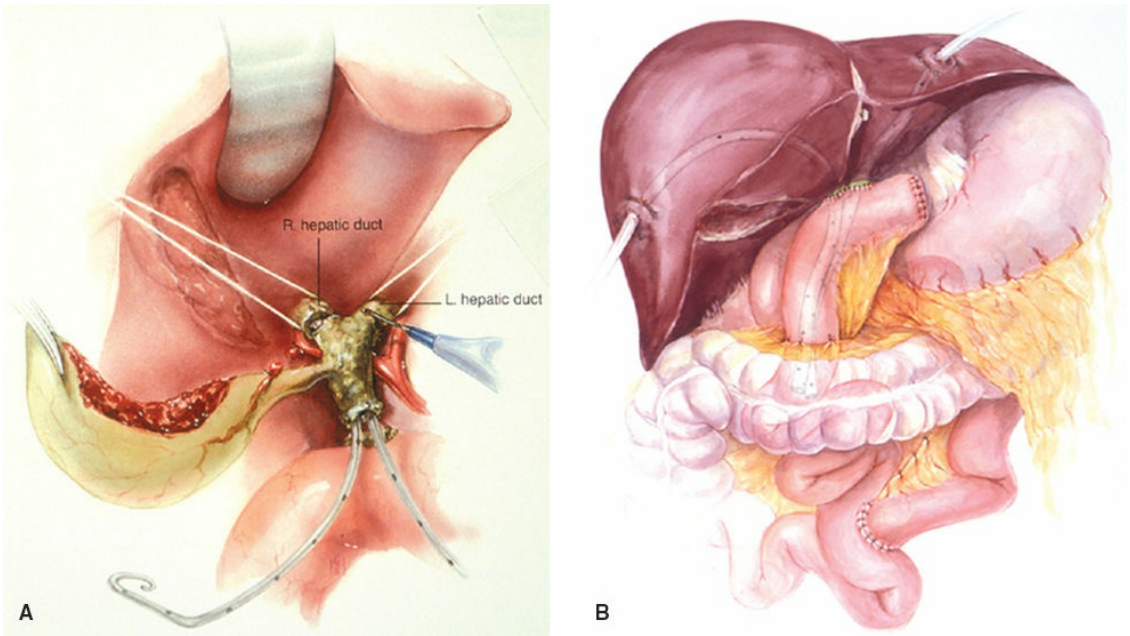

Figure 113.7. Overview of extrahepatic biliary tree (**A**) resection and (**B**) reconstruction with Roux-en-Y hepaticojejunostomy over transhepatic biliary stents.

The Roux limb is prepared by dividing the jejunum 40 cm distal to Treitz ligament. Carefully dividing the small bowel mesenteric arcade provides additional length to the limb, which is particularly helpful in patients with larger body habitus or short small bowel mesentery. The Roux limb is then brought through the transverse mesocolon to the right of the middle colic vessels, where it should lie in the hilum with no tension. Bilateral cholangiojejunostomies end-to-side are created with interrupted, absorbable sutures over the Silastic catheters. Chromic sutures placed at the stent exit site from the liver minimize bile leakage; titanium clips placed at the stent exit from the liver provide landmarks to facilitate future radiologic stent exchange.

Completion cholangiography is performed in the operating room to ensure optimal stent positioning and exclude anastomotic leak. The Silastic stents are brought through the abdominal wall in a subcostal position away from the incision. Incorporation of a gentle curve to stent passage through the abdominal wall is important to avoid kinking of the stent and to facilitate subsequent radiologic stent changes. Closed-suction drains are placed behind the cholangiojejunostomies and at the site of stent exit from the liver. Postoperative management and complications are described below.

Liver Transplantation

Indications for liver transplant in PSC patients are similar to those for patients with end-stage liver disease from other etiology, and generally include refractory complications of portal hypertension and liver insufficiency. Approximately 5% of all liver transplants in the United States are performed for end-stage liver disease secondary to PSC.

The Mayo model is a mathematical construct incorporating serum bilirubin, degree of hepatic fibrosis, presence of splenomegaly, and age. This model is widely used to predict survival and the optimal timing of liver transplantation. Interestingly, PSC patients with disease-related complications (pruritus, cholangitis) have a low priority based on MELD criteria, and recently have been receiving more living-related donor transplants. From a technical standpoint, the conduct of liver transplantation for PSC includes resection of the extrahepatic biliary tree in its entirety and the donor graft bile duct reconstruction by Roux-en-Y to a limb of jejunum.

Transplant for CCA

Unsuspected CCA is found in 3% to 9% of explanted livers of patients undergoing transplantation for PSC. Interestingly, small (<1 cm) unsuspected CCA does not affect the long-term survival. Liver transplantation is offered as a specific treatment for CCA only in highly selected patients. Transplant investigational protocols in this setting utilize rigorous neoadjuvant chemoradiotherapy and pretransplant laparotomy with lymphadenectomy to exclude lymph node metastasis. Using these extremely rigorous selection criteria, excellent outcomes of 65% 5-year survival have been achieved. Recently, such outcomes have been extended to multiple centers.

POSTOPERATIVE CARE AND COMPLICATIONS

Overall morbidity after extrahepatic biliary resection with Roux-en-Y cholangiojejunostomies is approximately 30% to 40%, and perioperative mortality in expert hands is less than 3%. Complications specific to bile duct resection include cholangitis, hemobilia, and bile leak.

Biliary surgeons should maintain a healthy respect for cholangitis; this problem is apparent around the time of transhepatic biliary stent placement and manipulation (including cholangiography). Periprocedural antibiotics should be maintained until the patient has been afebrile for 24 hours. Biliary stents are left to gravity drainage for 5 days postoperatively, at which time a cholangiogram is obtained to evaluate anastomotic integrity. The biliary stent is then internalized (closed), and closed-suction surgical drains are removed as long as their effluent is nonbilious. Biliary stents should be flushed twice daily with sterile saline solution; these stents should be replaced on approximately 3-month intervals. Long-term management of biliary stents should be individualized to each patient's specific anatomic and pathologic circumstance. Maintenance of transhepatic stent for 6 months appears to be associated with decreased stricture rate.

Other postoperative management of bile duct resection patients parallels that of those undergoing major laparotomy including aggressive early ambulation, slow diet advancement, pharmacologic thromboembolism prophylaxis. Bile leak from the cholangiojejunostomies anastomoses is largely self-limited if the anastomosis is constructed over a stent. This situation typically resolves by keeping the stent open for a period of time: diverting bile from the anastomosis permits time for

healing. The stent may be closed when repeat cholangiography documents healing.

A second specific situation involves bile leaking from the transhepatic stent exit sites from the liver. This situation is apparent when bile is visualized in the closed-suction drain adjacent to the stent exit site at the liver edge, and is usually caused by dislodgement of the stent side holes out of the liver parenchyma. This situation prevented by intraoperative cholangiography and may be remedied by adjustment or replacement of the stent in interventional radiology. However, stent adjustment in the early postoperative time period should be undertaken with caution to avoid disruptions of the biliary-enteric anastomoses.

Patients undergoing liver transplant for PSC have a somewhat higher retransplant rate at 2 years versus those transplanted for other indications —10% versus 5%. The major cause for retransplant is hepatic artery thrombosis. Relative to other indications, liver transplant for PSC is accompanied by somewhat higher rates of acute cellular and chronic ductopenic rejection as well as the development of biliary strictures.

OUTCOMES

Endoscopic Therapy

The precise incidence of dominant strictures in PSC is difficult to determine, but may affect as many as 50% of patients. Endoscopic therapy is clearly effective in improving biliary drainage and symptoms. However, the long-term effect of endoscopy on modifying disease progression has not been documented.

Bile Duct Resection

A small proportion of PSC patients will have isolated dominant stricturing of the extrahepatic bile ducts and/or a dominant hilar stricture. Patients undergoing resection of the extrahepatic biliary tree for PSC have improved overall and transplant-free survival compared to a cohort of patients managed endoscopically. These potential advantages must be weighed against the risks of surgery in this population. A small percentage of patients will develop recurrent intrahepatic bile duct structuring after resection of the extrahepatic bile ducts (Fig. 113.8).

Liver Transplant

Patients undergoing liver transplant for PSC enjoy some of the most successful outcomes relative to patients transplanted for other indications. Survival of patients after liver transplant for PSC is quite good—90% and 80% 1- and 5-year survival rates are common. Interestingly, recurrent PSC occurs in 20% to 25% of PSC patients undergoing liver transplant. Patients with IBD and an intact colon may be at increased risk for recurrent PSC after liver transplant. No specific medical therapy has been shown to decrease the incidence or PSC recurrence.



Figure 113.8. Magnetic resonance cholangiopancreatography demonstrating progressive intrahepatic bile duct strictures in a patient 9 years postresection of extrahepatic biliary tree for what then was isolated dominant extrahepatic stricture.

Additional Considerations

As discussed above, colonoscopy is indicated in PSC patients on a more aggressive schedule, not only to diagnose colonic neoplasia, but also to secure or exclude the diagnosis of IBD. Aggressive screening colonoscopy is warranted for postliver transplant PSC patients with IBD, as the risk of developing colonic malignancy in this population is higher after liver transplant. Ursodeoxycholic acid is commonly administered to decrease the risk of colon cancer in PSC patients with IBD, though little evidence exists to support this practice.

SUMMARY

The etiology of PSC is multifactorial, and its pathophysiology remains poorly understood. No specific medical therapy has been shown to affect the disease course. Magnetic resonance cholangiopancreatography is the gold standard for diagnosis and is also widely used for surveillance. Endoscopic intervention is currently reserved to treat dominant strictures and to evaluate and biopsy lesions suspicious for cholangiocarcinoma. CCA develops in 10% to 15% of patients with PSC; the diagnosis of this malignancy is notoriously difficult to differentiate from that of benign stricture. For selected patients with a dominant extrahepatic and/or hilar strictures, resection of the extrahepatic biliary tree provides durable therapy. In patients with established cirrhosis, liver transplantation is clearly the optimal therapy. Liver transplant patients have excellent outcomes in general, but may develop recurrent PSC in the transplanted organ. Current research efforts are directed toward better understanding the etiopathogenesis of PSC, developing effective medical therapy, and identifying more sensitive and accurate techniques with which to predict and diagnose cholangiocarcinoma.

Suggested Readings

Ahrendt SA, Pitt HA, Kalloo AN, et al. Primary sclerosing cholangitis: resect, dilate, or transplant? *Ann Surg* 1998;227:412–23.

Bangarulingam SY, Bjornsson E, Enders F, et al. Long-term outcomes of positive fluorescence in situ hybridization tests in primary sclerosing cholangitis. *Hepatology* 2010;51:174–80.

Boonstra K, Weersma RK, van Erpecum KJ, et al. Population-based epidemiology, malignancy risk, and outcome of primary sclerosing cholangitis. *Hepatology*

2013;58:2045–55.

Buckles DC, Lindor KD, Larusso NF, et al. In primary sclerosing cholangitis, gallbladder polyps are frequently malignant. *Am J Gastroenterol* 2002;97:1138–42.

Chapman R, Fevery J, Kalloo A, et al. Diagnosis and management of primary sclerosing cholangitis. *Hepatology* 2010;51:660–78.

Darwish MS, Kim WR, Harnois DM, et al. Efficacy of neoadjuvant chemoradiation, followed by liver transplantation, for perihilar cholangiocarcinoma at 12 US centers. *Gastroenterology* 2012;143:88–98.

Dave M, Elmunzer BJ, Dwamena BA, et al. Primary sclerosing cholangitis: meta-analysis of diagnostic performance of MR cholangiopancreatography. *Radiology* 2010;256:387–96.

Fevery J, Verslype C, Lai G, et al. Incidence, diagnosis, and therapy of cholangiocarcinoma in patients with primary sclerosing cholangitis. *Dig Dis Sci* 2007; 52:3123–35.

Goldberg DS, French B, Thomasson A, et al. Current trends in living donor liver transplantation for primary sclerosing cholangitis. *Transplantation* 2011;91:1148–52.

Kaya M, Petersen BT, Angulo P, et al. Balloon dilation compared to stenting of dominant strictures in primary sclerosing cholangitis. *Am J Gastroenterology* 2001;96:1059–66.

Lindor KD, Kowdley KV, Luketic VA, et al. High-dose ursodeoxycholic acid for the treatment of primary sclerosing cholangitis. *Hepatology* 2009;50:808–14.

Liu JZ, Hov JR, Folseraas T, et al. Dense genotyping of immune-related disease regions identifies nine new risk loci for primary sclerosing cholangitis. *Nat Genet* 2013;45:670–5.

Metzger J, Negm AA, Plentz RR, et al. Urine proteomic analysis differentiates cholangiocarcinoma from primary sclerosing cholangitis and other benign biliary disorders. *Gut* 2013;62:122–30.

Molodecky NA, Kareemi H, Parab R, et al. Incidence of primary sclerosing cholangitis: a systematic review and meta-analysis. *Hepatology* 2011;53:1590–9.

Pawlik TM, Olbrecht VA, Pitt HA, et al. Primary sclerosing cholangitis:Role of extrahepatic biliary resection. *JACS* 2008;206:822–30.

Razumilava N, Gores GJ, Lindor KD. Cancer surveillance in patients with primary sclerosing cholangitis. *Hepatology* 2011;54:1842–52.

Schaeffer DF, Win LL, Hafezi-Bakhtiari S, et al. The phenotypic expression of inflammatory bowel disease in patients with primary sclerosing cholangitis differs in the distribution of colitis. *Dig Dis Sci* 2013;58:2608–14.

Silveira MG, Torok NJ, Gossard AA, et al. Minocycline in the treatment of patients with primary sclerosing cholangitis: results of a pilot study. *Am J Gastroenterol* 2009;104:83–8.

Tabibian JH, O'Hara SP, Lindor KD. Primary sclerosing cholangitis and the microbiota: current knowledge and perspectives on etiopathogenesis and emerging therapies. *Scand J Gastroenterol* 2014;49:901–8.

Triantos CK, Koukias NM, Nikolopoulou VN, et al. Meta-analysis: ursodeoxycholic acid for primary sclerosing cholangitis. *Alimentary Pharm Therapeut* 2011;34:901–10.

EDITOR'S COMMENT

Although there have been few improvements in the treatment of primary sclerosing cholangitis there are clear areas of controversy in the diagnosis and management. Primary sclerosing cholangitis (PSC) is a rare but significant disease. As pointed out by the authors we normally think of this a cholestatic disorder with strictures of the biliary tree associated with inflammatory bowel disease, primarily ulcerative colitis. The factors involved with the association of the PSC and ulcerative colitis are complex and incompletely understood but thought to be an autoimmune mechanism. It is known that medical treatment of the ulcerative colitis or total colectomy does not lessen the severity or risk of PSC.

The spectrum of this diseases similar to PSC has been expanded to include a long list of differential possibilities that may be primary diseases of the biliary tree or secondary forms of sclerosing cholangitis as shown in Table 113.3.

Of the extensive list in Table 113.3, IgG4 disease–related sclerosing cholangitis is a most important differential diagnostic consideration. IgG4 disease was described in 1995 in a group of patients with pancreatitis and increased serum IgG4 levels that responded to treatment with corticosteroids. At the time this was named autoimmune pancreatitis. It was found that some patients with this disease do not have pancreatitis but rather extrahepatic biliary strictures associated fibrosis and lymphoplasmacytic infiltration of biopsy. IgG4-related sclerosing cholangitis is the most frequent extrapancreatic manifestation of type 1 autoimmune pancreatitis (IgG4 related), present in over 70% of such patients. Although it can be confused with PSC, the natural history is different. First, it usually presents in older patients. A 7:1 male predominance is observed compared to 1.5:1 in PSC. Jaundice has a more acute onset in IgG4 disease and the strictures are usually extrahepatic and long and smooth and tend to be located in the distal common bile duct. PSC strictures are characterized by beading, band like strictures and peripheral pruning. G4 SC is associated with inflammatory bowel disease in less than 10% of cases compared to 80% in PSC. An elevated IgG4 level however is not sufficient to diagnose IgG4 SC,

especially as the optimal cut-off value has not been defined and may differ for subgroups of IgG4 SC. An emerging consensus holds that the IgG4 antibodies in this disease are not pathogenic, but rather represent a downregulatory response to another primary process. Although clearly defined diagnostic criteria for IgG4-related sclerosing cholangitis are lacking, differentiation from primary sclerosing cholangitis is based upon tissue biopsy with infiltrates of IgG4+ plasma cells and severe interstitial fibrosis, increased IgG4 serum levels, and characteristic responsiveness to glucocorticoids. The initial response rate to steroids has been reported as high as 97% but the relapse rate upon discontinuation is as high as 50% and not predicted by initial or IgG4 response to steroid therapy. Patients with IgG4 SC have not been reported to develop cholangiocarcinoma a known significant risk of PSC.

TABLE 113.3 Differential Diagnosis of Primary Sclerosing Cholangitis

Autoimmune	IgG4-related sclerosing cholangitis Autoimmune sclerosing cholangitis Systemic vasculitis
Benign	Intrahepatic stone disease
Malignant	Cholangiocarcinoma
Infection	Cholangiopathy related to AIDS Recurrent pyogenic cholangitis
Injury	Post cholecystectomy Abdominal trauma
Vascular	Hepatic artery thrombosis Portal hypertension Chemoembolization Sickle cell disease
Other	TPN Cholangiopathy of critical illness Histiocytosis X

Ursodeoxycholic acid (UDCA) has a demonstrated efficacy in the management of cholestatic conditions such as primary biliary cirrhosis. Small prospective studies using UDCA at different doses in patients with PSC showed improvement in symptoms and liver biochemistry (8 to 16 mg/kg, 10 mg/kg), as well as histology (13 to 15 mg/kg) (Chazouilleres O, et al. Ursodeoxycholic acid for primary sclerosing cholangitis. *J Hepatol* 1990;11:120–3; O'Brien CB et al. Ursodeoxycholic acid for the treatment of primary sclerosing cholangitis: a 30-month pilot study. *Hepatology* 1991;14:838–47; Beuers U, Spengler U, Kruis W, et al. Ursodeoxycholic acid for treatment of primary sclerosing cholangitis: a placebo-controlled trial. *Hepatology* 1992;16:202–714). There has been no demonstration of a survival advantage or reduction in the risk of cholangiocarcinoma. More recent studies have shown no significant difference in mortality, histology, or cancer risk at both a standard and high dose and there was a significantly higher occurrence of serious adverse events in the high-dose group (Lindor KD, et al. High-dose ursodeoxycholic acid for the treatment of primary sclerosing cholangitis. *Hepatology* 2009;50:808–14). As the authors report current guidelines advise against the use of UDCA in PSC. In addition, although there is some information that UDCA may decrease the incidence of colorectal dysplasia the studies were underpowered and hence UDCA is not recommended for prevention of colorectal dysplasia in PSC.

The most challenging problem for the surgeon is the management of a dominant stricture. The most concerning differential diagnosis of a dominant stricture is cholangiocarcinoma (CCA). It is known that the risk of CCA in PSC is much greater than that of the general population. Approximately 7% of patients with PSC will develop CCA over an 11-year follow-up. The rate of developing CCA is estimated at 0.6% per year and the relative risk of CCA in PSC is significantly increased (RR = 1,560; 95% CI = 780,2793; $p < 0.0001$) (Burak K, et al. Incidence and risk factors for cholangiocarcinoma in primary sclerosing cholangitis. *Am J Gastroenterol* 2004;99:523–6). Thus when a dominant stricture is identified, a malignant etiology requires exclusion and therapy for symptomatic strictures offered. CA 19-9 can be helpful in screening patients with dominant strictures. A level over 130 U/mL is worrisome. However, a tissue diagnosis is required. Cholangioscopy allows for direct optical visualization and guided biopsies of the biliary epithelium and biliary lesions. In addition, this technique may allow clearance of biliary stones improving symptoms. ERCP and brushings are employed more often because of cannulation difficulty with cholangioscopy in the PSC patient. Use of fluorescence in situ hybridization (FISH polysomy) on ERCP brushing has been shown to sensitive and specific in the diagnosis of CCA but it is not overly accurate (Navaveethan U, et al. Fluorescence in situ hybridization for diagnosis of cholangiocarcinoma in primary sclerosing cholangitis: a systematic review and meta-analysis. *Gastrointest Endosc* 2014;79:943–950.e3).

Treatment of symptomatic dominant strictures is warranted. The current recommendation is for endoscopic dilation with or without stenting. Stiehl A, et

al. (Development of dominant bile duct stenoses in patients with primary sclerosing cholangitis treated with ursodeoxycholic acid: outcome after endoscopic treatment. *J Hepatol* 2002;36:151–6.) performed a study on 52 patients with dominant strictures and reported that survival free of transplantation was better at 3, 5, and 7 years when compared to the Mayo risk score. Surgical resection may be considered in some cases and the authors refer to the report by Ahrendt and that of Pawlik both of which support selective surgical intervention of dominant extrahepatic strictures in noncirrhotic patients. "In the appropriately selected patient, extrahepatic biliary resection affords patients with survival rates equivalent to that of transplantation. In fact, extrahepatic biliary resection can potentially significantly delay or avoid transplantation. Extrahepatic biliary resection is a good durable option for noncirrhotic patients with PSC and a dominant extrahepatic stricture" (Tsai S, et al. Primary sclerosing cholangitis: the role of extrahepatic biliary resection. *Adv Surg* 2009;43:175–88).

As pointed out in this chapter, liver transplantation is effective treatment for PSC. The Mayo risk score is helpful in predicting outcomes and may be accessed at http://www.mayoclinic.org/medical-professionals/modelend-stage-liver-disease/revised-natural-history-model-for-primarysclerosing-cholangitis. The indications are similar for other types of chronic liver disease but also include pruritus and recurrent cholangitis. Interestingly within 5 years recurrence of PSC may be as high as 20% in the transplanted liver. The 1-, 5-, and 10-year posttransplant survival is 93.7%, 86.4%, and 69.8%, respectively (Graziadei IW, et al. Long-term results of patients undergoing liver transplantation for primary sclerosing cholangitis. *Hepatology* 1999;30:1121–7). CCA is currently a contraindication to transplantation. However as noted by the authors unsuspected CCA is identified in 3% to 9% of explanted livers and CCA <1 cm does not impact long-term outcomes. The role of liver transplantation for small CCA is currently under additional investigation (De Vreede I, et al. Prolonged disease-free survival after orthotopic liver transplantation plus adjuvant chemoirradiation for cholangiocarcinoma. *Liver Transpl* 2000;6:309–16).

The take home messages are as follows. First, I think it is important to remember that sclerosing cholangitis is a spectrum of diseases. An elderly male patient with no inflammatory bowel disease with a dominant stricture or multiple strictures may not have PSC but IgG4 disease which is being increasingly recognized. This disease is treatable with steroids and has a better prognosis. UDCA has little role in the treatment of PSC. Patients with PSC have an extremely high risk of developing CCA regardless of the severity or treatment of the underlying inflammatory bowel disease. Dominant strictures require investigation to exclude CCA. Liver transplantation is effective in those with cirrhosis or recurrent cholangitis and the risk and outcomes may be determined by application of the Mayo score.

E. Christopher Ellison

This is an excellent chapter—bad disease; and once established needs a radical approach. The authors also note that they may not be able to spare the resection of the extra hepatic biliary tree, which is significant!

Also there are other methods for transplant treatment for survival. Node resection is essential as well as the excellent resections of hepatic artery and vein and divisions. Hepatic artery, vein, etc. and frozen section of hepatic artery, veins, etc. Roux limb must be prepared with freedom of the resected limb. The surgeon must be aware of an unsuspected cholangiocarcinoma. Overall morbidity is 30% to 40% and overall mortality in expert hands is 4%. Bile leak is largely self-limited. There is no specific medical therapy affecting the disease course. Finally, cholangiocarcinoma develops 10% to 15% with PSC (primary sclerosing cholangitis liver transplants).

J.E.F.

114 High Malignant Biliary Tract Obstruction

Richard A. Burkhart and Timothy M. Pawlik

ETIOLOGY AND PATHOPHYSIOLOGY

High malignant biliary tract obstruction is typically caused by a cholangiocarcinoma (CCA) arising at the liver hilum. Less frequent etiologies of obstruction include extrinsic compression of the biliary tree due to a metastasis to the periportal lymphatic drainage basin or a benign biliary stricture. Primary CCA arising at the hilum of the liver or proximal/mid CBD can obstruct the biliary tract early in the course of disease.

Hilar cholangiocarcinoma (hilar CCA) is a rare malignancy with an incidence that likely approaches 3,000 cases annually in the United States. Worldwide epidemiologic estimates are difficult to estimate. The disease is likely more prevalent in the Eastern hemisphere. This hypothesis is supported by the regional variation in risk factors for hilar CCA. These risk factors include diseases that increase inflammation of the proximal biliary tree such as cirrhosis, pancreatitis, choledocholithiasis, and biliary/hepatic parasitic infection. The strongest risk factor for development of hilar CCA is a diagnosis of primary sclerosing cholangitis (PSC), with as many as a third of patients developing CCA within 5 years of diagnosis with PSC.

Despite the improvements in patient outcomes for various malignancies, hilar CCA remains a devastating diagnosis. First described in 1957 by Altemeier et al., CCA was given the eponym “Klatskin tumor” following the publication of a comprehensive report from Gerald Klatskin in 1965. Within a decade of Klatskin’s description, reports demonstrated that an optimal chance for cure included a margin-negative surgical resection. Despite half a century of surgical progress, long-term prognosis remains poor with various series reporting 5-year survival in the range from 10% to 40%.

There are several anatomic considerations in and around the hilum that

are important to keep in mind when discussing presentation and management of hilar CCA. These features are illustrated to aid clarity in Figure 114.1. First, the presentation of patients with hilar CCA can be dictated by the location in which the tumor develops and the relationship between the confluence of the left and right hepatic ducts to form the main duct. As an example, the course of the left hepatic duct is longer than the right and the left duct travels over a greater extrahepatic length. In addition, the close relationship between the vascular and biliary structures can dictate treatment options and prognosis. Classically, the right hepatic artery is thought to be at risk for early invasion as it runs posterior to the bile duct and courses through the hilum. Similarly, management may be impacted by aberrant vascular anatomy such as a left hepatic arising from the left gastric artery or a right hepatic with its origin from the superior mesenteric artery.

CLINICAL PRESENTATION

Hilar CCA is more common in men and presents at a median age near 65 years old. Patients generally present with painless jaundice owing to their biliary tract obstruction. Symptoms may also include abdominal discomfort, weight loss, darkened urine, and acholic stool. Fatigue and pruritus are also frequently encountered. Patients are often initially managed in an urgent care setting, where an examination may elicit a relatively benign abdominal exam in the setting of a grossly abnormal hepatic function panel. Laboratory abnormalities include elevated alkaline phosphatase and total bilirubin in nearly all patients. The initial differential diagnosis may include both benign and malignant etiologies for biliary obstruction such as choledocholithiasis or benign biliary stricture.

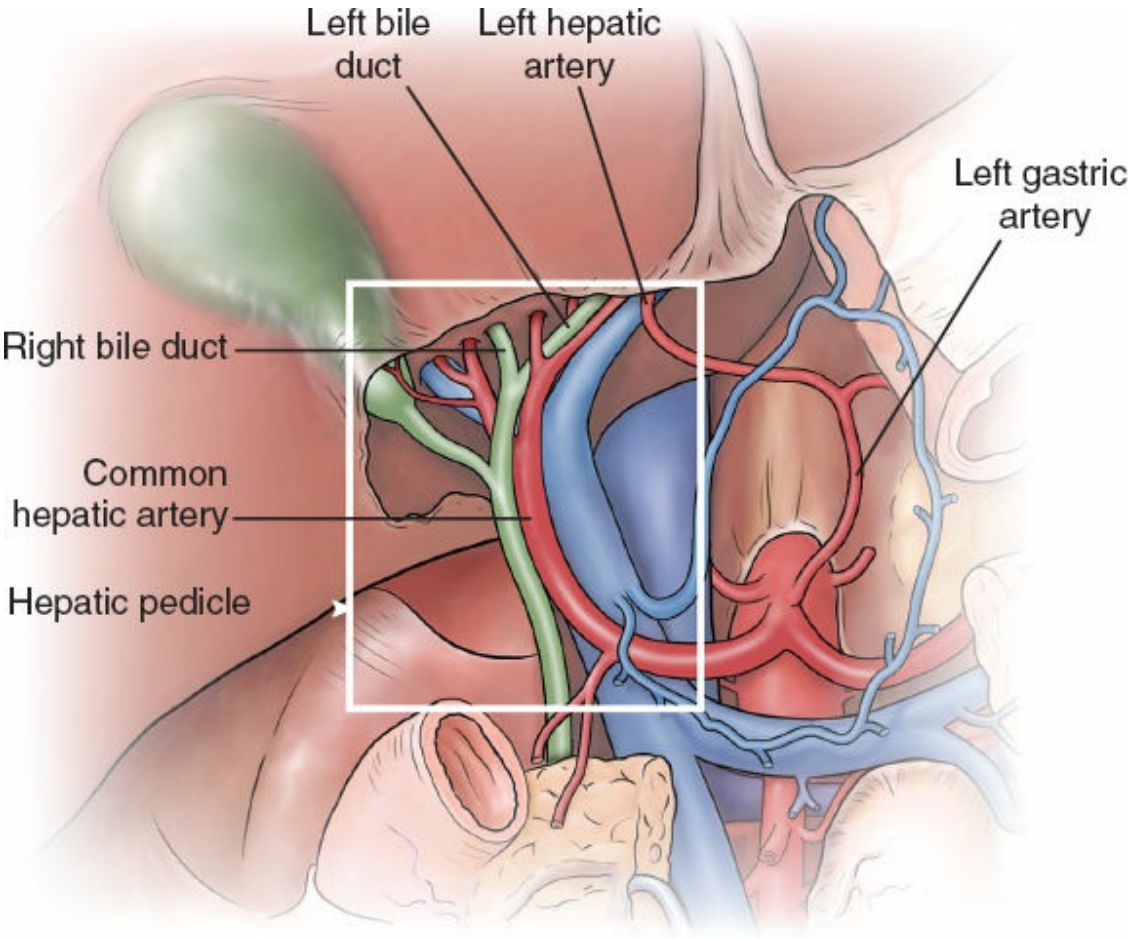

Figure 114.1. Anatomical features with particular implications in the management of hilar cholangiocarcinoma.

The serum tumor marker, CA19–9, is a commonly ordered test that may help to differentiate between benign and malignant obstruction. The sensitivity and specificity of this test during the acute presentation of patients with biliary obstruction remain limited. This tumor marker is particularly unhelpful for diagnosis when patients present with coexisting cholestasis or cholangitis. With this in mind, CA19–9 is likely most appropriately used as a serum biomarker of disease burden over time, with longitudinal kinetics of CA19–9 relating to response or failure to therapeutic interventions.

Initial imaging studies, such as ultrasound or cross-sectional computed tomography (CT), typically demonstrate dilation of the intrahepatic biliary tree with minimal or absent extrahepatic biliary tree dilation. It is unfortunately common that an obvious etiology is not apparent on these initial scans and the quality of initial imaging can be inadequate for treatment planning after a diagnosis has been made. Metastasis to locoregional lymph nodes, peritoneum, and liver is occasionally identified

when reviewing these initial studies.

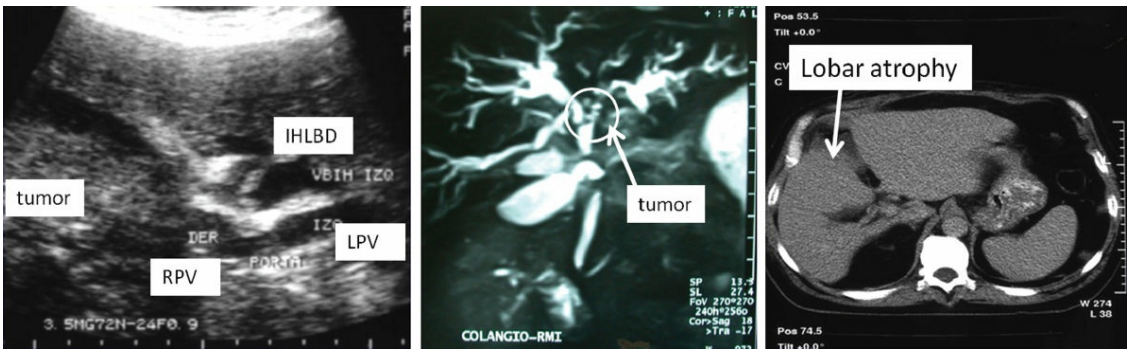

Figure 114.2. Hepatic ultrasound, magnetic resonance cholangiography, and abdominal computed tomography. RPV, right portal vein; LPV, left portal vein; IHLBD, intrahepatic left bile duct.

A definitive diagnosis of hilar CCA can be challenging, as initial signs of disease can be "indirect." These signs include intrahepatic biliary ductal dilation, an inability to appreciate the location of the biliary confluence on imaging, and a normal appearance of the mid and distal CBD. To narrow the differential, supplemental imaging that is biliary-focused, such as magnetic resonance cholangiography (MRC) or endoscopic retrograde cholangiography (ERC), is often required. The choice of modality used for additional workup should be determined by locoregional expertise and surgeon preference. At times, patients may require most of the studies outlined above to optimize clinical decision making (Fig. 114.2).

The relative value and additional risks for each study should be weighed carefully during a patient's evaluation, and there are two main principles of the workup that should be kept in mind. First, the proposed study should provide diagnostic value. Second, the study should support therapeutic decision making. Rapid-sequence, thin-section helical CT scanning is often an ideal way to evaluate resectability of a tumor (biliary extension, arterial involvement, portal venous involvement, lymphadenopathy, presence/absence of distant metastasis, and liver volume estimates). MRC, as a complementary study, offers a high-quality and noninvasive means to obtain detailed images of the biliary tree. Other methods to image the biliary tree include ERC or percutaneous transhepatic cholangiography. While these studies provide similar data, each can be associated with a distinct advantage or disadvantage compared with MRC. The major advantage of these approaches is the potential to

obtain tissue from duct brushings for histopathologic evaluation and potential diagnosis. The disadvantages, however, are their invasive nature (with all the inherent complications) and the potential for incomplete imaging of the biliary system that can result from a complete (and not traversable) blockage of the bile duct (i.e., ERC may be inadequate to image the proximal biliary tree and a percutaneous approach may be inadequate to image the distal). Evaluation of the biliary tree with an invasive means (ERC or percutaneous) does allow for treatment initiation with decompression of the biliary tree (either internal or external stent placement) and reversal of any biliary stasis that may have developed.

INDICATIONS AND CONTRAINDICATIONS

The mainstay of curative therapy in CCA remains complete surgical extirpation. The 5-year survival for patients undergoing an operation ranges from 10% to 44% (vs. 0% to 3% among patients who could not be resected). Unfortunately, only 30% of patients are candidates for surgical resection at the time of diagnosis. Modern improvements in operative technique and perioperative care have increased the capacity for attempts at surgical resection. Of particular note, the utilization of vascular reconstruction and transplantation in selected patients is now considered in selected high-volume centers. In addition, suspected lymphadenopathy in the hepatoduodenal ligament on preoperative imaging is no longer considered a contraindication to attempted resection.

Although resectability is ultimately determined in many cases at the time of operative exploration, in keeping with the contemporary management of tumors in other systems, the management of CCA is guided by an initial clinical assessment of disease stage. In general, this assessment is performed reliably only when viewing high-quality imaging and often requires multidisciplinary input. One of the earliest classifications of disease is derived from work completed by Bismuth and Corlette in 1975 (Fig. 114.3). This classification is grounded in the ability to accurately define the anatomical location and extent of tumor burden in the biliary tree. Although helpful in patients eligible for operative extirpation, the Bismuth and Corlette classification is not necessarily predictive of resectability as vascular invasion and extrabiliary disease spread are not considered.

Iterative improvements in the original Bismuth system were proposed by Jarnagin and colleagues that takes into account the disease's

involvement of the biliary, arterial, and portal venous systems (known as the Memorial Sloan Kettering Cancer Center, MSKCC, classification system). This T-staging system also takes into account lobar atrophy and has been correlated with ability to achieve R0 resection and overall patient survival. In the original report, as an example, patients with disease limited to the biliary confluence with or without extension into second-order biliary radicals had a 59% R0 resection rate with a 20-month median survival. The predictive capacity of this staging system has been validated in external work from multiple centers.

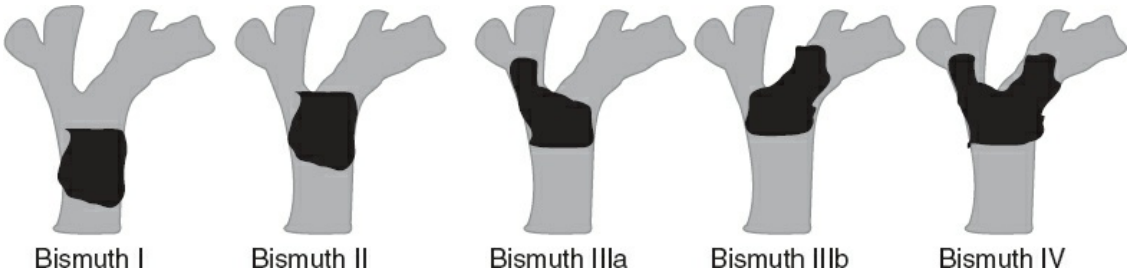

Figure 114.3. Bismuth and Corlette classification for hilar cholangiocarcinoma.

Importantly, the MSKCC classification system also proposed criteria for contraindications to a surgical approach. First, as is the practice in other tumor systems, patients with medical comorbidities that preclude a major abdominal operation should be excluded from operative consideration. Second, the presence of hepatic cirrhosis was also proposed as a relative contraindication to surgery. Lastly, and most importantly, local tumor-related factors were proposed as operative contraindications. These included bilateral tumor extension to second-order biliary radicals, encasement or occlusion of the main portal vein, atrophy of one hepatic lobe with encasement or occlusion of the contralateral portal vein branch, atrophy of one hepatic lobe with extension of tumor into the second-order biliary radicals of the contralateral hepatic lobe or extension of tumor into the second-order biliary radicals of one hepatic lobe with encasement or occlusion of the portal vein branch to the contralateral lobe. Metastatic disease, both to lymph nodes beyond the locoregional draining basin in the hepatoduodenal ligament and to systemic sites, was also proposed as a contraindication to operative resection.

PREOPERATIVE PLANNING

Preoperative Biliary Drainage

The effects of prolonged biliary obstruction are not particularly well understood. Although hyperbilirubinemia and jaundice are common, their effects on hepatic function and systemic physiology are debated in the literature. This has resulted in mild controversy regarding the role of routine preoperative biliary drainage. There are four distinct benefits to preoperative biliary drainage. First, perioperative morbidity (including liver insufficiency and failure) is higher in patients with extreme hyperbilirubinemia (greater than 10 to 15 mg/dL). Second, biliary drainage is the appropriate initial therapy for patients with signs or symptoms of cholangitis or new-onset liver insufficiency. From a technical standpoint, a biliary catheter in place (particularly if placed percutaneously) may serve as a landmark during surgical exploration. Lastly, placement of a biliary drainage catheter or stent allows for patients to seek additional therapies prior to attempted surgical resection. Some therapies routinely employed include antibiotics to treat sepsis, nutritional supplementation for malnourishment, or portal venous embolization to decrease perioperative risk.

Many surgeons have abandoned routine biliary drainage for patients who do not meet the criteria outlined above. Specific concerns that have decreased utilization of drainage procedures include procedure-based complications, an increased incidence of postoperative infections, and the risk of tumor seeding along a catheter track. Based on current evidence, modern surgical consensus suggests that preoperative biliary drainage should be done selectively in patients with cholangitis, malnutrition, sepsis, and those needing portal vein embolization (PVE). In turn, many patients evaluated for hilar CCA will meet criteria for preoperative biliary drainage.

Preoperative Portal Embolization

PVE is a procedure that can be utilized before hepatectomy to investigate the capacity of the liver to regenerate and potentially increase the size of the future liver remnant (FLR). This procedure occludes the portal vein branches feeding the hemiliver that a surgeon is planning on resecting. While classically described via either a percutaneous or open approach, it is most commonly performed percutaneously in the modern experience. In practice, the diversion of blood flow in the portal venous system can induce a slight atrophy of the hemiliver embolized with a compensatory

hypertrophy of the contralateral side. The decision to proceed with PVE and the interpretation of a liver's response is an evolving art. Utilization of PVE is most appropriately limited to patients in whom the volume of the FLR raises the possibility of postoperative liver insufficiency or failure. Classic teaching instructs that this threshold varies between 20% and 30% in a healthy liver and 30% and 40% in a liver with preexisting cirrhosis or a patient with underlying steatosis or steatohepatitis. When in doubt, surgeons can seek multidisciplinary support with this decision from radiology colleagues who can define the specific liver volume (through image-based volumetry), as well as interventional radiologists who perform percutaneous PVE.

Functionally, PVE minimizes the abrupt increase of portal pressure after resection and separates this physiologic stress in time from the stress and trauma of surgical hepatectomy. In addition, PVE may increase FLR mass prior to resection and minimize the risk of metabolic insufficiency. Taken together, these changes minimize the incidence of postoperative liver insufficiency. Interpreting the overall benefit of PVE in each patient can be difficult. While PVE is performed for patients with a borderline FLR, the post-procedure FLR volume is not the only outcome measure to note. Rather, the overall capacity of the FLR to hypertrophy, and speed at which it does so, can inform operative risk. For example, a patient after PVE with an original 18% FLR volume and without evidence of cirrhosis on preoperative workup may technically meet resection "criteria" (FLR 20% to 30%) with a hypertrophy of only 2% after PVE; however, most surgeons would be reluctant to undertake a major hepatectomy without more robust hypertrophy of the FLR following PVE. One unique consideration when using PVE in cases of hilar CCA (rather than other indications for hepatectomy) is that it can sometimes be difficult to know which hemiliver to embolize. When the side of the hilar CCA lesion is ambiguous, the operative planning can be more difficult.

SURGICAL TECHNIQUES

Staging Laparoscopy

Even though most patients undergo a comprehensive imaging workup for a presumed diagnosis of CCA, a subset of patients will be found to have occult metastasis at the time of surgical exploration. Based on the MSKCC experience, peritoneal or liver metastasis was reported at surgical exploration between 20% and 40% of the time. This includes one fifth of

patients with the most limited disease (T1) in the MSKCC system. For this reason, and to avoid the morbidity of an unnecessary laparotomy, staging laparoscopy should be considered at the time of surgery. While staging laparoscopy can identify nearly 50% of patients who harbor unresectable disease, the addition of laparoscopic ultrasound to delineate perihilar anatomy can increase the sensitivity of this approach. The major limitations of this approach include variability in the capacity to interpret intraoperative ultrasound findings and challenges in laparoscopic identification of lymphatic spread beyond the hepatoduodenal ligament.

Hepatectomy: Rationale and Planning

The standard management of patients with potentially curable CCA involves a margin-negative surgical resection. The biliary margin is most commonly at risk for failure to achieve an R0 designation. This is particularly true at the proximal (at times intrahepatic) biliary radicals and provides the bona-fide rationale for concomitant liver resection when treating a Klatskin tumor.

Most hilar CCA lesions will require an extended hepatectomy, in particular for those lesions either directly at the hilar plate or involving the right bile duct. A left hemi-hepatectomy can otherwise be considered for a hilar CCA originating from the left biliary tree. In particular, because of the anatomic characteristics of the hepatic ducts (e.g., a longer extrahepatic portion on the left), an extended right hepatectomy is often the operation of choice as it frequently provides a greater chance for a margin-negative resection. Preoperative variables that would dictate a left hepatectomy include imaging findings that suggest extensive involvement of the left duct (beyond the second-order) or compromise of the major vascular structures to the left side. Specifically, a Bismuth-Corlette type IIIB tumor in the presence of left lobe atrophy would be an indication for a left hepatectomy.

Resection of the caudate should be a routine addition to the hepatectomy performed for hilar CCA. Resection of the caudate lobe increases the chance of R0 resection as pathologic data suggest that hilar CCA can invade the caudate in roughly 31% to 98% of cases. The size and anatomy of the caudate can be variable at times; as such, resection can be partial (to include Spiegel's lobe and the paracaval portion) according to the type of liver resection performed (Fig. 114.4).

A complete resection should also include extirpation of the locoregional

draining lymphatic basin residing in the hepatoduodenal ligament and cystic triangle (at a minimum). There are robust data to support that this relatively limited dissection can provide prognostic and potentially therapeutic benefit (locoregional nodal control). The full extent of lymphadenectomy remains a relatively controversial topic. While an extended lymphadenectomy may improve prognostic value of the histopathologic surgical specimen, any potential therapeutic benefit is indeterminate. A recent meta-analysis of prognosis based upon nodal dissection noted that a lymph node count greater or equal to 7 is adequate for prognostic staging; in addition, a lymph node count greater than 15 did not improve detection of nodal metastasis. Most often, therefore, it is prudent to extend the lymphadenectomy to include nodes in the hepatoduodenal ligament, cystic triangle, and along the course of the hepatic artery. It remains unclear to what extent the lymphadenectomy should be extended to celiac, periduodenal, and perigastric nodes.

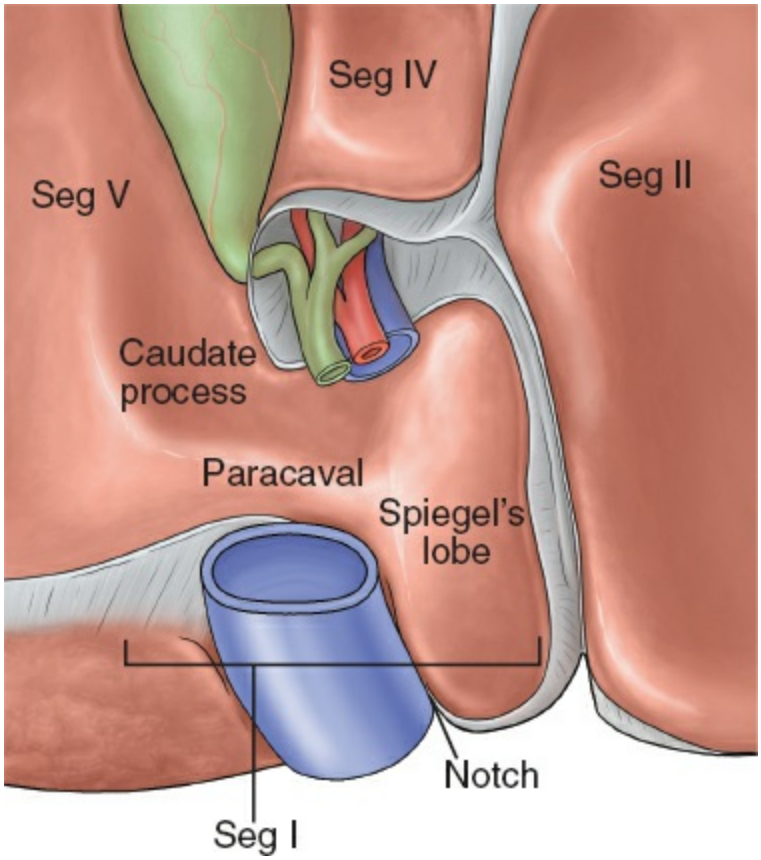

Figure 114.4. Anatomy of the caudate: Because of the frequency with which hilar cholangiocarcinoma involves the caudate, it is recommended that a caudate resection is routinely performed during hepatectomy.

Hepatectomy: Exposure and Portal Dissection

It is important to emphasize that techniques and operative procedures can vary among surgeons based on experience, and preference. Many advocate for routine staging laparoscopy with intraoperative ultrasound (as described above) to begin each procedure. The degree to which the remainder of the procedure can be completed in a minimally invasive fashion is variable; while complete laparoscopic or robotic resections for Klatskin tumors have been reported in the literature, a minimal invasive approach to resection of hilar CCA remains uncommon.

For surgeons approaching hilar CCA disease through a laparotomy, there are a variety of incisions that are favored: midline, bilateral subcostal, bilateral subcostal with midline extension ("Mercedes"), or modified Kocher ("hockey stick"). Similarly, there are a variety of preferred retraction methods that can be used with success to gain the necessary exposure to the operative field. Following exposure, an intraoperative exploration of the abdomen to exclude metastasis and an initial assessment of resectability should be performed.

Although many surgeons choose to approach the dissection from a variety of starting points, it is often recommended to begin with dissection of the distal CBD just above its insertion into the head of the pancreas. This allows for early transection of the CBD and frozen section pathologic analysis of this margin. A negative margin at this early juncture is encouraging; a positive margin, however, would necessitate re-examination of the planned procedure. For example, if the goal remains to ensure an R0 resection, the surgeon must decide whether additional distal CBD dissection is possible and, if not, if a pancreaticoduodenectomy with concomitant liver resection is an appropriate strategy for the patient (Fig. 114.5). After confirming this margin is free of tumor, the distal CBD at its entry into the head of the pancreas should be oversewn.

To determine resectability, meticulous dissection of the vascular inflow (hepatic artery and portal vein branches) in the porta hepatis is required. Sometimes, it is best to adopt a "no touch technique" in which the tumor is left in situ and undisturbed while the uninvolved structures are dissected away. A common place to begin vascular isolation is with dissection of the proximal proper hepatic artery (PHA) after the takeoff of the gastroduodenal artery. Ideally, the PHA can be circumferentially dissected free from the surrounding fibroadipose tissue to the level of its bifurcation into the left and right hepatic arteries. There are frequently small venous

tributaries encountered during this dissection that must be controlled. The dissection is carried distal along the right hepatic artery for enough length to pass a vessel loop in preparation for eventual ligation. The portal vein dissection is generally begun in the distal hepatoduodenal ligament and carried in a similar fashion toward the porta to identify the bifurcation into the right and left portal vein branches. The right is again circumferentially dissected free and a vessel loop can be passed. It is important to note that the portal vein tributary to the caudate will frequently branch off from the posterior aspect of the proximal right portal vein, and care must be taken not to injure this vessel during dissection. In cases with a low-lying tumor, it can be necessary to approach the portal dissection from the posterolateral aspect of hepatoduodenal ligament, particularly as you approach the porta hepatis. In so doing, the biliary structures are rotated anteriorly and to the patient's left to facilitate a safe dissection by the surgeon standing at the patient's right-hand side of the table. It should also be mentioned that the gallbladder, if not previously removed, is often taken early during the course of the operation and facilitates this approach to the portal vein.

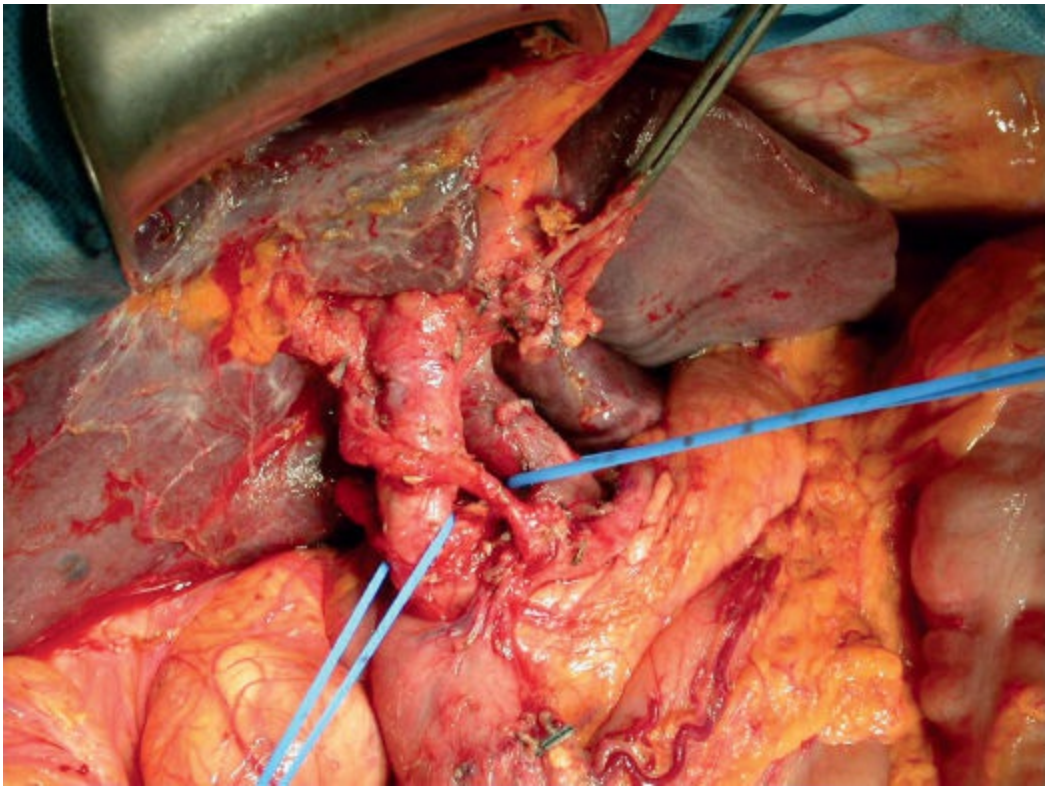

Figure 114.5. Hepatic hilum after lymph node dissection.

In the case of tumor involvement of the arterial or portal venous

branches to the FLR, it would be appropriate to consider the need for vascular reconstruction and plan accordingly by procuring a vascular conduit if primary reconstruction was not feasible. Arterial reconstruction can sometimes be necessary for a Bismuth type IIIB tumor where operative planning dictates a left hepatectomy and the right hepatic artery is involved with tumor as it passes posterior to the biliary confluence. One strategy for vascular reconstruction in this scenario involves preservation of the proximal (extrahepatic) left hepatic artery with transection in the substance of the liver and transposition to the uninvolved distal right hepatic artery. Additional options for vascular reconstruction include saphenous, external iliac, and internal jugular venous conduits. Similarly, a cadaveric donor graft can be considered. Following vascular control and appropriate planning, the inflow vasculature to the side of the liver being resected can be ligated and parenchymal transection begins.

It is critical to recall the potential anatomic variants of the hepatic arterial supply. First described in depth by Jefferson Medical College's Nicholas Michels in 1966, hepatic arterial abnormalities are relatively common and can alter surgical approach and at times render an apparently unresectable tumor operable. Two of the most common variants include a left hepatic artery that arises directly from the left gastric (around 15%) and a right hepatic artery that arises from the superior mesenteric artery (also around 15%). When the left hepatic artery arises from the left gastric artery, it often inserts directly into the liver without passing into the porta hepatis, thus reducing the chance of involvement by a hilar tumor. Similarly, when the right hepatic artery originates from the superior mesenteric artery, it typically courses through the porta laterally and posterior to the course of the PHA. Although this scenario may require a certain amount of technical precision on the part of the surgeon, ultimately the position of the right hepatic artery in this variant may similarly increase its distance from the biliary confluence and enable resection in an otherwise uncertain case.

Hepatectomy: Optimizing the Hepatic Duct Margin, Parenchymal Transection, and Reconstruction.

There are two approaches to identifying an optimal hepatic duct margin. The first is early dissection of the hepatic duct at the base of the FLR. The second involves division of the hepatic duct during the latter stages of the parenchymal dissection. The former is generally preferred, as the control

of the hepatic duct with a vessel loop or umbilical tape can serve as a key landmark during parenchymal transection. In order to maximize the chances of an R0 resection, the dissection of the hepatic duct can be carried to the first or second order radicals by lowering the hepatic plate.

With the vascular inflow and biliary margin identified, the hepatic veins should be isolated and the field prepared for parenchymal transection. If not completed earlier in the operation, the liver should be fully mobilized from its retroperitoneal attachments and the short branches from the liver to the IVC should be clipped or tied. The hepatic artery and portal vein to the side being resected should be test clamped and hepatic perfusion to the FLR confirmed by Doppler ultasonography. The right hepatic artery and right portal vein can then be transected by suture ligation or a vascular stapling device. The devascularized liver becomes apparent and the line of parenchymal transection can be marked by electrocautery. There are a plethora of techniques that have been used with success to swiftly and safely complete the parenchymal transection. Tools at a liver surgeon's disposal include clamps, sutures, ties, clips, monopolar and bipolar electrocautery, ultrasonic dissectors, and stapling devices. Adjuncts to assist with hemostasis can include the application of direct pressure, the intermittent use of Pringle's maneuver, as well as topical hemostatic agents. After removal of the specimen, the transected liver surface is checked for hemostasis and biliary leak while the pathologists complete a frozen section analysis of the FLR's biliary margin.

Reconstruction is typically completed with a Roux-en-Y hepaticojejunostomy. The anastomosis has been described using a variety of absorbable suture types, sizes, and with both running and interrupted techniques. If a percutaneous hepatic drainage catheter was placed through the FLR during the workup, this is typically left in place and passed back across the anastomosis prior to completion. In cases where there is no catheter in place, one is typically not left at the conclusion of the procedure.

PALLIATIVE PROCEDURES

There are a variety of scenarios in which an operation for attempted curative resection may need to be converted to palliation. Such circumstances include intraoperative findings of unresectability (e.g., main hepatic artery and main portal vein involvement) or in cases where the distal CBD margin is positive and the patient is not a candidate for a

combined hepatobiliary/pancreatic resection. Palliation of symptomatic jaundice can be accomplished operatively by biliary-enteric bypass. If unresectability is discovered early in the course of operative exploration, during laparoscopy for example, the surgeon must decide whether the tumor and anatomy favor operative bypass or nonoperative interventional procedures. Although surgical palliation is associated with greater rates of long-term patency, morbidity following these procedures can vary between 15% and 50%. There is no long-term survival benefit afforded by surgical palliation as compared to nonoperative palliative approaches. Percutaneous transhepatic biliary drainage and stent placement or ERC with stenting can be effective palliative procedures. Autoexpandable metallic stents tend to be favored in palliative settings due to superior long-term patency and the reduced need for repeated endoscopic interventions that is present with plastic stent placement. Finally, it is worth noting that surgical debulking and palliative resections are generally not necessary and provide no survival benefit.

LIVER TRANSPLANTATION

Liver transplantation for the treatment of hilar CCA is gaining popularity in select patient populations. Most experts currently recommend transplant only for those patients with locally advanced disease (i.e., unresectable) who have no progression after a year or more of combined neoadjuvant therapy. This neoadjuvant therapy was initially described by the group at the Mayo Clinic and includes cytotoxic chemotherapy, external beam radiotherapy, and transcatheter-delivered brachytherapy. Pretransplant surgical exploration to ensure each patient is free from metastatic disease is required after this neoadjuvant regimen. Transplant aims to achieve an R0 resection by removing all structures in the liver hilum that are involved with tumor, including the portal vein, bilateral hepatic ducts, and the hepatic artery. While initial outcomes suggested 5-year survival below 20%, more recent data are encouraging with a long-term survival of 50% or higher. The overall median survival in the patients who successfully reach transplant today approaches the survival seen in patients undergoing successful R0 resection. In 2009, the United Network for Organ Sharing formally recognized unresectable hilar CCA as an indication for liver transplant.

The indications for liver transplant in patients who have resectable hilar CCA remain unclear. In fact, the appropriateness of transplant in this

patient subset remains debated in the literature. Trials to directly compare transplant versus resection have not been performed, and existing level 2 or 3 data are difficult to interpret. Much of this difficulty is owed to patient selection. Transplant patients are heavily pretreated and selected very carefully after receiving extensive neoadjuvant therapy. One could argue that the survival of the transplant cohort is due as much to this extensive neoadjuvant course (i.e., the patients with "bad biology" drop out) as it is to differences in surgical technique (transplant vs. resection, for example). This hypothesis is strengthened by findings showing that similar outcomes are reached for both transplant and resection when patients are stratified by disease stage in retrospective database studies. Integrating the currently available data, most experts agree that liver transplantation should generally be reserved for patients who have unresectable disease or for patients with PSC-associated hilar CCA.

POSTOPERATIVE CARE

Initial Hospital Course

In general, the adage of preoperative patient selection driving successful postoperative outcomes is apt in this patient population. For example, postoperative liver insufficiency or failure is best prevented with preoperative patient selection and management (i.e., adequate FLR and PVE), rather than managed postoperatively.

Standardized pathways can contribute to improvements in patient care in a variety of ways, from accurately setting patient expectations to minimizing medical variability and error. Common pathway components often include preoperative prophylactic antibiotics, routine laboratory analyses, standardized dietary and bowel regimens, frequent ambulation, and early involvement of staff (such as physical therapists, case managers, and nutritionists) to facilitate smooth transitions to outpatient settings. These activities are often combined into *enhanced* recovery pathways that emphasize early hospital discharge as an endpoint.

COMPLICATIONS AND THEIR MANAGEMENT

The complex nature of biliary and hepatic resections can be associated with a moderately high incidence of perioperative morbidity ranging from 15% to 75%. Similarly, 90-day mortality can be much higher than hepatic resection for other indications reaching up to 10% to 20% in some series.

The most common types of complications following resection of hilar CCA include bleeding, biliary leak or fistula, intra-abdominal abscess, wound infection, cholangitis, liver abscess, and liver insufficiency or failure. Management of bleeding includes reoperation and endovascular interventions. Similarly, the most common management for infectious complications includes resuscitation, antibiotic support, and source control. Finally, patients with hepatic insufficiency or failure must be supported with careful fluid management, avoidance of additional complications such as infection or renal failure, and careful management of electrolytes and acid–base balance.

ADJUVANT THERAPIES

Data investigating the use of adjuvant therapy following successful resection of hilar CCA are predominantly limited to level II and III evidence. Given the relatively common incidence of locoregional disease recurrence and dismal outcomes associated with relapse, postoperative adjuvant therapy is recommended to many patients. The evidence to support adjuvant chemotherapy for hilar CCA is sparse and most is extrapolated from data of chemotherapy use in patients with advanced disease. The most commonly studied agents include single-agent gemcitabine, and gemcitabine combinations with platinum or antimetabolites. Response rates from most studies are on the order of 10% to 30% in advanced disease. A phase III study of gemcitabine alone versus gemcitabine plus cisplatin (ABC-02 trial) demonstrated that combination therapy provided an improved progression-free survival among patients with advanced disease. As such, gemcitabine plus cisplatin is often selected for use in the adjuvant setting.

Similarly, the use of radiation therapy for hilar CCA in the adjuvant setting remains poorly defined. Chemoradiation may involve chemosensitization with 5-FU or capecitabine. While virtually all studies have been retrospective in nature, several series have reported improved outcomes with chemoradiation among patients who had a margin positive (R1) resection at the hepatic duct. In the postoperative setting, multidisciplinary consultation is often beneficial, as additional therapy is often recommended for patients with either a positive margin or lymph node metastasis. Patients who undergo R0 resection with node-negative disease are not likely to derive a substantial benefit from additional therapy in the adjuvant setting. So for this small subset, there is no

adjuvant therapy routinely administered at most cancer centers.

OUTCOMES

The major determinant of overall survival among patients with hilar CCA is pathologic stage and disease recurrence. CCA is among one of the most highly lethal tumors, and recurrence can be common even after margin-negative resection of node-negative disease. Recurrence is most often local in nature and can occur in and around the porta hepatis and liver. Additional sites of disease recurrence include the peritoneum, lungs, and distant lymph nodes. The median time to recurrence following surgical resection is 12 to 43 months in most series. Five-year survival for "all comers" following curative intent surgery is typically around 25% to 50% (Table 114.1). Clinicopathologic factors associated with a better long-term outcome include well-differentiated tumors, tumors with papillary histology, and a lack of perineural invasion. Resection with negative margins remains the only modifiable factor of long-term survival, emphasizing the impact meticulous surgical technique can have in this disease.

TABLE 114.1 Survival Postresection for Hilar Cholangiocarcinoma

Author	Year	n	Resection%	R0%	3-Year OS	5-Year OS
Neuhaus	1999	95	84	61	—	37[a]
Lee	2000	128	87	78	55	24
Jarnagin	2001	80	78	78	—	30
Seyama	2003	67	87	64	55	40/46[a]
Inoue	2000	79	87	69	52[a]	40[a]
Hemming	2005	67	79	80	58	35
Nishio	2006	301	94	77	—	22/27[a]
Lang	2006	89	83	67	36/45[a]	25/28[a]

[a]R0 resection.

SUMMARY

Hilar CCA is a relatively rare diagnosis with a poor prognosis. The adverse long-term outcomes associated with hilar CCA are due to disease burden that is frequently advanced at presentation leading to an R1 margin, as well as a lack of effective systemic therapies. While challenging, the only potentially curative option for the treatment of hilar CCA remains surgical resection. Resections commonly require an extended

hepatectomy. Alternatively, for patients with unresectable disease and those with PSC-related hilar CCA, orthotopic liver transplantation may be an option at selected centers. Recommendations for adjuvant therapy are best determined by expert multidisciplinary consensus. Future research should be aimed at further characterizing the molecular biology of hilar CCA and identifying new systemic therapeutic approaches.

Suggested Readings

Aljiffry M, Abdulelah A, Walsh M, et al. Evidence-based approach to cholangiocarcinoma: a systematic review of the current literature. *J Am Coll Surg* 2009;208(1):134–47.

Jarnagin WR, Fong Y, DeMatteo RP, et al. Staging, resectability, and outcome in 225 patients with hilar cholangiocarcinoma. *Ann Surg* 2001;234(4):507–17.

Kambakamba P, Linecker M, Slankamenac K, et al. Lymph node dissection in resectable perihilar cholangiocarcinoma: a systematic review. *Am J Surg* 2015; 210(4):694–701.

Nagino M, Kamiya J, Arai T, et al. "Anatomic" right hepatic trisectionectomy (extended right hepatectomy) with caudate lobectomy for hilar cholangiocarcinoma. *Ann Surg* 2006;243(1):28–32.

Neuhaus P, Jonas S, Bechstein WO, et al. Extended resections for hilar cholangiocarcinoma. *Ann Surg* 1999;230(6):808–18.

Poruk KE, Pawlik TM, Weiss MJ. Perioperative management of hilar cholangiocarcinoma. *J Gastrointest Surg* 2015;19(10):1889–99.

Soares K, Kamel I, Cosgrove DP, et al. Hilar cholangiocarcinoma: diagnosis, treatment options, and management. *Hepatobiliary Surg Nutr* 2014;3(1):18–34.

Valero V, Cosgrove D, Herman JM, et al. Management of perihilar cholangiocarcinoma in the era of multimodal therapy. *Expert Rev Gastroenterol Hepatol* 2012;6(4):481–95.

Valley J, Wasan H, Palmer D, et al. Cisplatin plus gemcitabine versus gemcitabine for biliary tract cancer. *N Engl J Med* 2010;362:1273–81.

EDITOR'S COMMENT

Cholangiocarcinoma is the second most common primary liver cancer after hepatocellular carcinoma. Tumors in the hilum are frequently the source of highly malignant biliary tract obstruction and have been reviewed extensively over the past 150 years. Rokitansky proposed that biliary tract malignancies represented local advancement of disease from nearby organs. Durand-Fardel

then described the first case of bile duct cancer in 1840, with subsequent reports highlighting its poor clinical outcome. Interestingly, the 1910s witnessed an evolution in the surgical management of malignant obstruction from palliation to common bile duct resection with hepaticojejunostomy drainage. However, this approach did not result in significant cure rates due to the longitudinal and perineural infiltration that are the hallmarks of this disease. Dr. Gerald Klatskin sought "to draw attention to the unusual features of adenocarcinomas that arise in the hepatic duct at its bifurcation within the porta hepatitis" in his 1965 report in the *Journal of the American Medical Association.* Subsequent work by Launois and others demonstrated improved survival with hepatectomy, thus leading to the more aggressive approaches to this disease detailed in this chapter (Launois B, Campion JP, Brissot P, et al. Carcinoma of the hepatic hilus. Surgical management and the case for resection. *Ann Surg* 1979;190(2);151–7). However, many tumors are unresectable at time of presentation because of cholangiocarcinoma's silent clinical character, difficulties in early diagnosis, and limited therapeutic approaches (Rizvi S, Gores GJ. Pathogenesis, diagnosis, and management of cholangiocarcinoma. *Gastroenterology* 2013;145(6):1215–29; Bridgewater J, Galle PR, Khan SA, et al. Guidelines for the diagnosis and management of intrahepatic cholangiocarcinoma. *J Hepatol* 2014;60(6):1268–89). The authors are to be congratulated on their outstanding work on the surgical management of highly malignant obstruction from hilar cholangiocarcinomas. I will highlight several important aspects of the treatment of this disease including preoperative planning, neoadjuvant and adjuvant therapies, and indications for transplantation.

Preoperative cross-sectional imaging and endoscopic retrograde cholangiopancreatography help delineate tumor location, size, morphology, vascular involvement, volume of potential liver remnant, lymph node involvement, and presence of distant metastases (Deoliveira ML, Schulick RD, Nimura Y, et al. New staging system and a registry for perihilar cholangiocarcinoma. *Hepatology* 2011;53(4):1363–71). The data are unambiguous on the role of both CT and MRI in the management of these patients. A recent meta-analysis reported that CT scans are 86% (95% CI = 77–92) accurate in the evaluation of the degree of bile duct involvement in patients with cholangiocarcinoma. The sensitivity and specificity of CT scans for detecting portal vein involvement are 89% (95% CI = 80–94) and 92% (95% CI = 85–96), while sensitivity and specificity in the identification of hepatic artery involvement are 83% (95% CI = 63–94) and 93% (95% CI = 69–99). The sensitivity and specificity for lymph node involvement are 61% (95% CI = 28–86) and 88% (95% CI = 74–95), respectively (Ruys AT, van Beem BE, Engelbrecht MR, et al. Radiological staging in patients with hilar cholangiocarcinoma: a systematic review and meta-analysis. *Br J Radiol* 2012;85(1017):1255–62). Cross-sectional imaging with MRI allows for better delineation of the extent of the bile duct lesion relative to conventional CT scans, as this technique has an 89% sensitivity and 76% accuracy. Performing

concurrent MRI and MRCP examinations adds other important tumor information that facilitates preoperative planning. For example, if a definite finding on MRI alone was considered positive, its sensitivity would increase from 56% to 72% with the addition of MRCP (Charatcharoenwitthaya P, Enders FB, Halling KC, et al. Utility of serum tumor markers, imaging, and biliary cytology for detecting cholangiocarcinoma in primary sclerosing cholangitis. *Hepatology* 2008;48(4):1106–17). The role of PET/CT in the workup of patients with perihilar cholangiocarcinoma should also be discussed for completeness. Although the sensitivity and specificity of ^{18}F-FDG-PET for the primary tumor in cholangiocarcinoma is 60% to 92% and 93% to 100%, its sensitivity for regional lymph node metastases is poor, at only 13% to 50% (Kluge R, Schmidt F, Caca K, et al. Positron emission tomography with [(18)F]fluoro-2-deoxy-D-glucose for diagnosis and staging of bile duct cancer. *Hepatology* 2001;33(5):1029–35; Moon CM, Bang S, Chung JB, et al. Usefulness of 18F-fluorodeoxyglucose positron emission tomography in differential diagnosis and staging of cholangiocarcinomas. *J Gastroenterol Hepatol* 2008;23(5):759–65). The predominant role of ^{18}F-FDG-PET in the evaluation of hilar CCA is the identification of distant metastases in patients who present with this disease.

Endoscopic retrograde cholangiography is an invaluable approach in the initial evaluation of the biliary tree and as a first therapeutic step. The presence of a dominant stricture with or without upstream biliary duct dilatation as identified on cross-sectional imaging is an indication for cytologic evaluation through biliary brushings or ultrasound-guided lymph node biopsy. I would caution, however, that patients who are candidates for transplantation should undergo fine-needle aspiration of adjacent suspicious lymph nodes rather than tumor sampling because of the high risk of needle tract seeding, which would preclude transplantation (Heimbach JK, Sanchez W, Rosen CB, et al. Trans-peritoneal fine needle aspiration biopsy of hilar cholangiocarcinoma is associated with disease dissemination. *HPB (Oxford)* 2011;13(5):356–60; Levy MJ, Heimbach JK, Gores GJ. Endoscopic ultrasound staging of cholangiocarcinoma. *Curr Opin Gastroenterol* 2012;28(3):244–52).

Unfortunately, 23% of patients with hilar cholangiocarcinoma present with locally advanced tumors (Jarnagin WR, Fong Y, DeMatteo RP, et al. Staging, resectability, and outcome in 225 patients with hilar cholangiocarcinoma. *Ann Surg* 2001;234(4):507–17; discussion 517–9). Although surgical resection is the mainstay of treatment for patients with Klatskin tumors, a multidiscliplinary approach that includes neoadjuvant therapy in a select group of patients with locally advanced disease is warranted. These patients should be selected based upon clinical features that portend a poor clinical outcome. A meta-analysis of 7 studies with 2,132 patients revealed that older age, larger tumor size, presence of multiple tumors, lymph node metastasis, vascular invasion, and poor tumor differentiation were all negative prognostic indicators for patients with cholangiocarcinoma (Mavros MN, Economopoulos KP, Alexiou VG, et al.

Treatment and prognosis for patients with intrahepatic cholangiocarcinoma: systematic review and meta-analysis. *JAMA Surg* 2014;149(6):565–74). A reasonable approach to patients with these findings is to offer neoadjuvant therapy as a downstaging strategy prior to resection. McMasters et al. reported tumor downstaging in nine patients with initially unresectable hilar cholangiocarcinoma who were able to safely undergo an R0 resection after neoadjuvant 5-FU chemotherapy and radiation therapy. Interestingly, three of these patients demonstrated complete pathologic responses at resection. These data suggest a broader role of neoadjuvant therapy in unresectable or borderline resectable tumors (McMasters KM, Tuttle TM, Leach SD, et al. Neoadjuvant chemoradiation for extrahepatic cholangiocarcinoma. *Am J Surg* 1997;174(6):605–8; discussion 608–9). A Japanese trial of neoadjuvant gemcitabine and radiation therapy for cholangiocarcinoma was reported at the European Society of Surgical Oncology in 2008. An interim analysis of the subsequent phase II trial reported an R0-resection rate of 57.1% (8/14) based on intent to treat analysis. Although we await a report of the entire cohort, I expect that neoadjuvant therapy will continue to provide significant dividends in the treatment of this cohort of patients.

The opportunity to offer adjuvant therapy to patients who are found to have poor prognostic features after resection has been the subject of extensive research. To date, however, no data has demonstrated a survival benefit with postoperative chemoradiation while at the same time imparting a significant complication rate (Sagawa N, Kondo S, Morikawa T, et al. Effectiveness of radiation therapy after surgery for hilar cholangiocarcinoma. *Surg Today* 2005;35(7):548–52; Vern-Gross TZ, Shivnani AT, Chen K, et al. Survival outcomes in resected extrahepatic cholangiocarcinoma: effect of adjuvant radiotherapy in a surveillance, epidemiology, and end results analysis. *Int J Radiat Oncol Biol Phys* 2011;81(1):189–98; Schoenthaler R, Phillips TL, Castro J, et al. Carcinoma of the extrahepatic bile ducts. The University of California at San Francisco experience. *Ann Surg* 1994;219(3):267–74). However, adjuvant chemoradiation should be considered for patients with either positive margins (R1) or residual tumor. Systemic therapy with gemcitabine plus cisplatin, or 5-FU should also be considered in patients with positive lymph nodes.

Orthotopic liver transplantation is a promising treatment for cholangiocarcinoma because it would, by necessity, achieve tumor-free margins. However, experiences during the late 1980s and early 1990s were poor due to the aggressive biology of this disease; thus, hilar cholangiocarcinoma became a widely recognized contraindication to liver transplantation (Goldstein RM, Stone M, Tillery GW, et al. Is liver transplantation indicated for cholangiocarcinoma? *Am J Surg* 1993;166(6):768–71; discussion 771–2). Given that liver transplantation did result in long-term survival for select patients with negative margins and absence of regional lymph node metastases, selected groups considered to evaluate it as a treatment modality for cholangiocarcinoma

(Shimoda M, Farmer DG, Colquhoun SD, et al. Liver transplantation for cholangiocellular carcinoma: analysis of a single-center experience and review of the literature. *Liver Transpl* 2001;7(12):1023–33). The group at Mayo designed a protocol by combining the benefits of radiotherapy, chemosensitization, and liver transplantation patients with unresectable hilar cholangiocarcinoma. An initial report demonstrated an 82% 5-year survival for 28 patients (Heimbach JK, Gores GJ, Haddock MG, et al. Liver transplantation for unresectable perihilar cholangiocarcinoma. *Semin Liver Dis* 2004;24(2):201–7). In more recent publications, the survival rates have been adjusted to 65% to 70% (Gores GJ, Darwish Murad S, Heimbach JK, et al. Liver transplantation for perihilar cholangiocarcinoma. *Dig Dis* 2013;31(1):126–9). The Mayo experience has been criticized because two distinct patient populations were included in the experience. One group underwent neoadjuvant chemoradiation while the second group was high selected with early-stage disease (Bismuth H. Revisiting liver transplantation for patients with hilar cholangiocarcinoma: the Mayo Clinic proposal. Liver Transpl 2000;6(3):317–9; Rea DJ, Heimbach JK, Rosen CB, et al. Liver transplantation with neoadjuvant chemoradiation is more effective than resection for hilar cholangiocarcinoma. *Ann Surg* 2005;242(3):451–8; discussion 458–61; Rosen CB, Darwish Murad S, Heimbach JK, et al. Neoadjuvant therapy and liver transplantation for hilar cholangiocarcinoma: is pretreatment pathological confirmation of diagnosis necessary? *J Am Coll Surg* 2012;215(1):31–8; discussion 38–40). Mantel et al. identified 28 patients (19%) who met the strict selection criteria of the Mayo Clinic protocol, but had undergone neoadjuvant chemoradiation therapy. Five-year survival in this subgroup was 59%, which is comparable to patients with pretreatment pathologic confirmed hilar cholangiocarcinoma who were transplanted after completion of the chemoradiation protocol at the Mayo Clinic. Based upon these findings, one can cautiously conclude that improved survival after transplantation can be achieved with strict selection criteria (Mantel HT, Westerkamp AC, Adam R, et al. Strict selection alone of patients undergoing liver transplantation for hilar cholangiocarcinoma is associated with improved survival. *PLoS One* 2016;11(6):e0156127).

Again, this is an outstanding contribution to this edition of the mastery of Surgery. We appreciate the depth of the issues surrounding malignant biliary obstruction. Future opportunities include local therapies such as photodynamic therapy and other advanced intraluminal approaches to this disease.

John H. Stewart, IV

115 Cholecystojejunostomy and Choledocho/Hepaticojejunostomy

Herbert R. Freund and Michael R. Freund

CHOLECYSTOJEJUNOSTOMY

Favorable data have been published in recent years concerning curative surgery of periampullary carcinoma. The operative mortality of pancreatoduodenectomy in experienced hands ranges between 3% and 5%, and morbidity has dropped to 25% to 30% in high-volume institutions. Even in non-major referral centers, operative mortality (7% to 10%) and morbidity (30% to 40%) dropped significantly. Five-year survival rates for pancreatic cancer are reported to approach 12% to 24% for patients undergoing curative resection compared with a median survival of 6 to 10 months for patients undergoing bypass surgery or stenting by endoscopic retrograde cholangiopancreatography (ERCP) or percutaneous transhepatic cholangiography (PTC) procedures. In various large reports, however, only 20% of patients have resectable pancreatic tumors, the remaining requiring some sort of palliation for relief of jaundice, actual or pending duodenal obstruction, or severe, often debilitating pain.

Decompression of the biliary tract obstructed by malignant periampullary lesions is indicated for the relief of obstructive jaundice and its ensuing severe and often intolerable pruritus. There are also ample data to suggest that stenting in malignant obstructive jaundice improves physical and functional well-being. Three viable options are available for the palliation of obstructive jaundice caused by periampullary malignant lesions in patients whose disease is determined to be unresectable:

1. Percutaneous transhepatic external or internal permanent catheter drainage of the biliary system.
2. Endoscopic papillotomy with insertion of an internal biliary-duodenal stent catheter.
3. Operative biliary-enteric bypass by cholecystojejunostomy or choledochojejunostomy/hepaticojejunostomy with or without a gastroenteric bypass.

Without getting into the yet unresolved argument whether radiologic or endoscopic stenting is superior to a biliary-enteric surgical bypass, we believe that a surgical biliary-enteric bypass has a viable role in the palliation of patients who have periampullary carcinomas, particularly in younger more fit patients without evidence of peritoneal or distant metastases. However, it should be acknowledged that with the now widespread use of preoperative cross-sectional imaging, the likelihood of finding unexpected locally unresectable disease has been greatly diminished. These patients are also the ones in whom an additional gastrojejunostomy is advocated for actual or pending mechanical gastric outlet obstruction, because comparable postoperative morbidity and mortality have been reported after "double bypass," or biliary diversion only. As a rule, we prefer to perform a "double bypass," namely, a cholecystojejunostomy, choledochojejunostomy, or hepaticojejunostomy and a gastrojejunostomy.

This approach receives further support from a recent meta-analysis of three prospective studies (218 patients) comparing prophylactic palliative gastroenterostomy and bilio-digestive anastomosis with no bypass or a bilio-digestive anastomosis alone that has shown that for patients with gastroenterostomy the chance for gastric outlet obstruction was significantly lower with no added operative morbidity or mortality.

The use of the gallbladder for internal biliary drainage is quick, simple, effective, and safe, and is the biliary conduit of choice when the cystic duct is patent and enters the common duct well away (1 cm) from the tumor mass. The gallbladder should not be used if it was previously diseased (chronic cholecystitis or cholecystolithiasis, or both), or when the cystic duct is narrow or enters the common duct close to the tumor. In such situations, the common hepatic duct is the preferred conduit for bypass, and the gallbladder is removed. When creating a cholecystojejunostomy, which is the simplest and quickest bypass, a loop of jejunum is the preferred enteric component of the bypass, whereas with a choledochojejunostomy/hepaticojejunostomy, the Roux-en-Y technique is applied.

Cholecystojejunostomy with a simple loop bypass is almost exclusively used in patients who were operated for cure and found during exploration to have locally advanced disease, possibly small liver metastases or peritoneal implants. The first loop of jejunum that easily and comfortably reaches the subhepatic space is passed in an antecolic manner without

tension and approximated to the gallbladder with a posterior row of seromuscular interrupted absorbable (4-0 or 3-0) sutures (Fig. 115.1A,B). On the jejunum, the sutures are placed parallel and adjacent to the edge of the mesenterium. Using electrocautery, an incision as long as possible is made in the body of the gallbladder, and the bile evacuated and sent for culture. A similar, but shorter, incision is made on the antimesenteric part of the approximated jejunum (Fig. 115.1B). Beginning in the middle and suturing toward the corners, the full thickness of the gallbladder and of the jejunum is anastomosed with 3-0 or 4-0 monofilament absorbable interrupted sutures. This creates the posterior wall of the anastomosis with all sutures tied on the inside (Fig. 115.1C). Turning both corners, sutures are placed in an inside-outside-outside-inside fashion from both sides of the anterior wall with ties on the inside (Fig. 115.1C) The last sutures on the anterior wall (simple or gumby sutures) are all placed before tying them with their knots on the outside (Fig. 115.1D). We rarely approximate the anterior serosal layer, although, if the gallbladder is large and redundant enough, it could be done. A cholecystojejunal anastamosis can also be accomplished by using a circular stapler (EEA No 25) with the advantage of using the same enterostomy site for both biliary and enteric anastamoses (Fig. 115.2). In our experience, leakage from a cholecystojejunostomy is extremely rare, but we still leave a closed suction drainage for 2 to 4 days. It is our practice to always add a small, sutured, or GIA stapled gastrojejunostomy distal to the cholecystojejunostomy.

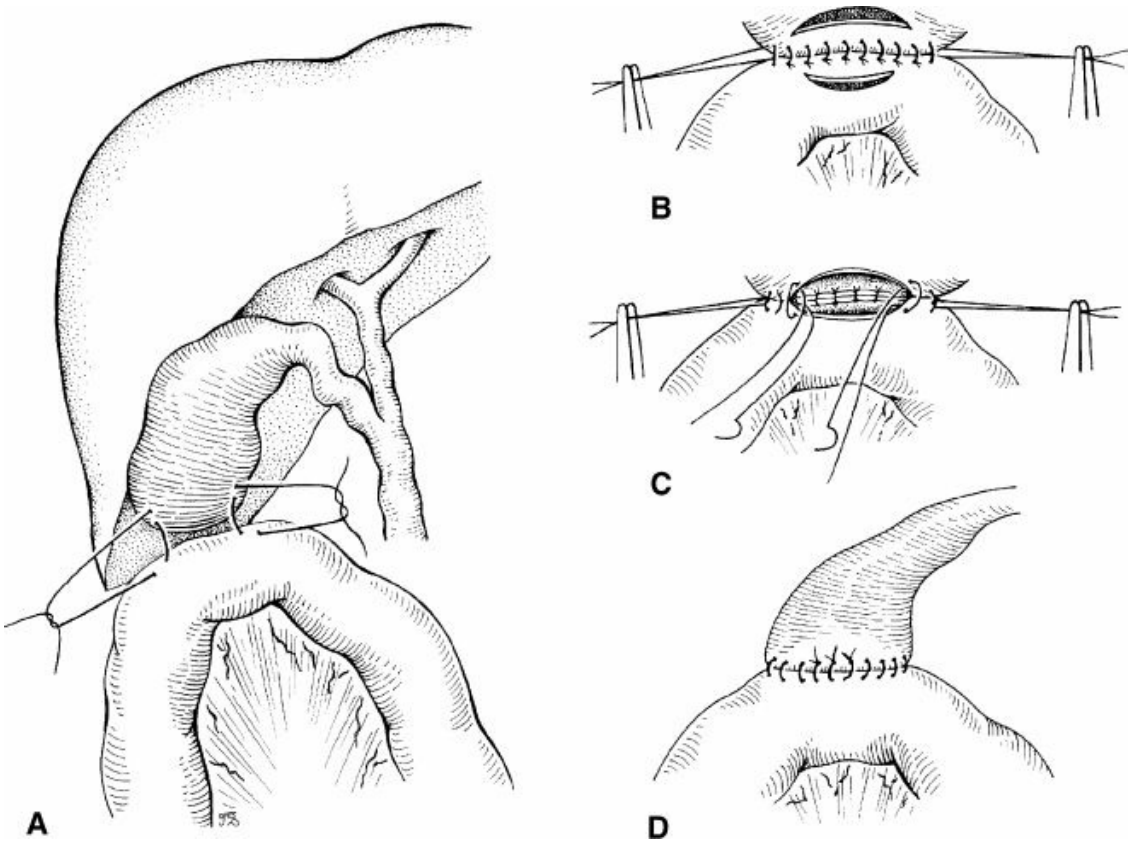

Figure 115.1. Side-to-side cholecystojejunostomy. **A.** The first loop of jejunum is approximated to the gallbladder with a posterior row of few interrupted sutures, which is seen completed in (B). **B.** After completion of the posterior layer, both jejunum and gallbladder are incised to the maximal length possible to create a good-sized anastomosis. **C.** A full-thickness posterior wall anastomosis between jejunum and gallbladder is constructed with the sutures tied on the inside and continued in a similar manner on the anterior part of the anastomosis. **D.** The last sutures of the anterior wall are all tied on the outside to complete the cholcystojejunostomy.

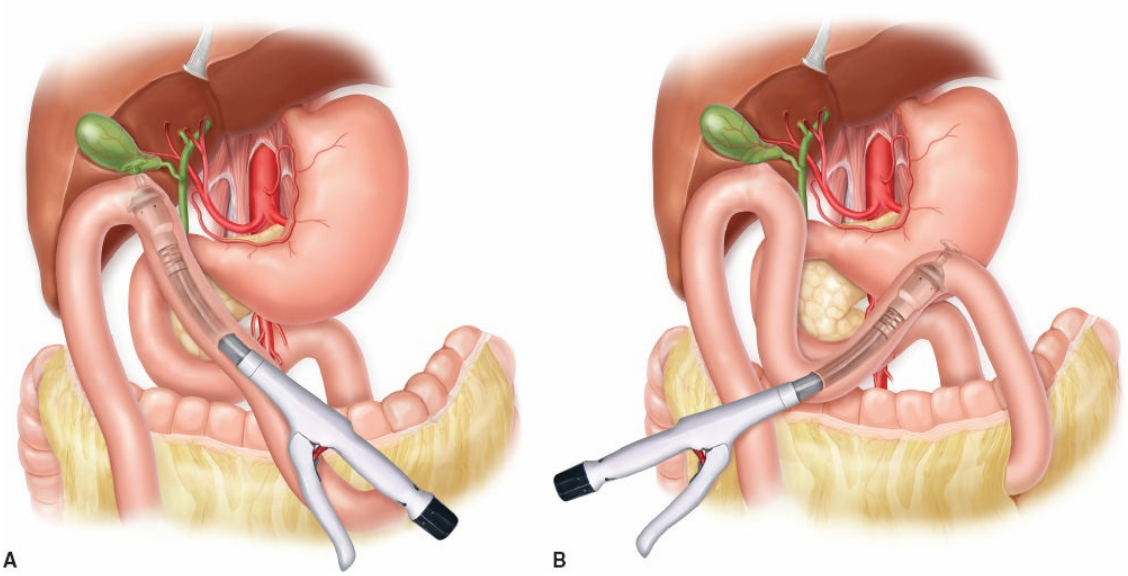

Figure 115.2. **A.** Double stapled technique in which an enterotomy is created in the jejunum and, using an intraluminal circular stapler, first a cholecystojejunostomy is created, the stapler removed and reinserted, and then (**B**) a gastrojejunostomy created, after which the enterotomy is closed. (Reproduced from Jarnagin W. *Master Techniques in Surgery: Hepatobiliary and Pancreatic Surgery*. Philadelphia, PA: Lippincott Williams & Wilkins; 2012.)

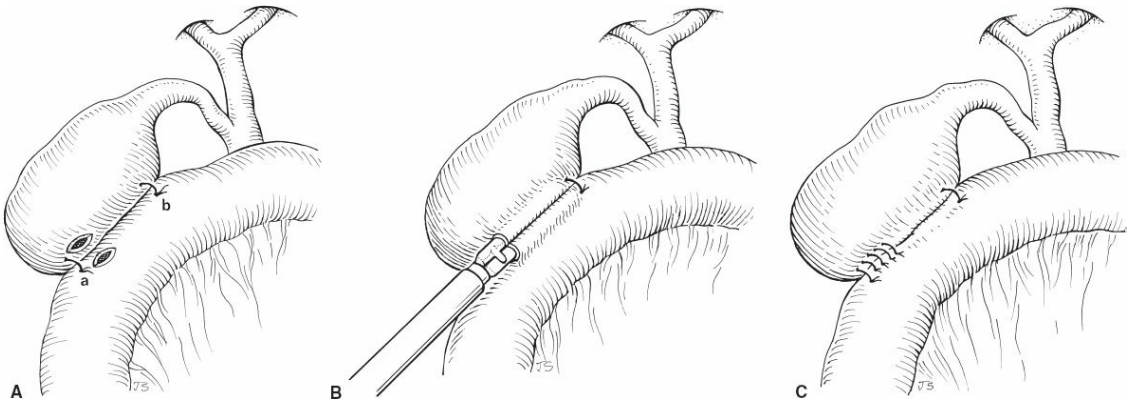

Figure 115.3. Laparoscopic cholecystojejunostomy. **A.** Placement of anchoring sutures (a,b) between gallbladder and proximal loop of jejunum. Two small incisions are created in the gallbladder and adjacent jejunum close to anchoring suture (a) for passage of the stapler. **B.** The entire length of the endoscopic linear stapler is introduced into gallbladder and jejunum and fired. **C.** The now common opening left by removal of the stapler is closed by interrupted sutures or a further application of the stapler.

Technical and technological advances in laparoscopic surgery make it

possible to safely perform the double bypass procedure laparoscopically, which results in reduced operative morbidity and possibly in a shorter and easier postoperative course and more rapid convalescence.

The laparoscopic cholecystojejunostomy is accomplished using 3 to 5 trocars. The first jejunal loop to comfortably reach the gallbladder is attached with 1 or 2 anchoring sutures to the gallbladder (Fig. 115.3A). A small incision is made close to the proximal anchoring suture (Fig. 115.3A) in the gallbladder and the adjacent jejunum. The jaws of the 35- or 45-mm linear stapler is introduced through these two incisions and pushed to its full length, closed and fired (Fig. 115.3B). The two entry sites, now combined into one, can be closed by a second stapler firing or with interrupted sutures (Fig. 115.3C).

The laparoscopic gastrojejunostomy is technically a similar straightforward procedure that provides excellent palliation for the 10% to 20% of patients who have unresectable pancreatic cancer and develop subsequently duodenal obstruction. Here too, two anchoring sutures are placed to approximate the jejunum to the stomach (Fig. 115.4A). Two small incisions in the stomach and the adjacent jejunum enable the introduction and firing of a 30- or a 45-mm linear stapler (Fig. 115.4B). The common opening left after removal of the stapler is stapled or sutured (Fig. 115.4C).

We believe that the use of the laparoscopic technique for the palliation of malignant biliary obstruction is associated with a lower operative risk while offering longer palliation without the risk of gastric outlet obstruction, recurrent cholangitis, and repeated endoscopic manipulations for stent placement and change.

CHOLEDOCHOJEJUNOSTOMY/HEPATICOJEJUNOSTOI

The main indications for a choledochojejunostomy/hepaticojejunostomy are benign, mainly iatrogenic, biliary strictures and malignant obstruction of the biliary tract caused by peri-ampullary tumors. Rare indications for choledochojejunostomy/hepaticojejunostomy are direct trauma to the biliary system, choledochal cyst reconstruction, and select instances of sclerosing cholangitis in which areas of dilatation occur. Because biliary tract strictures are essentially iatrogenic in 97% of instances (0.5% to 0.6% incidence of bile duct injury in laparoscopic cholecystectomy), and each unsuccessful repair poses increased morbidity and mortality, reconstruction should restore long-lasting primary functional and anatomic

integrity at the first attempt of repair.

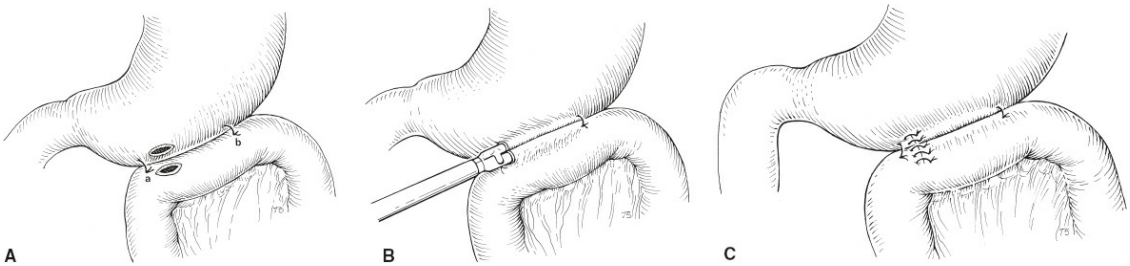

Figure 115.4. Laparoscopic gastrojejunostomy. **A.** Placement of two anchoring sutures (a,b) between body of the stomach and proximal loop of jejunum. Two small incisions are created in the stomach and jejunum close to anchoring suture (a) for passage of the stapler. **B.** The entire length of the linear stapler is introduced into stomach and jejunum and fired. **C.** The now common opening left by removal of the stapler is closed by interrupted sutures or a further application of the stapler.

PREOPERATIVE EVALUATION

The diagnosis should be established, and the anatomy of the biliary duct system and the nature and location of the obstruction should be characterized by PTC, endoscopic retrograde cholangiography, or magnetic resonance cholangiopancreatography (MRCP). At the same time, jaundiced patients can undergo drainage by either a percutaneous catheter or an endoprosthesis. The presence of such catheters, although reported to carry an increased operative morbidity, is a tremendous help for the surgeon exploring a scarred previously damaged or transected ductal system, particularly if this attempt to repair is not the first.

The transhepatic catheter might also be left in place during an operation for stenting and future imaging and removed only after the safety and patency of the anastomosis are ascertained by injection of contrast material 1 to 2 weeks following repair.

PREOPERATIVE PLANNING

Most patients who require a choledochojejunostomy/hepaticojejunostomy may have experienced cholangitis and jaundice, and should therefore receive antibiotics, and parenteral vitamin K perioperatively. Nutritional support should be offered when and where indicated. In our experience, most patients who have a diseased biliary system also harbor infected bile, with the most common pathogens being *Escherichia coli*, *Klebsiella*

species, and Enterococus. However, because many of these patients have had previous biliary tract operations and several interventions and instrumentations, infections with hospital-acquired anaerobes or resistant bacteria should be considered in the choice of perioperative antibiotics. Our preference is the combination of ampicillin and an aminoglycoside or a combination of a third-generation cephalosporin with metronidazole. Because the colon can be densely adherent to the gallbladder bed and liver, requiring meticulous dissection and separation, large bowel preparation is advised, but certainly not absolutely indicated.

SURGICAL TECHNIQUE

The biliary tract can be approached through a long right subcostal or a right paramedian incision. However, the best possible exposure is offered by the bilateral subcostal, better known as the "Bucket-handle incision," with or without the midline xiphoid extension. Figure 115.4 depicts the anatomic situation following the mandatory steps to release adhesions, dissection of the area of the hepatoduodenal ligament, and kocherization of the duodenum. It is important at this stage to perform meticulous dissection of the area between the undersurface of the right lobe of the liver and the duodenum. Sometimes, aspiration with a 25-gauge needle attached to a small syringe can be helpful in locating the dilated common duct. Favorable results have been reported with intraoperative sonographic detection of dilated common ducts, ductal stones, and pancreatic and ductal tumors. In dissecting out the common bile duct, the hepatic artery lying to its left is an important anatomic landmark (Fig. 115.5). However, one should be aware of the fact that this "textbook" arrangement of the common hepatic artery originating from the celiac trunk, giving off the left and right hepatic arteries is found in only 55% of patients. In the other 45% of patients, variations in the hepatic arterial supply exist. Of particular importance in this respect is the right hepatic artery arising from the superior mesenteric artery, which usually passes to the liver along the right side of the portal vein and the common bile and common hepatic ducts. Also frequent are anatomic variations in the extrahepatic biliary tree, most of them related to the confluence of the right and left hepatic ducts and of the cystic duct insertion into the common hepatic duct.

Once the common duct has been identified and dissected out, two 4-0 traction sutures are placed through the dilated common-duct wall just above the area of obstruction. The common duct is ligated below the

stricture with two 00 ligatures and is divided below the traction sutures (Fig. 115.6). The proximal end of the common duct is trimmed to achieve maximal diameter, good blood supply, and viable, free of scar duct tissue for anastomosis. Because the common hepatic and upper bile ducts depend on two axial arteries located along the lateral and medial borders of the ducts, undue mobilization and dissection should be avoided to ensure good blood supply to the anastomotic site.

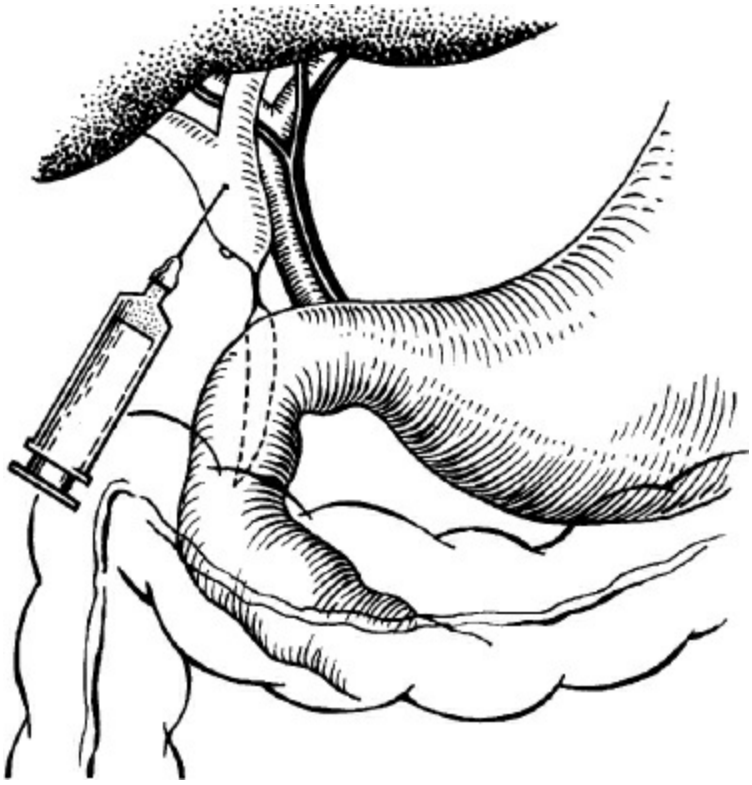

Figure 115.5. The location of the hepatic artery to the left of the common duct and exploratory aspirations with a fine needle are of great assistance in locating the common duct.

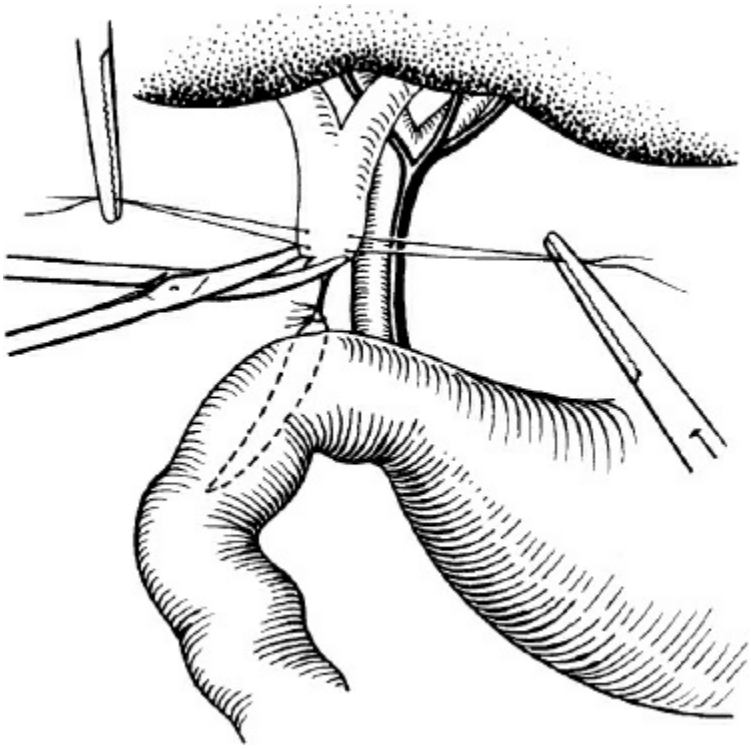

Figure 115.6. The distal part of the duct is ligated, and the proximal part is trimmed to achieve maximal diameter, good blood supply, and viable duct tissue.

Once the biliary system is opened, a bile specimen is sent for culture and sensitivity testing. In the case of choledocholithiasis, stones and debris are evacuated using Randall forceps, scoops, or a biliary Fogarty balloon catheter. After removal of stones, the duct system is irrigated with saline solution through a No. 8- or 10-Fr soft rubber catheter or a pediatiric (No. 5 or 8) feeding tube.

The first jejunal loop adjacent to the ligament of Treitz that comfortably reaches the subhepatic space is used to create a Roux-en-Y conduit. It is divided using the GIA stapler, and the distal part of it is brought through a window in the transverse mesocolon toward the severed common duct. The proximal afferent loop is sutured in an end-to-side manner to the ascending limb of defunctionalized jejunum (Fig. 115.7A), or is stapled with a GIA stapling instrument (Fig. 115.7B). The ascending limb is anchored to the mesocolon with few 000 absorbable sutures to avoid internal hernias. Care should be taken to use a limb of intestine 60 to 75 cm long between the biliary-enteric and the Roux-en-Y anastomosis to avoid cholangitis induced by reflux of gastrointestinal content (Fig. 115.7A,B).

When dealing with benign biliary tract strictures, two kinds of

anastomoses are commonly used. A greatly dilated biliary system is sometimes amenable to an end-to-end choledochojejunal anastomosis. This anastomosis is performed in one layer of interrupted 000 synthetic absorbable sutures (mono- or polyfilament), which offer favorable tissue drag, elasticity, and gradual loss of tensile strength. First to be placed are the two corners (Fig. 115.8A,B) and center (Fig. 115.8A,C) sutures of the posterior anastomotic wall. Each such interrupted suture is tied and used as a holding suture for the next suture. The rest of the posterior wall is completed with sutures placed every 3 mm, with care being taken to include the full thickness of both the jejunum and common duct. The knots of the posterior wall are all tied inside toward the lumen (Fig. 115.8B).

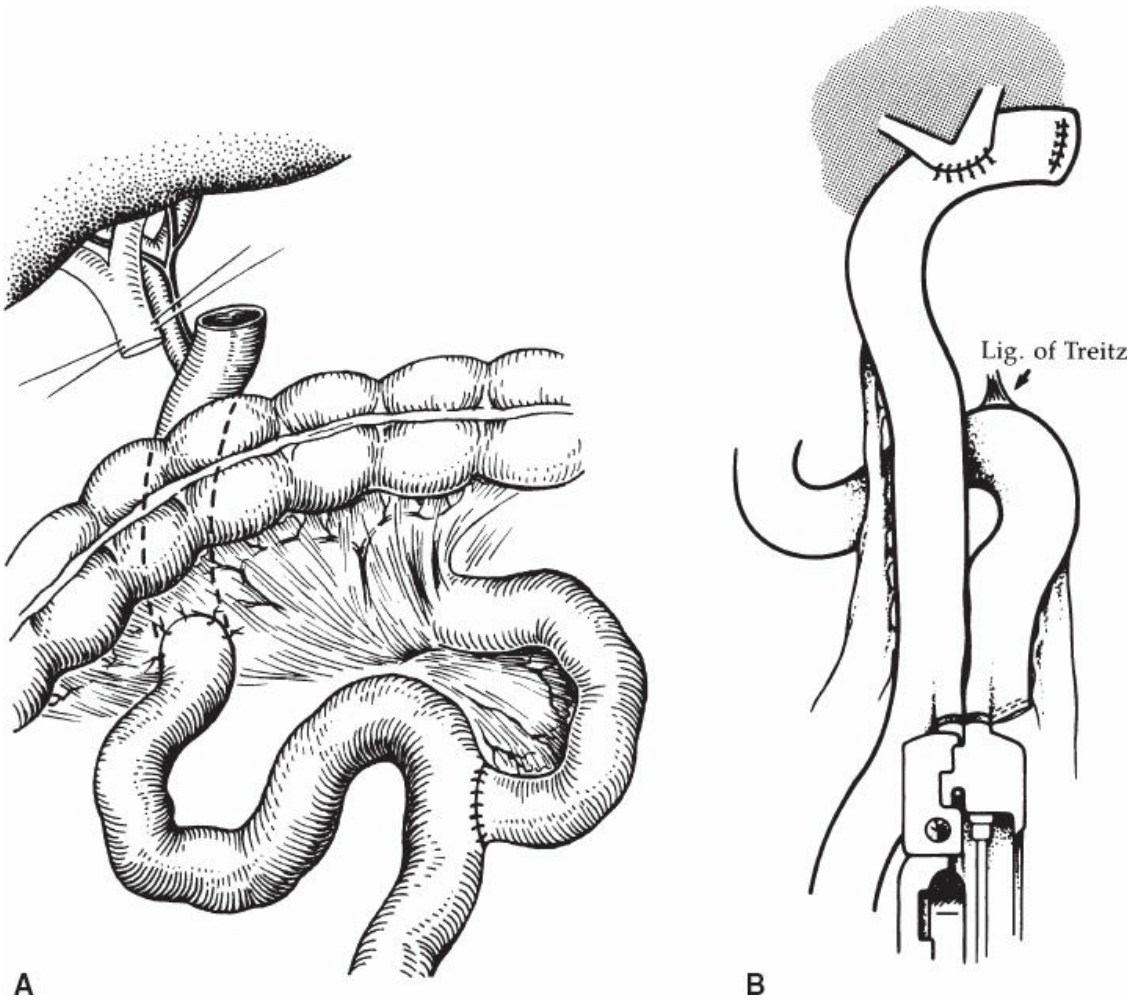

Figure 115.7. A. The end-to-side anastomosis of the Roux-en-Y is constructed, and the ascending limb of jejunum measuring approximately 45 cm is brought through the mesocolon toward the severed common duct. **B.** The construction of a Roux-en-Y enteroenterostomy using the linear stapler and the completed end-to-side hepaticojejunostomy.

The anterior wall of the end-to-end anastomosis is constructed in a similar manner. Starting on each corner, inside-outside-outside-inside sutures are placed and the knots tide inside the lumen, gradually working from both corners toward the center (Fig. 115.8C). The last sutures in the center of the anterior wall (simple or gumby sutures) are placed and tied on the outside. These last sutures are all placed before being tied to achieve secure closure and to avoid damage to the posterior anastomotic wall (Fig. 115.8D). When doing an end-to-end anastomosis, we find it unnecessary to use stents.

Much more commonly performed is the end-to-side mucosa-to-mucosa choledochojejunostomy or hepaticojejunostomy, which facilitates adjusting the size of the anastomosis to the diameter of the bile duct (Fig. 115.9). It is our conviction that all such biliary-enteric anastomoses should be performed under magnification to ensure exact mucosa to mucosa approximation. The proximal end of the jejunal limb, which was stapled by the GIA stapler, is secured with a second layer of absorbable sutures (Fig. 115.9). Approximately 5 cm proximal to this closure, on the antimesenteric aspect of the intestine, a one-layer biliary-enteric anastomosis is fashioned. Sometimes, it is convenient to approximate and align the seromuscular layer of the bile duct and the jejunal serosa by a few or 4-0 sutures (Fig. 115.9A).

Using electrocoagulation, the jejunum is opened longitudinally to accommodate the width of the bile duct (Fig. 115.9B). Care should taken not to open too much of the jejunum.

To facilitate an accurate and meticulous biliary-enteric anastomosis, we use and advocate the technique published by Blumgart (Fig. 115.10). The first step is to introduce the anterior layer sutures (4-0 or 5-0 absorbable, preferably monofilament) in the proximal duct, the needles being passed from inside-out and placed on rubber shods (Fig. 115.10A). The entire row of sutures so placed is carefully elevated enabling exact placement and tying of the sutures of the posterior layer (Fig. 115.10B).

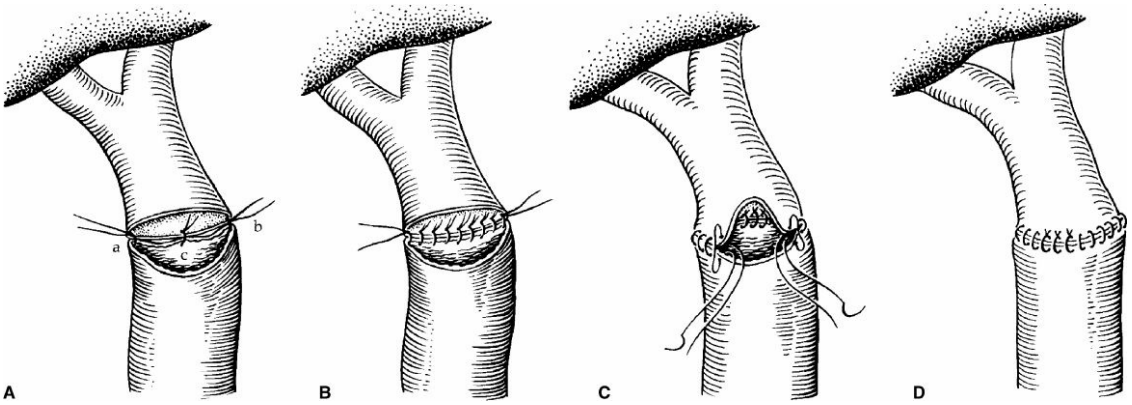

Figure 115.8. Construction of an end-to-end biliary-enteric anastomosis in a very dilated biliary system. **A.** Placing of the first anchoring sutures (a–c). **B.** The knots of the posterior wall are all placed inside toward the lumen, 2 to 3 mm apart. **C.** Note the inside-outside/outside-inside sutures when advancing toward the anterior wall. **D.** The last sutures in the center of the anterior wall are knotted on the outside.

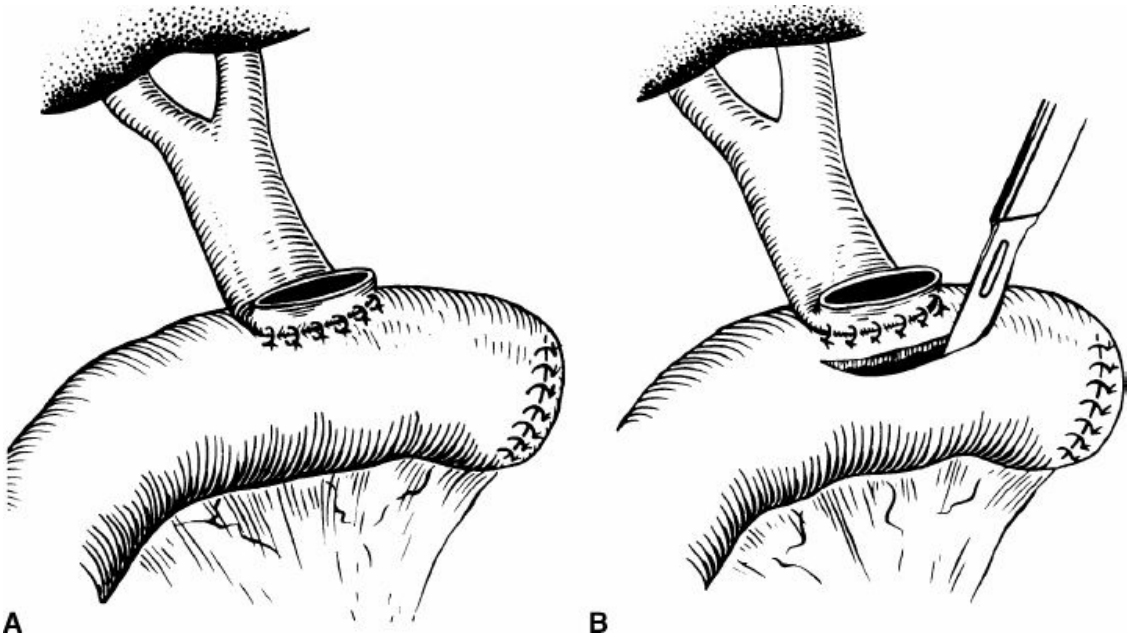

Figure 115.9. Construction of an end-to-side choledochojejunostomy. The proximal end of jejunum is stapled or sutured. **A.** Seromuscular layer of posterior wall, for approximation and anchoring. **B.** A longitudinal opening on the antimesenteric part of intestine.

Now the anterior wall closure is completed with the needles previously placed through the ductal anterior wall being placed through the jejunal wall from the outside inwards (Fig. 115.10C). The entire anterior row of sutures is passed before being securely tied with the knots inside.

Meticulous mucosa-to-mucosa approximation without tension is of prime importance for a safe and long-lasting patent anastomosis. This anastomosis is rarely stented. If needed, our preference is a T-tube with its short arm in the bile duct and the long one in the lumen of the intestine (Fig. 115.11A). The loosely fitting T-tube should be brought out through a stab wound in the anterior wall of the bile duct, if only possible. Bringing out the T-tube limb through a small incision in the jejunal loop is less desirable, because it can be dislodged by intestinal peristalsis. The external limb of the T-tube should never be passed through the anastomotic line. The long vertical portion of the T-tube is brought out through a separate stab wound in the abdominal wall (Fig. 115.11A) and should have some intra-abdominal redundancy to prevent traction and dislodgement of the tube if the patient's bowel becomes distended. Another option to stent the biliary-enteric anastomosis is to pass a long silicone tube with many holes cut along its length via the liver into the biliary system and through the anastomosis (Fig. 115.11B).

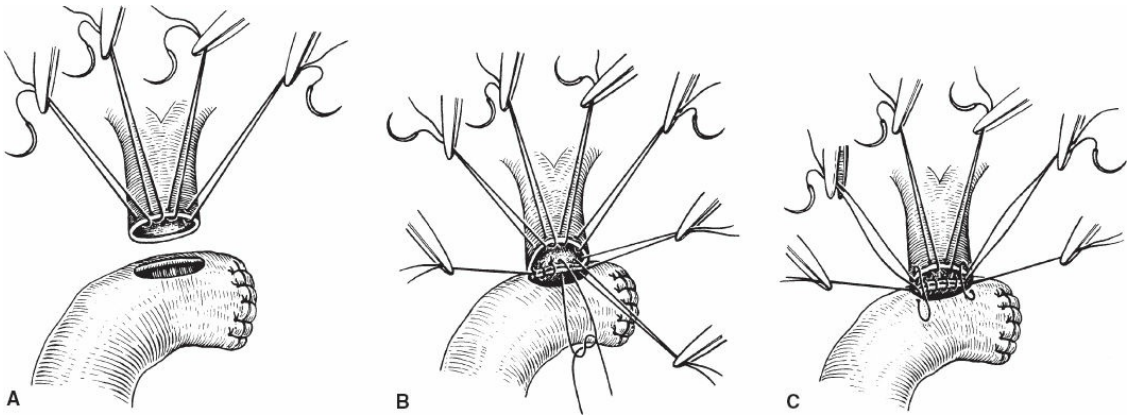

Figure 115.10. Modified after Blumgart surgery of the liver and biliary tract. **A.** The anterior layer of sutures on the bile duct is inserted first, with the sutures being passed from the inside out. The needles are retained and the sutures kept in order on rubber shods. **B.** The anterior layer of sutures is elevated to clearly display the posterior ductal wall. The posterior row of sutures is now placed and tied, using full thickness of duct and intestine with mucosa to mucosa approximation. **C.** The needles of the anterior layer are now passed through the jejunal wall from the outside inward. The entire anterior row of sutures is completed before being securely tied with the knots within. (Modified from Blumgart LH, ed. *Surgery of the Liver and Biliary Tract*. 2nd ed. London: Churchill Livingstone; 1994. Copyright Elsevier.)

Hepaticojejunostomy is the most commonly reconstructive procedure used for laparoscopic cholecystectomy-induced bile duct damage, 98% in a study of 200 repairs of damaged bile ducts.

The procedure is not only successful in about 93% of reconstructions but also affords favorable results that are comparable to patients undergoing uneventful laparoscopic cholecystectomy.

In small ducts one might anchor a short piece of a small bore silicon tubing to the center suture of the posterior layer for temporary stenting.

When the sutures dissolve, the stent passes out through the gastrointestinal tract.

At the completion of the anastomosis, the jejunal limb should be anchored to surrounding structures, mainly the hepatoduodenal ligament and scar tissue at the hilus of the liver to avoid unnecessary tension on the biliary-enteric anastamosis (Fig. 115.11A).

Some surgeons find it useful to suture a piece of the Roux limb to the abdominal wall and mark it with surgical clips for future injection of contrast material if and when radiography of the reconstructed biliary system is required.

If the biliary ductal system is narrow, we advocate the use of the side-to-side Y-type biliary-enteric bypass (hepatocholedochojejunostomy). A Y-shaped opening is made with two arms extending into the right and left hepatic ducts and the third arm extending longitudinally into the common hepatic duct. All limbs of the Y-shaped incision should be as long as possible (Fig. 115.12A). A 2- to 3-cm longitudinal incision is made in the jejunal loop that is brought up to the hilus of the liver, with care being taken not to open too much mucosa (Fig. 115.12B). A one-layer biliary-enteric anastomosis is constructed with 4-0 or 5-0 monofilament synthetic absorbable sutures. The posterior layer is created by first attaching points A to A′, B to B′, and C to C′ (Fig. 115.12B), and the rest of the posterior wall is completed with sutures placed approximately every 2 mm (Fig. 115.12C). The anterior layer is created by attaching D to D′ and suturing the rest of the distance between AA′ and BB′. The jejunal limb of the completed anastomosis should be anchored with a few sutures to fibrous tissue at the hilus and capsule of the liver.

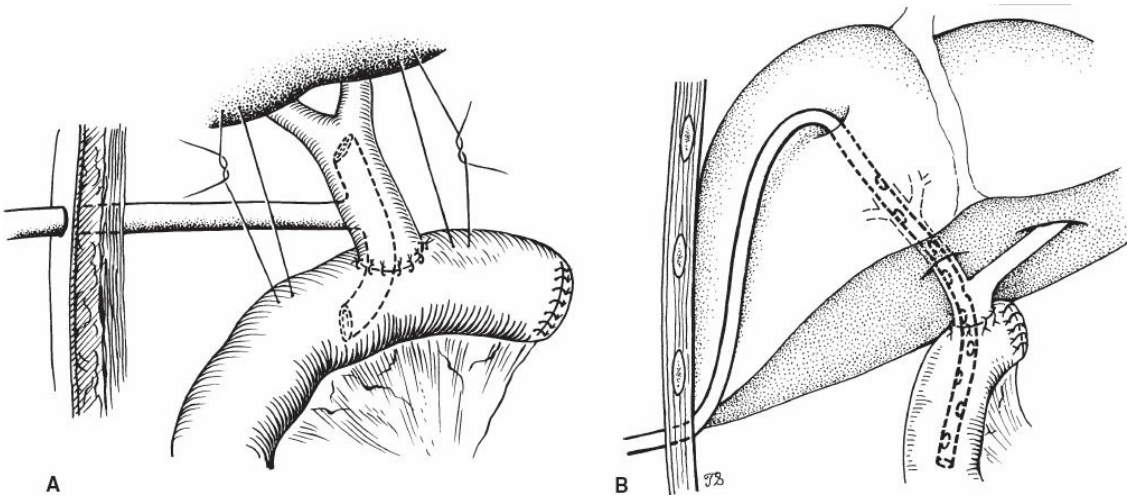

Figure 115.11. A. If required, a loosely fitting T-tube can be inserted through the anterior wall of the bile duct and passed through the biliary-enteric anastomosis into the intestine. The vertical portion of the T-tube is passed through a separate incision in the abdominal wall. The jejunal limb is anchored by two sutures to the undersurface of the liver or to surrounding structures. **B.** Another option to sent a biliary-enteric anastomosis is to pass a long silicone tube with several holes cut along it through the liver into the biliary ductal system and past the anastomosis into the intestine.

By patching the jejunum into the widest area of a narrow biliary ductal system, namely, at the confluence of the right, left, and common hepatic ducts, a widely open and effective biliary-enteric anastomosis is achieved.

When dealing with malignant obstructions of the biliary system, for which a bypass procedure only seems advisable and sufficient, we tend to use a simpler and less time-consuming biliary-enteric anastomosis. Either the dilated common duct proximal to the site of obstruction is divided and anastomosed in an end-to-side manner to the first loop of jejunum (Fig. 115.13), or an even simpler side-to-side choledochojejunostomy can be fashioned (Fig. 115.14). Both procedures are performed as a one-layer anastomosis. These two techniques of choledochojejunostomy (Figs. 115.13 and 115.14) offer better decompression and drainage of the biliary tract than does a cholecystojejunostomy and are thus preferable if the general condition of the patient and the local findings during the operation make it reasonable and feasible. As a general rule, we do not stent this anastomosis. Some patients will also undergo in addition a gastrointestinal bypass to avoid subsequent future gastric outlet obstruction.

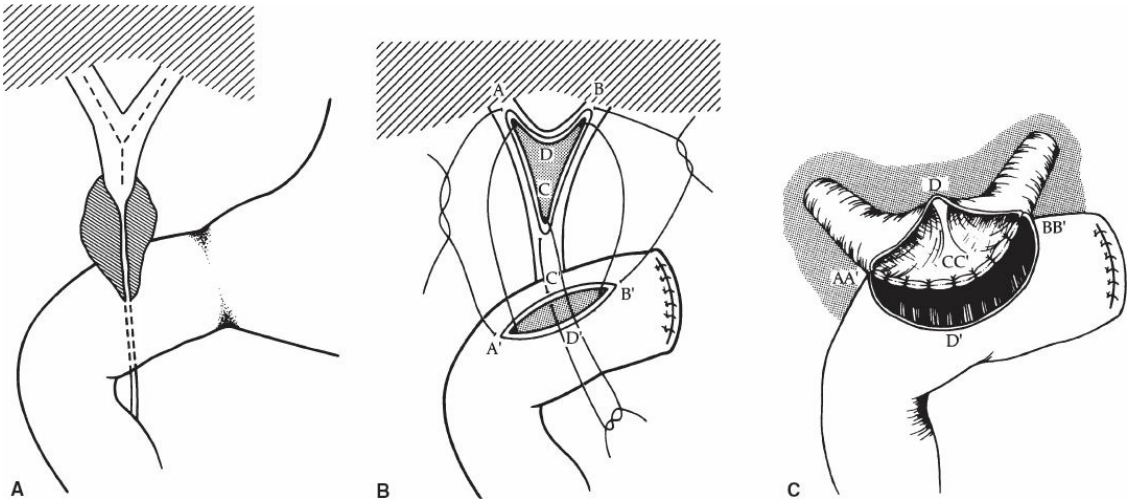

Figure 115.12. A. The Y-shaped incision is made above the point of obstruction with two arms extending into the right and left hepatic ducts and the third arm extending into the common hepatic duct. **B.** A longitudinal incision is performed in the defunctionalized loop of jejunum. The Y-shaped incision opens up into a three-angled opening. The posterior layer of the hepatocholedochojejunostomy is constructed by first attaching points A to A′, B to B′, and C to C′. **C.** The posterior layer of the hepatocholedochojejunostomy is completed. The anterior layer will be fashioned by attaching D to D′ and then suturing of the rest of the distance between AA′ and BB′.



Figure 115.13. End-to-side choledochojejunostomy using a loop of proximal small intestine. (The bowel can be passed retrocolic or antecolic.)

Although the basic principles of a tension-free, mucosa to mucosa, well-vascularized anastomosis that drains all parts of the liver still hold

true, recent publications suggested other techniques to cope with the very small or very short hepatic duct remnant. One such technique applied in a small number of patients described a sutureless cholangio-jejunostomy using an intraluminal stent, while another group utilized a side-to-side hepatico-jejunostomy technique in difficult post-laparoscopic cholecystectomy bile duct injury repairs.

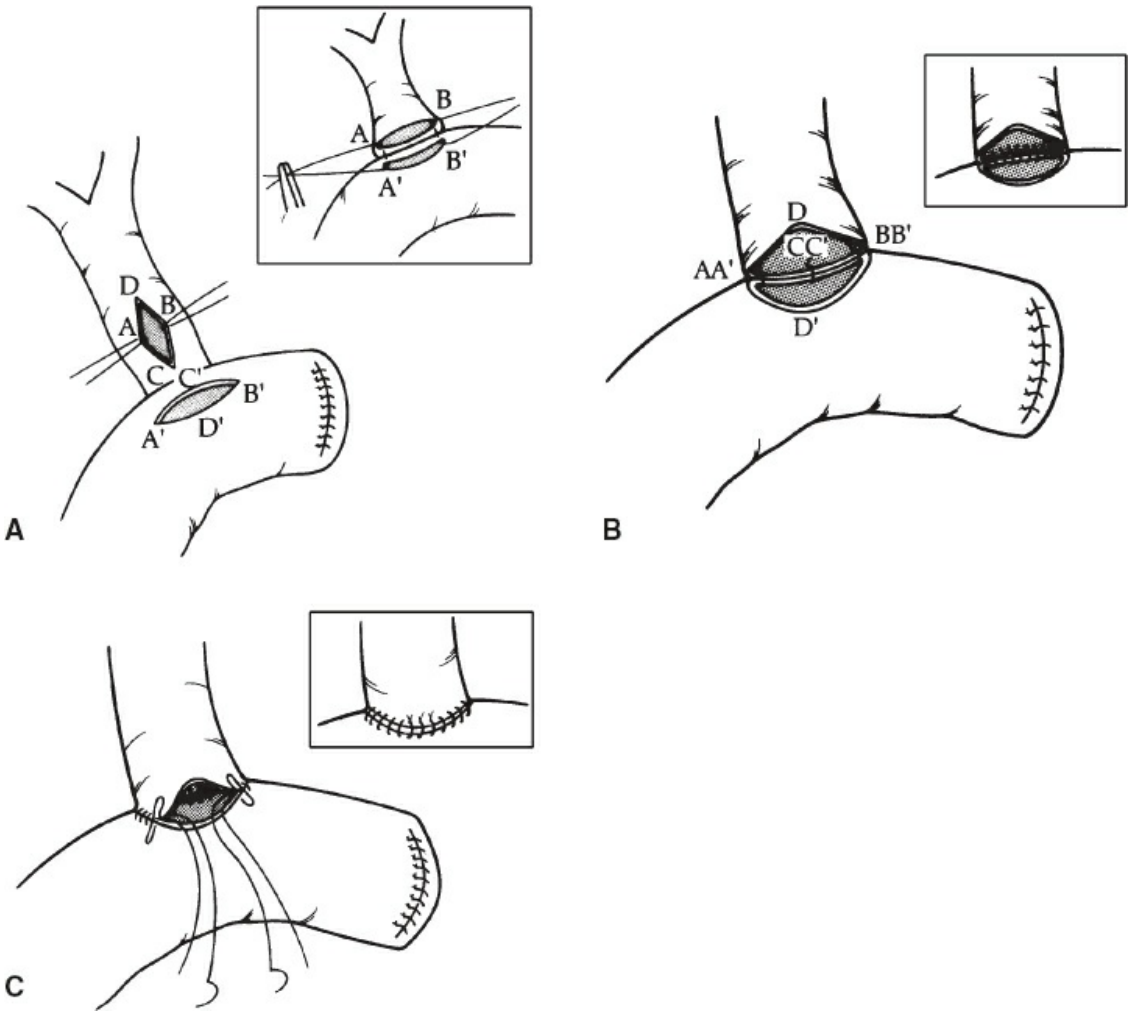

Figure 115.14. Side-to-side choledochojejunostomy. **A.** The longitudinal incisions in the common duct and the adjacently placed loop of excluded jejunum are converted by placing two anchor sutures into transverse incisions (**inset**). The diameter of the anastomosis should be made as large as possible, depending on the size of available common duct. **B.** The posterior wall of the choledochojejunostomy is initiated by placing the corner (AA′ and BB′) and center (CC′) sutures. The posterior wall is a one-layer anastomosis of interrupted synthetic absorbable sutures placed 2 to 3 mm apart (**inset**). **C.** The anterior wall is sewn by interrupted inside-outside-outside-inside sutures. The last sutures in the center of the anterior wall are placed and knotted on the outside

(**inset**).

For such injuries with short and/or small bile ducts, the anterior surface of the available bile duct is exposed and opened longitudinally on its anterior surface to its maximal available length. Mobilization of the duct should be minimal to avoid ischemia to the duct.

A 5-0 absorbable one-layer side-to-side bilio-digestive anastomosis was reported with a reasonable success rate in a limited and select group of patients with both benign and malignant diseases.

Compared to the end-to-side hepatico-jejunostomy, the side-to-side anastomosis requires less dissection, permits a wider anastomosis, and reports a 95% excellent functional end result.

LAPAROSCOPY

Despite major advances in laparoscopic surgery, the experience with laparoscopic choledoco/hepaticojejunostomy is still limited. Even more limited are data comparing laparascopic versus open biliary bypass surgery. Laparascopic choledocho/hepaticojejunostomy is a technically demanding procedure that requires advanced laparoscopic skills. However, if performed by an experienced laparascopic surgeon while maintaining the same principles of the open approach can offer the same biliary diversion success rates with reduced morbidity and mortality.

POSTOPERATIVE CARE

If the use of a drain seems appropriate, a closed system soft drain is placed in the foramen of Winslow and brought out through the abdominal wall, to be usually removed within 72 hours after the operation. In case of bile leak, the drain is left in place as long as necessary. Almost all such biliary fistulas close spontaneously within 1 to 3 weeks. We use nasogastric drainage and intravenous therapy for 3 to 5 days, depending on the general condition of the patient and the resumption of bowel sounds and movement. Antibiotics are continued for 3 to 5 days and should be adjusted in accordance with the cultures obtained during surgery.

Suggested Readings

Blumgart LH, Benaimin JS. Intrahepatic biliary-enteric anastomosis In: Blumgart LH, ed. *Surgery of the Liver and Biliary Tract.* 2nd ed. London: Churchill Livingstone; 1994:1051.

Fischer JE. Is damage to the common bile duct during laparoscopic cholecystectomy an inherent risk of the operation? *Amer J Surg* 2009;197:829–32.

Freund HR, Rivkind AI, Berlatzky Y. Construction of a wide open side to side hepatico- choledochoduodenostomy in a narrow biliary ducted system. *Surg Rounds* 1994;459.

Huser N, Michalski CW, Schuster T, et al. Systemic review and meta-analysis of prophylactic gastroenterostomy for unresectable advanced pancreatic cancer. *Br J Surg* 2009;96:711–9.

Lillemore KD, Melton GB, Cameron JL, et al. Postoperative bile duct strictures: management and outcome in the 1990s. *Ann Surg* 2000;232:430–41.

Sicklick JK, Camp MS, Lillemore KD, et al, Surgical management of bile duct injuries sustained during laparoscopic cholecystectomy: perioperative results in 200 patients. *Ann Surg* 2005;241:786.

Toumi Z, Aljarabah M, Ammori BJ. Role of the laparoscopic approach to biliary bypass for benign and malignant biliary diseases: a systematic review. *Surg Endosc* 2011;25(7):2105–16.

Way LW, Stewart L, Walter G, et al. Causes and prevention of laparoscopic bile duct injuries. *Ann Surg* 2003;237:460–9.

Winslow ER, Fialkowsky EA, Linhan DC, et al. “Sideways”: results of repair of biliary injuries using policy of side-to-side hepatico-jejunostomy. *Ann Surg* 2009;249:426–34.

EDITOR’S COMMENT

The introduction to this excellent chapter places these operations in proper perspective. The mortality of pancreaticoduodenectomy now is well below 3% to 5% and morbidity has dropped to 25% to 30% in high-volume centers. Even in nonmajor centers, mortality of 7% to 10% and morbidity of 30% to 45%, as Professor Freund says, are significantly reduced. As usual, despite the fact that survival following Whipple for 5 years may be improved the survival with biliary bypass remains up to 9 months if done properly. Today endoscopic stenting is far and away the most common technique. Distler et al. (*JOP* 2010;11:568–74) sought to determine if surgical or nonsurgical management was the most appropriate therapy for the treatment of obstructive jaundice in the palliative setting. In a carefully conducted study with a large number of patients, they showed that there was no evidence that stenting for obstructive jaundice does anything positive and in fact is associated with more common readmission and infection. They reviewed 342 patients over an 8-year period who were treated in one of three ways. Group 1 (138 patients or 56%) received only endoscopy and a prosthesis for drainage, Group 2 (68 patients or 28%) received

preoperative stenting followed by hepaticojejunostomy, and Group 3 (41 patients or 16%) received only a hepaticojejunostomy. Also, 261 patients or 76% had obstructive jaundice. The mortality in Group 1 was 2.2% and morbidity was 5.1%. In Group 2 morbidity was 17.6% but there was no mortality and in Group 3 mortality was 2.4% and morbidity 15%. The exchange of the endoscopic stent (if carried out) was required every 70 days and required hospitalization. Survival in Group I was 5.1 months and, in those that were stented and subsequently treated with hepaticojejunostomy (Group 2), 9.4 months. Median survival, however, in Group 3 was 6.4 months. The leakage rate in Group 3 was 9.8% while only two patients had a leak in Group 2. There was one patient with a pancreatic leak from an FNA. The results suggest that there is longer survival following hepaticojejunostomy. The data leave open the question as to whether or not preoperative stenting is helpful; previous studies have not shown any advantage to preoperative stenting. Although as per Table 2 in Distler's paper, patients who had undergone surgical bypass did not outlive those who had undergone endoscopic stenting, most of these studies are outdated; moreover, the ability to support patients with unresectable carcinoma of the pancreas or the lower end of the biliary tree has improved. What this study suggested at the time is that patients who have a life expectancy of greater than 6 months should have a hepaticojejunostomy without a stent prior to the operation. A similar conclusion was reached by van Heek et al. (*Acta Gastroenterol Belg* 2002;65:171–5).

Advances in the types of stents have improved the outcomes and reduced the need for stent changes. Usually a wall stent is deployed and this is very effective normalizing the bilirubin level. The studies comparing biliary bypass and stents are outdated and indeed the vast majority of patients are treated with stents and have a good outcome. There are no recent studies largely owing to the realization that endoscopic stenting for a terminal disease is superior to surgery. It corrects the problem and allows the patient to receive treatment without delay.

Still biliary enteric bypass with either hepaticojejunsotomy, choledochojejunostomy, or choledochoduodenostomy may be required in certain patients. Indeed choledochoduodenostomy may be superior as shown in some studies of liver transplantation. Bennett et al. (Choledochoduodenostomy is a safe alternative to Roux-en-Y choledochojejunostomy for biliary reconstruction in liver transplantation. *World J Surg* 2009;33:1022–5) have extensive experience in liver transplantation. In 619 liver transplants between 2000 and 2007, the usual biliary anastomosis was direct end to end, which was performed in 466 patients. Of 82 pediatric transplants with a cadaver liver, a direct common duct and duodenal anastomosis was carried out in 25 patients and choledochojejunostomy in 57. There were four leaks in the choledochojejunostomies, but none in the choledochoduodenostomies (Table 1 of that paper).

A somewhat different point of view was proposed by Wu et al.

(Choledochoduodenostomy as an alternative to choledochojejunostomy for biliary reconstruction in liver transplantation. *World J Surg* 2010;34:1727) in a letter in which they pointed out that the blood supply of the common duct that is pictured may be deficient because the biliary tract of the donor may be too long and may cause necrosis of the proximal biliary tract due to limited blood supply. They also raised questions concerning the incidence of cholangitis in the biliary choledochoduodenostomy patients. Campsen et al. (*World J Surg* 2010;34:1728–9) in their response to Wu's letter pointed out that they used the duodenum as the preferred site in a hostile abdomen and that with the portal vein clamping the duodenal blood supply may be superior to that of the bowel or the Roux-en-Y approach. Similarly, they pointed out that many of the pediatric transplants take place in children who have had neonatal enterocolitis and multiple perforations and may have short bowel syndrome, so that it is preferable to avoid further shortening of the bowel. They also pointed out that in the 40 patients who had choledochoduodenostomy there were no strictures and there is no bowel bile reflux as they ligated the native common bile duct. Tanaka et al. (Biliary reconstruction in pediatric live donor liver transplantation: duct-to-duct or Roux-en-Y hepaticojejunostomy. *J Ped Surg* 2010;45:1668–75) reviewed 60 pediatric patients who had biliary enteric anastomoses, with 14 having a choledochoduodenostomy and 46 having a Roux-en-Y jejunostomy. The leak rates were identical, with a 7.1% in the duodenal anastomosis and an 8.7% in the jejunal anastomosis. Strictures, however, were more common in the duodenal anastomosis (28.9% vs. 18.9% in the jejunal anastomosis). Years ago when debate raged about these procedures Bob Herman at the Cleveland Clinic made an excellent case for choledochoduodenostomy and had excellent outcomes.

Pilgrim et al. (Gallbladder carcinoma as a long-term complication of cholecystojejunostomy. *J Gastrointest Surg* 2009;13:2330–2) drew attention to various forms of carcinoma complicating various biliary enteric anastomoses. The initial case description was that of an 81-year-old patient who had a mistaken diagnosis of pancreatic carcinoma and was palliated with cholecystojejunostomy. He appeared 22 years later with a gallbladder cancer at the site of the anastomosis. In his review Tocci points out that the rate of cancer 30 years later in 1,003 patients was 5.5% and that this was higher in patients with choledochoduodenostomy as compared with hepaticojejunostomy or transduodenal sphincteroplasty (7.6% vs. 1.9% vs. 4.8%). He pointed out that most of the patients with cholangiocarcinoma had intermittent cholangitis. Tocchi et al. (*Ann Surg* 2002; 234:210–14). This raises the question as to whether patients with long-term biliary enteric anastomosis should undergo surveillance, especially with repeated episodes of cholangitis.

Whichever technique the surgeon chooses it should be the one he or she is most familiar with and most applicable to the patient situation.

J.E.F. and E. Christopher Ellison

116 Operative Treatment for Choledochal Cysts

Charles E. Bagwell and Hadley Katharine Wesson

INTRODUCTION

Choledochal cyst (CC) is a pathologic dilatation of the biliary system felt to be congenital in origin that can involve the common, hepatic, and intrapancreatic bile ducts in a variety of ways. These cysts are uncommon with an incidence of 1 in 100,000 to 150,000 live births, although in Asia the incidence is much higher. CCs are usually diagnosed in children; approximately 15% are discovered antenatally or in the first year of life and 60% in the first decade. However, the remaining 25% of CCs are diagnosed in the adult population, often presenting either as an incidental finding on imaging studies or with nonspecific symptoms such as abdominal pain. Treatment of CCs is based on the type of CC, presenting symptoms, and the potential for long-term serious sequelae, including malignancy. Accordingly, it is important for the general surgeon to understand an approach for both the recognition of and surgical options for CCs and how this approach may differ between children and adults.

ETIOLOGY AND PATHOPHYSIOLOGY

While the etiology of CCs is unknown, the most widely accepted theory involves an anomalous pancreaticobiliary duct junction (APBDJ). This malformation occurs in 50% to 80% of all CCs and between 80% and 96% of CCs in children. An APBDJ occurs when the common bile duct (CBD) and pancreatic duct join outside the duodenum (Fig. 116.1). It is thought that this common channel may allow pancreatic fluid to reflux into the biliary system and elevate the CBD pressure, causing ductal dilation and subsequent cellular damage. As a result, biliary epithelium may undergo dysplastic changes over time, increasing the risk of malignant transformation in the cyst wall.

CLASSIFICATION

CCs are classified according to their location (extra- or intrahepatic), extent of disease (segmental or complete), and shape (cystic, saccular, and fusiform) based on a system first proposed in 1959 by Alonso-Lej and modified nearly 20 years later (1977) by Todani (Fig. 116.2). Type I CCs are the most common, accounting for 80% to 90% of CCs. They involve dilated extrahepatic biliary ducts with normal intrahepatic ducts. Some recent schema subdivide type I CCs into subtypes A, B, and C based on dilation of the extrahepatic ducts only (A), isolated dilation of the distal CBD (B), or fusiform dilation of the extra hepatic ducts with APBDJ (C). In reality, this subdivision seems more arbitrary than beneficial in planning treatment or assessing outcome.

Type II cysts are true diverticula of the CBD and account for only 2% of all CCs. They may appear on ultrasound studies as cysts opposite the CBD with a normal appearing gallbladder and common hepatic duct.

Type III CCs are choledochoceles: cystic dilations of the most distal aspect of the CBD. Regarding the nomenclature, some argue, even quite emphatically, such as Ronald Martin in his recent critique of the CC classification scheme, that the term “type III choledochocele” is frequently used, but is incorrect. These cysts should either be referred to as type III CCs or choledochoceles. There is a further subclassification scheme for type III CCs, but given they are so rare (<1% of all CCs), the clinical application of this subclassification is arguably negligible. Due to their close proximity to the ampullary orifice, pancreaticobiliary outflow can become obstructed, making pancreatitis or biliary obstruction common presenting symptoms. Very large type III CCs can even obstruct the duodenum.

Type IV CCs are biliary duct cysts classified according to their involvement of the intra- and extrahepatic ducts. Type IVA cysts extend along the entire biliary system from the CBD into the intrahepatic biliary tree. Strictures within the ducts are often present. Type IVB involves the extrahepatic duct only and can present with multiple ductal dilations resembling a “string of beads” on cholangiography. The distinction between types A and B is important in terms of operative planning.

Type V CCs involve multiple dilations of the intrahepatic biliary ducts; contrast-filling multiple intrahepatic cystic dilations is pathognomonic, often termed Caroli disease. A “central dot sign” may be seen on magnetic resonance cholangiopancreatography (MRCP) or CT as portal vein enhancement within the dilated ducts. A type V CC is termed Caroli

syndrome when associated with congenital hepatic fibrosis and if severe enough, can present with cirrhosis.

CLINICAL PRESENTATION

CCs in children and adults often present with differing signs and symptoms. In children, the classic triad of abdominal pain, palpable abdominal mass, and jaundice occurs more frequently; 85% of children have at least two of these symptoms, compared to only 25% of adults. Unlike adults, infants can present with obstructive jaundice, acholic stools, and hepatomegaly—resembling patients with biliary atresia.

Adults are more likely to present with abdominal pain, cholangitis, pancreatitis, or history of prior cholecystectomy. Given these nonspecific symptoms, there may be a prolonged delay in making the diagnosis, with an average of 6 years in some series. Cholangitis results from chronic biliary tract inflammation; in type IVA and V CCs, recurrent cholangitis is due to bacterial colonization of intrahepatic cysts from bile stasis, sludge, and stones. Pancreatitis can result from proteinaceous plugs in the pancreatic duct as a result of chronic inflammation and mucin hypersecretion from dysplastic epithelium. CCs can also be asymptomatic, diagnosed incidentally from imaging studies obtained for other reasons.

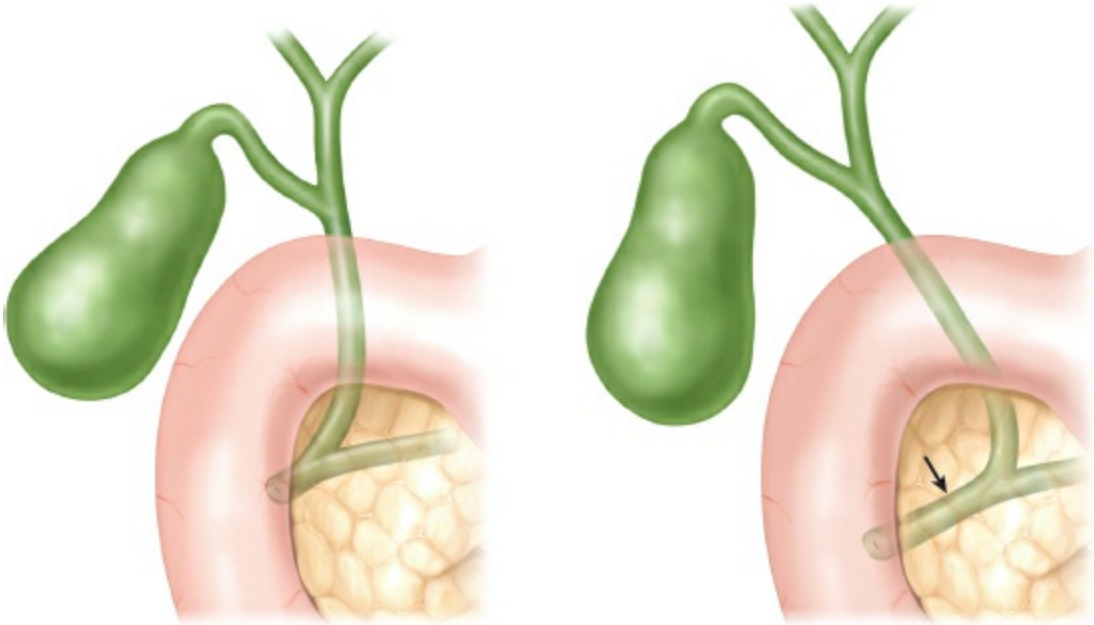

Figure 116.1. Normal anatomy (**left**); anomalous pancreaticobiliary duct junction (**right**).

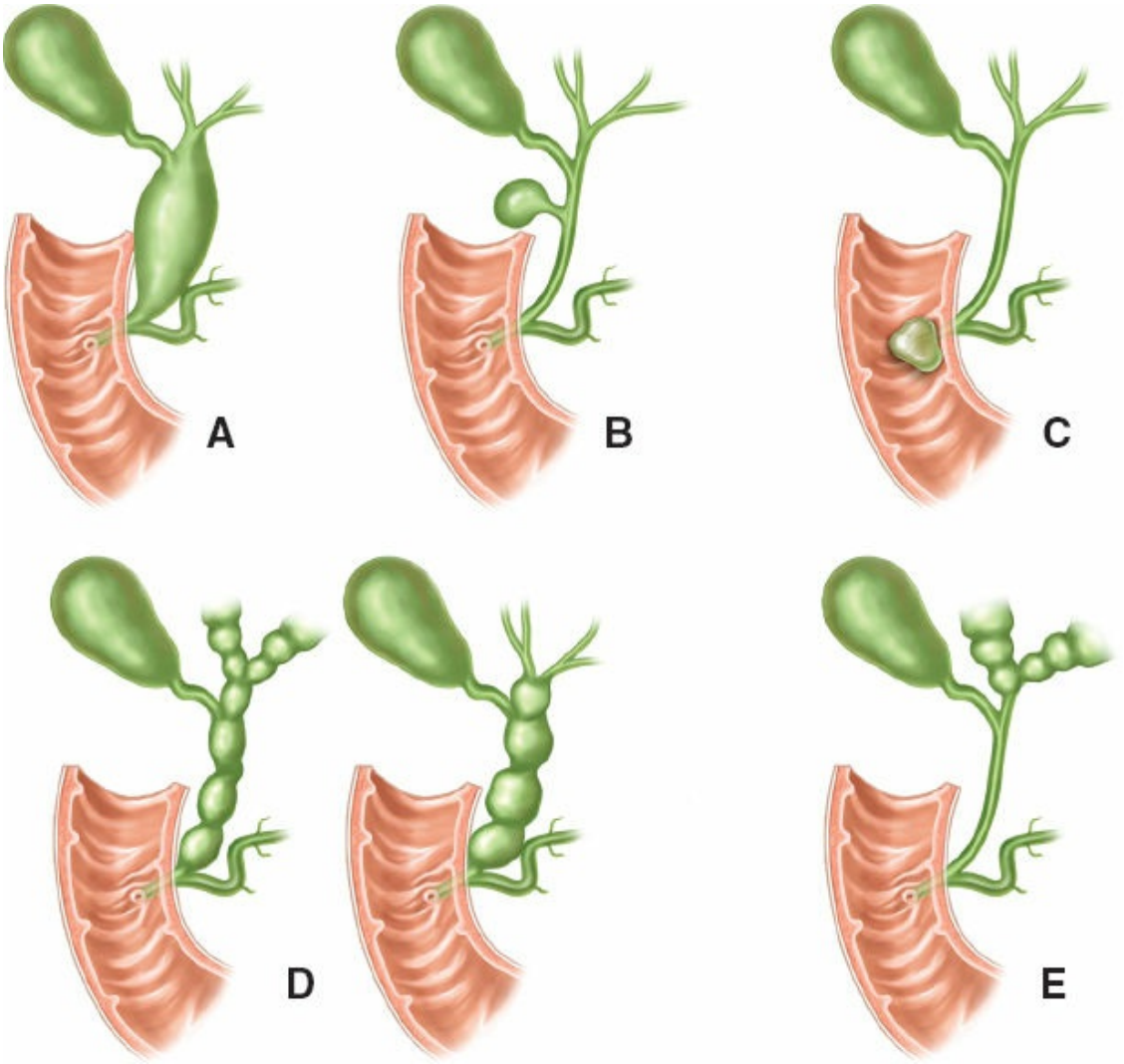

Figure 116.2. Classification of choledochal cysts. **A.** Type I; **B.** Type II; **C.** Type III (choledochocele); **D.** Type IV A (**left**); IV B (**right**); **E.** Type V (Caroli disease).

MALIGNANCY

Biliary malignancy occurs in 10% to 30% of CCs, with the age at diagnosis related to the risk of developing malignancy in the biliary system. Approximately 70% of biliary malignancies from CCs are cholangiocarcinoma and 24% are gallbladder adenocarcinoma. Children with CCs have a very low risk of developing cholangiocarcinoma. Sastry et al.'s 2015 review of 5,780 cases of CCs reported an incidence of only 0.42% in children younger than 18 years of age. This risk increases to 15% at age 20 and 45% at age 50. Previous episodes of cholangitis and internal drainage procedures are also associated with increased risk of CC-related malignancy. It is noteworthy that neoplasm rates are greatly influenced by the type of CC: the greatest risk is seen in cyst types I and IV, while types

II, III, and V have very low risks of cancer.

DIAGNOSIS

CCs can be diagnosed with multiple imaging modalities, including ultrasound, CT, MRCP, and endoscopic retrograde cholangiopancreatography (ERCP). Because right upper quadrant pain and jaundice are common presenting symptoms, ultrasound is usually the first imaging study obtained. Ultrasound can quantitate intrahepatic and CBD dilatation, particularly if the CBD is greater than 10 mm in diameter. Usually ultrasound can distinguish the gallbladder from a type II CC. On the other hand, ultrasound may fail to diagnose up to 30% of CCs; even if a dilated CBD is visualized, the differential diagnosis still remains broad and includes malignancy and stone impaction. Oftentimes, the clinician will obtain a CT scan next. Arguably this is of limited value, as CT does not adequately assess the extent of extra- and intrahepatic biliary ductal dilatation and usually requires follow-up imaging with MRCP.

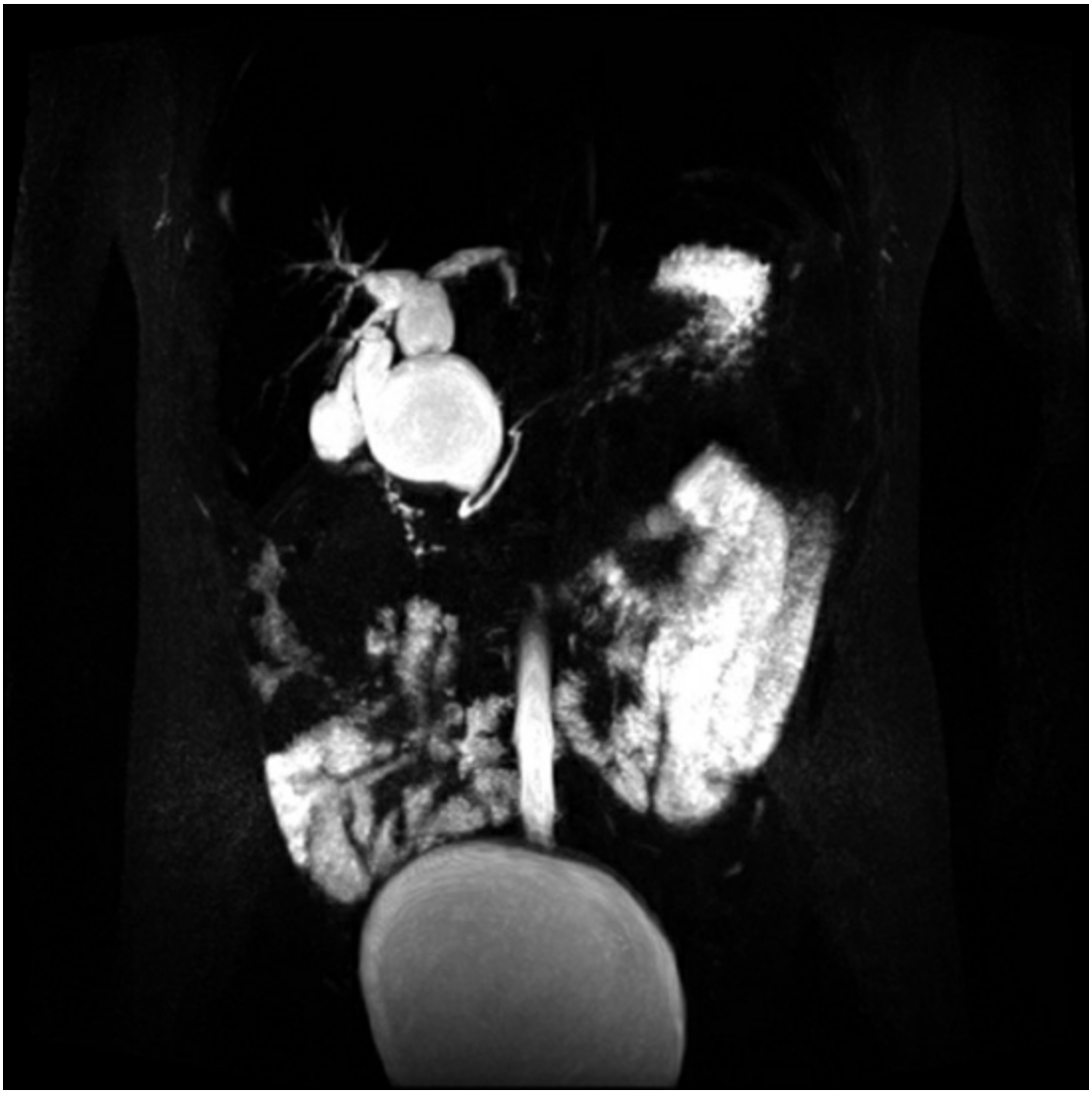

Figure 116.3. MRCP of type I choledochal cyst. Note dilated hepatic ducts and normal pancreatic duct.

At present MRCP is the diagnostic test of choice; it provides excellent imaging of the pancreaticobiliary ductal system and is both sensitive and highly specific for the anatomic definition of CCs, ranging from 70% to 100% and 90% to 100%, respectively (Fig. 116.3). It is noninvasive and can demonstrate the pancreatic and biliary ducts proximal to sites of obstruction as well as assess the presence of APBDJ, cholangiocarcinoma, and/or choledocholithiasis. However, MRCP may be of limited use in infants and younger children if the ducts are too small to be well visualized.

In adults, ERCP can be useful to outline the pancreaticobiliary duct system. For choledochoceles, ERCP can be both diagnostic and therapeutic, providing biliary drainage of the cyst with sphincterotomy, if

indicated. Percutaneous transhepatic cholangiography (PTC) may be necessary for some type IV and V cysts in order to visualize the entire biliary system (including intrahepatic cysts). In addition, PTC may be necessary for placement of transhepatic stents pre- or postoperatively. Although ERCP and PTC are sensitive imaging modalities, they may be technically challenging in the infant or small child, even under general anesthesia.

TREATMENT

The treatment of CCs is dependent on patient symptoms and the size and type of the cyst. Definitive treatment involves complete excision of the cyst to avoid the consequences of cholangitis, liver cirrhosis, pancreatitis, and malignancy. For type I cysts, management has evolved over the last 30 years from internal drainage of the cyst (cyst-duodenostomy) to complete excision, usually with Roux-en-Y hepaticojejunostomy reconstruction. This can be done either open or laparoscopically by first mobilizing the hepatic flexure and performing a Kocher maneuver to expose the cyst, and then encircling the cyst as it extends behind the duodenum (Fig. 116.4). Gallbladder mobilization will often assist in defining the cyst anatomy and serves as a retractor in subsequent dissection.

Further dissection of the cyst wall should proceed caudally onto the head of the pancreas, where the cyst should be divided as low as possible to remove all dysplastic epithelium but without compromise to the pancreatic duct (Fig. 116.5). In most cases, the posterior aspect of the cyst can then be dissected away from the underlying portal vein and hepatic artery (Fig. 116.6). If scarring is present, which may be the case in older patients with recurrent episodes of cholangitis, the cyst epithelium can be dissected off the fibrotic back wall, leaving behind only the fibrous layer of the posterior cyst wall (Lilly's procedure) (Fig. 116.7).

Once the hepatic duct confluence is exposed, the cyst can be transected proximally (Fig. 116.8). A note of caution: identifying the optimum level to transect the CC at the CHD may be challenging and can require frozen sections of the ductal wall to identify normal biliary mucosa and avoid leaving residual cyst remnants at the resection margin. Ideally, the proximal hepatic duct is transected at the point of visible caliber change of the duct at the cyst margin (Fig. 116.9). If intrahepatic duct dilation is present, strictures must be excluded as a cause—not infrequent with Type I CCs. Resection (or in some cases even balloon dilation) of a stenosis will

lessen the chance of late complications, such as recurrent cholangitis, stone formation, or anastomotic stricture.

Hepaticoenterostomy can be performed with either a Roux-en-Y hepaticojejunostomy or a hepaticoduodenostomy. Hepaticojejunostomy is the preferred technique, as the complication rate is thought to be much lower than from hepaticoduodenostomy. A recent meta-analysis by Narayanan et al. comparing hepaticojejunostomy and hepaticoduodenostomy in children following resection of CC showed hepaticojejunostomy did have a lower incidence of postoperative reflux, but otherwise long-term complications, including bile leak, anastomotic stricture, bowel obstruction, and cholangitis, were comparable. The length of the Roux limb of jejunum is dependent on the patient's age: 20 to 30 cm for children and up to 60 cm for adults. An end-to-end anastomosis of the jejunal limb to the upper remnant of the CBD may be considered if the diameters of the CBD and the proximal Roux-en-Y jejunum are similar. More commonly there is a size discrepancy such that an end-to-side hepaticojejunostomy is preferable for tailoring the anastomosis (Fig. 116.10).

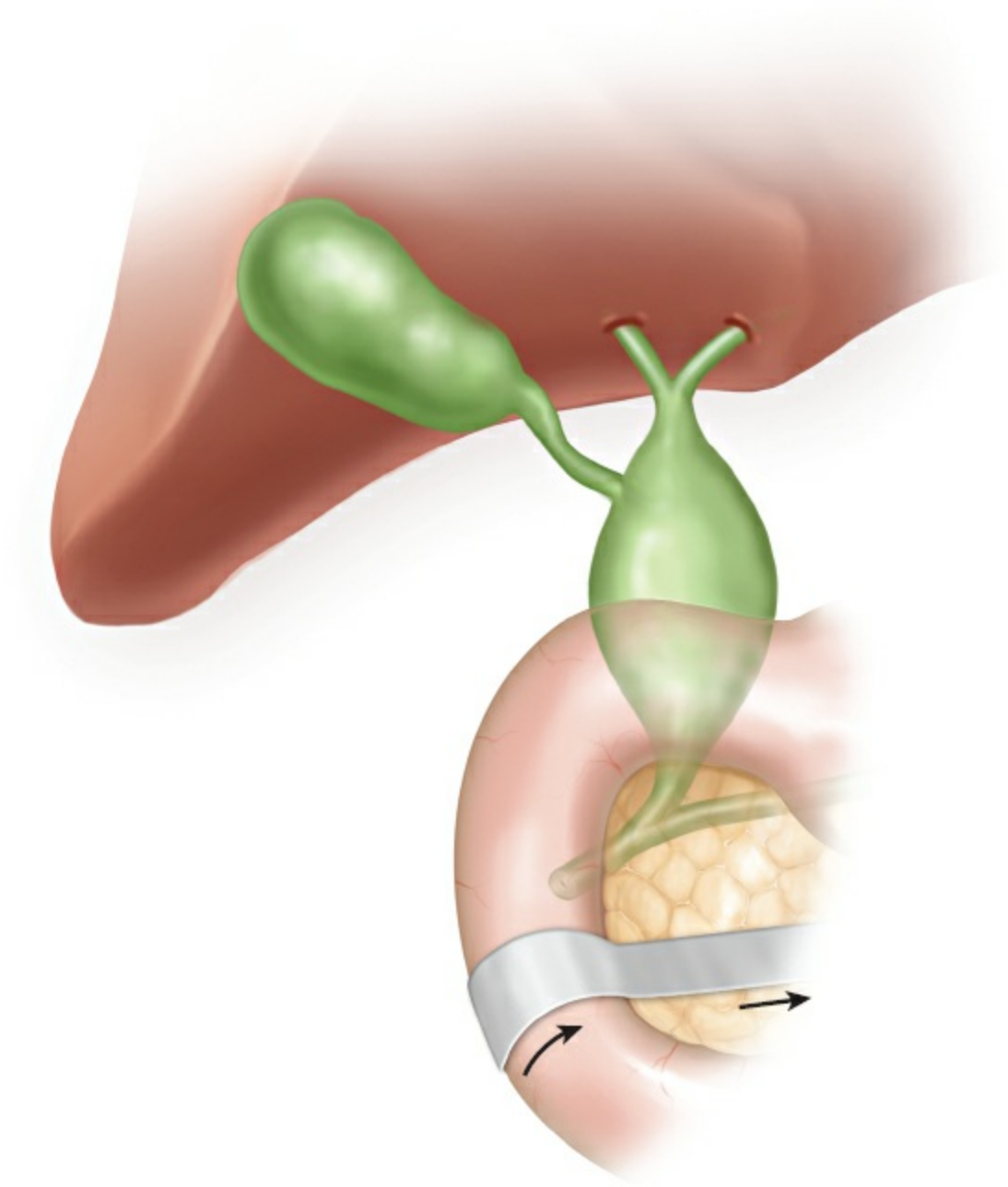

Figure 116.4. Mobilization of right colon by Kocher maneuver exposes duodenum and cyst behind.

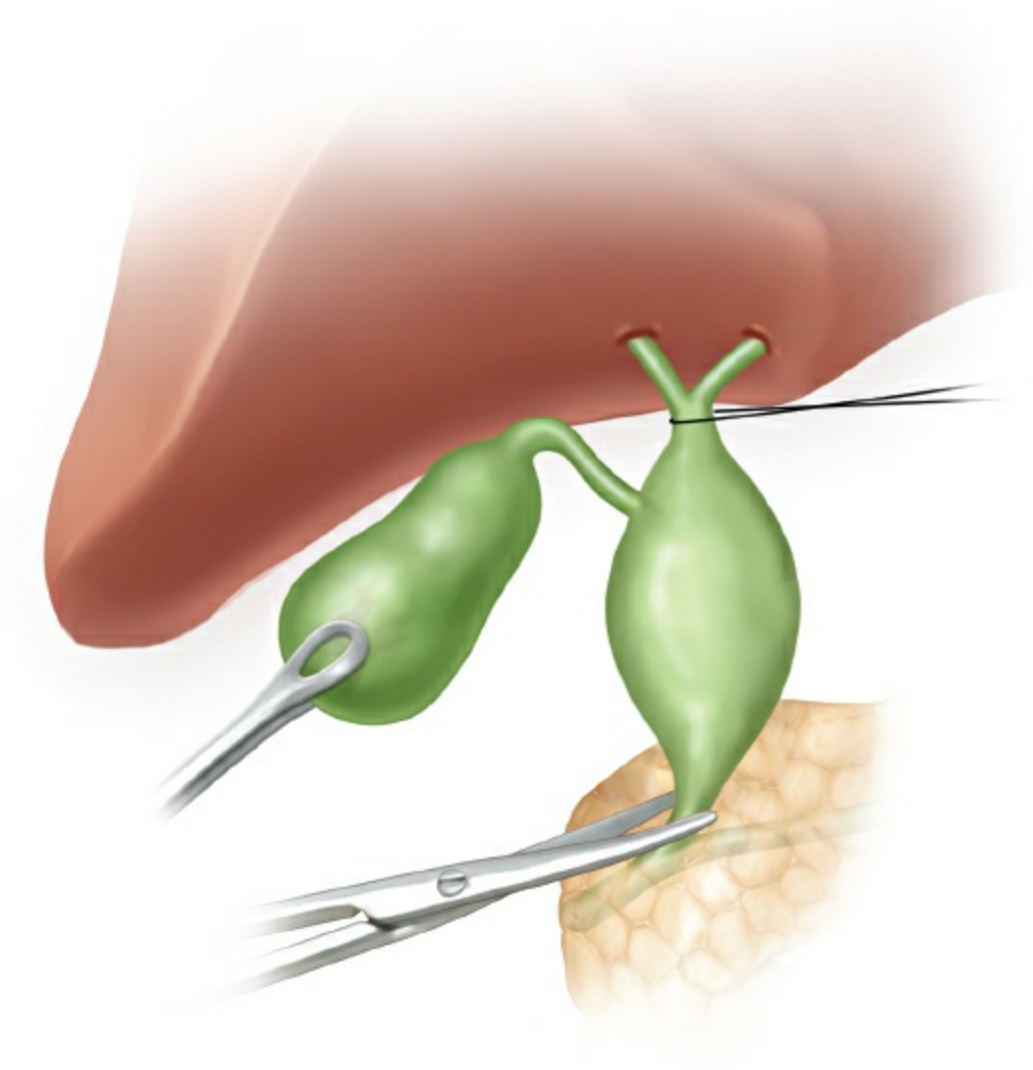

Figure 116.5. Distal resection of choledochal cyst as it enters the pancreas.

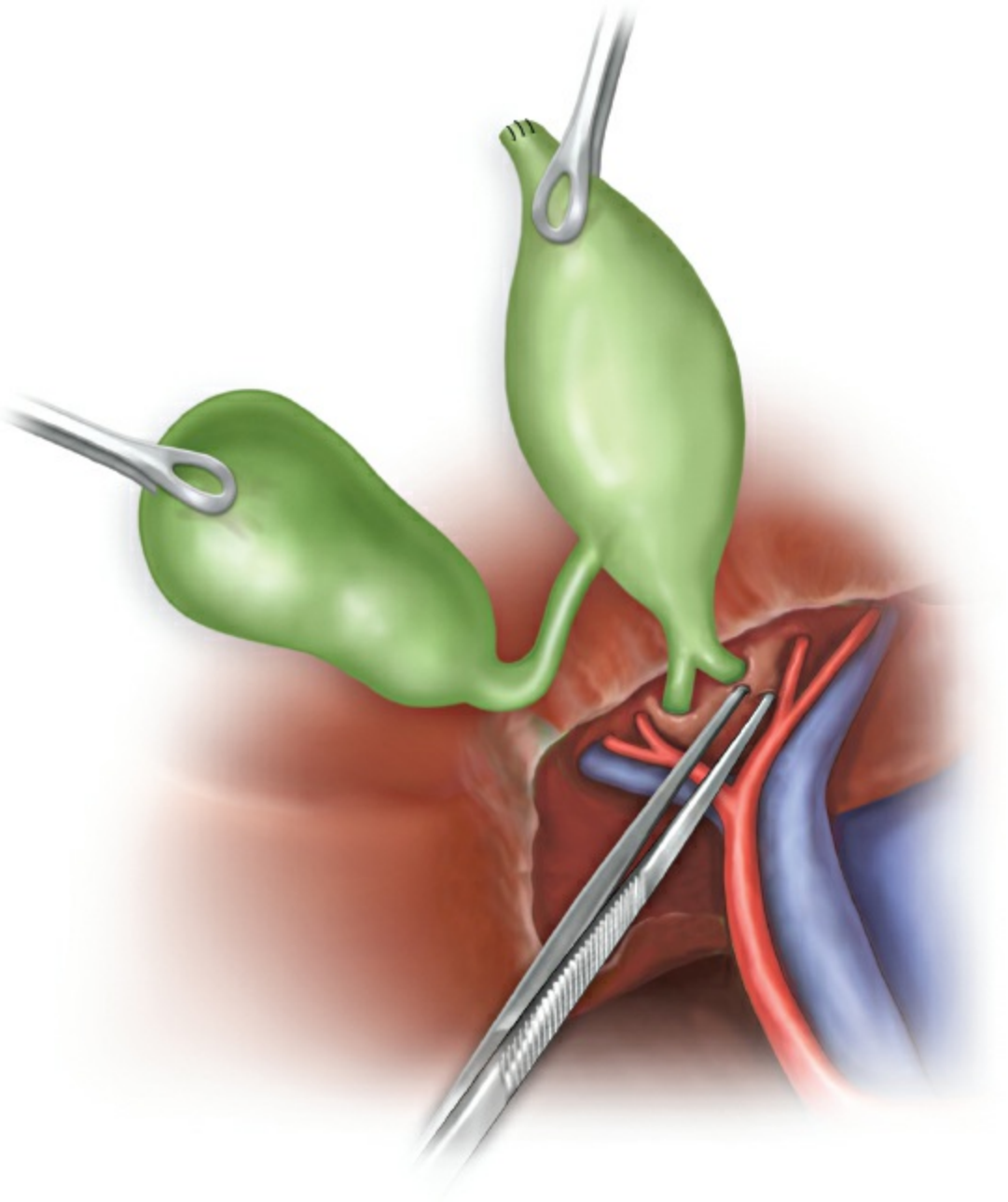

Figure 116.6. Proximal dissection of the cyst; note proximity of hepatic artery and portal vein posteriorly.

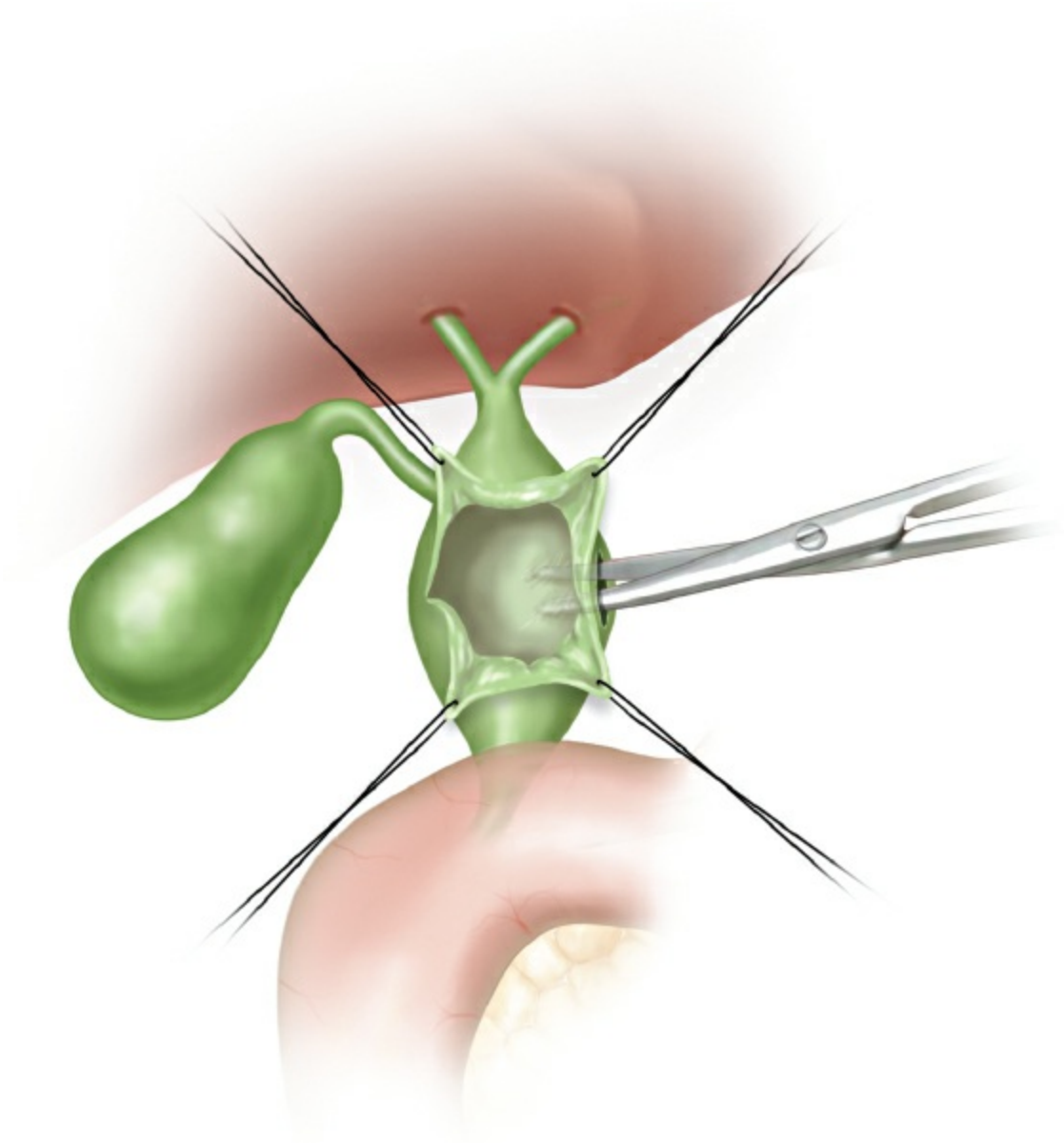

Figure 116.7. Dissection of the cyst epithelium from a scarred posterior wall is advised if the cyst wall is densely fibrotic.

For type II cysts, excision is the treatment of choice. This can be performed either with resection of the CBD and Roux-en-Y reconstruction or with complete excision of the cyst and primary closure over a T-tube. If only the cyst is excised, closure of the choleductotomy should be performed transversely to prevent narrowing of the CBD. Rarely can the cyst be excised flush with the wall of the common duct as this increases the risk of leaving cyst epithelium at the resection margin.

Type III cysts (choledochoceles) are associated with a low risk of malignancy and can usually be safely resected or drained into the duodenum. The decision to resect versus drain should be based on the

patient's age, symptoms, and comorbid conditions as well as the cyst's anatomic location relative to the duct and duodenal wall. Endoscopic therapy with ERCP is now considered the standard of care for symptomatic choledochoceles, with endoscopic sphincterotomy for small lesions. Larger choledochoceles may require an endoscopic incision along the cyst's luminal wall, and, in some cases, marsupialization of the cyst wall. Direct exposure via duodenotomy is an acceptable alternative for those lesions that do not have well-defined anatomy or if there is concern for malignancy.

Type IV cysts pose unique challenges in resection because cystic dilatation extends into the hepatic biliary tree and complete removal of the cyst is not always possible. Type IVA CCs have both intra- and extrahepatic cysts; complete extrahepatic cyst excision with biliary enteric anastomosis is recommended. The intrahepatic component must be addressed separately: if one lobe of the liver is involved (usually the left), some advocate resection of the lobe. Others suggest an approach that involves draining the intrahepatic cysts with large-bore Silastic stents and not resecting the hepatic parenchyma, considering the underlying low risk for subsequent malignancy. Proponents of this approach argue that by adequately decompressing the cysts, chronic inflammation can be minimized, which in turn minimizes long-term complications such as biliary stasis, cholangitis, and cirrhosis. If both hepatic lobes are involved or if there is recurrent and severe cholangitis or underlying cirrhosis, liver transplantation is a preferable option. Since type IVB CCs only have an extrahepatic component, treatment includes resection of the dilated extrahepatic cyst and Roux-en-Y hepaticojejunostomy.

Type V cysts may be particularly challenging and management remains controversial in terms nonoperative management versus liver resection or orthotopic liver transplantation (OLT), according to Soares et al.'s recent review of the literature. Hepatic resection is recommended when localized or unilobar cystic disease is present. If the disease is bilobar, but the patient is asymptomatic, nonoperative management is usually advised—with diligent follow-up given the risk of malignancy. OLT is recommended for bilobar Caroli disease with cholangitis, portal hypertension, or malignant transformation. Further debate remains surrounding the question of when to transplant, although it is generally considered better to transplant at an earlier stage of the disease to avoid further complications and need for emergent surgery.

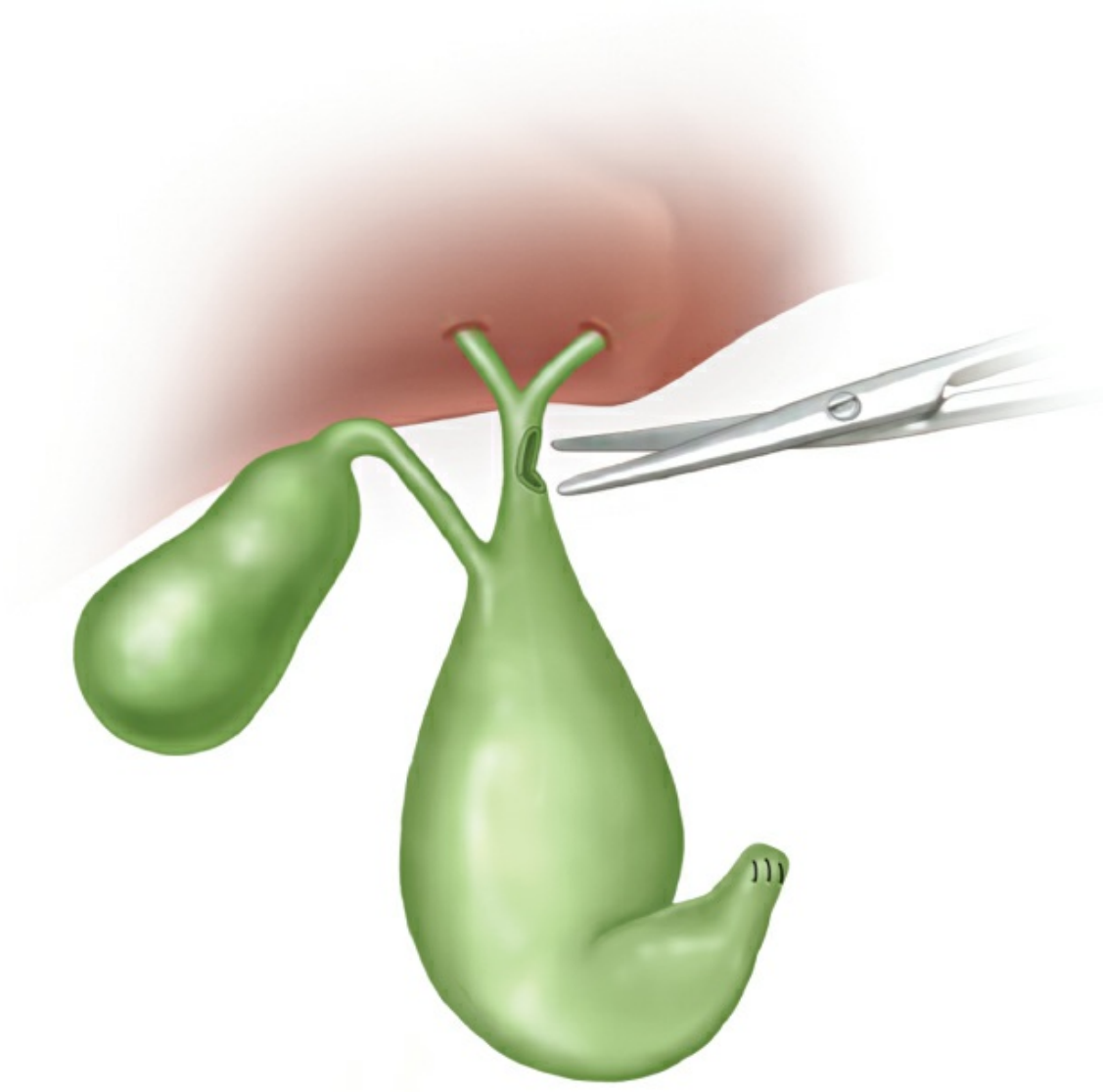

Figure 116.8. Proximal transection of the cyst.

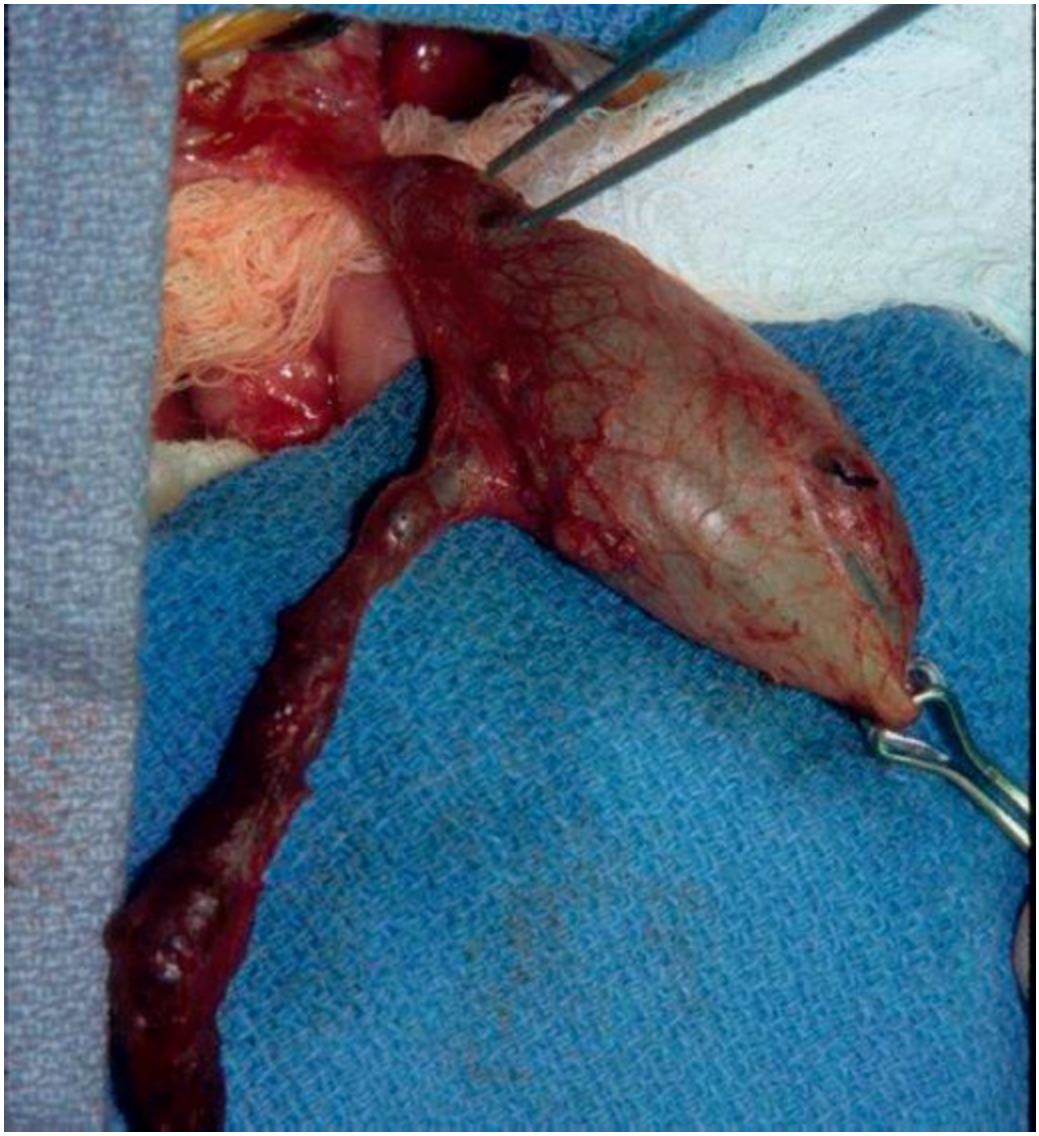

Figure 116.9. Operative specimen showing caliber change of type I cyst just distal to ductal bifurcation—recommended point of transection.

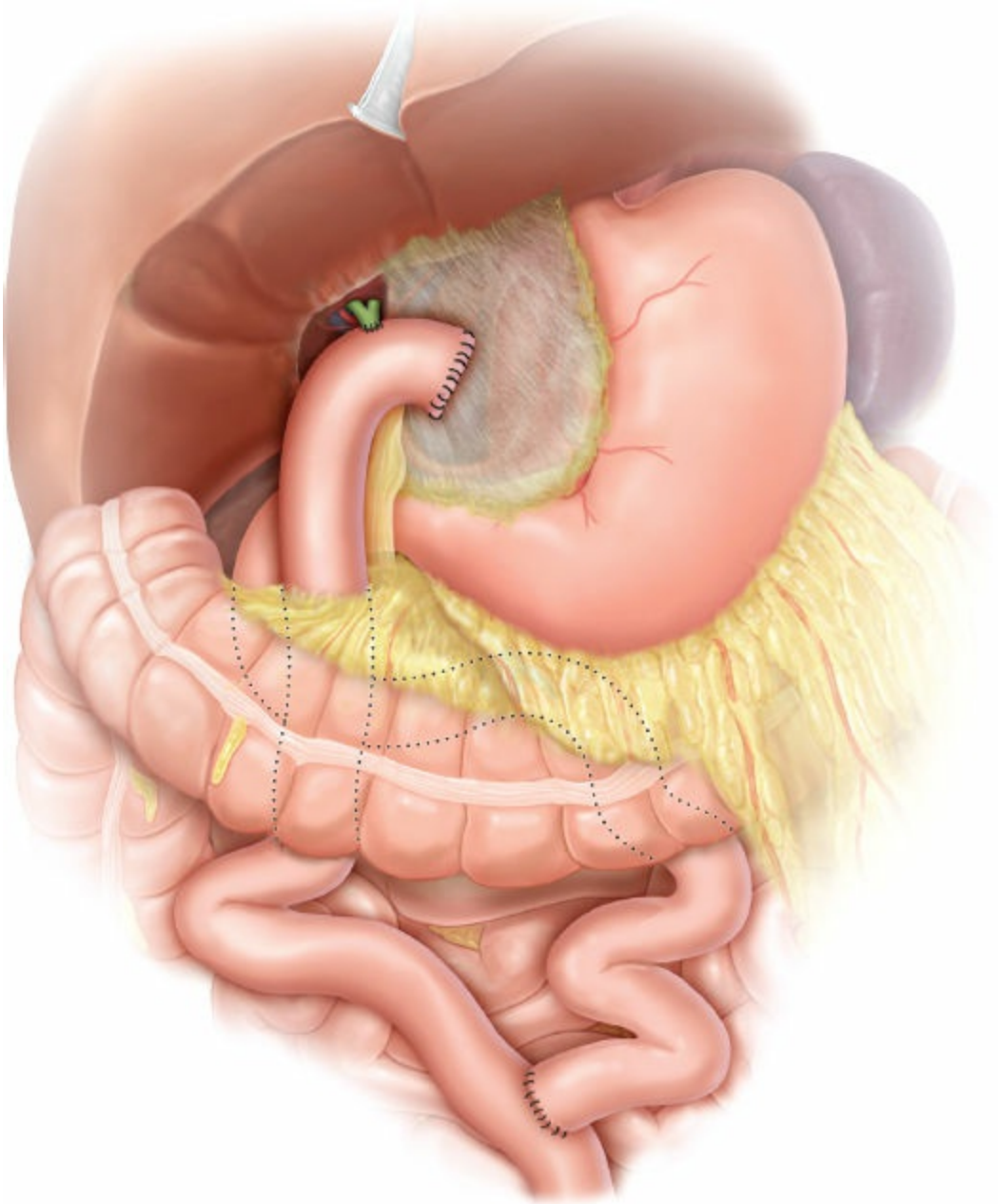

Figure 116.10. Reconstruction with retrocolic Roux-en-Y hepaticojejunostomy.

Laparoscopic cyst excision and hepaticojejunostomy for type I, type II, and type IV cysts is an alternative to open procedures. As shown in Nguyen's review of 190 patients and Jang's review of 82 patients, a laparoscopic approach is safe and effective, especially in the pediatric population where cysts are less likely to be adhesed from prior episodes of cholangitis. A handful of other studies show similar results, although their study sizes are smaller. Nevertheless, complete cyst excision can be challenging laparoscopically with a conversion rate to open of 35% in the adult population.

OUTCOMES

Overall results following surgical treatment are quite favorable, with a good prognosis in almost 90% of patients; both event-free and 5-year survival exceed 90%. Postoperative complications may be viewed as early or late. Early complications include pancreatitis, anastomotic leak, and cholangitis. Late complications include malignancy, cirrhosis, and recurrent pancreatitis. Type IVA CCs are associated with the highest postoperative risk from intrahepatic stones and strictures. Predisposing factors for stricture formation in the adult population include size and inflammatory cell infiltrate in the cyst wall. In children, long-term complications are mercifully rare.

The risk of biliary malignancy remains elevated 15 years after CC resection. Malignancy is associated with extremely unfavorable outcome —median survival is only 6 to 21 months. As such, all patients require long-term follow-up for biliary cancer with ultrasound, liver function tests, and CEA, CA 19–9, and CA 125 tumor markers.

A general surgeon should be knowledgeable about CCs. Although rare, CCs may present with symptoms suggestive of other, more commonly seen biliary disorders. Hazards from misdiagnosis and risks of complications from a delay in diagnosis, including malignancy, remain high. Accordingly, it seems prudent to appreciate the myriad ways CCs may present, what imaging studies may be most useful based on that presentation, and how to tailor the operative approach to both the patient and the underlying type of CC. While the rarity of CCs and the nuances of each type of CC have somewhat limited the development of a standardized surgical approach, the general goal of surgical treatment involves complete cyst excision with Roux-en-Y bilioenteric reconstruction. Following resection, patients must be followed long-term for the development of biliary malignancy. On the other hand, most patients with CCs will do well after operation, resuming a normal diet and activities with a low chance of recurrent symptoms or malignancy.

Suggested Readings

Diao M, Li L, Cheng W. Role of laparoscopy in treatment of choledochal cysts in children. *Pediatr Surg Int* 2013;29:317–26.

Jang JY, Yoon YS, Knag MJ, et al. Laparoscopic excision of a choledochal cyst in 82 consecutive patients. *Surg Endosc* 2013;27:1648–52.

Katabathina VS, Kapalczynski W, Dasyam AK, et al. Adult choledochal cysts: current update on classification, pathogenesis, and cross-sectional imaging findings. *Abdom Imaging* 2015;40:1971–81.

Martin RF. Biliary cysts: a review and simplified classification scheme. *Surg Clin N Am* 2014;94:219–32.

Narayanan SK, Chen Y, Narasimhan KL, et al. Hepaticoduodenostomy versus hepaticojejunostomy after resection of choledochal cyst: a systematic review and meta-analysis. *J Pediatr Surg* 2013;48:2336–42.

Nguyen TL, Hien PD, Dung LA, et al. Laparoscopic repair for choledochal cyst: lessons learned from 190 cases. *J Pediatr Surg* 2010;3:540–4.

Sastry AV, Abbadessa B, Wayne MG, et al. What is the incidence of biliary carcinoma in choledochal cysts, when do they develop and how should it affect management? *World J Surg* 2015;39:487–92.

Soares KC, Arnaoutakis DJ, Kamel I, et al. Choledochal cysts: presentation, clinical differentiation, and management. *J Am Coll Surg* 2014;219:1167–80.

EDITOR'S COMMENT

Choledochal cysts (CDCs) are interesting congenital anomalies with an incidence as high as 1 in 10,000 births in the far east to 1 in 100,000 births in the west. The authors present an overview of the relevant components of choledochal cyst management. As the authors note, CDCs were initially classified by Alonso-Lej with further modification by Todani where there are five anatomic variants defined by their location, extent of biliary tract involvement, and shape. Type I (extrahepatic fusiform) and IV (extra- and intrahepatic fusiform dilatation) are the most common CDCs with the remaining types rare. Type III (choledochocele) CDCs are the least common with a recent systematic review suggesting no more than 325 cases reported in the modern literature (71 case reports and 254 patients in CDC series; Lobeck IN, Dupree P, Falcone RA Jr, et al. The presentation and management of choledochocele (type III choledochal cyst): a 40 year systematic review of the literature. *J Pediatr Surg* 2017;52:644–9). Of note, the classification system is helpful as it defines anatomic abnormalities in the biliary system but the likelihood that the five types are pathogenetically related is small. Type I and IV CDCs are thought to be triggered by an anomalous pancreaticobiliary duct malunion but type II, III, and V CDCs are anatomically different and are derived from unique etiologies. For example, a type III CDC is thought to reflect either a bile duct that fails regression during embryogenesis (Tanaka T. The pathogenesis of choledochocele. *Amer J of Gastro* 1993;88:1140) or an acquired anomaly from ampullary inflammation resulting in ballooning of the CBD. The justification for the continued grouping of the five CDCs is for educational and reporting

purposes.

From a diagnostic standpoint, the authors summarize the common clinical manifestations of a patient with a CDC. Children tend to present with more of the classic symptom complex of the right upper quadrant pain, jaundice, and an abdominal mass. One population, germane to the pediatric surgeon, are those fetuses with an in utero diagnosis of a cystic abnormality found near or within the hilum of the developing liver. The differential diagnosis of a cystic mass in the hilum detected during prenatal screening includes cystic "correctable" biliary atresia (BA) and a CDC. The treatment strategy for cystic BA is markedly different from a CDC as intervention in the perinatal period is critical in the BA patient. In contrast, a patient with a CDC can be observed allowing some degree of physiologic maturation before operative intervention is employed. The passage of pigmented stools in a newborn that was diagnosed in utero with a cystic abnormality in the hilum of the liver is the simplest route to differentiate between a choledochal cyst (pigmented stool) and cystic BA (acholic stool). An ultrasound is typically performed and if a CDC is suspected, cross-sectional imaging obtained at some point before operative intervention is offered. Additional studies that may be required to differentiate between the two include a HIDA scan and a liver biopsy. If cystic BA is suspected, early exploration is warranted as intervention before 30 days of life is associated with better long-term drainage (Caponcelli E, Knisely AS, Davenport M. et al. Cystic biliary atresia: an etiologic and prognostic subgroup. *J Pediatr Surg* 2008;43(9):1619–24). If a CDC is diagnosed, operative intervention can be delayed until the child is older (excision and reconstruction typically around 12 months of age) allowing a wider range of surgical approaches including laparoscopy.

Patients with an undiagnosed giant CDC may present with spontaneous perforation and will have biliary peritonitis resulting in a classic "board-like" acute abdomen (Ando H, et al. Spontaneous perforation of choledochal cyst. *J Am Coll Surg* 1995;181(2):125–8). Determination of the diagnosis may not occur until the patient is in the OR undergoing either open or more commonly in the current era, laparoscopic exploration. Bile-stained ascites should tip the surgeon to the diagnosis. A patient presenting in this fashion should be treated conservatively with two goals: (1) Placement of drains to control the ongoing biliary contamination of the right upper quadrant by the perforated CDC and (2) Decompression of the biliary system via T-tube drainage at the perforation site, percutaneous transhepatic catheter placement or ERCP and stent placement decreasing the amount of ongoing biliary contamination. In the unlikely scenario that the contamination of the RUQ has resulted in minimal hilar inflammation, definitive repair at diagnosis can be considered but frequently, the perforation will result in significant inflammation making the hilar dissection hazardous. With drainage and decompression of the biliary system, the RUQ inflammation will decrease making a staged approach to definitive resection a much safer alternative.

As the authors observed, malignancy in a choledochal cyst is uncommon in children with higher incidence in adult patients. This is not surprising as the etiology of a malignancy in a CDC is thought to be caused by chronic pancreaticobiliary reflux interacting with biliary epithelium, leading to mucosal irritation, metaplasia, and malignant change (Xiao X, Li H, Wang Q, et al. Abnormal pancreatic isoamylases in the serum of children with choledochal cyst. *European journal of pediatric surgery: official journal of Austrian Association of Pediatric Surgery [et al] = Zeitschrift fur Kinderchirurgie*. 2003;13:26–30). Because of the chronicity, adults with late diagnosed CDCs are at more risk for malignant change.

Once diagnosed, all CDCs require correction. As the authors note, the operative approach to a type I and IV CDC requires excision of the dilated portion of the extrahepatic biliary system with reconstruction of biliary outflow. Reconstruction of biliary outflow can be accomplished by Roux-en-Y choledochojejunostomy or by choledochoduodenostomy but a Roux-enY drainage is recommended. Choledochoduodenostomy is a simpler reconstruction but because of increased reflux of enteric contents into the biliary system and reflux of bile into the stomach, has been associated with increased rates of both gastric cancer and cholangiocarcinoma (Takeshita N, Ota T, Yamamoto M. Forty-year experience with flow-diversion surgery for patients with congenital choledochal cysts with pancreaticobiliary maljunction at a single institution. *Ann Surg* 2011;254:1050–3; Shimotakahara A, Yamataka A, Yanai T, et al. Roux-en-Y hepaticojejunostomy or hepaticoduodenostomy for biliary reconstruction during the surgical treatment of choledochal cyst: which is better? *Ped Surg Int* 2005;21:5–7). If a choledochoduodenostomy is performed, longitudinal follow-up is critical.

Patients diagnosed with a CDC at an older age may have experienced recurrent bouts of cholangitis/pancreatitis resulting in significant chronic inflammation in the cyst and the surrounding hilum making dissection challenging. Anatomic differentiation and preservation of all branches of the hepatic artery and portal vein is critical for the health of the native liver but this can be quite difficult if there has been long-standing, chronic inflammation. In this circumstance, the cyst can be opened and a mucosectomy performed removing all biliary epithelium. Leaving the chronically scarred residual wall will protect the critical hilar vessels from inadvertent injury. The dissection is carried proximally up to the hilar plate where anastomosis can be performed. In this circumstance, we will consider sending the proximal most point chosen for anastomosis for frozen section histologic analysis to ensure integrity of the bile duct wall before completing the anastomosis as if no epithelium is present the risk for a postoperative stricture is high.

As with many operative procedures in the abdomen, laparoscopy and more recently, utilization of a Da Vinci robotic system has been applied to CDC correction. Retrospective studies demonstrate that the procedure can be done safely with excellent outcomes but require longer operative time with the

attendant higher costs (Nguyen T, Hein PD, Dung le A, et al. Laparoscopic repair for choledochal cyst: lessons learned from 190 cases. *J Pediatr Surg* 2010;45:540–4). As with many advance laparoscopic procedures, CDCs repaired in this fashion should be performed by teams well versed in laparoscopy and with the anatomy of the hilum of the liver.

Patients who have undergone CDC excision and reconstruction require long-term follow-up. The late affects following a CDC excision requires studies with better longitudinal as the patients are at risk for anastomotic stricture, hepaticolithiasis, and malignant transformation.

Gregory M. Tiao

The choledochal cyst is a difficult area with 5 manifestations of these rare congenital anomalies. Happily as skills proliferate outcomes are better.

J.E.F.

117 Biliary Atresia—Portoenterostomy

Gregory M. Tiao

Biliary atresia (BA) is a devastating cholestatic liver disease of infancy. The obliterative process of the extrahepatic biliary tree, coupled with progressive inflammatory destruction of the intrahepatic bile ducts, leads to the development of end-stage liver disease (ESLD) in the first 12 months of life. At present, there is no medical therapy to abate or reverse this process. Untreated, BA results in cirrhosis, hepatic failure, and death.

BA was first reported in the English language by Burns in 1817, who described the characteristic combination of early jaundice and acholic stools, ascribing this to "some incurable state of the biliary apparatus." Modern surgical treatment evolved from the histopathologic studies of the progression of BA by Morito Kasai who then suggested that the removal of atretic bile ducts before progression of an inflammatory process into the porta hepatis and intrahepatic biliary system might allow successful bile drainage. The portoenterostomy (Kasai procedure) he described has undergone modifications but remains the template for present surgical therapy. Unfortunately, most afflicted children even with a successful portoenterostomy progress to ESLD and require orthotopic liver transplantation (OLTxp) for salvage. With the advent of successful OLTxp, there was discussion that primary OLTxp should be considered in all patients diagnosed with BA; however, the very acceptable results in selected long-term survivors following the Kasai procedure, contrasted to the risks of liver transplantation and lifelong immunosuppression, support the sequential application of portoenterostomy followed, when necessary by OLTxp. BA is the most common indication for pediatric liver transplantation.

ETIOLOGY

Despite its importance to child health, the etiology of BA remains unclear. Proposed mechanisms include environmental, autoimmune, and infectious etiologies. Epidemiologic studies suggest that ethnic and genetic factors may also play a role in the pathogenesis of BA. In the United States, the

incidence of BA is about two times higher in African Americans as compared with white infants, and it is more common among Chinese than Japanese or Caucasian infants. Girls are more commonly affected.

In the 1970s, it was first proposed that a viral agent was the root cause of a group of neonatal obstructive cholangiopathies including BA. Initial attention focused on the hepatitis B virus. Subsequent studies found many different pathologic viruses in the liver of infants with BA, including rotavirus, reovirus, cytomegalovirus, and human papilloma virus; however, no single virus has been detected uniformly among the patient samples tested. A unifying concept that explains the patient-based results postulates that the clinical manifestations of BA represent an *end phenotype* caused by a variety of in utero or perinatal infections. These insults act as a trigger for a host immune response, which results in a progressive destruction of the biliary tract. The experimental model of BA first described in 1993 is important evidence in favor of a viral etiology in the pathogenesis of BA and has become a vital tool in BA research. In this model, rhesus rotavirus infection of newborn BALB/c mice results in an inflammatory cholangiopathy and pathologic phenotype similar to human BA, including (a) a clinical progression to obstructive jaundice as manifest by bilirubinuria, jaundice, acholic stools, growth retardation, and eventually death; (b) morphologic and histologic changes in the biliary tree that parallel those found in infants; and (c) a temporal relationship between neonatal exposure to the virus and disease induction.

Utilizing complementary data obtained from molecular profiling of patient samples and the murine model of BA, multiple investigators have begun to define how the host immune response contributes to the end phenotype of BA. Factors that govern the response include a Th1 response mediated in part by CD8 T cells, as well as overexpression of IFN-γ, IL2, CD25 (IL2 receptor), TNF, and CD71 (transferrin receptor). CD8, pDC, NK, and T regulatory cells cross-talk post insult governing biliary obstruction and a Th2 lymphoid and type 2 myeloid responses also play an integral role in biliary duct obstruction through the action of IL-13. IL-17A signaling through the DC-Th17 axis has been shown to control injury by inducing CCL2 production by cholangiocytes. This induction triggers Ly6C+CCR2+ macrophages leading to inflammation. Studies have shown that inactivation of the *Stat1* gene in mice (a gene critical to the Th1 response), resulted in complete biliary obstruction with cystic dilations of extrahepatic bile ducts. Interestingly, the basis for BA progression to

fibrosis has begun to be defined where the disease evolves from a pro-inflammatory type 1 initial response (i.e., viral insult based trigger) to a pro-fibrotic type 2 immune response through the action of IL33 (a type 2 cytokine) resulting in bile duct proliferation. The cholangiocyte proliferation occurs through activation of innate lymphoid cell (ILC2) through the release of IL13 that works in a paracrine fashion to activate IL33 secretion, which has been shown to activate hepatic stellate cells. Although these studies have been revealing, no treatment strategies have yet been advanced that alters the natural history of BA. As a result, surgical palliation remains the cornerstone of treatment.

ANATOMIC CLASSIFICATION

The anatomic classification of BA is descriptive of the degree of extrahepatic ductal destruction. The sclerosing obliterative destructive inflammatory process may affect any length of bile duct from the sphincter of Oddi to the porta hepatis. Type I (10%) demonstrates obliteration of the common bile duct; type II (2%) also includes common hepatic duct atresia. Both have relative sparing of the intrahepatic ducts and historically have been termed cystic “correctable” BA as within the hilum of the liver at the ductal bifurcation arises a bile containing cyst. The cyst wall is not lined with biliary epithelium rather an inner, dense cicatricial layer that nonetheless can be reconstructed by cyst-Roux-en-Y anastomosis that surprisingly results in sustained biliary drainage. Type III (88%) BA involves the right/left hepatic ducts and extends into the intrahepatic bile ducts as well. Patients with type III findings are candidates for Kasai portoenterostomy.

CLINICAL CLASSIFICATION

The clinical forms of BA can be divided into two subtypes: a *postnatal/sporadic* form that progresses after birth and a *fetal/embryonic* form that is present at birth and is associated with other congenital anomalies.

The postnatal presentation accounts for most of the cases of BA. These infants present with jaundice, which becomes apparent after the physiologic jaundice of the newborn should have resolved (3 to 4 weeks) and increases in severity within weeks. Hepatic histology is significant for the presence of bile duct remnants with acute and chronic inflammation within the portal triads. Associated anomalies are uncommon.

The fetal/embryonic subtype occurs in 10% of infants with BA, and is characterized by jaundice that is recognized and progresses during the first few days of life. In most cases, no jaundice-free interval can be identified. The probable in utero onset of this is suggested by the absence of patency in the biliary structures and an absence of bile duct remnants at early laparotomy. Associated congenital anomalies are common and follow one of the three patterns: (a) most common group (60%)—cardiovascular (atrioventricular canal defects, septal defects, valvular abnormalities, Tetralogy of Fallot, patent ductus arteriosus), genitourinary (kidney or collecting system), and gastrointestinal (Meckel diverticulum, midgut anomalies), (b) laterality sequence anomalies (30%)—situs inversus, polysplenia/asplenia, preduodenal portal vein, intestinal malrotation, cardiovascular anomalies (BASM), and (c) isolated intestinal malrotation (10%). Reviews of the US and UK experience have confirmed the worse overall prognosis for infants with the BASM phenotype.

DIAGNOSTIC EVALUATION

With advances in prenatal care and the widespread utilization of screening maternal ultrasound, efforts to detect BA in utero have been attempted but to date, no pathognomonic in utero abnormalities have been identified. In those patients with the cystic “correctable” form of BA, in utero detection of a cystic abnormality in the hilum of the liver is helpful but must be differentiated postnatally from a choledochochal cyst. The passage of pigmented stools in a patient with a cystic abnormality in the hilum of the liver is the simplest route to differentiate between a choledochal cyst (pigmented stool) and cystic BA (acholic stool). If cystic BA is suspected, early exploration is warranted as intervention before 30 days of life is associated with better long-term drainage.

To be successful, the Kasai procedure should be done before irreversible sclerosis of the intrahepatic bile ducts has occurred. Prompt evaluation is necessary for any infant older than 14 days with jaundice to determine if conjugated hyperbilirubinemia is present (Table 117.1).

To date, biochemical analysis that assists in the determination of BA is rarely definitive. Although biochemical evidence of cholestasis and hepatocellular damage is present, the biochemical tests are of no discriminating value in patients with suspected BA. The development of the Jaundice Chip, utilizing DNA extracted from whole blood, screens for all of the known genetic defects that cause cholestatic liver disease and is

helpful but remains a complimentary study as it is not rapidly performed assay and awaiting results could delay definitive treatment.

TABLE 117.1 Diagnostic Evaluation of a Cholestatic Infant

General Evaluation
Clinical evaluation (family and gestational history, feeding history, physical examination, assessment of stool color)
Index of hepatic synthetic function (prothrombin time)
Exclude Sepsis—cultures (blood, urine, spinal fluid) as indicated
Quantitative analysis of bile acids, urinary bile acid profile if abnormal
Serum electrolytes (exclude acidosis)
Specific Evaluation
$Alpha_1$ A—Antitrypsin phenotype
Thyroxine and thyroid-stimulating hormone
Sweat Chloride/mutational analysis (exclude cystic fibrosis)
Ferritin/transferrin concentration and saturation (exclude neonatal iron storage disease)
Metabolic screen (urine reducing substances, urine/serum amino acids, organic acids, succinyl acetone)
HbsAG, anti-HIV, and VDRL (in high-risk patients)
Jaundice Chip analysis
Abdominal ultrasonography
Liver biopsy
Exploratory laparotomy/ cholangiography

Abdominal ultrasonography excludes choledochal cyst, perforation of the bile ducts, or choledocholithiasis. In patients with suspected BA, the

gall bladder is either not visualized or atretic. When a hyperechogenic liver hilum is identified, known as a “triangular cord” sign, BA is likely. Associated anomalies such as a preduodenal portal vein, polysplenia/asplenia, inferior vena caval interruption, or malrotation can also be identified. These findings are helpful to the surgeon and suggest BA but are not diagnostic of the disorder. Cholescintigraphy is rarely helpful even with phenobarbital induction, and often delays critical surgical intervention.

If infectious, metabolic, and endocrine disorders are excluded, then liver biopsy most accurately identifies infants with suspected BA. Histologic examination of the liver is the most helpful step in evaluating the children with suspected BA and selecting appropriate candidates for laparotomy. The histopathologic findings that predict obstructive forms of neonatal cholestasis are portal ductal proliferation, bile plugs in portal bile ductules, portal–portal bridging, neutrophils, hepatocyte swelling, and multinucleated giant hepatocytes. In preoperative liver biopsies, the presence of giant cells, lobular necrosis, focal necrosis, bridging necrosis, and cholangitis are associated with poor clinical outcome, whereas the presence of bile in zone 1 is associated with improved clinical success. The degree of portal fibrosis is especially important in infants who present at a later age for evaluation. The combination of late presentation (>3 months of age) and severe fibrosis makes successful bile drainage unlikely; in these cases, primary liver transplantation should be considered as the preferred option.

The steps for rapid evaluation of the infant with suspected BA are outlined in Table 117.2. In these selected infants, exploratory laparotomy and intraoperative examination/cholangiogram should be done expeditiously by a surgeon who has experience undertaking the Kasai procedure.

OPERATIVE PROCEDURE

The operative procedure is undertaken through an abbreviated right upper quadrant chevron incision until the diagnosis of BA is confirmed. This can then be extended to a bilateral chevron appropriate for future liver transplantation if that becomes necessary.

TABLE 117.2 Recommended Steps in the Evaluation of a Child With

Possible Biliary Atresia

1. Recognize the newborn infant with prolonged jaundice (>14 days) and screen for conjugated hyperbilirubinemia
2. Exclude medically treatable causes of neonatal cholestasis (Table 117.1)
3. Abdominal ultrasound to exclude structural abnormalities of the biliary tree
4. Liver biopsy to differentiate biliary atresia from various forms of intrahepatic cholestasis
5. Exploratory laparotomy and intraoperative cholangiogram—Kasai portoenterostomy

CONFIRMING THE DIAGNOSIS

The initial step is to confirm the diagnosis of BA through observation of the extrahepatic biliary structures and, when necessary, intraoperative cholangiography. The liver in BA, even at its early stage, shows cholestatic green discoloration and the presence of subcapsular vascular telangiectasias (Fig. 117.1). When this gross anatomic picture is seen in conjunction with a fibrotic gall bladder remnant and no discernable extrahepatic biliary ducts, the diagnosis of BA is confirmed, and one can proceed with portoenterostomy. When the gall bladder is not atretic, a cholangiogram helps define further operative management. A purse-string of 5.0 monofilament suture in the fundus of the gall bladder secures a 20-gauge intravenous catheter for the cholangiogram. Very gentle infusion pressure is necessary as excessive pressure in an atretic biliary tract will lead to extravasation, which obscures necessary landmarks. When the cholangiogram shows a normal biliary tree, a generous wedge and needle biopsies are undertaken prior to closure.

Biliary hypoplasia is recognized by the presence of an anatomically intact ductal system to all liver segments by small threadlike ducts. This syndrome is seen in conjunction with cholestatic medical liver diseases (A-1 antitrypsin deficiency, cystic fibrosis), inborn errors of bile acid

metabolism, or any infectious or metabolic disease associated with severe neonatal cholestasis. In addition, syndromic (Alagille Syndrome) or nonsyndromic bile duct paucity conditions and progressive familial intrahepatic cholestasis (PFIC) syndromes (Byler syndrome and its variants) can all present with a small but anatomically correct extrahepatic biliary system. Generous liver biopsy will assist in their diagnosis; their primary treatment is medical. Portoenterostomy does not benefit this group and should not be undertaken. In the presence of flow into the distal biliary tree, with no flow into the intrahepatic radicals, a spring-loaded vascular occlusion clamp should be placed on the supraduodenal biliary structures with further attempts to demonstrate proximal patency. In the absence of proximal patency or when no flow occurs on the cholangiogram, BA is confirmed and a Kasai procedure undertaken.

The individual steps of the portoenterostomy include (a) the initial dissection of the extrahepatic biliary fibrous mass, (b) the extended lateral dissection, (c) division of the fibrous mass, and (d) the enteric anastomosis.

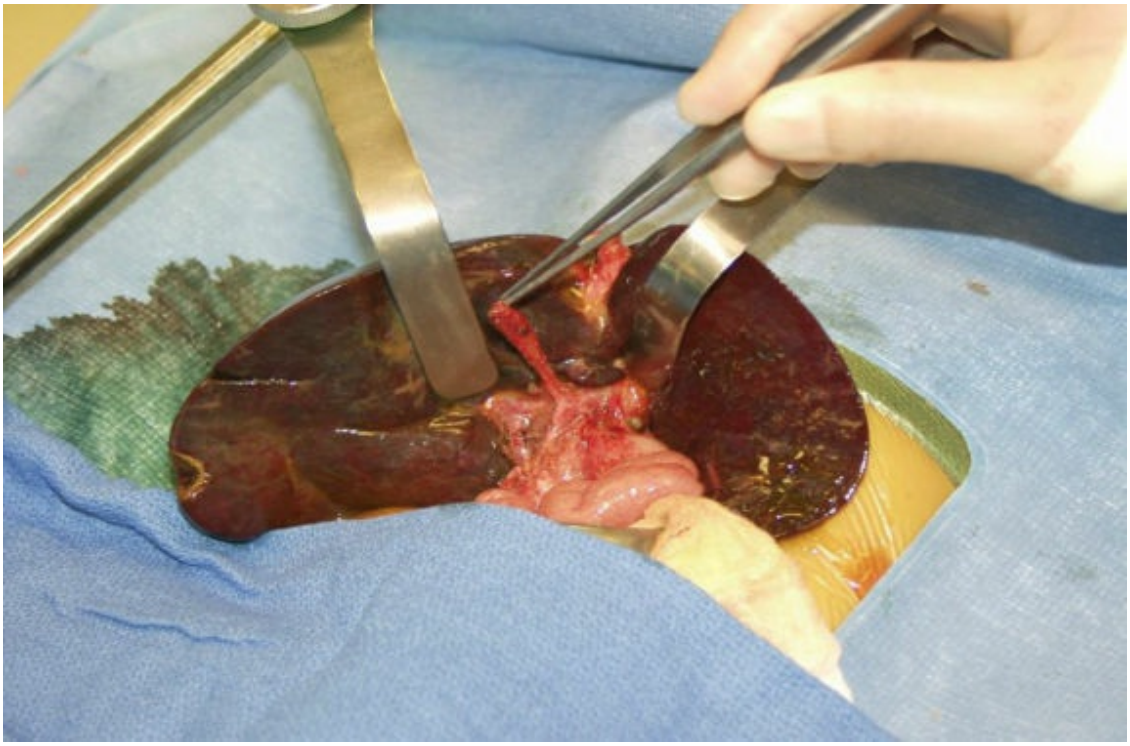

Figure 117.1. Cholestatic liver of a biliary atresia patient. Atretic gall bladder in forceps.

INITIAL FIBROUS REMNANT DISSECTION

When undertaking the initial dissection of the obliterated biliary ducts, it is important to appreciate that the ducts are not absent in BA, but rather obliterated by fibrosis. The anatomic course of the ductal remnants will follow the normal biliary position within the portal triad and hilum. To facilitate adequate visualization, the lateral portion of the triangular ligament and the anterior/superior portion of the falciform ligament are divided, allowing the liver hilum to rotate in an anterior-superior fashion. The fibrous obliterated biliary structures are usually visible superior to the duodenum in the anterior portal triad where they are tied and divided. The upper suture is left uncut to supply traction on the biliary remnant. The dissection ascends superiorly along the anterior surface of the portal vein, the gall bladder remnant is dissected from the liver bed, but the cystic duct structures are not divided. Anterior/superior traction on these combined structures lifts them from the anterior surface of the portal vein as the dissection proceeds into the hilum. The dissection should be confined to the anterior/posterior plane as the hilar fibrous tissue remnant is encountered, as the lateral dissection requires further definition of the portal vein anatomy. The fibrous tissue mass forms a thickened cone-like structure the “fibrous triangle” as it reaches the liver surface. The bifurcation of the portal vein serves as an important landmark, as the fibrous triangle courses between the branches of the portal vein. To reach the liver surface, the fibrous remnants course in a posterior/superior direction within the portal bifurcation. The key element to this stage of the dissection is the downward displacement of the portal vein bifurcation, allowing the dissection of the fibrous remnant to its junction with the anterior and posterior liver capsule. Several small direct portal branches into the fibrous mass should be divided between ties to allow complete separation of the portal vein from the fibrous mass (Fig. 117.2).

EXTENDED LATERAL DISSECTION

In the original Kasai procedure, the fibrous triangle was dissected and divided between the right and left branches of the portal vein at the level of the posterior surface of the portal vein. Further revision of this technique has shown that meticulous dissection of the lateral fibrous triangle tissues allows more of the segmental biliary structures to be potentially included in the divided hilar tissue. At the porta hepatis, the hepatic duct usually takes a course superior and medial to the main portal branches; and in the liver, it turns posteriorly toward the portal branches on the lateral sides.

Therefore, when conducting the lateral fibrous remnant mobilization, dissection of these potential ductal remnants from the dorsal aspect of the portal branches is very important. It is within this fibrous tissue that residual patent biliary ductules may be found. On the right, the dissection is carried to the dorsal aspect of the anterior portal branch over the bifurcation of the anterior and posterior portal vein branches. Small portal vein branches that pass medially toward the fibrous mass should be ligated to allow complete separation of the mass from the portal vein wall. The left lateral dissection is facilitated by dividing any parenchymal bridge that is present between liver segments S3 and S4, bringing the left porta hepatis clearly into view. The dissection separating the fibrous mass from the portal vein proceeds to the umbilical point where the obliterated umbilical vein joins the left portal vein. Division of the fibrous ligamentum venosum at this junction improves mobilization of the left portal vein. We have found this helpful but not essential in every case. Some surgeons place traction tapes around the left and right portal veins and the right anterior segmental branch to improve visualization of these structures; however, we prefer local retraction with an eyelid retractor without encircling the veins.

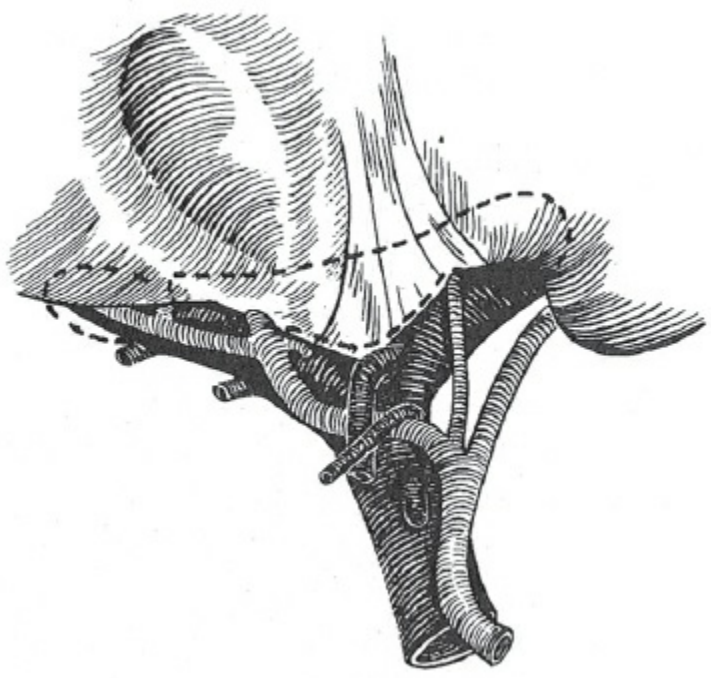

Figure 117.2. The initial dissection (*dashed line*) of the portal fibrous mass is facilitated by the inferior displacement of the portal vein and the hepatic artery and superior retraction of the fibrous triangular mass. The fibrous remnant terminates at the

hepatic capsule posterior to the bifurcation of the portal vein.

DIVISION OF THE FIBROUS MASS

The division of the fibrous mass is best approached from the right side, cutting the mass with sharp scissors or a knife. The division is facilitated by placing the fibrous mass on moderate traction. Several evenly spaced traction sutures can be placed along its transverse width when needed. The transection margin should be at the level of the liver capsule and parenchyma. Deeper dissection into the parenchyma encourages excessive scarring, and transection distant from the capsule risks missing potentially open biliary channels that terminate within the proximal fibrous mass.

The division of the right fibrous mass begins at the parenchymal entry of the posterior portal vein branch and proceeds around the anterior segmental branch from a posteromedial direction. On the left, dissection is extended to the posteromedial margin of the umbilical point, inclusive of the dorsal aspect of the portal vein. After completing the transection, the operative field is irrigated with warm saline, and a warm gauze pack is placed in the hilum to achieve hemostasis. As the ductules travel in concert with the microvascular structures within the fibrous mass, any bleeding that is encountered is best treated with local pressure and irrigation, rather than electrocautery that can damage the ductules (Fig. 117.3).

ENTERIC DRAINAGE

A 35-cm Roux-en-Y constructed of isoperistaltic jejunum and placed in a retrocolic position is used for drainage of the hilum. This should be fashioned from the most proximal loop of jejunum when possible to facilitate early bile return to the intestine, improving absorption of fat-soluble vitamins and medications as well as food. No antireflux valve is placed in the Roux-en-Y, but the anastomosis is fashioned to inhibit enteric flow into the drainage limb.

The blind end of the Roux-en-Y is closed, and a 2- to 2.5-cm antimesenteric enterotomy is used for the anastomosis to the hilum. The posterior wall of the anastomosis is performed with interrupted single-layer absorbable synthetic monofilament sutures placed just posterior to the cut margin of the fibrous mass, into the parenchyma of the caudate lobe, with the knots tied outside of the anastomotic area. Sutures should not be placed into the tissue of the fibrous mass where potentially draining ductules may reside. This technique places the posterior row of sutures

posterior to the portal vein within its bifurcation. The right anterior portal branch is usually within the right lateral extended dissection, with fibrous tissue on all but its posterior side. The anastomotic suture line should surround or invaginate these vascular branches, incorporating all of the fibrous tissue within the lumen. This technique excludes the portal vein wall from the cut surface, and inhibits its attachment and scarring to the potential ductal drainage area. The anterior wall of the anastomosis is completed to the tissue of the quadrate lobe just anterior to the cut surface margin (Fig. 117.4).

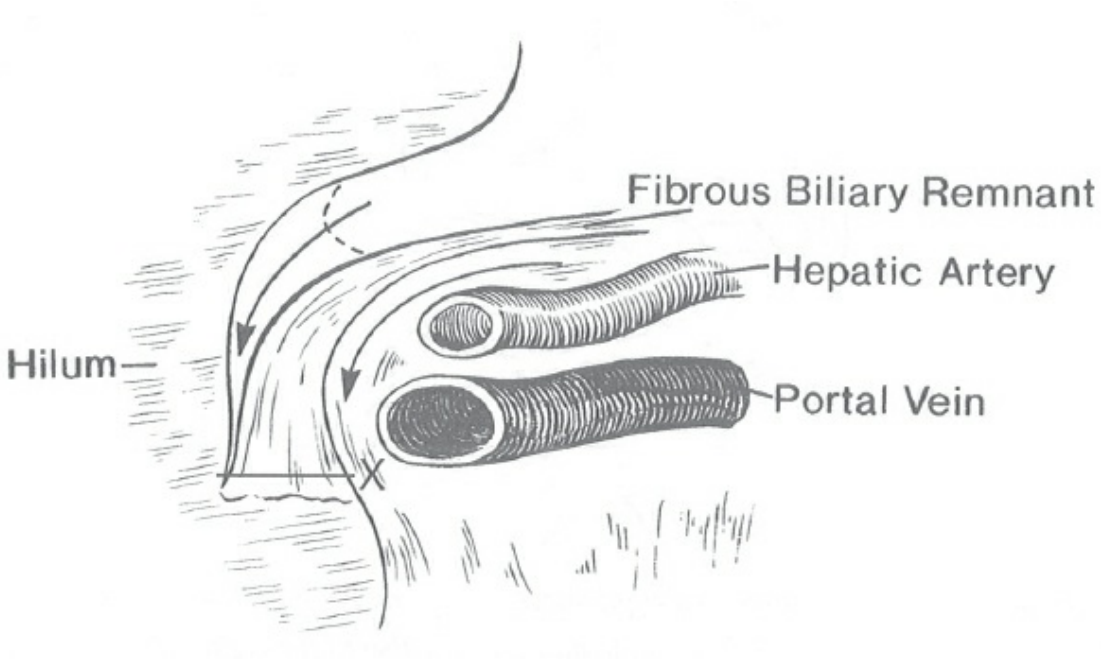

Figure 117.3. With the fibrous mass elevated off the vascular structures in the hepatic capsule, it is transected at the level of the hepatic capsular surface (marked by *X*).

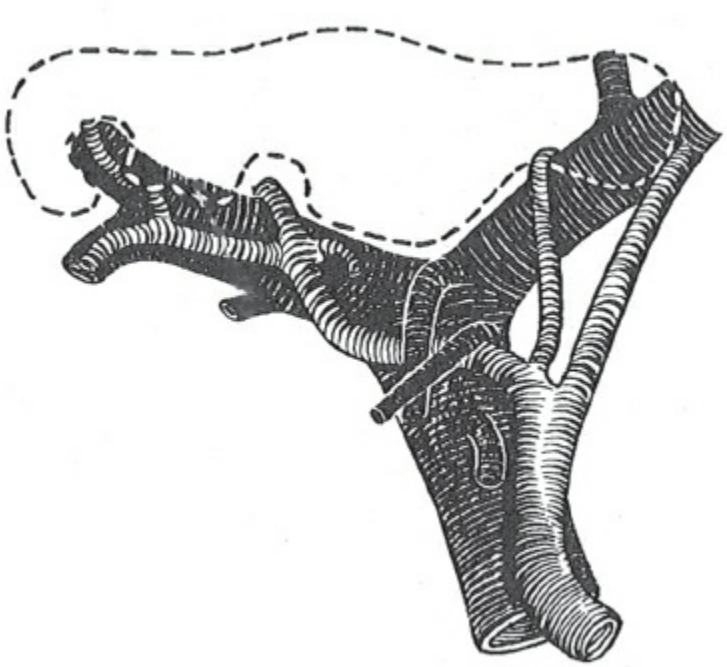

Figure 117.4. Roux-en-Y anastomosis to the gut surface "invaginating" the portal venous and hepatic arterial branches. The suture follows the course of the dotted line. This allows drainage of the right and left extended triangle as well as of the central hilum, but it excludes the vascular elements from the anastomotic site.

LAPAROSCOPIC PORTOENTEROSTOMY

As with many surgical procedures, laparoscopy has been utilized in place of open surgery for a portoenterostomy. Initial interest was tempered by studies in which reported outcomes were worse in patients who underwent the laparoscopic approach; however, more recent studies from centers in Japan report favorable outcomes. Given the significant consequences of a failed Kasai (i.e., early OLTxp), a laparoscopic approach should be considered only in the context of a controlled clinical trial performed by centers with significant expertise in laparoscopy.

POSTOPERATIVE CARE

As in all infants following laparotomy, careful attention to anesthetic recovery, postoperative nutritional support, and fluid management is necessary. All infants should receive supplemental fat-soluble vitamins A, D, E, and K and high-energy, high-protein feedings, usually employing 40% to 60% of fat as medium chain triglycerides. Intravenous perioperative antibiotics are given. The role of longer-term antibiotics to

prevent cholangitis is less clear. In the US multicenter BARC review, 60% to 70% of experienced centers used oral antibiotics for 1 to 3 months. We use sulfamethoxazole-trimethoprim (Bactrim or Septra) for 3 to 6 months. Administration of ursodeoxycholic acid (15 to 30 mg/kg/day) may stimulate bile flow and decrease toxin injury to hepatocytes.

The use of corticosteroids following Kasai procedure is controversial. Corticosteroids simulate the bile salt independent portion of bile flow and are as nonspecific anti-inflammatory agents. An uncontrolled "survey" in the Japanese BA Society showed improved anicteric survival in the steroid groups (58% vs. 36%; $P = 0.052$). A double-blind prospective randomized trial analyzing the effects of postoperative corticosteroids performed by the National Institutes of Health (NIH)-supported Childhood Liver Disease Research Network (ChiLDReN) revealed no benefit to a high-dose course of perioperative steroids. Studies conducted in the United Kingdom and Germany using lower doses of perioperative steroids demonstrated a similar lack of efficacy.

The initial establishment of successful bile flow following the Kasai procedure occurs when microscopic communicating biliary ducts form an epithelialized fistula, ultimately developing into an autoanastomosis between the ductal mucosa and the mucosa of the Roux-en-Y conduit. If bile flow is interrupted during this critical time, a persistent fistula will not form. If bile flow decreases during the early postoperative period and manifests as decreasing color to the stools and rising bilirubin, cholangitis should be excluded. Once excluded, the use of corticosteroids can be considered; however, no conclusive data support this practice.

INDICATIONS FOR REOPERATION

Infants with inadequate or no initial bile flow are poor reoperative candidates and should not be reexplored. The increased intraperitoneal and perihepatic adhesions that greatly complicate subsequent liver transplantation are most often the consequence of repetitive but misdirected attempts to reoperate on poorly selected candidates, or recurrent episodes of bacterial peritonitis.

Recent studies have reported the role of reoperation in a subgroup of patients who initially had a successful portoenterostomy. Reoperation is reserved for infants who after their Kasai had active bile drainage leading to an anicteric state followed by abrupt cessation of bile excretion. Ideally, they also have favorable hepatic histology and biliary ductal remnant

histopathology from their primary procedure. Reexploration with revision of their Kasai may be warranted as reconstitution of bile flow is successful in over one half of the patients. Recurrent cholangitis caused by a blind pouch is another relative indication for reexploration.

OUTCOME FOLLOWING KASAI PORTOENTEROSTOMY

There is no clinical, laboratory, or histologic factor that has been reliably predictive of success following portoenterostomy. Factors recognized to affect prognosis in BA are listed in Table 117.3. The patient's age at operation was shown to directly affect prognosis in Kasai's original series. However, the significance of age at operation is inconsistent. The French National study reported decreased 5-year survival with the native liver in patients >90 days of age at operation. Conversely, Davenport et al. in the King's College series showed no significant difference in clearance of jaundice or 2-year native liver survival with increasing age in isolated BA. Patients with BASM anomalies showed worse outcomes with advancing age. Success in achieving bile drainage correlated directly with the size of the bile duct remnants identified in the porta hepatis at surgery—bile duct profiles >150 microns have the best prognosis and ductal remnants <50 microns in size uniformly fair poorly.

TABLE 117.3 Factors Affecting Prognosis in Biliary Atresia

Age at hepatoportoenterostomy
Postoperative care
Degree of fibrosis/cirrhosis
Prevent cholangitis
Size of biliary remnant
Nutrition support
Coexisting anomalies
Experience of surgeon

The rate of decline of serum bilirubin concentration in the immediate postoperative period correlates with a positive outcome. One of the important findings of the ChiLDReN analysis was the predictive value of postoperative bilirubin in survival with the native liver. A total serum

bilirubin level of <2 mg/dL at 3 months postoperative correlated with good outcomes at 2 years (84% survival). Serum bilirubin >6 mg/dL had a poor prognosis (16% 2-year survival).

Ascending cholangitis is a risk particularly in infants with good bile drainage. As such, cholangitis is not associated with a worse prognosis, but recurrent attacks can damage biliary radicals. Recurrent or late cholangitis may suggest Roux-en-Y obstruction. A radioisotope scan can identify these cases. Since children with BA rapidly develop cirrhosis, markers of hepatic fibrogenesis such as serum hyaluronic acid select high-risk infants. When serum hyaluronic acid concentrations were elevated prior to the Kasai procedure, 15 of 16 patients died or underwent liver transplantation; only 2 of 8 patients with normal levels prior to the Kasai procedure had adverse outcomes.

A favorable impact from regionalization of care for BA has been demonstrated in several studies. In the United Kingdom, BA surgery was restricted to three centers in 1999 when significant patient survival and native liver survival differences were noted in centers with <5 cases/year operative volume. Regionalization improved the overall outcomes. The French National Study (1986 to 1996) also noted significantly improved native liver, post-liver transplant and overall patient survival in a high-volume (>20/year) center compared to the ones treating <5 cases per year. In both studies, surgeon experience with the Kasai Portoenterostomy and overall center experience with liver disease and liver transplantation were felt to be critical components. In the United States, success rates similar to those in the United Kingdom and France have been recorded by the ChiLDReN, representing 14 clinical centers with established liver care centers. This strongly suggests that BA patients achieve the best outcomes in the centers focused on their specific disease type and surgical needs.

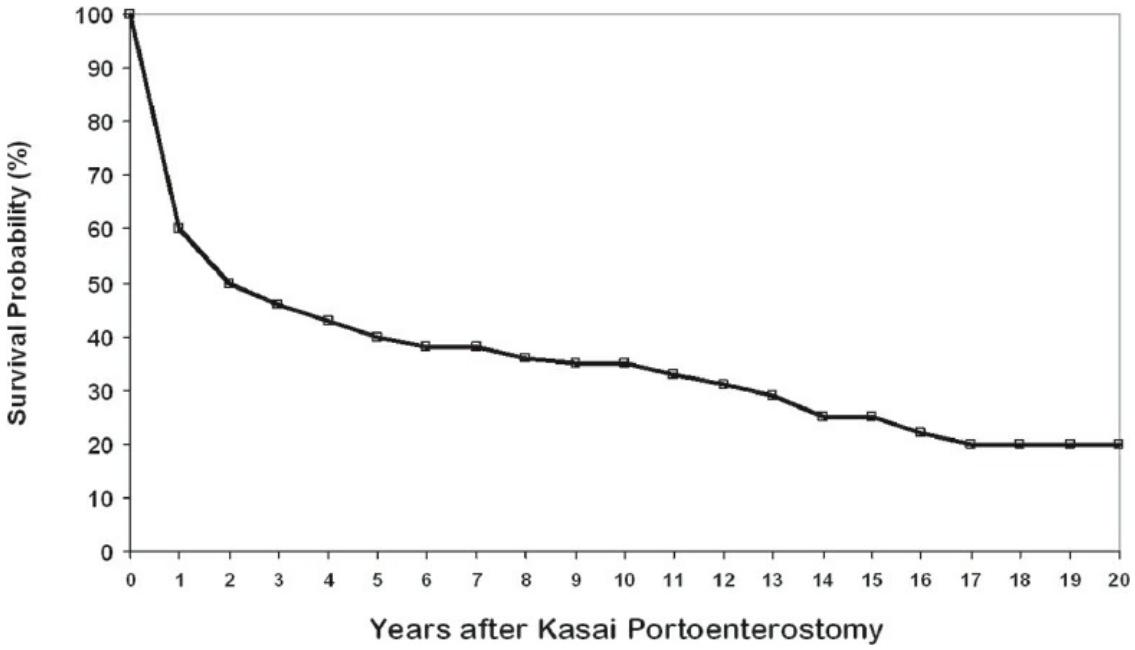

Figure 117.5. Survival probability without liver transplantation following the Kasai procedure.

For infants who do not drain bile and develop progressive cirrhosis and in children who develop progressive fibrosis and manifest complications of ESLD, OLTxp offers the only option for long-term survival. The combination of whole organ, reduced size, living donor, and split liver transplantation offers an excellent variety of options for transplant management. Using all of these possibilities, the pretransplant waiting list mortality in experienced pediatric centers is <5% at the present time. With present 5- and 10-year posttransplant survival approaching 90% in most pediatric centers, the overall prognosis for infants with BA is excellent, although this success is often achieved through many sequential and complimentary modes of treatment.

CONCLUSION

The outcome of infants with BA has been favorably influenced by the Kasai procedure. Left untreated, BA is fatal within 2 years, with a median survival of 8 months. The overall survival without liver transplantation 5 years following the Kasai procedure ranges from 40% to 60%, decreasing to 25% to 35% at 10 years, and 10% to 20% at 20 years (Fig. 117.5); however, this precludes for these patients the need for early OLTxp. The quality of life in these long-term survivors is generally good, with normal growth, development, and sexual development in most cases; however,

these patients do not have normal liver function developing progressive hepatic fibrosis/cirrhosis. With cirrhosis, portal hypertensive complications such as ascites, hypersplenism, and gastrointestinal hemorrhage may occur and complications of chronic liver disease including hepatopulmonary syndrome, portopulmonary hypertension, and hepatocellular carcinoma manifest. Long-term surveillance for all patients with BA is critical, and when the manifestations of ESLD become clinically significant, OLTxp is warranted.

Suggested Readings

Pathogenesis

Asai A, Miethke A, Bezerra J. Pathogenesis of biliary atresia: defining biology to understand clinical phenotypes. *Nat Rev Gastroenterol Hepatol* 2015;12(6):342–52.

Riepenhoff-talty M, Schaekel K, Clark H, et al. Group A rotaviruses produce extrahepatic biliary atresia in orally inoculated newborn mice. *Pediatr Res* 1993;33(4pt1):394–9.

Overall Evaluation

Balistreri WF, Bezerra JA, Ryckman FC. Biliary atresia and other disorders of the extrahepatic bile ducts. In: Suchy FJ, Sokol RJ, Balistreri WF, eds. *Liver Disease in Children,* 3rd ed. New York: Cambridge University Press; 2007:247–69.

Fawaz R, Baumann U, Ekong U, et al. Guideline for the evaluation of cholestatic jaundice in infants: joint recommendations of the North American Society for Pediatric Gastroenterology, Hepatology, and Nutrition and the European Society for Pediatric Gastroenterology, Hepatology, and Nutrition. *J Pediatr Gastroenterol Nutr* 2017;64(1):154–68.

Hartley JL, Davenport M, Kelly DA. Biliary atresia. *Lancet* 2009;374:1704–13.

Operative Treatment

Bondoc A, Taylor J, Alonso M, et al. The beneficial impact of revision of Kasai portoenterostomy for biliary atresia—an institutional study. *Ann Surg* 2012; 255(3):570–6.

Endo M, Masuyama H, Hirabayashi T, et al. Effects of invaginating anastomosis in Kasai hepatic portoenterostomy on resolution of jaundice, and long-term outcome for patients with biliary atresia. *J Pediatr Surg* 1999;34:415–9.

Hashimoto T, Otobe Y, Shimizu Y, et al. A modification of hepatic portoenterostomy (Kasai operation) for biliary atresia. *J Am Coll Surg* 1997;185:548–53.

Kasai M, Suzuki S. A new operation for “non-correctable” biliary atresia, hepatic portoenterostomy (in Japanese). *Shujutsu* 1959;13:733–9.

Nakamura H, Murase N, Koga H, et al. Classification of biliary atresia in the laparoscopic era. *Pediatr Surg Int* 2016;32(12):1209–12.

Ryckman FC, Alonso MH, Bucuvalas JC, et al. Biliary atresia—surgical management and treatment options as they relate to outcome. *Liver Transpl Surg* 1998;4:S24–S33.

Toyosaka A, Okamoto E, Okasora T, et al. Extensive dissection at the porta hepatis for biliary atresia. *J Pediatr Surg* 1994;29:896–9.

Outcome

Altman RP, Lilly JR, Greenfeld J, et al. A multivariable risk factor analysis of the portoenterostomy (Kasai) procedure for biliary atresia. Twenty-five years of experience from two centers. *Ann Surg* 1997;226:348–55.

Bezerra J, Spino C, Magee J, et al. Use of corticosteroids after hepatoportoenterostomy for bile drainage in infants with biliary atresia. *JAMA* 2014;311(17):1750–9.

Davenport M, De Ville de Goyet J, Stringer MD, et al. Seamless management of biliary atresia in England and Wales (1999–2002). *Lancet* 2004;363(9418):1354–7.

Nio M, Ohi R, Hayashi Y, et al. Current status of 21 patients who have survived more than 20 years since undergoing surgery for biliary atresia. *J Pediatr Surg* 1996;31:381–4.

Nio M, Ohi R, Miyano T, et al. Five and 10-year survival rates after surgery for biliary atresia: a report from the Japanese biliary atresia registry. *J Pediatr Surg* 2003; 38(7):997–1000.

Serinet MO, Broue P, Jacquemin E, et al. Management of patients with biliary atresia in France: results of a decentralized policy 1986–2002. *Hepatology* 2007;46(2):566–81.

Shneider BL, Brown MV, Haber B, et al. A multicenter study of the outcome of biliary atresia in the United States, 1997–2000. *J Pediatr* 2006;148(4):467–74.

Liver Transplantation

Lopez-Santamaria M, Gamez M, Murcia J, et al. Long-term follow-up of patients with biliary atresia successfully treated with hepatic portoenterostomy. The importance of sequential treatment. *Pediatr Surg Int* 1998;13:327–30.

Sandler AD, Azarow KS, Superina RA, et al. The impact of a previous Kasai procedure on liver transplantation for biliary atresia. *J Pediatr Surg* 1997;32:416–9.

EDITOR'S COMMENT

In their excellent review of biliary atresia, Drs. Ryckman and Tiao succinctly describe the diagnosis, management, and long-term sequelae of biliary atresia, and they provide expert insight into the role of both the Kasai procedure and liver transplantation in the operative management of the disease. Complementary to their review, we would like to offer additional discussion on two systems-level issues that are discussed within the field of pediatric hepatobiliary surgery: (1) the role of the multidisciplinary team within a health care system, and (2) regionalization in care across health care systems.

In pediatric medicine, the initial diagnosis of hyperbilirubinemia is largely the responsibility of primary care pediatricians or family medicine physicians who may never encounter a single case of biliary atresia throughout their career. Neonatal jaundice is usually diagnosed within the first couple of weeks of life and is very common in primary care pediatrics. When resolution of jaundice does not occur, most physicians will attain a conjugated bilirubin level and, if elevated, may refer to specialized care, usually pediatric gastroenterology. It is not uncommon for children to wait over 2 weeks to see a specialist. In communities that lack pediatric gastroenterology practices that know to expedite these referrals, patients can easily wait longer to be evaluated. If the appropriate evaluation is not initiated early, under the assumption that the child has biliary atresia until proven otherwise, then infants may not present to pediatric surgical care until they are outside the optimal window for Kasai portoenterostomy. Although large-scale screening practices have been deemed burdensome, we believe that children's hospitals with comprehensive liver centers including dedicated hepatobiliary and transplant programs are responsible for: (1) promoting community-based educational initiatives to facilitate early diagnosis; (2) developing methods for rapid screening and triage of jaundiced infants to appropriate specialists; (3) establishing multidisciplinary teams that can be activated early in the diagnostic algorithm so that delays in care can be avoided once referral has occurred; and (4) advocating for regionalization to improve outcomes. Although pediatric gastroenterologists are instrumental in the first two points, surgeons play a critical role in guiding multidisciplinary teams and providing evidence for regionalization, both of which have been shown to improve outcomes in pediatric patients.

Multidisciplinary Teams: Within the broader field of pediatric surgery, several models of cross-disciplinary collaboration are widely used in clinical practice. For example, congenital heart disease is managed within the broader context of a "Heart Center" in which cardiac surgeons, cardiologists, cardiac anesthesiologists, radiologists, intensivists, pharmacists, and allied health services work within a common mission and vision. Pediatric surgical oncology, similar to adult surgical oncology, frequently invokes a "tumor board" and cancer specific teams to provide multidisciplinary care plans. A less publicized

team, but one that is more analogous to caring for patients with biliary atresia, is the intestinal rehabilitation team. This team is usually comprised of gastroenterologists, pediatric surgeons, pharmacists, social workers, and nutritional support services with strong ties to pediatric liver and intestinal transplantation centers. A growing body of evidence suggests that intestinal failure patients have improved outcomes when cared for by such a team (Javid PJ, Malone FR, Reyes J, et al. The experience of a regional pediatric intestinal failure program: Successful outcomes from intestinal rehabilitation. *Am J Surg* 2010;199(5):676–9). In 2008, Modi et al. reported one of the first studies on the effects of a multidisciplinary team on outcomes in children with intestinal failure (Modi BP, Langer M, Ching YA, et al. Improved survival in a multidisciplinary short bowel syndrome program. *J Pediatr Surg* 2008;43(1):20–4). Although there was no significant improvement in intestinal autonomy, there was a 19% increase in survival among patients managed within the multidisciplinary team compared to a historical control at their institution. The authors contend that this mortality difference is likely due to the fully integrated care provided by the multidisciplinary team. This approach led to better coordination of surgical, medical, and nutritional management with improved monitoring of medications and development of coherent and integrated treatment plans. Other groups have reported improved survival and weaning of parenteral nutrition in intestinal failure patients managed with a multidisciplinary team approach (Hess RA, Welch KB, Brown PI, et al. Survival outcomes of pediatric intestinal failure patients: analysis of factors contributing to improved survival over the past two decades. *J Surg Res* 2011;170(1):27–31).

After several additional single-center reports emerged in the literature, Stanger et al. published a systematic review on outcomes from multidisciplinary intestinal rehabilitation programs in 2013 (Stanger JD, Oliveira C, Blackmore C, et al. The impact of multi-disciplinary intestinal rehabilitation programs on the outcome of pediatric patients with intestinal failure: a systematic review and meta-analysis. *J Pediatr Surg* 2013;48(5):983–92). They identified that the multidisciplinary approach led to significant reductions in septic episodes and improved overall survival. They also describe multidisciplinary teams as partially responsible for earlier surgical and transplant referral and improvement in overall coordination of care.

The effective and expeditious care of the patient with biliary atresia requires a similar approach. As described by Drs. Ryckman and Tiao, early referral of patients with biliary atresia to pediatric hepatobiliary surgeons is critical for maximizing the success of the Kasai portoenterostomy to establish bile flow. Collaborative discussion around the utility of specific preoperative diagnostic procedures, pathologic findings, and perioperative care is likely to reveal similar improvement in outcomes as those in the intestinal rehabilitation groups. Multidisciplinary teams are also critical for making challenging therapeutic decisions such as when to skip the Kasai and refer directly for transplantation,

or when to consider a portoenterostomy revision. From an academic perspective, multidisciplinary teams are better positioned to engage in novel research at both an institutional and a national level.

Advocating for Regionalization: Several reports from centers around the world have identified that higher-volume centers show superior results in terms of native liver survival following portoenterostomy (Serinet MO, Broue P, Jacquemin E, et al. Management of patients with biliary atresia in France: results of a decentralized policy 1986–2002. *Hepatology* 2006;44(1):75–84; Davenport M, De Ville de Goyet J, Stringer MD, et al. Seamless management of biliary atresia in England and Wales (1999–2002). *Lancet* 2004;363(9418):1354–7). Most widely cited is the study by Davenport et al. from the United Kingdom in which they reviewed postoperative outcomes from portoenterostomy following centralization of cases to one of three referral centers in the United Kingdom. They reported a clinically meaningful increase in both the rate of native liver survival and the actuarial survival (Davenport M, De Ville de Goyet J, Stringer MD, et al. Seamless management of biliary atresia in England and Wales (1999–2002). *Lancet* 2004;363(9418):1354–7). The volume–outcome relationship is not a novel concept in surgery. However, in order to create centers of excellence in the United States, regionalization would need to be supported within the broader community of physicians, health care systems, payers, and families. In the United States, there are several barriers to regionalization including a larger land mass compared to European countries and Japan; a relative inflexibility of both private and public health insurers; competition for market share in health care dense demographics; lack of transparency on volume–outcome relationships with the public; and family resources, preferences, values, support systems, and obligations (work, additional siblings, etc.), which need to be respected.

The etiology of biliary atresia remains to be elucidated, and the operative therapy for biliary atresia has advanced little in decades. Therefore, our biggest opportunities to improve outcomes in children with biliary atresia reside in improving our efficiency at early diagnosis, and insuring every child undergoes operation by an experienced, well-coordinated team.

Katherine J. Deans and R. Lawrence Moss

118 Liver Transplantation

Henrik Petrowsky, Lukasz Filip Grochola, and Ronald W. Busuttil

ETIOLOGY AND PATHOPHYSIOLOGY OF ACUTE AND CHRONIC LIVER INJURY

The loss of functional parenchyma of the liver can be caused by acute or chronic hepatic injury and result in a failure of this organ with an inability to perform its normal synthetic and metabolic function. Despite the fact that the mechanisms underlying the pathogenesis of both types of liver injury are distinct, they can ultimately lead to the need for organ replacement. Acute liver failure results from a rapid loss of hepatocyte function secondary to critical injury by a wide range of causes such as drugs, metabolic and genetic disorders, autoimmune and vascular causes (Table 118.1). Those insults lead either to apoptosis (programmed cell death), which is characterized by nuclear and cytoplasmic shrinkage, condensation, and blebbing without a loss of cell membrane integrity, or necrosis of liver cells, a less orderly process with cell swelling, loss of membrane integrity, and lysis. Chronic hepatic injury on the other hand is a slow process defined by fibrosis of hepatic parenchyma and the subsequent development of cirrhosis with irreversible end-stage liver disease (ESLD). Fibrosis, the first step in this process, is characterized by a reversible scarring of the liver tissue that is caused by chronic injury, which leads to the deposition and resorption of extracellular matrix. With time, in the presence of a continuous insult, this alteration of the extracellular matrix affects the portal tracts, central veins, and perisinusoidal spaces in a way that distorts hepatic vasculature, leading to shunting of the portal and arterial blood supply. In addition, it results in the formation of regenerative nodules and compromised hepatocyte function, and ultimately leads to ESLD (cirrhosis). The most common cause for this condition worldwide is hepatitis B, while abuse of alcohol and hepatitis C are the primary culprits in developed countries. Other factors, including metabolic or autoimmune disorders, are less common causes for chronic liver injury and are listed in Table 118.1. The development of effective

hepatitis C medication and the epidemic of diabetes mellitus and obesity will shift hepatitis C to nonalcoholic steatohepatitis as the most common indication of liver transplantation in the western geography.

CLINICAL PRESENTATION OF LIVER FAILURE

On the basis of duration of liver injury and the resulting symptoms, the clinical manifestation of hepatic failure is classified as fulminant, acute, acute-on-chronic, and chronic. The hallmark of fulminant and acute liver failure is severe hepatic injury with encephalopathy in the absence of preexisting liver disease, whereby the former is defined as the onset of encephalopathy within 8 weeks of the first symptoms of liver disease. Besides hepatic encephalopathy with cerebral edema, the clinical presentation of acute liver failure (inclusive of fulminant and acute-on-chronic conditions) includes most prominently coagulopathy (internationalized normalized ratio ≥1.5), jaundice, and elevated serum aminotransferase levels. In addition, hypotension, renal failure, infection, hypoglycemia, electrolyte abnormalities, and cardiac dysfunction may develop. Of note, portal hypertensive bleeding, which is frequently encountered in chronic liver failure, is not a clinical manifestation of an acute presentation of this condition.

TABLE 118.1 Etiologies of Underlying Liver Failure Requiring Liver Transplantation

Acute Liver Failure:	Chronic Liver Failure:
■ Drug toxicity	■ Alcoholic liver disease
■ Hepatitis A, B, E	■ Hepatitis B, C
■ Shock (acute ischemia)	■ Schistosomiasis
■ Wilson's disease	■ Congestive heart failure
■ Budd–Chiari syndrome (hepatic vein occlusion)	■ Budd–Chiari syndrome (hepatic vein occlusion)
■ Reye syndrome	■ Nonalcoholic steatohepatitis (NASH)
■ Pregnancy-related (fatty liver, HELLP)	■ Hereditary hemochromatosis
■ Autoimmune hepatitis	■ Autoimmune hepatitis
■ Indeterminate acute liver failure	■ Wilson's disease
	■ Primary biliary cirrhosis (PBC)
	■ Primary sclerosing cholangitis (PSC)
	■ Chronic obstruction of the biliary tract
	■ Byler's disease
	■ Cryptogenic cirrhosis

In the majority of cases, the diagnosis of chronic liver failure is made in

patients with compensated liver cirrhosis who present with no symptoms and intact synthetic liver function. In those patients, incidental screening tests show abnormal serum liver transaminase levels or radiologic findings that are suggestive of liver disease. However, in more advanced cases of cirrhosis when hepatocyte function and hepatic circulation are significantly compromised by cirrhotic processes, clinical signs of liver failure such as portal hypertension and coagulopathy with variceal bleeding, jaundice, hepatic encephalopathy, ascites, infection, and renal failure may develop with potentially life-threatening consequences. In contrast to acute liver failure, cerebral edema is not encountered in chronic hepatic failure.

INDICATIONS AND CONTRAINDICATIONS FOR LIVER TRANSPLANTATION

Liver transplantation is indicated in patients with life-threatening acute liver failure or irreversible ESLD. In addition, organ transplantation is also indicated in patients with normal liver function who suffer either from malignant liver tumors (hepatocellular carcinoma [HCC], cholangiocarcinoma, metastatic neuroendocrine tumor) or from noncirrhotic liver disease. The latter conditions present with a normal or well-compensated liver function and include inherited metabolic disorders (e.g., amyloidosis, primary hyperoxaluria) that can affect multiple organ systems, for which liver transplantation is applied as a curative modality, and polycystic liver disease.

In chronic, irreversible conditions (cirrhosis), which represent the most frequent cause for liver transplantation, the question arises as to when is the best time for liver transplantation. In this situation, broad indications for liver transplantation are as given:

1. Hepatic encephalopathy
2. Hyperbilirubinemia with intractable pruritus
3. Portal hypertension (varices, upper gastrointestinal [GI] bleeding, ascites, hypersplenism)
4. Synthetic dysfunction (coagulopathy, hypoalbuminemia)
5. Poor quality of life (QOL) (severe fatigue, lethargy)

If two of these five clinical features are present, the patient should be referred for liver transplant evaluation.

Other indications for liver transplantation include HCC, cholangiocarcinoma, and metastatic neuroendocrine tumor in selected

patients. For example, cirrhotic patients with small HCC within the Milan criteria (single lesion <5 cm or three lesions <3 cm each, no extrahepatic tumor involvement) are suitable candidates for liver transplantation. Even if the intrahepatic tumor load is above the Milan but within the University of California, San Francisco (UCSF) criteria (single lesion <6.5 cm or three lesions total diameter <8 cm, none of which >4.5 cm), patients are still considered for liver transplantation.

Donor organs are allocated to patients with ESLD according to the severity of their chronic liver disease. In the United States and other countries, the severity of liver disease is determined by the Model of End Stage Liver Disease (MELD) score, which considers the degree of liver and renal failure. The MELD score ranges from 6 in a healthy person to 40 in patients with advanced severe ESLD. The score is composed of serum total bilirubin, serum creatinine, and INR.[1] Patients without HCC who have a MELD score below 15 should not undergo liver transplantation since there is no benefit from liver transplantation in terms of survival. On the other hand, patients with MELD scores greater than 15 will benefit from transplantation. Patients with HCC or other conditions (hepatopulmonary syndrome, amyloidosis, metabolic diseases) who have a normal or well-compensated liver function will get MELD exception points since the calculated MELD score does not reflect the patient's medical urgency for liver transplantation.

Acute liver failure in the absence of an underlying chronic liver disease is another definitive indication for liver transplantation (Table 118.1). King's College and Clichy criteria define the urgent need for liver transplantation (Table 118.2). Patients who meet those criteria are urgently listed (status 1) and have the highest priority on the list. If these patients are not urgently transplanted, severe brain edema with herniation and finally brain death can occur. Another condition that requires urgent liver transplantation is the primary nonfunction of a transplanted graft.

Contraindications to liver transplantation include active alcohol or drug abuse, HCC beyond Milan and UCSF criteria, extrahepatic malignancy, severe and irreversible cardiac comorbidities, uncorrectable pulmonary hypertension (mean pulmonary artery pressure >35 mm Hg), uncontrollable infection, irreversible cerebral injury, extensive portal and mesenteric vein thrombosis, unstable psychiatric disease, and incompliance.

PREOPERATIVE PLANNING

The preparation of liver transplantation involves an extensive surgical, medical, and psychosocial evaluation process in order to determine which patients will benefit most from this procedure in terms of survival and have the best chances for postoperative recovery. Because of the chronic organ shortage, this evaluation aims to provide a survival benefit in a safe manner to the most individuals possible who suffer from liver disease. Therefore, this process includes an assessment of alternative treatment options for a given candidate, recurrence rate of the disease, his or her comorbidities and chances of survival of the operation, as well as an evaluation of whether the patient can comply with the elaborate medical regimen required after transplantation. Identifying candidates who are appropriate for transplantation is therefore an elaborate task that requires a multidisciplinary approach. It involves a medical (review of medical records, physical examination), laboratory (including blood typing with antibody screen, hepatitis tests, Epstein–Barr virus, Cytomegalovirus, HIV testing), cardiac (electrocardiogram, echocardiogram, nuclear stress test, coronary catheterization in selected cases), pulmonary (including chest radiograph, pulmonary function testing, arterial blood gas levels), neurologic (carotid doppler if age >60 years, neuroimaging in selected cases), and psychosocial evaluation (psychiatry, social work, financial counselor, and nutritionist consultation), as well as age-appropriate cancer screening (Papanicolau test, mammogram, colonoscopy, PSA). After the completion of this screening process, a committee composed of hepatologist, transplant surgeons and coordinators, psychiatrist, and social workers determines whether the candidate is appropriate for transplantation and can be placed on a national waiting list. While the patient awaits an organ on the waiting list (hereby, the prioritization of patients with ESLD is based on the above-described MELD score), the individual undergoes standard screening and surveillance procedures such as esophagogastroduodenoscopy in order to detect and treat varices, HCC screening, as well as treatment of other complications of ESLD. In addition, MELD scores are reevaluated and updated approximately every 3 months.

TABLE 118.2 Criteria Defining Liver Transplantation for Acute Liver Failure

King's College Criteria:

Acetaminophen-induced ALF
- pH <7.3, or
- INR >6.5 and
- Serum creatinine >3.4 mg/dL

Nonacetaminophen-induced ALF
- INR >6.5, or
- Any three of the following criteria:
  1. Age <10 years or >40 years
  2. Etiology: non-A, non-B hepatitis, idiosyncratic drug reaction
  3. Duration of jaundice before encephalopathy >7 days
  4. INR >3.5
  5. Serum bilirubin >17 mg/dL

Clichy Criteria:

Hepatic encephalopathy, and
Factor V level <20% in patients <30 years of age
Factor V level <30% in patients ≥30 years of age

ALF, acute liver failure; INR, international normalized ratio.
From Petrowsky H, Busuttil RW. Evolving surgical approaches in liver transplantation. *Semin Liver Dis* 2009;29:121; © Georg Thieme Verlag KG.

SURGICAL TECHNIQUES

Cadaver Donor Hepatectomy

The donor is placed in the supine position with both arms tucked. The sterile preparation and draping covers the entire chest, abdomen, and proximal thighs to ensure total access to both the thoracic and abdominal cavities. A midline incision is made from the suprasternal notch (two-cavity access) or xiphoid process (one-cavity access) to the symphysis pubis using electrocautery. An extended Balfour self-retaining retractor with penetrating clamps is used for appropriate abdominal exposure. If the

thoracic cavity is opened, a sternal retractor is placed, which improves the exposure especially of both upper abdominal quadrants. Before the start of surgical maneuvers, a thorough exploration of the liver and the abdominal cavity is mandatory to exclude pathologic conditions (malignancies, infectious, and other disease processes), which might preclude organ donation. The liver should be evaluated in terms of size and parenchymal quality. A perfect donor liver has sharp edges, a smooth surface with appearance of scratching marks, and a brownish surface color, while suboptimal organs might present with round edges, some degree of parenchymal yellowness, absence of scratching marks, and a too soft (steatosis) or increased parenchymal firmness (fibrosis). Based on the initial assessment, the procurement surgeon will decide to proceed or to abort the procurement procedure.

If the assessment of the donor organ is acceptable and there is no thoracic or cardiac organ retrieval planned, the chest is opened through a median sternotomy using a pneumatic saw or, if not available, the Lebsche knife. A self-retaining sternal retractor is used for adequate thoracic exposure. The pericardium is incised through the midline at the diaphragm and cranially extended to the right atrium. The abdominal dissection begins with dividing of the round ligament (ligamentum teres hepatis) between two heavy silk ties. Using electrocautery, the falciform ligament is taken down to the hepatic vein–suprahepatic vena cava confluence and the left coronary and triangular ligaments are divided. The left lateral segments of the liver (segments 2 and 3) are reflected toward the donor's right side to access the gastrohepatic ligament. It is of paramount importance to inspect the gastrohepatic ligament for a replaced or accessory left hepatic artery (Fig. 118.1), which can occur in up to 10% of donors. In the vast majority, a replaced or accessory left hepatic artery originates from the left gastric hepatic artery (type 2, Fig. 118.1) and runs within the gastrohepatic ligament to the umbilical fissure. This artery must be preserved and should be neither injured nor divided. In the presence of a replaced or accessory left artery, the ligament is divided above and below the artery.

The retroperitoneal dissection is initiated with the medial reflection of the ascending colon. The ascending colon and the second (descending) part of the duodenum are mobilized and reflected to the left. Afterward, the remaining small intestine is mobilized cephalad until the left renal vein is identified. Dissections above this level might be harmful due to the

potential risk to injure the superior mesenteric artery (SMA), left renal artery, and pancreas. The small intestine is cephalad reflected and the inferior mesenteric vein is isolated at the ligament of Treitz. The vein is distally ligated and then cannulated with a 12 French infusion tubing line for the precool perfusion. We use an isotonic saline solution with 5% dextrose for serum levels less than 160 mEq/gL and 5% dextrose in free water for sodium levels greater than 160 mEq/gL. The volume of the chilled solution, usually not more than 1,000 mL, is slowly infused during the preparation.

The distal abdominal aorta is exposed above the level of the bifurcation in preparation for cannulation. The peritoneum and the periaortal tissue are widely divided at the bifurcation and carried above the origin of the inferior mesenteric artery. It is recommended that the plane of transection above the aorta should be slightly lateral toward the right to avoid cross-sectional injury to the inferior mesenteric artery. The aorta is encircled with two umbilical tapes: The distal tape is placed at the level of the bifurcation and held by a Kelly clamp, while the proximal tape is snared with a Rommel tourniquet and positioned just below the takeoff of the inferior mesenteric artery. In some cases, the inferior mesenteric artery might be divided for better exposure.

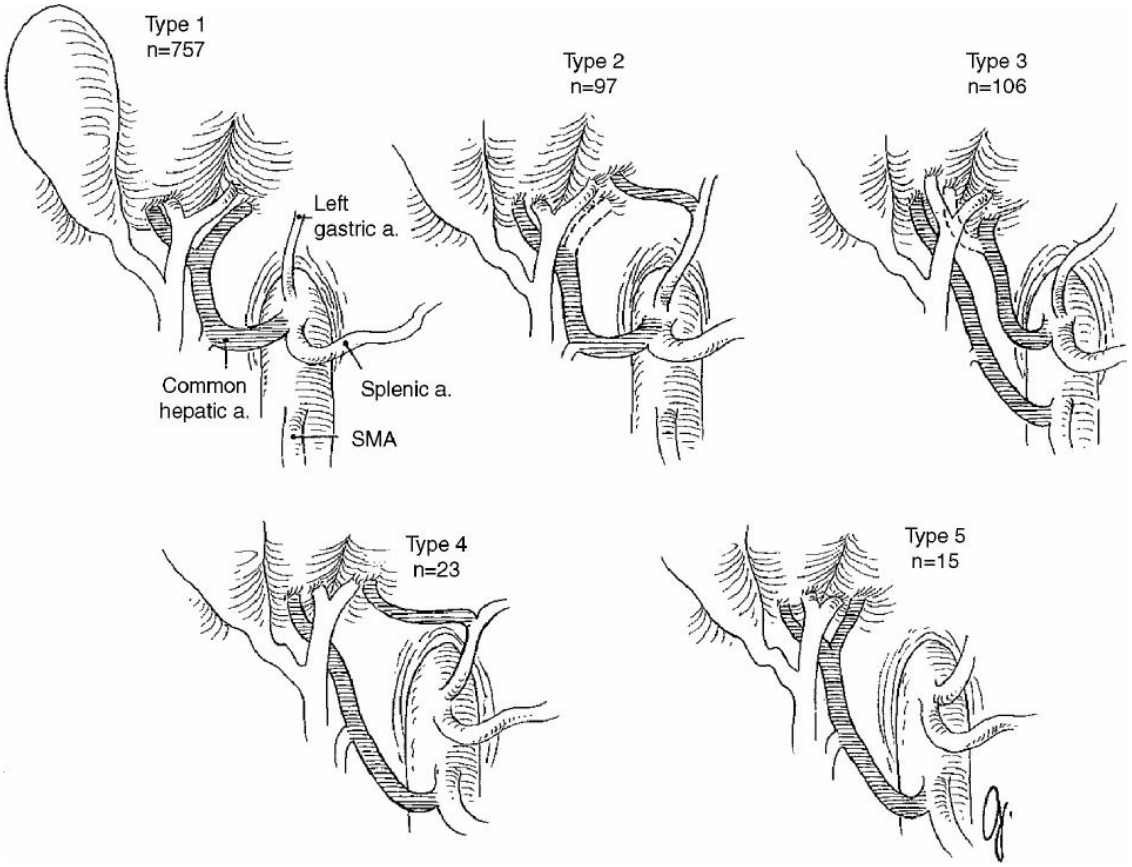

Figure 118.1. Hepatic arterial anatomy in 1,000 cases. Dotted lines indicate that the variant may be accessory (if branch shown by dotted line is present) or replaced (if absent). Type 1: normal (76%); type 2: replaced (accessory) left hepatic artery from left gastric artery (10%); type 3: replaced (accessory) right hepatic artery from superior mesenteric artery (SMA) (10%); type 4: double replaced system (2%); type 5: common hepatic artery from SMA (2%). (From Hiatt JR, Gabbay J, Busuttil RW. Surgical anatomy of the hepatic arteries in 1000 cases. *Ann Surg* 1994;220:50; Wolters Kluwer Health, Inc.)

The small intestine and ascending colon are reflected into the abdominal cavity and the porta hepatis is exposed. It is advisable to palpate the posterior hilum to identify a potential replaced right hepatic artery in arterial types 3, 4, and 5 (Fig. 118.1). The common bile duct above the duodenum (Fig. 118.2) is identified and carefully encircled with 2-0 silk. It is critical that the dissection does not extend into the hilum. The common bile duct is tied with 2-0 silk distally at the duodenal border and is half-way incised just above the tie. The gallbladder fundus is incised and flushed with saline solution until the effluent from the transected bile duct is clear.

The final maneuver before cannulation starts with the exposure of the supraceliac aorta. After the left lobe is elevated and retracted, a longitudinal incision of the right diaphragmatic crus is performed. This maneuver provides adequate access to the supraceliac aorta and might be more difficult in the presence of a replaced left hepatic artery. The preaortic fascia layer is sharply divided laterally with scissors, and the completely exposed aortic segment is encircled with an umbilical tape using a blunt-tipped large right-angle clamp. The tape easily identifies the position of accurate aortic cross-clamping.

The patient is then systemically heparinized with 300 to 500 IU heparin kg^{-1} per donor body weight allowing at least 3 minutes of circulation. After the abdominal aorta is ligated close to its bifurcation with the distal umbilical tape, an aortotomy is made and a 22 to 26 French reinforced cardiac catheter is inserted. The catheter is held in place with the Rommel tourniquet and a double ligation that includes catheter and tourniquet. In agreement with all recovering teams, the cross-clamp and the start of the perfusion are initiated. The cross-clamping is performed with a straight vascular clamp at the supraceliac position with the encircled umbilical tape. Immediately after this maneuver, the suprahepatic vena cava is transected at the caval–atrial junction and the dual perfusion with ice-cold preservation solution via abdominal aorta and inferior mesenteric vein is started. Slashed ice is immediately placed around the liver (including subdiaphragmatic space, hilum, and anterior and posterior to the liver), around both kidneys, and, in case of pancreas retrieval, into the lesser sac. At University of California, Los Angeles (UCLA), exclusively the University of Wisconsin (UW) solution is used at 4°C (39.2°F) as preservation solution infusing 2,000 to 3,000 mL via the aortic cannula and 1,000 mL via the inferior mesenteric vein.

After completion of cold perfusion and retrieval of cardiothoracic organs, the pericardium and the left and right diaphragm around the liver are divided. The cold dissection in the hilum starts with the arterial axis. Both the gastroduodenal artery and splenic artery are divided, and the celiac trunk is followed toward the aorta. The splenic vein and the superior mesenteric vein are transected, and the portal vein is dissected cephalad. In case of pancreas retrieval, the portal vein is divided to provide sufficient length for both the liver and the pancreas and to avoid pancreatic injury. The transection of the common bile duct is completed at the previous incision. If a replaced left or right hepatic artery is identified, each

structure is followed either to the left gastric artery or to the SMA (Fig. 118.1). The hilum dissection is completed after transecting the aorta with an aortal patch, including the orifice of the mesenteric artery and celiac artery. The inferior vena cava is divided proximal to the renal veins, and the liver is excised and packed in UW solution for transport.

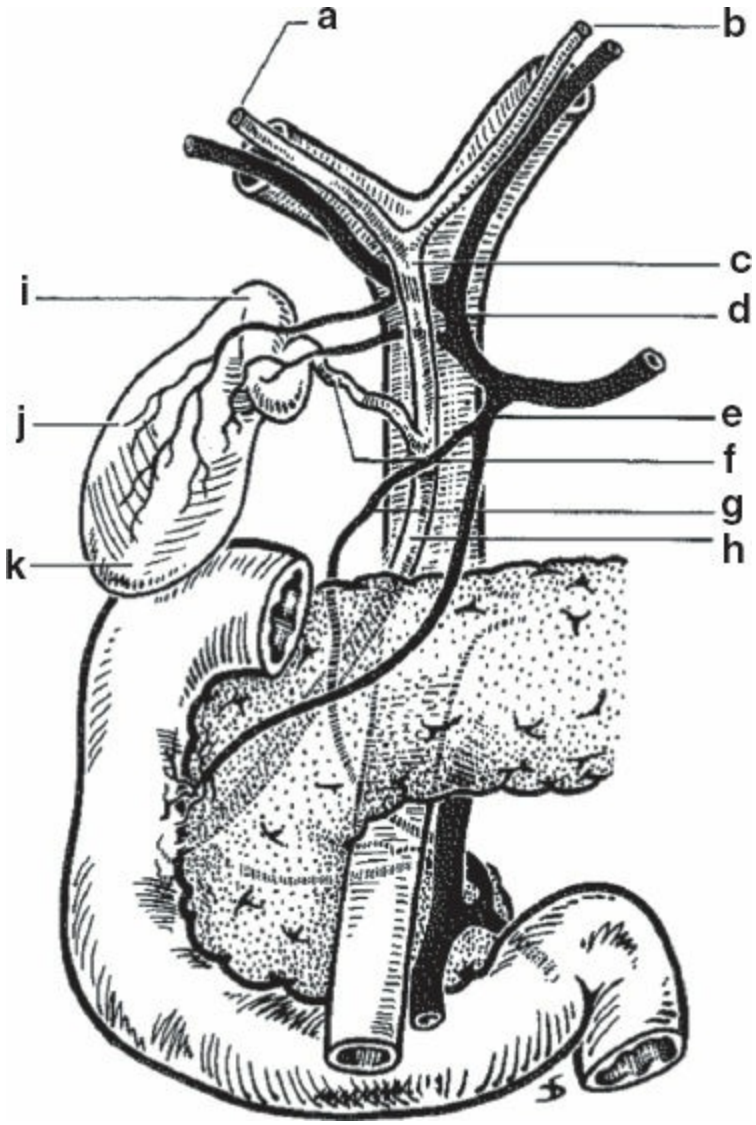

Figure 118.2. Anterior aspect of the biliary anatomy: **a**, right hepatic duct; **b**, left hepatic duct; **c**, common hepatic duct; **d**, hepatic artery; **e**, gastroduodenal artery; **f**, cystic duct; **g**, retroduodenal artery; **h**, common bile duct; **i**, neck of the gallbladder; **j**, body of the gallbladder; **k**, fundus of the gallbladder. Note particularly the situation of the hepatic bile duct confluence anterior to the right branch of the portal vein, the posterior course of the cystic artery behind the common hepatic duct, and the relationship of the neck of the gallbladder to the right branch of the hepatic artery. (Published in Blumgart LH,

Hann LE. Surgical and radiologic anatomy of the liver and biliary tract. In: Blumgart LH, Fong Y, eds. *Surgery of the Liver and Biliary Tract*. Philadelphia, PA: WB Saunders, 2000:14. Copyright 2000 Elsevier.)

Back-Table Preparation of the Donor Liver

Before the implantation into the recipient, the donor organ has to be prepared, which usually occurs during the recipient hepatectomy. The entire back-table preparation is performed in preservation solution at 4°C (39.2°F). The remnant diaphragm is removed and the suprahepatic vena cava is isolated. Phrenic vein orifices of the suprahepatic vena cava are identified and ligated or sutured. Next, the inferior vena cava is separated from adjacent tissue. The inferior vena cava is carefully inspected and the right adrenal vein and other small branches are ligated. The portal vein is isolated to the level of the bifurcation and cannulated for later flush with ice-cold lactated Ringer's with albumin solution. Finally, the entire arterial axis is skeletonized. Therefore, it is of paramount importance to identify any anatomic variations (types 2, 3, and 4) that would require reconstruction (Fig. 118.1). Dissection above the level of the gastroduodenal artery should be avoided due to potential injury to the proper hepatic artery.

Recipient Hepatectomy

Appropriate access to the upper abdominal cavity is achieved through a bilateral subcostal incision with midline extension. Except for the skin incision, the subcutaneous tissue, muscle, and fascia layers are divided with electrocautery. The right-sided incision extends more laterally than the left-sided incision. The midline incision is carried out to the xiphoid, requiring in some cases the resection of the xiphoid process. If the recipient has massive ascites, the subcostal incision should be placed 2 to 3 cm lower as compared with in recipients without ascites. The access is completed by dividing and ligating the round ligament. The falciform ligament is divided with electrocautery toward the suprahepatic vena cava. Afterward, a mechanical retractor system is placed with blades under both costal margins. The residual falciform ligament is taken down to the hepatic vein–suprahepatic vena cava confluence, and the left coronary and triangular ligaments are divided. The left lateral segments of the liver (segments 2 and 3) are reflected toward the recipient's right side, and the

gastrohepatic ligament is divided.

The common hepatic artery is dissected and clamped with a bulldog clamp (Fig. 118.3D). This step should avoid the arterial intima dissection after the left and right hepatic arteries are ligated (Fig. 118.3). Dissected arteries are associated with a very high risk for occlusion or are unusable for arterial reconstruction. The hilar dissection begins with incising the peritoneum at the superior border of the hilum in order to identify the left and right and sometimes the middle hepatic arteries. The hepatic arteries are dissected, ligated, and divided. The cystic duct and cystic artery (Fig. 118.2) are divided, which facilitates the circumferential dissection of the common hepatic duct. The isolated duct is then divided high in the hilum to ensure sufficient length of the recipient's duct for the later biliary anastomosis. In many cases, the dissection and division of the right hepatic artery are only possible at this point since the right hepatic artery crosses posteriorly to the common hepatic duct (Fig. 118.2). We then separate the arterial axis (proper hepatic artery) from the common bile duct. We routinely divide the gastroduodenal artery and follow the dissection toward the common hepatic artery until the position of the previously placed bulldog clamp. The portal vein is now skeletonized just until above the pancreatic border. During the distal dissection, the surgeon will find anterior and lateral portal vein branches that have to be ligated and divided. The portal vein dissection is completed by removing the posterior plane of lymphatic and connective tissue.

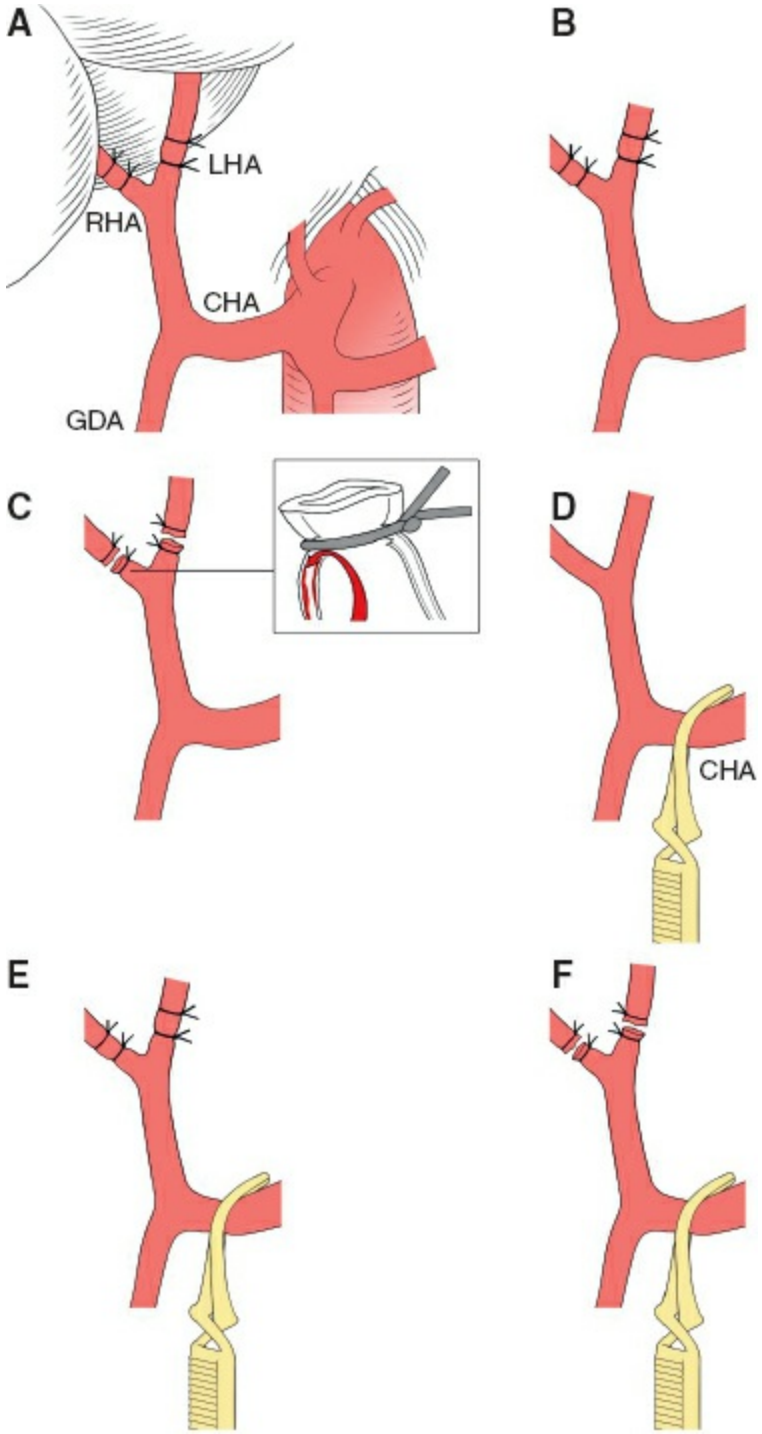

Figure 118.3. Dissection techniques of the arterial axis in the recipient. **A.** Normal hepatic anatomy. RHA, right hepatic artery; LHA, left hepatic artery; CHA, common hepatic artery; GDA, gastroduodenal artery. A dissection technique that, as a first step, directly ligates (**B**) and divides (**C**) the RHA and LHA should be avoided. This technique can lead to a dissection of the intima of the respective arteries due to the preserved blood flow and subsequently result in an occlusion of the vessels (inlay in C), which can significantly impair the patency of the anastomosis between the recipient and donor arteries. (**D**) In contrast to this

technique, at UCLA, an atraumatic bulldog clamp (yellow) is first placed at the CHA. Subsequently, the RHA and LHA are ligated (**E**) and divided (**F**). In the latter technique (**D**, **E**, and **F**), the risk of intima dissection is minimized. (Original work by the Graphic Department of the University Hospital Zurich.)

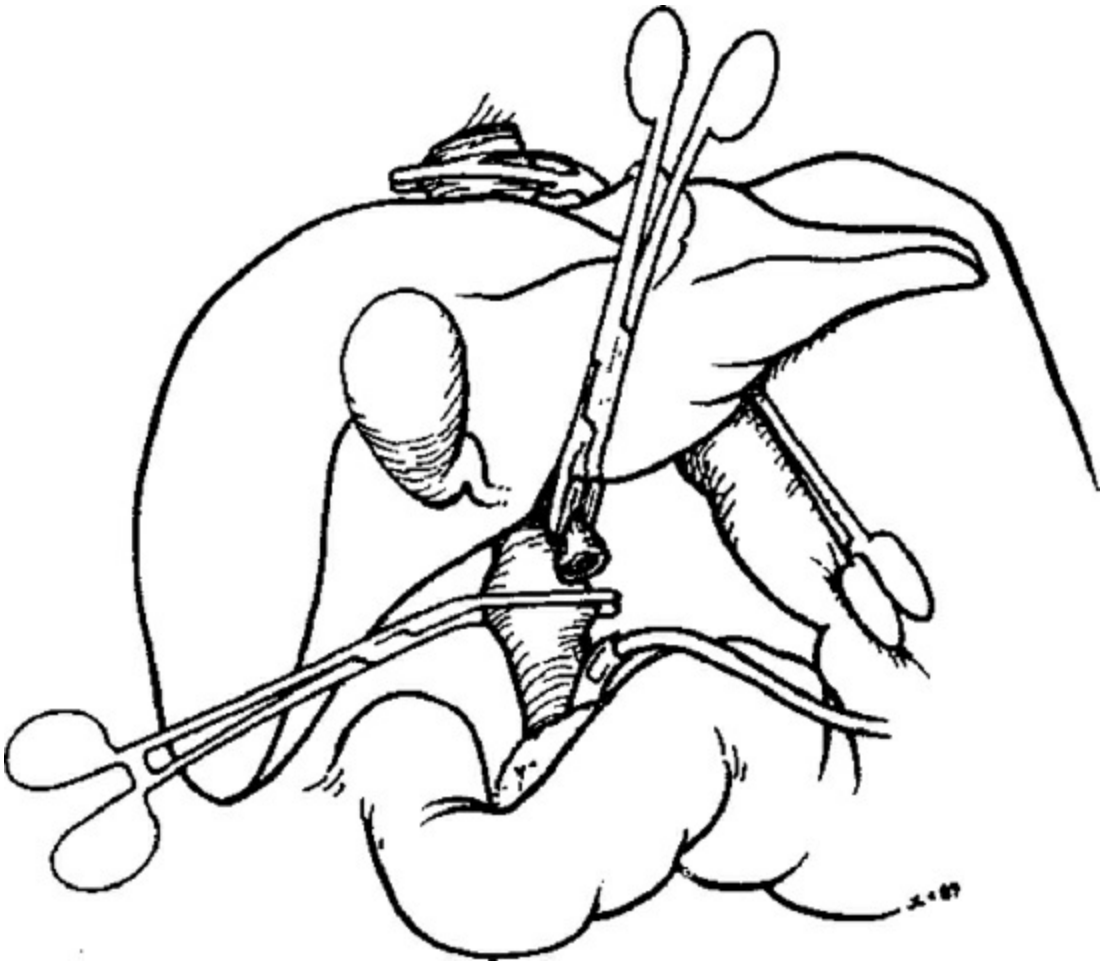

Figure 118.4. Horizontal placement of vascular clamps on suprahepatic and infrahepatic vena cava. (Reprinted from Klintmalm GB, Busuttiland RW. The recipient hepatectomy and grafting. In: Busuttil RW, Klintmalm GB, eds. *Transplantation of the Liver*. 3rd ed. Philadelphia, PA: Elsevier Saunders; 2015:604, with permission from Elsevier.)

The right lobe and the inferior vena cava are now mobilized. The right lobe is carefully elevated, and the right coronary and triangular ligaments are taken down with electrocautery. The dissection begins at the lateral inferior aspect and divides the ligament carefully all the way into the vena cava. After the peritoneum overlaying the anterior part of the infrahepatic vena cava is divided, the line of peritoneal dissection follows the plane

between left-sided vena cava and the peritoneal sheet all the way up to the suprahepatic vena cava. This maneuver often provides the window underneath the hepatic vena cava to the right side. The dissection is completed now on the right side. The right lobe is elevated, and the right adrenal vein is ligated and divided. Finally, the peritoneum is divided longitudinally along the vena cava. This results in the complete separation of the posterior aspect of the retrohepatic vena cava from the retroperitoneum.

The native liver is now ready for removal if no venovenous bypass (VVB) is applied. Vascular clamps are placed on the distal portal vein, infrahepatic and suprahepatic vena cava (Fig. 118.4). It is important that all clamps be oriented horizontally with the liver in the normal anatomic position to avoid rotation of the vessels. We use a large Satinsky vascular clamp for the suprahepatic vena cava, which should be placed on the very edge of the diaphragmatic reflection to avoid injuries to the phrenic nerve. The suprahepatic vena cava is first divided far into the hepatic veins. Next, the lower cava is divided as proximal as possible and finally the portal vein. The native liver is now removed (Fig. 118.5). Hemostasis of the bare area is achieved by retroperitonealization (Fig. 118.5, inlay). We use running sutures with 2-0 Prolene staring laterally and running centrally followed by a second running suture in the midline. For recipients with HCC, no residual liver tissue of the native liver should remain at the suprahepatic vena cava.

Venovenous Bypass

The VVB drains the infrahepatic caval and splanchnic blood into the superior vena cava (Fig. 118.6). Although not yet proven in randomized controlled trials, the VVB offers several advantages. The main advantage is related to the maintenance of venous return and splanchnic venous drainage, which results in improved hemodynamic stability during the anhepatic phase and reduction in mesenteric edema. The introduction of the VVB resulted initially in a decline of early morbidity and mortality; however, VVB is not routinely used and is likely less necessary for cava-sparing techniques (piggyback). In general, VVB is indicated in patients with hemodynamic instability after clamping, with fulminate hepatic failure to reduce volume overload, and with nondialysis-dependent hepatorenal syndrome.

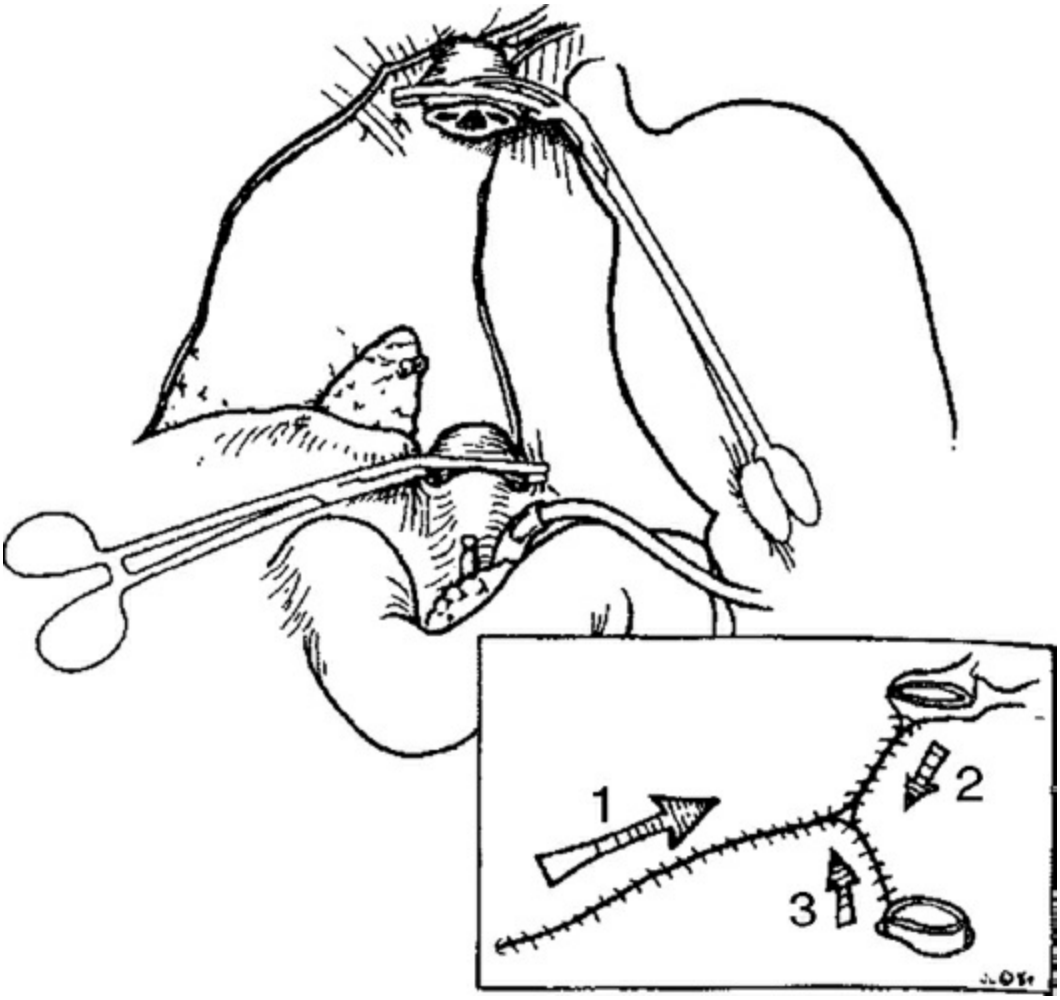

Figure 118.5. Upper abdominal situs after hepatectomy with vascular clamp on supra and infrahepatic vena cava. Portal vein is cannulated for venovenous bypass. The inlay illustrates the suture lines after retroperitonalization of the bare area. (Reprinted from from Klintmalm GB, Busuttil RW. The recipient hepatectomy and grafting. In: Busuttil RW, Klintmalm GB, eds. *Transplantation of the Liver.* 3rd ed. Philadelphia, PA: Elsevier Saunders; 2015:604, with permission from Elsevier.)

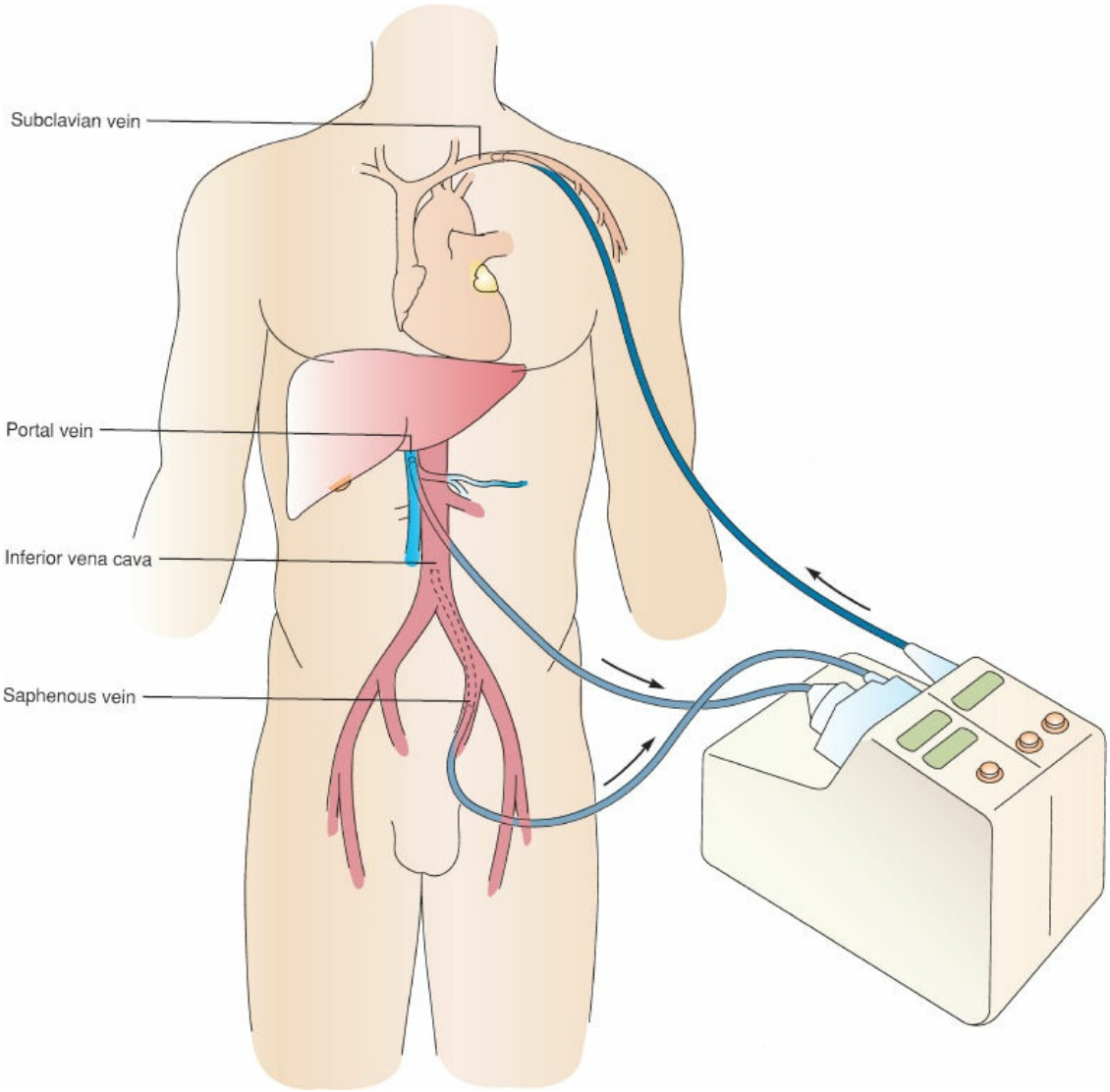

Figure 118.6. Setup for venovenous bypass during liver transplantation. (From Welling TH. Hepatic Transplantation. In: Mulholland MW, Lillemoe KD, Doherty GM, et al, eds. *Greenfield's Surgery: Scientific Principles and Practice*. 6th ed. Philadelphia: Wolters Kluwer; 2017:561, with permission.)

VVB of the subclavian and femoral vein can be performed as either a percutaneous or an open approach (Fig. 118.6). In both techniques, the cannulation of the portal veins is identical and performed by the surgeon. In the percutaneous technique, the femoral vein and the subclavian vein or alternatively the right internal jugular vein (IJV) are punctured and cannulated via the Seldinger technique. We use wire-inforced cannulas, 15 French for the femoral vein, and 12 French for the subclavian vein or right IJV. In the open technique, we cut down on the left axillary vein and left saphenofemoral junction using 20 and 18 French cannulas, respectively.

The cannulation of the saphenous vein should always be approached. In the absence of the saphenous vein, the cannulation of the femoral vein is possible but requires vascular reconstruction after the removal of the cannula. We usually start the cannulation of the portal vein with a ligation high up in the hilum. After placing an umbilical tape around the vein and a vascular clamp on the distal part of the portal vein, the proximal portal vein is incised and 22 French wire-reinforced cannula is introduced and advanced after the removal of the distal vascular clamp. The cannula is secured with tourniquet and ligations.

Implantation of Cadaver Whole Allograft

Suprahepatic Vena Cava Anastomosis

The implantation procedure begins with the preparation of the suprahepatic vena cava of the recipient. All hepatic vein bridges are divided to create a common suprahepatic vena cava cuff. At this point, the supra- and infrahepatic vena cuffs are carefully inspected for ostia, which are closed with 4-0 Prolene by placing the knots outside the caval cuff. After placing the donor liver into the situs, two corner stitches are placed at the opposite ends using 3-0 Prolene. In some cases with limited exposure, a stay suture of the middle posterior wall is helpful for better retraction. The posterior wall of the recipient and donor suprahepatic vena cava is anastomosed with a running suture from the left to the right corner sutures using 3-0 Prolene. We complete the anterior wall anastomosis using the same technique except that the suture is done from both the left and right side and tied down in the middle.

Infrahepatic Vena Cava Anastomosis

We proceed with the anastomosis of the infrahepatic vena cava. During the creation of the anastomosis, the liver is flushed with chilled lactated Ringer's and albumin (25 g per 1,000 mL) solution via the portal vein cannula. The purpose of this maneuver is to remove possible air and the high extracellular potassium from the preservation solution (UW). Depending on the size of the donor organ, we perform the rinsing of the allograft with 700 to 1,000 mL flush solution. The infrahepatic vena cava anastomosis is performed with 4-0 Prolene in the same fashion as the suprahepatic cava anastomosis. The suture is not tied down to facilitate flushing and venting maneuvers.

Portal Vein Anastomosis

If the patient is on VVB (Fig. 118.6), the bypass cannula is removed from the portal vein and the proximal portal vein is clamped. The donor portal vein is trimmed to the appropriate length. It is important to avoid a redundant portal vein, which can result in kinking and folding with severe compromise of portal flow. This principle also applies to the infrahepatic vena cava anastomosis. As for supra- and infrahepatic vena cava anastomosis, the portal vein is anastomosed with a running suture using 6-0 Prolene (Fig. 118.7). If there is a significant size mismatch between the donor and recipient portal vein, a fish mouth reconstruction is recommended. After completion of the portal vein, we reperfuse the liver through the portal vein and vent the reperfused blood through the open anterior suture line of the infrahepatic vena cava. Afterwards, sequential reperfusion through the infrahepatic vena cava and portal vein as well as simultaneous reperfusion through the portal vein and hepatic artery might be performed.

Arterial Anastomosis

The reconstruction of the hepatic artery is crucial to prevent any compromise of the arterial blood supply to the allograft. An imperfect anastomosis can result in early hepatic artery thrombosis with graft loss. However, the type of arterial reconstruction depends on the donor as well as on recipient arterial anatomy (Fig. 118.1). In normal cases with type 1 anatomy of the donor and recipient artery, the anastomosis can usually be created as end-to-end anastomosis between a Carrel patch of the donor aorta or artery and the common hepatic artery or branch patch of the bifurcation of the proper hepatic and gastroduodenal artery (Fig. 118.8). For regular-size arteries we use running sutures with 6-0 or 7-0 Prolene, while we prefer the interrupted suture technique with 7-0 or 8-0 Prolene for small-size arteries. The recipient gastroduodenal artery is always ligated and divided when the arterial anastomosis is performed with the recipient common hepatic artery. A replaced right hepatic donor artery stemming from the SMA (type 3 anatomy) is the most common arterial variant that requires reconstruction (Fig. 118.1). In these cases, a Carrel patch of the donor celiac artery can be anastomosed with a Carrel patch of the donor SMA (Fig. 118.9). The donor splenic artery is then anastomosed to the recipient common hepatic artery. Alternatively, an anastomosis between the donor-replaced right hepatic artery and the donor gastroduodenal artery can be created. If the arterial flow is unsatisfactory despite a technically perfect anastomosis, two important anatomic features

have to be considered. The arterial supply can be significantly compromised by a steel phenomenon of the splenic artery or the arcuate ligament syndrome. The steel phenomenon can be addressed through simple ligation of the splenic artery. In case of an arcuate ligament syndrome, the celiac arterial axis must be dissected down to the aorta and the ligament divided. If both of these maneuvers fail to improve the arterial flow, an infrarenal or supraceliac arterial conduit anastomosis using an iliac artery graft can be performed between the aorta and the iliac graft. Whenever possible, we prefer the infrarenal conduit, which is tunneled through the transverse mesocolon and anastomosed with the hepatic artery of the allograft.

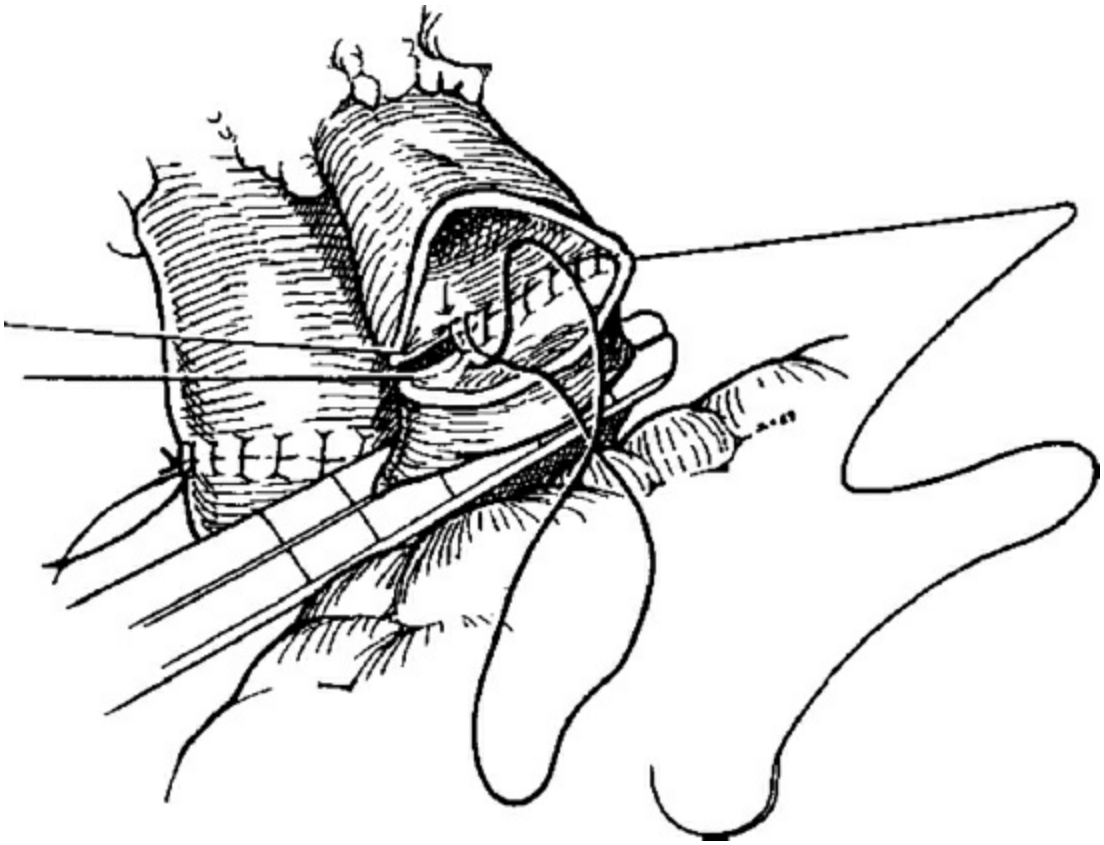

Figure 118.7. Completed infrahepatic vena caval anastomosis and running suture of posterior portal vein anastomosis. (Reprinted from Klintmalm GB, Busuttil RW. The recipient hepatectomy and grafting. In: Busuttil RW, Klintmalm GB, eds. *Transplantation of the Liver*. 3rd ed. Philadelphia, PA: Elsevier Saunders; 2015:606, with permission from Elsevier.)

Biliary Anastomosis

After the arterial anastomosis is completed, the biliary reconstruction starts

with the removal of the gallbladder. We usually perform a retrograde resection of the gallbladder from fundus downward with electrocautery. Whenever possible, the donor cholecystectomy includes the resection of the entire donor cystic duct. Both a duct-to-duct and a Roux-en-Y biliodigestive anastomosis can be used for biliary reconstruction. However, we prefer duct-to-duct reconstruction, whenever feasible, since this reconstruction has the advantage of future endoscopic access to manage biliary complications. For choledocho-choledochostomy, donor and recipient bile duct are shortened to an appropriate length. In case of a significant size mismatch of donor and recipient bile duct, a ductoplasty is created, which can be created by different techniques (Fig. 118.10). The choledocho-choledochostomy is performed as end-to-end anastomosis with interrupted 5-0 or 6-0 PDS (polydioxanone, Ethicon, Somerville, NJ) suture (Fig. 118.11). It is important to avoid redundancy and tension of the bile duct to prevent biliary obstruction and duct necrosis, respectively. We do not use T-tubes routinely except in patients with ductoplasty, extended donor criteria organs, and partial allografts. If a T-tube is indicated, it is brought out of the recipient duct approximately 1 to 1.5 cm downward the anastomotic suture line (Fig. 118.11). The T-tube exit side is narrowed with a figure-of-eight suture using absorbable material such as 6-0 PDS.

Choledochojejunostomy (Fig. 118.11) is performed for technical reasons (very small donor common hepatic duct) or disease-specific causes (primary biliary cholangitis, cholangiocarcinoma). The jejunum is divided 30 cm distal to the ligament of Treitz using a GIA stapler (Covidien autosuture). This is followed by creation of a 40-cm defunctionalized Roux-en-Y limb with a side-to-side jejunojejunostomy. The jejunojejunostomy is performed as a two-layer technique with 3-0 PDS running suture and silk Lembert sutures. The Roux-en-Y limb is brought through a retrocolic or retrogastric tunnel toward the liver. A very small hole is made distally to the Roux-en-Y limb using a pinpoint electrocautery. As in the case of choledocho-choledochostomy, choledochojejunostomy is created using interrupted 5-0 or 6-0 PDS suture. For small ducts, we insert small 6 French stents that are fixed to the internal back wall suture (Fig. 118.11). After all vascular and biliary anastomoses are completed, final rounds of hemostasis are undertaken. Although the role of prophylactic drainage is controversial, we routinely place three peritoneal Jackson–Pratt drains into the right and left subdiaphragmatic space as well adjacent to the biliary anastomosis.

Piggyback Technique

The piggyback technique is a commonly used alternative to the classic approach and preserves the native retrohepatic vena cava (Fig. 118.12). In this technique, the recipient hepatectomy has the mobilization of the right and left lobe and the dissection of the hepatoduodenal ligament with division of the vascular and biliary structures in common with the classic approach. The use of VVB is less likely in this technique since the venous return via the inferior vena cava is preserved. In order to decompress the splanchnic venous drainage, an end-to-side portacaval shunt might be performed using running 5-0 Prolene sutures. Next, the right lobe is elevated and the retrohepatic vena cava is exposed. All small liver veins are clipped or ligated and divided in the dissection plane between the retrohepatic vena cava and the posterior liver. The dissection starts from the infrahepatic vena cava and continues cephalad with encircling the right hepatic vein, which is clamped, divided, and oversewn with 3-0 Prolene. After clamping of the portal vein, the common trunk composed of the middle and left hepatic vein is occluded with a Satinsky clamp and the native liver is excised. If the common trunk is short, we usually divide the intervascular septum between the left and middle hepatic vein to create a common channel. Often, we extend the cava incision distally 3 to 4 cm to increase the cava orifice for sufficient outflow and to prevent technical Budd–Chiari syndrome (Fig. 118.13). After the donor liver is orthotopically placed into the situs, the posterior side of the donor retrohepatic vena cava is longitudinally incised according to the length of the incision of the recipient vena cava. The anastomosis is performed by running technique using 3-0 or 4-0 Prolene (Fig. 118.14). It is of paramount importance that the suture line or anastomosis does not compromise the hepatic venous outflow, which can result in a technical Budd–Chiari syndrome. During the creation of the vena cava anastomosis, the liver is flushed with chilled lactated Ringer's and albumin (25 g per 1000 mL) solution via the portal vein cannula. After completion of the anastomosis, the anastomotic reconstruction of the portal vein is performed as described for the classic approach. The anastomosis of the infrahepatic vena cava is not required in the piggyback technique (Fig. 118.12). We close the infrahepatic vena cava of the allograft during back-table preparation with a two-layer running 4-0 Prolene suture.

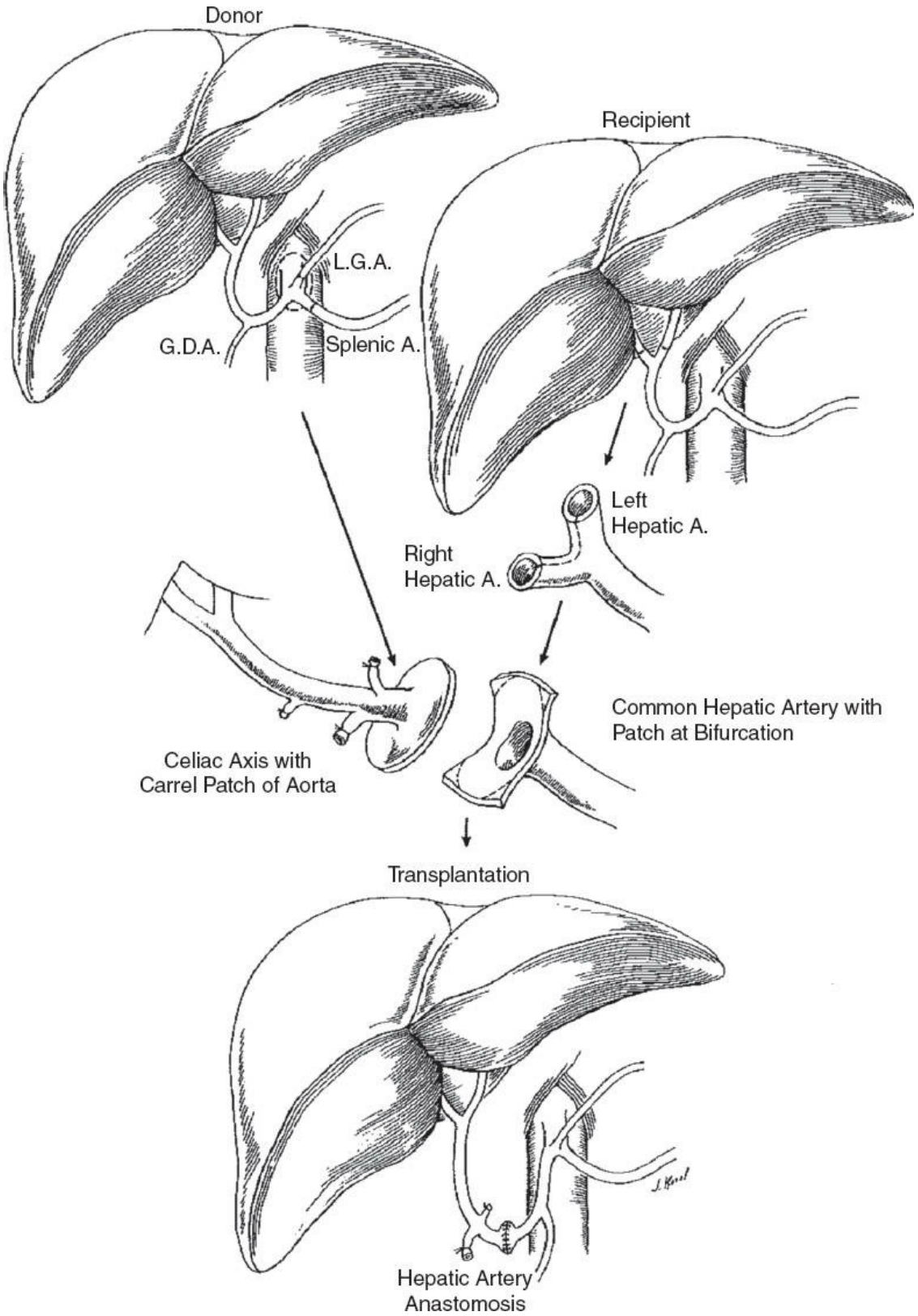

Figure 118.8. "Branch patch" technique for anastomosis of the donor celiac axis with a Carrel patch to the longitudinally opened recipient right and left hepatic artery branches. (Published in Kalayouglu M, Belzer FO. A new technique for arterilization of the hepatic duct. *Surg Gynecol Obstst* 1987;164:564. Copyright

Elsevier.)

Living Donor Liver Transplantation

Living donor liver transplantation (LDLT) is an alternative to cadaveric liver transplantation in which a partial liver graft is obtained from a living healthy donor and transplanted into a recipient. This surgical technique is the primary transplant procedure in certain Asian countries where cadaveric donation is extremely rare due to culture issues. LDLT has also been used as adjunct therapy in geographic regions with low cadaveric donation or in pediatric or adult patients who are otherwise disadvantaged by the current MELD allocation system.

The most important preoperative issue in LDLT is the selection of the appropriate donor and recipient. The irrefutable mandate of the donor operation is zero mortality and low morbidity, while quality and size of the partial allograft should dictate the recipient procedure. If the size or volume of the partial graft is below a critical threshold, the graft can fail to regenerate, which results in liver failure and life-threatening multiorgan failure. This clinical scenario is termed as “small-for-size syndrome.” In order to prevent small-for-size syndrome, a minimum graft-to-body weight ratio of 0.8% to 1% must be obtained. But size alone is not the only important factor that dictates the appropriate selection. Organ quality has to be evenly considered, and willing donors with diseased liver or significant steatosis should be excluded from living donation.

Living Donor Hepatectomy

The right donor hemihepatectomy (segments 4 to 8) is the most frequently performed donor procedure for an adult recipient (Fig. 118.15A), while the hepatectomy of the left lateral sector (segments 2 and 3) in an adult is used in pediatric LDLT (Fig. 118.16A). Regardless of which type of donor hepatectomy is performed, the donor procedure requires the highest degree of precision to prevent morbidity and mortality in the donor. For all types of donor hepatectomies, appropriate abdominal access and exposure are achieved as described under recipient hepatectomy. The right or left donor operation for LDLT is similar to the right or left hemihepatectomy in liver surgery but varies in few important steps. Specifically, in the right donor operation for LDLT, it is imperative that the transection of the right hepatic bile duct should be only performed after direct visualization of the biliary tree by intraoperative cholangiogram, which can be performed via

the cystic duct. After the biliary anatomy is verified, the right bile duct can be transected, leaving an approximately 2- to 3-mm-long stump to provide enough room to close the duct without compromising the donor duct. It is also of paramount importance to preserve the periductal tissue and blood supply to prevent any future strictures or bile leaks in the donor. The subsequent hilar dissection is limited to the right hepatic artery and the right portal vein, whereby the right hepatic artery dissection should be limited to the right side of the common hepatic duct, and the branch to segment IV should be preserved. After all right-sided vascular and biliary structures are defined, a short inflow occlusion of the right portal vein and right hepatic artery is applied to find the optimal line of parenchymal transection. The transection is performed after mobilizing the right liver, during which no excessive compression of the right liver must be applied in order to avoid an ischemic liver injury. During mobilization, any inferior right hepatic veins larger than 5 mm should be preserved for reconstruction in the recipient. The transection should be performed without inflow occlusion in order to minimize the ischemic insult to the partial graft. After complete parenchymal transection and dividing the right hepatic vein, the right partial graft can be perfused with preservation solution in situ or ex situ via the right portal vein. The technique for a full left donor hemihepatectomy (segments 2 to 4 with or without segment 1), which is not described in detail here, is performed analogous to the right hemihepatectomy with mobilization and perfusion of the left hemiliver. The living donation of the left lateral sector (segments 2 and 3), usually used for a pediatric recipient, is performed analogous to the corresponding split technique, which is described under split liver transplantation (Fig. 118.16A). In contrast to the split technique, the partial graft obtained from a living donor does not have the common axis of the hepatic artery, portal vein, and vena cava patch. Only the side-specific inflow and outflow vessels and bile duct are returned with the living donor graft.

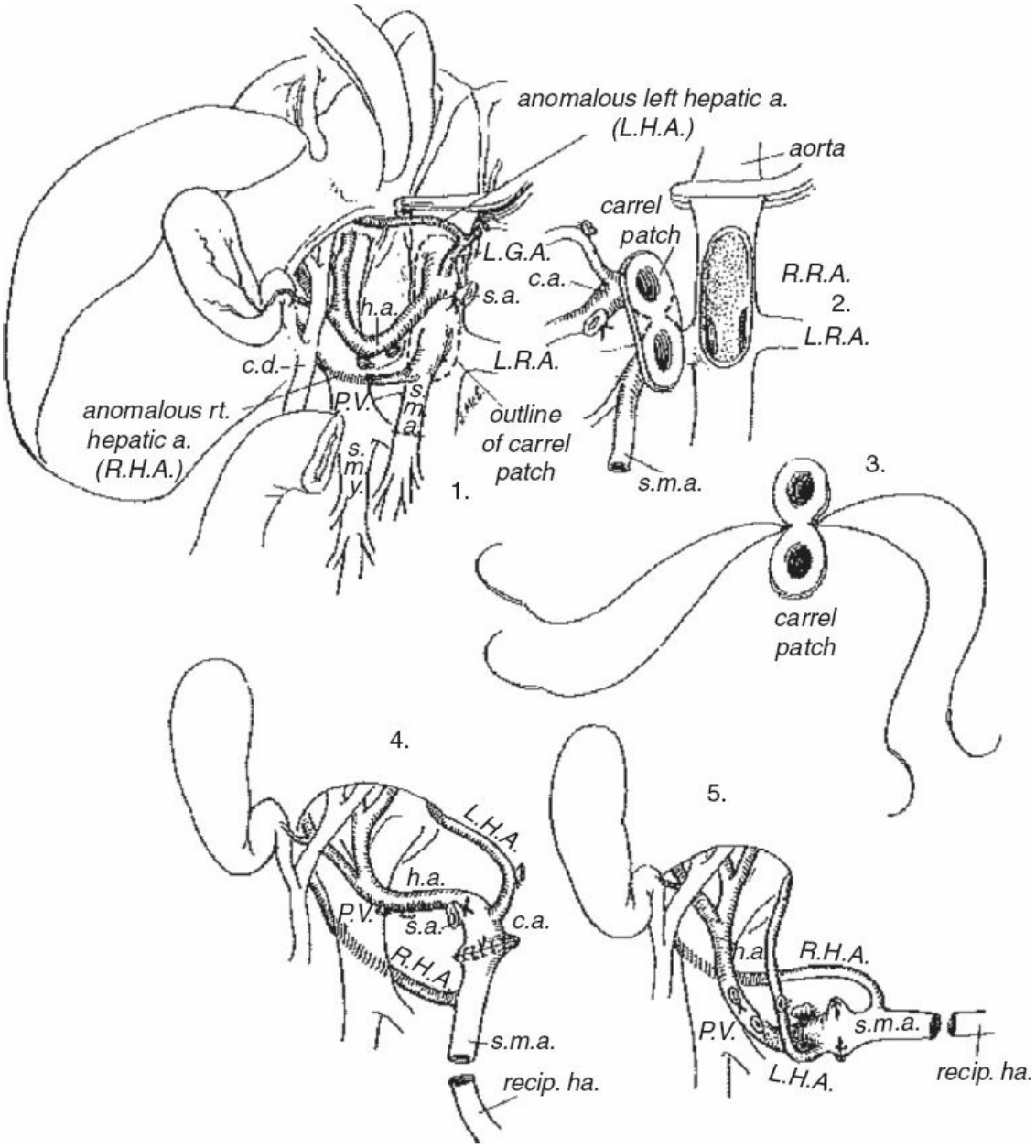

Figure 118.9. 1. Anomalous arterial supply to the donor liver with the right hepatic artery arising from the superior mesenteric artery (SMA). LGA, left gastric artery; sa, splenic artery; LRA, left renal artery; sma, superior mesenteric artery; smv, superior mesenteric vein; PV, portal vein; ha, hepatic artery; cd, common duct; LHA, left hepatic artery; RHA, right hepatic artery. 2. Removal of an aortic Carrel patch with the celiac axis and SMA orifices. RRA, right renal artery. 3. Folding of the aortic patch. 4. The SMA distal to the right hepatic artery is used for anastomosis to the recipient hepatic artery. 5. The newly constructed arterial supply can be rotated to approximate the orientation of the recipient vessel. (Published in Gordon RD, Shaw BW Jr, Iwatsuki S, et al. A simplified technique for revascularization of tomographs of the liver with a variant right hepatic artery from the superior

mesenteric artery. *Surg Gynecol Obstet* 1985;160:474. Copyright Elsevier.)

Implantation of Partial Living Donor Allograft

The recipient hepatectomy in LDLT follows the same rules as described under recipient hepatectomy for cadaveric whole liver transplantation but has one important exception. Similar to the piggyback technique in whole organ transplantation, the entire retrohepatic vena cava has to be preserved during hepatectomy since the implantation of all types of living donor grafts is performed using the piggyback technique (Figs. 118.15B and 118.16B). Great attention has to be directed to preserve maximal length of recipient portal vein and hepatic artery since partial grafts obtained from a living donor do not have the common axis of the hepatic artery and portal vein. There are many different reconstruction techniques for the hepatic vein, but all follow the principle of best hepatic outflow. Vascular and biliary anastomoses are performed as in the case of techniques described for the whole organ and split liver transplantation.

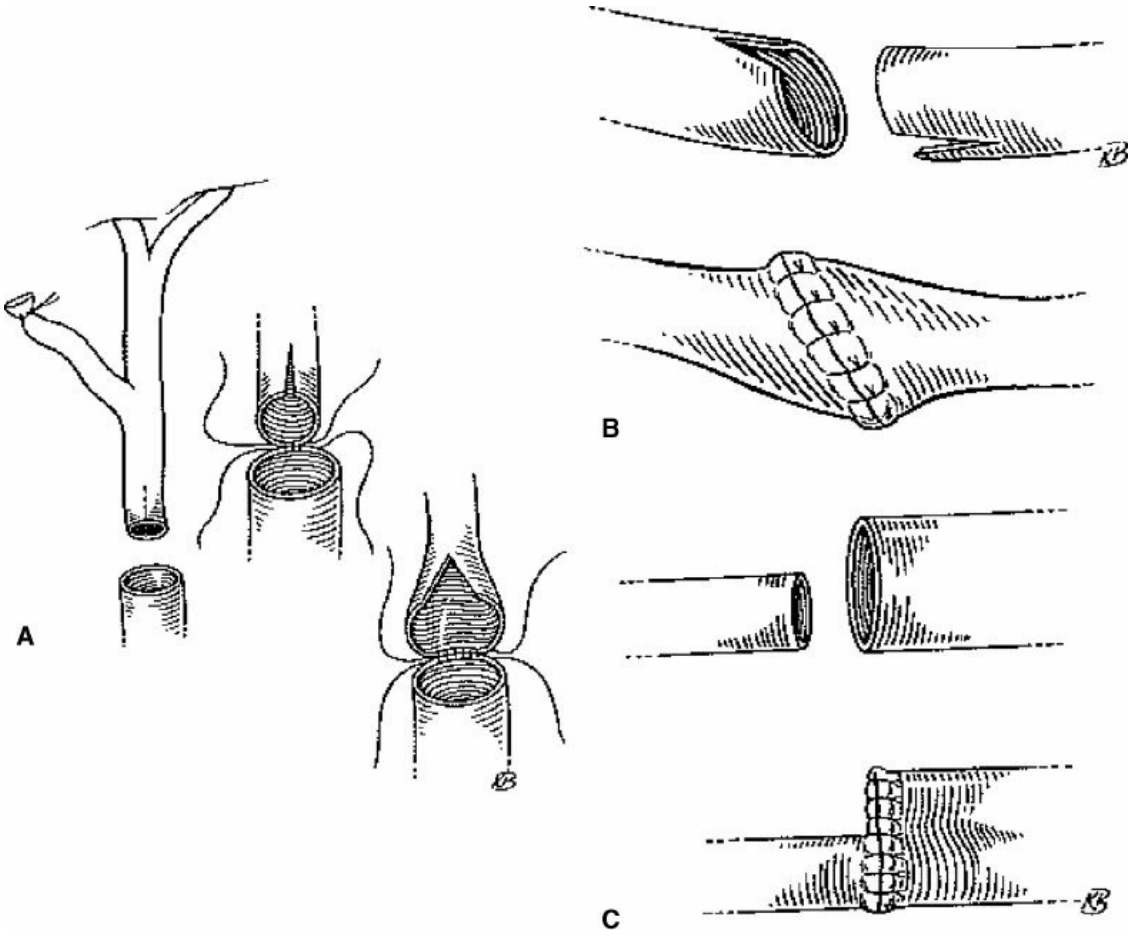

Figure 118.10. Techniques of biliary duct-to-duct anastomosis

with size mismatch of donor and recipient bile duct (sketches **A** and **C**). For equal but small-size bile ducts, the anastomotic diameter can be increased by a site cut in each duct (sketch **B**). (Reprinted from Klintmalm GB, Busuttil RW. The recipient hepatectomy and grafting. In: Busuttil RW, Klintmalm GB, eds. *Transplantation of the Liver*. 3rd ed. Philadelphia, PA: Elsevier Saunders; 2015:609. Copyright © 2015, with permission from Elsevier.)

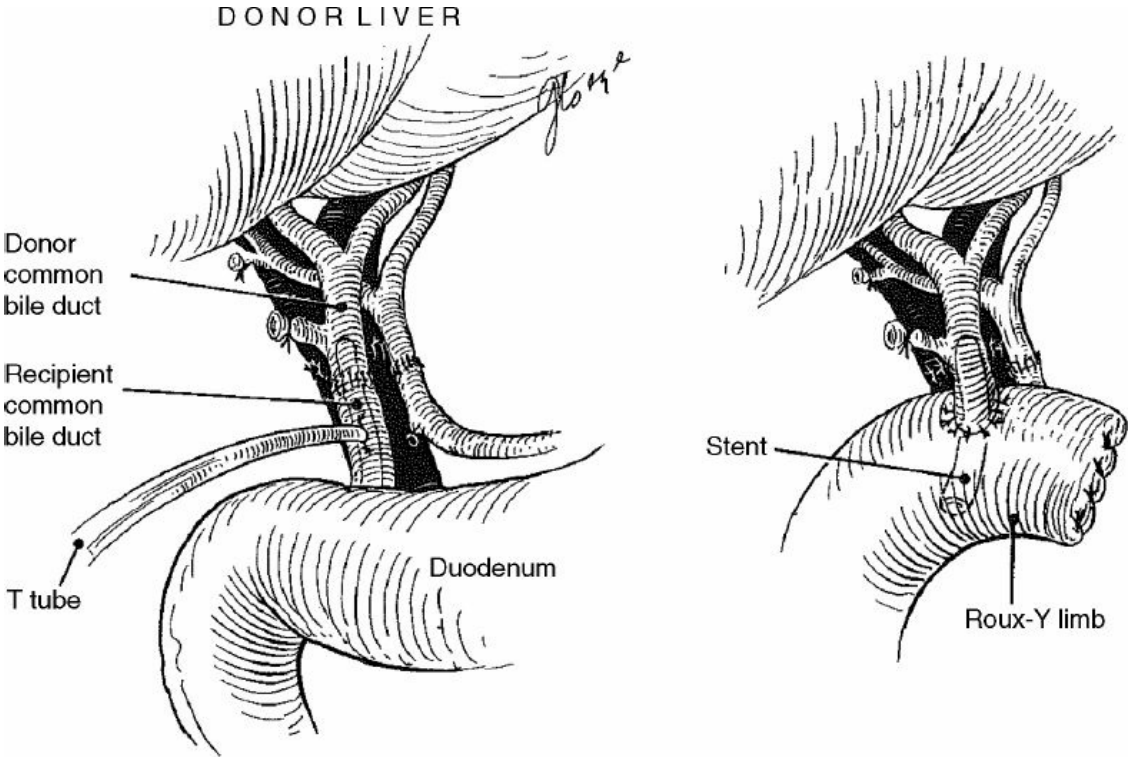

Figure 118.11. Biliary duct-to-duct anastomosis (choledocho-choledochostomy) with T-tube insertion and choledochojejunostomy with internal stent. (From Busuttil RW, Colonna JO II, Hiatt JR, et al. The first 100 liver transplants at UCLA. *Ann Surg* 1987; 206(4):392; with permission from Wolters Kluwer Health, Inc.)

Split Liver Transplantation

The split liver transplantation is a surgical technique that creates two partial grafts from one deceased donor for two recipients. The most commonly used splitting operation is the division of the whole organ into a left lateral sector graft (segments 2 and 3) for a pediatric recipient and a right trisector graft (segments 1, 4 to 8) for an adult recipient. Another approach is the splitting of the liver into two full hemilivers creating a left (segments 1 to 4) and a right (segments 5 to 8) hemiliver, which can be

donated to two adults or to an adult and child. The splitting operation is a complex procedure that requires the complete understanding of segmental liver anatomy.

Splitting Into a Left Lateral Sector Graft and a Right Trisector Graft

The splitting procedure can be performed either in situ or ex situ. At UCLA, exclusively the in situ splitting technique is used. The left lateral in situ splitting technique starts with mobilization of the left lateral sector (segments 2 and 3) as described for the cadaver donor hepatectomy. Before proceeding with the split procedure, the surgeon should determine if size and anatomy of the split graft are appropriate for the recipient. A dual arterial supply via a left and an accessory hepatic artery might be a contraindication for a left lateral as well as for a full hemiliver split. After dividing the Arantius ligament (ligamentum venosum), the left hepatic vein is encircled. The hilus dissection starts with taking down the peritoneum of the hilar plate. The left hepatic artery is identified and dissected out by sparing the arterial branch to segment 4. The left portal vein is dissected out, and its venous branches to segments 1 and 4 are ligated with silk sutures and divided. Also, the left bile duct is dissected with sparing the segment 4 bile duct. After all vascular and biliary structures are identified, the parenchymal transection is performed close to the right side of the falciform ligament. After the transection is completed, procurement flushing can be performed as described earlier. The excision of the left lateral sector and right trisector graft follows the same rules as for whole donor organ retrieval. Whether the main portal vein and common arterial trunk stay with the left or right partial graft depends on the individual donor and recipient anatomy.

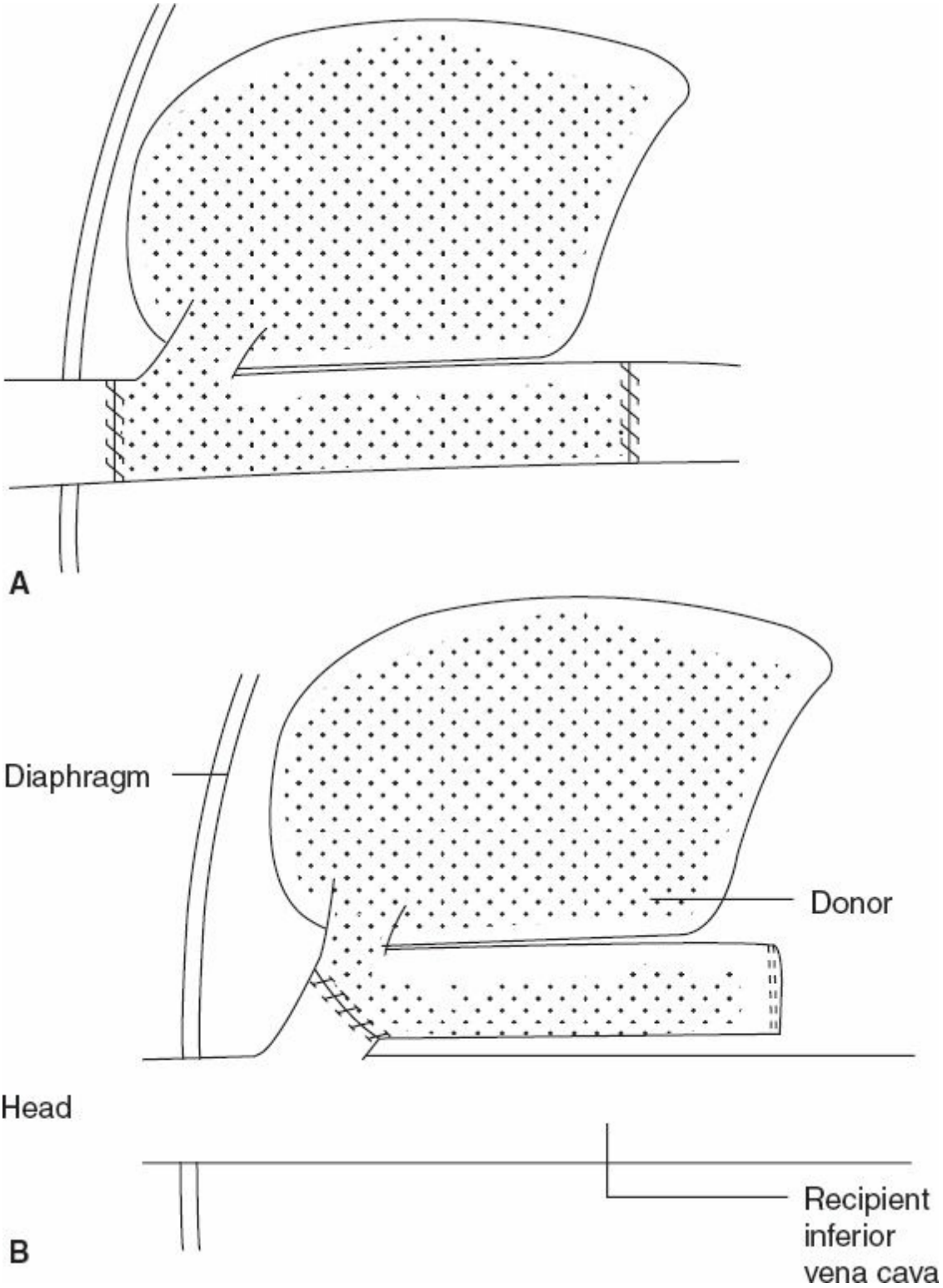

Figure 118.12. Principle of classic technique (**A**) and piggyback technique of orthotopic liver transplantation (**B**). (From Campbell DA, Magee JM, Rudich SM, et al. Hepatic transplantation. In: Greenfield LJ, Mulholland MW, Oldham KT, et al. eds. *Surgery: Scientific Principles and Parctice*. 3rd ed. Philadelphia, PA: Lippincott Williams & Wilkins, 2001:585.)

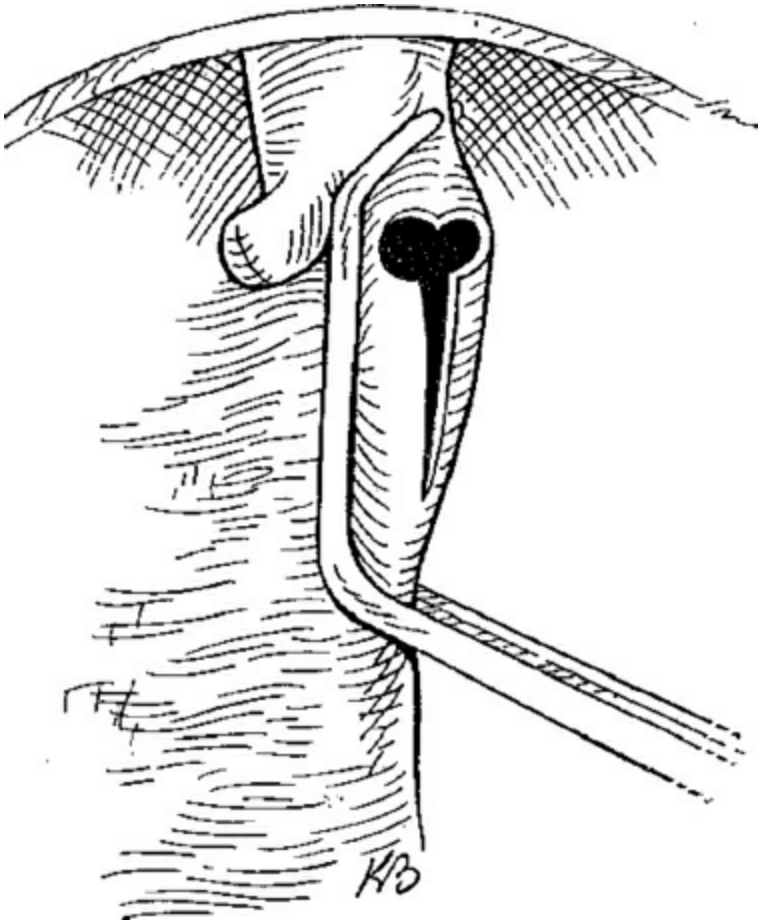

Figure 118.13. Side-occluded inferior vena cava with Satinsky clamp. The orifice of the middle and left hepatic vein is extended by a downward incision. (Reprinted from Klintmalm GB, Busuttil RW. The recipient hepatectomy and grafting. In: Busuttil RW, Klintmalm GB, eds. *Transplantation of the Liver*. 3rd ed. Philadelphia, PA: Elsevier Saunders; 2015:607. Copyright 2015, with permission from Elsevier.)

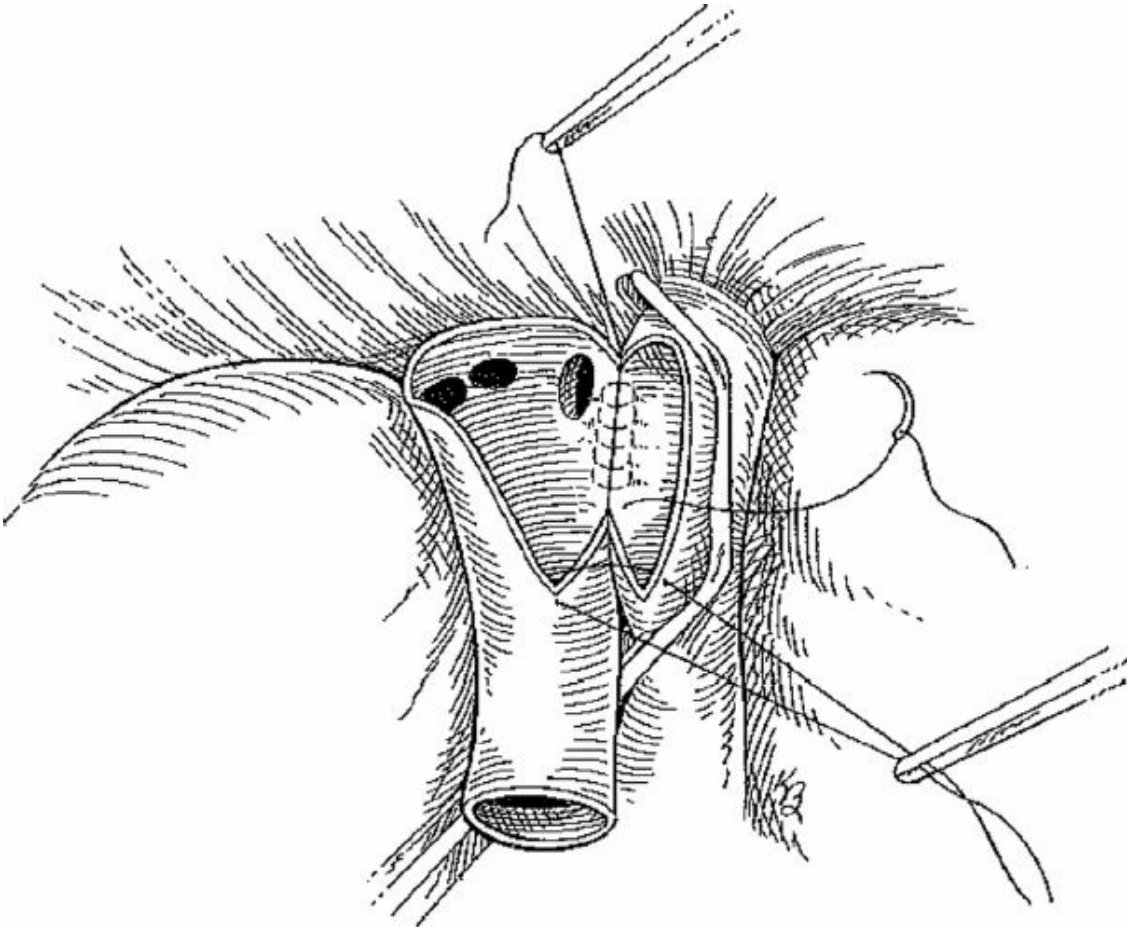

Figure 118.14. Vena cava anastomosis in piggyback technique. (Reprinted from Klintmalm GB, Busuttil RW. The recipient hepatectomy and grafting. In: Busuttil RW, Klintmalm GB, eds. *Transplantation of the Liver*. 3rd ed. Philadelphia, PA: Elsevier Saunders; 2015:607. Copyright 2015, with permission from Elsevier.)

Splitting Into a Full Left and Full Right Hemiliver

The splitting into a right (segments 5 to 8) and left (segments 1 and 2 to 4) hemiliver is analogous to that of the living donor hepatectomy for LDLT. In contrast to the falciform ligament in the left lateral splitting procedure, the splitting into two full hemiliver has no visible anatomical structure for orientation of the parenchymal transection. The advantage of the in situ technique is to apply a short inflow occlusion (Pringle maneuver) to determine the optimal anatomic line of transection. The parenchymal transection is performed as described above. However, whether the common bile duct and the common arterial trunk are given to the left or right partial graft has to be decided based on the individual anatomy. The division of the hepatic veins should be performed according to the

principle of the “best venous outflow.” There are various techniques ranging from simple separation of the left and right hepatic vein with or without the middle hepatic vein to complex reconstruction techniques with venous graft patches.

Implantation of Partial Split Graft

The implantation of partial split graft follows the same rules as for whole organ and living donor graft implantation depending on vascular and biliary situation of the split graft. The arterial anastomosis can range from a simple end-to-end anastomosis to anastomosis with graft interposition. If the partial graft comes with a common bile duct, a choledocho-choledochostomy can be performed while a choledochojejunostomy or hepaticojejunostomy should be performed for small ducts or if the biliary outflow is at the level of the secondary biliary radicle.

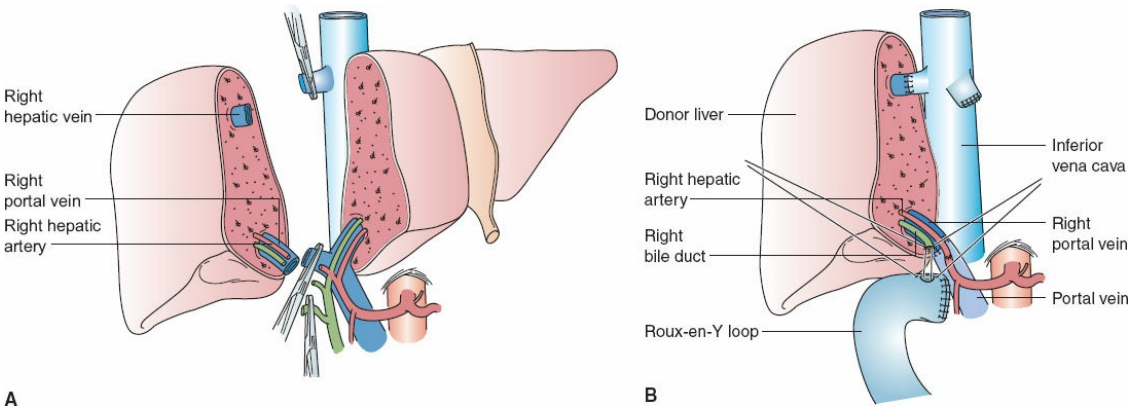

Figure 118.15. Technique of living donor right hemihepatectomy (**A**) and implantation of a right living donor graft (**B**). (From Welling TH, Pelletier SJ. Hepatic transplantation. In: Mulholland MW, Lillemoe KD, Doherty GM, et al. eds. *Surgery: Scientific Principles and Practice*. 5th ed. Philadelphia, PA: Lippincott Williams & Wilkins; 2011.)

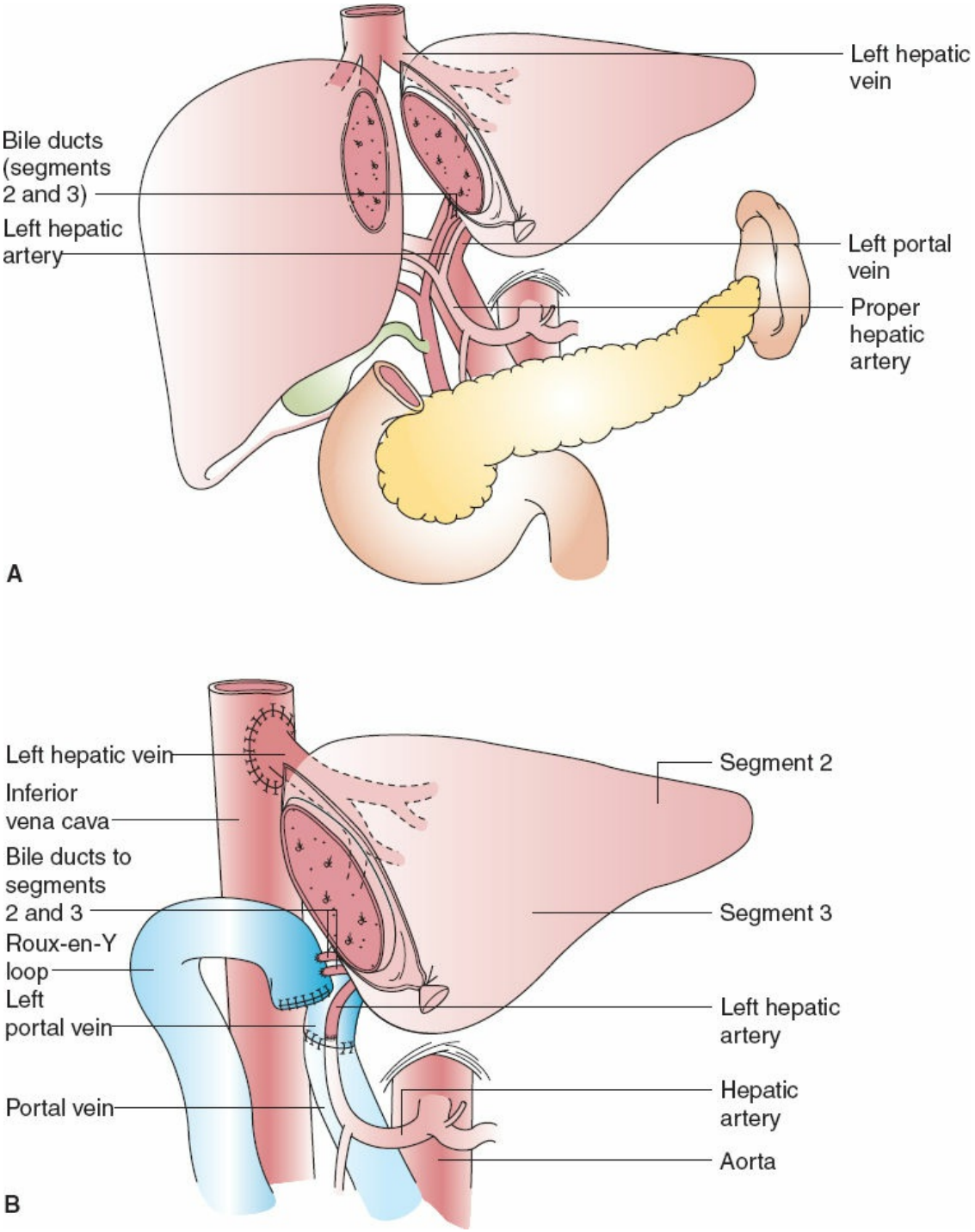

Figure 118.16. Technique of living donor left lateral sectorectomy (**A**) and implantation of a left lateral living donor graft (**B**). (From Welling TH, Pelletier SJ. Hepatic transplantation. In: Mulholland MW, Lillemoe KD, Doherty GM, et al. eds. *Surgery: Scientific Principles and Practice*. 5th ed. Philadelphia, PA: Lippincott Williams & Wilkins; 2011.)

In Situ and Ex Situ Splitting

Although ex situ splitting is performed in many centers, we routinely

perform the in situ technique, which has more advantages compared with the ex situ technique. In situ splitting minimizes cold ischemia time especially if both grafts are allocated to different centers. Furthermore, biliary structures are better identifiable during in situ transection. In addition, in situ splitting into two full hemilivers offers the advantage to apply a short inflow occlusion (Pringle maneuver) in order to identify the optimal anatomic line of transection.

INDUCTION AND MAINTENANCE IMMUNOSUPPRESSION

Our postoperative immunosuppression is broadly based on a “triple therapy” protocol, including calcineurin inhibitor (tacrolimus or cyclosporine), steroid (methylprednisone or prednisone), and DNA anti-metabolite (mycophenolic acid, MMF). We prefer tacrolimus as first-line calcineurin inhibitor, which we initially administer on the first postoperative day at a dose of 0.5 mg BID via the nasogastric tube. During the first postoperative month, the target level of tacrolimus is 5 to 12 ng/mL depending on the etiology of the liver disease, presence of acute kidney injury, and drug-related side effects. In uncomplicated cases, induction therapy is initiated with steroids before (50 mg methylprednisone) and during surgery (1 g hydrocortisone). The induction therapy with steroids is followed by intravenous taper during the first week after transplantation. This is followed by maintenance immunosuppression with oral prednisone at an initial dose of 20 mg daily. The reduction rate of oral prednisone depends on the individual situation. MMF, which is the third drug of the triple therapy, is started at the first postoperative day at a dose of 1,000 mg BID via the nasogastric tube. Patients with severely compromised kidney function or renal failure receive only 500 mg MMF BID. Drug monitoring of MMF is not commercially available and is, therefore, not performed.

Patients with severe renal compromise (hepatorenal syndrome) receive a quadruple therapy with addition of a monoclonal interleukin-2 receptor antagonist (daclizumab). This concept allows a sparing calcineurin therapy by minimizing the nephrotoxic side effects and through kidney protection. Our protocol includes a single intravenous application of 1 mg daclizumab per kilogram body weight at day 1 and day 4 after transplantation, allowing the tacrolimus level to below 8 ng/mL. If patients have significant adverse effects from tacrolimus, we switch to cyclosporine

before other alternatives are considered.

Patients with intolerance to calcineurin inhibitors or with ongoing rejection under calcineurin inhibitors might be candidates for sirolimus (rapamycin). Sirolimus is not a calcineurin inhibitor and mediates its immunosuppressive effect by inhibiting the mTOR pathway. Since sirolimus has antineoplastic effects, this drug might be used in patients transplanted for HCC or with other comalignant conditions after transplantation. We dose sirolimus at 1 to 2 mg daily to target a level of 5 to 10 ng/mL. The application of sirolimus during the early posttransplant period should be avoided due to the reported risk of drug-induced hepatic artery thrombosis and poor wound healing.

POSTTRANSPLANT OUTCOMES

Because of continued improvements in surgical techniques, significant advances in organ preservation, intra- and postoperative care, immunosuppressive therapy, monitoring of grafts, and transplant care protocols over the last decades, liver transplantation has been established as an effective and durable therapy for patients with acute liver failure, ESLD, selected malignancies, and other conditions that affect the liver, with outstanding survival outcomes and long-term functional recovery of the patients. In fact, the vast majority of recipients now have a life expectancy of at least 3 to 5 years, and nearly half of all patients who undergo liver transplantation survive 10 to 20 years after this procedure (Fig. 118.17A). Even individuals who undergo a transplant procedure for HCC have a remarkable life expectancy if transplanted within the Milan or UCSF criteria, whereby similar survival outcomes have been reported for patients who meet either criterion (Fig. 118.17B). In individuals who suffer from ESLD, the survival benefit is greatest in the sickest patients with the highest MELD scores, which are still deemed fit for surgery, as those individuals have the highest 3-month waiting list mortality rate (e.g., 80% to 100% for patients with MELD scores of 40). The current organ allocation system, which is based on the MELD system and therefore prioritizes patients based on medical urgency rather than time on the waiting list, takes this survival benefit into account and thus aims to maximize the appropriate use of the limited resource of available donor organs. Indeed, since the introduction of the MELD system in 2002, waiting list mortality has been reduced without adversely affecting posttransplant survival. However, this allocation system strikes a fine

balance between serving the sickest patients first and avoiding futile transplantation. Therefore, the transplant community has shown great interest in identifying factors that could help predict survival outcomes in order to achieve optimal outcomes in high-risk patients while avoiding futile liver transplantation in the face of organ shortage. The main factors that have been suggested to negatively affect survival after liver transplantation are high MELD scores (which by itself has a low predictive value for posttransplant survival), cardiac risk, pre-liver transplantation septic shock, comorbidities, history of previous transplantation, life support before transplantation, and long cold ischemia time. Those and other factors in different combinations have been used to establish predictive models that calculate risk scores for survival outcomes, such as the UCLA Futility Risk Scoring System, the Survival Outcomes Following Liver Transplantation (SOFT) score, and the Balance of Risk (BAR) score, which are utilized to varying degrees in the daily clinical routine.

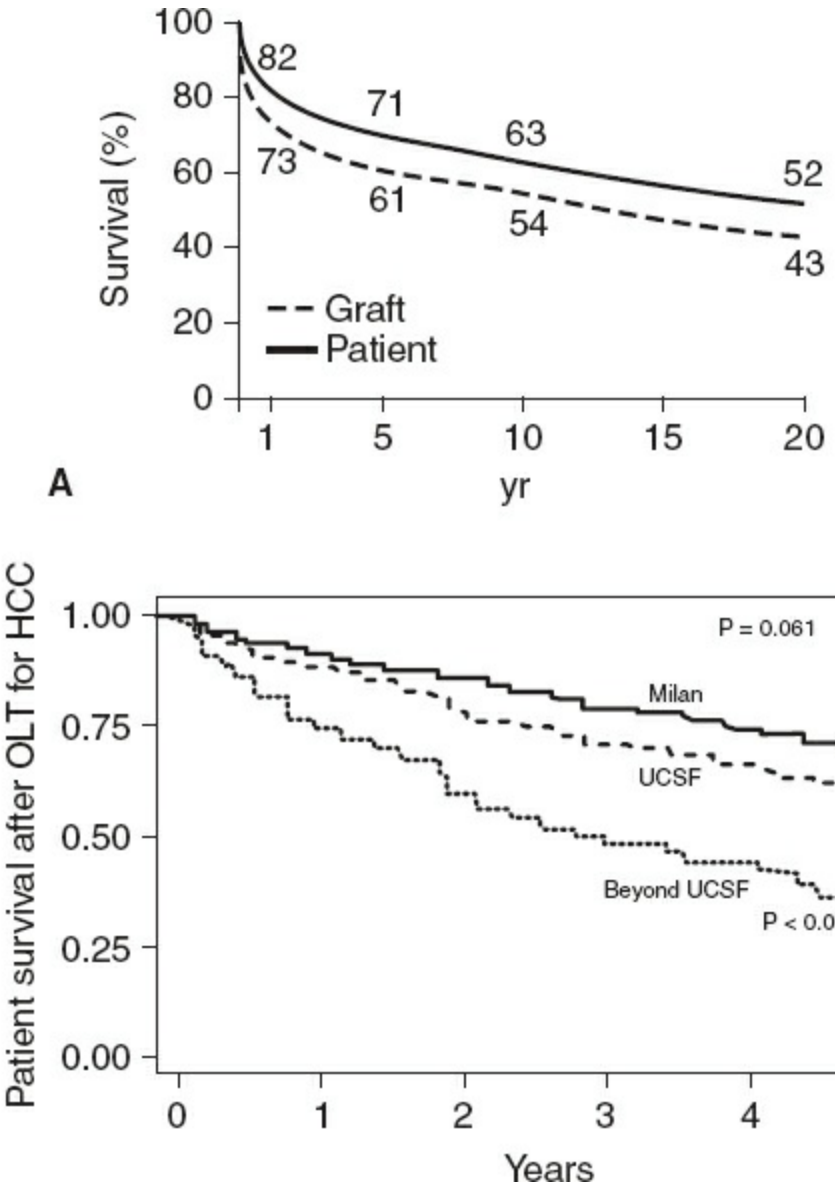

Figure 118.17. **A.** Overall patient and graft survival estimates after 5,347 liver transplantations in 4,574 adult and pediatric recipients from 1984 to 2012. (From Agopian VG, Petrowsky H, Zarrinpar A, et al. The evolution of liver transplantation during three decades: analysis of 5347 consecutive liver transplants at a single center. *Ann Surg* 2013;258:409.) **B.** Survival estimate after liver transplantation for HCC based on a 22-year experience with 467 patients at UCLA. Survival curves (here shown for pretransplant imaging) are similar for tumors within Milan and UCSF criteria, whereas patients with tumors beyond UCSF criteria have significantly worse survival. (From Duffy JP, Vardanian A, Benjamin E, et al. Liver transplantation criteria for hepatocellular carcinoma should be expanded: a 22-year experience with 467 patients at UCLA. *Ann Surg* 2007;246:502.)

In addition to the aforementioned significant survival benefit of liver transplantation, this procedure also provides encouraging results with regard to the functional outcome and health-related quality of life (HR-QOL). Hereby, HR-QOL is improved after liver transplantation relative to patients with chronic liver disease who did not undergo this procedure, though the overall QOL is impaired compared to normal healthy controls. Specifically, liver transplant patients score similarly to the general population with regard to cognitive efficiency, attention, frustration tolerance, verbal learning, and academic skills but have more global cognitive impairments and diminished physical QOL. In terms of reestablishment and maintenance of employment, another indicator of integration into society, about 50% of 20-year survivors have returned to work at some point after receiving an organ. However, 20 years after transplantation, two thirds of the patients are either unemployed or retired, a trend that may be overcome in the future with improvements of support systems and physical rehabilitation programs offered for liver transplant patients.

Suggested Readings

Agopian V, Petrowsky H. Liver transplantation for malignant tumors. In: Fong Y, Poon R, Tang ZY, et al. eds. *Hepatobiliary Cancer.* Shelton, CT: People's Medical Publishing House-USA, Ltd.; 2014.

Agopian VG, Petrowsky H, Zarrinpar A, et al. The evolution of liver transplantation during three decades: analysis of 5347 consecutive liver transplants at a single center. *Ann Surg* 2013;258:409.

Busuttil RW, Klintmalm GB, eds. *Transplantation of the Liver.* 3rd ed. Philadelphia, PA: Elsevier Saunders; 2015.

Fan ST, ed. *Living Donor Liver Transplantation.* Hong Kong: Takungpao Publishing Co., Ltd.; 2007.

Hiatt JR, Gabbay J, Busuttil RW. Surgical anatomy of the hepatic arteries in 1000 cases. *Ann Surg* 1994;220:50.

Keutgen XM, Petrowsky H. Procurement for visceral organ transplantation: where to cannulate and how to perfuse? *Curr Opin Organ Transplant* 2014;19:92.

Momenti E, Klintmalm G. *Atlas of Liver Transplantation.* Philadelphia, PA: WB Saunders Company; 2002.

Petrowsky H, Busuttil RW. Evolving surgical approaches in liver transplantation. *Semin Liver Dis* 2009;29:121.

Starzl TE, Shapiro R, Simmons RL. *Atlas of Organ Transplantation.* New York: Gower; 1992.

Tzakis A, Todo S, Starzl TE. Orthotopic liver transplantation with preservation of the inferior vena cava. *Ann Surg* 1989;210:649.

Yersiz H, Renz JF, Hisatake GM, et al. The conventional technique of in-situ split liver transplantation. *J Hepatobiliary Pancreat Surg* 2003;9:881.

EDITOR'S COMMENTS

The chapter on Liver Transplantation by Petrowsky, Grochola, and Busuttil is a comprehensive review of the medical and surgical aspects of evaluating, operating on, and following patients with end-stage liver disease (ESLD) who require liver transplantation, a field that has changed remarkably over the last decade and will continue to do so. For example, hepatitis C virus (HCV) infection, the most common disease indication for liver transplantation in adults today (Kim WR, Lake JR, Smith JM, et al. OPTN/SRTR 2014 Annual Data Report: Liver. *Am J Transplant* 2016;16(Suppl 2):69–98), is now relatively easily treated with new antiviral drugs and can be eliminated in almost all patients (American Association for the Study of Liver Diseases/Infectious Diseases Society of America HCV Guidance Panel. Hepatitis C guidance: AASLD-IDSA recommendations for testing, managing, and treating adults infected with hepatitis C virus. *Hepatology* 2015;62:932–54). HCV drug therapy will likely lead to the eventual elimination of HCV infection and its complications, cirrhosis and hepatocellular carcinoma (HCC) that are treated with liver transplantation. At the same time, the incidence of nonalcoholic fatty liver disease (NAFLD) and nonalcoholic steatohepatitis (NASH) is increasing in adults and children due to obesity, diabetes mellitus, and dyslipidemia, and make up an increasingly greater per cent of patients being listed for liver transplantation (Chalasani N, Younossi Z, Lavine JE, et al. The Diagnosis and Management of Non-Alcoholic Fatty Liver Disease: Practice Guideline by the American Association of the Study of Liver Diseases, American College of Gastroenterology, and the American Gastroenterological Association. *Hepatology* 2012;55:2005–23). Advances in drug therapy for HCV have also led to the effective treatment of recurrent HCV post-liver transplant (Curry MP, Forns X, Chung RT, et al. Sofosbuvir and ribavirin prevent recurrence of HCV infection after liver transplantation: an open-label study. *Gastrotenterology* 2015;148:100–7; Chen T, Terrault NA. Perspectives on treating hepatitis C infection in the liver transplantation setting. *Curr Opin Organ Transplant* 2016;21:111–9), a cause of significant morbidity, graft loss, and mortality, and also effective treatment in patients with decompensated cirrhosis leading to early improvements in liver function (Curry MP, O'Leary JG, Bzowej N, et al. Sofosbuvir and Velpatasvir for HCV in patients with decompensated cirrhosis.

N Engl J Med 2015;373:2618–28). Furthermore, preclinical research has identified a number of targets for antifibrotic agents, some of which have entered clinical trials, that may significantly impact the progression of cirrhosis in patients with liver disease and thus the need for liver transplantation (Schuppan D, Kim YO. Evolving therapies for liver fibrosis. *J Clin Invest* 2013;123:1887–901). All these advances will have major changes on the field of liver transplantation over the next decade.

The authors note that patients with HCC within Milan or UCSF criteria are candidates for liver transplantation, but it is important to note that a criterion for listing for transplant is that the tumor must be surgically unresectable. In most cases, unresectability is due to cirrhosis, portal hypertension, and inadequate liver reserve. These patients clearly benefit from liver transplantation. What is not discussed and is one of the major challenges managing patients with HCC are patients who would qualify for either liver resection or liver transplantation. Which therapy leads to better survival is an ongoing controversy. Unfortunately, no prospective randomized trials comparing liver resection and liver transplantation have been performed. A recent meta-analyses of 2,428 studies demonstrated that overall 5-year survival was statistically significantly better for liver transplantation (61%) compared with liver resection (49%), as was disease-free survival (58% vs. 34%, respectively) (Proneth A, Zeman F, Schlitt HJ, et al. Is resection or transplantation the ideal treatment in patients with hepatocellular carcinoma in cirrhosis if both are possible? A systematic review and metaanalysis. *Ann Surg Oncol* 2014;21:3096–107). The major limitation to liver resection is a high rate of recurrence in the liver remnant. The major limitation to liver transplantation is organ availability. However, intention to treat studies (n = 3) showed that there was no difference in outcomes between the two groups and the authors suggested that the patients waiting for a liver transplant (there is no waiting for a liver resection), who become ineligible based on tumor growth and drop off the list, affected their outcomes (Proneth A, Zeman F, Schlitt HJ, et al. Is resection or transplantation the ideal treatment in patients with hepatocellular carcinoma in cirrhosis if both are possible? A systematic review and metaanalysis. *Ann Surg Oncol* 2014;21:3096–107). They recommend that patients who were candidates for liver resection or liver transplantation first undergo liver resection. Another meta-analyses drew similar conclusions (Dhir M, Lyden ER, Smith LM, Are C. Comparison of outcomes of transplantation and resection in patients with early hepatocellular carcinoma: a meta-analysis. *HPB* 2012;14:635–45). Other studies have shown that based on quality of life-years gained, liver resection is more cost-effective than liver transplantation (Lim KC, Wang VW, Siddiqui FJ, et al. Cost-effectiveness analysis of liver resection versus transplantation for early hepatocellular carcinoma within the Milan criteria. *Hepatology* 2015;61:227–37). A recent analysis of liver resection and liver transplantation from five centers suggested, within the limitations of the study, that liver transplantation resulted in better overall and disease-free survival, particularly among patients

who would have been candidates for either therapy (Chapman WC, Klintmalm G, Hemming A, et al. Surgical treatment of hepatocellular carcinoma in North America: can hepatic resection still be justified. *J Am Coll Surg* 2015;220:628–37). The authors note that only about 10% of patients undergoing liver resection in their series would have qualified for liver transplantation based on tumor size/number and cirrhosis. Sadly the liver supply remains inadequate to offer transplant to all patients who might benefit. Future prospective studies of liver resection followed by rescue liver transplantation in the United States may inform the debate, although results in France showed inferior results compare to primary liver transplantation (Adam R, Azoulay D, Castaing D, et al. Liver resection as a bridge to transplantation for hepatocellular carcinoma on cirrhosis: a reasonable strategy? *Ann Surg* 2003;238:508–18; discussion 518–9).

The authors have briefly discussed selection of recipients that now includes HIV+ candidates (Terrault NA, Roland ME, Schiano T, et al. Outcome of HCV/HIV-coinfected liver transplant recipients: a prospective and multicenter cohort study. *Liver Transplant* 2012;18:716–26), but the selection of the deceased donor liver is just as critical. Advances in organ donation have been many and have included the elucidation of the characteristics associated with liver graft failure and a quantified donor risk index (DRI) (Feng S, Goodrich NP, Bragg-Gresham JL, et al. Characteristics associated with liver graft failure: the concept of a donor risk index. *Am J Transplant* 2006;6:783–90), increasingly aggressive liver utilization as the shortage of livers persists including the use of older donors, HCV+ and certain HBV+ donors (e.g., HBcAb+) enabled by new and better antiviral therapy, utilization of donors after circulatory determination of death (DCDD), and most recently the utilization of HIV+ donors in HIV+ kidney recipients that will undoubtedly be applied to liver transplantation as well (Muller E, Barday Z, Mendelson M, et al. HIV-positive-to-HIV-positive kidney transplantation–-results at 3 to 5 years. *N Engl J Med* 2015;372:613–20). The increased use of extended criteria donors has renewed interest in techniques to improve the quality of these organs by reducing ischemia-reperfusion injury through the use of hypothermic machine perfusion (Guarrera JV, Henry SD, Samstein B, et al. Hypothermic machine preservation facilitates successful transplantation of “orphan” extended criteria donor livers. *Am J Transplant* 2015;15:161–9), which has been used in kidney transplantation for decades, or normothermic machine perfusion (NMP) of the liver (Ravikumar R, Leuvenink H, Friend PJ. Normothermic liver preservation: a new paradigm? *Transpl Int* 2015;28:690–9; Perera MTPR, Mergental H, Stephenson B, et al. First human liver transplantation using a marginal allograft resuscitated by normothermic machine perfusion. *Liver Transplant* 2016;22:120–4). Guarrera et al. (Guarrera JV, Henry SD, Samstein B, et al. Hypothermic machine preservation facilitates successful transplantation of “orphan” extended criteria donor livers. *Am J Transplant* 2015;15:161–9) used hypothermic machine perfusion (HMP) in 31 adults receiving extended criteria livers declined by other centers and compared their outcomes to other extended

criteria livers and standard criteria livers. HMP was performed for 3 to 7 hours at 4°C to 8°C. They found a reduction in allograft dysfunction from 30% in the control group to 19% in the HMP group, but these differences were not statistically significantly different. Patient survival, primary nonfunction, and other complications were not statistically significantly different, except there was a lower incidence of biliary complications in the HMP group compared to the control group (13% vs. 43%, respectively, $P = 0.001$) and a shorter length of stay. There seems to be more interest experimentally and clinically, however, in NMP which as Ravikumar and his colleagues have pointed out is not a novel concept, but is technologically more complex (Ravikumar R, Leuvenink H, Friend PJ. Normothermic liver preservation: a new paradigm? *Transpl Int* 2015;28:690–9). Experimental studies suggest that NMP might be successful in resuscitating livers that have undergone warm ischemic injury prior to retrieval (e.g., donors after circulatory determination of death) and would not function after cold preservation (Ravikumar R, Leuvenink H, Friend PJ. Normothermic liver preservation: a new paradigm? *Transpl Int* 2015;28:690–9). In addition, NMP has the potential to defat steatotic livers with drugs delivered via NMP. Immunomodulation of the liver or the delivery of gene therapies has also been proposed. Currently there are at least three devices either in or soon to be in clinical trials including the Liver Assist device (Organ Assist, Groningen, the Netherlands), OrganOx Metra mobile perfusion device (OrganOx, Oxford, UK), and The TransMedics Organ Care System (Andover, MA) (Ravikumar R, Leuvenink H, Friend PJ. Normothermic liver preservation: a new paradigm? *Transpl Int* 2015;28:690–9). A recent report from Birmingham, UK, describes the successful transplant of a liver from a 29-year-old donor after circulatory determination of death that had 1 hour and 49 minutes of warm ischemia time, followed by 7 hours of cold preservation during transport and 7 hours of NMP (Organ Assist, Gronigen, the Netherlands) prior to transplantation into a 47-year-old patient with a MELD of 17 (Perera MTPR, Mergental H, Stephenson B, et al. First human liver transplantation using a marginal allograft resuscitated by normothermic machine perfusion. *Liver Transplant* 2016;22:120–4). During the perfusion portal venous flow, hepatic arterial flow, perfusate blood gases, lactate, and bile production were evaluated every 30 minutes, and biopsies were obtained before and after NMP. Their criteria for transplantation are assessed at 2 hours of NMP and include lactate <2 mmol/L and the graft must be making bile. The transplant was performed and the patient did well and was discharged on postoperative day 10 and has normal kidney and liver function at 15 months. A single case does not prove the value of NMP, but does add support for the ongoing and planned clinical trials.

The authors do an excellent job of describing and illustrating the surgical techniques for adult and pediatric deceased and live donor liver transplants. Although venovenous bypass is described as being performed either open or percutaneously, the percutaneous approach is the preferred and well-described approach and eliminates the problems of lymphoceles and other wound

complications that are common with open exposure of the saphenous and axillary veins (Johnson SR, Marterre WF, Alonso MH, et al. A percutaneous technique for venovenous bypass in orthotopic cadaver liver transplantation (OLTx) and comparison with the standard open technique. *Liver Transpl Surg* 1996;2:354–61). The authors note that venovenous bypass can be used in patients with dialysis dependent hepatorenal syndrome to allow better fluid and electrolyte management intraoperatively, but we have utilized intraoperative continuous venovenous hemodialysis or ultrafiltration via a percutaneously placed dialysis catheter managed by anesthesia, nephrology, and usually an intensive care nurse. This is due to the fact that we, as well as many programs today, rarely use venovenous bypass, but rather perform a piggyback transplant as described later in the chapter where the recipient vena cava is left in situ and the donor suprahepatic vena cava is anastomosed to the confluence of the hepatic veins and the donor infrahepatic cava is sutured or stapled. This reduces blood loss that can particularly be problematic around the posterior cava and adrenal gland and eliminates one anastomosis. One technical difference is that the authors describe clamping and dividing the right hepatic vein during mobilization of the liver and then using the confluence of the middle and left hepatic veins for the anastomosis to the donor suprahepatic vena cava. They note that when the orifice is insufficient, they extend a caval incision distally 3 to 4 cm to provide adequate outflow that will require partial or complete clamping of the vena cava, which can lead to hemodynamic instability. We prefer to utilize the confluence of the right, middle, and left hepatic veins for our anastomosis that does not require clamping of the vena cava and provides adequate outflow. During performance of the arterial dissection, the surgeon must be careful to avoid excessive traction on the hepatic artery because of the risk of arterial dissection that can preclude using the hepatic artery. Fortunately, it does not usually affect the splenic artery and the surgeon can dissect out the origin of the splenic artery along the superior border of the pancreas and perform an end-to-end anastomosis between the splenic artery and the donor hepatic artery obviating the need for an infrarenal or supraceliac conduit. It should be noted that although the authors prefer the infrarenal conduit, a supraceliac conduit is easily performed after the liver has been removed and prior to implantation. One final technical point. The authors describe preserving the Segment IV hepatic artery during a living donor hepatectomy that is important as they note. This is easily accomplished in most patients as the Segment IV artery usually arises from the left hepatic artery. This allows a long length of the right hepatic artery that can be divided to the left of the common bile duct. However, in 10% to 15% of patients the Segment IV artery arises from the right hepatic artery, which then results in a shorter right hepatic artery for the donor graft as it needs to be divided more distally, usually on the right side of the common bile duct in order to preserve the Segment IV branch.

Finally, the authors have nicely described the profound improvements in outcomes and quality of life that have occurred since the introduction of liver

transplantation and certainly Dr. Busuttil's many contributions to these advances should be recognized and celebrated along with his many colleagues at the Dumont-UCLA Liver Transplant Center. His commitment to advancing the field of liver transplantation in adults and children and to each individual patient is legendary and well illustrated by this outstanding contribution to the 7th Edition of Fisher's *Mastery of Surgery*.

Douglas W. Hanto

[1]The MELD score is calculated according to the following formula: MELD score = 0.957 ×ln(creatinine [mg/dL]) + 0.378 × ln(bilirubin [mg/dL]) + 1.12 × ln(INR) + 0.643.

119 Special Comment: The Unfinished Legacy of Liver Transplantation

Thomas E. Starzl and Noriko Murase

Legacy: Something immaterial, as a style or philosophy, that is passed from one generation to another. Anything handed down from, or as from, an ancestor.

During the last 30 years, the philosophy and practice of hepatology have been dramatically transformed by the wide acceptance of orthotopic liver transplantation. The extent that this has occurred is exemplified by the gratifying 1-, 3-, and 5-year survival after liver replacement described in the chapter by Dr. Busuttil. Nevertheless, the steady mortality rate during the first 5 postoperative years and beyond has been a persistent reminder that liver transplantation has not yet been fully optimized. The delayed losses have largely resulted from the ravages of long-term immunosuppression.

How to lighten the burden of immunosuppression requires an understanding of the full 60-year history of liver transplantation. Numerous milestones in the development of the procedure, including its first successful use in humans, were reached between 1955 and 1980 (Table 119.1). However, the immune response to hepatic allografts could not be controlled reliably enough to permit the wide use of liver replacement until the advent of cyclosporine in 1980. Even then, diffusion of the complex new multidisciplinary enterprise of liver transplantation into the national and international health care systems would be a prodigious task (Table 119.1). This was evident in the 2004 Action Plan for Liver Disease Research that was designed to "coordinate research efforts (to treat hepatic and biliary disease) across the NIH."

RESEARCH AND DEVELOPMENT OPPORTUNITIES

The National Institutes of Health (NIH) 2004 plan was divided into 16

chapters, one of which was devoted exclusively to liver transplantation, with primary emphasis on clinical research. The chapter on “Liver Transplantation” began with the simple declarative sentence, “Liver transplantation is now the standard of care for patients with end stage liver disease or acute liver failure.” It was a proud statement from the government agency whose unfailing support had made this possible. But, had liver transplantation matured so completely that there is nothing left to do but fine-tuning? This view was negated by links to liver transplantation in almost all of the 15 other chapters of the NIH prospectus. Most of these links were to targets of research opportunity that already had been enriched by, or even owed their provenance to, liver transplantation.

For example, techniques of liver procurement, preservation, and replacement have been adapted for nontransplant purposes (e.g., for subtotal hepatic resections). The discovery that portal venous blood contains substances important for maintenance of liver size, function, and the capacity for regeneration was the beginning of the still-evolving special field of hepatotrophic physiology that is concerned with the functional and hormonal interrelationships of the different splanchnic organs. The hepatotrophic studies ultimately led to the cure or palliation with liver replacement of numerous hepatic-based inborn errors of metabolism, providing the first examples of what might be accomplished in the future with gene therapy and the application of stem cell biology. Finally, religious beliefs, concerns about medical ethics, and public policy or legal issues that surfaced five decades ago with the first attempts of liver transplantation remained as unresolved agenda items in the NIH master plan of 2004, and today.

TABLE 119.1 Milestones of Liver Transplantation

Year	Description[a]
1955	First article in the literature on auxiliary liver transplantation
1956	Concept of liver replacement first mentioned
1958–1960	Results reported of canine total hepatectomy and liver replacement without immunosuppression
1960	Abdominal multivisceral transplantation described in nonimmunosuppressed dogs
1963	Azathioprine-prednisone cocktail introduced (kidneys first, then livers) and recognition of organ-induced tolerance
1963	Description of in situ preservation and procurement of cadaveric organs
1963	First attempts to transplant the human liver
1964–1965	Evidence reported of hepatotrophic (liver-supporting) factor(s) in portal venous blood
1965	Liver-induced tolerance under a short course of azathioprine reported in dogs
1966	First liver xenotransplantation on July 15, 1966 (chimpanzee donor)
1966	Clinical introduction of ALG for kidney, then liver recipients
1966–1970	Evidence that HLA matching would not be a major factor in cadaveric organ transplantation
1967	First 1-year survivals after human liver replacements
1967–1968	Acceptance of brain death concept
1967–1969	Liver-induced tolerance in pigs without immunosuppression
1969	First textbook of liver transplantation based on 25 Denver cases
1969	First palliation (or cure) of inborn error of metabolism with liver transplantation
1973–1983	Evidence accrued that the liver controls cholesterol homeostasis
1973	Description of the liver's resistance to antibody-mediated rejection
1973–1975	Principal portal blood hepatotrophic factor identified as insulin
1976	Causes of failure analyzed in first 93 Colorado cases of liver transplantation
1976	Improved slush liver preservation permitted long-distance procurement
1979	Systematic use of arterial and venous grafts for cadaveric liver revascularization
1979	Cyclosporine introduced for organ transplantation including two liver recipients
1980	Cyclosporine-steroid cocktail introduced clinically
1981	80% 1-year liver recipient survival reported using cyclosporine-prednisone
1982	Review of progress in liver transplantation generates widespread interest of hepatologists
1983	Introduction of pump-driven venovenous bypass without anticoagulation
1983–1995	USA consensus development conference conclusion that liver transplantation is a service (1983) is followed by rapid proliferation of transplant centers worldwide
1984	Standardization of in situ preservation-procurement techniques for cadaveric multiple organ donors
1984	Reversibility reported of B-cell malignancies (PTLD) in liver and other organ recipients
1984	Reports of reduced-size liver grafts for pediatric recipients
1984	Liver transplantation of patient with hypercholesterolemia verified hypothesis that the liver is the site of cholesterol homeostasis
1987–1989	First successful transplantation of liver-containing multivisceral grafts
1987	University of Wisconsin (UW) solution improves preservation of liver and other organs
1987	Successful extensive use of livers from "marginal" donors reported
1988	National adoption of Pittsburgh point system for cadaveric kidney and liver distribution complies with Organ Transplant Act of 1984
1989	Popularization of the "piggy back" variation of liver transplantation
1989	Clinical introduction of FK 506 (tacrolimus)-based immunosuppression
1989	First report of split cadaveric liver for transplantation into two recipients
1990	First use of live liver donors (left-side fragments)
1992–1993	Discovery of donor leukocyte microchimerism in liver (and other organ) recipients, placing organ and bone marrow cell transplantation on common ground
1998	Delineation of analogies between transplantation and infection immunology
1994–1999	Live donor transplantation of right-side liver fragments
2001	Mechanism-based tolerogenic immunosuppression proposed
2003	Double knockout of porcine α1, 3GT gene, and revitalizing hopes of clinical xenotransplantation
2003	Clinical use of tolerogenic immunosuppression
2005	Mechanisms of recurrent hepatitis under transplant immunosuppression elucidated

PTLD, posttransplant lymphoproliferative disorders.
[a]ALG, antilymphocyte globulin.

However, the most frequently identified potential research initiatives in the NIH strategic plan of 2004 concerned the immune response and/or the manifold consequences of modifying it, not only for transplantation, but also in the context of hepatitis, HIV, and oncology (to which separate chapters of the plan were devoted). Using today's sophisticated tools (particularly those of molecular biology), the time has come to expand the sphere of immunology in new directions, fill in knowledge gaps, explain long-standing enigmas, and contribute ultimately to better patient care. With this in mind, the following discussion will consider specific issues of immunology that are central to further development of liver transplantation

and to improvement of treatment under multiple nontransplant circumstances.

THE RELATION OF ALLOENGRAFTMENT TO ACQUIRED IMMUNE TOLERANCE

The Historical View

Bone Marrow Transplantation

Transplantation immunology was brought to its present state by a series of events that began in 1943 to 1944 with Medawar's demonstration that rejection is an immune response. A year later, Owen discovered mixed blood cell chimerism in freemartin cattle whose fused placentas had permitted fetal cross-circulation; such animals were subsequently shown to be mutually tolerant. Then, in 1953 to 1955, the strong association of donor leukocyte chimerism and acquired donor-specific tolerance was demonstrated in experiments in which allogeneic spleen and bone marrow cells were transplanted without immunosuppression into immunologically immature mice and into irradiated adult mouse recipients. After hematolymphopoietic cell engraftment, the recipients could accept all other donor tissues and organs. The mouse tolerance models escalated during the ensuing 15 years to clinical bone marrow transplantation in immunodeficient and irradiated patients. However, success depended on the use of human leukocyte antigen (HLA)-matched donors. Otherwise, the penalty for engraftment was lethal graft-versus-host disease (GVHD), that is, rejection of the host by the graft.

Organ Transplantation

In contrast to the "bench to bedside" chronology of bone marrow transplantation, organ transplantation (initially of the kidney) was accomplished in humans before proof of feasibility was demonstrated in an animal model and in the apparent absence of leukocyte chimerism. The first six kidney recipients with prolonged graft survival (1959 to 1962) were preconditioned with sublethal total-body irradiation, but were not infused with donor bone marrow cells. In 1960 to 1961, daily posttransplant azathioprine was shown to prolong kidney survival in dogs, and taken to clinical trials. Used alone or in combination with other cytotoxic agents, azathioprine was only marginally effective. However, its combination with prednisone made renal transplantation a practical service by exposing two features of the alloimmune response that later were

demonstrated with liver and all other kinds of organ transplantation and under all other regimens of immunosuppression.

The first unexplained observation was that rejections that developed under azathioprine were easily reversed with the addition of large doses of prednisone rather than being inexorable, as previously thought. Secondly, a successful rejection reversal frequently was succeeded by a greatly reduced requirement for maintenance immunosuppression (Fig. 119.1), suggesting that the graft was inherently tolerogenic. It also was learned that histocompatibility matching was not a prerequisite for success, that there was little threat of GVHD, and that perpetuation of organ graft survival almost always depended on lifetime drug treatment. In addition to these striking differences from bone marrow transplantation, none of the organ recipients were thought to have donor leukocyte chimerism (Table 119.2).

Because of these striking disparities, organ engraftment and successful bone marrow transplantation were considered for many years to involve fundamentally different mechanisms. Experimental therapeutic strategies were empirically developed with the objective of endowing organ recipients with the donor leukocyte chimerism-associated mechanisms of the bone marrow recipient while avoiding the penalty of GVHD. These strategies had in common the infusion of donor hematolymphopoietic cells into organ recipients that had been immunologically weakened by irradiation, antilymphoid antibody preparations, or other means (i.e., nonmyelotoxic cytoreduction). Although encouraging experimental results have been reported, such protocols have not found a significant niche in clinical organ transplantation practice because of their complexity, risks, and unpredictable consequences.

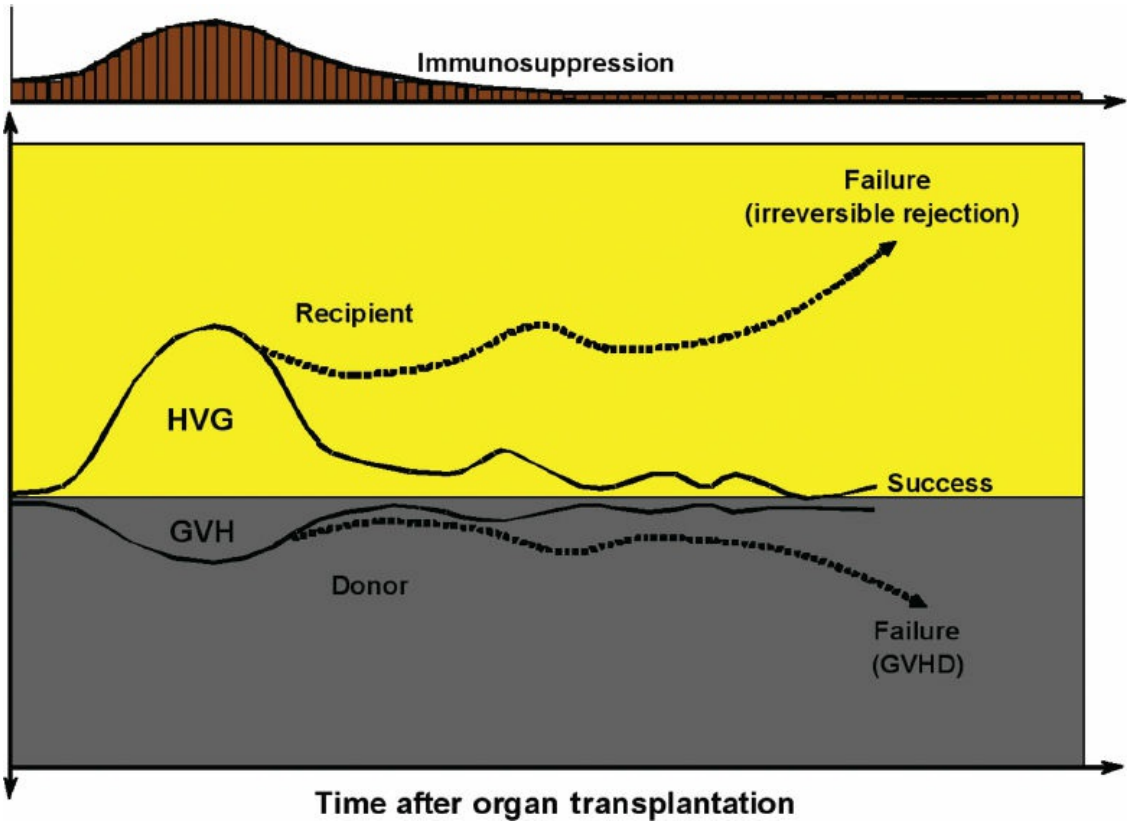

Figure 119.1. Contemporaneous host-versus-graft (HVG) and graft-versus-host (GVH) immune responses after transplantation. The presence of the weaker GVH response in organ recipients (the inverted curves on a gray background) was not recognized until the discovery of microchimerism in 1992. However, the demonstration in 1962 to 1963 that the HVG response (rejection) is reversible and may be succeeded by a state of variable tolerance (*yellow panel*) allowed the practical development of immunosuppression-aided clinical organ transplantation. GVHD, graft-versus-host disease.

TABLE 119.2 Differences Between Clinical Organ Transplantation and Bone Marrow Transplantation

Feature	Organ Transplantation	Bone Marrow Transplantation
Host cytoablation	No	Yes[a]
HLA matching	Not essential	Critical
Principal complication	Rejection	Graft-versus-host disease
Immunosuppression-free	Uncommon	Common
Term for success	Acceptance	Tolerance
Leukocyte chimerism	No	Yes

[a]This therapeutic step allows a relatively unopposed graft-versus-host reaction and accounts for the other differences.

Nevertheless, this body of experimental work demonstrated that the establishment of a hematolymphopoietic population composed of donor and recipient cells was possible in some models with a reasonably low risk of GVHD and could result in donor-specific tolerance, providing the donor cell contribution was at least 1% to 2% ("macrochimerism"). Levels below this ("microchimerism") were generally interpreted as either negative findings or artifacts. By so doing, the historical paradigm that attributed bone marrow and organ engraftment to different mechanisms required no substantive revision.

A Unification of Bone Marrow and Organ Transplantation

The historical paradigm was not challenged until 1992. When small numbers of multilineage donor hematolymphopoietic cells (microchimerism) were found in animal and human recipients of long-surviving kidney and liver allografts, it was postulated that the mechanisms of organ engraftment differed only in degree from the leukocyte chimerism-dependent ones of successful bone marrow transplantation. Organ engraftment was now defined as a variable form of tolerance that resulted from "responses of coexisting donor and recipient immune cells, each to the other, causing reciprocal clonal expansion followed by peripheral clonal deletion." The graft-versus-host arm of the double-immune reaction (the inverted curve in Fig. 119.1) usually was clinically inapparent.

The prerequisite for the donor-specific tolerance was migration of the graft's passenger leukocytes to host lymphoid organs and induction there of the host-versus-graft response. Because the multilineage passenger leukocytes of an organ are of bone marrow origin, their hematogenous migration into the recipient was, in essence, the equivalent of a bone marrow cell infusion. Exhaustion and deletion of the antidonor response explained the characteristic rejection reversal and subsequent decline in need for immunosuppression in organ recipients (Fig. 119.1). Cytoablation of bone marrow, but not of organ recipients, was the apparent reason for essentially all of the differences between the two kinds of transplantation, including the high risk to the bone marrow recipient of GVHD, and the need to restrict marrow donors to those with a histocompatibility match (Table 119.2). Importantly, essentially all cytoablated bone marrow recipients have a small residual population of their own hematolymphopoietic cells (i.e., mirror image microchimerism) rather than

complete bone marrow replacement.

This unified view of transplantation was controversial, in part because it was incompatible with dogmas that made up much of the foundation of transplantation immunology. One point of contention was our view that historically rooted alternative engraftment mechanisms (listed in Table 119.3) were either epiphenomena or "variants or stages" of the clonal exhaustion-deletion that followed the key event of leukocyte migration. In addition, the role of small numbers of persistent cells (the microchimerism) in perpetuation of long-term graft survival was not yet clear. Finally, the crucial mechanism of clonal exhaustion-deletion was still generally considered to be only a theory. Although we did not know it at the time, precisely these issues were being addressed independently in Zurich but in the context of immune responsiveness and unresponsiveness to noncytopathic microparasites (see later discussion).

TABLE 119.3 Mechanisms of Immune Nonreactivity

Essential

1. Clonal exhaustion-deletion
2. Immune ignorance

Alternative

1. Special recipient cells: T-regulatory, suppressor, veto
2. Antibodies: idiotypic, "enhancing"
3. Cytokines: self-perpetuating combinations
4. Inhibitory molecules: down regulation
5. Graft secretions: soluble HLA antigens
6. Antigen presentation: defective or deviant
7. Anergy: absence of second signal, or cytokine exhaustion

TOLERANCE FROM THE INFECTION PERSPECTIVE

The major histocompatibility complex-restricted mechanisms of T-cell recognition of, and response to, noncytopathic microorganisms, and to allografts, had been elucidated by Zinkernagel and Doherty in the 1970s,

but the mechanisms of acquired immune nonreactivity remained a puzzle. During the early 1990s, Zinkernagel and his associates in Zurich formally proved in mouse infection models that the antipathogen T-cell response could be exhausted and deleted, and concluded that this was the explanation for the carrier state that may develop after infection with noncytopathic (intracellular) viruses. As with transplantation, the critical step was migration of the pathogen or its peptide to host lymphoid organs. The presence of virus that failed to reach these destinations was not recognized by the host. This was termed *immune indifference* (now called *immune ignorance*). In essence, Zinkernagel et al. had clarified the interrelationship of immunity and tolerance to pathogens, and had defined tolerance in terms of two essential mechanisms: immune ignorance and clonal exhaustion-deletion. Moreover, they placed these mechanisms in the same dynamic context of antigen migration as that of transplantation.

Once the viral antigen reached lymphoid destinations and induced a cytolytic T-lymphocyte (CTL) response, the outcomes in the highly controlled models of lymphocytic choriomeningitis virus infection were determined by the balance between the amount of virus antigen and the number of induced antigen-specific CTLs. Analogous to the maximal flood of passenger leukocytes migrating from a transplanted organ, the critical period was during the first few days or weeks of viral replication. If the CTLs were induced in sufficient numbers, the result was disease control; if not, the result was clonal exhaustion-deletion and a carrier syndrome that ranged from asymptomatic to progressively more serious disease states. No matter what balance was established acutely, perpetuation of this balance (whether immunity, deletional tolerance, or some stage in between) depended on persistence of antigen with access to host lymphoid organs. The ability of small amounts of persistent virus to survive was attributed to its relocation in nonlymphoid sites that were inaccessible to host immune effector mechanisms. From these protected niches, the virus migrated secondarily to host lymphoid organs and could sustain immunity or, alternatively, maintain tolerance. Thus, persistent antigen was a two-edged sword.

THE BOUNDARY BETWEEN IMMUNITY AND TOLERANCE

The analogies between transplantation and infection were summarized in 1998 and generalized to other branches of immunology in the following

statement: “Migration and localization are the governing factors in immunologic responsiveness or unresponsiveness against infections, tumors and self, and against xenografts and allografts.” All of the clinical scenarios of transplantation, and those resulting from infection by noncytopathic pathogens, could be correlated with the routes of migration and the ultimate localization of the respective antigens. The “gray area” between unequivocal immunity and durable tolerance included a diversity of transplant outcomes short of outright acute irreversible rejection, as well as a panoply of analogous virus carrier states; all represented different degrees of partial tolerance. Such immunologic “compromises” included chronic allograft rejection and its analog, chronic hepatitis.

The Rejection Option

Organ Transplantation

The antigen migration is essentially the same with transplantation of the liver and any other surgically revascularized whole organ (Fig. 119.2A). Movement of the passenger leukocytes is selective at first to host lymphoid organs, where a clonal antidonor T-cell response is induced. The CTLs then target the transplanted organ as well as the peripheralized cells of the source graft (Fig. 119.2A).

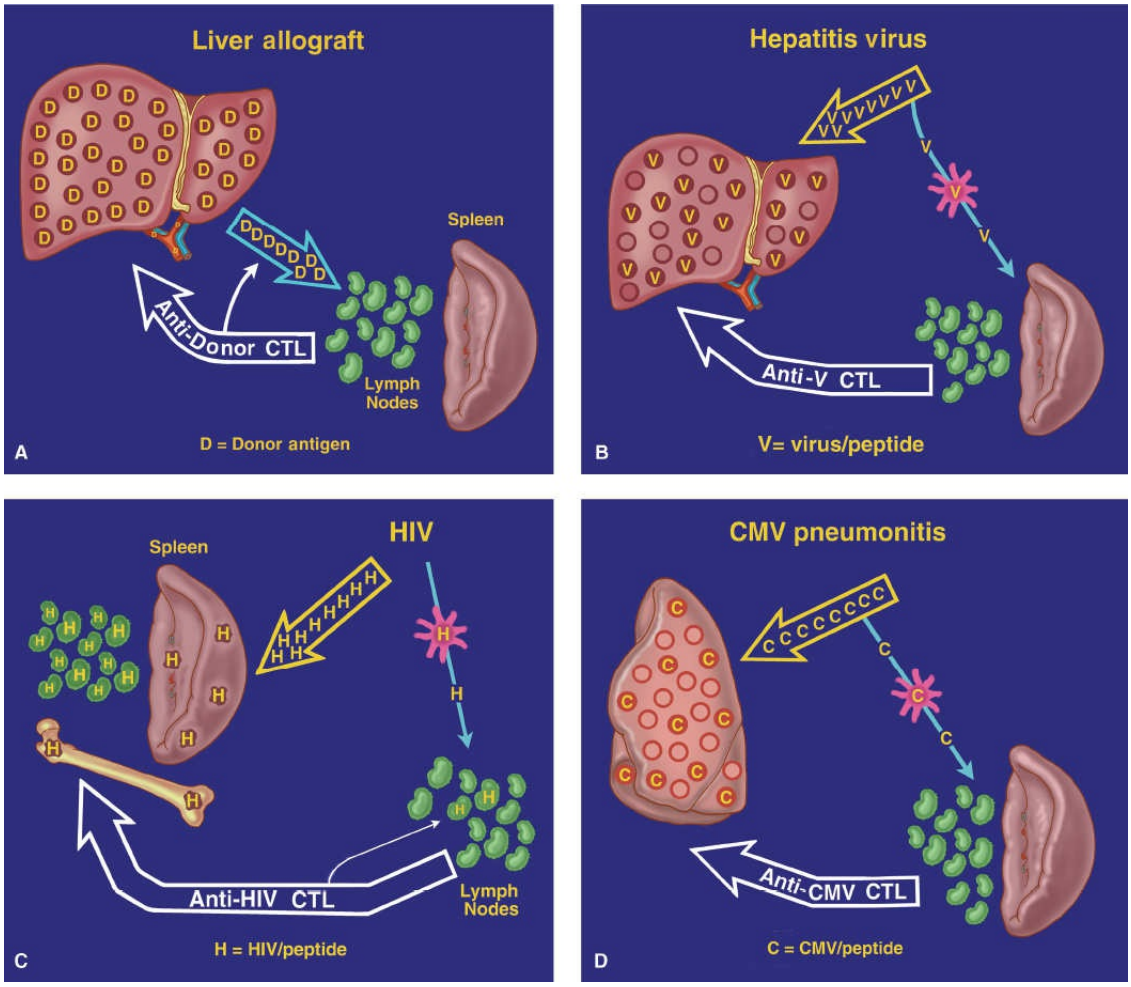

Figure 119.2. The consequences of antigen spread and localization (see text) with liver or other kinds of organ transplantation (**A**), with a viral hepatitis infection (**B**), with a HIV infection (**C**), and with a pulmonary cytomegalovirus (CMV) infection (**D**). CTL, cytolytic T-lymphocyte.

Infection

The migratory principles after infection by noncytopathic microparasites are the same as those of passenger leukocytes, but the details differ as both the pathways of microorganism migration and the targets of the CTL response are dictated by the tropism of the various pathogens (Fig. 119.2B–D). For example, because of the liver tropism of the hepatitis viruses, the quantity of viral antigen that migrates to host lymphoid organs is small compared with that homing to the liver (Fig. 119.2B). At the lymphoid organs, virus-specific CTLs are induced by infected antigen-presenting cells displaying complexes of major histocompatibility complex molecules and peptides derived from the pathogen. Because the induced CTLs then destroy infected host cells no matter where these “nonself”

cells are located, the principal disease expression is hepatic (Fig. 119.2B).

The Tolerance Option Without Immunosuppression

Organ Transplantation

Exceptions to the outcome of immunity (i.e., rejection) in untreated transplant recipients are rare. However, lifetime tolerance to liver allografts occurs without therapeutic manipulation in about 20% of outbred pig recipients, and with near 100% regularity using selected donor-recipient rat strain combinations and the majority of mouse strain combinations. Less well leukocyte-endowed mouse heart and kidney allografts also reliably self-induce tolerance, although in far fewer strain combinations. These models of spontaneous transplantation tolerance demonstrate that graft-induced immune nonreactivity is a normal potential option of the immune response (Fig. 119.3A). Importantly, the "spontaneous tolerance" may be abrogated in some of these models by administering immunosuppression.

Infection

After most infections by noncytopathic parasites, the balance between antigen and antigen-specific CTL tilts within a few weeks to immunity. The exceptions in which protective immunity frequently does not develop constitute a collection of some of the world's most difficult-to-treat diseases (e.g., AIDS, hepatitis, and malaria).

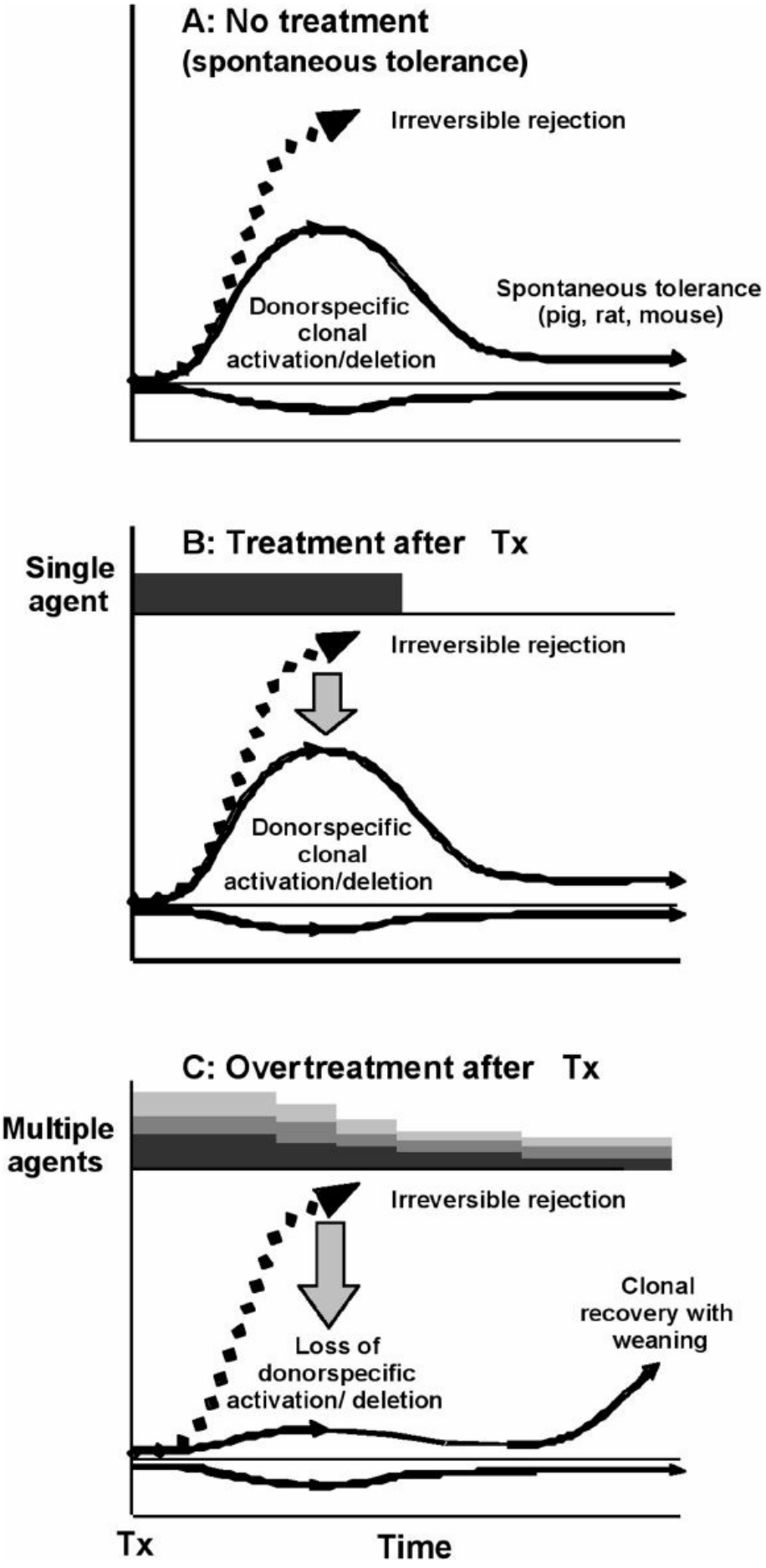
A: No treatment
(spontaneous tolerance)
Irreversible rejection
Donorspecific
clonal
activation/deletion
Spontaneous tolerance
(pig, rat, mouse)
B: Treatment after Tx
Single
agent
Irreversible rejection
Donorspecific
clonal
activation/deletion
C: Overtreatment after Tx
Multiple
agents
Irreversible rejection
Loss of
donorspecific
activation/ deletion
Clonal
recovery with
weaning
Tx
Time

Figure 119.3. Organ-induced tolerance. **A.** Spontaneous tolerance induced by the liver in experimental models in which the host-versus-graft immune response induced by the migratory donor leukocytes is too weak to eliminate the donor antigen and is exhausted and deleted (the rise and fall of the *continuous thin line*). Maintenance of engraftment depends on small numbers of persistent donor leukocytes (microchimerism). The less well leukocyte-endowed heart and kidney also can "self-induce" engraftment but in a much smaller number of models. **B.** Immunosuppression-aided tolerance in organ transplant models in which the recipient response that normally would cause rejection (*dashed line*) is reduced into a deletable range (*continuous thin line*) with a short course of early posttransplant immunosuppression. Lifetime tolerance after stopping immunosuppression was first convincingly demonstrated in canine liver recipients. **C.** A self-defeating consequence of excessive prophylactic overimmunosuppression (depicted with multilayered bars) with which clonal exhaustion-deletion is impaired. The initially overtreated recipient may be committed to unnecessarily high maintenance immunosuppression, an undesirable effect of too much immunosuppression that was not recognized until 2001. Tx, transplantation.

THERAPEUTIC IMPLICATIONS

Infections With Noncytopathic Microorganisms

In 1994, Zinkernagel and Hengartner discussed the comparative pathophysiology of HIV (a retrovirus) and hepatitis B virus ([HBV] a DNA virus) in the context largely developed with their studies of the lymphocytic choriomeningitis virus (an RNA virus). The authors argued that the consequences of HIV were caused principally by virus-specific cytotoxic T-cell-mediated immunopathology rather than by direct cytolytic effects or any other mechanism. The essence of their argument is shown in Figure 119.2C. After HIV antigen delivery to lymphoid organs by infected dendritic cells or other antigen-presenting cells, a CTL response is induced that targets CD4 (T helper) and all other infected cells. In an unknown number of cases, the CTL response is strong enough to establish disease control. However, the classical outcome is immunodeficiency. With the selective destruction of infected CD4 cells and eventual decimation of the infected antigen-presenting cell population, the inadequately renewed HIV-specific CTL clone is easily exhausted and deleted, and eventually

the entire CTL population dwindles. The outcome from the events shown in Figure 119.2C depends on the balance established at an early time between the amount and localization of the virus versus the CTL response. A similar pathogenesis, but with variable targets and outcomes, pertains with all noncytopathic microparasites, for example, hepatitis (Fig. 119.2B) and cytomegalovirus (Fig. 119.2D).

From this point of view, Zinkernagel and Hengartner had suggested in 1994 that the foremost therapeutic objective under most circumstances is to limit the extent of the infected cell targets, or in clinical terms, to reduce the viral load and restrict its spread. This has since been accomplished in HIV patients with zidovudine and protease inhibitors. It was also pointed out that once a large target is established, the deliberate resurrection of a strong CTL response could have the disastrous consequence of widespread host cell killing. It was suggested that a better option under these circumstances might be the administration of T-cell-directed immunosuppression in just the right amount to prevent the CTL-mediated destruction of massive numbers of host cells, but not so much that runaway viremia would merely expand the target for attack from a recovering CTL clone. Thus, the therapeutic aims in an intractable noncytopathic pathogen infection would be to predict, monitor, and equilibrate beneficial balances between the pathogen distribution and the absence of an immunopathologic T-cell response.

The Organ Engraftment Objective

Comparable antigen/CTL balances must be found and kept stable for successful transplantation. The best chance to establish a balance selectively favoring tolerance is during the first few posttransplant weeks, during which the maximal donor leukocyte migration provides the optimal conditions for reciprocal exhaustion-deletion of the double-immune response (Figs. 119.1 and 119.3). It was obvious that this one-time-only window of opportunity could be narrowed or closed by so much prophylactic immunosuppression that clonal activation is subverted. To the extent this were to occur, later reduction of the primary overtreatment predictably would lead to recovery of the ineffectively deleted clone with the clinical consequence of delayed rejection (Fig. 119.3C). Yet, the penalty of too little immunosuppression during the critical early period may be irreversible rejection. In 2001, it was suggested that this dilemma could be addressed by application of one or both of the therapeutic

principles depicted in combination in Figure 119.4.

The first principle (shown alone in Fig. 119.3B) consists of administration of no more posttransplant immunosuppression than the amount needed to prevent irreversible immune-mediated damage. Because of histocompatibility and other confounding parameters in the human population, such ideal immunosuppression in individual patients cannot be accurately predicted. With the second principle (recipient pretreatment), host global immune responsiveness can be reduced by nonmyeloablative conditioning before arrival of donor antigen, thereby bringing the anticipated donor-specific immune response into a more easily controllable and deletable range (Fig. 119.4). The two principles have been combined in a practical regimen using a single large dose of an antilymphoid antibody before transplantation followed by minimalistic posttransplant tacrolimus monotherapy with the intent of eventual weaning (Fig. 119.5). Satisfactory results in liver (Fig. 119.6) and other kinds of organ recipients with reduced overall exposure to immunosuppression have been obtained with the striking exception of liver recipients, whose chronic end-stage hepatic failure was caused by hepatitis C virus (HCV; discussion follows).

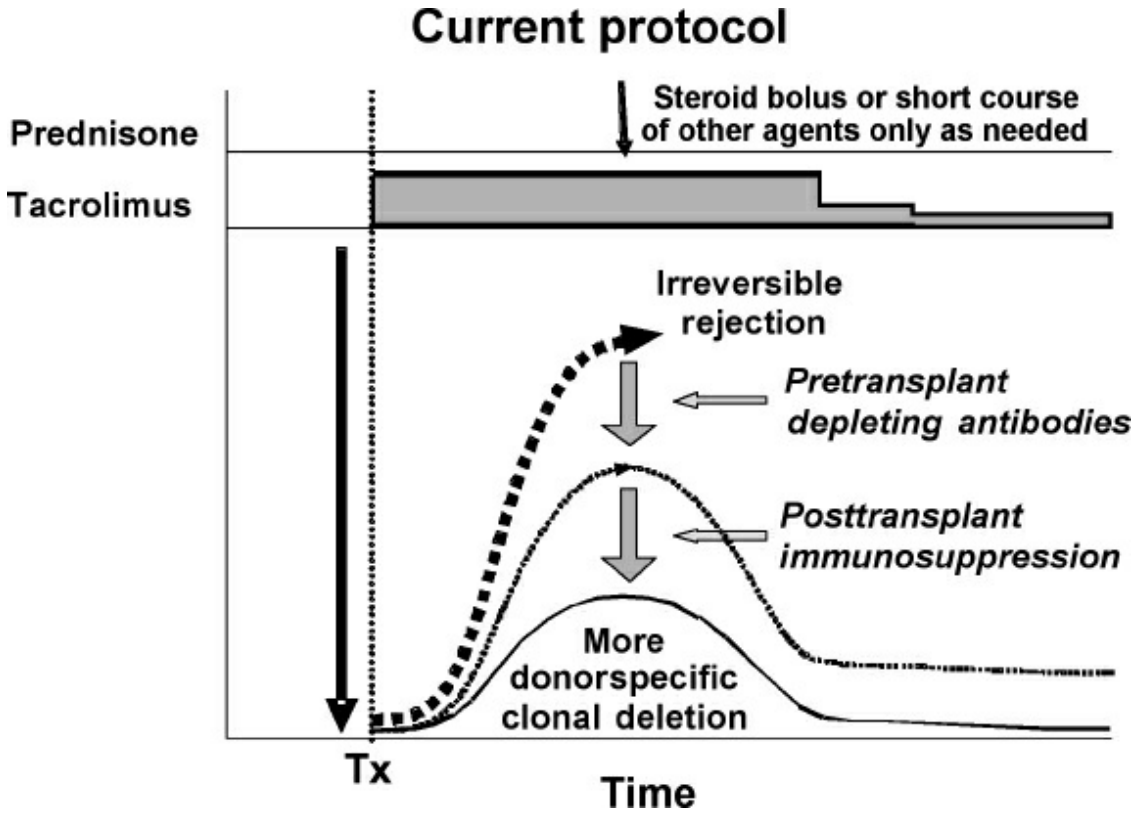

Figure 119.4. Protocol of "tolerance friendly" immunosuppression introduced at the University of Pittsburgh Medical Center. An antilymphoid antibody infusion prior to arrival of an allograft

reduces the anticipated antidonor response into a more readily deletable range and allows maintenance treatment to begin with daily monotherapy to which other agents are added only for rejection. Weaning from the monotherapy may be possible later. The inverted curve at the bottom shows the usually silent graft-versus-host reaction shown more clearly in Figure 119.1. Tx, transplantation.

The frequency and extent to which drug weaning can be accomplished in hepatitis-free liver recipients with such tolerance-facilitating immunosuppression have yet to be determined. Complete stoppage of treatment has been attempted only in a few of these recent cases. However, the feasibility of liberation from immunosuppressive drugs is evident from observations of our first 210 liver recipients: 184 at the University of Colorado (between 1963 and 1980) and 26 at the University of Pittsburgh (in early 1981). As of 2006, 35 (17%) of the 210 patients had reached or passed their posttransplant silver anniversary (Fig. 119.7). Thirty-two patients (15%) were still alive from 24.5 to 35.7 posttransplant years (mean, 27.1 ± 31 SD) and 3 died after 25 years from lung disease (no. 42 in Fig. 119.7), widespread metastases from colon carcinoma (no. 82), and *de novo* HCV infection (no. 93).

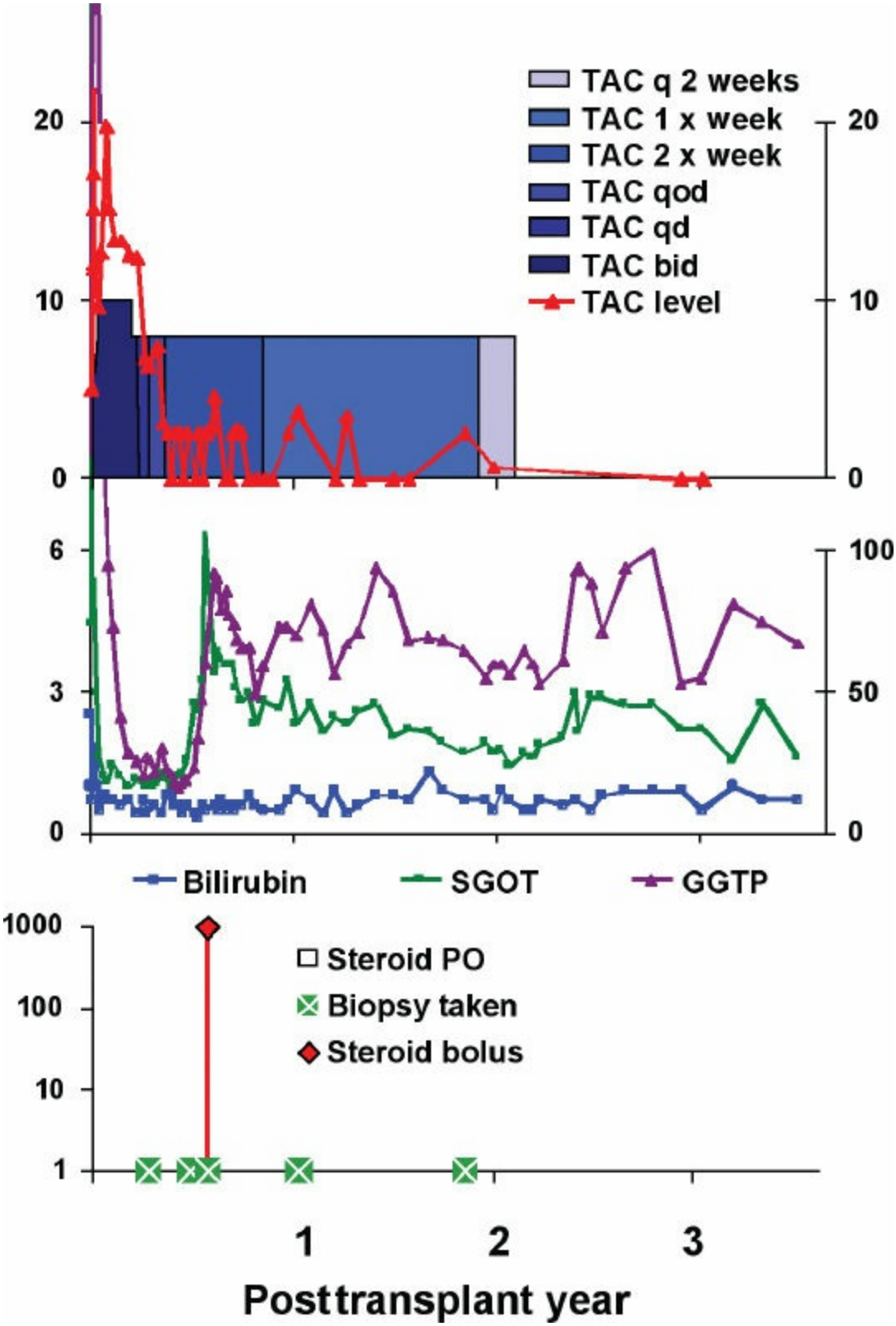

Figure 119.5. An example of the strategy shown in Figure 119.4. A woman with a hepatic hemangioendothelioma who was infused with 5 mg/kg antithymocyte globulin (Thymoglobulin) prior to liver allograft revascularization. Tacrolimus monotherapy was reduced from daily to every other day at 100 days, and to once per week by 10 months. Treatment was stopped at 22 months. She has

been immunosuppression-free for 5 years. Serum bilirubin and measures of hepatic parenchymal function have been normal throughout. Although enzyme levels have been stable, these have hovered at a high normal range or slightly above since a rejection at 6 months, which was treated with 1 g methylprednisolone. SGOT, serum glutamic-oxaloacetic transaminase; GGTP, gamma-glutamyl transpeptidase.

Importantly, 16 of the 35 quarter-century survivors had periods of 3 to 31 years off immunosuppression, as indicated by the green portion of the horizontal bars in Figure 119.7. In 5 of these 16 recipients, immunosuppression was resumed, but not because of breakthrough rejection in any case. The reason for treatment reinstitution in two patients was liver retransplantation necessitated by intractable biliary tract complications (no. 202 in Fig. 119.7) or because of HCV hepatitis (no. 125). A third recipient, whose cyclosporine-based immunosuppression was stopped after 11 years, was returned to treatment 6 years later because of cadaveric kidney transplantation (no. 192). The other two recipients, who were asymptomatic and had rejection-free biopsies, were restarted on treatment because of patient and physician anxiety (nos. 64 and 105 in Fig. 119.7).

The Price of Chronic Immunosuppression

The consequences of a decision to resume immunosuppression without a clear justification may not be evaluable for years, or decades. When a detailed account of our 210 first recipients was published in the June 1993 issue of *Hepatology*, 50 (23%) of the patients had survived for at least a decade (maximum, 23 years). However, 7 had died from 1 to 11 years after their 10th anniversary, leaving 43 (20.5%) survivors. Rejection had not caused any of the late deaths. Instead, the most common lethal etiologies were hepatitis, other infections, malignant neoplasms, and drug-specific side effects. The same pattern has been apparent in the further shrinkage of survivors between 1993 and 2005 (from 43 to 32) for reasons other than rejection. Chronic immunosuppression clearly has been the principal direct or indirect cause of late mortality.

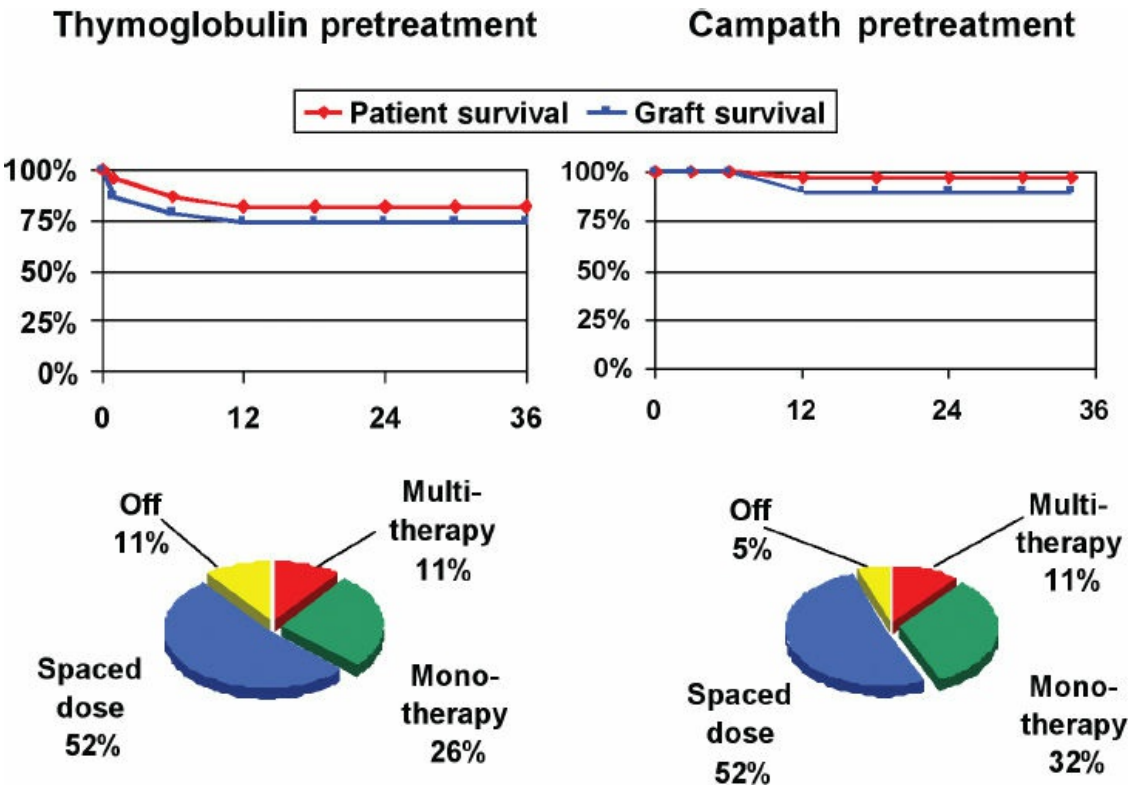

Figure 119.6. Patient and graft survival (*above*) and maintenance immunosuppression (*below*) of hepatitis-free primary liver transplant recipients treated in Pittsburgh with the principles of immunosuppression shown in Figure 119.4 and exemplified in Figure 119.5. *Left:* pretreatment was with an infusion of 5 mg/kg rabbit antithymocyte globulin (Thymoglobulin) (*n* = 23). *Right:* pretreatment was with 30 mg alemtuzumab (Campath) (*n* = 38).

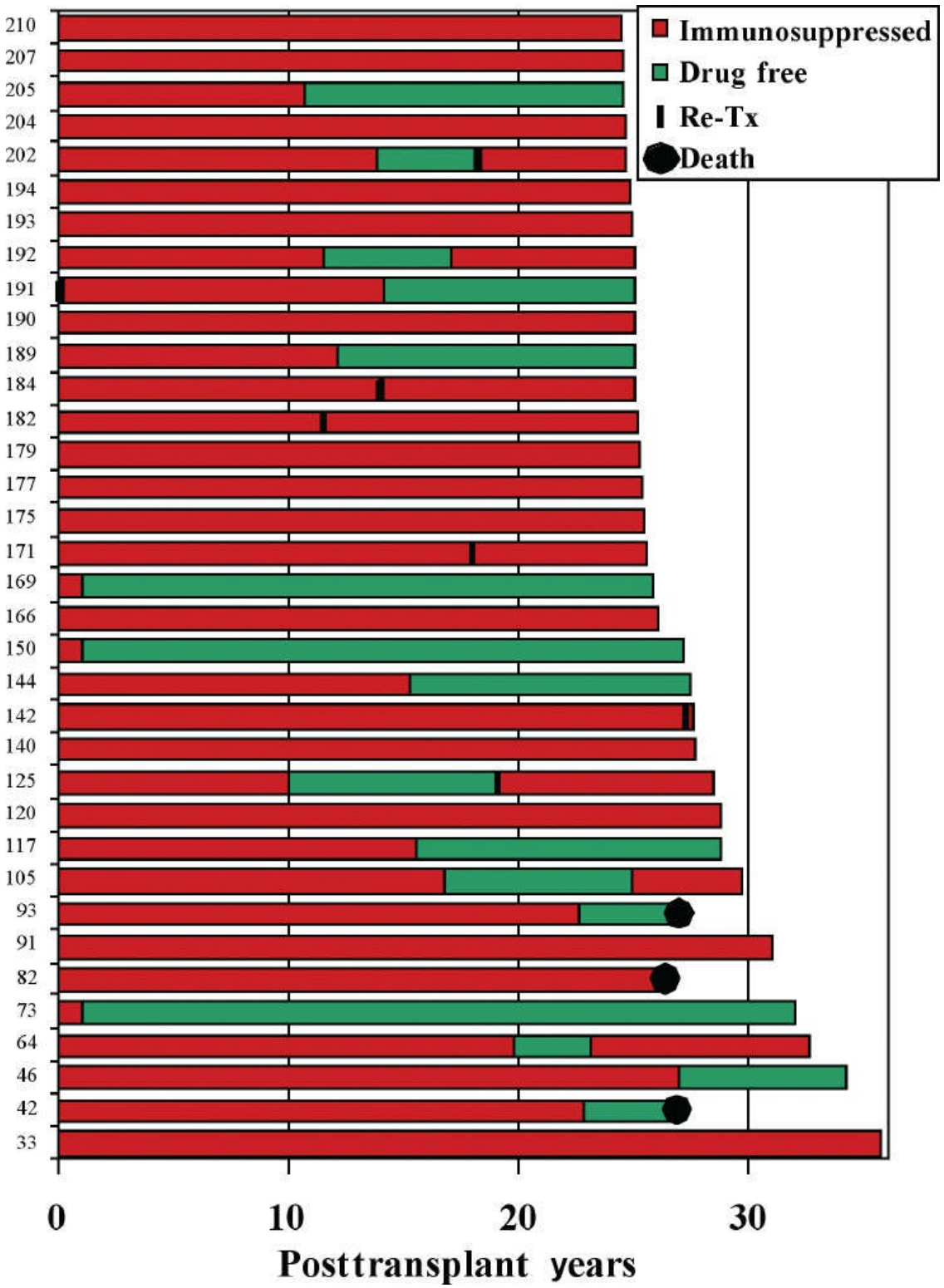

Figure 119.7. The 35 patients from the first 210 who survived 25 or more years after liver replacement at the University of Colorado (*n* = 184) or University of Pittsburgh (*n* = 26). The times on (red) and off (green) immunosuppression in individual patients are displayed in the horizontal bars. Note that 6 of the 32 still-surviving recipients as of 2006 had retransplantation (Re-Tx) 11 to 28 years after the primary procedure.

Organ Engraftment in HCV-Infected Patients

Although the importance of reducing or eliminating long-term immunosuppression is clear, when the tolerogenic strategy depicted in Figure 119.5 was applied in HCV-infected liver recipients, the results fulfilled the 1994 prophecy of Zinkernagel and Hengartner. First, the lymphoid depletion caused viremia. Then, when later attempts were made to wean from tacrolimus monotherapy, the heavily infected liver graft was targeted by recovering CTL, resulting in early and severe recurrent HCV disease. With recognition by Eghtesad et al. of what had happened, the explanation also was apparent for the worldwide epidemic of HCV recurrence that was associated with the various regimens of viremia-inducing heavy multiple drug immunosuppressions. Because strong prophylactic immunosuppression cannot be administered indefinitely without fatal consequences, such treatment eventually must be reduced. The consequent CTL recovery was leading to widespread destruction of infected allograft cells.

In contrast, light but continuous double-drug immunosuppression with tacrolimus and prednisone allows the systematic development of a relatively asymptomatic carrier state: a stable equilibrium between HCV and HCV-specific CTL. Thus, treatment protocols that minimize disease recurrence in HCV-infected liver allograft recipients must balance the desire to reduce immunosuppression or induce allotolerance with the need to prevent antiviral immunopathology. Avoidance of the epidemiologic implications of producing HCV-carrier recipients, and of the probability of insidious disease recurrence, will depend on containment of the viral load with HCV-specific drugs.

Tumor Surveillance

By the late 1960s, there was convincing evidence that immunosuppression in organ recipients could result in accidental engraftment of donor malignancies, accelerated growth of tumor metastases, or the development of new malignancies. Because the highest risk from these consequences has been in liver recipients, liver transplant centers have become hot beds of oncology research. Two tumors have been of particular interest because of their etiologic association with intracellular microorganisms: posttransplant lymphoproliferative disorders with the Epstein-Barr virus and hepatocellular carcinoma with HBV. The posttransplant lymphoproliferative disorders, most of which are B-cell lymphomas,

provided the first unequivocal proof of immune surveillance of a human malignancy when they disappeared after withdrawal of T-cell-directed immunosuppression.

The possibility of preventing virus-associated tumors with vaccines was demonstrated by Hilleman with proof of principle studies in primates of the simian virus 40 (SV_{40} virus), and extended to humans 20 years later with the recombinant HBV vaccine trials. The HBV-associated hepatoma scourge was virtually eliminated in immunized Asian populations. The research and therapeutic opportunities opened by these and other observations are too vast to dwell on here, beyond emphasizing that the mechanisms of immune reactivity and nonreactivity to tumors are the same as those of transplantation.

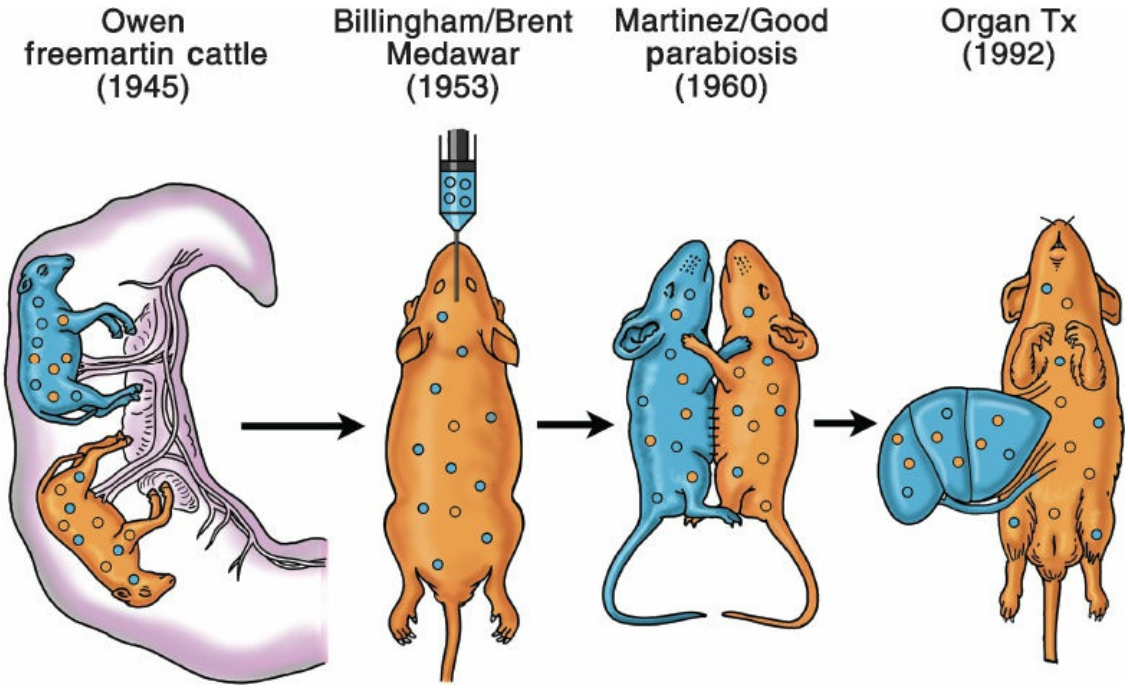

Figure 119.8. The relation of organ-induced engraftment (*right*) to classic models of spontaneous donor leukocyte chimerism-associated tolerance. Tx, transplantation.

Autoimmunity

The chimerism-dependent mechanisms of nonreactivity to allografts, all of which depend on mobile leukocytes, can be identified in a continuum of classic tolerance models that began with the observation by Owen of mixed blood cell chimerism in freemartin cattle, and ended in 1992 with the discovery of microchimerism in liver and other kinds of organ recipients (Fig. 119.8). Of historical interest, Paul Ehrlich recognized more

than a century ago that a patient's tissues could be destroyed by an immune system run amuck. Ehrlich's term of *horror autotoxicus* is today's autoimmune disease. He postulated that there must be mechanisms to prevent this by "a regulatory contrivance as yet undescribed." In the context of immunology described here, the contrivance that Ehrlich envisioned consisted of the mechanisms that have made transplantation feasible.

A NEED FOR CLOSURE

A coherent profile of immune function and governance has emerged from the studies of transplantation and infection summarized here. However, mechanisms of nonresponsiveness other than the essential ones of immune ignorance and clonal deletion (listed in Table 119.3) have generated a large body of historical and recent publications. In turn, these model-specific and poorly understood alternative mechanisms have become elements of recurring immunologic dogmas and theories. It may be asked if assigning them essential roles in transplantation tolerance is justifiable. Evidence of their existence derives from phenomena observed in experimental models in which the immune system is drastically perturbed (e.g., under conditions of lymphopenia) or the antigenic barriers to transplantation are significantly weakened (e.g., transplantation across minor histocompatibility mismatches). To complete the picture, it will be necessary to definitively determine the conditions for the development of these phenomena and to accurately assess their functional significance.

CONCLUSION

The article entitled "The Evolution of Liver Transplantation" published in 1982 in *Hepatology* concluded with the statement that "what was inconceivable yesterday, and barely achievable today, often becomes routine tomorrow." Liver transplantation proved to be a prime example. But the accomplishment was more than the addition of the crucial centerpiece for the treatment of otherwise lethal end-stage hepatic disease. Liver transplantation was from the beginning, and will continue to be, an instrument of scientific discovery in multiple fields, and above all in immunology.

Note: Some contents of this chapter were first published as an article in *Hepatology* (2006;43(2 Suppl 1):S151–63) and are reprinted with permission and slight modifications.

Suggested Readings

Bachmann MF, Hunziker L, Zinkernagel RM, et al. Maintenance of memory CTL responses by T helper cells and CD40-CD40 ligand: antibodies provide the key. *Eur J Immunol* 2004;34:317.

Brent L. *A History of Transplantation Immunology.* London: Academic Press, 1997:182.

Busuttil RW, Klintmalm GB, eds. *Transplantation of the Liver.* Philadelphia, PA: WB Saunders; 1996:1–903.

Calne R, ed. *Liver Transplantation.* London, England: Grune & Stratton LTD; 1983:1–399.

Calne R, Friend P, Moffatt S. Prope tolerance, perioperative campath 1H, and low-dose cyclosporine monotherapy in renal allograft recipients. *Lancet* 1998;351:1701.

Calne RY, Rolles K, White DJ, et al. Cyclosporin A initially as the only immunosuppressant in 34 recipients of cadaveric organs: 32 kidneys, 2 pancreases, and 2 livers. *Lancet* 1979;2:1033–6.

Calne RY, Sells RA, Pena JR, et al. Induction of immunological tolerance by porcine liver allografts. *Nature* 1969;223:472–6.

Eghtesad B, Fung JJ, Demetris AJ, et al. Immunosuppression for liver transplantation in HCV-infected patients: mechanism-based principles. *Liver Transplant* 2005;11:1343.

Ehrlich P, Morgenroth J. Uber H Molysine. *Funfte Mittheilung Berl Klin Wschr*. 1901;38:598–604. Reproduced. In: Himmelweit F, ed. The Collected Papers of Paul Ehrlich, vol. 2. London: Pergamon; 1957:234–45 (with English translation pp. 246–55).

Francavilla A, Hagiya M, Porter KA, et al. Augmenter of liver regeneration (ALR): its place in the universe of hepatic growth factors. *Hepatology* 1994;20:747–57.

Hilleman MR. Personal historical chronicle of six decades of basic and applied research in virology, immunology, and vaccinology. *Immunol Rev* 1999; 170:7–27.

Ichikawa N, Demetris AJ, Starzl TE, et al. Donor and recipient leukocytes in organ allografts of recipients with variable donor-specific tolerance: with particular reference to chronic rejection. *Liver Transplant* 2000;6:686.

Klenerman P. Commentary: T cells get by with a little help from their friends. *Eur J Immunol* 2004;34:313–6.

Moore FD. *Give and Take: The Development of Tissue Transplantation.* Philadelphia, PA: WB Saunders; 1964:1–182.

Murase N, Starzl TE, Tanabe M. Variable chimerism, graft versus host disease,

and tolerance after different kinds of cell and whole organ transplantation from Lewis to Brown-Norway rats. *Transplantation* 1995;60:158–71.

Starzl TE. *Experience in Hepatic Transplantation.* Philadelphia, PA: WB Saunders; 1969:1–353.

Starzl TE. Acquired immunologic tolerance: with particular reference to transplantation. *Immunol Res* 2007;38:6–41.

Starzl TE, Fung JJ. Themes of liver transplantation. *Hepatology* 2010;51:1869–84.

Starzl TE, Zinkernagel R. Antigen localization and migration in immunity and tolerance. *New Engl J Med* 1998;339:1905–13.

Starzl TE, Zinkernagel R. Transplantation tolerance from a historical perspective. *Nat Rev Immunol* 2001;1:233–9.

Starzl TE, Iwatsuki S, Van Thiel DH, et al. Evolution of liver transplantation. *Hepatology* 1982;2:614–36.

Starzl TE, Demetris AJ, Trucco M, et al. Cell migration and chimerism after whole-organ transplantation: the basis of graft acceptance. *Hepatology* 1993;17:1127–52.

Todo S, Fung JJ, Starzl TE, et al. Liver, kidney, and thoracic organ transplantation under FK 506. *Ann Surg* 1990;212:295–305; discussion 306–7.

United States Department of Health and Human Services. National Institutes of Health. Action Plan for Liver Disease Research. Dec, 2004. NIH Publication No. 04-5491.

Zinkernagel RM, Doherty PC. The discovery of MHC restriction. *Immunol Today* 1997;18:14–7.

Zinkernagel RM, Hengartner H. T-cell mediated immunopathology versus direct cytolysis by virus: implications for HIV and AIDS. *Immunol Today* 1994;15:262–8.

Zinkernagel RM, Ehl S, Aichele P, et al. Antigen localization regulates immune responses in a dose- and time-dependent fashion: a geographical view of immune reactivity. *Immunol Rev* 1997; 156:199–209.

EDITOR'S COMMENT

It is a sad note that Dr. Thomas E. Starzl, who performed the first successful liver transplant in a patient in 1967, passed away on March 4, 2017 at the age of 90. As a tribute to the lasting contributions that he and his teams at the University of Colorado and the University of Pittsburgh Medical Center over the years, we complement the chapter on Liver Transplant with this special comment by Dr. Thomas Starzl in association with Dr. Noriko Murase.

The name Thomas Starzl needs no introduction to anyone in the world. He has been a pioneer in the field of transplantation, specifically liver transplantation, having conceived of it, worked at it in difficult fashion, and finally brought it to the point where it is. While limited to academic medical centers, it is performed thousands of times a year all over the world. It is another example in which work in the clinic, as Dr. Starzl points out, then makes its way to the laboratory to continue to enhance what has been started clinically. The fact that most of the great advances in medicine are actually surgical in the 20th century, including in no particular order, transplantation, blood transfusion, vascular surgery, cardiac surgery, parenteral nutrition, and endocrine treatment for various diseases. Thomas Starzl carried out his great work at the beginning without much NIH support. He did this seemingly directed by himself, with enormous focus on what was an almost maniacal desire to perfect liver transplantation. The early years were not easy and required enormous expenditures of energy, people, time, and devotion to a goal that at that time seemed distant. Yet, it was accomplished and tens of thousands of patients all over the world owe their lives to the late Dr. Starzl and his group.

Allotolerance has been the “holy grail” of transplantation. The argument in this wonderfully conceived and written chapter, meticulously documented, is the proposal that perhaps less is more; in other words, in order to induce allotolerance, what is needed is not the type of immunosuppression that devastates all the immune mechanisms in the organism, but some type of balanced chimerism, if you will, into which the proposal of a pretransplant, antilymphocytic agent given in high dosage is then combined with a more moderate single-agent immunosuppression, in this case tacrolimus, with the ultimate hope of winning tolerance. This proposal alters the way in which we have traditionally done immunosuppression. The exception seems to be HCV-infected patients. Here, the goal is somewhat different: to induce allotolerance with the implications of the need to prevent autoantiviral immunopathology. This is the balance that Dr. Starzl had sought. As usual, the particular point is meticulously documented as he asks for global scientific resolution of the issue. This is the legacy of Dr. Starzl’s immense contributions to this field.

E. Christopher Ellison and J.E.F.

120 The Associating Liver Partition and Portal Vein Ligation for Staged Hepatectomy (ALPPS) Approach

Kenneth K. Tanabe, Fernando Andrés Alvarez, and Eduardo de Santibañes

BACKGROUND AND PATHOPHYSIOLOGY

Liver resection is the treatment of choice to prolong survival and offer a chance of cure for patients with primary or secondary liver malignancies. Significant improvements in imaging modalities, surgical techniques, anesthesia, chemotherapy regimens, and the expansion of resectability criteria among surgeons have increased the fraction of patients treated with resection. Nonetheless, resection is not always possible due to tumor location, involvement of critical vasculature, distribution in the liver, insufficient liver remnant, or patient comorbidities. *Resectability* in modern liver surgery has shifted from being limited by what is resected to being limited by what remains after resection. Oncologic liver surgery necessarily balances two objectives that are at times in conflict: achieving negative margins and preserving sufficient liver parenchyma to minimize the likelihood of liver failure. Major hepatectomies are often required to achieve an R0 resection, and these are associated with substantial rates of morbidity and mortality. Posthepatectomy liver failure (PHLF) is the main cause of death after major liver resections and is closely related to the volume and quality of the future liver remnant (FLR). In general, at least 30% of total liver volume (TLV) should be left behind after a major liver resection in healthy livers and at least 40% in patients with diseased liver parenchyma. Several strategies have been developed to minimize the risk of PHLF and expand resectability. These strategies may be grouped into those that reduce tumor burden (e.g., conversion chemotherapy, endovascular procedures such as intra-arterial chemotherapy or radioembolization, local ablation techniques) and those that tend to

increase the size of the FLR (e.g., preoperative portal vein embolization [PVE], two-stage resection procedures). For patients whose FLR size is regarded as insufficient to sustain liver function in the postoperative course, portal vein occlusion of the tumor-bearing lobe has become the gold standard to induce hypertrophy of contralateral healthy lobe. Right PVE is best used before surgery when the FLR is tumor-free, while portal vein ligation (PVL) is usually applied as part of two-stage procedures for patients with bilobar disease who initially require tumor removal in the FLR. Yet, when using the abovementioned classical approaches of portal vein occlusion, up to 40% of patients never arrive to tumor resection either because of insufficient hypertrophy or because of disease progression during the long interval periods (4 to 12 weeks) typically required to achieve hypertrophy. Moreover, recent studies have shown that patients who fail to complete the second stage usually have worst survival than patients treated with chemotherapy alone.

The most recent innovation in the field of staged liver resections is termed *A*ssociating *L*iver *P*artition and *P*ortal vein ligation for *S*taged hepatectomy (ALPPS). As originally described, the technique consists in right PVL combined with in situ splitting of liver parenchyma during the first stage, followed 7 to 10 days after by a second stage in which resection of the diseased hemi-liver is completed. This new approach considerably accelerates FLR hypertrophy and reduces the time interval between stages. This results in a higher rate of R0 resections—above 95% in most series published. The mean FLR hypertrophy obtained with ALPPS is around 85% (range: 45% to 200%) within a median time interval of 7 days (range: 6 to 14 days), where up to 80% of patients achieve a sufficient hypertrophy in <10 days. This hypertrophy profile is clearly faster than with the traditional strategies. A recent comparative study from the Mayo Clinic in Rochester demonstrated that ALPPS was significantly superior to PVE in terms of both the pace of hypertrophy (84.3% in 8 days vs. 36% in 40 days; $P < 0.001$) and the kinetic growth rate (32.7 cc/day vs. 4.4 cc/day; $P < 0.001$). Furthermore, the ALPPS has proven to be an effective salvage procedure to induce further hypertrophy and allow resection in patients who fail to achieve a sufficient FLR volume after PVE or PVL. Increasing evidence in both animals and humans indicates that rapid FLR volumetric increase observed in ALPPS is accompanied by histologic and molecular features of hepatocyte cell proliferation. Surgical interruption of bilateral cross portal circulation was initially considered to be the main catalyst of

enhanced liver hypertrophy; however, the exact stimuli remain poorly understood and are most likely multifactorial. The phenomenon could be explained by any or all of the following mechanisms: (1) PVL impairs collateral circulation and causes redistribution of portal blood flow and hepatotrophic factors to the FLR; (2) parenchymal partition creates surgical trauma that induces the systemic release of circulating proliferating factors; (3) a preconditioning phenomenon for the FLR whereby the diseased hemi-liver acts as a transitory auxiliary liver that assists the growing FLR in metabolic, synthetic, and detoxifying functions; and (4) FLR inflow modulation by the arterialized auxiliary liver may play an important role by alleviating acute hemodynamic stress on the FLR.

After it was first performed in 2007 by the German surgeon Hans Schlitt, ALPPS gained rapid acceptance in Germany. Subsequently, after the first formal reports in 2011 its worldwide spread has triggered many debates among the surgical community, many of which focus on the relatively high morbidity and mortality rates in most series published. The increasing interest for the ALPPS approach and the great passion involved in its development prompted the initiation of the international ALPPS registry in 2012, with over 600 patients enrolled, and the celebration of the "1st ALPPS International Consensus Meeting" at Hamburg in February 2015.

INDICATIONS AND CONTRAINDICATIONS

Preoperative multidisciplinary evaluation is mandatory for every patient with liver tumors and they should be considered eligible for surgery on a case-by-case basis taking into account risks, oncologic rationale, and resectability.

Indications: Patients with marginally resectable liver tumors are potentially eligible for ALPPS if an insufficient FLR is present. On preoperative computed tomography (CT) scan or magnetic resonance imaging (MRI)-based volumetric planning, an FLR of <30% of TLV in healthy livers or <40% in patients with cholestasis, steatosis, fibrosis, or long-course chemotherapy is generally used to define FLR insufficiency. If preferred, an FLR to body weight ratio of <0.5% could also be used to determine an insufficient FLR volume in patients with normal liver or <0.8% when abnormal liver parenchyma is present. We further restrict ALPPS to patients with an insufficient FLR and at least one of the

following: (1) a tumor margin close to the FLR or its vascular pedicles; (2) bilobar disease with contraindication for PVE as single stage strategy; (3) failure of PVE/PVL; or (4) the need for a large hypertrophy (>65%) in an extremely small FLR (e.g., single segment). With respect to tumor origin, the most accepted and frequent indication is colorectal liver metastases (CLM). In such patients, response to preoperative systemic therapy is a very important consideration, as they are the most likely to benefit from a surgical approach. If resectable extrahepatic disease is present, it should be treated either before or during ALPPS stage 1, in order to avoid stimulation of distant tumor metastases by circulating growing factors that are released after stage 1. We make an exception to this rule in cases of CLM with limited resectable pulmonary disease.

Contraindications: Unresectable lesions in the FLR or unresectable extrahepatic metastases, severe portal hypertension, high anesthesiologic risk, medical contraindications to major hepatectomy, inability to achieve an R0 resection, unresectable primary tumor or tumor progression on chemotherapy constitute contraindications to performing ALPPS. Although advanced age per se is not an absolute contraindication, above the cutoff of 67 years old there is a significantly higher risk of worse perioperative outcomes. In addition, ALPPS should also be used with utmost caution for indications other than metastatic liver tumors. ALPPS for peri-hilar cholangiocarcinoma and gallbladder carcinoma have been associated with higher morbidity (up to 83%) and mortality (up to 71%) in the international registry.

PREOPERATIVE PLANNING

In general, preoperative work-up does not differ from that of other major liver resections. Preoperative staging should include state-of-the-art abdominal imaging, which includes a multislice CT scan of the chest, abdomen, and pelvis utilizing tri-phase contrasted acquisitions, as well as a contrasted MRI for a better assessment in patients with small lesions, a fatty liver or having received preoperative chemotherapy. The use of F-18 fluorodeoxyglucose positron emission tomography (18 FDG-PET/CT) scan should be considered, especially in cases of tumor recurrence in patients with a previous liver resection or suspected distant metastasis. Regardless of which imaging technique is used, the accurate assessment of number and location of hepatic lesions is crucial for adequate treatment

planning and successful therapy. Liver volumetry (either by CT or MRI) including both TLV and FLR volume is mandatory before planning any major liver resection. If tumor volume is small, TLV may be calculated by imaging-based volumetry, but we generally rely on the following formula instead for calculation of ideal TLV: −794.41 cc + 1,267.28 cc × body surface area (M^2). Nuclear imaging techniques such as 99mTc-galactosyl serum albumin scintigraphy or 99mTc-mebrofenin hepatobiliary scintigraphy (HBS) have recently gained wider acceptance as they are capable of measuring both volume and sectorial FLR function, therefore potentially identifying patients at higher risk for PHLF. The group from the Academic Medical Center (AMC) in Amsterdam proposed an FLR function (FLR-F) cutoff corrected for the body surface area of 2.69%/min/m^2 using anterior projections only, able to predict PHLF in patients submitted to major hepatectomy regardless of the type and severity of parenchymal liver disease.

SURGICAL TECHNIQUE

The ALPPS approach is a two-stage major hepatectomy with a short interval between stages. The technique as originally described consists of a right PVL combined with in situ splitting of liver parenchyma during the stage 1, followed by a completion surgery performed at surgeon discretion once FLR sufficiency has been assured, usually within 7 to 10 days (Fig. 120.1). This approach involves a more invasive and time-consuming first surgical procedure, followed by a second procedure that is shorter and technically much simpler. This strategy has been adopted by most centers as the classical ALPPS technique. Some important aspects of the ALPPS technique as well as the several proposed variations will be summarized in this section.

Classical Technique

Stage 1: The abdominal cavity is approached by either a bilateral subcostal incision with midline extension or a J-shaped incision. A midline laparotomy can also be used if a simultaneous open resection of a primary colorectal tumor is planned. Resecting the primary during stage 1 rather than during stage 2 is recommended since an auxiliary liver is present during the interval period (Fig. 120.2). When a simultaneous low rectal resection is necessary, it is recommended to strongly consider fecal diversion in order to avoid the potentially catastrophic scenario of a

symptomatic anastomotic leakage in these patients. The initial step of the operation entails a detailed exploration of the abdominal cavity and intraoperative Doppler ultrasound (IOUS) examination of the liver to accurately assess the number, size, and location of all lesions. If bilateral lesions are present, a complete tumor resection (clean-up) of the FLR is performed, in order to allow for subsequent hypertrophy of only nontumor-bearing parenchyma. Subsequently, the portal vein of the diseased hemi-liver is divided and either total (up to the inferior vena cava) or partial (up to the middle hepatic vein) parenchymal transection is carried out as for a future right trisectionectomy (Fig. 120.3). Regardless of the type of transection, the middle hepatic vein should never be transected in order to assure a proper outflow of the diseased hemi-liver. The anterior approach, with or without the "hanging maneuver," may also be used to help liver transection, reduce tumor manipulation, and reduce inflammation and adhesions created by full right liver mobilization. Partial transection (to approximately the depth of the middle vein) has been demonstrated to offer similar FLR hypertrophy yet significantly lower morbidity than total transection (38.1% vs. 88.9%; $P = 0.049$) and zero mortality in the initial report at the Hospital Italiano de Buenos Aires. If partial transection is performed, we prefer to routinely use the anterior approach. Total transection should be performed when a tumor is located deep in the parenchyma and too close to the FLR boundaries in order to isolate the tumor and prevent FLR invasion. The ALPPS stage 2 is technically more difficult if partial transection was performed in the stage 1. The confirmation of complete deportalization of the diseased hemi-liver by IOUS is of paramount importance to avoid technical failures, typically related to a portal vein trifurcation that leads to ligation of only the right anterior or the right posterior portal branch. At the end of the procedure, it is advisable to perform a trans-cystic hydraulic test and cholangiography in order to prevent postoperative biliary leaks (Fig. 120.4), which have been reported at high rates in initial series (20% to 87%) and associated with increased morbidity and mortality. Bile duct ligation should never be performed as it might lead to cholestasis, infection, and bile leaks with increased risk of mortality. If the gallbladder is present, cholecystectomy is typically performed in stage 1 to provide exposure for and facilitate right portal dissection. Vasculobiliary structures in the diseased hemi-liver are marked with vessel loops, and a long tie is placed in the cystic duct to facilitate their identification during the stage 2. Finally, with the aim of

minimizing adhesions, some surgeons have proposed placement of a plastic sheet or biologic agent between both cut surfaces, or placement of the diseased hemiliver in a plastic bag. However, good results have been reported without the use of any material at the liver partition site. Two drains are placed in the abdominal cavity, one in-between the transection lines and the other in the right subphrenic space.

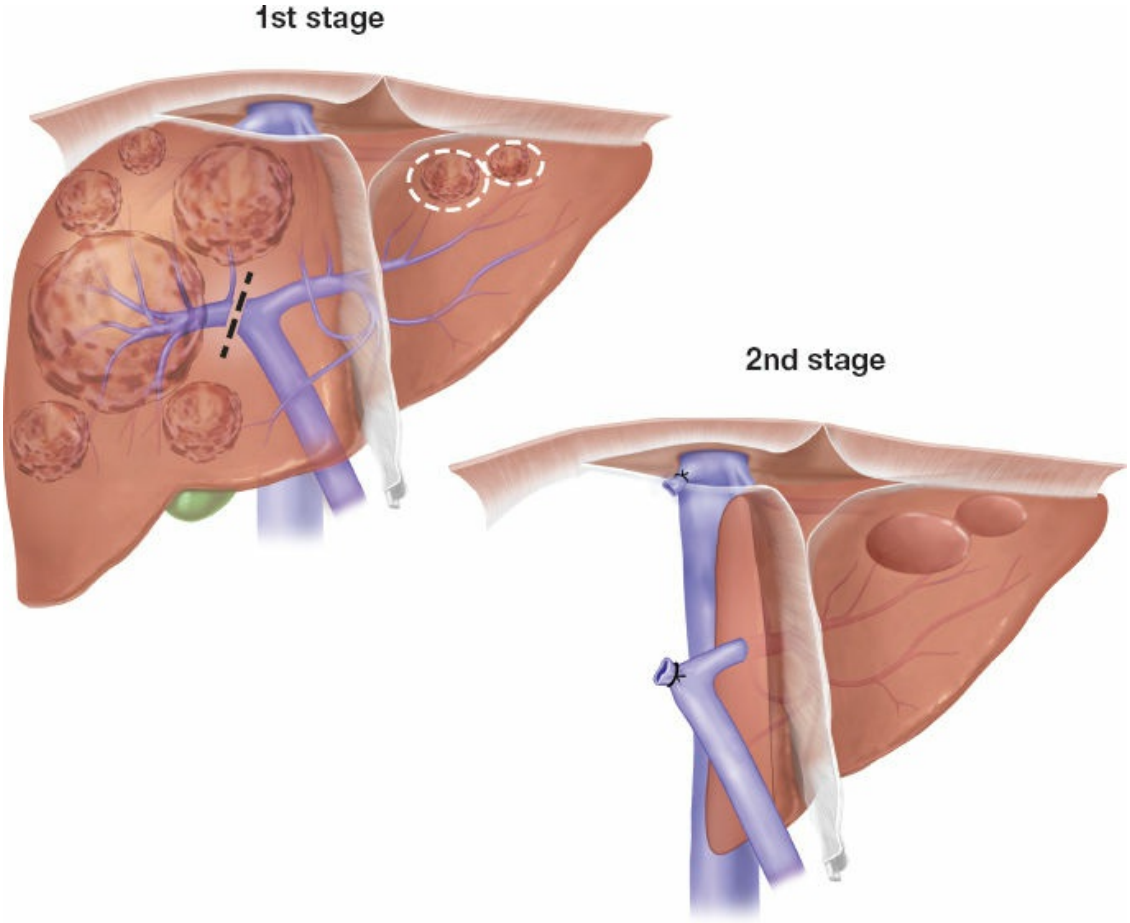

Figure 120.1. Diagram of procedures involved in the ALPPS approach. The stage 1 involves ligation of the right portal vein, resection or ablation of tumors in the FLR, and splitting of the parenchyma delineating the section(s) of liver to subsequently be resected. The stage 2 involves division of the right hepatic artery, right bile duct, and right venous drainage to allow resection of the tumor-bearing liver.

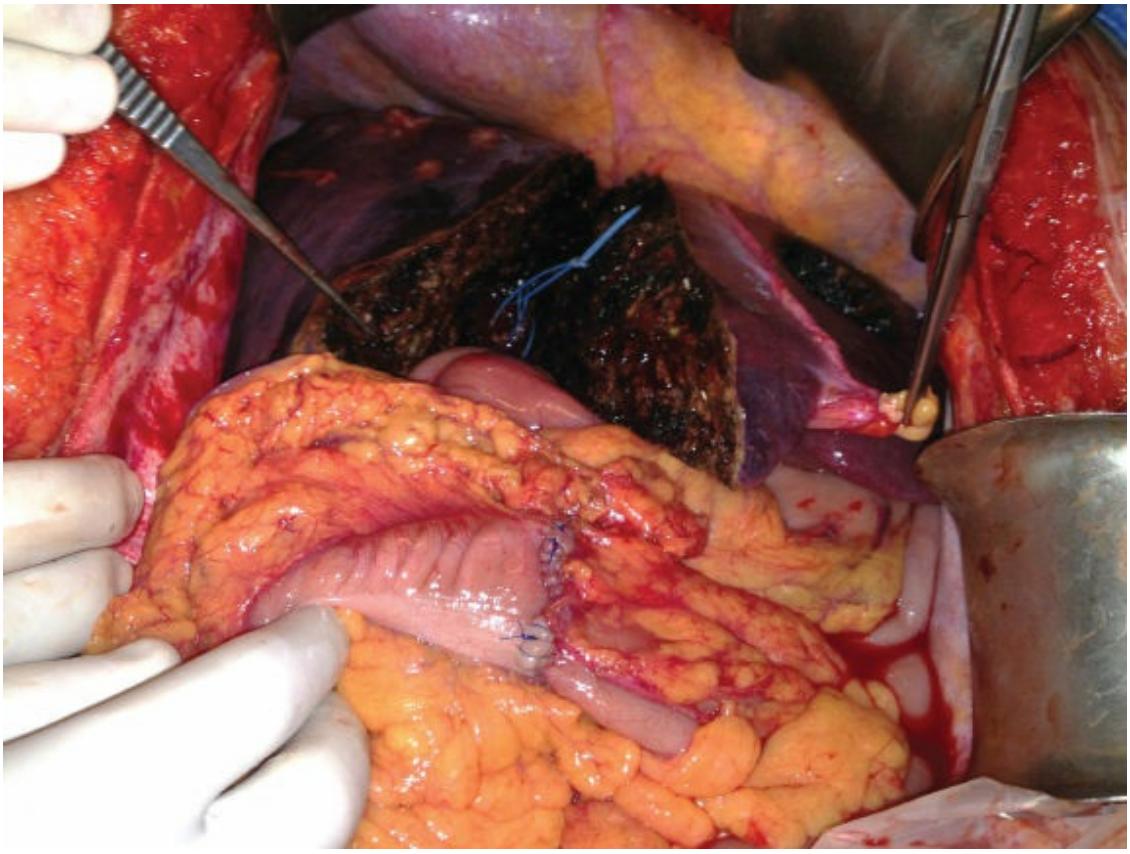

Figure 120.2. Simultaneous colectomy performed during ALPPS stage 1. Anastomosis after colectomy is shown in the foreground and the split liver parenchyma is shown with a blue vessel loop marking the right main glissonian vasculobiliary pedicle. A tumor has been resected from the FLR.

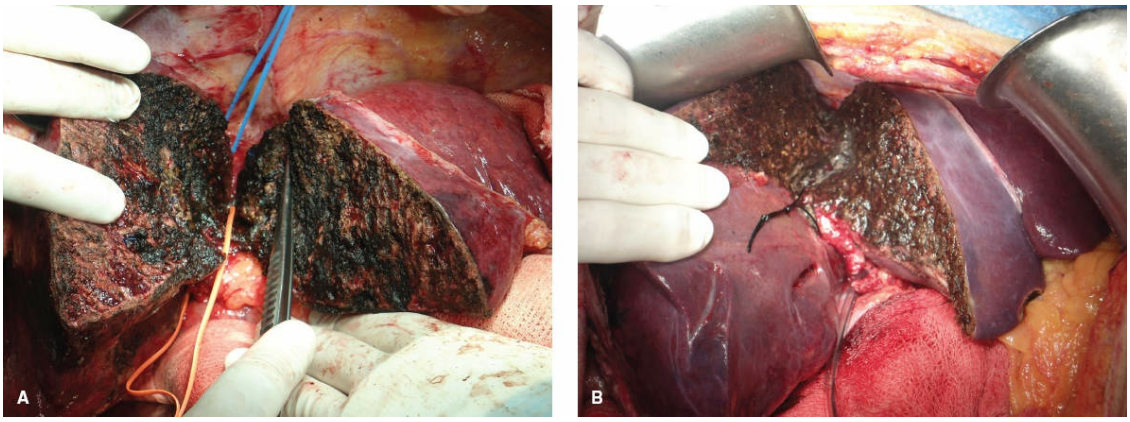

Figure 120.3. Parenchymal transection variants in ALPPS stage 1. **A.** The liver parenchyma has been totally divided between the diseased hemi-liver and FLR. A red vessel loop has been left to mark the right main glissonian vasculobiliary pedicle, and a blue vessel loop marks the right hepatic vein. **B.** In this case, partial parenchymal transection has been carried out. The suture with two knots marks the right main glissonian vasculobiliary pedicle.

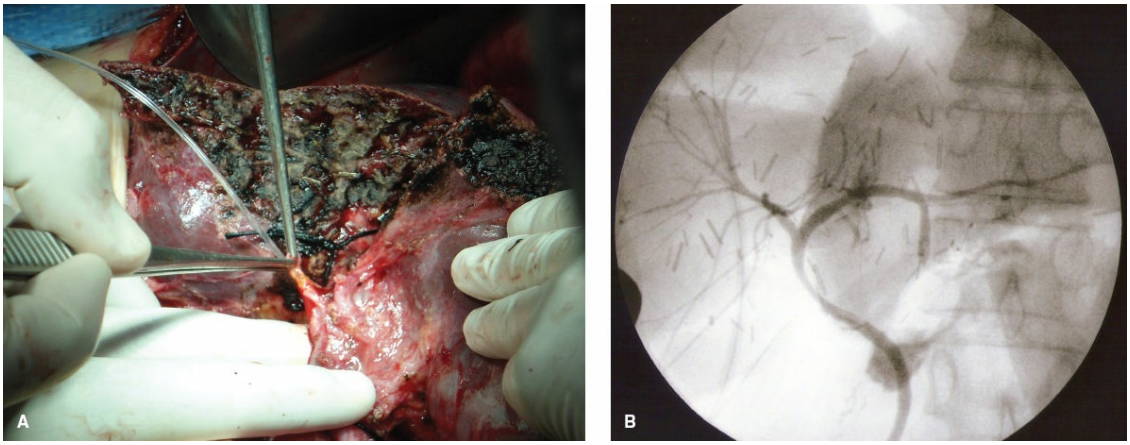

Figure 120.4. Biliary evaluation. **A.** The cystic duct is cannulated to perform a trans-cystic hydraulic test with either saline solution, propofol, or methylene blue to evaluate for evidence of biliary leaks. **B.** Intraoperative cholangiogram performed with this catheter shows an intact biliary tree and no evidence of biliary leaks.

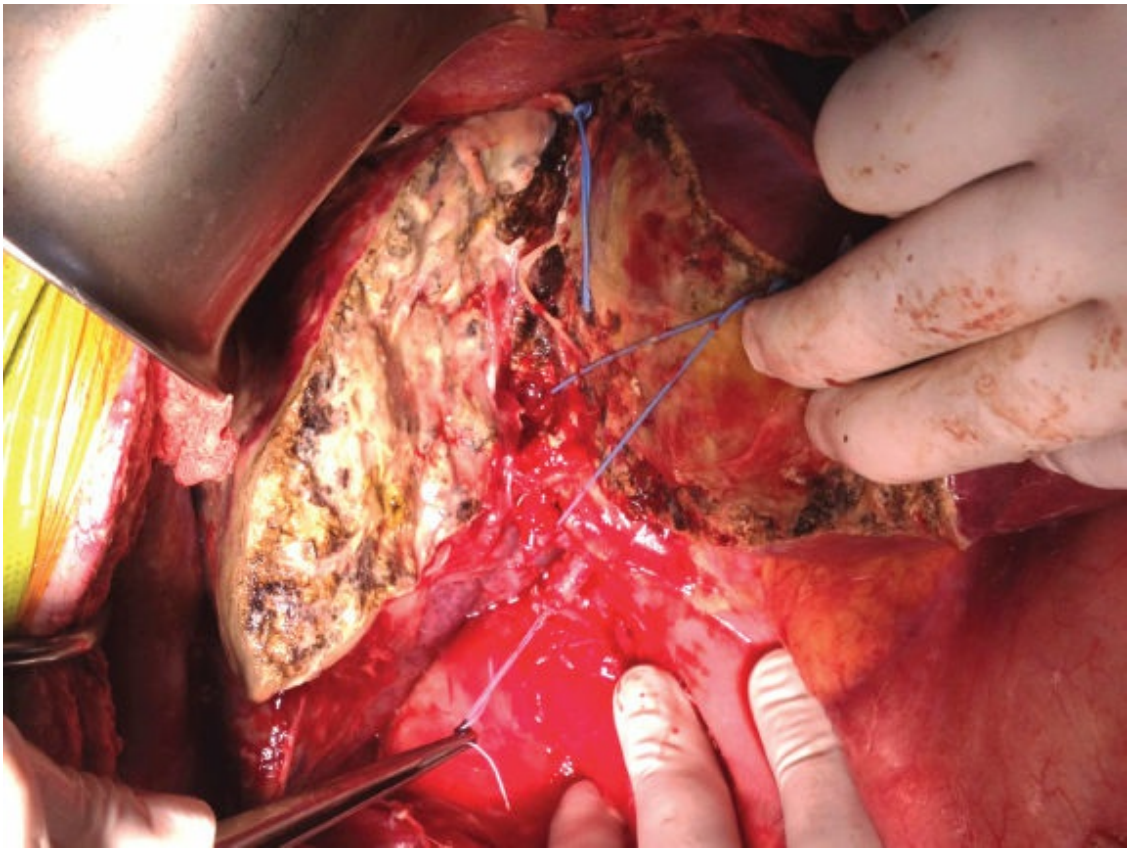

Figure 120.5. ALPPS stage 2. Once the plane between the diseased-right hemi-liver and FLR is divided with finger fracture to break up lax adhesions, the vasculobiliary structures of the diseased hemi-liver are easily recognized following the vessel loops around them. The blue stitch under traction is the cystic duct, while the right main glissonian vasculobiliary pedicle and

the right hepatic vein are marked with blue vessel loops in the depth of the transection plane.

Stage 2: Abdominal exploration is performed carefully after dividing adhesions. The vasculobiliary structures of the diseased hemi-liver are recognized by identifying the vascular tags around them (Fig. 120.5). The resection of the tumor-bearing lobe is achieved using vascular staplers for all vasculobiliary structures and the remaining liver parenchyma if present (Fig. 120.6). Finally, it is strongly recommended to perform an intraoperative cholangiography and hydraulic test through the cystic duct in order to prevent postoperative bile leaks.

Variations of the Classical Technique

Many different technical variations of the ALPPS approach have been proposed. Even though the original technique consisted on a right trisectionectomy, different technical variations have been later proposed, including the "left ALPPS," the "right ALPPS," and the so-called "rescue ALPPS" in patients with failed PVE/PVL. An additional alternative preserving only segments 1 and 4 as FLR after performing a left lateral sectionectomy has also been reported. However, concerning FLR variants in ALPPS, the most important breakthrough was accomplished after demonstrating that monosegment remnants can be safely left behind when applying the ALPPS approach. This constitutes an important paradigm change in liver surgery, given that resectability has been traditionally defined as the complete tumor removal preserving at least two contiguous Couinaud segments with intact vascular inflow, outflow, and biliary drainage.

Given that ALPPS has been associated in preliminary series with increased incidence of major complications and mortality, many different technical innovations and refinements have been introduced with the aim of improving outcomes. For example, a group from Murcia in Spain described the application of a tourniquet around a parenchymal groove of no more than 1 cm in the transection line and labeled this modification "ALTPS" (associating liver tourniquet and portal ligation for staged hepatectomy). Despite the theoretical attractiveness of the tourniquet, the 64% morbidity and 9% mortality in their series of 22 patients did not reflect a real improvement in terms of patient safety compared with most ALPPS series. Some have proposed substituting the parenchymal

transection with radiofrequency or microwave ablation (RALPP, LAPS) to create a virtual liver partition consisting of a necrotic plane between the diseased liver and FLR. These approaches provided a similar hypertrophic profile than the standard ALPPS approach but with only minor complications, no mortality, and a high feasibility of being performed by laparoscopy. The application of percutaneous interval PVE instead of PVL as method of portal vein occlusion, also known as "Hybrid ALPPS," is undoubtedly one of the most promising innovations among the different ALPPS proposals. This approach avoids portal pedicle dissection during first stage and thereby facilitates a less difficult second stage because of fewer adhesions. Finally, we recently published our latest ALPPS variation that we employed at Hospital Italiano de Buenos Aires, the so-called "Mini-ALPPS." This new proposal inverts the current paradigm, transforming the classical large stage 1 into a much less invasive procedure that could be performed by laparoscopy, and leaving the main surgical procedure for the stage 2. This variation incorporates partial parenchymal transection, intraoperative PVE and avoids portal pedicle dissection and liver mobilization, with the aim of maximally reducing the surgical impact of ALPPS first stage to promote rapid patient recovery and facilitate stage 2 (Fig. 120.7). This new philosophy seems promising and could in the future improve both safety and oncologic outcomes.

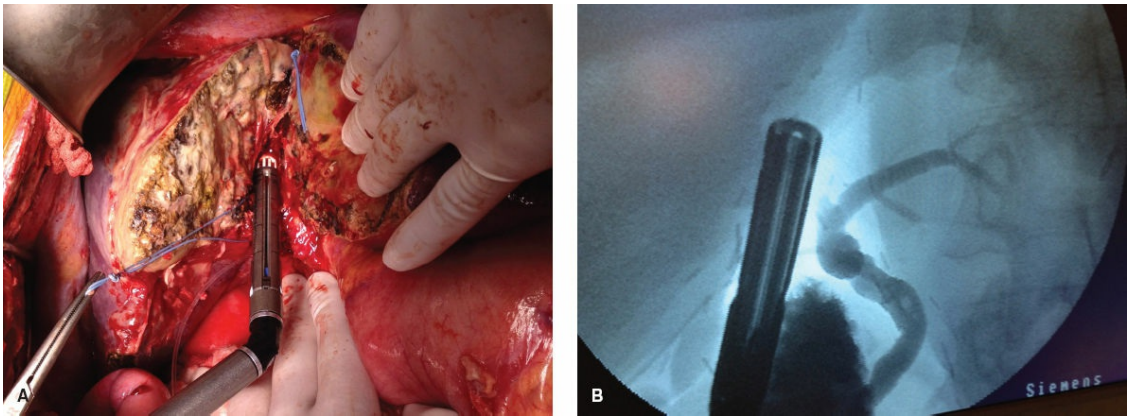

Figure 120.6. ALPPS stage 2. **A.** Traction is placed by one of the vessel loops held with a Kelly clamp allowing en bloc transection of the right main glissonian vasculobiliary pedicle with a vascular stapler. The blue vessel loop at the top of the field marks the right hepatic vein, which will subsequently be divided with another application of the vascular stapler. **B.** A trans-cystic cholangiogram is performed before firing the stapler to assure its correct position over the right bile duct and avoid accidental injuries of the bile duct bifurcation.

Given the existence of many technical variants with different names, the founding members of the International ALPPS registry have recently reported a “consensus” terminology in order to establish a common language to adequately compare and further develop different variants of the original ALPPS technique.

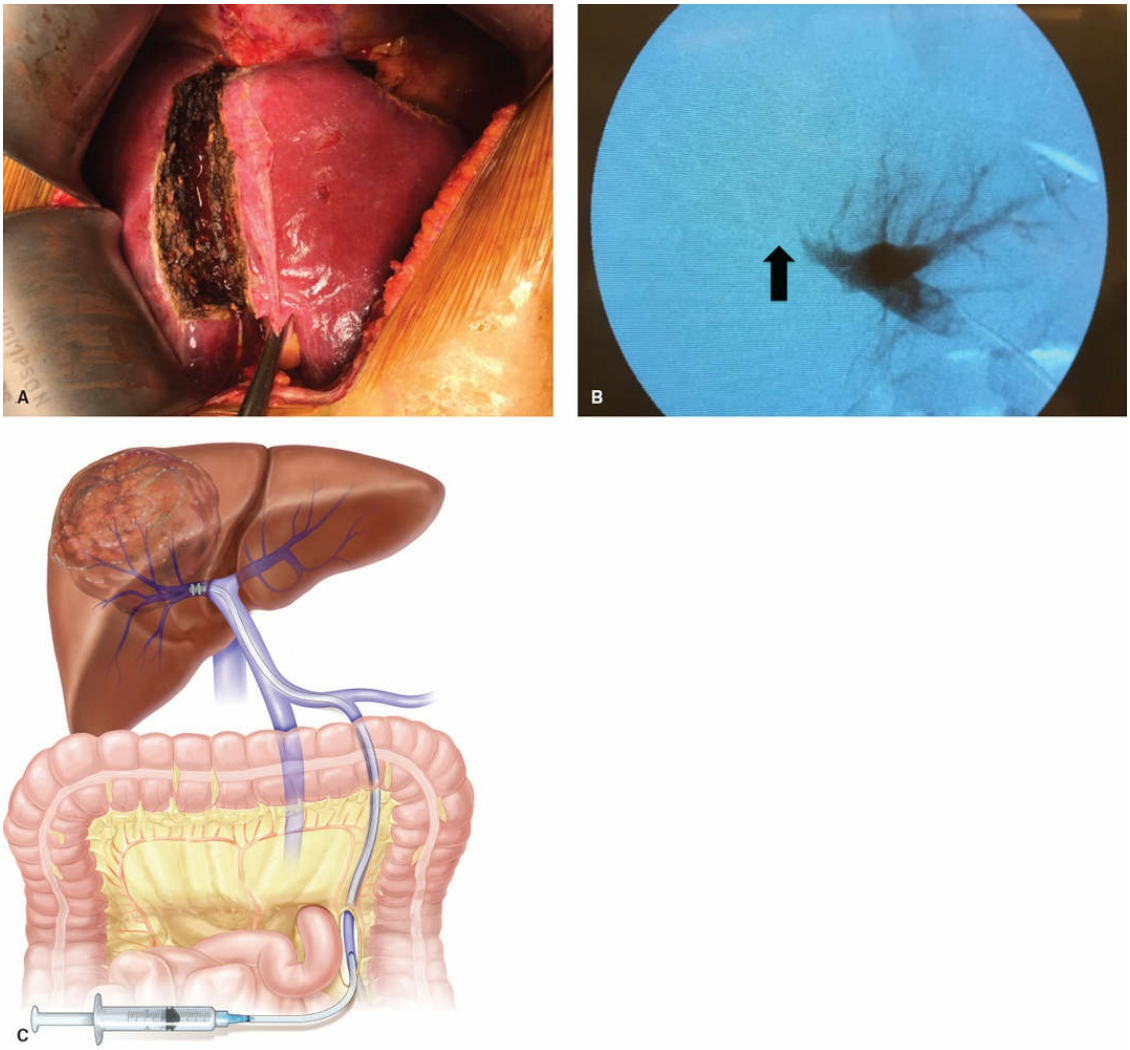

Figure 120.7. “Mini-ALPPS.” **A.** Partial parenchymal transection in the plane between the diseased hemi-liver and the FLR (down to the level of the middle hepatic vein, without any moblilization of the liver). **B.** Intraoperative right portal vein embolization via the inferior mesenteric vein. **C.** Diagram of the “Mini-ALPPS” procedure.

POSTOPERATIVE CARE

Patient management during the interval period between both stages is of paramount importance to reduce complications of ALPPS. After stage 1, early extubation is applied whenever possible and the patient is managed either directly in the general ward or at the intensive care unit (ICU) for the first 24 to 48 hours depending on patient comorbidities and/or intraoperative events. Once stabilized and without active complications, the patient is transferred to general ward. Oral nutrition is initiated as soon as possible, once the clinical condition is appropriate and maintained

during the interval period until reoperation. If oral intake is not tolerated, parenteral nutrition should be started without delay. During the interval period between stages, clinical evaluation and laboratory tests following the trend of transaminases, bilirubin, and international normalized ratio (INR) are performed. Volumetric measurement of the FLR is routinely performed on the sixth postoperative day after the first stage. In case of insufficient hypertrophy, an additional CT volumetry is performed weekly until a sufficient FLR volume is achieved. Stage 2 should be undertaken only when volumetric studies have demonstrated FLR sufficiency and the patient has returned to good medical condition. When a patient has a compromised clinical status, active complications, abnormal liver function tests on day 5 after stage 1 or a MELD score above 10, the stage 2 must be delayed or even abandoned in order to avoid mortality. If the patient is in good condition but FLR volume remains insufficient, the patient can be discharged home and readmitted for stage 2 once FLR sufficiency has been achieved, as assessed by periodic outpatient evaluation.

Although volumetry is still the standard method for determining whether a patient can safely undergo a major liver resection, the fact that PHLF remains the most important cause of death in the ALPPS Registry indicates that the established volumetric criteria being used to judge FLR sufficiency before reoperation might not be sufficient, particularly when taking into account that these volume measurements are applied to liver parenchyma that is growing extremely fast. Even though previous studies have observed proliferative and architectural changes at histologic level accompanying macroscopic FLR hypertrophy in ALPPS, rapid liver volume growth may not correlate with an immediate corresponding equal increase in function. In line with this notion is the observation of histologic findings of hepatocyte immaturity in nontumorous FLR parenchyma. Results from some studies suggest that FLR volumetric increase precedes its functional increase.

Even though there is agreement that stage 2 should be postponed until a satisfactory function has been reached, the key question yet unanswered is how good the FLR function has to be in order to avoid PHLF. In such scenario, the use of HBS, a more sophisticated tool capable of evaluating sectorial liver function, has been proposed to help determine the best timing for stage 2. In a previous study, we found that none of the patients with an FLR representing at least 30% of total liver function by HBS (%FLR-C) before stage 2 developed PHLF. However, a major drawback

of the %FLR-C is that it does not take into account if the overall liver function is indeed good or not, which could lead to misinterpretations and errors in clinical judgment. This fact, along with the impossibility of using the 2.69%/min/m² FLR-F cutoff proposed by the AMC group in Amsterdam since it was not established using modern HBS assessment of liver function (Gmean and SPECT analysis), leads us to develop a new formula to measure FLR function during ALPPS interval. *The Hospital Italiano de Buenos Aires Index* (*HIBA-index*) is a dynamic measure that represents the proportion of radionuclide accumulating in the FLR during the phase between 150 and 350 seconds postinjection and is calculated using the area under the time–activity curves (AUC) with the following formula expressed as $\%: HIBA\text{-}index = \frac{AUC\ liver - AUC\ blood\ pool}{AUC\ field\ of\ view} \times \frac{FLR\ counts}{Total\ liver\ counts}$ Between 2011 and 2016, 20 out of 39 patients (51%) underwent HBS before completion of ALPPS stage 2 at the Hospital Italiano de Buenos Aires. After comparing the individual performance of three interstage FLR functional parameters (%FLR-C, FLR-F, and HIBA-*index*), a HIBA-*index* with a cutoff value of 15% was found to be the most accurate parameter to predict clinically significant PHLF after ALPPS stage 2. The predicted risk of PHLF in patients with a HIBA-*index* lower than 15% was 80%, whereas no patient with a HIBA-*index* higher than 15% developed PHLF. This practical cutoff value may become of paramount importance to avoid futile indication of ALPPS stage 2, as current standard volumetric criteria have so far proved insufficient to adequately guide the safe timing of ALPPS stage 2 (Fig. 120.8). Given the increasing evidence supporting the use of HBS to quantify sectorial liver function, we encourage the routine use of this complementary noninvasive low-cost exam to facilitate decision making in every institution performing ALPPS (Fig. 120.9).

COMPLICATIONS AND THEIR MANAGEMENT

Single center and cooperative experiences with ALPPS reveal relatively high morbidity and mortality rates (Table 120.1). A meta-analysis including 295 patients with different tumor origins revealed a 90-day mortality of 11% and morbidity (Clavien-Dindo grade ≥IIIa) of 44%. More recent data from the ALPPS registry on 528 patients reveal better results, with an overall 90-day mortality of 8.9%. Of the different tumor types, CLM has shown the best safety profile, with a morbidity grade

(Clavien-Dindo ≥IIIa) of 29% and a 90-day mortality of 5% in 228 patients. Nonetheless, these morbidity and mortality rates are relatively high, and may be explained at least in part by the obligatory "learning curve" that typically exists for new innovations. Furthermore, ALPPS is composed of two complex surgical procedures instead of only one, which is being applied in patients with high tumor burden and prolonged chemotherapy regimens. More recent series of ALPPS, limited to patients with CLM that have a response to chemotherapy reveal results that compare favorably with most reported series of two-stage hepatectomies. For example, the morbidity and mortality of ALPPS do not appear significantly different to the recently reported 84% morbidity and 10% mortality from 87 patients who underwent a major hepatectomy after PVE or PVL at the Beaujon Hospital in France for initially unresectable CLM. Among 65 patients who underwent a two-stage hepatectomy at the MD Anderson Center in the United States, a 49% morbidity and 6.4% mortality were reported, and these figures included only the second stage. Similarly, the morbidity and mortality of two-stage hepatectomies in 59 patients at the Hôpital Paul Brousse in France were 59% and 7%, respectively. Furthermore, a recently published study from this last group comparing match populations of ALPPS and two-stage resection found nonsignificantly different 90-day mortality (0% vs. 5%; P = 0.891) and major complication rates (41% vs. 39%; P = 0.999) between this strategies.

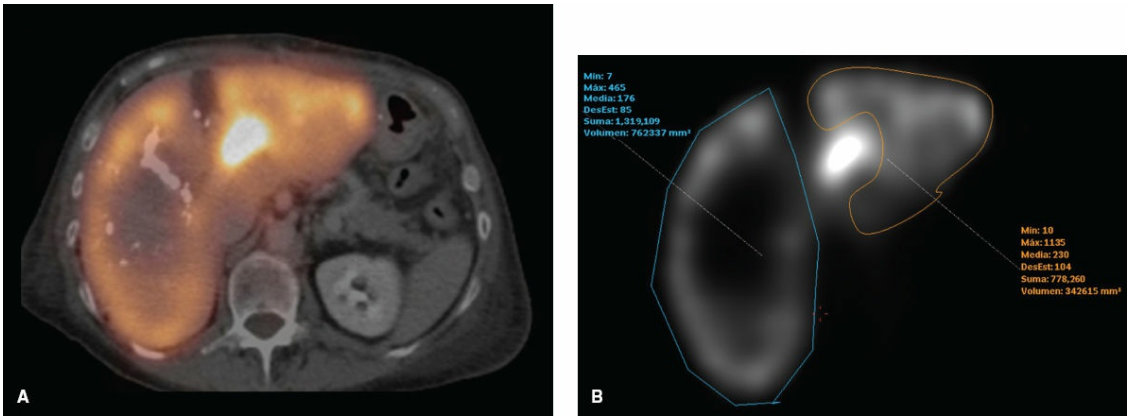

Figure 120.8. Hepatobiliary scintigraphy during ALPPS inter-stage interval in a 71-year-old woman with colorectal liver metastases. **A.** 3-dimensional distribution of function within the liver volume is calculated using a contrast-enhanced CT-scan linked to the SPECT images as a reference. **B.** Volumes of interest are manually outlined around the diseased hemi-liver and

the future liver remnant.

Possible complications after both ALPPS stages are essentially the same as in any major hepatectomy. The most frequent complications managed medically include PHLF, right pleural effusion, respiratory infections, and acute renal insufficiency. Data from the International Registry showed that the reported incidence of PHLF ranges from 14% after stage 1 to 31% after stage 2, even when theoretically sufficient FLR volumes are achieved. As noted previously, the rapid volumetric increase during ALPPS may not correspond to an immediate and equivalent increase in function. Preliminary reports using HBS for sectorial FLR function evaluation indicate a diffuse drop of total liver function after the stage 1 in patients who suffer from PHLF, most likely due to a loss of function in the excluded liver that is sharper than the function gain of the FLR. Regarding surgically managed complications, the most frequent are biliary fistula (12% to 25%), perihepatic collections, intra-abdominal bleeding and intra-abdominal septic complications from extrahepatic procedures. Even though morbidity rates are similar after stage 1 and 2, >90% of deaths occur after stage 2 and PHLF remains one of the most important causes of death (up to 77% of deaths) in most series. Age over 67, biliary tumors, operative time more than 5 hours during stage 1, and the administration of red blood cell transfusions during either stage have been identified as significant risk factors for severe complications and 90-day mortality. In addition, recent data from the ALPPS registry indicate that patients who develop PHLF after stage 1 or have a MELD score ≥10 before stage 2 are at higher risk, with an adjusted odds of 90-day mortality of 3.9 (CI 1.4 to 10.9) and 4.9 (CI 1.9 to 12.7) respectively. A recent prospective study at the Hospital Italiano de Buenos Aires found that total parenchymal transection was an independent risk factor of postoperative complications.

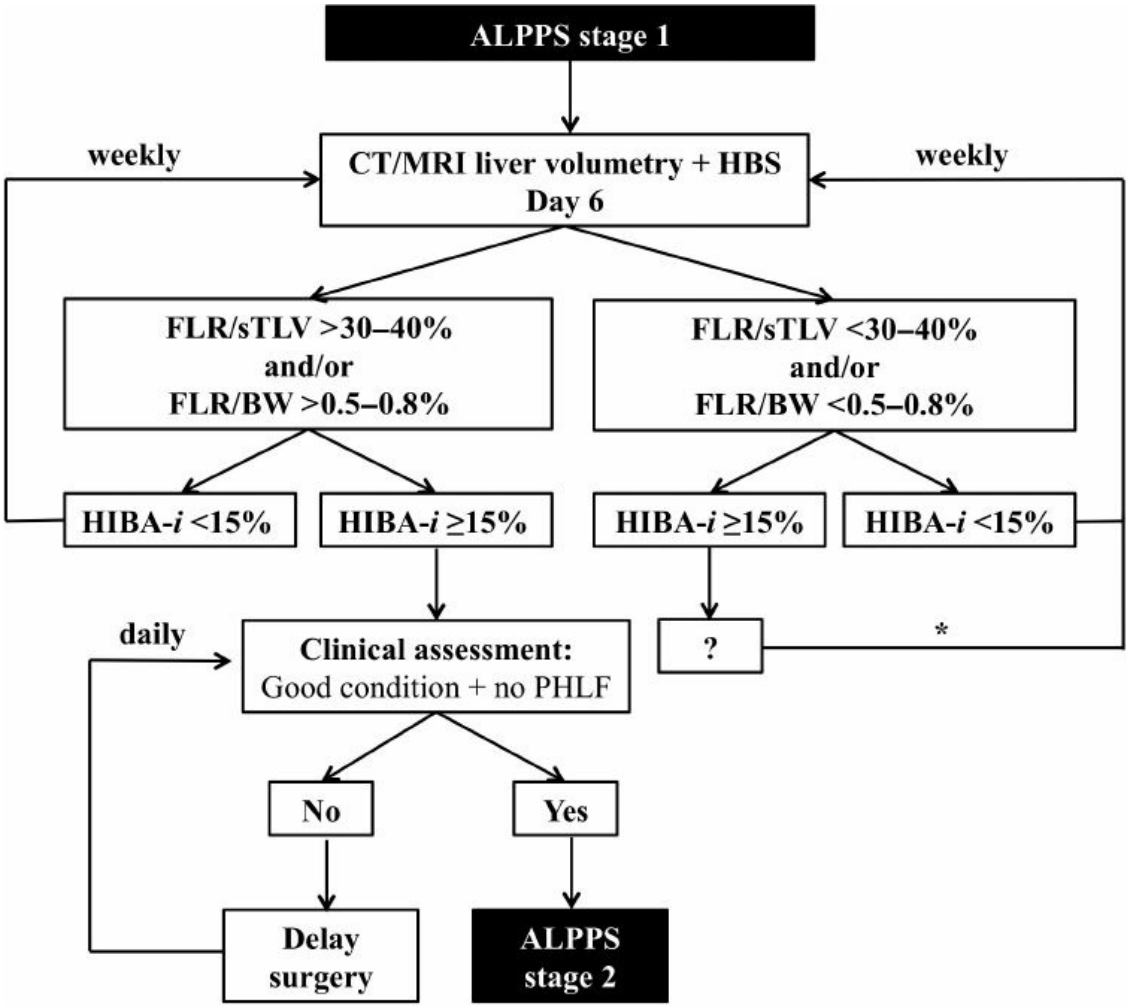

Figure 120.9. Current decision-making algorithm in the Hospital Italiano de Buenos Aires: volumetric assessment of the future liver remnant (FLR) is generally performed 6 days after stage 1 with computed tomography (CT) or magnetic resonance imaging (MRI). If sufficient volume is achieved, hepatobiliary scintigraphy (HBS) with a HIBA index (HIBA-*i*) ≥15% allows proceeding to stage 2. Assessment of patient general condition is always mandatory before completion of surgery.

The general management of complications does not differ from any other liver resection, and although they should be aggressively and treated early, their prevention is of utmost importance. Morbidity and mortality during ALPPS have been associated in most series with inappropriate patient selection, unsuitable timing of the second stage, and errors in clinical judgment due to the lack of experience with the application of this new technique. In order to increase ALPPS safety, current recommendations are based on the three pillars that determine outcomes: (1) *Patient selection*, the best candidates are patients younger than 67 years

old with CLM who respond to chemotherapy; (2) *Operative technique*, partial parenchymal transection without sacrificing the middle hepatic vein, intraoperative cholangiography and hydraulic test at both stages, avoidance of simultaneous pancreatic resections in case of metastatic neuroendocrine tumors, as well as fecal diversion in case of simultaneous left colonic or rectal resections are key rules, IOUS for cases of operative PVL to ensure ligation of all target portal branches; and (3) *Timing of second stage*, the 1-week interval dogma needs to be abandoned and patients should be operated once volumetric and functional studies have demonstrated FLR sufficiency, and only if patients are without complications and in good clinical condition, without complications, having normal liver function tests, and the MELD score <10, regardless of the number of days needed to achieve this status.

TABLE 120.1 Overview of ALPPS Series With More Than 20 Patients

Author	Year	Country	*N*	Hypertrophy (%)	Interval (Days)	Feasibility[c] (%)	Hospital Stay (Days)	Morbidity (%)	Mortality (%)
Linecker et al.	2016	Registry	528	70	10	98	20	40[b]	8.9
Røsok et al.	2016	Scandinavia	36	67	7	100	17	11[b]	2.8
Serenari et al.	2016	Italy[a]	50	63	10	96	—	54[b]	20
Truant et al.	2015	France[a]	62	49	10	95	29	80	12.9
Alvarez et al.	2015	Argentina	30	90	7	97	16	53	6.6
Clavien et al	2015	Switzerland	24	61	10	100	—	33[b]	16.6
Schadde et al.	2014	Meta-analysis	295	84	7	97	—	44[b]	11
Schadde et al.	2014	Multicenter	48	77	—	100	—	73	15
Torres et al.	2013	Brazil[a]	39	83	14	95	18	59	12.8
Schnitzbauer et al.	2012	Germany[a]	25	74	9	100	—	64	12

[a]Multicenter same country.
[b]Major complications.
[c]Completion of both stages.

OUTCOMES

Even several years after the inaugural publication of ALPPS and adoption of this approach by many centers, there remains a dearth of high-quality evidence in the existing literature, represented primarily by single-center, retrospective studies with limited numbers of patients. And given the novelty of the approach, the patient follow-up is necessarily short. The results obtained so far come from centers using different selection criteria, including heterogeneous groups of patients treated for different underlying pathologies, with variable use of chemotherapy and different technical variations being applied. These facts make very difficult the interpretation of outcome data from an oncologic point of view.

In general, there is already a good evidence demonstrating that ALPPS is superior to classical approaches in terms of tumor resectability and

achieving an R0 resection (Table 120.2). A multicenter comparative experience demonstrated that ALPPS had a higher efficacy in terms of achieving complete tumor resection when compared with PVE/PVL (83% vs. 66%; $P = 0.027$). The higher rate of complete resection is explained by the observations that nearly all patients achieve sufficient hypertrophy, the short interval makes tumor progression between stages unlikely, and liver splitting prevents direct tumor infiltration of the FLR. With regard to surgical margins, recent meta-analytic data from six studies including 295 patients showed an R0 resection rate of 91%. However, when it comes to oncologic outcomes, probably the most important question still unanswered is if the higher tumor resectability rates observed with ALPPS are translated into improved overall survival (OS) and disease-free survival (DFS). While the available evidence does not definitively answer this question, recent studies suggest that patients with CLM have similar short-term oncologic outcomes compared with patients treated by traditional surgical approaches. A recent comparative multicenter study showed that tumor recurrence occurred at a comparable rate in both groups at 12 months, with 54% in ALPPS and 52% in PVE/PVL. The largest available data from the ALPPS registry in patients with CLM indicate so far a 1- and 2-year OS of 76% and 62% as well as a DFS of 59% and 41%, respectively, with a median DFS of 14 months. This median DFS is more than acceptable when compared to the 7.5 months of median DFS recently reported in the updated experience from the Hôpital Paul Brousse in two-stage liver resections. Furthermore, the subgroup of CLM patients from the ALPPS Registry with age ≤60 years exhibited the best OS, being 88% and 74% at 1 and 2 years respectively, with a median survival of 24 months. Even though only short-term follow-up is available, this survival figures (on an intention to treat basis) are similar or even better than that in the few existing series of two-stage hepatectomies, despite the fact that most reports analyzed only the survival of patients who completed the second stage. Moreover, the 64% 3-year OS in patients with CLM from the German group leaded by Hans Schlitt compares favorably with that of conventional staged approaches. On the other hand, at the Hospital Italiano we have treated 39 patients with the ALPPS approach, 26 of whom (67%) had CLM. In this specific subgroup, 96% of patients had received preoperative chemotherapy and 62% received more than six cycles. The disease-specific OS and DFS at 3 years in our series of CLM are 49% and 9%, respectively. Such results should not be surprising in the light of an

aggressive tumor biology, as demonstrated by the fact that more than 80% of our patients had a node-positive primary cancers, synchronous presentation of their liver metastases, and bi-lobar metastases. Even more controversial data come from a recent study reported by the Paul Brousse group, aiming to compare the survival of ALPPS (n: 17) against two-stage liver resections (n: 41) for CLM as intent-to-treat analysis. Surprisingly, even though DFS was not significantly different between both strategies, they found that estimated 2-year OS was lower after ALPPS than two-stage hepatectomy (42% vs. 77%; $P = 0.006$). However, the results from this small sample study have to be interpreted carefully, as there could be potential selection biases inherent to its retrospective design. Furthermore, the positive margin rate in ALPPS was 64% versus 29% in the two-stage group, and later salvage surgery for liver recurrence was less often performed after ALPPS than after 2-stage hepatectomy. Therefore, in our opinion current evidence does not allow any firm conclusion regarding the oncologic superiority or inferiority of ALPPS compared with classical approaches. Results of randomized controlled trials are necessary to clarify this important issue.

TABLE 120.2 Outcomes of ALPPS Compared to Classical Two-Stage Hepatectomy in Patients With CLM of Largest Series With Available Data

	Author	Year	*N*	Major Morbidity (%)	Mortality (%)	OS (Years) 1	OS (Years) 2	OS (Years) 3	DFS (Years) 1	DFS (Years) 2	DFS (Years) 3
Classical 2-Stage	Lamb et al.	2013	459	40%	3%	—	—	59%	—	—	20%
	Brouquet et al.	2011	65	29%	6.4%	89%	80%	67%	39%	—	20%
	Tsai et al.	2010	45	28%	8.8%	88%	74%	57%	85%	68%	45%
	Adam et al.	2008	41	59%	7%	87%	76%	60%	60%	40%	26%
ALPPS	Hospital Italiano	2016	26	38%	0%	83%	67%	49%	40%	11%	9%
	Serenari et al.	2016	21	36%	4.5%	91%	—	—	55%	—	—
	Lang et al.	2015	16	—	—	86%	—	64%	50%	—	30%
	Alvarez et al.	2015	22	24%	0%	82%	—	—	56%	—	—
	ALPPS Registry	2014	141	36%	5%	88%	74%	—	59%	41%	—

CLM, colorectal liver metastases; OS, overall survival; DFS, disease-free survival.

CONCLUSIONS

ALPPS represents a significant advance in liver surgery as it induces a fast and robust liver hypertrophy in patients with insufficient FLR. ALPPS benefits include: (1) FLR hypertrophy unparalleled in its rapidity; (2) robust hypertrophy, most beneficial in patients with extremely small FLR; (3) aggressive FLR clean-up, with the possibility of leaving single liver

segments as sufficient liver remnant; (4) reduced interval between stages with fewer adhesions, easier definitive resection, and lower dropout rate from progression; (5) single hospitalization for both stages in the majority of patients; (6) ability to achieve liver hypertrophy even after unsuccessful PVE/PVL; and (7) higher resectability rates compared to classical approaches. However, it remains uncertain if the observed higher rates of tumor resectability translate into improved long-term survival compared with classical approaches. Recent evidence indicates that ALPPS can be performed with acceptable morbidity and mortality in experienced centers, comparable to that of conventional two-stage hepatectomies. Moreover, the safety profile of ALPPS will most likely improve in the future as a consequence of better patient selection and technical refinements as more experience is gained. Appropriate candidates for ALPPS presently are patients with failure of PVE/PVL or extensive bilateral CLM where an extremely small FLR might result as a consequence of tumor clean-up, and notably if there is tumor close to FLR boundaries. Given that ALPPS is a surgical innovation under development, it should be performed only at high-volume specialized centers, in patients selected by a multidisciplinary team and inside the ALPPS international registry.

Suggested Readings

Alvarez FA, Ardiles V, de Santibañes M, et al. Associating liver partition and portal vein ligation for staged hepatectomy offers high oncological feasibility with adequate patient safety: a prospective study at a single center. *Ann Surg* 2015;261:723–32.

de Santibañes E, Alvarez FA, Ardiles V, et al. Inverting the ALPPS paradigm by minimizing first stage impact: the Mini-ALPPS technique. *Langenbecks Arch Surg* 2016;401:557–63.

de Santibañes M, Alvarez FA, de Santibañes E. Hepatobiliary scintigraphy in associating liver partition and portal vein ligation for staged hepatectomy: all that glitters is not gold. *Ann Surg* 2016. [Epub ahead of print]

de Santibañes E, Clavien PA. Playing Play-Doh to prevent postoperative liver failure: the “ALPPS” approach. *Ann Surg* 2012;255:415–7.

Linecker M, Stavrou GA, Oldhafer KJ, et al. The ALPPS risk score: avoiding futile use of ALPPS. *Ann Surg* 2016. [Epub ahead of print]

Oldhafer KJ, Stavrou GA, van Gulik TM; Core Group. ALPPS—where do we stand, where do we go?: eight recommendations from the first international expert meeting. *Ann Surg* 2016;263:839–41.

Schadde E, Ardiles V, Slankamenac K, et al. ALPPS offers a better chance of complete resection in patients with primarily unresectable liver tumors compared with conventional-staged hepatectomies: results of a multicenter analysis. *World J Surg* 2014;38:1510–9.

Schadde E, Malagó M, Hernandez-Alejandro R, et al. Monosegment ALPPS hepatectomy: extending resectability by rapid hypertrophy. *Surgery* 2015;157:676–89.

Schadde E, Raptis DA, Schnitzbauer AA, et al. Prediction of mortality after ALPPS stage-1: an analysis of 320 patients from the international ALPPS registry. *Ann Surg* 2015;262:780–5.

Schnitzbauer AA, Lang SA, Goessmann H, et al. Right portal vein ligation combined with in situ splitting induces rapid left lateral liver lobe hypertrophy enabling two-staged extended right hepatic resection in small-for-size settings. *Ann Surg* 2012;255:405–14.

EDITOR'S COMMENT

ALPPS has been shown to dramatically induce rapid hypertrophy of the future liver remnant. This is a novel method of performing two-stage hepatectomy for patients that would otherwise not be resectable with traditional two-stage hepatectomy because of inadequate FLR. The procedure combines parenchymal transection with portal vein occlusion followed by hepatectomy in a second procedure performed in close proximity to the first procedure. The invention of this procedure, like the discovery of many other medical therapies and procedures, was quite serendipitous. Dr. Schlitt in Regensburg, Germany planned to perform an extended right hepatectomy on a patient in 2007, however, intraoperatively found the FLR to be inadequate. He then transected the liver parenchyma along the falciform ligament to facilitate performing the hepaticojejunostomy and performed right portal vein ligation to induce hypertrophy of the left lateral segment. He found, surprisingly, by a CT on postoperative day 8 that the left lateral segment had grown substantially. He proceeded to perform an extended right hepatectomy with good patient outcome (de Santibanes E, Clavien PA. Playing Play-Doh to prevent postoperative liver failure: the "ALPPS" approach. *Ann Surg* 2012;255:415–7). This is the first time a chapter dedicated to this procedure has been published in Mastery of Surgery. This in itself shows the growing recognition for the value of ALPPS for selected patients. Dr. Tanabe has very elegantly described this novel procedure and the technical details of performing the operation and the patient population in which to consider this procedure for. The adoption of this procedure has not been uniform, and especially slow to take hold in the United States, likely because of the high morbidity and mortality that has been associated with it.

Initially the mortality rates, even at experienced centers were reported up to 20% (Schadde E, Ardiles V, Slankamenac K, et al. ALPPS offers a better chance of complete resection in patients with primarily unresectable liver tumors compared with conventional-staged hepatectomies: results of a multicenter analysis. *World J Surg* 2014;38:1510–9; Nadalin S, Capobianco I, Li J, et al. Indications and limits for associating liver partition and portal vein ligation for staged hepatectomy (ALPPS). Lessons Learned from 15 cases at a single centre. *Z Gastroenterol* 2014;52:35–42). To decrease the morbidity and mortality, modifications from the initially described procedure have been undertaken such as mini-ALPPS, minimally invasive ALPPS, hybrid ALPPS, or terminal branches portal vein embolization liver partition for planned hepatectomy (TELPP) to name a few. Procedural modifications aimed to improve outcomes and safety include anterior approaches with minimal dissection, partial transection of liver parenchyma, PVE instead of operative ligation and tourniquet application or ablation instead of parenchymal transection. Mini-ALPPS reverses the aggressiveness of the surgical stages and essentially limits the first-stage operation to promote rapid recovery and then follows with the more complicated second stage. The first stage consists of partial transection of the liver parenchyma (no more than 3 to 5 cm in depth), minimal portal dissection, and PVE performed by accessing the inferior mesenteric vein thus avoiding portal dissection. The second stage then completes the resection. Hybrid ALPPS uses a combination of in situ splitting the liver with anterior approach, right PVE postoperatively by interventional radiology and finally second-stage hepatectomy. There are many modifications to the procedure currently published in the literature, all with the goal of reducing morbidity and mortality of ALPPS, and as research proceeds some of these modifications may be found to be an improvement from the initially described procedure.

One of the most critical learning points for surgeons adopting this procedure is not in the technical details of the surgery but in selecting the proper patients. This holds true in many surgical procedures and specialties but is especially important for a procedure with the potential for such high morbidity and mortality as ALPPS. A risk score has been published to assist in quantifying the risk to a patient who may have a futile outcome (Linecker M, Stavrou GA, Oldhafer KJ, et al. The ALPPS risk score: avoiding futile use of ALPPS. *Ann Surg* 2016;264(5):763–71). This paper developed a score based on 528 patients entered into the ALPPS registry from over 38 centers. The primary outcome examined was 90 day or in-hospital mortality from the time of the first surgery. Nine percent of patients had an in-hospital or 90-day mortality in this study. This is much lower than previously published mortality rates. Independent risk factors associated with poor outcome in the pre-stage 1 model includes age >67 years and biliary tumors. The pre-stage 2 model includes major complications after stage 1, elevated bilirubin or creatinine and cumulative pre-stage 1 score. Model scores were given for each of the risk factors. The model predicted

mortality of up to 50% for patients with a score of 6.9. Interestingly in this study, the FLR volume and the hypertrophy after stage 1 were not predictive of mortality.

Implementing new surgical procedures and techniques in the United States is not regulated by any government entity like diagnostics, drugs, and medical devices. Adopting new technologies and procedures in surgery is critical to continue to advance the field but must be done in a responsible fashion. Many new procedures were initially criticized before becoming widely accepted. When the first laparoscopic appendectomy was performed in 1980 by Dr. Kurt Semm, a German gynecologist, he was criticized harshly with colleagues reporting that "only a person with brain damage would perform laparoscopic surgery" (Bhattacharya K. Kurt Semm: a laparoscopic crusader. *J Minim Access Surg* 2007;3:35–6). In the early 1990s when laparoscopic cholecystectomy was performed, it was fraught with naysayers about the approach but also had much higher complications initially than the open procedure. The initial series of laparoscopic cholecystectomies had significant morbidity with several fold higher rates of bile duct injury compared with the open procedure (Southern Surgeons Club. A prospective analysis of 1518 laparoscopic cholecystectomies. The southern surgeons club. *N Engl J Med* 1991;324:1073–8; Williams LF Jr, Chapman WC, Bonau Ra, et al. Comparison of laparoscopic cholecystectomy with open cholecystectomy in a single center. *Am J Surg* 1993;165(4):459–65). However in less than 10 years, laparoscopic cholecystectomies were performed routinely with much improvement in complication rates and obvious benefits such as decreased postoperative pain and decreased length of stay, but still with higher rates of bile duct injury. Subsequently the adoption and education of future surgeons was not structured and consisted of loosely organized courses and training. Most recently, the use of the robotic platform for some procedures has become commonplace such as robotic prostatectomy but less common for others such as pancreaticoduodenectomy. Marketing has been credited by skeptics as to the rapid rise in robotic prostatectomies. Proponents of the procedure may point to a multidisciplinary collaboration between physicians and centers of excellence for propelling this to the most common technique for prostatectomy and most common robotic procedure in the United States.

The implementation of ALPPS has been slow and more methodical than many previous technologies or procedures. This may be because a company is not involved in marketing or profiting from a new piece of equipment for the ALPPS procedure. A registry was created by Drs. Santibanes, Lang, and Clavien to record outcomes of all cases performed across the world. The registry now has over 800 patients enrolled with over 300 hundred institutions participating and 32 projects registered and completed or in progress. To prospectively evaluate this procedure, a multicenter randomized trial of ALPPS versus Two-stage hepatectomy for colorectal liver metastasis is open to accrual. The trial is open to any center participating in the registry that has performed more than five cases. Many papers have now been published using the registry

data from the early learning curve to most recently the ALPPS risk score. The group should be commended for being transparent and inclusive when creating the registry and opening the clinical trial. This will be critical in evaluating the effectiveness and safety of ALPPS and its adoption worldwide as an option for patients that would otherwise have no other surgical alternatives.

Mary Dillhoff

E THE PANCREAS

121 Surgical Anatomy of the Pancreas

Petros Mirilas, Marios Loukas, and Lee J. Skandalakis

SURGICAL ANATOMY OF THE PANCREAS

The pancreas is a bland appearing yellowish organ situated in the retroperitoneum. Early historical descriptions of this gland are hardly more than a list of names of those who noticed it during their dissections, before moving on to more interesting organs. It was only with identification of the digestive enzymes by Claude Bernard in 1850 that the pancreas became recognized as a complete organ with an important function, and thus, worthy of study.

The retroperitoneal location and anatomic relationships of the pancreas combine to make its surgical removal difficult. Sir Andrew Watt Kay wrote in 1978, “For me, the tiger country is removal of the pancreas. The anatomy is very complex and one encounters anomalies.” The embryogenesis of the pancreas and its deep retroperitoneal anatomy are responsible for the designation “tiger country.” Prior to exploration, the surgeon should know whether the patient’s pancreas contains any anomalies of the parenchyma (annular pancreas or divisum), ductal system (divisum, obstruction, or aberrant location), or vasculature (replaced right hepatic artery behind the pancreatic head or other arterial anomalies). At operation, the surgeon must consider these possibilities, even if they are not evident on preoperative imaging. Furthermore, the pancreas is surrounded by numerous structures (i.e., the duodenum, stomach, spleen, left adrenal gland, transverse mesocolon and colon, left kidney, right ureter, and jejunum) making dissection of and around the pancreas potentially risky to multiple organs. The pancreas lies transversely in the retroperitoneal space, between the duodenum on the right and the spleen on the left. It is related anteriorly to the stomach, to the omental bursa

above, the greater sac below, as well as to the transverse mesocolon. It is a fixed organ. Figures 121.1 and 121.2 demonstrate the relationships of the pancreas and surrounding organs.

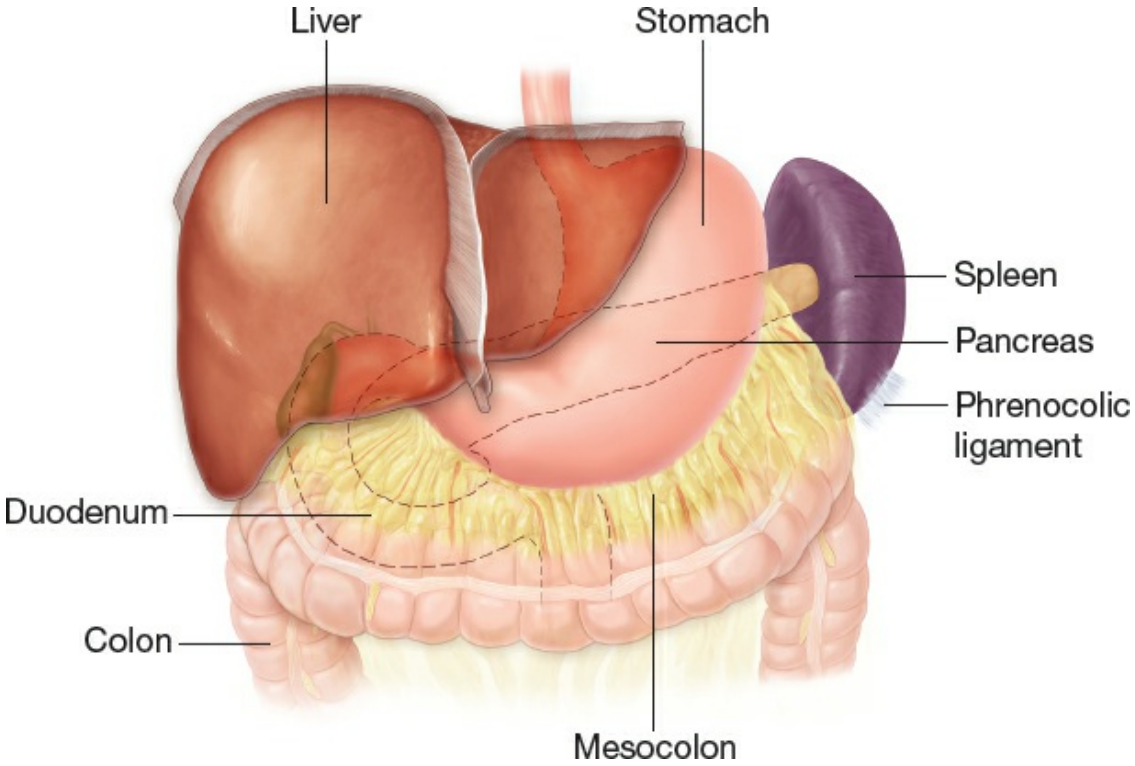

Figure 121.1. Anterior relationships of the pancreas.

EMBRYOLOGY

The pancreas develops from two buds originating from two endodermal primordia respectively: the dorsal diverticulum and the ventral diverticulum of the foregut (Fig. 121.3). The ventral pancreas develops at 4.5 to 5th week from the hepatic diverticulum, which also gives genesis to the gallbladder and the extrahepatic biliary ducts. The ventral pancreas is developmentally associated with the bile duct. The dorsal pancreas arises a bit earlier (4th week) in the mesentery of the duodenum (mesoduodenum) and has its own pancreatic duct.

With growth and development of the bile duct, the ventral pancreas is separated from the duodenum and the respective pancreatic duct exits at the common junction with the bile duct. “Rotation” of the duodenum brings the ventral pancreas and pancreatic duct-bile duct junction in the mesoduodenum to a caudal and posterior position to the dorsal pancreas. When the two pancreatic primordia come into contact, they fuse (end of 6th week). The ventral primordium forms the uncinate process and the

posterior head of the pancreas. The anterior head, the body, and tail are derived from the dorsal primordium.

The ducts follow the fusion of pancreatic primordia and join. The ventral duct usually persists and unites with the distal part of the dorsal pancreas to form the main pancreatic duct. The proximal part of the dorsal pancreas either persists and forms the accessory pancreatic duct, or disappears.

The secretory acini derive from the ducts (3rd month) and appear as clusters of cells around the duct endings. The acini secrete pancreatic enzymes and are the responsible for the exocrine pancreatic function. The pancreatic islets are endocrine cells and also originate from the terminal ducts. The islets organize into islands (Fig. 121.4), which comprise endocrine cells of various cell types. Each cell type secretes a different hormone, including glucagon (A cells), insulin (B cells), and somatostatin (D cells). In addition to the acinar and endocrine cells, the terminal ducts also give rise to the ductal epithelium.

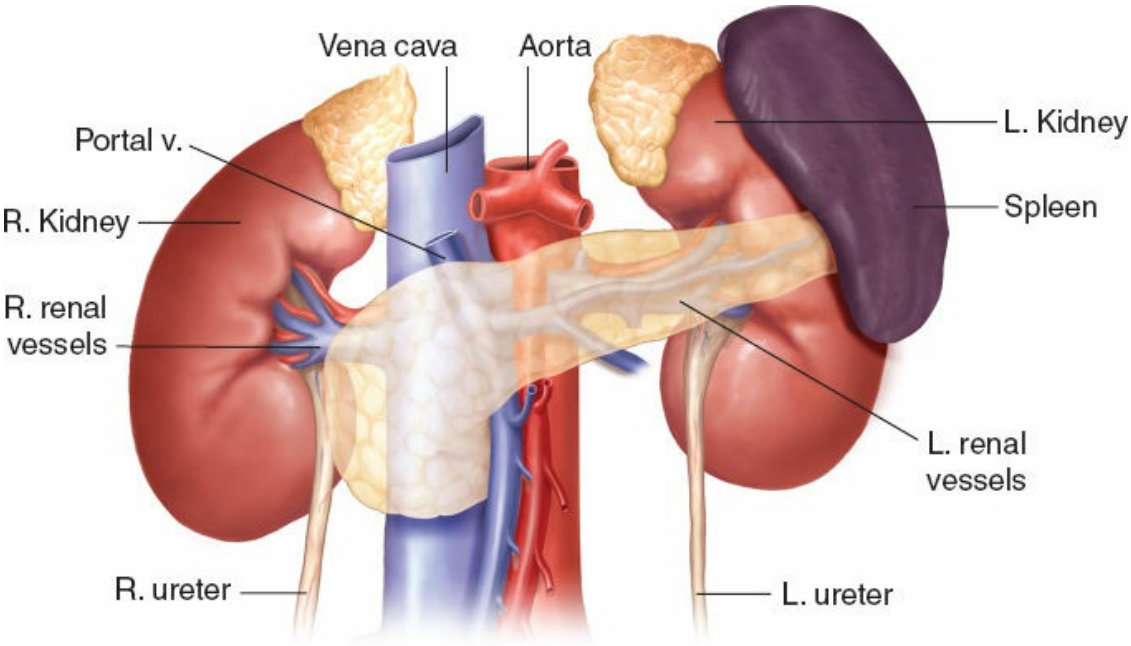

Figure 121.2. Posterior relationships.

The development of the omental bursa coincides with repositioning of the viscera of the upper abdomen (see Embryology section in chapter “Anatomic considerations of gastroduodenal surgery”). The mesentery of the duodenum (mesoduodenum) bends to the right, resulting in positioning the pancreas in contact with the posterior abdominal wall (Fig. 121.5A,B). Thus, the head of the pancreas and the second portion of the duodenum

become retroperitoneal organs. The peritoneum of the right side of the pancreas fuses with the parietal peritoneum of the posterior abdominal wall. The body and tail of the pancreas similarly become retroperitoneal when the peritoneum of the left side of the pancreas fuses with the posterior peritoneum (Fig. 121.5C,D). Thus the pancreaticorenal ligament disappears and the peritoneum around the spleen connects directly to the posterior wall with the splenorenal ligament. These changes create an avascular plane behind the pancreas called the fascia of Treitz, given by the fusion of the two leaves of peritoneum. It is this plane that permits surgical mobilization of the gland at the time of surgical exploration.

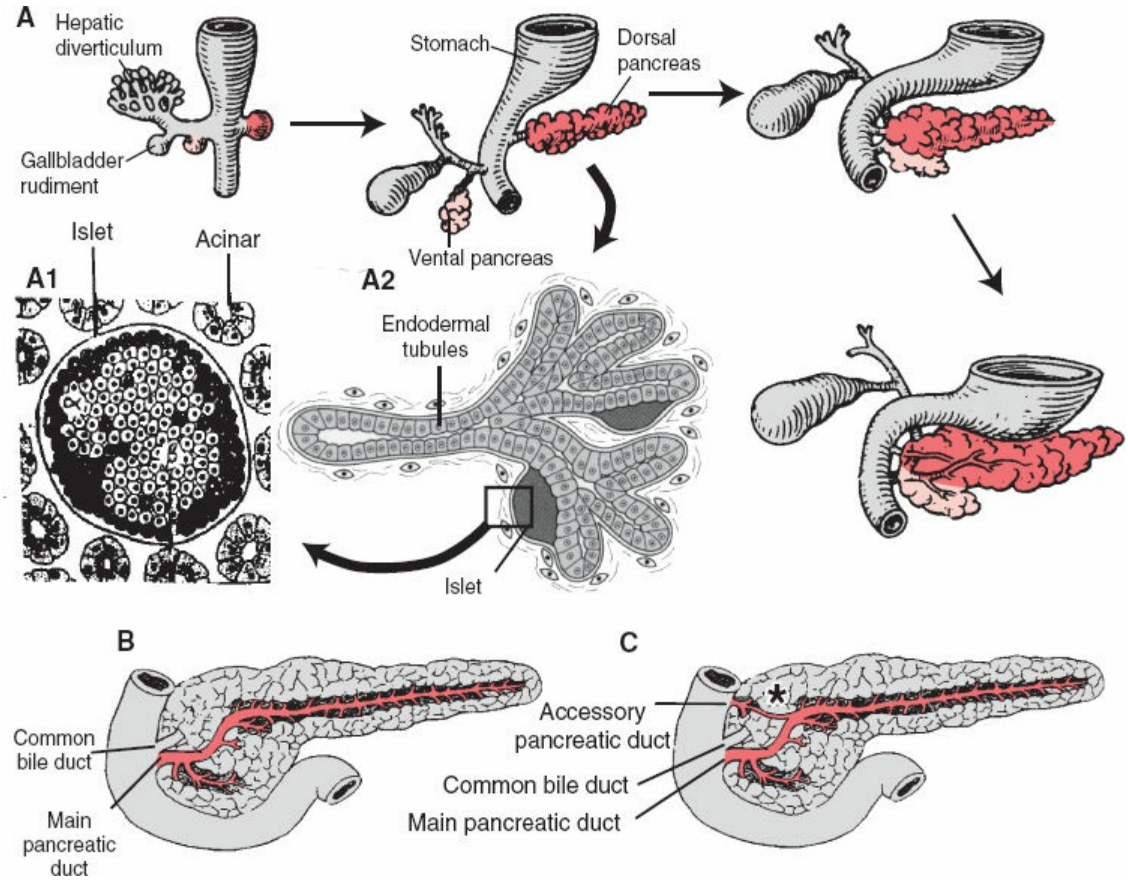

Figure 121.3. (**A**) Sequence of events in the development of the pancreatic buds from Week 4 through Week 7. Note that within the pancreatic buds endodermal tubules branch repeatedly to form the exocrine (acinar) pancreas (see **A2**). Subsequently, endodermal cells bud from the endodermal tubules to form the endocrine (islet) pancreas (see **A1**). (**B**) Normal pattern of the main pancreatic duct (48% incidence in the population). (**C**) Accessory Pancreatic Duct (33% Incidence in the Population). Note that the proximal one third of the dorsal pancreatic duct persists (*). (From Dudek RW. High-Yield Systems:

Gastrointestinal Tract. Philadelphia: Lippincott Williams & Wilkins, 2010.)

CONGENITAL ANOMALIES

Agenesia–Aplasia–Hypoplasia

Aplasia means failure of development, while agenesia is failure to form. With respect to pancreatic primordial, both conditions result in growth retardation and early death. Hypoplasia means incomplete development and is often compatible with life. There are case reports of absence of portions of dorsal pancreatic origin, including the distal body and tail. The uncinate process is absent in 10% of pancreatic head specimens.

Hyperplasia–Hypertrophia

Hyperplasia is the increase in cell number, and hypertrophia is the growth in volume and size of existing cells. Beckwith–Wiedemann syndrome (neonates with increased body weight, macroglossia, and omphalocele) may manifest with islet cell hypertrophy and hyperplasia with resultant hyperinsulinemia, and severe hypoglycemia. For the most part, treatment is conservative; however, partial pancreatectomy may be necessary in cases refractory to medical therapy.

Pancreas Divisum (Isolated Ventral Pancreas)

This malformation represents failure of the ventral and dorsal pancreas to fuse, resulting in the main and the accessory pancreatic ducts draining separately in the duodenum.

Pancreas divisum is encountered in 10% of specimens. It is also an incidental finding in 3% of patients undergoing endoscopic retrograde cholangiopancreatography (ERCP). In the subset of patients with pancreatitis, the incidence increases to 12%, suggesting that pancreas divisum predisposes to development of pancreatitis. Pancreatitis may occur due to stenosis or infraction of one or both pancreatic ducts. Others suggest that there is no association between pancreas divisum and pancreatitis. Insufficiency of the minor papilla may also play a role in development of pancreatitis.

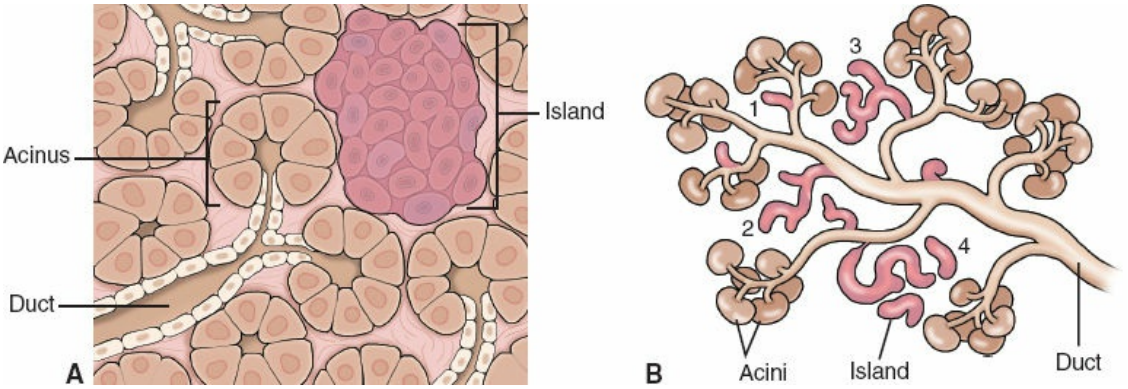

Figure 121.4. Differentiation of the human pancreas. **A.** Section, at 14 weeks, demonstrating the origin of acini and islands from ducts. (From Lewis FP. The development of the liver. In: Keibel F, Mall FP, eds. *Human Embryology.* Philadelphia: JB Lippincott; 1912.) **B.** Four progressive stages (1 to 4) in the organization of islands. (Published in Arey LB. *Developmental Anatomy: A Textbook and Laboratory Manual of Embryology.* 7th ed. Philadelphia, PA: WB Saunders; 1965. Copyright © 1965 Elsevier.)

Annular Pancreas

This malformation is characterized by a ring-like, thin, flat band of pancreatic tissue surrounding the second part of the duodenum at the origin of the ventral pancreas. The annulus is usually complete (Fig. 121.6) and may constrict the duodenum, resulting in poor gastric emptying, abdominal pain, and weight loss. The pattern of the pancreatic duct may also be affected, as there is usually a wide duct from the ring that meets the main pancreatic duct.

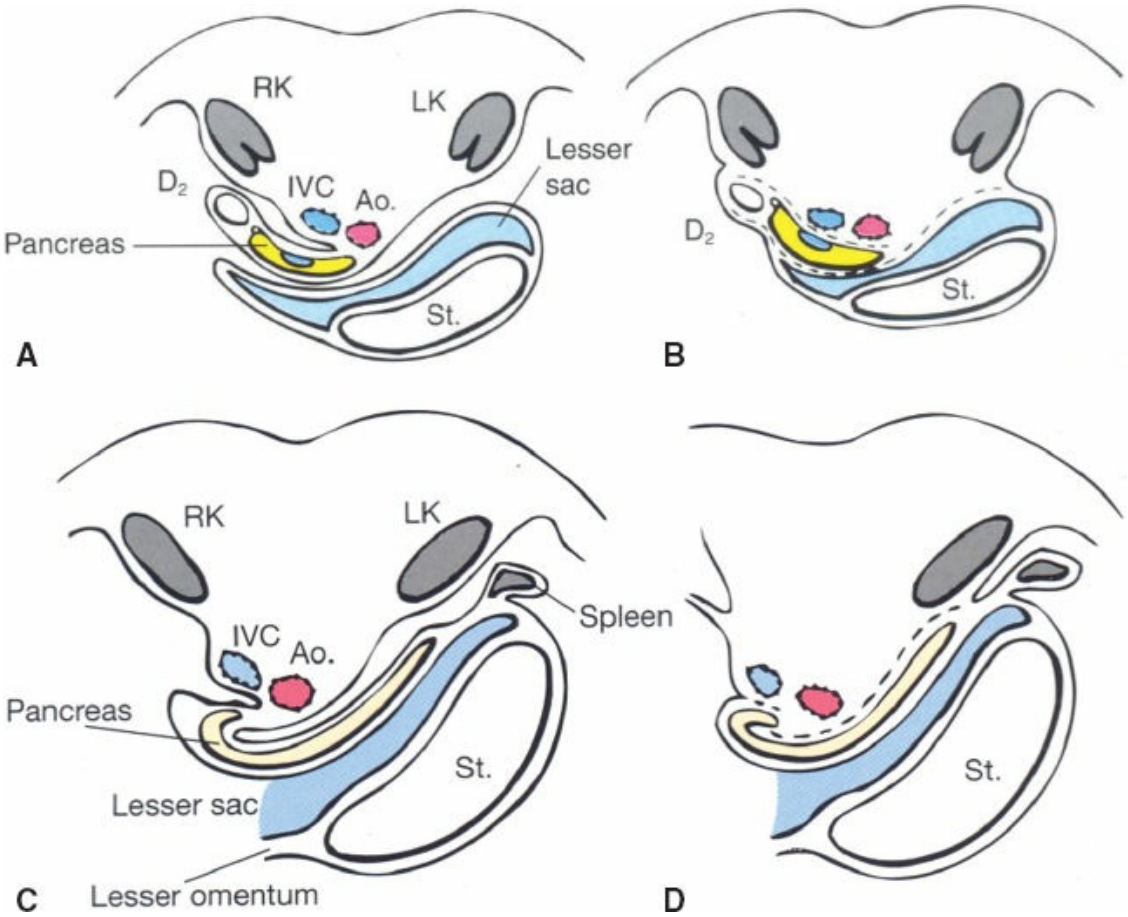

Figure 121.5. Schemas to show the fixation of duodenum and pancreas to the posterior abdominal wall. Transverse sections from the head of the pancreas and descending part of the duodenum (**A** and **B**) and from the body and tail of the pancreas (**C** and **D**). **A.** Duodenum and pancreas in the mesentery of the duodenum (mesoduodenum). **B.** The mesogastrium bends further and touches the peritoneum of the posterior abdominal wall. The two leaves of peritoneum fuse and form an avascular plane behind the duodenum and pancreas. The portal vein is embedded in the head of the pancreas. **C**. The mesentery continues from the stomach to the spleen (gastrospenic ligament) and, after enveloping the spleen, to the pancreas (splenopancreatic ligament); the body and tail of the pancreas are still contained in the mesentery which meets the posterior wall as the pancreaticorenal ligament. **D**. The body and tail of the pancreas fuse with the posterior wall, creating an avascular plane (*dashed line*). D2, second part of the duodenum; RK, right kidney; LK, left kidney; IVC, inferior vena cava; Ao, aorta; St, stomach. (Republished with permission of John Wiley & Sons, Inc. from O'Rahilly RO, Müller F. *Human Embryology and Teratology*. 3rd ed. New York: Wiley-Liss; 2001:252, permission conveyed through Copyright Clearance Center, Inc.)

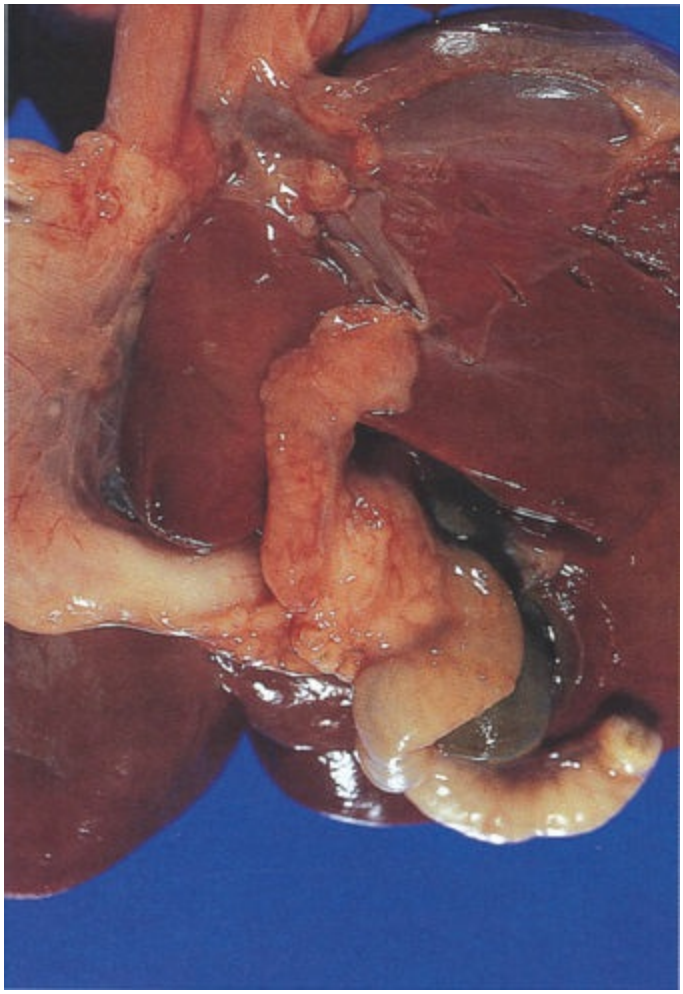

Figure 121.6. Annular pancreas. The annular pancreas wraps around the first portion of the duodenum. Note the lobulated appearance of the pancreatic tissue. (From Noffsinger AE, Fenoglio-Preiser's Gastrointestinal Pathology, 4th edition (2017); Wolters Kluwer.)

Several unconvincing theories have been proposed for the embryogenesis of the annular pancreas (Fig. 121.7). According to the most usually cited, an extension of the ventral pancreas may hook around the right side of the duodenum and fuse with the dorsal pancreas.

The anomaly is congenital; the affected neonates present with bilious vomiting. The radiographic finding of a "double-bubble" (air in the stomach and upper duodenum) with no air caudally signifies complete obstruction of the duodenum. The condition can also be encountered in adults, as 50% of patients present with symptoms in adulthood. Duodenoduodenostomy or duodenojejunostomy is the proper surgical correction. Division of the annular ring will likely result in injury to the pancreatic duct and should not be performed.

Ectopic, Heterotopic, and Accessory Pancreas

Ectopia and heterotopia of the pancreas signify development of pancreatic tissue in abnormal position. The term *accessory pancreas* is used when the original pancreas is in its normal place and there is additional pancreatic tissue in other positions. Accessory pancreatic tissue may be found in the neighboring organs such as the stomach and duodenal wall. Less frequently, the umbilicus, ileum, the colon, the gallbladder, or the omentum is affected. A Meckel diverticulum is an antimesenteric true diverticulum located 2 feet from the ileocecal valve. It is found in 2% of the population and can harbor two types of heterotopic tissue—pancreatic and gastric mucosa.

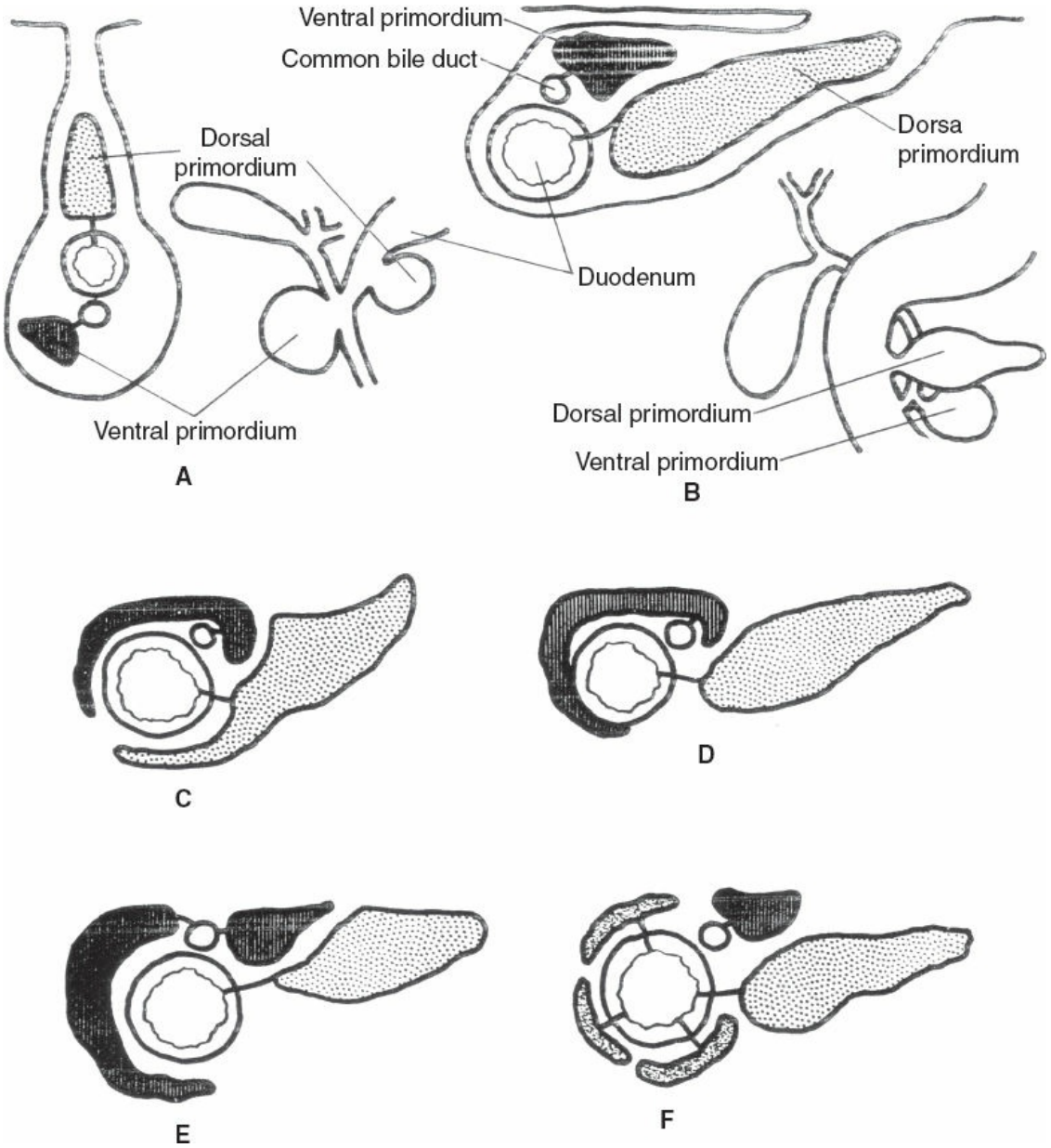

Figure 121.7. Several theories of the embryogenesis of annular pancreas. **A.** Normal relationship of dorsal and ventral pancreatic primordia at 6 weeks. **B.** At 7 weeks, just before the fusion of the primordia. The ventral primordium was migrated to the left, posterior to the duodenum. **C.** Hypothetical hypertrophy of both lobes, eventually coalescing to form the annulus. **D.** Hypothetical adhesion of the distal tip of the ventral primordium to the duodenal wall prior to its migration. **E.** Persistence of a hypothetical left ventral lobe, based on an assumption that the ventral lobe was originally a paired structure. **F.** Formation of the annulus by fusion of aberrant pancreatic tissue from the duodenum. (From Skandalakis JE, Gray SW, Ricketts RR, et al. The pancreas. In Skandalakis JE, Gray SW. *Embryology for Surgeons*. 2nd ed. Baltimore, MD: Williams & Wilkins; 1994.)

In most cases, the accessory pancreatic tissue is functional. Several theories regarding development of accessory pancreas have been described, including metaplasia of pluripotent endodermal cells into pancreatic cells and transplantation of pancreatic cells into the duodenum.

Neuroendocrine Tumors of the Pancreas

It is unclear if these tumors are congenital; however, a discussion regarding their localization facilitates understanding of pancreatic endocrine development. These tumors develop two distinct regions of the pancreas, which, topographically correspond to portions of the ventral and the dorsal anlagen.

Topographically, the area originating from the ventral pancreatic diverticulum is known as the gastrinoma triangle (Fig. 121.8), which is bounded by the cystic duct, the border of the second and third part of the duodenum, and the junction of the neck and body of the pancreas. In this triangle, 80% of gastrinomas, PPomas, and somatostatinomas are encountered, while insulinomas and glucagonomas, which develop from the islets concentrated in the dorsal bud, are more common (80%) in the neck, body, and tail.

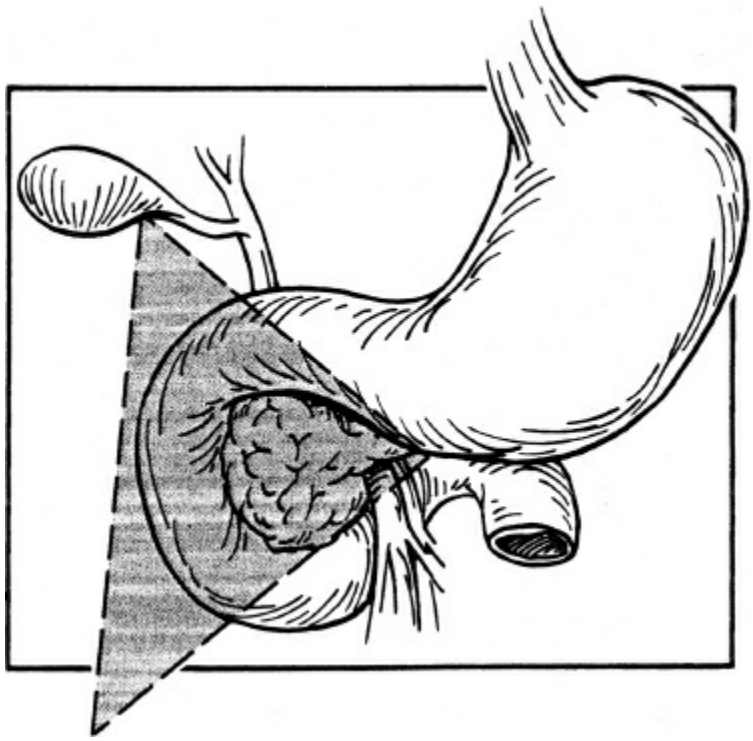

Figure 121.8. Gastrinoma triangle (Pessaro triangle). (From Bell RH Jr. Atlas of pancreatic surgery. In: Bell RH Jr, Rikkers LF, Mulholland MW, eds. *Digestive Tract Surgery: A Text and Atlas*. Philadelphia, PA: Lippincott-Raven; 1996:963.)

Localization of gastrinomas in peripancreatic sites, in the duodenum, and at the head of the pancreas is compatible with an origin from the ventral pancreas. It has been suggested that stem cells dispersed during the turn of the pancreatic diverticulum, and were entrapped by lympoid tissue or duodenal wall. This idea explains the increased localization of gastrinomas in sites outside the pancreas (40%) and in the lymph nodes (40%). These gastrinomas are distinct, as they are more often associated with development of hepatic metastases and poorer prognosis.

PERITONEAL RELATIONS OF THE PANCREAS

The pancreas lies in the retroperitoneal space, with its axis horizontal, from the descending part of the duodenum to the right until the spleen to the left. The tail of the pancreas is covered by peritoneum anteriorly and posteriorly as it projects into the splenorenal ligament. All the rest parts of the pancreas are retroperitoneal.

The transverse mesocolon attaches to a horizontal zone, from the right kidney, on to the descending duodenum and pancreas up to the left kidney, where it joins the base of the phrenocolic and splenorenal ligament (Fig.

121.9). The upper leaf of the mesocolon continues with the posterior leaf of the lesser omentum. Cranially to the zone of attachment of the mesocolon, the pancreas is covered by the peritoneum that forms the posterior wall of the omental bursa. The lower leaf of the mesocolon covers the lower anterior surface of the neck and body of the pancreas. From there, on the right, the peritoneum passes over the third and fourth part of the duodenum and continues as right leaf of the mesentery proper. On the left, the peritoneum continues immediately as parietal peritoneum of the greater sac.

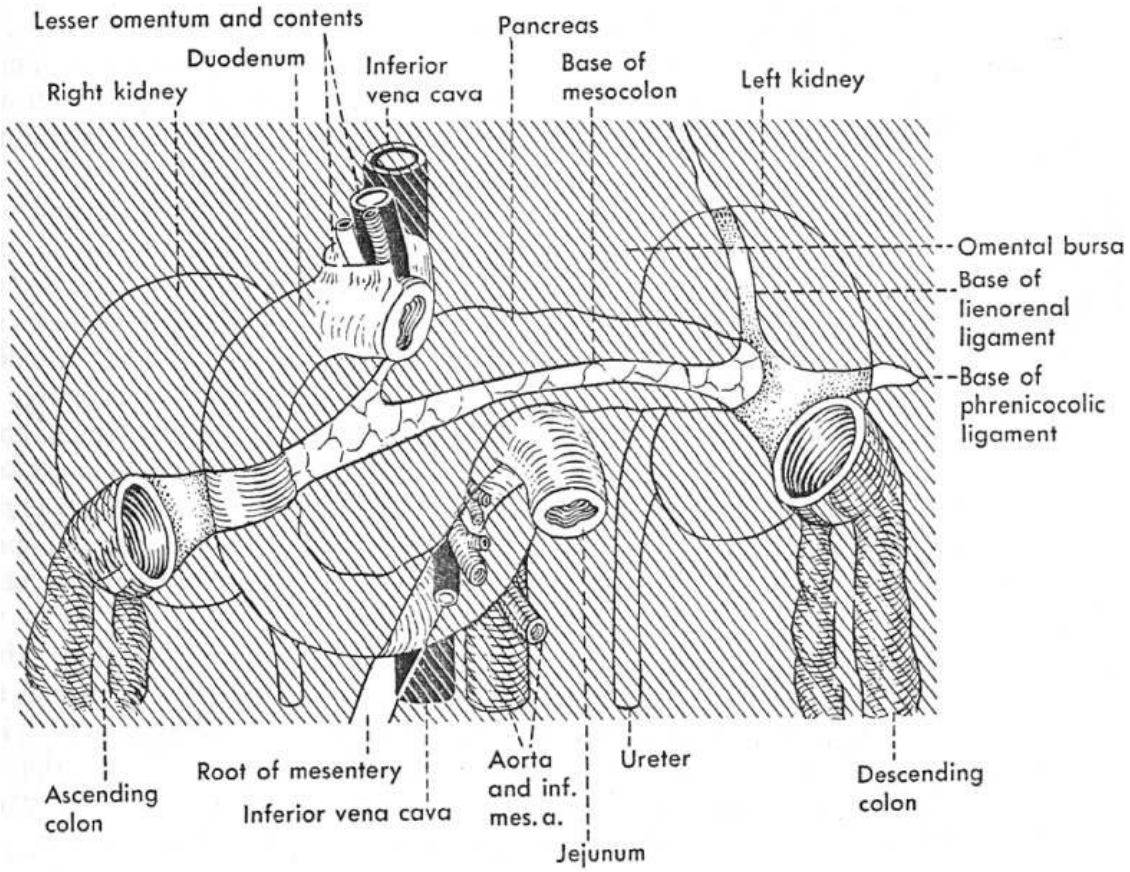

Figure 121.9. Peritoneal attachments onto the duodenum and pancreas. The oblique shading represents the parietal peritoneum. (From Hollinshead WH. *Anatomy for Surgeons, Vol. 2: The Thorax, Abdomen, and Pelvis*. New York: Hoeber-Harper; 1956:413, Fig. 299.)

PARTS OF THE PANCREAS

Anatomical Parts

Head

The head of the pancreas is flat and has an anterior and a posterior surface

(Fig. 121.10). The anterior surface is adjacent to the pylorus and the transverse colon. The anterior pancreaticoduodenal arcade can be seen on the ventral surface of the head of the pancreas, coursing roughly parallel to the duodenal curvature.

The posterior pancreaticoduodenal vascular arcade runs along the posterior surface of the head. This surface of the pancreatic head is close to the hilum and medial border of the right kidney, the right renal vessels and the inferior vena cava, the right crus of the diaphragm, and the right gonadal vein.

The head of the pancreas may be related to the third part of the common bile duct (CBD) in a variety of ways (Fig. 121.11).

Uncinate Process

An extension of the head of the pancreas (which is variable in size and shape) passes downward and slightly to the left from the principal part of the head. It further continues behind the superior mesenteric vessels and in front of the aorta and inferior vena cava. In sagittal section, the uncinate process lies between the aorta and the superior mesenteric artery (SMA), with the left renal vein above and the duodenum below (Fig. 121.12). If the junction of the superior mesenteric and portal vein is low, the anterior surface of the uncinate process is related to the superior mesenteric vessels and the portal vein.

The uncinate process may be absent, or it may completely encircle the superior mesenteric vessels (Fig. 121.13). If the process is well developed, the neck of the pancreas must be sectioned from the front to avoid injury to the vessels. Short vessels from the SMA and vein supply the uncinate process and must be carefully ligated and divided during a pancreatic head resection. An anomalous right hepatic artery (accessory or replaced) may pass through the uncinate process.

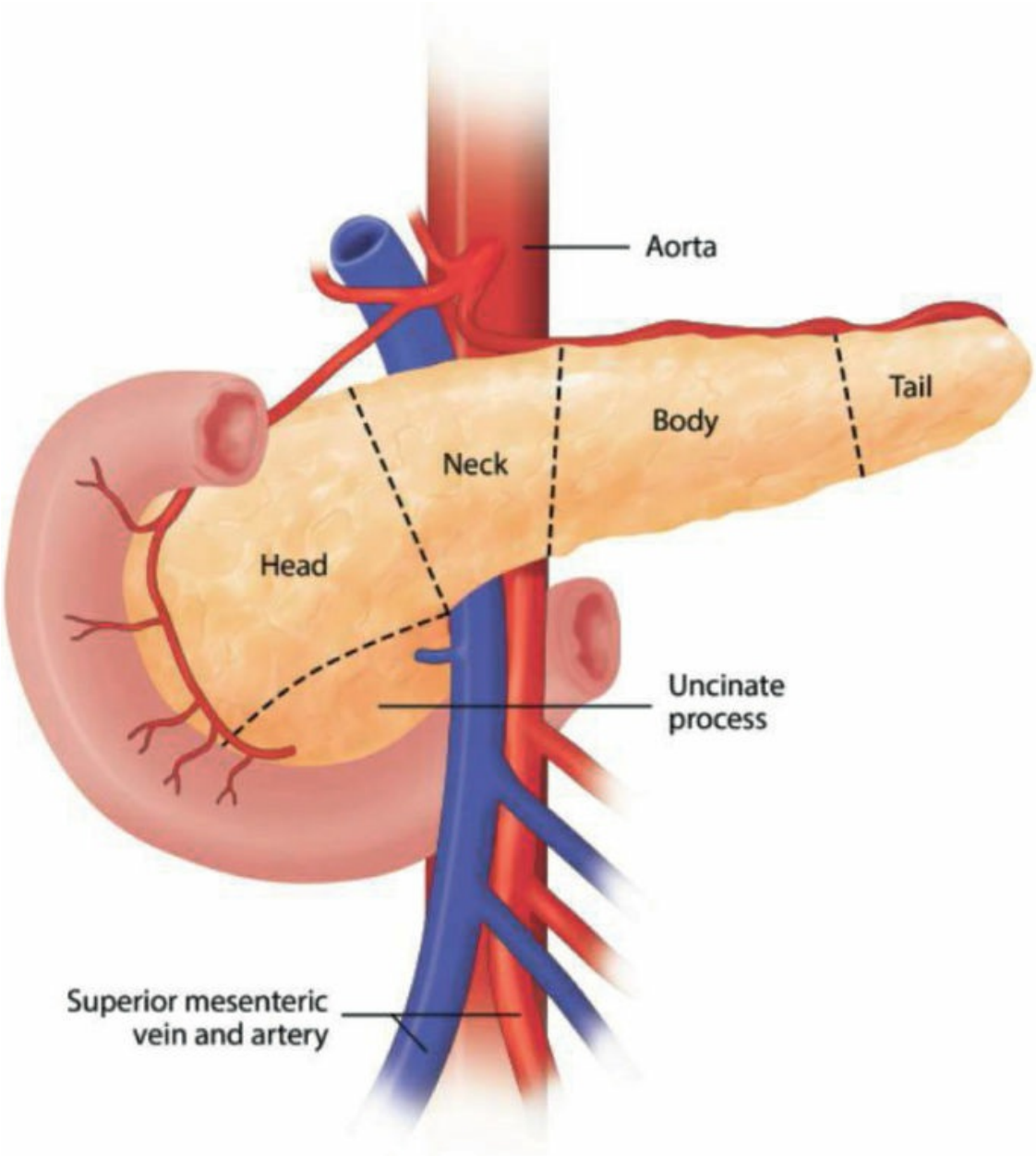

Figure 121.10. The five parts of the pancreas. The line dividing the body and tail is entirely arbitrary. (Modified from Skandalakis JE, Gray SW, Rowe JS Jr. *Anatomical Complications in General Surgery*. New York: McGraw-Hill; 1983.)

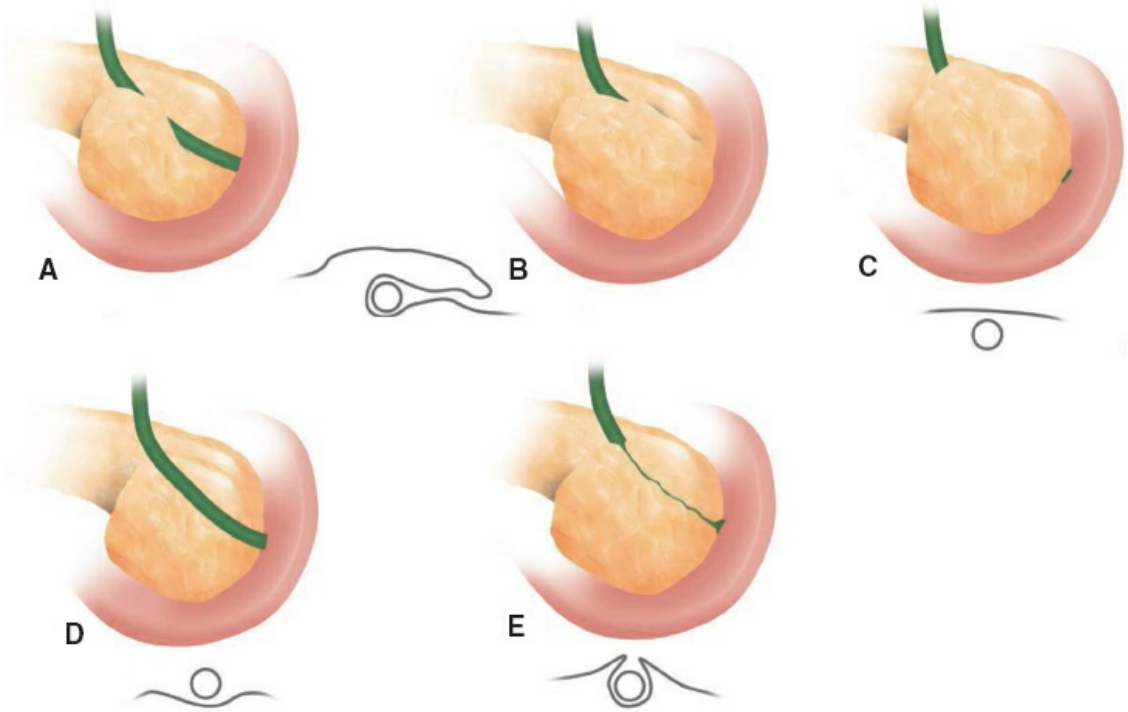

Figure 121.11. The relation of the common bile duct to the posterior surface of the pancreas. **A, B.** The most common arrangement (44%); the duct is partially or wholly covered by a tongue of pancreas. **C.** The duct lies within the pancreas (30%). **D.** The duct lies free in the surface of the pancreas (16.5%). **E.** The duct is covered by two small folds of pancreas (9%). (Modified from Skandalakis JE, Gray SW. *Embryology for Surgeons*. 2nd ed. Baltimore, MD: Williams & Wilkins; 1994.)

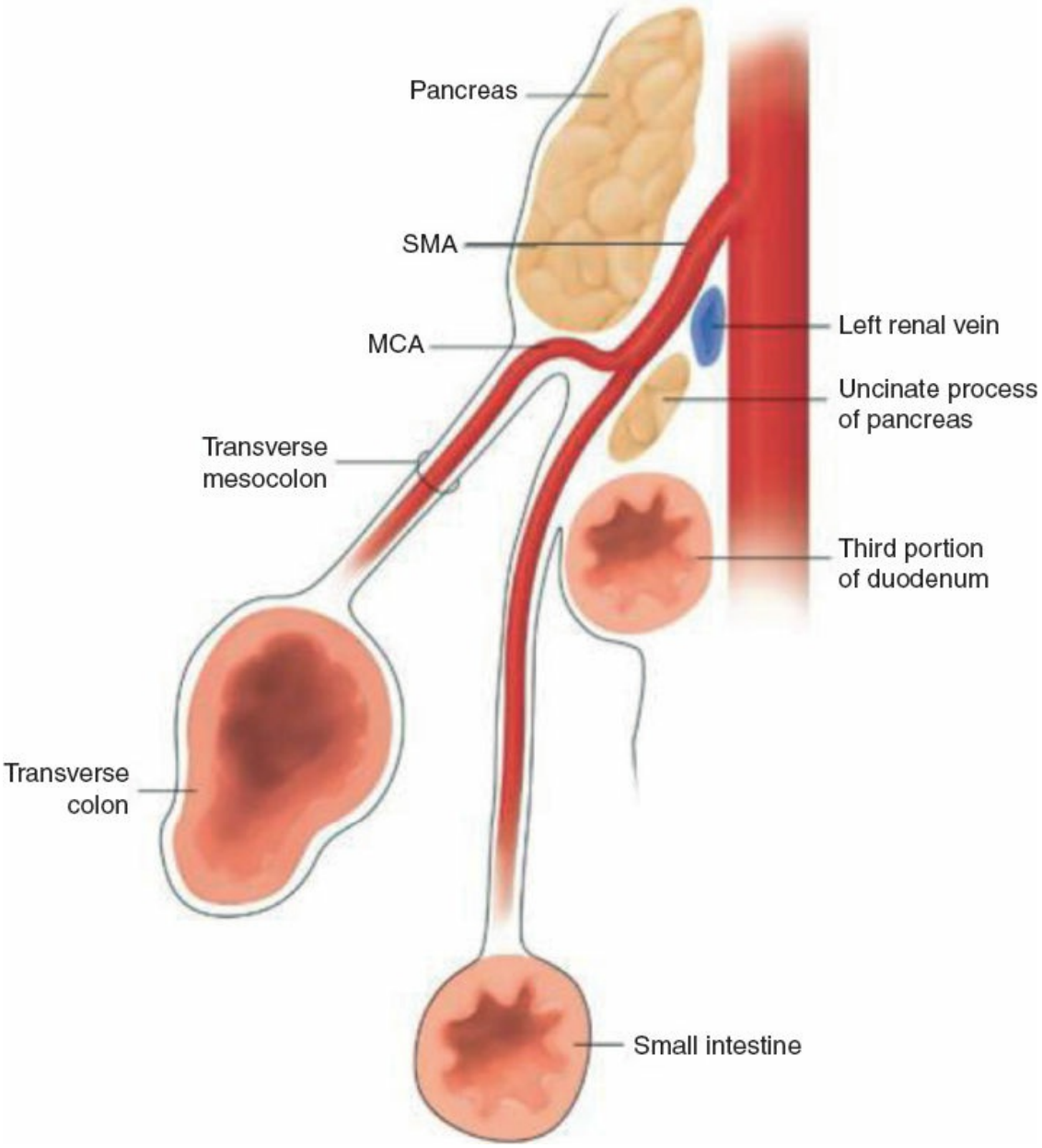

Figure 121.12. Highly diagrammatic sagittal section through the neck of the pancreas. The uncinate process and the third portion of the duodenum lie posterior to the superior mesenteric artery (SMA) and anterior to the aorta. The middle colic artery (MCA) leaves the SMA to travel in the transverse mesocolon. (Published in Akin JT, Gray SW, Skandalakis JE. Vascular compression of the duodenum: presentation of ten cases and review of the literature. *Surgery* 1976;79:515. Copyright © 1976 Elsevier.)

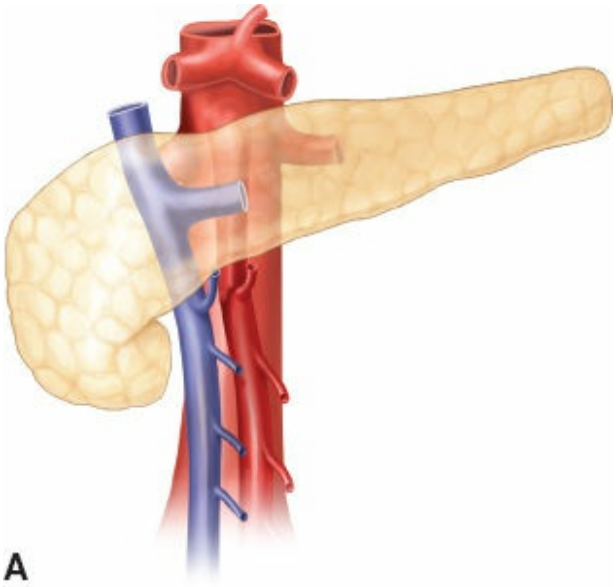
A

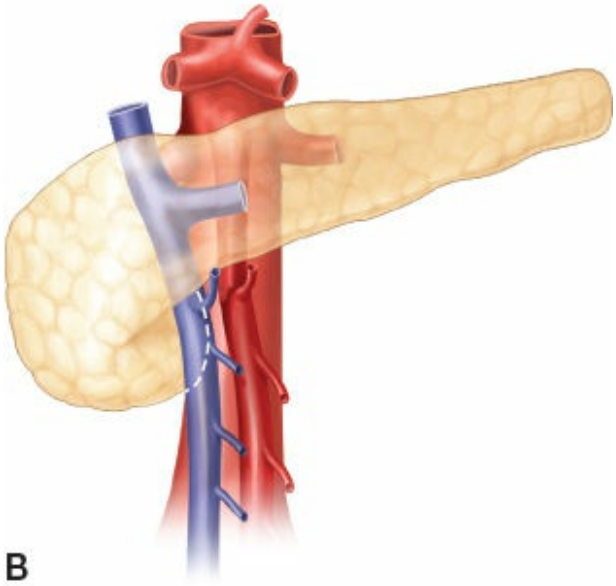
B

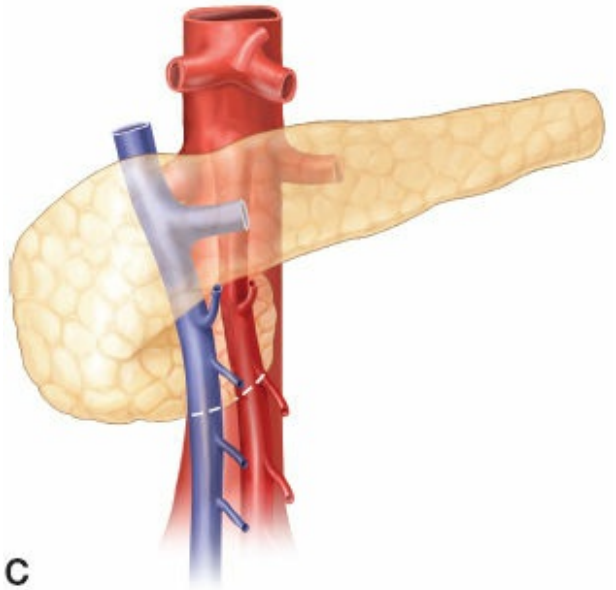
C

Figure 121.13. The uncinate process may or may not extend under the superior mesenteric vessels. **A.** Does not reach the superior mesenteric vessels. **B.** Reaches across the superior mesenteric vein almost to the superior mesenteric artery. **C.** Reaches beyond the superior mesenteric artery.

Neck

The neck of the pancreas is defined by the location of the superior mesenteric vessels running behind the gland, and by the beginning of the portal vein dorsal to the pancreas. This pancreatic segment is 1.5 to 2.0 cm long, and it is partially covered anteriorly by the pylorus.

The vascular relations of the neck of the pancreas are extremely important, because if these vessels are involved in pancreatic cancer, pancreatectomy is impossible. The gastroduodenal artery passes to the right of the neck and provides origin for the anterior superior pancreaticoduodenal artery (see Fig. 121.23). Posterior to the neck, the portal vein is formed by the confluence of the superior mesenteric and splenic veins. Near the inferior margin of the pancreatic neck, one can often see the terminations of the inferior pancreaticoduodenal vein and right gastroepiploic vein where they drain into the superior mesenteric or splenic veins or into the portal vein proper. The inferior mesenteric vein drains, with essentially equal frequency, into the splenic vein, the superior mesenteric vein (SMV), or the portal vein (see Figs. 121.30 and 121.31). Elevation of the neck and ligation of any anterior tributaries of the portal vein, if present, are necessary for many pancreatic resections. If hemorrhage occurs, evaluation of the entities found behind the neck is extremely difficult.

Body

The anterior surface of the body of the pancreas is covered by the posterior layer of peritoneum of the omental bursa that separates the stomach from the pancreas. The omental tuberosity (tuber omentale), a blunt upward projection of peritoneum from the body, contacts the lesser curvature of the stomach at the attachment of the lesser omentum. The body is also related to the transverse mesocolon, which divides into two leaves: the superior leaf covers the anterior surface and the inferior leaf passes inferior to the pancreas. The middle colic artery emerges from beneath the pancreas to travel between the leaves of the mesocolon.

Posteriorly, the body is related to the aorta and the origin of the SMA—

and to that portion of the celiac plexus related to these—to the left crus of the diaphragm, the left kidney and its vessels, the left adrenal gland, and the splenic vein. Small vessels from the pancreas enter this vein. They must be ligated during pancreatectomy if the splenic vein and the spleen are to be preserved.

Tail

The tail of the pancreas is relatively mobile; its tip reaches the hilum of the spleen. The relation of the tail to the splenic hilum is variable (Fig. 121.14). Together with the splenic artery and the origin of the splenic vein, the tail is contained between two layers of the splenorenal ligament. The outer layer of this ligament is the posterior layer of the gastrosplenic ligament and runs behind the short gastric vessels. Commonly, a caudate branch arises from the left gastroepiploic or an inferior splenic polar branch and passes to the tip of the tail of the pancreas. The vascular anatomy in this location is quite variable and care should be taken during dissection to avoid inadvertent vascular injury, especially during a laparoscopic approach.

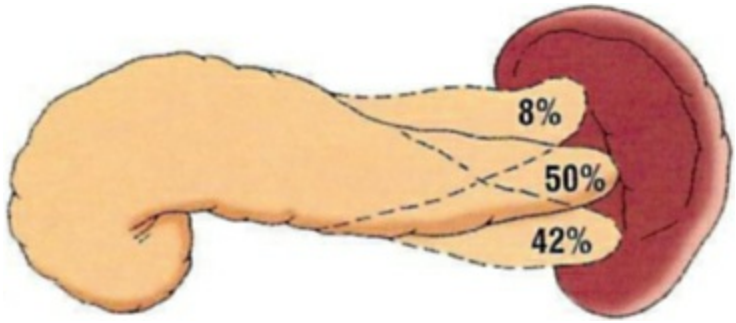

Figure 121.14. Relations of the tail of the pancreas to the splenic portas. (From Skandalakis JE, Skandalakis LJ, Kingsnorth AN, et al. Pancreas. In: Skandalakis JE, Colborn GL, Weidman TA, et al., eds. *Skandalakis' Surgical Anatomy: The Emryologic and Anatomic Basis of Modern Surgery*. Vol. 2. Athens, Greece: Paschalidis Medical Publications; 2004.)

Surgicoanatomical Segments

Similar to the segmentation that can be found in the liver, kidney, spleen, and other organs, anatomicosurgical segments have been described for the pancreas. Two segments were designated, the right (cephalocervical) segment and the left (corporocaudate) segment (Fig. 121.15). The segments of the pancreas are separated by a poorly vascularized area. They

are connected by the pancreatic duct and often by a small artery, the inferior pancreatic artery (see below) (Fig. 121.16). Both segments can be used for transplantation.

PANCREATIC DUCTS

Anatomy and Variations

The pancreatic ducts lie anterior to the major pancreatic vessels. The main pancreatic duct arises in the tail of the pancreas. Through the tail and body of the pancreas, the duct lies midway between the superior and inferior margins, slightly more posterior. It crosses the vertebral column between the 12th thoracic and 2nd lumbar vertebrae.

Fifteen to 20 short tributaries enter the duct at right angles in the region of the body and tail; superior and inferior tributaries tend to alternate. The main duct may receive a tributary draining the uncinate process, and, in some individuals, the accessory pancreatic duct empties into the main duct. Small tributary ducts in the head may open directly into the intrapancreatic portion of the CBD.

The main duct turns caudad and posterior upon reaching the head or neck of the pancreas. At the level of the major papilla, the duct turns horizontally to join the caudal surface of the CBD and enters the wall of the duodenum, usually at the level of the second lumbar vertebra.

The accessory pancreatic duct (of Santorini) may drain the anterosuperior portion of the head, either into the duodenum at the minor papilla or into the main pancreatic duct. Because of the developmental origin of the two pancreatic ducts, several variations are encountered. The usual configuration is seen in Figure 121.17A. The accessory duct (Santorini) is smaller than the main pancreatic duct (of Wirsung) and opens into the duodenum on the minor papilla. Configurations in Figure 121.17B–E show examples of progressive reduction in size of the accessory duct.

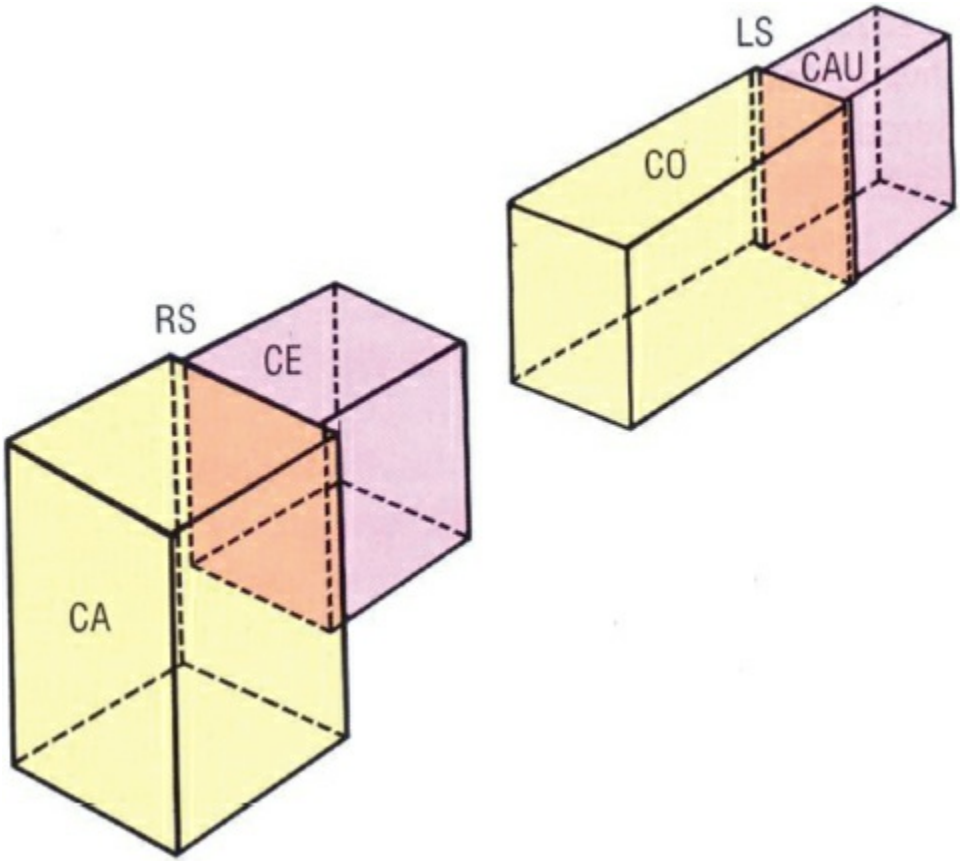

Figure 121.15. Diagrams of the surgicoanatomical segments of the pancreas. RS, right (cephalocervical) segment; LS, left (corpocaudate) segment. The right and left pancreatic segments are artificially separated at the pauci-arterial area. CA, caput (head); CE, cervix (neck); CO, corpus (body); CAU, cauda (tail). (From Skandalakis JE, Skandalakis LJ, Kingsnorth AN, et al. Pancreas. In: Skandalakis JE, Colborn GL, Weidman TA, et al., eds. *Skandalakis' Surgical Anatomy: The Emryologic and Anatomic Basis of Modern Surgery*. Vol. 2. Athens, Greece: Paschalidis Medical Publications; 2004.)

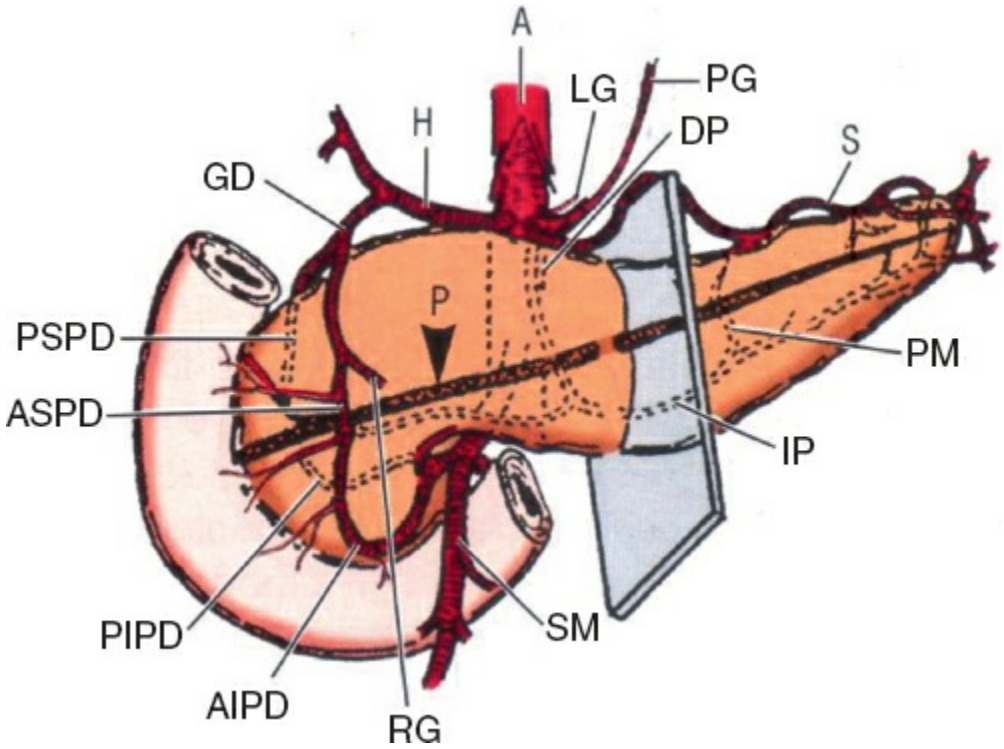

Figure 121.16. Surgicoanatomic segments of the pancreas. The intersegmental plane has been drawn on the left of the superior mesenteric artery. The right and left segments are united intraparenchymally only by the inferior pancreatic artery. A, aorta; LG, left gastric artery; PG, posterior gastric artery; DP, dorsal pancreatic artery; S, splenic artery; PM, pancreatic magna artery; IP, inferior pancreatic artery; SM, superior mesenteric artery; RG, right gastroepiploic artery; AIPD, anterior inferior pancreaticoduodenal artery; PIPD, posterior inferior pancreaticoduodenal artery; ASPD, anterior superior pancreaticoduodenal artery; PSPD, posterior superior pancreaticoduodenal artery; GD, gastroduodenal artery; H, hepatic artery; P (*arrow*), pancreatic duct. (From Skandalakis JE, Skandalakis LJ, Kingsnorth AN, et al. Pancreas. In: Skandalakis JE, Colborn GL, Weidman TA, et al., eds. *Skandalakis' Surgical Anatomy: The Emryologic and Anatomic Basis of Modern Surgery*. Vol. 2. Athens, Greece: Paschalidis Medical Publications; 2004.)

In approximately 10% of individuals, there is no connection between the accessory duct and the main duct (Fig. 121.17D). This fact is important to remember when contrast medium is injected into the main duct. There is no minor papilla in 30% of individuals (Fig. 121.17B–E). In some individuals who have a minor papilla, the terminal portion of the accessory duct is too small to permit the passage of any quantity of fluid. Three

papillae have been seen.

Length, Width, and Capacity of the Pancreatic Ducts

ERCP has made the determination of the length, diameter, and capacity of the pancreatic ductal system possible. The greatest diameter of the main pancreatic duct is in the head of the pancreas (2.6 to 4.8 mm), just before the duct enters the duodenal wall. From this diameter, the duct gradually tapers (2.0 to 3.5 mm) toward the tail (0.9 to 2.4 mm) (Fig. 121.18). Like the bile duct, the pancreatic duct is constricted in the wall of the duodenum. Reported length of the main pancreatic duct varies from 175 to 260 mm.

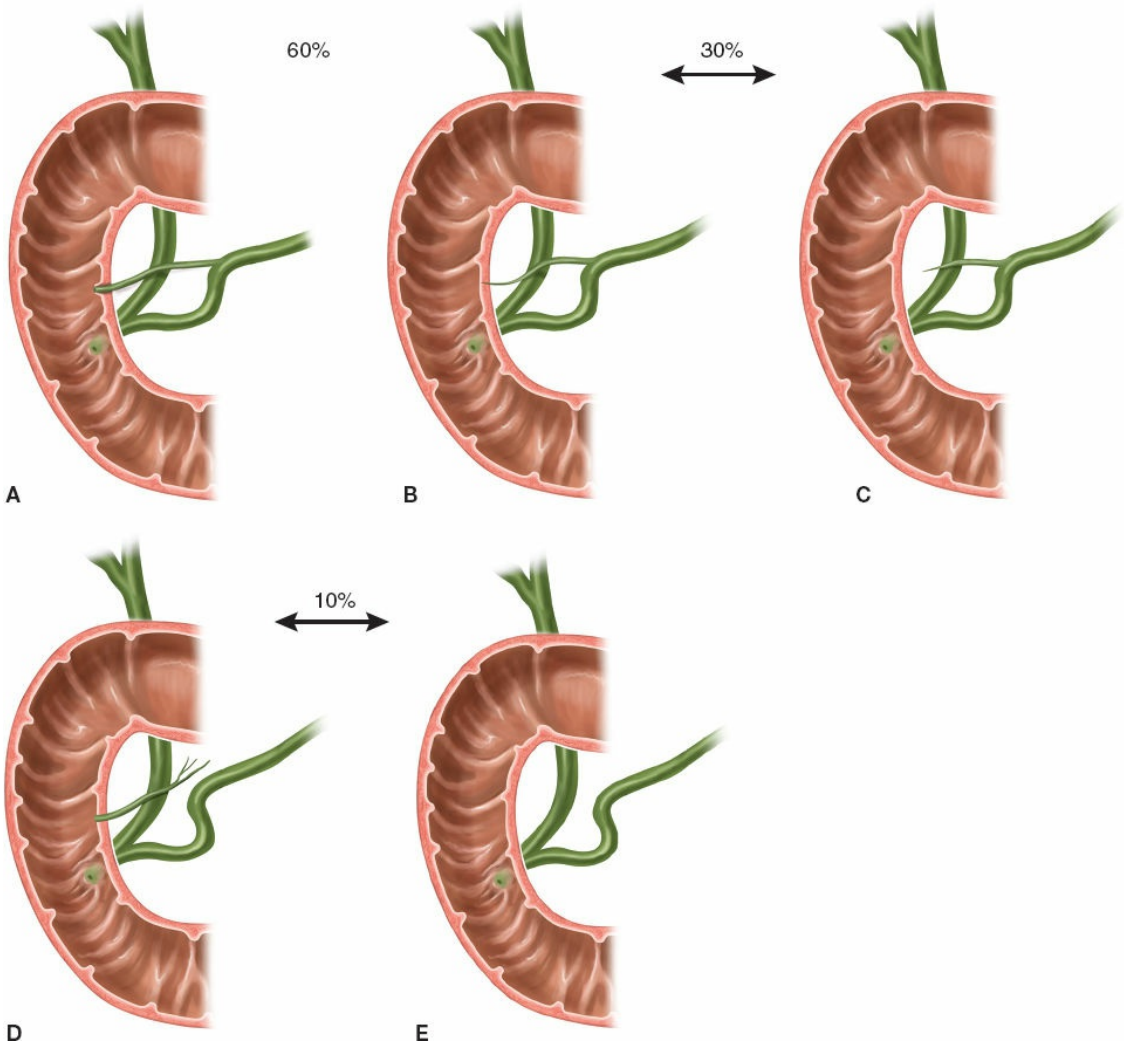

Figure 121.17. Variations of the pancreatic ducts. Degrees of suppression of the accessory duct. **A.** Both ducts open into the duodenum (60%). **B, C.** The accessory duct ends blindly (30%). **D.** The accessory duct does not communicate with the main duct (10%). **E.** The accessory duct is absent.

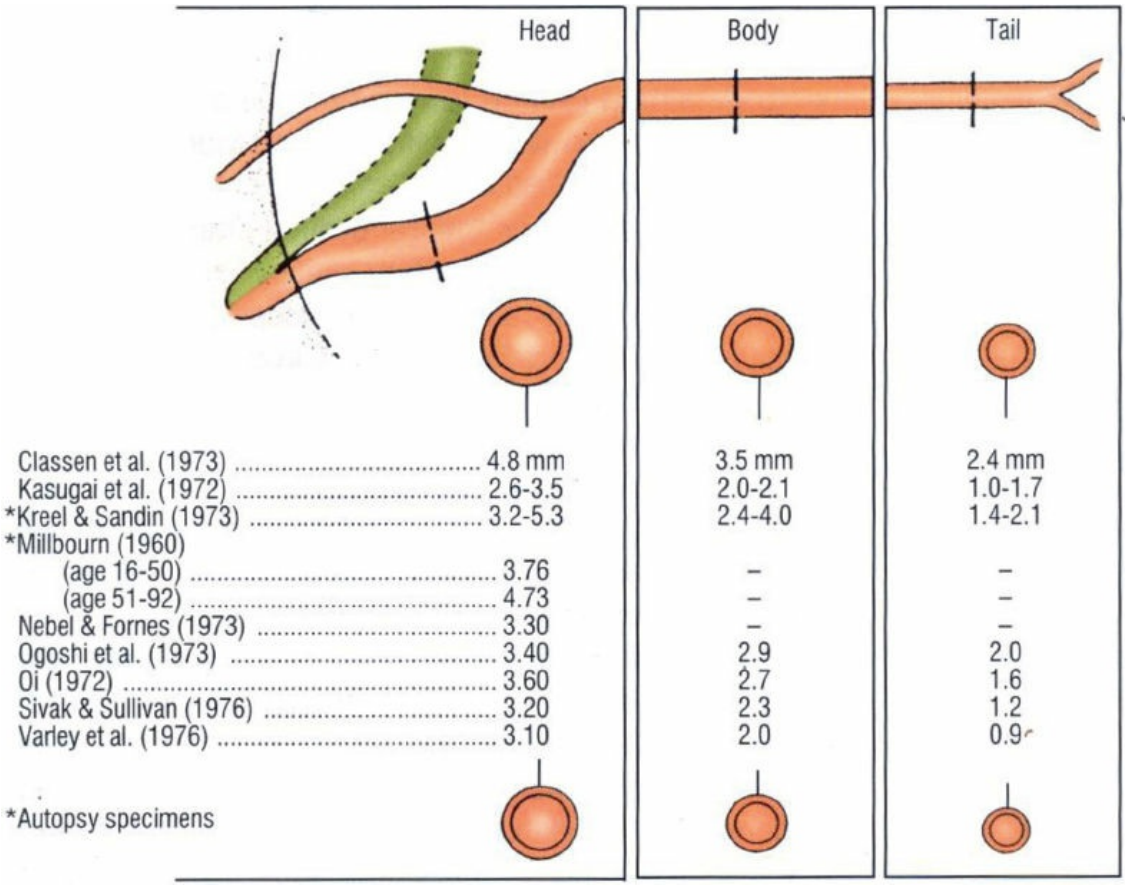

Figure 121.18. Diameter of the main pancreatic duct as reported by several authors. (From Skandalakis JE, Skandalakis LJ, Kingsnorth AN, et al. Pancreas. In: Skandalakis JE, Colborn GL, Weidman TA, et al., eds. *Skandalakis' Surgical Anatomy: The Emryologic and Anatomic Basis of Modern Surgery*. Vol. 2. Athens, Greece: Paschalidis Medical Publications; 2004.)

The normal pancreatic ductal system is quite small. Two to 3 mL of contrast medium fills the main pancreatic duct in the living patient; and 7 to 10 mL fills the branches and the smaller ducts. In autopsy specimens, 0.5 to 1.0 mL has been found to be sufficient to fill the duct system.

Major Duodenal Papilla and Hepatopancreatic Ampulla

There is confusion in the literature about the correct name, definition, and distinguishing points of the major duodenal papilla (often referred to as the papilla of Vater) and the hepatopancreatic or biliaropancreatic ampulla (often referred to as ampulla of Vater). The papilla is a nipplelike projection of duodenal mucosa, located where the main pancreatic duct and the CBD drain into the duodenum. The hepatopancreatic ampulla is the union of the lumen of the CBD with that of the pancreatic duct.

Major Duodenal Papilla

This papilla commonly bears the name of Abraham Vater (1684–1751), although there is controversy as to whether this eponym is historically accurate. As such, the most useful term is major (or greater) duodenal papilla.

The papilla is situated on the posteromedial wall of the second portion of the duodenum, 7 to 10 cm from the pylorus. Rarely, the papilla may be in the third portion of the duodenum, to the right of the superior mesenteric vessels.

Viewed from the mucosal surface of the duodenum, the papilla is found where a longitudinal mucosal fold meets a transverse mucosal fold to form a "T" (Fig. 121.19). The papilla may be difficult to distinguish as it may be covered by one of the transverse folds. On the other hand, too much traction may erase the folds. The papilla is "prominent" and easily identified in 60% of their specimens.

During duodenal exploration, if the papilla cannot be identified, compression of the gallbladder to induce effluence of bile or connotation of the cystic duct and passage of a probe to the papilla can help identify it. Uncommonly, a duodenal duplication cyst in the second portion may obscure the papilla.

Hepatopancreatic (Biliaropancreatic) Ampulla

Although the ampulla is named after Vater, there is much evidence that it was first described by Santorini. Vater actually described a diverticulum of duodenal mucosa, now referred to as perivaterian diverticulum.

The ampulla is a dilatation of the common pancreaticobiliary channel adjacent to the papilla and below the junction of the two ducts. The extent to which the CBD and the pancreatic duct are separated in the duodenal wall varies, and the ampulla is of variable length (Fig. 121.20). In cases where a septum is present at the duodenal orifice, the ampulla is considered absent (Fig. 121.20B). The CBD and the pancreatic duct may even open independently upon the papilla (Fig. 121.20C).



Figure 121.19. The “T” arrangement of the duodenal mucosal folds at the site of the major papilla. The papilla is rarely this obvious. This illustration by Santorini was published posthumously in 1775.

Michels collected data from 25 investigators representing 2,500 specimens and concluded that an ampulla was present in 64% of cases. Actual measurements of the distance between septal edge and papillary tip range from 1 to 14 mm, with 75% being 5 mm or less. The following classification, consisting of three types, was suggested by Michels and is the most useful.

Type 1. The pancreatic duct opens into the CBD at a variable distance from the opening in the major duodenal papilla (Fig. 121.20A,B).
Type 2. The pancreatic and bile ducts open close to one another, but separately, without an ampulla, on the major duodenal papilla (5%) (Fig. 121.20C).
Type 3. The pancreatic and bile ducts open into the duodenum at separate points without an ampulla (9%).

The basic embryologic explanation for the above three types is that growth of the duodenum absorbs the proximal bile duct up to its junction with the pancreatic duct. When absorption is minimal, there is a long

ampulla and the junction of the ducts is high in the duodenal wall (Fig. 121.20A) or even extramural. With increasing absorption of the terminal bile duct, the junction lies closer to the duodenal orifice until the ampulla does not exist (Fig. 121.20B). Maximal resorption results in separate orifices for the main pancreatic duct and the CBD (Fig. 121.20C).

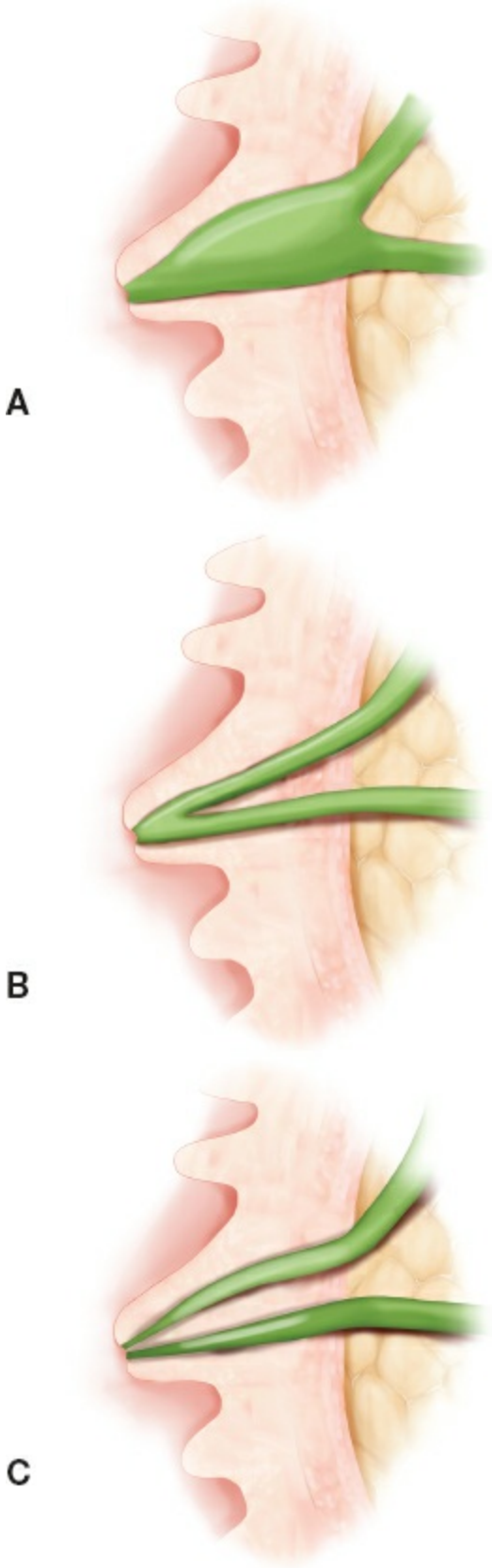

Figure 121.20. Variations of the common bile duct and the main pancreatic duct at the duodenal papilla. An ampulla is present in **A**; it is absent in **B** and **C.**

Smooth muscle ensheathes the ampulla forming the sphincter of the hepatopancreatic ampulla, which belongs to the broader sphincter complex of Boyden in the hepatopancreaticoduodenal area (see below).

The blood supply of the ampulla of Vater is not well defined, and may share common territory with the distal CBD and the pancreatic duct. The arterial plexus of the ampulla is mostly given by the posterior superior pancreaticoduodenal artery. The retroduodenal artery also provides small braches to the ampulla (Fig. 121.21**).** Dorsal and ventral branches are usually balanced, but dominance of either dorsal or ventral branch may happen.

During surgical or endoscopic sphincterotomy, or sphincteroplasty the incision should be at the 10 to 11 o'clock position and run 5 to 8 mm in length to minimize the risk of hemorrhage from a retroduodenal artery or anomalous right hepatic artery originating from the SMA, as these two vessels are located between the distal CBD and duodenum.

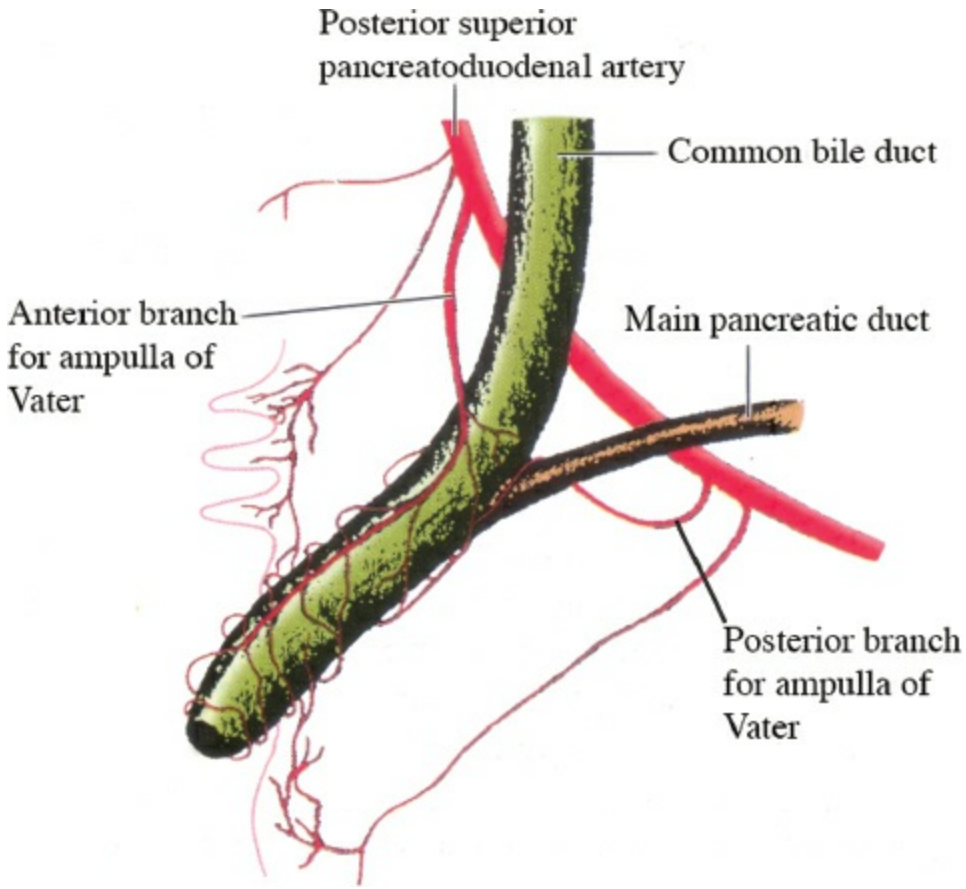

Figure 121.21. Blood supply of the hepatopancreatic (biliopancreatic) ampulla. The posterior superior pancreaticoduodenal artery crosses the common bile duct and gives rise to anterior and posterior branches. (Modified from

Skandalakis JE, Skandalakis LJ, Kingsnorth AN, et al. Pancreas. In: Skandalakis JE, Colborn GL, Weidman TA, et al., eds. *Skandalakis' Surgical Anatomy: The Emryologic and Anatomic Basis of Modern Surgery*. Vol. 2. Athens, Greece: Paschalidis Medical Publications; 2004.)

Sphincter of Boyden/Sphincter of Oddi

The present concept is that several sphincters composed of smooth-muscle fibers surround the intramural portion of the CBD, the main pancreatic duct, and the ampulla, if present (Fig. 121.22). This complex has a separate embryonic origin from that of the duodenal musculature and is functionally separate. Although the anatomy was well described by Boyden and others, the terminology remains confusing. We call the entire sphincter complex the sphincter of Boyden in recognition of his contribution to our understanding of the anatomy of this region, but it was originally described by Oddi in 1887, and other authors refer to it as the sphincter of Oddi.

The sphincteric complex may be as short as 6 mm or as long as 30 mm, depending on the obliquity of its path through the duodenal wall. In some instances, the sphincter may extend beyond the duodenal wall into the pancreatic portion of the bile duct, which is relevant when performing sphincterotomy.

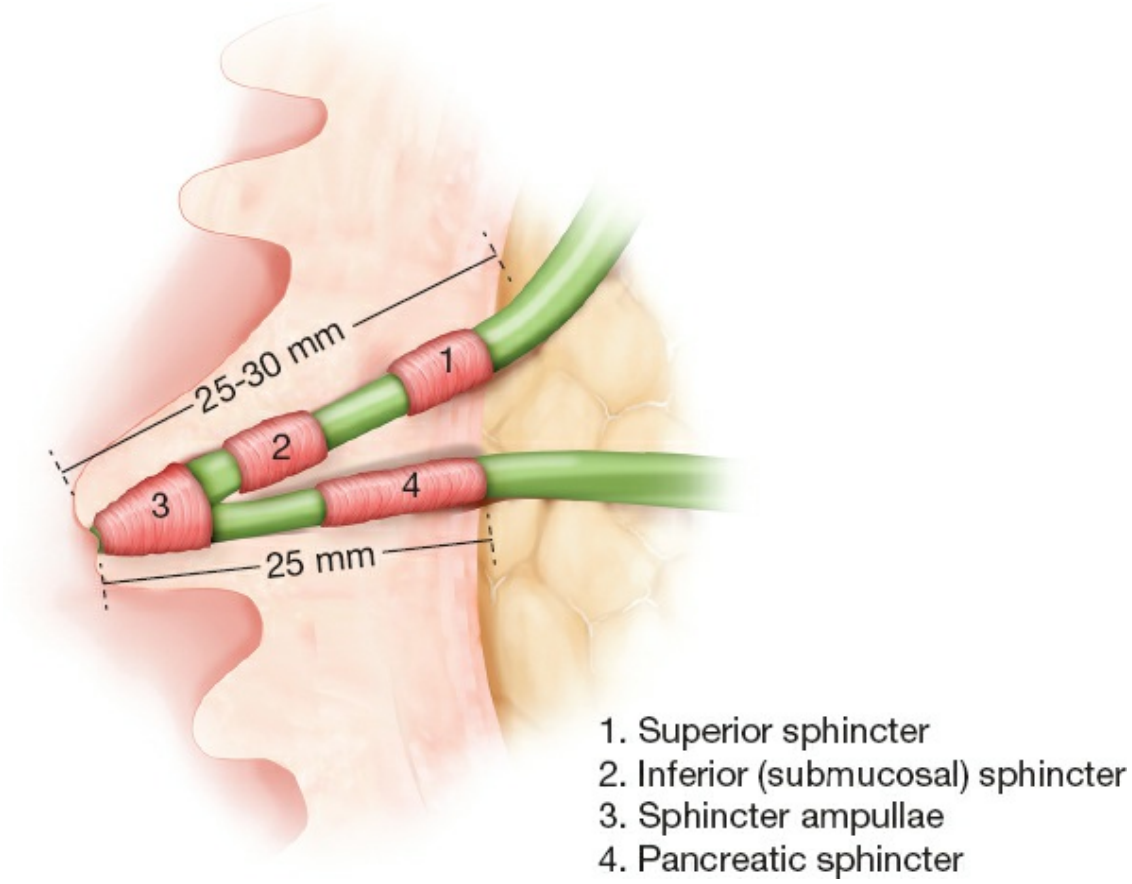

Figure 121.22. The four entities composing the sphincter of Boyden. The measurements are from White (1973).

Minor Duodenal Papilla

The minor duodenal papilla is situated approximately 2 cm cranial and slightly anterior to the major papilla. It is smaller, and does not bear the characteristic mucosal folds that mark the major papilla. It is debatable if the minor papilla is present in all people, as studies of specimens range from finding it in 0% to 100% of cases.

An excellent landmark for the minor papilla is the gastroduodenal artery, situated anterior to the accessory pancreatic duct (Santorini) and the minor papilla. During gastrectomy, duodenal dissection should end proximal to or at this artery. It becomes important in the few patients in whom the accessory duct carries the major drainage of the pancreas.

VASCULAR SYSTEM

The vascular system of the pancreas is complex and nontypical, with many different patterns.

ARTERIAL SUPPLY OF THE PANCREAS

The pancreas is supplied with blood from branches arising from both the celiac trunk and the SMA (Figs. 121.23 and 121.24). Variations are common. The head of the pancreas and the concave surface of the duodenum are supplied by two pancreaticoduodenal arterial arcades that are always present. These are formed by a pair (anterior and posterior) of superior arteries from the gastroduodenal branch of the celiac trunk. These arteries join a second pair of inferior arteries from the SMA. These vascular arcades lie on the surface of the pancreas but also supply the duodenal wall, which is why duodenal-preserving pancreatectomy is a complex endeavor.

At the neck of the gland, the dorsal pancreatic artery usually arises from the splenic artery, near its origin off the celiac trunk. More rarely, it may arise from the celiac axis (as a fourth branch) or even from the SMA. During laparoscopic distal pancreatectomy, this branch is at risk of injury, especially when the splenic artery is dissected out at its origin from underneath the pancreas. The dorsal pancreatic artery courses downward dorsal to the neck or body of the pancreas and ends in right and left branches. A right branch of the dorsal pancreatic artery supplies the head of the pancreas and usually joins the posterior arcade. It may also anastomose with the anterior superior pancreaticoduodenal (ASPD) artery. The left branch of the dorsal pancreatic artery is typically the transverse, or inferior, pancreatic artery. The left and right branches of the dorsal pancreatic artery characteristically lie within a groove on the inferior margin of the pancreas.

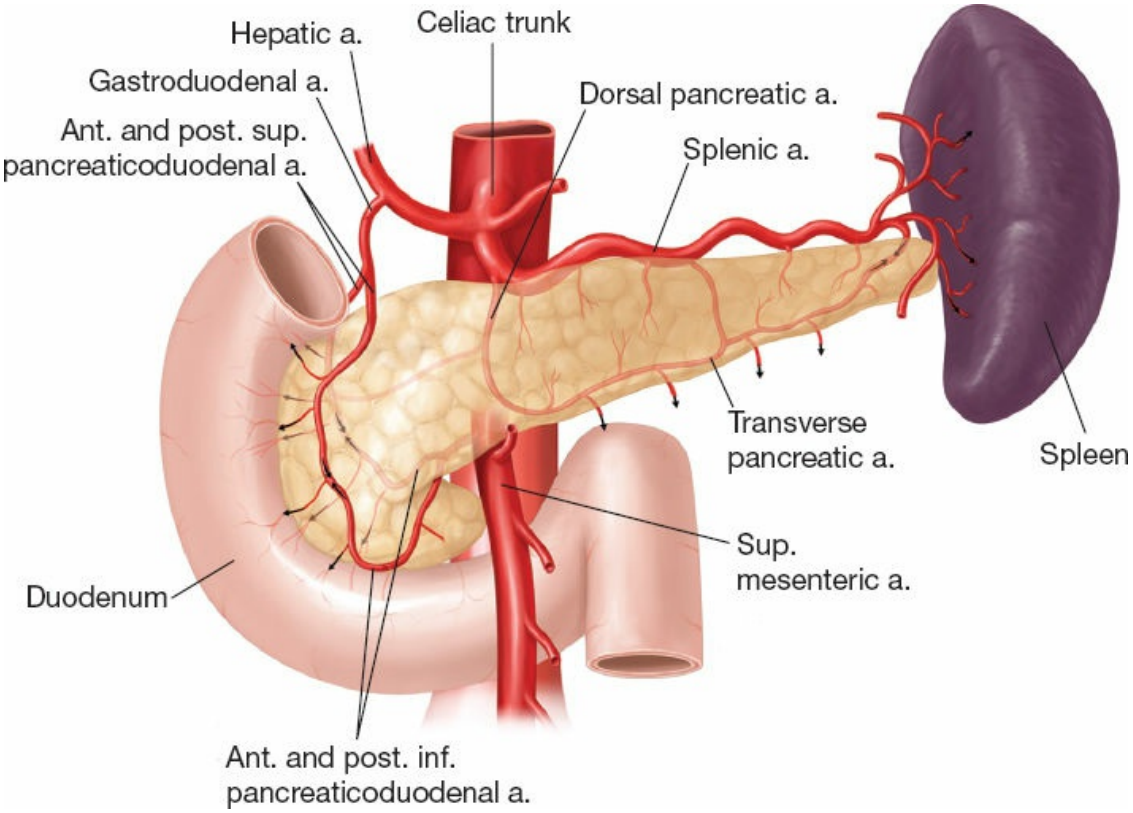

Figure 121.23. Anterior view of the major arterial supply to the pancreas (the left and right gastric arteries are omitted).

Pancreatic Arcades

The pancreatic or preferably pancreaticoduodenal arcades are formed by the union of the anterior superior and anterior inferior, posterior superior and posterior inferior, pancreaticoduodenal arteries. The anterior and posterior arcades give pancreatic and duodenal branches. The latter are also known as arteriae rectae and supply the surfaces of the duodenum indicated by their names. It is evident that any effort to separate the duodenum from the head of the pancreas will seriously affect the blood supply of the duodenum and is therefore avoided.

The pancreatic arcades vary in position, but it is generally accepted that the posterior is farther from the pancreaticoduodenal groove than the anterior one. The length of the arteriae recta also varies, but usually it does not exceed the 3.5 cm. The arcades are complete in the vast majority, but there have been reports that the arches are incomplete in about 25%.

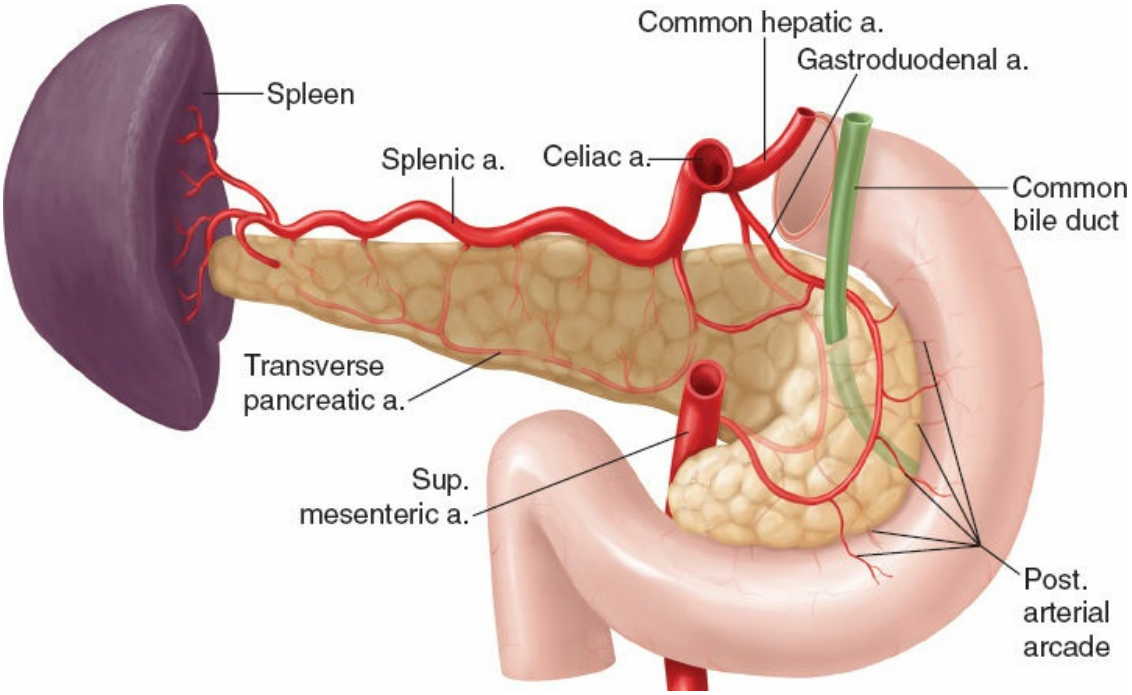

Figure 121.24. Posterior view of the major arterial supply to the pancreas (the left and right gastric arteries are omitted).

Anterior Superior Pancreaticoduodenal Artery

The ASPD artery is the end one of the two end-arteries of the gastroduodenal artery—the other one is the right gastroepiploc artery (for details on the gastroduodenal artery, see the chapter "Anatomic Considerations in Gastroduodenal Sugery"). The ASPD artery arises from the gastroduodenal at about the lower border of the duodenum.

The ASPD artery lies on the anterior surface of the head of the pancreas, where it contributes 8 to 10 branches to the anterior surface of the pancreas and the duodenum. In its course, the ASPD artery may be entirely upon the anterior surface of the head or partly embedded in it. The main stem of the APSD ends by anastomosing richly with the anterior inferior pancreaticoduodenal (AIPD) artery at the lower margin of the pancreatic head. According to Hollinshead, the lower part of the anterior arcade (given by ASPD and AIPD arteries) is closer to the pancreaticoduodenal groove than the upper part, and enters the head of the pancreas, to lie finally, at its lower origin posterior to the pancreas (Fig. 121.25).

Posterior Superior Pancreaticoduodenal Artery

The posterior superior pancreaticoduodenal (PSPD) artery arises from the

gastroduodenal artery. This is true in more than 90% of the cases. In small percentages, it may arise from a right hepatic artery from the SMA, from the common hepatic artery, or from the dorsal pancreatic artery (Fig. 121.26).

The gastroduodenal artery also gives the supraduodenal and retroduodenal arteries, which are much smaller branches than the PSPD. These are given off prior to the PSPD artery (see Figure 32 in the chapter "Anatomic Considerations in Gastroduodenal Surgery") and provide arterial supply to the first part of the duodenum and distal bile duct. Either or both of these arteries can arise separately or as branches of the PSPD artery.

The PSPD artery is given off the gastroduodenal artery above the upper border of the head of the pancreas. If the gastroduodenal artery lies to the left of the CBD, as usually happens, the PSPD artery passes in front of the CBD onto the posterior surface of the pancreas. The course of the PSPD artery follows the curvature of the duodenum and unites with the posterior inferior pancreaticoduodenal (PIPD) artery. As mentioned above, the posterior arcade tends to follow the duodenal curve less closely than the anterior arcade.

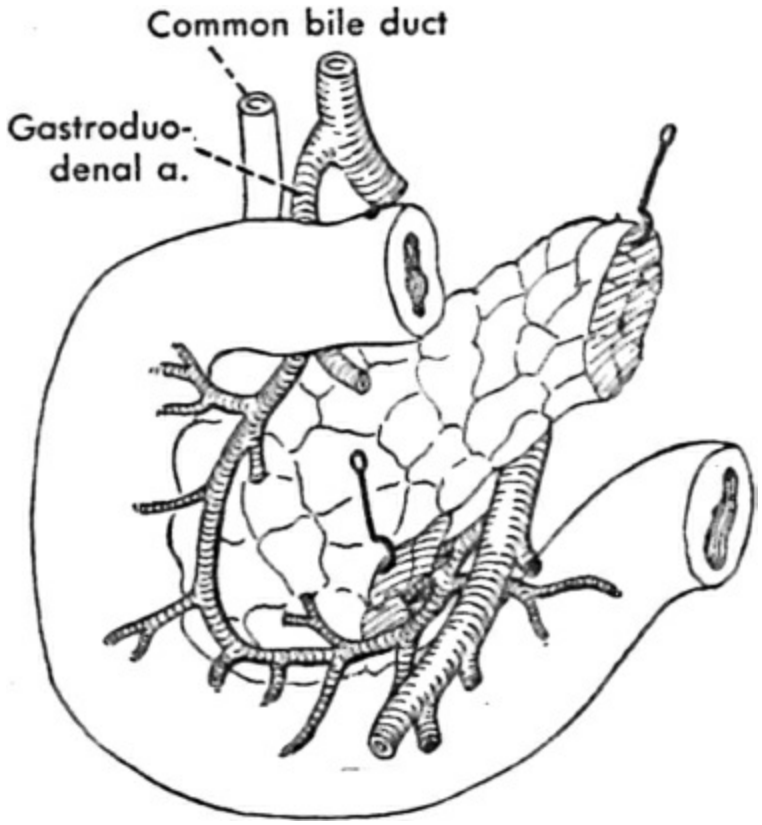

Figure 121.25. The anterior pancreaticoduodenal arcade. The

anterior superior pancreaticoduodenal artery, a terminal branch of the gastroduodenal has been separated from the right gastroepiploic (cut-off) behind the duodenum. The anterior inferior pancreaticoduodenal artery arises from the posterior surface of the superior mesenteric artery by a common stem with the posterior inferior pancreaticoduodenal artery (disappearing behind the pancreas). (From Hollinshead WH. *Anatomy for Surgeons, Vol. 2: The Thorax, Abdomen, and Pelvis*. New York: Hoeber-Harper; 1956.)

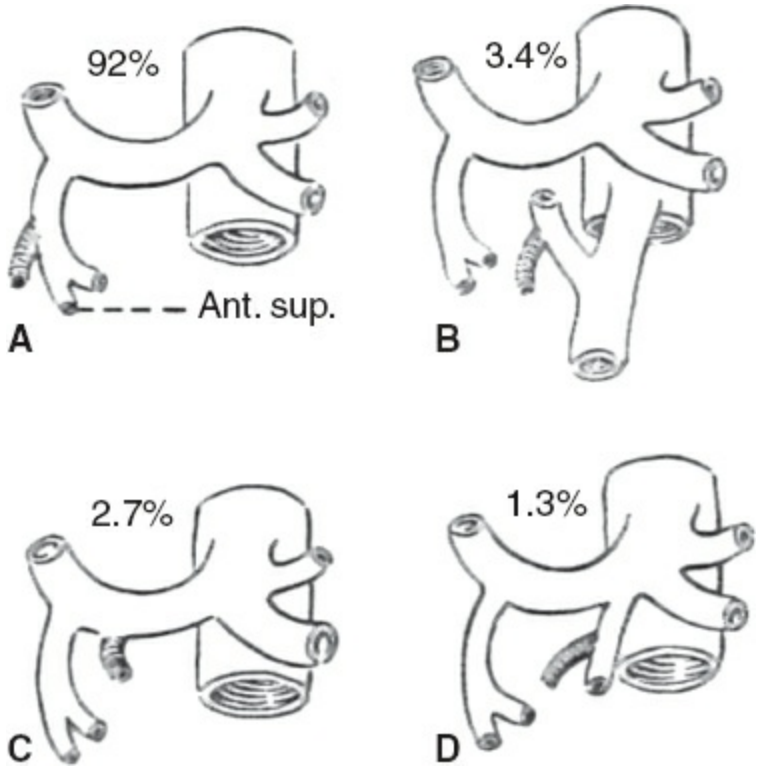

Figure 121.26. Origins of the superior pancreaticoduodenal arteries. The anterior superior (Ant. sup.) pancreaticoduodenal artery is always a terminal branch of the gastroduodenal. The posterior superior pancreaticoduodenal artery (shaded) usually arises from the gastroduodenal (**A**). In the percentages indicated, it might arise from a right hepatic branch of the superior mesenteric artery (**B**), from the hepatic artery (**C**), or from the dorsal pancreatic artery (**D**). (From Hollinshead WH. *Anatomy for Surgeons, Vol. 2: The Thorax, Abdomen, and Pelvis*. New York: Hoeber-Harper; 1956.)

The posterior arcade passes posterior to the intrapancreatic portion of the CBD. Like the anterior arcade, the posterior arcade may be doubled or tripled, with the extra arcades joining the PIPD artery or the SMA. The

posterior arcade may also anastomose with an aberrant right hepatic artery from the SMA, either separately or in combination with the anterior arcade.

Inferior Pancreaticoduodenal Arteries

The AIPD artery arises from the SMA at or above the inferior margin of the pancreatic neck. It may form a common trunk with the PIPD artery. In the first part of its course, the AIPD artery passes through the substance of the head of the pancreas. Then, it obtains a more superficial position toward the anterior surface of the head of the pancreas. The PIPD artery retains its posterior position, behind or embedded in the pancreas.

The AIPD and PIPD, both or just one vessel, may arise from the first or second jejunal branches of the SMA. Ligation of the jejunal branch endangers the blood supply to the fourth part of the duodenum, which may result in necrosis or stricture. Occasionally, a PIPD artery arises from an aberrant right hepatic artery off the SMA.

Branches of the Splenic Artery

The splenic artery courses to the left along the posterior surface of the body and tail of the pancreas, looping above and below the superior margin of the organ. This pathway may become more tortuous with age. If the posterior gastric artery is not present, the first major branch of the splenic artery is the dorsal pancreatic artery, which usually joins one of the posterosuperior arcades after giving off the inferior (transverse) pancreatic artery to the left.

The course of the inferior pancreatic artery is variable. It may be doubled or absent. It may or may not anastomose with the splenic artery in the body and tail of the pancreas (Fig. 121.27). The inferior artery often joins the gastroduodenal artery or the ASPD artery to the right. If anastomotic connections are absent, thrombosis of the inferior pancreatic artery may produce emboli, infarction, and necrosis of the tail and possibly of the distal body of the pancreas.

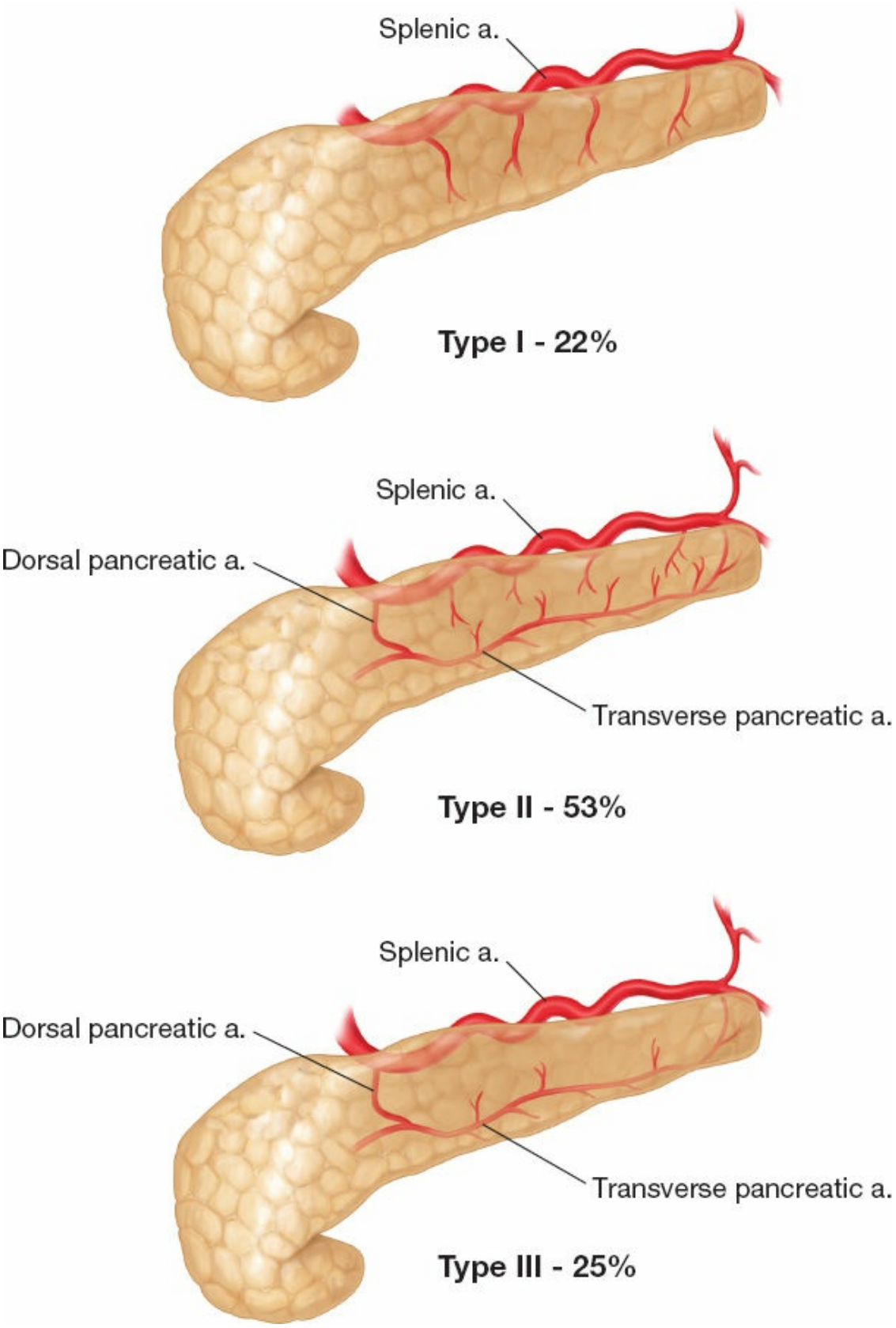

Figure 121.27. Diagram of the possible configurations of the blood supply to the distal pancreas. Type I (22%), blood supply from the splenic artery only. Type II (53%), blood supply from splenic and transverse pancreatic arteries with anastomosis in

the tail of the pancreas. Type III (25%), blood supply from splenic and transverse pancreatic arteries without distal anastomosis. This type is susceptible to infarction from emboli in the transverse artery.

Great Pancreatic Artery

The great pancreatic (pancreatica magna) artery arises from the splenic artery and reaches the pancreas near the junction of the body and tail. This artery commonly anastomoses with the inferior pancreatic artery.

Caudal Pancreatic Artery

The caudal pancreatic artery arises from either a distal segment of the splenic artery, the left gastroepiploic artery, or a splenic branch at the splenic hilum. It anastomoses with branches of the great pancreatic and other pancreatic arteries. The caudal pancreatic artery supplies blood to accessory splenic tissue when it is present at the hilum.

Anomalous Hepatic Arteries

The common hepatic artery (Fig. 121.28A) is usually a main branch of the celiac trunk, which arises cranial to the pancreas. The surgeon must always look for a possible anomalous hepatic artery before proceeding with a pancreatic resection. These aberrant arteries may be in addition to (accessory) or in place of (replaced) normal hepatic arteries.

In 2.0% to 4.5% of persons, an anomalous common hepatic artery arises from the SMA. It is related to the head or neck of the pancreas. Occasionally it passes through the head (Fig. 121.28B). It subsequently passes behind and to the right of the portal vein.

More commonly, an anomalous right hepatic artery arises from the SMA. This artery may pass behind the CBD or behind the portal vein (Fig. 121.28C). In a landmark study, an aberrant right hepatic artery was present in 26% of bodies examined by Michels. It may give off the inferior pancreaticoduodenal arteries.

An anomalous left hepatic artery presents a problem in operations on the pancreas only when it arises from the right side of the SMA (Fig. 121.28D) or from the gastroduodenal artery (Fig. 121.28E). Michels found an anomalous left hepatic artery in 27% of specimens, arising most commonly from the left gastric artery.

Anomalous Middle Colic Artery

A middle colic artery may pass through the head of the pancreas or between the head and the duodenum (Fig. 121.29). It may arise from the superior mesenteric, the dorsal pancreatic, or the inferior pancreaticoduodenal arteries.

VENOUS DRAINAGE OF THE PANCREAS

In general, the veins of the pancreas parallel the arteries and lie superficial to them. Both veins and arteries lie posterior to the ducts in the body and tail of the pancreas. All pancreatic veins drain into the inferior mesenteric, splenic, or portal vein (Figs. 121.30 and 121.31).

Veins of the Head of the Pancreas

Four pancreaticoduodenal veins form venous arcades, draining the head of the pancreas and the duodenum. The ASPD vein joins the right gastroepiploic vein. The right gastroepiploic receives a colic vein and forms a short gastrocolic vein. This becomes a tributary to the SMV. Otherwise known as the gastrocolic trunk, this vein should be identified, ligated, and divided before dissecting cephalad along the anterior aspect of the SMV during pancreatectomy (Whipple resection, extended distal pancreatectomy, or central pancreatic resection).

The PSPD vein enters the portal vein above the superior margin of the pancreas. The anterior and PIPD veins enter the SMV together or separately. Other small, unnamed veins in the head and neck drain independently into the SMV and the right side of the portal vein. While, in general, there are no anterior branches of the portal-SMV junction, there may be some exceptions, which bear relevance in pancreatic neck dissection.

Veins of the Neck, Body, and Tail of the Pancreas

The veins of the left portion of the pancreas form two large venous channels: the splenic vein above and the transverse (inferior) pancreatic vein below. A smaller superior pancreatic vein can sometimes be identified.

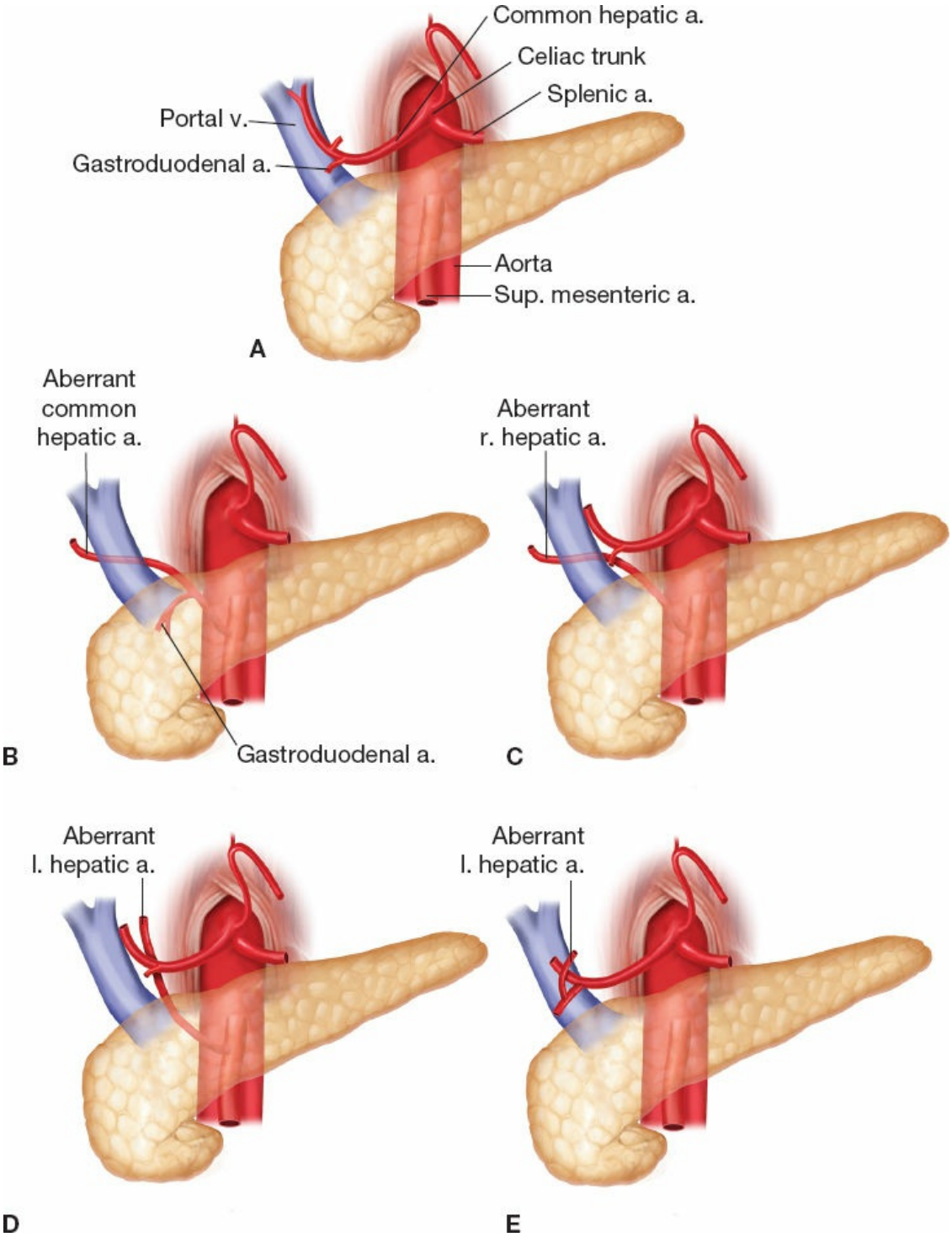

Figure 121.28. Variations of the hepatic arteries. **A.** Normal configuration; the common hepatic artery arises from the celiac trunk. **B.** An aberrant common hepatic artery arises from the superior mesenteric artery. **C.** An aberrant right hepatic artery arises from the superior mesenteric artery. **D.** An aberrant left hepatic artery arises from the superior mesenteric artery. **E.** An aberrant left hepatic artery arises from the gastroduodenal artery. These aberrant arteries may be accessory to, or may replace, normal hepatic arteries.

The splenic vein may receive from 3 to 13 short pancreatic tributaries. In a few instances, one such tributary enters the left gastroepiploic vein in the tail of the pancreas. The inferior mesenteric vein terminates in the splenic vein in approximately 38% of individuals, and the left gastric vein has a similar ending in 17% of individuals. The inferior pancreatic vein may enter the left side of the SMV, the inferior mesenteric vein, or occasionally the splenic or the gastrocolic veins.

Portal Vein

The portal vein is formed behind the neck of the pancreas by the union of the superior mesenteric and splenic veins. The inferior mesenteric vein enters at this junction in approximately one third of cases, directly into the splenic vein in another third, and into the SMV in the final third of cases.

The portal vein lies behind the pancreas and in front of the inferior vena cava, with the CBD on the right and the common hepatic artery on the left. In the absence of disease, the portal vein and the SMV can be separated easily from the posterior surface of the pancreas.

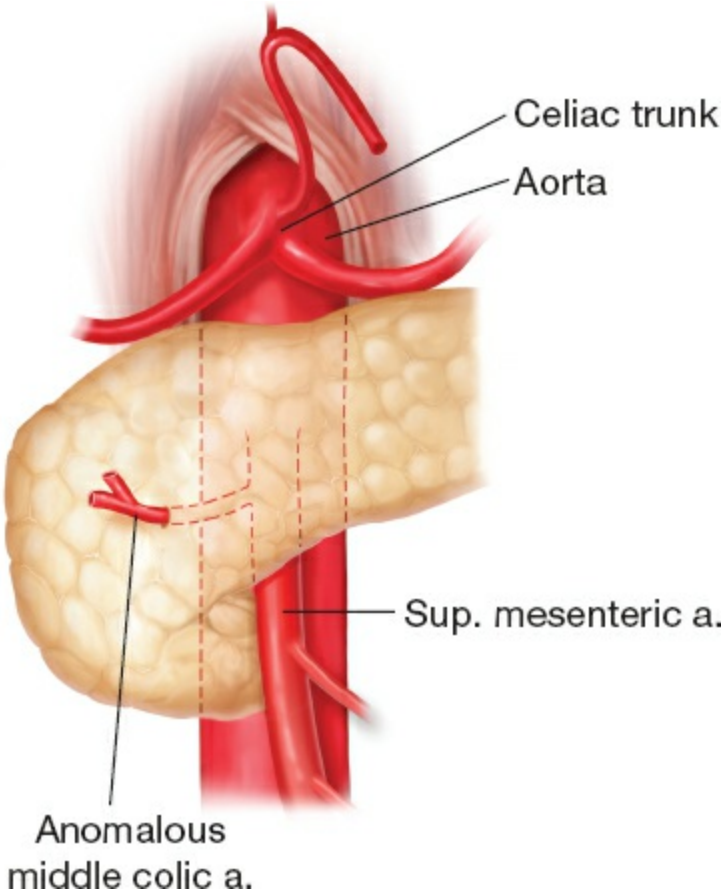

Figure 121.29. An anomalous middle colic artery passing through the head of the pancreas.

Rarely the portal vein may lie anterior to the pancreas and the duodenum (preduodenal portal vein; for embryogenesis of this congenital anomaly, see Embryology section in the chapter “Anatomic Considerations in Gastroduodenal Surgery”).

SURGICAL CONSIDERATIONS

The right branch of the dorsal pancreatic artery anastomoses with the PSPD artery. This branch typically does not provide enough blood for survival of the head and duodenum after the arcades are ligated. Preservation of the duodenum is difficult during pancreatic head resection due to shared blood supply.

The PSPD artery is the main supply for the ampulla through the epicholedochal plexus.

Injury may occur to the ASPD artery during the Puestow side-to-side pancreatojejunostomy.

The superior and inferior pancreaticoduodenal arteries should not be ligated until the neck of the pancreas can be elevated from the underlying vessels. Premature ligation could cause necrosis of the head of the pancreas and duodenum.

Noncommunication between the splenic and transverse pancreatic arteries is possible. It can result in infarction of a portion of the pancreatic tail. This may present as a stricture and may mimic malignancy.

Ligation of the splenic artery and vein will result in splenic infarction, and necessitates splenectomy unless the short gastric vessels are maintained between the stomach and the spleen. It is possible for the spleen to remain viable on these small vessels. Spleen-preserving distal pancreatectomy with splenic vessel sacrifice is known as the Warshaw technique. A small percentage of patients who undergo this procedure will develop delayed complications, such as splenic congestion, and bleeding gastric varices, and will require subsequent splenectomy.

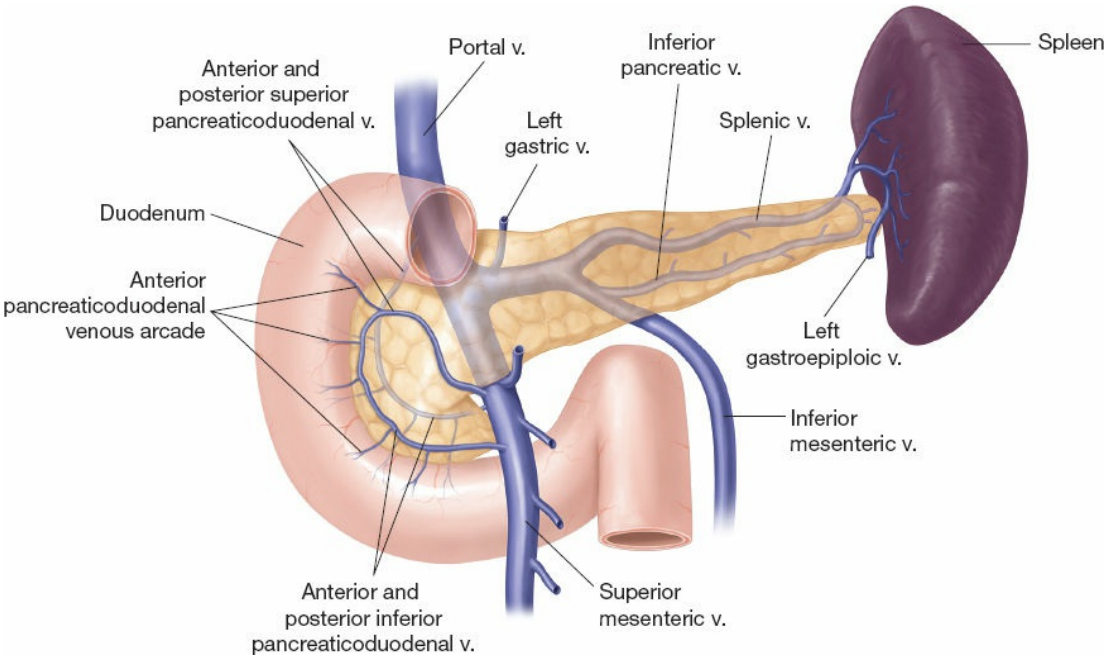

Figure 121.30. Anterior view of the venous drainage of the pancreas.

Collateral circulation can develop as a result of stenosis of the SMA or celiac artery. Abnormal blood flow through the pancreaticoduodenal arcade is found during angiographic examination.

Ligation of both pancreaticoduodenal arterial arcades results in duodenal ischemia and necrosis.

Veins of the pancreatic parenchyma are located posterior to the ducts and anterior to the arteries.

Pancreatic veins enter the lateral side of the portal vein or SMV from the pancreatic head and uncinate process. These are of varying sizes, and are a risk of tearing during pancreaticoduodenectomy. Furthermore, this is a common location of tumor invasion, which may necessitate resection and reconstruction of the portal vein and/or SMV to obtain clear margin.

The anterior surface of the portal vein is usually devoid of branches.

Laparoscopic management of pancreatic vasculature requires knowledge of the anatomy and potential anomalies. Visualization is often enhanced with angled scopes, allowing dissection in planes that would not be visible in open approaches. By contrast, new views open possibilities to new complications, such as inadvertent injury to hepatic or renal vasculature. Improvements in dissecting and ligating devices such as ultrasonic shears, bipolar cutting devices, and surgical staplers have allowed the area of laparoscopic pancreatic surgery to expand.

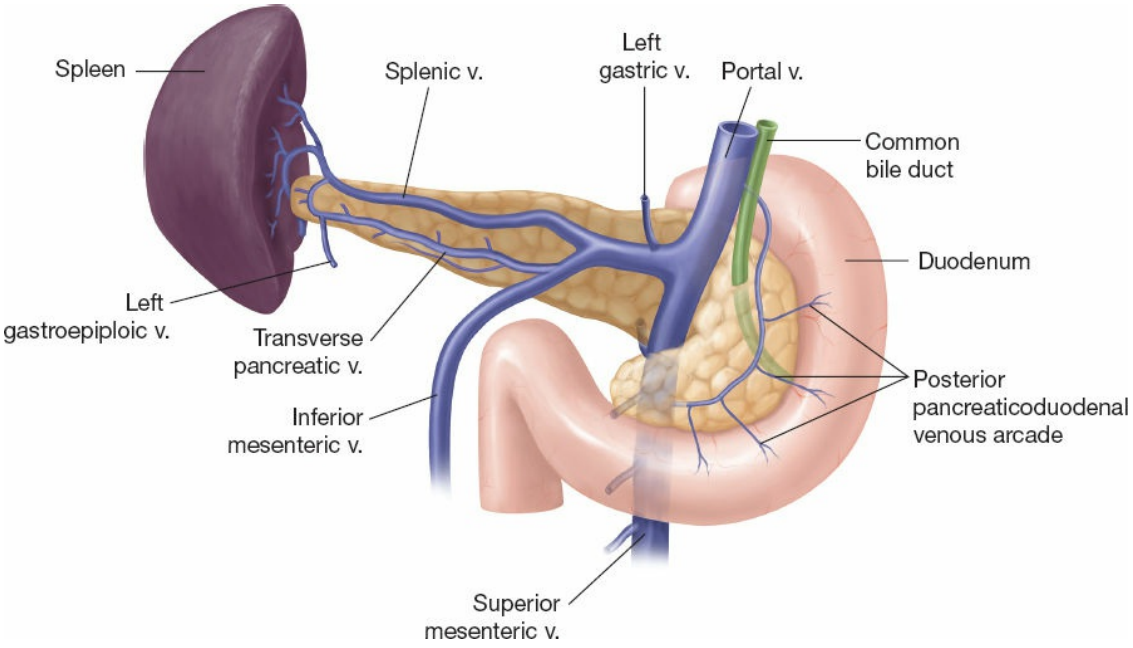

Figure 121.31. Posterior view of the venous drainage of the pancreas and the tributaries of the hepatic portal vein.

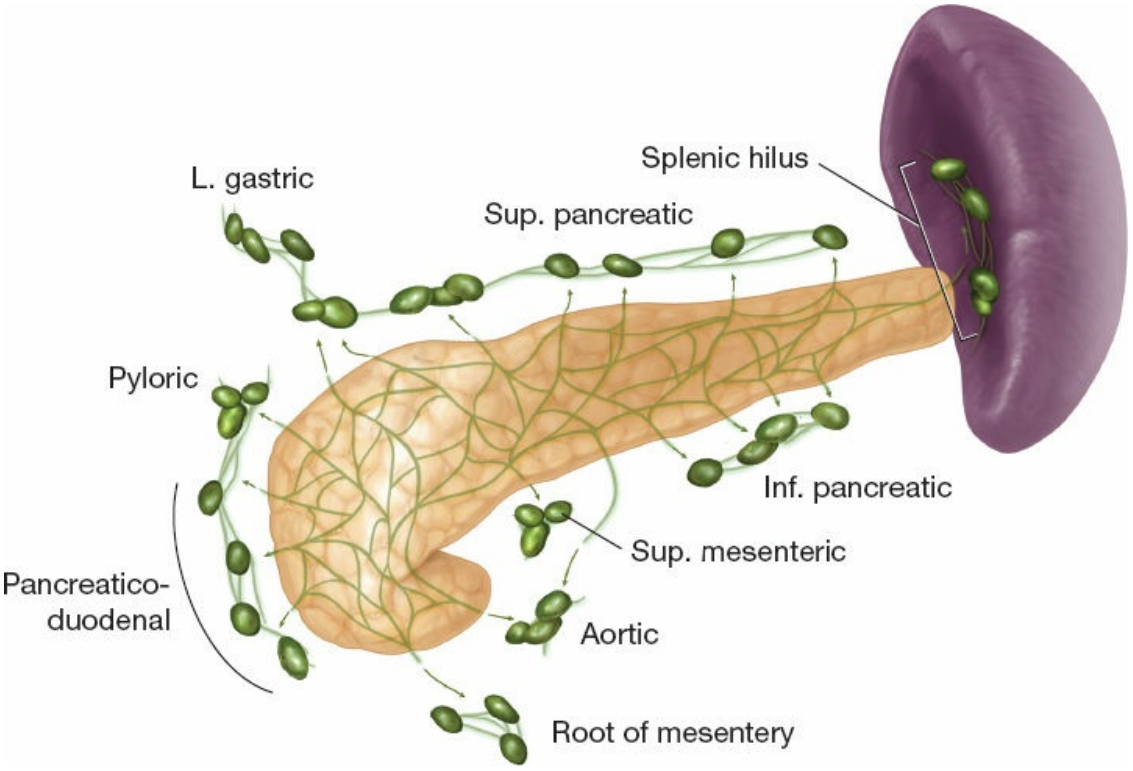

Figure 121.32. Lymphatic drainage of the pancreas. Flow is toward the nearest margin of the pancreas.

LYMPHATIC DRAINAGE OF THE PANCREAS

In general, lymphatic drainage of the pancreas is centrifugal to the surrounding nodes (Fig. 121.32). Attempts to map specific drainage basins

of the pancreas are uncertain; thus, no “standard terminology” for the nodes exists. The lymphatic vessels of the pancreas arise in a rich, perilobular, interanastomosing network. Channels course along the surface of the gland and in the interlobular spaces along with the blood vessels. Cubilla et al. divided the peripancreatic lymph nodes into five main groups with subgroups (Fig. 121.32): (i) Superior: superior head, superior body, and gastric; (ii) Inferior: inferior head and inferior body; (iii) Anterior: anterior pancreaticoduodenal, pyloric, and mesenteric; (iv) Posterior: posterior pancreaticoduodenal and CBD; and (v) Splenic: lymph nodes at hilum of spleen and at the tail of pancreas.

Superior Nodes

The collecting trunks of this group of nodes arise from the anterior and posterior superior half of the pancreas. Most end in the suprapancreatic lymph nodes located along the superior border of the pancreas. The names of the nodes typically reflect the areas drained, such as the superior head and the superior body. Some lymphatics occasionally terminate in the nodes of the gastropancreatic fold or in the lymph nodes of the hepatic chain.

Inferior Nodes

These collecting trunks drain the anterior and posterior lower half of the head and body of the pancreas. They lead into the inferior pancreatic group of lymph nodes, most of which are located along the inferior border of the head and body of the pancreas. Furthermore, they may extend into the superior mesenteric and left lateroaortic lymph nodes. Although infrequent, a collecting trunk may terminate directly in a lumbar trunk.

Anterior Nodes

Two collecting trunks run along the anterior surface of the superior and inferior portions of the head of the pancreas. They extend to the infrapyloric and anterior pancreaticoduodenal lymph nodes. They may also extend to some of the mesenteric lymph nodes located at the root of the mesentery (mesenteric-jejunal nodes).

Posterior Nodes

The posterior nodes follow the posterior surface of the superior and inferior portions of the head of the pancreas. They drain into the posterior pancreaticoduodenal lymph nodes, CBD lymph nodes, right lateroaortic

lymph nodes, and some nodes at the origin of the SMA. Lymphatics of the CBD and ampulla of Vater also end in the posterior pancreaticoduodenal group.

Splenic Nodes

The splenic lymphatics originate from the tail of the pancreas. They drain into nodes at the hilum of the spleen, splenophrenic ligament, and inferior and superior lymph nodes of the tail of the pancreas. A few lymphatic channels end in the lymph nodes superior and inferior to the body of the pancreas.

Surgical Considerations

The surgeon should be familiar with the anatomic topography of the peripancreatic nodes.

No lymphatic communications exist between the pancreas and the lymph nodes of the greater and lesser curvatures of the stomach; thus, omentectomy (lesser or greater) is generally not performed in conjunction with pancreatectomy.

Lymph flows from the pancreas to the duodenum. Furthermore, pancreatic cancers may directly invade the duodenum; thus, en bloc resection in cancer cases is the standard. Duodenectomy is not necessary to improve lymphatic harvest for pancreatic cancer.

Lymphatics of the anterior surface of the head of the pancreas terminate in the anterior pancreaticoduodenal and subpyloric nodes, and those on the posterior surface in the posterior pancreaticoduodenal nodes. Both groups are connected to the central superior mesenteric nodes and follow the superior mesenteric lymph flow.

The lymphatics of the anterior surface of the head and neck of the pancreas are associated with the common hepatic and superior mesenteric nodal group, which drain to a node situated to the right of the origins of the celiac trunk and the SMA. Behind this node lies another that receives drainage from the posterior surface of the head. The lymphatics of the left half of the pancreas terminate in a node to the left of the celiac trunk and SMA. Both the right and left nodes drain into the abdominal aortic nodes.

The lymphatics of the head and body of the pancreas do not drain toward the tail of the pancreas or the splenic nodes. Rarely, however, the lymph vessels from the tail of the pancreas can terminate in the superior body and inferior body subgroups of nodes.

The posterosuperior part of the head may follow the bile duct and the hepatic artery and terminate in the hepatic nodes.
The upper part of the body of the pancreas drains to the superior pancreatic nodes and may have few connections to the hepatic nodes.
The lower part of the body is drained toward the inferior pancreatic, central superior mesenteric, and paraaortic nodes.
The tail of the pancreas drains to the splenic nodes.
It is well known that pancreatic cancer disseminates rapidly because of the retroperitoneal position of the pancreas and its rich lymphatic and venous drainage. In particular, pancreatic exocrine adenocarcinomas appear to have an unusually efficient biologic capacity to metastasize.
A total pancreatectomy may include removal of 70 nodes. The Whipple partial pancreatectomy may involve removing 33 nodes.
To date, extended lymph node dissection for pancreatic cancer is associated with increased patient morbidity without evidence of improved patient survival; however, other data suggest that the ratio of positive to total lymph nodes assessed is important.
Node counts following surgery are dependent on surgical technique, pathologic assessment, and patient factors. Current consensus guidelines suggest assessment of 15 nodes in a pancreatic cancer resection to provide adequate staging.

NERVE SUPPLY OF THE PANCREAS

Innervation of the pancreas is by the sympathetic division of the autonomic nervous system through the splanchnic nerves and by the parasympathetic division through the vagus nerve (Fig. 121.33). These nerves generally follow blood vessels to their destinations. However, some authorities (Hollinshead) claim that, while the nerves to the duodenum follow the vessels, those to the pancreas (pancreatic plexus) arise directly from the celiac and superior mesenteric plexuses and enter the posterior surface of the pancreas (as shown in Fig. 121.33).

The sympathetic and parasympathetic divisions provide efferent (motor) fibers to the wall of the blood vessels, the pancreatic duct, and pancreatic acini. Furthermore, both contain visceral afferent (pain) sensory fibers. The distribution of these in the pancreas, however, is not well understood.

Preganglionic sympathetic innervation is from the greater and lesser thoracic splanchnic nerves. The former is composed of preganglionic efferent fibers from the 5th to the 9th or 10th thoracic segments. The latter

is composed of fibers from the 9th and 10th or the 10th and 11th segments. Some fibers may be contributed by the least splanchnic nerve.

The sympathetic nerves pierce the diaphragmatic crura to reach the celiac and superior mesenteric ganglia. Postganglionic fibers arising from neurons in these ganglia accompany branches of the celiac and superior mesenteric arteries to reach the pancreas.

Some afferent fibers cross over the midline in the celiac plexus. The celiac ganglion contains cell bodies of efferent fibers for the pancreas. Cell bodies of afferent fibers are in the dorsal root ganglia at the same spinal nerve levels as those that contribute the preganglionic sympathetic fibers. Interconnections of the afferent fibers from the pancreas with other sensory fibers from the body wall are presumably responsible for referral of pancreatic pain to the surface of the abdominal wall. Pain fibers from the pancreas pass cranially within the greater and lesser thoracic splanchnic nerve; they leave it by way of white communicating rami and enter the intercostal nerves. Then, the affected intercostal nerves perceive (project) the pain as coming from the respective area on the anterior abdominal wall, i.e., the major splanchnic nerve to the 5th to 9th dermatomes and the lesser to the 9th and 10th; thus the pain is located on the epigastrium, from below the nipple (5th dermatome) to the umbilicus (10th dermatome).

Parasympathetic innervation is by way of the celiac division of the posterior vagal trunk. The efferent fibers are preganglionic axons from cell bodies in the dorsal motor nucleus of the vagus nerve in the brain. The preganglionic vagal fibers synapse with terminal ganglion cells within the pancreas. The postganglionic fibers terminate at pancreatic islet cells. Almost 90% of the fibers carried by the vagus nerve are sensory in function, having to do with stretch, chemoreception, osmoreception, and thermoreception. These afferent fibers are processes of sensory neurons located in the sensory ganglia of the right vagus nerve at the jugular foramen of the skull. Vagal fibers pass through the esophageal hiatus of the diaphragm, usually as anterior and posterior trunks. The posterior trunk divides into a posterior gastric and celiac division near the lesser curvature of the stomach. The neuronal processes of the celiac division of the posterior vagus traverse the nerve plexuses at the origins of the celiac and superior mesenteric arteries and accompany the branches of these arteries to reach the organs supplied by them. None of the fibers carried by the vagus synapse within the celiac ganglia.

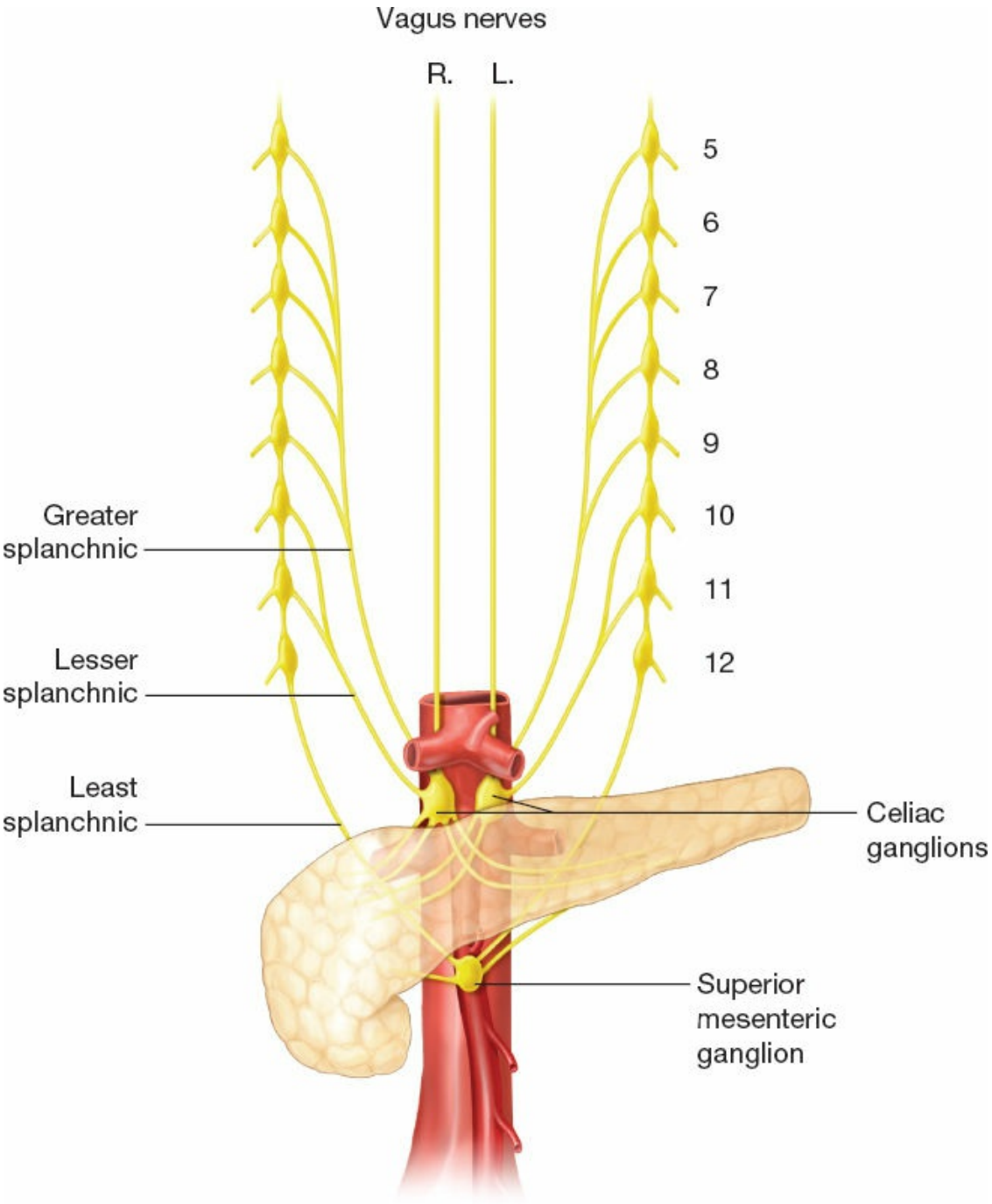

Figure 121.33. The nerve supply to the pancreas.

Two conditions commonly regarded as producing intense pain are pancreatic cancer and chronic pancreatitis, both of which have been linked to various procedures blocking the splanchnic nerves and celiac ganglia for pain management (splanchnicectomy, endoscopic ultrasonography [EUS]-guided celiac injection, percutaneous computed tomography [CT]-guided injection, operative injection at the time of laparotomy, thoracoscopic neurolysis, magnetic resonance imaging [MRI]-guided celiac plexus block

and paravertebral anesthesia).

A major complaint of chronic pancreatitis patients is the so-called “abdominal pain syndrome,” which is characterized by severe intermittent or by long-lasting and persistent pain. No current hypothesis on mechanisms of pain initiation and pain perpetuation in chronic pancreatitis can explain the various symptoms. However, several hypotheses about mechanisms of pain generation in chronic pancreatitis have been postulated; these include “increased intraductal pressure,” “interstitial hypertension,” “pancreatic fibrosis via single or multiple strictures,” “pancreatic ischemia,” and “pancreatic pseudocysts.” There is increasing evidence that pain in chronic pancreatitis and pancreatic cancer is triggered by pancreatic neuropathy. Damage to intrapancreatic nerves seems to support the maintenance and exacerbation of neuropathic pain. In chronic pancreatitis, intrapancreatic nerves are invaded by immune cells. This observation led to the hypothesis that neuro-immune interactions play a role in the pathogenesis of chronic pancreatitis and the accompanying abdominal pain syndrome. Specifically for chronic pancreatitis, two unique theories for the etiology have emerged: (i) pancreatic ductal hypertension and (ii) neural and perineural inflammation and fibrosis of the pancreas.

In contrast to patients with chronic pancreatitis, pancreatic cancer patients do not present with characteristic clinical symptoms, particularly in the early stages of the disease. Nonetheless, the two leading symptoms observed in pancreatic cancer patients at admission to the hospital are weight loss (92%) and jaundice (82%). Similarly, pancreatic cancer cells infiltrate the perineurium of local nerves, which may in part explain the severe pain experienced by the patients. Furthermore, perineural invasion extending into extrapancreatic nerves may preclude curative resection and thus often leads to local recurrence. In recent years, the involvement of a variety of neurotrophins and neuropeptides in the pathogenesis of pancreatic pain was discovered. Whereas the etiology of chronic pancreatitis is less concrete, pancreatic cancer pain is usually related to tumor invasion of the celiac and/or mesenteric plexus.

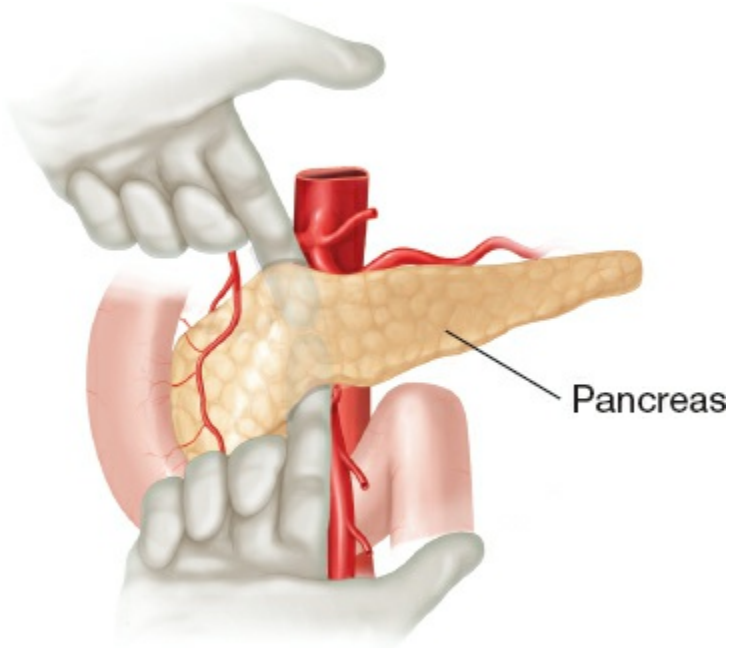

Figure 121.34. Exploration of the pancreas. The surgeon's fingers are shown passing behind the neck of the pancreas, which should separate easily from the underlying blood vessels.

Patients with pancreatic lesions suffer from back pain. The explanation to this may be related to somatic innervation by the spinal cord segments of the structures upon which the pancreas lies. Hollinshead notes, "Because of the close relationship between the pancreas and the body wall the parietal nerves innervating the latter may also be involved by pancreatic disease." Another explanation is that has been given is that visceral pain afferents result on excitation of somatic receptor neurons.

Surgical Considerations

The pain fibers of the pancreas ascend from the celiac plexus via the thoracic splanchnic nerves, namely the greater and lesser nerve. These nerves communicate with the thoracoabdominal nerves that refer the pain to the upper abdomen. Pain management aims at the celiac plexus and/or the splanchnic nerves.

Neurolytic treatment (block) at the celiac plexus requires exact details of anatomy of the plexus. The celiac plexus comprises right and left ganglia, found at the level of the celiac artery. The ganglia often join with each other and surround the aorta. The celiac plexus is located in the periaortic fat at the level of diaphragmatic hiatus and celiac artery. Between T12 and L2, we commonly meet two to five celiac ganglia.

Neurectomy of the splanchnic nerves is best effected by thoracoscopic

splanchnicectomy that gives an excellent view of the thoracic splanchnic nerves (Fig. 121.34). The target will be the greater and the lesser nerve.

Sympathectomy will not affect the pain produced by the direct stimulation of somatic nerves on which pancreas lies; this pain travels through somatic innervation.

Exploration of the Pancreas

Surgeons operating on the pancreas need to be familiar with the anatomy and diagnostic/imaging options. In most cases, when a pancreatic concern arises, a CT scan is performed. This should be a helical CT with thin cuts (2 mm) and appropriate timed contrast administration to obtain arterial and portal venous phase images. Beyond this, the surgeon can decide if further imaging with aid in surgical decision making. Other diagnostic options include dedicated pancreatic MRI, EUS with fine needle aspiration (FNA), and ERCP.

At exploration, it is valuable to understand potential transperitoneal, subperitoneal, and retroperitoneal manifestations of pancreatic diseases. Transperitoneal spread implies the process penetrates through the peritoneal layer and disseminates into the peritoneal cavity. Pseudocyst formation in the lesser sac is a typical example of transperitoneal disease process, as a ductal rupture extends transperitoneally into the space between the anterior surface of the pancreas and the posterior wall of the stomach. Pancreatic cancer can do this as well, and studies have assessed the significance of positive peritoneal cytology, and found this to be consistent with distant metastatic disease. Laparoscopic assessment is useful for identifying this finding prior to laparotomy. Many centers will perform diagnostic laparoscopy for high-risk patients with a cancer diagnosis. These include patients with high CA19–9 levels, indeterminant lesions on preoperative imaging, relatively poor performance status, and cancers of the body and tail.

Subperitoneal spread occurs when disease processes spread along the subperitoneal space of the peritoneal ligaments between the two layers of the peritoneum. The peritoneal layer need not be breached. This mode of spread is common in acute pancreatitis, in which the leakage of enzymes dissects into the subperitoneal space of the peritoneal ligaments and produces inflammation, edema, fat necrosis, and retroperitoneal pseudocysts. Pancreatic adenocarcinoma commonly invades the adjacent peritoneal ligaments subperitoneally, but unlike pancreatitis

adenocarcinoma tends toward local invasion. Pancreatic adenocarcinoma also commonly spreads via periarterial and perineural infiltration in the subperitoneal space.

The pancreas can be approached by dividing the gastrocolic ligament (part of the greater omentum) or the hepatogastric ligament (part of the lesser omentum). The gastrocolic ligament is incised widely providing good exposure of the entire pancreas if necessary. If this exposure proves to be inadequate, the hepatogastric ligament can be divided also (with preservation of the anterior branch of the vagus that runs in the upper part of the ligament toward the liver), and upward traction can be applied to the stomach. This route is useful in patients with exceptionally ptotic stomachs.

To palpate the head of the pancreas, kocherization of the duodenum is necessary. Mobilization of the duodenum is accomplished by mobilizing the hepatic flexure of the colon and then incising the peritoneum lateral to the second part of the duodenum. Next, the left index and middle fingers are placed posterior to the duodenum and the head of the pancreas, with the left thumb anterior. Palpation of the head of the pancreas and the pancreatic portion of the CBD is then possible. Lymph nodes can sometimes be felt at the distal portion of the CBD, near the upper part of the posterior surface of the head of the pancreas.

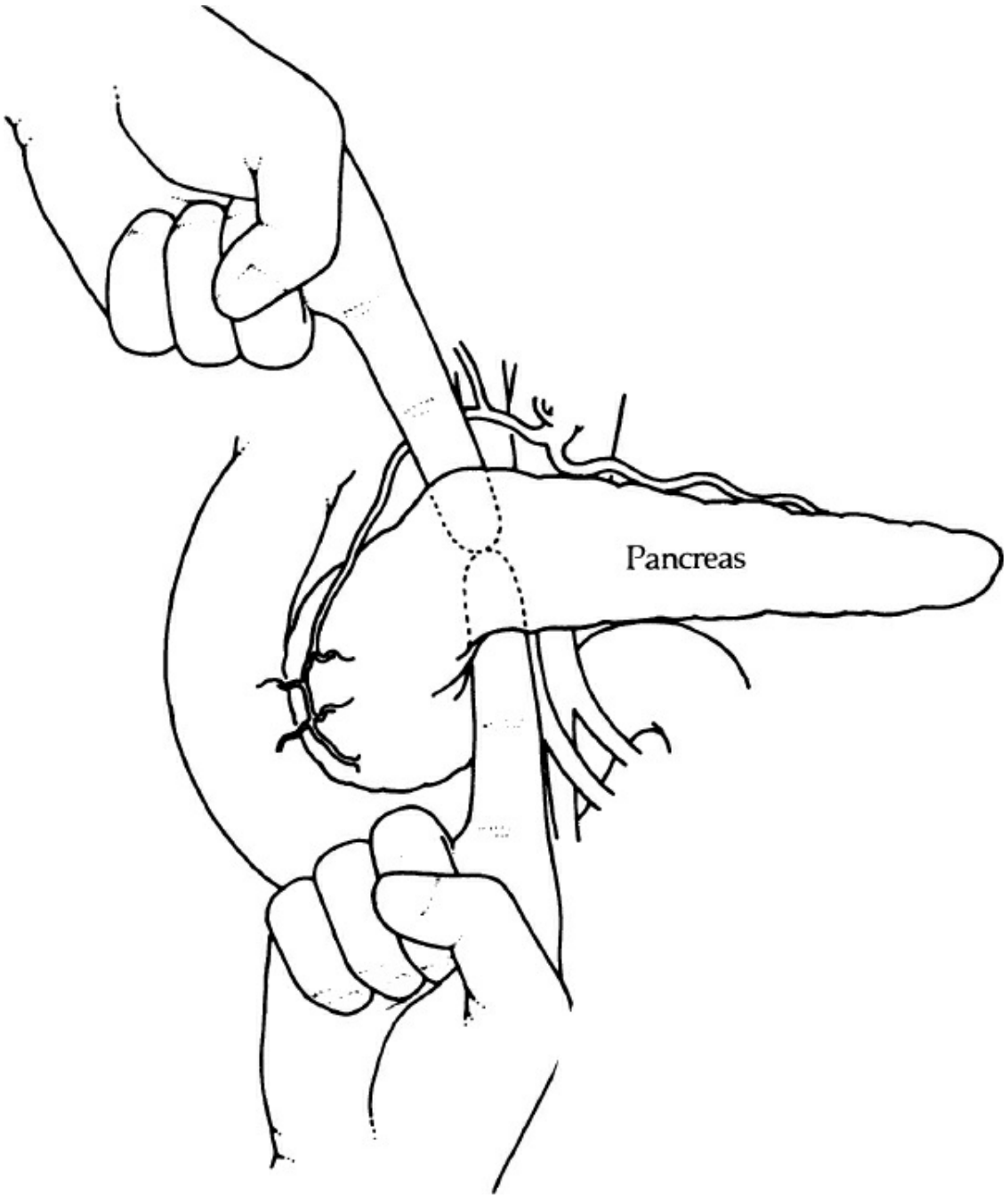

Figure 121.35. Exploration of the pancreas. The surgeon's fingers are shown passing behind the neck of the pancreas, which should separate easily from the underlying blood vessels. (From Skandalakis JE, Gray SW, Rowe JS Jr, et al. Anatomical complications of pancreatic surgery. *Contemp Surg* 1979;15:17.)

The surgeon can use his or her left or both index fingers to continue the exploration posterior to the neck of the pancreas (Fig. 121.35). The surgeon's left hand approaches the neck from above, with the left index finger posterior to the neck, and the right hand comes from below, with the right index finger also posterior to the neck. Palpation of the SMA pulse

and its proximity to the tumor was once thought to be a valuable way to assess resectability; however, this generally represents a crude assessment and the better method for assessing the arterial margin is by good quality preoperative imaging.

The ability to separate the neck from the underlying superior mesenteric and portal vein confluence is another maneuver used to assess resectability of pancreatic cancers. Vein involvement does not imply the tumor is unresectable, and being able to create the space between the pancreatic neck and the portal-SMV confluence does not provide the surgeon with confidence that the tumor is removable with completely negative margins. For further technical descriptions of specific operative maneuvers, please refer to the chapters relating to the particular procedure.

When gaining exposure to body of the body of the pancreas, it is necessary to detach the gastrocolic ligament from the transverse colon. This is time-consuming, but it provides improved visualization of the entire lesser sac.

Approach through the mesocolon is sometimes used to drain pancreatic pseudocysts. Disadvantages to this route include limited exposure of the pancreas and risk of injury to the middle colic blood vessels.

Mobilization of the splenic flexure inferiorly provides exposure to the spleen, and the tail of the pancreas.

An exciting novel area of exploration is laparoscopic pancreatic surgery. Recent reports show that laparoscopic distal pancreatectomy is associated with reduced blood loss, greater likelihood of splenic preservation, fewer postoperative complications, shorter hospital length of stay, and equivalent cancer-related outcomes (margin status, node harvest, and overall survival). The laparoscopic approach provides excellent visualization of retroperitoneal structures not typically observed in open approaches. Specific operative technique is beyond the scope of this chapter, and the reader is referred to the suggested reading list for more information.

ACKNOWLEDGMENT

The authors wish to thank the medical illustration team at St. George's University, Grenada, West Indies: Jessica Holland, MS, CMI; Angélica Ortiz, MScBMC; Charles Wesley Price, MS, CMI; and Xochitl Vinaja, MS; for the creation of color illustrations in this chapter.

Suggested Readings

Avisse C, Flament JB, Delattre JF. Ampulla of Vater: anatomic, embryologic, and surgical aspects. *Surg Clin North Am* 2000;80:201.

Busnardo AC, DiDio LJA, Thomford NR. Anatomicosurgical segments of the human pancreas. *Surg Radiol Anat* 1988;10:77.

Chu CK, Kooby DA. Laparoscopic surgery for pancreatic tumors. *Surg Oncol Clin North Am* 2010;19:311.

Cubilla AL, Fortner J, Fitzerald PJ. Lymph node involvement in carcinoma of the head of the pancreas. *Cancer* 1978;41:880.

Foster RS Jr. Pancreas [editorial comment]. In: Skandalakis JE, Colborn GL, Weidman TA, et al., eds. *Skandalakis' Surgical Anatomy: The Embryologic and Anatomic Basis of Modern Surgery*. Athens, Greece: Paschalidis Medical Publications; 2004:1194.

Hollinshead WH. *Anatomy for Surgeons, Vol. 2: The Thorax, Abdomen, and Pelvis.* New York: Hoeber-Harper; 1956:423, 430.

Jones WB, Jordan P, Pudi M. Pain management of pancreatic adenocarcinomas that are unresectable: celiac plexus neurolysis and splanchnicectomy. *J Gastrointest Oncol* 2015;6:445.

Kooby DA, Branum GD, Skandalakis LJ. Pancreas and duodenum In: Wood WC, Staley CA, Skandalakis JE., eds. *Anatomic Basis of Tumor Surgery.* 2nd ed. Berlin, Germany: Springer-Verlag; 2009:549.

Koshi T, Govil S, Koshi R. Problem in diagnostic imaging: pancreaticoduodenal arcade in splanchnic arterial stenosis. *Clin Anat* 1998;11:206.

Kubik S. Anatomy of the lymphatic system. In: Földi M, Földi E, Kubik S, eds. *Textbook of Lymphology.* Munich, Germany: Urban & Fischer; 2003:161.

Loukas ML, Klaassen Z, Merbs M, et al. A review of the thoracic splanchnic nerves and celiac ganglia. *Clin Anat* 2010;23:512.

Michels NA. *Blood Supply and Anatomy of the Upper Abdominal Organs.* Philadelphia, PA: Lippincott; 1955.

Mirilas P, Colborn GL, Skandalakis LJ, et al. Benign anatomical mistakes: "Ampulla of Vater" and "Papilla of Vater." *Am Surg* 2005;71:269.

O'Rahilly RO, Müller F. *Human Embryology and Teratology.* 3rd ed. New York: Wiley-Liss; 2001:268.

Vikram R, Balachandran A, Bhosale PR, et al. Pancreas: peritoneal reflections, ligamentous connections, and pathways of disease spread. *Radiographics* 2009;29:e34.

EDITOR'S COMMENT

The authors present a spectacular update of this chapter on surgical anatomy of the pancreas. The color illustrations new to the seventh edition are clean and add to the readers understanding as well as enjoyment of this chapter. Anatomy is sometimes boring but not when presented with such beautiful illustrations. The illustrations are so clean and accurate that one wish when operating in "Tiger Country" everything is as illustrated. The reality is unfortunately the contrary. For this commentary I have chosen to present some pearls on exposure and resection of the pancreas that I have learned over the years and will comment on lymph node primaries in gastrinoma and annular pancreas another pancreatic anomaly related to the complex process of fusion of the ventral and dorsal buds.

The pancreas is a difficult organ to approach by open or laparoscopic surgery. The organ is "hidden" in the retroperitoneum. The head is in intimate approximation to the duodenum and the tail so adjacent to the splenic hilum as shown in Figure 121.14. It lies posterior to the stomach in the lesser sac. Inferiorly it is adjacent to the mesentery of the colon and ligament of Treitz. Superiorly are the celiac axis and its branches. The pancreas head is more anterior than the body and tail and the gland runs at a slight angle from the anterior to posterior toward the tail which is the most posterior portion lying adjacent to the spleen and overlying the left adrenal gland and superior pole of the left kidney. The neck of the pancreas lies over the spine, accounting for its propensity for injury in forceful blunt abdominal trauma.

Exposure of the pancreas requires several steps. First complete mobilization of the duodenum must be accomplished with an extensive Kocher maneuver in order to be able to examine and palpate the head of the gland. The mobilization should be carried proximal with division of the lateral duodenal attachments stopping short of the hepatoduodenal ligament. This is a relatively avascular plane. As the surgeon lifts the head of the gland, the assistant can provide traction by gently pulling the duodenum and head to the left side of the patient and anteriorly. The inferior vena cava will come into view. The junction of the second and third portions of the duodenum and the proximal fourth portion should continue to be mobilized from posterior attachments until the surgeon can clearly see the left renal vein entering the inferior vena cava. The surgeon hand can palpate the portal vein and superior mesenteric artery anterior to the plane of dissection. The attachments are usually avascular. If the vein and artery are surrounded by a malignant tumor, the surgeon should be able to appreciate this. The inexperienced surgeon may stop the dissection short of this resulting in inadequate assessment of resectability and lead to exposure problems later in the course of a planned pancreaticoduodenectomy during the takedown of the ligament of Treitz and full mobilization of the fourth portion of the duodenum.

I think it is important to realize the variations in the uncinate process as

described in Figure 121.13. This has implications for pancreaticoduodenectomy in patients with uncinate process primary tumors.

The next step in exposing the pancreas is to enter the lesser sac to expose the anterior surface of the gland. This can be accomplished by dividing the avascular attachments of the omentum from the colon. I prefer to divide the gastrocolic omentum inferior to the course of the epigastric vessels. This is less time consuming than the former and avoids having to gain later exposure around a large fatty omentum attached to the stomach. The dissection is carried laterally to the short gastric vessels. Medially the dissection is carried beyond the neck of the gland stopping just short of the right gastroepiploic vein. If one is exposing the body and tail of the pancreas, the avascular posterior attachments between the stomach and anterior surface of the pancreas are divided allowing the antrum to be elevated anteriorly. Then inferiorly the retroperitoneum overlying the inferior edge of the pancreatic body can be incised and the glands mobilized by a combination of sharp and blunt dissection.

For a Whipple procedure dissection would continue at the point of right gastroepiploic vein to expose the anterior surface of the superior mesenteric vein as it becomes the portal vein. Although located inferiorly on the superior mesenteric vein, the middle colic vein may come into play at some point and may need to be divided. The traction necessary to gain exposure particularly in the obese patients may cause avulsion of the vein and troublesome bleeding. As described in the chapter, the surgeon will need to assess resectability of a pancreatic head lesion by passing her or his finger behind the neck of the pancreas in the avascular plane anterior to the portal vein. This looks easy in the illustration, but it is not. The space should be approached inferiorly along the superior mesenteric vein by dividing the overlying fibrofatty tissue. Continued superior dissection will identify the right gastroepiploic vein that should be divided and preferably in my experience suture ligated. In so doing the anterior surface of the superior mesenteric vein just inferior to its junction with the portal vein will be identified exposing the avascular plane between the neck of the pancreas and the anterior surface of the portal vein. The dissection of the space posterior to the stomach is the same for a planned pancreaticoduodenectomy as that described above. This will allow identification of the gastroduodenal artery; a critical step of the procedure as division of this vessel is required to complete the Whipple procedure. In some cases the artery requires division in order to further assess resectability and greater exposure of the superior aspect of the portal vein. As pointed out in the chapter, the blood supply to the duodenum and head of the pancreas are rich and hence division of the gastroduodenal artery may be done without proceeding with the Whipple procedure if unresectable disease is subsequently identified.

At this point a comment about the various anomalies of the hepatic artery is warranted. First, contrast-enhanced CT reconstruction in both the axial and coronal planes will usually demonstrate the anomalous vessels. The most

common variation is the right hepatic artery coming off the superior mesenteric artery. The artery usually originates posteriorly and inferiorly from the superior mesenteric artery and courses behind the portal vein exiting in the vascular groove and then coursing to run lateral to the common bile duct. I have found that this does not make the dissection more difficult. Rather there is natural plane created by the course of the anomalous right hepatic artery which facilitates the dissection of the superior portion of the head of the gland from the mesenteric vessels. The gland in these cases may receive direct branches from the right hepatic artery rather than the superior mesenteric artery. The anomalous common hepatic artery in my experience branches off the superior mesenteric artery more superiorly and close to the SMA origin. One needs to do a meticulous dissection in these cases so as to avoid injury to the common hepatic artery. I have seen one case in which the common hepatic artery coursed through the body of the pancreas requiring meticulous dissection in order to preserve the vessel during division of the pancreas.

For an open distal pancreatectomy, I have found that after the above exposure the spleen should be mobilized. This allows the tail of the pancreas to be completely mobilized from the retroperitoneum. Usually blunt dissection can effectively dissect the tail of the gland to the point at which the inferior mesenteric vein is identified. At this point small arteries and veins may require division with energy, clips or ties. If the spleen is not to be preserved, the dissection is continued medially. The splenic artery and vein are divided and ligated. In some cases, it may be easier to divide the next of the pancreas prior to dividing the splenic vein. If splenic preservation is intended, then the short gastric vessels should be preserved and dissection performed medial to lateral with preservation of the splenic artery and vein. Either open or by laparoscopic approach distal pancreatectomy with splenic preservation requires division of the pancreas neck as the initial step as the pancreas should be divided first. There are numerous small branches as the author’s note feeding the pancreas as direct branches from the splenic artery as well as draining veins feeding into the splenic vein. If the vein and artery must be divided, the spleen may retain blood supply from the short gastric vessels as described by Warshaw. In my experience splenic preservation with dissection of the splenic vein and artery is technically less demanding if done with the laparoscopic approach. In this approach, the spleen does not need to be mobilized.

The authors discuss the embryology of the pancreas and how this may be related to gastrinomas occurring outside the pancreas. They refer to suggestions that stem cells may be dispersed during the turn of the pancreatic diverticulum and entrapping neuroendocrine cells in the duodenum and lymph nodes. The duodenum is the site of at least 50% of gastrinomas and this may explain gastrinomas at this site. However, gastrin-producing cells are known in the antrum, pyloric area, and proximal duodenum. The frequency of lymph node primary gastrinomas is highly variable inmost reported series. In our experience less than 5% of primary tumors are what initially thought to be lymph node

primary gastrinomas and recurrence is high following resection indicating the possibility of an undetected primary with a metastatic node rather than a lymph node primary. The NIH group has reported a greater incidence. This will be further considered in the chapter on neuroendocrine tumors of the pancreas.

The description of the ampulla of Vater, the minor papilla, and pancreas divism are pertinent and will be expanded upon the chapter on surgical sphincteroplasty. As you read that chapter coming back to this section may be helpful.

Finally, although rare, additional discussion of annular pancreas is warranted as this may present in childhood as well as adults. As noted the pancreas develops from a dorsal and ventral bud that first appear of the primitive foregut at around the fifth week of gestation. As described in this chapter, the pancreas is formed by fusion of the ventral and dorsal analog. Annular pancreas results from failure of the ventral bud to rotate with the duodenum, resulting envelopment of duodenum by pancreatic tissue. The incidence is 5 to 15 per 100,000 adults (Ravitch MM. The pancreas in infants and children. *Surg Clin North Am* 1975;55:377). This is shown in Figures 121.6 and 121.7.

Three major theories have been proposed to explain the development of annular pancreas: (1) Lecco's theory which hypothesizes that there is adherence of the ventral bud to the duodenal wall prior to rotation, resulting in encirclement of the duodenum (Laughlin EH, Keown ME, Jackson JE. Heterotopic pancreas obstructing the ampulla of Vater. *Arch Surg* 1983;118:979), (2) Baldwin's theory (Baldwin W. A specimen of annular pancreas. *Anat Rc* 1910;4:299) in which it is theorized that there is enlargement of the left ventral bud, and (3) hypertrophy and fusion of the ventral and dorsal buds prior to rotation.

In annular pancreas, the annulus is usually comprised of a band of pancreatic tissue that encircles the second portion of the duodenum. On occasion, this encirclement is incomplete. The pancreatic band is usually interspersed in muscularis of the duodenum, although it can also be free. There are a number of variations of pancreatic ductal anatomy in annular pancreas. The most common are: (1) the annular duct connects directly to the main pancreatic duct or (2) the duct of Wirsung follows the course of the annular pancreas going around the duodenal circumference entering the major papilla. In addition, approximately one third to one half of patients with annular pancreas also have pancreas divisum. The ductal anatomy is usually well seen on a MRCP.

Two thirds of patients with annular pancreas are asymptomatic. Clinical presentation of the symptomatic patients occurs in two distinct age groups; the neonate and the adult. As pointed out in the chapter, in the neonate the primary symptom is difficulty tolerating feedings and nonbilious vomiting. Treatment is a bypass with duodenojejunostomy. Resection of the annulus should be avoided in the neonate as well as the adult since it is associated with pancreatitis, pancreatic fistula formation, and incomplete relief of obstruction. In the adult presentation is between the ages of 20 and 50. The presentation may be related

to partial duodenal obstruction or abdominal pain. Imaging will diagnose the annular pancreas. Some adult patients may present with acute or chronic pancreatitis and rarely biliary obstruction. Treatment is based on the clinical presentation.

The pathogenesis of pancreatitis in individuals with annular pancreas remains unclear. It is hypothesized that pancreatitis may result from fibrosis leading to partial obstruction of the pancreatic duct in the head of the pancreas. The pancreatic fibrosis is usually limited to the annulus and adjoining pancreatic head (Cunha JE, de Lima MS, Jukemura J, et. al. Unusual clinical presentation of annular pancreas in the adult. *Pancreatology* 2005;5:81; Glinsky NH, Lewis JW, Flueck JA, et al. Annular pancreas associated with diffuse chronic pancreatitis. *Am J Gastroentrol* 1987;882:681). The body and tail are usually normal. Pancreatic stones may develop as a result of the obstruction and in such cases of recurrent or chronic pancreatitis pancreaticoduodenectomy may be necessary to alleviate the symptoms.

E. Christopher Ellison

Sometimes when reviewing a component which is written in a commentary, one comes upon something written by a master. That master however did not rise de novo but came from a background of masters who raised the author. As is the way of Master of Surgery, we have that in this commentary where Dr. Ellison is the master. He rose from giants who trained him and they deserve to be recognized; those masters are the late Drs. Robert M. Zollinger, Olga Jonasson, and Jay L. Grosfeld, and Drs. Larry C. Carey, Dr Hiram C. Polk, Frank H. Lewis, Kirby I. Bland, and Josef E. Fischer.

122 Selection of Surgical Therapy for Chronic Pancreatitis

Peter Muscarella and William H. Nealon

INTRODUCTION

Chronic pancreatitis (CP) can result in substantial misery for people afflicted with this disease and may present unique challenges for surgeons and other health care professionals who manage these patients. In the modern era, it is crucial for pancreatic surgeons to work closely with a multidisciplinary team in order to optimize patient outcomes and to minimize the risk of what too commonly occurs in our experience: either inappropriate care or no care at all. Unfortunately for these patients, the association of this disease with ethanol abuse, the chronicity of symptoms, and the recidivism of presentation to emergency departments seeking adequate pain control all serve to have practitioners approach these patients with indifference and neglect. For this and other reasons, these patients may wander from practitioner to practitioner (surgeons, gastroenterologists, and primary care physicians) without ever being advised that there exist interventions, particularly surgical, which have a considerable statistical likelihood of success. The primary indication for interventions, and particularly for surgery, in CP is chronic unremitting abdominal pain, commonly requiring chronic narcotic analgesics.

The hallmark for establishing the diagnosis of CP is the documentation of some element of permanent injury to the pancreas. This permanent alteration can be structural (gland calcification, secondary ductular dilatation, main pancreatic duct [MPD] dilatation, irregularity, narrowing/stricture, or stone formation). There may be pseudocyst formation. In as many as 30% of patients there may be clinically relevant bile duct dilatation, and in a smaller percentage duodenal narrowing. For most patients, surgery is offered in order to improve quality of life and decrease pain and narcotic dependence. There are a subset of patients with complications of pancreatitis who may require surgical intervention as well. Numerous surgical procedures have been described and their results

have been compared to other procedures as well as to endoscopic management. One precept of surgery has historically been to preserve as much functioning pancreatic parenchyma as possible when choosing the most appropriate operative procedure to perform. Given the fact that each patient has a varying degree of preoperative endocrine or exocrine insufficiency, making a careful decision can be challenging. The purpose of this chapter is to review the various surgical options for the management of CP with particular emphasis on patient factors and outcomes in order to help pancreatic surgeons determine selection and timing of procedures as well as appropriate patient evaluation and preparation.

BACKGROUND

CP is characterized clinically by severe abdominal pain that may radiate to the back. Patients are often dependent on narcotics by the time that they are referred to a pancreatic surgeon. This is of considerable importance in determining the need for surgical intervention as improvement in quality of life and pain are the major goals of most interventions. Because alcohol plays a role in the etiology of CP for the majority of patients, it is not uncommon for patients to transfer their alcohol addiction to prescription narcotics and they may be convinced that narcotics are essential for their ongoing health care. It is crucial to establish early on that the main goal of intervention will be to render them completely free from their dependence on narcotics. Patients who are unwilling to proceed under these terms may not be psychologically ready for surgical intervention and outcomes can be adversely affected. Patient care can also be frustrating when the patient and the surgeon are not aligned with regard to goals of therapy. Patients with CP will often have exacerbations of pain that lead to emergency department evaluation and admission to the hospital. It is important to differentiate true CP from recurrent acute pancreatitis. In this disorder, patients have multiple recurrent episodes of acute pancreatitis that are characterized by pain and serum pancreatic enzyme elevation. These patients are usually asymptomatic in between acute episodes while patients with true CP typically have chronic pain. The phenomenon of “minimal change pancreatitis” has been described for patients with pain that is characteristic of that of pancreatitis, but for whom diagnostic evaluation has been unremarkable. These patients fall into a larger category of undifferentiated chronic abdominal pain and caution should be taken prior

to undertaking pancreatic surgery as the only benefit may be as a placebo.

As CP progresses, pancreatic function becomes impaired and is manifested by exocrine and endocrine insufficiency. Patients who develop diabetes require special attention. It is important to work with primary care physicians and endocrinologists in order to optimize glycemic control prior to surgical intervention. Insulin administration is essentially always necessary for the management of what has been termed pancreatogenic, or type 3, diabetes. Oral hypoglycemic agents offer minimal benefit. Symptoms of exocrine insufficiency include weight loss and steatorrhea. Measurement of fecal fats and elastase activities can help to confirm the diagnosis and management is with oral enzyme supplements. Measurement of serum fat-soluble vitamin concentrations should be considered with replacement as necessary.

Patients can present with a variety of complications of CP and some of these may prompt endoscopic or surgical intervention. Biliary dilatation is seen in as many as 30% of patients and clinically meaningful strictures occur in 10% to 15% of patients. Fortunately, cholangitis associated with CP is quite rare as is frank jaundice. We caution that ERCP and biliary stent placement be avoided at almost all times. If a stent is placed a cycle ensues. Once the stent is removed the patient develops cholangitis because the stricture remains. This prompts replacement of the stent and the cycle repeats itself.

Duodenal strictures can also occur and these can be managed surgically, but the selection of procedure should be based on anatomic and patient-specific criteria. Splenic vein thrombosis is not uncommon in patients with CP and no specific therapy is necessary unless gastric varices develop, in which case splenectomy should be considered as part of the treatment. The stated frequency of meaningful variceal bleeding with sinistral portal hypertension is no more than 2%. Pancreatic pseudocysts can be seen in CP as well. Again, there are numerous treatments available, but appropriate therapy should always address the underlying pancreatic duct abnormality. Many years ago, the observation was made that pseudocyst drainage could be combined with simultaneous ductal decompression with a Puestow procedure. We later demonstrated that duct drainage alone is sufficient in the management of pseudocysts associated with CP.

Finally, the possible presence of cancer should always be considered, particularly in older patients. Patients with CP have a 20-fold increased risk of pancreatitis as compared to matched controls, although the actual

frequency does not reach 1%. Cancers may not be obvious on imaging studies that are obscured by the chronic inflammatory changes commonly seen in CP. Symptoms of pain, jaundice, weight loss, and new onset of diabetes are nonspecific and can be seen in both CP and pancreatic cancer.

Etiology and Pathogenesis

Histopathologic evaluation of CP demonstrates loss of normal pancreatic acinar cells with atrophy and replacement of the normal pancreatic parenchyma with fibrosis and chronic inflammatory cells. There may be some preservation of ductal remnants and islet cells. It is believed that the diabetes seen in CP is related to prevention of release of insulin in the milieu of dense fibrosis.

There are myriad causes for CP and some of these may be multifactorial. Alcohol is the causative factor in up to 80% of patients with CP. Interestingly, as many as 50% of patients with alcoholic CP stop drinking because of the pain. Unfortunately, by then they have nearly all become dependent upon narcotic analgesics. In the absence of alcohol as the etiologic cause, the clinician should seek out other causes. Referral for professional substance abuse treatment is encouraged, but long-term success rates are poor. Complete abstinence from alcohol should be encouraged for most patients with CP, particularly those with alcoholic pancreatitis. Given the fact that the purpose of surgery is the relief of pain which we define as free of all narcotics, it is key to initiate discussions of drug detoxification starting from the first encounter with the patient.

Idiopathic pancreatitis is stated to be the second most common cause of CP. Genetic abnormalities are being increasingly recognized as a causative factor in many patients with CP. It is likely that some cases of idiopathic pancreatitis may be due to as yet unidentified genetic mutations and research continues on affected kindreds in order to identify potential abnormalities. Known causes of familial or hereditary pancreatitis include mutations in the cationic trypsinogen (*PRSS1*), cystic fibrosis transmembrane conductance regulator (*CFTR*), and serine protease inhibitor, Kazal type 1 (*SPINK1*) genes. Referral to a genetics counselor can be considered for patients with idiopathic CP, particularly the young and those with a positive family history for pancreatitis or pancreatic cancer. Patients with hereditary pancreatitis have a 40% life-time incidence of developing pancreatic cancer and this should be considered when selecting strategies for surgical treatment and surveillance.

Ductal obstruction by tumors, stones, or strictures can be considered as a cause for CP, but these abnormalities are just as likely to have arisen as a result of it. In fact, one method for inducing CP in experimental animals is to create a partial obstruction of the pancreatic duct. The most common understanding of the natural course of CP starts with an excessively viscid pancreatic juice leading to plugging of the secondary ductules inducing a low-grade inflammatory response resulting in fibrosis formation and subsequent main duct scarring.

Tropical pancreatitis is relatively common in tropical, underdeveloped areas such as southern India, Nigeria, Uganda, Southeast Asia, and some areas of South America. Patients develop chronic calcific pancreatitis, pain, and pancreatic insufficiency. Etiologic factors that have been implicated include malnutrition, cassava ingestion, genetic abnormalities, and trace element deficiencies. Pancreatic surgery has been used for the treatment of chronic pain, but this disease is rarely encountered by surgeons in developed nations. Systemic disorders such as hypertriglyceridemia, hypercalcemia, and autoimmune pancreatitis account for a minority of patients with CP. These disorders should not be ignored in the evaluation of CP, but have frequently been considered prior to referral to a pancreatic surgeon. Primary treatment should be directed toward the underlying disorder. Autoimmune pancreatitis is a rare disorder that typically presents with a characteristic appearance on cross-sectional imaging that has been referred to as a “sausage-like” appearance. This is probably the most specific diagnostic abnormality. Serum IgG4 levels may be elevated on IgG subclass evaluation, but normal levels do not rule out the possibility of autoimmune pancreatitis. The identification of autoimmune pancreatitis is crucial for these patients as they respond well to steroids or other medical therapies and surgical intervention is rarely needed. Although gallstones are the most common cause of acute pancreatitis in the United States, their role in the pathogenesis of CP appears to be minimal and most patients have already had their gallbladders removed prior to development of CP. Only 15% of CP patients have had prior episodes of acute severe pancreatitis.

Diagnosis and Evaluation

Patients with CP usually will have a long history of pain, admissions to the hospital, ED visits, increasing narcotic use and a uniform message by a cast of physicians, including surgeons, that no intervention exists for their

predicament. As time passes, patients may become dependent upon massive doses of narcotics. They typically have sustained significant nutritional deficit. One should determine the degree of pancreatic insufficiency and replacement therapy should be initiated so that nutritional deficits can be corrected prior to undertaking operative intervention. It is important to gauge the patient's quality of life and narcotic requirements as improvement in these are the primary goals of surgical therapies. Objective measurement by quality-of-life assessment is encouraged and provides a baseline. Numerous laboratory tests and endoscopic and imaging modalities have been used to evaluate CP with varying sensitivities. It should be emphasized that the diagnosis of pancreatitis is suggested by clinical features of pain and pancreatic insufficiency and confirmed by imaging abnormalities. Imaging modalities are also useful to identify complications of CP and to help determine appropriate surgical therapy with particular attention paid to pancreatic duct abnormalities and anatomic distribution of parenchymal changes.

Laboratory evaluation is largely performed to identify causes of pancreatitis and to assess for pancreatic insufficiency. Serum amylase and lipase levels, while useful for the evaluation of acute pancreatitis, are generally normal in these patients even during acute exacerbations and this may be due to the so-called "burnt-out" pancreas. Unfortunately, due to the absence of laboratory abnormalities during an episode of exacerbation, these patients can be inappropriately sent home in spite of severe symptoms. Elevated serum pancreatic enzyme levels can be seen in patients with pancreatic pseudocysts. Serum glucose and HgbA1C determinations should be performed for the evaluation of endocrine insufficiency and fecal fat concentrations and elastase activities can help to quantify exocrine insufficiency. With regard to etiologic factors, serum triglycerides, calcium levels, IgG subclasses, and CA 19-9 levels should be obtained when appropriate. Liver function tests should be obtained and can be particularly useful for identifying clinically significant biliary strictures.

Cross-sectional imaging by computed tomography (CT) and/or magnetic resonance imaging (MRI) are the initial imaging modalities of choice for patients with CP. Findings on CT typically demonstrate gland atrophy or hypertrophy with a large head of the pancreas, typically composed of dense scar tissue. Duct abnormalities such as dilation, irregularity, and dilatation of the secondary ductules traditionally termed secondary ductular ectasia, intraductal and parenchymal calcifications, and

varying degrees of acute inflammation may be seen (Fig. 122.1). CT is particularly useful for identifying calcifications, which may not be visualized with MRI imaging. MRI with magnetic resonance cholangiopancreatography (MRCP) offers much information and may be complementary to CT imaging. Low attenuation changes and inflammatory changes may be present in early CP that might not be identified on CT imaging. Furthermore, MRCP offers high-quality, noninvasive imaging of the pancreatic and bile ducts. Years ago, the gold standard was ERCP. Fortunately, post-ERCP acute pancreatitis is extremely uncommon in patients with CP. ERCP may still have a role for early CP in which the only structural abnormalities are secondary ductular ectasia. This subtle change is not well demonstrated by MRCP. In addition, MRCP offers visualization of the distal pancreatic duct in cases of duct obstruction that would not be visualized using ERCP. Cross-sectional imaging also offers potential to identify most complications, such as pseudocysts, that might require intervention.

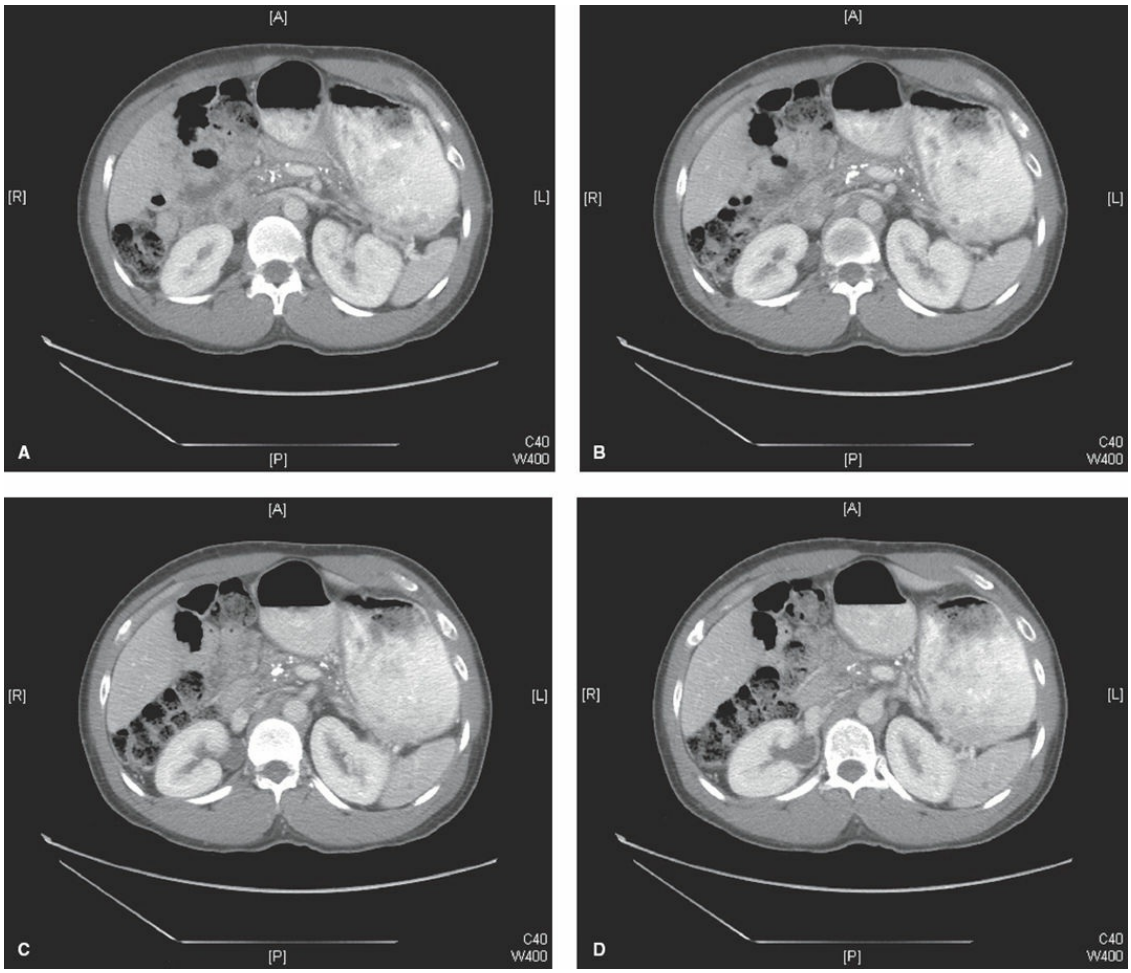

Figure 122.1. Computed tomography (CT) images demonstrating

characteristic imaging findings seen in chronic pancreatitis including gland atrophy, parenchymal calcifications, and duct abnormalities.

ERCP is almost exclusively used for therapeutic procedures and not diagnosis. EUS is a common diagnostic measure that can be overly sensitive in the evaluation of CP. Nonhomogeneity of tissue may lead to a diagnosis of CP when none exists. The Rosemont classification has been developed in order to standardize reporting of EUS findings, and abnormal findings are subclassified as major or minor criteria. Major criteria include hyperechoic foci >2 mm, major duct calculi, and lobularity in noncontiguous lobules while minor criteria include cysts, duct dilation, irregular duct contour, dilated side branches, hyperechoic duct walls, hyperechoic strands, hyperechoic foci, and lobularity in contiguous lobules. Disadvantages of EUS for diagnosis include inter- and intraobserver variability and nonspecific changes that may be associated with other factors such as male sex, age, obesity, and cigarette smoking. Blind EUS-guided final-needle aspiration (FNA) for the diagnosis of CP is not beneficial and should be discouraged, although FNA cytologic evaluation and cyst fluid analysis can be helpful for the evaluation of suspicious solid lesions and cysts. Notably, the sensitivity of EUS-FNA for detecting cancer in patients with CP is lower than that for patients with otherwise normal parenchyma. Inflammatory infiltrates may obscure malignant cells. EUS is recommended for the evaluation of pancreatic cystic lesions, particularly those with suspicious features on cross-sectional imaging.

PATIENT SELECTION AND PREPARATION FOR SURGERY

As is the case for so many surgical procedures, proper patient selection and preparation is a critical determinant of outcomes and may be more important than selection of procedure in this complex group of patients. In the modern era of health care, the evaluation and treatment of patients with CP mandates cooperation and coordination among a multidisciplinary team of providers that may include experts in pancreatic surgery, medical pancreatology, therapeutic endoscopy, interventional radiology and abdominal imaging, endocrinology, genetics, nutrition, pain management, psychiatry and social services. This is elective surgery and time should be

taken to maximize medical management. Endoscopic therapy has been evaluated and generally is not definitive. There is no question that surgery is preferable in patients with an inflammatory mass in the head of the pancreas. EUS-guided celiac plexus neurolysis is statistically better applied for palliation in patients with pancreatic pain associated with cancer. Improvement in pain after nerve ablation can be useful to confirm that the pancreas is the source of pain in patients with early CP.

Since a major goal of surgery is to render patients narcotic independent, almost all patients being considered for surgical treatment will have varying degrees of narcotic addiction as this can be challenging to manage before and after surgery. Due to the psychosocial issues that are so commonly associated with CP, many patients have essentially severed their relationships with referring physicians and primary care physicians. Appropriate management of CP in patients with an addictive personality, chronic pain syndrome, and subsequent narcotic dependence creates an enormous clinical challenge. The surgeon has a vested interest in the successful "detox" of these patients as this defines the success of the operative procedure. The pancreatic surgeon may become responsible for this aspect of the patient's care. At times a partnership with either a dedicated primary care physician, gastroenterologist, or pain specialist may be available. Unfortunately, referral to "pain clinics" and psychiatrists are often disappointing. There should be a clear establishment of goals of narcotic therapy and that the ultimate goal is to render the patient free from their addiction. Surgeons who prescribe narcotics should be aware of State Medical Board rules regarding prescription of narcotics for chronic pain. Patients should be seen in the office whenever a prescription is provided and documentation of an encounter is mandatory. Urine toxicology screens and query of regional databases tabulating recent prescriptions by the patients are encouraged when writing narcotic prescriptions. Noncompliant patients should be referred for substance abuse therapy and can be released from the physician's practice if they remain noncompliant.

SURGICAL PROCEDURES, SELECTION, AND OUTCOMES

Numerous procedures have been described for the treatment of CP. Over the last several decades there has been a gradual shift in surgical philosophy from formal resections (Whipple procedures), to drainage procedures, to hybrid procedures combining some element of a lesser

resection, with or without ductal drainage. There are advantages and disadvantages to all of these procedures, but the goal of all procedures should be to provide relief of symptoms while preserving organ function and minimizing surgical morbidity and mortality. Commonly performed procedures over the past 15 to 20 years employ varying degrees of pancreatic head resection, typically in the form of an “excavation” of the head of the pancreas using the C-loop of the duodenum as an anatomic boundary. An awkward term of “pacemaker” of the pancreas has been invoked as the epicenter of pain in CP. We are more comfortable simply stating that a large inflammatory mass may certainly be seen as a source of ongoing pain, which a drainage procedure alone would fail to address. The role for distal pancreatectomy (DP) for the treatment of CP is relatively limited with success rates for durable pain relief of only 50%. Denervation procedures have a limited role.

Finally, there has been considerable recent enthusiasm for the radical operation of total pancreatectomy with islet cell autotransplantation (TPIAT). Enthusiasm is a key descriptor, as much of this literature seems oddly promotional rather than investigational. This procedure remains highly controversial among experienced pancreatic surgeons. The primary and potentially damaging controversy lies in the exhortation by highly enthusiastic advocates of this operation that one should avoid conventional surgery for CP and move directly to TPIAT because some technical aspects of that operation are more challenging after conventional surgery. They attempt to paint a dark picture for the successes of conventional surgery when success rates between 75% and 90% have been reported in large series, including series reported by one of the authors over several decades. At least as disturbing is the fact that every report on TPIAT has been composed of a population unlike any other report on the management of CP, often predominantly female as compared the male dominance of all other reports. There is always a significant percentage of patients who have been given a diagnosis of “minimal change” CP. If one goes to the root report on this diagnosis one finds a 1992 article from “Gut” in which a surgeon and a pathologist review in minute detail 16 patients with unexplained abdominal pain. They describe a long list of obscure histologic findings that the pathologist admits would never have been found using conventional pathologic specimen handling practices. It is on the basis of this paper that the diagnosis has emerged. Having reviewed the pathology reports from more than a dozen TPIAT patients with this

diagnosis, in every case the specimen is described as “normal pancreas.” Outcomes after this operation are discussed later in this chapter.

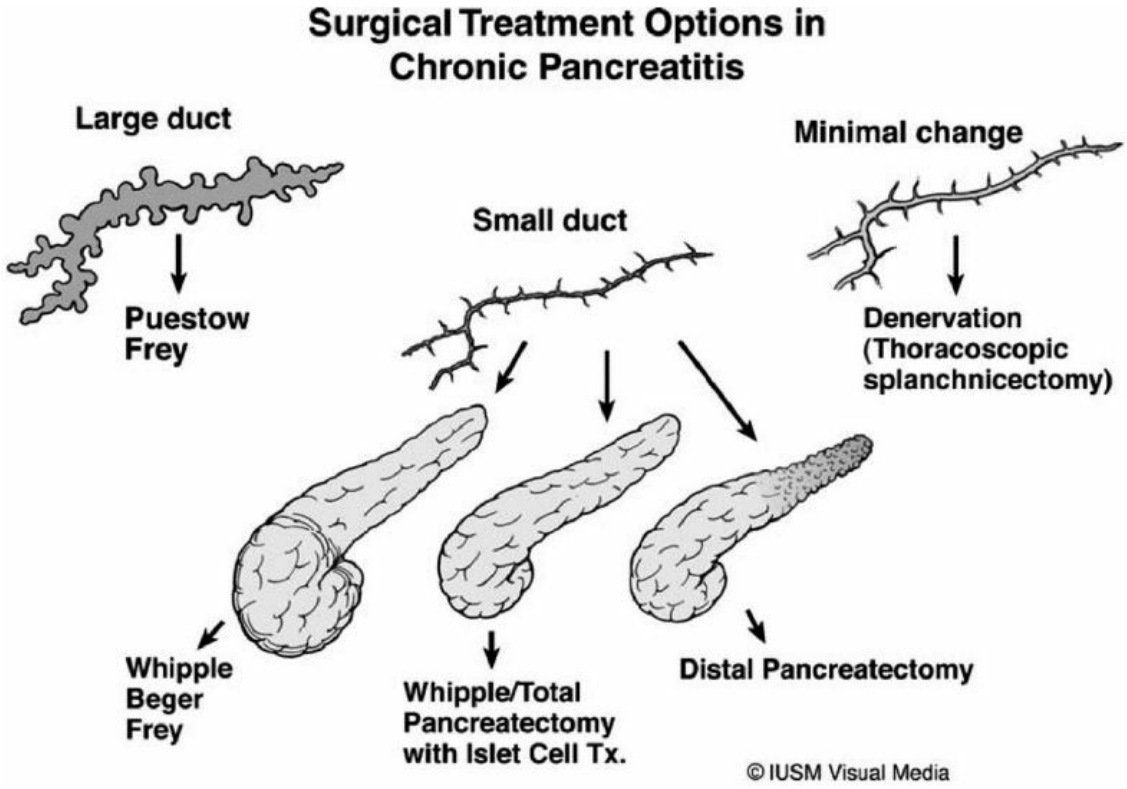

Figure 122.2. Types of operation based on anatomic and morphologic variables in chronic pancreatitis. (Reprinted from Howard TJ, Browne JS, Zyromski NJ, et al. Mechanisms of primary operative failure and results of remedial operation in patients with chronic pancreatitis. *J Gastrointest Surg* 2008; 12(12):2087–95; discussion 2095–6. Copyright © 2008, with permission from Springer.)

Various algorithms for choice of surgical procedure based on imaging findings have been suggested. These are usually based on the size and configuration of the pancreatic duct, presence and location of inflammatory lesions, evidence of biliary stricture, and overall gland morphology (Fig. 122.2). In general, patients can be classified by duct diameter into what is termed “small duct” and “large duct” CP. Drainage procedures can be employed for patients with large duct disease, often in combination with organ preserving excavations of the head of the pancreas. Formal resections (Whipple procedures) may be performed in patients with small duct disease or in those who have previously failed after a drainage procedure. Specific rationale for choice of procedures and outcomes are reviewed below.

Pancreaticoduodenectomy

Pancreaticoduodenectomy (PD) is typically performed for malignant or premalignant periampullary lesions, but considerable experience with this procedure for CP has been reported throughout the years. Although many pancreatic surgeons feel that outcomes are better and risks lower for the duodenum-preserving pancreatic head resections (DPPHR), PD is often performed by surgeons with little knowledge or experience with other choices. The great majority of American surgeons who identify themselves as pancreatic surgeons base that description on prior fellowship training in surgical oncology. Thus, their experience is often limited to formal resections, either PD or distal resection. Potential disadvantages of PD include high morbidity and higher rates of postoperative pancreatic insufficiency. We recommend that PD be reserved for selected patients, such as those with duodenal and/or biliary strictures, suspicion for or confirmed malignancies, or as a salvage procedure following the failure of less extensive procedures.

In a 5-year randomized trial of PD versus the Beger procedure, the authors found that patients in the Beger group had a lower incidence of nausea, vomiting, and diarrhea and improved quality of life and pain control. There were no differences in weight or pancreatic insufficiency. Notably, two patients in the Beger group required reoperation for biliary strictures. Based on these results and other previous reports, the authors concluded that the Beger procedure provides better outcomes than PD. A meta-analysis published in 2008 evaluated four trials comparing PD with DPPHR showed decreased blood loss, decreased hospital length of stay, and improved pancreatic exocrine function, weight gain, occupational rehabilitation, and quality of life in the DPPHR group. Both operations were equally effective regarding pain relief with 75% to 90% patients being pain free in follow-up. Another meta-analysis published in 2014, this time analyzing five studies, demonstrated improved global quality of life and decreased diarrhea and fatigue in the DPPHR group versus the PD group (Table 122.1). There were no differences identified in any of the other outcomes measured including pain, pancreatic function, or mortality. The authors of both meta-analyses concluded in favor of the head excavation procedures.

A 15-year follow-up report of a randomized trial of PD versus the Frey procedure in 64 patients raises questions about the long-term mortality associated with PD. Although there were no differences in pain or

pancreatic insufficiency, physical quality of life was improved in the Frey group. More notably, long-term mortality in the PD group was 53% versus 30% in the Frey group with mean survivals of 11.3 and 13.5 years. These findings underscore the considerable mortality associated with CP and further favor the excavation of the head of the pancreas rather than PD. In contrast, a study of 33 patients undergoing Frey or Berne procedures for CP showed that a relatively high number of patients require reoperation. In this study, seven patients required additional procedures for biliary strictures or cancer. As compared to the initial procedures, the morbidity associated with redo procedures was considerably higher, particularly with regard to pancreatic fistula, intra-abdominal infections, and the need for reoperation in the early postoperative period. The authors suggest, although well shy of statistical significance, that the need for reoperation with its associated considerable morbidity could be prevented by performing PD as the initial procedure. A large, multicenter randomized trial comparing outcomes for PD versus DPPHR has been designed and is currently accruing patients in order to better determine the optimal surgical procedure for patients with head dominant CP (ChroPac-trial).

Duodenum-Preserving Excavations of the Head of the Pancreas

Historically the operations available for use in the surgical management of CP were limited to the Puestow, or longitudinal pancreaticojejunostomy, and PD. During the late 1970s and into the 1980s several procedures were introduced (Fig. 122.3). The DPPHR was introduced by Beger in Ulm, Germany. In this procedure, which is now referred to as the Beger procedure, the pancreatic body/neck is divided as in a conventional Whipple and then the head of the pancreas is excavated to the boundary created by the C-loop of the duodenum. In the next decade, Frey introduced a procedure that was composed of a standard Puestow procedure combined with an excavation of the head of the pancreas in a manner essentially identical to the Beger procedure. Thus, one can describe the Beger procedure as a modified Whipple and the Frey procedure as a modified Puestow, or drainage procedure. In the end, the DHPPR procedures differ little with regard to technique or outcomes (Table 122.2).

TABLE 122.1 Results of a Meta-Analysis Comparing Outcomes for

Duodenum-Preserving Pancreatic Head Resections (DPPHR) Versus Pancreaticoduodenectomy (PD) for the Management of Chronic Pancreatitis

Outcome	Comparison	Effect Size, RR/WMD (95% CI; P; I^2)
Pain relief	DPPHR vs. PD	RR 1.08 (0.88–1.33; 0.46; 43%)
Morbidity	DPPHR vs. PD	RR 0.54 (0.20–1.46; 0.22; 77.6%)
Blood replacement	DPPHR vs. PD	WMD—1.28 (–2.32 to –0.25; 0.02, 88.7%)
	Frey vs. ppPD	WMD—2.09 (–2.30 to –1.87; 0.01, 0%)
Operation time	DPPHR vs. PD	WMD—53.03 (–134.96 to 28.89; 0.20; 99.2%)
	Frey vs. ppPD	WMD—112.45 (–164.07 to –60.84; 0.01; 88.6%)
Pancreatic fistula	DPPHR vs. PD	RR0.39 (0.08–1.97; 0.26; 0%)
Delayed gastric emptying	DPPHR vs. PD	RR0.23 (0.05–1.11; 0.07; 32%)
	Frey vs. ppPD	RR 0.06 (0.01–0.46; 0.01; 0%)
Hospital stay	DPPHR vs. PD	WMD—4.32 (–6.46 to –2.00; 0.01; 60.7%)
	Exclusion of Büchler et al.	WMD—5.26 (–6.67 to –3.86; 0.01; 0%)
Exocrine insufficiency	DPPHR vs. PD	RR 0.20 (0.06–0.66; 0.01; 57.7%)
Endocrine insufficiency	DPPHR vs. PD	RR 0.49 (0.22–1.09; 0.08; 0%)
Weight gain	DPPHR vs. PD	RR 1.93 (1.33–2.81; 0.01; 46.1%)
Occupational rehabilitation	DPPHR vs. PD	RR 1.36 (1.07–1.71; 0.01; 0%)
Quality of life	DPPHR vs. PD	WMD 25.07 (18.83–31.31; 0.01; 57.1%)

P values of 0.01 include all data of <0.01.
CI, 95% confidence interval; DPPHR, duodenum-preserving pancreatic head resection; I^2, degree of statistical heterogeneity; 0–25%, moderate; 26–50%, average; 51–100%, high statistical heterogeneity; PD, pancreatoduodenectomy; ppPD, pylorus-preserving Whipple procedure; RR, relative risk; WMD, weighted mean difference.
Reprinted from Diener MK, Rahbari NN, Fischer L, et al. Duodenum-preserving pancreatic head resection versus pancreatoduodenectomy for surgical treatment of chronic pancreatitis: a systematic review and meta-analysis. *Ann Surg* 2008;247(6):950–61, with permission from Wolters Kluwer.

Just as in a conventional Whipple procedure, preliminary measures for the Beger procedure include a generous Kocher maneuver so that "bimanual palpation of the head of the pancreas is possible." The lesser sac is opened along the gastrocolic omentum. The omentum is reflected superiorly and the transverse mesocolon is reflected inferiorly. The procedure requires division of the pancreatic neck over the portal/superior mesenteric vein (SMV) junction followed by local resection of the head of

the pancreas leaving a rim of 5 mm of residual pancreatic tissue along the medial border of the duodenum and between 5 and 10 mm at the floor of the excavation. The intrapancreatic portion of the common bile duct (CBD) is usually preserved, although the duct can be opened and incorporated into the reconstruction in order to allow for improved biliary drainage. Proponents of all of these procedures suggest that careful dissection and division of inflammatory fibrous tissue around the CBD should provide adequate decompression for biliary strictures. Reconstruction for the Beger procedure requires creation of two pancreaticojejunal anastomoses to the same Roux limb of jejunum, one encircling the edges of the excavated head and an additional anastomosis between the more proximal Roux limb and the remnant of the ventral pancreas. The opened intrapancreatic choledochotomy can be included in this anastomosis if one has been made. The pancreaticojejunostomy at the head of the pancreas simply requires sutures placed in the typically firm remnant rim around the C-loop of the duodenum. The anastomosis to the distal remnant can be performed using a standard duct-to-mucosa reconstruction, inversion pancreaticojejunostomy, or one can incorporate the rigid edge of pancreatic tissue as one often does in a Puestow or Frey procedure. For case with a particularly dilated dorsal pancreatic duct or a chain-of-lakes appearance, reconstruction with a longitudinal pancreaticojejunostomy can be considered. The Beger procedure has become popular in Europe, but is not performed frequently in the United States.

The Frey procedure was initially described in 1985 and essentially combines a local resection of the head of the pancreas with a longitudinal pancreaticojejunostomy. For this procedure, the head of the pancreas is excavated in a nearly identical fashion. First observed during a visit to Ulm in the early 1990s, one of the authors learned the crucial step of placing a series of deep sutures, using a CT-1 needle, circumferentially around the C-loop of the duodenum and maintaining a 5-mm rim. Each of these sutures are tied and clamped. This measure greatly reduces the risk of hemorrhage during excavation. Hemostasis and occasional ligation of the gastroduodenal artery is necessary. Ligation of the right gastroepiploic artery as it exits the plane between the pylorus and the head of the pancreas is mandatory. The anterior inferior pancreaticoduodenal artery should be identified overlying the uncinate process and may also require ligation. The dissection is carried posteriorly with the surgeon’s opposite

hand beneath the head of the pancreas until a plane lying over the intrapancreatic CBD is identified and entered. The MPD is opened along the entire length of the dorsal pancreas prior to the head resection and reconstruction is performed with a single anastomosis between a Roux limb of jejunum and the pancreatic duct and head defect (Fig. 122.4). It is crucial to begin by completing the posterior row using interrupted sutures. Care should be taken to assure that the distance between the sutures on the pancreas always exceed the distance between the Lembert sutures on the jejunum. Without taking this precaution one will be challenged by what proves to be a size mismatch between the open jejunum and the opening in the body and head of the pancreas. None of these sutures should be tied until that row is completed. For the anterior row one should first place the corner sutures, now directed inside-out on the pancreas. All sutures on the anterior row should be tied as you go. After the corners, place a central suture and then divide the distances in half. In this manner, you will achieve a uniform closure. The Frey procedure has become quite popular among American surgeons. It is felt that the risks of hemorrhage are decreased because the need for establishing a plane in the dense fibrosis often associated with CP posterior to the pancreatic neck and anterior to the portal vein-SMV is eliminated.

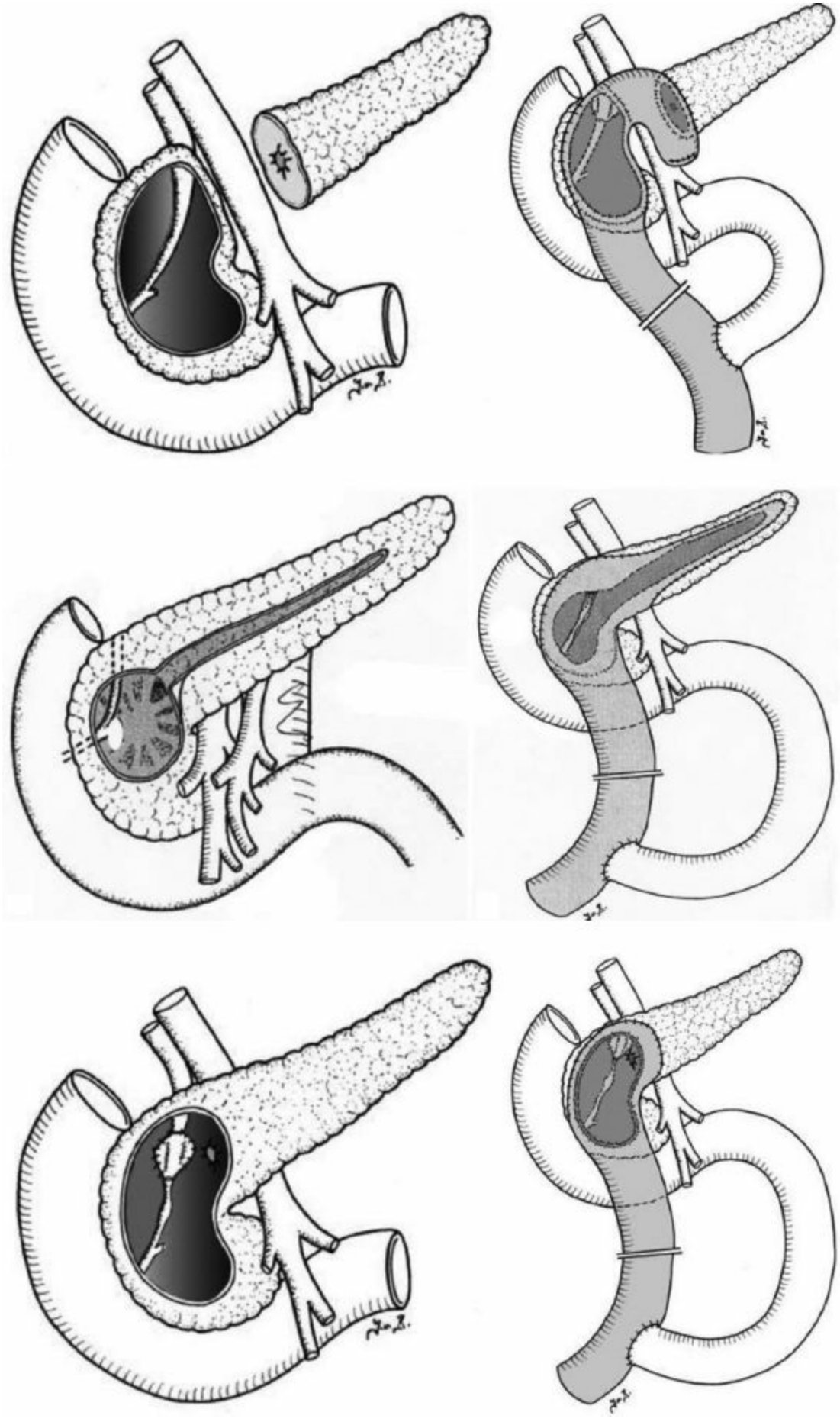

Figure 122.3. Duodenum-preserving pancreatic head resections (DPPHR): Beger procedure, Frey procedure, and Berne modification of the Beger procedure. (Reprinted from Strobel O, Buchler MW, Werner J. Duodenum-preserving pancreatic head resection: technique according to Beger, technique according to Frey and Berne modifications. *Chirurg* 2009; 80(1):22–7. Copyright © 2008 Springer Medizin Verlag, with permission from Springer.)

TABLE 122.2 Duodenum-Preserving Pancreatic Head Resections and Their Defining Characteristics

Procedure	Duodenum Preservation	Extent of Pancreatic Head Resection (E-Extended, L-Limited)	Neck Transection	Lateral Pancreatico-jejunsotomy
Beger	+	E	+	–
Frey	+	L	–	+
Berne	+	E	–	–

The Berne modification of the Beger procedure, or "central pancreatic-head resection," was described by Markus Buchler in 2001 in an attempt to achieve the benefits of the Frey and Beger procedures while minimizing their disadvantages. The procedure essentially involves an extensive, local resection of the head of the pancreas with preservation of the duodenum. For this procedure, the pancreatic neck is not transected. The pancreatic duct is essentially marsupialized to the surrounding pancreatic tissue (the bile duct can be as well if it is opened during the procedure) and reconstruction is performed between the edges of the head remnant and a Roux limb of jejunum. Reports indicate that the procedure can be performed with minimal mortality (1%) and morbidity (16%). In our opinion, there exist few indications for this modification. Currently, the procedure is performed only in selected centers with virtually all of the literature coming from a single center in Germany.

Data comparing DPPHR with PD have been discussed. There are relatively few studies comparing the various procedures to one another. In a randomized, prospective trial of 74 patients undergoing Beger or Frey procedures, no differences were identified between the groups for the parameters of quality of life, pain control, somatic symptoms, long-term

survival or mortality, and pancreatic insufficiency. These results suggest that both procedures offer similar outcomes for the treatment of CP. In another study comparing the Beger procedure with the Berne modification, the authors found the Berne procedure was associated with decreased operating room time and hospital length of stay. There were no significant differences in quality of life 2 years following surgery, but three patients who underwent Berne procedures required reoperation for ongoing pancreatitis and/or biliary strictures. This is consistent with other studies indicating that less invasive procedures are associated with lower rates of long-term failure due to biliary obstruction.

Distal Pancreatectomy

DP with or without splenectomy is commonly performed using a variety of open and minimally invasive techniques for the management of benign and malignant lesions of the pancreas with acceptable morbidity, mortality, and outcomes. In our study of minimally invasive pancreatectomy, 23% of patients developed endocrine insufficiency. This procedure is rarely indicated for the management of CP except in the exceedingly unusual circumstance where the inflammatory changes appear to be confined to the tail of the pancreas on imaging studies. Concern for underlying malignancy is a reasonable indication as well. The clear disadvantage of distal pancreatic resection versus drainage procedures for CP is the uniformly poor successes for pain relief. In the event that a patient has survived an episode of severe necrotizing pancreatitis with complete ductal disruption, or in patients who have sustained a ductal injury after trauma such as is seen after seat-belt injuries, the “disconnected duct syndrome” may be encountered. This entity nearly always results in localized CP in the remnant pancreas toward the spleen. This can be managed with a DP/splenectomy. We have reported managing this problem with significant success utilizing a lateral pancreaticjejunostomy to the remnant duct. Importantly, there is an increased risk of pancreatic insufficiency and surgical complications with the distal resection.

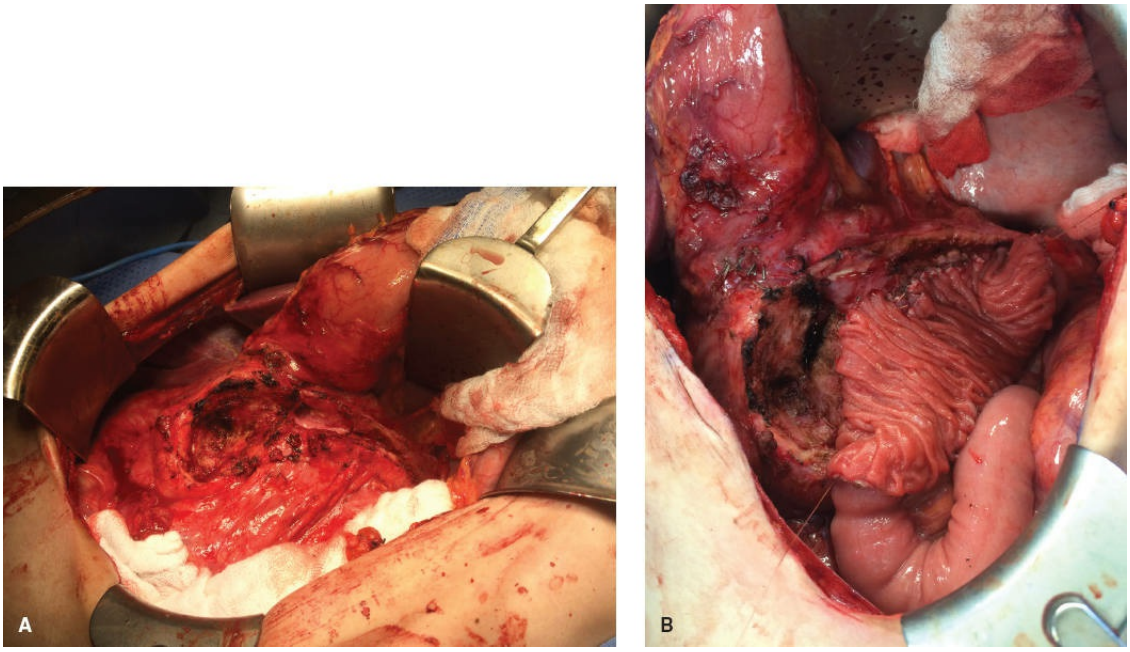

Figure 122.4. Frey procedure. **A.** Excavated pancreatic head and opened dorsal pancreatic duct. **B.** Reconstruction is performed using a single-layer, interrupted, absorbable suture.

Drainage Procedures

Drainage procedures such as the lateral pancreaticojejunostomy (LPJ or Puestow procedure) remain popular with American pancreatic surgeons. We reserve its use for patients with atrophic glands and essentially no inflammatory mass in the head of the pancreas (Fig. 122.5). The terms Puestow procedure and Partington–Rochelle are applied randomly to this procedure. Of historic note, before the more established procedures were validated, several authors examined the simple postulate that since the duct contained no valves one might solve the apparent obstructive and resulting dilatation of the duct by simply opening the duct at the ampulla or at the end of the tail. Doubollet explored the former without success and Duval promoted the latter with a small opening in the tail of the pancreas and a pancreaticojejunal anastomosis. Puestow, in our opinion, deserves credit for the longitudinal anastomosis, in spite of the fact that he essentially proposed this element in combination with Duval's tail resection. Partington–Rochelle simply excluded the tail resection for what became the LPJ as it currently exists today. For the Puestow procedure, again a generous Kocher maneuver is performed and "bi-manual" assessment of the head of the pancreas is performed. The entire pancreas is widely exposed after the gastrocolic ligament has been divided, the transverse mesocolon reflected inferiorly, and the omentum and stomach are reflected

superiorly. Often, dense adhesions can be encountered between the posterior surface of the stomach and the anterior surface of the pancreas. The inferior, allegedly avascular border of the pancreas should be mobilized so that the body and neck can be better palpated by placing the fingers posterior to the body of the pancreas and the thumb on the anterior surface of the body of the pancreas. In this manner, the duct can be palpated and an angiocatheter placed into the duct to confirm its location. Next, using electrocautery, the ductotomy is performed over the angiocath. Once entered, a tonsil clamp can assist in following the course of the duct. Incision is carried to the left toward the tail and well past the genu of the MPD into the uncinate process. It is in this location that an inflammatory mass may be encountered and the decision might be made to convert to a Frey procedure. It is common to encounter brisk bleeding as the uncinate is divided. The surgeon should be prepared with sutures for ligation if this occurs. Simple use of electrocautery for the vessels considerably raises the risk of postoperative hemorrhage. The pancreaticojejunostomy is performed in an essentially identical manner as described for the Frey procedure.

The advantage of the LPJ procedure is that it allows for adequate decompression of a dilated pancreatic duct while minimizing the morbidity, mortality, and pancreatic insufficiency associated with pancreatic resections. Ideal candidates for the procedure are patients with dilated ducts or multiple areas of stricturing and dilation throughout the length of the duct without an associated inflammatory mass in the head of the pancreas. The procedure may also be useful for patients who have obstructing intraductal stones. We have reported that duct drainage alone is sufficient in the management of pancreatic pseudocysts associated with CP. No simultaneous management of the pseudocyst is required (Fig. 122.6). It is generally taught that the procedure is neither feasible nor efficacious unless the pancreatic duct is at least 5 to 7 mm in diameter. Izbicki and colleagues have reported a series of 41 patients with “small duct” disease for whom extended drainage with “V-shaped” excavation along the length of the pancreatic duct was performed, essentially creating an LPJ in patients with small ducts (Fig. 122.7). The authors demonstrated that the procedure could be performed with no mortality and acceptable morbidity, and provided increased quality of life and decreased pain. There was a moderate incidence in diabetes (43%), although 78% of patients experienced preserved exocrine function. Postoperative imaging

demonstrated excellent drainage of pancreatic ducts in all but one patient.

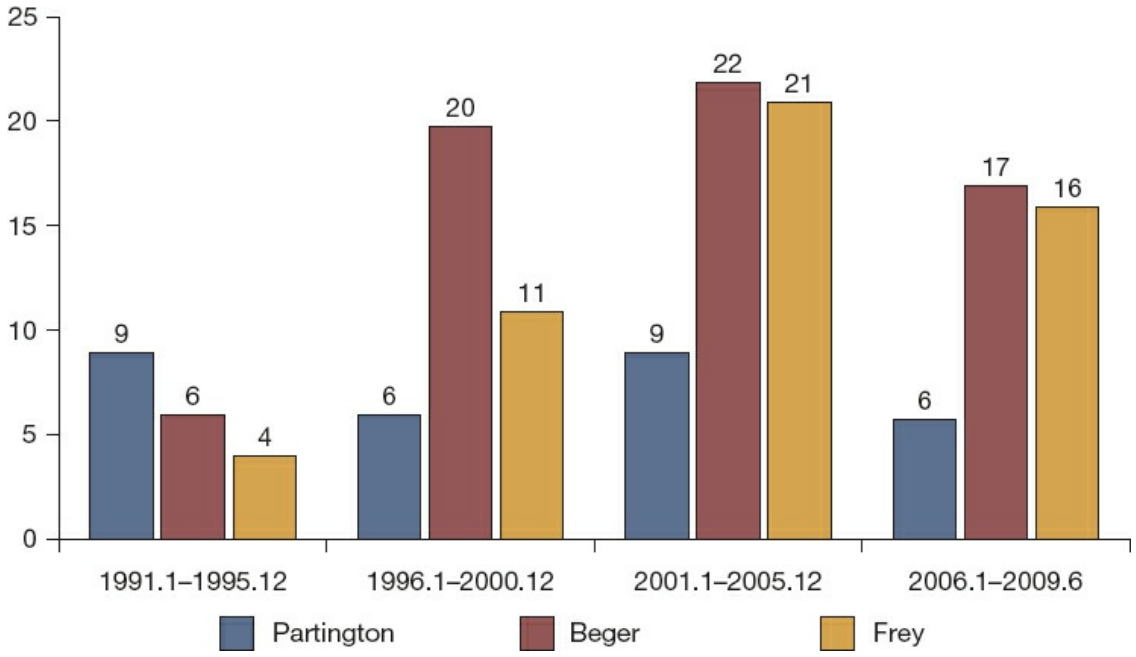

Figure 122.5. The number of studies published from January 1991 to June 2009 concerning Partington (lateral pancreaticojejunostomy or Puestow), Beger, and Frey procedures. These data suggest that pancreatic surgeons are increasingly utilizing the combined duodenum-preserving pancreatic head resections (DPPHR) while interest in pure drainage procedures appears to be waning. (Reprinted from Isaji S. Has the Partington procedure for chronic pancreatitis become a thing of the past? A review of the evidence. *J Hepatobiliary Pancreat Sci* 2010;17(6):763–9. Copyright © 2010 by John Wiley & Sons, Inc. Reprinted by permission of John Wiley & Sons, Inc.)

The LPJ has been shown to result in a high rate of pain relief in most patients (Table 122.3). Some have questioned the long-term durability of these outcomes. It is conceivable that some of these data are antecedent to the general acceptance of the added excavation of the head of the pancreas when a large, dominant inflammatory mass in the head of the pancreas exists. A 2007 review of American literature and a survey of members of the Pancreas Club indicated that many U.S. surgeons continue to favor the LPJ and have limited experience with any one of the excavation procedures. Preservation of endocrine function over time is a potential advantage to Puestow procedures. One of the authors has published data, including a long-term follow-up of a randomized controlled trial of operated and nonoperated CP patients that is published in the Cochrane

reviews, indicating that LPJ delays progressive loss of function when compared to nonoperated patients.

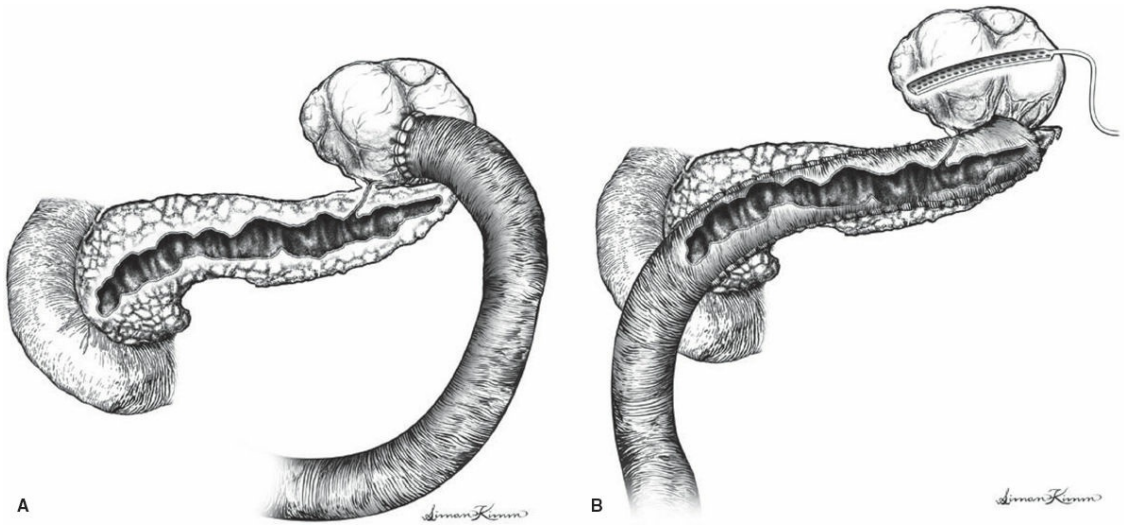

Figure 122.6. **A.** Internal drainage of pancreatic pseudocyst versus **B.** duct-directed therapy with pancreaticojejunostomy. (Reprinted from Bell RH, Jr. Current surgical management of chronic pancreatitis. *J Gastrointest Surg* 2005;9(1):144–54. Copyright © 2005, with permission from Springer.)

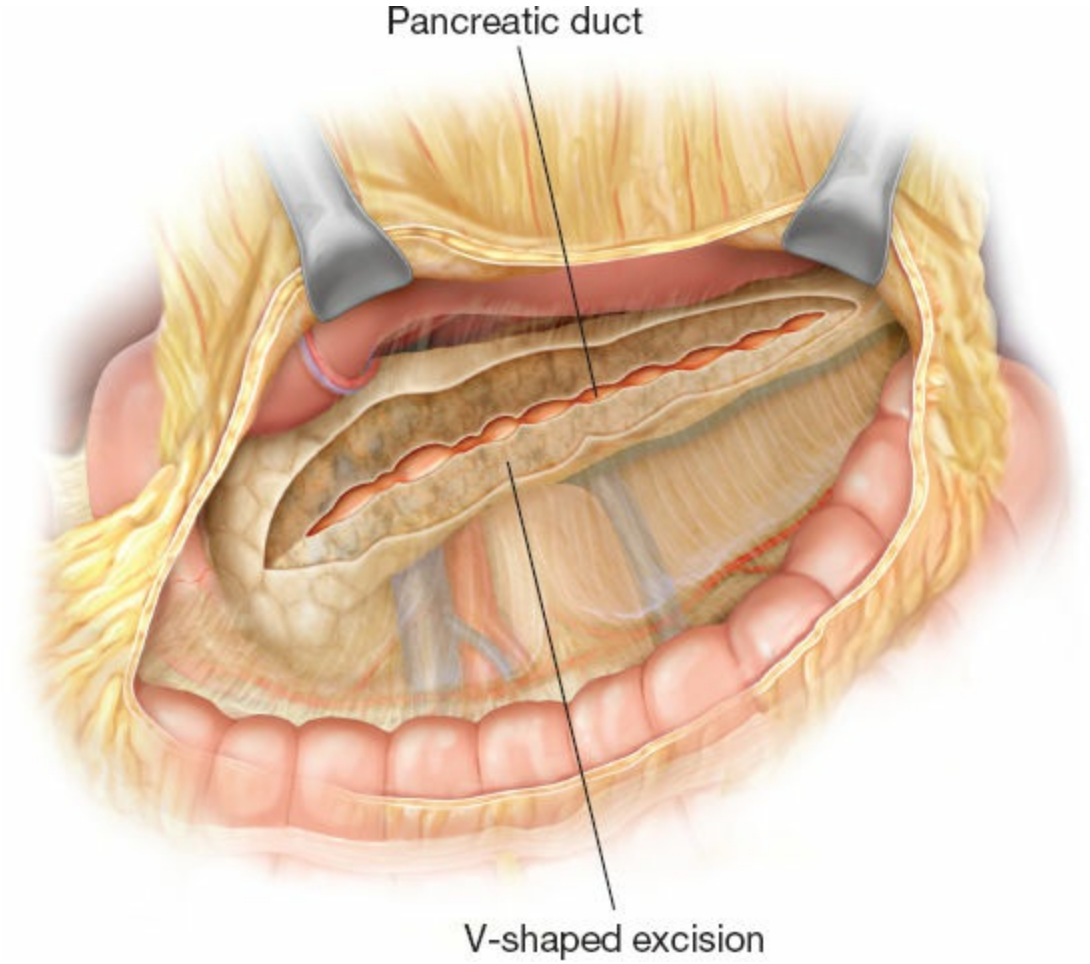

Figure 122.7. Longitudinal V-shaped excision of the ventral pancreas for chronic pancreatitis with a nondilated pancreatic duct.

Endoscopic Interventions

Little mention has been made here of endoscopic therapies for CP, but at least one well-designed randomized prospective trial and a recent Cochrane review both demonstrated that LPJ provides superior outcomes to endoscopic therapy for patients with pain, dilated ducts, and no inflammatory mass in the head of the pancreas. Patients undergoing endoscopic therapy frequently require numerous procedures and many eventually undergo surgery after endoscopic failures.

Denervation Procedures

The rationale for performing denervation procedures is based on the theory that pain related to CP is mediated by neural changes processed through the celiac ganglia and autonomic nervous system. These procedures essentially include chemical neourolysis procedures that can be performed

percutaneously, endoscopically, or at the time of open surgery and open or thoracoscopic thoracic bilateral splanchnicectomy procedures. Chemical neurolysis is a good option for patients who are not candidates for surgical procedures and can provide good short-term pain relief, although recurrence occurs almost universally. Neurolysis may be useful to confirm that pain is related to CP in patients for whom there is a question of etiology, or as a bridge to more definitive surgery while preoperative optimization of health and compliance are being established. Thoracic splanchnicectomy is a complex procedure that has little role in the management of CP pain, although the procedure enjoyed a period of enthusiasm some 10 or more years ago.

TABLE 122.3 Results of Lateral Pancreaticojejunostomy for Chronic Pancreatitis

Author	Year	No. of Patients	Operative Mortality (%)	Mean Follow-Up (Years)	Pan Relief (%)
Nealon et al.	2001	124	0	6.5	86
Delcore et al.	1994	28	—	3.5	86
Greenlee et al.	1990	50	4.2	7.9	82
Bradley	1987	48	0	5.8	66
Sato et al.	1986	43	0	9.1	91
Holmberg et al.	1985	51	0	8.2	72
Warshaw	1985	36	3.0	3.6	83
Sarles et al.	1982	69	4.2	5	85

Reprinted from Isaji S. Has the Partington procedure for chronic pancreatitis become a thing of the past? A review of the evidence. *J Hepatobiliary Pancreat Sci* 2010;17(6):763–9. Copyright © 2010 by John Wiley & Sons, Inc. Reprinted by permission of John Wiley & Sons, Inc.

Total Pancreatectomy With Islet Cell Autotransplantation (TPIAT)

Total pancreatectomy has traditionally been considered to be an almost prohibitive surgery due to considerable problems with postoperative pancreatic insufficiency, particularly brittle diabetes, and has been generally reserved as a remedial operation in cases where other procedures have failed. In order to minimize problems with postoperative endocrine insufficiency and preserve endocrine function, the procedure of total pancreatectomy with islet cell autologous transplantation (TPIAT) was initially developed in 1977. Only 140 of these procedures were performed worldwide until 2001, but several centers developed a renewed interest in the procedure in the early 2000s and relatively large series of reported

results have emerged in the literature.

The procedure essentially involves performing a total pancreatectomy, including resection of the duodenum, distal bile duct, and spleen (Fig. 122.8). Pylorus-preservation is generally preferred and reconstruction is performed with a hand-sewn choledochojejunostomy and an antecolic duodenojejunostomy. Care is taken to preserve the arterial blood supply (gastroduodenal artery and splenic artery) for as long as possible during the procedure in order to minimize islet cell ischemia. In “true” CP one will encounter considerable dense inflammatory adhesions with at times intimate adhesion to the portal vein-SMV juncture as well as the splenic vein, splenic artery, hepatic artery, and superior mesenteric artery. We apply the term “true” in describing CP in discussing this literature because, as previously mentioned, essentially all major reports on TPIAT are composed of a markedly atypical patient population and includes diagnoses, such as “minimal change CP,” which we believe have no place in the analysis of conventional CP.

Care is taken to preserve the arterial blood supply (gastroduodenal artery and splenic artery) for as long as possible during the procedure in order to minimize islet cell ischemia. Some surgeons will divide the pancreas prior to completing the resection of the head and hand off the specimen for islet cell harvesting in order to minimize harvesting time, although this could potentially decrease islet cell yield. For cases in which prior CP surgery has been performed, there may be additional challenges to dissection. The reconstruction is performed while islet cell harvesting is performed. Following this, the abdomen is closed temporarily and the patient remains under general anesthesia.



Figure 122.8. **A.** Surgical field following resection of the specimen for total pancreatectomy and islet cell autotransplantation (TPIAT). **B.** Resected specimen on the back

table.

For the islet cell harvesting, the pancreatic duct is cannulated with an IV angiocath through which a collagenase solution is infused (Fig. 122.9A). The specimen is brought to a certified laboratory for the remainder of the harvesting. Mechanical and chemical digestion of the pancreas is performed in a Ricordi chamber containing stainless steel ball bearings (Fig. 122.9B). Samples are periodically collected and observed with dithizone staining. When the islet cell yield appears to be suitable, the digestion is terminated with cold University of Wisconsin transplant solution. The chamber is emptied and digested tissue is washed away. At this point, all that remains is an islet cell pellet that is resuspended in 5% albumin with heparin (Fig. 122.9C and D). At this point, the abdomen is reopened and the islet cell suspension is infused directly into the portal vein under gravity pressure (Fig. 122.9E). Once the islet cell transplantation procedure has been completed, the catheter is removed from the portal vein, drains are placed, and the abdomen is closed. The patient should be maintained on an insulin drip in order to tightly control postoperative blood sugars as hyperglycemia has been shown to inhibit islet cell establishment and growth within the hepatic parenchyma. Daily insulin and C-peptide levels can be measured and there is usually evidence of insulin production in the early postoperative period. Close collaboration with a dedicated team of endocrinologists is strongly encouraged during all phases of the perioperative period. All patients will require some insulin administration following surgery.

TPIAT can be performed safely in experienced hands. Outcomes are modest at best. Considering that the classic CP patient is alcoholic, at least in the past, and also likely chronically narcotic dependent, we would argue that this population is immensely challenged by adding potentially brittle diabetes to their medical issues. Some of this reality is undoubtedly mitigated by the fact that the standard population to whom this operation is offered is not made up of a majority of ethanol abusers, as is seen in every report on the conventional operations for CP. Insulin dependence is seen in 60% to 70% of patients after TPIAT and narcotic dependence exceeds 60% in nearly all series in spite of the absence of all pancreatic tissue. The authors of many of these papers have presented creative metrics. For the question of the presence or absence of viable islet cells, they measure C-peptide which certainly confirms the presence of insulin production, but

does not equate to insulin independence. For their successes in pain relief, they rely upon a metric known as Morphine Equivalents. The patient remains narcotic dependent but may require fewer morphine equivalents. The reports on operative complications for TPIAT must again be viewed through the prism of this highly selected population. Considering that many of their patients lack the dense fibrosis seen in classic CP, it would be anticipated that their rate of complications should be lower than is seen after conventional surgeries for CP. Average blood loss for TPIAT is 635 mL with operating times of about 9 hours and hospital length of stay of 15 days. This is considerably more than results for conventional procedures and appears primarily to be related to nutritional and endocrine issues. Complications can occur in 68% of patients, although most are not life threatening.

Although there are many strong proponents of the TPIAT, we have mixed feelings. We would strongly advocate for separating the two categories of patients. As previously explained, the diagnosis of “Minimal Change CP” has no place in the discussion of classic CP. These are distinctly different clinical entities. They likely represent recurrent acute pancreatitis (RAP). We readily admit that we see few viable operative interventions for this diagnosis (RAP), and in that setting, we may recommend this procedure. We particularly admonish against the urging by advocates for TPIAT that conventional CP procedures be avoided. This is based upon the perspective of decades of strong evidence to favor their use when compared to the modest successes reported for TPIAT. Again, the utilization of this operation for the nonclassic CP patients may be warranted. The two diagnoses need to be evaluated separately. Good results have been reported for patients with hereditary pancreatitis for whom CP fibrosis is uncommon. Islet yields are considerably better in that setting. Again, this represents a different cohort compared to classic CP. In the case of classic CP there may be a role for TPIAT as a salvage procedure for patients who have undergone unsuccessful previous surgery for CP. Patients must have preserved endocrine function and this is generally evaluated preoperatively by insulin response to glucose tolerance testing or a mixed-meal challenge.

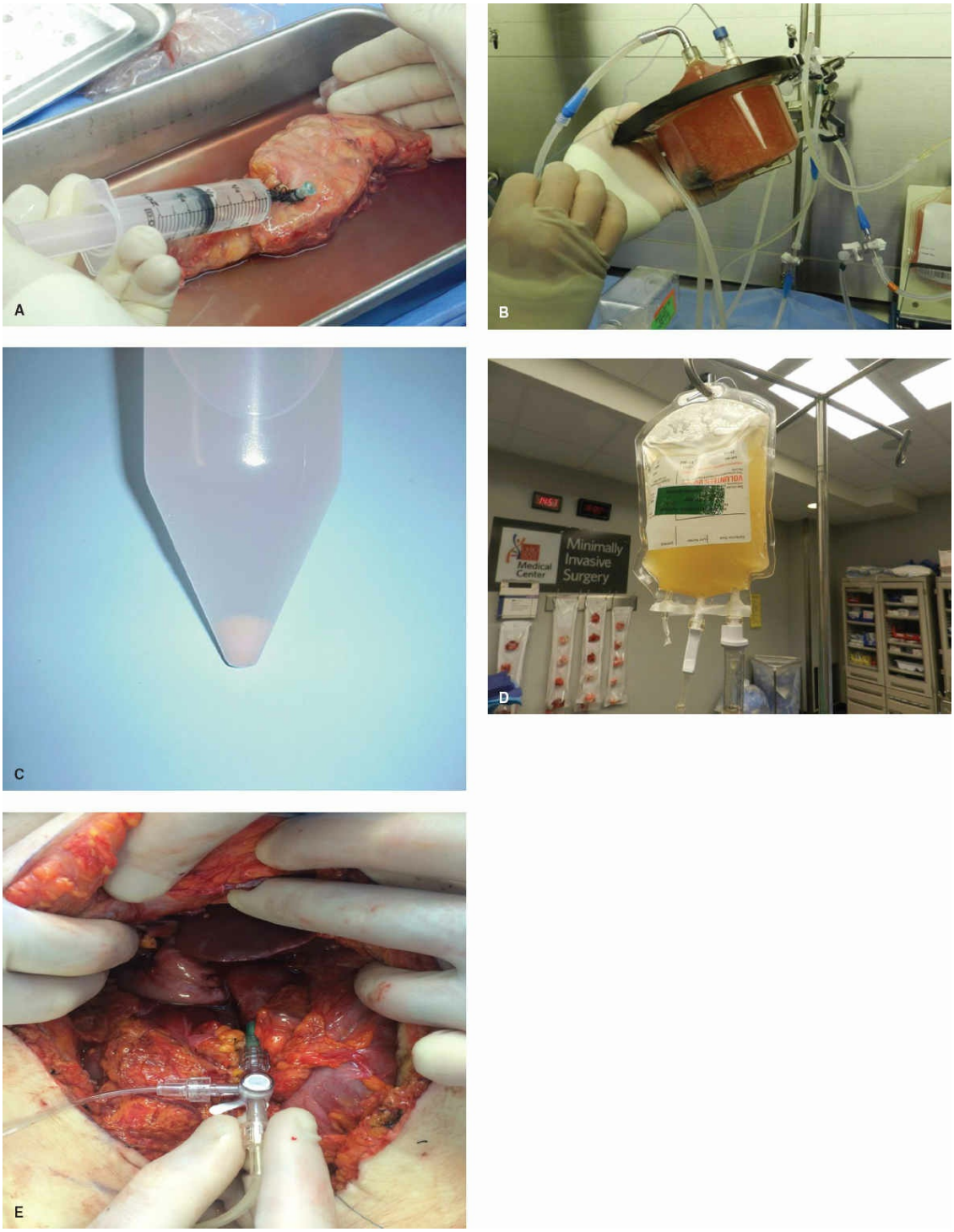

Figure 122.9. (**A**) Prior to islet cell harvesting for TPIAT, the pancreatic duct is cannulated with an angiocatheter and infused with collagenase solution. (**B**) Mechanical and chemical digestion of the pancreas is performed in a Ricordi chamber containing stainless steel ball bearings. (**C**) Following extraction, the islet cell pellet is resuspended in (**D**) heparinized 5% albumin. (**E**) Direct islet cell infusion into the portal vein.

CONCLUSIONS

There are a variety of procedures that have been described for the management of CP and selection of procedure depends on patient- and surgeon-related factors such as imaging findings and surgical experience. Appropriate patient selection is crucial for good outcomes following surgery for CP. The goals of most procedures should be to improve pain control and quality of life while maximizing preservation of organ function, although some procedures are performed for complications of CP and suspicion of malignancy. Patients should demonstrate commitment to their care and surgeons and patients should be aligned regarding goals of surgery. These should be clearly established prior to undertaking any procedure. Patient noncompliance can be an indication for forsaking surgical options or even terminating the patient–physician relationship. Current data support performing what we have termed the excavation of the head of the pancreas (Beger, Frey, Berne). Be reminded that these represent modifications of the traditional procedures of resection (PD) and drainage (Puestow). In the end, each of these procedures are quite similar. As a consequence of lack of experience on the part of most nonpancreatic specialists, one should consider either resorting to the traditional techniques or referral to experienced surgeons in dedicated centers.

Suggested Readings

Bachmann K, Kutup A, Mann O, et al. Surgical treatment in chronic pancreatitis timing and type of procedure. *Best Pract Res Clin Gastroenterol* 2010;24(3):299–310.

Bachmann K, Tomkoetter L, Kutup A, et al. Is the Whipple procedure harmful for long-term outcome in treatment of chronic pancreatitis? 15-years follow-up comparing the outcome after pylorus-preserving pancreatoduodenectomy and Frey procedure in chronic pancreatitis. *Ann Surg* 2013;258(5):815–20; discussion 820–1.

Beger HG, Kunz R, Poch B. The Beger procedure–duodenum-preserving pancreatic head resection. *J Gastrointest Surg* 2004;8(8):1090–7.

Bell RH, Jr. Current surgical management of chronic pancreatitis. *J Gastrointest Surg* 2005;9(1):144–54.

Delhaye M, Van Steenbergen W, Cesmeli E, et al. Belgian consensus on chronic pancreatitis in adults and children: statements on diagnosis and nutritional, medical, and surgical treatment. *Acta Gastroenterol Belg* 2014;77(1):47–65.

Diener MK, Rahbari NN, Fischer L, et al. Duodenum-preserving pancreatic head

resection versus pancreatoduodenectomy for surgical treatment of chronic pancreatitis: a systematic review and meta-analysis. *Ann Surg* 2008;247(6):950–61.

Howard TJ, Browne JS, Zyromski NJ, et al. Mechanisms of primary operative failure and results of remedial operation in patients with chronic pancreatitis. *J Gastrointest Surg* 2008;12(12):2087–95; discussion 2095–6.

Nealon WH, Thompson JC. Progressive loss of pancreatic function in chronic pancreatitis is delayed by main pancreatic duct decompression. A longitudinal prospective analysis of the modified puestow procedure.*Ann Surg* 1993;217(5):458–66; discussion 466–8.

Nealon WH, Walser E. Duct drainage alone is sufficient in the operative management of pancreatic pseudocyst in patients with chronic pancreatitis. *Ann Surg* 2003;237(5):614–20; discussion 620–2.

Wilson GC, Sutton JM, Abbott DE, et al. Long-term outcomes after total pancreatectomy and islet cell autotransplantation: is it a durable operation? *Ann Surg* 2014;260(4):659–65; discussion 665–7.

EDITOR'S COMMENT

The authors present an excellent review of the diagnosis and classification of chronic pancreatitis as well as the selection of various procedures for treatment. At the outset, I think the surgeon should understand that the treatment of chronic pancreatitis is multidisciplinary and ideally should involve gastroenterology, behavioral medicine and primary care, pain management, nutrition services as well as the surgeon. The comments of the authors are pertinent in the emphasis of the psychosocial implications of this disease that interface with every aspect of treatment. My commentary will focus on the practical aspects of the selection of surgical treatments for chronic pancreatitis.

The worldwide incidence of chronic pancreatitis (CP) ranges from 1.6 to 23 cases per 100,000 population per year. In the United States, CP results in more than 120,000 ambulatory visits and more than 56,000 hospitalizations annually. Some studies state that the global incidence of CP is between 2 and 200 per 100,000 persons and has been increasing year over year (Garg PK, Tandon RK. Survey on chronic pancreatitis in the Asia-Pacific region. *J Gastroenterol Hepatol* 2004;19:998–1004). In this report, India had the highest incidence of CP in the world at approximately 114 to 200 per 100,000 persons and the incidence of CP in China was approximately 13 per 100,000 persons. The annual incidence in France is about 7.8/100,000. Abdominal pain is the presenting symptom in more than 90% of patients with CP. Interestingly, the mechanism of abdominal pain is still not clear. It is generally accepted that pancreatic duct hypertension, pancreatic inflammation, and peripancreatic immune cell infiltration play an important role in the causation of the abdominal pain. In addition, at initial presentation there may be varying degrees of

exocrine and endocrine insufficiency. Surgical procedures designed to alleviate pain rarely if ever alter the natural progression of CP. If not initially present these conditions will develop during the progression of the disease. In my experience exocrine insufficiency usually predates the development of diabetes which usually is apparent about 10 years into the disease process. Although most cases are caused by excessive alcohol use there is increasing awareness that tobacco use may be a catalyst leading to CP. Some cases related to autoimmune pancreatitis or hereditary pancreatitis. The disease may be classified in phases. The early phase 1 to 5 years is characterized by acute pancreatitis episodes, pain and hospitalization. The middle phase occurs from 5 to 10 years. During this time acute symptoms are reduced, but morphologic changes of the pancreas lead to the formation of strictures of the bile and pancreatic duct and pseudocysts as well as chronic pain and the development of early pancreatic insufficiency. The late phase is beyond 10 years with worsening exocrine insufficiency and development of diabetes.

The median survival in CP is about 15 years. The death rate of patients is estimated as: 15% at 5 years, 34% at 10 years, 48% at 15 years, 62% at 20 years, 72% at 25 years, and 76% at 30 years (Levy P, Domínguez-Muñoz E, Imrie C, et al. *United European Gastroenterol J* 2014;5:345–54). In many studies that look at survival in CP, death was due to extrapancreatic consequences of alcohol, and tobacco over use such as lung or esophageal cancer, cirrhosis of the liver, or myocardial infarction.

It is well established that CP cannot be completely cured. The purpose of surgical therapy for CP is to relieve symptoms, especially pain; to improve the patient's quality of life; and to treat complications. In is generally known there seems to be a significant correlation between the severity of abdominal pain and the extent of intrapancreatic neural damage. Even though the mechanisms of pain have not been fully elucidated, accumulating evidence point to a process of neural inflammatory cell infiltration. This is hypothesized to lead to pancreatic neuritis eventually resulting in the formation of a dense neural network of nerve connections within the pancreas. Pain management strategies include the intake of pancreatic enzyme supplements, cessation of alcohol intake and smoking, and analgesic therapy. In case of persistence of symptoms or suspicion of pancreatic cancer, surgical procedures come into play. Decompression (drainage), resection, neuroablation, and decompression combined with resection are commonly used methods for the surgical treatment of CP. The methods of decompression and surgical resection are reviewed below.

The role of various imaging techniques is reviewed very nicely by the authors. As they point out there is little role for ERCP in establishing the diagnosis. Instead MRI is the preferred technique of diagnosing CP followed by CT and US. MRCP will demonstrate ductal dilation and pancreatic masses. The MRI is usually sufficient to detail the abnormal anatomy and aid the surgeon in planning an operation. If there is a mass it should be biopsied by EUS.

One major controversial issue about the treatment of painful obstructive CP

is whether surgical therapy is superior to endotherapy. Endoscopic treatment may involve sphincterotomy, stenting or stone removal. Prospective studies have shown that short-term pain relief is equivalent in endoscopic and surgical procedures. However, after 3 to 5 years after surgery is found to be superior in long-term pain reduction and weight gain. In order to analyze this issue, Díte et al. Additional studies have shown that nearly 50% of patients who undergo endoscopic treatment will eventually require surgery. Following chapters will review specific surgical procedures and outcomes.

The authors briefly comment on ablative techniques. In the past, there was some interest in thoracic sympathectomy. This has not gained wide support. Percutaneous celiac blocks are of variable effectiveness. These techniques have been replaced by blocks performed by endoscopic ultrasound. The results are satisfactory but require repeat treatment as the longevity of the treatment is not substantial.

My final comment is on minimal change chronic pancreatitis. This entity was first described by Walsh et al. (Minimal change chronic pancreatitis. *Gut* 1992:33:1566–71). They reported 16 cases. Partial resection was performed in 12 and 8 required total pancreatectomy. The histology of resected specimens showed chronic inflammatory changes accompanied by subtle noninflammatory changes in all but one. This is sometimes referred to as image negative chronic pancreatitis or noncalcific pancreatitis. EUS once thought to be of value in the diagnosis of this entity has recently been challenged by studies showing that patients without EUS criteria of CP had on histology fibrosis, atrophy, and inflammation. Medical treatment has generally poor results. The recent trend is to recommend total pancreatectomy and islet autotransplantation for this disease. The initial results seem promising but I advise caution before recommending this to your patients. As the authors note many of the pancreata have a normal histology. The long-term viability of the islet auto transplant is not fully established. In the end, the patient may be trading one disease for another that may be worse. My advice is proceed cautiously!

E. Christopher Ellison

123 Operative Interventions for Chronic Pancreatitis

Keith D. Lillemoe and Chad G. Ball

INDICATIONS FOR OPERATIVE INTERVENTION

Achieving effective treatment for patients with severe complications of chronic pancreatitis is one of the most difficult challenges in surgery. The essence of this disease process is the progressive destruction of the pancreatic parenchyma and its replacement with fibrotic tissue. Over time this often leads to both endocrine and exocrine insufficiencies. Irrespective of etiology (ethanol abuse; hypercalcemia; hyperlipidemia; certain medications; cationic trypsinogen mutation [PRSS1], pancreatic secretory trypsin inhibitor [SPINK1], and chymotrypsinogen C [CTRC] genes; cystic fibrosis; autoimmune disease; prior severe acute pancreatitis with necrosis; pancreatic ductal obstruction from developmental abnormalities [pancreas divisum]; sphincter of Oddi dysfunction; or obstruction from trauma or neoplasm), pancreatitis is also a disease that displays a notably worse actuarial survival compared to age-matched controls. The most significant complications associated with chronic pancreatitis are pain (50% at 15 years), diabetes (75% at 15 years), and exocrine insufficiency (80% at 15 years). Operative procedures to treat chronic pancreatitis, regardless of type, are classically indicated for specific symptoms including: (a) intractable pain (60%), (b) biliary obstruction (<5%), (c) duodenal stenosis (<5%), and (d) the need to exclude a diagnosis of malignancy (30%). Less common indications include: (a) bleeding, (b) complicated pseudocyst or walled off pancreatic necrosum, and (c) sinistral hypertension. In summary, chronic pancreatitis becomes an operative disease only when there is a need to treat complications of the underlying pathology.

Although intractable pain represents the most common indication for operative intervention, the precise etiology of this discomfort remains unclear. Popular theories defining the origin of pain include (a) ductal hypertension, (b) parenchymal hypertension, and (c) neural inflammation

among the primary afferent neurons. The neuronal theory holds particular weight given the dramatic increase in both the number and the size of nerves found within the gland in patients suffering from chronic pancreatitis.

Despite the above-mentioned operative indications, it is crucial to recognize that chronic pancreatitis is often a direct consequence of complex and long-standing social factors. More specifically, the surgeon must address the overall psychology of the patient, their ability to follow a treatment plan that includes abstinence from alcohol, cessation of smoking, as well as a commitment to engage in physician-guided weaning of narcotics after the operative procedure. Without this thorough evaluation on the part of the surgeon, and commitment on the part of the patient, a significant percentage of patients who undergo operative procedures will fail to achieve a successful therapy. This philosophy can be extended to all causes of chronic pancreatitis in that the underlying etiology must always be eliminated. As an example, if a patient continues to consume alcohol following an operation that results in insulin-dependent diabetes, the chances of life-threatening complications are substantial.

The technical armamentarium of the pancreatic surgeon currently includes both duodenal-preserving and drainage procedures (Frey, Beger, Puestow, Duval), as well as formal resection interventions (distal pancreatectomy, pancreaticoduodenectomy, total pancreatectomy +/− islet cell autotransplantation). The selection of one technique over another should be based on the primary location of disease (head versus body/tail), the size of the pancreatic duct, and the presence of a stricture of the bile duct and/or duodenum (and finally the potential risk of cancer in a new lesion). The use of these various operative interventions in the modern era also reflect a shift in the indications paradigm from parenchymal-based (1950s to 1980s), to duct size–based (1980s to 1990s), to resection and drainage-based (current) philosophies. In cases selected for a pancreaticoduodenectomy, the vast majority of the pancreatic inflammatory process should be located in the head of the gland. This view is particularly important for those who believe that the epicenter of inflammation, and therefore the “pacemaker” of intractable pain, is located in the head of the gland. Additional advantages of this procedure include concurrent decompression of a bile duct and/or duodenal stenosis, as well as the ability to safely perform a reconstruction in the presence of a small

pancreatic duct. Finally, pancreaticoduodenectomy is the appropriate "cancer operation" should consideration of the malignancy be part of the differential diagnosis.

It is interesting to note that multiple studies evaluating pancreatic duct size and pressure measurements have failed to consistently demonstrate a direct relationship between duct abnormalities and pain scores. In addition, significant numbers of chronic pancreatitis patients have essentially normal size pancreatic ducts (so-called "small-duct" or "minimal-change" chronic pancreatitis) but have significant pain. This can even occur early in the course of their disease. Furthermore, studies evaluating total pancreatectomy with islet cell autotransplant have shown that even this dramatic procedure fails to relieve pain in all patients, implying that more than simple mechanical mechanisms are at work in chronic pancreatitis.

Traditional dogma indicates that patients with chronic pancreatitis should experience pancreatic "burn out" (i.e., resolution of epigastric pain) with the long-term avoidance of surgery and intervention. This hypothesis is clearly incorrect given that patients randomized between medical and surgical interventions had significantly less pain over the ensuing 10 years of follow-up if they underwent surgery. A recent randomized trial also compared endoscopic with surgical interventions for chronic pancreatitis. This study was stopped early due to clear superiority at the interim analysis within the surgical arm.

In summary, the surgeon's choice of specific operative intervention for patients with chronic pancreatitis is reliant upon a strong understanding of the limitations and benefits of each procedure. This chapter will continue to discuss each common option.

PREOPERATIVE EVALUATION

Patients with chronic pancreatitis can present with a wide variety of clinical symptoms. The most common hallmark however, is chronic epigastric pain that is nonremitting in nature and radiates through to the back. Although the intensity of this symptom can be extreme, the correlation between radiologic changes reflecting long-term pancreatic damage and the intensity of the pain itself are often not well aligned. Not surprisingly, many of these patients arrive for assessment with a long history of chronic narcotic use/dependence. Of course, these patients can also present with complications of their endocrine and exocrine malfunction as well.

In addition to a thorough history and assessment of a patient's social risk factors, preoperative evaluation is heavily dependent on the use of modern diagnostic imaging. Options include, but are not limited to, contrast-enhanced computed tomography (CT), magnetic resonance cholangiopancreatography (MRCP), endoscopic ultrasound (EUS), endoscopic retrograde cholangiopancreatography (ERCP), and contrast-enhanced ultrasound (CEUS). Each technique offers varying degrees of information on both the pancreatic duct and the gland itself. The appropriate selection of these diagnostic techniques is crucial in both determining whether the extent of disease is appropriate for surgical management and also in guiding the choice of the most appropriate operative procedure for each individual patient based on ductal anatomy and gland morphology. A triple-phase intravenous contrast helical CT (fine-cut pancreas protocol) is typically the initial noninvasive imaging test for pancreatic disease. Helical CT displays the anatomy of the pancreas gland in considerable detail. It can also easily define pancreatic calcifications, inflammation, necrosis, atrophy, and masses. MRCP can be quite useful for noninvasively defining the anatomy and pathology of both the bile ducts and the pancreatic duct. MRCP can be especially helpful in the cases where the ampulla of Vater is not accessible (i.e., the patients who have previously undergone Roux-en-Y or Billroth II reconstructions). Specific EUS criteria exist to define parenchymal (echogenic strands, hyperechoic foci, calcifications, lobular contour, cysts) and ductal (wall hyperechogenicity, irregular duct wall, visible side branches, strictures, stones) disease, but technique is highly operator dependent. It also allows a biopsy for a potentially concerning discrete lesion as well. CEUS can be particularly helpful in identifying the "stiffness" of the pancreas gland. Finally, ERCP provides direct imaging of the pancreatic and bile ducts and is the gold standard for diagnosing chronic pancreatitis. ERCP also allows therapeutic stenting of biliary and pancreatic duct strictures both as temporary measures for short-term management or definitive treatment.

SURGICAL TECHNIQUE—OVERVIEW

Pancreaticoduodenectomy (Pylorus-Preserving)

Resection of the pancreatic head in the setting of chronic pancreatitis can be accomplished by means of either a pylorus-preserving pancreaticoduodenectomy (PPPD; Fig. 123.1) or the classic Whipple resection (including an antrectomy). Multiple randomized trials have failed

to show any significant differences between the two procedures in terms of either relative ease of performance or short- or long-term outcome in the patients with pancreatic cancer. As a result, the choice between procedures for either chronic pancreatitis or cancer is usually made on the basis of individual surgeons' preferences. Our preference is typically the pylorus-preserving modification. Preoperative mechanical bowel preparations are optional. Antibiotics directed at enteric bacteria are administered at induction of anesthesia. Antibiotic consideration must also account for the patients who have had biliary or pancreatic duct stents. Wound protectors are recommended to reduce the incidence of surgical site infections.

The peritoneal cavity is entered through an upper midline. The round ligament is divided at the liver and the portion between the liver and the umbilicus is excised. A fixed abdominal wall retractor system of the surgeon's choice is engaged after a wound protector is placed. Especially in the cases where a malignancy must be ruled out, the liver, the omentum, and the peritoneal surfaces are inspected and palpated. Any suspicious lesions are biopsied and submitted for frozen-section analysis.

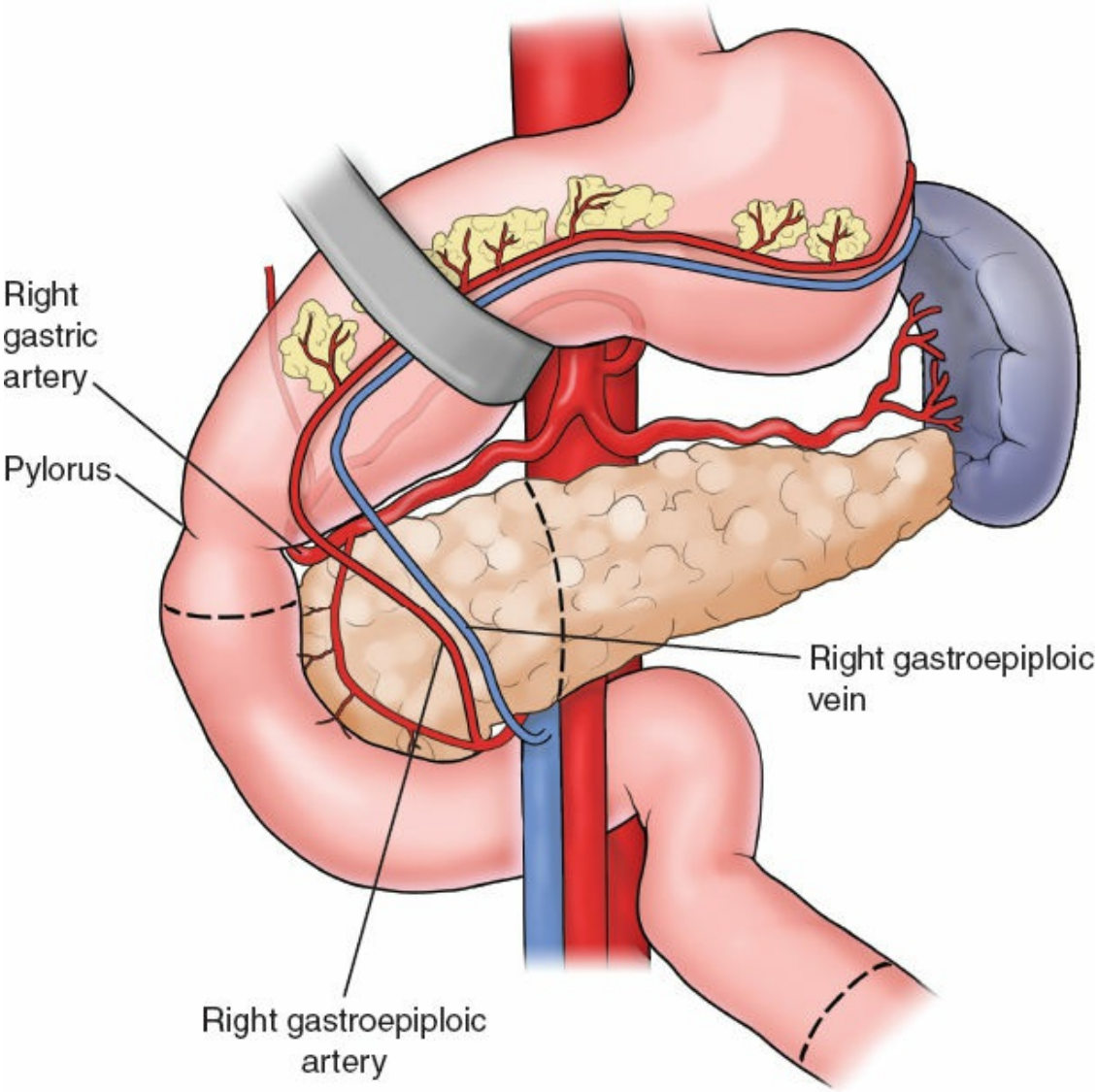

Figure 123.1. The areas to be resected with the pylorus-preserving pancreaticoduodenectomy are depicted: Head of pancreas, duodenum (parts 2, 3, and 4), and segment of proximal jejunum. The entire head of the gland is removed. The right gastroepiploic vessels are divided near their origins. The right gastric artery is divided away from the stomach near its origin. This allows the neurovascular supply of the antrum and pylorus to be preserved and may minimize the incidence of delayed gastric emptying.

Operative assessment begins with a wide Kocher maneuver and mobilization of the duodenum and the head of the pancreas from the underlying inferior vena cava and aorta. When the duodenum and head of the pancreas have been mobilized sufficiently, a hand is placed under the duodenum and the head of the pancreas to palpate the local anatomy. The lesser sac is then opened widely by incising the lesser omentum and by

removing the entire greater omentum off the transverse colon. Every attempt is made to preserve the greater omentum. The hepatic flexure of the colon is also mobilized and retracted downward out of the operative field early in the operative procedure.

Our preference is to dissect the superior mesenteric vein (SMV) and portal vein as an initial step. The inflammatory response associated with chronic pancreatitis can be considerable making this dissection somewhat tedious; therefore, early control is important if bleeding is encountered at any point in the case. Identification of the portal vein is greatly simplified if the common hepatic duct is divided early in the dissection. Once the hepatic duct has been divided, the anterior surface of the portal vein is easily and quickly identified. The lymph node tissue lateral to the hepatic duct and the portal vein should be dissected off the structures to be included in the surgical specimen. This is somewhat less important in cases of chronic pancreatitis where a malignancy is not the primary concern. It must be remembered that important variations in the hepatic arterial anatomy, including a replaced right hepatic artery, may be encountered during this dissection. If the appropriate plane is found along the anterior surface of the portal vein, it is often possible to pass the index finger of the left hand on top of the vessel posterior to the first portion of the duodenum and the neck of the pancreas (because usually there are no veins joining the anterior surface of the portal vein). If this maneuver proves difficult, which is not uncommon in cases of chronic pancreatitis because of adherence of the fibrotic pancreas gland to the SMV and portal vein, the gastroduodenal artery should be identified where it originates from the common hepatic artery. Once adequate dissection has been carried out, the artery should first be clamped with a nonoccluding vascular clamp; then, if the hepatic artery pulse is preserved, divided, and ligated with 2-0 silk ties. (The initial clamping of the gastroduodenal artery with a vascular clamp confirms that the arterial supply to the liver will not be interrupted should either variations in hepatic arterial anatomy or important collateral circulation be present in the face of celiac artery stenosis.) After the artery has been divided and ligated, an additional ligature of 3-0 polypropylene should be placed on the proximal stump. Division of the gastroduodenal artery unroofs part of the tunnel through which the index finger is slipped, thereby greatly facilitating the separation of the portal vein from the posterior aspect of the first portion of the duodenum and the neck of the pancreas. It should be re-emphasized that

severe inflammation and/or scarring around the portal vein mandates extensive caution and precision when dissecting around the portal vein. Portal vein injuries can be catastrophic due to an inability to quickly expose the underlying venous injury in the context of a hard inflamed pancreatic gland.

Once the anterior surface of the portal vein has been dissected posterior to the neck of the pancreas, the next step is to identify the SMV and dissect its anterior surface. This is most easily accomplished by extending the Kocher maneuver past the second portion of the duodenum to include the third and fourth portions. During this extensive kocherization, the first structure encountered anterior to the third portion of the duodenum is the SMV. The anterior surface of the vein can then be cleaned and dissected under direct vision by retracting the neck of the pancreas anteriorly. This dissection is continued until it connects to the portal vein dissection from above.

In a PPPD, the duodenum is first mobilized and divided ~2 cm distal to the pylorus with a gastrointestinal anastomosis (GIA) stapler. The posterior surface of the proximal first portion of the duodenum is dissected until the lesser sac is entered. At this point, the soft tissue attachments from the inferior border of the duodenum to the inferior border of the pancreas are divided. The right gastroepiploic vessels, which can be sizable, are clamped, divided, and ligated. In a similar fashion, the soft tissue areolar attachments found superiorly are divided with the electrocautery. The right gastric artery, which originates from the common hepatic artery, is also ligated.

In a classic Whipple procedure, an antrectomy is performed. The right gastroepiploic arcade and the right gastric vessels are divided to permit mobilization of the antrum. The stomach is then divided with a GIA stapler, usually at the level of the incisura. At this point, if the gastroduodenal artery was not divided earlier, it is identified, divided, and ligated as described (see above). During this step, particular care must be taken to ensure that the lumen of the common hepatic artery is not encroached on by one of the proximal ties.

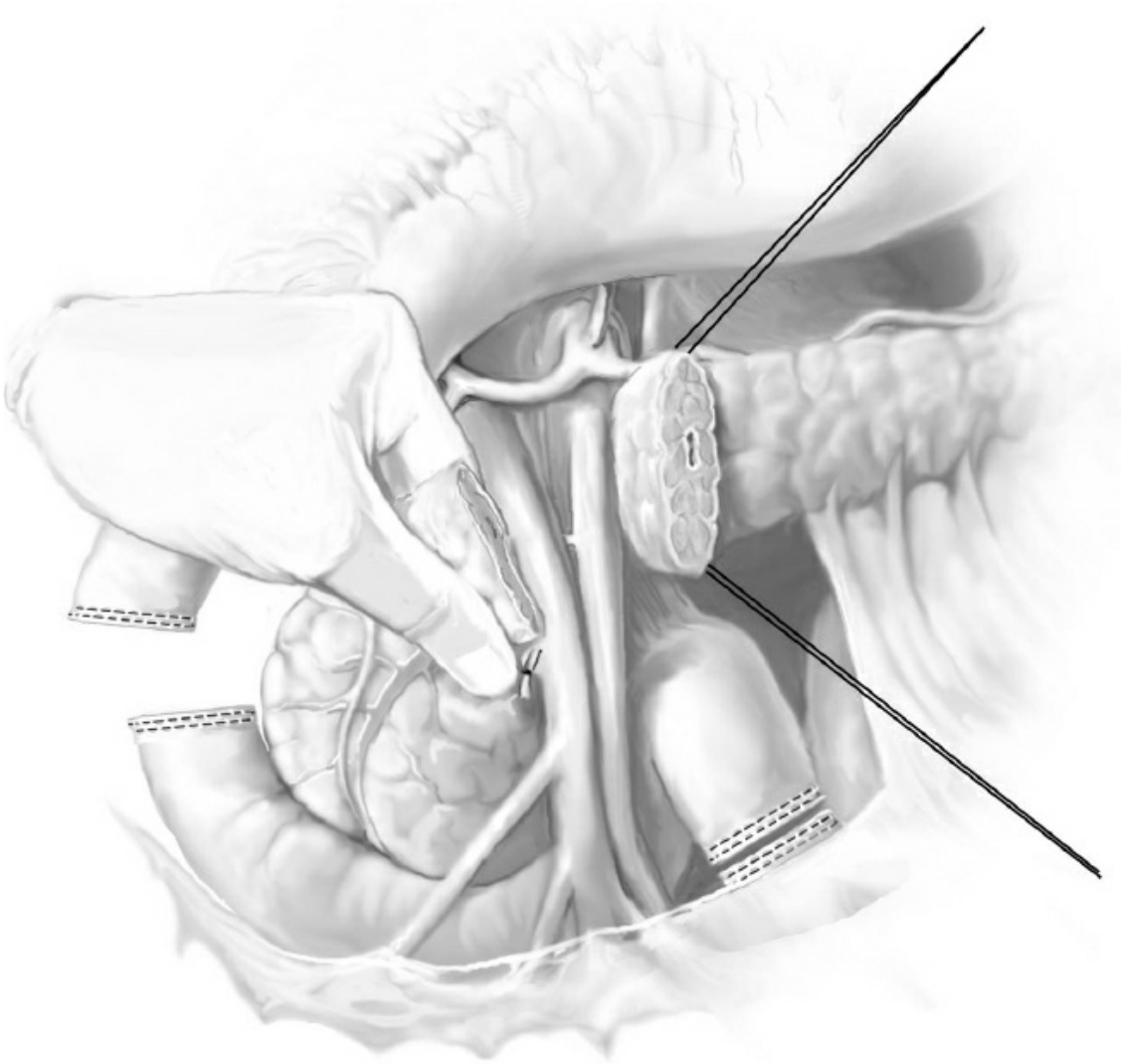

Figure 123.2. Hand compression of the specimen is used to control blood loss while the retroperitoneal attachments of the dorsal medial pancreatic head and uncinate process are divided from the superior mesenteric artery. The surgeon on the left side of the patient places his or her left hand on the stout lymph node—laden mesentery attaching the dorsal head and uncinate process to the SMA area. As this "mesentery" is sequentially divided from cephalad to caudad along the SMA, the hand pressure controls bleeding from the specimen and the clamps control bleeding from the SMA side.

The neck of the pancreas is then divided with the electrocautery, with care taken not to injure the underlying SMV and portal vein. The head of the gland is then reflected to the right and head and the uncinate process of the pancreas is dissected away from the portal vein and SMV. In the patients with chronic pancreatitis, this dissection can again be difficult because of adherence between the fibrotic gland and the SMV. Great

caution must be taken for all dissection around the SMV and portal vein to prevent a major vascular injury and subsequent hemorrhage. If a replaced right hepatic artery is present, its origin from the superior mesenteric artery (SMA) will be encountered at this point and must be preserved. The uncinate process can then be divided between clamps flush with the SMA, then ligated with 2-0 silk ties; alternatively, either an energy-based vessel-sealing system or ultrasonic shears may be used. The SMA is completely exposed during this dissection, which proceeds from cephalad to caudad, as shown in Figure 123.2. Unlike PPPD for cancer, the extent of this dissection, and therefore the inclusion of the lymphatic tissue adjacent to the SMA, is less critical in the patients with chronic pancreatitis. As a rule, there are two large veins joining the SMV inferiorly that must be dissected free, doubly ligated, and divided. The first jejunal branch can often be spared via cautious dissection.

Once the uncinate process has been completely divided, the specimen is attached only by the third portion of the duodenum. At this point, the upper abdomen is copiously irrigated with an antibiotic solution, inspected for hemostasis, and packed. The transverse colon, along with the greater omentum, is reflected cephalad. The proximal jejunum and the ligament of Treitz, along with the fourth portion of the duodenum, are dissected free, and the dissection is continued until it meets the right-side upper abdominal dissection. A hand-held energy device is often the most efficient method of achieving this mobilization. At a convenient point where there is a wide vascular arcade, the proximal jejunum is divided with a GIA stapler ~10 to 12 cm distal to the ligament of Treitz. The proximal jejunum is then grasped with a Babcock clamp and retracted cephalad. The mesentery to the proximal jejunum is divided between clamps and ligated with 2-0 silk suture (or divided with a vessel-sealing energy device). Alternatively, dividing the jejunum early, before dividing the uncinate process, can help with retraction and exposure especially in the face of local inflammation.

When division of the mesentery is complete, the specimen is free and can be removed from the operative field. The bile duct, the pancreatic neck, and the uncinate margins should be tagged. If there is any concern for malignancy, frozen-section analysis of all margins should be completed before reconstruction. The pancreatic bed should be carefully inspected for hemostasis.

If there is concern regarding the ductal system in the pancreatic

remnant, the residual duct can be interrogated via a probe, and/or imaged by intraoperative sonography or less commonly a fluoroscopic pancreatogram. This ensures complete main duct decompression. A partial longitudinal incision and lateral pancreaticojejunostomy to the body and tail may be indicated if there are significant chain-of-lake strictures seen on ductal evaluation, as displayed in Figure 123.3.

There are several technical options for restoring GI continuity after a pancreaticoduodenal resection. Our preferred technique is to bring the end of the divided jejunum through the transverse mesocolon to the right of the middle colic vessels in a retrocolic fashion and to perform an end-to-side pancreaticojejunostomy, as indicated in Figure 123.4. A row of interrupted 3-0 silk Lembert sutures is placed between the side of the jejunum and the posterior capsule of the end of the pancreas. A small enterotomy, matching the size of the pancreatic duct, is made in the jejunum, and an inner layer of interrupted 5-0 absorbable monofilament sutures is placed to create a duct-to-mucosa anastomosis, as displayed in Figure 123.5. Meticulous stitch placement is crucial, and many surgeons use some degree of magnification to complete the anastomosis in small ducts. Optional placement of a pediatric feeding tube (either externalized or cut short) positioned across the anastomosis should be considered as a temporary indwelling stent. This stent can be particularly helpful in constructing the anastomosis itself. The anastomosis is completed with an outer layer of 3-0 or 4-0 Lembert sutures placed between the anterior pancreatic capsule and the jejunum. This layer should be completed in a fashion to invaginate the gland into the seromuscular layer of the bowel. A popular alternative to this duct-to-mucosa technique is to create an enterotomy approximately the same size as the pancreatic neck and to place an inner continuous layer of 3-0 absorbable synthetic suture material circumferentially around the entire gland. (The pancreatic duct can be incorporated into the running suture line either posteriorly or both anteriorly and posteriorly.) The neck is then invaginated 1 to 2 cm into the lumen of the bowel, and an outer interrupted layer of 3-0 silk is placed to complete the anastomosis. The biliary-enteric anastomosis is performed 6 to 10 cm distal to the pancreaticojejunostomy. An end-to-side hepaticojejunostomy is fashioned with a single interrupted layer of 4-0 absorbable synthetic suture material. Generally, there is no need for a T-tube or a stent.

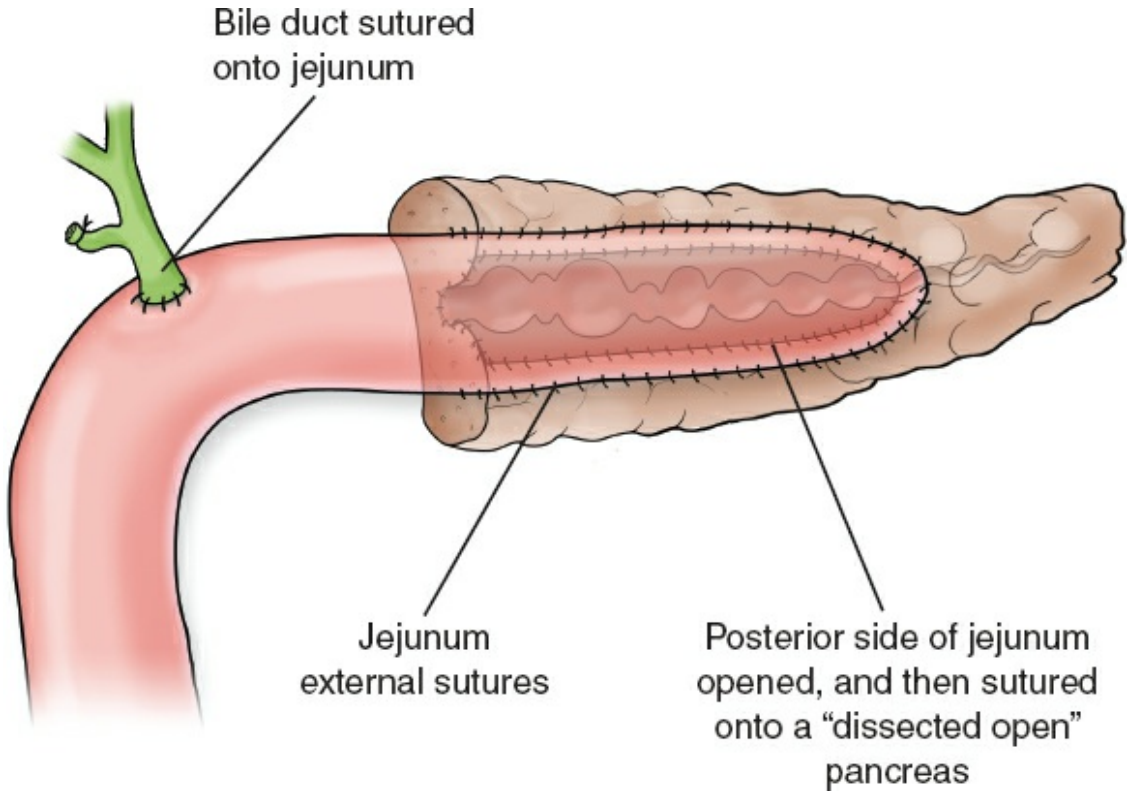

Figure 123.3. If multiple strictures from chronic pancreatitis are present in the pancreatic remnant, then the duct must be decompressed using a lateral pancreaticojejunostomy much like with the Puestow lateral drainage procedure.

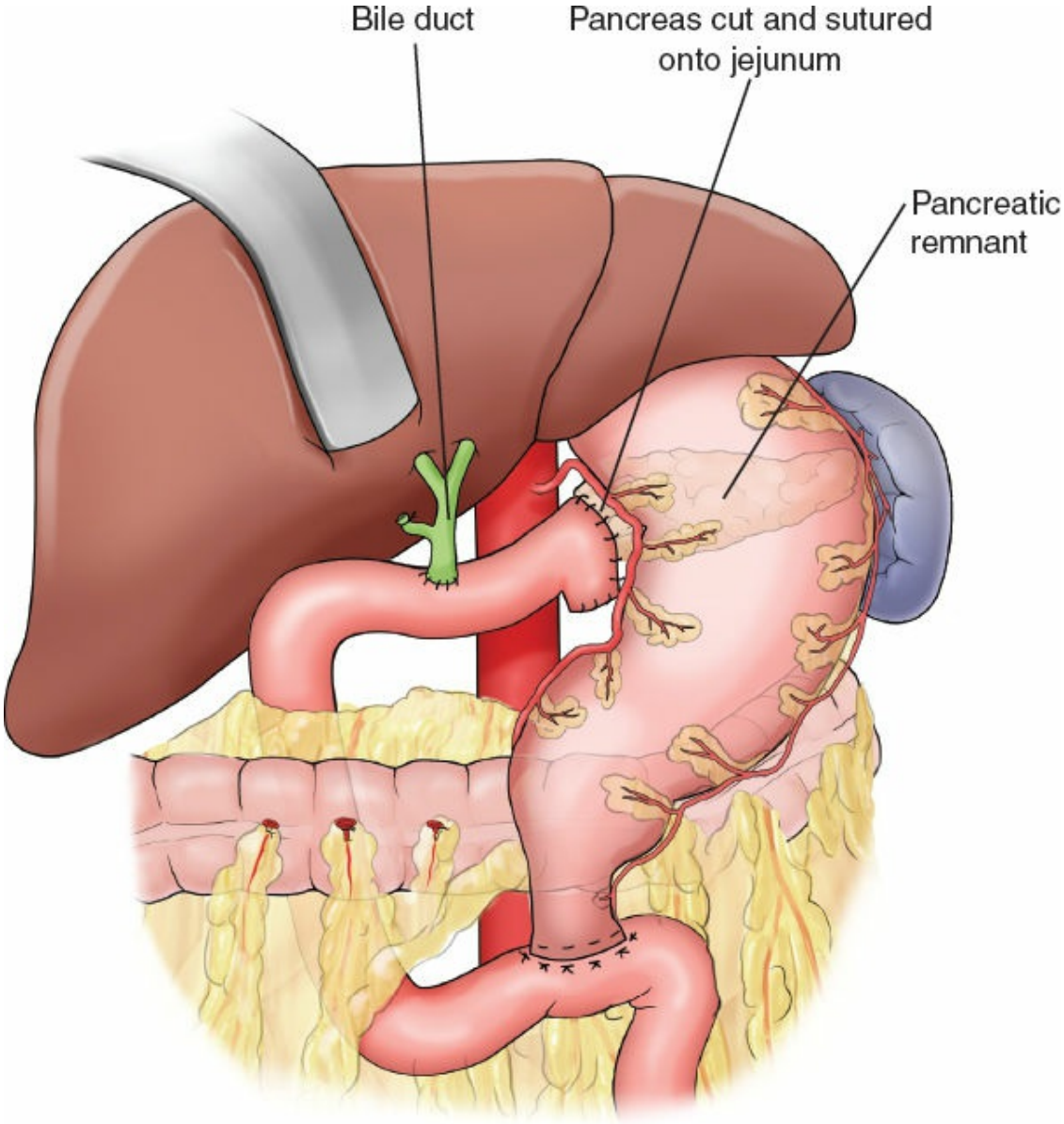

Figure 123.4. Reconstruction of the pancreatic duct and bile duct are in a retrocolic fashion. The end-duodenal to side-jejunostomy is in an antecolic position to isolate the duodenal anastomosis from the pancreatic anastomosis and to minimize delayed gastric emptying if the latter should leak.

Approximately 25 cm distal to the biliary-enteric anastomosis, an end-to-side duodenojejunostomy is performed with an inner continuous layer of 3-0 absorbable synthetic suture material and an outer interrupted layer of 3-0 silk. Some experienced pancreatic surgeons prefer to perform the duodenojejunostomy further distally in an antecolic position, in the belief that doing so reduces the incidence of early postoperative delayed gastric emptying. If an antrectomy was performed, the medial half of the gastric staple line can be reinforced with interrupted 3-0 silk seromuscular

Lembert sutures. The gastrojejunal anastomosis is completed to the lateral (greater curvature) aspect of the staple line as a two-layer Hofmeister-style anastomosis.

The abdomen is copiously irrigated. The jejunal loop is tacked to the rent in the transverse mesocolon with interrupted 3-0 silk sutures. The defect in the retroperitoneum previously occupied by the fourth portion of the duodenum is closed with a continuous 3-0 silk suture. Two closed suction Silastic drains are generally placed in the vicinity of both the hepaticojejunostomy and the pancreaticojejunostomy, which are brought out through a stab wound in the right upper quadrant. The abdomen is closed in a standard fashion.

In summary, the patients with a diagnosis of chronic pancreatitis who are eligible for a pancreaticoduodenectomy represent a highly selected subgroup. They display head-predominant disease in the setting of intractable pain, and not infrequently have a concurrent biliary duct stricture or duodenal stenosis. These patients do not typically overlap with those who would benefit from a pancreas-sparing procedure or distal pancreatectomy. If these prerequisites are strictly adhered to, the patients will have an excellent chance at good relief of their disabling pain.

Longitudinal Pancreaticojejunostomy (Puestow)

Puestow and Gillesby modified Duval's (1954) procedure to include a longitudinal opening along the main pancreatic duct within the neck, body, and tail of the gland. They also invaginated the distal gland into a Roux-en-Y limb of the jejunum. Partington then modified this procedure again to construct a side-to-side longitudinal pancreaticojejunostomy (now coined the "Puestow procedure").

The Puestow procedure is an excellent approach to pancreatic ductal decompression in cases where a definitive stricture is noted in conjunction with a significantly dilated upstream pancreatic duct (>5 mm) (Fig. 123.6). Patients with other sequelae of chronic pancreatitis such as biliary and/or duodenal obstruction or walled-off pancreatic necrosis or pseudocyst formation are best served with a different approach because the Puestow procedure will not address these concurrent issues.

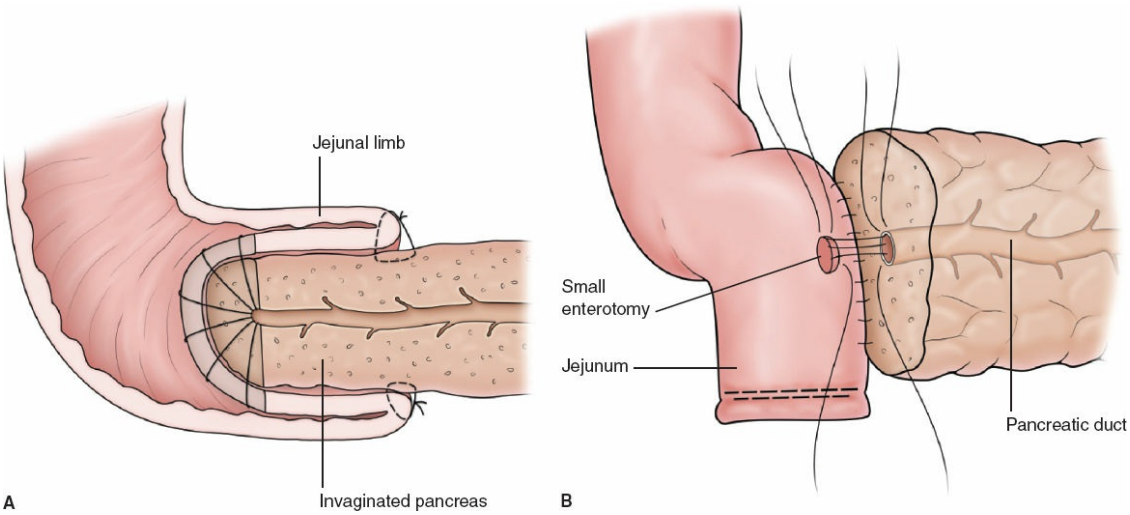

Figure 123.5. A. In the pancreaticojejunostomy, the end of the pancreas is invaginated into the end of the jejunum for ~2 cm. The anastomosis is done with an outer interrupted layer of 3-0 silk and an inner continuous layer of 3-0 absorbable synthetic suture material. **B.** In an alternative approach, an end-to-end mucosa-to-mucosa pancreaticojejunostomy is again done in two layers with an outer layer of interrupted 3-0 silk sutures and an inner layer of interrupted 4-0 absorbable synthetic sutures.

The peritoneal cavity is entered through an upper midline incision. The round ligament is divided at the liver and the portion between the liver and the umbilicus is excised. A fixed abdominal wall retractor system of the surgeon's choice is engaged after a wound protector is placed. A dual-ring wound protector is recommended.

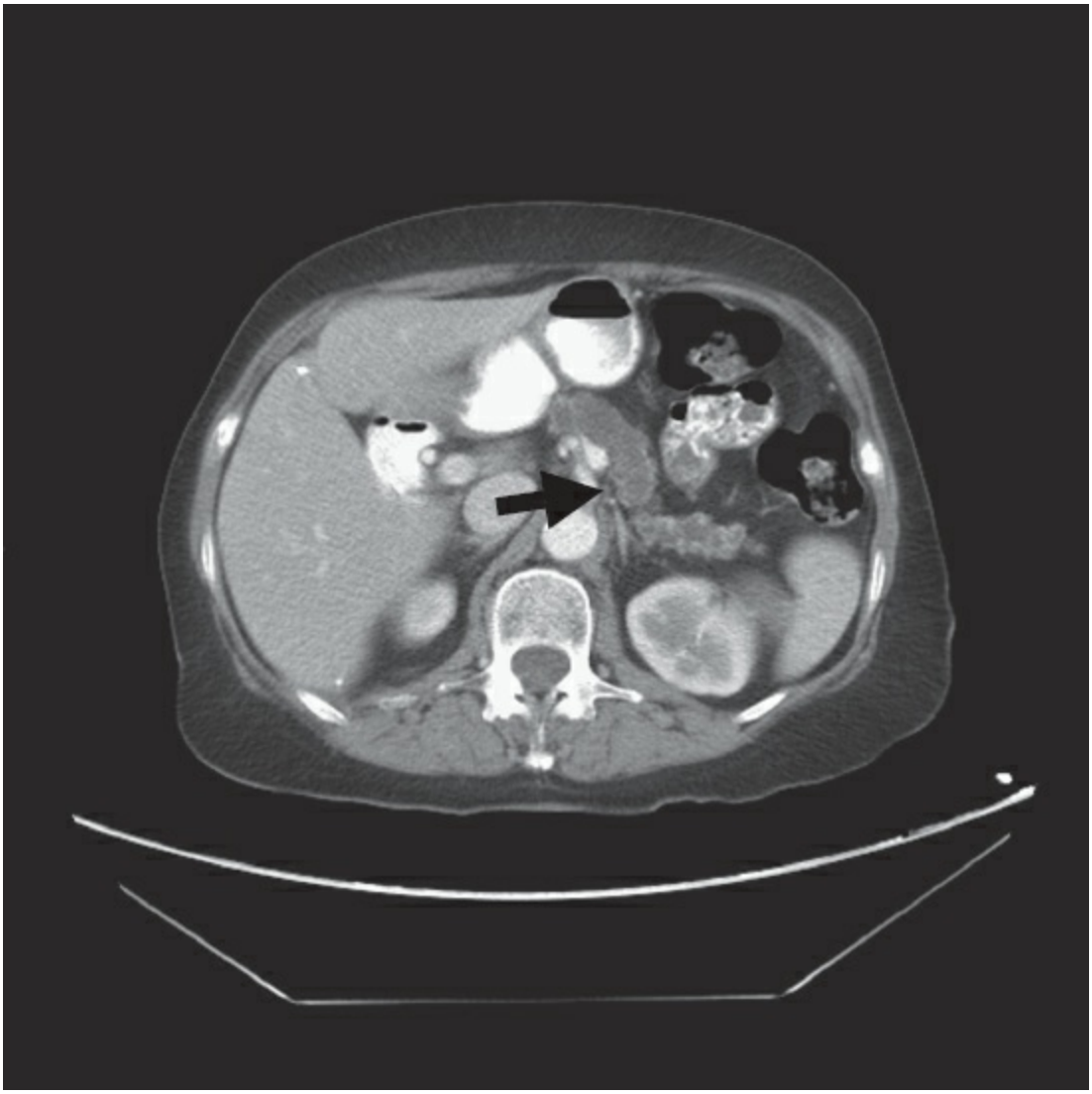

Figure 123.6. Dilated, irregular pancreatic duct throughout body and tail of pancreas indicated by *black arrow* in a patient with alcohol-associated chronic pancreatitis. The patient was symptomatic with abdominal pain from chronic pancreatitis and had an excellent response to a Roux-en-Y lateral pancreaticojejunostomy.

Operative assessment can begin with a wide Kocher maneuver and mobilization of the duodenum and the head of the pancreas from the underlying inferior vena cava and aorta. This is not mandated however, particularly when the procedure is limited to the pancreatic body/tail. The lesser sac is opened widely by incising the lesser omentum and by removing the entire greater omentum off the transverse colon. Any adhesions between the back wall of the stomach and the ventral surface of the pancreas are divided. The short gastrics are not divided. Every attempt is made to preserve the greater omentum. The hepatic flexure of the colon

is also mobilized and retracted downward out of the operative field early in the operative procedure. If a patient has not yet undergone a cholecystectomy, one is generally recommended. The gland is then evaluated both by digital inspection (palpate for the duct itself and potential stones) and ultrasonography to identify the pancreatic duct in particular. The perceived location of the duct should align well with the preoperative cross-sectional imaging. If the precise position of the duct is difficult to identify using these techniques, a 21- or 22-guage needle on a 10-cc syringe can be utilized to localize the duct (confirmed by aspiration of pancreatic juice). If blood returns within the syringe, it is typically venous from the underlying splenic vein. The needle should be immediately withdrawn and digital pressure applied for 5 minutes. If it is still difficult to identify the duct, a limited transverse parenchymal incision can be employed with the use of electrocautery. Once the duct is identified, it is then opened using electrocautery along its entire dilated length (ventral surface). The duct itself should also then be widened to ensure long-term patency with the planned jejunal anastomosis. All stones should be removed from the duct. Any obvious strictures should be biopsied and evaluated via frozen section.

Once the pancreatic duct is opened widely, the jejunum (approximately 20 to 30 cm from the ligament of Treitz) is divided using a GIA stapler and the staple line on the downstream side is oversewn with 3-0 sutures. The mesentery is then divided using ties or an energy device down through the outer vascular arcade. Following completion of the eventual pancreaticojejunostomy, a side-to-side jejunojejunostomy is created to ensure patency of the Roux-en-Y reconstruction. This is typically about 50 cm distal to the pancreaticojejunostomy. We utilize a handsewn two-layer, technique for the jejunojejunostomy, with closure of the associated mesenteric defect using interrupted figure-of-eight 3-0 sutures.

The Roux limb for the pancreatic anastomosis should be delivered via a small defect in the mesocolon. This defect is typically to the right of the middle colic vessels, but can also be better placed elsewhere depending on the specific anatomy of the patient. A lateral pancreaticojejunostomy is then fashioned. Two corner sutures are first placed between the apices of the opening along the pancreatic duct and the antimesenteric side of the small bowel. These are placed such that the knots will be on the outside of the anastomosis once tied down. The length of small bowel must be carefully assessed as it tends to stretch once opened, and the bowel is

opened with the electrocautery in a hemostatic manner (Fig. 123.7). The suture line is carried between the small bowel and the cut edge of the pancreas, using interrupted 3-0 silk sutures, creating the inner aspect of the pancreaticojejunostomy (Fig. 123.8). Full thickness bites of both the small bowel and pancreas are essential to avoid any leakage of pancreatic juice. Care is taken to incorporate both the pancreatic capsule and the duct mucosa when possible. The superior suture line is completed in a similar manner to complete the anastomosis (Fig. 123.9). This pancreatic jejunal limb is locked into place at the mesocolon level with interrupted 3-0 sutures. Closed suction drainage is generally not required given the low leak rate of this anastomosis between a healthy jejunum and a hard pancreatic gland.

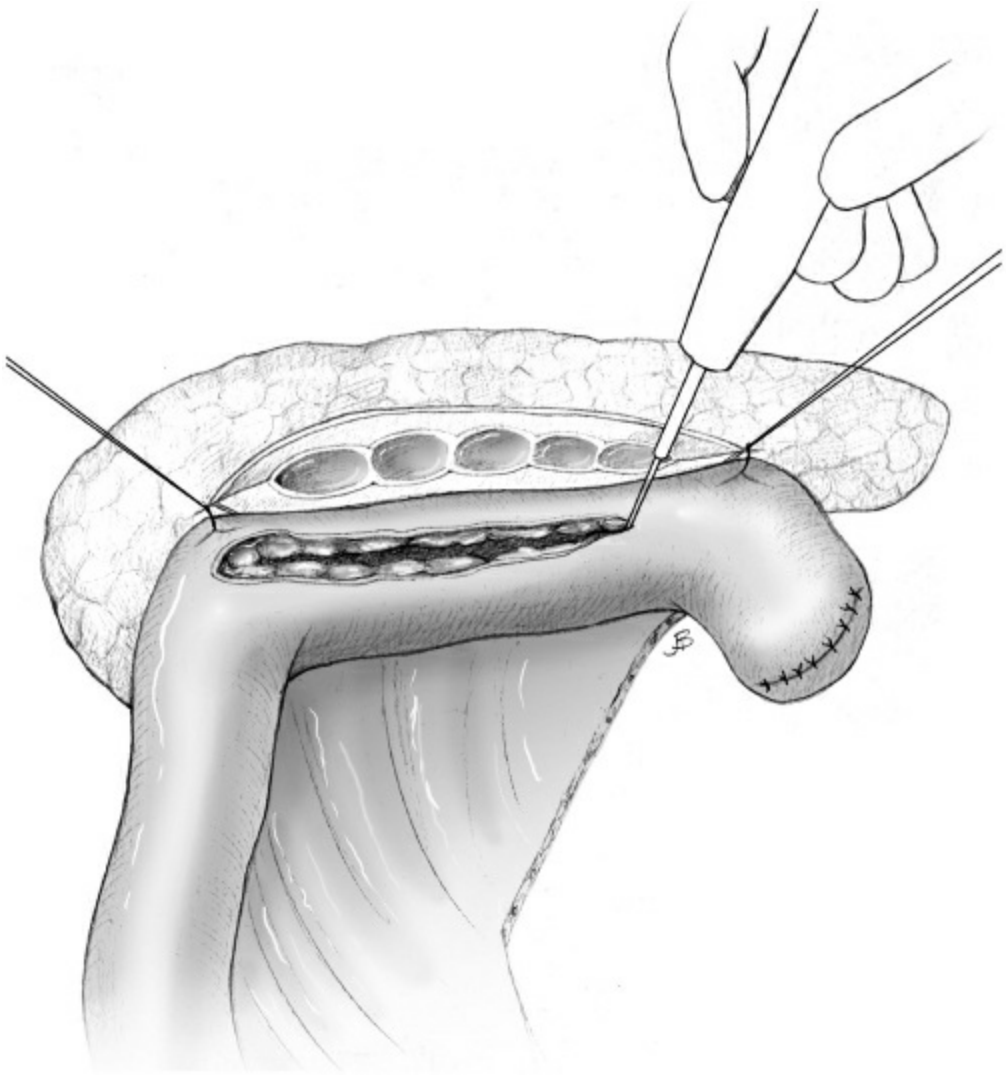

Figure 123.7. The Roux-en-Y limb is brought alongside the pancreas in an isoperistaltic fashion. The longitudinal pancreatic ductotomy is visible. Two corner stitches are placed between the

jejunum and the apices of the ductotomy. An enterotomy is then made lengthwise along the jejunum, in parallel to the pancreatic ductotomy.

It is reasonable to note that some surgeons also perform a celiac plexus neurolysis as an adjunct to this procedure to assist in addressing ongoing pain. A solution of 50% ethanol is injected into the area of the celiac plexus that is identified by palpation along the aorta, at the level of the thrill of the celiac artery. A 20-cc syringe is filled with the ethanol solution and fitted with a 21- or 22-gauge spinal needle. Then, 10 mL of the 50% ethanol is injected along each side of the aorta at the level of the celiac axis. If a nonoperative approach is selected for a chemical celiac plexus neurolysis, endoscopic targeting is far superior to percutaneous approaches (more than double the response rate).

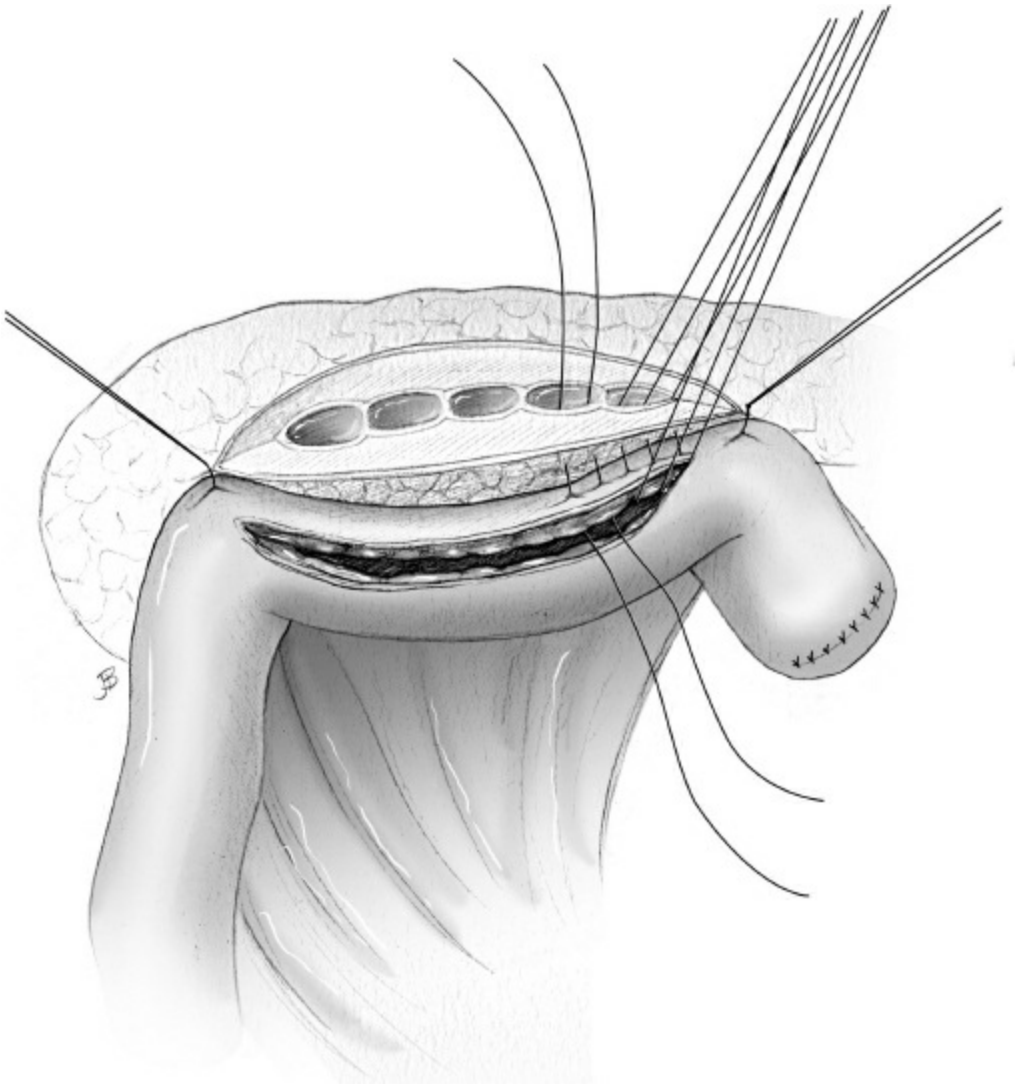

Figure 123.8. Interrupted 3-0 silk sutures are placed along the

inferior row of the pancreaticojejunostomy. Full thickness bites of the small bowel are first taken followed by a thickness bite of the transected edge of the pancreas. Both the pancreatic capsule and the pancreatic duct mucosa are incorporated in a single suture when possible. Note that these sutures are placed such that the knots will be on the inside aspect of the anastomosis once tied down.

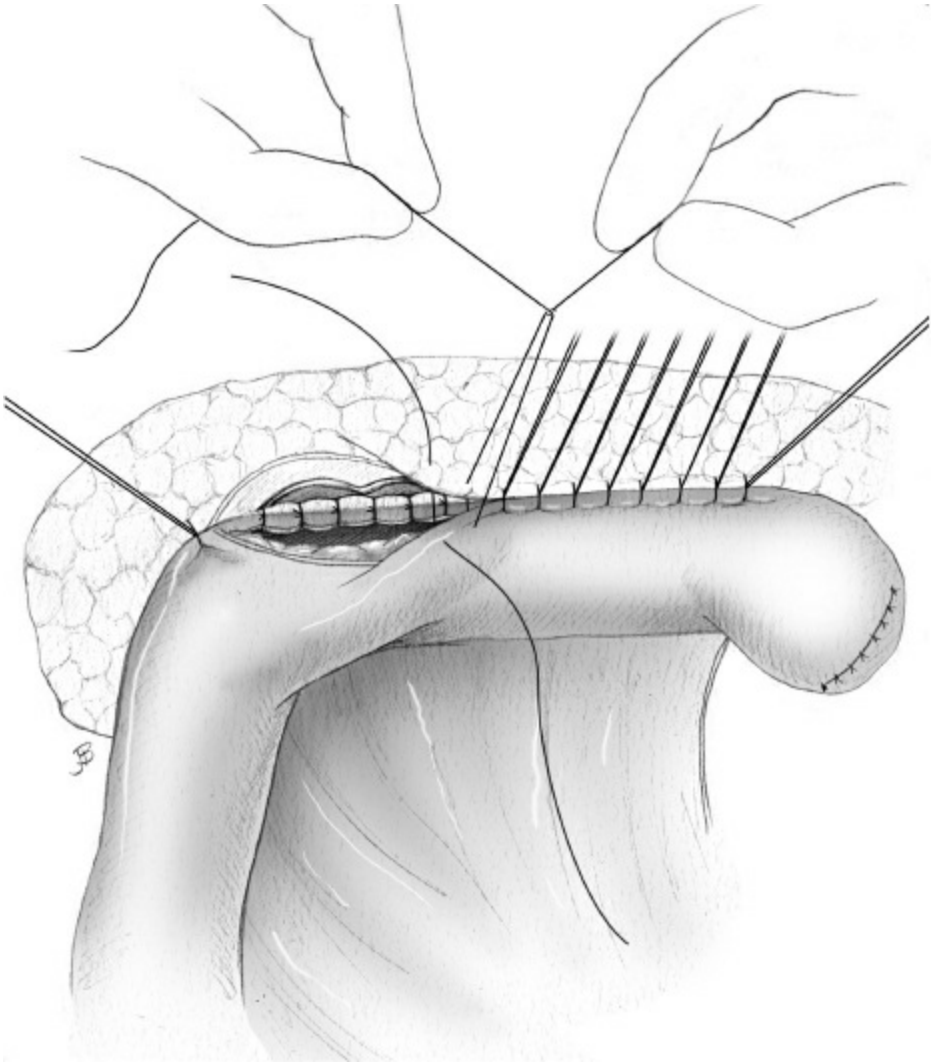

Figure 123.9. The superior row of the anastomosis is fashioned using 3-0 silk sutures, taking a full thickness bite of the jejunum from serosa to mucosa. The cut edge of pancreas is then taken with a full thickness bite, incorporating pancreatic duct and then capsule. The knots for this superior row are left on the outside of the anastomosis.

Frey/Beger Procedure

The Frey or Beger procedures combine both resectional and drainage

methodologies. They are particularly helpful for patients who present with a concurrent inflammatory mass in the head of the pancreas. These procedures will be described in the next chapter.

SURGICAL OUTCOMES

The success of PPPD for treating complications associated with chronic pancreatitis (typically intractable pain) have been reported by numerous authors over the past decade. Whereas perioperative mortality remains less than 2%, postoperative complications still approach 40%. Given these early results are similar to, or potentially better than, PPPD for patients with a malignancy, this procedure can be considered appropriate for those suffering from chronic pancreatitis. The frequently demonstrated volume–survival relationship for pancreatic resection and malignancy also appears to apply to resections for chronic pancreatitis. Perioperative mortality following pancreaticoduodenectomy is better regardless of indication if patients are referred to a high-volume center. In studies that include long-term follow-up (up to 8 years), resolution of intractable pain following PD has been observed to be as high as 88% with an associated return-to-work rate approaching 70%. Unfortunately, long-term mortality due to progression of the disease also ranges from 8% to 32%.

Given the myriad of operative procedures commonly described for the patients with complications of chronic pancreatitis, randomized controlled trials (RCTs) are particularly helpful in comparing various approaches/techniques. In the short term, it appears that pancreaticoduodenectomy is associated with significantly more complications (29% to 40%) than either the Frey (0% to 19%) or Beger (18%) procedures. More specifically, in five RCTs comparing pancreaticoduodenectomy to both types of duodenal-sparing pancreatic resections, the Frey and Beger procedures each displayed lower rates of subsequent diabetes mellitus and exocrine insufficiency. In other centers with extensive experience using the Frey and Beger operations, however, both duodenal-sparing procedures appeared to provide no significant benefit in terms of long-term pain control, exocrine insufficiency, endocrine function, quality of life scores, or survival when compared to pancreaticoduodenectomy. This is in part supported by the concept that during a pancreaticoduodenectomy (and therefore similar to a Frey or Beger procedure), most of the pancreatic tissue being excised is nonfunctional and fibrotic in nature. Furthermore, the typically delayed

development of endocrine failure after pancreaticoduodenectomy is further evidence of continued fibrosis in the pancreatic remnant, and not an overexcision of functioning tissue. It must also be remembered that methodologically sound comparisons of published studies are difficult due to a general lack of reported standard selection criteria for resection.

In the Indiana experience, patients with recurrent pain after a pancreaticoduodenectomy for chronic pancreatitis have been divided into two groups (mean time to pain recurrence is 47 months). There may be either a stricture at the pancreatojejunostomy (up to 80% of the patients with recurrent pain) or there has been progression of their pancreatic disease (20%). In the former, a remedial operative procedure to revise the anastomosis is associated with a 50% success rate. These operations should target only anastomotic abnormalities identified radiographically, and must not represent “fishing” expeditions. Among all patients who required operative revision, the 1-, 5-, and 10-year mortality rates were 8%, 18%, and 33%, respectively.

Upon review of the literature for lateral pancreaticojejunostomies (Puestow, Beger, Frey), all procedures are also associated with a low operative mortality and morbidity. Large series report operative mortality of less than 1%. As a result of the fibrotic nature of the pancreatic parenchyma, pancreatic anastomotic leaks are uncommon (2% to 4%). Overall complication rates approximate 20%. The initial reported intensity of pain relief is high (90%) across most published studies. With long-term follow-up however, only 45% to 50% of patients report persistent pain relief. Recurrent pancreatic duct strictures, particularly in the head of the pancreas, remain a source of long-term failure for patients undergoing longitudinal pancreaticojejunostomy. These patients are candidates for subsequent surgical intervention, often with resectional approaches. It has also become clear that taken as a whole, the available evidence indicates that lateral pancreaticojejunostomy rarely exacerbates exocrine or endocrine insufficiency of the pancreas, and may have some mild beneficial effect on both challenges. More specifically, despite a long-term progression to exocrine and endocrine insufficiency of nearly 30%, there is some evidence that patients managed surgically show a lower progression to pancreatic insufficiency when compared to those treated with medical management only. Presumably, this is related to improved drainage of the gland.

TABLE 123.1 Therapeutic Targets for Pancreatic Procedures

Procedure	Type	Pain	Biliary Obstruction	Duodenal Obstruction
PPPD	Resectional	X	X	X
Puestow	Drainage	X		
Frey	R+D	X	+/– X	
Beger	R+D	X	+/– X	

Given the increasing use of nonsurgical therapies (i.e., endotherapy) for patients with chronic pancreatitis, a sound understanding of the interactive role of these procedures with operative resections and drainage is crucial. Endotherapy can include papillotomy, pancreatic and biliary stenting, mechanical stone removal, lithotripsy, as well as combinations of the above. Whereas an in-depth discussion of each is beyond the scope of this chapter, a recent RCT has saddled endotherapy with a higher complication rate as well as significantly lower overall relief of pain. Patients undergoing endotherapy also required significantly more interventional procedures compared to the operative group. Although many endoscopic techniques have the ability to temporize patient complaints and alleviate their symptoms in the short term, the findings of this RCT are not overly surprising given the limited durability of many endotherapy interventions. Specific issues include poor stent patency and stone/calcification recurrence. The success of formal resective procedures such as pancreaticoduodenectomy in treating intractable pain is also highlighted by an obvious referral bias. Unfortunately, many of the patients referred to surgeons have already undergone numerous failed nonoperative/endotherapy approaches, and therefore represent the most difficult and opiate-dependent subgroup possible. The last remaining option for these patients is often an operative intervention such as pancreaticoduodenectomy.

SUMMARY

The role of surgical intervention for treating the complications of chronic pancreatitis (intractable pain, biliary obstruction, duodenal stenosis) and/or the need to rule out a malignancy are clear. Up to 90% of the patients, if properly selected, can achieve an improvement in their pain with an associated return-to-work rate approaching 70%. Patients who benefit most from a pancreaticoduodenectomy, as well as both purely drainage procedures and combined resection/drainage interventions for chronic

pancreatitis represent a highly selected cohort. The appropriate selection of a specific surgical intervention from a menu of choices is absolutely critical for long-term success and symptom resolution/improvement (Table 123.1). Successful care of these patients is also reliant upon a thorough evaluation of social factors (alcohol ingestion and smoking), selection of the proper operative approach, as well as a multidisciplinary care plan that involves many of our colleagues (chronic pain service, gastroenterology, interventional radiology, nutritionists).

Suggested Readings

Andersen DK, Frey CF. The evolution of the surgical treatment of chronic pancreatitis. *Ann Surg* 2010;251(1):18–32.

Cahen DL, Gouma DJ, Yeoh KG, et al. Endoscopic versus surgical drainage of the pancreatic duct in chronic pancreatitis. *N Engl J Med* 2007;356:676–84.

Diener MK, Rahbari NN, Fischer L, et al. Duodenum-preserving head resection versus pancreatoduodenectomy for surgical treatment of chronic pancreatitis: a systematic review and meta-analysis. *Ann Surg* 2008;247:950–61.

Farkas G, Leindler L, Daroczi M, et al. Long-term follow-up after organ preserving pancreatic head resection in patients with chronic pancreatitis. *J Gastrointest Surg* 2008;12:308–12.

Hill JS, McPhee JT, Whalen GF, et al. In-hospital mortality after resection for chronic pancreatitis: population-based estimates from the nationwide impatient sample. *J Am Coll Surg* 2009;209:468–76.

Howard TJ, Browne JS, Zyromski NJ, et al. Mechanisms of primary operative failure and results of remedial operation in patients with chronic pancreatitis. *J Gastrointest Surg* 2008;12:2087–95.

Klempa I, Spatny M, Menzel J, et al. Pancreatic function and quality of life after resection of the head of the pancreas in chronic pancreatitis. A prospective, randomized comparative study after duodenum preserving resection of the head of the pancreas versus Whipple's operation. *Chirurg* 1995;66:350–9.

Muller MW, Friess H, Martin DJ, et al. Long-term follow-up of a randomized clinical trial comparing Beger with pylorus-preserving Whipple procedure for chronic pancreatitis. *Br J Surg* 2008;95:350–6.

Nealon WH, Thompson JC. Progressive loss of pancreatic function in chronic pancreatitis is delayed by main pancreatic duct decompression. A longitudinal prospective analysis of the modified Puestow procedure. *Ann Surg* 1993;217(5):458–66; discussion 466–8.

Riediger H, Adam U, Fischer E, et al. Long-term outcome after resection for

chronic pancreatitis. *J Gastrointest Surg* 2007;11:949–60.

Schnelldorfer T, Lewin DN, Adams DB, et al. Operative management of chronic pancreatitis: long-term results in 372 patients. *J Am Coll Surg* 2007;204:1039–47.

Sohn TA, Campbell KA, Pitt HA, et al. Quality of life and long-term survival after surgery for chronic pancreatitis. *J Gastrointest Surg* 2000;4(4):355–64; discussion 364–5.

Strate T, Bachman K, Busch P, et al. Resection versus drainage in treatment of chronic pancreatitis: long-term results of a randomized trial. *Gastroenterol* 2008;134:1406–11.

EDITOR'S COMMENT

The authors describe the technique and outcomes of both pancreaticoduodenectomy and longitudinal pancreaticojejunostomy in chronic pancreatitis. Dr. Lillemoe is a world authority on the Whipple procedure and other pancreatic operations having trained under the iconic John Cameron.

It must be emphasized that careful patient selection is critical to obtaining superior outcomes. A clear understanding of the anatomic changes resulting from the chronic pancreatitis is critical. MRCP and EUS are most helpful in this regard. Of utmost importance is to verify that the patient considered for an operation for chronic pancreatitis has been abstinent for 1 year. Failure rates are high in those that continue to drink alcoholic beverages. In the ideal setting the surgeon is part of a collaborative team of a gastroenterologist, behavior medicine specialist and primary care physician, and a nutritionist. This could be defined as a virtual medical home for chronic pancreatitis. In addition caution is advised in recommending resection as treatment for minimal change pancreatitis as outlined in the preceding chapter. Again in these settings a multidisciplinary approach is advisable.

The technique described for the Whipple procedure for chronic pancreatitis is very similar to the one we use. They point out the need for the surgeon focus on variations in arterial anatomy which is particularly true in these cases because of the associated pancreatic inflammation and induration. A wide Kocher maneuver facilitates the operation as does a wide opening into the lesser sac. I agree with Dr. Lillemoe that approaching the portal vein and SMV early in the dissection is wise. Dividing the common hepatic duct opens the spaced anterior to the portal vein. Dividing the gastroduodenal artery after carefully identifying the anatomy of the hepatic artery further facilitates this portion of the dissection. Dissection along the inferior edge of the pancreas and the vascular groove is essential prior to dissection the neck of the pancreas and lifting it off the portal vein. As pointed out the associated inflammation can make this extraordinarily difficult. Injury to the vein may occur if there is adherence of the pancreas to the portal vein. In some cases placing vessel loops

around the SMV inferiorly and the portal vein superiorly may be of benefit so as to allow better control if there is injury to the vein. As pointed out the neck can be bluntly dissected with a finger or a large blunt clamp. Once the dissection of the neck is completed it can be encircled with a vessel loop or Penrose drain to allow traction which makes further dissection easier. If the surgeon enters the anterior surface of the portal vein bleeding will be brisk and difficult to control. Initially control may be achieved with bimanual pressure applied posteriorly under by placing a hand under the uncinate process. The hand is initially placed through the space opened by the Kocher maneuver. Lifting the hand upward and placing the thumb over the neck of the pancreas anteriorly allows pressure to be placed while vascular isolation is obtained. Once this is completed the bleeding should slow down. The neck of the pancreas can then be completely divided and this will expose the portal vein which can be repaired under direct vision with fine monofilament nonabsorbable sutures. Once the bleeding is controlled the surgeon can then return to the operation.

Once the specimen is removed reconstruction is completed. The pancreas is usually quite firm and the pancreatic duct may be enlarged. An end-to-side pancreaticojejunostomy is completed using jejunal pancreatic sutures for stabilization and a mucosal to mucosal duct anastomosis. In some cases the duct is very dilated, greater than 7 to 8 mm, and it may be lengthened and extended 4 to 5 cm along the anterior surface of the gland and a longitudinal pancreaticojejunostomy created. Pancreatic anastomotic stenting is not necessary in the majority of pancreaticoduodenectomies for chronic pancreatitis.

The first step in the longitudinal pancreaticojejunostomy is wide exposure of the head, body, and tail of the pancreas in the lesser sac. The pancreatic duct is usually seen as a bulging structure on the anterior surface of the gland. It is best identified in the mid body of the pancreas. The dilated duct can be palpated as a soft and compressible area in a firm pancreas. The use of intraoperative ultrasound is sometimes of help in localizing the duct. Once identified, I place a 25-gauge needle in the duct. The fluid should be crystal clear. The duct can then be opened longitudinally going on to the head of the pancreas up to the gastroduodenal artery and laterally to within 1 cm of the tip of the tail, if possible. All of the pancreatic stones should be removed. I have never had to divide the gastroduodenal artery. After creation of the Roux-en-Y jejunal limb it is brought into a retrocolic position and placed over the pancreas. I use a single layer absorbable monofilament suture to create the pancreaticojejunostomy. Although leak from the pancreaticojejunostomy is infrequent, I usually use a closed suction drain. If there is a mass-like enlargement of the pancreatic head it may be resected as described in subsequent chapters. In patients with small-duct disease (duct size <5 mm), a longitudinal pancreaticojejunostomy may not be feasible. Izbicki and his colleagues (Longitudinal V-shaped excision of the ventral pancreas for small duct disease in severe chronic pancreatitis: prospective evaluation of a new surgical procedure. *Ann Surg* 1998;227:213–9)

described a procedure in which a V-shaped wedge of tissue from the pancreas is removed and pancreaticojejunostomy is performed to the edge of the wedge defect in the pancreas rather than the duct.

Bleeding from the pancreas is the most frequent intraoperative complication. Bleeding can be controlled by suture ligation or application of energy. Postoperative gastrointestinal hemorrhage may occur and should be approached with CT angiography or celiac angiography and embolization if it occurs late, and potentially reoperation if it occurs in the first 48 hours. The bleeding is usually from the gastroduodenal artery or a branch of the splenic artery. In patients with symptomatic biliary obstruction and dilation of the bile duct, jaundice, or cholangitis, the biliary tree should be drained at the time of the pancreaticojejunostomy. If the bile duct is obstructed in the head of the pancreas the same loop may be used to create a choledochojejunostomy. I usually place the pancreaticojejunostomy as the first anastomosis. Alternatively a choledochoduodenostomy may be performed. In addition if there is an adjacent pseudocyst the same jejunal limb may be used to perform a cyst jejunostomy.

E. Christopher Ellison

124 Parenchyma-Sparing, Limited Partial and Total Pancreatic Head Resection for Inflammatory Tumor, Cystic Neoplasia, Neuroendocrine Adenoma, and Low-Risk Periampullary Malignant Tumor

Hans G. Beger, Bettina M. Rau, and Bertram Poch

Inflammatory tumors, cystic and neuroendocrine neoplasms, and periampullary adenomas are growing entities of pancreatic diseases. With the use of diagnostic and screening computed tomography (CT) scans, magnetic resonance tomography (MRT), and positron-emission tomography (PET), benign tumorous lesions of the pancreas are increasingly detected and discovered fortuitously, including when they are still small in size. Additionally, new generation CT and MRT scans provide more accurate noninvasive assessment for tumor staging regarding the ability to distinguish between solid and cystic, slow-growing noncystic neoplasms and fast-growing tumors, which may have the potential of transformation to cancerous lesions. Neoplastic tumors and a tumorous mass in the pancreatic head are challenging lesions, whether to observe or treat and thus how to operate?

In chronic pancreatitis and tropical nutritional chronic pancreatitis as well, an inflammatory mass in the head of the pancreas is frequently found in combination with local tissue pathomorphology and ductal changes. A tumor mass of the pancreatic head is observed in chronic pancreatitis more frequently in European and Asian than in American institutions. Local complications, including pseudocystic cavities, inflammatory head mass, leading to common bile duct (CBD) stenosis and compression or occlusion of the portal vein and stenosis of the periampullary duodenum, are frequent in alcoholic chronic pancreatitis. According to epidemiologic

studies, an association between chronic pancreatitis and pancreatic cancer developing years after diagnosis is observed in 1.8% to 8% of cases.

Cystic neoplastic lesions of the pancreas were first histologically identified in 1978 by Campagno and Oerdel. The prevalence of cystic neoplasm of the pancreas varies depending on the imaging procedure used, and is detected with a rate of 2.6% by multislice CT, 13.5% by magnetic resonance imaging (MRI), and 44.7% by magnetic resonance cholangiopancreatography (MRCP). Intraductal papillary mucinous neoplasia (IPMN), mucinous cystic neoplasia (MCN), and solid pseudopapillary neoplasia (SPN) are the most frequent and challenging benign cystic tumors of the pancreas. They display an increased risk for malignant transformation, which varies within the entities of cystic neoplasms. Pancreatic neuroendocrine tumors (PNETs) are relatively rare, accounting for 10% of all benign tumorous lesions of the pancreas. Through the application of high-resolution imaging technology, more PNETs are found as incidentalomas. The most frequent endocrine adenomas are insulinomas, presenting as islet-cell cancer in only 5% to 10% of cases. All gastro-pancreatic neuroendocrine tumors are considered to be potentially malignant.

The standard surgical treatment for benign tumors is currently multiorgan resection. For pancreatic head lesions, a pancreaticoduodenectomy (PD) type resection is performed, while for tumors in the body and tail, a pancreatic left resection with or without splenectomy is applied. However, the respective surgical procedures are associated with a substantial loss of functional pancreatic and extrapancreatic tissue regarding the stomach, duodenum, biliary tree, and spleen. PD and pancreatic left resections still carry considerable postoperative morbidity and risk of mortality.

The recent evolution of local surgical procedures for benign pancreatic tumors includes tumor enucleation, pancreatic middle-segment resection, and local resection of tumors of the pancreatic head applying duodenum-preserving total or partial head resection. They have the potential to preserve exocrine and endocrine pancreatic functions and for low procedure-related postoperative morbidity. The results after duodenum-preserving local pancreatic head resection compare favorably with published multi-institutional results after application of classical Whipple resections. A recently published meta-analysis revealed no change when comparing the exocrine and endocrine pancreatic functions before and

after duodenum-preserving total pancreatic head resection (DPPHR-T). However, when comparing DPPHR-T with PD, pancreatic functions after PD showed a significant decrease in short- and long-term outcomes, contrary to the results after DPPHR-T. Multi-institutional reports on the outcome after PD documented a considerably high level of severe postoperative complications and a substantial mortality risk of 2% to 7%. The impairment of endocrine pancreatic functions after PD has recently been reported; 18% of preoperative nondiabetic patients suffered postoperatively new onset of diabetes mellitus, while 48% of those with diabetes mellitus showed a deterioration in their medication requirements after PD.

The long-term status of the endocrine functions, determined by oral glucose tolerance testing, indicated an apparent complete preservation of the preoperative level after limited total pancreatic head resection, whereas after PD the glucose metabolism showed a significant deterioration. Determination of the plasma cholecystokinin level after food stimulation exhibited a significant reduction after PD compared to a nonchange after limited total pancreatic head resection. A similar difference was found postoperatively when determining the plasma secretin level over a 2-hour period following oral food stimulation, with PD patients showing a significant reduction compared to limited total pancreatic head resection. The postoperative deterioration of gastrointestinal (GI) motility determined by the propagation of phase III motility migration complex (MMC) in the upper GI tract showed a return to a normal physiologic level in DPPHR-T patients after a mean of 18.8 ± 4.3 postoperative days, whereas after PD, the phase III MMC remained reduced until 40.6 ± 4.8 postoperative days. When comparing nine patients after pylorus-preserving PD with six patients after limited, total pancreatic head resection with conservation of the duodenum and CBD, the mean plasma motilin level on the first appearance of phase III MMC after PD was significantly lower than in patients after limited total pancreatic head resection, who displayed almost normal values.

DIAGNOSTIC MAKE-UP

The diagnosis of tumors of the pancreas is based on contrast-enhanced CT as the gold standard. Endoscopic retrograde pancreatography and MRCP provide additional information about the duct changes, of the main pancreatic duct, side branches, and the intrapancreatic segment of the

CBD. In patients with advanced chronic pancreatitis, approximately 30% to 50% display narrowing of the intrapancreatic segment of the CBD with cholestasis and dilation of the extrahepatic biliary duct. In benign cystic neoplasm, the most important diagnostic goals are lesion size and location, the presence of solid tissue structures respectively of nodules, and the involvement of the pancreatic main duct and side branches. To evaluate the endocrine and exocrine functions, an oral glucose tolerance test, a pancreo-lauryl test, and fecal chymotrypsin estimation are recommended.

INDICATION FOR DUODENUM-PRESERVING PARTIAL OR TOTAL PANCREATIC HEAD RESECTION

Patients suffering benign tumorous lesions of the pancreatic head, which are associated with upper abdominal complaints, should receive surgical treatment (Table 124.1). Tumors detected as incidentalomas but suspected to be a cystic neoplasm of the IPMN, MCN, and SPN type are recommended for surgical treatment when the patient is fit for surgery. According to international guidelines, all IPMN lesions of the pancreatic main duct are recommended for surgical treatment. Side branch IPMN ≤2 to 3 cm have a lower risk of malignant transformation. However, should patients be fit for a surgical treatment, operative treatment is suggested. All patients suffering serous pseudopapillary neoplasm are candidates for surgery because of the high probability of a cure. MCNs are predominantly located in the body and tail of the pancreas, but up to 30% of MCNs are located in the pancreatic head; a size of ≥4 to 5 cm is a strong criterion for surgical treatment. Whenever imaging data indicate a suspicion of a malignant tumor inside the cystic neoplasm, a tumor extirpation should be performed without delay.

TABLE 124.1 Indications to Duodenum-Preserving Pancreatic Head Resection

1. Chronic pancreatitis with inflammatory mass of the pancreatic head,
   - CP +Common bile duct stenosis
   - CP +severe stenosis of duodenum
   - CP +compression of PV/SMV
   - CP +dystrophy of peripapillary duodenum
2. Pancreas divisum causing:
   - Chronic pancreatitis or recurrent acute pancreatitis (children/adults)
3. Cystic neoplasms:
   - IPMN, MCN, SCA, SPN
4. Benign neuroendocrine tumors (>2–3 cm)
5. Low-risk periampullary cancer (T1N0)
   - Adenoma and carcinoma of papilla of Vateri
   - Adenoma and carcinoma of peripapillary duodenum
   - Lower common bile duct cancer
6. Maljunction of biliopancreatic ducts
7. Severe injury of the pancreatic head in children with duct rupture (pancreatic trauma grades III and IV)

CP, chronic pancreatitis; PV, portal vein; SMV, superior mesenteric vein; IPMN, intraepithelial papillary mucinous neoplasm; MCN, mucinous cystic neoplasm; SCA, serous cyst adenomas; SPN, solid pseudopapillary neoplasia.

Most of the neuroendocrine tumors of the pancreatic head are benign, non-functioning tumors. Patients suffering a PNET of >1.5 to 2 cm are candidates for surgical treatment, irrespective of the functional status of the adenoma, according to international guidelines. A tumor enucleation should be performed in patients suffering an adenoma of up to 2 to 3 cm, possibly by laparoscopic approach. The limitations of enucleation are tumor proximity to the pancreatic main duct and a size >3 cm. Endocrine tumors with close contact to the duct should undergo tumor extirpation with an anastomosis of the pancreas using an excluded jejunal loop to avoid development of a pancreatic fistula of grade B/C (Table 124.2).

TABLE 124.2 Indications to Limited Partial or Total Pancreatic Head Resection

Which Pancreatic Head Resection Procedure to Apply?

1. **Partial pancreatic head resection (DPPHR-P):**
   Benign TM: IPMN, MCN, SCA >4 cm; CBD not involved
   Neuroendocrine TM ≥3 cm
   Severe pancreatic head trauma: Grade III/IV in children
2. **Subtotal pancreatic head resection (DPPHR-P):**
   Chronic pancreatitis with inflammatory mass
   or/and CBD stenosis
   or/and compression of PV/SMV
   or/and prepapillary PMD stenosis + distal duct dilation
   Pancreas divisum
3. **Total pancreatic head resection with segment of duodenum and CBD (DPPHR-T):**
   Large cystic neoplastic TM extended to anterior and posterior pancreatic head
   Cystic neoplasm and duodenal wall involvement
   Cystic neoplastic TM + carcinoma in-situ
   T1N0 low-risk cancer of papilla, prepapillary CBD, peripapillary duodenum
   Chronic pancreatitis with duodenal dystrophy
   Large islet-cell tumor
4. **Total pancreatic head resection with conservation of duodenum**
   Cystic neoplasm and tumor adherence to CBD
   Bilio-pancreatic maljunction

DPPHR-T has been successfully applied in cases of low-risk periampullary carcinoma of the papilla, duodenum, and the intrapancreatic CBD (Table 124.2). DPPHR-T with resection of the intrapancreatic segment of the CBD is applied in patients who suffer bilio-pancreatic maljunctions of the duct communications in the pancreatic head. A variety of institutional reports document successful application of partial pancreatic head resection for pancreatic head injuries of grades III to IV in children after blunt abdominal trauma (Table 124.2). Patients who suffer advanced chronic pancreatitis causing medically intractable pain and/or an inflammatory mass in the head of the pancreas and/or a narrowed intrapancreatic CBD associated with stenosis of the pancreatic main duct are candidates for a subtotal pancreatic head resection (Table 124.2). Children who suffer a pancreas divisum that has developed to chronic pancreatitis are successfully treated by duodenum-preserving subtotal pancreatic head resection, when pancreatic duct stenting has failed to improve the children's complaints.

SURGICAL TECHNIQUE

The surgical technique of partial, subtotal, and total pancreatic head resection comprises three principal technical steps (Table 124.3).

Exposure of the Pancreatic Head

The pancreatic head is exposed, dividing the gastro-colic and the duodenocolic ligaments, preserving the gastro-epiploic vessels. The duodenum is mobilized by a Kocher maneuver, avoiding extensive tissue dissection. After identification of the superior mesenteric vein at the lower margin of the pancreatic head, preparation of a tunnel between the portal vein and the pancreatic neck is performed. Should a tumorous lesion be present in the pancreatic head, the tunneling can be performed without major difficulties by blunt dissection. When an inflammatory tumor is found in chronic pancreatitis, the tunneling should be performed cautiously by blunt dissection along the wall of the superior mesenteric vein toward the portal vein. The common hepatic artery is identified superior of the pancreas and looped. The ligamentum hepato-duodenale is opened and the CBD identified and marked with a loop.

A tumor in the anterior level of the dorsal and ventral segments of the pancreatic head should be identified intraoperatively by ultrasonography. To make the dissection of the tumorous lesion from pancreatic tissue easier, a suture is placed through the wall of the lesion. The dissection through the pancreatic tissue outside the wall of the tumor is performed using dissection devices. Vessels are identified before transection and ligated using 6 × 0 sutures. After completion of tumor dissection, a frozen section investigation is recommended to test for cystic neoplasm. For reconstruction, an excluded jejunal loop is prepared for the anastomosis of the pancreatic head, performing a two-layer end-to-side or side-to-side anastomosis. A Roux-en-Y anastomosis completes the reconstruction after partial pancreatic head resection (Fig. 124.1A,B).

TABLE 124.3 Surgical Steps of Partial or Total Parenchyma-Sparing Duodenum-Preserving Resection of the Pancreatic Head for Benign Tumors and Low-Risk Periampullary Malignant Lesions

1. Exposure of the pancreatic head: Limited Kocher mobilization
2. Partial pancreatic head resection:
   after identification of tumor location and size (IOUS)
   local extirpation of the tumor with a few mm of pancreatic tissue, 2 frozen sections
   Total resection of pancreatic head:
   tunneling of pancreatic neck along the portal vein groove, transection pancreatic head preserving the neck,
   transection of the CBD above the pancreatic head,
   suprapapillary and infrapapillary dissection of the pancreas from the duodenal wall
   transection of the peripapillary duodenal segment.
3. Reconstruction after partial tumor extirpation: anastomosis with excluded jejunal loop (e-s) after total pancreatic head resection and segment resection of duodenum and CBD for DPPHR-S (+segment of duodenum):

Anastomoses	Duodenum:duodenum	e-e
	CBD–duodenum	e-s
	Pancreas–jejunum/stomach	e-s

Roux-en-Y anastomosis of jejunum

Subtotal Head Resection

A subtotal head resection has become a standard procedure for chronic pancreatitis with an inflammatory mass in the head of the pancreas. The resection of the pancreatic head is initiated with the transection of the pancreas at the duodenal edge of the portal vein, preserving the pancreatic neck (Fig. 124.2A). At the cut surface of the left pancreas, meticulous hemostasis using monofilament, 5/6×0, nonabsorbable sutures is performed. After rotation of the pancreatic head and the duodenum to the right, small branches entering the portal vein and the superior mesenteric vein from the pancreatic head tissue are carefully ligated. The head of the pancreas is resected, using the knife or a dissection device, from the retroperitoneal surface of the pancreas toward the uncinate process (Fig. 124.2B). The subtotal resection of the pancreas is concluded by excising the pancreatic head tissue at a distance of 5 mm from the duodenal wall. The intrapancreatic CBD segment is easily identified when using an intraductal Foley catheter introduced by a subpancreatic CBD incision. The wet weight of the operative specimen after subtotal pancreatic head resection is between 25 and 55 g. It has not proved to be necessary to preserve the anterior superior pancreatico-duodenal artery to ensure the normal blood supply to the duodenal wall. The supraduodenal vessels, the posterior superior pancreaticoduodenal arcade, and the mesoduodenal vessels maintain the blood supply of the suprapapillary duodenum. In most

cases, decompression of the intrapancreatic CBD can be achieved by dissecting the pancreatic tissue along the wall of the CBD. The dorsal capsula of the pancreatic head should be preserved. When an inflammatory process in the wall of the intrapancreatic segment of the CBD causes narrowing, a 15 × 5 mm tangential wall segment is resected to create an internal biliary fistula (Fig. 124.2D). The remaining pancreatic head along the duodenal wall after subtotal resection of the pancreatic head has a shell-like form 5 to 8 mm distant from the duodenal wall. Meticulous suturing of any bleeding vessels using 5/6×0 nonabsorbable suture material should be performed. The reconstruction is executed by excluding a jejunal loop and suturing a two-layer end-to-side anastomosis, applying a duct-to-mucosa technique (Fig. 124.2C). At a distance of 5 to 8 cm from the pancreatic anastomosis, a side-to-end anastomosis with the shell-like rest of the pancreatic head is performed as a two-layer anastomosis. For restoration of the food transit, a typical Roux-en-Y anastomosis is created 20 cm distal from the pancreatic anastomosis. When creating a biliary fistula of the intrapancreatic CBD segment, anastomotic suturing is unnecessary, because drainage of the bile occurs via an excluded jejunal loop (Fig. 124.2D). In patients with a dilated main pancreatic duct and multiple fibrotic duct stenosis of the main pancreatic duct and the first-order side branches, a longitudinal opening of the pancreatic main duct up to the tail of the pancreas is performed. The reconstruction is achieved by performing a side-to-side anastomosis as a Partington-Rochelle modification of the drainage of the pancreatic main duct (Fig. 124.2E). A double-layer suture between the jejunum and the pancreatic tissue is executed using nonabsorbable material.

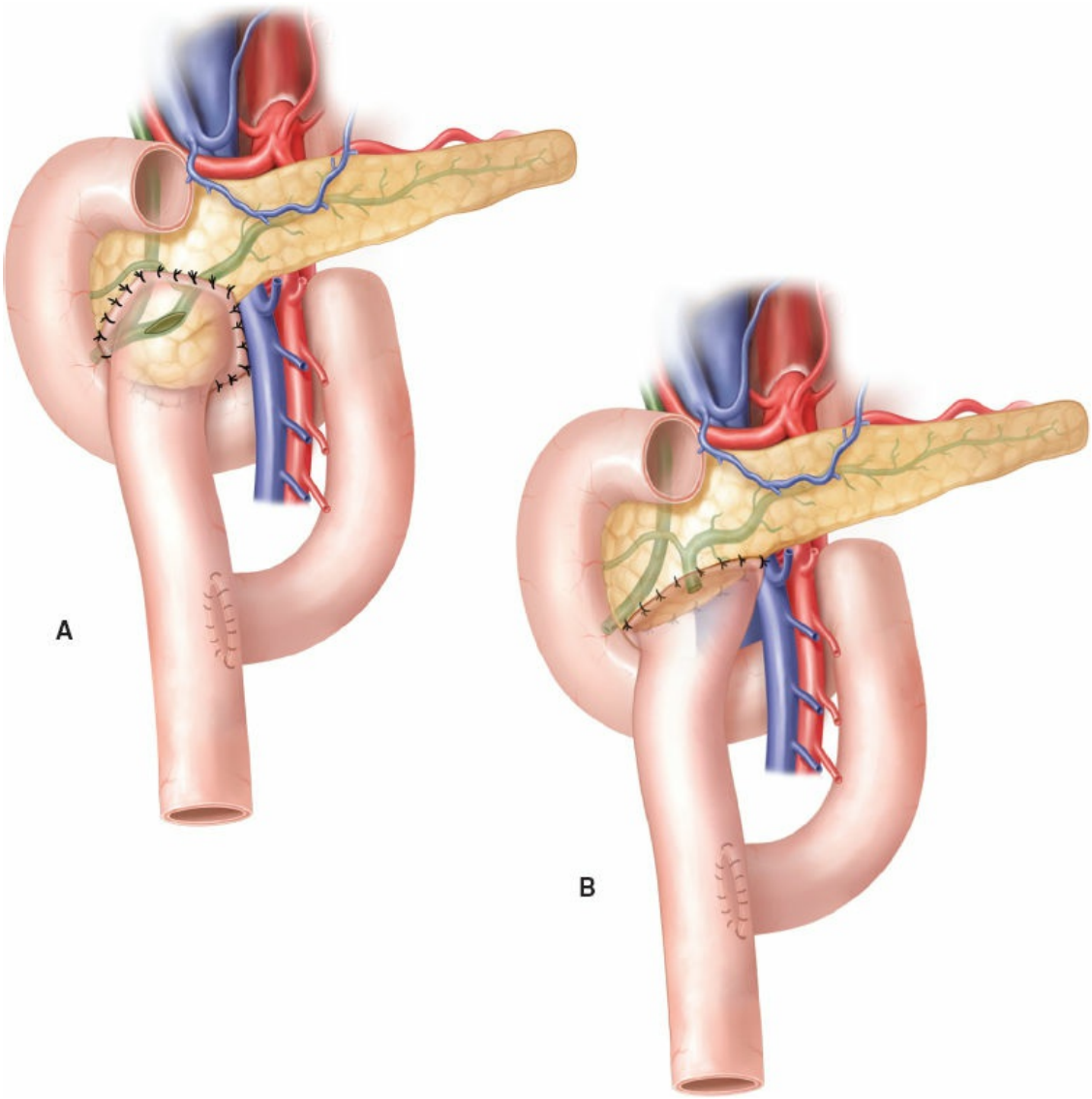

Figure 124.1. A. Duodenum-preserving partial pancreatic head resection (DPPHR-P). **B.** Duodenum-preserving partial pancreatic head resection: Uncinatectomy.

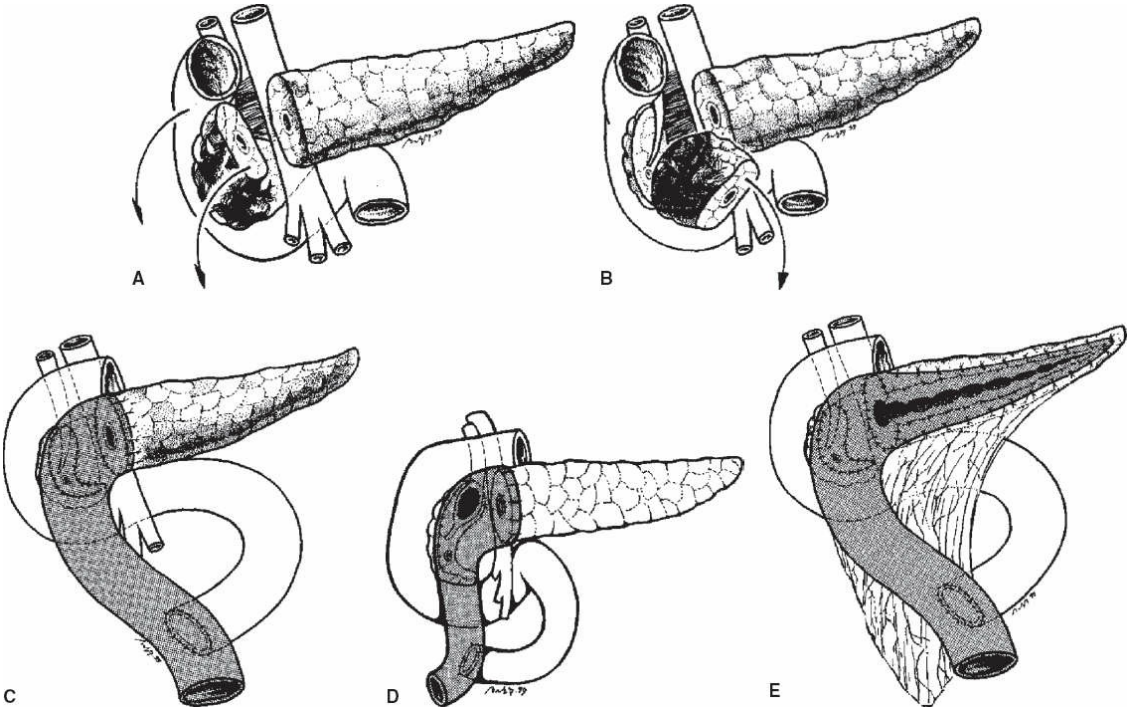

Figure 124.2. **A.** Duodenum-preserving subtotal pancreatic head resection: Tunneling and transection of the pancreatic head preserving the neck. **B.** Subtotal resection after rotation of the pancreatic head. **C.** Reconstruction using an excluded jejunal loop. **D.** Modification of duodenum-preserving subtotal pancreatic head resection with internal biliary anastomosis. **E.** Modification of subtotal pancreatic head resection with duct drainage: modification of the Partington-Rochelle procedure.

Total Pancreatic Head Resection Including the Periampullary Segment of the Duodenum and the Intrapancreatic CBD

The most frequent indications for a total pancreatic head resection and segment resection of the duodenum and CBD are large IPMN tumors, cystic neoplasm suspected of harboring a solid nodule, cystic lesions with inflammatory infiltration of the duodenal wall, insulinoma suspected to be malignant, and growing ampullary and peripapillary adenomas. After transection of the pancreatic head along the duodenal edge of the portal vein, the pancreatic head is mobilized up to the wall of the duodenum. After identification and looping of the common hepatic artery and transection of the pancreatic head toward the papilla along the duodenal wall, transection of the anterior branch of the superior gastroduodenal artery is necessary. Preservation of the posterior branch of the superior pancreaticoduodenal artery is recommended whenever possible. Dissection of the uncinate process is performed, with preservation of the

mesoduodenum facilitated by traction of the loop around the infrapapillary duodenum (Fig. 124.3A). Preservation of both the mostly visible anterior branch of the inferior pancreaticoduodenal artery and the posterior branch of the inferior pancreaticoduodenal arcade is recommended. Transection of the duodenum 2 to 4 cm above and below the papilla of Vater completes the total pancreatic head resection (DPPHR-S) (Fig. 124.3B). The transection of the CBD is performed at the level of the entrance of the CBD into the pancreatic head. In case of resection of a neoplastic lesion, a frozen section of both the resection margin and the solid tissue mass of the tumorous lesion are necessary to exclude an advanced infiltrative malignant process. The first step of reconstruction is the end-to-end anastomosis between the proximal and distal duodenum. After exclusion of the first jejunal loop and the interposition of the aboral loop to the left pancreas, a two-layer duct-to-mucosa end-to-side with the left pancreas is executed (Fig. 124.3C). The CBD is end-to-side sutured to the postpyloric duodenum or the jejunal interponate. The total pancreatic head resection is completed by a Roux-en-Y anastomosis between the jejunal loops. The implantation of the left pancreas into the stomach is increasingly used; performance of a more extensive mobilization of the pancreatic body is necessary, but is a disadvantage of this type of anastomosis.

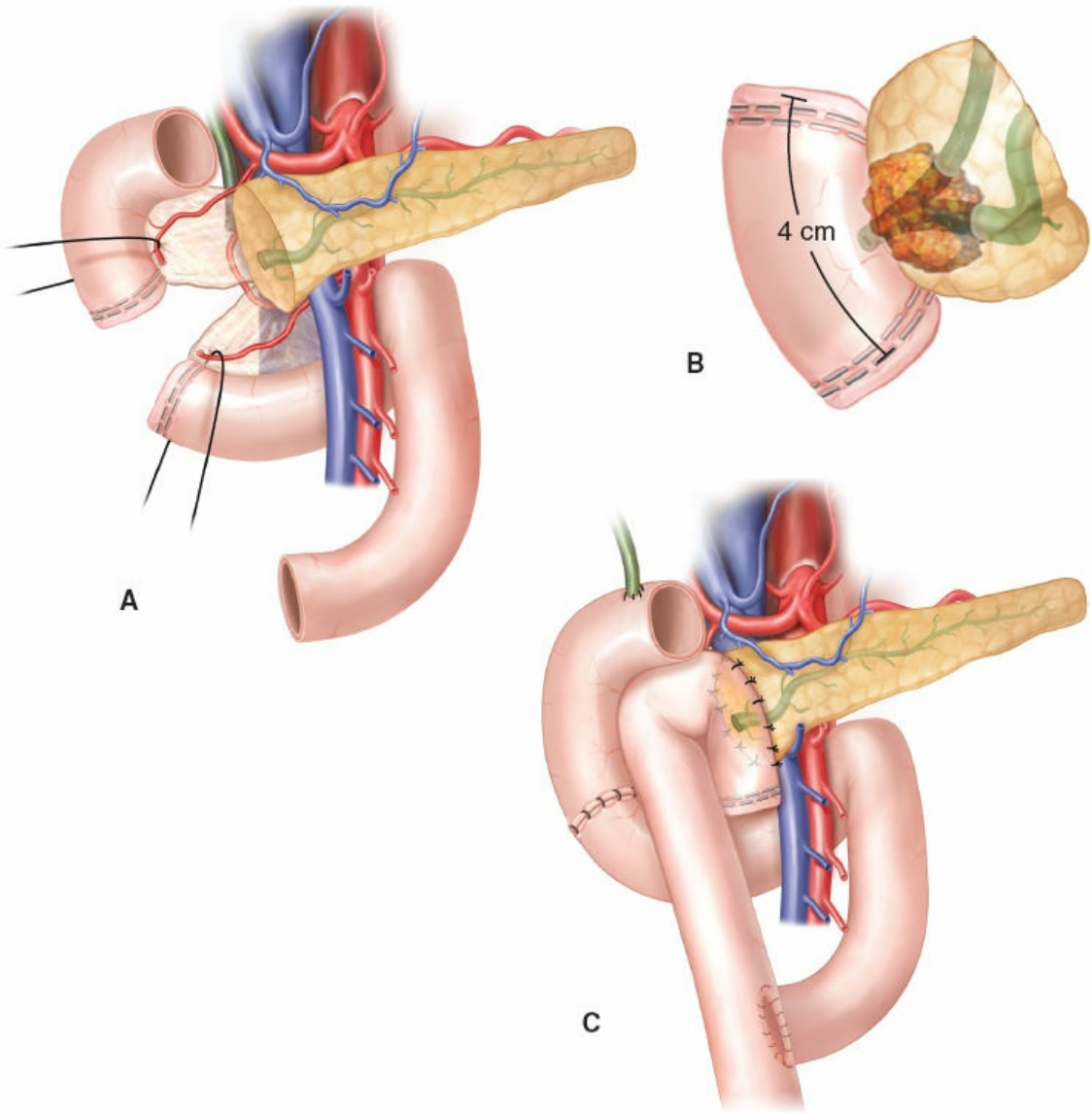

Figure 124.3. **A.** Duodenum-preserving total pancreatic head resection additionally resection of a segment of the duodenum and common bile duct. Dissection of the pancreatic head from the duodenum (DPPHR-S). **B.** Operative specimen after total pancreatic head resection additionally segment of duodenum and CBD. **C.** Reconstruction after total pancreatic head resection with additional segment resection of the periampullary duodenum and the CBD. The first jejunal loop is used for anastomosis with the pancreas.

Total Pancreatic Head Resection, Preserving the Duodenum

A total pancreatic head resection, preserving the duodenum (DPPHR-T), is performed in patients suffering a large cystic neoplasm located in the ventral or dorsal segment of the pancreatic head, which causes narrowing of the intrapancreatic CBD. In patients with a neuroendocrine tumor

located in the pancreatic tissue between the CBD and duodenum and patients suffering biliopancreatic maljunction, a DPPHR-T but resecting the intrapancreatic CBD, is a frequently applied modification to DPPHR-T (Fig. 124.4A). Dissecting the tumor-bearing tissue around the CBD implies a risk of injury to the CBD and of interruption to the nutritional blood supply of the prepapillary CBD. Biliary fistula and ischemia-related stenosis of the prepapillary CBD are observed as procedure-related local complications. Resecting the intrapancreatic CBD and creating a biliary anastomosis using the postpyloric duodenum or the jejunum of the excluded loop is a safe procedure, which avoids biliary complications (Fig. 124.4B). Total pancreatic head resection preserving the duodenum and CBD can be executed elegantly by an anastomosis with the stomach (Fig. 124.4C).

Results After Subtotal Duodenum-Preserving Pancreatic Head Resection

Clinical observation, immunologic data, and molecular-biologic indicators underline the hypothesis that the pancreatic head is the pacemaker of chronic pancreatitis. Resection of the pancreatic head removes the local complications and renders most of the patients pain-free in the long-term outcome.

In terms of hospital mortality rates, frequency of relaparotomy and complications, subtotal pancreatic head resection offers the major advantages of low postoperative morbidity (Table 124.4). A benefit of the application of subtotal resection of the pancreatic head in advanced chronic pancreatitis is the preservation of the endocrine and exocrine functions. In terms of oral glucose tolerance testing after duodenum-preserving subtotal head resection, glucose metabolism is completely maintained early postoperatively in most of the patients (Table 124.5). A small group of patients experienced an early postoperative improvement toward normalization of glucose metabolism. Pancreatic head resection results in a decrease of the preoperatively increased glucagon and somatostatin levels in the peripheral blood, enhancing a decrease of the anti-insulinic effect of these hormones. After a median follow-up of 5.7 years, 39% of the patients had normal findings in the oral glucose tolerance test and 17% had a reduced glucose tolerance, whereas 44% had insulin-dependent diabetes mellitus due to the natural course of chronic pancreatitis (Table 124.6). In terms of the pain status after an observation

period of up to 22 years, 79% of the patients were completely pain-free while 9% continued to experience upper abdominal pain. Further episodes of acute pancreatitis with the need for hospitalization in the late follow-up, with a median of 5.7 years and range up to 22 postoperative years, were occurred in only approximately 12% of the patients (Table 124.6). Regarding the quality of life after subtotal duodenum-preserving pancreatic head resection, approximately 66% of the patients were professionally rehabilitated. After a median observation period of 5.7 years, the late death rate after subtotal pancreatic head resection was between 3.6% and 13%. Of the patients who suffered mortality in the late follow-up period, 50% did so following development of GI-tract cancer (Table 124.6). In comparison with the classical PD, the subtotal duodenum-preserving pancreatic head resection offers the major advantage of preserving the extrahepatic biliary tree, stomach and duodenum. The results of five randomized controlled trials demonstrated the superiority of the duodenum-preserving technique compared to classical PD for patients suffering from advanced chronic pancreatitis. The coring-out technique of Frey is a modification of the Partington-Rochelle duct drainage procedure, resulting in duct decompression. However, according to Frey's publication, the inflammatory mass tissue in the head of the pancreas is conserved, because he propagates only coring-out the anterior region of the pancreatic head toward the duct. In contrast, the wet weight of the tissue specimen after duodenum-preserving subtotal head resection is reported to be 25 to 55 g of the pancreatic head.

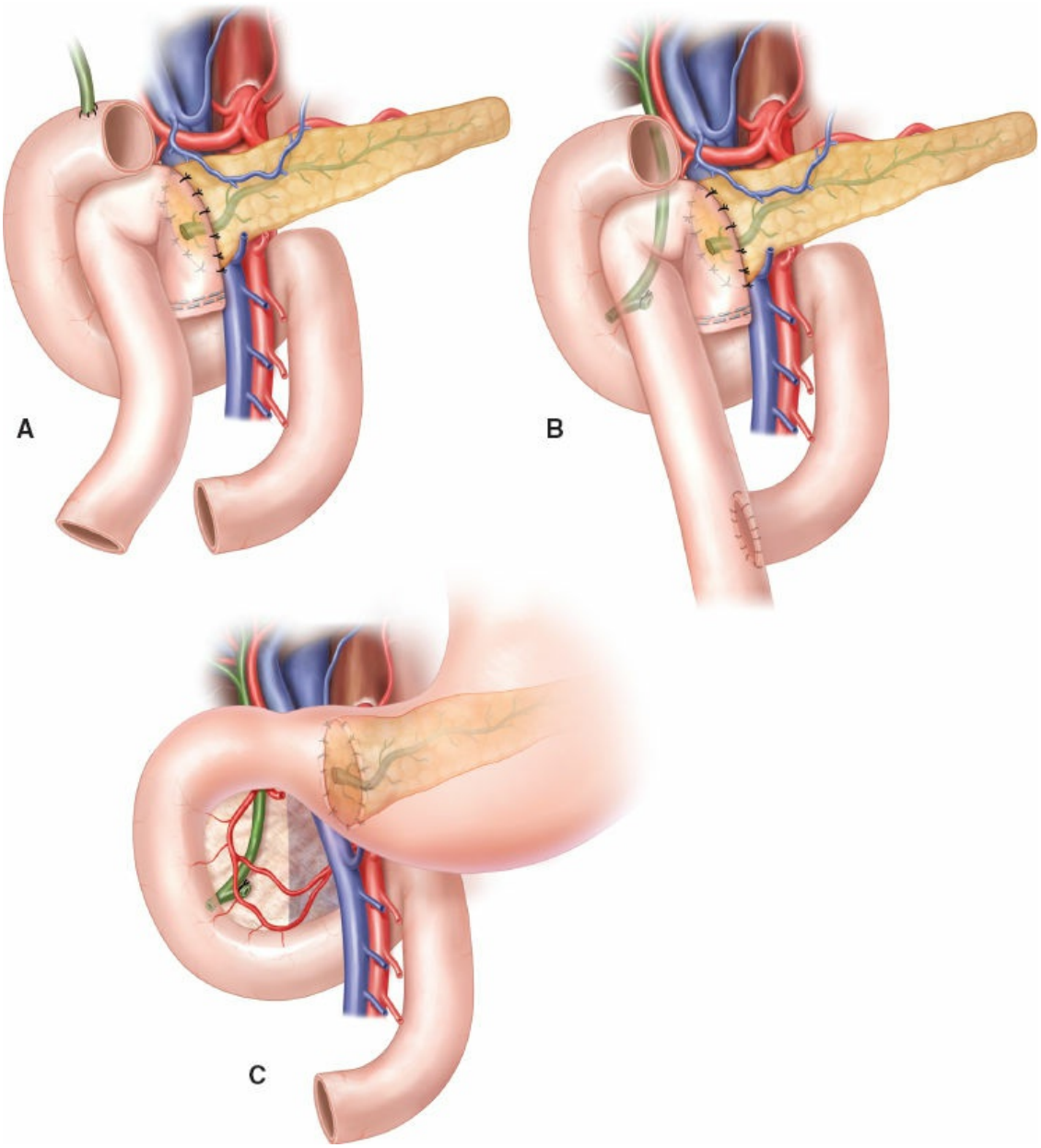

Figure 124.4. **A.** Reconstruction after total pancreatic head resection preserving the duodenum. The biliary anastomosis can be performed with the postpyloric duodenum or the jejunal loop (DPPHR-T). **B.** Total pancreatic head resection preserving the duodenum. Anastomosis with the jejunal loop. **C.** Total pancreatic head resection preserving the duodenum. Anastomosis with the stomach.

Results After Partial and Total Pancreatic Head Resection Applied for Neoplastic Tumors

Total pancreatic head resection with segment resection of the periampullary duodenum and resection of the intrapancreatic segment of the CBD are applied in patients with IPMN of the main and mixed duct

type (Table 124.7). IPMN lesions are predominantly located in the pancreatic head, as it is observed for serous cyst adenomas (SCA). MCN is found in the pancreatic head only in 25% to 32%. Total pancreatic head resection with segment resection of the duodenum and CBD is successfully used in patients suffering a cystic neoplastic tumor with an in-situ carcinoma and for patients with a low-risk malignant cancer of the periampullary region originating from the papilla and ampulla, the intrapancreatic CBD, and the peripapillary duodenum (Table 124.7). The different techniques of tissue resection of the pancreatic head—partial or total head resection—are determined by size, type, and location of the tumor. The selection of the extent of tissue resection is an additional advantage of the duodenum-preserving pancreatic head resection by tailoring the extent of the surgical resection of pancreatic head tissue. In a systematic review of a series of articles published up to March 2015 applying limited pancreatic head resections, 29% of the patients had a total pancreatic head resection with segment resection of the duodenum and CBD, 38% underwent total pancreatic head resection but with preservation of the duodenum, and 32% received a partial pancreatic head resection. In terms of the early postoperative morbidity, severe postoperative morbidity was observed in 12.7% of patients using the Clavien-Dindo classification, with a severity score >3 (Table 124.8). Pancreatic fistula grades B and C were observed in 14% out of a total of 20% of 462 patients. Resurgery was 2.7%, rehospitalization 3.2%, and hospital mortality 0.4% (Table 124.8). A systematic review of 503 patients, who had undergone a duodenum-preserving pancreatic head resection, revealed a low level of pancreatic fistula grades B and C, a low level of reoperation, and a very low level of hospital mortality. A delay of gastric emptying was observed in the majority of patients after total head resection with segment resection of the duodenum and CBD, whereas it was less frequently observed after DPPHR-T and almost absent after partial pancreatic head resection.

TABLE 124.4 Subtotal, Duodenum-Preserving Pancreatic Head Resection in Chronic Pancreatitits: Early Postoperative Results

Postoperative hospital stay	14.5 d mean (7–87)
Relaparotomy	5.6% (28 of 504 patients)
Hospital deaths	0.8% (4 of 504 patients)

From Beger HG, Schlosser W, Friess HM, et al. Duodenum-preserving head resection in chronic pancreatitis changes the natural course of the disease. A single-center 26-year experience. *Ann Surg* 1999;230:512, with permission.

The major benefits of the duodenum-preserving pancreatic head resection procedures are conservation of pancreatic and peripancreatic GI-tract tissue and maintenance of endocrine and exocrine pancreatic functions in the short- and long-term outcomes. Meta-analysis data demonstrated conservation of the endocrine functional capacity of the pancreas after total head resection. Similar results have been published after testing of the exocrine pancreatic functions. On evaluation of the endocrine pancreatic functions by determining HbA1C and blood glucose after oral glucose tolerance testing, both methods accordingly confirmed maintenance of the level of glucose metabolism in the short- and long-term outcomes after a limited head resection. In contrast, the results after application of PD showed postoperatively a significant decrease in glucose metabolism with a significant increase of new onset of diabetes mellitus. In total, 6.8% of cystic neoplastic lesions were found to be in-situ carcinoma by the final histologic assessment while 2.4% showed a minimally invasive carcinoma. In 20 of 504 patients (4%) extirpation of a low-risk periampullary cancer was performed (Table 124.7). In the vast majority of patients with a cancerous lesion, a total pancreatic head resection with segment resection of the duodenum and CBD was applied. After a median follow-up of 62.6 months, the frequency of tumor recurrence was 2.9%. No patient who suffered a cancerous lesion—carcinoma in-situ, minimal invasive carcinoma, or low-risk periampullary carcinoma—developed a recurrent disease in the long-term follow-up period.

TABLE 124.5 Endocrine Function After Subtotal Pancreatic Head Resection in Chronic Pancreatitis

	Preoperative	Late Postoperative		
	1972–1998 504 Patients No. (%)	1972–1983[b] 56 Patients 2.0 y[c] No. (%)	1972–1987[b] 109 Patients 3.6 y[c] No. (%)	1982–1996 303 Patients 5.7 y[c] No. (%)
OGTT normal	246 (49)	37 (66)	52 (48)	118 (39)
IDDM	124 (25)	—	29 (26)	134 (44)
Glucose-improved	—	3 (15.8)	3 (5.5)	34 (11)
New IDDM	—	2 (5.4)	11 (13.7)	64 (21)

[a]IDDM, insulin-dependent diabetes mellitus; OGTT, oral glucose tolerance test.
[b]Data from Beger HG, Krautzberger W, Bittner R. et al. Duodenum-preserving resection of the head of the pancreas in patients with severe chronic pancreatitis. *Surgery* 1985;97:467; and Beger HG, Schlosser W, Friess HM. et al. Duodenum-preserving head resection in chronicpancreatitis changes the natural course of the disease. A single-center 26-year experience. *Ann Surg* 1999;230:512.
[c]Median years of follow-up.

With benign cystic neoplasm and neuroendocrine tumors, many being asymptomatic, a majority of the patients were younger than 60 years. Application of a limited local resection of the pancreatic head implies a relief from the fear of cancer and the reestablishment of a normal quality of life.

TABLE 124.6 Subtotal Duodenum-Preserving Pancreatic Head Resection in Chronic Pancreatitis, Late Outcome Results After Follow-up of 5, 7 Years (Median)

	1972–1983 58 Patients 0–11 y 2 y (Median) 57 Patients % of subgroup	1972–1987 128 Patients 0–15 y 3.6 y (Median) 109 Patients % of subgroup	1972–1994 298 Patients 0–22 y 6 y (Median) 258 Patients % of subgroup	1982–1996 388 Patients 0–14 y 5.7 y (Median) 303 Patients % of subgroup
Follow-up rate	100	96	87	94
Pain-free or rare pain	92.8	89	88	91.3[d]
Continuing abdominal pain	7.2	11	12	8.3
Episodes of AP/hospitalization	14	11	10	12,5
Late death	3.6	4.7	8.9	13
Professional rehabilitation	88.7	67	63	69
Quality of life/Kamofsky index 80–100	—	—	—	82

Data from Beger HG, Krautzberger W, Bittner R, et al. Duodenum-preserving resection of the head of the pancreas in patients with severe chronic pancreatitis. *Surgery* 1985;97:467; Beger HG, Büchler M, Bittner R, et al. Duodenum-preserving resection of the head of the pancreas in severe chronic pancreatitis. *Ann Surg* 1989;209:273; and Büchler MW, Friess H, Bittner R, et al. Duodenum-preserving pancreatic head resection: long-term results. *J Gastrointest Surg* 1997;1:13.

TABLE 124.7 Histologic Type of Cystic Neoplasms and PNETs and Low-Risk Periampullary Cancers After Application of Limited

Pancreatic Head Resection

	Cystic Neoplasms			PNETs[b]		Periampullary[c] Low-Risk Cancer	Other Indications[d]
1994–2/2015	Cystic Neoplasms[a] Total	Carcinoma In Situ/ Severe Dysplasia	Minimal Invasive Cancer	Insulinoma	Carcinoma, Gastrinoma	Papilla, Duodenum, CBD, Pancr. Cancer 1 pt	
503 pts 100%	**67.2%**	**6.8%**	**2.4%**	**10.5%**	**13.2%**	**4.2%**	**17.5%**

[a]IPMN—250 pts; MCN—30 pts; SPN—20 pts; SCA—38 pts.
[b]Insulinoma—52 pts; Gastrinoma—1 pt, Islet cell cancer—6 pts.
[c]T_1 carcinoma papilla Vateri—10 pts; CBD—6 pts; Duodenum—4 pts; DPAC—1 pt.; metastases—3 pts.
[d]Other indications: Inflammatory tumor, bilio-pancreatic maljunction, GIST, lymphoma, lympho-epithelial cyst, duodenal adenoma, duodenal dystrophy.
From Beger HG, Mayer B, Rau BM; Parenchym-sparing, limited pancreatic head resection for benign tumors and low-risk periampullary cancer—A systematic review. *J Gastrointest Surg* 2015;20:206-17; with permission of Springer.

TABLE 124.8 Early Postoperative Morbidity After Partial or Total Pancreatic Head Resection of Benign Tumors and Low-Risk Periampullary Cancer

	Morbidity		POPF		Resurgery	Delay of Gastric Emptying	90-day Mortality	Rehospi-talization	Recurrence
1994–2/2015	Overall	Severe[a]	Total PF	PF B + C					
Total 503 pts	38.2%	12.7%	19.9%	13.6%	2.7%	12.3%	0.4%	3.2%	2.9%

[a]Clavien-Dindo ≥3.
From Beger HG, Mayer B, Rau BM; Parenchym-sparing, limited pancreatic head resection for benign tumors and low-risk periampullary cancer—A systematic review. *J Gastrointest Surg* 2015;20:206-217; with permission of Springer.

Suggested Readings

Bachmann K, Tomkoetter L, Kutup A, et al. Is the Whipple procedure harmful for long-term outcome in treatment of chronic pancreatitis? 15-years follow-up comparing the outcome after pylorus-preserving pancreatoduodenectomy and Frey procedure in chronic pancreatitis. *Ann Surg* 2013;258:815–21.

Beger HG, Gansauge F, Siech M, et al. Duodenum-preserving total pancreatic head resection for cystic neoplastic lesions in the head of the pancreas. *J Hepatobiliary Pancreat Surg* 2008;15:149–56.

Beger HG, Krautzberger W, Bittner R, et al. Duodenum-preserving resection of the head of the pancreas in patients with severe chronic pancreatitis. *Surgery* 1985;97:467–73.

Beger HG, Mayer B, Rau BM. Parenchyma-sparing, limited pancreatic head resection for benign tumors and low-risk periampullary cancer: a systematic review. *J Gastrointest Surg* 2016;20:206–17.

Beger HG, Nakao A, Mayer B, et al. Duodenum-preserving total and partial pancreatic head resection for benign tumors-systematic review and meta-analysis. *Pancreatology* 2015;15:167–78.

Beger HG, Poch B. High incidence of redo surgery after Frey procedure for chronic pancreatitis in the long-term follow-up. *J Gastrointest Surg* 2016;20:1076–7.

Beger HG, Poch B, Mayer B, et al. New onset of diabetes and pancreatic exocrine insufficiency after pancreaticoduodenectomy for benign and malignant tumors: a systematic review and meta-analysis of long-term results. *Ann Surg* 2017 – in press.

Diener MK, Rahbari NN, Fischer L, et al. Duodenum-preserving pancreatic head resection versus pancreatoduodenectomy for surgical treatment of chronic pancreatitis: a systematic review and meta-analysis. *Ann Surg* 2008;247:950–61.

Fischer TD, Gutman DS, Warner EA, et al. Local pancreatic head resection: the search for optimal indications through quality of life assessments. *Am J Surg* 2015;210:417–23.

Fujii T, Kanda M, Kodera Y, et al. Comparison of pancreatic head resection with segmental duodenectomy and pylorus-preserving pancreatoduodenectomy for benign and low-grade malignant neoplasms of the pancreatic head. *Pancreas* 2011;40:1258–63.

Schlosser W, Poch B, Beger HG. Duodenum-preserving pancreatic head resection leads to relief of common bile duct stenosis. *Am J Surg* 2002;183:37–41.

EDITOR'S COMMENT

The authors describe the parenchyma-sparing, limited partial and total head resection for inflammatory, benign, or low-risk periampullary malignant tumors. This procedure was first described by Professor Hans G. Beger, and the senior author and his colleagues reported results in a classic paper in 1980 and 1990 (Duodenum-preserving resection of the head of the pancreas in severe chronic pancreatitis. Early and late results. *Ann Surg* 1989;209:273–8). It is an honor to have him contribute this chapter as Professor Beger is a leading authority in the surgical management of chronic pancreatitis. As the authors state a pancreatic head mass associated with chronic pancreatitis seems more common in Europe than in the United States or Asia. Although the use of duodenal-preserving pancreatic head resections is less common in the United States, they are gaining momentum based on prospective studies showing equivalent morbidity and mortality to the Whipple procedure and pain control while yielding better nutritional outcome for the patient (Mihaljivic AL et al. Beger's operation and the Berne modification: origin and current results. *J Hepatobiliary Pancreat Sci* 2010;17:735–44).

The operation of a duodenum-preserving pancreatic head resection is technically challenging. However, new developments in energy devices have facilitated the dissection of the head of the pancreas. In Beger procedure, the

pancreas is dissected at the level of the portal vein. The pancreatic head is removed and the duodenum is preserved with a thin layer of pancreatic tissue. If the bile duct is obstructed, it can be opened and an internal anastomosis with the residual pancreatic head can be performed. The reconstruction is performed with two anastomoses, of the pancreatic tail remnant and of the residual pancreatic head with a single Roux-en-Y jejunal loop as shown in Figure 124.2C.

The expected outcome of the Beger procedure for chronic pancreatitis is very good with excellent pain relief. Pancreatic endocrine and exocrine function are better than after a pancreaticoduodenectomy. In addition, GI continuity, duodenal motility, and duodenal endocrine function are maintained. The latter is important for coordinating GI endocrine function. Hence, nutritional status of the patient may be superior to a Whipple procedure. It is important for the reader to know that the procedure does not change the natural progression of the cellular damage chronic pancreatitis and both exocrine and endocrine function will deteriorate over time.

Specific results for the Beger procedure demonstrate pain relief of 80% to 85% in a 5-year follow-up study and another 14-year follow-up study reported 78.8% of pain-free subjects. Diabetes incidence after DPPHR ranges within 8% to 21%, and some patients may have improvement in glucose metabolism. This may be related to duodenal preservation and more normal and coordinated postprandial GI endocrine function. Complications include risk of duodenum ischemia usually related to inadequate perfusion of the posterior branch of the gastroduodenal artery. This may result in perforation or development of duodenal stricture. In addition, stricture of the bile duct may develop.

Other techniques for duodenal-preserving pancreatic head resection in chronic pancreatitis include that described by Professor Charles Frey et al. (Description and Rationale for a new Operation for Chronic Pancreatitis. *Pancreas* 1987;2:701–7) and Bern modification. The Frey procedure is a modification of the Beger that is a combination of the Beger- and Partington-Rochelle procedures. Compared to the Beger procedure, the resection in the pancreatic head in the Frey-modification is smaller and combined with a lateral pancreaticojejunostomy to drain the entire pancreatic duct toward the tail. In contrast to the Beger procedure, reconstruction can be performed with one single anastomosis. This procedure is not suitable in patients with a large inflammatory mass in the pancreas without stenosis of the distal pancreatic duct as is not uncommonly observed. However, it appears advantageous in patients with less severe inflammation in the head combined with an obstruction in the distal pancreatic duct.

The Berne modification (Klaiber U et al. Duodenum-preserving pancreatic head resection: 10-year follow-up of a randomized controlled trial comparing the Beger procedure with the Berne modification. *Surg* 2016;160:127–35) represents a technical simplification of the Beger procedure with equal outcome. The removal of the pancreatic head can be performed with identical

extent compared to the Beger procedure. However, in contrast to the Beger procedure, the pancreas is not divided at the level of the portal vein, which is often difficult because of inflammation and portal hypertension. The reconstruction can be performed by one single anastomosis between a jejunal loop and the continuous pancreatic resection rim. As in the Beger procedure, a bile duct obstruction can be managed by internal bile duct anastomosis. The Bern modification of DPPHR appears ideal for patients with an inflammatory mass and without stenosis of the distal pancreatic duct.

If duodenal-preserving pancreatic head resection is chosen for treatment of chronic pancreatitis, an intraoperative biopsy and frozen section is advisable to rule out pancreatic adenocarcinoma unless a preoperative biopsy or tissue sampling for cytology has been performed. If the frozen section is suspicious for malignancy or if a cancer is suspected, then a pancreaticoduodenectomy is the best operation.

We have not employed this technique for IPMN, mucinous cystic neoplasms, and neuroendocrine tumors of the pancreas. However, the level of evidence local resection compared to standard oncologic resections appears presently low (Beger HG et al. Limited surgery for benign tumours of the pancreas: a systematic review. *World J Surg* 2015;39(6):1557–66). For localized side, branched IPMN, cystic mucinous neoplasms or benign neuroendocrine tumors with no suspicion of malignancy duodenal-preserving pancreatic head resection, central pancreatectomy, or local excision may make sense. Indeed, local excision techniques applied for benign tumors have equivalent postoperative morbidity and mortality with the Whipple operation with the advantages of conservation of pancreatic functions. However, in my opinion there is insufficient evidence to show that these procedures are equivalent to standard pancreaticoduodenectomy. As for main duct IPMNs, our group favors pancreaticoduodenectomy if the lesion is in the head of the pancreas or uncinate process. It is important to appreciate that based on the Mayo experience all patients with intra- or postoperative evidence of invasive carcinoma at the resection margin should undergo further resection to achieve a negative margin and that patients with evidence of IPMN at the transection margin (even with changes of high grade dysplasia) may not achieve any benefit from further resection. The incidence of recurrence in the residual gland is about 10 and not infrequently occurs 5 to 10 years from the initial procedure. The point is that main duct IPMNs have a propensity for malignant transformation and represent a field abnormality of the pancreas. Application of limited duodenal-preserving pancreatic head resection in this group of patients would require multicenter randomized prospective trials.

In my experience, all neuroendocrine tumors 2 cm or greater should be treated with an operation to achieve oncologic control. In most cases for a tumor in the head of the gland, this requires pancreaticoduodenectomy. Smaller tumors may be locally excised if the pancreatic duct is not too close to the lesion. Unfortunately, most of the time the duct is very close to the tumor and local

excision results in a pancreatic fistula that is difficult to control. Hence, pancreaticoduodenectomy is necessary in most cases. Neuroendocrine tumors at the neck of the gland are amendable to central pancreatic resection. We have applied this technique exclusively to small insulinomas as they are benign in 90% to 95% of patients.

E. Christopher Ellison

125 Necrosectomy for Acute Necrotizing Pancreatitis

Peter Muscarella and E. Christopher Ellison

INTRODUCTION

Acute pancreatitis remains a challenging and common problem for pancreatic surgeons and other health care professionals who manage these patients. Patients with severe acute pancreatitis (SAP) often present with a considerable systemic inflammatory response and varying degrees of organ dysfunction. These patients are at risk for the development of local complications of pancreatitis including pancreatic necrosis, pseudoaneurysms and bleeding, fistulas and strictures, and infected pancreatic necrosis (IPN). The development of IPN is known to be associated with almost universal mortality without adequate source control. Open necrosectomy was used successfully in the past to decrease mortality, but resulted in considerable morbidity such as fascial dehiscence, incisional hernia, and gastrointestinal fistulas. Considerable advances in the understanding and management of SAP have been made over recent years with regard to definitions and nomenclature, severity scoring, management of the early systemic response and organ failure, nutritional support, the role of antibiotics, patient monitoring and timing of intervention, and minimally invasive approaches for necrosectomy. Numerous studies have shown that both delays in intervention, and minimally invasive approaches, result in improved outcomes and decreased complications, although there is a lack of data proving that minimally invasive necrosectomy improves mortality compared to open necrosectomy for IPN. As is the case with so many other diseases that we treat, advances in knowledge and technology have mandated a multidisciplinary approach for the management of patients with SAP.

Acute pancreatitis is a common problem encountered by pancreatic surgeons and accounts for nearly 220,000 hospital admissions per year in the United States. Pancreatitis represents the most common gastrointestinal diagnosis for patients being discharged from the hospital and the frequency

of admissions has increased by 30% over the last decade. Approximately 80% of cases of acute pancreatitis represent a mild, self-limited disease. These patients do not develop ongoing systemic symptoms, organ failure, or local complications such as necrosis. Patients are treated with fluids and bowel rest, and symptoms resolve quickly over a few days. For patients with an initial attack of mild acute pancreatitis, a limited investigation for the etiology should be undertaken and steps should be taken to minimize the risk of recurrent acute pancreatitis. For example, cholecystectomy should be performed at the time of initial hospitalization in all patients who are fit for surgery and alcohol cessation should be encouraged for patients with alcohol-induced pancreatitis. The remaining 20% of patients will have a more severe form of pancreatitis that is associated with acute illness, organ failure, local complications, and considerable mortality. Approximately 15% of patients with SAP will develop pancreatic necrosis and IPN occurs in 30% to 70% of these patients. These patients will require some form of necrosectomy, but still have mortality rates that range from 19% to 24%. Although there is some controversy regarding the management of sterile necrosis, most pancreatologists would agree that there is no benefit for intervention in cases of sterile necrosis and that these procedures should be reserved for symptoms and persistent collections in patients who go on to develop walled-off pancreatic necrosis (WOPN) (Fig. 125.1).

Goals of therapy for patients with SAP and pancreatic necrosis include accurate severity scoring, the implementation of early measures to treat the massive systemic inflammatory response and support organ function, appropriate imaging and monitoring for local complications, accurate diagnosis of IPN, and appropriate timing and intervention for IPN. The importance of avoiding iatrogenesis cannot be stressed enough. Patients with SAP can be very ill and commonly exhibit signs and symptoms of sepsis. This may prompt inexperienced or poorly informed clinicians to initiate unnecessary or potentially dangerous therapies such as antibiotics, percutaneous catheter drainage, or surgical intervention due to a genuine desire to help the patient in the context of a critically ill patient for whom no specific therapy is being utilized other than supportive measures. In general, these interventions should be avoided and clinicians should be encouraged to exercise patience in managing individuals with SAP. Such interventions should be reserved for patients with proven infections, which are unlikely to occur in the early phases of SAP. There is no “fast-track” in

these situations. The damage to the pancreas most certainly occurred prior to presentation to the hospital and it is the physician's job to support the patient and manage sequelae as they arise. The purpose of this chapter is to review the evaluation and treatment of SAP with particular emphasis on techniques and outcomes for the management of IPN.



Figure 125.1. Computed tomography (CT) image from a patient with walled-off pancreatic necrosis (WOPN). There is a large fluid collection replacing the body and tail of the pancreas. Note the lack of contrast enhancement and compression of the stomach that lies anterior to the collection.

CLINICAL PRESENTATION

Etiology

There are numerous causes for AP (Table 125.1), although alcohol and gallstones account for the vast majority of cases, representing more than

one third of cases each. The pathogenic mechanisms through which alcohol causes AP appear to be multifactorial and complex. Although alcohol is responsible for a considerable number of cases of AP, most heavy drinkers will not develop AP suggesting that other cofactors (possibly genetic) are involved. There is some controversy regarding the contribution of smoking to acute pancreatitis, as this is a common habit among heavy drinkers. There is no clear causal relationship between smoking and AP, although it is generally agreed that prolonged smoking accelerates the progression of pancreatitis. There are also numerous theories regarding the underlying pathogenesis of gallstone pancreatitis, although choledocholithiasis and biliary involvement are known to incite AP. The role of the so-called biliary sludge is more controversial, but well-designed studies indicate that cholecystectomy is associated with a decreased incidence of recurrent AP in patients with biliary sludge on right upper quadrant ultrasonography. The effect of cholecystectomy, endoscopic biliary sphincterotomy, and bile acid therapy on the incidence of recurrent AP in patients with sludge identified on more sensitive tests such as magnetic resonance imaging (MRI) or endoscopic ultrasonography (EUS) is less clear.

Endoscopic retrograde cholangiopancreatography results in AP in 5% to 10% of patients undergoing these procedures and the etiology is usually clear in these cases. The underlying pathophysiology appears to be related to increased pancreatic duct (PD) pressures and trauma as technically difficult procedures and aggressive contrast injection into the PD are commonly associated with AP. Consequently, ERCP is typically reserved for therapy in patients with pancreaticobiliary disease and has been largely supplanted by other tests such as magnetic resonance cholangiopancreatography (MRCP) and EUS for diagnosis. Prophylaxis with various agents, such as protease inhibitors and nonsteroidal anti-inflammatory drugs (NSAIDs), have been evaluated in an attempt to decrease the incidence of post-ERCP pancreatitis, although the results are inconsistent, and none of these agents are widely used for this purpose at the current time. Trauma and surgery can result in pancreatitis and the cause is usually obvious in these cases. Specific treatment is individualized and generally focuses on management of fluid collections, sepsis, and associated duct disruptions if they are present. PD obstruction can certainly cause AP and the underlying lesions generally represent strictures, anatomic abnormalities, and benign or malignant tumors. There

is clearly a relationship between pancreatitis and pancreatic cancer. Pancreatic cancer can certainly present as AP and the grossly abnormal imaging so often seen in patients with SAP can easily mask malignant tumors that can often escape detection even under the best of circumstances. Clinicians should always be cognizant of the possibility of pancreatic cancer in patients with unexplained AP, particularly older patients. There has been considerable controversy related to congenital PD abnormalities and their relationship with AP. Pancreas divisum occurs in 5% to 10% of the normal population and represents an embryologic failure of fusion of the dorsal and ventral ducts resulting in the majority of the pancreatic exocrine secretions draining through the minor papilla. The incidence of pancreas divisum in the AP patient population appears to be similar to that of the general population, suggesting that this may not be a true cause of AP. Surgical and endoscopic minor duct sphincterotomy or "sphincteroplasty" were commonly recommended in the past, but appear to offer no benefit at this time.

TABLE 125.1 Causes of Acute Pancreatitis

A. Toxic
   1. Chronic alcoholism
   2. Scorpion venom
   3. Organophosphates
   4. Drugs
B. Obstructive
   1. Choledocholithiasis/microlithiasis
   2. Neoplasms (ampullary or pancreatic)
   3. Congenital anomalies (pancreatic divisum with accessory duct obstruction, annular pancreas)
   4. Foreign bodies obstructing the papilla
   5. Sphincter of Oddi dysfunction
C. Metabolic
   1. Hypertriglyceridemia (types I, IV, and V)
   2. Hypercalcemia (primary or secondary)
D. Traumatic
   1. Accidental, blunt trauma to the abdomen
   2. Iatrogenic, post-ERCP, postoperative, endoscopic sphincterotomy
E. Genetic/hereditary
   1. Cationic trypsinogen mutation (PRSS-1)
   2. CFTR mutation
   3. SPINK-1 mutation
F. Infectious
   1. Parasitic, Ascariasis, Clonorchis
   2. Viral, mumps, Rubella, Hep A, B, C, Coxsackie virus B, Echo virus, adenovirus, CMV, EBV, HIV
   3. Bacterial, Mycoplasma, *Campylobacter jejuni*, Leptospirosis, Legionella, Mycobacterium tuberculosis, Mycobacterium avium complex
G. Vascular
   1. Ischemic, hypoperfusion, embolism
   2. Vasculitis, SLE, PAN, malignant hypertension
H. Tropical (usually chronic, initial episode may present as acute pancreatitis)
I. Idiopathic, early/late onset (usually chronic)
J. Others, penetrating peptic ulcer, Crohn disease

Adapted from Trivedi CD, Pitchumoni CS. Drug-induced pancreatitis: an update. *J Clin Gastroenterol* 2005;39(8):709–16; with permission from Wolters Kluwer Health, Inc.

Toxins and drugs are a rare, but probably underreported, cause of AP. Every medical student is fascinated with the possibility that their patient may have received a scorpion sting, but this is an exceedingly rare cause of pancreatitis in most areas. Toxins present in gila monster venom, however, may be indirectly associated with AP as a peptide found in gila monster saliva forms the basis for the glucagon-like peptide 1 (GLP-1) receptor agonist class of agents used for the management of diabetes and these are known to result in AP. It is less clear whether other diabetic medications are associated with AP. Innumerable other medications have been reported to be associated with AP and these are generally organized by class

(antimicrobials, cardiovascular agents, neuropsychiatric agents, antineoplastic agents, anti-inflammatory agents, GI agents, hormones, and immunomodulators). It is likely that drug-induced pancreatitis is more common than most clinicians appreciate, as many cases may be ascribed to alcohol or other causes, and the diagnosis is essentially one of exclusion. There are really no specific tests that can be used to determine whether AP was caused by a specific medication and the timing of prescription may not temporally relate to the onset of AP. Nevertheless, astute physicians should suspect drug-induced AP in high-risk subpopulations such as geriatric patients on multiple medications, HIV+ patients, cancer patients, and patients receiving immunomodulating agents.

Metabolic and other causes are rare, but will eventually be seen by most physicians who treat AP frequently. Serum triglyceride levels are markedly elevated in patients with AP related to hypertriglyceridemia, typically in the thousands. There is some evidence that elevated triglyceride levels may be associated with persistent organ failure in patients with SAP, regardless of the etiology. Hypercalcemia is a rare cause of AP and can be primary or secondary. Our group has seen at least two cases of hypercalcemia-related AP in patients with disseminated neuroendocrine tumors, essentially representing a paraneoplastic syndrome. Autoimmune pancreatitis is a rare disorder that typically presents with a characteristic appearance on cross-sectional imaging that has been referred to as a “sausage-like” appearance. This is probably the most specific diagnostic abnormality. Serum IgG4 levels may be elevated on IgG subclass evaluation, but normal levels do not rule out the possibility of autoimmune pancreatitis. The identification of autoimmune pancreatitis is crucial for these patients as they respond well to steroids and other medical therapies.

Genetic abnormalities are increasingly recognized as the causative factor in many patients with AP. It is likely that some cases of idiopathic pancreatitis may be due to yet unidentified genetic mutations and research continues on affected kindreds in order to identify potential abnormalities. Known causes of familial or hereditary pancreatitis include mutations in the cationic trypsinogen (PRSS1), cystic fibrosis transmembrane conductance regulator (CFTR), and serine protease inhibitor, Kazal type 1 (SPINK1) genes. Referral to a genetics counselor can be considered for patients with idiopathic AP, particularly the young and those with a positive family history for pancreatitis or pancreatic cancer. Recent

research into the molecular mechanisms leading to AP based on the cationic trypsinogen and SPINK1 gene products offers great insight into the underlying pathophysiology that most likely occurs in all patients with AP and this appears to be based on inappropriate intraacinar activation of trypsinogen. The activated trypsin subsequently cleaves other proenzymes resulting in a complex cascade of events that result in autodigestion of the native pancreatic tissue and the consequent release of inflammatory mediators responsible for the systemic inflammatory response and related organ failure (Fig. 125.2).

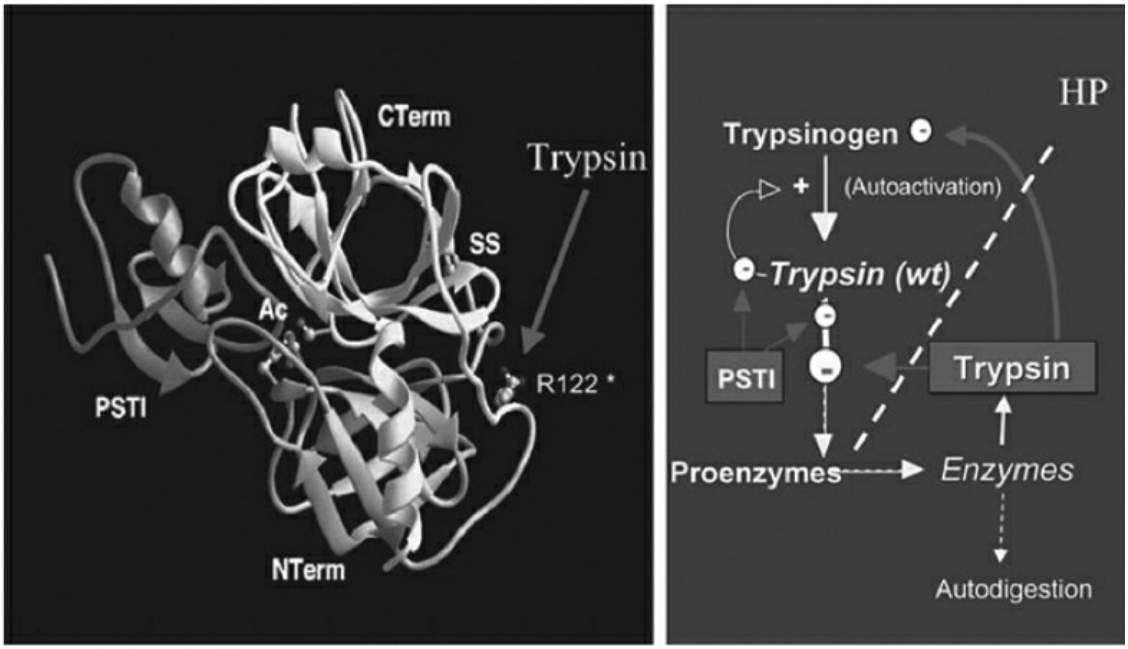

Figure 125.2. Molecular model for trypsin inactivation. Trypsinogen is made by the pancreas in an inactive form. Trypsinogen is normally cleaved in the intestine by enterokinase and contributes to the activation of essentially all of the other digestive enzymes. Inappropriate pancreatic activation of trypsinogen results in acute pancreatitis. The trypsin inhibitor SPINK1/PSTI blocks the active site and prevents trypsin from activating other trypsinogen molecules and digestive enzymes. In order to further protect the pancreas from activated trypsin activity, normal trypsin attacks itself at arginine #122 (R122). This causes destruction of activated trypsin and prevents an ongoing cascade of intrapancreatic enzymatic activation. The PRSS-1 mutation is located at R122. This elegant model explains how mutations of PRSS-1 or SPINK1/PSTI can result in hereditary pancreatitis and offers insight into the pathogenesis for other forms of pancreatitis. (Reprinted from Whitcomb DC. Hereditary pancreatitis: a model for understanding the genetic basis of acute

and chronic pancreatitis. *Pancreatology* 2001;1(6):566–71. Copyright © 2001, with permission from Elsevier.)

Signs and Symptoms

Patients with AP almost universally present with the acute onset of severe epigastric abdominal pain that often radiates to the back. This is commonly ascribed to a precipitating alcohol binge or a fatty meal, although it should be clear that food itself is not a cause of AP and there is very little evidence that "stimulation" of the pancreas by enteral feeding results in persistent inflammation or adversely affects outcomes for SAP. In fact, the frequent observation that enteral nutrition provides benefit for patients with SAP suggests quite the opposite. Patients may have varying degrees of organ failure depending on severity and can be quite ill with hypotension, tachycardia, respiratory distress/failure, and acute kidney injury (AKI). Nausea and vomiting can be seen, but are generally not the predominant clinical symptoms. NG decompression can be useful for these patients, but is generally not otherwise beneficial. Physical examination findings are generally nonspecific, although there are some rare signs that are extremely specific for AP. Patients generally will have diffuse abdominal tenderness, particularly in the epigastric region, with abdominal distension. The abdomen is generally soft, but may become more distended and rigid for patients who receive aggressive resuscitation and this can lead to abdominal compartment syndrome in some cases. Peritoneal signs are generally absent, although patients generally complain of severe pain. Their presence should suggest the possibility of other acute abdominal processes that may require emergent surgical intervention. Grey-Turner and Cullen's signs represent flank and periumbilical ecchymosis that can result from retroperitoneal edema and bleeding. Although these can be seen with other disorders, they are classically associated with SAP. Pancreatic panniculitis represents small erythematous skin lesions that can be present throughout the body, but are generally identified on the dorsal aspect of joint surfaces (Fig. 125.3). These are quite rare, but may occur when systemic levels of pancreatic enzymes are high enough for digestion of soft tissue to occur. This can be seen in patients with pancreaticoportal or pancreaticosplenic fistulas.

Diagnosis

The diagnosis of acute pancreatitis should be based on clinical presentation

and laboratory studies. Patients with the characteristic presentation of abdominal pain who are noted to have elevated serum pancreatic enzyme levels should be given a diagnosis of acute pancreatitis. Serum amylase and lipase levels can both be measured and these tests may offer complementary information. Serum amylase is generally less accurate. False-positive results may be seen in patients with disorders resulting in increased salivary amylase (mumps, parotitis) or macroamylasemia. False negatives may be seen in several situations. Patients with a history of chronic pancreatitis may develop a “burned-out” pancreas due to acinar atrophy and these patients can have acute exacerbation with considerable inflammation of the pancreas, yet have normal serum amylase levels. Extremely elevated serum triglyceride levels can interfere with the assay for measuring serum amylase, and these values will appear normal. Finally, patients with a delayed presentation may have normal serum amylase levels, as they may have peaked prior to presentation and were unmeasured. Serum amylase generally peaks prior to serum lipase. Serum lipase levels are considered to be more sensitive than amylase levels and may be more useful in patients with a delayed presentation.

Radiologic evaluation should be reserved for selected patients, as the diagnosis of acute pancreatitis is generally not made based on the results of imaging studies. For the majority of patients with mild AP, abdominal imaging is completely unnecessary. Computed tomography (CT) imaging can be useful for patients for whom the diagnosis remains questionable, or for patients in whom other diagnoses are being considered. CT imaging is also considered to be mandatory for the evaluation of patients with SAP as it provides considerable information about complications of pancreatitis such as fluid collections, fistulas, and pancreatic necrosis. The timing of CT imaging for these patients has been the subject of some debate, but most pancreatologists would agree that it is reasonable to wait several days after presentation because necrosis might not be apparent on early imaging. Furthermore, the use of intravenous (IV) contrast may be dangerous in patients with compromised organ function as it can exacerbate AKI. Some investigators have evaluated MRI for the evaluation of SAP, but this has not become widely adopted.



Figure 125.3. Pancreatic panniculitis. Characteristic painful and erythematous skin lesions that are generally located on the dorsal aspect of joint surfaces in patients with acute pancreatitis.

Severity Scoring and Nomenclature

Due to the stark contrast in clinical course and outcomes between patients with mild AP and SAP, an accurate and early determination of severity should be performed for all patients with AP. Numerous severity scoring systems have been utilized and these are based on clinical parameters, physiologic data, and/or radiologic findings. Perhaps the most well-known system is the Ranson criteria, which are based on 11 clinical parameters that are measured at the time of initial presentation and 48 hours after admission (Table 125.2). Mnemonic for Ranson criteria are GA LAW and C HOBBS. Ranson criteria have been shown to accurately predict mortality for AP and most health care providers are familiar with their use. Patients with ≥3 criteria are considered to have SAP. Disadvantages of Ranson criteria include missing data for patients transferred to a tertiary care center many days after their initial presentation and the inability to track changes in severity over time. The APACHE II scoring system is a physiologic scoring system that involves the collection of variables and the

calculation of a combined score. An APACHE II score ≥8 is considered to signify SAP. This scoring system is more complex, but does offer the advantage of allowing for the evaluation of trends in severity over time and has become popular with intensivists who manage SAP. Radiologic severity scoring systems, such as the computed tomography scoring index (CTSI), utilize CT imaging data that usually include the presence and extent of pancreatic necrosis and peripancreatic fluid collections. These systems provide objective scoring of pancreatic imaging findings, but are clearly not useful for triaging patients to undergo CT imaging.

TABLE 125.2 Ranson Criteria for the Evaluation of Acute Pancreatitis Severity

At admission:
Age in years >55 years
White blood cell count >16,000 cells/mm^3
Blood glucose >11 mmol/L (>200 mg/dL)
Serum AST >250 IU/L
Serum LDH >350 IU/L

48 hours:
Serum calcium <2.0 mmol/L (<8.0 mg/dL)
Hematocrit fall >10%
Oxygen (hypoxemia PaO_2 <60 mm Hg)
BUN increased by 1.8 or more mmol/L (5 or more mg/dL) after IV fluid hydration
Base deficit (negative base excess) >4 mEq/L
Sequestration of fluids >6 L

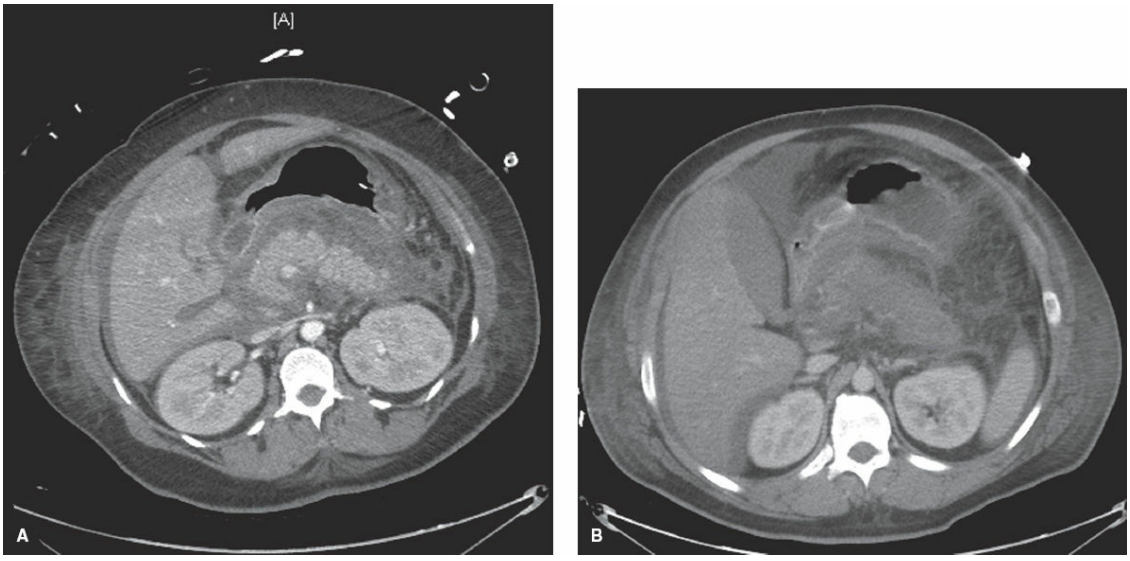

Figure 125.4. Computed tomography (CT) images from patients with acute edematous interstitial pancreatitis (**A**) and necrotizing

pancreatitis (**B**). Both studies demonstrate findings of pancreatic edema, swelling, and inflammation. Contrast enhancement of the pancreatic parenchyma is absent in the patient with necrotizing pancreatitis.

The revised Atlanta classification and definitions were published in 2012 in order to standardize reporting of research and improve communication between physicians caring for patients with AP. This consensus report addressed several areas of concern that include diagnosis, severity scoring, phases of disease, and an appropriate classification of imaging findings. According to the revised Atlanta classification, the diagnosis of AP can be made when two of three criteria are met: (1) characteristic abdominal pain; (2) serum amylase or lipase activities greater than three times the upper limit of normal; and (3) characteristic findings on cross-sectional imaging. Onset of pancreatitis is defined as the time of onset of abdominal pain, not the time of admission or transfer. Types of AP are classified as either acute edematous interstitial pancreatitis or necrotizing pancreatitis, with or without fluid collections (Fig. 125.4). Severity is further divided into mild, moderate, and severe forms. Mild acute pancreatitis is characterized by lack of organ failure, moderate acute pancreatitis by transient organ failure, and SAP by persistent organ failure. Phases of pancreatitis are described as early (<1 week) and late (weeks to months). Although organ failure and a severe systemic inflammatory response can be seen in the early phase, IPN is exceedingly rare during this time. Perhaps one area that has caused the most confusion among clinicians caring for patients with AP is the classification of peripancreatic fluid collections. The revised Atlanta classification has nicely addressed this issue by characterizing these fluid collections according to timing (> or <4 weeks) and the presence or absence of pancreatic necrosis (Table 125.3). The ambiguous term “pancreatic abscess” has been abandoned. Although there can be disagreement regarding some of the classifications and definitions described in the consensus report, this represents an important attempt to provide uniformity, and physicians who provide care for patients with AP should be familiar it.

TABLE 125.3 Revised Atlanta Definitions of Peripancreatic Fluid Collections

	Timing (Weeks)	Presence of Necrosis
Acute peripancreatic fluid collection	<4	–
Pancreatic pseudocyst	>4	–
Acute necrotic collection	<4	+
Walled-off necrosis	>4	+

INITIAL MANAGEMENT

As alluded to previously, the most important thing that clinicians can do for patients with AP during the initial management of the disease is to perform early and accurate measurement of disease severity. Regardless of the system or definitions used, all decision-making that follows is based on this determination. For patients with mild AP, symptoms will resolve within several days. Treatment for these patients should consist of bowel rest, IV fluids, and observation. A careful history, limited laboratory evaluation, and right upper quadrant abdominal ultrasonography should be performed in an attempt to identify the etiology. The underlying cause should be addressed if possible. For patients with gallstone pancreatitis, cholecystectomy should be performed at the time of the initial hospitalization in an effort to prevent a subsequent episode of SAP. Cholecystectomy is typically deferred for patients with SAP or local complications such as fluid collections. Once symptoms have resolved, and the pancreatic enzyme levels appear to be normalizing, the patients' diets can be advanced and they can be discharged with appropriate follow-up.

Timely intervention can be life saving for patients with SAP. Early transfer to an intensive care unit at a tertiary care center specializing in pancreatitis management should be considered in order to allow for aggressive fluid resuscitation, physiologic monitoring, and support of organ dysfunction. CT imaging with IV contrast should be performed for all patients with SAP in order to identify local complications, including necrosis. It is generally agreed that this study can be deferred for 5 to 7 days in order to allow for necrosis to evolve, and possibly to minimize the risk of renal toxicity due to IV contrast material.

There has been considerable research regarding the use of nutritional support in patients with SAP. Most studies indicate that total parenteral nutrition (TPN) is associated with an increased risk of adverse outcomes, particularly infections, as compared to enteral nutrition with feeding tubes.

Most studies comparing these modalities utilize nasojejunal feeding tubes. There is a common misconception among clinicians that feeding proximal to the duodenum somehow results in pancreatic stimulation and promotes ongoing inflammation. Clinical data really do not support this supposition as numerous studies have shown that the nasogastric, and even a trial of oral feeding, can be safe in patients who tolerate them. We recommend a trial of oral feeding or nasogastric feeding in patients with SAP. If this is not tolerated, feeding through a nasojejunal or postpyloric feeding tube should be instituted. TPN should be reserved for patients who do not tolerate nasoenteric feeding, or for patients in whom there are issues with feeding tube placement. Withholding nutritional support altogether is probably not beneficial for these patients.

The use of prophylactic antibiotics in an effort to decrease the incidence of IPN was controversial in the past. Furthermore, clinicians are inclined to start antibiotics during the initial inflammatory phase of SAP because of numerous clinical findings that can lead them to believe that an infection is present such as tachycardia, fever, and organ failure. Current guidelines universally recommend against starting antibiotics in these patients as numerous randomized, prospective trials and comprehensive reviews have demonstrated no benefit for prophylactic antibiotics. Again, there is universal agreement that infection is exceedingly rare in the first week. Antibiotics should be reserved for patients with proven iatrogenic infections or for those in whom IPN is proven or suspected, usually more than 1 week after presentation. Although IV antibiotics are appropriate for the treatment of IPN, they should not be used in lieu of adequate source control except in selected patients.

Numerous agents such as octreotide and anti-inflammatory molecules have been evaluated as specific therapy for AP with somewhat mixed findings. None of these therapies have demonstrated proven benefit in well-designed studies. As such, there are really no targeted therapies for AP that are currently in use.

MANAGEMENT OF PANCREATIC NECROSIS

Sterile Necrosis

It is generally accepted that patients with sterile pancreatic fluid collections, with or without necrosis, should be treated conservatively with observation and serial imaging. It is our practice to perform periodic imaging studies as an outpatient until fluid collections have resolved.

Intervention should be reserved for symptoms and infection. Symptoms generally include abdominal fullness, possibly with a palpable mass, pain, difficulty eating, weight loss, and pain. For patients with areas of WOPN that fail to resolve and result in symptoms, there are several options for management including percutaneous catheter drainage, endoscopic drainage, and open or laparoscopic internal drainage. Percutaneous catheter drainage is relatively noninvasive, but has many disadvantages. Particulate debris may not adequately drain through the small catheters and effective management is generally labor intensive, requiring multiple procedures with upsizing and placement of multiple catheters. There is also a risk of introducing infection into a sterile collection in cases of inadequate drainage. Numerous studies have shown that PD involvement, as documented by duct disruption or communication, is associated with a high rate of recurrent collections in patients undergoing percutaneous drainage. Furthermore, fluid collections associated with isolated distal pancreatic segments that arise when a portion of the middle of the pancreas has essentially been destroyed by pancreatitis are not likely to resolve unless some sort of internal drainage or resection of the isolated segment is provided. It is for these reasons that we recommend liberal use of pancreatography by ERCP or MRCP for planning of therapy in patients requiring drainage of WOPN.

Endoscopic transgastric and/or transpapillary drainage of WOPN has become more widely accepted and decision-making regarding treatment of these patients should involve multidisciplinary consultation with medical pancreatologists and advanced therapeutic endoscopists. Transgastric endoscopic drainage is performed under sufficient anesthesia. EUS is utilized in order to identify the area of WOPN and access to the fluid collection is gained using a needle-knife. The tract is then serially dilated over a wire under fluoroscopic visualization and one or more stents are placed in order to maintain internal drainage. In the past, standard plastic endoscopic stents were utilized, but larger metal stents are currently available and these may provide durable internal drainage in patients with duct involvement (Fig. 125.5). In cases where the endoscopist is able to create a large communication with the cavity, endoscopic debridement and removal of particulate debris can be performed. For some patients with proximal PD strictures or limited areas of duct involvement, transpapillary PD stenting can facilitate transgastric drainage of WOPN.

For patients who are not candidates for, or fail endoscopic drainage,

open or laparoscopic internal drainage can be performed. The procedure is generally referred to as cystgastrostomy, but many pancreatic surgeons now refer to this procedure as transgastric necrosectomy. Access is gained to the abdomen through an open incision or laparoscopically. A transverse anterior gastrotomy is created with cautery or energy. Stay sutures can facilitate visualization and allow for minimizing the length of the gastrotomy. The area of WOPN is usually identified by visualization of a bulge in the posterior wall of the stomach or palpation. Intraoperative ultrasonography (IOUS) can facilitate identification of the area of WOPN. The collection should be aspirated with an 18-gauge needle prior to entering the cavity in the rare event that a pancreatic pseudoaneurysm is present. Once the location is confirmed by aspiration of cyst fluid, an incision is created in the posterior gastric wall and continued through the wall of the cavity. Fluid is then aspirated and the length of the communication should be extended to 3 to 5 cm. Mechanical debridement of necrotic material is then performed. The wall of the cavity should be sent for frozen section in order to rule out a cystic neoplasm, but this would be fairly unlikely in a patient with a history of pancreatitis resulting in WOPN. The communication is then marsupialized with interrupted sutures and the anterior gastrotomy can be closed with a stapling device. Gastrojejunostomy feeding tube placement can be considered for patients with malnutrition.

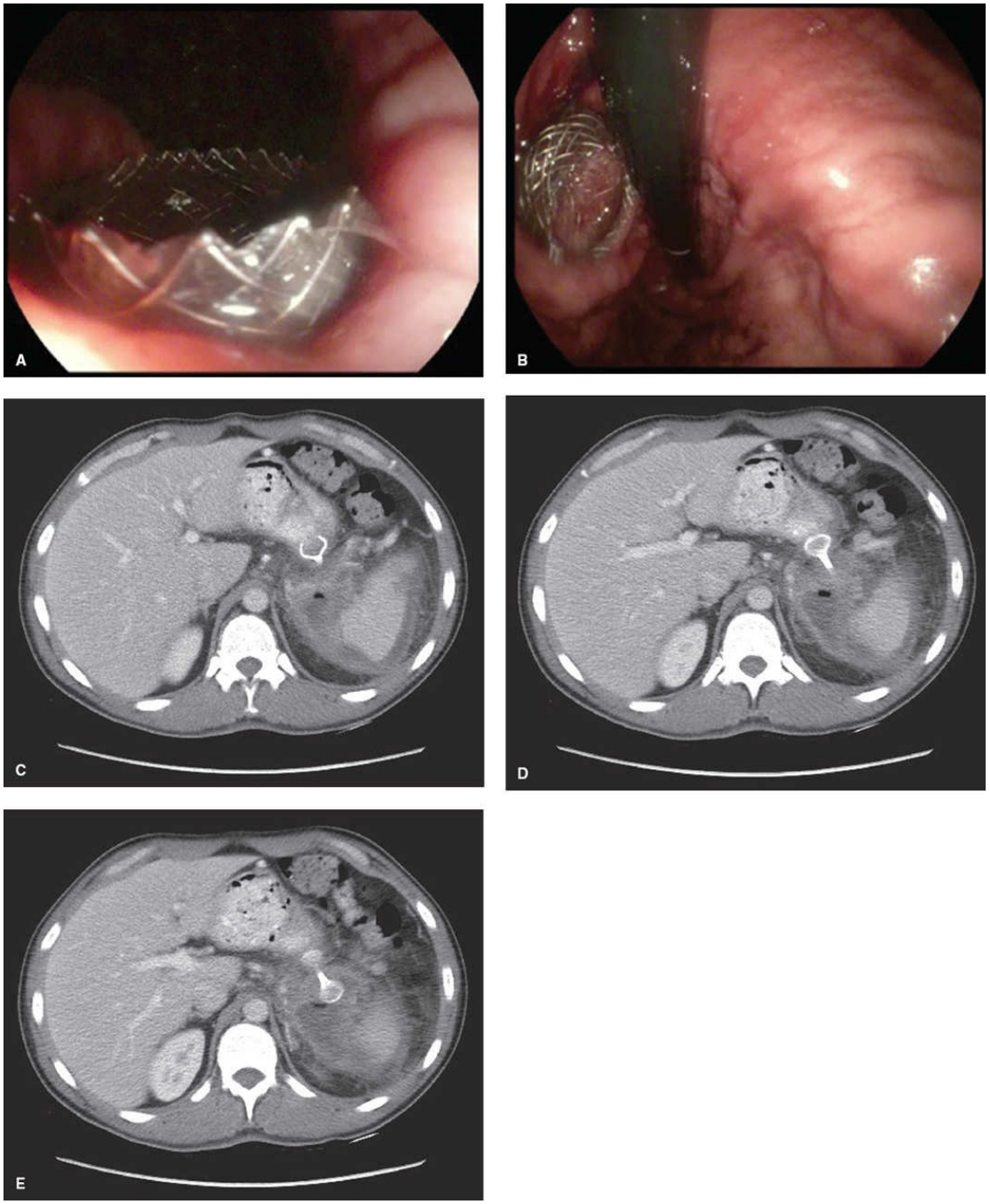

Figure 125.5. Transgastric endoscopic drainage of pancreatic necrosis. Endoscopic images (**A** and **B**) and computed tomography (CT) images (**C** to **E**).

Infected Pancreatic Necrosis

Pancreatic necrosis is complicated by infection in approximately 30% of patients. It is unusual for IPN to develop in the early phase of SAP, although this can happen rarely. It is generally agreed that intervention for drainage and mechanical debridement is required for patients who develop

IPN. Until recently, open necrosectomy has been the treatment of choice, but the procedure is associated with numerous disadvantages. These include stress of surgery in patients who are already extremely ill and often malnourished, and the risk of complications such as bleeding, abdominal wall defects, and small bowel fistulas. There have been considerable advances in minimally invasive techniques and their outcomes over the last two decades and these findings have resulted in significant changes in the management of IPN.

The diagnosis of IPN should be considered in any patient with SAP with necrosis who develops signs of infection, or clinical deterioration, after the acute inflammatory phase has resolved. It is important to rule out iatrogenic infections such as pneumonia, urinary tract infection, Clostridium difficile colitis, and catheter-associated bloodstream infections as these are common in this group of patients. Classically described indicators of IPN include the presence of air on imaging (emphysematous pancreatitis), positive fine-needle aspiration (FNA) culture of infected pancreatic fluid (Fig. 125.6), or unexplained clinical deterioration after resolution of the initial inflammatory phase. The presence of air within the necrotic cavity on imaging is thought to be the result of gas-producing organisms in patients with IPN, but fistulous communication to the GI tract is increasingly recognized as a cause for air. Nevertheless, gastrointestinal contamination of sterile necrosis will result in infection and should prompt intervention in appropriate clinical circumstances. Although emphysematous pancreatitis is certainly an indication for intervention in patients with IPN, it is a rare finding and the absence of air does not rule out the possibility of infection. FNA culture of pancreatic fluid was considered to be the gold-standard test for the diagnosis of IPN in the past, although many modern pancreatologists will proceed with intervention in patients with suspected IPN since the initial step is usually percutaneous catheter drainage. That being said, aspiration of sterile appearing fluid by the interventional radiologist should prompt reconsideration of catheter placement since management of sterile fluid collections is generally conservative and catheter placement can result in infection in these cases. False-negative FNA cultures can occur and do not rule out the possibility of infection. Unexplained clinical deterioration of patients with necrotizing pancreatitis after initial resolution of the inflammatory phase should be considered to be an indication for intervention. As stated previously, this would be extremely rare before 7

days following initial presentation and usually does not occur until at least 14 days. Unless patients are clinically unstable, it is usually wise to defer treatment until 3 to 4 weeks after presentation as this has been shown to result in improved outcomes. Although it was thought that undrained IPN was associated with 100% mortality in the past, there are selected patients who may be treated with antibiotics and supportive management alone. Criteria for conservative management include clinical stability with no signs of sepsis. Patients with IPN can be generally classified into two groups: (1) those with sepsis and organ failure and (2) those with failure to progress. Sepsis, organ failure, and critical illness related to IPN usually present earlier and their management is more difficult. Initial catheter drainage may reduce abdominal pressures and provide source control sufficiently to allow for deferred definitive minimally invasive or endoscopic drainage. Patients who do not respond to catheter drainage and who are not candidates for minimally invasive or endoscopic therapy due to critical illness may benefit from traditional open necrosectomy. The development of IPN with failure to progress can happen weeks to months after the initial presentation and is associated with a much lower mortality. These patients can also be treated with minimally invasive strategies and tolerate multiple procedures much better.

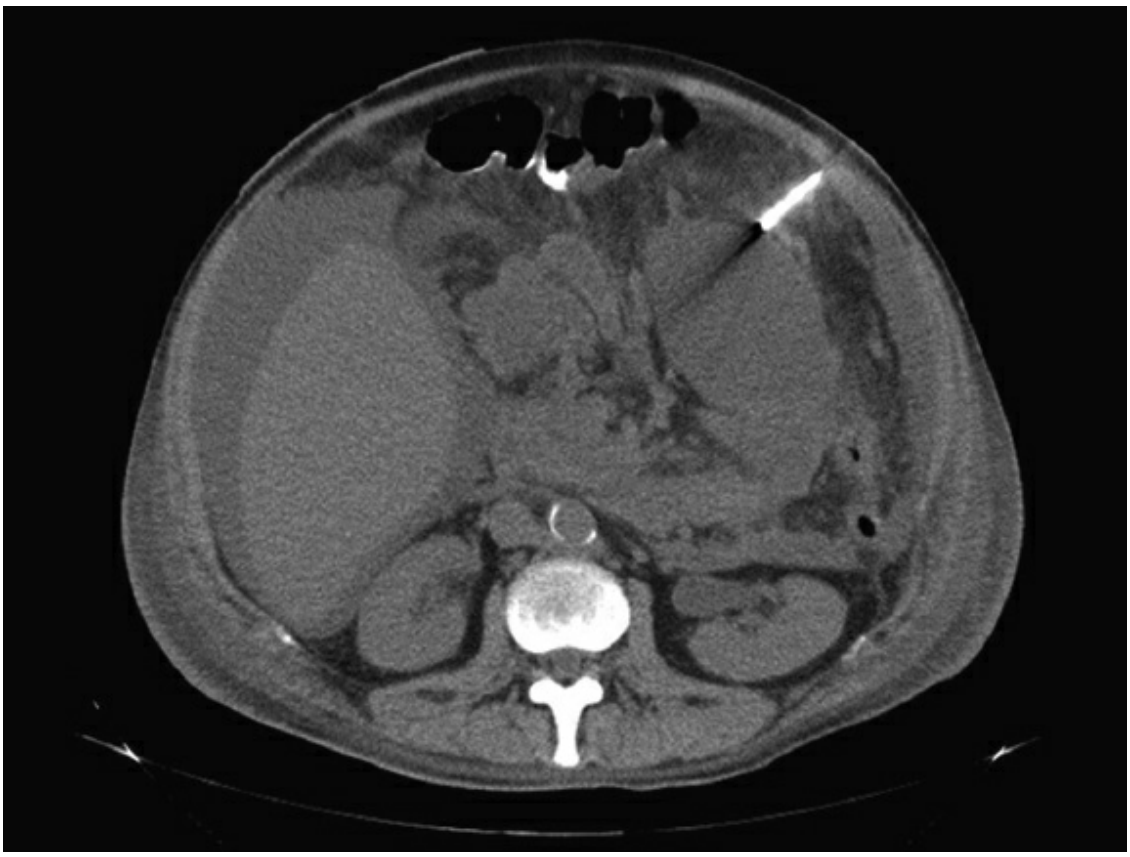

Figure 125.6. CT-guided fine-needle aspiration (FNA) culture in a patient with suspected infected pancreatic necrosis.

There are currently a variety of techniques available for the management of IPN and there has been a trend toward minimally invasive management, including percutaneous, endoscopic and minimally invasive surgical techniques. Furthermore, there is good evidence that minimally invasive techniques can be useful for controlling sepsis temporarily in unstable patients who are poor candidates for surgery, even if they eventually require more invasive procedures for complete debridement. Decision-making for therapy should be made on an individual basis with input from members of the multidisciplinary team including surgery, therapeutic endoscopy, interventional radiology, and critical care.

PERCUTANEOUS CT-GUIDED CATHETER DRAINAGE AND THE "STEP-UP" APPROACH

As treatments for IPN evolve, the role of percutaneous catheter drainage continues to change. The main advantage is that this is the least invasive technique with a relatively low risk for complications. There are numerous disadvantages. The procedures must be performed in interventional radiology under image-guidance and require skilled interventional radiologists who are willing to attempt these procedures. There must be a suitable window for accessing collections, but this can generally be performed through the left flank safely. Risks include bleeding, introduction of infection into sterile collections, and injury to adjacent structures such as the colon or spleen. If the catheter is passed through the pleura, this can lead to effusions or empyema. Since there is a considerable amount of particulate debris and necrotic material, this technique frequently requires multiple catheter exchanges, upsizing, and placement of additional catheters consuming considerable time and resources. Nevertheless, this technique has been become more popular recently after the publication of studies demonstrating improved outcomes.

A recently published randomized, multicenter trial comparing open necrosectomy to a "step-up" approach suggests that this strategy should be considered for most patients with IPN. Patients with IPN were randomly assigned to open necrosectomy or a "step-up" approach, including percutaneous catheter drainage followed by minimally invasive retroperitoneal necrosectomy through the drain tract if necessary.

Percutaneous catheter drainage alone was successful in 35% of patients assigned to the “step-up” group, although 60% of patients eventually required necrosectomy and two patients died before they were able to undergo any further procedures. The median time interval between catheter drainage and necrosectomy was 10 days. There was a decreased incidence in new-onset multiple-organ failure in the “step-up” group (12% vs. 40%), but there were no differences in mortality (19% vs. 12%). Other benefits associated with the “step-up” approach included decreased risk of incisional hernia and endocrine insufficiency. Other studies have demonstrated that surgery can be avoided in almost 50% of patients and that sepsis can be suitably managed in most patients with percutaneous catheter drainage.

ENDOSCOPIC TRANSLUMINAL DRAINAGE AND NECROSECTOMY

Open and minimally invasive necrosectomy are frequently associated with complications and there have been considerable technical advances in endoscopic therapies for the management of pancreatic necrosis in recent years. These techniques may involve transluminal endoscopic drainage procedures or direct endoscopic necrosectomy (DEN) (Fig. 125.7). These procedures require skilled advanced therapeutic endoscopists and may not be suitable for critically ill or unstable patients. DEN has been shown to be superior to endoscopic drainage alone for the management of WOPN. The DEN procedure is performed under general anesthesia with the use of carbon dioxide insufflation. After initial endoscopic evaluation, the area of necrosis is identified with standard linear echoendoscopy (EUS). An endoscopic needle catheter is used to puncture the area of necrosis and fluid is aspirated and sent for culture and Gram stain. Water-soluble contrast is injected into the area off necrosis and this is visualized fluoroscopically. A guidewire is then advanced into the cavity and the needle is withdrawn. The tract between the stomach and the cavity is then serially dilated with endoscopic balloons. Endoscopic debridement through the tract can then be performed with a therapeutic endoscope using snares, nets, and forceps. Once adequate debridement has been performed, the necrosis cavity is vigorously irrigated and endoscopic stents are placed in order to provide ongoing drainage. The procedure is usually tolerated well, but can be time consuming.

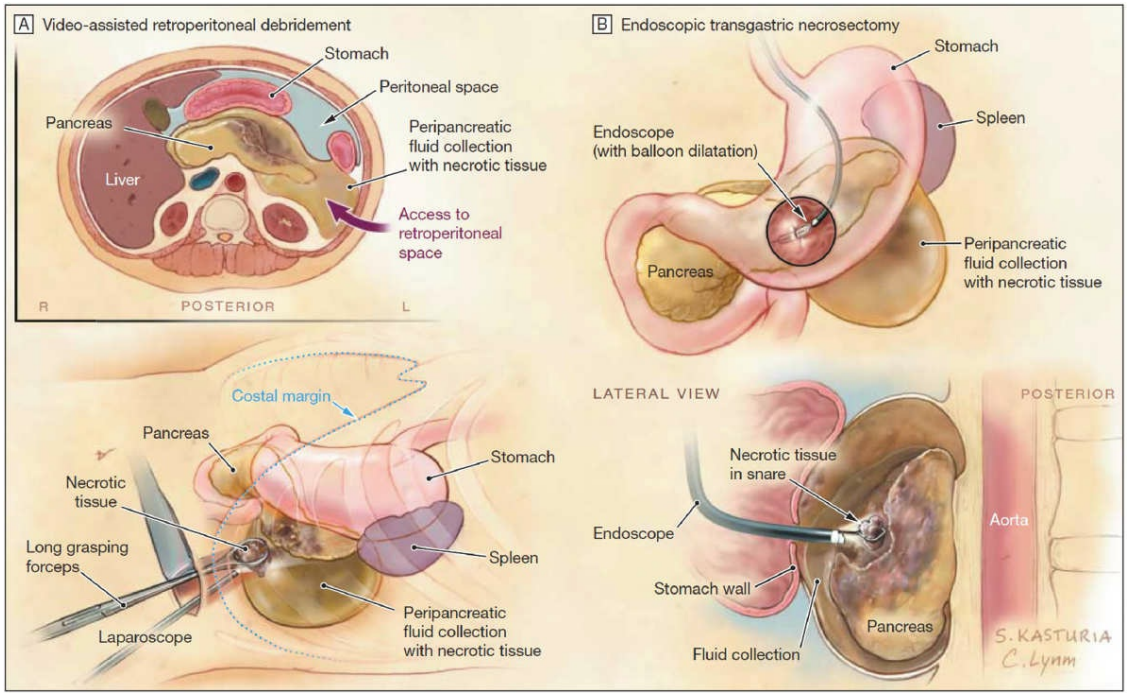

Figure 125.7. Comparison of endoscopic transgastric and minimally invasive surgical approaches for pancreatic necrosectomy. Access to the infected cavity is usually by a retroperitoneal approach through the left flank for surgical management, while endoscopic access is generally achieved through the posterior wall of the stomach using endoscopic ultrasound (EUS) guidance as necessary. (Reprinted from Bakker OJ, van Santvoort HC, van Brunschot S, et al. Endoscopic transgastric vs surgical necrosectomy for infected necrotizing pancreatitis: a randomized trial. *JAMA* 2012;307(10):1053–61, with permission from the American Medical Association).

Recent data for the DEN procedure provide encouraging results for the management of IPN. Results from the PENGUIN trial demonstrate that DEN results in reduced overall inflammatory states and lower rates of new-onset multiple-organ failure and complications as compared to open necrosectomy. A recent matched cohort study comparing DEN to the "step-up" approach demonstrated improved efficacy in that 11/12 patients were managed with endoscopy alone while 9/12 patients in the "step-up" group required surgical intervention. DEN was also associated with decreased antibiotic use, pulmonary failure, endocrine insufficiency, shorter length of stay, and decreased health care utilization. It is likely that these techniques will continue to improve and will be utilized for more patients with IPN in the future.

MINIMALLY INVASIVE SURGICAL NECROSECTOMY

Minimally invasive surgical techniques for the management of IPN are well described and have been developed as the field of minimally invasive surgery has expanded and become widely accepted for the treatment of many surgical diseases. Specific advantages for the management of IPN include the potential for effective debridement of particulate matter and disruption of loculations, the use of small incisions, and the avoidance of laparotomy and associated complications such as abdominal wall defects and bowel fistulas. Access can be approached through the anterior abdominal incisions or the flank and retroperitoneum, usually along the tract of a pre-existing percutaneous drain catheter. As described previously, minimally invasive techniques are commonly used as part of a "step-up" strategy for patients who fail percutaneous catheter drainage alone, although they can be utilized for primary therapy as well.

Traditional surgical dogma has dictated that complete debridement of all infected and necrotic material is essential for the treatment of IPN. Experience with minimally invasive techniques suggests that this is not true since many patients improve with catheter drainage alone. It is clear that minimally invasive approaches are associated with decreased systemic inflammatory responses. Although repeated procedures may be necessary, these usually result in minimal physiologic effects on the patient. This indicates that multiple small procedures may be preferable to one large procedure. An additional advantage of most minimally invasive surgical procedures is that direct access to the necrotic cavity prevents contamination of the peritoneal cavity that is associated with open necrosectomy. There are essentially three types of procedures that have been described: (1) anterior laparoscopic necrosectomy; (2) trangastric "endoscopic" necrosectomy; and (3) retroperitoneal necrosectomy with or without video assistance.

Laparoscopic necrosectomy through an anterior approach is similar to traditional open necrosectomy except that access to the abdomen is gained through ports with peritoneal insufflation. A window is created in the gastrocolic ligament in order to enter the infected cavity. Alternatively, collections in the right or left paracolic gutters can be entered laterally after mobilization of the colon on that side. Removal of infected fluid and debris can be performed with a suction irrigator and instruments. Large pieces of debris are collected in an endocatch bag and removed prior to the end of the procedure. Large sump drains are placed in the cavity and can

be used for irrigation following surgery. Although this procedure does offer many of the benefits of minimally invasive surgery, it is technically demanding and visualization can be difficult in critically ill patients who may be swollen and on high levels of ventilatory support. In addition, there is a risk of peritoneal contamination. As such, this procedure is rarely performed.

Transgastric “endoscopic” necrosectomy is essentially a variation of the more commonly performed transoral endoscopic drainage and necrosectomy procedures. For these procedures, access to the lumen of the stomach is gained by placing a percutaneous gastrostomy tube and replacing it with a specifically designed laparoscopic port that allows for transluminal visualization and instrumentation. The necrotic cavity is then identified as a bulge in the posterior gastric wall. This is punctured and a guidewire is inserted under fluoroscopic visualization. The tract can then be fenestrated with monopolar cautery and necrosectomy is performed with 3-mm laparoscopic instruments under direct visualization. Tract patency is maintained by placement of large-bore pigtail catheters. This technique clearly requires advanced endoscopic and minimally invasive surgical skills. Access through a gastrotomy appears to be inferior to standard transoral endoscopic techniques. It is likely that this procedure will be replaced by standard endoscopic approaches as experience and technical advances improve.

As minimally invasive surgical approaches for the management of IPN have evolved, access through retroperitoneal incisions, usually on the left side through a previously placed image-guide percutaneous catheter tract, have become the preferred technique. These procedures can be performed through a single port or multiple adjacent ports, with or without video-assisted guidance. For procedures utilizing direct visualization, assessment and debridement of the necrosectomy cavity can be facilitated with the use of a flexible endoscope, an operating nephroscope, or a rigid rectoscope. Various terms have been used to describe these procedures, the most common being video-assisted retroperitoneal debridement (VARD) and laparoscopic intracavitary pancreatic necrosectomy (Lap-ICPN) (Fig. 125.8). After positioning and draping, access to the necrosectomy cavity is gained by creating an incision along the tract of the catheter and performing dilation. This can be facilitated with the use of flexible guidewires and fluoroscopic visualization. Drainage of fluid and debridement of necrotic debris can be performed under direct visualization

or directly through the ports with intermittent inspection of the cavity with the laparoscope. Care must be taken to avoid injuring pulsatile structures as bleeding can be catastrophic and might require conversion to a standard open procedure. Pulsatile irrigation can be useful for performing gentle debridement around pulsatile structures. Upon completion of debridement, large drain catheters are placed through the tract and sutured to the skin. Red rubber Robinson catheters, 32-French chest tubes, and sump drains can all be used. Drains allow for continued drainage, postoperative irrigation of the necrosectomy cavity and access for additional procedures when necessary.

OPEN NECROSECTOMY

Open necrosectomy was considered to the standard treatment for IPN in the past, but has slowly been replaced by minimally invasive techniques and conservative approaches for reasons previously alluded to. Although some have called for an end to this procedure altogether, it is appropriate for surgeons who care for patients with SAP and IPN to be familiar with and comfortable performing this technique in the rare circumstance that it is required. Acceptable indications for open necrosectomy include: (1) lack of equipment or expertise in performing advanced minimally invasive techniques; (2) complications of pancreatitis mandating an open surgical approach such as intestinal perforation or necrosis; and (3) as salvage therapy for patients who fail or suffer complications of alternative techniques.

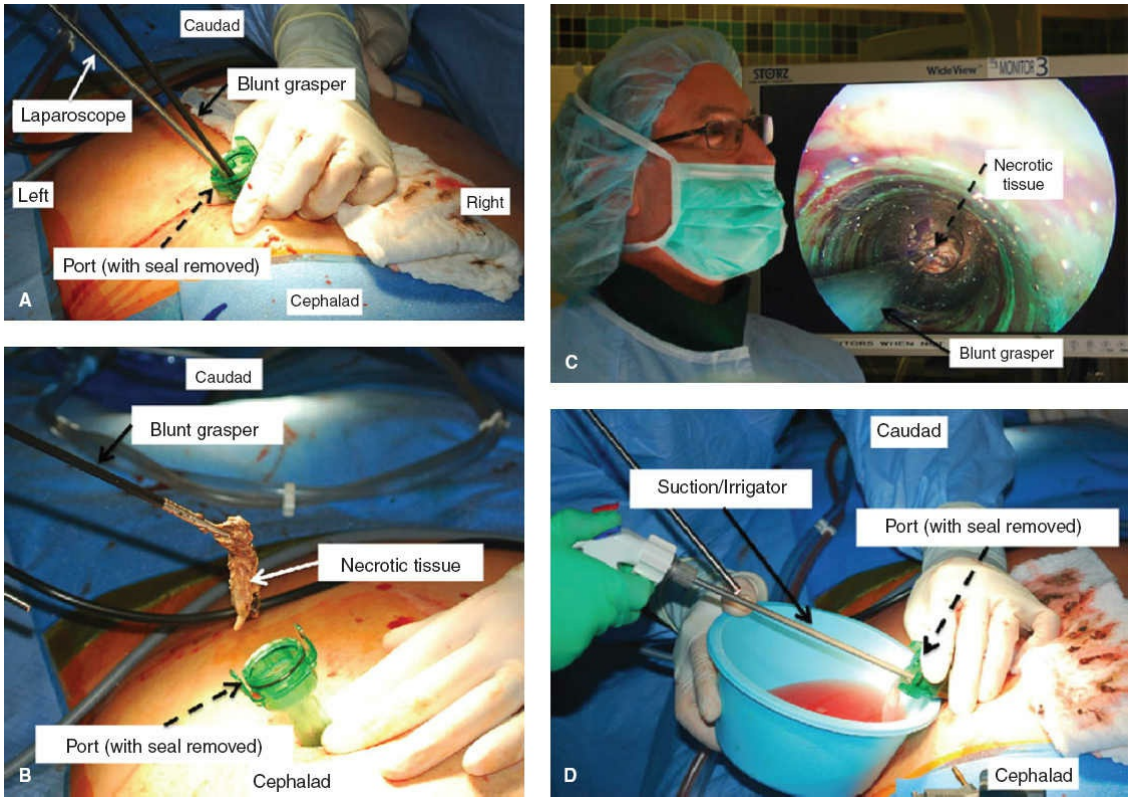

Figure 125.8. Minimally invasive retroperitoneal necrosectomy. Access is generally achieved using ports placed at the site of a percutaneous drain catheter, usually in the left flank (**A**). Debridement of necrotic tissue is performed using instruments placed alongside or through a working port of the instrument used for visualization (**B** and **C**). Irrigation of the cavity can be performed intraoperatively (**D**). (Reprinted from Fink D, Soares R, Matthews JB, et al. History, goals, and technique of laparoscopic pancreatic necrosectomy. *J Gastrointest Surg* 2011;15(7):1092–7. Copyright © 2011, with permission of Springer.)

Open pancreatic necrosectomy is generally performed through a midline incision, although retroperitoneal approaches may be appropriate for selected patients, generally those with failure to thrive and loculated collections close to the flank. The procedure is performed under general anesthesia with appropriate monitoring. Patients are generally already on therapeutic antibiotics. It is important to confirm that tissue levels are adequate by reviewing the dosing schedule, but no additional prophylactic antibiotics are necessary. The abdomen is entered through a midline incision and explored. Ascites may be present and this should be drained and cultured. Fluid can be sent for amylase if there is a concern for pancreatic ascites. The small bowel should be evaluated and may be adherent to the transverse mesocolon. This should be freed up if possible,

but an extensive lysis of adhesions may result in small bowel injury and should be performed at the discretion of the surgeon. The necrotic cavity is generally located posterior to the stomach and is most commonly entered through the gastrocolic ligament using blunt dissection. Care should be taken to avoid injury to the crossing or gastroeploic vessels as there can be considerable bleeding and hemostatic maneuvers such as suture ligation can be challenging and may result in visceral ischemia. Some collections may require drainage through the transverse mesocolon or through a lateral approach after mobilizing the left or right colon as necessary. Limited dissection is recommended and the goal of performing adequate debridement with minimal intervention should be considered when performing these procedures. Murky, purulent, or green fluid can be encountered upon entering the necrosectomy cavity and this should be aspirated and a sample sent for Gram stain and culture. Adequate and thorough debridement of necrotic debris should be performed through the site of access. Although instruments such as ringed forceps and sponge sticks can be utilized, these may result in injury to major vascular structure such as the splenic vessels. In our experience, manual debridement using the surgeon's fingers or hand is best and allows for appropriate debridement while avoiding unnecessary injuries. Upon completion of debridement, the cavity should be irrigated and temporarily packed while other maneuvers are performed if necessary. This will allow the surgeon to assess for hemostasis at a later time. Cholecystectomy should be considered for stable patients, particularly those with gallstones or gallbladder sludge. This can generally be performed safely in almost all cases if the surgeon is patient and utilizes the standard dome-down approach for open cholecystectomy. Intraoperative cholangiography may be performed at this time, but can be challenging. Feeding tube access should also be considered. We favor the use of gastrojejunostomy tubes as these allow for gastric decompression and jejunal feeding. Passing the jejunal limb through the pylorus and duodenum can be challenging, but is usually possible. Alternatively, separate gastrostomy and jejunostomy tubes can be placed, but we feel that there are higher risks for complications associated with jejunostomy tubes such as bowel obstructions and leaks. At this point, the packs should be removed and the necrosectomy cavity evaluated. If hemostasis is an issue, packs can be left in placed with plans for reexploration, usually in 24 to 48 hours. Two large bore sump drains are placed in the cavity and brought out of the abdomen

through separate stab incisions in the right upper quadrant. A drain can also be left in the gallbladder fossa if there is concern for a potential bile leak from an inflamed cystic duct stump. Every effort should be made to close the fascia primarily as an open abdomen is clearly undesirable. These patients will require further procedures for abdominal wall closure or ventral hernia repair and are at risk for complications of the open abdomen including bleeding and small intestinal fistulas. Certainly, most of the disadvantages of open necrosectomy are related to abdominal wall defects and small bowel fistulas. If the fascia cannot be closed, a variety of techniques can be used to manage the open abdomen including negative pressure devices, Velcro patches, or prosthetic mesh. The skin should be left open and packed to heal by secondary intention. Drains should be secured to wall suction postoperatively and the sump ports can be flushed if they become occluded with debris. The sump ports should not be clamped. As the patient begins to recover, the sump drains can slowly be advanced until they are removed, usually many weeks after surgery. We have found it useful to actually cut the drains 3 to 4 cm from the skin 1 to 2 weeks after surgery and place an ostomy appliance over both of them to facilitate ambulation and allow for protection of the surrounding skin. Although pancreatic fistulas are reported to be common after open necrosectomy, we have found that drainage will resolve in almost all patients if this drain management strategy is followed.

CONCLUSIONS

The management of acute pancreatitis continues to evolve as technology and our understanding of the disease improves. Treatment of pancreatic necrosis and IPN remains challenging with considerable associated morbidity, mortality, and health care costs. The initial management of SAP is generally conservative and consists of appropriate severity scoring, imaging, nutritional support, and resuscitation in an intensive care setting. Antibiotics should be reserved for patients with confirmed IPN or iatrogenic infections. It is important to evaluate the patient for the underlying cause and address this if necessary, but some patients may never have an etiology identified. It is rare for IPN to develop less than 7 to 14 days after initial presentation and outcomes are generally improved if interventions can be delayed for as long as possible. There are a variety of treatment strategies available for IPN including percutaneous, endoscopic, minimally invasive, and open surgical techniques. There has been a trend

toward minimally invasive management, commonly utilizing a “step-up” approach employing percutaneous drainage followed by minimally invasive retroperitoneal necrosectomy if necessary. These approaches result in decreased morbidity and resource utilization, but the effects on overall mortality remain unclear. Endoscopic drainage and necrosectomy offer an appealing alternative with many potential advantages. Open necrosectomy should be performed rarely, but continues to play a role for management in selected patients, and surgeons caring for patients with SAP should be familiar with this procedure.

Suggested Readings

Alverdy J, Vargish T, Desai T, et al. Laparoscopic intracavitary debridement of peripancreatic necrosis: preliminary report and description of the technique. *Surgery* 2000;127(1):112–4.

Babu RY, Gupta R, Kang M, et al. Predictors of surgery in patients with severe acute pancreatitis managed by the step-up approach. *Ann Surg* 2013;257(4):737–50.

Bakker OJ, van Santvoort HC, van Brunschot S, et al. Endoscopic transgastric vs surgical necrosectomy for infected necrotizing pancreatitis: a randomized trial. *JAMA* 2012;307(10):1053–61.

Bakker OJ, van Brunschot S, van Santvoort HC, et al. Early versus on-demand nasoenteric tube feeding in acute pancreatitis. *N Engl J Med* 2014;371(21):1983–93.

Banks PA, Bollen TL, Dervenis C, et al. Classification of acute pancreatitis—2012: revision of the Atlanta classification and definitions by international consensus. *Gut* 2013;62(1):102–11.

Bausch D, Wellner U, Kahl S, et al. Minimally invasive operations for acute necrotizing pancreatitis: comparison of minimally invasive retroperitoneal necrosectomy with endoscopic transgastric necrosectomy. *Surgery* 2012;152(3 Suppl 1):S128–34.

Eatock FC, Chong P, Menezes N, et al. A randomized study of early nasogastric versus nasojejunal feeding in severe acute pancreatitis. *Am J Gastroenterol* 2005;100(2):432–9.

Fink D, Soares R, Matthews JB, et al. History, goals, and technique of laparoscopic pancreatic necrosectomy. *J Gastrointest Surg* 2011;15(7):1092–7.

Freeman ML, Werner J, van Santvoort HC, et al. Interventions for necrotizing pancreatitis: summary of a multidisciplinary consensus conference. *Pancreas* 2012;41(8):1176–94.

Horvath KD, Kao LS, Wherry KL, et al. A technique for laparoscopic-assisted percutaneous drainage of infected pancreatic necrosis and pancreatic abscess. *Surg Endosc* 2001;15(10):1221–5.

Isenmann R, Runzi M, Kron M, et al. Prophylactic antibiotic treatment in patients with predicted severe acute pancreatitis: a placebo-controlled, double-blind trial. *Gastroenterology* 2004;126(4):997–1004.

Kellogg TA, Horvath KD. Minimal-access approaches to complications of acute pancreatitis and benign neoplasms of the pancreas. *Surg Endosc* 2003;17(11):1692–704.

Kumar N, Conwell DL, Thompson CC. Direct endoscopic necrosectomy versus step-up approach for walled-off pancreatic necrosis: comparison of clinical outcome and health care utilization. *Pancreas* 2014; 43(8):1334–9.

Nakasaki H, Tajima T, Fujii K, et al. A surgical treatment of infected pancreatic necrosis: retroperitoneal laparotomy. *Dig Surg* 1999;16(6):506–11.

Pamoukian VN, Gagner M. Laparoscopic necrosectomy for acute necrotizing pancreatitis. *J Hepatobiliary Pancreat Surg* 2001;8(3):221–3.

Traverso LW, Kozarek RA. Pancreatic necrosectomy: definitions and technique. *J Gastrointest Surg* 2005;9(3):436–9.

Trivedi CD, Pitchumoni CS. Drug-induced pancreatitis: an update. *J Clin Gastroenterol* 2005;39(8):709–16.

Uhl W, Warshaw A, Imrie C, et al. IAP Guidelines for the Surgical Management of Acute Pancreatitis. *Pancreatology* 2002;2(6):565–73.

van Santvoort HC, Besselink MG, Bakker OJ, et al. A step-up approach or open necrosectomy for necrotizing pancreatitis. *N Engl J Med* 2010;362(16):1491–502.

Villatoro E, Mulla M, Larvin M. Antibiotic therapy for prophylaxis against infection of pancreatic necrosis in acute pancreatitis. *Cochrane Database Syst Rev* 2010(5):CD002941.

Whitcomb DC. Hereditary pancreatitis: a model for understanding the genetic basis of acute and chronic pancreatitis. *Pancreatology* 2001;1(6):565–70.

EDITOR'S COMMENT

Please see Dr. Ellison's commentary after Chapter 126, which addresses both Chapters 125 and 126.

126 Management of Complications of Acute and Chronic Pancreatitis: Endoscopic, Laparoscopic, and Open Approaches to Pancreatic Pseudocysts and Pancreatic Necrosis

Gary C. Vitale, Brian R. Davis, and Michael Bahr

Advancements in endoscopic and laparoscopic technology have greatly reduced the morbidity suffered from complications of acute and chronic pancreatitis. Advanced endoscopic techniques allow safe access to peripancreatic fluid collections (PFCs) and necrosis following severe pancreatitis thus reducing the surgical morbidity. The Dutch Pancreatitis Group's (PENGUIN Study 2012) "step-up" approach demonstrates in randomized controlled trials that combinations of endoscopic and percutaneous therapies have lower endpoints of death or major morbidity when compared with an open surgery group. Aggressive treatment and novel therapies for debridement and drainage of pancreatic necrosis are providing better outcomes through a reduced incidence of multi-system organ failure and pancreatic insufficiency. Early use of minimally invasive therapies can preserve greater function of the pancreas while limiting the complications of this complex inflammatory process. The purpose of this chapter is to assist the surgeon in selecting the proper treatment options to maximize patient outcomes in this morbid complex disease.

PFCs were initially defined by the Atlanta Classification described by Bradley (1993). The revised Atlanta Classification (2012) categorizes collections into four categories based on computed tomography (CT) findings. Acute fluid collections occur within the first 4 weeks following an attack of acute interstitial edematous pancreatitis and may resolve spontaneously. Pancreatic pseudocysts are defined as having a fibrous wall of granulation tissue and result from fluid collections persisting more than 4 weeks after the onset of an episode of acute or chronic pancreatitis.

According to Jacobson (2005), pancreatic necrosis (>25%) is a risk factor for pseudocyst development, and these fluid collections persist and form pseudocysts in 5% to 15% of patients with acute pancreatitis and up to 40% of patients with chronic pancreatitis. Acute necrotic collections occur in the early phase of acute necrotizing pancreatitis before demarcation, and walled-off necroses (WONs) occur 4 weeks after the onset of pancreatitis with an identifiable capsule. The presence of irregular wall definition, fat attenuation, and debris distinguish WON from pseudocysts. Surgical laparotomy has previously been the procedure of choice for pancreatic, necrosis but endoscopic and laparoscopic techniques have become routine whether treating pseudocysts or WON.

CHOICE OF TREATMENT FOR PANCREATIC PSEUDOCYST

Most patients with pancreatic pseudocysts can be managed nonoperatively if presenting symptoms are well controlled. Up to 40% of acute pseudocysts reabsorb after pancreatitis resolves. When pancreatic pseudocysts are large enough to cause symptoms (6 cm or greater) the success of conservative therapy is low (between 3% and 39%) according to Bradley (1979). More recent studies by Vitas and Sarr (1992) have demonstrated that approximately half of acute pancreatic pseudocysts remain asymptomatic regardless of size or duration. Pseudocysts greater than 6 cm in diameter that demonstrate symptomatic complications of abdominal pain, nausea, and early satiety should be considered for therapeutic intervention. Observation for cyst resolution should occur for 6 weeks following the incidence of pancreatitis to allow for cyst maturation.

Mouli et al. (2013) recently published in meta-analysis involving 324 patients finding that primary nonoperative management of infected necrosis without necrosectomy was successful in 64% of cases. Study of interventions in pancreatic necrosis demonstrate improved survival when the immune system encapsulates the necrotic tissue with lowest mortality of 8% with intervention at 30 days compared with 45% in the 15- to 29-day group and 75% in the 1- to 14-day intervention group.

Endoscopic retrograde cholangiopancreatography (ERCP) should be performed for pseudocysts resulting from blunt abdominal trauma since there is a high incidence of pancreatic duct disruption in these cases. Complications from pancreatic pseudocysts include infection, hemorrhage, rupture, obstruction, and malignancy. Most commonly, patients present for

surgical therapy complaining of persistent abdominal pain, gastric outlet obstruction, jaundice, and dyspepsia with weight loss.

Percutaneous drainage can be utilized for the treatment of immature and infected pseudocysts. This technique can be complicated by formation of an external pancreatic fistula, secondary infection of the pseudocyst, as well as a high recurrence rate. Another risk of percutaneous drainage is that drain infections have been reported as high as 50%. Contraindications to percutaneous drainage include intracystic hemorrhage and pancreatic ascites. Heider (1999) reviewed the use of percutaneous catheter drainage in 66 patients, which demonstrated successful drainage in only 43% of patients with a 16% mortality rate and a 64% incidence of complications. Comparison of outcomes between endoscopic and percutaneous drainage demonstrate that patients managed by endoscopic procedures had fever interventions (1.8 vs. 3.3), lower rates of residual collections (21% vs. 67%) and lower needs for surgical intervention (4% vs. 11%).

The most effective treatment of pancreatic pseudocysts involves internal drainage into the enteric lumen whether performed by endoscopic transmural versus transpapillary therapy, laparoscopic pseudocyst enterostomy, or standard laparotomy. Pancreatic resection is also indicated when there is severe pancreatic duct disruption or a suspicion of malignancy. Procedure selection depends on the condition of the patient; the size, number, and location of the pseudocysts; the presence or absence of communication of the pseudocyst with the pancreatic duct; the presence or absence of infection; and any suspicion of malignancy. Endoscopic pseudocyst drainage is applicable in approximately 80% of PFCs located in the central region of the pancreas and is less invasive, less expensive, and carries a lower risk of creating an external pancreatic fistula than laparotomy or laparoscopic techniques.

ENDOSCOPIC DRAINAGE

The endoscopic approach is the procedure of choice for pancreatic pseudocyst drainage, and is becoming more effective in debridement of pancreatic necroses (WON). The index ERCP should demonstrate a complete pancreatogram. Endoscopic transpapillary drainage is effective for pseudocysts that communicate with the pancreatic duct while endoscopic transmural drainage offers the best results in the management of suitably located pancreatic pseudocysts that complicate chronic pancreatitis. Technically, endoscopic management of pancreatic

pseudocysts is most effective when either there is communication with the pancreatic duct for transpapillary drainage or there is a visible indentation of the enteric lumen for a transmural approach.

The use of endoscopic ultrasound (EUS) to assist pseudocyst and WON drainage further enhances the success of these procedures. EUS allows visualization and puncture of the targeted collections independent of a visible bulge into the stomach and color Doppler allows avoidance of vessels in the puncture tract. EUS also allows distances of up to 2 cm to be traversed safely in approach to pseudocysts and WON. More extensive necrotic debris, severe pancreatic duct disruption, or deep retroperitoneal extension of necrosis should lead the surgeon to use adjuvant therapy such as percutaneous drainage or video assisted retroperitoneal debridement.

INDICATIONS

Endoscopic Techniques

Transpapillary Drainage

To obtain transpapillary drainage the ampulla is injected to opacify the biliary and pancreatic ductal systems. Biliary access is obtained by directing the sphincterotome superiorly and anteriorly in the ampulla toward the 11 o'clock direction. Sphincterotomy is first performed on the bile duct and then selectively on the pancreatic duct. Selective pancreatic sphincterotomy is accomplished by directing a guidewire with a hydrophilic tip inferiorly in the 3–4 o'clock position, posterior and to the right of where the biliary orifice is located. If the anatomy demonstrates pseudocyst opacification, an attempt is made to pass a guidewire through the ampulla and pancreatic duct into the cavity. A straight tip hydrophilic guidewire is attempted at first followed by an angled tip wire. A stent with appropriate length and a caliber of 7 French is then passed over the guidewire into the pseudocyst (Fig. 126.1A to C). Decompression of the pancreatic duct including stenting can be helpful when there is direct communication with the pseudocyst. The transpapillary approach reduces the risk of hemorrhage and retrogastric perforation.

The stent remains in the pancreatic duct until the pseudocyst resolves or significantly decreases in size. Stent removal, reevaluation, and replacement should occur in 6 to 8 weeks. If the tail of the pancreas is not opacified at initial ERCP, it is likely that the distal duct is obstructed and may be feeding the pseudocyst. In these cases, concomitant transmural drainage may be necessary to adequately drain the tail if the cyst is

enlarging. A magnetic resonance cholangiopancreatogram (MRCP) should be done in these cases to determine pancreatic tail duct anatomy to direct future therapeutic options.

Transmural Drainage

Upon examination of the gastric or duodenal lumen, those patients with pseudocyst indentation of the enteric lumen are candidates for transmural drainage by direct cyst-gastrostomy or duodenostomy. Previous University of Louisville techniques included access to the pseudocyst with a needle knife followed by wire exchange and stent insertion. The most current techniques in endoscopic transmural drainage have introduced the use of the Cremer cystotome, first described in 1990, which combines a removable electrocautery needle knife with a circumferential 10-French electrocautery ring to allow for cyst puncture, guidewire passage, and cyst-gastrostomy enlargement using a single catheter. The cystotome facilitates difficult cyst access since no catheter exchange is necessary and the guidewire can be passed directly through the cutting device. This cystotome allows for rapid advancement of a guidewire into the cyst cavity when the visual field is obscured by fluid. Guidewire placement into the cyst cavity before catheter removal facilitates rapid stent deployment. Other advantages include the ability to perform cystography, and the small cauterized cyst-enterostomy prevents hemorrhagic complications. This is currently the preferred technique at the University of Louisville.

The pseudocyst is then drained with one to two 10-French stents, side by side (Fig. 126.2A to G). Double stenting is more effective than a single stent because the pseudocyst can drain alongside the stents as well as through them. Single stents can be encased by gastric mucosa and induce infection when their lumen becomes occluded. Since these stents remain in place long term, drainage alongside the stent may be more important than drainage through the stent, thus supporting the use of double stenting. The University of Louisville experience routinely dictates leaving stents in place for approximately 1 year. Stents are removed after 1 year unless the tail of pancreas depends on stenting for duct drainage as determined by ERCP or MRCP. If MRCP identifies a disconnected duct in the tail of the pancreas, transenteric stents can be left in place indefinitely to facilitate drainage.

Plastic stent–related adverse events can be as high as 18% in regard to premature occlusion as a result of the small diameter of the working channel leading to inadequate PFC drainage. Nasocystic irrigation

(Siddiqui et al., 2013) assists in pancreatic necrosis debridement and maintains stent patency in collections with evidence of infection or extensive debris. Larger caliber diameter stents enable more effective resolution of PFCs and WON. Gardner et al. (2012) reported a goal of initial cyst-enterostomy of 15 to 20 mm with placement of multiple plastic stents or a single fully covered self-expanding metallic stent (FCSEMS). Gardner found that larger cyst-enterostomy size has been correlated with clinical success of pancreatic necrosectomy. Recent trials of FCSEMS for pancreatic pseudocyst and WON have demonstrated a success rate of 78% to 100%. Complications of stent deployment include risk of migration, abutment against the luminal wall causing bleeding and injury and lack of apposition of the cyst-enterostomy leading to risk of fluid leak and perforation.

Issues with metallic stenting lead to the development of the novel “saddle-shaped” fully covered AXIOS TM lumen opposing metallic stent LAMS (Xlumena, Mountain View, CA). The AXIOS LAMS has proximal and distal flanges that ensure luminal apposition between the enteral and cyst wall. Initial visualization for LAMS deployment has been performed using EUS followed by initial puncture with a 19-gauge needle and a 0.035-in guidewire. The tract was then dilated with a 6- to 8-mm wire guided balloon or an 8- to 10-French Soehendra dilator followed by LAMS deployment over a catheter. Siddiqui et al. (2016) in a multicenter retrospective review demonstrates successful deployment of the AXIOS stent with PFC resolution in 100% of pseudocysts and 88.2% of WON. Patients who failed endoscopic drainage had occlusion of the LAMS with debris and were sent for surgical necrosectomy. A benefit of LAMS up to 15 mm in size was that it allowed direct endoscopic debridement of WON by passage of the endoscope through the stent lumen (Fig. 126.3). Romanelli et al. (2011) describe a peroral endoscopic stapler (SurgAssist™ SLC 55 Power Medical Interventions, Langhorne, PA) with creation of cyst-enteric anastomoses between 5.5 and 8 cm to further facilitate pancreatic necrosectomy (Fig. 126.4).

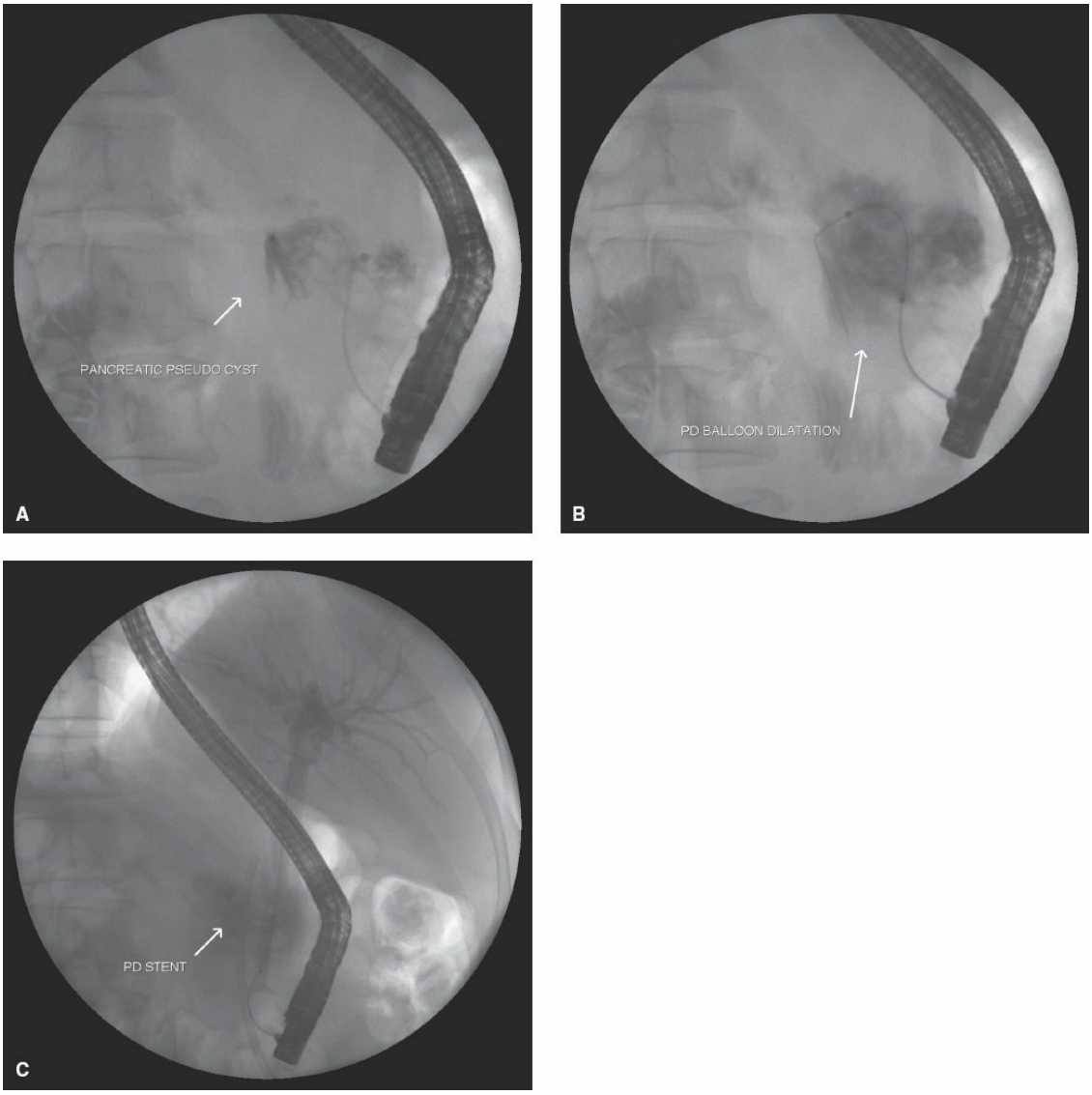

Figure 126.1. Techniques of transpapillary drainage of the pancreatic pseudocyst (**A**) ERCP demonstrating injection of pancreatic pseudocyst with catheter in pseudocyst, (**B**) ERCP of transpapillary approach to pancreatic pseudocyst with pancreatic duct balloon dilatation, (**C**) pancreatic pseudocyst drainage with transpapillary approach, pancreatic stent in place.

EUS-Guided Transmural Pseudocyst Drainage

An innovation that has allowed for more effective drainage of pancreatic pseudocysts and prevention of hemorrhagic complications is the use of EUS. EUS is especially attractive in patients who have a small window of entry into the pseudocyst determined by CT, in patients in whom there is no enteric indentation, when the patient has a coagulopathy or thrombocytopenia, or where there are varices between the enteric lumen and pseudocyst. Studies have demonstrated that EUS has a superior safety

profile when compared with esophagogastroduodenoscopy EGD-directed transmural drainage. EUS enables identification of collateral vasculature, providing a safe window for transmural drainage. A prospective randomized trial performed by Varadarajulu (2008) demonstrated significantly greater technical success for EUS-guided drainage (100%) than for EGD-directed transmural drainage (33%), adjusting for luminal compression by the pseudocyst. Park (2009) addressed the issue of luminal compression and technical success rates in a prospective randomized trial. This trial demonstrated a success rate of 94% for EUS-guided drainage compared with 72% for EGD-guided drainage (Fig. 126.5).

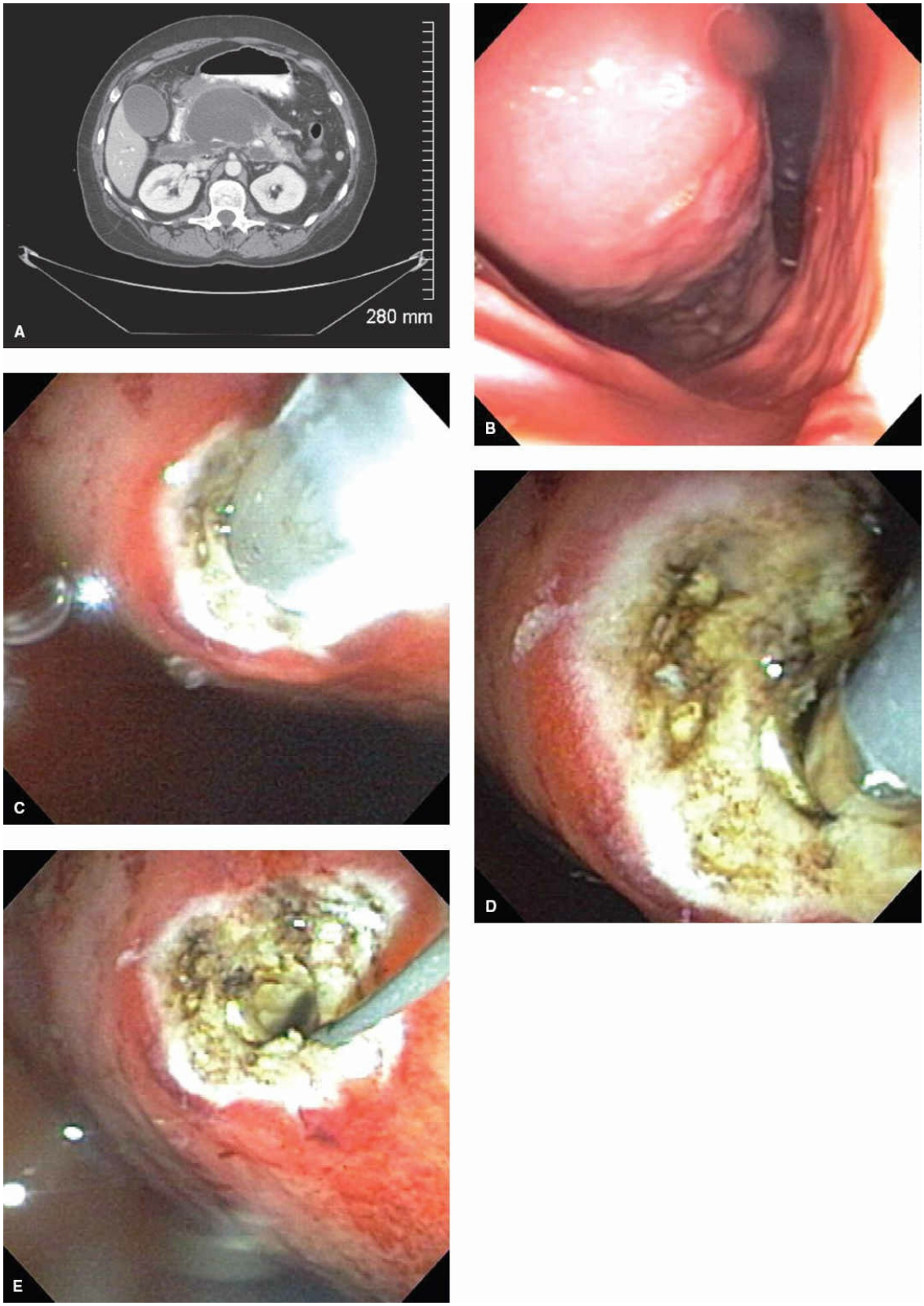
A
280 mm
B
C
D
E

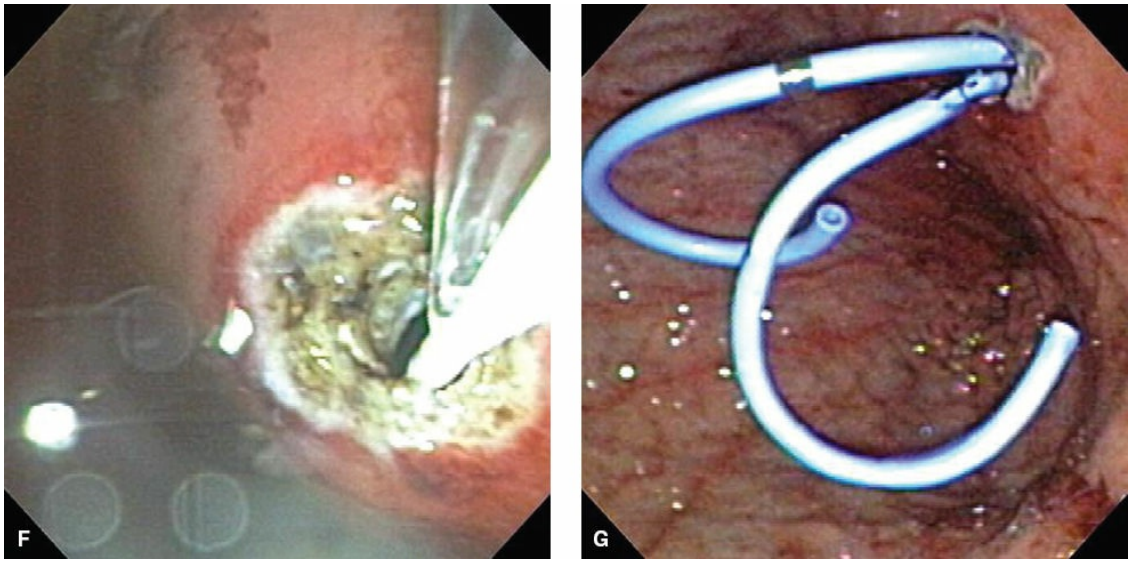

Figure 126.2. Techniques of transmural drainage of pancreatic pseudocyst (**A**) CT demonstrating pseudocyst in retrogastric position, (**B**) endoscopic view of bulging pseudocyst in stomach, (**C**) initial use of cautery to enter into the pseudocyst, (**D**) further cautery using circumferential cautery ring of cystotome, (**E**) guidewire placed through cyst-gastrostomy, (**F**) balloon dilatation of cyst-gastrostomy using wire-guided technique, (**G**) gastric view of pseudocyst stents entering into the pseudocyst.

Endoscopic Drainage of Abscesses and Walled-Off Necrosis

Infection and abscess formation in a pancreatic fluid collection has previously been associated with failure of endoscopic therapy. Pancreatic abscesses can be found in 2% to 5% of patients admitted to the hospital for pancreatitis with an incidence as high as 25% in severe pancreatitis. Surgical laparotomy has been associated with a mortality rate from 10% to 59% and a morbidity rate as high as 60% to 93%. Percutaneous drainage of these collections carries a rate of pancreatic fistula formation as high as 39%. The Louisville experience (35 patients) reported by Vitale (2009) demonstrated an 80% success rate in draining pancreatic abscesses (15-month follow-up) utilizing both transmural and transpapillary drainage techniques. Similar studies by Binmoeller (1993) and Venu (2000) demonstrated success rates of 74% to 80% on long-term follow-up for abscess drainage. The Louisville experience demonstrated independent predictors for successful outcome including location of the cyst in the pancreatic head, insertion of multiple stents into the pseudocyst cavity, and drainage of the pseudocyst cavity for longer than 6 weeks. Moderate abscess debris was the primary independent predictor for failure of

endoscopic drainage in this study.

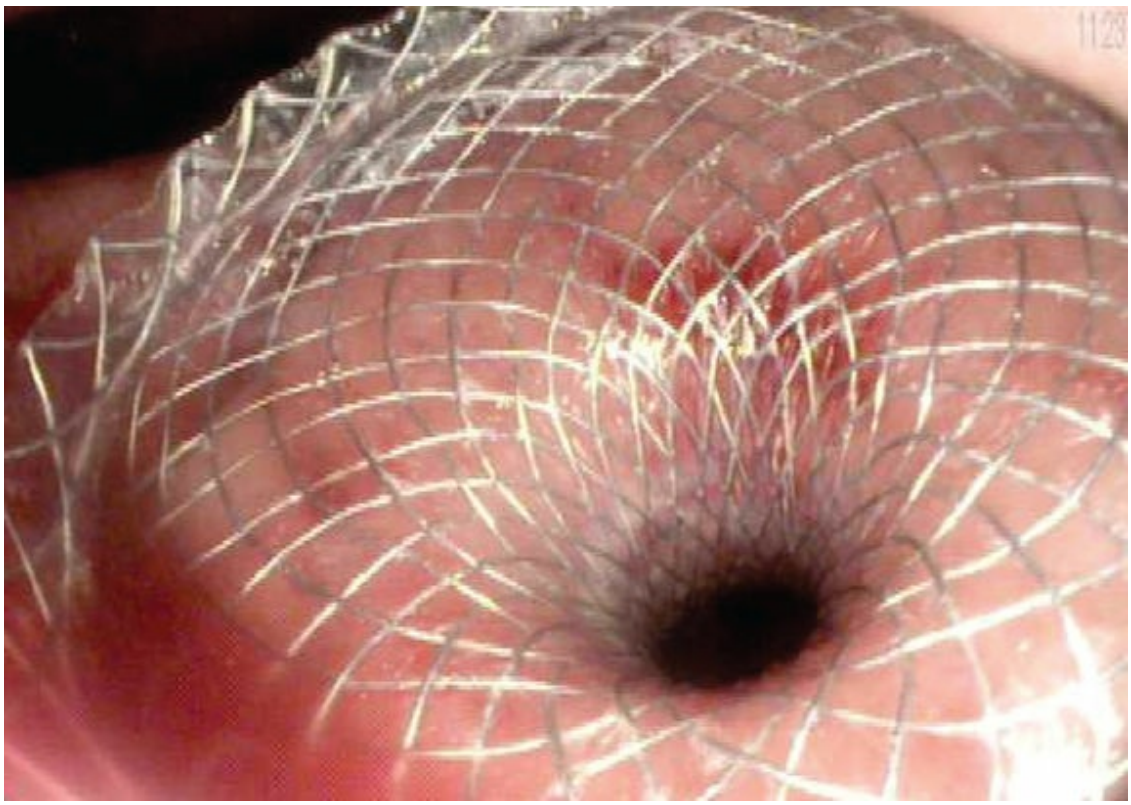

Figure 126.3. Axios lumen opposing metallic stent (LAMS) (XLumena, Mountainview, CA).

Direct Endoscopic Necrosectomy

The presence of extensive necrosis within a pancreatic fluid collection has been defined by the Revised Atlanta Classification (2012) as WON. Baron et al. (2002) compared resolution of pancreatic fluid collections in a series of 138 patients, demonstrating a 92% rate for chronic pseudocysts compared with 74% in acute pseudocysts and 72% in the setting of pancreatic necrosis. Gardener (2009) demonstrated successful resolution of WON in 88% of patients who underwent direct endoscopic necrosectomy compared with resolution in 45% of patients who received standard transmural drainage. Direct endoscopic necrosectomy begins with transmural access to a pancreatic fluid collection with fistula tract dilation between 8 and 20 mm. Necrotic pancreatic tissue identified within the cavity is then removed using a combination of several devices including 10-French irrigation probes, 15-mm stone retrieval balloons, Roth retrieval baskets, stone retrieval baskets, tripod retrieval forceps, rat-toothed and pelican forceps. The goal of necrosectomy is to uncover pink granulation tissue lining the wall of the collection. Stenting is then used to maintain the

patency of the transmural access site to allow further drainage of fluid and necrotic debris. Voermans (2007) described serial transmural pancreatic debridement under direct vision including nasocystic catheter irrigation with a long-term (16-month) success rate of 93%. Gardner et al. (2011) described the largest series to date (104 patients) with direct endoscopic necrosectomy with successful resolution of WON in 91% with a median of 3 debridements.



Figure 126.4. SurgAssist Stapler for power medical interventions.

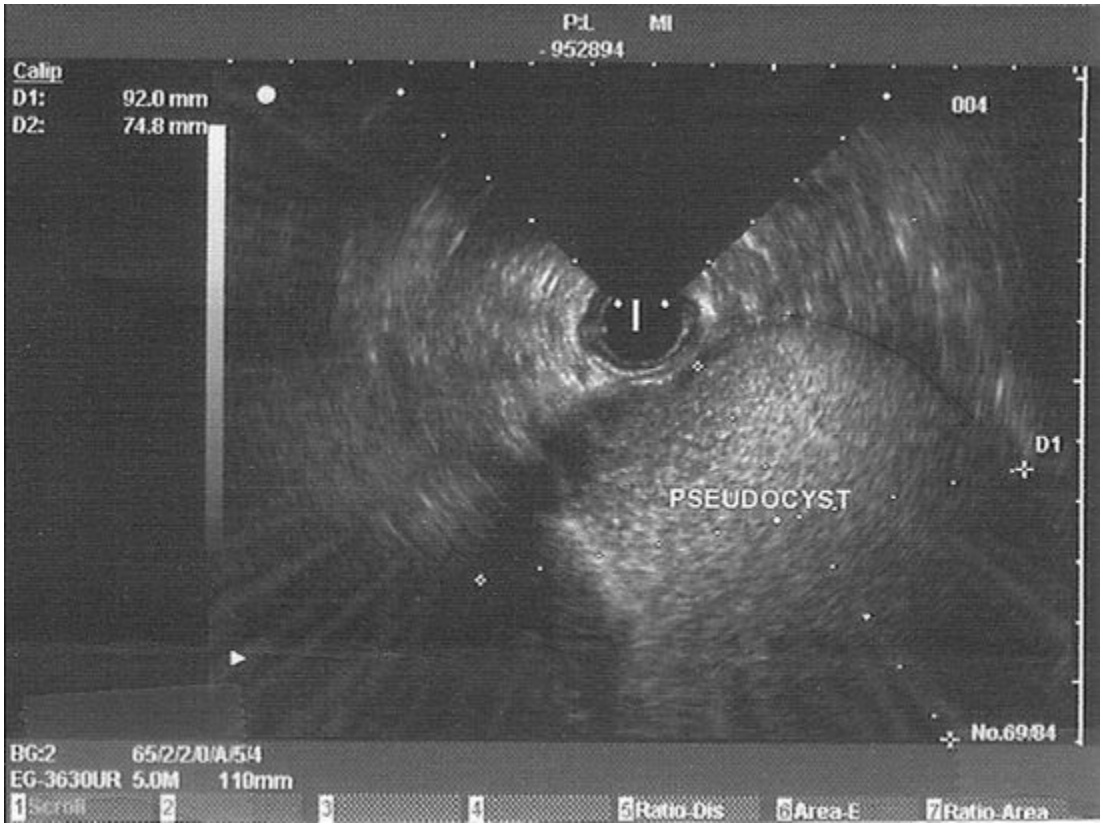

Figure 126.5. Picture of EUS gastroscope and ultrasound pictures of pseudocyst.

Further innovations in direct endoscopic necrosectomy have challenged the limitations to clearance of necrotic debris. Hydrogen peroxide irrigation during endoscopic necrosectomy has been demonstrated to reduce the number of interventions to a median of 1.4 by Abdelhafez et al. (2013). Spraying of a 0.1% to 0.2% solution under direct vision over tightly necrotic debris followed by irrigation with saline helped loosen necrotic material that was removed with suction or Roth net. Additional innovations include deployment of an endoscopic vacuum-assisted closure device into the pancreatic cavity that allowed for demarcation and debridement of necrotic tissue. Varadarajula et al. (2012) described a multi-gateway approach for WON >8 cm where two transmural fistulas are created to facilitate rapid drainage with one channel serving as irrigation and the other as an exit conduit for necrotic debris.

Step-Up Approach: Endoscopic Versus Minimally Invasive Necrosectomy

Complications and choice of therapeutic options in necrotizing pancreatitis carry a significant long-term cost to the critically ill patient. The Dutch Pancreatitis Group published results from a randomized controlled trial of

a “Step-up Approach” (2010) that compared minimally invasive to open necrosectomy. The minimally invasive approach was composed of percutaneous or endoscopic drainage (35%) followed by retroperitoneal video-assisted necrosectomy (65%). The minimally invasive approach demonstrated significant decreased incidence of multiorgan failure, incisional hernia, and new-onset diabetes. The PENGUIN trial (2012) reported randomized comparison of endoscopic and minimally invasive retroperitoneal necrosectomy with similar findings and a reduced incidence of pancreatic fistulas of 10% versus 70%. The critical difference was that minimally invasive necrosectomy was used to treat patients earlier (average 34 days) in the course of the disease who suffered from sepsis versus (average 54 days) endoscopic necrosectomy.

Video-Assisted Retroperitoneal Debridement (VARD)

Video-assisted retroperitoneal pancreatic debridement is an integral part of the “step-up approach” when percutaneous drainage (PCD) does not provide adequate drainage to adequately resolve complications of infected pancreatic necrosis. Percutaneous drainage followed by VARD is best utilized for extrapancreatic collections (perinephric space and paracolic gutters) that cannot be accessed by transenteric techniques. The rationale behind percutaneous drainage is to drain infected fluid under pressure to temporize sepsis thus allowing further encapsulation or absorption of the necrotic pancreatic collection. The PANTER trial (2010) demonstrates that 35% of patients can be successfully treated by endoscopic drainage alone. This same trial introduced the “step-up approach” demonstrating that PCD and VARD significantly reduce end-points of morbidity and multisystem organ failure when compared with laparotomy.

Gambiez (1998) was the first to report a large series (20 patients) treated with retroperitoneal video-assisted drainage. His technique utilized a 23-cm mediastinoscope inserted through a 6-cm incision centered on the 12th rib. The spleen and the colon were mobilized anteriorly without entering the peritoneum and necrotic pancreatic tissue was debrided by blunt dissection. The overall mortality from this study was 10% with a short- and long-term complication rate of 30% and a technical success rate of 85%. Horvath et al. (2001) were first described VARD utilizing laparoscopic visualization along PCD tracts in a series of six patients. The laparoscopic technique starts with a 5-cm incision between the left lower costal margin and the iliac crest in continuity with a percutaneous drain tract that is utilized to gain access to the retroperitoneum. Two 12-mm

ports are placed side by side within the drain tract with subsequent insufflation and visualization of pancreatic debridement with a 10-mm laparoscope and blunt laparoscopic instruments. Two large bore drains are placed through the incision for large-volume saline lavage and drainage of the cavity. In this study there was no noted mortality and an overall technical success rate of 66%. The largest series to date of retroperitoneal laparoscopic–assisted access (47 patients) is described by Connor (2005). The technique in this study has been described as sinus tract endoscopy that involves dilation of a percutaneous drain tract with pancreatic debridement through an operating nephroscope. Santvoort et al. (2007) performed a case-matched comparison of the retroperitoneal laparoscopic–assisted approach with laparotomy demonstrating a comparable postoperative complication rate with a significant decrease in mortality with the laparoscopic approach (6% vs. 40%). Horvath et al. (2010) confirmed the benefits of VARD over laparotomy in a multicenter prospective study in the reduction of complications and multisystem organ failure. VARD has been associated with a complication and mortality rate of 35% and 13%, respectively compared to cohorts of open necrosectomy that report complication rates of 34% to 95% and mortality of 11% to 39%. The most common complications associated with VARD are pancreatic fistulae (17%) and bleeding requiring intervention (13%). These minimally invasive interventions have demonstrated significantly decreased mortality when compared with surgical laparotomy for pancreatic necrosis, although the techniques need to be perfected in large series to reduce complications.

Complications and Management

Complications of endoscopic procedures can include perforation, bleeding, and infection. De Palma (2002) reported experience in 49 patients with endoscopic drainage. Complications included stent blockage with pseudocyst infection in three patients, pseudocyst wall perforation in one, and massive hemorrhage requiring surgery in one patient. De Palma also reported a complication rate of 24.5%. Eight patients had pseudocyst infections; five patients had pancreatic necrosis while three had clogged stents. Other complications included two patients with bleeding and two with mild pancreatitis following the procedure. Sharma (2002) studied 38 patients with transmural drainage, demonstrating a 13% complication rate with one hemorrhagic complication, one perforation, and three pancreatic pseudocyst infections.

Complication rates of approximately 30% have been reported for direct endoscopic necrosectomy. Recent systematic review (2011) of 1,100 necrosectomy procedures in 260 patients demonstrated a morbidity rate of 27% and mortality of 5%. Bleeding is the most common complication and may occur during direct debridement of necrotic material. Perforation or disruption of the cavity wall is another severe complication. Gardner et al. (2011) described successful nonoperative management of five patients with perforation. Other complications of necrosectomy include infection of necrotic materials, air embolism, gallbladder perforation, stent migration, fistula, and bowel obstruction. Endoscopic drainage of pancreatic fluid collections and necrosectomy are aggressive interventions in critically ill patients, so endoscopists should have multidisciplinary backup available at their institution in the event of complications.

Recurrent Pancreatic Pseudocyst

Endoscopic pancreatic pseudocyst drainage has a reported recurrence rate from 8% to 20%. Recurrences are most common in patients with alcohol-induced pancreatitis. In the study by Sharma of 38 pseudocyst drainage procedures, after a 44-month follow-up, three patients had symptomatic recurrence and three had asymptomatic recurrences (16%), all initially presenting with alcohol-induced pancreatitis. De Palma (2002), with a follow-up of 26 months, demonstrated a 20.9% recurrence rate. The etiology of recurrent pancreatic pseudocysts usually involves the obstruction of a cyst-enterostomy or stent in the presence of persistent pancreatic disease or ductal stricture. Hookey (2007) reported the largest series to date (116 patients), with an overall clinical success rate with pseudocyst resolution in 87.9%. Collections recurred in 15.5% of cases at a median of 7 months. Necrotic drainage was associated with significantly higher failure rates for endoscopic drainage and a higher incidence of recurrence in this series. Factors that predict failure of endoscopic therapy include necrotic cavity size >15 cm, deep retroperitoneal extension, presence of diabetes mellitus, and comorbid conditions.

Systematic review of multiple series by Aljarabah (2007) demonstrated that recurrence rates following endoscopic pseudocyst drainage of 14.4% were comparable with those reported after open surgery (5% to 20%). These results suggest that pancreatic pseudocysts that complicate acute necrotizing pancreatitis with significant pancreatic necrotic debris would be drained best by the surgical approach. Surgical pseudocyst drainage is also best suited for cysts with a wall thickness of greater than 1 cm and

those located in the tail of the pancreas. A series followed by Lawrence (2008) demonstrated that out of 29 patients with pancreatic pseudocysts and complete duct disruption, 50% had recurrent fluid collections following surgical and endoscopic pseudocyst drainage and required long-term follow-up for symptoms related to this disorder.

Conventional Surgery

In acute pancreatitis, the incidence of subsequent pseudocyst formation is between 5.1% and 16%. It has been estimated in many studies that the spontaneous resolution of these acute cystic collections can vary from 40% to 85%. However, those cystic collections that persist often require intervention with drainage or resection. Despite the innumerable number of ways to approach pancreatic and peripancreatic fluid collections that have been ever evolving over the past decade, open surgical drainage is still an important part of contemporary pancreatic surgical techniques. The "gold-standard" approach to pancreatic cystic drainage is changing in the present era; with many more experts considering open techniques less standard than endoscopic methods. As a matter of fact, for a pancreatic surgeon to encounter a patient whom has not had an endoscopic evaluation of their pancreas and cystic fluid collection prior to referral is certainly the minority. We reserve open surgery for patients with: recurrent pseudocysts, pseudocysts with concomitant duodenal and/or biliary stenosis, symptomatic pseudocysts with associated main duct dilation, and those cysts that have been either nonamenable or refractory to minimally invasive drainage techniques. Moreover, reoperative pancreatic surgery for poorly drained peripancreatic fluid collections especially in the setting of inadequate dependent drainage by prior cyst-gastrostomy is becoming more commonplace as the sizes of pseudocysts drained by endoscopic methods are becoming more aggressive. Conventional surgery does offer an additional advantage of a more definitive pathologic diagnosis via intraoperative wedge resection of the cyst wall to rule out neoplasm as well as affording excellent access for retroperitoneal and cystic contents debridement in the setting of pancreatic necrosis with or without concomitant infection. Open techniques are generally divided into external drainage, internal drainage via cyst-enterostomy, and pancreatic parenchymal resection.

Cystic lesions of the pancreas are becoming increasingly recognized due to advances in imaging techniques. With this increased frequency

comes the need for improvements in diagnostics in order to rule out neoplastic cystic lesions and cystic sarcoma. Neoplastic cysts of the pancreas are easily misdiagnosed as pseudocysts often resulting in inappropriate drainage rather than resection. The differential diagnosis between inflammatory pancreatic pseudocysts and noninflammatory cystic neoplasms can usually be made by examining CT imaging characteristics in conjunction with an adequate patient history. Patients in whom radiographic modalities and history afford little diagnostic accuracy, transcutaneous cyst aspiration and fluid analysis can aid operative decision-making. Though not the focus of this chapter, the differential diagnosis of cystic lesions including: intraductal papillary mucinous neoplasms (IPMNs; either main-duct and/or side-branch), mucinous cystic neoplasms, serous cystadenomas and cystadenocarcinomas, solid pseudopapillary tumors, lymphoepithelial cysts, and other true epithelial cysts are among a few of the types of noninflammatory cystic lesions of the pancreas that can often be seen and further classified by EUS with transcystic fluid analysis by fine-needle aspiration (FNA) and cytologic evaluation.

Surgical management of pancreatic pseudocysts has been successful with a low morbidity and mortality rate. Usatoff (2000) reported on 112 patients consecutively treated for pancreatic pseudocysts resulting from pancreatitis. The overall morbidity rate was 28%, with an operative mortality rate of 1% and a cyst recurrence rate of 3%. Vitas and Sarr (1992) and Yeo et al. (1990) cite similar mortality rates approaching 1%. The choice of surgical procedure depends on a multitude of factors, namely: size, number, and location of the pseudocyst(s); the presence of infection; suspicion of malignancy; communication of the cyst with the main pancreatic duct; and vascular involvement.

Resection versus drainage is usually the first decision to make after operative intervention has been chosen. Pancreatic parenchymal resection is usually reserved for patients with cystic lesions confined to the distal body and/or tail of the gland, those lesions where diagnosis is ambiguous, heterogeneous lesions, and those lesions without well-formed walls amenable to suturing techniques.

We tend to reserve external drainage for those patients in whom operative drainage was required early in the inflammatory process where a well-formed cystic wall had not had the time to form and parenchymal resection would not be possible. The choice of surgical technique for

internal drainage is merely based on cyst geometry and location. Cyst-enteric communication via cyst-gastrostomy or -duodenostomy is considered for fluid collections that closely juxtapose the enteric lumen to reduce the risk of bleeding from the surrounding pancreatic parenchyma. The preferred technique for cysts that are either not indenting the gastroduodenal lumen or are large enough to not allow dependent drainage by cyst-gastrostomy is cyst-jejunostomy, especially if there are more than one cyst requiring drainage or an associated main pancreatic ductal dilation. Another concern is the presence of associated pathologies of duodenal stenosis with symptomatic gastric outlet obstruction, biliary strictures, and pancreatic strictures which usually require Roux-en-Y bypasses at the time of cyst-enterostomy.

Timing of Drainage

The key to successful management of any patient with a history of inflammatory pancreatitis and its subsequent sequelae is whether or not to intervene, and if so when is the correct timing of said intervention. As outlined by the 1992 Atlanta International Symposium, there is certainly a difference between an acute pancreatic fluid collection and an acute pancreatic pseudocyst. The timing of intervention is critical to success as well as reduction of perioperative risk. If intervention is performed too early, often there is need for parenchymal necrosectomy in tissue that has not been well demarcated resulting in hemorrhage, pancreatic fistulae, and poor source control of infection. However, if intervention is delayed the potential for pseudocyst rupture, hemorrhage, and infection are increased. Building on canine models from the 1950s, Edward Bradley and colleagues' clinical experience with the management of pancreatic pseudocysts lead to seminal publications in the 1970s citing the need for 6 weeks since the onset of clinical symptoms and/or 6 cm in size as cutoffs for operative intervention. Once the cyst wall had reached 4 to 6 weeks, the fibrous inflammatory capsule was often thick enough and had enough integrity to allow for suturing techniques without gross leak and/or hemorrhage. Moreover, physiologically the acute inflammatory process of pancreatitis had become more subacute and stable at this time interval without further progression of disease.

Current evidence has been challenging the prior dictums of 6 weeks and 6 cm for intervention, especially in patients with asymptomatic cystic disease. Definite indications for drainage are the presence of symptoms,

persistent progressive enlargement of the cyst, complications such as infection, hemorrhage, rupture, obstruction, and the suspicion of malignancy. Shatney and Lillehe (1981) analyzed 114 patients from the perspective of timing and operative intervention. Their study demonstrated that patients undergoing surgical therapy during the first 6 weeks following pseudocyst formation had higher morbidity, mortality, and recurrence rates than those treated later in the course of disease. Continued observation and radiographic surveillance by ultrasound or CT should be followed in patients with acute PFCs that develop less than 4 to 6 weeks since the onset of clinical symptoms. Observation should continue in those patients whom are asymptomatic, especially if the overall size of the cyst is less than 6 centimeters or the cyst is decreasing in size. Vitas and Sarr (1992) addressed operative versus expectant management in patients with acute pancreatic pseudocysts, and found that nearly 50% of acute cystic collections remained asymptomatic regardless of size and duration. Significant debate still exists regarding the management of asymptomatic cysts that are greater than 6 cm in size, and most clinicians now agree that the decision for intervention in these patients need to be made on a case-by-case basis with special attention given to concomitant biliary and duodenal disease as well as the complexity of medical comorbidities. Therapy is indicated in patients with symptoms and cysts that are increasing in size and greater than 6 cm, those pseudocysts that are increasing in size, those cysts that demonstrate signs of infection, or the suspicion of malignancy. If malignancy is not a concern or if parenchymal resection is not needed or not possible, then the preferred surgical therapy in these patients is internal drainage. The presence of serum isoamylase is a reliable indicator for the safety of internal pseudocyst drainage as it seems to predict a patient population that has developed more of a chronicity to their pancreatitis inflammation. Warshaw and Rattner (1985) observed that in the presence of serum isoamylase, 14 of 14 pseudocysts were suitable for internal drainage whereas those patients possessing an absence of isoamylase, 4 of 5 pseudocysts, required external drainage regardless of the length of the prior observation period.

Elective Versus Urgent Surgery

Approximately 87% of surgical interventions for pancreatic pseudocysts are elective. Urgent surgical intervention involves a higher postoperative morbidity of 67% versus 10%. Hemorrhagic complications of pseudocysts

can occur with erosion into peripancreatic vasculature, resulting in hemorrhage and pseudoaneurysm formation. Dynamic CT angiography is the most useful initial diagnostic tool for evaluation if hemorrhagic sequelae are suspected in this patient population. Selective visceral angiography is the procedure of choice for pseudoaneurysm localization and treatment, and ever-evolving endovascular techniques in these situations with angioembolization and occlusive stenting modalities have avoided open surgical treatment.

Emergent surgical intervention is indicated in patients whom are hemodynamically unstable or those in whom endovascular techniques for pseudoaneurysmal bleeding were unsuccessful. Massive hemorrhage occurs in 5% to 10% of patients with pseudocysts, and inflow and outflow control with proximal and distal ligation of the affected vessel is the method of choice for vascular control. The most common presentation is bleeding directly into the GI tract from surrounding vessels (splenic artery, pancreaticoduodenal arcade, gastroduodenal artery, left gastric artery, hepatic arteries), followed by intraperitoneal/retroperitoneal bleeding and finally hemosuccus pancreaticus from intrapancreatic vascular arcades is possible, though rare. Balthazar (2001) reported that out of 1,910 patients diagnosed as having pancreatitis, 26 developed hemorrhagic complications (1.3%). The cause of hemorrhage was a bleeding pseudoaneurysm in 16 (61%); diffuse bleeding with pancreatic necrosis in 5 (19.5%); and hemorrhagic pseudocysts in 5 (19.5%). In a study by Carr (1996), 16 patients presented with pancreatic pseudoaneurysms. Ten patients initially underwent surgery and six were initially treated with endovascular therapies. The surgical morbidity rate was 62% with three deaths (30% mortality), compared with an endovascular embolization morbidity of 50% and no mortality. The study demonstrated an increased risk of mortality in patients undergoing emergent surgical therapy complicated by necrotizing pancreatitis. The mean size of the pseudoaneurysms that required intervention for secondary complications was 13.9 cm compared with a mean size of 7.7 cm in the endovascular group.

TECHNIQUE

General Considerations

If open internal drainage is the choice of surgical management, the method to establish a cyst-to-enteric system drainage is at the discretion of the surgeon. No method has clearly emerged as being superior in all patients.

Newell et al. analyzed 98 patients, 39 of which underwent cyst-gastrostomy and 59 had cyst-jejunostomy drainages. Their conclusions found that cyst-gastrostomy was faster and had a shorter hospital stay whereas cyst-jejunostomy had a lower rate of GI bleeding but a higher rate of intra-abdominal abscess formation. Most importantly, the two procedures had equivalent rates of morbidity, mortality, and recurrence. Large pseudocysts (>10 cm, or complex geometry) often need more gravity-dependent drainage and it is the preference of these authors to perform cyst-jejunostomy in this patient population due to the many reoperative surgeries we have performed due to inadequate drainage with cyst-gastrostomy and subsequent infection.

Cyst-Gastrostomy

Preoperative assessment of the pseudocyst geometry will dictate such operative decision-making due to size, location, thickness of the inflammatory wall, and proximity to surrounding structures, most especially perigastric vascular anatomy to minimize intraoperative bleeding and/or postoperative hemorrhage or pseudoaneurysm formation. We begin by making a generous midline or subcostal incision and then attempting to gain access to the lesser sac through the gastrocolic ligament. We feel this to be an important step as true postinflammatory collections such as a pseudocyst will be fused to the posterior wall of the stomach and not allow access at this site, whereas noninflammatory collections such as those seen in cystic neoplasms often still have a preserved plane of dissection. Once an appropriate location is chosen for cyst-gastric anastomosis, two stay sutures are placed on the anterior wall of the stomach and it opened with electrocautery directly over the site of proposed posterior stomach-anterior pseudocyst capsule connection. After the anterior gastric wall is opened and gastric contents evacuated, a spinal needle is used to aspirate an aliquot of the cyst contents. A right-angled clamp is placed flush with the gastric luminal mucosa on the needle before it is removed to gauge the depth of penetration needed to access the pseudocyst cavity thereby giving reference to the overall thickness of the wall itself. Sometimes we do send the cyst contents to microbiology to assess for organismal growth and/or to the chemistry laboratory to look for mucin, CEA, and amylase contents. Electrocautery is then used to incise the posterior gastric wall directly over the site of needle localization, and this can be aided by intraoperative ultrasound in cases of cyst location

ambiguity. Once accessed, an elliptical portion of the posterior gastric wall is removed, often ~4–6 cm in size but at least large enough for cystic decompression. A portion of the cyst wall that is removed is sent to pathology for cytologic evaluation to rule out malignancy. The posterior gastric wall is then affixed to the anterior wall of the pseudocyst capsule with 2-0 or 0 absorbable suture in a figure-of-eight, full-thickness fashion in four quadrants to improve exposure. Our preference is to then oppose the posterior gastric wall to the anterior pseudocyst capsule circumferentially with interrupted 2-0 absorbable sutures in a figure-of-eight fashion spaced ~7–10 mm apart. This interrupted method is not only hemostatic but does not run the risk of loosening as the tissue edema subsides in comparison to a running, continuous suture. After the cyst contents have been evacuated and the frozen section of the wall has returned as benign, hemostasis is assured and the anterior gastric wall is closed with either stapling techniques or suturing in two layers. We also do leave a nasogastric tube for decompression down alongside the anastomosis for the first few postoperative days. In addition, we have utilized a mobilized omental pedicle flap over the anterior gastric wall closure as a kind of modified Graham patch in those patients whom potential gastric leak could present to be an issue.

Though covered elsewhere in this chapter regarding laparoscopic techniques for pseudocyst drainage, analogous stapling techniques may be utilized to affix the cyst wall to the posterior wall of the stomach after the anterior gastric wall has been entered as outlined above. Our preference is a thick load (blue or green) GIA 75-mm linear cutting stapler between the posterior gastric wall and the pseudocyst capsule after access has been obtained by electrocautery. It should be noted that we rarely utilize this method as those patients that have been chosen for open surgical techniques often have a very thick inflammatory capsule and obtaining good hemostasis after crushing and stapling techniques is quite difficult. Moreover, as the edema of the inflamed tissue subsides, the staples can become loosened leading to a staple line disruption and subsequent leak.

Cyst-Duodenostomy

As with most periduodenal manipulations, if the native anatomy and lumen can be maintained the postoperative physiology seems to be more normal. We begin this procedure with a wide Kocher maneuver if possible to allow for better exposure through the lateral wall of the duodenum as

well as minimizing any undue tension with the cyst-duodenal anastomosis as well as the closure of the lateral duodenal wall. The point of maximal indentation is chosen and then two stay sutures are placed along the antipancreatic side of the duodenum and the lateral duodenal wall is opened longitudinally with electrocautery. Special attention is given to the location of the ampulla at this time, and if this cannot be located then we either perform a concomitant cholecystectomy with transcystic catheter access and cholangiography in those patients whom have not has a cholecystectomy, or a needle cholangiogram directly into the common bile duct in those patients whom have already undergone cholecystectomy. Once the native ampulla has been identified, the location as well as depth of the pseudocyst cavity is again localized with needle aspiration. If access to the cyst is proximal to the ampulla in the first or proximal second portion of the duodenum we tend to utilize intraoperative ultrasound as well as Doppler to identify both the common bile duct as well as major surrounding vasculature such as the gastroduodenal arterial arcade before access is obtained to the cyst cavity. If the cyst seems to be indenting the duodenal lumen distal to the ampulla, then the posterior duodenal wall is open, a portion of the wall sent for frozen sectioning, and the pseudocyst wall is affixed to the duodenal wall in a manner similar to that performed with the cyst-gastrostomy listed above. It is important to note that the plane of the pancreatic parenchyma should be noted during the placement of each suture as inadvertent impingement of the pancreatic duct and/or the intrapancreatic portion of the bile duct could lead to significant postoperative complications. For this reason, we do often perform completion needle-access cholangiography to ensure unperturbed biliary drainage upon the completion of the cyst-duodenostomy. The lateral duodenostomy is then closed in two layers, usually in a longitudinal fashion without luminal narrowing. A small silastic drain is left posterior to the duodenum along the anterior aspect of the inferior vena cava, keeping in mind to not have this directly opposed to the duodenal closure; omental pedicle flaps are often used here for tissue buttressing as well.

Cyst-Jejunostomy

Cyst-jejunostomy is our preferred choice of drainage if open techniques are needed as it seems to give the best dependent drainage and affords the greatest variability to “tailor make” the connection based on the cyst location and geometry. A direct loop cyst-jejunostomy with or without a

Braun enteroenterostomy, though an accepted technique, is generally not performed. Leakage or dehiscence from the anastomosis with a loop cyst-jejunostomy leads to an uncontrolled pancreaticoenteric fistula and disruption of oral intake, whereas a Roux-en-Y reconstruction can be managed with percutaneous drainage if necessary without interrupting enteral nutrition.

The jejunum is usually divided ~15–30 cm distal to the ligament of Treitz with a 75 mm GIA linear cutting stapler. We tend to choose a position along the proximal jejunum that will reach to the anterior gastric wall in an antecolic fashion and divide the jejunum at this location, thereby ensuring that there is enough length to reach the pseudocyst capsule. If there is foreshortened mesentery or the patient is morbidly obese, the peritoneum along the mesentery can be perforated as to provide additional length. When the pseudocyst is bulging through the transverse mesocolon, a small rent can be made into the transverse mesocolon/pseudocyst capsule at this location and the cyst-jejunal anastomosis can be made in a similar fashion to that described above for cyst-gastrostomy and cyst-duodenostomy. Alternatively, if the lesser sac can be entered through the gastrocolic ligament, then a small rent can be made in the transverse mesocolon and the Roux limb of jejunum can be brought up through this rent an anastomosed to the pseudocyst capsule within the lesser sac. The mesenteric defect is then closed, and the Roux-en-Y is completed with either an end-to-side or side-to-side jejunojejunostomy for drainage of the biliopancreatic limb distal to the site of cyst-jejunal anastomosis.

Although it is unusual, if there are multiple pancreatic pseudocysts that do not seem to communicate to one another they can be drained serially with two or more cyst-jejunal anastomoses. Care must be taken to space these connections appropriately so as not to lead to serosal ischemia. Moreover, the consideration for a longitudinal pancreaticojejunostomy (Puestow) procedure for drainage of pancreatic pseudocysts which communicate to a dilated pancreatic duct is also an acceptable method of ductal decompression as well as cyst drainage.

LAPAROSCOPIC DRAINAGE

Evolution of laparoscopic pancreatic pseudocyst drainage has followed different strategies, but all have relied upon the basic tenets of pancreatic surgery. The first tenet is that the pseudocyst should be drained in a dependent location based on the cysts anatomic location. The second tenet

is biopsy of the cyst wall to rule out a cystic neoplasm. The third tenet is to perform adequate pseudocyst exploration and debridement. The final fourth tenet is to maintain hemostasis whether through the use of a stapler or through an interrupted suture ligation.

Indications for laparoscopic pseudocyst drainage are the same as described previously for endoscopic interventions (Table 126.1). Symptomatic pseudocysts greater than 6 cm in size that have been present for more than 6 weeks are considered for drainage. Pseudocysts associated with an inflammatory mass or a dilated duct with calculi within the head of the pancreas may be best treated by pancreatic head resection (Whipple procedure). Patients with pancreatic ductal strictures and pseudocysts in the tail of the pancreas can be treated with a distal pancreatectomy. Pseudocyst communication with the main pancreatic duct is not a contraindication to laparoscopic drainage, except in patients with multiple pancreatic duct strictures. Consideration for an ERCP-placed stent in the pancreatic duct in combination with laparoscopic drainage may be helpful in preventing recurrence.

The laparoscopic approach is best suited for pseudocysts that demonstrate debris and pancreatic necrosis since laparoscopy provides improved pancreatic drainage and direct visualization for debridement. The argument has been made that larger size of the opening made with laparoscopy is a distinct advantage in cases with significant necrosis and may lead to quicker recovery with a single intervention in comparison to the endoscopic approach. This has not been subjected to comparative trial but does make sense. Some authors have described delayed debridement of infected pancreatic necrosis through a cyst-gastrostomy in patients with a favorable response to systemic antibiotics. This approach should also be considered for patients in whom suspicion of carcinoma requires biopsy and inspection of the pseudocyst wall. Other possible candidates for the laparoscopic approach include patients with portal hypertension or coagulopathy. The laparoscopic treatment of pseudocysts may confer an advantage in those with chronic pancreatitis and ongoing alcohol abuse because this approach minimizes disruption of other intra-abdominal organs with minimal dissection allowing for easier reoperation especially when attempting more extensive pancreatic debridement or a subtotal pancreatectomy. A secondary advantage of the laparoscopic approach is the ability to remove the gallbladder if necessary at a single operation.

Localization of the Pseudocyst

The standard of care for localization of pseudocysts prior to drainage is a CT with thin cuts through the pancreas. Pseudocysts that are asymptomatic or less than 6 cm in diameter can be managed conservatively and those greater than 10 cm in diameter should be managed operatively because of the high incidence of complications. ERCP should also be completed prior to surgery because it may affect treatment options since up to 80% of pseudocysts demonstrate a pancreatic duct stricture or duct disruption. Intraoperative needle aspiration is most commonly used to localize the pseudocyst. Finding the pseudocyst can sometimes be difficult and if it is anticipated to be problematic preoperatively a transgastric catheter can be placed by CT or US guidance into the pseudocyst to mark the potential best spot for transgastric drainage. Laparoscopic ultrasound and EUS have also been utilized for cysts that do not readily indent the enteric lumen.

TABLE 126.1 Indications for Therapeutic Intervention for Pancreatic Pseudocysts

Clinical Presentation and Complications

Local complications
Infection of pancreatic pseudocyst
Hemorrhage into pancreatic pseudocyst
Rupture (can cause pancreatic ascites, shock, and peritonitis)

Involving adjacent organs
Gastrointestinal tract:
Esophagus (secondary achalasia, mechanical dysphagia)
Stomach (clinically relevant gastric outlet stenosis, fistula, intramural gastric mass)
Duodenum (clinically relevant duodenal stenosis, fistula)
Colon (clinically relevant colonic stenosis and/or rectal bleeding)
Liver (stenosis of the common bile duct with jaundice due to compression)
Vascular:
Arterial (erosion of gastroduodenal and/or splenic artery)
Venous (thrombosis of portal and/or splenic vein)
Spleen (splenic rupture)
Genitourinary tract (stricture, fistula, ureter obstruction)
Chest (pancreaticopleural fistula, pleural effusion, mediastinal extension)
Skin (subcutaneous fat necrosis)

Symptomatic pancreatic pseudocyst
Abdominal distension
Nausea and vomiting
Pain
Upper gastrointestinal bleeding

Relative indications for intervention in asymptomatic pancreatic pseudocyst
Pseudocyst >5 cm, unchanged in size and morphology for more than 6 wk (Bradley, 1993)
Pseudocyst >4 cm and extrapancreatic complications in patients with chronic alcoholic pancreatitis (Gouyon et al., 1997)
Cyst wall >5 mm (mature cyst) (Beckingham et al., 1999)
Chronic pancreatitis with advanced pancreatic duct changes (Gouyon et al., 1997)
Suspected cystic pancreatic tumor (requiring surgery) (Levy, 2006 and Ridder, 1996)

With permission from Zerem E, Hauser G, Loga-Zec S, et al. Minimally invasive treatment of pancreatic pseudocysts. *World J Gastroenterol* 2015;21(22):6850–60.

The Intragastric Cyst-Gastrostomy Approach

Way and Gagner (1994) were the first to perform laparoscopic pancreatic pseudocyst drainage using an intragastric approach. Initially, a Veress needle is used to gain insufflation of the abdomen and a periumbilical trocar is placed for visualization of the stomach. Stomach insufflation is then achieved using a nasogastric tube or gastroscope. Pneumoperitoneum is maintained at 8 to 10 mm Hg while the stomach is inflated and transgastric ports are placed through the fascia into the stomach. Multiple techniques have been described for placing these transgastric ports, including specialized trocars with balloons at their tip that can be cinched

up to the gastric wall, radially dilating trocars (Inner-Dyne Inc., Sunnyvale, CA) that are placed into the stomach over a Veress needle to create a seal with the stomach, and standard laparoscopic trocars sutured in place with purse-string sutures. Three trocars are placed through the greater curvature of the stomach, accommodating an intragastric laparoscope and two operating instruments (Fig. 126.6).

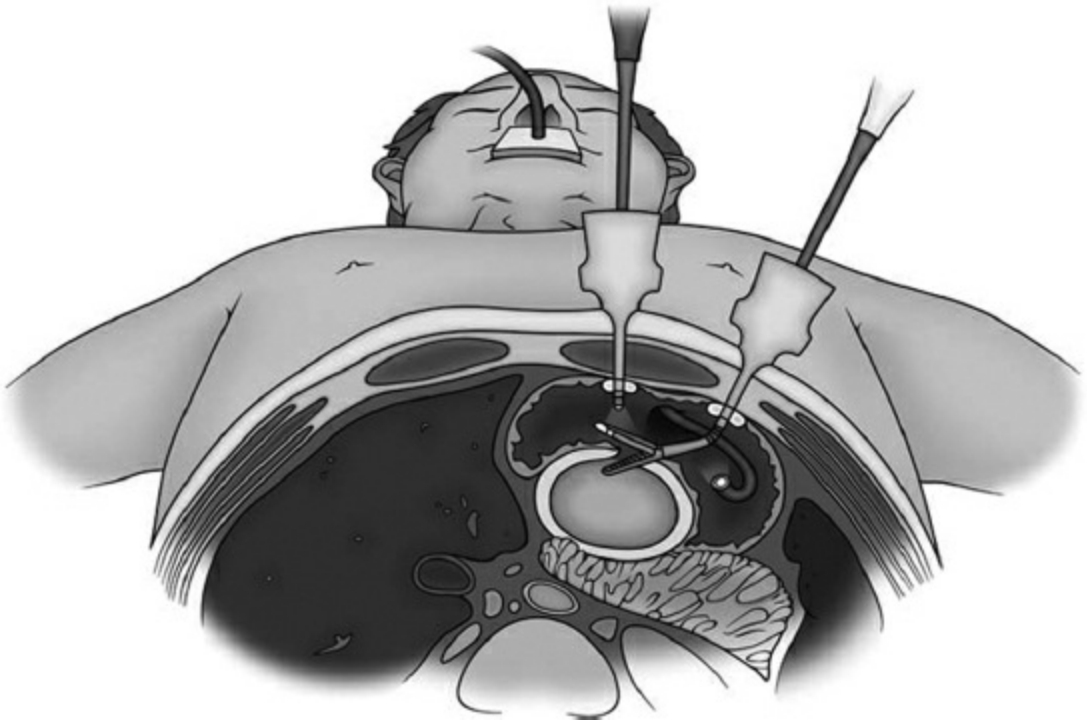

Figure 126.6. Intragastric approach to pancreatic pseudocyst drainage. (From Rosen MJ, Heniford BT. Endoluminal gastric surgery: the modern era of minimally invasive surgery. *Surg Clin North Am* 2005;85(5):989–1007.)

The cyst is localized with either needle aspiration or a laparoscopic ultrasound. The cyst cavity can be entered with either hook electrocautery or harmonic scalpel dissection. A wedge of the cyst wall is sent for frozen section to rule out a cystic neoplasm. A cyst-gastrostomy is then fashioned for a length of 4 to 5 cm using either the harmonic scalpel or a laparoscopic stapler. If the collection of necrotic debris is extensive a larger opening is made. When the harmonic scalpel is used, then the gastrostomy is usually reinforced with interrupted sutures to prevent bleeding complications. After the cyst-gastrostomy is complete, the trocars are withdrawn and the gastrostomies are closed using figure-of-eight sutures. Park and Heniford (2002) describe a variation of this technique

where the stomach is insufflated and intragastric ports are placed directly through the skin into the stomach without creating a pneumoperitoneum. This technique utilizes a stapler to complete the cyst-gastrostomy. This technique obviates the need for pneumoperitoneum and gastrostomy closure utilizing mini laparoscopy instruments that are 2 mm in diameter. The main limitation of the intragastric approach is that it can be technically difficult secondary to a limited operative space and bleeding from the friable cyst-gastrostomy.

The Anterior Transgastric Cyst-Gastrostomy Approach

The technical challenges of the intragastric approach led to the development of the anterior transgastric approach in which a 5- to 6-cm gastrotomy is performed (Fig. 126.7). An anterior gastrotomy allows improved access to the posterior wall of the stomach. A laparoscopic stapler is placed through the gastrotomy to create a cyst-gastrostomy that is hemostatic. Gibson et al. (2014) demonstrate good results using a new port dilating system. The “Step Port” dilating system (Covidien PLC) facilitates access and the first stapler application. The port is inserted through the abdominal wall, through the posterior wall of the stomach after anterior large gastrotomy and then dilated. After it is expanded there is a 12-mm access to the cyst cavity with radial pressure maintained by the dilating sleeve. After cyst aspiration the port is removed with a suction cannula being left in place to maintain access as the stapler is placed. The anterior gastrotomy is then closed with interrupted sutures or a stapler. The primary disadvantage to this procedure is the creation of two gastrotomies with an increased risk of spillage of gastric contents. This would seem to be a minimal risk and the exposure of the posterior gastric wall for more traditional laparoscopic dissection may outweigh any small increased risk of infection or leakage.

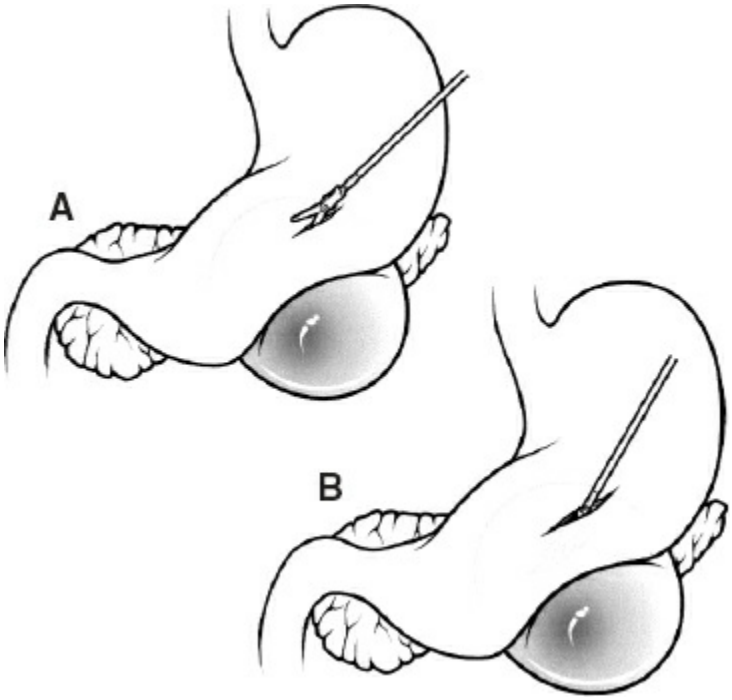

Figure 126.7. Cystostomy performed through anterior gastrostomy.

The Lesser Sac Approach

Park and Heniford (2002) describe a technique that addresses the risk of gastric spillage by approaching the pseudocyst through the lesser sac and creating a single gastrotomy for effective dependent pseudocyst drainage. The surgery is started with the patient in lithotomy position, and pneumoperitoneum is created with a Veress needle. A periumbilical port as well as a left upper quadrant port and a subxiphoid port are placed. The gastrocolic omentum can be divided using an ultrasonic dissector, diathermy, or stapler. The posterior wall of the stomach is then divided from the pancreatic pseudocyst. Needle aspiration is used to localize the pseudocyst, and a cystotomy is made with cautery proceeding to a cyst wall biopsy. The stomach is simultaneously explored using a gastroscope to determine the optimal position for a posterior gastrotomy. A gastrotomy is then made juxtaposed to the pancreatic cyst, and a laparoscopic stapler is introduced to fashion a large cyst-gastrostomy. Laparoscopic instruments can be inserted into the cyst to break loculations and debride necrotic pancreas. The opening in the cyst-gastrostomy is then closed using interrupted sutures (Fig. 126.8). Following completion of the cyst-gastrostomy the gastroscope insufflates the stomach under direct laparoscopic visualization to ensure an airtight anastomosis.

The Cyst-Jejunostomy Approach

This approach was developed to obtain the most dependent and anatomic drainage for pseudocysts that are not easily accessible through the stomach. The operation is begun with the patient in the lithotomy position and two trocars are placed lateral and superior to the umbilicus on the left. A third trocar is placed in the upper abdomen just lateral to the right rectus muscle. A fourth left lateral, upper abdominal trocar is also placed for the laparoscopic stapler. Pseudocyst localization through the transverse mesocolon is determined by visual inspection, aspiration decompression, or laparoscopic ultrasound. The preferred site of pseudocyst access is just superior and lateral to the ligament of Treitz. Cyst-jejunostomy can be created either with a loop of jejunum or with a Roux-en-Y reconstruction. Roux-en-Y reconstruction is preferred because it lessens the risk of pseudocyst infection and the potential leakage of intestinal contents. For Roux-en-Y reconstruction, the jejunum is transected approximately 30 cm distal to the ligament of Treitz and the pseudocyst is opened through the transverse mesocolon. Laparoscopic instruments can be used to disrupt loculations and debride pancreatic necrosis. An enterostomy is then performed in the jejunum and a lateral cyst wall-to-jejunal anastomosis is performed with a laparoscopic stapler. The cyst-jejunostomy is then closed with a running permanent suture layer. The jejunojejunostomy is created 50 to 60 cm distal to the cyst-jejunostomy to prevent reflux of enteric contents into the cyst cavity.

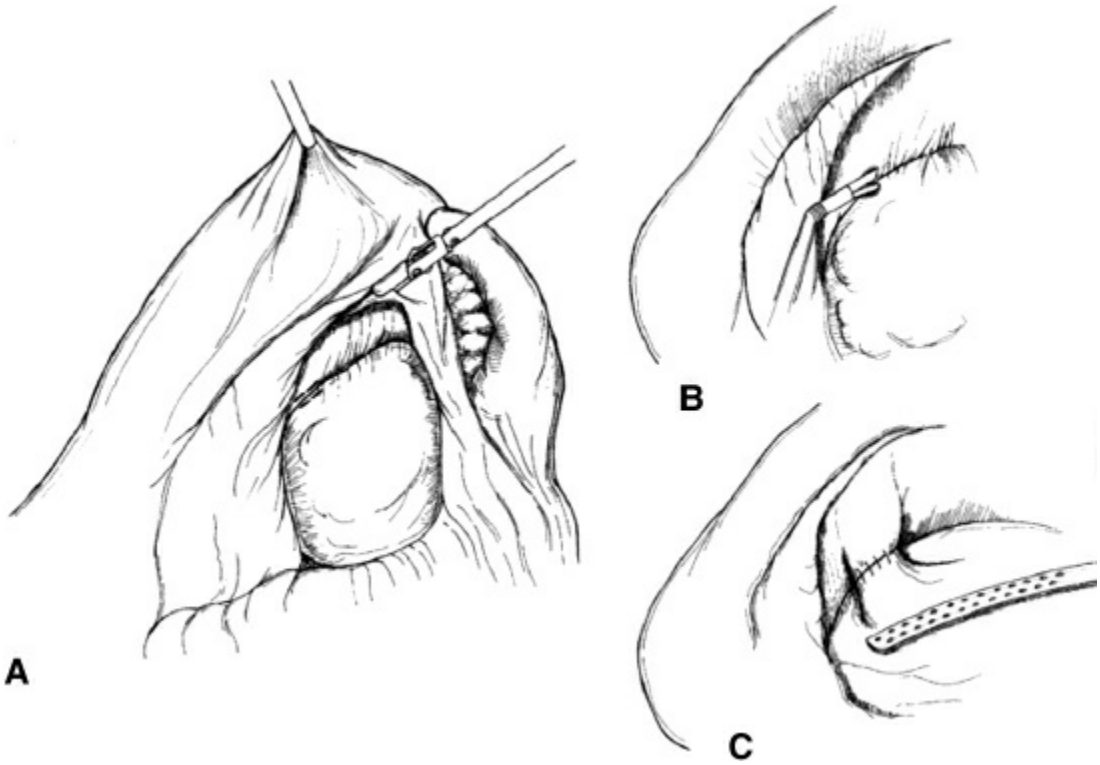

Figure 126.8. The lesser sac approach to pancreatic pseudocyst drainage.

Results of Laparoscopic Pancreatic Pseudocyst Drainage

Way, who first described intragastric laparoscopic pseudocyst drainage (1994), later (2000) reported a series of 18 patients, with successful completion of the procedure in 14 of these patients. Four patients had to be converted to an open approach due to bleeding at the cyst-gastrostomy. All patients in this series were noted to have resolution of the pseudocyst on long-term follow-up. Trias (1995) described modification of the intragastric technique using a stapler for creation of the anastomosis, which reduced bleeding complications. The intragastric approach proved technically demanding and led to the development of the anterior transgastric approach first described by Obermeyer (2003) in a series of five patients with a mean length of hospital stay of 7.5 days with no complications or recurrences. Khaled et al. (2014) demonstrated shorter operating time, shorter hospital stay, and smoother recovery with the laparoscopic approach compared to open in a matched cohort study. In that study operating time was 62 versus 95 minutes favoring the approach, hospital stay was shorter 6.2 versus 11 days for laparoscopic and morbidity less 10% versus 60% in the laparoscopic group. The single death in this study of 54 patients occurred in the open group.

Hauters (2004) compared the outcomes of the intragastric and anterior transgastric technique in six patients. This study found comparable results between the two techniques, with no differences in the length of hospital stay or pseudocyst recurrence. Teixeira (2003) reported a series of nine patients who received laparoscopic cyst-jejunostomy. This study demonstrated a minor complication rate of 20% with no major complications or mortality, with total resolution of the pseudocysts and no recurrences. The largest single series in the literature (28 patients), described by Park and Heniford (2002), uses all four described approaches to pseudocyst drainage and detailed a mean postoperative length of stay from 3 to 4 days, depending on the procedure performed. The most common complication noted was bleeding from the cyst-enteric anastomosis, which was managed with blood transfusions and did not require operative intervention. Long-term follow-up demonstrated cyst resolution with two recurrences. One patient developed necrotizing pancreatitis requiring serial debridements and another required conversion to external pseudocyst drainage with a sump drain. Aljarabah (2007) reviewed the outcomes of laparoscopic pseudocyst drainage in 118 patients, sampled from multiple different series in the literature, revealing a mean length of hospital stay of 5.7 days with resolution of pseudocyst in 98.3% of patients.

TABLE 126.2 Ten Steps of Laparoscopic Transgastric Endoluminal Cystogastrostomy and Pancreatic Debridement

1. Intra-abdominal access and placement of four ports
2. Transgastric laparoscopic ultrasound of the pseudocyst
3. Insufflation of the stomach via gastroscope
4. Creation of three small gastrotomies and transgastric placement of balloon trocars
5. Endoluminal ultrasonic confirmation of pseudocyst cavity
6. Creation of a posterior gastrostomy
7. Cystgastrostomy anastomosis performed with linear stapler and suture reinforcement
8. Debridement of pseudocyst
9. Placement of nasogastric tube into pseudocyst cavity
10. Closure of gastrostomy sites

With permission from Simo KA, Niemeyer DJ, Swan RZ, et al. Laparoscopic transgastric endoluminal cystogastrostomy and pancreatic debridement. *Surg Endosc* 2014;28:1465–72. Copyright © 2014 Springer, with permission from Springer.

Laparoscopic Pancreatic Necrosis Debridement

Laparoscopic approaches for pancreatic pseudocyst drainage can also be utilized to debride infected pancreatic necrosis. Initial description of the feasibility of these techniques was by Gagner (1996) who operated on eight patients using transgastric, retrogastric retrocolic, and retroperitoneoscopic approaches to debridement. These techniques resulted in no mortalities and in a 25% reintervention rate for complications. Cuschieri (1998) described a laparoscopic infracolic approach in three patients, opening the lesser sac through the root of the transverse mesocolon to debride the pancreas with pulse irrigation and graspers. The largest series to date from Parekh (2006) evaluates laparoscopic-assisted pancreatic necrosectomy in 19 patients. This technique utilized a hand port for digital dissection and two 12-mm trocars to perform necrosectomy using an infracolic approach. This series demonstrated an 11% mortality and 26% morbidity rate, with 74% of patients experiencing therapeutic successful after initial debridement using this approach. The emphasis on reducing surgical morbidity has led to the development of retroperitoneal laparoscopy-assisted access approaches utilized to debride necrotic pancreas. Worhunsky et al. (2015) report on laparoscopic transgastric debridement with success using a single procedure in 19 of 21 patients with a mean hospital stay of 5 days. Gerin et al. (2015) describe a laparoscopic-assisted open cyst-gastrostomy and pancreatic necrosis debridement technique with good results. Simo et al. (2014) report on 22 patients treated with a laparoscopic transgastric endoluminal cyst-gastrostomy of which 15 were completed laparoscopically. Median time between cyst presentation and surgery was 86 days and average length of stay was 14.9 days. Mean operative time was 220 minutes with 8 complications, with one procedure related bleeding requiring operative intervention. Table 126.2 itemizes steps in this procedure. Although critics of minimally invasive necrosectomy argue that minimally invasive approaches are and Simo et al. (2014) higher risk due to limited and inadequate exposure for hemorrhage control, Cirocchi et al. (2013) demonstrate the opposite. Meta-analysis of 336 patients, 215 of who underwent minimally invasive necrosectomy, demonstrated that postoperative multisystem organ failure occurred in the minimally invasive group in 21% versus 49% in the open group ($P < 0.0001$). Incisional hernia was more common in the open group not unexpectedly. There was a higher incidence of diabetes and postop pancreatic enzyme requirement in the open necrosectomy group. No difference was found for mortality,

intra-abdominal bleeding or fistula development. Another benefit of this approach is shown in a study by Kulkarni (2015) which demonstrates pancreatic fistula formation rate of zero with transgastric technique for debridement of pancreatic necrosis.

Overall it would appear that minimally invasive approaches to pancreatic pseudocyst and necrosis in selected cases can be performed safely and with an efficacy equaling or exceeding open operative results.

Suggested Readings

Aljarabah M, Ammori BJ. Laparoscopic and endoscopic approaches for drainage of pancreatic pseudocysts: a systematic review of published series. *Surg Endosc* 2007;21:1936–44.

Baron TH, Harewood GC, Morgan DE, et al. Outcome differences after endoscopic drainage of pancreatic necrosis, acute pancreatic pseudocysts and chronic pancreatic pseudocysts. *Gastrointest Endosc* 2002;56:7–17.

Beckingham, IJ, Krige JE, Bornman PC, et al. Long term outcome of endoscopic drainage of pancreatic pseudocysts. *Am J Gastroenterol* 1999;94:71–4.

Bradley EL 3rd. A clinically-based classification system for acute pancreatitis. Summary of the International Symposium on Acute Pancreatitis, Atlanta GA, September 11–13, 1992. *Arch Surg* 1993;128:586–90.

Cirocchi R, Trastulli S, Desiderio J, et al. Minimally invasive necrosectomy versus conventional surgery in the treatment of infected pancreatic necrosis: A systematic review and a meta-analysis of comparative studies. *Surg Laparosc Endosc Percutan Tech* 2013;23(1):8–20.

Cremer M, Deviere J, Baize M, et al. New device for endoscopic cystoenterostomy. *Endoscopy* 1990;22:76–7.

DePalma GD, Labboro G, Puzziello A, et al. Endoscopic drainage of pancreatic pseudocysts: a long-term follow-up study of 49 patients. *Hepatogastroenterology* 2002;49:1113–5.

Gardner TB, Chahal P, Papacristou GI, et al. A comparison of direct endoscopic necrosectomy with transmural endoscopic drainage for the treatment of walled-off pancreatic necrosis. *Gastrointest Endosc* 2009;69:1085–94.

Gerin O, Prevot F, Dhahri A, et al. Laparoscopy-assisted open cystogastrostomy and pancreatic debridement for necrotizing pancreatitis (with video). *Surg Endosc* 2016;30:1235–41.

Gibson SC, Robertson BF, Dickson EJ, et al. “Step-port” laparoscopic cystgastrostomy for the management of organized solid predominant post-acute fluid collections after severe acute pancreatitis. *HPB* 2014;16:170–6.

Gouyon B, Levy P, Ruszniewski, P, Zins M, et al. Predictive factors in the outcome of pseudocysts complicating alcoholic chronic pancreatitis. *Gut* 1997;41:821–5.

Heider R, Meyer AA, Galanko JA, et al. Percutaneous drainage of pancreatic pseudocysts is associated with a higher failure rate than surgical treatment in unselected patients. *Ann Surg* 1999;229:781–9.

Hookey LC, Debroux S, Delhaye M, et al. Endoscopic drainage of pancreatic-fluid collections in 16 patients: a comparison of etiologies, drainage techniques and outcomes. *Gastrointest Endosc* 2006;63:635–43.

Horvath KD, Kao LS, Wherry KL, et al. A technique for laparoscopic assisted percutaneous drainage of infected pancreatic necrosis and pancreatic abscess. *Surg Endosc* 2001;15:1221–5.

Karakayali FY. Surgical and interventional management of complications caused by acute pancreatitis. *World J Gastroenterol* 2014;20(37):13412–23.

Khaled YS, Malde DJ, Packer J, et al. Laparoscopic versus open cystgastrostomy for pancreatic pseudocysts: a case-matched comparative study. *J Hepatobiliary Pancreat Sci* 2014;21:818–23.

Kulkarni S, Bogart A, Buzbaum J, et al. Surgical transgastric debridement of walled off pancreatic necrosis: an option for patients with necrotizing pancreatitis. *Surg Endosc* 2015;29:575–82.

Lévy P, Jouannaud V, O'Toole D, et al. Natural history of intraductal papillary mucinous tumors of the pancreas: actuarial risk of malignancy. *Clin Gastroenterol Hepatol* 2006;4:460–8.

Park AE, Heniford BT. Therapeutic laparoscopy of the pancreas. *Ann Surg* 2002;236:149.

Ridder GJ, Maschek H, Klempnauer J. Favourable prognosis of cystadeno- over adenocarcinoma of the pancreas after curative resection. *Eur J Surg ONcol* 1996;22:232–6.

Romanelli JR, Desilets DJ, Earle DB. Pancreatic pseudocystgastrostomy with a peroral flexible stapler: human natural orifice transluminal endoscopic surgery anastomoses in 2 patients. *Gastrointest Endosc* 2008;68:981–7.

Sharma SS, Bhargawa N, Govil A. Endoscopic drainage of pancreatic pseudocysts: a long-term follow-up. *Endoscopy* 2002;34:203–7.

Simo KA, Niemeyer DJ, Swan RZ, et al. Laparoscopic transgastric endolumenal cystogastrostomy and pancreatic debridement. *Surg Endosc* 2014;28:1465–72.

Tarleja JP, Kahale M. Endotherapy for pancreatic necrosis and abscess: endoscopic drainage and necrosectomy. *J Hepatobiliary Pancreat Surg* 2009;16:605–12.

Varadarajulu S, Cristein JD, Tamhane A, et al. Prospective randomized trial

comparing EUS and EGD for transmural drainage of pancreatic pseudocysts. *Gastrointest Endosc* 2008;68:1102–11.

Vitale GC, Davis BR, Vitale M, et al. Natural orifice translumenal endoscopic drainage for pancreatic abscesses. *Surg Endosc* 2009;140–6.

Worhunsky DJ, Qadan M, Dua MM, et al. Laparoscopic transgastric necrosectomy for the management of pancreatic necrosis. *J Am Coll Surg* 2014;219:735–43.

Zerem E, Hauser G, Loga-Zec S, et al. Minimally invasive treatment of pancreatic pseudocysts. *World J Gastroenterol* 2015;21(22):6850–60.

EDITOR'S COMMENT

A single commentary will address the materials in Chapter 126 by Vitale and Chapter 125 by Muscarella. Dr. Gary Vitale from the University of Louisville is a leading authority on interventional endoscopic techniques. Dr. Peter Muscarella, currently at Albert Einstein and working at Montefiore, is a busy general surgeon and who during his time at Ohio State was the go to surgeon for necrotizing pancreatitis. The perspectives of each are valuable contributions.

Pancreatic Cysts

Not all pancreatic cysts are pseudocysts. The first priority is for the physician to establish if the cyst is of the inflammatory variety or a neoplastic cyst. If it is a cystic neoplasm then the worst thing one can do is an enteric drainage. If there is no history of pancreatitis or for that matter lack of a recent or remote acute abdominal episode in a patient without any history of alcohol use or gallstones and imaging without showing any acute changes of the pancreas or peripancreatic tissues, then the patient likely has a cystic neoplasm of the pancreas. Today we are fortunate to have available endoscopic ultrasound (EUS) to permit examination of the cyst and cyst sampling for amylase, tumor markers, and cytology. In the past we had referrals of patients with recurrent "pseudocysts" after cyst-gastrostomy that in fact had serous cystadenocarcinoma, mucinous cystadenocarcinoma, or other cystic neoplasms. The incidence of these occurrences can be greatly reduced by appropriate diagnostic testing including EUS.

As pointed out by Dr. Vitale not all pancreatic pseudocysts require drainage. Indeed, up to 40% will resolve spontaneously during a period of observation. Today we still honor the "6-week rule." That is the surgeon or endoscopist should wait a period of 6 weeks prior to drainage. Many cysts will resolve or decrease in size during this period and may not need drainage. In addition, the time allows the inflammatory process to create a fibrous adherence between the cyst and surrounding structures.

Since the last edition there has been a great deal of enthusiasm for endoscopic and nonsurgical methods to drain pancreatic pseudocysts. Surgical

drainage is the standard to which all treatment modalities should be compared. In comparative studies endoscopic techniques appear equally effective to surgical approaches.

Catheter Drainage

Caution is advised in routine percutaneous aspiration of a presumed pancreatic pseudocyst. It must be recognized that it is useful for initial treatment of an infected pseudocyst, to establish a diagnosis or as a temporizing measure. Percutaneous catheter drainage is the procedure of choice for treating infected pseudocysts, allowing for rapid drainage of the cyst and identification of any microbial organism. However with an uninfected pseudocyst, the failure rate is 54% with a 63% recurrence rate. In addition, this technique has a relatively high risk of infecting the pseudocyst. Percutaneous catheter drainage is contraindicated in patients who are poorly compliant and cannot manage a catheter at home. It is also contraindicated in patients with strictures of the main pancreatic duct and in patients with cysts containing bloody or solid material. It is generally recognized that percutaneous drainage has a higher complication rate and inpatient mortality rate than surgical drainage.

Endoscopic Drainage

Endoscopic drainage may be either transmural or transpapillary (via endoscopic retrograde cholangiopancreatography [ERCP]). Both modalities require careful patient selection to ensure success and safety. Based on the most current literature endoscopic treatment of pancreatic pseudocysts has the same clinical success, recurrence, complication, and mortality rate as surgical treatment but with a shorter hospital stay and lower costs. It is becoming the preferred drainage technique and first therapy for pancreatic pseudocysts. There has been an evolution to using endoscopic ultrasound to guide the transmural cyst-gastrostomy. This technique allows visualization vasculature adjacent to the pseudocyst thereby helping the endoscopist to avoid such structures when draining the cyst and placing a stent. In addition, flexible metal stents rather than plastic stents are used to prevent premature closure of the of cyst-gastrostomy. Dr. Vitale covers this in detail. Two recent studies are instructive.

Zhao X et al. (Endoscopic versus surgical treatment for pancreatic pseudocyst. *Dig Endos*c 2016;28(1):83–91) systematically searched PubMed and the Cochrane Library to identify all comparative trials investigating endoscopic versus surgical treatment for pancreatic pseudocyst. In this study the main outcome measures included treatment success rate, adverse events, recurrence rate, length of hospital stay, and hospital cost. They identified five comparative studies with 255 participants for a meta-analysis. The surgical group exhibited a higher treatment success rate than the endoscopic group (OR, 0.43; 95% CI, 0.20–0.95; P = 0.04). However, there was no difference in the rates of adverse events (OR, 0.67; 95% CI, 0.33–1.36; P = 0.27) or recurrence

(OR, 1.53; 95% CI, 0.37–6.39; *P* = 0.56) between the endoscopic and the surgical groups. Evidence from included studies demonstrated that the endoscopic group was associated with shorter length of hospital stay and lower hospital cost compared to the surgical group.

Saul A et al. (EUS-guided drainage of pancreatic pseudocysts offers similar success and complications compared to surgical treatment but with a lower cost. *Surg Endosc* 2016;30:1459–65) retrospectively reviewed data obtained prospectively from 2000 to 2012. This report included 64 procedures in 61 patients: 21 (33%) cases were drained endoscopically guided by EUS and 43 (67%) cases were drained surgically. The clinical success of the endoscopic group was 90.5 compared to 90.7% for the surgical group, with a complication rate of 23.8% and 25.6% and a mortality rate of 0% and 2.3% for each group. The hospital stay was lower for the endoscopic group: 0 (0 to 10) days compared with 7 (2 to 42) days in the surgical group. The cost was lower in the endoscopic group ($P < 0.001$). The recurrence rate was similar in both groups: 9.5% and 4.5%, respectively ($P = 0.59$). The two recurrences found in the endoscopic group were associated with stent migration, and the recurrence in the surgical group was due to the type of surgery performed (open drainage).

Another study compared percutaneous and endoscopic techniques. Kean MG, et al. (Endoscopic versus percutaneous drainage of symptomatic pancreatic fluid collections: a 14-year experience from a tertiary hepatobiliary centre. *Surg Endosc* 2016;30(9):3730–40) reported a retrospective comparison of endoscopic transmural drainage or percutaneous drainage for the initial management of patients with symptomatic pancreatic fluid collections between January 2000 and December of 2013. There were 164 patients included in the study; 109 patients underwent endoscopic; and 55 had percutaneous drainage alone. There were no procedural deaths. During the 14-year study period, the incidence of endoscopic drainage increased. In the 109 patients who were managed by this technique, treatment success was 70% compared to 31% in those managed by percutaneous drainage. Those patients managed by endoscopic techniques required fewer interventions (median of 1.8 vs. 3.3), had lower rates of residual collections (21% vs. 67%) and need for surgical intervention (4% vs. 11%). Interestingly, in the endoscopic group treatment for walled-off pancreatic necrosis was 67% compared to 72% for pseudocysts. The authors concluded that compared to percutaneous drainage, endoscopic drainage was associated with higher rates of treatment success, lower rates of reintervention, including surgery and shorter lengths of hospital stay. This has been the experience at our center as well.

Transpapillary Drainage

Although transpapillary drainage may be safer and potentially more effective than transmural drainage in some situations, it requires cyst communication with the pancreatic duct. In addition, this technique is technically challenging because it requires wire passage and stenting through the pancreatic duct to the

pseudocyst. The success rate is about 80%. The recurrence rate is 10% to 14%, and, in most series, the complication rate (mainly pancreatitis) is approximately 13%. Endoscopic drainage seems the preferred modality. Yang D et al. (Transpapillary drainage has no added benefit on treatment outcomes in patients undergoing EUS-guided transmural drainage of pancreatic pseudocysts: a large multicenter study. *Gastrointest Endosc* 2016;83:720–9) studied whether transpapillary drainage should be used in conjunction with transmural drainage and found that it was unnecessary.

I think it is important to consider situations in which endoscopic drainage may not be considered the first line of treatment. First the cyst needs to be in close proximity to the stomach. Usually within 1 cm is required. If there has been hemorrhage into the pseudocyst surgical drainage is preferred. Also giant pseudocysts may not respond well to endoscopic drainage and may require a surgical approach and possibly a Roux-en-Y cyst-enterostomy.

Walled-Off Pancreatic Necrosis

We have come a long way in the treatment of walled-off pancreatic necrosis and infection. Recall in the 1990s these patients required multiple debridements and packing and some surgeons even advocated for the placement of zippers to allow ready access to the pancreatic bed and peripancreatic tissues. Advances in interventional radiology, endoscopy, and minimally invasive surgery are responsible for a paradigm shift in the treatment of this complication of acute pancreatitis. The chapter by Muscarella nicely outlines the progression of acute pancreatitis to necrosis and infection. The controversial issues are the role of antibiotics in pancreatic necrosis, the timing of intervention and the type of intervention; surgery, laparoscopy, step up approach, endoscopic or dual modality (percutaneous and endoscopic).

The development of pancreatic infection is associated with the development of a progressive necrosis and systemic inflammatory response leading to a high morbidity and mortality. There is general agreement that in mild pancreatitis there is no need to use antibiotics; in severe pancreatitis there has been an ongoing debate on whether to use antibiotics to prevent secondary pancreatic infection in an attempt to decrease associated mortality. A nonsystematic review of current evidence, meta-analyses and randomized controlled trials found mixed evidence to support or refute the role of prophylactic antibiotics in acute pancreatitis (Mourad MM, Evans RPT, Kalidindi V, et al. Prophylactic antibiotics in acute pancreatitis: endless debate. *Ann R Coll Surg Engl.* 2017;99(2):107–12). Indeed the majority of studies have failed to demonstrate much benefit from routine antibiotic use. Data from the authors clinical unit suggest minimal benefit of their routine use, and observed that the mortality of those treated with antibiotics was 9% compared to 0% for patients not treated with antibiotics. In addition, in the antibiotic group the morbidity was 36% compared to 5% in the nonantibiotic group. It is our current practice that antibiotics should be used in patients who develop sepsis, infected pancreatic

necrosis, multiple-organ dysfunction syndrome or pancreatic and extrapancreatic infection. Elevation of inflammatory markers such as C-reactive protein, procalcitonin, or interleukin-6 levels may prompt antibiotic therapy. Unfortunately, in several studies there is no clear benefit to prophylactic antibiotics. In sum, there remain many unanswered questions regarding the indications for antibiotic administration and the patients who benefit from antibiotic treatment in acute pancreatitis.

As indicated in the previous paragraph there has been a substantial evolution in the surgical management of pancreatic necrosis. It is known that pancreatic or peripancreatic tissue necrosis confers substantial morbidity and mortality. New modalities have created a wide variation in approaches and timing of interventions for necrotizing pancreatitis. The dogma for many years was that patients with pancreatic necrosis should not undergo surgical debridement before 30 days. Earlier surgery was associated with increased morbidity and bleeding complications. Unfortunately owing to the heterogeneous nature of pancreatic necrosis and the variability of the disease itself, it is difficult to compare studies or even conduct randomized controlled trials. We have a variety of techniques that can be applied but the treatment for each patient requires an individual approach. A sampling of the current literature below underscores the difficulty in making sweeping recommendations for the treatment of walled-off pancreatic necrosis from clinical experience.

A review by J van Grinsven summarizes the current the state (Timing of catheter drainage in infected necrotizing pancreatitis. *Nat Rev Gastroenterol Hepatol* 2016;13(5):306–12). He and co-authors indicate that “the current standard treatment of infected necrosis is a step-up approach, consisting of catheter drainage followed, if necessary, by minimally invasive necrosectomy.” He goes on to challenge the current international guidelines recommending that catheter drainage be postponed for 4 weeks until the stage of “walled-off necrosis” (WON) has been reached. He argues that this “recommendation stems from the era of primary surgical necrosectomy” and “postponement of catheter drainage might not be necessary” and “that earlier detection and earlier drainage of infected necrosis may improve outcome.” As high-level evidence and consensus are lacking future clinical, preferably randomized, studies should focus on timing of catheter drainage in patients with infected necrotizing pancreatitis.

Additional insight can be gained by reviewing the results of an online survey including case vignettes that was sent to 118 international pancreatologists (van Grinsven J, van Brunschot S, Bakker OJ, et al. Diagnostic strategy and timing of intervention in infected necrotizing pancreatitis: an international expert survey and case vignette study. *HPB (Oxford)* 2016;18(1):49–56). The purpose of this study was to evaluate the use and timing of fine-needle aspiration (FNA), antibiotics, catheter drainage, and (minimally invasive) necrosectomy. The response rate was 74% (N = 87). The authors concluded that “the step-up approach was observed to be the preferred treatment strategy in infected

necrotizing pancreatitis among expert pancreatologists. However, there was no uniformity regarding the use of FNA and timing of intervention in the first 2 to 3 weeks of infected necrotizing pancreatitis."

In this study the specific results were:

1. None of the respondents used FNA routinely, 85% selectively, and 15% never.
2. Most respondents (87%) used a step-up approach in patients with infected necrosis.
3. WON was considered a prerequisite for endoscopic drainage and percutaneous drainage by 66% and 12%, respectively.
4. 55% routinely postponed invasive interventions after infected necrosis was diagnosed, whereas 45% proceeded immediately to intervention.
5. There was a lack of consensus about timing of intervention on day 14 with proven infected necrosis (58% intervention vs. 42% noninvasive) as well as on day 20 with only clinically suspected infected necrosis (59% intervention vs. 41% noninvasive).

In the United States, a recent systematic review of the MEDLINE database using PubMed was performed to explore current practice (Mowery NT, Bruns BR, MacNew HG et al. Surgical management of pancreatic necrosis: A practice management guideline from the Eastern Association for the Surgery of Trauma. *J Trauma Acute Care Surg* 2017;83(2):316–27). Topics of investigation included operative timing, the use of adjuvant therapy and the type of operative approach. Eighty-eight studies were included and underwent full review. Increasing the time to surgical intervention had an improved outcome in each of the time periods evaluated (72 hours, 12–14, 30 days) with a significant improvement in outcomes if surgery was delayed 30 days. The use of percutaneous and endoscopic procedures was shown to postpone surgery and potentially be definitive. The use of minimally invasive surgery for debridement and drainage was shown to be safe and associated to less morbidity and mortality. The authors recommend (Systematic review/guideline, level 3):

1. In adult patients with pancreatic necrosis, pancreatic necrosectomy be delayed until at least day 12.
2. During the first 30 days of symptoms with infected necrotic collections, surgical debridement only if the patients fail to improve after radiologic or endoscopic drainage.
3. With documented infected necrosis, patients should undergo a step-up approach to surgical intervention as the preferred surgical approach.

Shenvi S et al. (*Pancreatology* 2016;16(5):778–87) conducted a randomized controlled trial to attempt to determine the optimum timing of surgical intervention in patients with infected pancreatic necrosis not responding to percutaneous drainage. Patients who did not improve by day 10 after percutaneous drainage were included in the present study and were managed

with step-up approach with the intention to avoid surgery. Of 35 patients, 24 patients were managed by percutaneous drainage alone and 11 patients required surgery. In patients who did not require surgery; levels of serum high sensitivity C-reactive protein, interleukin-6 and prealbumin showed a falling trend. This group also had higher baseline albumin and higher albumin at 4 weeks. The step-up approach with the intention to avoid surgery had a success rate of 68.5%. However, this study failed to predict the optimal timing of surgery after percutaneous drainage. The treatment groups were very heterogeneous and patients who needed surgery were more ill at the time of admission, had higher incidence of organ failure, and spent more time in the ICU compared to patients who did not need surgery. Hence no conclusions could be made regarding the definitive timing of intervention.

Sugimoto M et al. (Better outcomes if percutaneous drainage is used early and proactively in the course of Necrotizing pancreatitis. *J Vasc Interv Radiol* 2016;27(3):418–25) tried to make a case for earlier intervention. Between September 2010 and August 2014, they studied 39 consecutive patients with pancreatic necrosis in whom CT-guided percutaneous drainage was the primary treatment. The indication for percutaneous drainage was the clinical finding of uncontrolled pancreatic juice leakage rather than infected necrosis. Subsequent to drainage, the protocol called for the drains to be proactively studied with fluoroscopic contrast medium every 3 days to ensure patency and position. Drains were ultimately maneuvered to the site of leakage. These 39 patients were compared with 43 patients from the Pancreatitis, Necrosectomy versus Step-up Approach (PANTER) trial. The CT severity index was similar between studies (median of 8 in each). Time from onset of acute pancreatitis to drainage was shorter in the present series (median, 23 days vs. 30 days). The total number of procedures (drainage and subsequent fluoroscopic drain studies) per patient was greater in the present series (mean, 14 vs. 2). More patients in the PANTER trial had organ failure (62% vs. 84%), required open or endoscopic necrosectomy (0% vs. 60%), and experienced in-hospital mortality (0% vs. 19%; $P < 0.05$ for all). They concluded that even though patients in the present series had a similar CT severity index as those in the PANTER trial, the former group showed lower incidences of organ failure, need for necrosectomy, and in-hospital mortality. They further opined that the use of a proactive drainage protocol early, before the development of severe sepsis, appeared to be effective. This treatment protocol seems labor intensive, but may be beneficial.

In summary, for walled-off pancreatic necrosis antibiotics should be reserved for patients with evidence of systemic inflammatory response and elevated biomarkers of sepsis. Although the timing of intervention is controversial, there seems to be a consensus that planned percutaneous drainage of the WON be done to avoid open surgical intervention. This is usually followed by percutaneous minimally invasive necrosectomy or endoscopic necrosectomy. I am certain that continued experience will further define the treatment paradigms for pancreatic necrosis.

E. Christopher Ellison

127 Pancreaticoduodenectomy and Total Pancreatectomy for Cancer

Douglas B. Evans, Parag P. Tolat, and Kathleen K. Christians

Pancreatic cancer (PC) is a rising public health threat and is anticipated to account for over 48,000 cancer-related deaths by 2030—a death rate which will be surpassed only by lung cancer. Significant advances in surgical technique have resulted in decreased perioperative morbidity and mortality after pancreatic resection, but this has not changed the median overall survival duration of patients with localized operable PC. One of the most revolutionary changes in the management of PC has been a greater appreciation for the early metastatic potential of PC; tumor biology which has important implications for treatment sequencing. A growing number of clinicians and scientists now support the hypothesis that the majority of patients with PC have systemic disease at the time of diagnosis, even in the absence of radiographic evidence of distant metastases. Therefore, treatment strategies have evolved to prioritize early systemic therapy for patients with localized PC. At present, the majority of patients who undergo surgical resection for localized PC receive an operation as part of a multimodality program which most often includes neoadjuvant therapy of some kind, either on- or off- of a clinical trial.

Pancreaticoduodenectomy was first formally described by Whipple, Parsons, and Mullins in 1935 in the *Annals of Surgery*. The original operation was completed in two stages. The first stage consisted of a gastroenterostomy, ligation of the common duct, and cholecystogastrostomy. Three to 4 weeks later, the descending portion of the duodenum and a portion of the pancreatic head were resected and the ducts of Wirsung and Santorini were ligated. The pancreas was not internally drained, but rather, was simply ligated. Between 1927 and 1935, 80 cases were reported and were associated with an operative mortality rate of 35%. By 1945, modifications of the two-stage procedure were numerous, and Whipple himself “condemned” the operation, advocating instead the one-stage procedure with choledochojejunostomy and implantation of the pancreatic duct into the jejunum. Waugh and Clagett

from the Mayo Clinic reported in 1946 that a pancreaticojejunostomy, choledochojejunostomy, and a retrocolic, antiperistaltic gastrojejunostomy distal to the biliary and pancreatic anastomoses were the most effective operation. Waugh and Clagett stated that the objective of an operation for the cure of malignant lesions in any location should be constant; (1) the procedure should provide a reasonable opportunity for cure, (2) the operative mortality should not outweigh the prospects for cure, and (3) the patient should be left in as normal a condition as possible. These basic principles still stand true today.

Recent advances in surgical technique, anesthesia, and critical care have resulted in pancreaticoduodenectomy now being considered a very safe operation when performed at major referral centers by experienced surgeons. If patients are selected appropriately and the operation is performed carefully, perioperative mortality should be rare and certainly less than 1% to 2%. Achieving such a low surgery-related mortality rate is a function of the level of experience of the individual surgeon as well as the institution. High-volume hospitals tend to have more surgeons specializing in specific procedures, more consistent postoperative care, better-staffed ICUs, and greater resources to deal with postoperative complications. In 2017, support has emerged, in the medical and lay press, for major pancreatic surgery to be limited to hospitals which perform 20 or more pancreatectomies per year. A reasonable level of experience with major pancreatic resection is necessary to achieve good results.

Current treatment strategies for patients with localized PC are based on knowledge of the disease’s natural history and patterns of treatment failure. Patients who receive multimodality therapy that includes pancreaticoduodenectomy for adenocarcinoma of the pancreatic head have a long-term survival rate approaching 30% and a median survival of 3 years or greater based on biomarker profile and pathology results. While vastly improved over the past decade, this relatively modest median survival mandates that treatment-related morbidity be low and treatment-related mortality be rare. Accurate preoperative imaging and proper surgical technique can minimize local recurrence. Routine use of multimodality therapy (systemic therapy and chemoradiation) maximizes survival duration by treating the microscopic metastatic disease present in most patients at the time of surgery. Operations resulting in grossly positive margins (R2 resections) offer no survival benefit over chemotherapy and radiation alone. Therefore, pancreaticoduodenectomy

should only be performed when there is a reasonable expectation that all gross disease can be removed. In addition, the development of endoscopic stents has allowed most patients with locally advanced, unresectable disease to avoid laparotomy for biliary or gastric decompression. This chapter focuses on the proper use of preoperative diagnostic studies and the technical maneuvers involved in the performance of pancreaticoduodenectomy and total pancreatectomy. Investigational techniques for early diagnosis and details of multimodality therapy are beyond the scope of this chapter but have been reviewed in recent publications listed in suggested readings.

PRETREATMENT DIAGNOSTIC EVALUATION

Advanced imaging technology has improved preoperative clinical staging so that "exploratory surgery" to determine resectability for known or suspected pancreatic or periampullary cancer is not necessary and should not be performed in 2017.

Preoperative evaluation should include a detailed history and physical examination (including functional status), chest imaging, laboratory studies including tumor markers (CA 19-9 and CEA at present, and an expanded list of biomarkers will be available soon), contrast-enhanced pancreas-protocol computed tomography (CT) of the abdomen and further evaluation of comorbid conditions as indicated. CT allows assessment of the tumor's relationship to the superior mesenteric artery (SMA), the superior mesenteric vein (SMV) and SMV-portal vein confluence (SMV-PV), the celiac artery (CA), and hepatic artery (HA). CT also defines any arterial or venous aberrations (replaced left or right HA, inferior mesenteric vein [IMV] draining directly into the SMV, jejunal branch of the SMV draining anterior to the SMA, etc.) and highlights potential lymph node or extrapancreatic metastases. Clinicians can then place the patient into one of four categories based on appropriately performed CT imaging: (1) resectable, (2) borderline resectable, (3) locally advanced (now to include type A and type B), and (4) metastatic. These categories help guide multidisciplinary management as will be discussed later in this chapter.

The aim of a pancreas-protocol CT is to delineate/detect the primary pancreatic tumor, to define tumor-vascular relationships (e.g., abutment or encasement), and to detect metastatic disease (e.g., locoregional lymph nodes, liver, peritoneum, and lung bases). This is accomplished by

advanced imaging with multidetector CT (MDCT). MDCT has rapidly evolved over the last several years and has become commonplace in most radiology departments. The advantages of MDCT are that it allows for improved spatial resolution (three-dimensional submillimeter isotropic voxel resolution) and rapid image acquisition to optimally evaluate the pancreas and peripancreatic structures. To achieve high spatial resolution, MDCT has been designed with detector elements with projected resolution of 0.4 to 0.7 mm at isocenter and submillimeter detector rows of 0.5 to 0.75 mm. MDCT systems can be configured at 16-channel (or slices), 64-channel, 128-channel, 256-channel or variant configurations by the manufacturer. The advantage of larger detector row systems (64-channel or greater) is rapid image acquisition in the z or longitudinal (cranio-caudal) axis.

Intravenous contrast medium is required for pancreas-protocol CT. Optimal contrast enhancement depends upon appropriately linking the iodine delivery system with image acquisition at defined circulation phases/times. Contrast delivery should be on the order of 4 to 6 mL/sec (350 to 370 mg of iodine/mL), preferably via an 18- to 20-gauge intravenous catheter placed in an antecubital vein and delivered via a programmed power injector. Individual patient circulation times vary considerably and it is critical that the contrast delivery be tailored to each individual patient. This can be done either with a preliminary mini test-bolus or bolus-tracking software. For pancreatic imaging, the stomach and duodenum are distended with 800 mL of water (negative enteric contrast) administered 15 to 30 minutes prior to the study and an additional 200 mL of water immediately prior to the scan.

The “pancreatic phase” (or late arterial phase) is the phase of optimum pancreatic parenchymal enhancement and is a capillary phase acquisition occurring 15 seconds after abdominal aortic arrival of the contrast medium following the peripheral intravenous bolus injection. Antecubital vein to abdominal aortic circulation time can vary between 12 and 30 seconds in individual patients, thus explaining the critical role of circulation timing in providing consistent reproducible pancreatic contrast enhancement. The pancreatic phase also corresponds in timing to the initial opacification of the SMV and PV which predictably occurs 10 to 15 seconds after aortic arrival of contrast material in the SMA. Thus, while this phase provides optimum delineation of the pancreas and peripancreatic arteries (Fig. 127.1), the opacification of the splenic vein, SMV, and PV is not yet at

peak.

A second phase, commonly referred as the “portal-venous phase” (or hepatic phase) occurs 45 seconds after the pancreatic phase (Fig. 127.2). In this phase, the spleen becomes uniformly homogeneous (previously heterogeneous in the pancreatic phase) and the hepatic vein becomes uniformly enhanced/homogeneous (previously unenhanced in the pancreatic phase). In addition, the liver parenchyma becomes more enhanced than the pancreas (previously less enhanced than the pancreas in the pancreatic phase) due to contrast material inflow from the portal vein into the hepatic sinusoids. The two phases as defined, “pancreatic” (or late arterial) and “portal-venous” (or hepatic) phases, have different roles in the evaluation of pancreatic pathology.

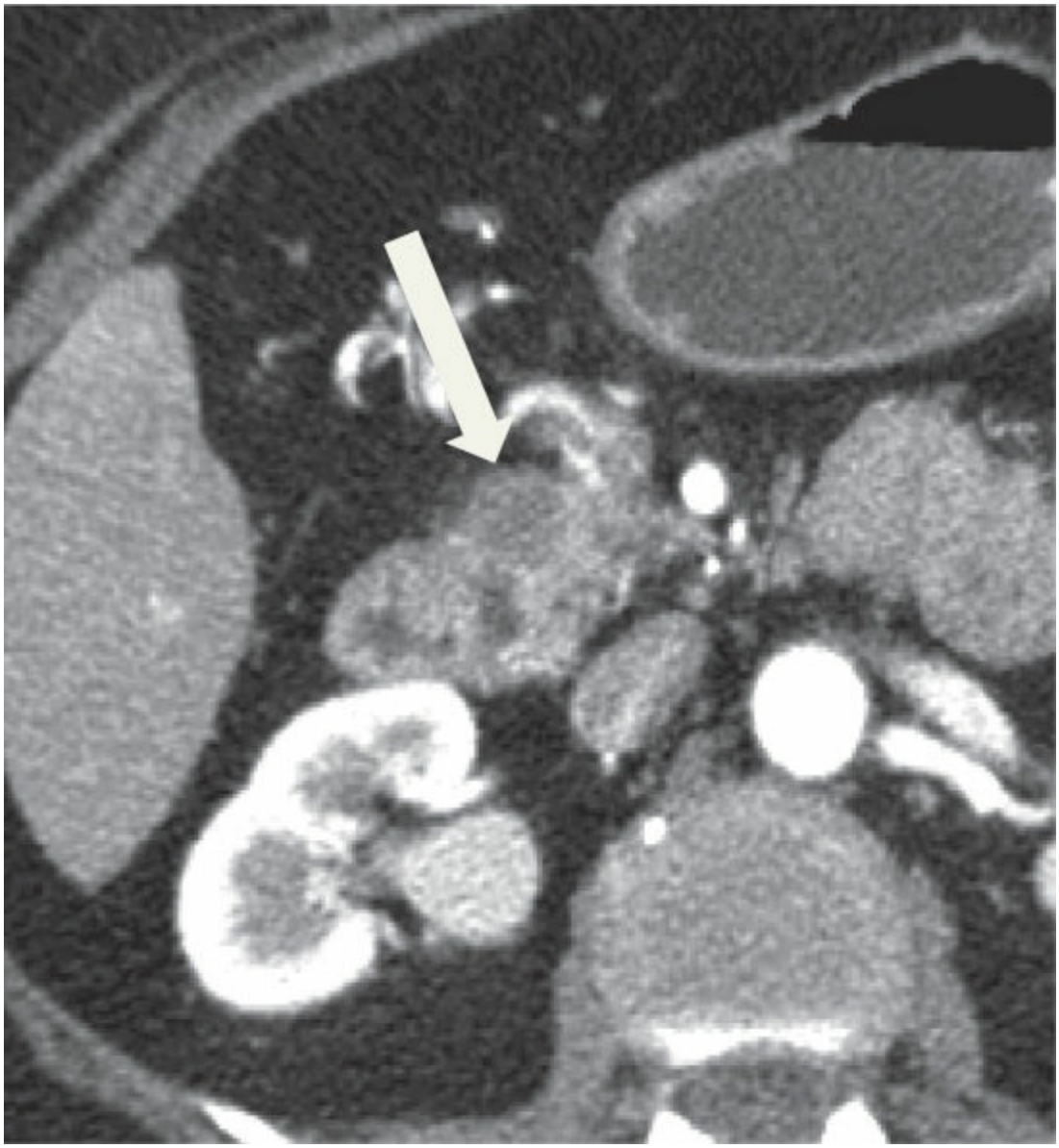

Figure 127.1. Axial CT image in the late arterial phase of a resectable adenocarcinoma of the pancreatic head at the pancreaticoduodenal groove (*arrow*). Note the tumor is distant from the SMA and SMV with no evidence of abutment.

The pancreatic phase provides maximum contrast differentiation between tumors and pancreatic parenchyma. Relatively hypovascular, hypoattenuating tumors (most commonly pancreatic adenocarcinoma) or hypervascular, hyperattenuating tumors (most commonly neuroendocrine tumors) against the normal background pancreatic parenchyma, are best seen in the pancreatic phase. In addition, the pancreatic duct and intrapancreatic common duct are best defined in the pancreatic phase. Finally, arterial anatomic variants (aberrant or replaced right HA and left HA) and critical tumor-arterial relationships (e.g., abutment or encasement with the celiac, HA, splenic artery, and SMA) are best delineated in the pancreatic phase.

The portal-venous phase best delineates the portal and mesenteric venous systems allowing delineation of venous anatomy/variants (e.g., IMV draining directly into the SMV or the jejunal branch of the SMV draining anterior to SMA) and critical tumor-venous relationships (e.g., abutment or encasement of the PV, splenic vein, SMV-PV, and/or SMV and its proximal tributaries including gastroepiploic, middle colic and jejunal veins). Peripancreatic lymphadenopathy and hepatic metastases are generally best defined in the portal-venous (or hepatic) phase. However, the liver is also completely imaged in the pancreatic phase and metastases from pancreatic adenocarcinoma may be recognized as ring enhancing lesions that become uniformly hypoattenuating in the hepatic phase.

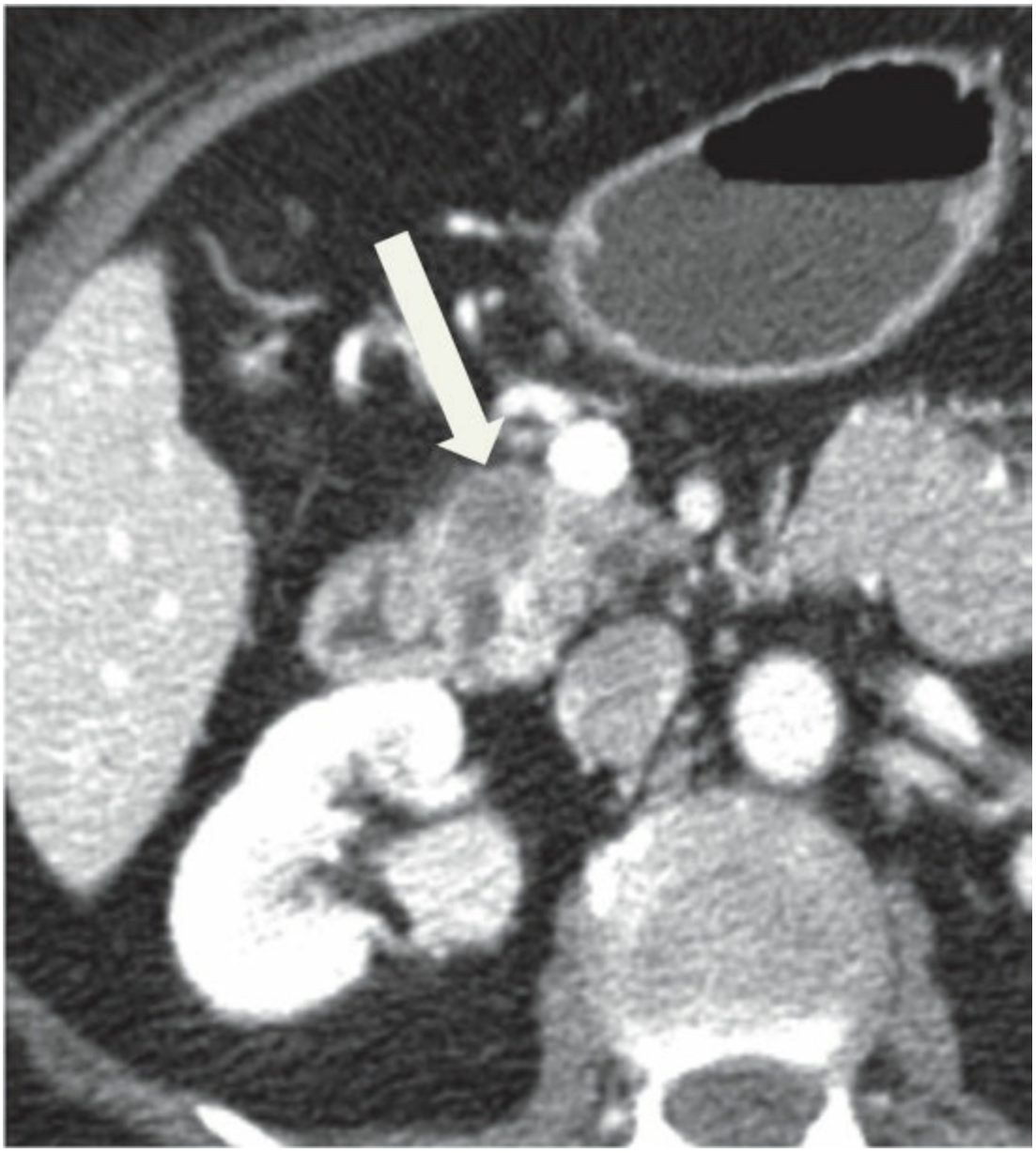

Figure 127.2. Axial CT image in the portal-venous phase of a resectable adenocarcinoma of the pancreatic head at the pancreaticoduodenal groove (*arrow*). Note the tumor is separate from the SMA and SMV with no evidence of abutment.

Our current algorithm for the diagnosis and treatment of patients with presumed or biopsy-proven adenocarcinoma of the pancreatic head or periampullary region is illustrated in Figure 127.3. CT imaging should always be performed prior to any interventional (endoscopic) procedures to avoid procedure-related pancreatitis which can make accurate imaging impossible. Patients with a visible mass on pancreas-protocol CT should then undergo endoscopic ultrasound-guided fine-needle aspiration biopsy (EUS-FNA) for tissue diagnosis. Cytopathologists should, whenever

possible, be present in the endoscopy area at the time of the procedure to provide immediate assessment of the adequacy of the biopsy specimen. Their presence at the time of EUS-FNA has considerably improved the diagnostic yield of this procedure to well over 90%. Patients who are jaundiced will then undergo ERCP with placement of an endobiliary stent (preferably as a combined procedure with EUS). Those patients with a low-density mass in the pancreatic head on CT imaging and a positive tissue diagnosis are eligible for neoadjuvant therapy (hopefully as part of a clinical trial). In those patients with tissue diagnosis of cancer, we prefer a metal stent (vs. plastic) to avoid stent occlusion during neoadjuvant therapy.

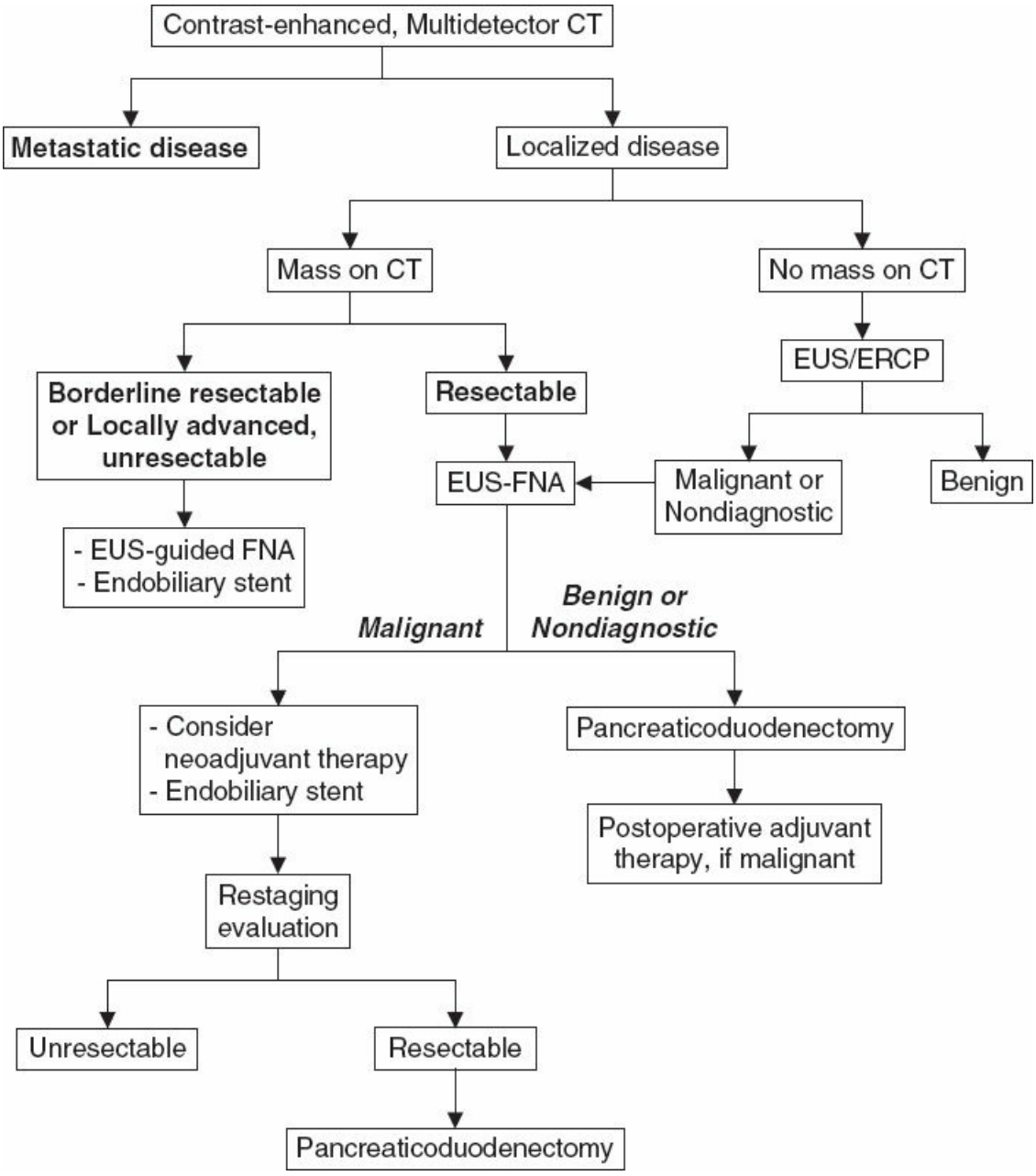

Figure 127.3. Management algorithm for patients with suspected or biopsy-proven adenocarcinoma of the pancreatic head or periampullary region. Patients without a histologic or cytologic diagnosis of adenocarcinoma who have a low-attenuation, resectable mass in the pancreatic head on MDCT undergo endoscopic ultrasonography (EUS)-guided fine-needle aspiration (FNA) biopsy. This management philosophy is based on the ongoing use of protocol-based neoadjuvant therapy at our institution. In the absence of a mass on CT, diagnostic EUS has become the appropriate next step. When there is no obvious mass to biopsy, or if pretreatment biopsies are nondiagnostic, patients who have clinical and radiologic findings suggestive of a malignant bile duct stricture or periampullary neoplasm undergo pancreaticoduodenectomy. In 2017, it is unusual to consider pancreaticoduodenectomy for a diagnostic dilemma in the absence of a tissue diagnosis of cancer. Endoscopic retrograde cholangiopancreatography (ERCP) is performed in patients with biliary obstruction as both a diagnostic study (when the etiology of the biliary obstruction is not apparent), or as a therapeutic modality to place an endobiliary stent when surgery is to be delayed (for the delivery of preoperative therapy).

Patients with extrahepatic biliary obstruction without a CT-defined mass in the pancreas also undergo EGD/EUS. Endoscopic evaluation may discover an ampullary tumor or related pathology, and EUS may define a mass in the pancreas or distal bile duct not seen on CT. If the etiology of biliary obstruction remains unclear, ERCP (or magnetic resonance cholangiopancreatography [MRCP]) is usually necessary. At the time of ERCP, a malignant obstruction of the intrapancreatic portion of the common bile duct (CBD) is characterized by an abrupt cutoff, or irregular stenosis of the CBD. This is in contrast to the long, smooth tapering stricture often seen in chronic pancreatitis or a filling defect or meniscus found in choledocholithiasis. In a patient who presents with extrahepatic biliary obstruction, a malignant-appearing stricture of the intrapancreatic portion of the CBD, and no history of recurrent pancreatitis or alcohol abuse, the absence of a mass on CT or EUS images does not exclude carcinoma of the pancreas or bile duct. Instead, the results of EUS, with or without FNA, should be considered within the clinical context, as a complement to CT and ERCP findings. If a tissue diagnosis is not obtained, and the biliary stricture is malignant in appearance, pancreaticoduodenectomy is the next logical intervention assuming the

patient is of suitable operative risk. However, in 2017 this is an uncommon scenario.

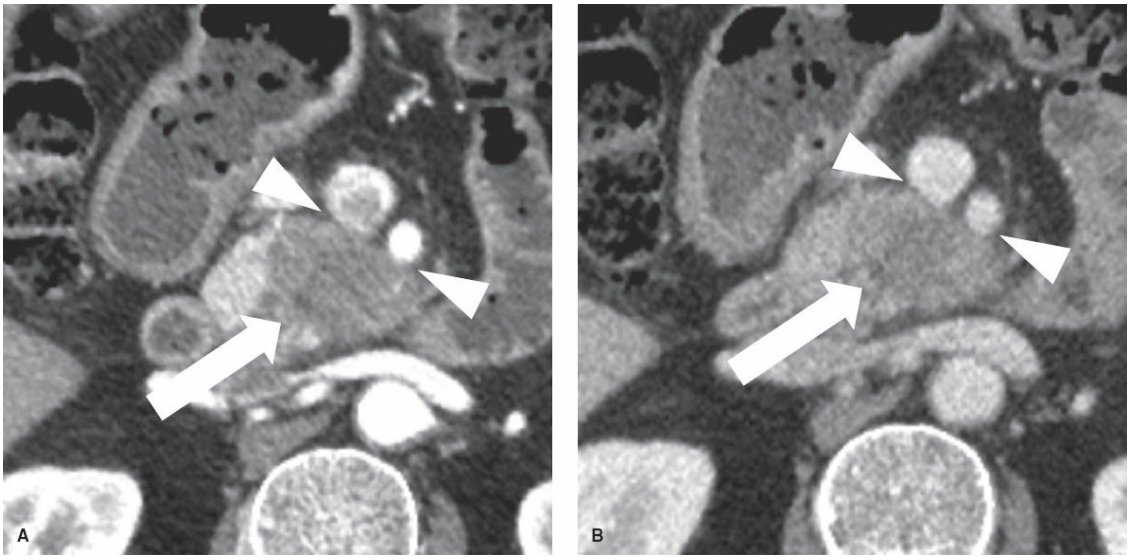

Figure 127.4. Axial late arterial (figure A) and portal venous (figure B) CT images of a borderline resectable adenocarcinoma of the pancreatic head/uncinate process (*arrow*) with tumor abutment (*arrowheads*) of the SMA and SMV. Note the low-attenuation soft-tissue that abuts the SMA and SMV for 180 degrees or less and obliterates the expected normal fat plane.

For patients with a pancreatic head mass, CT imaging is used to define the extent of disease. Classifications include resectable, borderline resectable, locally advanced or metastatic. Usually patients characterized as resectable or borderline resectable are considered eligible for pancreaticoduodenectomy.

CT criteria for a resectable tumor include: (1) the absence of extrapancreatic metastatic disease; (2) absence of, or minimal, abutment/distortion of the SMV-PV confluence; and, (3) no direct tumor extension to the HA, celiac axis, or SMA, to include a clear soft tissue plane around these vessels. Many experts are taking a more conservative view of venous involvement and define resectable tumors as those with no radiographic evidence of SMV and PV abutment, distortion, tumor thrombus, or venous encasement. The extent of SMV-PV abutment/encasement allowed to still be considered a resectable tumor remains an area of controversy but is of limited importance for those clinicians who prefer a neoadjuvant treatment approach to all patients with biopsy-proven localized PC.

Borderline resectable patients are described to encompass three types: Type A patients have tumor-artery abutment of ≤180 degrees of the circumference of the SMA or celiac axis (Fig. 127.4), tumor abutment or encasement (>180 degrees) of a short segment of the HA (usually at the origin of the gastroduodenal artery [GDA]), or short segment occlusion of the SMV, PV, or SMV-PV confluence with a suitable PV above and SMV below for reconstruction. Type B patients have CT findings suspicious for, but not diagnostic of, metastatic disease—most commonly indeterminate lesions in the liver. Type C patients are borderline resectable due to a marginal performance status as well as those with severe pre-existing comorbidities requiring protracted evaluation that precludes immediate operation. This category does not include those patients with no potential for eventual operation due to pre-existing medical comorbidities which cannot be significantly modified. Colon and/or mesocolon invasion is not included in the definition of borderline resectable cancer, both because it is not quantifiable, and because removal of the mesocolon or colon is unrelated to the risk for a margin-positive resection.

Patients with borderline resectable tumors as defined above should not be taken directly to surgery. The rationale for delivering neoadjuvant therapy to patients with borderline resectable tumors is based on: (1) the early treatment of micrometastatic disease which exists in the majority of patients—systemic therapy is provided for a systemic disease; (2) providing a time interval to gauge the aggressiveness of the cancer in order to select patients for surgery who have stable or responding disease. Those with disease stability or treatment response have the greatest likelihood of achieving clinical benefit from surgery; and (3) the potential for tumor downstaging (tumor destruction, particularly at the periphery) to maximize the potential for an R0/R1 resection.

Locally advanced tumors are defined as those with encasement (>180 degrees) of adjacent arteries (Fig. 127.5) or an occluded SMV-PV with no technical option for resection and reconstruction. Locally advanced tumors are considered unresectable in the absence of surgical excision of the celiac or superior mesenteric arteries—arteries which traditionally would not be removed at the time of pancreatectomy for pancreatic adenocarcinoma. With regard to the CA, increasing experience has demonstrated the safety of celiac resection in carefully selected patients with tumors of the pancreatic body which have responded to induction therapy. However, the SMA is even more complicated and we are not yet

at a point, with this disease, where we are resecting and reconstructing the SMA. The unresolved question is what degree of SMA abutment (<180 degrees) or encasement (>180 degrees) should be approached surgically. Because the visceral arteries have a perineural sheath which envelopes them, there is often a plane of dissection between the adventitia of the artery and the neural sheath which allows for sharp dissection of the tumor off of the artery. Because complete 360-encasement would require that one cuts through tumor to separate the SMA from the tumor, SMA encasement of this magnitude is considered nonoperable at our institution. Our threshold for considering surgery following induction therapy, based on the degree of SMA encasement, is evolving and our current thoughts on how to objectively classify the locally advanced patient are described in Table 127.1.

TABLE 127.1 Classification of Locally Advanced Pancreatic Adenocarcinoma Into Type A and B and the Comparison to the Definitions Used for Resectable and Borderline Resectable Disease

Vascular Structures Which Determine the Stage of Disease for Localized Pancreatic Cancer		Resectable	Borderline Resectable	Locally Advanced	
				Type A	Type B
Tumor-Artery Anatomy	**SMA** (usually pertains to a tumor of the head or uncinate process)	No radiographic evidence of abutment or encasement	≤180 degrees (abutment)	>180 degrees (encasement) but ≤270 degrees	>270 degrees encasement
	Celiac artery (usually pertains to a tumor of the pancreatic body)	No radiographic evidence of abutment or encasement	≤180 degrees (abutment)	>180 degrees (encasement) but does not extend to the aorta and amenable to celiac resection (with or without reconstruction)	>180 degrees and abutment/encasement of the aorta
	Hepatic Artery (HA) (usually pertains to a tumor of the pancreatic neck/head)	No radiographic evidence of abutment or encasement	Short segment abutment/encasement without extension to celiac artery or HA bifurcation	>180 degrees encasement with extension to celiac artery and amenable to vascular reconstruction	>180 degrees encasement with extension beyond bifurcation of proper HA into right and left hepatic arteries
Tumor-Vein Anatomy	**SMV-PV**	≤50% narrowing of SMV, PV, SMV-PV	>50% narrowing of SMV, PV, SMV-PV **with** a distal and proximal target for reconstruction	Occlusion **without** obvious option for reconstruction.	
Traditionally Considered for Resection After Neoadjuvant Therapy		Yes	Yes	No	No

SMA, superior mesenteric artery; SMV, superior mesenteric vein; PV, portal vein; SMV-PV, superior mesenteric-portal vein
Modified from Evans DB, George B, Tsai S. Non-metastatic pancreatic cancer: resectable, borderline resectable, and locally advanced-definitions of increasing importance for the optimal delivery of multimodality therapy. *Ann Surg Oncol* 2015;22(11):3409–13.

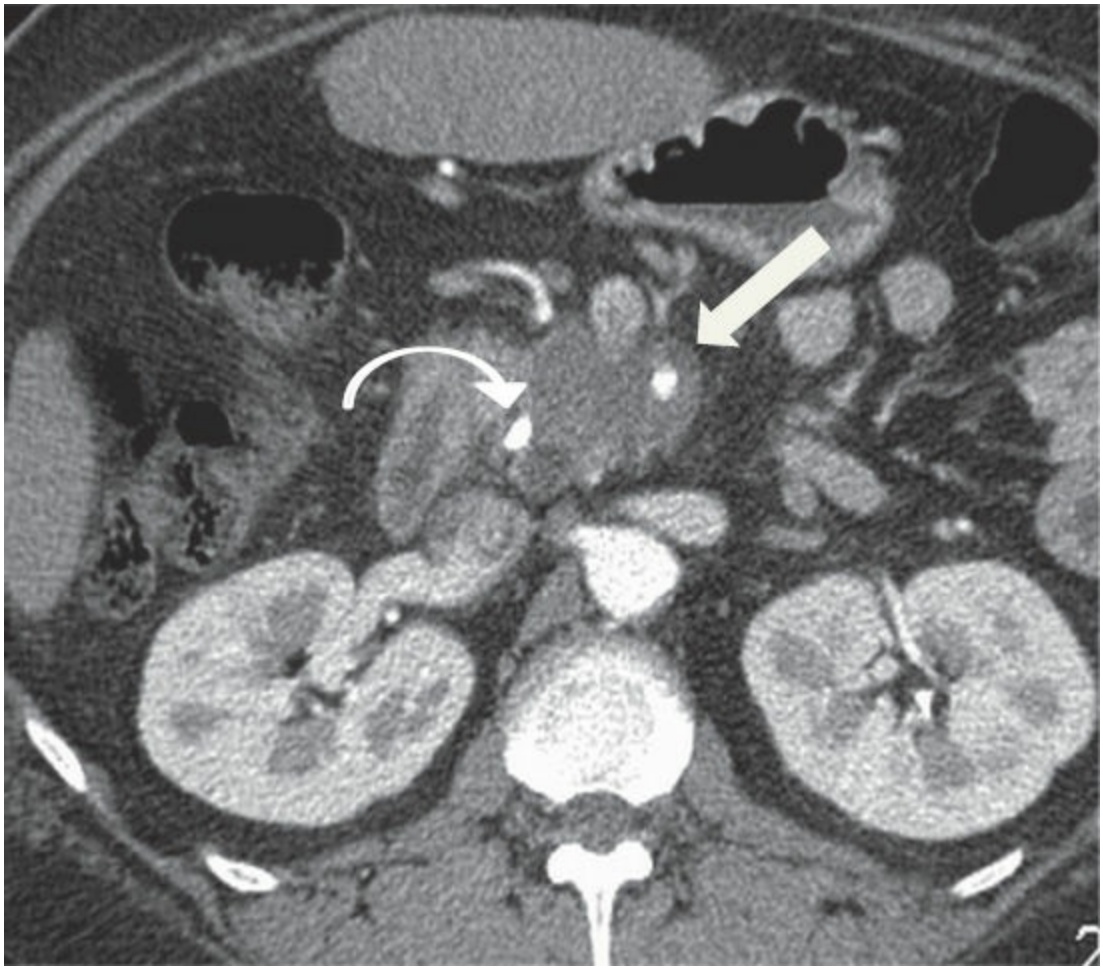

Figure 127.5. Axial CT image in the late arterial phase of a locally advanced adenocarcinoma of the uncinate process of the pancreas with tumor encasement of the SMA (*arrow*). Note the low-attenuation soft tissue which encases the SMA for 360 degrees of the vessel. A plastic endobiliary stent is in the bile duct (*curved arrow*).

Laparoscopy has been used in patients with radiographic evidence of localized PC to detect extrapancreatic tumor not seen on CT imaging, thereby allowing laparotomy to be limited to patients with localized disease. Laparoscopy prior to laparotomy (under a single anesthesia induction) is routinely used by the authors in patients with biopsy-proven or suspected potentially resectable PC in whom a decision has been made to proceed with pancreaticoduodenectomy. Data are not available to support the cost-effectiveness of laparoscopy's routine use as a staging procedure under a separate anesthesia induction prior to treatment planning. In addition, laparoscopy should not be a substitute for inadequate CT imaging.

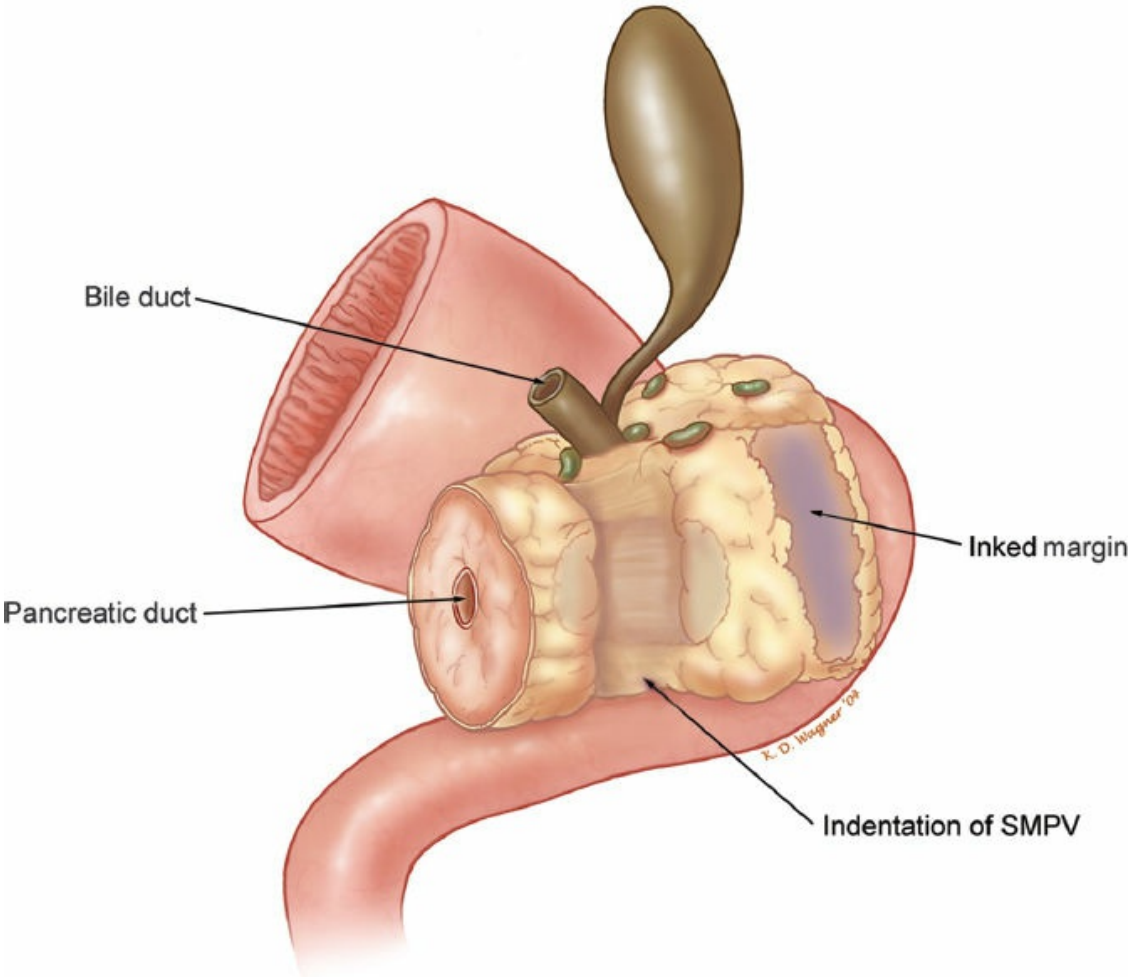

Figure 127.6. Illustration of a standard pancreaticoduodenectomy specimen as it appears when sent to the pathology suite. The SMA margin (also termed retroperitoneal margin, mesenteric margin, or uncinate margin) is the tissue adjacent to the superior mesenteric artery and should be inked for evaluation of margin status. Complete permanent-section analysis of the pancreaticoduodenectomy specimen requires that it be oriented to enable the pathologist to accurately assess the SMA margin to determine the adequacy of resection (R status). SMPV, superior mesenteric-portal vein.

The SMA margin of resection is the soft tissue margin adjacent to the proximal 3 to 4 cm of the SMA (Fig. 127.6). This margin has also been referred to as the retroperitoneal margin, uncinate margin or the mesenteric margin of resection. The surgical technique described herein emphasizes the direct identification of the SMA and removal of all perivascular and lymphatic tissue to the right of this vessel. This more aggressive retroperitoneal/mesenteric dissection combined with the other components of multimodality therapy improves local disease control, alters patterns of

recurrence, and represents a logical strategy to maximize length and quality of patient survival.

PANCREATICODUODENECTOMY

Pancreaticoduodenectomy involves removal of the pancreatic head, duodenum, gallbladder, and bile duct with or without removal of the gastric antrum. It represents the standard surgical procedure for neoplasms of the pancreatic head and periampullary region. While there is a growing body of literature on the use of laparoscopic and robotic pancreatectomy, this chapter will focus on the principles of open surgery. The criticisms of minimally invasive pancreaticoduodenectomy have included the morbidity/mortality associated with the learning curve (for each individual surgeon) and the marked increase in postpancreatectomy arterial hemorrhage from the GDA stump, the common hepatic artery (CHA), and the SMA. Indeed, arterial complications are of great concern even in the most experienced centers. The potential complications associated with a modest midline incision are rarely life threatening and therefore, the future of minimally invasive pancreaticoduodenectomy remains controversial at the time of this writing of *Mastery*.

At the time of surgical exploration for pancreatic head cancer, a Kocher maneuver was commonly taught to be the first step performed to allow assessment of the relationship of the tumor to the SMA by palpation. By mobilizing the pancreatic head and duodenum from their retroperitoneal attachments, the surgeon attempts to palpate a plane of normal tissue between the firm tumor and the posterior pulsation of the SMA. In reality, this step is a crude assessment subject to individual surgeon bias. The relationship of the tumor to the right lateral wall of the SMA is the most critical aspect of the pretreatment staging evaluation. This tumor-vessel relationship must be accurately evaluated prior to taking the patient to the operating room (on preoperative high-quality CT imaging) and cannot be accurately assessed intraoperatively following a Kocher maneuver. In addition, for larger tumors, for those tumors containing significant peritumoral fibrosis, or for reoperative cases, palpation of the relationship of the primary tumor to the SMA after Kocher maneuver with any reasonable degree of accuracy is usually impossible.

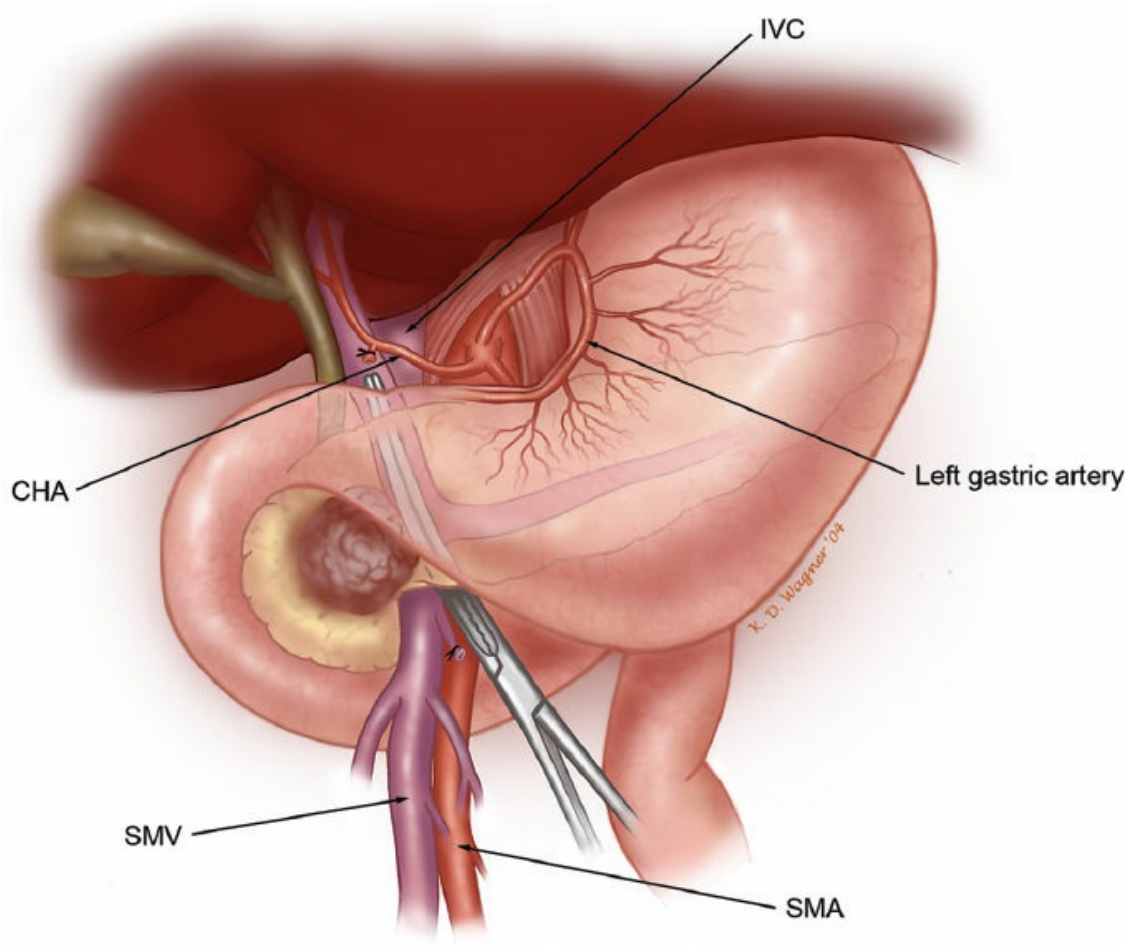

Figure 127.7. Illustration demonstrating a maneuver commonly performed early in the operation to detect tumor invasion of the superior mesenteric vein (SMV) or superior mesenteric-portal vein confluence. We do not perform this maneuver because a tumor-free plane often can be developed despite fixation of the tumor to the lateral or posterior wall of the SMV. This maneuver may incorrectly suggest that tumor adherence to the SMV does not exist, and may result in unnecessary bleeding if the SMV or portal vein is injured. CHA, common hepatic artery; SMA, superior mesenteric artery; IVC, inferior vena cava.

The second maneuver traditionally performed to assess resectability is to develop a plane of dissection between the anterior surface of the SMV-PV confluence and the posterior surface of the neck of the pancreas to exclude tumor involvement of the SMV or SMV-PV confluence (Fig. 127.7); such tumor involvement, in the opinion of most surgeons, precludes resection. However, the rationale for this maneuver early in the operation is also unclear. Tumors of the pancreatic head or uncinate process are prone to invade the lateral or posterior wall of the SMV-PV

confluence, not the anterior wall. The anterior wall is rarely involved in the absence of encasement of the celiac axis or SMA origin (as seen with locally advanced tumors of the pancreatic neck or body), and this finding should be visible on preoperative CT images. In addition, the relationship of a pancreatic head tumor to the lateral and posterior walls of the SMV-PV confluence (and the SMA) can be directly inspected only after dividing the stomach/duodenum and the pancreatic neck, by which point the surgeon has already committed the patient to resection. Therein lies the rationale for detailed preoperative imaging using high-quality, contrast-enhanced CT, with laparotomy undertaken only in patients who have operable tumors as defined on CT. Both of the above described maneuvers are founded in surgical tradition rather than surgical anatomy—they are not accurate techniques for the assessment of resectability of a primary carcinoma of the pancreatic head.

PANCREATIC RESECTION

Our recommended technique for pancreaticoduodenectomy utilizes a modest midline upper abdominal incision (after routine laparoscopic exploration confirms the absence of extrapancreatic metastatic disease). Lymph node biopsy for frozen-section analysis is uncommonly performed. Positive lymph nodes are a prognostic factor (along with poorly differentiated histology, microscopically positive resection margins, etc.) predictive of decreased survival duration. In a good-risk patient with localized, resectable PC, we do not view lymph node metastases as an absolute contraindication to pancreaticoduodenectomy when performed as part of a multimodality approach to PC. Therefore, in general, we do not perform random lymph node sampling for frozen-section analysis at the time of pancreaticoduodenectomy. However, each case should be considered individually such as in the case of a high-risk patient (due to medical comorbidities) with perhaps an unfavorable response to induction systemic therapy (high serum level of CA 19-9); suspicious adenopathy, if positive on intraoperative frozen section, may be viewed as a contraindication to proceeding with pancreaticoduodenectomy.

The surgical resection is divided into the following clearly defined steps:

1. The purpose of Step 1 is to isolate the infrapancreatic SMV and separate the colon (and its mesentery) from the duodenum and pancreatic head (Fig. 127.8). The lesser sac is entered by taking the

greater omentum off of the transverse colon, and the loose attachments of the posterior gastric wall to the anterior surface of the pancreas. The hepatic flexure of the colon is mobilized from its retroperitoneal attachments. The visceral peritoneum along the inferior border of the pancreas from a point medial to (to the patient's left of) the middle colic vessels is incised and carried out laterally (to the patient's right) and inferiorly to expose the junction of the middle colic vein and the SMV. The middle colic vein may enter directly into the anterior surface of the infrapancreatic SMV or arise as a common trunk with the gastroepiploic vein (gastrocolic trunk). If the middle colic vein and gastroepiploic vein share a common trunk, the common trunk can be preserved (and the gastroepiploic vein divided) or the entire trunk divided. Otherwise, the gastroepiploic vein is left intact and divided later in the operation following pancreatic transection. When necessary, the middle colic vein can be divided proximal to its junction with the SMV; this is often needed when operating on obese patients where a traction injury of the middle colic vein may occur if the vein is not divided. Division of the middle colic vein is especially important when dealing with large tumors or tumors extending inferiorly from the uncinate process. In fact, the base of the transverse mesocolon and the anterior leaf of the small bowel mesentery can be left attached to the tumor and resected en bloc with the pancreatic head. Such caudal or inferior tumor extension is not a contraindication to pancreaticoduodenectomy but does add complexity during this step when the infrapancreatic SMV needs to be identified.

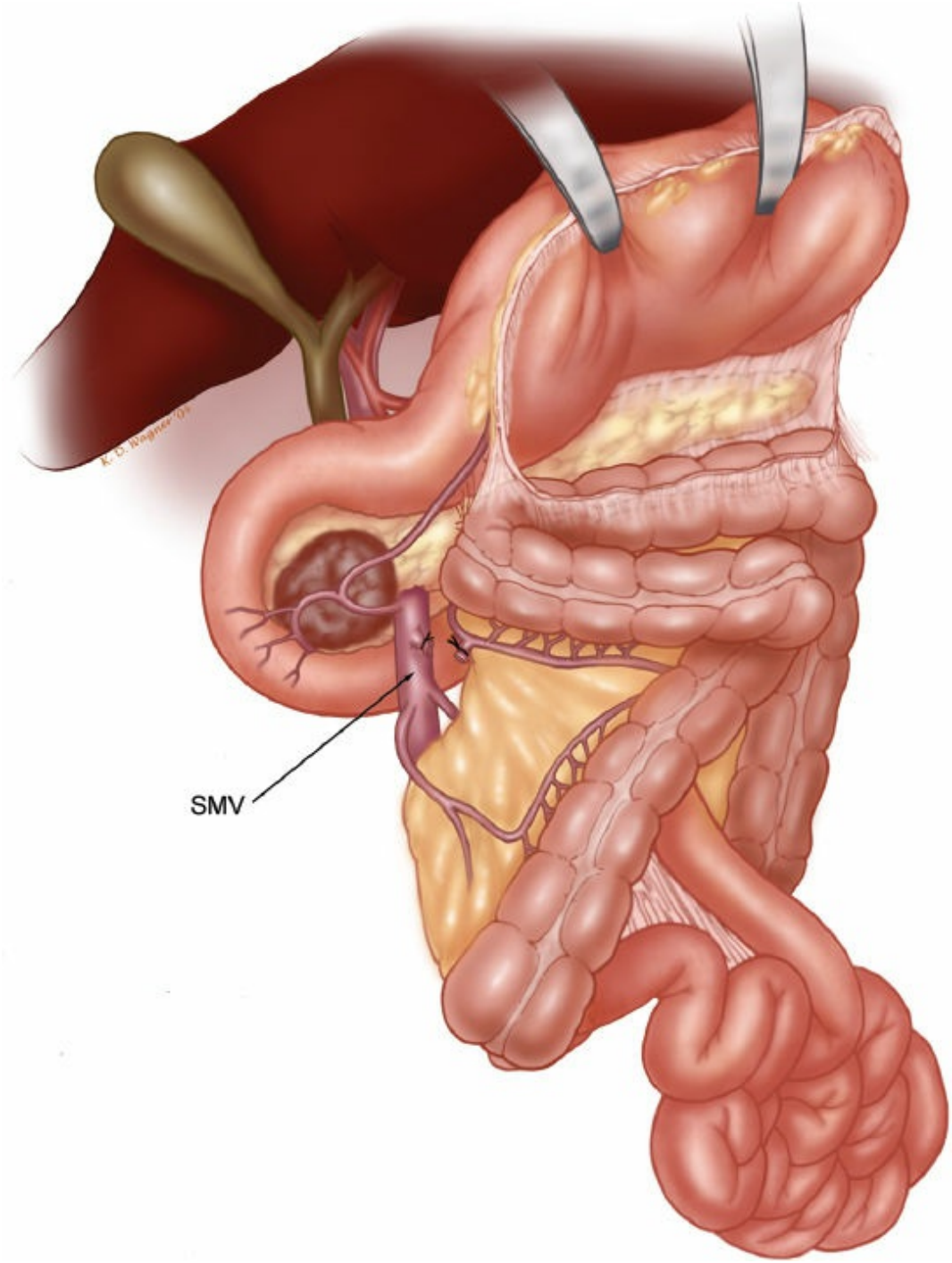

Figure 127.8. Illustration of Step 1. The lesser sac is entered, and the hepatic flexure of the colon is taken down. The inferior body of the pancreas is identified at the level of the proximal body of the gland. The visceral peritoneum and root of mesentery is incised from this point, in a lateral direction, heading toward the junction of the second and third portions of the duodenum in an effort to expose the anterior wall of the superior mesenteric vein (SMV). The SMV is exposed at the inferior border of the neck of the pancreas adjacent to the uncinate process. The middle colic vein and gastroepiploic

vein often arise from a common trunk which occasionally also involves the right colic vein. Any or all of these veins may require ligation and division to safely expose the SMV. When the need for venous resection is anticipated, the entire right colon and the root of the small bowel mesentery are mobilized in the fashion of Cattell and Braasch. This involves incision of the visceral peritoneum to the ligament of Treitz and allows anterior reflection of the colon off of the duodenum and pancreatic head. This maneuver is also helpful when operating on obese patients with thick mesentery and a deep abdomen. When dealing with a reoperative situation (previous unsuccessful attempt at resection) or with tumor extending into the root of mesentery, we may not identify the SMV early in the operation and expose this vessel after pancreatic transection by following the anterior surface of the portal vein in a caudal direction—this maneuver should only be considered by the most experienced pancreatic surgeons.

Mobilization of the retroperitoneal attachments of the small bowel and right colon mesentery is performed in patients with uncinate tumors extending into the small bowel mesentery and in some patients who require venous resection and reconstruction or when visual access to the posterior aspect of the SMA is needed due to tumor abutment in this difficult area. This maneuver was first described by Cattell and Braasch for exposure of the duodenum. The visceral peritoneum of the small bowel mesentery is incised to the ligament of Treitz, thereby mobilizing the small bowel mesentery. When complete, this maneuver allows cephalad retraction of the right colon and small bowel, exposing the third and fourth portions of the duodenum.

Occasionally, when there is extensive inflammatory change or scarring at the root of mesentery usually due to a prior attempt at resection, we may not identify the SMV early in the operation. In such cases, the SMV will be exposed during Step 6 when the pancreas is divided in a caudal direction from the level of the portal vein. Due to lack of vascular control, this can be dangerous but it is a valuable technique for the experienced surgeon who deals with more complicated pancreatic resections, especially in a reoperative setting.

2. The Kocher maneuver is begun at the transverse portion (third portion) of the duodenum by identifying the anterior aspect of the inferior vena cava. All fibrofatty and lymphatic tissue medial to right gonadal vein

and anterior to the inferior vena cava is elevated, along with the pancreatic head and duodenum (Fig. 127.9). The Kocher maneuver is continued to the left lateral edge of the aorta, with exposure of the anterior surface of the left renal vein. The right gonadal vein serves as a good landmark coursing anterior/medial to the right ureter thus helping prevent inadvertent ureteric injury. The Kocher maneuver is extended superiorly to widely open the foramen of Winslow. A complete Kocher maneuver is necessary for the subsequent dissection of the pancreatic head from the SMA (Step 6). Particularly important is the division of the leaf of visceral peritoneum that is posterior to the mesenteric vessels; incision of this portion of peritoneum, as it extends from the retroperitoneum to the right lateral aspect of the root of the small bowel mesentery, is necessary prior to performing the SMA dissection.

3. The portal dissection (Fig. 127.10) is initiated by exposing the CHA proximal and distal to the right gastric artery and the GDA. The CHA is exposed by removing the large lymph node(s) which lies directly anterior to this vessel; this cluster of lymph nodes is in continuity with the nodes extending laterally into the retroportal space and also medially, along the left gastric artery origin. When removing the lymph nodes anterior to the CHA, try to avoid entering the left gastric vein which runs transversely and enters the portal or distal splenic vein —this vein can be preserved or ligated if necessary. The right gastric artery, and subsequently the GDA are ligated and divided. The GDA often has a small proximal branch which may originate anteriorly or just along its right lateral border. It is often helpful to ligate and divide this branch separately to obtain adequate length on the proximal GDA such that it can be safely ligated and divided. If tumor extends to within a few millimeters of the GDA, proximal and distal control of the HA is obtained and the GDA is divided flush at its origin. The resulting arteriotomy can be closed with interrupted 6-0 Prolene (Ethicon, Inc., Somerville, NJ) sutures. Overly aggressive dissection at the GDA origin can result in intimal dissection of the HA; this is avoidable and usually the result of blunt dissection due to inadequate vascular control of the proximal and distal HA. Dissection of the HA should be performed with gentle, sharp dissection, especially in patients who have received prior external-beam radiation therapy and in those with extensive scar formation from prior surgery. Division of the GDA allows mobilization of the hepatic (common-proper) artery off of the underlying PV. The PV can be found within the triangle

formed by the CHA (superiorly), GDA (laterally), and the superior border of the pancreas (inferiorly); the PV is deep (posterior) and also medial to the CBD. The PV should always be exposed prior to dividing the common hepatic duct. Cholecystectomy is then performed and the common hepatic duct is transected at its junction with the cystic duct. An anomalous location of the right or left HA should come as no surprise based on careful review of the preoperative CT and careful palpation of the porta hepatis prior to division of the bile duct. A replaced or an accessory right HA arising from the proximal SMA (or occasionally directly from the aorta) may course posterolateral to the PV. Rarely, the entire CHA may arise from the SMA (type IX hepatic arterial anatomy). If the foramen of Winslow was initially obliterated due to adhesions, it should have been re-established at the time of the Kocher maneuver (Step 2). Access to the foramen of Winslow is necessary to palpate the porta hepatis and appreciate the pulsation of an anomalous HA. Rarely, the right HA arising from the proper HA courses posterior to the PV. Following transection of the bile duct, biliary fluid cultures may be sent and any indwelling endobiliary stents are removed. Intraoperative bile cultures may be used to guide therapeutic antibiotic treatment postoperatively in the event of an intra-abdominal or superficial wound infection. A gentle bulldog clamp is placed on the transected hepatic duct to prevent the contaminated bile (if a stent has been in the bile duct, the bile is no longer sterile) from gaining free access to the abdomen until the time of bile duct reconstruction.

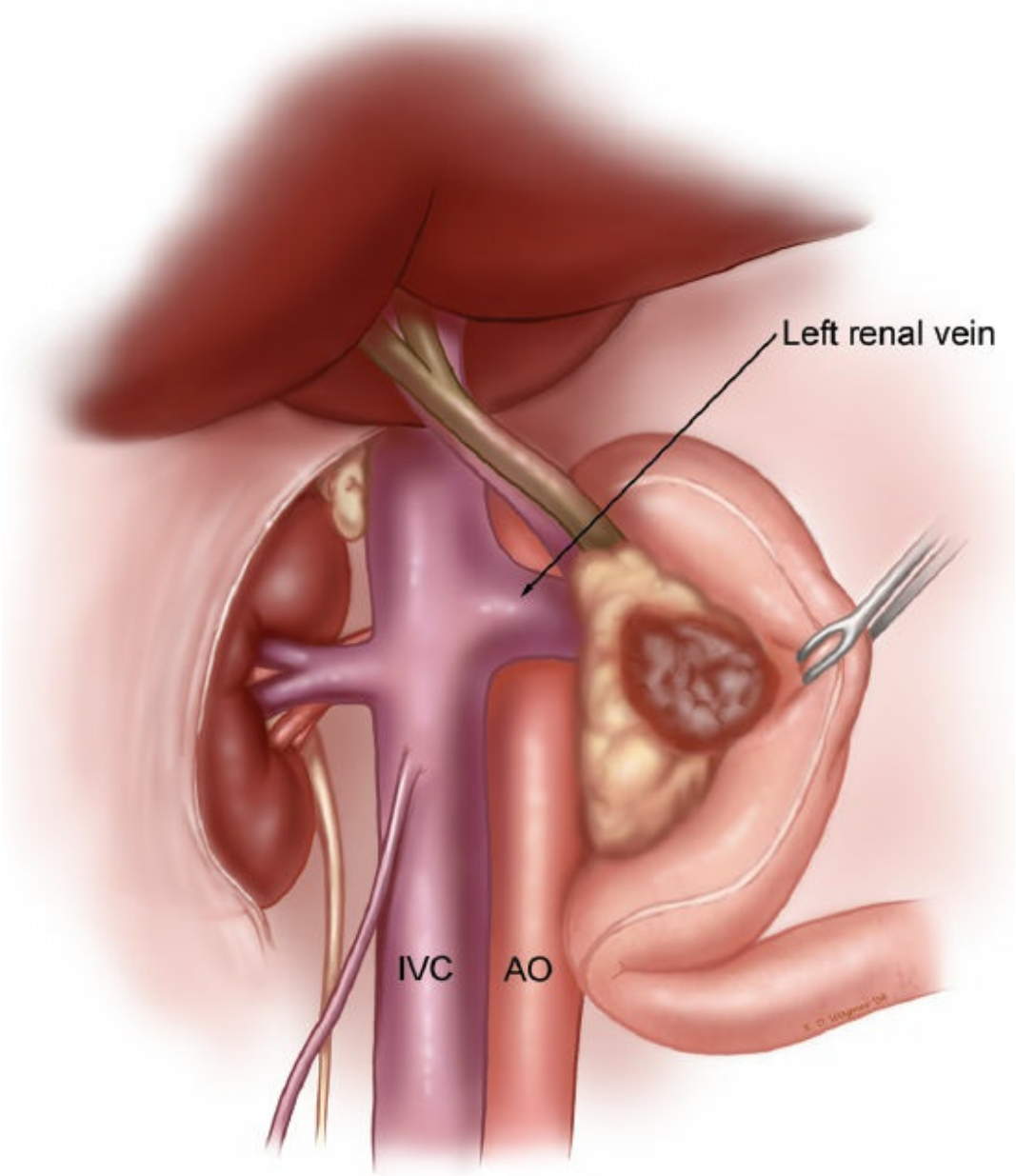

Figure 127.9. Illustration of Step 2. A Kocher maneuver has been performed by first identifying the inferior vena cava (IVC) at the level of the proximal portion of the transverse segment of the duodenum (D3). One can then mobilize the duodenum and pancreatic head off of the IVC in a cephalad direction thereby removing all soft tissue anterior to the IVC. The right gonadal vein is usually preserved, if possible, as it serves as a good landmark to help prevent inadvertent injury to the underlying ureter (which is usually posterior and slightly lateral to the gonadal vein). Note that the Kocher maneuver is continued to the left lateral border of the aorta (AO). An accessory renal artery (which is an end artery) may travel anterior to the IVC and should be seen and preserved; rarely, the main right renal artery may be anterior to the IVC.

The anterior wall of the PV is further exposed following division of the common hepatic duct and medial retraction of the CHA. The PV itself should be identified but not extensively mobilized until Step 6, at which time the stomach and pancreas have been divided. The superior pancreaticoduodenal vein is a constant venous tributary of the PV which drains the cephalad aspect of the pancreatic head and is located at the superolateral aspect of the PV. Bleeding caused by traction injury to this venous tributary may be difficult to control at this time in the operation.

4. The stomach is transected with a gastrointestinal stapler at the level of the third or fourth transverse vein on the lesser curvature and at the confluence of the gastroepiploic veins on the greater curvature (Fig. 127.11). The extent of gastric resection is probably of little importance and we often divide the stomach more distal in location thereby performing a very modest antrectomy. The terminal branches of the left gastric artery are ligated and divided along the lesser curvature of the stomach prior to gastric transection. When opening the lesser omentum, one should specifically look for an accessory or replaced left HA arising from the left gastric artery. Overly aggressive division of the filmy lesser omentum in a caudal direction can easily injure a replaced left HA. The omentum is then divided at the level of the greater curvature transection with the harmonic scalpel (Ethicon Inc., Somerville, NJ) or LigaSure device (Valleylab, Boulder, CO).

   Pylorus-preservation may be considered in patients with small periampullary neoplasms, but should not be performed in patients with bulky pancreatic head tumors, duodenal tumors involving the first or second portions of the duodenum, or lesions associated with grossly positive pyloric or peripyloric lymph nodes. To ensure adequate blood supply to the duodenojejunostomy, the anastomosis is created no more than 2 cm distal to the pylorus.

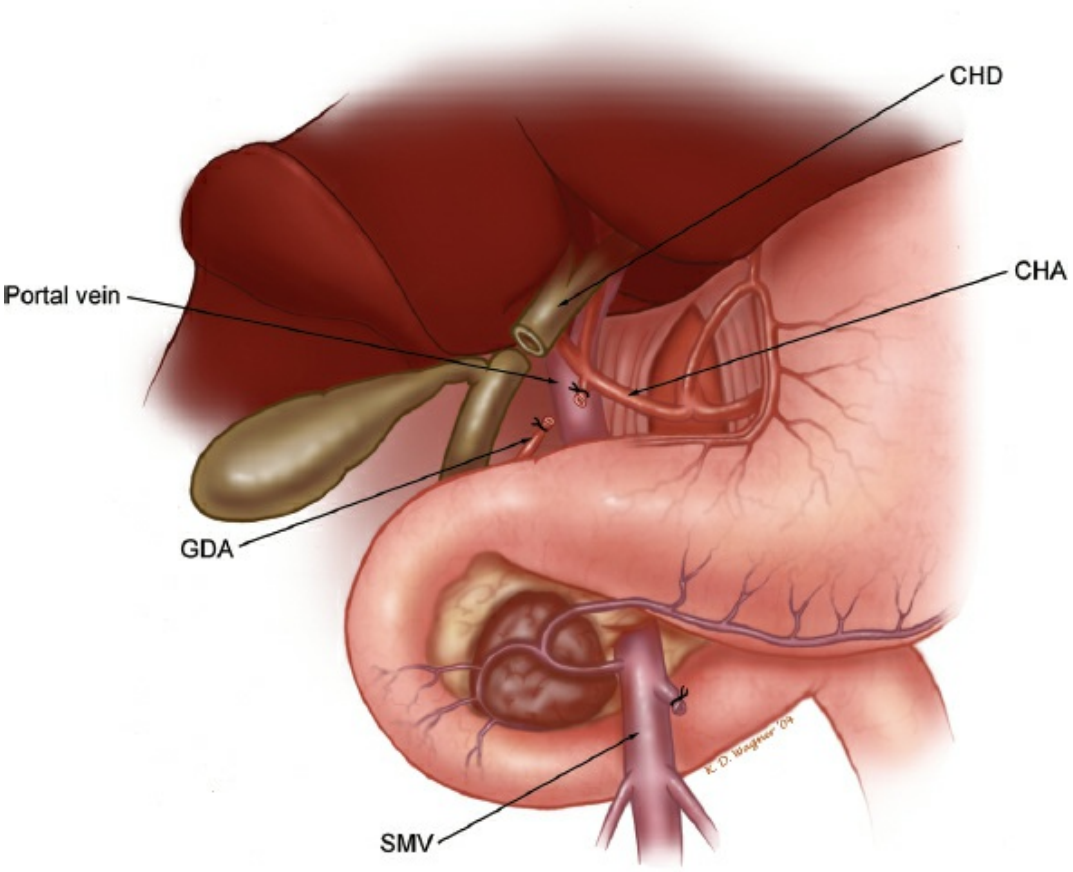

Figure 127.10. Illustration of Step 3. Dissection of the porta hepatis begins with identification of the common hepatic artery (CHA), by removal of the large lymph node which commonly sits anterior to this vessel. The CHA is then followed distally to allow identification and ligation and division of the right gastric artery (not shown) and the gastroduodenal artery (GDA). This allows the CHA-proper hepatic artery to be mobilized cephalad and medial off of the underlying anterior surface of the portal vein (PV). The PV is always identified prior to division of the common hepatic duct (CHD). Careful palpation of the porta hepatis prior to division of the bile duct should alert one to the possibility of an accessory or replaced right hepatic artery traveling posterior to the bile duct and lateral to the portal vein. The CHD is divided at the level of the cystic duct. SMV, superior mesenteric vein.

5. The loose attachments of the ligament of Treitz are taken down with care to avoid injury to the IMV. The jejunum is then transected with a linear GIA stapler approximately 7 to 10 cm distal to the ligament of Treitz, and its mesentery is sequentially ligated and divided (Fig.

127.12). This can be done with ties, the Harmonic scalpel or the LigaSure device. This dissection is continued proximally to involve the fourth and third portions of the duodenum. The duodenal mesentery is divided to the level of the aorta, allowing this devascularized segment of duodenum and jejunum to be reflected beneath the mesenteric vessels into the right upper quadrant.

6. The oncologically most important and difficult part of the operation is Step 6. After traction sutures are placed on the superior and inferior borders of the pancreas, the pancreas is transected (usually with electrocautery) at the level of the PV. If there is evidence of tumor adherence to the PV or SMV, the pancreas is divided more distally (to the patient's left) in preparation for segmental venous resection. The specimen is separated from the SMV by ligation and division of the small venous tributaries to the uncinate process and pancreatic head (Fig. 127.13). Complete removal of the uncinate process from the SMV is required for full mobilization of the SMV-PV confluence and subsequent identification of the SMA. Failure to fully mobilize the SMV-PV confluence risks injury to the SMA (because it is not adequately exposed) and often will result in a positive SMA resection margin. The more difficult it is to expose the SMA, the more important it is to do this dissection—the SMA is unlikely to be injured if the surgical team can see it. The SMA dissection should result in removal of all of the mesenteric soft tissue adjacent to (to the right of) the SMA (Fig. 127.14). In addition, exposure of the SMA is necessary for direct ligation of the inferior pancreaticoduodenal artery (IPDA) or arteries. Mass ligation of the IPDA(s) with mesenteric soft tissue is a major cause of postoperative hemorrhage as this vessel retracts from its poorly placed tie or ligature; again often a preventable complication.

   Once the pancreatic head and uncinate process are completely separated from the SMV and SMV-PV confluence, one may experience bleeding from the specimen due to venous hypertension. This bleeding indicates that the IPDAs from the SMA are still intact. One option is to leave the superior pancreaticoduodenal vein (located at the superolateral aspect of the PV) intact until the more caudal inferior IPDA is ligated. This usually does not limit the mobilization of the SMV at the level of the uncinate process and still allows exposure of the SMA.

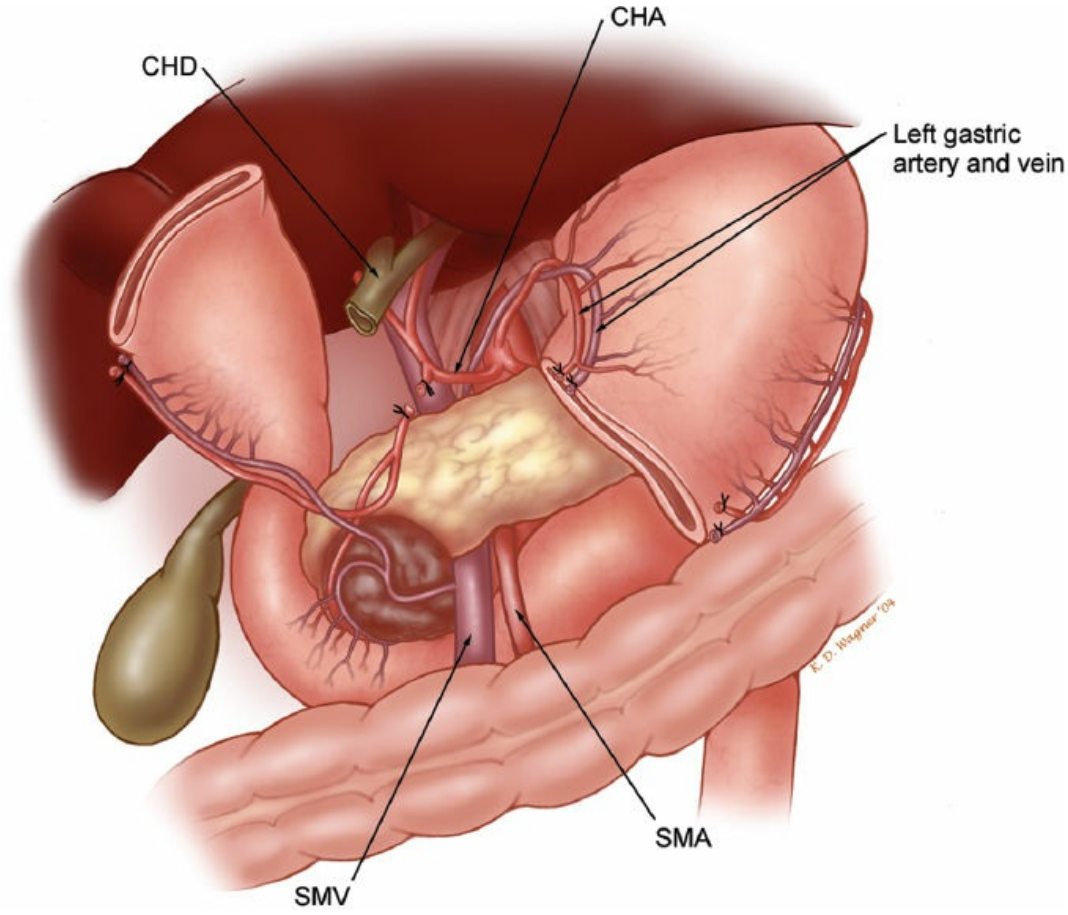

Figure 127.11. Illustration of Step 4. The antrum of the stomach is resected with the main specimen by dividing the stomach at the level of the third or fourth transverse vein on the lesser curvature. CHA, common hepatic artery; CHD, common hepatic duct; SMA, superior mesenteric artery; SMV, superior mesenteric vein.

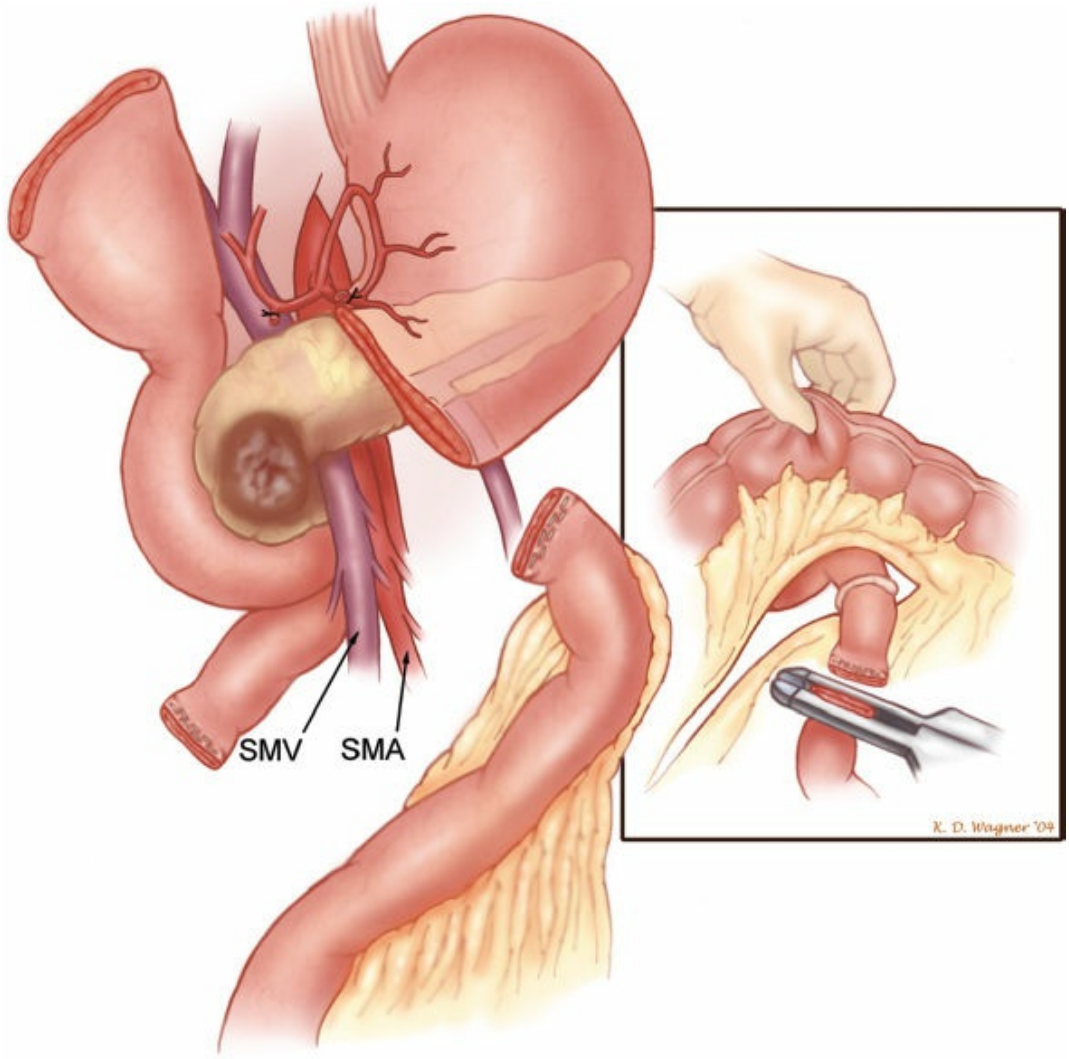

Figure 127.12. Illustration of Step 5. Transection of the jejunum is followed by ligation and division of its mesentery. The loose attachments of the ligament of Treitz are taken down, and the fourth and third portions of the duodenum are mobilized by dividing their short mesenteric vessels. The duodenum and jejunum are then reflected underneath the mesenteric vessels in preparation for the final and most important part of pancreaticoduodenectomy. SMA, superior mesenteric artery; SMV, superior mesenteric vein.

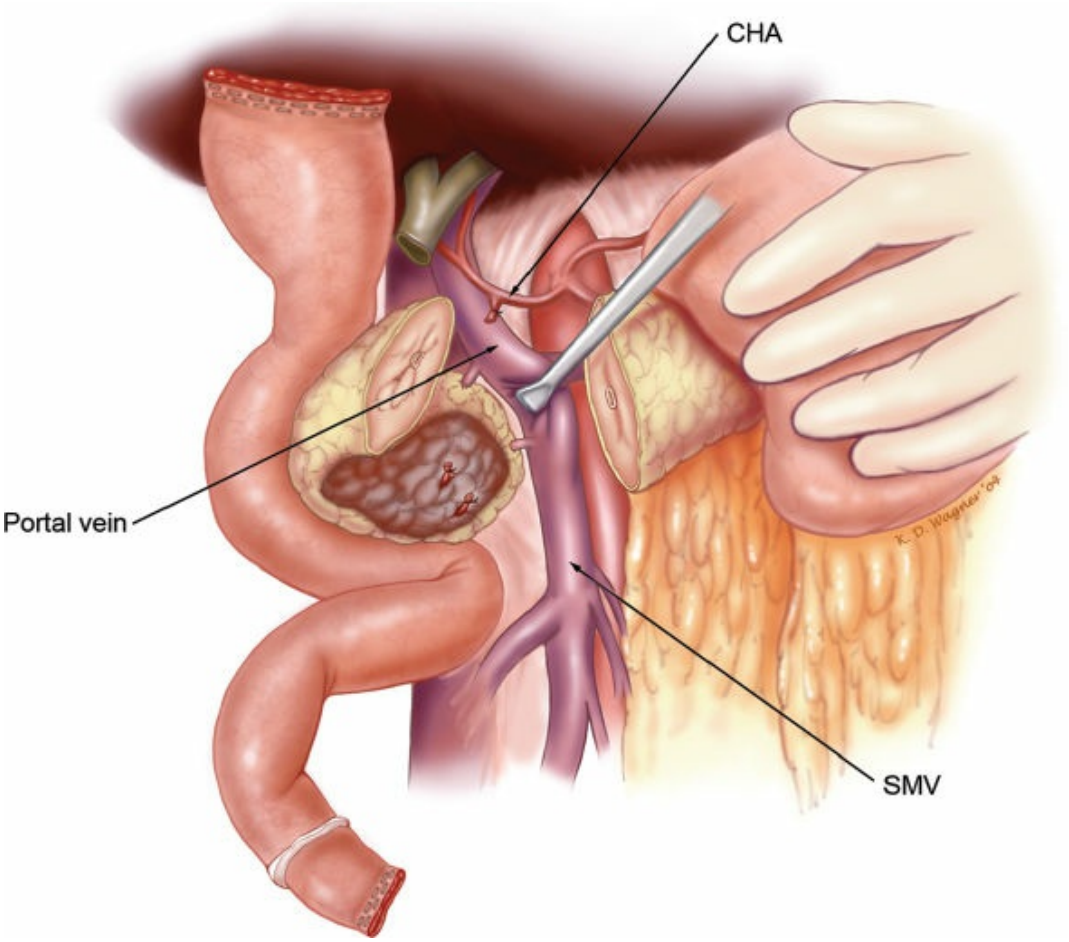

Figure 127.13. Illustration of Step 6. The pancreatic head and uncinate process are separated from the superior mesenteric-portal vein confluence. The pancreas has been transected at the level of the portal vein and the pancreatic head is reflected laterally, allowing identification of small venous tributaries from the portal vein and superior mesenteric vein (SMV). These tributaries are ligated and divided. There is one fairly constant venous tributary of the portal vein to the most cephalad pancreatic head often referred to as the superior pancreaticoduodenal vein. Some surgeons prefer to leave this venous branch intact until they have divided at least one of the more caudal inferior pancreaticoduodenal arteries (off of the superior mesenteric artery) thereby minimizing venous hypertension in the specimen which contributes to increased blood loss during this portion of the dissection. CHA, common hepatic artery.

Proper mobilization of the SMV involves identification of the jejunal branch of the SMV (also often referred to as the first jejunal branch). This branch originates from the right posterolateral aspect of the SMV (at the

level of the uncinate process), most often travels posterior to the SMA, and enters the medial (proximal) aspect of the jejunal mesentery (Fig. 127.15). Rarely, the jejunal branch may course anterior to the SMA, a situation which makes this dissection a bit easier. The jejunal branch usually gives off at least two venous tributaries to the uncinate process; these tributaries should be divided (Fig. 127.15B). If tumor involvement of the SMV (at the level of the jejunal branch) prevents dissection of the uncinate process from the SMV, the jejunal branch should be divided (in this case we expose the SMA medial to the SMV before dividing the jejunal branch). Injury to the distal SMV at this level, or a tangential laceration in its jejunal branch (as it courses posterior to the SMA), is difficult to control and probably represents the most frequent cause of iatrogenic SMA injury as one attempts to suture a venous injury prior to adequate exposure of the SMA (which is just medial in location and can be injured with a suture quite easily). Once the uncinate process is separated from the distal SMV, medial retraction of the SMV-PV confluence allows one to expose the SMA if it had not been exposed previously. As noted above, if mobilization of the distal SMV is challenging, exposure of the SMA medial to the SMV is a helpful technique and one that is under-utilized. This will also allow for medial exposure of the jejunal branch of the SMV and separation of the specimen from the SMA and the SMV at the level of the uncinate process. The specimen is then separated from the right lateral wall of the SMA, which is dissected to its origin at the aorta (Fig. 127.16). Direct exposure of the SMA avoids iatrogenic injury and ensures direct ligation of the IPDA(s). Most patients have two IPDAs that are identified and ligated at their origins from the SMA. As mentioned previously, the soft tissue adjacent to the proximal 3 to 4 cm of the SMA represents the SMA (or retroperitoneal) margin. A grossly positive SMA margin (R2 resection) should not occur if high-quality preoperative imaging is performed and accurately interpreted. A microscopically positive SMA margin (R1) can result from tumor spread along perineural sheaths and does not always result from direct tumor extension.

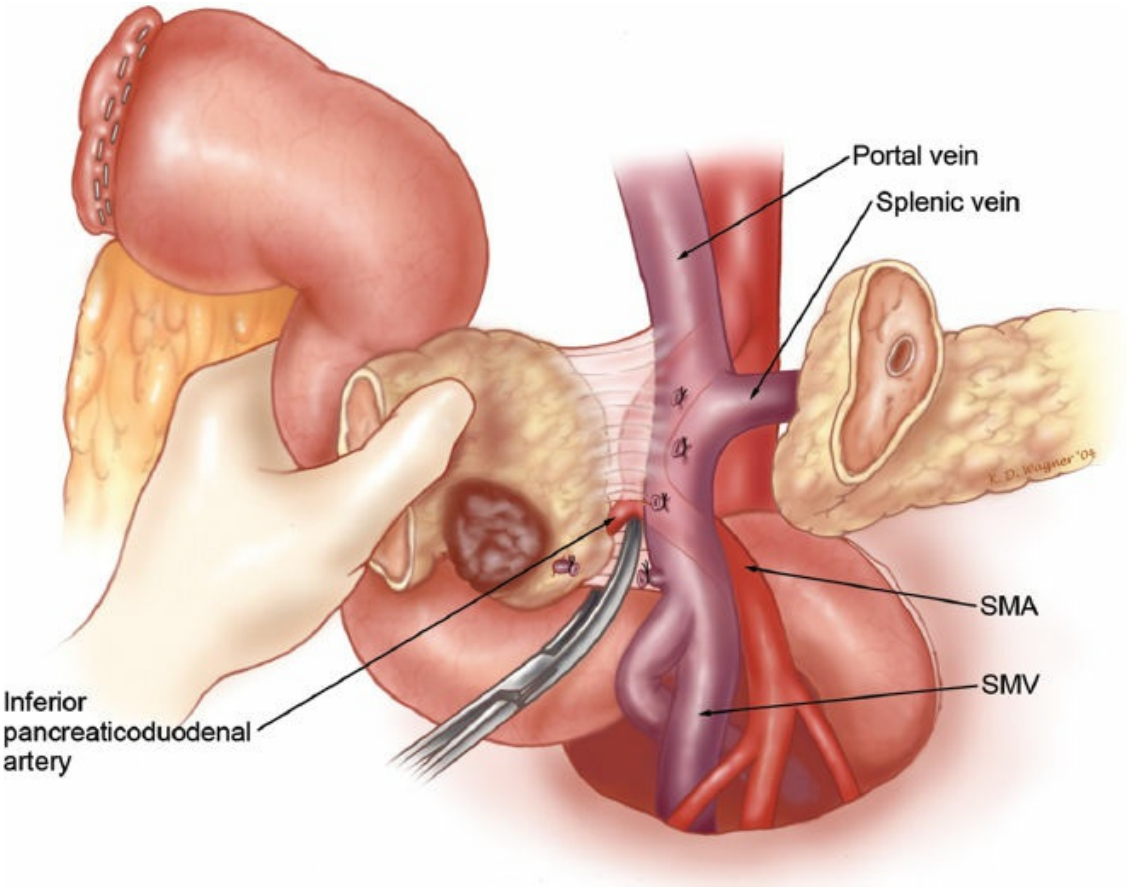

Figure 127.14. Illustration of attempted removal of the pancreaticoduodenectomy specimen from the mesenteric vessels without mobilization of the superior mesenteric vein (SMV) and direct identification of the superior mesenteric artery (SMA). This maneuver should not be performed, as it risks injury to the SMA and inadequate control of the inferior pancreaticoduodenal arteries due to their mass ligation with adjacent soft tissue. Failure to directly identify and individually ligate the inferior pancreaticoduodenal arteries is the major cause of postoperative hemorrhage. SMA injury and postoperative hemorrhage are avoidable complications if the SMA is routinely exposed for identification (rather than the surgeon relying on palpation). This technique also facilitates a complete retroperitoneal/mesenteric dissection minimizing the potential for a margin positive resection.

Frozen-section evaluation of the pancreaticoduodenectomy specimen is limited to analysis of the pancreatic and common hepatic duct transection margins. Positive resection margins on the biliary or pancreatic duct mandate further resection until clear margins are achieved. Changes due to chronic pancreatitis may result in dysplastic cells at the pancreatic

transection margin on frozen-section evaluation. Further resection of the pancreas should be performed only if there is histologic evidence, on frozen-section analysis, of invasive carcinoma at the margin. Low-moderate grade dysplasia without carcinoma is not usually an indication for further pancreatic resection. Invasive carcinoma extending along the main pancreatic duct is uncommon in the absence of adenocarcinoma in the background of intraductal papillary mucinous neoplasm (IPMN).

Complete permanent-section analysis of the pancreaticoduodenectomy specimen requires that it be oriented for the pathologist to enable accurate assessment of the SMA margin and other standard pathologic variables. By removing all tissue to the right of the SMA, further resection at this margin is not possible. However, the SMA margin must be identified and inked, it cannot be accurately assessed in a retrospective fashion.

To summarize, the operation as described above emphasizes full mobilization of the SMV-PV confluence, exposure of the SMA, and removal of all mesenteric soft tissue and perineural tissue to the right of this vessel. Direct exposure of the SMA should be a routine part of pancreaticoduodenectomy, will minimize the risk for iatrogenic injury of this vessel, and will ensure direct ligation of the IPDA(s) thereby minimizing the chance for early postoperative intra-abdominal hemorrhage. The high incidence of local recurrence following pancreaticoduodenectomy mandates that greater attention be paid to the SMA margin—the soft tissue margin along the right lateral border of the proximal 3 to 4 cm of the SMA.

Vascular Resection

Venous resection should only be performed in carefully selected patients who have tumor adherence to the SMV or SMV-PV confluence but no evidence of tumor extension to the SMA or celiac axis. With high-quality CT imaging, the need for venous resection should be anticipated and the surgical strategy decided preoperatively, thereby obviating lengthy operating room delays from indecision and increased morbidity/mortality from technical misadventures. Surgeons who perform pancreaticoduodenectomies should be familiar with standard vascular techniques for resection and reconstruction of the SMV-PV confluence.

Steps 1 through 5 of pancreaticoduodenectomy are completed as described above. If a Cattell–Braasch maneuver had been performed, the right colon is returned to its normal anatomic position, removing the

clockwise twist in the mesentery that often occurs during the retroperitoneal/mesenteric dissection; this is important to do before segmental resection of the SMV-PV confluence. Tumor adherence to the lateral wall of the SMV-PV confluence prevents dissection of the SMV and PV off the pancreatic head and uncinate process, thereby inhibiting medial retraction of the SMV-PV confluence (and lateral retraction of the specimen). Historically, division of the splenic vein was considered standard practice. This allowed complete exposure of the SMA medial to the SMV and provided increased SMV and PV length (PV no longer tethered by the splenic vein) for a primary venous anastomosis following segmental vein resection (Fig. 127.17). The retroperitoneal dissection is then completed by sharply dividing the soft tissues anterior to the aorta and to the right of the exposed SMA leaving the specimen attached only by the SMV-PV confluence. Vascular clamps are placed 2 to 3 cm proximal (on the PV) and distal (on the SMV) to the involved venous segment, and the vein is transected, allowing tumor removal. A generous 2- to 3-cm segment of SMV-PV confluence can be resected without the need for interposition grafting if the splenic vein is divided. Venous resection is always performed with inflow occlusion of the SMA (Rommel tourniquet) to prevent small bowel edema (which makes pancreatic and biliary reconstruction more difficult). Systemic heparinization (2,500 to 4,000 U of systemic heparin) is employed prior to occluding the SMA. The free ends of the vein are reapproximated using interrupted 6-0 Prolene sutures. It is very important to mark the anterior surface of the SMV and PV with a marking pen prior to venous resection to prevent a small twist in the SMV when performing the anastomosis.

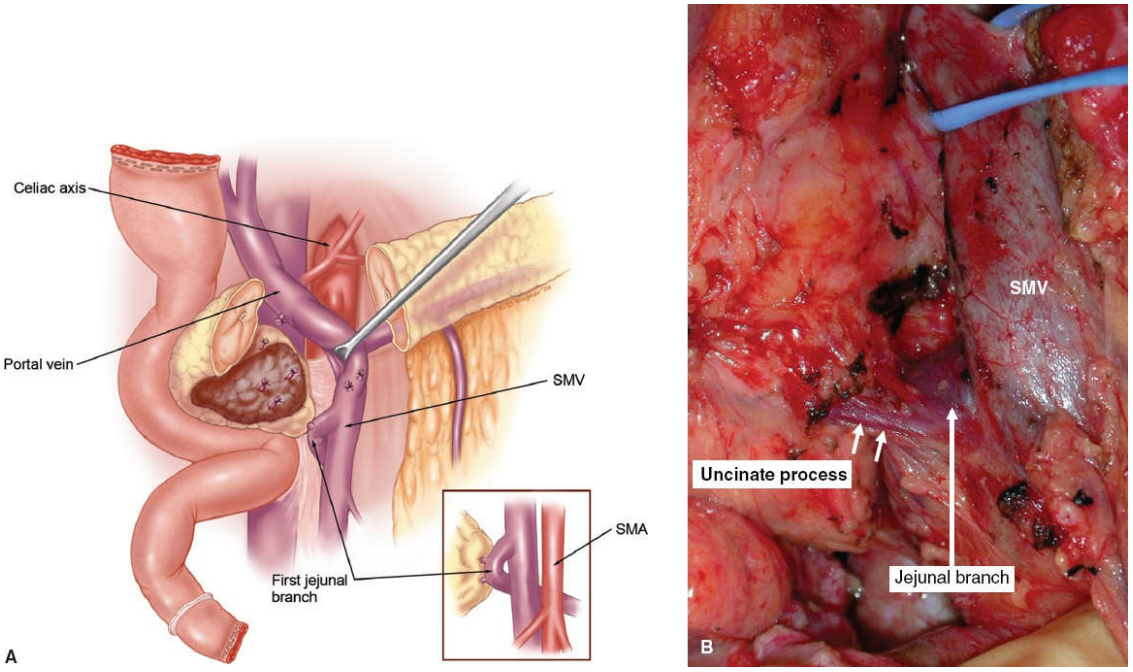

Figure 127.15. Illustration (**A**) and intraoperative photograph (**B**) of the important surgical anatomy of the superior mesenteric vein (SMV) at the level of the uncinate process. The SMV usually bifurcates into two main branches, one to the ileum and one to the jejunum. Adequate venous return from the small bowel requires that one or the other of these two main SMV tributaries are intact. The jejunal branch of the SMV (often referred to as the first jejunal branch) drains the proximal jejunum, travels posterior to the superior mesenteric artery (SMA), and enters the SMV along its posterolateral wall. The jejunal branch usually has a few venous tributaries that drain the uncinate process (*inset*). If necessary, the jejunal branch can be divided. The most feared complication during this part of the operation is a tangential laceration of the jejunal branch extending posterior to the SMA. In an attempt to control such an injury, poorly placed sutures may result in an injury to the SMA. Very rarely the jejunal branch will travel anterior to the SMA which simplifies this part of the operation. Intraoperative photograph (**B**) of the jejunal branch of the SMV and a small venous tributary (*white arrows*) to the uncinate process.

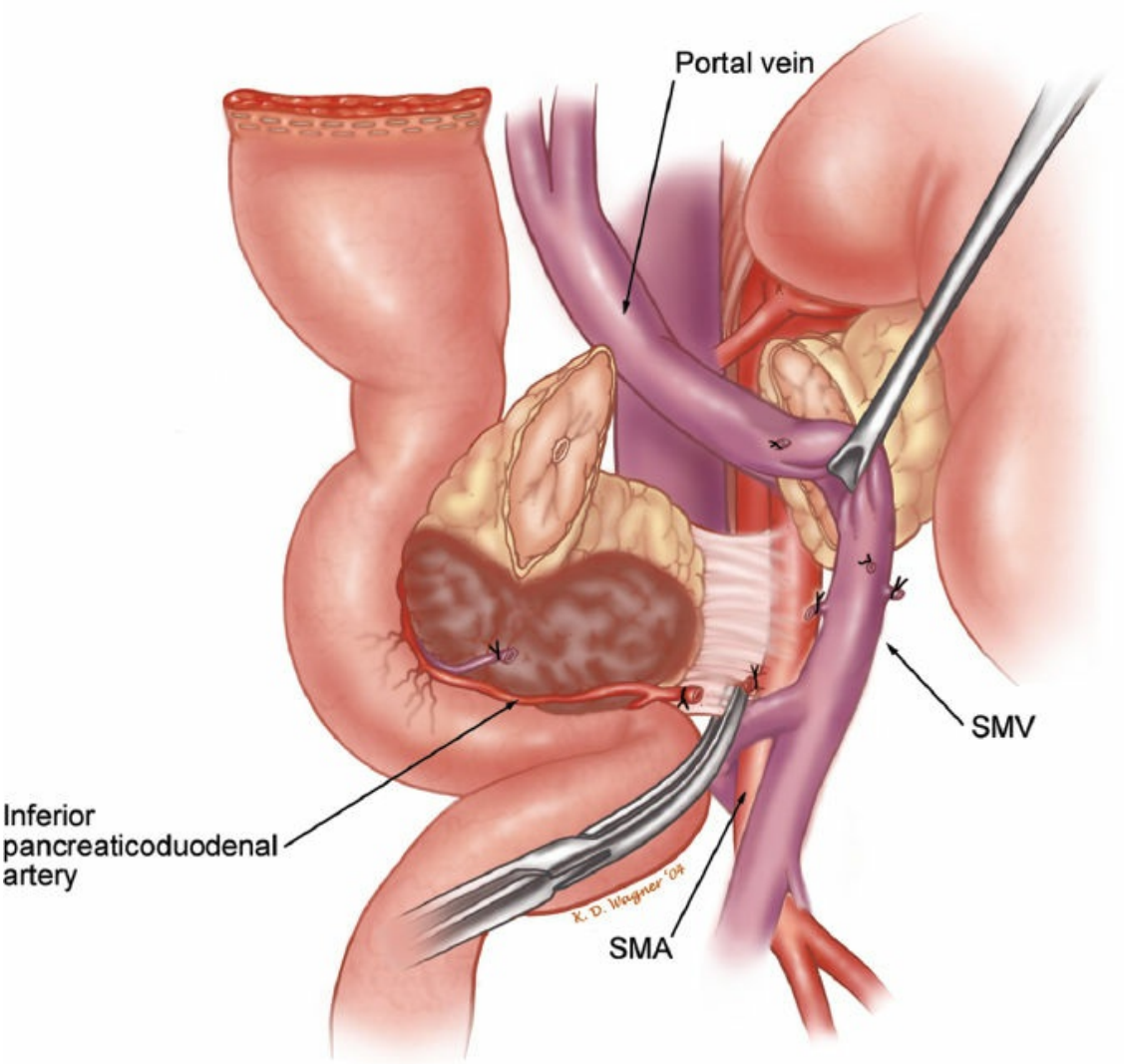

Figure 127.16. Illustration of the continuation of Step 6, and the final step in resection of the specimen. Medial retraction of the superior mesenteric-portal vein confluence facilitates dissection of the soft tissues adjacent to the lateral wall of the proximal superior mesenteric artery (SMA); this site represents the SMA margin. The inferior pancreaticoduodenal artery (or arteries) is identified at its origin from the SMA, ligated, and divided. SMV, superior mesenteric vein.

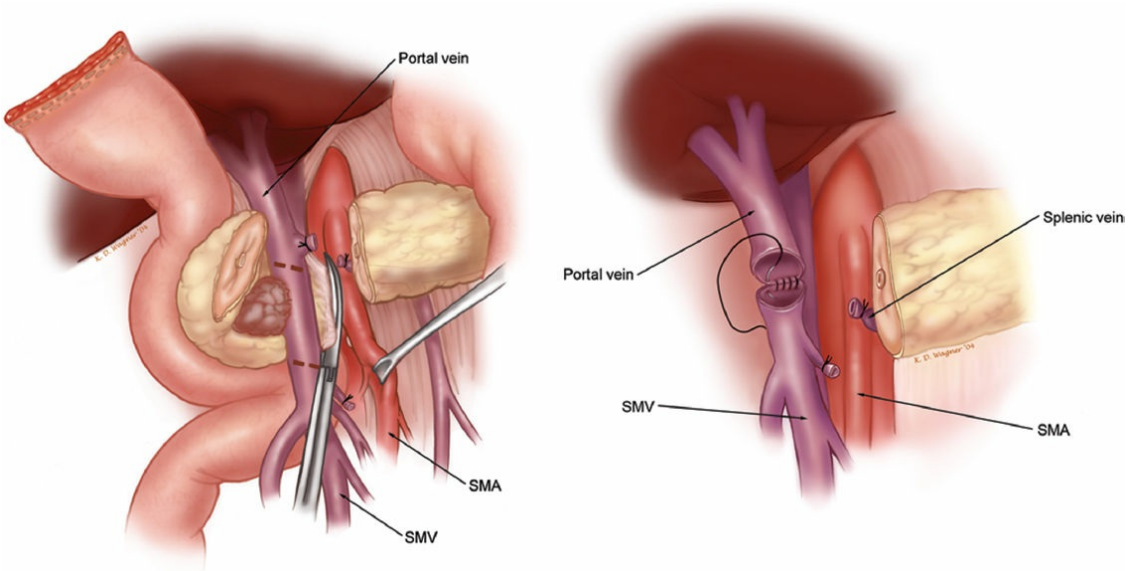

Figure 127.17. Illustration of the final step in pancreaticoduodenectomy when segmental venous resection is required and the decision is made to divide the splenic vein. In the early experience with resection and reconstruction of the superior mesenteric-portal vein (SMPV) confluence, splenic vein ligation was routine. Currently, we ligate the splenic vein only when the tumor involves the splenic vein confluence. By dividing the splenic vein, the superior mesenteric artery (SMA), which is identified medial to the superior mesenteric vein (SMV), can be exposed to its origin from the aorta and the pancreatic head removed from the right lateral border of the SMA. This dissection is considerably more difficult when the splenic vein-SMV–portal vein confluence is intact. The tumor is then attached only by the SMPV confluence, which can be divided proximal and distal to the involved segment. Reconstruction is performed (during inflow occlusion) by an end-to-end anastomosis of the portal vein and the SMV with 6-0 interrupted Prolene sutures. The anastomosis can be run (as shown) or interrupted; the authors frequently interrupt the anastomosis, especially when there is a size discrepancy between the portal vein and the SMV.

Upper gastrointestinal hemorrhage due to sinistral portal hypertension following splenic vein ligation can occur. This is possible if the IMV enters the SMV rather than the splenic vein; something which is usually apparent on preoperative CT imaging. In contrast, when the IMV enters the splenic vein, it provides a route for collateral (retrograde) venous flow (when the splenic vein is divided) from the splenic vein to the systemic venous circulation. When the splenic vein must be divided and the IMV

does not enter the splenic vein, we prefer to create a splenorenal anastomosis to allow decompression of the stomach and spleen into the systemic venous circulation.

Ideally, the splenic vein–PV junction should be preserved if possible, especially if the IMV enters the SMV. However, splenic vein preservation is possible only when tumor invasion of the SMV or PV does not involve the splenic vein confluence (Fig. 127.18). Preservation of the splenic vein–SMV–PV confluence significantly limits the mobilization of the PV and prevents primary anastomosis of the SMV after segmental SMV resection unless it is limited to ≤2 cm. Therefore, most patients who undergo SMV resection with splenic vein preservation require an interposition graft. Our preferred conduit for interposition grafting is the (left) internal jugular vein. Preservation of the splenic vein adds significant complexity to venous resection because it prevents direct access to the most proximal 3 to 4 cm of the SMA (medial to the SMV). Venous resection and reconstruction can be performed either before the specimen has been separated from the right lateral wall of the SMA or after complete mesenteric dissection by separating the specimen first from the SMA. Both techniques require significant experience with pancreaticoduodenectomy and are described in detail in previous publications (see Suggested Readings). The different forms of venous resection and reconstruction are illustrated in Figure 127.19.

An aberrant right HA may arise from the SMA as an accessory right HA (type VI, VII, or VIIIb hepatic arterial anatomy), in which case a normal right HA also arises from the celiac axis; ligation of the accessory artery in such a case would not affect hepatic or bile duct arterial flow. A replaced right HA arising from the SMA (type III or VIIIa), unlike an accessory right HA, represents the only direct arterial inflow to the right hepatic lobe. Because the right and left hepatic arteries communicate within the liver, ligation of the right HA should be tolerated assuming a normal level of serum bilirubin and normal PV flow. However, because the proximal bile duct receives virtually all of its arterial supply from the right HA following interruption of cephalad flow from the GDA, we prefer to revascularize the right HA when possible. In addition, following pancreaticoduodenectomy and the resulting hepaticojejunostomy, there will be life-long communication of the biliary system with the gastrointestinal tract resulting in contaminated bile and the risk for hepatic abscess in the setting of “relative” ischemia of the right hepatic lobe due to

right HA ligation. Fortunately, an accessory right HA arising from the SMA infrequently requires resection at the time of pancreaticoduodenectomy because the majority of resectable tumors are located more anteriorly in the pancreatic head or uncinate process. Rarely, the entire CHA may arise from the SMA (type IX). Failure to recognize this anatomic variant and inadvertent ligation of the HA may result in fatal hepatic necrosis.

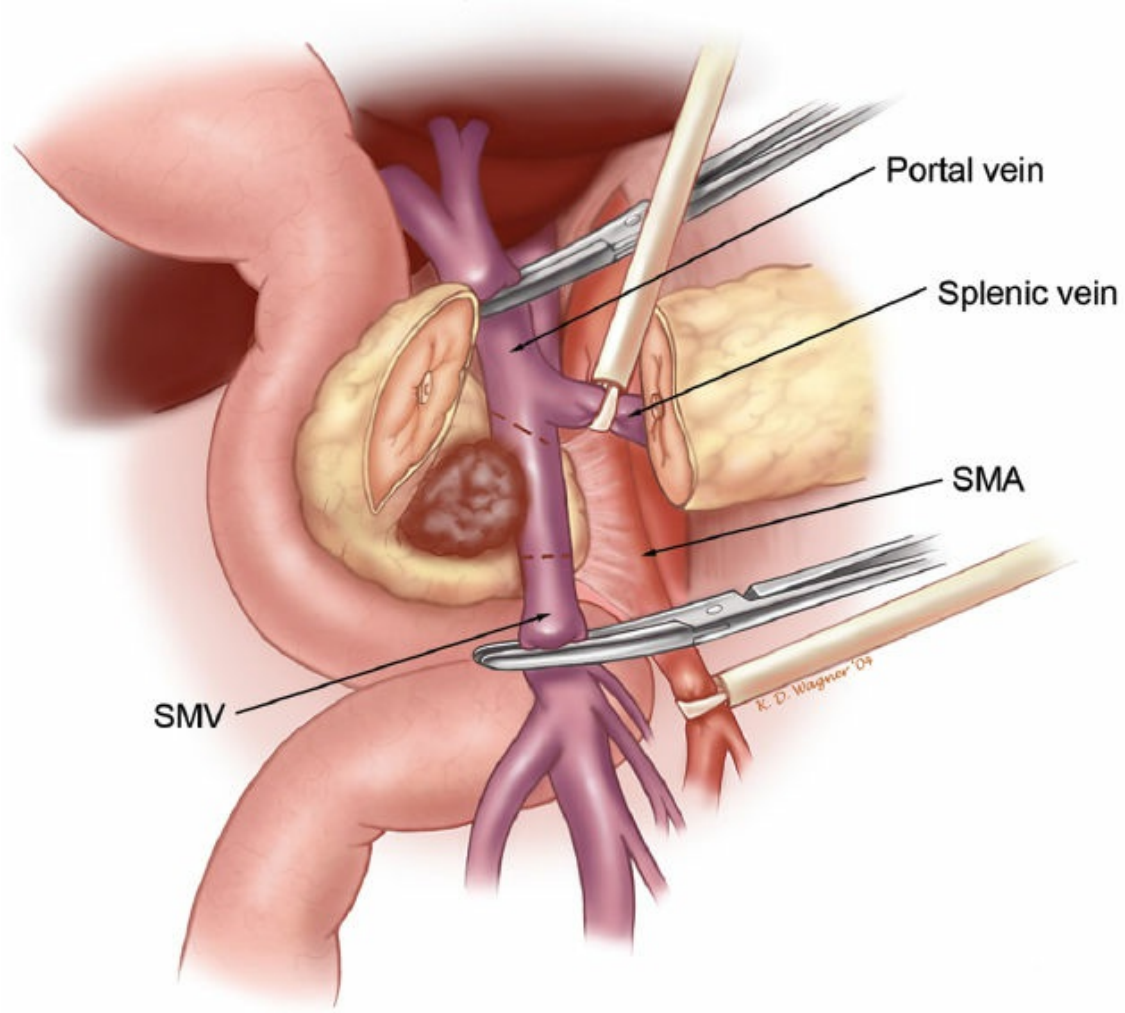

Figure 127.18. An illustration of resection of the superior mesenteric vein (SMV) with splenic vein preservation. The intact splenic vein tethers the portal vein, making a primary anastomosis impossible in most cases. With the splenic vein intact, one cannot complete the dissection of the specimen from the right lateral border of the superior mesenteric artery (SMA) to the origin of this vessel in standard fashion. Therefore, options include either placing the graft prior to specimen removal, or separation of the pancreatic head from the SMA by medial rotation of the specimen as described by Leach et al (see

Suggested Readings). Segmental resection of the SMV with splenic vein preservation adds significant complexity to this operation but prevents the potential complications of hypersplenism (which may result in mild to significant thrombocytopenia, thereby possibly complicating the delivery of cytotoxic chemotherapy) and sinistral portal hypertension (with the risk for gastroesophageal varices and hemorrhage).

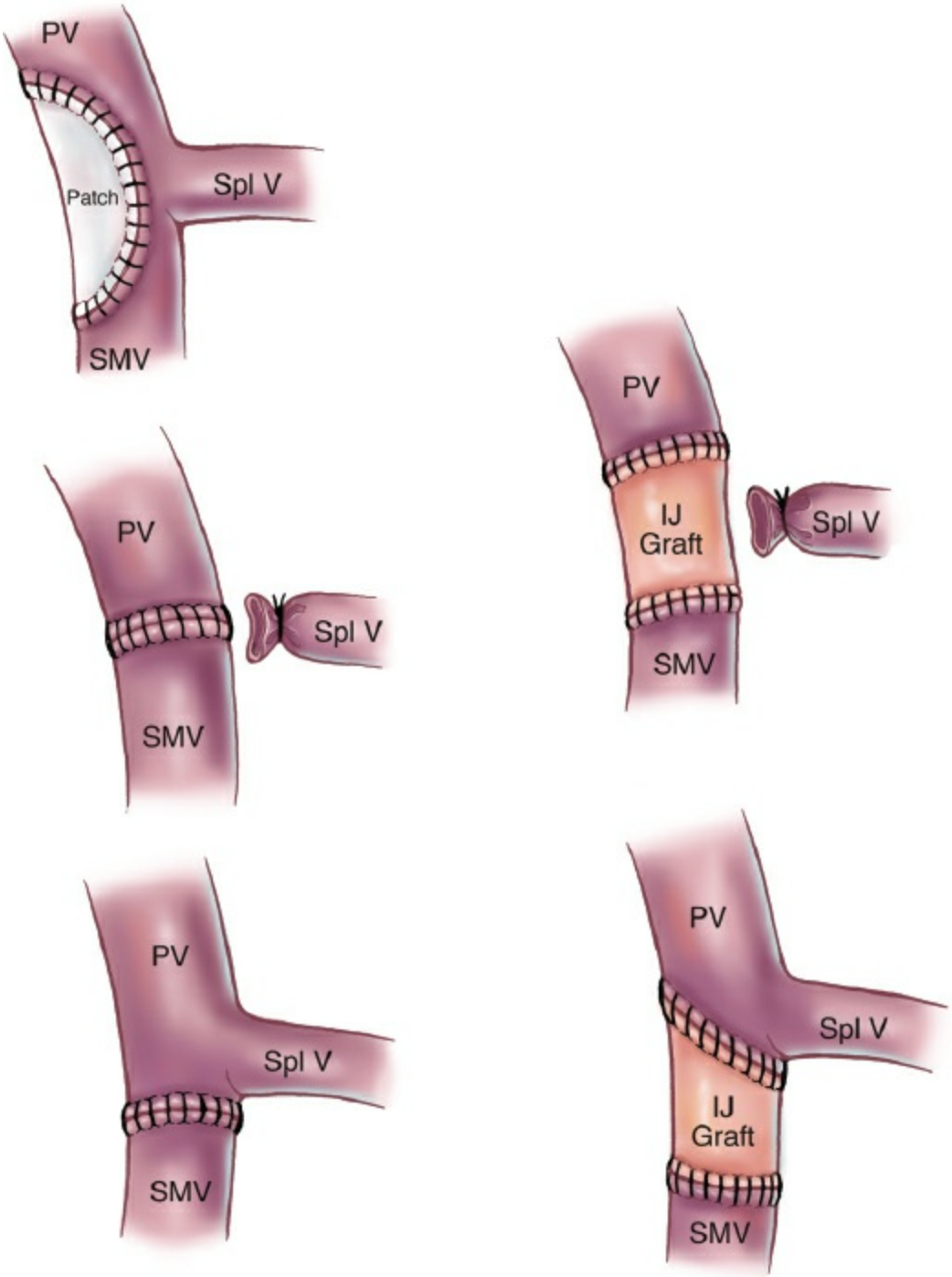

Figure 127.19. Illustration of the different types of venous reconstruction used at the time of pancreaticoduodenectomy.

When a patch is needed we use the saphenous vein and when an interposition graft is needed we use the left internal jugular (IJ) vein. PV, portal vein; SMV, superior mesenteric vein; Spl V, splenic vein. (Modified from Tseng JF, Raut CP, Lee JE, et al. Pancreaticoduodenectomy with vascular resection: margin status and survival duration. *J Gastrointest Surg* 2004;8(8):935–50; with permission of Springer.)

Celiac axis stenosis with compensatory retrograde flow in the GDA from the SMA may result from atherosclerotic disease, median arcuate ligament syndrome, or inflammatory entrapment (the latter two being the most common). We always assess the HA pulse at the time of surgery; if the pulse is significantly decreased in intensity or disappears upon ligation of the GDA, the CHA is then dissected to its origin at the celiac axis (and the diaphragmatic median arcuate ligament divided) in an attempt to differentiate extrinsic compression (most common) from atherosclerotic disease. If flow is not improved, a reversed saphenous vein interposition graft between the aorta and the HA at the site of the GDA origin is performed.

PANCREATIC, BILIARY, AND GASTROINTESTINAL RECONSTRUCTION

Reconstruction after pancreaticoduodenectomy proceeds first with the pancreatic anastomosis.

1. The pancreatic remnant is mobilized from the distal splenic vein and proximal splenic artery for a distance of 2 to 2.5 cm. Failure to adequately mobilize the pancreatic remnant results in poor suture placement at the pancreaticojejunal anastomosis, especially in large patients with deep abdominal cavities. Injury to the proximal splenic artery can occur when mobilizing the pancreatic remnant if one does not appreciate the location of this vessel. The transected jejunum is brought through a generous incision in the transverse mesocolon to the left of the middle colic vessels. By using a defect in the transverse mesocolon to the left (rather than right) of the middle colic vessels, the jejunal mesentery is under no tension as it extends directly cephalad. The jejunum is brought retrocolic rather than retroperitoneal (posterior to the mesenteric vessels in the bed of the resected duodenum). A one- or two-layer, end-to-side, duct-to-mucosa pancreaticojejunostomy is performed. If the pancreatic duct is not dilated, we use a small Silastic

stent (Dow Corning, Midland, MI) (Fig. 127.20). The anastomosis between the pancreatic duct and the small bowel mucosa is completed with 4-0 or 5-0 monofilament sutures (we prefer PDS). Each stitch incorporates a generous bite of the pancreatic duct and a full-thickness bite of the jejunum. The posterior knots are tied on the inside and the lateral and anterior knots on the outside. Prior to the anterior sutures being tied, the stent (when utilized) is placed across the anastomosis so that it extends into the pancreatic duct and small bowel for a distance of approximately 2 cm.

When the pancreatic duct is not dilated and/or the pancreatic substance is soft, one can perform an anastomosis that invaginates the cut end of the pancreas into the side of the jejunum using a running, double-armed, 4-0 nonabsorbable monofilament suture. This technique is rarely used by the authors because even a nondilated pancreatic duct can usually be anastomosed using a careful duct-to-mucosa technique. Another option for the high-risk anastomosis (soft gland, nondilated duct) is a pancreaticogastrostomy as recently championed by Dr. George Kazantsev and colleagues.

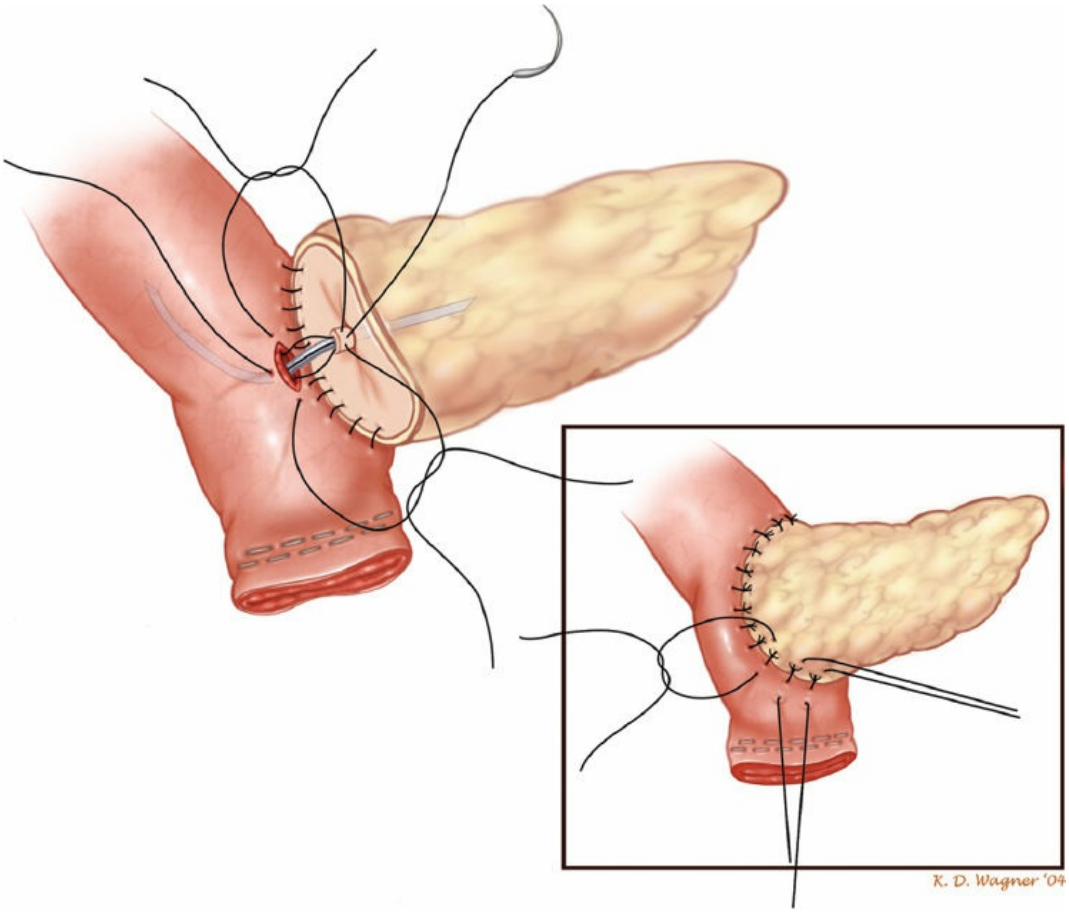

Figure 127.20. Illustration of pancreaticojejunostomy. A two-

layer, end-to-side, duct-to-mucosa retrocolic pancreaticojejunostomy is performed with (when the pancreatic duct is not dilated) or without a small stent. When used, the stent (4 to 5 cm long) is sewn to the pancreatic duct with a single absorbable monofilament suture.

2. A single-layer biliary anastomosis is performed using interrupted 4-0 or 5-0 absorbable monofilament sutures (Fig. 127.21). An interrupted technique is utilized to avoid purse-stringing of the anastomosis. It is important to align the jejunum with the bile duct to avoid tension on the pancreatic and biliary anastomoses. A stent is rarely used in the construction of the hepaticojejunostomy even when the bile duct is not dilated.
3. An antecolic, end-to-side gastrojejunostomy is constructed in two layers. Starting from the greater curvature, approximately 6 cm of the gastric staple line is removed. A posterior row of 3-0 silk sutures is followed by a full-thickness inner layer of running monofilament sutures; the anterior row of silk sutures completes the anastomosis. The distance between the biliary and gastric anastomoses should be at least 50 cm, thereby allowing the jejunum to assume its antecolic position (for the gastrojejunostomy) without tension, and also preventing bile reflux into the liver. An antecolic gastrojejunostomy is favored to prevent possible outlet obstruction caused by the colonic mesentery. Finally, the jejunal limb should be aligned so that the efferent limb is adjacent to the greater curvature of the stomach. A 10-Fr feeding jejunostomy tube may be placed distal to the gastrojejunostomy. Prior to abdominal closure, the abdomen is carefully irrigated and the small bowel is run to ensure proper alignment. In patients with endobiliary stents, the bile is contaminated and often has had free access to at least the right upper quadrant of the abdomen when completing the biliary anastomosis; careful irrigation may prevent postoperative infectious complications. The use of drains remains an active area of controversy in the field of pancreatic surgery, and many surgeons still drain both the hepaticojejunostomy and the pancreaticojejunostomy (the authors do not). We do place a single drain in the right upper quadrant as lymphatic leak is common following the dissection described above and a drain for 3 to 4 days prevents ascites formation. We remove this drain when the output is less than approximately 200 to 250 mL/day; we do not check amylase levels in the drain fluid. Finally, the mobilized falciform ligament (carefully preserved when the abdomen

was opened) is placed between the HA, at the level of the GDA stump, and the afferent jejunal limb to cover the GDA stump (Fig. 127.22). A tongue of omentum can be utilized if the falciform is attenuated. This is a simple strategy to minimize the risk for pseudoaneurysm formation at the site of the GDA stump in the event of a pancreatic anastomotic leak and resulting abscess formation. Indeed, careful attention to the use of vascularized tissue to cover the CHA can come very close to eliminating vascular complications associated with this operation.

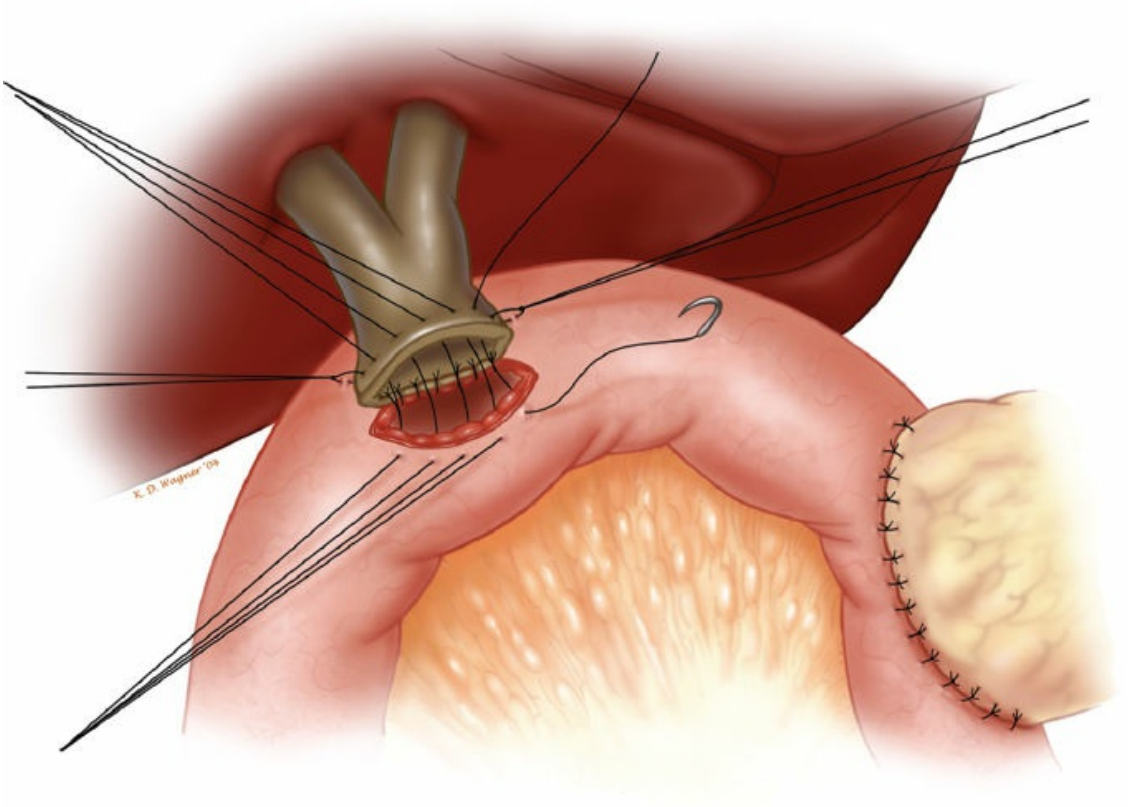

Figure 127.21. Illustration of hepaticojejunostomy. A one-layer, end-to-side hepaticojejunostomy is performed with 4-0 or 5-0 absorbable monofilament sutures distal to the pancreaticojejunostomy. A stent is rarely placed in this anastomosis. Care is taken to allow enough distance between the pancreatic and biliary anastomoses so the falciform ligament can be placed between the anastomoses anterior to the hepatic artery and posterior to the jejunal limb.

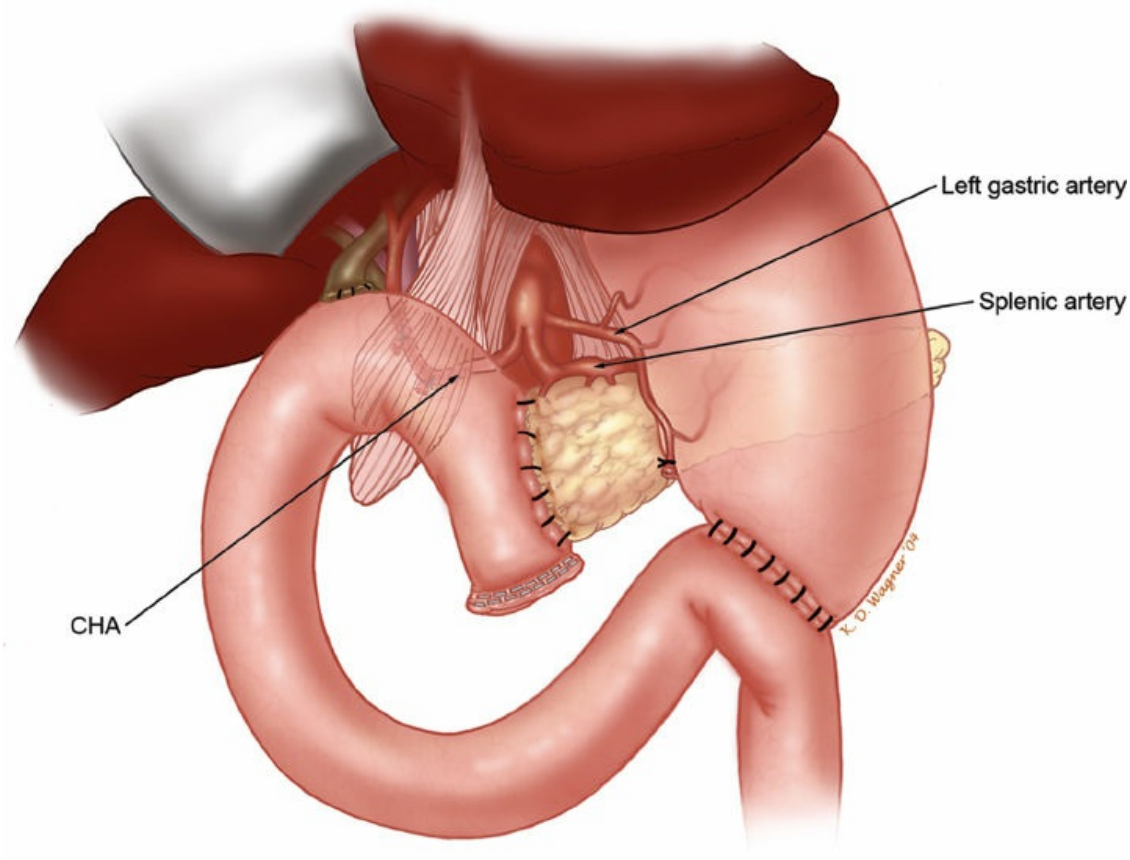

Figure 127.22. Illustration of the completed reconstruction after pancreaticoduodenectomy. The falciform ligament, mobilized upon opening the abdomen, is placed over the hepatic artery to cover the stump of the gastroduodenal artery, thereby separating the hepatic artery from the afferent jejunal limb. We are careful to leave at least 50 cm between the biliary and the gastric anastomoses to prevent the possible complication of reflux cholangitis. CHA, common hepatic artery.

PYLORUS PRESERVATION

Pylorus preservation in combination with pancreaticoduodenectomy was first described by Traverso and Longmire in 1978. Since then, increasing numbers of pancreatic surgeons have employed this modification of the procedure, particularly for patients with benign disease or small periampullary lesions. Proponents of the technique argue that preservation of the antropyloric pump mechanism results in improved long-term upper gastrointestinal tract function with enhanced weight gain. Detractors of pylorus preservation counter that the reported improvements in gastrointestinal function and nutrition are small, if any, and that they come at the expense of an increased incidence of early postoperative delayed gastric emptying. Further, leaving the distal stomach and duodenum may

compromise margins of excision and prevent adequate peripyloric lymphadenectomy. Published data to date involve retrospective comparisons that have yielded mixed results. Despite the controversy, most pancreatic surgeons would agree that pylorus preservation should not be performed for patients with bulky tumors of the pancreatic head, duodenal tumors involving the first or second portions of the duodenum, or lesions associated with grossly positive pyloric or peripyloric lymph nodes.

The steps in pylorus-preserving pancreaticoduodenectomy are identical to those in standard pancreaticoduodenectomy except in the approach to the antrum, pylorus, and duodenum (Steps 3 and 4). Pylorus preservation involves proximal division of the gastrointestinal tract beyond the pylorus and, most importantly, preservation of sufficient blood supply to the proximal duodenum and preservation of vagal innervation to the antrum and pylorus. Therefore, appropriate caution must be exercised during the portal dissection to avoid unnecessary injury to the nerves of Laterjet. This is the fundamental technical difference in the pylorus-preserving procedure and is essential to avoid postoperative gastroparesis. The duodenum is divided approximately 2 to 3 cm beyond the pylorus with the linear gastrointestinal stapler (Ethicon, Inc.) and the gastroepiploic arcade divided at that level. The staple line is removed prior to performance of the duodenojejunostomy so as to leave approximately 2 cm of duodenum distal to the pylorus. A short segment of duodenum ensures adequate vascularity of the remaining duodenum as the right gastric artery is divided (stomach blood supply based on the left gastric artery and the short gastrics from the splenic artery). The pylorus is often gently dilated with a Kelly clamp or an index finger. The duodenojejunostomy is performed in an end-to-side fashion in a single layer (author’s preference) with monofilament absorbable sutures (Fig. 127.23).

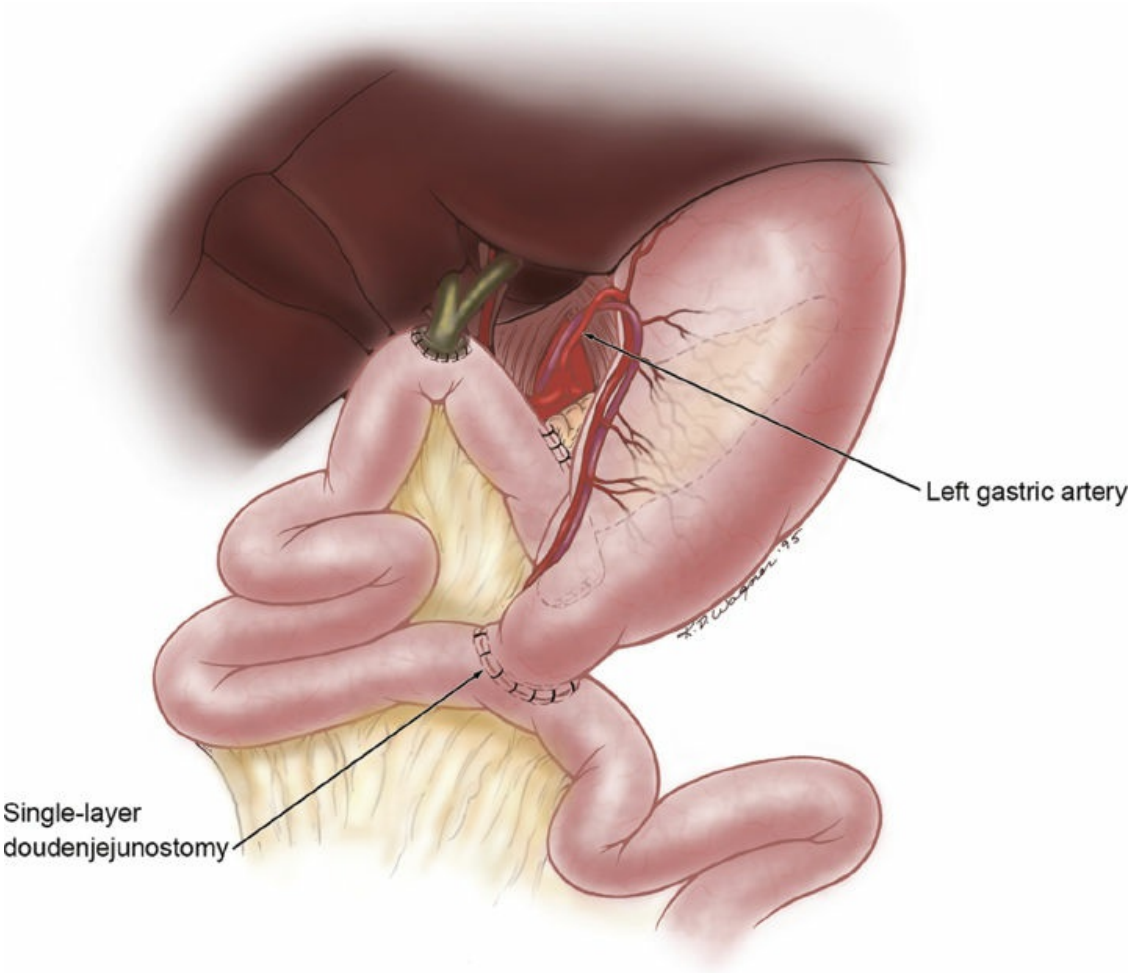

Figure 127.23. Illustration of the completed reconstruction following pylorus-preserving pancreaticoduodenectomy. The duodenojejunostomy can be placed either retrocolic or antecolic (colon not shown in this illustration); we prefer an antecolic anastomosis so that there is no potential for obstruction of the jejunum as it exits the transverse mesocolon. When pylorus preservation is performed, we often place a jejunostomy tube distal to the duodenojejunostomy due to the concern for poor gastric emptying in the first couple weeks following surgery.

TOTAL PANCREATECTOMY

Traditionally, total pancreatectomy was rarely performed for adenocarcinoma of the pancreas but is being considered more often now that we have much more effective systemic therapies and patients are presenting with more complicated local tumor anatomy after a lengthy period of systemic therapy (in the absence of metastatic disease). The presenting complaints of most patients with pancreatic body tumors are pain and gastrointestinal dysfunction due to tumor invasion of the neural

plexus surrounding the celiac axis and SMA, symptoms which should alert the surgeon to the potential for celiac or SMA encasement.

Total pancreatectomy is accomplished by identifying the proximal splenic artery and dissection of the left upper quadrant of the abdomen, following Steps 1 and 3 of our six-step pancreaticoduodenectomy. After identification of the infrapancreatic SMV and completion of the portal dissection, the proximal splenic artery is exposed and if possible, ligated (but often not divided). The greater omentum is separated from the left side of the transverse colon, and the splenic flexure is mobilized. The peritoneum lateral to the spleen is then incised in a cephalad direction to the gastroesophageal junction. The short gastric vessels are ligated and divided, allowing medial and cephalad retraction of the stomach. Mobilization of the spleen and pancreas from their retroperitoneal attachments to the kidney and adrenal gland is then completed. The IMV is divided if it enters the splenic vein, and the mesenteric root divided from the left lateral border of the SMV to the left lateral border of the aorta, staying anterior/lateral (to patient's left) to the SMA. Exposure of the SMA inferior to the neck of the pancreas will allow the dissection to proceed directly anterior to this vessel under direct vision. If possible, it is important to leave several of the autonomic nerves on the adventitia of the SMA to preserve some degree of small bowel innervation and prevent rapid gastrointestinal transit. Division of the splenic vein is often delayed until the completion of Steps 4 (gastric or duodenal transection) and 5 (ligament of Treitz, proximal jejunum, and duodenum). Then, in preparation for completion of the retroperitoneal dissection, the spleen and distal pancreas are again reflected medially (left to right), exposing the distal splenic vein–SMV junction; the splenic vein is then ligated and divided usually with the vascular stapler (Fig. 127.24). The splenic artery was ligated (but often not divided) prior to division of the splenic vein. However, exposure of the origin of the splenic artery may not be optimal for division until after the splenic vein has been divided.

When dealing with tumors in the pancreatic neck, there are two noteworthy technical points:

1. Preservation of islet cell function is particularly important in younger patients with cystic neoplasms, solid pseudopapillary neoplasms, or islet cell (neuroendocrine) tumors. When a tumor arises in the pancreatic neck or proximal body of the pancreas, a complete distal pancreatectomy may leave only a small portion of pancreatic head and

uncinate process. In so doing, the patient may not have adequate islet cell mass for normal glucose metabolism and therefore may become insulin dependent. Therefore, in patients with relatively small tumors of the pancreatic neck of favorable histology (i.e., neuroendocrine carcinoma, solid pseudopapillary neoplasm, mucinous cystic neoplasm), segmental resection of the pancreatic neck and proximal body (otherwise termed central or middle-segment pancreatectomy) with preservation of the splenic artery and vein is preferred to ensure adequate islet cell reserve. Reconstruction requires Roux-en-Y pancreaticojejunostomy to the remaining segment of distal pancreas.

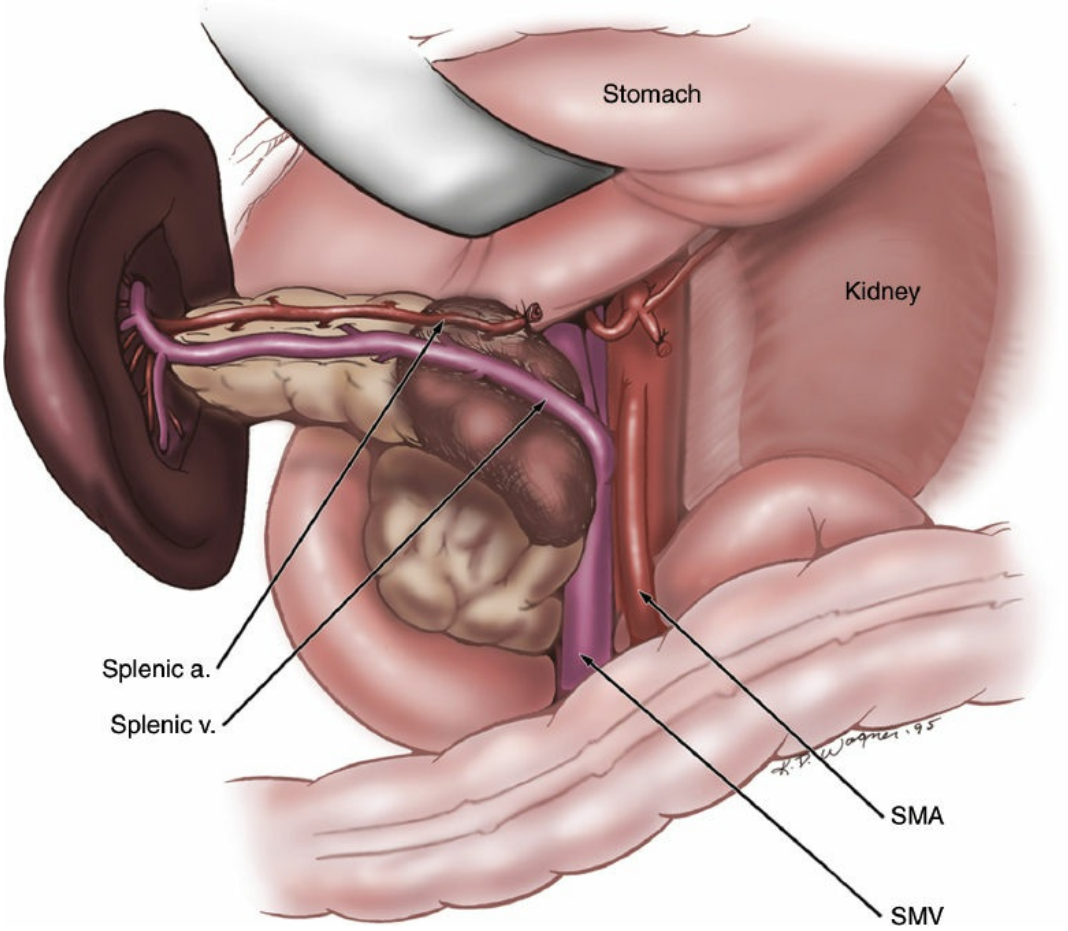

Figure 127.24. Illustration demonstrating medial rotation of the spleen and distal pancreas as performed when completing a total pancreatectomy. In this illustration, the splenic artery has been divided in preparation for division of the splenic vein at its junction with the superior mesenteric vein (SMV). However, as discussed in the text, while we always *ligate* the splenic artery before *dividing* the splenic vein, frequently we delay *dividing* the splenic artery until after the splenic vein has been divided – once the splenic vein has

been divided, the exposure to the celiac-splenic artery junction is much improved. It is important not to narrow the SMV during ligation of the splenic vein. The authors prefer to close the SMV-splenic vein junction with either a vascular stapler or a running 6-0 Prolene suture. SMA, superior mesenteric artery.

2. In occasional patients with tumors of the pancreatic neck, it may be unclear both on preoperative CT scans and intraoperatively whether the patient should undergo extended right (pancreaticoduodenectomy) or left (distal) pancreatectomy. Because most surgeons desire to perform the less complicated procedure, one might elect to perform distal pancreatectomy, only to discover on frozen-section analysis that the pancreatic transection margin is positive and that completion pancreaticoduodenectomy is needed. This situation can be avoided by completing the proximal pancreatic transection prior to committing to distal pancreatectomy. Frozen-section analysis of the proximal transection margin, if negative, enables one to perform a distal pancreatectomy with negative margins. A positive proximal transection margin requires extended pancreaticoduodenectomy. In either situation, total pancreatectomy may not be necessary.

When distal pancreatectomy is performed, the most important step is identification and suture ligation of the pancreatic duct. Those who prefer to staple the pancreas (possible when the pancreas is not too thick) note that the staple line secures the pancreatic duct, preventing its retraction into the pancreatic substance. One can even consider an additional 5-0 monofilament suture for the pancreatic duct within the staple line. When the pancreas is divided just medial to the intrapancreatic portion of the CBD, the pancreatic transection line is virtually always too thick for a stapling device and suture closure (we often use pledgets) is necessary. Again, identification of the pancreatic duct is critical to prevent pancreatic leak. We routinely bring the mobilized falciform ligament through the lesser omentum and allow it to cover the stump of the splenic artery and the pancreatic transection site—analogous to the use of the falciform ligament following pancreaticoduodenectomy discussed previously.

PERIOPERATIVE MANAGEMENT AND COMPLICATIONS

As with all complex surgery, a good outcome after pancreatectomy

depends on meticulous perioperative care. Intraoperative hemodynamic management includes an arterial line in all patients. Antibiotics are given on induction and re-dosed, if indicated, based on length of the operation and the individual drug pharmacokinetics. We always culture the bile in patients with indwelling biliary stents and in such patients, continue the antibiotics (culture-directed) for a minimum of 3 days after surgery. Patients with vascular resections/reconstructions are prescribed aspirin, 300 mg per rectum daily, beginning in the recovery room and prophylactic subcutaneous heparin if the INR is less than 1.5. Glucoses are followed at regular intervals and the diabetes management team consulted for anyone who will require insulin at discharge from the hospital. Limited sips of clears are allowed as soon as the patient is awake and alert, presuming the NG is in place and functional. For patients with jejunostomy tubes, jejunostomy feeding is initiated at a rate of 10 mL per hour on postoperative day 2 and then slowly increased daily if gastrointestinal function has returned. With the institution of an oral diet, low-rate jejunostomy feeding is converted from continuous to nighttime administration. Patients are frequently discharged receiving supplemental continuous or nighttime jejunostomy feedings.

Fevers occurring after postoperative days 3 to 4 demand careful evaluation. Potential sources of fever include those common to all major abdominal surgery; pneumonia, deep venous thrombosis, central line sepsis, urinary tract infection, and wound infection. Patients who undergo pancreaticojejunostomy are at risk for the development of intra-abdominal abscess as a result of leakage from the pancreatic anastomosis. Because leaks from either the biliary or gastric anastomoses are very uncommon, intra-abdominal sepsis is considered to be due to a pancreatic anastomotic leak until proven otherwise. The study of choice for evaluation of presumed intra-abdominal sepsis is CT of the abdomen and pelvis with IV contrast. The finding of a localized fluid collection in the region of the pancreaticojejunostomy should be considered for CT-guided aspiration and drainage. Selective use of CT-guided aspiration is based on the general condition of the patient, standard laboratory evaluation (especially the degree of leukocytosis) and the presence or absence of an air-fluid level in the fluid collection. Percutaneous catheter drainage is indicated if the aspirated fluid appears grossly purulent or confirmed positive on Gram stain. It is common to identify nonloculated ascitic fluid on postoperative CT scans in pancreatectomy patients; this finding rarely represents

infection or anastomotic leak and does not demand aspiration or drainage unless clinical signs of infection persist and another source of infection has not been identified. Pancreaticojejunostomy anastomotic leaks generally close once adequate drainage is established. Octreotide and antibiotics are utilized when treating established pancreatic anastomotic leaks that have required percutaneous drainage.

Postoperative gastrointestinal or drain tract bleeding should prompt immediate evaluation with arteriography. While very uncommon, an arterial-enteric fistula occasionally occurs in the postoperative setting (rarely before postoperative day 10). The most common cause (when the operation is done open using the technique described herein) is a pancreatic anastomotic leak with surrounding inflammation and infection resulting in blowout of the GDA stump. This complication is much more common in patients who undergo a minimally invasive pancreaticoduodenectomy (laparoscopic or robotic) possibly due to the use of energy devices near visceral arteries and/or the frequent use of clips and staple lines rather than surgical ties to secure the GDA and the IPDAs. Gastrointestinal or drain tract bleeding represents a true emergency; the only patients likely to survive are those in whom the diagnosis is made immediately. The HA may be embolized or stented. Surgical control of hemorrhage from the stump of the GDA is exceedingly difficult in a postoperative pancreaticoduodenectomy patient and carries a higher mortality than that associated with management in the interventional radiology suite or hybrid OR room.

Patients are ready for discharge when they are afebrile, independent with the majority of self-care, and have adequate caloric intake from either oral intake, or a combination of oral and jejunostomy feedings. All patients are discharged on enteric coated aspirin (DVT prophylaxis), acid suppression (usually an H_2 blocker) and pancreatic enzyme replacement.

SUMMARY

A detailed preoperative assessment of resectability prevents needless laparotomy in patients with advanced PC, and a standardized technique of tumor resection minimizes perioperative complications. Pancreaticoduodenectomy is divided into six well-defined maneuvers. Attention to detail and a standardized approach to postoperative care minimize patient morbidity and hospital stay. Optimal results can be achieved with careful attention to patient selection for surgery,

preoperative assessment of resectability, surgical technique, and postoperative care. Importantly, all physicians involved in the care of patients with localized, potentially resectable (or borderline resectable) PC should support available clinical trials.

ACKNOWLEDGMENTS

The authors would like to thank Wendy Behrs for assistance with manuscript preparation. The Pancreatic Cancer Program at MCW is grateful for the courageous patients and families who have formed the basis of our experience and reinforce the importance of multimodality care.

Suggested Readings

Cattell RB, Braasch JW. A technique for the exposure of the third and fourth portions of the duodenum. *Surg Gynecol Obstet* 1960;111:378–81.

Christians KK, Pilgrim CH, Tsai S, et al. Arterial resection at the time of pancreatectomy for cancer. *Surgery* 2014;155(5):919–26.

Christians KK, Tsai S, Mahmoud A, et al. Neoadjuvant FOLFIRINOX for borderline resectable pancreas cancer: a new treatment paradigm? *Oncologist* 2014;19(3):266–74.

Evans DB, George B, Tsai S. Non-metastatic pancreatic cancer: resectable, borderline resectable, and locally advanced-definitions of increasing importance for the optimal delivery of multimodality therapy. *Ann Surg Oncol* 2015;22(11):3409–13.

Evans DB, Tsai S. Volume-outcome in cancer surgery: why has the data not affected policy change? *Ann Surg Oncol* 2014;21(13):4056–8.

Fathi A, Christians KK, George B, et al. Neoadjuvant therapy for localized pancreatic cancer: guiding principles. *J Gastrointest Oncol* 2015;6(4):418–29.

Hiatt JR, Gabbay J, Busuttil RW. Surgical anatomy of the hepatic arteries in 1000 cases. *Ann Surg* 1994; 220(1):50–2.

Katz MH, Fleming JB, Pisters PW, et al. Anatomy of the superior mesenteric vein with special reference to the surgical management of first-order branch involvement at pancreaticoduodenectomy. *Ann Surg* 2008;248(6):1098–102.

Leach SD, Davidson BS, Ames FC, et al. Alternative method for exposure of the retropancreatic mesenteric vasculature during total pancreatectomy. *J Surg Oncol* 1996;61:163–5.

Mullen JT, Lee JH, Gomez HF, et al. Pancreaticoduodenectomy after placement of

endobiliary metal stents. *J Gastrointest Surg* 2005;9(8):1094–105.

Pilgrim CH, Tsai S, Evans DB, et al. Mesocaval shunting: a novel technique to facilitate venous resection and reconstruction and enhance exposure of the superior mesenteric and celiac arteries during pancreaticoduodenectomy. *J Am Coll Surg* 2013;217(3):e17–20.

Pilgrim CH, Tsai S, Tolat P, et al. Optimal management of the splenic vein at the time of venous resection for pancreatic cancer: importance of the inferior mesenteric vein. *J Gastrointest Surg* 2014;18(5):917–21.

Tsai S, Evans DB. Neoadjuvant and adjuvant therapy for localized pancreatic cancer. In Cameron JL, Cameron AM, eds. *Current Surgical Therapy.* 12th ed. Philadelphia, PA: Elsevier; 2017:559–64.

Tyler DS, Evans DB: Reoperative pancreaticoduodenectomy. *Ann Surg* 1994;219:211–21.

Waugh JM, Clagett OT. Resection of the duodenum and head of the pancreas for carcinoma. An Analysis of Thirty Cases. *Surgery* 1946;224–32.

Whipple AO. Pancreaticoduodenectomy for Islet Carcinoma. A five-year follow-up. *Ann Surg* 1945;121(6): 847–52.

Whipple AO, Parsons WW, Mullin CR. Treatment of carcinoma of the ampulla of vater. *Ann Surg* 1935; 102:763–79.

Wolff RA, Crane CH, Li D, et al. Neoplasms of the exocrine pancreas. In Bast RC, Croce CM, Hait WN, et al, eds. *Holland-Frei Cancer Medicine.* 9th ed. Hoboken, NJ: Wiley Blackwell; 2017:1129–50.

Younan G, Tsai S, Evans DB, et al. Techniques of vascular resection and reconstruction in pancreatic cancer. *Surg Clin North Am* 2016;96(6):1351–70.



EDITOR'S COMMENT

In this cogently written and beautifully illustrated chapter, Dr. Evans and his team once again make another invaluable contribution to *Mastery* and to the field of complex gastrointestinal surgery at large. A master of his craft, Dr. Evans distills what is perhaps the most complicated operation in all of GI surgery into a simple, well-defined series of 6 steps, making this chapter required reading for any surgical trainee preparing to scrub on this procedure. Perhaps even more importantly, in this chapter Dr. Evans and colleagues summarize several other critical contributions that they have made to this field, including: (1) the safety of endobiliary stent placement to permit the administration of neoadjuvant therapy and to potentially obviate the need for a palliative biliary bypass; (2) the paramount importance of high-quality, cross-sectional preoperative imaging to define tumor resectability; (3) the concerted

emphasis on the systemic nature of the disease of pancreatic cancer and thus the rationale for neoadjuvant therapy prior to surgery; and (4) the technical contributions of the direct identification and dissection of the proximal SMA during PD (to limit injuries to this vessel and to achieve a wider SMA margin) as well as the safety and feasibility of venous resection and reconstruction in patients with borderline resectable tumors.

Though these contributions when considered today seem almost laughably self-evident, it was not all that long ago (certainly during my residency training) when these assertions were actually viewed as *laughable.* Indeed, for decades the standard approach to the newly diagnosed patient with a cancer in the head of the pancreas was immediate surgery, for even if the patient was deemed to be unresectable at the time of surgery either due to local tumor invasion (however that was assessed!) or the presence of occult metastatic disease, a double bypass (choledochojejunostomy and gastrojejunostomy) was nonetheless "necessary" for palliation even though most patients had no symptoms of gastric outlet obstruction. For those deemed to be resectable, the SMA was rarely if ever directly identified and dissected, in preference for the surgeon palpating and protecting the SMA with his or her left hand while bluntly clamping, cutting, and tying the tissues to the right of the unvisualized SMA. Venous resection and reconstruction was simply out of the question—tumor stuck to the vein was simply left on the vein. Rarely was consideration given to the administration of neoadjuvant chemotherapy and/or radiotherapy as a means to shrink the primary tumor or to serve as a biologic test to distinguish those patients most likely to benefit from radical surgery. It was Dr. Evans and the group at M. D. Anderson who preached this gospel at meetings and published the neoadjuvant therapy trials and technique papers throughout the 1990s and 2000s that formed the principles of how we define resectability and treat pancreatic cancer today.

The vast majority of patients with pancreatic cancer present with metastatic or locally advanced disease, and historically, neoadjuvant chemoradiation therapy rendered approximately one third of these locally advanced tumors resectable. However, despite resection, these patients often recurred, with a median survival of less than 2 years (Andriulli A et al. Neoadjuvant/preoperative gemcitabine for patients with localized pancreatic cancer: a meta-analysis of prospective studies. *Ann Surg Oncol* 2012;19:1644–62). With the demonstration in the ACCORD trial of the superiority of the chemotherapy regimen of fluorouracil, leucovorin, oxaliplatin, and irinotecan (FOLFIRINOX) over gemcitabine in the treatment of metastatic pancreatic cancer (Conroy T et al. FOLFIRINOX versus gemcitabine for metastatic pancreatic cancer. *N Engl J Med* 2011;364:1817–25), it was a rational choice to extend these data to the locally advanced setting to learn whether neoadjuvant FOLFIRINOX might increase the rate of tumor resectability. Indeed, preliminary data from both the MGH (Ferrone C et al. Radiological and surgical implications of neoadjuvant treatment with FOLFIRINOX for locally advanced and borderline resectable pancreatic cancer. *Ann Surg* 2015;261:12–17) and Dr.

Evans' group at the Medical College of Wisconsin (Christians KK et al. Neoadjuvant FOLFIRINOX for borderline resectable pancreas cancer: a new treatment paradigm? *Oncologist* 2014;19:266–74) examining patients with locally advanced or borderline resectable pancreatic cancers receiving neoadjuvant FOLFIRINOX +/– chemoradiation therapy demonstrate that the regimen is safe and is associated with high rates of R0 resection and (though very preliminary) encouraging survival outcomes. Interestingly, the traditional imaging criteria for resectability appear to no longer be accurate after treatment with FOLFIRINOX, which though it effectively kills the tumor, it replaces the tumor abutting vessel wall with fibrosis abutting vessel wall (Ferrone CR et al. Radiological and surgical implications of neoadjuvant treatment with FOLFIRINOX for locally advanced and borderline resectable pancreatic cancer. *Ann Surg* 2015;261:12–7), and these two entities are not distinguishable radiographically. As such, a more aggressive surgical approach is recommended even in the face of posttreatment imaging demonstrating borderline resectability, as a significant percentage of these patients will have negative resection margins.

Though many studies have confirmed the safety of portal/superior mesenteric vein resection and reconstruction at the time of PD, one might reasonably ask how often the vein is histologically invaded by tumor and what the impact on survival is. Roch AM et al. (Significance of portal vein invasion and extent of invasion in patients undergoing pancreatoduodenectomy for pancreatic adenocarcinoma. *J Gastrointest Surg* 2016;20:479–87) at Indiana University studied 90 patients undergoing vein resection at the time of PD from 2000 to 2014 and found that 58% of the vein specimens showed evidence of histologic invasion by the cancer but that such invasion did not significantly influence overall survival (14 vs. 21 months, $p = 0.08$) but was associated with a significantly shorter median disease-free survival (11.3 vs. 15.8 months, $p = 0.03$), predominantly due to a higher rate of local recurrence. Wang J et al. (Histologic tumor involvement of superior mesenteric vein/portal vein predicts poor prognosis in patients with stage II pancreatic adenocarcinoma treated with neoadjuvant chemoradiation. *Cancer* 2012;118:3801–11) at M. D. Anderson evaluated 85 patients with stage II pancreatic cancer who underwent neoadjuvant therapy followed by PD with vein resection from 1999 to 2007. Similar to the findings of the group at Indiana, they found that 67% of patients had histologic evidence of tumor invasion of the vein and that such patients tended to have larger tumors as well as a higher rate of R1 resection. However, in contrast to the findings of the Indiana group, Wang et al. found that tumor involvement of the vein was in fact an independent predictor of both disease-free and overall survival, though the depth of tumor invasion into the vein wall did not correlate with prognosis. Most authors would still agree that provided that a portal/mesenteric vein resection can be performed safely that it should be offered to patients undergoing PD for pancreatic cancer, as a certain percentage of these patients will enjoy long-term survival. Furthermore, the vein should be

carefully evaluated histologically for evidence of tumor invasion, as this appears to be a poor prognostic factor.

Dr. Evans and his group at MCW do not routinely place a drain near the pancreaticojejunostomy to monitor for, and to manage, a potential pancreatic fistula. Rather, they opt for a right upper quadrant drain to control a potential lymphatic leak, and they do not routinely check drain amylase values. Now there are few topics in all of pancreatic surgery more controversial than that of whether to place a drain after PD. The Memorial Sloan Kettering group demonstrated in both a prospective randomized trial (Conlon KC et al. Prospective randomized clinical trial of the value of intraperitoneal drainage after pancreatic resection. *Ann Surg* 2001;234:487–93) and in a large follow-up retrospective study (Correa-Gallego C et al. Operative drainage following pancreatic resection: analysis of 1122 patients resected over 5 years at a single institution. *Ann Surg* 2013;258:1051–58) that patients who had operative drains placed did not experience decreased rates of pancreatic fistula but in fact had higher rates of serious morbidity, infectious complications, and readmission. They concluded that routine prophylactic drainage after pancreatic resection could be safely abandoned. However, this viewpoint was seriously challenged by the subsequent publication of a prospective, randomized, multicenter trial of PD with and without routine intraperitoneal drainage (Van Buren G et al. A randomized prospective multicenter trial of pancreaticoduodenectomy with and without routine intraperitoneal drainage. *Ann Surg* 2014;259:605–12). In this trial, 137 patients were randomized to either the drain (n = 68) or no drain (n = 69) groups, and there were no differences in the baseline clinicopathologic or treatment characteristics of these two groups. PD without drainage was associated with an increase in the number and severity of complications as well as a higher incidence of gastroparesis, intra-abdominal fluid collections and abscesses, the need for a postoperative percutaneous drain, and a prolonged length of stay. In fact, the Data Safety Monitoring Board terminated the study prematurely because of an increase in the mortality rate from 3% to 12% in the no-drain group. As a result, these authors cautioned against the routine abandonment of intraperitoneal drains after PD. I seriously doubt that we've heard the last word in this debate.

In sum, it is particularly gratifying to see how far we have come in the multimodality treatment of localized pancreatic cancer. Cloyd et al. (Preoperative Therapy and Pancreatoduodenectomy for Pancreatic Ductal Adenocarcinoma: a 25-Year Single-Institution Experience. *J Gastrointest Surg* 2017;21:164–74) from M. D. Anderson recently published their 25-year (1990–2014) single-institution experience of more than 620 patients treated with neoadjuvant therapy and PD for pancreatic cancer. Despite increases in case complexity, with more operations performed for borderline resectable and locally advanced tumors and requiring vascular resection, locoregional recurrence rates have remained similar while overall survival rates have improved significantly, such that the median survival for the most recent 5-year

cohort (2010–2014) is more than 43 months, a truly astounding number for such a deadly malignancy. Undoubtedly, further improvements in survival will require significant advances in systemic therapies for this disease.

John T. Mullen

128 Operative Management of Pancreatic Trauma

David V. Feliciano

ANATOMY

The retroperitoneal pancreas crosses the upper abdomen at the level of the first and second lumbar vertebrae, and "posttraumatic pancreatitis" occasionally results from a spinal fracture at this level. The gland has a thin mesothelial capsule and is 15 to 20 cm in length, 1.0 to 1.5 cm in thickness, and ~3.0 cm in width.

The proximity of the pancreas to all the major named vessels of the upper abdomen complicates operative management of injuries, especially in patients with penetrating trauma. The head of the pancreas has a shared blood supply with the duodenum through the anterior and posterior branches of the superior and inferior pancreaticoduodenal arteries. In addition, the head overlies the inferior vena cava, right renal vessels, and the left renal vein as it enters the cava. The uncinate process encompasses the inferior pancreaticoduodenal artery and wraps around the superior mesenteric vein and artery. The neck of the pancreas overlies the superior mesenteric vein and may have to be divided to expose injuries to the confluence of this vein and the splenic vein or to the proximal portal vein. The body of the pancreas lies over the visceral portion of the suprarenal aorta (origins of celiac axis, superior mesenteric artery, and bilateral renal arteries) and the left renal artery and vein. Finally, the body and tail of the pancreas encircle or are intimately adherent to the splenic artery or vein.

The duct of Wirsung (main pancreatic duct) passes through the entire length of the gland just above a line halfway between the superior and inferior edges and enters the left side of the common bile duct to form the ampulla of Vater. The duct of Santorini (accessory pancreatic duct) most commonly branches out superiorly from the duct of Wirsung in the neck of the pancreas and enters the duodenum at the minor papilla ~2.5 cm proximal to the major papilla.

ETIOLOGY AND PATHOPHYSIOLOGY

Isolated injuries after blunt abdominal trauma are noted in only 20% of the patients with pancreatic injuries, and the most common associated injuries are to the duodenum, liver, and spleen. Associated injuries including to the vessels previously mentioned are almost always present in patients undergoing laparotomy for penetrating wounds and depend on the location of the wound. Wounds of the head of the pancreas are most commonly associated with perforations of the stomach and transverse colon. Wounds of the body and tail of the pancreas are associated with injuries to the stomach, transverse colon, splenic flexure of the colon, splenic vessels, and the spleen.

CLINICAL PRESENTATION

A direct blow with compression of the upper abdomen and its viscera/vessels against the spine is the most common blunt mechanism of injury. Examples would include compression from the lower rim of the steering wheel in an unrestrained driver in a deceleration-type motor vehicle crash, by a misplaced lap-style restraint device in a child, or by direct contact with the handlebars of a bicycle in a frontal crash. Many patients with blunt injuries to the pancreas have minimal clinical symptoms and signs when first evaluated after trauma. The major reason for this is the retroperitoneal location of the organ, which precludes the early development of peritonitis. The second reason is the tamponading effect of the retroperitoneum which may prevent significant blood loss in the absence of other vascular injuries or extravasation of pancreatic juice from the injury. Therefore, the surgeon cannot rely on the traditional serial physical examinations, diagnostic peritoneal lavage, or surgeon-performed ultrasound to make an early diagnosis of a blunt injury.

When symptoms are present, the most common is deep epigastric steady pain occasionally associated with nausea and vomiting. Pain in the upper lumbar area has not been a common complaint in the author’s experience unless a fracture of an adjacent vertebra is present. Because the epigastric pain is usually mild, it was not uncommon in the pre-CT era for a patient with a major injury such as complete transection of the pancreas over the spine to be discharged from the emergency room with a missed diagnosis.

Patients with penetrating wounds to the abdomen that injure the pancreas almost always have associated intra-abdominal injuries as noted

earlier and present with the classic indications for an emergency laparotomy, namely, peritonitis, hypotension, or, rarely, evisceration.

DIAGNOSIS

With the difficulty in making a diagnosis of a blunt pancreatic injury as described earlier, there is reliance on laboratory testing and the use of contrast-enhanced CT in the modern era. Unfortunately, the laboratory finding of hyperamylasemia on admission to the emergency center is not a precise marker for an injury to the pancreas. Salivary rather than pancreatic amylase elevations are present in 30% to 40% of patients admitted with trauma associated with acute alcoholic intoxication. Also, approximately one third of patients with blunt transection of the pancreatic duct have a normal amylase level on admission. Therefore, the presence of hyperamylasemia, while raising suspicion of a pancreatic, duodenal, or enteric injury, does not mandate an exploratory laparotomy in the absence of the aforementioned hypotension, peritonitis, evisceration, or CT-evidence of a significant pancreatic injury (to be discussed). A progressive rise in the amylase level over the first 24 to 48 hours of hospitalization is, however, strongly suggestive of injury to the pancreas or duodenum or for the development of the rare entity of posttraumatic pancreatitis.

Contrast-enhanced CT using a 128-slice scanner is the current diagnostic modality of choice in hemodynamically stable and asymptomatic or minimally symptomatic patients with possible or suspected injuries to the pancreas. This would include patients who have sustained blunt abdominal trauma or those who have sustained a penetrating injury to the flank or back. In the latter groups, triple-contrast (intravenous, oral or by nasogastric tube, and rectal) CT has been performed for 30 years. Its use, however, has decreased significantly in recent years with the increased resolution available with modern multislice CT scanners. CT findings *suggestive or diagnostic* of injury to the pancreas are listed in Table 128.1. Injuries to the pancreas noted on contrast-enhanced CT or at laparotomy are defined according to the Organ Injury Scale developed by the American Association for the Surgery of Trauma in 1990 (Table 128.2). As with most other Organ Injury Scales, these range from Grade I (minor pancreatic contusion or superficial laceration) to Grade V (massive disruption of the pancreatic head). Pitfalls in diagnosing pancreatic injuries include the presence of minimal extraperitoneal fat in some patients, artifacts from dense oral contrast, and

nonopacification of adjacent duodenum or small bowel so that the edges of the pancreas are difficult to define.

TABLE 128.1 CT Diagnosis of Pancreatic Injuries

Suggestive of Injury
Fluid in the lesser sac
Fluid between pancreas and splenic vein
Hematoma of transverse mesocolon
Thickening of left anterior renal fascia
Duodenal hematoma or laceration
Injury to spleen, left kidney, left adrenal gland
Chance (transverse) fracture of lumbar spine, especially in a child
Diagnostic of Injury
Parenchymal hematoma or laceration
Obvious transection of the parenchyma/duct with fluid in the lesser sac
Disruption of head of pancreas
Diffuse swelling characteristic of posttraumatic pancreatitis

Adapted from Feliciano DV. Operative management of pancreatic trauma. In Fischer JE, ed. *Fischer's Mastery of Surgery*. 6th ed. Philadelphia, PA: Wolters Kluwer; 2012:1480–5.

In the presence of an equivocal CT with or without associated hyperamylasemia or when CT is not available, endoscopic retrograde cholangiopancreatography (ERCP) is appropriate to rule out an injury to the main pancreatic duct. A separate classification system of pancreatic injuries diagnosed by ERCP is available as well. There are minimal data on the use of MRCP in assessing a possible traumatic ductal transection.

NONOPERATIVE MANAGEMENT

In the absence of hypotension, peritonitis, evisceration, and CT scan evidence of significant injuries to other organs or vessels, Grade I and II

pancreatic injuries (do not involve duct) are managed nonoperatively. This would include a parenchymal hematoma in the head of the pancreas which may cause transient obstructive jaundice (Fig. 128.1). Though a rare Grade II injury ("major contusion/laceration") may progress to a parenchymal pseudocyst (Fig. 128.2), it is very uncommon to have to intervene for a peripancreatic fluid collection during the period of observation with this low magnitude of injury. A follow-up abdominal CT scan at 5 to 7 days after injury is appropriate when a significant Grade II injury is present or earlier whenever new symptoms in the upper abdomen or increasing hyperamylasemia develop.

TABLE 128.2 Pancreas Organ Injury Scale of the American Association for the Surgery of Trauma

Grade[a]	Type of Injury	Description of Injury	ICD-9[b]	AIS-90
I	Hematoma	Minor contusion without duct injury	863.81–863.74	2
	Laceration	Superficial laceration without duct injury		2
II	Hematoma	Major contusion without duct injury or tissue loss	863.81–863.74	2
	Laceration	Major laceration without duct or injury or tissue loss		3
III	Laceration	Distal transection or parenchymal injury with duct injury	863.92–863.94	3
IV	Laceration	Proximal[c] transection or parenchymal injury involving ampulla	863.91	4
V	Laceration	Massive disruption of pancreatic head	863.91	5

[a]Advance one grade for multiple injuries up to Grade III.
[b]863.51, 863.91, head; 863.99, 862.92, body; 863.83, 863.93, tail.
[c]Proximal pancreas is to the patient's right of the superior mesenteric vein.
Moore EE, Cogbill TH, Malangoni MA, et al. Organ injury scaling II: pancreas, duodenum, small bowel, colon, and rectum. *J Trauma* 1990;30:1427–9.



Figure 128.1. An 85-year-old man with hematoma in the head of the pancreas after motor vehicle crash. Patient developed obstructive jaundice which resolved during a period of observation.

PREOPERATIVE PREPARATION

In all patients who are to undergo an emergency or urgent laparotomy after sustaining abdominal trauma, preparations are similar. An identification bracelet is placed on the patient, venous blood is withdrawn for routine laboratory tests and for type-and-crossmatch of blood products, and an intravenous line is initiated at the same site.

Rapid evaluation of the patient's pericardial sac (rule out tamponade after either blunt or penetrating trauma), pleural cavities, and abdominal cavity is attained by a surgeon-performed ultrasound using a 3.5-MHz probe in an adult.

A second- or third-generation cephalosporin antibiotic is administered intravenously. A nasogastric tube and a bladder catheter are inserted in either the emergency room or operating room depending on the patient's hemodynamic state. In patients who are in ATLS Class III or IV shock, a phone call is made to the blood bank to initiate a massive transfusion protocol. This protocol now commonly known as "damage control

resuscitation" emphasizes the administration of blood and blood products (rather than overuse of crystalloids such as lactated Ringer's solution) for the patients who are bleeding. While rarely attained, the desired goal of "damage control resuscitation" is to infuse packed red blood cells, fresh frozen plasma, and platelet packs in a 1:1:1 ratio. An example of such a protocol (after administration of the initiation package) is as follows.

PRBC	FFP	Platelet	Cryo
6 u	6 (AB)	1 aph.	—
6 u	6 (TS)	—	10 u pooled
6 u	6 (TS)	1 aph.	—
6 u	6 (TS)	—	10 u pooled



Figure 128.2. A 60-year-old woman with posttraumatic pseudocyst in the head of the pancreas after a motor vehicle crash.

In one recent study (June, 2016) a massive transfusion protocol directed by viscoelastic assay thromboelastography (TEG) rather than conventional coagulation tests (INR, PTT, fibrinogen, D-dimer) resulted in improved

survival in injured patients.

As hypothermia occurs in patients in shock, those undergoing evaluation in poorly heated trauma rooms or CT-suites, or during subsequent prolonged trauma laparotomies, prophylaxis against this problem is initiated in the emergency center. Standard maneuvers would include wrapping the patient's head and covering the trunk and lower extremities with a warming device and infusing all blood products and fluids through in-line warmers.

SURGICAL TECHNIQUE

Operative management of pancreatic trauma is determined by complete visualization of the organ to assess the magnitude of the parenchymal injury and to see if a ductal injury is present or not. During a "damage control" laparotomy in the patient with associated injuries and intraoperative hypothermia, acidosis, and a coagulopathy, detailed inspection of the pancreas is delayed till a reoperation once peripancreatic hemorrhage is controlled. In more stable patients a Kocher maneuver is necessary to properly visualize an injury to the head or neck of the pancreas, whereas the body of the pancreas is approached by dividing the gastrocolic omentum and the retroperitoneum on the inferior edge of the pancreas to allow for circumferential palpation of the gland. Injuries to the distal body and tail of the pancreas are evaluated by division of the gastrocolic omentum and elevation of the spleen and tail of the pancreas as in performing a distal pancreatectomy. All hematomas surrounding the pancreas or under the thin mesothelial capsule of the pancreas are explored after either blunt or penetrating trauma.

Injuries to the main pancreatic duct are usually characterized by extensive fat necrosis in the lesser sac, even if the patient's exploratory laparotomy has occurred shortly after trauma. Other intraoperative indicators of transection of the main pancreatic duct are listed as follows: (a) leakage of clear pancreatic fluid; (b) complete transection of the gland; (c) central perforation from gunshot wound (Fig. 128.3); (d) blunt laceration including half the width of the gland (Fig. 128.4); and (e) significant disruption of the parenchyma at any location. When there is a stab wound or blunt laceration that may involve the duct, a brief period of observation is appropriate. Clot is evacuated from the area of injury, any local bleeding is cauterized or sutured, the surgeon puts on magnifying lenses, and the area of injury is observed for 3 to 5 minutes. The presence

of clear fluid draining from the area of trauma indicates that an injury to the main duct is present. On occasion, it may be necessary to inject the patient with l mg/kg secretin intravenously to stimulate pancreatic secretion during the period of observation.

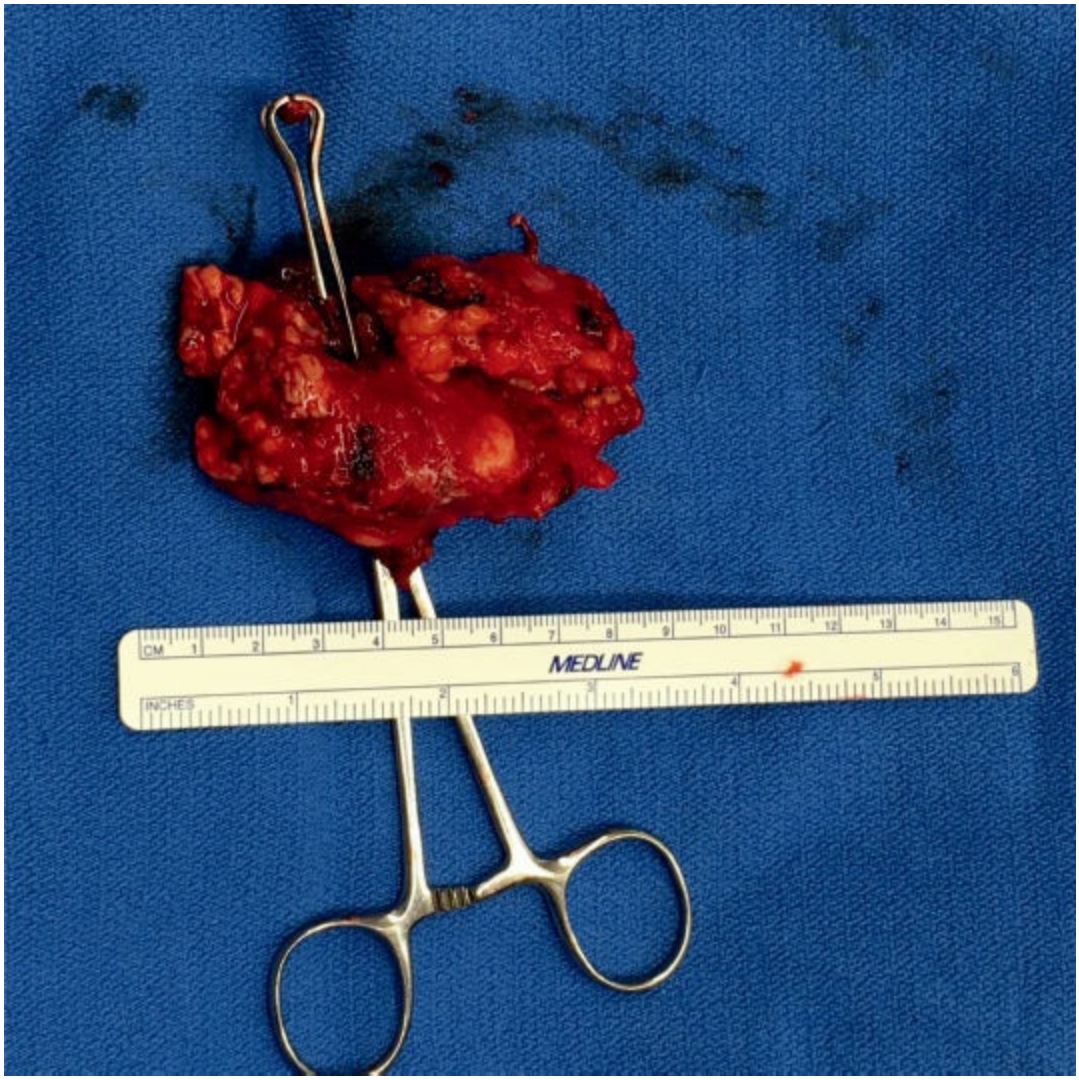

Figure 128.3. Bullet wound through mid-pancreas mandated distal hemipancreatectomy at first reoperation after an original "damage control laparotomy."

Some textbooks recommend intraoperative pancreatography to assess the status of the duct in a hemodynamically stable patient. One option is to perform a very distal pancreatectomy, cannulate the pancreatic duct with polyethylene tubing or a 5-French pediatric feeding tube, and inject 3 to 5 mL of contrast. This approach is not recommended as it includes removal of normal distal pancreas and an uninjured spleen, as well as the risk of a postoperative pancreatic fistula. The second option is to open the

duodenum, cannulate the papilla, and perform a retrograde pancreatogram. The disadvantage of this approach is that it converts whatever pancreatic injury is present into a combined pancreaticoduodenal injury. The third option is to perform a cholecystocholangiogram or cystic duct cholangiogram using methylene blue/saline solution while the anesthesiologist injects intravenous fentanyl. The fentanyl causes spasm of the sphincter of Oddi, and this would direct the methylene blue/saline solution toward the pancreatic duct with any extravasation demonstrating the point of injury.



Figure 128.4. Pancreatic injury evident based on peripancreatic fluid. Axial reconstruction of a contrast-enhanced abdominal CT study performed on an 8-year-old present following blunt abdominal trauma shows low attenuation consistent with fluid in the peripancreatic retroperitoneum (*arrow*). (From Iyer RS, Chapman T (2016). Pediatric Imaging The Essentials; Wolters Kluwer).

TABLE 128.3 Operative Options for Pancreatic Injuries

Parenchymal, but no ductal injury
- Omental plug vs. none
- Closed suction drain vs. none

Ductal transection in tail, body, neck
- Distal pancreatectomy with or without splenectomy
- Roux-en-Y distal pancreatojejunostomy

Ductal transection in head, macerated head, destruction of ampulla, combined pancreaticoduodenal disruption
- Whipple procedure

Combined pancreaticoduodenal injuries
- Simple repair (duodenum)/drainage (pancreas)
- Complex repair(s)—consider adding diversion procedure
- Resection

Table 128.3 lists operative options for pancreatic injuries. In the absence of a ductal injury, there are no convincing data that a Grade I ("minor contusion/superficial laceration") or Grade II ("major contusion/major laceration") pancreatic injury noted at a laparotomy for other injuries needs to be drained. Some surgeons tack a pedicle of viable omentum into a Grade I or II laceration to plug any small ductal leak and bring macrophages to the area of injury (Fig. 128.5), though there are no data documenting the value of this adjunct.

With Grade III or some Grade IV injuries (transection of the duct to the left or right of the superior mesenteric vessels), one option is distal pancreatectomy with splenic salvage in a child or adolescent or without splenic salvage in an adult (Fig. 128.6). When splenic salvage is to be performed, fine ties are placed on pancreatic vessels on the splenic artery and vein side and small metal clips on the pancreatic segment to be resected. If the distal, hemi-, or subtotal pancreatectomy is to include a splenectomy, the splenic artery and vein are suture-ligated with 4-0

polypropylene sutures 2 cm proximal to where the pancreas is to be divided. This maneuver along with the coverage of the vessels by a viable omental pedicle isolates the vessels from any distal leak of the pancreatic stump in the postoperative period.

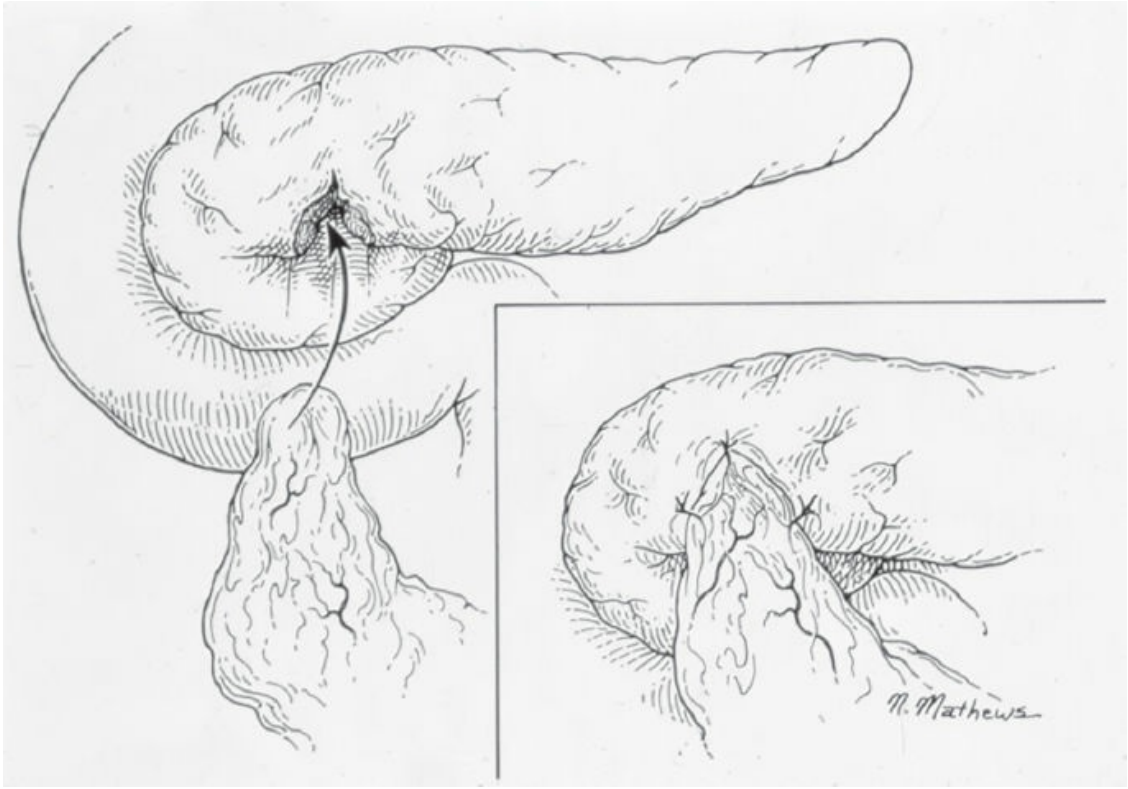

Figure 128.5. A pedicle of viable omentum may be tacked to a Grade I or II pancreatic laceration to plug any leak from a small duct. (From Cushman JG, Feliciano DV. Contemporary management of pancreatic trauma. In: Maull KI, Cleveland HC, Feliciano DV, et al., eds. *Advances in Trauma and Critical Care*, Vol. 10. St. Louis: Mosby; 1995:309–36, with permission.)

Either sutures or staples can be used to close the stump of the remaining pancreas. Some surgeons ligate the open end of the pancreatic duct prior to parenchymal closure, but there are no clear-cut data that this changes the incidence of postoperative pancreatic fistulas from this site. One popular approach to closure is to use absorbable sutures placed in a U-stitch fashion with knots tied on the anterior pancreas. As most elective distal pancreatectomies are performed laparoscopically in the modern era, the use of a stapler to close the parenchyma has become more popular. It should be emphasized, however, that there are no convincing historical data that staple closure leads to a lower postoperative rate of pancreatic

fistulas as compared to suture closure. There are preliminary data that closure with newer staplers that create two triple-staggered rows of titanium staples may decrease the fistula rate as compared to previous reports.

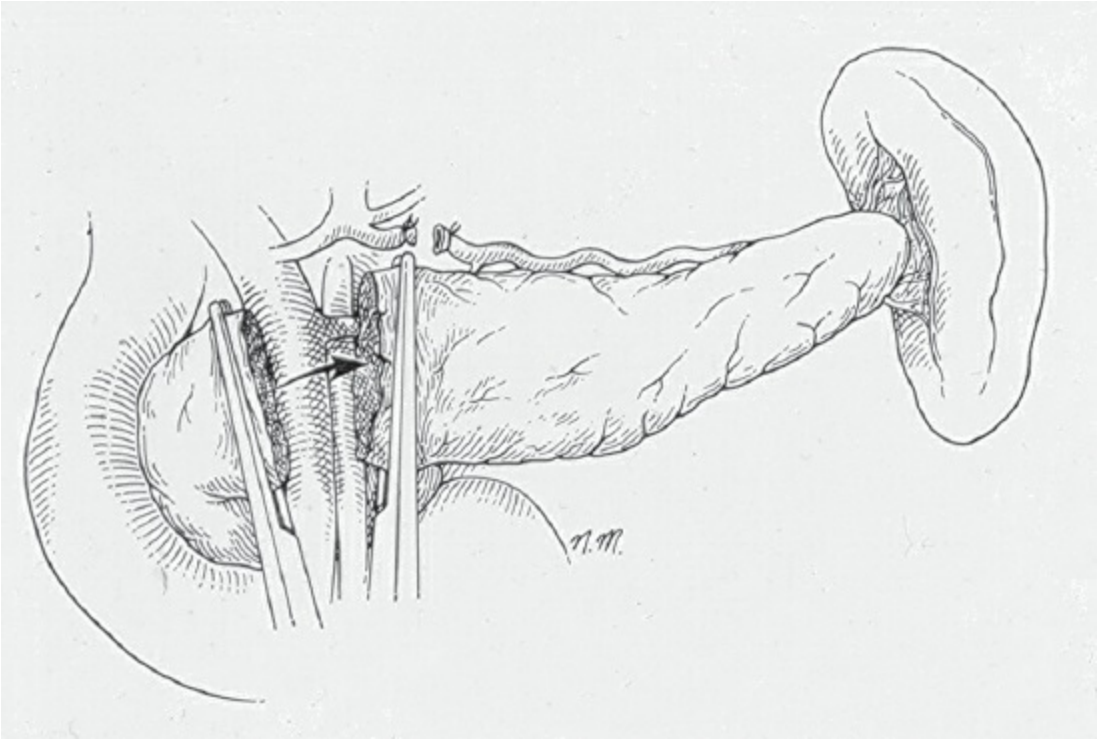

Figure 128.6. Distal pancreatectomy with splenectomy is most commonly performed after ductal transection in the neck of the pancreas or to the left of the mesenteric vessels. (From Cushman JG, Feliciano DV. Contemporary management of pancreatic trauma. In: Maul KI, Cleveland HC, Feliciano DV, et al., eds. *Advances in Trauma and Critical Care*, Vol. 10. St. Louis: Mosby; 1995:309–36, with permission.)

Another option to manage a ductal transection in the body or neck of the pancreas is oversewing or stapling the proximal end of the transection and performing a distal Roux-en-Y end-to-end or end-to-side pancreatojejunostomy (Fig. 128.7). As this option is appropriate in only the most stable patients with more proximal transections (to the right of the superior mesenteric vessels; Fig. 128.6) and no significant associated injuries, it is not commonly performed in adults (only five times in the author's personal experience). The advantage is preservation of 70% to 80% of the pancreas depending on the level of the transection for the rest of the patient's life. The operative technique includes completion of the

parenchymal transection, oversewing or stapling of the proximal end, and a cuff-type pancreatojejunostomy in one of the conformations listed earlier. Because this operation is usually performed on a normal (soft) pancreas, one option is to place a polyethylene tube stent through the anastomosis to theoretically lower the incidence of a postoperative pancreatic fistula. The stent is first passed through the abdominal wall in the right upper quadrant and then though the Roux limb ~5 cm from the pancreatojejunostomy *after* the posterior suture time has been completed. Finally, it is placed into the pancreatic duct for a distance of 2 cm and secured in place with a 3-0 absorbable suture attached to the end of the duct. The anterior anastomosis is completed, and one or two closed suction drains are placed nearby.

Ductal transections in the head of the pancreas are difficult to manage because of the thickness of the pancreas. Either of the two options described earlier for transections more to the left are appropriate, but technically more challenging. There is *no* indication to perform an anterior Roux-en-Y pancreatojejunostomy over both ends of the transection to "sump" the area as illustrated in older textbooks.

In the rare patient with combined pancreaticoduodenal destruction, maceration of the head of the pancreas, or destruction of the ampulla of Vater, a Whipple procedure is indicated. In hemodynamically stable patients, it is appropriate for an experienced surgeon to complete the Whipple procedure immediately. In some patients with blunt trauma, much of the dissection has been completed by the injury itself. When patients have associated injuries, hypotension, and signs of intraoperative "metabolic failure," bleeding from the area of injury is controlled and peripancreatic/periduodenal packs are placed. Closed suction drains may be placed underneath the packs to aspirate any bile or pancreatic juice not absorbed by the packs. As patients undergoing such damage control procedures after abdominal trauma often have marked distension of the midgut (perhaps less with the new blood-banking paradigm using 1 RBC:1 FFP:1 platelets), choosing the time of reoperation is difficult. In general, once the patient's hypothermia, acidosis, and coagulopathy have resolved, oxygenation and ventilation are reasonable, and there is an appropriate urine output, reoperation is indicated. In the borderline patient, the Whipple operation should be performed in two stages—resection, and then reconstruction. A Witzel jejunostomy should be performed in all these patients to allow for early postoperative enteral feeding once the patient is

stable and edema of the midgut starts to resolve. Some surgeons use postoperative subcutaneous injections of somatostatin analog to lower the incidence of pancreatic fistulas after Whipple resections or distal pancreatectomies performed in injured patients. Prospective data using this agent in large numbers of patients with major pancreatic trauma are lacking.

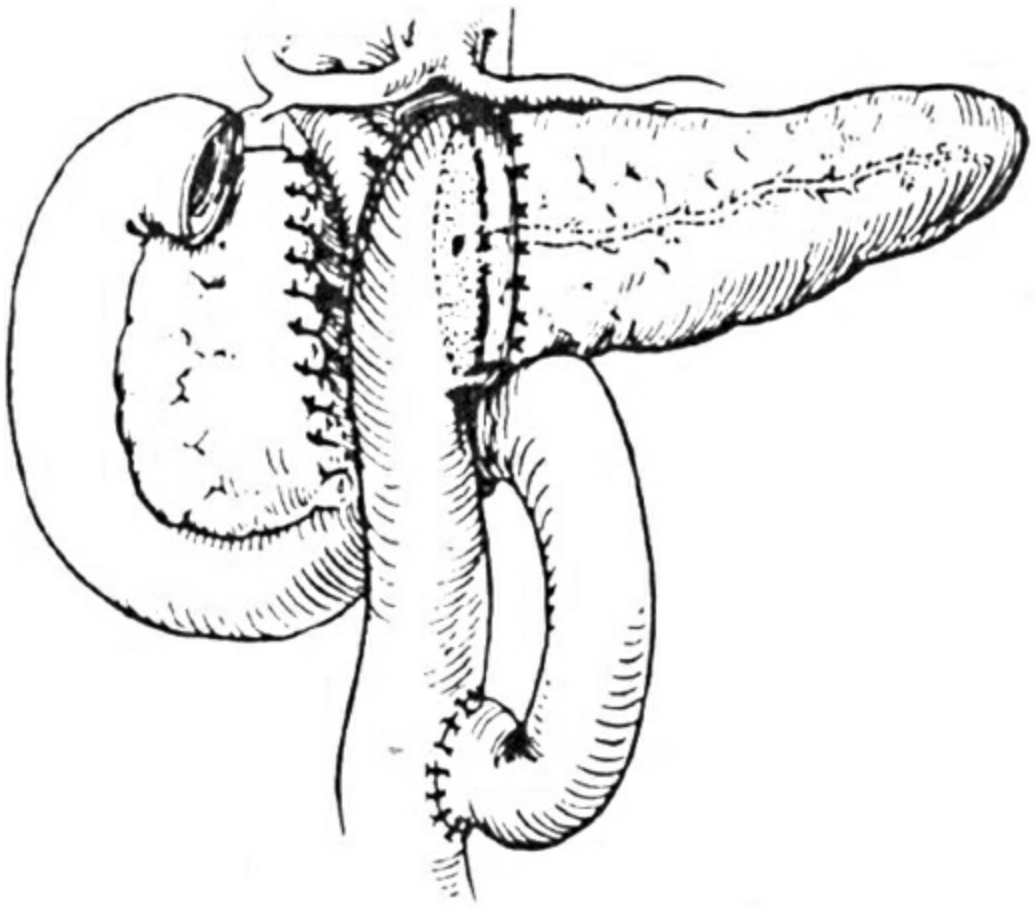

Figure 128.7. Oversewing of proximal segment and distal Roux-en-Y pancreatojejunostomy to preserve parenchyma in a patient with an AAST Grade IV injury. (Drawing adapted from Letton AH, Wilson JP. Traumatic severance of pancreas treated by Roux-Y anastomosis. *Surg Gynecol Obstet* 1959;109:473–8. Copyright © Elsevier.)

Combined pancreaticoduodenal injuries, particularly those involving the head of the pancreas and the C-loop of the duodenum, are more common in patients who have suffered penetrating wounds. The general principle of management when one of these organs is severely injured and the other is not, or when both organs are severely injured but resection is not indicated, is to perform an appropriate repair for each and place closed

suction drains in the area. Enthusiasm for adding a diversion procedure has decreased significantly in recent years presumably related to the lack of perceived benefit. As these procedures have only been used in patients with the most complex injuries (severe duodenal or combined pancreaticoduodenal), it has always been true that these subgroups of patients have the most postoperative complications. Diversion procedures modulate the severity of complications, a fact overlooked by the younger generation of trauma surgeons.

Pyloric exclusion with gastrojejunostomy is the easiest and most commonly performed diversion procedure. Through a dependent gastrotomy, the pyloric muscle ring (not the prepyloric antrum) is grabbed with Babcock clamps at the 12 o'clock and 6 o'clock positions. A #1 polypropylene suture in two layers is used to close the longitudinal slit in the pylorus created by separating the Babcock clamps. An antecolic gastrojejunostomy is then performed to allow for postoperative feeding. The pylorus remains closed for 2 to 3 weeks and then reopens in 94% of individuals, thereby protecting the injured duodenum as it heals. Should a duodenal fistula occur from the breakdown of the repair, it will be an end rather than a side fistula as the pylorus is closed. All patients in whom the gastrojejunostomy is performed should be screened for the presence of *Helicobacter pylori* in the stomach before discharge. An alternate approach is to perform the "Cali" pyloric exclusion described at the Hospital Universitario del Valle, Universidad del Valle, Cali, Colombia. This modified approach involves passing a nasojejunal feeding tube through the pylorus, performing the pyloric exclusion tight against the feeding tube, and eliminating the antecolic gastrojejunostomy. The second diversion procedure is the *duodenal diverticulization* originally described in 1968. This procedure includes a truncal vagotomy, antrectomy, gastrojejunostomy, tube duodenostomy, choledochostomy, and external drainage of the duodenal repair. While accomplishing diversion of esophageal and gastric secretions away from the duodenal repair, it sacrifices normal vagus nerves and the gastric antrum/pylorus. In addition, the insertion of a choledochostomy tube into a normal 4 to 6 mm common bile duct would be considered to be unwise technically by most surgeons. The third diversion procedure is the *triple tube approach* described at Denver General Hospital in 1978. Some combination of decompressive tubes such as a Stamm gastrostomy, tube duodenostomy or retrograde jejunostomy (into duodenal C-loop) and a standard Witzel jejunostomy for

enteral feedings is inserted. Decompression of the healing duodenum is obviously achieved by proximal, local, or retrograde tube decompression, though there is a risk of associated gastrointestinal leaks from the numerous new tubes inserted for decompression or feeding.

In a review of 1,000 patients undergoing operation for a pancreatic injury in 1995, the most common procedures were simple drainage (72.6%), distal or subtotal resection (16.9%), other (7.1%), Whipple (1.8%), and diversion (1.7%).

POSTOPERATIVE MANAGEMENT

In the patients who have undergone a pancreatic resection or the rare diversion procedure because of a combined pancreaticoduodenal injury, postoperative somatostatin analog at a dose of 50 to 100 μg subcutaneously every 8 hours for 5 to 7 days is used in some trauma centers. As noted previously, there are no prospective data in favor of this approach. This agent can be administered intravenously as well, but should not be mixed with a total parenteral nutrition solution as it loses its efficacy.

Early nutritional support via a nasojejunal feeding tube or Witzel jejunostomy is imperative in the patients who needed a resection or diversion. A postoperative pancreatic fistula or abscess will increase the catabolism related to the stress of trauma, and this can be reversed more quickly with early enteral feedings.

Peripancreatic closed suction drains are left in place for 7 to 10 days after a resection or diversion is performed. Should a postoperative pancreatic fistula occur, the daily volume is monitored and the drain left in place till drainage ceases.

COMPLICATIONS AND RESULTS

In the aforementioned review of 1,000 patients with pancreatic injuries, the most common postoperative intra-abdominal complications were a pancreatic fistula in 6% (range 3% to 17%), intra-abdominal abscess in 5% (range 5% to 18%), and postoperative pancreatitis in 2% (range 1% to 13%). Mortality obviously depends on the mechanism of injury, magnitude of the pancreatic injury, and the presence of associated injuries to the gastrointestinal tract, liver, and abdominal vessels. Overall mortality in review articles is ~20% and has a wide range (stab wound 2.8% to 5%; gunshot wounds 15.4% to 22%; blunt trauma 16.9% to 19%; shotgun

wounds 46.1% to 50%). In the patients undergoing operative management of combined pancreaticoduodenal injuries, major postoperative complications in one series from 1987 included pancreatic fistulas (26%), intra-abdominal abscesses (17%), and duodenal fistulas (6%), and the overall mortality was 29.5%.

Suggested Readings

Asensio JA, Demetriades D, Berne JE, et al. A unified approach to the surgical exposure of pancreatic and duodenal injuries. *Am J Surg* 1997;174:54–60.

Biffl WL, Moore EE, Croce NM, et al. Western Trauma Association critical decisions in trauma: management of pancreatic injuries. *J Trauma Acute Care Surg* 2013;75:941–6.

Cushman JG, Feliciano DV. Contemporary management of pancreatic trauma. In: Maull KI, Cleveland HG, Feliciano DV, et al., eds. *Advances in Trauma and Critical Care. Vol. 10.* St. Louis: Mosby; 1995:309–36.

Feliciano DV, Martin TD, Cruse PA, et al. Management of combined pancreatoduodenal injuries. *Ann Surg* 1987;205:673–80.

Jacobs LM, Luk S. *Advanced Operative Trauma Management*. Woodbury, CT: Cline-Med 2010.

Martin TD, Feliciano DV, Mattox KL, et al. Severe duodenal injuries. Treatment with pyloric exclusion and gastrojejunostomy. *Arch Surg* 1983;118:631–5.

Moore EE, Cogbill TH, Malangoni MA, et al. Organ injury scaling: Pancreas, duodenum, small bowel, colon, and rectum. *J Trauma* 1990;30:1427–9.

Okano K, Kakinoki K, Yachida S, et al. A simple and safe pancreas transection using a stapling device for a distal pancreatectomy. *J Hepatobiliary Pancreat Surg* 2008;15:353–8.

Peck GL, Blitzer DN, Bulauitan CS, et al. Outcomes after distal pancreatectomy in the modern era. *Am Surg* 2016;82:526–32.

Phelan HA, Velmahos GC, Jurkovich GJ, et al. An evaluation of multidetector computed tomography in detecting pancreatic injury: results of a multicenter AAST study. *J Trauma* 2009;66:641–7.

Seamon MJ, Pleri PG, Fisher CA, et al. A ten-year retrospective review: does pyloric exclusion improve clinical outcome after penetrating duodenal and combined pancreaticoduodenal injures? *J Trauma* 2007;62:829–33.

Subramanian A, Feliciano DV. Pancreatic trauma revisited. *Eur J Trauma Emerg Surg* 2008;1:3–10.

Takishima T, Hirata M, Kitaoka Y, et al. Pancreatographic classification of

pancreatic ductal injuries caused by blunt injury to the pancreas. *J Trauma* 2000;48:745–51; discussion 751–2.

EDITOR'S COMMENT

We are honored to have Dr. Feliciano write this chapter on pancreatic trauma. He needs no introduction and is considered by all a leading authority in the management of trauma. Pancreatic injury is challenging because of the difficulty in establishing the diagnosis as well as the complexity of associated injuries. Duodenal and pancreatic injuries are uncommon, occurring in 3% to 5% of patients sustaining abdominal injuries. Injury to these retroperitoneal structures may be suspected based upon the injury mechanism and the identification of injury to organs in close proximity to the duodenum or pancreas. Approximately 75% to 85% of blunt injuries to the duodenum and pancreas are caused by motor vehicle crashes. The usual mechanism is the forceful compression of these fixed retroperitoneal organs between the vertebral column and steering wheel or seatbelt. Falls and assaults account for the remainder of blunt injuries to these organs. Blunt duodenal and pancreatic injury may also result from bicycle accidents in which the duodenum and pancreas are crushed between the spinal column and bicycle (or motorcycle) handlebar. Penetrating injures may occur as well. Gunshot wounds are more common that stab wounds.

Associated injuries are common. In a review of 1,153 cases of duodenal injury by Asensio et al. (Management of duodenal injuries. *Curr Probl Surg* 1993;30:1023–93.), there were 3,047 associated injuries. The liver was the most commonly injured organ, accounting for 17%, duodenum and pancreas (12%), small bowel (12%), colon (12%), and stomach (9%). A second review by Asensio et al. (Management of pancreatic injuries. *Curr Probl Surg* 1999;36:325–419.) included 3,465 injuries involving the pancreas. In this report, there were 7,526 associated injuries. The liver was also the most commonly injured, accounting for 19% of associated injuries followed by the stomach (16%), spleen (11%), colon (8%), and duodenum (8%). The close proximity of the major vascular structures to the pancreas and duodenum, including the aorta, vena cava, and portal vein, predisposes them to associated injury with subsequent exsanguinating hemorrhage. In the first review discussed above, major abdominal veins were injured in 10% of patients, mostly involving the inferior vena cava, and major arteries (usually the aorta) were injured in 7% of patients. Penetrating injury is more likely to result in vascular injury, with one review documenting that 37% of patients with penetrating pancreatic injury had major vascular injuries (Vasquez JC, Coimbra R, Hoyt DB, et al. Management of penetrating pancreatic trauma: an 11-year experience of a level-1 trauma center. *Injury* 2001;32:753–9). Stone and Fabian reported that major venous injuries were present in 20% of patients with blunt duodenal injury, but

there were no associated arterial injuries (Stone HH, Fabian TC. Management of duodenal wounds. *J Trauma* 1979;19(5):334–9).

I think it will be helpful to review the classification of duodenal and pancreatic injuries. The most widely used injury classification system is from the American Association for the Surgery of Trauma (AAST) (Moore EE, Cogbill TH, Malangoni MA, et al. Organ injury scaling, II: Pancreas, duodenum, small bowel, colon, and rectum. *J Trauma* 1990;30:1427–9). It should be emphasized that injury management is not dictated by grade, yet such injury scales provide a standard way to describe and communicate the severity of injury. Injury severity is based on findings of computed tomography or during exploratory laparotomy.

Duodenal Injury Scale

- Grade I: Hematoma involving a single portion of duodenum or partial-thickness laceration without perforation
- Grade II: Hematoma involving more than one portion or disruption of <50% circumference or major laceration without duct injury or tissue loss
- Grade III: Laceration with disruption of 50% to 75% circumference of second portion or disruption of 50% to 100% circumference of first, third, and fourth portions
- Grade IV: Laceration with disruption of >75% circumference of second portion or involving ampulla or distal common bile duct
- Grade V: Massive laceration with disruption of duodenopancreatic complex or devascularization of duodenum

Pancreas Injury Scale

- Grade I: Minor contusion without duct injury or superficial laceration without duct injury
- Grade II: Major contusion without duct injury or tissue loss or major laceration without duct injury or tissue loss
- Grade III: Distal transection or parenchymal/duct injury
- Grade IV: Proximal transection or parenchymal injury involving ampulla
- Grade V: Massive disruption of the pancreatic head

Grade I and II injuries are the most common. With these injuries, nonoperative management is safe and preferred. Contrarily, nonoperative management is not supported for penetrating injuries. Regardless of the mechanism of injury, patients with pancreatic duct disruption require intervention. At exploration, the pancreas may exhibit a hematoma and this should be explored. It is very difficult to diagnose pancreatic ductal injury at the time of exploration in this type of injury, and hence, it is advisable to place a closed suction drain over the pancreas.

Nonoperative management includes gastrointestinal decompression and

nutritional support. For patients with obstructing duodenal hematoma, a nasogastric tube is placed and parenteral nutrition initiated. Imaging should be repeated 5 to 7 days after the injury. If the obstruction has resolved, an oral diet can be initiated. After 14 days, if the obstruction is still present, laparotomy is warranted. Careful follow-up is essential to monitor for complications that indicate the need for surgical exploration.

Velmahos GC et al. (Velmahos GC, Tabbara M, Gross R, et al. Blunt pancreatoduodenal injury: a multicenter study of the Research Consortium of New England Centers for Trauma (ReCONECT). *Arch Surg* 2009;144(5):413–9) support the role of nonoperative management. They reported a retrospective multicenter study evaluating the outcomes of 230 patients with blunt pancreatic and/or duodenal injury. They found that of the 97 patients managed nonoperatively, 10 patients (6 pancreatic, 3 duodenal) failed nonoperative management and required surgery.

As described by Dr. Feliciano, in those patients who require operative intervention, the initial consideration is stabilization of the patient and then laparotomy. Management of the injury is based on the finding as described in the chapter. In my opinion, for transection, the distal pancreas should be resected in the stable patient. If the patient is unstable, it may be prudent to close the proximal pancreatic stump and place a pediatric feeding tube or other silastic catheter to exteriorize and control the drainage of the distal pancreas with a planned pancreaticojejunostomy in 3 months. Doing a pancreaticojejunostomy in the acute setting is difficult at best and likely to result in a pancreatic fistula and will take too much time exposing the patient to the cold environment of the OR and delay stabilization and continued resuscitation in the ICU. Likewise, this is no time for the surgeon to do a Whipple procedure unless needed to control bleeding and, then it may be a better option to do damage control and come back another day to do the reconstruction.

E. Christopher Ellison

129 Splanchnic Denervation of the Pancreas for Intractable Pain

Joshua S. Tierney, Gary C. Vitale, and Keith D. Lillemoe

INTRODUCTION

The management of intractable pain can be one of the most challenging aspects of caring for patients with either chronic pancreatitis or pancreatic cancer. The pancreas is innervated by the autonomic nervous system for the neurohormonal regulation of the organ's endocrine and exocrine function. The visceral afferent pathway of these autonomic nerves transmits pain in the diseased state. Past research regarding the precise etiology of pancreatic pain has focused on two main theories: pancreatic ductal hypertension and inflammatory damage of the intrapancreatic nerves, more recently termed *pancreatic neuritis.* The former is often a component of the pain in chronic pancreatitis, which provides the rationale for treatment with endoscopic and surgical drainage procedures of the pancreatic duct. Pancreatic neuritis is a result of inflammatory and/or malignant cells that infiltrate and damage intrapancreatic nerves, thereby stimulating the afferent pain pathways. Studies have shown that the intensity of abdominal pain correlates with increasing levels of malignant or inflammatory cell infiltration into the perineural tissues of the pancreas in patients with both pancreatic malignancy and chronic pancreatitis. These two theories fail to account for various complexities such as the upregulation of pain mediators, neurohormonal changes, and abnormal feedback mechanisms (i.e., sensitization) that develop over time in patients with chronic pain. The anatomic basis of pancreatic pain is afferent nociceptive nerve endings in the pancreatic parenchyma that are stimulated by inflammation, high pressure, ischemia, and exposure to pancreatic proteases. The long processes of these nerve endings pass first through the celiac plexus and then coalesce through the greater (T5 to T9), lesser (T10 to T11), and least (T12) splanchnic nerves in the thorax to the nociceptive neuron located in the dorsal root of the spinal cord. The pain signal is then transmitted via second- and third-order neurons in the central nervous

system. Techniques to interrupt the pain signal through the celiac plexus and splanchnic nerves are the focus of this chapter.

The pain is typically in the upper epigastrium and radiates toward the T12 to L2 region of the lower spine. It is described as sharp, dull, or boring in quality and can be exacerbated by eating. There is often associated nausea, anorexia, weight loss, and depression. Significant variability exists from patient to patient regarding the nature and severity of the pain, highlighting the importance of an individualized approach to treatment. Patients with chronic pancreatitis can have one of two pain patterns: either short, relapsing episodes of pain lasting days to weeks separated by pain-free intervals or a more prolonged course with unremitting and severe pain. Patients with chronic pancreatitis were once thought to enter a “burn-out” phase where late in the course of their disease the pain gradually abates as the pancreas atrophies and looses function, but recent prospective studies suggest that the pain actually becomes more resistant to treatment later in the course. For patients with pancreatic cancer, the pain is initially poorly localized and can vary in nature and severity from day to day and week to week. As the disease progresses, the pain often becomes unremitting and severely debilitating, with studies suggesting that patients with poorly managed pain have shorter survival. The development of effective treatment strategies for chronic pain of pancreatic origin is central to improving the quality of life and well-being for these patients.

ANATOMY

The celiac ganglion innervates the upper abdominal viscera and is the largest plexus of nerves in the abdominal aortic sympathetic plexus. It contains both preganglionic and postganglionic sympathetic fibers, preganglionic parasympathetic fibers, and visceral afferent (pain) fibers. The celiac plexus is composed of bilateral celiac ganglia, located in front of and on both sides of the abdominal aorta at the level of the celiac artery. Plexus fibers cross in front of the aorta both above and below the celiac axis. Organs innervated by the celiac ganglia include the stomach, liver, gallbladder, pancreas, adrenal glands, kidneys, and intestines to the level of the transverse colon. The sympathetic plexus ganglia vary in number from one to five on each side of the aorta, and range from an aggregate size of 0.5 cm to 4.5 cm. Without extensive dissection, the origin of the celiac artery can be identified intraoperatively by palpation of the common hepatic and splenic arteries, the two most consistent arterial branches off

the celiac artery. Radiographically, the plexus can be found by identification of both the celiac and superior mesenteric arteries.

The splanchnic nerves, usually three (greater, lesser, and least), consist primarily of preganglionic sympathetic and accompanying visceral afferent fibers. These nerves vary much in their origin; however, the greater splanchnic nerves usually arise from the 5th through 9th thoracic ganglia (Fig. 129.1). The unison of these roots forms a nerve of considerable size (larger than the continuation of the sympathetic trunk into the abdomen) that descends on the front of the vertebral column and pierces the muscular part of the diaphragm to end in the celiac ganglion. The lesser splanchnic nerve usually arises from the 9th and 10th (and sometimes 11th) thoracic sympathetic ganglia. It runs parallel and medial to the greater splanchnic nerve but lateral to the sympathetic trunk. The least splanchnic nerve is identifiable in some patients and arises from the last thoracic sympathetic ganglia at T11 or T12. The nerve trunks are constituted at or above the level of the 10th thoracic vertebra, and descend along the spine where they are bound by the parietal pleura. The lesser splanchnic nerve generally supplies the submesenteric organs and forms from the trunks of the 10th and 11th thoracic ganglia and runs parallel to the greater splanchnic nerve in the chest. All nerves penetrate the crus of the diaphragm and enter the abdomen. The greater splanchnic nerve ends in the celiac ganglia, the lesser splanchnic nerve ends in the aorticorenal ganglion, and the least splanchnic nerve in the renal plexus. The vagus nerves run in the lower thoracic cavity along the esophagus below the parietal pleura. The role of the vagal fibers in the transmission of pain sensation from the pancreas is unclear. Bilateral vagotomy has been advocated in early series of celiac plexus neurolysis (CPN) as a method of increasing the completeness of splanchnic denervation. Currently, most surgeons limit their operation to the splanchnic nerves as the postvagotomy sequelae of delayed gastric emptying and diarrhea can often be formidable.

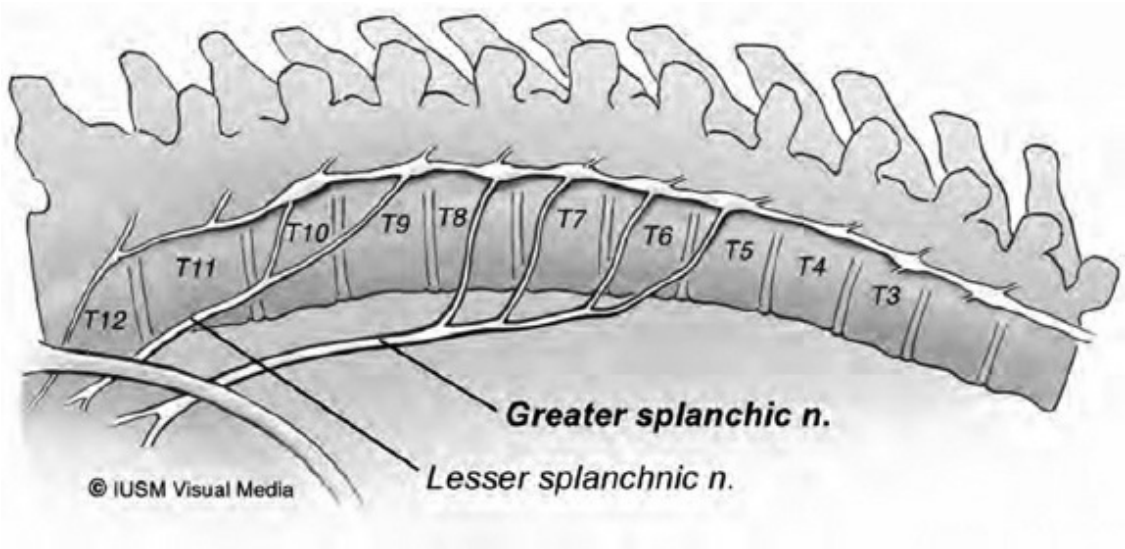

Figure 129.1. Diagram showing the standard location of the greater splanchnic nerve as viewed through the right chest in the prone position. It is composed of the rami communicans of the 5th through the 8th thoracic sympathetic ganglia, funneling down toward the diaphragm. The lesser splanchnic nerve is derived from fibers arising from the 9th and 10th thoracic sympathetic ganglia and courses parallel to the greater splanchnic nerve.

PAIN MANAGEMENT AND INDICATIONS FOR SPLANCHNIC DENERVATION OF THE PANCREAS

Chronic Pancreatitis: The initial management of pain in patients with chronic pancreatitis begins with imaging studies to identify any readily treatable complications, such as pancreatic pseudocysts, biliary or duodenal strictures, or cancer. In addition, it is important to identify patients with a dilated pancreatic duct, with or without pancreatic duct strictures or stones, who may be candidates for endoscopic or surgical drainage procedures. Surgical drainage has been shown to be more effective and durable than endoscopic stenting in this setting. The importance of alcohol abstinence and a low-fat diet must be stressed to the patient. A trial of pancreatic enzyme supplementation is often advocated as a pain relief adjunct to reduce the native production of pancreatic proteases, but the benefit is usually limited. A step-wise approach to pharmacologic pain relief is recommended, beginning with nonsteriodal anti-inflammatory drugs (NSAIDs) and adding opioids as needed in increasing potency and frequency until adequate relief is achieved. Using multimodal therapy with antidepressants and gabapentoids in an effort to reduce opioid use is recommended. Pregablin is the only adjunct that has

been shown to reduce pain and opioid use for patients with chronic pancreatitis in a randomized controlled trial. The medical management of pain in chronic pancreatitis is summarized in a position statement by the American Gastroenterologic Association (AGA) (see Table 129.1).

Failure of the above measures to provide extended symptomatic relief should lead to the consideration of surgical management as guided by the anatomic features of the gland. With careful patient selection, a 70% to 80% long-term success rate in achieving postoperative pain control can be anticipated. There are little data to support concomitant use of CPN during pancreatectomy or drainage procedures for chronic pancreatitis. If in the end all medical, endoscopic, and surgical measures have failed to provide relief, consideration is then given to performing bilateral thoracoscopic splanchicectomy (BTS). At our institution, this procedure is usually reserved as a rescue option for patients who have failed surgical management, but for those who are high-risk surgical candidates or otherwise refuse surgery, it can be offered earlier in the treatment algorithm. Endoscopic ultrasound-guided celiac plexus block (EUS-CPB) is also an option and readily employed in some centers even as an adjunct prior to consideration of surgery. The efficacy of EUS-CPB is limited to up to 10 weeks of pain relief and thus can require many repeated interventions. Celiac plexus block (CPB) refers to the instillation of long-acting local analgesic (usually 0.1% bupivacaine with or without the addition of a steroid) to temporarily inhibit function of the celiac plexus function thereby reducing pain, whereas CPN refers to injections of absolute ethanol to permanently destroy nerve fibers in order to facilitate longer pain relief. CPN induces a dense fibrotic process that could complicate future surgery and is thus not usually employed in the setting of chronic pancreatitis.

In our experience, currently in press, BTS is less effective in achieving resolution of abdominal pain and reduction in opioid use in patients with chronic pancreatitis than in the population with pancreatic malignancy. We performed BTS in 75 patients with chronic pancreatitis from July 1998 to March 2016. After 32 months follow-up, 57% of patients still experienced abdominal pain and only 32% of patients had a reduction in opioid use. This likely has to do with the longer length of time patients live with chronic pancreatitis. This long duration of chronic pain and opioid use promotes the sensitization of pain pathways to essentially become stuck in the “on” position independent from stimulus. Some patients still have pain

even after the most aggressive measures such as total pancreatectomy. This has led some surgeons to advocate for early surgical treatment of chronic pancreatitis before sensitization has occurred. A few retrospective studies support this, showing improved outcomes when surgical treatment occurs within 3 years of the diagnosis. A recent systemic review from 2104 examined outcomes of 484 patients from 16 studies who underwent BTS for chronic pancreatitis and found that preoperative opioid use was associated with worse postoperative pain scores suggesting that early BTS prior to sensitization will improve outcomes in this patient population. More research is needed to elucidate the most effective timing for surgery and splanchnic denervation for pain relief in chronic pancreatitis.

TABLE 129.1 American Gastroenterologic Association (AGA) Medical Position Statement on the Treatment of Pain in Chronic Pancreatitis

Initial therapy			
Abstain from alcohol	Nonnarcotic analgesics	Low-fat diet	Quality of life questionnaire
No response			
	Gastric acid suppression	8-week trial of high-dose pancreatic enzymes	
No response			
	Consider endoscopic therapy		
No response			
Watchful waiting versus narcotic analgesics versus surgery			
Surgery decided			
Small ducts		Large ducts	
Nerve ablation		Surgical Drainage	
Pancreatic resection			

Pancreatic Cancer: Survival of patients with locally advanced, unresectable pancreatic cancer is 6 to 12 months while patients with metastatic disease to the liver or peritoneal cavity survive approximately 3 to 6 months. The preferred initial pain management in these patients includes the use of transdermal or long-acting narcotic analgesics to provide a steady-state basal plasma level, supplemented with the intermittent use of short-acting narcotic analgesics for breakthrough pain. As in medical treatment of chronic pancreatitis, antidepressant medications

are also used as an adjunct to pain medication in patients with pancreatic cancer. The majority of patients with advanced pancreatic cancer will have pain requiring increasing doses of opioid analgesics during the course of their illness. EUS-CPN, image-guided CPN, or BTS are three minimally invasive neurolytic procedures that are commonly employed in this setting.

The trials comparing the efficacy of CPN versus BTS are either nonrandomized or small in size and have not clearly identified superiority of either procedure. The choice of which to employ is dependent on local expertise. EUS-CPN has been shown to have reduction in pain scores in 70% to 80% patients with pancreatic malignancy, but studies have failed to demonstrate a reduction in opioid use. Minor complications such as diarrhea and transient hypotension occur in 21% and the risk of serious complications is approximately 0.2% and includes reports of serious bleeding, visceral injury, and one report of paralysis from spinal cord ischemia. A systematic review examined the efficacy and safety of non–EUS-guided CPN compared with standard treatment in five randomized controlled trials involving 302 patients with unresectable pancreatic cancer (four computed tomography [CT] or fluoroscopy-guided CPN trials, one intraoperative CPN). The primary outcome of pain was lower in the CPN group on a visual analog scale (VAS) at 2, 4, and 8 weeks (weighted mean difference [WMD], 0.60; 95% confidence interval [CI], −0.82 to −0.37). Opioid usage (in mg/dL oral morphine) was also reduced at 2, 4, and 8 weeks (WMD, 85.9, 95% CI, −144.0 to 129.9). Our experience with BTS in 48 patients with pancreatic malignancy found that after 8 months follow-up, only 27.6% of patients had ongoing abdominal pain after the procedure and 67% had weaned off opioids completely. Complications from BTS are rare and reported to be between 4% and 16% and include chylothorax and pneumothorax.

In patients where the tumor is found to be unresectable at the time of laparotomy, intraoperative chemical CPN should be done in conjunction with appropriate surgical palliative procedures such as biliary bypass and/or gastrojejunostomy. This procedure is indicated whether or not the patient has significant pain at the time of surgery as the natural history of the disease includes pain that becomes progressively more severe and unrelenting as the malignancy progresses. The same technique is applicable whether the tumor arises in the head, body, or tail of the gland. The data do not support prophylactic CPN in patients who undergo a complete R_0 surgical resection despite the fact that almost 50% of such

patients will eventually develop retroperitoneal tumor recurrence as a component of disease relapse and pain recurrence with this development. This question was definitively answered in 2015 with the first prospective, randomized, double-blind placebo controlled trial by Yeo and colleagues comparing ethanol CPN to saline injection in 467 patients with resectable pancreatic malignancy. They found no statistically significant difference in pain between preoperative baseline and at 12 months follow-up between the two groups.

OPERATIVE TECHNIQUES

Open CPN

Open CPN has become a standard approach to pain management in patients with advanced, unresectable pancreatic cancer who require laparotomy to perform palliative bypasses or for patients who were either found to be unresectable at laparotomy or found to have occult metastatic disease. The procedure was first described by Copping and colleagues in 1969. In an update of their series in 1978, including 41 patients with pain due to pancreatic cancer, 88% of patients experienced relief of pain postoperatively. Most patients underwent palliative biliary and gastrojejunal bypass at the same operation. These results were compared with a group of historic controls in which only 21% of patients had pain control after similar palliative procedures. Since that time, this procedure has been advocated by a number of authors in anecdotal reports describing successful control of pain in the majority of patients. In 1993, a prospective, randomized, placebo-controlled study of this treatment was completed with results demonstrating that open chemical neurolysis with a 50% alcohol solution significantly reduces or prevents pain in patients with unresectable pancreatic cancer when compared with a placebo injection with saline. This beneficial effect was observed in all randomized patients including both subgroups of patients, those with and without preoperative pain. Interestingly, this study also showed a significant improvement in survival in patients with significant preoperative pain who received the alcohol neurolysis when compared with placebo, implying that better pain control and a reduced requirement for narcotic analgesics may prolong survival as well as improve the quality of life in patients with end-stage pancreatic cancer.

Through an upper midline or bilateral subcostal incision, the abdomen is entered and careful assessment of the tumor for resectability is done.

After determining that the cancer is unresectable, the operating surgeon's focus should switch from aggressive tumor extirpation to palliation. After completion of the appropriate operative bypasses of the biliary system and/or gastric outlet, chemical neurolysis should be considered. Forty milliliters of a 50% alcohol solution is prepared in a sterile fashion by diluting 20 cc of absolute ethanol with 20 cc of sterile injectable saline solution (1:1). A 20-cc syringe with a 22-gauge spinal needle is used for delivery of this solution to the para-aortic tissues. The lesser omentum is incised over the bare area and the celiac axis can be palpated through the retroperitoneum as it arises from the aorta, behind the stomach, near the diaphragmatic crura. A palpable thrill due to the high blood flow through the celiac axis is usually apparent. The operating surgeon, using his or her left hand, then straddles the celiac axis putting the index finger on the splenic artery and the middle finger on the common hepatic artery while stabilizing this orientation with the thumb on the left side of the abdominal aorta (Fig. 129.2). The 22-gauge spinal needle is then advanced into the soft tissue on both sides of the aorta—both below and above the level of the celiac artery (10 cc of 50% alcohol solution is injected into all four quadrants). Both before and episodically during the injection, the syringe should be aspirated to ensure that the inferior vena cava, coronary vein, aorta, or adjacent lumbar vessels have not been inadvertently cannulated. If blood flow is obtained with this maneuver, simply withdraw the needle, reposition, aspirate again, and resume infiltration of the ethanol solution into the para-aortic soft tissue. Instillation of at least 40 cc of 50% ethanol solution is considered necessary in order to achieve an adequate celiac neurolysis.

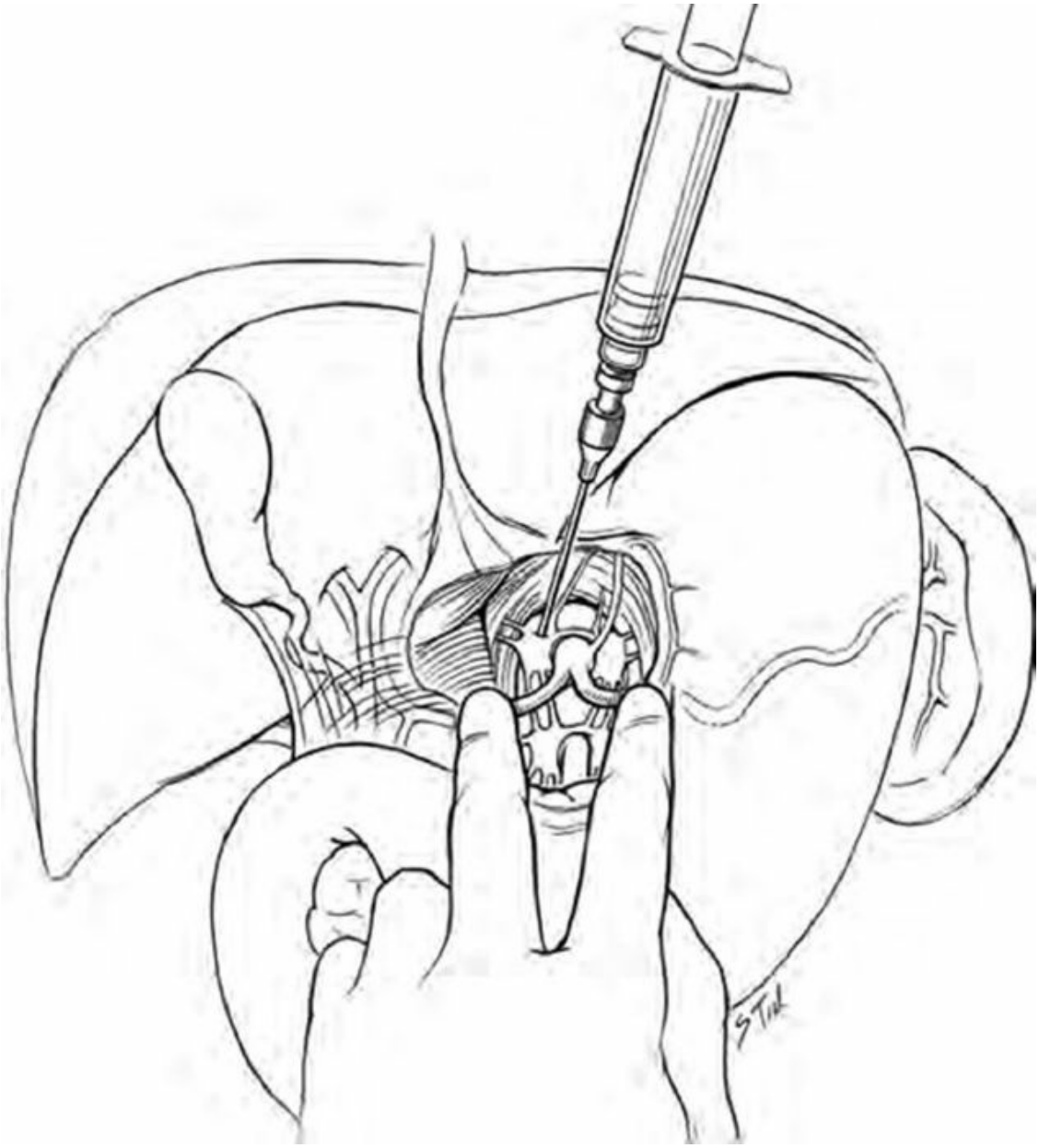

Figure 129.2. Intraoperative celiac plexus neurolysis. After incising the avascular area of the hepatogastric ligament, the celiac trunk is palpated by placing the surgeon's left index finger on the splenic artery and the left third finger on the common hepatic artery while steadying their hand by abutting their thumb to the left lateral aspect of the aorta. The surgeon's right hand uses the 10-cc syringe to inject 50% ethanol into four quadrants around the celiac axis.

After completing the injection in all four quadrants, the sites are inspected for hemostasis. If minor bleeding is observed, the area is packed and compressed for a short period of time. At the time of injection, the anesthesiologist should be notified of the procedure. Occasionally, with an

adequate sympathetic blockade, some degree of hypotension may be observed. This situation can generally be managed easily by the anesthesiologist giving additional intravenous fluids or the judicious use of pharmacologic blood pressure support. As a general rule, CPN is quite well tolerated with fewer complications, and it requires no alteration in the postoperative management of patients undergoing laparotomy and palliative bypass procedures for unresectable pancreatic cancer. Mild complications include bleeding and postural hypotension, both are generally self-limiting and easily managed. Bleeding can generally be controlled by direct pressure intraoperatively. During the first attempts at postoperative ambulation, the patient should be observed for any evidence of orthostatic hypotension. However, this effect, if noted at all, is seldom long lasting. In patients who have only had exploration and biopsy for tissue diagnosis in which a CPN is also done, oral intake can be resumed as tolerated, and the patient can be discharged as soon as possible after the procedure. Serious complications are rare but include diarrhea, gastroparesis, chylothorax, retroperitoneal abscess, superior mesenteric vein thrombosis, extradural abscess, and reversible paralysis. There has been a single case report of paraplegia after CPN.

The predominant reasons for failure of pain control following CPN are either poor localization of the injection to the celiac plexus or use of an inadequate volume of neurolytic agent. With large tumors involving the pancreatic neck/proximal body, or tumors with extensive associated celiac lymphadenopathy, identification of the appropriate intraoperative anatomy is often problematic and these patients are often better approached percutaneously using CT guidance as a separate procedure after recovery from the operation. Pain relief even with a successful CPN will often be poor when the tumor is extensive enough to involve somatically innervated sites in the abdominal wall, Glisson capsule, or the diaphragm.

Bilateral Thoracoscopic Splanchnicectomy

The transthoracic approach for pancreatic splanchnic denervation has gained increasing popularity particularly in today’s era where endoscopic stenting technology and expertise have, in many cases, obviated the need for palliative gastrojejunostomy and/or biliary bypass in patients with unresectable pancreatic malignancy and intractable pain. Pancreatic denervation to interrupt the flow of painful stimuli from the pancreas through the central nervous system has conceptually intrigued surgeons

since its first report by Mallet-Guy in 1943. The ability to relieve pain from chronic pancreatitis with a single therapeutic intervention without disrupting the pancreas or digestive tract or reoperating through a scarred abdomen remains an extremely attractive option for these patients as well. In 1993, two groups combined the theories of Mallet-Guy with the technology of video thoracoscopy to report on the use of thoracoscopic splanchnicectomy to treat the pain from pancreatic cancer. This provided the surgical community a simple, straightforward procedure to address the vexing problem of pain from advanced pancreatic malignancy. The operation was extended to patients with chronic pancreatitis, modified to include bilateral nerve ablation through a posterior approach, and patients were screened by the use of a differential epidural anesthetic to identify those individuals who would have a high likelihood of success with the procedure.

Our technique of BTS is similar to that as described in a report by Jones et al. The procedure is performed under general endotracheal anesthesia using a single lumen endotracheal tube. Early in our experience we used a double lumen tube for dual lung ventilation, but we have found that insufflation of the thorax is sufficient to provide working space without the necessity of having an anesthesia team facile in placement of a double lumen tube. An orogastric tube is placed to decompress the stomach, which when distended can elevate the left diaphragm and obscure exposure. Patients are placed in the prone position with arms extended and flexed at the elbow. Great care is taken to adequately pad all pressure points. With respirations suspended by the anesthesia provider, a 5-mm trocar is placed at the inferior scapular apex on the side chosen to begin the procedure (Fig. 129.3). Carbon dioxide is insufflated to achieve a target pressure of 8 mm Hg. After confirmation of trocar placement with a 30-degree 5-mm thoracoscope, respirations are resumed and a second trocar is placed two intercostal spaces below and 2 cm anterior to the first trocar under direct vision. After the splanchnic nerves are identified inferior and medial to the sympathetic trunk, the pleura is incised on both sides of each of the nerves using the heal of the right angle cautery. The tip of the right angle is then used to elevate and divide each of the nerves. Occasionally, mediastinal fat or thickened parietal pleura due to prior pleural disease (effusions, inflammation) obscures identification of the nerves. In this situation, we open the entire length of the mediastinal pleura in a cephalad-to-caudad direction perpendicular to the vertebral bodies. The greater

splanchnic nerve is then identified by following small ramus fibers from the 5th to 8th sympathetic ganglia up to where they coalesce into the main trunk. The trunk of the greater splanchnic nerve is then divided with the hook electrocautery (Fig. 129.4). The dissection of the mediastinal pleura then is continued inferiorly to the diaphragm to expose rami communicans from the 8th to 12th intercostal space (lesser and least splanchnic nerves). These small branches are then disrupted using the hook electrocautery when identified. We try to limit inferior mediastinal dissection on the right side when possible as the thoracic duct resides in this location and can be vulnerable to injury. Some surgeons advocate for the division of the main sympathetic truck, but we have found this to be unnecessary and is prone to troublesome venous bleeding. If bleeding is encountered, direct pressure with a laparoscopic Kittner is usually sufficient to achieve hemostasis. Resisting the urge to coagulate bleeders with electrocautery is good advice as this will sometimes result in more profuse bleeding. After successful splanchnicectomy, insufflation is released, the working port trocar is removed and the lung is reinflated under direct vision, then finally the camera trocar is removed. Port sites are closed with a deep layer 3-0 Vicryl suture and the skin is closed with 4-0 Vicryl suture, and then the procedure is repeated on the contralateral side. The usual operative time is 20 to 30 minutes per side. A chest x-ray is obtained immediately in the postanesthesia recovery unit and then again on the morning of the first postoperative day to check for an immediate and delayed pneumothorax, respectively.

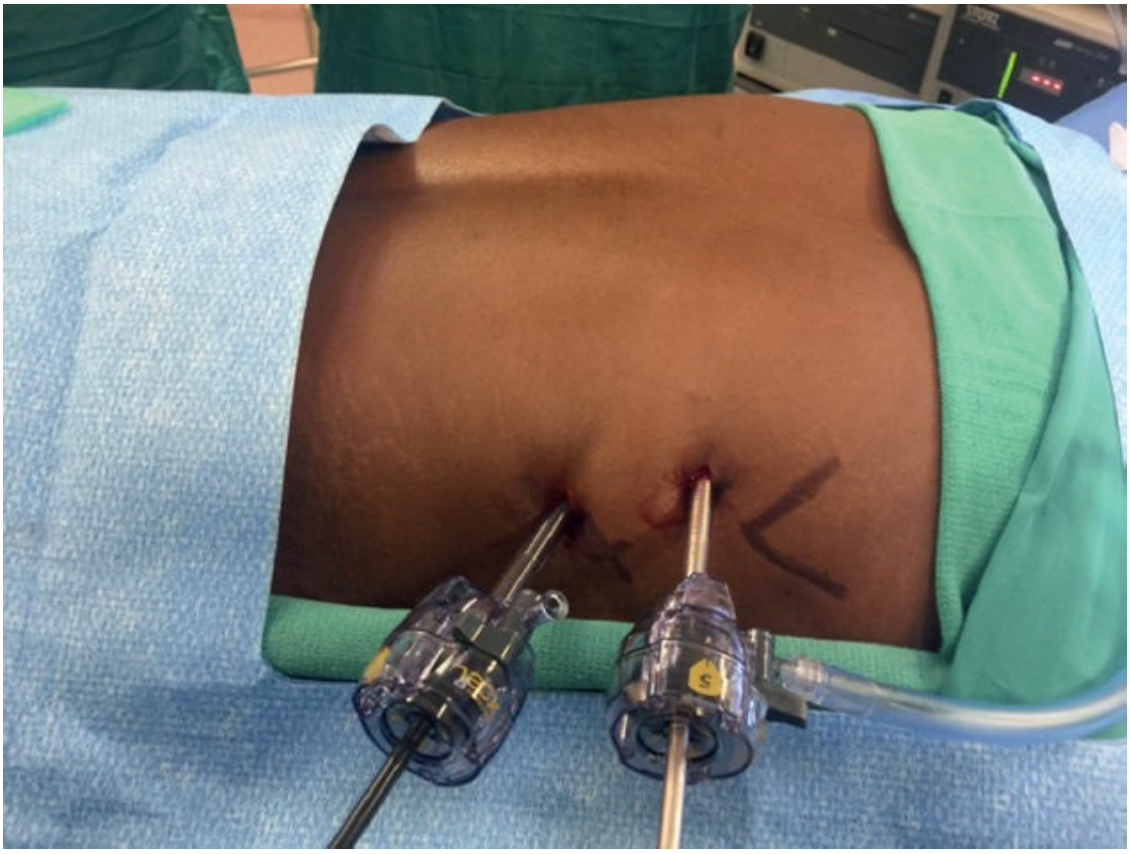

Figure 129.3. This image shows the trochar positioning for bilateral thoracoscopic splanchnicectomy. In our setup, we use the rib space just caudal to the tip of the scapula as the landmark (marked with a “V” in the picture) for placement of the first 5-mm port for the camera. The second 5-mm working port is placed one rib space caudal and slightly anterior to the camera port.

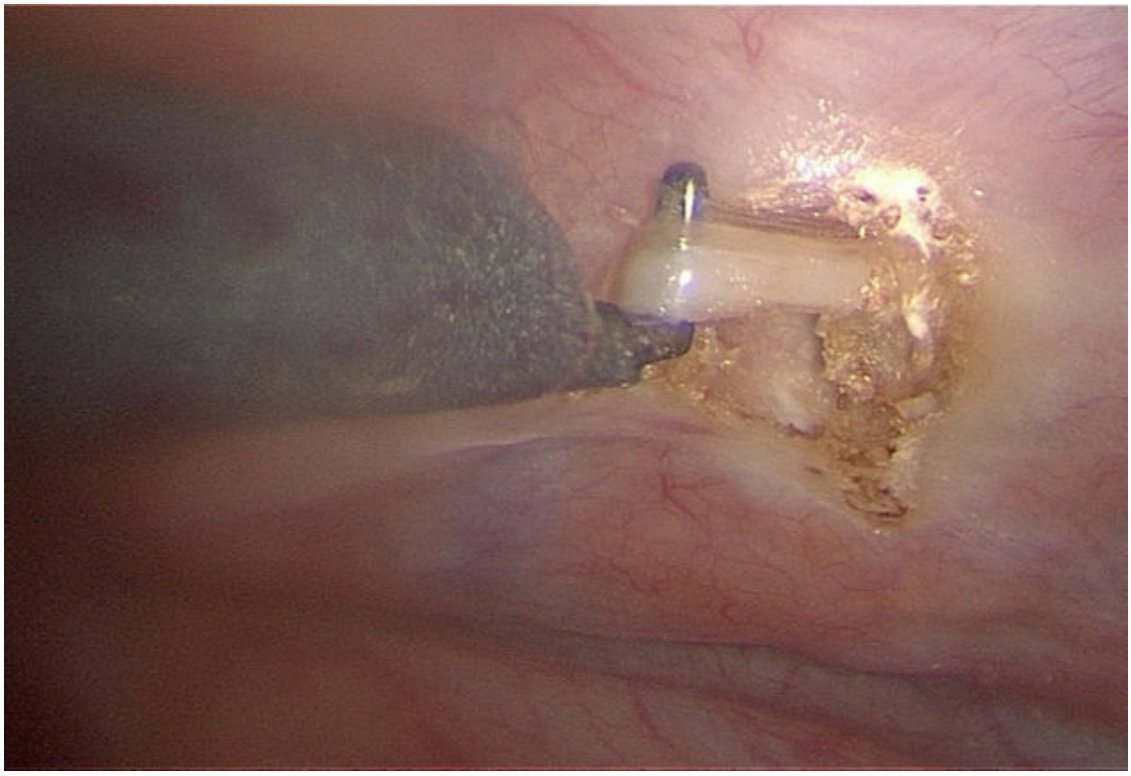

Figure 129.4. Intraoperative photo demonstrating our technique using the hook cautery to dissect and transect the splanchnic nerves.

Perioperative morbidity rate in our own series of 123 patients from June 1998 to March 2016 was low at approximately 4%. These consisted of 1 chylothorax requiring reoperation, 1 persistent pneumothorax, and a total of 3 other patients who required chest tubes for pneumothoraces. The postoperative hospital stay for most patients is short at 12 to 24 hours, usually only requiring one night in the hospital. The 30-day readmission rate was 8% for the pancreatic malignancy group and 5% for the chronic pancreatitis group. There were no deaths and no conversions to open thoracotomy. These low rates of morbidity were confirmed in a systematic review in 2008 of 302 patients undergoing BTS for chronic pancreatitis, which found an overall morbidity of 16.6%, a 1.3% conversion rate to open thoracotomy, a 1.3% reoperation rate to manage complications, and a 0% mortality. The most common causes of failure from this operation are either misidentification of the greater splanchnic nerve or incomplete mobilization of the nerve (particularly T7 and T8 in the inferior part of the dissection) to ensure that all rami communicans through the splanchnic nerve to the abdomen are ablated.

This systemic review from 16 published series on outcomes of BTS in

patients with chronic pancreatitis found a success rate of 90% during the first 6 months, but these rates diminished with the length of follow-up evaluation to approximately 50% at 3 years. In the more recent systemic review from 2014, analyzing opioid use and BTS in patients with chronic pancreatitis that was mentioned earlier in the chapter found a median success rate of 62% in this patient population. These results are more in line with our group's experience that both the short- and long-term success of BTS is generally poor in chronic pancreatitis with only 57% initial success rate of pain reduction and only 32% of patients being off opioids at long-term follow-up. This is in stark contrast to outcomes of BTS in the population with pancreatic malignancy where we have found outcomes of pain palliation and opioid reduction to be excellent. It is now recognized that patients who have become sensitized to opioid pain medications preoperatively have less successful long-term pain control likely related to a permanent hyperalgesic state that is not ameliorated by splanchnicectomy. This highlights the importance of proper timing and patient selection when BTS is considered for treatment of chronic pain in patients with pancreatic malignancy or chronic pancreatitis. Although when successful, pain palliation has been associated with improvement in these patients' quality-of-life indices.

CONCLUSION

Splanchnic denervation has a role in managing intractable pancreatic pain in properly selected patients with pancreatic malignancy and chronic pancreatitis.

Suggested Readings

Ahmed Ali U, Nieuwenhuijs VB, van Eijck CH, et al. Clinical outcome in relation to timing of surgery in chronic pancreatitis: a nomogram to predict pain relief. *Arch Surg* 2012;147(10):925–32.

Baghdadi S, Abbas MH, Albouz F, et al. Systematic review of the role of thoracoscopic splanchnicectomy in palliating the pain of patients with chronic pancreatitis. *Surg Endosc* 2008;22:580–8.

Bradley EL, Bem J. Nerve blocks and neuroablative surgery for chronic pancreatitis. *World J Surg* 2003;27:1241–8.

Copping J, Williz R, Draft R. Palliative chemical splanchnicectomy. *Arch Surg* 1969;98:418–20.

Cuschieri A, Shimi SM, Crothwaite G, et al. Bilateral endoscopic splanchnicectomy through a posterior thoracoscopic approach. *J R Coll Surg Edinb* 1994;39:44–7.

Davis BR, Vitale M, Lecompte M, et al. An objective study of pain relief in chronic pancreatitis from bilateral thoracoscopic splanchnicectomy. *Am Surg* 2008;74(6):510–4.

Howard TJ, Browne JS, Zyromski NJ, et al. Mechanisms of primary operative failure and results of remedial operations in patients with chronic pancreatitis. *J Gastrointestinal Surg* 2008;12(12):2087–95.

Howard TJ, Swofford JB, Wagner DL, et al. Quality of life after bilateral thoracoscopic splanchnicectomy: long-term evaluation in patients with chronic pancreatitis. *J Gastrointest Surg* 2002;6:845–54.

Issa Y, Ahmed Ali U, Bouwense SA, et al. Preoperative opioid use and the outcome of thoracoscopic splanchnicectomy in chronic pancreatitis: a systematic review. *Surg Endosc* 2014;28:405–12.

Johnson CD, Berry DP, Harris S, et al. An open randomized comparison of clinical effectiveness of protocol-driven opioid analgesia, celiac plexus block or thoracoscopic splanchnicectomy for pain management in patients with pancreatic and other abdominal malignancies. *Pancreatology* 2009;9(6):755–63.

Jones W, Jordan P, Pudi M. Pain management of pancreatic head adenocarcinomas that are unresectable: celiac plexus neurolysis and splanchnicectomy. *J Gastrointest Oncol* 2015;6(4):445–51.

Lavu H, Lengel HB, Sell NM, et al. A prospective, randomized, double-blind, placebo controlled trial on the efficacy of ethanol celiac plexus neurolysis in patients with operable pancreatic and periampullary adenocarcinoma. *J Am Coll Surg* 2015;220(4):497–508.

Lillemoe KD, Cameron JC, Kaufman HS, et al. Chemical splanchnicectomy in patients with unresectable pancreatic cancer: a prospective randomized trial. *Ann Surg* 1993;217:447–57.

Mallet-Guy PA. Late and very late results of resections of the nervous system in the treatment of chronic relapsing pancreatitis. *Am J Surg* 1983;145:234–8.

Moore JC, Adler DG. Celiac plexus neurolysis for pain relief in pancreatic cancer. *J Support Oncol* 2009;7:83–90.

Warshaw AL, Banks PA, Fernàndez-del Castillo C. AGA technical review on treatment of pain in chronic pancreatitis. *Gastroenterology* 1998;115:765–76.

Woodham MJ, Hanna MH. Paraplegia after celiac plexus block. *Anaesthesia* 1989;44(6):487–9.

EDITOR'S COMMENT

The authors present a very pragmatic view of pancreatic pain and its management. In preparing this commentary, I found an excellent article that reports consensus information. I highly recommend that the interested reader review this article. A recent publication by the United European Gastroenterology Group (Löhr JM, Dominguez-Munoz E, Rosendahl J, et al. United European Gastroenterology evidence-based guidelines for the diagnosis and therapy of chronic pancreatitis (HaPanEU). *United European Gastroenterol J* 2017;5:153–99) summarizes the answers of 12 multidisciplinary review groups to 101 questions. The consensus opinions were arrived at by an extensive review of the literature by this group of European authorities. In response to questions on pancreatic pain in chronic pancreatitis (CP), they concluded in the article:

1. The most disabling and dominant symptom in patients with chronic pancreatitis is pain. It is usually the first symptom. **(GRADE 1B, strong agreement)**
2. There is no evidence to support "burnout" of those pain symptoms in all patients with ongoing chronic pancreatitis. Although some reports describe this phenomenon, it is extremely variable and shows no consistent pattern. **(GRADE 2C, moderate agreement)**
3. There is no convincing evidence that the development of endocrine and exocrine pancreatic insufficiencies is associated with pain relief and "burnout." (**GRADE 2C, moderate agreement)**
4. Quality of life is reduced by pain intensity and the pain pattern over time (constant vs. intermittent pain). **(GRADE 1A, strong agreement)**
5. In the individual patient, pancreatic and extrapancreatic complications may contribute to pain and should be thoroughly investigated, particularly if pain symptoms are worsening. **(GRADE 1B, strong agreement)**
6. Cessation of alcohol and possibly smoking will improve pain in CP. **(GRADE 1B, moderate agreement)**
7. Pancreatic enzyme supplementation is not effective in alleviating pain in CP. **(GRADE 1B, moderate agreement)**
8. Antioxidants are not recommended for pain treatment in CP. Although there was one study in India that supported this treatment, it could not be reproduced in the west. This is thought to be due to the difference in etiologies of CP (tropical calcific pancreatitis in India and alcohol-related etiology in the United States). **(GRADE 1B, moderate agreement)**
9. Pain in CP should be assessed using an approach that should include evaluation of pain intensity, pain pattern, and its impact on daily function and QoL. **(GRADE 1B, strong agreement)**
10. The standard guideline for medical analgesic therapy in CP follows the principles of the "pain relief ladder" provided by the World Health

Organization (WHO). **(GRADE 1B, strong agreement)**

11. Treatments such as EUS-guided plexus block, splanchnic nerve block, spinal cord stimulation, transcranial magnetic stimulation, and acupuncture may be effective in selected cases of painful CP. The paper references use of intrathecal morphine pumps and spinal cord stimulation. **(GRADE 1C, moderate agreement)**
12. Resection, decompression, or mixed surgical techniques achieve pain relief that is maintained over time in approximately 80% of patients. However, the conclusion was that as studies were not sham-controlled, the effect of surgery is still debatable. **(GRADE 1B, strong agreement)**

It is apparent that pain continues to be a major factor in causing disability in chronic pancreatitis. There is no "silver bullet" that is effective correcting the pain associated with this condition. A multidisciplinary approach is highly recommended.

E. Christopher Ellison

The treatment and evaluation of chronic pain is among the most difficult in evaluation of chronic pain especially in chronic pancreatitis. It is particularly difficult because patients have had so much experience that it is difficult whether pain is real or not. My own experience with these patients is that it is extremely difficult to know who has pain and who is habitulalized with drugs. Although there are "experts" who claim they can tell who is real, I doubt it.

Thus, my own approach is to give chronic drugs once the testing characteristics have been done. In such patients, one should administer chronic pain medicine instead of having to steal to get pain meds at gunpoint.

There are institutions which claim they can tell who is legitimate and who is not. I doubt it, but maybe I am wrong. This is a tough area and I am happy not to confront this too often.

J.E.F.

F INTRODUCTION TO PORTAL HYPERTENSION

Josef E. Fischer

INTRODUCTION TO THE TREATMENT OF PORTAL HYPERTENSION

The treatment of portal hypertension has become a critical issue in preserving lives of cirrhotic patients. Whereas previously in this country alcoholism was the principle reason for bleeding esophageal varices, the increased incidence of hepatitis B and hepatitis C have resulted in a reservoir of patients that may bleed from esophageal varices and ultimately are candidates for hepatic transplantation. In considering hepatic transplantation, it is important to carry out whatever therapy for portal hypertension one can and at least try to preserve the opportunity to carry out a liver transplant later. The principal anatomic necessity means that whatever mechanism one uses to carry out the control of bleeding esophageal varices, it should, whenever possible, leave the porta hepatis free of previous surgery.

For the most part, many centers of liver transplantation will also deal with patients with bleeding esophageal varices. This is done either by endoscopy, as detailed elsewhere in this section, either by injection or by rubber band obliteration of bleeding esophageal and gastric varices. When these techniques fail, a transjugular intrahepatic portosystemic shunt (TIPS) procedure is done, in which one provides an egress of high-pressure portal flow from the portal system into the systemic system by means of a shunt traversing the hepatic parenchyma. For the most part, in the present state of knowledge, TIPS cannot be used as definitive therapy for bleeding esophageal varices, but are used as a bridge in patients who must by necessity undergo liver transplantation in the finite future. The stenosis rate of the TIPS conduit is high, ranging between 30% and 50% or even higher at the end of the first year. Thus, there are many techniques for actually dilating stenoses so that the patient can undergo subsequent hepatic transplant.

However, there remains a group of patients in whom cessation and arrest of bleeding esophageal varices and gastric varices cannot be accomplished with TIPS and other means of controlling the often-torrential hemorrhage. In these patients, shunt surgery then becomes a necessity.

In addition, there are a group of patients, mostly Class A patients, in whom the state of hepatic function is such that it is thought they can survive for a long period of time without liver transplant. In these patients, some type of shunt surgery, which is described in the subsequent chapters, then becomes a necessity. The hypothetical equation in carrying out shunt surgery is to do enough to decrease portal pressure to a reasonable level so that bleeding from esophageal varices stops in this instance and can be prevented from happening again. The obverse of this equation is to provide enough forward portal pressure to allow hepatic perfusion so that hepatic failure is not the result of shunt surgery. In order to understand the complexities of this pressure equation, it is necessary to understand the basics.

The liver is supplied by two perfusion systems, the hepatic artery, a splanchnic artery that is usually responsible from between 20% and 25% of hepatic flow under normal circumstances. The portal vein is not generally oxygen-deprived; thus, the hepatic artery, rather than most organs supplying all of the essential oxygenation, supplies only 50% of the oxygen requirement of the liver. The portal vein, which normally supplies between 75% and 80% of the flow, also supplies 50% of the oxygen requirement of the liver, as well as the lion’s share of nutrients derived from the gut and its absorption of nutrients. The liver, sitting astride the portal vein, absorbs and processes and, in some cases, stores for release into the general circulation the nutrients, which appear in the portal vein. The liver probably processes nearly 100% of the carbohydrate presented to it. It also processes the majority of the amino acids presented to it, notably the aromatic amino acids, of which two in particular, phenylalanine and its hydroxylated product tyrosine, are principal components of hepatic protein synthesis, but also form the substrate for the sympathetic nervous system as well as many of the amines, which perform vital functions within the brain. Lipids are separately absorbed, and are usually absorbed in their triglyceride form in the lymphatics, which then enter the venous system through the thoracic duct and thus do not pass through the liver.

The age-old question that has persisted for a century is, does the liver

require all of the nutrients that pass through it for its own structural integrity, including structural protein synthesis, or does it only require a portion of it, and the rest can be distributed to the periphery? The evidence that is slowly building up seems to indicate that the liver does in fact require all of these nutrients in order to maintain its integrity. This is surprising, because some of the older, classic data from the 1950s and 1960s indicate that, of a protein load that is given enterally in dogs, only approximately 21% ends up as amino acids, which are available in the general circulation. More than half finally end up as urea, after going through gluconeogenesis. The question this raises is, if there is something special about the glucose which is produced from protein, is it required at a certain place at a certain time? With the advent of knowledge of the cytoskeleton, in which the location of various nutrients as close to the various enzyme systems that do not float free in the cell as a bag but are firmly fixed to the cell membrane, or other aspects of the cytoskeleton, there appears to be an answer to this important question. The answer is that glucose, which is created through gluconeogenesis, does end up as glycogen immediately adjacent to certain enzyme systems, which then use the substrate for specific functions such as aerobic glycolysis, as our laboratory showed in the 1990s and in the first years of this century.

Aerobic glycolysis produces considerably less adenosine triphosphate than glucose that goes through the Krebs cycle—considerably less. However, it is important because of its location in the cytoskeleton to a series of membrane-bound enzymes that make the glucose, which ends in glycogen, a very valuable commodity for essential cellular functions. It has also created the controversy as to whether lactate, which remains elevated in response to epinephrine (James JH, et al. Lactate is an unreliable indicator of tissue hypoxia in injury or sepsis. *Lancet* 1999;354:505; James JH, Fischer JE. Epinephrine and gut lactate production. *Crit Care Med* 2001;29:454; James JH, et al. Stimulation of both aerobic glycolysis and Na(+)-K(+)-ATPase activity in skeletal muscle by epinephrine or amylin. *Am J Physiol* 1999;277:E176)—and thus overresuscitating a patient simply on the basis of elevated blood lactate, when in fact every other parameter indicates complete resuscitation—may be injurious to the entire organism.

In addition to the nutrients that course in the portal vein, there are trophic factors that seem to be essential for the integrity and normal functioning of the liver. Beginning in the late 1950s and in the early 1960s, there was a great deal of interest in insulin and glucagon and other putative

peptides that appear to originate in the pancreas. In addition, the needs of regeneration of the liver appear to involve a substance known as *ileal factor,* which results from grinding up ileum and giving it in experiments of hepatic regeneration. This probably consisted of the vascular endothelial and epidermal growth factors and also some putative peptides present in the liver, which were essential, and not only permissive, for hepatic regeneration.

As bridging necrosis and replacing the reticulum elastic framework with fibrosis occurred in a liver that was progressively being destroyed by whatever disease was operant, the resistance to portal flow, either presinusoidal, sinusoidal, or postsinusoidal, depending on the pattern of the disease, elevated the resistance to portal flow. Under normal circumstances, flow would drop. Here, however, a feature of portal hypertension enters, and that is the presence of pumps, as it were, in which arterial admixture with portal flow provided increased positive pressure to the portal vein perfusion, thus maintaining portal flow to the liver. To the surgeon, portal flow is a nuisance. It results in variceal bleeding, collaterals around the rectum, gastric varices, the caput medusae at times, and large variceal collaterals in adhesions in the abdominal wall, varices around such structures as ileostomies, which, of course, are deleterious to the entire organism. To the liver, however, portal hypertension is probably a good thing, an attempt to maintain flow despite increased resistance. Thus, in all of the chapters that follow, there is always the question of balance: balance between forward perfusion of portal flow to the liver, and decompressing the portal system sufficiently so that the patient did not exsanguinate from variceal bleeding.

Early studies from Rousselot in the 1950s revealed that following end-to-side portacaval shunt and using flow meters around the hepatic artery so that those patients that did well following end-to side hepatic portacaval shunt were those who had the ability to increase hepatic artery flow to take the place of portal flow and perfuse the liver. I prefer to look at this phenomenon as indicating the stage of liver disease. Those patients who could increase their portal flow had an earlier stage of cirrhosis, and for those who could not, that inability to increase hepatic artery flow indicated a late stage of the disease. Unfortunately, the advent of transplantation decreased research in this area, so that for many of the mystical concepts concerning hepatic regeneration, trophic factors necessary for the integrity of the liver now became irrelevant if one was going to replace a diseased

liver that was fibrotic with a newly transplanted liver in which the portal flow was delivered, and normal hepatic function might result.

Finally, as one reads these various chapters and reads the claims of various individuals concerning specific shunts: For example, as one will read in the subsequent chapter, there were claims made that a distal splenorenal shunt was somehow magical and could prevent the inexorable desire, as it were, of blood at high pressure to seek a lower pressure. Indeed, Maillard et al. (Chandler JG Selectivity of the distal splenorenal shunt. *Surgery* 1979;86:663), among others, demonstrated by primitive angiography that within 24 hours of the distal splenorenal shunt, collaterals between the portal system and the systemic system arose rather quickly, thus robbing the liver of forward flow. The answer was the portal azygos disconnection—an operation that is beyond the technical abilities of most surgeons—to prevent this phenomenon from occurring. However, I believe this is futile, and our own studies have shown that in time, comparing distal splenorenal shunts with central splenorenal shunts, forward flow decreases progressively and the rates of encephalopathy, as a good mark for diminished hepatic function, proceeded at the same pace (Fischer JE, et al. Comparison of distal and proximal splenorenal shunts: a randomized prospective trial. *Ann Surg* 1981;194:531).

These are the choices one has to make in portal hypertension. The idea that somehow one can magically lower the pressure, leaving some portal hypertension to perfuse the liver, is superior to one shunt or another may be a goal that cannot be reached. However, what is clear is that there are certain operations that do preserve some portal flow; these are either small interposition shunts, distal splenorenal shunts, and/or central splenorenal shunts whose diameter is controlled, as Dr. Robert Linton taught me when I was his resident and a young staff person, so that forward perfusion of the liver occurs.

This whole area remains a fascinating area of physiology in which surgeons have always been interested because it applies directly to the welfare of their patients.

130 Anatomy of the Portal System and Experience With Portacaval Shunt

Marshall J. Orloff

INTRODUCTION

The excellent chapter on Anatomy of the Portal System by Drs. Richard Bell and Alan Koffron in the 5th and 6th editions of *Mastery of Surgery* bears repeating in substantial part. Therefore, much of it is presented in the 7th edition. It is supplemented by a detailed description of the side-to-side portacaval shunt (PCS) and a section titled "Author's Experience with Portacaval Shunt," based on the experience of the author with over 4,000 PCSs over a period of 54 years.

The word *portal* is derived from the Latin word *porta*, meaning "gate" or "passage." In Babylon, the livers of sacrificed animals were interpreted to predict the future. The Babylonians considered the liver the seat of the soul; the port of entry to this structure was therefore accorded special significance. Similarly, for modern surgery of the liver, pancreas, and portal hypertension, the portal vein has special importance. Knowledge of its anatomy and variants is crucial to ensure surgical success in performing such procedures.

DESCRIPTIVE ANATOMY

The portal vein arises from the postduodenal plexus of the embryonic vitelline veins. Rarely, the preduodenal plexus persists, giving rise to a portal vein that lies anterior to the duodenum. This anomaly, which is potentially lethal if it is not recognized and the portal vein is transected during surgery in this area, is associated with annular pancreas, malrotation, and biliary tract anomalies.

In the adult, the portal vein and its tributaries have no valves—those that existed during fetal circulation having been resorbed. Thus, the portal system can be decompressed at any point by creating a connection to the

systemic venous system. The vein delivers blood from the spleen, the pancreas, and the digestive tube to the liver. It provides ~75% of hepatic blood flow and 50% of the oxygen delivery to this organ.

The portal vein can be thought of as the trunk of a tree, with the visceral veins (superior mesenteric, inferior mesenteric, and splenic) forming the roots, and the intrahepatic portions of the right and left portal veins forming the branches (Fig. 130.1). The vascular delta formed by the mixing of portal venous and hepatic arterial blood in the sinusoids of the liver then drains into the inferior vena cava (IVC) through the three hepatic veins.

The portal vein trunk is 4.8 to 8.8 cm long, with an average length of 6.4 cm, and 0.6 to 1.2 cm wide, with an average width of 0.9 cm. It is formed behind the neck of the pancreas, at the level of the second lumbar vertebra, by the confluence of the superior mesenteric vein (SMV) and the splenic vein (Fig. 130.2). In approximately one third of the population, the inferior mesenteric vein joins the portal vein directly at this point, forming a trifurcation; in the remaining cases, it drains into the splenic vein (38%) or the SMV (29%). The portal vein then passes to the right and cephalad behind the first portion of the duodenum and into the hepatoduodenal ligament, which forms the ventral boundary of the foramen of Winslow. Within the hepatoduodenal ligament, the portal vein lies posterior to the hepatic artery and common bile duct, usually slightly to the left of the duct. It bifurcates in the porta hepatis at the right aspect of the hilar plate—a thickening of the liver's fibrous capsule at the hilum. The right branch, which supplies the right hepatic lobe, is shorter (0.5 to 1.0 cm long), wider, and more variable than its sinistral counterpart. It often divides into anterior and posterior branches at its point of entry into the liver parenchyma. The more constant and longer left portal vein, with a 4-cm average length, supplies the left hepatic lobe and runs left in the hilar plate as the pars transversa until it enters the fissure for the ligamentum venosum. At this point, the vein receives the attachment of the ligamentum venosum and then curves anteriorly, becoming the pars umbilicus, which ends by attaching to the ligamentum teres hepatis in the umbilical fissure. The caudate lobe is supplied by two to three branches arising from the bifurcation of the portal vein or from its right or left branches.

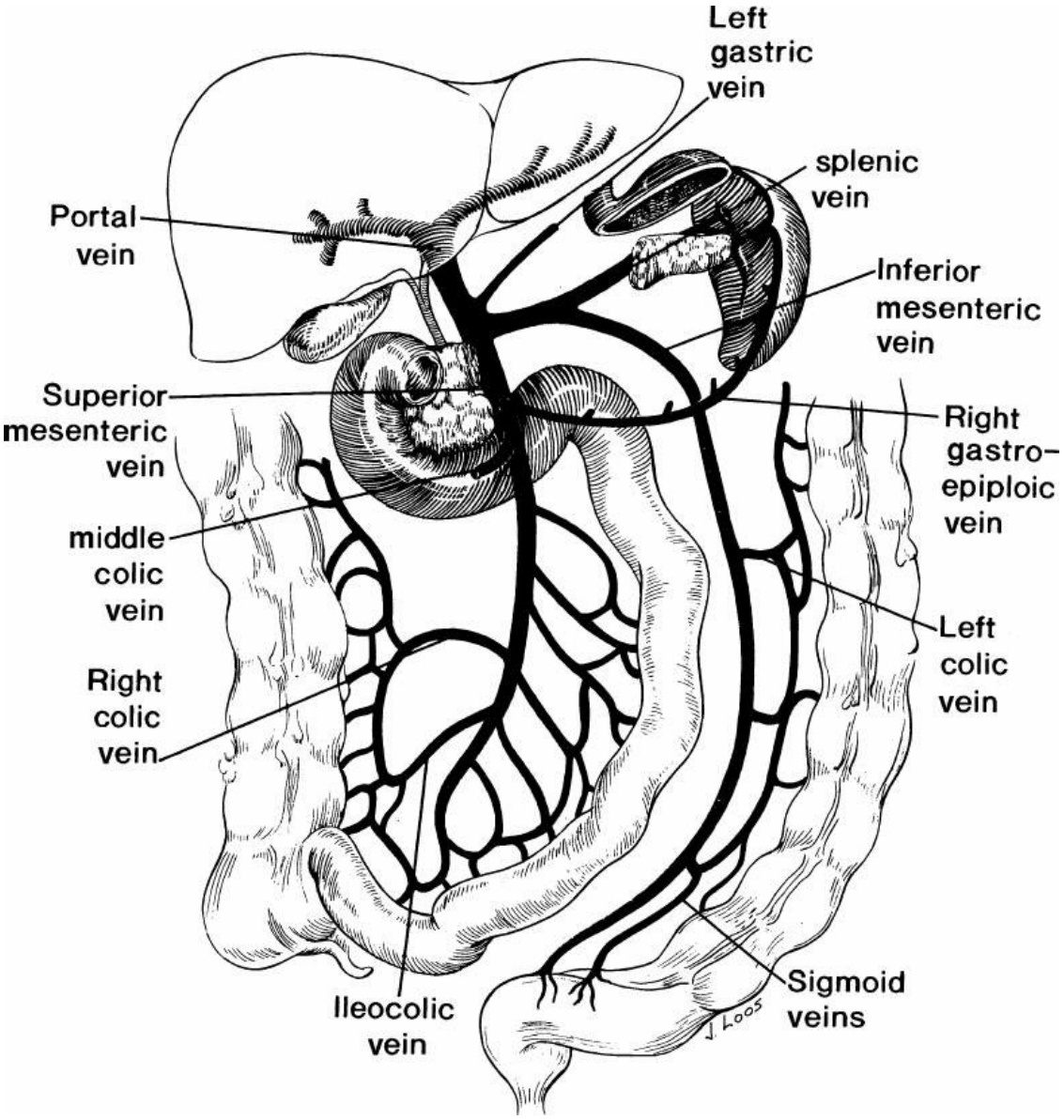

Figure 130.1. Overview of the entire portal venous system within the abdominal cavity. (Data from Monsen H. Anatomy of the portal system. In: Nyhus LM, Baker RJ, eds. *Mastery of Surgery*, 2nd ed. Boston: Little Brown and Company, 1992; and from Williams PL, Warwick R, eds. Gray's Anatomy, 36th ed. New York: Churchill Livingstone, 1980.)

Of great importance to the surgeon are the sundry side branches that feed into the portal vein as it forms behind the pancreas and runs cephalad in the hepatoduodenal ligament (Fig. 130.2). The portal vein usually receives the pancreaticoduodenal vein(s) and the pyloric vein, which is also known as the *right gastric vein.* More variable in their point of insertion is the coronary vein, which is also known as the *left gastric vein*, and the accessory pancreatic vein. The superior pancreaticoduodenal vein

usually enters the right aspect of the portal vein at or just above the superior margin of the pancreas. The inferior pancreaticoduodenal vein usually enters the right aspect of the SMV just before it joins the splenic vein to form the portal vein proper. In ~38% of cases, there is only a single pancreaticoduodenal vein, which joins the portal vein at the same juncture as the superior pancreaticoduodenal vein. The pyloric vein is present in 80% of the population and, in 75% of the population, terminates in the anterior aspect of the portal vein (inside the hepatoduodenal ligament), within 3.0 cm of the portal vein bifurcation. The coronary vein inserts at the superior aspect of the junction of the splenic and SMVs in 60% of the population, in the portal vein proper in 25% of the population, and in the splenic vein (just before its junction with the SMV) in 15% of the population. In a series of 92 dissections, 29 specimens had an accessory pancreatic vein terminating in the superior aspect of the midportal vein.

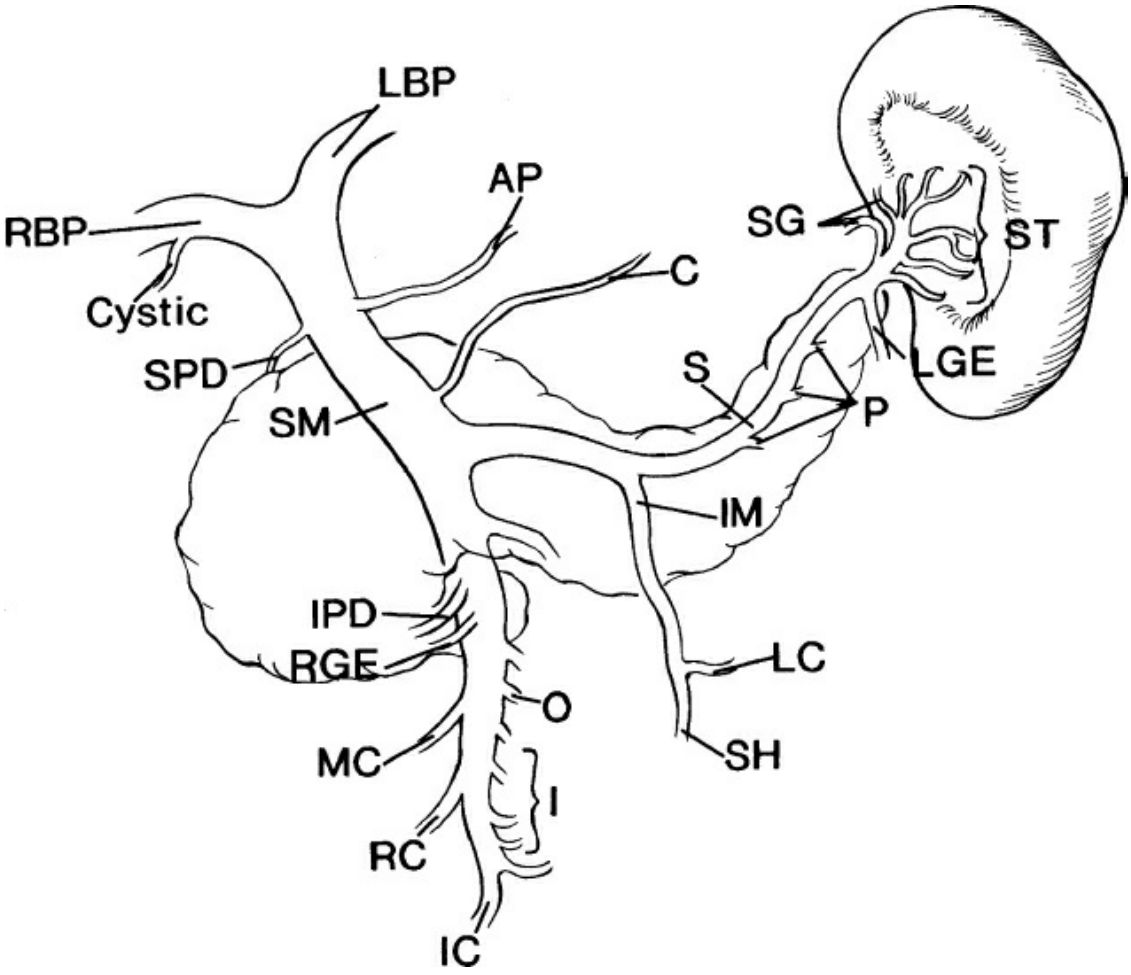

Figure 130.2. Anatomy of the extrahepatic portal venous system. AP, accessory pancreatic vein; C, coronary vein; I, ileal veins; IC, ileocolic vein; IM, inferior mesenteric vein; IPD, inferior pancreaticoduodenal vein; LBP, left branch of portal vein; LC, left

colic vein; LGE, left gastroepiploic vein; MC, middle colic vein; O, omental vein; P, pancreatic veins; RBP, right branch of portal vein; RC, right colic vein; RGE, right gastroepiploic vein; SG, short gastric veins; SH, superior hemorrhoidal vein; SPD, superior pancreaticoduodenal vein; ST, splenic trunks. (Modified from Douglass B, Baggenstoss A, Hollinshead WH. The anatomy of the portal vein and its tributaries. *Surg Gynecol Obstet* 1960;91:564. Copyright © Elsevier.)

Another anatomic aspect of the portal system that is of importance to the surgeon are the points of communication between the portal and systemic (caval, azygos, and hemiazygos) venous systems (Fig. 130.3). Normally, these anastomotic channels are small, but the combination of portal hypertension and the lack of valves in the adult portal system lead to reversal of flow, with consequent dilatation and tortuosity. Clinically, the most important portosystemic anastomoses are the veins of the proximal stomach and distal esophagus, which receive flow from the coronary and short gastric veins and drain into the superior vena cava via the azygos system (labeled *1 and *2 in Fig. 130.3). Dilatation and tortuosity in this plexus of relatively unsupported veins results in varices that can rupture, causing exsanguinating hemorrhage. Other significant anastomotic areas shown in Figure 130.3 include the following:

1. The submucosal venous plexus in the rectum between the superior hemorrhoidal veins (the portal system) and the middle and inferior hemorrhoidal veins (the caval system) (labeled *4). Large bleeding rectal varices, although uncommon, can arise here in patients with portal hypertension.
2. The paraumbilical veins, which connect the left portal vein via a recanalized umbilical vein to the epigastric venous network of the abdominal wall, which drains into the caval system (labeled *3). This plexus can become the variceal “caput Medusae” in patients with portal hypertension and produce the Cruveilhier–Baumgarten syndrome. Unintentional transection of these varices during surgery that involves the anterior abdominal wall can result in significant blood loss.
3. Retzius veins: a group of small but numerous retroperitoneal veins that connect abdominal viscera, both tubular and solid, with the caval system via intercostals, phrenic, lumbar, and renal veins (labeled *5). In the patient with portal hypertension, bleeding from these veins can

make any upper abdominal operation dangerous depending on the amount and location of retroperitoneal dissection required.

4. Finally, significant venous collaterals can form in surgical adhesions, making reoperative surgery and stomal takedowns more dangerous in patients with portal hypertension.

APPLIED ANATOMY

Portosystemic Shunts

One of the common categories of surgical operations in which a detailed knowledge of portal anatomy is essential is that of portosystemic shunts. Because the portal venous system contains no valves, it is possible to decompress the system and relieve portal hypertension by connecting the portal vein or its tributaries to the systemic venous system at a number of sites, provided the systemic vein is of sufficient size to handle the large portal blood flow. Figure 130.4 shows various types of portosystemic shunts. Not shown is the TIPS, which is a radiologic procedure that creates a side-to-side shunt within the liver. A detailed review of the various causes of portal hypertension and the advantages and disadvantages of the several kinds of shunts is beyond the scope of this chapter. Rather, the anatomic points of portal vein anatomy relevant to performance of a side-to-side portacaval shunt (SSPCS) are discussed since, in the large experience of the author with the treatment of portal hypertension, the direct SSPCS has been used in over 90% of the patients.

The indications for an SSPCS are (a) bleeding esophageal or gastric varices due to portal hypertension caused by cirrhosis of the liver or, much less commonly, by other liver diseases such as schistosomiasis; (b) bleeding from portal hypertensive gastropathy unresponsive to pharmacologic therapy; (c) Budd–Chiari syndrome (BCS) with occluded hepatic veins and patent IVC; (d) intractable ascites unresponsive to nonsurgical therapy; and (e) failed TIPS.

The position of the patient on the operating table is crucial and can make the difference between an easy and difficult operation (Fig. 130.5). Specifically, the patient is placed on the operating table with the right side elevated at an angle of 30 degrees to the table, and the table is adjusted so as to widen the space between the right costal margin and right iliac crest, and make it possible to perform the operation easily through a long right subcostal incision.

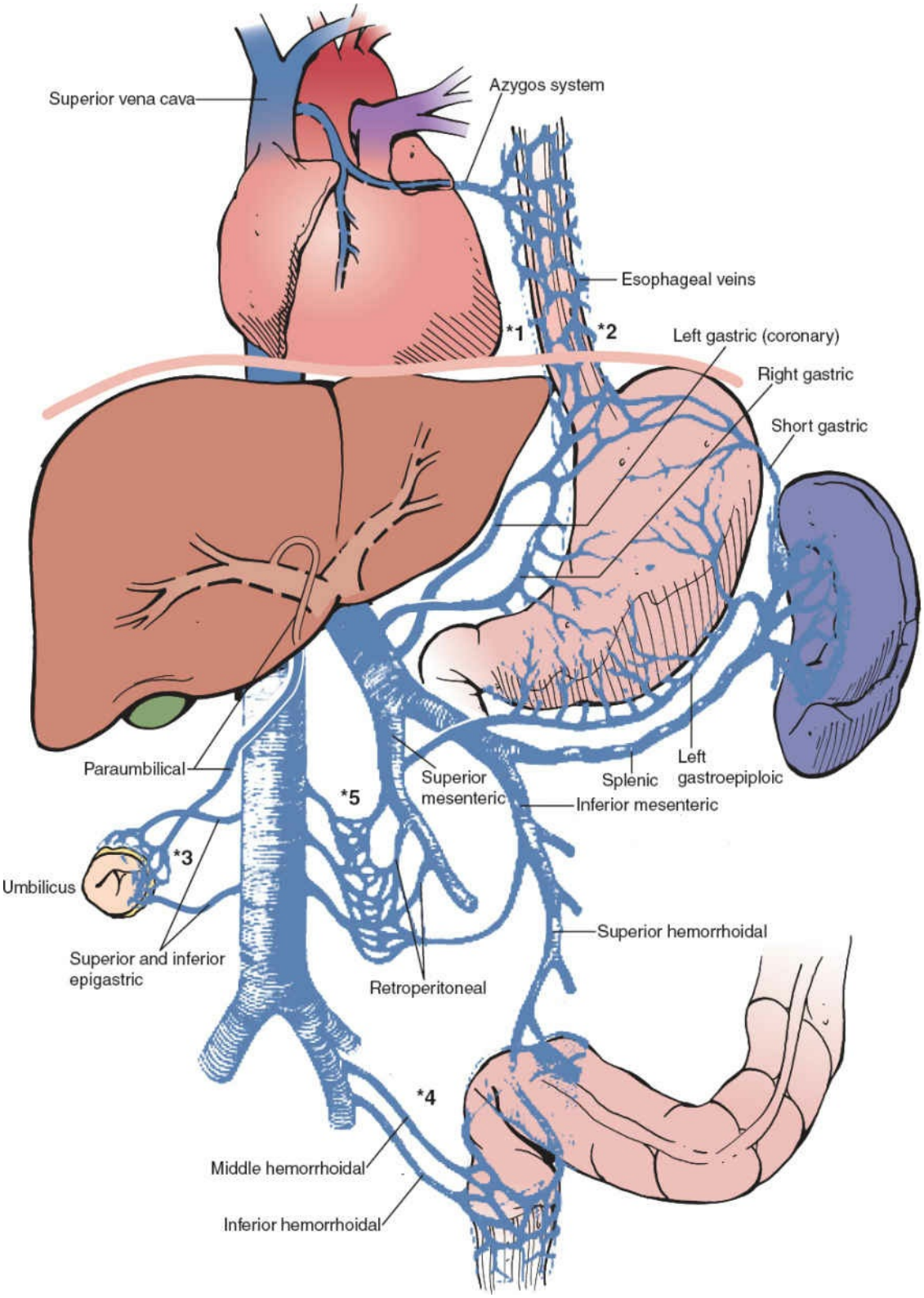

Figure 130.3. Sites of formation of portosystemic collaterals in patients with portal hypertension. Connections between the portal and systemic venous system are normally present, but they carry increased flow when there is a block to portal venous flow through the liver. The sites of portosystemic collateral connections shown in this figure are (**A**) from the portal vein

through the right and left gastric veins to the esophageal veins and the hemiazygos vein to the superior vena cava labeled *1 and *2; (**B**) from the superior mesenteric vein (SMV) through retroperitoneal veins to the inferior vena cava (IVC) labeled *5; (**C**) from the left portal vein through the (recanalized) umbilical vein to epigastric veins to the vena cava labeled *3; and (**D**) from the inferior mesenteric vein through the superior hemorrhoidal vein to the middle and inferior hemorrhoidal veins to the iliac veins labeled *4.

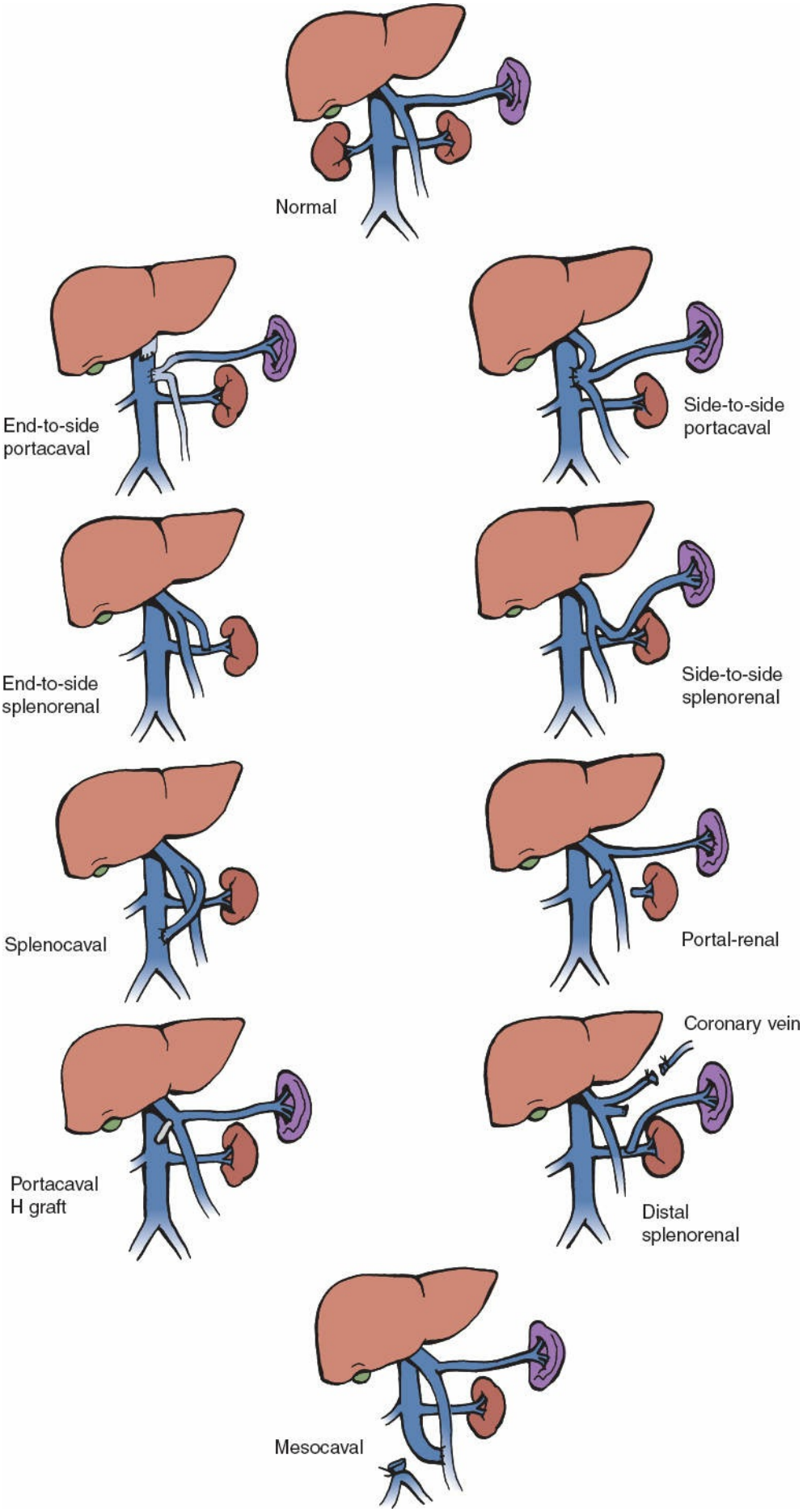
Normal
End-to-side portacaval
Side-to-side portacaval
End-to-side splenorenal
Side-to-side splenorenal
Splenocaval
Portal-renal
Coronary vein
Portacaval H graft
Distal splenorenal
Mesocaval

Figure 130.4. Types of portal-systemic venous shunts used to relieve portal hypertension.

Once inside the peritoneal cavity, retractors are placed and the posterior peritoneum overlying the IVC is incised with electrocautery by an extended Kocher maneuver (Fig. 130.6). The anterior surface of the IVC is cleared of fibroareolar tissue, and the IVC is isolated around its entire circumference by blunt and sharp dissection from the entrance of the right and left renal veins, below, to the point where it disappears behind the liver, above. The IVC is encircled with an umbilical tape (Fig. 130.7). To accomplish the isolation, several tributaries must be ligated in continuity with fine silk ligatures and then divided. These tributaries often include the right adrenal vein, one or two pairs of lumbar veins that enter the posterior surface, and the caudal pair of small hepatic veins from the caudate lobe of the liver that enter the anterior surface of the IVC directly from the liver.

When the IVC has been mobilized completely, it can be lifted up toward the portal vein (Fig. 130.8). Failure to isolate the IVC circumferentially is one major reason for the erroneous claim that the SSPCS often cannot be performed because the portal vein and IVC are too widely separated.

The superior retractor is repositioned medially so that it retracts the liver at the point of entrance of the portal triad. The portal vein is located in the posterolateral aspect of the portal triad and is approached from behind. The fibrofatty tissue on the posterolateral aspect of the portal triad, which contains nerves, lymphatics, and lymph nodes, is divided by blunt and sharp dissection. This technique is a safe maneuver because there are no portal venous tributaries on this aspect of the portal triad. As soon as the surface of the portal vein is exposed, a vein retractor or Gilbernet retractor is inserted to retract the common bile duct medially. The portal vein is mobilized circumferentially at its midportion and is encircled with an umbilical tape (Fig. 130.9). It is then isolated up to its bifurcation in the liver hilum. Several tributaries on the medial aspect are ligated in continuity with fine silk and divided.

Using the umbilical tape to pull the portal vein out of its bed, the portal vein is cleared to the point where it disappears behind the pancreas. The tough fibrofatty tissue that binds the portal vein to the pancreas must be divided (Fig. 130.10). Several tributaries that enter the medial aspect of the portal vein and one tributary that enters the posterolateral aspect are

divided. It is usually not necessary to divide the splenic vein. Wide mobilization of the portal vein is essential for performance of a side-to-side portacaval anastomosis. Failure to mobilize the portal vein behind the pancreas is a second major reason for difficulty in accomplishing the side-to-side shunt. In some patients, it is necessary to divide a bit of the head of the pancreas between right-angled clamps to obtain adequate mobilization of the portal vein. Bleeding from the edges of the divided pancreas is controlled with suture ligatures. Division of a small amount of the pancreas is a very helpful maneuver and we have never observed postoperative complications, such as pancreatitis, from its performance. Before incising the pancreas, the surgeon should insert his index finger into the tunnel between the portal vein and the pancreas to determine by palpation if there is a replaced common hepatic or right hepatic artery arising from the superior mesenteric artery and crossing the portal vein. Since the portal venous blood flow to the liver is diverted through the PCS, ligation of the hepatic arterial blood supply may be lethal.

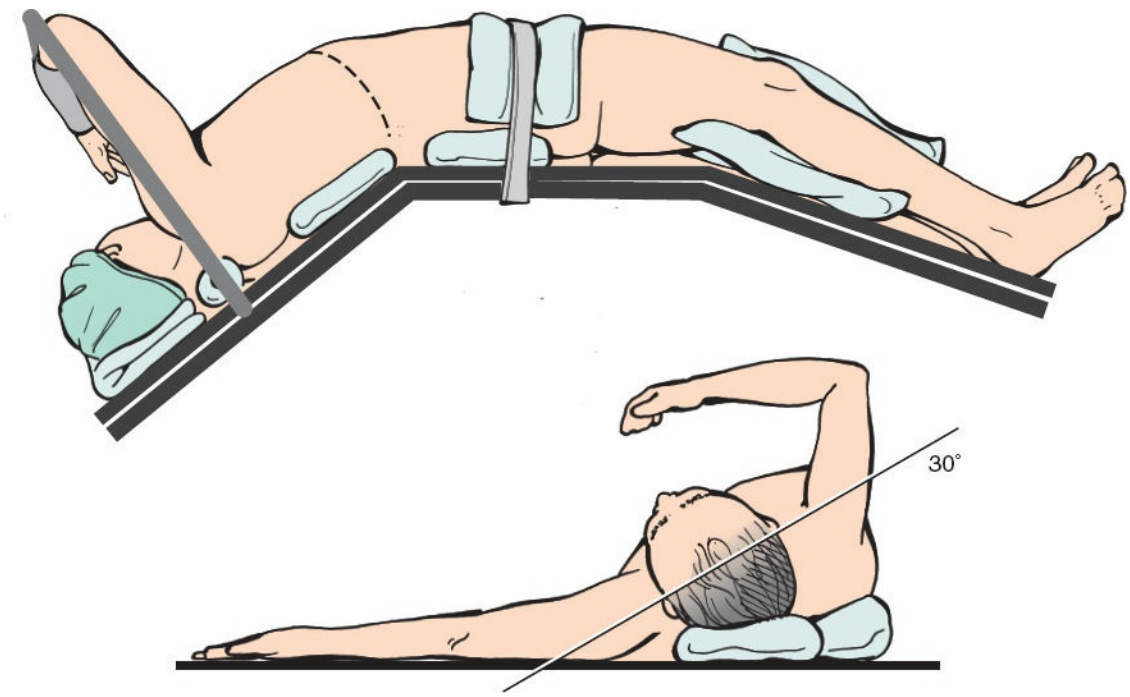

Figure 130.5. The position of the patient on the operating table in preparation for a side-to-side portacaval shunt. The table is “broken” at the level of the costal margin and at the knees so as to widen the space between the right costal margin and right iliac crest, and to make it possible to perform the operation easily through a right subcostal incision, which extends from the xiphoid to well into the flank and is made two fingerbreadths below the costal margin.

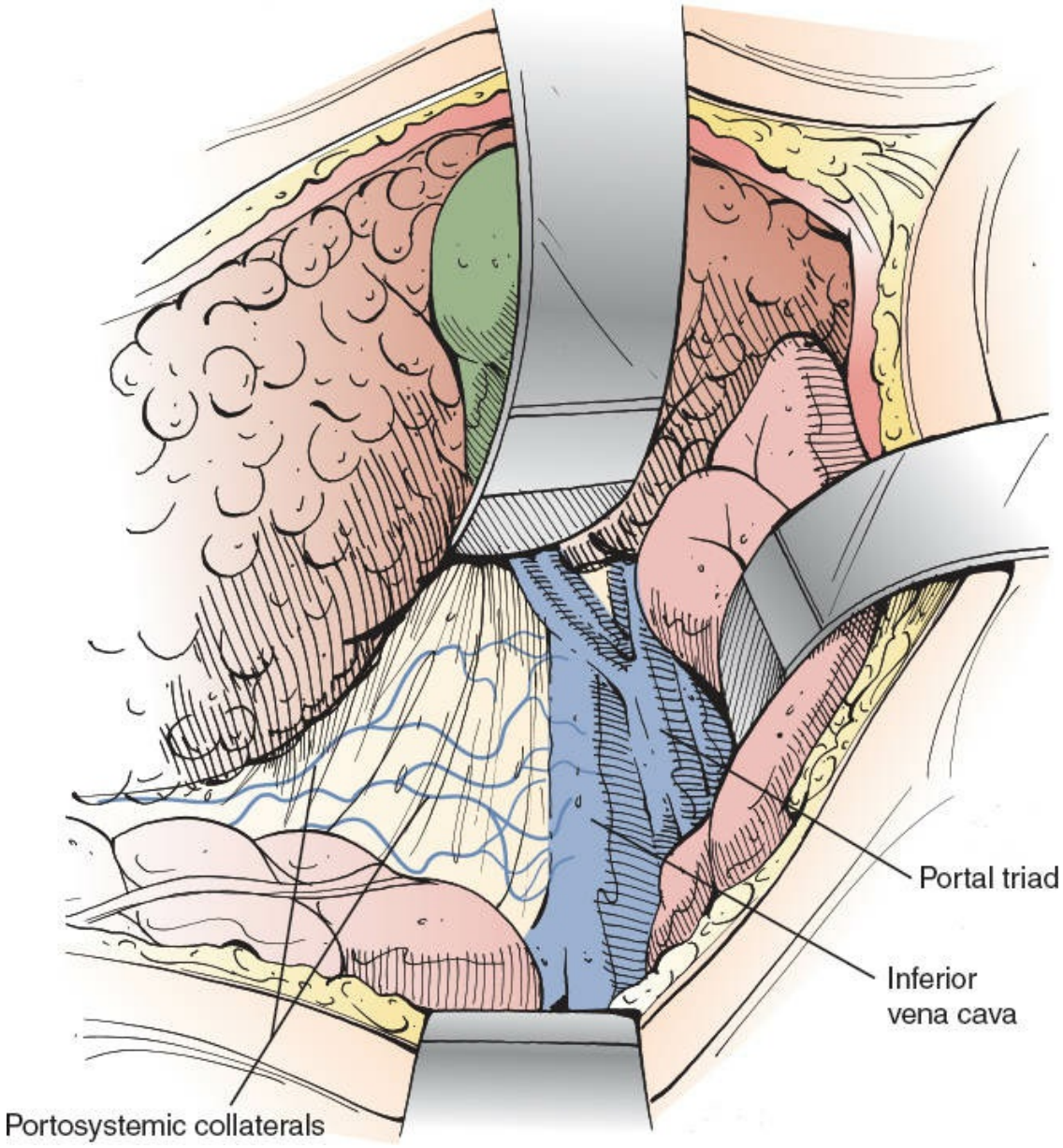

Figure 130.6. Exposure of the operative field for a side-to-side portacaval shunt.

To determine the adequacy of mobilization of portal vein and IVC, the two vessels are brought together by traction on the umbilical tapes that surround them (Fig. 130.11). It is essential to determine that the two vessels can be brought together without excessive tension. If this cannot be done, it is almost always because the vessels have not been adequately mobilized, and further dissection of the vessels should be undertaken. Resection of part of an enlarged caudate lobe of the cirrhotic liver, recommended by some surgeons to facilitate bringing the vessels together, is associated with some difficulties and, in our opinion, is neither

necessary nor advisable.

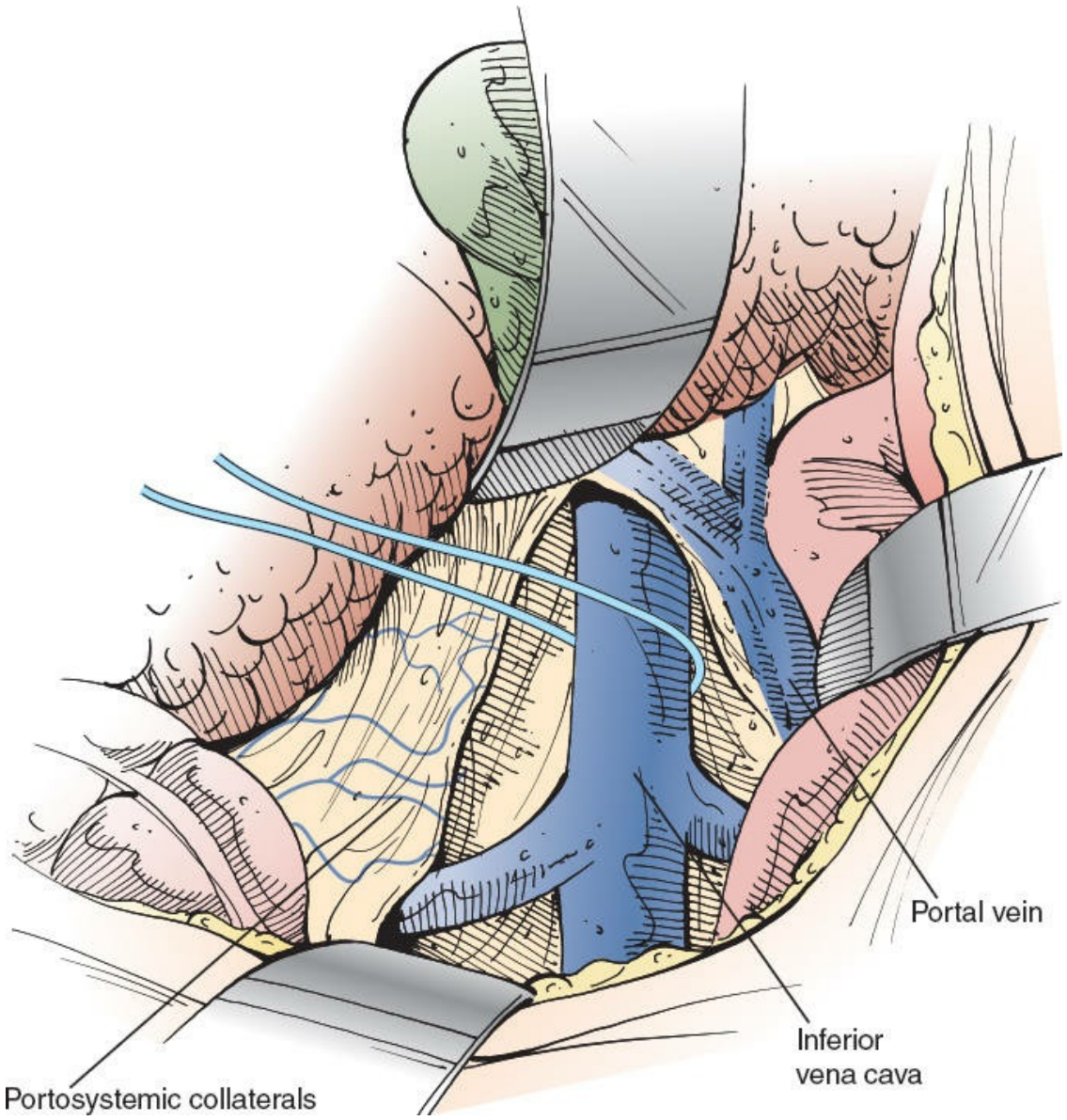

Figure 130.7. Isolation of the inferior vena cava (IVC) around its entire circumference from the entrance of the right and left renal veins below, to the point where it disappears behind the liver above. The IVC is encircled with an umbilical tape.

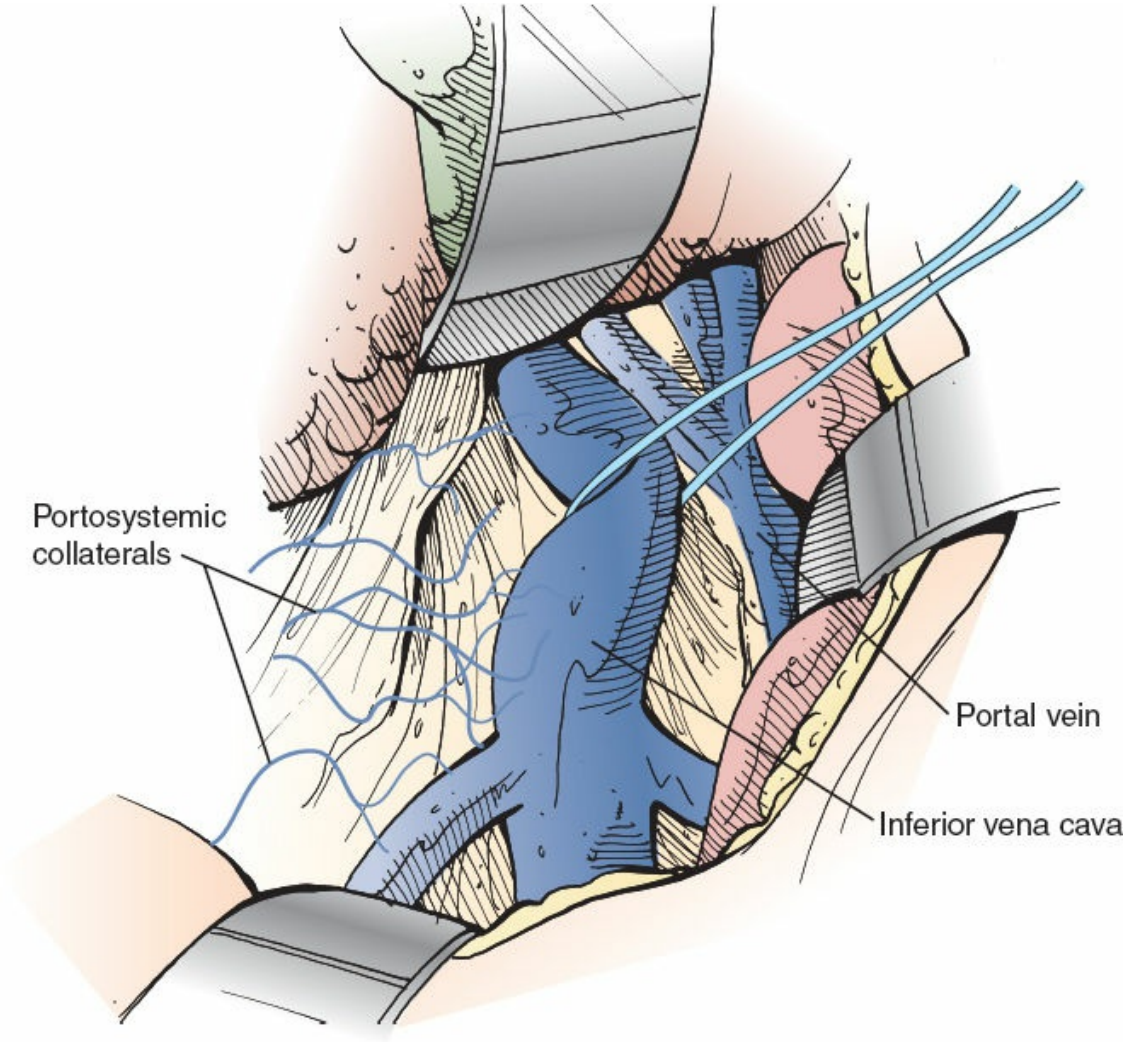

Figure 130.8. Testing the adequacy of IVC mobilization. When the IVC has been mobilized completely, it can be lifted up toward the portal vein. Failure to isolate the IVC circumferentially is one major reason for the erroneous claim that the side-to-side portacaval shunt often cannot be performed because the portal vein and IVC are too widely separated.

Pressures in the IVC and portal vein are measured with a saline (spinal) manometer by direct needle puncture before performance of the portacaval anastomosis. A portal vein-IVC pressure gradient of 150-mm saline or higher represents clinically significant portal hypertension. Most patients with bleeding esophageal varices (BEV) have a portal vein-IVC gradient of 200-mm saline or higher.

The steps in performing the side-to-side portacaval anastomosis are as follows:

1. A Satinsky clamp is placed obliquely across a 5-cm segment of the anteromedial wall of the IVC in a direction parallel to the course of the

overlying portal vein and the IVC is elevated toward the portal vein. A 5-cm segment of the portal vein is isolated between two angled vascular clamps and the portal vein is depressed toward the IVC, bringing the two vessels into apposition (Fig. 130.12).

2. A 2.0- to 2.5-cm long strip of the IVC and a 2.0- to 2.5-cm long strip of the portal vein are excised with scissors (Fig. 130.13). It is important to excise a longitudinal segment of the wall of each vessel rather than simply making an incision in each vessel. A retraction suture of 5/0 silk is placed in the lateral wall of the IVC opening and is weighted by attachment to a hemostat to keep the IVC orifice open. The clamps on the portal vein are momentarily released to flush out any clots and then the openings in both vessels are irrigated with saline.
3. The anastomosis is started with a posterior continuous over-and-over suture of 5/0 vascular suture material. The posterior continuous suture is tied at each end of the anastomosis.
4. The anterior row of sutures consists of an everting continuous horizontal mattress stitch of 5/0 vascular suture material started at each end of the anastomosis (Fig. 130.14). The suture started at the inferior end of the anastomosis is discontinued after three or four throws and is deliberately left loose so that the interior surface of the vessels can be visualized as the anastomosis is completed. In this way inadvertent inclusion of the posterior wall in the anterior row of sutures is avoided. The suture started at the superior end of the anastomosis is inserted with continuous tension until it meets the inferior suture, at which point the inferior suture is drawn tight and the two sutures are tied to each other. Before drawing the inferior suture tight, the clamps on the portal vein are momentarily released to flush out any clots, and the anastomosis is thoroughly irrigated with saline.
5. Upon completion of the anastomosis, a single interrupted tension suture is placed just beyond each end of the anastomosis to take tension off the anastomotic suture line. The clamp on the IVC is removed first, the clamp on the hepatic side of the portal vein is removed next, and finally, the clamp on the intestinal side of the portal vein is removed (Fig. 130.15). Bleeding from the anastomosis infrequently occurs; it can be controlled by one or two well-placed interrupted sutures of 5/0 vascular suture material.

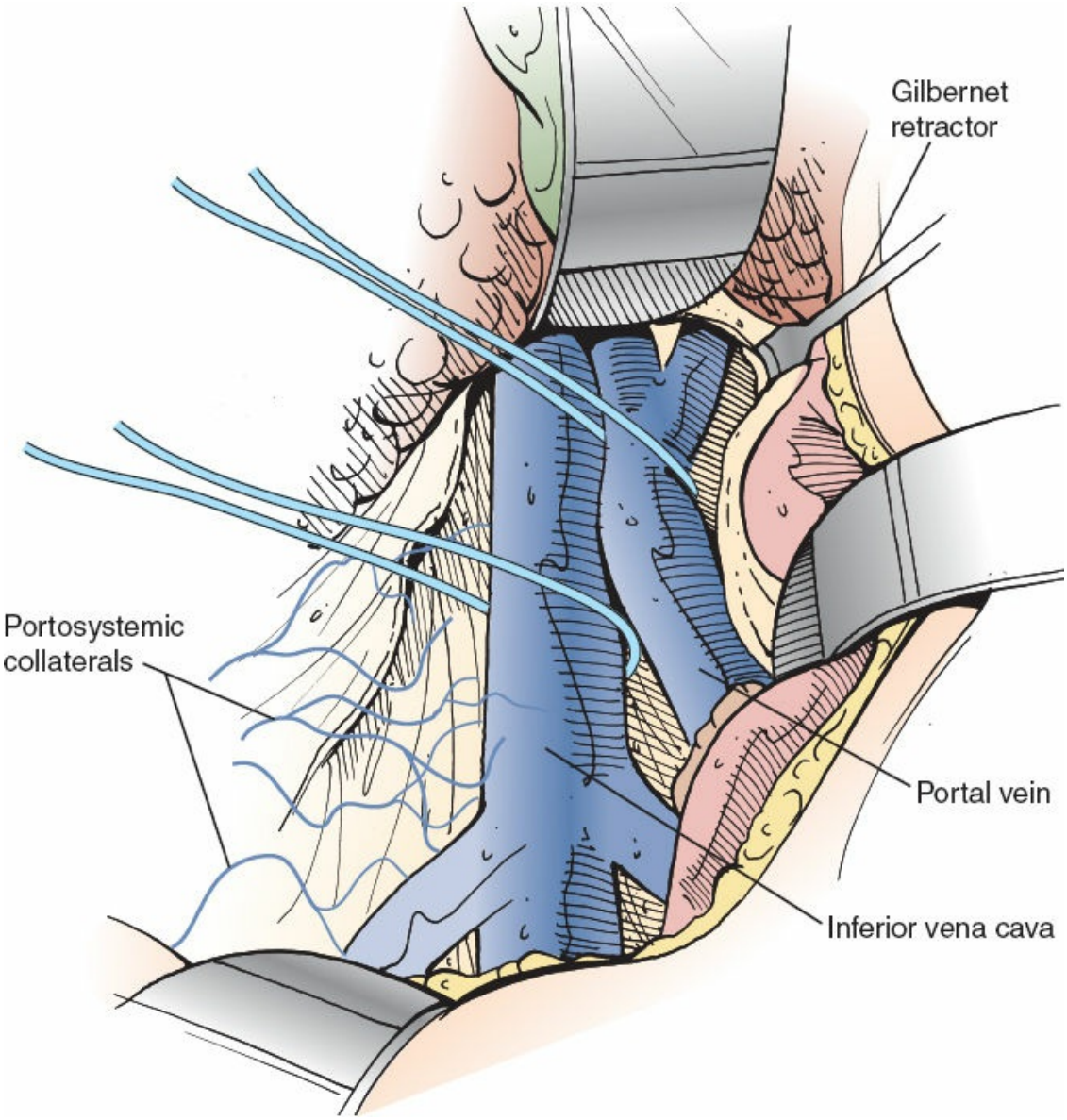

Figure 130.9. Isolation of the portal vein. The portal vein is mobilized circumferentially at its midportion and is encircled with an umbilical tape. It then is isolated up to its bifurcation in the liver hilum.

Pressures in the portal vein and IVC must be measured after the anastomosis is completed. Usually, the postshunt pressures in the portal vein and IVC are identical. A pressure gradient of >50-mm saline between the two vessels indicates an obstruction in the anastomosis, even when no obstruction can be palpated. In such circumstances, the anastomosis should be opened to remove any clots and, if necessary, the entire anastomosis should be taken down and redone. It is essential that there be no more than a 50-mm saline gradient between the portal vein and IVC to achieve permanently adequate portal decompression and to avoid ultimate

thrombosis of the shunt.

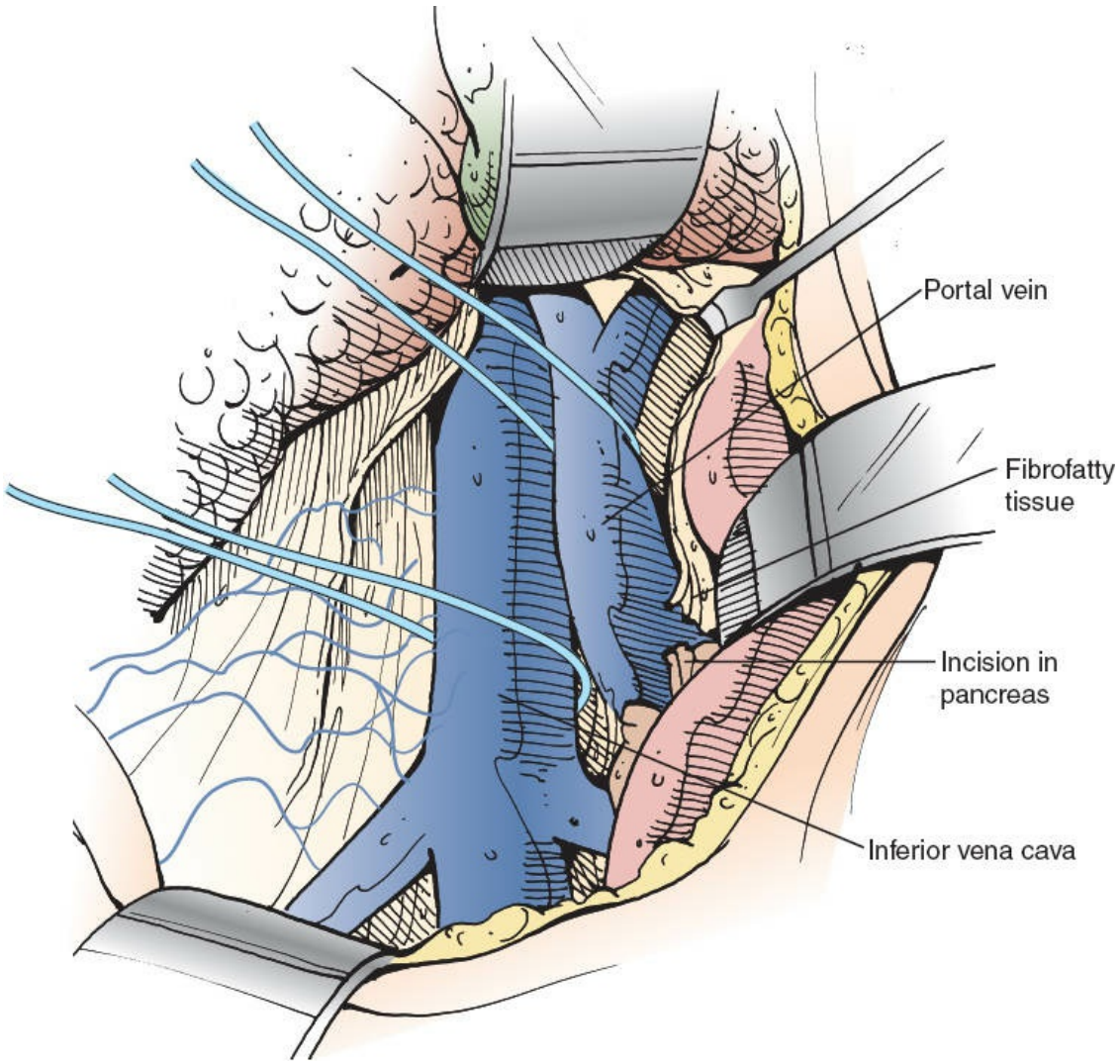

Figure 130.10. Mobilization of the portal vein behind the pancreas. Using the umbilical tape to pull the portal vein out of its bed, the portal vein is cleared to the point where it disappears behind the pancreas. The tough fibrofatty tissue that binds the portal vein to the pancreas must be divided. Wide mobilization of the portal vein is essential for performance of a side-to-side portacaval anastomosis. Failure to mobilize the portal vein behind the pancreas is a second major reason for difficulty in accomplishing the side-to-side shunt. In some patients, it is necessary to divide a bit of the head of the pancreas between right-angled clamps to obtain adequate mobilization of the portal vein. Before incising the pancreas, the surgeon should insert his or her index finger into the tunnel between the portal vein and the pancreas to determine by palpation if there is a replaced common hepatic or right hepatic artery arising from the superior mesenteric artery and crossing the portal vein. Since the portal

venous blood flow to the liver is diverted through the portacaval shunt, ligation of the hepatic arterial blood supply may be lethal.

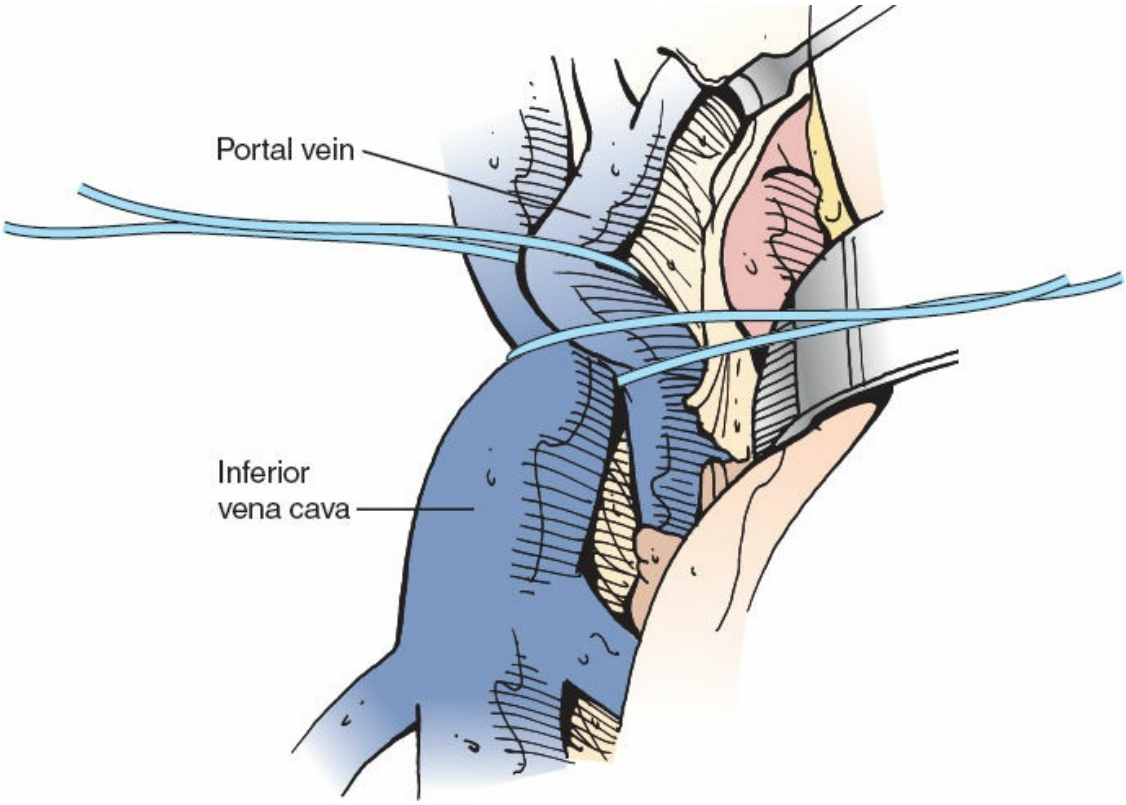

Figure 130.11. Testing adequacy of mobilization of portal vein and IVC. To determine the adequacy of mobilization of portal vein and IVC, the two vessels are brought together by traction on the umbilical tapes that surround them. It is essential to determine that the two vessels can be brought together without excessive tension. If this cannot be done, it is almost always because the vessels have not been adequately mobilized, and further dissection of the vessels should be undertaken. Resection of part of an enlarged caudate lobe of the cirrhotic liver, recommended by some surgeons to facilitate bringing the vessels together, is associated with some difficulties and, in our opinion, is neither necessary nor advisable.

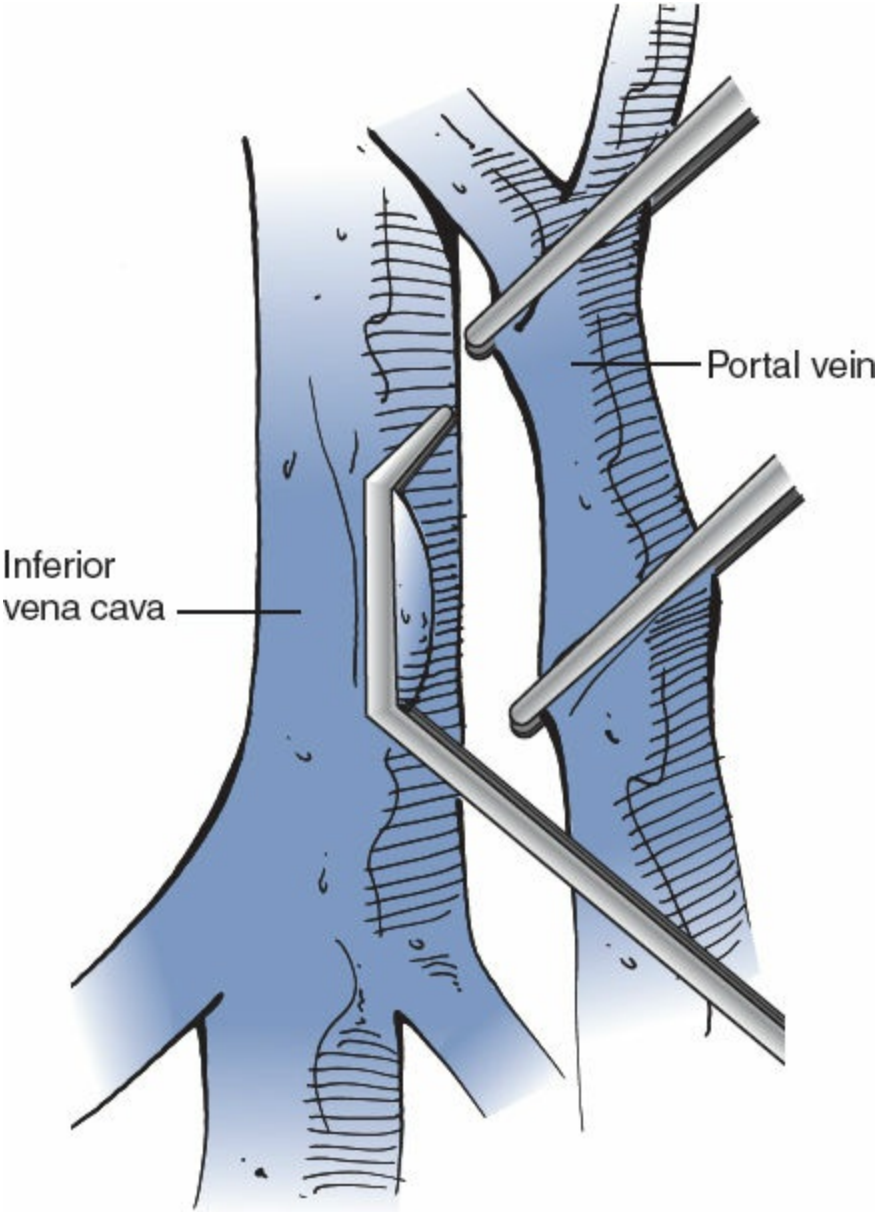

Figure 130.12. Clamping the IVC and portal vein in preparation for a side-to-side portacaval anastomosis. A Satinsky clamp is placed obliquely across a 5-cm segment of the anteromedial wall of the IVC in a direction parallel to the course of the overlying portal vein and the IVC is elevated toward the portal vein. A 5-cm segment of the portal vein is isolated between two angled vascular clamps and the portal vein is depressed toward the IVC, bringing the two vessels into a position.

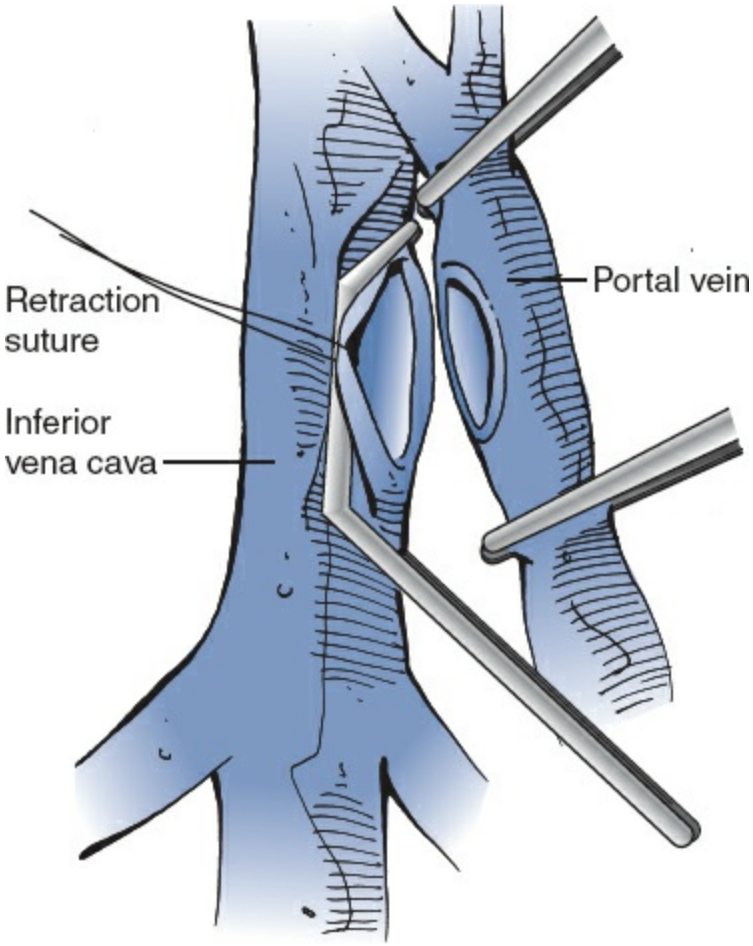

Figure 130.13. Excision of a segment of the wall of each vein in preparation for the side-to-side portacaval anastomosis. A 2.0- to 2.5-cm-long strip of the IVC and a 2.0- to 2.5-cm-long strip of the portal vein are excised with scissors. It is important to excise a longitudinal segment of the wall of each vessel rather than simply making an incision in each vessel. A retraction suture of 5-0 silk is placed in the lateral wall of the IVC opening and is weighted by attachment to a hemostat to keep the IVC orifice open. The clamps on the portal vein are momentarily released to flush out any clots and then the openings in both vessels are irrigated with saline.

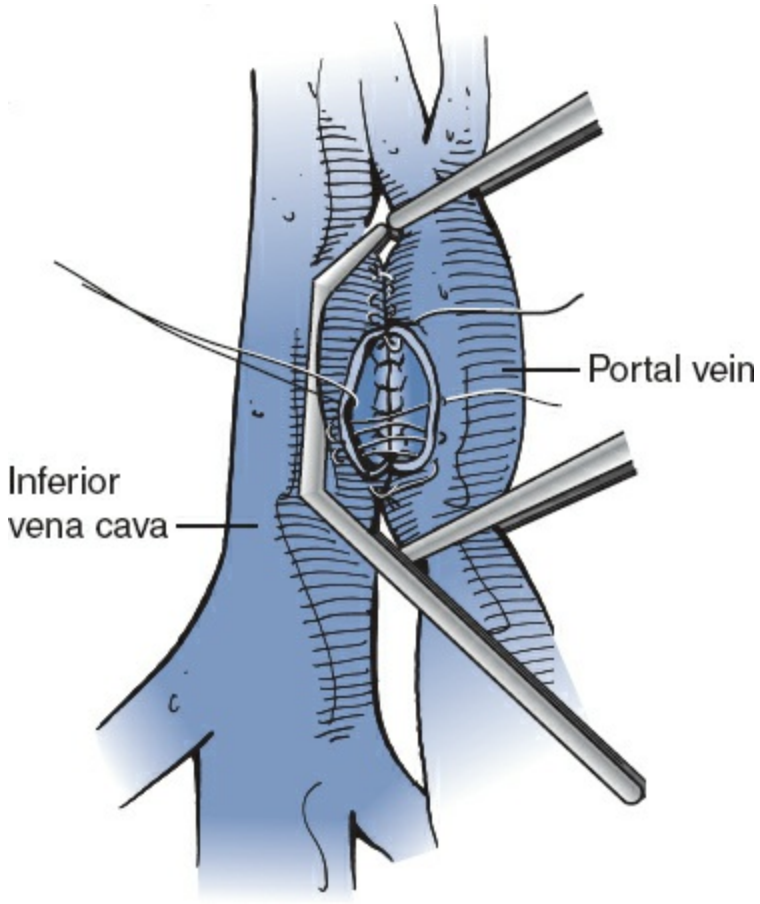

Figure 130.14. Suturing the IVC and portal vein together in a side-to-side portacaval anastomosis.

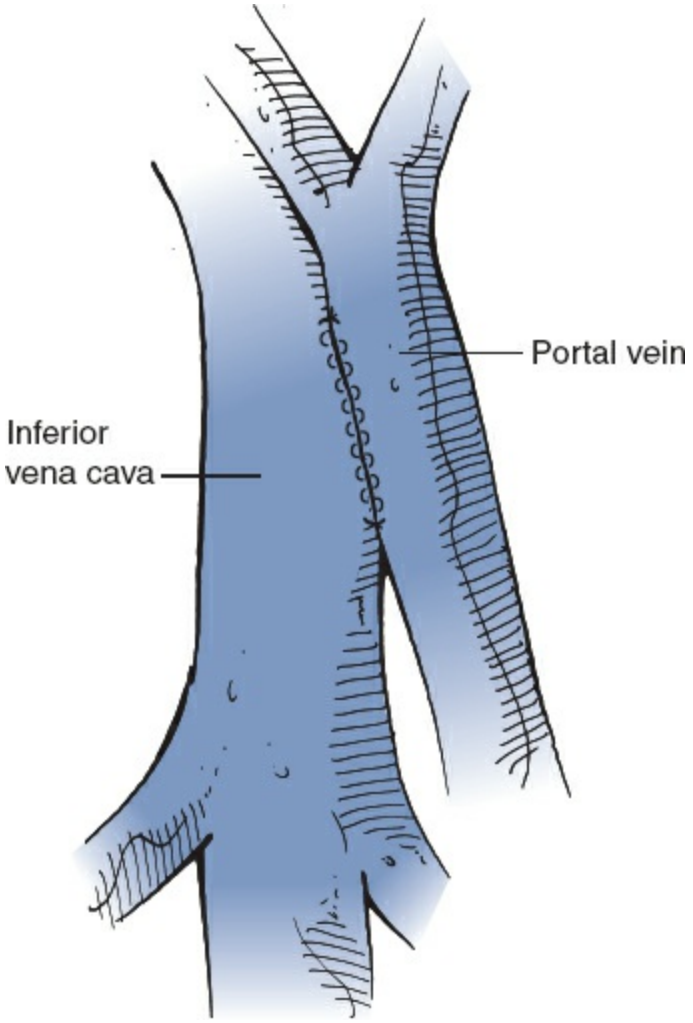

Figure 130.15. The completed side-to-side portacaval anastomosis. Pressures in the portal vein and IVC must be measured after the anastomosis is completed. Usually the postshunt pressures in the portal vein and IVC are identical. A pressure gradient of >50-mm saline between the two vessels indicates an obstruction in the anastomosis, even when no obstruction can be palpated. In such circumstances, the anastomosis should be opened to remove any clots and, if necessary, the entire anastomosis should be taken down and redone. It is essential that there be no more than a 50-mm saline gradient between the portal vein and IVC to achieve permanently adequate portal decompression and to avoid ultimate thrombosis of the shunt. (Republished with permission of SPRINGER-VERLAG BERLIN/HEIDELBERG, from Orloff MJ, Orloff MS, Orloff SL. Portacaval shunts: side-to-side and end-to-side. In: Clavien PA, Sarr MG, Fong Y, Georgiev P, eds. *Atlas of Upper Gastrointestinal and Hepato-Pancreato-Biliary Surgery.* Berlin Heidelberg: Springer-Verlag, 2007:687–702, permission conveyed through Copyright Clearance Center, Inc.)

In summary, the following are important points:

1. The position of the patient on the operating table is crucial and can make the difference between an easy and difficult operation.
2. A long right subcostal incision is associated with many fewer postoperative complications than a thoracoabdominal incision and is much to be preferred.
3. Use of the electrocautery throughout the operation substantially reduces the operating time and the blood loss.
4. Bleeding from the many portosystemic collateral vessels is best managed by pressure with gauze sponge packs, particularly as most of the bleeding stops as soon as the portacaval anastomosis is completed and the portal hypertension is relieved. Attempts to control each of the bleeding collaterals with ligatures and sutures prolong the operation and increase the blood loss. The objective is to decompress the portal system as rapidly as possible.
5. Circumferential mobilization of the IVC between the entrance of the renal veins and the liver is essential for the side-to-side anastomosis and is neither hazardous nor difficult to perform. Apposition of the two vessels is greatly facilitated by elevation of the vena cava toward the portal vein.
6. Mobilization of a long segment of portal vein, which includes division of the tough fibrofatty tissue that binds the portal vein to the pancreas and sometimes includes division of a bit of the head of the pancreas, is essential for the side-to-side anastomosis and sometimes for the end-to-side anastomosis.
7. Beware of the replaced hepatic artery crossing the portal vein behind the head of the pancreas. Palpate it with the index finger in the tunnel between the head of the pancreas and portal vein. Ligation of the hepatic artery may be lethal.
8. Resection of an enlarged caudate lobe of the cirrhotic liver to facilitate apposition of the two vessels is hazardous and unnecessary.
9. Pressures in the IVC and portal vein should always be measured after completion of the PCS. A pressure gradient of >50-mm saline is unacceptable and requires revision of the anastomosis.

AUTHOR'S EXPERIENCE WITH PORTACAVAL SHUNT

Emergency Portacaval Shunt

BEV is a common and highly lethal complication of cirrhosis of the liver. The mortality rate associated with BEV is highest during the period

surrounding the episode of acute bleeding. It is clear that emergency treatment of acute bleeding is of paramount importance in the care of patients with portal hypertension and esophagogastric varices. Accordingly, for the past half-century, the author and his colleagues have conducted and published prospective studies of emergency therapy, and particularly of emergency portacaval shunt (EPCS). Our studies have been distinguished by three features: (1) all patients ("all comers") with BEV as a result of cirrhosis of the liver, regardless of their condition, have been included without selection; (2) the specific emergency treatment undergoing evaluation has been administered within 8 hours of initial contact; and (3) our studies have been prospective, meaning that a well-defined protocol was consistently used and data were collected online.

One of our recent and most definitive studies have been two randomized controlled trials (RCT), supported by a grant from the National Institutes of Health. The first of these RCTs compared endoscopic sclerotherapy (EST) with EPCS in cirrhotic patients with acute variceal hemorrhage. A total of 211 unselected, consecutive patients with cirrhosis and acute BEV who required at least 2 units of blood transfusion were randomized to EST (n = 106) or EPCS (n = 105). Diagnostic workup was completed within 6 hours and EST or EPCS was initiated within 8 hours of initial contact. Long-term EST was performed according to a deliberate schedule. Ninety-six percent of patients underwent more than 10 years of follow-up, or until death. The percent of patients in Child's risk classes were: A, 27.5; B, 45.0; and C, 27.5. EST achieved permanent control of bleeding in only 20% of patients; EPCS permanently controlled bleeding in every patient ($P \leq 0.001$). Requirement for blood transfusions was greater in the EST group than in the EPCS patients. Compared with EST, survival after EPCS was significantly higher at all time intervals and in all Child's classes ($P \leq 0.001$). Figure 130.16 shows the 15-year Kaplan–Meier estimated survival plots for the EST and EPCS groups, overall and according to Child's risk classes at the time of entry in the study. As expected, survival rate was related to the severity of hepatic disease.

An important factor responsible for the success of EPCS was a low incidence of early and long-term PCS thrombosis, which was determined yearly by ultrasonography. The shunt remained permanently patent in 98% of the patients. This outcome was consistent with our past experience with ~2,500 SSPCSs in which occlusion of the anastomosis developed in only

0.5%.

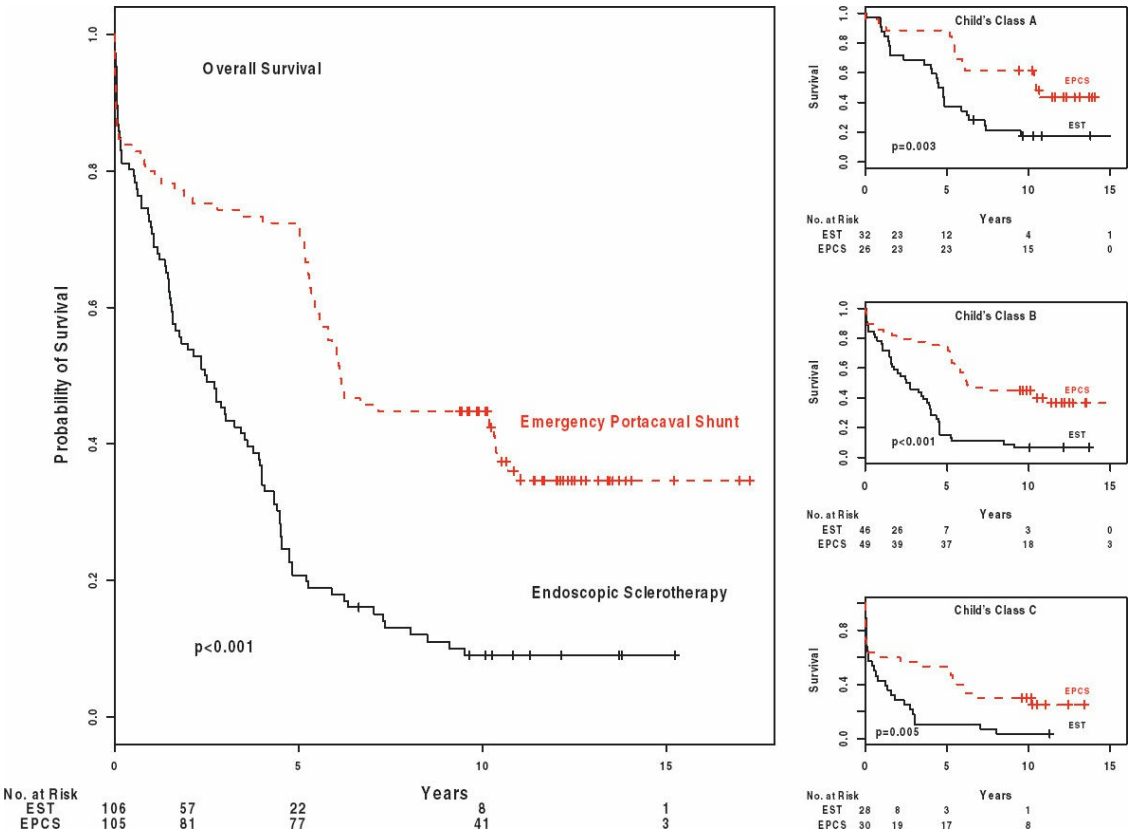

Figure 130.16. Kaplan–Meier estimates of overall survival, and survival in Child's risk classes A, B, and C in a randomized controlled trial (RCT) of endoscopic sclerotherapy (EST) versus emergency portacaval shunt (EPCS) in 211 unselected patients with bleeding esophageal varices (BEV) due to cirrhosis. (From Orloff MJ et al. Randomized trial of emergency endoscopic sclerotherapy versus emergency portacaval shunt for acutely bleeding esophageal varices in cirrhosis. *JACS* 2009;209:25–40. Copyright © 2009, with permission from Elsevier.)

There is a widespread belief that portosystemic shunts are associated with a high incidence of portal-systemic encephalopathy (PSE), and that this serious complication undermines and indeed negates the life-saving benefits achieved by surgical control of bleeding. In our recently reported RCT, PSE was quantitated by a "blinded" senior faculty gastroenterologist during regular follow-up that was 100% and lasted for more than 9.4 years or until death. Four variously weighted components of PSE were graded on a scale of 0 to 4: (a) mental state, (b) asterixis, (c) number connection test, and (d) arterial blood ammonia. The incidence of recurrent PSE in the two groups of patients over a period of 15 years is shown in Figure 130.17.

PSE occurred in 35% of EST patients and only in 15% of EPCS patients ($P \leq 0.001$). These results were facilitated by rigorous, frequent, and lifelong follow-up that included regular counseling on dietary protein restriction and abstinence from alcohol, and by long-term patency of the PCS in 98% of patients. Furthermore, these results call into question the practice of avoiding PCS because of fear of PSE, and thereby foregoing the life-saving advantage achieved by surgical control of bleeding.

An important part of our first recent RCT was continuous assessment of disability to create a Disability Index (DI) based on nine factors: (a) change in Child's class, (b) recurrent PSE, (c) number of PSE episodes, (d) number of blood transfusions, (e) number of readmissions to the hospital, (f) days of hospitalization during readmissions, (g) alcoholism, (h) return to work, and (i) PCS patency. These factors were assigned numerical weights from which a DI score was calculated. The lower the DI score, the less was the disability. Overall, DI score was significantly lower (i.e., better) in patients treated by EPCS than in those treated by EST throughout the long period of follow-up ($P < 0.001$).

Another important assessment included in our RCT was a determination of the total costs of care of EPCS and EST. All hospital and outpatient facility charges and all professional fee bills from our medical center and from referring hospitals and physicians were obtained continuously for every patient entered in the RCT for 10 years. Mean charges per year were \$168,100 in the EST patients and \$39,400 in the EPCS patients ($P < 0.001$). EPCS was strikingly superior to EST with regard to direct costs of care measured for 10 years.

Liver transplantation (LT) is the only curative treatment of cirrhosis, and some transplant centers have considered BEV in cirrhosis to be an indication for LT. This issue was examined as part of our RCT. The analysis was supplemented by 1,300 unrandomized cirrhotic patients in whom we had previously performed PCS, with 100% follow-up. Only 4 RCT patients (2%) and only 19 unrandomized PCS patients (1.5%) underwent LT. Mean 1- and 5-year LT survival rates were 0.68% and 0%, compared to 81% and 73% after EPCS. We concluded that cirrhotic patients with BEV seldom require LT-provided bleeding is permanently controlled, as occurs following EPCS. Furthermore, should LT be required, numerous studies have shown that PCS does not increase mortality rate or complications. LT is beset by a number of limitations that include unavailability of donor livers, failure to qualify for LT for medical,

social, and economic reasons; and lifelong costs that are more than three times those of EPCS.

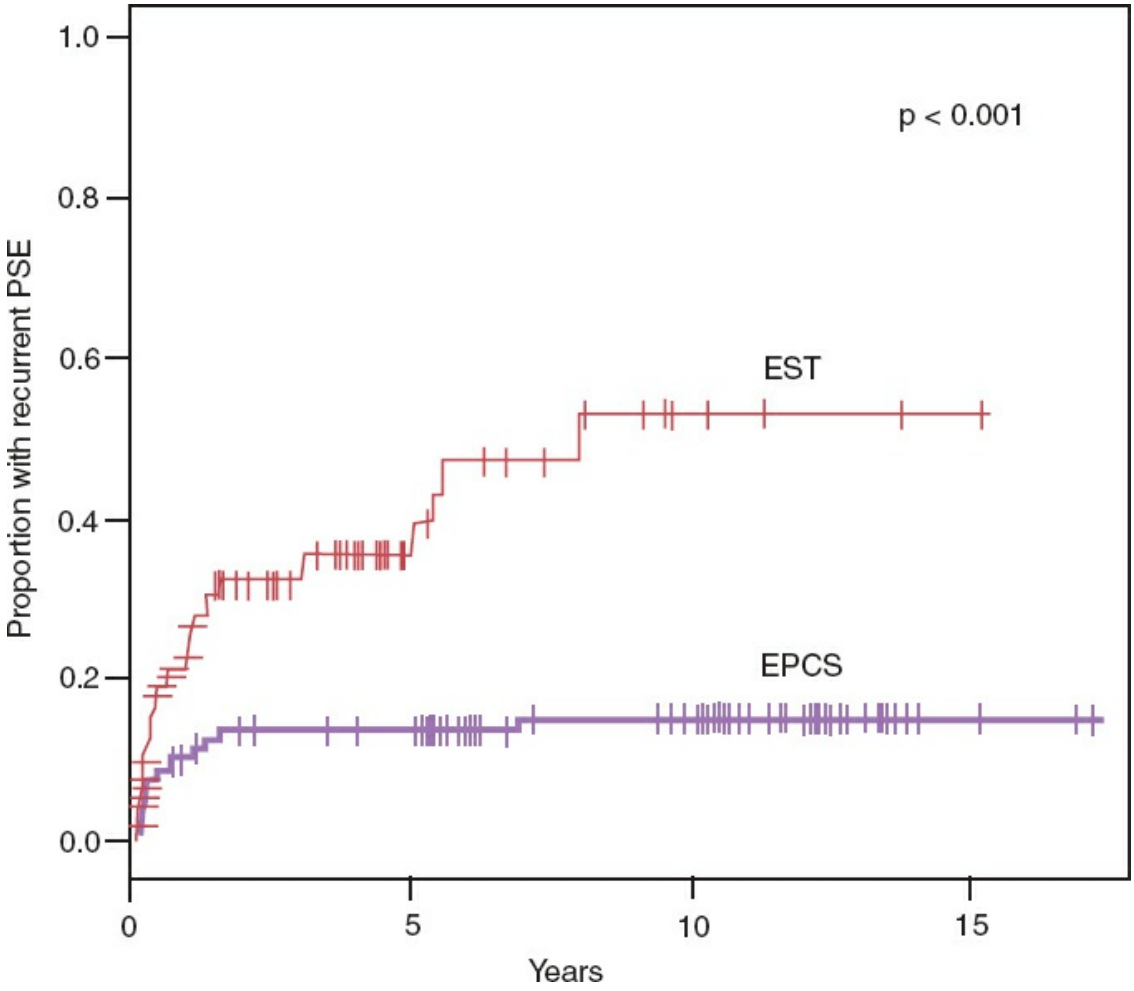

Figure 130.17. Incidence and timing of recurrent portal-systemic encephalopathy (PSE) in patients who were randomized to EST (*n* = 93) or EPCS (*n* = 89) and survived >30 days and were discharged from the hospital.

Alcoholic cirrhosis is the most common cause of BEV. Yet, it has been proposed that portosystemic shunts should be avoided in alcoholic cirrhosis because, according to retrospective, unrandomized observations of elective treatment of BEV by portosystemic shunts, survival rate was significantly lower in alcoholic than in nonalcoholic cirrhotics, especially with regard to distal splenorenal shunt. We examined this important issue in our RCT and found no difference between alcoholic and nonalcoholic cirrhotics with regard to (a) permanent control of bleeding, (b) survival, (c) incidence of PSE, (d) improvement in Child's class, (e) QOL, and (f) cost of care.

EPCS is infrequently used today because of the belief, unsubstantiated by long-term randomized trials, that PCS causes frequent PSE and liver failure. The main use of PCS today is as rescue therapy when endoscopic and pharmacologic therapies have failed. Since the protocol of our RCT involved crossover rescue PCS when EST failed, we had the unique opportunity to evaluate in 50 patients the widely used practice of rescue PCS for EST failure to permanently control BEV. EPCS was strikingly superior to EST as well as to the combination of EST and rescue PCS in regard to all outcome measures, specifically bleeding control, survival, incidence of PSE, improvement in liver function, DI, and cost of care ($P < 0.001$) (Fig. 130.18). The results of every aspect of our RCT strongly support use of EPCS as the first line of emergency treatment of BEV in all forms of cirrhosis.

In our second recent RCT currently in press, we compared TIPS and EPCS in 154 unselected, consecutive cirrhotic patients ("all comers") with acute BEV. TIPS ($n = 78$) and EPCS ($n = 76$) were compared with regard to effect on survival, control of bleeding, PSE, disability index, and economic costs. Diagnostic workup was completed within 6 hours and TIPS or EPCS was initiated within 24 hours. Regular follow-up was accomplished in 100% of patients and lasted for 5 to 10 years in 85%, and 3 to 4.5 years in the remainder.

The clinical characteristics of the two groups were similar, and the distribution of Child's classes A, B, and C was almost identical. TIPS was successful in controlling BEV for 30 days in 80% of patients, but achieved long-term control of BEV in only 22%. In contrast, EPCS controlled BEV immediately in all patients, and permanently in 97% ($P < 0.001$). TIPS patients required almost twice as many units of blood transfusion as EPCS patients. Survival rate at all time intervals and in all Child's classes was significantly greater following EPCS than after TIPS ($P < 0.001$) (Fig. 130.19). Median survival was over 10 years following EPCS, compared to 1.99 years following TIPS. Stenosis or occlusion of TIPS was demonstrated in 84% of patients who survived 21 days, 63% of whom underwent TIPS revision, which failed in 80%. In contrast, EPCS remained permanently patent in 97% of patients. Recurrent PSE was threefold more frequent following TIPS than after EPCS, 61% versus 21%. In conclusion, EPCS was uniformly effective in treatment of BEV, while TIPS was disappointing. EPCS accomplished long-term survival while TIPS resulted in a survival rate that was less than one fifth that of EPCS.

The results of this RCT in unselected, consecutive patients provide further support for use of EPCS as a first-line emergency treatment of BEV in cirrhosis.

Elective Portacaval Shunt

Elective PCS is the most widely used form of portosystemic shunt. In general, it has been used in highly selected patients who have recovered from one or more episodes of BEV and are in sufficiently good condition to undergo a major operation. In general, patients in Child's risk class C have been excluded from elective PCS. We have analyzed our results of elective PCS in 1,000 patients with cirrhosis who were referred to us from other institutions after having recovered from BEV. Eighty-five percent of them had chronic alcoholic cirrhosis with or without chronic viral hepatitis. Child's risk classes were: A, 11%; B, 58%; and C, 31%. Survival rates were 98.4% at 30 days, 95% at 1 year, 71% at 5 years, 65% at 10 years, and 61% at 15 years. Survival rates of EPCS in unselected patients ("all comers") in our RCT were not significantly different from the survival rates in these highly selected patients following elective PCS. During 15 years of follow-up, three patients had recurrent BEV (0.3%), three patients developed thrombosis of the PCS (0.3%), and 7% of patients developed recurrent PSE. Liver function improved in 75% of patients. After 5 years, only 6% of patients were in Child's risk class C compared to 31% in class C preoperatively. It is important to recognize that many patients with BEV died without being referred for elective PCS, and that the patients who were referred to us for elective portal decompression were highly selected and not comparable to the patients in our RCT.

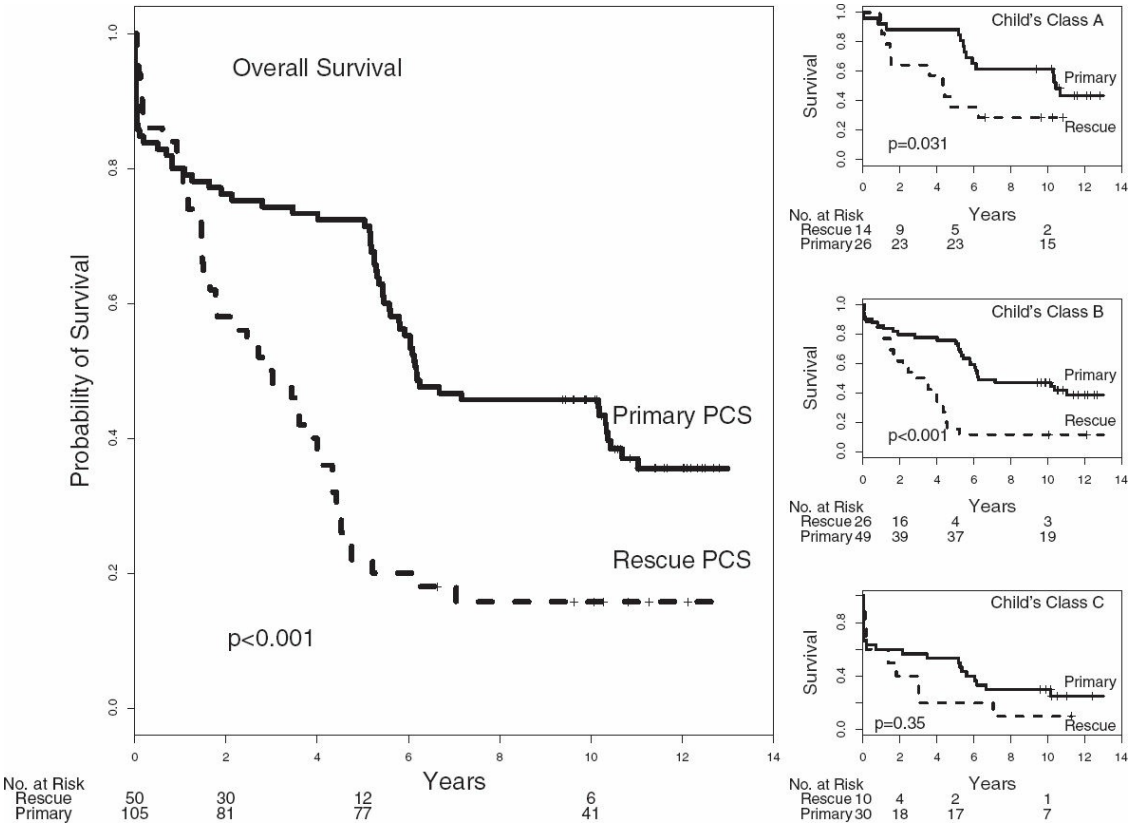

Figure 130.18. Kaplan–Meier estimates of overall survival after emergency portacaval shunt (EPCS, *n* = 50) and after failed endoscopic sclerotherapy (EST) with rescue portacaval shunt (PCS, *n* = 50). (From Orloff MJ et al. Emergency portacaval shunt versus rescue portacaval shunt in a randomized controlled trial of emergency treatment of bleeding esophageal varices in cirrhosis. *J Gastrointest Surg* 2010;14:1782–95.)

Extrahepatic Portal Hypertension

Extrahepatic portal hypertension (EHPH) is responsible for 8.4% of the cases of portal hypertension in our large series. It is usually caused by thrombosis of the portal vein. This condition is strikingly different from EHPH resulting from cirrhosis. The patients are usually much younger and often are children. They have normal liver function, are otherwise in good health, and tolerate variceal bleeding without the development of hepatic decompensation, coagulopathy, PSE, and exsanguination. Except in infancy, they rarely have ascites, and hepatic coma resulting from liver cell failure does not develop. Because the portal vein is obliterated, a direct anastomosis from the portal vein to the IVC cannot be performed for portal decompression. Finally, age and the related technical matter of adequate vessel size influence treatment.

Patients with EHPH come to medical attention usually because of bleeding from esophagogastric varices or splenomegaly. On physical examination, splenomegaly is almost always found, but the liver is not palpable. Liver function tests are usually normal, but hematologic studies often reveal peripheral cytopenia that reflects hypersplenism. The hypersplenism is infrequently severe. Esophagogastroscopy demonstrates varices. Ultrasonography of the abdomen regularly shows occlusion of the PV. Splenic or superior mesenteric arteriography, with indirect portography, is an important diagnostic procedure that provides crucial information about the site of portal obstruction and the size of the vessels available for portal decompression.

The definitive treatment of EHPH is portosystemic shunt. However, emergency shunt operations are rarely necessary. From 1958 to 1999, we conducted a prospective, unrandomized study of portosystemic shunt treatment of 200 unselected, consecutive children and adults with portal vein thrombosis who had bled two or more times from esophagogastric varices. All patients had undergone regular follow-up and 93% have been observed for 10 or more years. Etiology of portal vein thrombosis was neonatal omphalitis in 15%, peritonitis in 7%, umbilical or portal vein catheterization in 7%, trauma in 4%, thrombotic coagulopathy in 3%, and unknown in 65% of the patients. Liver function test results and liver biopsies were normal in all patients, and none had stigmata of liver disease. All patients with an intact spleen had hypersplenism. Esophagogastric varices were demonstrated by angiography, endoscopy, and contrast x-rays. Previous therapy had failed to stop recurrent bleeding in 95% of patients; splenectomy had been tried and failed in 58 (29%) and repetitive EST or variceal banding had been tried and failed in 106 (53%). Ninety-one percent had three or more bleeding episodes. The extent of occlusion and the veins available for PSS were determined by angiography. Thrombosis involved portal vein alone in 134 patients (67%), portal vein and splenic vein in 56 (28%), and portal vein and SMV in 10 (5%) (Fig. 130.20). Accordingly, central side-to-side splenorenal shunt without splenectomy was done in 94 patients (47%), conventional central splenorenal shunt with splenectomy was done in 40 (20%), and mesocaval (SMV-IVC) shunt was done in 66 (33%) (Fig. 130.21). Portosystemic shunt reduced the mean PV-IVC pressure gradient (mm saline) from 296 to 25.

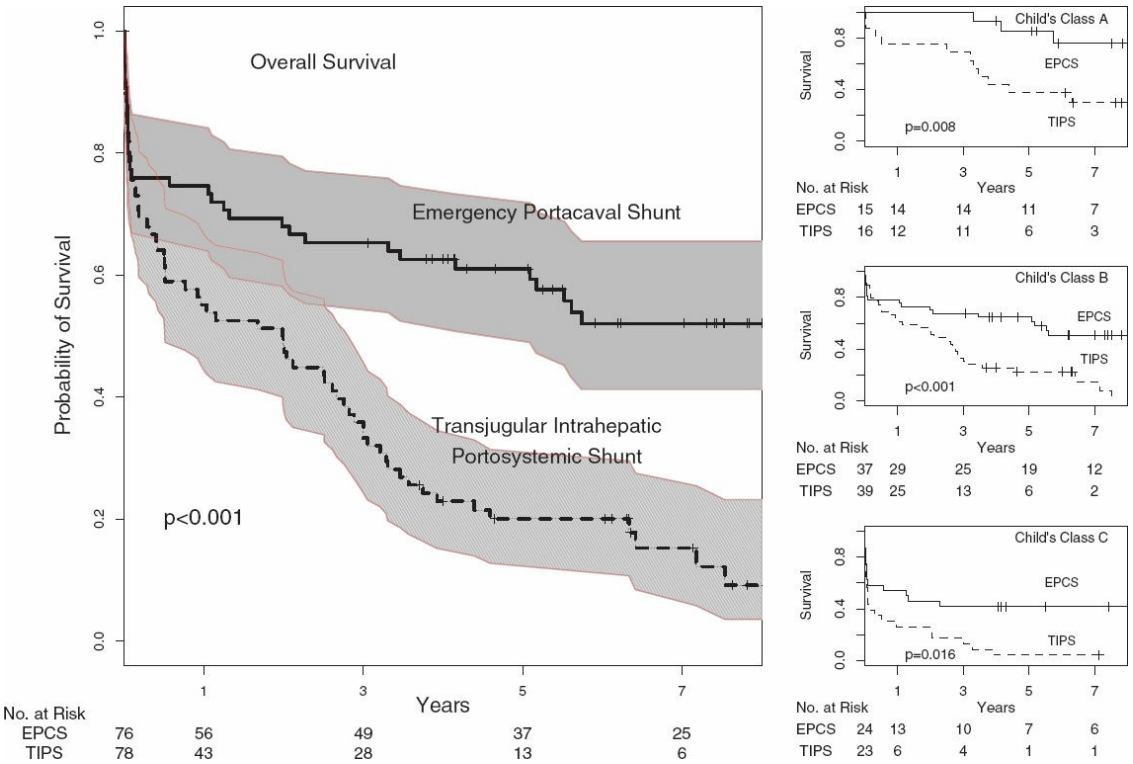

Figure 130.19. Kaplan–Meier estimates of overall survival and survival in Child's risk classes A, B, and C following emergency portacaval shunt (EPCS) (*n* = 76) and TIPS (*n* = 78). Confidence intervals are represented by shaded areas. (From Orloff MJ, Vaida F, Haynes KS, et al. Randomized controlled trial of emergency transjugular intrahepatic portosystemic shunt versus emergency portacaval shunt treatment of acute bleeding esophageal varices in cirrhosis. *J Gastrointest Surg* 2012;16(11):2094–111. Copyright © 2012 The Society for Surgery of the Alimentary Tract, with permission of Springer.)

Postoperative survival to leave the hospital was 100%. 5-, 10-, and 15-year actuarial survival rates were 99%, 97%, and 96%, respectively. Angiography and/or Doppler ultrasonography every 1 to 2 years demonstrated thrombosis of the portosystemic shunt in five patients (2.5%), all of whom developed rebleeding. All other patients remained free of bleeding with patent shunts, normal liver function tests, and no instance of PSE. Hypersplenism was corrected and the platelet count was restored to a level above 100,000/mm^3 in all patients.

Based on our 50-year experience with 100% follow-up of 200 patients, we conclude that PSS is consistently effective in bleeding varices due to PVT and EHPH, resulting in long survival, freedom from rebleeding, and no PSE. No other therapy, including endoscopic therapy, drugs, and TIPS

is consistently effective in this disorder.

Budd–Chiari Syndrome

BCS is a group of disorders in which obstruction to hepatic venous outflow results from occlusion of the hepatic veins and/or the adjacent IVC. The most common conditions that predispose to BCS are hematologic disorders with thrombotic tendencies such as polycythemia rubra vera and paroxysmal nocturnal hemoglobinuria, use of oral contraceptives, and pregnancy and the postpartum period. The pathologic lesion of BCS is thrombosis of the major hepatic veins and/or the IVC, which results in hepatic venous outflow obstruction, intrahepatic and portal hypertension, dilatation of the liver sinusoids, intense centrilobular congestion of the hepatic parenchyma and ischemia, pressure necrosis, and atrophy of the parenchymal cells in the center of the liver lobule. The usual clinical manifestations are abdominal distension due to massive ascites, hepatomegaly, abdominal pain, weakness, wasting, and anorexia. When the IVC is obstructed, an important additional sign is edema of the lower extremities and lower trunk.

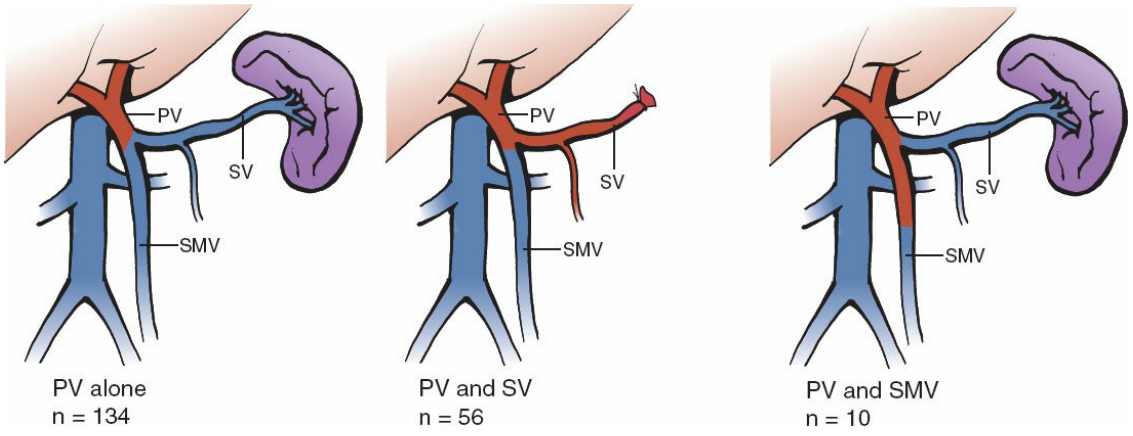

Figure 130.20. Sites of portal vein thrombosis in 200 patients with extrahepatic portal hypertension.

The diagnosis of BCS is based on finding the typical symptoms and signs combined with abnormal results of several diagnostic studies, the two most important of which are angiographic examination of the IVC and hepatic veins with pressure measurements and percutaneous needle biopsy of the liver. Hepatic venography shows occlusion of the major hepatic veins. Liver biopsy reveals the typical lesion of obstruction to hepatic venous outflow, namely, intense centrilobular congestion and centrilobular

loss of parenchyma and necrosis.

On the basis of experiments in our experimental research laboratory that demonstrated relief of BCS in animals by SSPCS, we undertook a prospective unrandomized study of the treatment of BCS in 77 patients. In 39 patients with BCS due to hepatic vein occlusion alone, SSPCS had an operative mortality rate of 2.6%, and 95% of the patients are currently alive 5 to 37 years postoperatively, with freedom from ascites and normal liver function. Eighteen patients with BCS due to IVC occlusion were treated by a bypass procedure that we devised in the experimental laboratory consisting of a high flow combination SSPCS and IVC-to-atrium synthetic shunt graft (Fig. 130.22). There were no operative or long-term deaths, and the shunts have functioned effectively during 5 to 25 years of follow-up. Permanent anticoagulation therapy has been used in all patients with synthetic grafts.

Fifteen patients with advanced cirrhosis in Child's class C were referred too late to benefit from surgical portal decompression, and they were approved and listed for LT. Four patients died from liver failure while on the list awaiting LT, and five patients died after LT. The 5-year survival rate was 67%. It should be emphasized that LT and SSPCS are not competing forms of treatment. SSPCS is the appropriate treatment in the early and middle stages of BCS when portal decompression will sustain life by reversing or stabilizing the liver disease. LT is the appropriate treatment in the late stages of BCS when the liver disease is no longer reversible and when stabilization of progressive hepatic decompensation is not possible. By and large, patients who are candidates for LT should be in Child's class C.

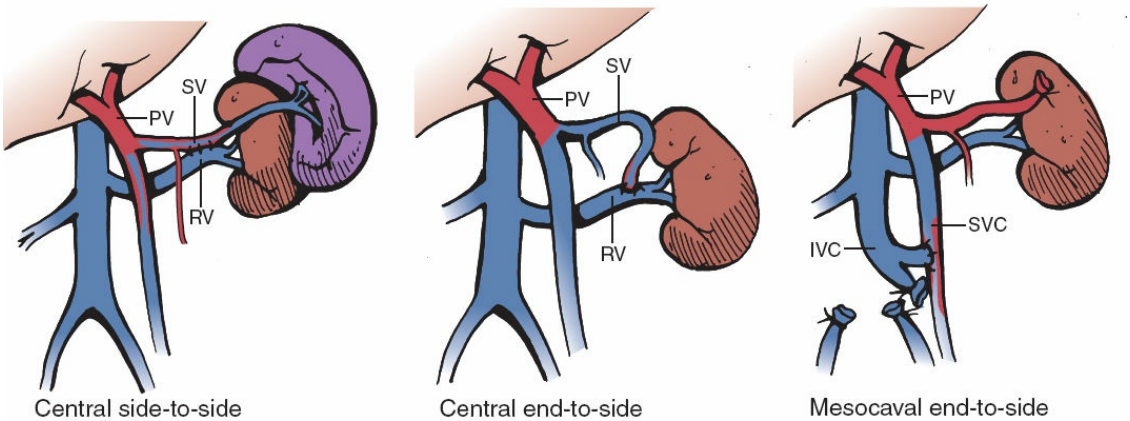

Figure 130.21. The three types of elective therapeutic portal-

systemic shunt procedures performed in 200 patients with extrahepatic portal hypertension caused by portal vein thrombosis.

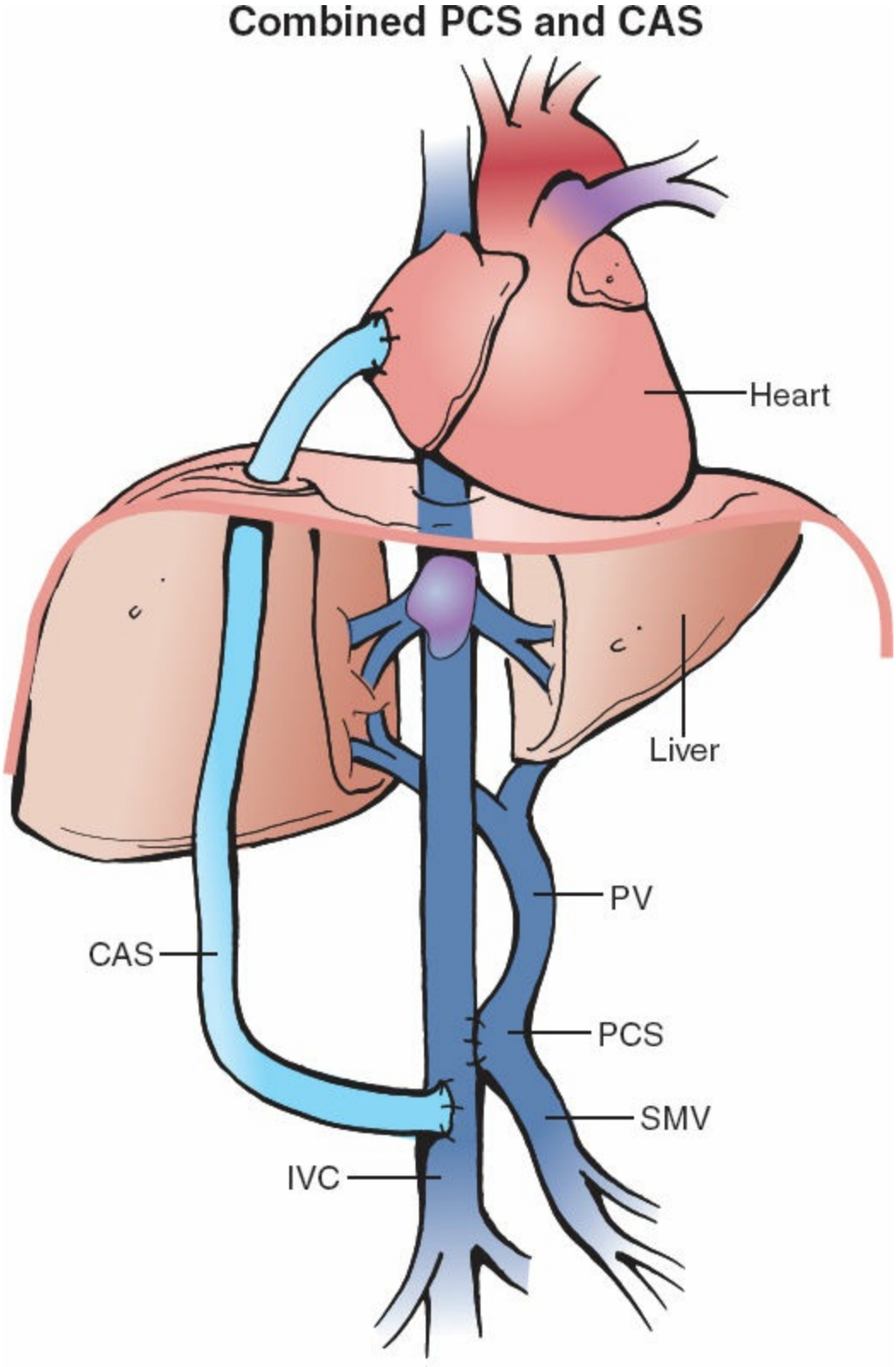

Figure 130.22. Combined side-to-side portacaval shunt and

caval-atrial shunt using a 20-mm ring-reinforced Gore-Tex graft performed in 12 patients with Budd–Chiari syndrome (BCS) secondary to IVC occlusion. PCS, portacaval shunt; CAS, caval-atrial shunt.

EXPLODING SOME MYTHS

1. MYTH #1: EPCS has a high mortality rate. RESPONSE: Our studies over the past 50 years, including our two RCTs in unselected, consecutive patients with BEV, have consistently demonstrated a low mortality rate when the diagnostic workup and operation were undertaken within 24 hours of the onset of bleeding. In our two RCT of this highly lethal disease, EPCS had a 30-day survival rate of 87% and 77%, respectively, and a 5-year survival rate of 73% and 61%, respectively.
2. MYTH #2: EPCS and other uses of direct PCS control bleeding at the expense of an unacceptably high incidence of PSE. RESPONSE: Our studies over the past 50 years, including our recently reported RCT, have consistently demonstrated a low incidence of PSE, which is significantly lower than the PSE incidence following endoscopic therapy of BEV and TIPS. Regular long-term follow-up with emphasis on dietary protein restriction and abstinence from alcohol plays an important role in achieving a low incidence of PSE.
3. MYTH #3: EPCS and other uses of direct PCS produce liver failure by depriving the liver of essential portal blood flow. RESPONSE: A fundamental physiologic response to diversion of portal venous flow is a compensatory increase in hepatic arterial blood flow to the liver. In the final analysis, the long-term improvement in liver function following EPCS observed in all our studies, including our two recent RCTs, provides meaningful objective information that contradicts the suggestion that PCS causes liver failure.
4. MYTH #4: Surgical decompressive procedures that involve the hepatic hilum should be avoided in potential liver transplant candidates because they affect the outcome of LT. RESPONSE: Our RCT demonstrates that LT is seldom required in patients with BEV treated by EPCS. Furthermore, at least 10 reports of retrospective studies in the literature concluded that portosystemic shunts do not affect the results of subsequent LT.
5. MYTH #5: Patients with cirrhosis in Child’s class C should not undergo portosystemic shunts because of a high mortality rate.

RESPONSE: In 1992, we reported the results of EPCS in 94 unselected patients with Child's class C cirrhosis. Eighty percent left the hospital alive, 72% survived 1 year, and 64% survived 5 years. Recurrent PSE developed in 9%. Liver function improved in 82%. In our two recent RCTs, 57% and 42%, respectively, of Child's class C patients treated by EPCS survived 5 years, and none of them developed PSE.

6. MYTH #6: Severe thrombocytopenia in patients with cirrhosis is best treated by splenectomy and is a contraindication to portosystemic shunt. RESPONSE: A substantial number of our patients with BEV have had severe thrombocytopenia. We have undertaken EPCS in many patients with platelet counts below 50,000/mm^3. Effective portal decompression by EPCS has invariably relieved hypersplenism and thrombocytopenia.

PANCREATICODUODENECTOMY

Another category of surgical procedure that requires a working knowledge of the portal vein is pancreaticoduodenectomy. When this operation is performed for a neoplasm of the pancreatic head, it is crucial to determine whether the portal and SMVs are free from tumor invasion as they course posterior to the neck of the pancreas. Exposure of the neck of the pancreas can be considerably improved by division of the right gastroepiploic vein as it courses across the anterior surface of the neck of the gland to insert into the SMV. Portal and SMV involvement by tumor can then be determined before resection, by establishing a "tunnel" underneath the neck of the pancreas, anterior to the portal vein. First, the anterior surface of the portal vein within the hepatoduodenal ligament is identified. Then, with a Kuttner dissector or other blunt-tipped instrument, the anterior surface of the portal vein is gently separated from the posterior aspect of the pancreas. Once a few centimeters have been cleared, the tunnel should be completed from below. This step involves entering the lesser sac, incising the peritoneum over the inferior margin of the pancreas, and identifying the SMV where it runs underneath the pancreas by following the middle colic vein down the cephalad aspect of the transverse mesocolon to the junction of the two veins. The vein (initially the SMV, then the portal vein proper) is gently separated from the posterior aspect of the pancreas. In the absence of neoplastic invasion, the vein should separate easily from the pancreas. The patency of the tunnel can be confirmed with a finger or a long, blunt clamp. It is stated in some texts

that venous tributaries do not enter the anterior surface of the portal or SMV. Others have disputed this observation, however, and cadaveric dissections have documented the frequent insertion of the pyloric vein and the right gastroepiploic vein into the anterior surface of the portal and SMV, respectively. Therefore, this dissection must be performed with care.

Once respectability has been established, pancreatic neck is transected, allowing full exposure of the portal outflow system including the portal vein, SMV, and splenic vein. The head of the pancreas must now be separated from the portal vein. This necessitates the careful identification, ligation, and division of the branches running from the pancreatic head and uncinate process into the right lateral aspect of the portal vein and SMV. These include, with some variability, the superior and inferior pancreaticoduodenal veins, the right gastroepiploic vein, and other anomalous branches arising as a result of the nearby neoplastic process. These venous branches must be managed carefully to control hemorrhage, preserve hepatic arterial inflow in the presence of a replaced right hepatic artery, and preserve the enteric venous outflow.

HEPATIC RESECTION

Knowledge of portal vein anatomy is also useful in performing hepatic resections. As mentioned in “Descriptive Anatomy,” the portal vein usually bifurcates in the fibrous tissue at the right lateral aspect of the hilar plate. It is therefore possible to ligate and divide either branch at this point before resecting hepatic parenchyma when undertaking a formal right or left hepatic lobectomy. Exposure of the right portal vein can be improved by mobilizing the liver (i.e., incising the coronary, triangular, and falciform ligaments) and retracting the right lobe to the left and anteriorly. In 12% of patients, the anterior and posterior branches to the right lobe arise directly from the portal trunk (as opposed to the branching off of a proper right portal vein trunk as it enters the hepatic parenchyma), giving the appearance of a trifurcation in the porta hepatis. The left portal vein can usually be exposed with minimal dissection where it runs as the pars transversa in the left lateral aspect of the hilar plate. When performing a right trisegmentectomy (right lobe plus left medial segment) or a left lateral segmentectomy, the surgeon must be cognizant of the portal blood supply to the left medial and lateral segments, and thus avoid resection through the umbilical fissure. The previously described pars umbilicus of

the left portal vein runs in the umbilical fissure, heading anteriorly until it fuses with the ligamentum teres hepaticus. The portal branches to the left medial segment run from the pars umbilicus in the fissure back toward the right. The branches to the left lateral segment feed from the pars umbilicus in the fissure toward the left (Fig. 130.22). Therefore, in the case of right trisegmentectomy, hepatic parenchymal dissection should be performed to the right of the umbilical fissure to avoid devascularizing the remaining left lateral segment. Conversely, in the case of left lateral segmentectomy, dissection should be performed to the left of the fissure to avoid devascularizing the left medial segment.

IMAGING PORTAL ANATOMY

The modern practitioner of pancreatic, hepatic, and portal hypertensive surgery must not only recognize portal anatomy intraoperatively, but also know the methods to image it preoperatively and postoperatively. Principal reasons for performing such assessments include checking for thrombosis in the portal vein or its tributaries before attempting a portosystemic shunt or hepatic transplant, postoperative documentation of shunt or portal vein patency, and determining proximity to or invasion of the portal vein by neoplasms.

Portography used to be the “gold standard” for imaging the portal vein. However, helical computed tomography (CT) has become the diagnostic tool of choice for imaging the portal vein. Portography and CT are expensive and can result in serious complications. Duplex ultrasonography (DU) costs much less than CT and has no known complications.

Despite potential limitations of ultrasonography, DU is highly sensitive for demonstrating postoperative patency of surgically placed PCSs. It is also useful preoperatively to screen for thrombosis in the portal system. However, if a complete evaluation of the SMV and splenic vein is required but not obtainable by DU, CT should be performed. If DU demonstrates an apparently normal portal vein and an incompletely visualized splenic vein in a patient with an enlarged spleen and bleeding gastric varices helical CT should be carried out to clarify the diagnosis before a surgical procedure is performed. An additional use of DU is for determining patency of the portal vein prior to portosystemic shunt or TIPS. In the emergency treatment of BEV, the author and his colleagues routinely perform DU at the bedside in the ICU, thereby avoiding transport of the bleeding patient to distant facilities. Other imaging procedures are unnecessary in the

emergency situation and only serve to delay treatment aimed at controlling bleeding.

Intraoperative ultrasonography has also proved to be more sensitive and specific than regular ultrasonography, CT, and portography for diagnosing portal venous invasion by pancreaticobiliary carcinomas. Intraportal endovascular ultrasonography is a new diagnostic procedure that may prove even more sensitive in evaluating tumor involvement of the portal vein. These advances in ultrasonic diagnostics may prove particularly useful for preoperative planning in light of recent evidence that tumor invasion of the portal vein is not a contraindication for pancreatic resection.

Magnetic resonance (MR) imaging has become a valuable diagnostic tool in portal vein evaluation. This modality is noninvasive and without significant complications. With improved technology, the spatial resolution is approaching that of CT, further augmented by the ability to perform MR three-dimensional reconstruction. MR angiography and MR venography are superior to DU in imaging the splenic vein and SMV, as well as in detecting either thrombus or deep portosystemic collaterals. More recently, the development of MR cholangiopancreatography has added the ability to accurately define extrahepatic biliary and intrapancreatic ductal anatomy and pathology that may influence operative conduct. Additional uses of MR angiography and MR venography include: (a) planning major hepatic resection in which portal vein resection and reconstruction is a possibility, (b) planning the surgical approach in hepatic transplantation to avoid large collateral vessels in the porta hepatis or manage the removal of the increasing numbers of TIPSs, (c) evaluation and surgical management of the portal vein during live-donor LT, and (d) the ability to simultaneously evaluate arterial, venous, and ductal anatomy using a single imaging modality.

Suggested Readings

Douglass BE, Baggenstoss AH, Hollinshead WH, et al. The anatomy of the portal vein and its tributaries. *Surg Gynecol Obstet* 1950;92:562.

Orloff MJ. *Emergency portacaval shunt: three decades of experience from Philadelphia to San Diego.* In: Rhoads JE, ed. *80th Birthday symposium.* Philadelphia, PA: Lippincott, 1989:49–61.

Orloff MJ. Portal hypertension and portacaval shunt. In: Souba W, Wilmore D, eds. *Surgical Research.* San Diego: Harcourt Brace, 2001:637–701.

Orloff MJ, Isenberg JI, Wheeler HO, et al. Direct costs of care in a randomized controlled trial of endoscopic sclerotherapy versus emergency portacaval shunt treatment of acutely bleeding esophageal varices in cirrhosis. *Ann Surg* 2011;15:38–47.

Orloff MJ, Isenberg JI, Wheeler HO, et al. Emergency portacaval shunt versus rescue portacaval shunt in a randomized controlled trial of emergency treatment of bleeding esophageal varices in cirrhosis—part 3. *J Gastrointest Surg* 2010;14:1782–95.

Orloff MJ, Isenberg JI, Wheeler HO, et al. Portal-systemic encephalopathy in a randomized controlled trial of endoscopic sclerotherapy versus emergency portacaval shunt treatment of acutely bleeding esophageal varices in cirrhosis. *Ann Surg* 2009;250:598–610.

Orloff MJ, Isenberg JI, Wheeler HO, et al. Randomized trial of emergency endoscopic sclerotherapy versus emergency portacaval shunt for acutely bleeding esophageal varices in cirrhosis. *J Am Coll Surg* 2009;209:25–40.

Orloff MJ, Orloff MS. Budd-Chiari syndrome and veno-occlusive disease. In: Blumgart LH, ed. *Surgery of the Liver, Biliary Tract and Pancreas.* 4th ed. Philadelphia, PA: Saunders Elsevier; 2007:1654–89.

Orloff MJ, Orloff MS. Operative Procedures: surgical management of ascites. In: Zinner MJ, Schwartz SI, Ellis H, eds. *Maingot's Abdominal Operations.* 10th ed. Stamford, CT: Appleton & Lange; 1997:1623–48.

Orloff MJ, Orloff MS, Girard B, et al. Bleeding esophagogastric varices from extrahepatic portal hypertension: 40 years' experience with portal-systemic shunt. *J Am Coll Surg* 2002;194(6):717–28; discussion 728–30.

Orloff MJ, Orloff SL, Orloff MS, et al. Portacaval shunts: side-to-side and end-to-side. In: Clavien PA, Saar MG, Fong Y, eds. *Atlas of Upper Gastrointestinal and Hepato-pancreato-biliary Surgery.* Springer-Verlag: Berlin Heidelberg; 2007:687–702.

Orloff MJ, Orloff MS, Orloff SL, et al. Three decades of experience with emergency portacaval shunt for acutely bleeding esophageal varices in 400 unselected patients with cirrhosis of the liver. *J Am Coll Surg* 1995;180:257–72.

Orloff MJ, Orloff MS, Rambotti M, et al. Is portal-systemic shunt worthwhile in Child's class C cirrhosis? Long-term results of emergency shunt in 94 patients with bleeding varices. *Ann Surg* 1992;216:256–68.

Skandalakis U, Rowe JS Jr, Gray SW, et al. Surgical anatomy and embryology of the pancreas. In: Skandalakis JE, ed. *Surgical Anatomy and Embryology.* Philadelphia, PA: WB Saunders; 1993.

EDITOR'S COMMENT

The contributions of Professor Orloff on portal hypertension remain relevant also an important historical perspective. Most surgeons today have not seen nor will they see let alone do a portocaval shunt or surgical decompression. Indeed Dr. Rosemurgy and his colleagues (Portal hypertension over the last 25 years: Where did it go? *J Am Coll Surg* 2016;222:1164–70) published an article which tracks the disappearance of portal hypertension as a disease treated by general and vascular surgeons. In this study data from the Agency for Health Care Administration for 33,166,201 hospital inpatients in Florida for the periods 1988 to 1992, 1998 to 2002, and 2008 to 2012 were analyzed. They found that "admissions with a diagnosis of portal hypertension dramatically increased: 5,473 patients from 1988 to 1992, 7,366 patients from 1998 to 2002, and 36,554 patients from 2008 to 2012." In addition, endoscopic treatment of esophageal varices increased while the number of decompressive shunts placed nominally increased. The use of endoscopic therapy increased significantly faster than the application of decompressive shunts ($P < 0.0001$). Finally, the percentage of patients who underwent shunting dramatically and significantly decreased ($P < 0.0001$), and surgeons undertook proportionally fewer shunts (42% in 1992 to 4% in 2012; $P < 0.0001$). Importantly, for patients with a diagnosis of portal hypertension, in-hospital mortality progressively decreased, from 9% in 1988 to 1992 to 3% in 2008 to 2012 ($P < 0.0001$). They concluded that in the state of Florida, over 25 years, there has been a sevenfold increase in the number of patients admitted with a diagnosis of portal hypertension, with a 65% reduction of in-hospital mortality. With the advances in endoscopic therapy and TIPS portal hypertension has disappeared from the purview of surgery and has migrated toward the world of medical and endoscopic therapy, probably never to return.

When Dr. Orloff was asked to write the chapter on anatomy of the portal system, he immediately agreed but asked whether or not the namesake of this surgical atlas would be interested in him writing about portosystemic shunts, utilizing his experience in many of the randomized trials that he had done with Jon Isenberg, his GI collaborator, over the years, and giving his results in his approach to portal decompression, which is emergency portacaval shunt, most of the time side-to-side but sometimes end-to-side. Dr. Orloff has written voluminously and worked long and hard in the vineyards of surgery in this area, which some people might consider a thankless task, given the clientele that one deals with. However, I might add that, having dealt with any number of portosystemic shunts, mostly splenorenal shunts as semielective shunts, but there is nothing like a big scar on a patient's abdomen and the presence of two members of Alcoholics Anonymous in the recovery room to get one to change one's ways. The size of the incision seems to have a dramatic effect on future behavior, if something else can substitute, and in this case it is the 12-step

program which has saved, I believe, any number of lives.

Dr. Orloff is not a shy person and has been, as has the editor of this book, the center of some controversies. There are people who have doubted his results. I would say that Dick Bell, who was in the department for a while in Cincinnati, told me that with many of the data, he himself he had done it, and it was true. The key to Dr. Orloff's success has been not so much his skill at doing the shunts which are there but the 8-hour rule. The 8-hour rule is paramount to getting these people through. The alternative, as variceal obliteration, using whatever method you want, including Sengstacken–Blakemore tubes, octreotide or its cogeners, and propranolol and its cogeners, is really to a certain number of patients a death sentence. The reason for that is that the patients will stop bleeding temporarily. Sclerotherapy works well in class-A cirrhotics. The worse the class, the less well it works. The patients who are most at risk, the class-B-minus and the class-Cs, then go through the usual dance of sclerotherapy, stopping variceal bleeding, rebleeding followed by repeat sclerotherapy, at which time they have now received 10 units of blood, in patients whose clotting parameters are not sterling and whose platelet count may be slightly low to begin with. Sengstacken–Blakemore tubes or nasogastric tube or alcoholic stupor or hepatic coma also contribute to aspiration, which may be subclinical, and pneumonia. By the time most surgical services in the country get to a variceal bleeder, they are well down the course of destruction. Dr. Orloff, on the other hand, has a long time ago realized that what happens to patients in the hospital, particularly when they rebleed, vomit, aspirate, develop pneumonia, is something that we do to patients that results in mortality; and the secret therefor, to all of this work is moving rapidly to the operating room, carrying out an expeditious shunt, well done without hemorrhage, making certain that it is done side-to-side when the hepatic side of the portal vein is serving at least temporarily as an exit conduit of hepatic blood flow, and then avoiding all the other horrendous things that happen to these patients if they continue to bleed.

In the editor's technique of doing an emergency portacaval shunt (for elective shunts, he does a central splenorenal shunt *á la* Linton), we first free up the portal vein first in the portal triad. The reason this is done, first of all, is because it is easy, because, as the chapter points out, there are rarely veins on the anterior side of the portal vein, so it is easy to dissect free without getting into troublesome bleeding; and then, once I get the portal vein exposed, I go directly posterior and then start to open the retroperitoneum on top of the vena cava, which is invariably directly posterior to the portal vein, especially when the patient is up on 30 degrees on a roll, as Dr. Orloff's diagrams indicate. Dr. Fischer does not mobilize the vena cava as pictured. The surgeon between sutures will take the rind of large lymphatics by suture ligation as it overlies the IVC, and get out a significant length of vena cava anteriorly, but do not mobilize it from the retroperitoneum unless absolutely necessary. The reason for the ligation is the retroperitoneal rind, as I call it, and anything around the vena cava is that it either bleeds or leaks lymph. One thing one does not need is

a lymph leak, and that is why I will divide the retroperitoneal rind between nonabsorbable macrosutures. I mobilize the vena cava far enough so that one can get a Satinsky clamp on it, and then cut a little section off the anterior part of the vena cava that will accept the anastomosis of the portal vein. The side-to-side shunt is a little more difficult, and needs a little more mobilization of the portal vein, and also some vessel loops on either side in case things get out of hand; but, once one gets the portal vein sufficiently mobilized that it will reach and transects it, I oversew the proximal end with 4-0 Prolene and then take the posterior wall of the portal vein and sew it with a running everting mattress, so that there is never any suture material which is visible within the anastomosis, and then do a horizontal mattress of interrupted 4-0 Prolene and flushing before I take the clamps off.

A side-to-side shunt is probably appropriate in patients with schistosomiasis, although, quite frankly, in Brazil and other countries in which they have a plethora of portal hypertension from schistosomiasis, a splenorenal shunt is basically what is preferred. The side-to-side shunt or the central splenorenal shunt has the advantage of dealing appropriately with patients with ascites, who promptly diureses and letting the liver, which I am certain has fatty infiltration during an acute bleeding episode, sort out which way it wants portal blood to flow. Once the patient abstains from alcohol, so that alcoholic hepatitis is no longer present, the portal flow may be adjusted by the liver itself. Doing an end-to-side portacaval shunt robs the liver of needed nutrients for the rest of one's life, although Rousselot in the 1950s pointed out that those patients who did well after an end-to-side portacaval shunt could increase hepatic artery flow significantly, so as to make up for the lost blood flow of the portal vein. Not really dealt with during those studies by Rousselot was the fact that the portal vein comes from the gut containing most first-class nutrients like glucose and amino acids and fat, and one cannot make that up in hepatic artery flow, although the hepatic artery flow increases substantially in patients who survive and probably have higher concentrations of the nutrients than they ordinarily would, since the liver does not get first-pass clearance.

Once the patient is out of the operating room, then one must be very careful about how one manages coagulation factors, further sclerotherapy, renal functions, electrolyte imbalance, etc., and the ever-present threat of hepatic encephalopathy. I believe that hepatic encephalopathy is caused by amino acid imbalance at the blood–brain barrier and therefore treat these patients should they develop encephalopathy with hepatamine, which is a high branch chain low aromatic amino acid hepatic solution, which has been shown in a number of randomized prospective trials to improve survival.

The other thing about nonportal flow was written about in 1964, I believe, by Dame Sheila Sherlock, the great British hepatologist who held court, which is a statement they use appropriately in the Royal Free Hospital, but to get to the sessions, one had to go up to the roof or climb over the roof with ladders, etc. It was a session well worthwhile of attending. Professor Sherlock pointed out that

patients with extrahepatic portal block, no matter what the etiology, died of premature “aging” in their 40s and 50s but not in their 50s and 60s. I agree there and have always wondered whether the portal vein made the liver depend on a rich nutrient supply, which if it were not supplied started the process of premature death from premature aging.

An occasional patient will have thrombocytopenia because of a highly enlarged spleen and although the portacaval shunt will decrease the number of patients with thrombocytopenia, nonetheless, in Dr. William McDermott’s series in 1962, published in the *New England Journal of Medicine*, there seven patients whose thrombocytopenia did not respond to an end-to-side portacaval shunt.

Likewise, there are a number of patients who will accumulate massive ascites if an end-to-side portacaval shunt was done, and in fact, the hepatic side of the portal vein was decompressing the liver. I have on occasion opened up the left branch of the portal vein as it is in the liver (connecting to the left hepatic vein) and run the saphenous veins subcutaneously dilate the obliterated umbilical vein, which I could open up with a Bakes dilator and anastomose to saphenous veins, decompressing the liver. When I did that the first time, I was surprised to see the blood from the umbilical vein shoot, which is the only way I can describe it, out of the liver under really enormous pressure. However, the patient did decompress and he diuresed his ascites only to die of a perforated pulmonary artery by a Swan-Ganz catheter.

Whereas previously the end-to-side portacaval shunt has been under a cloud and TIPS has been remarkably utilized, that is no longer the case. Pierce et al. (Cost-effective analysis of transjugular intrahepatic portosystemic shunt versus surgical portacaval shunt for variceal bleeding in early cirrhosis. *Am Surg* 2011;77:169–73), carried out a cost-effective analysis of TIPS versus surgical portacaval shunt for variceal bleeding in early cirrhosis. The key to this paper is that reinterventions in emergency portacaval shunt (I do not know how much of an emergency it is, whether they went to the operating room within 8 hours, but I suspect not) showed a reintervention between 6.3% and 11%, rebleeding between 1% and 11%, hepatic encephalopathy between 12% and 26%, and the mortality between 8% and 20% in 30 days. TIPS, however, rebled 10.5% to 30%; the reintervention, which was dilating the TIPS or relating it, 48% to 82%; hepatic encephalopathy 14% to 52%; and mortality of 15% to 40% in 30 days. It is the reintervention rate, which increases the cost of doing TIPS. In dollars per life-year saved, emergency portacaval shunt was 17,771 dollars and TIPS was 21,438 dollars. However, the average life expectancy was 5 years for TIPS and 7 years for portacaval shunt. Thus, it was more than 3,000 dollars per life-year saved, which given the parlous state of our economy, is real money.

The next three papers are from Dr. Orloff’s emporium and represent a variety of papers written principally with Jon Isenberg and Henry O. Wheeler. The first paper is “Randomized Trial of Emergency Endoscopic Sclerotherapy Versus Emergency Portacaval Shunt for Acutely Bleeding Esophageal Varices in

Cirrhosis," Orloff et al. (Randomized trial of emergency endoscopic sclerotherapy versus emergency portacaval shunt for acutely bleeding esophageal varices in cirrhosis. *J Am Coll Surg* 2009;209:25–40) that in a group of 211 consecutive patients with cirrhosis who were unselected and who were known to have acutely bleeding esophageal varices and had required two units of blood were randomized to endoscopic sclerotherapy (EST) or portacaval shunt (EPCS). As many as 106 were randomized to EST and 105 to EPCS. However, Class A was 27.5%, Class B, 45%, and Class C 27.5%. EST achieved permanent control of bleeding in 20% of the patients, and EPCS had permanent control of bleeding in 100% of the patients; requirement for blood transfusions was greater in the EST group than in the EPCS group. The results suggest that there is lesser risk of encephalopathy in the portacaval shunt group than in the sclerotherapy group, especially since portal-systemic encephalopathy developed in 35% of the sclerotherapized patients, which is probably associated with bleeding, and there was only 15% occurrence in the emergency portacaval shunt group.

Orloff et al. (Emergency portacaval shunt versus rescue portacaval shunt in a randomized controlled trial of emergency treatment of acutely bleeding esophageal varices in cirrhosis–Part 3. *J Gastrointestin Surg* 2010;14:1782–95), looked at emergency portacaval shunt versus rescue portacaval shunt; in other words, the patients were randomized for endoscopic therapeutic ablation. Endoscopic therapy, with respect to emergency portacaval shunt was inferior because there were significant differences in outcome as far as survival after 5 years (72% vs. 22%), in 10 years (46% vs. 16%), and at 15 years (46% vs. 0%). Enough said here. Finally, as far as direct costs are concerned, Orloff et al. (Direct costs of care in a randomized controlled trial of endoscopic sclerotherapy versus emergency portacaval shunt for bleeding esophageal varices in cirrhosis–Part 4 *J Gastrointestin Surg* 2011;15:38–47) looked at direct costs in a randomized controlled trial of emergency portacaval shunt versus endoscopic sclerotherapy. Here again, the direct charges for all aspects of care were significantly lower in the patients treated for emergency portacaval shunt and less than emergency sclerotherapy followed by long-term repetitive sclerotherapy.

I think the tide has turned from what it was 5 years ago in that now I think that most surgeons dealing with portal hypertension believe that shunting is a better way to stop and prevent further variceal bleeding, which is the title of the commentary by Pedroso and Koniaris (Shunting: A better way to prevent variceal bleeding. *J Surg Res* 2011;167:e1–3). They have come to the conclusion that portal decompression is a much better way than emergency sclerotherapy.

However, "the horse is out of the barn" and the vast majority of cases are treated nonoperatively today. Impressively the mortality today is less than in the past owing to advances in medical treatment, endoscopic therapy, and TIPS. That said we would merely add that the management of patients with end-to-

side portocaval shunt should theoretically take place within 8 hours of the first encounter and one would get a larger percentage of patients who survive emergency portocaval shunt.

J.E.F. and E. Christopher Ellison

I am grateful to Dr. Ellison for mentioning hepatamine, the high branch chain low aromatic amino acid hepatic solution, which is now accepted worldwide to improve survival.

I remember Dame Sheila Sherlock, the great British hepatologist, with great affection who as Dr. Ellison recalls one took a course in mountain climbing to reach her office by climbing over the roof of her office. Those visits were always delightful even if Dame Sheila could be acerbic at times.

I am also delighted that Dr. Ellison mentions Dr. William McDermott, my mentor, and whose named chair I hold; a great mentor and gentleman who was a profound influence on me.

J.E.F.

131 Small-Diameter Prosthetic Interposition Shunt

Alexander S. Rosemurgy

Operative shunting using partial portal decompression gained popularity through efforts by Dr. Jim Sarfeh et al. in the early 1980s. Numerous publications and works since then have shown that the concept is efficacious and well tolerated. Sarfeh et al. also studied patients undergoing various degrees of partial portal decompression and found that smaller (8 to 10 mm) prosthetic H-graft portacaval shunts lead to superior salutariness relative to larger (12 to 16 mm) prosthetic H-graft shunts because the smaller grafts maintained a more physiologic (i.e., normal) pressure gradient between the portal and systemic venous systems. Utilization of the prosthetic graft ensures the portal vein–inferior vena cava (IVC) stoma will not dilate, thereby maintaining the physiologically important (albeit small) portal vein–IVC pressure gradient. My experience over the last 30 years with partial portal decompression promotes application of small-diameter (e.g., 8 to 10 mm) prosthetic H-graft portacaval shunting for complicated portal hypertension.

Currently, operative shunting for portal hypertension has disappeared except at a few centers across the United States. This is truly unfortunate. This has occurred because of the perceived adequacy of transjugular intrahepatic portosystemic shunts (TIPS), undertaken by radiologists and nonsurgeons. TIPS are convenient for admitting nonsurgeon physicians because they can be ordered, not unlike morning labs. With the progressive exclusion of surgeons in the care of patients with portal hypertension, the role for nonsurgeons has continuously expanded. For example, the American Association for the Study of Liver Diseases recently published self-serving guidelines which recommend that “the decision to perform a TIPS, especially in a high-risk patient, should be reached by a team consisting of a gastroenterologist/hepatologist, interventional radiologist, and where appropriate, a transplant physician.” This statement conveys the widely held belief that surgeon expertise is superfluous in the decision to apply portal decompression and how portal

decompression should be obtained. It is furthermore stated by the National Guidelines Clearinghouse, in cooperation with the guideline authoring organizations, that “as with any complex intervention, the decision to create a TIPS should be reached by a gastroenterologist or hepatologist who is experienced in the management of these patients in concert with an interventional radiologist.” To me, the exclusion of surgeons from the decision process is to the detriment of patient care. The use of polytetrafluoroethylene (PTFE)-covered stents is now preferred in applying TIPS, but without convincing data that it improves outcomes; I doubt it does because covering the stents does not alter the portal hemodynamic changes introduced by TIPS.

Hepatic transplantation has further diminished the role of operative shunting in the management of patients with complicated portal hypertension. Hepatic transplantation has become widely available and represents a potentially curative modality for patients with liver disease, including those with complicated portal hypertension, demonstrating 1-year and 5-year patient survival rates of approximately 90% and 80%, respectively. Hepatic transplantation is, however, predicated upon organ availability, which is limited. In addition, transplantation is encumbered by cost considerations and psychosocial requisites that are often lacking in potential candidates. As well, it must be recognized that the number of candidates for transplantation far exceeds the number of organs allocated. Nevertheless, the possibility, not the probability, for hepatic transplantation has served as an impetus for widespread implementation of TIPS given its supposed efficacy as a “bridge” to imminent transplantation. It must be noted that transplantation after TIPS is almost never “imminent.” This “bridge” is often built but is infrequently crossed, as currently less than 10% of patients undergoing TIPS eventually undergo hepatic transplantation. Furthermore, as alluded to earlier, the portal hemodynamic changes associated with TIPS promote progressive hepatic dysfunction, relative to prosthetic H-graft portacaval shunting, thereby hastening the need for transplantation to forestall death (Table 131.1).

TABLE 131.1 The Impact of Small-Diameter Prosthetic H-Graft Portacaval Shunts and TIPS on Effective Hepatic Blood Flow Measured Utilizing Low-Dose Galactose Clearance

Effective Hepatic Blood Flow	H-graft Portacaval Shunts	TIPS	*P*-value
Preshunt (mL/min)	1901 ± 1819	1684 ± 2162	NS
Postshunt (mL/min)	1662 ± 1035[a]	676 ± 451[b]	$P < 0.03$
P-value	NS	$P < 0.01$	—

[a]More than after TIPS, $P < 0.03$, Student's t-test.
[b]Less than before shunting, $P < 0.01$, Student's t-test.
Adapted from Rosemurgy AS, Zervos EE, Goode SE, et al. Differential effects on portal and effective hepatic blood flow. A comparison between transjugular intrahepatic portosystemic shunt and small-diameter H-graft portacaval shunt. *Ann Surg* 1997;225:601–7; discussion 607–8.

The role of TIPS is important herein only because it is the current alternative of choice to operative portosystemic shunting. TIPS should, however, play a role in the management of patients with portal hypertension, irrespective of the possibility for imminent (i.e., within 6 months) transplantation. TIPS should preferentially be undertaken, relative to operatively placed portosystemic shunts, in patients with a history of, or current, variceal hemorrhage failing or in patients not amenable to endoscopic therapy with concomitant relative contraindications to operative shunting. Relative contraindications to operative shunting include significant congestive heart failure, severe tricuspid regurgitation, severe pulmonary hypertension (mean pulmonary artery pressures >45 mm Hg), severe mitral regurgitation with aortic stenosis, morbid obesity, and/or a hostile abdomen (secondary to significant previous right upper quadrant surgery).

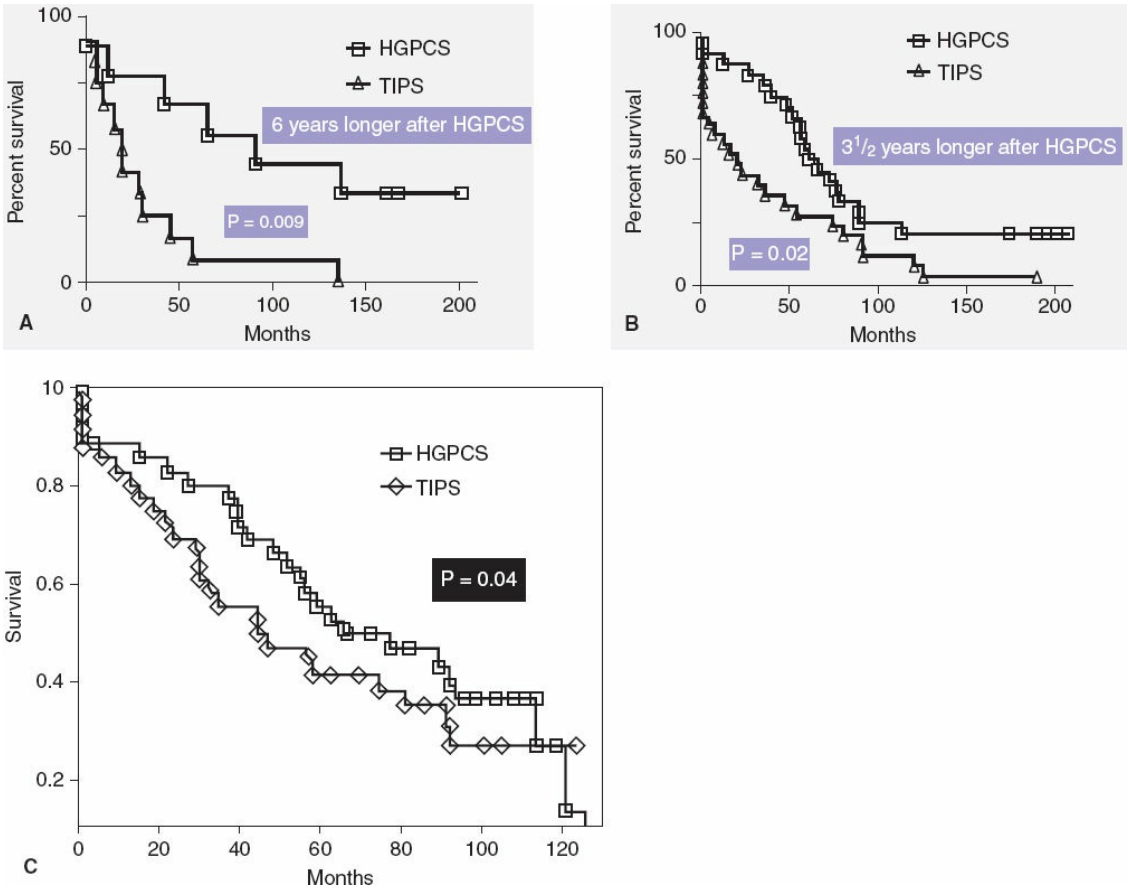

Figure 131.1. Kaplan–Meier survival curves for patients undergoing small-diameter prosthetic H-graft portacaval shunts (HGPCS) or intrahepatic portosystemic shunt (TIPS) with 18-year follow-up with Child class A liver disease (**A**) or Child class B liver disease (**B**). **C**. Kaplan–Meier survival curves for patients with MELD scores less than 13 undergoing small-diameter prosthetic H-graft portacaval shunts (HGPCS) or transjugular intrahepatic portosystemic shunt (TIPS) with follow-up at 10 years.

OPERATIVE INDICATIONS FOR SMALL-DIAMETER PROSTHETIC H-GRAFT PORTACAVAL SHUNTS

Exclusive of the small patient subpopulation mentioned above where TIPS may be preferentially applied, sufficient data exists to support preferential application of surgical shunts, in general, and small-diameter prosthetic H-graft portacaval shunts, in particular, over TIPS in the management of patients with portal hypertension complicated by variceal bleeding refractory to or not amenable to endoscopic therapy. In particular, I have demonstrated a survival advantage for patients with decent hepatic reserve undergoing small-diameter prosthetic H-graft portacaval shunts relative to patients undergoing TIPS (Fig. 131.1); survival was significantly longer

after small-diameter prosthetic H-graft portacaval shunt for patients of Child class A (91 vs. 19 months; $p = 0.009$) or class B (63 vs. 21 months; $p = 0.02$). The survival advantage, I believe, derives from relative preservation of nutrient hepatic blood flow (i.e., effective hepatic blood flow) for patients undergoing small-diameter prosthetic H-graft portacaval shunts (Table 131.1). Therefore, to promote survival, appropriate surgical candidates with adequate hepatic reserve (i.e., Child class A or B or Model for End-Stage Liver Disease [MELD] score less than 13) should undergo small-diameter prosthetic H-graft portacaval shunts. Patients with poor hepatic reserve, defined as Child class C or a MELD score of 13 or more, experience relatively high 30-day mortality rates (e.g., near 20%) irrespective of the type of portal decompressive shunt utilized. Although small-diameter prosthetic H-graft portacaval shunts impart no early survival advantage relative to TIPS for patients with poor hepatic reserve, they do promote preservation of resources (e.g., blood transfusions, intensive care unit (ICU) days, rehospitalizations) after shunting relative to TIPS and should be preferred unless hepatic transplantation is truly imminent (i.e., planned to be undertaken within 6 months). Notably, hepatic transplantation is only very infrequently undertaken in patients having undergone TIPS.

SURGICAL TECHNIQUE

The original approach to prosthetic H-graft portacaval shunting has evolved a bit over the past 30 years: I now use a shorter graft and more often I am forced to remove a portion of the caudate lobe to accommodate placement of the shorter graft. As well, I do not aggressively attempt to ligate collaterals from the portal venous system. If necessary, occlusion of these collaterals can be easily completed during a postshunt transfemoral shunt study, which I routinely obtain on postoperative day 2 to 4 to document patency. Such an approach avoids an intraoperative retroperitoneal retrogastric exploration.

A diligent first assistant is important to the operation. Such an assistant is necessary to suction accumulating ascites while the graft-cava anastomosis is undertaken and to keep the graft full of heparinized saline during portal vein-graft anastomosis. The operating surgeon stands to the patient's right side while undertaking this operation, while the first assistant stands to the patient's left.

After the patient is positioned supine on the operating table, an

endotracheal tube is placed, and then a urinary drainage catheter and a nasogastric tube are placed. Neither vasopressin nor octreotide is given perioperatively, unless there is active bleeding. Although such agents may decrease operative blood loss, I have found that blood loss is not significant without these agents; the operation can be undertaken without significant blood loss and almost always without blood transfusions. Prophylactic antibiotic therapy is always used.

The patient is rolled into a 30-degree left lateral decubitus position by means of a bedsheet rolled tightly and placed just to the right of the spine. After being prepared and draped in the usual manner, the patient is operated on through a transverse upper abdominal incision. The exact placement of this incision depends on the size of the liver, which is often palpable below the costal margin. I place the incision over the liver edge, and generally do not cross the midline. In making this incision, I usually incise only a small portion of the musculature lateral to the rectus muscle. As is my preference, I use a wound protector and Clorpactin solution for irrigation. Once the peritoneal cavity is entered, I irrigate the wound liberally with this solution and place a wound protector so that the wound is bathed by Clorpactin solution throughout the remainder of the operation. A table-mounted Omni bariatric retractor is utilized. All retractor blades are well padded, and the sternal blade of the Omni bariatric retractor is placed in the midportion of the incision to retract it cephalad.

If the falciform ligament is divided during the incision to improve exposure, it is divided carefully because large collaterals may be present. If it is divided, suture ligation of the falciform ligament is usually employed. A case for dividing it can be made, as it is a potential source of venous outflow from the portal system, and thereby, it can promote loss of effective hepatic blood flow. Its preservation is without point, but its division is not routine.

The foramen of Winslow is a key landmark. A limited Kocher maneuver is undertaken, always maintaining orientation with, and beginning at, the foramen of Winslow. High-energy electrocautery is liberally used, although large visible venous collaterals are ligated before division, as are lymphatic channels. A common mistake in the early part of this operation is that, with the patient in a 30-degree left lateral decubitus position, the dissection is undertaken in a much too lateral direction, deviating from the vena cava. With this error in dissection, the renal capsule or hilum is often exposed needlessly. The foramen of Winslow is a

landmark to keep the dissection oriented. The Kocher maneuver does not need to be extensive but just enough to expose approximately 5 cm of IVC to allow for placement of a side-biting vascular clamp. The exposed segment of the IVC should include the portion of the IVC that forms the caudal boundary of the foramen of Winslow. The cephalad portion of this segment of cava may lie dorsal to the inferior tip of the caudate lobe. If necessary, this portion of the caudate lobe is excised to expose the vena cava, so that the portal vein can be bridged to the vena cava easily with a short segment (i.e., 3 cm) of PTFE graft. A portion of the caudate lobe is usually excised. More on this later.

It is very important that the IVC be well exposed medially and laterally so that a vascular clamp can be placed on the IVC easily and without tension, which will insidiously pull the vena cava out of the clamp. I generally try to expose at least half the circumference of a 4 to 5 cm segment of the IVC to facilitate clamp placement and anastomosis. After the IVC is exposed, a traction suture is placed into the loose tissue adjacent to the right side of the IVC. This suture is further placed into the lateral abdominal wall and then tied to retract this tissue laterally to optimize exposure.

Once the IVC has been adequately exposed, attention is turned to the hepatoduodenal ligament. With the splanchnic blade of the Omni retractor placed carefully over a well-padded gallbladder, the gallbladder is retracted toward the patient's left shoulder. This lifts and rolls the gallbladder and the common bile duct ventrally and medially. The hepatoduodenal ligament is opened posteriorly and laterally. This area is rich with lymph vessels, and ligation of lymphatic structures is important in minimizing ascites. The dissection in the hepatoduodenal ligament is undertaken along the length of the ligament, parallel and dorsal to the common bile duct, to minimize chances of ductal injury. Often, the portal vein is not readily identified because of thick lymphatic tissue in this area. Once the portal vein is identified, further dissection should be undertaken only to better define the portal vein. The common bile duct should be retracted ventrally and medially with a vein retractor held by the first assistant to facilitate exposure of the portal vein. Palpation of this area is important to detect and locate an accessory/replaced or aberrant right hepatic artery. Such an artery must not be injured because such an injury can greatly interfere with necessary blood flow to the liver after shunting. If present, an aberrant, replaced, or accessory right hepatic artery should be

retracted with the common bile duct and, thereby, retracted ventrally and medially. As the portal vein comes into view, a Russian forceps is used to grasp the portal vein. A substantial portion of vein should always be grasped to minimize chances of tearing it. Dissection of the portal vein is greatly facilitated with use of a plastic Yankauer sucker (Fig. 131.2). I use this technique because it works, efficiently and bloodlessly. This technique does not injure any side branches off the vein and greatly speeds circumferential dissection of the portal vein.

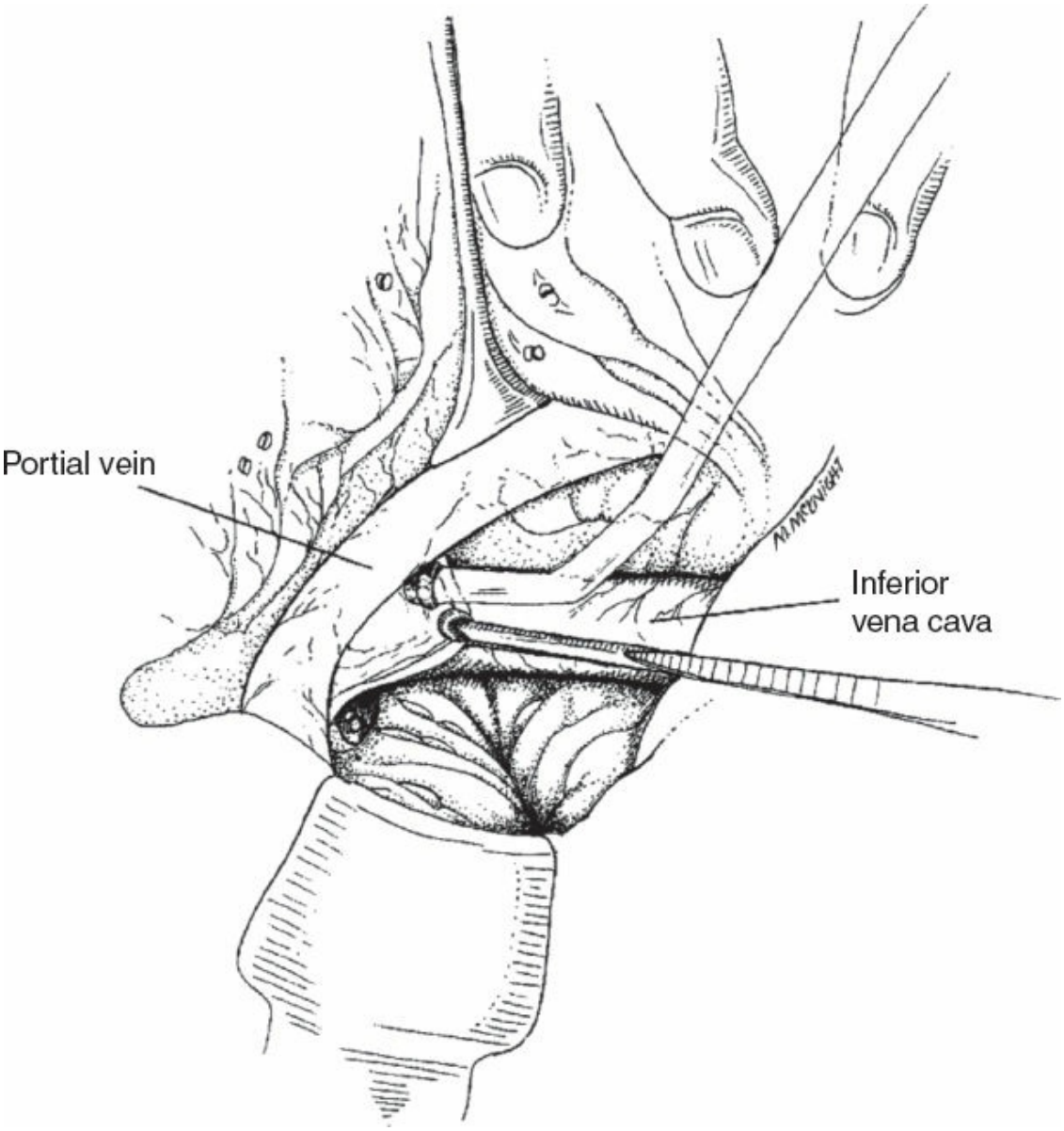

Figure 131.2. The Yankauer sucker is used to raise the portal vein off the tissue of the posterior hepatoduodenal ligament. A Russian forceps is used to minimize chances of tearing tissue. A vein retractor is helpful in the dissection. Here, it is retracting tissue containing the common bile duct ventrally and medially.

The vena cava is seen at the base of this view. A portion of the caudate lobe has already been excised. The line of excision of the caudate lobe lies posterior to the cephalad aspect of the portal vein. The patient's head is to the left. This view is from the patient's right side, where the surgeon is standing.

With Russian forceps holding the enveloping tissue of the posterior hepatoduodenal ligament, a vein retractor is placed under the portal vein, retracting it ventrally and medially. The Yankauer sucker is then used to separate the portal vein from the posterior enveloping tissue. Once this dissection is carried quite medially, the portal vein is released from the vein retractor, and the vein retractor is placed on the tissue ventral to the portal vein. With this tissue, including the common bile duct, drawn ventrally and medially, the portal vein is grasped with the Russian forceps; the ventral surface of the portal vein is freed from overlying structures with the Yankauer sucker. At this point, a right angle may be passed over the ventral surface of the portal vein and around the vein. Circumferentially, the portal vein can thus be controlled by a vessel loop. This vessel loop may useful in subsequent placement of the side-biting Satinsky clamp on the portal vein; it is also helpful if bleeding problems develop because it can provide secure control of the portal vein in the proximal hepatoduodenal ligament. If circumferential control of the portal vein is excessively difficult, lateral exposure of the vein can suffice. Having said all this, I usually do not circumferentially control the portal vein as it seems superfluous.

Pressures in the portal vein and IVC are then measured. I measure these pressures using a 25-gauge needle and a pressure-transducing setup identical to that used for an arterial line. A gradient of about 20 mm Hg is usually present between the portal vein and the IVC before shunting, with a pressure of approximately 25 to 30 mm Hg in the portal vein and approximately 5 to 10 mm Hg in the vena cava. It is important that the pressure measuring system is not moved up or down by the anesthesia team because subsequent measures will then be relatively different.

Externally reinforced PTFE graft, 8 to 10 mm in diameter, is used for the portacaval shunt. This graft is no longer than 3 cm from toe-to-toe and 1.5 cm from heel-to-heel, with the bevels of the graft at 90 degrees to each other. Orienting the bevels at 90 degrees allows the graft to be oriented to both the portal vein and the vena cava, as they are not parallel. The graft is usually 8 mm in diameter. My "rule of thumb" is that the graft should be

about half the diameter of the portal vein. With a large portal vein or if portal pressures or portal vein–IVC pressure gradients do not sufficiently decrease with application of an 8-mm graft, a 10-mm graft is used. The "short" length of the graft usually requires some resection of the caudate lobe, as previously mentioned. The length of the graft is kept short because long-term patency with this length has been a certainty.

Once the graft is cut, it is placed in a syringe full of heparinized saline. With the tip of the syringe occluded by a fingertip, suction is placed on the syringe and air bubbles can be seen to emanate from the graft. With a rather firm tapping on the side of the syringe, the air bubbles are dislodged and, with removal of the suction, the PTFE graft should no longer float, as heparinized saline replaces the dislodged air.

The graft is then placed on the IVC to determine whether a portion of the caudate lobe needs to be excised for graft placement. To remove a portion of the caudate lobe, the caudad tip of the caudate lobe is first grasped using a ringed forceps. Visible collaterals between the caudate lobe and the IVC are ligated, and divided as need be. A vein retractor is placed on the portal vein to ensure that it is not injured. Electrocautery at a high-energy level is used to score and remove the designated portion of the caudate lobe. Traction is placed along the ringed forceps as the cautery is applied to facilitate this excision. This traction pulls the piece of the caudate lobe up and off the vena cava so as to protect the cava. Blood loss during excision of a portion of the caudate lobe is much less than might be expected. Once the portion of caudate lobe is excised, a small cotton gauge sponge is placed over the cut edge of caudate lobe and pressure applied. Pressure for a minute or two will stop most bleeding. Continued bleeding can generally be controlled with electrocautery, but suture ligation may occasionally be necessary.

Once bleeding from the cut edge of caudate lobe has stopped, a side-biting Satinsky clamp is placed on the ventral surface of the IVC. A ringed forceps is used to pull the ventral wall of the IVC "up" to facilitate placement of the side-biting clamp. This clamp should be closed completely so that the vena cava does not slip out of the clamp (Fig. 131.3). Volume loading of the patient before application of the clamp is generally not necessary. Hypotension is virtually never a problem because the vena cava is not completely occluded with this clamping. Once the side-biting Satinsky clamp is placed on the ventral surface of the vena cava, a window must be cut from the vena cava so that outflow from the

graft is promoted; merely opening the vena cava is not sufficient. The window is cut in a downward, or ventral-to-dorsal, direction, rather than in a caudad-to-cephalad direction (Fig. 131.4). The primary orientation of the cut must be downward, otherwise, the window is insufficient and much longer than necessary. The "window" of vein excised should be approximately 4 mm long and 2 mm wide ex vivo. This will provide an adequate hole in the vena cava (Fig. 131.5).

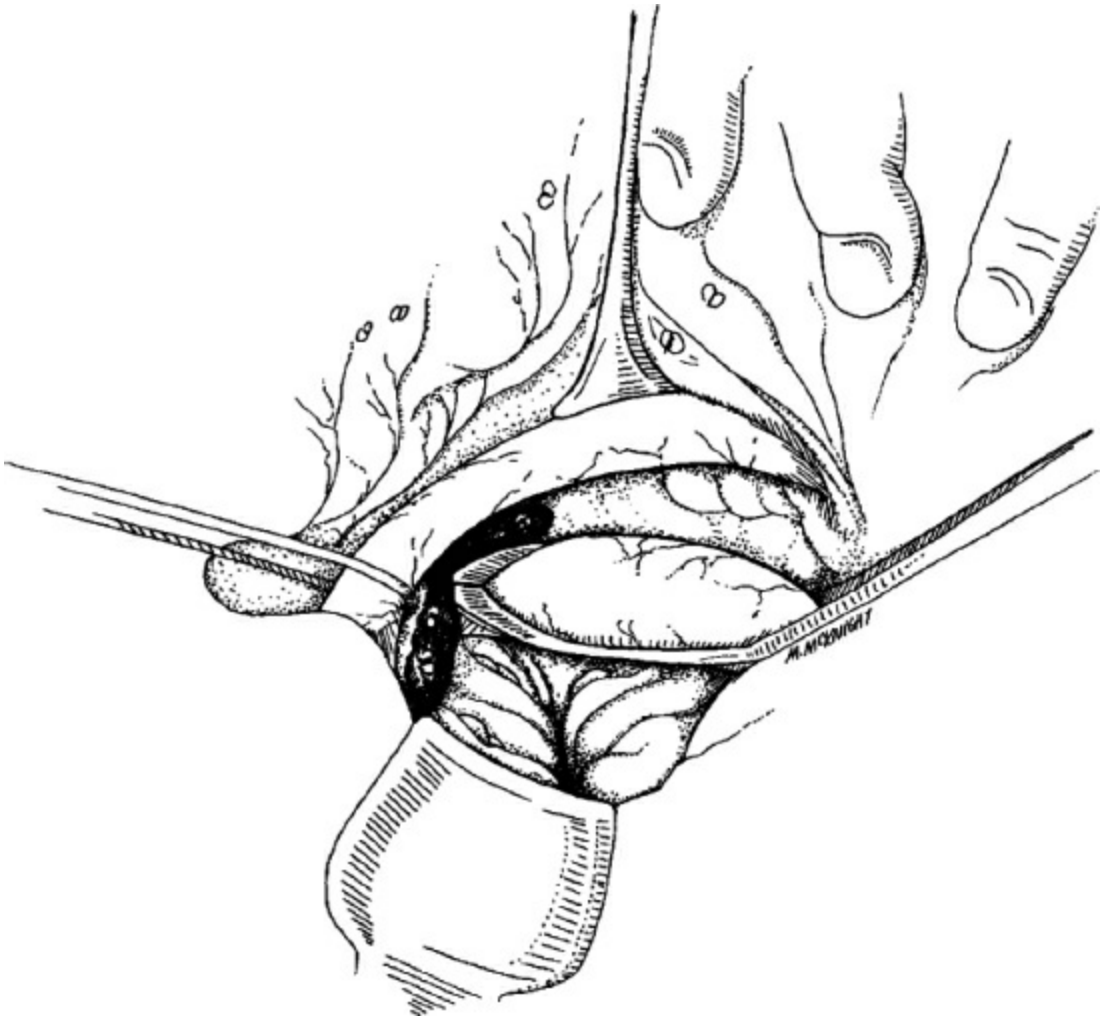

Figure 131.3. A Satinsky clamp has been placed across the anterior surface of the inferior vena cava. A vessel loop is around the cephalad portion of the portal vein. The cauterized edge of the caudate lobe is the black area at the tip of the Satinsky clamp. A generous portion of inferior vena cava is controlled by the Satinsky clamp. The patient is positioned so that the head is to the left in this drawing. This view is from the patient's right, where the surgeon stands.

The graft is placed on the vena cava so that the bevel in the graft allows

the graft to lean cephalad (Fig. 131.5). Suturing with 5-0 polypropylene is undertaken in a running fashion to construct the anastomosis. The suture is initially placed as a horizontal mattress stitch at the most cephalad aspect of the anastomosis (i.e., the "heel" of the graft) (Fig. 131.6). This anastomosis is initiated in this manner so that sewing along the length of the anastomosis is always from inside → out on the vein and outside → in on the graft, allowing easy and precise placement of the sutures in the vein. The back wall (i.e., the left side) of the anastomosis is constructed first. The initial sutures are placed so that the graft is parachuted down on the IVC (Fig. 131.6). This facilitates placement of the first few sutures, which otherwise can be quite difficult to appropriately space and see. Once the graft has been parachuted down on the vena cava, tension is maintained on the suture line as the anastomosis is sewn so that the anastomosis is not loose and so that the sutures need not be tightened with a nerve hook on completion of the anastomosis. Once the midline of the anastomosis (or toe of the graft) is crossed, the suturing returns to the most cephalad aspect of the anastomosis, using the other limb of the double-armed 5-0 polypropylene suture. The front wall (i.e., the right side) of the anastomosis is then completed. Before the knot is tied, a suture is reversed so that the knot is tied across the anastomosis. The anastomosis should be visually inspected for defects and gaps before the suture is tied. As well, a nerve hook may be used to test for tautness of the sutures before the knot is tied.



Figure 131.4. When the vena cava is opened, it should be opened with a not-so-deep and not-so narrow window, as shown in this drawing. A window is cut, as opposed to a simple venotomy in the IVC, to improve graft outflow. This window elongates considerably and easily accommodates the graft anastomosis.

Once the anastomosis has been completed and the knot tied, a right-angled clamp is placed across the graft, and the side-biting Satinsky clamp is removed from the IVC (Fig. 131.7). This tests the anastomosis; it should not leak, and it should bleed only at needle holes and only minimally, if at all. The side-biting Satinsky clamp is then replaced on the vena cava, and the right-angled clamp is removed from the graft. The graft is then vigorously irrigated with heparinized saline delivered as a focused stream through an 18-gauge angiocatheter attached to a 30-mL syringe.

The portal vein-graft anastomosis is now constructed. The common bile duct and accessory right hepatic artery, if present, are retracted ventrally and medially with a vein retractor, well exposing the portal vein. A Russian forceps is used to grab the posterolateral wall of the portal vein and retract it laterally. A right-angled side-biting Satinsky clamp is then placed on the portal vein. Though it may, the clamp does not have to occlude all flow in the portal vein. Clamping of the portal vein must provide sufficient portal vein to work with and be sufficiently secure to prevent bleeding after the portal venotomy. Once the Satinsky clamp has been placed, the posterolateral aspect of the portal vein is opened with a No. 11 blade. Once the vein is entered, Potts scissors are used to lengthen the opening to accommodate placement of the graft. A window does not need to be cut in the portal vein. A 5-0 polypropylene suture is placed in the ventral edge of the portal venotomy to act as a retraction suture, so as to ‘open up’ the venotomy in the portal vein (Fig. 131.8). With this exposure, the posterior wall of the portal vein is then sewn to the graft with a double-armed 5-0 polypropylene suture. The anastomosis is initiated by placing a horizontal mattress suture in the midportion of the posterior wall of the portal vein opening. This suture is passed inside → out on the portal vein and outside → in on the graft with both ends of the polypropylene suture. Once this horizontal mattress suture has been placed, all sewing of this anastomosis is inside → out on the portal vein and outside → in on the graft. When one of the corners is crossed, a rubber-shod clamp is placed on that end of the polypropylene suture, and sewing is initiated with the other end of the suture. As sewing is carried around both the cephalad and caudad corners of the anastomosis, the sutures along the back wall are drawn taut with a nerve hook. This is the last time that this back wall of the anastomosis will be visible, and it is important that the sutures be drawn taut at this time. As the sewing continues toward the middle of the anterior portion of the anastomosis, the clamp on the portal vein is

momentarily opened so that clot and debris within the portal vein are blown out of the portal vein before completion of the anastomosis. After this, heparinized saline is applied liberally to dislodge debris from inside the graft. An 18-gauge angiocatheter, attached to a 30-mL syringe filled with heparinized saline, is placed through the anterior defect in the anastomosis and heparinized saline is injected forcefully down the graft to clear blood and debris. It is sometimes helpful to bend the needle a bit in its middle to facilitate sewing of the ventral aspect of the portal vein-graft anastomosis. The anastomosis is then completed, with one of the sutures being reversed so that the knot is tied across the anastomosis. The clamp on the vena cava is removed first, and is followed by the removal of the clamp on the portal vein (Fig. 131.9). The clamp on the portal vein can sometimes be difficult to remove because space is limited.

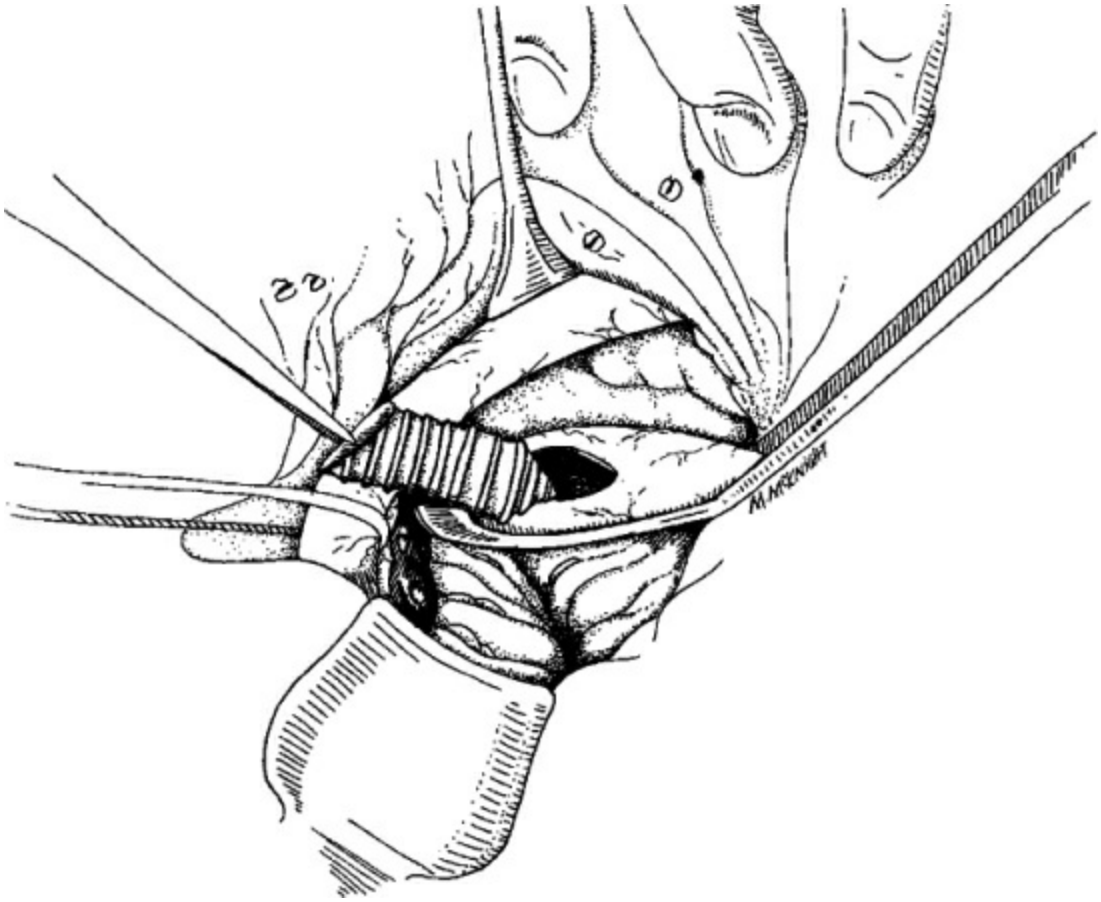

Figure 131.5. A window has been cut in the inferior vena cava. The graft is being placed into position for completion of the anastomosis. Note the orientation of the beveled ends of the graft. The patient's head is to the left. This view is from the patient's right side, where the surgeon is standing.

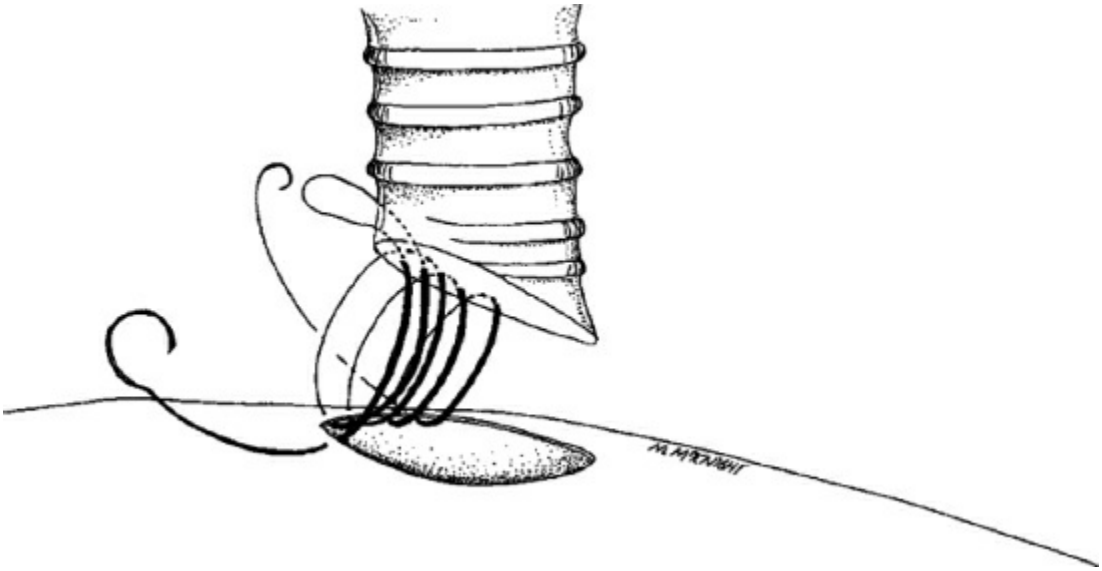

Figure 131.6. The inferior vena cava–graft anastomosis is begun at the cephalad aspect of the anastomosis. The suturing begins with a horizontal mattress suture at the heel of the graft. The left-sided portion of the suture line (i.e., the “back wall” relative to the surgeon standing on the patient’s right side) is constructed first, with sutures being placed inside → out on the vein and outside → in on the graft. After the first few sutures are placed, the graft is parachuted down. This view is from the patient’s right side, where the surgeon is standing.

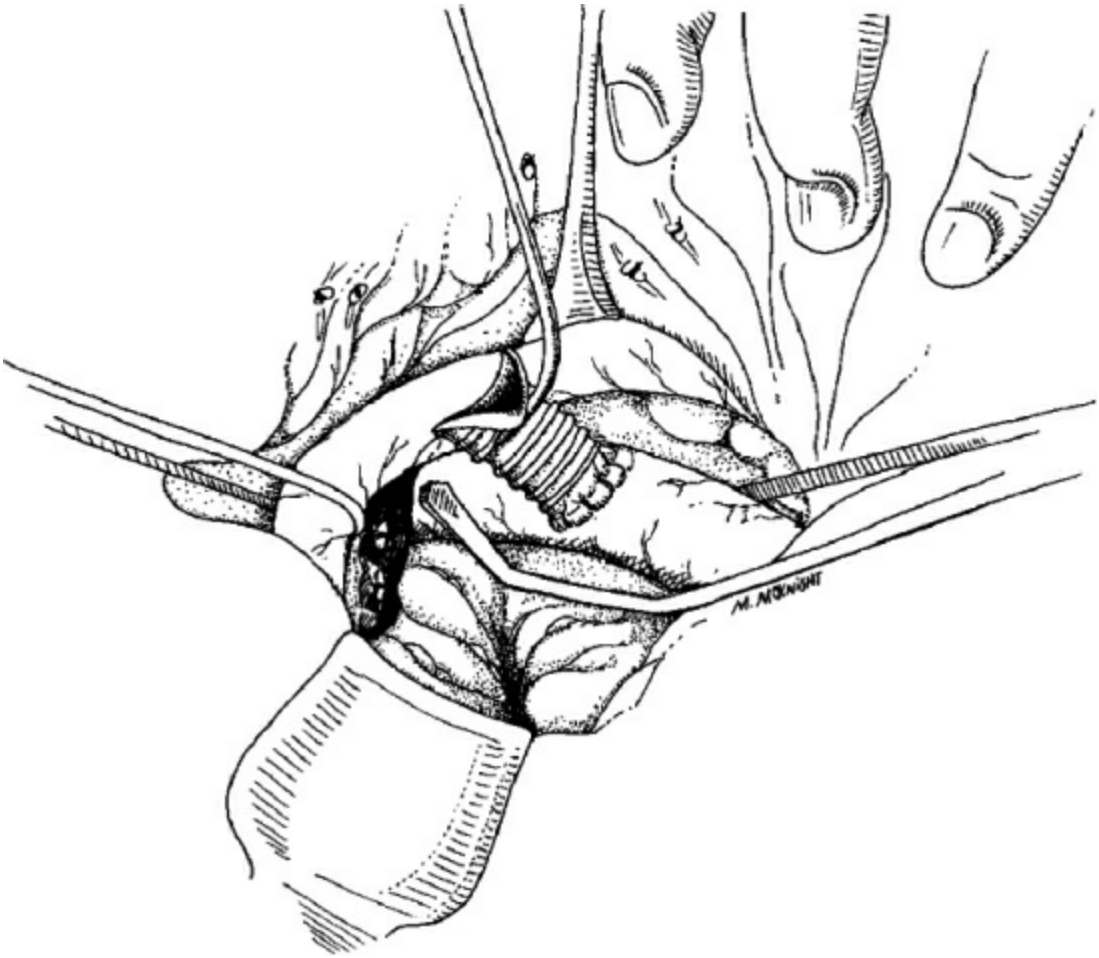

Figure 131.7. After the inferior vena cava–graft anastomosis has been completed, a right-angled clamp is placed to occlude the graft. The Satinsky clamp is then opened, and the anastomosis is tested. The Satinsky clamp is then reapplied and the graft cleansed of blood and debris.

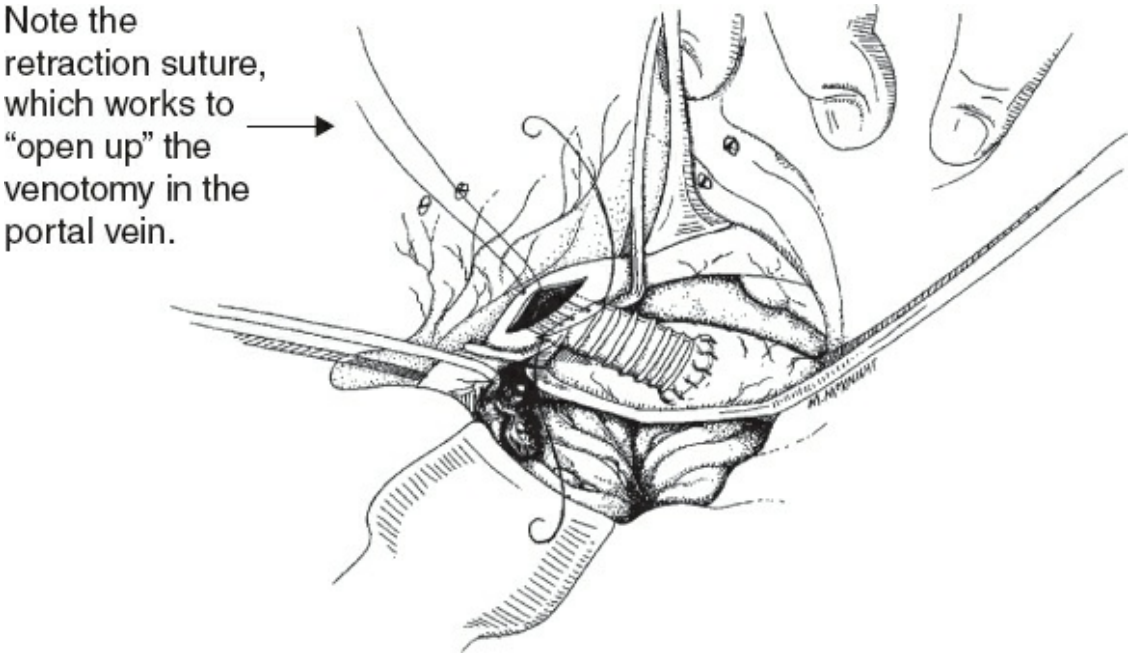

Figure 131.8. With the vena cava again occluded, the lateral wall of the portal vein is controlled with a small Satinsky clamp. The portal vein is opened posterolaterally. A traction suture of 5-0 polypropylene is placed to retract the anterior lip of the venotomy, thereby facilitating placement of sutures along the posterior anastomosis. The graft–portal vein anastomosis is begun in the midportion posteriorly. The anastomosis is begun with a horizontal mattress suture placed inside → out on the vein and outside → in on the graft. This view is from the patient’s right side.

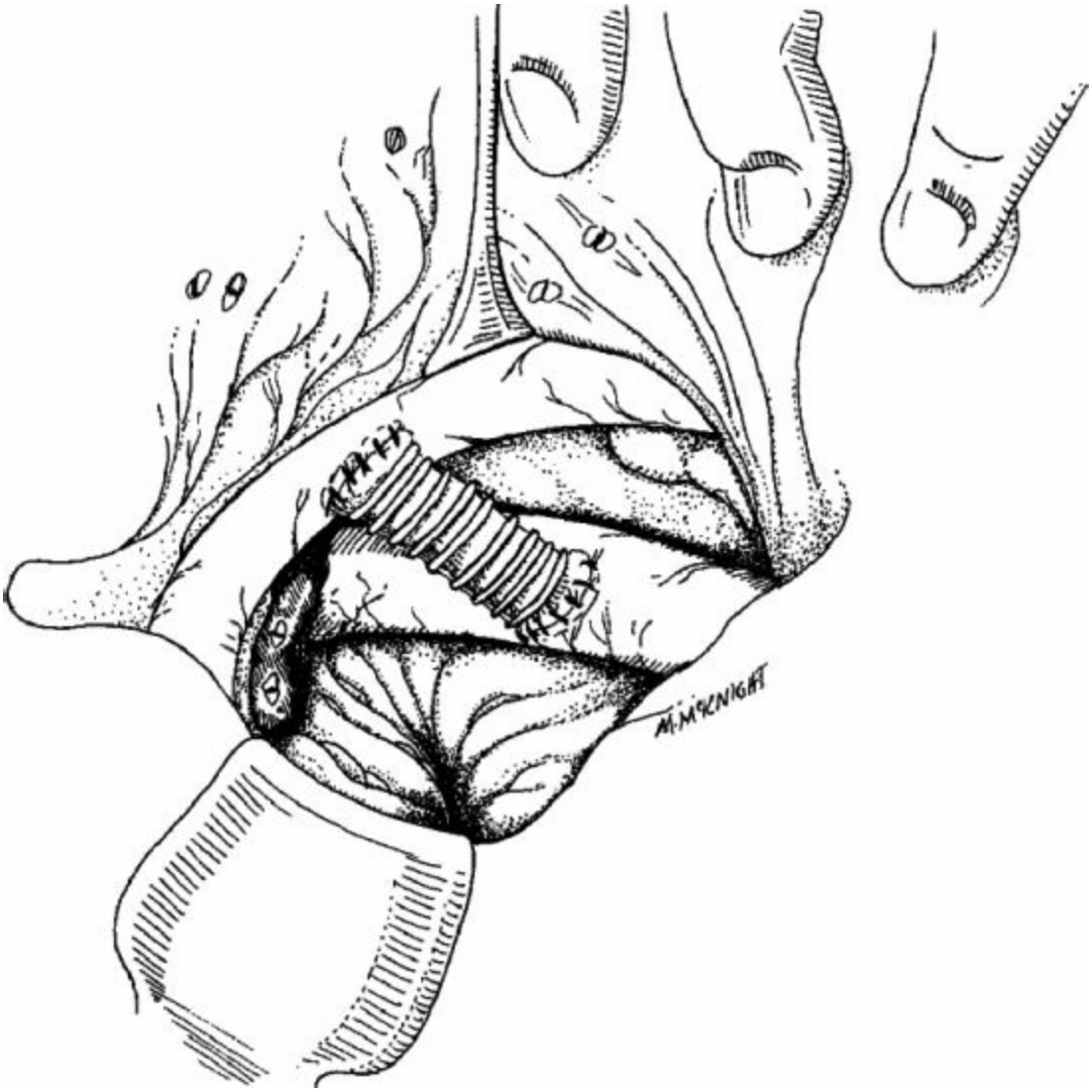

Figure 131.9. The completed prosthetic H-graft portacaval shunt. There should be a thrill in the inferior vena cava just cephalad to the anastomosis once both Satinsky clamps are removed. This view is from the patient's right, where the surgeon is standing.

There should be a thrill in the vena cava just cephalad to the anastomosis. This becomes more prominent over the next few minutes. This thrill should be felt by means of exquisitely light palpation to the vena cava just cephalad to the graft-IVC anastomosis. If no thrill is felt, it is unlikely that the shunt will prove to be patent or sufficiently decompressing.

On completion of the shunt, pressures in the portal vein and IVC are measured again. Pressures in the IVC generally rise a bit with construction of the shunt, and portal pressures should fall significantly. Accordingly, the portal vein–IVC pressure gradient should fall considerably with shunting. With shunting, I look for four things:

1. Pressures within the portal vein should fall by 10 mm Hg or more with shunting.
2. The portal vein–IVC pressure gradient should decrease by more than 10 mm Hg with shunting.
3. The portal vein–IVC gradient should be less than 10 mm Hg on completion of the shunt, with gradients of 6 to 8 mm Hg being common.
4. As mentioned, there should be a thrill in the IVC just cephalad to the cava-graft anastomosis.

If all four parameters are met, postoperative graft patency in the immediate and late postoperative periods is certain.

The vena cava–graft anastomosis is marked by large hemoclips placed on tissue adherent to the vena cava on each side of the anastomosis. These clips allow the radiologist to easily identify and cannulate the anastomosis when undertaking routine postoperative transfemoral cannulation of the shunt. Transfemoral cannulation of the shunt is undertaken to document shunt patency and function (i.e., portal decompression) 2 to 4 days after shunting and during late follow-up, generally at 1, 3, 5, and 10 years after shunting.

The operative field is copiously irrigated, the retractors are removed, and the wound is closed along anatomic layers using large polypropylene suture. Sutures must be placed with good purchase of fascia and in propinquity so that the chances of postoperative ascitic leak are minimized. The fascia is closed in two layers. The polypropylene sutures are started in each corner of the incision and then run to the middle, where they are tied, for both the anterior and posterior layers of rectus fascia. All knots are buried. The subcutaneous tissues are copiously irrigated, and the skin is closed with a running nylon suture if there is ascites before shunting; without ascites, the skin is closed with steristrips. The skin sutures are removed once they are loose, which signals wound contraction, the *sine qua non* of healing. Wound morbidity can be a problem in patients with liver disease, but I have been pleased with this method of wound closure.

Suggested Readings

Clark W, Golkar F, Luberice K, et al. Uncovering the truth about covered stents: is there a difference between covered versus uncovered stents with transjugular intrahepatic portosystemic shunts? *Am J Surg* 2011;202:561–4.

Rosemurgy AS, Frohman HA, Teta AF, et al. Prosthetic H-graft portacaval shunts vs transjugular intrahepatic portosystemic stent shunts: 18-year follow-up of a randomized trial. *J Am Coll Surg* 2012;214:445–53.

Rosemurgy AS, Zervos EE. Management of variceal hemorrhage. *Curr Prob Surg* 2003;40:263–343.

Rosemurgy AS, Zervos EE, Bloomston M, et al. Post-shunt resource consumption favors small-diameter prosthetic H-graft portacaval shunt over TIPS for patients with poor hepatic reserve. *Ann Surg* 2003;237:820–5; discussion 825–7.

Rosemurgy AS, Zervos EE, Goode SE, et al. Differential effects on portal and effective hepatic blood flow. A comparison between transjugular intrahepatic portasystemic shunt and small-diameter H-graft portacaval shunt. *Ann Surg* 1997;225:601–7; discussion 607–8.

Sarfeh IJ, Rypins EB, Mason GR. A systematic appraisal of portacaval H-graft diameters: clinical and hemodynamic perspectives. *Ann Surg* 1986;204:356–63.

Toomey PG, Ross SB, Golkar FC, et al. Outcomes after transjugular intrahepatic portosystemic stent shunt: a "bridge" to nowhere. *Am J Surg* 2013;205:441–6.



EDITOR'S COMMENT

Since the first report by Sarfeh and Rypins (Partial versus total portacaval shunt in alcoholic cirrhosis. Results of a prospective, randomized clinical trial. *Ann Surg* 1994;219:353–61) of a randomized prospective trial of end-to-side portacaval shunts and small-diameter interposition shunt showing the superiority of the latter, numerous institutions have taken up the cry that the interposition shunt should be utilized for patients that fail sclerotherapy and I would add "early" so that the patient does not deteriorate while repeated episodes of sclerotherapy or variceal banding are tried so that the patient gets aspiration pneumonia, hepatorenal syndrome, and so on.

In doing the procedure I have a couple of technical comments. First, I do not think it is necessary to ligate and divide the falciform ligament. Spare it if possible. If the patient gets over the operation, the direction of flow in the liver and its perfusion will change. Rarely, one may want to utilize the falciform ligament and dilate the lumen of the obliterated umbilical vein. The collaterals that exist within the falciform ligament may be utilized spontaneously by the patient (as it were) following recovery, in case of stricture or clot in the portal vein.

I also do not utilize a Kocher maneuver in doing a shunt of any sort that is a portacaval shunt or an interposition shunt. There is too much bleeding and too much lymphatic leakage if one enters the retroperitoneum. If one positions the patient with the right side up about 30 degrees and does a generous transverse or perhaps a Kocher incision, identifies the portal triad first and dissects out the

portal vein, and dissects directly posteriorly to the vena cava it is not necessary to kocherize the duodenum to obtain control of the IVC. The superior mesenteric vein is then relatively easy to find as one follows the portal vein caudal to the superior mesenteric vein. If then one goes directly posterior in the retroperitoneum, the vena cava is right there encased with giant, succulent lymphatics, which need to be divided and suture ligated. The interposition shunt can take place in a relatively clear field without extraneous bleeding and lymphatic leakage that one achieves when kocherizing the duodenum.

Several papers have now begun to pay attention to the fact that endoscopic sclerotherapy or banding does not result in better outcome and going directly, without too much waiting, to some type of portosystemic shunt is the best procedure. Martin Wolff and Andreass Hirner (Current state of portosystemic shunt surgery. *Langenbecks Arch Surg* 2003;388:141–9) had argued vigorously for either selective distal splenorenal shunt (Warren) or the small-diameter interposition shunt, which is the subject of this nice chapter by Professor Rosemurgy. This is especially true if transjugular intrahepatic portosystemic shunt (TIPS) fails to stop the bleeding. While some may argue for orthotopic liver transplantation as the only therapy that significantly prolongs long-time survival in patients with cirrhosis and variceal bleeding, between 20% and 30% of all comers may be Child A class and may not require transplantation. Thus many people might then have flocked to the application of TIPS as a tempering procedure, as a side-to-side portacaval shunt. It can be performed under local anesthesia with a mortality of 0.5% and 4% and probably represents a better option for patients with ascites, poor liver function, and a high operative risk. However, it has a high rate of dysfunction caused by stenosis and occlusion and requires close observation by Doppler ultrasound. It is difficult to give an exact Figure for TIPS stenosis or occlusion but the requirement for one reintervention per year is between 30% and 70%.

The authors quote a mortality in emergency situations from 20% to 60%, which is similar in both procedures. Emergency TIPS in class C has a probability of survival of less than 50% although some papers have noted higher survival. They do accept Dr. Orloff's claims of low mortality but correctly surmise that this is brought about by a very experienced surgical team and avoidance of shock and hypotension by immediate operation and rigorous follow-up. It is nice to see somebody come out in support of portal decompression after everybody has realized that there is no change in outcome in sclerotherapy or banding alone, but there does need to be a randomized prospective trial of TIPS versus at least interposition shunts.

There have been few recent reports on surgical portosystemic shunts reflecting the trend toward TIPS. Historical reports support the efficacy of these techniques. The Italians have reported an extensive experience, however, one must remember that they are dealing with a different group of patients; generally approximately 50% are posthepatitic cirrhosis and the other half are alcoholic cirrhosis. Batignani et al. from Florence (Small diameter H-graft

porta-caval shunt performed at different stages of liver disease. *Hepatobiliary Pancreat Dis Int* 2004;3:516–21) recall 29 cirrhotic patients who underwent either partial portacaval shunt with an 8-mm interposition prosthesis in 20 patients or a 10-mm shunt in 9 patients. Of the patients, 12 (41%) were Child A, 11 (38%) Child B, and 6 (21%) Child C. Eleven of their patients or 38% suffered from hepatic encephalopathy preoperatively. Of the 29, 41% were operated on in emergency/urgency. They documented portacaval pressure gradient with either prosthesis and the early mortality was 14% and morbidity 48%. There are obviously differences between the classes as the patients are divided between Child A and Child B and compared with Child C. Not surprisingly, mortality was 0% in Child A and Child B and 67% in Child C; morbidity was 35% in Child A. Late mortality was 40% in Child A and Child B and 64% (why not 67%?) in Child C. Actual survival at 3 and 5 years was 92% and 75% for Child A, 70% and 60% for Child B, and 0% and 0% for Child C, which raises the question of carrying out an interposition shunt on a Child C patient, although other than allowing the patient to bleed to death I am not certain what one would propose. We all know that Child C patients do not do well but if one does not want to operate on them then one must inform the blood bank so that no further blood is given. As long as blood is given, these patients need to have the benefit of surgery to stop the bleeding but under no circumstance should anybody think that long-term survival is going to occur.

Another historical randomized prospective trial that seems to be correctly designed was by Capussotti et al. (Liver function and encephalopathy after partial vs direct side-to-side portacaval shunt: a prospective randomized clinical trial. *Surgery* 2000;127:614–21) from Torino, Italy. They reported a series of 46 patients who were considered good risks with cirrhosis, of which half had alcoholic cirrhosis and the other half presumably had posthepatitic cirrhosis, randomized for either side-to-side portacaval shunt or partial shunt procedure by a 10-mm interposition H-graft. The side-to-side portacaval anastomosis was of small diameter. It does appear that following the shunt in the direct side-to-side portacaval shunts that the portal vein pressure was 22 cm of water whereas the other was 23. Thus there was not too much diversion of portal flow. However, we need to remember that in the alcoholic group, patients have usually been drinking and once the fat infiltration of the liver is reduced they generally have a greater diversion of flow. At least that is how it would seem since in the follow-up period only three patients in the interposition shunt and nine in the direct suture group ($P = 0.04$) developed hepatic encephalopathy. Also, encephalopathy-free survival was significantly longer in the partial shunt group (interposition $P = 0.025$). This was a highly select group in which only 5 of the 46 patients were operated on under urgent or emergency circumstances. However, given the data, I would agree that a 10-mm shunt that retains its resistance to the bleeding from the liver probably yields better survival.

In addition, the current authors and their group presented two papers in the year 2007 concerning predictors of survival and how the conventional

predictors predict survival with H-graft portacaval shunts (Cowgill SM, Thometz D, Clark W, et al. Conventional predictors of survival poorly predict and significantly underpredict survival after H-graft portacaval shunts. *J Gastrointest Surg* 2007;11(1):89–94) and survival and rehemorrhage after shunting in the same group (Rosemurgy A, Thometz D, Clark W, et al. Survival and variceal rehemorrhage after shunting support small-diameter prosthetic H-graft portacaval shunt. *J Gastrointest Surg* 2007;11:325–32). In both papers the Child class was 10% class A, 28% class B, and 62% class C. Actuarial 5- and 10-year survival by Child class was 67% and 33% for A, 49% and 16% for B, and 29% and 7% for C. They carried out a multiple variable regression analysis and concluded, not surprisingly, that the variation survival was greatest for the Child class, less so by the MELD and DF, Emory Score, with the Child Pugh score not being predictable. I am certain that that is so and the reason probably is that patients' behavior following shunt may be somewhat different.

In the same group and in the second paper in November, cirrhosis was caused by alcohol or hepatitis in 12 and both in 11; the cause was unknown in 21. Thirty-three patients had died by 6 months, 54 by 24 months, 87 by 5 years, 112 by 10 years, generally because of liver failure. Rehemorrhage was documented in three (2%) patients. Thus the authors conclude that variceal rehemorrhage in patients with a well-done, small-diameter prosthetic H-graft is rare. The actual survival was superior than predicted by MELD score.

The study using propensity matching by Hosokawa et al. (Outcomes of surgical shunts and transjugular intrahepatic portosystemic stent shunts for complicated portal hypertension. *Br J Surg* 2017;104:443–51) is helpful. This group concluded that surgical shunting achieved better results than TIPS in patients with complicated portal hypertension and low MELD scores. The study design and data are presented below. The authors reported a retrospective study of 471 consecutive patients undergoing portosystemic shunts from 1994 to 2014 at a single institution. Of these 334 patients with cirrhosis who underwent elective surgical shunting (34) or TIPS (300) for repeated variceal bleeding or refractory ascites were evaluated. Propensity score matching was done and resulted in 31 pairs of patients. The primary study endpoints as described by the authors were overall survival and shunt failure; defined as major variceal rebleeding, relapse of refractory ascites, irreversible shunt occlusion, liver failure requiring liver transplantation, or death. There were no differences in morbidity and 30-day mortality rates between the groups. Shunt failure was found to be less frequent after surgical shunting than TIPS (6 of 31 versus 16 of 31; P = 0·016). The 5-year shunt failure-free survival (77 versus 15%; P = 0·008) and overall survival rates were higher for patients with surgical shunts than TIPS (93 versus 42 per cent; P = 0.00.03737). Multivariable analysis revealed that a MELD score exceeding 14 and TIPSS were independently associated with shunt failure. They found that in patients with MELD scores of 14 or less, the 5-year overall survival rate remained higher after surgical shunting than TIPS (100% versus 40%; P <0.001).

There is very little doubt in our minds that stopping the bleeding and preventing rebleeding is the sine qua non of caring for these patients. We do not know why people persist in having these patients rebleed without doing some kind of decompressive procedure. Perhaps it is because there are few surgeons that have the surgical experience needed or because of the realization that the mortality rates have decreased and that temporizing the bleeding and medical management with lifestyle changes seems to be more effective than previously thought. However, it is nice to see that there are reports that support the better outcomes in portocaval shunts in patients with MELD scores of 14. In these groups the key is to stop the bleeding and keep it stopped.

J.E.F. and E. Christopher Ellison

132 Distal Splenorenal Shunts: Hemodynamics of Total Versus Selective Shunting

Atef A. Salam



This Chapter can be accessed in the accompanying eBook edition (see inside front cover for access instructions).

INTRODUCTION

The goal of any portosystemic shunt is effective decompression of the gastroesophageal veins. There are two distinct types of portosystemic shunts: those that are associated with total diversion of portal blood away from the liver (i.e., total shunts), and those that maintain portal blood supply to the liver (i.e., selective shunts). Examples of total shunts include portacaval, mesocaval, and central splenorenal shunts (CSRSs). An example of a selective shunt is the distal splenorenal shunt (DSRS), for which the terms *selective* and *DSRS* are often used interchangeably. The only other truly selective shunt, the coronocaval shunt, is rarely used today.

The concept of selective shunting was first introduced by Warren and his associates in 1967. These authors emphasized the increased morbidity and mortality associated with liver failure and hepatic encephalopathy after total shunting procedures. They attributed these problems to loss of liver portal perfusion. Their goal for the ideal operation for the treatment of patients with variceal bleeding was to achieve effective variceal decompression while preserving portal blood flow to the liver. The operation they devised to achieve these objectives was the DSRS.

The DSRS is created by anastomosing the splenic end of the divided splenic vein to the side of the left renal vein. The portal end of the splenic vein is oversewn. A functioning DSRS achieves variceal decompression by establishing a route for gastric venous drainage that offers less vascular resistance than the anastomotic channels between the gastric and

esophageal veins. This route is sequentially made of the short gastric and splenic veins, splenorenal shunt, and left renal vein.

The second important goal of the selective shunt is to maintain portal blood flow to the liver. Because the splenorenal anastomosis is not in direct communication with the superior mesenteric or portal veins, the pressure in these vessels remains elevated. Such pressure elevation is crucial in maintaining portal blood flow to the cirrhotic liver in the face of increased vascular resistance. Portal blood flow to the liver, however, can be maintained only if the high-pressure portomesenteric venous compartment is anatomically disconnected from the low-pressure splenic venous zone. This is the rationale for combining the selective shunt with interruption of the coronary gastroepiploic and inferior mesenteric veins. Any overlooked communicating channels between these two pressure zones are likely to develop into a major conduit for diversion of portal blood away from the liver to the decompressed splenic vein.

INDICATIONS

In the early years after the introduction of the DSRS, it was the practice with my group to recommend the procedure for nearly all patients who presented with or had a documented history of variceal bleeding. The only exceptions were the patients with intractable ascites or signs and symptoms of hepatic decompensation. Increased popularity of sclerotherapy in the 1970s prompted us to conduct a prospective trial in which we compared sclerotherapy with the DSRS operation. We concluded that patients who received sclerotherapy with the DSRS as a safety net for sclerotherapy failure had better overall survival than those who received DSRS as their first line of treatment. Meanwhile, reports began to appear in the literature showing improved survival of patients with advanced liver disease treated by liver transplantation. In view of these developments, our current policy is to treat all patients initially with sclerotherapy. Patients with rebleeding after obliteration of the variceal bed are stratified according to their degree of liver function. Patients with adequate liver reserve (Child Class A or B) receive DSRS. Patients with severe liver dysfunction are evaluated for liver transplantation. Patients with intractable ascites are unsuitable for DSRS. Patients with bleeding gastric varices who are good operative candidates are considered for DSRS as initial treatment because these varices are difficult to sclerose.

PREOPERATIVE PLANNING

Preoperative evaluation for DSRS should include liver function tests, liver serologic evaluation, splenoportography, and left renal venography. Hepatic wedge venography and pressure measurement are useful in differentiating between presinusoidal and postsinusoidal portal hypertension. An angiographic evaluation of the inferior vena cava and hepatic veins is indicated in patients with Budd–Chiari syndrome. Liver ultrasonography or computed tomographic scanning is used to determine the liver volume and to uncover nodules that may suggest hepatoma formation. Such nodules should be subjected to biopsy preoperatively for histologic verification. Liver biopsy is also indicated to determine the nature of the underlying liver disease in atypical cases and in patients with clinical evidence of active viral or alcohol-related liver disease.

It is our policy to postpone the operation until the liver function and nutritional status of the patient are maximally improved. Patients who are actively drinking alcohol are referred to appropriate centers, and the operation is deferred until there is a reasonable chance that they will abstain. Patients with ascites are treated medically until the problem is resolved. Intractable ascites is a contraindication to DSRS operation.

SURGICAL TECHNIQUE

The patient is placed in the supine position. Slight hyperextension of the lumbar spine helps improve surgical exposure. The procedure is most commonly performed from a subcostal incision. The incision begins in the left midaxillary line and extends one fingerbreadth below the costal margin, across the midline, to the lateral border of the right rectus muscle. This incision provides excellent exposure, particularly to the region of the tail of the pancreas and hilum of the spleen. It may, however, weaken the abdominal wall. The midline incision (Fig. 132.1) is also adequate for this procedure and has, in fact, become my preference in recent years. In the patients who have previously undergone midline abdominal operations, fewer adhesions may be encountered if the subcostal incision is used. Abnormal bleeding from the skin edges and abdominal muscles is common in patients with portal hypertension. Well-developed venous collaterals are often encountered around the umbilicus and in the falciform ligament. All bleeding should be securely controlled before proceeding with the operation. Persistent incisional bleeding can cause considerable perioperative blood loss in patients with portal hypertension. Another

potential source of bleeding in these patients is the portosystemic collateral veins, which form in the adhesions between the abdominal contents and the abdominal wall. These adhesions should be meticulously divided by appropriate hemostatic techniques.

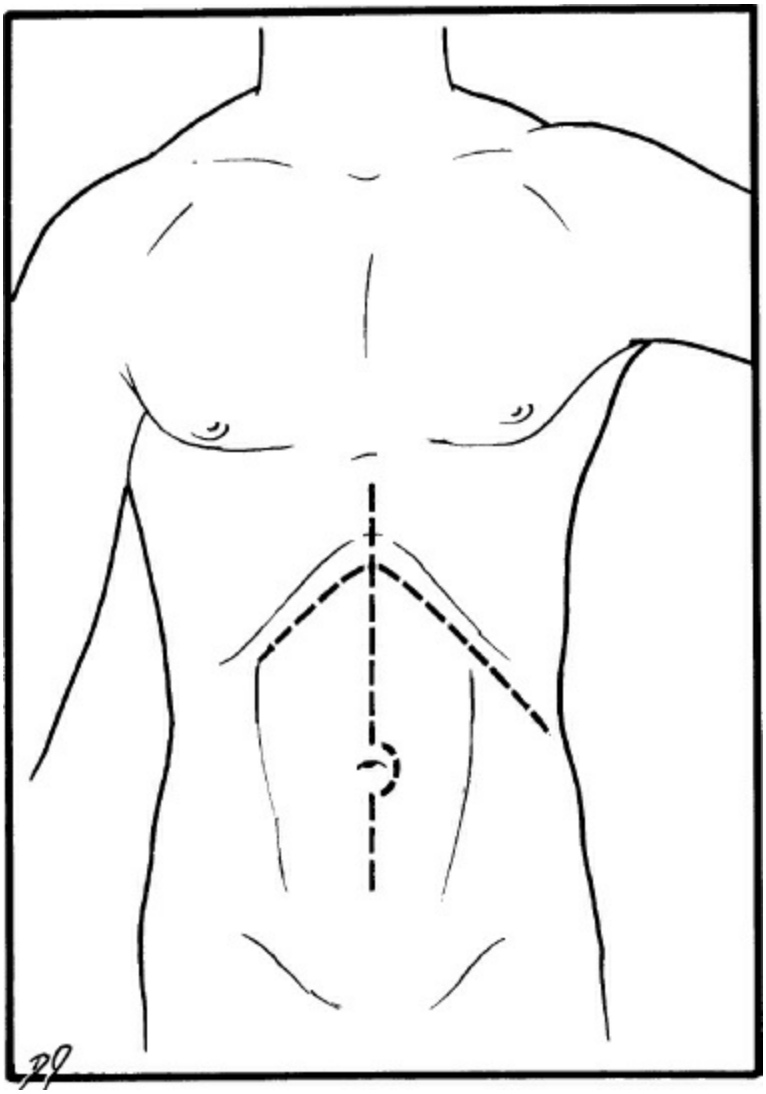

Figure 132.1. Bilateral subcostal and midline incisions, both suitable for the distal splenorenal shunt operation.

After all the adhesions crossing the surgical field are lysed, the abdomen is explored. Any suspicious nodule in the liver is sampled and examined for malignancy. The gallbladder is palpated for stones. In patients with cirrhosis, one should avoid cholecystectomy if at all possible. The morbidity and mortality from this procedure are quite high in such patients. Enlargement of the gallbladder is common among these patients, and this finding should not be mistaken for acute obstructive cholecystitis unless there are obvious signs of acute inflammation.

Adequate exposure is of crucial importance in the DSRS operation because of the depth of the operative field. In our experience, the Omni retractor is extremely useful for this purpose, particularly during dissection of the splenic and left renal veins. It should be remembered, however, that the tissues of patients with portal hypertension are congested and, if injured, can cause troublesome bleeding. This fact is especially true for the mesentery and spleen. Thus, it is important to use gentle retraction and to use proper padding under the retractor blades. The next step is to proceed with devascularization along the greater curvature of the stomach (Fig. 132.2). The gastric vessels are isolated individually, then divided between clamps and ligated according to proper surgical techniques. Devascularization is carried close to the wall of the stomach in a stretch extending from the pylorus to the first short gastric vein. The right and left gastroepiploic veins are suture-ligated for the aforementioned reasons. Next, the splenic flexure is carefully mobilized by dividing its peritoneal attachment to the lower pole of the spleen. The stomach is then retracted superiorly, and the transverse colon is retracted inferiorly, using appropriate retractor blades. This procedure brings the pancreas into view. The stage is now ready for exposure of the splenic vein.

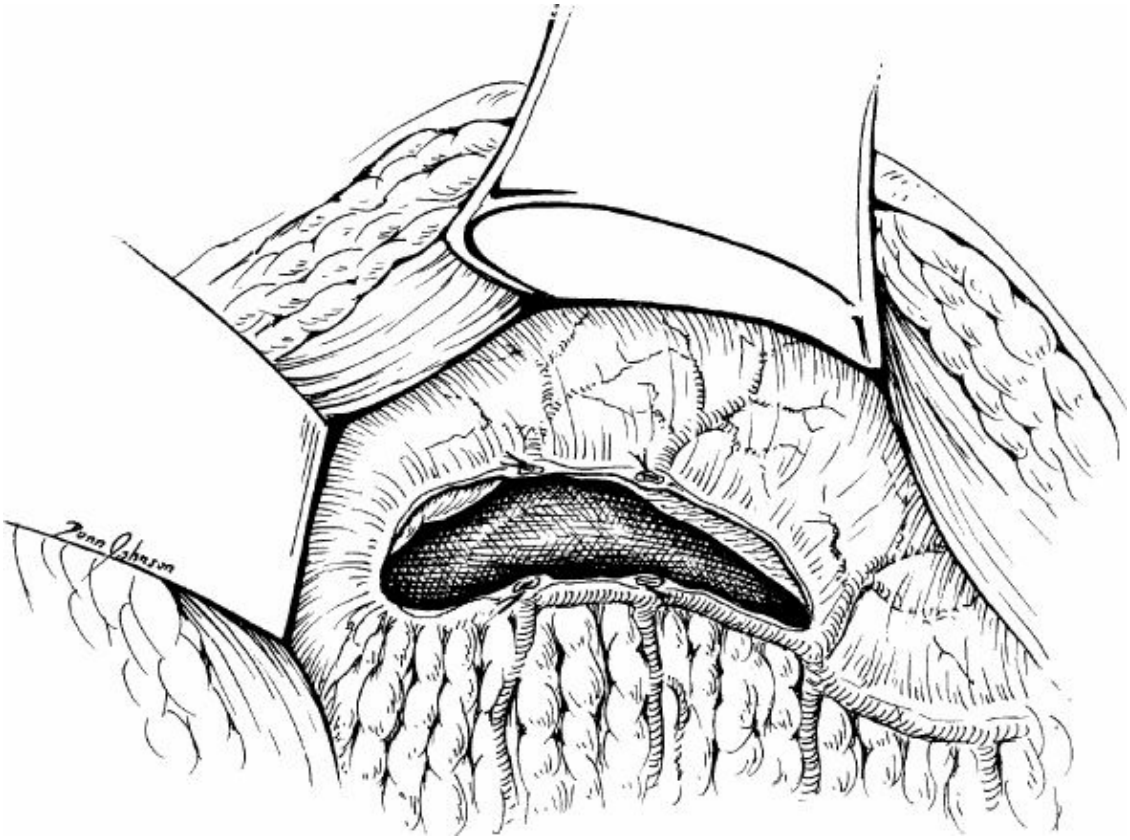

Figure 132.2. The lesser sac is entered by dividing the

gastrocolic ligament. The gastroepiploic vessels are disconnected from the stomach. Both right and left gastroepiploic veins are ligated to prevent mal diversion of portal blood to the decompressed splenic vein.



Figure 132.3. The posterior peritoneum is divided along the lower border of the pancreas. The latter is retracted gently to visualize the splenic vein.

We routinely use headlight and magnifying loupes for mobilization of the splenic vein. First, the pancreas is mobilized by dividing the peritoneum along its inferior border (Fig. 132.3). Mobilization of this border is completed before dissection is carried deeper in the retropancreatic space. With the pancreas carefully retracted, the surgeon starts looking for the splenic vein. In most instances, it loops inferiorly as it approaches the superior mesenteric vein. It is, therefore, easier to identify the splenic vein first medially, then to proceed with its mobilization in the direction of the hilum of the spleen. The inferior mesenteric veins may be used as a guide to find the splenic vein unless it is joining the superior mesenteric vein (Fig. 132.4).

The splenic vein should be mobilized first inferiorly, then anteriorly, and posteriorly, leaving dissection of its superior border until adequate length of the vein has been exposed. The pancreatic veins along this border of the pancreas require special handling because they are friable and, if torn, can cause troublesome bleeding. Our technique for isolation of these

veins starts with careful dissection until a sufficient length of the vein is exposed. A fine silk suture is then applied around the mobilized vein and ligated flush with the splenic vein. A fine-tip clamp is applied to the other side, and the vein is transected between the clamps. The pancreatic end of the divided vessel is then ligated using meticulous surgical technique (Fig. 132.5). These veins are sometimes too short to be safely controlled with simple ligatures, in which case it is safer to use 5-0 Prolene to suture the divided veins. Dissection of the pancreatic veins is the most challenging part of the DSRS operation. In my experience, the tearing of these vessels is most often caused by excessive pancreatic retraction, a premature attempt to encircle the splenic vein, or a premature attempt to encircle the pancreatic veins. Another complicating factor in this dissection is the coronary vein, which joins the upper border of the splenic vein in approximately one-fifth of the patients. In some cases, the coronary vein may be as large as the splenic vein. Tearing of the coronary vein can cause severe bleeding and may lead to irreversible damage to the splenic vein. The safest way to deal with this situation is to free the upper border of the splenic vein and encircle it on both sides of the coronosplenic venous junction. Gentle traction on the splenic vein facilitates further mobilization of the coronary vein (Fig. 132.6). The mobilization is continued until there is sufficient room for safe clamping and division of the coronary vein.

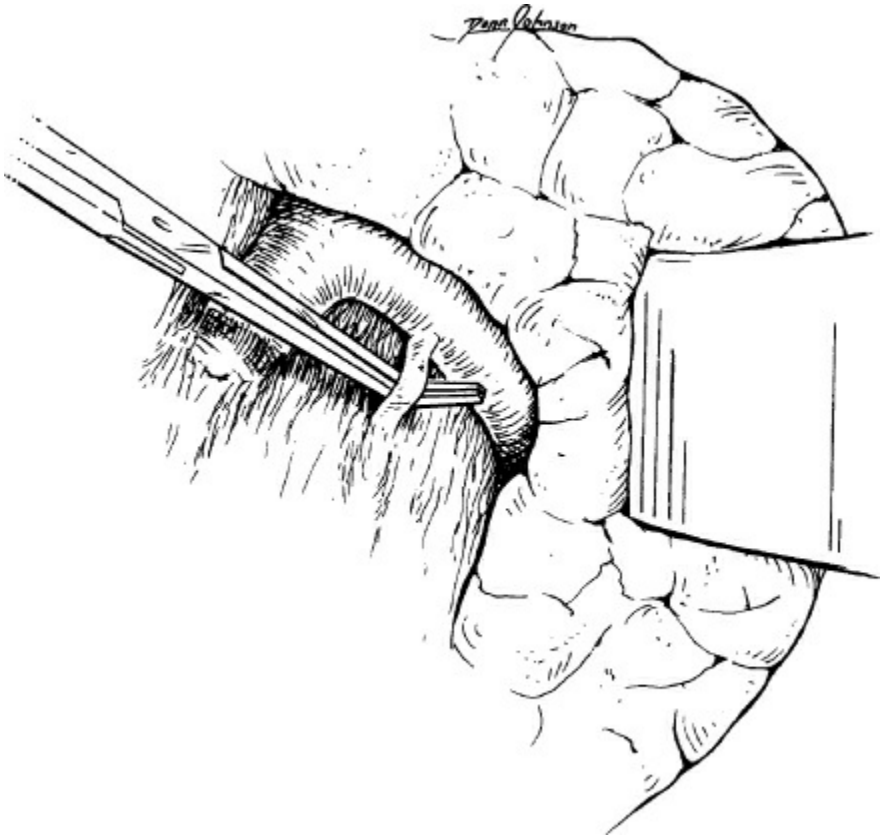

Figure 132.4. The inferior mesenteric vein is identified in preparation for its division. In some cases, the inferior mesenteric vein is used as a guide for the splenic vein.

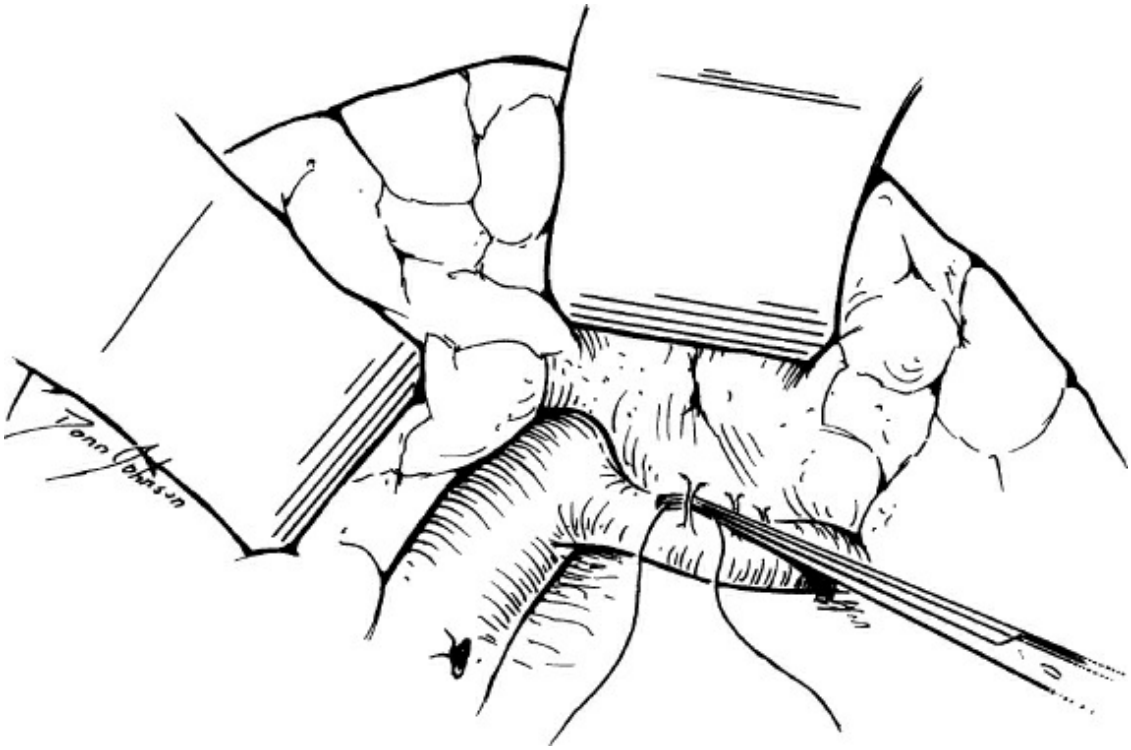

Figure 132.5. Technique for isolation and division of the pancreatic veins. These veins are encircled, ligated, and then

divided using meticulous surgical technique. Laceration of these fragile veins causes troublesome bleeding.

Once an adequate segment of the splenic vein is mobilized, attention is shifted to the left renal vein. This vessel can be approached either above or below the transverse mesocolon. In the superior approach, the colon is retracted inferiorly, and the duodenojejunal junction is exposed. The posterior peritoneum and the underlying tissue are divided along an imaginary line that stretches from the lateral border of the fourth part of the duodenum to the hilum of the left kidney. Once the left renal vein is identified, it is mobilized by dividing as many tributaries as necessary, including the adrenal and gonadal veins (Fig. 132.7).

In the infracolonic approach to the left renal vein, the colon is retracted superiorly, and the third part of the duodenum is exposed. The duodenum is mobilized by dividing the peritoneum along its inferior border, and the dissection is advanced superiorly until the left renal vein is exposed. Once the left renal vein is identified, the colon is retracted inferiorly, and mobilization of the left renal vein is completed as described previously. The advantage of this approach is the ability to locate the left renal vein with minimal untargeted dissection in the retroperitoneal space. This advantage is important because the retroperitoneal tissue of the patients with portal hypertension is often dense and loaded with distended lymph vessels and collateral veins. Any transected tissue in this dissection should be securely ligated to minimize perioperative blood loss and postoperative lymphatic leakage. Uncontrolled lymphatic leakage causes postoperative ascites, and, if the intestinal lymphatics are involved, chylous ascites may develop—a condition that is often difficult to treat.

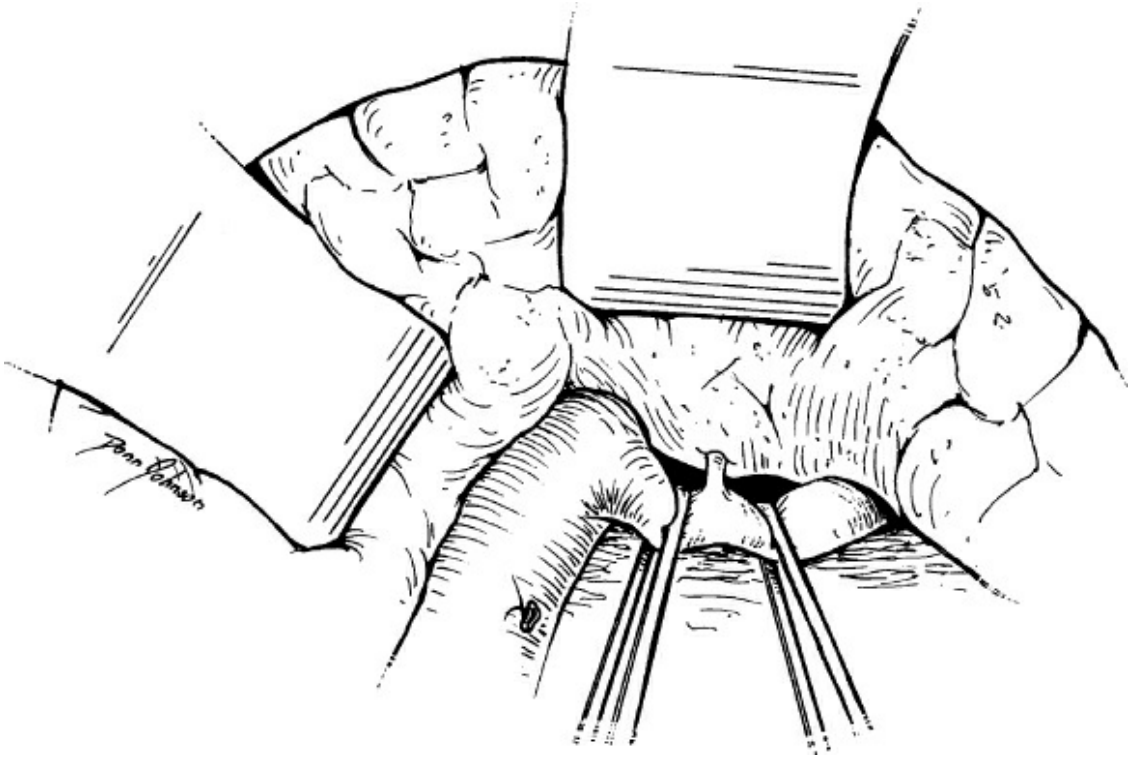

Figure 132.6. Technique for exposure of the coronary vein when it is draining into the splenic vein instead of the portal vein. The splenic vein is encircled on either side of the coronary vein. Traction on the tape encircling the splenic vein facilitates exposure of the coronary vein.

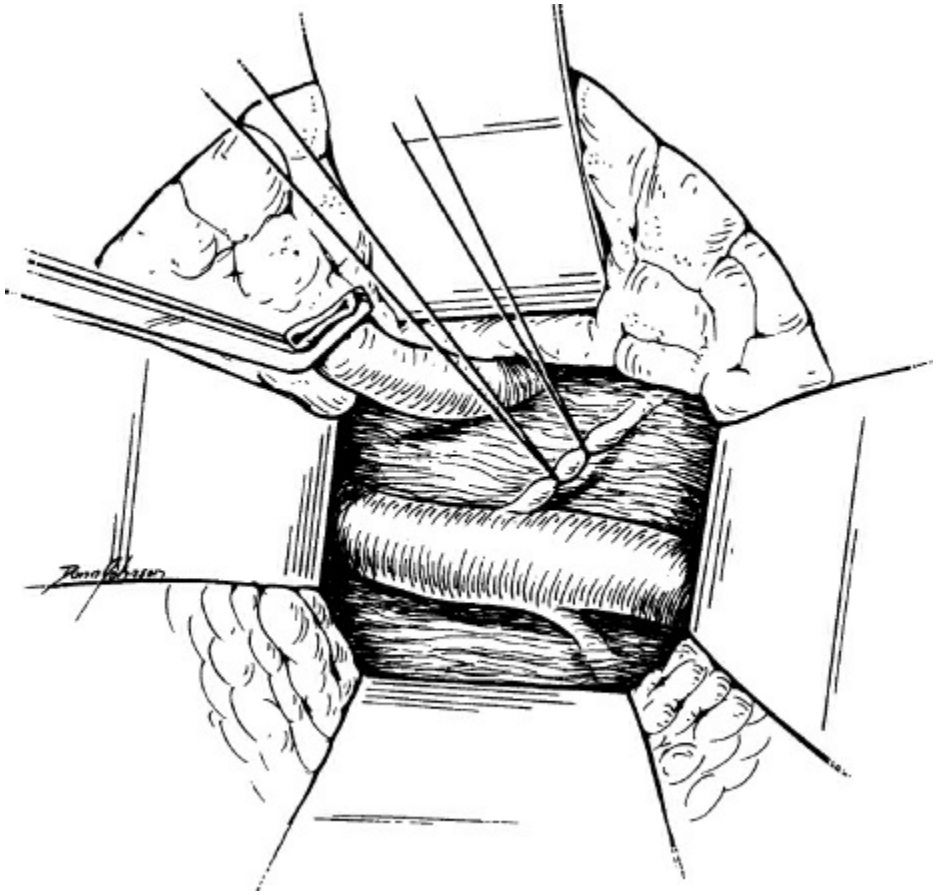

Figure 132.7. The left renal vein is exposed by dividing the overlying peritoneum. The vein is mobilized by dividing its tributaries, including the gonadal and adrenal veins.

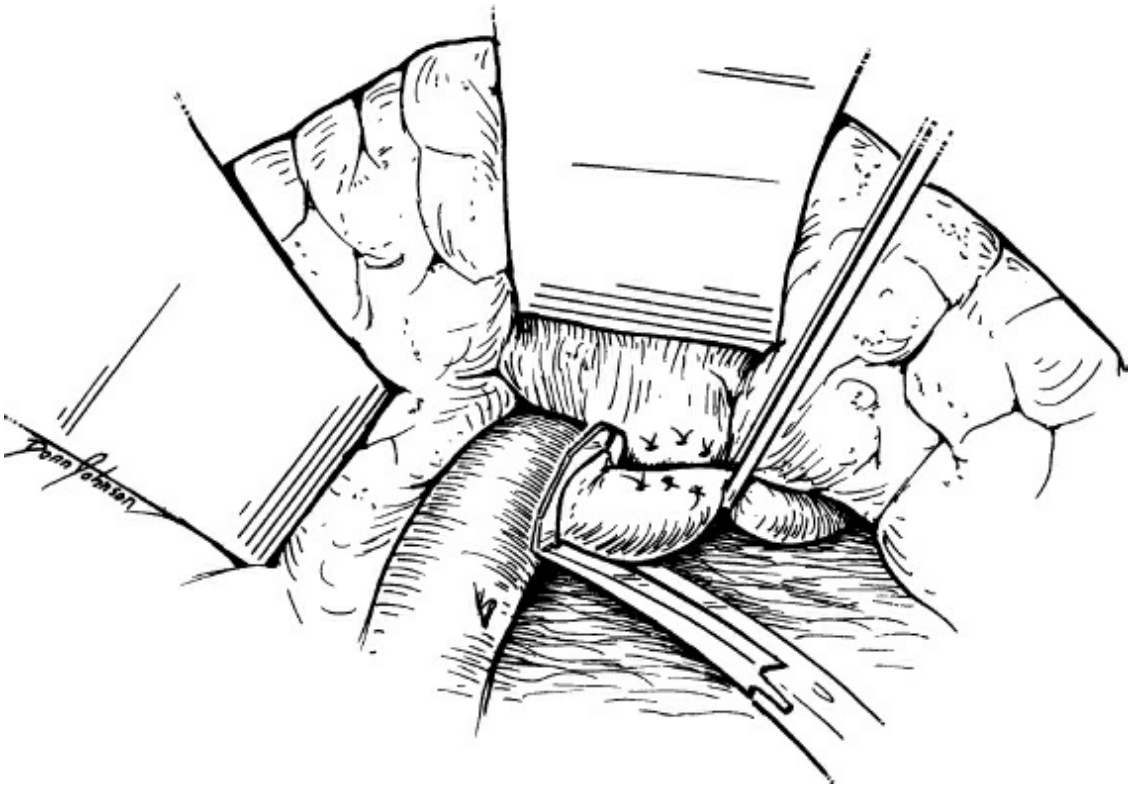

Figure 132.8. The splenic vein has been mobilized and encircled. A Cooley clamp is applied to the splenic vein at its junction with the superior mesenteric vein.

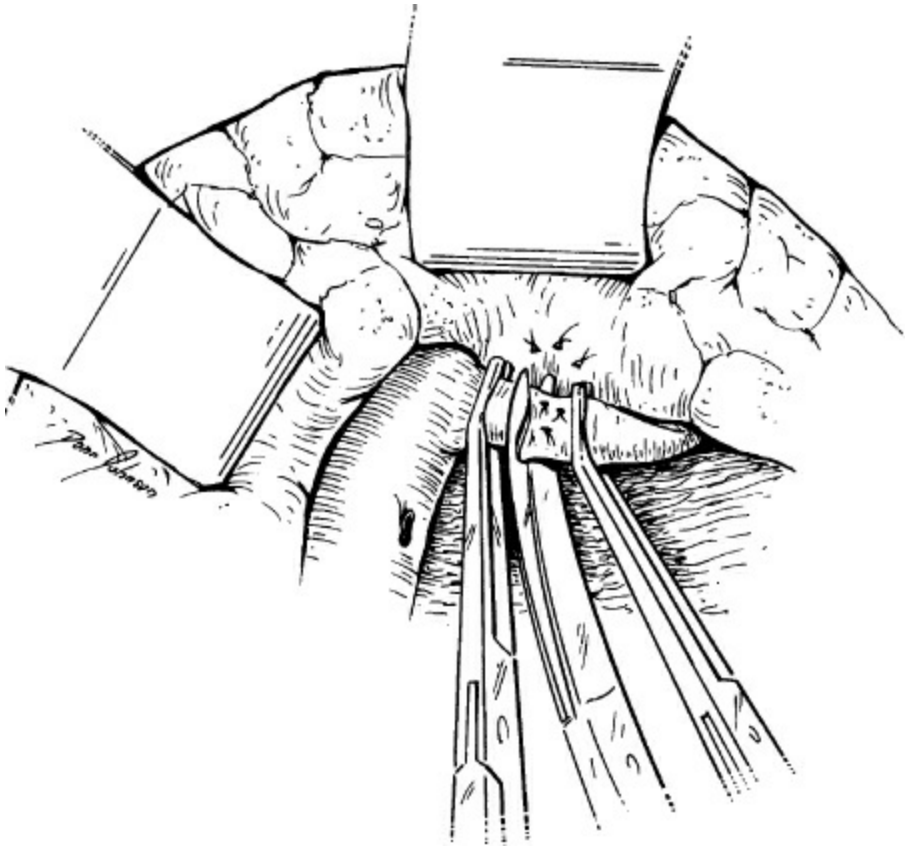

Figure 132.9. The splenic vein is divided between clamps, leaving sufficient rim medially to allow safe control of the stump of the splenic vein. Accidental slippage of the clamp or faulty stump closure may cause bleeding and tearing of the splenomesenteric-portal vein junction.

With the left renal vein fully exposed, the surgeon turns back to the splenic vein, dividing it between vascular clamps near its junction with the portal vein. We use a Cooley clamp on the portal end of the splenic vein flush with the portal vein (Figs. 132.8 and 132.9). It is important to leave a sufficient rim exposed to ensure secure closure of the stump of the splenic vein. A 5-0 Prolene stitch is used for the closure (Fig. 132.10). The splenic end of the splenic vein is now less anchored in place; hence, more of the deeply located pancreatic veins can be readily brought into view (Figs. 132.11 and 132.12). Mobilization of the splenic vein is advanced laterally until an adequate length of the vessel is exposed.

The stage is now set for shunt construction. A Satinsky clamp is applied

to the left renal vein (Fig. 132.13). The splenic end of the splenic vein is then approximated to the clamped segment of the left renal vein. Any apparent tension should be corrected by further mobilization of either of the two veins. It is also important to trim any excess in the splenic vein; otherwise, it will become acutely angulated when circulation is restored. Optimal orientation of the two vessels can usually be achieved by rotating the splenic vein in a clockwise direction for 45 degrees. The shunt is placed as medially as possible in relation to the left renal vein to prevent sharp bending of the splenic vein.

With the two veins properly approximated, shunt construction is begun by removing a disk 10 × 15 mm from the superior wall of the left renal vein (Fig. 132.14). A stay stitch is used to keep the opening in the vein well exposed. The anastomosis is started at the most medial end (or toe) using double-armed 5-0 Prolene. One needle is passed from the outside to the inside of the left renal vein. This needle is used as a running stitch to close the posterior wall. A new 5-0 Prolene corner stitch is then applied at the lateral corner (or heel) of the anastomosis and ligated. One end of this suture is tied to the one used for the posterior row. At this stage, there is one stitch at each corner of the anastomosis. These two stitches are advanced so that the anastomosis is finished in the middle of the anterior row (Figs. 132.15 to 132.19). Both veins are adequately flushed before the anastomosis is completed. The potential purse-string effect of the running suture is minimized by interrupting the suture line at the toe and heel of the anastomosis. In children, we routinely interrupt the entire anterior row to allow for growth.

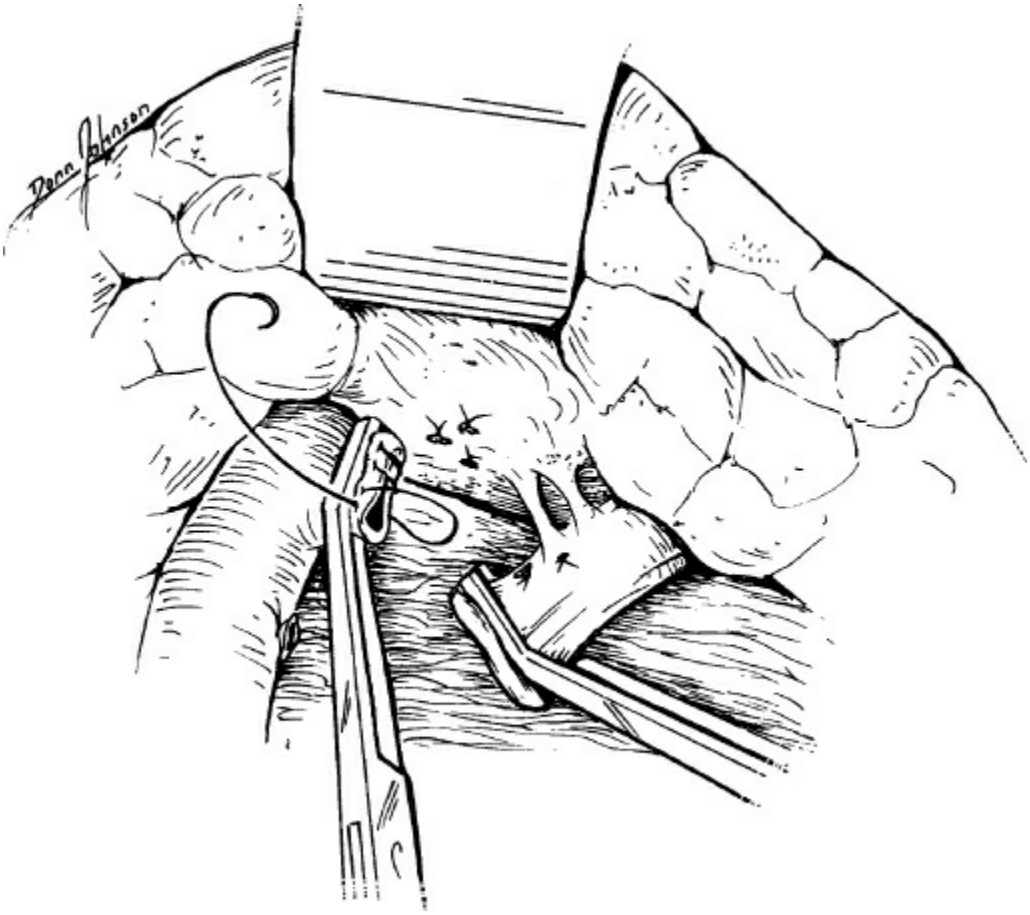

Figure 132.10. Oversewing of the stump of the splenic vein using 5-0 running Prolene.

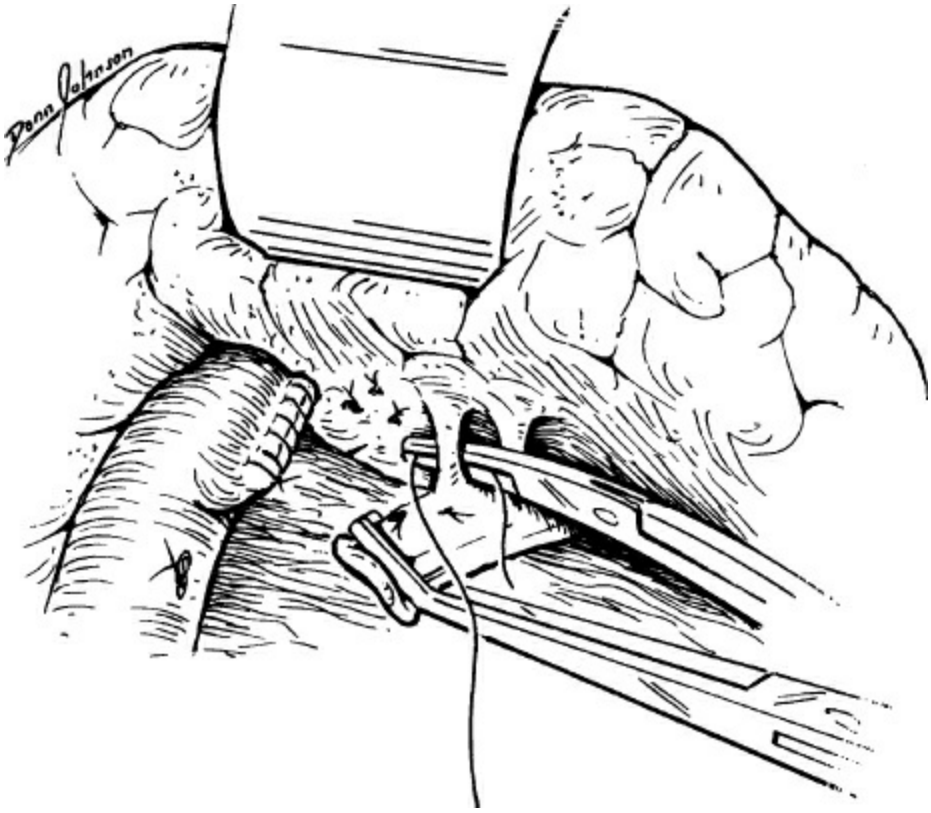

Figure 132.11. The splenic end of the divided splenic vein is retracted inferiorly to expose more of the pancreatic veins laterally.

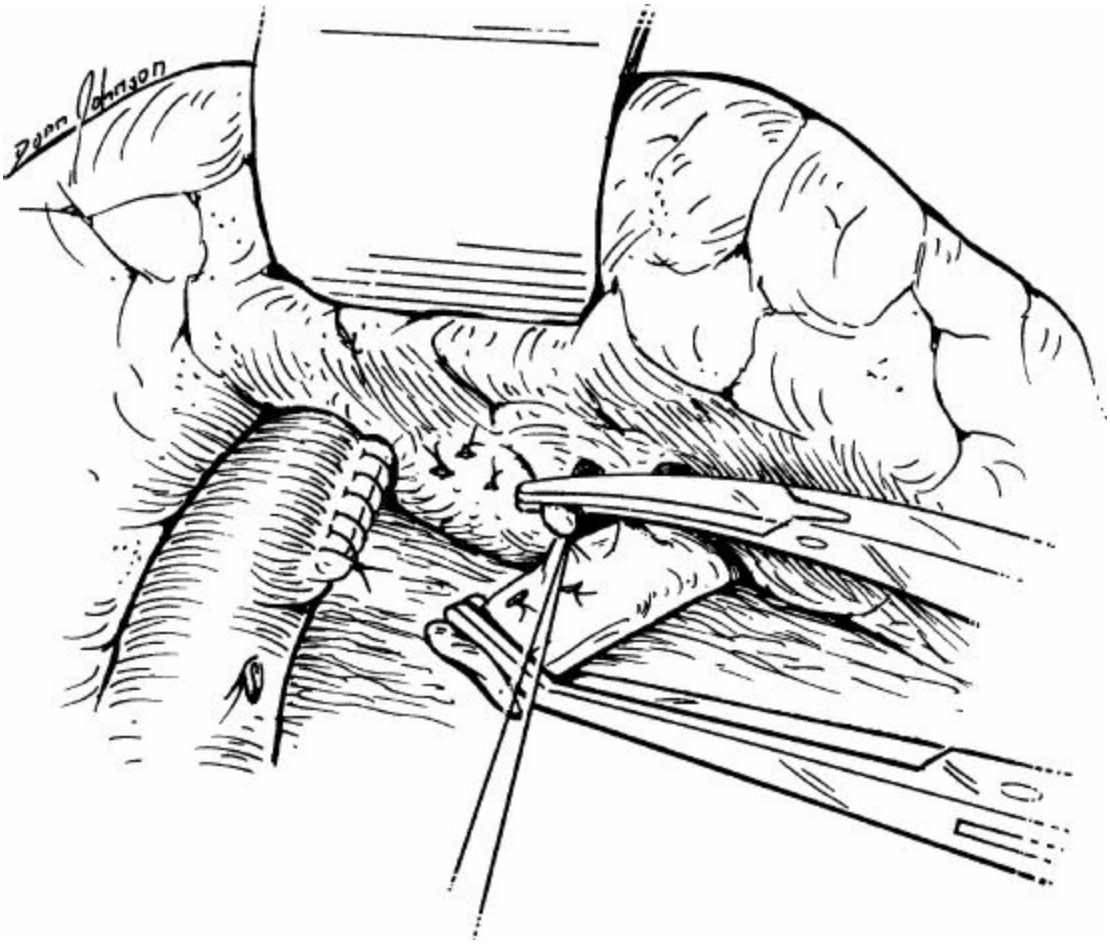

Figure 132.12. The splenic and pancreatic veins are divided until a sufficient length of the splenic vein is disconnected from the pancreas.

The final step in the DSRS procedure is coronary vein ligation. The stomach is retracted anteriorly and superiorly, and the peritoneal fold stretching between the highest point of the lesser curvature and the posterior wall of the lesser sac is exposed. The coronary vein is identified and ligated in this location. Any accessory coronary veins in the region should also be ligated. It is important to protect the nerve of Latarjet while exposing the coronary vein.

The operative field is then thoroughly examined, and any remaining bleeding points or lymphatic leaks are controlled. The abdomen is closed without any drains. Draining the abdominal cavity in the presence of ascites leads to massive postoperative fluid loss and profound electrolyte

disturbances. Abdominal drains also enhance the risk of secondary bacterial invasion.

MODIFICATION OF THE DSRS OPERATION

Temporary Clamping of the Splenic Artery

In patients with hyperdynamic splenic circulation and massive splenomegaly, I routinely clamp the splenic artery until the shunt construction is completed. In patients with schistosomiasis, for example, the spleen, which is usually quite large, grows even larger with clamping of the splenic vein. The difficult exposure is compounded by the extreme engorgement of the pancreatic and splenic veins. The decongestive effect of splenic arterial clamping helps reduce the size of the spleen and congestion in the operative field.

Renosplenic End-to-Side Shunt

In a renosplenic end-to-side shunt (Fig. 132.20), the left renal vein is divided near the hilum of the kidney, and its central (or caval) end is swung upward to be anastomosed to the side of the left renal vein. The total shunt thus created is then converted into a selective shunt by ligating the splenic vein at some point between the renosplenic anastomosis and the portal vein. Patients with portal hypertension tolerate well the interruption of the renal vein because of pre-existing collateral venous circulation. Normally, a longer segment of a free vessel can be procured by mobilizing the left renal vein as compared to the splenic vein. The renosplenic technique is therefore advantageous when a long conduit is needed to cross the gap between these two veins. Compression of the left renal vein by the superior mesenteric artery is a potential problem with this technique and is usually caused by excessive traction on the left renal vein.

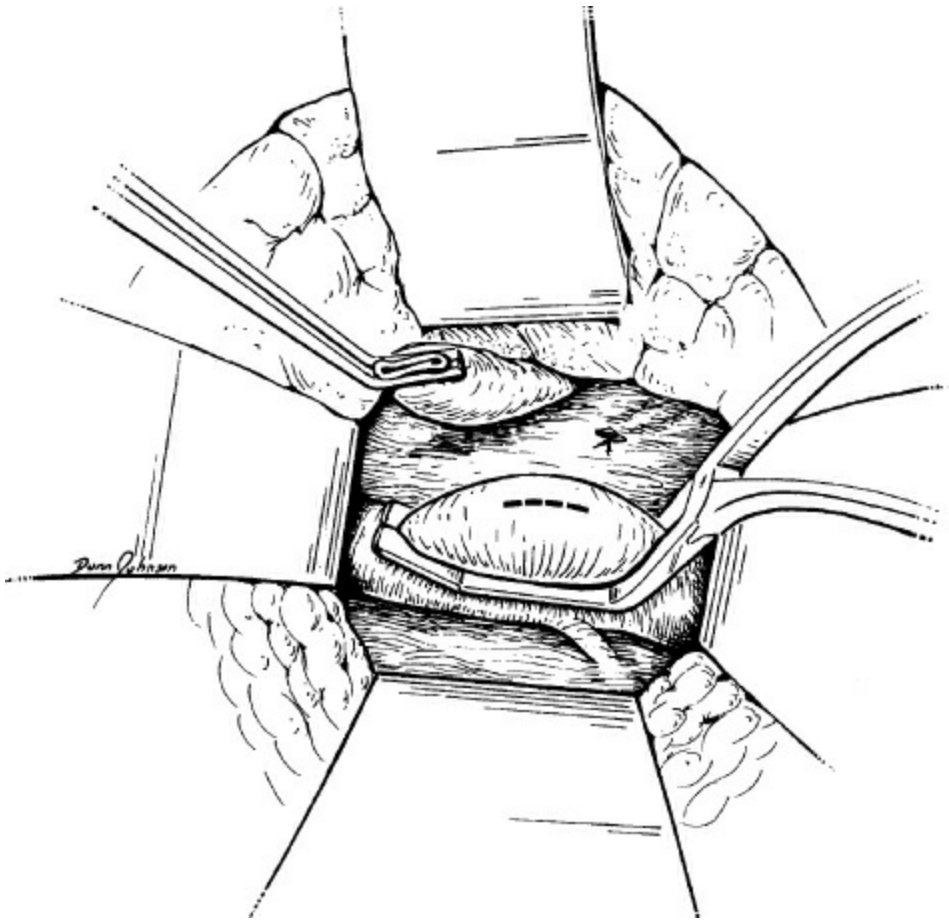

Figure 132.13. A Satinsky clamp is applied to the left renal vein. The more medial the segment of the vein selected for the shunt, the better the angle of the meeting of the splenic and left renal veins.

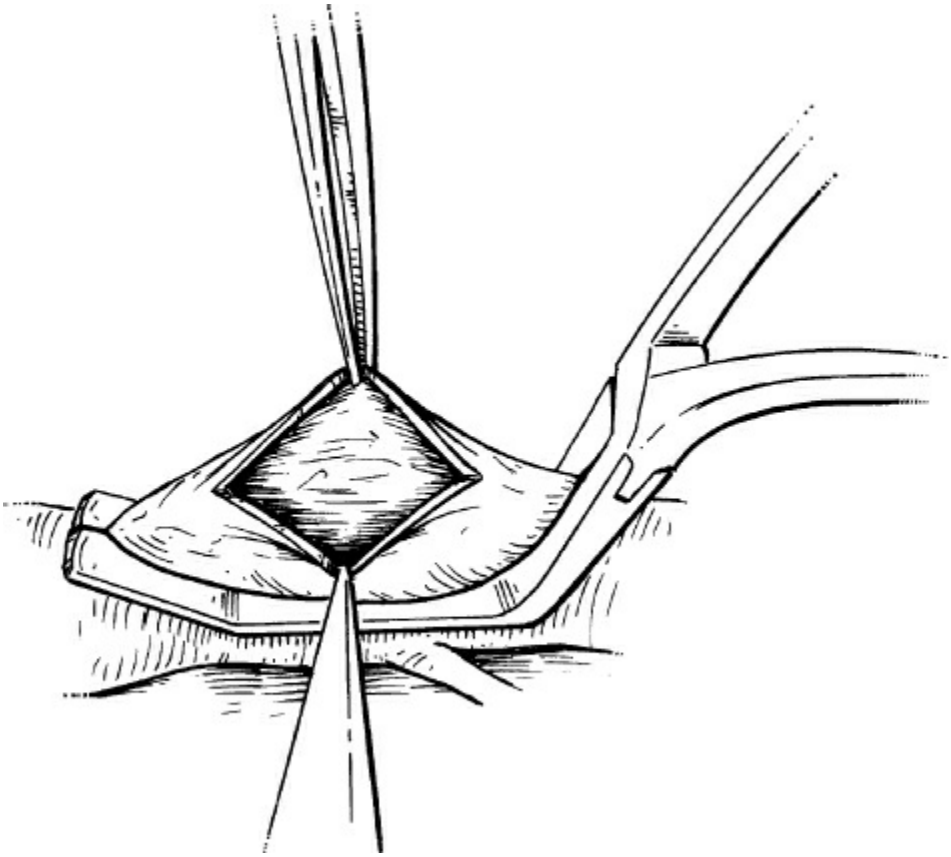

Figure 132.14. A disk is removed from the wall of the left renal vein. Stay stitches may be used to retract on the anterior rim of the vein.

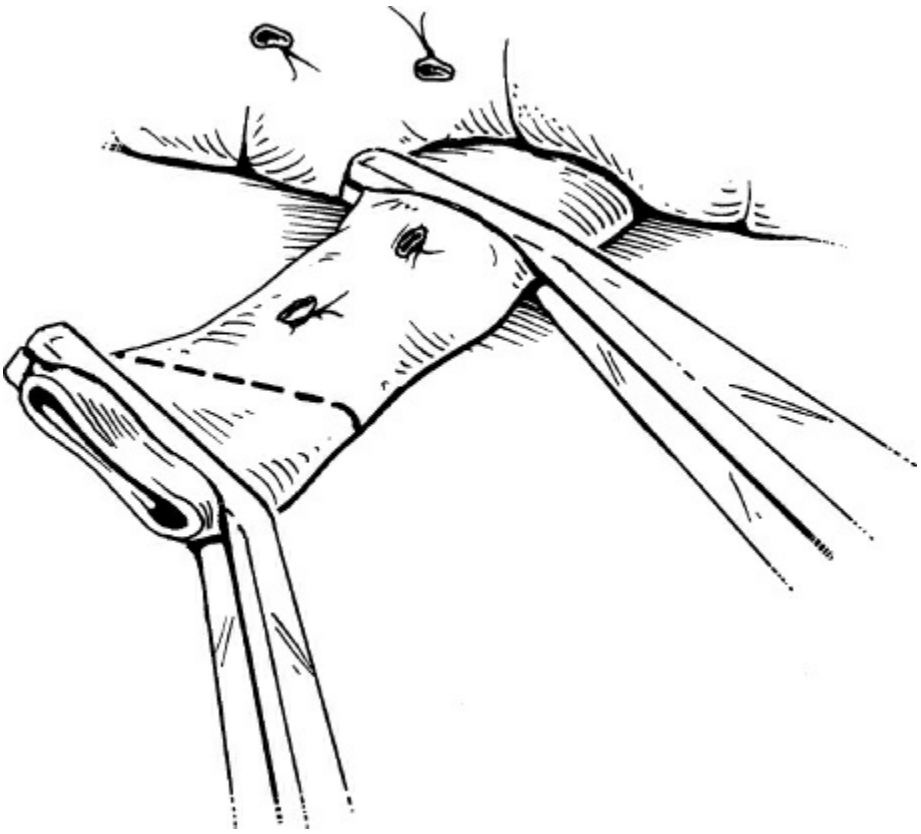

Figure 132.15. The splenic vein is being prepared for the shunt. The vessel is rotated one fourth of a circle clockwise. The splenic vein is shortened to avoid any redundancy that might lead to kinking of the vessel when the flow is restored.

Splenocaval Shunt

For the patients whose left renal veins are absent or unsuitable, a selective shunt can be created by anastomosing the splenic end of the divided splenic vein to the side of the inferior vena cava (Fig. 132.21). The splenocaval shunt is also useful when one is dealing with an unusually tortuous splenic vein. The tortuosity of the vessel is partly corrected as it is stretched in a straight line to meet the inferior vena cava. Conversely, these angulations may be accentuated as the direction of the splenic vein is changed, first inferiorly and then posteriorly, to reach the left renal vein.

POSTOPERATIVE MANAGEMENT

Fluid and electrolyte balance should be monitored carefully because patients with cirrhosis have an increased tendency to retain fluid and salt. The aim is to slow down the rate of postoperative ascitic accumulation. Approximately half of the daily fluid requirement is given as 5% albumin in the first 24 to 48 hours. Ranitidine is administered to reduce gastric

acidity. Cephalosporin is used for antibiotic prophylaxis, with the first dose given 1 hour before operation and the coverage extended during the procedure and for 24 to 48 hours after the operation. Diuretic therapy is started on the third postoperative day in the form of spironolactone. Furosemide (Lasix) may be added in the management of problematic ascites.

QUESTIONS FREQUENTLY ASKED ABOUT THE SELECTIVE SHUNT

How Effective is the Shunt in Preventing Rebleeding?

Rebleeding after a selective shunt occurs in 5% to 7% of cases; this compares favorably with the incidence for total shunts. In an emergency situation, a selective shunt may not be as effective as a total shunt in controlling the bleeding. In most instances, however, recurrent bleeding in the presence of a patent DSRS can be controlled with variceal injection.

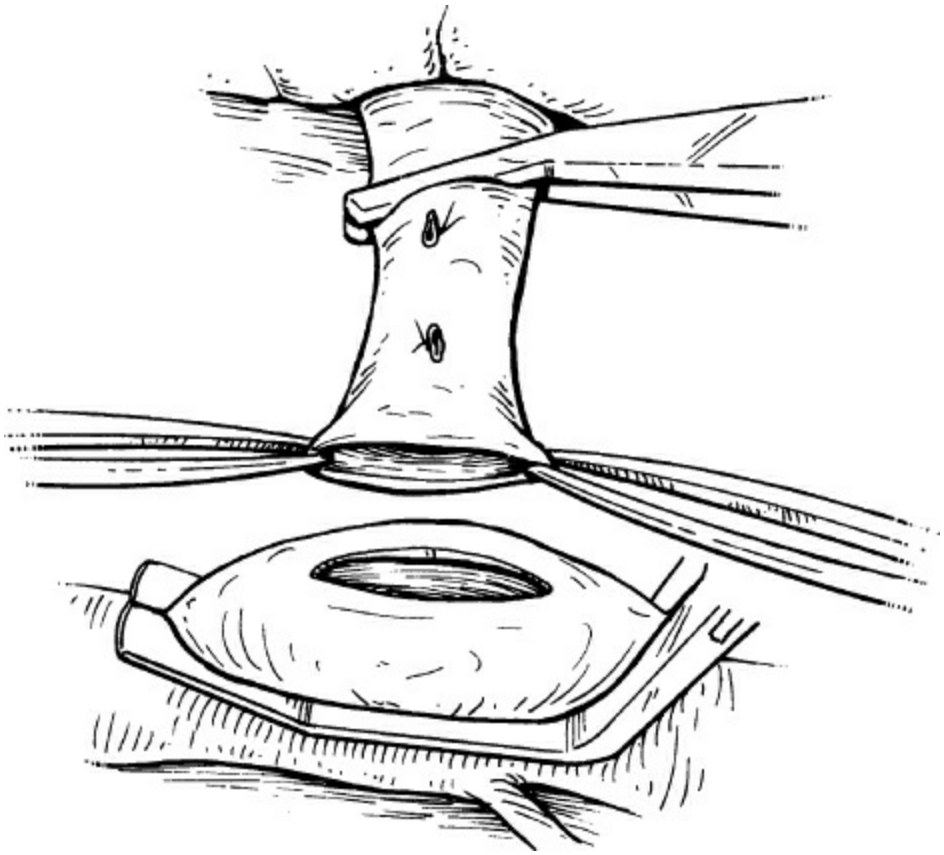

Figure 132.16. The splenic vein is approximated to the left renal vein.

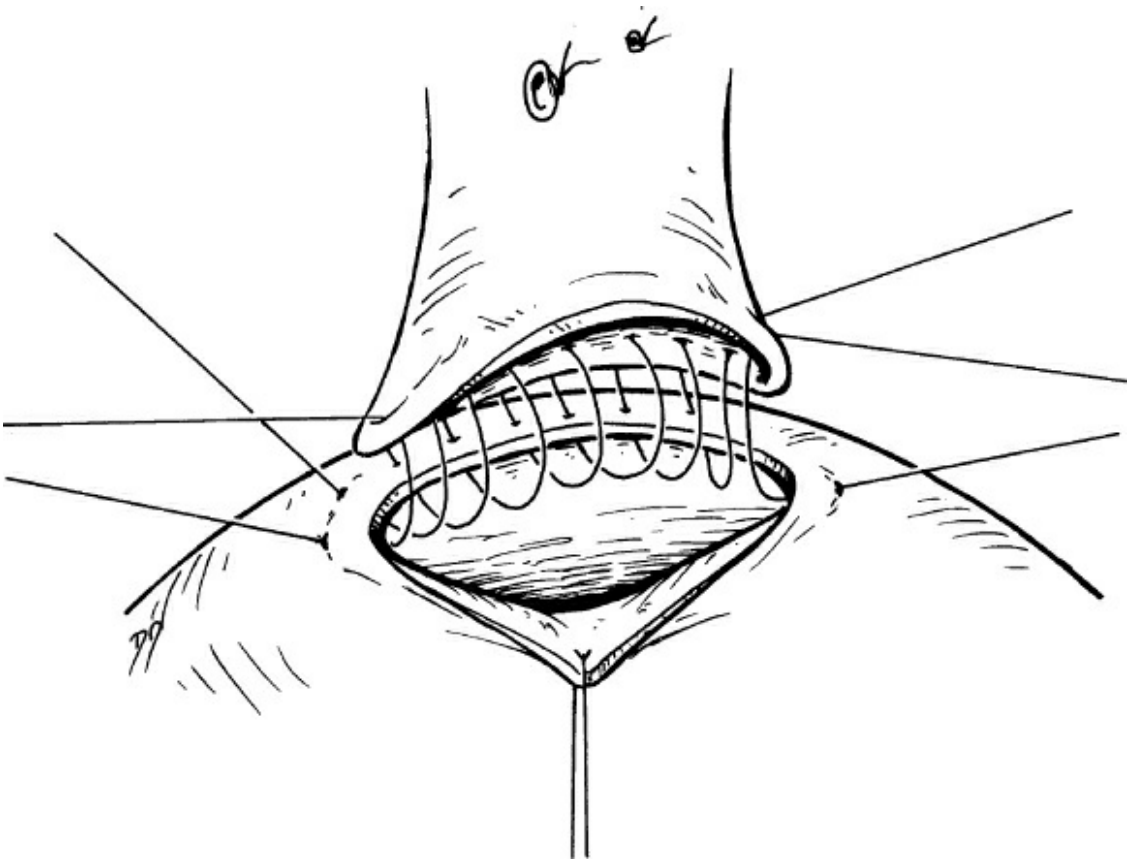

Figure 132.17. Shunt construction: First, double-armed 5-0 Prolene suture is placed at each corner of the anastomosis. The medial corner suture is ligated. One end of this suture is used for the posterior wall.

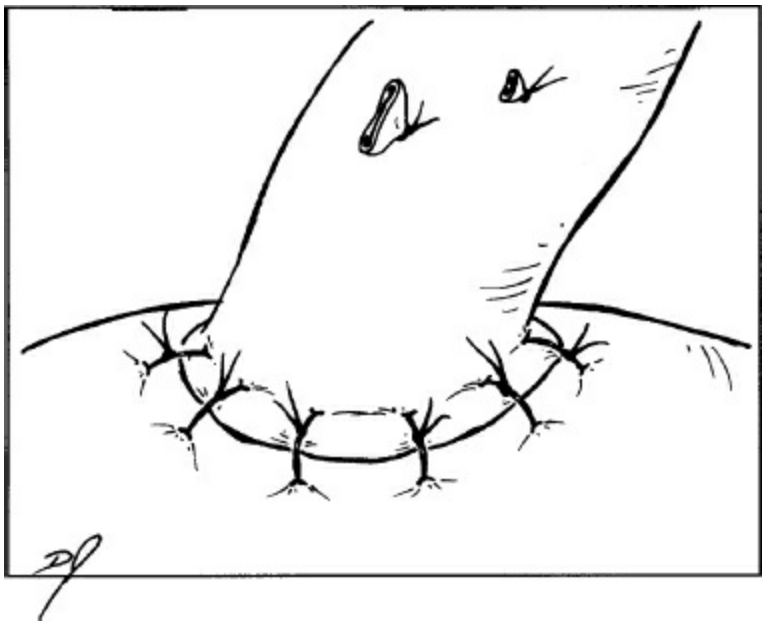

Figure 132.18. Shunt construction. In children, the anterior row of sutures is interrupted.

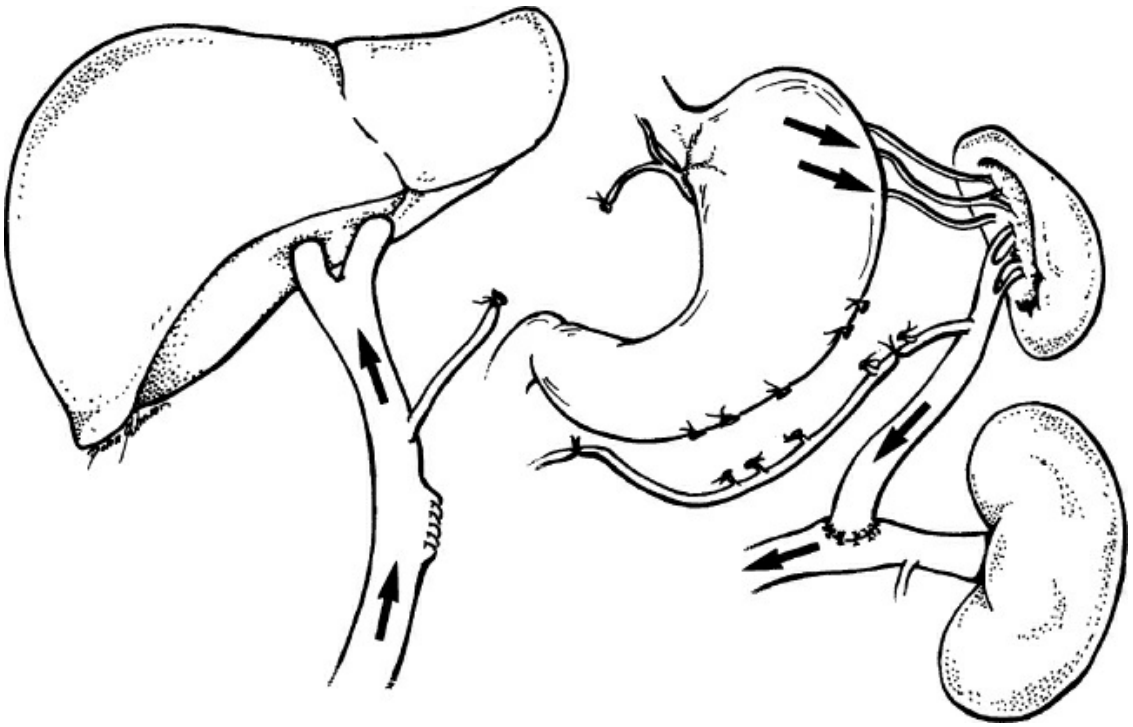

Figure 132.19. A diagrammatic illustration of the distal splenorenal shunt.

What is the Incidence of Shunt Occlusion?

Shunt failure is usually caused by faulty technique. The incidence of this complication should not exceed 5%. Excessive tension, kinking, twisting, and renal venous hypertension secondary to tenting of the left renal vein are among the main causes of early shunt failure. Poor selection of patients may be another reason for this complication. The risk of shunt thrombosis is high in the patients with alcohol-related pancreatitis and a small splenic vein. Late shunt occlusion is rare, but late stenosis has been seen infrequently.

Is There a Role for the Selective Shunt in Patients with Ascites?

Existing preoperative ascites is likely to get worse after DSRS. First, cirrhotic patients with ascites have an increased tendency to retain fluid after major operations. Second, the selective shunt does not correct the major cause of ascites in such patients—the high pressure in the portal and superior mesenteric veins. Third, lymphatic leakage is known to occur after the selective shunt because several retroperitoneal lymph vessels are likely to be transected during mobilization of the left renal vein. Therefore, the selective shunt is not suitable for the treatment of patients who present with intractable ascites. On the other hand, ascites precipitated by the

selective shunt is usually easily controlled with medical treatment. Chylous ascites, however, is more difficult to treat and may require prolonged periods of hospitalization. Intravenous hyperalimentation and repeated paracentesis is the recommended treatment for this condition.

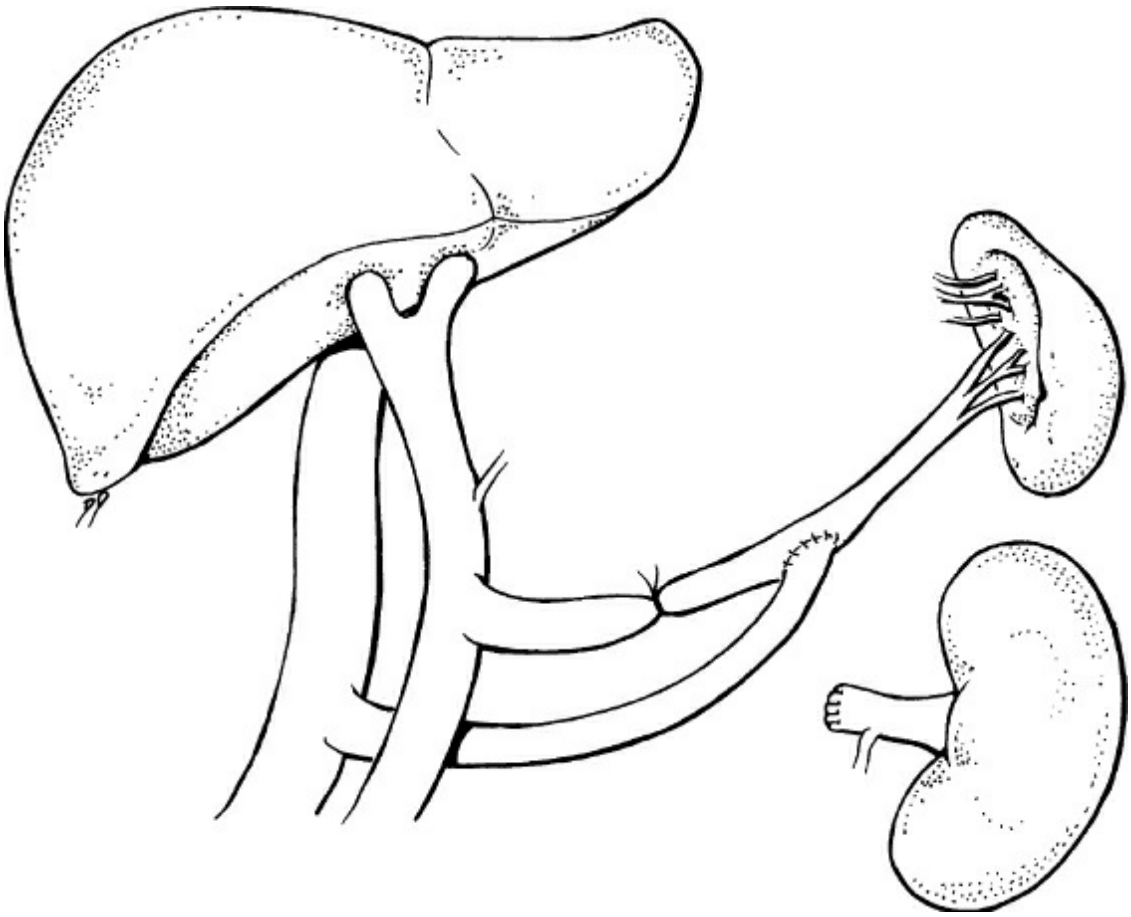

Figure 132.20. Renosplenic shunt. The left renal vein is divided near the hilum of the kidney. The central end of the divided vein is anastomosed end-to-side to the splenic vein. The splenic vein is ligated between the shunt and the portal vein.

What is the Incidence of Encephalopathy After the Selective Shunt?

Early encephalopathy after DSRS occurs in 5% of the patients. This percentage compares favorably with the reported incidence of 30% to 40% after total shunts. Assessment of the available data suggests that encephalopathy seen in the patients with total shunts is more likely to be severe and incapacitating.

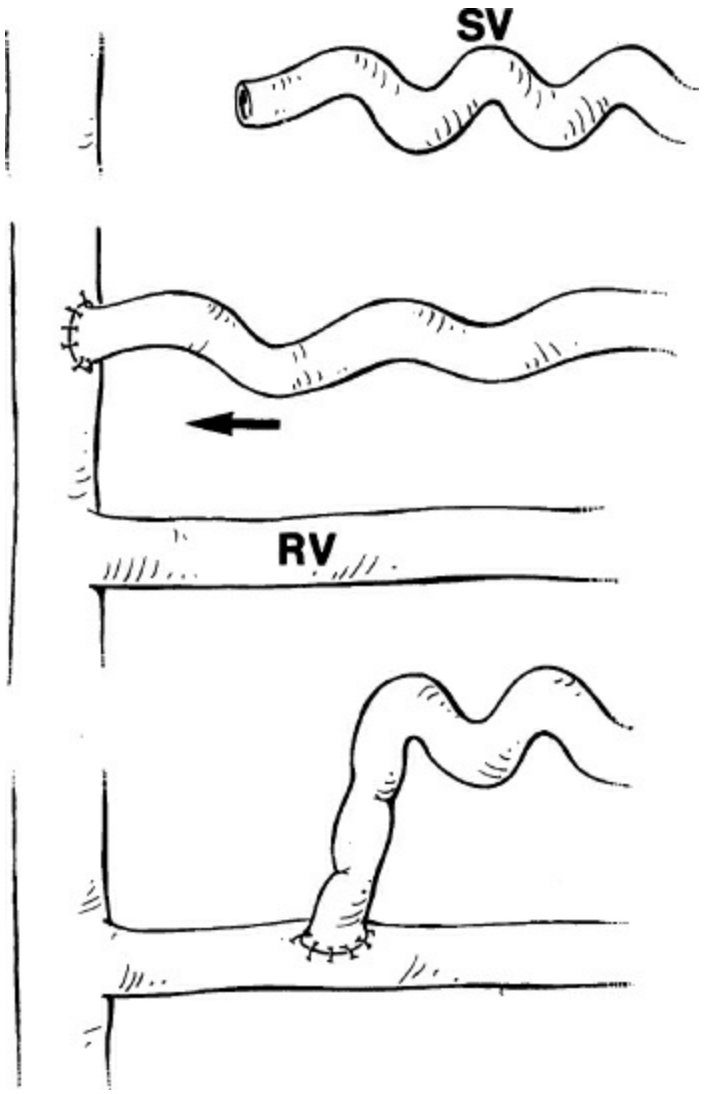

Figure 132.21. A splenocaval shunt is desirable in patients with tortuous splenic vein (SV) because a standard distal splenorenal shunt may be difficult to construct without the risk of kinking the splenic vein. RV, renal vein.

Long-term studies of patients with selective shunts have shown that the incidence of encephalopathy increases from 5% to a range of 10% to 15% in 3 to 5 years. Deterioration of liver function from worsening of underlying liver disease, together with progressive reduction in the level of liver portal venous perfusion, accounts for delayed-onset encephalopathy in these patients.

How Durable is Selectivity of the Selective Shunt?

Early postshunt angiography has shown continuing portal perfusion in most cases. Late follow-up studies, however, have shown progressive formation of collaterals, reduction of portal vein diameter, and decreasing

prograde portal flow after DSRS. Three main routes for mesoportal to splenic venous collaterals have been described: (a) the transpancreatic (pancreatic syphon) pathway, (b) the transgastric pathway, and (c) the colosplenic pathway. It has been proposed that to minimize transpancreatic collateralization, the operation be modified so that the splenic vein is disconnected from the pancreas as far as the hilum of the spleen. Splenopancreatic disconnection, however, adds to the technical difficulty of the operation, and there is some evidence that it may compromise the decompressive effect of the procedure.

Is There a Difference in Survival after Selective as Opposed to Total Shunt Operation?

Studies have shown a trend in favor of the selective shunt in patients who have adequate liver reserve (Child Classes A and B). This trend, however, did not reach statistical significance. Survival advantage of one type of shunt as compared to another is difficult to demonstrate in alcoholic patients. As the majority of these patients continue to drink postoperatively, death from hepatic failure remains high irrespective of the type of shunt operation. Conversely, patients with schistosomiasis tend to live longer because of the relative stability of their underlying liver disease. It is of interest to note that reports from Egypt and Brazil have shown that DSRS does improve survival of these patients.

Operative Technique for CSRS

In CSRS procedure (Fig. 132.22), the spleen is removed and the central end of the splenic vein is anastomosed to the side of the left renal vein. The CSRS diverts all the portal blood away from the liver; hence, it has no physiologic advantage over the portacaval shunt. Furthermore, it may be technically more difficult because of the problems associated with removing the spleen in patients with portal hypertension. In addition, the patency rate of the CSRS may not be as good as the portacaval shunt. Hypercoagulability after splenectomy and a slower flow rate across the shunt may adversely affect shunt patency.

CSRS procedures are performed from an extended subcostal incision. The first step in the operation is to remove the spleen according to standard operative techniques. Because of the hypervascularity of the field, it is advisable to ligate the splenic artery before attempting to mobilize the spleen.

The splenic vein is divided near the hilum of the spleen. After removal of the spleen, the splenic vein is mobilized by dividing the pancreatic veins. These veins are easier to deal with in CSRS than in DSRS because they become less congested after the spleen has been removed. The central end of the mobilized splenic vein is then anastomosed to the side of the left renal vein. The technical aspects of CSRS are similar to those described for DSRS.

POSTOPERATIVE MANAGEMENT

The outline for postoperative care after DSRS also applies to CSRS. Ascites is less of a problem after CSRS. Rebleeding is usually secondary to shunt occlusion. This complication can generally be successfully treated with sclerotherapy because the varices are partially decompressed after removal of the spleen. In contrast, rebleeding associated with DSRS usually requires reoperation. Finally, encephalopathy occurs in 30% to 40% of the patients after CSRS, although the incidence may be falsely reduced if the patients with silent shunt occlusion are not excluded.

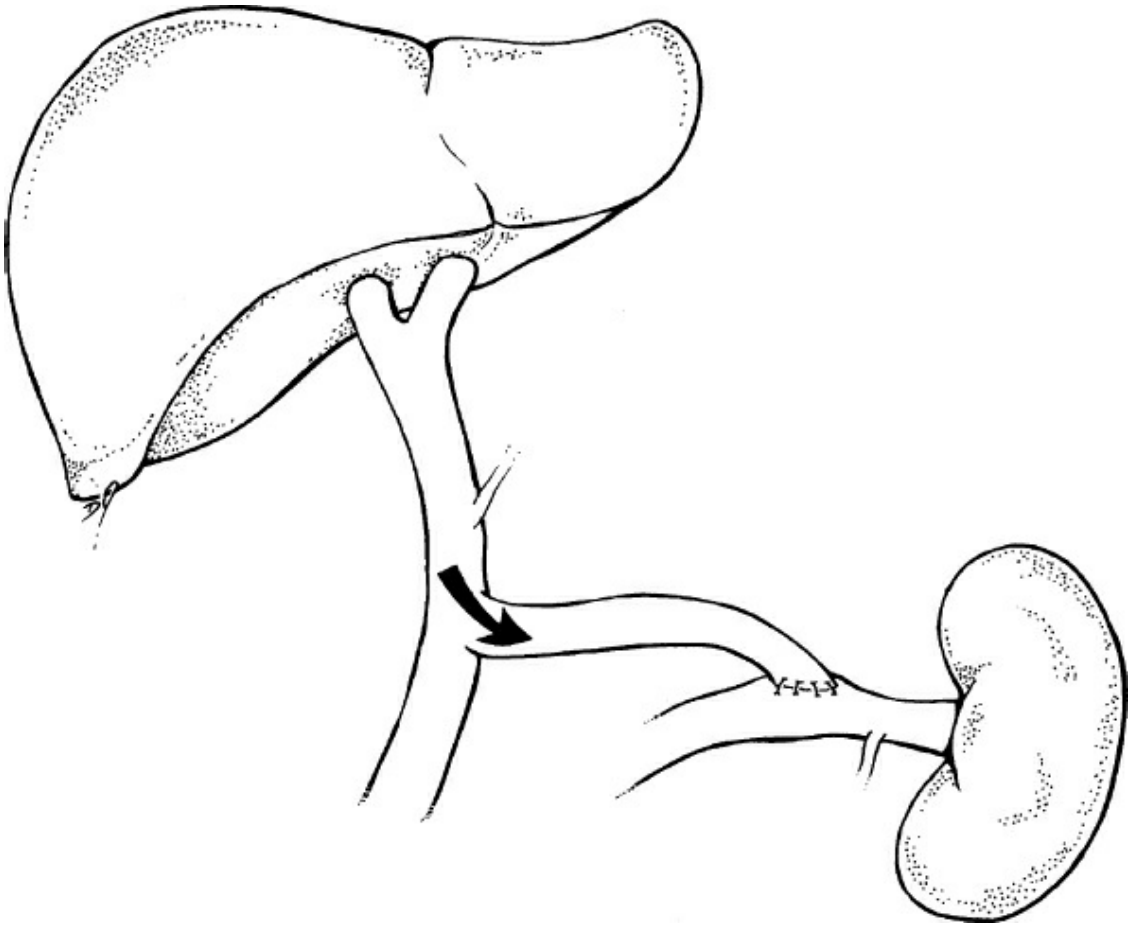

Figure 132.22. A diagrammatic illustration of the central

splenorenal shunt. The *arrow* indicates total diversion of portal blood away from the liver across the shunt to the left renal vein.

Suggested Readings

Abdel-Wahab M, el-Ebidy G, Gad el-Hak N, et al. Fundal varices: problem and management. *Hepatogastroenterology* 1999;46:849.

Ezzat FA, Abu-Elmagd KM, Sultan AA, et al. Schistosomal versus nonschistosomal variceal bleeders: do they respond differently to selective shunt (DSRS)? *Ann Surg* 1989;209:489.

Hasegawa I, Tamada H, Fukui Y, et al. Distal splenorenal shunt with splenopancreatic disconnection for portal hypertension in biliary atresia. *Pediatr Surg Int* 1999;15:92.

Henderson JM, Millikan WJ, Galloway JR. The Emory perspective of the distal splenorenal shunt in 1990. *Am J Surg* 1990;160:54.

Inokuchi K, Sugimachi K. The selective shunt for variceal bleeding: a personal perspective. *Am J Surg* 1990; 160:48.

Jenkins RL, Gedaly R, Pomposelli JJ, et al. Distal splenorenal shunt: role, indications, and utility in the era of liver transplantation. *Arch Surg* 1999;134:416.

Langer B, Taylor BR, Greig PD. Selective or total shunts for variceal bleeding. *Am J Surg* 1990;160:75.

Lopes Filho G de J, Haddad CM. Late clinical, biochemical, endoscopic, and electroencephalographic evaluation of patients with schistosomal portal hypertension treated with distal splenorenal shunt. *Int Surg* 1998;83:42.

Maffei-Faccioli A, Gerunda GE, Neri D, et al. Selective variceal decompression and its role relative to other therapies. *Am J Surg* 1990;160:60.

Richards WO, Pearson TC, Henderson JM, et al. Evaluation and treatment of early hemorrhage of the alimentary tract after selective shunt procedures. *Surg Gynecol Obstet* 1987;164:530.

Rikkers LF. The changing spectrum of treatment for variceal bleeding. *Ann Surg* 1998;228:536.

Salam AA, Ezzat FA, Abu-Elmagd KM. Selective shunt in schistosomiasis in Egypt. *Am J Surg* 1990;160:90.

Selim N, Fendley MJ, Boyer TD, et al. Conversion of failed transjugular intrahepatic portosystemic shunt to distal splenorenal shunt in patients with Child A or B cirrhosis. *Ann Surg* 1998;227:600.

Spina G, Santambrogio R, Opocher E, et al. Improved quality of life after distal splenorenal shunt. *Ann Surg* 1988;208:104.

Zacks SL, Sandler RS, Biddle AK, et al. Decision-analysis of transjugular intrahepatic portosystemic shunt versus distal splenorenal shunt for portal hypertension. *Hepatology* 1999;29:1399.

133 Central Splenorenal Shunts

Josef E. Fischer



This Chapter can be accessed in the accompanying eBook edition (see inside front cover for access instructions).

INTRODUCTION

The nature of therapy for bleeding varices and cirrhosis has changed dramatically since the introduction and popularization of hepatic transplantation. However, it remains largely believed that unless the patient has demonstrated abstinence from alcohol for a period, it is inappropriate to consider hepatic transplantation. Therefore, arrest of variceal bleeding and the use of shunting procedures remain appropriate, if there is any question as to abstinence.

In considering shunting procedures, it is best that such procedures do not involve the porta hepatis so that future transplantation is not compromised. Thus, the central and distal splenorenal shunts have gained increasing acceptance by those who previously carried out portacaval shunts because they do not interfere technically with the opportunity to do an expeditious liver transplant at some future time. One should not lose sight of the fact that, in a patient with bleeding esophageal varices who shows no signs of stopping despite aggressive therapy, one should move early either to some form of emergency portacaval shunt or to transjugular intrahepatic portosystemic shunt (TIPS), if varices cannot be eradicated by sclerotherapy, to stop the bleeding before the patient becomes coagulopathic and unsalvageable. Although this would make future liver transplantation difficult, it does not render it impossible.

Central and distal splenorenal shunts are generally not emergency procedures, as the decrease in portal pressure is not usually sufficient to arrest bleeding acutely. One should rely on pitressin, or its analogues, somatostatin, iced saline lavage, Sengstaken-Blakemore tubes, and sclerotherapy to provide immediate cessation of bleeding. The patient should be prepared for operation carefully at an interval, in the hospital, if

possible, or at home, with abstinence from alcohol, good nutrition, vitamins, and modest exercise. If the patient is protein intolerant, a high branched-chain amino acid diet should be used to minimize encephalopathy, in addition to lactulose or neomycin, or both. The patient should be admitted to the hospital the evening before operation, and a central venous pressure or Swan-Ganz catheter placed if there is doubt about the cardiovascular status. The prevalence of left-right dissociation makes a Swan-Ganz catheter particularly useful to indicate volume status. Antibacterial washes to the abdomen and chest should have been carried out several days before to minimize the skin bacterial count and vitamin K administered to get a maximum prothrombin time. Because the Child's class is directly related to mortality (Table 133.1), one should seek to obtain maximum improvement in nutrition, albumin, and overall nutritional and functional status before undertaking operation. I used a standard Nichols-type bowel preparation, in the past, with erythromycin and neomycin, in case the colon is entered inadvertently during the procedure, and it is also probably useful in preventing encephalopathy. I do use a mechanical preparation. The patient should be hydrated overnight; 10% glucose or a branched-chain-enriched amino acid parenteral nutrition solution may be used. Perioperative antibiotics are given as a single dose, usually of a first-generation cephalosporin, at the induction of anesthesia, and repeated every 3.5 hours of the operative procedure.

TABLE 133.1 Child's Classification of Liver Cirrhosis

	Class		
Finding	A	B	C
Ascites	None	Controlled	Uncontrolled
Bilirubin	<2.0	2.0–2.5	>3.0
Encephalopathy	None	Minimal	Advanced
Nutritional status	Excellent	Good	Poor
Albumin	>3.5	3.0–3.5	<3.0
Operative mortality (%)	2	10	50

CENTRAL SPLENORENAL SHUNT

The central splenorenal shunt (Fig. 133.1) is carried out through a tenth rib thoracoabdominal incision, as popularized by Linton. The patient should be carefully positioned in the right lateral decubitus position, with the left

side turned up at 45 degrees (Fig. 133.2). The entire abdomen and chest are prepared. The incision is carried out from the area of the umbilicus through the tenth rib proximally to the posterior axillary line. The tenth rib is removed (Fig. 133.3). I find it easier to enter the abdomen through the peritoneum anterior to the tenth rib and then work posteriorly to resect the rib. If the break in the table is properly placed under the opposite tenth rib, the operator is positioned right over the splenic vein and where the renal vein is ultimately located centrally in the operative field (Fig. 133.4).

The key to the operative procedure is not to lose control of the splenic vein or the spleen with respect to hemorrhage and blood loss during the splenectomy. I have found it helpful to ligate the splenic artery before attacking the spleen. This generally can be carried out by identifying the splenic artery at a convenient point at the superior border of the pancreas, passing 2-0 silk ties around it, and ligating it (Fig. 133.5). This decreases the blood loss if there is an inadvertent tear in the spleen. The splenic vein may be encircled with a vessel loop.

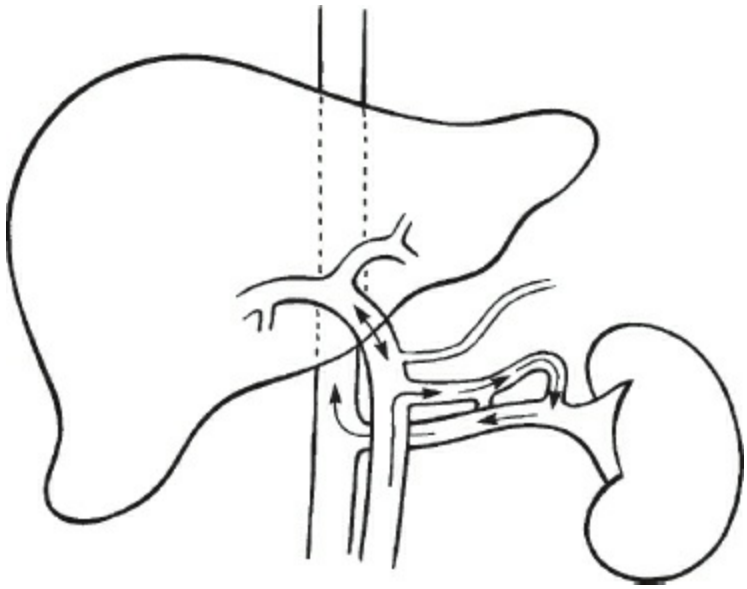

Figure 133.1. The path of flow (*arrows*) after central splenorenal shunt. Intestinal flow and some proximal portal flow tend to be diverted into the shunt. Flow from the short pancreatic branches and the proximal portal vein probably continues to perfuse the liver at a pressure of 10 to 15 mm Hg.

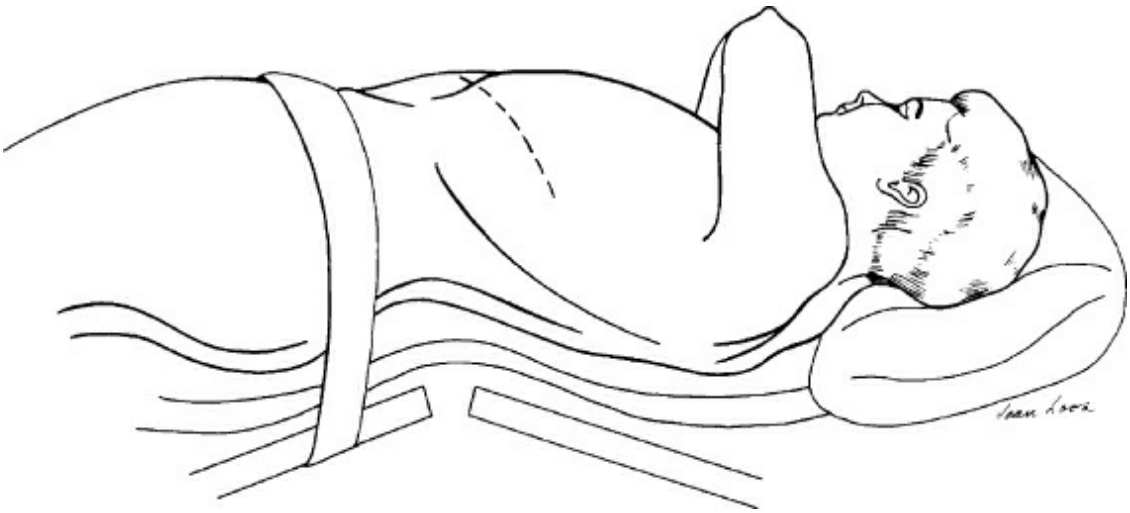

Figure 133.2. Positioning of the patient. The thoracoabdominal incision centered over the 10th rib (*dotted line*) is carried from the midaxillary line toward, but not to, the umbilicus.

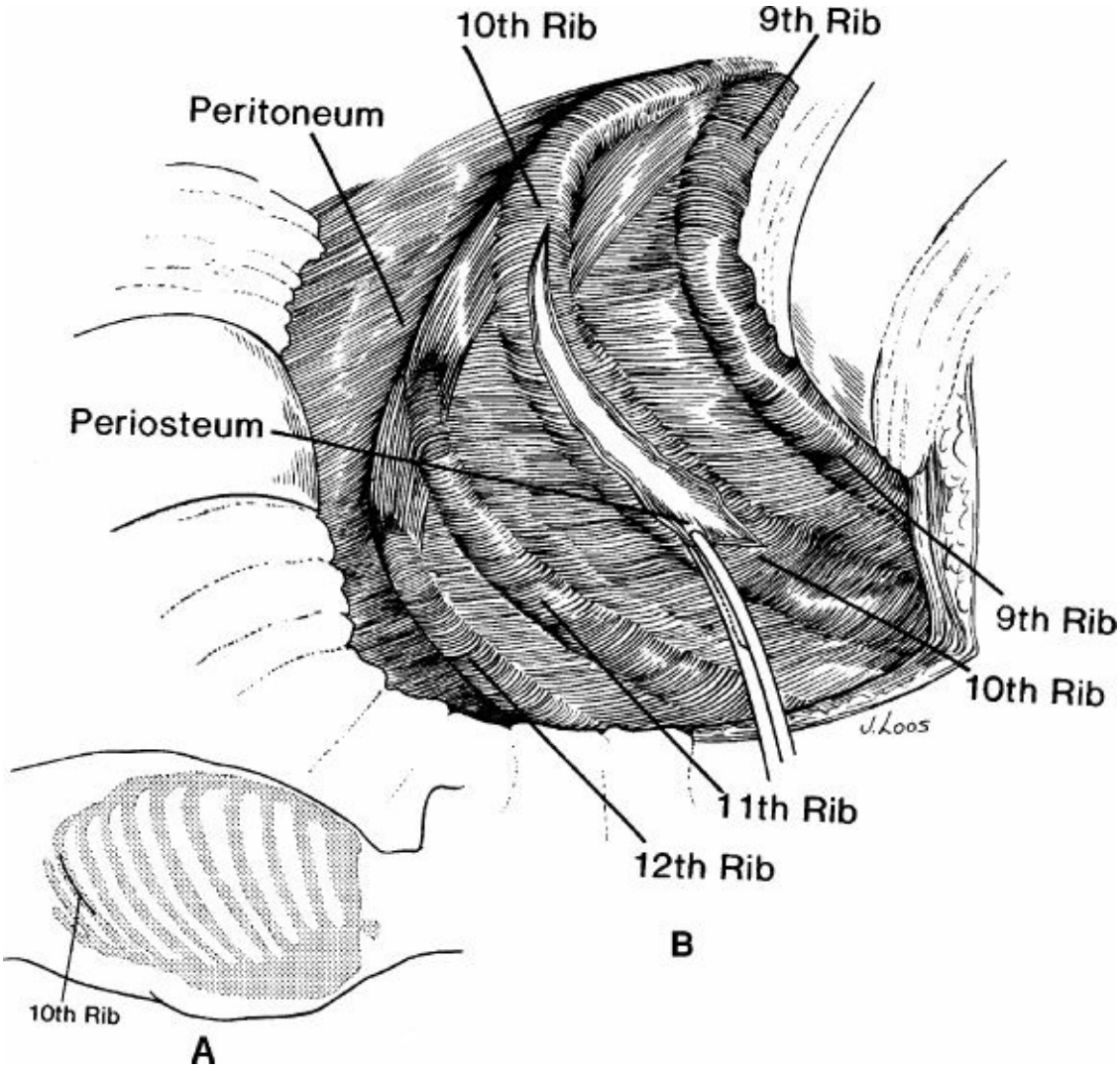

Figure 133.3. **A:** Extent of 10th rib resection. **B:** The 10th rib is resected.

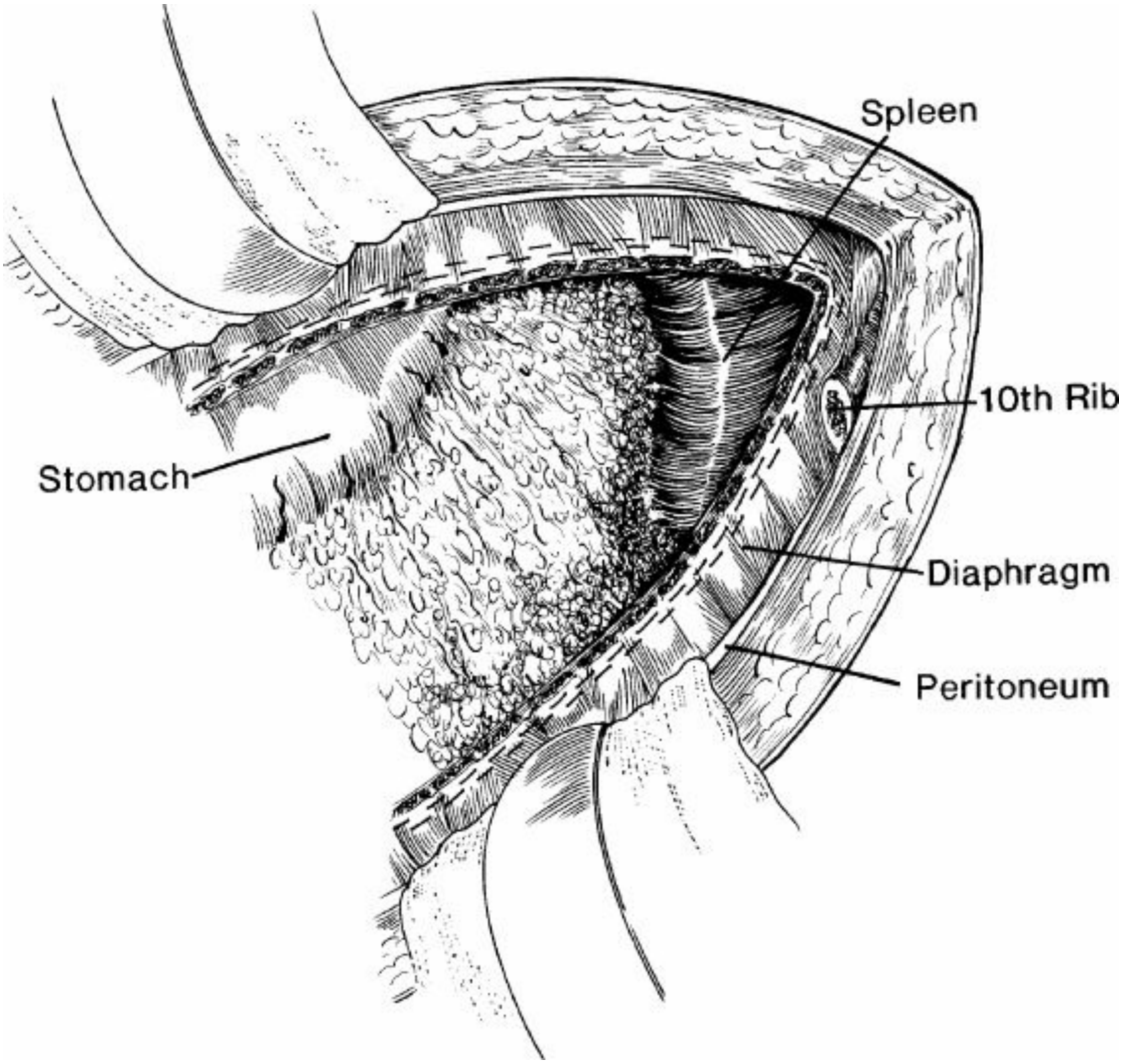

Figure 133.4. View on opening the diaphragm, incising the diaphragm, and oversewing diaphragm cut edges with mattress sutures.

The splenectomy is carried out by taking down the attachments to the colon between Kelly clamps and tying with cotton, if available, or silk if it is not. The retroperitoneum is then entered between Schmitt or Rienhoff clamps and suture-ligated on both sides with 2-0 silk. This is the most tedious part of the procedure, but it is essential if one is to dissect the splenic vein free in controlled fashion. One then proceeds laterally along the entire border of the spleen. It is best to take down the spleen 2 cm lateral to its peritoneal attachment (Fig. 133.6) because one can get a good purchase on the retroperitoneum, and suture ligation is relatively easy; it is also less bloody in that plane. Remember that the basic idea of carrying out a central splenorenal shunt is to get behind the spleen and the pancreas and

bring the pancreas anterior so that the splenic vein, which is a retroperitoneal structure, can be easily identified and managed. Do not try to take out the lateral border of the spleen bluntly; torrential hemorrhage will follow.

The short gastric vessels are then ligated in continuity with 2-0 silk. The highest short gastric vessel may be especially difficult because it is very short and the stomach may be inadvertently entered. The greater curvature should be oversewn with individual 4-0 silk sutures where the short gastric vessels have been ligated to prevent the uncommon complication of perforation of the greater curvature.

After the spleen has been mobilized medially, the hilum is addressed. The splenic vein is then dissected free and its branches are ligated, as are the branches of the splenic artery. If the splenic artery has not been previously ligated, it should be ligated so that postoperative hemorrhage can be avoided. The spleen is then delivered. One must take care not to involve the pancreas in the resection or dissection of the splenic hilum.

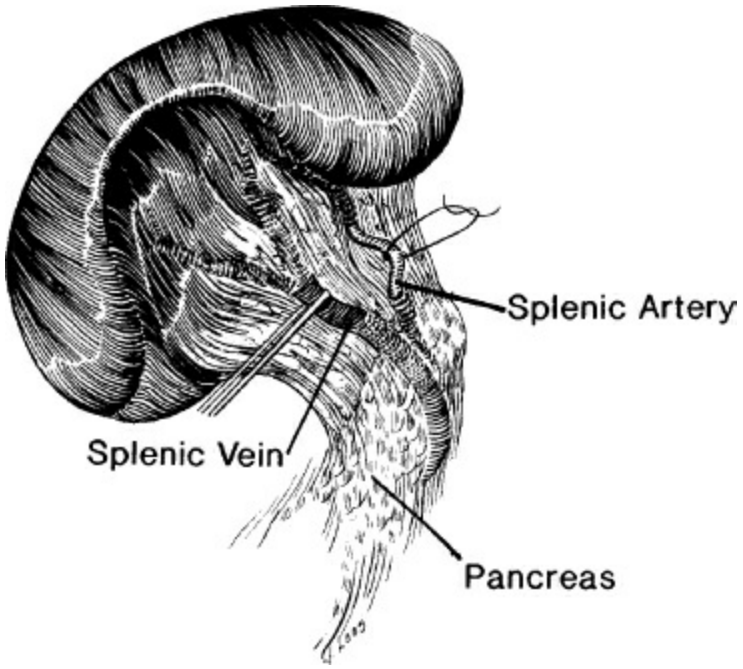

Figure 133.5. Ligating the splenic artery.

After the splenic vein has been isolated and the tail of the pancreas elevated in the wound, the next step is to identify the renal vein (Fig. 133.7). This is to make certain that one does not mobilize too much of the splenic vein, making it redundant. One identifies the renal vein by palpating the upper and lower borders of the kidney and then feeling the

renal artery. Between clamps, and with suture ligation of the divided retroperitoneum, the renal vein is identified. It is necessary to clamp the fatty areolar tissue in this area, not only because of bleeding, but also because of the lymph vessels that abound here and the proximity to the cisterna chyli. The renal vein is identified and vessel loops are then passed around the renal vein. It may be necessary to ligate the adrenal vein later in the procedure to obtain a reasonable spot for the anastomosis.

After the renal vein is identified, an appropriate portion of the splenic vein is dissected out. There are no branches of the splenic vein on the posterior aspect of the splenic vein, and the overlying peritoneum may be sharply divided; the branches of the splenic vein to the pancreas occur laterally at approximately 1-cm intervals. They are fine, but do not be fooled: ripping one of these branches may result in torrential hemorrhage if portal pressure is high, which it usually is. I use the technique of insinuating a right-angle Jacobson clamp, grasping 4-0 silk on either side (Fig. 133.8) and tying it proximal and distal, and then cutting between these silk sutures with a knife. Others may use different techniques, but the purpose is to elevate a portion of the splenic vein from the pancreatic bed.

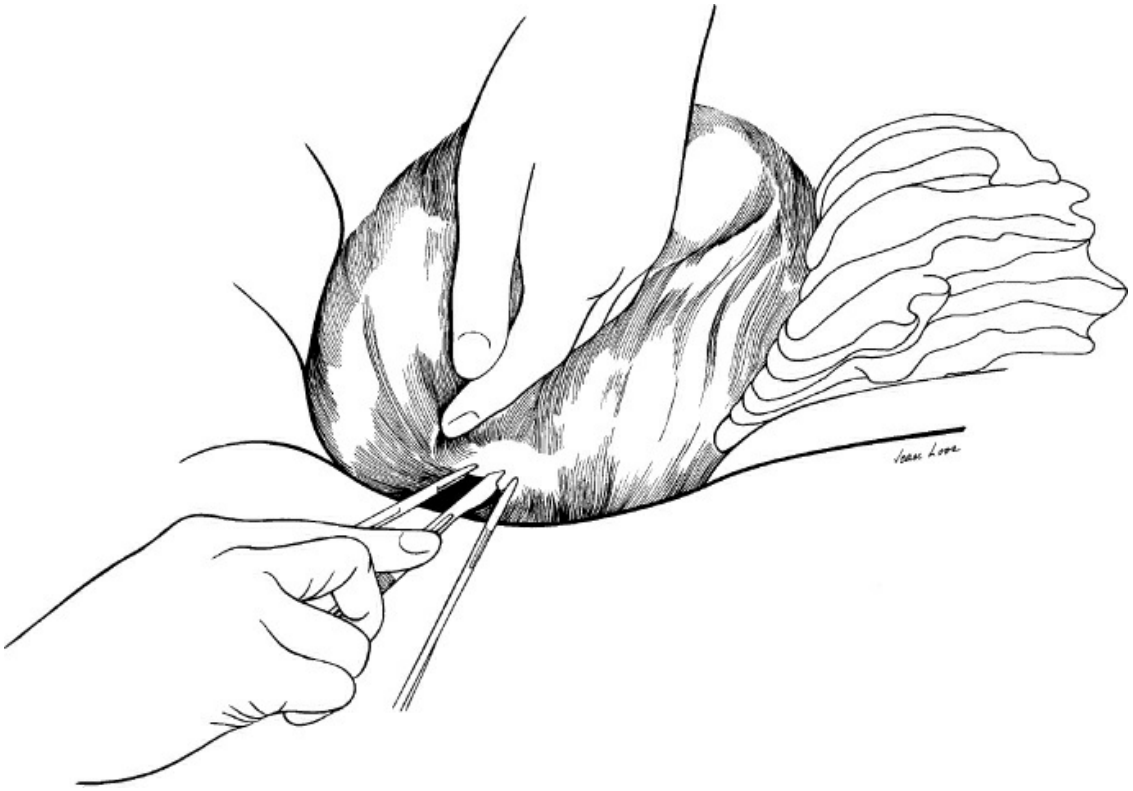

Figure 133.6. The critical maneuver of removing the spleen. Clamps are placed ~2 cm lateral to the splenic edge in the areolar tissue of the retroperitoneum, which contains large

collaterals. These are subsequently suture-ligated with nonabsorbable sutures of 2-0 silk.

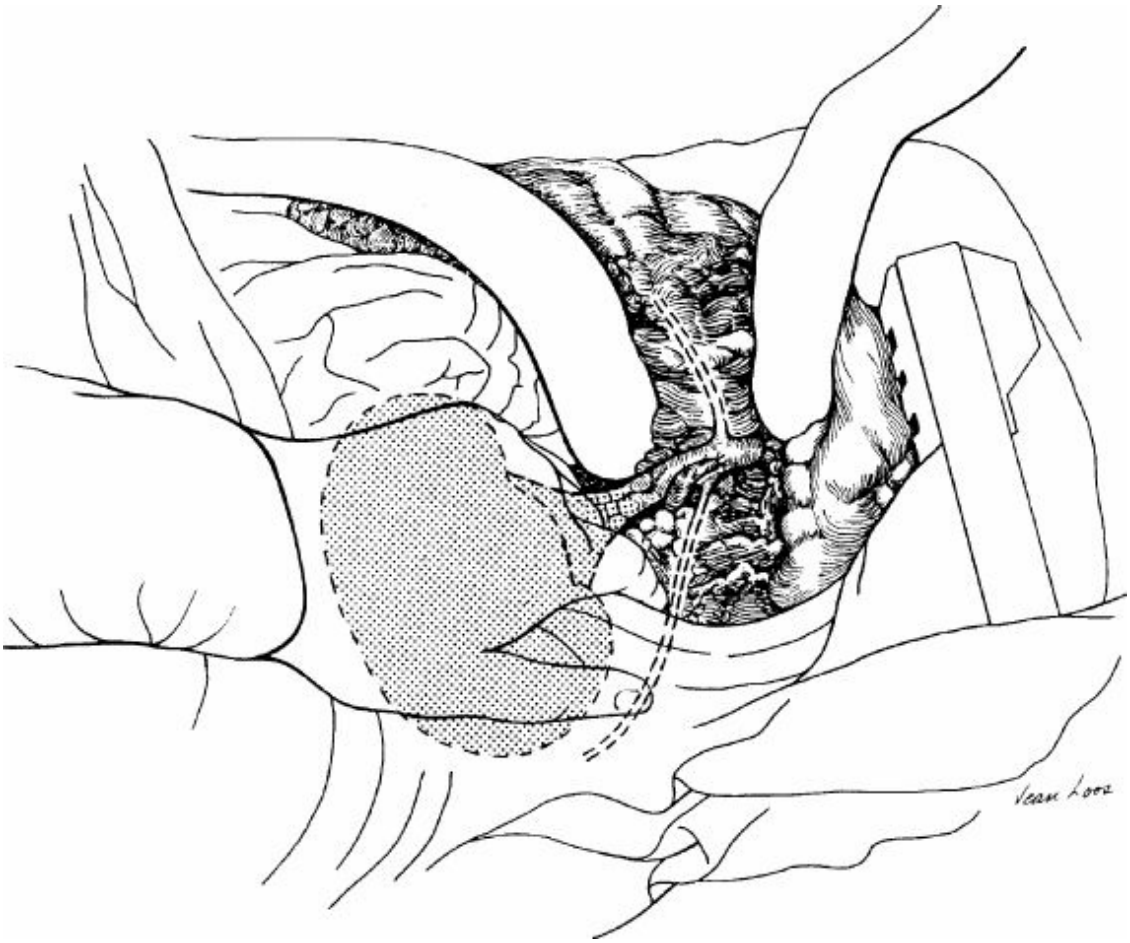

Figure 133.7. Identifying the renal vein.

Once an appropriate portion of splenic vein is elevated, one must then judge what will happen to the anastomosis when the pancreas is replaced back in its natural position. Vascular clamps are then applied to the splenic vein, and a miniature Satinsky clamp is applied to the renal vein. A small ellipse of renal vein is then excised (Fig. 133.9A). The back wall of the splenic vein is then anastomosed in running everting mattress fashion to the renal vein, as illustrated in Figure 133.9B,C. The front wall is then sutured with interrupted horizontal mattress sutures of 5-0 Prolene (Fig. 133.10A). The renal vein clamp is released just before completion of the anastomosis to vent the anastomosis and get rid of clots (Fig. 133.10A,B). The splenic vein clamp is then released. Any leaks are sutured with doubly armed 6-0 Prolene. Dr. Linton frequently liked to resect the tail of the pancreas so that the splenic vein would lie better, whereas I have not found it necessary to do this and it is meddlesome.

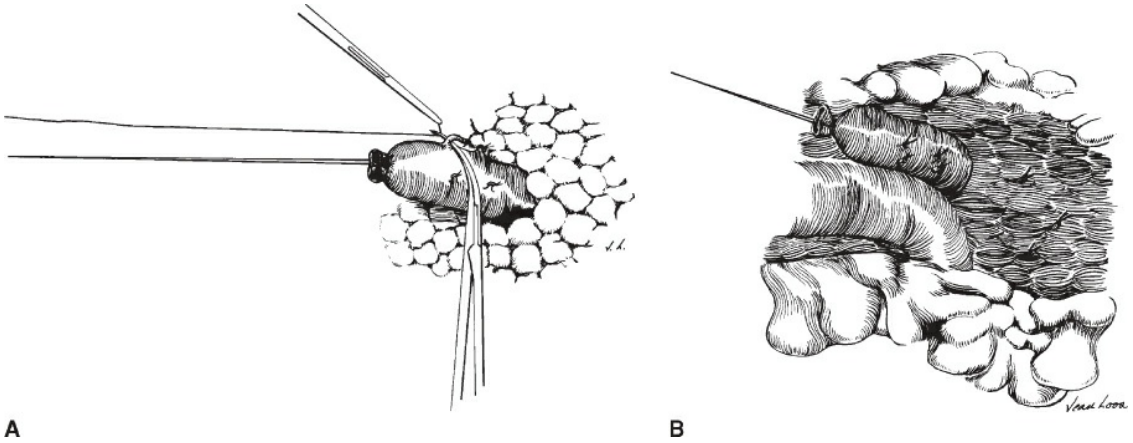

Figure 133.8. **A:** Dissecting the splenic vein. There are short branches, which are paired ~1 cm apart. These must be taken carefully. **B:** A length of splenic vein is now available.

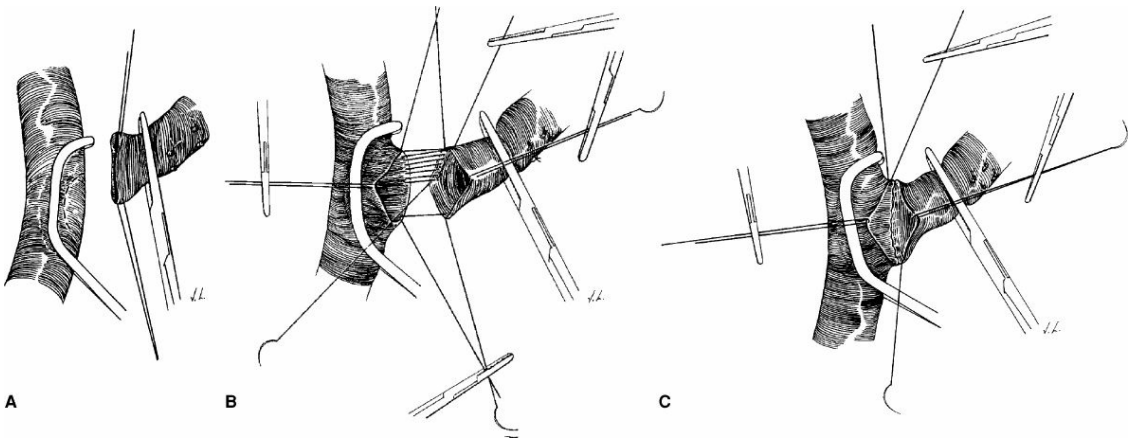

Figure 133.9. **A:** Stay sutures at corners of splenic vein. A specially fashioned Satinsky clamp is placed on the splenic vein and an ellipse is excised. **B:** Stay sutures are placed between the corners of the renal vein incision and the splenic vein. A horizontal everting mattress of 5-0 sutures is then used to bring the two veins together posteriorly. **C:** The horizontal everting mattress is then snugged up posteriorly. Properly performed, there should be little or no suture material showing on the posterior wall.

After irrigation, one should oversew the lateral border of the retroperitoneum where the spleen has been removed with a running suture to secure hemostasis (Fig. 133.11). The abdominal closure is carried out carefully in multiple layers, making certain that if the patient accumulates ascites, there is no ascitic leak. The diaphragm, which has been taken down to provide access to the spleen, is then closed with mattress sutures of 0 silk and a running nonabsorbable suture over the cut edge to secure

hemostasis. It can be expected that ascites will be well controlled. An open shunt can frequently be estimated clinically by measuring serial urinary sodium concentrations. If the concentration is higher than 10 mg/dL, the shunt is almost certainly open.

Postoperatively, sodium-containing fluids are minimized, and the urinary sodium is measured frequently. Abdominal girths are measured to make certain that ascites are not accumulating. The nasogastric tube may be removed on the 2nd or 3rd postoperative day, as gastric ileus usually occurs after this procedure. A chest tube that has been placed in the event of a diaphragmatic leak or bleeding is removed 48 hours postoperatively.

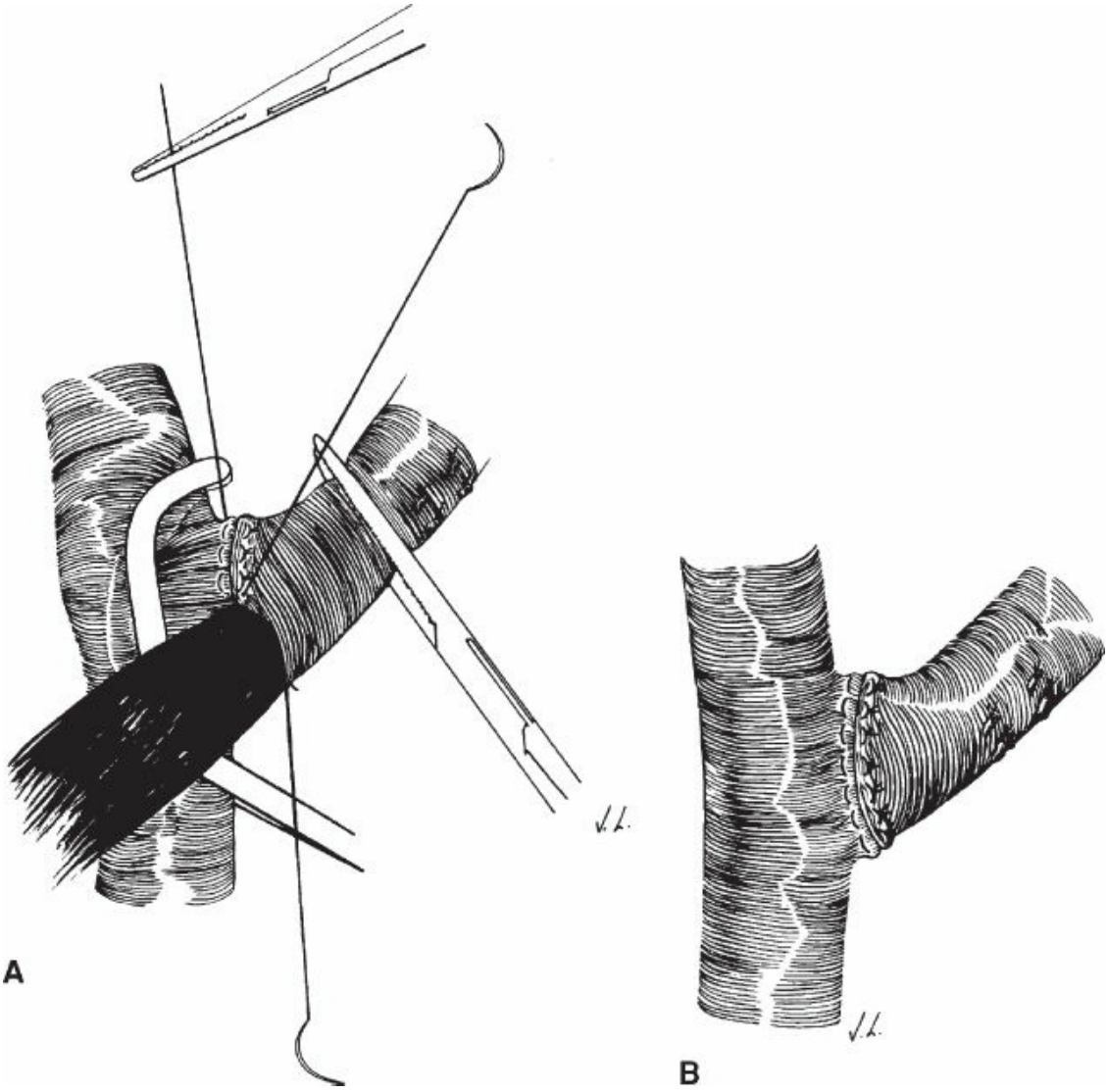

Figure 133.10. A: The anastomosis is partially completed on the anterior wall, with interrupted horizontal mattresses of 5-0 Prolene. The vein is flushed. The remainder of the sutures are then held before being finally tied. **B:** The completed anastomosis. The anastomosis should be between 1.0 and 1.2

cm. The splenic vein is rarely larger than this. A thrill may be felt by placing a finger along the renal vein. It is customary to place a needle through the renal vein and pull back the needle, measuring pressures across the splenic vein. A gradient of >3 or 4 mm suggests that the anastomosis should be redone.

If the patient experiences hepatic failure, it is treated with fluid restriction and total parenteral nutrition with a branched-chain-enriched amino acid solution. Encephalopathy is similarly treated, with the addition of neomycin or lactulose, or both.

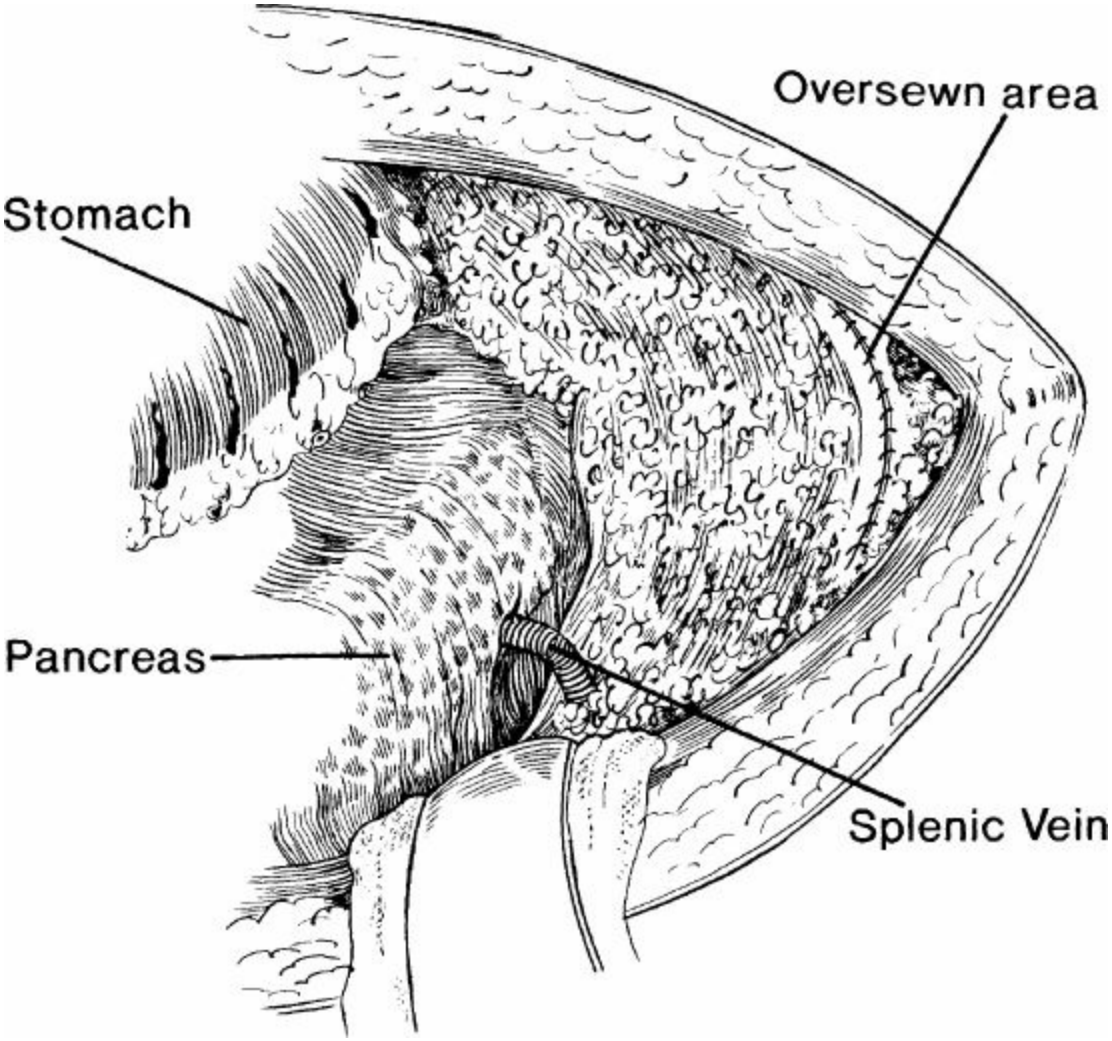

Figure 133.11. Oversewing the cut edge of the splenic bed with a running chromic suture.

The critical aspect of central splenorenal shunt is meticulous hemostasis at the time of operation. Some have used a hypotensive spinal anesthesia, which is perfectly appropriate. However, one must make certain that the

normal blood pressure has been restored before closing. If not, bleeding may supervene postoperatively when normal pressure is restored.

In a time when distal splenorenal shunts have become most popular as a bridge to transplantation, or in relatively good-risk patients who are not thought to require transplantation, the central splenorenal shunt should be performed in patients with tight ascites. The experience of my group and that of others have shown that these patients are not likely to do well after distal splenorenal shunt. Others have argued that the central splenorenal shunt turns into a total shunt before long. This is not true in our experience when we have measured portal flow. The reason is that one must limit the size of the anastomosis to between 1.0 and 1.5 cm. When pressures are measured under these circumstances, the splenic vein pressure should remain between 10 and 15 cm of water so that some flow to the liver persists. The central splenorenal shunt is a side-to-side shunt. However, it should be a small side-to-side shunt, not a total shunt. In this, we disagree with the late Dean Warren and Dr. Salam in Chapter 132, and others who are the devotees of the distal splenorenal shunt, as we have had excellent results with the central splenorenal shunt.

The other group that may benefit from a central splenorenal shunt, as opposed to a distal splenorenal shunt, are patients with hypersplenism. After end-to-side portacaval shunt in McDermott's early series published in the *New England Journal of Medicine* in 1962, there were a number of patients who responded, with amelioration of their hypersplenism, but some did not. Similarly, in our experience, an occasional patient with hypersplenism has not done well from the standpoint of thrombocytopenia. Those patients probably would have done better with a central splenorenal shunt. In addition, patients with schistosomiasis as etiology for their portal hypertension have better outcomes (survival) with splenorenal shunts as opposed to portacaval shunts, and the more normal liver of schistosomiasis does not do well after total diversion.

This remains a good operation that can be performed with low mortality and morbidity, provided it is carefully done. It requires the utmost in surgical technique and gentleness in handling of tissues and, because the splenic vein tends to be a thin vein, one must use maximum care in its anastomosis. However, if one does so, the results are gratifying and many patients continue to do well years after surgery, with a minimum of encephalopathy.

Suggested Readings

Boyer TD, Henderson JM, Heerey AM, et al. Cost of preventing variceal rebleeding with transjugular intrahepatic portal systemic shunt and distal splenorenal shunt. *J Hepatol* 2008;48(3):407.

Elwood DR, Pomposelli JJ, Pomfret EA. Distal splenorenal shunt: preferred treatment for recurrent variceal hemorrhage. *Arch Surg* 2006;141(4):385.

Fischer JE. The technique for central splenorenal shunt. In: Schwarz S, ed. *Modern Techniques in Surgery Vol. 13: Abdominal Surgery.* New York: Futura Publishing; 1982:1.

Fischer JE, Bower RH, Atamian S, et al. Comparison of distal and proximal splenorenal shunts: a randomized prospective trial. *Ann Surg* 1981;194:531.

Lillegard JB, Hanna AM, McKenzie TJ, et al. A single-institution review of portosystemic shunts in children: an ongoing discussion. *HPB Surg 2010*; 2010:964597. Epub 2010 May 6.

Linton RR. The definitive treatment of bleeding esophageal varices. In: Linton RR, ed. *Atlas of Vascular Surgery.* Philadelphia, PA: WB Saunders; 1973:168.

Livingstone AS, Koniaris LG, Perez EA, et al. 507 Warren-Zeppa distal splenorenal shunts: a 34-year experience. *Ann Surg* 2006;243(6):884–92.

Nussbaum MS, Schoettker PJ, Fischer JE. Comparison of distal and proximal splenorenal shunts: a ten-year experience. *Surgery* 1993;114:659.

Pedroso FE, Koniaris LG. Shunting: a better way to prevent variceal bleeding. *J Surg Res* 2011;167(1):e1.

Rezende-Neto JB, Petroianu A, Santana SK. Subtotal splenectomy and central splenorenal shunt for treatment of bleeding from Roux en Y jejunal loop varices secondary to portal hypertension. *Dig Dis Sci* 2008; 53(2):539.

EDITOR'S COMMENT

Variceal bleeding is a problem of significant magnitude in patients with cirrhosis. Treatment alternatives include medical management (beta blocker and/or 5-isosorbide mononitrate therapy), sclerotherapy, endoscopic band ligation, transjugular intrahepatic portosystemic shunt (TIPS), and surgical shunts. There have been many surgical shunts described including portocaval, mesocaval, distal splenorenal, and the distal splenorenal combined with splenopancreatic disconnection. A nonshunting surgical procedure that directly addresses the esophageal varices was described by Sugiura in 1973 (*J Thorac Cardiovasc Surg* 1973:66;677–685). In this chapter of *Mastery*, Dr. Fischer describes the central splenorenal shunt, an operation that many of the younger readers of this text have probably not seen; the advent of the TIPS procedure

has greatly reduced the use of open surgical procedures for the management of portal hypertension. Although many surgeons may not perform this operation, the anatomy of the left upper quadrant, proper surgical exposure, and the management of the spleen and distal pancreas are techniques beautifully described by Dr. Fischer (in this chapter) and relevant to left upper quadrant surgery in general, both laparoscopic and open.

An alternative to the thoracoabdominal incision described in this chapter would be the left-sided "J" incision, otherwise termed the reverse Makuuchi incision (Chang, *Arch Surg* 2010;145:281–284). Makuuchi first described the "J" incision for right upper quadrant surgery involving the liver (Makuuchi, in *Pitfalls and Complications in the Diagnosis and Management of Hepatobiliary and Pancreatic Diseases*. Stuttgart: George Thieme; 1993;86–88) and when combined with a suitable retractor (we prefer the Thompson [Thompson Surgical Instruments, Inc.]), it provides excellent exposure with a relatively modest incision size. For operations involving the left upper quadrant, a similar left-sided "J" incision provides adequate exposure and avoids the need for a thoracic extension.

As described herein, early ligation of the splenic artery is always helpful when performing splenectomy. The splenic artery is often accessible at the superior border of the proximal body of the pancreas where it is both anterior in location and fairly redundant. At this location it can be ligated without injuring venous collaterals that are abundant in the patient with portal hypertension. When separating the splenic vein from the pancreatic parenchyma, a useful devise is the LigaSure vessel sealing system (Valleylab; Boulder, Colorado) that has also been tested in patients with portal hypertension (Yao, *Am J Surg* 2011;202:82–90). While some of the tributaries of the splenic vein are best divided with fine silk ties, the LigaSure can be effectively used for many of the small venous branches. As discussed, medial rotation of the pancreas exposes the splenic vein posteriorly and is the best way to approach this vessel when trying to separate the splenic vein from the pancreas (working along the inferior border of the pancreas is possible but usually takes more time). As also discussed by Dr. Fischer, ligation of the left adrenal vein increases the amount of available left renal vein for the vascular anastomosis and will prevent an iatrogenic tear (in the left renal vein) at the left adrenal vein–splenic vein junction. The LigaSure or a similar vessel-sealing devise can also assist in dividing the tissue anterior to the left renal vein. When beginning the dissection to expose the left renal vein, be aware of the anatomic location of the inferior mesenteric vein to avoid an inadvertent venotomy and unnecessary bleeding.

Successful surgery in the left upper quadrant (for portal hypertension, or benign or malignant disease) requires a three-dimensional understanding of the anatomy, proper exposure, and a detailed plan for the operative procedure. The description of the operative technique for performing a central splenorenal shunt can be used as a template for the creation of many other operative plans—It is detail oriented and each step follows a logical sequence. For the surgeon in

training, this type of approach should be used in the planning of all abdominal procedures.

D.B.E.

134 Endoscopic Therapy in the Management of Esophageal Varices

Jake E. J. Krige and Sandie R. Thomson

PORTAL HYPERTENSION

Portal hypertension is a clinical syndrome defined by a portal venous pressure gradient exceeding 5 mm Hg. A portal venous pressure gradient above the critical threshold value of 12 mm Hg causes clinically significant manifestations of portal hypertension in the form of compensatory portosystemic venous collateral formation, increased splanchnic blood flow, and disturbed intrahepatic and pulmonary circulation. These hemodynamic changes give rise to the important complications of portal hypertension, especially when due to chronic liver disease, and include variceal bleeding, hepatic encephalopathy, ascites, hepatorenal syndrome, recurrent infection, and coagulopathy. Esophagogastric varices are part of the collateral venous system that diverts high pressure portal blood via the coronary, short gastric, and esophageal perforator veins *en route* to the azygous system. These varices are the major source of hemorrhage and mortality, although bleeding from congestive gastropathy and anorectal varices and other sites may also occur. Epigastric and abdominal wall collateral vessels may enlarge with recanalization of the umbilical vein, and multiple retroperitoneal collaterals may form, which complicate surgical intervention. Splenomegaly and hypersplenism develop with impeded splenic vein outflow.

Cause

Two mechanisms lead to portal hypertension: (a) increased portal resistance and (b) increased portal flow. Increased resistance to flow is classified as presinusoidal, sinusoidal, and postsinusoidal (Table 134.1). Increased flow is uncommon and is caused by either arteriovenous fistulae

or increased splenic arterial flow. The geographic prevalence and causes of portal hypertension vary widely; while cirrhosis is the most common cause in the Western world, schistosomiasis is the leading cause in many other countries.

Natural History

Variceal bleeding is the final step in a sequence of events initiated by an increase in portal pressure, and followed by the development of varices with a progressive increase in size. A key factor in variceal bleeding is an increase in the hydrostatic pressure inside the varix, with a resultant increase in variceal size and a decrease in wall thickness. Variceal rupture and bleeding occur when transmural variceal pressure and the increased tension in the thin wall exceed a critical value determined by the elastic limit of the vessel wall.

Variceal bleeding is the most serious complication of portal hypertension and substantially alters the natural history of patients with compensated cirrhosis. One third of deaths from cirrhosis are related to portal hypertension, and are due mainly to esophageal variceal bleeding. Up to 20% of initial variceal bleeding episodes are fatal, and as many as 70% of survivors, if inadequately treated, have recurrent variceal bleeding. In Western countries, variceal bleeding accounts for approximately 10% of all causes of upper gastrointestinal bleeding, although this varies geographically depending on the regional prevalence of alcoholic liver disease and viral hepatitis.

TABLE 134.1 Causes of Portal Hypertension

1. **Increased resistance to blood flow**
   a. **Presinusoidal**
      i. **Extrahepatic**
         Portal vein thrombosis
         Splenic vein thrombosis
      ii. **Intrahepatic**
         Schistosomiasis
         Primary biliary cirrhosis
         Sarcoidosis
   b. **Sinusoidal**
      Cirrhosis
      Hemochromatosis
      Wilson disease
      Congenital hepatic fibrosis
   c. **Postsinusoidal**
      Budd–Chiari syndrome
      Veno-occlusive disease
      Congestive heart failure
      Constrictive pericarditis
2. **Increased portal blood flow**
   Increased splenic blood flow
   Arterial-portal venous fistula

Treatment Principles

The ideal treatment of portal hypertension and bleeding varices should be universally effective, safe, easy to administer, and inexpensive. Currently no such treatment exists and the clinician is obliged to select the most appropriate intervention from a menu of available therapeutic options, none of which is ideal or applicable to all patients. The rational treatment of esophageal varices depends on a clear understanding of the risks of rebleeding and the response to each specific intervention. The optimal management of bleeding esophageal varices requires a full appreciation of portal, gastric, and esophageal venous collateral anatomy; the pathogenesis and hemodynamic consequences of variceal bleeding; and the utility of each available therapy at specific stages in the natural history of portal hypertension. Careful assessment of hepatic functional reserve is necessary before selecting the appropriate treatment. The Child–Pugh and the model for end-stage liver disease (MELD) scores are currently the most useful

and practical predictors of survival in cirrhotic patients (Table 134.2). For example, the operative mortality for Child–Pugh grade A patients is less than 5%, while for Child–Pugh grade C it exceeds 25%.

The treatment of variceal hemorrhage has evolved markedly in the past decade. Although these advances in treatment have reduced overall mortality, uncontrolled or recurrent bleeding from varices and the consequences of progressive liver failure remain the commonest causes of early death in alcoholic cirrhotic patients. The spectrum of interventions required to control variceal bleeding and achieve efficient and successful treatment of the severe and potentially life-threatening complications of portal hypertension are invasive, complex, and may necessitate advanced skills. No single modality is applicable to all patients, and knowledge of the alternatives allows the well-informed clinician to choose the appropriate therapy for each clinical situation. A coordinated multidisciplinary team approach integrating the skills of critical care specialists, endoscopists, hepatologists, interventional radiologists, and hepatobiliary and transplant surgeons is essential as each of various therapies may be required at different stages in different patients.

TABLE 134.2 The Child–Pugh Classification of Functional Liver Status

	Number of Points		
	1	2	3
Bilirubin (μmol/L)	<34	34–51	>51
Albumin (g/L)	>35	28–35	<28
INR	<1.3	1.3–1.5	>1.5
Ascites	None	Mild–moderate	Severe
Encephalopathy	0	I/II	III/IV

Grade A: 5–6 points.
Grade B: 7–9 points.
Grade C: 10–15 points.
INR, international normalized ratio.

Endoscopic treatment has become the principal first-line intervention in patients with bleeding esophageal varices, both during the acute event and for long-term therapy to prevent recurrent bleeding. After control of the index bleed, there is a 70% chance of rebleeding. The risk of rebleeding is greatest during the first few days after initial variceal hemorrhage. Survival after variceal bleeding depends largely on the rapidity and efficacy of initial primary hemostasis and the presence and severity of

underlying liver disease and hepatic functional reserve. Early rebleeding has been shown to be a strong predictor of overall mortality, and recurrent variceal bleeding substantially increases the risk of complications, which further contribute to mortality, emphasizing the need for rapid and sustained control of variceal bleeding as the principal imperative of endoscopic intervention.

MANAGEMENT OF ACUTE VARICEAL BLEEDING

Choice of Therapy

The possibility of variceal bleeding should be considered in all patients who present with upper gastrointestinal bleeding and have known risk factors for chronic liver disease or clinical evidence of portal hypertension. The modern management of acute variceal bleeding requires a variety of therapeutic options to be available for use either sequentially or in combination in individual patients (Table 134.3). Several important clinical considerations influence the choice of therapy, as well as the prognosis in individual patients. These include the natural history of the disease causing the portal hypertension, the location of the bleeding varices, residual hepatic function, the presence of associated systemic disease, continuing drug or alcohol abuse, the patency of major splanchnic veins, and the response to each specific treatment.

General Strategy

Variceal bleeding is a medical emergency, and all patients with suspected acute variceal bleeding require urgent hospitalization and resuscitation as for any major hemorrhage. The immediate aims of emergency treatment are hemodynamic stabilization, blood-volume replacement, control of bleeding, support of vital organ function, and prevention of complications due to hypovolemic shock and impending liver failure. Patients should be managed in an intensive or high-care unit with a full multidisciplinary staff complement available. Although variceal bleeding may stop spontaneously in up to 60% of patients, it is not possible to predict which patients will continue to bleed and require further specific emergency therapy. If an experienced medical team is not available at a peripheral hospital, patients should be transferred to a center with appropriate facilities, resources, and expertise as soon as they have been adequately resuscitated and are stable because subsequent management may be complex should bleeding

continue or recur and may later require advanced multidisciplinary investigations and therapy. A suggested management algorithm is given in Figure 134.1.

TABLE 134.3 Management of Acute Variceal Bleeding

Treatment Options
1. Pharmacologic agents
a. Somatostatin
b. Glypressin
c. Octreotide
2. Endoscopic therapy
a. Band ligation
b. Injection sclerotherapy
i. Sclerosants
ii. Cyanoacrylate ("superglue")
3. Balloon tamponade
4. TIPS
5. Surgery
a. Shunt procedures
b. Esophageal transection

TIPS, transjugular intrahepatic portosystemic shunt.

Initial Measures

Many patients with acute variceal hemorrhage also have liver decompensation with encephalopathy, ascites, coagulopathy, bacteremia, or malnutrition. The extent and urgency of initial therapy depend primarily on the severity of bleeding. Stable patients with intermittent bleeding are candidates for endoscopic therapy, while the infrequent patient with exsanguinating bleeding may require balloon tamponade to control bleeding before endoscopy is performed. In the acute situation, the essential history and examination are obtained and basic investigations including full blood count, coagulation profile, liver and renal function, blood group, and cross-match are requested. Ascitic fluid, blood, and urine should be obtained for culture.

Maintenance of a secure airway and prompt resuscitation with

restoration of circulating blood volume are vital and precede any diagnostic studies. Intravenous access is obtained via a wide bore central venous cannula. While blood is being cross-matched, crystalloid solution is rapidly infused until the blood pressure is restored and the urine output (as measured with a Foley catheter) is adequate. Infusions of normal saline may aggravate ascites and must be avoided. Overzealous expansion of circulating blood volume should be avoided as this may cause an increase in portal pressure and precipitate further variceal bleeding. The goal is to maintain the hematocrit between 25% and 30%, and the central venous pressure should be no greater than 2 to 5 cm H_2O, measured from the sternal angle. Hemodynamic status is monitored with continuous blood pressure, pulse, and oxygen recording. Patients who are hemodynamically unstable, or elderly or those who have cardiac or pulmonary disease should be monitored using a pulmonary artery catheter because injudicious administration of crystalloids, combined with vasoactive drugs, may lead to rapid onset of edema, ascites, and hyponatremia. Clotting factors are often deficient and fresh blood, fresh frozen plasma, and Vitamin K_1 are frequently required. Platelet transfusions may be necessary. Sedatives should be avoided if possible. Prophylactic antibiotics have been shown to improve survival and are mandatory.

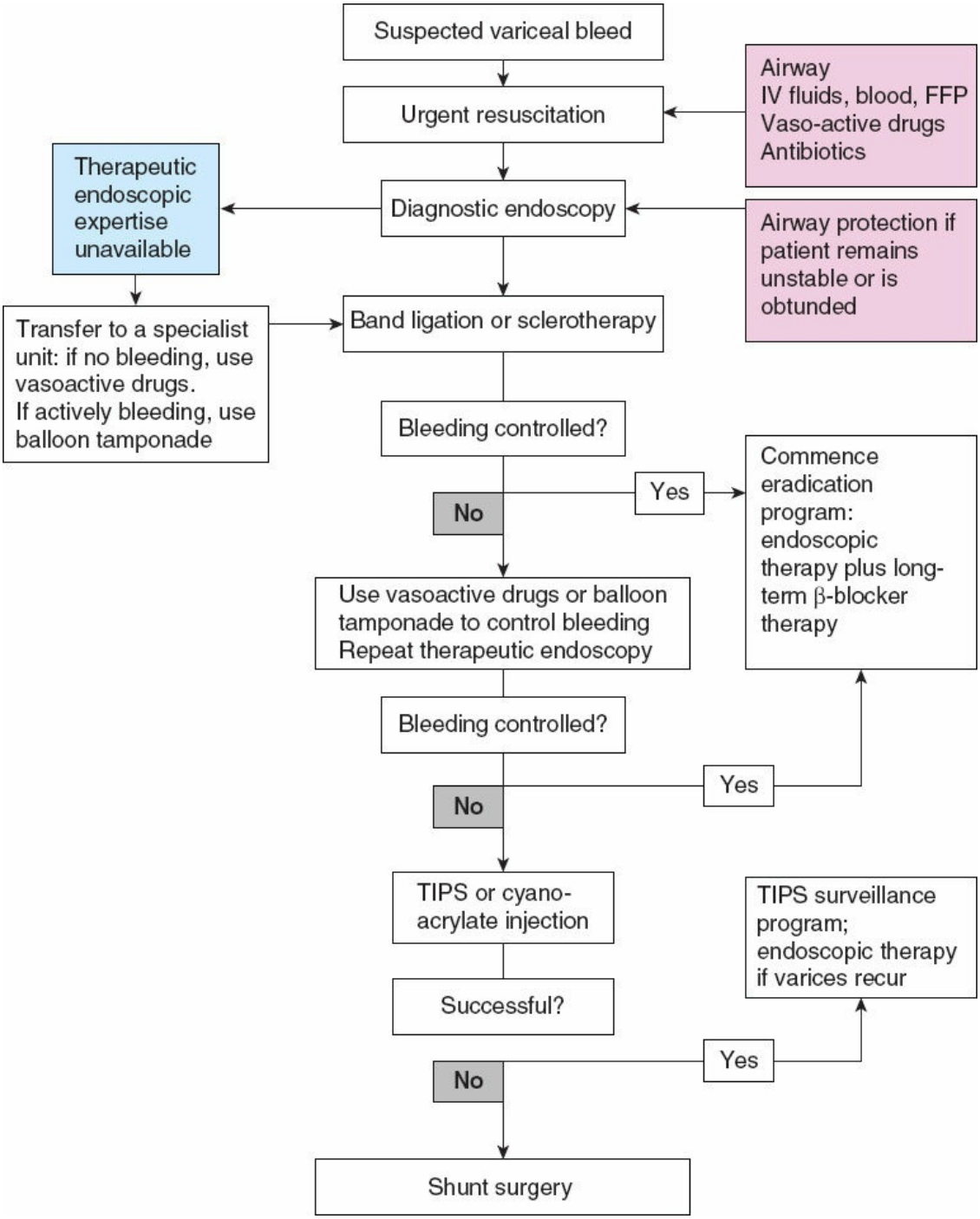

Figure 134.1. Algorithm for the management of acute variceal bleeding.

PHARMACOLOGIC THERAPY

The role of vaso-active drugs is to reduce variceal pressure by decreasing variceal blood flow. The selection of a specific drug depends on local resources. The most widely used drugs are terlipressin, somatostatin, and octreotide. Terlipressin (glypressin), the synthetic analog of vasopressin, has the advantage of being effective in 2 mg intravenous bolus doses

administered 4 to 6 hourly and is simpler to administer. Early administration of glypressin in a French study showed improved survival. Somatostatin reduces splanchnic and hepatic blood flow and is administered empirically as an initial bolus dose of 250 μg, followed by a continuous intravenous infusion of 250 μg per hour. This is maintained until the patient has been free from bleeding for 24 hours. Therapy may be maintained for up to 5 days to prevent early rebleeding. Major side effects with somatostatin are uncommon, although minor side effects such as nausea and hyperglycemia occur in one third of patients. Octreotide is a somatostatin analog with a longer half-life. This is given as an initial bolus of 50 μg followed by an infusion of 50 μg per hour that can also be maintained for up to 5 days. The safety profile of octreotide is similar to somatostatin.

Most endoscopy units recommend that pharmacologic therapy be commenced when a diagnosis of variceal bleeding is suspected and before emergency endoscopy is performed. This policy has the theoretical advantage of controlling bleeding before the initial endoscopy and facilitating both diagnosis and immediate endoscopic therapy.

Emergency Endoscopy and Immediate Endoscopic Therapy

Emergency diagnostic endoscopy is essential to confirm that a patient is bleeding from esophageal varices. Patients with varices can usually be divided into three groups: those with active variceal bleeding, those with variceal bleeding that has stopped, and those who have varices but are bleeding from another site such as a peptic ulcer, hemorrhagic gastritis, or portal hypertensive gastropathy. These other lesions are treated appropriately.

Emergency endoscopy should be performed in an endoscopy unit with all the necessary equipment available. Many units have a fully equipped mobile emergency endoscopy stack that can be wheeled into the intensive care unit or the operating room. It is imperative that full resuscitation facilities are available, together with skilled staff experienced in dealing with emergencies. Two endoscopy assistants should be present throughout the procedure. Adequate monitoring and effective suction are also essential during endoscopy. Emergency endoscopy should not commence until satisfactory venous access and central venous pressure measurement are established and volume replacement and resuscitation procedures including blood transfusions have been initiated to correct hypovolemia. If

bleeding is profuse or if the patient is stuporous, endotracheal intubation is essential before starting endoscopy to protect the airway and avoid aspiration of blood or gastric contents.

Patients with endoscopically proven active variceal bleeding or those in whom variceal bleeding has stopped should have immediate endoscopic intervention using variceal band ligation (Fig. 134.1). If endotherapy is deferred until the next elective endoscopy list in patients who have stopped bleeding, there is a distinct danger of further major acute variceal bleeding during the interval period, with substantial morbidity and mortality. If acute or recurrent major variceal bleeding continues despite endoscopic and pharmacologic therapy, mechanical control by balloon tamponade or esophageal stenting is required.

FAILED EMERGENCY ENDOSCOPIC THERAPY

Endoscopic therapy is successful in controlling acute variceal bleeding in over 90% of patients after one or two treatment sessions. Any patient who rebleeds after two successive emergency endoscopy treatments during a single hospital admission has a prohibitively high mortality if further endoscopic therapy is pursued. Such patients should have a balloon tube inserted, be resuscitated, and then be treated by an alternative technique. A transjugular intrahepatic portosystemic shunt (TIPS) procedure is recommended for patients who continue to bleed despite two endoscopic banding or sclerotherapy sessions. In patients being considered for liver transplantation, a TIPS procedure is now the preferred treatment to provide a bridge to transplantation.

BALLOON TUBE TAMPONADE

Acute esophageal variceal bleeding can be temporarily controlled in most patients by a correctly placed balloon tube (Fig. 134.2). The four-lumen Minnesota tube is the most widely used balloon tube; control of bleeding allows time for resuscitation and planning for management. Although the initial bleeding episode is effectively controlled, if no additional measures are used, 60% of patients will rebleed after removal of the tube with a high associated mortality rate; therefore, endotherapy should be performed when the tube is removed.

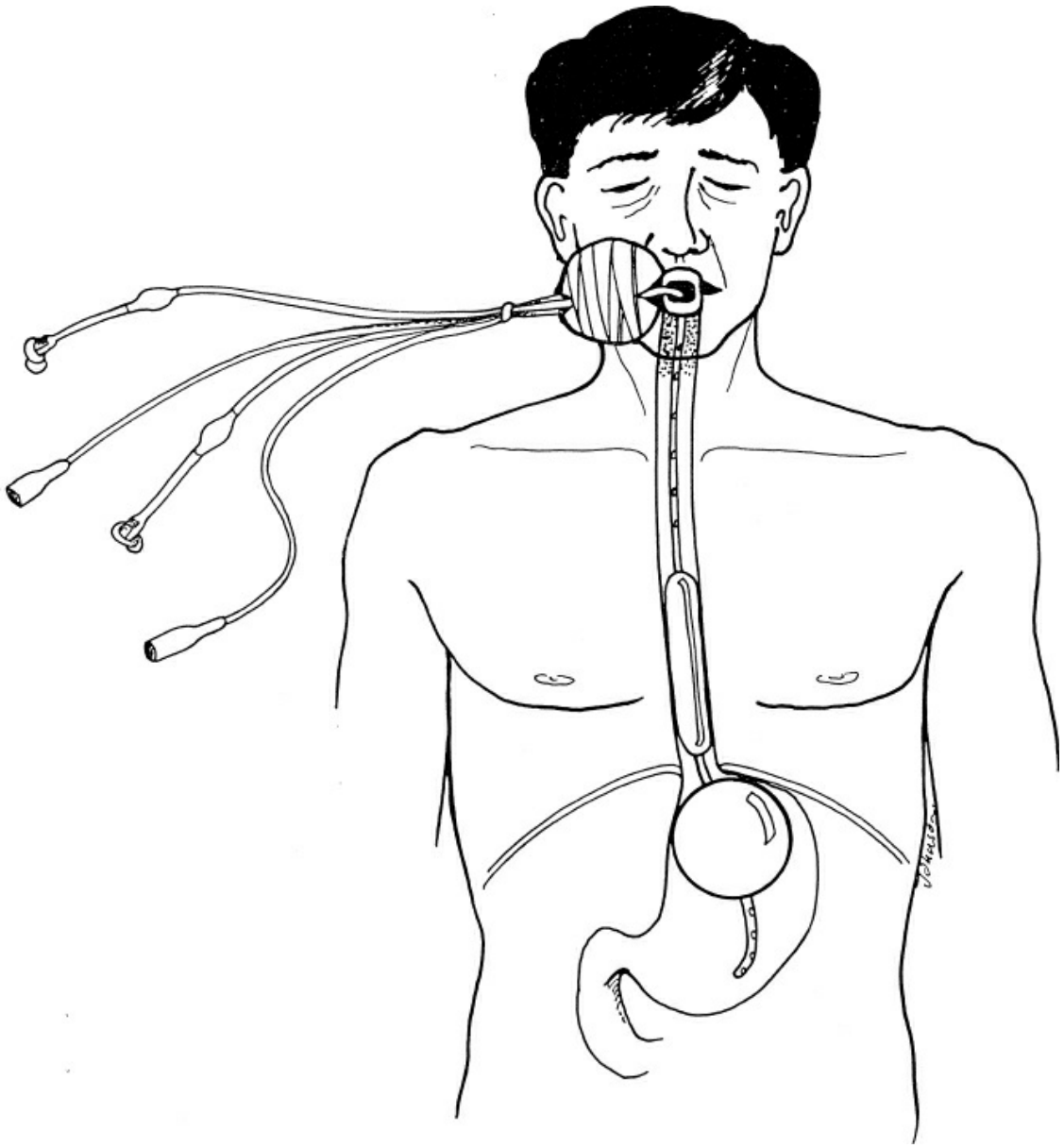

Figure 134.2. Four lumen balloon tube. The gastric balloon that is filled with air is held firmly against the esophagogastric junction by fixing a split tennis ball to the tube outside the patient's mouth.

Before a balloon tube is inserted in a stuporous or comatose patient, the airway should be protected by placing an endotracheal tube to prevent aspiration. A new balloon tube should be used, and the integrity of the balloons should be tested prior to use by inflating them under water to confirm complete air seals. The deflated lubricated balloon tube is passed through a bite-guard via the mouth, after adequate topical pharyngeal anesthesia. Awake patients are instructed to swallow while the tube is being passed. In a stuporous patient, placing the index finger within the mouth assists in guiding the tip of the tube over the posterior tongue and

through the cricopharyngeus, thereby preventing coiling of the tube in the pharynx. At times it may be difficult to negotiate the tube through the cricopharyngeus, particularly in patients who have an endotracheal tube in place. Under these circumstances, a McGill forceps and laryngoscope are used to assist insertion, and the tube is passed under direct vision. The tube is inserted as far as possible until the esophageal balloon is well into the esophagus.

The correct position of the balloon in the stomach is confirmed by injecting air into the aspirating lumen of the gastric tube using a 50-mL syringe and auscultating over the epigastrium, while instilling air. An x-ray of the upper abdomen provides additional confirmation of the correct position of the balloon. Thereafter, the gastric balloon is carefully inflated with 50 mL increments of air until a total of 250 mL has been inserted. The air should be easy to inject; if the tube is kinked or curled in the esophagus, resistance to injection is felt and inflation must be stopped and the balloon deflated. An incorrectly positioned and inflated gastric balloon within the esophagus may perforate the esophagus. The tube is then pulled back until the inflated gastric balloon is positioned firmly against the esophagogastric junction, thus compressing the varices.

The tube is held in place by a split tennis ball that is strapped to the tube just outside the mouth and adjacent to the mouth guard. The central portion of the tube is thereby kept taut between the gastric balloon below and the tennis ball above. This method has proven to be an effective method of maintaining tamponade at the esophagogastric junction, although football helmets have been used to attach the tube by others. Adequate tension on the gastric balloon can be checked regularly at the mouth. The mouth guard helps to protect the patient’s lips from the pressure of the tennis ball. Inflation of the esophageal balloon is not usually necessary as pressure from the inflated gastric balloon on the esophagogastric junction is generally sufficient. If esophageal balloon inflation is used, this is done using a three-way tap and a blood pressure manometer. The esophageal balloon is inflated to 40 mm Hg and the tube is then clamped. This pressure should be checked regularly. The third lumen, which opens in the esophagus, is placed on constant suction to keep the esophagus clear of saliva to avoid aspiration. The fourth gastric lumen is used for either nasogastric suction or for administering medication, such as lactulose to reduce encephalopathy.

Patients with a balloon tube in place should be monitored carefully in

an intensive care unit to avoid complications. The position of the inflated gastric balloon must be checked by an abdominal radiograph. Once the balloon tube has been inserted and tension applied and bleeding has been arrested, resuscitation is continued, clotting defects are corrected, and the patient is made as fit as possible for the necessary subsequent management. The balloon tube should be removed after 6 to 12 hours as a prelude to further endoscopic intervention.

ALTERNATIVE EMERGENCY MANAGEMENT OPTIONS

The main secondary alternatives to primary pharmacologic and endoscopic therapy for acute variceal bleeding are TIPS stenting, portosystemic shunts, esophageal transection operations, and liver transplantation. In patients with recurrent bleeding, it is crucial to identify the cause and site of bleeding, because the management of recurrent variceal bleeding, gastric varices, injection-induced esophageal ulceration, and portal hypertensive gastropathy differs.

A TIPS shunt is the emergency procedure of choice in patients in whom endoscopic therapy has failed to control bleeding. Recent data confirm the utility and efficacy of TIPS stent as a salvage procedure for refractory variceal bleeding unresponsive to endoscopic and pharmacologic treatment. Immediate control of variceal bleeding is achieved in over 90% of patients who have undergone a TIPS stent. However, TIPS in patients with uncontrolled variceal bleeding still has a high mortality. Prognosis is also poor if patients have developed sepsis, require inotropic support and ventilation, or have deteriorating liver and renal function. Established renal failure in a decompensated cirrhotic patient with uncontrolled bleeding is a contraindication to TIPS placement in most units.

The need for emergency surgical shunts to control acute variceal bleeding has diminished dramatically in the past decade due to the improved efficacy of pharmacologic, endoscopic, and radiologic treatment. While a successful surgical shunt effectively stops acute variceal bleeding and prevents recurrent bleeds, the role of emergency shunting procedures is currently restricted to patients who have failed endoscopic therapy and cannot be salvaged by a TIPS stent for technical reasons. This is because emergency shunt surgery has an operative mortality of up to 25%, which is largely determined by the degree of liver decompensation.

A variety of devascularization and transection operations that disconnect the high-pressure portal system from the esophageal varices

have been devised. As a basic principle, the most simple procedure should be used. Simple esophageal transection using a staple gun is the preferred procedure for patients in whom endoscopic therapy has failed and TIPS or an operative shunt is not feasible. Previous sclerotherapy may increase the difficulty and risk of performing the operation due to sclerosant-induced ulceration and periesophageal fibrosis. Esophageal transection combined with extensive esophageal and gastric devascularization is not justified in the emergency setting.

Although emergency liver transplantation has been advocated, it is best performed after initial control of variceal bleeding, preferably using an endoscopic technique, as this will interfere least with a subsequent transplant. For the failures of endoscopic therapy in potential transplant recipients, a TIPS shunt may be used as a bridge to transplantation.

Patients with uncontrolled variceal bleeding and end-stage liver disease, deteriorating renal function requiring inotropic support and on ventilation, and who do not respond to emergency treatment should be considered for conservative treatment only. While this decision poses difficult moral and ethical issues, this category of patients with a high MELD score and a Child–Pugh score over 13 seldom survive despite heroic efforts.

LONG-TERM MANAGEMENT

Evaluation of Liver Function

Once the acute bleeding episode has been controlled and the patient is stabilized, a detailed evaluation is undertaken to identify the cause of the portal hypertension, the severity of any underlying liver disease, and the likely natural history. The comprehensive medical assessment includes documentation of clinical and biochemical factors that might influence variceal rebleeding, liver function, and prognosis. A detailed history is obtained regarding current and previous bleeding episodes, the duration and amount of alcohol intake, family history of liver disease, and previous exposure to viral hepatitis. The physical examination should document the presence of stigmata of chronic liver disease, including jaundice, peripheral and sacral edema, spider angiomata, gynecomastia, palmar erythema, testicular atrophy, Dupuytren contractures, clubbing, fetor hepaticus, flapping tremor, cutaneous purpura, and petechiae. Abdominal examination should note the presence of a firm or nodular liver, splenomegaly, ascites, caput medusa and the Cruveilhier-Baumgarten syndrome with a paraxiphoid venous hum due to retrograde flow in a

patent umbilical vein. Clinical examination, in addition, seeks to establish clinical evidence of encephalopathy with asterixis and cognitive dysfunction.

All patients require full laboratory studies including hematologic, biochemical, and specific serologic testing. Patients' fluid and electrolyte status is evaluated by measuring serum electrolytes, urea, and creatinine. Standard biochemical tests of liver dysfunction include serum albumin, bilirubin, gamma glutamyl transpeptidase, alkaline phosphatase, aspartate aminotransferase, alanine aminotransferase, and alpha fetoprotein levels. All patients should have hepatitis B surface antigen and anti-HBc core antigens tested. Hepatitis C is assessed by antibodies to hepatitis C virus (HCV) using enzyme-linked immunoabsorbent assay with positive results confirmed by recombinant immunoblot assay. Patients without an evident cause of cirrhosis are screened for hemochromatosis including serum ferritin and transferrin saturation levels, alpha-1-antitrypsin deficiency, and Wilson disease. Autoimmune hepatitis is tested by antinuclear and smooth muscle antibodies and serum immunoglobulin G (IgG) levels. In selected patients in whom the diagnosis is unclear, ultrasound-guided plugged or transjugular liver biopsy can be done and transjugular portal wedge pressures measured. Transcutaneous abdominal ultrasound is performed to assess liver size and appearance including the features of steatosis, cirrhosis, atrophy-hypertrophy complex, portal vein patency and diameter, direction of portal vein flow, spleen size, duplex Doppler assessment of portal flow velocity and to screen for an underlying HCC.

Although the risks of recurrent variceal bleeding diminish with time, up to 70% of patients will have further variceal bleeding if left untreated. For this reason, all patients who have had a variceal bleed should be considered for secondary prophylaxis aimed at preventing further variceal bleeds. Endoscopic therapy is the primary treatment of choice. The options and second line alternatives are summarized in Table 134.4 and are detailed below.

Injection Sclerotherapy

In the past, injection sclerotherapy was the most widely used endoscopic treatment. Endoscopic variceal ligation has now replaced sclerotherapy as the first-line endoscopic therapy. If banding is not available sclerotherapy, when used, is performed using a video endoscope and a freehand injection technique. Unlike most other forms of therapy used in the management of

esophageal varices, sclerotherapy techniques are less standardized. The injections may be placed directly into the varices ("intra-variceal") with the objective of thrombosing the varices, or into the submucosa adjacent to the varices ("para-variceal") to produce submucosal edema to stop acute variceal bleeding and to cause thickening of the mucosa to prevent later bleeding. Many endoscopists use a combination of these two techniques (Fig. 134.3).

TABLE 134.4 Long-Term Management Options to Prevent Variceal Rebleeding

Treatment Options
1. Endoscopic therapy
a. Variceal band ligation
b. Injection sclerotherapy
2. Pharmacotherapy
a. β-blockers
b. Other drugs
3. Surgery
a. Shunt
i. DSRS
ii. Portocaval
b. Nonshunt
i. Esophageal transection and esophagogastric devascularization
ii. Splenectomy for gastric varices due to splenic vein thrombosis
4. TIPS
5. Liver transplantation

DSRS, distal splenorenal shunt; TIPS, transjugular intrahepatic portosystemic shunt.

Sclerotherapy is performed with different skill levels and protocols and variable frequencies of injections and endoscopic review. When used, a combined para- and intravariceal technique is preferred for acute variceal bleeding and a predominantly intravariceal technique is used for long-term management when varices are smaller. Our sclerosant of choice is 5%

ethanolamine oleate. Injection treatments are continued at two weekly intervals until the varices have been eradicated and are no longer visible during endoscopic surveillance. Thereafter, the patient is assessed at 3 months and then at 6-monthly and subsequently at yearly intervals. Whenever recurrent varices are diagnosed, a repeat course of sclerotherapy is undertaken until re-eradication is achieved.

Esophageal Variceal Ligation

The use of endoscopic band ligation represented a seminal development in the endoscopic treatment of varices. The concept of endoscopic variceal ligation is similar to the technique used for treating hemorrhoids, and was devised by Stiegmann from Denver, Colorado. Hemostasis is achieved by physical constriction of the base of the varix by a rubber band. Ischemic necrosis of the strangulated mucosa and submucosa trapped within the band occurs, followed by sloughing of the banded varix. The resulting shallow mucosal ulcer re-epithelializes over the next 14 to 21 days, with scarring and shrinkage of the residual varix by maturing fibrous tissue. Two different types of ligating devices are used—(i) the initial single-band delivery system and (ii) the newer multiband ligator. The original Stiegmann apparatus allowed the placement of one variceal band at a time and required the use of an overtube to allow multiple withdrawals and re-insertions of the endoscope. The newer multiband apparatus allows the sequential placement of 8 to 10 bands during a single insertion of the endoscope, obviating the need for an overtube. The multiband variceal ligator has replaced the single shot banding equipment in most endoscopy units. The band ligation procedure is repeated at 2 to 3 weekly intervals until all the varices are obliterated.

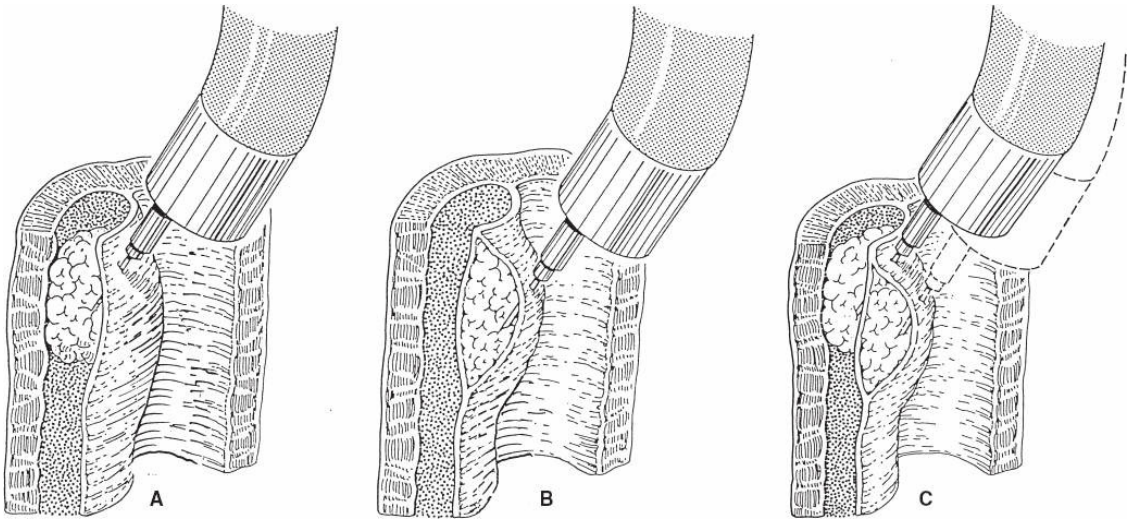

Figure 134.3. Technical variants of injection sclerotherapy. **A.** Intravariceal injection. **B.** Paravariceal or submucosal injection. **C.** Combined intravariceal and paravariceal injections.

Endoscopic variceal ligation has been shown to be as effective as injection sclerotherapy in the emergency management of bleeding esophageal varices. Furthermore, variceal eradication using ligation requires fewer endoscopic treatment sessions, and causes substantially less local esophageal complications. Current data demonstrate a clear advantage for ligation in preference to sclerotherapy in elective variceal treatment. Ligation is now the endoscopic treatment of choice in the management of all esophageal varices.

ALTERNATIVE LONG-TERM MANAGEMENT OPTIONS

Although we prefer endoscopic therapy as the primary therapy for most patients, pharmacologic therapy with propranolol alone or in combination with nitrates is an acceptable alternative primary long-term therapy in selected patients.

Pharmacologic Therapy

The use of nonselective beta-blockers (NSBB) as primary long-term therapy has considerable support in the current literature. Several meta-analyses have concluded that beta-blockers, principally propanolol, significantly reduce the incidence of recurrent bleeding and improve long-term survival when compared with placebo. Unfortunately, β-blockade is not without its drawbacks. There are a number of relative contraindications to β-blockade, including bronchial asthma, chronic obstructive pulmonary

disease, peripheral vascular disease, congestive cardiac failure, and unstable insulin-dependent diabetes mellitus. Once treatment is initiated, β-blocker-induced side-effects may also be a problem. The most common side effects are loss of energy, depression, impotence, and headaches. In a minority of patients, these side effects may be sufficiently severe to cause discontinuation of treatment. Thus, a significant proportion of the population at risk may be unsuitable for treatment with β-blockers or may stop taking the drug as a result of side effects. In addition, one third of patients treated with standard doses of β-blockers do not achieve significant reduction in portal venous pressures.

Where patient compliance is good, long-term propranolol therapy is an alternative to endoscopic management. If patients have a recurrent variceal bleed while on adequate propranolol therapy, endoscopic band ligation should be used to eradicate varices while continuing with β-blockers. The risk of side effects has led to the evaluation of other drugs to reduce portal hypertension. The main group of alternative drugs are nitrates, with isosorbide-5-mononitrate being increasingly used in clinical practice.

SURGICAL SHUNTS

Portosystemic shunts are classified as (i) nonselective, (ii) selective, or (iii) partial. Successful nonselective end-to-side or side-to-side portacaval shunts effectively control acute variceal bleeding and prevent recurrent bleeding, and were the gold standard in the past. Portacaval shunts are, however, major operations in poor-risk patients and may be associated with severe and unpredictable side effects, particularly encephalopathy and deterioration in liver function. The most popular shunts for long-term management at present are the small diameter (8 mm) externally reinforced polytetrafluoroethylene interposition graft between the portal vein and the vena cava and the distal splenorenal shunt. Operative details of these shunts are presented in preceding chapters.

Devascularization and Transection Operations

Although esophageal transection was mainly used for acute variceal bleeding, a more extensive gastric and esophageal devascularization with transection of the lower esophagus has also been used in some centers for long-term management. These major procedures are particularly popular in Japan. Controlled trials have shown that although this procedure is as effective as repeated endoscopic therapy, long-term endoscopic therapy is

simpler and far less costly. Devascularization and transection procedures are generally therefore reserved for patients with recurrent variceal bleeding despite endoscopic and pharmacologic treatment who are not candidates for TIPS and have vasculature unsuitable for shunt operations.

Transjugular Intrahepatic Portosystemic Shunt (TIPS)

Previously major surgery was the only method available to create portosystemic shunts. The advent of TIPS, a nonoperative interventional radiologic stent that can be inserted under local or general anesthesia, has become an established treatment for the complications of portal hypertension. The principal indication is for variceal bleeding refractory to endoscopic and medical therapy.

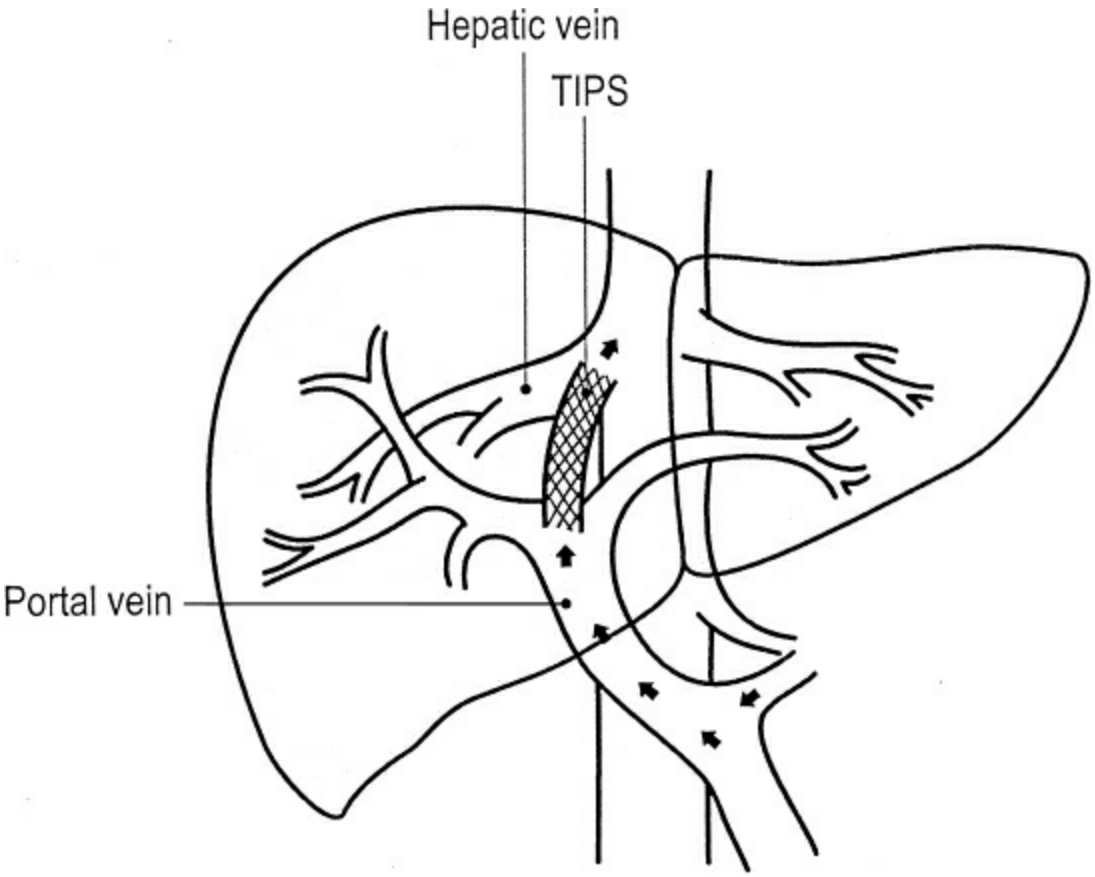

Figure 134.4. Transjugular intrahepatic portosystemic shunt (TIPS). A catheter is passed into the hepatic vein via the jugular vein. A needle, inserted through the catheter, is passed from the hepatic vein through liver tissue into a major portal vein branch. This is followed by the placement of a guidewire and dilatation of the tract through liver tissue with an angioplasty balloon catheter. The tract is kept open and functions as an intrahepatic portosystemic shunt after deployment of an expandable metal

stent.

TIPS insertion can be a technically demanding procedure and should only be performed by an experienced interventional radiologist. Patency of the portal vein should first be confirmed by Duplex ultrasound or other cross-sectional imaging. In principle, percutaneous internal jugular vein access allows a catheter to be passed into the superior and the inferior vena cava. The tip is positioned in the right or middle hepatic vein, and a rigid needle is passed from the hepatic vein through a bridge of intervening liver tissue and into a major portal vein branch. The tract within the liver parenchyma is dilated with a 10-mm angioplasty balloon catheter, and the communication between the hepatic vein and the portal vein is held open by deployment of an expandable metal stent, usually a 10-mm Wall stent (Fig. 134.4). In some patients with persistent varices, the left gastric vein can be embolized with coils during TIPS placement.

The major indication for TIPS is the salvage use in treating failures of endoscopic therapy in patients with refractory or ongoing acute variceal bleeding. The procedure can be performed with low morbidity and mortality by an expert interventional radiologist, even in poor-risk patients. TIPS is an ideal bridge to liver transplantation in patients with acute variceal bleeding as it does not disturb the porta hepatis in patients requiring subsequent surgery.

Disadvantages of the TIPS procedure include the cost (each stent costs in the region of $1,000), particularly when more than one procedure is required. In the past, TIPS procedures used mainly uncovered metal stents that were prone to stenosis and occlusion within 1 to 2 years and that required close surveillance and had high rates of re-intervention. Another disadvantage was the substantial encephalopathy rate. The introduction new covered TIPS stents promises improved of patency rates but requires precise placement.

LIVER TRANSPLANTATION

Liver transplantation is the only treatment that cures the underlying liver disease and the portal hypertension. All patients presenting with variceal bleeding and significant liver decompensation should be considered for hepatic transplantation even though only a small percentage of patients will ultimately become transplant candidates.

In potential transplant candidates with acute variceal bleeding,

emergency endoscopic therapy is considered the treatment of choice. If endoscopic therapy fails to control active variceal bleeding and if a donor liver is not immediately available, an urgent TIPS should be considered as a salvage procedure to control bleeding before transplantation. Once the patient has recovered from the acute variceal bleed, early transplantation should be performed if further evaluation confirms that the patient is a suitable liver transplant candidate. Patients with good liver function can be considered for a distal splenorenal shunt rather than a transplant.

INJECTION SCLEROTHERAPY

Technical Variants

Three basic techniques are used (Fig. 134.3). The aim of direct intravariceal injection (Fig. 134.3A) is to thrombose the varices, thereby preventing recurrent hemorrhage. Paravariceal or submucosal injection (Fig. 134.3B) produces submucosal edema that stops acute bleeding by compression and later causes mucosal thickening, thereby preventing recurrent bleeding. The combined paravariceal and intravariceal technique is used to enhance the advantages of each individual technique (Fig. 134.3C).

Elective Sclerotherapy Technique

Elective sclerotherapy is performed in an outpatient clinic with two assistants trained in endoscopy techniques. One assistant reassures the patient, provides suction of the patient's mouth to avoid aspiration, and ensures that the mouth guard is correctly postioned between the teeth and does not become dislodged. The other assistant advances and retracts the injector needle at the back of the endoscope and administers the sclerosant under the direction of the endoscopist.

The patient is placed in the left lateral decubitus position at the top of the endoscopy bed, with the head on a pillow and the neck slightly flexed. The pharynx and posterior tongue are anesthetized with three puffs of 10% *xylocaine* spray. A small butterfly needle is inserted into a superficial hand vein for administration of sedation. We usually administer small incremental doses of *midazolam* to a total of 2.5 mg. All the instruments, including the endoscope, are checked before use, and commands such as "advance needle" and "retract needle" are rehearsed, if a new or inexperienced assistant is present. Each time an injection is required, this

is indicated by the endoscopist and acknowledged by the assistant. The assistant is instructed to comment if resistance is encountered during injection, as resistance may indicate that the varix is thrombosed or that the needle is not correctly positioned.

The endoscope is inserted through the mouth guard and is passed under direct vision, keeping the lumen of the esophagus in view while controlling the position of the endoscope tip. The complete esophagus is examined and the presence of esophageal varices noted and documented, including their number, size, and extent. In the elective setting, bleeding will usually not be present and a full diagnostic panendoscopy is performed first to exclude other lesions before commencing injection of varices. The presence, position, extent, and size of gastric varices and the degree of portal hypertensive gastropathy are noted and documented.

Once full panendoscopy has been completed, the endoscope is withdrawn into the esophagus and positioned above the esophagogastric junction so that the varices in the lower 5 cm of the esophagus can be injected. The endoscope is maneuvered into position, and the target varix is identified. The assistant advances the needle on instruction, and a small volume of sclerosant solution is injected and discarded into the lumen of the esophagus to ensure that the injector is filled. The endoscopist then inserts the needle directly into the center of the most prominent part of the varix, near to the esophagogastric junction, by advancing the injector a further 5 to 10 mm. Once the needle has been satisfactorily placed within the lumen of the varix, the assistant is instructed to inject 1 mL of sclerosant (Fig. 134.5). If this is achieved without resistance, further sclerosant is injected under instruction. The varix will be seen to distend at the injection site and become paler; this indicates that sufficient sclerosant has been injected into this varix. A total of no more than 5 mL of ethanolamine oleate is usually required for a large varix; smaller varices usually require less sclerosant. Thereafter, any additional varices are injected at the same level. A second injection is placed 2 to 3 cm higher in large varices. Usually, only 2 to 3 mL of sclerosant is injected into the upper site. No attempt should be made to inject the varices while the patient is restless or retching. Such uncontrolled injections may result in laceration of the varix by the needle with resultant major bleeding.

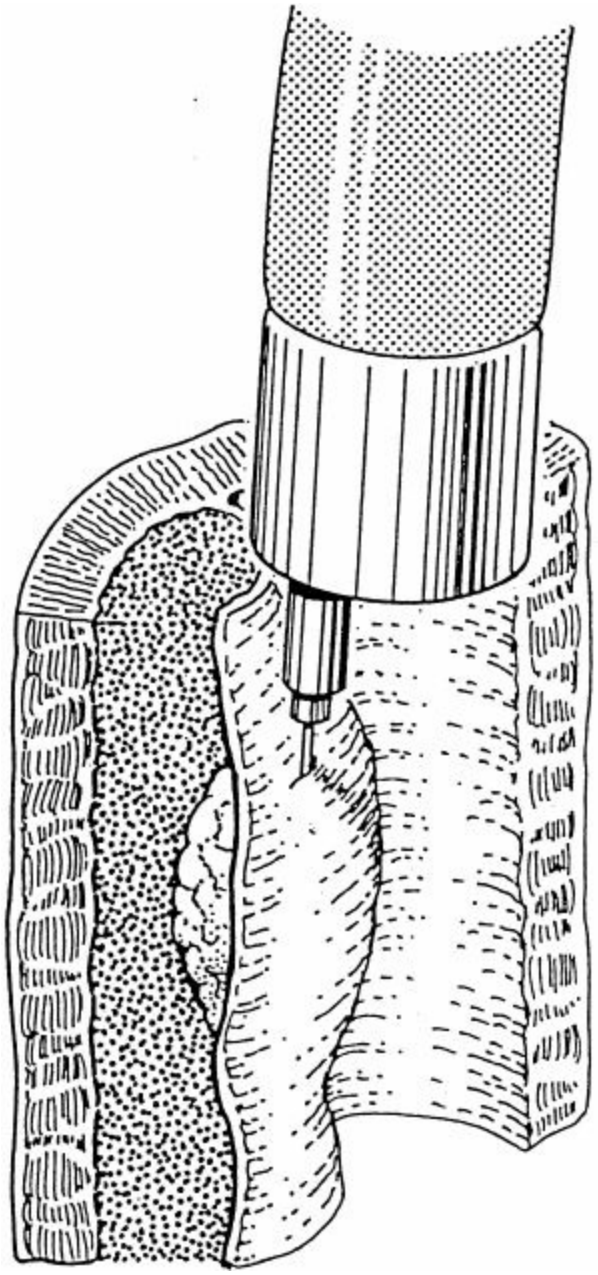

Figure 134.5. Intravariceal injection technique. After an initial test injection of 1 mL of sclerosant, up to 5 mL of ethanolamine oleate is injected directly into the varix immediately above the esophagogastric junction.

After the procedure, the patient is observed in the outpatient endoscopy suite recovery room for an hour. If the patient is stable and there is no pain or discomfort, the patient is discharged home. It is unusual for bleeding to complicate an elective sclerotherapy session.

Subsequent sclerotherapy injections are performed at 2 to 3 weekly intervals until all the varices have been eradicated. Severe local esophageal mucosal ulceration or slough may delay injection of the underlying varix,

but the other variceal channels should be injected. Once eradication of the varices has been achieved, a further endoscopic assessment is performed at 3 months to confirm continued eradication. Further surveillance evaluations are performed every 6 months for 2 years and then annually for life. If recurrent varices are noted at any time, repeat endoscopy and injections are performed at weekly intervals until the varices have again been eradicated.

EMERGENCY SCLEROTHERAPY

Intravariceal Injection

An intravariceal injection technique similar to that described for elective sclerotherapy can be used (Fig. 134.6). However, some endoscopists prefer the combined paravariceal and intravariceal injection technique described below for patients with active variceal bleeding.

Combined Paravariceal and Intravariceal Injection

The needle is inserted in a paravariceal position in the submucosa of the varix immediately superior to the bleeding point, and 1 mL of 5% ethanolamine oleate solution is injected. The objective is to raise a submucosal wheal (Fig. 134.7A) and thereby control the active bleeding by compression (Fig. 134.7B). If this does not completely control the acute bleeding, a further paravariceal injection is performed alongside the bleeding point. Once the bleeding has been controlled, the intervention for that varix is completed by an intravariceal injection of 3 to 5 mL of ethanolamine oleate (Fig. 134.7C). All additional variceal channels are injected either with a combined or an intravariceal technique. Large varices are injected with a further intravariceal injection 2 to 3 cm superior to the initial injection site. If the bleeding is profuse and visibility obscured despite irrigation, sclerotherapy cannot be completed safely, and under these circumstances, a balloon tube is inserted, as described previously.

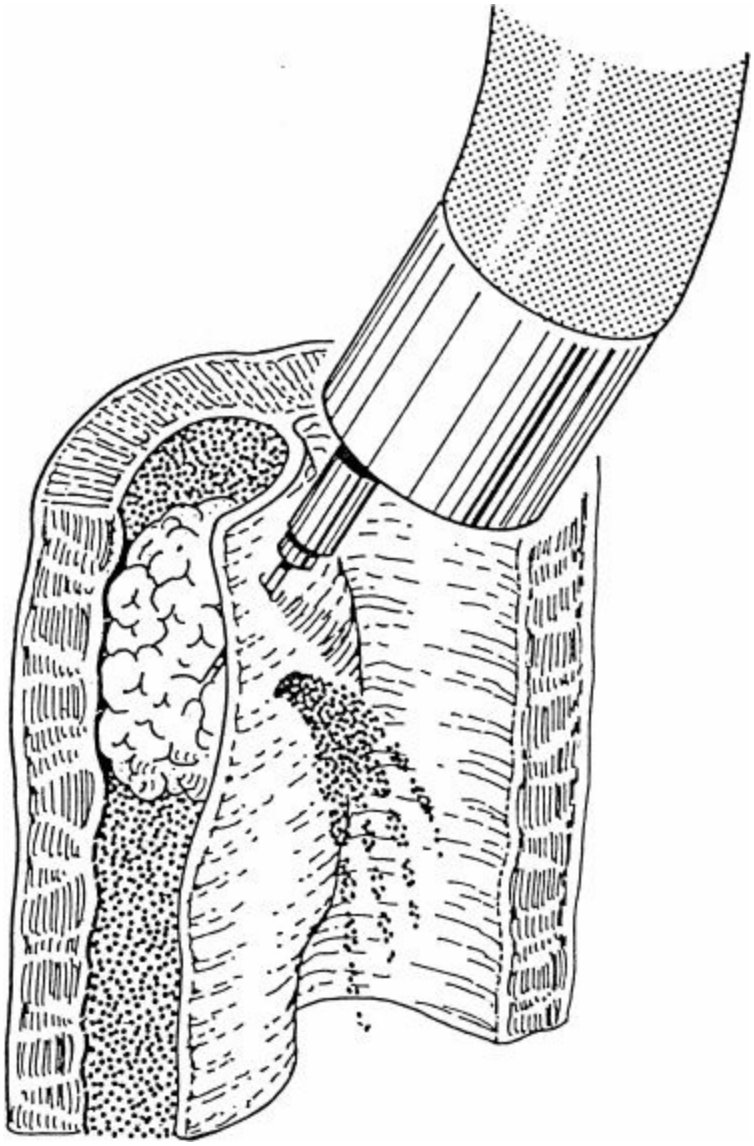

Figure 134.6. Emergency sclerotherapy. An intravariceal injection technique is used to treat an actively bleeding varix.

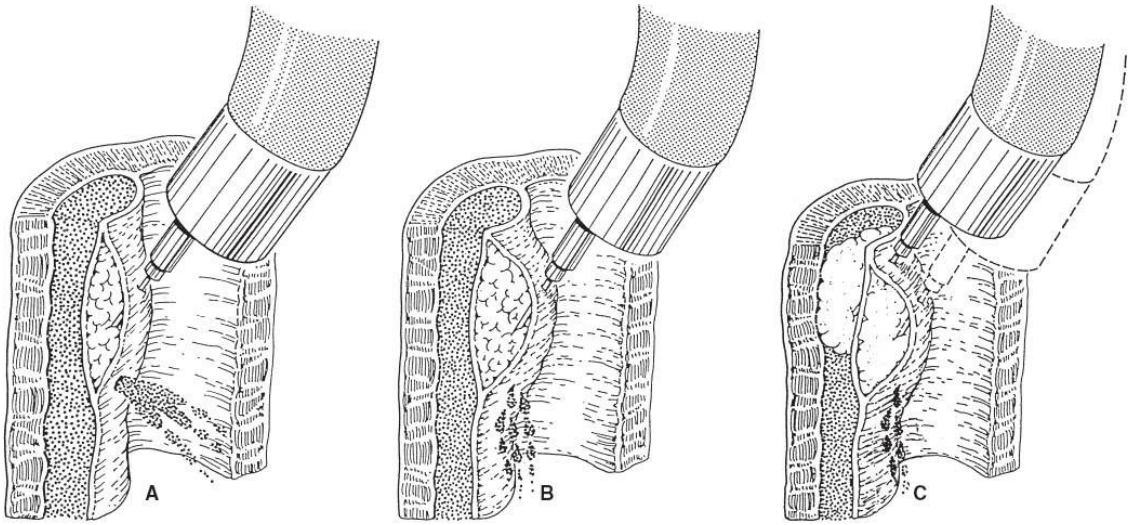

Figure 134.7. Emergency sclerotherapy: Combined paravariceal

and intravariceal technique. **A.** Initial paravariceal injection immediately proximal to the bleeding point. **B.** Bleeding controlled by the paravariceal injection. **C.** An intravariceal injection completes the procedure.

Most patients (70%) respond to a single injection treatment and have no further bleeds. If bleeding does recur, the patient must be re-endoscoped urgently. Further bleeding after two injection treatments during a single hospital admission is defined as failure of emergency endoscopic therapy. If the patient is hemodynamically unstable, a balloon tube should be inserted to control active bleeding. After resuscitation, the patient should have an alternative procedure, which is usually a TIPS procedure, or occasionally, when appropriate, injection of the varices with cyanoacrylate. A recent innovation has been the short-term interim use of self-expanding covered metal esophageal stents instead of a balloon tube to compress bleeding varices. The esophageal stent is removed after definitive treatment.

COMPLICATIONS

The most serious complication after sclerotherapy is esophageal perforation caused by inadvertent esophageal wall injection of sclerosant instead of into the lumen or submucosally. This is fortunately uncommon and usually occurs as a result of excessive sclerosant injected during active bleeding with incorrect positioning of the needle during injection. Less severe complications include a minor injection site leak. This is visible on a contrast swallow and is usually treated with parenteral nutrition or nasogastric feeding through a fine-bore silastic tube and antibiotics. Minor leaks usually resolve on conservative therapy. The most common esophageal complication is mucosal ulceration, which although frequent, is usually of no consequence and heals without further morbidity. Pneumonia may occur in patients with acute variceal bleeding, irrespective of the management used, and may be aggravated by aspiration of blood. With repeated sclerotherapy, complications are cumulative but with increasing endoscopic experience can be either prevented or minimized.

ENDOSCOPIC VARICEAL BAND LIGATION

Single Band Application

The original endoscopic variceal banding device (C.R. Bard, Tewksbury,

MA) has a housing, or outer cylinder and a banding, or inner cylinder. It is completed with a trip wire on the inside and a single latex **O** ring stretched to fit over the banding cylinder (Fig. 134.8). The outer housing cylinder is attached to the end of the endoscope via a silastic friction mount. The banding cylinder is a smaller cylinder fitted with a clasp that allows insertion of the trip wire. It is constructed to fit snugly yet slide smoothly inside the housing cylinder. The trip wire consists of a monofilament strand, to which a flange is attached at the distal end. The small latex **O** rings are mounted on the banding cylinder (Fig. 134.8).



Figure 134.8. Loaded multiband (**left**) and single band (**right**) endoscopic devices.

The banding technique is the same whether performed for an acute variceal bleed or for an elective banding procedure. A diagnostic panendoscopy is performed first, when possible. After confirming the need for variceal banding, the endoscope is removed and reinserted after backloading an overtube. After reinserting the endoscope into the stomach,

the overtube is carefully advanced and passed through the cricopharyngeus and into the upper esophagus. The endoscope is removed again, and the banding device is attached to the end of the endoscope. A trip wire is passed through the vacuum lock of the biopsy channel entry port and exits via the distal biopsy channel opening. The trip wire is secured to the clasp in the banding cylinder, and the banding cylinder is "backed" into the housing cylinder. The banding cylinder is positioned so that approximately 1 mm of the cylinder protrudes beyond the **O** ring, which is seated against the end of the housing cylinder. The endoscope is reinserted into the patient's esophagus via the overtube. The endoscope is passed repeatedly for each banding procedure and then removed to disconnect the used inner cylinder and replace it with a fresh cylinder with a new **O** ring.

The varix that is to be banded must be clearly identified. The endoscope is advanced under direct vision until the banding cylinder is in full 360-degree contact with the varix (Fig. 134.9A). Once full contact is made, suction is applied. This draws the varix and the surrounding mucosa into the banding chamber (Fig. 134.9B). Once the chamber is completely filled with the varix, a "red-out" view is visible through the endoscope. The trip wire is pulled and the latex **O** ring is dislodged from the inner cylinder and becomes securely fixed around the base of the target varix (Fig. 134.9C,D). A technical disadvantage of the single band applicator is that if several varices must be ligated, the endoscope must be removed and reinserted on every occasion, with a new band for each individual variceal ligation.

The treatment begins with ligation of the bleeding varix or the most inferior part of the target variceal column. Each column has a single band placed at its lower end. Large varices have additional bands placed more proximally, 2 to 5 cm higher up the esophagus. On average, a total of six to nine bands are applied during the initial session, and progressively fewer bands are required at subsequent sessions as the varices decrease in size. After banding, patients are advised to eat soft meals for 24 hours, and are able to eat normally thereafter. Repeated banding treatments are performed at 2-week intervals until the varices have been eradicated.

Multiband Application

The multiband ligator that can deploy 6, 8, or 10 bands is now the endoscopic variceal equipment of choice (Fig. 134.8). The preloaded bands on the cap barrel are deployed one by one by a drawstring that

passes from the ligator through the biopsy channel and is attached to a trigger unit mounted on the biopsy channel port of the endoscope, which allows repeated individual firing of the bands. The multiband system obviates the need for an overtube. As with the single band applicator, treatment begins with ligation of the bleeding varix or the most distal part of the target variceal column (Fig. 134.10). A single band placed at its lower end and the next band applied to the adjacent variceal column at a slighter higher level in a spiral pattern.

Three tips are useful when using the multiband ligator. As the ligating cap and attached bands are larger than the end of the endoscope, the endoscopist may have difficulty passing the tip of the endoscope through the cricopharyngeus and the patient may gag while trying to swallow the enlarged tip of the endoscope. Liberal lubrication with KY jelly and flexing the patient's neck will usually resolve any difficulty in passing the endoscope. The endoscopist should ensure that the silastic friction mount of the banding chamber is snugly attached to the end of the endoscope with no air leaks. The nursing staff confirm that the wall suction is at maximum flow to ensure that the varix will be sucked fully into the ligating chamber and to allow the band to be deployed correctly at the base of the varix and encompass the entire varix.

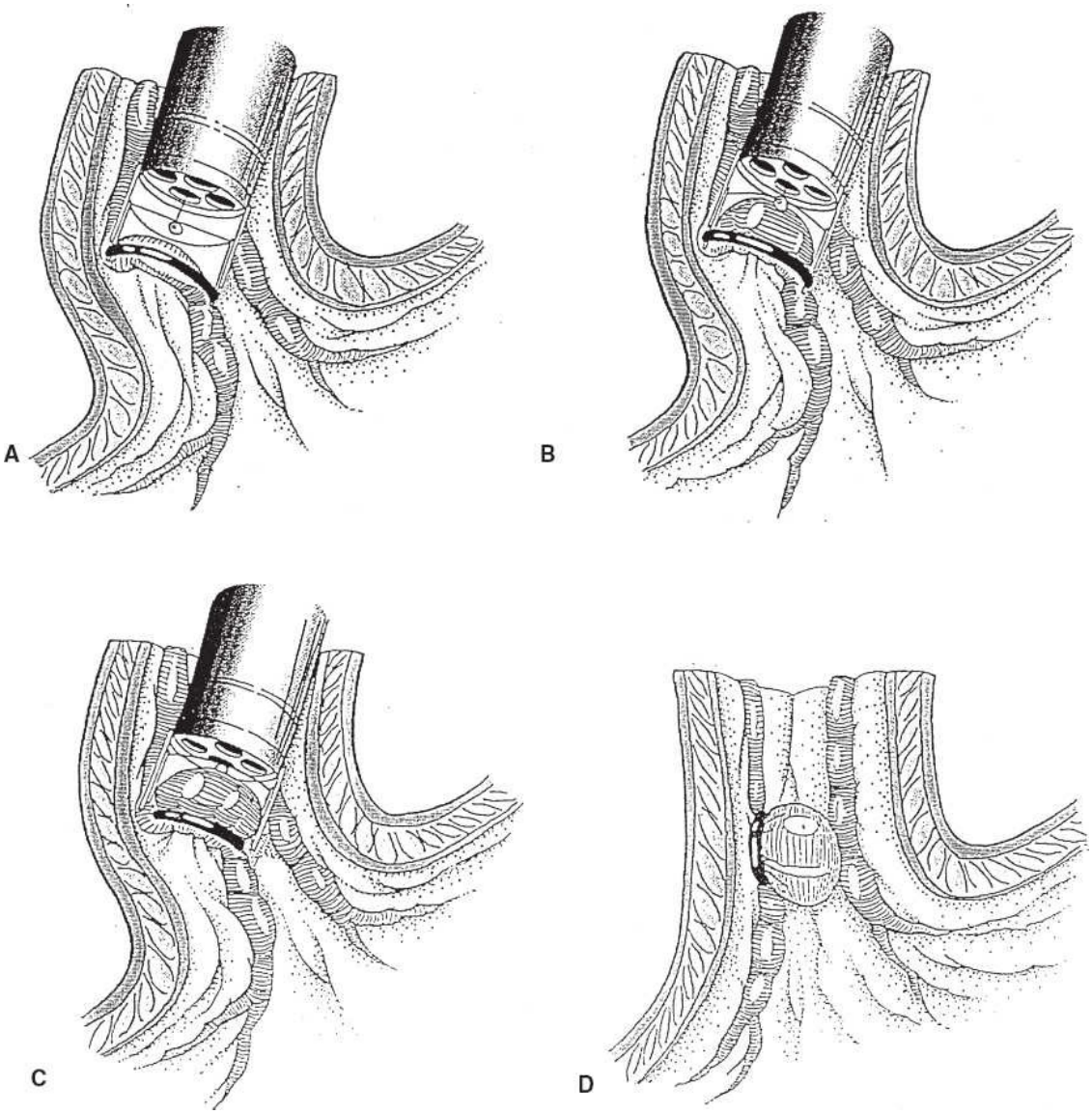

Figure 134.9. Endoscopic ligation of esophageal varices using the flexible endoscope. **A.** Varix is approached under direct vision by the endoscopist. Full contact is made between the end of the ligating device and the tissue to be ligated. **B.** Endoscopist activates the endoscopic suction, which results in aspiration of esophageal mucosa, submucosa, and the varix into the ligating device. **C.** Trip wire (which runs through the biopsy channel of the endoscope) is pulled, which moves the inner cylinder (over which the elastic **O** ring is stretched) toward the endoscope, displacing the small elastic band. **D.** Elastic band encircles the neck of the now ligated tissue, resulting in strangulation and thrombosis.

Technical difficulties with band deployment may occur during major variceal bleeding if blood clot fills the chamber while the endoscopist attempts to suck the bleeding varix into the chamber before releasing the

band. In this situation, elevation of the head of the table and vigorous irrigation through the endoscopy channel will usually dislodge the clot from the chamber and improve visibility. Once the bleeding varix is banded and bleeding is controlled, further bands can be applied to the remaining varices. The multiband variceal ligator is a significant technical advance over the single shot device, but because the unit is disposable and cannot be re-used the current retail cost of $200 per unit has limited its universal use.

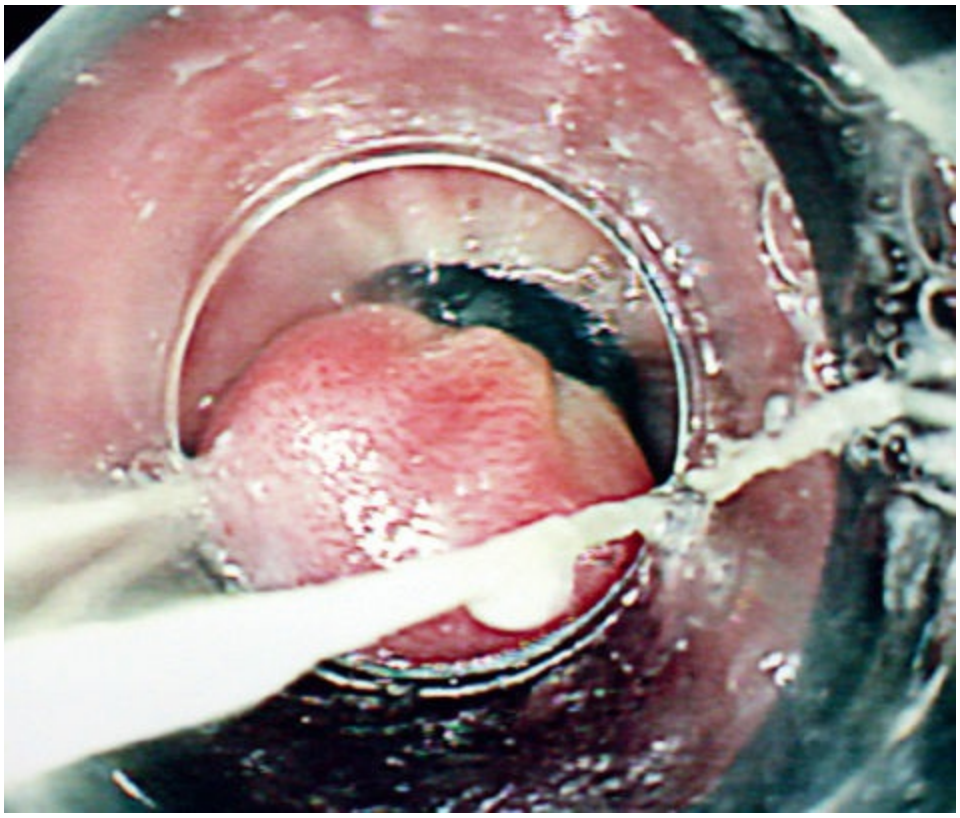

Figure 134.10. Endoscopic view of a ligated varix with a deployed band at the variceal base.

COMPLICATIONS

Complications as a consequence of variceal ligation occur in two categories. The first relates to the overtube and the second to the elastic bands. The esophagus can be injured by inadvertantly pinching the esophageal wall in the gap between the overtube and the endoscope while advancing the overtube over the endoscope. This has led to mucosal tears and rarely esophageal perforation. Overtubes with a new improved design should eliminate this problem. The second problem has been engorgement of the varices in the distal esophagus due to compression by the tube that

may lead to variceal bleeding before banding and that may be life-threatening. If this occurs, the overtube should be withdrawn until the distal end just protrudes through the cricopharyngeus into the esophagus. The engorgement should then resolve. Complications related to the banding itself are uncommon. Bleeding at an ulcer site after the band has fallen off has been a less frequent complication than that occurring with sclerotherapy ulcers. The widespread use of the multiband ligator has eliminated the use of and the complications related to the overtube.

GASTRIC VARICES

Gastric varices are the source of bleeding in 10% to 20% of patients with variceal hemorrhage. However, gastric variceal (GV) bleeding is more severe and has a worse outcome than esophageal variceal bleeding. Gastric varices are classified into four types based on their relationship with esophageal varices and their location in the stomach. Gastro-esophageal varices (GOV) are continuous with esophageal varices along the lesser curve of the stomach for 2 to 5 cm (GOV1) or into the fundus of the stomach (GOV2). Isolated gastric varices occur in the fundus (IGV1) or elsewhere in the stomach including body and antrum (IGV2). Any patient with suspected variceal bleeding should be resuscitated as described above in the section “Management of Acute Variceal Bleeding.” Once endoscopy has identified gastric varices as the source of bleeding, the initial treatment options include therapeutic endoscopic intervention and long-term NSBB, with TIPS, radiologic procedures, and surgery reserved as salvage procedures.

Endoscopic Therapy for Gastric Varices

Endoscopic intravariceal injection of glue is the treatment of choice for bleeding gastric varices and is preferable to either banding or sclerotherapy. which have higher rebleeding rates. Endoscopic gastric variceal injection is performed using tissue adhesives such as N-butyl-2-cyanoacrylate or 2-octyl-cyanoacrylate. Because of the special chemical properties of these tissue glues, particular precautions must be taken and the injection protocol closely observed during injection of the glue. Intravariceal glue injection utilizes a similar technique to conventional sclerosant injection but with several modifications to avoid complications due to spillage or hardening of the glue before completion of the injection.

Histoacryl (N-butyl-2-cyanoacrylate) polymerizes and rapidly hardens

on contact with blood which makes endoscopic injection technically difficult. There are potentially serious risks of equipment damage by tissue adhesives in inexperienced hands and care must be taken to ensure that the adhesive does not come into contact with the endoscope and block the channels of the instrument. It is therefore necessary to dilute the glue with the oily contrast agent lipiodol to retard the chemical reaction and prevent premature polymerisation of the glue in the injection needle. A 50/50 mixture of histoacryl and lipiodol is used for injection. Patients who have allergies to iodine should not receive this therapy because lipiodol is an iodized oil emulsion. The mixture of histoacryl and lipiodol should be prepared immediately before the injection in patients with suspicion of gastric variceal bleeding with each dose containing 1 mL of histoacryl and 1 mL of lipiodol. For the glue injection, a therapeutic gastroscope with at least a 3.2-mm channel is required to allow the injection catheter to pass when the gastroscope is retroverted. A 23-gauge needle attached to a 7-Fr 240-cm injection catheter should be checked before use to confirm free passage through the endoscope channel when in a retroflexed position. This ensures that the needle can be advanced and withdrawn completely within the scope in the stomach.

Because of the rapid adhesive properties of the glue, the patient’s eyes must be protected. The endoscopist and the endoscopy nurses must wear gloves and goggles and should be well versed with the equipment and the injection technique, especially with regard to the needle insertion and withdrawal sequences and injection volumes. The injection catheter is primed with distilled water. Several catheters should be available because the catheters may become clogged with glue and need to be replaced. The 2-mL syringe containing the histoacryl/lipiodol mixture is mixed ready for injection.

The gastroscope is placed in a retroflexed position adjacent to the target varix in preparation for injection and the suction is turned off. The previously prepared catheter is inserted into the biopsy channel, and observed endoscopically. The catheter, with the needle still withdrawn, is advanced without variceal contact to ensure that the direction of the catheter beyond the tip of the scope leads to an appropriate site for injection into the varix. The needle is then advanced and placed directly into the gastric varix. The prepared histoacryl/lipiodol mixture is rapidly injected into the varix, and the catheter is then flushed with water to clear any remaining glue from the catheter. The needle is withdrawn from the

varix but not into the endoscope. The injection process is repeated if another injection of glue is needed. The endoscopist continually insufflates the stomach with air. The needle can now be withdrawn into the sheath and the catheter tip can be used to palpate the injected varix (or varices) to ensure that the varix is hard. If the varix is soft, further injections are needed. It is important not to inject more than 2 mL of histoacryl/lipiodol at a time to avoid embolization. However, several separate injections can be made into one varix during one session. If the needle cannot be retracted into the catheter, the catheter is removed via the biopsy channel and a new catheter is used.

A single injection is usually effective for control of acute bleeding with success rates of more than 90% but repeat injection sessions every 4 weeks may be needed for complete obturation of varices. Complications are uncommon after glue injections if the injection protocol is carefully followed, but may include thromboembolic phenomena involving splenic, renal, pulmonary, and other vessels, needle entrapment in a varix, gastric ulceration, visceral fistula, bacteremia, and sepsis. Interventional radiologic techniques such as TIPS with PTFE-covered stent or balloon-occluded retrograde transvenous obliteration (B-RTO) are effective rescue techniques after failure of first-line therapies. The need for surgical intervention has diminished with the success of endoscopic intervention and is either splenectomy for patients with splenic vein thrombosis or a portal-systemic shunt for those with portal hypertension and preserved liver function. Secondary prophylaxis with NSBB is recommended after variceal eradication.

CONCLUSION

The range of treatment options for bleeding esophageal varices has expanded markedly during the past two decades. Increasingly sophisticated methods of management have developed in response to the evolving understanding of the pathophysiologic processes underlying portal hypertension. Endoscopic treatment has become the principal first-line intervention in patients with bleeding esophageal varices, both during the acute event and in combination with NSBB for long-term prevention of recurrent bleeding. The treatment of both acute and persistent recurrent variceal bleeding is best accomplished by a skilled, knowledgeable, fully equipped, and well-organized team using a multidisciplinary integrated approach. Optimal management should provide the full spectrum of

treatment options, including pharmacologic therapy, endoscopic treatment, interventional radiologic procedures, and surgical shunts with liver transplantation reserved for selected patients.

Suggested Readings

American Society for Gastrointestinal Endoscopy. The role of endoscopy in the management of variceal haemorrhage. *Gastrointestinal Endoscopy* 2014;80:221–7.

Carey W. Portal hypertension: diagnosis and management with particular reference to variceal haemorrhage. *J Dig Dis* 2011;12:25–32.

de Franchis R. Revising consensus in portal hypertension: report of the baveno V consensus workshop on methodology of diagnosis and therapy in portal hypertension. *J Hepatology* 2010;53:762–8.

Garcia-Tsao G, Abraldes JG, Berzigotti A, Bosch J. Portal hypertensive bleeding in cirrhosis: risk stratification, diagnosis and management: 2016 practice guidance by the American Association for the Study of Liver Diseases. *Hepatology* 2017;65:310–35.

Garcia-Tsao G, Bosch J. Management of varices and variceal haemorrhage in cirrhosis. *N Engl J Med* 2010;362;823–32.

Krige JEJ, Beningfield SJ, Bornman PC. Liver and portal circulation. In: Burnand K, Young A, Rowlands BJ, et al., eds. *New AIRD'S Textbook of Surgery*. 3rd ed. London: Churchill Livingstone; 2005.

Krige JEJ, Kotze U, Bornman PC, et al. Recurrence, rebleeding and survival after endoscopic injection sclerotherapy in alcoholic patients with bleeding esophageal varices. *Ann Surg* 2006;244:764–70.

Krige JEJ, Beningfield SJ, Shaw J. Management of bleeding oesophageal varices. In: Johnson C, Taylor I, eds. *Recent Advances in Surgery*. Vol 30. London: Royal Society of Medicine; 2007:105–25.

Krige JE, Shaw, JM, Bornman PC. The evolving role of endoscopic treatment for bleeding esophageal varices. *World J Surg* 2005;29:966–73.

Triantos C, Kalafateli M. Endoscopic treatment of esophageal varices in patients with liver cirrhosis. *World J Gastroenterol* 2014;20:13015–26.

Tripathi D, Stanley AJ, Hayes PC, et al. UK guidelines on the management of variceal haemorrhage in cirrhotic patients. *Gut* 2015;64:1680–704.

EDITOR'S COMMENT

Professors Krige and Thomson have written a very comprehensive chapter on the role of endoscopy in the management of esophageal variceal bleed (EVB).

They have also discussed in this chapter about other means of stopping variceal bleeding including balloon tamponade, transjugular intrahepatic portosystemic shunts (TIPS), and surgical shunts. Professor Krige's commitment on the management of EVB is reflected in the series of his published papers starting from 1989 to this date. All his publications are masterly reflected in this chapter on the endoscopic management of esophageal varices.

In this commentary, I will review the steps in management of EVB in the light of my diverse training and clinical practice in Pakistan, Canada, and United States. Management of EVB starts with resuscitation of patients followed by vasopressors and endoscopic intervention. Afterward start of nonselective beta blocker and serial EBL is helpful. These steps have been proven to be effective in control of initial bleeding, reduction of rebleed and mortality. Use of balloon tamponade as a bridge to TIPS in failure of endoscopic intervention is also recommended. Most critical aspect of managing patients with portal hypertension and varices is the timing of the intervention and the severity of liver disease. On review of literature and during clinical practice, I found and readers would agree that there are certain delays in assessing who would fail initial endoscopic intervention and then in timing of TIPS insertion.

There is no doubt that improvement in rebleeding rate and mortality is achieved but the progress has been slow in the last few decades. Endoscopic sclerotherapy (EST) use dates back to 1936, when it was first used. However, its use was ignored until 1970, when Johnston and Rodgers used and controlled bleeding in ~90% of patients (Johnston GW et al. A review of 15 years' experience in the use of sclerotherapy in the control of acute haemorrhage from oesophageal varices. *Br J Surg* 1973;60:797–800). Superiority of endoscopic band ligation (EBL) is well established over EST. EBL not only reduces rebleeding and complications such as esophageal stricture but also mortality. Ulceration, bleeding, perforation, or strictures are uncommon with EBL. Importantly, life-threatening complications of sclerotherapy including mediastinitis, pericarditis, esophageal fistula, and spinal cord paralysis are no more witnessed.

Various octreotide and vasopressin analogs have been used as vasoactive agents in order to reduce rebleeding as an adjunct to endoscopic intervention in late 1990s. I was involved in one of the earliest RCTs in 1998 comparing octreotide combined with EST versus EST alone in adult cirrhotic patients who had EVB. We reported that the combination is more effective than EST alone in controlling and prevention of early variceal rebleed. Overall mortality at the end of hospitalization was similar in the two groups (Shah HA et al. Sclerotherapy plus octreotide versus sclerotherapy alone in the management of gastro-oesophageal variceal hemorrhage. *J Ayub Med Coll Abbottabad* 2005;17:10–4).

Data are scarce on the head-to-head comparison of efficacy of terlipressin and octreotide as an adjuvant therapy. We published a noninferiority trial including 324 patients comparing the efficacy and safety of terlipressin (*n* =

163) with octreotide (n = 161) as an adjuvant therapy to EBL in patients with EVB (Abid S et al. Terlipressin vs. octreotide in bleeding esophageal varices as an adjuvant therapy with endoscopic band ligation: a randomized double-blind placebo-controlled trial. *Am J Gastroenterol* 2009;104:617–23). We found that the efficacy of terlipressin was not inferior to octreotide as an adjuvant therapy for the control of EVB and in-hospital survival. However, a reduction in length of stay was found in terlipressin group which possibly has clinical implications to ultimately cost savings.

In order to reduce the rebleeding after EBL various nonselective beta blockers (NSBB) have been used along with serial ligation. NSBB did reduce the risk of rebleeding from varices, however, no significant benefit was observed in terms of mortality.

Despite the fact, that last 20 to 30 years have seen significant improvement in survival in patients with EVB the progress is slow. Thirty-day mortality has improved from 40% to 50% in early 90s to approximately 20% in the last decade. Substantial improvements in rebleed rates have also been reported in UK and US national databases. Addition of vasoactive agents and NSBB are effective in control of bleed and rebleeds, but fails to show reduction in mortality. Not only it is important to improve on bleeding, rebleeding, and mortality with endoscopic interventions, but also reduction in cost of care must also be targeted. Each patient usually requires three to five sessions of serial EBL after the control of AEVB and use of multiband ligator incurs a reasonable amount of cost. We used an innovative idea of reloading the original ligator set and reusing it for subsequent sessions on the same patient (Abbas Z et al. Cost saving by reloading the multiband ligator in endoscopic esophageal variceal ligation: a proposal for developing countries. *World J Gastroenterol* 2008;14:2222–5). We found that EBL using reloaded multiband ligators for the follow-up sessions on patients undergoing variceal eradication is safe and effective in cost saving.

The improvement in management of patients with EVB has not been reported solely due to advancement in endoscopic intervention, but also accounted by multiple factors. These factors include improvement in access to a quality of high dependency and ICU care, improvement in general supportive measures, use of vasopressors, prophylactic antibiotics, access to endoscopy and NSBB. Access to out of hours emergency endoscopy, multidisciplinary team approach including anesthesiology and interventional radiology services for TIPS have been demonstrated in numerous randomized controlled trials.

Role of balloon tamponade device (BTD) including Sengstaken—Blakemore and Minnesota tube is limited in the control of EVB. Possible indications include unavailability of urgent endoscopy in a remote area to facilitate transfer to a multidisciplinary center; delay in performing endoscopy while patient is exsanguinating, moving patient from emergency or ward to ICU after intubating. Current AASLD and Baveno guidelines recommend the use of BTDs only as a bridge to TIPS within 24 hours in patients with endoscopically

uncontrollable EVB. In this situation BTD may be placed as a temporizing measure for up to 24 hours until definitive treatment such as placement of TIPS. A retrospective study by Nader et al. reviewed 34 patients with BTD usage over a period of 11 years as a bridge to TIPS procedure (Nadler J et al. *Am J Emerg Med* 2017;S0735–6757). Only 59% of patients survive at the time of discharge after TIPS procedure. This paper demonstrated limited utility of BTD in recent era which may further be reduced with endoscopic esophageal stenting. Self-expandable, esophageal covered metal stents are placed endoscopically, without radiologic guidance; they are removable and can be left in place for up to 2 weeks. A recent multicenter RCT involving 28 patients, removable metal stents were compared to BTD in patients with cirrhosis and EVB refractory to initial endoscopic treatment. Survival to day 15 and control of bleeding was better in the stent group. Evidence suggests that use of BTD is on decline and will soon be replaced by esophageal stents.

Hepatic venous pressure gradient (HVPG) has been proven to be the main predictor of developing varices. HVPG of >10 mm Hg has good correlation with various complications of portal hypertension. EVB is unlikely to occur when the HVPG is <12 mm Hg and a HVPG > 20 predicts failure to control bleeding, higher risk of recurrent bleeding within 1 week, higher risk of failure to control bleeding as well as higher 1-year mortality. Unfortunately, use of HVPG in clinical practice is not common. The available approaches to reducing HVPG include vasopressors, NSBBs, and TIPS used in the same order. Evidence is not supportive of significant role of vasoactive and NSBBs in reducing HVPG, hence there is a need to change the order of management of AVB in patients with high risk of rebleed.

Finally regarding TIPS, we know that it has been proven to be very useful but an underutilized intervention. Procrastinating and repeating endoscopies are usual practices that result into delays in contemplating for TIPS. A recent meta-analysis of 12 clinical trials using TIPS showed that it significantly decreased the number of EVB and reduced mortality. Current treatment guidelines recommend the use of TIPS with covered stents in patients who fail endoscopic and pharmacologic treatment. Identification of patients who would fail the endoscopic treatment with HVPG and consideration for early TIPS is the demand of the time.

In the end, I would conclude that there is improvement in management of EVB in terms of control of bleed, rebleeding, and mortality, however, progress is sluggish. There is need to adapt to a proactive approach in patients with EVB with available assessment and intervention tools. Measurement of HVPG is a valuable assessment tool of rebleed and TIPS has been shown to improve the outcomes. Need of the time is to assess patients who would fail initial EBL with the help of HVPG measurement and a proactive approach with early TIPS. Therefore, future research is needed to improve treatment algorithm with available strategies. There is also need for novel endoscopic techniques with better efficacy, lower cost, and fewer adverse events.

G SURGERY OF THE SMALL INTESTINE

135 Small Bowel Obstruction

Susan Galandiuk

INTRODUCTION

The diagnosis and treatment of small bowel obstruction can be one of the most challenging tasks facing the general or specialist surgeon. Both differential diagnosis and timing of intervention may differ significantly, depending upon whether or not the patient has had previous abdominal surgery as compared with patients who have not had prior abdominal surgery. Generally speaking, postoperative adhesions have long been the most common cause for small bowel obstruction; however, this may change with the increasing use of minimally invasive surgery and the presumed lesser incidence of observed postoperative adhesions associated with minimal access surgery. Along with this minimally invasive surgery, we are also seeing an increase in the incidence of small bowel obstruction due to internal hernias. The old adage “the sun never sets on a small bowel obstruction” may still apply, but only in select cases, those with signs of closed loop obstruction or vascular compromise. Discerning this, and differentiating those patients, in whom watchful waiting is in order and those in whom prompt intervention is required, is the surgeon’s priority.

ETIOLOGY AND PATHOPHYSIOLOGY

The etiology of small bowel obstruction can be divided into extrinsic obstruction or intrinsic obstruction (Table 135.1). Extrinsic obstruction occurs most commonly due to postoperative adhesions, but can also be due to volvulus (Fig. 135.1A,B), from obstruction in confined spaces such as hernias as well as due to mesenteric desmoids (in the case of familial adenomatous polyposis) (Fig. 135.2). Hernias that can cause small bowel

obstruction include inguinal and femoral hernias and incisional and internal hernias resulting from prior surgery. Intrinsic compression or obstruction can result secondary to inflammation due to benign disease such Crohn disease, diverticulitis (including Meckel's), tuberculosis, or due to obstruction of malignant disease from primary small bowel neoplasms such as adenocarcinoma or lymphoma or from metastatic disease such as that seen with cutaneous malignant melanoma. Importantly, small bowel obstruction can occur secondary to an obstructing cecal cancer. Obstruction can also occur secondary to foreign bodies, bezoars, or impacted calculi such as is the case with gallstone ileus.

TABLE 135.1 Causes of Small Bowel Obstruction

Extrinsic	
Adhesions	Postoperative
	Inflammatory
Neoplasms	Carcinomatosis
	Desmoids (familial adenomatous polyposis)
Hernias	
Postoperative	Incisional
	Parastomal
	Mesenteric defects
Acquired	Inguinal
	Umbilical
	Femoral
	Diaphragmatic
Congenital	Midgut volvulus
	Malrotation
	Intestinal duplication/cyst
Intrinsic	
Inflammation/stricture	Crohn disease
	Diverticulitis
	Ischemia
	Tuberculosis
	Actinomycosis
Neoplastic	Small bowel adenocarcinoma
	Other primary small bowel neoplasms
	Metastatic neoplasms (malignant melanoma)
Other intraluminal abnormalities	Impacted calculus (gallstone ileus)
	Traumatic hematoma
	Bezoar
	Foreign body

CLINICAL PRESENTATION

In the patient with small bowel instruction, clinical presentation will often reveal a patient with a distended, tympanitic abdomen. It is important to examine the patient for any healed surgical incisions. A patient history is vital, since many patients can now have significant abdominal procedures through barely visible minimal incisions. In a patient older than 50 years, who presents with a small bowel obstruction and a virgin abdomen, the potential for a cecal cancer must always be considered. The patient will frequently report the absence of any bowel movements for a matter of hours or days and often the absence of passing flatus as well. Nausea or vomiting is frequently present.

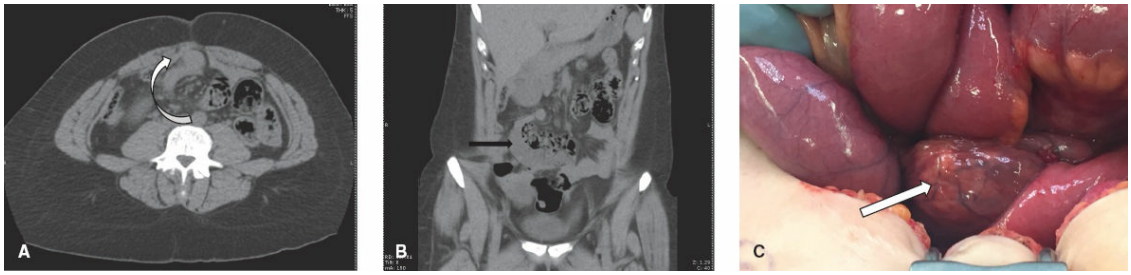

Figure 135.1. **A.** Computed tomography (CT) scan axial view showing volvulus of a loop of small bowel causing small bowel obstruction (*arrow*). **B.** CT scan coronal section showing volvulus of a loop of small bowel causing small bowel obstruction (*arrow*). **C.** Operative findings of case shown in A,B, with loop of small bowel (*arrow*) wrapped around base of small bowel mesentery causing both small bowel obstruction and ischemia.

Plain abdominal films show significant edema between adjacent loops of bowel and a “step ladder”-type appearance with air fluid levels on the upright films (Fig. 135.3A,B). In today’s medical climate with the ubiquitous computer tomographic (CT) scanning, CT scans show dilated loops of small bowel (Fig. 135.4) and may, in some cases, even show a clear transition point or identify the point of obstruction or suggest the etiology of the obstruction (Fig. 135.5A,B). In addition, the oral contrast agent used in CT scans is sometimes useful for helping to resolve small bowel obstructions through its osmotic action. If a small bowel follow-through is to be ordered in a patient with a small bowel obstruction in order to delineate the point of obstruction, it is imperative that only water-soluble contrast media be utilized. This is for two reasons. Gastrografin (diatrozate meglumine and diatrozate sodium solution) administration via nasogastric tube frequently results in a resolution of an adhesive small

bowel obstruction due to its hyperosmolar nature. Secondly, use of barium as a contrast agent can lead to disastrous consequences should an unrecognized perforation be present, or in the event that a subsequent surgery is necessary and barium becomes extravasated within the abdomen, resulting in barium (and fecal) peritonitis.



Figure 135.2. Mesenteric desmoid in a 32-year-old woman with familial polyposis who had undergone a total proctocolectomy. The rapidly enlarging desmoids were causing symptoms of small bowel obstruction until the patient was started on imatinib, which led to substantial symptom resolution.

Clinical evaluation should include a complete blood count and basic metabolic panel. An elevated white blood cell count and/or peritoneal signs are concerning for nonviable bowel. In cases where there is uncertainty, an elevated serum lactate level may be helpful to differentiate ongoing bowel ischemia. It is imperative to obtain a history from the patients regarding any malignancy or abdominal and/or pelvic radiation therapy that they might have received. In addition, it is important to obtain a history of prior vascular disease, embolic disease, or cardiac dysrhythmias that would heighten awareness of the possibility of ischemic bowel. In all patients, but particularly, in the absence of any surgical or medical history, the patient should be carefully examined for the presence of any hernias that might be causing small bowel obstruction. These include inguinal, femoral, umbilical, Richter, and of course, ventral

hernias, if there are any incisions.

CONSERVATIVE THERAPY

Conservative therapy of small bowel obstruction includes intravenous (IV) hydration and close observation. Depending upon the clinical circumstances, it may also include the use of nasogastric tube decompression, stomal decompression tubes, and antiemetics. An essential component of quality care is frequent reexamination of the patient with dated and timed notes in the medical record.

INDICATIONS AND CONTRAINDICATIONS

Small Bowel Obstruction Within 6 Weeks of a Prior Laparotomy

In electing to operate or not to operate on a patient, it is important to determine whether or not the patient has had recent surgery. In the era of laparoscopic surgery, it is more than ever important to obtain a good history since the examination of the abdomen for scars may no longer give even the observant physician accurate documentation of the patient's surgical history. It is important to thoroughly examine the patient for the presence of any hernias, including inguinal, femoral, umbilical, and incisional hernias that might be present and responsible for the patient's symptoms. In the case of the patient developing a small bowel instruction **postoperatively**, it is imperative to consider the timing time of the most recent laparotomy. If the patient has undergone an open laparotomy, it is essential to identify the time of the most recent laparotomy, and if at all possible, **avoid re-operating on that patient during the time from 7 days postoperatively until 6 to 8 weeks postoperatively**. During this time, there is a normal healing process within the abdomen in which "obliterative peritonitis" occurs (i.e., there are incredibly dense intra-abdominal adhesions). Any surgery during this time is fraught with **extreme** difficulty. The chance of performing more inadvertent enterotomies is far higher than the chance of benefiting the patient! Unless the patient has signs of peritonitis or a definition indication for surgery, such an abscess not drainable by other means, an attempt at watchful waiting (**conservative therapy**) should be performed with parenteral nutrition and nasogastric decompression. With the advent of laparoscopy, and the reduced adhesions observed following minimally invasive surgery, this adage has changed somewhat. As there are far fewer adhesions, an

attempted laparoscopy may be warranted, with initial insertion of a port to determine if there are significant adhesions and if an operation can safely be performed. In patients in whom intestinal stomas were constructed, particularly in the case of ileostomies, edema at the level of the fascia is a common cause of postoperative small bowel obstruction. In these patients, digital examination through the stoma is essential and will often confirm this, and placement of a Foley catheter or other decompression tube through the stoma will often result in alleviation of the obstruction. I often utilize a 30-Fr Marlen ostomy straight catheter (Marlen Manufacturing, Cleveland, Ohio) for this purpose, as the holes at the end of the tube are large enough to drain intestinal contents without clogging.

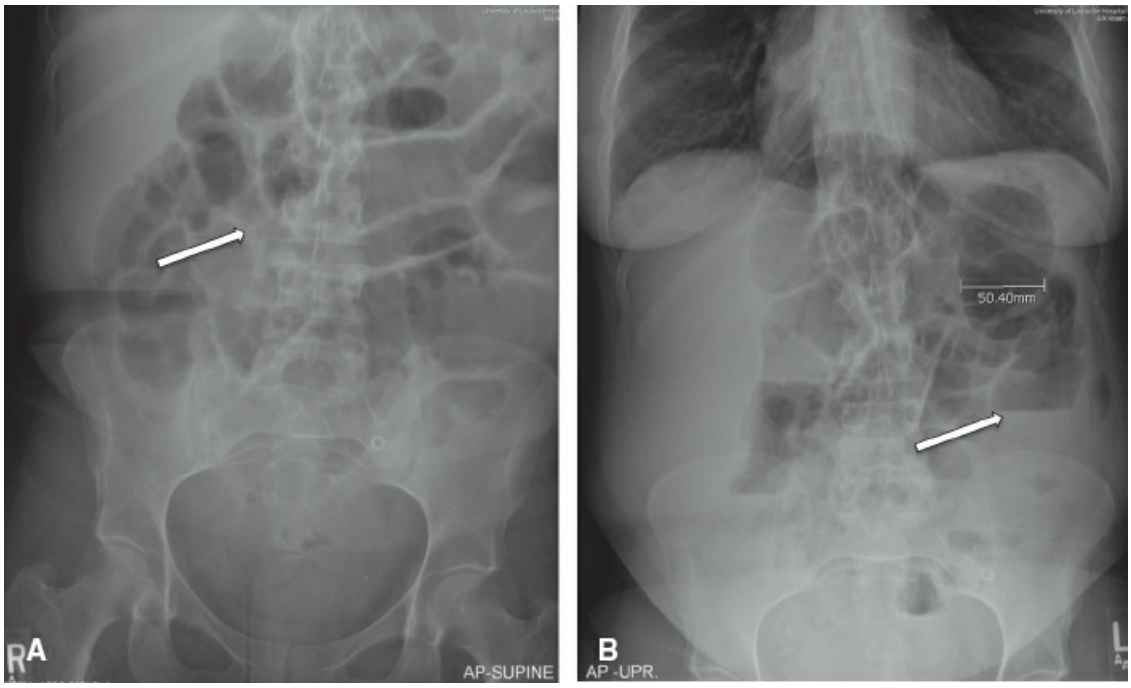

Figure 135.3. A. Abdominal film (supine) in patient with small bowel obstruction showing significant separation of loops of small bowel (*arrow*), indicating significant bowel wall edema. **B.** Abdominal film (upright) in patient with small bowel obstruction showing significant air-fluid levels (*arrow*).

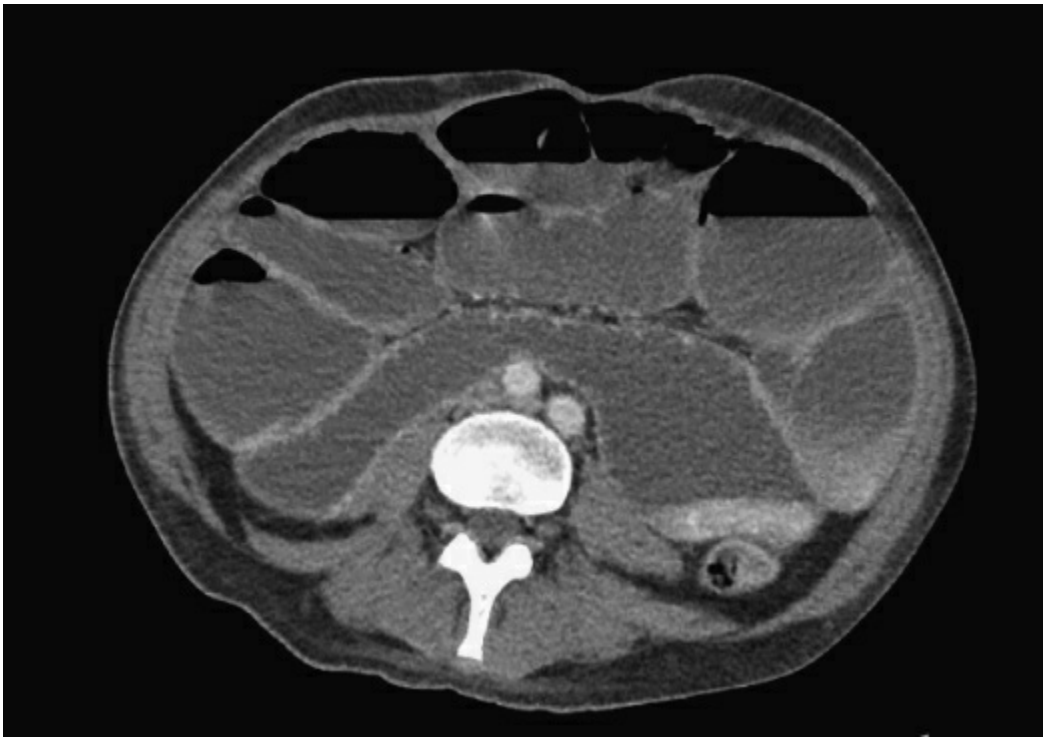

Figure 135.4. CT scan (axial view) showing extremely dilated loops of small bowel indicative of small bowel obstruction.

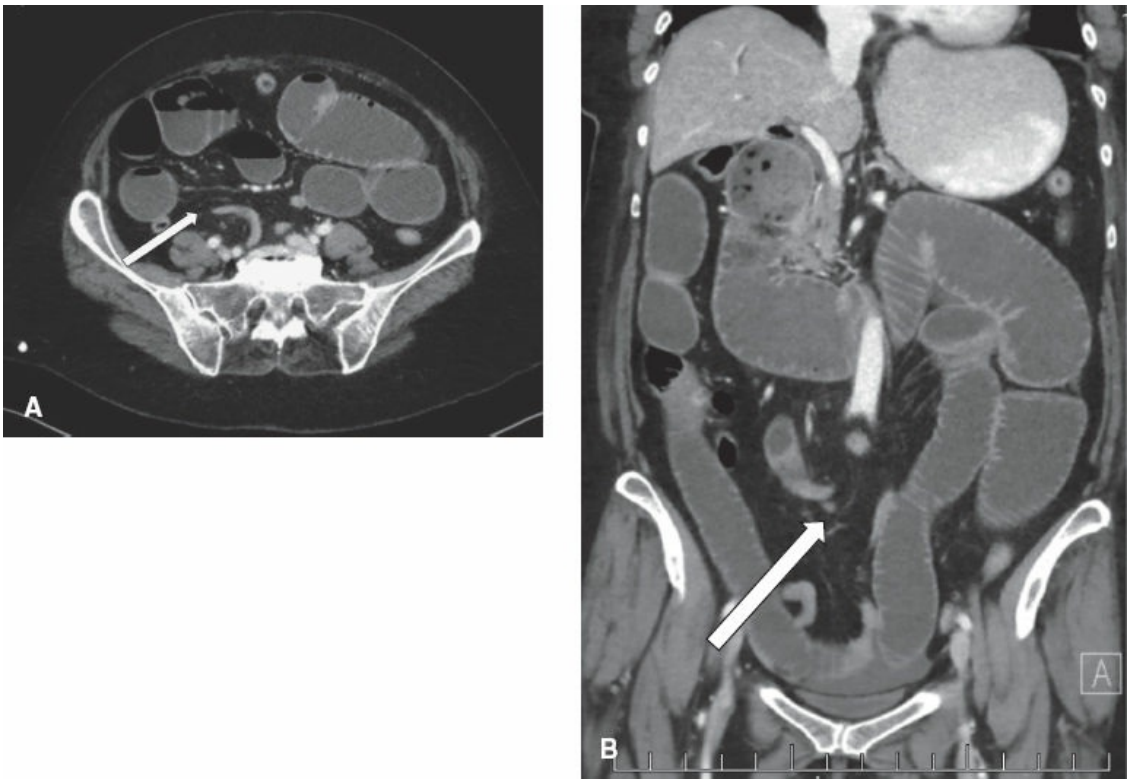

Figure 135.5. CT scan in a patient with small bowel obstruction showing a transition point to collapsed distal bowel (*white arrow*). **A.** Axial view. **B.** Coronal view.

Small Bowel Obstruction Following a Remote Laparotomy

Generally speaking, if a patient presenting with a small bowel obstruction following a remote laparotomy does not “open up” following 72 hours of conservative management, he is unlikely to, and surgery is usually indicated.

Small Bowel Obstruction Without Antecedent Surgery

Conservative therapy in this group of patients must be pursued with caution, as one must assume there is a mechanical source of obstruction unless proven otherwise. Careful serial monitoring of vital signs, physical examination for peritoneal signs, and monitoring of white blood cell count are in order with surgery if there are signs of worsening (**see algorithm,** Fig. 135.6).

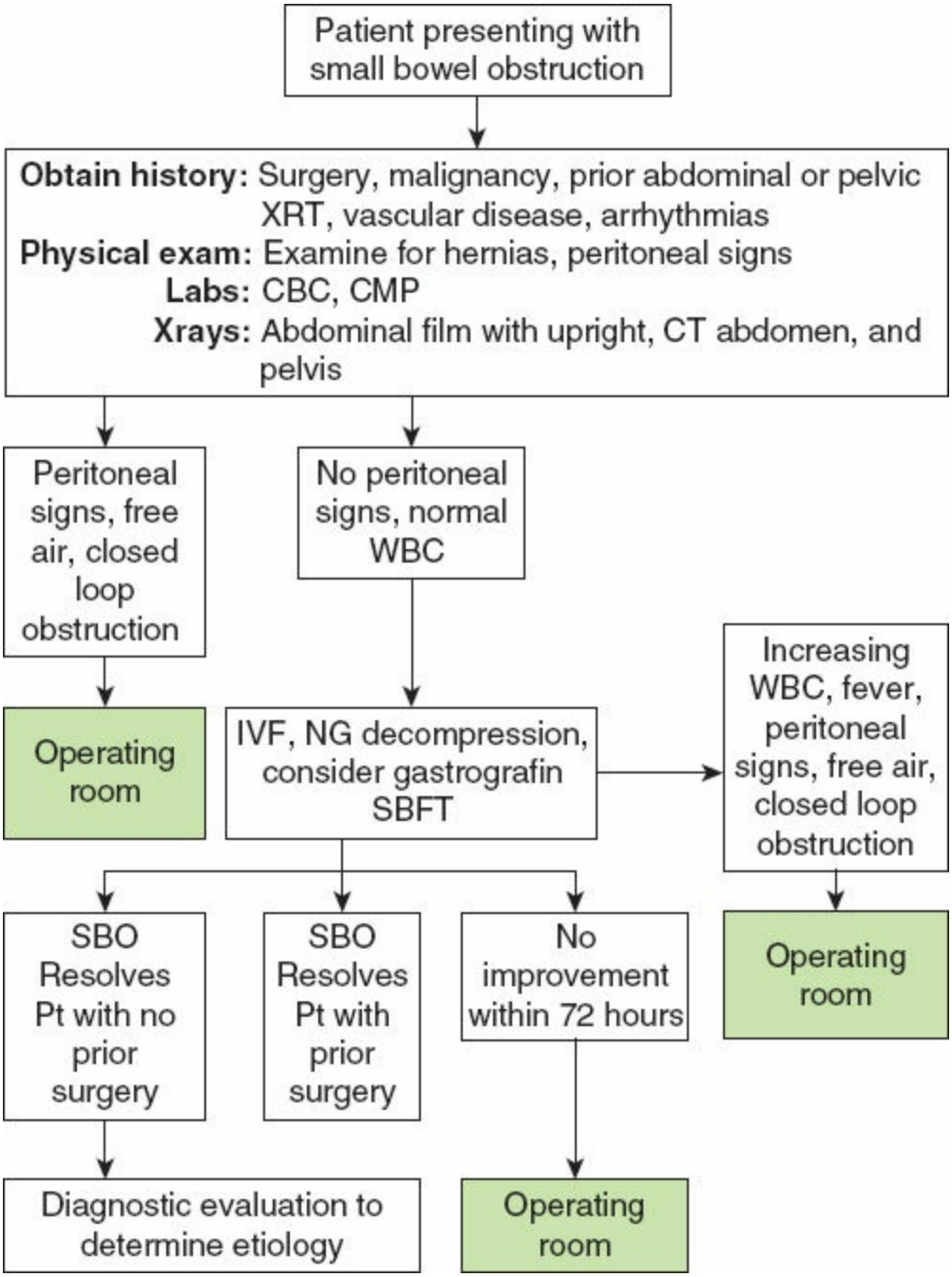

Figure 135.6. Algorithm for management of small bowel obstruction.

PREOPERATIVE PLANNING

Strong consideration should be given to placing a nasogastric tube in patients with small bowel obstruction needing surgical intervention. There is a significant risk of aspiration at the time of endotracheal intubation despite rapid sequence intubation. Great care and expertise are required on the part of the anesthesiologist. There can also be significant coexisting hypovolemia secondary to sequestration of large amounts of fluid within

the obstructed loops of small bowel and associated electrolyte disturbances. A very distended abdomen will also result in a significant degree of respiratory compromise, since there is less ability for normal excursion of the diaphragm.

The choice of mode of surgical access for a patient with small bowel obstruction depends largely on the degree of obstruction and expertise of the surgeon. If the patient has a very grossly distended abdomen with loss of domain, a laparoscopic approach is not feasible and an open approach will likely be required. Much of this is surgical judgment and relies on the expertise of the surgeon. If there is so much distended bowel that one cannot clearly visualize the abdominal contents, it is almost certainly not safe to approach laparoscopically. Patients who have had significant pelvic surgery should be placed in modified lithotomy position, so that one has access to the anal canal and rectum should this be required. In addition, if the patient has had extensive prior surgery, it is always safest to start the incision above or below the prior incision in a "virgin area" of the abdomen and work toward the more difficult area. This is particularly true in patients who have had extensive pelvic radiation and multiple prior abdominal procedures. Care needs to be taken in planning one's own professional schedule to allow an appropriate (lengthy) time for re-operative cases, especially in cases with significant adhesions following multiple prior operations and/or prior pelvic radiation. Preoperative discussion with the patient regarding the possibility of a temporary ostomy and preoperative marking for a stoma are **always** a good idea **even** if you think it unlikely.

SURGICAL TECHNIQUE

Lysis of Adhesions

In the patient with suspected adhesive bowel obstruction in whom one is performing an open lysis of adhesions, it is important to proceed systematically. The skin should be opened sharply with a knife, the subcutaneous tissue divided using electrocautery down to the level of the fascia, being on the lookout for any "Swiss cheese"-type small fascial hernias that may not have been obvious on physical exam. The fascia is best opened sharply using a curved Mayo scissors (Fig. 135.7). This allows only the fascia to be opened without harming the underlying small bowel, which may be densely adherent. Once the midline incision is opened, adhesions are taken down from the anterior abdominal wall on either side

of the abdominal wall by placing a laparotomy sponge on the abdominal contents and a Kocher clamp on the fascia. The assistant retracts gently upward on the fascia, while the operator incises, working from the opposite side of the abdomen, the adhesions from the anterior abdominal wall, while placing gentle downward and medial traction on the laparotomy sponge with his/her nondominant hand (Fig. 135.8A,B). Once both sidewalls have been freed of adhesions, the central abdominal contents are then separated from each other. Loops of small bowel are best separated from each other by upward, outward traction eliminating the need to use forceps or sharp instruments other than the Mayo scissors to incise the adhesions. Sero-myotomies are closed using interrupted sutures as they are made, since in the event that the patient has a prolonged ileus, these may leak. In the event of a prolonged lysis of adhesions, a secure gastrostomy tube should be placed. This is beneficial for both the surgeon and patient. To date, although there are no conclusive studies that adhesion barriers prevent the need for subsequent surgery for small bowel obstruction, if there are extensive adhesions, and no bowel anastomosis, it may be worthwhile to place an adhesion barrier over the bowel at the greatest risk to lessen subsequent adhesion formation.

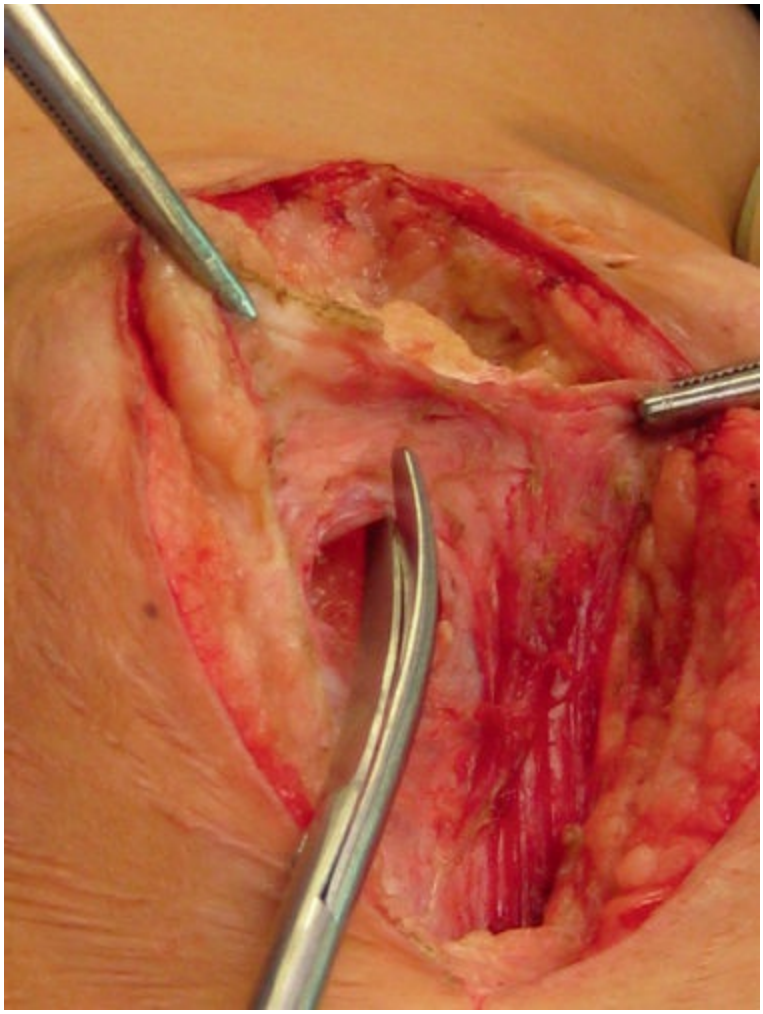

Figure 135.7. Opening of fascia using sharp dissection with a Mayo scissors.

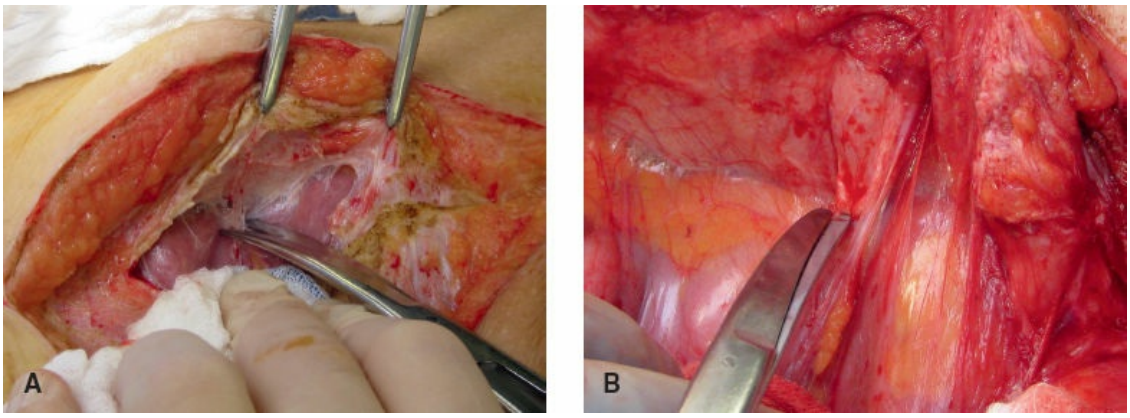

Figure 135.8. **A.** Lysis of adhesions. The surgeon stands on the opposite side of the table, while the assistant applies mild upward traction on the fascia using Kocher clamps, while the surgeon uses his or her nondominant hand to apply gentle downward and medial traction. **B.** The adhesions become clearly visible as filmy areolar tissue that is sharply divided using Mayo scissors.

Laparoscopy

The decision whether or not to approach the patient with small bowel obstruction laparoscopically depends upon a number of factors:

The skill of the surgeon as a laparoscopist
In the case of postoperative small bowel obstruction, the time from the original surgery. Since fewer adhesions form following a laparoscopic surgery, the time guidelines listed above may not always apply following laparoscopic procedures.
If there is tremendous distention of the small bowel and "loss of abdominal domain," a laparoscopic procedure should not be undertaken.
In addition, when establishing a pneumoperitoneum, this should be done under direct vision (i.e., using a Hasson or optical nonbladed trocar).
In performing lysis of adhesions, scissors **without** thermal energy should be used.

Desmoids

If the patient has a history of familial adenomatous polyposis and desmoids are suspected to be the cause of a small bowel obstruction, conservative therapy should be attempted **first**, as these operations are also an extremely difficult, frequently associated with a large amount of blood loss, and may result in loss of large segments of small bowel. Conservative therapy that may mitigate the need for surgery includes long-term medications such as tamoxifen, toremifine, or imatinib.

Crohn Disease

Crohn disease is a common cause of small bowel obstruction. This can occur either through fibrostenosing terminal ileal Crohn disease, or through the more difficult-to-diagnose short fibrotic strictures that can be seen in the jejunum or ileum without other areas of disease involvement (Fig. 135.9). These can lead to significant distention of proximal loops of bowel and are typically treated by stricturoplasty as described in Chapter 140. Ultimately, a surgeon or gastroenterologist familiar with Crohn disease may assist with longer-term care.

Intra-Abdominal Abscesses

Loops of small bowel will often try to "wall off" an infection or abscess. As such, if the bowel becomes entrapped in the inflammatory mass, small

bowel obstruction may occur. This obstruction will sometimes resolve with resolution of the inflammation by nonoperative measures, such as CT-guided abscess drainage, but occasionally surgery is required to sharply separate the small bowel from the inflammatory mass. These cases are always best approached by beginning from the normal area and slowly working toward the area of maximum inflammation, freeing up all noninvolved loops of small bowel and moving them out of the way. Once the isolated loop of bowel is identified, this bowel is subject to less injury if the surgeon's hand is placed posterior to the mesentery and slowly brought up toward the area of inflammation, and the surgeon's thumb and forefinger are used to gently finger fracture or pinch the inflammatory adhesions to divide them (Fig. 135.10).

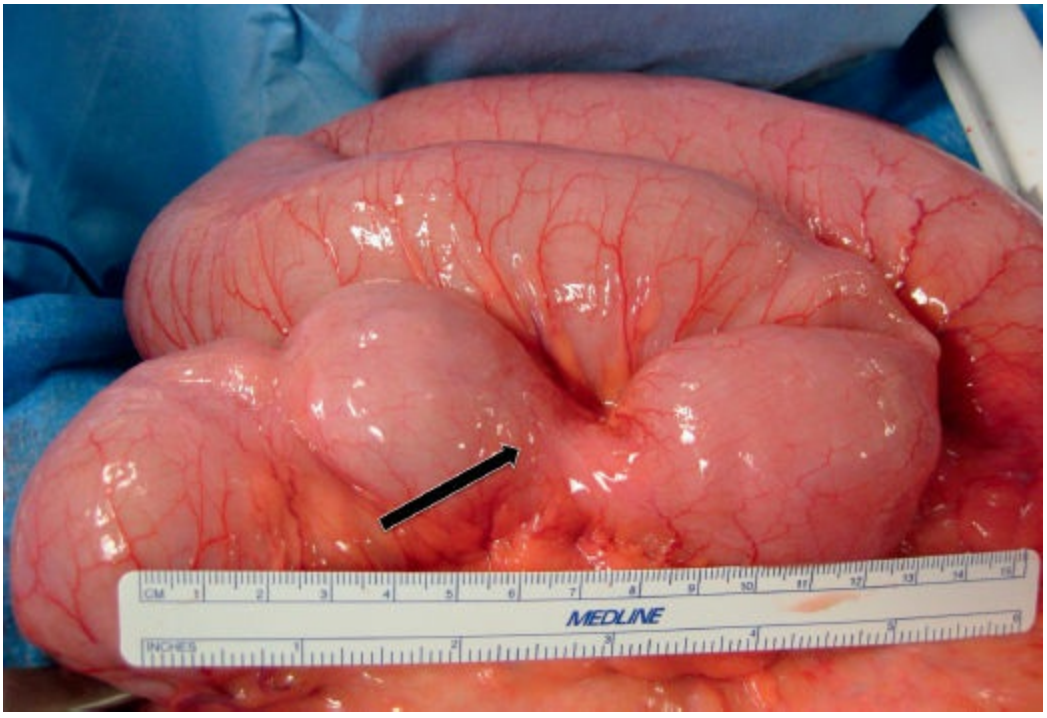

Figure 135.9. A short fibrotic ileal stricture (*arrow*) causing small bowel obstruction in a patient with Crohn disease.

Special Scenario of Small Bowel Adherent in the Pelvis After a Prior Pelvic Procedure

Small bowel tends to become adherent to the low pelvis following the many pelvic procedures. The safest way to approach such adhesions is from posteriorly. Following the root of the mesentery of the small bowel and freeing it up from posterior to anterior are often the safest and with least risk for injury to the bowel. Ureters and prior urinary diversions can

be important concerns.

Radiation

In the patient who has had extensive pelvic radiation, strong consideration should be given to entering the abdomen in an area where the patient has not had prior surgery. This means extending the incision proximally into a virgin area. Severe radiation enteritis gives the bowel a characteristic appearance with thickening and prominence of the blood vessels on the serosa (Fig. 135.11). In some cases, bypassing such segments of bowel may be an option rather than resection.

Assessing for Ischemic Bowel

If there has been a longstanding bowel obstruction and a great degree of luminal distention, there may be concern regarding bowel viability. This impacts whether to perform a resection, and if this is done, whether or not to perform an anastomosis or to divert the patient. Generally speaking, intestinal perfusion can be assessed in a number of ways: (1) visually by inspection, by snipping a small piece of the mesenteric fat and checking for bleeding (if the bowel is to be resected, one can check for bleeding from the bowel edge); (2) Doppler signals at the base of the mesentery; (3) administration of IV fluorescein and illumination of the surgical field with ultraviolet light using a Wood lamp; or (4) indocyanin green angiography whereby indocyanine green is given intravenously, and the surgical field illuminated using near infra-red light and a special imaging system (Spy or Pinpoint, Novodaq, Bonita Springs, FL) (Fig. 135.12).

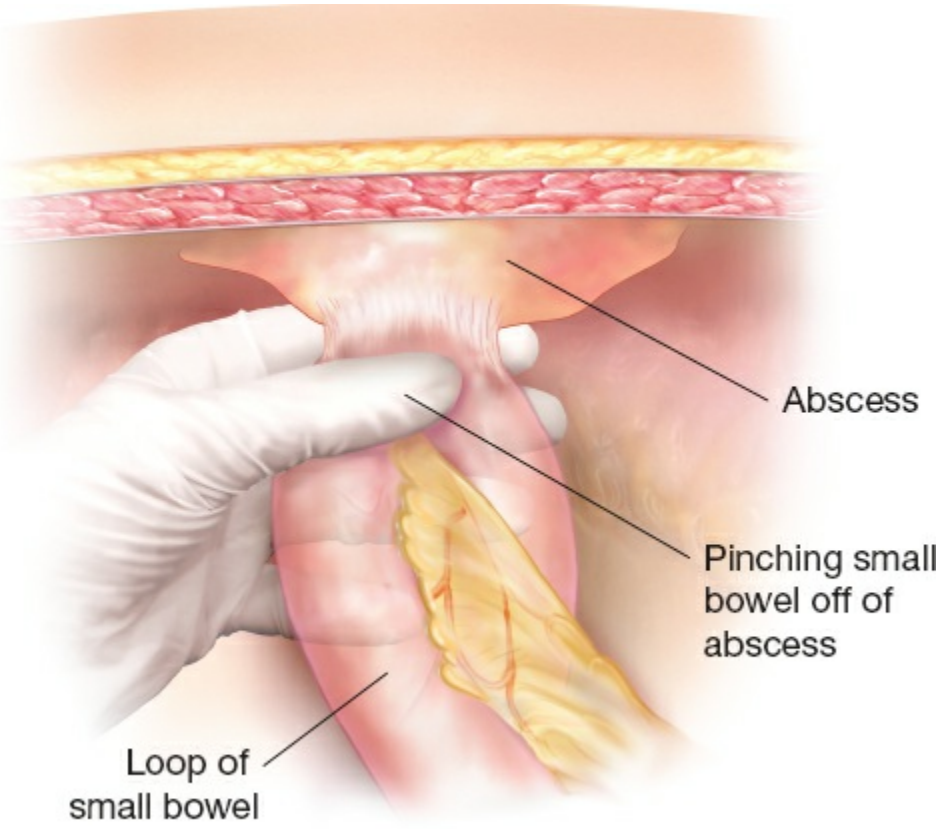

Figure 135.10. Illustration of the approach to separate small bowel from sources of inflammation, such as abscess cavities or intra-abdominal phlegmons. The involved loop of small bowel is freed posteriorly, and the surgeon's hand is placed posterior to the mesentery, and the surgeon's thumb and forefinger are used to apply a gentle "finger-fracture" technique to separate the small bowel from the inflammatory mass.



Figure 135.11. Macroscopic view of severe radiation enteritis affecting the terminal ileum. Note the blanched whitish appearance of the bowel and the prominent appearance of the serosal vessels.

POSTOPERATIVE CARE

Postoperative patient care has taken a dramatic change in the last several years. Patients with small bowel obstruction have already dramatic fluid shifts in their intestines and generally have extremely edematous bowel wall. This can be further exacerbated by excessive administration of fluids postoperatively. While these patients must receive resuscitation, this should be done with careful monitoring. Effort must be made to avoid excessive narcotic use, and to use nonsteroidal anti-inflammatory drugs, epidural analgesia, and other tools of enhanced recovery pathways to minimize postoperative ileus. Agents that reduce the length of postoperative ileus, such as alvimopam, can be utilized in addition to early ambulation. Use of gastrostomy tubes in patients who are expected to have a prolonged ileus lessens pulmonary comorbidity and allows patients some resumption of limited PO intake, which flows out of the gastrostomy immediately.

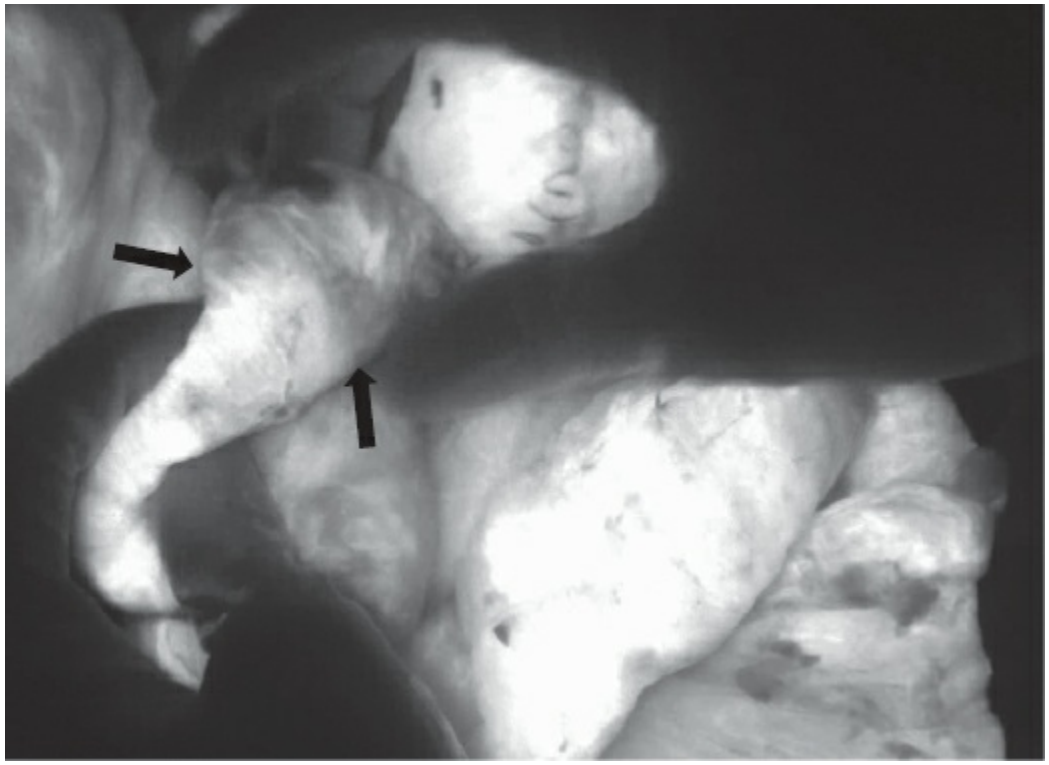

Figure 135.12. Intraoperative photograph of indocyanine green angiography illustrating an area of relative hypoperfusion (*arrows*) in a patient undergoing surgery for small bowel obstruction.

COMPLICATIONS AND THEIR MANAGEMENT

The most feared complication of small bowel obstruction is the occurrence of an entracutaneous fistula following an inadvertent enterotomy at the time of lysis of adhesions. These are best managed according to the same guidelines described elsewhere in this chapter, with respect to reoperation for obstruction following a recent laparotomy. If these enterocutaneous fistulas occur after 7 days postoperatively, the patient should be placed on parenteral nutrition, an ostomy appliance placed over the fistula, and the patient managed conservatively until it is safe to reoperate. This is usually 8 weeks at the earliest, but is frequently later. Timing for reoperation can often be assessed by palpation of the patient's abdomen. If it is soft, the adhesions have softened. If it is firm, the adhesions are firm, and one should wait longer before re-operating on the patient.

Prolonged postoperative ileus is a common complication following operations for small bowel obstruction. This can be lessened by adherence to enhanced recovery pathways as described in the section on postoperative care. In addition, if the patient has a prolonged ileus,

gastrografin injected either through a nasogastric or gastrostomy tube can be helpful for instigating bowel function as described in the Clinical Presentation section of this chapter. Erythromycin ethylsuccinate suspension given per nasogastric or gastrostomy tube can sometimes be helpful in cases of gastroparesis, as can IV metoclopromide.

Short bowel syndrome is defined as <200 cm remaining small bowel. This can occur in cases in which significant resections have already been performed or in patients in whom bowel obstruction has led to ischemia and loss of a large segment of bowel. While in the past, this was seen as a dismal scenario, the development of a glucagon-like-peptide-2 analog, teduglutide, which can be self-administered subcutaneously, has been an important development in care of these patients. Many have a dramatic reduction in the volume of gastrointestinal output and are able to reduce or eliminate reliance on parenteral nutrition or fluids.

OUTCOME

The patient's outcome following small bowel obstruction will largely depend on the responsible etiology. Despite a successful outcome following treatment of adhesive small bowel obstruction, these patients still have a significant lifetime risk of developing another such episode.

Suggested Readings

Diaz JJ Jr, Bokhari F, Mowery NT, et al. Guidelines for management of small bowel obstruction. *J Trauma* 2008;64:1651–64.

Hongo N, Mori H, Matsumoto S, et al. Internal hernias after abdominal surgeries: MDCT features. *Abdom Imaging* 2011;36(4):349–62.

Klaristenfeld DD, McLemore EC, Li BH, et al. Significant reduction in the incidence of small bowel obstruction and ventral hernia after laparoscopic compared to open segmental colorectal resection. *Langenbecks Arch Surg* 2015;400(4):505–12.

Matsui A, Winer JH, Laurence RG, et al. Predicting the survival of experimental ischaemic small bowel using intraoperative near-infrared fluorescence angiography. *Br J Surg* 2011;98(12):1725–34.

Mizrahi S, Polk HC, Reissman P, eds. *Reoperative Abdominal Surgery*. London: JP Medical Publishers; 2014.

Turina M, Mulhall A, Mahid SS, et al. Radiation induced complications requiring surgical care. *Arch Surg* 2008;143:46–52.

Zielinski MD, Bannon MP. Current management of small bowel obstruction. *Adv Surg* 2011;45:1–29.

EDITOR'S COMMENT

Small bowel obstruction (SBO) is common condition that continues to challenge the general surgeon. Adhesions account for 74% of admissions for SBO. Using the Nationwide Inpatient Sample 2001 to 2011, there were an estimated 3,948,987 SBO admissions. In this study, admissions increased by 3.1% annually, whereas nonoperative management increased by 3.8% annually (Jafari MD, Jafari F, Foe-Paker JE, et al. Adhesive small bowel obstruction in the United States: has laparoscopy made an impact? *Am Surg* 2015;81(10):1028–33). As demonstrated in this study and likely reflected in your hospital, there is an increasing trend to treat SBO due to adhesions nonoperatively. The safety and duration of nonoperative treatment however remain controversial. As many, I was taught to never let the sun rise or set on a patient with intestinal obstruction. Nonoperative treatment requires rigorous attention to repeated and frequent physical examination, serial radiologic examinations in some cases, and laboratory examination to detect early physical and laboratory signs of ischemia. Careful fluid and electrolyte correction is essential as is monitoring urine output and output of the nasogastric tube. Ischemia of the small intestine due to strangulation may cause no increase or change in abdominal pain until perforation occurs. At this point, the patient usually develops constant abdominal pain and peritoneal signs and the high-pitched tinkling bowel sounds, characteristic of SBO, disappear and the abdomen becomes ominously silent. Ideally surgical intervention should take place before perforation.

The pathophysiology of small bowel ischemia in obstruction has been well described. Obstruction occurs resulting in increasing intestinal secretions and hyperperistalsis. With continued dilation, there is increasing pressure placed on intestinal wall causing venous congestion. Nasogastric decompression is usually effective in clearing the excess secretions. However, nasogastric decompression will fail in a closed loop obstruction characterized by an unchanging dominant and isolated air- and fluid-filled loop on serial plain abdominal radiographs. In this situation, the bowel continues to secrete fluid in the obstructed segment increasing pressure in the obstructed segment and on the intestinal wall and eventually the venous pressure exceeds the arterial perfusion pressure. Ischemia occurs resulting in eventual perforation. There is no simple test to diagnose ischemia; hence if nonoperative management is chosen, the surgeon is obligated to follow the patient closely.

Indeed, nonoperative treatment outcomes have been well documented. A retrospective analysis of 123 patients admitted with a diagnosis of adhesive SBO following an initial period of nonoperative treatment was performed to

assess the safety of nonoperative treatment and determine the optimal duration of nonoperative treatment in adhesive SBO (Cox MR, Gunn IF, Eastman MC, et al. The safety and duration of non-operative treatment for adhesive small bowel obstruction. *Aust NZ J Surg* 1993;63:367–71). They found that 70% of patients will have complete resolution of the SBO within 72 hours, the majority within 48 hours. Thirty percent of patients required operative intervention: 2.4% for small bowel strangulation within the first 24 hours, 3% within 48 hours, and 25% longer than 48 hours. There were no deaths in the group having an initial period of nonoperative treatment. The authors concluded in the absence of any signs of strangulation, patients with an adhesive SBO can be managed safely with nonoperative treatment. Most cases of adhesive SBO that will resolve do so within 48 hours of admission. A study reported in 2015 showed that there were no statistically significant differences in the outcomes between immediate and delayed groups regardless of duration of delay. Among patients observed with complete adhesive SBO, 24.6% resolved without surgery or readmission. The authors concluded that delaying operative management did not affect surgical findings or complication rates (Bauer J, Keeley B, Kreiger B, et al. Adhesive small bowel obstruction: early operative versus observational management. *Am Surg* 2015;81(6):614–20). A more recent assessment sponsored by Società Italiana di Chirurgia d'Urgenza e del Trauma (Costa G, Ruscelli P, Balducci G, et al. Clinical strategies for the management of intestinal obstruction and pseudo-obstruction. A Delphi Consensus study of SICUT [Società Italiana di Chirurgia d'Urgenza e del Trauma]. *Ann Ital Chir* 2016;87:105–17) used Delphi methodology to define a consensus in treatment of SBO. The panel recommended a surgical admission, a multidisciplinary approach, and a water-soluble contrast swallow for patients presenting with suspected a nonstrangulated adhesive SBO. Criteria for urgent surgery were agreed to include: presence of strangulated hernia, >10-cm cecal dilatation, ileal dilation >6 cm, signs of ischemia, and persistence of metabolic acidosis. Moreover, they concluded that the protocol for nonoperative management (to be conducted for maximum 72 hours) should include a nasogastric drainage placement, IV fluid and electrolyte replacement, and clinical and laboratory controls each 12 hours. It was recommended that nonoperative treatment should be suspended as there is suspicion of intra-abdominal complications, high level of lactate, leukocytosis (>18.000/mm^3 or Neutrophils >85%), or a doubling of creatinine level comparing admission. Conversely, consensus was not reached regarding the exact timing of computed tomography (CT) scan.

There is controversy regarding open versus laparoscopic exploration for SBO. The laparoscopic approach is becoming more common. A study conducted by Jafari and colleagues noted that above 36.7% underwent operative management and laparoscopy was performed in 26.5% with a 22.5% conversion rate. Operative management increased by 1.8% annually, whereas laparoscopic surgery increased by 8.9% annually and open surgery decreased by 0.6% annually. Laparoscopic small bowel resection increased by a mean of 25%

annually. Interestingly laparoscopic surgery was associated with 24.4% in-hospital morbidity with intra-abdominal abscess/enteric fistulas (8.3%) and ileus (8.9%) as the most common complications. In-hospital mortality was 0.9% with length of stay of 13 ± 9 days. In this study, the majority of patients were operated on hospital day (HD) 1 (43.0%). Patients who underwent laparoscopic surgery 7 or more days after admission had a higher risk-adjusted mortality. There has been an increase in admissions for SBO and an increase in laparoscopic surgery over the past 11 years. There seems to be an increase in mortality and morbidity with surgery >7 days after admission. These results should give us pause and the need to reassess the role of laparoscopy in the surgical management of SBO.

What is the ideal test for the diagnosis of SBO? Plan films usually show multiple air fluid levels. Ileus on plain abdominal films may show an air fluid level but usually not multiple. Contrast studies or CT with IV and oral contrast may be considered. Two older studies looked at this (Fevang BT, Jensen D, Fevang J, et al. Upper gastrointestinal contrast study in the management of small bowel obstruction—a prospective randomised study. *Eur J Surg* 2000;166: 39–43; Burkill G, Bell JC, James RG, et al. The utility of computed tomography in acute small bowel obstruction. *Clin Radio* 2001;56:350–9).

These looked a prospective comparison to determine the sensitivity and specificity of water-soluble contrast examination and contrast-enhanced CT in 65 patients with clinical suspicion of adhesive postoperative SBO. There was no statistically significant difference in sensitivity, specificity, accuracy, positive predictive value, and negative predictive value between the two investigations in differentiating simple from a complete/complicated obstruction. However, CT was quicker to perform, could diagnose closed loop obstruction and strangulation, in addition to finding the cause. However, they noted the high cost of CT and lack of availability at most small hospitals in the developing world. Thus, a water-soluble contrast study may be adequate where CT is not available. A water-soluble contrast study is also useful in differentiating partial from complete obstruction in the early postoperative phase, and thus predicting the risk of development of complications.

CT may help distinguish patients with strangulated obstruction. The presence of pneumatosis of the intestine or air in the portal vein is ominous signs and suggests intestinal ischemia and the need to surgical exploration.

As noted by Dr. Galandiuk, the window for safe reoperation in early postoperative (<6 weeks) small bowel obstruction (ESBO) is short and intimately dependent on elapsed time from the initial operation. Most surgeons would agree with the author's statement "avoid re-operating on that patient during the time from 7 days postoperatively until 6 to 8 weeks postoperatively." How is timing of surgery changed if the original operation was performed by laparoscopy? It is thought that laparoscopic procedures create fewer inflammatory changes than open laparotomies. Hence, it has been hypothesized that it is safer to re-operate early for early SBO after laparoscopic procedures

than open. In a meta-analysis, the risk of early SBO laparoscopic surgery was associated with reduced rates of early (odds ratio 0.62) and late (odds ratio 0.61) bowel obstruction than open procedures (Yamada T, Okabayashi K, Haseqawa H, et al. Meta-analysis of the risk of small bowel obstruction following open or laparoscopic colorectal surgery. *Br J Surg* 2016;103(5):493–503). A recent study suggested operation at or beyond 14 days in patients with early SBO after laparoscopic surgery was associated with fewer complications than after open surgery (Goussous N, Kemo KM, Bannon MP, et al. Early postoperative small bowel obstruction: open vs laparoscopic. *Am J Surg* 2015;209:385–90). The laparoscopic group had a severe complication rate of 5% versus 25% in those having the initial operation by an open approach. They also found that the obstruction was more commonly caused by a focal source following an initial laparoscopic procedure than an open operation (85% vs. 63%). The authors concluded that "laparoscopic approaches confer a lower rate of adhesive disease and severity of complications in early SBO as compared with open surgery even if performed after 2 weeks of index procedure."

Dr. Galandiuk refers to short bowel syndrome and its current management. The aim of treatment is to maximize intestinal absorption; minimize the inconvenience of diarrhea; and avoid, reduce, or eliminate the need for parenteral nutrition and support in order to achieve the best possible quality of life for the patient. Conventional treatments include dietary manipulations, oral rehydration solutions, and antidiarrheal and antisecretory treatments. Teduglutide is a newly available treatment that has some promise. An analog of glucagon-like peptide 2, it has been shown to improve intestinal rehabilitation by promoting mucosal growth and possibly by restoring gastric emptying and secretion, thereby reducing intestinal losses and promoting intestinal absorption. Treatment with teduglutide has been associated with enhancement or restoration of the structural and functional integrity of the remaining intestine. This results in a reduction in diarrhea and an equivalent reduction in the need for parenteral nutrition in patients with short bowel syndrome and intestinal failure (Schwartz LK, O'Keefe SJD, Fujioka K, et al. Long-term teduglutide for the treatment of patients with intestinal failure associated with short bowel syndrome. *Clin Transl Gastroenterol* 2016;7(2)).

SBO continues to be a challenging problem for surgeons. Each patient should be assessed carefully, treated with nasogastric decompression and correction of fluid and electrolyte imbalance. Operative intervention may be required in up to 70% of patients. Nonoperative management requires diligent observation on a surgical service with a low threshold for operative intervention. The risk and benefit of laparoscopic surgery should be carefully considered in each case. It is not the best approach for all patients.

E. Christopher Ellison

136 Metabolic Surgery and Intestinal Bypass for Hypercholesterolemia

Henry Buchwald



This Chapter can be accessed in the accompanying eBook edition (see inside front cover for access instructions).

METABOLIC SURGERY AND THE METABOLIC SYNDROME

In 1978, Richard L. Varco and I published a book titled *Metabolic Surgery*, in which we defined metabolic surgery "as the operative manipulation of a normal organ or organ system to achieve a biological result for a potential health gain." This discipline has actually been practiced for nearly 100 years. The most popular seminal application was peptic ulcer surgery, where various gastrectomies and vagal nerve interventions, carried out on normal tissues, were devised to cure pyloric and duodenal ulcer pathology, which itself remained surgically untouched. Intestinal metabolic surgery originated in 1953 to 1954 with the advent of the jejunoileal bypass for morbid obesity. Over the years, this was followed by gastric bypass, constriction, resection, and distention procedures, as well as gastric and vagal electrical stimulation, independent or in concert with intestinal bypasses, transpositions, resections, and intraluminal barriers—all to achieve weight loss and to ameliorate the comorbidities of obesity.

About 15 years ago, the term *Metabolic Syndrome* was added to the lexicon of diseases. This complex of independent entities was defined as consisting of obesity, type 2 diabetes mellitus, hypertension, and hyperlipidemia. Once designated a syndrome by internists, the nonsurgical specialties have searched for a treatment(s) and a cure, often failing to recognize that bariatric surgery, or more precisely metabolic/bariatric surgery, can resolve essentially all of the manifestations of the metabolic syndrome. It should be stated that the so-called metabolic syndrome has

not been identified with a specific etiologic agent, and, in the light of current knowledge, can be thought to include the primary disease of obesity and three of its comorbid conditions.

In this chapter, we will concentrate on a metabolic surgery procedure—the partial ileal bypass—that was developed specifically for the management of hyperlipidemia, one aspect of the metabolic syndrome, and that does not engender noticeable weight loss.

BASIC RESEARCH ANTECEDENTS

The first partial ileal bypass operation specifically for reduction of circulating cholesterol was performed on May 29, 1963. Since then, the series has grown to approximately 600 patients, and the operation has been performed by many others throughout the world. This procedure was used in a multi-institutional secondary atherosclerosis intervention trial funded by the National Heart, Lung, and Blood Institute in 1972, designated the Program on the Surgical Control of the Hyperlipidemias (POSCH). This study has been the only surgical randomized clinical trial to test the efficacy of cholesterol lowering in the management of atherosclerosis and its clinical manifestations, and the first of the statistically significant trials confirming the clinical benefits of cholesterol, in particular low-density lipoprotein (LDL) cholesterol reduction.

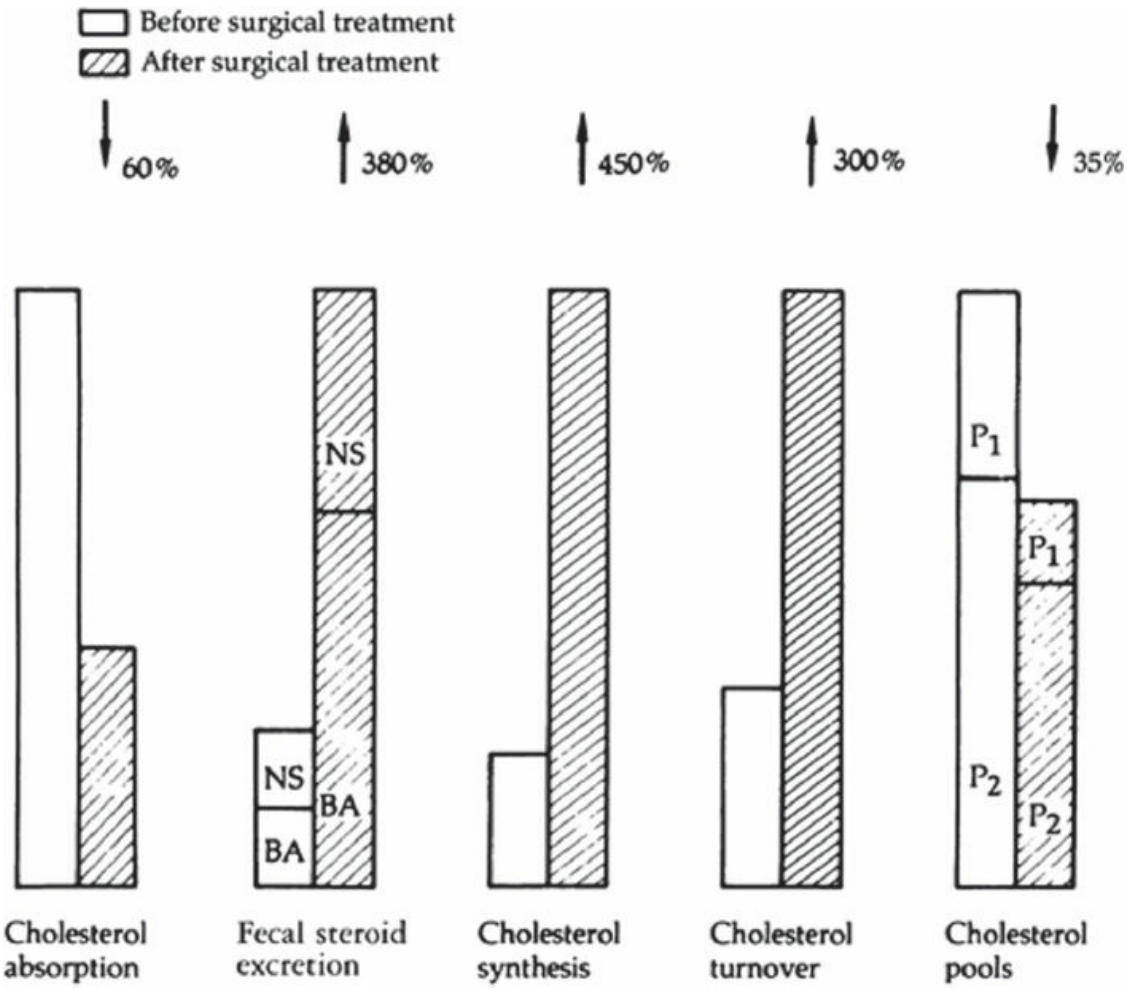

Figure 136.1. Metabolic studies in patients who underwent partial ileal bypass. Preoperative (*open bars*) and postoperative (*crosshatched bars*) values for cholesterol absorption, fecal sterol excretion, cholesterol synthesis, cholesterol turnover, and cholesterol pool sizes. NS, neutral sterols; BA, bile acids; P_1, freely miscible pool; P_2, slowly miscible pool. (From Buchwald H, Moore RB, Varco RL. Surgical treatment of hyperlipidemia. *Circulation* 1974;49(5S1):1, with permission of Wolters Kluwer Health, Inc.)

The rationale for partial ileal bypass is interference with the enterohepatic cholesterol and bile acid cycles to achieve a direct loss of cholesterol from the body and an indirect cholesterol drain by the forced conversion of part of the cholesterol pool to bile acids. This hypothesis has been confirmed in the laboratory and by clinical investigation.

In 1963 my associates and I devised a method of measuring cholesterol absorptive capacity using blood radioactivity levels after a standard oral test dose of ^{14}C-4-cholesterol in butter. In 30 patients studied before and 3

months after partial ileal bypass, the cholesterol absorptive capacity was reduced an average of 60% (Fig. 136.1). Cholesterol absorptive capacity was retested in certain of these patients at intervals throughout the follow-up period. No trend to return to the preoperative cholesterol absorptive capacity was noted. Fecal steroid excretion was measured in selected patients before and after partial ileal bypass, using an isotope balance technique after a single intravenous injection of ^{14}C-4-cholesterol. After the operation, a 3.8-fold increase was seen in total fecal sterol excretion, with a much greater increase in bile acids than in neutral steroids (Fig. 136.1). The same magnitude of sterol excretion was observed in patients studied 1 year after the operation, demonstrating the apparently lasting effect of ileal bypass on fecal sterol excretion.

Using an in vivo method for estimating cholesterol biosynthesis based on the incorporation of tritium from body water into plasma cholesterol, we showed a 5.7-fold increase in cholesterol synthesis at 3 months and at 1 year (Fig. 136.1). Direct and indirect methodologic confirmation of these results has been offered by Miettinen and Moutafis. Understandably, the isotopic cholesterol turnover rate increases approximately threefold after this procedure (Fig. 136.1). Finally, using a method similar to that of Goodman and Noble, we calculated the freely miscible, slowly miscible, and total exchangeable cholesterol pools before and 1 year after partial ileal bypass. The total miscible pool was reduced by nearly one-third, and in each patient a relatively greater reduction was seen in the slowly miscible cholesterol pool than in the freely miscible pool, which suggests a loss of cholesterol from tissues other than the blood, liver, and intestinal mucosa (Fig. 136.1).

There is also information available from the laboratory with respect to partial ileal bypass and the management of atherosclerosis. In adult and infant cholesterol-fed rabbits, my associates and I demonstrated not only prevention of atherosclerosis by partial ileal bypass but also reduction of the lipid content of established atherosclerotic plaques concurrent with their evolution from the proliferative phase to a healing phase.

ATHEROSCLEROSIS AND HYPERCHOLESTEROLEMIA

Atherosclerosis is an ancient disease. Autopsies of Egyptian mummies have disclosed severe arterial occlusive disease. From clinical obscurity through the centuries, atherosclerosis has come to the forefront during the past 50 years. Atherosclerosis today remains the most common serious

affliction in the Western world, and its complications, such as myocardial infarction and peripheral vascular disease, are the leading causes of death in industrialized countries. Approximately 600,000 deaths from coronary heart disease occur in the United States yearly. The deaths from cardiac, cerebral, and peripheral atherosclerotic cardiovascular disease in the United States account for approximately half of the national death rate, exceeding the combined rate for cancer, accidents, and all other causes. This disease is not a geriatric problem. Battlefield autopsies from Korea and Vietnam showed that 45% to 77% of young American soldiers killed in action had evidence of coronary atherosclerotic involvement.

In 1847, Vogel showed that cholesterol was a constituent of the atherosclerotic plaque lesion. Subsequently, a long succession of pathologists, clinicians, and epidemiologists have provided undeniable evidence, terminating in the prospective analyses of the last 30 years, for the tenet that circulating cholesterol concentration is a primary, if not the primary, indicator of atherosclerotic risk and more than likely a major causal agent in the formation of the atherosclerotic plaque.

The average lowering of cholesterol concentration obtained by strict dietary management is 3% to 10%. Drug therapy was equally unimpressive until the 1990s and the introduction of the 3-hydroxy-3-methylglutaryl coenzyme A (HMG-CoA) reductase inhibitors. These statin agents are effective, convenient, and quite safe. Reported side effects of the HMG-CoA reductase inhibitors include changes in bowel function, headaches, nausea, fatigue, insomnia, and skin rashes. Two to three percent of patients have changes in liver function tests that require discontinuation of these agents. Muscle cramps are not rare with these agents, and myositis has been reported. Rhabdomyolysis leading to acute renal failure has occurred in patients treated with HMG-CoA reductase inhibitors in combination with immunosuppressive therapy after cardiac transplantation and in patients treated with a combination of a statin and gemfibrozil.

SURGICAL TECHNIQUE OF PARTIAL ILEAL BYPASS

Open

The open technique for partial ileal bypass has remained essentially unchanged since 1963. Intestinal preparation is carried out the evening before operation, with a clear-liquid diet, nonabsorbable oral antibiotics, and cathartics; enemas are not used. The skin is antiseptically washed

preoperatively and in the operating room. An intravenous infusion is started through a central catheter and low molecular weight heparin is given. Intravenous administration of antibiotics is begun at the time of incision (2 g of a cephalosporin) and may be maintained for 24 hours after the operation.

General anesthesia is preferred to a regional block because general anesthesia provides better cardiovascular control, an advantage in these patients, who often have threatening arterial disease. Anesthesiologists prefer a gradual barbiturate induction, intubation, and light inhalation anesthesia with muscle paralysis.

Unless a concomitant procedure is planned, entrance is gained into the abdominal cavity by a right lower quadrant transverse incision approximately 2 cm below the umbilicus (Fig. 136.2). As a rule, only the right rectus muscle, the linea alba, and a few centimeters of the oblique muscles are divided. General hemostasis and muscle division are performed with the cautery; the inferior epigastric vessels are ligated. The abdomen is carefully explored, and the nasogastric tube placed by the anesthesiologist in the operating room is appropriately positioned along the greater curvature of the stomach by the surgeon, who stands on the right side of the operating table. Antibiotic-soaked laparotomy pads are inserted along the edges of the incision, and a plastic wound protector (5-in diameter) is placed.

The cecum is delivered into the operative field. On occasion, this necessitates cutting the peritoneal reflection at the white line of Toldt posterior and inferior to the cecum and the terminal ileum, and gentle retroperitoneal freeing of these structures. The appendix, if still present, is removed, with ligature of the appendiceal mesenteric vessels, ligature of the stump with 3-0 chromic catgut, inversion of the stump with a 4-0 nonabsorbable purse-string suture, and reinversion of the area with a 4-0 Z stitch.

The small intestine is next delivered into the field and measured with a marked umbilical tape knotted every 25 cm. The tape is placed along the mesenteric border of the intestine because this surface is less variable in its dimensions than the antimesenteric length. When the operator, measuring retrograde from the ileocecal valve, reaches 200 cm (Fig. 136.3), he or she places marking sutures of different colors through avascular windows in the mesentery and around the intestine. Measurement is then continued to the ligament of Treitz, and 25 cm is added for the duodenum to obtain the

total length of small intestine. In my experience, the intestinal length has varied from 400 to 700 cm. If the measurement is greater than 600 cm, the marking sutures are moved 50 cm cephalad and the segment to be bypassed is increased from 200 to 250 cm.

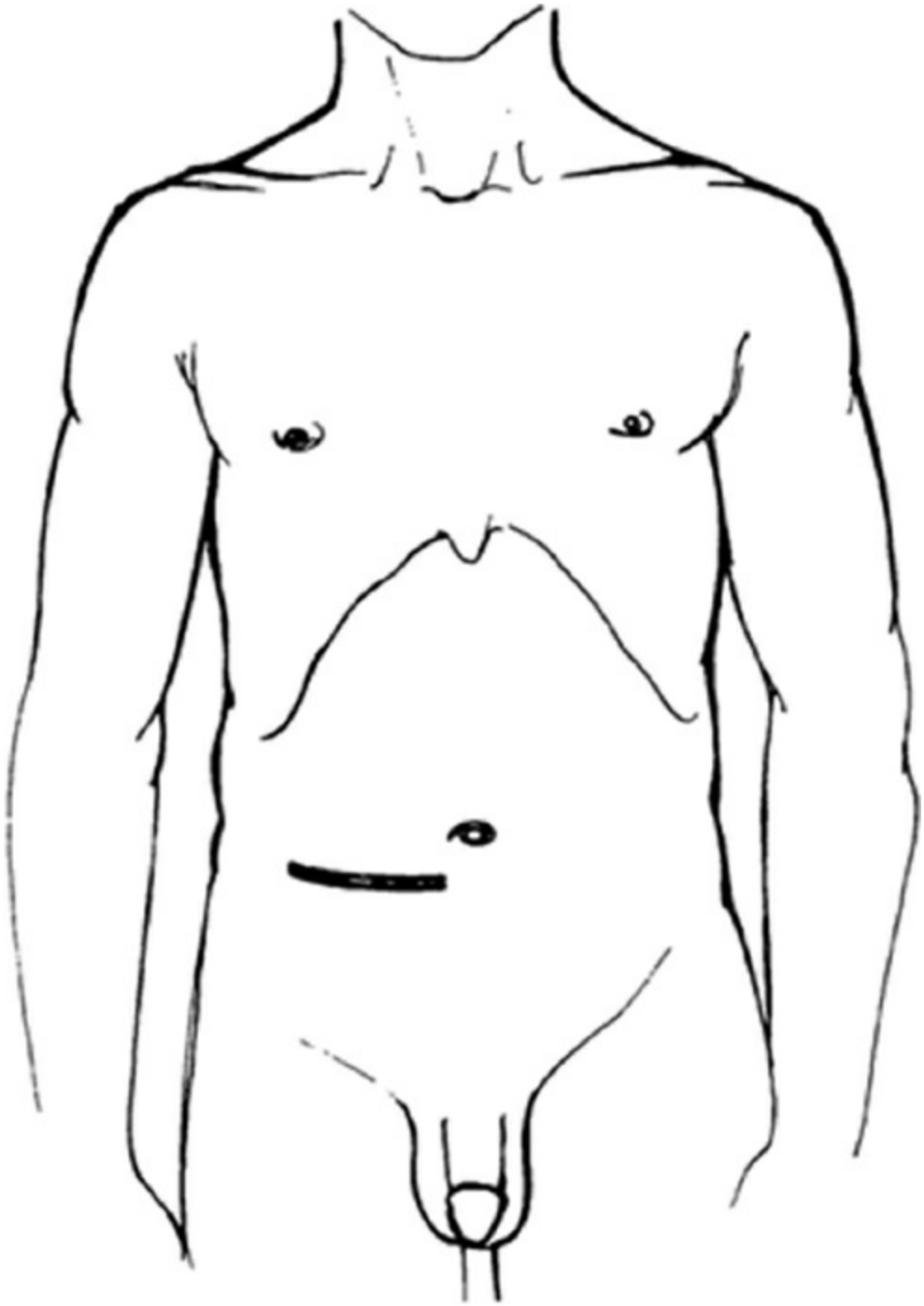

Figure 136.2. Standard incision site for partial ileal bypass.

Between the different-colored marking sutures, a small area of mesentery is cleared, with 5-0 Tevdek (braided polyester, Teleflex

Medical, Mansfield, MA) ligature of mesenteric vessels if necessary. A Dennis clamp is placed straight across the prepared intestine on the distal side, and a Kocher–Allen clamp is placed at a slight angle on the proximal aspect (Fig. 136.4). The small intervening segment of intestine is resected, and the ends of the intestine are cauterized at the clamp margins.

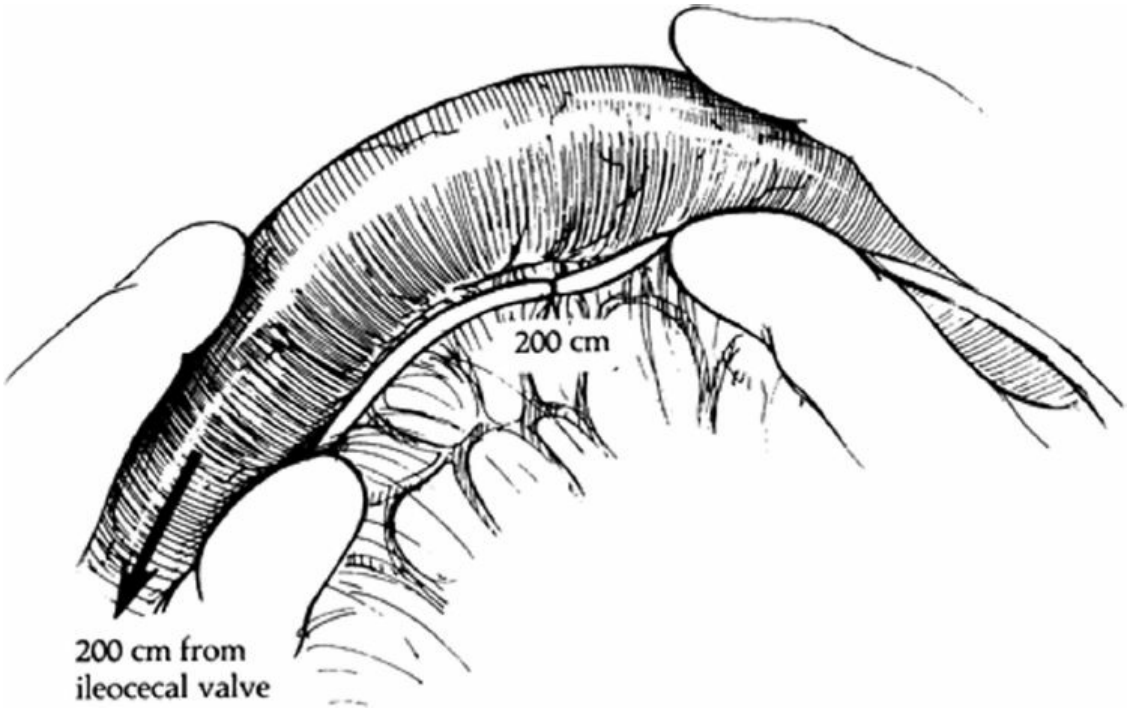

Figure 136.3. Measurement of the small intestine.

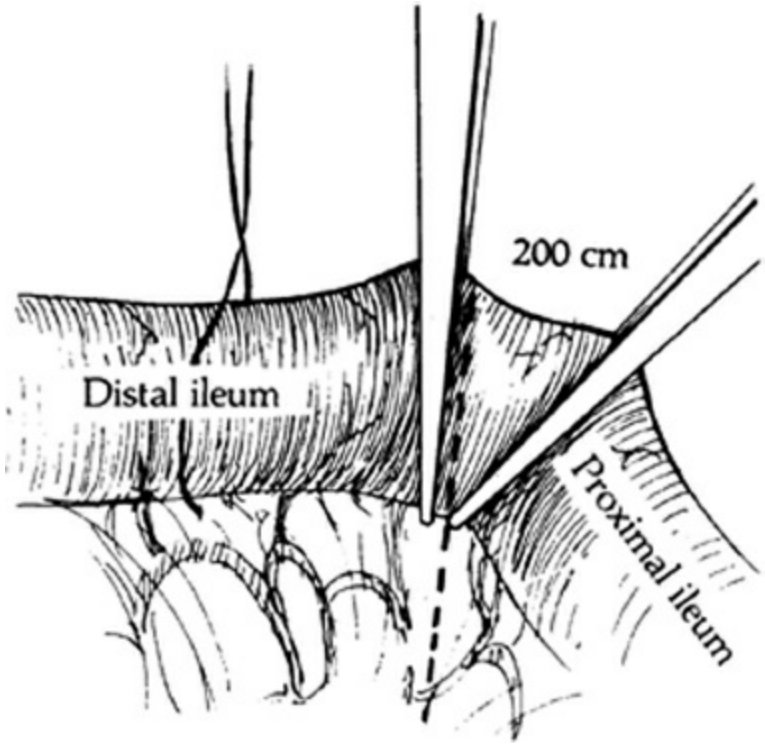

Figure 136.4. Division of the intestine.

The distal end of this division, or what is to become the proximal end of the bypassed segment, is closed in two layers. I prefer an inner row of 4-0 absorbable Vicryl (polyglactin 910, Ethicon, Inc, Somerville, NJ) sutures, taken in a Parker–Kerr manner, and an outer reinverting row of interrupted 5-0 Tevdek sutures. The two corner and the middle sutures are not cut but are retained for future tacking of the closed end of intestine (Fig. 136.5).

Anastomosis is then accomplished between the proximal small intestine and the cecum. The cecum is retained to maximize the water-absorbing surface, and anastomosis is made distal to the ileocecal valve to minimize ileal retention of cholesterol and bile acids and their resorption. Anastomosis is made in an end-to-side manner on the anterior taenia approximately 6 cm above the inverted appendiceal stump (Fig. 136.6). I use a two-layer open anastomosis. The posterior row of interrupted 5-0 Tevdek sutures is placed and, except for the corners, tied and cut. The crushed portion of the ileum is cut off sharply with the clamp, and hemostasis of the fresh surface is obtained by careful use of the cautery. An equidistant incision is made into the cecum, approximately in the middle of the taenia. A whip-lock inner row of 4-0 Vicryl (Ethicon, Inc, Somerville, NJ) sutures is started in the inferior corner, run to the upper corner, taken around the upper corner, and run back in the Connell manner. The anastomosis is then completed by an anterior row of interrupted 5-0 Tevdek sutures in the Lembert manner, with reinforcement of both corners (Fig. 136.7).

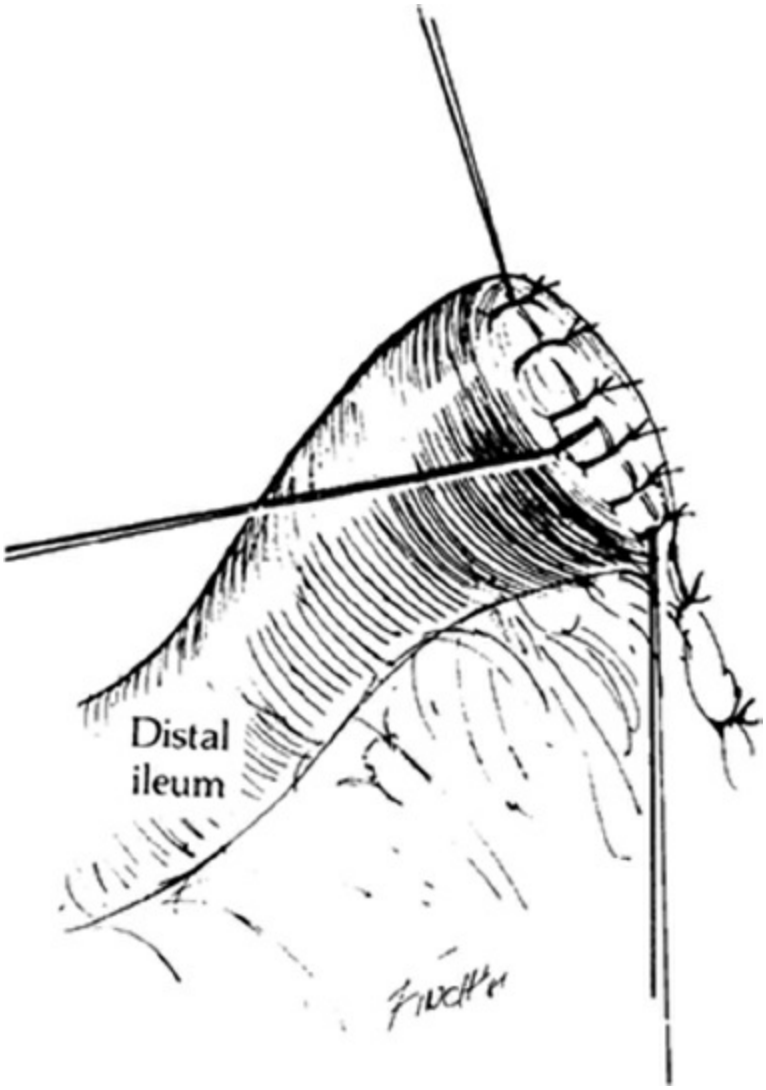

Figure 136.5. Closed end of bypassed segment.

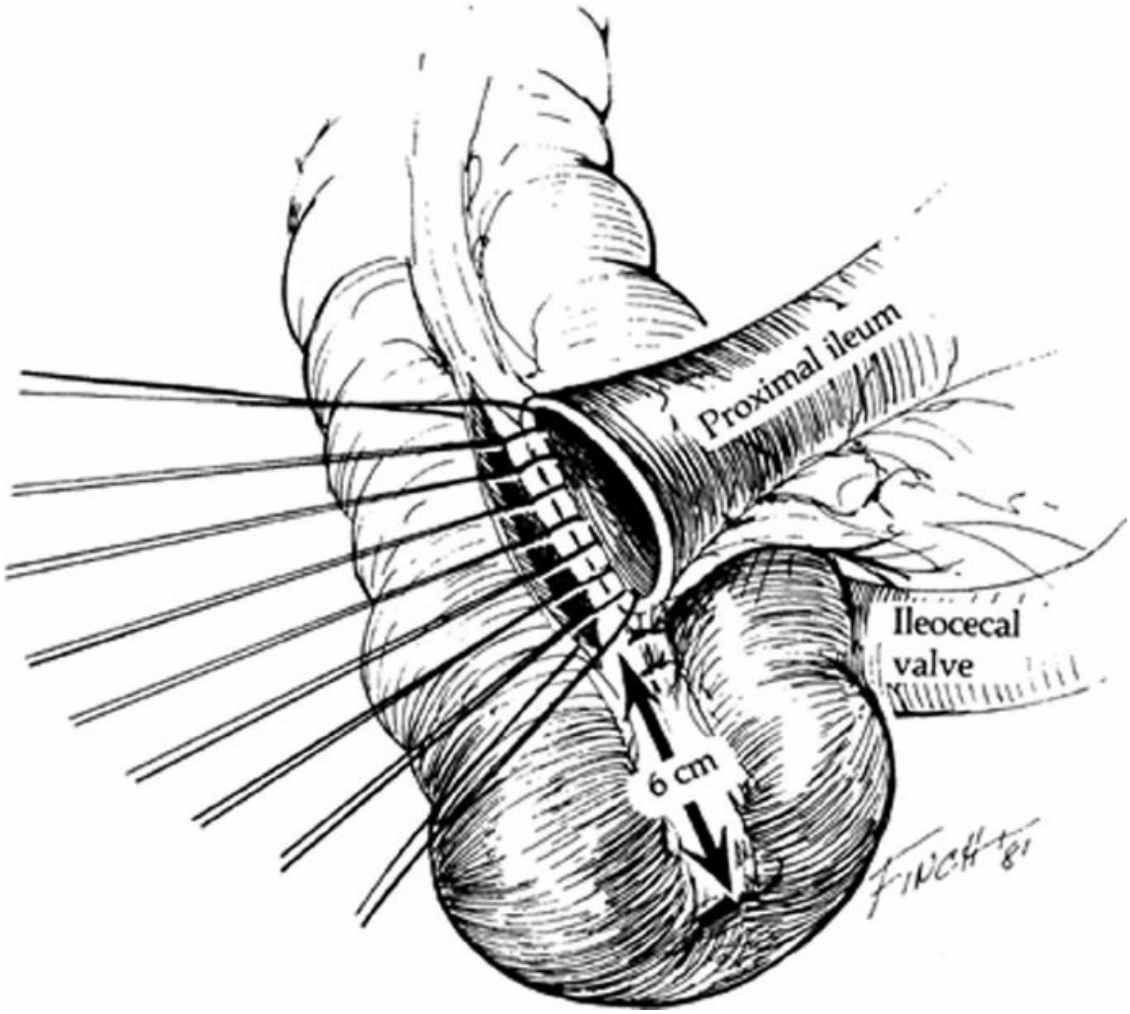

Figure 136.6. Start of end-to-side anastomosis.

The procedure is completed by tacking, with the previously retained sutures, the proximal end of the bypassed segment between the anastomosis and the appendiceal stump, to prevent future intussusception. The small divisional and the large rotational mesenteric defects are carefully closed with interrupted 5-0 Tevdek sutures to prevent internal herniation (Fig. 136.8). The rotational mesenteric defect can be defined by placement of the left hand of the operator below the ileocecostomy and the tacked upper segment of the bypassed intestine.

Surgeons and the scrub nurse change gloves and gowns, and closure is carried out using a separate set of instruments. Closure is done in layers after thorough irrigation with saline solution and antibiotic solution. For the fascial closure, I prefer 00 Tevdek; for the subcutaneous tissues, 2-0 Vicryl; for the skin, a running 4-0 subcuticular Monocryl. No drains are used. A light dressing is applied.

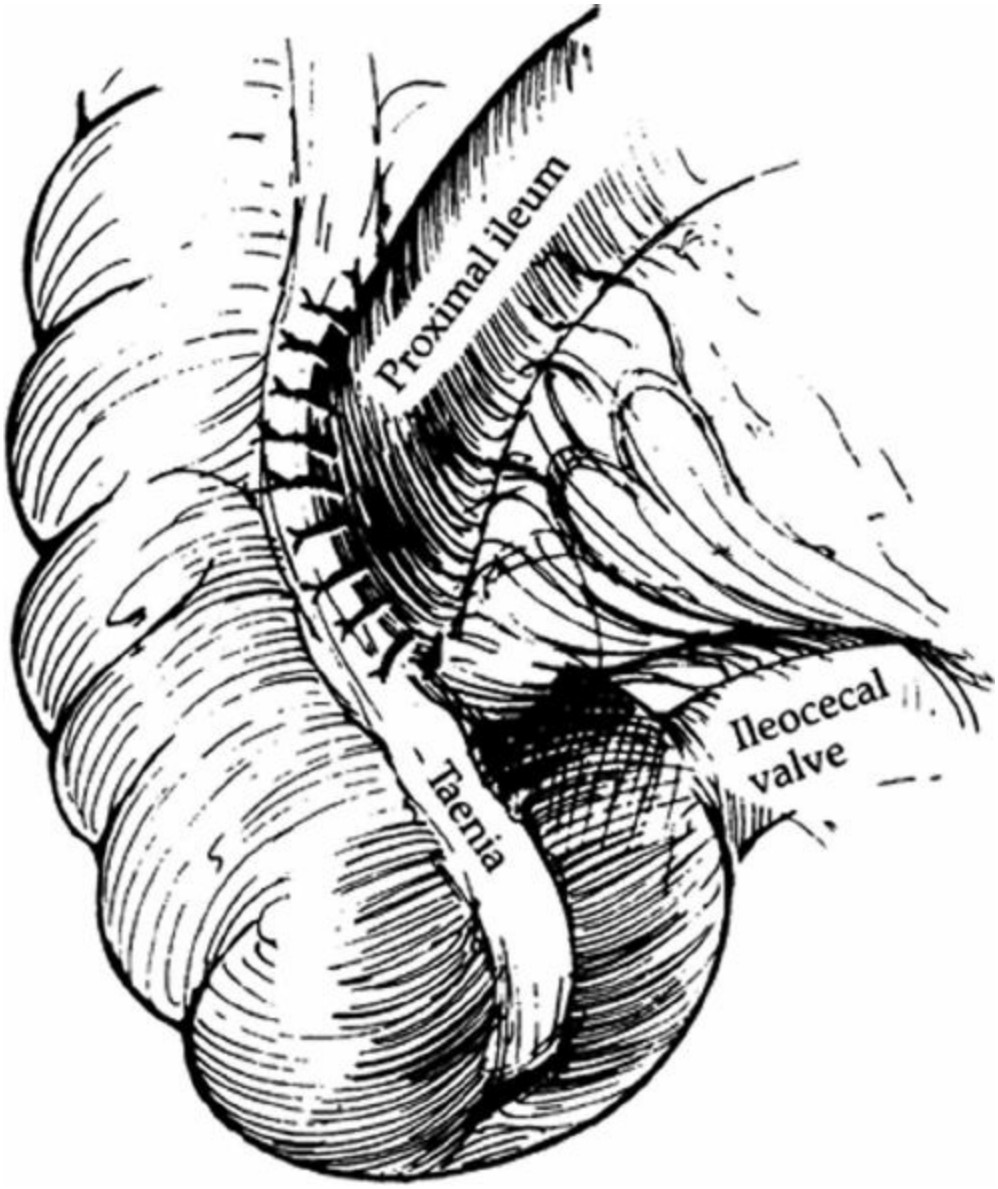

Figure 136.7. Completion of two-layer open anastomosis.

Postoperatively, the patient, as a rule, is extubated in the operating room and may be maintained overnight in the intensive care unit for cardiac monitoring. Early ambulation is instituted, intravenous antibiotics may be maintained for approximately 24 hours, and careful fluid and respiratory management is practiced. The nasogastric tube is removed after demonstrable intestinal activity is present, and diet can usually be progressed rapidly. On the average, the patient is discharged on the 3rd or 4th postoperative day.

Laparoscopic and Stapling

When partial ileal bypass was described and gaining acceptance, there was

no laparoscopic surgery and stapling of intestine was not practiced. Today, a partial ileal bypass can be performed laparoscopically via a 5 to 6 port exposure, using laparoscopic instruments and staples, with essentially the same technical outcome as the open approach.

Further, the procedure can be done by open surgery using stapling instruments. The initial ileal division can be carried out with an intestinal linear stapler; the ileocecostomy can be constructed with the intestinal linear stapler in a side-to-side manner. I have always oversewn all my staple lines with inverting 5-0 nonabsorbable sutures taken in the Lembert manner. This precaution sacrifices speed for safety and a leak-free record for primary intestinal anastomoses.

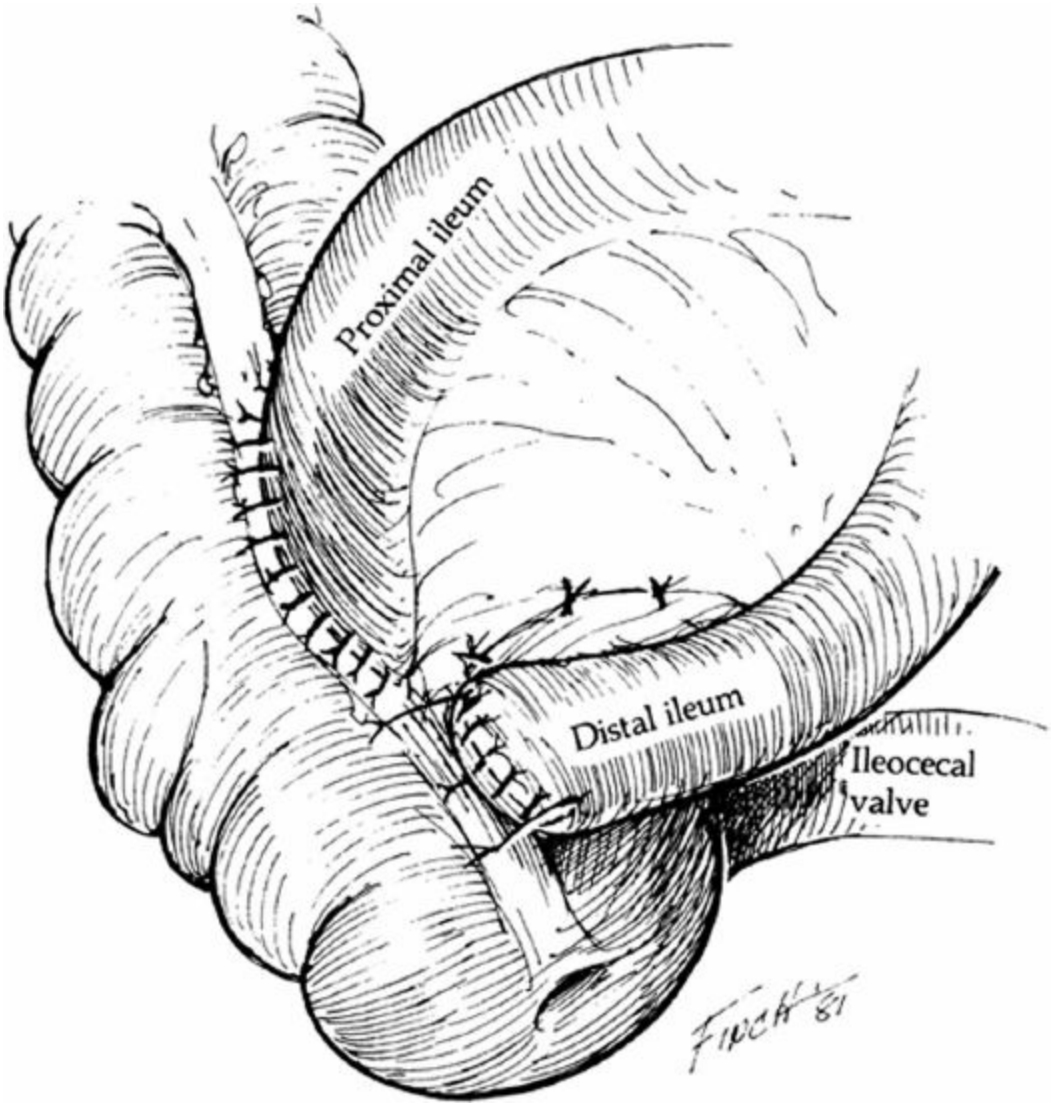

Figure 136.8. Tacking of closed end of bypassed segment and closure of mesenteric defects.

>

Micro-orifice

In 2009, we successfully introduced in the experimental laboratory the micro-orifice technique under intravenous sedation with Propofol and supplemental local anesthesia, and no general anesthesia, abdominal insufflation, and endotracheal intubation. In essence, this approach permits the performance of abdominal surgery, using a 6–7 cm incision, with exteriorization of the bowel and/or laparoscopic instruments and hand assistance. It allows for rapid postoperative recovery and for essentially the same-day or overnight surgery. Metabolic/bariatric sleeve gastrectomies and implantation of stimulating gastric electrodes are being performed clinically in 2011. This approach can readily be utilized for the partial ileal bypass procedure.

SPECIAL SURGICAL CONSIDERATIONS

Approach for Cholecystectomy

When a concomitant cholecystectomy is planned, a supraumbilical transverse or a midline incision is suitable, or laparoscopic technique can be employed. As a rule, for open surgery only a right-sided transverse incision is needed; however, additional superior and inferior exposure can be gained by extending the incision to the left of the midline.

Approach for Pelvic Gynecologic Operations

Although I have performed pelvic gynecologic operations such as tubal ligation and resection and hysterectomy in association with a partial ileal bypass infrequently, I prefer the infraumbilical incision, with extension to the left of the midline when necessary.

Approach for Arterial Operations

Aortic, renal, and iliac arterial reconstructive procedures can be performed, when indicated, concurrently with a partial ileal bypass, if no prosthetic material is used. A transverse infraumbilical incision is usually adequate. The recommendation is that the arterial operation, such as endarterectomy, be done before the intestinal bypass. If a prosthetic graft is used, the partial ileal bypass operation should not be done at the same time. An imminent vascular threat dictates that initial consideration be given to the arterial

operation. If the decision between an arterial operation and the partial ileal bypass is elective, I prefer doing the intestinal procedure first, so that any risk of contamination of the vascular field is avoided.

CLINICAL RESULTS WITH PARTIAL ILEAL BYPASS

Cholesterol

In the original patient series, the average reduction in cholesterol level after partial ileal bypass, from the preoperative but postdietary baseline of 359 mg per 100 mL, was 41.4%. All patients had had appropriate dietary therapy for at least 3 months before the operation; the operation was effective in patients with poor or no response to previous diet or drug programs.

The mean cholesterol reduction in this series for a 9-year follow-up interval is plotted in Figure 136.9. The plasma cholesterol reduction can be seen to have remained essentially unchanged over this entire time span, which indicates the lasting effect of the procedure.

In 1968, my associates and I reported on a study of 24 heterozygous type II patients with an average premanagement plasma cholesterol concentration of 423 mg per 100 mL. Three months after judicious adherence to a stringent low-cholesterol, low-saturated fat diet, an average reduction of 11% in circulating cholesterol was achieved. The average plasma cholesterol level of this cohort 1 year after partial ileal bypass was 224 mg per 100 mL, which represents an additional 42% lowering of the average plasma cholesterol level. Thus, the combination of dietary and partial ileal bypass management is capable of essentially halving the cholesterol concentration (Fig. 136.10).

Results in homozygous type II patients, on the other hand, were disappointing. The postoperative cholesterol levels in our three homozygotes were only 13%, 20%, and 21% below their preoperative values. Balfour and Kim, however, reported better results in two type IIA children: a 42% and a 33% sustained cholesterol reduction for more than 3 years. Other investigators reporting on the use of partial ileal bypass have had clinical results similar to ours, with an average cholesterol lowering of approximately 40%.

My associates and I have published the lipid results of POSCH. Of the 838 participants, 734 (348 control and 386 surgery patients) completed a 5-year lipoprotein evaluation. After partial ileal bypass, the total plasma cholesterol level decreased 23.3% ± 1.0% (mean ± standard error of the

mean) and the low-density lipoprotein cholesterol level fell 37.7% ± 1.2%, in comparison with control values. A significant increase in the high-density lipoprotein cholesterol level of 4.3% ± 1.8% also occurred. The apolipoprotein B-100 level was significantly lower and the apolipoprotein A-1 and high-density lipoprotein 2 levels were significantly higher in the surgical group—all favorable lipoprotein modifications.

Triglycerides

The available triglyceride data are not as extensive as those for cholesterol; nevertheless, marked changes in triglyceride concentration have been well documented. The type IV patients, all with elevated preoperative plasma triglyceride levels, sustained an average reduction of 52%; the response in patients with mixed-type hyperlipoproteinemia was 30% at 1 year; and in the type IIB patients (those with hypertriglyceridemia accompanying hypercholesterolemia), I have seen an average lowering of the circulating triglyceride concentration by 17%. On the other hand, in the type IIA patients, those hypercholesterolemic patients with low or normal preoperative triglyceride concentrations, a paradoxic increase in triglyceride levels of 21% has been seen at 1 year, although even with this increase the average level has remained within the accepted normal range. In POSCH, an average increase in triglyceride level of 19.8% ± 6.5% was observed at 5 years.

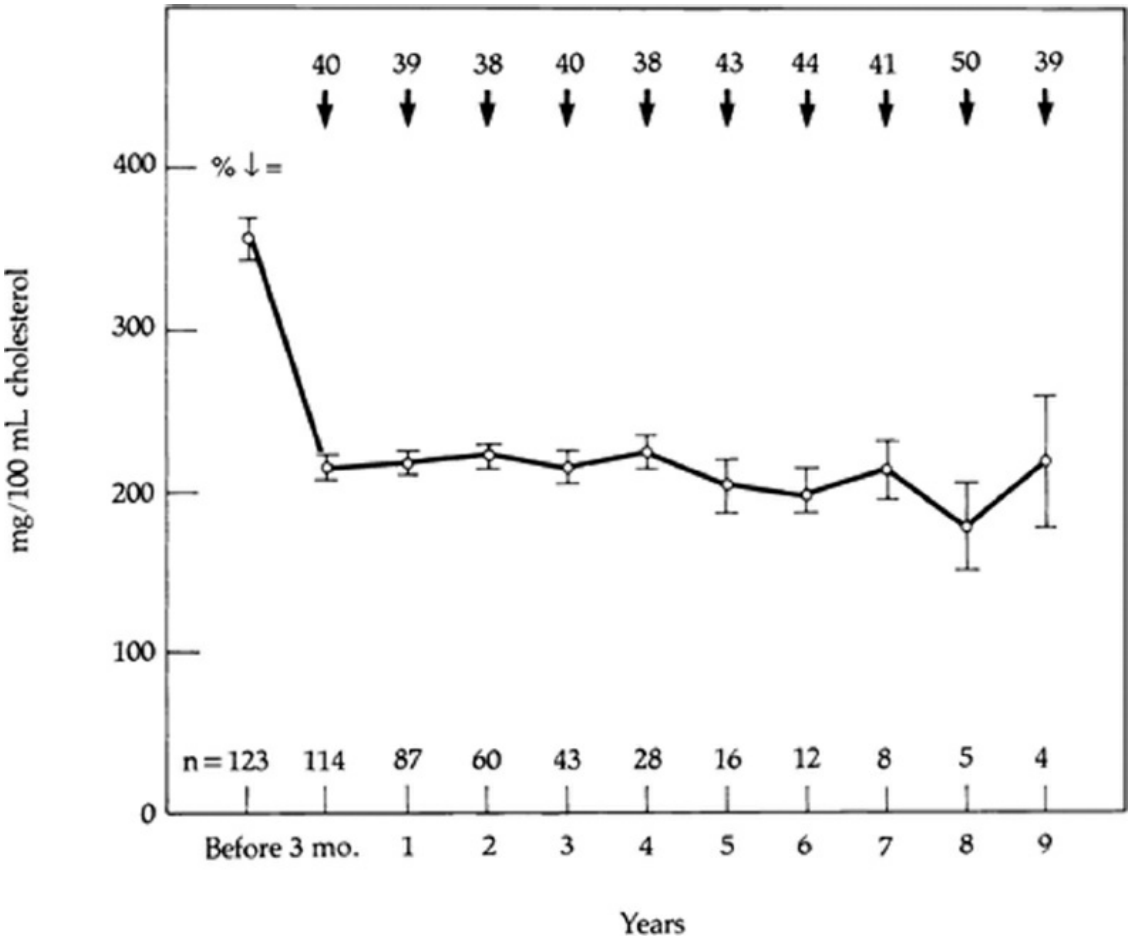

Figure 136.9. Average plasma cholesterol concentrations before and after partial ileal bypass (±1 standard deviation), excluding three homozygous type II patients. Number of patients (*n*) at each time interval is given. (From Buchwald H, Varco RL, eds. *Metabolic Surgery*. New York: Grune & Stratton, 1978, with permission.)

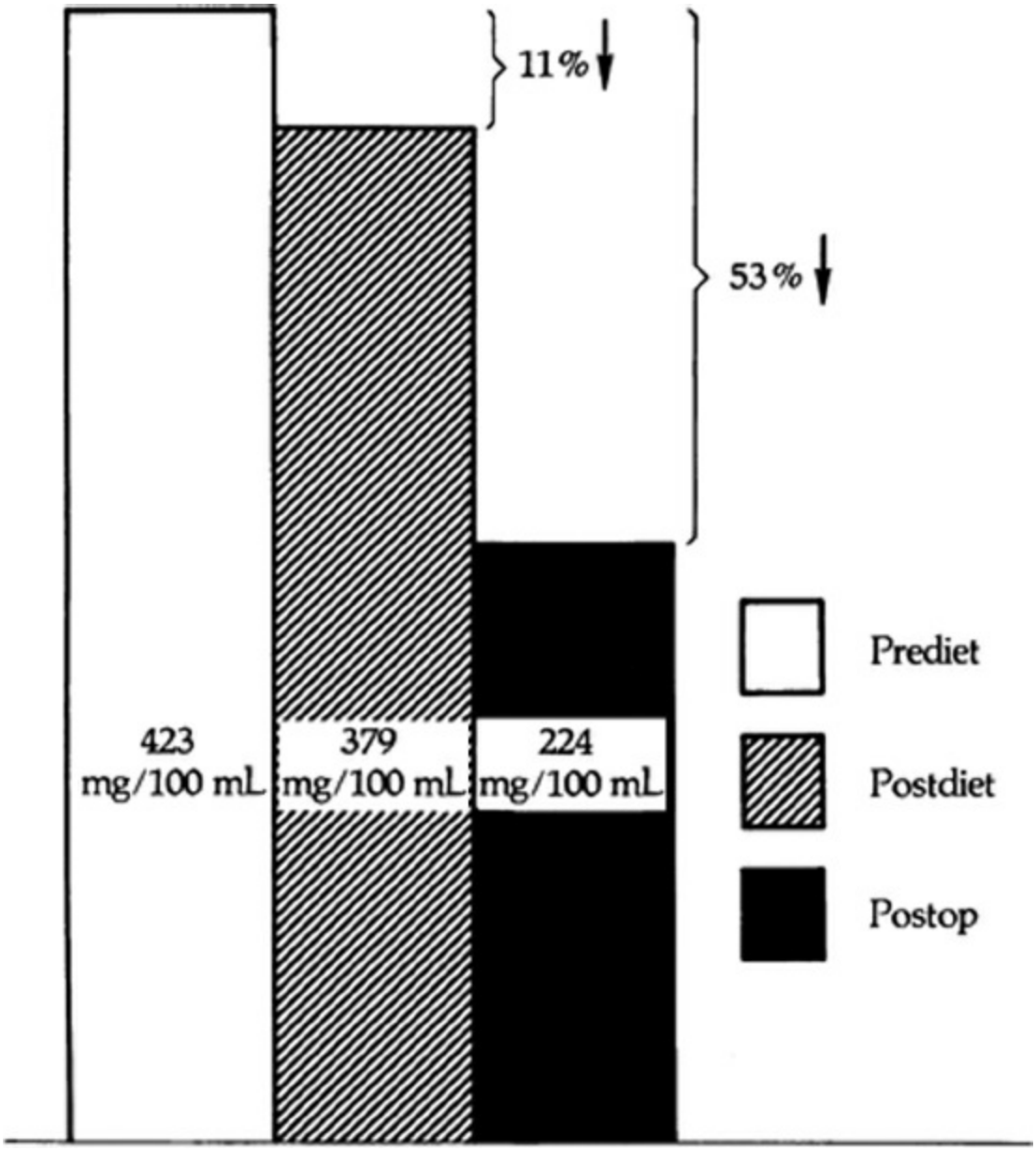

Figure 136.10. Effect of cholesterol-lowering diet and partial ileal bypass on plasma cholesterol levels in 24 type II patients. (From Buchwald H, Moore RB, Varco RL. Surgical treatment of hyperlipidemia. *Circulation* 1974;49(5S1):1, with permission of Wolters Kluwer Health, Inc.)

MORTALITY AND MORBIDITY

Among our patients, one postoperative death occurred, from a myocardial infarction; this yielded an immediately postoperative mortality for partial ileal bypass of well below 1%. An immediately (30-day) postoperative death has not been reported in any other series. Thus, this operation, although often performed in persons with compromised coronary vessels, is safe.

Most patients experience some degree of diarrhea after partial ileal bypass. One year or longer after the procedure, 85% of my patients had fewer than five stools per day when not taking bowel-controlling drugs. With time, patients report an improvement in firmness and consistency of stools.

Occasionally, we have seen the development of a gas-bloat syndrome. A brief course of metronidazole followed by long-term use of this antianaerobe (one 250-mg tablet daily) has usually given total relief.

Minimal long-term weight change is engendered by partial ileal bypass, in sharp contradistinction, of course, to the jejunoileal bypass or other bariatric surgery procedures. No change in serum electrolyte concentrations has been recorded. Vitamin B_{12} absorption may be regained by some patients some time after the operation. This is unpredictable, however, and I have prescribed parenteral administration of vitamin B_{12} routinely every 2 months.

In the POSCH study, we were made aware of an increased incidence of oxalate kidney stones in patients who have had a partial ileal bypass. A controlled trial to test the efficacy of citrate administration in preventing this problem is warranted; preliminary results have been promising. In addition, all patients are recommended to decrease oxalate in the diet and maintain adequate fluid intake.

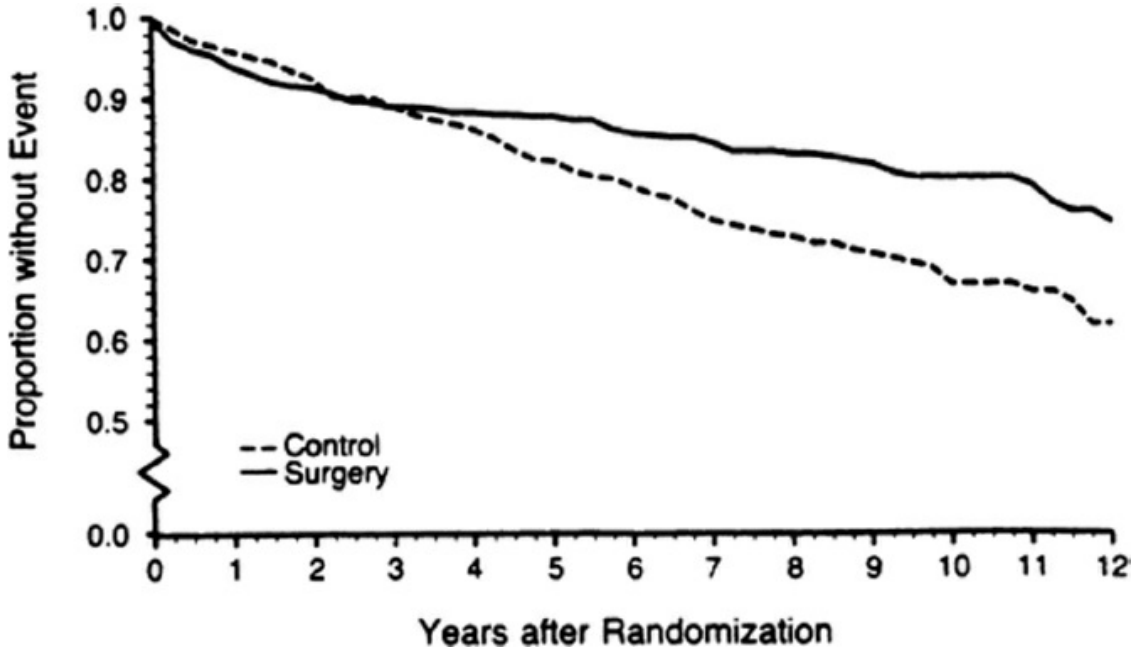

Figure 136.11. Combined end point of death from coronary heart disease and confirmed nonfatal myocardial infarction in the control and partial ileal bypass groups in the Program on the

Surgical Control of the Hyperlipidemias. (From Buchwald H, Varco RL, Matts JP, et al. Effect of partial ileal bypass surgery on mortality and morbidity from coronary heart disease in patients with hypercholesterolemia. *N Engl J Med* 1990;323(14):946. Copyright © 2017 Massachusetts Medical Society. Reprinted with permission from Massachusetts Medical Society.)

Long-Term Mortality

In the POSCH study, analysis of the combined end point of death from coronary heart disease and confirmed nonfatal myocardial infarction showed a 35.0% reduction in risk ($P < 0.001$) at formal trial termination on July 19, 1990 (Fig. 136.11). All other mortality analyses in POSCH combining overall mortality or coronary heart disease mortality with confirmed or suspected nonfatal myocardial infarctions and episodes of unstable angina showed comparable reductions in risk, with highly significant *P* values. In a data-derived, subgroup analysis, the study population was divided into two groups according to left ventricular ejection fraction. In the subgroup with an ejection fraction of 50% or higher, a 36.1% reduction in overall mortality ($P = 0.052$) was obtained. In the 1990 POSCH analysis, the differences for the end points of overall mortality and mortality from atherosclerotic coronary heart disease did not reach statistical significance.

At 5 years after the trial, statistical significance was obtained for differences in overall mortality ($P < 0.049$) and mortality from atherosclerotic coronary heart disease ($P = 0.03$). Long-term follow-up results for the other POSCH end points included overall mortality in patients with a left ventricular ejection fraction of 50% or higher ($P = 0.01$), mortality from atherosclerotic coronary heart disease in patients with a left ventricular ejection fraction of 50% or higher ($P = 0.05$), mortality from atherosclerotic coronary heart disease and confirmed nonfatal myocardial infarction ($P < 0.001$), confirmed nonfatal myocardial infarction ($P < 0.001$), mortality from atherosclerotic coronary heart disease, confirmed and suspected myocardial infarction, unstable angina ($P < 0.001$), incidence of coronary artery bypass grafting or percutaneous transluminal coronary angioplasty ($P < 0.001$), and onset of clinical peripheral vascular disease ($P = 0.02$). No statistically significant differences were seen between groups with regard to cerebrovascular events, mortality from nonatherosclerotic coronary heart disease, and cancer.

In 2010, we published the 25-year mortality follow-up in POSCH using the POSCH database, supplemented by the 2006 National Death Index. The difference between the control and surgery groups in the restricted mean survival and the logrank (Mantel-Haenszel) statistics were statistically significant, with survival probabilities of 0.57 (surgery group) and 0.51 (controls). Cause of death data indicated a significant increase in cardiovascular deaths in the control group; cancer deaths were also greater in the control group but this was not significant. The most compelling subgroup analysis was a significant increase in survival, starting at 5 years after randomization, in the surgery group for patients with an ejection fraction ≥50%, with relative probabilities of 0.61 (surgery) and 0.51 (control). The estimated incremental increase in years of life expectancy over 25 years of follow-up was, in a sense, disappointing, with 1.0 year overall and 1.7 years in the cohort with an ejection fraction ≥50%. Yet, to the individual patient, this increase in survival was more than a statistically significant outcome; it represented a significant time increment with a better quality of life less encumbered with cardiovascular morbidity.

Xanthomata

I have noted a decrease in size and disappearance of periorbital xanthelasma, subcutaneous xanthomata, and even tendon xanthomata after partial ileal bypass. This phenomenon has not been uniform or predictable; however, it has been reported by others.

Angina Pectoris

Approximately 70% of patients with preoperative angina state that this symptom is reduced or disappears within weeks after the bypass procedure. The specific cause for mitigation of hypoxic symptoms remains unknown, but data relate this finding to an improvement in oxygen release by red blood cells subsequent to cholesterol lowering.

Cardiac Procedures

During the formal POSCH trial, coronary artery bypass grafting was performed in 137 control group patients and 52 surgery group patients ($P < 0.0001$). Repeat operations were required in nine control group patients and two surgery group patients. In addition, 33 control group patients and 15 surgery group patients underwent percutaneous transluminal coronary

angioplasty with or without coronary artery bypass grafting ($P = 0.005$). Three control group patients and two surgery group patients underwent cardiac transplantation. The total number of cardiac procedures in the surgery group was reduced 62% ($P < 0.0001$) compared with the control group. Again, this trend persists to the present.

Arteriographic Results

In POSCH, coronary artery disease progressed in patients in both the control group and the surgery group. However, the percentage of patients with progression was consistently greater in the diet-treated control group than in the group treated with partial ileal bypass and diet: 41% versus 28% at 3 years, 65% versus 38% at 5 years, 77% versus 48% at 7 years, and 85% versus 55% at 10 years ($P < 0.001$ for all comparisons). Furthermore, statistically significant evidence ($P < 0.01$) for angiographic coronary artery disease regression was observed at 5- and 7-year follow-up. In addition, we demonstrated in POSCH that coronary arteriographic changes can be used in atherosclerosis intervention trials as a limited surrogate end point for certain clinical coronary events. This relationship is statistically compelling for overall mortality and coronary heart disease mortality. For an individual patient, changes in the severity of coronary atherosclerosis seen on sequential coronary arteriograms can serve as a prognostic indicator for subsequent coronary events.

CONCLUSIONS

A prominent field in surgery today is metabolic surgery. Partial ileal bypass was a primary example of a metabolic operation; the various bariatric surgery procedures have catapulted metabolic surgery into the national spotlight.

Until the 1990s, partial ileal bypass was the only effective, lasting, and safe means of treating hypercholesterolemia. Subsequently, effective lipid reduction therapy has entered the era of the statin drugs. The results of several excellent drug trials have been comparable with the POSCH findings: reductions of 25% in total plasma cholesterol and 35% in low-density lipoprotein cholesterol in the secondary intervention Scandinavian Simvastatin Survival Study and reductions of 20% in total plasma cholesterol and 26% in low-density lipoprotein cholesterol in the primary intervention West of Scotland study.

Partial ileal bypass, however, remains a therapeutic alternative for

patients for whom various drug regimens have failed or who have experienced toxic effects from drug protocols. We perform several such operations annually, and I have been asked to consult by other surgeons on appropriate lipid therapy, using the partial ileal bypass, when the statin drugs have not proven to be efficacious.

The bariatric surgery procedures, as a rule, markedly reduce plasma total cholesterol and low-density lipoprotein cholesterol. This was clearly indicated in a meta-analysis by Buchwald et al. published in *JAMA* in October 2004. There are morbidly obese patients, however, in whom hypercholesterolemia is of such concern that the primary intervention should consist of a bariatric procedure and a partial ileal bypass. Here I would recommend combining the partial ileal bypass with a strictly restrictive procedure—either vertical banded gastroplasty or laparoscopic adjustable gastric banding.

In retrospect, the POSCH legacy among lipid atherosclerosis trials includes the following: it was the first trial to demonstrate clinical benefits of hypercholesterolemia management, including a statistically significant reduction in overall mortality, the longest follow-up trial (more than 20 years), a trial with both clinical and arteriographic findings that demonstrated the validity of changes observed on serial coronary arteriograms as end points for clinical events, a trial demonstrating benefits in peripheral vascular disease, and a trial supported by public monies through a National Heart, Lung, and Blood Institute grant.

In conclusion, the surgeon has a major role in managing hypercholesterolemia and, even more so, in demonstrating that doing so can result in the prevention, retardation, arrest, and reversal of atherosclerotic disease.

Suggested Readings

Buchwald H. Lowering of cholesterol absorption and blood levels by ileal exclusion: experimental basis and preliminary clinical report. *Circulation* 1964;29:713.

Buchwald H, Varco RL, eds. *Metabolic Surgery*. New York: Grune and Stratton; 1978.

Buchwald H, Matts JP, Fitch LL, et al. Changes in sequential coronary arteriograms and subsequent coronary events. *JAMA* 1992;268:1429.

Buchwald H, Varco RL, Matts JP, et al. Effect of partial ileal bypass surgery on mortality and morbidity from coronary heart disease in patients with

hypercholesterolemia. *N Engl J Med* 1990;323:946.

Buchwald H, Campos CT, Varco RL, et al. Effective lipid modification by partial ileal bypass reduced long-term coronary heart disease mortality and morbidity: five-year posttrial follow-up report from the POSCH. *Arch Intern Med* 1998;158:1253.

Buchwald H, Avidor Y, Braunwald E, et al. Bariatric surgery: a systematic review and meta-analysis. *JAMA* 2004;292:1724.

Buchwald H, Menchaca HJ, Michalek VN, et al. Micro-orifice metabolic/bariatric surgery under IV sedation/local anesthesia. *Obes Surg* 2010;20(4):500–5.

Buchwald H, Rudser KD, Williams SE, et al. Overall mortality, incremental life expectancy, and cause of death at 25-years in the program on the surgical control of the hyperlipidemias (POSCH). *Ann Surg* 2010;251(6):1034–40.

Campos CT, Matts JP, Fitch LL, et al. Lipoprotein modification achieved by partial ileal bypass: five-year results of the program on the surgical control of the hyperlipidemias. *Surgery* 1987;102:424.

Menchaca HJ, Michalek VN, Rohde TD, et al. Decreased blood oxygen diffusion in hypercholesterolemia. *Surgery* 1998;124:692.

Miettinen TA. Comparison of cholestyramine, ileal bypass and portacaval shunt in the treatment of familial hypercholesterolemia. In: Gotto AM Jr., Smith LC, Allen B, eds. *Atherosclerosis.* New York: Springer-Verlag; 1980.

Moore RB, Frantz ID Jr, Buchwald H. Changes in cholesterol pool size, turnover rate, and fecal bile acid and sterol secretion after partial ileal bypass in hypercholesterolemic patients. *Surgery* 1969;65:98.

Scandinavian Simvastatin Survival Study Group. Randomized trial of cholesterol lowering in 4444 patients with coronary heart disease: the Scandinavian Simvastatin Survival Study (4S). *Lancet* 1994;344:1383.

Shepherd J, Cobbe SM, Ford I, et al. Prevention of coronary heart disease with pravastatin in men with hypercholesterolemia. *N Engl J Med* 1955;333:1301.

EDITOR'S COMMENT

This experiment, and that is what it is, needs to be taken as a landmark in human experimentation, which actually has been able to show based on metabolic principles that patients with hypercholesterolemia can be dealt with from the standpoint of absorption and their ability to minimize their hypercholesterolemia. Professor Buchwald in the *Annals of Surgery* (251:1034–40) has reported the 25-year incremental life expectancy of intestinal partial ileal bypass and the cause of death in the Program on the Surgical Control of the Hyperlipidemias (POSCH). The POSCH is a randomized controlled trial in

which there are approximately 838 patients; 421 were randomized to surgery and 417 for control. At 25 years follow-up, the restricted mean survival rate was statistically significant with a survival probability of 0.57 in surgery and 0.51 in controls. Cancer deaths were also greater in the control group, but this was not statistically significant. The improvements in survival rate started approximately 5 years following randomization and the expected incremental increase in life expectancy over more than 25 years was unfortunately only 1-year overall life expectancy and in the cohort with an ejection fraction of greater than 50%, it was 1.7 years. As the author says in this very well-written chapter, it is particularly unfortunate that the advantage is only modest but it is at least an attempt to reduce mortality due to hyperlipidemia.

These patients, however, remain heavy and with morbid obesity and an attempt to deal with both the hyperlipidemia and the morbid obesity, Auyang et al. (*Obes Surg* 2009;19:121–4) chose a patient who had a body mass index (BMI) of 45, a 56-year-old female, who underwent both a laparoscopic Roux-en-Y gastric bypass and a partial ileal bypass in 2002. She had sustained excess body loss and her lipid profile has approached normal ranges, albeit with less medication. She experienced no comorbidities related to surgery or hyperlipidemia. The authors conclude that this, in fact, may be the best option for a patient who was morbidly obese and who has hyperlipidemia. I agree with this recommendation. As Professor Buchwald has shown in his long-term 25-year follow-up study, the survival rate is somewhat disappointing with the ileal bypass alone. Nonetheless, it is a start and this “experiment” on humans shows that there may be a better way (gastric bypass) in addition to jejunoileal bypass to ensure prolonged survival.

Ashrafian et al. (*Obes Rev* 2010;11:907–20) summarizes the history of metabolic surgery including both ileal bypass in humans and rodent models and biliopancreatic diversion. It may be that the POSCH study may be the best and earliest program for jejunoileal bypass, but in fact, it has not been the only study. They also point out, how in this particular study, that a number of the operations that have been developed and carried out such as biliopancreatic diversion, adjustable gastric banding, sleeve gastrectomy, and Roux-en-Y gastric bypass have all had experimental studies carried out on experimental animals to devise the operation, which will hopefully be put into place. Not all of the experiments that are carried out in humans worked out as one would hope. For example, the drop of cholesterol from 40% to 75% was shown by partial ileal bypass in white New Zealand rabbits (Buchwald H et al., *Surg Clin North Am* 1967;47:1353–62 and Tijerina O et al., *Surgery* 1988;104:796–805). Regrettably, the results in humans have not proven to be as good as those in rabbits. Atherosclerosis in white New Zealand rabbits appears to be a much more dangerous disease and leads to atherosclerotic lesions much more readily in rabbits than in humans; hyperlipidemic rabbits showed both a decrease in cholesterol and a parallel drop in atherogenesis (Niekirk JL, *Atherosclerosis* 1983;48:242–52). Although the rabbits showed such a parallel increase in

atherogenesis, apparently this did not happen in humans. However, this does not negate the value of the POSCH study that took an enormous expenditure of effort by Professor Henry Buchwald and had a profound effect on all areas of the scientific endeavor including all experiments on humans. It is true that the life expectancy has been disappointing, but it does not negate the value of the studies. As the authors conclude, further insights from these animal models can reveal genetic and molecular systemic effects and obviously they are also concerned about the risk of diabetes, heart disease, and cancer.

Finally, Professor Buchwald and coworkers have continued their research in trying to have new models of metabolic/bariatric surgery, which does not require general anesthesia. In a porcine feasibility study (Buchwald H et al., *Obes Surg* 2010;20:500–5), they have shown that one can do a micro-orifice bariatric surgery under IV sedation in pigs, and thereby achieve a laparoscopic approach to bariatric and experimental obesity surgery. The outcomes of this, I am certain, will bear fruit with various experiments and I wish Professor Buchwald continued success in his various attempts to bring metabolic surgery into its own and enable patients to be benefitted by using animals as experimental subjects before attempting this in humans.

J.E.F.

137 The Continent Ileostomy

Eric J. Dozois and Roger R. Dozois


This Chapter can be accessed in the accompanying eBook edition (see inside front cover for access instructions).

INTRODUCTION

The continent reservoir ileostomy, commonly referred to as the *Kock pouch*, comprises an internal ileal reservoir that stores stool and gas between intubations, a stoma and outflow tract needed to intubate and evacuate the contents of the reservoir, and a surgically created biologic valve interposed between the other two components to act as a pressure barrier and provide continence. The major advantages of this operation over the conventional spout ileostomy are the elimination of the necessity for the patient to continually wear an external appliance and a much less conspicuous stoma.

HISTORICAL BACKGROUND AND RATIONALE

Although patients and their caregivers recognize the benefits of proctocolectomy and Brooke ileostomy, a curative operation that restores the patient's health, it has become evident that for many ileostomates, the need to constantly wear an external appliance to collect the effluent of an incontinent stoma can interfere with some of their daily activities and their social life, and can be detrimental to their overall quality of life. Also, the material necessary to pouch the stoma is expensive. Although an incontinent Brooke-type stoma is acceptable to most ostomy patients, primarily because they regain their general health, as many as 40% of these patients long for a better alternative. By surgically devising an internal reservoir capable of collecting the bowel contents and by rendering it continent by adding a valve mechanism so that patients no longer have to wear an external appliance, Nils Kock of Göteborg, Sweden, revolutionized the concept of surgically created continence and unknowingly paved the way for the ileal pouch anal anastomosis.

The construction of an intestinal reservoir to substitute for the loss of rectal capacity evolved rapidly when a U-shaped, double-folded reservoir was designed by Kock and his colleagues. The means to achieve continence, however, were slower to evolve. At first, Kock hoped that continence could be achieved by external compression of the outflow tract brought through the rectus abdominis muscle, but this proved unreliable. Interposition of an antiperistaltic segment of ileum between the reservoir and the stoma also proved inefficient. In 1972, Kock ingeniously devised the intussusception ileal valve, the so-called nipple valve, using an isoperistaltic portion of the outflow tract, which resulted in a far more reliable continence mechanism.

A number of technical refinements were later added to compensate for the weaker mesenteric side of the intussuscepted ileal segment, including stripping off the peritoneum and defatting the mesentery of the valve, placement of “rotation” sutures, reinforcement by a mesenteric sling of synthetic mesh encompassing the outflow tract, and stapling the antimesenteric side of the valve to the side wall of the reservoir.

At the Mayo Clinic, the efforts to construct and perfect the continent ileostomy were spearheaded by Oliver H. Beahrs in the early 1970s. Initially, the valve was made 3 cm in length and anchored in place with through-and-through nonabsorbable silk sutures. Subsequently, and with the hope of reducing valve slippage and valve fistula, the nipple was made longer (5 cm), and was anchored in place with both absorbable sutures and staples, and then interrupted sutures were added between the base of the reservoir and the outflow tract to further anchor the intussusceptum. We have been reluctant to use Marlex mesh, which may result in fistula formation across the nipple valve.

CURRENT INDICATIONS AND CONTRAINDICATIONS

Although the ileal pouch anal anastomosis is now preferred by most patients requiring proctocolectomy, the continent ileostomy remains a viable alternative to the Brooke ileostomy for certain categories of patients, which include (a) patients with an existing conventional Brooke ileostomy with no possibility of an ileal pouch anal anastomosis (no anal sphincter) who want to improve their quality of life, (b) patients requiring a proctocolectomy who wish to preserve continence but are not suitable candidates for an ileoanal anastomosis, most often because of poor anal sphincter function, (c) the rare patients whose daily work takes them away

from toilet facilities for long periods of time and who prefer a continent ileostomy to an ileoanal anastomosis, and (d) patients with a failed ileoanal anastomosis who desire to preserve continence and avoid an external appliance if the failure is unrelated to Crohn disease or severe pouchitis.

Use of the Kock pouch should be discouraged in (a) older patients who may be more prone to postoperative complications, including valve dysfunction, and may not tolerate reoperation, (b) patients with Crohn disease, (c) obese patients, (d) critically ill patients such as those with toxic megacolon, (e) psychologically unfit patients who may not be able to intubate properly or tolerate complications and reoperations, and (f) patients in whom a significant amount of small intestine has already been removed.

THE OPERATION

The distal 45 cm of the ileum is used to construct the reservoir, the valve, and the outflow tract (efferent limb). Beginning 15 cm from the cut end of the distal ileum, a 30-cm segment of ileum is measured and fashioned into a U (Fig. 137.1). The antimesenteric borders of the two 15-cm limbs of the U are approximated with continuous suture of 2-0 chromic catgut. The two limbs are then incised on their antimesenteric borders, with the incision extending 4 to 5 cm longer on the afferent limb than on the efferent limb so that the two limbs separate as the pouch is constructed. A second layer of continuous chromic catgut is used to approximate the mucosa and complete the posterior wall of the reservoir (Fig. 137.2).

The valve is then fashioned. The serosal surface of the efferent limb of the ileum is scarified, with the electrocautery beginning at the pouch and extending for a distance of 10 cm toward the cut end. The peritoneum of that same segment is also stripped from the adjacent mesentery, which is also defatted. These maneuvers are designed to promote the adherence of the ileum and its mesentery when the efferent limb is intussuscepted into the pouch to fashion the valve.

The 10-cm efferent limb is intussuscepted into the pouch to form a nipple valve of ~5 cm in length. The intussusceptum is fixed in place with through-and-through sutures of 2-0 Vicryl (polyglactin 910) and three cartridges of stainless steel staples along both sides of the mesentery, care being taken to avoid injury to the vascular supply, and immediately opposite the mesentery using the GIA (U.S. Surgical Corp., Norwalk, CT, USA) autosuture apparatus (Fig. 137.3). The placement of the staples and

sutures is facilitated by “stenting” the lumen of the intussusceptum with a No. 28 French catheter.

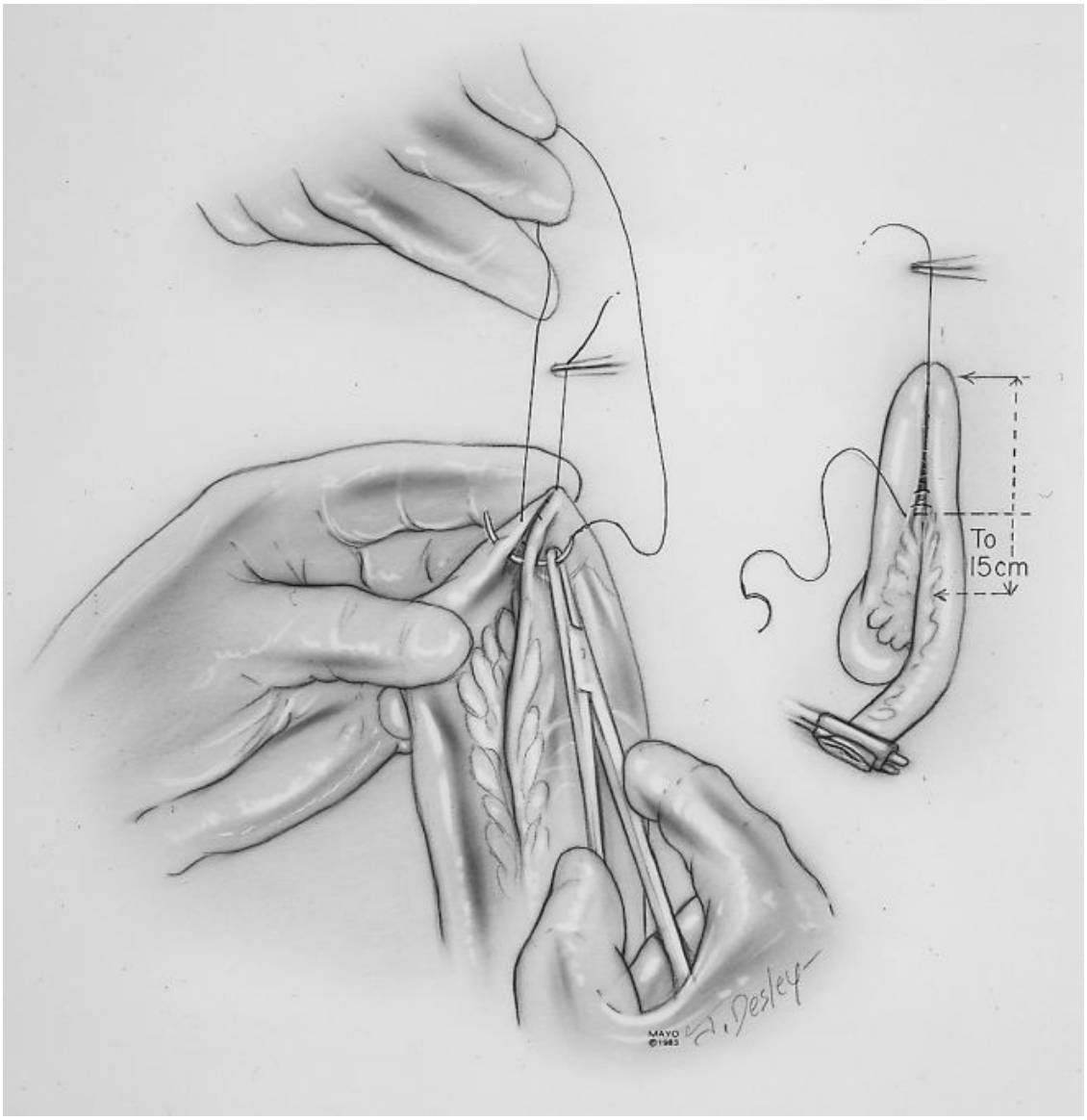

Figure 137.1. The two 15-cm limbs of the folded 30-cm loop are approximated with continuous 2-0 chromic catgut placed near the mesenteric border of the bowel. (Modified from Beahrs OH. Continent ileostomy. In: *Surgical Techniques Illustrated.* Vol 3. Boston, MA: Little, Brown and Company; 1978, with permission.)

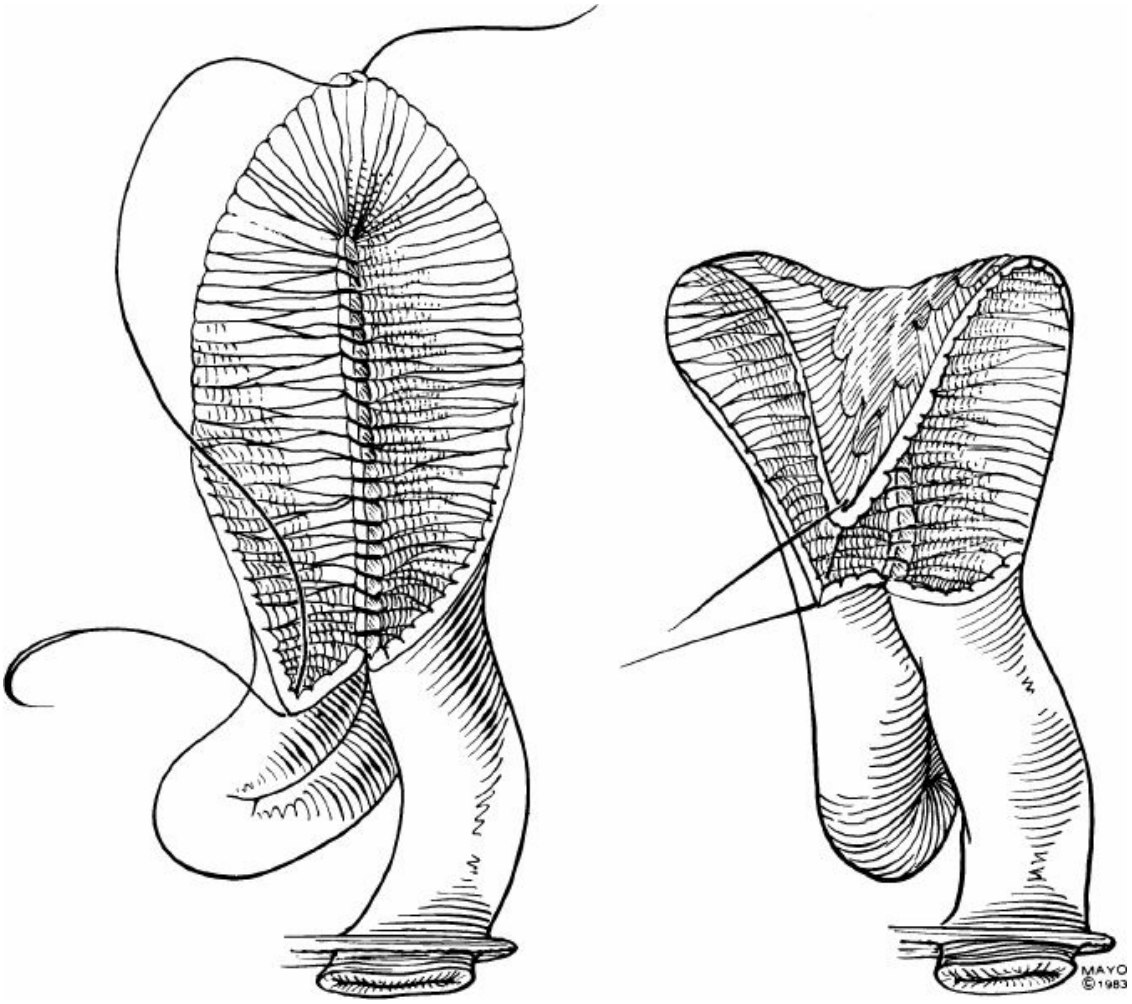

Figure 137.2. The two approximated limbs are incised and a second row of continuous 2-0 chromic catgut sutures is used to approximate the mucosa before the apex of the opened loop is folded over. (Published in Dozois RR, Kelly KA, Beart RW, et al. Continent ileostomy: the Mayo Clinic experience. In: Dozois RR, ed. *Alternatives to Conventional Ileostomy.* Chicago: Year Book Medical Publishers; 1985. Copyright Elsevier.)

The bottom of the U is then folded over to construct the anterior wall of the reservoir, using two layers of continuous 2-0 chromic catgut (Fig. 137.2). The outflow tract is sutured to the base of the pouch with interrupted 3-0 nonabsorbable sutures at the exit of the limb from the pouch to further anchor the intussusceptum in place (Fig. 137.3).

A circumferential defect is created through the abdominal wall just above the pubic hairline in the right lower quadrant, and the outflow tract is brought through the defect and amputated flush with the skin and matured into a stoma with interrupted 3-0 chromic catgut. The length of ileum between the pouch and the stoma should be kept short to avoid

tortuosity and facilitate later intubation of the reservoir. This is aided by suturing the pouch to the undersurface of the anterior abdominal wall so that the nipple valve is perfectly aligned with the stoma (Fig. 137.4).

A No. 28 French catheter is passed through the stoma, efferent limb, and nipple valve, and its tip is positioned within the lumen of the pouch before the incision is closed. A suture of heavy silk is tied around the catheter at the level of the stoma so that the exact position of the catheter can easily be ascertained in the postoperative period. These precautions help prevent pouch perforation or tube slippage during postoperative recovery.

POSTOPERATIVE AND POSTHOSPITALIZATION CARE

In the immediate postoperatiave days, the ileal pouch is irrigated with 25 mL of physiologic saline twice a day to maintain the patency of the catheter, which is connected to a drainage bag. When spontaneous bowel function returns, oral alimentation can be resumed. Before dismissal from the hospital, approximately 8 to 10 days postoperatively, patients are taught self-catheterization by the stoma therapist.

On leaving the hospital, patients are given a catheter designed to drain the pouch (either an ileostomy catheter, M8730 [Atlantic Surgical Co. Inc., Merrick, NY, USA], or an ileal pouch catheter [Dow-Corning Co., Midland, MI]). The Atlantic ileostomy catheter has a diameter of ~9 mm (No. 28 French) and a length of 30 cm, whereas the Dow-Corning ileal pouch catheter has a diameter of approximately 1 cm (No. 30 French) and a length of approximately 64 cm. Each catheter has a thin wall and large holes at the insertion end just proximal to its bullet-shaped blunt tip. The patient keeps the catheter in a small plastic case, which is carried at all times.

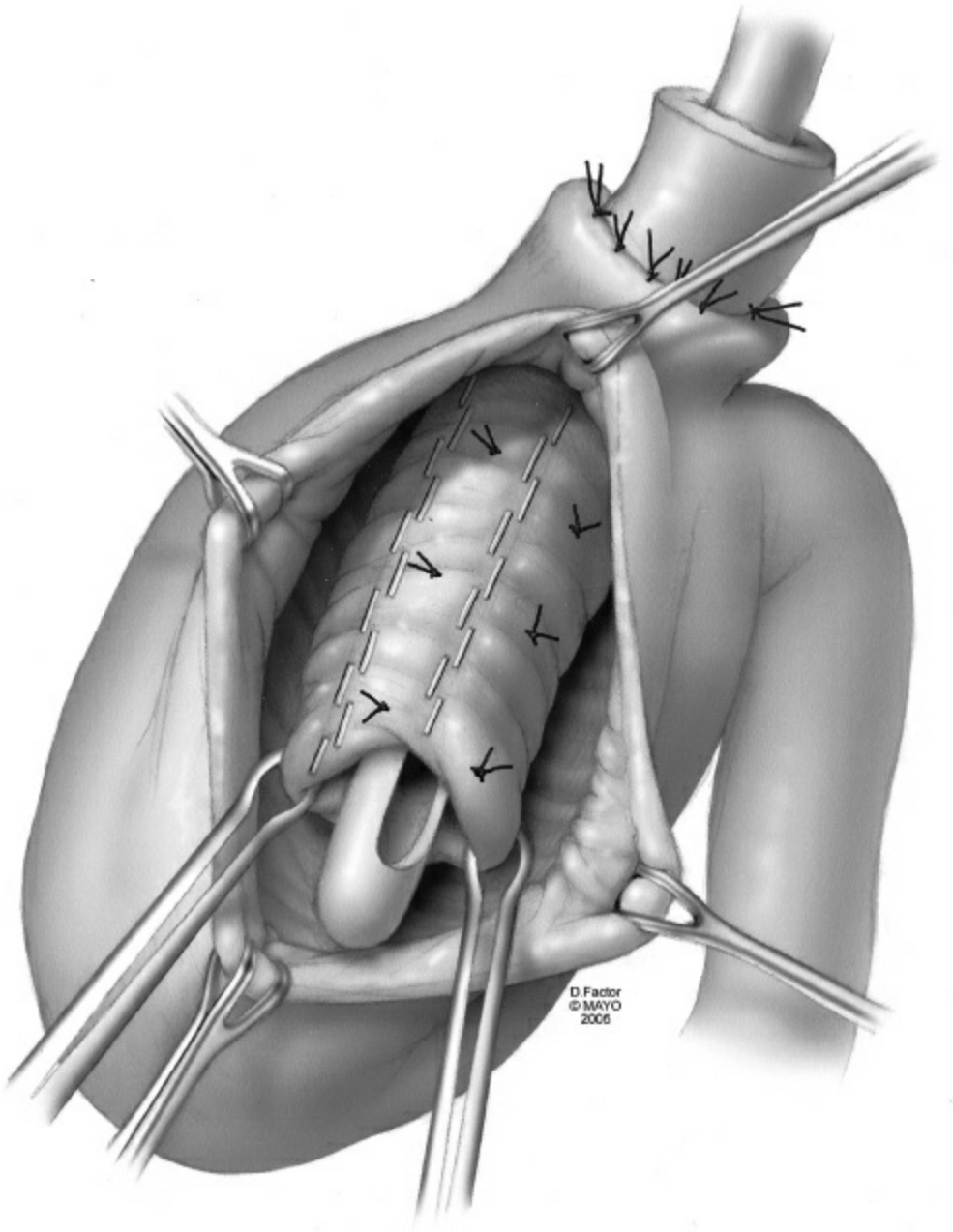

Figure 137.3. Prior to suturing the entire anterior wall of the pouch, the surgically intussuscepted efferent limb is held in place with interrupted sutures of 2-0 polyglycolic acid and three rows of stainless steel staples to form the nipple valve. This is facilitated if done over a catheter. Interrupted sutures of 2-0 polyglycolic acid placed between the base of the reservoir and efferent ileal limb help anchor further the intussuscepted segment within the pouch. Suturing of the anterior wall of the pouch is then completed in two rows. For revisions caused by valve slippage, the same procedure can be performed after the anterior wall of the pouch is reopened and the valve pulled back into the reservoir with Babcock clamps.

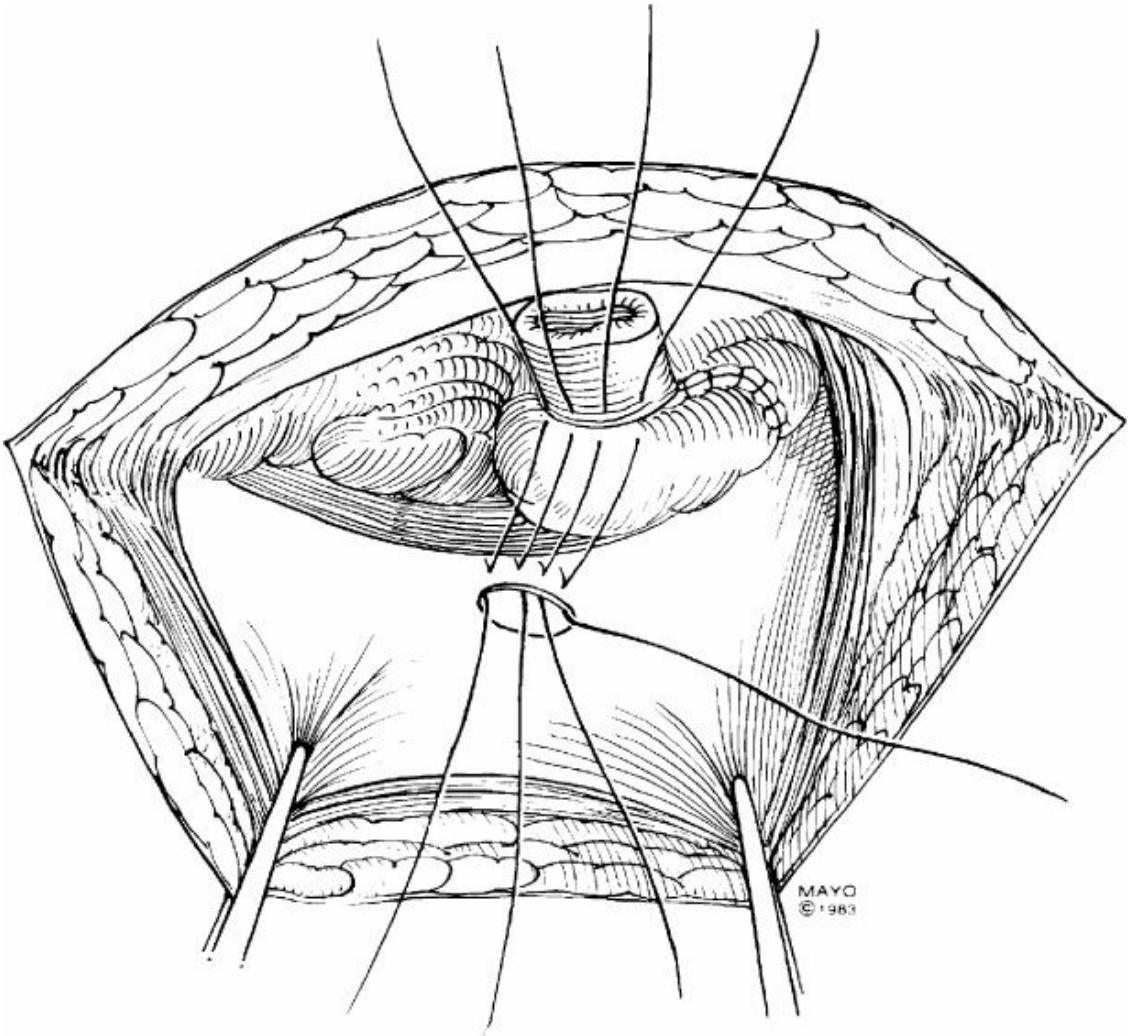

Figure 137.4. The reservoir and outflow tract are anchored to the undersurface of the abdominal wall immediately underneath the stoma site to facilitate future intubation. (Published in Dozois RR, Kelly KA, Beart RW, et al. Continent ileostomy: the Mayo Clinic experience. In: Dozois RR, ed. *Alternatives to Conventional Ileostomy.* Chicago: Year Book Medical Publishers; 1985. Copyright Elsevier.)

When the patient experiences a sensation of fullness, the pouch requires emptying. To empty the pouch, the patient passes the catheter through the stoma into the pouch, usually in the sitting position. The ileal contents spontaneously drain by gravity through the catheter directly into the toilet or another suitable receptacle. The Valsalva maneuver and direct manual compression of the abdomen over the pouch area may at times facilitate drainage, but routine irrigations are not required. The catheter then is removed from the pouch, rinsed clean, and replaced in its case for later use. A soft gauze pad with a waterproof surface is taped over the stoma to

absorb any mucus secreted by the stoma. Patients rapidly become proficient at this procedure, which requires 5 to 10 minutes to complete. None of our patients has ever perforated the pouch with the catheter.

Some patients have found that partially digestible substances, such as seeds, apple skins, celery, and mushrooms, may plug the catheter, so they have avoided these foods. Others, however, have found that all foods can be eaten, provided they are thoroughly masticated before being swallowed.

Four to 6 weeks after operation, restrictions on physical activities are removed. Pregnancy is not contraindicated. Many patients who have undergone this procedure have become pregnant and have delivered healthy babies, either vaginally or by cesarean section.

RESULTS

Between November 1971 and December 1981, 460 patients had a continent ileostomy constructed at the Mayo Medical Center in Rochester, Minnesota. Since 1982 and with the advent of the ileal pouch anal anastomosis, approximately 12 continent ileostomies are either constructed or revised each year.

In our series of patients, no pouch-related deaths occurred intraoperatively or postoperatively. The mean postoperative hospital stay was 10 days. Because of careful patient selection, greater experience, avoidance of a Kock pouch in patients with Crohn disease, and favoring of valve revision over pouch excision when serious complications occur, we have had to excise the reservoir in fewer than 3% of the cases.

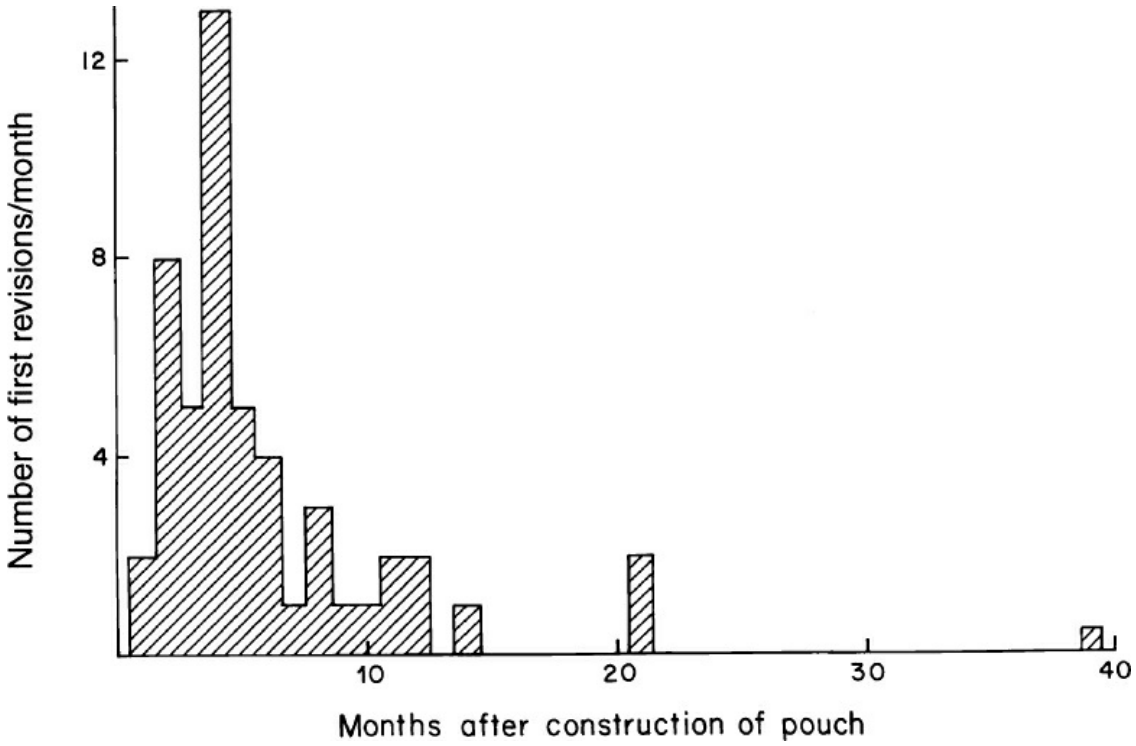

Figure 137.5. The number of patients needing valve revision is greatest 2 to 6 months after the construction of the pouch. (Published in Dozois RR, Kelly KA. The surgical management of ulcerative colitis. In: Kirsner JB, ed. *Inflammatory Bowel Disease.* 5th ed. Philadelphia, PA: WB Saunders; 2000:626. Copyright Elsevier.)

REVISIONAL SURGERY

Persistent difficulties with pouch intubation and/or incontinence related to nipple valve malfunction have necessitated reoperation in 10% to 20% of the patients. In most patients, valve dysfunction occurs within 6 months after construction of the pouch (Fig. 137.5), after which the need for revision decreases dramatically. Malfunction is most often caused by extrusion of the valve and its mesentery, which results in elongation and tortuosity of the efferent limb. As a consequence, the pouch is difficult to intubate as the tip of the catheter may not be maneuvered easily into the pouch lumen, and the pouch leaks. A pouchogram can confirm the clinical suspicion of valve deintussusception. If intubation by the patient or the treating physician is impossible, bowel obstruction will ensue, and a rigid endoscope must be inserted into the pouch lumen to aspirate its contents and place a catheter.

Factors that influence the need for valve revision include age, gender, type of operation, and body habitus (Table 137.1).

Pouch Malfunction from Valve Failure

When valve malfunction occurs, most often reoperation is necessary. The nature of valve revision needed depends on the type of complication and the anatomic configuration of the valve at the time of surgical exploration. After the stoma, the efferent limb, and the reservoir are dissected free from the abdominal wall and fully mobilized, the pouch lumen is entered through an incision in its anterior wall. If the valve has become deintussuscepted into the mesenteric side of the reservoir and outflow tract, the existing nipple valve is pulled back into the reservoir with Babcock clamps and the valve is reanchored with a combination of sutures and stainless steel staples. The pouch incision is closed in two layers, the pouch is again fixed to the undersurface of the abdominal wall, and the stoma is rematured in the same location. If the existing valve cannot be used because of extensive fibrosis, stenosis, or a fistula through the valve, then the stoma, the efferent limb (outflow tract), and the valve are excised and a new valve is created from the afferent limb (inflow tract), which is transected approximately 15 cm proximally (Fig. 137.6A). The proximal cut edge is then anastomosed to the ileal pouch at the site of the excised valve (Fig. 137.6B) after the pouch has been rotated clockwise.

TABLE 137.1 Factors Influencing Valve Revision in the Patients Undergoing the Kock Pouch Procedure

Factor	Revisions (%)	*P* value[a]
Age[b]		
<40 y	20	<0.05
≥40 y	35	
Gender[b]		
Women	17	<0.05
Men	28	
Operation[b]		
Colectomy and pouch	16	<0.05
Conversion of ileostomy	30	
Obesity[c]		
Yes	75	<0.05
No	23	

[a]Estimates of cumulative probability were based on multivariate analysis.
[b]Data from Dozois RR, Kelly KA, Ilstrup E, et al. Factors affecting revision rate after continent ileostomy. *Arch Surg* 1981;116:610.
[c]Data from Schrock TR. Complications of continent ileostomy. *Am J Surg* 1979;138:162.

Failed Ileoanal Anastomosis Converted to Kock Pouch

On rare occasions, a poorly functioning ileal pouch–anal anastomosis can be converted into a continent ileostomy using the existing ileal reservoir. In order to qualify for this type of revisional surgery, failure of the ileoanal anastomosis must **not** be attributable to either Crohn disease or severe, recalcitrant pouchitis. Indeed, in our institution, the patients who have had their ileoanal converted to a Kock pouch were the ones with poor functional results primarily due to the result of inadequate anal sphincters, and who had a strong desire to preserve continence.

If the patient still elects to have the failed ileal pouch–anal anastomosis converted to a Kock pouch after detailed and frank discussions about the limitations and risks of such an attempt, the existing ileal reservoir may be used, as long as the pouch can be fully mobilized from the pelvis intact

after disconnection it from the anal canal (Fig. 137.7A). The ileum immediately above the reservoir is then transected 15 cm proximally and serves to construct the valve, the efferent limb, and stoma (Fig. 137.7A,B). The proximal cut end is then anastomosed to the defect in the reservoir, resulting from disconnecting the ileal reservoir from the anal canal area (Fig. 137.7B).

POUCHITIS SYNDROME

Some patients develop a nonspecific inflammation of the reservoir characterized clinically by the sudden onset of diarrhea, cramping, low-grade fever, and, at times, bleeding. Endoscopic findings include mucosal erythema, friability, and easy bleeding. In the majority of patients, symptoms and signs of pouchitis abate readily with administration of oral antibiotics such as metronidazole or ciprofloxacin, which suggests that overgrowth of anaerobic bacteria in the pouch or the more proximal jejunoileum may be responsible for the diarrhea syndrome. In some cases (<5%), however, the pouchitis recurs soon after the discontinuation of therapy or may be recalcitrant to the treatment and may lead to failure.

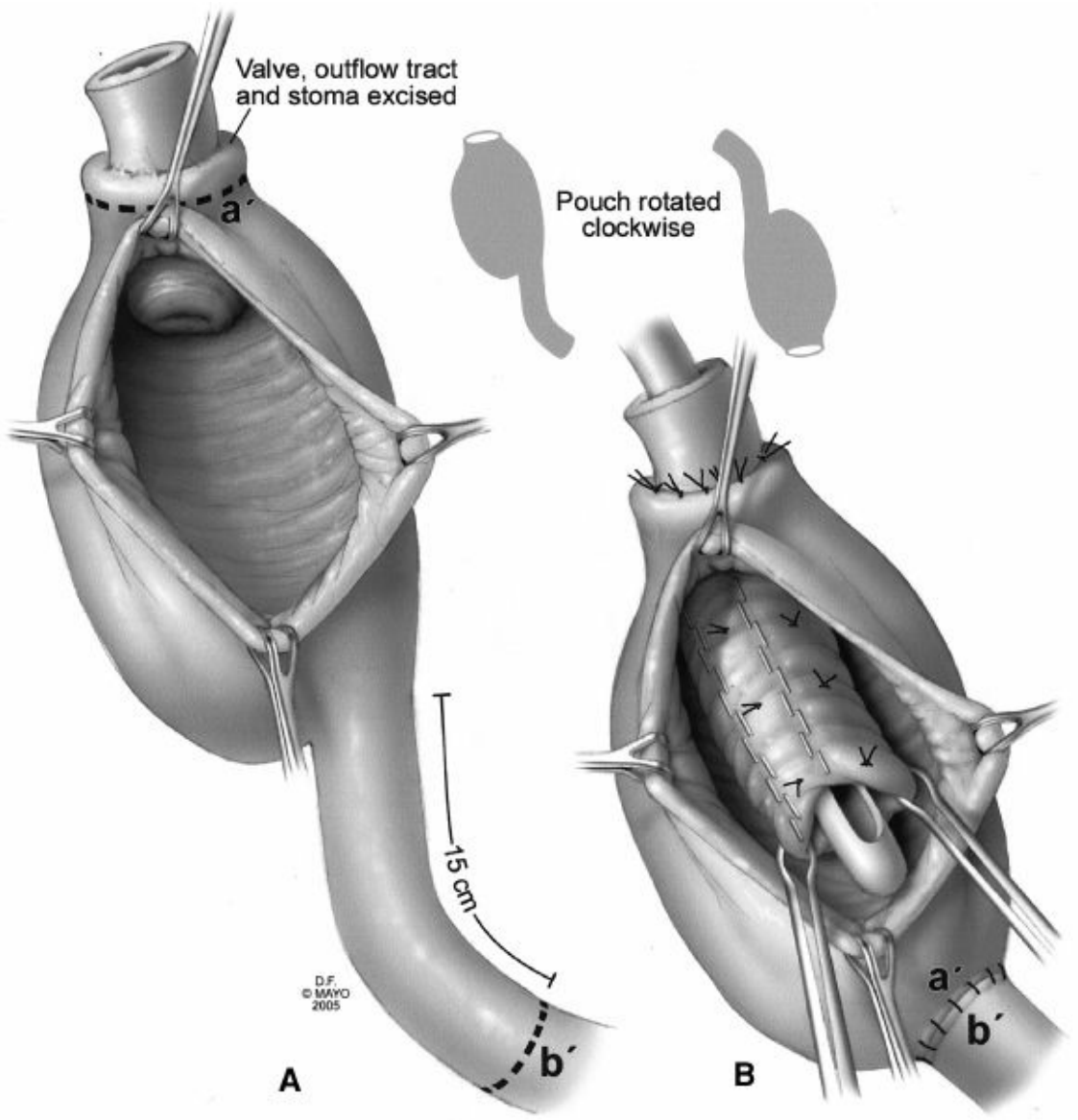

Figure 137.6. If the existing valve cannot be used because of extensive valvular fibrosis, ischemia, or a fistula, the existing outflow tract and valve need to be excised (*dotted line*, a′) (**A**), the pouch is rotated clockwise after transecting the inflow tract, and a new valve, outflow tract, and stoma are reconstructed from the "old" inflow tract (**A**). The operation is completed by suturing the proximal cut end of the inflow tract (b′) to the defect created by removing the dysfunctional valve (a′) (**B**).

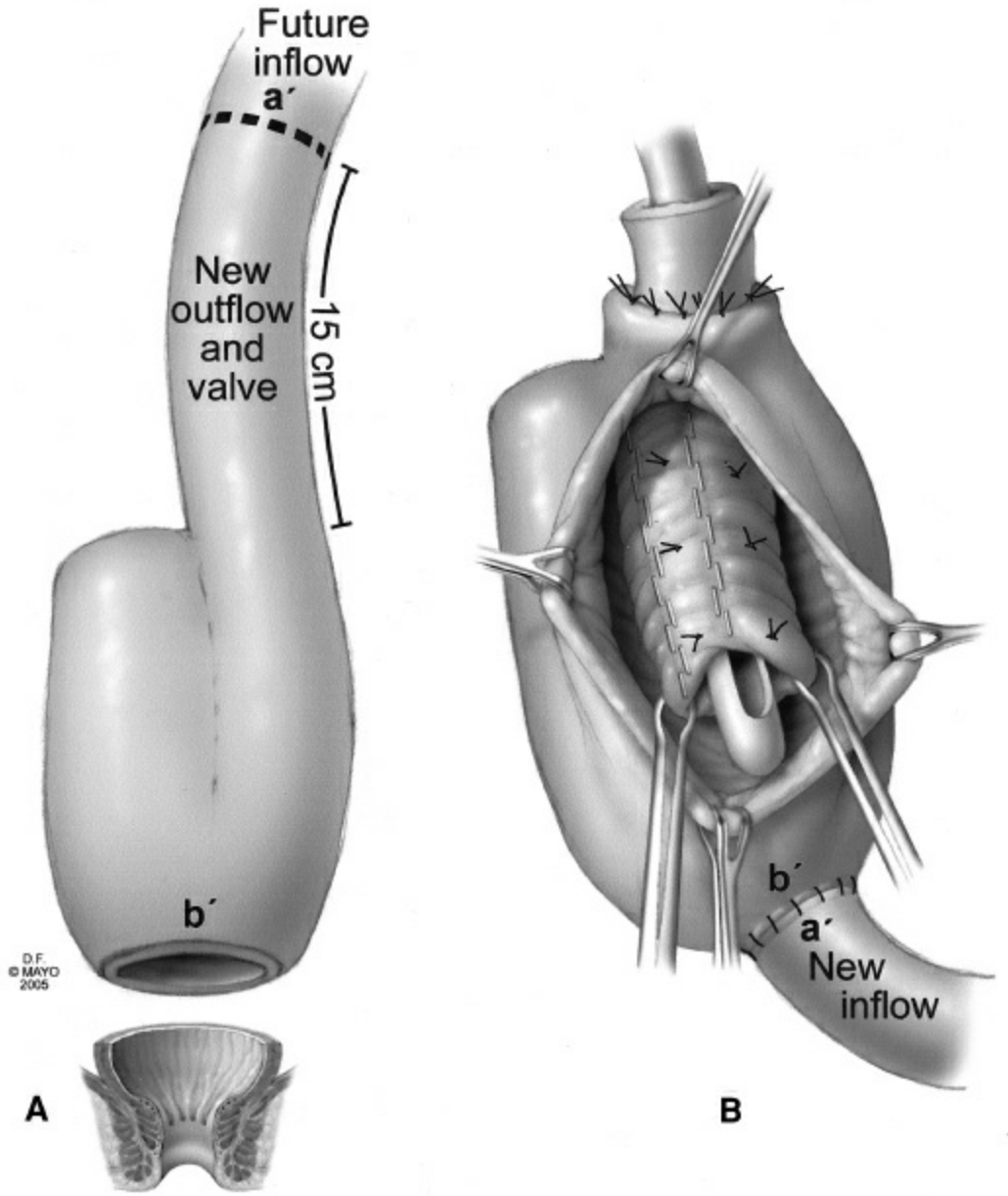

Figure 137.7. Conversion of failed ileoanal anastomosis to Kock pouch. After mobilization of the entire ileal reservoir through an abdominal incision, the ileal reservoir is transected proximal to the anal anastomosis (**A**). The ileum is then transected 15 cm proximal to the pouch. The latter segment of ileum is then used to create the valve mechanism and outflow tract (**B**). The operation is completed by anastomosing the cut end of the proximal ileum (a′) to the transected ileal reservoir (b′), thus creating a new inflow tract.

QUALITY OF LIFE

The crucial consideration in assessing the value of the continent ileostomy is whether it is sufficiently continent for the patient to avoid the need to

wear an external appliance. In our experience, as well as that of the others, >90% of the patients eventually are continent enough that they never have to wear an appliance (Table 137.2). Also, when quality of life after continent ileostomy was compared with that after a Brooke ileostomy, satisfaction was found to be greater, and the desire to change to a different alternative was found to be less in the patients with a Kock pouch than in those with a Brooke ileostomy. Finally, in each performance category, more patients with a Kock pouch than patients with an incontinent Brooke ileostomy improved in their daily activities. Although the role of continent ileostomy is more limited since the advent of the ileoanal anastomosis, our experience as well as that of many others confirms the favorable results of Kock himself, and encourages its continued use in specific circumstances.

Because of its substantial physical and psychological benefits over the conventional ileostomy, the appliance-free continent ileostomy continues to have an important place in the overall armamentarium for dealing with ulcerative colitis or familial polyposis.

TABLE 137.2 Quality of Life After Continent Ileostomy

Reference	Never Wear Appliance (%)
Kock (1985)	98
Cohen (1982)	97
Fazio and Church (1988)	91
Ecker (1999)	98
Mullen et al. (1995)[a]	92
Schrock (1979)	90
Dozois and Kelly (2000)	95

[a]Used Barnett continent intestinal reservoir, a modification of the Kock pouch that includes a "living collar" of small bowel wrapped around the outflow tract to help improve continence.

The current refined operative approach offers a high probability of

complete continence. Careful selection of patients further increases the chances of success and reduces the need for reoperation. The operation is most attractive to young people, especially the unmarried, who have great concerns about the social, psychological, and sexual disadvantages of the Brooke ileostomy. The long-term effects of the continent ileostomy are unknown. As yet, metabolic, nutritional, hepatic, renal, and oncologic complications have not appeared after continent ileostomy. The Kock pouch procedure should be done primarily in the centers where the operation is performed in sufficient numbers to enable the surgical team to become proficient, and where careful follow-up is available.

ACKNOWLEDGMENTS

The senior author is deeply indebted to Oliver H. Beahrs for his invaluable teaching of this operation, and to Kathleen Polikowsky and Rosemary Armstrong for their expert assistance in the conduct of several of these operations during a period of more than 20 years.

Suggested Readings

Beahrs OH, Kelly KA, Adson MA, et al. Ileostomy with ileal reservoir rather than ileostomy alone. *Ann Surg* 1974;179:634.

Cohen Z. Evolution of the Kock continent ileostomy. *Can J Surg* 1982;25:509.

Dozois RR, Kelly KA, Beart RW. Improved results with continent ileostomy. *Ann Surg* 1980;192:319.

Dozois RR, Kelly KA, Ilstrup D, et al. Factors affecting revision rate after continent ileostomy. *Arch Surg* 1981;116:610.

Fazio VW, Church JM. Complications and function of the continent ileostomy at the Cleveland Clinic. *World J Surg* 1988;12:148.

Kelly DG, Phillips SF, Kelly KA, et al. Dysfunction of the continent ileostomy: clinical features and bacteriology. *Gut* 1983;24:193.

Kock NG. Continent ileostomy: historical perspectives. In: Dozois RR, ed. *Alternatives to Conventional Ileostomy*. Chicago: Year Book Medical Publishers; 1985:133.

Kock NG, Darle N, Kewenter J, et al. Quality of life after proctocolectomy and ileostomy: a study of patients with conventional ileostomies converted to continent ileostomies. *Dis Colon Rectum* 1974;17:287.

Mullen P, Behrens D, Chalmers T, et al. Barnett continent intestinal reservoir: multicenter experience with an alternative to the Brooke ileostomy. *Dis Colon*

Rectum 1995;38:573.

Pemberton JH, Dozois RR. The continent ileostomy. In: Farnell MB, McIlrath DC, eds. *Problems in General Surgery.* Philadelphia, PA: JB Lippincott; 1984;1:27.

Pemberton JH, Phillips SF, Ready RR, et al. Quality of life after Brooke ileostomy and ileal pouch-anal anastomosis: comparison of performance status. *Ann Surg* 1989;209:620.

Schjonsby H, Halvorsen JF, Hofstad T, et al. Stagnant loop syndrome in patients with continent ileostomy (intra-abdominal ileal reservoir). *Gut* 1977;18:795.

EDITOR'S COMMENT

It is clear from the writings and the literature that, except for a few centers, namely, University of Gotheborg and the Barnett Clinics, most patients who end up with a continent ileostomy fall into two categories: the first being a failed ileal pouch–anal anastomosis and the second being conversion from a standard ileostomy. As the authors state, many of their patients, in whom they have performed almost 500 procedures, are the patients who would like to have converted a standard ileostomy to a continent ileostomy. The reasons for the standard ileostomy are not difficult to understand. Many patients are quite ill when undergoing proctocolectomy and their focus is on getting better. It is only when they do get better and they review their situation that they would like a better quality of life, which, one suspects, is the principal reason why most patients receive a continent ileostomy.

One should make the point that a continent ileostomy only restores quality of life when, in fact, it is continent, which is of course its Achilles heel. Reoperations are common, and not infrequently—perhaps up to 30% or 40%—one has to deal with a slipped valve. Nor is it necessarily true, as the authors state, that some patients undergo continent ileostomy because they are somewhat tired of having to worry about finding a bathroom when they go outside. Indeed, Berndtsson et al. (*J Wound Ostomy Continence Nurs* 2005;32(5):321) described long-term adjustment for the patients with a continent ileostomy. There were 68 patients (25 male and 43 female) who apparently underwent continent ileostomy and proctocolectomy as their initial operation for ulcerative colitis. The mean time of follow-up was 31 years (range: 29 to 36) and the median subject age at this point was 60, which makes sense as ulcerative colitis tends to be a young person's disease. A 36-item questionnaire was used to assess adjustment to the continent ileostomy, and subjects used a 6-point Likert scale for grading. If they did not like the question, they could avoid it. High median adjustment ratings were found for all 36 statements, but the maximum median rating of 6 appeared on 28 items. Eight items had low median ratings which included embarrassing situations, activity, body image, sexuality, and good care. Despite the analysis, which indicated that

the patients, for the most part, were self-reliant, impediments to bowel evacuation outside the home were common in their responses to the questionnaire, indicating that they had limited outside-the-home activity. Specifically, they mentioned the quality and availability of public restrooms, which reduced their daily activities away from home. Apparently, this finding is for the patients with continent ileostomies and not incontinent ileostomies, which, if occurs, tends to really interfere with activity and requires revision.

The authors state that Kock probably was the person who ultimately was responsible for the concept of the pouch. This subsequently evolved with the aid of Sir Alan Parks, who proposed the S-pouch initially, but with a long spout, which necessitated that these patients catheterized themselves. Lester Martin, a pediatric surgeon in Cincinnati with whom I had the pleasure of working, probably is responsible for taking the concept of the Soave procedure in Hirschsprung disease and, with the mucosal stripping, applying it to the ileal pouch–anal anastomosis with a short spout, thus obviating the need for self-catheterization. Dr. Ollie Beahrs at the Mayo Clinic was among the first to apply the Kock pouch to the American population. The main problem with a Kock pouch is the nipple. There have been innumerable ways of trying to stabilize the nipple so that it does not slip. These methods include through-and-through nonabsorbable sutures, through-and-through absorbable sutures, scarification of the serosa, stripping of the mesentery, Marlex mesh, and stapling. The authors have stated that they have not used Marlex mesh for fear of fistula, which I suppose is a possibility. In the patients whom I have operated on for continent ileostomies, I have tended to use mesenteric stripping, almost to the point of rendering the nipple ischemic (my response to the residents who point out that the nipple is blue is that at least it’s not black). I then use Marlex mesh and four rows of staples. The problem is, however, on the side that is close to the ileal wall, generally the side of the mesentery. And here one must use through-and-through sutures because stapling is too difficult to carry out with the ileostomy adjacent to the wall. This probably provides the most secure form. In addition, a flat abdominal film can always be obtained if one is concerned about slippage, and whether or not the staples form a line then becomes easily known to the surgeon.

Castillo et al. (*Dis Colon Rectum* 2005;48(6):1263) reviewed 24 patients: 13 were operated on for a Brooke ileostomy, who wanted continent; 7 for a failed ileal pouch; 3 for colonic inertia and incontinence; and 1 patient with multiple failed operations for Hirschsprung disease. Twenty-eight revisions were performed in 14 patients (58%), with 6 patients requiring multiple procedures. This is not unusual. Of these revisions, 11 operations were for valve repairs and 12 were for skin level revision for stenosis. Two patients lost their pouches, one because of Crohn disease and the other because of inability to manage the pouch. In a report on a conference in Israel headed by Rachmilewitz, Kock reported on a group of patients; 92% were continent, but some required six revisions. In this chapter the need for revision in 12 months was 29%, but the

average time period before the first revision was 24 months. Total failure rate was 8.3%. Ninety percent of the patients still have their pouches and are satisfied with pouch function, although this was not formally evaluated. The unhappiness with the pouch has led some, including the group headed by Dr. Robert Beart Jr. at the Keck School of Medicine, University of Southern California (Kaiser AM, et al. *Dis Colon Rectum* 2002;45(3):411), to try to adapt a T-pouch valve concept, which has been used for urinary reservoirs by Dr. Skinner and his group in the creation of an ileostomy. The valve is apparently created by embedding a segment of bowel with blood supply intact in a serosa-lined tunnel of two apposed limbs of bowel that will form the pouch reservoir. They reported six patients with complete continence of the pouch. This is an interesting, but sounds like a very complicated, solution to a difficult problem. I have been unable to locate any article written in follow-up of the report.

Another problem that has not received a great deal of publicity is neoplasia in the patients with familial adenomatous polyposis who undergo pouch surgery (Church J, *Dis Colon Rectum* 2005;48(9):1708). We are all familiar with the ileal pouch–anal anastomosis and anastomotic cancers, and this is variously blamed on rectal mucosa, which is not completely stripped or is covered by the pouch. However, the risk factors with adenomas or adenomatous epithelium in contact with rectal epithelium are not known. Therefore, it comes as some surprise that, in this review of the literature, the median time from pouch construction to pouch adenomas was 4.7 years. Eight patients with cancer at the ileal pouch–anal anastomosis site were diagnosed a median of 8 years after pouch construction. What was of interest was that there were eight case reports of cancer described in ileostomy in the patients with familial adenomatous polyposis, in which the problem of a rectal segment interacting with the ileostomy presumably was not present. Here, the median time from construction of the ileostomy to the discovery of the cancers was 25 years, with a range of 9 to 40 years. The author blames fecal stasis, adenomatous epithelium, a germline APC mutation, with the emphasis on fecal stasis, as a recipe for epithelial neoplasia. Although it does happen in ileostomy, it seems to happen much faster in an ileal pouch. One assumes that this is the same possibility that one must be on guard for with a continent ileostomy, in which stasis is a continuing issue.

Pouchitis is a continual problem in these patients, as it is in the patients with ileal pouch–anal anastomosis. My technique differs slightly, not only with the nipple, but in the use of a Malecot or perhaps the Pezzer catheter, which does not run the risk of dislodgement, although it is a little more difficult to get the catheter out, especially if it’s large (No. 28 or 30), without damaging the bowel.

All in all, the continent ileostomy remains a reasonable alternative to the patients who would like to be continent, particularly if sexual difficulties are paramount in their minds. It is true that these patients have second thoughts about the ileostomy, which they may have accepted the first time but not as time went on. After 400 ileal pouch–anal anastomoses, with quite a low complication rate, except for pouchitis (chronic pouchitis in 6%), which I attribute to too long

a spout, to my mind this is a useful alternative under the circumstances in which the sphincter has been removed, and one does not get a wink and total removal of the anal and rectal mucosa.

J.E.F.

138 Technique of Ileostomy Construction and Closure

Harvey G. Moore and Christopher R. Mantyh

INTRODUCTION

Approximately 100,000 people in the United States annually undergo an operation that involves creation of a stoma, including ileostomy. A recent study of National Surgical Quality Improvement Project (NSQIP) data revealed a 37% complication rate for elective cases involving an ostomy, and a 55% complication rate for emergency operations involving ileostomy creation. Ileostomy creation may be a procedure unto itself, or often the last step of a long, often emergent procedure. Consequently, many times the use of an ileostomy for fecal diversion has not been well thought out preoperatively. Furthermore, creation of an ileostomy is often relegated to a junior member of the surgical team, without the benefit of experienced supervision. Common indications for ileostomy, categorized by both the type of ileostomy (end or loop) and the intention of the ostomy (permanent or temporary fecal diversion), are summarized in Table 138.1. In order to achieve optimal results with any ostomy, particularly ileostomy, adequate thought must be given to the risks and benefits of ileostomy creation, the nature of the diversion (small bowel or colon), whether the stoma is temporary or permanent, and the optimal site for ostomy creation. Meticulous care must also be taken in the actual construction of the stoma.

PREOPERATIVE PLANNING

A detailed conversation should occur between the operating surgeon and the patient, family members, and any potential caregivers to discuss the planned procedure, the possibility of a diverting ostomy, the type of ostomy, and whether the ostomy will likely be permanent or temporary. This conversation should occur as early as possible in the preoperative setting to allow the patient as much time as possible to adjust psychologically to the idea of a stoma. The patient should be availed of

potential resources and support groups available through organizations such as the United Ostomy Association and the American College of Surgeons.

Of paramount importance to successful creation of a well-functioning ileostomy is careful preoperative planning of the proposed stoma site. Whenever possible, preoperative consultation should occur with an enterostomal therapy (ET) nurse certified by the Wound, Ostomy and Continence Nurses Society (WOCN) for ostomy site marking. A poorly placed stoma may impact several outcomes including ostomy leakage and resulting skin complications, patient's ability to care for their stoma independently, and overall health care services and costs. Lack of preoperative site marking has been shown in numerous studies to be a risk factor for having a problematic stoma, defined as one that requires extra care and equipment to maintain an appliance for 24 hours. The site selection protocol recommended by the WOCN includes the use of multiple positions (standing, siting, bending at the waist) to identify optimal sites, avoidance of folds, scars, and drain sites, as well as the costal margin and iliac crest, consideration of beltline/clothing, and ideally placement at the summit of the right paramedian infraumbilical fat pad, within the rectus abdominus muscle. Placement through the rectus abdominus muscle likely reduces the risk of forming a parastomal hernia. In obese patients, stoma sites must not be located below a large abdominal pannus where visualization will be poor. Upper abdominal sites may be preferable in obese patients. In the absence of an ET nurse, preoperative site marking is often performed by the operating surgeon. Surgeons performing gastrointestinal surgery should be familiar with the principles of stoma siting. Collaboration between the enterostomal therapist and surgeon regarding choice of stoma site is ideal. Once the optimal site or sites are identified, they can be marked with a permanent marker, or alternatively by using a hypodermic needle and ink to tattoo the skin. The stoma appliance may also be fixed to the proposed site and worn for 24 hours or more to check for proper positioning. At the time of surgery, a needle may be used to scratch the skin at the proposed ostomy site to avoid the marks being washed off during skin preparation.

TABLE 138.1 Indications for Ileostomy Creation

Temporary end ileostomy

Following emergent subtotal colectomy:
- *Inflammatory bowel disease*
- *Clostridium difficile colitis*
- *Ischemia*
- *Lower gastrointestinal hemorrhage*

Following emergent resection of the cecum, ascending colon, or small bowel:
- *Ischemia*
- *Perforation*

Permanent end ileostomy

Following total proctocolectomy:
- *Ulcerative colitis or familial adenomatous polyposis when ileal pouch anal anastomosis (IPAA) contraindicated*
- *Crohn's colitis with severe anorectal involvement*

Severe fecal incontinence

Severe congenital abnormalities

Temporary loop ileostomy

Protection of distal anastomosis:
- *Ileal pouch anal*
- *Ileorectal*
- *Low colorectal/coloanal following low anterior resection*

Colorectal obstruction with incompetent ileocecal valve

Prophylactic diversion for near-obstructing rectal cancer receiving preoperative neoadjuvant chemoradiation

Treatment of anastomotic leak

Temporary fecal diversion
- *Rectal or perineal trauma*
- *Fournier gangrene*
- *Severe fecal incontinence*
- *Radiation proctitis*
- *Pelvic sepsis*
- *Sacral decubitus ulcer*
- *Symptomatic rectovaginal fistula*

Following complex anorectal repair:
- *Sphincteroplasty*
- *Rectovaginal and rectourethral fistula repair*
- *Fistula-in-ano*

Preoperative stomal education should also occur, ideally provided by the ET nurse at the time of stoma site marking. Preoperative education prior to ostomy creation is associated with decreased hospital stay, decreased need for unplanned healthcare interventions after discharge, faster time to proficiency with ostomy care, as well as cost savings. Recommended preoperative topics include GI anatomy and physiology, planned surgical procedure, demonstration of ostomy appliances and other products, and psychological preparation.

SURGICAL TECHNIQUE

End Ileostomy

Indications

An end ileostomy may be constructed as a temporary or a permanent fecal diversion. A temporary end ileostomy may be created following emergent subtotal colectomy for inflammatory bowel disease, *Clostridium difficile* colitis, ischemia, diverticular hemorrhage, or other pathology. An end ileostomy may also be utilized as a temporary fecal diversion following emergent resection of the cecum, ascending colon, or small bowel secondary to ischemia or perforation, in conjunction with a mucous fistula, when a primary anastomosis cannot be safely performed. An end ileostomy is occasionally created as a permanent ostomy following total proctocolectomy for ulcerative colitis or familial adenomatous polyposis when creation of an ileal pouch with coloanal anastomosis is contraindicated or not technically feasible, and for Crohn's colitis with severe anorectal involvement. A permanent end ileostomy may also be required for severe fecal incontinence or congenital abnormalities (Table 138.1).

Stoma Construction

Patient position (supine or lithotomy) is determined by nature of the procedure that will be performed and whether access to the rectum/perineum will be required (i.e., for colonoscopy or passage of an EEA stapler). Patients receive intravenous antibiotics prior to incision. In elective procedures, the optimal stoma site will ideally have been determined and marked by an experienced ET nurse (Fig. 138.1). In situations where the site has not been previously marked, applying the faceplate of the ileostomy appliance in the right lower quadrant may help identify an appropriate position and avoid positions where the faceplate would contact the costal margin, anterior superior iliac spine, or the umbilicus. In the case of an intraoperative decision to create an ileostomy when no consideration has been given to stoma site, a stoma 5 cm lateral to the midline and 4 cm below the umbilicus will generally be suitable.

In general, construction of an end ileostomy will generally take place in the context of an abdominal operation with a midline incision already made. At the marked site, the skin is grasped and elevated with a Kocher clamp and a 2-cm, nickel-sized circular incision is made with a scalpel or cutting current on the cautery, and the resulting disc of skin is amputated

(Fig. 138.2A). It should be kept in mind that the skin will stretch to create a larger aperture than the original incision. It is not necessary to core out a column of subcutaneous fat; in fact, preservation of the fat provides support for the ostomy and may make parastomal hernia and prolapse less likely. A linear incision is made in the subcutaneous fat and small Richardson retractors may be used to expose the anterior rectus abdominus fascia. A cruciate or linear fascial incision is made and the underlying rectus abdominus muscle is exposed. The fibers of the rectus abdominus can be spread with a large Kelly hemostat and the underlying posterior fascia and peritoneum are incised (Fig. 138.2B). The resulting abdominal wall opening is dilated to allow passage of two fingers (Fig. 138.2C). A Babcock clamp is then placed through the abdominal opening and applied to the distal end of ileum and the small bowel is gently delivered through the abdominal wall with the mesentery in a cephalad orientation, ideally with pushing from inside rather than traction on the Babcock clamp, until 4 cm of small bowel protrudes above skin level. It is not necessary to suture the small bowel serosa to either the peritoneum or fascia. It is important not to devascularize the ileum by stripping excessive mesentery from the bowel wall (Fig. 138.2D). In the case of significant difficulty exteriorizing the ileum, some of the subcutaneous fat can be excised or a small Alexis (Applied) wound protector may reduce resistance.



Figure 138.1. Preoperative marking of the ileostomy site. The

ileostomy is placed in the right lower quadrant of the abdomen in a right paramedian, infraumbilical position. (From Daniel Albo, ed. Chapter 4: End and diverting loop ileostomies: creation and reversal. *Operative Techniques in Colon and Rectal Surgery*. Philadelphia, PA: LWW; 2015:27–40.)

For permanent end ileostomies, it is recommended to close the paracolic gutter to reduce the chance of internal herniation and small bowel obstruction. This can be achieved by running a 2-0 Vicryl suture between the cut end of the ileal mesentery and the cut edge of the paracolic peritoneum (white line of Toldt).

Ideally the midline incision will be closed and covered prior to stoma maturation. The ostomy is immediately matured with the intention of creating a stoma that extends a minimum of 2 cm above the abdominal wall (Brooke ileostomy), as recommended by the ASCRS practice parameters (see Suggested Readings). Full thickness 3-0 absorbable (e.g., Vicryl) sutures are placed in four quadrants through the distal end of the ileum incorporating mucosa and serosa. Each suture is then used to take a seromuscular (Lembert) bite just proximal to the skin, followed by a bite of dermis, all in the same vertical plane (three-point sutures) (Fig. 138.2E). Sutures are marked with a hemostat until all four quadrant sutures are placed. As these are tied, the bowel will evert to form a 2- to 3-cm "nipple" (Fig. 138.2F). One to two additional 3-0 Vicryl sutures are placed between each of the four quadrant sutures, attaching the full thickness edge of ileum to the dermis layer of skin (2-point sutures).

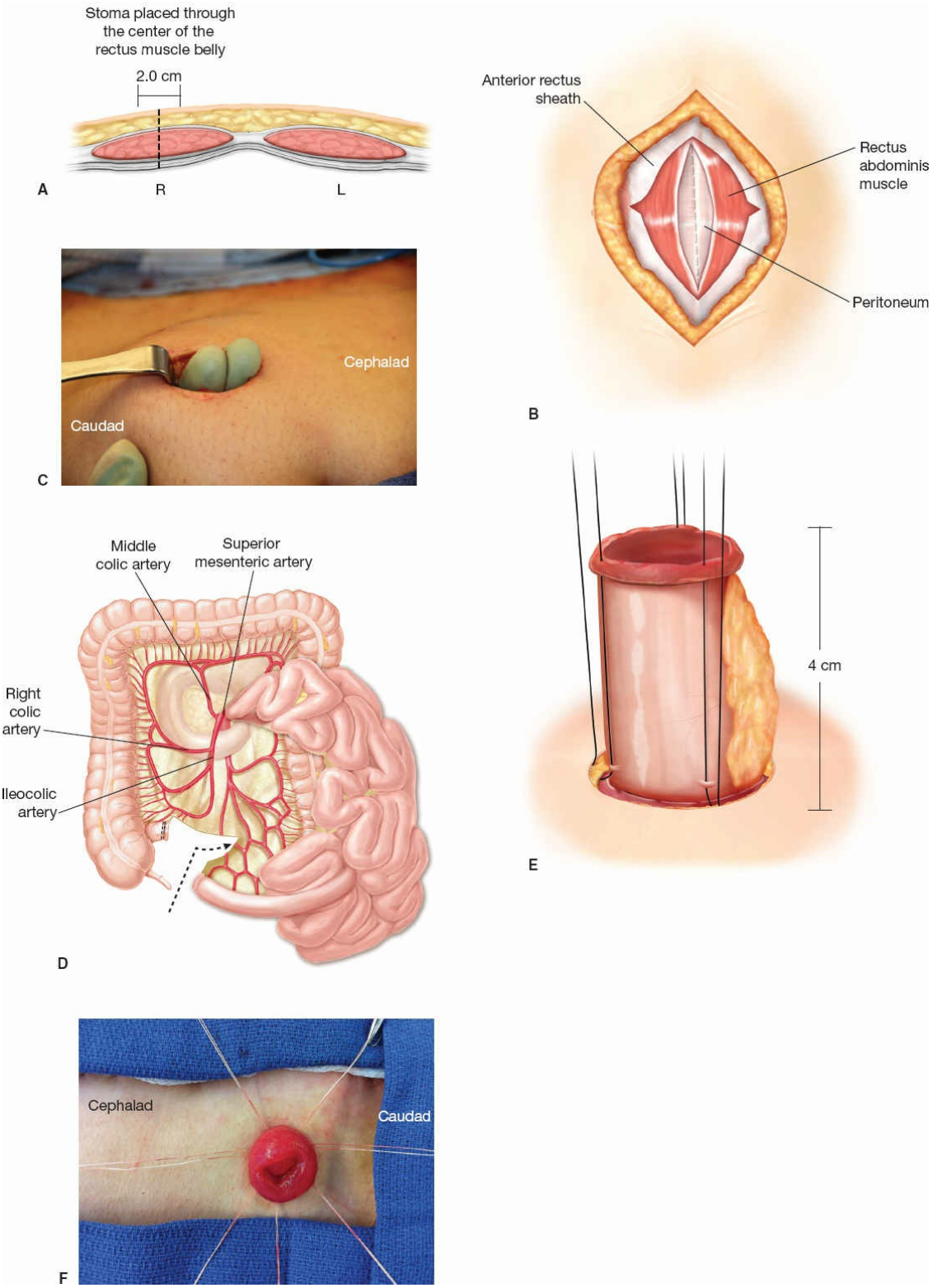

Figure 138.2. Creation of an end ileostomy. **A.** A circular skin incision for the ileostomy is made over the center of the rectus muscle belly and carried through the subcutaneous fat. **B.** A cruciate incision is made in the anterior rectus sheath to expose the underlying rectus muscle. The rectus muscle is split bluntly along the direction of its fibers to expose the posterior sheath and peritoneum. **C.** The peritoneum is incised longitudinally, and the

incision is widened by stretching it with two digits to obtain the desired aperture. **D.** The vascular end arcade and the mesentery are preserved on the ileal segment that is to be used for the end ileostomy (*dotted arrow*). **E.** The ileum is advanced through the abdominal wall stoma aperture so that it protrudes for about 4 cm beyond the skin level. Following removal of the staple line, three-point sutures are placed through the end of the ileum (full thickness), the seromuscular layer at the base of the stoma 4 cm from the end of the ileum, and the dermis, respectively. No epidermis should be included in stitch. **F.** The sutures are placed circumferentially. They are only tied after all of them have been placed, everting the ileum to create a 2-cm–high ileostomy. (From Daniel Albo, ed. Chapter 4: End and diverting loop ileostomies: creation and reversal. *Operative Techniques in Colon and Rectal Surgery*. Philadelphia, PA: LWW; 2015:27–40.)

An appropriate sized aperture is cut in the ileostomy faceplate to just allow the stoma to pass through with a 1- to 2-mm margin. The peristomal skin is cleaned with mild soap and water, and a skin barrier spray is applied. A transparent, drainable, two-piece ileostomy appliance facilitates inspection and frequent emptying without the need to remove the faceplate. An ileostomy bag is attached and oriented to hang sideways off the bed as this will be dependent drainage during the initial postoperative period while the patient is supine.

Loop Ileostomy

Indications

A loop ileostomy is generally used to divert the fecal stream in order to protect a downstream anastomosis such as following an ileorectal anastomosis, an ileal pouch anal anastomosis (IPAA), or following low anterior resection with distal/coloanal anastomosis; particularly following preoperative chemoradiation. Other indications may include colon or rectal obstruction in patients with an incompetent ileocecal valve, prophylactically in patients with near obstructing rectal cancers undergoing preoperative chemoradiation, and rarely in combination with a transverse colon “blowhole” colostomy in patients with fulminant colitis (Turnbull procedure). Other indications include treatment of anastomotic leak, diversion for rectal or perineal trauma and severe perianal infection such as Fournier gangrene, severe fecal incontinence, radiation proctitis, pelvic sepsis, sacral decubitus ulcer, complex anorectal disease such as

symptomatic rectovaginal fistula, and following anorectal repair including sphincteroplasty, rectovaginal, and rectourethral fistula repair, and repair of complex fistula in ano (Table 138.1).

In general, a loop ileostomy is preferred over a loop colostomy when temporary fecal diversion is required. Existing literature, including several randomized trials, supports the fact that both loop ileostomy and transverse loop colostomy effectively divert the fecal stream and minimize the consequences of an anastomotic leak. Although both loop colostomy and loop ileostomy have similar complication rates, their morbidity profiles differ. Loop ileostomy has a lower incidence of infectious complications and prolapse. In addition, patients with a loop ileostomy appear to have a better overall quality of life. However, loop ileostomy is associated with a significant incidence of small bowel obstructions both before and after stoma reversal, and also a higher incidence of dehydration and renal failure. Overall, a loop ileostomy is the preferred fecal diversion of colorectal surgeons and is advocated in the practice parameter on ostomy creation of the American Society of Colon and Rectal Surgeons. However, in certain situations a loop colostomy may be preferable, such as a left-sided colon obstruction with a competent ileocecal valve and impending cecal perforation, where immediate colonic decompression is required.

Stoma Construction

For open cases where loop ileostomy is required, the abdominal wall opening is created in the fashion previously described for end ileostomy. A mobile loop of ileum approximately 20 to 30 cm proximal to the ileocecal valve or ileal pouch that easily reaches the proposed ileostomy site without tension is identified (Fig. 138.3A). It may be useful to mark the afferent and efferent limbs with large hemoclips or different colored sutures in order to assure that correct orientation is maintained (Fig. 138.3B). The chosen ileal loop is carefully grasped with a Babcock clamp placed through the abdominal wall opening and gently pulled through onto the abdominal wall. It is important to avoid twisting the mesentery supplying the loop; the bowel should be oriented with the proximal or afferent limb oriented cephalad. Alternatively, the bowel and its mesentery can be rotated 90 degrees so that the afferent lumen is located caudally, although there is no evidence that the position of the afferent lumen, if matured properly, matters with regard to completeness of diversion. Consideration should be given to the use of a sodium hyaluronate and carboxymethylcellulose-based bioabsorbable membrane (Seprafilm) to

reduce adhesion formation around the ileostomy and facilitate future reversal. In one study, adhesion formation was significantly decreased in cases where Seprafilm was placed around the intrabdominal ileal limb (14% vs. 31%). An avascular window is created in the mesentery at the midpoint of the loop and a tonsil clamp is used to pull an 18-Fr red rubber catheter through the mesenteric window to serve as a supporting rod. The red rubber catheter is cut to the appropriate length and anchored to the skin with 3-0 nylon sutures. Although many surgeons prefer the use of a supporting rod, it may not be absolutely necessary in cases where no excessive tension on the ileal loop is present. There is no need to suture the bowel to the peritoneum or to the anterior fascia. The abdominal incisions are generally closed prior to maturing the stoma to limit contamination of the wound. Following closure of the abdominal incision, the anterior ileal wall is opened with electrocautery 2 to 3 cm distal to the apex of the loop, within the efferent portion of the loop (Fig. 138.3C). The ileal incision should extend to within 2 to 3 mm of the mesentery on either side (75% circumference of loop). Similar to that described for end ileostomy, 3-0 Vicryl sutures are placed through the full thickness of the bowel wall, followed by a seromuscular bite just proximal to the skin, and finally a bite of the dermal layer of skin. These are then tied, everting the bowel and emphasizing the proximal lumen while deemphasizing the distal lumen. One or two additional 3-0 Vicryl sutures are placed between each of the three quadrant sutures, between the full thickness cut edge of bowel and the dermal layer of skin. The distal lumen is also matured by suturing full thickness bowel wall to the dermal layer of skin (Fig. 138.3D). An ileostomy appliance is applied as described above. The edges of the aperture in the ileostomy faceplate are placed beneath the stoma rod on both sides. The stoma rod may be removed 7 to 10 days after surgery.

End Loop Ileostomy

In clinical situations where an end ileostomy is required but technically difficult due to a foreshortened or thickened mesentery and/or thickened abdominal wall in obese patients, one alternative is the end-loop ileostomy. When creating an end loop ileostomy, a loop of ileum just proximal (10 cm) to the closed distal end is brought through the abdominal wall opening and matured as loop ileostomy (Fig. 138.4A). This results in a short efferent limb distal to the loop stoma. The afferent and efferent ileum can be marked with large clips or sutures to ensure proper

orientation. The stapled end of the efferent limb is oversewn with seromuscular 3-0 silk interrupted sutures. If intended to be a permanent stoma, the edge of the ileal mesentery is sutured to the abdominal wall. Following closure of the abdominal incisions and coverage, the loop is matured in the manner described for loop ileostomy (Fig. 138.4B).

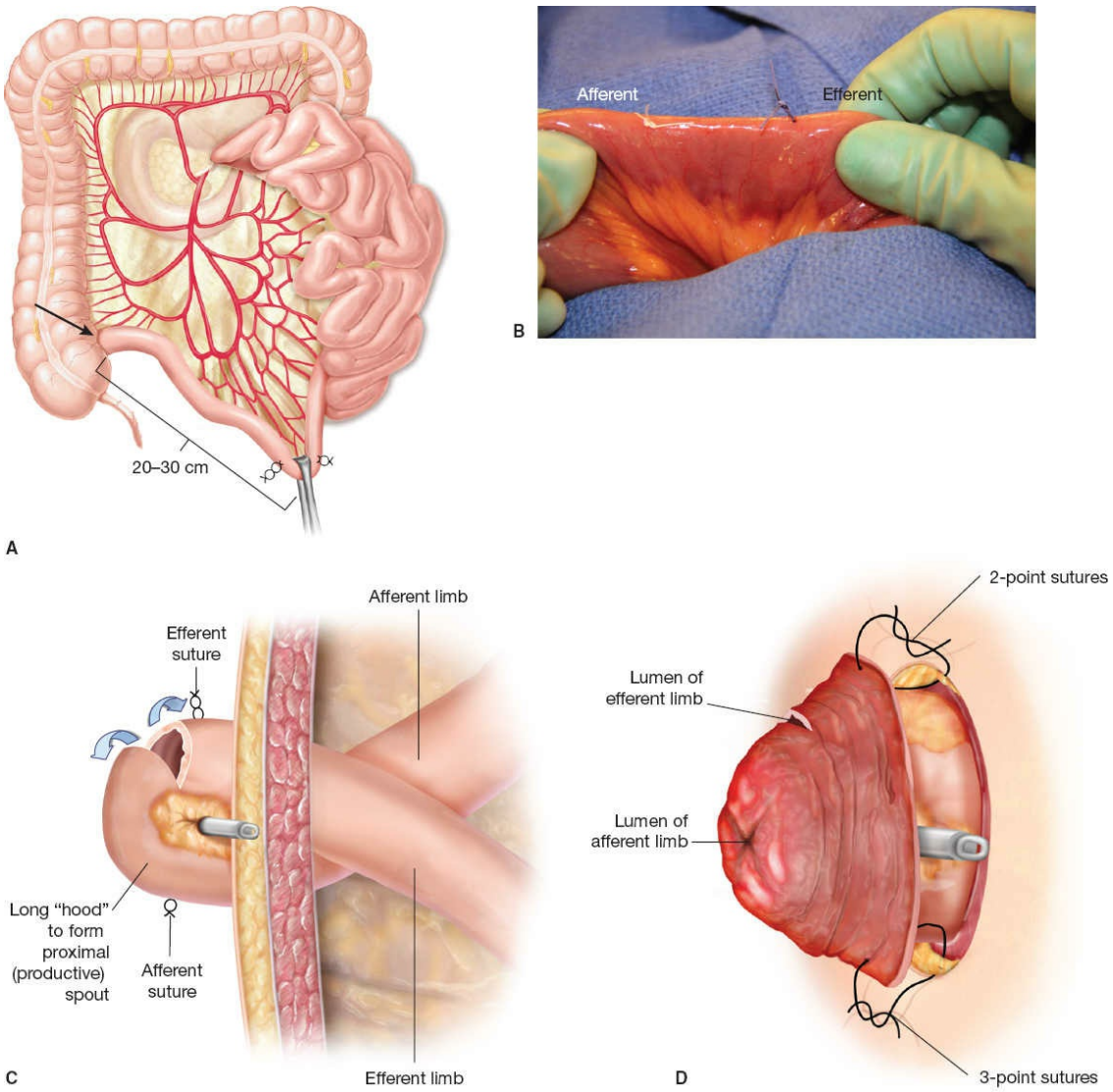

Figure 138.3. Creation of a loop ileostomy. **A.** An ileal segment that is 20 to 30 cm proximal to the ileocecal junction (*arrow*) is identified. The segment's mesentery and vasculature are preserved. **B.** Marking sutures (e.g., sutures of different colors or with differing numbers of knots) are placed on the afferent and efferent limbs. The ileum is advanced through the abdominal wall stoma aperture so that it protrudes for about 3 to 4 cm beyond the skin level. **C.** The ileum is incised 1 cm above the skin level on the efferent limb side for 75% of the circumference to create a large afferent spout. **D.** The loop ileostomy is matured by placing two-point sutures (full thickness through the end of the ileum and the dermis) on the efferent limb and three-point sutures (full thickness through the end of ileum, the seromuscular layer at the base of stoma, and the dermis) on the afferent limb to evert the ileum. (From Daniel Albo, ed. Chapter 4: End and diverting loop ileostomies: creation and reversal. *Operative Techniques in Colon and Rectal Surgery*. Philadelphia, PA: LWW; 2015:27–40.)

Other techniques that may be employed when difficulty is encountered getting the chosen bowel to reach without tension are selective mesenteric vessel ligation and use of upper abdominal sites in obese individuals.

Divided Loop Ileostomy

Although diverting loop ileostomy generally provides excellent fecal diversion, an alternative technique that may result in more complete diversion is the divided loop ileostomy. The procedure involves division of the ileum with a linear stapler 20 to 30 cm from the ileocecal valve (Fig. 138.5A). The stapled proximal limb is brought through the ostomy site such that approximately 4 cm is above the skin. The staple line is removed and the bowel is matured as a Brooke ileostomy with a three-point stitch (full thickness ileum, seromuscular bite just above skin, and dermal bite) technique. The antimesenteric corner of the distal limp is brought through the same abdominal wall opening (Fig. 138.5B). The corner of the efferent limb is excised and matured inferior to the proximal lumen using a two-point stitch (full thickness ileum and dermis). Two transition sutures are used to secure the efferent lumen to the serosa of the afferent limb as well as the dermal layer of skin (Fig. 138.5C). Alternatively, the antimesenteric corner of the efferent limp may be left intact to ensure complete diversion. This type of stoma can generally be reversed without the need of laparotomy, as both limbs of the bowel are located in close proximity within the abdominal wall. A divided loop stoma can sometimes be performed via a local revision of an existing loop ileostomy if fecal diversion is inadequate, but laparotomy may be required.

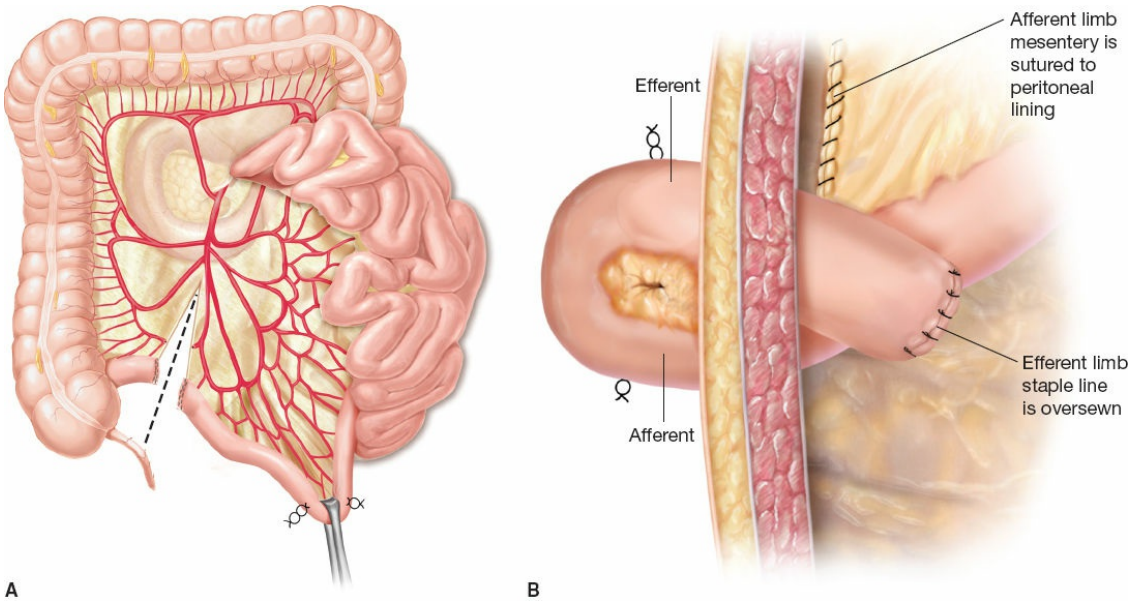

Figure 138.4. Creation of an end-loop ileostomy. **A.** The mesentery and vasculature are divided proximally to obtain as much length as possible. **B.** Marking sutures are placed on the afferent and efferent limbs. The staple line closing off the ileum is oversewn with Lembert sutures and remains in the abdomen. A more proximal segment of ileum to be used for the ileostomy, approximately 10 cm proximal to the oversewn ileal staple line, is externalized so that the afferent limb is in the inferior position on the abdominal wall. The mesentery may be affixed to the abdominal wall to prevent stoma prolapse, torsion, or an internal hernia. (From Daniel Albo, ed. Chapter 4: End and diverting loop ileostomies: creation and reversal. *Operative Techniques in Colon and Rectal Surgery*. Philadelphia, PA: LWW; 2015:27–40.)

Laparoscopic Ileostomy

A diverting loop ileostomy, as well as an end or end-loop ileostomy, can be created laparoscopically, either in the context of a larger laparoscopic procedure or as a primary procedure. Whenever possible, laparoscopic creation of a loop ileostomy is the preferred approach, with all of the reported advantages of laparoscopic surgery including decreased pain and narcotic requirements, shorter hospital stay, earlier return of bowel function, and fewer overall complications. The lack of an incision also facilitates placement of a stoma appliance. In addition, laparoscopic loop ileostomies may be easier to reverse, likely due to decreased peristomal adhesions, and may also have a lower incidence of small bowel obstruction. When performed in the context of a larger colorectal resection, existing ports and camera placement can be utilized to create the ileostomy. When performed as a primary procedure, a supraumbilical Hassan trocar is used as well as suprapubic and left lower quadrant 5-mm trocars. For an end ileostomy, the ileal limb is identified and is carefully elevated to the proposed ileostomy site to ensure it reaches without tension. Care is taken to ensure the mesentery supplying this segment is intact and that it is not twisted. For a loop ileostomy, the terminal ileum is identified and the small bowel is followed proximally until a mobile loop approximately 20 to 30 cm from the terminal ileum is identified. The loop should be able to be elevated easily to the proposed ileostomy site without tension. The bowel is then marked to identify proximal and distal direction with either large hemoclips or laparoscopically placed sutures of different color. At this point, the abdominal wall opening is created as described for

end ileostomy, down to the level of the posterior fascia and peritoneum. A 15-mm trocar is then placed through the peritoneal layer, maintaining the pneumoperitoneum. An endo-Babcock clamp is placed through the 15-mm trocar, and the ileal limb or previously marked loop of ileum is passed to the endo-Babcock clamp under direct laparoscopic visualization. The 15-mm trocar is removed and the ileal loop is gently delivered through the ostomy site until a sufficient loop of ileum is above the abdominal wall. A red rubber catheter is passed through a window in the mesentery for loop ileostomies and secured to the abdominal wall as described above. Pneumoperitoneum can generally be maintained throughout this process and the ileum can be inspected laparoscopically to confirm that the mesentery is not twisted and confirm the proximal and distal orientation of the bowel. The pneumoperitoneum is then released and the ileostomy is matured as either an end or loop ileostomy as described above.

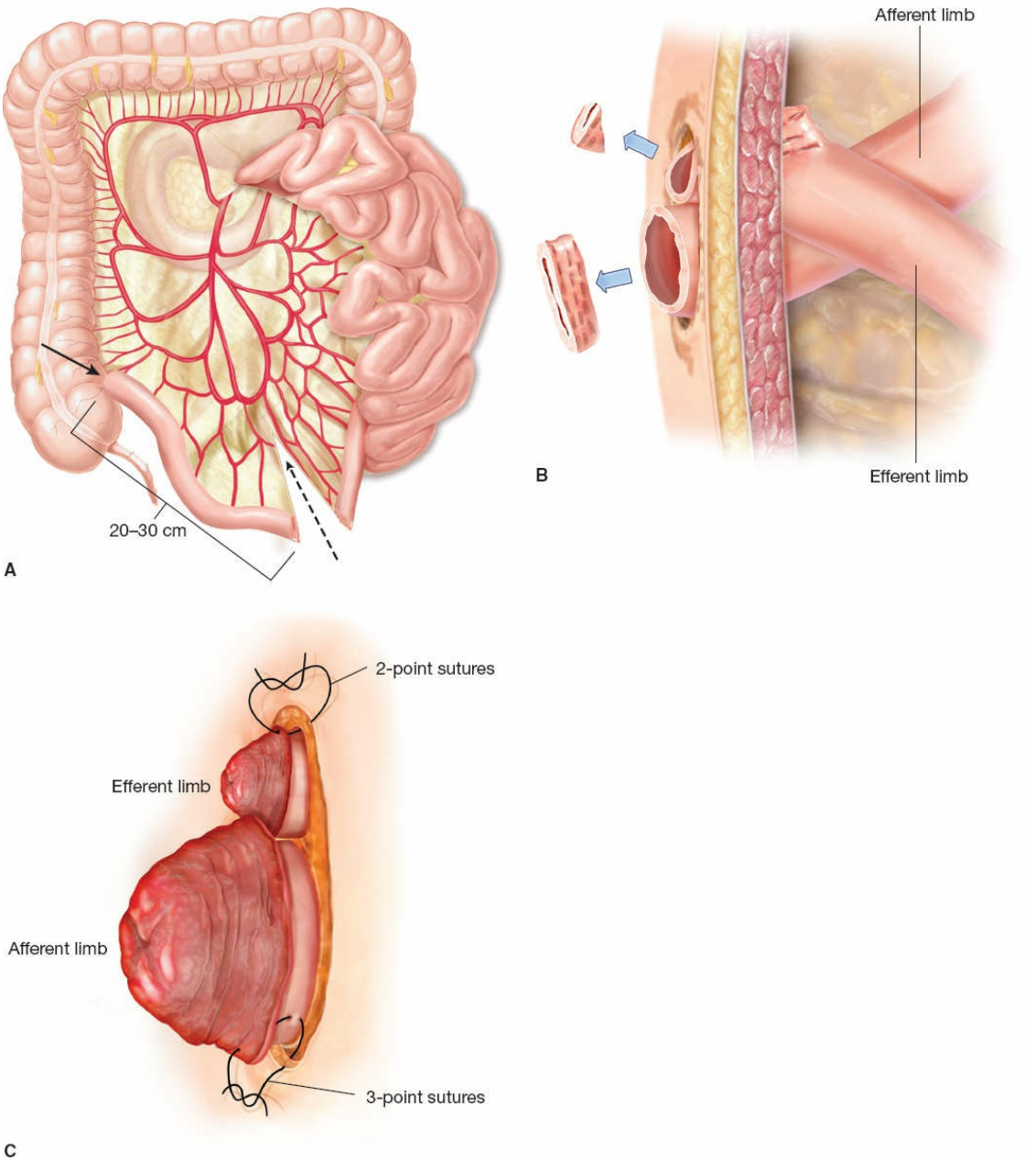

Figure 138.5. Creation of a divided loop ileostomy. **A.** The ileum is divided using a linear cutting stapler, 20 to 30 cm proximal to the ileocecal valve (*solid arrow*). The mesentery and vasculature are only minimally divided (*dotted arrow*). **B.** The stapled afferent limb is advanced through the abdominal wall aperture so that it protrudes for about 4 cm beyond the skin level, and the entire staple line is then cut off. Optionally, if distal decompression is desired for the efferent limb, only the antimesenteric corner is externalized, excised, and matured. The staple line may also be left intact on the efferent limb for total diversion. **C.** The afferent limb of the ileostomy is matured with three-point sutures. The efferent limb can be matured with two-point sutures. (From Daniel Albo, ed. Chapter 4: End and diverting loop ileostomies: creation and reversal. *Operative Techniques in Colon and Rectal Surgery*.

Philadelphia, PA: LWW; 2015:27–40.)

Trephine Ileostomy Creation

An alternative method of minimally invasive ostomy creation involves the use of a small incision at the chosen ostomy site, or so called “trephine” ostomy creation. This technique is successful approximately 89% to 94% of the time (avoidance of laparotomy) and results in function equivalent to open or laparoscopic creation.

Stoma Closure

Traditionally, temporary stoma closure typically occurs at approximate 3 months after creation when used as a protective stoma for a low colorectal or IPAA. Prior to closure, integrity of the anastomosis or ileal pouch is usually confirmed with a contrast enema, although in most cases the contrast enema does not provide any new information not already suspected clinically or seen on other routine imaging. It is also important to rule out distal obstruction. Lower endoscopy may also be performed to inspect the anastomosis or pouch. In the case of a problematic stoma, such as a high output stoma or when there is difficulty with appliance management, early stoma closure may be considered and has been shown to be safe as early as 3 weeks postoperatively assuming the abovementioned diagnostic studies do not reveal any significant anastomotic abnormalities.

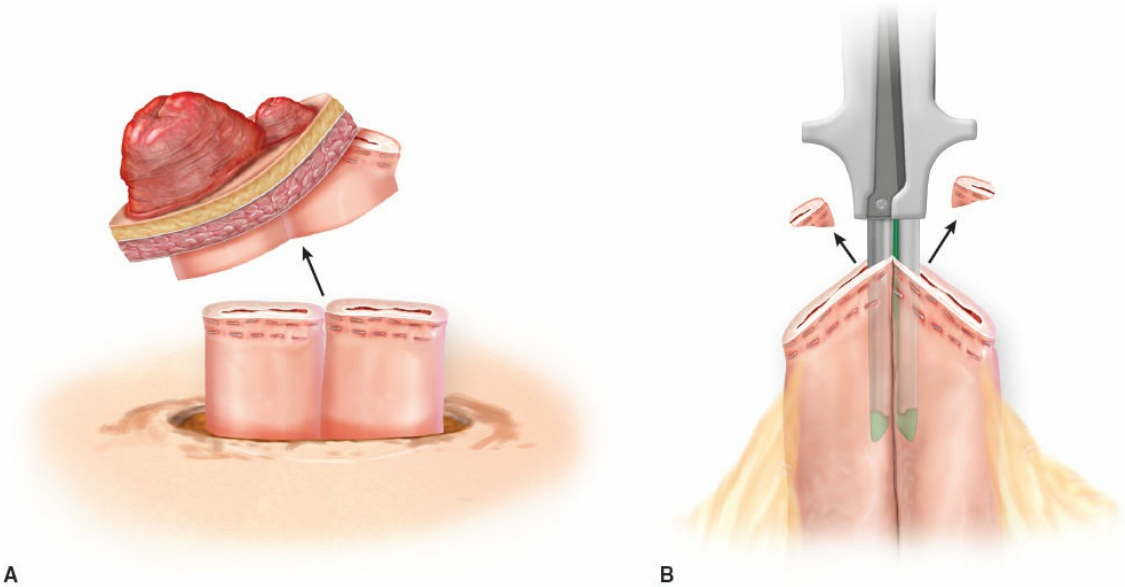

Figure 138.6. Reversal of a loop ileostomy: option 1 (results in

larger anastomotic cross section). **A.** The ileum is mobilized from the abdominal wall. The stoma itself (including the staples in case of a divided loop ileostomy) and adjacent fibrofatty tissues are resected with a linear cutting stapler to a level where both limbs are completely separated. **B.** A side-to-side (functional end-to-end) stapled anastomosis is created with a linear cutting stapler inserted into the antimesenteric aspect of each ileal limb. The remaining ileal opening is closed off with a linear stapler application or by using a hand-sewn technique. (From Daniel Albo, ed. Chapter 4: End and diverting loop ileostomies: creation and reversal. *Operative Techniques in Colon and Rectal Surgery*. Philadelphia, PA: LWW; 2015:27–40.)

Reversal of an end ileostomy typically requires a laparotomy to restore intestinal continuity. Loop ileostomy reversal however can typically be performed through a peristomal incision. The procedure begins with suture closure of the proximal lumen followed by coverage of the stoma with a small gauze dressing and a Tegaderm dressing. The stoma can then be prepped into the operative field with chlorhexidine skin preparation. A peristomal skin incision is made 1 to 2 mm from the mucocutaneous junction and deepened into the subcutaneous fat. This is carried down to the anterior fascia with great care to avoid injury to the small bowel as well as the bowel mesentery. The attachments to the fascia are carefully divided circumferentially and the peritoneal cavity is carefully entered. The surgeon's finger can then be carefully passed along the circumference of the bowel dividing any remaining adhesions until the ileal loop is completely mobilized. A GIA 80 stapler with 3.8-mm staples is used to divide the small bowel just proximal and distal to the stoma (Fig. 138.6A) and the intervening mesentery is divided with an energy device (LigaSure) or suture ligation. Antimesenteric corners of the proximal and distal limbs are cut off, and the arms of the GIA 80 stapler are inserted and the stapler fired a third time to create a side-to-side, functional end-to-end anastomosis (Fig. 138.6B). The common enterotomy is closed with a TA 60 stapler, or alternatively hand sewn with absorbable suture.

Alternatively, a primary transverse closure of the enterotomy at the stoma site may be performed in layers, including a running closure of 3-0 Vicryl followed by Lembert sutures of 3-0 silk (Fig. 138.7A,B). The defect may also be closed with a TA stapler (Fig. 138.7C). Following the anastomosis, the bowel is reduced back into the peritoneal cavity and the fascial opening is closed with interrupted number 1-PDS figure-of-eight

sutures. The stoma site is typically closed partially with a purse string suture of 2-0 Vicryl, followed by packing the remaining wound with betadine-soaked gauze. Alternatively, the wound can be managed by simple wound packing or delayed primary closure. Laparoscopy can be added to traditional loop ileostomy closure with possibly a lower complication rate and shorter length of hospital stay, although additional evidence is required before this technique can be widely recommended.

POSTOPERATIVE CARE

Following ileostomy creation, the patient's postoperative care is dictated by the nature of the operation performed (major colon or rectal resection vs. ileostomy creation alone). In general, postoperative patients are managed by an Enhanced Recovery after Surgery (ERAS) protocol that emphasizes early ambulation and initiation of oral diet, avoidance of nasogastric tubes and drains, narcotic-sparing pain regimens, use of selective peripheral mu-opioid receptor antagonists (alvimopan) and selective pro-motility agents.

Patients receive additional education from an enterostomal therapist in the early postoperative setting, and the patient's discharge needs related to ostomy care are assessed and appropriate arrangements are made. Significant evidence points to the value of postoperative in-hospital stoma education. Recommended education topics include anatomy and function of the ostomy, pouching procedural training, nutrition, clothing, medications, body image, psychological issues, sexual and intimacy issues, common complications including leakage and dermatitis, and available resources including support groups and online resources. Patients who have teaching from an enterostomal therapist as an inpatient seem to have better overall adjustment to having a stoma and view the enterostomal therapist as one of the most important elements of their recovery.

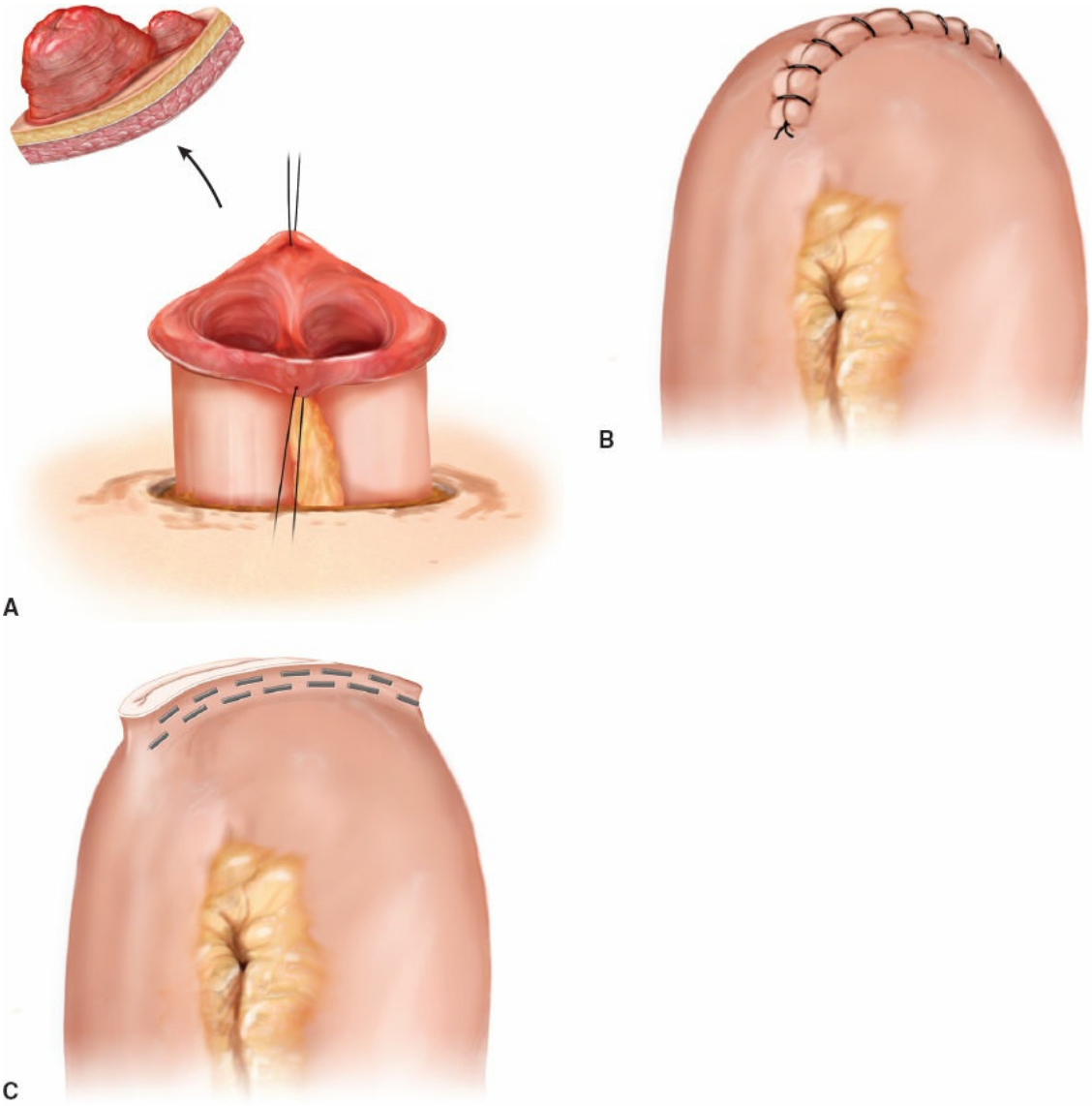

Figure 138.7. Reversal of a loop ileostomy: option 2. **A.** The ileum is mobilized from the abdominal wall. The stoma itself and adjacent fibrofatty tissues are resected sparingly so that the connecting bridge of ileum on the posterior/mesenteric aspect of the loop ileostomy is left intact. (**B**) The ileal defect is closed with a transverse two-layer hand-sewn technique or (**C**) with a linear stapler. (From Daniel Albo, ed. Chapter 4: End and diverting loop ileostomies: creation and reversal. *Operative Techniques in Colon and Rectal Surgery*. Philadelphia, PA: LWW; 2015:27–40.)

Creation of an ileostomy results in loss of the ileocecal valve as well as the water reabsorption provided by the colon, with the resulting risk of dehydration and electrolyte derangement. Early postoperative output can often be >1,000 mL/day; however, adaptation occurs with increased ileal water reabsorption over several weeks' time. Daily output should ideally

between 500 and 750 mL. Patients are educated on the importance of maintaining adequate hydration and are given discharge prescriptions for Lomotil (diphenoxylate and atropine) tablets with instructions on how to titrate to stoma output. Other medications that may be helpful in managing high ileostomy output include psyllium (Metamucil), cholestyramine (Questran), loperamide (Imodium), and tincture of opium. If necessary, arrangements may be made for the patient to receive outpatient vitamin B_{12} supplementation. A custom fit stoma belt may be made for the patient prior to discharge.

Outpatient follow-up with the enterostomal therapist is arranged prior to discharge. Outpatient follow-up is also a vitally important aspect of overall perioperative care. Shorter postoperative hospital stays make in-house teaching more challenging, which often needs to be supplemented with outpatient or in-home ostomy care teaching and support. A number of studies have shown that postdischarge ostomy support is associated with fewer ostomy-related problems, more independence, improved ostomy adjustment, and improved quality of life.

Following ostomy reversal patients are managed by the same ERAS pathway and are often discharged as early as POD 1, once adequate PO intake allows the use of oral pain medications. Data from our institution support the safety of ileostomy reversal in the ambulatory setting with a 23-hour postoperative stay. Patients and their families are generally taught to manage dressing changes at the old ostomy site.

COMPLICATIONS AND MANAGEMENT

Ileostomy Creation Patients

Skin Irritation and Pouching Issues

Over 80% of patients may experience one or more stoma-related complications. Common problems include skin irritation (up to 60%), appliance fixation difficulties (up to 50%), and peristomal leakage of the ileal effluent (up to 40%). Because of the liquid nature of the ileal effluent, the incidence of leakage is more frequent and consequences of leakage are more severe in patients with an ileostomy compared to a colostomy. Undoubtedly the incidence of leakage and pouching difficulties is much higher in patients with suboptimal stoma siting. Comprehensive stoma management is beyond the scope of this chapter, but consultation with an experience ET nurse is likely to resolve many of these issues, likely with

simple changes in the type of stoma appliance and other stoma care. However, as ET nurses are not universally available, surgeons who create intestinal stomas should be familiar with basic principles of stoma management, including common ostomy products. Issues related to ileostomy retraction may be dealt with simply by choosing an appliance with a convex faceplate that results in more protrusion of the stoma above the level of the skin. As with other stoma-related complications, consideration should always be given to whether an ileostomy may be safely reversed as a definitive way to solve many of these problems.

Stoma Necrosis

Although ischemia of a new ileostomy, particularly a loop ileostomy, is unusual, careful attention to the color of the mucosa is important. Use of a transparent stoma bag in the early postoperative period facilitates inspection. Edema and swelling and some venous congestion are relatively common, but a dark or black stoma requires immediate attention. Superficial mucosal necrosis may occur in up to 20%, but full thickness ischemia/necrosis occurs much less frequently (1% to 5%). The level of bowel ischemia can often be assessed with a Vacutainer tube and a flashlight; if stoma necrosis extends below the fascia, immediate operative revision is required to avoid peritonitis. If only the very distal mucosa is necrotic, this can generally be managed expectantly with likely mucosal sloughing revealing viable mucosa underneath.

Dehydration, Renal Failure, Readmission

Following creation of an ileostomy, patients are at significant risk for dehydration, both as an inpatient in the perioperative period and following discharge. Outpatient dehydration often results in readmission and in severe cases acute kidney injury. Use of an ileostomy care pathway that includes careful patient measurement and tracking of output with prompt notification of the patients care team may reduce the incidence of dehydration with resulting readmission and renal failure. In one study, readmissions for dehydration were reduced from 15.6% to 0% following implementation of an ileostomy care pathway. Avoidance of foods associated with diarrhea such as those high in glucose and fat may also be helpful.

Prolapse

Stomal prolapse occurs more commonly in loop stomas compared to end

stomas, and more commonly in loop colostomy compared to loop ileostomy. A contributing factor to stoma prolapse may be an unnecessarily large opening in the abdominal wall, and indeed stomal prolapse is often associated with a concomitant parastomal hernia (see below). Minor degrees of prolapse don't necessarily require treatment, as long as the stoma functions properly, but may require modifications of the ostomy appliance. In patients with pronounced prolapse, consideration should be given to the possibility of stoma reversal, which will eliminate the problem and often can be done via a peristomal incision in the case of loop ileostomies. Ostomy reversal does not differ from that for nonprolapsed loop ileostomies. In the case of a permanent ileostomy or in cases when reversal will not be possible for a prolonged period, local revision with stoma mobilization, resection of redundant ileum, and rematuration can often obviate the need for laparotomy.

Bleeding

The finding of bright red blood in the ostomy is often determined to be the result of direct mucosal trauma to the stoma from the edge of the appliance faceplate. Enlargement of the aperture cut in the appliance to assure 1 to 2 mm of clearance for the bowel will generally solve this problem. If bleeding is judged to be intraluminal, endoscopic evaluation of the bowel proximal to the stoma may be required.

Parastomal Hernia

Parastomal hernia in many cases is due to an opening in the abdominal wall that is too large. Siting the stoma through the rectus abdominus muscle may reduce the incidence of parastomal hernia. In the case of a temporary ileostomy, conservative management of a nonincarcerated and/or minimally symptomatic parastomal hernia until the ileostomy can safely be reversed, along with primary repair or mesh repair of the resulting fascial defect, is generally the best approach. In the case of permanent ileostomies, relocation of the ileostomy with repair of the original site may be required.

Parastomal hernia repair, either laparoscopic or via laparotomy, may be performed with either prosthetic or biologic mesh. Although the use of prosthetic mesh has historically been discouraged due to a perceived risk of mesh infection and erosive injury to the bowel, the literature reveals a mesh infection rate of only 2% to 2.6% and only one case of mesh erosion in 16 reported studies.

Laparoscopic repairs appear to have equivalent rates of recurrence to open repairs, although the two options have not been compared in a randomized trial. The two most common procedures performed laparoscopically are the keyhole/slit mesh technique, in which an aperture is cut to accommodate the bowel as it exits the abdominal wall, and the Sugarbaker technique, which is essentially an underlay of the ostomy site with the stoma limb exiting the mesh lateral to the fascial defect. Reported rates of recurrence for the keyhole technique range between 21% and 73%, compared to 7% and 15% for the Sugarbaker technique.

Stone Formation

Patients with ileostomies suffer from urinary stones in 12% of cases and may also have a higher incidence of gallstones. Both of these problems may be more pronounced when there has been resection of terminal ileum. Urinary stones seem to result from high levels of uric acid with formation of uric acid crystals and secondary precipitation of calcium oxylate. Treatment involves avoidance of dehydration, uric acid monitoring and possibly treatment with allopurinol, and avoidance of foods high in oxalate such as spinach and leafy vegetables. Gallstone formation is most likely due to loss of terminal ileum with resulting loss of bile salt reabsorption, rather than the ileostomy itself. Depletion of the bile salt pool results in decrease solubility of cholesterol and formation of gallstones. Bile salt binders such as cholestyramine may be helpful.

Small Bowel Obstruction/Food Bezoars

Small bowel obstruction may occur in up to 20% of patients undergoing an ileostomy, and is more frequent following loop ileostomy than after loop colostomy. Although the obstruction may be related to adhesions from the underlying surgical procedure and not from the ileostomy itself, ileostomy-related causes include internal herniation, looping or volvulus around the stoma, incarcerated parastomal hernia, mechanical obstruction at the ileostomy site due to angulation, inadequate fascial opening, and food bezoars. Management depends on the cause of the obstruction and generally includes initial expectant management with nasogatric tube decompression and intravenous hydration, unless peritonitis or signs of bowel ischemia are present. If imaging suggests volvulus around the ostomy, prompt surgical intervention is indicated. In temporary ileostomies, obstruction at the level of the stoma due to angulation or other technical issues can often be managed by stoma catheterization with a

urinary or red rubber catheter until stoma reversal is possible. Consideration should also be given to the possibility of obstruction due to a food bolus or bezoar. Careful digitalization of the stoma with a lubricated finger may identify an intraluminal bolus obstructing the stoma; gentle irrigation with saline through a red rubber catheter may resolve the obstruction in many cases.

Ileostomy Reversal Patients

Small Bowel Obstruction/Anastomotic Leak

Despite the lack of a formal laparotomy for loop ileostomy reversal, the procedure is not trivial and is associated with a reported morbidity of 17%, a 0.4% to 0.6% mortality, a 4% incidence to conversion to laparotomy, and a 7% incidence of small bowel obstruction. This should be considered when weighing the risk-benefit ratio of a protective loop ileostomy. Studies of stapled anastomosis versus hand-sewn closure of the stoma reveal an incidence of ileus of approximately 13% regardless of technique. There was a trend toward less frequent bowel obstruction with stapled anastomosis, but also a slight increase in anastomotic complications. The anastomotic leak rate is approximately 2% with either technique. Management of small bowel obstruction following DLI reversal does not differ from that for small bowel obstruction in other postoperative scenarios. Management options for anastomotic leakage after diverting loop ileostomy reversal depend on clinical severity and include bowel rest and antibiotics, percutaneous drainage of contained abscesses/collections, and laparotomy with end ileostomy and mucous fistula.

Wound Complications

The incidence wound infection depends on the manner in which the ileostomy site is managed. Purse string suture closure is associated with a wound infection rate of 0% to 7%, compared to up to 20% after delayed primary closure and up to 37% following primary closure.

Suggested Readings

Chaudhri S, Brown L, Hassan I, et al. Preoperative intensive, community-based vs. traditional stoma education: a randomized controlled trial. *Dis Colon Rectum* 2005;48:504–9.

Chow A., Tilney HS, Paraskeva P, et al. The morbidity surrounding reversal of defunctioning ileostomies: a systematic review of 48 studies including 6,107 cases.

Int J Colorectal Disease 2009;24:711–23.

Hansson BM, Slater NJ, van der Velden AS. Surgical techniques for parastomal hernia repair: a systematic review of the literature. *Ann Surg* 2012;255:685–95.

Hendren S, Hammond K, Glasgow SC, et al. Clinical practice guidelines for ostomy surgery. *Dis Colon Rectum* 2015;58:375–87.

Kalady MF, Fields RC, Klein S, et al. Loop ileostomy closure at an ambulatory surgery facility: a safe and cost-effective alternative to routine hospitalization. *Dis Colon Rectum* 2003;46:486–90.

Loffler T, Rossion I, Bruckner T, et al.; HASTA Trial Group. Hand suture versus stapling for closure of loop ileostomy (HASTA Trial): results of a multicenter randomized trial. *Ann Surg* 2012;256:828–35.

Nagel D, Pare T, Keenan E, et al. Ileostomy pathway virtually eliminates readmissions for dehydration in new ostomates. *Dis Colon Rectum* 2012;55:1266–72.

Rondelli F, Reboldi P, Rulli A, et al. Loop ileostomy versus loop colostomy for fecal diversion after colorectal or coloanal anastomosis: a meta-analysis. *Int J Colorect Dis* 2009;24:479–88.

Salvadalena G, Hendren S, McKenna L, et al. WOCN Society and ASCRS position statement on preoperative stoma site marking for patients undergoing colostomy or ileostomy surgery. *J Wound Ostomy Contin Nurs* 2015;42:249–52.

Sands LR, Marchetti F. Intestinal stomas. In: Beck DE et al., eds. *The ASCRS Textbook of Colon and Rectal Surgery.* 2nd ed. New York: Springer Science and Business Media, LLC; 2011:517–32.

Sheetz KH, Waits SA, Krell RW. Complication rates of ostomy surgery are high and vary significantly between hospitals. *Dis Colon Rectum* 2014;57:632–7.

EDITOR'S COMMENT

The chapter by Moore and Mantyh addresses many aspects of ileostomy construction and closure. Ileostomies have come into the spotlight over the last few years with the special emphasis on readmission as a measure of quality care of surgical patients. Readmission of patients with temporary ileostomy has been a topic of many recent publications as readmissions following ileostomy closure have occurred in over one quarter of patients undergoing this procedure (Fish DR, Mancuso CA, Garcia-Aguilar JE, et al. Readmission after ileostomy creation: retrospective review of a common and significant event. *Ann Surg* 2017;265(2):379–87). In a study of 1,114 new ileostomates in two large urban hospitals over a 30-month period, 39% of patients returned to hospital of which 28% of patients required readmission. Dehydration was the most common

reason for hospital admission. There have been several publications proposing pathways directed at postoperative patient education to decrease hospital readmission rates (Nagle D, Pare T, Keenan E, et al. Ileostomy pathway virtually eliminates readmissions for dehydration in new ostomates. *Dis Colon Rectum* 2012;55(12):1266–72; Hardiman KM, Reames CD, McLeod MC, et al. Patient autonomy-centered self-care checklist reduces hospital readmissions after ileostomy creation. *Surgery* 2016;160(5):1302–8). Nagle and her colleagues showed that such a pathway was able to decrease hospital readmission rates from 35% before initiation of this pathway to 21% after its implementation. Similarly, Hardiman and colleagues were able to decrease their readmission rate following ileostomy closure from 28% to 20% following introduction of a patient-centered checklist. It is this author's preference that such patient education material is discussed with the patient both before and during hospital admission and also then be given to the patient on a laminated card, which is provided at the time of hospital discharge. So many of the numerous sheets of paper that are given to patients on discharge are meaningless information and need to be supplanted by something more likely to be noticed and not discarded or misplaced.

While it is not mentioned in nearly sufficient data in Table 138.2 in this chapter, there are some detailed recommendations elsewhere in the chapter that give the essence of care. The reader is encouraged to refer to the chapter on Care of Stomas for more details regarding management. One of the most important points is that a majority of complications can be avoided by selection of a good stoma site. This is made all the more important by the changing body habitus of our population. According to recent data from the National Institute of Health Overweight and Obesity Statistics, more than two thirds (68.8%) of adult Americans are considered to be obese or overweight (https://www.niddk.nih.gov/health-information/health-statistics/Pages/overweight-obesity-statistics.aspx). In such patients who are undergoing a variety of procedures, such as anterior resection for cancers, sigmoid resection for diverticular disease, ileostomy diversion may be the preferred method of diversion, not only for the ease of closure, but for the much greater ease of constructing and ileostomy in an overweight, obese, or even super-obese individual as compared to a colostomy.

One should note that these readmissions have not been reduced to zero. Patients with ileostomy can be readmitted for other reasons, such as intra-abdominal infection, and intestinal obstruction. A symptom of both of these can be initially increased stoma output; patients can become weak and thoroughly dehydrated, especially in patients with heart disease and/or diuretic therapy. If this is foreseen, it is very easy for the patient, in their hometown and with their primary care physician and/or referring doctor, to get simple intravenous therapy as an outpatient, check up on what they are using for antidiarrheal medications, and many readmissions and related travel can be readily avoided. If the diarrhea is a manifestation of small bowel obstruction, this will soon

become apparent.

TABLE 138.2 Management of Common Ileostomy Complications

Skin irritation/ pouching difficulty		■ Consultation with WOCN-certified ET nurse ■ Consider convex appliance for retracted stoma ■ Try alternative ostomy appliance/products ■ Consider reversal
Stoma necrosis	Viable above fascial level	■ Expectant management
	Nonviable at fascial level	■ Emergent re-exploration and stoma revision
Dehydration/ renal failure	Prophylactic management	■ Use of ileostomy care pathway ■ Avoidance of foods causing diarrhea ■ Stool modification and antimotility medications ■ Rehydration
	Treatment	■ Slow output with antimotility medications
Prolapse	Minor, asymptomatic	■ Expectant management, modify appliance, consider reversal
	Large, symptomatic	■ Stoma reversal if possible vs. local revision
Bleeding	Peristomal	■ Enlargement appliance aperture to avoid mucosal trauma
	Luminal	■ Management as for GI bleed, endoscopic or angiographic evaluation
Parastomal hernia	Temporary ileostomy	■ Symptomatic management, reversal when clinically safe, primary or mesh repair of defect
	Permanent ileostomy	■ Stoma relocation with repair of fascial defect vs. laparoscopic/open Sugarbaker mesh repair
Stone formation	Urinary stones	■ Allopurinol ■ Avoidance of foods high in oxylate ■ Maintain hydration
	Gallstones	■ Bile salt binders (cholestyramine)
Small bowel obstruction/ food bolus	Likely adhesive etiology	■ Expectant management with NPO, NGT
	Concern for volvulus around stoma or internal herniation	■ Emergent operative management
	Due to food bolus stoma-level obstruction	■ Digitalization of stoma, gentle saline irrigation, intermittent stoma catheterization

Because of the numerous complications associated with ileostomies, there have been attempts to omit them from care, for example, in the case of patients undergoing anterior resection for rectal cancer. In a recent randomized prospective trial in which patients were randomized to receive temporary diversion with ileostomy versus no diversion, the absence of a stoma was associated with a significantly higher anastomotic leak rate (Mrak K, Uranitsch S, Pedross F, et al. Diverting ileostomy versus no diversion after low anterior resection for rectal cancer: a prospective, randomized, multicenter trial. *Surgery* 2016;159(4):1129–39). In yet another study, in an attempt to reduce the complications of loop ileostomy, investigators undertook early closure of ileostomy following surgery for rectal cancer, randomizing patients to have their ileostomies closed between 8 and 13 days postoperatively, as compared to more than 12 weeks postoperatively (Danielsen AK, Park J, Jansen JE, et al. Early closure of a temporary ileostomy in patients with rectal cancer: a multicenter randomized controlled trial. *Ann Surg* 2017;265(2):284–90). They found fewer complications following the index operation up to 1 year postoperatively in those patients undergoing early ileostomy closure. It is likely that our practice will continue to evolve as we identify more ways in which to minimize morbidity of diversion, while maximizing its benefits.

Susan Galadiunk

I find it difficult to believe that there is this much difficulty with ileostomies. Instead of trying to explain it away (a variation of "blame the patient") I think the blame should be placed squarely on the shoulders of the surgeon—sloppy anastomosis, a rush to get out of the OR, and a rush to discharge the patient. In my experience, one should wait until the effluent decreases, the effluent thickens, and the patient knows how to control the ileostomy. Ostomy nurses in the postop period can assist until the patients and those who surround the patient know how to care for him or her. I thought the days of "blaming the patient" are over, but it seems that I am wrong.

J.E.F.

139 Gastrointestinal-Cutaneous Fistulas

Josef E. Fischer and Amy R. Evenson

Enterocutaneous fistulas (ECFs) represent a catastrophic complication of abdominal disease, usually following surgical procedures. At least 85%, and perhaps as many as 95%, follow abdominal operations. Spontaneous fistulas usually occur as a complication of inflammatory bowel disease, cancer, or radiation. Spontaneous fistulas complicating cancer usually occur in advanced disease, and the prognosis, for the most part, is poor. Modern management strategies have resulted in improved overall mortality from upward of 50% to 60% between the 1940s and 1950s to between 10% and 20% from the 1960s through the turn of the century. At present, in the proper hands, mortality may range from only 0% to 2%, usually from complications of sepsis.

When a fistula follows operation, it is usually the result of an unrecognized enterotomy or leaking anastomosis, often because of poorly prepared or distended bowel, or emergency operation with the patient nutritionally or immunologically in suboptimal condition. A fistula may also follow inadequate blood supply to the bowel or, in many situations, distended or weakened small bowel due to a delay in relieving partial or near-total intestinal obstruction.

Recently, a new cause has appeared for postoperative fistulas and this is gastrointestinal cutaneous fistulas following open or especially laparoscopic ventral abdominal herniorrhaphy. The fistula seems to be caused by one of two etiologies: the first being an inadvertent enterotomy; the second, and more common, is the use of permanent mesh which may become infected and erode into the bowel, or a fastening tack that may injure the bowel inadvertently causing arcing of an electrical current which may in turn also cause bowel injury. In the case of the infected mesh, it is rare for fistula to close without removing the offending mesh. Rarely, mesh removal alone is sufficient for the fistula to close without bowel resection. Frequently, however, bowel resection is also required. At the present rate of presentation, this may become one of the more common

causes of gastrointestinal fistula, as in some series antecedent ventral abdominal herniorrhaphy is responsible for 10% of ECFs.

ETIOLOGY AND PREVENTION

ECFs result from one of the following several conditions:

1. Extension of bowel disease to surrounding structures;
2. Extension of adjacent nonbowel disease to normal bowel;
3. Inadvertent or unrecognized injury to the bowel; or
4. Anastomotic disruption.

As stated earlier, 85% to 95% of fistulas occur in the postoperative period. Operation for complications of inflammatory bowel disease, resection of malignancy, adhesiolysis for intestinal obstruction, and herniorrhaphy are the most common antecedent procedures. Preoperative factors may increase the likelihood of development of an ECF. These factors include malnutrition, infection, emergency procedures with preoperative hypotension, anemia, hypothermia, or poor oxygen delivery. In elective procedures, these aggravating factors should be corrected prior to operation with nutritional support, bowel preparation, and control of abnormal physiologic parameters such as cardiac output, hyperglycemia, and anemia. Ideally, serum albumin should be >3.3 g/dL (better yet, 3.5 g/dL) and the patient should not have lost >10% or 15% of body weight in the preceding four months. Diabetes should be controlled, and if time permits, 5 days of parenteral nutrition should be administered. Our experience is that within 5 days of adequate nutritional support, the patient begins to feel better and serum transferrin will increase. However, serum albumin will not increase because of the half-life of ~20 days. Mechanical and antibiotic bowel preparation, if feasible, should be carried out, although some doubt the efficacy of both mechanical and antibiotic bowel preparation. The current view is that it is not harmful except for *Clostridia difficile* if antibiotics are given orally as a preparation. All agree, however, that the administration of intravenous antibiotics within one half hour of the incision and maintenance of satisfactory blood antibiotic levels throughout the procedure, which may be prolonged sometimes, are necessary. While this preparation will not obviate the occurrence of fistulas completely, they may diminish their occurrence. Abscesses will be minimized at the very least.

In the patient undergoing an emergency procedure, however,

optimization of resuscitation and performance of a technically meticulous procedure may be the only steps the surgeon can take to prevent ECF. Maintenance of oxygenation, warm room temperatures, optimization of cardiac output, and adequate monitoring may improve the outcome. Sound surgical technique includes an adequate incision, good lighting so that one can visualize the procedure completely, adequate mobilization, and the use of healthy bowel with good blood supply for anastomosis with avoidance of tension, hemostasis, and adequate transfusion, which minimizes the risk of formation of a fistula. In addition, prior to abdominal closure, the bowel should be inspected for inadvertent bowel injury and all enterotomies should obviously be repaired. It is our practice to repair enterotomies when they occur, as they may be difficult to find later. It is our custom to repair serosal injuries with fine nonabsorbable sutures such as 4-0 or 5-0 Prolene when they occur contrary to what some have proposed.

SPONTANEOUS ENTEROCUTANEOUS FISTULAS

Spontaneous ECF most commonly occurs in the setting of inflammation, malignancy, or irradiation. Inflammatory causes of ECF include Crohn disease, and, less commonly, ulcerative colitis, peptic ulcer, appendicitis, diverticulitis, pancreatitis, especially when pancreatic necrosis is treated by repeated dressings, and ischemic bowel. In inflammatory bowel disease, ECFs in the patients with Crohn disease represent a special concern for the surgeon. Often a fistula in these patients will resolve with nonoperative management only with parenteral nutrition, only to reopen on resumption of enteral feedings. Some of the newer, immunologic-type drugs may result in more frequent closure; however, it is not clear that these fistulas once closed will not recur. Our practice to close the fistula nonoperatively when possible and then operate on the patient to resect that portion of bowel when infection in the abdominal wall is quiescent. A second important distinction that is pertinent to the patients with Crohn disease involves whether the patient’s fistula arises in healthy bowel (following resection of the diseased segment) or from diseased bowel not necessarily following bowel resection. The former type is probably no different than in the patients without inflammatory bowel disease and has a high likelihood of spontaneous closure. The latter, as stated earlier, has a lower rate of nonoperative closure. Patients with this type of fistula may benefit from early resection especially if it can be closed spontaneously prior to operation, as these fistulas tend to reopen.

In the patients with malignancy or following radiation therapy, different tactics may be used because many of these fistulas will not close without resection. In patients with cancer, occurrence of a spontaneous fistula is a grave sign indicating a poor outcome. An understanding of the etiology may provide information about the likelihood of successful closure with or without intervention.

It must be remembered that more than one of these predisposing conditions may exist in any patient and the risks are compounded when multiple factors are present.

CLINICAL PRESENTATION

Recognition of a postoperative ECF follows a distinct pattern. The patient does not do well immediately following the operation. There is a slow course with fever and a prolonged ileus as well as a feeling of malaise. Abdominal distention may also be part of the picture. Most of all is a lack of progression and recovery from the original operation with a low-grade fever sometimes up to 101°F or even 102°F and more abdominal tenderness than one would ordinarily expect if the operation were uneventful. On the fifth or sixth postoperative day, a “wound infection” presents which is then drained; defervescence follows and the patient improves. There is some relaxation on the part of the surgeon as perhaps the patient will now do well. However, within 24 hours, enteric contents drain from the wound and the surgeon knows that one is dealing with a gastrointestinal cutaneous fistula.

At this point there is a decision to be made. There are data from experienced centers that indicate that immediate reoperation before 9 or 10 days postoperatively results in 10% mortality, whereas operation between 10 and 120 days results in 20% mortality. However, we would caution operating on the patient at this time. The operation is not risk-free because the patient is in suboptimal condition (i.e., some of the same conditions are present that contributed to this patient getting a fistula in the first place, which include the following: suboptimal nutritional condition, distended bowel, early obliterative peritonitis, and probably a suboptimal immunologic status). Operation at this point may yield another fistula which will make things worse and probably have a higher mortality. A second alternative, and one which I would support, is to accept the fistula, not reoperate, and counsel the patient that one will try nonoperative closure, and that if this does not work, then reoperation after an interval of

4 or 5 months lies ahead. This will be difficult on the patient and his or her family, but this is likely to result in long-term survival. One needs the support and cooperation of the patient and his or her family to be successful.

NUTRITIONAL SUPPORT

As soon as the fistula has been discovered, one evaluates the patient. It is likely that the patient is nutritionally deficient and intravascularly depleted with multiple electrolyte deficiencies, especially sodium, potassium, phosphate, and magnesium. There is often a lack of intravascular volume as the patient has been third spacing. Bowel distention leads to movement of fluid as well as protein and electrolytes into the extravascular space as well as within distended bowel. These need to be replenished. Given the sophisticated electrolyte monitoring available, it is surprising that these deficiencies in electrolytes occur quite frequently—patients escape from tight monitoring. In addition to measuring serum electrolytes, one can get an idea of what the composition of fluid lost is by sending some of the fistula fluid for electrolyte determinations (Table 139.1). This will help maintenance of normal electrolytes in the serum, as one replaces what is being lost.

TABLE 139.1 Electrolyte Composition of Body Fluids[a]

Source	Volume (mL/d)	Na	K	HCO_3	Cl
Gastric	2,000–2,500	60	10		90
Pancreatic	1,000	140		5 90–110	30–45
Bile	1,500	140	5	35	100
Small bowel	3,500	100–130	15	25–35	100–140
Diarrhea	1,000–4,000	60	10–20	10	45–65
Urine	1,500	20–40	20–40		20
Urine + Lasix		40–60	20–40		60–100
Sweat		50	5		55

[a]All electrolyte values are mEq/L.
From Grant JP. *Handbook of Total Parenteral Nutrition* 2nd ed. Philadelphia, PA: WE Saunders, 1992:174. Copyright © Dr. John Grant, with permission.

The patient should be kept NPO and hard candy may be allowed to keep saliva flowing, avoiding sialadenitis. Aggressive restoration of intravascular volume should take place at once, utilizing 5% Albumisol as well as crystalloid. One must be careful as to how much crystalloid is

administered, as one does not want to get an edematous patient after resuscitation, so judicious administration of crystalloid is necessary. Supplementation of magnesium, phosphate, and potassium as well as sodium is required to prevent further electrolyte disturbances. Malnutrition that complicates ECF is multifactorial. Postoperative patients have often endured 1 to 2 weeks of starvation with essentially no oral intake prior to recognition of the fistula. As for those patients with spontaneous fistulas, they have inflammatory bowel disease or malignancies which may lead to poor nutrition for some time. Some patients may have limited absorptive areas of the bowel. Further, ECFs are often accompanied by sepsis and inflammation which increase the metabolic needs.

NUTRITIONAL STATUS

Depleted nutritional status interferes with the ability to resuscitate the patient and is one of the principal determinants of mortality, whereas the ability to reverse poor nutritional status improves outcome. In one large series, patient serum albumin level, at first discovery, was a major factor in survival. Patient serum albumin of <2.5 g/dL had an increased mortality, whereas patients with a normal serum albumin level (>3.5 g/dL) suffered no mortality. Hypoalbuminemia may also inhibit wound healing and may lead to bowel dysfunction, complicating efforts to feed the patient enterally. Other serum markers of nutrition which may predict mortality include transferrin, retinol-binding protein, and thyroxine-binding prealbumin; these should be monitored on at least a weekly basis as it has been shown that they predict morbidity and mortality in patients with ECFs. Enteral feeding, if it can be successfully provided, at least in part, appears to have a salutary effect on hepatic, intestinal, and respiratory integrity. This is true even if most of the direct nutritional support is given parenterally, but the presence of a significant enteral component is certainly beneficial.

The ability to optimize nutritional status in patients with ECFs depends on successful control and, when possible, elimination of sepsis. The leading cause of mortality in contemporary series is sepsis and multiorgan system failure in the patients with ECFs. Fistula formation is only one of several possible outcomes of bowel perforation or anastomotic breakdown. Enteric contents escaping the bowel lumen may be contained in the local abscess or may spill freely throughout the peritoneal or thoracic cavities, or may track through the abdominal wall and form an ECF. Closed-space

sepsis, such as an abdominal abscess, must be drained before the patient will be able to establish positive nitrogen balance. The liberal, early (emphasize early, not repeatedly) use of computerized tomography, ultrasound, or magnetic resonance imaging will allow early identification and percutaneous management of intra-abdominal abscesses. Peritonitis resulting from free circulation of enteric contents requires urgent laparotomy to contain the spillage and prevent further soilage. If all else fails, a proximal diverting enterostomy may be necessary to control local wound sepsis, which is also treated with antibiotics and wound care techniques employed to protect the surrounding abdominal wall.

Intra-abdominal sepsis is not the only cause of catabolic fever. Blood, urine, and sputum cultures should be obtained to evaluate concomitant infections. In considering antibiotic use in patients with ECFs, one must be very judicious in a choice of antibiotics to avoid selection of multi-agent-resistant organisms, and therefore antibiotics should only be used to treat identified infection using the narrowest spectrum agent available for the shortest duration of time. In the classic study written by Soeters in the 1970s, the average number of antibiotics used throughout such a course of a patient with an ECF was eight or nine, emphasizing the need to think very carefully as to whether antibiotics are needed, and if so, what spectrum should be used. In my view, it is better to tolerate a low-grade fever if the patient is not ill rather than use antibiotics which may be needed later in the course. Finally, it is important to remember that when an abscess is drained, a bacteremia occurs and therefore one should refrain from placing a central line for 12 hours following the drainage of an abscess to avoid contamination of a new catheter.

MANAGEMENT

The goal of treating ECFs is to restore bowel continuity, to achieve enteral nutrition, and to close the fistula. Whether achieved with or without surgical intervention, management of this complex patient is probably best conceptualized in stages with specific goals for each stage (Table 139.2). One of my mentors, Dr. Francis D. Moore, long-time Chief of the Peter Bent Brigham (at that time), was a master at dividing complex problems into more easily manageable phases.

Stabilization of the patient with identification of the fistula, initial resuscitation, the steps taken to contain fistula drainage, and the beginning of resuscitation take place within the first 24 to 48 hours. Obvious

abscesses should be drained, the extracellular fluid space minimized, and the intravascular space resuscitated and expanded to normal levels. Electrolyte disturbances should be corrected, hypoalbuminemia treated, and severe anemia corrected by the judicious use of packed cells. If sepsis is present, appropriate antibiotics should be started. Though these important steps should take place within the first 24 to 48 hours, they may not be completed for up to 5 days, at which point the patient should be stable and not overtly septic. Sometime between 7 and 10 days, if the patient can tolerate it, the surgeon and a senior radiologist should carry out fistulograms to see whether operative intervention will finally be required. The decision as to definitive therapy is considerably later and usually takes place 5 to 6 weeks after the initial discovery. If the decision is made that operative therapy will be required, it is purely elective unless the patient is septic, in which case immediate operation is necessary and it is for patient salvage rather than definitive therapy. If the surgeon is not pushed by sepsis to do this definitive therapy, he or she should wait until the obliterative peritonitis subsides, usually at 4 to 5 months with a patient who has been totally restored with the exception of the fistula, and taken to the operating room. Prior to this, the patient must be sustained with appropriate nutritional support, enteral or parenteral or both, and have physical and emotional rehabilitation during the healing phase which is a continuation of that which takes place prior to operation. Following successful operation, continued rehabilitation, nutritional counseling, and emotional support are necessary to return the patient to his or her original level of function.

TABLE 139.2 Phases of Management for Enterocutaneous Fistulae

Phase	Description	Timing
Stabilization	■ Rehydration ■ Correction of anemia ■ Electrolyte repletion ■ Drainage of sepsis ■ Control of fistula drainage ■ Local skin care measures ■ Commencement of nutritional support	■ 24–48 hr
Investigation	■ Fistulogram to define anatomy ■ CT/US/MRI to localize collections and guide drainage	■ 7–10 d
Decision	■ Assess likelihood of nonoperative closure ■ Plan therapeutic course ■ Decide optimal surgical timing	■ 7–10 d to 4–6 wk
Definitive therapy	■ Plan operative approach ■ Bowel resection with end-to-end anastomosis ■ Secure abdominal closure (+/– flap) ■ Gastrostomy ■ Jejunostomy	■ >4 months if spontaneous closure unlikely
Healing	■ Continue nutrition support ■ Transition to total oral/enteral feedings ■ Physical and emotional rehabilitation	■ 5–10 d after closure

CT, computed tomography; US, ultrasound; MRI, magnetic resonance imaging.

PHASE I: STABILIZATION

By the time a postoperative fistula has become apparent, the patient already has significant deficits in lean body mass, intravascular volume, red cell mass, various serum electrolyte, and serum proteins such as serum albumin and acute phase reactants. Resuscitation should begin with protein-containing solutions such as 5% Albumisol, provided there is no sepsis-related capillary leak, as concentrated salt-poor albumin is too expensive. One could begin with some crystalloid; however, one must be very careful not to overwater the patient and make the patient edematous. It is helpful, as stated earlier, to measure the fistula drainage to get some idea as to what electrolytes are being lost and use these values as a guide to replacement. Electrolyte values should be monitored as replacement continues until stable values are achieved. Red cell mass should be

increased to optimize oxygen delivery. Though the current thinking is that a hematocrit of 21% is adequate. This is too low for the patients who are critically ill and opt for a value of a hematocrit of 30 for oxygen delivery. Although some may be happy with a serum albumin in the in the range of 2.5, we believe we are better off with an albumin of 3.0 to 3.3 at the very least in order to make certain that there is not interstitial edema, that the edema does not interfere with wound healing, and that nutrients are absorbed and get to their destination. Albumin should be administered unless there is sepsis-induced capillary leak. Invasive monitoring and central venous or pulmonary artery catheters may be necessary to guide therapy in the patients with poor cardiopulmonary reserve.

DRAINAGE OF SEPSIS

Review of most series of gastrointestinal cutaneous fistulas indicates that sepsis is the most likely cause of death. Because of this, a patient manifesting evidence of ongoing sepsis, such as fever, hypotension, low systemic vascular resistance, elevated white blood cell count especially with a shift to the left, and certainly a positive blood culture, should trigger an exhaustive search for septic foci. In addition to a careful abdominal and chest examination including a careful rectal exam and search for masses or tenderness which are unexplained, a CT scan should be obtained as well as an ultrasound of the abdomen and pelvis which may reveal abscesses that may be drained percutaneously. Before doing so, one should be ready to inject the abscess with water-soluble dye once the percutaneous drain has been placed. One may get information from the early films as to where the abscess is tracking from and thus the etiology of the fistula and the abscess. Pus from the abscess should be Gram stained as well as microbiologic culture along with blood, urine, and sputum samples. Patients with peritonitis, which is uncontrolled, are in terrible shape but must be explored expeditiously to prevent further deterioration and peritoneal contamination. It is highly unlikely that under those circumstances anything other than meticulous debridement and copious lavage with antibiotic solution can be carried out. Any resections and anastomoses are unlikely to hold but proximal diversion may be lifesaving to control ongoing leakage.

CONTROL OF FISTULA DRAINAGE AND SKIN CARE

The goal in the care of these patients is for them to ultimately undergo re-

exploration after 4 months if they do not close spontaneously. In order to do so, one must prevent continued cellulitis of the abdominal wall and destructive infection of the original wound. Fistula drainage must be managed in a way that it can be both contained and quantified. Only very low-output fistulas can be managed with a dry or a wet dressing while the fistula is active. However, should the external opening of the fistula close, an abscess will result. This is, however, so rare that we mention it only in passing. For most patients, it is not possible to care for fistula drainage by dressings alone. I usually manage the effluent from gastrointestinal cutaneous fistulas with homemade sumps created from latex Robinson nephrostomy tubes with a #14 Intracath inserted (Fig. 139.1) so that it breaks the suction at the end of the catheter. An extra hole placed 3 cm proximal to the end of the catheter will help collect the effluent. This catheter is soft at body temperature and will not erode the bowel and does a good job collecting the effluent. These nephrostomy catheters come in sizes from 12 to 36 French, and thus can be customized for the thickness of the effluent. The catheter is connected to continuous wall suction. The skin and subcutaneous tissue should be protected with DuoDerm, Ion exchange resin, which keeps the skin acidic, preventing activation of the pancreatic enzymes, ileostomy cement, and the other protectants. Engaging an ostomy therapist is essential to instruct the nurses on the floor and to maintain the integrity of the skin and the surrounding tissues.



Figure 139.1. Sump system for management of fistulae.

Recently, several groups reported the use of vacuum-assisted closure devices to aid in the management and closure of these wounds. They can be very helpful especially with large open areas in the case of low-to-moderate output fistulas (Fig. 139.2), and a 12- to 14-French nephrostomy catheter is also used at the most distal opening to administer enteral feedings. One must remember that in addition to closing fistulas, these devices can also cause fistulas even when the original fistula has been closed, as we have reported. In addition, some groups advocate the use of split-thickness skin grafts around the fistula opening as a biologic dressing

that reduces protein and fluid loss, thus positively affecting the patient's nutritional status. The contraction induced by split-thickness skin grafts may narrow the fistulous field, but we have not noted this to be definitive in fistula closure. A large defect usually requires component separation or a myocutaneous flap.

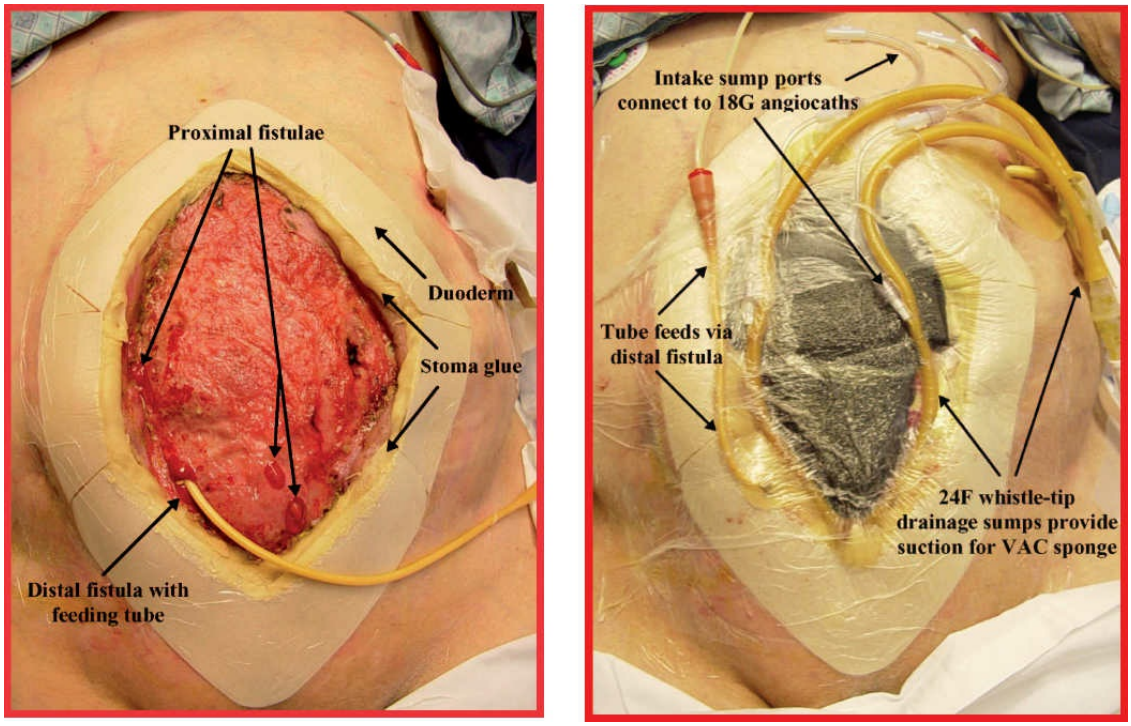

Figure 139.2. Vacuum-assisted closure (VAC) dressing in situ.

REDUCTION OF FISTULA OUTPUT

It is obviously advantageous to have less effluent to contaminate the wound and have to deal with. There are only a few medications which have been used with some efficacy to decrease GI secretions. Histamine H_2 antagonists or proton pump inhibitors reduce the production of gastric acid and output. Sucralfate, a gastric mucosal protective agent, may also reduce gastric output and may contribute to constipation and thus decrease fluid loss. Nasogastric drainage is useful only in cases of distal obstruction or ileus; the long-term use of nasogastric drainage may result in alar necrosis, chronic sinusitis, or distal esophageal stricture particularly in the patients with reflux or hiatus hernia. Pneumonitis is also more common. If the patient has a gastrostomy, this is useful when put to drainage; some consideration should be given for the placement of a Stamm gastrostomy under local with a short transverse left-upper quadrant incision or an endoscopically placed gastrostomy tube which may be more dangerous in

the obliterative peritonitis that follows gastrointestinal cutaneous fistula.

Somatostatin and its long-term analog octreotide have also been proposed in the management of the ECFs to decrease output. There is little question that pancreatic and biliary secretions are generally decreased; however, it is not clear that octreotide has any beneficial long-term effect on spontaneous closure except in biliary and pancreatic fistulas. Octreotide does have adverse side effects on the incidence of gallstones and cholecystitis. Some authors suggest a 48-hour trial of these agents should be attempted, and if the output is decreased, it should be utilized. We do not use octreotide in the management of our patients, as in addition to cholecystitis, hyperglycemia, mucosal atrophy, and interruption of intestinal adaptation are its side effects. There is little question, at least in our minds, that octreotide is efficacious in pancreatic fistulas.

Infliximab, a monoclonal antibody to tumor necrosis factor alpha, has been extensively evaluated and utilized in fistula secondary to Crohn disease, and a recent large randomized controlled trial suggests that maintenance of patients with fistula secondary to Crohn disease with infliximab reduces hospitalizations and the need for surgery in this population. In addition, others have proposed that tacrolimus be given orally in addition to infliximab in these patients. Several small studies have suggested that it may aid in both closing persistent fistulas and allowing patients be weaned from steroid and other immunosuppressive therapy. In addition, there are several case reports of patients with chronic, non-Crohn fistulas that have achieved closure permanently following a single infusion of infliximab. Though these results are intriguing, further studies will be required before a recommendation can be made for the use of these agents in the routine management of ECFs, particularly because acute infection is always a danger.

NUTRITIONAL SUPPORT

Nutritional support should only be delayed to treat or drain sepsis. These patients lose 300 to 500 g of lean body mass daily, so delay is expensive. The best nutritional support is a combination of parenteral and enteral support. The use of enteral support, while desirable, is also accompanied by an increase in fistula output which has no long-term effect, as ultimately this does not affect ultimate closure. However, in reviews of series in which enteral and parenteral nutrition had been compared, the spontaneous closure rate with parenteral nutrition is only slightly higher

than was closure with enteral nutrition. On the other hand, enteral nutrition has distinct advantages with respect to hepatic function and synthesis of short turnover proteins, some possible immunologic advantages, and thickening of the bowel wall should operation be required. However, one must be careful with the administration of enteral nutrition to avoid pneumatosis and other dangers to the bowel especially in the patients whose blood supply may not be optimal ("the challenged bowel"). It takes about 5 or 10 days of judicious increases first in volume and then in osmolality. Thus, one begins with parenteral nutrition to decrease the loss of lean body mass.

Metabolic needs may be estimated using the Harris–Benedict equation and appropriate stress factors, but it usually underestimates the need for protein. Frequent use of a metabolic cart and indirect calorimetry may be helpful as a general guideline. Our practice is to provide 32 calories/kg with a calorie nitrogen ratio of 100:1 later increasing the ratio to 125:1 and 150:1 as sepsis and hypermetabolism decreases. Essential fatty acids should be administered three times weekly in the form of a lipid emulsion, and one can finally provide between 15% and 20% of the caloric needs with intravenous fat. As one is increasing parenteral nutrition, one can begin supplementation with enteral nutrition and must expect an increase in fistula output initially. Monitoring of serum electrolytes, serum albumin, calcium, phosphate, and magnesium should occur every other day as one begins with utilizing the smallest amount of blood possible. Liver chemistries, serum transferrin, retinal-binding protein, and thyroxine-binding prealbumin should be performed weekly. As the patient stabilizes, blood chemistries can be obtained twice weekly and then weekly. Serum transferrin and other short-term proteins may provide prognostic parameters as to outcome.

Enteral support requires 4 ft of small bowel for absorption. It does not matter whether the 4-ft area is connected to the distal stomach or one feeds the fistula and the 4-ft area is distal to the fistula. A small nasoenteric tube can be passed without bothering the patient too much, but it must be in the small bowel beyond the ligament of Treitz to prevent aspiration especially when sepsis may occur suddenly and gastric and enteral motility stop. If enteral nutrition is continued, a sudden cessation of motility may result in aspiration.

One must be very careful of hyperosmolality of the enteral feeds. The manufacturer's recommendations must not be followed because these are

overly optimistic as to the bowel's ability in a sick patient to dilute a hyperosmolar bolus. Remember that many of these patients have what is called a "challenged bowel" and may not be able to increase blood flow sufficiently to dilute a hyperosmolar effect. We have noted that the patients with a nasoenteric tube have a lower incidence of pneumatosis and intestinal necrosis than those with a feeding jejunostomy, for reasons that we do not understand. We generally start tube feedings at an osmolality of 150 milliosmoles/L and gradually increase the osmolality never exceeding 250 to 275 milliosmoles/L, in that way avoiding the possibility of intestinal necrosis. This process takes 5 days or longer, so parenteral nutrition is absolutely essential. It may not be possible to achieve full-strength enteral feeds defined as 320 milliosmoles/L; we do not try and accept 275 milliosmoles/L as the maximum osmolality administered.

PHASE II: INVESTIGATION

Assuming that there is no reason to obtain a CT scan for unexplained fever or other indications of sepsis in which case it should be carried out urgently, one should allow the patient to recover without going down to x-ray for ~7 to 10 days. The x-ray table is hard and the x-ray department is always cold. At this point, the patient begins to feel better, and if one measures transferrin or other short-term proteins, one will see improvement. One can then undertake radiologic examination in order to get some idea of what one is dealing with. I believe that a fistulogram is the only examination radiologically one needs in order to determine what the patient's course is likely to be, provided that one follows the dye distally to make certain that there is no distal obstruction. The radiologic examination should be a collaboration between a senior surgeon and a senior radiologist. Water-soluble dyes should be used, and the early films are most important as these will give detail about the fistula and the surrounding bowel. Small flexible feeding tubes should be utilized to inject all the orifices with spot films obtained. Review of the early films reveal information concerning the diameter of the tract, the site of the bowel wall defect, the health of the adjacent bowel, the presence of strictures or adjacent cavities, the length of the tract between the fistula and the abdominal wall, and distal obstruction. An end fistula represents anastomotic disruption or an inadvertent injury to the bowel wall. These characteristics will enable one to predict whether the patient will close spontaneously or require operation.

We do not obtain additional contrast examinations such as upper gastrointestinal series or barium enemas. These examinations rarely demonstrate fistula tracts and give less information that can be obtained with a well-executed fistulogram. Unless the patient is septic, computerized tomographic scans are unnecessary, although they can reveal unexpected abscesses. If additional studies are required, it is important to avoid the effects of residual contrast on subsequent studies.

PHASE III: DECISION

The goal of this portion of the patient's course is to determine the likelihood that the fistula will close with continued nonoperative management or will require definitive surgical therapy. If surgical intervention is required, usually fistula output, though it may decrease somewhat, will not decrease substantially, suggesting that the fistula will not close. A good marker is that if the fistula does not close spontaneously within 5 weeks of sepsis-free adequate nutrition, it is unlikely to do so if one persists. Ileal fistulas may take longer, up to 40 to 50 days, and are less likely to close, even if the characteristics of the fistula are favorable. Even in the most optimistic series, the closure rate for ileal fistulas was <40%. This is not to say that if fistulas do not close after 5 to 6 weeks, the patient should be operated on at that point in time. Indeed, it takes 4 months for the obliterative peritonitis to subside. In the experience of the Cleveland Clinic, the mortality is 10% in reoperation prior to 10 days and after 120 days, but 20% during that time period. It may be difficult for the patient and the family to wait for that period of time, but it is essential that they understand. In addition, there are certain sites that tend to close, as given in Table 139.3. Fistulas arising from the oropharynx, esophagus, duodenal stump or lateral duodenum, pancreatic and biliary tree, and jejunum are likely to resolve without operative intervention than are fistulas originating from the stomach, ligament of Treitz, or ileum. Longer fistula tract length also suggests a greater likelihood of closure, and short tract for some reason unlikely to spontaneous resolve, perhaps because enteral mucosa grows up to the surface.

Fistulas may be classified according to the amount of fluid drained daily. Small output fistulas are defined as those with <200 mL a day, likely to be colonic in origin. These may close while the patient is ingesting oral diet, and constitute less of a challenge than in the patients with higher outputs. High-output fistulas are usually defined as those that drain >500

mL daily and these carry with them a more complex management challenge.

TABLE 139.3 Predictors of Spontaneous Closure

Factor	Likely to Close	Unlikely to Close
Anatomical location	Oropharyngeal Esophageal Duodenal stump Lateral duodenal Pancreaticobiliary Jejunal	Gastric Ligament of Treitz Ileal
Tract length	>2 cm	<2 cm
Defect size	<1 cm^2	>1 cm^2
Fistula output	Decreasing	Stable or increasing
Surrounding bowel	Healthy	Distal obstruction or stricture Abscess Active inflammation Bowel discontinuity
Etiology	Appendicitis Diverticulitis Postoperative	Crohn disease Malignancy Radiation Foreign body (mesh)
Nutritional status	Well nourished	Malnourished
Sepsis	Absent	Present

The output does not clearly determine spontaneous closure, but most fistulas that close spontaneously demonstrate decrease in output. Thus, close monitoring of fistula output can provide evidence that future closure is likely.

The status of the bowel surrounding the fistula also affects whether nonoperative management will be successful. Those fistulas likely to close arise in otherwise healthy bowel. As stated earlier, the presence of distal obstruction or stricture, adjacent abscess, active inflammation or inflammatory bowel disease, and, of course, intestinal discontinuity diminishes or makes unlikely spontaneous closure. The presence of malignancy, radiated tissue, or foreign bodies makes closure unlikely. A new issue is the presence of nonabsorbable mesh in the repair of ventral hernia defects, and this represents the most rapidly increasing cause of gastrointestinal cutaneous fistulas. Although mesh may be required for the successful treatment of large abdominal wall defects, adhesions between

the bowel and the mesh should be expected unless measures were taken to keep the surfaces separate during the healing phase. Interposition of omentum or placing the mesh as an overlay may minimize the development of adhesions and subsequent fistulas resulting from erosion of the mesh. Once the fistula has developed in association with mesh, the mesh must be removed for spontaneous healing to occur, which happens occasionally. Most often, however, there is sufficient residual inflammation to prevent spontaneous closure.

PHASE IV: DEFINITIVE THERAPY

In most instances, elective operation for closure of ECFs allows one's flexibility to make certain that optimal nutritional resuscitation and complete freedom from other sources of infection are present. Enteral feedings should be tapered in the days preceding the operation to allow for mechanical and antibiotic prep, but parenteral nutrition should be compensated to make up for the lost calories. Intravenous perioperative antibiotics should be chosen based on the review of the patient's microbiologic data and the pattern of known hospital pathogens. An infectious disease consultation may be helpful. The patient and his family should be mentally and emotionally prepared to participate fully in the difficult recovery and rehabilitation that follows procedures of such magnitude. Remember that the ravages of the episode have cost the patient lean body mass not only of peripheral muscle but also of brain protein, which also has undergone breakdown and may require up to a year to a year and a half to restore full mental faculties. The patient should be prepared for the latter eventuality and should not make any decisions concerning career for a considerable period of time, but to be reassured that the recovery will take place.

The surgical team should anticipate a long procedure, and in complicated cases, the reconstructive team may include plastic surgery in the event that a musculocutaneous flap closure to the abdominal wall is necessary or a component separation if the surgeon is not comfortable carrying this out. It is essential, when possible, that the incision be made in a fresh area, free of adhesions. If there is a room above a vertical midline-type incision, which there often is, below the xiphoid this is a good place to start. If not, a fresh transverse incision may allow the best opportunity to enter the abdomen without injury and damage to the adherent bowel. The initial approach is all important. One must enter the abdomen in a fresh

area so as not to perform an inadvertent enterotomy. If this occurs, it changes the nature of the operation and allows a pall to fall over the proceedings. It often takes me between 1 and 2 hours to get into the abdomen. I prefer to use a No. 15 blade, using Kocher clamps to elevate the fasciae (Fig. 139.2). Where there is available incision below, using my index finger to gently peel the bowel from the abdominal wall is the best way to mobilize the small bowel (Figs. 139.3 to 139.6). After a significant space free of bowel has been achieved and the incision lengthened, one probes laterally with the index finger to find a soft space which is always present to enter an area free of adhesions. Once this is achieved, one can develop this area laterally until one can get one's finger behind the adhesions so that one could take down the adhesions from the side and not directly from in front. This lessens the opportunity to create enterotomies. As the opportunity to open the incision without making an enterotomy proceeds, one can use Kocher clamps to elevate the incision away from the underlying bowel, thereby preventing enterotomies, leaving the area of the fistula for last. It is very difficult to clear the area of the fistula from the peritoneum to which it is adherent. However, the area of the fistula and adherent bowel is rarely longer than 12 to 18 in and is usually very stuck, and multiple enterotomies may be impossible to prevent. However, this is generally a short segment of bowel that is usually sacrificed. The goal of the initial phase of the operation is to free whole bowel from adhesions, drain all abscesses, and identify all areas of obstruction; this procedure in the past was called "refunctionization," by Dr. Claude Welch, one of my mentors and the Dean of Boston Surgeons.

The dissection is not likely to proceed in one direction encompassing the entire length of the bowel. It is often easier to tackle areas of least dense adhesions first. My practice is to proceed with a No. 15 blade on the scalpel and Metzenbaum scissors to avoid inadvertent injuries from tension on the bowel. Approaching adhesions from the side rather than head-on minimizes enterotomies. If one is stuck, one should place an antibiotic-soaked laparotomy pad on the bowel and go elsewhere. The fluid in the pad creates edema that facilitates further dissection. If an enterotomy is made inadvertently and the bowel is not intended to be resected, closure should take place at that point and not left for later, as in the long case, there may be soilage to the peritoneum or one may not be able to find the injury later. I used an internal layer of interrupted buried 4-0 silk and an outer layer of 4-0 or 5-0 Prolene interrupted sutures. Prolene

does not cause a microabscess as does 4-0 silk used as the outer layer. I also close serosal tears with 5-0 Prolene interrupted sutures.

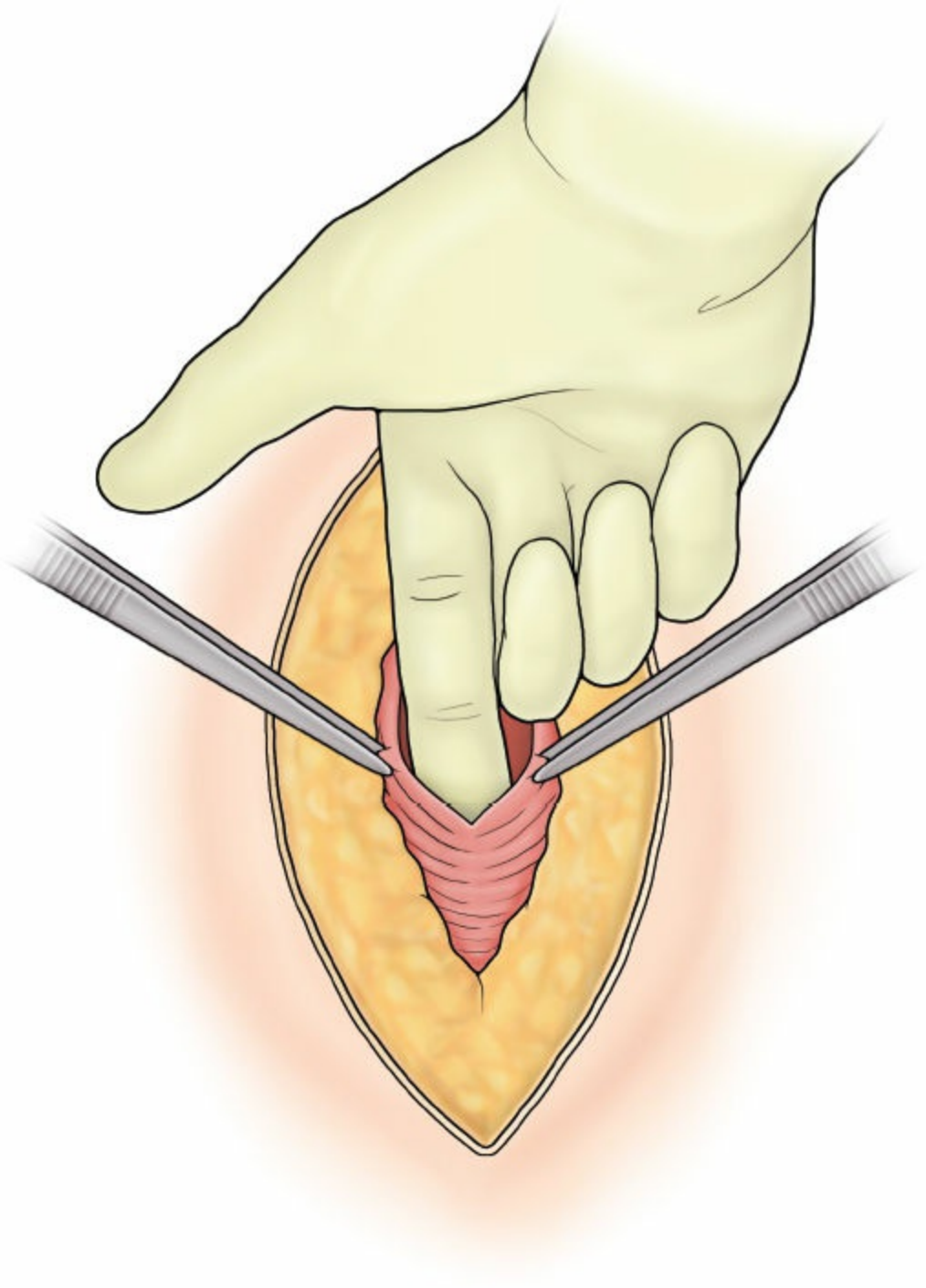

Figure 139.3. Once one has made the skin incision and clears the subcutaneous tissue from the fascia, one lifts up the fascia with Kocher clamps so one can see and then uses either index finger to separate the bowel from the underside of the fascia, without making an enterotomy.

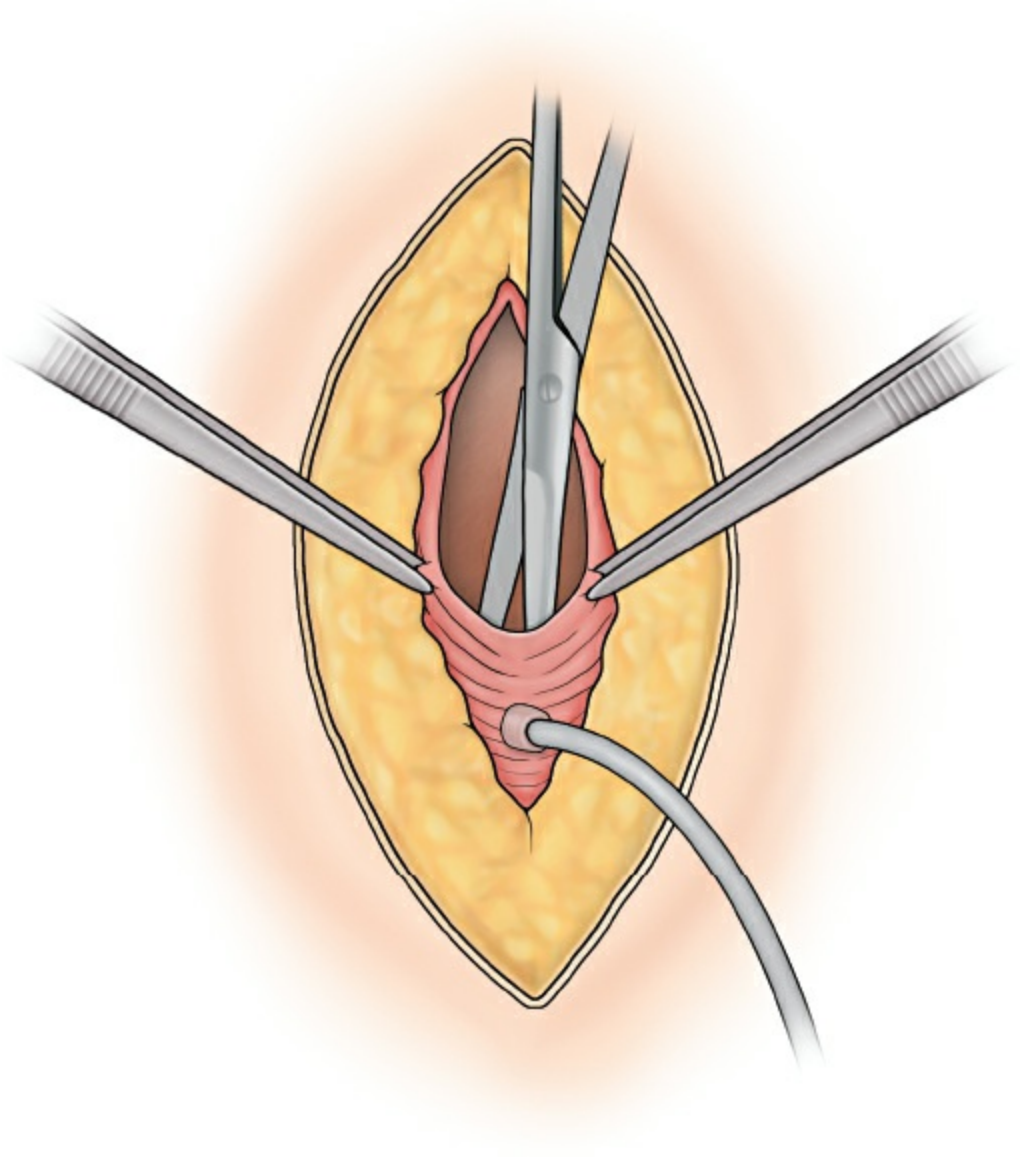

Figure 139.4. Both the skin incision and the fascia incision are lengthened carefully as the underside of the fascia is separated from the bowel and one can see clearly, the fascia may be divided with Metzenbaum scissors or a No. 15 blade scalpel.

It is best that the section of fistulized or injured bowel be resected with an end-to-end anastomosis with an inner layer of buried 4-0 silk interrupted sutures with the knots in the lumen and an outer layer of 4-0 or 5-0 Prolene interrupted sutures. Roux-en-Y drainage, simple closure, or wedge resection of the fistula should not be carried out as recurrence is much more common. It should be noted that in the papers in which this was elucidated, this was carried out only when no other option presented itself.

Avoidance of tension and assurance of a good blood supply maximize

the chances of a successful repair. If one is unhappy with the repair and cannot do any better, consideration should be given to the protection of the anastomosis with a loop ostomy proximal to the repair, and closed-suction drains not far but not adjacent to the anastomosis.

Given the magnitude of the laparotomy performed, many patients will have a prolonged postoperative ileus. In order to avoid prolonged nasogastric tube drainage, a Stamm gastrostomy should be carried out making certain to suture the latex tube (#18 French) to the stomach with absorbable suture and the stomach itself and the anterior abdominal wall around the exit hole with nonabsorbable sutures. Similarly, a feeding jejunostomy (#14 latex nephrostomy tube) should be placed with a Witzel tunnel being careful not to narrow the bowel and to surround the exit site with nonabsorbable sutures to the anterior abdominal wall.

Prior to abdominal closure, the entire bowel surface should be run and inspected to ensure that no unrecognized injuries exist. Irrigation with copious amounts of antibiotic solution should be performed. Closed-suction drainage catheters such as Blake drains may be left in the abscess cavities or in raw areas where oozing cannot be controlled. Optimally, the omentum should be placed between the anastomosis and the abdominal incision to prevent formation of adhesions between the bowel and the anterior abdominal wall. Blake or other drains should not be placed next to an anastomosis.

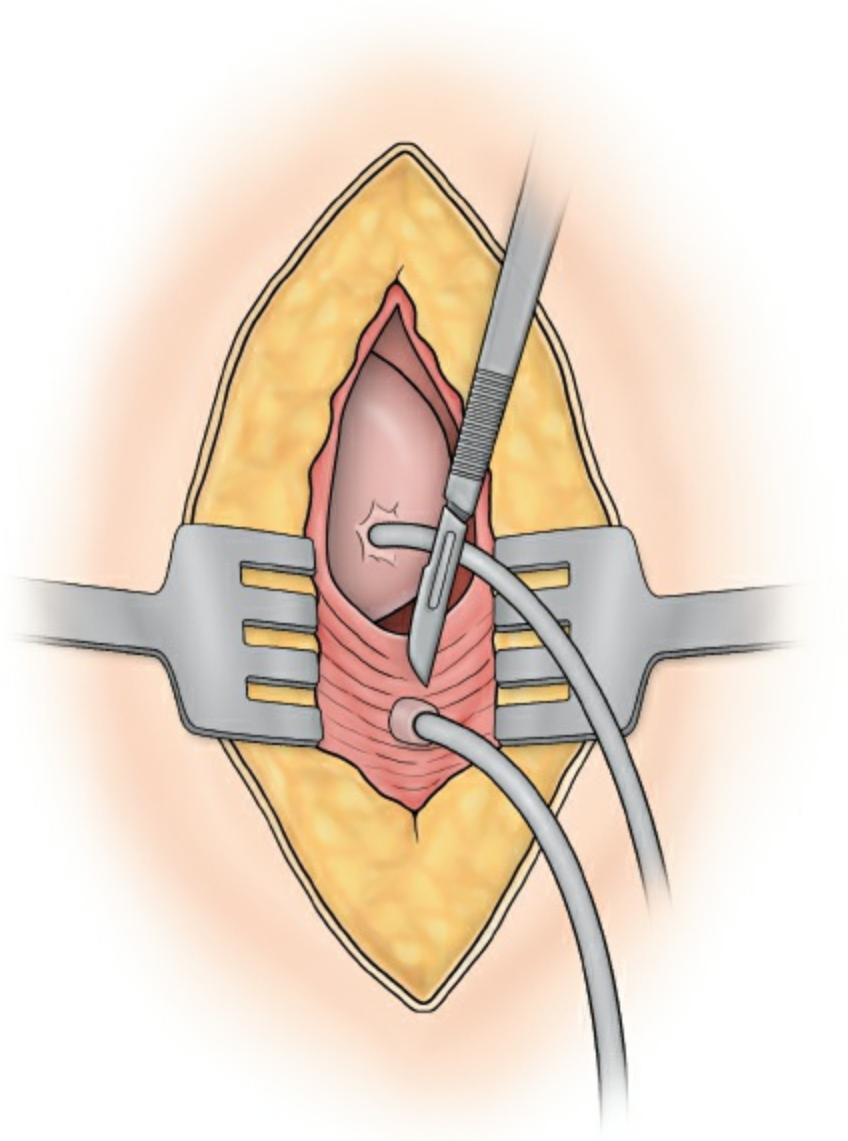

Figure 139.5. Further dissection of the abdomen: The bowel and fistula are clearly seen at the bottom of the wound. The fascia can be incised without fear of enterotomy. The goal is to reach the area where the fistulas are. The really adherent area is rarely longer than 12 in of bowel. Enterotomies are unavoidable but only 8 to 12 in of bowel need to be resected.

A secure abdominal closure is essential with native tissue. When native tissue is not available, a reconstructive team should have been planned for an advanced component separation or a musculoskeletal flap. Without native tissue, it is likely that the fistula will recur.

Several groups recently reported experience with laparoscopic approaches to operative management of ECFs with minimal complications or conversions to open procedures. They may provide advantages over

laparotomy that include decreased pain, faster return of bowel function, and shorter length of stay. As expertise with laparoscopic approaches to complex abdominal problems increases, one can expect to see more procedures performed with these techniques. One must remember, however, that these procedures require advanced laparoscopic skills, and also require a steep learning curve. Given the significant investment in time and resources in these patients, the choice of operation and technique must provide the best possible outcome.

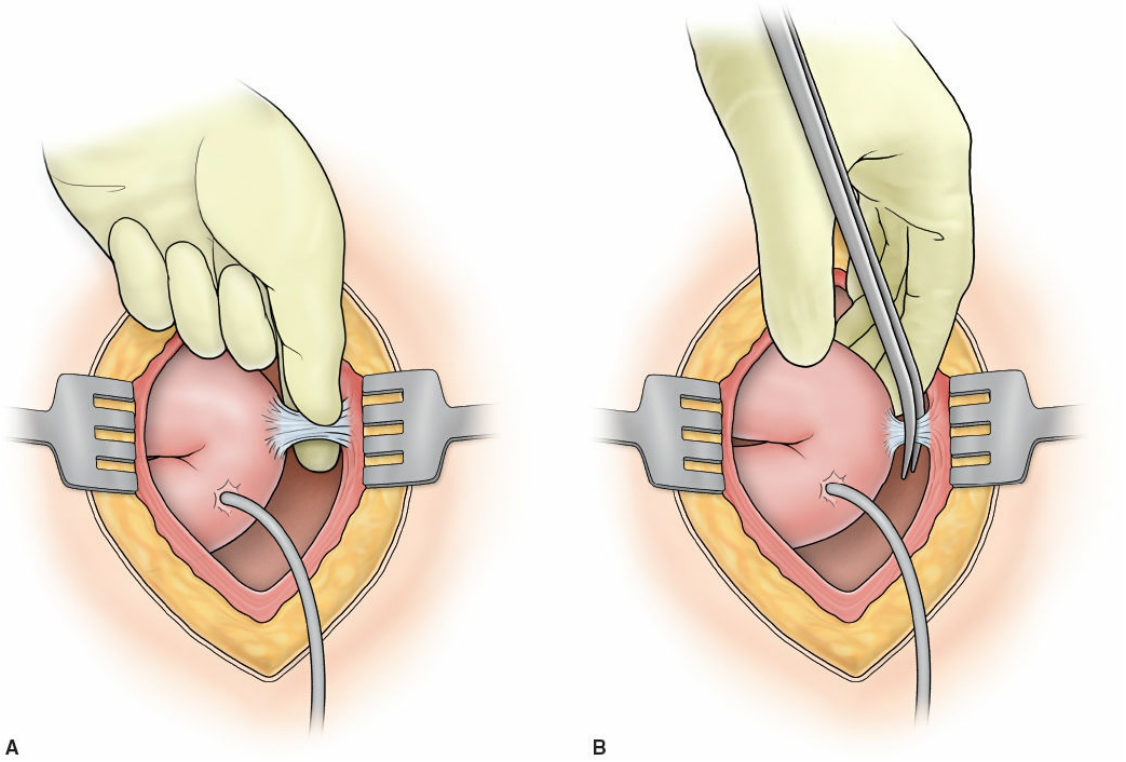

Figure 139.6. Adhesions can sometimes be dealt with by compressing the adhesions from a broad base to a narrow base **A** to **B.** When the adhesion is narrowing and is easily visible, the narrowed adhesion can be sharply divided.

PHASE V: HEALING

Regardless of what approach is used for nonoperative management and closure, nutritional support will be required in the postoperative period. These patients have not eaten for a long time and oral intake in many will be limited. Oral intake is commenced after the postoperative ileus has resolved. The traditional diet advancement protocol (sips of clear liquids to full liquids to a regular diet) may not be attractive to somebody who has not eaten for 4 to 6 months. Appetite is poor especially since one is still

providing artificial nutrition. I typically start patients on a soft diet and, since they have very poor appetite, encourage the patient's family to bring in favorite foods. Liquor or wine may help. Enteral or parenteral feedings may be cycled during the nighttime hours to supplement oral nutrition until the patient is able to consume at least 1,500 calories. Zinc supplementation may improve taste and increase oral intake.

After a 4- to 6-month medical ordeal, patients are often physically and emotionally exhausted. Limitations imposed by cumbersome wound dressings as well as the metabolic and septic challenges endured by these patients often lead to limited ambulation and deconditioning. Use of inpatient physical and occupational therapy can limit some of the losses, but intense rehabilitation will be required upon discharge from the hospital. Social worker or psychiatric consultation services may be required to help the emotional and financial ordeals associated with this disease. A coordinated rehabilitation program may be necessary to allow for patient's successful reintroduction to society and an active lifestyle. A consistent and continued involvement of the senior surgeon in the patient's care is essential as this individual undoubtedly looks up to the surgeon as his or her savior. The senior surgeon must be the final arbiter of the patient's health care.

Hopefully, a nasogastric tube (a gastrostomy is preferred) has not been left in place too long—if it has been, especially with reflux, esophageal stricture may result. Any dysphagia should be promptly investigated.

DUODENAL FISTULAS

Duodenal fistulas are the exception to the rule that fistulas are best dealt with by resection and end-to-end anastomosis. In this case, whether this does result from sphincterotomies, in which case the defect is lateral in the second or third portion of the duodenum posteriorly, or in the duodenal fistulas following a blown duodenal stump following a gastrectomy, resection of the duodenum and pancreas is not appropriate. Instead, we personally have had excellent results bypassing the fistula with a Roux-en-Y gastrojejunostomy. The Roux-en-Y is now preferred as opposed to a Billroth II type of gastrojejunostomy because of the 20% incidence of long-term complications following a gastrojejunostomy as is detailed elsewhere in this volume (Chapters 81 and 82). Though some have argued for a 40 cm distance between the stomach and the anastomosis between the ligament of Treitz and the distal jejunum, the literature would support a 60

cm distance so that bile reflux is completely obviated.

The majority of biliary, pancreatic, and duodenal fistulas will close spontaneously or nonoperatively. Octreotide, 50 to 100 μg every 8 hours, decreases the output and probably decreases the time of closure. In the event that spontaneous closure does not occur, a direct attack on the area is not judicious and will do a lot of damage. Both a Stamm gastrostomy and a feeding jejunostomy as previously described should be included in the procedure to enable early discharge and enteral feedings either at home or in a rehabilitative setting.

We do not believe that a vagotomy should be included in this procedure. In the first place, when gastrectomy has been the antecedent procedure, the ulcer diathesis has already been dealt with. If the procedure is carried out because of the biliary-pancreatic type of injury, there is no ulcer diathesis and a vagotomy is meddlesome.

THE INFLUENCE OF ARTIFICIAL FEEDING ON MORTALITY OF GASTROINTESTINAL CUTANEOUS FISTULAS

Though one would expect that the decrease in mortality accompanied the introduction of TPN, this is not the case. First, some form of nutritional support was introduced in the 1960s, whether this was tube feedings or 10% dextrose, albumin, lipomul (an early and somewhat imperfect fat supplement), large volumes of intravenous amino acids, and 10% dextrose as various forms of oral supplementation. When Dr. Claude Welch had a patient with a gastrointestinal cutaneous fistula, he always had the patient keep a large bottle of peanut butter at the bedside. When I asked him why, he would tell me that peanut butter was sticky and perhaps the fistula would close in that fashion. Of course, peanut butter was a great source of protein and fat. Given these various forms of nutritional supplementation, the mortality actually dropped between 1960 and 1970 probably because of intensive care, more intelligent use of increasingly available antibiotics, and greater expertise in respiratory support.

TABLE 139.4 Mortality

1946–1959	45% (138 patients—MGH)
1960–1970	15% (119 patients—MGH)
1970–1975	19% (145 patients—MGH)
1982–1991	20% (79 patients—UH)

As shown in Table 139.4, the introduction of TPN did not result in any decrease in mortality in two centers that were accustomed to dealing with gastrointestinal cutaneous fistulas. Thus, from the standpoint of parenteral nutrition, it was intensive care rather than a breakthrough in nutritional support which resulted in the decrease in mortality in this catastrophic complication. In my latest series of patients with gastrointestinal cutaneous fistulas which was reviewed by the residents, the mortality was zero in 50 patients. I have no idea why my own mortality dropped so precipitously. The patients were difficult and were referred. However, it indicates that meticulous care, in and out of the operating room, can result in an excellent outcome. Possibly the waiting of 6 months before reoperation was significant.

Suggested Readings

de Weerd L, Kjaeve J, Aghajani E, et al. The sandwich design: a new method to lose a high-output enterocutaneous fistula and an associated abdominal wall defect. *Ann Plast Surg* 2007;58(5):580–3.

Edmunds LH, Williams GH, Welch CE. External fistulas arising from the gastrointestinal tract. *Ann Surg* 1960;152:445.

Fischer JE. The Importance of reconstruction of the abdominal wall after gastrointestinal fistula closure. *Am J Surg* 2009;197(1):131.

Jamshidi R, Schechter WP. Biologic dressings for the management of enteric fistulas in the open abdomen: a preliminary report. *Arch Surg* 2007;143(8):793–6.

Joyce MR, Dietz DW. Management of complex gastrointestinal fistula. *Curr Probl Surg* 2009;46(5):384.

Kuvshinoff BW, Brodish RJ, McFadden DW, et al. Serum transferring as a prognostic indicator of spontaneous closure and mortality in gastrointestinal fistulas. *Ann Surg* 1993;217:615.

Osborn C, Fischer JE. How I do it: gastrointestinal cutaneous fistulas. *J Gastrointest Surg* 2009;13(11):2068.

Schechter WP, Asher H, Chang DS, et al. Enteric fistulas: principles of management. *J Am Coll Surg* 2009;209(4):484.

Soeters PB, Ebeid AM, Fischer JE. Review of 404 patients with gastrointestinal fistulas: impact of parenteral nutrition. *Ann Surg* 1979;190:189.

von Rentein D, Denzer UW, Schachschal G, et al. Endoscopic closure of GI fistulae by using an over-the-scope clip (with videos). *Gastrointest Endosc* 2001;72(6):1289.

EDITOR'S COMMENT

Dr. Fischer and Dr. Evenson authoritatively discuss the management of enterocutaneous fistulas, one of the most dreaded complications following abdominal surgery. Little has changed in the management of enterocutaneous fistulas over the last 10 to 15 years, other than the development of more effective wound management products. The development of large wound collector appliances has greatly facilitated the management of high-output and multiple enterocutaneous fistulas. This and the explosion of negative pressure wound appliances have perhaps been the developments that have most aided the surgeon in the overall management of these patients (de Leon JM. Novel techniques using negative pressure wound therapy for the management of wounds with enterocutaneous fistulas in a long-term acute care facility. *J Wound Ostomy Continence Nurs* 2013;40(5):481–8). The availability of special "cut to fit" fistula appliances has made fitting negative pressure dressings around fistulas to aid in wound healing around these sites much easier (Heineman JT, Garcia LJ, Obst MA, et al. Collapsible enteroatmospheric fistula isolation device: a novel, simple solution to a complex problem. *J Am Coll Surg* 2015;221(2):e7–14).

As Dr. Fischer elegantly describes, enterocutaneous fistulas can arise from a variety of causes. The likelihood of healing depends upon whether they arise postoperatively or whether they occur as a result of patient disease and/or distal obstruction. The latter clearly will not heal until the distal obstruction has been relieved and/or the disease has been treated. Examples of such fistulas are those that occur secondary to colon cancer or obstructing Crohn disease. Postoperative fistulas that occur as a result of inadvertently overlooked enterotomies or due to anastomotic leaks can heal with conservative therapy without requiring further surgery, *if* they are associated with a low output or can be made to have low output by antidiarrheal medication, NPO status with intravenous hyperalimentation or the addition of intravenous or subcutaneous somatostatin (Rahbour G, Siddiqui MR, Ullah MR, et al. A meta-analysis of outcomes following use of somatostatin and its analogues for the management of enterocutaneous fistulas. *Ann Surg* 2012;256(6):946–54).

In such circumstances, adjuncts such the judicious use of negative pressure wound therapy, if there is no clearly visible bowel segment in the wound and if the output is low, can often result in healing of low-output fistulas, by promoting formation of granulation tissue over the external opening. One of the

great difficulties with this is that negative pressure therapy to close fistulas is *not* an approved use of this therapy and currently not reimbursed by insurance carriers. This treatment is expensive, being on the order of approximately $150/day. There are few convincing reports of the efficacy of this treatment in the literature, and only small series have been reported (Pepe G, Magalini S, Callari C, et al. Vacuum Assisted Closure (VAC) therapy™ as a swiss knife multi-tool for enteric fistula closure: tips and tricks: a pilot study. *Eur Rev Med Pharmacol Sci* 2014;18(17):2527–32).

There have been reports of other types of "minimally" invasive approaches to close enterocutaneous fistulas. One such method involves the use of large "bear claw" OVESCO over the scope clips (Donatelli G, Cereatti F, Dhumane P, et al. Closure of gastrointestinal defects with Ovesco clip: long-term results and clinical implications. *Ther Adv Gastroenterol* 2016;9(5):713–21). In order to use these clips, the tissue has to be soft enough to allow it to be to be "captured" within the jaws of the clip. Use of such techniques can often save the patient the necessity of having to undergo further operations.

Prevention of fistulas is of course better than treating them. Meticulous attention to surgical technique is important. Another important point is to avoid relaparotomy in a patient after an open procedure if possible in the period between 7 and 8 days postoperatively and 8 weeks postoperatively. During this period of time, there is a normal inflammatory reaction within the abdomen that some have called "obliterative" peritonitis. This is the condition, or part of normal healing where "everything" fuses together and reoperation is EXTREMELY difficult. During this period, reoperation should only be undertaken for life-threatening emergencies. All other conditions should be temporized, with interventional radiology drainage of abscesses, percutaneous gastrostomy placement and intravenous hyperalimentation for small bowel obstruction. In addition, one technique that is very useful at the conclusion of a difficult case where there has been an extensive lysis of adhesions, a lot of intestinal edema, and an abdomen that is difficult to close, is the concept of direct peritoneal resuscitation (DPR). This is a technique on which much research has been done in my own unit pioneered by Dr. Neal Garrison and his colleagues. The effects of peritoneal dialysate fluid to increase intestinal blood supply and reduce intestinal edema are utilized perioperatively. Briefly, large bore (19F) abdominal drains are placed and a temporary "vac pack" type of temporary abdominal closure is performed. The abdomen is continuously irrigated through one drain with Delflex®, a commercially obtainable peritoneal dialysate fluid and the effluent is aspirated through the other drain. In a prospective randomized study in trauma patients undergoing damage control surgery, this technique has been shown to dramatically reduce intestinal edema and facilitate abdominal wall closure (Smith JW, Matheson PJ, Franklin GA, et al. Randomized controlled trial evaluating the efficacy of peritoneal resuscitation in the management of trauma patients undergoing damage control surgery. *J Am Coll Surg* 2017;224(4):396–404). As others have shown, primary

closure of patients with enterocutaneous fistulas can be difficult (Slater NJ, Bokkerink WJ, Konijn V, et al. Safety and durability of one-stage repair of abdominal wall defects with enteric fistulas. *Ann Surg* 2015;261(3):553–7). Adjunctive techniques such as DPR may therefore prove to be very beneficial. I believe it will also result in a decreased gastrointestinal fistula rate in those difficult cases in which a primary closure of the abdomen is difficult, and the intestines are significantly traumatized during the course of a long and difficult procedure. Such a scheme would allow for the intestinal edema to subside, and allow for a more leisurely inspection of the intestines at a second exploration, to ensure that there are no injuries or enterotomies that need repair, with definitive abdominal closure at that time.

A good tip on knowing when the patient is ready for reoperation is simple palpation of the abdominal wall. If the abdominal wall is soft to palpation, this is signifies that the intra-abdominal adhesions have softened and reoperation will be less dangerous. If the abdominal wall is still fairly rigid or stiff on palpation, this means that the adhesions are still fairly dense within the abdomen and an additional waiting period is indicated before reoperation should be attempted.

Susan Galandiuk

140 Surgical Treatment of Small Bowel Crohn Disease

Erin O. Lange, Linda Ferrari, Mukta Krane, Fabrizio Michelassi, and Alessandro Fichera

ETIOLOGY AND PATHOPHYSIOLOGY

Crohn disease (CD) is a chronic inflammatory disorder of the gastrointestinal tract that can result in strictures, inflammatory masses, fistulas, abscesses, hemorrhage, and cancer. It may affect any region of the gastrointestinal tract from the mouth to the anus, and often involves multiple sites simultaneously. Crohn, Ginsberg, and Oppenheimer first identified it as a unique clinical entity in 1932.

The pathogenesis of CD remains incompletely understood, but the prevailing theory states that, in patients with a genetic predisposition, exposure to particular environmental stimuli triggers an altered immune response, resulting in inflammation and ulceration of intestinal tissues. The histopathology of CD is characterized by transmural inflammation with multiple lymphoid aggregates seen in the submucosa. Early in the disease process, one typically sees small mucosal ulcerations, called *aphthous ulcers.* These lesions eventually progress to larger ulcerations that can penetrate through the submucosa to form intramural channels with further potential to bore deeply into the bowel wall and create sinuses, abscesses, or fistulas.

The incidence and prevalence of CD are increasing worldwide, with a recent systematic review reporting the highest annual incidence in Australia (29.3 per 100,000), Canada (20.2 per 100,000), and northern Europe (10.6 per 100,000). In the United States, the incidence of new Crohn's diagnoses is 4 per 100,000 annually, with a prevalence rate of 80 to 150 per 100,000. CD is more commonly seen among white patients compared with African Americans, Hispanics, and Asians. CD can affect patients of all ages, but the peak incidence is seen in the second and third decades of life, with equivalent involvement of men and women.

To ensure optimal patient outcomes, a multidisciplinary approach is

essential, with active involvement of gastroenterologists, surgeons, and, for children, pediatricians. Patients with active disease can suffer greatly and often have a poor quality of life due to repeat hospital admissions, medication side effects, poor nutritional status, and risk of malignancy. While treatment for CD is not curative, modern medical therapy can often be effective in limiting and halting disease progression, and may induce long-term remission. In the modern era, surgery is typically required to manage disease complications. The basic principles of surgical therapy for CD emphasize bowel-sparing approaches, anticipating the likely need for future operations. Limited resections without wide margins of normal tissue are appropriate.

CLINICAL PRESENTATION

CD is commonly characterized according to the affected site of the gastrointestinal tract with the small bowel most frequently affected. Any portion of the small bowel may be diseased, but the terminal ileum is most commonly involved, with distal ileal disease with or without involvement of the right colon present in approximately 40% of patients. Proximal small bowel disease without colonic involvement is observed in 30% of patients.

CD may also be categorized by its clinical manifestations and grouped into one of three general entities: stricturing, perforating, or inflammatory disease. These are not truly distinct forms of the disease, but rather are terms that are used to describe the predominant gross pathologic manifestation. Stricturing CD results in the development of fibrotic scar tissue that constricts the intestinal lumen and may result in a partial or complete obstruction. These fibrostenotic scars are not reversible with medical therapy; therefore, surgical intervention is required once they become symptomatic. Perforating CD is caused by deep mucosal ulcerations that can develop into sinus tracts, fistulas, and abscesses. The inflammatory pattern of CD is characterized by mucosal ulceration and bowel wall thickening that may lead to an adynamic segment of intestine with luminal narrowing, causing obstructive symptoms in the small intestine and diarrhea in the colon.

Clinical features vary according to disease location but include chronic diarrhea (>4 weeks with or without blood or mucus), abdominal pain, and weight loss. Ninety percent of patients with CD of the small bowel experience abdominal pain caused by obstructive or septic complications,

which may be associated with fevers, anorexia, or weight loss. Patients may also develop clinical manifestations of disease complications, including abdominal masses, pneumaturia, or perianal pain/swelling. On physical examination, a palpable mass may be present, usually located in the right lower quadrant, representing an abscess, phlegmon, or a thickened loop of bowel. The differential diagnosis for small bowel CD includes irritable bowel syndrome, acute appendicitis, intestinal ischemia, radiation enteritis, intestinal malignancy, pelvic inflammatory disease, endometriosis, and gynecologic malignancies.

Typical laboratory findings in the presence of CD include increased levels of inflammatory markers, especially C-reactive protein and erythrocyte sedimentation rate, iron deficiency anemia, and low levels of vitamin B_{12} and folate. Fecal calprotectin, a neutrophil cytosolic protein, is an effective marker for intestinal inflammation and can be measured if clinical suspicion is high. Ileocolonoscopy and biopsy, ideally performed in a referral center, can demonstrate discontinuous colonic or ileal inflammation or ulceration with a “cobblestone” appearance. Histology characteristically shows patchy or focal inflammation, crypt granularity, and granulomas. However, no test is definitively diagnostic, causing providers to rely on the synthesis of history, physical examination, imaging, and histopathology in making the diagnosis.

INDICATIONS AND CONTRAINDICATIONS

Even with the introduction of more effective medical treatment such as antitumor necrosis factor alpha (TNFα) agents that allow long-term remission, surgery is still required in 70% to 90% of individuals during their lifetime and 50% of those require more than one surgical procedure. Surgical intervention should treat complications and reduce symptoms of disease and is indicated in several scenarios.

Fistulae

One third of patients with CD will develop an intestinal fistula, but this is rarely the primary indication for surgery. Surgical treatment is generally reserved for intestinal fistulas that connect with the genitourinary tract and result in repeated urinary tract infections or renal impairment; enterocutaneous and enterovaginal fistulas that cause the patient personal embarrassment or discomfort; and fistulas that result in the functional bypass of a major intestinal segment, causing malabsorption and diarrhea.

Rarely patients develop cologastric, enteroduodenal, and enterosigmoid fistulae, which are indications for surgical intervention.

Abdominal Abscess and Inflammatory Masses

Abscesses that occur in the setting of CD are often the result of sealed bowel perforations. They are most frequently located in the right lower quadrant of the abdomen or along the descending colon. Most abscesses can be treated initially with percutaneous CT-guided drainage and antibiotics. However, an abscess usually originates from a severely diseased segment of bowel and thus is likely to recur or result in an enterocutaneous fistula if this segment is not resected. Therefore, after successful interventional drainage, elective surgical resection is recommended. The presence of abscesses not amenable to percutaneous drainage, such as multilocular abscesses, multiple interloop abscesses, or inflammatory masses that are refractory to antibiotic therapy, is an indication for surgical intervention.

Perforation

Free perforation of the small or large bowel only occurs in approximately 1% of patients with CD. The clinical signs of peritonitis or the identification of free intraperitoneal air on a plain radiograph or CT scan is diagnostic of free perforation. Once diagnosed, urgent surgery is required, with resection of the perforated bowel and any associated involved segments. A stoma may be necessary in the presence of significant intra-abdominal contamination.

Obstruction

Partial or complete intestinal obstruction may require surgical intervention. A partial obstruction caused by acute inflammation and bowel thickening can often be treated nonoperatively in the acute setting. However, obstructions due to high-grade fibrostenotic lesions will not respond to medical management and are an indication for surgery. In an effort to limit the length of bowel resected, attempts should be made to initially treat these obstructions conservatively with administration of intravenous corticosteroids to decrease local inflammation, nasogastric decompression, and intravenous hydration allowing for resection of the affected area electively after decompression is achieved.

Carcinoma

CD is a risk factor for adenocarcinoma of the small bowel, with relative risk 27 times that of the general population. Small bowel adenocarcinoma occurs in <1% of patients with CD, and its incidence correlates with the duration and extent of disease. Because its radiologic characteristics are similar to inflammatory disease, the diagnosis can be difficult to achieve preoperatively and most cases (73%) are discovered postoperatively. The risk of malignancy also increases in defunctionalized segments of bowel. Therefore, bypass surgery of the small intestine should be avoided.

Intestinal Hemorrhage

Severe hemorrhage in the setting of CD is extremely rare and often requires definitive surgical treatment. Massive gastrointestinal hemorrhage occurs most frequently from Crohn colitis. Hemorrhage from CD of the small bowel tends to be indolent with episodic or chronic bleeding that may require intermittent blood transfusions, but rarely requires emergent surgical intervention. However, the risk of a recurrence is high with spontaneous cessation of a small bowel hemorrhage; therefore, elective surgery of the actively diseased segment should be considered after the first episode of hemorrhage. Angiography or endoscopy can be helpful in identifying the source of bleeding preoperatively, due to the difficulty of locating these areas intraoperatively and the frequency of multiple bleeding sites.

Growth Retardation

Twenty-six percent of children with CD experience growth retardation as a result of either steroid treatment or the malnutrition associated with active intestinal disease. Persistent growth retardation in the face of adequate medical and nutritional therapy is an indication for surgical intervention.

Failure of Medical Treatment

Failure of medical treatment, the most common indication for surgery, occurs when (a) maximal medical treatment proves inadequate, with worsening symptoms or development of disease complications; (b) patients who are asymptomatic on maximal induction medical therapy develop recurrence of symptoms with tapering of these medications that do not have an acceptable safety profile for use as maintenance therapy; or (c) the patient experiences significant treatment-related complications.

PREOPERATIVE PLANNING

A complete assessment of the gastrointestinal tract is required prior to surgery to evaluate the full extent of disease and any associated complications that may require management before surgical intervention. Clinical history and physical examination focusing on abdominal and perianal manifestations of disease can help define the need for further testing.

The use of mechanical bowel preparation is controversial in patients with CD during an acute attack and in the presence of severe diarrhea, and is clearly contraindicated when a perforation or a complete obstruction is present. All patients should be administered prophylactic broad-spectrum antibiotics and DVT prophylaxis, and patients on long-term steroid therapy should receive stress-dose steroids. In the event that the patient cannot undergo primary restoration of the gastrointestinal continuity, a potential stoma site should be marked preoperatively by a certified enterostomal nurse.

To avoid clinical deterioration prior to elective surgery, we instruct our patients to continue to take 5-ASA and steroid therapy as previously prescribed until the day before surgery. Patients on methotrexate are asked to discontinue this medication at least 2 weeks prior to surgery. Given the lack of definitive data to support adverse perioperative effects from anti-TNFα therapy, we often plan the operation to take place between two scheduled infusions, rather than hold any doses.

Poor preoperative nutritional status increases morbidity rates and intra-abdominal septic complications. Crohn's patients suffer nutritional deficiencies from multiple sources: insufficient dietary intake, malabsorption, and systemic inflammation. In cases of malnourished patients, defined using albumin levels <3.5 g/dL, total parenteral nutrition should be considered for 2 to 4 weeks prior to surgery to reestablish nutritional store and reduce the risk of postoperative complications.

Imaging

Small Bowel Radiography

Small bowel follow-through and magnetic resonance enterography (MRE) are the best means for assessing the small bowel for CD. Radiographic abnormalities are often distinctive. With early CD, mucosal granulomas with ulceration and nodularity can be identified. Thickening of the mucosal folds and edema of the bowel wall itself can be demonstrated as the disease progresses. With more advanced disease, cobblestoning

becomes radiographically apparent. Small bowel contrast studies can also provide information regarding thickening of the mesentery and formation of an inflammatory mass or abscess. Such findings are demonstrated by a general mass effect separating and displacing contrast-filled loops of small intestine. Small bowel contrast studies can demonstrate some of the complications of CD, including high-grade strictures and fistulas. It is important to note, however, that small bowel radiography may not identify all such lesions. For instance, many enteric fistulas including ileosigmoid and ileovesical fistulas are not typically demonstrated on contrast radiography. Thus, the absence of radiographic evidence for fistulization does not exclude this possibility. Additionally, small bowel studies may fail to demonstrate all clinically significant strictures. While small bowel imaging may underestimate the extent of complicated CD, when performed by an experienced gastrointestinal radiologist they are very effective as a diagnostic tool. Besides their diagnostic utility, small bowel radiographs can also help in assessing the extent of the disease by identifying the location and length of involved and uninvolved intestine, and by recognizing whether the disease is continuous, or discontinuous with skip lesions separated by areas of normal intestine. Experienced radiologists can also assess areas of luminal narrowing and determine if they are more likely the result of acute inflammatory swelling or are related to fibrostenotic scar tissue. Such a distinction provides valuable information regarding the value of medical therapy versus early surgical intervention.

Endoscopy

Upper and lower endoscopy allows for inspection of mucosal disease and provides an opportunity for biopsies for histologic evaluation. Upper endoscopy is useful in the diagnosis of mucosal lesions of the esophagus, stomach, and duodenum, and can identify and grade the severity of strictures in these regions. Diagnosis of terminal ileal CD can be usually made at ileocolonoscopy.

Computed Tomography and Computed Tomography Enterography

Computed tomography (CT) findings of uncomplicated CD are nonspecific, and routine CT is not necessary for the diagnosis of CD. CT, however, is very useful in identifying the complications associated with CD, including thickened and dilated intestinal loops, inflammatory masses, or abscesses. CT scan can also demonstrate hydronephrosis resulting from

retroperitoneal fibrosis and ureteral narrowing. CT scans are often the most sensitive indicator for the presence of an enterovesical fistula as identified by the presence of air within the urinary bladder.

Computed tomography enterography (CTE) exploits the high spatial resolution and speed of modern CT, using large volumes of neutral oral contrast agents to generate detailed images of the small bowel wall, lumen, and mesentery. In addition, CTE has several potential advantages over barium studies in the identification of fistulizing disease. Unlike traditional fistulography, CTE does not suffer from superimposition of bowel loops, and CTE displays the perienteric mesentery, retroperitoneal and abdominal wall musculature, typically involved by fistulas. Sinus tracts and abscesses can also be readily characterized by CTE. CTE has been shown to have a higher sensitivity than barium small-bowel follow-through, and at some institutions, CTE combined with ileocolonoscopy has become a first-line test for the diagnosis and staging of CD. However, given the recent concerns about radiation-induced cancer arising from medically necessary imaging, particularly for patients with CD who will likely need significant imaging over their lifetime and also carry a baseline increased risk of cancer, the role of CTE in assessing younger patients is being increasingly discussed. Supported by the need for a small-bowel imaging technique that provides the advantages of CTE without exposure to ionizing radiation, magnetic resonance enterography (MRE) has been shown in a recent study to have similar sensitivities for detecting active small-bowel inflammation, although image quality across the study cohort was better with CTE. At present, MRE is considered a valid alternative to CTE when radiation exposure is a concern, particularly as an adjunct to ileocolonoscopy in the diagnosis of CD.

SITE-SPECIFIC DISEASE

Esophagus, Stomach, and Duodenum

Gastroduodenal involvement in CD is reported in only 2% to 4% of cases and is rarely seen in the absence of other disease sites in the GI tract. In general, more than 50% of patients have known distal involvement before the diagnosis of gastroduodenal disease, and approximately 30% of patients present with duodenal and distal CD simultaneously. The most common distribution of gastroduodenal CD is contiguous involvement of the gastric antrum, pylorus, and the duodenal bulb. However, in a series of 89 patients from the Lahey clinic, isolated duodenal disease with gastric

sparing was reported in 40% of patients.

CD of the upper gastrointestinal tract may produce symptoms of nausea, vomiting, dysphagia, or odynophagia and is often misdiagnosed as peptic ulcer disease. The failure of antiulcer medications to resolve symptoms often leads to further investigation, including endoscopy and upper gastrointestinal imaging.

The use of medications to suppress gastric acid secretion and corticosteroid therapy is effective for patients with mild or moderate gastrointestinal CD. However, approximately one third of patients affected by gastroduodenal CD will require surgical intervention in their lifetime, most commonly for obstruction resulting from stenotic disease. Intractable pain, bleeding, and fistulas are also indications for surgical treatment. Options for surgical management of complicated gastroduodenal CD include bypass, stricturoplasty, and, less frequently, resection.

Traditionally, the “gold standard” for treating obstruction of the first and second portion of the duodenum has been to bypass the duodenum via a gastrojejunostomy with a highly selective vagotomy. If the stricturing disease is limited to the third or fourth portions of the duodenum, a Roux-en-Y duodenojejunostomy to the proximal duodenum is preferred over a gastrojejunostomy to avoid development of acid-induced marginal ulceration.

Because gastrojejunostomy carries a high risk of morbidity and disease recurrence, alternatives to bypass procedures have been sought. Given the focal nature of stricturing disease of the duodenum, stricturoplasty is a viable option, with optimal method dictated by the location, length, and number of strictures present. Strictures in the second and proximal third portion of the duodenum can effectively be managed with a Heineke-Mikulicz stricturoplasty. In order to safely accomplish a Heineke-Mikulicz stricturoplasty, the duodenum must be fully mobilized with a generous Kocher maneuver. Strictures of the first and fourth portion of the duodenum are best handled with a Jaboulay and a Finney stricturoplasty, respectively, constructed by creating an enteroenterostomy between the greater curvature of the stomach and the first portion of the duodenum, or the fourth portion of the duodenum and the first loop of the jejunum.

The safety and efficacy of stricturoplasty in the management of obstructive gastroduodenal CD have been studied in a number of series. In a retrospective study conducted by Yamamoto et al., 13 patients underwent stricturoplasty for obstructive duodenal CD. At a mean follow-up of 8

years, 23.1% required further surgery because of early postoperative complications, and 46.2% developed recurrent strictures at the previous stricturoplasty site. Worsey et al. retrospectively compared stricturoplasty to bypass surgery for the treatment of duodenal CD and found that after a mean follow-up of 8 years, 1 of 21 bypass patients (4.8%) required reoperation for recurrent disease, compared to 1 of 13 stricturoplasty patients (7.7%) after a mean follow-up of 3.6 years, a difference that was not significant. They concluded that despite shorter follow-up for stricturoplasty, it afforded the same rates of symptom relief and reoperation, and fewer complications than traditional bypass surgery.

In recent years stricturoplasty, which has the advantage of avoiding a blind-loop syndrome or stomal ulceration, has replaced bypass as the operation of choice for treatment of short obstructive duodenal CD. However, if the duodenal stricture is lengthy, multiple strictures are present, or the tissues around the stricture are too rigid or unyielding, then an intestinal bypass procedure remains the appropriate therapeutic option.

Ileoduodenal or coloduodenal fistulas may also complicate gastroduodenal CD. The fistula usually arises from a diseased ileocolic segment after a previous ileocolic resection or from the transverse colon, and drains into the duodenum or stomach secondarily. Most duodenoenteric fistulas are small in caliber and asymptomatic, and are therefore identified with preoperative small bowel radiography or discovered at the time of surgery. Larger fistulas may present with symptoms of malabsorption and diarrhea caused by the shunting of duodenal contents into the distal small bowel. Most duodenal fistulas are located away from the juncture of the duodenal wall at the head of the pancreas; and, therefore, after adequate mobilization, resection of the primary segment (ileocolic or transverse colon) with primary closure of the duodenal defect is often sufficient. Larger or complex fistulas with a significant degree of inflammation need to be handled with great care at surgery to limit the size of the duodenal defect resulting from resection of the fistula. When a large duodenal defect is present, a Roux-en-Y duodenojejunostomy or a jejunal serosal patch may be required for adequate closure. Duodenal resections are almost never necessary from gastroduodenal CD and should be considered the surgical option of last resort.

Small Bowel

Surgical intervention in patients with CD of the small bowel is limited to

the treatment of acute and chronic complications that do not respond to medical management. A study conducted at the Cleveland Clinic found that with disease of 10 years' duration, 90% of patients with ileocolitis and 70% of patients with only ileal involvement required surgery. The researchers found that the indication for surgery was intestinal obstruction in 55% of patients and intestinal fistulas or abscesses in 32% of patients. Although the surgical approach may differ based on the indication for surgery and the site of disease, adherence to the principle of bowel conservation is preferred.

SURGICAL TECHNIQUE AND OUTCOMES

Small Bowel Resection

A small bowel resection may be performed using a laparoscopic or open approach. Exploration of all four abdominal quadrants and of the entire small bowel for evidence of coexisting CD should always be done as up to 15% of patients will present with skip lesions. If areas of stenosis are suspected but not evident on serosal inspection, a Foley catheter with a balloon inflated to 2 cm and inserted through an enterotomy can be used to assess these sites. Before and after resection, the length of bowel should be measured and documented. The length of the diseased segment, the length of the resected segment, and the distance between strictures should be measured and recorded as well. The margins of macroscopic disease are then tagged with stay sutures, and the diseased segment and its adjacent normal bowel are mobilized and isolated to minimize the possibility of contamination. In addition, the contents of the small bowel are milked either proximally or distally beyond the margins of the potential anastomosis. Matted loops of small bowel or omentum are often found adjacent to the diseased segment, especially if the terminal ileum is involved. Care must be taken to adequately mobilize the affected areas, and mobilization of the ascending colon may be required. The matted loops of bowel can then be separated with a combination of blunt and sharp dissection, and the area to be resected can be inspected. The length of the resection margin has been debated, but numerous randomized trials have reported that disease recurrence is not increased by the presence of macroscopically involved bowel at the anastomotic line, as evidenced by the long results obtained with stricturoplasty or when microscopic involvement is present at the resection margin. As wider margins do not improve surgical outcome, resection margins need only incorporate

grossly apparent disease.

Division of the thickened mesentery of the involved small bowel is often the most challenging aspect of the procedure. Because the extent of mesenteric dissection does not affect long-term results, the mesentery should be divided at the most advantageous level. Sealing devices that employ bipolar technology allow for safe control of vessels up to 7 mm in diameter. These instruments have reduced blood loss and the length of the procedure, and have simplified intraoperative management of the often thickened and friable mesentery of patients with CD. In spite of the technical challenges posed by the hyperemic and thickened mesentery, the risk of postoperative hemoperitoneum requiring surgical intervention has been reported to be <0.5%.

Recently a new antimesenteric functional end-to-end handsewn anastomosis (Kono-S-anastomosis) has been developed to restore intestinal continuity after resections involving either the small or large bowel for CD. Once the segment to be resected has been identified, the extent of resection is based on the principles of bowel-sparing surgery. After the bowel and the corresponding mesentery are mobilized, a small window is created at the proximal and distal resection margins. The mesentery is divided close to the bowel wall using a tissue sealing device. The bowel is then divided proximally and distally with the GIA stapler oriented perpendicular to the axis of the mesentery (Fig. 140.1). The corners of the two staple lines are imbricated and reinforced with 4-0 silk Lambert sutures, and the two stumps approximated by tying together the corresponding corner sutures. The two staple lines are sewn together with interrupted 4-0 silk sutures spaced apart creating the “supporting column.” The spacing of these sutures is used to evenly distribute any mismatch in segment caliber. An antimesenteric longitudinal enterotomy is performed on each stump, starting 1 cm away from the staple line (Figs. 140.2 and 140.3). The length of the enterotomy should facilitate creation of a 7- to 8-cm transverse lumen, with a longer lumen favored on the colon (Fig. 140.4). The anastomosis is performed by closing the longitudinal openings transversely in two layers: the outer layer is created using 4-0 silk Lembert interrupted sutures, and the inner layer using running 3-0 absorbable sutures starting in the middle of the posterior (mesenteric) aspect of the anastomosis and joining together on the anterior (antimesenteric) aspect with no closure required (Figs. 140.5 to 140.7).

A retrospective study conducted by Kono et al. demonstrated that the

median Rutgeerts endoscopic recurrence score (Table 140.1) in the Kono-anastomosis group (2.6, 69 patients) was significantly lower than in the conventional anastomosis (handsewn side-to-side or end-to-end, or stapled side-to-side) group (3.4, 73 patients). At 5 years, the surgical anastomotic recurrence rate was lower in the Kono-S-group than in the control group (0% vs. 15%; p = .0013). The Kono-S anastomosis appears promising in preventing surgical anastomotic recurrence in CD, and a randomized control trial is currently being conducted.

Stricturoplasty

When managing CD of the small bowel, it is important to consider the natural history of the disease. Reoperative rates have been reported to be as high as 60%, especially in patients undergoing resection of the small bowel. With each subsequent resection, the potential for intestinal insufficiency and short-gut syndrome increases. Therefore, nonresectional options such as stricturoplasty have gained popularity as an alternative to lengthy resections in the treatment of stricturing CD of the small intestine. The advantage of a stricturoplasty lies in the preservation of the intestinal absorptive capacity of the normal segments of bowel located between strictures. Stricturoplasties can either be performed alone or in conjunction with a resection. However, they are best performed in the presence of either long segments of stricturing disease or multiple short strictures in which a resection would result in the loss of a lengthy segment of bowel or in patients with multiple prior resections. Stricturoplasties are also indicated when they offer a simpler alternative to resection, as is the case with short recurrent disease at a previous anastomotic site. Stricturoplasties are contraindicated in the presence of generalized intra-abdominal sepsis, acutely inflamed phlegmonous intestinal segments, fistulas, abscesses, or long, tight strictures with thick unyielding intestinal walls. The choice of when to perform a stricturoplasty and what technique is used depends on the number of strictures, the length of each stricture, and the distribution of strictures and intervening normal small bowel.

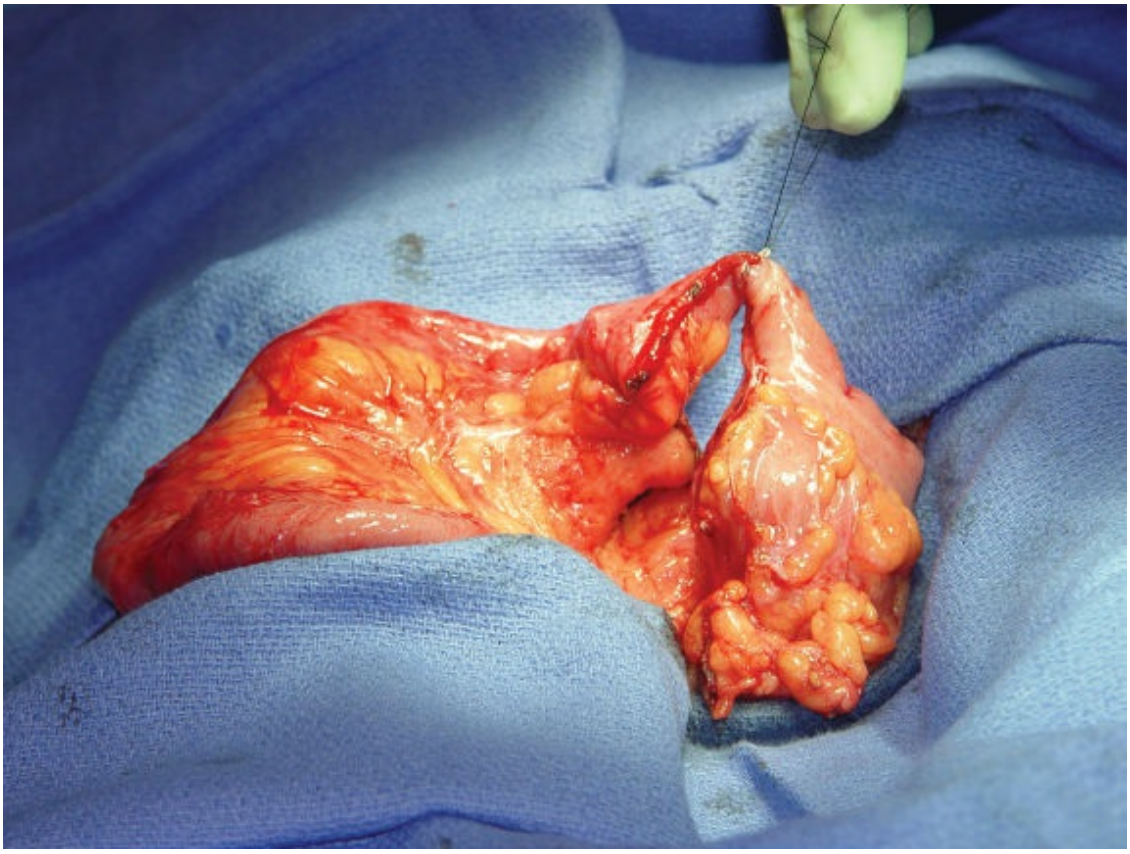

Figure 140.1. Bowel transection perpendicular to the axis of the mesentery.

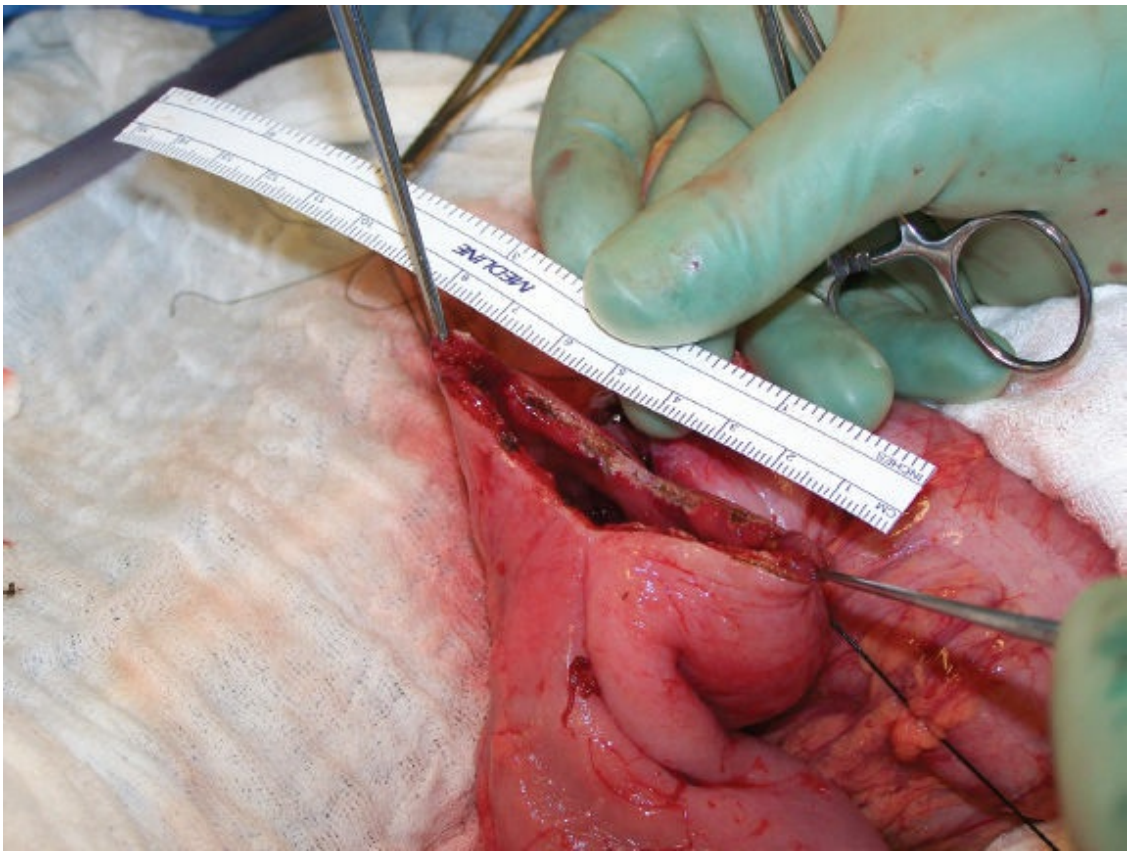

Figure 140.2. An antimesenteric longitudinal enterotomy with a transverse lumen of 7 cm is created on the small bowel.

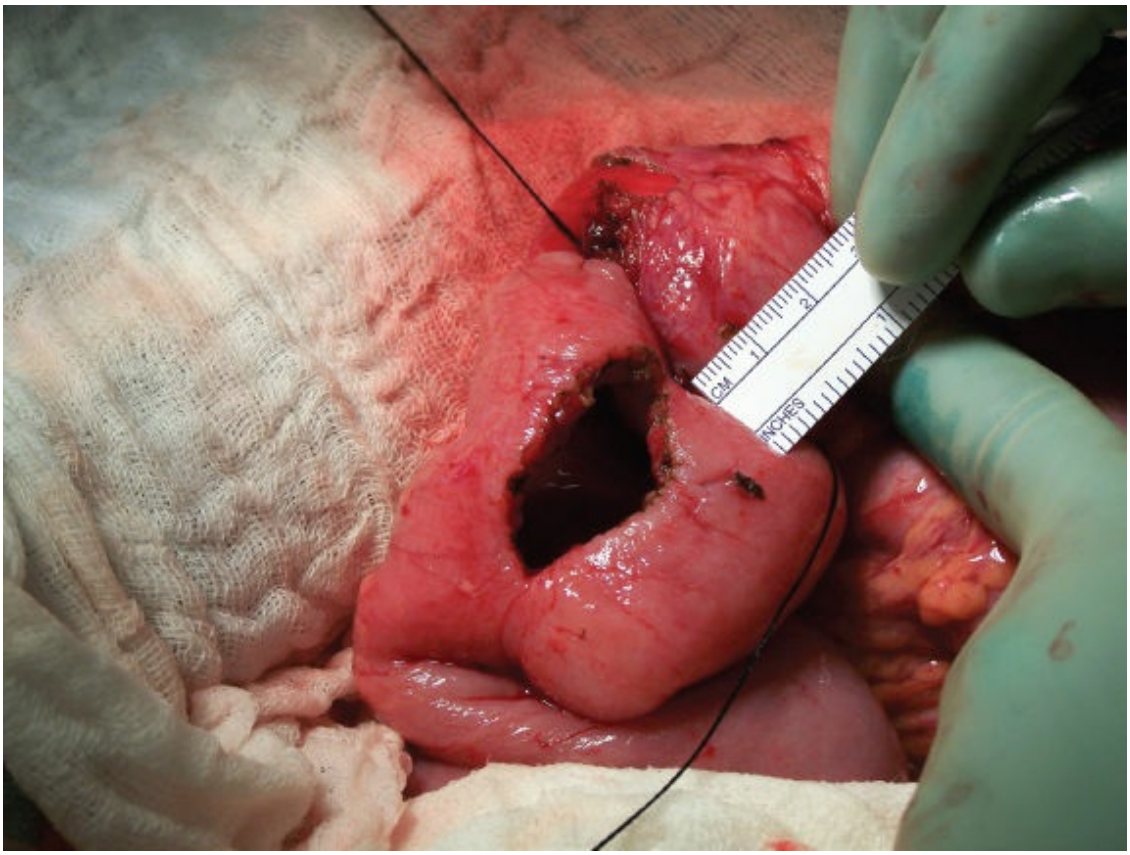

Figure 140.3. The distance between the enterotomy/colotomy and the supporting column should be no more than 1 cm.

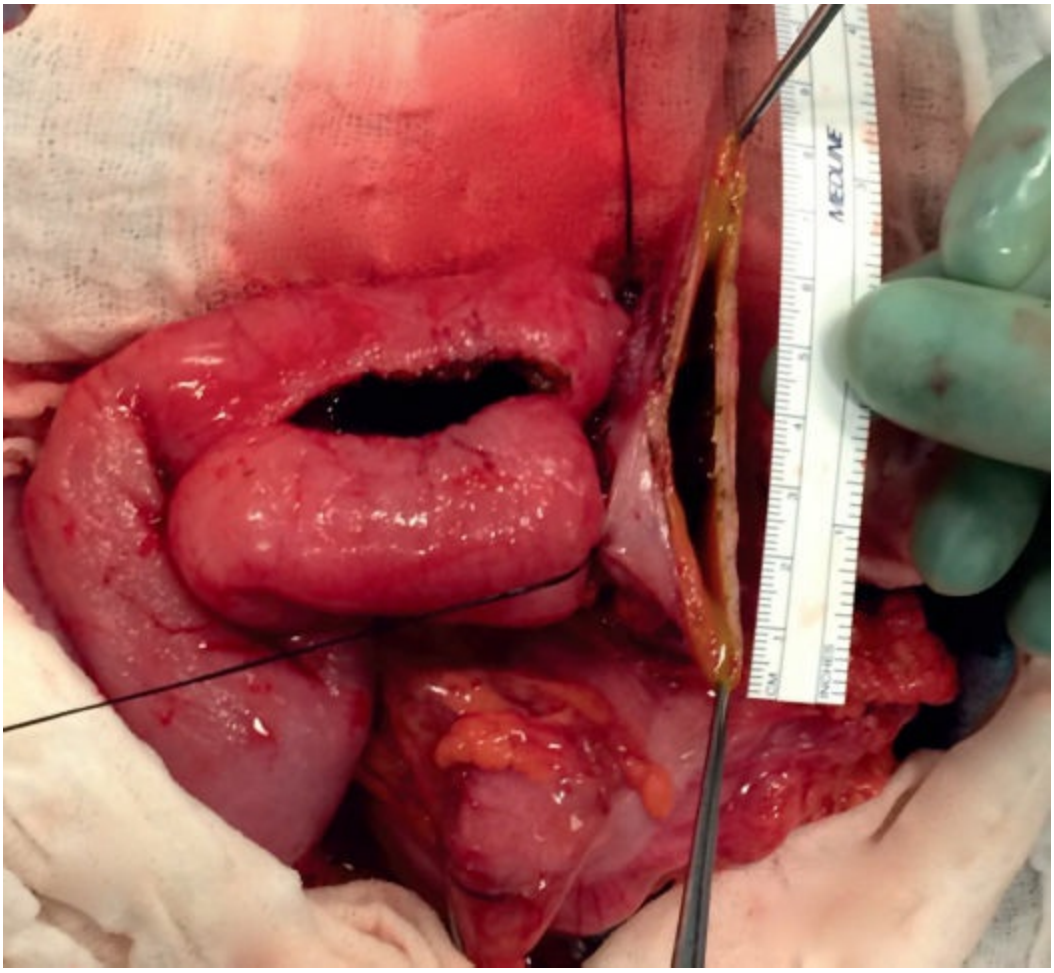

Figure 140.4. Measurement of the enterotomy on the colon side, which should be about 8 cm.

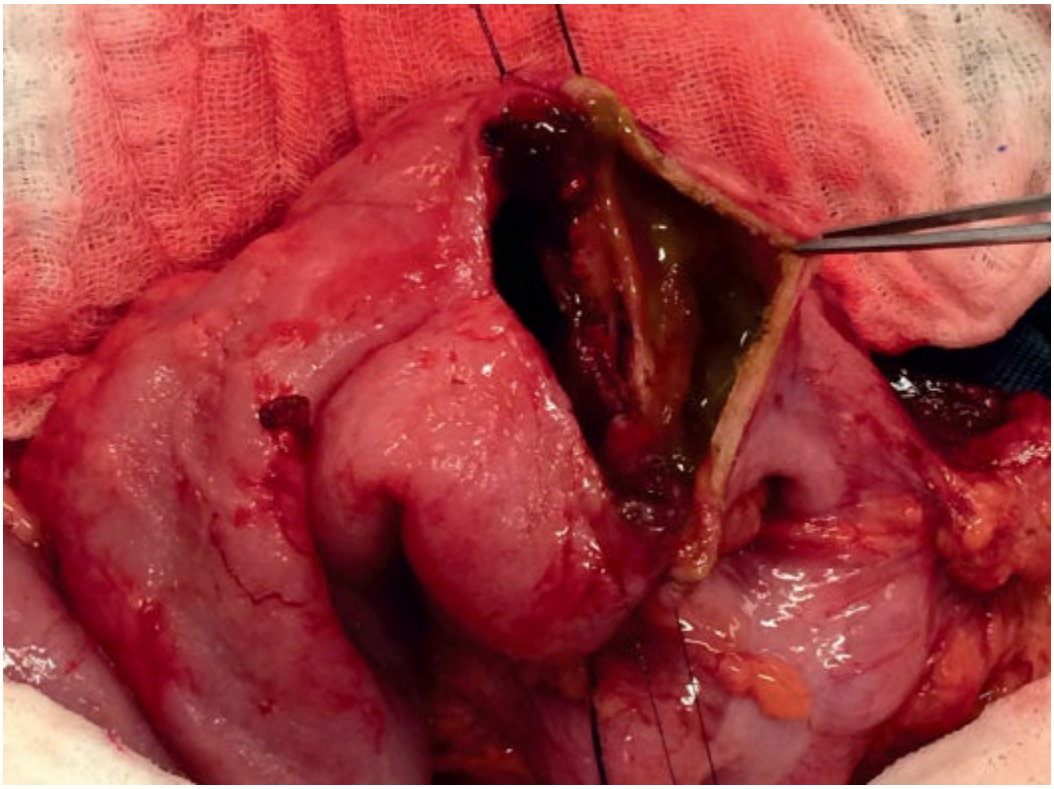

Figure 140.5. The two enterotomies are juxtaposed. Note that the colonic diameter is slightly larger and the difference in caliber is corrected with placement of the posterior outer layer of interrupted sutures.

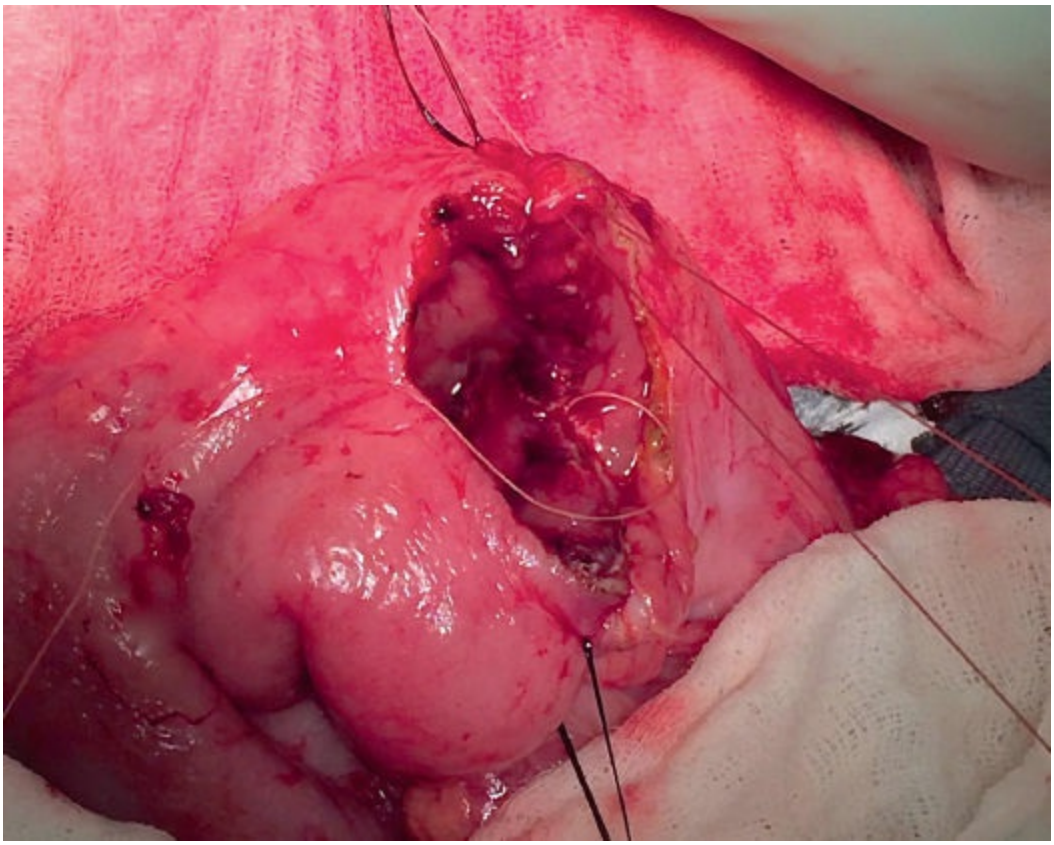

Figure 140.6. The inner layer of the anastomosis is fashioned using two running absorbable sutures starting in the middle of the posterior (mesenteric) wall of the anastomosis and then joining together on the antimesenteric aspect.

Heineke-Mikulicz Stricturoplasty

The most commonly performed stricturoplasty is the Heineke-Mikulicz stricturoplasty; this is appropriate for strictures 2 to 3 cm in length (Fig. 140.8). As with bowel resection, when a stricturoplasty is performed, the entire small bowel must first be inspected with careful attention paid to the location and length of the strictures and the length of the remaining bowel. Two stay sutures are placed along the antimesenteric border approximately 1 cm proximal and distal to the stricture site. A longitudinal incision is made along the antimesenteric border of the stricture. This incision should extend for 1 to 2 cm into the normal pliable bowel on either side of the stricture. Once the enterotomy is made, the area of the stricture should be closely examined. A biopsy with frozen section should be obtained if there is any concern that the stricture may harbor a malignancy. The lumen of the bowel should also be inspected for other areas of stricturing disease. If needed, a Foley catheter can be introduced through the enterotomy, as previously described. Hemostasis should be obtained with precise application of electrocautery. The longitudinal enterotomy is then closed in a transverse fashion with either a single or double suture layer.

Finney Stricturoplasty

The Finney stricturoplasty is appropriate for strictures up to 15 cm in length. A stay suture is placed on the midportion of the strictured site. The strictured segment is then folded onto itself into a U shape (Fig. 140.9). A row of seromuscular sutures is placed between the two arms of the U, and a longitudinal U-shaped enterotomy is then made, paralleling the row of sutures. The mucosal surface is examined and biopsies with frozen section are taken if there are concerns for malignancy. Full-thickness sutures are then placed in a continuous single layer beginning at the posterior wall of the apex of the stricturoplasty and continued down to approximate the proximal and distal ends of the enterotomy. This full-thickness suture line is continued anteriorly to close the stricturoplasty. A row of seromuscular Lembert sutures is then placed anteriorly. One drawback of this procedure is that a very long Finney stricturoplasty may result in a functional bypass with a large lateral diverticulum, which can be at risk for bacterial

overgrowth.

TABLE 140.1 Endoscopic Recurrence Score

Endoscopic Score	Definition	Clinical Recurrence (%)
i0	No lesions	<10
i1	≤5 aphthous lesions	<10
i2	>5 aphthous lesions with normal intervening mucosa or skip areas of larger lesions or lesions confined to the ileocolonic anastomosis	20
i3	Diffuse aphthous ileitis with diffusely inflamed mucosa	50–100
i4	Diffuse inflammation with already larger ulcers, nodules, and/or narrowing	50–100

Adapted from Rutgeerts P, Geboes K, Vantrappen G, et al. Predictability of the postoperative course of Crohn's disease. *Gastroenterology* 1990;99(4):956–63.

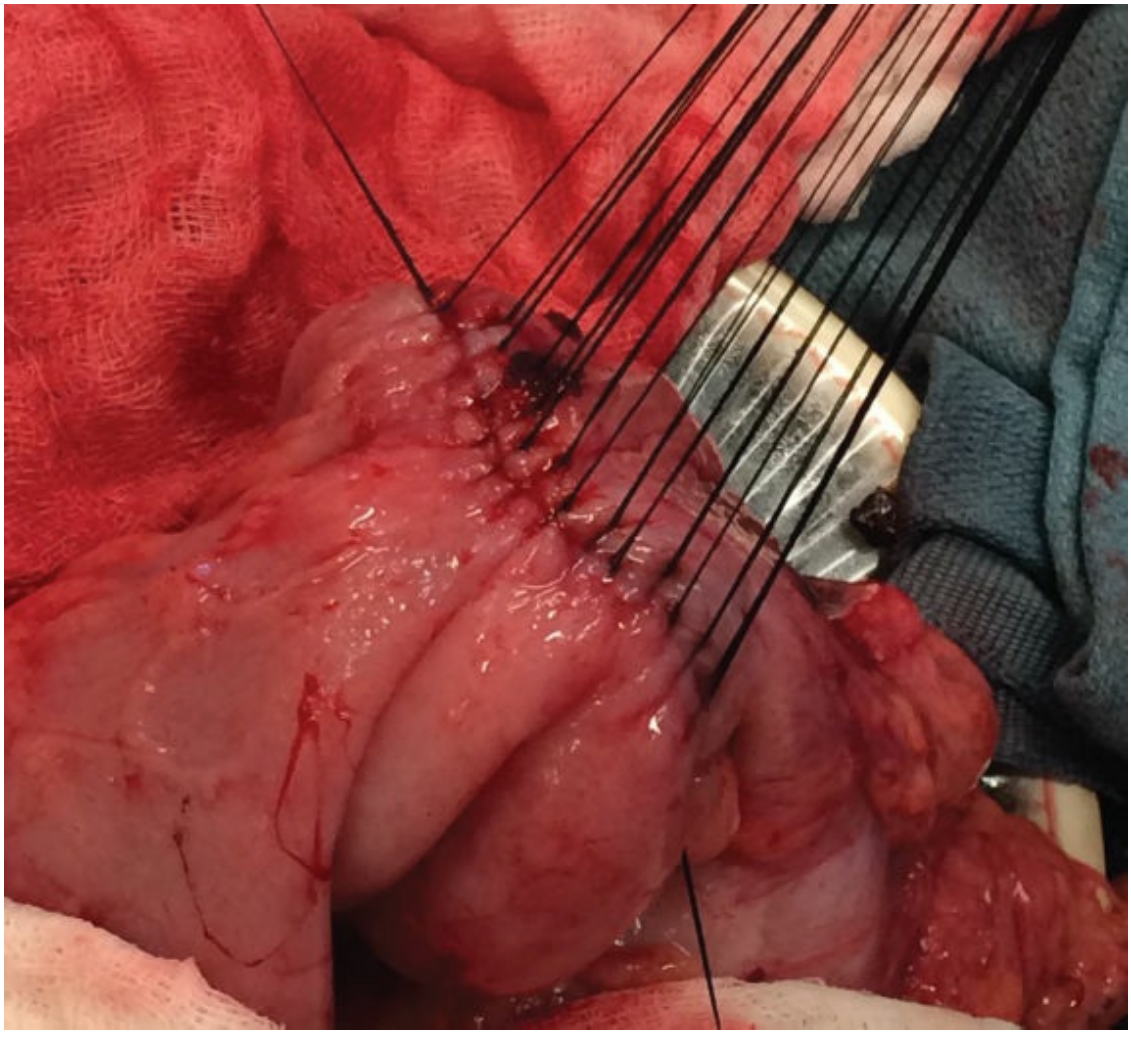

Figure 140.7. Closure of the outer layer with 4/0 silk Lembert

interupted sutures.

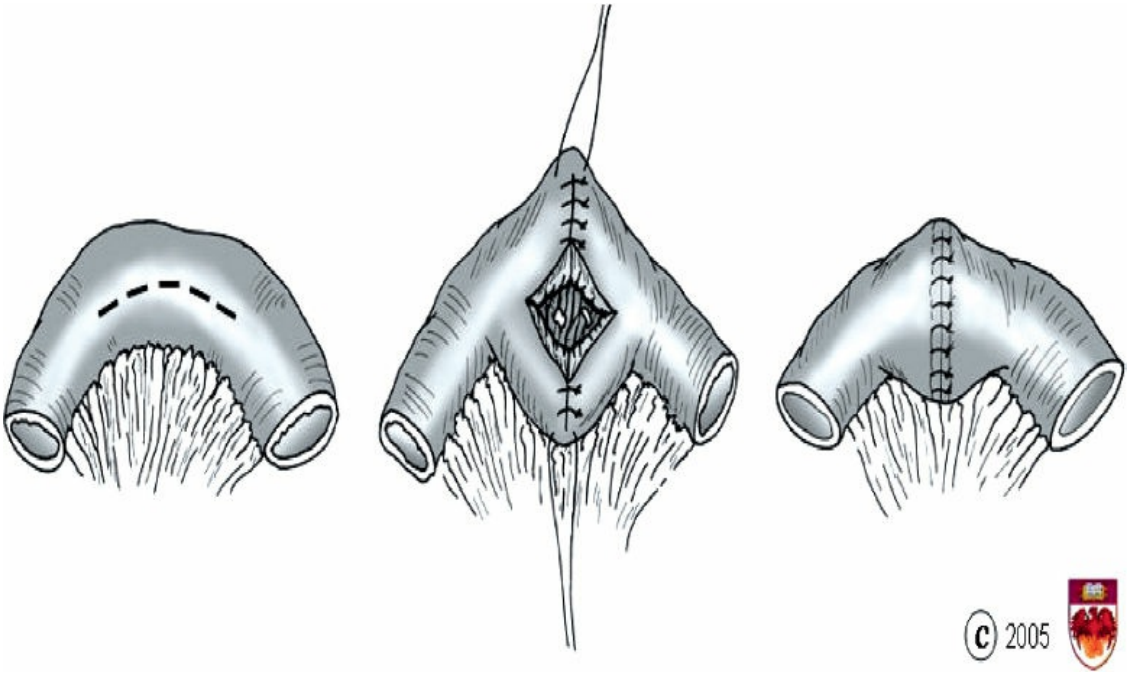

Figure 140.8. Heineke-Mikulicz stricturoplasty. A longitudinal incision is made along the antimesenteric border of the stricture (*dashed line*) and is then closed in a transverse fashion with either a single or double suture layer.

Side-to-Side Isoperastaltic Stricturoplasty (Michelassi Stricturoplasty)

In some cases, multiple stricturoplasties may be required to avoid a long resection. In general, repeated Heineke-Mikulicz or Finney stricturoplasties should be separated from each other by at least 5 cm to avoid forming a bulky segment of intestine and placing tension on each suture line. Patients with multiple strictures that are grouped close together or a long segment of stricturing disease (>20 cm in length) are best managed with an isoperistaltic side-to-side stricturoplasty. With this technique, the mesentery of the strictured segment is first divided at its midpoint and the diseased loop of small bowel is severed between atraumatic intestinal clamps. The proximal and distal ends of bowel are then placed in an isoperistaltic side-to-side fashion. Stenotic regions of one loop are placed adjacent to dilated areas of the other loop. Division of some of the mesenteric vascular arcades may facilitate the positioning of the two limbs over each other. A layer of interrupted seromuscular Cushing stitches using nonabsorbable 3-0 suture is used to approximate the two loops of bowel. Longitudinal enterotomies are then performed on both

loops (Fig. 140.10), with the intestinal ends tapered to avoid blind stumps. After obtaining adequate hemostasis with suture ligation or electrocautery, an internal row of full-thickness 3-0 absorbable sutures is placed anteriorly as a running Connell stitch and reinforced with an outer layer of interrupted seromuscular Cushing stitches using nonabsorbable 3-0 suture.

Unlike resection with primary anastomosis in which the tissue is removed to grossly normal margins and sutures are placed in healthy bowel, stricturoplasty is fashioned in affected bowel and suture lines are placed within scarred and diseased tissue, raising concerns of rapid recurrence and perioperative complications. However, a number of studies have reported that stricturoplasties result in prompt resolution of symptoms and weight gain without a significant increase in dehiscence, abscesses, or enteric fistulas when compared with traditional intestinal resections. In addition, disappearance or attenuation of disease that existed at the stenotic site has been observed. Long-term results from Hurst and Michelassi demonstrate an overall complication rate of 12%, with a dehiscence rate of 1.7%, and a 2- and 5-year recurrence rate of 15% and 22%, respectively. This recurrence rate is similar to that reported in a large series published by Ozuner and Fazio with a 5-year recurrence rate of 28%. Tichansky conducted a meta-analysis of 15 studies addressing stricturoplasties performed for small bowel CD with a follow-up of more than 2 years in most studies. They reported an overall postoperative complication rate of 13% (66 of 506 patients), and a 25.5% recurrence rate requiring 132 surgical procedures. Interestingly, the majority of recurrences occurred at sites distant from the stricturoplasty sites; the rate of recurrence at the stricturoplasty sites was only 8.5%.

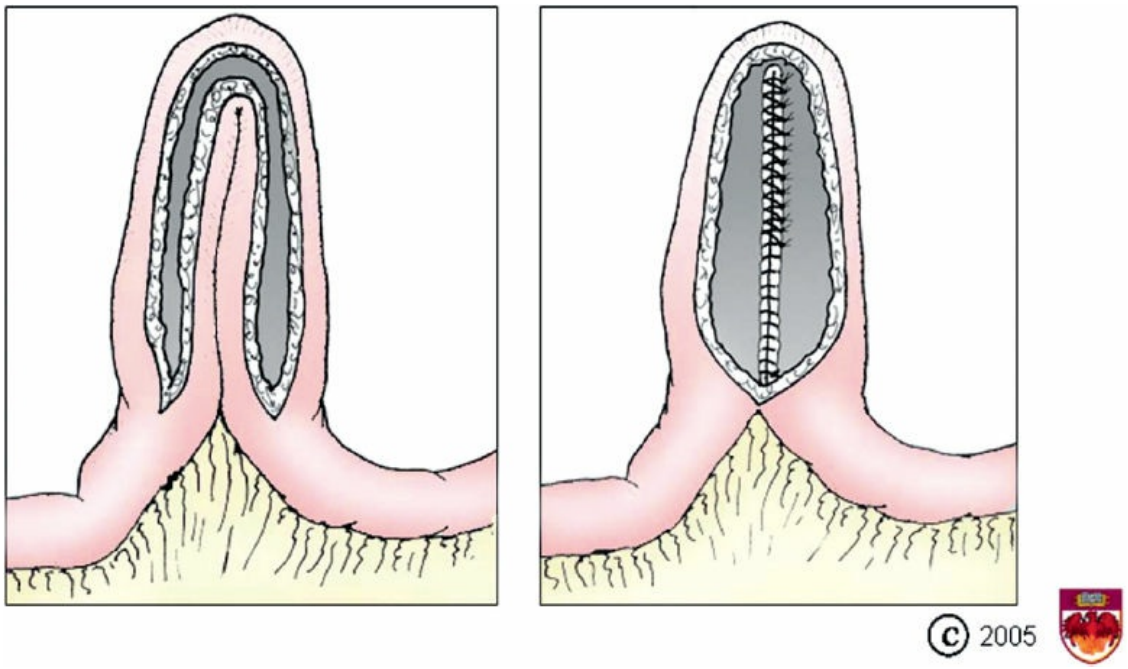

Figure 140.9. Finney stricturoplasty. The strictured segment is folded onto itself in a U shape (**left**). An enterotomy is made over the strictured area and the opposed surfaces of bowel are sutured together.

Although intestinal obstruction is the most common indication for surgical treatment of small bowel CD, fistula or abscess formation may also warrant surgery. For example, in perforating disease, the terminal ileum may adhere to a segment of normal sigmoid colon, resulting in an ileosigmoid fistula. Ileosigmoid fistulas do not generally require surgical intervention in and of themselves; however, many fistulas are associated with symptomatic terminal ileal disease. The surgical treatment of ileosigmoid fistulas consists of simple division of the fistulous adhesion and resection of the ileal disease in approximately 75% of cases. The defect in the sigmoid colon is then debrided and closed. A sigmoid resection may be necessary if the fistulous opening is particularly large, the tract enters the sigmoid colon in proximity to the mesentery, or there is extensive fibrosis.

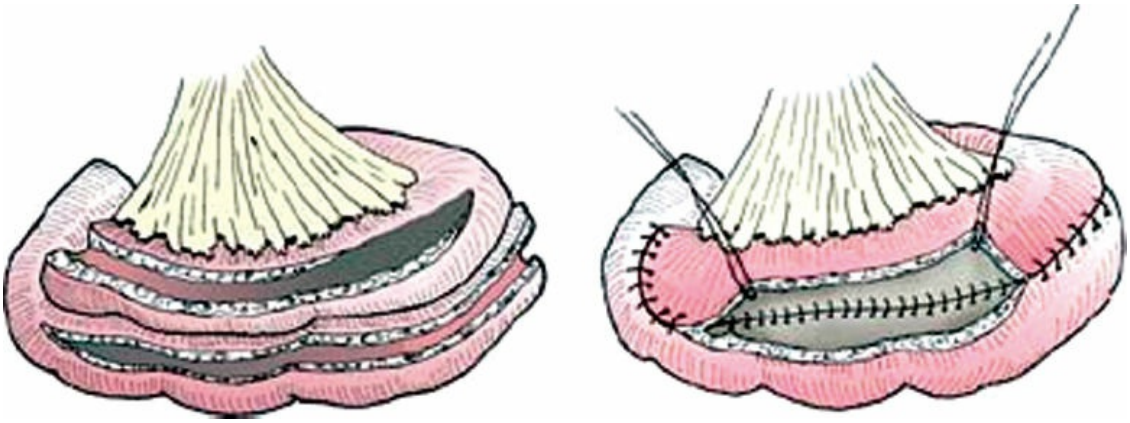

Figure 140.10. Side-to-side isoperistaltic stricturoplasty. The two overlapping bowel loops are divided longitudinally and a side-to-side longitudinal enteroenterostomy is fashioned.

Up to 5% of patients with CD will develop an ileovesical fistula. Most ileovesical fistulas are diagnosed by a history of hematuria or fecaluria and can be managed medically for extended periods of time. However, they usually do not heal, and eventually surgical intervention is required for recurrent urinary tract infections or worsening renal function. Surgical treatment involves resection of the ileal disease with debridement and primary closure of the bladder defect. If the bladder defect is large, an omental flap may be laid over the bladder repair.

Small bowel CD may also be complicated by the formation of intra-abdominal abscesses. These abscesses tend to follow a rather indolent course and may not even demonstrate clinical signs of localized infection. However, when an abscess is suspected or found during the workup of an abdominal mass, a CT scan can delineate its size, location, and relationship to other structures, including the ureters, psoas muscles, duodenum, and inferior vena cava. Most abscesses resulting from CD are small collections contained within the area of diseased intestine and its mesentery, and can therefore be extirpated during the resection of the diseased segment. Larger abscesses are best managed initially with CT-guided percutaneous drainage. Surgical resection of the affected segment of intestine can then be performed 4 to 6 weeks later.

Minimally Invasive Techniques

Minimally invasive approaches for CD offer several perioperative and long-term advantages over an open approach. Two prospective randomized control trials and five meta-analyses or systematic reviews

comparing laparoscopic to open surgery for ileocolonic CD reinforce several pertinent advantages to laparoscopic surgery, despite prolonged operative times: shorter duration of postoperative ileus, shorter hospital stay, lower incidence of early postoperative complications, and fewer postoperative small bowel obstruction. In addition, because of the significantly shorter length of stay, a trend toward lower overall costs was noted with laparoscopic surgery.

Although early reports of laparoscopic surgery for CD reserved this approach for "uncomplicated patients," increasing surgeon experience and improved instrumentation have facilitated a trend toward laparoscopy even for recurrent or fistulizing disease. Goyer et al. compared 54 complex patients with CD, defined as recurrent or complicated by abscess and/or fistula, to an uncomplicated group. Despite longer operative times, more frequent conversion to open, and increased use of temporary stoma, no differences were noted in overall postoperative morbidity based on complexity of disease.

The rate of conversion to open surgery remains high, ranging from 5% to as high as 70%, but more often 20% to 25%. These variations are due to case definition; some series include only ileocolonic resection, while others include those with fistulas, abscesses, and previous operations. Preoperative factors predictive of conversion include history of more than three acute episodes of CD, preoperative steroid use longer than 3 months, preoperative malnutrition, previous abdominal surgical procedures, and extracecal colonic disease. Regarding intraoperative findings, Alves et al. and Casillas et al. demonstrated that the most common reasons for conversion were the presence of a large inflammatory mass, adhesions, ileosigmoid fistula, pelvic abscess, inability to assess anatomy, failure to identify the ureter, and bleeding. More recently, a study from Cleveland Clinic has evaluated which radiologic findings using CT enterography or MRE are predictive of conversion, and identified positive correlations with pelvic fistula ($p = 0.003$), complex fistulas ($p = 0.017$), and pelvic abscess ($p = 0.009$). This study indicates that preoperative imaging can predict intraoperative findings that would lead to a conversion, therefore improving preoperative planning.

With respect to long-term outcomes, laparoscopy is associated with a reduction of adhesions likely facilitating subsequent resections, which is important given that patients with CD are often young and 50% of patients require more than one surgical operation during their lifetime. In addition,

reduction of pelvic adhesions might improve postoperative female fecundity.

Laparoscopic-assisted ileocolic resection is currently the most commonly performed laparoscopic procedure for treatment of CD. Small bowel resection is also straightforward to perform unless the small bowel is affected by a large inflammatory mass or is adherent to other loops of bowel through fistulas or intervening abscesses. Laparoscopic-assisted stricturoplasty is particularly advantageous when conducted with a bowel resection, usually an ileocolic resection. The diseased area or areas can be marked with intracorporeal stitches, exteriorized through a small abdominal incision needed for removal of the resected specimen, and the stricturoplasty performed extracorporeally in standard fashion. Fecal diversion and closure of stomas are good indications for laparoscopy in CD. This may obviate a laparotomy and allows for a full evaluation of the gastrointestinal tract.

Diagnostic laparoscopy is an important and underused tool. It can be especially helpful in unusual circumstances when the diagnosis of CD is unclear, or in the pediatric population. With a systematic approach, it is possible to visualize the entire gastrointestinal tract from the stomach to the rectum, and when combined with intraoperative colonoscopy, one can obtain a detailed road map of the extension of the disease and differentiate CD from other pathologic processes, such as ulcerative colitis or lymphoma. Using this approach, Singh et al. were able to avoid an otherwise unnecessary laparotomy in 14 of 23 patients with an unclear preoperative diagnosis.

Laparoscopic-Assisted Ileocolic Resection

The patient is placed on the operating table in the modified lithotomy position. Rectal irrigation with diluted iodine solution is performed, especially in patients with fistulas involving the rectosigmoid. An epidural catheter is usually inserted at the time of surgery. The sympathectomy achieved with epidural administration of local anesthetics and opioids prevents bowel distention and facilitates exploration of the gastrointestinal tract and handling of the bowel. Every operation for CD, whether open or laparoscopic, should start with a complete examination of the entire gastrointestinal tract, starting from the ligament of Treitz. The patient is positioned in the reverse Trendelenburg position and right lateral decubitus, with the assistant standing on the patient’s left side, retracting the transverse colon into the upper quadrants, and the surgeon standing

between the patient's legs, evaluating the intestine from the ligament of Treitz all the way to the ileocolic pedicle. This maneuver is facilitated by progressively rotating the patient from the reverse Trendelenburg to a full Trendelenburg position and left lateral decubitus. In the presence of skip areas of involvement from CD, these are marked intracorporeally with sutures in order to facilitate retrieval of the diseased segments when the specimen is exteriorized.

A technique with four 5-mm trocars is used (Fig. 140.11A). The 5-mm trocars allow placement of a 5-mm 30-degree camera, which offers the optimal resolution, and introduction of appropriate instrumentation for control and division of the vascular pedicles. After the bowel has been evaluated in its entirety, the surgeon joins the assistant on the left side of the patient (Fig. 140.11B) and the assistant places the ileocolic pedicle under tension. The surgeon dissects the mesentery and divides the ileocolic vessels (Fig. 140.12). The ascending colon is mobilized in a medial-to-lateral fashion in the submesenteric plane to the hepatic flexure (Fig. 140.13). The assistant lifts the colon to allow clear visualization of the submesenteric plane. When the submesenteric mobilization is completed, the lateral colonic peritoneal reflection is divided to the hepatic flexure (Fig. 140.14). The terminal ileum is completely mobilized by dividing the peritoneum at the level of the pelvic rim to allow a tension-free anastomosis through a small incision. It is often necessary to completely mobilize the hepatic flexure in order to facilitate exteriorization of the specimen; this assures avoidance of a difficult anastomosis through a small incision or the need for a larger incision (Fig. 140.15). With a full mobilization accomplished, the instruments are removed and the umbilical port site or the right lower quadrant port site is enlarged, in preparation for the exteriorization of the specimen. The pneumoperitoneum is evacuated and, after having placed a wound protector, the specimen is exteriorized. In the presence of skip areas of disease marked intracorporeally, these are identified and either a resection or a stricturoplasty is performed. In the presence of isolated terminal ileal disease, an ileocolic resection is performed with an extracorporeal anastomosis.

POSTOPERATIVE CARE

Postoperative care in colorectal surgery has significantly changed in the last 20 years. Enhanced Recovery after Surgery (ERAS) was first developed and described by Henri Kehlet in the 1990s, with the aim of

reducing surgical stress response and inducing a faster recovery for patients after an operation. ERAS pathways are based on basic principles that include preoperative, intraoperative, and postoperative patient management. Focused preoperative patient education is targeted to create patient awareness of and cooperation with their care plan, including preoperative fluid and carbohydrate loading, use of antibiotic and thromboembolic prophylaxis, early postoperative mobilization, and stoma teaching when appropriate. Intraoperative guidelines include the use of short-acting anesthetic agents, placement of midthoracic epidural, avoidance of opioid analgesics, avoidance of salt and fluid overload, and maintenance of normothermia and normoglycemia. Postoperative management includes early return to oral fluid intake, early mobilization, prevention of nausea and vomiting, avoidance of fluid overload, use of nonopioid oral analgesia, and early removal of urinary catheters and drains.

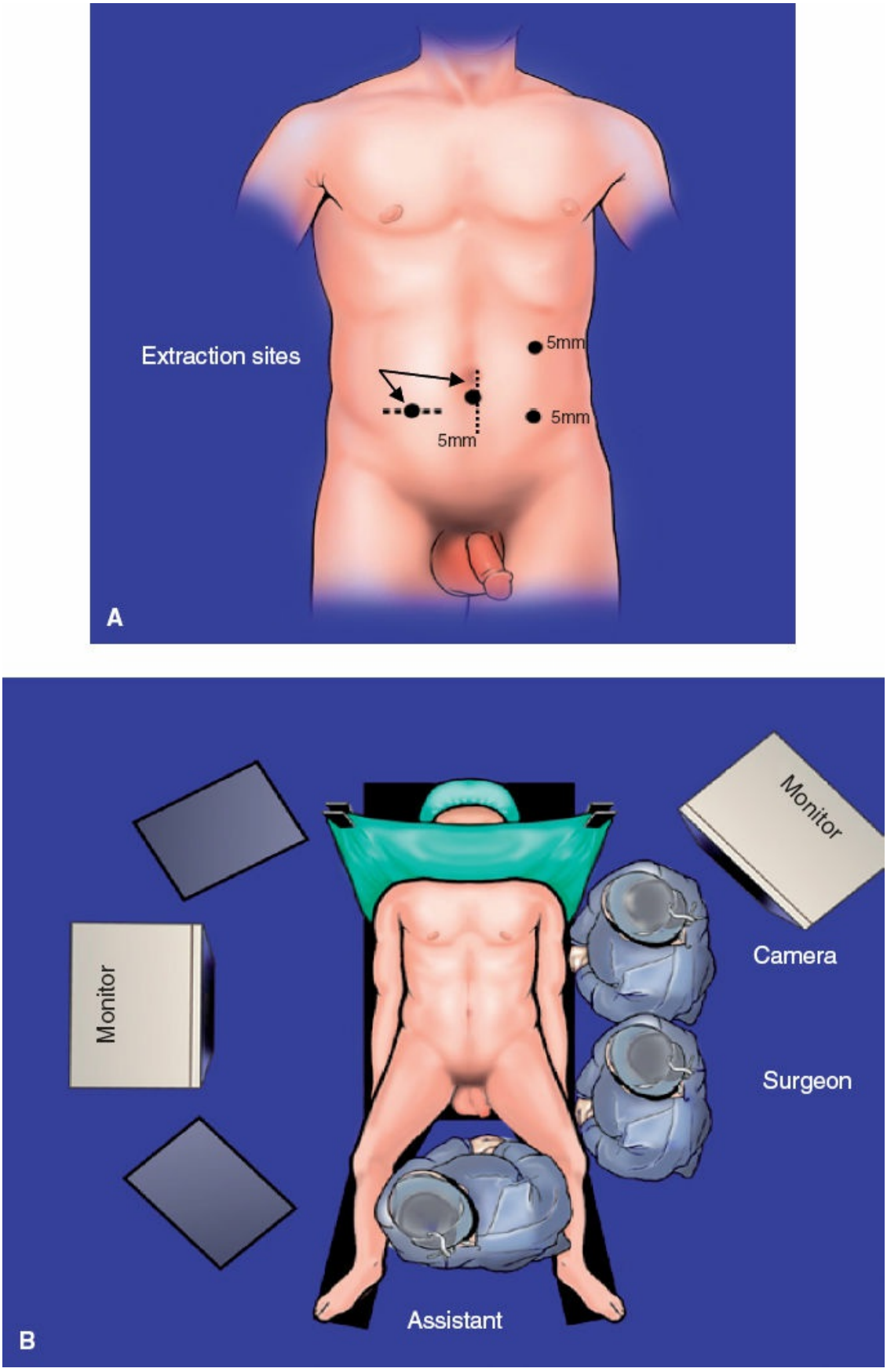

Figure 140.11. Laparoscopic ileocolic resection. **A.** Trocar placement and specimen extraction sites. **B.** Operating room

setup.

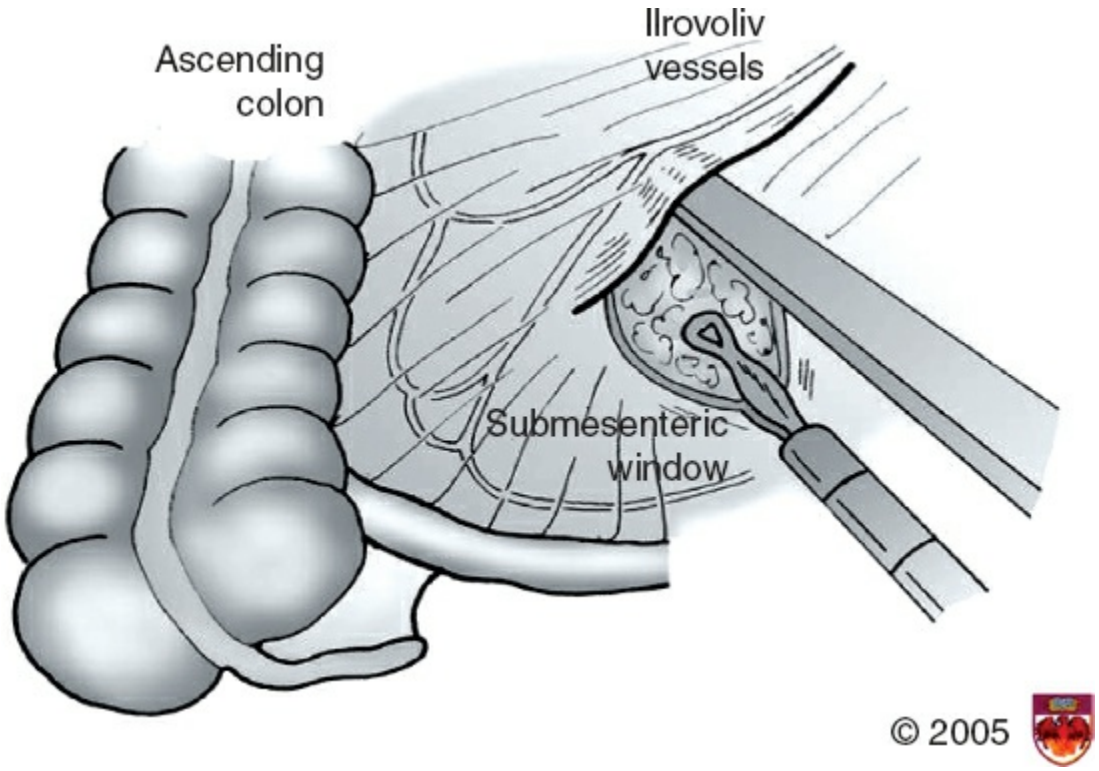

Figure 140.12. Dissection of the ileocolic vessels.

Several studies have demonstrated the advantages of an ERAS protocol in colorectal surgery compared with the standard of care. Two systematic reviews by Spanjersberg et al. and Varadhan et al. have cited shorter hospital stay, decreased morbidity and mortality, and no increase in readmission rates for patients treated under ERAS protocols. ERAS also enhances the benefits of minimally invasive surgery.

Spinelli et al. published the benefits of ERAS in patients with CD who underwent laparoscopic ileocolic resections, compared to a group of patients managed with standard postoperative care. They found that patients enrolled in an ERAS protocol had a significant earlier return of bowel function ($p = 0.002$) and a shorter postoperative hospital stay (5.3 vs. 6.8 days, $p = 0.04$). The lack of preoperative fasting, the use of opioid-sparing intraoperative analgesia and opioid-free postoperative analgesia, prevention and treatment of postoperative nausea and vomiting, and the early mobilization and dietary intake of solids among patients on the ERAS protocol are likely responsible for the faster recovery in this group. Further studies are necessary to evaluate the feasibility and value of the protocol for other operations for CD.

COMPLICATIONS AND THEIR MANAGEMENT

Abdominal septic complications, including abscess and anastomotic leak, are more frequent in patients with CD. Several factors can contribute, including chronic inflammatory status, poor nutritional status, presence of abscess, use of steroids, and recurrent episodes of disease.

Alves et al. reviewed intra-abdominal septic complications after the first ileocecal resection for CD in 161 patients; of these, 15 developed abscess and anastomotic leaks (9%). Multivariate analysis found four independent risk factors for intra-abdominal septic complications: poor nutritional status (defined by weight loss >10% within the last 10 months), intra-abdominal abscess discovered during surgery, preoperative steroid use more than 3 months, and recurrent clinical episodes of CD. Yamamoto et al. reported similar rates of intra-abdominal septic complications (13%); these were significantly associated with preoperative low albumin levels (<30 g/L), preoperative steroid use, abscess at the time of laparotomy, and fistula at time of laparotomy. The intra-abdominal septic complication rate was 50% in patients with all of these four factors, 29% in patients with three risk factors, 14% in patients with two risk factors, 16% with one risk factor, and 5% in those with no risk factor ($p < 0.0001$). While these factors are not all modifiable, poor nutritional status can be improved by total parenteral nutrition before surgery, which allows patients to increase albumin levels and reduce inflammatory status. Careful preoperative evaluation for abscess and fistula may allow better timing of surgery, and coordination with the medical team may facilitate appropriate preoperative steroid taper.

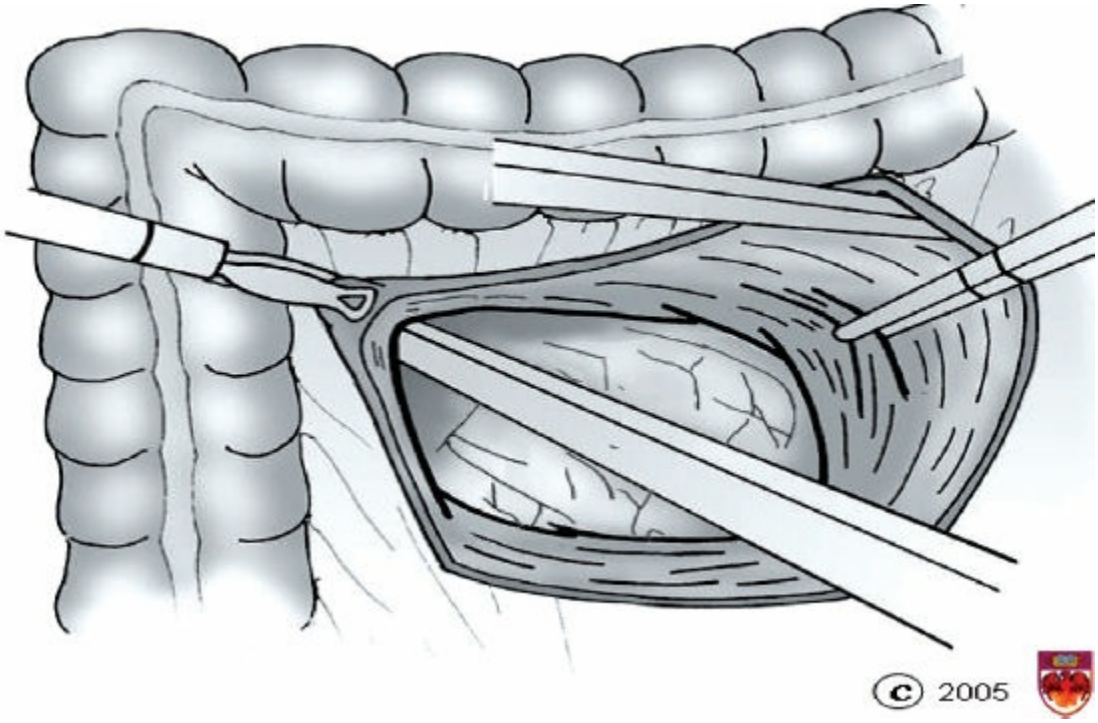

Figure 140.13. Submesenteric mobilization of the ascending colon to the hepatic flexure.

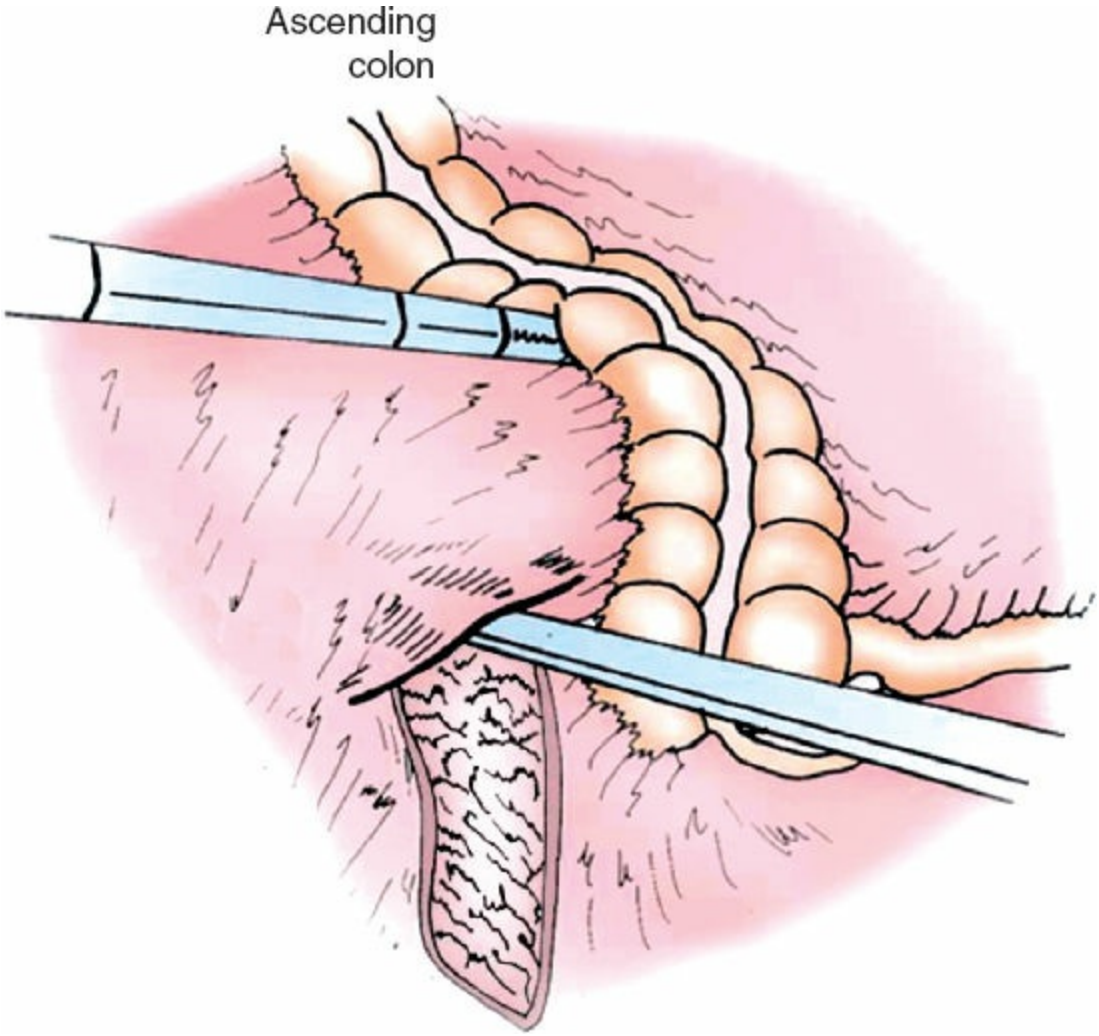

Figure 140.14. Division of the lateral attachments of the ascending colon.

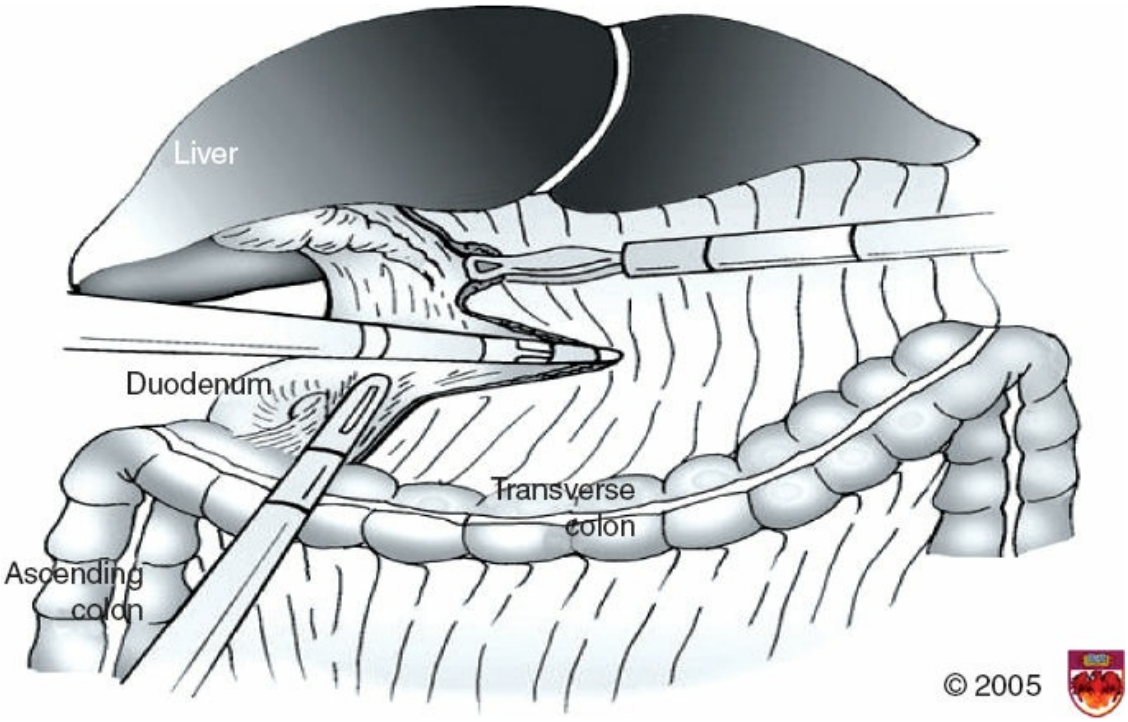

Figure 140.15. Final mobilization of the hepatic flexure.

Inflammatory bowel disease is a well-known risk factor for venous thromboembolism (VTE), with 1.5- to 3-fold increased risk over the general population. Disease flares are associated with increased risk of VTE, with the highest absolute risk in those requiring hospitalization. Multiple authors have reported VTE risk factors for IBD patients, including steroid use, surgery within 90 days, anemia, and prolonged anesthesia time. Compared with non-IBD patients, IBD patients are less likely to present with pulmonary embolism and more likely to have abdominal vein thrombosis. IBD patients with VTE are less likely to be on anti-TNFα agents or 5-ASA derivatives, and more likely to require steroids for disease management.

OUTCOMES

CD is a recurrent disease. Endoscopic evidence of recurrence occurs in 70% to 90% of patients 1 year after intestinal resection. Symptomatic recurrence occurs in 30% of patients at 3 years and 60% of patients at 10 years. After an intestinal resection and anastomosis, recurrence usually develops at or proximal to the gastrointestinal anastomosis; patients with a proximal diverting stoma are more likely to have a recurrence after restoration of intestinal flow. Several factors are related to recurrence: smoking, NOD2/CARD15 gene mutation, young age at diagnosis, short

duration of disease prior to operation, extent of disease >100 cm, and multiple sites of disease.

Smoking doubles the risk of clinical and surgical recurrence. Smoking cessation has a beneficial effect and reduces clinical and surgical recurrence rate to baseline after 10 years.

Recurrence is also influenced by surgical technical decisions such as the type of anastomosis, resection margin, and choice of stricturoplasty versus resection. Endoscopic recurrence usually develops at or proximal to the anastomosis, and luminal diameter seems to play a role; the only randomized control trial (CAST) comparing side-to-side and end-to-end anastomosis after intestinal resection found no significant differences at 12 months postoperation in endoscopic or symptomatic recurrence. More recently, the Kono-S-anastomosis has been suggested to have a protective effect on recurrence. The Rutgeerts endoscopic recurrence score correlates with the likelihood of clinical and surgical recurrence, and can be used in the surveillance period to help guide therapy (Table 140.1).

Fazio et al. conducted a randomized trial enrolling 131 patients undergoing intestinal resection to a limited resection margin (2.5 cm) versus extended margin (12.5 cm). At follow-up, the surgical recurrence was in favor of the extended resection margin (17.5% vs. 25.3%), but the difference was not statistically significant ($P = 0.38$).

A recent systematic meta-analysis by Yamamoto et al. including 1,100 patients with 3,300 stricturoplasties identified a stricturoplasty site-specific recurrence rate of 3%, much lower than would be expect after intestinal resection and anastomosis. This suggests that stricturoplasty may confer a protective effect against recurrence.

The role of anti-TNFα therapy in reducing the incidence of surgical recurrence is still unknown, but the impact of these agents can be inferred from mucosal healing. Regueiro et al. demonstrated in a placebo-randomized control trial that endoscopic recurrences were significantly less frequent in the infliximab group compared to controls at 1 year (9.1% vs. 84.6%, $p = 0.0006$) but the sample size was too small to detect differences in clinical recurrence. Similar results were obtained by Yoshida et al. who found the clinical remission rate with infliximab was 100% versus 68% in the placebo group ($p < 0.03$) at 1 year.

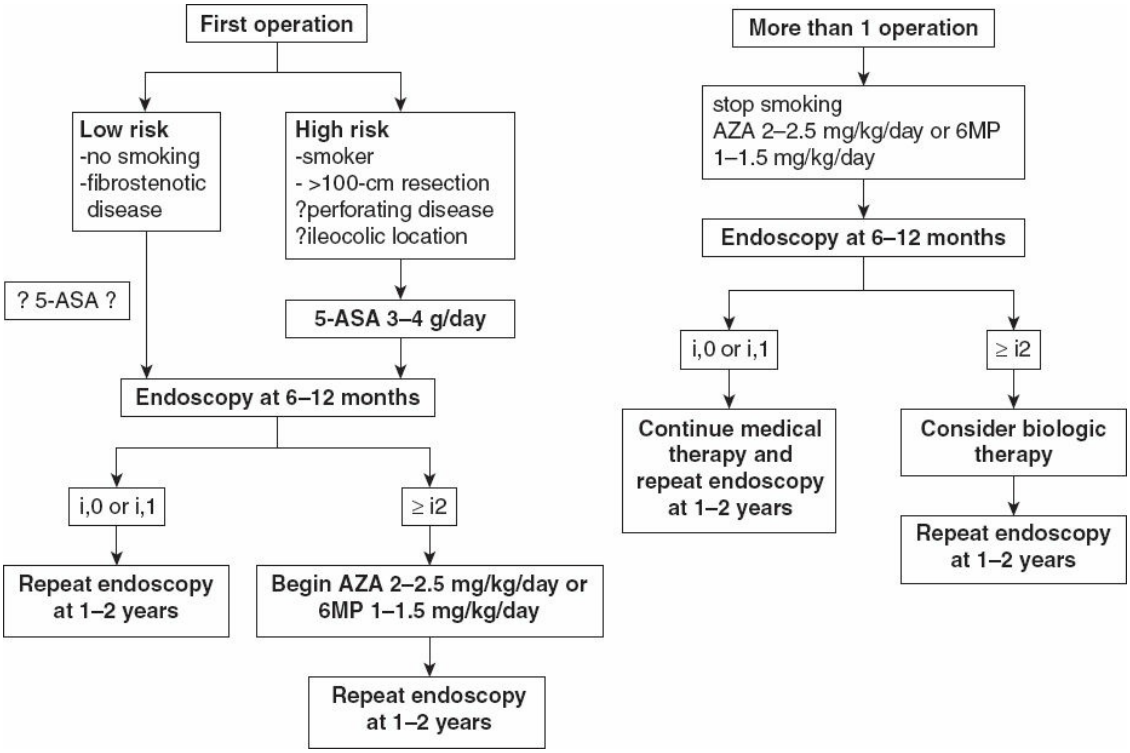

Figure 140.16. Treatment algorithm. (From Blum E, Katz JA. Postoperative therapy for Crohn's disease. *Inflamm Bowel Dis* 2009;15(3):463–72.)

TABLE 140.2 Suggested Prophylaxis According to Risk of Disease Recurrence

	Low Risk	Intermediate Risk	High Risk
Criteria	Long-standing disease First surgery Short stricture	<10 yrs of disease Long stricture Inflammatory disease	Penetrating disease More than 2 surgeries
Prophylaxis	Smoking Cessation No therapy ? Metronidazole ? ASA	?ASA 6MP or AZA with or without metronidazole	6MP AZA Anti-TNF

Colonoscopy in 1 to 2 years to assess disease progression and reassign risk class based on endoscopic score.

Postoperative treatment plans, given the limited data regarding pharmacologic prophylaxis, should be tailored to the individual patient. The first step in treatment planning would be to risk stratify the patient as low, intermediate, or high risk as shown in Table 140.2. Treatment is then

modified, if needed, based on clinical recurrence or endoscopic recurrence at the 6- to 12-month interval (Fig. 140.16).

CONCLUSION

Even with improvements in medically induced remission using new regimens including anti-TNFα agents and immunomodulators, surgery is still frequently required for patients with small bowel CD. Key surgical principles include sparing bowel length and utilizing stricturoplasty to help prevent future issues with short bowel syndrome. Risk factors for recurrence, and subsequent need for multiple operations, include smoking, the NOD2/CARD15 gene mutation, young age at diagnosis, short duration of disease prior to an operation, long segment disease, and multiple sites of disease. Patients with CD require thoughtful multidisciplinary management, with close cooperation between the surgeon, gastroenterologist, and other adjunct specialists to design an individualized approach, which optimizes the timing of needed operative interventions.

Suggested Readings

Alves A, Panis Y, Bouhnik Y, et al. Risk factors for intra-abdominal septic complications after a first ileocecal resection for Crohn's disease: a multivariate analysis in 161 consecutive patients. *Dis Colon Rectum* 2007;50(3):331–6.

Greenstein AJ, Sachar DB, Mann D, et al. Spontaneous free perforation and perforated abscess in 30 patients with Crohn's disease. *Ann Surg* 1987;205:72.

Greenstein AJ, Sachar D, Pucillo A, et al. Cancer in Crohn's disease after diversionary surgery. A report of seven carcinomas occurring in excluded bowel. *Am J Surg* 1978;135:86.

Hyman NH, Fazio VW, Tuckson WB, et al. Consequences of ileal pouch-anal anastomosis for Crohn's colitis. *Dis Colon Rectum* 1991;34:653.

Kono T, Ashida T, Ebisawa Y, et al. A new antimesenteric functional end-to-end handsewn anastomosis: surgical prevention of anastomotic recurrence in Crohn's disease. *Dis Colon Rectum* 2011;54(5):586–92.

Kornbluth A, Legnani P, Lewis BS. Video capsule endoscopy in inflammatory bowel disease: past, present, and future. *Inflamm Bowel Dis* 2004;10(3):278–85.

Maggiori L, Khayat A, Treton X, et al. Laparoscopic approach for inflammatory bowel disease is a real alternative to open surgery: an experience with 574 consecutive patients. *Ann Surg* 2014;260(2):305–10.

Michelassi F, Hurst RD, Melis M, et al. Side-to-side isoperistaltic strictureplasty in

extensive Crohn's disease: a prospective longitudinal study. *Ann Surg* 2000;232:401.

Michelassi F, Sultan S. Surgical treatment of complex small bowel Crohn's disease. *Ann Surg* 2014;260(2):230–5.

Milsom JW, Hammerhofer KA, Böhm B, et al. Prospective, randomized trial comparing laparoscopic vs. conventional surgery for refractory ileocolic Crohn's disease. *Dis Colon Rectum* 2001;44:1.

Munoz-Juarez M, Yamamoto T, Wolff BG, et al. Wide-lumen stapled anastomosis vs. conventional end-to-end anastomosis in the treatment of Crohn's disease. *Dis Colon Rectum* 2001;44:20.

Nugent FW, Roy MA. Duodenal Crohn's disease: an analysis of 89 cases. *Am J Gastroenterol* 1989;84:249.

Solem CA, Loftus EV Jr, Fletcher JG, et al., Small-bowel imaging in Crohn's disease: a prospective, blinded, 4-way comparison trial. *Gastrointest Endosc* 2008;68(2):255–66.

Spinelli A, Bazzi P, Sacchi M, et al. Short-term outcomes of laparoscopy combined with enhanced recovery pathway after ileocecal resection for Crohn's disease: a case-matched analysis. *J Gastrointest Surg* 2013;17(1):126–32.

Yamamoto T, Watanabe T. Surgery for luminal Crohn's disease. *World J Gastroenterol* 2014;20(1):78–90.

EDITOR'S COMMENT

Dr. Fichera and colleagues provide a thorough overview of the treatment of CD affecting the upper gastrointestinal intestinal tract and small bowel. Some clarifications are needed, however. The authors list the three different phenotypes of CD, namely inflammatory, stricturing, and penetrating. These have been described as discrete phenomena, any one of which could happen in a particular patient. In reality, these represent a continuum of a disease process that we at any moment are only observing at one snapshot in time. By this I mean is that CD is initially associated with significant inflammation, and edema. At this point, anti-inflammatory medications work well. Over time, and this is frequently over years of disease progression and chronic inflammation, the disease slowly transforms to fibrosis, which as the authors correctly state is not amenable to nonoperative therapy. When this fibrotic process becomes severe enough to cause significant obstruction, Crohn ulcerations proximal to this obstruction will in turn perforate, resulting in a peri-intestinal abscess. Such abscesses then drain spontaneously into whatever structure(s) is/are adjacent to them, be it sigmoid colon, bladder, or skin. Thus, just as the different phenotypes of CD are a continuum in the disease process, just so is the

development of fistula from an intestinal perforation with or without subsequent abscess. This progression of disease has led to development of the "top-down" treatment algorithm increasingly used by gastroenterologists. This top-down method refers to the up-front or initial treatment of CD with anti-tumor necrosis factor α (TNFα) antibody therapy (or other stronger immunomodulators) rather than the traditional initial treatment with anti-inflammatory medications and antibiotics (bottom-up therapy, i.e., starting with safer, less effective drugs initially). It is hoped that initial aggressive top-down treatment with such agents will stop disease progression to the fibrosing and penetrating phenotypes of disease and perhaps avoid surgery.

Notwithstanding the eagerness and enthusiasm for "modern" medical therapy, there is still role for steroids in managing patients with small bowel CD. No medication is as readily available or works as quickly at reducing bowel edema and in some cases reducing bowel obstruction. In patients needing surgery for bowel obstruction due to CD, the worst thing that one can do is have them to taper their steroids prior to surgery. This often results in a worsening of the bowel obstruction.

The authors do not discuss the role of capsule endoscopy in the diagnosis of small bowel CD. I have found this helpful in some cases in which the diagnosis is unclear. Diagnosing an obstruction in these patients can, however, be difficult since the only clue one often has to the obstruction is persistence of the capsule in the same bowel segment for a long time—in some cases hours. The authors also discuss the use of conventional barium small bowel follow-through studies in preoperative patient evaluation. These studies can be very valuable in that they provide functional information about the CD, that is, information about delayed transit, the degree of proximal bowel distention, etc. Barium studies should of course not be performed in the presence of an obstruction, since the barium may become inspisated in the bowel and become a source of major morbidity if the patient comes to surgery. Sadly performing these studies is becoming a lost art nowadays, since many radiologists are loath to touch patients and prefer studies like CT and MR enterography that can be performed long-distance without patient contact. *(This is unfortunately the usual way that patients end up. The only way I know to prevent this is to have the senior surgeons attend to the study and have such studies take place. – JEF.)*

The authors' discussion of intestinal bypass does not mention one of the most historic operations performed in US history, namely the historic bypass that was performed on President Eisenhower many years ago with nonetheless a good outcome with the long follow-up (Michelassi F, Sultan S. Surgical treatment of complex small bowel Crohn disease. *Ann Surg* 2014;260(2):230–5). President Eisenhower was a long-time cigarette smoker, a factor no doubt leading to exacerbation of his CD. His operation went relatively smoothly, he had a nasogastric tube for 5 days, a 3-week hospital stay, and developed a wound infection. Nonetheless, he was able to run for and successfully complete a second term as president. Later in life he ultimately required a lysis of

adhesions for bowel obstruction, but had no further issues with his CD.

The authors' contribution to the field of strictureplasty is substantial (Pappas TN. President Eisenhower's bowel obstruction: the story of his surgeons and their decision to operate. *Ann Surg* 2013;258(1):192–7). It is still a mystery as to why this operation works as well as it does, and why if one operates for another reason on the same patient, months or years later, the areas of bowel that were indurated and severely inflamed at the site of the strictureplasty are now pliable and nearly normal appearing. Also, why are recurrence rates at the sites of Strictureplasty lower than for anastomoses? As with many things in surgery, more questions evolve than answers. One area where I differ with the authors is their praise of energy devices for division of very thickened Crohn's small bowel mesentery. I do not find these devices always to perform as well in this scenario and frequently rely on old-fashioned sharp dissection and suture ligation! *(I agree entirely. – JEF)*

As with many things, we continue to learn about risk factors for surgery and optimizing our patients' condition. With CD there have for years been contradictory reports on the effect of the so-called biologic drugs or anti-tumor necrosis factor α (TNFα) antibody therapy that has been used so widely for treatment. Many studies suggested higher rates of infectious complications in inflammatory bowel disease (IBD) patients receiving these drugs preoperatively, while others found no such relationship. A recent report from a large IBD center suggests that there may be an increased risk of complications in Crohn's patients who have high serum levels of these anti-TNFα drugs preoperatively (Lau C, Dubinsky M, Melmed G, et al. The impact of preoperative serum anti-TNFα therapy levels on early postoperative outcomes in inflammatory bowel disease surgery. *Ann Surg* 2015;261(3):487–96). In comparing patients with high and low serum anti-TNFα drug levels preoperatively, patients with high drug levels had higher rates of postoperative morbidity and hospital readmission. This is not surprising, since TNFα mediates neutrophil chemotaxis and adhesion and patients receiving these drugs are at higher risk of opportunistic infection.

One of the challenges in operating on patients with CD is the risk of disease recurrence. As the authors note, smoking is the one environmental factor definitively associated with a higher risk of recurrent disease. Discussions about behavior modification are an important part of patient care for all physicians taking care of Crohn's patients, be they surgeons or other types of physicians. Recently there has been increased focus on the role of the intestinal microbiome in intestinal disease and the role of probiotics in modifying it. An interesting prospective study of Crohn's patients undergoing ileocolic resection found that patients with disordered intestinal microbial populations at the ileocolic anastomosis were more prone to endoscopically discovered postoperative recurrence (Mondot S, Lepage P, Seksik P, et al.; GETAID. Structural robustness of the gut mucosal microbiota is associated with Crohn's disease remission after surgery. *Gut* 2016;65(6):954-62. doi: 10.1136/gutjnl-2015–

309184. In the future, we may be able to have greater control of disease recurrence rates by combinations of probiotics to modify the intestinal microbiome, postoperative behavioral modification by our patients to avoid harmful environmental factors such as smoking and perhaps other medications to obtain better overall and long-term outcomes in this very challenging set of patients.

Susan Galandiuk

H SURGERY OF THE COLON

141 Clinical Anatomy for Procedures Involving the Small Bowel, Colon, Rectum, and Anus

Uri Netz and Susan Galandiuk

INTRODUCTION

A good understanding of anatomy is critical for the surgeon performing colon and rectal procedures. Knowledge and awareness of important anatomical structures can dramatically reduce complications, such as bleeding, ischemia, and nerve damage. Approaching critical structures and planes in the correct fashion and with the proper respect can mean the difference between a straightforward case with minimal blood loss and a surgical nightmare. This chapter does not proclaim to cover all aspects of basic anatomy, but instead focuses on the *practical* aspects of the anatomy, including adjacent structures such as nerves and ureters, which are not part of the gastrointestinal (GI) tract but are very relevant for surgical procedures. We also provide clinical tips and solutions with the purpose of making future operations smoother and safer. For details on other aspects of basic anatomy, please review the Suggested Readings section at the end of the chapter.

SMALL BOWEL ANATOMY FOR COLORECTAL PROCEDURES

The jejunum and ileum together measure approximately 2.5 to 3 meters in vivo (and significantly longer after removal from the body due to loss of longitudinal muscle tone) and are responsible for nearly 90% of the absorption of the GI system (Fig. 141.1). For the surgeon, it is more important to judge the length of small bowel remaining than what has been removed in the past. In general, patients with less than 200 cm of small

bowel remaining are in danger of developing short bowel syndrome. Preserving the terminal ileum is especially important for the absorption of vitamin B12 and bile salts.

The jejunum and ileum are anchored to the posterior abdominal wall by the small bowel mesentery, consisting of a double layer of peritoneum that connects them to the posterior abdominal wall in an oblique direction toward the right iliac fossa (Fig. 141.2). The blood vessels, nerves, and lymphatics branch through the mesentery to supply the intestines. The blood supply of the jejunum and ileum is from the superior mesenteric artery (SMA) that provides blood to several arteries, which branch to form a series of arterial arcades that increase in complexity as one proceeds distally (Fig. 141.3). This marginal arcade is important when performing ileal pouch anal anastomosis. The surgeon can attain additional small bowel length, while still maintaining terminal ileal blood supply, by dividing the ileocolic artery or the SMA (distally to the origin of the ileocolic artery), but not both.

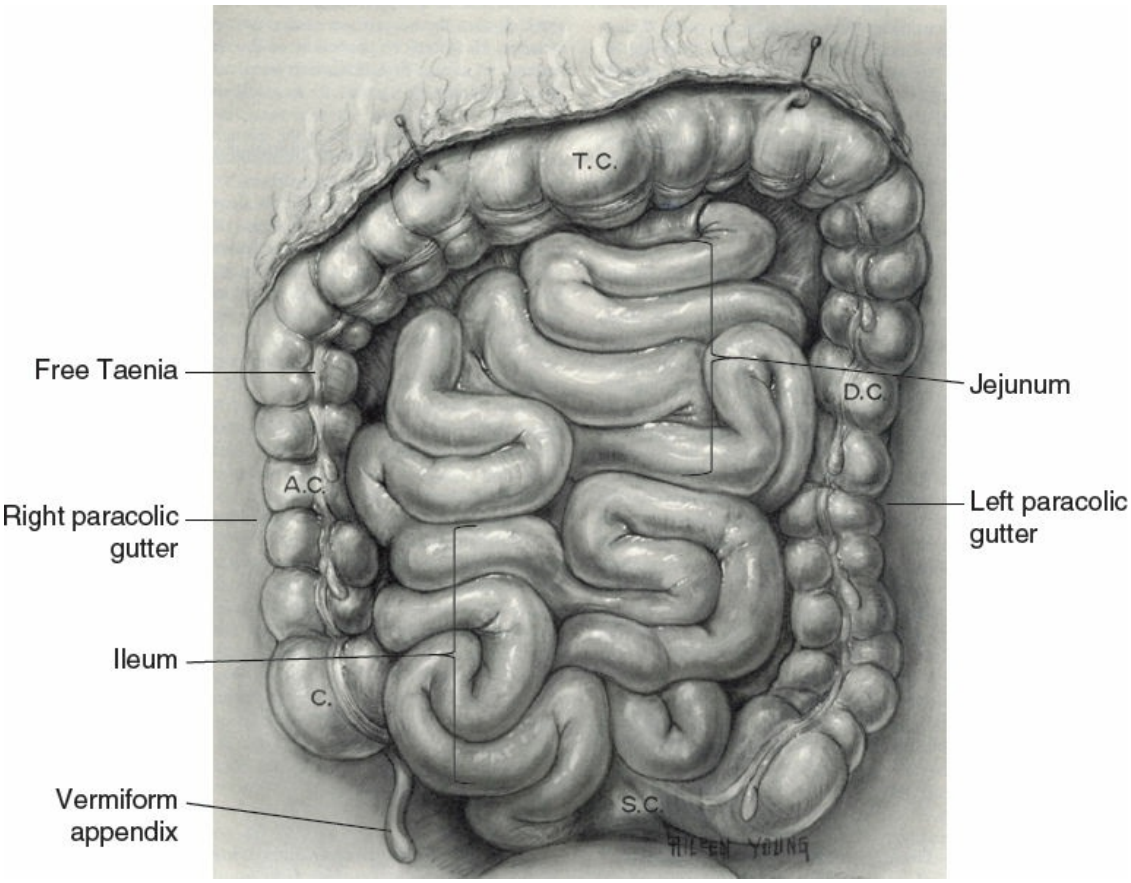

Figure 141.1. The large intestine, with the transverse colon elevated and the greater omentum removed. C is the cecum; A.C., T.C., D.C., and S.C. identify, respectfully, the ascending,

the transverse, the descending, and the sigmoid colon. (With permission from Hollinshead WH. *Anatomy for Surgeons, volume 2. The Thorax, Abdomen and Pelvis*. 2nd ed. New York: Harper and Row; 1971.)

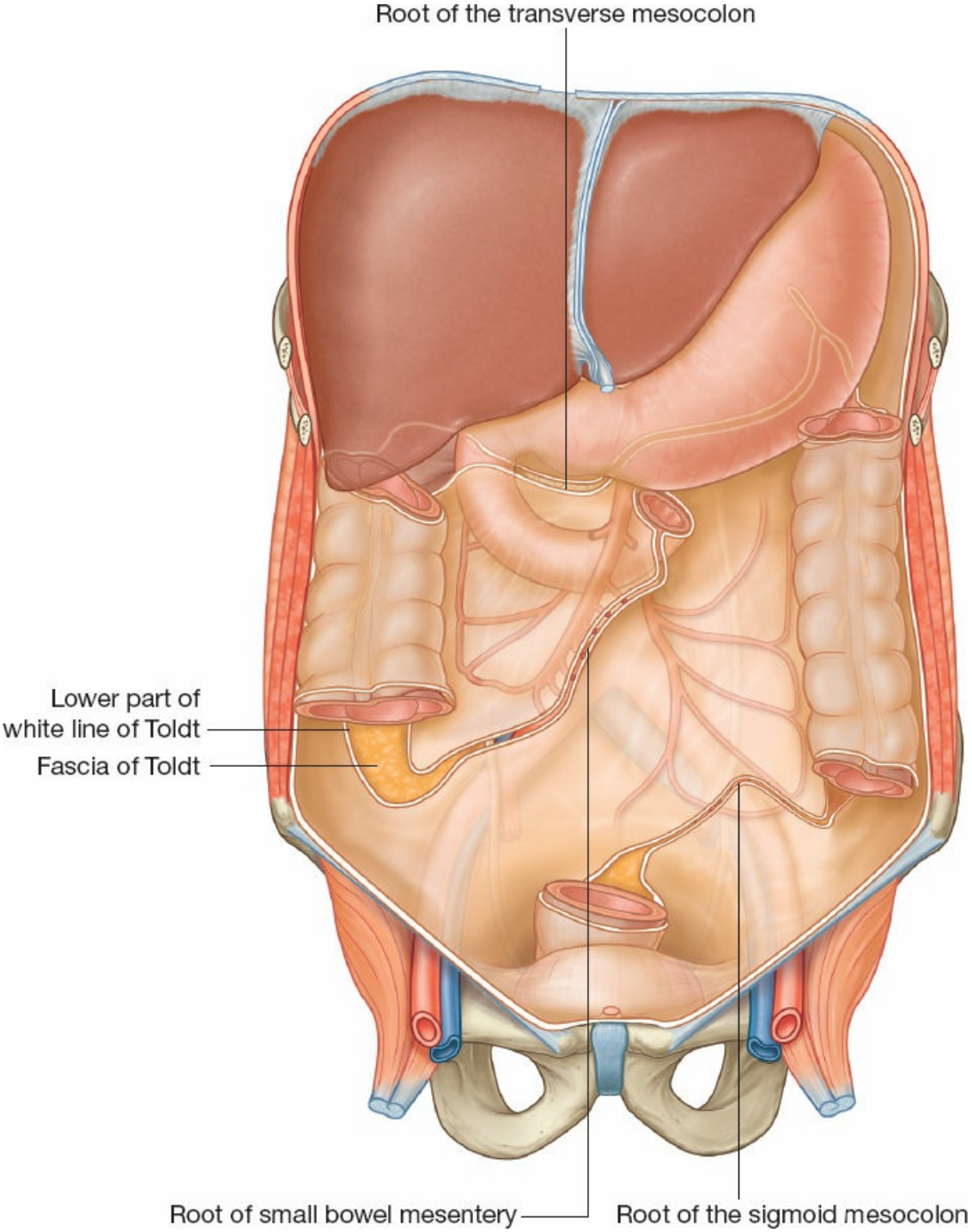

Figure 141.2. Attachment or root of mesentery of small bowel and colon along posterior abdominal wall.

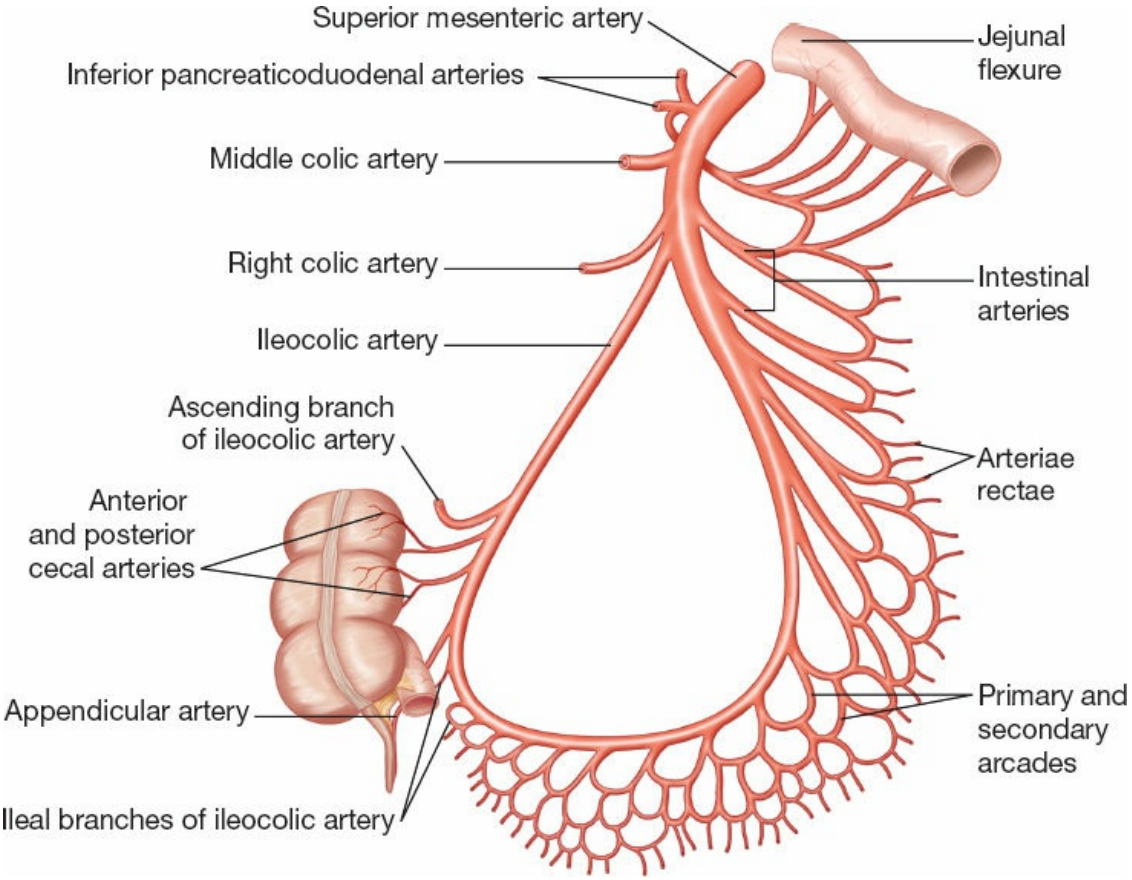

Figure 141.3. The blood supply of the jejunum and ileum; the arteriae rectae are shown very schematically. Other branches of the superior mesenteric artery, and the terminal branches of the ileocolic, are also identified. (With permission from Hollinshead WH. *Anatomy for Surgeons, volume 2. The Thorax, Abdomen and Pelvis*. 2nd ed. New York: Harper and Row; 1971.)

CECUM AND APPENDIX

The cecum is the saccular beginning of the colon. It lies in the right iliac fossa. It is completely covered by peritoneum and is, therefore, considered an intraperitoneal structure (Fig. 141.1). In general, it has no mesentery. It is variably connected to the posterior abdominal wall by the peritoneal reflection. Twenty percent of individuals have a cecum completely free from dorsal attachment (Fig. 141.4). An abnormally mobile cecum in concordance with an abnormally mobile ascending colon can be found in a small proportion of patients and can predispose to volvulus (torsion), or cecal bascule (upwards folding of the cecum), due to the fixation of the hepatic flexure. The wall of the cecum is thin compared to the rest of the colon. In accordance with the law of Laplace, and considering its large diameter, it is the site most likely to perforate in cases such as adynamic

ileus, Ogilvie syndrome, etc. Also, because of its thinness, it is easier to perforate in cases of colonoscopic polypectomy. Most surgeons choose to incorporate the taeniae for cecotomies, cecopexy, and anastomosis, as it includes an extra layer of muscle.

The vermiform appendix originates from the posteromedial border of the cecum. Its size is variable, averaging 5 to 10 mm in diameter and 8 to 10 cm in length. It is most commonly found in a retrocecal position. Locating the appendix in the setting of inflammation and adhesions can be challenging, but one can reliably reach its base by following the anterior taenia to its junction with the other two taeniae.

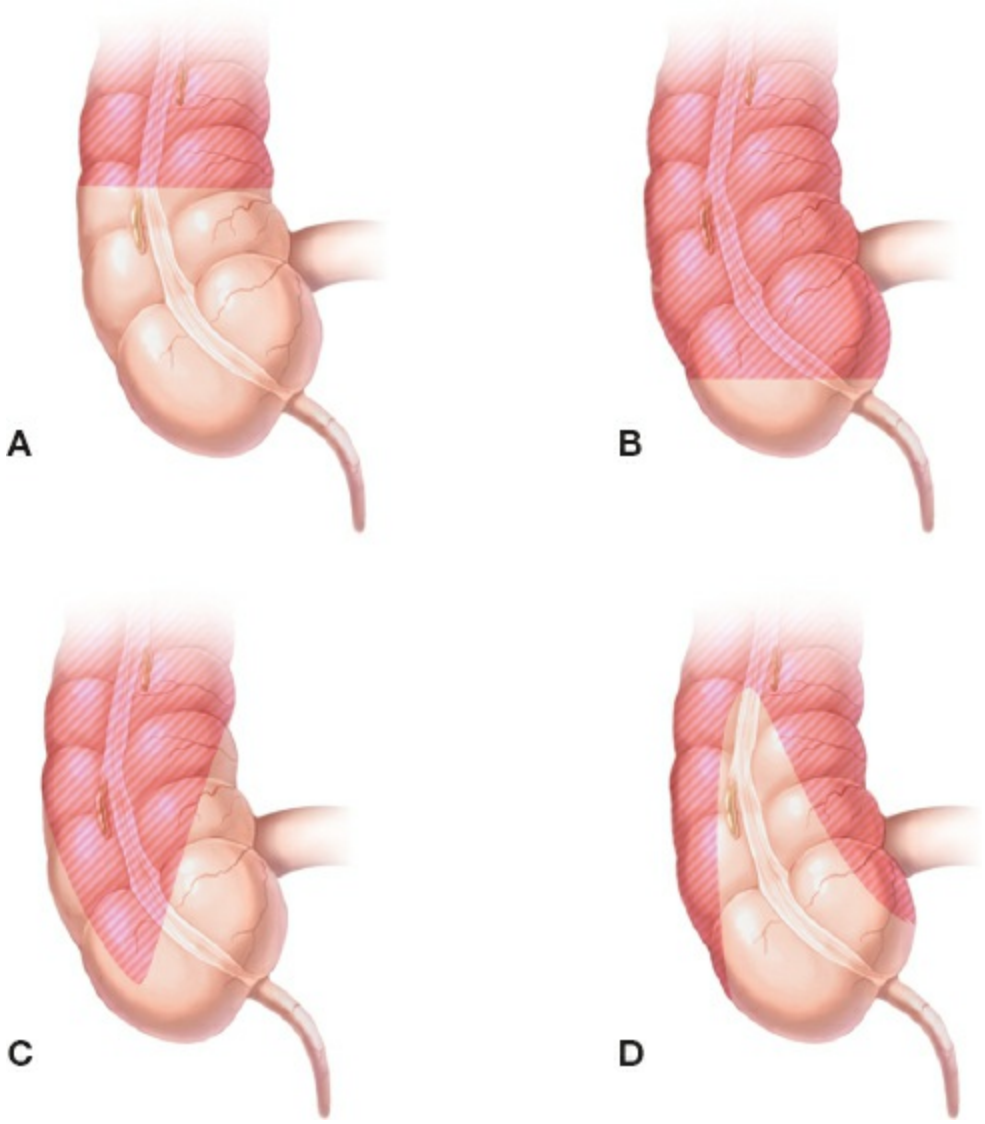

Figure 141.4. Some variations in the posterior peritoneal attachments of the cecum—the areas of attachment are obliquely shaded. (**A**) shows an unattached cecum, the line of peritoneal reflection being on the ascending colon; in (**B**) the cecum is

almost completely fused to the posterior wall; in (**C**) there is an incomplete and oblique attachment; and in (**D**) there is a concave line of attachment enclosing a large retrocecal. (With permission from Hollinshead WH. *Anatomy for Surgeons, volume 2. The Thorax, Abdomen and Pelvis*. 2nd ed. New York: Harper and Row; 1971.)

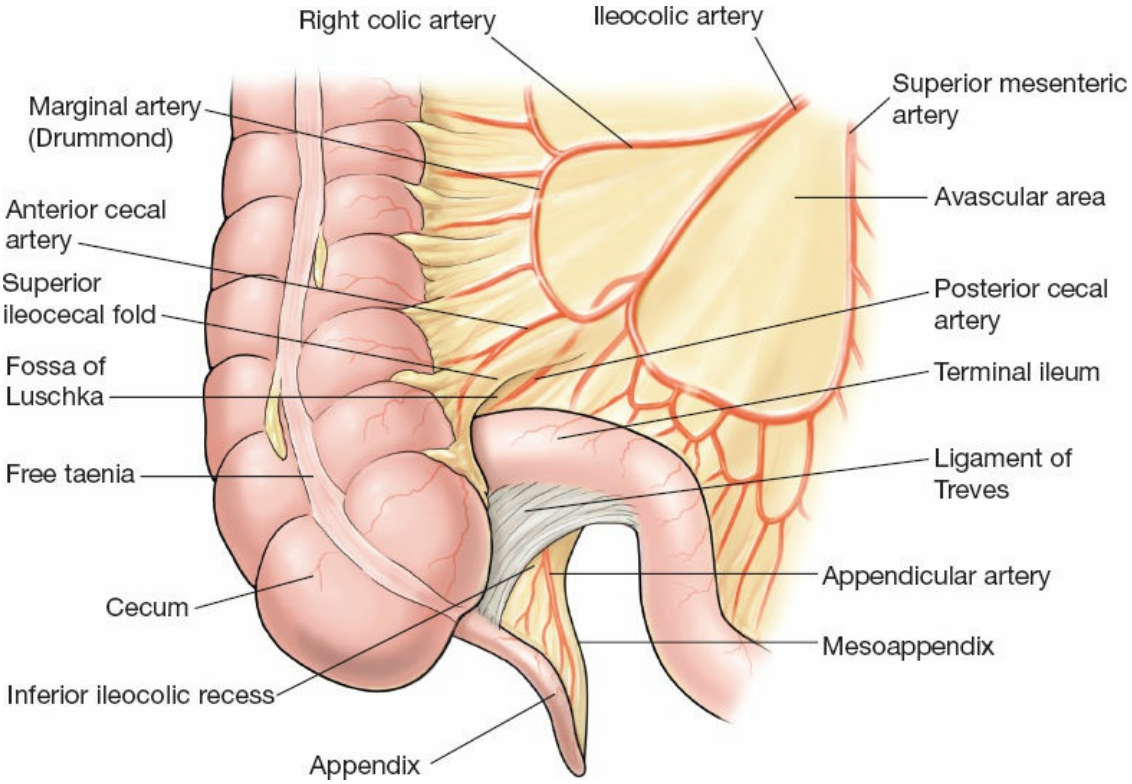

Figure 141.5. The ileocecal region and blood supply. (From Lowry SE, Davidov T, Shiroff AM. Appendicitis and appendiceal abscess. In: Fischer JE, Jones DB, Pomposelli FB, et al., eds. *Fischer's Mastery of Surgery*, 6th ed. Wolter Kluwer; Lippincott Williams & Wilkins. Chapter 149, Figure 3.

The ileum enters the cecum along its medial border (Fig. 141.5). This opening is surrounded by two flaps that protrude into the lumen and contain circular muscle derived partly from the ileal musculature and partly from the cecal musculature. This structure is referred to as the ileocecal valve. The valve's role, however, as a functional sphincter is debatable.

The superior ileocecal recess (fossa of Luschka) lies anterior to the terminal ileum. It is formed by a peritoneal fold, the superior ileocecal or vascular fold, which extends from the mesentery of the terminal ileum, and, after crossing the ileum, attaches to the lowest part of the colon and

cecum. This fold contains the anterior cecal artery (Fig. 141.5). Similarly, the inferior ileocecal recess lies between the mesoappendix and a fold of peritoneum referred to as the inferior ileocecal fold or the bloodless fold of Treves. This fold extends from the antimesenteric border of the terminal ileum to the base of the appendix or the anterior surface of the mesoappendix, or to both areas. This fold contains no sizable blood vessels. Since it is the only part of the ileum that has a fold on the antimesenteric side of the bowel, it can help in the recognition of the ileocecal region. Both folds are perceived to be functionally important in maintaining the correct angulation of the ileocecal valve.

The ileocecal valve is clinically important in cases of large bowel obstruction. A competent valve does not allow the reflux of cecal contents into the small bowel causing a "closed loop obstruction," a surgical emergency, whereas an incompetent valve that allows retrograde flow into the small bowel leads to less distention and a less acute clinical scenario. Surgeons take advantage of the valve mechanism of the ileocecal valve in the creation of continent stomas such as the Indiana Pouch, for urinary diversion, and the antegrade continence enema (ACE) operation, which assists evacuation of colon contents in cases of constipation or neurologic dysfunction.

ASCENDING COLON

The ascending colon begins at the ileocecal junction and extends distally and superiorly to the hepatic flexure (Fig. 141.6). It is usually covered by peritoneum on its anterior and lateral aspects. Posteriorly, it is connected to the peritoneum by the fascia of Toldt, an areolar and relatively avascular tissue. At the hepatic flexure, the colon takes an abrupt turn medially. It is suspended there by the nephrocolic ligament to the Gerota fascia of the right kidney. At the lower pole of the right kidney, the iliacus muscle and the aponeurotic origin of the transversus abdominis muscle lie posterior to the ascending colon.

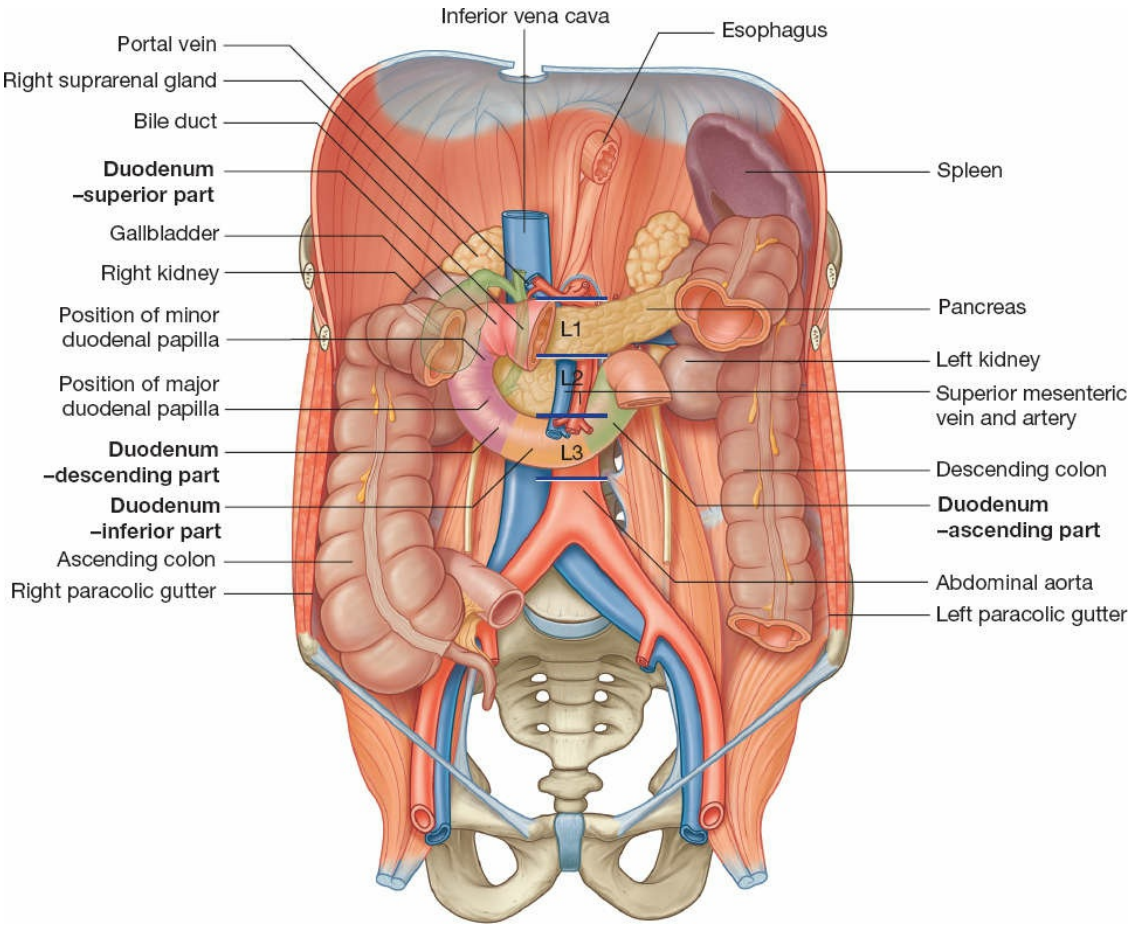

Figure 141.6. Structures posterior to the left and right colic flexures.

The right paracolic sulcus, or gutter, is lateral to the colon. Fluid and pus tend to traverse along this gutter either from the appendicular region to the hepatorenal recess or from the liver and epigastrium to the pelvis.

The ascending colon is best mobilized along the lateral peritoneal reflection by incising the "white line of Toldt" (Fig. 141.2), continuing posteriorly and medially close to the colon, in order to avoid the kidney and right ureter. After releasing the hepatic flexure and lifting the colon medially, one must be aware of the proximity of the second part of the duodenum (Fig. 141.6), which can be injured inadvertently, especially in inflammatory conditions such as Crohn disease or in cases of cancer in which the anatomy can be distorted. In these conditions, it is a common location of fistulas between the duodenum and colon.

TRANSVERSE COLON

The transverse colon begins at the right colic flexure and passes to the left, ending at the left colic or splenic flexure. It is intraperitoneal and

suspended from the posterior abdominal wall by the transverse mesocolon (Fig. 141.2). The transverse colon hangs between the two flexures in a U-shaped curve, which can reach the pelvis in some individuals, depending on body position. This redundancy and shifting position can pose a risk for a volvulus (although rare) and make traversing it (as well as the sigmoid colon) during colonoscopy challenging. Recognizing this variability in position is extremely important when attempting to exteriorize the transverse colon with a "target incision" for a transverse colostomy. Although its posterior relationships can vary due to its mobility, the transverse colon is usually anterior to the hilus of the right kidney, the descending (second) part of the duodenum, and the head of the pancreas (Fig. 141.6). Its cranial surface is in contact with the liver, the gallbladder, the greater curvature of the stomach, and the spleen. Its caudal surface is in contact with the small intestine, and its anterior surface is in contact with the anterior layer of the greater omentum and the abdominal wall.

Just inferior to the spleen, the transverse colon turns downward, forming the left colic or splenic flexure. This flexure is higher and is situated more posteriorly than the right colic flexure. It is suspended from the diaphragm by the left phrenicocolic ligament, a distinct peritoneal fold. The splenic flexure is connected posteriorly via the renocolic, splenocolic, and pancreaticocolic ligaments to the Gerota fascia, which surrounds the left kidney, the lower pole of the spleen, and the tail of the pancreas. These ligaments are usually linked into one continuous avascular connection (Fig. 141.7). The splenic flexure can be completely released without dividing any major blood vessels, if one is in the correct plane. In open procedures, one should approach the splenic flexure after first mobilizing the descending colon and the transverse colon proximal to the flexure. The most common cause of bleeding is from avulsion of a portion of the splenic capsule from excessive downward traction.

DESCENDING COLON

The descending colon begins at the left colic flexure, where the intestine loses its mesentery. Posteriorly, the descending colon is related to the lower pole of the left kidney and lies on top of the iliacus muscle and the aponeurotic origin of the transversus abdominis muscle. Posteromedially, the descending colon is in contact with the left psoas major muscle. The descending colon is similar to the ascending colon with regard to its peritoneal coverage anteriorly and on the medial and lateral sides, with the

fascia of Toldt posteriorly. The left paracolic sulcus (gutter) is immediately lateral to the descending colon. Dissection of the descending colon is best performed on the lateral side from inferior to superior, along the white line of Toldt.

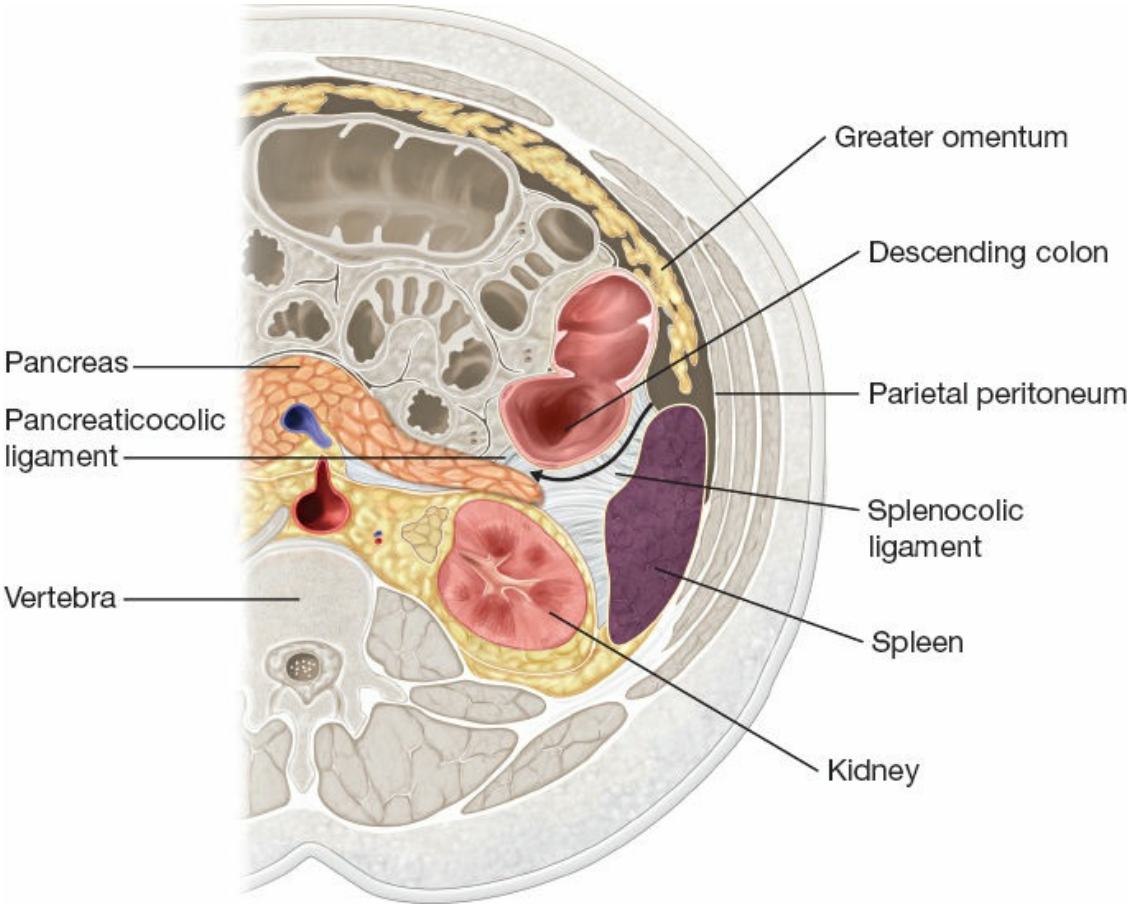

Figure 141.7. Ligaments of the splenic flexure. *Arrow* indicates potential plane of dissection.

SIGMOID COLON

At or below the crest of the ileum, the colon acquires a mesentery, covered bilaterally with peritoneum, and becomes the sigmoid colon. This section of the colon continues inferiorly until it loses its mesentery, usually between the level of the sacral promontory and the S3 vertebra, where it becomes the rectum. The end of the sigmoid colon can also be identified as the point where the colonic taeniae confluence to form a complete longitudinal muscle layer. Reaching the rectosigmoid junction is important surgically when performing sigmoid resection for diverticular disease. If the entire sigmoid colon is not removed, and the distal anastomosis is not made to the rectum, there is a much higher risk of recurrence. The sigmoid

colon is attached at its junction with the descending colon and rectum to the posterior abdominal wall, but mobile throughout its length. This mobile portion is attached by the sigmoid mesocolon, which is connected to the posterior abdominal wall and pelvis, in the pattern of an inverted V (Fig. 141.2). When mobilizing the sigmoid colon, it is important to identify the fold of the sigmoid peritoneum and not to dissect off the lateral pelvic peritoneum in order to avoid injury to the ureter and gonadal vessels.

BLOOD SUPPLY OF THE COLON

The vascular supply to the colon is through the SMA and the inferior mesenteric artery (IMA), both anterior branches of the abdominal aorta (Fig. 141.8). The SMA arises opposite the lower border of the L1 vertebra and descends in a groove on the posterior surface of the body of the pancreas (Fig. 141.6). The artery crosses anterior to the left renal vein, the uncinate process of the pancreas, and the horizontal third portion of the duodenum. It gives off three major branches to the colon. The first branch is the middle colic artery, followed by the right and ileocolic arteries.

The ileocolic artery runs directly toward the ileocecal junction along the root of the mesentery. As this branch approaches the ileocecal junction, it gives off several branches: the anterior cecal artery, which passes in a vascular fold to the cecum; the posterior cecal artery, which passes retroperitoneally behind the cecum; and the appendicular artery, which descends behind the ileum, and enters the mesoappendix (Fig. 141.5). The appendicular artery may also appear as a branch of the posterior cecal artery.

The avascular space between the ileocolic artery and the SMA is useful both as a safe location to initialize dissection of the blood supply in a laparoscopic right colectomy and as a space where the transverse or right colon can be pulled through to gain bowel length in cases of “retro-ileal” colon-rectal anastomoses.

The right colic artery, which approaches the ascending colon retroperitoneally, divides into ascending and descending colic branches. It is absent in a significant proportion of patients.

The middle colic artery enters the transverse mesocolon and divides into right and left branches supplying the hepatic flexure and proximal transverse colon on the right, all the way to the splenic flexure on the left. In about a third of the cases, it is the main blood supply to the splenic

flexure. When lifting the transverse colon, one can follow the middle colic artery to the base of the mesentery to reach the SMA just to the right of the ligament of Treitz (Fig. 141.9). In order to access the proximal SMA, for example, when performing an embolectomy in the setting of acute mesenteric ischemia, it is customary to also release the ligament of Treitz.

The second major artery supplying the colon, the IMA, arises approximately 4 cm above the aortic bifurcation at the level of the L3 vertebra, roughly at the level of the umbilicus in most patients. Its major branches to the colon are the left colic artery, which runs retroperitoneally to the left, dividing into ascending and descending branches, the sigmoidal arteries, usually consisting of two to four branches, and the superior rectal artery, which is the distal part of the IMA, after it crosses the pelvic brim.

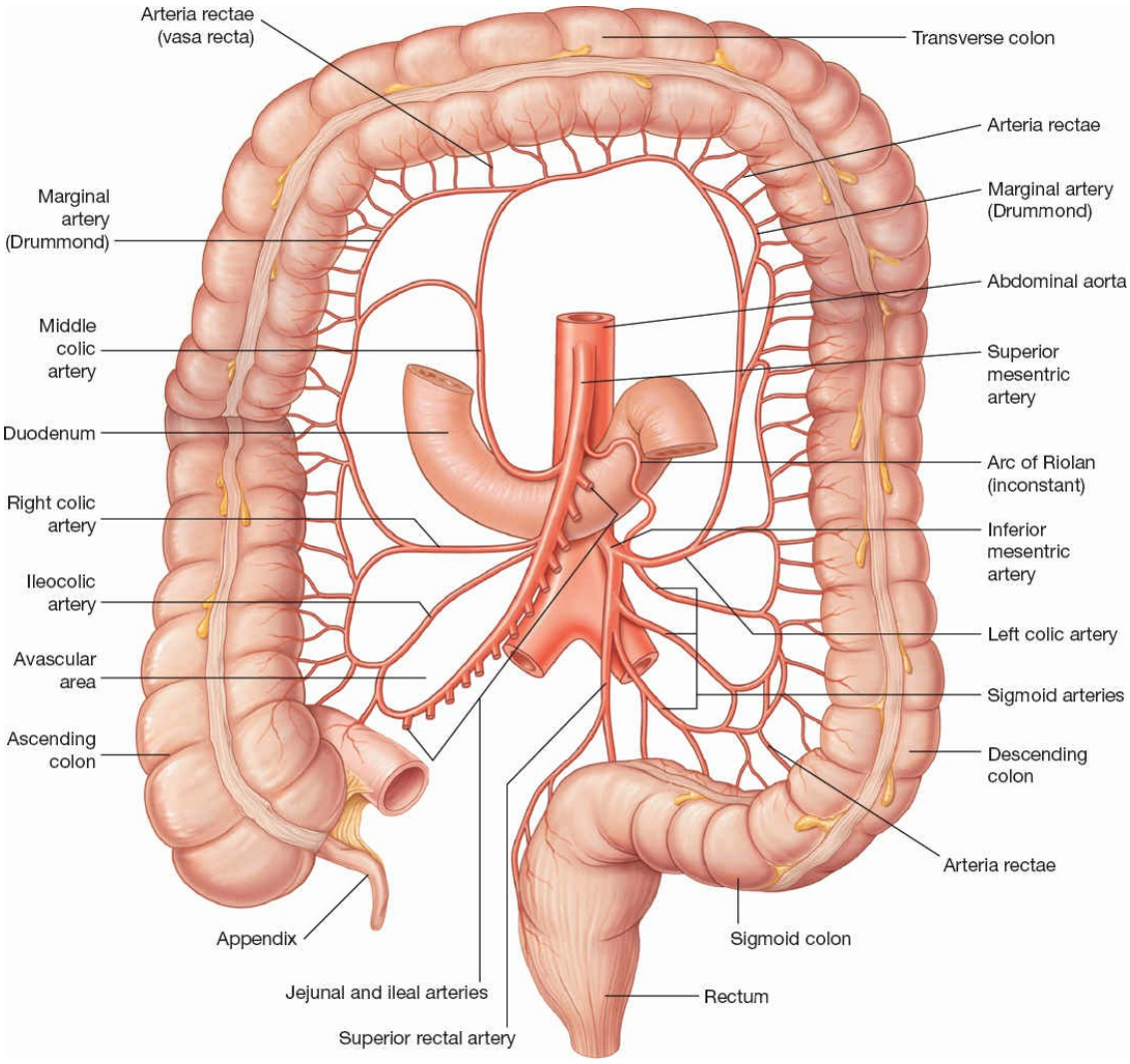

Figure 141.8. The vascular supply to the colon is from the superior and inferior mesenteric arteries. The distribution of these arteries and their branches is shown.

All of the arteries mentioned previously contribute to the formation of a continuous arterial channel that runs along the inner (mesenteric) margin of the colon, from the cecocolic junction to the rectosigmoid junction, and is called the marginal artery of Drummond. The marginal artery is important clinically. When an artery is obstructed for various reasons (emboli, atherosclerosis etc.), the bowel can receive its blood supply through the marginal artery. Surgically, when performing anastomosis low in the pelvis, it is possible to divide the IMA as it comes off the aorta proximal to the origin of the left colic artery to achieve extra colonic length, with the blood supply to the splenic flexure coming from the SMA through the marginal artery.

The meandering mesenteric artery, or “arch of Riolan,” is an

uncommon finding and indicates a collateral vessel that connects the SMA or middle colic artery to the IMA or left colic artery close to the base of the mesentery. It can have an important role in blood delivery in cases of SMA or IMA occlusion (Fig. 141.8).

Venous drainage of the colon generally parallels the arteries through the superior mesenteric veins (SMV) and inferior mesenteric veins (IMV), which contribute to the formation of the portal vein. Importantly, the IMV continues beyond the origin of the IMA superiorly along the window at the base of the mesentery, entering the portal vein adjacent and to the left of the ligament of Treitz, at the base of the splenic flexure mesentery, as a vertically oriented blood vessel (Fig. 141.9). As with the IMA, one can divide the IMV in order to achieve extra colonic length for low pelvic anastomoses.

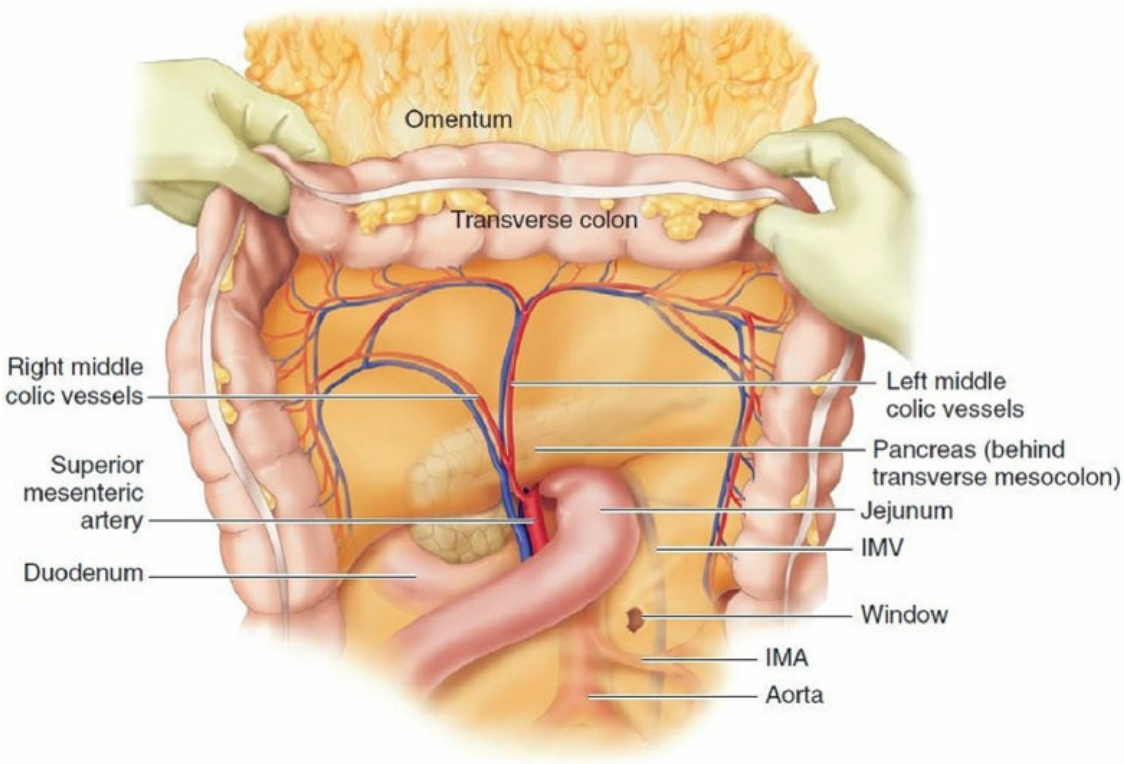

Figure 141.9. The blood supply of the transverse colon. (This figure was published in Hunt SR. Extended left colectomy with right colon-to-colon anastomosis (Chapter 4). In: Fleshman J, ed. *Atlas of Surgical Techniques for the Colon, Rectum, and Anus.* New York: Elsevier; 2013. Copyright Elsevier.)

LYMPHOID DRAINAGE AND INNERVATION OF THE COLON

Lymphoid drainage from the colon generally follows with the regional vascular supply. There are four levels of lymph nodes: epicolic (under the serosa of the wall of the intestine), paracolic (along the marginal artery), intermediate (along the large arteries), and principal (at the root of the superior and inferior mesenteric arteries). Most of the lymphatic drainage goes in this direction, but communications are found between groups of lymph nodes, especially at the level of the paracolic groups. In addition, there is some degree of dual drainage into the superior and inferior mesenteric lymph nodes, from the left third of the transverse colon and from the left colic flexure.

The techniques of total mesorectal and total mesocolic resection have highlighted the importance of performing complete mesenteric lymph node excision when performing surgery for colorectal cancer. The middle colic artery is relatively short, impeding the ability to achieve an adequate lymphadenectomy in cases of transverse colon cancer, leading to poorer outcomes with these types of lesions.

The innervation of the large intestine has both sympathetic and parasympathetic components, which generally follow the blood supply.

THE URETERS

Although the ureters are not part of the GI tract, their location and potential for injury during surgery make knowledge of their course of paramount importance when performing procedures involving the colon and rectum. The ureters begin at the renal pelvis, go downward, along the psoas muscle, under the gonadal vessels, over the junction of the common iliac vessels to external iliac vessels, and then descend into the pelvis (Fig. 141.10).

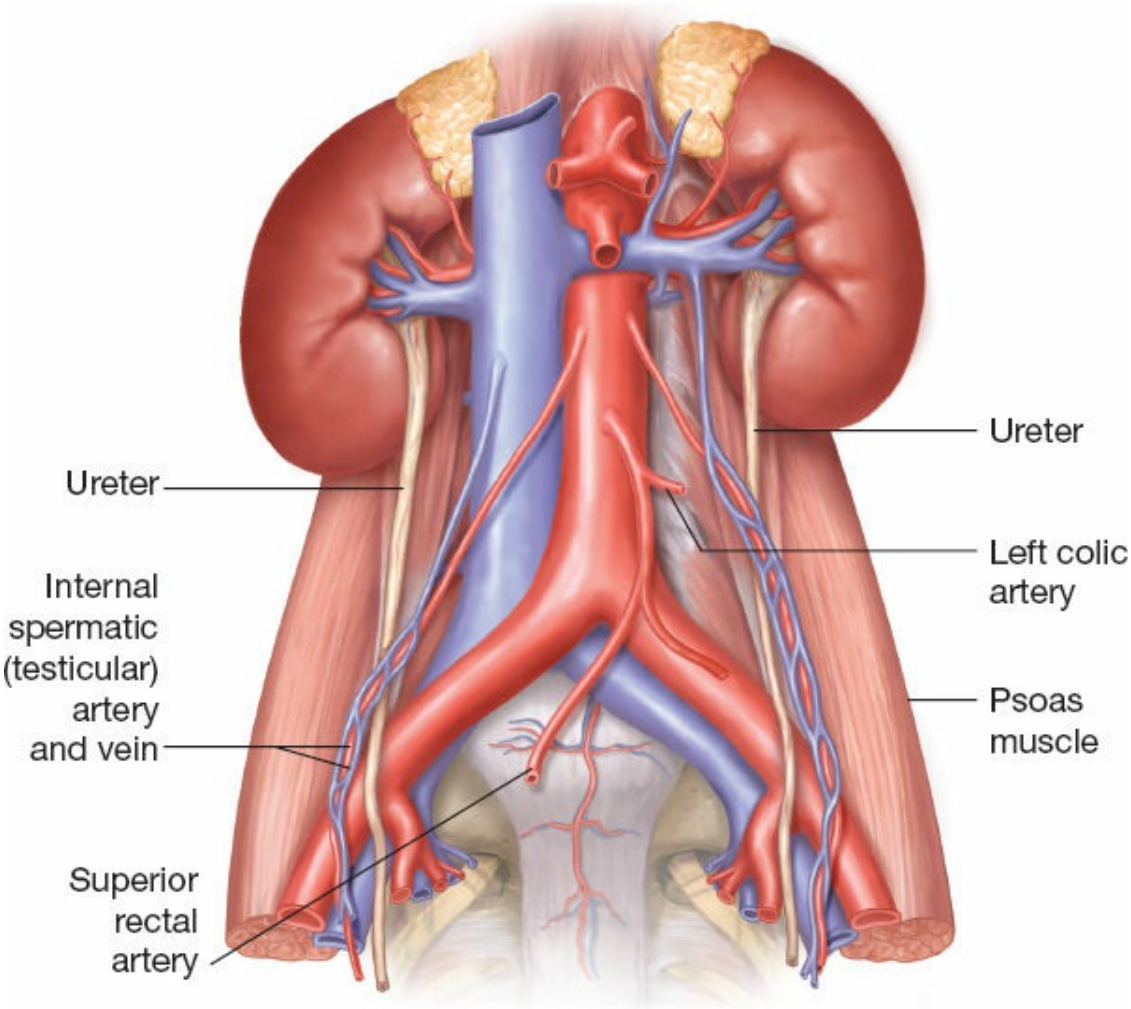

Figure 141.10. The abdominal course of the ureters. The branches of the SMA to the ascending colon that lie in front of the right ureter have been removed. If this were an illustration of a female, the ovarian vessels would be seen crossing the pelvic brim just below and lateral to the ureters. (With permission from Hollinshead WH. *Anatomy for Surgeons, volume 2. The Thorax, Abdomen and Pelvis*. 2nd ed. New York: Harper and Row; 1971.)

The abdominal course of the ureter is identical in men and women. The most consistent place to locate the ureter is where it crosses the iliac vessels. When compressed with forceps, one can see its distinctive peristalsis. On the right, it is slightly closer to the midline and tends to be adjacent to the posterior part of the ascending colon, stressing the importance of developing a dissection plane close to the colon during right colon mobilization.

On the left, the ureter travels close to the IMA, passing under it and then continuing under the attachment of the mesentery at the apex of the inverted “V” of the sigmoid mesocolon through the intersigmoid fossa

(Fig. 141.11).

The pelvic course of the ureter begins after it passes anterior to the internal iliac artery and its anterior division. It then travels along the pelvic sidewall following a medial direction at the base of the broad ligament in the female and over the uterine artery entering obliquely into the urinary bladder. In the male pelvis, the ureter travels medially, posterior to the ductus deferens and above the seminal vesicles before entering the urinary bladder. During or following inflammation, the ureter tends to be pulled medially toward the inflammation. The same is true in the presence of colorectal cancer. Inserting ureteral catheters can sometimes be helpful with ureteral localization in such situations.

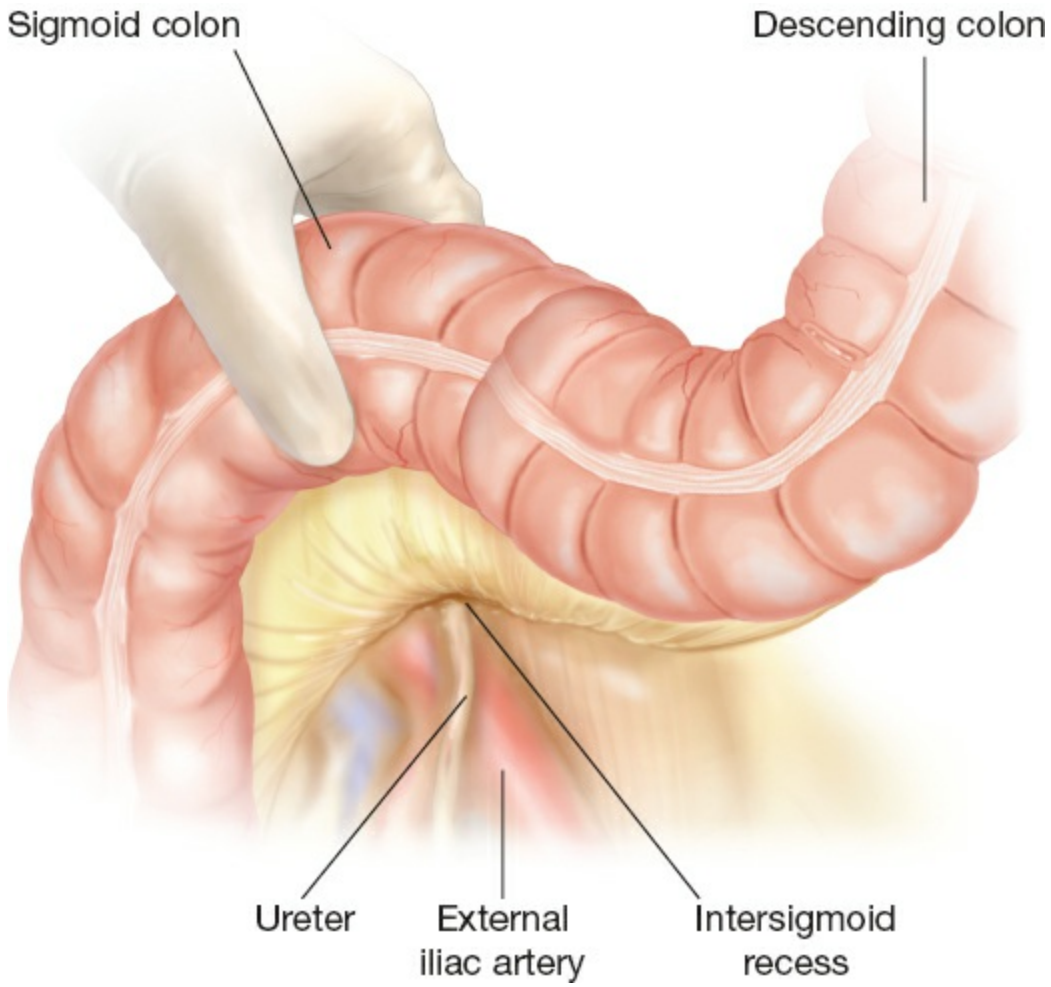

Figure 141.11. The intersigmoid recess, the sigmoid colon being retracted upward and to the right. (With permission from Hollinshead WH. *Anatomy for Surgeons, volume 2. The Thorax, Abdomen and Pelvis*. 2nd ed. New York: Harper and Row; 1971.)

OMENTUM

The greater omentum is largely viewed by surgeons as a protective structure, filling in cavities and helping control spread of infection. It has two parts—the superior gastrocolic ligament composed of two serous layers and the inferior apron-like part, draping over the anterior abdominal cavity, composed of four serous layers. It is usually filled with fat. Its size and volume are highly variable, although in most cases, this is correlated with body weight.

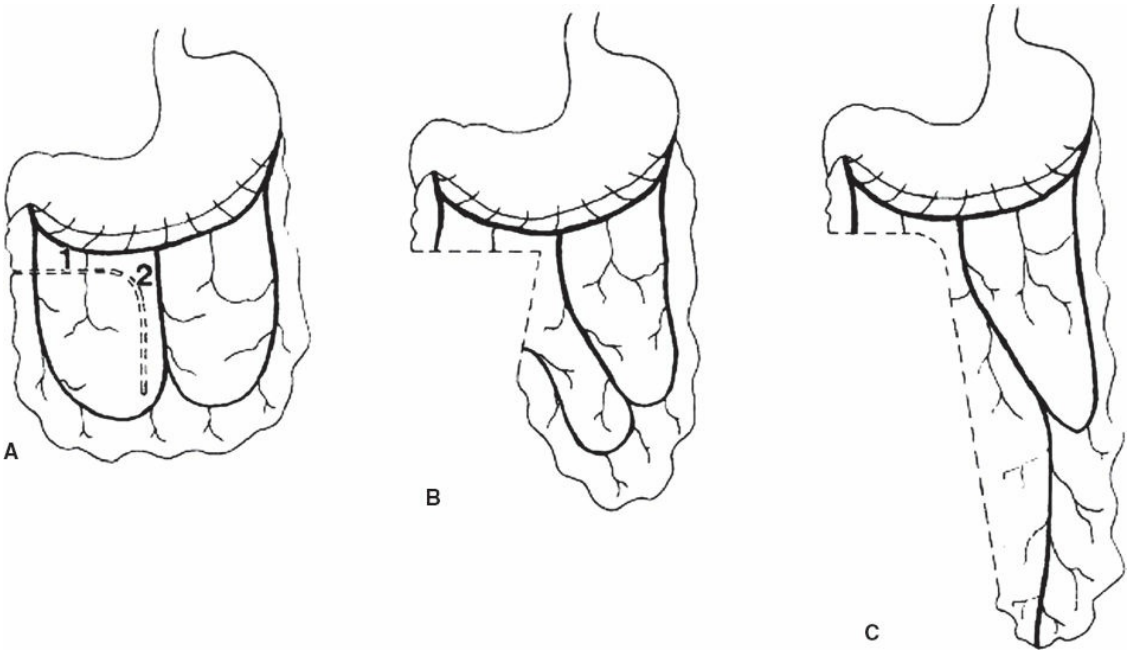

Figure 141.12. Incision and lengthening of the omentum. **A.** Line indicating the course of a transverse incision (1) from right to left below the gastroepiploic arch to the middle omental artery, (2) indicates an oblique, longitudinal continuation of the transverse incision toward the marginal erterial arcade. **B.** The omentum still cannot reach the pelvic floor after a transverse incision has been made as described in (1). **C.** Lengthening of the omental flap after making a tranverse oblique, longitudinal incision as described in (2). The omentum can now easily reach the pelvic floor. (With permission from Topor B, Acland RD, Kolodko V, et al. Omental transposition for low pelvic anastomoses. *Am J Surg* 2001;182:460–4.)

Upwards traction on the greater omentum and downward traction of the transverse colon will reveal an avascular plane adjacent to the colon. This plane is useful when separating these two structures and can be most easily identified close to the midline. On both right and left sides of the omentum, the attachment is more difficult to separate from the transverse

mesocolon.

The greater omental blood supply originates from the left and right gastroepiploic vessels that can be found within the gastrocolic ligament adjacent to the greater curvature of the stomach. They give rise to the left, right, and occasionally middle omental arteries. These arteries traverse in the posterior part of the greater omentum and create arterial arcades between them (Fig. 141.12). When considering an omental transposition, for example, in order to create an omental pedicle that reaches the pelvis, it is possible to ligate and detach one side, achieving extra omental length while the blood supply is adequately maintained by the distal arcade from the other side.

RECTUM

The rectum extends from the rectosigmoid junction to the anus (Fig. 141.13). The distal border being defined by anatomists as the pectinate (dentate) line based on the mucosal surface or defined by surgeons, as the level of the levator ani (about 2 cm above the dentate line). Structurally, the rectum lacks distinct taeniae coli, epiploic appendices, and sacculations (haustra of the colon). The rectum has three lateral curves—the upper to the right, the middle to the left, and the lower to the right—and expands inferiorly into the rectal vault before becoming the anal canal.

For surgeons, the rectum is also divided into thirds, with a total length of around 15 to 20 cm, based largely upon its peritoneal relationships. The superior third is covered by peritoneum anteriorly and laterally, defined as being 10 to 15 cm above the dentate line. The middle part is covered by peritoneum only anteriorly and extends from 5 to 10 cm above the dentate line, while the lower third of the rectum is totally extraperitoneal, extending from 1 to 5 cm above the dentate line. The rectovesicular (males) or rectouterine (females) pouch formed by the peritoneum between the rectum and anterior structures is clinically important as a common location of fluid and pus accumulation, being the lowest dependent part of the peritoneal cavity (Fig. 141.14). This typically is found at the lower part of the middle third of the rectum, except in patients with rectal prolapse, in which it can extend much further distally. The relationship of the rectum to the peritoneal cavity is especially important in cases of colorectal, coloanal, or ileal pouch anal anastomoses, where extraperitoneal anastomoses are more prone to be associated with pelvic fluid collections, since there is no peritoneum with its absorptive capabilities in this area.

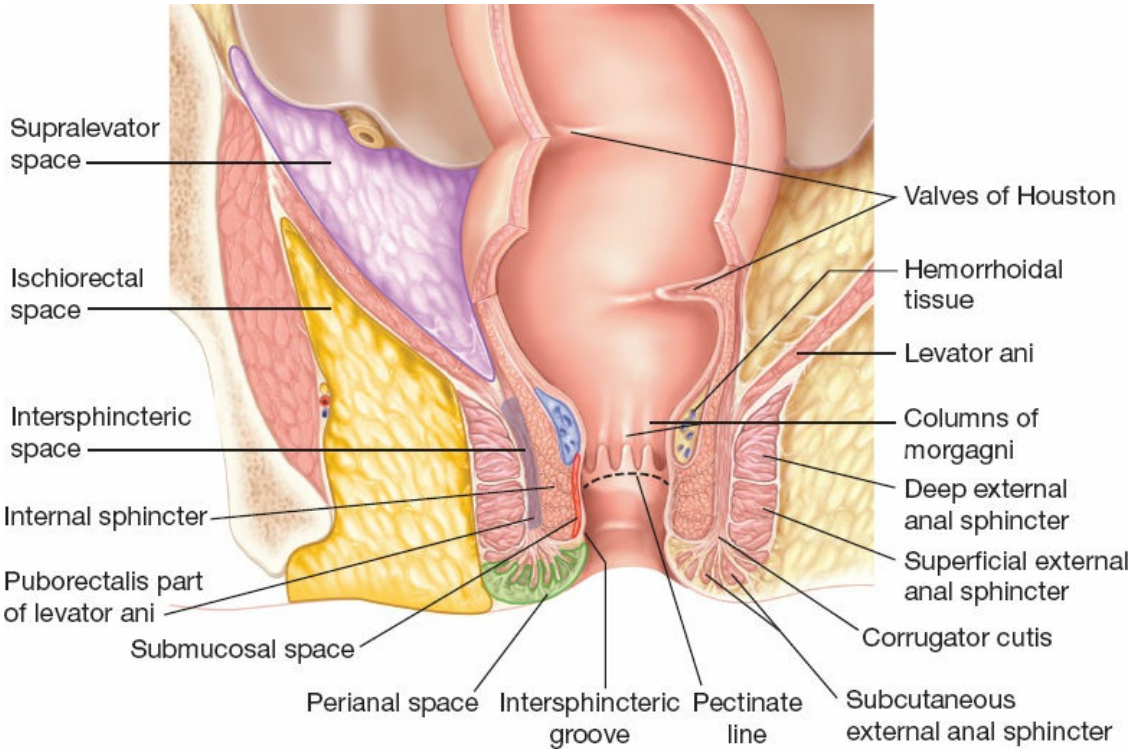

Figure 141.13. The rectum and anus in coronal section.

Anatomic structures adjacent to the rectum are clinically important with respect to direct extension of tumors and/or fistulas. Anteriorly and extraperitoneally in males, the rectum is adjacent to the prostate, seminal vesicles, vas deferens, ureters, and urinary bladder. In women extraperitoneally, the rectum is adjacent to the posterior vaginal wall and uterine cervix, and intraperitoneally to the upper part of the posterior vaginal wall, uterus, tubes, and ovaries. The small bowel and colon fill the intraperitoneal pelvis in both genders. Posteriorly, the rectum is adjacent to the sacrum, sacral vessels, and sacral nerve roots.

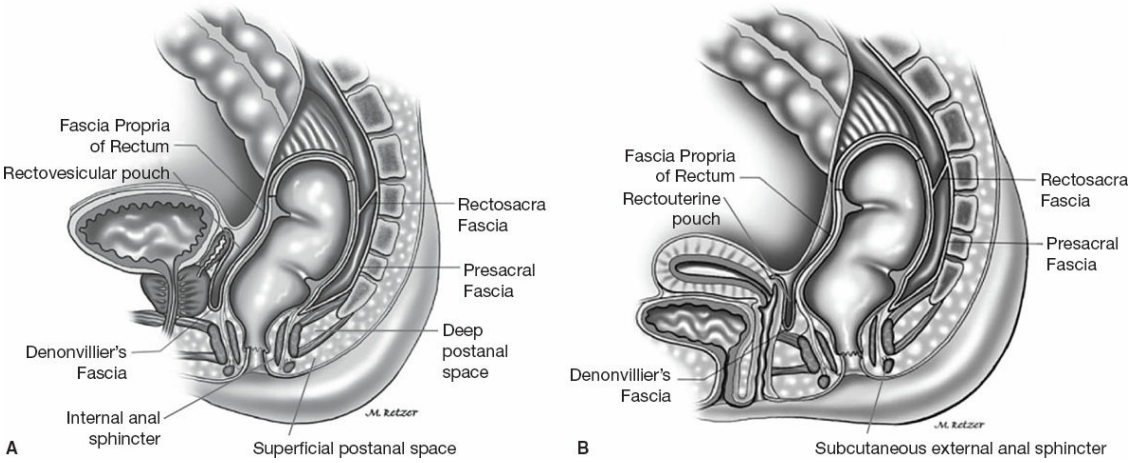

Figure 141.14. Fascial relationships of the rectum: (**A**) male, (**B**)

female. The intersigmoid recess, the sigmoid colon being retracted upward and to the right. (With permission from Jorge JMN, Habr-Gama A. Anatomy and embryology of the colon, rectum, and anus. In: Beck DE, Wexner SD, Hull TL, et al., eds. *The ASCRS Manual of Colon and Rectal Surgery*. 2nd ed. New York: Springer; 2014.)

The mesorectum is the visceral mesentery of the rectum. It is unlike the colonic mesentery in that it does not form a "true" mesentery covered on both sides with peritoneum. Surgically, knowledge of mesorectal planes is very important, as dissection along its border results in a relatively bloodless dissection plane, with reliable excision of the relevant lymphatic tissue and preservation conservation of urinary and sexual function. The mesorectum is relatively thick posteriorly, thinner along the sides, and very thin anteriorly (Fig. 141.15).

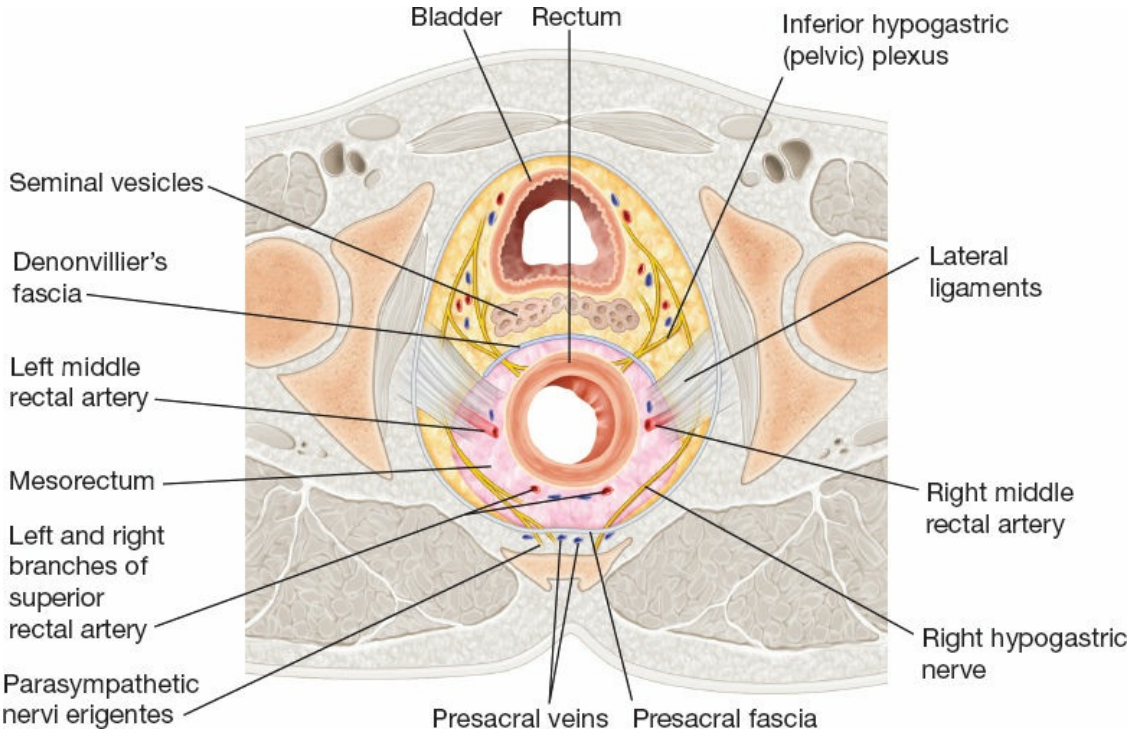

Figure 141.15. Cross-section of mesorectum and surrounding structures.

A good understanding of the extraperitoneal fascial relationships of the rectum is critical in achieving the correct plane of dissection when performing a total mesorectal excision (TME). The rectum itself is covered by the thin visceral fascia propria of the rectum. Anterior to the rectum, a bilaminar extension of the inferior peritoneal reflexion extends to the

perineal body. This fascial layer (Denonvillier fascia) separates the rectum from the previously mentioned anterior structures and is included as the anterior border of the TME. Laterally, the rectum is connected to the pelvic sidewall by the “lateral stalks” or ligaments, which are fibrous condensations of the pelvic fascia, shaped like a triangle with the base on the pelvic sidewall and the apex joining the rectum. These are located low down in the pelvis at the level of the prostate or mid-vagina and can only be appreciated once posterior and anterior mobilization has been performed. When cutting through these structures, it is important to remember that in about a quarter of the cases, a branch of the middle rectal artery traverses them and may cause bleeding. Posteriorly, the mesorectum is limited by the presacral fascia, covering the anterior sacrum and coccyx. The presacral veins, a series of veins on the presacral periosteum, drain into the sacral foramina. Dissection deep to the presacral fascia can cause dramatic, and sometimes life-threatening, bleeding from the underlying presacral venous plexus. Such bleeding can be challenging to control, as the torn vessels tend to retract into the sacral foramina. The rectosacral fascia (Waldeyer fascia) connects the presacral fascia around the level of S4 to the posterior–inferior rectum. It is typically divided close to the presacral fascia during a TME procedure (Fig. 141.14).

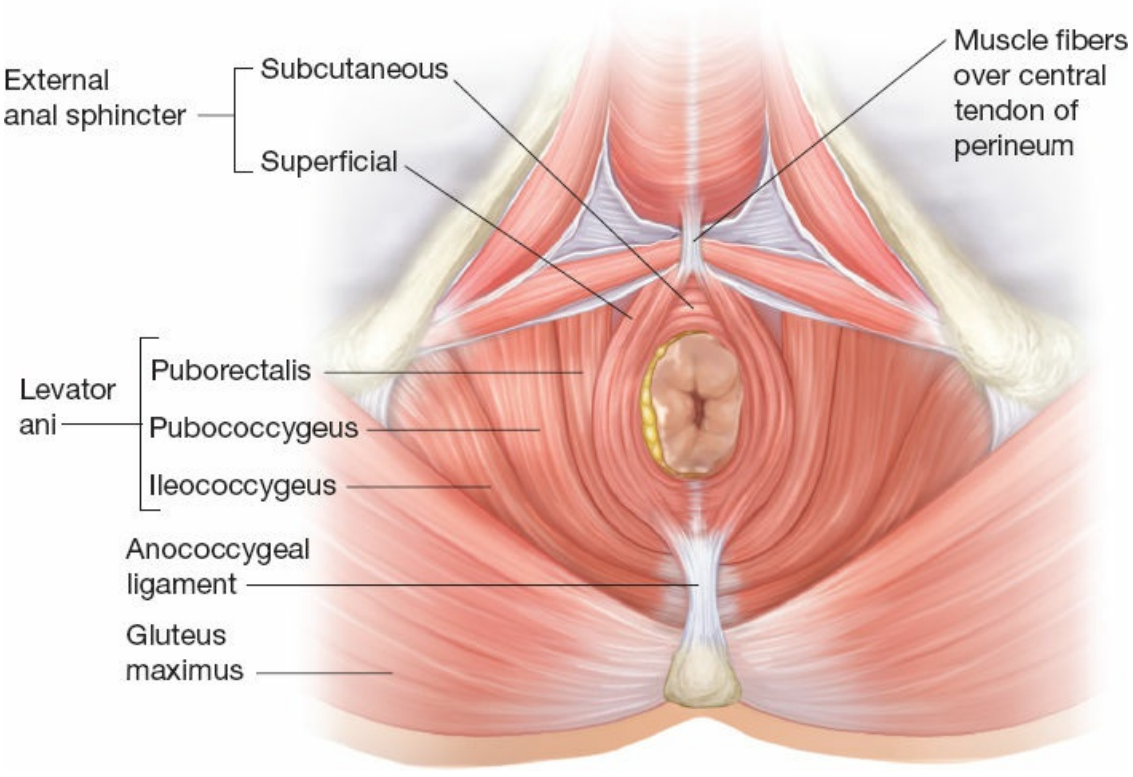

Figure 141.16. The pelvic musculature and innervation from

below. The deep external anal sphincter muscles are hidden under the superficial part.

ANUS

The last portion of the GI tract is the anus (Fig. 141.13). From a surgical standpoint, its length is approximately 4 cm, beginning at the level of the anorectal ring (the levator ani) and ending at the anal verge, where the epithelium acquires skin characteristics (hair, etc.). The dentate line marks the transition from enteric columnar to stratified squamous epithelium.

The internal anal sphincter (IAS), a thickened continuation of the rectal circular muscle, is composed of smooth muscle and is in a state of continuous contraction. By placing the anus under tension with a retractor, one can easily see the groove between the internal and external anal sphincters. This intersphincteric groove is the plane used for left internal sphincterotomy in cases of anal fissure and for intersphincteric or endoanal proctectomy in inflammatory bowel disease or other benign pathology.

The external anal sphincter (EAS), composed of skeletal muscle encircling the anus, has three main divisions: the subcutaneous part, found distally and laterally to the IAS; the superficial portion, which slings around the anus and connects to the coccyx posteriorly, and to the perineal body anteriorly (Fig. 141.16); and the deep part, which is connected anteriorly and contiguously to the puborectalis muscle. The conjoined longitudinal muscle, composed of fibers from the longitudinal muscle of the rectum and fibers from the levator ani, descends between the internal and external anal sphincters and inserts into perianal skin through the subcutaneous EAS as the corrugator cutis.

The levator ani is composed of three parts: the puborectalis, the pubococcygeus, and the iliococcygeus. The maintenance of continence is performed through lateral and circumferential compression by the pubococcygeus and anal sphincters and maintenance of angulation by the puborectalis.

There are a number of anorectal spaces of clinical significance (Fig. 141.13). The submucosal space lies between the anal mucosa and the IAS; it is continuous with the submucosal space of the rectum. The internal hemorrhoidal plexus is found in this space.

The intersphincteric space lies between the EAS and the IAS. The anal glands are found in this space and empty into the anal crypts at the level of the dentate line. Most cryptoglandular infections begin in this space and

spread to other spaces.

The perianal space is at the lowest part of the anal canal, including the subcutaneous EAS, the lower part of the IAS, and the external hemorrhoidal plexus. This space communicates with the intersphincteric space and ischiorectal space and is the most common location for abscesses and hematomas.

The ischiorectal (ischioanal) space is lateral to the EAS, inferior to the levator ani, and medial to the ischial tuberosity and obturator fascia. The pudendal and inferior rectal vessels and nerves traverse this space (see below). The two ischiorectal spaces communicate posteriorly through the deep postanal space (Fig. 141.14) between the levators and the anococcygeal ligament, and between the anococcygeal ligament and the skin through the superficial postanal space. Both postanal spaces are the connection through which horseshoe abscesses commonly form.

The supralevator space is lateral to the rectum, above the levator ani, and is located infraperitonealy. Infections can spread to this space upward through the intersphincteric space or can spread downward to this space from a pelvic source. Haphazard crossing of the levator ani during drainage of an ischiorectal abscess can iatrogenically infect this space.

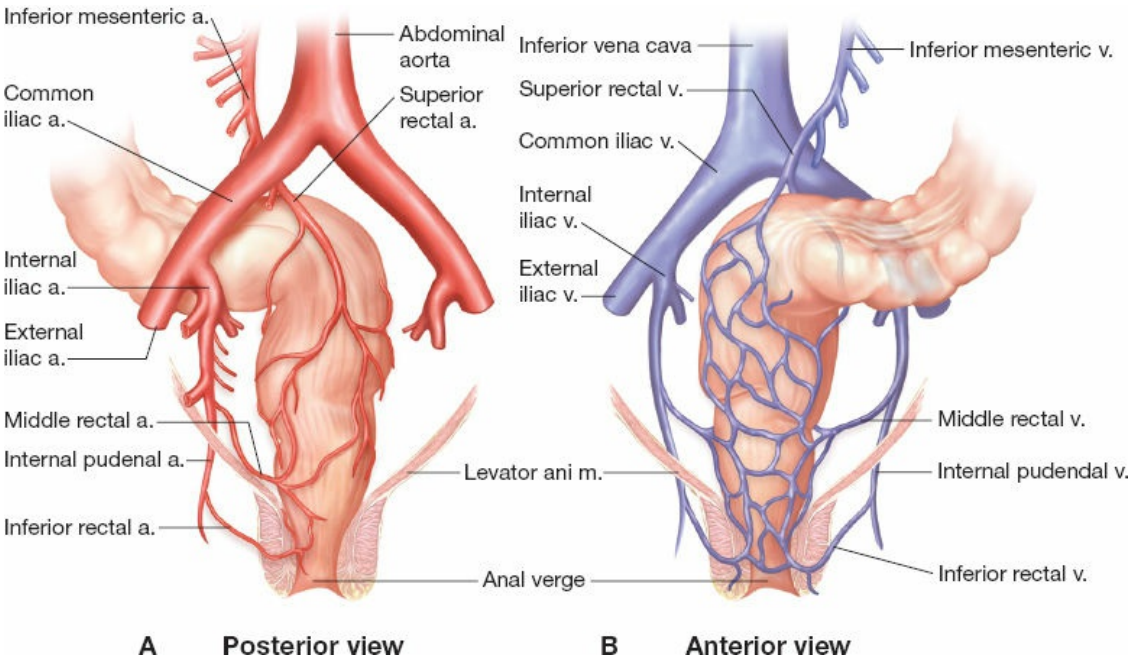

Figure 141.17. The vascular supply to the rectum. **A.** Arteries. **B.** Venous drainage.

ANORECTAL BLOOD SUPPLY

The vascular supply includes the superior rectal artery from the IMA; the middle rectal artery from the internal iliac artery; and the inferior rectal artery from the internal pudendal artery, a branch of the internal iliac artery (Fig. 141.17). The rectum has an intense anastomotic network within its wall connecting these three arteries. This accounts for the fact that the rectum remains viable after dividing the superior rectal artery during sigmoid and anterior rectal resections.

The superior rectal (hemorrhoidal) artery is the main blood supply of the rectum. It is the end branch of the IMA after it gives out the sigmoid branches. The artery descends to the posterior upper wall of the rectum, dividing there into right and left branches, running within the rectal wall down to the dentate line.

The middle rectal (hemorrhoidal) arteries are paired vessels running from the internal iliac vessels to the lower rectum around the level of the levator ani or slightly higher. They are not considered to be a major blood supply to the anorectum and some consider them inconstant. The middle rectal arteries can be injured when dissecting the low anterolateral region close to the levator ani.

The paired inferior rectal (hemorrhoidal) arteries are branches of the internal pudendal arteries and generally supply the anus distal to the pectinate line.

The superior rectal vein generally drains the superior two thirds of the rectum, draining into the IMV and portal system. The paired middle and inferior rectal veins drain the lower rectum and anus and collect into the internal iliac and systemic circulation, accounting for the higher incidence of pulmonary metastases with low rectal cancers, as compared to the hepatic metastases seen with advanced mid and upper rectal cancers. The rich anastomotic connection between the superior rectal venous drainage and systemic circulation classically becomes apparent in cases of portal hypertension causing engorged hemorrhoids and impressive rectal varices.

LYMPHATIC DRAINAGE OF THE ANORECTUM

The lymph from the rectum primarily moves in an upward direction in association with the superior rectal artery, reaching the inferior mesenteric lymph nodes. This is practically the only direction of drainage for the upper two thirds of the rectum. The lower part of the rectum drains in two directions, cephalad toward the inferior mesenteric nodes and laterally and inferiorly toward the internal iliac nodes. Below the dentate line, the

lymph drains toward the inguinal lymph nodes. The latter accounts for the occasional observation of extensive inguinal metastases in patients with aggressive recurrent rectal cancers affecting the distal rectum.

INNERVATION OF THE ANORECTUM

The rectum receives sympathetic innervation from the superior hypogastric plexus forming from branches of L1 to L3, anterior and inferior to the aortic bifurcation, dividing around the sacral promontory to left and right hypogastric nerves, traveling on both sides of the pelvis. Here, they are joined by parasympathetic fibers (nervi erigentes), originating from the S2 to S4 foramina, and form the inferior hypogastric (pelvic) plexus on both anterolateral sides of the rectum (Fig. 141.18). In addition to supplying the rectum, these nerves send branches to the genitourinary system anteriorly.

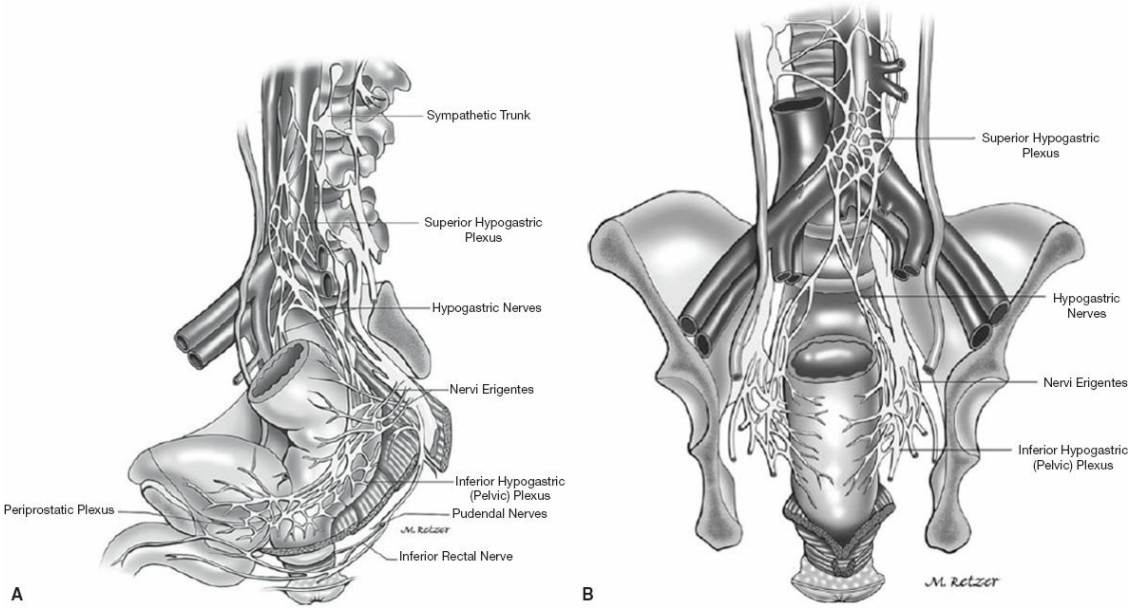

Figure 141.18. Innervation of the colon and anus. **A.** Coronal view. **B.** Sagittal view. (With permission from Jorge JMN, Habr-Gama A. Anatomy and embryology of the colon, rectum, and anus. In: Beck DE, Wexner SD, Hull TL, et al., eds. *The ASCRS Manual of Colon and Rectal Surgery*. 2nd ed. New York: Springer; 2014.)

The autonomic nerves to the pelvis are at risk of injury when performing pelvic operations, highlighting the need to be aware of their location and avoid them, if possible. When ligating the IMA, it is critical to dissect close the underside of the artery so as to avoid injury to the superior hypogastric plexus, which can cause retrograde ejaculation. When

dissecting anterior to the promontory and sacrum, it is important to stay anterior to the presacral fascia and to identify the hypogastric nerves on both sides of the pelvis. The nervi erigentes and pelvic plexus can be injured if the lateral stalks of the rectum are divided too close to the lateral pelvic sidewall and cause disturbances in erectile function. The periprostatic plexus can be injured when dissecting anteriorly to Denonvillier fascia near the prostate and seminal vesicles, which can also cause sexual and bladder dysfunction. In general, when performing a rectal resection for benign disease, one should remain close to the rectal wall to reduce the risk of injuring these plexuses affecting bladder and sexual function.

The pudendal nerve branches off the sacral plexus S2 to S4 and exits the pelvis posterior-laterally between the piriformis and ischiococcygeus muscles. In cases of incontinence, these ventral sacral nerve roots can be directly stimulated (usually S3, but in some cases S2, S4) through the dorsal sacral foramina, stimulating the levator and EAS, promoting continence. This nerve is accompanied by the internal pudendal vessels as it travels through the pudendal (Alcock's) canal on the lateral wall of the ischioanal fossa. It gives out the inferior rectal nerve that travels anteromedially, crossing the ischioanal fossa to supply the EAS as well as sensation to the lower part of the anal canal and the circumanal skin (Fig. 141.16). The pudendal nerve also gives out the larger perineal nerve, which runs forward to the external genitalia, but also innervates the anterior part of the EAS and levator ani and participates in skin innervation of the perineal area.

The pudendal nerve can be found reliably over the ischial spine and can be blocked by infiltration with a local anesthetic. Deep incisions in this region and anteromedially to it for abscess drainage and blunt dissection can injure the pudendal nerve and its inferior rectal branches.

Knowledge of anatomy reduces the incidence of complications; increases surgeon confidence; and provides for smooth, uneventful surgery that is both a joy to learn and teach.

Suggested Readings

Acland RD. *Acland's Video Atlas of Human Anatomy* (online video atlas). Philadelphia, PA: Wolter Kluwer Health; 2010.

Hollinshead WH. *Anatomy for Surgeons: volume 2, The Thorax, Abdomen and Pelvis.* 2nd ed. New York: Harper and Row; 1971.

Jorge JMN, Habr-Gama A. Anatomy and embryology. In: Beck DE, ed. *The ASCRS Textbook of Colon and Rectal Surgery*. 2nd ed. New York: Springer; 2011.

Milsom JW, Bohm B, Nakajima K, eds. *Laparoscopic Colorectal Surgery*. 2nd ed. New York: Springer; 2006.

Skandalakis JE, Colborn GL, Weidman TA, eds. *Skandalakis Surgical Anatomy: The Embryologic and Anatomic Basis of Modern Surgery*. Athens, Greece: Paschalidis Medical Publications; 2004.

Topor B, Acland RD, Kolodko V, et al. Omental transposition for low pelvic anastomoses. *Am J Surg* 2001;182(5):460–4.

EDITOR'S COMMENT

Dr. Netz and I have endeavored to make this chapter a "*non-traditional*" anatomy chapter. There are many anatomy books that are available to the surgeon to serve as anatomy references, some of which are listed in the Suggested Readings at the end of the chapter. What we wished to do herein is to describe anatomy that is particularly relevant for the surgeon, and to inform the surgeon why the particular anatomy is relevant. There has been a virtual explosion in "anatomy-based" surgery over the last 20 years, where knowledge of anatomy has helped surgeons (1) restore lost organ function, (2) avoid tension on small bowel or colon anastomoses, and (3) provided improved healing by buttressing anastomoses with either omentum, muscle, or other types of pedicled flaps.

Replacement of Organ Function

The ileocecal valve is perhaps the most valuable structural component of the abdomen with respect to replacing organ function. This segment of bowel has been "borrowed" by surgeons to be used in a variety of ways for different continence procedures, utilizing its ingenious valve mechanism for continent urinary diversions (Myers JB, Lenherr SM. Perioperative and long-term surgical complications for the Indiana pouch and similar continent catheterizable urinary diversions. *Curr Opin Urol* 2016;26(4):376–82), as well as it and the appendix for continent catherizable stomas for antegrade continence enema procedures in both children and adults (Chan DS, Delicata RJ. Meta-analysis of antegrade continence enema in adults with faecal incontinence and constipation. *Br J Surg* 2016;103(4):322–7). In addition, with proper knowledge of vascular anatomy, segments of the transverse colon can be utilized to replace the bladder in patients who have received extensive pelvic radiation (Leissner J, Fisch M, Hohenfellner R. Colonic pouch [Mainz-pouch III] for continent urinary diversion. *BJU Int* 2006;97:417–30).

Obtaining Extra Bowel Length

Knowledge of vascular supply can be used to gain bowel length to obtain a tension-free anastomosis. This includes a variety of maneuvers ranging from utilizing the avascular space adjacent to the ileocolic artery to perform a retro-ileal colorectal anastomosis, in cases where the left colon is absent, to division of either the ileocolic or superior mesenteric artery branches, in order to obtain extra mesenteric length so that an ileal pouch can be brought down to the low pelvis with less tension, in cases of ileal-pouch anal anastomosis. In extreme cases, knowledge of vascular anatomy has permitted an ileal pouch to be constructed with ligation of the distal superior mesenteric and ileocolic arteries, but with preservation of the right middle colic and right marginal colon arteries (Chu DI, Tognelli J, Kartheuser AH, et al. Strategy for the difficult-to-reach ileal pouch-anal anastomosis: technical steps of an in vivo application of a mesenteric-lengthening technique. *Tech Coloproctol* 2015;19(11):705–9).

Buttressing Anastomoses/Repairs

With respect to anastomotic healing, knowledge of vascular supply is also important in order to permit surgeons to create omental pedicles. These can be utilized to aid healing following multiple different types of procedures, as well as for creation of vascular pedicled seromuscular flaps from segments of out-of-circuit small bowel (Aho J, Winocour S, Hammoudeh ZS, et al. Seromuscular colonic flap for intrapelvic soft-tissue coverage: a reconstructive option for plastic surgeons when traditionally used flaps are not available. *Case Rep Surg* 2015;2015:563641).

Importance of Anatomical Knowledge in Avoiding Organ Injury

Knowledge of anatomy allows a surgeon to be safe, confident in pursuing surgery knowing where adjacent structures are, and what can be injured at the time of surgery. As a recent study using the National Inpatient Sample (NIS) database has shown, this is still something that is frequently done (Al-Qurayshi Z, Srivastav S, Slakey DP, et al. Risk of intraoperative injury of nearby structures: national trend, distribution, and burden. *J Am Coll Surg* 2016;222(4):624–31). In this study of nearly 64 million inpatient records, 61,667 cases of intraoperative injury were identified, with procedures involving the digestive tract accounting for the largest group (38%). Such injuries were more common in patients over the age of 60 years (odd ratio [OR] 4.00, 95% confidence interval [CI] 3.76 to 4.26, $p < 0.001$). In addition intraoperative injuries were associated with a higher risk of complications (OR 2.44, 95% CI 2.36 to 2.54, $p < 0.001$) as well as a higher mortality (OR 2.33, 95% CI 2.15 to 2.51, $p < 0.001$). Knowledge of anatomy can also predict sites of cancer recurrence and provide for more economical targeted cancer follow-up. For example, cancers of the lower rectum due to their venous drainage through the internal iliac system are more likely to metastasize to the lungs, in contrast to cancers of the upper rectum, draining through the portal system to the liver.

My original intention was to have Robert Acland, author of the well-known *Acland's Video Atlas of Human Anatomy* (Acland's Video Atlas of Human Anatomy. Wolters Kluwer. aclandanatomy.com/) be a coauthor on this chapter. Unfortunately, he was diagnosed with a serious illness and passed away early in 2016 (www.legacy.com/obituaries/louisville/obituary.aspx?pid accessed January 20, 2016). Dr. Acland was a true master of anatomy, a consummate surgeon, and a true artist. His statement "an anatomical structure has no moral obligation to be where you think it should be" was well-known by his many students and residents over the years. His pioneering video-anatomy atlas was created using the most mundane of materials: a rotating plywood disk covered by black velvet. With this, he was able to "choreograph" the most visually stunning, creative video anatomy atlas one could imagine—this truly made anatomy come to life. His attention to detail and joy at dissecting were amazing to watch.

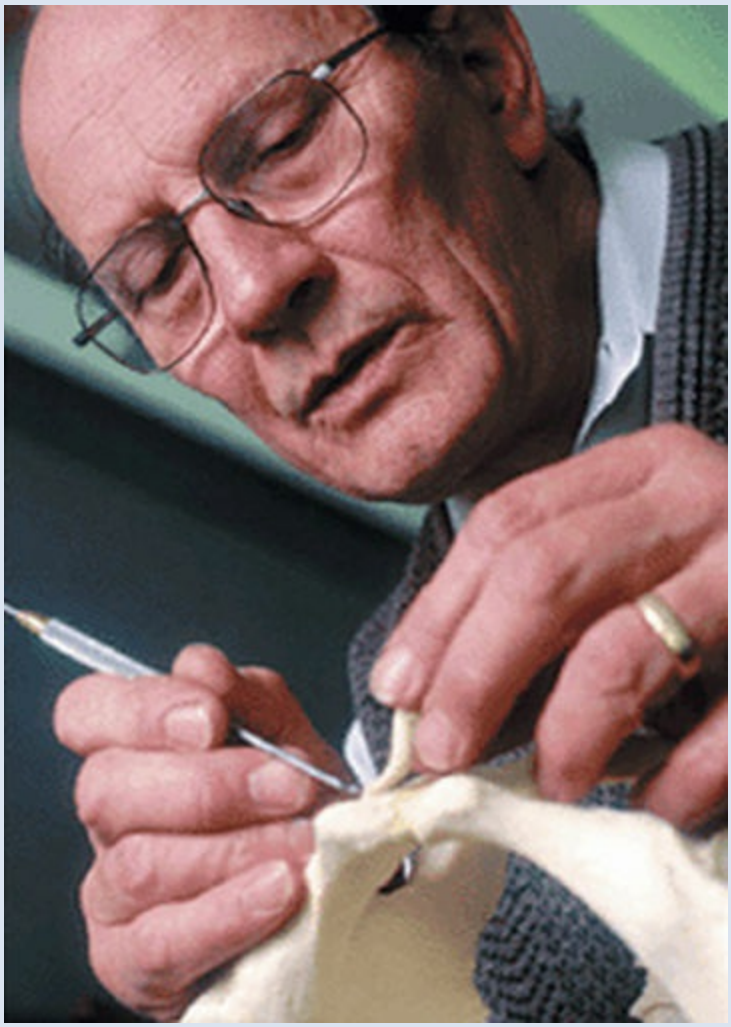

Robert D. Acland, MD

Robert D. Acland graduated from London Hospital Medical College in 1964 with a Bachelor in Medicine (MB), receiving his MBBS from London

University in 1969. He completed internships in the United Kingdom and Tanzania, and residencies in plastic surgery in Glasgow (FRCS in 1969) and London (FRCS in 1970). He first came to Louisville in 1976 at the invitation of Dr. Joseph Kutz of the Kleinert and Kutz Hand Care Center to run their microsurgery laboratory within the Price Institute of Surgical Research at the University of Louisville Department of Surgery and also received a teaching appointment in the department. During this time, he developed some of the first microsurgical instruments and 10-0 sutures and needles that are still in use. He became Professor of Plastic and Reconstructive Surgery in 1986 and held Associate appointments in the Departments of Physiology and Biophysics, and of Anatomical Sciences and Neurobiology. Upon his retirement from teaching microsurgery, he began a second career as a clinical anatomist and became a pioneer in the field of fresh tissue dissection. Dr. Acland established the Fresh Tissue Anatomy Dissection Laboratory for surgeons and students at the University of Louisville, which was the first of its kind in the United States, using a technique of “light embalming” that gave tissues a near-life-like touch and feel. His Video Atlas of Human Anatomy began in 1993 and took 9 years to create. The atlas depicts moving structures—muscles, tendons, and joints—making the same movements that they make in life. While working on his atlas, Dr. Acland developed new effective techniques of anatomical videography using innovative camera rotation techniques to achieve a unique 3-D perspective that gives the viewer a clear three-dimensional understanding of spatial relationships of anatomical structures. Dr. Acland will be greatly missed by all of his friends and colleagues and lovers of anatomy.

Susan Galandiuk

142 The Appendix

Vic Velanovich

INTRODUCTION

Appendectomy remains one of the most commonly performed operations worldwide. Up to 8% of the United States population will have an appendectomy in their lifetime. Although acute appendicitis is the most common indication for appendectomy, the appendix may also harbor tumors with a spectrum of malignant potentials. Options for the management of inflammatory and neoplastic appendiceal diseases have evolved, and a thorough understanding of these options is essential for the practicing general surgeon.

ANATOMY

The appendix is located at the base of the cecum where the teniae coli coalesce. Although this location is constant, the position of the appendix is variable. The appendix is located about 2.5 cm inferior to the ileocecal valve and is attached to the terminal ileum by the ligament of Treves, which the mesoappendix extending from the mesentery contains its vascular supply. The appendix is usually about 6 to 12 cm long, but may reach over 16 cm in length, with a diameter of about 0.8 cm, with a range between 0.3 and 1 cm. The appendiceal position is variable (Fig. 142.1), with the most common being intraperitoneal extending toward the pelvic brim and iliac fossa. However, there are many other appendiceal positions including intraperitoneal retrocecal, extraperitoneal retrocecal (i.e., posterior to the cecum but in the retroperitoneal space), toward the sacral promontory, and anterior or posterior to the ileum. To further complicate matters, malrotation and nonrotation of the intestine can place the appendix in the mid-abdomen or left upper quadrant. In addition, although rare (about 4 per 100,000 persons), appendiceal duplications do occur. These variable positions can lead to atypical presentations of appendiceal disease; and, hence the surgical dictum, “appendicitis should always be in the top three differential diagnoses of acute abdominal pain in any

location."

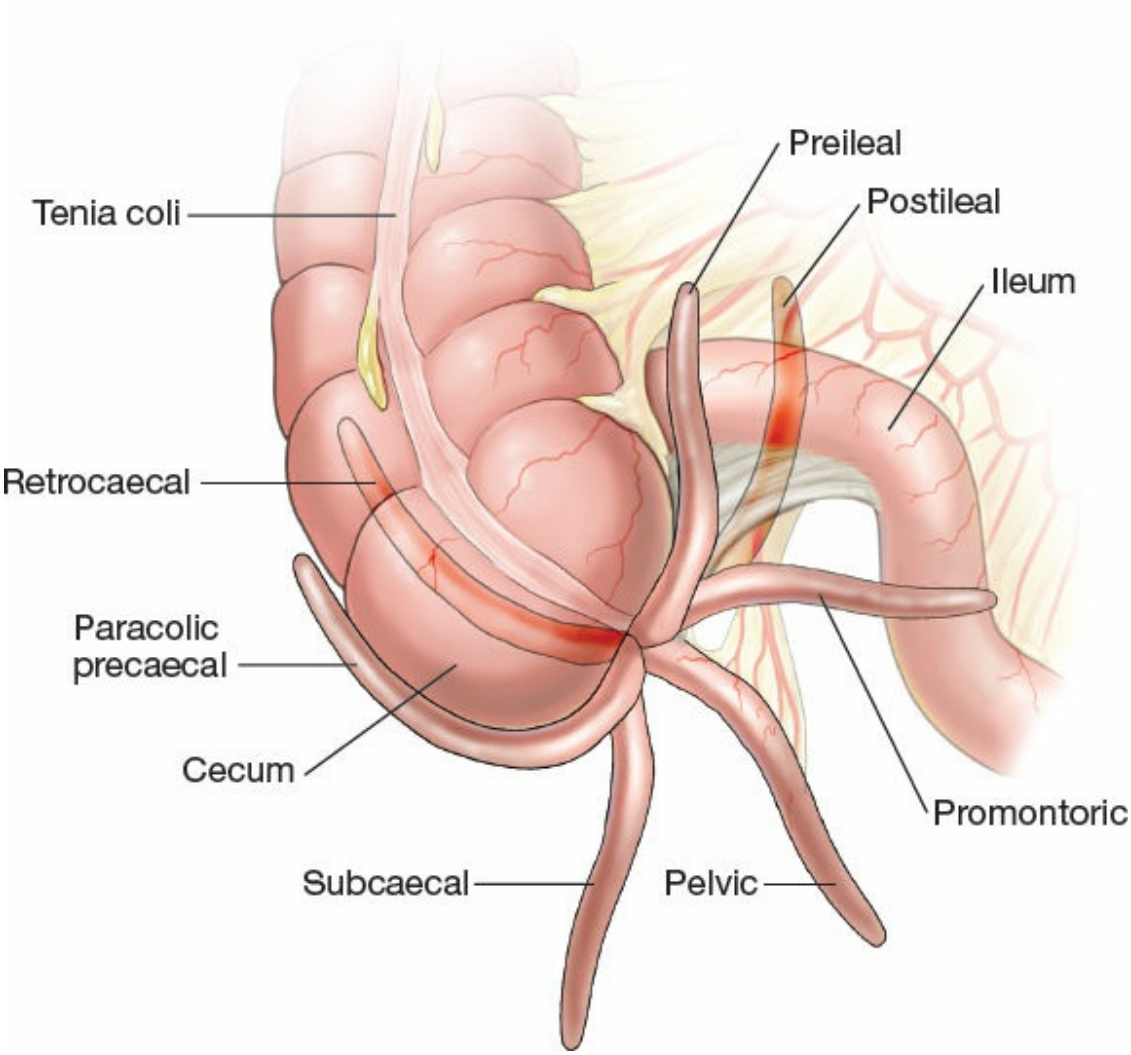

Figure 142.1. Variations in the position of the appendix in relation to the cecum, ileum, and peritoneum.

The blood supply to the appendix is from ileal branch of the ileocolic artery. The appendiceal blood is variable with usually a single appendicular artery, but two or more arteries possible. However, there is no overlap with the blood supply to the cecum.

The appendix can be considered a true diverticulum of the cecum, containing all three intestinal layers and a lumen. In addition, the appendix has a wealth of gut-associated lymphoid tissue which may be immunologically active (the appendix may not be a "vestigial" organ after all). The appendiceal lumen is in continuity with the cecal lumen, with the appendiceal orifice covered by the mucosal fold. Identification of the appendiceal orifice during colonoscopy signifies that the entire colon can

now be visualized and is considered a quality indicator. As humans age, the appendiceal lumen narrows and, eventually, completely obliterates, which is one of the reasons that the incidence of appendicitis decreases with age.

ACUTE APPENDICITIS

Etiology and Pathophysiology

Acute appendicitis is the most common of the appendiceal diseases. Its peak incidence occurs in the second and third decades of life, with a lower rate in children <4 years old and a progressively reducing incidence in adults over 30 years old. However, the risk of mortality occurs at the extremes of age.

Acute appendicitis occurs as a result of obstruction of the appendiceal lumen. In young patients who have an abundance of lymphoid tissue, lymphoid hyperplasia can be the cause of the obstruction. In older patients, fecaliths may be the cause. In either event, the obstruction of the appendiceal lumen leads to accumulation of mucus, which causes increased intraluminal pressure. This pressure leads to occlusion of blood and lymph vessels within the appendiceal wall causing necrosis. With the breakdown of the appendiceal mucosal barrier, colonic bacteria cause infection and further inflammation. This can result in a phlegmon or inflammatory mass. Eventually, there is full thickness necrosis of the appendix, with perforation and spillage of bacteria into the intraperitoneal space. This can result in an intraabdominal/pelvic abscess or generalized peritonitis with progressive sepsis.

Clinical Presentation

The presentation of appendicitis is protean. The “classic” presentation is vague periumbilical pain which over the course of a few hours localized to the right lower quadrant at McBurney point (one third the distance from the anterior superior iliac spine to the umbilicus). This mirrors the progression of midgut visceral pain due to distention of the appendix “hollow viscus” to somatic parietal pain as the peritoneum covering the appendix becomes inflamed. This is generally associated with anorexia; urge to defecate; occasional nausea, diarrhea, and fevers. However, because of the variable location of the appendix, other presentations are possible, such as right flank/back pain, suprapubic/pelvic pain, or

generalized abdominal pain.

Classically, physical examination demonstrated right lower quadrant pain with localizing signs of peritonitis. Other signs of peritonitis associated with appendicitis include Rovsing sign (right lower quadrant pain with palpation of the left lower quadrant), Dunphy sign (right lower quadrant pain with coughing), psoas sign (pain on extension of the right hip), and the obturator sign (pain with internal rotation of the right hip). Patients with appendices extending into the pelvis may also have right lower quadrant pain with a rectal and/or pelvic (in females) examinations.

Laboratory and Imaging Diagnosis

When history and physical examination suggest appendicitis, laboratory testing and imaging may help secure the diagnosis. Although leukocytosis is helpful, up to one third of patients may have a normal white blood cell count. A “left shift” with increased proportion of polymorphonuclear neutrophils and immature cells are typical, but, once again, not always present. C-reactive protein is generally elevated. However, none of these findings carries sufficient sensitivity and specificity to secure a diagnosis.

Although traditionally acute appendicitis was a clinical diagnosis, advances in imaging have improved diagnostic accuracy, leading to a lower rate of negative appendectomy without an increase in perforated appendicitis. Plain abdominal radiographs can be useful if a fecalith or some other intra-abdominal pathology is found (such as free air), but, in general, these films do not aid in diagnosis. Ultrasonography, in skilled hands, can identify an enlarged appendix in patients who present with equivocal findings or women where pelvic pathology may be a concern. However, the overall positive and negative predictive values are in the 80% to 100% range. Although ultrasonography is not as accurate as CT scanning, it may be the imaging test of choice in patients for whom limiting radiation exposure is desirable, such as pregnant women and children.

CT scanning has become the mainstay of imaging. This can be done with “reduced radiation” protocols. Typically, these scans use IV, p.o., and rectal contrast, although there is evidence that these agents may not be required. The signs of acute appendicitis included an enlarged appendix of >6 mm in diameter, thickened appendiceal wall of >2 mm (referred to as the “target” sign), periappendiceal inflammation (fat stranding), presence of a fecalith, and a thickened cecum funneling contrast to the appendix

("arrowhead" sign). With this, diagnosis accuracy can exceed 95% (Fig. 142.2).

Nonoperative Management of Acute Appendicitis

Traditionally, appendicitis has been a surgical disease. Over the last decade, there has been an increased interest in primary nonoperative antibiotic treatment of "uncomplicated" appendicitis. These studies have used a variety of means to diagnose appendicitis preoperatively, a variety of antibiotic regimens, and both open and laparoscopic approaches. This has led to several meta-analyses consolidating the data generated (Table 142.1). Because of the heterogeneity in treatment approaches, it is difficult to make definitive conclusions. However, what can be said is that appendectomy has a "cure" rate for appendicitis approaching 99%, with almost no recurrences of appendicitis, but a measurable surgical complication rate, mostly infectious in nature. Antibiotic therapy has a "cure" rate of 70% to 90%, but with a recurrent appendicitis rate 15% to 30%, yet a small number of serious adverse events. Certain findings, such as the presence of a fecalith increased the risk of recurrent appendicitis, and other factors, such as advanced age, increase the risk of the presence of unsuspected appendiceal neoplasia. Therefore, primary nonoperative antibiotic therapy may be appropriate in selected individuals with uncomplicated appendicitis, and these patients still require follow-up to assess for recurrence.



Figure 142.2. CT scan of acute appendicitis, coronal view. (Courtesy of John Feldman, MD. Tampa General Hospital.)

Nonoperative Management of Appendiceal Phlegmon and Periappendiceal Abscess

"Complicated" appendicitis includes those cases which have already progressed to gangrenous or perforated disease. These cases can have generalized peritonitis, localized phlegmon, or abscess. In those cases with generalized peritonitis, surgery to evaluate infected fluid and appendectomy for infectious source control to prevent further progression

of peritonitis is indicated. However, in patients with localized inflammatory/infectious processes, consensus on treatment is wanting.

TABLE 142.1 Studies Comparing Antibiotic Therapy Only to Appendectomy for Acute Appendicitis

Study	Sample Size	Antibiotic Regimen	Conclusion
Styrud et al., 2006	252	IV cefotaxime/tinidazole p.o. ofloxacin/tinidazole	Acute nonperforated appendicitis can be treated successfully with antibiotics
Farahnak et al., 2007	42	IV gentamicin/metronidazole p.o. amoxicillin/clavulanic acid	
Malik & Bari, 2009	80	IV ciprofloxacin/metronidazole	Antibiotics effective in the acute appendicitis
Hansson et al., 2009	369	IV cefotaxime/metronidazole p.o. ciprofloxacin/metronidazole	Antibiotic treatment safe first-line therapy for acute appendicitis
Vons et al., 2011	239	IV amoxicillin/clavulanic acid	Antibiotic therapy only not noninferior
Salminen et al., 2015	530	IV ertapenem p.o levofloxacin/metronidazole	Antibiotic treatment did not meet criteria for noninferiority
Cochrane Review. Wilms et al., 2001	5 RCTs 901 patients	Various	"Cure" defined as no major complications in 2 wks and no recurrences in 1 yr Antibiotics: 73.4% cured Appendectomy: 97.4% cured

Appendiceal phlegmons can be managed nonoperatively with antibiotic therapy, with or without "interval" appendectomy or by immediate appendectomy. A meta-analysis of nonoperative management reported an overall "failure rate" of antibiotics of about 7%. However, the risk of recurrent appendicitis has been reported to be 7% to 40%. In addition, neoplasia or "important" benign disease has been found in up to 7% of patients presenting with appendiceal inflammatory masses. On the other hand, immediate appendectomy is certainly very challenging in these patients. Surgical complications can occur in up to 20% of patients, with need for cecectomy or ileocolectomy in up to 30%. However, there are almost no recurrences of appendicitis with appendectomy. Therefore, an initially nonoperative approach, with subsequent interval appendectomy is certainly a reasonable strategy, although it cannot be definitively stated that interval appendectomy is mandatory.

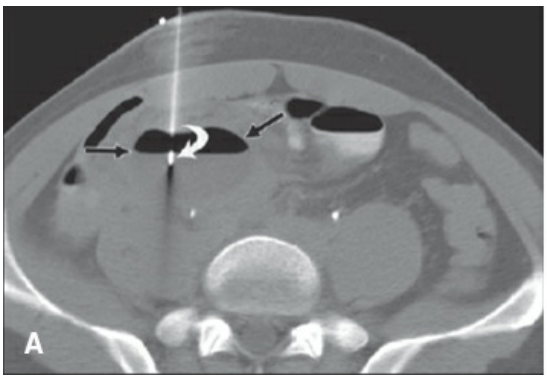



Figure 142.3. CT scan of percutaneous drainage of appendiceal abscess. **A.** Placement of needle into abscess cavity. **B.** Complete drainage of abscess with pigtail catheter left in abscess cavity. (From Marin D, Ho LM, Barnhart H, et al. Percutaneous abscess drainage in patients with perforated acute appendicitis: Effectiveness, safety and prediction of outcome. *AJR* 2010;194:422–9.)

The approach to appendiceal abscess has similar controversy. Approximately 7% of adults with acute appendicitis will present with an abscess. These are generally diagnosed preoperatively because imaging is now a routine part of the diagnostic process. There are three general approaches management: percutaneous drainage with appendectomy, percutaneous drainage without appendectomy, and immediate operative drainage and appendectomy. These approaches have been subject to randomized trials and meta-analyses; yet, a definitive answer remains elusive. Percutaneous drainage is technically "successful" (i.e., the catheter is placed within abscess and pus drained) in about 90% of cases (Fig. 142.3). Ill-defined abscess and extraluminal appendicoliths are predictors of clinical failure. Compared to immediate appendectomy, nonoperative management has overall fewer complications, especially wound infections, ileus, and bowel obstruction. On the other hand, nonoperative management requires more frequent interventions, including additional invasive procedures, such as multiple percutaneous catheters and interval appendectomy. Some of the issues with respect to immediate appendectomy in patients with appendiceal abscess are mitigated by a laparoscopic approach, although still 10% required bowel resection, 13% underwent an "incomplete" appendectomy, and 7% required additional percutaneous drainage. Long term, in patients undergoing nonoperative management, recurrent inflammation and/or abscesses requiring surgery occur in about 20% of cases and a few, but not insignificant number, will have missed neoplasms or other significant benign disease. Depending on specific clinical circumstances, each approach may be appropriate.

Operative Approaches to Acute Appendicitis

Preoperative Preparation

Preoperative preparation of the patient with acute appendicitis is the same as with any patient with an acute abdomen, namely, intravenous access, fluid resuscitation with crystalloids, broad-spectrum antibiotics with

coverage for enteric organism, and general anesthesia with vomiting/aspiration precautions. Of course, special consideration based on the needs of specific patients, such as cardiac or pulmonary medications, must be addressed.

Open Appendectomy

The patient is positioned in the supine position. If the patient has recently voided, a urinary catheter may not be necessary; however, if a long operation is anticipated, a urinary catheter should be placed. A nasogastric tube may also not be necessary if the patient has had nothing per os for an adequate length of time; but, nasogastric or orogastric decompression may be useful if the patient has recently eaten. If the appendix is located in the right lower quadrant, the surgeon has the following choices for the incision: McBurney, modified McBurney, Rockey–Davis (with extensions) (Fig. 142.4), or low midline. In general, the Rockey–Davis incision is the preferred and most commonly used incision because of ease of extending the incision medially (Fowler–Weir extension) or laterally (Rutherford Morison extension) and generally good cosmetic result. A low midline incision can be used if preoperatively there is some uncertainty as to the diagnosis or if it appears to be a very complicated disease and the need for operative flexibility is apparent. The incision is taken to the external oblique aponeurosis, which is divided to expose the internal oblique muscle. The internal oblique and transversus abdominis muscles are split with clamps at right angles to each other until the peritoneum is exposed. The peritoneum is open and the abdomen entered. If purulent fluid is encountered and bacterial cultures desired, now is the time to sample the fluid for cultures.

As much purulent fluid as is feasible is aspirated. Frequently, the appendix can be identified by palpation of a firm, tubular structure. If the appendix is mobile, it can be delivered into the wound. If the appendix is fixed, or retrocecal or retroperitoneal in location, the teniae of the cecum are followed to the base of the cecum and appendix can be identified (Fig. 142.1). Once the appendix is delivered, the mesoappendix can be divided. This can be divided between clamps, then suture ligate the appendiceal artery contained in the mesoappendix (Fig. 142.5) or with a stapling device, as per the surgeon’s preference. Usually, the inflammation is at the distal end of the appendix; therefore, the base of the appendix at the cecum is crushed with a straight clamp, divided and ligated with a 2-0 or 3-0 absorbable suture. The mucosa of the appendiceal stump is obliterated

with electrocautery. Alternatively, the stump can be inverted and secured with a purse-string suture of a 3-0 suture. Stump inversion used to be common practice, but there is no evidence that it is either associated with lower intra-abdominal abscess rates or lower small bowel obstruction rates.

Rarely, the appendix is inflamed and gangrenous to the cecum, in which case division and ligation at the appendiceal base may lead to cecal perforation or fistula. In this circumstance, inclusion of the cecum in the resection is indicated. This is done by mobilizing the cecum by dividing the ligament of Treves and white line of Toldt, as necessary. An appropriate sized stapling device, usually with 3.5-mm staplers, is placed across the cecum with care taken to avoid narrowing or obstructing the ileocecal valve (Fig. 142.6).

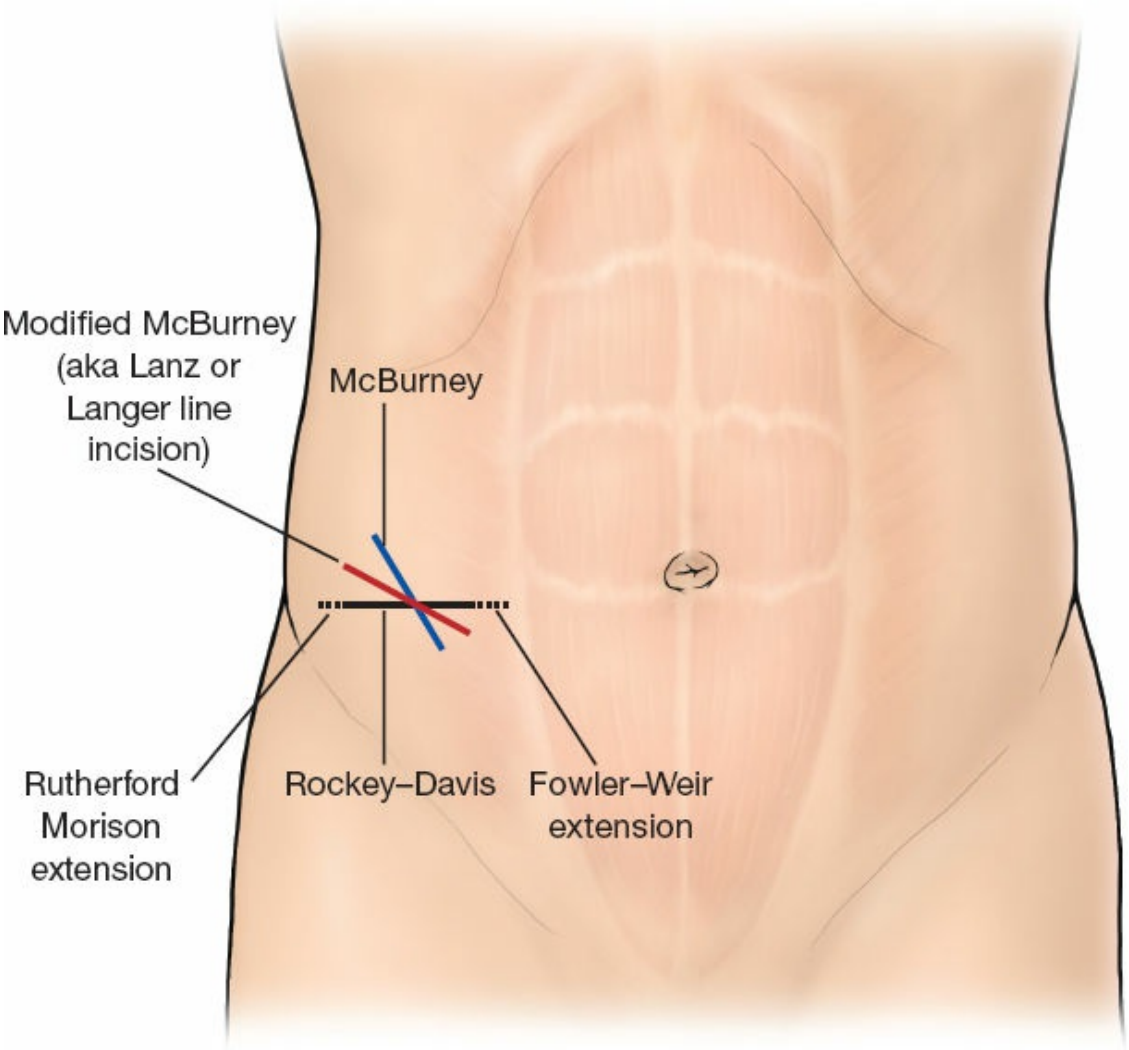

Figure 142.4. Incisions used in open appendectomy. (From Lowry SF, Davidov T, Shiroff AM. Appendicitis and appendiceal

abscess. *Fischer's Mastery of Surgery*, 6th ed. 2012.)

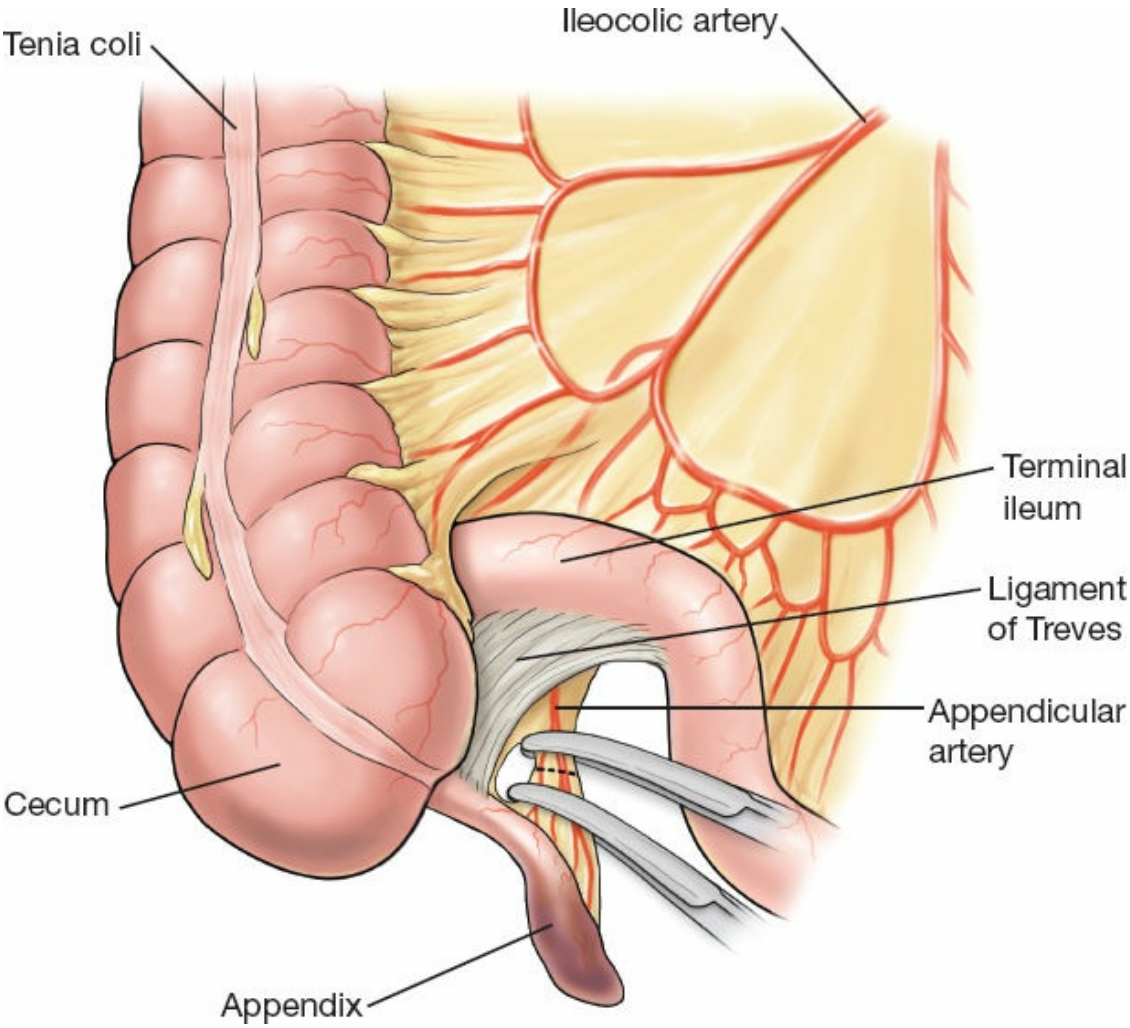

Figure 142.5. Division of the mesoappendix between clamps with subsequent suture ligature. (From Lowry SF, Davidov T, Shiroff AM. Appendicitis and appendiceal abscess. *Fischer's Mastery of Surgery,* 6th ed. 2012.)

The right iliac fossa and pelvis should be aspirated of all purulent fluid. There are differences of opinion on whether the region should be irrigated as well. Those who advocate for irrigation argue that it will reduce the inoculum of bacteria that may lead to postoperative abscess formation, while those that are against cite that it will reduce the number of activated polymorphonuclear neutrophils in the region and potentially spread bacteria to other regions of the abdomen. The abdominal wall is closed in layers with running or interrupted 2-0 or 0 absorbable suture. The skin can be closed as per the surgeon's preference, unless the extent of contamination mandates that the skin be left open.

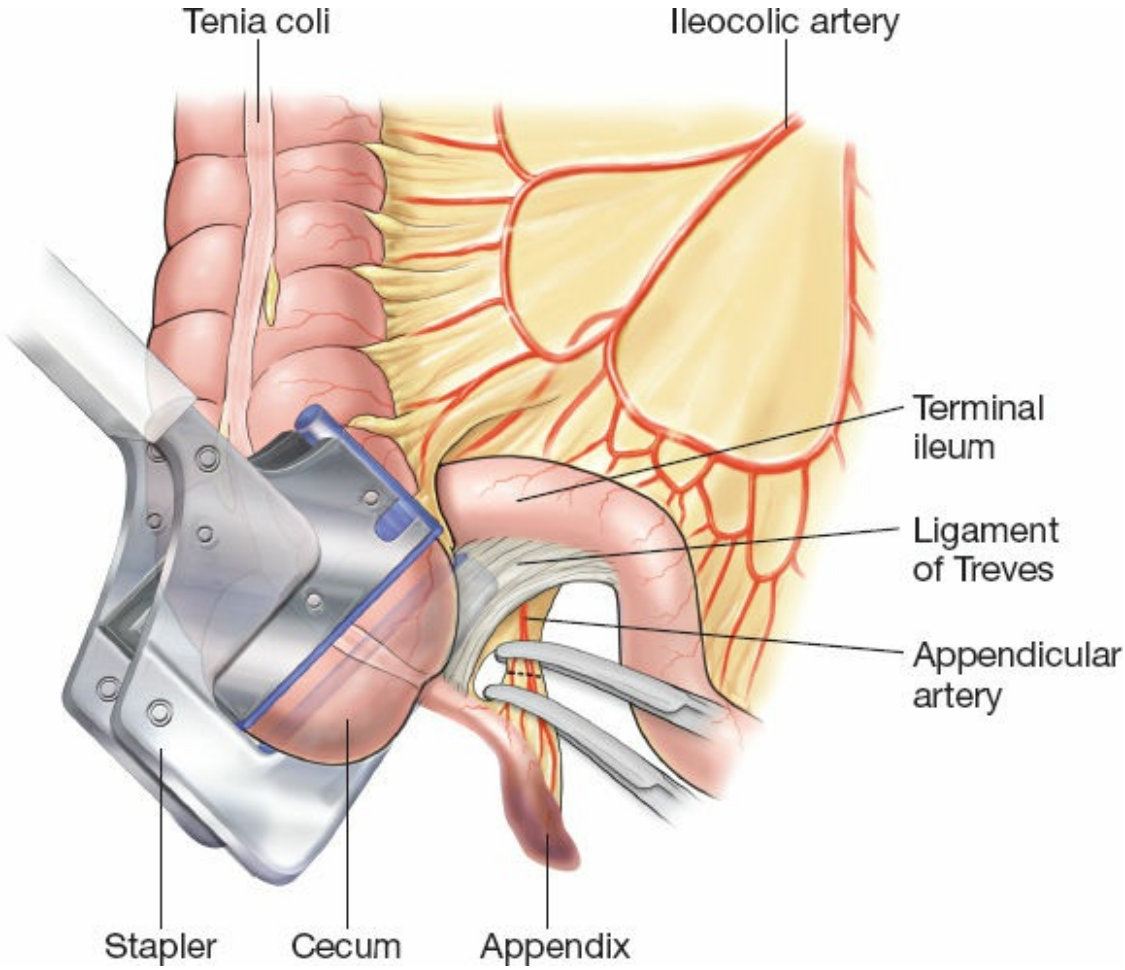

Figure 142.6. Appendo-cecectomy if the base of the appendix is involved with inflammation or necrosis.

Laparoscopic Appendectomy

With the rise of laparoscopy in the 1990s, laparoscopic appendectomy has become the predominate approach to appendectomy. In addition to smaller incisions and better cosmesis, it provides the surgeon with the ability to visually explore the entire peritoneal cavity, in case the original diagnosis of appendicitis was in error.

The patient is positioned supine. However, in a female for whom concern about pelvic pathology exists, a lithotomy position is used. In this case, a uterine manipulator should be placed to allow for maneuvers to optimize visualization of the pelvic organs. A urinary catheter is used to decompress the bladder during the operation.

The abdomen is entered through an infraumbilical incision either with a Veress needle or under direct visualization with a Hasson cannula, as per surgeon's preference. The abdomen is insufflated with CO_2 gas to a pressure of 15 mm Hg. The second port is placed in the suprapubic region

with 12-mm trocar. This will be used for passage of a stapling device, if that is the surgeon's preference. The third port, usually a 5-mm trocar, can be placed in one of two alternate positions, either in the right anterior axillary line at the level or just superior to the umbilicus (my preference) or in the left lower quadrant (Fig. 142.7). At this point, a general diagnostic laparoscopy is done to confirm appendicitis, or seek other pathology if the appendix is normal or if periappendicitis is present.

The appendix is mobilized with laparoscopic graspers with care taken not to rupture the inflamed appendix. Depending on the circumstances, the surgeon can elect to divide the mesoappendix first with an endoscopic stapling device using 2.5-mm "vascular" staples, and then divide the appendix at its base with 3.5-mm "bowel" staples. If the surgeon prefers, the base of the appendix can be secured with an endoloop suture. There has been no reported difference in outcomes between the use of the endoloop or stapler with respect to securing the base of the appendix. If the anatomy presents itself, the surgeon can divide the appendix first, and then the mesoappendix. Alternative to using a stapler for division of the mesoappendix are the endoscopic energy devices, such as ultrasonic harmonic shears or electrothermal bipolar vessel sealing devices. Some advocate that these energy devices can be used for division of the appendix as well.

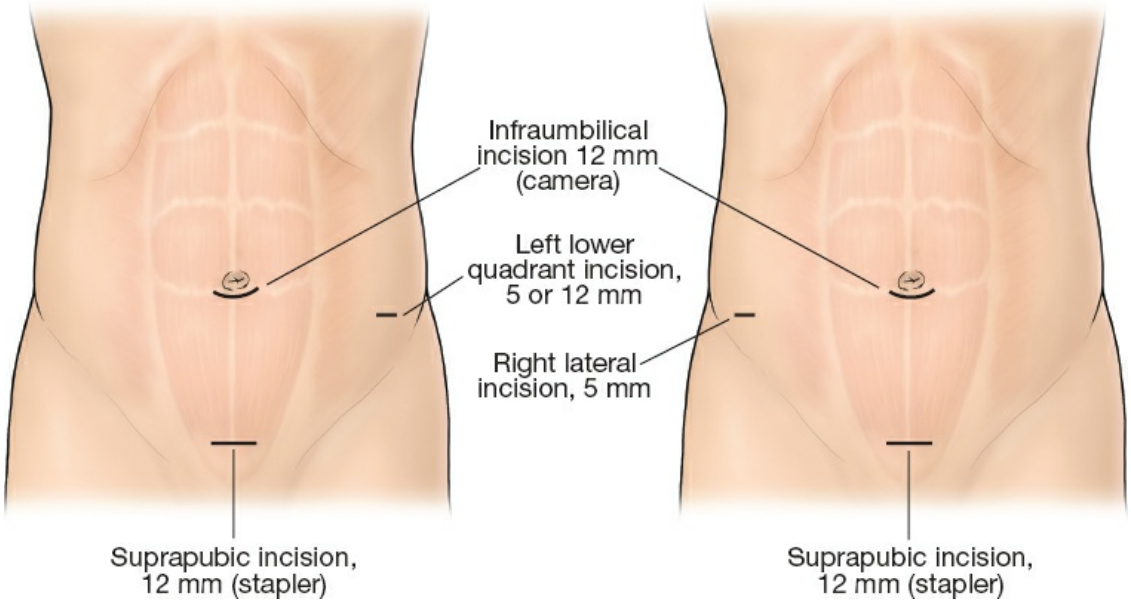

Figure 142.7. Options for port placement in laparoscopic appendectomy.

Once the appendix and mesoappendix are divided, it is placed in an

endoscopic extraction bag and delivered, usually through the suprapubic port. The fascia of the larger port sites should be closed with an absorbable 0 suture and the skin closed as per the surgeon's preference.

Postoperative Care

In uncomplicated acute appendicitis, a single preoperative dose of antibiotics is all that is necessary. The urinary catheter and, if present, the naso/orogastric tube should be removed. Once recovered from anesthesia, the patient may be given liquids and, eventually, food. Discharge to home the same day may be appropriate.

In patients with gangrenous or perforated appendicitis, prolonged antibiotic treatment may be necessary. The most common organisms include *Bacteroides fragilis, Escherichia coli, Enterococcus* spp., other *Streptococcus* spp., *Pseudomonas* spp., and *Klebsiella* spp. Duration of antibiotics depends on patient response. Although some surgeons advocate for specific durations such as 7 or 10 days, a more logical approach is continuation of antibiotics until the patient is afebrile, with a normal white blood cell count and normal white blood cell differential for 24 hours, and then discontinuation of antibiotics. While the patient is hospitalized, venothrombosis prophylaxis is necessary. While the patient is still nothing per os, stress ulceration prophylaxis should be considered.

Complications and Their Management

Although any complication associated with an operation or general anesthesia can occur after an appendectomy, the most common complications are infectious. Wound infections occur proportional to the degree of contamination and whether the wound was closed or left open. In general, as laparoscopic incisions are smaller with less subcutaneous surface area exposed to a bacterial inoculum, laparoscopic appendectomy has a lower wound infection rate compared to open appendectomy. However, intra-abdominal abscess seems to occur more frequently after laparoscopic appendectomy, 9% to 24%, compared to open appendectomy, 3% to 4%. This may be related to spread of bacteria from the right lower quadrant due to insufflation or use of laparoscopic instruments from remote sites.

Outcomes

In general, complete recovery and return to normal life with no effect on longevity is the norm. However, appendectomy may the cause of future bouts of small bowel obstruction, although this is uncommon. Women who suffered from perforated appendicitis, especially with pelvic abscess, have an increased risk of infertility. This does not seem true for uncomplicated appendicitis.

There is data to suggest that in patients over 40 years of age who developed appendicitis, the potential cause is a neoplasm obstructing the appendiceal orifice. Some data suggest that the incidence of colon cancer in this group of patients is 40 times that of the general population. Therefore, some have advocated follow-up colonoscopy of all appendectomy patients greater than 40 years old, especially if there was no prior colonoscopy or a prolonged interval since the last colonoscopy.

SPECIAL CONSIDERATIONS

Incidental Appendectomy

Incidental appendectomy is the removal of a grossly normal appearing appendix while the surgeon is performing another abdominal operation. Although once considered a “routine” practice, over the last 2 or 3 decades, its value has been challenged. The main issue is the decreased incidence of acute appendicitis as one ages weighed against the risk of complications by performing the appendectomy. Although there is no consensus, it is generally felt that incidental appendectomy is not indicated after the age of 25 years. There are some authors who advocate routine incidental appendectomy during laparoscopic hysterectomy or open colorectal procedures, but this is not widely practiced. However, there are some circumstances where it may be of value. These include patients being operated upon for Crohn disease and chronic abdominal or pelvic pain, where elimination of the appendix as a possible source of pain may help in future management. Nevertheless, there are specific contraindications to incidental appendectomy, including active Crohn disease involving the cecum, inaccessible appendix, planned radiation treatment, immunosuppression, vascular grafts, or other intra-abdominal foreign material.

Appendicitis in Pregnancy

Appendicitis in pregnancy is a particularly vexing problem as both the

disease and the diagnostic process can place the mother and fetus at risk. Although the symptoms of appendicitis are similar in the pregnant and nonpregnant woman, as the uterus becomes more gravid, the location of the appendix shifts more laterally and superiorly, occasionally confusing the physical examination. Ionized radiation in the diagnostic process should be avoided; therefore, imaging should include either ultrasound or magnetic resonance imaging (Fig. 142.8). Nevertheless, if suspicious for acute appendicitis is high, surgery should be performed as rupture and pelvic abscess formation can lead to fetal loss. Early in pregnancy, a laparoscopic approach is both feasible and safe. However, late in pregnancy, laparoscopy may be more difficult as the gravid uterus may obstruct visualization and an open approach may be required. This choice is obviously based on the judgment of the treating surgeon.

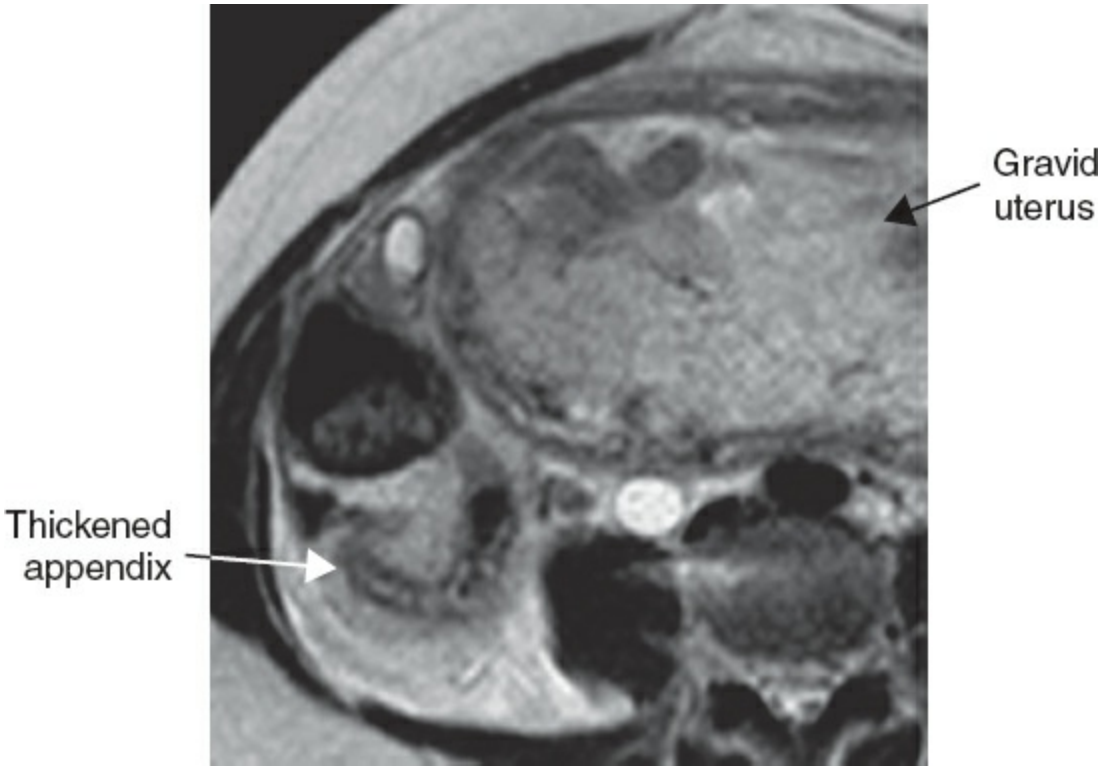

Figure 142.8. MRI in pregnant patient with acute appendicitis. (Courtesy of John Feldman, MD. Tampa General Hospital.)

Stump Appendicitis

Stump appendicitis is the clinical entity of recurrent inflammation of an appendiceal remnant after an appendectomy. The underlying cause is incomplete removal of the appendix during the first appendectomy. The incidence has been estimated to be 1 of every 50,000 appendectomies. The

time interval between the index bout of appendicitis and the stump appendicitis has been reported from as short as 1 week to as long as 50 years. Signs and symptoms are similar to acute appendicitis and imaging with a CT scan can help secure the diagnosis. Treatment is similar to appendicitis, with nonoperative management with antibiotics or “stump appendectomy” being appropriate depending on the clinical circumstances.

Appendiceal Diverticulitis

Diverticuli of the appendix are relatively rare. They are false diverticuli similar to other colonic diverticuli. Unlike the typical cause of acute appendicitis, which is obstruction of the appendiceal lumen, inflammation due to appendiceal diverticuli are due to diverticular rupture. Patients with appendiceal diverticulitis tend to be older, more commonly male, and present with periappendiceal inflammatory masses or abscesses. Having said all this, management is the same as with acute appendicitis from the more typical cause.

Appendicitis in the Elderly

Older patients with the acute abdomen present a special problem. They are subjects to more causes of the acute abdomen and are at a higher risk of adverse events. About 10% of patients >65 years of age presenting with an acute abdomen have appendicitis as the cause, while only about 3% to 4% of all patients with appendicitis will be >65 years of age. In addition, elderly patients are more likely to have complicated appendicitis, such as gangrenous and/or perforated disease. Therefore, the surgeon evaluating the older patient with the acute abdomen needs to consider the myriad of causes and be prepared for many contingences. Because older patients may not have “classic” symptoms, CT scanning is helpful in preoperatively identifying a cause of the abdominal pain. Preoperative preparation must not only be directed at fluid resuscitation and antibiotic therapy, but also at addressing comorbidities and medications that can affect the operation.

Most elderly patients with appendicitis can be approached laparoscopically. In addition to the other advantages of laparoscopic appendectomy, this approach affords the surgeon the opportunity to explore the abdomen for other causes. If the preoperative imaging documents periappendiceal abscess and percutaneous drainage is elected, colonoscopy and interval appendectomy should be strongly considered because of the higher incidence of neoplasm in this group of patients.

Appendicitis in Children

Acute appendicitis is one of the most common diagnoses in children. The peak incidence is in the second decade of life with an incidence of 250 per 100,000 children between the ages of 10 and 17. It is more uncommon in younger children with an incidence of 10 to 20 per 100,000 children <4 years old. However, it is in this age group specifically that the diagnosis becomes more difficult due to appendicitis being an *a priori* uncommon cause of abdominal pain in this age group and the child's inability to provide a description of his or her pain. Ultrasound is a valuable diagnostic tool as it will not expose the child to radiation and can help secure the diagnosis. The combination of the Pediatric Appendicitis Score and Ultrasound of the appendix yielded very high negative and positive predictive values (Tables 142.2 and 142.3).

TABLE 142.2 Pediatric Appendicitis Score (PAS)

Component of PAS	Risk Level	% With Appendicitis
Fever Migration of pain Anorexia Nausea/Vomiting Maximal pain RLQ Guarding Rebound RLQ pain with hopping, cough, or percussion WBC >10,000/mm^3 >75% neutrophils	<4 components: low risk 4–6 components: medium risk 7–10 components: high risk	~5% ~35% ~70%

Adapted from Bachur RG, Callahan MJ, Monuteaux MC, et al. Integration of ultrasound findings and a clinical score in the diagnostic evaluation of pediatric appendicitis. *J Pediatr* 2015;166(5): 1134–9; with permission from Elsevier.

Once the diagnosis is secure, the approach is similar to that of adults. There is data to support nonoperative management with antibiotics. Whether there is a need for an interval appendectomy is unclear. Certainly, the legal guardian of the child needs to be appraised about the risk of recurrent appendicitis. Appendectomy is still considered the standard treatment. Laparoscopic appendectomy is the preferred approach, leading to shorter hospital stay, fewer wound infections, and a more rapid return to normal activity. In patients presenting with periappendiceal abscess, there is support for both immediate laparoscopic appendectomy with operative

abscess evacuation and percutaneous drainage with interval appendectomy. This choice needs to be made individually.

Chronic Appendicitis

The entity of chronic appendicitis is controversial. Certainly, there is no uniformed agreement that this entity exists. Having said this, there is a group of patients with chronic, either unrelenting or recurrent right lower quadrant pain, but without the signs of acute, progressive inflammation or sepsis seen in acute appendicitis. Unlike acute appendicitis, which is pathologically characteristic by transmural acute inflammation with neutrophilic infiltration, ischemia, and necrosis, the pathology of chronic appendicitis shows chronic inflammation with lymphocytes and eosinophils, fibrosis, granulomatous and foreign-body giant cell reaction, and obliteration of the appendiceal lumen. Patients are generally not acutely ill, but complain of right lower quadrant pain of varying character and intensity over the course of several weeks, months, or even years. They otherwise have no signs of sepsis and a search for the cause of the pain has been fruitless. CT scan findings, if present, include an enlarged, dilated appendix with thickening of the appendiceal wall and periappendiceal fat stranding. However, a normal scan is frequently the case.

TABLE 142.3 Positive and Negative Predictive Values of Combining the PAS With Ultrasound Findings

PAS Group	US Positive (%)	US Equivocal (%)	US Negative (%)
Low	73	9	0
Medium	90	13	6
High	97	47	19

Adapted from Bachur RG, Callahan MJ, Monuteaux MC, et al. Integration of ultrasound findings and a clinical score in the diagnostic evaluation of pediatric appendicitis. *J Pediatr* 2015;166(5):1134–9; with permission from Elsevier.

There is no consensus on the management of these patients. Appendectomy may lead to pain relief, although this frequently may not be the case. Therefore, before preceding the surgical extirpation, the patient needs thorough counseling on the vagaries of the diagnosis and possibility that appendectomy may not lead to symptomatic relief.

Periappendicitis

Periappendicitis is inflammation of the serosa of the appendix, but with a normal appendiceal lumen and mucosa. It can be found in 1% to 5% of appendectomy specimens removed for acute appendicitis. The pathophysiology of acute appendix is an “inside-out” phenomenon where luminal obstruction leads to increased intraluminal pressure causing mucosal necrosis and subsequent bacterial invasion and infection. Periappendicitis, on the other hand, is an “outside-in” phenomenon where inflammation starts at the serosal surface of the appendix toward the lumen. The importance of periappendicitis is that the pathology causing the inflammation is not the appendix itself, but from some other intra-abdominal structure. Most commonly, it is pelvic inflammatory disease, salpingitis, diverticulitis, inflammatory bowel disease, or a perforated hollow viscus, such as duodenal ulcer (so-called Valentino’s appendicitis). Occasionally, no other source can be found. Patients present with signs and symptoms of acute appendicitis and the appendix appears inflamed by gross inspection. The concern is that the underlying “true” pathology causing the periappendicitis is left untreated allowing for continuation of source of sepsis.

As acute appendicitis is generally the working diagnosis, an appendectomy is usually performed. Periappendicitis can be suspected when the appendix is transected on the back table and inspection of the mucosa demonstrated no necrosis. In such a circumstance, a search for another cause should be performed. If the appendectomy was done laparoscopically, it is relatively easy to explore the abdomen for another source. If the appendectomy was done open, this can be more difficult through a small Rockey–Davis incision.

APPENDICEAL TUMORS

Neoplasms of the appendix are relatively uncommon. They account for 1% or less of all gastrointestinal neoplasms and are found in less than 2% of all appendectomy specimens. Nevertheless, during the course of routine practice, the general surgeon can expect to encounter these lesions. Understanding the appropriate treatment of these lesions is essential.

There are a variety of tumors which can occur in the appendix (Table 142.4). These can generally be divided into primary and metastatic, and epithelial and nonepithelial. It is not the purpose of this chapter to discuss the treatment of each type of tumor in detail, but address the tumors

generally present in the acute setting.

Carcinoid Tumor/Neuroendocrine Tumor

What has been traditionally referred to as carcinoid tumors are now being categorized as well or intermediately differentiated neuroendocrine tumors, which can arise from the foregut, midgut, or hindgut. Poorly differentiated or high-grade neuroendocrine tumors are often referred to as neuroendocrine carcinomas. Embryologically, appendiceal carcinoid tumors are midgut tumors. It is these midgut tumors that are more likely to cause carcinoid syndrome. The overall annual incidence of neuroendocrine tumors of the appendix is about 0.16 per 100,000, with similar incidence between male and female patients, but a somewhat higher incidence in Caucasian and African American patients compared to Asian and Pacific Islander patients.

TABLE 142.4 Tumors of the Appendix

Primary

- *Epithelial*
  - Benign
    - Hyperplastic polyp
    - Serrated adenoma
    - Colonic-type adenoma
  - Malignant
    - Low-grade mucinous neoplasm/ Pseudomyxoma peritonei
    - Adenocarcinoma/High-grade mucinous neoplasm
- *Nonepithelial*
  - Carcinoid
  - Goblet-cell carcinoid/ adenocarcinoid
  - Mesenchymal tumors
  - Gastrointestinal stromal tumors
  - Neuroma/schwannoma
  - Leiomyoma/sarcoma
  - Lymphoma

Metastatic

- Ovarian
- Colonic
- Melanoma
- Very rare other metastatic tumors

Adapted from Murphy EM, Farguharson SM, Moran BJ, et al. Management of an unexpected appendiceal neoplasm. *Br J Surg* 2006;93(7):783–92. Copyright © 2006 by John Wiley & Sons, Inc. Reprinted by permission of John Wiley & Sons, Inc.

Etiology and Pathophysiology

Neuroendocrine tumors arise from the enterochromaffin cells within the gut. These tumors can retain the capacity for amine precursor uptake and decarboxylation (APUD system). Because of this ability, they can produce a variety of vasoactive substances, including serotonin, substance P, prostaglandins, histamine, and kallikreins. Most of these are removed by the liver during the “first-pass” phenomenon; therefore, the vasoactive

symptoms of carcinoid syndrome generally occur when liver metastasis is present, when these substances are secreted directly into the systemic circulation. However, most neuroendocrine tumors are not hormonally active.

Clinical Presentation

The clinical presentation of neuroendocrine tumors of the appendix can either be insidious or acute. Although not frequent, patients with neuroendocrine tumors of the appendix can present as acute appendicitis and the intraoperative finding of these tumors is unexpected. On the other hand, patient can also present a vague, poorly localized abdominal pain, cramping, bloating, and occasional diarrhea. It is not unusual for these patients to be misdiagnosed as having irritable bowel syndrome. Physical examination is usual not helpful, as palpable masses are rare. Classic carcinoid syndrome symptoms of flushing and diarrhea related to serotonin release is usually associated with liver metastasis.

Laboratory and Imaging Diagnosis

If patients present acutely, laboratory findings are similar to that of acute appendicitis. If a carcinoid tumor is suspected preoperatively, chromogranin A, 24-hour urinary 5-HIAA, and neuron-specific enolase are useful both diagnostically and in follow-up.

CT scanning is the obvious choice in the acute setting, as usually acute appendicitis is suspected. The tumor may not be detected if small in a background of appendiceal and periappendiceal inflammation. However, in the nonacute setting, neuroendocrine tumors are vascular and may be demonstrated as contrast-enhancing tumors with IV contrast during the arterial phase with rapid washout during the venous phase. Not uncommonly, the primary tumor is small, and the mass noted is a mesenteric lymph node metastasis. For patients with contrast allergies, MRI is the alternative imaging modality.

Octreotide scanning is useful in that the whole body may be imaged. The sensitivity for detecting neuroendocrine tumors is around 80%. I-MIBG and PET scanning are generally not as useful.

Management

Management of patient with carcinoid tumors of the appendix depends on presentation. In the acute setting, patients are managed as if they have acute appendicitis. In the nonacute setting, without signs of carcinoid

syndrome, patient management will depend on tumor size and presence of lymph node metastasis. If carcinoid syndrome is present, patients will require preoperative physiologic preparation and planning for surgical management of both the primary tumor and liver metastases, if present.

Preoperative Preparation

If patients present acutely and are diagnosed with acute appendicitis, then preoperative preparation is similar to that of the acute appendicitis patient. If patients present with a preoperative diagnosis of suspected neuroendocrine tumor, then an evaluation of the presence of both a functional tumor and metastatic disease is needed. If a functional tumor is present, especially carcinoid syndrome, preoperative consultation with anesthesia is prudent, as this will influence anesthetic management. Preoperative use of H_1 or H_2 blockers can reduce gastrointestinal manifestations, bronchospasm may need to be treated, octreotide is effective to blunt the manifestations of carcinoid syndrome, antibiotic prophylaxis specifically for carcinoid-related valvular heart disease may be needed, and drugs that release histamine should be avoided. Invasive arterial monitoring and central venous access should be considered.

Operations

Extend of resection of carcinoid tumors of the appendix is depended on the size of the tumor. The majority of tumors are located in the distal appendix and do not involve the base. The risk of lymph node metastasis in well-differentiated tumors <2 cm is low, but can exceed 30% when tumors are >2 cm. Therefore, well-differentiated tumors, <2 cm in size, involving the distal appendix where a margin-negative complete resection can be accomplished can be safely managed with appendectomy alone. On the other hand, incomplete resection by appendectomy, tumors >2 cm, tumors involving the proximal or base of the appendix, invasion of the mesoappendix, high-grade histologic features, lymphovascular invasion, or “mixed” histologies, such as goblet cell or adenocarcinoid features, should be treated with right hemicolectomy with en bloc resection of lymph node bearing mesentery (description of a right hemicolectomy is in another chapter in this book). Special mention should be made of goblet cell carcinoids which have histologic features of neuroendocrine and goblet cell differentiation. These are sometime referred to as adenocarcinoids or mucinous adenocarcinoids. These are more aggressive tumors than well-differentiated neuroendocrine tumors and should be treated more like

adenocarcinomas than carcinoids.

Postoperative Care

In patients who have small, nonfunctional tumors treated by appendectomy, postoperative care is similar to an appendectomy for acute appendicitis. For requiring right hemicolectomy, the patient may be placed on enhanced recovery protocols (see chapter pertaining to colon resection).

Complications and Their Management

The complication profile is similar to that of appendectomy for acute appendicitis. In patients who undergo a right hemicolectomy, the most feared complication is an anastomotic leak. Patients will have persistent or worsening abdominal pain, fevers, and leukocytosis. Evaluation could be done with a CT scan demonstrating intra-abdominal fluid with or without gas, consistent with an abscess, or extravasation of contrast. If the patient is not toxic, this can be treated with percutaneous drainage to create a controlled fistula. If this does not control the source of infection, operation is indicated. If peritonitis is present, then surgical exploration is warranted. If the anastomotic disruption is small, with minimal inflammation, primary repair may be considered. However, the safest choice is creation of an ileostomy after drainage of any intra-abdominal fluid.

Outcomes

The prognosis for carcinoid tumors is generally good with 5-year survival rates approaching 90% for localized disease and 80% for regional disease. Survival diminishes significantly with distant disease falling to 25%. Tumor stage, positive margins, and older age are associated with worsening outcomes.

Low-Grade Mucinous Neoplasms and Adenoma of the Appendix

Etiology and Pathophysiology

Appendiceal adenomas and mucinous tumors are rare tumors. They account for <1% of all appendectomy findings and can run a spectrum of aggressiveness. At the lower end of the spectrum are low-grade mucinous neoplasms, which have been historically called “mucoeles” of the appendix. These tumors arise in the luminal mucosa of the appendix and produce thick, tenacious mucus. These lesions are pathologically flat or villous with associated epithelial mucin. The serosal surface may appear completely normal. The risk with these lesions is that the mucin continues

to fill the lumen and eventually the appendix may rupture. This can lead to peritoneal seeding of mucin-producing cells. The abdomen will start to fill with mucinous ascites, a condition known as pseudomyxoma peritonei. Nevertheless, nodal and hematogenous metastases are uncommon, and even in the setting of pseudomyxoma peritonei, there is controversy as to whether these are truly malignant lesions.

Clinical Presentation

Low-grade mucinous neoplasms of the appendix can be protean in its presentation. These tumors tend to occur in the sixth decade of life, more commonly in women than men. As these tend to be indolent tumors, they are frequently "incidental" findings on imaging for other reasons. When symptoms occur, right lower quadrant abdominal pain is the most common, which can mimic acute appendicitis. An abdominal mass may be present. If the tumor has ruptured, drop ovarian metastasis is common and patient can present with large ovarian tumors, which are frequently confused for the primary tumor. Distention is generally a sign of advancement to pseudomyxoma peritonei.

Laboratory and Imaging Diagnosis

Although patients can present with signs suggestive of acute appendicitis with associated leukocytosis, in general, laboratory findings are unremarkable. CT scan is the most useful imaging test with a dilated, thickened appendix the most common early finding and ovarian masses and mucinous ascites findings consistent with peritoneal dissemination and pseudomyxoma peritonei.

Management

Preoperative Preparation

If patients are presenting with signs of acute appendicitis and the diagnosis of a mucinous tumor is not suspected, then preoperative preparation is the same as for the patient with acute appendicitis. However, if the patients present electively, then the normal preoperative risk assessment depending on comorbidities should be performed. Whether a bowel preparation is performed and how is a matter of choice for the surgeon (see chapter on colectomy).

Operations

For tumors localized to the appendix, an appendectomy is adequate

treatment. Extreme care is taken to prevent rupture of the appendix during manipulation to avoid iatrogenic dissemination of mucin-producing cells. Although controversial, it appears that microscopically a positive margin at the base of the appendix does not increase the risk of local or distant recurrence. The risk of nodal metastasis for T1 and T2 lesions is <6%; therefore, a more extensive resection is not indicated. The need for a right hemicolectomy in more advanced disease is controversial. Some argue that in metastatic disease, right hemicolectomy only increases risk of complications without improvement in survival. On the other hand, for larger T3 or T4 tumors, without dissemination of disease, a right hemicolectomy may be beneficial as the rate of nodal disease is over 30%.

Once pseudomyxoma peritonei occurs, treatment becomes more complicated. At this point, aggressive cytoreductive surgery, including greater and lesser omentectomy, cholecystectomy, peritonectomy of any involved peritoneal surface, and oophorectomy and/or hysterectomy if involved with tumor, should be performed. This is then followed by hyperthermic intraperitoneal chemotherapy (HIPEC). Obviously, this may require referral to a specialized center with this capacity.

Outcomes

Low-grade mucinous tumors are confined to the appendix and generally cured by appendectomy with a very low risk of recurrence. The most important issues come with pseudomyxoma peritonei. This disseminated disease does not directly lead to death, but overwhelmingly affects quality of life. It can lead to secondary causes of death, such as bowel obstruction. Therefore, controlling mucinous ascites is important. HIPEC has been shown to decrease the recurrence rate of pseudomyxoma peritonei and decrease mortality related to the disease. In follow-up, however, up to 13% of patients with low-grade mucinous neoplasms will have synchronous or metachronous neoplasms of the colon. Therefore, colonoscopy is strongly considered in follow-up.

High-Grade Mucinous Neoplasms and Adenocarcinoma of the Appendix

Etiology and Pathophysiology

High-grade mucinous neoplasms and adenocarcinomas are very rare. They account for <0.2% of all appendectomy specimens. These lesions are divided into adenocarcinoma not otherwise specified, mucinous

adenocarcinoma, signet ring cell adenocarcinoma, and undifferentiated adenocarcinoma. The mucinous tumors account for about 40% of all appendiceal adenocarcinomas. Pathologically, these lesions resemble the spectrum of colonic adenocarcinoma; similarly with colon adenocarcinoma and in contrast with low-grade mucinous neoplasms.

Clinical Presentation

Most patients with appendiceal adenocarcinoma are in the fifth to seventh decades of life. There is equal distribution between men and women. Nearly 90% of patients with appendiceal adenocarcinoma will present with signs and symptoms of acute appendicitis. Other presentations include abdominal mass, bowel obstruction, occult or overt gastrointestinal hemorrhage, and signs of metastasis.

Laboratory and Imaging Diagnosis

As the vast majority of patients present with acute appendicitis, the laboratory profile with be that of acute appendicitis. Imaging may show a right lower quadrant mass, although it may be difficult to differentiate this finding with an inflammatory appendiceal mass. CT scanning may show evidence of nodal or distant metastasis.

Management

Preoperative Preparation

As most patients present with acute appendicitis, preoperative preparation is similar to that of the acute appendicitis patient. However, in the rare circumstance where the diagnosis is suspected preoperatively, patients should be prepared as for a right hemicolectomy.

Operation

The operation of choice for locoregional disease is a right hemicolectomy with en bloc mesenteric resection of the draining lymph node basin. However, some suggest that there is no survival advantage for right hemicolectomy in the presence of metastatic disease.

Complications and Their Management

The complication profile is that of a right hemicolectomy (see chapter on colectomy).

Outcomes

The reported 5-year survival of patients with appendiceal adenocarcinoma is 18% to 55%. In general, mucinous tumors have a better survival than nonmucinous tumors.

Suggested Readings

Barlow A, Muhleman M, Gielecki J, et al. The vermiform appendix: a review. *Clin Anat* 2013;26:833–42.

Baucher RG, Callahan MJ, Monuteaux ML, et al. Integration of ultrasound findings and a clinical score in the diagnostic evaluation of pediatric appendicitis. *J Pediatr* 2015;166:1134–9.

Bourdreaux JP, Klimstra DS, Hassan MM, et al. The NANETS consensus guideline for the diagnosis and management of neuroendocrine tumors: well-differentiated neuroendocrine tumors of the jejunum, ileum, appendix and cecum. *Pancreas* 2010;39:753–66.

Chaudhury P, Nabi I, Arora MP. Periappendicitis: our 13 year experience. *Int J Surg* 2014;12:1010–13.

Ito D, Miki K, Seiichiro S, et al. Clinical and computed tomography findings of appendiceal diverticulitis vs. acute appendicitis. *World J Gastroenterol* 2015;21:3921–7.

Kao LS, Boone D, Mason RJ. Antibiotics vs. appendectomy for uncomplicated appendicitis. *J Am Coll Surg* 2013;216:501–5.

Misdraji J. Mucinous epithelial neoplasms of the appendix and pseudomyxoma peritonei. *Mod Path* 2015;28:567–79.

Shah S, Gaffney R, Dykes T, et al. Chronic appendicitis: An often forgotten cause of recurrent abdominal pain. *Am J Med* 2013;126:e7–e8.

Similis C, Symeonides P, Shorthouse AJ, et al. A meta-analysis comparing conservative treatment versus acute appendectomy for complicated appendicitis (abscess or phlegmon). *Surgery* 2010;147:818–29.

Wray CJ, Kao LS, Millas SR, et al. Acute appendicitis: controversies in diagnosis and management. *Curr Prob Surg* 2013;50:54–86.

EDITOR'S COMMENT

Dr. Velanovich has done an outstanding job clearly detailing the controversies in the management of both benign and malignant disease of the appendix. No longer does acute appendicitis equate with need for appendectomy. More patients are being treated nonoperatively with antibiotics with either interval appendectomy or no appendectomy at all. As has been pointed out, clinical

trials have so far shown controversial results with regard to the standard of care for treating uncomplicated acute appendicitis.

In a review of five randomized trials that have evaluated conservative management to primary surgical therapy, the authors concluded that all five trials considered antibiotics alone as an efficient and noninferior option in comparison to surgery. However, primary antibiotic therapy was characterized by a longer length of stay, a higher recurrence rate but a lower rate of postoperative complications compared to primary surgical therapy. Taken one step further, the authors concluded in a reasonable fashion that in high-risk patients, an appropriate treatment regimen with antibiotics was considered for uncomplicated acute appendicitis (Abongwa HK, Cervellin G, Tarasconi A, et al. Antibiotics alone for uncomplicated acute appendicitis in high operative risk adult patients: Analytical review of RCTs and proposal of evidence based treatment decision. *Acta Biomed* 2017;87:334–6).

Nevertheless, the conclusion that antibiotic therapy is equivalent to surgical resection for acute appendicitis is a cause for significant debate. In their review of randomized trials and meta-analysis, Podda et al. concluded that there was a higher rate of treatment efficacy based on 1-year follow-up in the surgical group (98.3% vs. 75.9%, P <0.0001), recurrence at 1 year was reported in 22.5% of patients treated with antibiotics. Rate of complicated appendicitis with peritonitis identified at the time of surgical operation was higher in the antibiotics group (19.9% vs. 8.5%, P = 0.02). No statistically significant differences were found when comparing primary antibiotic therapy and surgical therapy groups for the outcomes of overall postintervention complications (4.3% vs. 10.9%, P = 0.32), postintervention complications based on the number of patients who underwent appendectomy (15.8% vs. 10.9%, P = 0.35), length of hospital stay (3.24 ± 0.40 vs. 2.88 ± 0.39, P = 0.13), and period of sick leave (8.91 ± 1.28 vs. 10.27 ± 0.24, P = 0.06). The authors concluded that with significantly higher efficacy and low complication rates, appendectomy remains the most effective treatment for patients with uncomplicated acute appendicitis.

Laparoscopic appendectomy is clearly accepted as an excellent treatment approach and likely the gold standard in uncomplicated appendicitis. Recently, authors have reviewed the technical feasibility, effectiveness, and safety between single incision versus conventional three-incision laparoscopic appendectomy. In 2013, authors reviewed eight original randomized trials investigating 760 adults and 684 children, 1,444 patients in total, of whom 721 received single incision and 723 received conventional three-port laparoscopic appendectomy. Pooling the results for single incision laparoscopic appendectomy and conventional laparoscopic appendectomy revealed no significant difference in pain scores, wound infection rate, overall complications, and postoperative hospital stay. The authors concluded that single incision laparoscopic appendectomy failed to show any obvious advantages over conventional laparoscopic appendectomy in perioperative and postoperative outcomes. Therefore, it represents a possible alternative to

conventional three-port laparoscopic appendectomy (Gao J, Li P, Li Q, et al. Comparison between single-incision and conventional three-port laparoscopic appendectomy: a meta-analysis from eight RCTs. *Int J Colorectal Dis* 2013;28(10):1319–27).

More recently, in a review of 11 randomized trials of 1,489 patients undergoing single incision laparoscopic versus conventional laparoscopic appendectomy, the patients in the single incision laparoscopic appendectomy group had a significantly shorter hospital duration and return to activity but experienced a longer operating time and higher rate of conversion ($p < 0.00001$). There were no differences between the two groups in pain scores, doses of analgesics, overall complication rates, wound infection, or cosmesis. The authors concluded that single incision laparoscopic appendectomy is safer and more effective that conventional three incision laparoscopic appendectomy in both pediatric and adult patients (Deng LH, Xiong JJ, Xia Q. Single incision versus conventional three incision laparoscopic appendectomy: a meta analysis of randomized controlled trials. *J Evid Based Med* 2016. Doi:10.1111/jebm.12238. [Epub ahead of print]). Differences in interpretation could account for variations in the conclusions from reviews published in similar numbers of patients undergoing laparoscopic appendectomy in contemporary time periods. It is also possible that with technologic improvements in laparoscopic equipment, at present, single incision laparoscopic appendectomy may offer some small benefits over conventional laparoscopic appendectomy.

A concern remains whether laparoscopic appendectomy is appropriate and feasible in complicated appendicitis. In a systemic review and meta-analysis, Yu et al. reviewed two randomized trials and 14 retrospective cohort studies of patients undergoing laparoscopic or open surgery for complicated appendicitis. The meta-analysis showed that laparoscopic appendectomy could reduce the rate of surgical site infections (OR = 0.28, 95% CI: 0.25 to 0.31, $p < 0.00001$), but laparoscopic appendectomy did not increase the rate of postoperative intra-abdominal abscess. Furthermore, the operating time in the laparoscopic appendectomy groups was much longer than that in the open appendectomy groups. However, the length of hospital stays in the laparoscopic appendectomy groups were significantly shorter than those in the open appendectomy groups. The time until oral intake was much earlier in the laparoscopic groups than in the open appendectomy groups. It was concluded that laparoscopic appendectomy was safe for complicated appendicitis and was associated with advantages such as reducing surgical site infection (Yu MC, Feng YJ, Wang W, et al. Is laparoscopic appendectomy feasible for complicated appendicitis? A systemic review and meta-analysis. *Int J Surg* 2017;40:187–97).

The management of patients with appendiceal tumors has become more complicated as knowledge concerning the biology of these tumors increases. Appropriate care is often best performed in a multidisciplinary environment as treatment approaches can vary from appendectomy alone to right

hemicolectomy to hyperthermic intraperitoneal chemotherapy and extensive cytoreductive surgery. The clinical course of appendiceal mucinous neoplasms is determined by the pathologic degree of differentiation and the stage of disease at diagnosis. More than 50% of appendiceal mucinous neoplasms present with diffuse mucinous ascites (Smeenk RM, van Velthuysen ML, Verwaal VJ, et al. Appendiceal neoplasms and pseudomyxoma peritonei: a population based study. *Eur J Surg Oncol* 2008;34:196–201). In a recent pooled analysis of hyperthermic intraperitoneal chemotherapy following cytoreductive surgery in 163 patients with appendiceal mucinous neoplasms, 60 patients had diffuse peritoneal adenomucinosis, 88 had peritoneal mucinous carcinomatosis, and 15 had peritoneal mucinous carcinomatosis with indeterminate features. Complete surgical resection was achieved in 76 patients. Hyperthermic intraperitoneal chemotherapy was used in 79 patients. The median overall survival was 77 months for patients who received hyperthermic intraperitoneal chemotherapy compared with 25 months for patients who did not. In a confirmation of the role of the intraperitoneal chemotherapy, on multivariate analysis, complete surgical resection, histopathologic subtype, and the use of the intraperitoneal chemotherapy were independent predictors of improved overall survival. In addition, a survival advantage for appendiceal mucinous neoplasms was observed at hyperthermic intraperitoneal chemotherapy treating centers (Shaib WL, Martin LK, Choi M, et al. Hyperthermic intraperitoneal chemotherapy following cytoreductive surgery improves outcome in patients with primary appendiceal mucinous adenocarcinoma: A pooled analysis from three tertiary care centers. *Oncologist* 2015;20(8):907–14).

Some appendiceal tumors such as goblet cell carcinoids exhibit unique clinical and pathologic features. This tumor likely arises from intestinal crypt base stem cells and have frequent loss of Notch signaling as well as other mutations which favor them progressing and behaving similar to adenocarcinoma with minimal neuroendocrine differentiation. High-grade versions of appendiceal goblet carcinoids are poorly characterized. In a recent report, high-grade goblet cell carcinoid was found to have distinctive morphology that is recognizable at metastatic sites and recapitulates crypt cells (appendiceal crypt cell adenocarcinoma). Unlike intestinal-type adenocarcinoma, it occurs predominantly in women, is disguised as gynecologic malignancy, and spreads along peritoneal surfaces with only rare hematogenous metastasis. It appears to be significantly more aggressive than appendiceal mucinous neoplasms. An increased understanding of the diverse spectrum of appendiceal tumors, through further molecular investigations, may lead to an enhanced role for targeted molecular therapy for such neoplasms (Shenoy S. Goblet cell carcinoids of the appendix: Tumor biology, mutations and management strategies. *W J Gastrointest Surg* 2016;27:660–9; Reid MD, Basturk O, Shaib WL, et al. Adenocarcinoma ex-goblet cell carcinoid (appendiceal-type crypt cell adenocarcinoma) is a morphologically distinct entity with highly aggressive behavior and frequent association with

peritoneal/intra-abdominal dissemination: an analysis of 77 cases. *Mod Pathol* 2016;29(10):1243–53).

Steven N. Hochwald

Suggested Readings

Podda M, Cillara N, Di Saverio S, et al.; ACOI (Italian Society of Hospital Surgeons) Study Group on Acute Appendicitis. Antibiotics-first strategy for uncomplicated acute appendicitis in adults is associated with increased rates of peritonitis at surgery. A systematic review with meta-analysis of randomized controlled trials comparing appendectomy and non-operative management with antibiotics. *Surgeon* 2017;pii:S1479–666X(17)30056–2.

143 Large Bowel Obstruction

Neil H. Hyman and Konstantin Umanskiy

ETIOLOGY AND PATHOPHYSIOLOGY

Large bowel obstruction can be caused by a variety of etiologic factors and is broadly defined as an intestinal blockage distal to the ileocecal valve. The obstruction may be mechanical or functional, partial or complete, intrinsic or extrinsic. The most common mechanical causes of large bowel obstruction are colorectal carcinoma, followed by diverticulitis and volvulus (Table 143.1). Mechanical obstruction should be differentiated from a functional obstruction (e.g., acute colonic pseudoobstruction). The presentation of large bowel obstruction can be acute or subacute/chronic. For example, colonic obstruction in Crohn disease could occur insidiously due to progressive inflammation and fibrosis. Mechanical obstruction due to malignancy or volvulus usually results in rapid onset of symptoms of abdominal distention and pain and can lead to bowel compromise and perforation.

TABLE 143.1 Common Causes of Large Bowel Obstruction

1. Intraluminal mass
   a. intrinsic mass, colonic neoplasm
   b. extrinsic mass such as multivisceral cancer
2. Extraluminal compression
   a. metastatic intra-abdominal disease
   b. retroperitoneal fibrosis
3. Stricture
   a. Diverticular stricture
   b. Crohn disease
   c. Radiation
4. Volvulus
   a. Sigmoid
   b. Cecal
5. Hernia
   a. Inguinal
   b. Ventral/incisional
   c. Internal
6. Intussusception
7. Hirschsprung disease
8. Luminal blockage
   a. foreign body
   b. bezoar
   c. fecal impaction
   d. gallstone
9. Nonmechanical obstruction
   a. Acute colonic pseudoobstruction
   b. Paralytic ileus
   c. Toxic megacolon

CLINICAL PRESENTATION

The symptoms of large bowel obstruction will vary depending on whether the obstruction is partial or complete, and acute versus chronic.

Acute Large Bowel Obstruction

Acute colonic obstruction can be rather dramatic in its presentation, particularly if associated with a closed loop obstruction. Individuals may present with obstipation of several hours to several days duration. This is

usually accompanied initially by colicky abdominal pain progressing to constant pain. On examination, varying degrees of abdominal distention may be present. Vomiting is uncommon but may be present in approximately one third of the patients. Peritoneal signs or signs of systemic toxicity including confusion, fever, chills, and hypotension are ominous finding suggesting colonic hypoperfusion or perforation.

Obstruction due to Colorectal Cancer

Colorectal carcinoma presents with acute intestinal obstruction in 7% to 30% of cases. The majority of colonic obstructions due to malignancy occur at the rectosigmoid junction where the luminal diameter of the bowel is the narrowest. Obstruction at the level of the sigmoid colon is also quite common, while obstruction at the cecum, and ascending and transverse colon typically occurs only when the mass has grown to a very large size. Most of the malignant lesions in the right and transverse colon tend to be diagnosed prior to the onset of obstructive symptoms as patients are likely to present with anemia or abdominal pain. Rectal cancers, though often large at the time of diagnosis, rarely present with symptoms of complete large bowel obstruction, instead causing symptoms of constipation, bleeding, and change in caliber of the stool.

Acute colonic volvulus most often involves the cecum or sigmoid colon as the colon rotates around its long mesentery; volvulus can also involve other segments such as the transverse colon but this is less commonly observed. Sigmoid volvulus, a condition most prevalent in West Africa and Middle East, commonly presents with constipation, abdominal pain, and occasionally vomiting. In the United States, sigmoid volvulus tends to occur in elderly patients with chronic constipation. In contrast, cecal volvulus generally occurs in younger individuals. The clinical presentation of cecal volvulus includes rapid onset of abdominal distention, pain, nausea, and vomiting. Massive bowel distention due to closed loop obstruction can lead to ischemia, perforation, and peritonitis. In the setting of suspected peritonitis, free intraperitoneal air, or sepsis, the patient should be taken to the operating room for urgent resection. Resection with colostomy is typically required in the setting of sigmoid volvulus with compromised bowel, whereas primary anastomosis is still often possible in this setting with a cecal volvulus.

In the patient without evidence of peritonitis, diagnostic workup usually includes plain abdominal x-rays and a computed tomography (CT) scan if necessary. CT imaging often demonstrates a characteristic whirl sign

where the bowel rotates around its mesenteric axis. In the absence of signs of bowel compromise, sigmoid volvulus should initially be treated with endoscopic detorsion and decompression. A rectal tube is subsequently placed for continued decompression of the previously twisted segment, to prevent recurrent volvulus and to prepare the patient for more elective resection. Cecal volvulus is generally addressed directly with right colon resection and anastomosis. Definitive operation, either right colectomy or sigmoid colectomy, is generally indicated during the same admission in order to avoid recurrence, reported to be as high as 86%, and alleviate the potential need for emergency surgery in the future. The decision of whether to perform an anastomosis or a Hartmann's in sigmoid volvulus should be individualized based on the patient's preoperative anal sphincter function, degree of disability, comorbidities, and overall prognosis.

Obstruction due to Intussusception

Patients with colonic intussusception present more commonly with melena or guaiac positive stool and less so with abdominal pain, nausea, or vomiting. CT scan is the most useful diagnostic test often demonstrating a target-shaped area of colon (target sign). Unlike the pediatric equivalent, almost all cases of adult colonic intussusceptions are caused by a pathologic condition that serves as a lead point, such as carcinomas, polyps, Meckel diverticulum, colonic diverticulum, strictures, or benign neoplasms. Malignancy is found in up to 65% of lead points of colonic intussusception. Surgical resection adhering to oncologic principles without reduction is the preferred treatment. Left-sided lesions typically approached in two stages with Hartman procedure and subsequent colostomy takedown. An anastomosis with or without diverting ostomy is a viable option and should be individualized based on intraoperative findings, status of the bowel, and overall patient condition.

Subacute/Chronic Large Bowel Obstruction

Chronic large bowel obstruction may develop over weeks and occasionally even months based on the slow progress of a stricturing process or slow-growing obstructing lesion. Symptoms of chronic bowel obstruction may be characterized as local or systemic. If the stricture is secondary to a neoplastic process, systemic symptoms may include unintended weight loss and anorexia. Obstruction secondary to an inflammatory process, such as seen in Crohn colitis, may include symptoms of general malaise, fever,

chills, or one of the extraintestinal manifestations that accompany the disease. Local symptoms will be similar regardless of the cause and include change in bowel habits, constipation, abdominal distention, lower abdominal pain, and in late stages vomiting with feculent smelling material (stercoraceous vomiting). In some cases, bowel obstruction may be intermittent, such as those associated with self-limited episodes of sigmoid or cecal volvulus.

Chronic Obstruction as a Result of Inflammatory Disease

Colonic obstruction from inflammation may be secondary to an active process (acute diverticulitis or Crohn disease) superimposed on preexisting fibrosis. Chronic colonic strictures may be the sequelae of prior episodes of diverticulitis, pelvic radiation, or a strictured bowel anastomosis. Generally these patients present with chronic constipation and partial obstructive symptoms. Under most circumstances, patient should undergo evaluation to rule out malignancy and subsequently undergo an elective resection. The patients with a limited life expectancy who may not be candidates for resection could be considered for a stent placement; however, stenting should not be viewed as a definitive long-term solution for most patients. A colostomy or ileostomy is always a viable option for those patients who cannot undergo resectional surgery.

Pseudoobstruction, Oglivie Syndrome

Patients with colonic pseudo-obstruction are commonly elderly and typically have a concomitant acute medical comorbidity or recent surgical intervention. Massive dilatation of large bowel can result in ischemia and if left untreated can lead to perforation, which in turn would necessitate urgent operative intervention. All potentially offending agents that reduce colonic motility such as narcotics and anticholinergics should be discontinued. After the causes of mechanical obstruction have been excluded, the patient can be treated with IV neostigmine in a monitored setting if there is no medical contraindication. The side effects of neostigmine include severe bradycardia with hypotension, nausea, vomiting, and bronchospasm. Colonoscopic decompression can also be performed; however this may be technically challenging in the setting of an unprepped bowel and may be associated with an increased risk of perforation. If all nonoperative measures fail to resolve symptoms and the colonic diameter suggests impending perforation, the patient may need to

undergo an operative intervention that could include tube cecostomy, or bowel resection with an intestinal stoma.

INDICATIONS AND CONTRAINDICATIONS

Indications for operative intervention in acute complete colonic obstruction are fairly straightforward. The patient needs to be resuscitated and plans for urgent intervention should be made. In the patients with chronic or partial obstruction, the decision to proceed with an intervention should be based on the severity and trajectory of symptoms over time. The patients with stable chronic colonic obstruction due to a postinflammatory stricture related to diverticulitis or Crohn disease may be well compensated and with properly adjusted bowel regimen may be able to attempt a trial of nonoperative management. Those patients presenting with frequent recurrent episodes of partial bowel obstruction should be considered for an operative intervention. The decision should be based on the patient's functional status, comorbidities including cardiac and pulmonary disease, and overall prognosis. Moreover, the surgeon should prepare and discuss alternative operative strategies in the event that the planned intervention cannot be safely carried out.

PREOPERATIVE PLANNING

A thoughtful diagnostic workup informs surgical decision making. Elucidating the likely cause of the obstruction and the degree of anatomic and physiologic derangement are usually the initial steps in the workup. A careful history with focus on an accurate account of any prior operations, medical comorbidities, and epidemiologic factors can often suggest a specific cause. Although rare, colonic obstruction could occur due to incarcerated inguinal or ventral/incisional hernia that can usually be diagnosed by an attentive physical examination. The presence of fever, tachycardia and peritoneal signs, or other signs suggestive of perforation, usually necessitate an urgent laparotomy.

Plain films of the abdomen will usually suggest the diagnosis of a large bowel obstruction and the most appropriate next step in imaging and/or management. For example, patients with classic radiologic findings of a sigmoid volvulus may be triaged directly to endoscopic decompression. CT evaluation of the abdomen and pelvis has emerged as the most effective diagnostic imaging modality for most patients and can be readily obtained through the emergency department. CT scanning provides for an

accurate diagnosis and can detect additional findings that can further guide the surgical management. Contrast enemas can also be useful in pinpointing the precise localization of the obstruction and determine whether the obstruction is partial or complete.

Surgical planning in the event of complete malignant obstruction depends on the viability of bowel, location of the obstruction, resectability of the tumor, and the overall goals of care. Careful deliberation, including the natural history of the disease, likely treatment options down the line (e.g., chemotherapy) with their potential consequences, patient values and goals, predicted functional outcomes, and available patient support systems, is critical to providing thoughtful, individualized, and expert care. Patients may either go straight to surgery or pursue nonsurgical palliative options. Nonsurgical therapy for malignant obstruction has evolved since the introduction of stents in 1991. Stents have been successfully applied as a bridge to surgery, providing a temporizing measure to allow for preoperative bowel preparation and correction of physiologic derangements. Stents may also enable single-stage resection with anastomosis as opposed to staged operations with an intestinal stoma or may be used as a definitive palliative measure in patients with advanced disease. Stenting by an experienced operator is successful in relieving the obstruction in greater than 90% of cases.

Most patients with malignant large bowel obstructions are treated with surgery. Right-sided lesions are usually best managed with a single-stage colectomy and primary ileocolic anastomosis. Left-sided lesions historically have been approached with a two- or three-staged procedure. Traditional options include preliminary transverse colostomy to avoid acute cecal perforation based on the law of Laplace, followed later by resection of the tumor with primary anastomosis and ultimately closure of the transverse colostomy. This option is seldom necessary or appropriate with the modern armamentarium of treatment options. A Hartmann procedure with resection of tumor and end colostomy followed later by colostomy takedown is another long-standing approach that continues to play a prominent role. Selected patients with left-sided colonic obstruction may be managed with a single-stage procedure (with or without on table colonic lavage) with acceptably low rates of anastomotic and other complications. Obstructions proximal to the sigmoid can usually be managed by subtotal colectomy with ileocolic anastomosis. Synchronous tumors have been found in up to 11% of patients, and most patients would

prefer a single operation without the need for a temporary stoma provided that the functional outcome is acceptable. The role of primary ileorectal anastomosis for obstructing sigmoid lesions is more controversial and requires a more cautious assessment. The addition of on table lavage may be onerous and is probably unnecessary. The decision to perform a protective ileostomy to decrease the chance of anastomotic complications must be individualized based on the specific circumstances.



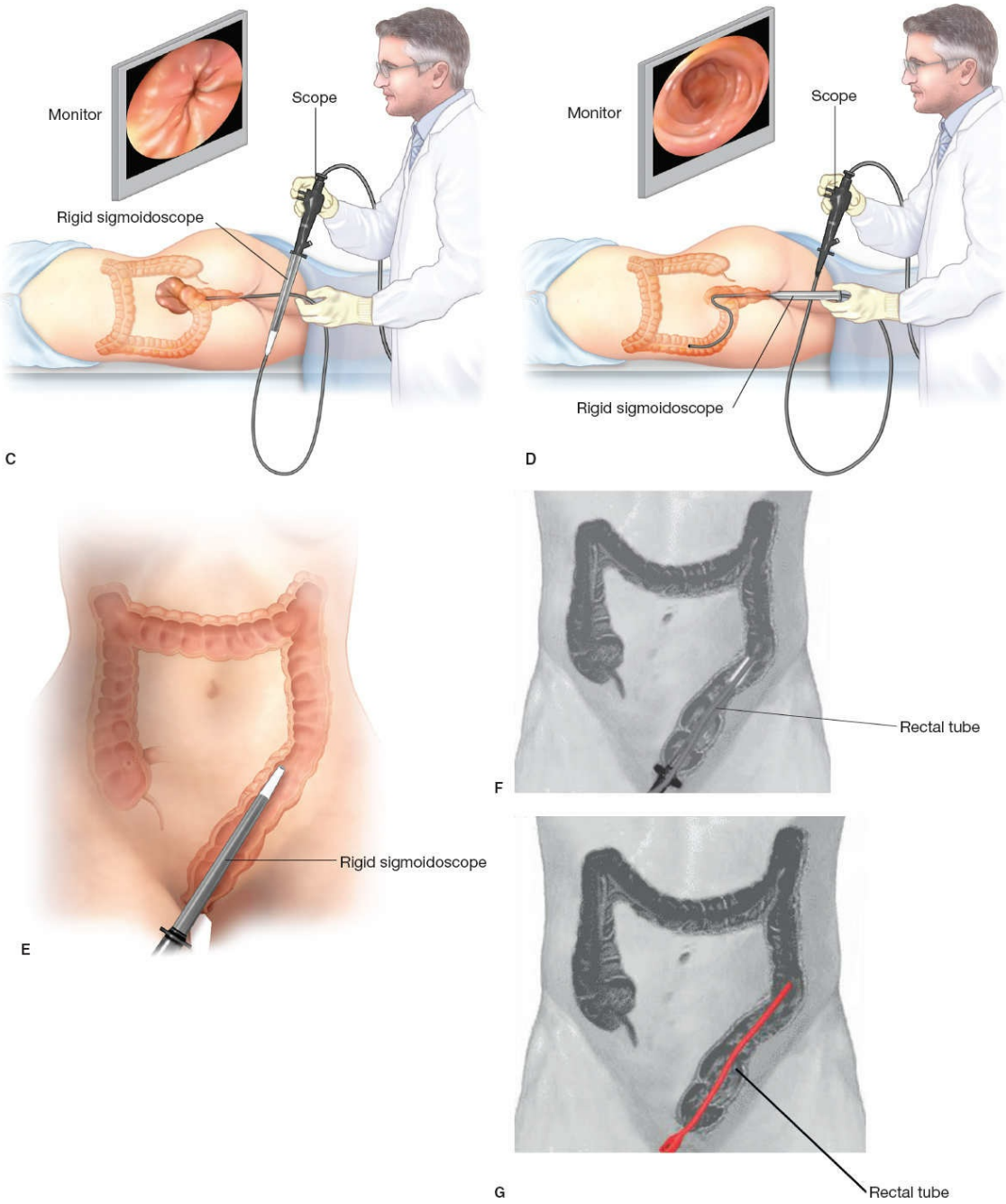

Figure 143.1. A. Flexible and rigid sigmoidoscope equipment. **B.** Rigid sigmoidoscope loaded over flexible sigmoidoscope. **C.** Volvulus detorsed with flexible sigmoidoscope. **D.** Well-lubricated rigid sigmoidoscope advanced into sigmoid colon over flexible sigmoidoscope using Seldinger technique. **E.** Flexible sigmoidoscope is withdrawn while rigid sigmoidoscope is kept in sigmoid colon. **F.** Rectal tube placed into sigmoid colon through rigid sigmoidoscope. **G.** Rigid sigmoidoscope is withdrawn while rectal tube is kept in place and secured to buttocks.

If complete resection cannot be achieved either due to the involvement

of vital organs or widely metastatic disease, a palliative diversion rather than formal resection should be considered. The patient's condition, expected patient survival, burden of disease, and other comorbidities should be taken into account, especially when approaching elderly or frail patients with a limited life expectancy. The goal in these individuals is to address the immediate problem with as little risk of morbidity and mortality as possible while relieving the large intestinal obstruction.

The operative planning for individuals with chronic or partial large bowel obstruction may proceed in a more deliberate fashion, with the degree of obstruction and its progression taken into consideration. In most instances, patients with a partial large bowel obstruction are suitable for primary anastomosis.

SURGICAL TECHNIQUE

The aim of this section is to address the unique technical aspects of management of acute colonic obstruction.

Technique of Colonic Decompression in Sigmoid Volvulus

Colon detorsion in sigmoid volvulus can be accomplished with either rigid or flexible sigmoidoscope. The goals of this maneuver, regardless of the choice of the instrument, are to (1) relieve obstruction due to volvulus, (2) prevent re-volvulization, and (3) allow time for bowel preparation prior to surgery. While the rigid sigmoidoscope provides a wide lumen that would accept a large size decompressive tube, its length may not be quite sufficient to traverse the "whirl" of the volvulus. The surgeon may visualize the "whirl" but it seems to be pushing away as the tip of the rigid sigmoidoscope is advancing. The flexible sigmoidoscope allows for better maneuverability and reliably provides sufficient length to traverse the obstruction. Upon entry into the proximal segment, one encounters a large cavernous lumen of massively distended sigmoid colon. Following endoscopic detorsion, it is common practice to leave a rectal tube, which may be threaded through the working (suction) channel of the sigmoidoscope. The caliber of the rectal tube, however, is limited by the inner diameter of the working channel of the scope. Such small caliber tubes are often not very effective at decompressing and maintaining the "floppy" sigmoid colon in its proper orientation.

A technique combining the benefits of rigid sigmoidoscope with the reach and maneuverability of flexible sigmoidoscope is shown in Figure

143.1. Step 1 (Fig. 143.1A,B): Prior to insertion of the flexible sigmoidoscope, a rigid sigmoidoscope without the attached light source is loaded onto the flexible scope and advanced as far back as possible toward the controls. Step 2 (Fig. 143.1C): Flexible sigmoidoscopy is performed to detorse the colon. Step 3 (Fig. 143.1D): The well-lubricated rigid scope is carefully advanced over the flexible sigmoidoscope, which essentially acts as a guide wire, into the more proximal sigmoid colon. After decompression the colon shortens and the length of the rigid sigmoidoscope is now sufficient to traverse the point of volvulization. Step 4 (Fig. 143.1E): The flexible sigmoidoscope is withdrawn while the rigid sigmoidoscope remains in place. Step 5 (Fig. 143.1F): A large caliber rectal tube can now be placed through the lumen of the rigid sigmoidoscope. Step 6 (Fig. 143.1G): The rigid sigmoidoscope is withdrawn while maintaining the rectal tube in position. The rectal tube is secured to the perianal region with tape or suture and connected to a drainage bag.

Technique of Colon Decompression With Self-Expanding Metallic Stent (SEMS)

Successful preoperative insertion of a self-expanding the metallic stent (SEMS) eliminates the need for a high-risk emergency surgery and may allow elective surgery to proceed in a planned, deliberate fashion following careful preoperative planning and bowel preparation. The first description of endoscopic placement of prosthesis for colorectal disease was by Dohmoto for palliation of rectal cancer using a rigid Celestin tube. Subsequently, Spinelli in 1992 reported endoscopic placement of a self-expandable metal stent for treatment of a malignant rectal obstruction. Since then, there have been numerous publications on the use of SEMS for management of malignant colonic obstruction. There are a variety of SEMS specifically designed for colonic use. Most of the modern SEMS are delivered through the therapeutic channel of the endoscope. The commercially available self-expanding stents for colonic use in United States are uncovered and have various degrees of shortening during deployment. The stent diameter varies between 20 and 30 mm after deployment. Patients with incomplete obstructions who have a lumen wide enough to admit a therapeutic colonoscope are unlikely to benefit from stent placement as this is associated with high rate of migration. Most through-the-scope (TTS) stents insertion is enabled by fluoroscopic

guidance.

Endoscopic colonic stent placement is technically challenging and should be performed by an experienced practitioner, often with previous experience in placement stents in other areas of the gastrointestinal tract such as the esophagus or biliary tree. Patients with colonic obstruction may be clinically ill and unable to tolerate prolonged procedures. The potential for perforation and intraperitoneal spillage of fecal content is a risk that needs to be discussed with the patient and the family prior to the procedure and steps taken to minimize this complication, particularly avoiding dilatation of the stricture. The success rate of the stent placement can be negatively affected by use in a longer stricture, angulation, or challenging anatomy. Distal location of the obstructing lesion is usually more favorable for successful stent placement compared to location within a tortuous segment of sigmoid colon or around the splenic flexure. However, there must be ample room to “seat’ the distal end of the stent far enough above the anal canal to avoid unacceptable local side effects.

The steps involved in the TTS colonic SEMS placement:

1. Adequate endoscopic visualization is critical in allowing optimal stent placement. While formal bowel preparation is not possible in cases of complete obstruction, an enema to clear the distal bowel is required. In those patients who continue to pass colonic contents owing to a partial obstruction, a judicious bowel prep can be attempted. The procedure can be initiated with the patient in the left lateral decubitus position; however, supine position allows for better fluoroscopic imaging and is often preferred. The endoscope is passed to the site of the obstruction. In patients who present with complete obstruction, consideration should be given to use carbon dioxide instead of room air for insufflation; when air is used, the least possible amount should be insufflated to avoid overdistention of the proximal bowel.

   The choice of an endoscope (upper endoscope vs. colonoscope) can be tailored to the location of the lesion; for distal colonic lesions, it is preferable to use an upper endoscope so that the stent can be passed through the working channel. A smaller diameter endoscope that is more flexible can be used to deploy a guidewire that can be left in place. A more rigid therapeutic endoscope can then be advanced over wire loaded through its therapeutic channel. Occasionally, highly trained endoscopists use a side viewing endoscope to allow the guidewire to be deployed through a sharply angulated and obstructing

lesion in the distal colon. The stricture can be further visualized using fluoroscopic contrast injection. Contrast can be injected directly through the working channel of the endoscope to delineate the stricture. However, in the cases of complete obstruction, the contrast may fail to enter the stricture. In such circumstances, the biliary stone retrieval balloon inflated to a large diameter (15 mm) can be advanced and placed against the lesion (Fig. 143.2), enabling contrast material to delineate the stricture.

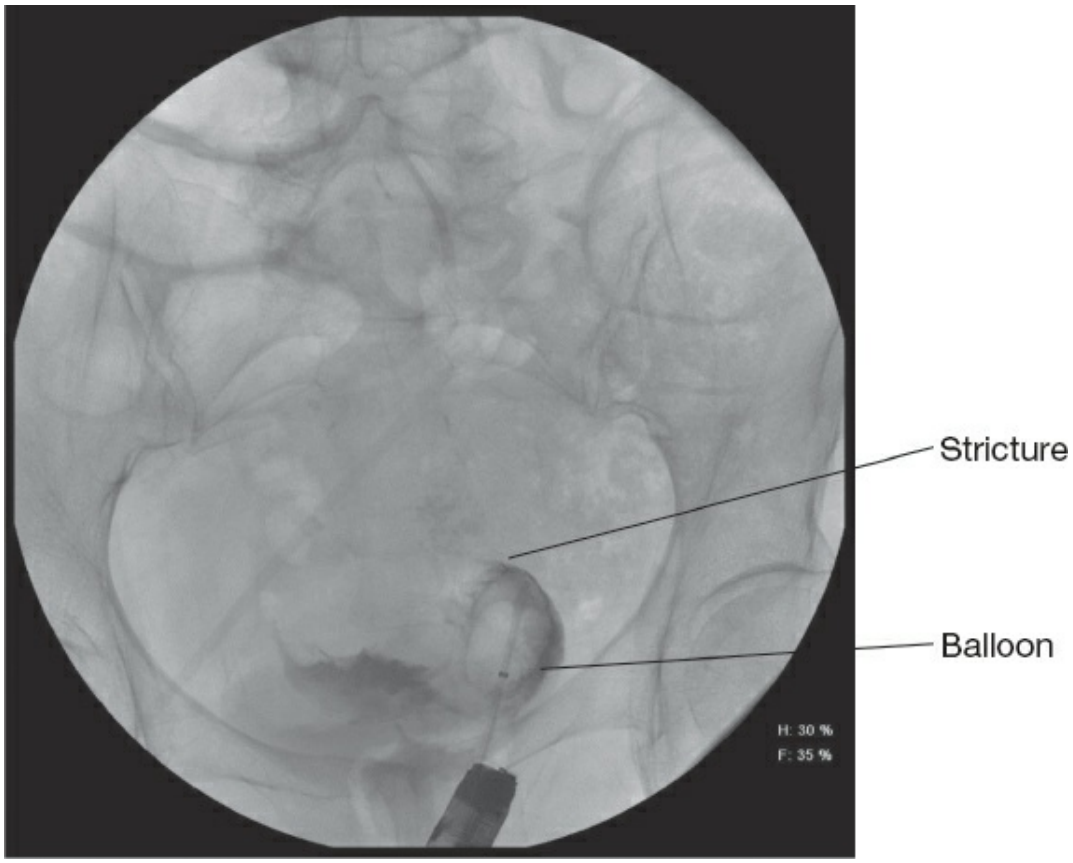

Figure 143.2. Stricture visualization with fluoroscopic contrast injection. Balloon inflated to a large diameter is placed against the lesion. Contrast material is injected through the stricture. (Image courtesy of Andres Gelrud, MD, MMSc Associate Professor of Medicine, University of Chicago.)

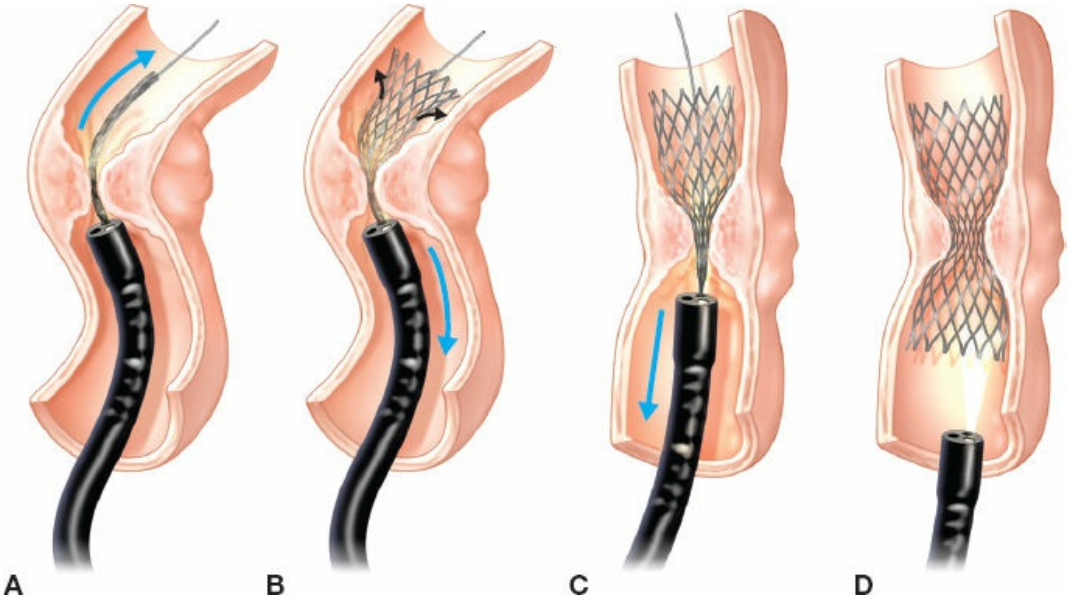

Figure 143.3. A–D. Technique of colon decompression with self-expanding metallic stent (SEMS).

2. The obstruction is then traversed with the guidewire (Fig. 143.3A). Passage of a guidewire is often a rate-limiting step to successful SEMS placement. In the patient with complete obstruction, the technique for traversing a stricture and stent placements is similar to the techniques used during endoscopic retrograde cholangiopancreatography (ERCP); surgeons who have ERCP experience typically have familiarity with appropriate accessories, catheters, and fluoroscopy. Hydrophilic biliary guide wires (e.g., Navipro, BostonScientific, Natick, MAorTerumoGlidewire, and TerumoMedicalCorporation, Somerset, NJ) can be helpful in traversing the lesion (Fig. 143.4A,B). For lesions located at the splenic flexure or with severe angulation, use of the clear cap on the tip of the endoscope similar to the one used during endoscopic mucosal resection may enable a better view.
3. Based on the fluoroscopic imaging, the length of the stent should be determined. The suitable length of the stent should be sufficient to bridge the stricture and extend at least 2 cm on each side of the lesion both proximally and distally. The predeployed stent is advanced through the working channel of the endoscope and position across the lesion (Fig. 143.3B). The stent is then deployed by withdrawing the constraining sheath or unraveling the string, depending on the device used (Fig. 143.3C). The TTS SEMS are deployed from the proximal (oral) end. The surgeon must anticipate some shortening of the stent particularly as it moves away from the scope while the sheaths are withdrawn (Fig. 143.5A,B). Following successful placement of the

stent, flow of fecal material can be observed and correct position can be confirmed by demonstrating a “waist” within the stent (Fig. 143.3D). If the “waist” appears to be very narrow, careful balloon dilatation can aid in stent expansion, but such a maneuver may increase the risk of perforation and should be considered carefully.

The non-TTS SEMS are used less frequently and usually can be deployed with the help of a smaller caliber endoscope. This stent placement requires a stiff guidewire (Savary, CookMedical, Bloomington, IN, or Amplatzwire, BostonScientific) on which the stent is being deployed through the entire length of insertion, since the support of the endoscope is not present. The endoscope is usually utilized to follow the deployment of the stent alongside the guidewire, as the stent is being inserted.

Colonic stenting as a bridge to surgery is designed to allow temporary decompression of the colon, reduce its proximal diameter, and to allow bowel preparation in order to facilitate a one-stage procedure with primary anastomosis. In order to promote decompression after successful stent deployment, a colonic drainage tube can be left across the stent if the immediate passage of stool through the stent is not noted at the time stent deployment. The timing of surgical intervention varies, but often occurs within 2 weeks when the stent is intended as a bridge to definitive surgery, to avoid the risk of stent migration. Perforation is the most severe complication of colonic SEMS, occurring in 3.8% to 10% of patients. Predeployment dilation has been associated with an increased risk of perforation and hence is discouraged. Other potential factors contributing to perforation include puncture of the colonic wall during guidewire passage, erosion of the colonic wall by free wires at the end of the stent, and administration of bevacizumab-based chemotherapy regimens. Stent migration and obstruction are generally delayed complications reported in 10% to 11.8% and 7.3% to 10% of patients, respectively.

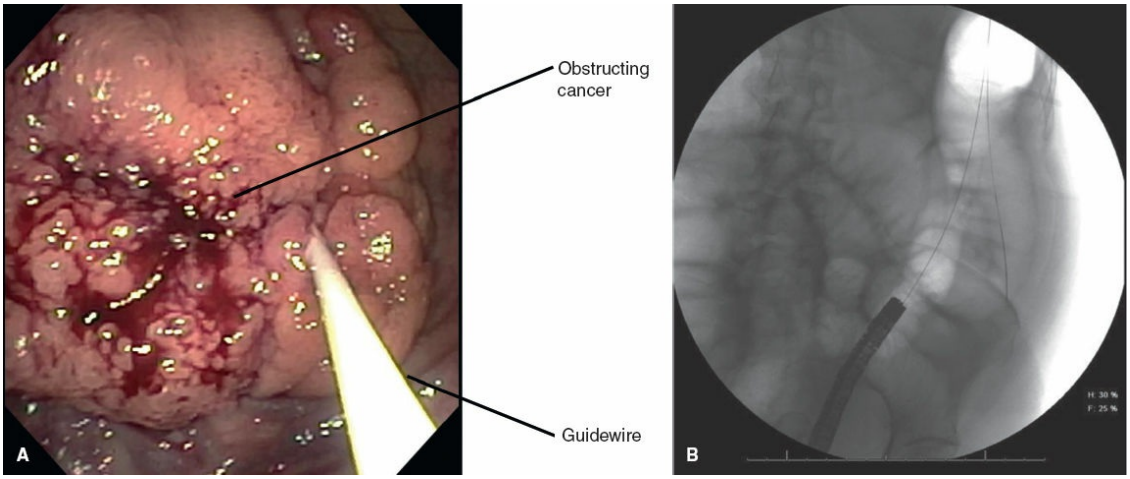

Figure 143.4. A, B. Traversing malignant obstruction with guidewire. (Images courtesy of Andres Gelrud, MD, MMSc Associate Professor of Medicine University of Chicago.)

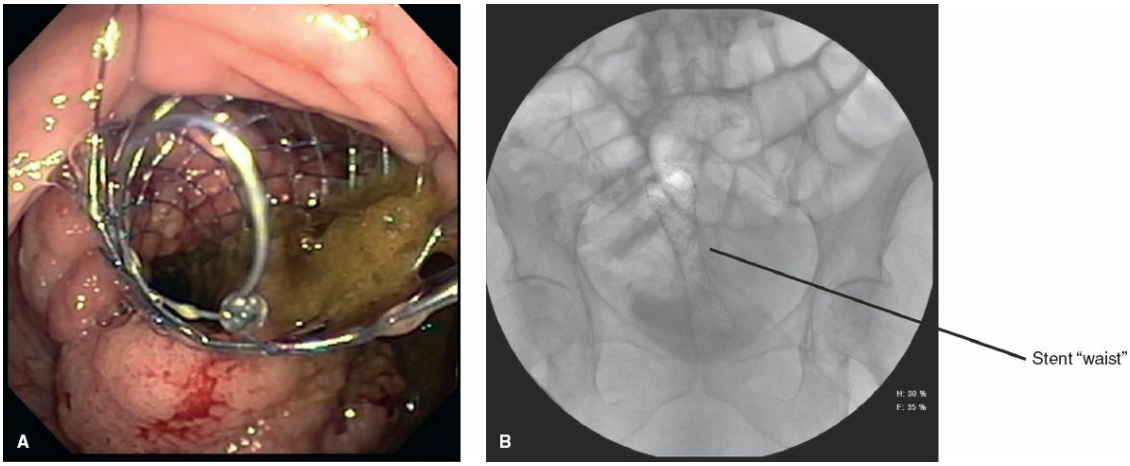

Figure 143.5. A, B. Colonic stent deployed. (Images courtesy of Andres Gelrud, MD, MMSc Associate Professor of Medicine, University of Chicago.)

Stent placement low in the rectum can lead to severe tenesmus. One study of 44 patients that provided long-term follow-up reported a complication rate of 51%, which included stent migration in 22%, obstruction 17%, perforation 7%, and tenesmus in 5%. Colonic stent placement for luminal obstruction secondary to extrinsic lesions is associated with a low success rate including a rate of stent migration of 13% of patients in one study.

The bridge to surgery strategy with the SEMS is currently becoming a more commonly considered initial treatment option for malignant large bowel obstruction. Initial concerns about suboptimal oncologic outcomes due to risk of perforation or tumor dissemination have been addressed in

multiple studies and summarized in a recent meta-analysis. Even though there are no randomized controlled trials validating the efficacy and safety of SEMS as a bridge to surgery (most of the studies were closed prematurely due to the high rates of complications related to SEMS), the wealth of clinical data seems to point toward a reasonable degree of safety and efficacy with stents in appropriately selected patients.

The role of a stent as definitive management of a large bowel obstruction in the palliative setting is probably far more controversial and problematic. From the functional standpoint, stents do usually resolve the "crisis" of an acute large bowel obstruction. However, the tumor-laden segment tends to act as a "functional" obstruction, and patients commonly suffer from symptoms of a low-grade, chronic large bowel obstruction. Quality of life is often superior with a diverting colostomy. Furthermore, the long-term risk of migration, re-obstruction, and perforation should not be underestimated.

Ontable Colonic Lavage With Segmental Colectomy and Primary Anastomosis

Intraoperative colonic irrigation, with or without ontable colonoscopy, can be a useful alternative if stenting is unavailable or unsuccessful. Intraoperative lavage allows for decompression of the proximal colon and provides an opportunity to evaluate the colon for synchronous lesions if desired (e.g., suspicion is raised on preoperative imaging). Successful colonic lavage can be followed by primary anastomosis with or without a diverting ileostomy. Colonic irrigation may be performed in an antegrade fashion by using the appendiceal lumen (Fig. 143.6). This is carried out by inserting a large bore Foley catheter into the cecum through an appendicostomy or distal ileal enterotomy secured with a purse-string suture. The ileal enterotomy may be later used to construct a loop ileostomy if desired. The Foley catheter is connected to a large bag of warm saline solution and infused by gravity. A large corrugated tube, such as anesthesia ventilator tubing, is then placed in the open end of the descending colon proximal to the obstruction and secured with an umbilical tape or a suture to the bowel wall. The other end of the tubing is placed into a bucket on the floor where the effluent is collected. It may be necessary to manually propel solid stool toward the distal end; this maneuver may require mobilization of the flexures and can be cumbersome in dilated, obstructed bowel.

A proximal stoma diversion in addition to a colorectal anastomosis may be a prudent adjunct to the operative procedure. Although relatively high rates of surgical site infections have been reported with this technique, contamination can be minimized with careful technique with a correspondingly lower rate of wound infection. The procedure takes a motivated operating room team and requires thoughtful planning; some surgeons find on table lavage burdensome and unnecessary.

Resection With End Colostomy (Hartmann Procedure)

Preoperative marking, optimally performed by an enterostomal therapy nurse, reduces stoma-related complications and improves patient quality of life for those patients in whom a stoma is being considered. Managing the ostomy is facilitated by appropriate stoma location and construction, and can make the difference between discharge to home versus discharge to a nursing facility based on the ability of the patients to provide independent care of their new ostomy.

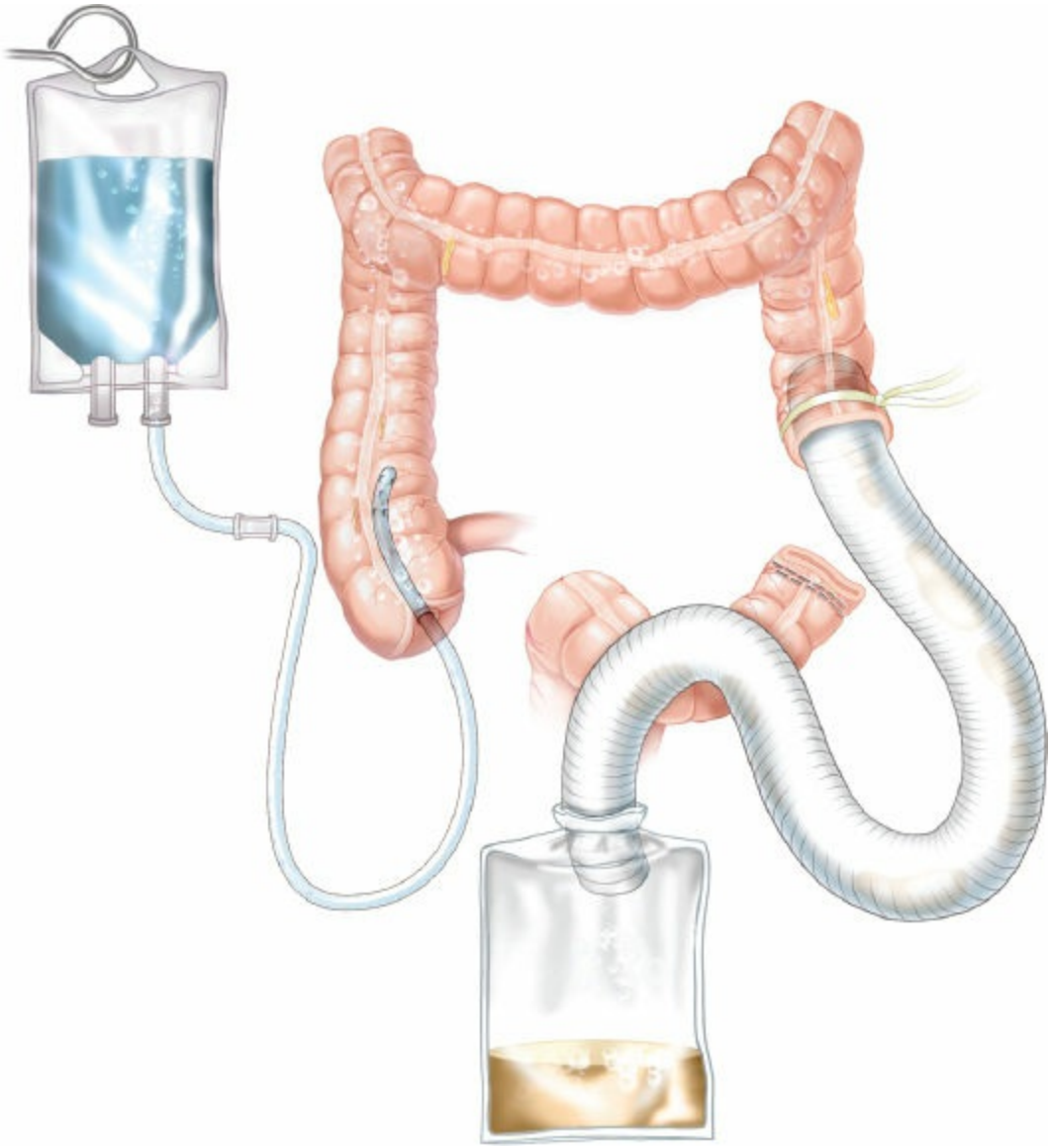

Figure 143.6. On table colonic lavage setup.

While the technical aspects of the Hartmann procedure are well known to most surgeons and are outlined elsewhere in the book, there are certain unique aspects of operating on the massively dilated colon that are worth mentioning in this chapter. Upon laparotomy, the surgeon is often confronted with a markedly dilated colon that occupies the entire operative field and can be exceedingly difficult to manage. Performing a colectomy while handling distended bowel may be fraught with the risk of inadvertent perforation with massive spillage and contamination. The colon may be preemptively decompressed by inserting a Foley catheter through a small opening secured with a purse string at the site of the proposed bowel transection (Fig. 143.7). While the catheter might be insufficient to remove the solid fecal material, it may be sufficient to

decompress some of the air and liquid stool within the colon and decrease the associated distention.

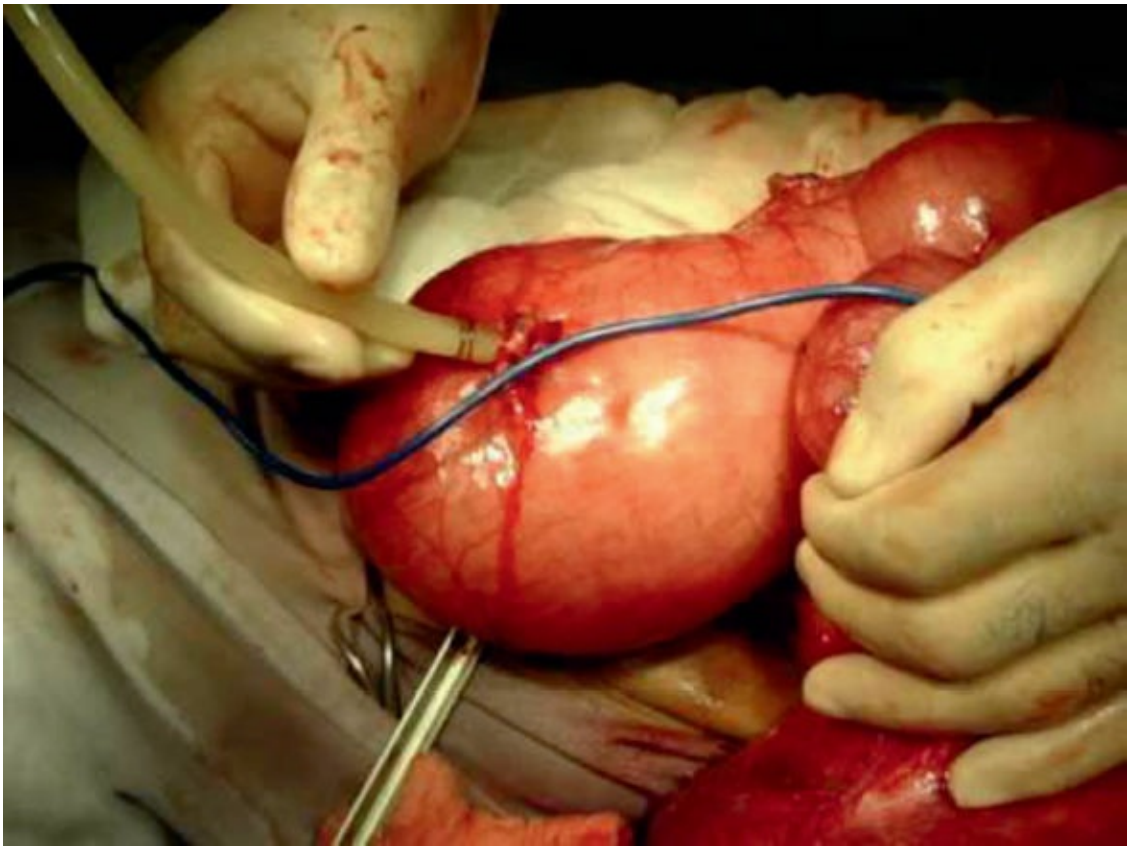

Figure 143.7. Intraoperative colon decompression.

After resection of the affected segment is performed, the distal end of the large intestine should be tacked to the lateral peritoneum and marked with nonabsorbable sutures for identification during the second stage procedure, when colostomy reversal is performed.

In the case of obstructed bowel and a locally advanced malignancy, an optimal oncologic resection may simply not be possible at initial presentation. In this setting, the patient's chance for long-term cure should not be compromised by an ill-fated procedure. It is far preferable to come back another day when the colon is not massively distended, the patient is not physiologically challenged, and appropriate colleagues and specialists are available. If tumor resection cannot be accomplished, a simple loop stoma proximal to the obstructing neoplasm without tumor manipulation represents sound and mature surgical judgment; alternatively, an end colostomy with mucus fistula either through the same site (end-loop colostomy) or through a separate site (Fig. 143.8) may be fashioned. The

opening in the fascia for colostomy construction should be made sufficiently large to admit dilated and thickened colon and its mesentery. Failure to do that may result in stoma congestion or even ischemia leading to complications ranging from delay of ostomy function to frank necrosis requiring colostomy revision.

Loop Colostomy

The technique of construction of a diverting loop colostomy is covered elsewhere in this textbook. A loop colostomy is considered in the setting where a limited palliative operation or a temporizing procedure needs to be performed in a patient who is otherwise deemed not a candidate for a more extensive procedure as described above. Construction of loop colostomy in the setting of a large bowel obstruction often results in an extremely large and difficult-to-manage ostomy that is prone to prolapse, especially if transverse or ascending colon is used. As a result, these types of colostomies often result in poor patient satisfaction.

Loop Ileostomy

Loop ileostomy may be an alternative to diverting colostomy; in many cases of large bowel obstruction, the small bowel maintains its relatively normal caliber if the ileocecal remains relatively competent. Even in the face of a massively dilated colon, the distal small bowel can be identified and brought up as a loop ileostomy. In most instances, colonic distension decreases following ileostomy construction. Colonic decompression can be further facilitated by aspiration and gentle antegrade irrigation of the colon by placing a catheter into the distal end of the loop ileostomy. Similar to a loop colostomy, this approach should be used in the setting where a more extensive operation cannot be performed, or a stent as a bridge to surgery is not possible. In expert hands, laparoscopic loop ileostomy can performed in the patient with even moderate colonic dilatation as long as insufflation and a working space can be established.

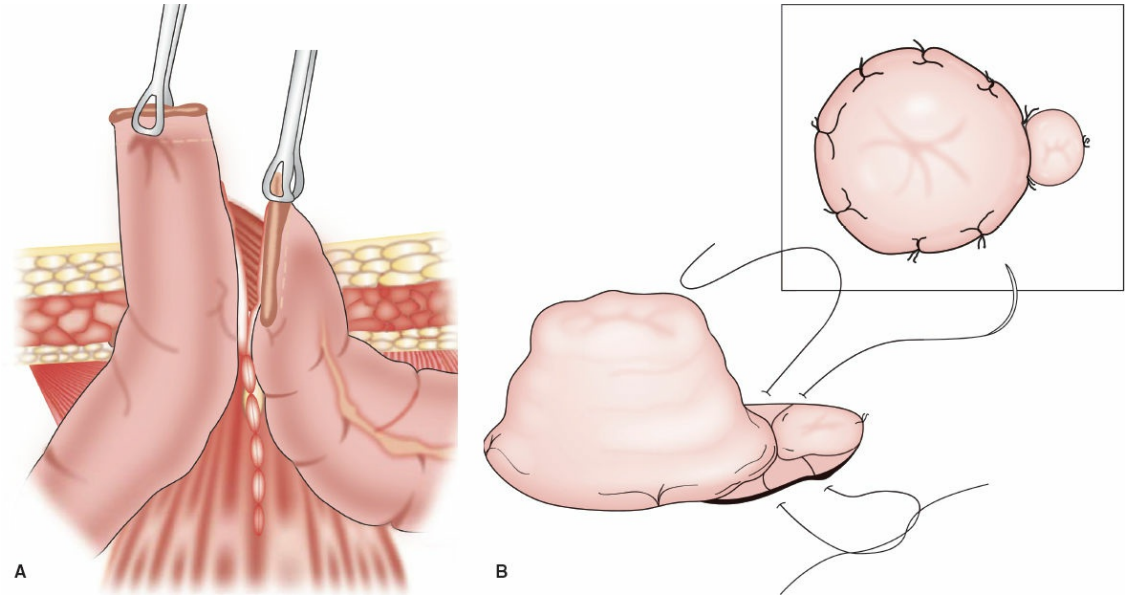

Figure 143.8. A, B. Prasad end-loop stoma. (Reproduced from Dimick JB, Upchurch Jr GR, Sonnenday CJ. *Clinical Scenarios in Surgery Decision Making and Operative Technique*. Philadelphia, PA: Lippincott Williams & Wilkins; 2012.)

POSTOPERATIVE CARE

Postoperative care should be tailored to the procedure that was performed. The patients who underwent successful SEMS placement should be monitored for signs of perforation with serial abdominal exams. Gentle bowel preparation with polyethylene glycol or similar agent could be performed if the patient is actively passing stool. If the patients do not have the desired therapeutic effect, they may be candidates for repeat stenting if the stent has migrated or is otherwise inadequately positioned. In patients in whom a colostomy was constructed, postoperative care should be focused on stoma teaching preferably by a skilled enterostomal therapy nurse. The challenges of managing a new, unexpected ostomy constructed in the face of an acute large bowel obstruction may be exacerbated by the large size of the obstructed bowel that can be difficult to pouch and may have copious output.

COMPLICATIONS AND THEIR MANAGEMENT

Stent-related perforation and migration are the two most worrisome common complications associated with stenting, with reported rates of 2% to 5% and 49%, respectively. Patients may experience transient abdominal pain and bleeding per rectum. Perforations can occur immediately during

or after the procedure but can be delayed, especially when a large-caliber stent with high radial force is used. Perforations are more likely to occur in the sigmoid colon, where angulation and redundancy make stent deployment more technically challenging. In a systematic review, Cirocchi and colleagues reported perforation rates similar to what was described above, but also noted that two of the randomized controlled trials were prematurely discontinued because of high rates of perforation.

Several factors have been associated with a high risk of perforation; patient-related factors include previous radiation therapy, certain types of chemotherapy, and procedural factors such as predilation with a balloon before stent deployment. Radiation therapy appears to predispose to stent-related perforation; however, the data to support this observation are limited. Use of the angiogenesis inhibitor bevacizumab may be associated with an increased risk of post stent perforation.

Stent migration tends to occur within the first 5 to 7 days after stent placement. Factors that contribute to stent migration include suboptimal length of the stent, small caliber stents relative to the diameter of the lumen, and nonobstructing lesions. Stents used for benign strictures are associated with unacceptably high rate of migration (63%). Stent failure is defined as the inability of the stents to restore luminal patency and may occur immediately after stent placement or in a delayed manner after tumor recurrence or progressive growth. Immediate stent failure may be related to technical errors or a mismatch between stent length and stricture length. The rate of immediate stent failure has been reported to be as high as 12% in the postprocedural period; the most common reason is a very tight “waist” in the stent. Stent occlusion after a period of clinical improvement denotes late recurrence of obstruction and may be caused by tumor ingrowth resulting in luminal compromise. Endoscopic intervention often involves placing another stent through the original stent or restoring luminal patency by tissue ablation, often by argon plasma calculation or less commonly by tumor debulking with a laser. In general, experienced endoscopists are able to achieve a rate of technical success higher than 90% and a low rate of procedure-related complications.

OUTCOMES

Emergency surgery remains the most reliable intervention to relieve colonic obstruction, and is effective in 99% of cases. As noted earlier, colonic stenting as a bridge to elective surgery has emerged as an attractive

alternative to emergency surgery in recent years. However, there are no significant differences in 30-day mortality between emergency surgery and colonic stenting group. A recent meta-analysis by Cirocchi and colleagues reported the overall complication rate to be similar: 48.5% in the colonic stent group as compared with 51% in the emergency surgery group. The rate of primary anastomosis was significantly higher following stent placement (65%) compared with the emergency group (55%), and the overall stoma rate was significantly lower in patients who underwent stent placement (45%) compared with emergency surgery (62%); however, the risk of a permanent stoma appears to be similar between the two groups (46.7% vs. 51.8%, respectively). The anastomotic leak rate appeared to be similar between the groups (9% in the stent group and 3.7% in the surgical group), although the authors did not report whether a diverting stoma was constructed at the time of anastomosis. There was no significant difference in the risk of an intra-abdominal abscess or wound infection.

The bulk of experience with stents in the colon has been in the relief of left-sided colonic obstruction. Published reports have demonstrated success rate that ranges from 66% to 100% with a median of 94% and clinical success rate that ranges from 55% to 100% with a median of 91% in the patients undergoing colonic stenting for a palliative indication. In one study, a group of 39 patients with acute left-sided malignant colonic obstruction were randomly assigned to undergo stenting, followed by elective colonic resection, or to immediate surgery. The authors noted no difference in mortality; however, there were significantly less surgical complications in the group who underwent stenting. The number of days spent in the intensive care was also significantly less in the stent recipients. Stent migration occurred in 11% of patients, and approximately 20% of patients require an intervention to reestablish luminal patency. It has been reported that the duration of luminal patency after colonic stent placement can range from 68 to 288 days with a median of the 160 days. The wide range of outcomes highlights the heterogeneity of outcomes in the studies and should be taken into account during preoperative planning and patient counseling.

Suggested Readings

ASGE Technology Committee, Varadarajulu S, Banerjee S, et al. Enteral stents. *Gastrointest Endosc* 2011;74(3):455–64.

Baron, TH. Technique of colonic stenting. *Tech Gastrointest Endosc*

2014;16(3):108–11.

Chudzinski AP, Thompson EV, Ayscue JM. Acute colonic pseudoobstruction. *Clin Colon Rectal Surg* 2015; 28(2):112–7.

Cirocchi R, Farinella E, Trastulli S, et al. Safety and efficacy of endoscopic colonic stenting as a bridge to surgery in the management of intestinal obstruction due to left colon and rectal cancer: a systematic review and meta-analysis. *Surg Oncol* 2013;22(1):14–21.

Gajendran M, Umapathy C, Nasr J, et al. Clinical outcomes of colonic stent in a tertiary care center. *Gastroenterol Res Pract* 2014;2014:138724.

Matsuda A, Miyashita M, Matsumoto S, et al. Comparison of long-term outcomes of colonic stent as "bridge to surgery" and emergency surgery for malignant large-bowel obstruction: a meta-analysis. *Ann Surg Oncol* 2015;22(2):497–504.

Sasaki K, Kazama S, Sunami E, et al. One-stage segmental colectomy and primary anastomosis after intraoperative colonic irrigation and total colonoscopy for patients with obstruction due to left-sided colorectal cancer. *Dis Colon Rectum* 2012;55(1):72–8.

Unti, JA, Abcarian, H, Pearl, RK. Rodless end-loop stomas: Seven-year experience. *Dis Colon Rectum* 1991;34:999–1004.

EDITOR'S COMMENT

In their chapter, Drs. Hyman and Umanskiy provide a good overview of a very common clinical problem, namely management of the patient with large bowel obstruction. Differential diagnosis of such patients can often be challenging, and establishing the correct diagnosis, in other words, differentiating malignant from benign obstruction, is very important with respect to determining the urgency with which to proceed, as well as the goals of the operation. One aspect the authors may not have stressed enough is the increasing frequency of patients under the age of 50 who are being diagnosed with colorectal cancer. Because of this, even in a young patient, one should keep in mind that a large bowel obstruction may be due to malignancy. In our hospitals, it seems that one has to only walk or to be transported across the threshold in a stretcher and one already has undergone a CT scan! Because of this, it is currently easier to establish a diagnosis of volvulus than it once was, when the only diagnostic imaging one had was a plain film of the abdomen. The characteristic signs of volvulus seen on a plain film are not always as characteristic as one would like.

It is always easier to construct an anastomosis at the primary operation, even though one may not wish to do so, than to come back at another sitting to a pelvis that may have significant adhesions and inflammation to do a colorectal anastomosis at another later date. As with all operations for large bowel obstruction, the question of whether or not to divert, in my opinion, is

determined by the resiliency of the patient. In other words, if the patient could tolerate the infectious sequelae if the patient would suffer an anastomotic leak, then if the surgeon deems it prudent and if the circumstances warrant doing a primary anastomosis without diversion, then I believe that it is justified. If, however, the patient's physiologic status is such that they could not withstand the sequelae of an anastomotic leak, if it occurred, then the patient should be diverted. As the authors nicely outline in their chapter, in most cases a loop ileostomy is a preferred diversion. It is easy to construct even in the very obese individual; it is a much more manageable stoma than a transverse loop colostomy and it is easier to close.

In their discussion of colonic stenting as a "bridge to surgery," the authors do mention the controversy regarding stenting patients with colorectal cancer and a possible adverse effect on outcome. There have been several papers that suggest that stents may lead to tumor microperforation and a worse prognosis with respect to the colorectal cancer itself. Kim and colleagues found that there was no difference between the stenting as a bridge to surgery and surgery alone groups with respect to 3-year overall and recurrence free survival (Kim SJ, Kim HW, Park SB, et al. Colonic perforation either during or after stent insertion as a bridge to surgery for malignant colorectal obstruction increases the risk of peritoneal seeding. *Surg Endosc* 2015;29(12):3499–506). However, there was an odds ratio of 46 for seeded metastasis if perforation occurred either during or after stent placement (95% CI 2.0 to 1,047, $p = 0.016$) (Kim SJ, Kim HW, Park SB, et al. Colonic perforation either during or after stent insertion as a bridge to surgery for malignant colorectal obstruction increases the risk of peritoneal seeding. *Surg Endosc* 2015;29(12):3499–506). There has recently been much debate as to whether or not this should be used for patients who are good operative candidates and who have curable cancers. Some publications report no difference in oncologic outcome and report higher rates of laparoscopy with lower conversion rates and lower rates of wound infection (Park SJ, Lee KY, Kwon SH, et al. Stenting as a bridge to surgery for obstructive colon cancer: does it have surgical merit or oncologic demerit? *Ann Surg Oncol* 2016;23(3):842–8). I refer readers, however, to the very extensive and authoritative *Clinical Guidelines* of the European Society of Gastrointestinal Endoscopy (van Hooft JE, van Halsema EE, Vanbiervliet G, et al.; European Society of Gastrointestinal Endoscopy [ESGE]. Self-expandable metal stents for obstructing colonic and extracolonic cancer: European Society of Gastrointestinal Endoscopy [ESGE] Clinical Guideline. *Gastrointest Endosc* 2014;80(5):747–61.e1–75). These guidelines have also been endorsed by the American Society of Gastrointestinal Endoscopists (ASGE). The main points of these thorough, very carefully prepared guidelines are as follows:

- Prophylactic colonic stent placement is not recommended for patients without obstructive symptoms
- Stent placement as a "bridge-to-elective-surgery" is not recommended as a

standard treatment for malignant obstruction due to left-sided colon cancer

- Colonic stents may be used as an alternative to emergent surgery in individuals with a high risk for postoperative death (e.g., patients with American Society of Anesthesiologists [ASA] physical status ≥III and or age ≥70 years)
- Colonic stent placement is the preferred palliative treatment for malignant obstruction except for patients treated with anti-angiogenic agents (e.g., bevacizumab)

These Clinical Guidelines (van Hooft JE, van Halsema EE, Vanbiervliet G, et al.; European Society of Gastrointestinal Endoscopy [ESGE. Self-expandable metal stents for obstructing colonic and extracolonic cancer: European Society of Gastrointestinal Endoscopy [ESGE] Clinical Guideline. *Gastrointest Endosc* 2014;80(5):747–61.e1–75) also clearly state that the outcomes with stenting *extra*-colonic cancer are inferior to those obtained for colonic cancer. Some of these statements have to be taken with caution. In one large multicenter study, it was exactly the ASA ≥III and patients >70 years of age in whom stenting was less likely to be successful (Geraghty J, Sarkar S, Cox T, et al. Management of large bowel obstruction with self-expanding metal stents. A multicentre retrospective study of factors determining outcome. *Colorectal Dis* 2014;16(6):476–83).

The technique of intraoperative colonic lavage has fallen out of favor, largely because it is time-consuming and it adds an additional 45 minutes to an operation. Many have advocated performing this after an operation has concluded, through the efferent limb of a loop ileostomy and through the anastomosis. This is done by inserting an irrigating catheter (such as a large bore Foley) through the efferent limb of the loop ileostomy, and connecting this to a warming 3-liter bag of fluid as would be used for a cystoscopy, and inserting a rigid proctoscope through the constructed colorectal anastomosis and letting the lavaged stool run exit out of the body through the proctoscope into a waste receptacle. There are several reasons for performing a colonic washout. The main reason is to avoid leaving an entire column of stool in a colon that has been diverted especially when constructing a primary anastomosis, i.e., having less stool in the vicinity of the anastomosis. Either method of lavage works, but again they both are time-consuming. Although surgery for large bowel obstruction due to diverticular disease is handled in much greater detail in Dr. Roberts' excellent chapter on diverticular disease (Chapter 149), of importance here is that when operating on patients for large bowel obstruction, there is no need to do extensive surgery for diverticular disease, and the most common mistake that surgeons perform is that they go too low down into the pelvis. Diverticular disease is a disease of the sigmoid colon. Unless there is a fistula to the rectum or some other infection or fistula extending to the pelvis, the rectum does not have to be resected with sigmoid diverticular disease. The proximal margin is determined solely by where the bowel is palpably normal and no

longer affected with the muscular hypertrophy, which characterizes the diverticular disease.

With respect to large bowel obstruction arising in the setting of Crohn disease, as has been discussed in the chapter on colonic Crohn disease by Dr. Fichera (Chapter 150), there is a controversy as to which operation is best. However, the recurrence rates are generally lower with total colectomy than with segmental resection. In the acute setting, however, medical therapy with steroids (hydrocortisone 100 mg intravenously every 6 hours) may result in relief of the obstruction so that an elective operation can be planned and the patient appropriately counseled about all surgical options. Of importance, as has been emphasized in nearly every chapter in this section, *preoperative marking of stoma sites is essential*, even in the emergency cases. This avoids undue morbidity secondary to poor stoma siting, which can also lead to significant amount of added expenses for the patient.

Susan Galandiuk

144 Surgical Treatment of Colonic and Perianal Crohn Disease

Linda Ferrari, Erin O. Lange, Mukta Krane, Fabrizio Michelassi, and Alessandro Fichera

Crohn disease (CD) is a chronic transmural inflammatory process that can affect the entire gastrointestinal tract. Colonic involvement has been observed in 30% of patients and can affect an isolated segment or the entire colon as pancolitis. Crohn colitis may be seen in isolation or, more commonly, in conjunction with small bowel and/or perianal disease. While Crohn colitis is often successfully treated with medical therapy, one third of patients will undergo surgery and up to 25% will require permanent fecal diversion within 10 years from the initial diagnosis.

Perianal CD is a unique phenotype associated with earlier age of onset, more severe luminal disease, and colonic and rectal involvement. About 30% to 70% of CD patients have anal involvement, ranging from minor skin tags to complex fistulae, which may represent the initial presentation of CD or develop later in the disease course. Isolated perianal disease can typically be managed with medical therapy and local operations for treatment of fistula or abscess, with proctectomy rarely required in the absence of rectal involvement (5% to 10% vs. 25% in presence of rectal involvement). However, in cases of severe perianal disease, preservation of sphincter function and continence is challenging even in the hand of experienced surgeons. The introduction of anti-TNFα therapy has increased the success of sphincter preservation.

COLONIC CROHN DISEASE

Clinical Presentation

Isolated colonic involvement without small bowel disease occurs in approximately 25% of patients. The clinical presentation of colonic CD often includes diarrhea (70% to 80%), abdominal pain (45% to 65%), rectal bleeding (30%), and perianal disease (10%). Abdominal pain may be due to colon obstruction or peritoneal irritation caused by transmural

inflammation. Rectal bleeding occurs in 50% of patients with colonic involvement, but it is often of limited severity. Patients with Crohn colitis, as compared to those with primarily small bowel disease, are less likely to experience systemic symptoms such as weight loss and vitamin deficiency, but more likely to have associated extraintestinal manifestations of CD. Manifestations related to disease activity include erythema nodosum (5% to 10%), acute arthropathy (6% to 12%), conjunctivitis (3% to 10%), and aphthous ulceration (10%); those unrelated to disease activity include sacroiliitis (10% to 15%), ankylosing spondylitis (1% to 2%), primary sclerosing cholangitis (rare), gallstones (15% to 30%), and renal calculi (5% to 10%).

Diagnostic assessment should always include colonoscopy, to determine extent of disease, with intubation of the terminal ileum to rule out small bowel involvement, and multiple biopsies for histologic confirmation. The differential diagnosis includes ulcerative colitis, infectious colitis, collagenous colitis, ischemic colitis, Behçet disease, colonic neoplasm, solitary rectal ulcer syndrome, and NSAID colitis.

Indications for Surgery

Patients with CD localized primarily to the colon may present with fistulas, abscesses, toxic megacolon strictures, failure to thrive in the pediatric population, or colorectal cancer (CRC) but the most common indication for surgery is the presence of persistent abdominal pain and diarrhea that is unresponsive to medical therapy.

Fistulae and Abscesses

Patients with Crohn colitis are at risk of developing enterocolic (Figs. 144.1 and 144.2), colocutaneous, and cologastric fistulae as a consequence of full thickness inflammation. Fistulae may also develop as a complication of surgical resection, with fistulas developing from the anastomotic sites. Principles of treatment include resection of the actively diseased segment and repair or resection of the secondarily involved segment (innocent bystander).

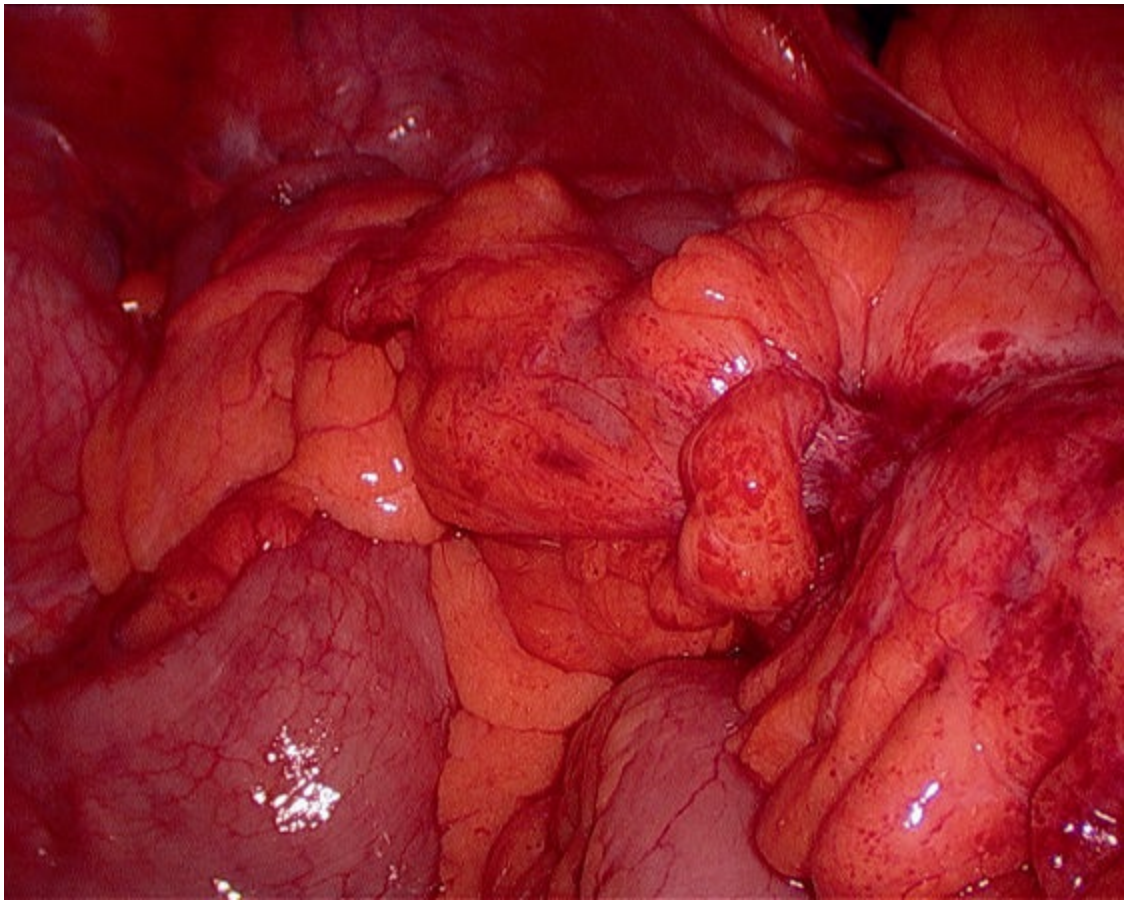

Figure 144.1. Fistula between the small bowel and sigmoid colon.

Abscesses are often related to full thickness bowel involvement and may present in the right lower quadrant, along the sigmoid colon or in the pelvis. Percutaneous image-guided drainage and antibiotics is generally the first line of treatment with subsequent resection of the involved bowel segment after medical optimization due to the high risk for recurrence.

Toxic Megacolon

Toxic megacolon is a rare but potentially fatal complication of pancolonic CD. Unstable patients or patients who do not readily respond to supportive measures, including adequate fluid resuscitation, antibiotics, and medical therapy, require surgery. A subtotal colectomy with creation of an ileostomy is the preferred surgical option. The decision between creating a mucous fistula and closing the distal rectosigmoid stump with drainage is based on the severity of inflammation and general condition of the patient.

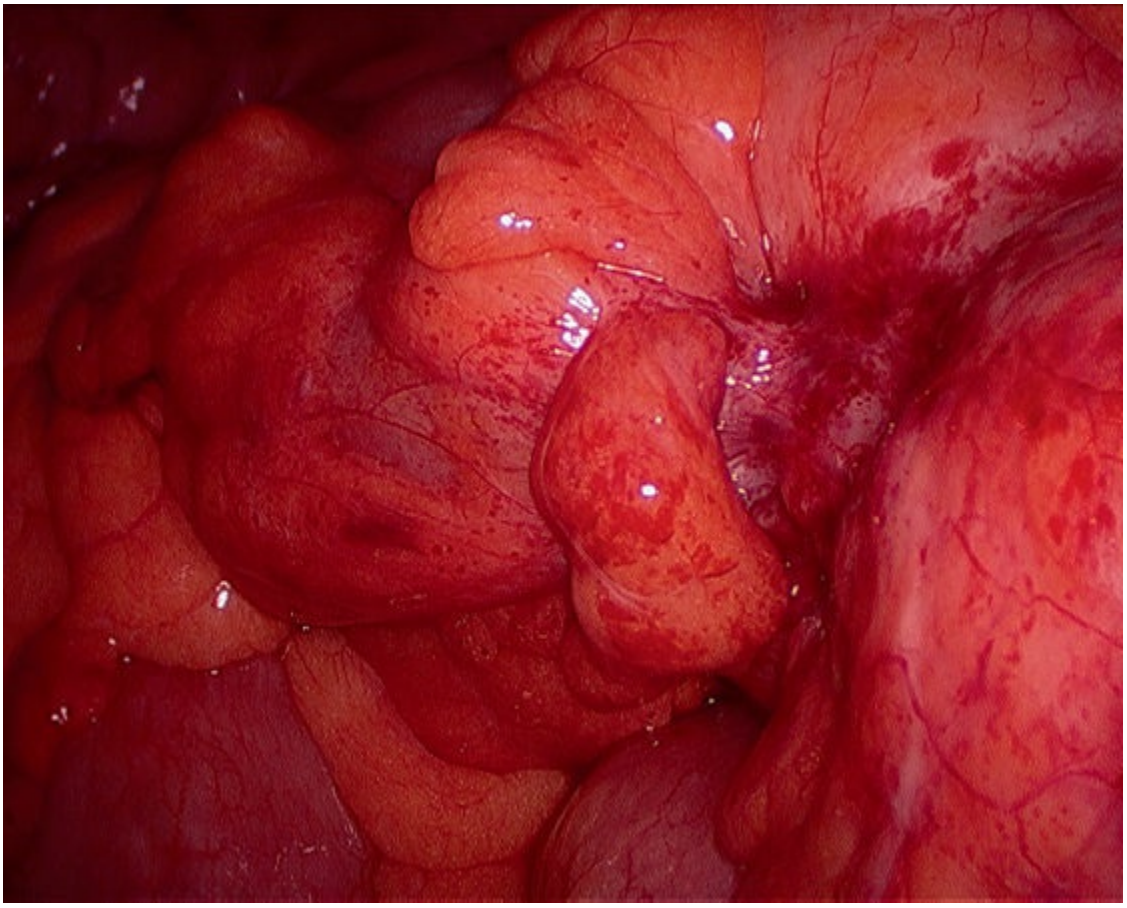

Figure 144.2. Enterosigmoid fistula.

Colorectal Cancer

As in ulcerative colitis, Crohn colitis increases the risk of CRC 4 to 20 times, with direct correlation with extent and duration of disease. Current guidelines mimic those for ulcerative colitis and call for surveillance colonoscopy beginning 7 to 10 years after diagnosis. Colonic resection may also be required for high-grade or multifocal low-grade dysplasia, stenosis preventing complete colonoscopic evaluation or raising concern for malignancy, and extensive pseudopolyposis limiting accurate surveillance.

Preoperative Planning

Colonoscopy

Colonoscopy with ileoscopy is an essential tool in the preoperative evaluation to determine the extent of colonic CD through direct mucosal visualization and to obtain biopsies for histologic evaluation. Characteristic colonoscopic features of CD include aphthous ulcers, longitudinal ulcerations, skip lesions (often with rectal sparing),

pseudopolyps, and strictures.

Due to the increased CRC risk, routine surveillance colonoscopy should begin no later than 8 years after symptoms onset and sooner in patients with a diagnosis of primary sclerosing cholangitis or strong family history of CRC (first-degree relative diagnosed before age 50). Colonoscopy at regular intervals (every 1 to 2 years) may help reduce the incidence of CRC. During the initial colonoscopic evaluation, at least two biopsies should be taken from five sites throughout the bowel, including ileum and rectum, in order to make an accurate diagnosis. However, accurate differentiation between CD and ulcerative colitis can be challenging, even for experienced gastrointestinal pathologists, due to the overlap in clinical symptoms and histologic appearance. Among patients with isolated colonic involvement, 5% to 10% will receive an initial diagnosis of indeterminate colitis, which may be modified later in the disease course.

In addition to routine surveillance, colonoscopy should be performed 6 to 12 months following partial colectomy or ileocolonic resection to evaluate for mucosal recurrence, which typically occurs at the surgical anastomosis or in the preanastomotic segment. Endoscopic recurrence generally precedes symptom relapse and may occur in 70% to 90% of patients within 1 year of surgery.

Chromoendoscopy facilitates detection of dysplastic premalignant lesions in both CD and ulcerative colitis over standard colonoscopy. Topical contrast dyes, such as 0.1% methylene blue or 0.03% to 0.5% indigo carmine, are sprayed segmentally onto the colonic mucosa, which facilitates visualization of mucosal nodularity and topographic abnormalities such as elevation and depression that can be missed on standard colonoscopy. This technique allows the endoscopist to target biopsies to high-risk areas, allowing better detection of dysplasia and malignancy.

Barium Enema

Barium enema (BE) often completes the evaluation of CD patients with colonic strictures or fistulae. Large abnormalities, including masses and high-grade strictures, can be seen on single-contrast studies. Double- or air-contrast studies, in which the rectum is filled with barium and then air, allow fine detailed assessment of the colonic wall and can be helpful in identifying low-grade strictures, mucosal abnormalities, and fistula tracts. This technique can be particularly advantageous for fistulae suspected clinically, but not clearly demonstrated on standard colonoscopy or body

imaging.

Computed Tomography

When an abscess is suspected, preoperative assessment should include CT of the abdomen and pelvis to localize it and to guide preoperative drainage. Preoperative optimization includes control of sepsis and nutritional support when needed.

As previously and more extensively described in the small bowel chapter, computed tomography enterography (CTE) takes advantage of the high spatial resolution and speed of modern CT scanners, and using large amounts of neutral oral contrast agents generates detailed images of the small bowel wall, lumen, and mesentery and it is excellent in identifying fistulizing disease. It has been shown that CTE has a higher sensitivity than barium small-bowel follow through and at some institutions, CTE combined with ileocolonoscopy has become a first-line test for the diagnosis and staging of CD.

However, given the concerns regarding radiation-induced neoplasia and the fact that CD patients will likely requite repeat imaging over their lifetime, magnetic resonance enterography (MRE) has been widely utilized in this patient population and it is currently considered a valid alternative to CTE.

Surgical Technique

Optimal surgical management of Crohn colitis often involves a resection, but the extent of colonic resection depends on the location, extent, and duration of disease, presence of small bowel disease, the urgency of intervention, the presence of complications, and the patient’s general health status.

Right Hemicolectomy

Colonic disease limited to the cecum is almost always associated with terminal ileal disease. In fact, terminal ileitis is often the predominant component of ileocecal disease; thus surgical management usually involves resection to grossly normal margins with an anastomosis between the neoterminal ileum and the proximal ascending colon. Recurrent disease is common at the anastomosis or the preanastomotic ileum, but rarely observed within the distal colon or rectum.

Disease of the entire right colon is also often accompanied by terminal

ileitis. Surgical management consists of a standard right hemicolectomy to grossly uninvolved margins, with an anastomosis between the ileum and the transverse colon. With a standard right hemicolectomy, the anastomosis often lies in proximity to the duodenum, placing the patient at risk, in the event of recurrence at the anastomosis, of a duodenal fistula. Therefore, the procedure should include interposing omentum between the duodenum and the ileocolonic anastomosis when feasible.

Total Abdominal Colectomy and Ileorectal Anastomosis

Total abdominal colectomy with ileorectal anastomosis (IRA) is the operation of choice for multifocal or extensive disease with rectal sparing. IRA is only appropriate if the rectum is truly disease-free on close endoscopic examination, fecal continence is adequate, and the patient does not have extensive perianal septic complications. Recurrence rates of 46% and 60% at 5 and 10 years, respectively, have been reported for CD patients undergoing IRA, as compared to rates of 10% and 21% for patients treated with a proctocolectomy with an end ileostomy. Disease recurrence does not necessarily translate into permanent fecal diversion. Cattan et al. reported that despite recurrence rates as high as 83% at 10 years, approximately 63% of patients still had a functioning IRA. Longo et al. found that 86% and 48% of 131 patients who had undergone a colectomy with IRA had a functioning IRA at 5 years and 10 years, respectively, consistent with other studies reporting 40% to 50% rate of subsequent proctectomy with permanent ileostomy due to recurrent rectal disease.

On the other hand, patients who are medically unfit, malnourished, or with severe acute colitis may require a total abdominal colectomy with creation of an end ileostomy. Management of the rectal stump is controversial. Some surgeons prefer to bring the rectal stump to the abdominal incision and open it as a mucous fistula. We typically prefer to staple it and utilize rectal tube drainage to keep the stump decompressed. After the patient has recovered from the acute episode, an IRA can be performed, depending on the extent of disease, fecal continence, and rectal compliance. Patients who are not candidates for IRA should undergo a completion proctectomy to avoid the risk of cancer in the rectal stump.

Total Proctocolectomy With Permanent Ileostomy

Multisegment colonic disease, especially with distal involvement, is best treated with a total proctocolectomy with permanent ileostomy. In the

absence of significant perianal disease, an intersphincteric proctectomy should be considered to reduce the risk of perianal wound complications associated with a wider dissection. In the presence of active perianal sepsis, a perineal wound should be avoided and the procedure should be performed in two stages leaving a very short rectal stump to be removed at a second stage as a perineal proctectomy. Unfortunately, in cases of extensive rectal and perianal disease, a wider dissection must be performed encompassing the entire sphincter mechanism. When the proctectomy results in extensive loss of perianal skin and subcutaneous tissue, the resulting defect may require tissue transfer such as gluteal, gracilis, or myocutaneous rectus abdominis pedicle flaps for closure.

Ileal Pouch Surgery for Crohn Disease

Restorative procedures such as an ileal pouch-anal anastomosis (IPAA) or continent ileostomy are not recommended for CD patients because of high risk of recurrence resulting in pouch loss and permanent fecal diversion. However, there is a small subset of patients with disease limited to the colon and rectum without any history of small bowel or perineal involvement who have a low risk of recurrence with pouch failure and should be considered for restorative proctocolectomy with a J-pouch ileo-anal anastomosis.

Panis et al. evaluated 31 patients with preoperative diagnosis of CD limited to the colon and rectum who underwent IPAA. Of these, 6 (19%) had short-term complications, including pouch–perineal fistula (2,6%), CD of the pouch (2,6%), pouch–vaginal fistula (1,3%), and abscess (1,3%). Two patients (6%) had a pouch failure, described as need for diversion or excision of the ileo-anal reservoir. After 10 years of follow-up, the rate of CD complications and pouch excision were 35% and 10%, respectively. Another study from Cleveland Clinic reported outcomes of IPAA for CD, and noted that despite higher rates of pouch failure compared with patients with ulcerative colitis or familial adenomatous polyposis (odds ratio 2.0; 95% confidence interval, 1.2–3.3; $p = 0.01$), 82% of patients retained their pouch at 10 years, and good functional outcome was reported. The Cleveland Clinic has also reported on the outcome of IPAA in CD as it relates to the timing of diagnosis (preoperative, immediately postoperative, or delayed postoperative). The overall 10-year pouch retention rate was 71%, with rates for patients with preoperative, immediately postoperative, and delayed postoperative diagnosis reported as 85%, 87%, and 53%, respectively. Complications were more common in the delayed diagnosis

group, with pouchitis (54%), fistula (35%), and IPAA stricture (24%) the most frequently reported.

In summary, IPAA in CD should be reserved for a carefully selected subset of patients with disease limited to the colon and rectum without perianal disease, with adequate sphincter function, and who are motivated to accept possibility of pouch loss over time. We do not offer IPAA for Crohn patients in our practice given the rare presentation of a CD patient with colorectal CD without small bowel or perianal involvement.

Proctectomy

CD limited to the rectum is rare. Surgical management of Crohn proctitis often involves a proctectomy, but the amount of proximal colon that is resected is controversial. Total proctocolectomy with end ileostomy has been recommended for many patients due to risk of stomal complications and recurrent disease in proximal colon after abdominoperineal resection (APR). However, certain patient subgroups who may benefit from preservation of colonic absorptive capacity (elderly patients, patients with a prior small bowel resection at risk for either high ileostomy output or short bowel syndrome), and others who lack any gross evidence of disease in the abdominal colon should still be offered proctectomy and end sigmoid colostomy.

The abdominal portion of the procedure is best performed with the patient in low lithotomy position. The open approach is performed through either a vertical midline or an infraumbilical transverse incision. Irrespective of the surgical approach, it is essential to fully examine the bowel to accurately assess the extent of disease and the presence of any synchronous lesions. In cases of total proctocolectomy, the abdominal colon is mobilized in typical fashion, taking care to assure adequate hemostasis during division of the often thickened and inflamed mesentery. The terminal ileum is divided using a linear stapler in a nondiseased area, minimizing the length of resected small bowel. The proctectomy part of the operation starts by dividing the attachment of the sigmoid colon to the lateral abdominal wall and opening the peritoneum along the lateral reflection. The layer of connective tissue that lies underneath the peritoneum, the fusion fascia, should be incised parallel to the divided peritoneal reflection, allowing the mesentery of the colon to be fully mobilized while the ureters and gonadal vessels remain in the retroperitoneum. The superior hemorrhoidal pedicle is divided using a vessel sealing device and the dissection is carried to a level below the

sacral promontory. The sympathetic neural plexus, which lies directly behind the inferior mesenteric artery, is identified and dissected free of these vessels, safely allowing the subsequent division of the superior hemorrhoidal vessels. The parietal peritoneum is then incised from the point of ligation of the superior hemorrhoidal vessels inferiorly and laterally to gain access to the presacral space. The left and right ureters are identified and the rectum is retracted anteriorly, allowing division of the loose areolar tissue along the presacral space under direct vision using electrocautery. Care must be taken to ensure that the dissection continues in the plane between the fascia propria of the rectum and the presacral fascia, which covers the presacral venous plexus, in order to avoid excessive bleeding from injury of the presacral plexus. Even when in the proper plane, bleeding from small communicating vessels between the rectum and the presacral plexus may be encountered. Thus, mobilization of the rectum with blunt hand dissection should be avoided. They typically follow the dissection plane of mesorectal excision to limit bleeding and to preserve autonomic innervation.

Posterior mobilization of the rectum should continue beyond the level of the coccyx with Waldeyer fascia incised using electrocautery, allowing for clear definition of the lateral ligaments. Anterior and superior traction is then placed on the rectum using a right-angle bowel clamp and the lateral rectal ligaments are divided close to the rectal wall, carefully avoiding injury to the parasympathetic nerves. Following the posterior and lateral mobilization of the rectum, superior traction results in the unfolding of the recesses of the rectovaginal or rectovesical pouch, which greatly facilitates anterior dissection. With the rectum retracted toward the sacral promontory, the anterior dissection of the rectum is carried to the distal border of the prostate in male patients and to the thickening of the perineal body and the anal sphincters in female patients. The rectum should now be circumferentially mobilized to the level of the levator ani muscles. The rest of the rectal dissection is completed through the perineum. In staged procedures, the rectum is closed with a TA stapling device and divided proximally, leaving a short rectal stump to be removed via perineal proctectomy at a later date. A drain is placed deep into the pelvis and brought out through an incision in the lower abdominal wall far from the planned stoma.

To create the stoma, a circular incision is made over the previously marked ostomy site. The subcutaneous fat is divided and the anterior

rectus sheath is opened with a longitudinal incision. The fibers of the rectus muscle are bluntly separated and the posterior rectus sheath is incised. The stapled end of the small bowel (or sigmoid colon if APR performed) is delivered through this incision until it ideally protrudes approximately 4 cm above the skin. The abdominal cavity is irrigated and the celiotomy incision closed. The stoma is matured using interrupted 3-0 absorbable sutures in the standard Brooke fashion. Everting sutures are placed on the antimesenteric edge of the colon, with a full-thickness bite of the intestinal wall, and a subcuticular bite of the skin. After these everting sutures are placed, they are tied, resulting in a stoma that protrudes approximately 1 to 2 cm above the abdominal wall. To allow complete approximation of the mucocutaneous junction, additional simple sutures are then placed between the cut edge of the intestine and the dermis.

The perineal portion of this procedure is performed with the patient placed in the lithotomy or prone position, depending on surgeon preference. The rectum is gently irrigated with a povidone-iodine solution, and a povidone-iodine–soaked gauze is placed into the rectum. The anus is then closed with a purse-string suture at the level of the anal verge. The perineum, including the vagina for female patients, is prepared in sterile fashion. Removal of the specimen is carried out in the intersphincteric plane (Fig. 144.3), beginning with a circular incision in the palpable groove between the internal and external sphincters using a needlepoint electrocautery. In patients with perineal disease, the incision may need to be extended to include the damaged and diseased tissue near the anal canal. The intersphincteric plane is best identified laterally; thus, dissection should begin at the lateral aspects and proceed to connect posteriorly and then anteriorly. The pelvic cavity is entered posteriorly and the dissection is continued until the rectum is completely free. The proximal colon, rectum, and anus are removed through the perineal incision (Fig. 144.4). To close the perineum, the external sphincters are approximated in layers using absorbable suture. The skin edges are trimmed and closed with interrupted absorbable vertical mattress sutures. In the presence of significant perineal sepsis, the skin edges and the subcutaneous tissues may be left open or a flap used to safely close the defect.

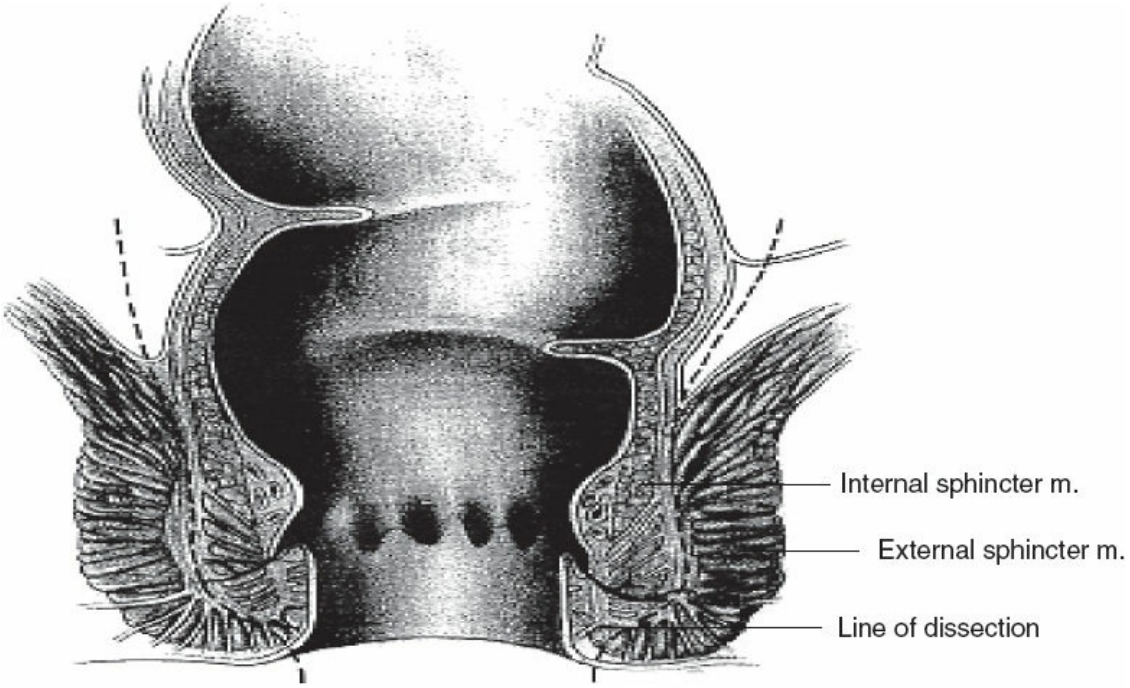

Figure 144.3. The intersphincteric plane (*dashed line*) is chosen as the plane of dissection in a proctectomy for inflammatory bowel disease.

Laparoscopic Total Proctocolectomy for Crohn Colitis

Because Crohn colitis is less common than ileocolic CD, occurring in 30% versus 75%, much of the literature focuses on laparoscopic surgery in the ileocolic region. While operative time is longer in patients with extensive Crohn colitis, our group has noted significant advantages of laparoscopic surgery in this population including reduced intraoperative blood loss, earlier return of bowel function, and shorter length of stay. Some series have also shown a reduction in complications, including wound infection, thromboembolic events, pneumonia, and myocardial infarction. Conversion to an open procedure occurs in only 10% to 16% of cases, and laparoscopic procedures have been performed successfully even in patients with prior abdominal surgery.



Figure 144.4. Specimen after total proctocolectomy for colonic Crohn disease.

To begin the laparoscopic proctocolectomy, the patient is placed in lithotomy position. A 12-mm trocar is introduced into the abdomen using open technique at the ileostomy site. After establishment of pneumoperitoneum and visual exploration of the abdominal cavity, the other 5-mm trocars are introduced in the left lower quadrant, bilateral upper quadrants, and umbilicus.

The small bowel is evaluated in its entirety. Mobilization of the colon then proceeds from right to left by dividing the major vascular pedicles and lateral attachments. The greater omentum is divided distal to the gastroepiploic arcade with the specimen. After the identification of the left ureter and transection of the superior hemorrhoidal pedicle, the rectum is mobilized to the level of the levator ani muscles in the avascular mesorectal plane in a similar fashion as described in the open procedure.

The terminal ileum is divided intracorporeally with an endoscopic stapling device and the proximal end of the terminal ileum is delivered through the future ileostomy site. A soft pelvic drain is placed in the pelvis. All port site incisions are closed and the stoma is matured using Brooke technique. The proctectomy is completed from the perineal side

and the specimen extracted through the perineal incision. The perineal incision and perineum are closed in layers.

Postoperative Care

Enhanced recovery after surgery (ERAS) programs has been used in colorectal surgery over the last 15 years in Europe and more recently in the United States. These programs optimize perioperative care pathways using a multimodality approach to reduce postoperative complications, length of hospital stay, and hospital costs. These protocols include preoperative counseling and education, minimal preoperative fasting, laparoscopic surgical approaches, intraoperative fluid restriction management, avoidance of insulin resistance, use of epidural analgesia and NSAIDs in lieu of systemic narcotics, and early mobilization. CD patients may particularly benefit from a quick return normal state of health. Inflammatory bowel disease (IBD) patients frequently find themselves managing a permanent stoma, making the role of stoma nurses essential in the perioperative period for education and triage of complications such as low stoma output, dehydration, and stoma retraction. Finally, IBD patients often benefit from early return to their preoperative medication regimen, including corticosteroids, immunomodulators, and anti-TNFα inhibitors.

Complications and Their Management

Patients with CD develop more frequent abdominal septic complications, including abscess and anastomotic leak due to chronic inflammatory status, poor nutritional status, steroid use, and recurrent episodes of disease. Alves et al. reported four independent risk factors for intra-abdominal septic complications: poor nutritional status, defined by weight loss >10% within the last 10 months, intra-abdominal abscess discovered during surgery, preoperative steroid use more than 3 months, and recurrent clinical episodes of CD. Patients should be carefully assessed and optimized prior to elective operations in order to decrease the risks of complications.

Yamamoto et al. found that after single-stage proctocolectomy the most common postoperative complications were delayed perineal wound healing (35%), followed by intra-abdominal sepsis (17%) and stomal complications (15%). In 23 patients, the perineal wound healed between 3 and 6 months after proctocolectomy, whereas in 13 patients the wound remained open for more than 6 months. Chronic perineal wound, defined

by lack of healing at 6 months, occurs in 11% to 57% of CD patients. Up to 33% of cases of persistent perianal sinus are not healed at 12 months, after which the chances of spontaneous healing are rare. Surgical treatment for persistent perianal sinus is excision with or without rectus abdominis myocutaneous (RAM) flap for perineal reconstruction.

In addition to delayed wound healing, 30% of Crohn patients experience recurrence at the stoma site after proctocolectomy. Risk factors for stomal recurrence include penetrating phenotype and pre-existing ileal disease. When this occurs, ileoscopy and small bowel imaging should be used to assess the luminal extent of disease and extraluminal complications, such as stoma retraction and fistula. Recurrence of ileal CD after construction of an end ileostomy can affect the peristomal area as well, including enterocutaneous fistulae, stoma retraction, abscess, strictures (with or without obstruction), and parastomal pyoderma gangrenosum. Fistula formation is the result of the penetrating transmural inflammation at the origin of the fistula tract and presents with localized abscess. Patients with recurrent disease at the stoma site may present with small bowel obstruction, with symptoms including reduced or absent ileostomy output, abdominal pain, and vomiting. Although conservative management with nasogastric tube and bowel rest may improve symptoms, most patients eventually need surgical intervention. For all ileostomy complications, after evaluation of disease recurrence and extent of complication, patients should undergo ileostomy revision, often requiring resection of the involved small bowel segment and ileostomy revision either in the same location or resiting to the opposite side of the abdomen.

As we previously described for surgical treatment of small bowel CD, IBD is a risk factor for venous thromboembolism (VTE), with 1.5- to 3-fold increased risk compared to the general population. Disease flares are associated with increased risk of VTE and higher incidence of portomesenteric thrombosis, which may be incidentally discovered in otherwise asymptomatic patients.

Outcomes

In our practice, a prospective analysis of 179 patients undergoing surgical resection for colonic CD revealed a significant relationship between extent of resection and recurrence rates. Patients who underwent a segmental colectomy had recurrence rates of 38% and 55% at 5 and 10 years, respectively, compared with 24% and 30% in patients treated with a total

abdominal colectomy, and 9% and 20% in patients with total proctocolectomy. After adjusting for the extent of disease, the segmental colectomy group had a significantly greater risk of recurrence compared with the total proctocolectomy group, with a hazard ratio of 5.76. Despite higher risk of recurrence, segmental resection, with the benefits of preserving colonic absorptive capacity, may be appropriate for elderly patients or in patients with a prior small bowel resection who are at risk for high ileostomy output. Young healthy patients, whose longer life expectancy creates more opportunity for recurrent disease requiring reoperation, are likely to derive more benefit from a proctocolectomy with ileostomy.

PERIANAL CROHN DISEASE

Clinical Presentation

Anorectal/perianal CD, with or without concurrent bowel disease, is seen in only 5% of patients, and is characterized by the development of fissures, ulcers, fistulae, abscesses, and anal strictures. These often complex lesions occur in about one third of patients with intestinal CD, and are more commonly associated with colitis or proctitis (47%) rather than isolated small bowel involvement (25%). Anorectal CD tends to be recurrent, complex, and progressive. The goal of surgery is control of sepsis and relief of symptoms with preservation of adequate sphincter function. Once diagnosed most CD patients with anorectal disease will require surgical intervention, including incision and drainage of abscess, fistulotomy, or seton placement for deep/complex fistulas.

Anal Stenosis or Stricture

A mild-to-moderate degree of anal stenosis, generally caused by circumferential scarring from chronic perianal inflammation or previous surgery, is common in patients with CD. Mild anal stenosis is rarely symptomatic because of the liquid or semisolid nature of stool in patients with CD, and therefore does not necessitate intervention. If symptomatic, anal stenosis can often be effectively treated with gentle finger dilatation in the office or with sequential mechanical dilatation under conscious sedation or general anesthesia. If symptoms worsen, or if severe sepsis develops, fecal diversion may become necessary. In a previously published series from our group, 41 of 69 patients with CD had anal stenosis as their isolated manifestation of perianal disease. Among these patients, 8 were

asymptomatic and required no surgical intervention. Sixteen of the remaining 33 patients ultimately underwent anal dilatation and 17 underwent proctectomy or creation of a diverting stoma, usually because of concomitant severe rectal disease or fecal incontinence.

Fissures

Anal ulcerations and fissures are often associated with perianal CD. Unlike typical fissures, Crohn fissures are typically multiple, deep, and present in locations other than the posterior midline. Medical management is the first line of treatment, often including anti-TNF–directed therapy. Surgery, including sphincterotomy and anal dilatation, should be avoided because of high rates of nonhealing wounds and subsequent incontinence. Differential diagnosis of atypical deep lateral fissures, particularly those not healing despite conservative management, includes cancer, infection, radiation injury, and HIV. Examination under anesthesia and colonoscopy with ileal intubation and biopsy are needed to accurately direct treatment options for fissures refractory to conservative therapy.

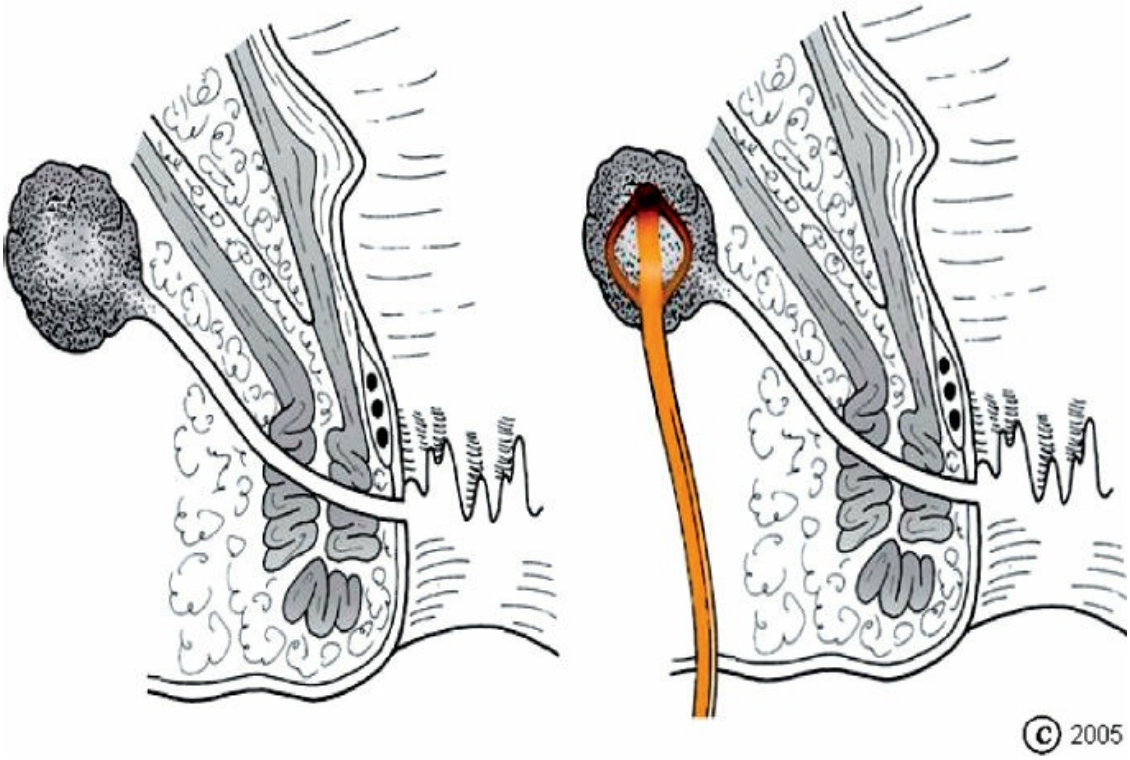

Figure 144.5. Incision and drainage of a perianal abscess with placement of a Pezzer catheter.

Abscesses

Medical management of Crohn associated perianal abscesses with

antibiotics is rarely successful, and surgical incision and drainage are required for definitive treatment. The incision should be placed close to the anal verge in order to minimize the length of any subsequent fistula. Following drainage and washout, the cavity should be packed with ribbon gauze if very superficial, or drained with a Pezzer catheter if deep in the ischiorectal space (Fig. 144.5). If the internal opening of a fistula is easily identified, a loose noncutting seton should be placed along the fistulous tract and through the abscess cavity to ensure adequate drainage. In one reported series, complete abscess cavity healing was achieved in 67.7% of patients when a fistulous tract was not found at the time of the incision and drainage. A fistula-in-ano developed in the remaining 32.3% of patients. Because the majority of patients do not develop a fistula-in-ano, we advise against an aggressive search for an internal fistulous opening beyond a careful anoscopy at the time of initial drainage. This careful and conservative approach avoids the risk of creating a false passage, a complication that can easily occur with aggressive searches for the internal opening in the setting of acute inflammation.

Anal Fistulas

Perianal fistulas may arise from anal crypts or from full-thickness ulcerations in the mucosa of the lower rectum. Fistulization continues through the perirectal tissue and either forms an abscess or erupts through the skin. Initial management of a perianal fistula depends on the severity of symptoms, the complexity of the fistula, and the extent of rectal involvement. The diagnostic evaluation of fistulas should include an examination under anesthesia to determine the extent of disease and the presence of any associated sepsis, ultrasound, or MRI and a colonoscopy with ileal intubation to assess the degree of rectal, colonic, and small bowel involvement. Successful management of perianal fistulas can be achieved with a series of procedures, with the optimal approach dictated by the number and location of the fistulas and the extent of sphincter involvement (Fig. 144.6).

Crohn fistulas can be superficial or deep, and are characterized based on their relationship to the anal sphincters (Fig. 144.7). Asymptomatic or well-tolerated fistulas require no medical or surgical intervention. Symptomatic and uncomplicated submucosal or intersphincteric fistulas are best treated with an initial trial of either metronidazole or ciprofloxacin. These antibiotics are moderately effective in promoting healing of Crohn fistulas and are associated with a low risk for

complication. If a low-lying submucosal or intersphincteric fistula fails to heal with antibiotic treatment, then a surgical fistulotomy can be performed. These low-lying fistulas typically heal well after fistulotomy and the risk of incontinence is low. In our experience, 27 of 33 (82%) symptomatic low fistulas healed permanently with a superficial fistulotomy, a rate of success similar to the 79% reported by McKee and Keenan.

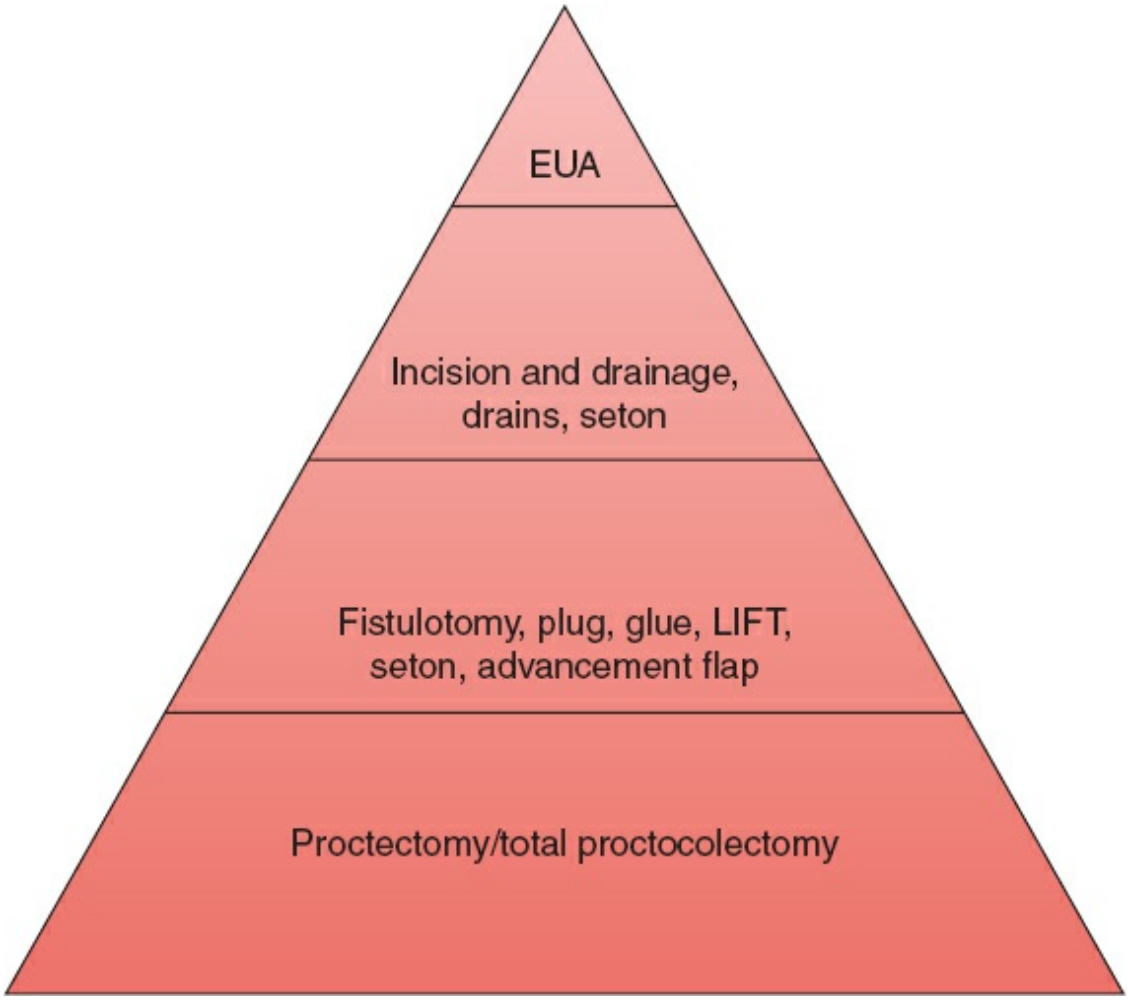

Figure 144.6. Surgical management of fistulizing perianal Crohn disease. The initial step is an Examination under Anesthesia (EUA) to evaluate the extent of the disease. Concomitant sepsis is managed with incision and drainage along with placement of drains and/or setons. If symptoms persist, more aggressive surgical treatment should be considered, including fistulotomy, fibrin plug or glue, endorectal advancement flap, and LIFT. At this level of difficulty, the need for fecal diversion should be evaluated. In case of persistent failure, proctectomy and permanent colostomy is the only option.

Surgical fistulotomies should not be used for suprasphincteric fistulas and should also be avoided for most transsphincteric fistulas. Medical treatment for extensive Crohn fistulas includes the use of 6-mercaptopurine, azathioprine, and cyclosporine. Infliximab is considered superior in promoting healing of perianal fistulas related to CD, with 60% success rate currently reported. Fistula recurrence rates remain high (up to 59% in some series) and initial healing with medical treatment is limited if there is persistent stasis or sepsis within the fistula tract. Setons improve drainage through the tract, and may enhance the overall effectiveness of infliximab (Fig. 144.8). In a series reported by Topstad et al., seton placement, infliximab, and maintenance immunosuppression achieved complete healing in 67% of Crohn perianal fistulas and partial healing in 19%. Typically, the seton is placed prior to the initiation of infliximab therapy. Management of the draining seton in Crohn patients responding to anti-TNF–directed therapy remains controversial.

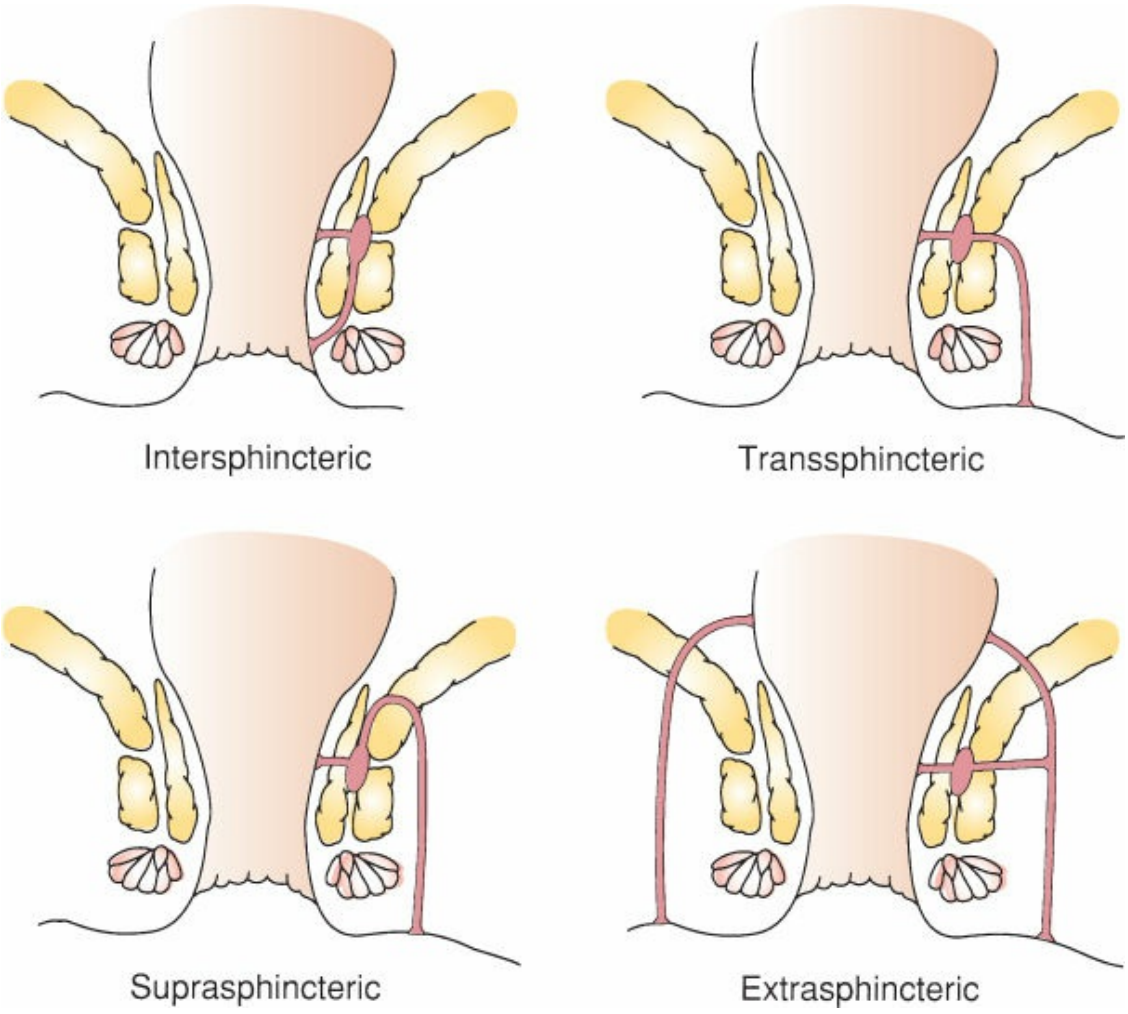

Figure 144.7. Types of fistulas. (From Mulholland MW, Lillemoe

KD, Doherty GM, et al. *Greenfield's Surgery: Scientific Principles and Practice*. 4th ed. New York: Lippincott Williams & Wilkins, 2005; with permission.)

When adequate drainage of the tract has been achieved, and in the absence of rectal disease, a rectal advancement flap is a viable option to close the internal opening of the fistula and promote healing. Kodner et al. reported a 92% success rate in patients with complex fistulas secondary to CD who underwent rectal advancement flaps, with primary healing reported in 17 of 24 patients and secondary healing in 5 of 24 patients. The ligation of intersphincteric fistula tract (LIFT) procedure has been reported with good success in the treatment of transsphincteric fistulas, but there are no reports currently focusing on its utility in Crohn patients. Other sphincter-sparing options, including fistula plug and fibrin glue, may be effective in some fistulas, although their success specifically in CD has not been well studied. One small series by O'Connor et al. reported 80% success in healing Crohn fistulas in 20 patients after use of the fistula plug. However, a systematic review by O'Riordan et al. evaluating the fistula plug reported pooled fistula closure rates of 54% for non-Crohn fistulas and 55% for Crohn fistulas, with only 42 Crohn patients included from 20 studies. If definitive healing cannot be achieved with medical therapy or surgical intervention, many patients have a reasonable quality of life with long-term seton drainage, as this accomplishes the goal of sepsis management and maintenance of continence.

Severe cases of perianal fistulas that do not respond to aggressive medical and surgical management may require fecal diversion.

Diversion of the fecal stream often results in significant relief of local inflammation and can assist in the healing of perianal fistulas, but recurrences are common and intestinal continuity often cannot be restored. Yamamoto et al. found that, in 31 patients who underwent fecal diversion for perianal CD, 81% (25) achieved early remission, but complete remission was only achieved in 26% (8) of patients, with 68% (21) eventually requiring proctectomy. Only three patients (10%) underwent restoration of intestinal continuity at follow-up ranging 3 to 30 years.



Figure 144.8. Complex perianal Crohn disease managed with multiple setons.

Proctectomy is indicated when perianal disease is unrelenting or results in damage to the sphincters, causing debilitating incontinence. However, a combination of catheter drainage, seton placement, and intensive medical therapy results in the avoidance of a proctectomy or fecal diversion in the majority of patients. In our previous experience, 224 of 717 patients with CD presented with anorectal complications. Of these, 139 patients (62%) retained anorectal function, with complete healing in 84 patients, control of sepsis in 25 patients, and observation in the remaining 30 patients. Eighty-five patients (38%) required a proctectomy with a permanent stoma. Patients with rectal involvement had significantly higher rates of proctectomy compared to patients with rectal sparing (77.6% vs. 13.6%, respectively). Therefore, although complete healing and control of sepsis can often be achieved in patients with anorectal CD, the presence of active rectal disease and multiple synchronous complications significantly increases the need for a rectal ablative procedure. Patients should be counseled early regarding the indications for proctectomy and diversion, in order to establish appropriate expectations about their disease course when perianal lesions are present.

CD-associated Anal Adenocarcinoma of the Fistula Tract

The development of carcinoma within a chronic perianal fistula is a rare complication of CD, with an incidence of 0.3% to 0.7% according to Iesalnieks et al. Traube et al. suggested that the environment of constant mucosal regeneration occurring within a fistula may cause dysplastic changes, which may ultimately lead to adenocarcinoma. According to Tokunaga et al., patients with longstanding CD, diagnosed before 30 years of age, and with fecal diversion are at greater risk of developing carcinoma arising in association of perianal fistula. The gold-standard treatment in this case is neoadjuvant radiochemotherapy followed by APR.

Rectovaginal Fistulas

A rectovaginal fistula is a debilitating complication of CD that is characterized by the discharge of stool or gas from the vagina. It is usually caused by a fistula that arises from the anorectum and eventually erodes through the vaginal wall, usually at the introitus. In one third to one half of patients, the rectovaginal fistula is either asymptomatic or presents with minimal symptoms and requires no treatment. However, symptomatic fistulas may result in dyspareunia, perineal pain, difficulty maintaining adequate hygiene, or repeated vaginal infections and must be treated aggressively. Fistulas may be initially treated with antibiotics and, if needed, the insertion of a noncutting seton. Once the infection is ablated, a transrectal or vaginal mucosal advancement flap may be used to aid in the closure of the fistula in patients without significant anorectal disease. A recent systematic review of the literature comparing transanal and vaginal mucosal advancement flap did not show a difference in terms of healing rates between the two approaches with the limitation of small sample size studies.

Preoperative Planning

After conducting a thorough history eliciting the nature and severity of symptoms, the extent of concurrent small- and large-bowel disease, and the degree of functional continence, a physical examination is performed to look for clinical manifestations of perineal CD. If pain or anal stenosis precludes adequate exposure, the patient should undergo an examination under anesthesia. External examination of the anal region may reveal hemorrhoids, skin tags, anorectal abscesses, and anal fissures. A digital rectal examination should be performed to assess the status of the

sphincters and the presence of any anorectal stricture or palpable masses. Anoscopy and proctoscopy should be performed to search for fistulous tracts and to obtain biopsies to confirm the diagnosis of CD. In women, the rectovaginal septum should also be inspected for the presence of fistulas. MRI or ultrasound may be helpful imaging adjuncts, particularly prior to repeat exploration after failed attempt to identify fistula tracts. All suspicious lesions found on physical examination should undergo biopsy to rule out a malignancy.

Surgical Technique

Fistulotomy

The patient is placed in the prone jackknife position. A probe is carefully inserted into the external opening and advanced through the tract until it emerges from the internal opening. The probe should never be passed forcefully. A combination of direct visualization with an anal retractor and digital palpation can be helpful in guiding the fistula probe safely along the tract. If the path of the tract or the internal opening is difficult to find, methylene blue or dilute hydrogen peroxide can be injected into the external opening. The use of transrectal ultrasonography in the operating room may assist in finding the fistula tract. Using electrocautery, the fistulotomy is performed over the probe, starting at the external opening and carried to the internal opening while carefully maintaining meticulous hemostasis. If a significant portion of the sphincters are encountered in the fistulous tract, the fistulotomy is stopped and a seton is placed to drain the remainder of the tract. The seton should be loose to prevent inadvertent cutting or necrosis of the underlying muscle. A curette is then used to clear the unroofed fistula tract of all infected granulation tissue. This material may be sent for culture, particularly in the setting of a concomitant abscess or for cytology if cancer is suspected. Marsupialization of the fistulotomy edges does not provide any advantage other than in presence of bleeding.

Rectal Advancement Flap

A rectal advancement flap can be used to cover the internal opening of a perianal fistulous tract or a rectovaginal fistula if the rectal mucosa is free of active disease. The patient is placed in a prone jackknife position if the fistula opening is anterior and in high lithotomy position if the opening is posterior. After making an incision at the dentate line, a thick, U-shaped flap inclusive of mucosa, submucosa, muscle fibers of the internal

sphincter, and muscularis propria is elevated 4 to 5 cm cephalad with the apex of the flap at the internal opening of the fistula. Using electrocautery, care is taken to obtain adequate hemostasis. The fistulous tract is then curetted and closed in layers with 3-0 or 4-0 absorbable sutures. The distal end of the flap is appropriately trimmed, pulled down over the repaired defect, and secured to the dentate line with a series of interrupted absorbable sutures. A temporary stoma may be considered for the difficult or recurrent repairs, although there are no data in the literature providing evidence that the healing rate is increased by fecal diversion.

CONCLUSION

Colonic and perianal involvement is common in CD, especially in association with small bowel disease. Careful comprehensive evaluation of the entire GI tract is essential in order to plan an appropriate treatment strategy. Patients with colonic disease have an increased risk of malignancy, and require careful surveillance. Perianal disease poses significant challenges to the treating team to achieve a balance between control of the disease and preservation of continence. Unfortunately even with the development of novel and more effective medical therapies proctectomy may still be required in severe disease nonresponsive to medical and surgical management. Multidisciplinary management of these patients is mandatory to achieve optimal outcomes.

Suggested Readings

Blum E, Katz JA. Postoperative therapy for CD. *Inflamm Bowel Dis* 2009;15(3):463–72.

Fichera A, McCormack R, Rubin MA, et al. Long-term outcome of surgically treated Crohn's colitis: a prospective study. *Dis Colon Rectum* 2005;48(5):963–9.

Holder-Murray J, Zoccali M, Hurst RD, et al. Totally laparoscopic total proctocolectomy: a safe alternative to open surgery in inflammatory bowel disease. *Inflamm Bowel Dis* 2012;18(5):863–8.

Hyman NH, Fazio VW, Tuckson WB, et al. Consequences of ileal pouch-anal anastomosis for Crohn's colitis. *Dis Colon Rectum* 1991;34(8):653–7.

Longo WE, Oakley JR, Lavery IC, et al. Outcome of ileorectal anastomosis for Crohn's colitis. *Dis Colon Rectum* 1992;35(11):1066–71.

O'Riordan JM, Datta I, Johnston C, et al. A systematic review of the anal fistula plug for patients with Crohn's and non-Crohn's related fistula-in-ano. *Dis Colon*

Rectum 2012;55(3):351–8.

Peyrin-Biroulet L, Deltenre P, Ardizzone S, et al. Azathioprine and 6-mercaptopurine for the prevention of postoperative recurrence in CD: a meta-analysis. *Am J Gastroenterol* 2009;104(8):2089–96.

Present DH. Review article: the efficacy of infliximab in CD–healing of fistulae. *Aliment Pharmacol Ther* 1999; 13:23–8; discussion 38.

Present DH, Rutgeerts P, Targan S, et al. Infliximab for the treatment of fistulas in patients with CD. *N Engl J Med* 1999;340(18):1398–405.

Reese GE, Nanidis T, Borysiewicz C, et al. The effect of smoking after surgery for CD: a meta-analysis of observational studies. *Int J Colorectal Dis* 2008;23(12):1213–21.

Regueiro M, Schraut W, Baidoo L, et al. Infliximab prevents CD recurrence after ileal resection. *Gastroenterology* 2009;136(2):441–50 e441; quiz 716.

Schwartz DA, Pemberton JH, Sandborn WJ. Diagnosis and treatment of perianal fistulas in Crohn disease. *Ann Intern Med* 2001;135(10):906–18.

Tekkis PP, Purkayastha S, Lanitis S, et al. A comparison of segmental vs subtotal/total colectomy for colonic CD: a meta-analysis. *Colorectal Dis* 2006;8(2):82–90.

Topstad DR, Panaccione R, Heine JA, et al. Combined seton placement, infliximab infusion, and maintenance immunosuppressives improve healing rate in fistulizing anorectal CD: a single center experience. *Dis Colon Rectum* 2003;46(5):577–83.

Yamamoto T, Allan RN, Keighley MR. Audit of single-stage proctocolectomy for CD: postoperative complications and recurrence. *Dis Colon Rectum* 2000;43(2):249–56.

Yamamoto T, Allan RN, Keighley MR. Effect of fecal diversion alone on perianal CD. *World J Surg* 2000; 24(10):1258–62; discussion 1262–3.

EDITOR'S COMMENT

In this chapter, Dr. Ferrari and colleagues discuss the treatment of colonic and perianal CD, two very challenging entities for the practicing surgeon. Treatment of colonic CD has undergone a significant change over the last 20 to 30 years. Much of this has been influenced by the recognition of the important role that the colon plays in water absorption. The other reason for this has been the development of more effective medical therapy, including the so-called "biologic" class of medical therapy for CD. This includes agents such as anti-TNF–targeted therapies, including infliximab, adalimumab, and certolizumab. Recently this category has been expanded to include agents targeting adhesion molecules and those targeting interleukin-12 (vedolizumab, ustekinumab). The

authors in their 2005 publication described a much higher rate of CD recurrence in patients undergoing segmental colon resection for colonic CD than following proctocolectomy. Regular use of these and other similar types of medications postoperatively may lead to improved results with respect to recurrence (Fichera A, McCormack R, Rubin MA, et al. Long-term outcome of surgically treated Crohn's colitis: a prospective study. *Dis Colon Rectum* 2005;48(5):963–9). Time will tell and further studies on this are needed with longer follow-up.

The authors do not describe in detail the clinical criteria used to select a patient to undergo a colon-sparing (i.e., an intestinal continuity-sparing) resection for CD. This can often be a very difficult decision. Rectal sparing is not a very common feature in these patients. In addition to rectal sparing, one must have a patient who has adequate sphincter function. In many of these patients, a useful test to determine how good their results will be after surgery, is to examine how much their colon distends on insufflation of air, either at the time of a colonoscopy, flexible sigmoidoscopy, or proctoscopy. A bowel that has not been affected significantly by transmural inflammation will distend significantly when insufflated with air or carbon dioxide, whereas one that has significant transmural disease will not. Patients who have very significant transmural disease do not have significant reservoir capacity. These individuals will have numerous bowel movements with significant urgency, and will perhaps be better served with having an ileostomy. There have been some efforts to quantify the structural damage in patients who have longstanding CD. One of these has been the recent description of the Lémann Index (Pariente B, Mary JY, Danese S, et al. Development of the Lémann index to assess digestive tract damage in patients with Crohn's disease. *Gastroenterology* 2015;148(1):52–63.e3). This rather complicated index uses both criteria of previous surgical resection, as well as radiologic evidence of strictures among other factors, to try to quantify the degree of structural damage in patients with CD and to permit physicians to follow disease progression over time. This is currently, at least in my eye, a somewhat cumbersome method of patient evaluation. Some type of simpler evaluation method is needed in order to identify exactly how pliable intestinal strictures are and how likely they are to respond to medical therapy. Magnetic resonance imaging (MRI) has increasingly been used to quantify strictures and intestinal anatomy in order to spare Crohn patients from radiation exposure, since many of these will undergo repeated testing over their lifetime. This can also give physicians a good idea of the degree of associated fibrosis and fistulas.

Another area of debate with respect to colon-sparing surgery has been the issue of whether or not to perform segmental resection in patients with CD who have been previously diagnosed with colon cancer or dysplasia. With respect to colon cancer there have already been several studies that have documented the subsequent diagnosis of metachronous cancer (Kiran RP, Nisar PJ, Goldblum JR, et al. Dysplasia associated with Crohn's colitis: segmental colectomy or more extended resection? *Ann Surg* 2012;256(2):221–6; Maser EA, Sachar DB,

Kruse D, et al. High rates of metachronous colon cancer or dysplasia after segmental resection or subtotal colectomy in Crohn's colitis. *Inflamm Bowel Dis* 2013;19(9):1827–32). Maser and colleagues reported that 19 of 47 Crohn patients (40%) undergoing segmental colectomy for colon cancer and 6 of 17 patients (35%) undergoing a subtotal colectomy developed a metachronous cancer. Kiran and colleagues reported on 50 Crohn patients undergoing surgery for dysplasia. In nearly half of the patients undergoing subtotal colectomy or proctocolectomy, the dysplasia was found to be multifocal. In addition, in a personal study in which tumorigenic mutations were tracked longitudinally over years in a small group of patients with longstanding CD, such mutations were seen to spread to other areas of the colon as well as to predate colon cancer by several years (Galandiuk S, Rodriguez-Justo M, Jeffery R, et al. Field cancerization in intestinal epithelium of patients with Crohn's ileocolitis. *Gastroenterology* 2012;142:855–64). If one does encounter a patient with CD that has a CRC, the best course of action in my opinion would be a total proctocolectomy and end ileostomy. With respect to dysplasia, when confirmed by more than one pathologist, the same course is wise.

Moving on to perianal CD, although the authors state that this occurs only in approximately 5% of Crohn patients, this is very dependent upon where one practices and the type of Crohn population one is dealing with. For example, in the area where I practice in Kentucky, perianal CD occurs in approximately 25% of our Crohn population. I believe that this is almost certainly in large part due to the very high rate of cigarette smoking, leading to a much more aggressive Crohn phenotype.

There are many controversies in the treatment of perianal CD, the most important with respect to how aggressive one wishes to treat. As the authors in this chapter highlight, the presence or absence of a significant Crohn anal canal stricture will in many cases determine the likelihood of success of therapy. I have found the presence of a rigid Crohn anal canal stricture to be a very poor prognostic indicator of the ability to avoid permanent fecal diversion. Only in the most motivated patient who is willing to do regular anal canal dilatations using a Hegar or similar dilator is permanent diversion able to be deferred or avoided. It is hoped, similar to colonic CD, that the development of more targeted therapy and earlier institution of such therapy will avoid the development of structural damage such as fibrosis and fistulizing disease, in effect preventing the development of perianal CD, so that local surgery can in fact be avoided. The success of procedures such as plug procedures or procedures utilizing fibrin glue in my experience is poor. In many cases of persistent fistulas, particularly rectovaginal fistulas that have not responded to local attempts at repair, muscle flap procedures such as gracilisplasty may be necessary. Treatment of Crohn perianal fistulas with adipose-derived stem cells may hold promise. In a recent report of a prospective randomized trial at 49 hospitals in 7 European countries and Israel, investigators were able to demonstrate a 50% response rate at 24 weeks in patients with Crohn perianal

fistulas treated with adipose-derived stem cells as opposed to a 34% response rate in patients treated with placebo (Panés J, García-Olmo D, Van Assche G, et al.; ADMIRE CD Study Group Collaborators. Expanded allogeneic adipose-derived mesenchymal stem cells (Cx601) for complex perianal fistulas in Crohn's disease: a phase 3 randomised, double-blind controlled trial. *Lancet* 2016;388(10051):1281–90). Overall, the treatment of perianal CD, as well as colonic CD, continues to challenge both the surgeon's and patient's perseverance and patience.

Susan Galadiunk

145 Surgery for Toxic Megacolon

Scott R. Kelley and David W. Larson

ETIOLOGY AND PATHOPHYSIOLOGY

Toxic megacolon is a syndrome characterized by acute colitis, ≥5.5-cm nonobstructive segmental or complete dilation of the colon, and signs of systemic toxicity. Initially described in 1950 by Marschak and colleagues, toxic megacolon typically occurs as the initial manifestation of a disease process, though it may also be the result of an acute exacerbation of chronic colitis. Although rare, it is most commonly associated with inflammatory bowel disease (ulcerative, Crohn, indeterminate colitis) and pseudomembranous (*Clostridium difficile*) colitis. Other exceedingly rare cases resulting in toxic megacolon include additional infectious colitides (*Salmonella typhi, Shigella, Campylobacter jejuni, Yersinia enterocolitica, Entamoeba histolytica, Cryptosporidium,* Cytomegalovirus), ischemia, chronic obstructive pulmonary disease, diabetes, immunosuppression, kidney failure, cystic fibrosis, chemotherapeutic drugs, Kaposi sarcoma, and colonoscopic overdistention in cases of colitis.

The incidence of toxic megacolon in inflammatory bowel disease ranges from 1% to 5% and has diminished significantly secondary to earlier recognition and better management of the underlying disease. *C. difficile* colitis has seen an increasing prevalence (3%) since 2000, which is attributable to a more virulent strain (BI/NAP1/027) with less responsiveness to standard therapies and a higher relapse.

The pathophysiology is not entirely understood, though local inflammatory mediators such as interleukins and nitric oxide are thought to be contributing factors. Nitric oxide generated by smooth muscle cells and macrophages is increased in the presence of inflammation, and inhibits smooth muscle tone, thus contributing to colonic dysmotility and toxic dilation. Inflammation through all layers of the colon wall may result in bacterial translocation with subsequent bacteremia and sepsis.

INITIAL PRESENTATION

Patients with toxic megacolon often present critically ill (fever, tachycardia, leukocytosis) with abdominal distention and tenderness, tympany, and diarrhea. Symptoms may be nonspecific or masked by medications (steroids, immunosuppressants, narcotics/opioids) or other factors (elderly, debilitated) making a high index of suspicion essential for identification. Opiates/narcotics, antidepressants, antidiarrheal agents, anticholinergics, hypokalemia, and barium enemas are known to induce and exacerbate the condition. Systemic toxicity differentiates patients with toxic megacolon from those with colonic dilation due to other processes (pseudo-obstruction, Hirschsprung disease, neuronal intestinal dysplasia, Chagas disease).

Diagnosis is based on clinical criteria outlined by Jalan and colleagues and includes three components: radiologic evidence of colonic dilation, at least three of the following (fever >38°C/101.5°F, heart rate >120/min, WBC >10.5 × 10^6/L, hemoglobin and hematocrit <60% of normal), and at least one of the following (dehydration, altered consciousness, electrolyte disturbances, hypotension). The diameter of the colon is not as important as the patient's overall clinical picture. The ascending and transverse colon are typically more dilated than the descending and sigmoid, and the rectum is rarely distended.

A multidisciplinary approach to patient management with early surgical consultation is imperative. Mortality rates as high as 20% have been documented in cases of colonic perforation, in comparison to 4% without. Surgery should be aggressively pursued in the face of deterioration or a lack of measurable improvement within 24 to 72 hours given the high complication and mortality rate if surgery is withheld.

INDICATIONS AND CONTRAINDICATIONS

Absolute indications for emergency surgery include diffuse peritonitis, pneumoperitoneum, uncontrolled sepsis, and major hemorrhage. Relative indications for urgent surgery include increasing abdominal pain and/or colonic distention, progressive physiologic deterioration, a lack of objective improvement within 24 to 72 hours, and sustained transfusion requirements. Some advocate continuation of aggressive medical therapy for a period of up to 7 days if clinically stable and no deterioration is appreciated. This must be pursued cautiously and understood in the context of a significantly higher mortality if perforation occurs. Early surgical intervention should be pursued for patients who are

immunocompromised, severely debilitated, malnourished, or have multiple comorbidities.

Initial Management

For patients who do not require emergent surgical intervention, aggressive medical therapy should be pursued with a goal of reversing physiologic defects and the toxic state. Patients should be closely monitored with serial examinations and resuscitated in a critical/intensive care unit. A history of inflammatory bowel disease, immunocompromised status, and recent medications, barium enemas, and travel must be ascertained. Baseline laboratory tests, blood, urine, and stool cultures, and radiographic imaging is carried out. A flat and upright abdominal x-ray can track the progression of colonic distention. Abdominal and pelvic computed tomography may help determine etiology and evaluate for pneumatosis, subclinical perforation, and abscesses. Appropriate intravenous access, placement of an indwelling urinary catheter to closely monitor output, and bowel rest should be initiated. Incentive spirometry is started and pneumatic lower-extremity compression devices placed. Nasogastric tubes do not decompress the colon and are not necessary unless the patient is experiencing emesis. Electrolyte abnormalities should be corrected. Appropriate antibiotics are introduced for infectious etiologies, and if recently treated with steroids, stress-dose corticosteroids should be initiated. Medications that slow colonic motility and function must be avoided. Deep venous thrombosis and gastric acid suppression prophylaxis are recommended. For significant gastrointestinal bleeding and anemia transfusion may be necessary.

Patients presenting with toxic megacolon without a history of inflammatory bowel disease should be empirically treated for *C. difficile* colitis until proven otherwise. These patients are more likely to present with an ileus and therapy should not be delayed since failure to make an early diagnosis will result in worse outcomes.

Positional therapy (knee-elbow or prone for a few minutes every 2 to 3 hours) has been shown to be beneficial in redistributing and expelling colonic gas.

Endoscopy

In patients presenting with an ileus limited lower endoscopy with minimal air insufflation by an experienced endoscopist may be helpful in obtaining

biopsies, evaluating for pseudomembranes, and therapeutically decompressing the colon. Pseudomembranes are seen in nearly 90% of patients with *C. difficile* colitis, though rectosigmoid sparing is present in up to 20% to 30%. Continuously diseased mucosa with deep ulcerations and extensive mucosal pseudopolyps may indicate severe ulcerative colitis, whereas intervening normal mucosa, rake ulcers, and aphthous ulcers is more suggestive of Crohn disease. If decompression is performed, a small bore colonic decompression tube can be placed at the same time and flushed with a small volume of saline every 6 to 8 hours to promote patency.

Clostridium difficile

Treatment for severe complicated *C. difficile* colitis (WBC >15 × 10^6/L, Cr >1.5 mg/dL, hypotension, shock, ileus, megacolon) includes vancomycin 500 mg by mouth every 6 hours and metronidazole 500 mg by mouth or intravenously every 8 hours. For those unable to tolerate oral intake, medications can be administered through a nasogastric tube. Fidaxomicin has not been proven to be more beneficial than vancomycin in cases of complicated *C. difficile* colitis. Patients with an ileus may have vancomycin introduced through a retention enema (500 mg/100 mL normal saline) every 6 hours, or directly instilled colonoscopically since adequate intracolonic concentrations of vancomycin may not be achieved with oral administration. One small study revealed resolution of toxic megacolon in 57% of patients treated with colonoscopic spraying. Another documented resolution after colonoscopic decompression and placement of a small bore decompression tube into the proximal colon is followed by instillation of vancomycin through the tube.

For patients with refractory *C. difficile* infection, fecal microbiota transplantation (FMT) has been shown to have an efficacy rate of >90%, and recently small studies have shown benefit in treating patients with acute colitis and toxic megacolon. FMT is a procedure in which fecal matter is collected from a suitable and tested donor, mixed with liquid, strained, and instilled into the patient. There is no clear consensus regarding the most appropriate method of delivery (upper endoscopy, nasoenteric tube, colonoscopically, enema), preparation, donated volume, or volume instilled. Some advocate fecal transplant if no improvement with aggressive pharmacotherapy is noted within 48 hours, and more than one transplant may be required to obtain maximal benefit.

Inflammatory Bowel Disease

Therapy for patients with severe/fulminant colitis secondary to inflammatory bowel disease includes the initiation of intravenous corticosteroids with a daily dose equivalent of 300 mg for hydrocortisone or 60 mg for methylprednisolone. Higher doses have not been proven to be beneficial, 20% to 40% will fail to respond to therapy, and treatment beyond 7 to 10 days adds no benefit. Increased rates of colonic perforation have not been documented with high-dose steroids. Studies have been unable to confirm any incremental advantage in administering or continuing oral 5-ASA compounds and topical regimens. Intravenous cyclosporine (2 to 4 mg/kg/day continuous infusion) has been shown to be an effective adjuvant (82% response) in those lacking improvement while being treated with maximal medical therapy over a period of 3 to 5 days, though unsubstantiated in cases of toxic megacolon. Tissue necrosis factor alpha (TNF-α) inhibitor infliximab (5 mg/kg) has shown efficacy in a few small studies, though unproven at this time. The utilization of empiric broad-spectrum antibiotics, although routinely administered, has not shown benefit when treating patients with severe colitis lacking infection. Fecal transplant has shown promising results in treating inflammatory bowel disease, though unstudied in the setting of toxic megacolon.

Other Colitides

Management of patients with toxic megacolon associated with colitides other than *C. difficile* or inflammatory bowel disease should follow the same general principles while focusing treatment on the underlying etiology.

PREOPERATIVE PLANNING

For patients undergoing emergent surgery, or failing maximal medical management and requiring urgent surgical intervention, the goal is to continue to stabilize and resuscitate in addition to treating the underlying cause of toxic megacolon. Preoperative endotracheal intubation, hypoalbuminemia, altered mental status, and vasopressor requirements have been shown to be significant predictors of increased mortality. Informing the patient and family of the risks, benefits, and alternatives of operative approaches, the high likelihood of a stoma, and postoperative expectations is imperative. If time permits it is crucial to have the patient

evaluated, educated, and marked for an ileostomy and mucous fistula by an enterostomal therapist.

In the operating room the patient is positioned in a perineal lithotomy position to provide concomitant access to the abdomen and perineum. Stress-dose steroids, if indicated, and broad-spectrum antibiotics are administered. If not already completed a urologic catheter is inserted, pneumatic antithrombotic devices are placed to the bilateral lower extremities, an orogastric tube is placed for decompression, and deep venous thrombosis prophylaxis is administered. Adequate intravenous access, and if necessary lines for monitoring (arterial, central venous) should be placed. Prior to prepping a rigid or flexible endoscope can be carefully inserted to decompress the colon using minimal to no air insufflation. The patient is then prepped and draped in a normal sterile fashion.

SURGICAL TECHNIQUE

The surgical approach for toxic megacolon, whether performed emergently or urgently, most commonly involves a total or subtotal colectomy with creation of an end ileostomy, and possibly decompressive rectosigmoid mucous fistula or subcutaneous exteriorization of a segment of closed distal bowel. Laparoscopic-assisted approaches have historically been avoided secondary to the purported risk of iatrogenic perforation and increased time to perform the procedure, though in the hands of skilled laparoscopic surgeons not an absolute contraindication (Table 145.1).

Exploration and Planning

On entry into the abdominal cavity the goal is to assess for perforation and control contamination if present. If perforation is appreciated laparoscopically conversion to open is recommended. The site of perforation can be used as a point to decompress the colon proximally and distally, followed by suture closure of the defect. The abdomen is then thoroughly lavaged with warm saline, with or without antibiotics (gentamicin, kanamycin), and suctioned to remove gross contamination prior to proceeding with any further exploration or mobilization.

TABLE 145.1 Operative Options

Diversion procedures
- Turnbull procedure
- Loop ileostomy and colonic lavage

Total/subtotal colectomy and end ileostomy with:
- Hartmann pouch
- Mucous fistula
- Subcutaneous exteriorization of proximal rectosigomid stump

Proctocolectomy with end ileostomy
- Conservative proctocolectomy

Restorative procedures
- Ileocolonic/rectal anastomosis
- Ileal pouch anal anastomosis

Exploration is continued and serosal tears that could progress to full thickness defects are oversewn. A walled off perforation may be appreciated and typically occurs in the area of the splenic flexure. Evaluating the tissue quality of the rectosigmoid region prior to resection is imperative to determine whether a Hartmann pouch, mucous fistula, or subcutaneous exteriorization of bowel will be fashioned since some require more length to create than others.

Typically the colon is massively dilated and visualization of the intracoelomic cavity is hindered, which necessitates decompression. For laparoscopic exploration it is helpful to have an experienced endoscopist continually decompress the colon from the perineum to enhance visualization. Techniques to decompress through a laparotomy incision include needle, suction, lavage, and endoscopic.

For needle decompression a purse-string suture using a small needle is placed through the tenia of an accessible portion of dilated colon (Fig. 145.1). A 14-guage angiocath is placed through the middle of the purse-string and the needle is removed leaving the soft flexible catheter sheath in the lumen of colon. The sheath is then connected to suction to decompress gas. Needle decompression works well to decompress gas, though it is too small to decompress stool and blood. If unable to decompress adequately a pool tip suction catheter can be placed through the same defect after making a small colotomy. Once adequate decompression is obtained the

catheter can be removed and the purse-string suture secured (Fig. 145.2).

A good lavage approach, previously described by Khoo and colleagues, is to place a large diameter catheter with multiple distal holes connected to a Y-connector through the ileocecal valve into the right colon. One limb of the Y-connector is connected to irrigation and the other suction. If the catheter becomes clogged it can be readily irrigated. After decompression is achieved the catheter can be removed and the purse-string secured, or pushed into the ascending colon and removed with the specimen (Fig. 145.3).

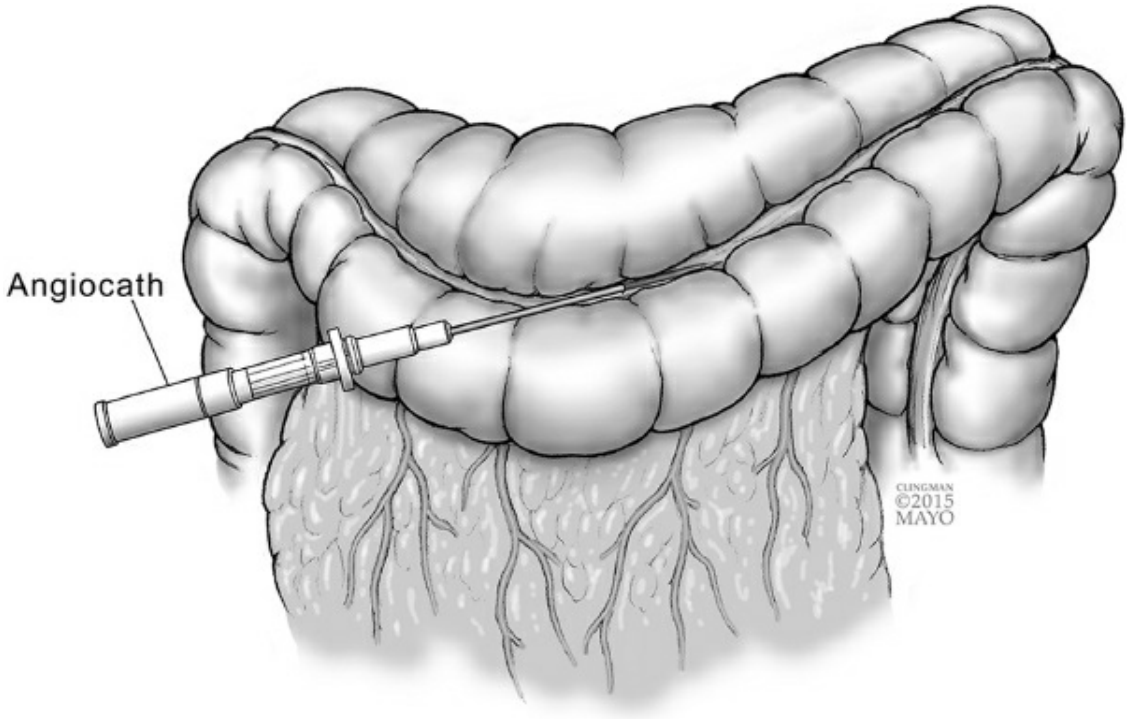

Figure 145.1. Needle decompression of colon. (Used with permission of Mayo Foundation for Medical Education and Research, all rights reserved.)

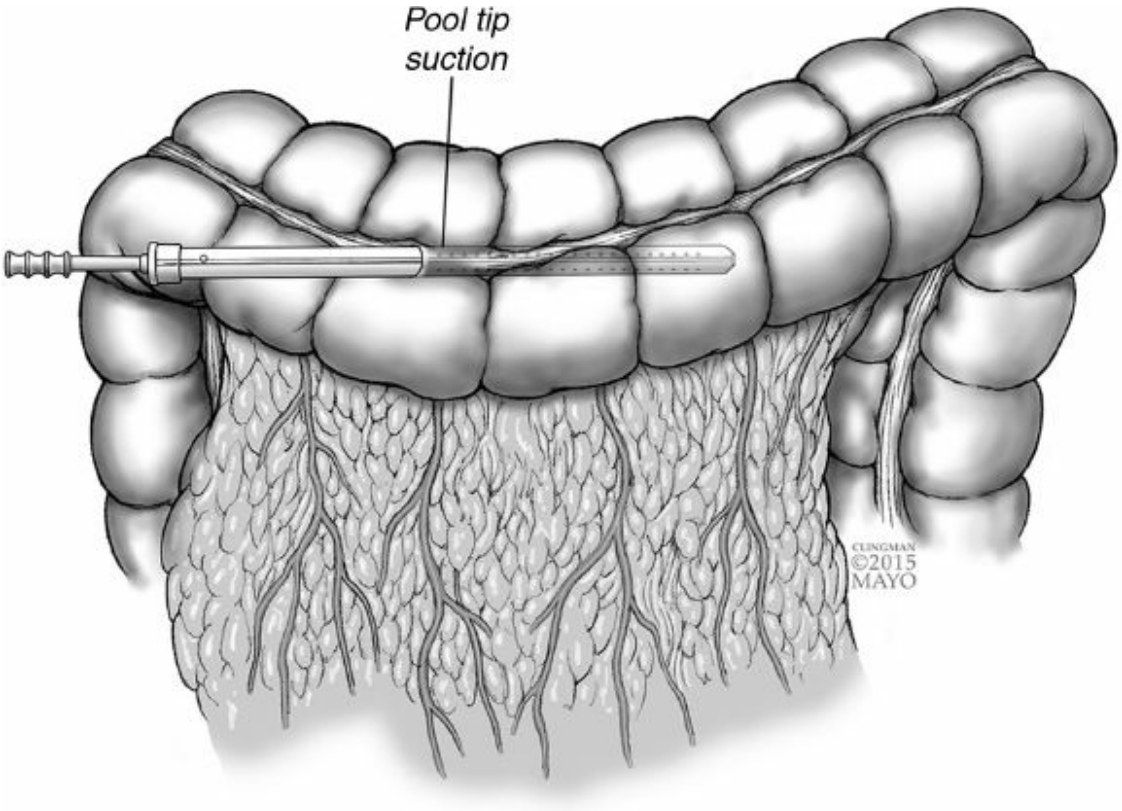

Figure 145.2. Pool suction decompression of colon. (Used with permission of Mayo Foundation for Medical Education and Research, all rights reserved.)

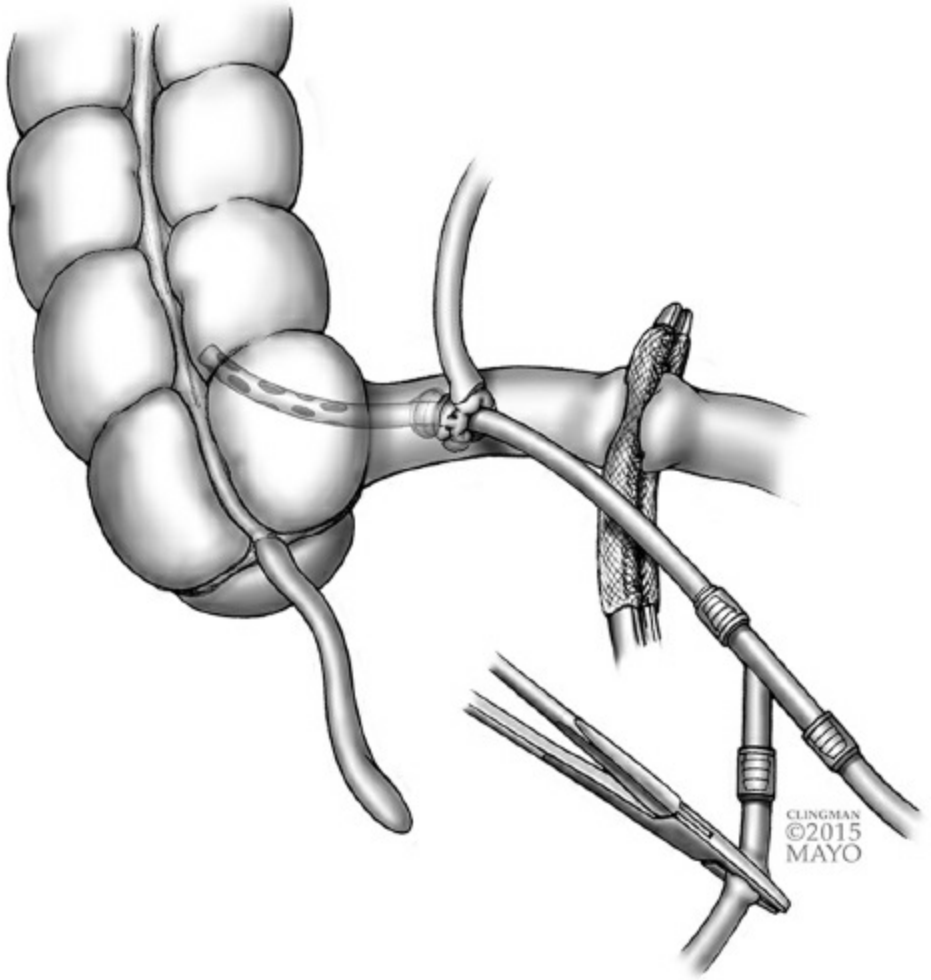

Figure 145.3. Catheter lavage of ascending colon. (Used with permission of Mayo Foundation for Medical Education and Research, all rights reserved.)

Endoscopic decompression is beneficial for laparoscopic-assisted procedures and newer larger channel flexible endoscopes with water irrigation capability work well, other than for large amounts of solid stool. If not available a rigid large diameter sigmoidoscope is also an option. Both approaches can also be utilized with a laparotomy incision and are sometimes necessary to further decompress the distal colon.

Diversion Procedure (Ileostomy–Colostomy)

Historically, the Turnbull “blow-hole” procedure was used in severely debilitated (septic, malnourished) patients with megacolon who could not withstand a major abdominal operation. A loop ileostomy, skin level transverse colostomy, and if needed a skin level sigmoid colostomy is created. This allows for fecal diversion, minimal handling of the bowel,

and patient convalescence (usually over several months) for future colectomy, but does not eliminate the colitis and physiologic impact of the inflammation on the patient (Fig. 145.4). In rare circumstances (advanced pregnancy and toxic megacolon), the Turnbull approach could be considered. Recent experience in pregnant patients with fulminant disease suggests that total abdominal colectomy and Brooke ileostomy can be completed with low rates of maternal and fetal morbidity and mortality.

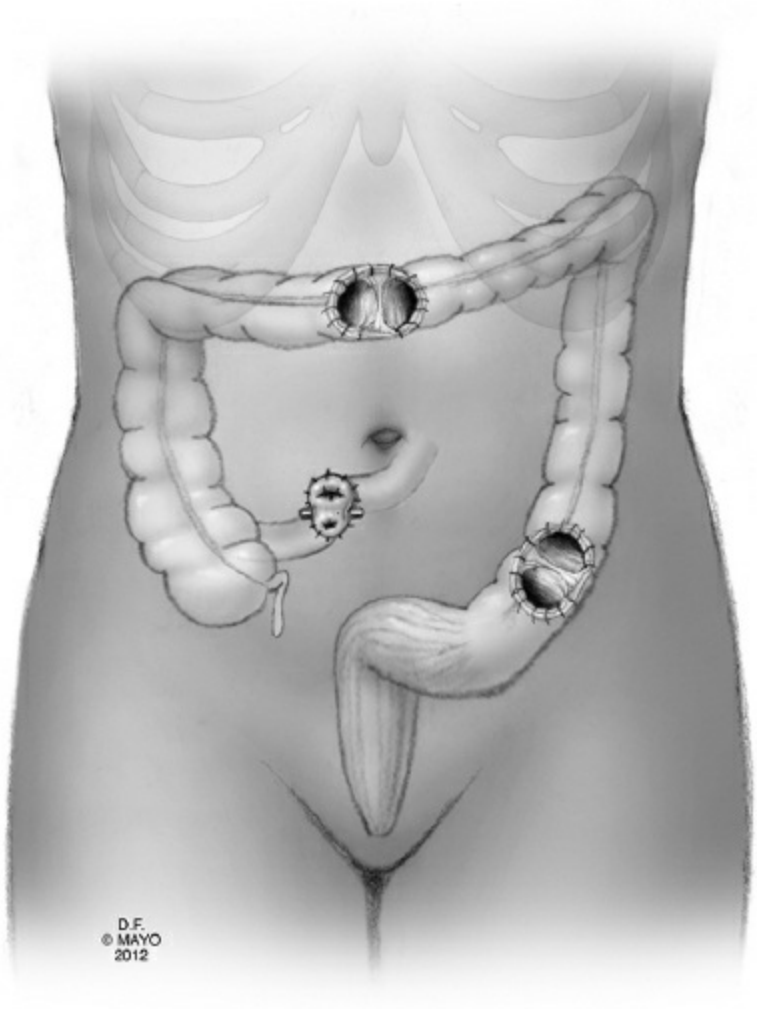

Figure 145.4. Turnbull procedure. (Used with permission of Mayo Foundation for Medical Education and Research, all rights reserved.)

Colonic Lavage Through Diverting Loop Ileostomy

For patients with severe complicated *C. difficile* colitis creation of a diverting loop ileostomy followed by colonic lavage has demonstrated lower mortality (19% vs. 50%) and higher rates of colonic preservation (39

of 42 patients) based on the protocol developed by Neal and colleagues at the University of Pittsburg. A diverting loop ileostomy is created, laparoscopically if possible, and once the incisions are closed and stoma matured a Malecot or similar catheter is inserted into the distal limb of the stoma and passed into the cecum. The colon is then lavaged with 8 L of warm polyethylene glycol 3350/electrolyte solution in the operating room. A fecal drainage system is employed transanally to collect the irrigant. Postoperatively 500 mg of vancomycin mixed in 500 mL of lactated ringers is instilled in an antegrade gravity-fed fashion over 15 to 30 minutes every 8 hours through the catheter. Metronidazole, 500 mg IV every 8 hours, is continued as well. Any deterioration or lack of improvement following lavage necessitates proceeding with a colectomy.

Subtotal or Total Colectomy

Total or subtotal abdominal colectomy with creation of a Brooke ileostomy and preservation of the rectum for a potential future restorative procedure is most commonly performed and recommended. It eliminates most of the disease and allows for restoration of health. Deferring the proctectomy reduces potential complications (bleeding, infection, autonomic nerve damage) and will simplify a restorative procedure by maintaining pelvic and presacral tissue planes.

Whether open or laparoscopic the principles of colonic mobilization and transection are essentially the same. The colon should be manipulated as little as possible to decrease the chance of an iatrogenic perforation. The mesocolon is typically edematous and foreshortened and care must be taken not to apply excessive traction on either the hepatic or splenic flexures. If the omentum is uninvolved and moves freely it can be separated from the transverse colon; otherwise remove it with the specimen.

Once the colon is completely mobilized, points of transection are decided upon. Proximally a small defect is made in the terminal ileal mesentery staying close to the ileocecal valve and the terminal ileum is transected with a linear cutting stapler. The tissue quality of the rectosigmoid junction is taken into consideration and a decision regarding creation of a Hartmann pouch or mucous fistula is made. If the tissue is not overly thick and friable the rectosigmoid junction can be stapled or transected sharply and sutured closed, although neither approach has been shown to be superior. Oversewing the staple line with interrupted sutures

can be performed. The superior rectal artery is preserved to decrease the possibility of rectal devascularization. In order to more easily identify the Hartmann stump in the future, a long permanent suture can be placed on each side of the transverse staple/suture line. To decrease the risk of a stump blowout, and resultant pelvic and abdominal abscesses, the rectum should be irrigated with a rigid proctoscope prior to leaving the operating room to remove bloody mucous, stool, and pus. A rectal tube can be left in place for at least 48 hours to decompress and decrease pressure on the closed stump. If omentum is preserved it can be mobilized and placed over the rectal stump to potentially decrease issues if breakdown occurs. Studies evaluating the outcome of a retained rectal stump have been conflicting. Some portend that leaving a diseased thickened rectal stump is not associated with increased rates of postoperative pelvic sepsis or complications. Others encourage exteriorization (mucous fistula or subcutaneous placement) of long stumps having found rates of pelvic sepsis as high as 12%, increased disease activity in the retained rectum, and subsequent pelvic dissection for restorative procedures more difficult with a retained short stump.

If a decision is made not to proceed with a Hartmann stump, adequate length must be available to create either a mucous fistula or subcutaneously exteriorize the proximal rectosigmoid stump. A mucous fistula is constructed to decompress the remaining colon and rectum. It can be combined with the end ileostomy, created through a separate stoma extraction site, or incorporated into the inferior edge of a laparotomy or laparoscopic extraction incision. If the bowel wall is too edematous and friable to accept suture it can be extracorporealized and held against the anterior abdominal wall with a moist sponge. Once the inflammation and edema subside the mucous fistula can be matured. In order to avoid a second stoma the closed end of the proximal rectosigmoid stump can be subcutaneously extracorporealized and placed in similar locations as a mucous fistula, or wherever it can reach without tension (Fig. 145.5). In the event the staple/suture line breaks down it will create a controlled mucous fistula instead of opening in the abdomen/pelvis. As with a Hartmann pouch, the subcutaneously exteriorized segment can be irrigated and decompressed for at least 48 hours.

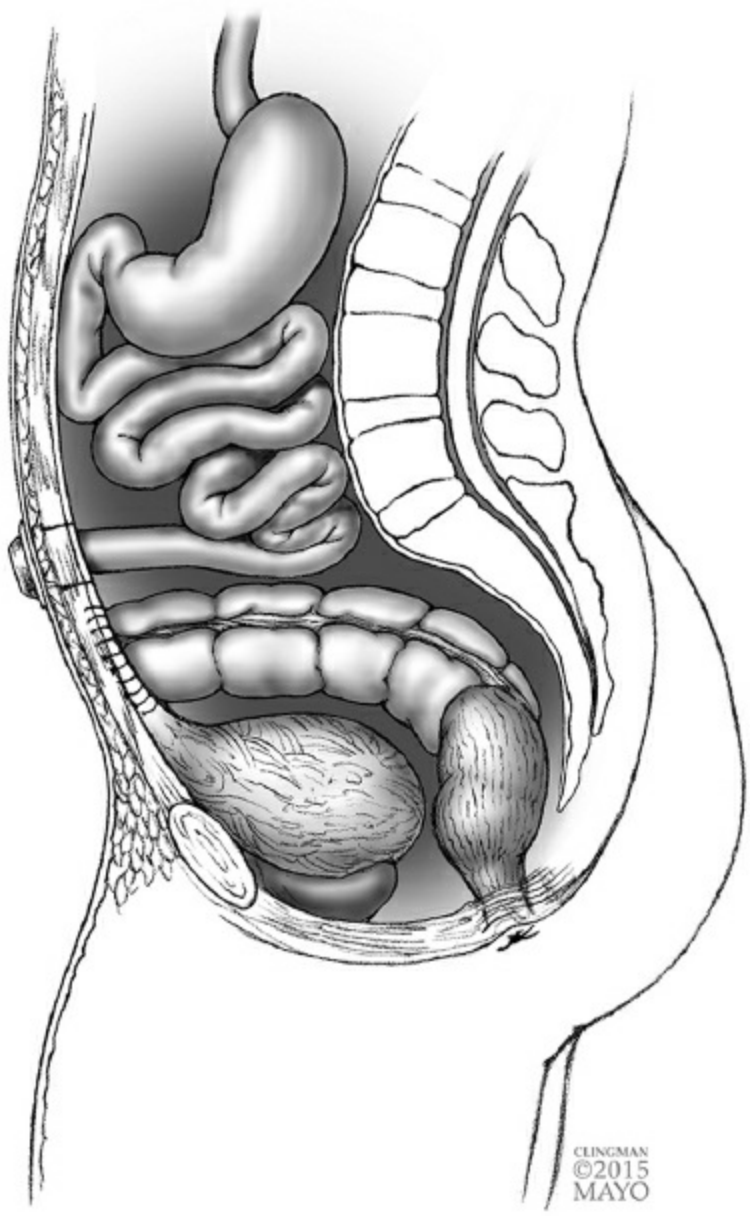

Figure 145.5. End ileostomy with subcutaneously extracorporealized rectosigmoid stump. (Used with permission of Mayo Foundation for Medical Education and Research, all rights reserved.)

After closure of the abdomen the ileostomy is matured in a standard evaginated Brooke fashion, with an attempted ideal projection of 2.5 cm (Fig. 145.6). A mucous fistula, if present, is matured flush against the skin.

Proctocolectomy With End Ileostomy/Restorative Procedure

A proctocolectomy with end Brooke ileostomy is very rarely performed and typically only in cases of life-threatening rectal hemorrhage, severe disease preventing creation of a Hartmann pouch or mucous fistula,

perforation, or when reestablishment of continuity or a restorative procedure will not be considered in the future.

Reestablishment of intestinal continuity (ileocolonic/rectal anastomosis) or a restorative procedure (ileal pouch anal anastomosis) is not recommended in unstable patients, and should only rarely be entertained when surgery proceeds without issue in stable, healthy, well-nourished patients with good tissue quality. If either is performed protecting the anastomosis with a temporary diverting loop, ileostomy is recommended.

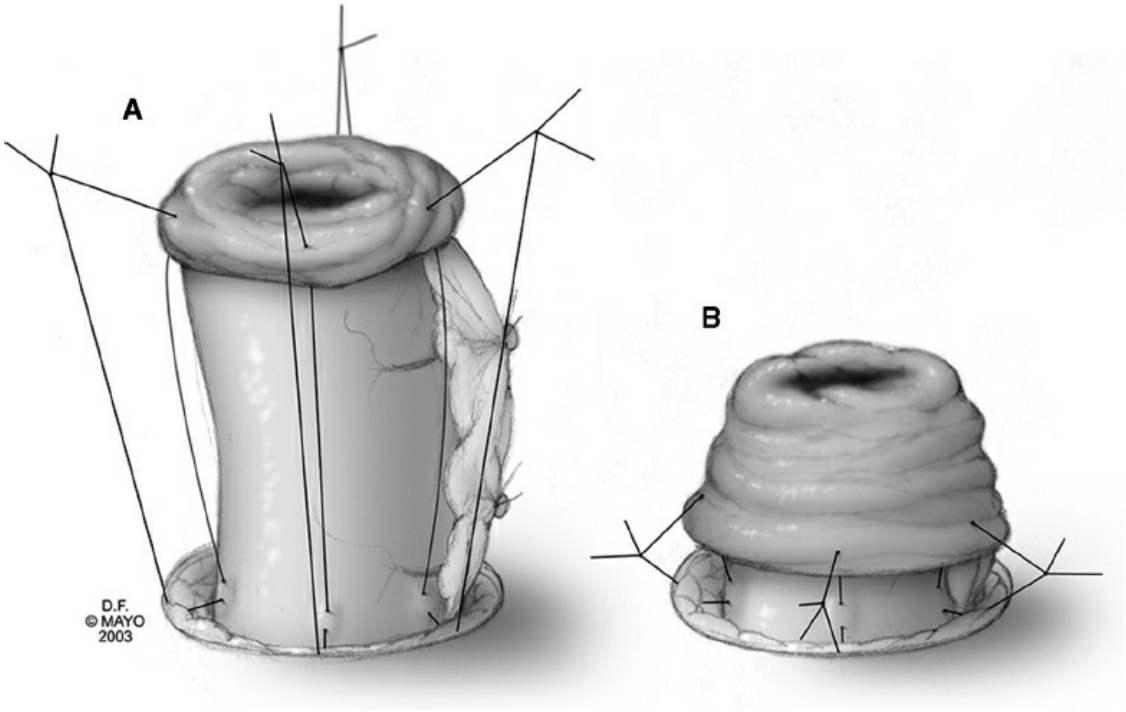

Figure 145.6. End Brooke ileostomy. (Used with permission of Mayo Foundation for Medical Education and Research, all rights reserved.)

POSTOPERATIVE CARE

Postoperatively resuscitation is continued along with medical management for the underlying cause of toxic megacolon. As signs of systemic toxicity start to resolve intravenous agents are transitioned to oral and the diet is advanced as tolerated. Plans for discharge are made when physiologically stable, tolerating enteral nutrition, and having bowel function. Once comorbidities (debility, protein calorie malnutrition, anemia, cause of toxic megacolon) have resolved/improved dramatically plans for reestablishment of intestinal continuity are pursued if indicated.

COMPLICATIONS AND THEIR MANAGEMENT

According to Teeuween and colleagues the most frequent surgical complications following surgery for severe colitis are wound infection/dehiscence (18.4%), intra-abdominal abscess (9.2%), small bowel obstruction (6.2%), ileostomy-related problems (5.5%), and hemorrhage (4.6%), and the most common medical complications were septicemia (18.0%), pneumonia (11.2%), deep venous thrombosis (7.2%), pulmonary embolism (7.0%), and urinary tract infection (4.3%).

Wound Infection/Fascial Dehiscence

Wound infection and fascial dehiscence is more common in malnourished, anemic, and debilitated patients, especially in the face of intra-abdominal contamination. Facial closure in the presence of contamination should be performed with interrupted inert permanent or delayed absorption monofilament sutures. For contaminated wounds delayed primary closure (around postoperative day 3) of the abdominal incision has been shown to significantly lower the rate of superficial surgical site infection as well as fascial dehiscence, and reduces the mean complete incision healing time and hospitalization. The skin can also be allowed to heal by secondary intention with or without the utilization of a negative pressure wound closure device.

Intra-abdominal/Pelvic Abscesses

For cases of perforation and abdominal contamination the abdomen should be thoroughly lavaged with warm saline, with or without antibiotics (gentamicin, kanamycin), and suctioned until clear. Fibrinous rinds can be manually debrided. Though these maneuvers will not prevent abscess formation, they can decrease the risk. Abscesses can also form from a retained stump leak. Drainage of abscesses through catheters placed percutaneously with radiographic guidance is recommended.

Stomas

Stoma complications including retraction, peristomal skin excoriation, stenosis, prolapse, and herniation can occur, with up to 30% of patients requiring operative revision. Though at the end of the procedure, it is imperative that creation of a stoma is not rushed and proper technique is utilized. Stoma complications can be disastrous for patients, especially for

those with a permanent stoma.

Hemorrhage

In cases of toxic megacolon the mesocolon is typically thickened and inflamed and excessive traction during mobilization can result in tearing of the splenic capsule or thin walled veins. Division and ligation of the mesocolon can also result in hemorrhage, both intraoperatively and postoperatively. If the mesentery is overly thick suture ligatures are utilized to decrease issues with bleeding. For postoperative hemorrhage correction of coagulopathies and transfusion is carried out. If unable to control reexploration is recommended.

OUTCOMES

With maximal medical therapy a large percentage of patients with toxic megacolon can avoid surgery, with one study documenting a rate of 67%, although a high rate of recurrence requiring surgery has also been documented, albeit in earlier studies. Grant and Dozois at the Mayo Clinic prospectively followed 38 patients for an average of 13 years with toxic megacolon (32 CUC and 6 Crohn) successfully treated nonoperatively. Eleven developed a second episode and in total 18 (47%) wound up requiring a colonic resection, of which 15 (83%) were performed on an emergent/urgent basis. In a series from the Cleveland Clinic reported by Fazio only 7 of 115 (6%) patients were successfully treated with medical management, of which 5 eventually required a colectomy in later years.

Although early recognition and better management has decreased mortality rates for inflammatory bowel disease significantly (currently 0% to 2%), the presence of *C. difficile* colitis has been increasing since 2000 with mortality rates ranging from 37% to 80%. Pepin and colleagues, in a multivariate analysis, noted risk factors for mortality were age, preoperative lactate ≥5.0 mmol/L, leukocytosis ≥50.0 × 10^9/L, and albumin less than 15 g/L.

Colonic lavage and FMT both show promising results, tough it is still too early to draw any definitive conclusions.

Suggested Readings

Brady RR, Collie MH, Ho GT, et al. Outcomes of the rectal remnant following colectomy for ulcerative colitis. *Colorectal Dis* 2008;10(2):144–50.

Castro Fernández M, García Romero D, Sánchez Muñoz D, et al. Severe ulcerative colitis, with toxic megacolon, resolved with infliximab therapy. *Rev Esp Enferm Dig* 2007;99(7):426–7.

Costello SP, Chung A, Andrews JM, et al. Fecal microbiota transplant for *Clostridium difficile* colitis-induced toxic megacolon. *Am J Gastroenterol* 2015;110(5):775–7.

Grant CS, Dozois RR. Toxic megacolon: ultimate fate of patients after successful medical management. *Am J Surg* 1984;147:106–10.

Hall JF, Berger D. Outcome of colectomy for *Clostridium difficile* colitis: a plea for early surgical management. *Am J Surg* 2008;196:384–8.

Neal MD, Alverdy JC, Hall DE, et al. Diverting loop ileostomy and colonic lavage: an alternative to total abdominal colectomy for the treatment of severe, complicated *Clostridium difficile* associated disease. *Ann Surg* 2011;254(3):423–7.

Sheth SG, LaMont JT. Toxic megacolon. *Lancet* 1998;351:509–13.

Shetler K, Nieuwenhuis R, Wren SM, et al. Decompressive colonoscopy with intracolonic vancomycin administration for the treatment of severe pseudomembranous colitis. *Surg Endosc* 2001;15:653–9.

Sinagra E, Orlando A, Renna S, et al. Is really megacolon a contraindication to infliximab in Crohn's disease? *Acta Gastroenterol Belg* 2013;76(4):442–4.

Teeuwen PH, Stommel MW, Bremers AJ, et al. Colectomy in patients with acute colitis: a systematic review. *J Gastrointest Surg* 2009;13(4):676–86.

EDITOR'S COMMENT

Clostridium difficile now is one of the most common hospital-acquired infections in surgical patients. The surgeon needs to be particularly prepared to face the issue of toxic megacolon, perhaps more frequently than ever has existed as a complication either of Crohn colitis or ulcerative colitis, as was true 25 years ago (Autenrieth DM, Baumgart DC. Toxic megacolon. *Inflamm Bowel Dis* 2012;18(3):584–91). Over recent years the rates of toxic megacolon due to infectious colitis have increased, while toxic colitis due to inflammatory bowel disease has decreased. It is estimated that the cost for inpatient hospital services for *C. difficile* infection in the United States currently range from 1.14 to 1.62 billion (https://www.cdc.gov/HAI/pdfs/hai/Scott_CostPaper.pdf)!

The critical nature and the surgeon's role in the care of the patient with suspected toxic megacolon requires immediate attention and a realization that there may be no disease in the colon itself except as a passive edematous conduit for an invasive bacterial infection of its own origin. The *C. difficile*–infected colon is characterized by tremendous edema of the colonic wall; it seldom bleeds and less often perforates. Conversely, the timeliness of surgical

involvement in these patients is absolutely vital and important, assuming that the surgeon uses reasonably good common sense and must be prepared to take the patient to the operating room at the slightest evidence of deterioration. Ileus in a patient with suspected *C. difficile* is an ominous sign. It does not indicate that the patient is better, but that the colon is simply beginning to dilate and that colonic ileus may predispose to massive deterioration of the patient.

There is substantial argument regarding the ideal nonoperative treatment for a patient with *C. difficile* colitis. It is clear that vancomycin and/or metronidazole are the antibiotic agents of choice. Fidaxomicin is an expensive alternative to vancomycin and metronidazole for patients with recurrent disease. Fecal microbiota transplant is a very promising therapy that may supplant surgery (Li YT, Cai HF, Wang ZH, et al. Systematic review with meta-analysis: long-term outcomes of faecal microbiota transplantation for *Clostridium difficile* infection. *Aliment Pharmacol Ther* 2016;43(4):445–57). There are currently significant administrative details, need for family members to donate fecal samples, need for fecal donor hepatitis and HIV testing, and sample processing which are all very time consuming and cumbersome for the very ill patient. In the future, biobanks of frozen samples should make this a much more attractive and manageable option (http://www.openbiome.org/). There has even been a report of fecal microbiota transplantation being used to successfully treat *C. difficile* toxin-induced toxic megacolon (Costello SP, Chung A, Andrews JM, et al. Fecal microbiota transplant for *Clostridium difficile* colitis–induced toxic megacolon. *Am J Gastroenterol* 2015;110(5):775–7)!

If the normal signs of an acute abdomen are present, such as leukocytosis, fever, and tenderness, then one must carefully make clinical judgments as to the likely need for operation. A better bit of news is that it appears to have become clearer, that is, the procedure of choice. The procedure promulgated by the surgeons at the University of Pittsburgh has included a diverting loop ileostomy and access to the colon itself for administration of vancomycin (Neal MD, Alverdy JC, Hall DE, et al. Diverting loop ileostomy and colonic lavage: an alternative to total abdominal colectomy for the treatment of severe, complicated *Clostridium difficile* associated disease. *Ann Surg* 2011;254(3):423–7). The improvement in in-hospital mortality is dramatic. Reports of large series of fulminant colitis up to this time had reported very high mortality rates, such as the report by Sailhamer et al., nearly 35% (Sailhamer EA, Carson K, Chang Y, et al. Fulminant *Clostridium difficile* Colitis: Patterns of Care and Predictors of Mortality. *Arch Surg* 2009;144(5):433–9). Age >70, severe leukocytosis (>35,000/μL), leukopenia (<4,000/μL), or neutrophil bandemia (>10%) and cardiorespiratory failure (intubation or pressor requirement) were independent predictors of mortality.

The Turnbull procedure, with ileostomy, and “blow-hole” transverse colostomy is seldom needed now. The technique that the authors mention, of placing the Hartmann stump subcutaneously in the lower aspect of the incision is one that I practice. This is very useful. In many of these patients, the distal

bowel is very diseased; it does not hold staples well, and despite being oversewn, will tend to dehisce at some point in the postoperative period. If this segment of bowel is left in the pelvis, one then has to contend with a pelvic abscess and treat this with transrectal or interventional radiology drainage, neither of which are pleasant for the patient. When one has, however, implanted the Hartmann stump subcutaneously and this same event occurs, one is left with a simple wound infection. When treated, this is in essence a low output mucus fistula—very safe, low maintenance, and easy to care for. I believe that we are seeing so much less inflammatory bowel disease–related toxic megacolon due to the greatly expanded medical therapy options available for those patients, especially the entire range of “biologic” anti-tumor necrosis factor-α therapies.

Susan Galadiunk

146 Total Proctocolectomy and Inter-Sphincteric Proctectomy for Benign Disease

Javier Salgado Pogacnik and David S. Medich

INDICATIONS FOR TOTAL ABDOMINAL PROCTOCOLECTOMY AND INTERSPHINCTERIC PROCTECTOMY FOR BENIGN DISEASE

Even though restorative total proctocolectomy (TPC) with ileal pouch anal anastomosis (IPAA) has become the treatment of choice for chronic, medically refractory mucosal ulcerative colitis (UC), indeterminate colitis (IC), and familial adenomatous polyposis (FAP), several absolute and relative contraindications exist. In the subgroup of patients, where IPAA is contraindicated, total abdominal proctocolectomy with intersphincteric proctectomy is the procedure of choice. The presence of toxic megacolon in ulcerative colitis patients should preclude an attempt for IPAA. In addition, poor preoperative sphincter functions as well as the presence of intra-abdominal desmoid tumors are absolute contraindications. Relative contraindications are also diverse. Advance age, previous small bowel resections, severe comorbidities, obesity with narrow pelvis, and Crohn disease (CD) are considered relative contraindications. Finally, there are some patients who will opt for TPC with end ileostomy despite being adequate candidates for restorative proctocolectomy for social or personal considerations.

Inflammatory Bowel Disease

Inflammatory bowel disease (IBD) has emerged as a growing problem in industrialized nations. In 1875 Wilks and Moxon introduced the term *ulcerative colitis* into the medical linguistic. In 1932 Crohn, Ginzburg, and Oppenheimer published a paper in *JAMA*, describing patients with "regional ileitis." Remarkably the surgeon involved in the care of the majority of the patients, Dr. A.A. Berg, did not want his name included in

the article. Later, Brooke in 1959 and Lockhart-Mummery and Morson in 1960 distinguished Crohn disease from ulcerative colitis. Since then, the incidence of ulcerative colitis and Cronh disease has increased in Western nations and in newly industrialized countries.

Currently 1.4 million persons in the United States suffer from these diseases, causing overall health care cost of more than $1.7 billion. IBD accounts for more than 700,000 physician visits, 100,000 hospitalizations, and disability in 119,000 patients. At some point in their lives 75% of patients with Crohn disease and 25% of those with ulcerative colitis will require surgery.

In developing the clinical decision tools, the standard assessment of the disease activity (as mild, moderate, or severe) is insufficient in guiding the selection therapy. Current *models* have included demographic and disease characteristics as predictors for colectomy, incorporating natural course of the disease, endoscopic disease activity, history of *Clostridium difficile* or *Cytomegalovirus* infection, chronicity of inflammation, and biomarkers (i.e., fecal calproctein).

Surgical management in ulcerative colitis is influenced by the nature of the presentation. In elective cases, TPC with Brooke ileostomy has been traditionally the gold standard in patients who are not candidates for IPAA. Indications include medical intractability, risk of malignancy, presence of incapacitating extracolonic disease, and growth retardation in children.

In addition to these, operative indications in Crohn disease will also depend in the specific anatomic location of the disease. Those patients with extensive colonic disease, proctitis, and ano-perineal sepsis should undergo a TPC with Brooke ileostomy.

Beside these current models, it is imperative for surgeons to understand the types of IBD-associated dysplasia as well as the correlation and risk between IBD and colorectal cancer in order to guide the adequate surgical management. Colorectal cancer has been documented as the cause of death in up to 15% of IBD patients. Presently, there is a vast variety of studies available on dysplasia and risk of progression to cancer in IBD patients, demonstrating the association between immune dysregulation, genetic susceptibility, environmental triggers, and IBD. Surveillance and treatment paradigms are often similar in the two groups despite different pathophysiologies. In both ulcerative colitis and Crohn disease, the incidence of dysplasia and colorectal cancer is increased based upon the duration of colitis, extent of colitis, age at diagnoses, gender (relative risk

in males: 2.6 vs. females: 1.9), severity of inflammation, family history of CRC, and coexisting PSC.

The treatment of IBD-associated dysplasia is guided by each type of dysplasia's risk of synchronous and metachronous lesions as well as the risk of progression to CRC. Because of "field effect" of cellular and molecular changes, both synchronous and metachronous dysplasia and carcinoma are more frequent in IBD population versus sporadic CRC.

	Synchronous Tumor Rate	Synchronous Dysplasia
CD	4%	30%
UC	14%	55%

The surgical decision rules in dysplasia and IBD can be summarized to the following:

1. Low-grade dysplasia (LGD); necessitates examination by second pathologist.
2. LGD versus high-grade dysplasia (HGD) should be viewed similarly, and both require TPC in the appropriate surgical candidate.
3. Multifocal dysplasia mandates a TPC.
4. Flat dysplasia mandates a TPC.
5. Dysplasia-associated lesions of masses (DALMs) mandate surgery.
6. Adenoma-like DALMs; most surgeons will propose surgery.
7. With pseudopolyps or strictures, effective surveillance may be impossible, and therefore it may require TPC.

Familial Adenomatous Polyposis

FAP is an autosomal dominant inherited syndrome caused by the mutation of the APC gene situated on chromosome 5q21, with an incidence of 1:10,000. The main clinical feature as a result of the mutation of this tumor suppressor gene is the development of hundreds of colorectal adenomatous polyps that appear in the adolescence, with capacity of malignant transformation. Once FAP has been diagnosed, the aim is to perform prophylactic surgery. The timing of prophylactic surgery is influenced by the clinical variant of the FAP. Severe polyposis (more than 1,000 colonic or more than 20 rectal polyps) should undergo surgery early in their course. Other clinical variants such as attenuated FAP, milder disease, or

MYH polyposis surgery can be deferred until it is optimal from a social and educational perspective.

The surgical options include colectomy with ileorectal anastomosis, TPC with IPAA and TPC, intersphincteric perineal resection, and permanent end ileostomy. The latter is indicated in patients with intra-abdominal desmoid tumors, poor preoperative sphincter function, or when technically the creation of an IPAA is impossible.

PREOPERATIVE PLANNING

The patient undergoing an elective colorectal procedure should undergo a systematic and comprehensive preoperative risk assessment. Special attention should be given to prior exposure to anesthesia, current medications, allergies, and associated comorbidities. All patients should have a preoperative medical clearance with thorough evaluation of the cardiovascular, renal, hematologic, and nutritional status. In addition to investigating the pulmonary and hepatic function, it is essential to have a detailed discussion about the technical details of the procedure, risks, benefits, different surgical options, as well as to postoperative expectations. Patients who will undergo a TPC with creation of permanent end ileostomy should receive preoperative teaching and stoma marking.

In recent years, the development of enhanced recovery after surgery (ERAS) protocols in colorectal surgery has been implemented and well-documented data have shown abundant advantages. These include shorter length of hospital stay, and postoperative complications. It is our preference in elective noncombined colorectal surgery cases to implement this pathway at our institution. This requires a respectable collaboration of a multidisciplinary team, including surgeons, anesthetists, nurses (in the outpatient clinic, preoperative room, as well as in the surgical ward), physical therapists, and nutritionists. In addition, these guidelines should be conversed with the patient prior to the surgical procedure. Lastly, ERAS colorectal feedback and discussion meetings should be planned methodically every 3 months to analyze compliance as well as discuss improvement approaches.

SURGICAL TECHNIQUE

TPC with intersphincteric proctectomy can be achieved via open and minimally invasive approaches. The later includes straight laparoscopy, hand-assisted laparoscopy, or robotic-assisted techniques.

Minimally Invasive Approach

A structured and specialized surgical team is essential in obtaining an adequate preparation and positioning of the patient. All patients (unless contraindicated) should receive preoperative DVT prophylaxis prior to induction of general anesthesia. In addition, patients should have sequential compression devices in bilateral lower extremities. After general anesthesia is induced, the patient is repositioned in a modified lithotomy position in Yellowfin stirrups. Special attention should be given to avoid sural nerve damage. Both arms should be appropriately padded and tucked. The chest should be tapped to avoid the patient to slide during the procedure. After the patient is satisfactorily positioned, communication with anesthesia is essential to confirm pressure cuffs, peripheral access, and arterial lines are functioning appropriately. In order to minimize the risk of surgical site infection, proper preoperative antibiotic prophylaxis should be given within 30 minutes of skin incision.

I favor on performing hand assisted laparoscopic approach using the Gelport device. A low Pfannenstiel incision is used with the thought of having lowers rates of incisional hernias as well as obtaining superior cosmetic results. As an alternative, a suprapubic midline 5 cm incision can be used. The Gelport device is introduced. A supraumbilical 5-mm balloon port is placed under direct visualization; 15 mmHg of pneumoperitoneum is achieved and subsequently 4 extra 5 mm balloon ports are introduced (Fig. 146.1).

The abdominal cavity is inspected, and dissection is initiated by mobilizing the right colon in a medio-lateral and inferior to superior fashion. The patient is repositioned in Trendelenburg, tilted to the left side. The ileocolic pedicle is identified and using atraumatic bowel graspers, it is tented anteriorly and superiorly (Fig. 146.2A). Using an energy source of the surgeon's preference, the visceral peritoneum over the ileocolic pedicle is scored in a V-shaped fashion. Dissection is carried over Gerota's fascia, identifying the retroperitoneal structures including right ureter, gonadal vessels, as well as the duodenum that is dissected free with gentle blunt dissection (Fig. 146.2B). It is crucial to accomplish adequate traction and counter traction triangulating the instruments in synchronized fashion with the assistant. This maneuver will allow a high ligation of the ileocolic pedicle using the energy source of surgeon's choice. The dissection is carried through the avascular plane superiorly until the inferior border of the liver is encountered and lateral to the abdominal wall. The second step

of the right colon mobilization is to take down the lateral and superior attachments of the proximal transverse colon, and hepatic flexure. Careful traction of this area is required due to the fact that there are vessels of different size that may require ligation. Finally the lateral colonic attachment through the white line of Toldt is completed, mobilizing the right colon to the midline.

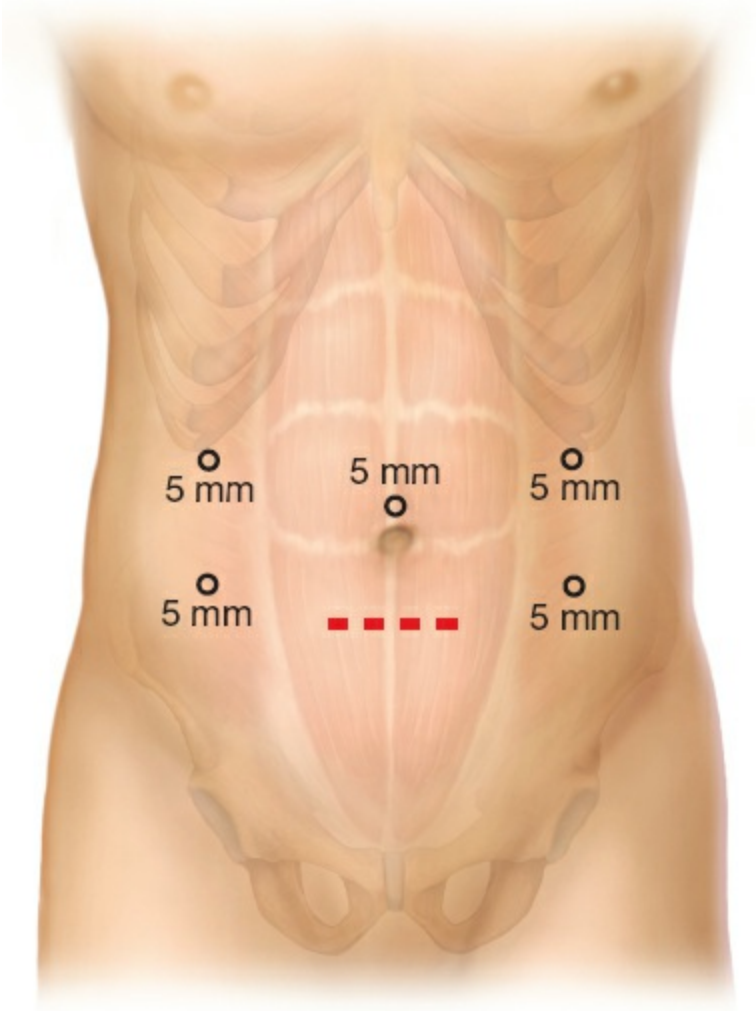

Figure 146.1. Port placement.

Consecutively, the transverse colon is mobilized. The omentum is lifted off the transverse colon, and if possible preserved in order to accomplish an omental flap that will be used to shelter the pelvic inlet. The lesser sac is entered, identifying the posterior wall of the stomach as well as the body of the pancreas. This maneuver allows to clearly recognize the origin of the middle colic vessels that are again ligated safely with the energy device. The dissection is carried caudally toward the splenic flexure.

Step 3 involves the mobilization of the left colon. The patient is placed

in Trendelenburg position tilted toward the right side. The surgeon is positioned in between the legs and both assistants to the right side of the patient (Fig. 146.3). Identification of the duodenal-jejunal junction as well as the origin of the inferior mesenteric vein (IMV) is achieved (Fig. 146.4A). Dissection is carried under the IMV, on top of Gerota's fascia, cephalad until the body of the pancreas is encountered, laterally to the abdominal wall, and caudally to the origin of the inferior mesenteric artery (IMA) (Fig. 146.4B). This avascular plane is very consistent, easy to develop, and facilitates the splenic flexure mobilization. The IMV is taken in a high ligation with the energy device. Subsequently, the visceral peritoneum to the right of the sacral promontory is scored up to the origin of the IMA. The retroperitoneal structures including left gonadal vessels and left ureter are identified and preserved. Once this is accomplished, both planes of dissection are connected, allowing to perform a high ligation of the IMA with preservation of the preaortic sympathetic plexus (Fig. 146.4C). Finally, the lateral colonic attachments are taken from the recto-sigmoid junction cephalad toward the splenic flexure.

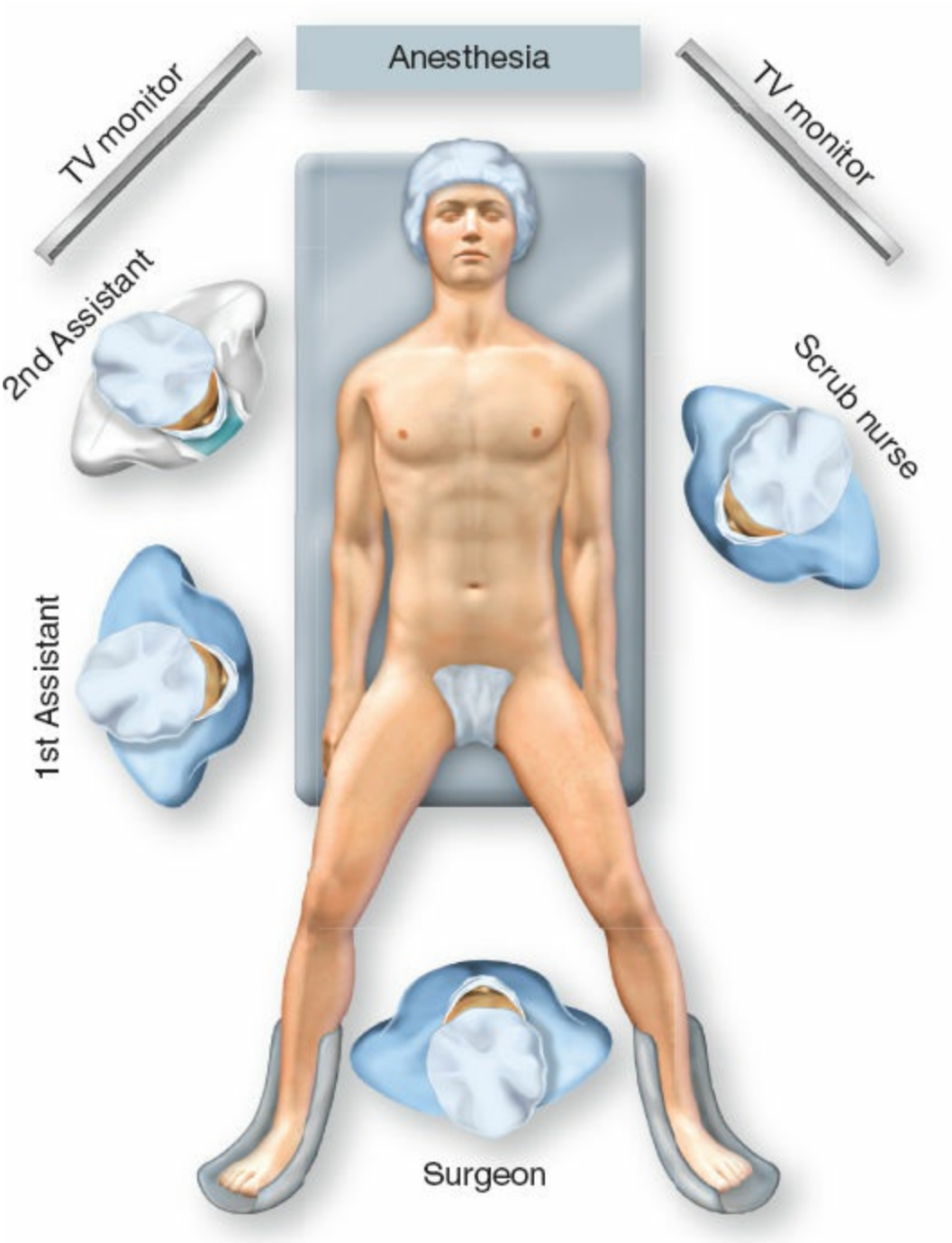

Figure 146.2. **A.** Identification of the ilecolic pedicle. **B.** Right colon medial to lateral mobilization.

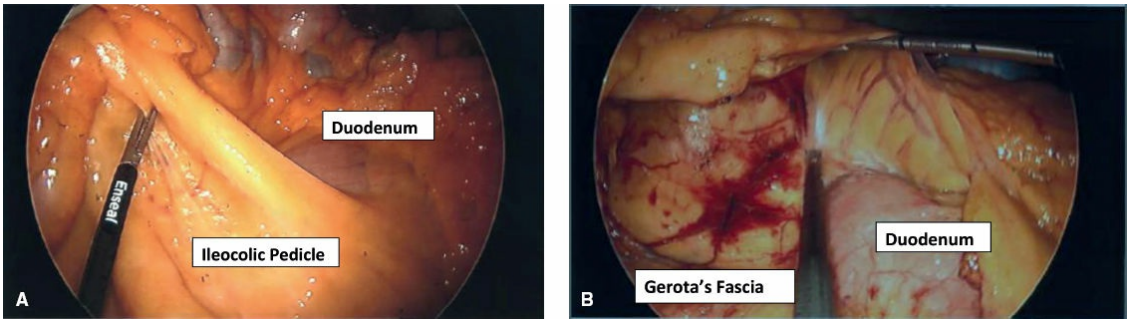

Figure 146.3. Surgical team position.

After the colon mobilization is concluded, it is my preference to deflate the pneumoperitoneum, extract the Gelport lid, and eviscerate the terminal ileum. The two unnamed vessels of the terminal ileum as well as the marginal artery are taken with Kelly clamps and 0-Chromic ties. The terminal ileum is transected with a GIA 60-mm blue load in an antimesenteric to mesenteric orientation. The small bowel is packed in the upper abdomen. The remainder of the colon is eviscerated. The proctectomy is completed directly through the Gelport using lighted St. Mark's or a curved Toy retractor.

I begin the rectal mobilization in posterior and posterolateral plane staying in the potential space between the fascia propria and presacral fascia with special care taken to avoid injury to the superior hypogastric plexus, right and left hypogastric nerves, and lateral pelvic side wall plexus. The mobilization is carried down posteriorly through Waldeyer's fascia to the pelvic floor. Anteriorly, in males it is imperative to carry the dissection on the rectal side of Denovilliers fascia, identifying the seminal vesicles as well as the posterolateral neurovascular bundles and minimizing the use of energy sources that could cause thermal spread injury during this part of the procedure. In women, visualization and preservation of the posterior wall of the vagina should be attained. This maneuver will allow complete mobilization of the rectum down and including the endopelvic fascia.

The perineal dissection can be done with the patient in the modified lithotomy position or repositioning the patient in prone jackknife that will require the creation of the end ileostomy and closure of the surgical wound prior to flipping the patient. Proning the patient has the advantage of better exposure and visualization of the surgical field, leading to superior oncologic outcomes. Furthermore, it allows the surgeon and the assistants to remain in a healthier posture. On the other hand, disadvantages include

the fact it prolongs the operative time, and necessitates an extremely respectable coordination between all team members. My inclination for benign disease is to complete the perineal dissection without modifying the patient's position if the patient's body habitus is favorable.

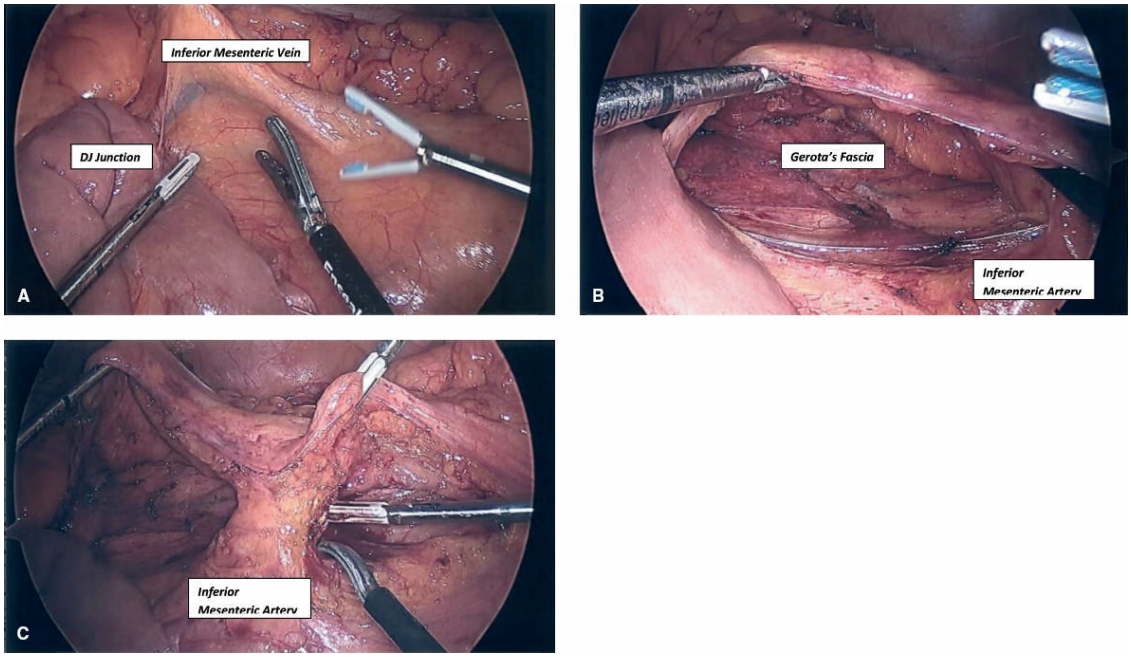

Figure 146.4. **A.** Identification of duodenal-jejunal junction and IMV. **B.** Left side medial to lateral mobilization. **C.** Dissection of IMA.

A 2-0 Surgipro purstring suture is placed in the anus to minimize fecal contamination. An elliptical incision just outside the intersphincteric groove is performed and continued in the intersphincteric groove using bovie electrocautery (Fig. 146.5). It should be approached first, posteriorly through the anococcygeal ligament into the previously dissected pelvis and then laterally. When 270 degrees postero-lateral dissection is accomplished, the specimen is retroflexed out of the anus in order to complete the anterior dissection. In males care must be taken not to injure the urethra and in women the posterior wall of the vagina. After adequate hemostasis is verified, the perineal wound is closed in layers, closing the puborectalis and external sphincter and skin separately with interrupted Polysorb suture. The skin is closed with vertical mattress of 2-0 Polysorb suture with telfa wicks placed between to minimize the surgical site infection rates. The stoma aperture is then made through the right rectus muscle at a site previously marked by the enterostomal therapy nurses. A 19-Fr round Blake drain is placed in the pelvis, and finally the omental

flap is used to obliterate the pelvic inlet to avoid small bowel loops from entering the deep pelvis. Those patients with active perianal sepsis/fistula disease, the tract should be curetted and a 12-Fr mushroom catheter should be left in place in the external os. The external sphincter muscle can be closed leaving the perineal skin partly of completely open in order to decrease surgical site infection rates and postoperative perineal wound complications.

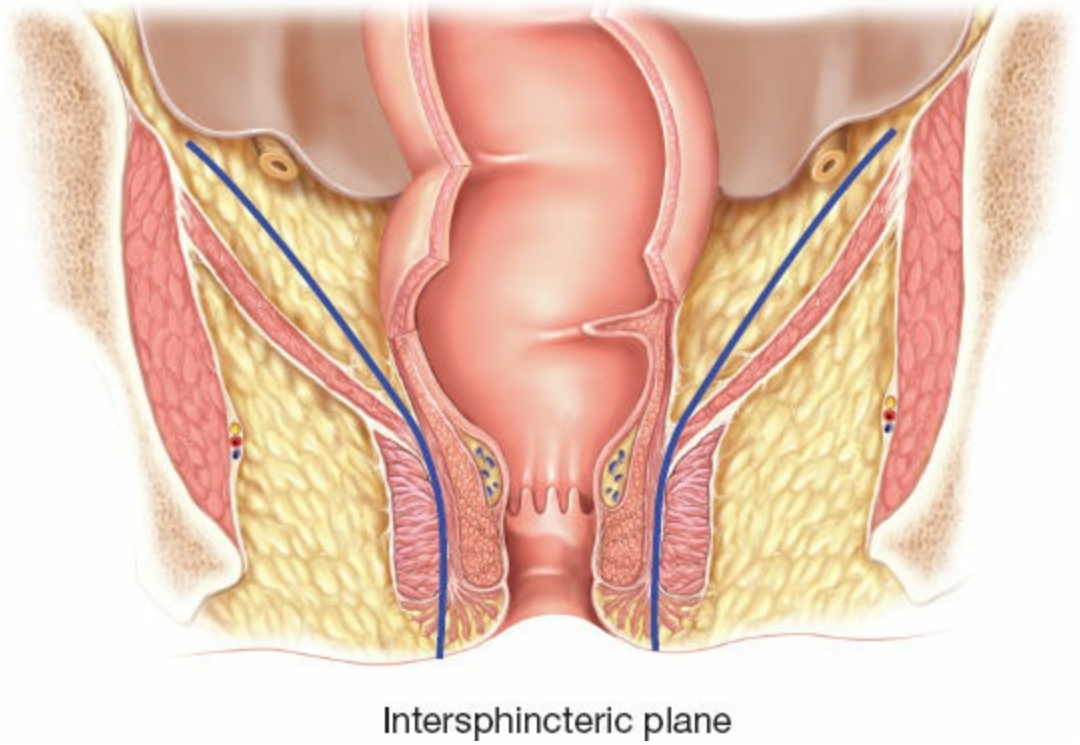

Figure 146.5. Intersphincteric plane.

Conventional Laparotomy

When conventional open surgery is performed, the surgical principles should be maintained. A midline laparotomy is performed and the abdomen is explored in a 4-quadrant systematic fashion, running the small bowel from the ligament of Treitz to the terminal ileum to rule out incidental pathology or the presence of concomitant small bowel Cronh disease. The main difference in the surgical approach is the fact that the dissection of the large intestine is mobilized in a lateral to medial fashion.

POSTOPERATIVE CARE

As part of my preference adhering to the of ERAS protocol, the postoperative care is divided into different phases. Postoperative 0 Phase;

patients are admitted to a monitored bed. Vital signs are obtained every 4 hours for the first 24 hours and then every 8 hours. Patients are encouraged to be out of bed to the chair at least 2 hours ambulate with assistance the night of surgery, elevate the head of the bed, and perform cough and deep breathes every 1 hour while awake. Sequential compression devices are placed in bilateral lower extremities while the patient is in bed. Noncarbonated clear liquid diet is ordered immediately after surgery. Lactated Ringer's is infused for 18 hours at a rate of 40 mL/hr. Pain controlled is focused in minimizing perioperative use of IV narcotics. A lidocaine drip is infused for 24 hours with the concomitant administration of acetaminophen and ketorolac when not contraindicated. Oxycodone immediate release tablet is ordered in a prn (as needed) basis.

On postoperative day 1, the patient is advanced to a GI (easy to digest) diet, encouraging 2,000 mL of noncarbonated clears, and the Foley catheter is removed. Patients and family members receive postoperative stoma care education and teaching.

POSTOPERATIVE COMPLICATIONS

The incidence of postoperative complications after total abdominal proctocolectomy with Brooke ileostomy is usually less when compared to patients undergoing IPAA. Minor complications can occur in up to 39% of patients and major complications in 17%, sometimes requiring reoperation and readmission to the hospital. Perineal wound infection, with delayed healing occurs in up to 25% of patients leading to significant morbidity, and associated frustration of the patient. Intersphincteric dissection improves blood supply to the area and minimizes the surgical wound decreasing wound-related complications. It is my preference to pack the perineal wound with Telfa wicks that will be removed in postoperative day 3. This allows the wound to drain and reduce this event. On those cases when superficial surgical site infection occurs leading to wound dehiscence, local wound care with packing or the use of negative pressure devices may be required for an extensive period of time.

Sexual dysfunction as a result of injury the sympathetic or parasympathetic lateral pelvic side plexus resulting in permanent impotence, retrograde ejaculation, or bladder dysfunction can occur in 1% of the cases. In woman, up to 30% can complain of postoperative dyspareunia as a consequence of perineal scarring. Adherence and knowledge of the precise pelvic anatomy, identification of the nerves, and

minimizing the use of energy devices in specific anatomic sites are mandatory to diminish this complication.

Ileostomy-related complications are diverse. Peristomal dermatitis as a result of pouch dysfunction, stoma prolapse, retraction, and strictures can occur between 5% and 25%. Readmission ates secondary to dehydration as a result of newly formed stoma are reported in 18% of the patients. Identification of factors that might predict readmission could help avoid early discharge and the application of precautionary actions to avoid this preventable ileostomy-related complication. Moreover, the enterostomal care education, adequate preoperative marking, clear understanding of the physiologic changes, and implementation of diaries with strict inputs and outputs will help minimize these events.

Small bowel obstruction as a result of this operation can occur in up to 20% of patients and is usually a consequence of postoperative adhesions formation to the large raw surface area, especially in the deep pelvis. The use of minimal invasive techniques, and when technically feasible the creation of an omental flap pedicle to obliterate the pelvic inlet is recommended.

CONCLUSIONS

Despite the fact that restorative total proctocolectomy (TPC) with ileal pouch anal anastomosis (IPAA) has become the treatment of choice for chronic, medically refractory mucosal ulcerative colitis (UC), indeterminate colitis (IC), familial adenomatous polyposis (FAP), and a select group of patients with Crohn disease (CD), total proctocolectomy with Brooke ileostomy remains a safe and effective operation in the appropriate surgical candidate with outstanding short- and long-term outcomes.

Suggested Readings

Dassopoulos T, Cohen RD, Scherl EJ, et al. Ulcerative colitis care pathway. *Gastroenterology* 2015;149:238–45.

Dozois E. Proctocolectomy and brooke ileostomy for chronic ulcerative colitis. *Clin Colon Rectal Surg* 2004; 17:65–70.

Fazio VW, Ziv Y, Church JM, et al. Ileal pouch-anal anastomoses complications and function in 1005 patients. *Ann Surg* 1995;222(2):120–7.

Kaplan GG. The global burden of IBD from 2015 to 2025. *Nat Rev Gastroenterol*

Hepatol 2015;12:720–7.

Kiran RP, Khoury W, Church JM, et al. Colorectal cancer complicating inflammatory bowel disease: similarities and differences between Crohn's and ulcerative colitis based on three decades of experience. *Ann Surg* 2010;252(2):330–5.

Messaris E, Sehgal R, Deiling S, et al. Dehydration is the most common indication for readmission after diverting ileostomy creation. *Dis Colon Rectum* 2012;55(2):175–80.

Wolff BG, Garcia-Aguilar J, Roberts PL, et al., eds. *The ASCRS Textbook of Colon and Rectal Surgeons.* New York: Springer Science+Business Media, LLC; 2007.

EDITOR'S COMMENT

Drs. Medich and Pogacnik describe the technique of intersphincteric proctectomy that has also been termed "endo-anal" proctectomy, namely the operation whereby the external anal sphincter and levator muscles are left in situ for cases of proctectomy where benign disease is present. This is an important technique in the armamentarium of the busy abdominal or colon and rectal surgeon. It differentiates itself from abdominoperineal resection (APR) for cancer, in that there is a smaller, stronger perineal wound. Unlike abdominoperineal resection for cancer, in which the perineal wound basically consists of fat sewn to fat, with intersphincteric proctectomy the wound is smaller since the external anal sphincter, puborectalis, and levator muscles are left in place and muscle is apposed to muscle in the wound.

The approach to Crohn's perianal disease differs somewhat in the United States and in England. For example, in the United Kingdom, in operating on a patient with extensive perianal Crohn disease, the approach would typically be to perform wide excision and utilize plastic surgeons for flap reconstruction, whereas in the United States, the approach has been more conservative. There are pros and cons to both approaches. With the more extensive use of immunosuppressive medications in this country, the fear that there will be more disturbances of wound healing with more extensive procedures, is in my opinion justified. However, there is the real concern that leaving chronic fistula tracts in situ might be associated with subsequent occurrence of adenocarcinoma in these longstanding fistula tracts. Although this is a real concern, it is of very low incidence.

Although the authors discuss performing this operation for patients with Crohn disease, as well as for those with familial polyposis and those with ulcerative colitis, this type of procedure can also be performed in patients who have received extensive radiation. In fact, in such patients, depending on the scenario one may want to go so far as to leave the anal canal in situ because of the significant wound-healing disturbances.

An important part of preoperative counseling, especially in patients with Crohn disease, is to advise patients that fully one third of patients will have delayed perineal wound healing. These wounds will often dehisce after the patient has been discharged from the hospital and then heal by secondary intention. This will sometimes take months, rarely even years, to completely heal. This will often challenge the patience of both the patient and the surgeon. Treatments that can help hasten wound healing are either cauterization of these wounds with silver nitrate, repeated curettage in the operating room, or if the patient is motivated, packing these wounds with 1/8th strength Dakin solution moistened 4 × 4 gauzes, changed two or three times daily is another treatment alternative. Occasionally, excision of the anal sphincter is required for wound healing to occur (Nisar PJ, Turina M, Lavery IC, Kiran RP. Perineal wound healing following ileoanal pouch excision. *J Gastrointest Surg* 2014;18(1):200–7). In some patients flap reconstruction may be necessary (Kamrava A, Mahmoud NN. Prevention and management of non-healing perineal wounds. *Clin Colon Rectal Surg* 2013;26(2):106–11).

Regarding the indications for total proctocolectomy that are listed in the chapter with respect to the presence of dysplasia, these are controversial. Many gastroenterologists and surgeons would disagree. As with many things in medicine, there has been a pendulum swing regarding the willingness to endoscopically closely follow rather than operate on patients with dysplasia. There has been increasing recognition that the risk of invasive cancer in particular with low-grade dysplasia is low (Allen PB, Kamm MA, De Cruz P, et al. Dysplastic lesions in ulcerative colitis: changing paradigms. *Inflamm Bowel Dis* 2010;16(11):1978–83; Murphy J, Kalkbrenner KA, Blas JV, et al. What is the likelihood of colorectal cancer when surgery for ulcerative-colitis-associated dysplasia is deferred? *Colorectal Dis* 2016;18(7):703–9). While there are many studies one could quote citing both sides of the equation, there are some things that most physicians taking care of these patients agree upon. Having a second pathologist review the finding of dysplasia is paramount. In addition, an adenoma-like dysplasia that is found in a region not affected by colitis, is not necessarily thought to be associated with the colitis, and can be treated like a sporadic polyp, that is, removed endoscopically.

Many raised lesions can be safely removed if the patient is willing to be appropriately and closely followed with surveillance endoscopy. This is an important caveat. If a patient is not willing to undergo very close endoscopic surveillance, this is not a good strategy and colectomy should be performed. Odze and colleagues have an impressive series of patients treated in this manner with long follow-up where endoscopic removal of dysplastic lesions with close follow-up has been shown to be an acceptable and safe strategy (Odze RD, Farraye FA, Hecht JL, et al. Long-term follow-up after polypectomy treatment for adenoma-like dysplastic lesions in ulcerative colitis. *Clin Gastroenterol Hepatol* 2004;2(7):534–41). On the other hand, there are other examples where less than a total proctocolectomy has clearly doomed the patient to development

of multiple cancers, eventually resulting in death (Galandiuk S, Rodriguez-Justo M, Jeffery R, et al. Field Cancerization in intestinal epithelium of patients with Crohn's ileocolitis. *Gastroenterology* 2012;142:855–64). Currently, the only thing that is certain is that we still do not have an ideal biomarker to delineate or assess cancer risk.

Susan Galandiuk

147 Ileoanal Pouch Procedure for Ulcerative Colitis and Familial Adenomatous Polyposis

Susan Galandiuk, Jeffrey R. Jorden, Russell W. Farmer, and Josef E. Fischer

INTRODUCTION

Total colectomy and ileal pouch-anal anastomosis (IPAA) has been the operation of choice for the elimination of disease and restoration of intestinal continuity for ulcerative colitis (UC) and familial adenomatous polyposis (FAP) for over 30 years. This operation has its beginnings in pediatric surgery, initially with straight ileoanal anastomosis. It was not until the mid-1970s when ileal "reservoirs" constructed using the terminal ileum led to adequate functional results (an acceptable number of bowel movements and satisfactory continence) and wide clinical adoption of these operations. In the mid-1970s, Sir (later Lord) Allen Parks and Dr. Joshi Utsonimia jointly described IPAA, Parks using an S-pouch and Utsonimia utilizing the much simpler and technically less demanding J-pouch. These operations were initially described with a transanal mucosectomy of the distal rectal mucosa and a hand-sewn ileo-pouch anal anastomosis. Because of its technical demands, this operation was largely only performed by specialists and high-volume surgeons. In the latter part of the 1980s and early 1990s, the technique of stapled IPAA was introduced, in which the mucosectomy was abandoned in favor of leaving a short residual rectal cuff. This had advantages and disadvantages in that it provided improved continence by preserving the transition zone and allowed a larger number of surgeons to perform the procedure, since mucosectomy was no longer needed, and the procedure therefore technically less demanding. It has, however, led to new problems associated with the retained rectal cuff, which in patients with inflammatory bowel disease was associated with residual inflammatory bowel disease with its associated risk of both disease activity and neoplastic transformation and in patients with FAP, the risk of polyp

development, and neoplastic change over time. IPAA can be performed open, laparoscopic, hand-assisted, or robotic-assisted. Major challenges for the surgeon lie in preoperative patient assessment in terms of avoiding healing complications in severely immunocompromised inflammatory bowel disease patients who may still be taking immunosuppressive medications, and deciding which patients are best treated by a standard two-stage as compared to a three-stage approach. As always major technical difficulties lie in getting the small bowel to reach to the anal canal/lower rectum, and complications associated with the temporary ileostomy that is performed in patients taking such immunosuppressive medication or in patients in whom there is excessive tension. This is particularly true in the increasingly obese patients we are encountering.

Normal Physiology Function and Principles

The major physiologic function of the colon is twofold, fluid absorption and a reservoir function in storage of fecal matter. When the colon is removed for a specific disease state, whether it be inflammatory bowel disease or FAP or hereditary nonpolyposis colon cancer, the resulting fecal matter expelled by the small bowel is more liquid due to the lesser amount of water absorbed and is of the consistency of toothpaste or pudding, because there is a loss of reservoir function, it is expelled more frequently. There have been many suggested reservoir formations with IPAA as pouches, J-pouches, H-pouches, and W-pouches, schematically shown in Figure 147.1. For all intents and purposes, the only ones that are used nowadays are the J-pouch in the vast majority of patients and occasionally the S-pouch if there is extreme difficulty in getting the reservoir to reach to the anal canal/lower rectum. Normally, an ileal pouch does not completely empty even in the best of cases. Therefore, constructing a larger pouch does not give you better function, only more fecal stasis.

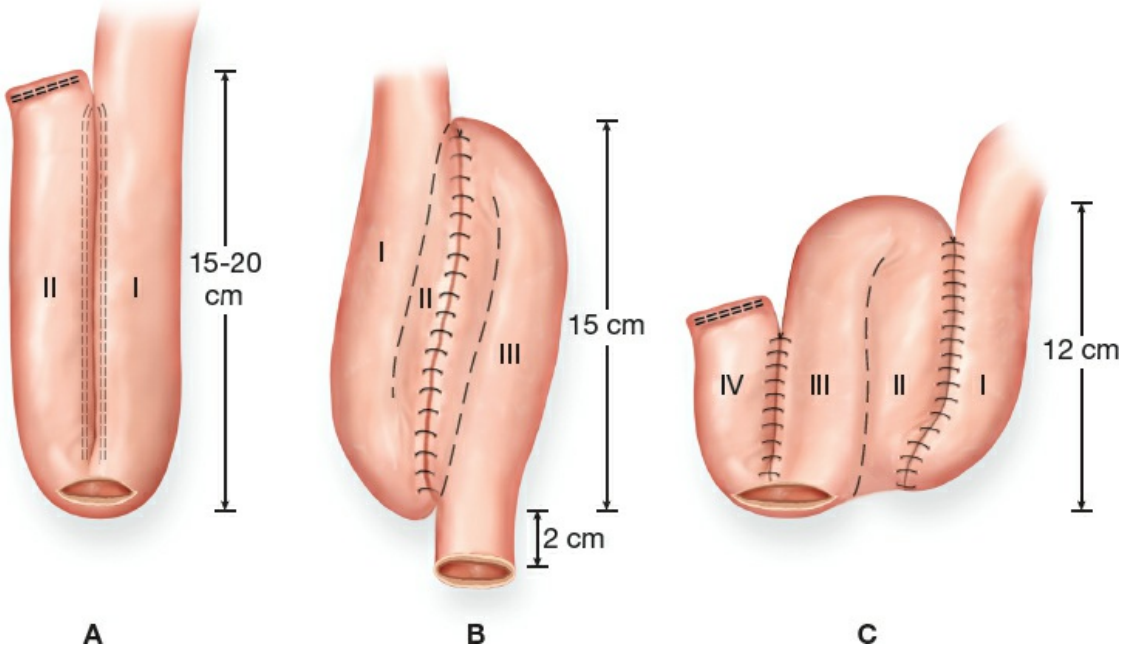

Figure 147.1. There have been many suggested reservoir formations of ileal pouches: J-pouches, H-pouches, and W-pouches, which as shown schematically. The J-pouch has proven the easiest to construct and is most frequently performed.

Also we have learned that with stapled operations preserving the anal transitional zone there is improved continence for both stool and gas, with improved continence both day and night as compared to the hand-sewn IPAA with mucosectomy. However, other factors have to be accounted for. For example, will a patient with FAP follow up? Do the polyps extend to the dentate line? Is there rectal cancer or rectal dysplasia in the lower third of the rectum? Intestinal transit is also important in selecting patients who do well with this operation. There are some patients with severe diarrhea-predominant irritable bowel syndrome who will have very poor functional results following this surgery. This is often very hard to differentiate from the overlying symptoms of inflammatory bowel disease. Similarly, patients requiring radiation therapy for rectal cancer often will have very poor functional results. Because of the rapid cell turnover of small bowel epithelium, these tissues will frequently sustain very significant radiation toxicity and subsequent poor postoperative functional outcome.

CLINICAL PRESENTATION

Indications for IPAA can be broken down into three major categories: inflammatory bowel disease, FAP and other cancer syndromes, and an

"other" category.

Inflammatory Bowel Disease

By far, the vast majority of IPAA procedures performed for inflammatory bowel disease will be performed for ulcerative colitis. However, within the last 10 years, with the improving medical therapy for Crohn disease and the increasing realization that many patients with Crohn disease can do well with IPAA, there has been an increasing willingness on the part of many surgeons to perform IPAA for cases of overt Crohn colitis without perianal or small bowel involvement *provided that the patient understands the significant associated risks* should small bowel disease subsequently develop. This includes development of perianal and pouch fistulae and abscesses, extirpation of the pouch, and permanent ileostomy. *This should not be undertaken without prolonged and in-depth preoperative patient counseling.* There are currently no absolute diagnostic tests to ensure that patients with Crohn colitis will not develop subsequent small bowel or perianal disease and also *no* absolute diagnostic tests to ensure that a patient with colitis limited to the colon is indeed ulcerative colitis and not Crohn disease. Approximately 65% of patients with Crohn disease will not exhibit granuloma on histology and therefore failure to identify granuloma on biopsy is not a sine qua non for the diagnosis of Crohn disease. Similarly, the finding of crypt abscesses is nonspecific. These can be seen in a variety of conditions, and is not diagnostic of ulcerative colitis. There have been many studies discussing the fate of patients with Crohn disease who have undergone IPAA based upon an initial presumed diagnosis of ulcerative colitis. By and large all of the results are less favorable than patients with ulcerative colitis who perform these procedures. Many patients with Crohn disease are willing to take this risk. In patients with ulcerative colitis, overall the chance of a favorable outcome is on the order of 90% to 95%.

Familial Adenomatous Polyposis

For FAP, again the vast majority of patients prefer IPAA to the other option of total colectomy and ileostomy or to the option of subtotal colectomy and ileal rectal anastomosis and every 6-month flexible sigmoidoscopy and polypectomy. In our experience, patients with FAP are notoriously poor at follow-up. In many series, the risk of rectal cancer forming during subsequently follow-up is as high as 30%. For that reason,

many surgeons prefer removing all of the at-risk mucosa (i.e., performing mucosectomy). It is my own preference to perform a hand-sewn IPAA whenever possible to eliminate the need to survey the distal mucosa if a stapled anastomosis can not be obtained very distally, which may be a problem in patients who are very obese or patients with a very long torso.

"Other" Conditions

There are a variety of other conditions in which IPAA may be indicated, such as in cases of pan-colonic inertia, colonic aganglionosis, megarectum among others (Fig. 147.2). Provided that there is normal pelvic floor function and an intact anal sphincter, good results are usually obtained. Overall, functional results are typically better in patients who have IPAA for a noninflammatory condition, as opposed to an inflammatory condition. Many people feel that this is due to a better sphincter function, without pre-existing chronic inflammation, or this may also be due to a less fatigued sphincter secondary to less problems with pre-existing diarrhea.

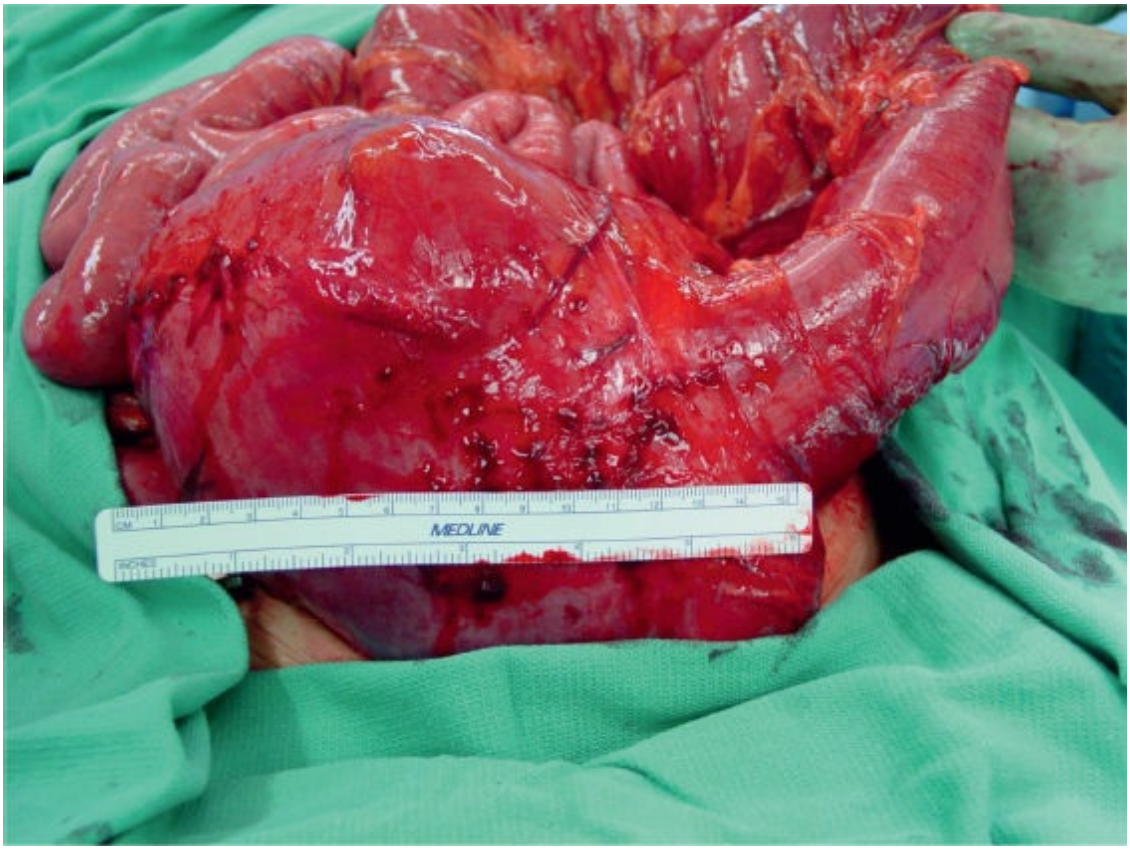

Figure 147.2. Megarectum with pan-colonic inertia, an uncommon indication for ileal pouch-anal anastomosis. The rectum *has not yet been mobilized* and extends well into the

abdomen. Rectum of the patient (*left*); sigmoid colon at right of image.

INDICATIONS AND CONTRAINDICATIONS

Fulminant Colitis

Fulminant colitis is defined as colitis requiring hospitalization, and not responding to maximal medical therapy. These patients are commonly on immunosuppressive medications such as steroids and anti-TNF antibodies or vedolizumab and as such pose a higher risk of postoperative complications. Over the last 5 years, there has been increasing recognition that many of these so-called “biologic” drugs significantly increase the risk of postoperative complications and more and more surgeons are opting for a three-stage procedures: performing a colectomy Hartmann and ileostomy first, followed by the proctectomy and J-pouch fat the next operation, and finally by loop ileostomy closure at the third and final procedure. This is as opposed to the more typical two-stage procedure where the colectomy, proctectomy, and J-pouch would be performed at the first procedure, and the ileostomy closure at the second procedure. In many cases, if the patient has fulminant colitis, one cannot easily distinguish whether or not the patient has Crohn colitis or ulcerative colitis and the disease is termed “indeterminate colitis.”

Toxic Megacolon

Toxic megacolon is defined as patients having such severe colitis that they are septic from it. The mucosa of the colon acts as a barrier to end of toxins within the lumen. If the mucosa sloughs, endotoxin can be absorbed into the blood stream and cause signs of sepsis, namely fever, tachycardia, and leukocytosis. Because of their severe diarrhea, these patients are often hypoalbuminemic. If there is an associated colonic ileus, the patient can develop a “megacolon,” which is defined as a transverse colon diameter greater than 5 cm on a plain abdominal film. In these patients, the bowel is extremely friable and stapling off of the distal colon is often complicated by a Hartmann stump “blowout” due to the extreme fragility of the bowel wall. This can be avoided in many cases by incorporating the Hartmann stump between the leaves of the fascia of the midline incision or the specimen retrieval site so that if this occurs the patient merely has a wound infection and the wound can easily be opened to treat this (Fig. 147.3A,B).

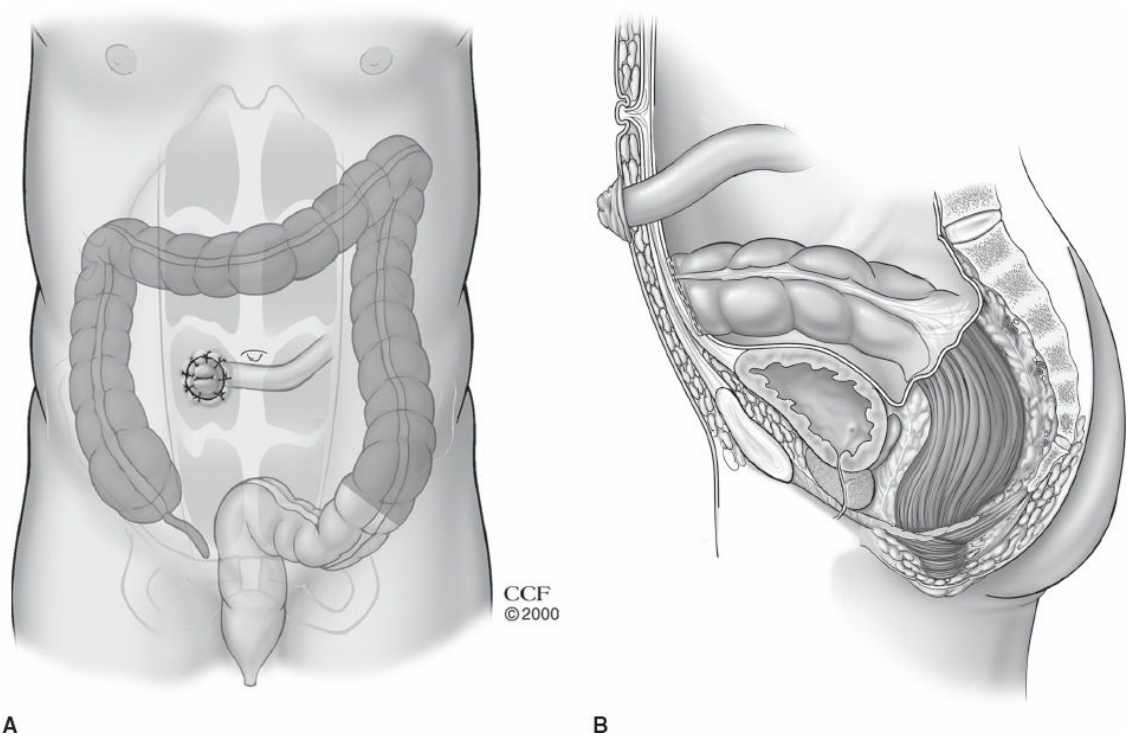

Figure 147.3. A. Subtotal colectomy with end ileostomy. **B.** The Hartmann stump is sutured between the leaves of the fascia of the midline incision or specimen retrieval site (for minimally invasive procedures) and the skin and subcutaneous tissues closed over this. In the event of a Hartmann stump "blow-out" or dehiscence, rather than developing a pelvic abscess and systemic illness, the patient merely has a wound infection that can be treated by local incision and drainage.

Primary Sclerosing Cholangitis

Ulcerative colitis patients with a primary sclerosing cholangitis typically have a higher rate of pouchitis postoperatively and worse functional results than other patients with ulcerative colitis undergoing this procedure. They should be very carefully counseled before undergoing IPAA.

Incompetent Anal Sphincter

Patients who have had prior sphincter injury, especially women with previous childbirth injury should be carefully counseled prior to undergoing IPAA. As patients age, their sphincter function tends to worsen, and many women who have had childbirth injury will have worsening problems with continence. The availability of sacral nerve root stimulation has been a significant improvement in some of these individuals. Incontinence due to sphincter injury must be differentiated

from incontinence due to tenesmus due to severe inflammatory bowel disease.

FAP Patients Requiring Whipple

FAP patients who have significant duodenal adenomatous disease need to be very carefully counseled. Patients with IPAA who subsequently require a Whipple procedure have terrible functional results.

PREOPERATIVE PLANNING

Inflammatory Bowel Disease Elective Versus Urgent

IPAA should never be performed as an emergent operation due to the unacceptable increase in complications. Preoperative planning varies as to whether surgery is elective as compared to urgent. In patients with inflammatory bowel disease, in those patients with significant disease activity, attention should be paid to minimizing rectal disease activity in order to optimize healing of the distal rectal staple line. If there is a very significant distal rectal disease, we favor the use of nightly preoperative 5-ASA suppositories. In addition, if the patients have been placed on oral steroids, maintaining the patients their steroid dose rather than trying to wean them preoperatively helps maintain the rectal mucosa in better condition. Attention should be paid to the patient's nutritional status by monitoring either serum albumin or pre-albumin. With significant weight loss, there may be merit in some attritional supplementation preoperatively either enteral or parenteral. In patients who are significantly malnourished, optimizing this will help lessen complications. If the patient is on anti–TNF-α antibody therapy (infliximab, adalimumab, certulizumab, or similar agents), we prefer to have these withheld for at least one dose prior to surgery. Although there are controversy and conflicting reports, many feel that the use of these drugs prior to surgery is associated with a significantly higher rate of infectious postoperative complications. Many surgeons, in fact, avoid doing two-stage procedures in patients on these medications for this reason.

Familial Adenomatous Polyposis

In FAP patients, there is always a question of the best time to operate in newly diagnosed patients. In adolescents, this is typically done during their summer vacation from school; however, it should not be delayed much

longer as cancers can even develop in individuals below 20 years old.

Preoperative Planning in the Setting of Rectal Cancer

In patients with inflammatory bowel disease or FAP, in whom a rectal cancer has been diagnosed and in whom the patient has expressed a strong desire for a sphincter sparing operation (i.e., IPAA), the cancer should first be staged using endorectal ultrasound or magnetic resonance imaging (MRI). If the patient has a T3 or node-positive cancer, the patient will require neoadjuvant chemotherapy and radiation. There will be far less radiation damage to the terminal ileum if radiation is given preoperatively as compared to postoperatively. In any event, patients with IPAA who have undergone prior pelvic radiation therapy generally do not have good postoperative functional results. They have a greater number of bowel movements and inferior continence as compared to patients who have not undergone radiation therapy.

SURGICAL TECHNIQUE

We will first discuss common aspects of surgical technique irrespective of mode of access. Following this, we will describe issues of surgical technique unique to open, laparosopic, and robotic approaches, respectively.

Common Techniques to Obtain Small Bowel Mesenteric Length Regardless of Method of Access

One of the difficult aspects of surgery is getting the small bowel to reach to the pelvis, specifically to the top of the anal canal. This is difficult in individuals who:

- are obese
- have a short mesentery
- have an extremely long torso
- have had a prior small bowel resection
- have small bowel mesenteric desmoid disease

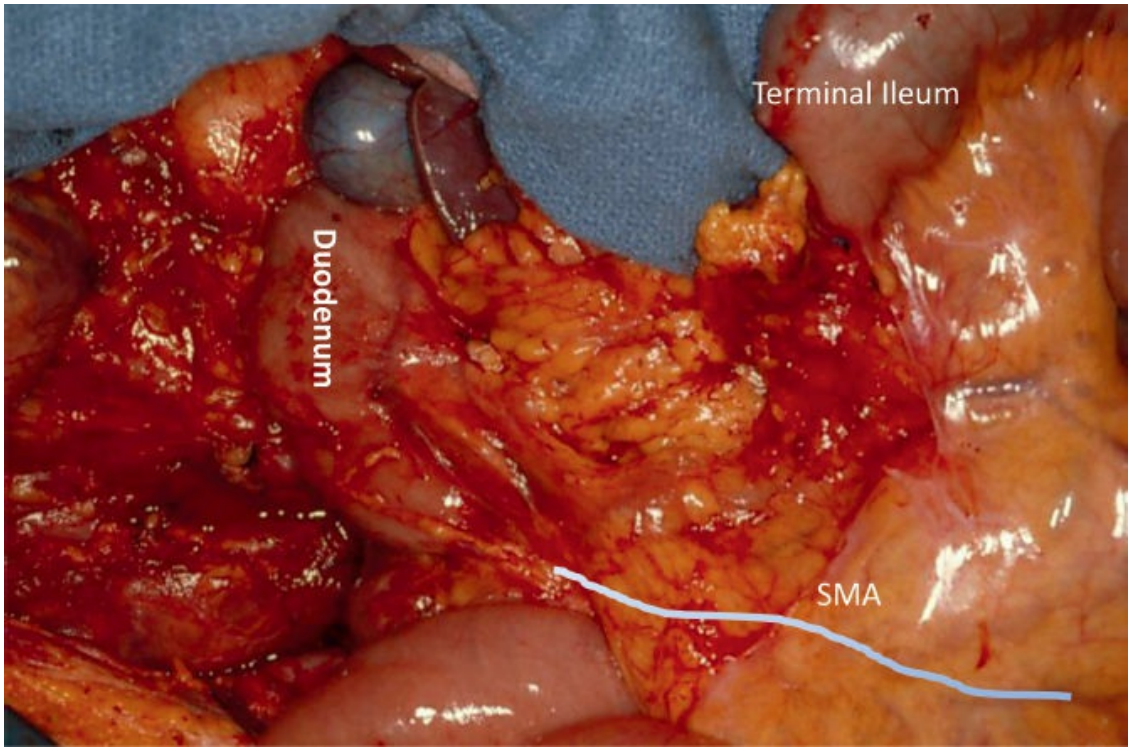

Figure 147.4. Mobilization of the small bowel mesentery away from the retroperitoneum to the level of the third portion of the duodenum and away from the third portion of the duodenum (labeled). The patient's foot is to the left of the photo and head to the right of the photo. Note the course of the superior mesenteric artery (SMA) shown by the white line, for subsequent peritoneal windowing.

The most important technique to facilitate the small bowel mesentery to reach the anal canal is complete posterior mobilization of the small bowel mesentery away from the retroperitoneum to the level of the third portion of the duodenum (Fig. 147.4). If required, scoring of the peritoneum overlying the mesentery on both the anterior and posterior aspects of the mesentery can be performed to gain additional mesenteric length (peritoneal windowing) (Fig. 147.5), division of either the ileocolic or superior mesenteric artery can be done to gain length (Fig. 147.6), or the pouch rotated so that the mesentery is anterior to the pouch. The hand-sewn technique by definition will require a greater amount of mobilization. In performing a hand-sewn anastomosis, either a LoneStar retractor, Gelpi retractors, or sutures are used to efface the anal canal and evert it in order to provide good visualization of the dentate line (Fig. 147.7). This in effect brings the anal canal externally and distally for a distance of approximately 3 cm. Even more mobilization is therefore required than

with a stapled technique where *the reverse is true*; that is, the distal rectum is actually pushed into the pelvis so *less length* is required. There have been many different methods of ileal pouch construction. For all intents and purposes, the majority of pouches that are constructed now, due to their simplicity of construction and good function, are J-pouches that are constructed using two firings of a GIA stapler, either a 75-mm stapler or 100-mm stapler. Conventionally the J-pouch is 15 cm in length, or, if operating on children, is constructed 1 cm in length for each age of the child above 5 years of age. It is important to oversew the blind stapled end of the ileum (the end of the short limb of the "J"), since this is a frequent site of leaks. There are many different ways to construct the IPAA. If it is a stapled anastomosis, this can be done using either through a purse-string or a triple-staple technique. If using a hand-sewn approach, we prefer to perform the stapling through an enterotomy in the mid-portion of the pouch, which is then closed through a standard two-layer technique and a second firing of the GIA stapler used to divide the spur of the pouch. There are occasions when a J-pouch will fail to reach the anal canal. In these circumstances, an S-pouch, which by definition needs to be hand-sewn, may be required. This should seldom be necessary. A major disadvantage of the S-pouch is the fact that it can result in obstructed defecation due to stretching and "kinking" of the efferent limb. This will sometimes require the patient to perform intubation of the pouch to permit defecation. Diversion is performed in patients in whom there is tension, or in patients who are on immunosuppressant medications in whom there would be an increased risk of nonhealing, such as steroids, immuosuppressives, or antitumor necrosis factor antibodies (such as infliximab, adalimumab, or others) or significant malnutrition or other factors that might impair healing, that is, history of radiation. In cases in which there are no adverse factors that might impair healing and no tension, this operation can safely be performed without temporary ileostomy (Fig. 147.8A). When diversion is required, it is typically performed at approximately 40 cm proximal to the ileal pouch (Fig. 147.8B).

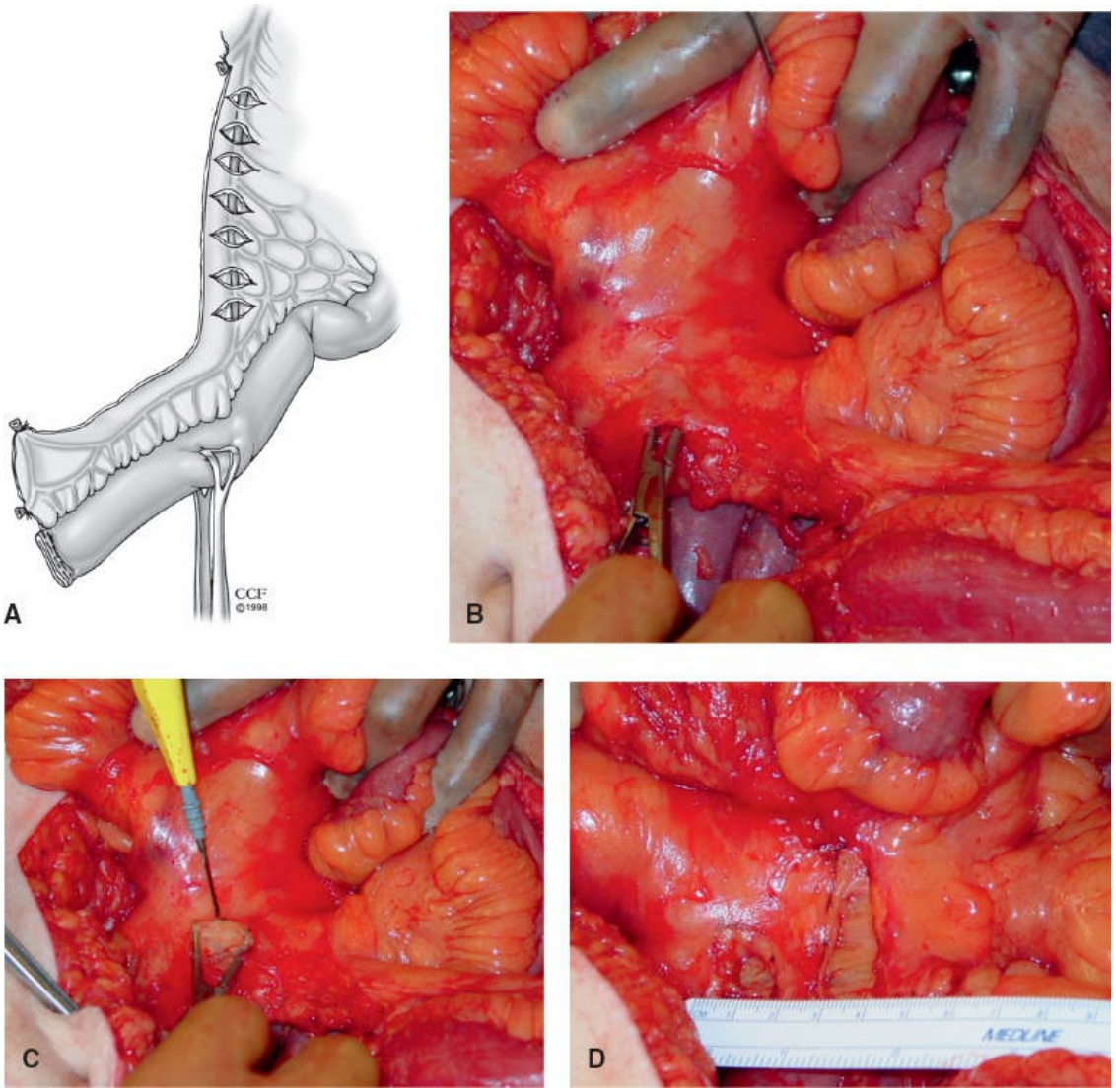

Figure 147.5. **A.** Peritoneal Windowing Schematic presentation. The peritoneum overlying the small bowel mesentery of the bowel used to construct the J-pouch is divided in a step-ladder type fashion, thus gaining several centimeters extra mesenteric length. **B.** Peritoneal Windowing. Intraoperative photo showing a hemostat lifting the peritoneum away from the underlying mesenteric vessels, (**C**) the electrocautery is used to divide the peritoneum, and (**D**) once the peritoneum has been divided, several extra centimeters of mesenteric length are obtained.

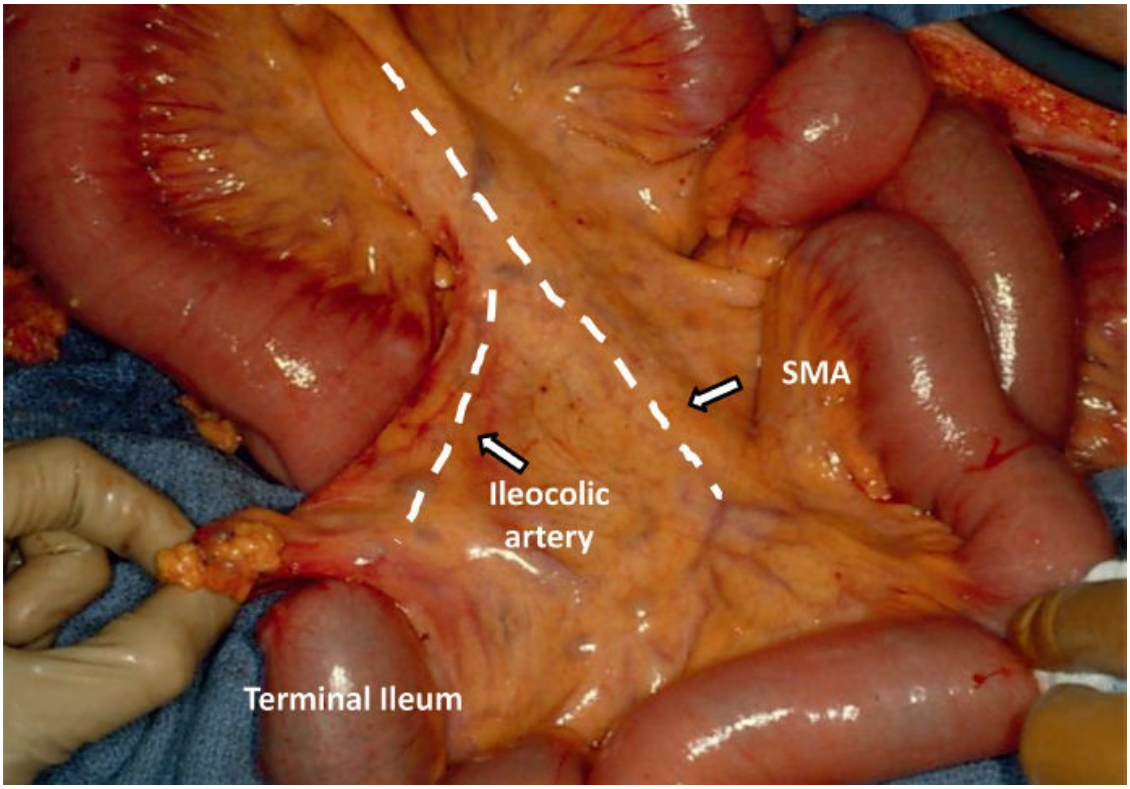

Figure 147.6. Division of either the ileocolic artery (*arrow*) or distal portion of the superior mesenteric artery (SMA) will also obtain an additional 2 to 3 cm mesenteric length.

Diversion can be difficult simply because the blood supply of the ileal J-pouch is tethered along the spine due to the tension involved in bringing the J-pouch to the anal canal. For this reason, the small bowel mesentery is not that mobile and it may be difficult to bring the mesentery to the anterior abdominal wall and through a stoma aperture. This is particularly challenging in the obese patient or the patient with a very thick abdominal wall. It is very helpful for making the closure of the ileostomy technically much less difficult, to wrap the segment of bowel to be used as an ileostomy with a sheet of hyaluronate film (Seprafilm). This greatly reduces peristomal adhesion formation and makes subsequent takedown of the ileostomy much easier. In obese individuals, or those in whom there is significant tension on the pouch, it may be necessary to place the much farther proximal than in patients with an ideal body habitus and those without tension on the IPAA.

Operations for Benign Versus Malignant Disease

IPAA can be performed for benign versus malignant disease. Different techniques need to be undertaken on the left side of the colon. Typically

the inferior mesenteric artery is usually taken high, just for ease of resection of the colon, so the dissection is typically similar. Also, in removing the rectum, total mesorectal excision is typically performed regardless of the indication. However, the major difference in operative technique lies if there is a right-sided colon cancer or possibility of this, that is, large colon polyps that could possibly harbor carcinomas. In performing the dissection on the right side of the colon, it is typical that one would leave both the ileal and colic branches of the ileal colic artery in place, ligating very close to the right colon so that if additional mesenteric length is needed (see below) either the ileocolic or superior mesenteric vessel can be divided to obtain that increased length. If a right colon cancer is suspected or present, this clearly should not be done, and these vessels, as well as a 10-cm segment of ileum, should be resected en block with the colon, and extra mesenteric length cannot be obtained by dividing the ileal colic, since this has already been removed. With respect to rectal cancer, as stated above, if preoperative radiation is required for a stage III rectal cancer, these patients typically would have very poor functional results and one should give serious thought to counseling the patient regarding the choice of operation for this reason. With respect to operations involving a distal rectal dysplasia or a distal rectal cancer, we favor performing a mucosectomy with hand-sewn approach, simply because this removes all affected distal rectal mucosal tissue. However, as stated previously, ileal pouches tolerate radiation poorly and my bias would be to advise a patient against having an IPAA in this setting. However, if this would be performed, it would be performed using a hand-sewn technique.

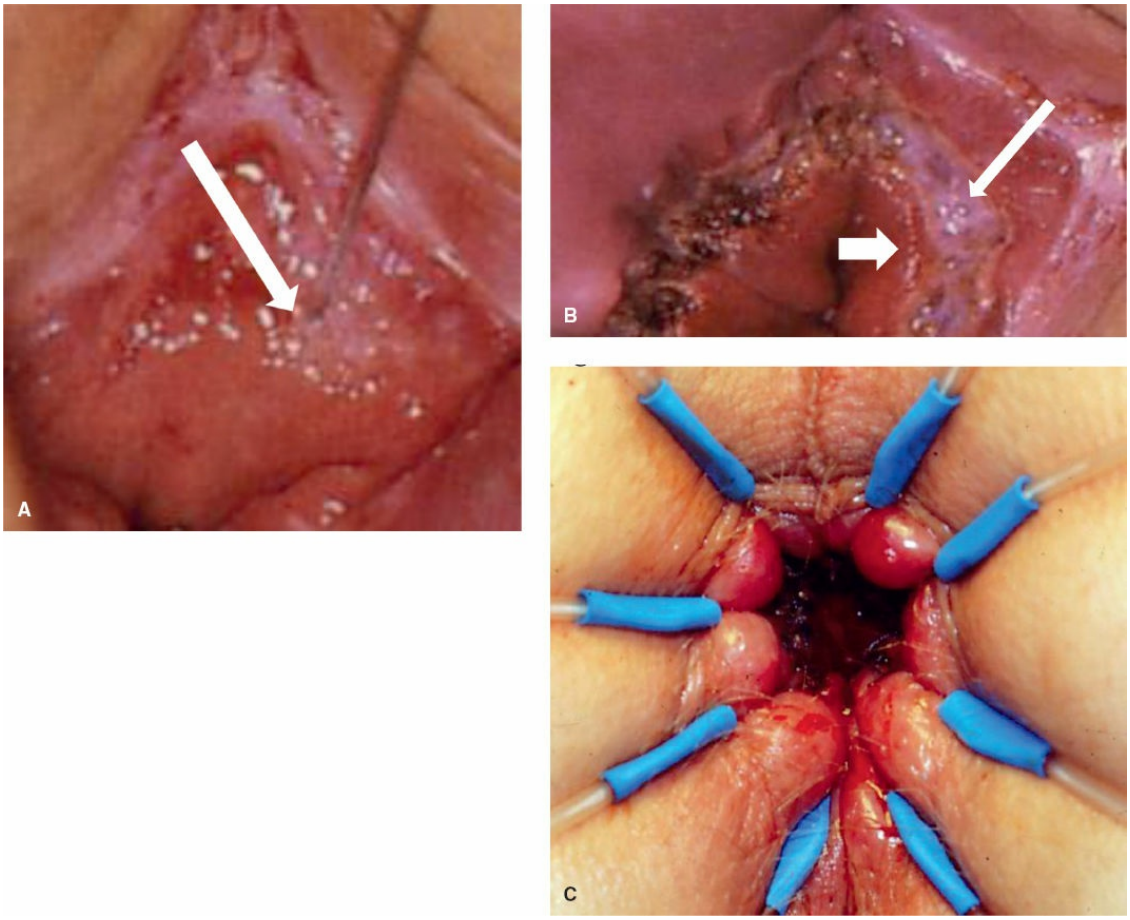

Figure 147.7. Approach with a hand-sewn ileal pouch anal anastomosis. **A.** An epinephrine containing solution such as 0.25% Marcaine with 1:200,000 epinephrine is injected submucosally beginning at the level of the dentate line (shown with *white arrow*). **B.** The electrocautery is used to score the mucosa circumferentially just proximal to the dentate line, exposing the aereolar tissue (*narrow white arrow*) underlying the mucosa (*broad white arrow*) that can then be dissected away from the underlying internal anal sphincter for a distance of 2 cm using the electrocautery. **C.** A Lonestar retractor facilitates construction of the single layer anastomosis using a single layer of 2-0 polyglactin.

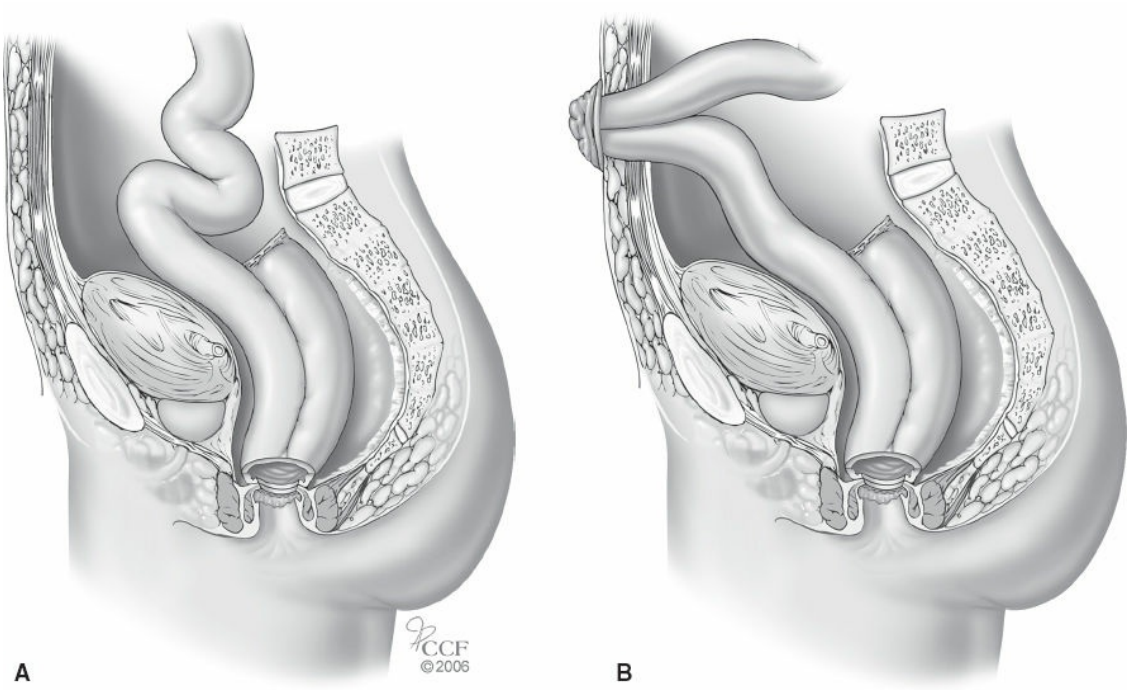

Figure 147.8. **A.** Ileal pouch anal anastomosis without diverting loop ileostomy, **B.** Ileal pouch anal anastomosis with diverting loop ileostomy, the loop ileostomy ideally is located 40 cm proximal to the ileal pouch, in individuals in whom there is tension on the pouch and in obese individuals, it may be necessary to go much further proximally.

Special Considerations for Robotic and Laparoscopic Surgery

In considering patients for minimally invasive procedures, one should consider patient body habitus, prior surgery, and body mass index (BMI). Patients who are significantly overweight may not be suited for this approach, especially the morbidly obese. This approach will also not be appropriate for patients who have had multiple prior extensive abdominal operations with significant intra-abdominal adhesions. In addition, if there is concern about the pouch reaching to the pelvis, such as with prior surgery, prior small bowel resection, or other factors, robotic access limits the number and quality of lengthening techniques that can be reasonably employed. This must not be undertaken unless the surgeon has extensive robotic experience. Total proctocolectomy and IPAA can be performed using either a laparoscopic or robotic approach. Many who perform this operation through a minimally invasive approach prefer to use a Pfannenstiel incision for open creation of the ileal pouch.

If the patient's habitus is favorable, the entirety of the colon and rectum can be eviscerated through an enlarged ostomy site incision. Through this

incision, the pouch can then be created and returned to the abdomen for creation of a stapled IPAA. Special care must be taken in this case to measure the size of the pouch using a pre-cut suture as well as determining the level of anastomotic tension. If this method of pouch creation is chosen, appropriate counseling for the possibility of a visceral hernia at the stoma site must be undertaken with the patient.

The availability of the Xi da Vinci robot has recently allowed for "single-dock" access for what has previously been a multi-dock procedure and allowed for the ability to exchange instruments and exchange the camera more easily. With this newer technology, the arms of the robot can be allowed to rotate and invert. One can combine laparoscopic and robotic approaches if necessary for expediency, with the addition of a 5-mm assistant trocar. The availability of a robotic stapler and vessel sealer has shortened the duration of the operation and improved the ability to reach to the pelvis. Figure 147.9A,B shows suggested port placements for a robotic total proctocolectomy and IPAA using the Intuitive Xi robot. The procedure is begun by initial placement of a periumbilical Optiview 5-mm trocar, which is later exchanged for the DaVinci camera port. Once robotic instruments are placed on the field, the Xi's targeting feature is not used in order to allow for maximum mobility of the arms throughout the case. The right lower quadrant 12-mm port is used for robotic stapling to include major vascular division and visceral division. This is a unique aspect of the Xi, as vascular staple loads are currently not approved for use on any other robotic platform. Until the stapler is needed, we place an 8-mm collar on the larger port to prevent loss of pneumoperitoneum with instrument manipulation. A reducer is available to decrease the inner diameter of this cannula to 8 mm, but it is bulky and requires altered motion of the right hand during dissection, and we often chose not to use it for this reason. Initial placement of the robotic arms is aimed at the pelvis to facilitate pelvic dissection and cecal dissection (Fig. 147.10A,B). The case begins with standard pelvic dissection of the inferior mesenteric artery and medial to lateral access of the sigmoid colon and rectum proceeding with a routine total mesorectal excision and low division of the rectum with the stapler, in anticipation of a stapled IPAA. Following this the cecum/appendix and right colon are mobilized in a lateral to medial fashion so as to preserve the ileocolic artery and maintain distal ileal blood supply for the eventual creation of the pouch. Once the arms are perpendicular to the patient during the dissection, the assigned hands are reversed to complete the

dissection. The change in assignment allows for inversion of the robotic arms around their remote centers, facilitating dissection in the upper abdomen. This positioning is shown in Figure 147.11A,B. The left colon, splenic, and transverse colons are divided from their blood supply using a robotic vessel sealer progressively. This is the most difficult portion of the dissection. With the colonic mobilization complete, a small Pfannensteil incision is made and the specimen extracted. Following this, the ileal pouch is constructed in an open manner through the pelvic incision and a laparoscopic-assisted stapled IPAA is constructed using a 29-mm circular stapler passed through the short remaining rectal stump. Laparoscopy is essential to ensure appropriate pouch positioning and to prevent torsion of the pouch around the terminal branches of the superior mesenteric artery.

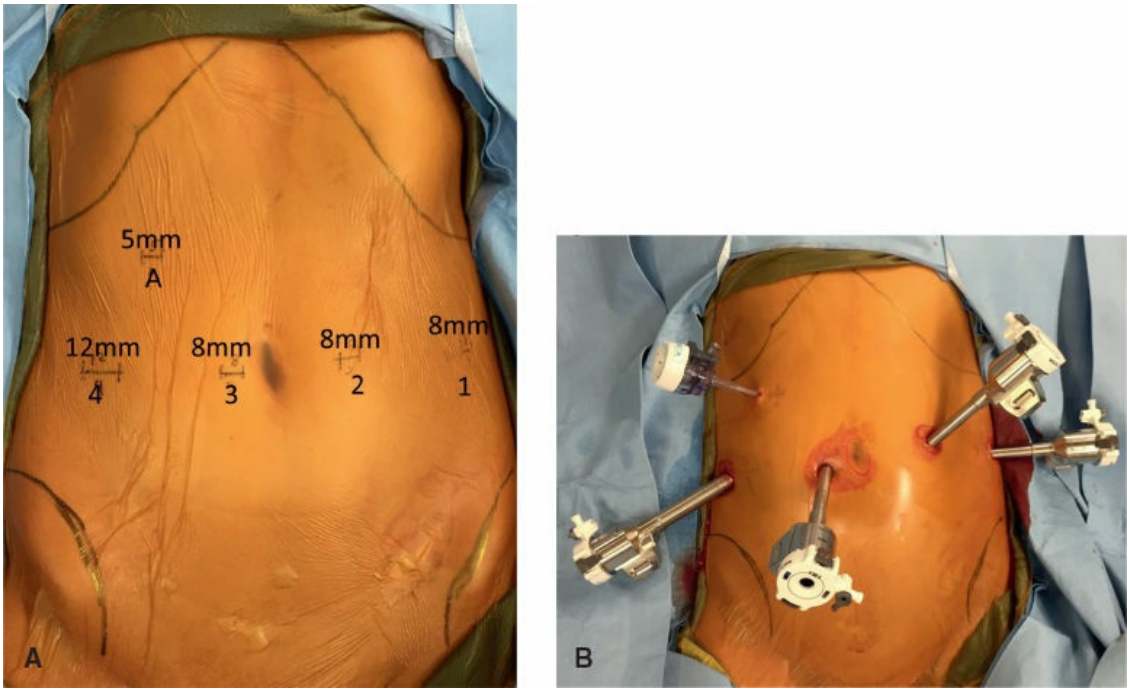

Figure 147.9. **A.** Port placement for a robotic total proctocolectomy and ileal pouch anal anastomosis using the Davinci Xi Robot. The top number indicates port size, the bottom number corresponds to the arm of the Xi patient cart; "**A**" denotes assistant port. **B.** Ports in place.



Figure 147.10. **A.** Initial assignment of robotic instruments as shown on console. **B.** Photo of initial robot instrument assignment for pelvic and cecal dissection.

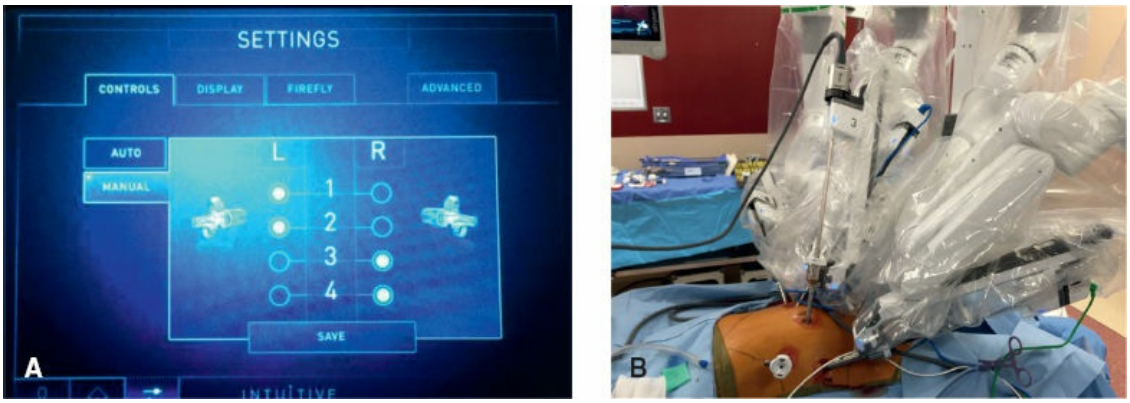

Figure 147.11. **A.** Final assignment of robotic instruments as shown on console. **B.** Photo of final robot instrument assignment for dissection in upper abdomen.

POSTOPERATIVE CARE

Because of the tension on the mesentery associated with the loop ileostomies in patients undergoing IPAA, it is often necessary for the patient to have convex stoma appliances with a belt in order to obtain good diversion (see Chapter 151). It is occasionally necessary to go farther proximal in the ileum in order to obtain enough bowel length to be able to construct an adequately protruding stoma. In some cases, these patients actually will require intravenous fluids postoperatively due to the high output. The 24-hour stoma output should not exceed 1,000 mL. If this is the case, patients should be started on either 2.5-mg diphenoxylate or 2-mg loperamide before meals and at bedtime. If the 24-hour output still exceeds 1,000 mL, this dose should then be doubled.

COMPLICATIONS AND THEIR MANAGEMENT

Postoperative complications can be divided into early and late postoperative complications. Early postoperative complications include those associated with the stoma, such as high-output ileostomy, obstruction at the level of the ileostomy, sepsis due to peri-pouch complications such as abscess and/or leak.

Late postoperative complications include IPAA stricture formation due to tension, IPAA leak, IPAA fistula, and in women, pouch-vaginal fistula. Pouch-vaginal fistula can occur as a technical complication of surgery, by erroneous inclusion of the vaginal wall into the IPAA as shown in Figure 147.12. Other late complications include the development of Crohn disease in a patient initially diagnosed with ulcerative colitis, as well as the occurrence of pouchitis. Late complications can also include the development of cancers within the pouch or in the anal transition zone. This can occur in both patients with inflammatory bowel disease and patients with FAP. This can occur in patients who have had mucosectomy, as well as in patients who have had stapled IPAA, both in retained mucosa, presumably overlooked areas of mucosa in the event of a mucosectomy, and from even within the ileal pouch itself. Continued surveillance of these patients is therefore warranted.

Pouchitis will occur in approximately 50% of ulcerative colitis patients undergoing IPAA for ulcerative colitis, but is much less common in patients with FAP. This is generally very easily treated with antibiotics such as metronidazole or ciprofloxacin. Pouchitis can, however, also manifest itself as chronic pouchitis, in which patients require chronic suppressive antibiotics to control symptoms of diarrhea. In these cases, one must ensure that there is no distal obstruction, such as a stricture, which impairs emptying of the pouch.

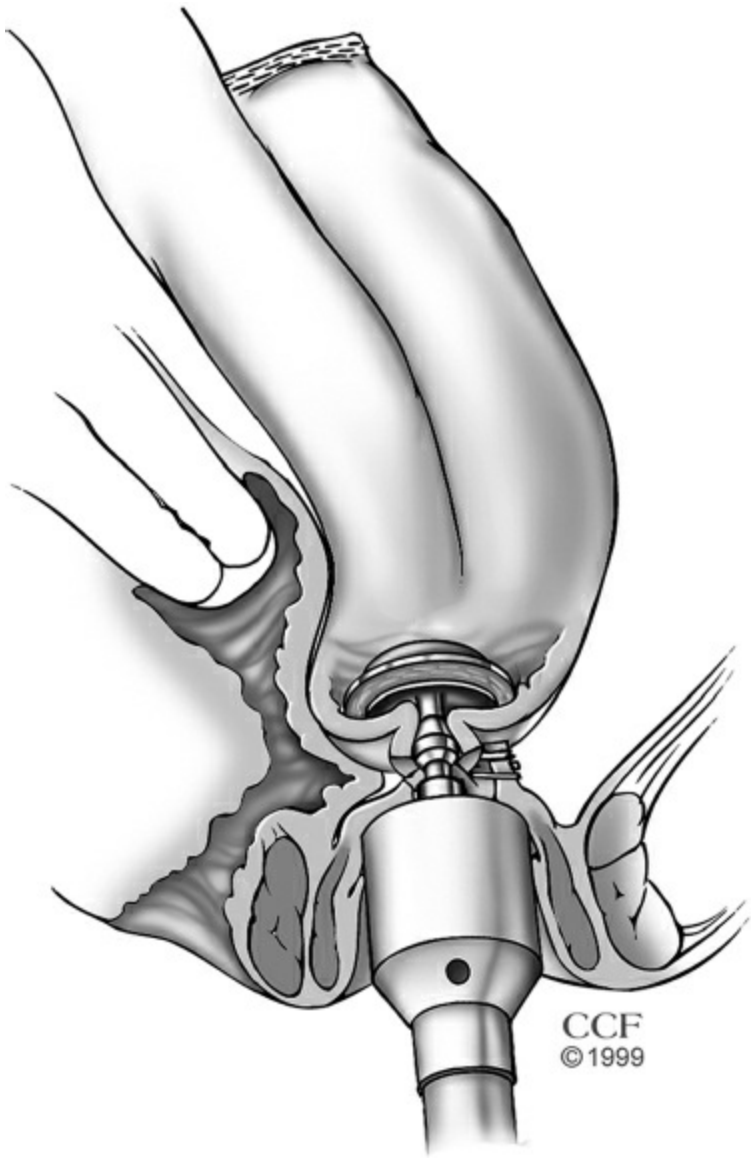

Figure 147.12. Inclusion of the posterior wall of the vagina in the stapled anastomosis will result in a pouch-vaginal fistula.

Technical complications that can predispose to pouchitis include leaving in a long rectal stump, which leads to a complication known as “cuffitis,” in which there is a significant amount of inflammatory bowel disease left behind that can become symptomatic. This can actually require a repeat abdominal approach to remove the retained rectum. This can occasionally be removed transanally with pouch advancement. One can have symptoms of a pouch that is too large that empties inadequately that might require a pouch revision. The frequency of chronic pouchitis where patients require constant suppressive antibiotic therapy to suppress symptoms of diarrhea varies among series, but can in some circumstances be so severe that patients chose to be converted to an end ilesotomy.

Another reason for “pouch failure” is the late diagnosis of Crohn disease. In most cases, this can be treated with medical therapy; however, the presence of aggressive fistulizing disease may require pouch excision and end ileostomy.

OUTCOME

Overall, when performed correctly, IPAA will provide an improved quality of life for the majority of patients with ulcerative colitis and FAP and is currently increasingly performed in patients with isolated Crohn disease after extensive preoperative counseling of these patients describing to them the risk of development of Crohn disease in the small bowel. As more effective treatments for Crohn disease become available, the number of patients who are candidates for this procedure will likely expand. No matter the type of access, key elements of this procedure include adequate mobilization, and a relatively tension-free anastomosis with attention to avoiding rotation of the bowel and avoiding constructing a pouch that is too long and keeping the retained rectum to a minimum.

Suggested Readings

Bharadwaj S, Philpott JR, Barber MD, et al. Women’s health issues after ileal pouch surgery. *Inflamm Bowel Dis* 2014;20(12):2470–82.

Fazio VW, Kiran RP, Remzi FH, et al. Ileal pouch anal anastomosis: analysis of outcome and quality of life in 3707 patients. *Ann Surg* 2013;257(4):679–85.

Klos CL, Safar B, Jamal N, et al. Obesity increases risk for pouch-related complications following restorative proctocolectomy with ileal pouch-anal anastomosis (IPAA). *J Gastrointest Surg* 2014;18(3):573–9.

Le Q, Melmed G, Dubinsky M, et al. Surgical outcome of ileal pouch-anal anastomosis when used intentionally for well-defined Crohn’s disease. *Inflamm Bowel Dis* 2013;19(1):30–6.

Mukewar S, Wu X, Lopez R, et al. Comparison of long-term outcomes of S and J pouches and continent ileostomies in ulcerative colitis patients with restorative proctocolectomy-experience in subspecialty pouch center. *J Crohns Colitis* 2014;8(10):1227–36.

O’Mahoney PR, Scherl EJ, Lee SW, et al. Adenocarcinoma of the ileal pouch mucosa: case report and literature review. *Int J Colorectal Dis* 2015;30(1):11–8.

Pavlides M, Cleland J, Rahman M, et al. Outcomes after ileal pouch anal anastomosis in patients with primary sclerosing cholangitis. *J Crohns Colitis* 2014; 8(7):662–70.

Selvaggi F, Pellino G, Canonico S, et al. Effect of preoperative biologic drugs on complications and function after restorative proctocolectomy with primary ileal pouch formation: systematic review and meta-analysis. *Inflamm Bowel Dis* 2015;21(1):79–92.

Shannon A, Eng K, Kay M, et al. Long-term follow up of ileal pouch anal anastomosis in a large cohort of pediatric and young adult patients with ulcerative colitis. *J Pediatr Surg* 2016;51(7):1181–6.

Singh S, Stroud AM, Holubar SD, et al. Treatment and prevention of pouchitis after ileal pouch-anal anastomosis for chronic ulcerative colitis. *Cochrane Database Syst Rev* 2015;(11):CD001176.

EDITOR'S COMMENT

Ileoanal-pouch anastomosis (IPAA) is the preferred method of restorative reconstruction after total colectomy and proctectomy for ulcerative colitis and familial polyposis. The concept of an ileal reservoir originated in the 1970s and has gained wide popularity and wide application. The authors outline the historical evolution of the procedure from mucosal proctectomy to stapled IPAA and review the indications and contraindications. As they point out, it is critical to have extensive counseling with the patient prior to the surgery. This should include a detailed discussion of the management of frequent bowel movements and potential complications including pouchitis, pouch fistula, and recurrence of inflammation in cases of indeterminate colitis and anastomotic stricture. In addition, women of childbearing age may need to be counseled regarding fertility. IPAA increases the risk of infertility in women with ulcerative colitis by approximately threefold. Further studies of modifiable risk factors are needed (Waljee A, Waljee J, Morris AM, et al. Threefold increased risk of infertility: a meta-analysis of infertility after ileal pouch anal anastomosis in ulcerative colitis. *Gut* 2006;55(11):1575–80).

Technical considerations include open versus laparoscopic, the role of protective ileostomy or one-stage IPAA, type of reservoir (W, J, or S), the type of anastomosis (hand-sewn vs. stapled). Despite extensive experience, there is much controversy regarding these considerations. Sofo L et al. (Restorative proctocolectomy with ileal pouch-anal anastomosis for ulcerative colitis: a narrative review. *World J Gastrointest Surg* 2016;8(8):556–63) reviewed studies published in the MEDLINE, EMBASE, and Ovid databases through March 2016. They noted that there were few large, randomized, controlled studies which limit the conclusions. They concluded that laparoscopic surgery has no clear advantages compared with open surgery, that one-stage IPAA (no ileostomy) may be acceptable in selected cases, that the long-term results regarding the pouch type show that the W- and J-reservoirs do not differ significantly, although the J pouch is generally preferred by surgeons. Hand-

sewn and stapled ileal pouch-anal anastomoses have their own advantages, and there is no clear benefit of one technique over the other. Although the authors include a section on robotic-assisted procedures, in a PubMed search performed on May 22, 2017, I could find few, if any, reports of applying robotic techniques to IPAA.

Most surgeons have transitioned to using the J Pouch rather than the S or W pouch. One of the not so infrequent problems the surgeon encounters is obtaining sufficient length of the small bowel to allow it to reach the anus. The authors point out several techniques that are illustrated in Figures 147.4 and 147.5. These techniques are critical in obtaining sufficient length.

There is controversy in performing restorative proctocolectomy and IPAA in older populations. The main concern is potential problems with sphincter control. However, most studies show little difference in outcomes. A relatively recent study by Pellino G et al. (Complications and functional outcomes of restorative proctocolectomy for ulcerative colitis in the elderly. *BMC Surg* 2013;13(Suppl 2):S9.) is instructive. They gathered data on a prospective database of patients undergoing IPAA for UC over 70 years of age from January 1990 through January 2010. Patients were compared with randomly selected younger controls in a 1:3 ratio. Patients underwent IPAA in 2 or 3 stages. Demographical data, disease characteristics, comorbidities, concomitant medications, perioperative management, intra- and postoperative complications were analyzed. Function and quality of life were assessed by clinical visit and Inflammatory Bowel Disease Questionnaire, 1 and 3 years after ileostomy takedown. They identify 27 elderly patients who underwent IPAA for ulcerative colitis and compared with them 81 younger patients. Those over 70 years had more comorbidities and higher ASA score. All patients underwent loop ileostomy closure. There were no differences between groups concerning the rate of major complications, but elderly patients had more problems due to high stoma output. They observed that the younger patients experienced significantly more episodes of small bowel obstruction. Using a validated instrument, they detected no significant differences in bowel control or health-related quality except for a higher rate of elderly patients taking antidiarrheal medication at 1 year after surgery but not at the 3-year follow-up. There was a minimal decrease in continence in the elderly group but overall satisfaction was not affected. They conclude and most would likely agree that IPAA can be safely offered to selected elderly UC patients who are highly motivated, as long as they have no preoperative disturbances of continence.

Pouch complications are relatively common, with de novo inflammation of the ileal reservoir (pouchitis) occurring in 12% to 50% of patients. Current medical therapy includes use of antibiotics, mesalamine, corticosteroids, immunomodulators, and probiotics, either alone or in combination. Up to 20% can also develop a Crohn’s disease–like inflammation of the pouch. The hallmark findings are inflammation in the afferent limb (pre-pouch ileitis), presence of proximal small bowel strictures, or perianal/abdominal fistulae

unrelated to surgery. A unique group (4% to 8%) may also develop complications such as pouch fistulas. Diverting ileostomy may be considered or pouch excision in refractory cases.

Recent data indicate that infliximab may be helpful in resolving symptoms and sparing the pouch. Kelly OB et al. (Infliximab to treat refractory inflammation after pelvic pouch surgery for ulcerative colitis. *J Crohns Colitis* 2016;10(4):410–7.) collected and reviewed data from individuals who underwent colectomy and IPAA between 2000 and 2014 for ulcerative colitis. Patients with chronic refractory pouchitis (CP) and Crohn disease (CD)–like outcomes treated with infliximab were included. They reported 152 patients with chronic pouchitis or the CD-like pouchitis. Forty-two were treated with infliximab (33% male; age 32.6 ± 2.6 years, 28.5% CD-like). The initial response rate was 74% (48% complete) with a sustained response in 62.6%, and a complete response in this group was observed in 29.6%. They concluded that infliximab can effectively treat inflammatory pouch complications.

There is continued debate about IPAA versus ileorectal anastomosis in the treatment of familial adenomatous polyposis (FAP). The incidence of FAP is 1 in 7,000 to 12,000 live births. Surgically untreated patients with FAP inevitably develop colorectal cancer because they carry the APC gene. Thus, prophylactic total proctocolectomy is warranted. Although IPAA was the focus of this chapter, there are four surgical options: ileorectal anastomosis, restorative proctocolectomy with IPAA, proctocolectomy with ileostomy, and proctocolectomy with continent ileostomy. Some prefer ileorectal anastomosis because of better functional results and quality of life than with IPAA; however, the risk for rectal cancer is increased by 30%. Inadvertent small mucosal residual islands that carry cancer potential remain even after IPAA. How common is cancer recurrence after IPAA? Smith JC et al. (Adenocarcinomas after prophylactic surgery for familial adenomatous polyposis. *J Cancer Ther* 2013;4(1):260–70) reviewed the literature (1975–2012) and identified 24 studies reporting 92 pouch-related cancers; 15 case reports, 4 prospective and 5 retrospective studies. Twenty three of 92 cancers (25%) developed in the pouch mucosa and 69 (75%) in anal transit zone. The data suggest lifetime surveillance of these patients.

In summary, IPAA has become the standard technique for restorative proctectomy for surgical treatment of ulcerative colitis and FAP. The authors combine an excellent hands-on experience with practical tips to provide the reader with an excellent overview of the procedure.

E. Christopher Ellison

148 Total Colectomy and Ileorectal Anastomosis

David J. Maron and Steven Wexner

INTRODUCTION

Total colectomy (also referred to as *subtotal colectomy* or *total abdominal colectomy*) is the removal of the entire colon with preservation of the rectum. Intestinal continuity is restored by ileorectal anastomosis, also known as *ileoproctostomy*.

The role of total colectomy and ileorectal anastomosis in the treatment of colonic pathology is being redefined as the understanding of these different surgical pathologies is becoming more elucidated. Total colectomy has been replaced by total proctocolectomy with ileoanal J-pouch reconstruction as the surgical approach for treatment of ulcerative colitis. Patients with Crohn's disease will sometimes require a total colectomy and patients with the attenuated form of familial adenomatous polyposis (FAP) syndrome are also candidates for a total colectomy as the rectum may not be involved by the polyposis. Other patients with neoplastic disease such as hereditary nonpolyposis coli carcinoma syndromes or even sporadic colon cancers may benefit from total colectomy and surveillance of the remaining rectum.

Total colectomy can be performed using a laparotomy; however, advances in minimally invasive surgery have made laparoscopic resection an appealing alternative to open resection. The surgeon may elect not to perform an ileorectal anastomosis at the time of total colectomy based on the patient's overall health and/or clinical condition. Patients who have fulminant colitis with severe anemia, leucopenia or leukocytosis, malnutrition, and severe concomitant systemic diseases are better approached by a multistage procedure. In this situation, the rectal stump is closed and an end ileostomy is created. Alternatively, the proximal aspect of the distal stump may be exteriorized as a mucous fistula, particularly if the rectum is involved by severe inflammation or infection such as in *Clostridium difficile* colitis. Regardless of the choice of either open mucus

fistula or closed Hartmann's stump, the presacral space should be left undisturbed. Violation of the presacral space at the initial operation may lead to presacral hemorrhage and injury to the sympathetic and parasympathetic nerves during subsequent reoperation.

INDICATIONS FOR TOTAL COLECTOMY WITH ILEORECTAL ANASTOMOSIS

Inflammatory Bowel Disease

The surgical treatment of patients with ulcerative colitis is best accomplished by a restorative total proctocolectomy with ileal J-pouch. This procedure has the advantage of removing all or nearly all of the diseased mucosa by removing the entire colon and rectum. A small subset of patients with ulcerative colitis may present with "rectal sparing"; however, this finding is more likely due to enema therapy or a misdiagnosis of Crohn's disease. For those patients with ulcerative colitis who develop toxic colitis or disease that is unresponsive to medical therapy, a total colectomy with creation of an end ileostomy is the preferred operation as it removes the diseased colon but avoids pelvic dissection.

In the past, total colectomy with ileorectal anastomosis was favored by some surgeons for the treatment of ulcerative colitis. Injury to the hypogastric nerves or nervi eregenti during rectal dissection that can lead to postoperative sexual dysfunction, as well as pelvic adhesions that can lead to infertility in females, led some surgeons to recommend this procedure in younger patients. Although this operation has been abandoned, however in select patients, proctectomy may be delayed while the remaining rectum is regularly surveyed with endoscopy and the patient continues to receive both local and potentially systemic medical therapy for ulcerative colitis.

Total colectomy with ileorectal anastomosis may be a good option in patients with Crohn's colitis if the rectum is relatively spared and the patient has satisfactory sphincter function. Indications for surgery in patients with Crohn's colitis include worsening of symptoms despite aggressive medical treatment, development of colonic strictures or fistulae, or the development of colorectal neoplasia. Determining whether a patient should undergo anastomosis at the time of colectomy is dependent on a number of factors. Patients' conditions may vary along the spectrum of

nutritionally replete to profoundly malnourished and markedly immune suppressed. The medical treatment of Crohn's disease with steroids and immune-modulatory drugs exacerbates immune dysfunction and is detrimental to wound and anastomotic healing. In addition, the disease may involve the rectum and anus, which may severely compromise both rectal and anal sphincter function and thus continence. It is therefore necessary to carefully assess for the presence of anorectal Crohn's disease during the history and physical examination. Inspection for ulcers and stenosis is mandatory as the presence of one or more of these entities may preclude anastomosis.

Patients with a history of abscess or fistula should be carefully examined, and the extent and complexity of any fistulous tracts should be documented. Any abscess or fistula should be treated prior to consideration of an ileorectal anastomosis. It may be necessary for the patient to initially undergo a total colectomy with end ileostomy to allow for resolution of anorectal sepsis or fistula. If a patient had undergone a prior fistulotomy causing damage to the anal sphincters, an ileorectal anastomosis may be contraindicated as a patient with poor continence may not be capable of controlling the resultant diarrhea following the procedure. This assessment includes quantification using a validated incontinence score such as the Cleveland Clinic Florida Fecal Incontinence Score (CCF-FIS), as well as anal ultrasonography or pelvic magnetic resonance imaging (MRI).

Anorectal manometric studies can also be helpful in objectively quantifying anal sphincter function and rectal compliance. Examination of the rectum with flexible sigmoidoscopy is also important in assessing the extent of involvement of the rectum by inflammation or scarring. Distensibility can be judged by insufflation of air through the sigmoidoscope as well as during anal manometry. If the rectum is found to be nondistensible due to severe involvement by Crohn's disease, it is best to perform either a total proctocolectomy with end ileostomy or a total colectomy with Hartmann's closure of the rectum.

Many patients with Crohn's disease without anorectal disease or sphincter damage may be well adjusted and tolerant of diarrheal bowel movements. These individuals may prefer to live with mild to moderate diarrhea following an ileorectal anastomosis rather than having an ileostomy. Unfortunately, the risk of subsequent proctectomy and end ileostomy due to progression of Crohn's disease and/or rectal dysfunction

may be as high as 60% to 70%.

Neoplasia

Total colectomy with ileorectal anastomosis may be indicated in patients with specific genetic syndromes that carry a high risk for the development of colon cancer. These neoplastic conditions include FAP, hereditary nonpolyposis colorectal cancer (HNPCC) syndrome, and genetic mutations that lead to sporadic colon cancer. In addition, synchronous or metachronous colon cancers represent high-risk patients who may be managed by a total or completion colectomy with ileorectal anastomosis.

FAP syndrome accounts for <1% of cases of colorectal cancers in the United States. The syndrome is characterized by the presence of hundreds to thousands of colonic and rectal polyps that, if left untreated, will eventually become cancerous. A germline mutation in the adenomatous polyposis coli (APC) gene, located on the long arm of chromosome 5, is responsible for the FAP phenotype, and is inherited in an autosomal dominant pattern with 100% penetrance.

Patients with the APC mutation are often asymptomatic, although some younger patients may present with nonspecific complaints of abdominal pain, diarrhea, or rectal bleeding. Identification of these patients at a young age is very important as phenotypic expression in the form of colorectal polyps typically begins in early adolescence, followed by inevitable progression to cancer by the age of 40. In families suspected of having FAP, surveillance consisting of flexible sigmoidoscopy and genetic testing should begin early in the teenage years. Once polyps are identified, patients should undergo colectomy to reduce the risk of cancer. The majority of patients with FAP will have rectal involvement by polyps and are best treated with a restorative proctocolectomy.

In a small subset of patients with FAP, the rectum may not be involved by polyposis or it may contain only a few polyps. These patients may have attenuated FAP or MUTYH-associated polyposis (MAP), both of which are variants of FAP. Patients with attenuated FAP suffer from APC gene mutation in regions different from the classic FAP syndrome. They typically have fewer than 50 colonic polyps, which tend to develop more proximally in the colon. The age of the onset of polyposis and colorectal cancer in patients with attenuated FAP is later than in classic FAP, averaging in the mid-30s and 50s, respectively. Approximately 10% to 20% of patients with FAP do not have the APC mutation but rather have

MAP, which is an autosomal recessive condition characterized by mutations in the DNA repair gene known as MUTYH. These patients are difficult to distinguish from classic FAP patients but tend to have fewer than 100 polyps and rectal involvement also tends to be minimal. Patients with attenuated FAP or MUTYH-associated polyposis may be good candidates for total colectomy with ileorectal anastomosis.

HNPCC is the most common genetically inherited colorectal cancer disorder, accounting for 2% to 5% of newly diagnosed colorectal cancers. The onset of cancer in patients with HNPCC is usually earlier than in the general population with these patients presenting in their mid-40s as opposed to 60 to 65 years in patients with sporadic cancer. These tumors tend to be located more proximally in the colon, and patients are at increased risk of development of other tumors, including endometrial carcinoma, ovarian carcinoma, and transitional cell carcinoma of the urinary tract.

Prior to identification of the genetic basis of this syndrome, many criteria were used to identify these patients and their family members. The modified Amsterdam criteria are currently used to identify patients with HNPCC by evaluating their family history, which includes: (a) three or more relatives with histologically proven colorectal carcinoma, one of whom is a first-degree relative of the other two; (b) colorectal carcinoma involving at least two generations; and (c) one or more cases of colorectal carcinoma diagnosed before the age of 50 years. Mutations in DNA-mismatch repair genes such as the most commonly affected MLH1, MSH2, and MSH6 are responsible for predisposition to cancer development over a patient's lifetime. These mutations are inherited in an autosomal dominant pattern and lead to approximately an 80% disposition to developing colorectal cancer. Failure of DNA repair during replication, due to defective mismatch repair proteins, leads to development of microsatellite instability (MSI) in the DNA of colorectal cancer. This characteristic finding is often used as a marker for HNPCC as 90% of both cancerous lesions and polyps contain MSI. The revised Bethesda criteria incorporate the findings of MSI in pathologic specimens and are another set of criteria that may be used to identify these patients: (a) colorectal carcinoma identified in a patient <50 years of age, (b) synchronous or metachronous colorectal cancer or other HNPCC-associated cancer, (c) colorectal cancer with finding of MSI in pathologic specimens in patients <60 years, (d) colorectal cancer or other HNPCC cancer in a first-degree

relative with one of these cancers in a family member <50 years old, and (e) colorectal cancer in two or more first- or second-degree relatives along with HNPCC-associated tumors regardless of age.

Patients with known HNPCC or those having a family history of HNPCC should undergo regular endoscopic surveillance with colonoscopy every 1 to 3 years starting at the age of 20 to 25 years or 5 to 10 years earlier than the age of the youngest relative diagnosed with colon cancer. The frequency of screening should increase to every 1 to 2 years after the age of 40. In female patients, screening of the endometrium and ovaries should also be done starting at age 30 to 35 and includes examinations, transvaginal ultrasound, and endometrial biopsy every 1 to 2 years.

The role of prophylactic colectomy in patients with HNPCC is debatable as it may be unnecessary in 15% to 20% of patients who would not develop colon cancer due to the incomplete penetrance of this disease. Patients who refuse yearly colonoscopies or are poorly compliant may be good candidates for a prophylactic total colectomy with ileorectal anastomosis. For patients who have already had a colon cancer associated with HNPCC, total colectomy with ileorectal anastomosis is the ideal procedure to eliminate their risk of subsequently developing a metachronous cancer in the remaining colon. These patients must undergo yearly flexible sigmoidoscopies for surveillance of the rectum, as 6% to 20% will eventually develop a cancer in the remaining rectum. Women who have a strong family history of endometrial cancer in association with HNPCC may also be candidates for prophylactic hysterectomy and salpingoophorectomy.

Total colectomy with ileorectal anastomosis may also be indicated in patients with colon cancer in several specific scenarios. Obstructing cancers of the sigmoid or left colon may result in marked dilation of the proximal colon, making primary resection and anastomosis using the dilated colon unsuitable. Alternatives include a staged approach with Hartmann’s colostomy or the use of on-table washout with primary colonic or colorectal anastomosis. Nonobstructing cancers of the distal transverse or proximal descending colon can also be treated by total colectomy with ileorectal or ileosigmoid anastomosis. This procedure avoids anatomically awkward attempts to restore the continuity of the hepatic flexure to the sigmoid colon or rectum and avoids the possibility of an anastomosis in a vascular watershed region of the colon.

Lower Gastrointestinal Hemorrhage

Severe bleeding from the colon can develop from conditions such as hemorrhagic diverticulosis or an arteriovenous malformation. Oftentimes, the hemorrhage spontaneously stops, possibly due to the resultant hypotension. In patients with ongoing lower gastrointestinal bleeding, aggressive diagnostic evaluation including colonoscopy, radionuclide scanning, and angiography can often localize the bleeding. Choice of localization modality is dependent upon many factors, including patient stability, rate of bleeding, and available institutional expertise. Clinical resuscitation and nonoperative treatment with selective embolization or selective vasopressin infusion of the distal colonic vessels often control the hemorrhage. Colonoscopic investigation in the acute phase may be both diagnostic in terms of localization of the source and therapeutic in terms of its treatment. Therapeutic options include monopolar diathermy, bipolar electrocautery, laser coagulation, vasoconstrictor and/or sclerosant injection, and direct hemoclip placement. Patients rarely present with hemorrhage from two possible sources (typically, angiodysplasias in the right colon and severe diverticulosis in the left colon). These patients may be candidates for total colectomy with ileorectal anastomosis to eliminate both potential sources of bleeding.

Chronic Constipation and Colonic Inertia

A few carefully selected patients with severe chronic constipation that is refractory to medical management may be candidates for total colectomy with ileorectal anastomosis. These conditions are referred to as intestinal motility disorders. When the motility disorder resides within the colon, it is termed colonic inertia. In the majority of cases, the cause for inertia is unknown; however, disorders in motility may be related to specialized neural ganglion in the intestine such as Meissner, Auerbach plexus, or the cells of Cajal.

Patient selection for surgical treatment of functional disorders is critical, and physiologic investigation to distinguish isolated colonic inertia from panenteric dysmotility is very important. Colonic motility is assessed with the use of radiopaque markers; gastric emptying is evaluated with scintigraphy, and small-bowel motility is most easily and inexpensively examined by a lactulose breath hydrogen transit study. While patients with colonic inertia may potentially benefit from a colectomy, patients with panenteric dysmotility typically do not. In addition, pelvic floor

dysfunction in these patients must be excluded as colectomy will not alleviate their symptoms. Anorectal functional assessment including cinedefecography, anal electromyography, and anal manometry can be used to evaluate rectal function and to exclude pelvic outlet dysfunctions such as nonrelaxing puborectalis syndrome.

SURGICAL TECHNIQUE

Open Resection

Although total colectomy can be accomplished with the patient in the supine position, the authors prefer to place the patient in the modified lithotomy position. This position gives the surgeon the advantage of access to the anus for intraoperative colonoscopy or sigmoidoscopy, creating a stapled anastomosis, and for inspection of the anastomosis for integrity. Proper positioning should include placement of intermittent compression stocking or other means for deep venous thrombosis prevention; compression stockings may also assist in preventing sural nerve damage. With the patient in heel and calf stirrups, the rectum can be examined, and if desired, irrigation of the rectum can be performed prior to skin preparation and draping.

The position of the surgical team depend on the experience and the anticipated role of the assistants. If the first assistant is capable of dissection under guidance, it is advantageous for the surgeon to stand on the patient's left side. The surgeon thus has control of retraction and exposure of the right and transverse colon. The following description of technique assumes this arrangement. When the left colon is dissected, the assistant retracts with one hand and dissects with the other while the surgeon laterally displays the tissues to be incised. In a teaching setting, there is sometimes a shifting of positions around the operating table.

A midline incision is standard for gaining access to the peritoneal cavity to perform a colectomy. This approach is preferred for patients with chronic inflammatory bowel disease, which often leads to a shortened colon and mesorectum. A transverse incision below the umbilicus and Pfannenstiel incision are possible approaches for patients with a low body mass index (BMI). Some surgeons prefer a transverse incision with the thought that it is less painful and may decrease the incidence of incisional hernias; however, low incisions may not always facilitate mobilization of the splenic flexure and may interfere with stoma creation.

After inspection of the abdomen, mobilization of the colon begins on

the right side. The surgeon retracts the colon medially being careful to protect the bowel from injury and an incision is made in the peritoneal reflection lateral to the cecum. The peritoneal incision is made close to the cecum to expose the retroperitoneal avascular plane and facilitate dissection of the right colon from its posterior attachments. Electrocautery is usually used to accomplish this incision and minimize bleeding from small peritoneal vessels, but energy-free sharp dissection can also be used. Once the lateral peritoneal reflection is opened, the surgeon inserts the left index finger into the defect, retracting the cecum and right colon more medially as the lateral peritoneum is incised further cephalad (Fig. 148.1). The peritoneal incision should be made close to the colon so as not to unnecessarily expose Gerota's fascia by overly lateral dissection. The gonadal vessels and the right ureter will be exposed in the retroperitoneum; as the dissection proceeds immediately adjacent to the mesocolon, the ureter should remain untouched in the retroperitoneum.

As the dissection is continued cephalad toward the hepatic flexure, the anterior surface of the duodenum is encountered (Fig. 148.2). The mesocolon is separated from the duodenum by division of the filmy tissue attachments, which may contain small vessels. Full mobilization up to the pancreas is unnecessary in most cases; however, in cases where the resection is being performed for cancer, it is necessary to mobilize fully and ligate the mesenteric vessels close to their origins from the superior mesenteric artery. At this point, the hepatic flexure requires separation from its lateral attachments, which contain vessels of varying sizes, some of which are large enough to require ligature. One must be careful during the medial retraction of the hepatic flexure to avoid tearing of the middle colic vein near the superior mesenteric vein. A venous injury in this region is often difficult to control and must be immediately addressed to avoid the rapid and significant blood loss that results from such tears.

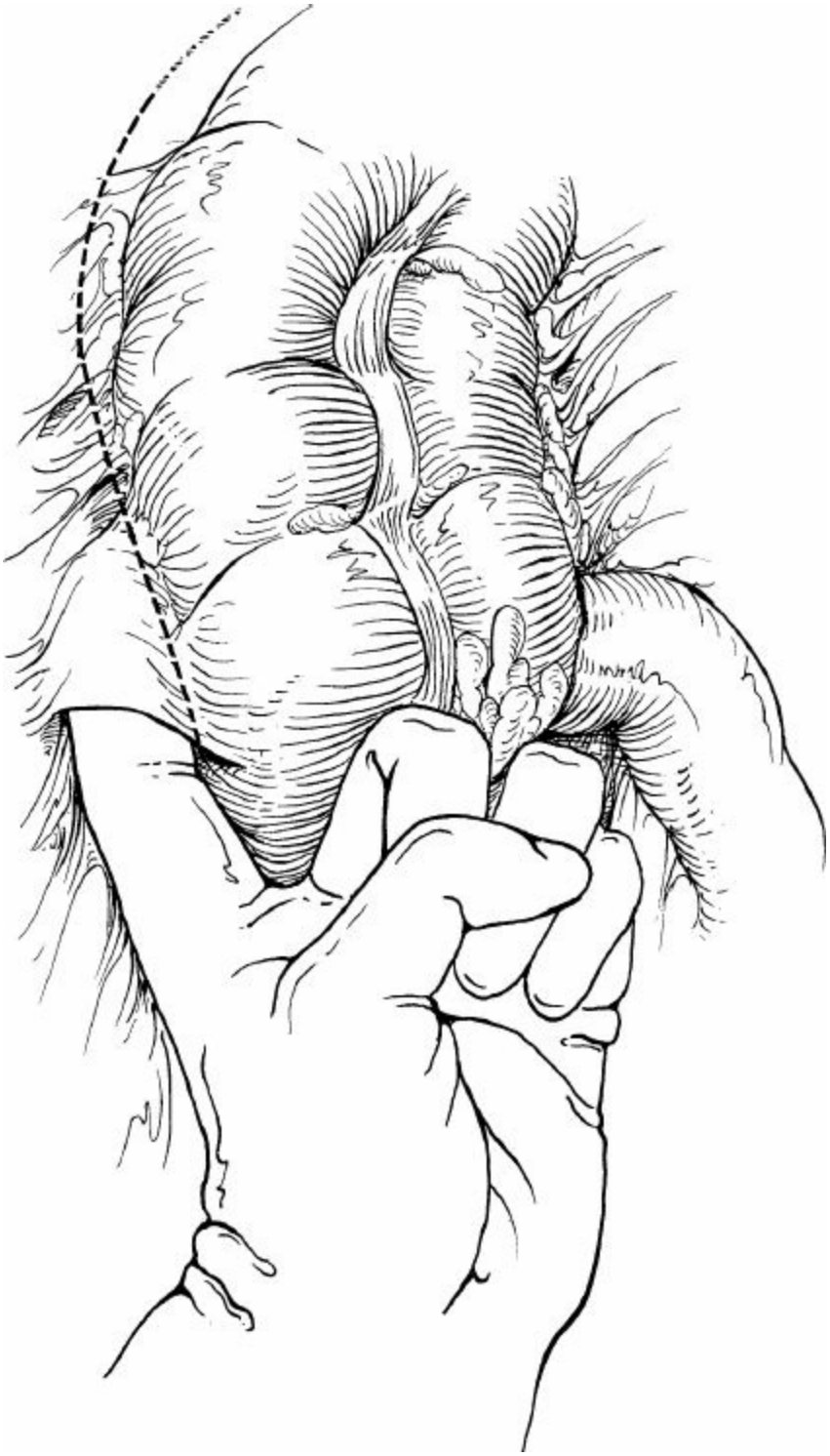

Figure 148.1. Finger beneath peritoneum adjacent to the right colon.

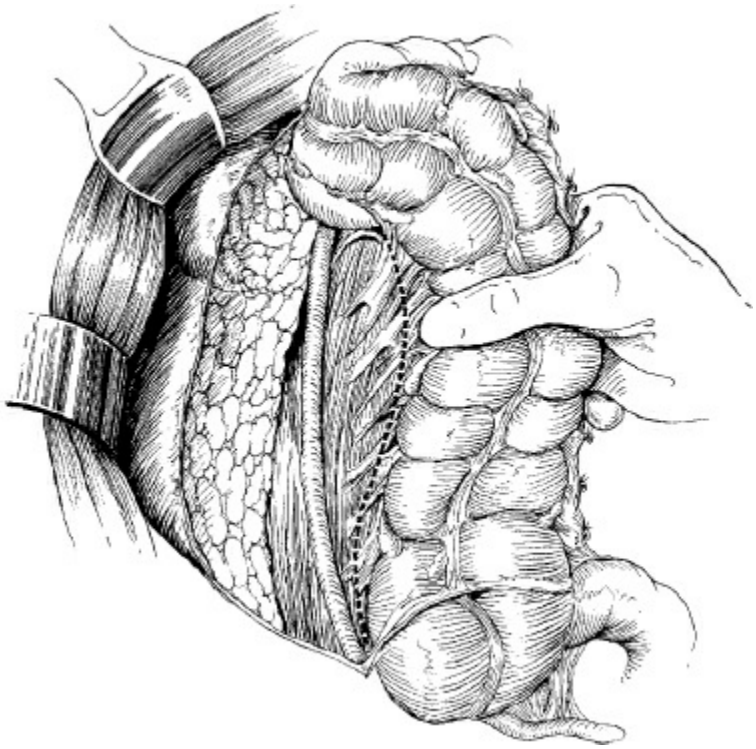

Figure 148.2. Duodenum and ureter exposed behind the right colon.

The decision whether to preserve or remove the greater omentum depends on the preference of the surgeon and the ease of preservation. If it is to be preserved, the omentum is detached from the transverse colon along its entire length to gain access to the lesser peritoneum. If the omentum is to be removed, the gastrocolic ligament is serially divided and ligated distal to the gastroepiploic vessels. Although the omentum may be a valuable “ally” after most abdominal operations, it can also become a “foe” as the source of adhesions and can adhere to both small bowel loops and the abdominal wall. In addition, if the omentum becomes fenestrated, strands may become a source of obstruction.

It is often advantageous to enter the lesser sac to the left of the midline before the hepatic flexure is taken down completely. Once in the lesser sac, adhesions of stomach to the transverse mesocolon are lysed, the gastrocolic ligament is serially divided and ligated distal to the gastroepiploic vessels (Fig. 148.3), and the hepatic flexure is approached from the left.

The mesocolon is left intact until it is fully separated from the gastrocolic, duodenal, and pancreatic attachments. The ileum is divided from the cecum using a linear cutting stapler. The mesentery is then divided by ligating the ileocolic, right colic (if present), and middle colic

vessels at the appropriate level depending on the nature of the underlying disease for which the resection is being done (Fig. 148.4). The ileocolic branches are preserved by ligating the mesentery close to the bowel wall in nonmalignant cases to preserve the vasculature for a possible subsequent ileoanal pouch or to avoid potential injury to structures close to main vessels. If pouch construction is deferred to a later time, preservation of the ileocolic artery and its peripheral branches may protect the essential arcades needed for mesenteric lengthening maneuvers future reservoir construction.

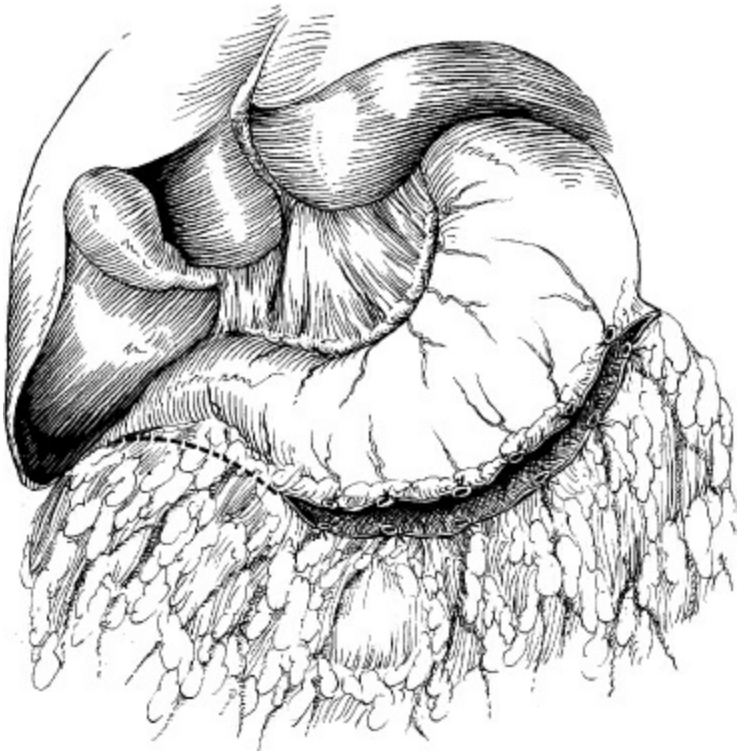

Figure 148.3. Dividing and ligating the gastrocolic ligament between the stomach and transverse colon.

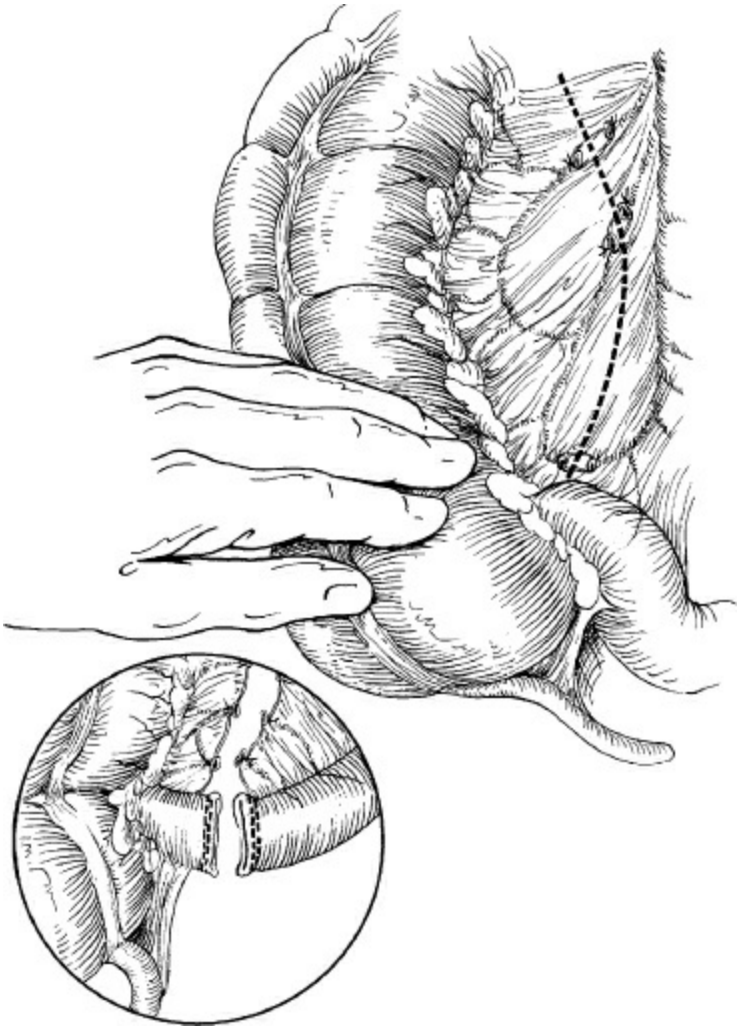

Figure 148.4. Dividing vessels to right colon and dividing the ileum with stapler.

Attention is then turned to the left side of the colon beginning at the sigmoid colon and moving toward the splenic flexure. The sigmoid colon and its mesocolon are medially retracted after which congenital or acquired adhesions of the appendices epiploicae, colon, and mesocolon to the peritoneum are divided. It is again important to remain in this avascular embryologic plane (also referred to as the white line of Toldt) to avoid injury to retroperitoneal structures (Fig. 148.5). Dissecting through fat while mobilizing the sigmoid colon indicates that one has strayed from the correct plane of dissection as the fat may signify an appendix epiploica, the mesocolon, or retroperitoneal tissue. The sigmoid colon is continuously rolled in a medial and slight cephalad direction after division of its lateral peritoneal attachments to facilitate freeing it from the retroperitoneum. As this mobilization is being done, the ureter is exposed and should be laterally swept to avoid injury. Once the sigmoid colon is

medial to the left ureter, it can be freed in a cephalad direction by carrying the peritoneal incision longitudinally and parallel to the course of the colon. As the dissection of the sigmoid colon approaches the pelvic inlet, it is important for the surgeon to be cognizant of the presence of the parasympathetic nerves on the surface of the aorta roughly 1 cm posterior to the superior hemorrhoidal vessels. Once the left ureter is identified, it is unnecessary to continue dissection in this area if the resection is being done for benign disease. Further dissection here may risk injury to nerves and therefore impair ejaculatory function in male patients. The mesocolon is incised at its base on the right side (Fig. 148.6).

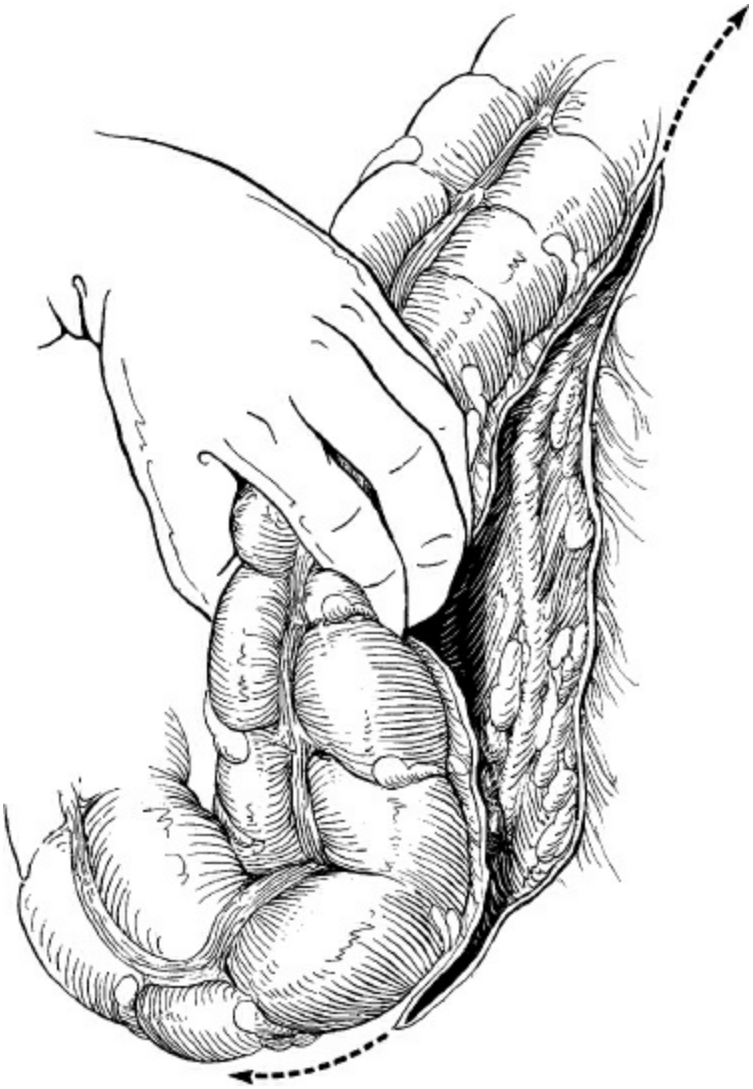

Figure 148.5. Mobilizing the sigmoid and mesosigmoid by dividing attachments laterally.

The descending colon's lateral peritoneal attachments are incised close to the colon to prevent potential dissection into Gerota's fascia. The

splenic flexure is then approached from the left, from below, and from behind as the descending colon is mobilized (Fig. 148.7). The surgeon must be careful when retracting the colon inferiorly or to the right, as traction on the distal transverse colon or omentum may result in avulsion injuries or tears to the splenic capsule and underlying parenchyma. It is important that the dissection remain within a few millimeters of the colon as the flexure is taken down because the omental attachment in this plane is relatively avascular. Once this part of the dissection is accomplished, the remaining omentum is either separated from the colon or the remaining portion of the gastrocolic ligament is ligated thus connecting the plane established earlier during the course of opening the lesser sac; this completes the mobilization of the splenic flexure.

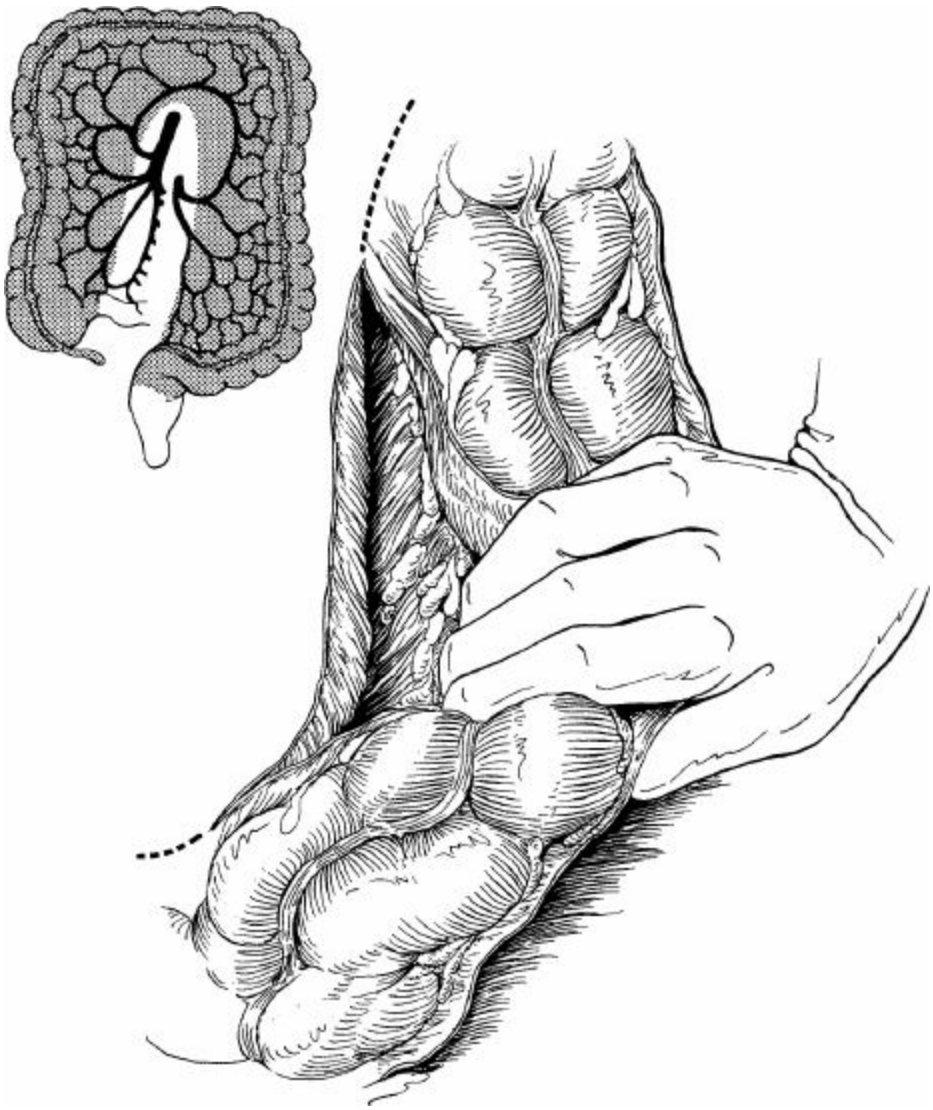

Figure 148.6. Incising the sigmoid mesocolon at base on the right.

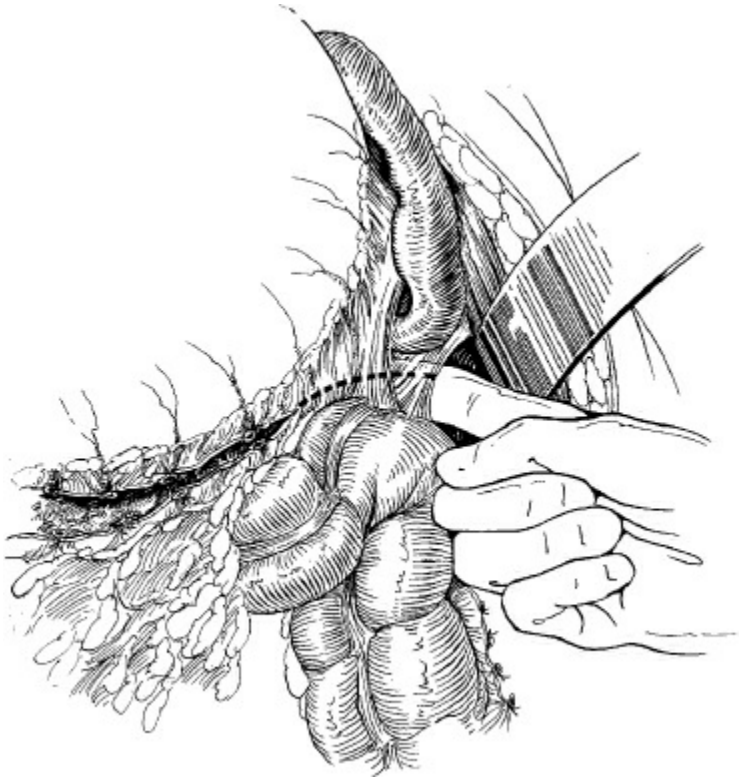

Figure 148.7. Taking down the splenic flexure.

Division of the inferior mesenteric artery and vein should be separately done when the resection is being undertaken for malignant disease. Dissection of the artery should be carried out as close as possible to the vessel to minimize risk of nerve injury, which may occur with traction on the arterial trunk. The inferior mesenteric vein is then ligated at the level of the duodenum. In male patients undergoing total colectomy for colitis or other benign disease, it is preferable to divide the sigmoidal branches near the colon wall, leaving the inferior mesenteric and superior rectal vessels intact to avoid dissection in the vicinity of the sympathetic nerves. Remaining colonic vessels may be divided at either proximal or distal levels contingent upon operative indication and surgeon preference.

The proximal rectum is prepared for transection by division of the mesorectum. The rectosigmoid is a 4-cm long transitional zone at the sacral promontory; here, the taenia coli merge into a confluent circular muscle coat and the lumen widens. The exact level is best confirmed by intraoperative endoscopy. The remaining mesentery is dissected close to the rectal wall, and the rectum is divided between clamps or with a linear stapler (Fig. 148.8) and the entire colon is removed. Prior to creation of an anastomosis, it is the authors' preference to perform a flexible sigmoidoscopy with the pelvis filled with saline to evaluate the staple line

at the rectal transection.

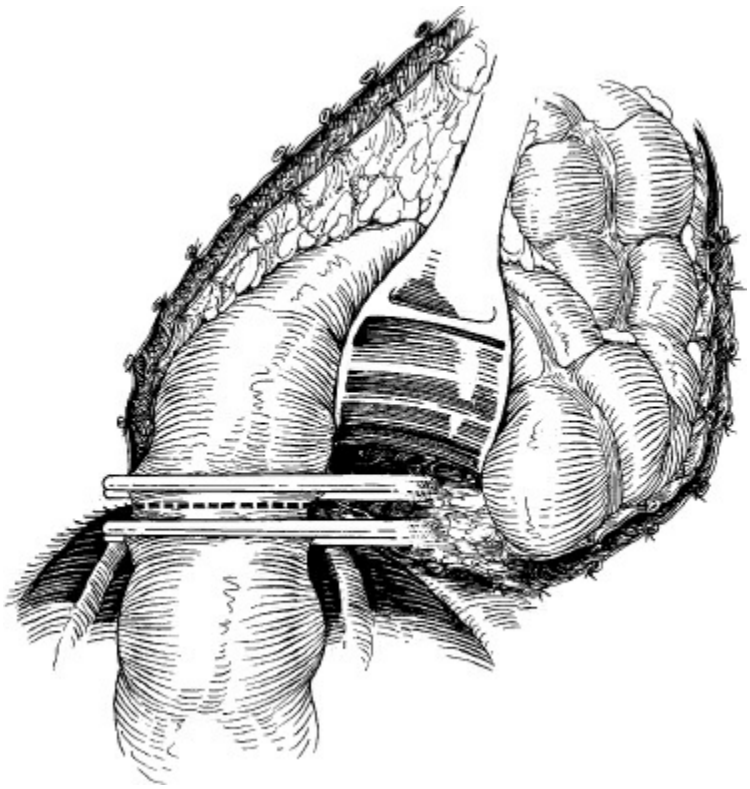

Figure 148.8. Dividing the rectum between clamps.

There are multiple techniques employed to create an ileorectal anastomosis based on the personal preference and experience of the surgeon; both stapled and hand-sewn anastomoses yield similar results. One can perform an end-to-end or end-to-side hand-sewn or stapled anastomosis (Fig. 148.9). In making an end-to-end hand-sewn anastomosis, the ileum may be enlarged by making a longitudinal slit in the antimesenteric border (a Cheatle procedure) to overcome the size discrepancy between the two lumens. If a side-to-end anastomosis is selected, the ileum is opened on its antimesenteric border and arranged so that the cut edge of the mesentery is positioned to the patient's right. The two bowel edges are approximated in a single layer using simple, interrupted sutures.

To create an end-to-end stapled anastomosis, a purse-string suture is placed at the cut edge of the open ileum. An end-to-end stapling device is then inserted transrectally. The stapler is advanced under direct guidance by the assistant who remains at the abdomen to help inspect the rectum and later unite the stapling device for construction of the anastomosis. Once the stapler is positioned so that its head is aligned at the midline of

the rectal stump staple line, the trocar of the instrument is advanced to pierce the rectal staple line. The anvil is then docked into position with the rectal stapler. The device is then closed so that the ileum and rectum are in close apposition and after verification of appropriate bowel and mesenteric orientation is fired. Once fired, the stapler is opened and removed slowly from the rectum. Two intact “donuts” should be obtained. The anastomosis is then checked for integrity and hemostasis by inserting a flexible sigmoidoscope through the anus and insufflating the rectum with air, while the pelvis is filled with saline and the newly made anastomosis is visualized. Alternatively, a distal purse-string suture can be placed by either manual or mechanical means to avoid the double-stapled “dog-ears.” In addition, intravenous indocyanine green assessment can be performed to evaluate both serosal and mucosal perfusion. Drains are usually not required and a diverting loop ileostomy is rarely necessary following total colectomy and ileorectal anastomosis.

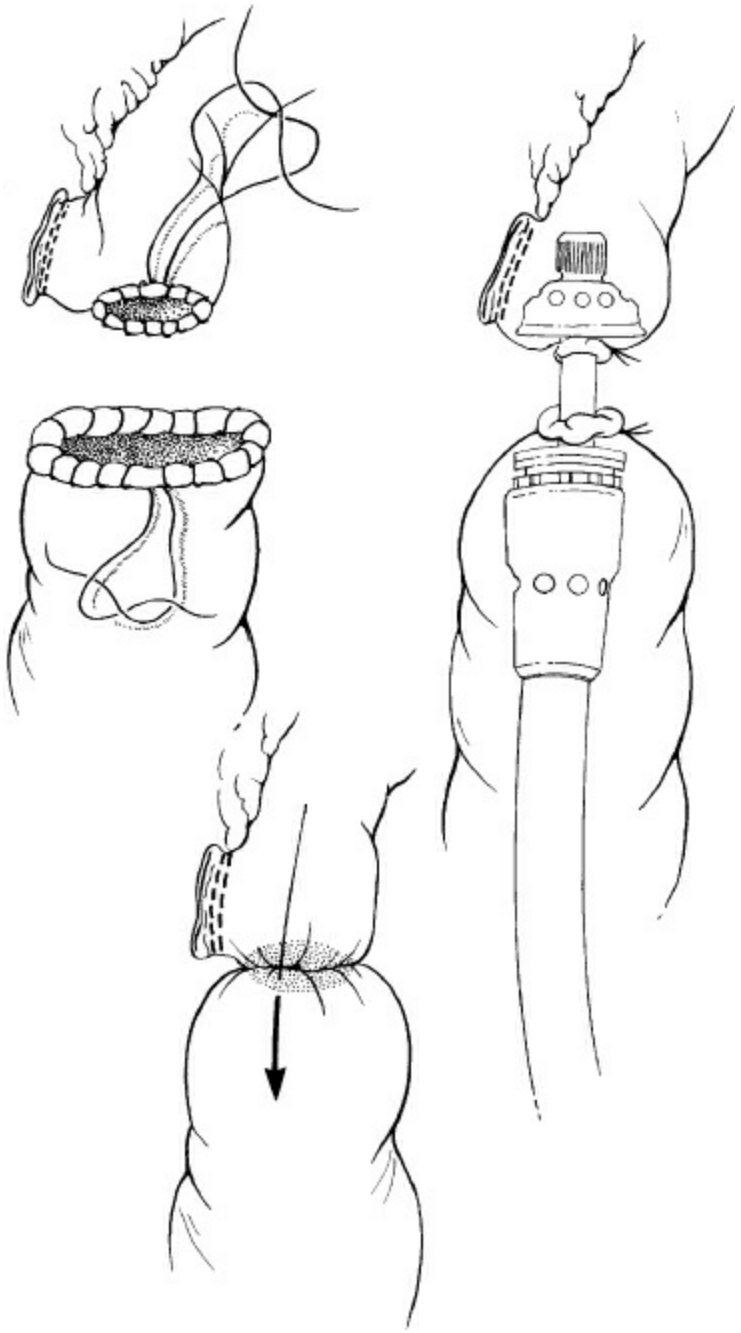

Figure 148.9. Side-to-end ileorectal anastomosis with intraluminal stapler.

Laparoscopic Resection

The principles of laparoscopic resection are similar to those followed during open total colectomy. The patient is positioned in lithotomy with the arms tucked at the patient's side to allow for easier positioning of the operating surgeon and the assistant in relation to the patient's body during the mobilization of the colon. The patient's position may be changed multiple times during the procedure to accommodate retraction of the

colon during mobilization. Placement of the patient in Trendelenburg or reverse Trendelenburg positions with left side up or down helps to facilitate retraction of the colon and to allow for the small bowel to fall out of the operative field by the assistance of gravity. Because of the extremes of position often employed during laparoscopy, securing the patient to an inflatable bean bag may be helpful.

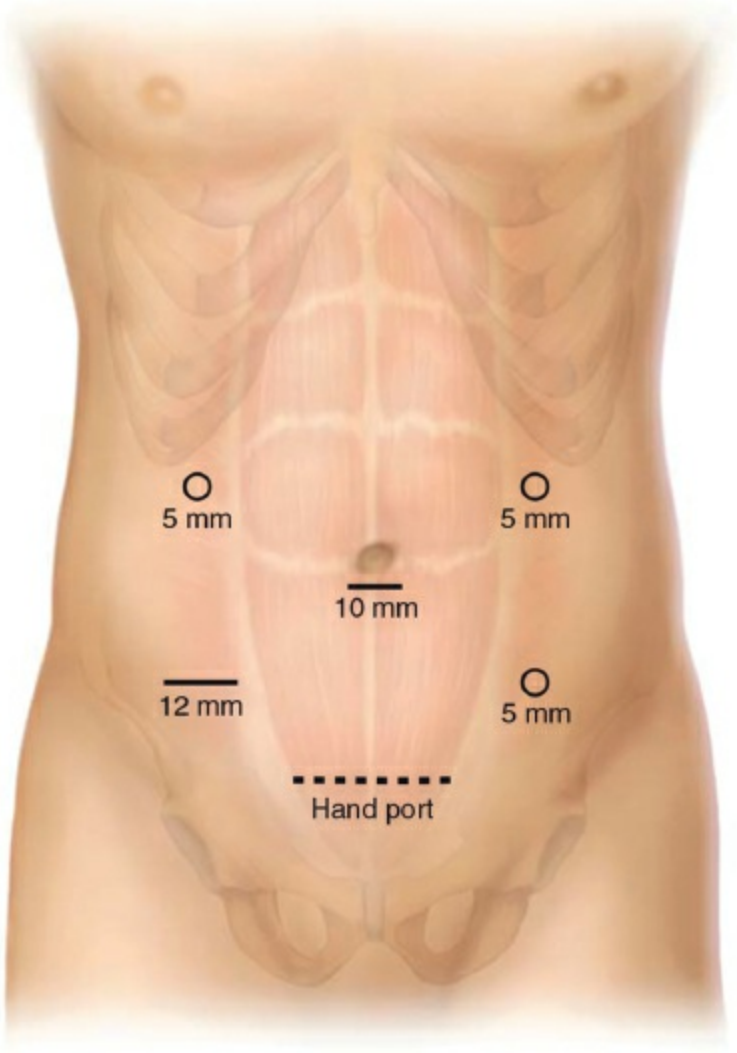

Figure 148.10. Port placement for laparoscopic total colectomy. (With permission from Margolin D. Hand-assisted. In: Wexner SD, Fleshman JW, eds. *Colon and Rectal Surgery: Abdominal Operations*. Philadelphia, PA: Wolters Kluwer; 2011.)

A total of five laparoscopic ports can be used to accomplish colonic mobilization (Fig. 148.10). First, a small midline incision is made just above or below the umbilicus to accommodate a 10-mm port through which a 30-degree telescope is placed. The abdomen is then insufflated

with carbon dioxide to a pressure of 15-mm mercury after which the camera is inserted. Inspection of the peritoneal cavity for adhesions, liver metastasis, or carcinomatosis should then follow. Four additional ports (5- or 10-mm ports, depending on surgeon preference) are then placed under direct visualization in the left upper quadrant, left lower quadrant, right lower quadrant, and right upper quadrant. Using a laparoscopic approach, the colon can be mobilized and devascularized from a lateral-to-medial approach or a medial-to-lateral approach.

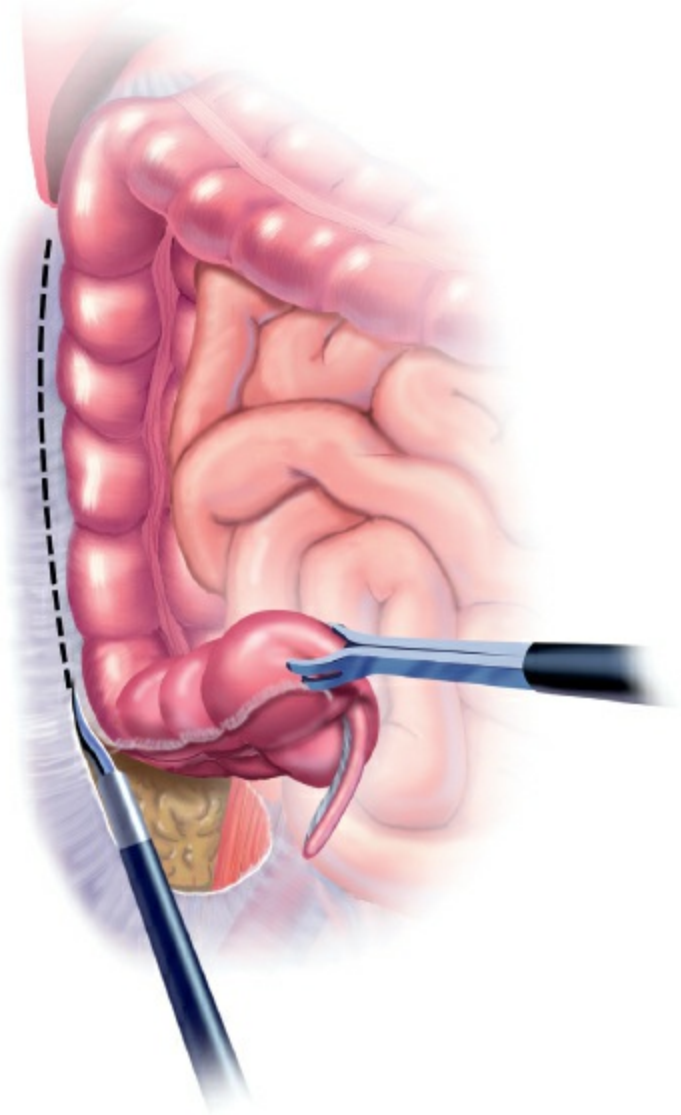

Figure 148.11. Laparoscopic division of the lateral retroperitoneal attachments of the right colon. (Adapted from Atlas of Minimally Invasive Surgery published by Cine-Med Publishing, Inc., 2006, www.cine-med.com.)

Lateral-to-Medial Approach

The right colon is mobilized first after placing the patient in Trendelenburg position with the right side up. Atraumatic bowel graspers are used to retract the colon while an energy source is employed for dissection and mobilization. This step is usually done through the two left-sided ports; however, the positioning of instruments may be interchanged as needed during the procedure to facilitate better retraction and mobilization. The right lower quadrant port may also be utilized to assist in retracting the cecum and the rest of the ascending colon. Once good retraction is obtained, the lateral peritoneal attachments are incised using endoscopic shears or an energy source, similar to that done in the open procedure (Fig. 148.11). The colon is lifted away from Gerota's fascia by maintaining the dissection in a medial direction as the kidney is approached. The duodenum is also visualized at this point and the thin, filmy attachments between it and the colon are divided. The hepatic flexure is reached and its most lateral attachments are separated using an energy source to ligate the small vessels contained in the hepatocolic attachments. As dissection proceeds in this plane, it becomes necessary to approach the transverse colon from a medial direction by opening the lesser sac. It is therefore usually necessary to retract the transverse colon from the inferior aspect by gently by grasping it with an instrument placed in the left lower quadrant port. Placing the patient in a reverse Trendelenburg position at this point improves exposure by allowing the omentum and colon to fall inferiorly along with the small bowel. The lesser omentum can then be retracted by the assistant in an upward direction with a grasper from the right lower quadrant port. The lesser sac is best identified and opened by using an energy source to separate the lesser omentum from its attachment to the colon taking care not to injure the gastroepiploic artery in the process (Fig. 148.12). Once the lesser sac is fully opened, the transverse colon mesentery is fully exposed and any remaining hepatocolic attachments are divided. The dissection is then carried along the transverse colon, opening the lesser sac toward the splenic flexure. As the splenic flexure is approached, the omentum may be more difficult to divide from this medial direction and will likely require that the flexure be mobilized from the lateral position.

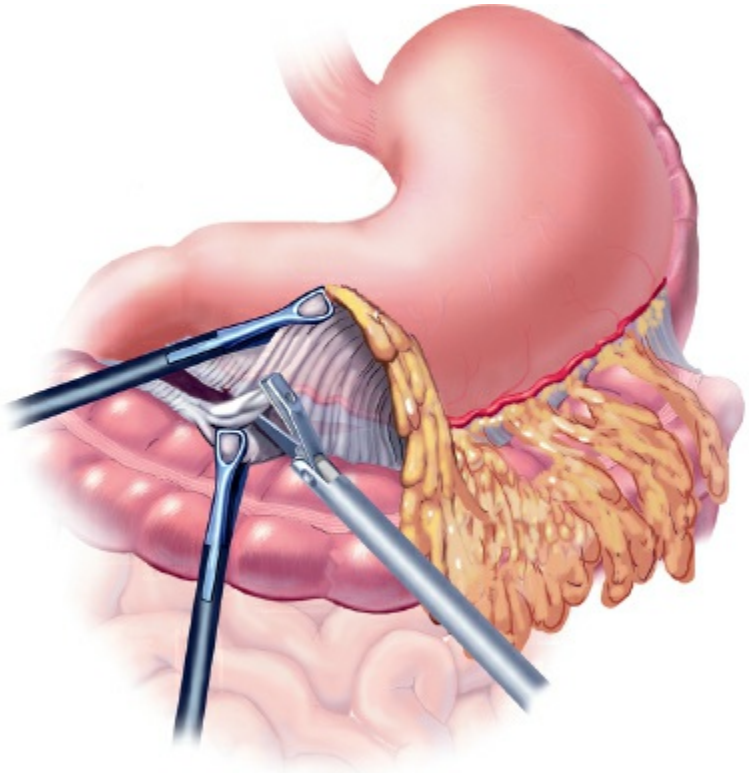

Figure 148.12. Laparoscopic detachment of the omentum from the transverse colon. (Adapted from Atlas of Minimally Invasive Surgery published by Cine-Med Publishing, Inc., 2006, www.cine-med.com.)

Attention is then turned to the sigmoid and descending colon. Mobilization of the sigmoid is done by gentle retraction of the colon with a grasper from a right-sided port while the patient is in Trendelenburg and left side up position. The lateral peritoneal attachments are again incised using an energy source, and the colon is pulled medially as mobilization proceeds and is lifted off of the retroperitoneum (Fig. 148.13). The gonadal vessels are usually encountered and the left ureter can typically be found medial to those vessels. The ureter may be closely associated with the colonic mesentery and will require being gently swept inferiorly as the colon is retracted superiorly and to the right. The descending colon's peritoneal attachments are also incised as the dissection proceeds superiorly, using the same principle of remaining close to the colon wall during the dissection of the descending colon off of Gerota's fascia. The splenic flexure is mobilized by rolling the colon medially with the retracting instrument placed in the right lower quadrant and dividing the retroperitoneal attachments with an energy source from the left lower quadrant port (Fig. 148.14). Placing the patient in the reverse

Trendelenburg position at this point may allow for better exposure of these attachments. The lesser sac is fully opened by resuming the dissection at the gastrocolic ligament and fully separating the colon from its attachments to the stomach and the medial aspect of the spleen. Once the pancreas is exposed, the dissection is complete in this plane.

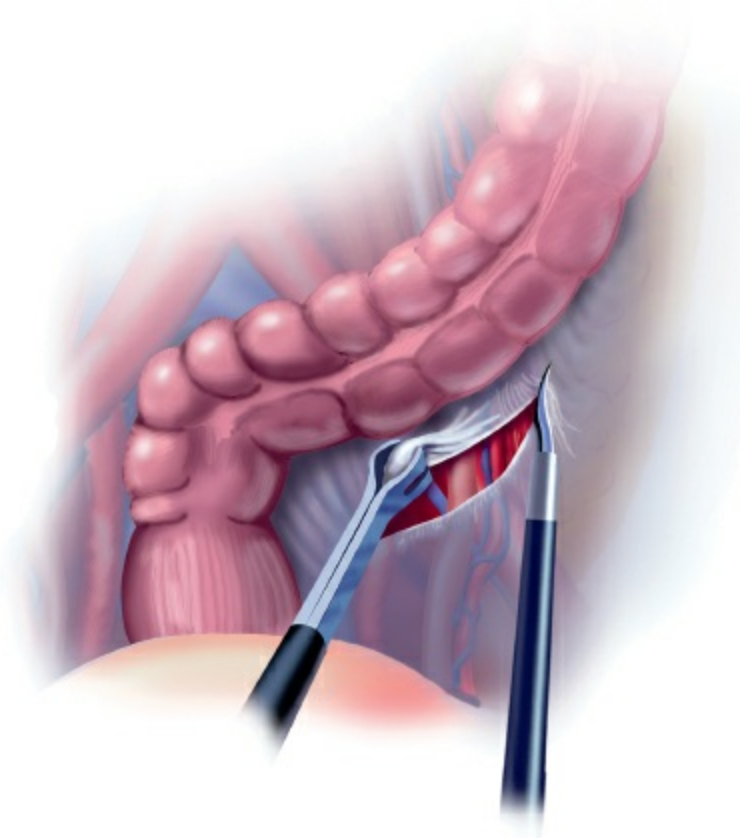

Figure 148.13. Laparoscopic division of the lateral retroperitoneal attachments of the sigmoid colon. (Adapted from Atlas of Minimally Invasive Surgery published by Cine-Med Publishing, Inc., 2006, www.cine-med.com.)

At this stage, all colonic attachments are mobilized and the vessels may be ligated using an energy source. For benign disease, as in the open procedure, it is not necessary to perform a high ligation of the inferior mesenteric artery. The sigmoidal branches near the colonic wall are ligated using an energy source from the right lower quadrant port, and the superior rectal vessels are preserved. The ligation proceeds to the inferior mesenteric vein and left colic artery. If high ligation of the inferior mesenteric artery is necessary, the vascular pedicle is identified at its origin superior to the aortic bifurcation by grasping the sigmoid colon and placing upward retraction of the colon toward the abdominal wall with a

grasping instrument in the right upper quadrant port (Fig. 148.15). The arterial pulsation is identified and the artery is skeletonized and any nerve fibers are dissected and reflected posteriorly. It is critical to ensure that the ureter is protected prior to ligation of the artery by reflecting the colon medially after applying the ligating device around the artery. The artery and separately the vein are ligated and transected near their respective origins. The division of the mesentery proceeds with the energy source located in the left upper quadrant port to ligate the transverse and right colon vessels (Fig. 148.16). Again, for benign pathology ligation of the vessels is accomplished near the colonic wall while for malignant disease ligation of the main vascular pedicles (middle colic and ileocolic arteries) is done near their origin.

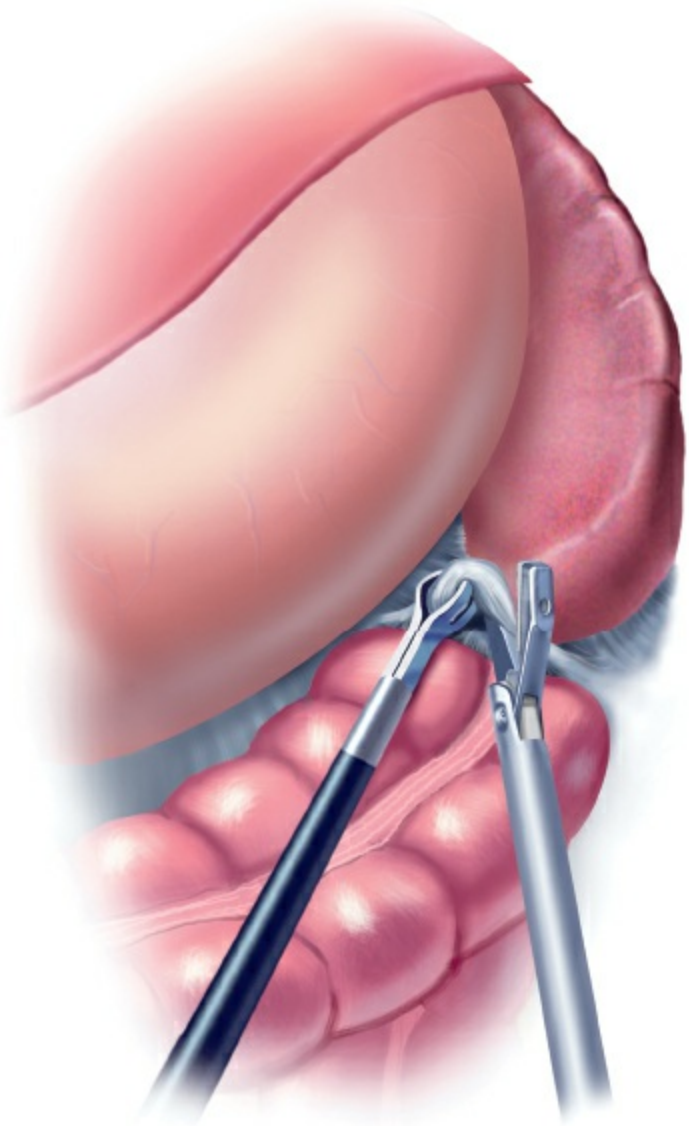

Figure 148.14. Laparoscopic mobilization of the splenic flexure. (Adapted from Atlas of Minimally Invasive Surgery published by

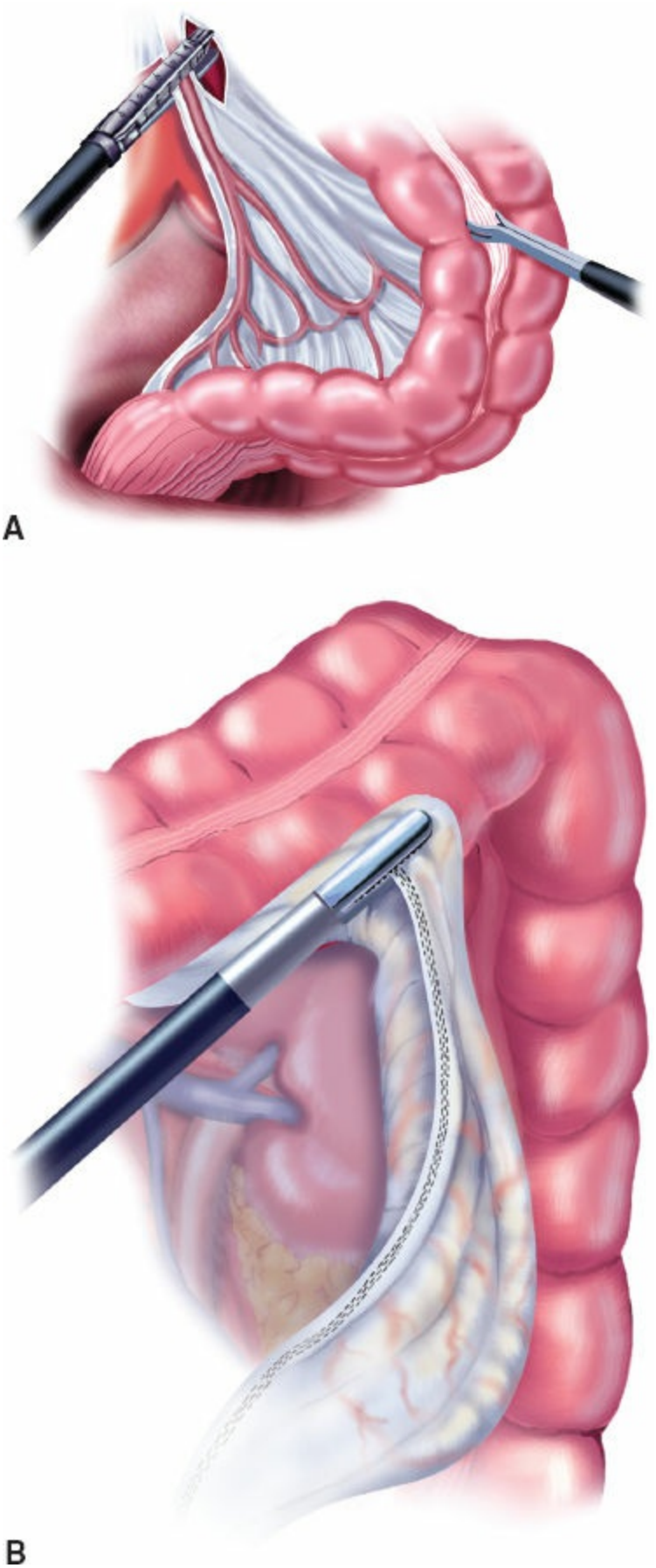

Figure 148.15. Laparoscopic division of the sigmoid and

descending colon mesentery. (Adapted from Atlas of Minimally Invasive Surgery published by Cine-Med Publishing, Inc., 2006, www.cine-med.com.)

The ileum is divided using an endoscopic linear cutting stapler that can be placed through the left upper quadrant port. The rectosigmoid junction is also divided in the same manner by grasping the sigmoid with gentle upward retraction while applying the stapling device on the rectosigmoid junction. If necessary, the position of the rectosigmoid junction can be verified by using endoscopy. It is helpful to leave a grasper on the stapled end of the ileum to aid in identifying it after the colon has been removed.

Once the colon is transected, it can be removed from the peritoneal cavity in a variety of ways. If there are no plans to make an anastomosis, the colon may be removed from the future ileostomy incision. If there are plans for making an anastomosis, a small Pfannenstiel, vertical suprapubic umbilical, or port site incision can be made. In patients with inflammatory bowel disease, an iliac fossa incision should be avoided to obviate violation of future potential stoma sites. Regardless of the site selected, wound retraction with a protective expandable retractor is very helpful in maximizing wound size. In general a 3- to 5-cm skin incision is ample for specimen removal.

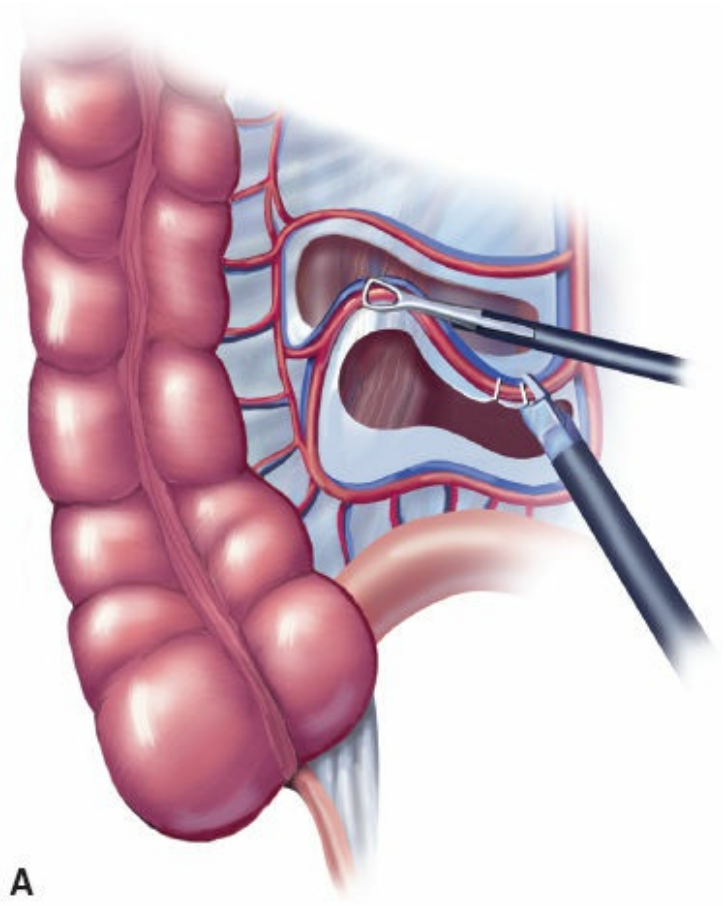

A

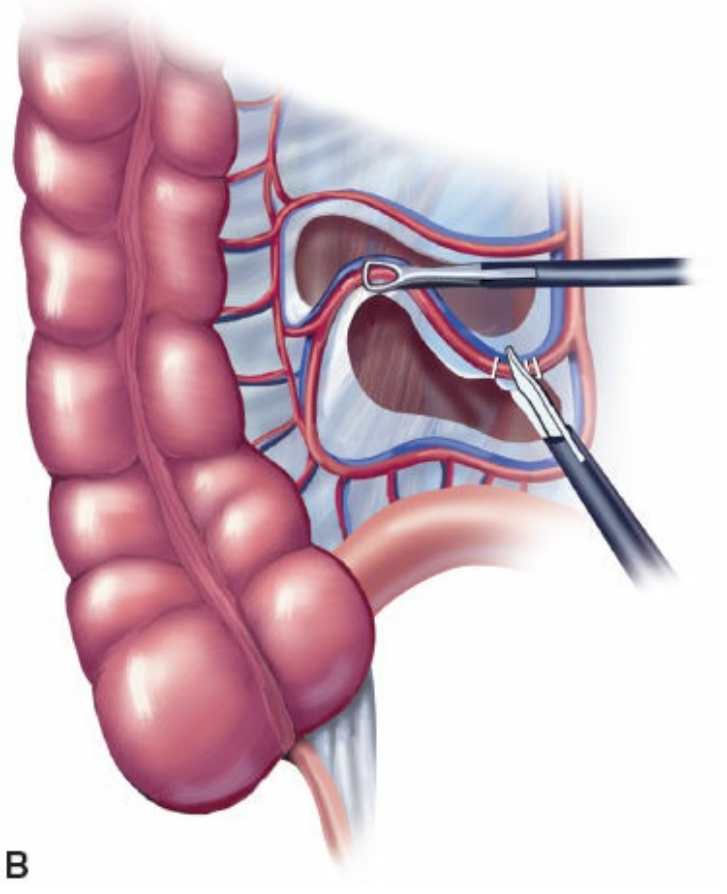

B

Figure 148.16. Laparoscopic division of the right colon mesentery. (Adapted from Atlas of Minimally Invasive Surgery published by Cine-Med Publishing, Inc., 2006, www.cine-med.com.)

The same principles are followed for the creation of the ileorectal anastomosis as during an open procedure. The ileum is brought into the abdominal wound and exteriorized, and the preparation of the anastomosis is done in a similar manner. If a suprapubic incision was made, it may be possible to unite the anvil and stapling trocar under direct vision while the wound is open; however, the laparoscopic approach is generally much easier and affords vastly superior visualization. This method requires closure of the abdominal incision or port and reinsufflation of the peritoneal cavity with carbon dioxide. It is necessary to ensure that the ileum has not twisted around its axis during the process of mobilization or preparation of anastomosis. To verify appropriate orientation, the small bowel should lie in the left side of the abdomen, while the cut edge of the mesentery should be straight and oriented on the right of the patient. A laparoscopic anvil grasper is used from the right upper quadrant port and the anvil is united with the trocar under direct vision after which the stapler is closed and fired. The two resulting “donuts” are checked for completeness. The integrity of the anastomosis is assured by first placing a noncrushing bowel clamp on the ileum and filling the pelvis with saline. The anastomosis is inspected with a flexible endoscope, which has the advantage of directly visualizing the anastomosis and air-testing it while it is submerged under saline. In addition, intravenous indocyanine green assessment can be undertaken to verify sensual and mucosal perfusion.

Medial-to-Lateral Approach

While the laparoscopic lateral-to-medial approach is similar to the dissection in an open colectomy, some surgeons prefer the medial-to-lateral approach. Using this technique, the vessels are ligated prior to colonic mobilization and the lateral peritoneal attachments are kept intact as they help provide retraction by suspension of the colon while the mesentery is being divided. The omentum is first superiorly reflected, and the small bowel is placed on the left side of the abdomen to expose the mesentery of the right colon. The ileocolic pedicle is then identified by grasping the cecum from the left lower quadrant port and placing tension

on the mesentery. The peritoneum overlying the pedicle is incised, and the retroperitoneum is gently swept downward. This maneuver creates a window through the mesentery, which allows identification of the duodenum. For malignant disease, the vessel is ligated at its origin near the duodenum, while for benign processes it should be kept intact and instead its branches divided. After the vessel is divided, the retroperitoneal plane is better exposed and blunt dissection is used to further separate the mesentery from the retroperitoneum. The dissection proceeds superiorly to separate the ascending colon and hepatic flexure from Gerota's fascia. The proximal transverse colon is also carefully dissected from the duodenum in the same manner. Once this step is done, the lateral peritoneal attachments of the ascending colon as well as the hepatocolic attachments that remained can now be divided. The transverse colon mesentery is then placed under tension, and the peritoneum is incised. Division of the mesentery can be approached from the right side by entering the lesser sac at the level of the pancreatic head or by creating a mesenteric window to the left of the middle colic artery and working back toward the hepatic flexure.

Ligation of the sigmoid and left colon mesentery follows the same principles outlined earlier. First, the inferior mesenteric artery pedicle is identified slightly superior to the aortic bifurcation; this can be accomplished by using the sacral promontory as a landmark and tracing the colonic mesentery superiorly up to the aortic bifurcation. Once identified, the inferior mesenteric artery along with the sigmoid colon is lifted superiorly toward the abdominal wall with a grasper placed through the right upper quadrant port. The peritoneal lining inferior to the vascular pedicle is incised to create a window through which the left ureter and pelvic nerve plexus can be identified. The visualization of the ureter is critical to allow it be reflected posteriorly into the retroperitoneum and separated away from the artery. The pelvic plexus of nerves is also reflected posteriorly in the same manner. The artery is skeletonized and ligated at its origin for malignant disease, while the sigmoidal branches are ligated in operations performed for benign disease. Once the artery is ligated, the mesentery is separated from Gerota's fascia and the retroperitoneum by placing an instrument under the colon mesentery with upward traction while using the right lower quadrant instrument to push down and separate the retroperitoneum. The inferior mesenteric vein is then divided, and the dissection proceeds superiorly to separate the splenic

flexure from its posterior attachments. Once this maneuver has been completed, the lateral peritoneal attachments of the sigmoid colon and descending colon are easily divided. The lesser sac is opened in the same manner as the lateral-to-medial approach, and mobilization of the splenic flexure is also completed following the same principles.

Hand-Assisted Laparoscopic Approach

Hand-assisted surgery has emerged as another alternative technique that can be used depending on the preference of the operating surgeon. Proponents claim that the hand-assisted approach may be useful during mobilization particularly when the colon is involved by severe inflammation, which makes grasping and retraction difficult with laparoscopic instruments. Positioning the patient is identical for hand-assisted surgery as for laparoscopy. Incisions differ in that the hand-port incision is made first followed by camera port and other port placement. A Pfannenstiel or lower midline incision is made for the placement of the hand port. Once the hand port is positioned, one may choose to place a trocar directly through the hand port and insufflate gas or place the camera port under direct visualization in the infraumbilical or supraumbilical position prior to gas insufflation. The remaining ports are placed in a similar position and manner as for laparoscopy.

Mobilization of the colon also proceeds in a similar way as the laparoscopic procedure. The most obvious difference is the operator's hand being placed in the hand port to retract and manipulate the colon. The anastomosis is also accomplished in the same manner as mentioned earlier for the laparoscopic approach; however with a lower midline or Pfannenstiel incision, it is often easier to fashion the anastomosis through the incision.

POSTOPERATIVE MANAGEMENT

Enhanced recovery protocols have been developed for the perioperative and postoperative care of patients and have been widely applied in colorectal surgery. The main goals of these programs are acceleration of postoperative recovery, and reducing complications, length of hospital stay, and subsequent readmissions. These goals are accomplished by optimizing the patient's preoperative status and providing education to patients regarding their recovery process and expectations. Preoperative bowel preparation is often not utilized and intravenous fluids are

minimized both intraoperatively and postoperatively. The process also incorporates minimally invasive surgery as the surgical approach of choice as numerous studies have demonstrated decreased recovery times and less postoperative pain. Use of narcotic alternatives including epidural analgesia, regional blocks with local anesthetic agents, and nonsteroidal anti-inflammatory medications may help to reduce narcotic-associated side effects and decrease the length of postoperative ileus. Oral or intravenous acetaminophen, gabapentin, and alvimopan have also been successfully utilized in these pathways. Active prevention of hypothermia as well as high concentrations of oxygen are also elements of many enhanced recovery protocols.

Nasogastric tubes are not routinely used, and patients are given oral clear liquid diets immediately following surgery. Once patients have tolerated clear liquids without evidence of nausea or vomiting, they are offered solid food. Patients are mobilized out of bed early during their hospital course and are encouraged to walk beginning on the first postoperative day. Discharge is possible after the patient meets criteria of adequate oral intake, return of bowel function, and no evidence of complications or infections.

Postoperative care of patients with Crohn’s disease is similar to the care provided to patients undergoing total colectomies for other etiologies. Restarting medical therapy following surgery may decrease the severity or delay the onset of disease recurrence. It is well known that endoscopic recurrence is seen in 70% to 90% of patients 1 year following surgery, 10% to 20% of whom are symptomatic. The timing for restarting medical therapy is not well described is often based mainly on individual practices; however when used, these medications are typically restarted within 4 to 8 weeks following surgery. Patients who were receiving steroids prior to surgery need to continue taking steroids after surgery during an appropriate taper.

COMPLICATIONS

Intraoperative complications include inadvertent injury to nearby structures such as small bowel or the ureters. Small-bowel enterotomies may take place during lysis of adhesions or colonic dissection, and if unrecognized may result in peritonitis and need for subsequent exploration. During laparoscopy injury to the bowel may occur during exchange of instruments, particularly when the patient is tilted to the side.

Ureteral injury is very rare during colonic mobilization; predisposing factors are related to previous surgery involving the retroperitoneal plane, prior radiation, active retroperitoneal and/or pelvic sepsis, and technical errors that occur when straying from the correct surgical plane. The ureters may also be injured during laparoscopic mobilization by thermal spread from various energy sources or from direct injury during dissection. Use of ureteral stents has been demonstrated in aiding the intraoperative recognition of ureteral injury but has not been shown to decrease the incidence of injury. Splenic injuries can also be avoided by careful visualization, retraction, and paracolic dissection as previously detailed. The most common site of injury is the capsule of the inferior pole. Fortunately, most injuries respond to electrocautery and application of topical hemostatic agents.

Surgical wound infections are unfortunately a common complication following colorectal surgery with up to 30% incidence. Measures taken to reduce the risk of wound infection include perioperative antibiotics and tight glycemic control. Some predisposing risk factors such as obesity and other systemic diseases as well as the perioperative use of steroids in patients with inflammatory bowel disease, however, are difficult to control.

Anastomotic leak is more common in patients with inflammatory bowel disease than in patients who undergo total colectomy with other indications. Pelvic abscesses may occur in association with an anastomotic leak or may be due to an infected hematoma or contamination during surgery. Small, contained leaks can usually be managed nonoperatively with bowel rest and percutaneous drainage of associated abscesses. Large leaks or anastomotic disruptions associated with systemic manifestations will require reoperation with proximal diversion and possible resection of the anastomosis. Three to 6 months after the patient has recovered, another attempt at restoring continuity may be considered. Verification of the integrity of the anastomosis can be undertaken by air testing and indocyanine green perfusion assessment.

OUTCOMES

Functional outcomes following subtotal colectomy with ileorectal anastomosis depend on the indication for the operation, presence of rectal disease, age, and comorbid factors. Generally, otherwise healthy patients who undergo this procedure will have between three to five stools per day

for the remainder of their lives. This stool pattern typically does not preclude physical activity or daily life. Diarrhea is not uncommon following total abdominal colectomy and may be accompanied by urgency and even minor incontinence. Bulking agents, cholestyramine, and loperamide hydrochloride or diphenoxylate may help combat diarrhea, and incontinence should also improve once stools slow and thicken.

Some patients undergoing subtotal colectomy for constipation may have persistent symptoms following surgery. Despite having strong evidence of isolated slow transit constipation on preoperative studies, 50% to 80% of patients may have persistent abdominal pain following surgery, although some report improvement in intensity. A smaller number of patients, 6% to 10%, continue to have persistent or recurrent constipation and may still require the use of enemas or laxatives to induce bowel movements. One to two percent of patients require conversion to end ileostomy due to symptoms of intractable constipation.

The risk of developing metachronous rectal carcinoma in patients with FAP varies from 12% to 43%, and necessitates the prophylactic removal of the rectum. In carefully selected patients with attenuated FAP who have fewer or no rectal polyps, leaving the rectum in place may be feasible. Spontaneous regression of rectal polyps following total colectomy and ileorectal anastomosis has been described in up to 50% to 64% of patients. Twenty percent to 38% of patients have complete resolution, while 15% to 26% show partial resolution of the rectal polyps. It is theorized that colectomy is responsible for causing regression of rectal polyps by decreasing rectal mucosal proliferation. The mechanism behind this decrease in mucosal proliferation is attributed to changes in the chemical composition of stool to which the rectum becomes exposed. Changes in the fecal flora, concentrations of primary bile acids, and reduction of carcinogenic factors have all been noted to occur following a total colectomy. These effects may be temporary or permanent, but still do not prevent later redevelopment of polyps and subsequent cancer. Approximately 55% of patients who had initial regression are eventually found to have rectal polyps during long-term follow-up.

Rectal polyps and carcinoma may still develop, and therefore rigorous follow-up is required to identify these patients and perform polypectomy prior to progression to carcinoma. Nonsteroidal anti-inflammatory drugs have been used to induce at least partial regression of rectal polyps; however, their long-term use must be balanced against their potential for

causing harmful side effects.

Suggested Readings

Boushey RP, Marcello PW, Martel G, et al. Laparoscopictotal colectomy: an evolutionary experience. *Dis Colon Rectum* 2007;50(10):1512–9.

Feinberg SM, Jagelman DG, Sarre RG, et al. Spontaneous resolution of rectal polyps in patients with familial polyposis following abdominal colectomy and ileorectal anastomosis. *Dis Colon Rectum* 1998;31(3)169–75.

Fillppakis GM, Zografos G, Pararas N, et al. Spontaneous regression of rectal polyps following abdominal colectomy and ileorectal anastomosis for familial adenomatous polyposis, without sulindac treatment: report of four cases. *Endoscopy* 2007;39:665–8.

Gouvas N, Tan E, Windsor A, et al. Fast-track vs. standard care in colorectal surgery: a meta-analysis update. *Int J Colorectal Dis* 2009;24:1119–31.

Hassan I, Pemberton JH, Young-Fadok TM, et al. Ileorectal anastomosis for slow transit constipation: long-term functional and quality of life results. *J Gastrointest Surg* 2006;10(10):1330–6; discussion 1336–7.

Kehlet H, Wilmore DW. Evidence-based surgical care and the evolution of fast-track surgery. *Ann Surg* 2008;248(2):189–98.

Lubowski DZ, Chen FC, Kennedy ML, et al. Results of colectomy for severe slow transit constipation. *Dis Colon Rectum* 1996;39(1):23–9.

Lynch HT, Lynch JF, Attard TA. Diagnosis and management of hereditary colorectal cancer syndromes: Lynch syndrome as a model. *CMAJ* 2009;181(5);273–80.

Lynch HT, Lynch PM, Lanspa SJ, et al. Review of the Lynch syndrome: history, molecular genetics, screening, differential diagnosis, and medicolegal ramifications. *Clin Genet* 2009;76:1–18.

Lynch P. Prevention of colorectal cancer in high risk population: the increasing role for endoscopy and chemoprevention in FAP and HNPCC. *Digestion* 2007;76:68–76.

Mollen RM, Kuijpers HC, Claassen AT. Colectomy for slow-transit constipation: preoperative functional evaluation is important but not a guarantee for a successful outcome. *Dis Colon Rectum* 2001;44(4):577–80.

Pikarsky AJ, Singh JJ, Weiss EG, et al. Long-term follow-up of patients undergoing colectomy for colonic inertia. *Dis Colon Rectum* 2001;44(2):179–83.

Schuetz A, Jauch KW. Lower gastrointestinal bleeding: therapeutic strategies, surgical techniques and results. *Langenbeck's Arch Surg* 2001;386:17–25.

Yamamoto T. Factors affecting recurrence after surgery for Crohn's disease. *World J Gastroenterol* 2005; 11(26):3971–9.

EDITOR'S COMMENT

Drs. Maron and Wexner accurately describe the different indications for which subtotal colectomy and ileorectal anastomosis are performed, as well as both open and laparoscopic approaches. For the latter, both lateral-to-medial and medial-to-lateral dissection methods and the hand-assisted approach are discussed.

First for some comments regarding indications for subtotal colectomy and then some comments about technical aspects of the procedure: a condition for which colectomy is increasingly performed albeit as a staged procedure, which is not fully addressed, is that of *Clostridium difficile* colitis. This is an increasingly common condition, with a 117% rise in hospitalizations due to this condition in the United States between 2000 and 2005 (Lee DY, Chung EL, Guend H, et al. Predictors of mortality after emergency colectomy for *Clostridium difficile* colitis: an analysis of ACS-NSQIP. *Ann Surg* 2014;259(1):148–56). There is an extremely high morbidity and mortality associated with colectomy for this condition (Bhangu A, Nepogodiev D, Gupta A, et al.; West Midlands Research Collaborative. Systematic review and meta-analysis of outcomes following emergency surgery for *Clostridium difficile* colitis. *Br J Surg* 2012;99(11):1501–13). This led to the development of an innovative treatment approach, which may decrease the rate of colectomy while decreasing morbidity and improving outcome (Neal MD, Alverdy JC, Hall DE, et al. Diverting loop ileostomy and colonic lavage: an alternative to total abdominal colectomy for the treatment of severe, complicated *Clostridium difficile*-associated disease. *Ann Surg* 2011;254(3):423–7), as described by Drs. Neal, Zuckerbraun, and colleagues whereby patients with acute toxic *C. difficile* colitis, rather than undergoing colectomy, undergo a loop ileostomy and intraoperative lavage of the colon with 8 liters of warmed polyethylene glycol, with postoperative antegrade irrigation of the colon with vancomycin via the efferent limb of the ileostomy. In those patients with *C. difficile* colitis or others who have undergone urgent colectomy for reasons such as lower GI bleeding, re-establishing intestinal continuity can be difficult. These patients are often infirm and elderly. The operating surgeon often does not have a perspective of the patients prior to their illness and does not know if they truly would not be better off keeping their ileostomy rather than subjecting them to what might be a major operation with uncertain postoperative functional results. The surgeon who is asked to re-establish intestinal continuity (reverse the ileostomy) may also not be the same surgeon who performed the emergency colectomy complicating matters even more. Performing a gastrografin enema is sometimes useful in assessing the amount of residual rectum. I have seen patients in whom

an overzealous surgeon has resected to the level of the mid rectum at the time of the emergency colectomy, leaving only a small effective amount of residual rectum to act as a fecal reservoir. In such cases, performing a straight ileorectal anastomosis can have disastrous functional consequences for the patient, with large numbers of bowel movements and incontinence due to the loss of reservoir capacity of the rectum. This combined with the more liquid consistency of bowel movements following a colectomy and diminished sphincter function associated with age or due to prior occult obstetric injury can make these patients a virtual prisoner of their home or bathroom, accentuated by the decreased mobility that many of these patients may have due to age-related arthritis. Thus, the decision to reverse a stoma in these patients must be made very carefully. Although the authors nicely describe anorectal physiology testing that does have its role, a very easy, almost primitive, test that I have long utilized is an "oatmeal enema" (Parés D, Duncan J, Dudding T, et al. Investigation to predict faecal continence in patients undergoing reversal of a defunctioning stoma (Porridge enema test). *Colorectal Dis* 2008;10(4):379–85) (people always wonder why we have oatmeal in our office?). Oatmeal can be mixed to a consistency that is similar to a loose porridge-like bowel movement that would be typical after a colectomy. Giving a diverted patient an "oatmeal enema" allows one to assess the patient's ability to retain a mass of similar quantity and consistency as a bowel movement, and allows determination of the time and degree of its retention in different positions, standing, sitting, and walking. Such testing is often as reassuring for the surgeon as for the patient. Typically, I tell the patients that they must be prepared to have as many bowel movements as the number of times they are emptying their ileostomy, although it is often less since the rectum does provide for some significant water absorption. There usually is a period of adjustment before this occurs.

In performing ileorectal anastomosis in someone with Crohn disease or other inflammatory condition or history of inflammatory condition (prior pelvic sepsis), it is important to determine the degree of rectal distensibility on insufflation of air during flexible or rigid sigmoidoscopy as the authors describe. This helps determine the quality of the functional result postoperatively; that is, if the rectal wall distends nicely, the patients will be able to hold their bowel movements and defer defecation if they are not near a bathroom. In contrast, if the rectal wall does not distend well, they have a "lead pipe"-type rectum, will have significant urgency, and will have to rush to the bathroom whenever stool enters the rectum, with little ability to defer defecation.

Hereditary nonpolyposis colorectal cancer (HNPCC) can also be an indication for ileorectal anastomosis and subtotoal colectomy as the authors describe. New developments in this field have occurred that may reduce the frequency for which this operation is needed. The Colorectal Adenoma/Carcinoma Prevention Programme (CAPP) 2 trial focused on 937 patients with HNPCC who were entered into a trial where they were randomly

assigned in a two-by-two factorial design to receive either aspirin 600 mg/day, or aspirin placebo for up to 4 years (Burn J, Gerdes AM, Macrae F, et al. Long-term effect of aspirin on cancer risk in carriers of hereditary colorectal cancer: an analysis from the CAPP2 randomised controlled trial. *Lancet* 2011;378(9809):2081–7). While the initial results of the trial were negative, long-term results showed a dramatic reduction in the incidence of colorectal cancers. At a mean follow-up of nearly 5 years (55.7 months), 18 of 427 patients in the aspirin group had developed a colorectal cancer as compared with 30 of 434 in the aspirin placebo group. For patients who completed 2 years of treatment (258 in the aspirin group, 250 in the aspirin placebo group) the per-protocol analysis showed a hazard ratio of 0.41 (0.19–0.86, $p = 0.02$) and in incidence rate ratio of 0.37 (0.18–0.78, $p = 0.008$). Further studies are needed to establish the optimum duration and dose of aspirin treatment in these patients. It may be that the use of aspirin in such patients may decrease the need for colectomy in the future.

I must stress the importance of excluding pelvic floor disorders prior to performing colectomy for the indication of constipation. Patients who have obstructed defecation (e.g., disorders such as nonrelaxing puborectalis in which their pelvic floor muscles do not relax appropriately to allow feces to pass) do not benefit from a colectomy. In addition, the "obstruction" to defecation from this disorder may actually lead to a greater risk of anastomotic leak due to a relative distal obstruction. There was initial optimism regarding the use of sacral nerve root stimulation for patients with slow transit colonic constipation. Although there have been many contradictory results, results of a recent prospective randomized trial as well as a Cochrane review do not support use of this technology for constipation at present (Dinning PG, Hunt L, Patton V, et al. Treatment efficacy of sacral nerve stimulation in slow transit constipation: a two-phase, double-blind randomized controlled crossover study. *Am J Gastroenterol* 2015;110(5):733–40; Thaha MA, Abukar AA, Thin NN, et al. Sacral nerve stimulation for faecal incontinence and constipation in adults. *Cochrane Database Syst Rev* 2015;8:CD004464). In patients with familial adenomatous polyposis that is not attenuated FAP or MUTYH-associated polyposis, there is a significant risk of rectal cancer development and I am very reluctant to perform ileorectal anastomosis due to this risk of rectal cancer as the authors so well describe.

Lastly, two technical comments regarding subtotal colectomy and ileorectal anastomosis: the authors correctly stress the importance of preserving the ileocolic artery with its branches and ligating these vessels close in proximity to the cecum in patients undergoing colectomy with benign disease that might eventually require an ileal pouch anal anastomosis. This includes patients with familial adenomatous polyposis process and possibly patients with HNPCC or toxic colitis due to inflammatory bowel disease.

In patients who have a very small amount (one half or less) of remaining rectum, function (the number of bowel movements) can be dramatically

improved by constructing an ileal pouch and then performing an ileal pouch rectal anastomosis. When I do this, I do perform a temporary diverting loop ileostomy in these patients, since they are usually frail and just recovered from their earlier severe illness.

Susan Galandiuk

149 Surgery for Diverticulitis

Patricia L. Roberts

Diverticulitis is the fifth most costly gastrointestinal disease in the United States and accounts for approximately 300,000 admissions to acute care hospitals each year. For every patient admitted to the hospital, a much larger number are treated on an outpatient basis. In addition, about one third of colectomies and colostomies are performed for diverticular disease. In the last decade, the recommendations for evaluation and treatment of diverticulitis have changed markedly due to the widespread use of computed tomography (CT) scanning, further understanding of the natural history of the disease based on severity stratification between uncomplicated and complicated disease, and the adoption of minimally invasive techniques including laparoscopic colectomy and laparoscopic lavage.

ETIOLOGY AND PATHOPHYSIOLOGY

Diverticula are acquired lesions associated with aging. They are quite common and occur in 15% of individuals by the fifth decade and increase with time. By the ninth decade, over 70% of individuals have diverticula. While it is widely quoted that 10% to 25% of patients with diverticulosis develop diverticulitis over the course of their lifetime, a recent study suggests that the number is actually only 2% to 5%.

In the United States, over 95% of symptomatic diverticula occur in the sigmoid and descending colon. Diverticula in the sigmoid colon are “false diverticula” representing partial thickness herniations of the mucosa and muscularis mucosa at the point where the vasa recta enter the colonic wall. True diverticula include all layers of the bowel wall and are generally believed to be congenital. Right-sided diverticula may be true or false diverticula.

The classic teaching has been that the aging process and the Western diet that includes inadequate dietary fiber intake are the major risk factors for the development of diverticular disease. The fiber deficiency hypothesis was put forth by Painter and Burkitt based on their

observational studies on diet and stool transit time in Sub-Saharan Africa in the 1970s. The lack of fiber resulting in constipation was felt to lead to mucosal herniation from a process of segmentation, the development of high pressure in the sigmoid colon. They noted that diverticula were rare in underdeveloped nations who had a diet high in fiber and were more common in more developed countries with higher consumption of processed food and low fiber intake. The studies were performed when the life expectancy in such countries was low and thus, it is not clear if diverticula were not noted because the population did not live long enough. The common teaching that nuts, corn, seeds, and popcorn cause diverticulitis has been debunked by a detailed study of over 50,000 individuals in the US male health professionals study. They were followed for 18 years and ingestion of these foods did not increase the risk of diverticulitis. In fact, men who had higher consumption of most nuts and popcorn had a decreased risk of developing diverticulitis compared with men who had a lower consumption of these foods. The US Health Professionals follow-up study of 51,529 men noted the development of 385 new cases of diverticular disease over a 6-year period and noted an inverse association with insoluble fiber intake and the development of diverticular disease.

The ongoing practice has been to continue to recommend a high fiber diet to patients both to prevent the development of diverticula and presumably to decrease recurrent attacks of diverticulitis. Two recent studies have looked at the role of dietary fiber and the development of diverticular disease. Crowe and colleagues performed a prospective cohort study of 47,000 individuals in the United Kingdom assessing dietary factors and the risk of admission to the hospital or death from diverticular disease. Self-reported vegetarians had a 31% lower risk of developing diverticular disease and individuals in the highest fifth of dietary fiber intake had a 42% lower risk of hospitalization for diverticular disease compared with those in the lowest fifth of dietary fiber intake. A somewhat contradictory study was done by Peery and colleagues and looked at 2,014 individuals who were undergoing screening colonoscopy. They were assessed by a questionnaire on dietary fiber intake, and this information was compared to the presence of diverticulosis noted on the colonoscopy report. Diverticulosis was noted in 878 patients (41%). Surprisingly, increased fiber consumption was associated with an increased risk for the development of diverticulosis. In this study,

constipation was not a risk factor for the development of diverticulitis and patients who had regular bowel movements (defined as seven bowel movements per week) had a 34% chance higher risk of developing diverticula than patients with less than seven bowel movements per week.

The relationship between lack of dietary fiber and the development of diverticulitis continues to be evaluated, although there are relatively fewer recent studies. There are additional potential health benefits of fiber, and the current general practice is to continue to recommend a high fiber diet for individuals with diverticular disease.

While the major focus has been on environmental factors, there is increasing evidence of the contribution of genetic factors with respect to the development of diverticular disease. A Swedish study of over 100,000 twins showed that the odds ratio of a sibling developing diverticular disease was 7.15 for monozygotic twins and 3.2 for dizygotic twins. A nationwide study in Denmark showed similar results and suggested that there may be a “young onset cohort” of diverticular disease with high genetic susceptibility. Additional work from the Penn State Colorectal Disease Biobank has shown that mutations in the TNTFS15 gene are associated with a higher risk of severe diverticulitis requiring surgery.

Triggering factors for an attack of diverticulitis are largely unknown. Patients frequently report what they believe to be dietary triggers such as ingestion of a large quantify of popcorn or nuts, but there is no conclusive evidence that such dietary indiscretion causes diverticulitis. Several studies have cited obesity as a risk factor for the development of diverticulitis potentially from low-grade systemic inflammation. We have found a seasonal variation to the development of diverticulitis, similar to appendicitis. Analyzing the Nationwide Inpatient Sample, the largest all payer database of hospital discharges in the United States, the peak incidence of episodes of diverticulitis in the United States is August. Other investigators have shown similar findings and have also correlated low UV light exposure and low vitamin D levels with the development of diverticulitis.

CLINICAL PRESENTATION

The initial presentation for the majority of patients with acute diverticulitis is left lower quadrant pain, fever, and leukocytosis. An abdominal mass or fullness may be present. Patients with a redundant sigmoid colon, which extends from the left lower quadrant to the right side, may also present

with right-sided abdominal pain, which on occasion is confused with appendicitis. Urinary symptoms including pressure and urinary frequency may be present especially if there is a significant inflammatory phlegmon. The presence of pneumaturia or fecaluria is consistent with an associated bladder fistula. Some degree of obstipation may be present. Diarrhea may occur in association with diverticulitis but is more common with infectious diarrhea or inflammatory bowel disease. Bleeding is uncommon and more likely associated with inflammatory bowel disease, colorectal cancer, or ischemic colitis. The differential diagnosis is broad (Table 149.1). While the diagnosis of diverticulitis may be made on the basis of history and physical examination, CT has played an increasing role both in the diagnosis, staging of diverticulitis and for patients with diverticular abscess, the treatment of the disease. For patients presenting in the emergency department, CT is often obtained prior to evaluation and consultation by a surgeon. CT findings associated with a diagnosis of diverticulitis include colonic wall thickening; streaky fat consistent with inflammatory change; and the presence of abscess, extraluminal air, or air remote from the colon (Table 149.2). Ultrasound and magnetic resonance imaging (MRI) may also be used as alternatives; ultrasound is user dependent and may be limited in obese patients. MRI is generally not widely available at many centers for acute evaluation of abdominal pain.

TABLE 149.1 Differential Diagnosis of Diverticulitis

Appendicitis
Bowel obstruction
Colorectal cancer
Gynecologic disease
Kidney stones
Ischemic colitis
Inflammatory bowel disease
Irritable bowel syndrome
Urinary tract infection/pyelonephritis

TABLE 149.2 Severity of Computed Tomography (CT) Findings and Associated Outcomes

Severity Grading	CT Findings	Outcome
Moderate	■ Localized thickening of colonic wall ■ Inflammation of pericolic fat	■ Failure of medical treatment, 4% ■ Index episode (nonoperative) associated with 17% incidence of recurrence or complication
Severe	■ Localized thickening of colonic wall ■ Inflammation of pericolic fat ■ AND (at least one) ■ Abscess ■ Extraluminal air ■ Extraluminal contrast	■ Failure of medical treatment, 26% ■ Index episode (nonoperative) associated with 36% incidence of recurrence or complication

Data from Ambrosetti P, Becker C, Terrier F. Colonic diverticulitis: impact of imaging on surgical management: a prospective study of 542 patients. *Eur Radiol* 1002;12(5);1145–9; and Regenbogen SE, Hardiman KM, Hendren S, Morris AM. Surgery for diverticulitis in the 21st century-a systematic review. *JAMA Surgery* 2014;149(3):292–302.

Depending on the severity of disease, patients may be treated as an inpatient or outpatient. Patients who are ideal candidates for outpatient treatment are able to tolerate po; are reliable with no cognitive, social, or psychiatric impairment; are not immunosuppressed; and have no signs of toxicity. Dietary restriction to either clear liquids or a low residue diet is common, but not supported by evidence. Outpatient management compared with inpatient management, when appropriate, saves costs to the health care system. Antibiotics aimed at coverage of gastrointestinal flora have been the mainstay of treatment with the prevailing wisdom that diverticulitis represents a primary bacterial infection with associated microperforation. This presumption has been challenged by an alternate hypothesis suggesting that diverticulitis represents an inflammatory process. Several studies have looked at treatment with no antibiotics with equivalent results to patients treated with antibiotics. The AVOD (antibiotics in uncomplicated diverticulitis) study was a multicenter study that looked at 623 patients with uncomplicated left-sided diverticulitis diagnosed by CT scan. Patients were randomized to be treated with intravenous fluid or intravenous fluid and antibiotics. There was no difference in outcome in patients treated with antibiotics versus those patients who were not treated with antibiotics. A subsequent Cochrane review of three randomized trials of patients with uncomplicated diverticulitis who were randomized to antibiotics or no antibiotics had the same findings. These studies challenge our conventional principles with

respect to treatment of diverticulitis. The studies on omitting antibiotics have been done on inpatients, and there are no studies thus far of outpatient treatment omitting antibiotics.

Following treatment of uncomplicated diverticulitis, the majority of patients improve and have no further attacks of diverticulitis. Current clinical practice guidelines recommend colonic evaluation approximately 6 to 8 weeks following recovery from an attack of diverticulitis to visualize the mucosa and exclude another diagnosis such as inflammatory bowel disease or cancer (in patients who have not had recent colonic evaluation).

MANAGEMENT OF UNCOMPLICATED DIVERTICULITIS AND INDICATIONS FOR SURGERY

The previous teaching for recommendations for surgery was to recommend resection after two attacks of uncomplicated diverticulitis (Fig. 149.1) and after one attack of complicated diverticulitis. The number of attacks is no longer a determinant in recommending surgery, and recommendations are individualized based on a number of patient- and disease-related factors, including the risk of subsequent attacks of diverticulitis, the severity of recurrent attacks of diverticulitis, the risk of perforation and the need for emergency surgery, and the risk for the development of complicated diverticulitis. Despite recommendations that the recommendations for elective sigmoid colectomy following recovery from uncomplicated diverticulitis should be individualized, the following factors (in my opinion) should be taken into consideration:

Risk of subsequent attacks of diverticulitis
Risk of developing complicated diverticulitis after recovery from an attack of uncomplicated diverticulitis
Risk of free perforation and the need for emergency surgery

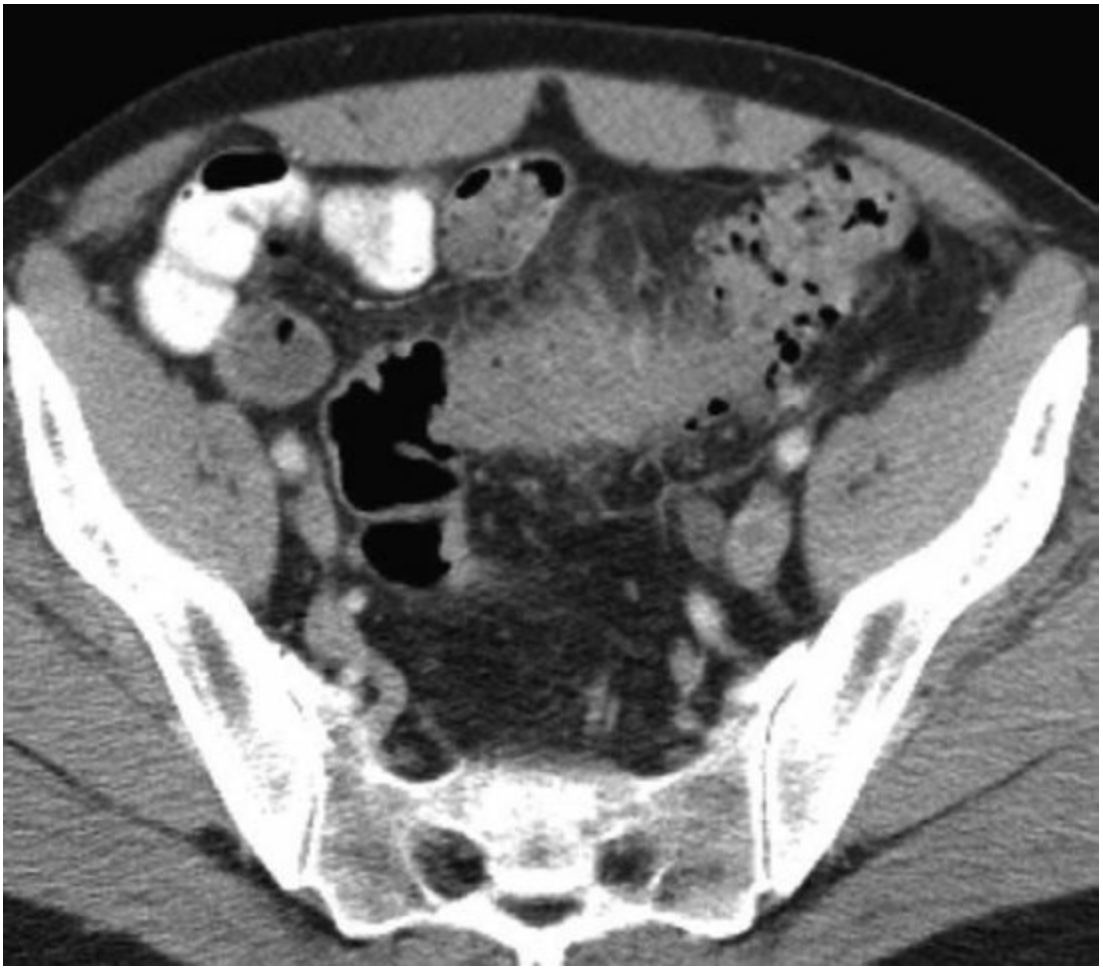

Figure 149.1. CT shows a long segment of uncomplicated diverticulitis.

Risk of Subsequent Attacks of Diverticulitis

Following recovery from an attack of uncomplicated diverticulitis, the risk of developing a subsequent attack of diverticulitis has been quoted as up to 30% to 36%. We have noted a risk of recurrence in 36% of patients who were hospitalized for diverticulitis and diagnosed by clinical criteria in addition to objective findings on CT scan. However, the majority of patients have no further attacks of diverticulitis, and therefore in approaching patients who have had one attack of uncomplicated diverticulitis, we should focus our attention on which patients are at high risk for the development of recurrent attacks of diverticulitis and which patients are at low risk. We have noted that patients with a long segment of diverticulitis (>5 cm) on CT scan and those with a family history of diverticulitis are at increased risk for subsequent attacks. A cohort of patients may also have multiple attacks over a short span of time. These patients most likely have an ongoing attack of diverticulitis that has not

totally resolved or what some groups have called “smoldering diverticulitis.” These patients fail to resolve symptoms despite multiple courses of antibiotics and require sigmoid resection.

Risk of Developing Complicated Diverticulitis

The clinical course of diverticulitis appears to be determined by the first attack. Patients who present with uncomplicated diverticulitis do not necessarily progress to have subsequent attacks of complicated diverticulitis. A number of large studies have noted that the risk of having a subsequent attack of complicated diverticulitis after recovery from an attack of uncomplicated diverticulitis is under 5%.

Risk of Developing Free Perforation/Risk of Requiring Emergency Surgery and Stoma After Recovery From an Episode of Uncomplicated Diverticulitis

Patients have often been counseled to have an elective sigmoid resection after recovery from diverticulitis to avoid requiring an emergency resection and possible stoma with a subsequent attack. However, a number of studies have shown that the most severe attack of diverticulitis tends to be the first attack and an emergency stoma and/or urgent Hartmann resection is rarely required. A population based study reviewed 25,058 patients with diverticulitis from 1987 to 2001. Emergency operation was required by 19.6% of patients on the initial attack. Of those patients who recovered, 5.5% required a subsequent emergency operation (7% of young patients). A systematic review of 85 papers showed that after recovery from one attack of diverticulitis, the risk of urgent Hartmann operation was 1 in 2,000 patient years follow-up. There is a cohort of patients at high risk for subsequent perforation after recovery from an uncomplicated attack of diverticulitis. Patients who are immunosuppressed, have chronic renal failure, or collagen vascular disease have a five times higher risk of perforation with subsequent attacks of diverticulitis and should be considered for resection.



Figure 149.2. CT shows severe diverticulitis with evidence of microperforation and free air.

Severity of Disease and Likelihood of Requiring Surgery

The widespread use of CT scanning as the initial modality in patients with suspected diverticulitis in addition to history and physical examination has allowed for a more thorough assessment and grading of the severity of disease. CT findings in diverticulitis include the presence of diverticular, pericolic inflammation, colonic wall thickening, and the presence of abscess or fistula. The findings that correlate with severe disease include the presence of abscess, extraluminal air, and extraluminal contrast, while the findings associated with mild disease include localized sigmoid wall thickening and inflammation of the pericolic fat (Fig. 149.2). The presence

of any of the severe findings on CT scan predicts a poorer outcome with a greater chance of recurrent disease and the need for surgical intervention. In a study of 312 patients with acute left colonic diverticulitis who underwent CT scanning, the findings of abscess and extraintestinal gas 5 mm in diameter or larger correlated with unfavorable outcome of nonoperative treatment.

We have also noted that patients with a longer segment of disease are more likely to have recurrent attacks of diverticulitis in addition to patients with a family history of diverticulitis. We have developed a scoring system based on points that we have used on inpatients to determine the risk of surgery within 90 days. The points are given for abscess >4 cm (2 points), pericolic free air (2 points), segment >5 cm (2 points), pericolic abscess (5 points), and distant free air (7 points). Patients with 0 to 4 points have a <25% risk of surgery in 90 days, patients with 5 to 9 points have a 25% to 50% risk of surgery, and patients with >9 points have over a 50% risk of requiring surgery within 90 days of presentation.

While recommendations for surgery for uncomplicated diverticulitis are individualized and consider the risks of operative therapy and the comorbid disease of the patient, colectomy should be strongly considered in those patients with multiple attacks of diverticulitis in a short time period and those patients who have ongoing diverticulitis (smoldering diverticulitis) with persistent symptoms. Inability to exclude carcinoma and significant impact on lifestyle are additional factors to consider.

Young Patients and Diverticulitis

The prior recommendations for resection after a single attack of diverticulitis in a young patient (defined as under the age of 50 years old) have been reexamined. From a historical standpoint, diverticulitis in younger patients was previously felt to be virulent and more likely to require surgery. All series of young patients with diverticulitis have a striking male predominance. Earlier series have shown a high rate of resection and may be because patients were operated on for a presumed diagnosis of appendicitis in the pre-CT scan era and found to have diverticulitis. Younger patients seem to have the same rate of recurrent diverticulitis but have many more years of life to develop recurrent disease. The clinical course of acute uncomplicated diverticulitis in young patients is similar to older patients, and therefore resection is generally not required after the first attack of diverticulitis. However, increasing

numbers of younger patients with diverticulitis are being seen and a cohort of younger patients appears to have more severe disease. We recently reviewed 932 patients treated with diverticulitis confirmed by clinical diagnosis and CT scan findings. There were 243 patients (26%) who were 50 years or younger. Young patients compared to the older cohort were more likely to present with severe disease on CT scan (22% vs. 12%) and more likely to have evidence of extraluminal air (22.4% vs. 13.15%, p = 0.014). Additional studies from the state of California have shown an increase in number of sigmoid colectomies and hospitalizations for diverticulitis, which was due to an increasing number of young patients with the disease.

COMPLICATED DIVERTICULITIS

Complicated diverticulitis includes patients with associated abscess, fistula, obstruction, and perforation and is further subcategorized as acute complicated diverticulitis (including diverticular abscess, perforation, and obstruction) and chronic complicated diverticulitis (including diverticular stricture an fistula). A large number of patients with complicated diverticulitis ultimately undergo sigmoid resection, and the goal of treating such patients is to optimize the patient condition and to ultimately convert an urgent or emergent operation into an elective procedure performed as a single stage with primary anastomosis and without the need for fecal diversion.

Diverticular Fistulas

Fistulas associated with diverticulitis may occur to any adjacent organ and include colovesical, colovaginal, coloenteric, and colocutaneous fistulas. Many patients with diverticular fistulas present with relatively fewer abdominal symptoms as the septic process has necessitated to an adjacent organ. Many patients present to another specialist first such as a woman with a colovaginal fistula presenting to a gynecologist with complaints of vaginal discharge.

Colovesical fistulas are the most common. Presenting signs and symptoms include pneumaturia, fecaluria, and polymicrobial urinary tract infections. In taking a history from the patient, there may be no obvious prior attack of diverticulitis. The best test to diagnose a colovesical fistula is a CT scan; the presence of air in the bladder in the absence of prior instrumentation is diagnostic of a fistula. While the majority of colovesical

fistulas occur from diverticular disease, it is important to exclude a diagnosis or colorectal cancer (which would change the operative approach). Cystoscopy or cystogram may also be utilized for evaluation. Colonoscopy is helpful to visualize the mucosa and exclude a diagnosis of a perforating colon cancer. The majority of patients with a colovesical fistula may undergo a single-stage open or laparoscopic sigmoid resection where the fistula is pinched off, omentum (if available) is used to interpose between the anastomosis and the bladder, and a Foley catheter is left in place. The fistula orifice to the bladder is sutured or if not readily apparent left in situ without suture repair. I do not routinely utilize ureteral stents, but they may be considered on a case-by-case basis, particularly in the presence of a significant inflammatory phlegmon. A cystogram is generally performed to confirm healing prior to removing the Foley catheter.

Colovaginal fistulas occur almost exclusively in women who have undergone prior hysterectomy. Presenting signs and symptoms include vaginal discharge and passage of air or stool per vagina. A limited gastrografin enema is helpful to delineate the fistula tract if it is not apparent on CT scan. On occasion a vaginogram is needed to delineate the fistula. A perforated colon cancer can present with similar signs and symptoms, and colonoscopy is helpful to visualize the mucosa. A similar operative approach is used to that of a colovesical fistula, pinching off the fistula (the vaginal side is generally left open for drainage and not sutured) and using omentum to interpose between the vagina and the anastomosis.

Colocutaneous fistulas may occur after percutaneous drainage of a diverticular abscess (in which case resection is generally the next step) or as a consequence of an anastomotic leak after a prior anastomosis. In a large series of 93 patients with colocutaneous fistulas, residual sigmoid colon distal to an anastomosis (i.e., not performing the anastomosis after sigmoid resection for diverticular disease to the proximal rectum) was a major risk factor for the development of such a fistula.

Diverticular Stricture

Strictures and resultant partial large bowel obstruction may also occur as a result of multiple attacks of diverticulitis. Many patients do not present with complete large bowel obstruction but rather with progressive constipation and obstructive symptoms. Once again, endoscopic visualization of the mucosa is helpful to exclude other diagnoses such as

colon cancer, ischemic colitis, or inflammatory bowel disease. Colonic stenting to treat large bowel obstruction from diverticular disease can be considered but is generally less successful than stenting for colon cancer.

Diverticular Abscess

Diverticulitis may be associated with an abscess in approximately 10% of patients hospitalized for diverticulitis (Fig. 149.3). The incidence of diverticular abscess had almost doubled from 5.9% in 1995 to 9.6% in 2005 in review of the discharge data from the Nationwide Inpatient Sample; the increase may be due to increased use of imaging with CT scan for evaluation of abdominal pain with increased detection of abscess and not a true increase in the number of patients with abscesses. A number of staging systems have been used, but the Hinchey system (with modifications thereof) remains the most commonly used (Table 149.3). Smaller abscesses (generally defined as <4 cm) may be treated with antibiotics without the need for percutaneous drainage or repetitive CT scans (particularly if the patient is clinically improving with decreasing pain, fever, and leukocytosis). A recent systematic review and meta-analysis looked at 22 studies with 1,051 patients with acute diverticulitis and abscess (modified Hinchey Grade IB and II). Percutaneous drainage was successful in 49% and antibiotics alone were successful in 14%. Urgent surgery was performed in 30% of patients, while 36% of patients had elective resection. Only 28% of patients had no recurrence of abscess and no surgery in the follow-up period.



Figure 149.3. CT shows adjacent abscess.

Perforated Divertculitis With Purulent or Fecal Peritonitis

The optimal treatment for perforated diverticulitis with associated peritonitis continues to evolve. Options include Hartmann resection, sigmoid resection with primary anastomosis (in selected patients), sigmoid resection and primary anastomosis with proximal diversion, on-table lavage with primary anastomosis, and laparoscopic lavage without resection. Hartmann resection, a procedure initially utilized for rectal cancer, remains one of the most common operations performed for perforated diverticulitis but has a number of drawbacks. Approximately one third of patients never undergo reversal of the stoma. The operation has considerable morbidity and a reported mortality of up to 18.8%. Over the years, a number of other surgical options have been proposed. Fibrin glue with suture repair and omental patching of the perforation has been reported. Two studies (both underpowered) looked at the role of defunctioning the diseased segment with suture of the peroration and proximal diversion versus resection and reached different conclusions. The

role of on-table lavage and subsequently performing a primary anastomosis in approaching patients with colonic emergencies has largely been abandoned since the need for bowel preparation has been challenged by a number of reviews. A systematic review of 569 cases from 50 studies suggested that primary anastomosis with or without diversion was "safe in certain patients with peritonitis" but noted a mortality of 9.9% and an anastomotic leak rate of 13.9%.

TABLE 149.3 Classification of Perforated Diverticulitis

Hinchey Classification
Stage I Pericolic abscess or phlegmon
Stage II Pelvic, intra-abdominal or retroperitoneal abscess
Stage III Generalized purulent peritonitis
Stage IV Generalized fecal peritonitis
Modified Hinchey Classification
Stage 0 Mild clinical diverticulitis
Stage Ia Confined pericolic inflammation/phlegmon
Stage Ib Confined pericolic abscess
Stage II Pelvic, distant intraabdominal or retroperitoneal abscess
Stage III Generalized purulent peritonitis
Stage IV Fecal peritonitis

Published in Hinchey EJ, Schaal PG, Richards GK. Treatment of perforated diverticular disease of the colon. *Adv Surg* 1978;12:85–109. Copyright Elsevier.

An additional trial randomized a total of 62 patients with left-sided colonic perforation (Hinchey Stage III or IV) to either Hartmann resection or primary anastomosis with fecal diversion (ileostomy). There was no difference in outcome after initial resection, and mortality and morbidity were no different. However, the rate of stoma reversal was higher in the primary anastomosis and ileostomy group (90%) compared to the

Hartmann resection group (57%). In addition, there was an increase in serious complications in the Hartmann takedown group and accrual in the trial was stopped.

An additional consideration is whether all patients with evidence of perforation require an operation. It is important to distinguish between patients who have evidence of peritonitis on physical examination and those patients who have CT findings consistent with perforation but no objective findings of toxicity. While many surgeons trained in the 1970s and 1980s were taught that the finding of free air on a chest x-ray or KUB was an absolute indication for laparotomy, the findings of free air on CT imaging do not necessarily translate into a similar recommendation. Dharmarajan and coworkers evaluated CT findings of perforated diverticulitis and devised a grading system based on the local and the amount of abnormal air, which may assist with clinical decision making. I rely more heavily on the clinical status of the patient and based my recommendations on these findings.

There has been renewed interest in the role of laparoscopic lavage without resection for treatment of patients with perforated diverticulitis and purulent peritonitis. The initial series in 1996 included 8 patients with perforated diverticulitis and purulent peritonitis who underwent laparoscopic lavage as the sole treatment with no interval resection. Following lavage, patients were maintained on intravenous antibiotics. At a follow-up of 12 to 48 months, no patients required subsequent resection and no patient required an emergent colostomy. The technique received little attention until the publication of a prospective multi-institutional trial in 2008 of 100 patients with perforated diverticulitis who underwent laparoscopic lavage. Lavage was carried out through umbilical, suprapubic, and right lower quadrant ports, with 4 L of fluid or until the returns were clear. No attempt was made to identify and/or suture the perforation. The median age was 62.5 years, and patients were followed for 36 months. Eight patients were found to have feculent peritonitis and converted to an open Hartmann procedure. Ninety-two patients were managed with laparoscopic lavage and no patient required subsequent resection for diverticulitis. Two patients developed a pelvic abscess in the postoperative period and required drainage and 2 patients presented with a subsequent attack of diverticulitis. The morbidity was 4% and the mortality was 3% much lower than what has historically been reported for the Hartmann procedure.

The role of lavage has continued to evolve. Questions to be answered include which patients should be selected for lavage, should patients have subsequent resection, and what are the long-term results. The number of patients who have undergone lavage remains small and in general includes small nonrandomized single institution studies. Many series include patients initially thought to have perforated diverticulitis but ultimately noted to have perforated colon cancer that highlights the importance of colonoscopic evaluation at some point in the postop period for patients in whom subsequent resection is not recommended. A recent review article evaluated 12 nonrandomized studies of 301 patients with a mean age of 57 years. Although the majority of patients had purulent peritonitis (Hinchey Stage III), 25% of the patients had Hinchey II disease. In the multi-institutional study of 100 patients reported in 2008, 25% of patients also had Hinchey II disease suggesting that some of these patients may have been appropriately treated with antibiotics and/or percutaneous drainage. The combined conversion rate was 4.9%, the complication rate was 18.9%, and the mortality was 0.25%. Subsequent resection was performed in 51% of patients, and the majority of resections were laparoscopic. The ideal candidate for lavage has not been identified, and further classification such as use of the Mannheim peritonitis index or the peritonitis severity score may help define such patients.

A number of clinical practice guidelines have been refined to include a statement on the role of lavage. The Association of Coloproctology of Great Britain and Ireland states that “laparoscopic lavage may play a role in some patients with acute diverticulitis. Whilst this is an alternative to resection in the acute setting for some patients, it is not certain whether it is an acute alternative to delayed resection.” The Clinical Practice Guidelines of the American Society of Colon and Rectal Surgeons states that “in patients with purulent or feculent peritonitis, operative therapy without resection is generally not an appropriate alternative to colectomy.” It was noted that a number of randomized controlled trials were underway that “may clarify the role of lavage in the management of patients with perforated diverticulitis.”

At least three randomized trials have or are in the process of looking at the role of laparoscopic lavage in the treatment of patients with perforated diverticulitis. The largest trial the SCANDIV trial randomized patients to laparoscopic lavage versus primary resection at 21 centers in Sweden and Norway. Of the 509 patients who were screened, 415 were eligible for

enrollment and 199 patients were ultimately enrolled. Patients with feculent peritonitis underwent resection. The primary outcome was severe postoperative complications within 90 days that occurred in 30.7% of patients in the laparoscopic group and 26.0% of patients in the resection group (no statistical difference). Reoperation was much higher in the lavage group (20.3% vs. 5.7%, $p = 0.01$). The authors concluded that lavage did not reduce severe postoperative complications and led to worse outcomes.

SURGICAL TECHNIQUE AND PREOPERATIVE ASSESSMENT

Elective Resection

The goal of treatment for acute diverticulitis is to convert an urgent or emergent operation into an elective procedure. After the decision has been made to proceed with elective sigmoid resection, a 4- to 6-week waiting period is generally recommended to allow the inflammatory phlegmon to resolve and maximize the change of an uncomplicated single-stage resection. For patients who have not had recent evaluation of the colon, colonoscopy is performed to evaluate the more proximal colon and exclude other pathology such as an underlying colon cancer or inflammatory bowel disease. While mechanical bowel preparation is not necessary prior to colon surgery, my preference is for a mechanical bowel preparation. Recent data suggest that the inclusion of oral antibiotics decreases the risk of surgical site infection. Bowel preparation also makes handling of the colon easier (particularly helpful with laparoscopic surgery) and facilitates passage of the stapler through the rectum. Standard intravenous antibiotic prophylaxis is administered as is deep venous thrombosis prophylaxis. Enhanced recovery pathways are used for appropriate patients. Ureteral stents may be employed selectively and are move commonly used for reoperative surgery or in patients with an associated hydronephrosis from the inflammatory phlegmon.

Single-stage sigmoid resection may be performed by an open or laparoscopic technique. A laparoscopic technique results in lower length of stay, quicker recovery, and less pain. Increasing numbers of colectomies for diverticular disease are performed by a laparoscopic approach, and there are increasing data of a lower incidence of surgical site infections and sepsis, less postoperative ileus, and less adhesions with laparoscopic

surgery. The Sigma trial, a prospective randomized trial at five centers of laparoscopic versus open sigmoid resection, showed a longer operating time, less blood loss, less pain, and improved quality of life (as measured by the SF 36) with a laparoscopic approach and more major complications (9.6% vs. 2.5%) with an open approach.

Open Sigmoid Colectomy

The patient is positioned on the operating room table in lithotomy position or if available, our preference is supine with the legs abducted on the split leg table. A Foley catheter is inserted. The abdomen is entered through a vertical midline incision and exploration carried out. For a lateral to medial approach, the line of Toldt is incised and the colon is retracted medially. In the course of the dissection, the ureter and gonadal vessels are identified and preserved. Prior phlegmon or inflammation may make identification of these structures difficult; in such cases, staying close to the bowel and not performing a wide resection of the mesentery mitigate the risk of injury to the ureter. Some studies have suggested that preservation of the superior rectal artery may improve blood flow and decrease the risk of anastomotic leak. Dissection is carried down to the pelvic brim/sacral promontory and distally as needed to allow for passage of a sizer and ultimately the circular stapler. Splenic flexure mobilization is generally performed to facilitate a tension-free anastomosis. The proximal resection margin is soft pliable bowel, and the distal resection margin is the proximal rectum as evidenced by where the tenia splay out. The extent of resection is the sigmoid colon. It is helpful to place a sizer through the rectum to ensure adequate mobilization and subsequent easy passage of the circular stapler. The rectum is transected with a linear stapler, and a pursestring is placed in the proximal bowel. If there has been a significant prior phlegmon, it is occasionally necessary to resection a portion of the rectum to get to pliable bowel. A hand-sewn or stapled anastomosis may be performed; a stapled anastomosis is generally preferred with the circular stapler. An air leak test is performed to test the integrity of the anastomosis by occluding the bowel proximal to the anastomosis and insufflating through a proctoscope or flexible sigmoidoscope with the pelvis filled with saline. Standard abdominal closure is performed.

Laparoscopic Colectomy (Straight)

The preoperative considerations are similar to open surgery with exceptions of consideration of prior surgery and body mass index.

Adhesions from prior abdominal surgery may preclude the ability to safely perform a laparoscopic resection. Morbidly obese patients should be counseled of a higher risk of conversion because of technical challenges with a laparoscopic procedure (although on occasion, a laparoscopic approach is easier than an open approach on such patients) or even the inability of patients to physiologically tolerate Trendelenburg position that is needed in the course of the resection. The patient is placed on the split leg table with the legs abducted or if such a table is not available in modified lithotomy position. The arms are tucked and the patient is secured to the table with a beanbag and with taping.

Entry into the abdominal cavity is either by a Hasson technique (which we prefer) or with a Veress needle and pneumoperitoneum is established. Port placement may vary based on patient anatomy and surgeon preference but generally includes a supraumbilical port, right and left lower quadrant ports, and a right upper quadrant port. A lateral to medial or a medial to lateral approach for mobilization of the colon may be employed depending on the surgeon's preference.

For a lateral to medical approach, the sigmoid and rectosigmoid are retracted medially and incision is made along the line of Told and continued up toward the splenic flexure and down to the sacral promotonory/rectosigmoid junction. The ureter and gonadal vessels are identified. The peritoneum is incised and a window created to ligate the inferior mesenteric artery. The ureter can at times be confused with the superior rectal artery, and both should be identified prior to transection.

With laparoscopic surgery, there has been a trend to perform medial to lateral mobilization. This technique allows for immediate identification of the plan between the retroperitoneum and the mesocolon. The inferior mesentery artery is identified and transected, and the colon is then mobilized along the line of Toldt (Fig. 149.4). Both techniques are safe, and it is helpful for the surgeon to be facile with both techniques. A significant inflammatory phlegmon and foreshortened mesentery as is seen in cases of recurrent diverticulitis can render the medial to lateral technique difficult and at times impossible to accomplish.

Proximal and distal resection margins are identified as outlined above and anastomosis is more commonly done extracorporeally, although an intracorporeal anastomosis may also be performed. Air leak testing is routinely performed.

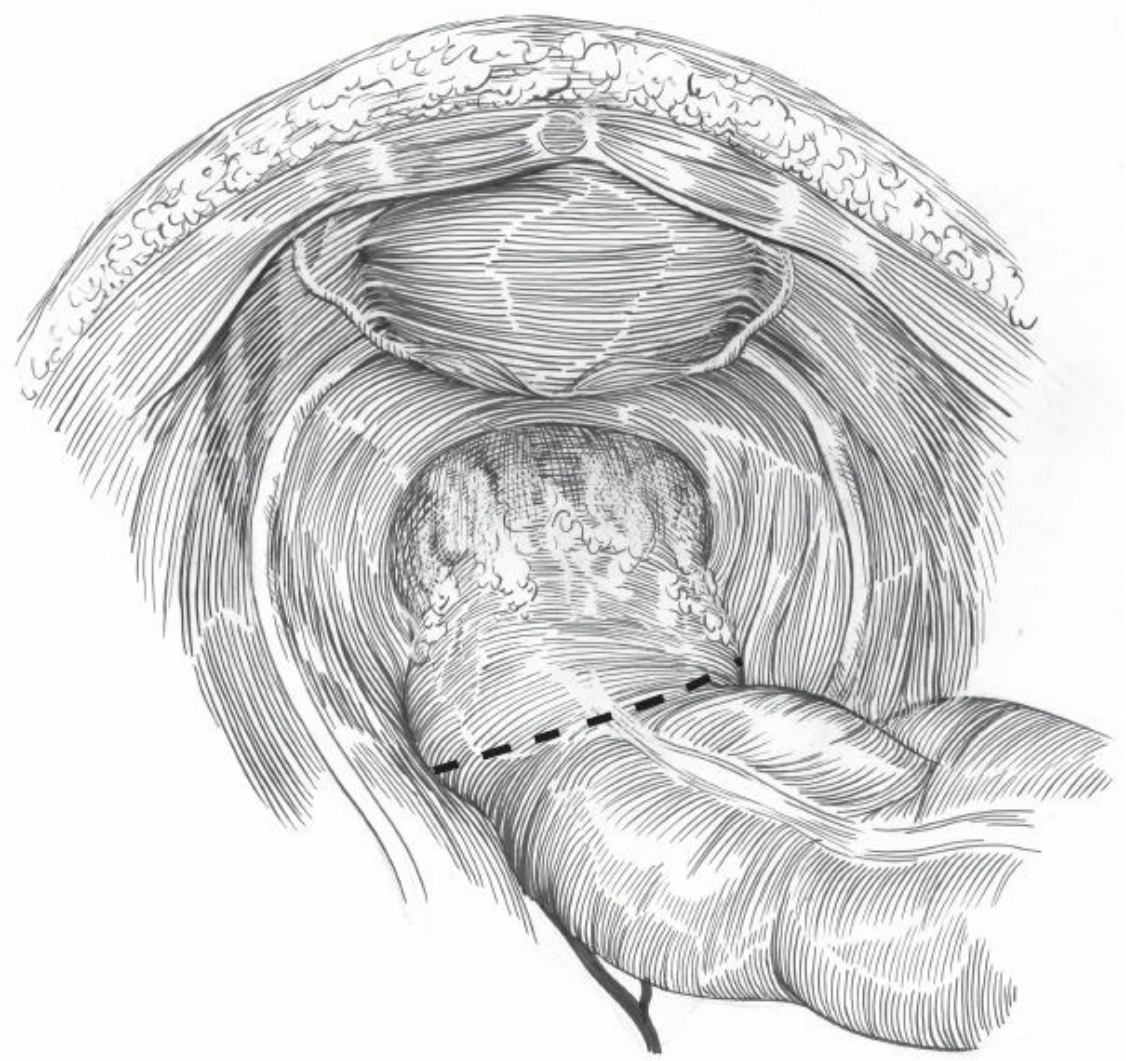

Figure 149.4. The distal resection margin should be in the proximal rectum where there are no diverticula and the tenia splay out.

Hand-Assisted Laparoscopic Sigmoid Colectomy

The indications for use of the hand-assisted laparoscopic sigmoid colectomy are the same as for straight laparoscopic procedures. Hand-assisted colectomy may be used for all procedures or selectively. Earlier studies showed better adoption of laparoscopic surgery with a hand-assisted technique for novices in addition to shorter operative times with no difference in short-term results. Insertion of the hand may facilitate dissection in cases with significant fibrosis or phlegmon where the ability to use a hand to “pinch off” adhesions is helpful. Some studies have shown a lower conversion rate with a hand-assisted technique compared to a straight laparoscopic technique. In addition, if a straight laparoscopic technique is used, a hand-assisted approach may offer an alternative to

conversion of an open procedure.

The patient is positioned on a split leg table with the legs abducted or in a modified lithotomy position if such a table is not available. The incision for the handport can be placed in the midline or as a Pfannenstiel incision. The camera port is placed in the supraumbilical position, with working ports in the right lower quadrant and left lower quadrant. The patient is placed in Trendelenburg position with the small bowel retracted cephalad. A medial to lateral or lateral to medial dissection may be performed. Our preference is the medial to lateral approach that is accomplished by grasping the inferior mesenteric artery with the right hand, incising the peritoneum and ultimately sweeping the ureter and gonadal vessels to the retroperitoneum, transecting the artery with a stapler, endoloop, or an energy sealing device and then proceeding medially to laterally to mobilize the sigmoid colon up toward the splenic flexure and inferiorly to the pelvis. The specimen is ultimately extracted through the hand port and anastomosis generally performed with a circular stapler. Air leak testing is routinely performed. The Pfannenstiel and port sites are closed in routine fashion.

Robotic Sigmoid Resection

Robotic-assisted sigmoid resection may be performed for sigmoid diverticulitis, but the overall benefit of this technique compared to laparoscopic resection has not been determined.

Emergency Procedures

Hartmann Resection

The Hartmann resection was originally described in 1923 as an alternative to abdominoperineal resection in patients with rectal cancer. The procedure quickly became the procedure of choice for the majority of patients who underwent surgery for perforated diverticulitis in the second half of the 20th century, replacing the three-stage procedure of initial colostomy, subsequent resection, and ultimately colostomy takedown that was advocated by Lockhart Mummery and Smithwick. It is commonly performed for perforated diverticulitis associated with purulent peritonitis or fecal peritonitis and for other urgent or emergent resections for diverticulitis. While a laparoscopic approach may be performed, it is more commonly done by an open approach in the emergency setting.

The patient is fluid resuscitated and antibiotics and DVT prophylaxis

are administered. Stoma marking is performed by an enterostomal nurse (if available) or the surgeon. The abdomen is entered through a midline incision and explored. The sigmoid colon is retracted medially and mobilized ultimately identifying ureter and gonadal vessels and if not possible, keeping the dissection and ultimate mesenteric transection as close to the colon as possible. The proximal transection line is ultimately in soft pliable bowel that will have adequate length to bring up a tension-free colostomy in the left lower quadrant. Splenic flexure mobilization is often necessary. The distal transection point is ultimately the proximal rectum; however, one option is to only resect the perforated segment leaving a portion of the distal sigmoid. This facilitates the subsequent reversal surgery as the pelvic peritoneum has not been opened and the residual sigmoid colon may be resected at this time.

Laparoscopic Lavage

Nonresectional treatment for diverticulitis associated with purulent peritonitis has had renewed interest. Laparoscopic lavage is performed with a three-port technique with a camera port in the supraumbilical site and two other working ports in the right upper, right lower quadrant and/or suprapubic area. The diagnosis is confirmed and the abdomen lavaged with saline until the returns are clear. If fecal peritonitis is present or if the site of perforation is noted, most surgeons convert the procedure to a sigmoid resection with fecal diversion. There have been anecdotal reports of laparoscopic repair of the perforation. If lavage is performed, it is essential to ensure the patient has had a recent colonic evaluation and if not, consider colonoscopy to exclude a diagnosis of perforated colon cancer.

Reoperative Surgery

Reoperative surgery for complicated diverticular disease occurs for two main reasons—as a planned procedure to restore intestinal continuity after resection, stoma, and Hartmann closure of the rectum or as an unplanned procedure to treat complications or unanticipated events after initial resection and primary anastomosis. Hartmann takedown still has appreciable morbidity and mortality and up to a third of patients, for a variety of reason, never have the stoma reversed.

Hartmann Takedown (Reversal)

After Hartmann resection for perforated diverticulitis, most patients are eager to proceed as soon as possible with reversal of the stoma. These patients often had never been ill before and had never anticipated leaving the hospital with a stoma after treatment for diverticulitis. Reversal surgery may be undertaken early (<3 months from the initial surgery) or later (>3 months from the initial procedure). There are advocates of each approach and no randomized trials to guide recommendations. Proceeding with Hartmann takedown close to the time of initial surgery has several disadvantages, predominantly due to adhesions and the acute inflammatory response after initial surgery that may lead to a difficult dissection, potential enterotomies, and difficulty with identification of the Hartmann stump. While waiting for at least 3 months will presumably allow the patient sufficient time to heal and facilitate identification of the Hartmann stump, waiting longer may make identification of the stump more difficult secondary to fibrosis.

Prior to surgery, my preference, especially if I have not performed the original procedure, is to perform a gastrografin enema through the rectum to provide an assessment of the length and configuration of the rectal segment and give an assessment of any residual sigmoid colon and/or diverticula. Another advantage to this procedure is that residual fecal residue is evacuated, which ultimately helps with passing the circler stapler and sizer. Colonoscopy or barium enema is performed through the stoma, and my preference is a mechanical bowel prep prior to surgery. The patient is positioned in low lithotomy position or (preferably) on the split leg table with the legs abducted. The procedure may be done in an open or laparoscopic fashion and some have advocated use of a “peek port” to assess the degree of adhesions and then proceeding with either laparoscopic or open surgery. Initial dissection is focused on lysing adhesions of the small bowel to be able to identify the Hartmann pouch; in the majority of cases, this involves lysing all adhesions from the ligament of Treitz to the ileocecal valve. With few exceptions, there are generally small bowel adhesions or omental adhesions to the top of the Hartmann. While some have advocated tacking the top of the Hartmann with a long suture, I have rarely found this helpful. Passing a scope or sizer per rectum is more useful to identify the Hartmann. It is also common for the ovary and fallopian tubes to be adherent to the top of the Hartmann pouch. Ureteral stents can be used at the preference of the surgeon and do not prevent ureteral injury but facilitate the recognition of such injury.

Mobilization of the Hartmann is carried out as needed to be able to easily pass a sizer. My preference is to re-resect the top of the Hartmann pouch. The stoma is taken down and resected, a pursestring suture is placed, and the anvil secured. My preference is a circular stapled anastomosis but a handsewn anastomosis may also be performed. In cases where it is difficult to pass the stapler, the trocar can be brought through the anterior rectal wall, performing an end to colon, and side to rectum anastomoses. Standard air leak testing is performed.

POSTOPERATIVE CARE

Postoperative care following elective colon resection has been relatively standardized with early mobilization, DVT prophylaxis, minimization of narcotic pain medications, and early postoperative resumption of diet. Nasogastric tubes are not routinely used. Enhanced recovery pathways are frequently employed.

Following emergency colon surgery and the fecal diversion, patients are instructed, generally by an enterostomal nurse, in the care and pouching of the colostomy or ileostomy.

OUTCOME AFTER RESECTION

Following resection, combined series report a postoperative infection rate of 10% to 20% with the higher rates including patients with a higher proportion of urgent compared with elective operations.

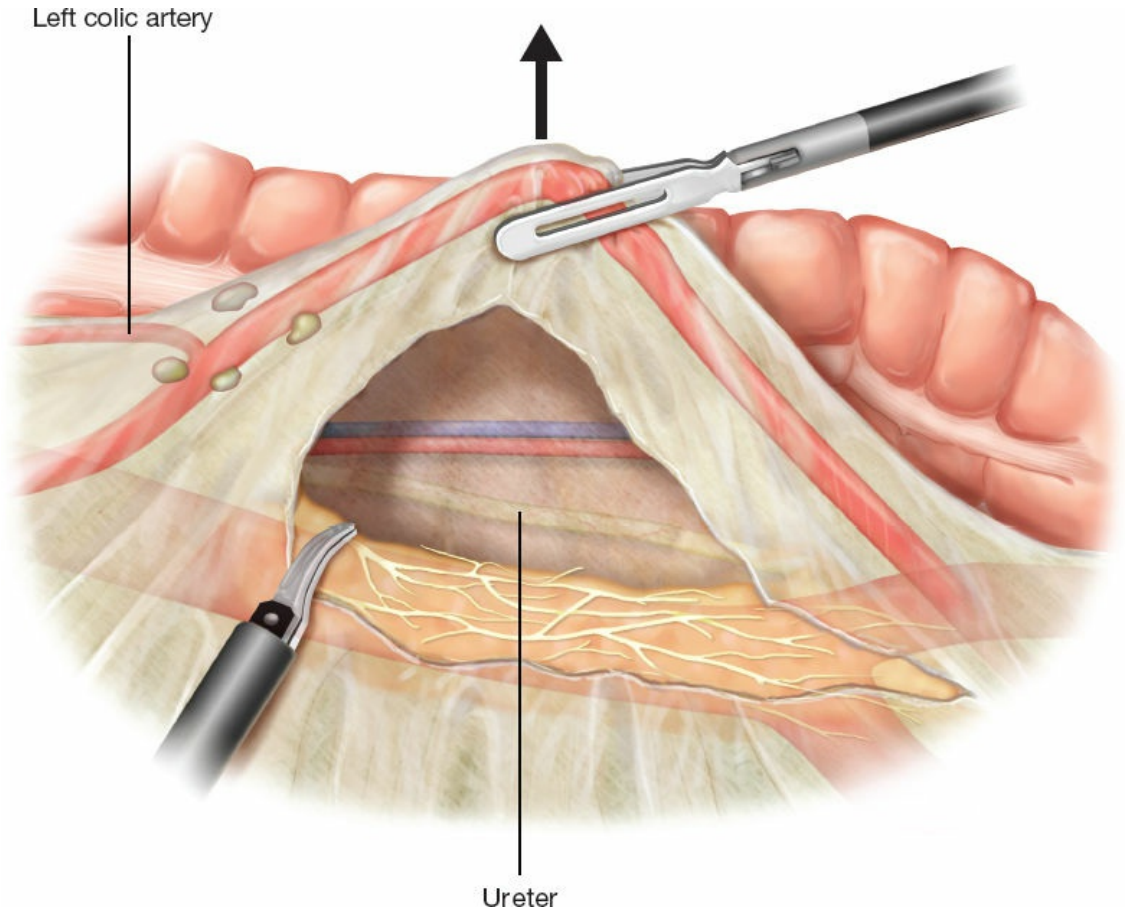

Figure 149.5. During laparoscopic mobilization of the colon during sigmoid resection, a medial to lateral approach is utilized and the inferior mesenteric artery retracted anteriorly toward the abdominal wall. The ureter and gonadal vessels are swept down to the retroperitoneum.

Risk of Persistent Abdominal Symptoms After Resection

In series with patient-reported outcomes, most patients had some relief of symptoms following resection. There are, however, a number of patients who have persistence of abdominal symptoms following resection for diverticulitis in the absence of documented recurrent diverticulitis. Therefore in approaching patients with recurrent abdominal symptoms following resection for diverticulitis, one must distinguish between other causes of abdominal pain such as irritable bowel syndrome and functional disease from recurrent diverticulitis. In one series, 22% of patients noted ongoing diffuse chronic abdominal pain despite sigmoid resection.

Risk of Recurrent Diverticulitis After Resection

Two studies have specifically addressed the risk of recurrent diverticulitis

following sigmoid resection and have similar results. Benn and colleagues reviewed 501 patients who underwent sigmoid resection for diverticular disease at the Mayo Clinic. In 321 patients, the anastomosis was performed to the distal sigmoid colon and 12.5% of patients had recurrent diverticulitis. Anastomosis to the proximal rectum was performed in 180 patients who had a 6.7% incidence of recurrent diverticulitis. The authors concluded that the distal resection margin should be the proximal rectum (as evidenced by the area where the tenia fan out) to decrease the risk of recurrent diverticulitis (Fig. 149.5). A subsequent study at the Cleveland Clinic of 236 patients who underwent sigmoid resection for diverticular disease had similar conclusions and the risk of recurrent diverticulitis was four times higher in patients who had a colosigmoid versus a colorectal anastomosis. Of interest, there has been little focus on the proximal resection margin and clinical practice guidelines suggest that the margin should use "soft, pliable bowel." It has also been suggested that "limited resections" have a greater tendency to develop recurrent symptoms, and the Association for Coloproctology of Great Britain and Ireland has suggested that the splenic flexure should be routinely mobilized in patients undergoing resection for diverticulitis. As the bowel tends to be somewhat foreshortened in diverticular disease, mobilization of the splenic flexure is often necessary to perform a tension-free anastomosis. An additional study showed no relationship between an emergency index procedure and the development of recurrent diverticulitis.

CONCLUSION

Diverticulitis is one of the most common gastrointestinal diseases. The trends in management of acute diverticulitis over the last decade have been guided by a greater understanding of the disease and a more "personalized" approach to the patient. For uncomplicated disease, the evidence suggests that resection may be safely avoided. In the future, selective resection in the acute setting and further refinements in the role of laparoscopic surgery may further drive decision making. The role of triggering factors, UV light exposure and vitamin D, and the role of genetics may allow us to further individualize and improve our management of diverticular disease.

Suggested Readings

Connelly TM, Berg AS, Hegarty JP, et al. The TNFSF15 gene single nucleotide

polymorphism rs784647 is associated with surgical diverticulitis. *Ann surg* 2014;259;1132–7.

Feingold D, Steele SR, Lee S, et al. Practice parameters for the treatment of sigmoid diverticulitis. *Dis Colon Rectum* 2014;57:284–94.

Hall JF, Roberts PL, Ricciardi R, et al. Colonic diverticulitis: does age predict severity of disease on CT imaging. *Dis Colon rectum* 2010;53(2):121–5.

Lamb NM, Kaiser AM. Elective resection versus observation after nonoperative management of complicated diverticulitis with abscess: a systematic review and meta-analysis. *Dis Colon Rectum* 2014;57:1430–40.

Maguire LH, Song M, Strate LL, et al. Association of geographic and seasonal variation with diverticulitis admissions. *Jama Surg* 2015;150(1):74–7.

Oberkofler CE, Rickenbacheer A, Raptis DA, et al. A multi-center randomized clinical trial of primary anastomosis or Hartmann's procedure for perforated left colonic diverticulitis with purulent or feculent peritonitis. *Ann Surg* 2012;256:819–27.

Regenbogen SE, Hardiman KM, Hendren S, et al. Surgery for diverticulitis in the 21st century. A systematic review. *JAMA Surg* 2014;149(3);292–302.

Ricciardi R, Roberts Pl, Read TE, et al. Cyclical increase in diverticulitis in the summer months. *Arch Surg* 2011;146(3):319–27.

Schultz JK, Yacub S, Wallon C, et al. Laparoscopic lavage vs primary resection for acute perforated diverticulitis. The SCANDIV randomized clinical trial. *JAMA* 2015;314(13):1364–75.

Templeton AW, Strate LL. Updates in diverticular disease. *Curr Gastroenterol Rep* 2013;15:339.

EDITOR'S COMMENT

Fewer operations have undergone such a dramatic change over the last 20 years as have operations performed for sigmoid diverticulitis. Dr. Roberts's chapter clearly addresses many different aspects of surgery for diverticulitis, the chapter containing many priceless pearls of surgical technique hidden among its pages. However, before we address these, some comments are in order about diverticulitis itself especially in today's healthcare environment. It is not unusual for a surgeon to see a patient in the office referred to them for "surgery for diverticulitis." The patient comes, attesting to "x" number of attacks of diverticulitis over an "y"-month period. Invariably, upon questioning, the surgeon learns that these "attacks" were treated by the primary care or referring physician with the antibiotics, usually ciprofloxacin and/or metronidazole, and rarely were accompanied by documentation of fever, leukocytosis, or CT

changes compatible with acute diverticulitis. In many cases, the main symptom initiating prescription of an antibiotic is merely the presence of left lower quadrant abdominal pain. Sadly, much of our current knowledge and literature of diverticulitis is biased by such patients. Do these patients really have diverticulitis? Or do they just have irritable bowel syndrome? That is the real question. Many of these attacks that are empirically treated by family physicians or others with antibiotics, whether by placebo effect or spontaneous improvement on their own, defervesce. Some of these same patients are sent for unindicated operations.

As with the development and wide acceptance of laparoscopic cholecystectomy, the development and dispersal of laparoscopic colectomy has made the indications for colectomy much more “acceptable” for patients, as well as surgeons. As with many other types of operations, the “easier access” provided by laparoscopic surgery has decreased the threshold for surgery in the minds of both the surgeon and the patient. This can be seen most clearly in a recent report by Flum and colleagues using the Washington State Comprehensive Hospital Abstract Reporting System (CHARS) database (Simianu VV, Strate LL, Billingham RP, et al. The impact of elective colon resection on rates of emergency surgery for diverticulitis. *Ann Surg* 2016;263(1):123–9). Review of a 25-year period from 1987 to 2012 showed a more than a doubling in the rate of elective colon resection, with an increase in the number of laparoscopic procedures from 17.5% in 2008 when the laparoscopic code was introduced to 47.5% in 2012! Of note, during this same time period, there was also an increase in the rate of emergent/urgent colectomy, an increase in the number of nonelective percutaneous interventions, as well as an increase in the rate of nonelective hospital admissions for diverticulitis. In other words, the people who were operated upon were possibly not the high-risk patients who are likely to develop complicated diverticular disease. In the US current health care climate, where one would like to optimize resource allocation, this does not bode well!

One of the most valuable items in Dr. Roberts’s chapter is the scoring system she provides to predict the likelihood of patients hospitalized with diverticulitis to require surgery within the next 90 days. Identifying patients at high risk of needing further surgery remains the crux of patient selection in this complicated and heterogeneous group of patients. As a recent systematic review has pointed out, the overall recurrence rate of patients hospitalized for acute diverticulitis remains quite low, with approximately 13% experiencing a recurrence and 4% a second recurrence over 8.9 years follow-up (Morris AM, Regenbogen SE, Hardiman KM, et al. Sigmoid diverticulitis: a systematic review. *JAMA* 2014;311(3):287–97). As is highlighted, the risk of a sepsis decreases rather than increases with each recurrence, stressing proper patient selection in order to identify appropriate individuals to which to recommend surgery.

Among the most useful technical points that Dr. Roberts provides is the importance of constructing the distal anastomosis to the upper rectum and not to

the colon. If one does not do this and constructs a colo-colic anastomosis (with retained distal sigmoid colon) as opposed to a colorectal anastomosis, one has both a higher risk of recurrent diverticulitis and a higher risk of leak and subsequent colocutaneous fistula. Dr. Roberts also stresses the importance of constructing anastomoses using pliable bowel. This applies to the proximal anastomosis using pliable bowel not affected with the muscular hypertrophy of severe diverticular disease to lessen the risk of recurrence of diverticulitis. The use of pliable bowel, however, also applies to the distal bowel, as is the case when there is a significant pelvic phlegmon. In such cases, the proximal rectum may be so indurated that a stapler will not easily close across it. In this scenario, resection of the top segment of the rectum to a softer segment is warranted. The same applies to the Hartmann stump in the setting of closure of a colostomy, where the end of the Hartmann may be too fibrotic or narrowed and may need to be resected further to facilitate construction of the anastomosis.

Other important tips for performing a secure colorectal anastomosis include splenic flexure mobilization to provide for a tension-free anastomosis as well as performing air leak tests whenever one is constructing a colorectal anastomosis. This is not described in detail in the chapter, but merely involves instilling air (via either rigid or flexible sigmoidoscope) just distal to or through the anastomosis, while the colon proximal to the anastomosis is occluded (either with a clamp or manually) and the anastomotic site is covered with saline. Any sign of air bubbles coming from the anastomosis denotes a leak, which can then be repaired primarily and/or diverted with a loop ileostomy at the surgeon's discretion. A gastrografin enema performed prior to planned closure of a Hartmann procedure allows the surgeon to assess the anatomy as well as helping to empty the rectum of retained fecal matter and inspisated mucus, thereby facilitating subsequent transanal passage of a circular stapler.

Lastly, Dr. Roberts touches on an unresolved issue in colon and rectal surgery, the issue of laparoscopic lavage for perforated diverticulitis. This is still an issue of controversy. In the last few months, prospective randomized trials with contradictory findings have been published (Schultz JK, Yaqub S, Wallon C, et al.; SCANDIV Study Group. Laparoscopic lavage vs primary resection for acute perforated diverticulitis: the SCANDIV randomized clinical trial. *JAMA* 2015;314(13):1364–75; Angenete E, Thornell A, Burcharth J, et al. Laparoscopic lavage is feasible and safe for the treatment of perforated diverticulitis with purulent peritonitis: the first results from the randomized controlled trial DILALA. *Ann Surg* 2016;263(1):117–22). This will likely require much more study such as a meta-analysis to assimilate results of multiple trials with different primary outcome measures and sample sizes.

Notwithstanding the above, it is important for the surgeon to be aware of the changing trends in management of diverticular disease. There is now a variety of operations, and types of access that can be chosen from, ranging from traditional open resections, to laparoscopic, to robotic to the ultimate "no touch" surgery of laparoscopic lavage, perhaps combined with suturing of the area of

colonic perforation. In fact, one of my acquaintances who was traveling in England recently told me that his wife had an episode of acute diverticulitis there. She was hospitalized, underwent surgery with a laparoscopic lavage and oversewing of the colonic perforation. All turned out well; however, what a dramatic change in surgical behavior and outcome! Only time and long-term follow-up will tell regarding the ultimate outcome of such procedures. One thing is, however, certain: many patients who undergo conventional sigmoid resection and Hartmann procedure for diverticular disease never have their colostomies closed. Also, such colostomy closure after a Hartmann procedure can in itself be a very morbid procedure and itself result in significant complications and problems for the patient.

Susan Galandiuk

150 Technique of Colostomy Construction and Closure

Aaron Saunders and Moshim Kukar

INTRODUCTION

Multiple methods and indications for colostomy creation exist, and techniques may be tailored to the patient in complex circumstances. The surgeon will select either an end colostomy or a loop colostomy, and should be capable of constructing these both with conventional open maneuvers when laparotomy has been otherwise required, and with minimally invasive techniques, particularly when the only indication for surgery is fecal diversion or decompression. In all cases, a properly functioning stoma that minimizes patient inconvenience and morbidity will depend upon meticulous planning and construction, ideally with thorough preoperative counseling of the patient.

INDICATIONS

Colostomy creation may be necessary after colon or rectal resection for benign or malignant disease. Creation of a colostomy may also be necessary when performing emergency laparotomy for trauma or peritonitis, including proximal diversion for penetrating rectal trauma or when Hartmann procedure is performed for perforated diverticulitis. A colostomy may also be needed for fecal diversion in other situations, such as a patient with incontinence and/or nonhealing decubitus wounds, or for decompression of distal obstruction, as in a patient with an obstructing tumor or benign stricture from inflammatory bowel disease or radiation injury. Indications for colostomy should be considered permanent or temporary, and care should be taken in construction to maximize durability of a permanent stoma, to facilitate future closure of a temporary stoma, and to maximize function and minimize morbidity of both. A permanent colostomy will generally be an end colostomy, while either an end or a loop colostomy can be constructed with the intent for later reversal. When not contraindicated, a loop colostomy should be preferred in patients with

a temporary indication, because reversal of a loop colostomy can often be achieved with less morbidity compared to an end colostomy.

PREOPERATIVE PLANNING

When a colostomy is to be created electively, preoperative counseling and psychological preparation of the patient are desirable. Meeting with an enterostomal therapist at least once prior to surgery is helpful. Print and multimedia materials are also available for patient education, and patients may additionally be referred to support groups for individuals with stomas.

Selecting an appropriate location for colostomy placement is of great importance. The objective is to provide an anatomically stable opening, facilitating reliable placement of an ostomy pouch that will not leak or require frequent replacement. A poorly placed stoma is likely to cause inconvenience and morbidity to the patient and may ultimately require surgical revision. Locating the site for the stoma is frequently made more challenging by obesity, or by prior surgical scars and associated irregularity in abdominal wall musculature. Therefore, when possible, an appropriate site should be identified and marked with the patient awake, and confirmed in supine, seated, and bending positions. An appropriately sized piece of stoma equipment or prepared disk of the same dimensions is used. Particularly when complex surgery is planned, it is prudent to identify acceptable alternative sites. Once the optimal sites are determined, the skin is marked with indelible ink, or in some cases tattooed, so that when the abdomen is prepared and opened and the anatomic relationships are distorted, the correct site is used. The site selected in an average individual is a few centimeters inferolateral to the umbilicus, overlying the rectus abdominis (Fig. 150.1A).

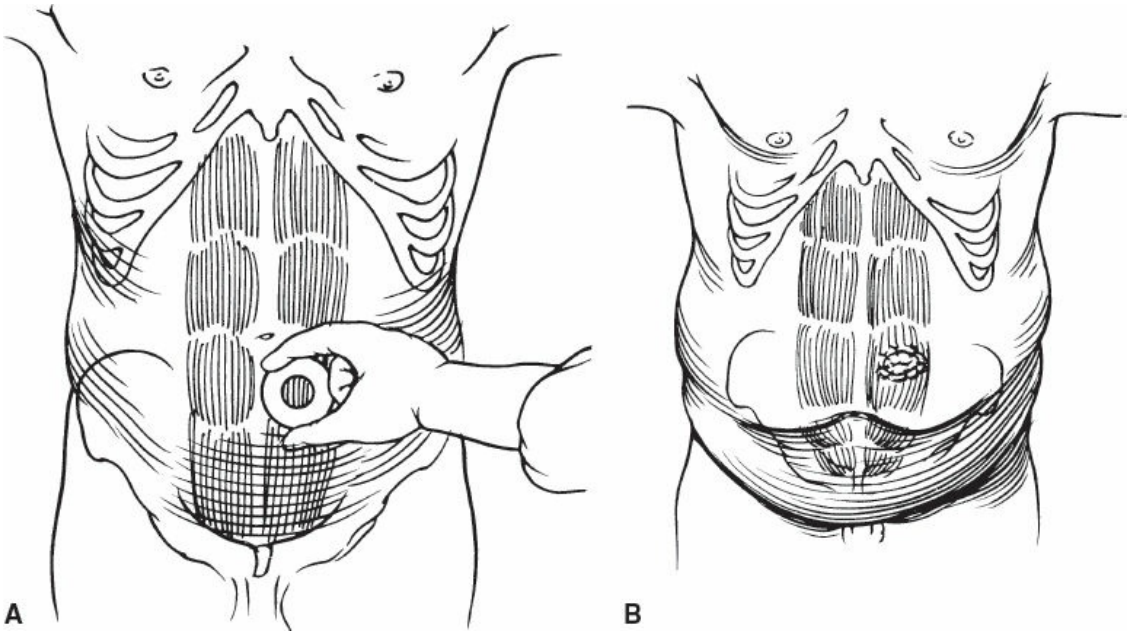

Figure 150.1. In a normal abdomen, the colostomy site is often marked a few centimeters inferolateral to the umbilicus, overlying the rectus abdominis (**A**). In an obese patient, it may be necessary to choose a site in the upper abdomen where it will be visible to the patient and the surrounding skin will be appropriate for pouch placement (**B**).

The primary consideration is that the stoma is constructed where it will be visible to the patient (i.e., not located on the inferior surface of a pendulous abdomen). The stoma should be away from the umbilicus, skin creases, scars, and bony prominences. Skin damaged by radiation or skin grafts should be avoided. In an obese individual with a large pannus, the stoma may be located in the upper abdomen, away from creases, where it will be visible and surrounded by a flat skin surface (Fig. 150.1B).

APPROACH AND EXPOSURE

Laparoscopic Surgery

Both loop and end colostomies can be constructed with either conventional open or laparoscopic techniques. When the sole indication for surgery is creation of a colostomy, we prefer a minimally invasive approach. Initial access is obtained in the infraumbilical midline with a Hasson technique. A vertical incision is carried down to the linea alba, which is exposed with retractors and incised vertically. The preperitoneal fat is divided, and the peritoneum is lifted and sharply opened. A sweep of the surgeon's finger confirms peritoneal entry and absence of adherent abdominal content. Stay

sutures are placed in the fascia and a 12-mm Hasson port is advanced and secured in position. Alternatively, a Veress needle is advanced into the peritoneal space at either Palmer point or infraumbilically, confirming position with a saline drop test. Pneumoperitoneum is then achieved and the laparoscope is inserted with a 5-mm transparent port at the infraumbilical location, allowing visualization of abdominal wall layers and the point at which the port enters pneumoperitoneum.

Based on preoperative planning and findings of laparoscopy, a selection is typically made between the transverse colon and the descending or sigmoid colon for colostomy creation. If the descending or sigmoid colon is to be used, two 5-mm ports are placed in the right upper quadrant and the right lower quadrant, respectively (Fig. 150.2A). If the transverse colon is to be used, the two ports will be placed on the right side of the abdomen and in the hypogastric region, respectively (Fig. 150.2B). If use of a stapling device is necessary, the lower of the two 5-mm ports can be upsized to a 12-mm port. Ports should be placed away from the costal margin, anterior superior iliac spine, and pubis, to prevent a fulcrum effect that would limit range of motion for the laparoscopic instruments. It is crucial to place the ports under visualization, to avoid inadvertent injury to viscera or vasculature.

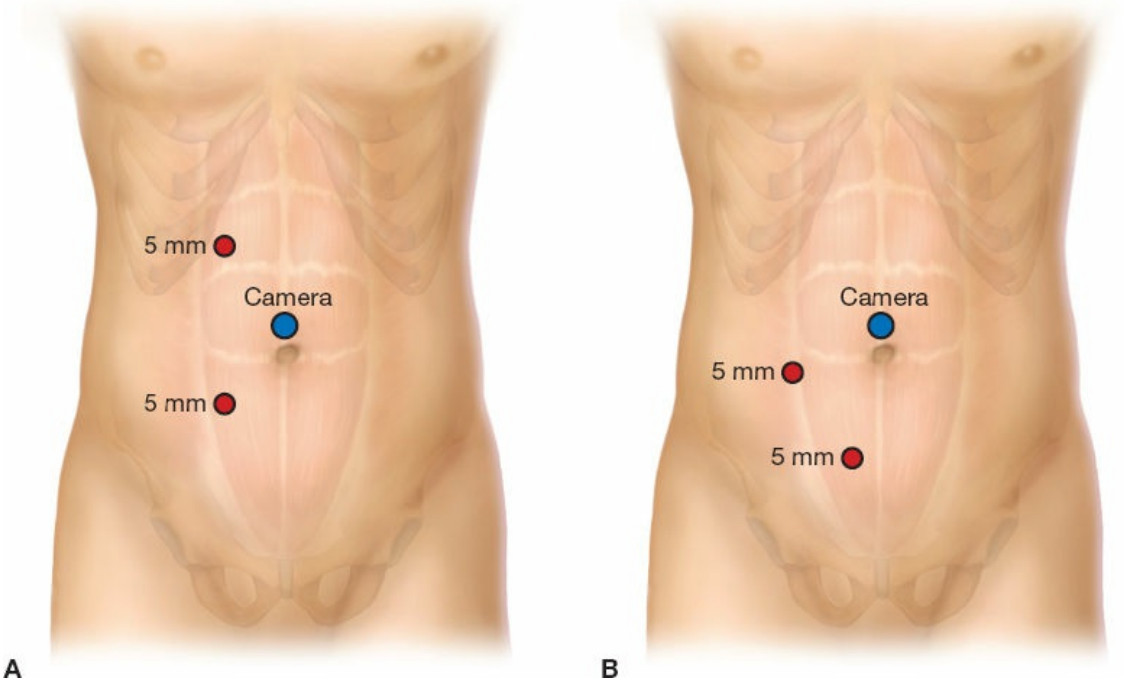

Figure 150.2. Suggested laparoscopic port placement sites for descending or sigmoid colostomy creation (**A**) or distal transverse colostomy creation (**B**).

Open Surgery

When the surgeon considers that stoma creation may be included in an open abdominal operation, or contraindications to pneumoperitoneum or laparoscopy exist, a midline laparotomy incision is recommended so that bilateral rectus sheaths and all quadrants of the abdominal wall are preserved for stoma siting and possible subsequent stoma revision or relocation. The length and position of the incision is dictated by the target segment of bowel for resection or the need for exposure in emergency or trauma laparotomies. A self-retaining abdominal wall retractor is used to provide exposure of the target segment of colon. The small bowel is gently packed away from the field of view. When other maneuvers are included in the operative plan, colostomy construction is typically reserved for the reconstruction phase of the case, after other objectives have been achieved.

PREPARING THE COLON

Unless the selected segment of colon is extremely redundant or has previously been mobilized, it is generally necessary to mobilize the colon from some attachments. The goal is for the colon to reach a level 3 to 4 cm above the skin surface without tension. This helps to protect perfusion and prevent retraction. In laparoscopic cases, it is helpful to remember that pneumoperitoneum exaggerates the distance the colon must cover. Mobilization of the descending colon commences at the peritoneal reflection in the left paracolic gutter, with sharp division extending superiorly along the white line of Toldt (Fig. 150.3). Dissection can then be carried medially in the avascular plane anterior to the gonadal vessels and the ureter. The more obese the patient, the more mobilization may be necessary, and in some cases splenic flexure mobilization is required. Mobilization and preparation of the transverse colon typically includes partial release of the omentum and may also require mobilization of the hepatic or splenic flexure.

It is absolutely essential that the colon to be brought out for colostomy creation has adequate perfusion. Careful observation should confirm that it is pink and appears well perfused. If there is a cut edge, the blood flow should be bright and pulsatile. Doppler examination of the mesenteric blood flow can also be performed to help confirm intact perfusion. This is of particular importance when a colostomy is performed in conjunction with a rectal or rectosigmoid resection for cancer. In this situation, sacrifice of the inferior mesenteric and/or left colic arteries may be

necessary to achieve adequate lymphadenectomy (Fig. 150.4). When this is done, the collateral circulation via the marginal artery to the distal extent of the remaining left colon must be carefully evaluated and preserved. If compromised perfusion of the end intended for colostomy construction is suspected, it should be cut back to a healthy, bleeding edge. If Doppler examination or visual inspection suggests that the marginal artery supply is insufficient, the remaining left colon is removed so that the new transection edge is at the distal transverse colon and perfused via the middle colic artery.

If an end colostomy is planned, the colon is frequently divided with a stapling device, and the stapled end is left in place until it has been delivered through the abdominal wall. If there is an open end or colotomy, it should be closed with suture before it is delivered. This allows the bowel to be brought through the abdominal wall with minimal contamination.

If a loop colostomy is planned, the loop of colon that will reach the marked stoma site with the least tension is identified. Taking care not to injure the blood supply, a window is dissected through the mesocolon adjacent to the bowel wall. A Robinson catheter is placed through this window and both ends are grasped together. These ends will later be delivered through the stoma site and used to place gentle traction on the colon and guide the loop into position.

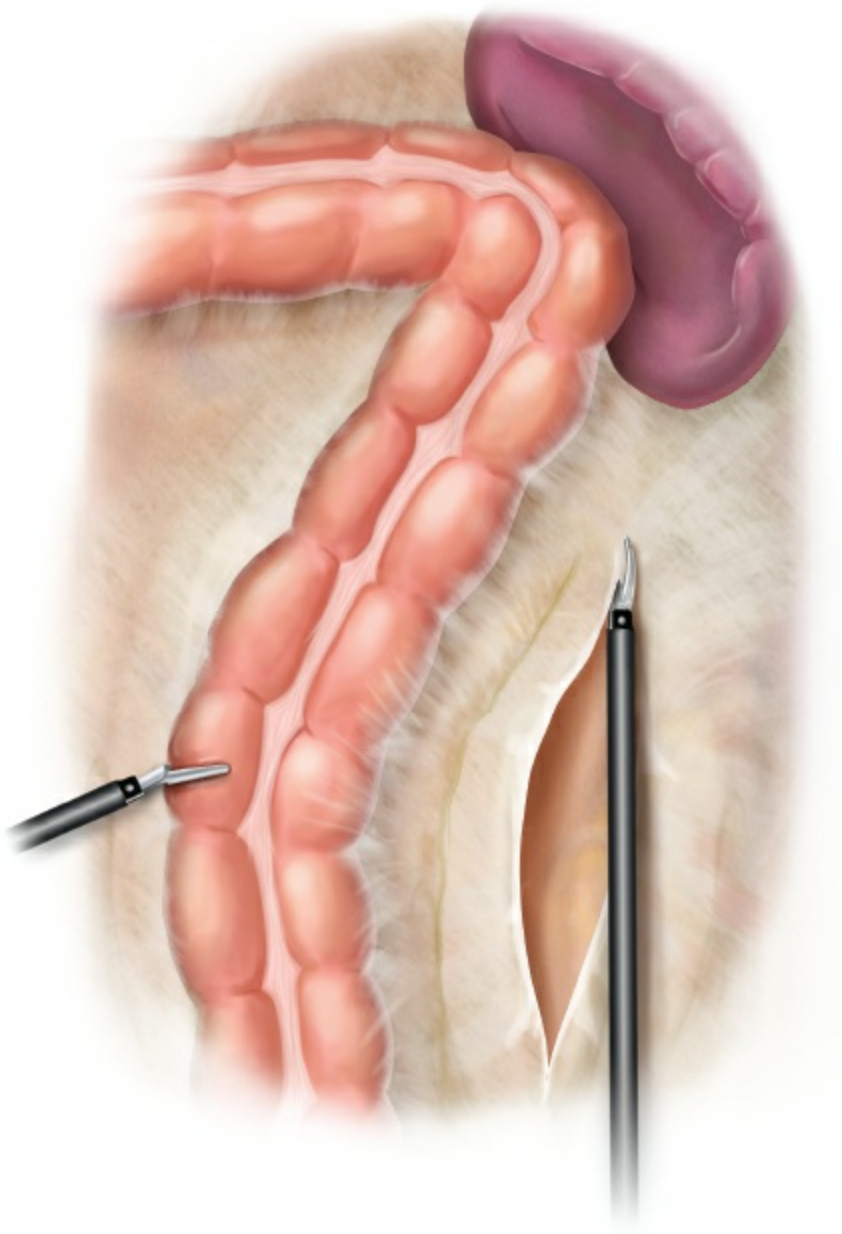

Figure 150.3. Incising the peritoneal attachments of the left colon along the line of Toldt. (Reprinted from Wexner SD, Fleshman JW. *Colon and Rectal Surgery: Abdominal Operations (Master Techniques in Surgery)*; LWW; 2011.)

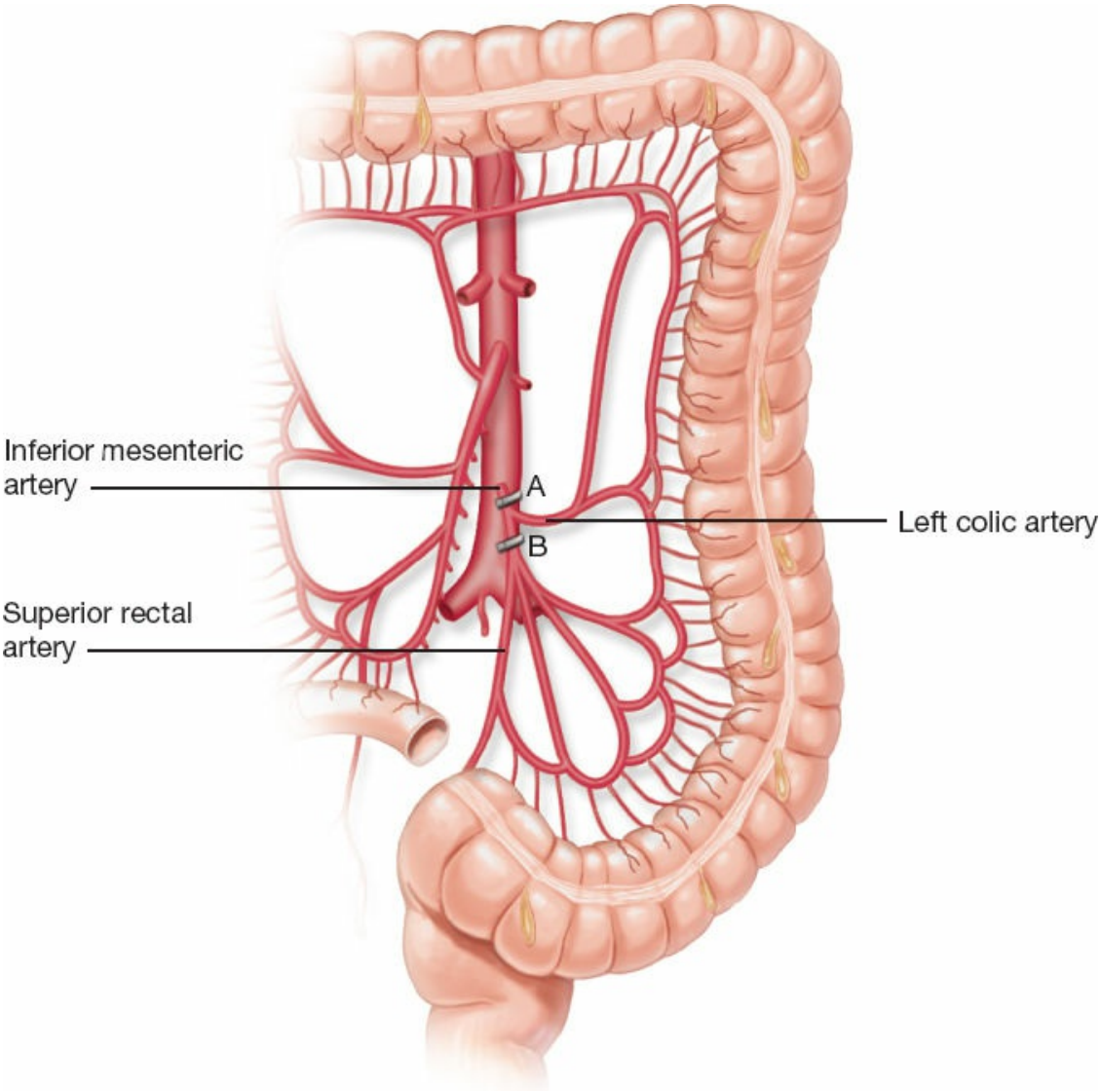

Figure 150.4. A rectal or rectosigmoid resection for cancer may require a high ligation of the inferior mesenteric artery (**A**) for adequate lymphadenectomy, devascularizing the left colic artery so that perfusion to the remaining descending colon is based on collateral flow through the marginal artery. The left colic artery is preserved in low ligation (**B**). (Reprinted from Wexner SD, Fleshman JW. *Colon and Rectal Surgery: Abdominal Operations (Master Techniques in Surgery)*; LWW; 2011.)

PREPARING THE STOMA SITE

Attention is then turned to preparation of the stoma site. In open surgery, the layers of the abdominal wall are held in anatomic alignment with the help of clamps placed at the edge of the rectus sheath and dermis. A circular incision of 2 to 3 cm diameter is made at the marked location using a scalpel or cutting monopolar device, and this disk of skin is

removed. The subcutaneous fat is then incised vertically, down to the anterior rectus sheath. A linear or cruciate incision is made in the anterior rectus sheath, and the exposed rectus muscle is split longitudinally by spreading with a blunt instrument perpendicular to the line of the muscle fibers. This procedure results in little or no bleeding unless the deep inferior epigastric vessels are lacerated posterior to the rectus muscle. Caution should be taken to avoid this injury, as it can cause troublesome bleeding. If necessary, hemostasis is secured by ligating the vessel. In open surgery, this is achieved by reflecting the abdominal wall to reveal the peritoneal surface of the operative field, where the vessel can be exposed. Otherwise, the vessel must be exposed by retracting the rectus muscle fibers through the colostomy site wound.

Once the rectus muscle has been split, the fibers are retracted medially and laterally, and the posterior rectus sheath is longitudinally incised. In open surgery, a lap sponge is held behind the posterior rectus sheath to prevent inadvertent injury (Fig. 150.5A). The opening through all layers of the abdominal wall should be large enough to permit passage of two average-sized fingers up to the second phalanx. Gentle, blunt dilation of the opening may be performed with the insertion of the surgeon's fingers (Fig. 150.5B). Creating an opening larger than this will increase the risk of parastomal herniation or prolapse, although it is sometimes necessary to extend the opening in situations involving bulky mesentery or an unusually thick abdominal wall. The technique of routing the stoma through the split rectus muscle maximizes durability of the colostomy, as the intestine is supported by the rectus muscle fibers as well as the fibers of the anterior and posterior rectus sheaths.

CONSTRUCTION TECHNIQUES

After preparation of the stoma opening, the prepared end or loop of colon is gently delivered through the abdominal wall so that 3 to 4 cm protrudes without tension. This is performed with a Babcock clamp placed through the abdominal wall at the stoma site and placed on the end of divided colon, which is then delivered into position. Alternatively, for a loop, this is accomplished by delivering the ends of the Robinson catheter through the stoma site and placing gentle traction on the colon to guide the portion for loop colostomy into place. Torsion of the colon on its mesentery must be avoided. The protuberant colon should be critically inspected for any signs of ischemia, such as a shift to a dusky or purple hue. If this is

observed, the bowel should be returned into the abdomen. The size of the opening should be assessed to ensure that it is not too tight, potentially causing compression of the blood supply. If it is, the opening is enlarged. The colon should be seen to regain perfusion before the delivery maneuver is reattempted. In laparoscopic cases, visualization is maintained under low-pressure insufflation to confirm the correct orientation of the bowel and mesentery.

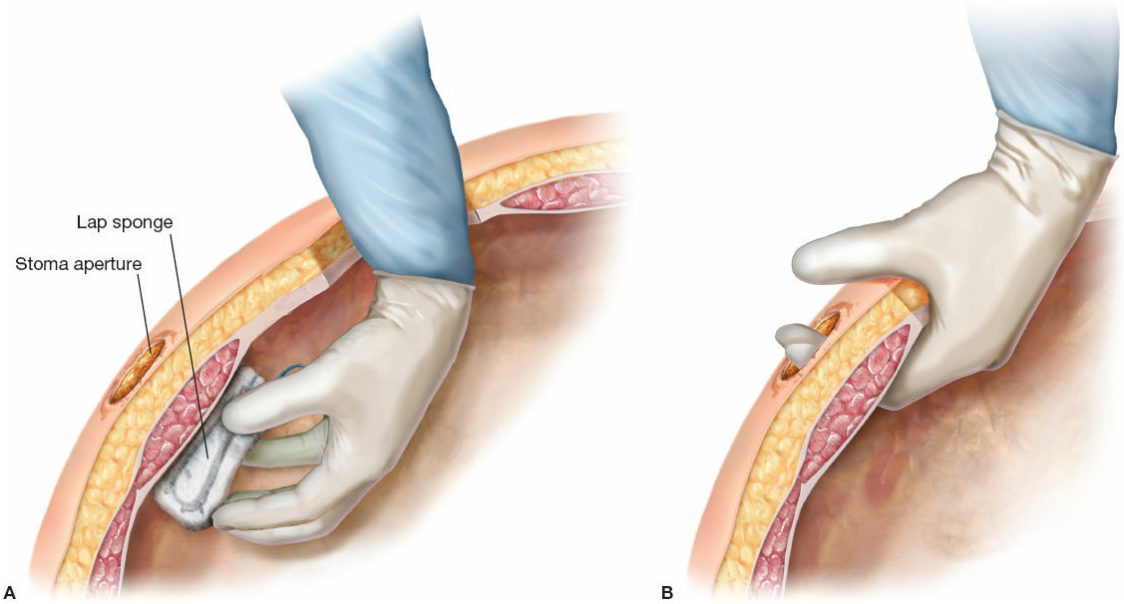

Figure 150.5. A lap sponge may be held behind the abdominal wall to place the tissues on stretch and protect the abdominal organs (**A**). Two fingers are passed through the opening, and may be used to gently dilate (**B**). (Reprinted from Wexner SD, Fleshman JW. *Colon and Rectal Surgery: Abdominal Operations (Master Techniques in Surgery)*; LWW; 2011.)

The remainder of the intraperitoneal operation is now completed and abdominal wounds are closed, including the skin. All incisions are covered to prevent contamination during the maturation of the colostomy. For an end colostomy, the terminal staple line or suture line is then excised. It is reassuring to see bright and pulsatile bleeding from the cut edge; judicious use of cautery at the edge may be used to slow this and prevent subsequent hematoma formation. The stoma is then everted with the placement of four to eight sutures at equal intervals around the circumference of the stoma, for a partial Brooke technique, using 3-0 absorbable suture. These are three-point sutures that create eversion of the stoma end by including the dermis, full-thickness colon wall at the cut edge, and a seromuscular “bite”

of colon wall 2 to 3 cm away from the cut edge (Fig. 150.6). Care must be taken to avoid placing a suture through any perfusing vessels. Additional simple stitches are placed to complete approximation of the colon edge to the dermis. Some surgeons elect to mature the colostomy flush with the level of the skin using simple interrupted stitches.

For a loop colostomy, a transverse colotomy is made on the downstream aspect of the loop. This incision should be long enough to allow eversion of the stoma without causing a tear in the bowel wall. Sutures are placed at equal intervals around the circumference of the stoma in the Brooke fashion, as above, and additional simple stitches are placed as needed. The ends of Robinson catheter that was used for are sutured together so that the catheter is used as a bar to prevent retraction. Alternatively, the catheter may be replaced with a commercially available rod for this purpose. This will be removed 1 to 2 weeks later. Once a colostomy has been matured, a stoma appliance is placed. If the stoma works in the early postoperative period, the appliance will prevent contamination of other surgical sites and spare the patient the indignity of fecal spillage.

PROPHYLACTIC MESH PLACEMENT WITH PERMANENT END COLOSTOMY

When creating a permanent end colostomy, as in the case of a patient undergoing abdominoperineal resection, attention is given to minimizing the risk of subsequent parastomal herniation. Reinforcement of the permanent end colostomy with a prophylactic placement of onlay mesh, also known as the modified Sugarbaker technique, has been evaluated in a few small, randomized trials. It is associated with decreased rates of parastomal hernia formation and no difference in other colostomy-related complications. Thus, it appears to be safe, and may prevent subsequent need for reoperation. In this technique, a macroporous, synthetic mesh with antiadhesiogenic coating is placed as an onlay over the intraperitoneal aspect of the colostomy. The mesh should be large enough to cover a 4- to 5-cm margin in all directions from the stoma opening. It is secured to the abdominal wall on three sides (superior, medial, and inferior) with absorbable suture or laparoscopic fixation device, leaving space for the colon on the lateral side.

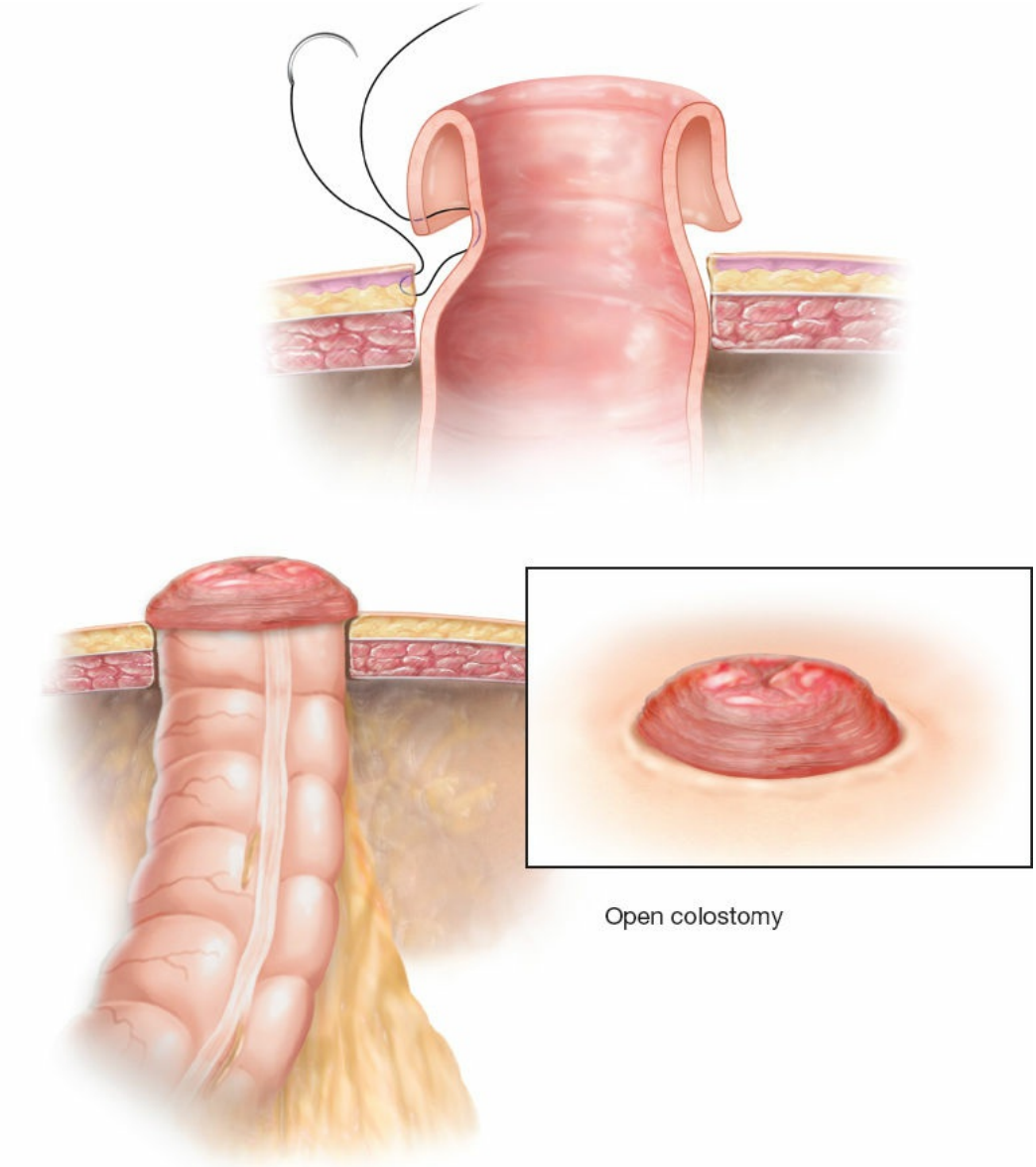

Open colostomy

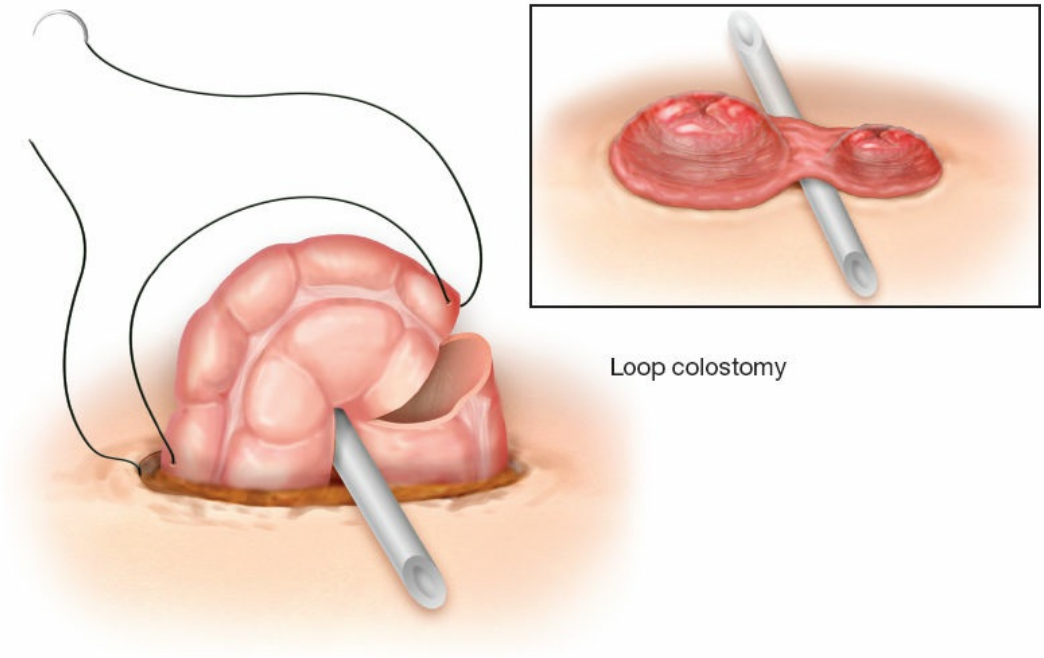

Loop colostomy

Figure 150.6. The colostomy is matured with a partial Brooke technique, using three-point sutures that incorporate the full thickness of the bowel wall at the cut edge, a seromuscular purchase of the bowel wall a few centimeters proximal, and the dermis. This creates eversion of the matured stoma.

SPECIAL CONSIDERATIONS

Obesity

The morbidly obese patient increases the difficulty of every aspect of colostomy construction. Preoperative marking of a stoma site on flat skin where the patient will be able to see and reach it becomes both more challenging and more crucial. Colon mobilization must be more extensive to allow the colon to reach the skin without tension. Removal of a portion of omentum from the colon, scoring of the visceral peritoneum leaflets over the mesentery, or even division of the inferior mesenteric vein at the inferior border of the pancreas are all maneuvers that can provide significant additional length, when necessary.

It is unwise to have an opening in the abdominal wall so small that it is a struggle to bring the bowel through. The opening in all layers of the abdominal wall, except the skin, must frequently be made significantly larger in order to allow passage of the colon with its mesentery up to the skin level without compression of the blood supply, which would lead to ischemia and stoma necrosis. Moreover, if the incision in the abdominal wall is too small, attempts to bring the colon to the skin cause trauma to the mesentery and to the blood vessels to the bowel. Although creating a larger defect increases the risk of parastomal hernia formation, this is preferable to having an ischemic or stenotic stoma in the immediate postoperative period. Once the bowel is positioned correctly, a loose layered closure of the abdominal wall defect is performed around the bowel and mesentery within the abdominal wall. Additional interrupted stitches of absorbable suture may be placed between the seromuscular layers of the bowel and the fascia or parietal peritoneum of the abdominal wall to provide support and perhaps decrease the risk of parastomal hernia.

Ascites

When construction of a colostomy in a patient with ascites is unavoidable, every effort should be made to minimize ascites leakage around the stoma site. This can be helped with extraperitoneal tunneling of the colon. The

peritoneum is divided in the paracolic gutter and blunt dissection is used to create a wide tunnel in the extraperitoneal plane to the abdominal wall opening (Fig. 150.7). Additional colon mobilization may be necessary to cover this additional distance without tension. With bowel satisfactorily in position, the tunnel is closed by suturing the cut edge of the peritoneum to the serosa of the bowel and to the mesentery, taking care not to compromise the blood supply to the colostomy.

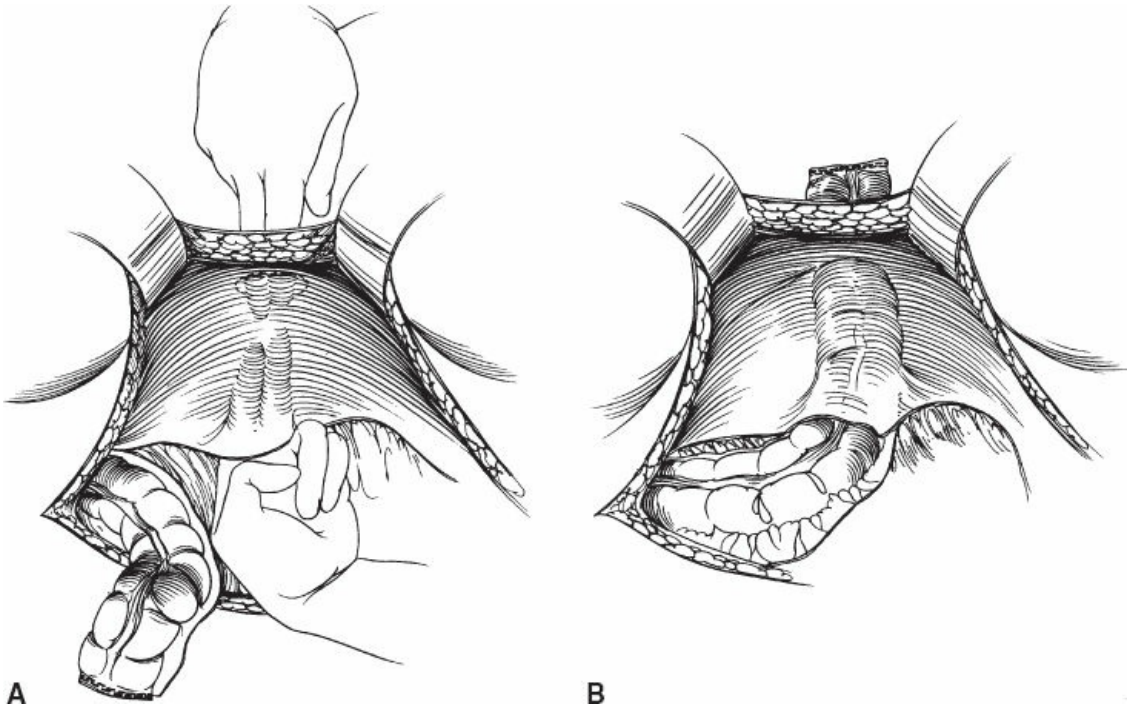

Figure 150.7. An extraperitoneal tunnel for the colon may be created with manual dissection (**A**). The colon is then brought through this tunnel to the skin opening (**B**).

Colonic Obstruction

An obstructed colon may be markedly dilated, with a thickened and edematous wall. Manipulation of the bowel, and colostomy construction, may be facilitated by needle decompression. A large-bore needle (14 to 18 gauge) is placed obliquely through the bowel wall at the site of the intended colostomy, and gas is evacuated. More solid contents are milked proximally and distally as much as possible, to reduce the bulk that must pass through the abdominal wall. The opening in all layers of the abdominal wall needs to be sufficiently large to accommodate the bulk of the bowel without compressing the blood supply. Special care is needed when creating a window through the mesentery, to avoid injury to the

marginal artery. The blood supply to the proximal end of a future anastomosis may depend on this, if the inferior mesenteric artery is ligated as part of a cancer operation, or if mobilization of the descending colon is needed to reach a coloanal anastomosis.

CECOSTOMY

A cecostomy may occasionally be useful for colon decompression in cases of obstruction or refractory pseudo-obstruction, or as a point of fixation and drainage for the cecum after volvulus or a repaired perforation. A tube cecostomy is constructed by first placing two concentric pursestring sutures at the planned tube site. An opening in the cecum is then created and the tube is inserted. The pursestrings and the opening should be appropriately sized for a 30-French or larger Malecot or Foley catheter. The catheter is inserted through the colotomy and the pursestring sutures are tied around the shaft of the tube in layers (Fig. 150.8A). When performed laparoscopically, a 12-mm port may be placed under visualization at the intended cecostomy site and the catheter introduced through this port and into the bowel. The port can then be removed; it may be necessary to cut off the outer end of the catheter if it has a bifurcation or dilation. In open surgery, the catheter is brought out directly through the abdominal wall via a stab incision. Just enough traction is then placed on the catheter to create approximation between the parietal peritoneum and the bowel wall, and this approximation is reinforced with interrupted stitches of 2-0 absorbable suture placed at equal intervals around the circumference of the cecostomy site between the seromuscular layers of the cecum and the abdominal wall (Fig. 150.8B). Postoperatively, tube patency is maintained with irrigation. Leakage around the tube is a risk. Once the need for the cecostomy has passed, removal of the tube typically allows the fistula to close by secondary intention.

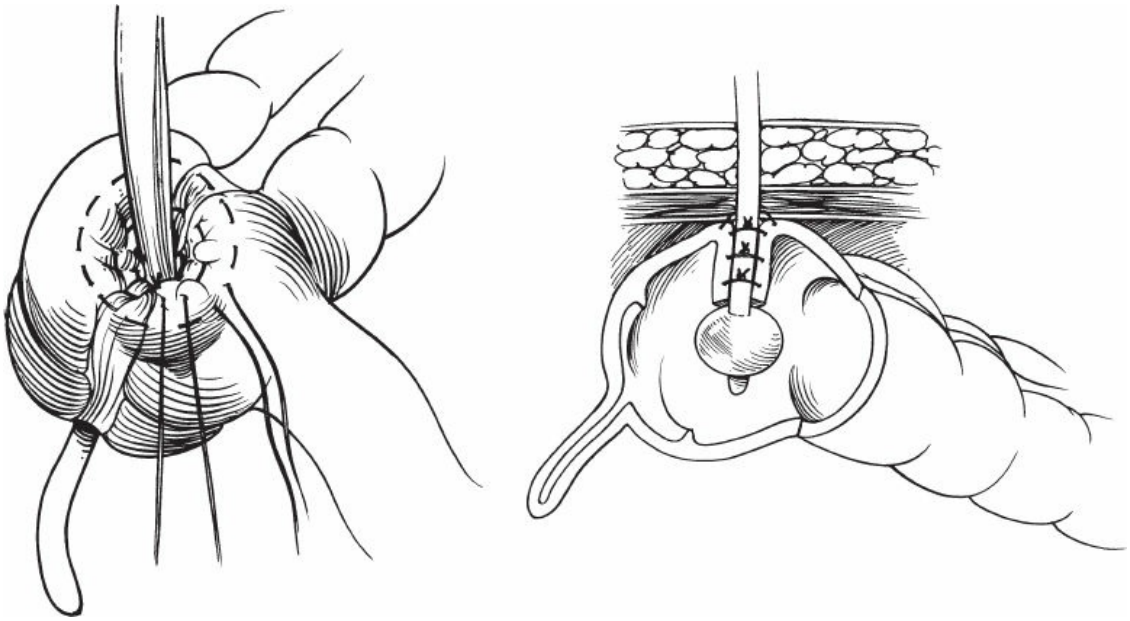

Figure 150.8. Cecostomy construction.

COLOSTOMY CLOSURE

Restoration of bowel continuity and reversal of a temporary colostomy is typically performed between 3 and 6 months after its construction, which allows time for resolution of inflammation and dense adhesions. Waiting longer may be associated with increased rates of complication.

Loop Colostomy Closure

A loop colostomy can usually be closed without opening the abdomen. The colostomy is mobilized by making a circumferential skin incision around the stoma, just outside the mucosal edge (Fig. 150.9). The excised skin is grasped to provide traction, and countertraction is applied on the opposing skin and subcutaneous fat layers to define the plane of dissection (Fig. 150.9). Dissection is carried down circumferentially, exposing the fascial and muscular layers, and then entering the peritoneal cavity. A finger is inserted between the bowel and the abdominal wall, which exposes and allows division of the remaining peritoneal and serosal attachments. The skin and subcutaneous fat are completely trimmed away from the mucocutaneous junction. The bowel edges may need to be trimmed back to healthy tissue, as well. The defect in the colon wall is closed transversely with interrupted absorbable suture (Fig. 150.10). This closure must be performed meticulously. Alternatively, this closure may be accomplished with a firing of a transverse bowel stapling device. When closed, the bowel is irrigated and gently returned to the peritoneal cavity

by methodically returning one limb of bowel, followed by the second. Relaxation of the abdominal wall is helpful in returning the bowel to the abdominal cavity and in repairing the defect in the abdominal wall. The anterior and posterior rectus sheaths are closed transversely with interrupted or figure-of-eight stitches. The skin is closed with a circumferential pursestring stitch in the dermis, using 2-0 PDS (Fig. 150.11). This closure allows drainage and is associated with low rates of wound infection; the wound is cared for with packing changes until healing is complete.

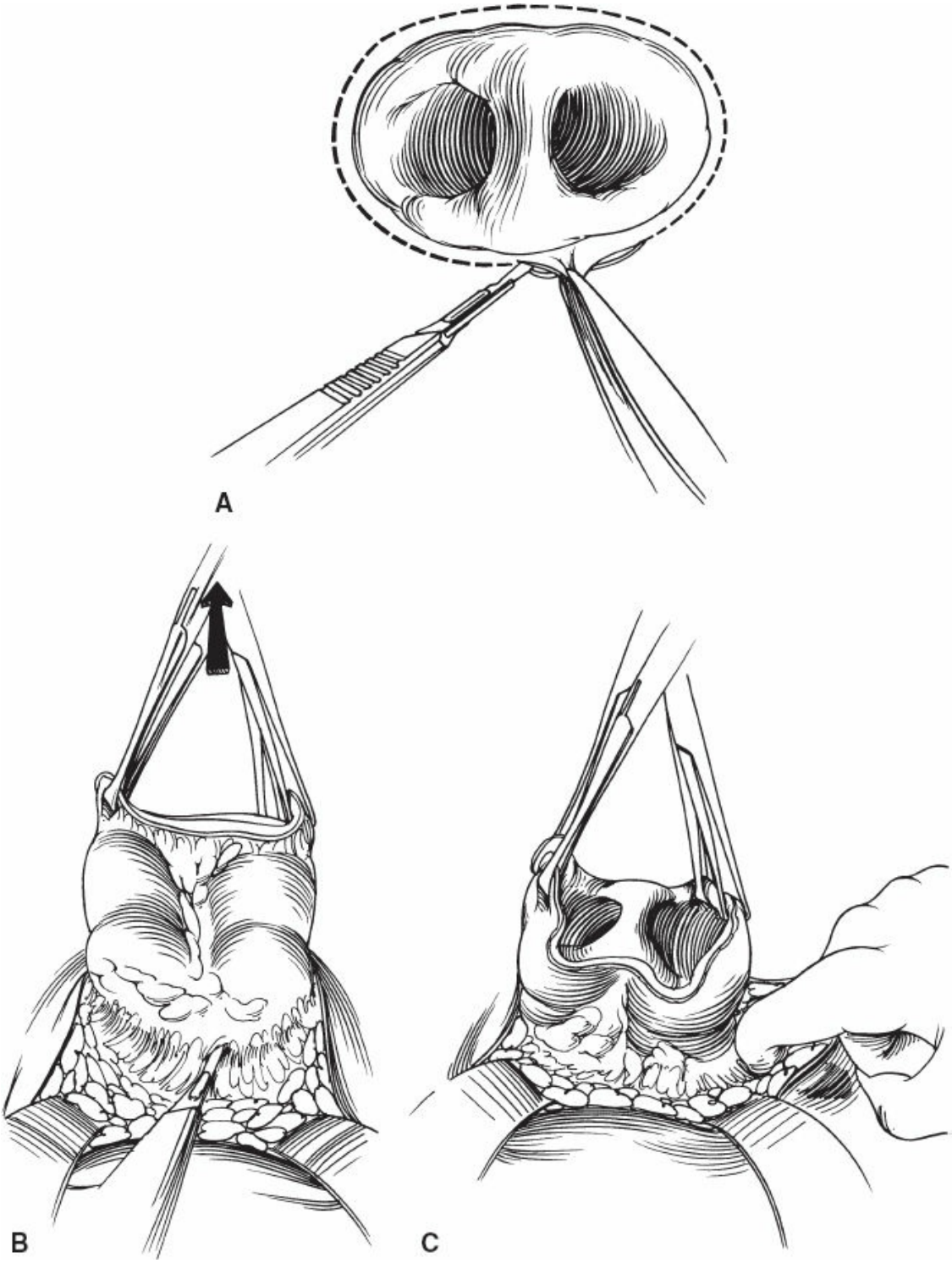

Figure 150.9. A circular incision is made around the stoma, including a thin margin of skin (**A**). Traction and counter-traction facilitates dissection away from the abdominal wall layers (**B** and **C**).

End Colostomy Closure

Closure of an end colostomy requires exposure of the rectum for creation

of a colorectal anastomosis. This can be accomplished with a laparotomy, or with a minimally invasive approach. Laparoscopic access is achieved either with Veress needle insertion into the peritoneal space at the lower edge of the umbilicus followed by insufflation and placement of a transparent port with laparoscopic visualization, or with a Hasson technique in the infraumbilical midline, as described previously. After creating pneumoperitoneum, a 5-mm port is placed in the right upper quadrant, and another in the right lower quadrants (Fig. 150.12). The patient is positioned in Trendelenburg position with left side up and the small bowel is swept toward the liver. The residual rectum must be identified and mobilized from any adhesions, and the end of the stump must be sufficiently cleared to allow creation of an anastomosis. Once this is accomplished, the colostomy is mobilized as described above. The anvil for an end-to-end anastomosis (EEA) stapling device is placed in the end colostomy and secured with a pursestring suture before the bowel is reduced into the abdomen. The anterior and posterior rectus sheaths are closed at the stoma site so that pneumoperitoneum can be maintained. The proximal colon is checked to be sure that it reaches the rectal stump without tension; if necessary, mobilization maneuvers described previously may be employed. The handle of the EEA stapler is deployed via the rectum, and the anvil and post are connected. The device is closed, and a circular stapled anastomosis is created. The anastomosis is submerged with irrigation and the rectum is insufflated, to perform a leak test of the anastomosis. With a satisfactory anastomosis created, pneumoperitoneum is evacuated. A pursestring stitch is placed for partial closure of the dermis at the stoma site.

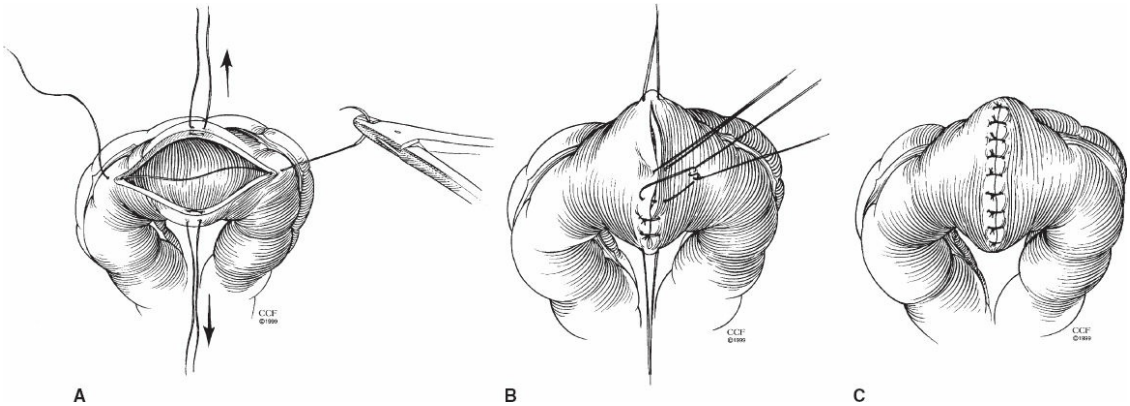

Figure 150.10. The colon defect is closed transversely with interrupted, absorbable stitches. Stay stitches may be placed at the edges, as shown, to maintain a transverse orientation for the

closure (**A**). An additional stitch may be placed in the center of the closure to maintain alignment, as shown (**B**). The remainder of the interrupted stitches are then placed and tied (**C**).

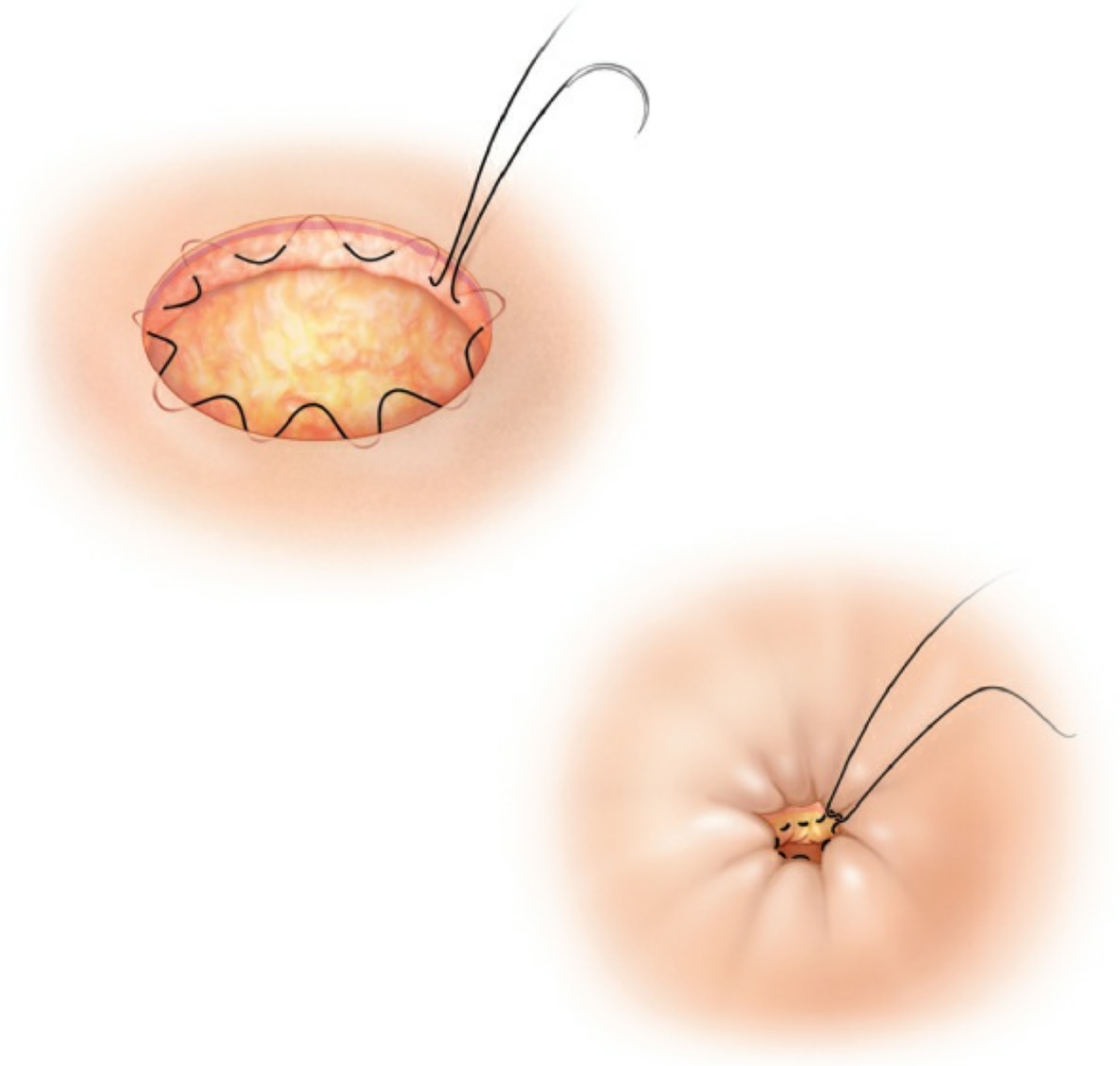

Figure 150.11. A running, circular, pursestring closure can be performed to tighten the stoma closure site to a narrow opening that can be packed and irrigated while healing.

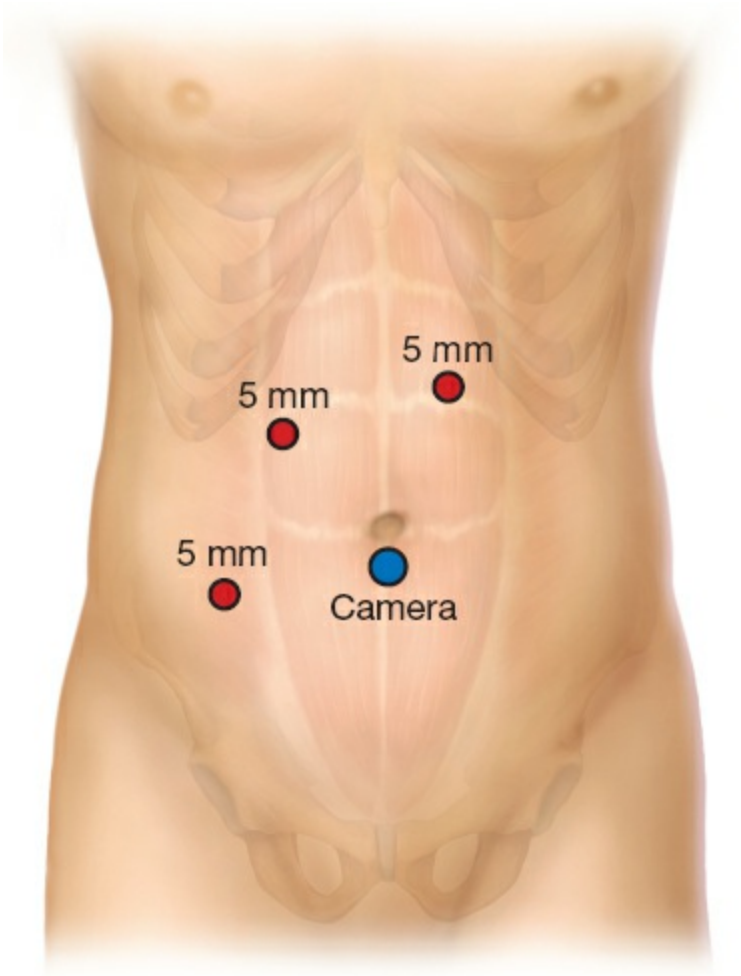

Figure 150.12. Suggested laparoscopic port placement sites for reversal of Hartmann procedure.

POSTOPERATIVE CARE

A follow-up visit from an enterostomal therapist should occur before the patient leaves the hospital. Education for the patient and family during the same admission, with time to practice stoma cleaning and pouch placement, is important to facilitate the patient's smooth transition to colostomy care at home. The appliance placed at the time of surgery may be left in place for the first few days, unless leakage requires replacement or a complication is suspected and the appliance must be removed for inspection of the stoma.

ACUTE POSTOPERATIVE COMPLICATIONS AND THEIR MANAGEMENT

Complications in the immediate postoperative period may include bleeding, ischemia, retraction, or infection. Ischemia of the colostomy may

lead to stoma stenosis. Concern may also arise if the stoma does not produce gas or stool within the anticipated time period, and technical error in construction of the colostomy must be ruled out. If a complication is suspected, the stoma appliance is removed and a careful examination of the colostomy is performed. The color and apparent perfusion of the mucosa is noted. The peristomal skin is checked for erythema or induration. The adjacent abdominal wall is palpated for any abnormal mass. A gloved finger is inserted through the colostomy to confirm patency. If the mucosa is discolored, dusky, or sloughing, a test tube may be used with a light source to examine the mucosal surface of the colostomy lumen. The test tube is inserted gently into the colostomy and allows additional visualization. If the extent of ischemic change is limited, it is often best to observe, and re-examine the stoma at a later time.

In some cases, a bedside exploration of the colostomy may allow successful management of a bleeding or infectious problem. The skin is cleaned and nearby surgical incisions are covered to prevent contamination. Local anesthetic may be used, but is often unnecessary. A few stitches are removed at the suspected location of the problem, which may allow for exposure and hemostasis of a bleeding edge, or probing and evacuation of a hematoma or peristomal abscess. Care is taken not to injure the bowel or its blood supply.

When bedside exploration is unable to control bleeding or infection, a return to the operating room for exploration and stoma revision is necessary. This is also true when extensive ischemia and necrosis is noted within days of surgery, when severe retraction and dehiscence of the colostomy construction occurs, or when torsion or obstruction is identified at the colostomy site.

ACKNOWLEDGMENT

We wish to acknowledge Dr. Ian Lavery, whose work in the previous edition of this text provided a valuable basis for our chapter.

Suggested Readings

Bruns BR, DuBose J, Pasley J, et al. Loop versus end colostomy reversal: has anything changed? *Eur J Trauma Emerg Surg* 2015;41(5):539–43.

Li LT, Hicks SC, Davila JA, et al. Circular closure is associated with the lowest rate of surgical site infection following stoma reversal: a systematic review and multiple treatment meta-analysis. *Colorectal Dis* 2014;16(6):406–16.

Liu J, Bruch HP, Farke S, et al. Stoma formation for fecal diversion: a plea for the laparoscopic approach. *Tech Coloproctol* 2005;9(1):9–14.

Lopez-Cano M, Serra-Aracil X, Mora L, et al. Preventing parastomal hernia using a modified Sugarbaker technique with composite mesh during laparoscopic abdominoperineal resection. *Ann Surg* 2016;264:923–8.

EDITOR'S COMMENT

Dr. Kukar and colleagues provide a thorough description of laparoscopic and open creation of end and loop colostomies as well as cecostomies. The creation of a colostomy often occurs at the conclusion of an emergency operation for an acute abdomen or following a lengthy operation for a pelvic cancer. As such, it may be constructed when the surgeon is tired, thinking that the difficult part of his/her case is already over and therefore, occasionally be constructed with less attention to detail than other portions of the procedure. This is; however, a grave error! In many cases the patient has to deal with the colostomy for the remainder of their life.

As with ileostomy, *failure* to mark a patient for a suitable colostomy site ***prior*** to an operation in which there is a chance of needing diversion is a serious medical error. Even with a seriously ill patient, it takes little time, with the help of a nurse or several assistants to place the patient in a sitting position, in order to identify the patient's major abdominal folds and creases, and to identify the best location for a colostomy. With the increasing obesity of our population, the best site for a colostomy in an obese individual is often in the upper abdomen, where the abdominal wall thickness is often much less than in the lower abdomen. In addition, in very large individuals, the thickness of the lower abdominal wall is not the only problem. There is also often a thickening of the skin of the dependent portion of the pannus, frequently leading to a "peau d'orange" type of skin, with a lower abdominal skin that is almost leathery in consistency, and to which it is difficult for a colostomy appliance to adhere.

Although typical colostomy output is semisolid, the surgeon should be able to modify his or her surgical technique in the presence of patient factors that may affect this. For example, in a patient who has undergone significant small bowel resections, or an ileocolic resection, or in the patient who has undergone significant radiation therapy, or the patient who will be receiving chemotherapy, the colostomy output may be much more liquid. In these circumstances, although a colostomy is typically created flush with the surrounding skin, and generally not protruding more than 1 cm; in these patients, it will be in the patient's interest to create a colostomy that is constructed more like an ileostomy, that is, that is protruding above the level of the skin to a greater degree (>1 cm) in order to facilitate pouching and a leak-proof seal, to prevent subsequent skin excoriation and associated skin breakdown.

Several studies have shown that colostomies constructed in the urgent setting

are frequently never closed. Attention to detail, that is, construction of a good stoma in a good location, is paramount. Many surgeons feel that a transverse loop colostomy provides for good fecal diversion. These types of stomas are; however, notoriously difficult to manage, both because of their size, requiring extremely large stoma appliances, by their difficulty to camouflage under clothes because of their upper and mid-abdominal location, as well as because of their tendency to prolapse that is perhaps greater than for any other stoma location. For this reason, despite its ease of creation, transverse loop colostomies are a type of diversion that I infrequently use.

Colostomies are generally associated with more technical complications during construction relating to intestinal perfusion than ileostomies, particularly in overweight individuals. In one study evaluating 100 patients each with either a loop ileostomy or loop colostomy performed at two centers over a 6-year period, the study authors noted a higher rate of dermatitis and renal insufficiency in loop ileostomy patients. At the time of stoma closure; however, patients with loop colostomy experienced more wound infections and had a longer length of hospital stay (Klink CD, Lioupis K, Binnebösel M, et al. Diversion stoma after colorectal surgery: loop colostomy or ileostomy? *Int J Colorectal Dis* 2011;26(4):431–6). Common postoperative complications such as partial circumference and even full circumference mucocutaneous separations can be managed by good enterostomal therapy. This even applies to cases of full-thickness necrosis extending down to the fascia level. Patients with full-thickness necrosis will; however, develop skin level strictures, which make stoma care difficult. Short of re-operation and stoma revision, these patients can often be managed by colostomy self-dilatation using Hegar dilators on a daily basis performed by the patient. The patient can also be taught to irrigate the colostomy to maintain function without obstructive symptoms. A motivated patient with agile hand function is a prerequisite for this. In patients who are very obese, construction of a proper sigmoid or descending colostomy may involve ligation of the inferior mesenteric artery at its origin, much as one would do for a full cancer resection, in order to gain enough mobility for the stoma to reach to the abdominal wall without tension.

Due to the increasing body mass index seen in patients, particularly in the United States, parastomal hernias involving colostomies are a common postoperative complication. There have been several trials that have evaluated use of techniques to decrease the frequency of hernia formation at the primary operation at which the colostomy is constructed. López-Cano et al. reported results of a randomized, prospective, double blind trial in rectal cancer patients undergoing laparoscopic abdominoperineal resection (López-Cano M, Serra-Aracils X, Mora L, et al. Preventing Parastomal Hernia Using a Modified Sugarbaker Technique With Composite Mesh During Laparoscopic Abdominoperineal Resection: A Randomized Controlled Trial. *Ann Surg* 2016;264(6):923–8). Patients were randomized to undergo placement of a lightweight large-pore composite mesh in an onlay fashion using a modified

Sugarbaker technique versus no peristomal mesh. Patients underwent computed tomography (CT) scanning at a minimum of 12 months postoperatively in order to detect the presence of parastomal hernia. Morbidity did not differ between groups; however, with a median 26-month follow-up, the rate of parastomal hernia was 25% in the mesh group, as compared to 64% in the no-mesh group. In yet another much larger study, the "Dutch PREVENT-trial," a prospective, single-blinded trial in which patients were randomized to undergo standard colostomy construction or construction of a colostomy with placement of a retromuscular lightweight polypropylene mesh above the posterior sheath of the rectus muscle (Brandsma HT, Hansson BM, Aufenacker TJ, et al.; Dutch Prevent Study group. Prophylactic Mesh Placement During Formation of an End-colostomy Reduces the Rate of Parastomal Hernia: Short-term Results of the Dutch PREVENT-trial. *Ann Surg* 2017;265(4):663–9). Patients underwent CT scans if there were symptoms suggestive of parastomal hernia. At 1-year follow-up, 3/67 (5%) mesh patients had developed a parastomal hernia as compared to 24% of the non-mesh group. It should be noted that since both of these studies are European, the mean BMI of patients in all groups in these studies was less than 27, making these populations unlike the typical United States populations. An earlier systematic review and meta-analysis that did not include these two studies also concluded that prophylactic placement of mesh at the time of colostomy construction resulted in a reduced risk of parastomal hernia and a reduced risk of reoperation for parastomal hernia (Wang S, Wang W, Zhu B, et al. Efficacy of Prophylactic Mesh in End-Colostomy Construction: A Systematic Review and Meta-analysis of Randomized Controlled Trials. *World J Surg* 2016;40(10):2528–36). However, this study was limited by the heterogeneity of included studies.

The authors briefly refer to cecostomy construction and supply a Figure illustrating this. Cecostomies work well, provided that they are cared for properly. This requires insertion of a tube of large enough diameter that will not easily clog and which will permit for adequate venting of fecal contents and gas —for example, a 32-French Malecot catheter. In placing such a tube in order for them to function properly it is essential that these tubes are irrigated regularly postoperatively. This involves irrigation of the tube every 2 hours with saline to ensure patency. Another modification of technique that may reduce the incidence of complications is the placement of the Malecot tube through omentum prior to fixing the bowel to the abdominal wall. Recently, successful percutaneous cecostomy placement has been reported for the treatment of selected patients with colon obstruction due to cancer (Tewari SO, Getrajdman GI, Petre EN, et al. Safety and efficacy of percutaneous cecostomy/colostomy for treatment of large bowel obstruction in adults with cancer. *J Vasc Interv Radiol.* 2015;26(2):182–8). In these patients, positioning the catheter tip within luminal gas rather than in a mixed gas/stool collection results in a greater decrease in the maximum colonic distension.

As a final comment, many patients with end colostomies can change the

frequency of bowel evacuation with the technique of colostomy irrigation. In a recent systematic review, colostomy irrigation was found to be associated with a reduction in pouch usage, and allows some patients not to require use of an appliance (Kent DJ, Long MA, Bauer C. Does colostomy irrigation affect functional outcomes and quality of life in persons with a colostomy? *J Wound Ostomy Continence Nurs.* 2015;42(2):155–61). Sadly, many patients with permanent colostomies are never told or instructed about the availability of this technique.

Susan Galandiuk

151 Care of Stomas

Marc C. Osborne and Ann C. Lowry

Approximately 100,000 patients in the United States will have a colostomy or ileostomy created each year. Complications of operations involving an ostomy are unfortunately common. Managing a difficult or problematic stoma has a significant negative effect on quality of life for the patient and leads to increased health care costs in prolonged length of stay, hospital readmissions, increased outpatient care and supplies. This chapter will review the basics of stoma anatomy, proper stoma siting, optimal stoma care, the role of the Wound, Ostomy, and Continence Nurse (WOCN), management of common stoma complications, and patient education.

STOMA ANATOMY AND PHYSIOLOGY

An intestinal stoma is constructed when a portion of the gastrointestinal tract is brought through the abdominal wall, opened and matured by suturing the bowel wall to the skin. Most commonly done to divert the fecal stream, it can also be done to divert the urinary stream as well. The stoma may be constructed as an end, loop, double barrel, or "end-loop" stoma. The stoma may arise from the jejunum, ileum, or portion of the colon. Two other chapters cover the technique of creation of an ileostomy and colostomy (Chapters 138 and 150, respectively). An end stoma is created by dividing the bowel completely and bringing the proximal end through the abdominal wall and matured by everting the opened edge of the end of the bowel and suturing it to the skin. The distal portion may be removed, closed off and left in the abdomen, brought through the abdominal wall at the same site, and left in the subcutaneous tissue for possible later stoma reversal. If the distal bowel is not removed, it will continue to produce mucus and exhibit peristalsis. Patients will occasionally discharge this mucus via the anus and this may be associated with a sensation similar to the urge to have a bowel movement. Patients who have undergone a Hartmann's procedure are encouraged to evacuate this mucus by administering a small tap water enema via the anus twice a month. This may begin 6 weeks after surgery or when the patient seems to

have sufficiently recovered. A loop stoma is created by bringing a loop of intestine through the abdominal wall above the level of the skin. The bowel is partially opened, usually in a transverse manner, and both ends are everted and matured. The proximal loop is usually cephalad and everted to a height greater than the distal limb. A double-barrel stoma is created similarly except that the bowel is completely divided and both limbs are matured. To fashion an end-loop stoma, the bowel is divided and the proximal limb is brought through the abdominal wall as a loop with a short efferent limb. This technique allows for less tension on the mesentery and is particularly useful in patients with a large amount of subcutaneous fat. The stoma is then matured similarly to a loop stoma.

A jejunostomy is created using jejunum; stoma output will be watery, bilious, and high volume. Patients are at the high risk of dehydration, electrolyte imbalances, and need for parenteral hydration and nutrition. Because of these challenges, jejunostomies are usually created in the setting of Crohn disease, trauma, ischemic bowel, or prior bowel resections.

An ileostomy is created from the distal portion of the small bowel. The most common indications are inflammatory bowel disease, familial adenomatous polyposis, cancer, or to protect a distal colorectal anastomosis…All small bowel stomas should protrude at least 2 cm above the skin as this will greatly facilitate proper pouching. Initially after surgery, the stoma output will be watery with volumes exceeding 1 L per day. This can lead to dehydration, which is the most common reason for hospital readmission after creation of an ileostomy. Care pathways and patient education, discussed later, are critical to preventing this complication. With time, the bowel will accommodate and increase its absorption of fluid. Patients can expect 500 to 1,000 cc of output per day with a variable consistency, but mostly commonly that similar to thin oatmeal, and typically with little odor.

A colostomy is created from any portion of the colon, although this is mostly commonly done in the sigmoid and transverse colon. Common indications include cancer, Crohn disease, volvulus, fecal incontinence, trauma, congenital malformation, or neurologic disorders. A colostomy should protrude 1 cm above the skin. The output will vary depending on the stoma location.

A urostomy is usually created using a portion ileum or colon as a conduit, although it can be made as an ureterostomy. This procedure is

typically done by taking a portion of the bowel out of continuity, re-establishing intestinal continuity, and then using the discontinuous loop as a conduit. Normal output will depend on level of hydration and patient weight.

Role of the Wound, Ostomy, and Continence Nurse

The need for nurses with specialty training in the care of patients with stomas has been recognized for decades, dating back to the creation of the first enterostomal therapist (ET) training program by Dr. Rupert Turnbull and one of his patients, Norma Gill, at the Cleveland Clinic. Although the name has changed from ET to Wound, Ostomy, and Continence Nurse (WOCN), these nurses provide significant value to patients. Ostomy surgery creates significant anatomic and physiologic changes for the patient and may result in significant psychosocial challenges. Optimal care for patients undergoing ostomy surgery includes preoperative, perioperative, and postoperative care by an ostomy nurse specialist, such as nurse certified by the Wound, Ostomy, and Continence Nurses Society Certification Board. Studies demonstrate significant differences in the quality of stoma site selection between surgeons and WOCN. Randomized trials demonstrate that ostomy nurse care after discharge results in greater ability of patients to care for themselves independently and improved quality of life. Although the clinical condition or remote location of the patient may not allow for the utilization of WOCN specialists in all circumstances, they should be consulted whenever possible for preoperative teaching and marking, perioperative care and training, and postoperative follow-up.

Ostomy Siting

Creation of the perfect stoma involves picking the optimal site on the abdominal wall for stoma creation and meticulous technique in the operating room. A well-sited stoma will lessen the risk of common complications such as appliance leakage and peristomal skin irritation, improved predictability of appliance wear time, improved patient adaptability to the stoma, and lead to improved patient satisfaction.

Prior to marking the patient, it is important to consider any positioning issues such as posture, mobility, contractures, use of a wheelchair, or walker. Patients should be marked with a marking pen that will not wash off when the patient’s abdomen is prepped. This mark is often protected

with a piece of transparent dressing if done in the outpatient setting.

Begin by asking the patient to remove any clothing covering the abdomen. Examine the patient in the supine, sitting, standing, and bending forward positions to note creases, scars, skin folds, and valleys. One should note where the patient wears their pants. Use a marking pen that will wash off to mark some of these landmarks. Examine the patient in the supine position and identify the rectus muscles by having them raise their head and back off the bed. The ideal site will be through the rectus muscle in the appropriate quadrant for the planned surgery and in the patient's visual field, usually at the apex of either the supraumbilical or infraumbilical ridge. Visualize the site in the supine, standing and sitting positions to ensure that site does not fall into a crease or retract in different positions.

Care should be taken to choose a flat site to allow for easy pouching and avoid scars or creases. A site below the belt line is preferable as it will allow for the concealment of the pouch. However, this consideration should be secondary to ensuring the stoma is visible to the patient and allows for flat pouching surface. The site should be 2 to 3 in away, perpendicularly, from a midline incision. Obese patients and patients with a rounded abdomen may benefit from marking in the upper abdomen since the subcutaneous fat layer is less prominent here. Figure 151.1 details four common stoma sites. Note the supraumbilical and infraumbilical ridge noted mosin the sitting position.

Ostomy Appliances

The ideal pouching system will provide a receptacle to catch the effluent, protect the surrounding skin, and allow for easy emptying and replacement and predictable timing of the need for replacement. Multiple products are available. The appliance will generally consist of a skin barrier (sometimes called a wafer), a pouch, and a closure device. The appliance can come with the pouch and skin barrier connected as a one-piece appliance or separately as a two-piece system. One-piece appliances tend be lower profile (Fig. 151.2A). Two-piece appliances allow for the pouch to be changed without changing the skin barrier (Fig. 151.2B). Most appliances are disposable and are made to last 3 to 7 days. Reusable appliances also have to be changed every 3 to 7 days and require the extra maintenance to wash and reuse them.

The skin barriers consist of a pectin like material surrounded by a strip

of adhesive. Two-piece systems will have an additional plastic ring where the pouch which collects the fluid will attach. Barriers come in either extended or standard wear models. The extended wear models are designed to have the pectin like material breakdown less under exposure to watery output and are usually recommended for an ileostomy or urostomy. Conversely, the appliance tends to be less flexible. The standard wear barrier is recommended for a colostomy. The pectin like material is cut to match the contour of the stoma. Skin barriers come in cut-to-fit or precut models. The cut-to-fit model is cut by the patient usually with the aid of a stencil. During the early postoperative period, the cut-to-fit model is preferred as the stoma changes size often. Similarly if the stoma is not completely round, the cut-to-fit model is often used. The skin barrier may be flat or convex (Fig. 151.2C). Convexity allows the skin barrier to mirror the peristomal skin plane; it is very important with a stoma that lies within a crease or is not sufficiently everted above the skin level. Paste, strips, or rings can be added to the skin barrier to smooth out irregular surfaces, promote a good seal, and protect the peristomal skin (Fig. 151.2D). A stoma belt which connects to the skin barrier can also support the barrier and help provide a good seal.

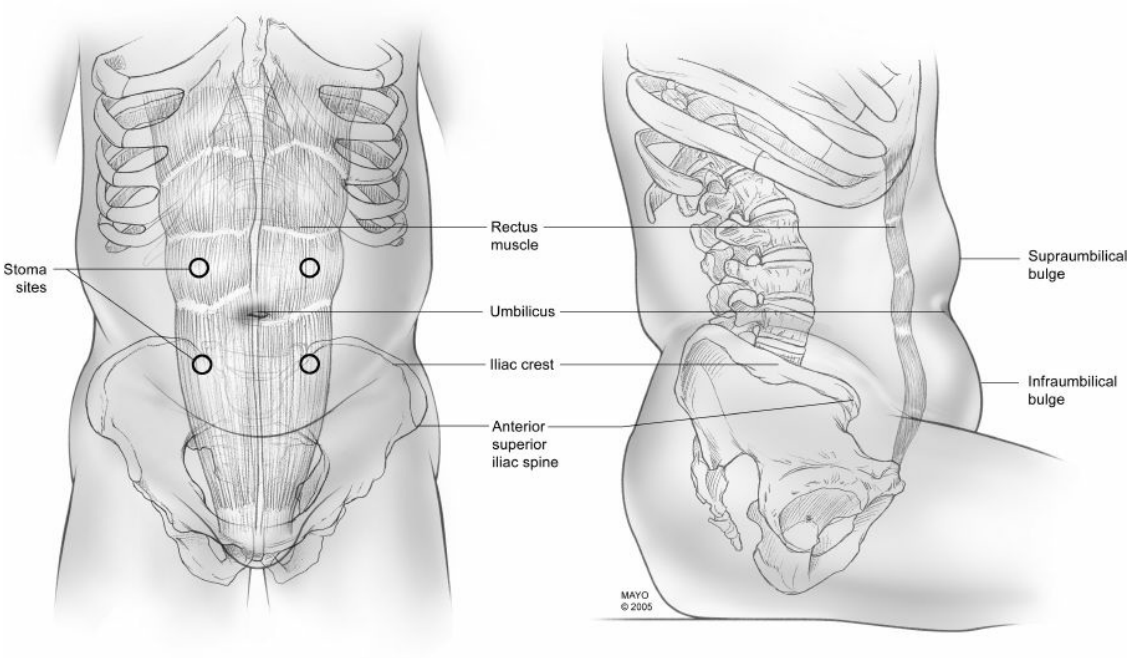

Figure 151.1. Four commonly used stoma sites. (From Fischer J. Masters of Surgery The Gastrointestinal Tract. *Care of Stomas*, Chapter 52. 2012, e38.)

The pouch is the bag that holds the effluent. They are available in either transparent or opaque materials as well as vented or nonvented. The vents often contain a charcoal filter to reduce odor. In the immediate postoperative period, it is recommended to use a nonventing, transparent pouch to allow for easy inspection of the stoma and to identify the presence of gas and stool. The pouch should be emptied when one third to one half full of liquid or gas. A pouch for a urostomy will commonly have a valve which can be turned to empty urine. A pouch for an ileostomy will commonly be open at the end to allow for emptying and will close with a clip or Velcro type mechanism. Some pouches are available in a nondrainable model and require removal from the body to empty and can be reused. Deodorants, either as a powder or spray, are available to reduce the odor from the pouch (Fig. 151.2E).

Peristomal Skin Care

The keys to maintaining healthy peristomal skin are a properly fitting appliance and well constructed stoma. The most common cause of peristomal skin irritation is stool in contact with the skin. The appliance is removed by lifting the edge of the skin barrier and pushing down on the skin. Warm water and adhesive remover help remove the skin barrier without injury to the skin and fully remove any adhesive residue. The skin should be washed with warm water and soap and well dried. Avoid products with alcohol or oil on the skin. Peristomal hair can be shaved or clipped. Properly cutting the appliance to fit the stoma will ensure protection of the peristomal skin. Skin irritation is treated with skin barrier powder and then a skin sealant is applied over the powder to ensure a good seal to the appliance.

Diet, Medications, and Lifestyle

The creation of an intestinal ostomy does not mandate lifelong dietary restriction. However, there are short-term restrictions to prevent a food blockage in the immediate postoperative period. Patients are advised to chew their food well and to cut food into small pieces. For the first 2 to 6 weeks after surgery, patients should follow a low residue diet. A food blockage can occur, particularly with an ileostomy, when highly fibrous food, poorly chewed lodges in the distal small bowel. This produces the typical colic type pain of a small bowel obstruction and patients will note a decreased or watery output. This may lead to abdominal distention,

nausea, and vomiting. Patients are advised to lie in the supine position or in a knee chest position. Massaging the abdominal wall may help. If the symptoms become severe, patient should present to a health care provider for evaluation. Treatment includes IV hydration, NPO, and NG tube decompression. The stoma can be irrigated and this will often dislodge the blockage.

Once past the immediate postoperative state, the patient should introduce new foods slowly. Patients should be advised on how their diet will affect ostomy output, stool consistency, odor, and gas production (Tables 151.1 and 151.2). To avoid excess gas, patients should avoid smoking, use of straws, eating too fast, chewing gum, sucking on ice, drinking carbonated beverages, skipping meals, or gas-forming foods.

Dehydration is common in patients with an ileostomy. A patient with an ileostomy will usually empty their pouch four to six times per day for a total of 1 L output in 24 hours. More than 1 L output per day is defined as high output and puts the patient at the risk of dehydration. Patients should be monitor their output and contact their health care provider when they have high output. Treatment includes increasing fluid intake, particularly an electrolyte rich drink such as a sports drink, and eating more foods that will thicken the stool such as applesauce, bananas, and tapioca. Psyllium will also thicken the stool. Patients may need to take antidiarrheal medications such as loperamide or diphenoxylate. Rarely, tincture of opium or codeine is used for the chronic treatment of high ileostomy output.

Patients with colostomies may choose to regulate the timing of stomal output by irrigating the stoma at regular intervals. Irrigation is done with warm tap water through a catheter attached to a cone inserted into the stoma opening (Fig. 151.2F).



A

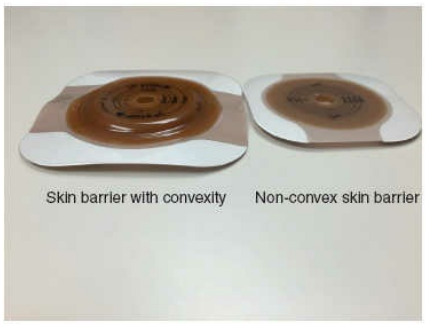
Skin barrier with convexity
Non-convex skin barrier

C


High output pouch
Pouch with folding bottom
Pouch with clipped bottom
Skin barrier

B


Adapt
79300
Paste
7905
Karaya
UNI-SOLVE
Brava
Adhesive Remover Wipe
Coloplast
3M
Cavilon
No Sting Barrier Film
3345

D



Figure 151.2. Ostomy supplies. **A.** One-piece appliance with clips. **B.** Two-piece appliance with various pouches. **C.** Skin barrier with convexity. **D.** Stencil, paste, powder, rings, adhesive remover, and skin protectors. **E.** Deodorizer. **F.** Colostomy irrigation kit and colostomy cover. **G.** Stoma belt and hernia belt.

Once a stoma is created, patients may need to have their chronic medications adjusted due to changes in absorption. Time released or coated medications may need to be changed to a chewable or liquid form. Laxatives should not be used in anyone with an ileostomy. In addition, diuretics may need adjustment because of the additive risk of dehydration.

Patients will have concerns regarding the effect of the stoma on their lifestyle; they should be reassured that the stoma will not result long-term activity restrictions. Common questions focus upon bathing, showering, swimming, clothing choices, and sexual activity. Patients may be reluctant to bring these concerns forward; providers may have to elicit them as part of the perioperative teaching. Some patients may have difficulty to adjusting to life with a stoma either related to difficulty in caring or the psychological impact of the stoma or the underlying diagnosis requiring stoma surgery. In addition to optimizing any medical issues, providers should be alert and recognize psychological signs of anxiety or depression. In addition to WOCN, there are multiple avenues for patients to find support and education. The United Ostomy Association of American provides education and support for patients, including a listing of local stoma support groups found at www.ostomy.org.

TABLE 151.1 Affect of Food on Stoma Output

Foods That Thicken Output	Foods That Increase Output	Foods That Increase Gas
Pasta, rice, soda crackers, pretzels	Ice cream	Fried or fatty foods
Cheese, yogurt	Prunes and prune juice, raisins, figs, grape juice, leafy vegetables, large amounts of fruits, rhubarb	High sugar foods
Applesauce, bananas, potatoes	Syrup, cookies, pudding, pastries, cake, pies, chocolate, licorice, caffeine, soda pop, beer, gelatin, spicy foods	Milk, cheese, eggs
Peanut butter, tapioca		Beans, chickpeas, lentils
		Peanuts
		Cabbage, broccoli, Brussels sprouts, cauliflower, beets, rutabagas, turnips, radishes, onions, chives, leeks, lettuce, parsley, corn, cucumbers, pickles, peppers

Patients may bathe, shower, and swim with a stoma. A well-fitted appliance is waterproof and will not leak. Patients may choose to bathe or shower with the appliance off and should be advised to do so when the stoma is less active.

Most patients will be able to wear their regular clothes after surgery. To prevent leakage, it is important that clothing does not limit effluent from reaching the bottom of the pouch. Adjustment in belt lines or clothing choices may be necessary.

Patients who have undergone proctectomy or pelvic radiation are at the risk of sexual dysfunction such as impotence, retrograde ejaculation, dyspareunia, and loss of vaginal lubrication as well as changes in fertility. These risks should be discussed preoperatively. Women with a stoma may get pregnant. Adjustments in the appliance may be needed as the abdominal wall changes during and after the pregnancy.

TABLE 151.2 Food and Stoma Odor

Foods to Add to Reduce Odor	Foods to Avoid to Reduce Odor
Buttermilk	Alcohol, especially beer
Yogurt	Fish
Kefir	Eggs
Parsley	Dried beans and peas
Cranberry juice	Onions and garlic
	Asparagus
	Brussels sprouts
	Green peppers

Perioperative Care Pathways

Recently care pathways have been developed to reduce the morbidity of ostomy creation, especially as it relates to the prevention of dehydration and readmissions, as well empowerment of patients to provide self-care. These pathways include scheduled preoperative, inpatient postoperative, and post discharge visits with a WOCN, structured preoperative and postoperative education with handouts, observation of the patient changing their own appliance prior to discharge, discharge with a graduated cylinder for adequate measurement of ileostomy output, scheduled phone calls from a clinic nurse regarding hydration status, bowel function, and appliance issues.

To assist with preoperative education, the American College of Surgeons developed a home skills kit that patients can use to acquire some of the basic stoma care skills prior to their operation. The kit includes a booklet and DVD with instructions on how to empty and change an appliance, a stoma model and supplies to practice, and an evaluation tool. These kits and the video are available through https://www.facs.org/education/patient-education/skills-programs/ostomy-program.

STOMA COMPLICATIONS

The adage “an ounce of prevention is worth a pound of cure” is never truer than in caring for stomas and dealing with complications. In addition to using proper siting and surgical techniques, regular follow-up with a

WOCN is critical to prevention and treating complications. Unfortunately, minor and major complications are common and are addressed here.

Parastomal Hernia

The risk of a parastomal hernia is directly proportional to the length of time the patient has the stoma. A hernia develops when the fascial opening enlarges around the stoma allowing loops of bowel or intra-abdominal fat to protrude above the fascia. Several small randomized trials have demonstrated that placement of synthetic mesh at the time of permanent ostomy creation can lower the incidence of parastomal hernia formation.

While many patients with a parastomal hernia will be asymptomatic or minimally symptomatic, some notice a change in the fitting of their appliance and require a change to a different system or in the opening of the skin barrier. A hernia belt may reduce symptoms (Fig. 151.2G). Care should be exercised in irrigating a stoma with a parastomal hernia.

Repair should be reserved for patients with significant symptoms or inability to adequately pouch the stoma. Repair of parastomal hernias can be done with primary suture repair, relocation of the stoma, and mesh repair. Primary suture repair is associated with a very high recurrence rate. For patients who no longer require a stoma, presence of a symptomatic parastomal hernia may be an indication for ostomy reversal. Mesh repair can be done with a variety of techniques with placement of mesh in an onlay, retromuscular, and intraperitoneal positions. Intraperitoneal placement may include keyhole, slit, and Sugarbaker techniques. There have been no randomized controlled trials that compare these techniques.

Prolapse

Stoma prolapse is most commonly associated with loop stomas (particularly loop colostomy), obesity, parastomal hernia, increased intra-abdominal pressure, and pregnancy. Either or both limbs of a loop stoma may prolapse. When a prolapse occurs, patients should be assessed for pain, incarceration, bowel ischemia, and condition of the peristomal skin. In most cases, the prolapse can be reduced with gentle continuous pressure on the stoma with the patient in the supine position. Reassurance or a small dose of IV sedation or analgesia to relax the abdominal wall may be necessary to achieve reduction. Application of sugar to the mucosa can draw out edema from the bowel wall and facilitate reduction.

Asymptomatic prolapse can be managed nonoperatively. Patient may

benefit from a hernia belt with a prolapse over belt or a support binder. The pouching system may need to be revised to accommodate changes in the size of the stoma. Obstruction, ischemia, and incarceration are indications for surgery usually with local resection of the prolapsed segment (Fig. 151.3).

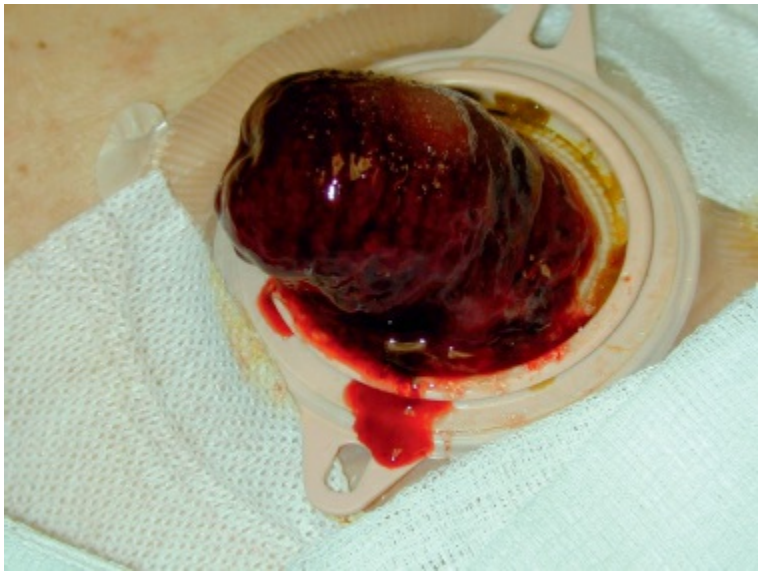

Figure 151.3. Stoma prolapse with ischemia.



Figure 151.4. Mucocutaneous separation.

Mucocutaneous Separation

Mucocutaneous separation between the bowel wall and the skin can occur in the immediate postoperative period and in a delayed fashion. It is important to assess for stoma retraction, or necrosis, abscess, and fistula.

Treatment starts with optimization of general wound healing parameters such as nutrition, smoking cessation, control of diabetes, control of underlying inflammatory bowel disease, and adequate drainage of infection. Avoiding early use of convexity in the pouching system may help prevent early mucocutaneous separation. The area of separation is cleansed with saline and any necrotic tissue is gently debrided. The wound is probed with a swab to assess the extent of separation (Fig. 151.4). The wound is then filled with an absorptive product such as hydrofiber, skin barrier powder, or barrier paste. The skin barrier the opening cut to cover the separation is then applied. The wound is treated daily in this manner. Changing to a two-piece system or any easy to change system may facilitate the multiple appliance changes.

Necrosis

Stomas will naturally become edematous, usually accompanied by a change in the mucosa to a darker red from pink, in the first 24 to 72 hours after surgery. Cyanosis of the mucosa or sloughing indicates necrosis. Hypovolemia, hypotension, edema, and tension or tearing of the mesentery can contribute to stoma necrosis and need to be assessed and addressed. Changing to a transparent pouch allows for frequent inspection. Digital exam of the stoma can ensure that the fascial opening is adequate. The extent of ischemia and necrosis can be assessed at the bedside by inserting a clear test tube into the stoma and inspection with a flashlight. Necrosis that extends below the level of the fascia in a stable patient requires exploration, probable bowel resection, and creation of a new stoma. Necrosis above the level of the fascia can be managed expectantly with surgical intervention reserved for the development of infection or sepsis. Full-thickness necrosis may result in stoma stenosis or mucocutaneous separation.

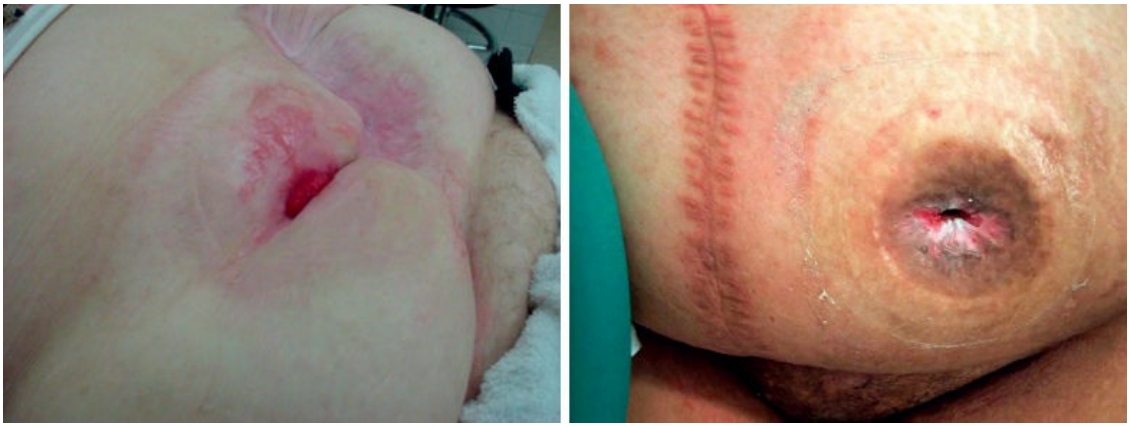

Figure 151.5. Stoma partially retracted in a crease in obese patient.

Retraction

Stoma retraction can occur by two mechanisms. Tension on the mesentery related to obesity or mesenteric edema may pull bowel down to the level of the skin. Alternatively, the skin around the bowel sinks in relative to the regular contour of the abdomen to cause the stoma to sit within a crease. Poor initial siting or significant weight change is common causes (Fig. 151.5).

Patients should be evaluated in both the sitting and standing position without the appliance. Peristomal skin irritation is common due to inadequate seal of the appliance. Often, convexity is added to the skin barrier in the hopes of gaining adequate drainage into the pouch. A stoma belt can also help maintain a seal. Patients with persistent pouching difficulties may require local revision or relocation of the ostomy.

Stenosis

Stenosis can occur at the level of the fascia, the skin or both (Fig. 151.6). It may be an early complication from an inadequate skin opening, ischemia, mucocutaneous separation, or abscess. Late stenosis should trigger assessment for Crohn's disease, malignancy, and scarring. Digital exam determines the degree of stenosis at the skin and fascia. Patients may experience obstructive symptoms with pain and bloating. Output may be erratic and patients may note squirting of stool under pressure.



Figure 151.6. Stoma stenosis.

Short-term relief may be achieved with gentle dilation with the examining finger or a dilator. Repeated dilatation should be avoided as it may cause scarring and further stenosis. A low residue diet may ease symptoms and allow easier passage of stool. Severe cases will require surgical intervention.

PERISTOMAL SKIN COMPLICATIONS

There is a common misconception that the skin around the stoma is expected to be chronically inflamed or altered. In fact, despite being covered by an adhesive, the skin should be of normal color and texture. The most common skin complications are irritant and allergic dermatitis, pseudoverrucous lesions, cellulitis, folliculitis, candidiasis, pressure ulcer, mucosal transplantation, psoriasis, peristomal varices, and pyoderma gangrenosum.

Dermatitis

Dermatitis presents as confluent or uniform erythema, tenderness, and epithelial erosion with resulting moisture. Hypersensitivity to a particular skin care product and chemical irritation from stoma effluent is the most frequent causes of dermatitis. Treatment is aimed at the removal of the underlying offending agent. Use of routine skin care products, such as lotions, should be avoided unless used for a specific indication. A proper sized and fitting appliance can prevent and treat chemical dermatitis from intestinal effluent. Patch testing can be used to identify a specific allergen.



Figure 151.7. Pseudoverrucous lesion.

Pseudoverrucous Lesions or Hyperplasia

Chronic irritation can lead to hyperkeratosis and development of overgrowth, warty-like, lesions within the area of chronic irritation (Fig. 151.7). These lesions are usually gray or red and can bleed easily. Treatment is directed at removal of the offending irritant use of a barrier powder can promote wound healing. Alternatively, silver nitrate may be applied to speed shrinkage of the excess tissue and allow for easier pouching.

Cellulitis, Folliculitis, and Candidiasis

Although all of these are infectious complications, the etiology and treatment of cellulitis, folliculitis, and candidiasis are different. Candidiasis will present in an area of chronic moisture as pustules with a bright red center and advancing border (Fig. 151.8). Treatment includes eradication of moisture and use of topical antifungal powder. Cellulitis is most commonly due to *Staph aureus* and *Streptococcus* species in the setting of ulceration or laceration of the skin. It presents with classic signs of erythema, tenderness, and swelling. Oral and topical antibiotics should be prescribed. Folliculitis is due to traumatic removal of peristomal hair and presents with erythema and pustules of the hair follicles (Fig. 151.9). In addition to topical antimicrobial powder as needed, the patient should be advised on proper techniques regarding clipping of peristomal hair and pouch removal including use of an adhesive removal product.



Figure 151.8. Peristomal candida.



Figure 151.9. Folliculitis.

Mucosal Transplantation

If the suture needle is passed from the mucosa and bowel wall though all the layers of the skin at the time of stoma creation, the needle can seed the epidermis with mucosal cells and create small islands of mucosa within the skin (Fig. 151.10). The consequence is discharge of mucus and irritation of the skin. These areas can be treated with a skin barrier powder to absorb the moisture or be cauterized with silver nitrate or electrical cautery. Good surgical technique includes through the subcuticular layer rather than through the epidermal layer.

Psoriasis

Although the underlying cause is unknown, psoriasis is due to hyperproliferation of the epidermal layer resulting in raised red plaques with a white scaly covering often underneath the skin barrier (Fig. 151.11). There may be a family history of psoriasis or personal history of inflammatory bowel disease. It is usually treated with topical steroids. Referral to dermatology may be warranted.



Figure 151.10. Mucosal transplantation.

Stoma Varices

Portal hypertension and venous engorgement can cause a bluish discoloration of the peristomal skin. Bleeding from these varices can be spontaneous and profuse. Bleeding will usually stop with direct pressure, sclerotherapy, or suture ligation but recurrence is common. For repeated episodes, treatment is directed at the liver disease and portal hypertension with propranolol, transjugular intrahepatic portosystemic shunt, surgical shunt, or liver transplantation.

Pyoderma Gangrenosum

A rare complication, it presents as an exquisitely painful, well-demarcated ulcer often have fibrinous exudate and an underlying necrotizing inflammatory process. It is commonly associated with inflammatory bowel disease, rheumatoid arthritis, and multiple myeloma. Patients should be assessed for underlying ongoing intestinal inflammation. Treatment consists of topical high-dose corticosteroids, topical tacrolimus, pain control, and careful attention to local wound care and pouching concerns.



Figure 151.11. Peristomal psoriasis.

CONCLUSIONS

Caring for a new stoma can be a stressful experience for patients. Complications and difficulty in caring for a new stoma can be avoided with proper preoperative education, meticulous stoma creation, proper siting, and regular postoperative education and follow-up. In addition to training in the basic skills of emptying and changing the appliance, patients will require dietary advice and psychosocial support. In follow up they will need assessment of pouch fit and peristomal skin condition to ensure a successful transition to self care. The skills of a WOCN can prove invaluable in caring for these patients.

EDITOR'S COMMENT

Drs. Osborne and Lowry have written a nice chapter containing practical advice for clinicians with regard to the care of all kinds of stomas. Any surgeon who takes emergency general surgery call is likely to be faced with the prospect of needing to create a stoma and to care for a patient with a freshly created stoma. As nicely described in this chapter, when an ostomy is a planned result of an elective procedure, the involvement of a WOC nurse in advance to help select a proper stoma site and to educate the patient can positively impact the patient experience and outcome. Marking the optimal location for a stoma preoperatively enhances the likelihood of a patient's independence in stoma care, predictable pouching system wear times, and resumption of normal activities. Unfortunately, in emergency settings WOC nurses or surgeons with extensive experience in selecting the proper stoma site or creating an ideal stoma are often not readily available. General surgeons who take emergency call should familiarize themselves with the information in this chapter.

A couple of issues brought forth warrant further discussion. Readmissions

following surgical procedures have become an important quality indicator. The Affordable Care Act introduced the Hospital Readmission Reduction Program, which allows the Centers for Medicare and Medicaid Services to penalize hospitals with greater-than-expected rates of readmission. Reducing readmissions has thus become an integral strategy in controlling costs and improving patient care. The rates of readmission following colon resection have been demonstrated to be around 15%. In the state of Pennsylvania, of the more than 10,000 patients undergoing colectomy in 2011, 14.7% were readmitted within 30 days of the procedure. Construction of an ileostomy was among the most significant risk factors for readmission (odds ratio [OR] 2.31, $p < 0.001$). Strikingly similar findings were observed from colectomy cases abstracted for the National Surgical Quality Improvement Program in the Upstate New York Surgical Quality Initiative from June 2013 to June 2014. The implementation of an "ileostomy pathway" has been demonstrated to decrease readmissions, especially related to dehydration in patients with a new ileostomy. In one such pathway, a standardized set of patient education tools was developed. Patient education started with the preoperative visit. All patients were directly engaged in ostomy management and trained in a stepwise progression. Patients were discharged from the hospital with flow sheets, supplies for recording intake/output, and visiting nurse services. Overall readmission rate was 35.4% in a historical cohort of patients prior to implementation of the pathway and 21.4% after implementation. The readmission rate for dehydration was 15.5% prior to pathway implementation, but dropped to 0% in the study group. An understanding that a patient with a new ileostomy is at the significant risk of readmission is essential to decreasing preventable readmissions in these patients.

Parastomal hernias remain a common and challenging problem for patients, WOCN, and surgeons alike. Parastomal hernias can be painful, may lead to hospital admission for obstruction, and can lead to difficulties getting a stoma appliance to fit correctly. Prevention of parastomal hernias when the stoma is created in the original procedure is an inexact science. The technical nuances of properly placing a stoma in the rectus muscle are well described in this chapter. Some surgeons have taken prevention of stoma formation to the next level and prophylactically place mesh at the time of creation of the original stoma. A systematic review and meta-analysis identified six randomized controlled studies including 309 patients randomized to mesh or no mesh placement at the time of colostomy construction. Parastomal hernia occurred in 24.4% of patients with mesh and 50.3% of patients without mesh. Meta-analysis showed a lower incidence of parastomal hernia (relative risk [RR] 0.42, 95% confidence interval [CI] 0.22–0.82) and reoperation related to parastomal hernia (RR 0.23, 95% CI 0.06–0.89) in patients with mesh. Stoma-related morbidity was similar between mesh group and nonmesh group (RR 0.65, 95% CI 0.33–1.30). The authors conclude that prophylactic placement of a mesh at the time of a stoma formation seems to be associated with a significant reduction in the incidence of

parastomal hernia and reoperation related to parastomal hernia after surgery for rectal cancer, but not the rate of stoma-related morbidity.

When parastomal hernias do occur, surgical repair can be associated with significant potential morbidity and a high recurrence rate. A recently published study evaluated all patients with a parastomal hernia repair registered in the Danish Hernia Database from January 1, 2007 to December 31, 2010. The study included 174 patients with a parastomal hernia repair (142 elective and 32 emergency repairs; 56 open and 118 laparoscopic repairs). Median follow-up was 20 months (range, 0 to 47). A total of 13.2% of patients underwent a reoperation in 30 days because of postoperative complications. Mortality in the first 30 days was 6.3%. After 3 years, the cumulated reoperation rate for recurrence was 10.8% (open 17.2% and laparoscopic 3.8%). A systematic review of the literature included 30 studies and evaluated different techniques of parastomal hernia repair. Suture repair resulted in a significantly increased recurrence rate when compared with mesh repair (OR 8.9, 95% CI 5.2–15.1; $p < 0.0001$). Recurrence rates for mesh repair ranged from 6.9% to 17% and did not differ significantly. In the laparoscopic repair group, the Sugarbaker technique had a lower recurrence rate than the keyhole mesh technique (OR 2.3, 95% CI 1.2–4.6; $p = 0.016$). Morbidity did not differ between techniques. The overall rate of mesh infections was low (3%, 95% CI 2) and comparable for each type of mesh repair. The authors of this systematic review concluded, “suture repair of parastomal hernia should be abandoned because of increased recurrence rates. The use of mesh in parastomal hernia repair significantly reduces recurrence rates and is safe with a low overall rate of mesh infection. In laparoscopic repair, the Sugarbaker technique is superior over the keyhole technique showing fewer recurrences.”

Proper creation of a stoma and how to manage complications from a freshly created stoma are important topics for all general surgeons to understand. The utility of a WOCN in helping patients transition to life with a stoma cannot be overestimated. This is an excellent chapter that does a nice job covering the spectrum of issues pertaining to proper care of a stoma.

Jon C. Gould

Suggested Readings

Hansson BM, Slater NJ, van der Velden AS, et al. Surgical techniques for parastomal hernia repair: a systematic review of the literature. *Ann Surg* 2012;255(4):685–95.

Helgstrand F, Rosenberg J, Kehlet H, et al. Risk of morbidity, mortality, and recurrence after parastomal hernia repair: a nationwide study. *Dis Colon Rectum* 2013;56(11):1265–72.

Kocher RP, Adashi EY. Hospital readmissions and the affordable care act:

paying for coordinated quality care. *JAMA* 2011;306:1794–5.

Kulaylat AN, Dillon PW, Hollenbeak CS, et al. Determinants of 30-d readmission after colectomy. *J Surg Res* 2015;193(2):528–35.

Nagle D, Pare T, Keenan E, et al. Ileostomy pathway virtually eliminates readmissions for dehydration in new ostomates. *Dis Colon Rectum* 2012;55(12):1266–72.

Salvadalena G, Hendren S, McKenna L, et al. WOCN Society and ASCRS Position Statement on Preoperative Stoma Site Marking for Patients Undergoing Colostomy or Ileostomy Surgery. *J Wound Ostomy Continence Nurs* 2015;42(3):249–52.

Wang S, Wang W, Zhu B, et al. Efficacy of Prophylactic Mesh in End-Colostomy Construction: A Systematic Review and Meta-analysis of Randomized Controlled Trials. *World J Surg* 2016;40(10):2528–36.

152 Open and Minimally Invasive Right Hemicolectomy for Cancer

Martin R. Weiser

INTRODUCTION

Complete surgical resection of a primary nonmetastatic colon cancer is the mainstay of treatment and holds the best chance for potential cure. Adequate resection involves removal of the involved segment of large bowel, mesentery, and associated vascular supply to completely excise the locoregional lymphatics at risk for harboring metastatic disease. Complete mesocolic excision should be performed with evaluation of at least 12 lymph nodes. Laparoscopic colectomy after diagnosis of colon cancer is now an accepted approach, with outcomes comparable to those of conventional open surgical resection. Patients treated with minimally invasive approaches have faster recovery, less pain, and similar perioperative and oncologic outcomes. Robotic surgery has come to the forefront as a modality that provides improved optics and overcomes mechanical limitations of straight laparoscopic surgery. The decision on which technique to proceed with depends on surgeon expertise and experience along with patient- and tumor-related factors.

CLINICAL PRESENTATION

In a representative case, a 62-year-old male presented with weakness and fatigue. Workup including a complete blood count (CBC) revealed anemia with hemoglobin of 7.5 g/dL. Upper endoscopy was unrevealing, and colonoscopy identified a 5-cm lesion in the ascending colon. Biopsy confirmed moderately differentiated invasive adenocarcinoma. A computed tomography (CT) scan of the chest, abdomen, and pelvis with oral and intravenous contrast identified an ascending colon lesion with enlarged lymph nodes along the ileocolic artery but no evidence of distant metastatic disease.

INDICATIONS AND CONTRAINDICATIONS

Indications for right colectomy include invasive cancers or noninvasive neoplastic lesions not amenable to endoscopic removal. Patients with history of malignant polypectomy should undergo colectomy if margins are not cleared or there is a significant risk of nodal metastases. The probability of metastases to regional lymph nodes is related to pathologic features including poor differentiation, vascular or lymphatic invasion, and invasion below the submucosa. In general, the presence of one or more of these features is an indication for resection.

Indications for an extended right colectomy include a cancer located in the proximal to mid-transverse colon, synchronous ascending and transverse colon cancers, and multiple adenomas, which may or may not be part of a genetic syndrome. Extended right hemicolectomy proceeds similarly to a standard right hemicolectomy; however, the middle colic pedicle is ligated at its origin. Anastomosis is then created between the terminal ileum and distal transverse colon or descending colon, depending on vascular supply.

The decision to proceed with a minimally invasive or open surgical approach depends on the surgeon's expertise and experience. There are no absolute contraindications for laparoscopic colon cancer surgery; however, cases with intestinal obstruction, large fistulizing tumors, or previous multiple abdominal surgeries with expected extensive abdominal adhesions can be challenging for inexperienced laparoscopic surgeons. Ultimately, the specific surgical approach should be selected with the goals of maximizing the chance of a margin-negative resection, limiting complications, and optimizing recovery.

PREOPERATIVE PLANNING

Preoperative workup includes a complete history and physical examination, including family history, routine laboratory analysis (including carcinoembryonic antigen), radiographic imaging, and medical evaluation for risk stratification. Patients should undergo a full colonic evaluation, with histologic analysis of the colon lesion, prior to initiation of treatment. In general, if colonoscopy is incomplete, then a short-interval postoperative colonoscopy should be performed. In the setting of near obstructing right colon lesions, resection will include the unseen portion of colon, making the latter recommendation unnecessary. Radiologic staging includes CT of the chest, abdomen, and pelvis with oral and intravenous contrast. MRI and PET scans are used selectively if an abnormality noted

on a CT scan needs further definition and would change surgical management. Preoperative medical consultation is obtained based on the patient's history, including geriatric evaluation for fragile patients and those older than 80 years.

Patients receive mechanical bowel preparation including a clear liquid diet and a polyethylene glycol-based agent, in combination with oral antibiotics, on the day prior to surgery. Although controversial, this approach is supported by recent literature. In a study involving over 8,400 patients from the National Surgical Quality Improvement Program-targeted colectomy dataset, patients receiving mechanical bowel preparation with oral antibiotics had lower rates of surgical-site infection, anastomotic leak, and postoperative ileus than other patients.

Thromboembolism prophylaxis includes preoperative subcutaneous heparin, sequential compression devices, postoperative low–molecular-weight heparin, and early ambulation. Modifications of the Surgical Care Improvement Project (SCIP) measures are followed, including maintenance of normothermia, glucose control, appropriate hair removal, and appropriate use of intravenous antibiotics, including administration prior to incision, re-dosing during the procedure, and discontinuation postoperatively.

Patients are managed according to enhanced recovery pathways and are counseled preoperatively on expectations, including early ambulation on the day of surgery and discharge once tolerating diet and passing flatus. Patients are allowed to consume a clear liquid diet the morning of surgery and are given a complex carbohydrate drink including electrolytes and minerals 4 hours before induction of anesthesia. In the preoperative care unit, patients are given gabapentin, diclofenac, and alvimopan. Epidural catheters are utilized for open surgery, and transverse abdominis plane (TAP) blocks are used for minimally invasive procedures. Intraoperatively, intravenous fluids are limited with goal-directed fluid therapy. Ketamine infusions, minimal opioids, and standardized antiemetics are utilized.

SURGICAL TECHNIQUE

Open Right Hemicolectomy

The patient is positioned supine with arms out. A midline incision is typically used. A self-retaining retractor is placed, and the abdomen is thoroughly explored. The surgeon is on the right, and the assistant is on the left. The assistant retracts the right colon to the left, while the surgeon

incises the lateral peritoneal reflection (white line of Toldt) with cautery (Fig. 152.1). The right colon is mobilized off the retroperitoneum, including Gerota fascia, the duodenum, and the head of the pancreas. Care is taken to avoid traction injury to the small veins around the head of the pancreas, and bleeding at this site often requires suture ligatures for control (Fig. 152.2). The cecum and terminal ileum are then dissected anteromedially with care to identify the right gonadal vessels and ureter. This dissection continues to the third portion of duodenum. The hepatic flexure is taken down similarly with cautery.

The right portion of omentum is generally resected en bloc and divided below the right gastroepiploic arcade. The omentum is dissected off the mid-transverse colon and divided between clamps and ties or with the use of a vessel sealing device. The lesser sac is entered. Next, the ileocolic pedicle is identified by retracting the cecum to the right. The ileocolic vessels are located at the caudal portion of the root of the mesentery. The right colic vessels are variable; they are predominantly a branch of the ileocolic pedicle but in rare circumstances are a separate takeoff from the superior mesenteric artery and vein. The ileocolic vessel is cleared at their junction with the superior mesenteric artery and vein, ligated, and divided between clamps and ties or with a vessel-sealing device.

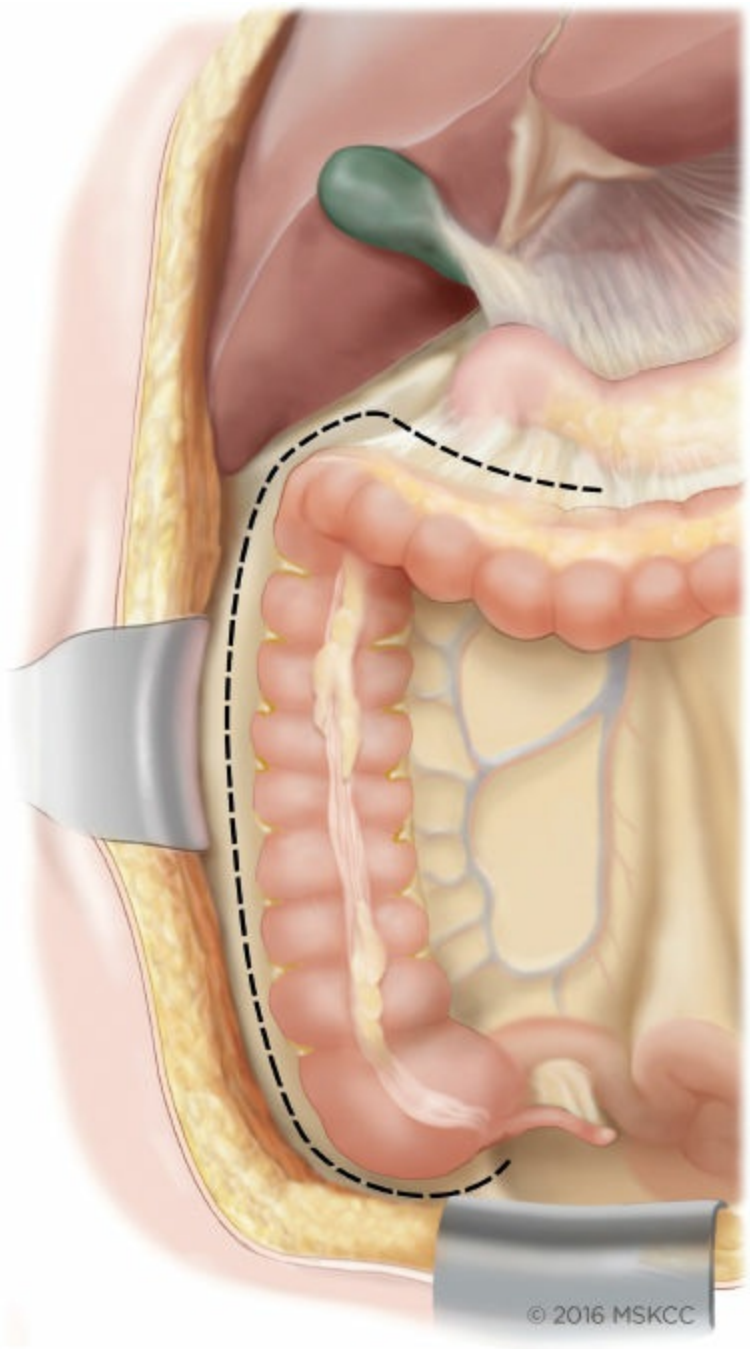

Figure 152.1. In open right hemicolectomy, the assistant retracts the right colon to the left, and the surgeon incises the lateral peritoneal reflection (white line of Toldt) with cautery. (©2016, Memorial Sloan Kettering Cancer Center.)

Dissection continues along the superior mesenteric vein, consistent with the principles of total mesocolic excision, and the middle colic pedicle is identified. Care is taken to resect the right colon mesentery without breach of the visceral fascia. In a standard resection, the right branch of the middle colic pedicle is ligated, and dissection continues along the

mesentery to the proximal/mid-transverse colon. In an extended resection, the middle colic vessels are ligated at their origin with anastomosis between the terminal ileum and distal transverse colon or descending colon (Fig. 152.3). An anastomosis-in-continuity is performed with creation of an enterotomy and a colostomy, deployment of a GIA-80 stapler, and closure of the common enterotomy/colostomy with a TA-90 stapler (Fig. 152.4). A reinforcement suture is placed at the base of the anastomosis, and the mesenteric defect is not routinely closed. The anastomosis is inspected for sufficient vascularity by identifying visible pulsations in the mesentery and checking the color of the mucosa and serosa. Care is taken to ensure proper bowel orientation. A separate, clean set of instruments is utilized for closure.

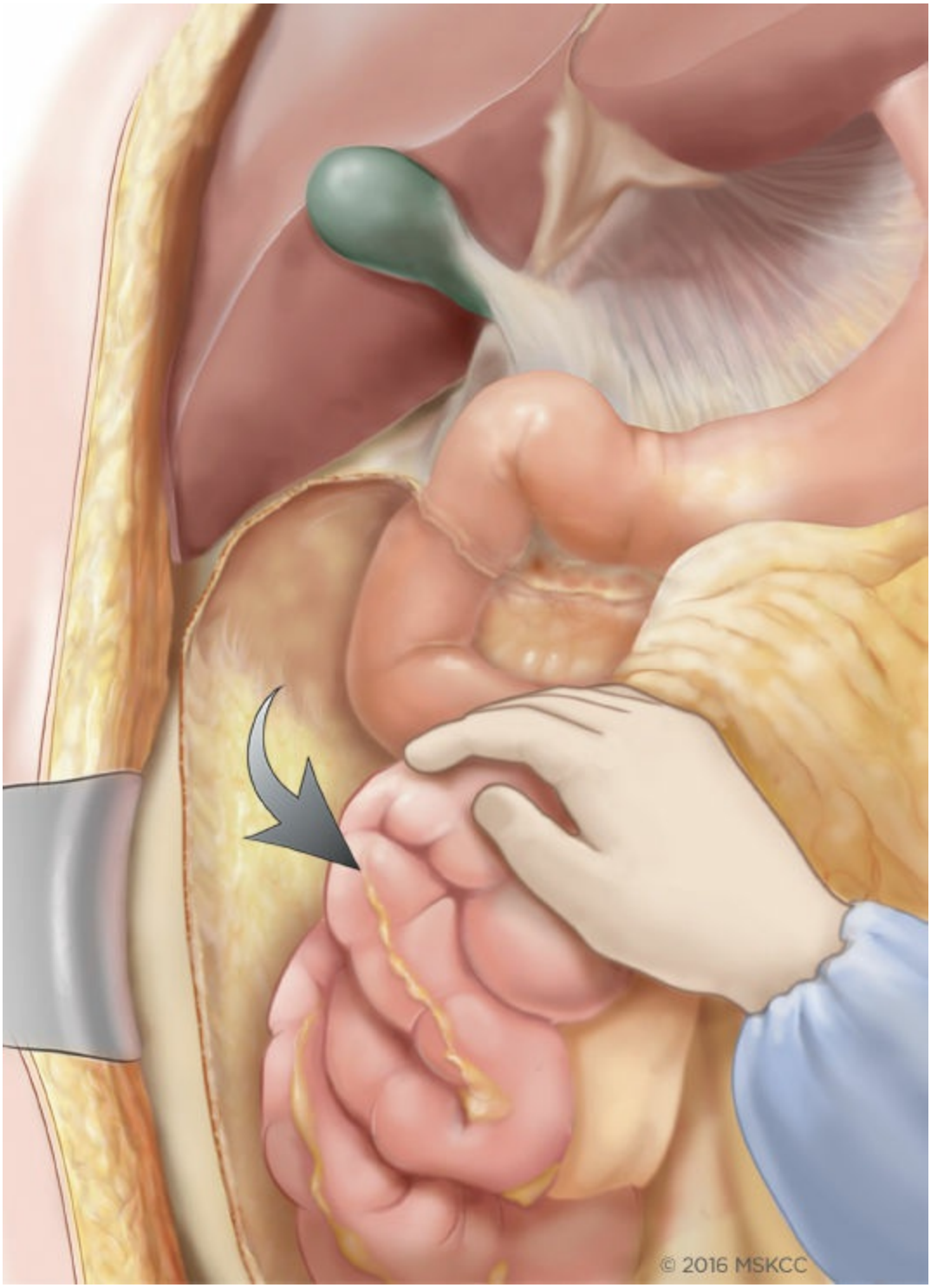

Figure 152.2. Mobilization of the right colon off the retroperitoneum, including Gerota fascia, the duodenum, and the head of the pancreas. (©2016, Memorial Sloan Kettering Cancer Center.)

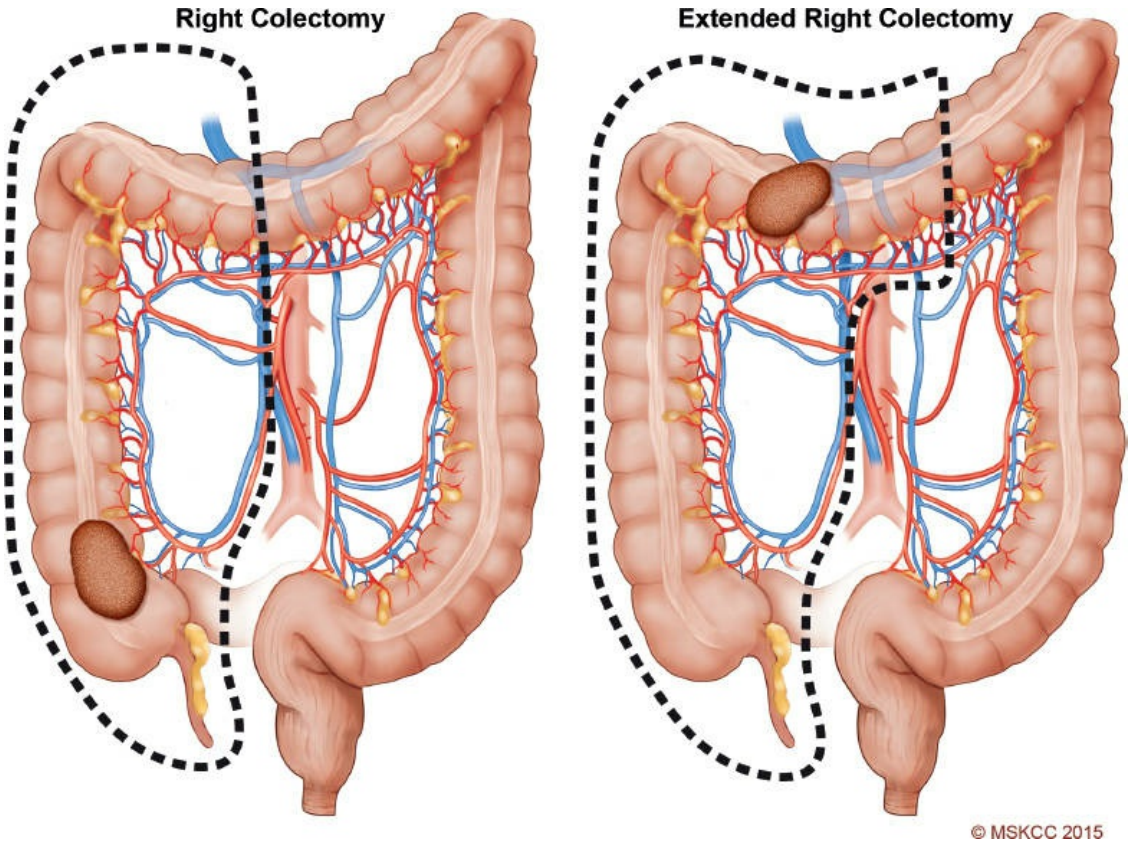

Figure 152.3. In an extended right hemicolectomy, the terminal ileum is anastomosed to the distal transverse colon or descending colon. (©2016, Memorial Sloan Kettering Cancer Center.)

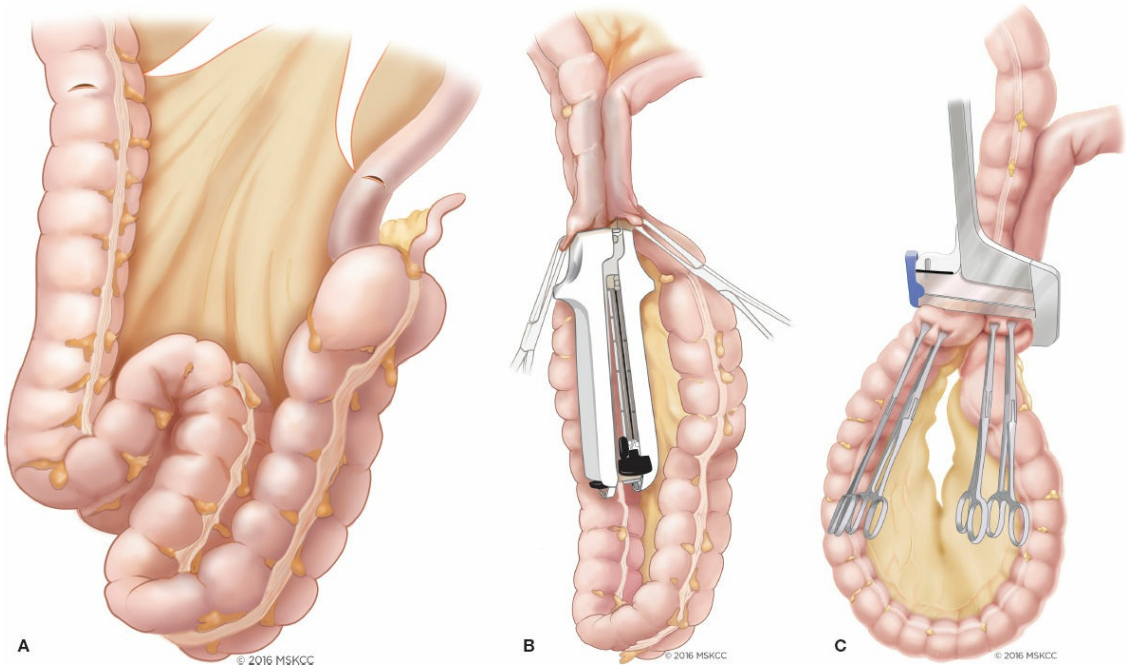

Figure 152.4. Once the colon has been mobilized and pedicles ligated, an anastomosis-in-continuity is fashioned. An enterotomy and a colostomy are then performed (**A**), the GIA 80 stapler is

inserted and deployed (**B**), and the common enterotomy/colostomy is closed by deploying a TA-90 stapler (**C**). (©2016, Memorial Sloan Kettering Cancer Center.)

Laparoscopic Right Hemicolectomy

The patient is positioned supine on the operating room table with both arms tucked, padded, and properly strapped for security. A nonskid cushioned pad is placed under the patient to prevent movement during extremes of tilt. In contrast to the configuration used for open right hemicolectomy, both surgeons usually stand on the left side. Access to the abdomen can be attained via a Veress needle or a cut-down technique utilizing a Hasson trocar. For a Veress needle, the left upper quadrant, 3 cm below the left subcostal border in the midclavicular line (Palmer point), is preferred.

A 5-mm trocar is then placed in the supraumbilical region at the site of planned incision for extraction of the right colon. A zero-degree laparoscope is utilized in this trocar, and then three additional 5-mm trocars are placed in the supraumbilical region and the left upper and left lower quadrants of the abdomen, lateral to the rectus musculature (Fig. 152.5). The patient is put into the Trendelenburg position, and the right side of the table is tilted upward. The omentum is retracted cephalad, and the small bowel is retracted to the patient's left, in order to expose the colonic mesentery and the origin of the ileocolic vessels.

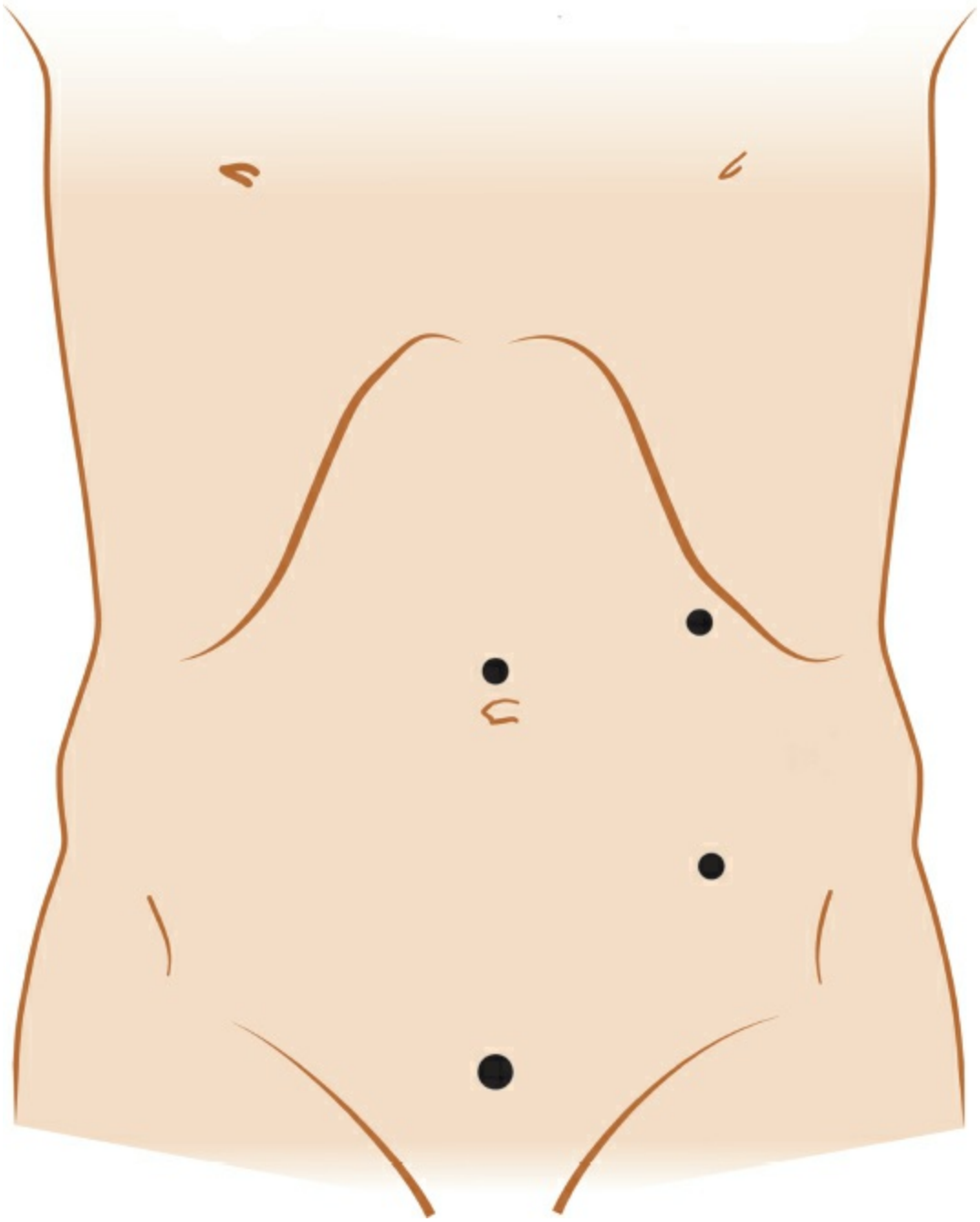

Figure 152.5. Port placement for laparoscopic right hemicolectomy. Filled circle, 8-mm port. (©2016, Memorial Sloan Kettering Cancer Center.)

A medial-to-lateral approach is utilized, and the terminal ileum is placed under tension in the right lower quadrant. The ileocolic pedicle, on tension, becomes apparent, and dissection begins at the level of the duodenum. The peritoneum is incised below the ileocolic pedicle, and in a medial-to-lateral fashion submesenteric dissection proceeds to raise the right colon mesentery off the retroperitoneum, including the duodenum,

Gerota fascia, gonadal vessels, and ureter. Care is taken to avoid breach of the visceral fascial layer around the mesentery. The ileocolic pedicle is cleared, ligated, and divided at its origin with the superior mesenteric artery and vein using a vessel sealing device, endoscopic vascular stapler, or clips. The transverse colon is then placed on tension, and the middle colic pedicle is identified. The transverse mesocolon is scored, and the origin of the right middle colic pedicle is ligated and divided. The mesentery is fully divided to the transverse colon. The omentum is dissected off the distal transverse colon with entry into the lesser sac and prior dissection plane.

Next, the transverse colon is retracted caudal, and the omentum and hepatic flexure attachments are divided medial to lateral. Dissection continues along the white line of Toldt. Again, previous medial-to-lateral submesenteric dissection had freed this area, maintaining the ureter, kidney, and gonadal vessels in the retroperitoneum. The small bowel mesentery is dissected to the level of the duodenum. Finally, the terminal ileum mesentery is divided to the bowel wall. The umbilical port site is enlarged, a wound retractor placed, and the cecum delivered with the help of a laparoscopic bowel grasper. The terminal ileum, right colon, and proximal transverse colon are exteriorized for an anastomosis-in-continuity as outlined for open colectomy. An intracorporeal anastomosis can also be completed laparoscopically with a 12-mm stapler after upsizing the left lower quadrant or suprapubic port. Once the anastomosis is completed, it is returned to the abdominal cavity. The pneumoperitoneum is re-established by closing the wound protector. A final inspection of the abdomen is completed, and the other trocars are removed under direct visualization. The extraction site fascia is closed with interrupted sutures, and the skin is closed with absorbable running suture. Care is taken to avoid the umbilicus when extending the port site for extraction to avoid postoperative hernia.

Robotic Right Hemicolectomy

For the da Vinci Xi platform, the robot is positioned on the patient’s right side. The bedside operating assistant stands on the patient’s left side, and the scrub technician and instrument table should be positioned on the left side near the patient’s feet. The anesthesia team retains its normal position at the head of the bed. The robot is docked from the patient’s right and perpendicular to the operating room table. Video monitors, intravenous

fluid poles, equipment booms, and the anesthesia cart are positioned so as to avoid interference with the cart or robotic arms. Figure 152.6 shows an overhead view of the recommended configuration.

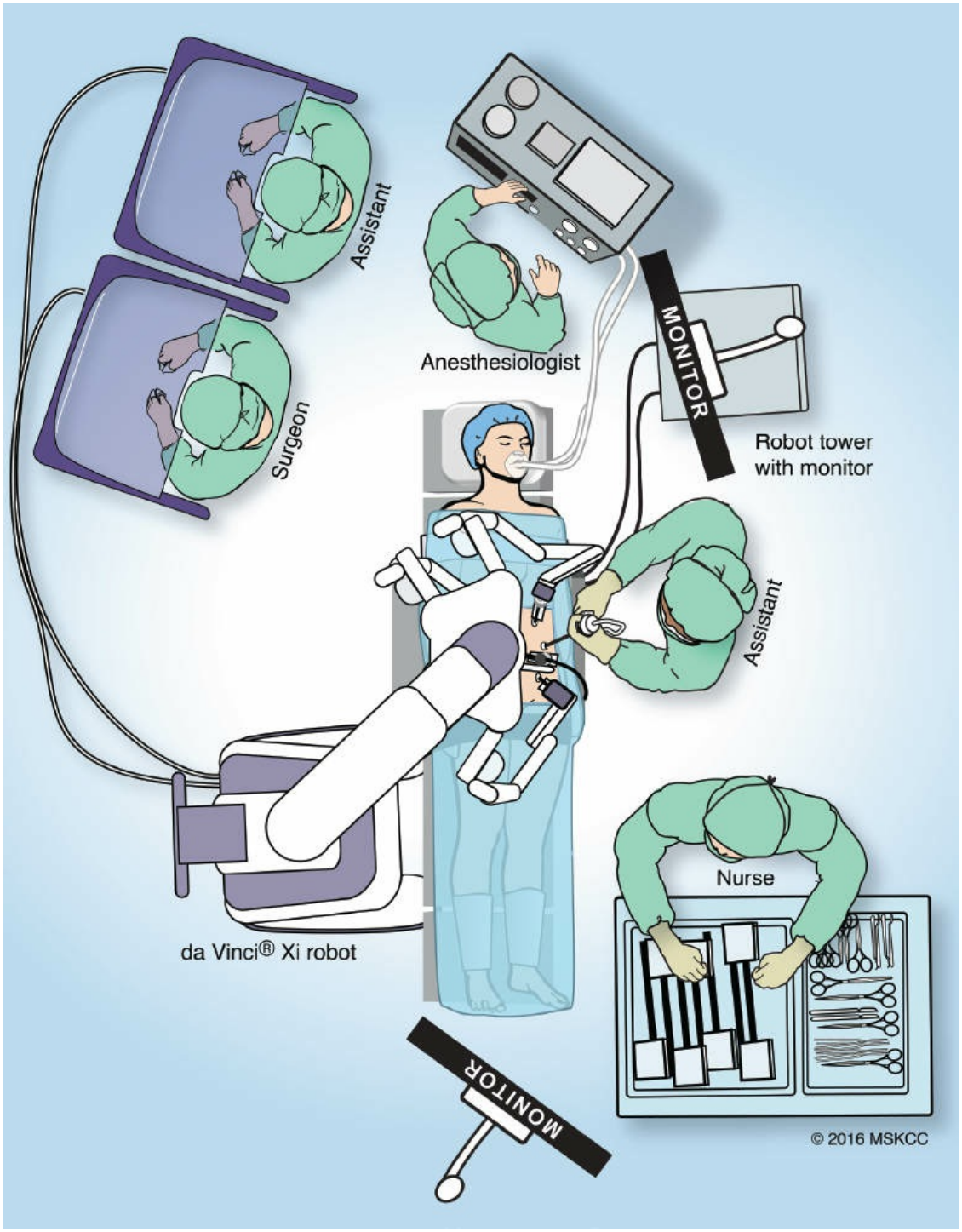

Figure 152.6. Recommended configuration of the operating room for robotic right hemicolectomy. (©2016, Memorial Sloan Kettering Cancer Center.)

A 5-port approach is utilized: 4 robotic ports and an accessory port. Pneumoperitoneum is established with a Veress technique. The umbilical port is placed first. Ports are generally placed midline and to the left of the midline. There is slight variation depending on whether intracorporeal

stapling is planned (Fig. 152.7). Intracorporeal anastomosis utilizes a robotic or laparoscopic stapler introduced through a larger, 12- to 15-mm, supraumbilical port that is extended to become the extraction site. For extracorporeal anastomosis, the specimen is generally extracted via the umbilical port site.

Following placement of ports and prior to docking the robot, the bed's left side is tilted down with slight Trendelenburg positioning. After inspection of the peritoneal cavity, the omentum and the transverse colon are pushed cephalad over the liver tip using laparoscopic instruments. The small intestine is gently moved to the left to expose the ileocolic pedicle and duodenum.

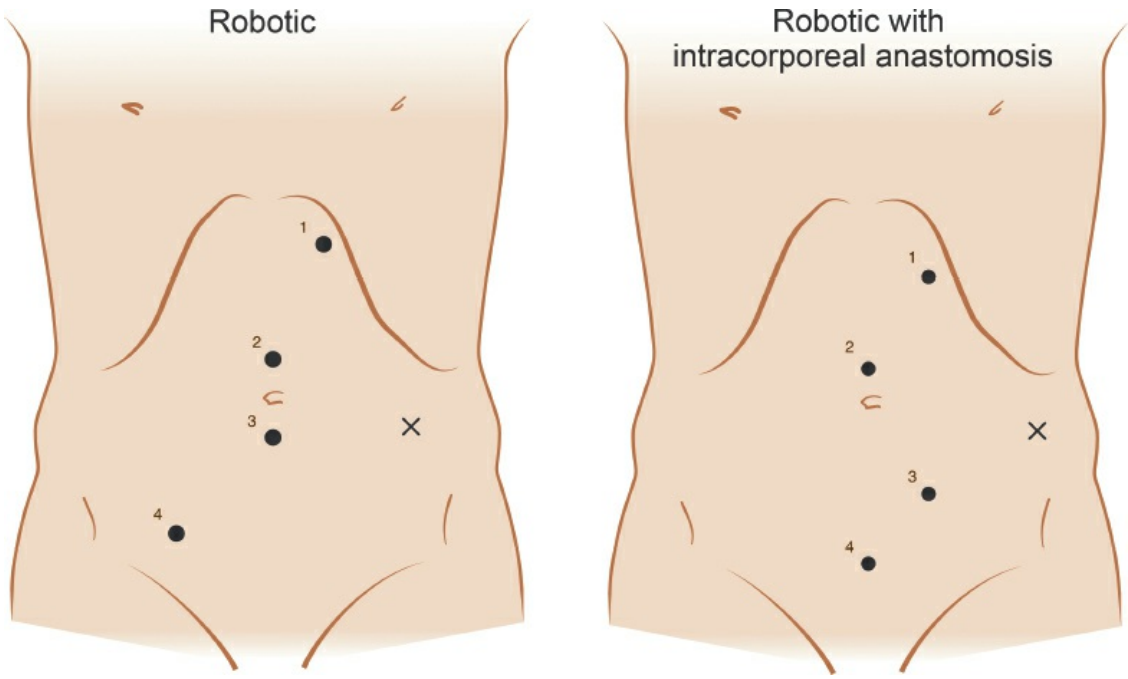

Figure 152.7. Port placement for robotic right hemicolectomy. Filled circle, 8-mm robotic port; ×, accessory port. (©2016, Memorial Sloan Kettering Cancer Center.)

The robotic cart should approach the operating table from the right, perpendicular to the bed. When docking, automatic targeting by focusing the camera on anatomy ensures proper arm alignment to maximize the range of motion and limits arm collision. A robotic 0-degree endoscope is inserted into the #2, supraumbilical port. Arm 1 is typically used with monopolar curved scissors or the robotic vessel sealer. Arm 3 is used with the fenestrated bipolar instrument, and arm 4 is used with the Cadiere grasper. A 5-mm assistant port accommodates the suction irrigator and

laparoscopic bowel grasper used by the bedside assistant during the procedure.

A medial-to-lateral approach is utilized, analogously to laparoscopic right hemicolectomy. The terminal ileum and cecum are retracted to the right lower quadrant with arm 4, which elevates and places the ileocolic pedicle on tension (Fig. 152.8). Using the fenestrated bipolar grasper in arm 3 and the bipolar scissor in arm 1, the peritoneum is incised below the ileocolic pedicle, and the submesenteric dissection is initiated just below the level of the duodenum. Submesenteric dissection continues, visualizing and maintaining the duodenum, Gerota fascia, gonadal vessels, and ureter in the retroperitoneal position (Fig. 152.9). The dissection continues laterally, using the bipolar forceps to provide counter-tension until the abdominal wall is reached. The dissection continues along this plane superiorly and medially over the duodenum and the head of the pancreas.

Once the right colon mesentery is dissected off the retroperitoneum, the vascular pedicles are addressed. Dissecting the anterior wall of the superior mesenteric vein inferior to the ileocolic takeoff facilitates total mesocolic excision and high pedicle ligation. Wristed instruments expedite this dissection. Once the ileocolic artery and vein are ligated and divided, the bedside assistant provides anterior and cephalad retraction on the transverse colon mesentery to facilitate dissection along the superior mesenteric vein. The middle colic vein and then artery are identified, and the right branch is ligated and divided. The right colic pedicle is most commonly a branch of the ileocolic pedicle but on occasion can have separate takeoff from the superior mesenteric vein between the ileocolic and middle colic pedicles. For proximal transverse colon lesions, the base of the middle colic pedicle is ligated and divided, and the gastrocolic vein (gastrocolic trunk of Henle) is divided for resection of the proximal omentum en bloc with the right colon. The mesentery is fully divided to the transverse colon.

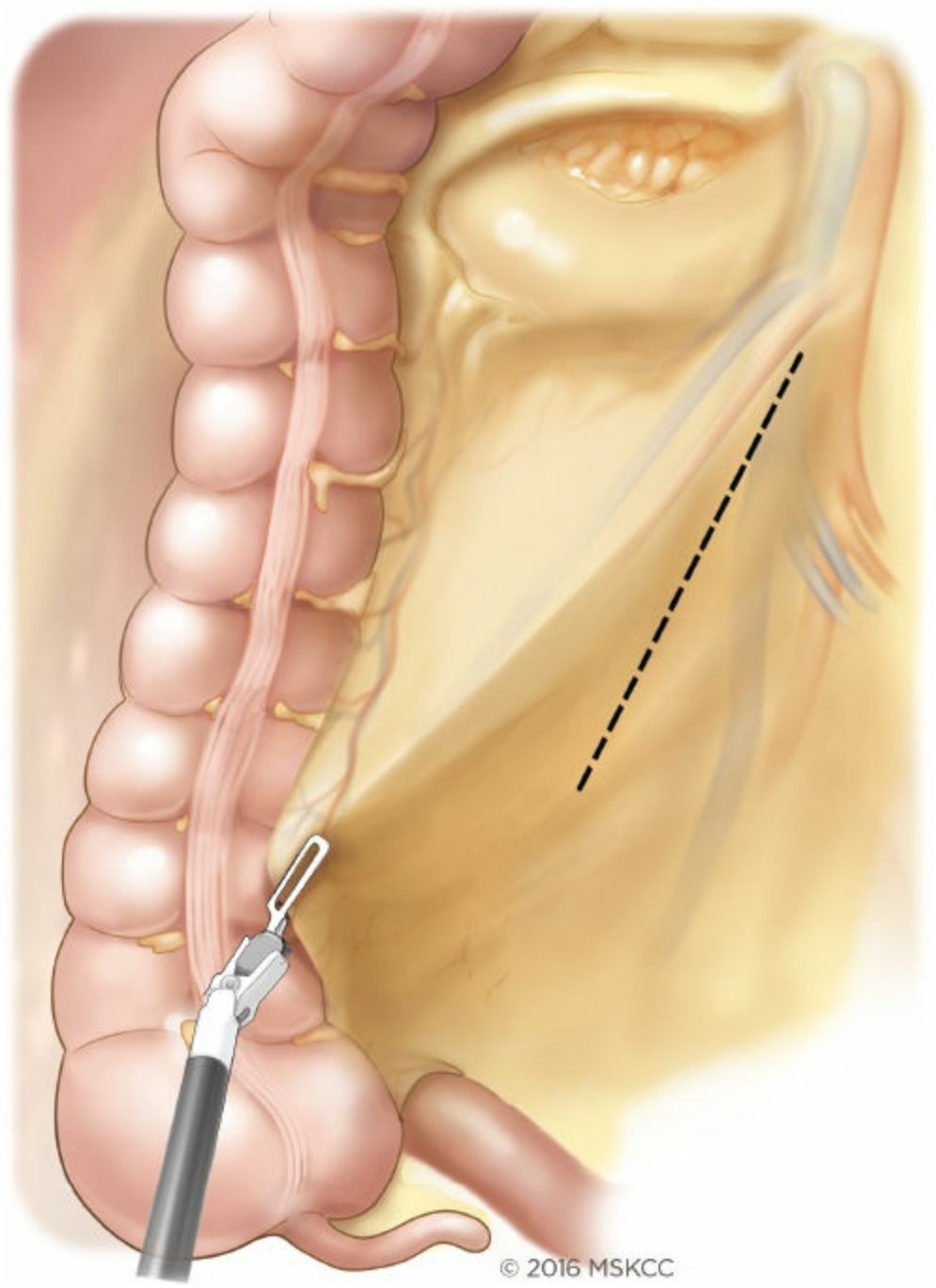

Figure 152.8. The initial step in robotic right hemicolectomy is placing the terminal ileum and cecum under tension to allow identification and incision of the peritoneum below the ileocolic pedicle. (©2016, Memorial Sloan Kettering Cancer Center.)

Next, the omentum is dissected off the distal transverse colon with entry into the lesser sac. The omentum attached to the proximal transverse colon is generally divided outside the gastroepiploic arcade. For proximal transverse colon lesions, the arcade is dissected with the specimen. With the transverse colon placed on caudal tension, omental attachments and the

hepatic flexure are divided in a medial-to-lateral fashion. This dissection is facilitated by previous submesenteric dissection. Arms 2 and 4 provide retraction, while the scissor or vessel sealer divides tissue. Finally, the cecum, appendix, and terminal ileum are mobilized by dividing the peritoneal attachments in the right lower quadrant.

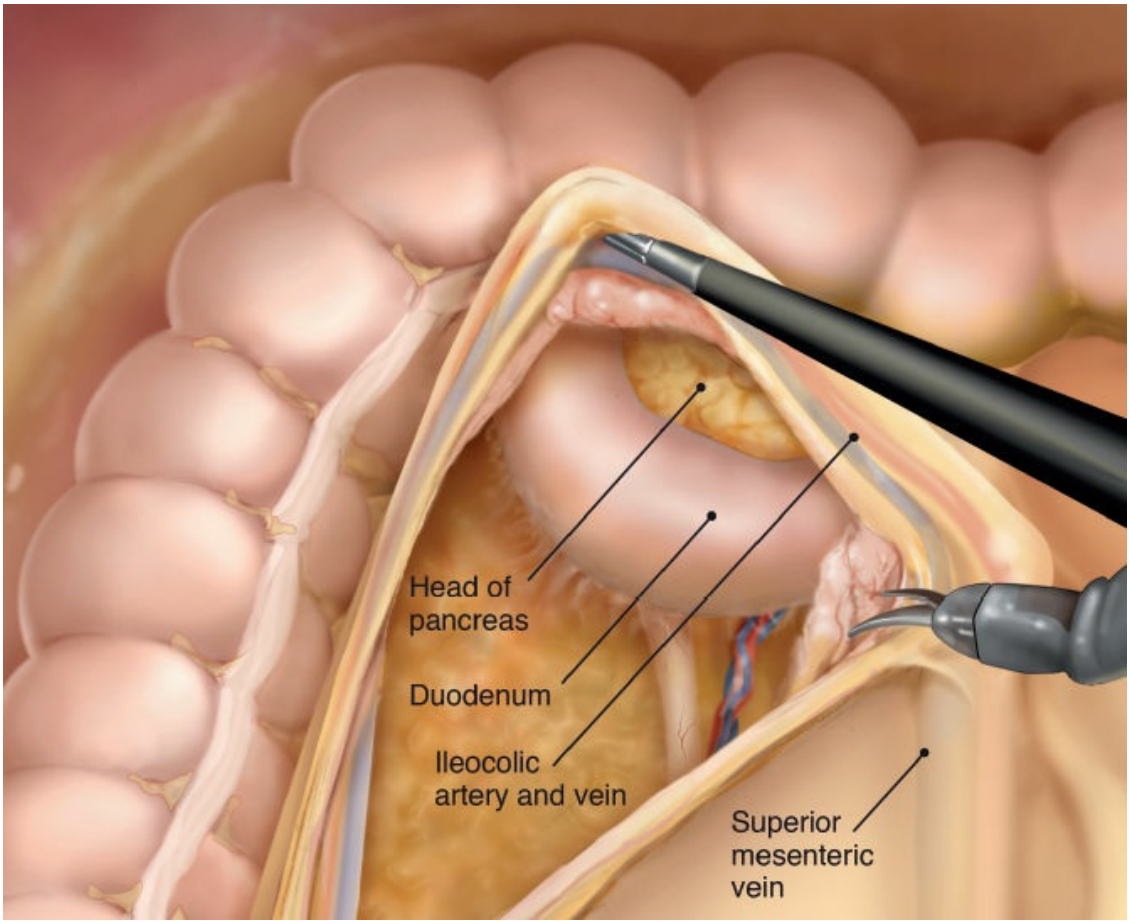

Figure 152.9. Medial-to-lateral dissection of the mesentery off the retroperitoneum, including the duodenum and the head of the pancreas. (©2016, Memorial Sloan Kettering Cancer Center.)

The terminal ileum and cecum are then dissected off the retroperitoneum, and dissection continues, inferior to superior, along the white line of Toldt until the prior superior dissection is met. Again, previous medial-to-lateral submesenteric dissection had freed this area, and the ureter, kidney, and gonadal vessels will be in the retroperitoneum. The small bowel mesentery is freed to the level of the duodenum. Finally, the terminal ileum mesentery is divided to the bowel wall.

For extracorporeal anastomosis, since the entire right colon is mobilized and hemostasis is confirmed, the terminal ileum is held with a laparoscopic

bowel grasper through the assistant port. The robot is then undocked, releasing the robotic arms but leaving the trocars in place. The robotic cart is backed away from the patient. The camera port incision is extended to a length that will accommodate specimen removal, and a wound protector is placed. The terminal ileum and right colon are delivered through the wound protector. An anastomosis-in-continuity is fashioned in a stapled side-to-side, functional end-to-end anastomosis manner. After the procedure is completed, the base of the anastomosis is reinforced with suture, and mesenteric defect is not closed. The wound protector is closed, and repeat insufflation allows for laparoscopic inspection for hemostasis with visualization of port removal. The fascia from the specimen retrieval site is irrigated, and interrupted sutures are used to close the fascia with absorbable monofilament sutures. The extraction site is closed in two layers with interrupted absorbable monofilament facial sutures and absorbable skin sutures.

For intracorporeal anastomosis, the terminal ileum and the transverse colon are divided with a laparoscopic or robotic stapler. An isoperistaltic side-to-side anastomosis is created with alignment of the distal terminal ileum medial and adjacent to the transverse colon. To ensure antimesenteric orientation, an enterotomy and a colostomy are created at the distal aspect of the ileum. The broader jaw of the robotic or laparoscopic stapler is first inserted into the colotomy, and then the ileum is brought over and the slimmer stapler jaw is positioned in the enterotomy. The stapler is deployed, and the common enterotomy/colostomy is closed with intracorporeal interrupted or running suture. The suprapubic stapling port is enlarged (generally by creating a Pfannenstiel incision) for specimen extraction after placement of a wound protector. The wound protector is then closed, insufflation is re-established, the abdomen is inspected for hemostasis, and ports are removed under direct visualization.

POSTOPERATIVE CARE

As mentioned above, patients undergoing colectomy are managed according to enhanced recovery pathways. Patients are given clear liquids in the recovery room and ambulate the day of surgery. Narcotic use is minimized with use of nonsteroidals. The diet is advanced to regular, and the Foley catheter is removed on postoperative day 1. The goal is to discharge minimally invasive surgery patients on postoperative day 2 and

open surgery patients on postoperative day 3. Patients are discharged home on regular diet and nonsteroidals with limitation on heavy lifting, pushing, and pulling.

The National Comprehensive Cancer Network, American Society of Clinical Oncology, and American Society of Colon and Rectal Surgeons all recommend adjuvant chemotherapy for patients with stage III colon cancer. Controversy remains regarding the use of adjuvant therapy for stage II patients, and a medical oncology consultation is advised.

EXTENT OF LYMPHADENECTOMY

Complete mesocolic excision (CME), which includes dissection in the mesocolic plane with central vascular ligation, has been proposed as a means of improving lymph node yield and subsequent outcomes. The goal is to remove the entirety of the mesocolon along embryologic tissue planes with transection of the critical vasculature at the origin. The surgical group in Erlangen, Germany, reported 5-year survival rates of >85% for patients undergoing CME. This technique does require detailed knowledge of anatomical planes and avoidance of any breaches of visceral fascial layers, which theoretically could lead to tumor cell contamination of the peritoneum and metastases. In addition, work from Japan indicates that a D3 lymphadenectomy along with CME may further improve outcomes, in keeping with resecting at least 10 cm proximal and distal to the tumor edge (pericolic lymph node metastases beyond 10 cm are quite rare). D3 lymphadenectomy consists of skeletonizing and ligating the vasculature flush with the origin of the involved vessels (e.g., ileocolic) followed by en bloc removal of the lymphatics along the lateral and ventral portion of superior mesenteric vein to Henle's gastrocolic trunk and final transection of the involved distal vasculature (e.g., right colic and right branch of middle colic vessels) at the respective origins. The principles of CME are sound, and the procedure can be completed using both minimally invasive and open approaches as appropriate for each patient.

OUTCOMES

The laparoscopic approach to colon resection for cancer has several advantages over the open approach, such as shorter hospital stay, reduced postoperative ileus, earlier resumption of oral nutritional intake, reduced pain, and improved cosmesis. A number of prospective randomized trials have proven that laparoscopic colectomy improves short-term outcomes

and provides oncologic outcomes similar to those achieved with open colectomy.

The benefits of robot-assisted colectomy compared to the conventional laparoscopic approach are debatable. Retrospective reviews and a recent meta-analysis indicate that robotic and laparoscopic colectomies are associated with similar complication rates and short-term outcomes. The robotic approach shows trends for lower rates of conversion to open surgery and higher rates of intracorporeal anastomosis. In the only randomized clinical trial comparing laparoscopic to robotic right hemicolectomy, surgical and oncologic outcomes were similar. However, time, operating room charges, and overall costs are higher for robotic colectomy.

Patient selection criteria for robotic right hemicolectomy are similar to those of traditional laparoscopic surgery. Due to the enhanced visualization and increased dexterity provided by the robotic platform, this approach is particularly helpful in patients with bulky lymphadenopathy requiring dissection close to the superior mesenteric artery and vein. The robotic platform also facilitates the performance of a total mesocolic excision.

COMPLICATIONS

With the use of Enhanced Recovery After Surgery protocols and perioperative care bundles, the rate of complications after right hemicolectomy is 5% to 10%. Leak rates are 0.5% to 1% and can usually be managed with bowel rest, antibiotics, and possible percutaneous drainage if clinically necessary. Wound infection rates are <5% and can usually be managed with local care.

CONCLUSION

Complete surgical resection is the mainstay of treatment and holds the best chance of potential cure for patients with primary nonmetastatic colon cancer. Adequate resection entails the removal of the involved segment of bowel, mesentery, and associated vascular supply to completely excise the lymphatics. Precise surgical technique along with CME should allow for complete lymphadenectomy and evaluation of at least 12 lymph nodes for accurate staging. Minimally invasive approaches such as laparoscopic colectomy are preferred; however, the ultimate choice of technique depends on surgical expertise along with patient and tumor factors. Robot-

assisted surgery has come to the forefront as a modality that provides improved visualization, avoids the mechanical limitations of laparoscopic surgical techniques, and does not compromise oncologic outcomes.

Suggested Readings

deSouza AL, Prasad LM, Park JJ, et al. Robotic assistance in right hemicolectomy: is there a role? *Dis Colon Rectum* 2010;53(7):1000–6.

Fleshman J, Sargent DJ, Green E, et al. Laparoscopic colectomy for cancer is not inferior to open surgery based on 5-year data from the COST Study Group trial. *Ann Surg* 2007;246(4):655–62; discussion 62–4.

Jackson TD, Kaplan GG, Arena G, et al. Laparoscopic versus open resection for colorectal cancer: a metaanalysis of oncologic outcomes. *J Am Coll Surg* 2007;204(3):439–46.

Kiran RP, Murray AC, Chiuzan C, et al. Combined preoperative mechanical bowel preparation with oral antibiotics significantly reduces surgical site infection, anastomotic leak, and ileus after colorectal surgery. *Ann Surg* 2015;262(3):416–25; discussion 23–5.

Liao G, Zhao Z, Lin S, et al. Robotic-assisted versus laparoscopic colorectal surgery: a meta-analysis of four randomized controlled trials. *World J Surg Oncol* 2014;12:122.

Nelson G, Kiyang LN, Crumley ET, et al. Implementation of Enhanced Recovery After Surgery (ERAS) across a provincial healthcare system: The ERAS Alberta colorectal surgery experience. *World J Surg* 2016;40(5):1092–103.

Park JS, Choi GS, Park SY, et al. Randomized clinical trial of robot-assisted versus standard laparoscopic right colectomy. *Br J Surg* 2012;99(9):1219–26.

Vlug MS, Wind J, Hollmann MW, et al. Laparoscopy in combination with fast track multimodal management is the best perioperative strategy in patients undergoing colonic surgery: a randomized clinical trial (LAFA-study). *Ann Surg* 2011;254(6):868–75.

Weeks JC, Nelson H, Gelber S, et al. Short-term quality-of-life outcomes following laparoscopic-assisted colectomy vs open colectomy for colon cancer: a randomized trial. *JAMA* 2002;287(3):321–8.

West NP, Hohenberger W, Weber K, et al. Complete mesocolic excision with central vascular ligation produces an oncologically superior specimen compared with standard surgery for carcinoma of the colon. *J Clin Oncol* 2010;28(2):272–8.

EDITOR'S COMMENT

Dr. Weiser in his excellent chapter on right colectomy covers all aspects from open to laparoscopic to robotic, in a tour de force fashion to describe conventional lymphadenectomy, as well as complete mesorectal excision, as well as the Japanese D3 lymphadenectomy. It is clear that wide resection will give superior oncologic results. A minimally invasive procedure with a minimal resection will clearly not help the patient as much. As is true in multiple different areas of this text, Dr. Weiser has shown here, performing a technique well, no matter what type of access, is essential.

Perhaps the prototypical operation today combining the special skill of Colorectal Surgeons, General Surgeons, and Surgical Oncologists are lesions involving the right colon. It is a common operation well done and tolerated nicely by patients well into their eighties and older. Lesions of the right colon are remarkable in that due to the large diameter of the right colon they may often reach a fairly advanced stage prior to diagnosis and may often only be diagnosed based on the presence of the significant anemia. Obstructive symptoms are typically uncommon unless lesions involve the ileocecal valve become quite large. Because right hemicolectomy and in fact segmental colectomy is done by so many different types of surgeons as described above, It has been and will likely continue to be used as a "Quality barometer" by many different types of organizations including insurance carriers, health care bodies such as the centers for Medicare and Medicaid Services (CMS) and others. The death rate for this operation in most teaching hospitals is approximately 1.5% and there is a very narrow range of acceptable practices (mean ± SD 1.56% ± 1.27%) (Billeter AT, Polk HC Jr, Hohmann SF, et al. Mortality after elective colon resection: the search for outcomes that define quality in surgical practice. *J Am Coll Surg* 2012;214(4):436–43; discussion 443–4). Individuals have been encouraged to monitor these rates and use them as an index of overall quality of surgical and anesthesia care, and this is probably an ideal operation for that purpose. There are abundant standards by which one can judge oneself and one should see that they are used and implemented widely.

Several years ago there was much furor among colorectal and general surgeons regarding the explosion of studies regarding the avoidance of bowel preparation and the association of this with improved surgical outcomes of decreased complication rates including lower rates of surgical site infection. This was a relative nonissue in the right colon, since it had been long recognized that one could safely operate in the right colon without a formal bowel preparation.

There has long been recognition that surgical technique is important in conducting cancer surgery. This has often been debated, similar to the debates raging many decades ago regarding the "no touch technique" proposed by Dr. Turnbull. Most recently refinements in technique regarding colon cancer surgery have focused on completeness of mesenteric excision as discussed in this chapter by Dr. Weiser. Hohenberger and colleagues have introduced the concept of complete mesocolic excision (CME) analogous to total mesorectal

excision as proposed by since the mid-1980s. This type of wide mesenteric excision has been associated with impressive 5-year survival rates. Recently, reports of a modified complete mesocolic excision by Cho et al. in a series of nearly 800 patients undergoing this technique for right-sided colon cancer with a mean follow-up of over 60 months, shows an impressive overall 5-year disease-free survival rate of 83% (Cho MS, Baek SJ, Hur H, et al. Modified complete mesocolic excision with central vascular ligation for the treatment of right-sided colon cancer: long-term outcomes and prognostic factors. *Ann Surg* 2015;261(4):708–15). Even their 5-year disease-free survival time for stage III disease was 68.5%.

Several papers have evaluated differences between the Eastern and Western approaches to lymph node and mesenteric resection (Xie D, Yu C, Gao C, et al. An Optimal Approach for Laparoscopic D3 Lymphadenectomy Plus Complete Mesocolic Excision (D3 + CME) for right-sided colon cancer. *Ann Surg Oncol* 2017;24(5):1312–13). Xie et al. reported on the combination of are forming a laparoscopic D3 lymphadenectomy in addition to complete mesocolic excision for right-sided colon cancer with a short follow-up; however, they found that this is technically possible, at the median 12-month follow-up there was no case of recurrence (Kobayashi H, West NP, Takahashi K, et al. Quality of surgery for stage III colon cancer: comparison between England, Germany, and Japan. *Ann Surg Oncol* 2014;21 Suppl 3:S398–404). Several recent studies have stressed the importance of preoperative evaluation of venous anatomy in laparoscopic cases for right colon cancer (Ogino T, Takemasa I, Horitsugi G, et al. Preoperative evaluation of venous anatomy in laparoscopic complete mesocolic excision for right colon cancer. *Ann Surg Oncol* 2014;Suppl 3:S429–35). Also, although right hemicolectomy is generally a simple, straightforward operation, because of the proximity of the duodenum with locally advanced right-sided colon cancer, it can quickly turn into a very difficult operation if it is locally involving the duodenum in some cases requiring partial duodenectomy or even en bloc pancreaticoduodenectomy (Cirocchi R, Partelli S, Castellani E, et al. Right hemicolectomy plus pancreaticoduodenectomy vs partial duodenectomy in treatment of locally advanced right colon cancer invading pancreas and/or only duodenum. *Surg Oncol* 2014;23(2):92–8; Zhang J, Leng JH, Qian HG, et al. En bloc pancreaticoduodenectomy and right colectomy in the treatment of locally advanced colon cancer. *Dis Colon Rectum* 2013;56(7):874–80).

As in many other chapters of Mastery, in the part of Mastery of Surgery devoted to colorectal surgery, Dr. Weiser brings up the issue of enhanced recovery after surgery pathways and emphasizes the earlier mobilization and avoidance of narcotic pain medication to facilitate an earlier hospital discharge. In addition, giving patients a carbohydrate drink 4 hours before induction of anesthesia, has also been shown to result in improved postoperative outcomes, as has been the use of epidural catheters, as well as transverse abdominis plane blocks and goal-directed fluid therapy, all of which he mentions.

The enhanced recovery after surgery (ERAS) concept has gained traction

around the world. It is safe in the majority of patients, but it is the creation of expectations in the patient's mind on the occasion of a preoperative visit that makes this work best, that is, one is expected to be out of bed the night after operation, one is expected to be walking around the hospital unit the next morning, and having some oral intake that same day. This is the essence of the process. If the patient's expectations are realistic, while this comes much later, the most important piece of the case, aside from technical issues, may be in the creation of clear laminated handouts that can be placed in the hands of the patient, and/or the lead caregiver at the time of the final preoperative office visit. These sort of things are lost in the torrent of paper that is thrown at discharging hospital patients in the United States now. This is the time to emphasize things to be watched for in the postoperative care and to address issues of anxiety and unnecessary readmission.

Whether one should or should not use oral antibiotics in addition to the prevailing use of systemic cephalosporins for operative would site evaluation remains to be proven. It is essential to choose a systemic antibiotic whose properties include wound penetration, and persistence in the wound is important. The SCIP program has led to proper preoperative initiation in more than 95% of the cases and termination within a 24- to 48-hour period, in more than 90% of patients. Both of these are desirable trends.

There is a token commentary on venous thromboembolism prophylaxis. Much of this discussion has been distorted by pharmaceutical manufacturers of anticoagulants. Those patients who have had prior thromboembolic events, and/or have severe varicose veins represent a different and legitimate higher-risk group. No one has yet to prove the superiority of these agents over well-used programs of early ambulation and inexpensive compressive hose use in average-risk patients. Do recall that the data very clearly show that VT prophylaxis is not warranted in patients undergoing ambulatory care or outpatient operations.

The open operation is increasingly disappearing for right hemicolectomy. Again, the reader needs to be reminded that transverse incisions are uncommonly well tolerated by elderly patients, and provides the ideal approach to the middle colic vessel. Regarding the extended right colectomy shown in Figure 152.3, in the patient with significant vascular disease, care should be taken to ensure that there is sufficient collateral blood supply. Techniques such as near infrared angiography are useful and are available on many robotic platforms.

Susan Galandiuk

153 Open and Minimally Invasive Left Hemicolectomy for Neoplasms of the Descending Colon, Sigmoid, and Upper Rectum

Zuri Murrell and Michael J. Stamos

LEFT COLECTOMY FOR NEOPLASMS OF THE DESCENDING COLON, SIGMOID, AND UPPER RECTUM

Definition

Colectomies for neoplasms in the descending and sigmoid colon, and the upper rectum are surgical operations that are defined by the colorectal vascular anatomy that parallels the lymphatic drainage (Fig. 153.1). Adequate treatment and staging of colorectal cancer is dependent upon the excision (and identification) of a minimum of 12 lymph nodes and obtaining adequate margins of bowel wall and mesentery both proximal and distal to the neoplasm. A left hemicolectomy is generally defined as a resection from the distal transverse colon to the junction of the descending/sigmoid colon. When utilized for cancer, this includes a high ligation of the left branch of the middle colic and left colic arteries, thus ensuring removal of an adequate number of lymph nodes. In reality, this is an uncommon operation, primarily due to the relative infrequency of neoplasms of the descending colon. A sigmoid resection for cancer involves removal of the sigmoid segment of the colon from its junction with the descending colon (or more proximal as needed to attain adequate margins) to the proximal rectum (or recto sigmoid junction), which is identified by the taenia confluence and/or the sacral promontory. This procedure entails a high ligation of the sigmoidal arterial pedicle, or the inferior mesenteric artery (IMA), near its origin. It is important to remember that tumors of the upper rectum are treated similarly to sigmoid colon cancers, with resection as initial treatment in a patient without

distant metastasis. For malignancies of the upper rectum, this should always include a high ligation of the IMA. It is also important to remember that no matter how this operation is performed, the resected specimen should be the same. We will further refer to these various operations as “left-sided colectomies” in this chapter.

Presentation

Colon cancer commonly presents asymptomatically or with minimal symptoms, and is typically discovered by colonoscopy. When symptoms are present, they often include abdominal pain and changes in bowel habits. Upper rectal and sigmoid cancers often present with the passage of bright red blood per rectum. Severe changes in bowel habits can signify a large bulky tumor. Presenting symptoms can impact the planned surgical approach, as up to 20% of patients present with obstruction or perforation.

Preoperative Planning

A successful surgical outcome begins well before the actual operation starts. A detailed history and physical examination are the key, with special attention given to any obstructive like symptoms and presence of any palpable abdominal mass. If present, these findings can portend a large bulky tumor, affecting both the types of imaging studies needed, and the surgical approach (laparoscopic vs. open). The patient should also be thoroughly questioned about any pre-existing anal incontinence as this can be exacerbated by left hemicolectomy, sigmoid colectomy, and an anterior resection due to postoperative alterations in the consistency and volume of stool. A sphincter exam also needs to be performed to determine any sphincter laxity at rest. The external anal sphincter is evaluated by having the patient perform an anal squeeze while a digit is inserted in the anus. If the patient has pre-existing symptoms of anal incontinence and the sphincter complex is weak, there should be careful consideration for the placement of a stoma as opposed to performing an anastomosis.

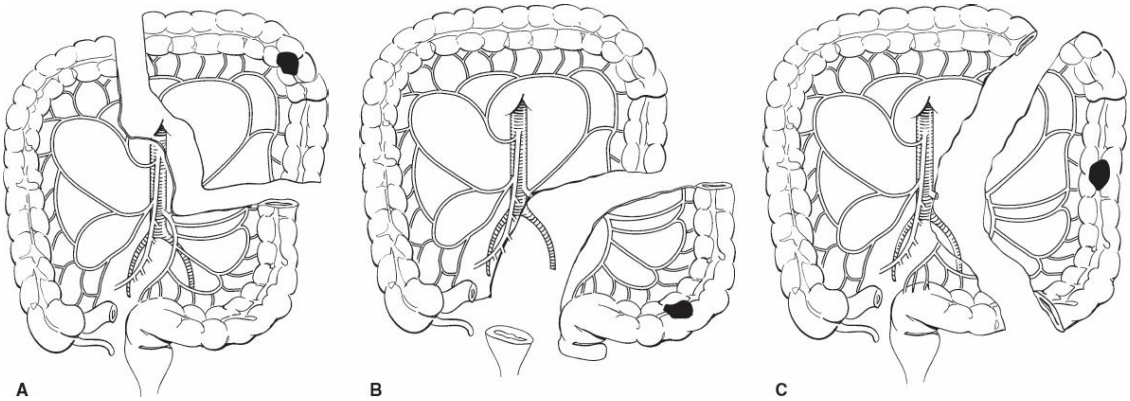

Figure 153.1. Recommended lines of resection for tumors within the various areas of the left colon. Note that resections are based on the vascular supply to the tumor. **A.** Tumors located at the splenic flexure and left colon require resection of lymph nodes along the left branch of the middle colic, left colic, and first sigmoidal pedicles. **B.** Tumors in the sigmoid colon generally require lymphadenectomy along the inferior mesenteric artery. **C.** Rarely, there may be lesions at the junction of the left and sigmoid colon, which lies in the narrow area between the left colic and first sigmoidal pedicles; these may benefit from ligation of the inferior mesenteric artery at its origin to include lymphadenectomy along all the left colic and superior rectal pedicles.

Per NCCN (National Comprehensive Cancer Network) guidelines, a computed tomography (CT) scan of the chest, abdomen, and pelvis should be performed to rule out any distant metastasis, which if present may require further workup and a different initial therapy. The authors recommend the surgeon perform his or her own endoscopy for any tumor within the sigmoid or rectum to properly identify the site of the tumor, as colonoscopy reports are notoriously inaccurate when only the distance from the anal verge is used for tumor localization. For minimally invasive operations, the location of the tumor has to be explicitly defined in order to determine port placement and specimen extraction site. A mechanical bowel prep is performed that empties the colon of stool so that intraoperative endoscopy is possible for tumor and margin determination, and so that the colon can be easily manipulated, especially during minimally invasive surgery.

Intraoperative patient positioning is a common feature of all approaches for a left hemicolectomy, sigmoid colectomy, and anterior resection. The patient is placed in lithotomy position with the arms tucked bilaterally

(Fig. 153.2). The bilateral tucking of the arms prevents brachial plexus injuries and allows for retractor placement in case of conversion to an open approach, and for surgeon comfort during minimally invasive approaches. In cases of morbidly obese patients whose size does not allow bilateral tucking of the arms on the table, the right arm should always be tucked. The lithotomy position allows easy access to the rectum for intraoperative endoscopy, for circular stapler placement for anastomotic creation, and endoscopic leak testing of the anastomosis. Padded Allen-type stirrups are used to help prevent peroneal nerve injury. For minimally invasive approaches, the authors recommend the patient be placed on a foam pad and secured to the bed to ensure the patient does not slip while in steep positional changes that are key to performing this operation successfully. Rotating the bed 10 to 20 degrees counterclockwise before starting can open up the right side of the patient for the surgeon and first assistant, a useful maneuver for a laparoscopic operation. Within 30 minutes before the first incision, preoperative intravenous antibiotics are given; the authors prefer 2 g of cefotetan or 1 g of ertapenem. The authors also like to use a rectal irrigation catheter (30-cc Foley catheter with a large three-way connector), which serves the purpose of further cleaning the colon and allowing creation of an anastomosis in a stool-free environment, and also has the benefit of keeping the distal colon and rectum decompressed during the operation, facilitating handling of the bowel segments and minimizing chance of inadvertent injury.

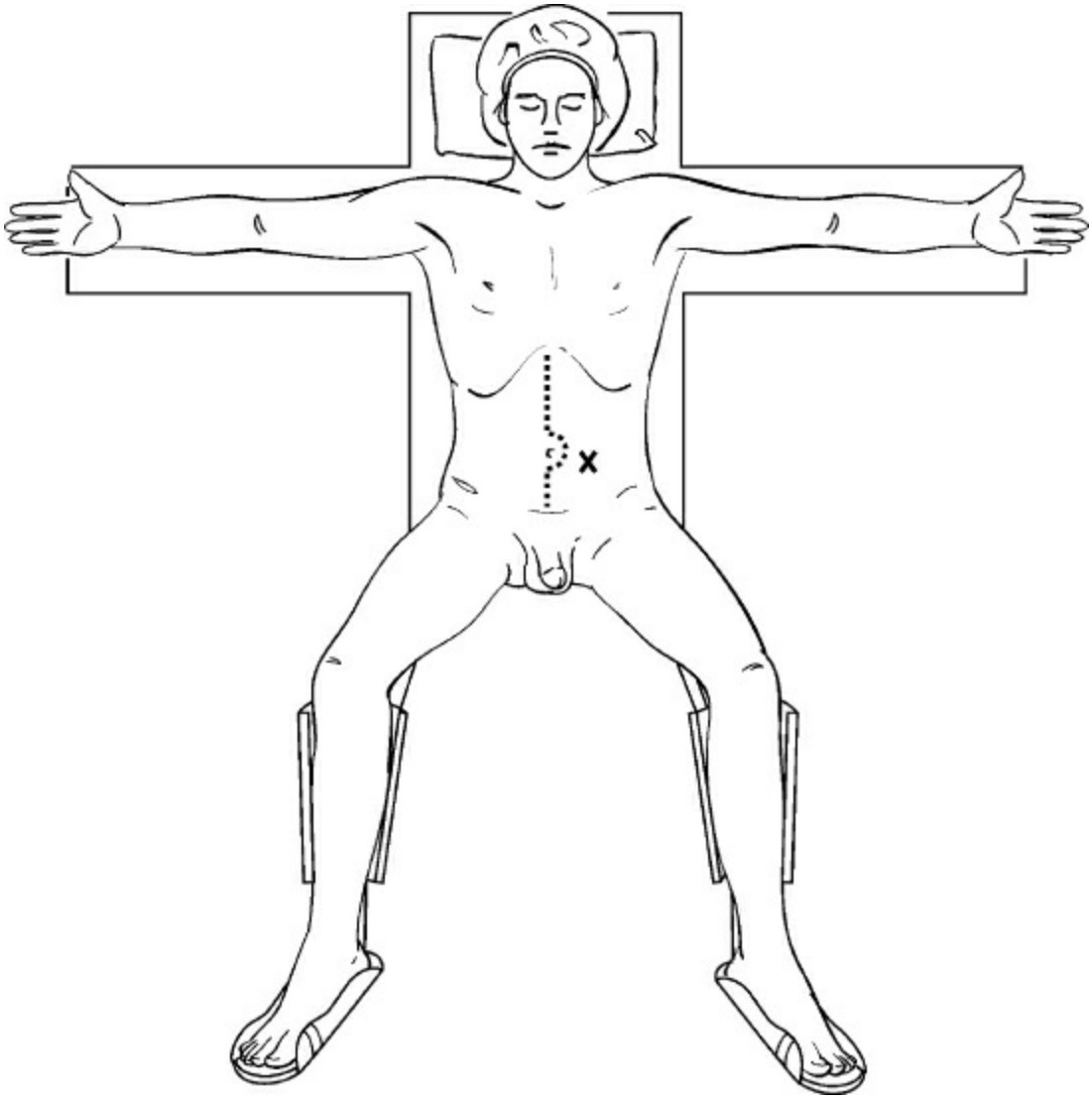

Figure 153.2. Recommended positioning of a patient for left hemicolectomy. Note that the arms are in the abducted position to allow placement of a self-retaining retractor. The patient is marked preoperatively for optimal placement of a colostomy, should this prove necessary. Access to the rectum should be available to facilitate a stapled low anastomosis.

Open Left-Sided Colectomy

The left colon and/or sigmoid can be mobilized from a medial to lateral or a lateral to medial approach. For the open operation, the authors prefer the “traditional” lateral-to-medial approach. However, for surgeons trying to ascend the learning curve of minimally invasive left colectomy, a medial to lateral approach should be utilized to facilitate the understanding of this anatomic perspective. After a midline incision is performed, a self-retracting wound protector is placed in the abdomen. This has the dual

function of keeping the incision free of contamination, and serves as a hands-free retractor that provides excellent exposure. A Bookwalter retractor is our preferred option. The small bowel contents are swept to the right upper quadrant and covered and protected with a moist lap pad. The white line of Toldt is incised from the sigmoid colon to the splenic flexure. The colonic mesentery is elevated off the retroperitoneum, and the left ureter is identified and left alone, while the colonic mesentery is brought to the midline. Mobilizing the ureter is meddlesome and unnecessary and will make any later reoperation much more difficult. The IMA is ligated just distal to the origin at the aorta, or just distal to the left colic takeoff, at surgeon's discretion, and the inferior mesenteric vein (IMV) is ligated just below the inferior border of the pancreas, or at the level at the IMA ligation. The splenic flexure can be taken down by carefully dividing the splenocolonic attachments laterally, and the renocolic attachments posteriorly. Medially, the omentum can be dissected from the anterior surface of the left side of the transverse colon and the lesser sac entered. The mesentery of the distal transverse colon and proximal descending colon needs to be preserved, ensuring that the marginal artery and other collateral vessels (Arc of Riolan) remain intact. This requires mobilization of the mesentery off of the retroperitoneum. Adhesions between the proximal descending colon and the distal transverse colon, which are commonly seen, should be sharply divided at this time to ensure adequate length for the anastomosis. Occasionally the left branch of the middle colic will need to be ligated to allow the creation of a tension-free anastomosis. The bowel is then transected proximally using two Kocher clamps at the selected location, largely based on blood supply and lymphatic drainage, but at least 5 cm proximal to the tumor. The bowel is then transected distally, again 5 cm distal to the neoplasm (2 cm for the rectum), typically using either a GIA stapler or a TA stapler. A 2-0 monofilament suture is then used to secure a purse-string in the proximal segment after dividing the colon just proximal to the Kocher clamp, using Allis clamps to triangulate the bowel and facilitate a baseball stitch purse-string. It is also important to confirm adequacy of blood supply at this time. It is important to shield off the abdominal incision and to "segregate" all instruments from this dirty part of the operation to minimize surgical site infections (SSI). Gloves of all team members are then also changed and an end-to-end stapled anastomosis is performed using a circular stapling device (Figs. 153.3 and 153.4). After firing the circular stapler, the two "donuts"

are inspected to ensure that they are complete. Next the anastomosis is submerged under water and occluded proximally and a flexible sigmoidoscope is used to insufflate air to directly visualize the anastomosis as well as evaluate for a leak. The authors also recommend taking a picture of the anastomosis to have further objective evidence of completeness.

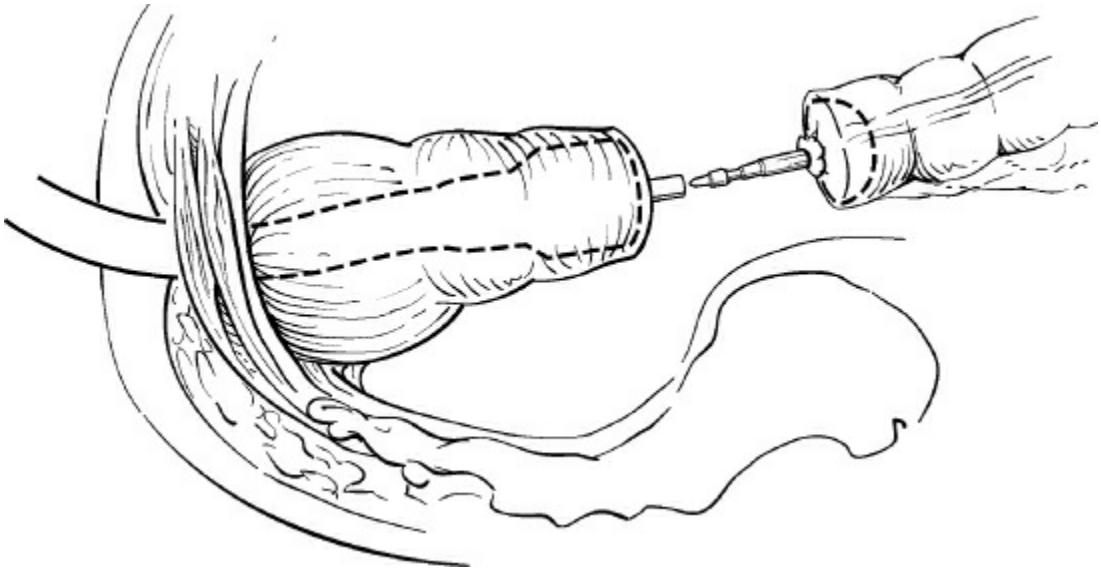

Figure 153.3. The anvil is secured in the descending colon with a purse-string suture, and the shaft of the stapler placed per anus and advanced to the stapled end of the rectum.

Laparoscopic Left-Sided Colectomy

When performing a left-sided colectomy laparoscopically, the importance of the operating room table position through various stages of the procedure cannot be stressed enough. Correct positioning allows gravity to help retract various organs, such as the small bowel, away from the operative field. The positioning for this procedure is the same as previously discussed with the caveat that a foam “egg crate” style pad is placed on the operating room table and the patient is secured to it. This prevents patient slippage and thus possible nerve injury to both upper and lower extremities when patients are in steep Trendelenburg and other gravity-defying positions during surgery.

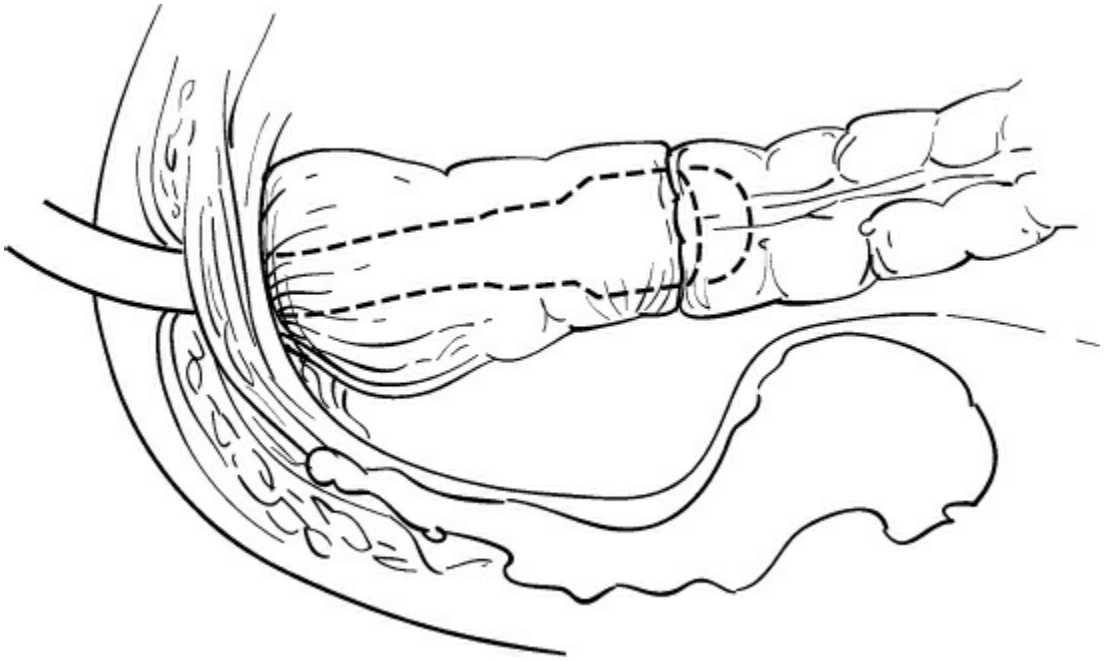

Figure 153.4. The anvil is secured to the shaft of the stapler, closed, and deployed.

This operation is begun by making an incision for a 5-mm trocar 2 fingerbreadths lateral and to the upper right of the umbilicus. The authors prefer this port placement for the camera to provide improved optics for the surgery and decrease tunnel vision as well as to minimize the interference of the small bowel. Many surgeons use the umbilicus for the camera port placement, but the only advantage of this location is cosmetic. After an incision is made, the fascia is elevated, and a Veress needle is placed and a pneumoperitoneum to 15 mm Hg is established. After the 5-mm trocar is placed, the abdomen is explored with the intention of determining if there is any evidence of metastatic disease. Steep reverse Trendelenburg position is used to evaluate the liver, and steep Trendelenburg position is used to evaluate the pelvis. Another 5-mm trocar is placed under direct visualization, at the epigastric area, 2 fingerbreadths below the xiphoid and just to the right of midline to avoid the falciform ligament. A 12-mm trocar (to accommodate a planned stapling device) is placed at the right lower quadrant location, lateral to the rectus abdominis muscle (Fig. 153.5). The patient is then placed in steep Trendelenburg position with the left side slightly tilted up and the small bowel is swept to the upper abdomen away from the pelvis. A medial-to-lateral approach is begun. The mesosigmoid is grasped, exposing the inferior mesenteric vascular pedicle, which is then grasped and elevated via an atraumatic instrument, and the visceral peritoneum is incised with cautery just

posterior to this vessel, and this incision is extended from just distal to the IMA origin down below the sacral promontory in the pelvis (Fig. 153.6). The visceral peritoneum is elevated and a retromesenteric plane is developed. This plane, which is a natural embryonic tissue plane, should be avascular. The atraumatic instrument in the epigastric port is used to elevate the IMA and visceral peritoneum anteriorly, while the instrument in the RLQ port brushes the retroperitoneal structures in a posterior motion, until the ureter is identified (Fig. 153.7). Once this structure is seen and confirmed (by visualizing its vesiculations), the ureter is left in its normal position and this dissection is carried laterally to the posterior medial border of the colon. This dissection is where most errors are seen. Once the IMA is identified and the dissection is to the left of this vessel, it is critical to angle anteriorly to avoid dissecting into the retroperitoneum. This can initially seem counterintuitive due to the angle of the camera and the dissecting device. Once this is done, a high ligation of the IMA vessel can be done in a safe manner, most commonly with a bipolar energy device (Fig. 153.8). The IMV is ligated at the same level, unless a low anastomosis is planned, in which case it is divided more cranially just below the inferior border of the pancreas. The retromesenteric dissection is carried out upward toward the splenic flexure and distally at least 5 cm distally to where the tumor is located. Using the same table position, the lateral dissection is begun. The colon is grasped and retracted medially and the white line of Toldt is incised, typically starting at the sigmoid and carried superiorly to splenic flexure (Fig. 153.9). Midway through this dissection, the patient is placed in the reverse Trendelenburg position. This allows gravity to participate and help drop the colon and flexure into a more advantageous position. It is important to stay close to the colon laterally, and as the splenic flexure is released, the lesser sac can be entered. Alternatively, while in this position, the omentum can be elevated superiorly, dissected off of the distal transverse colon and the lesser sac entered in this fashion, from a medial approach. This medial-to-lateral supracolic approach to the splenic flexure can be very useful in cases of high or difficult splenic flexures. Once the omentum is dissected off of the anterior surface of the left side of the transverse colon, the entire left “hemi colon” should now be freely mobile. As mentioned above in the description of an open left colectomy, adhesions between the proximal descending colon and the distal transverse colon, which are commonly seen, should be sharply divided at this time to ensure adequate length for

the anastomosis. The dissection can be continued medially or even to the right of midline when necessary, depending on the location of the pathology. If indicated by the planned extent of the resection, the mesentery of the middle colic vessels can be divided. Once this mobilization is done, it is important to confirm the planned extent of resection, and to be certain that the proximal site of resection will easily reach into the pelvis to anastomose to the planned site of distal resection without tension. The patient is then placed back into Trendelenburg position and the distal site of resection is fully mobilized. Endoscopic visualization and confirmation of tumor location can be critical at this time for small tumors. Tattoo marks are often not accurate enough to select the resection margins. Once the distal transection site is chosen, the mesentery is then divided with a bipolar device up to the bowel wall. A linear stapler is then inserted into the RLQ trocar and the distal colon divided, typically at the recto sigmoid junction. At this time, the proximal colon staple line is grasped with a locking grasper through the RLQ trocar and a small pfannenstiel incision is made (typically 4 to 6 cm). A transverse incision is made through the fascia, and it is dissected from the rectus muscle superiorly toward the umbilicus and inferiorly down to the pubis. The rectus muscles are then retracted laterally, the linea alba is incised and the peritoneum is entered sharply and a wound protector/ retractor is placed in the wound. The colon is delivered and then divided at the planned proximal resection site, at least 5 cm proximal to the site of the tumor, and sent off of the field for pathologic evaluation. If there is any doubt about the margins or the presence of the tumor within the specimen, it is essential to grossly confirm its presence before proceeding. It is also important to confirm adequacy of blood supply at this time. The proximal end of the colon is then opened, and a circular stapler anvil is inserted after a running 2-0 monofilament purse-string suture is placed. At this time, all dirty instruments are isolated and gloves are changed to avoid contamination. The colon containing the anvil is then returned to the abdominal cavity, a locking grasper is placed through the RLQ trocar and the anvil grasped in preparation for completion of the circular stapled anastomosis, and pneumoperitoneum is reestablished. This can be accomplished with the retractor in place or more easily by closing the pfannenstiel incision. The circular stapler sizers are then placed sequentially transanally into the rectum and guided carefully to the staple line. This is done so the operator learns the luminal course for easy circular

stapler placement, and it also ensures that the stapler will reach the staple line. Once the stapler is placed into position, the anvil and stapler are joined. The stapler spike should come out of the rectal or colon stump adjacent to the staple line. It is the authors' preference to bring it out just anterior to the staple line to avoid stapling through the mesorectum. However, in low anastomoses in female patients it is preferred that the pin is brought out just posterior to the transverse staple line, to avoid possible vaginal entrapment. As the stapler ends are brought together, care is taken to make sure the colon is straight and the mesentery is not twisted, and that the small intestine has not migrated under the descending colon mesentery. In women it is preferred that the pin is brought out posterior to the transverse staple line, to avoid possible vaginal entrapment. After the anastomosis is created, it is air tested as previously discussed. In review, the three key steps in performing a successful laparoscopic left colectomy are high vessel ligation, full mobilization of the descending colon and splenic flexure, and dissection of the omentum from the anterior surface of the colon. These steps ensure the creation of a tension-free anastomosis, and decrease the chance of an anastomotic leak.

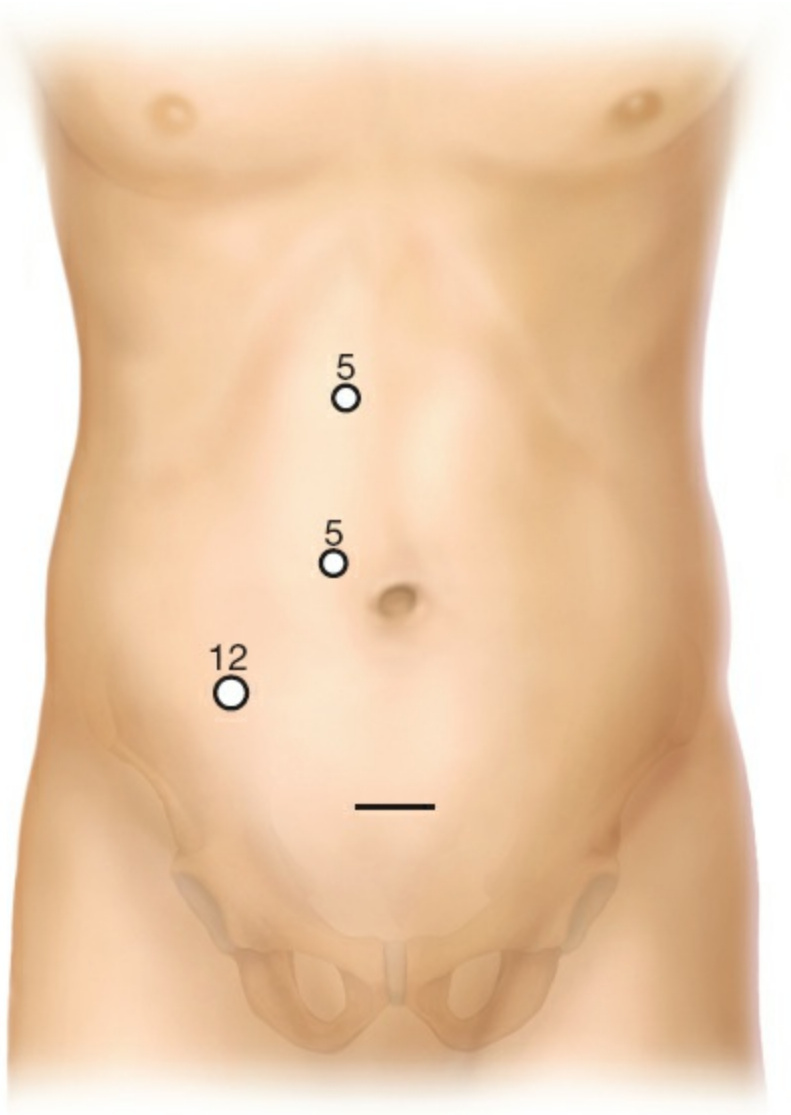

Figure 153.5. 12-mm trocar (to accommodate a planned stapling device) is placed at the RLQ location, lateral to the rectus abdominis muscle.

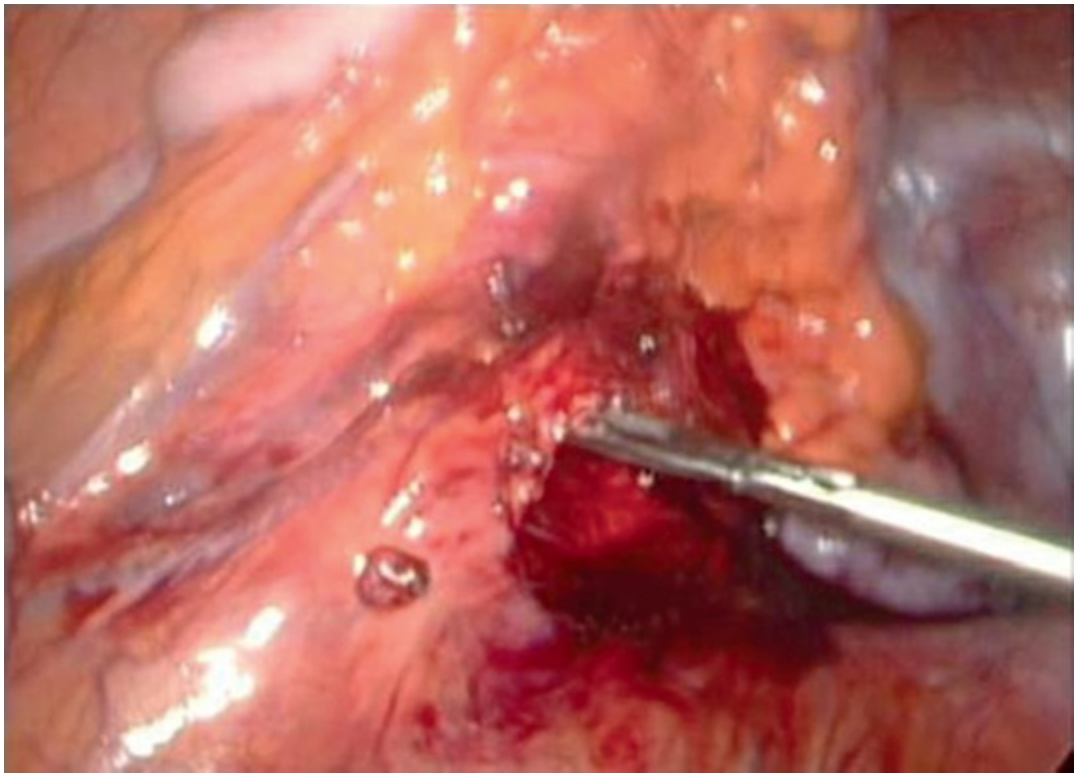

Figure 153.6. The inferior mesenteric vascular pedicle is then grasped, and the visceral peritoneum is incised with cautery just posterior to this vessel.

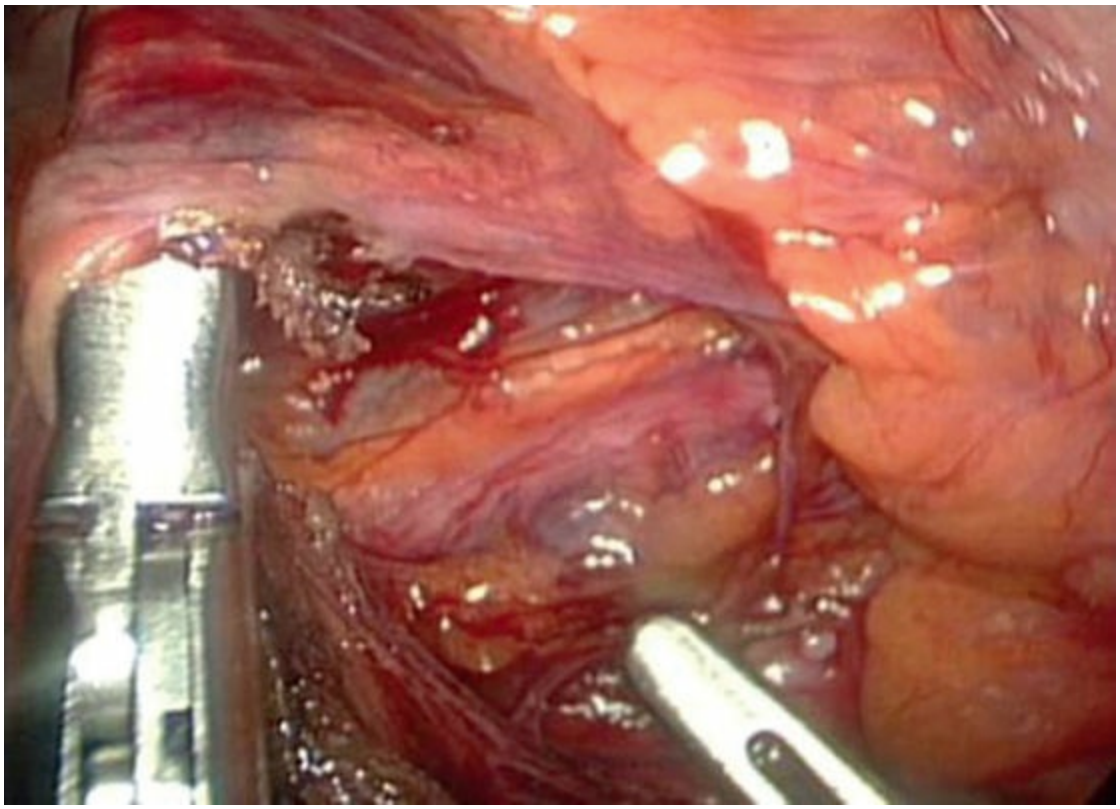

Figure 153.7. The ureter is identified.

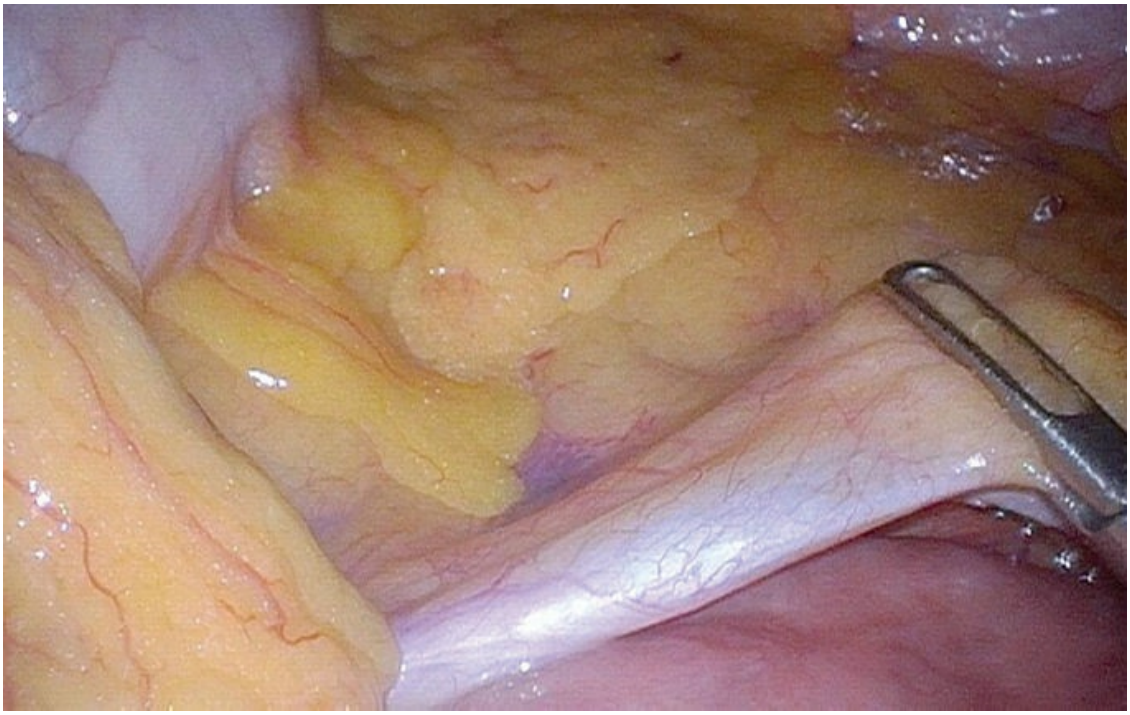

Figure 153.8. High ligation of the IMA.

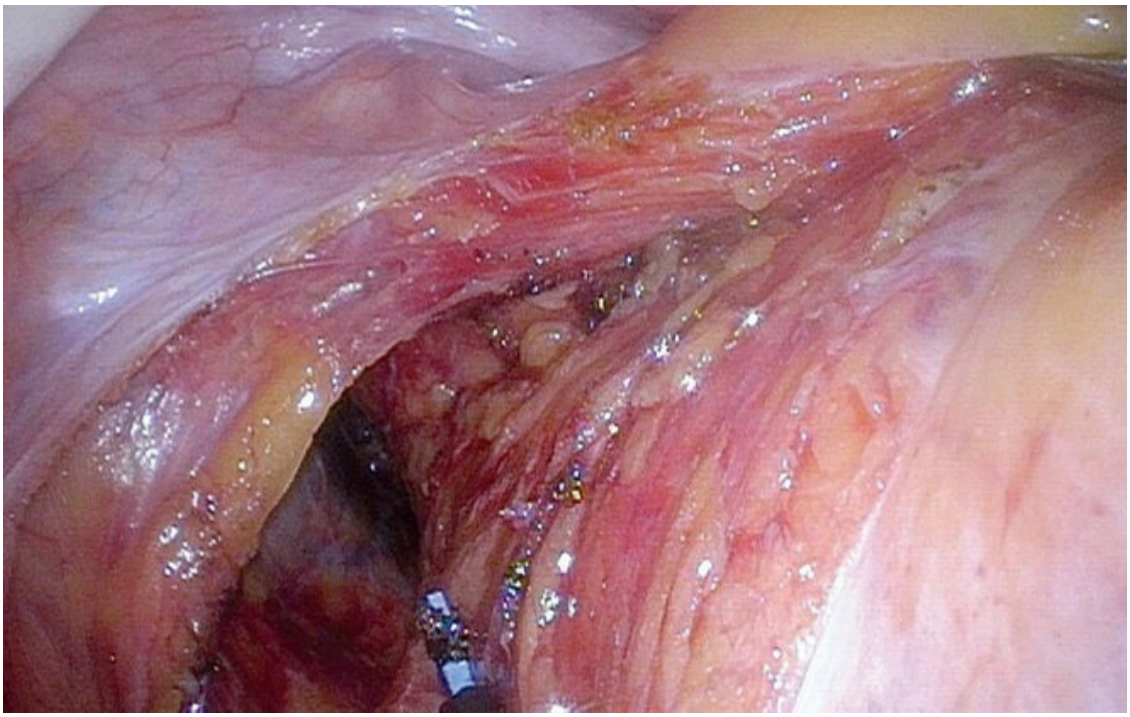

Figure 153.9. White line of Toldt is incised, typically starting at the sigmoid and carried superiorly to splenic flexure.

Robotic Left-Sided Colectomy

The process of performing a left colectomy robotically is similar to the laparoscopic approach with two main differences.

The first is that the operating room table position cannot be changed once the robot is docked. The patient is placed in lithotomy secured on an egg crate, with the table in steep Trendelenburg position with left side up, and is maintained as such throughout the robotic portion of the case. Because of this limitation, it may be necessary to redock the robot for the splenic flexure mobilization, or perform this portion of the operation laparoscopically either in advance or following the robotic portion.

Secondly, the procedures differ in the trocar site placement and number (total of six). Once a pneumoperitoneum is established, the 12-mm camera port is placed 1 cm above the umbilicus. A da Vinci instrument arm port 13 mm (stapler port) is placed along the spinoumbilical line (SUL) 1 cm medial to the mid-clavicular line (MCL). The spinoumbilical line is a line joining the left anterior superior iliac spine and the umbilicus. A second instrument arm port 8 mm is placed 1 cm medial to the left MCL and 2 cm superior to the SUL. A third arm port 8 mm is placed 1 cm to the right MCL, 2 to 3 cm below the costal margin. A fourth port 8 mm is placed 6 to 8 cm superior to the umbilicus on the left anterior axillary line, and the third arm is moved here during the pelvic part of the operation. Lastly a port for the surgical assistant is placed 8 to 10 cm cephalad to the instrument arm and 2 cm medial to the right MCL. It is important to note that all of these measurements are done after insufflation (Fig. 153.10).

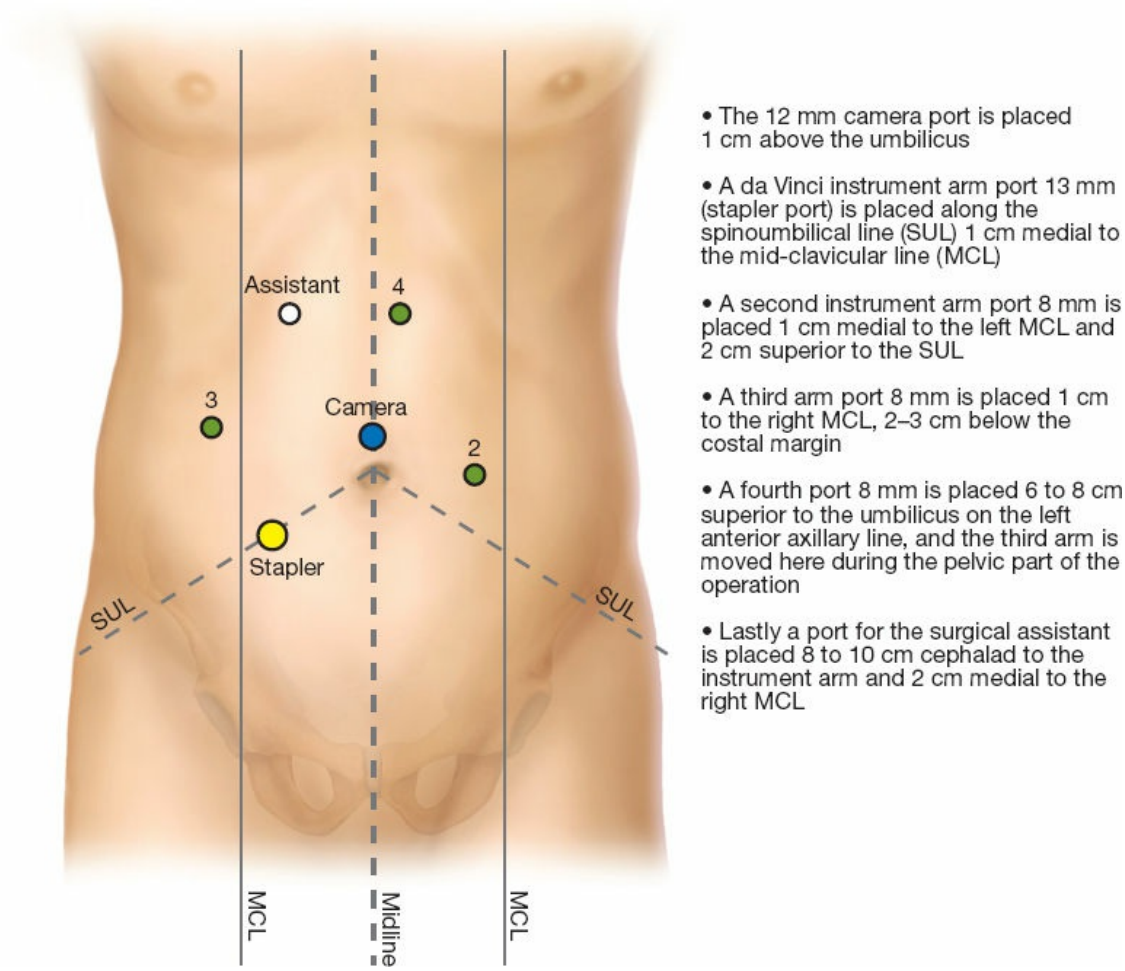

Figure 153.10. Port placement for robotic colectomy.

The patient cart is positioned and the robot is docked. The surgery is performed in a medial-to-lateral approach as with the laparoscopic approach, with a pfannenstiel incision made for colonic extraction.

Anterior Resection

Anterior resections are traditionally done for high rectal and recto-sigmoid cancers that are treated the same as colonic neoplasms, with surgery being the first-line therapy for nonmetastatic disease. It is important that a proper tailored (e.g., not a complete mesorectal excision) mesorectal excision be performed no matter which surgical approach is used. Adoption of a proper mesenteric excision (e.g., TME) has resulted in improved oncologic outcomes with a decrease in loco-regional recurrence.

Preoperative planning for this procedure as well as patient positioning is the same as for a left colectomy.

The authors perform this procedure in an identical fashion to a left-sided colectomy in terms of incision, mobilization, and blood vessel

division. Prior to distal bowel transection however, a proximal mesorectal dissection and excision are done. The aim of this procedure is to remove the upper rectum along with its mesorectum that contains the draining lymph nodes. The retro-mesenteric plane established during the left-sided colectomy is continued inferiorly, anterior to the presacral fascia and staying posterior to the fascia propria of the rectum. This dissection is carried 2 to 5 cm distal to the tumor in the upper rectum. The authors prefer to begin this dissection posterior to the rectum until the distal margin of resection is reached, then proceeding laterally, and lastly anteriorly. It is critically important to divide the mesorectum tangentially with the rectum at the location of the planned distal resection. It is important to be aware of the hypogastric nerves at the sacral promontory, which should be preserved if not involved with tumor (Fig. 153.11). After the distal bowel transection site is identified, the mesorectum is dissected from the rectum, and transected using bipolar energy. The rectum is then transected using a GIA stapler, or alternatively (for an open case) a linear TA stapling device, with a bowel clamp proximally to avoid spillage. The rest of this procedure is performed as previously mentioned in the left colectomy section.

Postoperative Care

The authors have adopted an accelerated recovery program. For the aforementioned operations, we employ the use of our pain team, and patients are given an epidural or a transverse abdominis plane block along with a patient-controlled anesthetic device. Unless a pelvic dissection is done, the foley catheter is removed within the first 24 hours postoperatively, or when the epidural is removed (when used). In cases involving a pelvic dissection, the catheter is removed 3 days after surgery. Clear liquids are started on postoperative day 1 with diet advanced to a regular diet as soon as tolerated. Patients are encouraged to ambulate within 24 hours of surgery. This pathway is adopted for all patients undergoing left colectomy and anterior resection for all surgical approaches, and has been proven safe and decreased patient length of stay.

COMPLICATIONS

Leaks

The most dreaded complication is an anastomotic leak. Two factors

associated with anastomotic leaks include low anastomosis and preoperative chemo-radiation. While these are not major issues in the aforementioned surgical procedures discussed, leaks can still occur (approximately 2% to 5% for the discussed procedures). This complication should be suspected in patients with severe abdominal or pelvic pain, persistent ileus, a high postoperative fever, tachycardia, and an elevated white count. If the patient is otherwise stable, a CT scan can be performed as early as postoperative day 4, and if an abscess is seen it can usually be drained during this procedure. If the patient has diffuse peritonitis, then a reexploration is required with possible resection of the anastomosis and creation of a Hartmann pouch.

Pulmonary Embolus/DVT

This can be a devastating complication that is best “treated” by prevention. For patients whose only risk factors are cancer and surgery itself, 5,000 u of Heparin sq TID is started from within an hour of the incision up to 24 hours in the postoperative period. In addition, sequential compression devices are placed and activated before the operation begins. An additional important step in prevention is early ambulation. Postoperatively, patients should be out of bed and sitting in a chair on the day of surgery, and ambulating by the evening of postoperative day 1 at the latest. Post discharge chemical prophylaxis can be considered in high-risk patients (obese patients, open operations, stage 4 cancer, patients suffering septic complications).

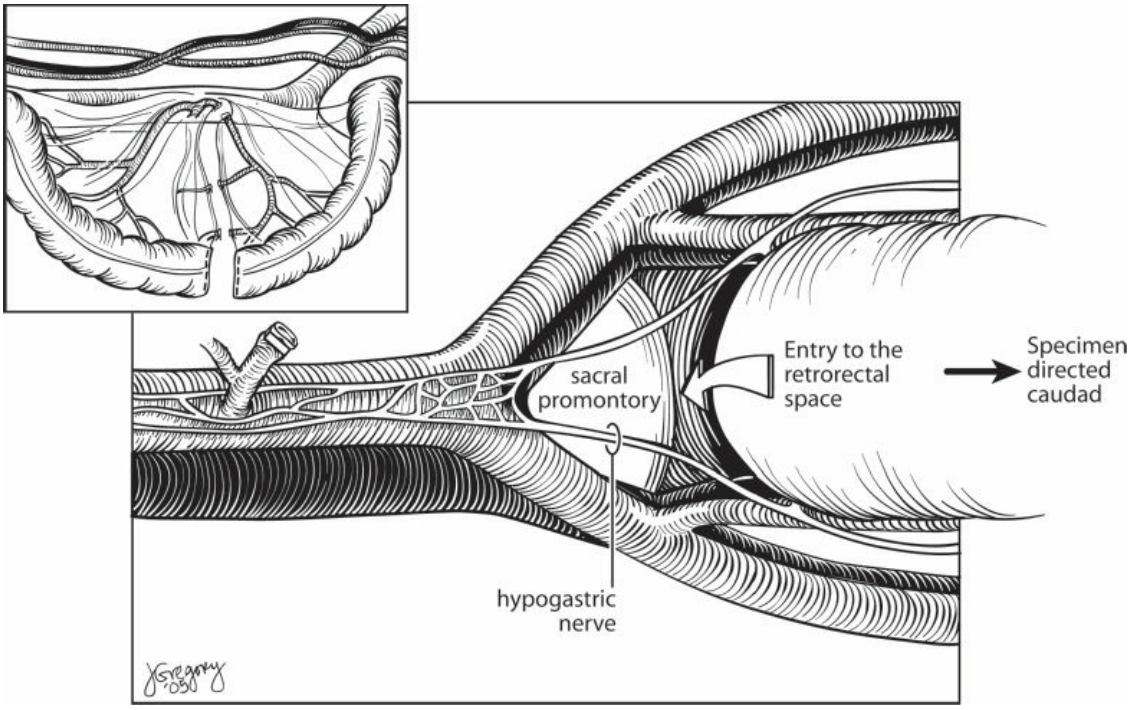

Figure 153.11. Lateral view of the fascia in the pelvis (presacral, fascia propria, retrorectal, rectovesical, Waldeyer fascia).

Urinary Retention

This complication is more common after low anterior resection. It is usually temporary after injury to the hypogastric nerves during pelvic dissection. While the foley catheter can be removed postoperative day one in a typical left colectomy and sigmoid colectomy, the authors leave it in for 3 postoperative days after anterior resection. If the patient is unable to void within 6 hours of removal, the Foley is replaced and the patient will be discharged with it. It is kept for 5 more days and removed as an outpatient.

Retrograde Ejaculation

Damage to the superior hypogastric plexus during high ligation of the IMA, or to the hypogastric plexus at the sacral promontory in male patients, can lead to retrograde ejaculation. This complication is more common in low anterior and abdominal perineal resection. Sildenafil can be effective in treating this postoperative complication.

Suggested Readings

Aarts MA, Okrainec A, Glicksman A, et al. Adoption of enhanced recovery after surgery (ERAS) strategies for colorectal surgery at academic teaching hospitals

and impact on total length of hospital stay. *Surg Endosc* 2012;26(2):442–50.

Madoff R, Melton G. Anterior and low anterior resection of the rectum. In: *Fischer's Mastery of Surgery*. 6th ed. Philadelphia, PA: Lippincott Williams & Wilkins; 2011:1731–4.

Masoomi H, Buchberg B, Dang P, et al. Outcomes of right vs. left colectomy for colon cancer. *J Gastrointest Surg* 2011;15(11):2023–8.

Moghadamyeghaneh Z, Hanna MH, Carmichael JC, et al. A nationwide analysis of postoperative deep vein thrombosis and pulmonary embolism in colon and rectal surgery. *J Gastrointest Surg* 2014;18(12):2169–77.

Young-Fadok. Laparoscopic left hemicolectomy. In: *Fischer's Mastery of Surgery*. 6th ed. Philadelphia, PA: Lippincott Williams & Wilkins; 2011:1655–60.

EDITOR'S COMMENT

Performing a left hemicolectomy for neoplasms of the descending colon, sigmoid, or upper rectum may seem a relatively simple operation. However, if not done correctly it can result in disastrous consequences for the patients in terms of infectious complications, including anastomotic leak, delays in administration of chemotherapy, cancer recurrence, and even death.

Today's operative scenario has become much more complex with different types of access: open, laparoscopic, and robotic; however, sound surgical principles still apply no matter the mode of access. There are major components of preoperative planning that are often overlooked. One of the most common of these that the authors highlight is relying on someone else (often a referring physician) to describe the lesion location. As they state this is most common when one is referred a patient from another physician with a colonoscopy report stating that the lesion is at, for example, "45 centimeters," only for the surgeon to discover intraoperatively that the lesion is at an entirely different area! Always be suspicious if the lesion has not been tattooed and if a discrete anatomic location is not mentioned as well as if the lesion has not been identified by another imaging modality such as a CT scan or by rigid or flexible proctoscopy. It is a common health insurance conundrum as to whether or not the surgeon receiving the referral can recolonoscope the patient to verify lesion location; however, this does clearly avoid this intraoperative scenario of the erroneously located lesion.

There has been an ongoing debate in the surgical world regarding whether or not patients undergoing colon and rectal surgery should undergo preoperative mechanical bowel preparation. There is still no real consensus on this. Most feel that patients undergoing a right-sided colon resection do not require a mechanical bowel preparation. The French Research Group of Rectal Cancer Surgery (GRECCAR III trial) established that there were worse outcomes (major morbidity and infectious complications) when mechanical bowel

preparation was omitted with rectal resections. As the authors here discuss, there is also the technical concern with minimally invasive operations about the bowel not being as easily manipulated if there are large amounts of solid stool within the lumen, in addition to the difficulty of dividing a bowel filled with solid stool using a surgical stapler, or inserting a surgical staplers into a rectum filled with large volumes of solid stool. Most preoperative areas are ill equipped to give patients larger volume enemas the morning of surgery. Although it is old-fashioned, we may actually be seeing the return of the oral antibiotic preparation as this does truly seem to reduce the incidence of wound infections! Colorectal anastomoses most frequently leak due to impaired blood supply and this is often accentuated due to tension. Such leaks can result in anastomotic stenosis. The easiest ways to relieve tension on the anastomosis are (1) division of the inferior mesenteric vein just adjacent to the jejunum at the ligament of Treitz and (2) splenic flexure mobilization. Although these maneuvers take extra time, they are often well worth it in terms of gaining extra mobility of the left colon. The senior author has published on use of intraoperative indocyanine green angiography to assess margin perfusion. This can be done during open, laparoscopic, or robotic procedures and can even be done via proctoscope to assess the anastomosis. Utilization of a stapler of sufficient diameter will also help avoid anastomotic stricture formation. A stapler of a 29 mm diameter minimum should be utilized for the colorectal anastomosis. Several studies have shown that performing an intraoperative leak test for colorectal anastomoses by insufflating air into the rectum in a pelvis filled with water with the bowel above the anastomosis occluded and looking for air leaks will identify many unsuspected leaks. These can then be repaired or the patient diverted with a temporary ileostomy to avoid the untoward sequela of an anastomotic leak.

Over the last decade, use of laparoscopy for colon surgery has increased. There have been several trials documenting the safety of laparoscopic surgery as performed for colon cancer. It is now becoming increasingly recognized that laparoscopic surgery is particularly safe especially for high-risk patients such as the elderly and very elderly (Allardyce RA, Bagshaw PF, Frampton CM, et al.; Australasian Laparoscopic Colon Cancer Study Group. Australasian Laparoscopic Colon Cancer Study shows that elderly patients may benefit from lower postoperative complication rates following laparoscopic versus open resection. *Br J Surg* 2010;97(1):86–91). One of the important points brought out by the authors is the fact that cancers of the upper rectum do not have to be treated with total mesorectal excision, but rather with excision of the portion of the rectal mesentery appropriate to the tumor. One needs to excise the rectal mesentery for 2 to 5 cm distal to the lesion as they state in their chapter. I prefer to error on the 5 cm side and sharply divide the mesentery either with an energy device or by ligation in an open case. The same principles of posterior mesorectal dissection do apply with respect to dissecting the entire posterior aspect of the mesentery away from the presacral space, exactly as if one were performing a total mesorectal excision. It is imperative to open the specimen in

the operating room, in order to ensure that one does indeed have the lesion within the specimen and that one has adequate margins of resection. Notwithstanding completion and reporting of the Clinical Outcomes of Surgical Therapy (COST), and Colon Cancer Laparoscopic or Open Resection (COLOR) and the Conventional versus Laparoscopic-Assisted Surgery in Patients with Colorectal Cancer (CLASSIC) trials, further trials are ongoing in order to confirm the safety and suitability of laparoscopy for more advanced colon cancers. One of the most anticipated trials is that of the Japan Clinical Oncology Study Group. This study has focused on a evaluating laparoscopic versus open D3 (extensive central lymph node) dissection for stage II and III colon cancer. Short-term outcomes have shown lower morbidity (14.3% vs. 22%) in the laparoscopic as opposed to the open surgery group (Yamamoto S, Inomata M, Katayama H, et al.; Japan Clinical Oncology Group Colorectal Cancer Study Group. Short-term surgical outcomes from a randomized controlled trial to evaluate laparoscopic and open D3 dissection for stage II/III colon cancer: Japan Clinical Oncology Group Study JCOG 0404. *Ann Surg* 2014;260(1):23–30). Similar to this concept of performing extensive lymph node dissection for colon cancer is the concept espoused by Hohenberger who has applied the concept of total mesorectal excision to colonic surgery as "total mesocolic excision." Kobayashi and colleagues recently compared the total number of lymph nodes retrieved, number of positive lymph nodes, completeness of the mesenteric dissection plane, and other variables among colon cancer resection specimens from surgeons in England who use a low vascular tie technique, to surgeons in Germany using a total mesocolic excision technique, to surgeons in Japan utilizing a D3 (central) lymphadenectomy technique (Kobayashi H, West NP, Takahashi K, et al. Quality of surgery for stage III colon cancer: comparison between England, Germany, and Japan. *Ann Surg Oncol* 2014;21:S398–S404). Not surprisingly, fewer lymph nodes were obtained with left-sided as compared to right-sided colon lesions. Both the total mesocolic excision and D3 lymphadenectomy specimens yielded more complete mesocolic plane excision specimens with a lower lymph node ratio (number of positive lymph nodes divided by the total number of excised lymph nodes).

Another recent development with respect to surgery for left-sided colonic cancers is the changing philosophy toward colonic stenting. For lesions that may have thought to be partially obstructing, it is now generally accepted that prophylactic stenting is to be avoided as there appears to be a higher rate of local recurrence, and greater chance of perforation. This has been described in a number of studies and guidelines including that of the European Society of Gastrointestinal Endoscopy (Sabbagh C, Browet F, Diouf M, et al. Is stenting as "a bridge to surgery" an oncologically safe strategy for the management of acute, left-sided, malignant, colonic obstruction? A comparative study with a propensity score analysis. *Ann Surg* 2013;258(1):107–15; van Hooft JE, van Halsema EE, Vanbiervliet G, et al.; European Society of Gastrointestinal Endoscopy. Self-expandable metal stents for obstructing colonic and

extracolonic cancer: European Society of Gastrointestinal Endoscopy [ESGE] Clinical Guideline. *Endoscopy* 2014;46(11):990–1053). Whether this is true or not remains to be seen. The role of covered stents in the treatment of anastomotic leaks is still evolving.

In conclusion no matter which type of access we use to resect left-sided and upper rectal neoplasms, adherence to sound surgical principles should yield both good short-term results and the desired superior long-term oncologic outcomes.

Susan Galandiuk

154 Historical Perspectives on Total Mesorectal Excision

R.J. Heald

INTRODUCTION

Since the first chapter of "Mastery" was written, it is surprising how much has changed and how much the author still believes should change further. Rectal cancer is overwhelmingly a disease where surgical detail decides outcomes, but surgeons spend their time in ORs and the world has become "multidisciplinary"—often without the wholehearted involvement of surgeons. Multidisciplinary team (MDT) management should be welcomed and the use of preoperative staging by magnetic resonance imaging (MRI) and of chemoradiotherapy in selected cases are certainly major steps forward. There is little evidence, however, of a major survival benefit from radiation and clear evidence that fertility is abolished, sexual function impaired, and bowel function often grossly damaged by the combination of a low anastomosis with radiation—especially when given postoperatively. MRI can show clearly which patients really need RT, namely, those with threatened margins and others with a poor possibility of survival (e.g., N2 disease, extramural large vein invasion on MRI). There is much to be gained by more selectivity by the preoperative MDT meeting.

The surgery itself presents many new and exciting possibilities. Total mesorectal excision (TME) remains the key objective—can it, however, be achieved as well or better by laparoscopy? Or by the Da Vinci Robot? When truly necessary, can the poor results so often obtained by the "standard" APE be improved upon by superior access, for example, the Kocher Holm position face down with excision of the coccyx?

Repeatedly, the story of progress in this field is of better visualization and more precise dissection, improved hemostasis, and less collateral damage by diathermy (e.g., the use of traverse monopolar and ligature bipolar electricity). Gradually, surgeons performing open, laparoscopic, and robotic procedures are learning to recognize all the components of the

autonomic nervous system of the pelvis. Indeed, they are rewriting the anatomy books as surgical technology advances. A great part of human happiness and dignity depends on the preservation of these crucial nerves. In this chapter, the author has tried to set down the steps that can contribute both to reducing unnecessary damage to them and to ensuring optimal cure rates by the delivery of more perfect specimens.

There are few branches of surgery where care and effort in the craft of surgery yield so much benefit to our patients.

BASIC PRINCIPLES

The implications of decisions made in rectal cancer management are grave indeed—cure of cancer, local control of one of Nature's cruelest malignancies, the necessity for a permanent stoma, the preservation of sexual function, and much more. Decisions regarding both radiotherapy and chemotherapy now present major challenges in a field of ever-increasing complexity, so that multidisciplinary discussion must constantly be recognized by the true long-term consequences for the patient.

We must recognize that, even at its most scientific, surgery is primarily a craft with very special challenges and rewards for excellence. Surgery is not amenable to study by the same methods as those applicable to drugs or medicines or to measurable interventions such as irradiation, yet surgical technique has by far the greatest impact on rectal cancer outcomes. The randomized controlled clinical trial has so far contributed remarkably little to the development of surgical techniques because, particularly in the difficult and complex surgery of cancer, "the devil is in the details." As a basic principle of any cancer operation, however, the block of tissue to be removed should be precisely defined and subjected to scrutiny. Thus, surgical anatomy and histopathologic audit should become exact sciences in their own right and surgical practice refined to include meaningful judgment on the oncologic quality of the specimen by an independent pathologist after every surgical excision. It is rewarding to report that, since the first edition of this book, naked eye evaluation of the excised specimen has become mandatory in Germany. My own teaching workshops always emphasize the importance of "specimen-orientated surgeons," that is, surgeons whose first priority during the procedure is the quality of the fascial covered untorn envelope of tissue that he will extract and which constitutes an optimal TME specimen.

HISTORICAL CONSIDERATIONS

Most of the literature in the Western world has paid scant attention to detail of how the actual dissection around a rectal tumor should be carried out. The diagrams in current textbooks bear witness to the crude manual extraction techniques that bedevil “conventional” surgery for rectal cancer (Fig. 154.1). However, both the Japanese with their special interest in the detailed vascular and neuroanatomy of the pelvis, and we, with our TME initiative, have attempted to improve on the simplistic concept of abdominoperineal excision (APE), an operation originally described in 1907 by the Englishman Ernest Miles. His concept of a cylinder of maximal size that “empties the whole pelvis” was at least an attempt at defining in advance a block of tissue to be excised by the surgeon. This idea, illustrated in Figure 154.2, has dominated the minds of doctors throughout the twentieth century. Indeed, if surgeons had really produced perfect “oncologic cylinders,” there would have been far fewer local recurrences and failures, though the morbidity in terms of sexual and pelvic autonomic function would have been formidable while the dead space would have required packing for many months. The famous John Golligher used to comment, “If you haven’t made the patient impotent, you probably haven’t cured him of rectal cancer.”

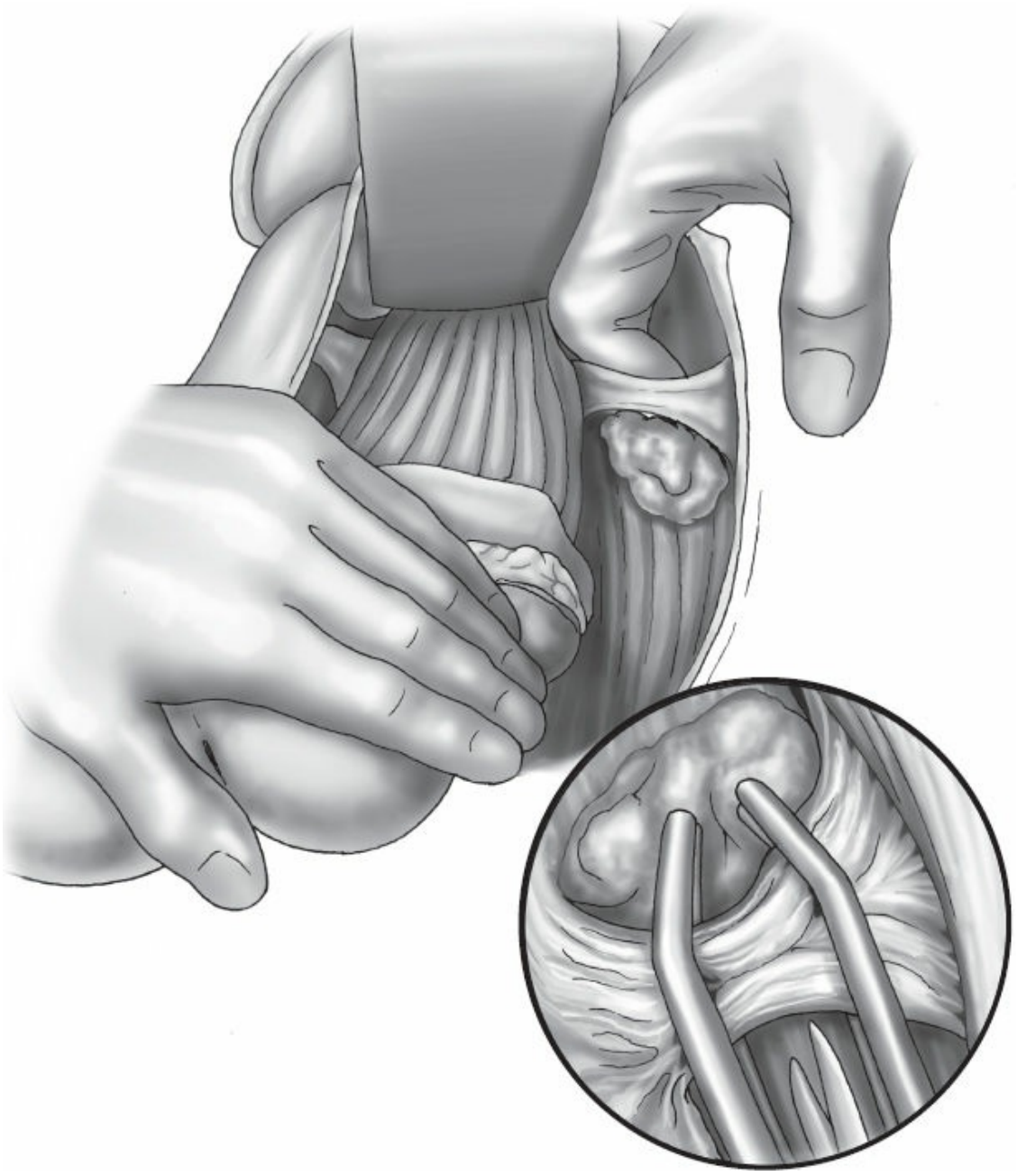

Figure 154.1. This would make a patient impotent.

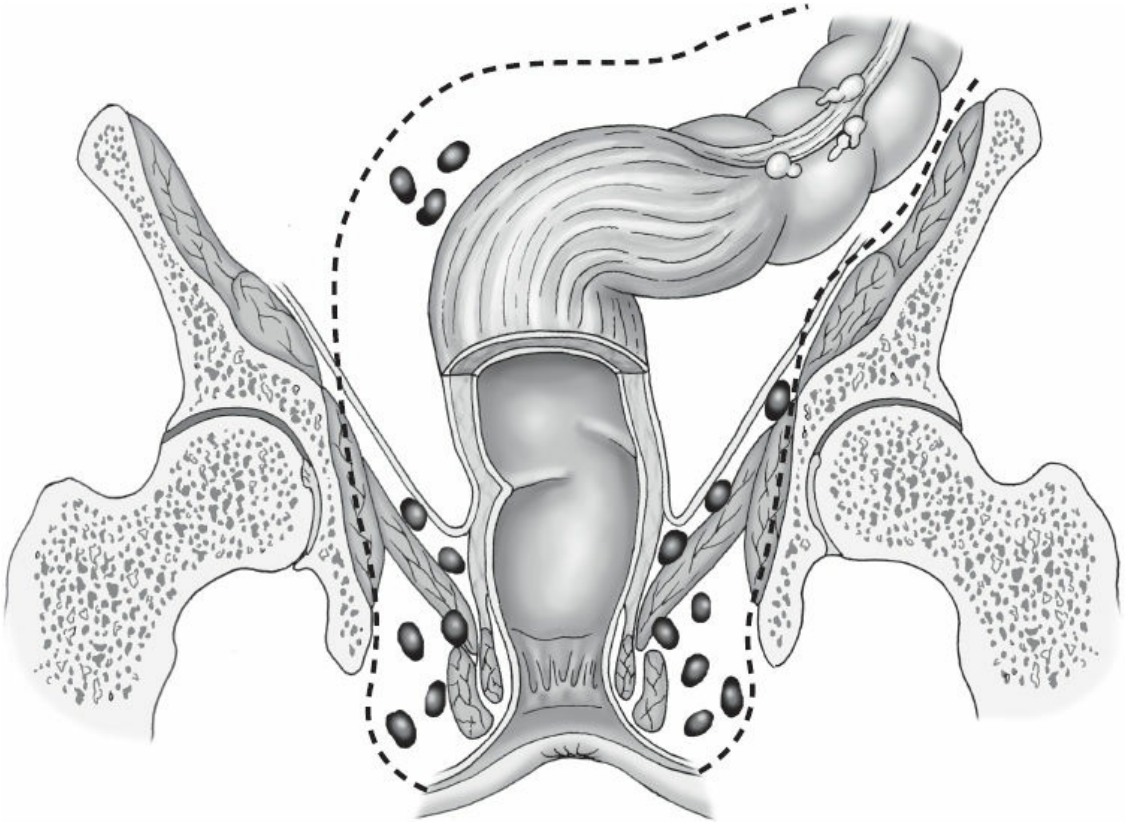

Figure 154.2. Original concept of many nodes in the ischiorectal fossa, and along the upper surface of the levators—Miles' "highly dangerous tissues."

Miles considered that spread occurred, particularly in the lymphatics, in all directions and included very clearly in his diagrams his perception of why he had seen 31 perineal recurrences in the wound of his operations (Figs. 154.2 and 154.3). He believed that the reason for these was that he had failed to encompass by his operation, the spread that had occurred into the ischioanal fat via nodes around the inferior hemorrhoidal (rectal) vessels. The same diagram also shows many nodes sitting on the surface of the levator muscles within the imagined "cylinder" of spread. He clearly also believed that, for this reason, only the widest possible clearance at this level had any hope of curing the patient and it was commonplace for tumors as high as 15 to 25 cm to suffer the same fate. So it was that permanent colostomy became established as the necessary price for cure and became a very common and widely dreaded association of bowel cancer in the public mind. Similar thought processes about spread govern most extended surgical lymphadenectomies, but careful studies of ischioanal fossa node involvement to justify this heavy price have never been undertaken. Furthermore, long surgical experience teaches us that

multiple nodes on the surface of the levators or in the ischiorectal fat such as those in the diagram are simply never seen.

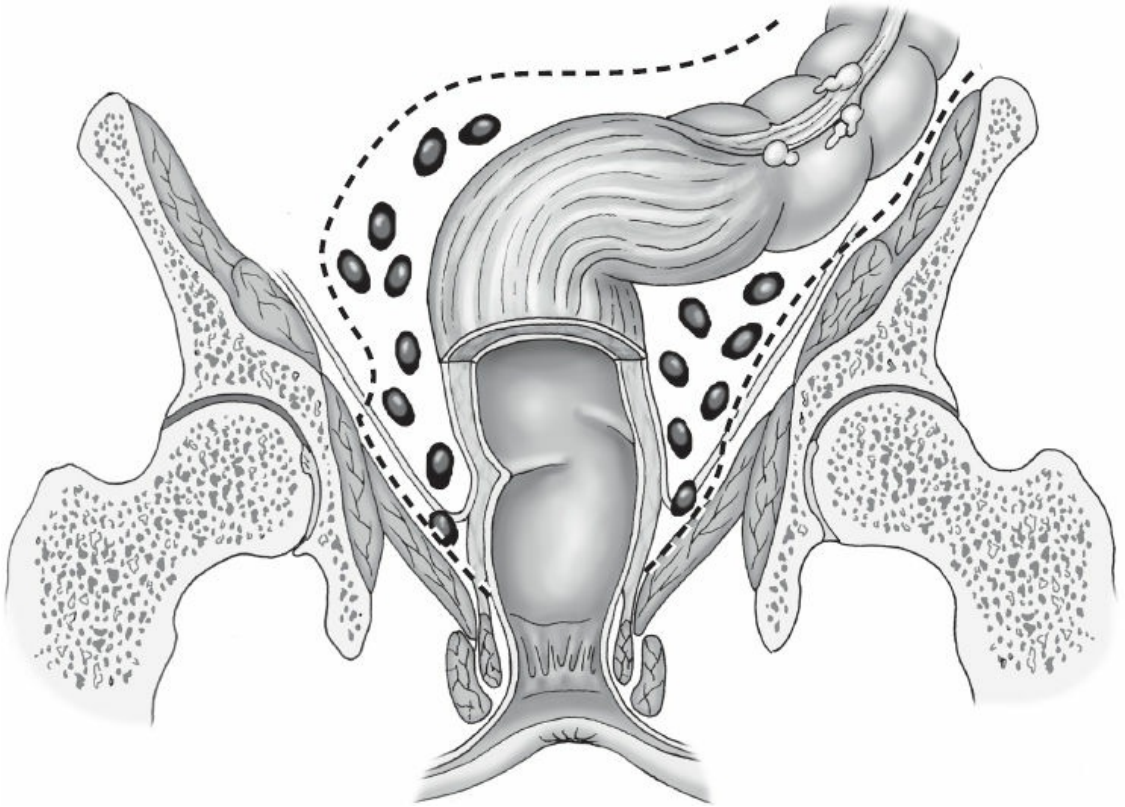

Figure 154.3. Our concept of the field of spread. Adenocarcinoma of the rectum is a visceral (mesorectal) and supra-levator field spread disease total mesorectal excision.

Such studies were certainly not attempted by Miles, who simply regarded the whole of the surrounding cylinder of tissue as "highly dangerous tissues," particularly, "the levators, the ischioanal fat, and the perianal skin."

REDEFINITION OF MILES' "HIGHLY DANGEROUS TISSUES"

So it is that the background to our current attempts to move toward an optimal cancer operation is a standard but empirical procedure designed more than a century ago. Virtually, no detail of how the actual dissection should be effected appears in the literature. The Miles' operation was certainly radical in the sense that it appeared in the diagrams to remove the cancer with much of the surrounding tissue. It was also an operation that could be completed at great speed—often in less than an hour. In the early

years of the last century, such speed often meant the difference between a live patient and a dead one at the end of the operation! However, the term “radical” refers to radix, a root in Latin. Leave part of the root and the plant regrows. In cancer terms, this implies a need for real understanding of where the satellites of cancer commonly occur since the ideal radical cancer operation should encompass only the common fields of spread that do not exact too high a penalty from the patient. The design of the optimal operation that modern surgery can now offer should take into account the field of spread amenable to surgical removal with the primary tumor, the disabilities inflicted by each component of the surgery, and the point in time at which cure becomes impossible by local surgery because metastases have already become established.

The first major steps toward minimizing mutilation can be attributed to many surgeons who embarked upon anterior resection (AR) to avoid sacrifice of the anal sphincters. Initiated on both sides of the Atlantic, before and after World War II, the proportion of rectal cancers undergoing sphincter-preserving surgery has risen steadily to a current level of 90% in specialized units and above 50% in most general hospitals.

Modern rational surgical planning should consider each of the possible fields of spread of rectal cancer in turn, and the disabilities and sacrifices paid by the patient for their removal. In each case, we should, to give the patient what we would wish for ourselves, try to balance the benefit of an extra chance of cure against the functional and anatomic price to be paid. At the time of going to press, this implies that preoperative assessment should supplement full clinical and endoscopic appraisal with a computed tomography (CT) scan of the whole body for metastatic spread and a specialized MRI for the most precise picture of the primary cancer and its locoregional spread. MRI scan for appraisal of the primary cancer within the pelvis.

THE EMBRYOLOGIC BASIS OF CANCER SURGERY—EXEMPLIFIED BY COLORECTAL CANCER

Recent Advances in Understanding

Conceptually, TME has a basis in scientific thought, which is attractive to all members of the modern MDT with background training in basic science. The theory behind it is that cancer spread will tend, initially at least, to remain within the embryologic hindgut “envelope.” The gut spent

its early fetal existence actually outside the abdomen. When secondarily rectum and mesorectum became “plastered” back onto the retroperitoneal structures and into the developing pelvis, they retained their midline lymphovascular integrity and remained separate from the surrounding paired organs and parietes. Their adherence to them is by a collagenous cobweb of areolar tissue, which allows a degree of movement, is recognizable by the surgeon as a “surgical dissection plane” at about the 10-mm stage, and is almost entirely avascular. In a number of publications, the author has drawn attention to this “holy plane of rectal surgery” and attempted to point out the value of painstakingly following the perimesorectal avascular plane around the midline hindgut into the depths of the pelvis as a practical surgical policy. This was eventually shown to improve local recurrence rates in a dramatic way. Straying into the field of cancer spread within the mesorectum was, and still is, in conventional practice, an extremely common cause of involved surgical margins and residual pelvic disease: straying out can damage the autonomic nerve layers and is a common cause of impotence. Publications from the Karolinska Hospital, Solna, Sweden, demonstrate that more than one half of all local recurrences referred these for investigation are associated with residues of mesorectum left behind by the surgeon. In other words, inadequate TME, that is, incomplete emptying of the central compartment (within the nerve layer) is a far more important course of failure than ignoring the internal iliac and other compartments outside the visceral mesorectal “core.” This is of great practical importance because, although a challenging dissection, TME is a standard teachable reproducible operation. The lateral compartments are much more varied and difficult, and much less rewarding—perhaps best left to a few high-volume specialist surgeons along with other procedures such as sacrectomy extended because of threatened margins or secondary nodal spread.

Some workers in the past postulated a physical barrier to the spread of cancer at this interface that I call the “holy plane”: it seems intrinsically more probable, in the light of Judah Folkman’s work, that tumor angiogenesis is impeded by the avascular nature of the areolar interface between midline hindgut and surrounding parietes. So it is that embryology is the true key to defining the oncologic package that will encompass the relevant field of spread. The surgeon should bear in mind that the tapering hindgut “package,” surrounded by the “holy plane,” is inserted into the funnel-shaped sloping levators, which merge with the

parietal voluntary skeletal external sphincters distally.

THE MESORECTUM FOR THE SURGEON—THE PLANES OF THE PELVIS

Surgical Anatomy

The original idea of TME was born from the practice of surgery. The mesorectum only becomes a reality for each individual surgeon from enthusiasm for slow, meticulous, painstaking dissection in difficult but achievable planes. These, once recognized and identified, become the defining objectives of the surgery and the redefined building blocks of the anatomy.

Once the surgeon has grasped the new system of anatomy, as Stelzner originally did from his diagram, it also becomes clear that the basis for the planes does indeed lie in the embryology (Fig. 154.4).

The innermost “holy plane” is that which surrounds the midline hindgut within its lymphovascular envelope—the core—while the two surrounding lamellae comprise a neural layer and a Wolffian ridge layer, which develop from the paired structures outside the hindgut. This concept has been made relatively simple to comprehend by the Japanese suggestion of comparing pelvic anatomy with the layers of an onion.

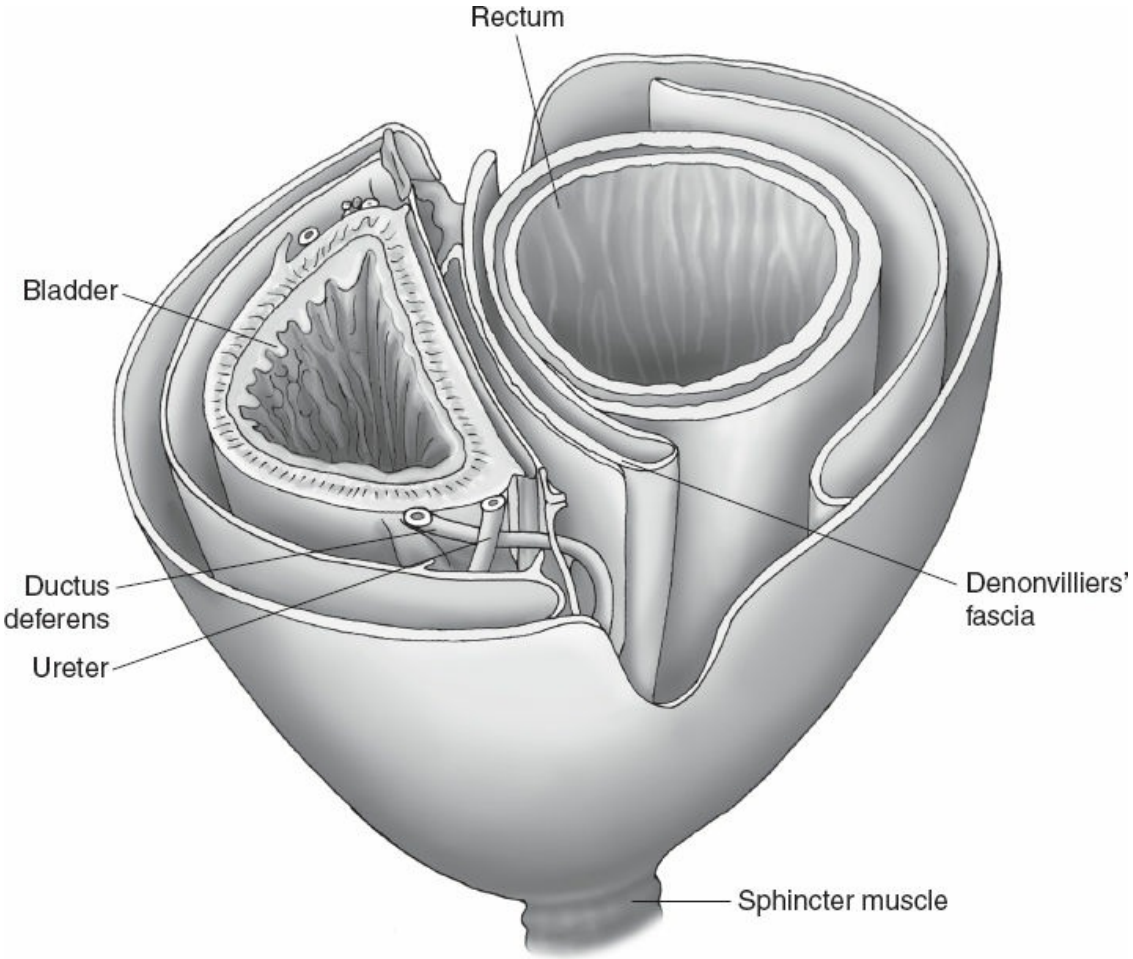

Figure 154.4. The fascial layers of the pelvis (after Stelzner). "Like the layers of an onion—or two onions with Denonvilliers' septum between."

Much of surgery of the whole gastrointestinal tract is a question of pursuing the planes between embryologically separate lymphovascular entities. The careful and thoughtful surgeon who is mobilizing any part of the large intestine by sharp dissection becomes aware of a choice of two relatively avascular, and therefore surgically satisfying planes, which are of special value in his or her journey down into the pelvis. The innermost "holy plane" envelopes the integral visceral mesentery of the hindgut or "mesorectum." This "safety margin" is a complete fatty and lymphovascular surrounding on all aspects in the middle third of the rectum, which constitutes the greater part of the organ and the most common site for cancer. In the upper third, the anterior aspect is covered only by the peritoneum with "mesorectum" at the back and the sides as the peritoneal reflection tapers forward toward the "cul-de-sac" or rectovesical pouch. In the lower third of the rectum, little or no fatty tissue intervenes

between the anterior aspect of the rectum and the back of the prostate. Posteriorly, the prostate has an important posterior condensed fascial covering called Denonvilliers septum. The surgeon has to divide this layer from above to enter the plane between the rectum and the prostate in the male. The upper part of the septum is usually adherent to the anterior mesorectal fat of the middle third. In the female, the middle third has a rather thin and tenuous fatty layer between the rectum and vagina with Denonvilliers fascia being often scant and difficult to identify, certainly a recognizable condensed "septum" is often not found as in the male. Is this perhaps because of its dissolution during childbirth or sexual activity? I use the term "Denonvilliers septum" to describe the shiny anterior surface of the excised middle third of the specimen and its distal continuation to fuse with the back of the prostate (Figs. 154.2 and 154.3). This seems logical because Denonvilliers septum is recognized by some embryologists as the downward prolongation of the peritoneum, which has become distally obliterated as a cavity. Fritsch has preferred to call it the "rectogenital septum," which certainly conveys the reality of a substantial rectangular or trapezoidal layer—like a "bib" between hindgut behind and vesicles and prostate in front. Just as peritoneum is the integral surface of the anterior aspect of the upper intraperitoneal third of the rectum, Denonvilliers septum is integral to the fatty anterior mesorectum in the middle third in the male. Denonvillier was one of the great French surgeon anatomists who described anatomical concepts of importance to surgeons —how far ahead of his time he was! It is only now that, improved vision in open surgery and the amazing magnification available to the robotic surgeon, his description of "two layers" of his septum begins to become apparent during operations on the live human. It is now clear to surgeons that, in the human male at least, the trapezoidal "bib" with defined lateral margins just medial to the all important neurovascular bundles is indeed a reality.

Posteriorly and posterolaterally, the areolar plane is well defined around the globular expanding bilobed mesorectum. A condensation of the fascia called the rectosacral ligament or Waldeyer fascia often presents a barrier to the surgeon posteriorly below the promontory. It is essential that this be positively divided either with diathermy or scissors. Beyond it, the plane is easy to recognize except that the forward angulation demands strong anterodistal retraction to facilitate direct visualization. Understanding the importance of this forward angulation is critical to mastering the traction

and counter-traction instruments necessary in open, laparoscopic, and robotic TME. Confusingly, the middle third of the rectum is often called the horizontal segment because MRIs are typically viewed as if the patient is vertical.

AUDIT OF THE MESORECTUM BY THE PATHOLOGIST

For proper independent audit, the surgeon should not cut the specimen except to open the bowel away from the tumor to let in the fixation liquid. The pathologist Quirke identified that there is a high positive predictive value of circumferential margin involvement (CMI) for the subsequent development of locally recurrent cancer. This implies that completeness and intactness of the specimen are crucial factors—ideally that it should be one recognizable block of tissue whose orientation and former relations can be identified. While "specimen-orientated surgery" has become the established practice in our unit, recognition of the features of the TME specimen and the freedom of its margins from cancer involvement become the key factor of audit. In most cases, naked-eye inspection provides the initial necessary quality control, with microscopic examination of the suspected areas of margin involvement as a logical primary objective for the surgeon. Visual inspection of the front of a well-performed TME specimen should show three clear landmarks (Fig. 154.5):

- The cut edge of the peritoneal reflection (Fig. 154.5)
- The smooth shiny anterior surface of the anterior mesorectum of the middle third—Denonvilliers fascia—or the rectogenital septum
- The almost bare anterior aspect of the anorectal muscle—in the lowest ARs or APE specimens only

Laterally, the fatty mesorectum expands distally beyond an anteroposterior groove made by the nerve erigentes so that an embryologically perfect specimen has a lateral dilatation distally, corresponding with the part related to the inside of the levator muscles beyond their origins from the pelvic sidewall. Posteriorly, a perfect specimen exhibits perfectly curved "buttocks" with a central midline groove corresponding to the anococcygeal raphe (the pubococcygeus muscle)—the most posterior of the levator muscle bundles.

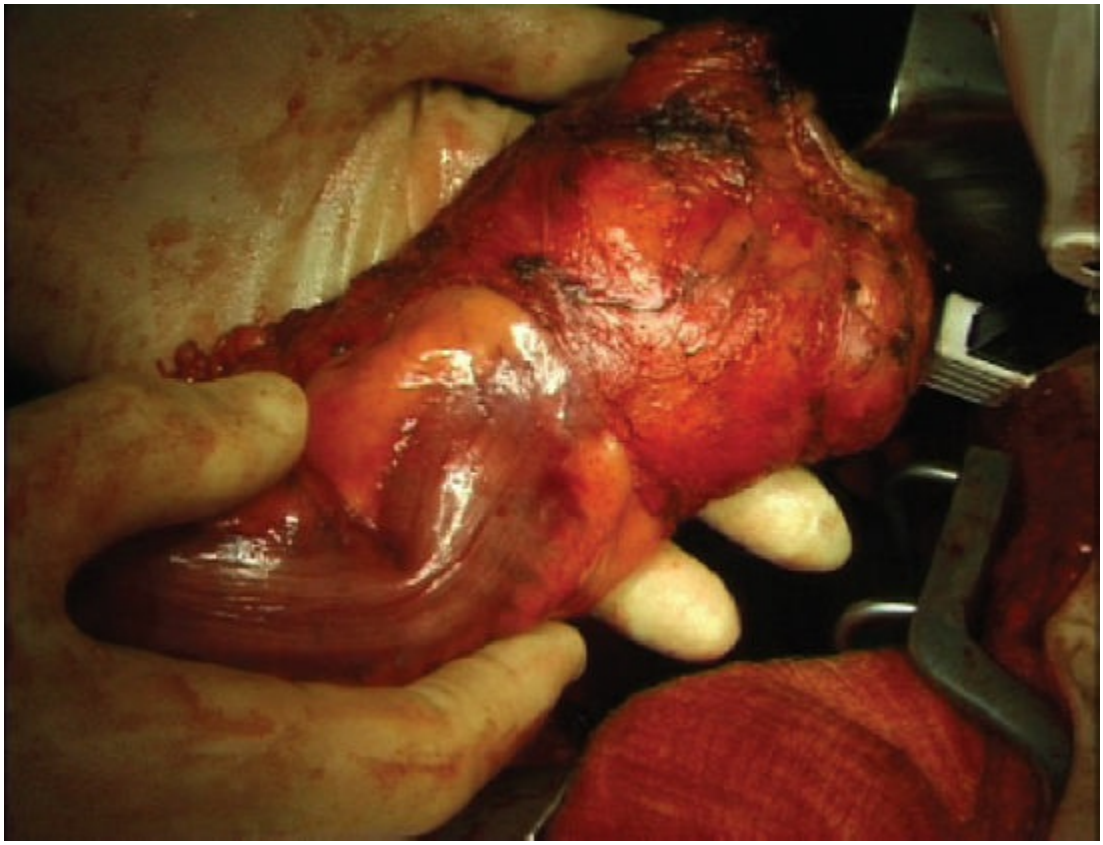

Figure 154.5. Front of a total mesorectal excision specimen.

MULTIDISCIPLINARY TEAM MANAGEMENT

Modern Imaging—Fine-Slice High-Resolution MRI

The great step forward of the new millennium is the establishment by Brown, Blomquist, and others that specialized fine-slice high-resolution MRI can visualize this “holy plane” before the surgery and thus predict the detail of the oncologic specimen that the surgeon endeavors to remove, its probable contours, and their relationship to the tentacles of tumor. TME principles are now more readily comprehended by nonsurgeons in the MDT because of the development by these specialist MRI radiologists of images that are far superior to anything previously achievable. The fine-slice high-resolution methods are demonstrably superior to any x-ray–based modality, which inevitably suffers limitations in differentiating tumor tissue from muscle wall. MRI demonstrates, for the first time, the contours of the mesorectum and the distribution of the cancer within it. The recent “Mercury” study from the Pelican Center in Basingstoke has demonstrated reliable equivalence between MRI prediction and histopathologic reality (Fig. 154.4). It also demonstrates that a 1-mm mesorectal “clearance” does indeed predict a “safe margin,” provided the

surgeon is faithfully following the “holy plane.”

Lymph Nodes Close to the Margin

The pelican Mercury Study showed that extramural vascular invasion was an even more important prognostic indicator than nodal involvement at the N1 level. We therefore take this as an indication for giving preoperative CRT.

Conversely, nodal “threats” by proximity to margin did not appear to lead to local recurrence (0/63). This almost certainly reflects the extra care taken by the surgeon to keep clear of such a node by the surgeon who is thus forewarned by the MRI.

This clearance on MRI between cancer within and mesorectal fascia without can be reliably used to predict the need for neoadjuvant “downstaging.” Also, it can warn the surgeon when the mesorectal margin is in danger of being breached during surgery. It can thus provide a “workshop guide” for the detailed surgery, whether this can be performed laparoscopically or open. This may become particularly crucial as a “route map” for laparoscopic surgeons as they increasingly extend their dissections into the challenging depths of the true pelvis where the inability to feel the cancer can be a serious disadvantage. We emphasize the importance of displaying MRIs in the OR during the actual surgery, and the robot might well be adjusted to show them within the console during the operation.

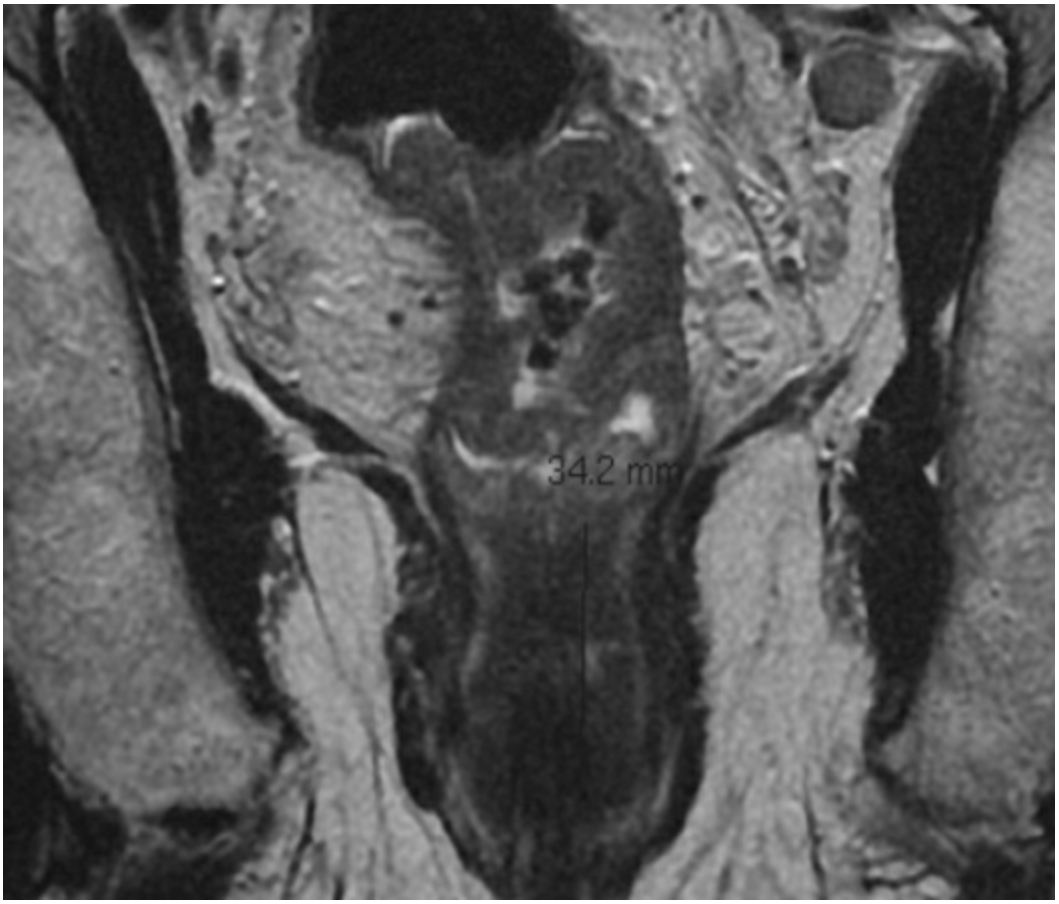

Figure 154.6. Coronal oblique magnetic resonance imaging showing large low rectal cancer with lower margin at 4.5 cm, but clear margin within puborectal sling.

CRITICAL MRI DECISIONS IN LOWER-THIRD CANCERS

One focal area of current controversy centers on the anatomic and embryologic fact that the mesorectal envelope tapers down in this (infralevator) lower third to appear very thin indeed—particularly on the crucial coronal oblique MRI cuts on which decisions in modern MDTs are made (Fig. 154.6). On such an MRI it is extremely tempting to predict that this tapering and narrowing area of the mesorectum will constitute a hazardous margin; thus, a decision may be made to administer preoperative downstaging neoadjuvant therapy or even choose APE for fear of margin involvement, when in fact, a carefully orientated axial oblique sequence with the axial cuts precisely at right angles to the tumor segment may demonstrate a potentially safe clearance. Figure 154.7 shows anterior black “excrescences” of extramural venous cancer spread. In such cases, where the cancer is below the levator origins on MRI, it is essential

that an experienced surgeon examines the patient to establish free mobility of the tumor in reference to the sphincter in the conscious patient (with muscle tone). In the author's opinion, this clinical observation on the sphincter complex and adjacent organs does almost invariably mean that a TME will be an achievable surgical objective. It does not confront the other tendentious issue of the higher incidence of internal iliac and particularly obturator node involvement in tumors <4 cm from the anal margin.

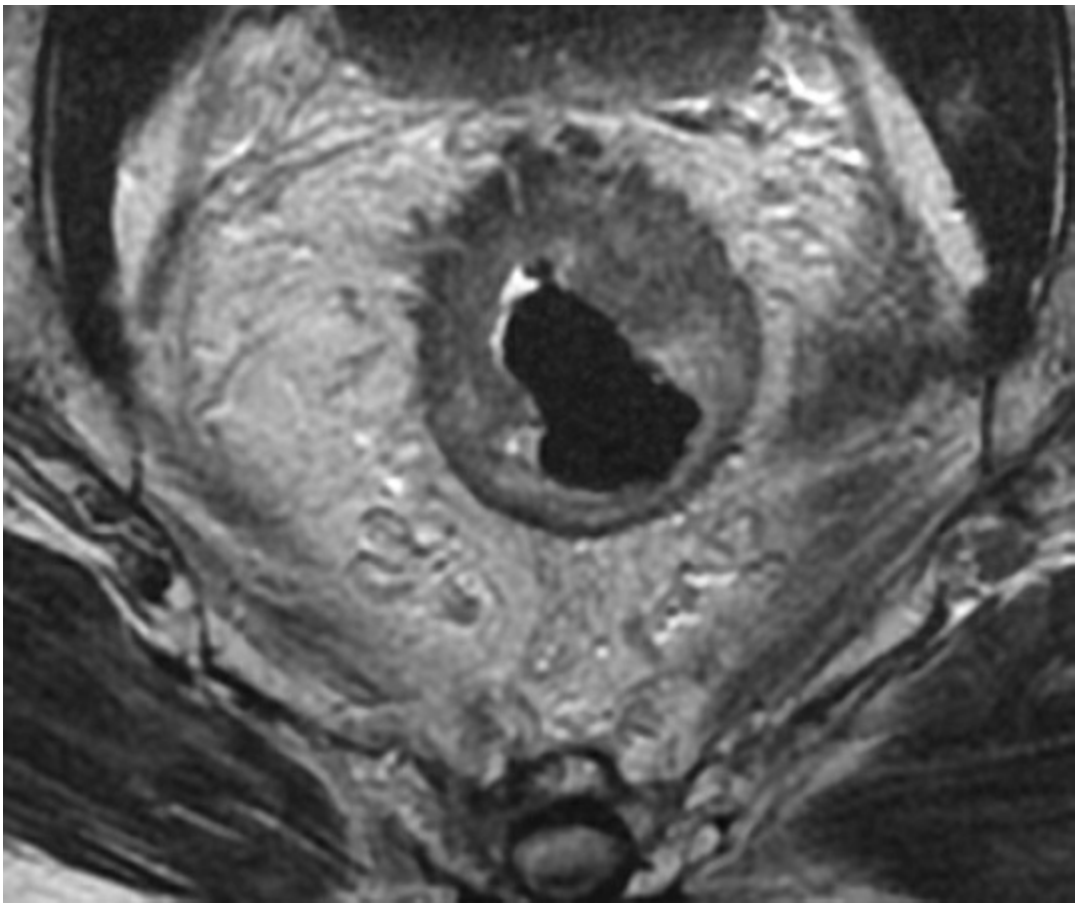

Figure 154.7. Axial magnetic resonance imaging of anterior cancer with EMVI extending close to but just 1 mm clear of the anterior mesorectal margin.

MDT management is now mandatory for all major malignancies in the United Kingdom and is increasingly a standard practice in many institutions throughout the world. The focal point of the decision-making process is becoming the MRI images, which can be readily understood by all, but the surgeon must always have the last word. Nevertheless, the idea that the decision to do an AR or APE is finally made in the OR is disappearing fast. It is wise to have the patient's permission but the

conscientious modern surgeon and MDT will almost always have decided ahead of time.

SUMMARY OF THE MULTIDISCIPLINARY TEAM SEQUENCE

The TME concept can now be extended to embrace a multidisciplinary six-stage process. It is essential that each case is discussed at two meetings: (a) before the operation for overall planning and (b) after receipt of the histopathology reports—for reasons of audit quality control, follow-up, and further adjuvant therapy.

Preoperative: Multidisciplinary Team 1

Clinical
CT to exclude metastatic disease and comorbidity. Various sequences, especially including coronal obliques in the long axis of the anal canal (for low rectal tumors) and fine slice (3 mm) axial obliques at right angles to the tumor segment to assess margins (Fig. 154.1).
Phased-array-coil fine-slice MRI, no endorectal coil—no bowel preparation.
MDT planning.
Preoperative neoadjuvant therapy in cases selected on the basis of preoperative MRI staging of the pelvis plus whole-trunk CT for the detection of metastases.

Postoperative Review of Patient Recovery Specimen and Histology: Multidisciplinary Team 2

Detailed precision surgery—TME or "TME plus." "TME minus" or "partial TME" for upper one third cancers implies that the mesorectum is divided 5 cm below the tumor and a rectal and mesorectal remnant remain—in the interests of creating a "smaller" operation with no temporary stoma.
Detailed audit of the specimen after removal with special emphasis on naked-eye assessment of mesorectal integrity and microscopic evaluation of the margins.
MDT assessment and decision regarding postoperative therapy.

The Surgery

Surgery TME for the surgeon comprises six basic principles:

Perimesorectal “holy plane” sharp dissection by monopolar diathermy and scissors under direct vision. Three-directional traction and countertraction is a vital principle for diathermy dissection as it is essential that the areolar tissue be “on stretch” if “holy plane” dissection is to be accurate (Fig. 154.8).

“Specimen-orientated” surgery and histopathology, of which the object is an intact mesorectum with no tearing of the surface and no CMI—naked eye or microscopic.

Personal naked-eye assessment as audit for obvious CMI as the principal immediate outcome measure. Combined with objective assessment of the whole specimen by the pathologist, this confirms the optimal planning and execution of the surgery. Surgeons and oncologists may also base postoperative therapy on this pathology report, though these must always be a sense of the “horse having bolted” if cancer has been exposed and CRT had not been given before surgery. This was a failure of either planning or surgical technique.

Recognition during surgery of, and preservation of, the autonomic plexuses and nerves, on which sexual and bladder function depend.

A major increase in anal preservation and reduction in the number of permanent colostomies by skilful extension into the depths of the pelvis.

Stapled low pelvic reconstruction, usually using the Moran triple stapling technique, plus creation of a short colon pouch or a side to end anastomosis to low rectum or anal canal.

Before the Operation—Bimanual Pelvic Examination

CT scans and colonoscopy report should always be at hand in the operating room. Never commence surgery without having examined the patient digitally when awake plus performing bimanual examination under anesthesia. This is especially true in the female, so as to establish whether the tumor is fully mobile on the posterior vaginal wall. MRI may already have demonstrated invasion but it is still of value to confirm it. The decision as to whether to excise a part of the posterior wall is finally made at this time by a combination of rectal and vaginal examination, and the latter must never be omitted. Sometimes, if AR is possible, a disc of the posterior wall may be circumscribed around an area of tethering using the angled-point diathermy from below. This is often best performed before the abdominal dissection is started. Routine excision of the posterior vaginal wall is not usually necessary unless it is actually involved.

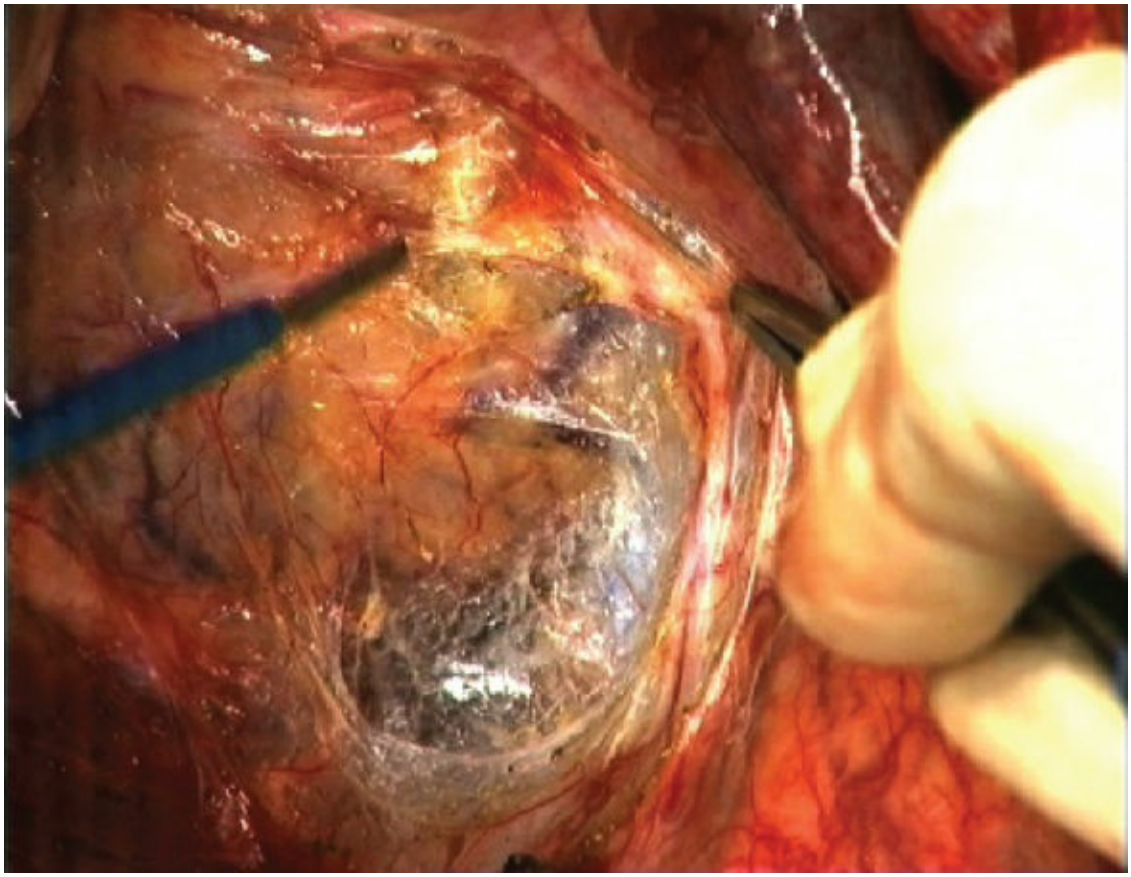

Figure 154.8. Areolar dissection.

Steps of the Operation

The key principle is that dissection should only proceed in the areolar tissue plane (the “holy plane”) within (and thus sparing) the autonomic nerve plexuses, the nonvisceral presacral fat pad (when present), the parietal sidewall fascia of the small pelvis, the hypogastric plexus, the vesicles and the prostate in the male, and the vagina in the female. All of the dissection should be performed sharp with diathermy or scissors under direct vision with good light (Fig. 154.6). Throughout, the dedicated assistants should provide three-directional traction to open up the planes for the operator—diathermy can only be used safely when the areolar tissue is on stretch. Compared with traditional methods of manual extraction, the difference in time can be considerable. A careful TME plus pouch to anus reconstruction takes 3 to 5 hours according to the detail of the patient’s build and the particular cancer; a conventional APE was often completed in 1 hour.

The Incision—Open Surgery

A long midline incision is made from the symphysis pubis to within a few

centimeters of the xiphisternum. If possible, at least 5 to 7 cm is best left at the top as this facilitates tidy packing away of the small intestine in the right upper quadrant.

Some young ladies may prefer a suprapubic skin crease incision combined with a vertical midline between the rectus muscles.

Laparoscopic Anterior Resection

The author takes a major interest in this area of extending laparoscopic practice but continues himself to perform open surgery for rectal cancer as detailed. The principles remain the same and there is no doubt that excellent clearance of relatively small cancers can be achieved laparoscopically and by some surgeons of the great majority. The author would suggest that only very experienced laparoscopic gastrointestinal surgeons should embark upon the deep dissection for cancer and that special caution, if not total avoidance, is appropriate for very large cancers, especially in narrow male pelvises. The elevation of an intact mesorectal package, safely encompassing a large cancer, requires carefully applied but substantial upward traction, which is very difficult to achieve with laparoscopic instruments. At present, the author would counsel great caution with tumors >8 cm in any dimension, but most importantly in axial diameter. A further area of limitation is the cross-clamping and washout of the anorectal muscle tube for which laparoscopic instrumentation often remains imperfect. Multiple bites with the endo GIA often go hand in hand with the catching of some of the puborectal sling posteriorly rather than a clean join to the smooth muscle tube.

At the time of going to press, rather few laparoscopic instruments exist that bend effectively round a large cancer to apply upward traction in a safe gentle way. The use of small “peanuts” or gauze pledgets is infinitely better than applying graspers to the mesorectal surface which can so easily be torn. Graspers may be applied to cut peritoneal edges and special expanding retractors can, to some extent, replace the crucial forward and lateral retraction for which the St. Marks’ retractor is key in the open operation.

OPEN SURGERY

Manual Palpation and Inspection—Laparotomy

This must be thorough, with particular emphasis on liver and peritoneum.

Careful assessment of the para-aortic nodes in the lesser sac is easy to forget. At this stage, it is a good routine to review the CT scan and the colonoscopy report and to palpate the whole gastrointestinal tract carefully.

Packing

Careful packing and retraction of the intestines upward and to the right is crucial to provide clear access to the pelvis. Adhesions in the right lower quadrant commonly require division. “Starting right”—the pedicle package—the clue to the top of the “holy plane” (Fig. 154.9). Starting correctly involves three-directional traction on the colon and retroperitoneum to identify the plane between the back of the pedicle package and the gonadal vessels, ureter, and preaortic sympathetic nerves —all of which must be carefully preserved. The key to this phase is the recognition of the shiny fascial-covered surface of the back of the pedicle —like a tapering longitudinal “sausage” with the inferior mesenteric vessels within. This must be gently lifted forward. It is usual in open surgery to start on the left of the sigmoid mesocolon. It is equally satisfactory, as commonly performed in laparoscopic surgery, to start on the right. In either case, the identification of the shiny fascial envelope behind, what I like to call the “pedicle package,” is crucial to proper entry into the pelvis and to the preservation of the nerves.

High Ligation of the Inferior Mesenteric Vessels

With the pedicle package lifted gently forward the dissection behind it can be extended up to its proximal end; separate high ligations of the inferior mesenteric artery and vein can be performed with the pedicle controlled by the left index finger with the surgeon standing on the patient’s left side (Figs. 154.10 and 154.11). The artery is taken 1 to 2 cm anterior to the aorta so as to spare the sympathetic nerve plexuses; the vein is divided above its last tributary close to the pancreas. These two high ligations are an integral part of the otherwise avascular planes, which need to be developed upward extensively for a full mobilization of the splenic flexure. The need for this is dictated by the decision to perform a TME and therefore an anastomosis 3 to 6 cm from the anal verge. The mobilized colon must lie without tension in the hollow of the sacrum.

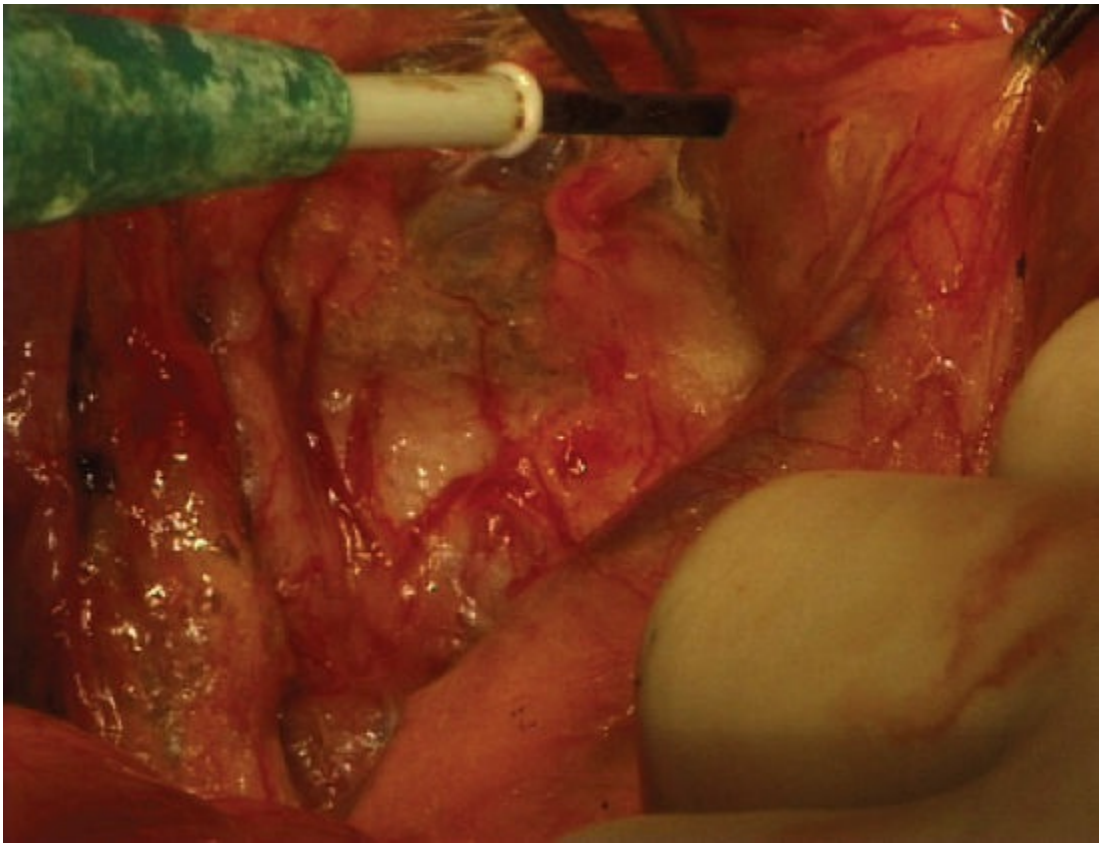

Figure 154.9. Pedicle package. “Starting right.”

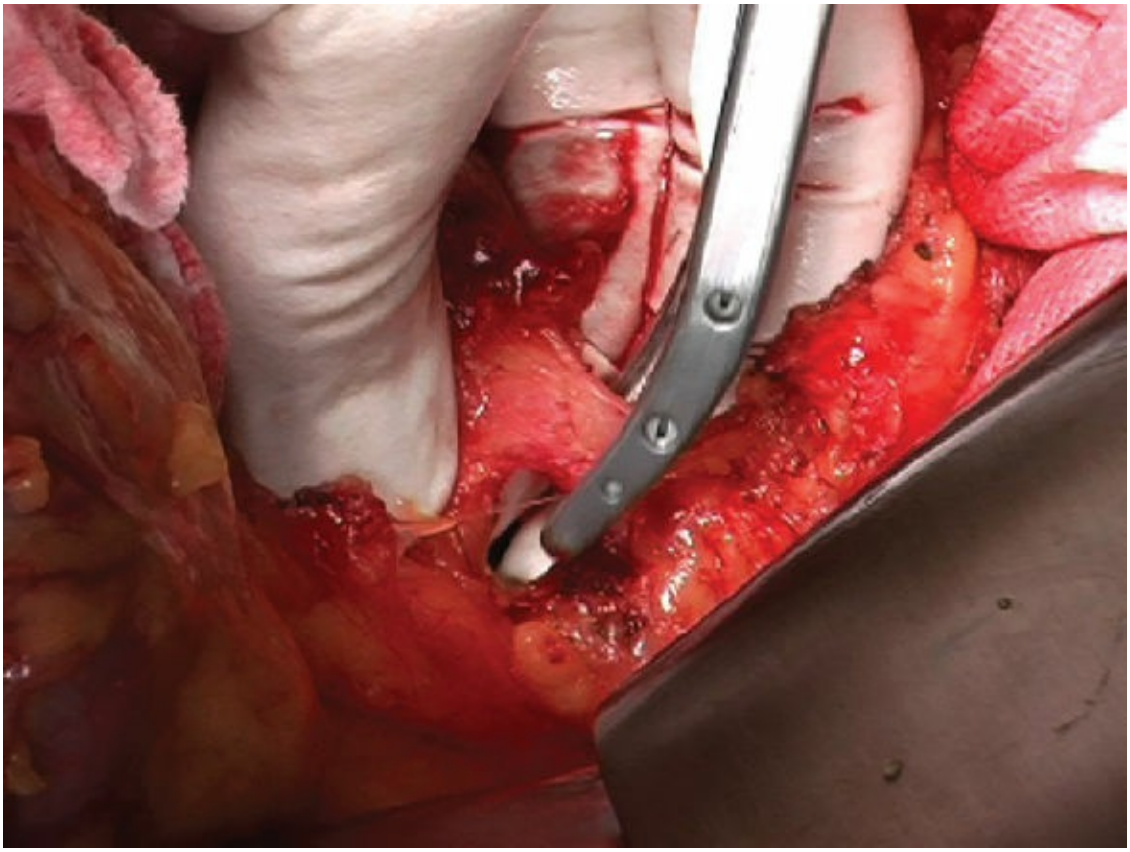

Figure 154.10. High ligation of artery.

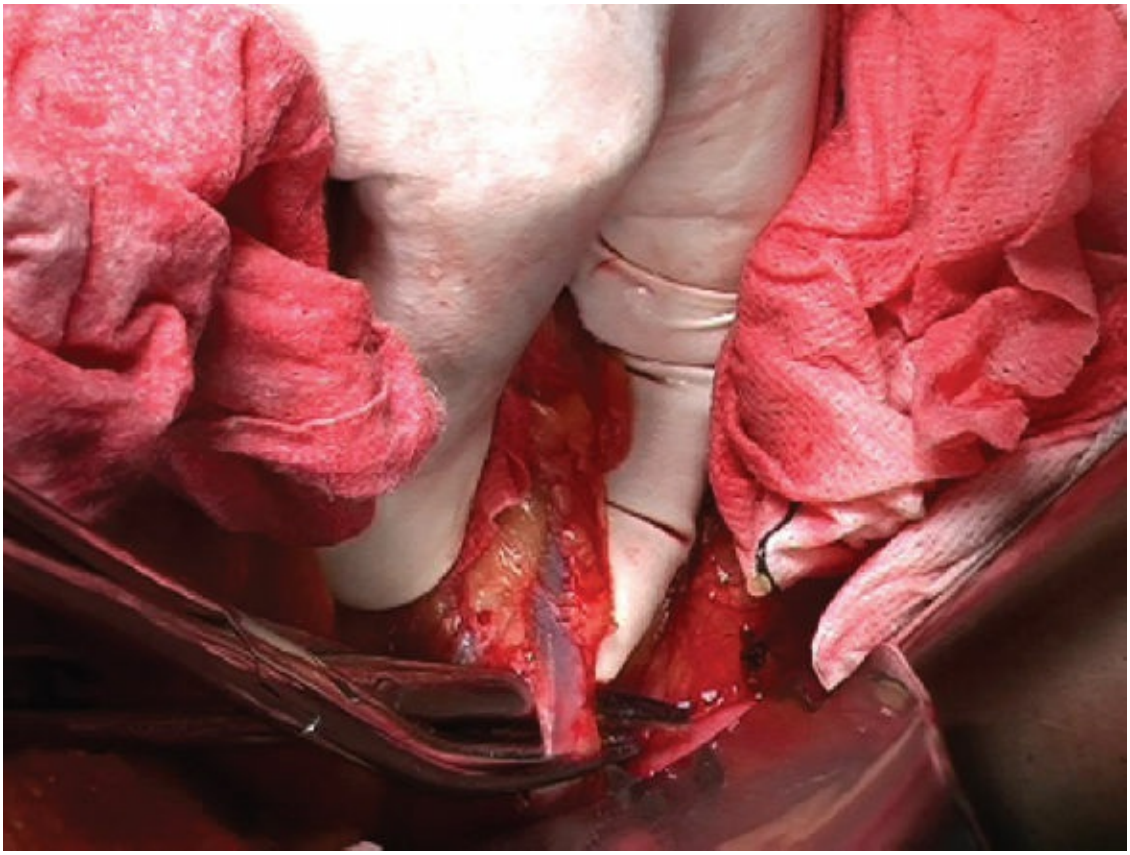

Figure 154.11. High ligation of vein.

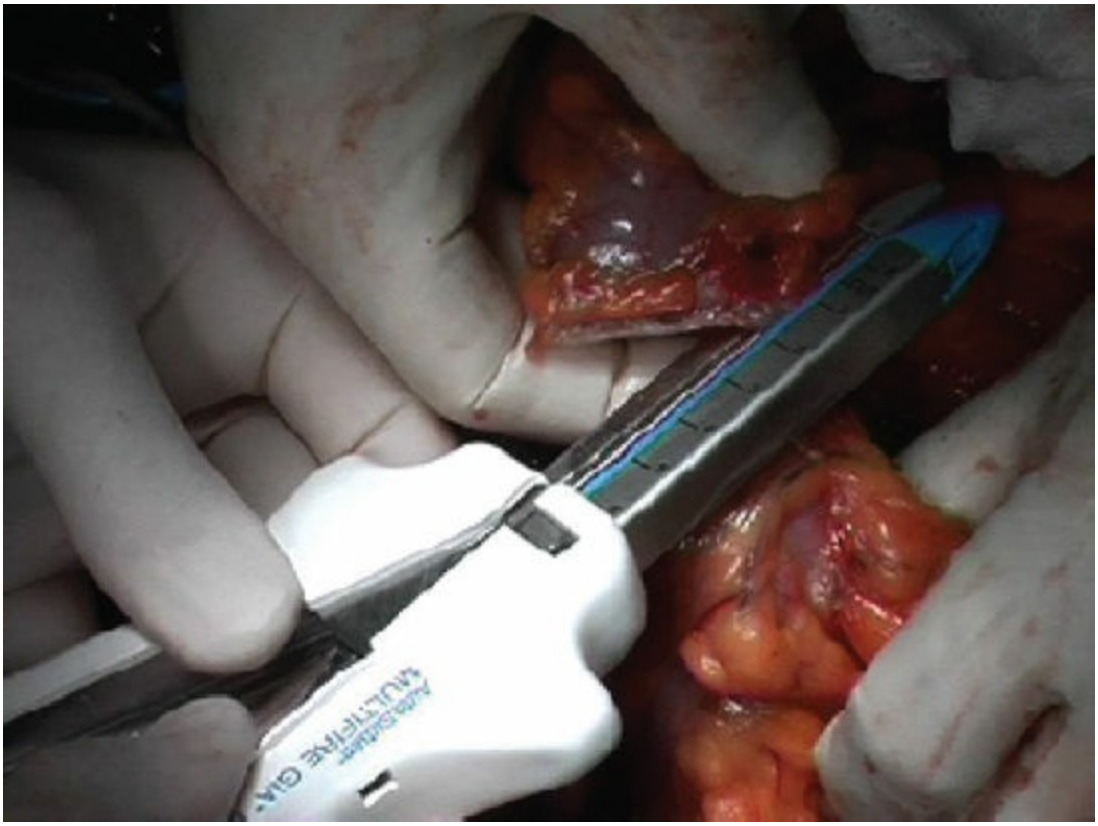

Figure 154.12. Division of convenience.

The ascending left colic artery and either the accompanying inferior mesenteric vein or its last tributary from the left colon may also need to be divided separately to complete the vascular isolation of the specimen with full mobilization for ultra-low pouch anastomosis.

In a minority of cases, a particularly long and healthy sigmoid may obviate the need for this full mobilization process, which is not entirely without risk (e.g., to the spleen itself). Thus, it is logical, if a decision is made to use such a long healthy sigmoid and thus avoid the splenic flexure, to ligate the inferior mesenteric artery just distal to the ascending left colic, which is essentially a part of its primary blood supply. Particular care over the ligation is necessary as the stump will pulsate vigorously.

The "Division of Convenience"

The sigmoid mesentery and the sigmoid colon are divided well above the cancer (Fig. 154.12). This is an important step in every cancer dissection as optimal mobility of the top of the specimen facilitates gentle opening of the perimesorectal planes by traction and countertraction in any direction throughout the pelvic dissection. After the division, there is also the best possible visualization of the pelvis with all of the gut to be retained drawn upward and to the right. Most laparoscopic surgeons do not find that this division helps them.

Commencing the Pelvic Dissection

The surgeon is now optimally placed to identify the key planes that must be developed circumferentially around the mesorectum. He or she starts at the back and then follows identifiable areas of the "holy plane" at various points on the mesorectal circumference in a stepwise manner. If lower down in the pelvis, bleeding in one area is troublesome due to inaccessibility, it is sensible to tackle the opposite circumference so that pressure is applied while progress continues.

High Posterior Dissection

There is no real substitute in open surgery for the St. Marks' retractor or my own reverse concavity (Heald Retractor)—both available from Bolton Surgical of Sheffield—or from many instrument manufacturers. Forward traction demonstrates the shiny posterior surface of mesorectum within the bifurcation of the superior hypogastric plexus. This plane is extended

downward toward and eventually beyond the tip of the coccyx, step by step as other sectors of the circumference are developed.

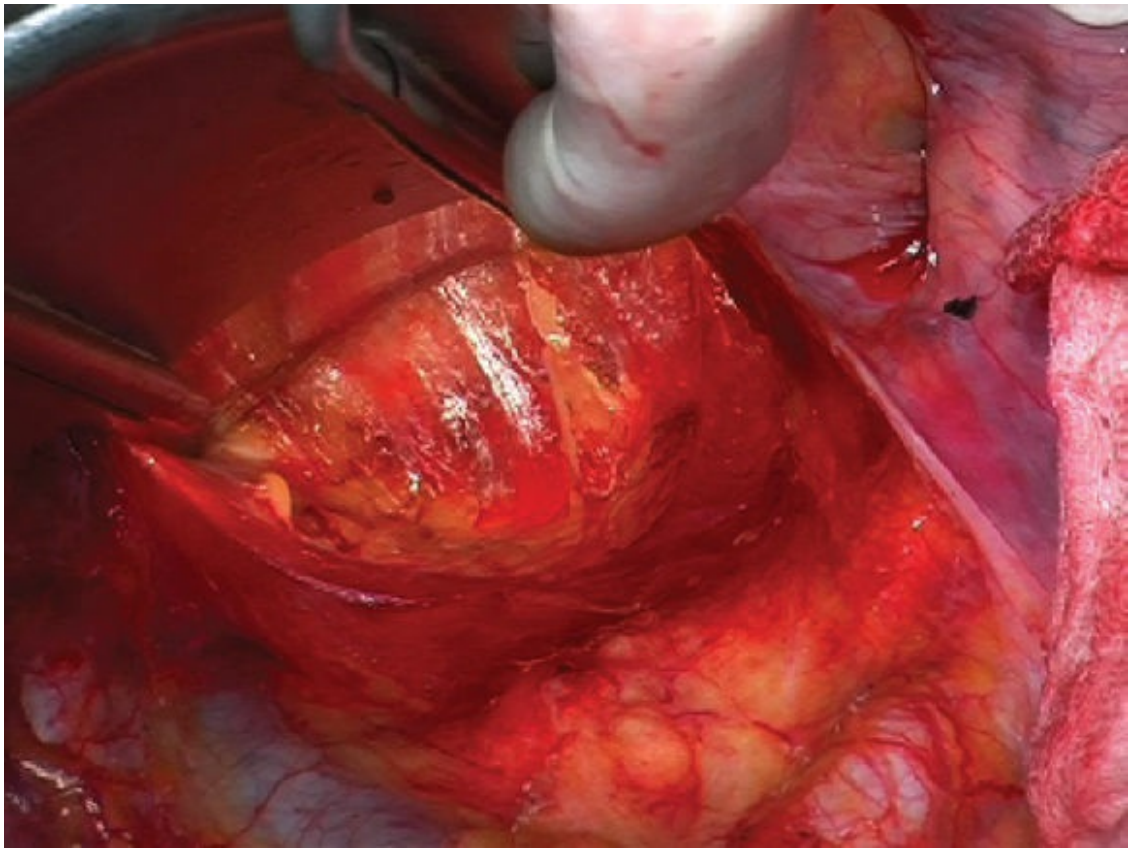

Figure 154.13. Rectosacral ligament.

Division of the Rectosacral Ligament or Fascia

This condensation may constitute an apparent barrier to downward progress posteriorly, requiring positive division with scissors or diathermy (Fig. 154.13). Just in front of it, within the mesorectum, the superior rectal vessels can often be seen through the back of the mesorectal fascia, and around them cancerous nodes are likely to occur only millimeters away. An intact shiny visceral fascia over these must be jealously guarded and tearing avoided at all costs. This poses one of the greatest dangers of blunt manual extraction or of any haste or roughness, since the rectosacral ligament may be stronger than the surface fascia over the nodes. Thus, tearing into the lymphatic field by the inserted hand becomes a real risk and must have occurred frequently in the past. Sharp dissection under direct vision is crucial and lighting essential. A further safety factor in identifying positively the “holy plane” posteriorly in front of the presacral fat pad (when present) is that one avoids the risk of tearing thin-walled

presacral veins, which often have no valves and can bleed prodigiously when cut or torn. These will never become a problem if the correct plane is followed and tearing is avoided; if they should be torn, a small pack and a considerable period of anterior dissection away from them will provide the safest way forward. The key to this dissection is always to remain on the yellow mesorectal anterior and medial side of the dissection plane, which is held widely open by traction and countertraction.

Lateral Pelvic Dissection

This involves forward extension of the plane around to the sides, gently easing the adherent hypogastric nerves laterally off the mesorectal surface under direct vision. The freedom to lift the divided rectosigmoid forward often means that the tangentially running hypogastric nerves are first positively identified at this stage, the superior hypogastric plexus itself only becoming obvious proximal to the nerves after they have been dissected away from the mesorectal surface on each side. The superior hypogastric plexus may have been ensheathed by fatty tissue and not immediately recognized as a nerve bifurcation.

These nerves are far more important than hitherto appreciated because they subserve many of the functions of orgasm in both sexes, while the inferior, more distal plexus is necessary for the more obvious parasympathetic function of erection—certainly in the male and presumably clitoral function in the female as well.

The “Lateral Ligament” Area

These so-called ligaments were the subject of an international consensus conference in Tokyo where I asserted that they did not actually exist (Figs. 154.14 to 154.17). The following account represents a personal view of the difficult anatomy in the distal anterolateral sector as experienced by the operating surgeon in the live patient.

The holy plane is followed downward toward the vesicles with the expanding plexiform band of inferior hypogastric plexus outside it, but increasingly adherent to it. In essence, there is no actual ligament, but there is an area of adherence between mesorectum medially and plexus laterally: small branches of nerves and vessels penetrate through at this point but none generally reaches more than 1 to 2 mm in diameter. The key nerves entering this flattened band from above are largely sympathetic hypogastric nerves, curving distally from the superior plexuses and more

distally the “erigent” parasympathetic nerves coming forward to it from behind. These arise from the front of the roots of the sacral plexus (especially S3, out of sight behind the parietal sidewall fascia). This fascia is quite robust laterally and the surgeon will note that he or she usually cannot even see the internal iliac vessels, which are outside it. Posteriorly, these “erigent pillars” from the roots around S3 curve forward outside the parietal fascia but medial to the branches of the internal iliac vessels. Together they form a layer of the “onion”—inside this layer the holy plane, outside a “tiger country” of internal iliac vessels and veins, which can cause serious bleeding (Figs. 154.15 to 154.18).

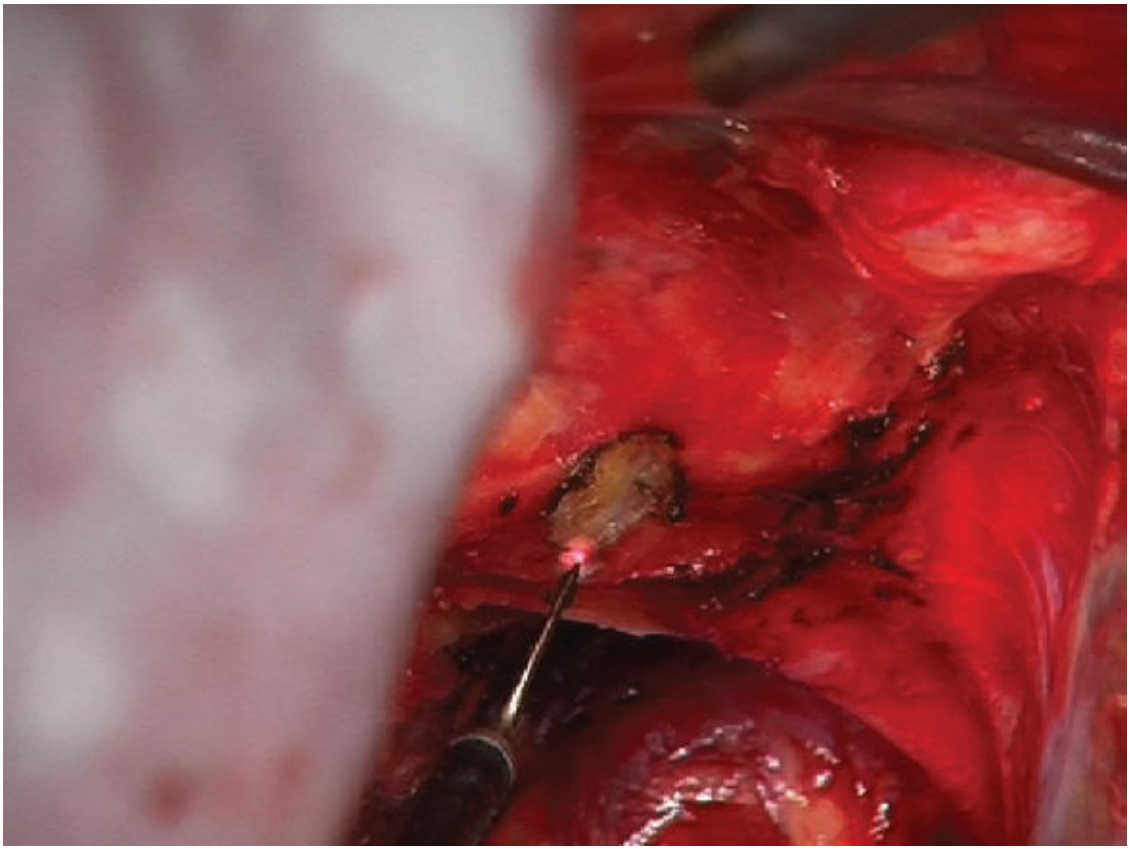

Figure 154.14. Dividing the lateral “ligament.”

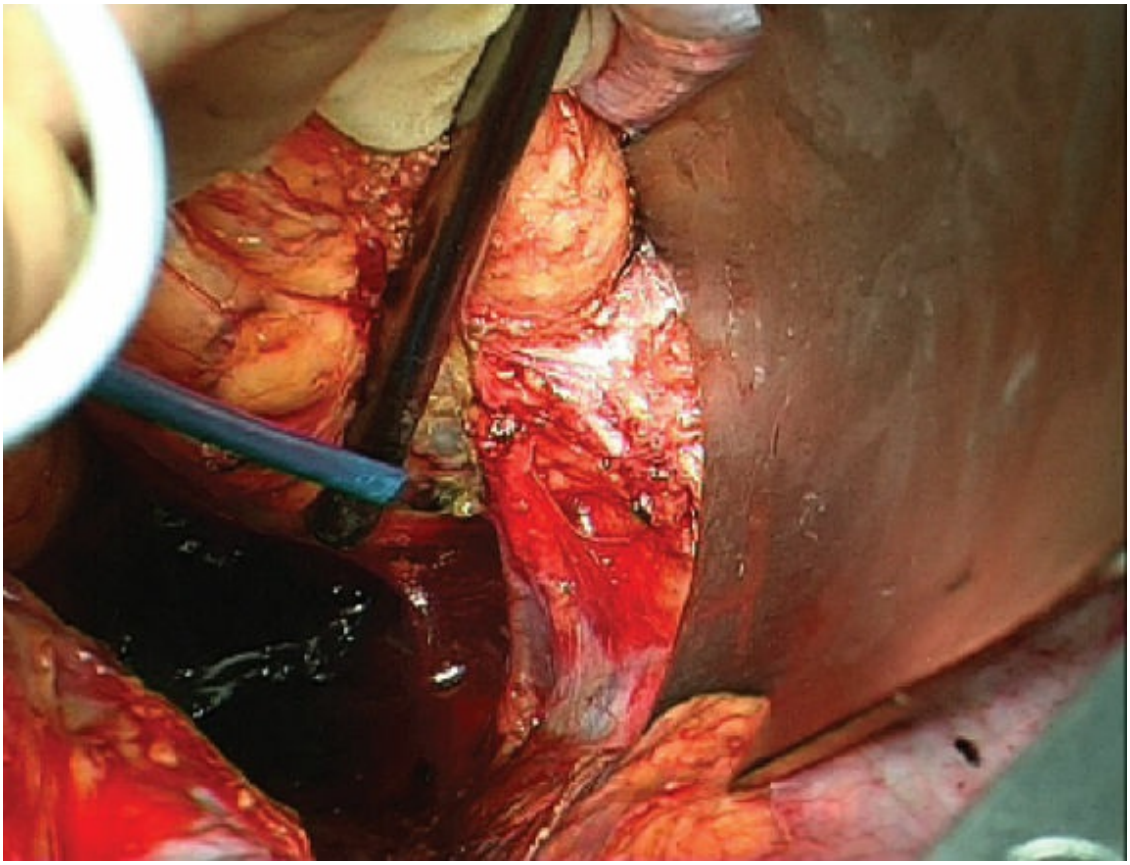

Figure 154.15. “Lateral ligament” area.

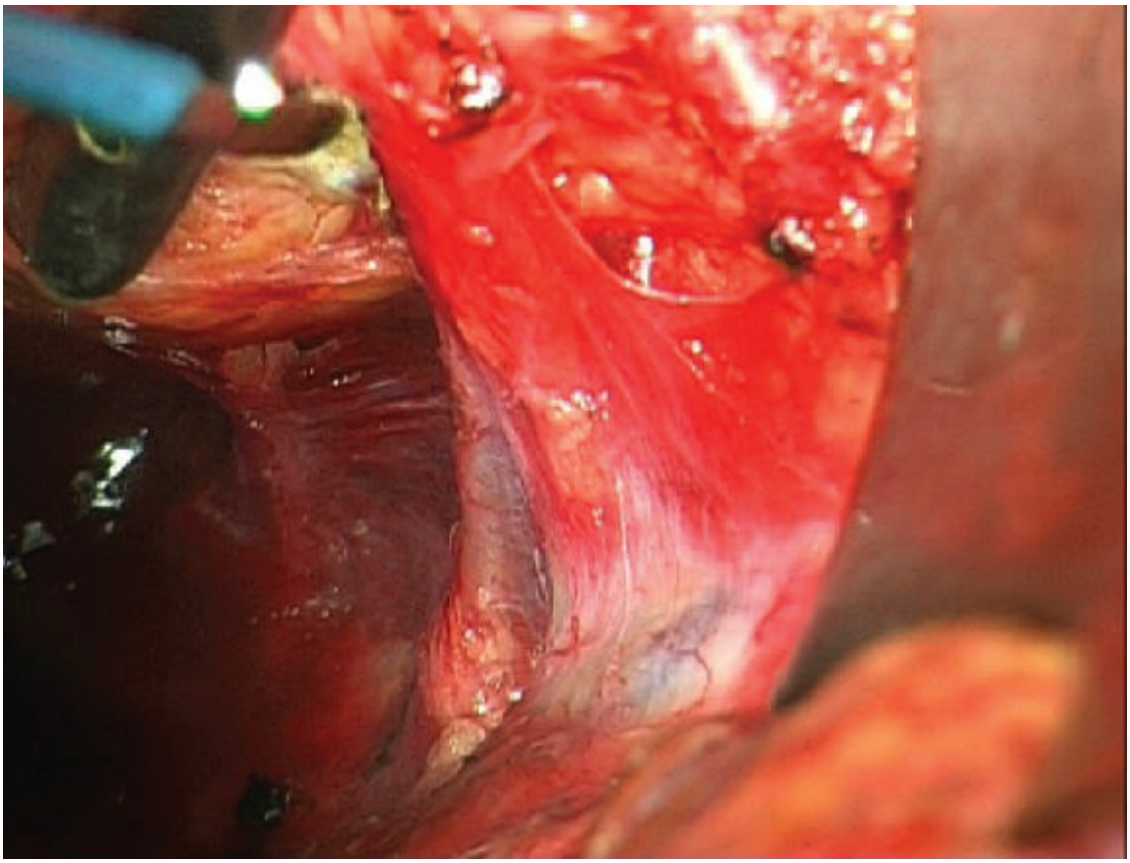

Figure 154.16. Erigent pillar.

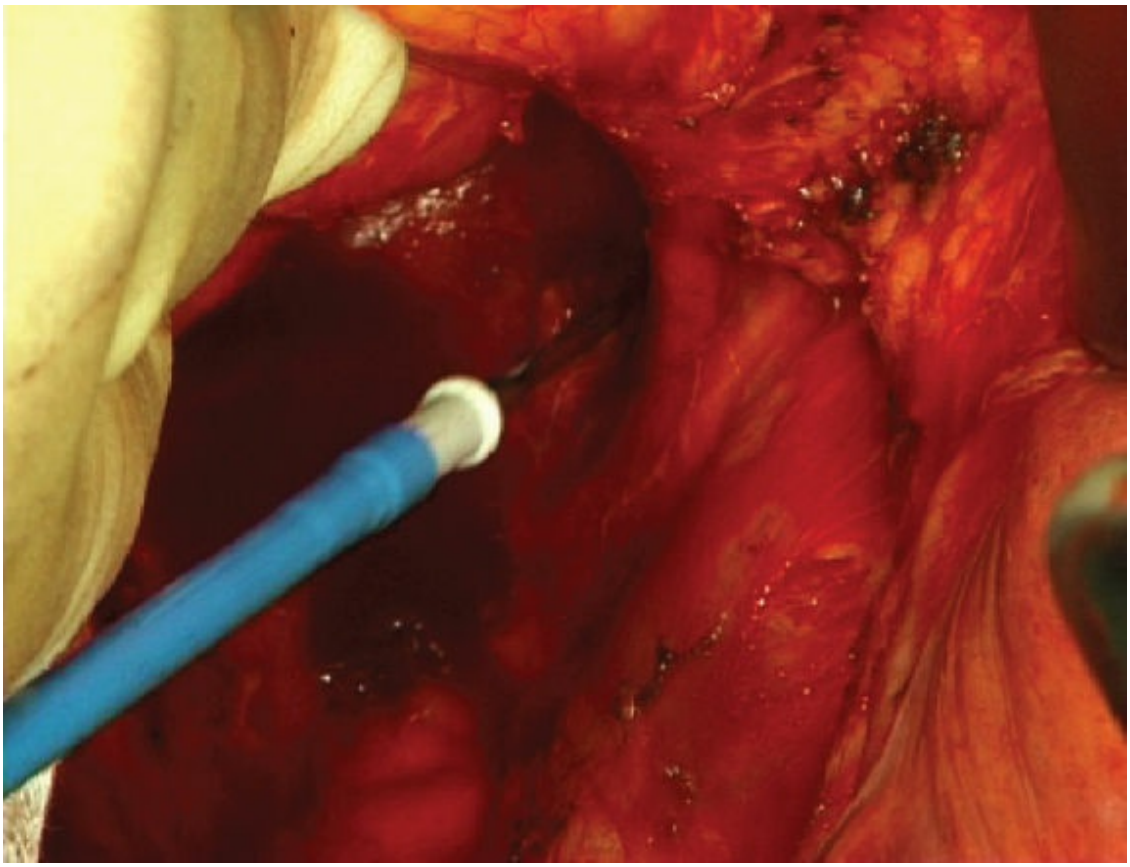

Figure 154.17. Bifid root.

A little way behind the vesicles the erigent pillars pierce the fascia to join the inferior hypogastric plexus and often contribute nerve branches to the mesorectum and rectum. These “neural T junctions” are the nearest structures to “lateral ligaments” that the most careful surgeon will find with precise dissection. Another often described structure that I believe to be found only rarely by the surgeon during this dissection is a true middle rectal artery. I believe that in past days what the surgeon believed to be a middle rectal artery was most often a lateral intramesorectal artery, and the so-called “stalk” being divided represented a “coning in” to the mesorectum.

The surgeon dissecting perfectly between the mesorectum and the inferior hypogastric plexus discovers nothing more than a tiny vessel that requires no more than a touch of diathermy. Similarly, Sato and Sato have shown by careful anatomic studies in cadavers that a true middle rectal artery exists in <20% of patients and then on one side only. When the surgeon “cones” or tapers in too far medially, he comes across a

substantial intramesorectal vessel, when too far lateral a pelvic sidewall vessel. Thus, the clamp and cut routine implied a poor quality of the dissection, damaged nerves, and left a substantial residue of dangerous tissue, probably all a part of the prodigious 30% to 40% local recurrence rate that was once commonplace.

Neither of these is a true middle rectal vessel since neither is passing from the internal iliac to the rectum. “Coning in” does, of course, compromise the oncologic quality of the “block dissection” because it implies that part of the distal mesorectum is being left in the pelvis. A more distal vessel from the prostatic branch or from the pelvic floor is often found later and lower down where it can cause troublesome bleeding. We feel that the minimal nature of a true middle rectal blood supply also implies a minimal lymphatic component. In our view, this is a less common mode of spread than is often believed in Japan or it is even possible that there is an ethnic difference with this regard. It is our belief that most surgeons have in the past thus strayed either outward into the plexus or inward into the mesorectum and created surgical artifacts that they have called “lateral ligaments” because they tethered the rectum at these points and “middle rectal arteries because they bleed ferociously.” If the cancer is truly adherent at this point, or if preoperative MRI shows invasion, then “straying” outward to the internal iliac becomes justified, though it may cause damage to the nerves involved, which can be avoided in the standard TME operation for most cancers. The surgeon should generally attempt to dissect at this point of adherence precisely between the outer aspect of the mesorectum and the triangulated neural band of nerve plexus that should be left intact. This technique can be dubbed “mesorectal fat surface dissection” because no actual loose areolar tissue exists in those areas where mesorectum and plexus are adherent. The final specimen will often lack the shiny fascial covering over this area.

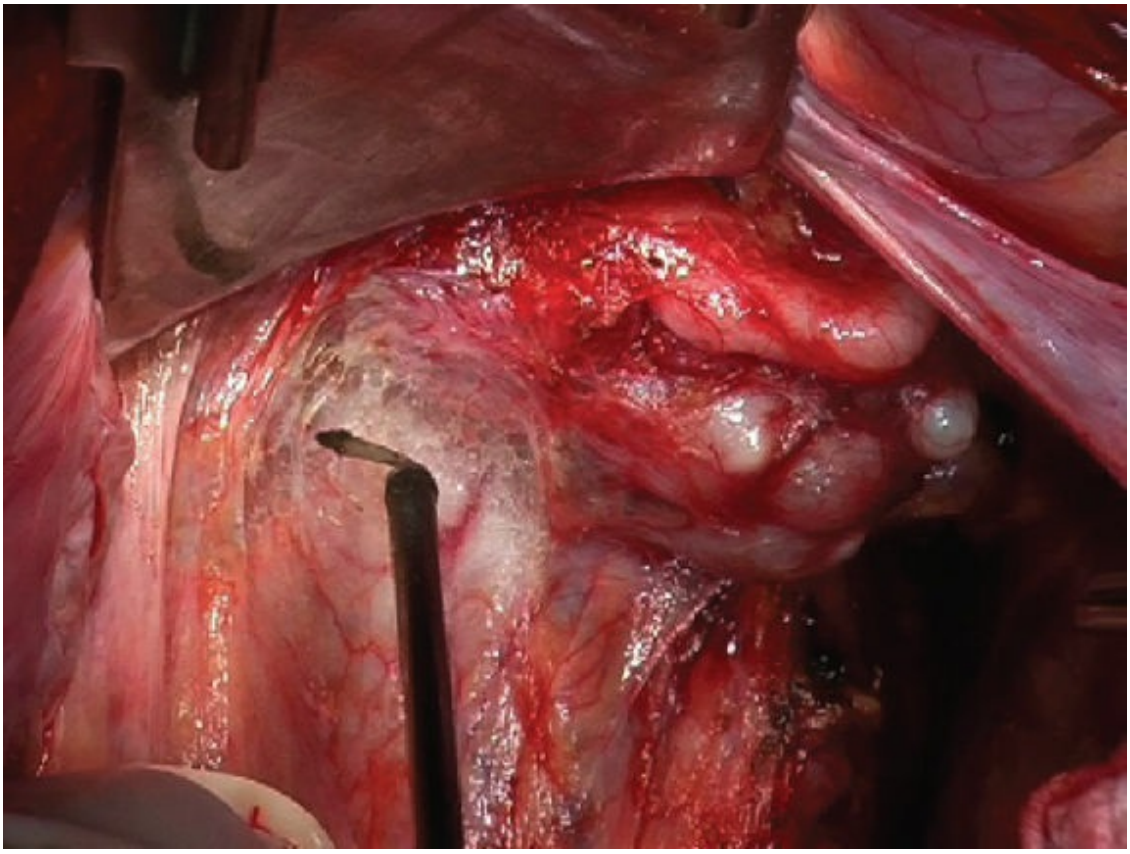

Figure 154.18. Vesicles and Denonvilliers' fascia.

The Anterior Dissection—Denonvilliers Septum

Dissection anterolaterally and anteriorly following the correct plane forward will encompass the peritoneal reflection that remains on the specimen, and thus allows positive identification of the backs of the seminal vesicles (Figs. 154.18 and 154.19). Forceful forward retraction on these with a St. Mark's retractor will facilitate the development of the areolar space between the vesicles and the smooth front of the mesorectal specimen (Fig. 154.17). We call this smooth surface that is generally adherent to and clearly a part of the mesorectum Denonvilliers fascia or the rectogenital septum. As one works distally, there comes a point where this fascia must be divided transversely as it becomes adherent to the posterior capsule of the prostate. Particular care is necessary during this step to avoid damage to the neurovascular bundles (of Walsh) that constitute the distal condensation of the inferior hypogastric plexuses, joined by numerous veins and small arteries; hence the title neurovascular.

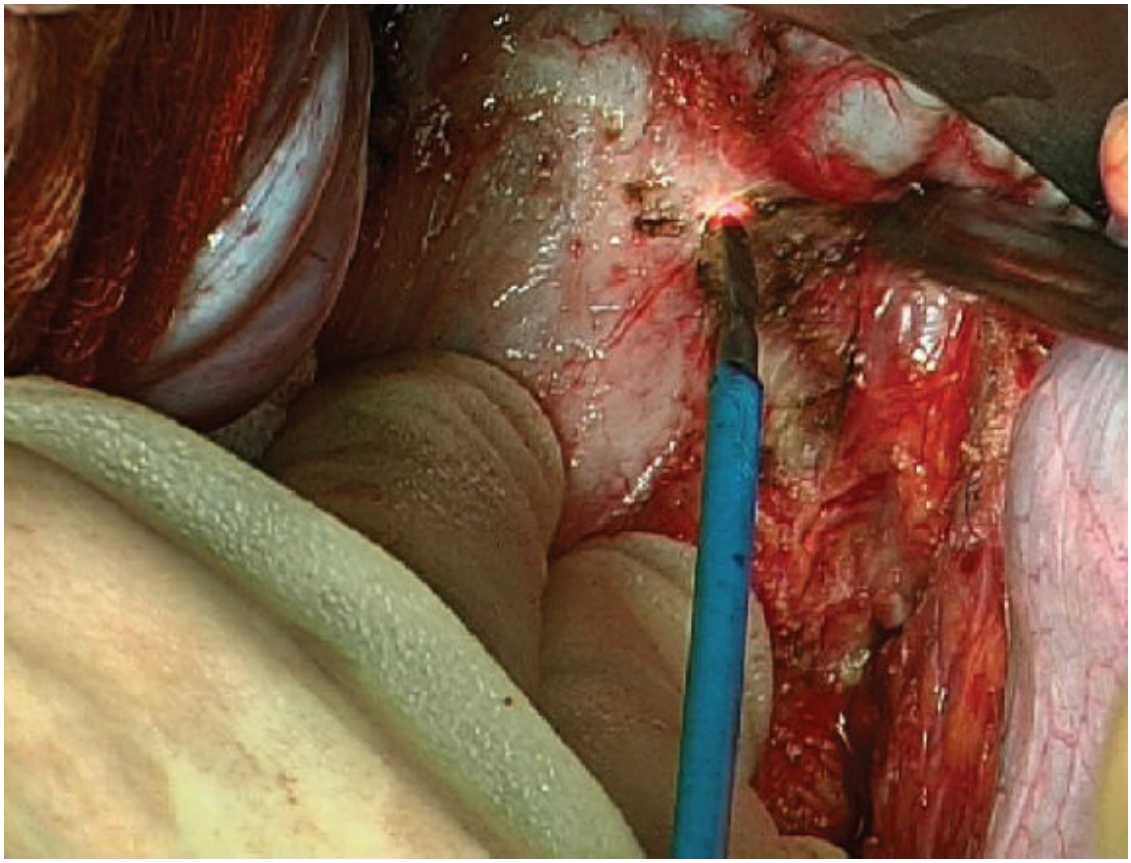

Figure 154.19. Cutting through Denonvilliers fascia.

In a low anterior tumor, this can be exceedingly critical: It is essential to avoid exposing malignant tissue on the front of the specimen at the very point where the nerves are curving acutely medially. Since they are often impossible to see in open surgery because of forward angulation behind the vesicles, bladder, and prostate, they are in particular danger. In addition, surgeons who “take a slice off the back of the prostate” are highly likely to cause impotence because of the close relationship of the neurovascular bundles to the back of the prostate.

Hand in hand with this anterior dissection goes the development of the lateral sidewall dissection. The whole area of the rectoprostatic interface is a major current challenge in technical surgery—both open and laparoscopic.

The Face-Down Position (The Kocher/Holm Position) for Extra Levator Abdominoperineal Excision

True understanding of what happens to these nerves after they leave the area of vision of the abdominal operator has only become possible for us since introducing the prone jackknife position. This provides posterior

access to the rectoprostatic interface so that the lowest part of the rectum can be gently dissected clear of the nerves as they course toward the back of the penis. Figure 154.27 is a unique picture of the neurovascular bundles from behind after removal of the rectum. More detail for the dissection is provided later.

The Nervi Erigentes or "Erigent Pillars"

The parasympathetic erigent nerves form posteroanterior lateral "pillars" on the pelvic sidewall—the distal margin of the neural layer of the "anatomical onion" (Figs. 154.14 to 154.17; see also Fig. 154.21). Cadaver dissections have led us all to be taught that the pelvic parasympathetic outflow is tripartite S2–3–4. However, to the surgeon, there is no doubt that a recognizable landmark is often a single or bifid "pillar" comprising a nerve root arising from the front of the S3 component of the main sacral plexus (Fig. 154.17), which is out of sight posteriorly. The pillar-like appearance is in part due to the forcible forward traction on the prostate and bladder to see the structures during an open operation, and this tends to bow the nerves medially and thus make them stand out. This retraction does not occur to the same extent in a laparoscopic operation, which may account for the reported higher incidence of nerve damage recorded from several centers. These pillars and the hypogastric plexuses curve medially toward the back of the prostate, where they form the neurovascular bundles, which taper toward the urethra at the apex of the prostate. Here they become the erectile nerves of the corpora cavernosa or cavernous nerves. The pillars or roots arise outside the parietal fascia that they penetrate obliquely at the point of adherence to the anterolateral aspect of the mesorectum (Fig. 154.18). Further forward and more medially, as stated above, removal of a "slice of prostate" will probably cause impotence and is not often really necessary. This part of the low anterior dissection is made more confusing by the *perineal body*—the midline fibrous interdigitation of the transverse perineal muscles. The surgeon often finds dissection through this confusing because he is not in a proper "surgical plane," but, at this one point, this is good because the front of the cancer specimen and the urethra are rather close together and a little perineal body tissue on each is probably optimal.

Dissection of the Most Distal Mesorectum

The anatomy of the insertion of the mesorectal "package" into the pelvic

floor becomes difficult for the surgeon to grasp from above because of its inaccessibility behind the vesicles and prostate and behind the vagina in the female (Figs. 154.20 and 154.21). The situation is further complicated by the fact that the levators are like a “flower pot” in continuity with the tube of external sphincter distally. Conceptually, and because of the distortion introduced by upward traction, surgeons tend to think of the pelvic floor as being much flatter than it is in vivo, especially if an assistant applies upward pressure on the perineum. If one doubts this, a careful look at the layers on a coronal MRI scan will make it evident. A clear three-dimensional perception of the now globular bilobed mesorectum in the depth of the pelvis and the surrounding neural lamella is the most elusive and challenging conceptual acquisition for the aspiring rectal cancer surgeon.

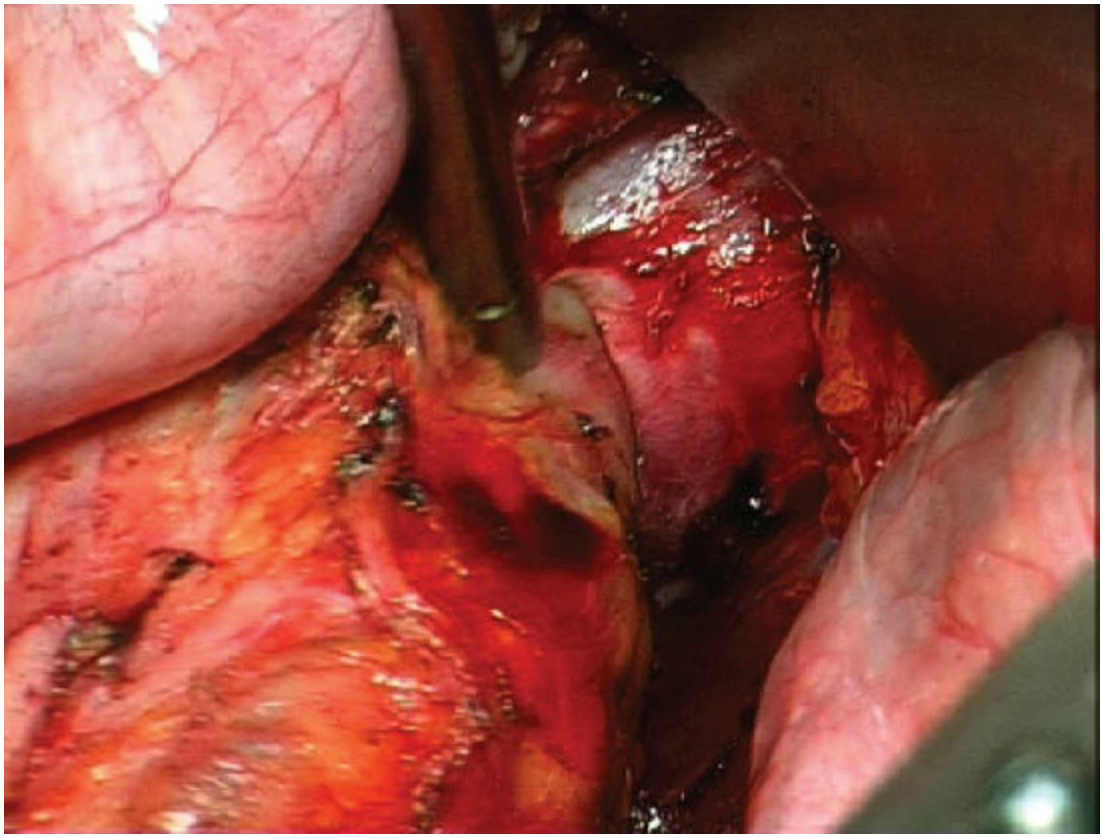

Figure 154.20. The tapering mesorectum.

Careful pursuit of the plane at this level eventually liberates the mesorectal package and takes the operator down to a clean muscle tube. Although crossed by a few small arteries and veins from the puborectal sling and some slips of sphincter muscle, the “holy plane” here becomes the intersphincteric plane, which is familiar to proctologists from below—

a tube of red skeletal muscle outside a tube of whiter smooth muscle within.

Partial Mesorectal Excision (i.e., High Anterior Resection and Mesorectal Transection)

Below which level of, or what height of tumor above the anal verge does TME become necessary? Height measurement, by general agreement, is from the anal verge in the conscious patient using a rigid sigmoidoscope. In the new world of MRI, the MRI height should also be recorded, and there is an argument for considering as truly "low" cancers extending below the origins of the levator muscles on the coronal slice. Heights measured under anesthesia need to be from the dentate line since the external sphincter dilates and retracts (add about 1.5 cm). Care is necessary: any instrument can push a mobile tumor up; flexible ones often give falsely high measurement. With these qualifications it can be said that, in our view, most cancers with the lower edge at or below 12 cm should have TME as the key component of a radical cancer operation because the mesorectum is the primary field of lymphovascular spread. However, the decision as to whether the smaller *partial* mesorectal excision is adequate is finally confirmed after the mobilization has been completed to the point where the mesorectum must be liberated from the adherent inferior hypogastric plexus—the region usually referred to as the "lateral ligament." It has long been a convention and a very sound rule, borrowed from German surgical practice, that a minimum of 5 cm of mesentery should always be excised both proximal and distal to any colorectal cancer. While muscle tube margin may safely be reduced to 1 cm in the interest of anal conservation, we have always believed that, if less than a TME is contemplated, a minimum of 5 cm of mesorectum distal to the lower edge of the cancer must be dissected in the perimesorectal (holy) plane. If, therefore, after initial mobilization there is a clear 5 cm of mesorectum, then tapering into the mesentery, in the interest of making a more minor operation and a higher anastomosis, becomes acceptable.

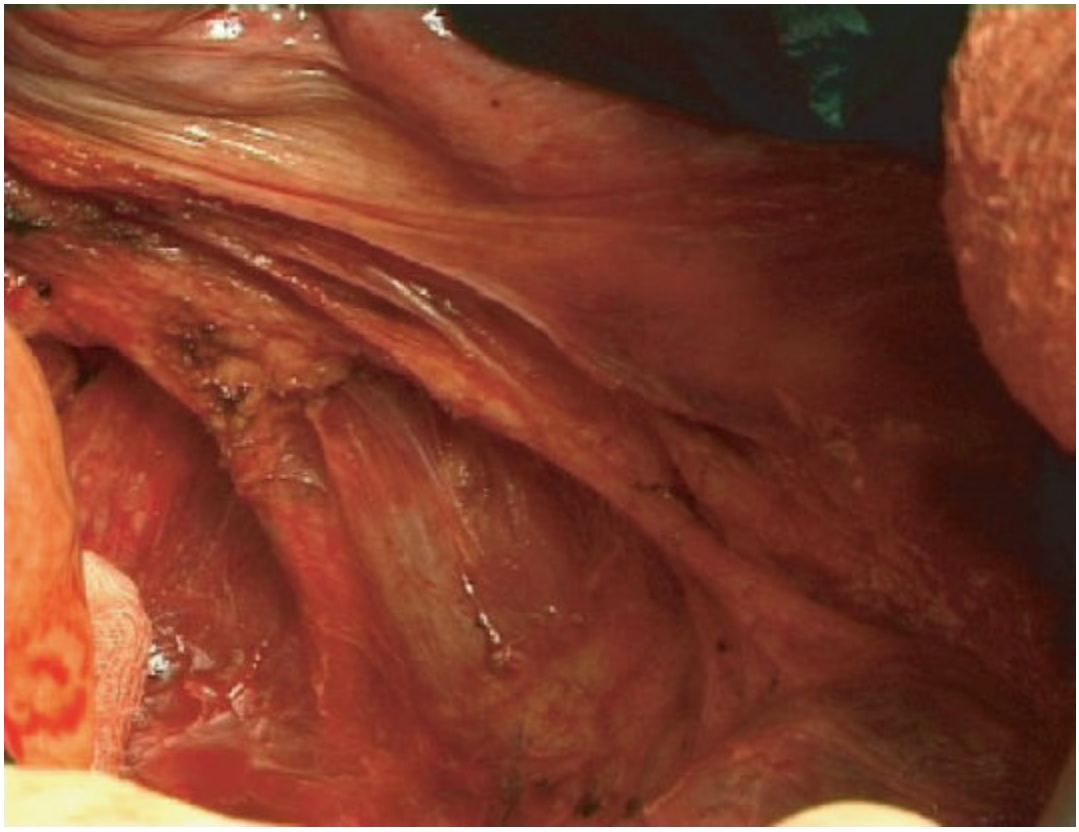

Figure 154.21. Pelvic sidewall and plexuses.

The operation then becomes perimesorectal mobilization, mesorectal transection, AR, and primary anastomosis for rectal cancers above around 12 cm. Either 5 cm of mesorectum distal to the tumor or the whole mesorectum must be removed intact with the same preoccupation with clear circumferential margins.

MANAGEMENT OF THE ANORECTUM DISTAL TO THE CANCER—STAPLING TECHNIQUES

The Avoidance of a Permanent Colostomy

In >90% of rectal cancers, it is technically feasible, though not necessarily optimal in terms of future function, to extend the dissection down to a clean muscle tube where a cross clamp may be applied with a “finger and thumb” clearance beyond the lowest edge of the cancer (Figs. 154.22 to 154.24). This is a difficult and challenging moment requiring both skill and experience. We have developed a preference for the use of the long linear stapler in place of the right-angled clamp (the Moran triple stapling technique). The first TA-45, TA-30, or PI-30 (Covidien) staple line seals the muscle tube so that the anorectal lumen beyond can be washed out

with water or a tumoricidal solution. The risk of incorporating viable exfoliated intraluminal cells in the second staple line is thus eliminated and a second TA-45 or TA-30 is fired through the washed bowel, while the anatomy is distorted by upward traction on the first (pathologist's) stapler. This process, in our view, justifies the cost of a second stapler because of the greater security against spillage of potentially malignant bowel contents. Only this washed staple line remains within the patient.

The first of these two linear staple lines should be safely clear of the palpable distal edge of the cancer. This is usually, though not absolutely invariably, the microscopic edge. Downward spread along the muscle tube is not a significant factor in recurrence—a 2-cm clearance is more than adequate and 1 cm plus the "donut" is acceptable when the survival of the anal sphincters depends on it. Careful examination of the bowel end in the upper stapler will confirm clearance; no frozen section is generally necessary. Only after checking this should the distal (patient's) staple be removed. In the unlikely event of the upper staple line being through the cancer, the distal one could be pulled up hard and a further cartridge fired beyond the distal one.



Figure 154.22. Washout transanally.

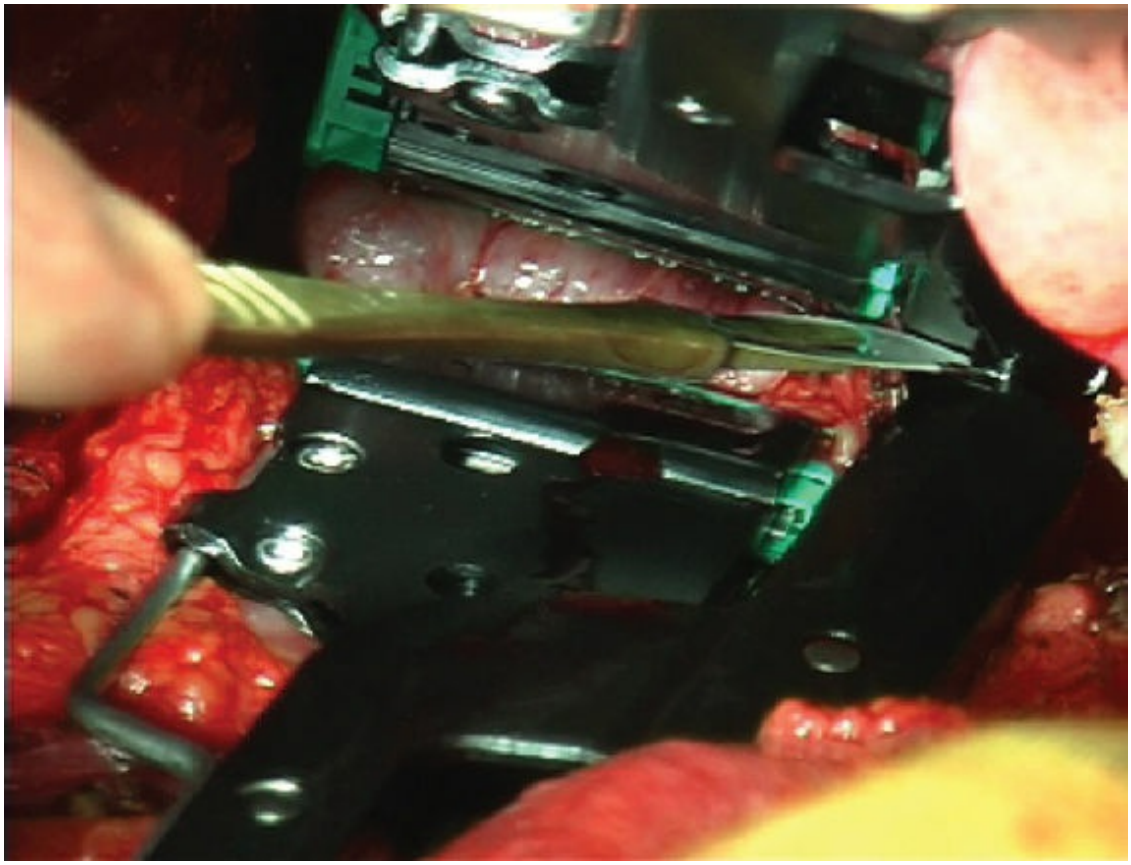

Figure 154.23. Division after washout.

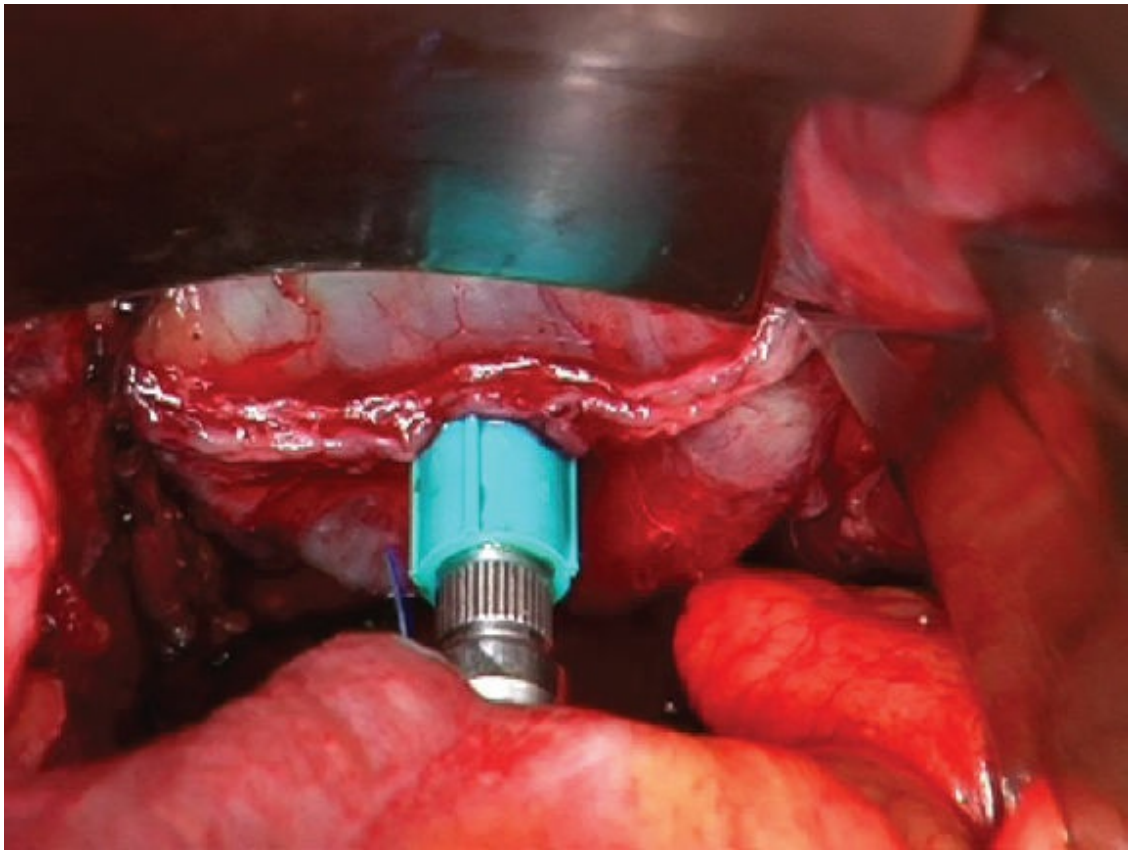

Figure 154.24. Linear plus circular stapling.

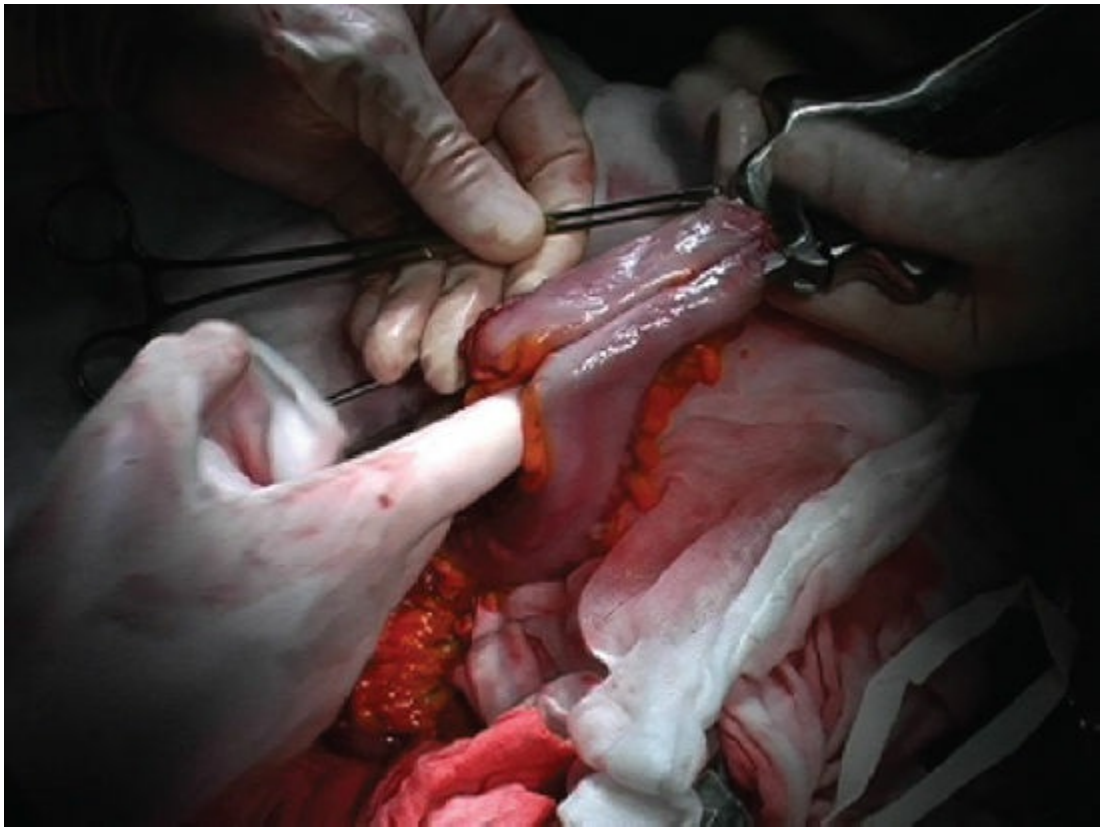

Figure 154.25. Short 2 × 5 cm colon pouch.

The Colon Pouch or Coloplasty?

Several variations of pouch construction are available—typically, a GIA-60 is inserted 5 cm from the end of the fully mobilized colon to create a J pouch (Fig. 154.25). The anvil of the CEEA-31 staple anvil is inserted into the same colostomy, which is "purse stringed" around the shaft with 00 Surgipro. The body of the circular stapler, usually the CEEA-31, is inserted from below transanally. It is essential with ultra-low anastomoses to be certain that only the internal sphincter is purse stringed into the instrument. To this end it must be confirmed from above that only one thickness of muscle can be felt around the periphery of the cartridge. Adequate length of colon from the splenic flexure mobilization is essential for the pouch to lie without tension in the hollow of the sacrum, and demonstrably pulsatile blood supply at the top is the essence of success. Two low-suction Abdovac drains are used for 48 hours unless there is copious drainage when they may need to be left for longer. The objective is to avoid hematoma in the hollow of the sacrum, which may become infected, form an abscess, and point into the bowel at or near the

anastomosis, thus creating a “late leak” around 10 to 20 days later.

THE “BUILDING BLOCKS” OF THE CANCER SPECIMEN

The Mesorectum (TME)

From the tapering pedicle at the top down the globular bilobed expansion at the bottom, this core specimen is the objective of cancer surgery for all middle and lower third cancers.

TME Plus

Where directly involved by visible and palpable cancer spread, or indeed when adherence implies the possibility of such adherence to the adjacent mesorectal margin, it may be necessary to excise in continuity with the TME the following, in selected cases. In modern practice, these extra building blocks can usually be predicted on MRI and appropriate plans made in advance.

TME Plus—The Levators, Ischiorectal Fossa, and Perianal Skin Extra Levator Abdominoperineal Excision

Conventional APE has in many countries earned a poor reputation in the last decade. Extra care is required to perform the perimesorectal dissection that is inherent in TME, but only as far distally as the origin of the levator muscles from the pelvic sidewall, that is, the obturator internus muscles.

Exposed circumferential margins are almost twice as common after conventional APE than after AR, except in units where special care has been taken. This implies that the operation is often less well done than it could be. We believe that the conventional performance of APE in the United Kingdom, particularly involving synchronous combined excision by two surgeons, has often been less precise than a fastidious AR performed from above—largely because the planes cannot be readily defined and followed, and possibly because of the moving target created by the other operator.

Optimal performance of an APE, especially when undertaken for a laterally spreading cancer, should incorporate a covering of levators and the surgeon should avoid the lowermost “holy plane” dissection within them (i.e., to avoid dissection in the lowest part of the plane where it is within contact with the levators). In this way, a more generous clearance of the cancer may be achieved and the commonly observed “waist” on the

specimen avoided. This “waist” is 3 to 5 cm from the anal verge, corresponds with the location of the low cancers that require APE, and has been the common site for perforation and/or exposed cancer margins in the past.

The Prone Jackknife Position for the Perineal Dissection

The views into the pelvis from “behind” are considered by many surgeons to be superior to those in the conventional steep Trendelenburg position. In particular, spectacular access is provided if the coccyx is excised with the cancer. This also means that provided all the abdominal operation has been completed, the colon and rectum can be fully delivered below to provide maximum access to the interface between cancer specimen and prostate. It can, and even make possible the visualization and preservation of the cavernous nerves (Figs. 154.26 and 154.27).

The author has a particular preference for the avoidance of removing the macroglobular ischiorectal fat so well adapted to sitting upon (and also elegant in a swimming costume!) (Fig. 154.28). Apart from rare extremely advanced cancer, whose MRI clearly shows invasion through the levator muscle, the inferior hemorrhoidal vessels and lymphatics are *not* a field of spreads for adenocarcinoma; even when a cancer threatens or invades the sphincters from within, the face-down APE can therefore usually be commenced in a tidy bloodless way following a perfect surgical plane outside the external sphincters but within the macroglobular fat. This reduces the ultimate size of the dead space and hopefully the need for plastic surgeons’ assistance to fill it.

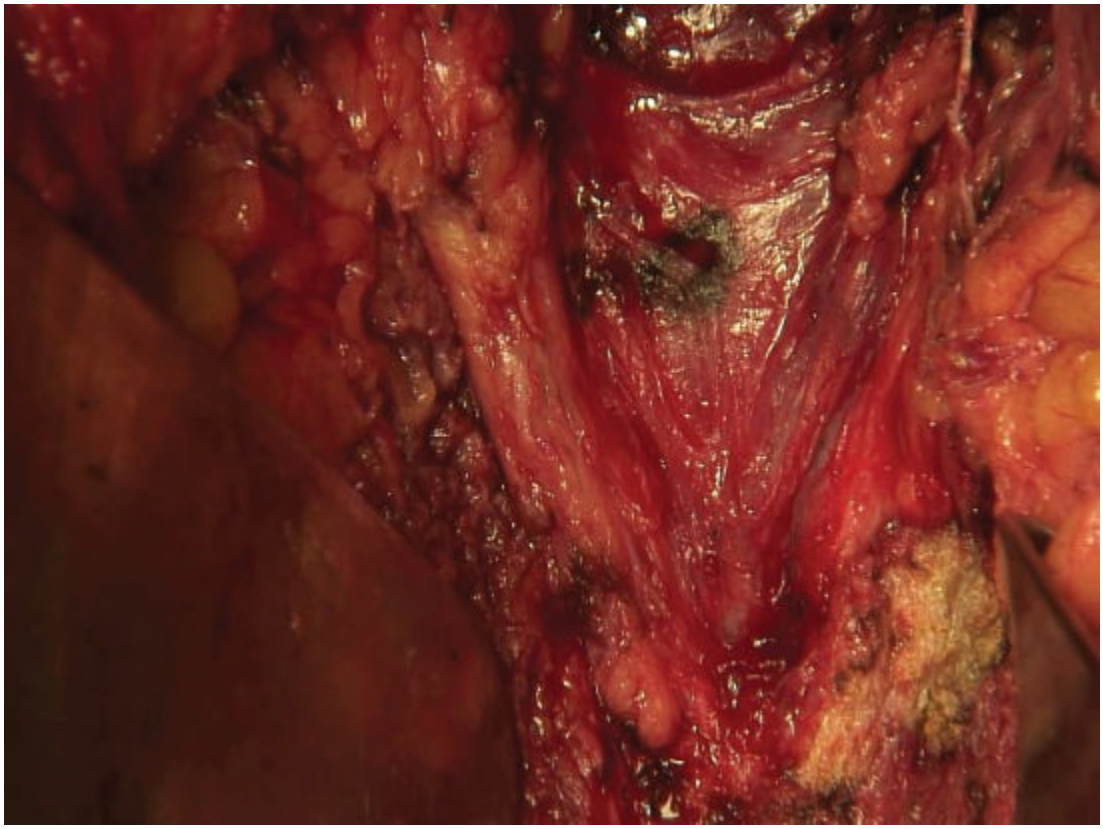

Figure 154.26. Patient face-down—abdominoperineal excision specimen just removed right puborectal sling shows white with right neurovascular bundle just medial to it.

Once the coccyx has been liberated by diathermy and osteotome, the presacral fascia is incised—hopefully on to the gauze swab left on the abdominal side. It is then relatively simple, using a ligature device to divide almost all the origins of the levators wide out near their origins from the obturator internus muscles.

As this dissection progresses, the liberated bowel segment can be eased downward to open the recto prostatic planes (12 o'clock), upward through the transverse perineal muscles and perineal body (6 o'clock), and then laterally (3 and 9 o'clock). The advantage becomes even greater as the neurovascular bundles are carefully identified coursing toward the bulb of the penis. Random fatty tissue tends to obscure these and it helps to identify them if a ligaclip has been placed on the top of the neurovascular inferior hypogastric plexuses by the abdominal operator.

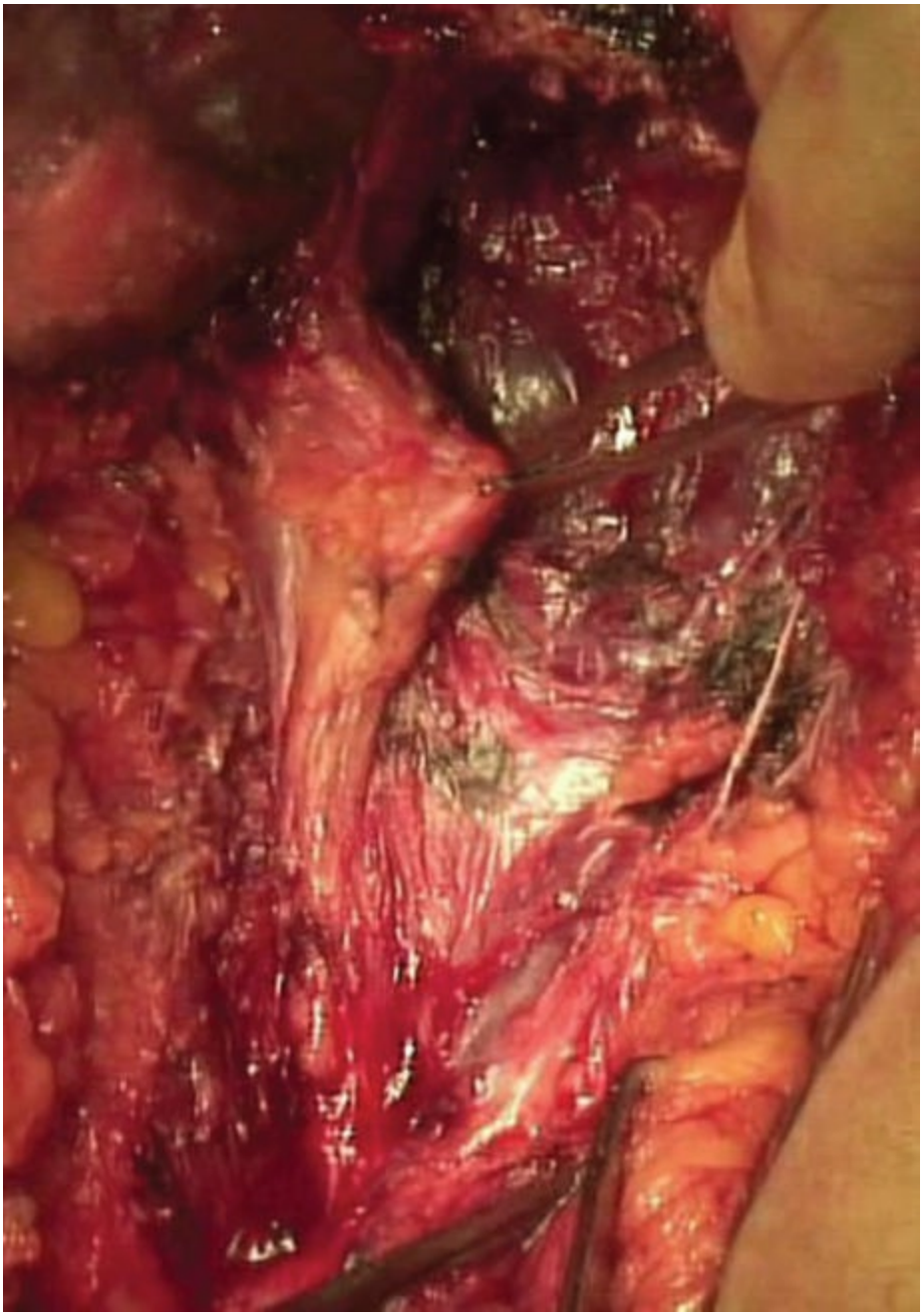

Figure 154.27. Patient face-down clip was placed at the most distal visible point of left hypogastric plexus. Patient now face-down and left neurovascular bundle drawn medially just behind seminal vesicles.

The key to not damaging these hitherto unrecognized nerves is care in dividing the puborectal sling which can be seen just after its division on the right side of the prone male in a white divided muscle bundle in close proximity to the longitudinally running nerve bundle, now called the cavernous nerves.

The *urethra* is not far away anteriorly—it should always have a

substantial (easy to feel) catheter in place—even if this is removed at the end and its function taken over by the supra-pubic catheter, which is our preferred routine for both AR and APE.

The perineal body is worrying for the surgeon because it is fibromuscular and dissection through it is not in a recognizable surgical plane. The rectourethralis remains something of a practical challenge but the essence of this part of the procedure is carefully to find a safe covering for the urethra on one hand and for the tumor specimen on the other.

The ideal APE specimen is a perfect TME with its distal component wrapped in levators and sphincter muscles (Fig. 154.29). Does the space left by extralevator APE require surgical "filling"? Various techniques exist for the swinging of musculocutaneous flaps to combat the poor healing. This is so common since radiotherapy, hence frequently used in APE. The author's personal preference is for the MR to be used, applying similar principles to those outlined above but using as the defined margin the plane outside the anal sphincters and levator muscles.

This latter plane very rarely breaches, therefore, APE in the author's opinion does not routinely require radiotherapy.

An ideal alternative to closure by plastic surgery is to mobilize the cecum to fill the pelvic cavity possibly plus the omentum when adequate. A biologic mesh such as Permacol can be added for extra safety.

The Option of Starting the Operation From Below

There are considerable advantages in commencing the operation from below with the patient in the prone jackknife position. This is particularly true if there are likely to be major problems with the abdominal surgery—as, for example, when performing APE for a local recurrence after AR. Commencing from below has the advantage that the patient does not need to be turned completely twice (i.e., at the end of the major procedure). The disadvantages are that the pneumoperitoneum necessary for a laparoscopic "top end" may not be achievable and that "turning" may be required. Starting at the perineal end, however, is in the author's view, a crucial advantage if APE is being performed for low local recurrence as it provides optimal tissue planes for the dissection around the cancer before the inevitable difficulties with a second time round pelvis are encountered.



Figure 154.28. ELAPE specimen in situ after careful dissection between anorectal musculature (*central*) and preserved ischiorectal “cushions” laterally coccyx excised (*central top*).



Figure 154.29. Perfect ELAPE specimen showing nice mesorectal planes above and sphincter and levator wrap around more distal mesorectum.

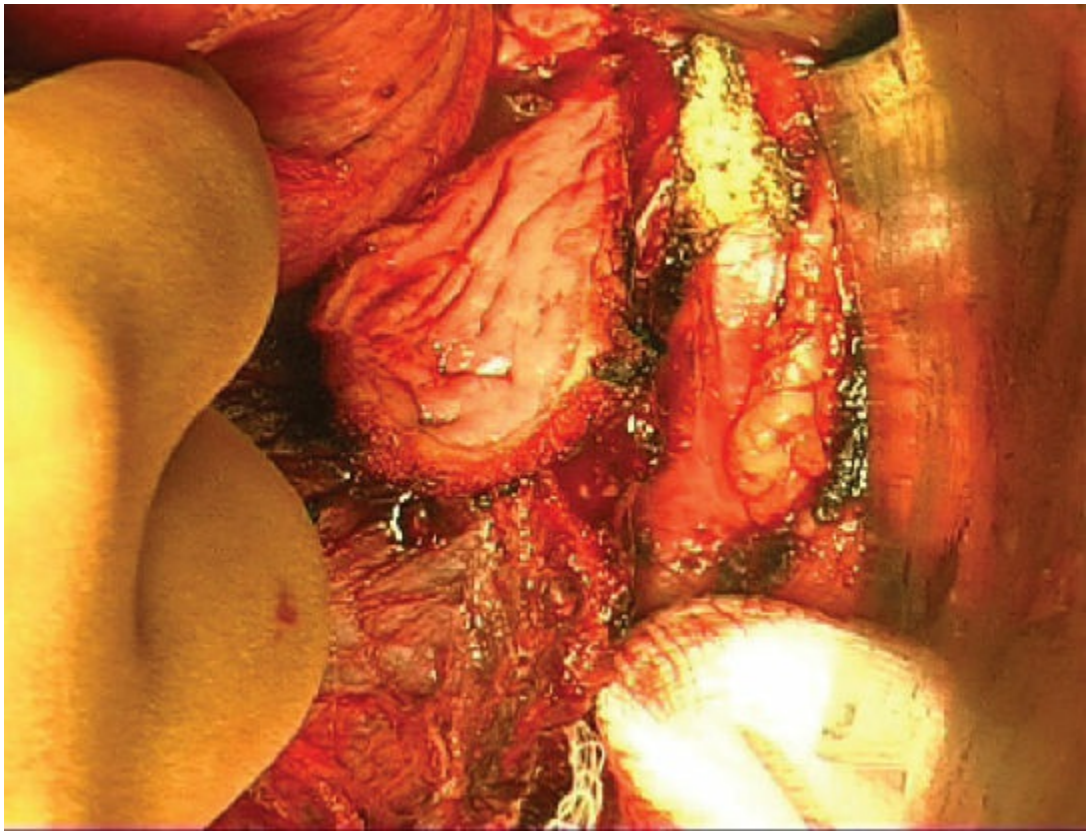

Figure 154.30. Sometimes a disk of vagina.

The Posterior Vaginal Wall

Bimanual examination via the rectum and the vagina in the anesthetized patient is essential (Fig. 154.30). If there is free mobility of the cancer on the posterior vaginal wall, then it need not be excised. If tethered over a small area, a disc of vagina may be taken with the tumor, or in a case that requires APE, because of proximity to the sphincters, the whole or most of the posterior wall from the perianal skin upward may need to be removed. We now only perform this once standard procedure when there appears no alternative due to the anterior extension of the cancer, as ultimate vaginal function may be much impaired. When it does have to be excised, it is not essential for the vagina to be resutured though the long-term function and lubrication must be in some doubt.

Other organs occasionally requiring en bloc removal on account of direct invasion seminal vesicles. These can sometimes provide an extra anterior safety margin, and the most anterior “layer” of vesicles sometimes has a dissectible, though vascular, plane between it and the adherent or invaded posterior vesicles.

One or both ureters—in a modern hospital the management of the ureter

shortened by the excision of its lower part will be in the hands of a urologist. If not, ureteroureterostomy over a ureteral stent is a perfectly achievable solution.
Ileum.
The folded-over sigmoid—with advanced sigmoid cancer, when the colon is folded down and invading the anterior aspect of the upper rectum, an extensive en bloc resection of both may be required. A large tumor mass blocking the upper true pelvis is a formidable undertaking for which ureteric stenting is a wise precaution.

Neoadjuvant Chemoradiotherapy May Be Considered First

One or both hypogastric plexuses.
Parts of the neural lamella may have to be removed in continuity with the primary or even a node—going laterally until a clear plane can be identified.

Other Pelvic Sidewall Structures

Appendix
Small like appendix etc.
Uterus, ovaries, and adnexal structures
Bladder

Block dissection of an internal iliac compartment is possible, but has not been part of our routine. When there are obvious extramesorectal lymph nodes, we will usually excise these as cleanly as possible, preferably without damaging the autonomic nerves.

The Basingstoke Experience of Total Mesorectal Excision 1978–1997

In 1998, we published data on 519 consecutive surgical patients with adenocarcinoma of the rectum, receiving surgical treatment for cure or palliation under the direct supervision of or performed by one surgeon. These may be important data as follow-up approached 20 years and use of radiotherapy and chemoradiotherapy had been so minimal and recent that they can be regarded as “virtually pure” surgical results updated follow-up references are provided, but these data stand for this reason. Cancer-specific survival of all surgically treated patients, including those considered palliative or with metastases on presentation, was 68% at 5

years and 66% at 10 years. The local recurrence rate was 6% (95% confidence interval, 2% to 10%) at 5 years and 8% (95% confidence interval, 2% to 14%) at 10 years. In 405 "curative" resections (no obvious residual disease), the local recurrence rate was 3% (95% confidence interval, 0% to 5%) at 5 years and 4% (95% confidence interval, 0% to 8%) at 10 years. Disease-free survival in this group was 80% at 5 years and 78% at 10 years. An analysis of histopathologic risk factors for recurrence indicated only the Dukes stage, extramural vascular invasion, and tumor differentiation as variables in these results.

CONCLUSION

Rectal cancer surgery is probably the most rewarding of all the challenges to the aspiring gastrointestinal surgeon. Arguably, there is no cancer operation where proper decisions, the judicious selective use of adjuvant therapy, and, most of all, surgical skill of the highest order can bring so much benefit to the patient. Cancer cure, normality of bowel function, avoidance of a lifelong stoma, and sexual function—all of these hang in the balance for the patient. The profession still has a long way to go in using its many skills and disciplines to deliver what is possible and affordable to every patient. In doing so, it will advance the science and craft of pelvic surgical anatomy in a very important way.

Suggested Readings

Adam IJ, Mohamdee MO, Martin IG, et al. Role of circumferential margin involvement in the local recurrence of rectal cancer. *Lancet* 1994;344:707–11.

Birbeck K, Macklin C, Tiffen N, et al. Rates of circumferential resection margin involvement vary between surgeons and predict outcomes in rectal cancer surgery. *Ann Surg* 2002;2354:449–57.

Dukes CE. The classification of cancer of the rectum. *J Pathol Bacteriol* 1932;35:323–32.

Heald RJ. The "holy plane" of rectal cancer. *J Royal Soc Med* 1988;81:503–8.

Heald RJ, Moran BJ, Ryall RD, et al. The Basingstoke experience of total mesorectal excision 1978–1997. *Arch Surg* 1998;133:894–9.

Hermanek P, Wiebelt H, Staimmer D, et al. Prognostic factors of rectal carcinoma —experience of the German Multicentre Study (SGCRC). German Study Group Colo-Rectal Carcinoma. *Tumori* 1995;81:60–4.

Holm T, Ljung A, Haggmark T, et al. Extended abdominoperineal resection with

gluteus maximus flap reconstruction of the pelvic floor for rectal cancer. *Br J Surg* 2007;94:232–8.

Jass JR, Atkin WS, Cuzick J, et al. The grading of rectal cancer: histological perspectives and multivariate analysis of 447 cases. *Histopathology* 1986;10:437–59.

Karanjia ND, Schache DJ, North WR, et al. "Close shave" in anterior resection. *Br J Surg* 1990;77(5):510–2.

MacFarlane JK, Ryall RD, Heald RJ. Mesorectal excision for rectal cancer. *Lancet* 1993;341(8843):457–60.

Miles WE. A method of performing abdomino-perineal excision for carcinoma of the rectum and terminal portion of the pelvic colon. *Lancet* 1908;35:320–1.

Moran MR, James EC, Rothenberger DA, et al. Prognostic value of positive lymph nodes in rectal cancer. *Dis Colon Rectum* 1992;35(6):579–81.

Moriya Y. *The "onion rings" of Rectal Fascia.* In: Heald R, ed. 2002.

Quirke P, Scott N. The pathologist's role in the assessment of local recurrence in rectal carcinoma. *Surg Oncol Clin North Am* 1992;1:1–17.

Quirke P, Durdey P, Dixon MF, et al. Local recurrence of rectal adenocarcinoma due to inadequate surgical resection. Histopathological study of lateral tumour spread and surgical excision. *Lancet* 1986;2(8514):996–9.

Silen W. Mesorectal excision for rectal cancer. *Lancet* 1993;341:1279–80.

Syk E, Torkzad MR, Blomqvist L, et al. Radiological findings do not support lateral residual tumour as a major cause of local recurrence of rectal cancer. *Br J Surg* 2006;93(1):113–9.

Syk E, Torkzad MR, Blomqvist L, et al. Local recurrence in rectal cancer: anatomic localization and effect on radiation target. *Int J Radiat Oncol Biol Phys* 2008;72(3):658–64.

West NP, Anderin C, Smith KJ, et al. Multicentre experience with extralevator abdominoperineal excision for low rectal cancer. *Br J Surg* 2010;97:588–99.

Wolmark N, Wieand HS, Rockette HE, et al. The prognostic significance of tumor location and bowel obstruction in Dukes B and C colorectal cancer. Findings from the NSABP clinical trials. *Ann Surg* 1983; 198(6):743–52.

EDITOR'S COMMENT

Please refer to the Editor's Comment in chapter 154a

154A Advances in Total Mesorectal Excision

Steven Nurkin, Rupen Shah, Aaron Saunders, and Steven N. Hochwald

HISTORY OF RECTAL CANCER TREATMENT

The treatment of rectal cancer continues to evolve with the use of magnetic resonance imaging (MRI) for preoperative staging and improved understanding of the oncologic appropriateness of administration of chemotherapy (neoadjuvant vs. adjuvant) and radiation therapy (long course vs. short course). However, what has remained a constant is the importance of a complete total mesorectal excision (TME).

Until the 1980s when Prof. Richard Heald brought about a renewed interest in the circumferential margins, pelvic dissection was mostly carried out in a blunt fashion. Abdominoperineal excision (APE), an operation originally described by Ernest Miles in 1908, conceptualized this procedure as a cylinder of maximal size that "empties the whole pelvis." His was an attempt at defining in advance an area of tissue to be excised by the surgeon. He considered that lymphatic spread occurred in all directions as illustrated in Figure 154a.1A, and believed that local recurrences he encountered was due to a failure to encompass the spread that had occurred into the ischioanal fat via nodes around the inferior hemorrhoidal (rectal) vessels. He observed that the "perineal portion of the operation should be carried out as widely as possible so that the lateral and downward zones of spread may be effectively extirpated."

This was however a very morbid operation, associated with sexual and autonomic dysfunction and packing of the dead space for several months. In addition to the morbidity of the procedure, a permanent colostomy (or the "abdominal anus" as it was referred to in Dr. Miles's writings) was inevitable. However, this notion of spread to the ischioanal fossa/ischiorectal fat has never been proven and surgical experience teaches us otherwise; hence, the concept of spread from adenocarcinoma of the rectum into the mesorectal fat and supralevator lymphatic tissue

gained acceptance (Fig. 154a.1B). This concept of the field of spread with the embryologic and anatomical understanding of the development of the hindgut and its mesentery described below was the basis for the excellent outcomes of a TME popularized by Dr. Heald.

In 1996, he published his experience with 115 patients in whom curative resection was attempted. Priority was given to complete excision of the visceral rectal mesentery or the mesorectum. At a median follow-up of 4.2 years, three pelvic recurrences had developed and the corrected cumulative probability of survival at 5 years was 87% and the disease-free survival by Dukes stage was A, 94%; B, 87%; and C, 58%. Patients with lower tumors had similar oncologic outcomes to those with high tumors, when treated by anterior resection (AR) and a total excision of the mesorectum. Based on this evidence, he concluded that it was often safe to limit mural clearance and thus preserve the anal sphincters, provided that the mesorectum was excised intact with the cancer.

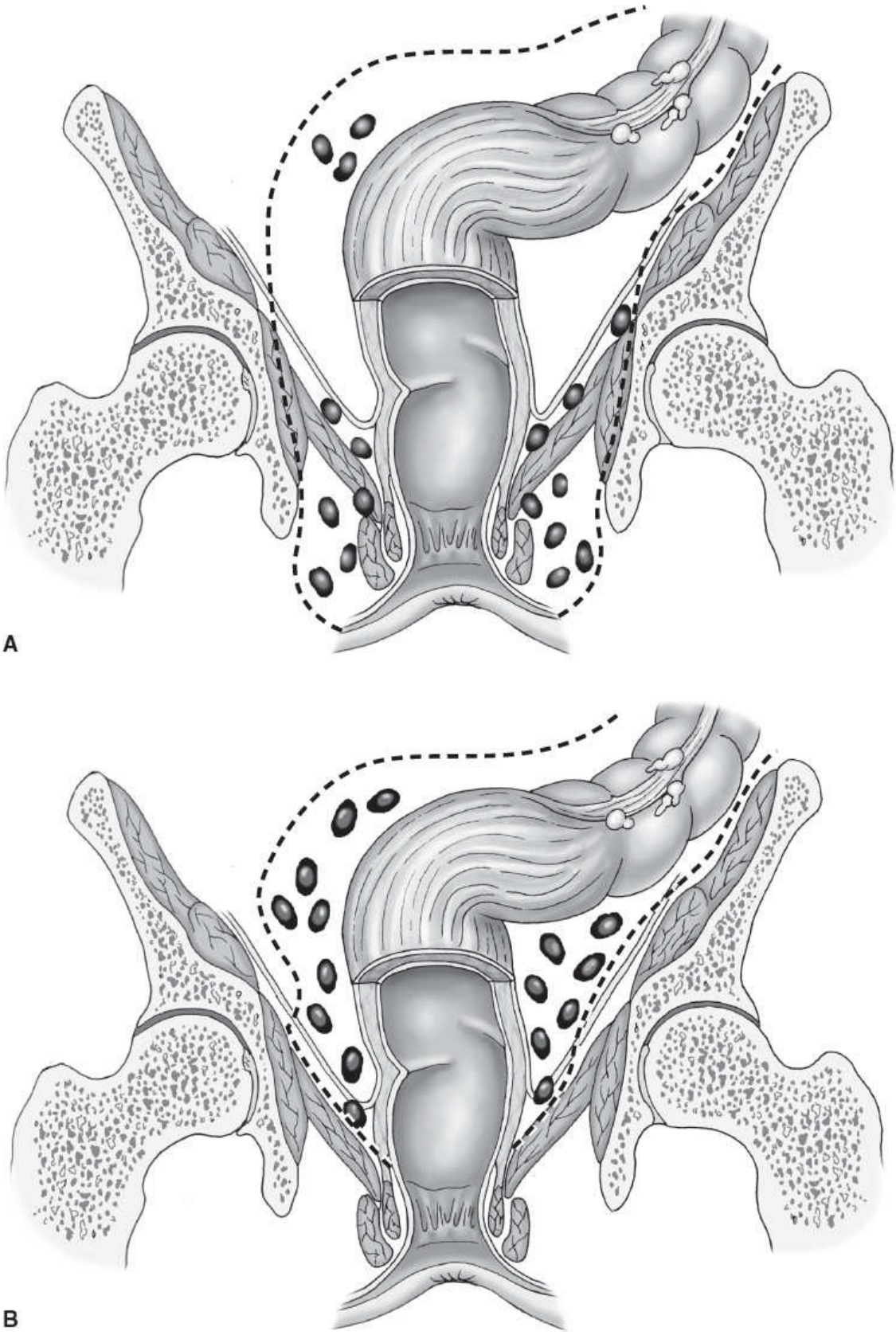

Figure 154a.1. **A:** Mile's original concept of "highly dangerous tissues" spread to many nodes in the ischiorectal fossa and upper surface of the levators. **B:** Heald's concept of spread of rectal cancer to the mesorectum and supralevator field.

This technique was groundbreaking as local recurrence rates were reduced from as high as 30% to 40% without TME to as low as <5% with TME. Subsequent studies have confirmed this and it is now generally accepted that a local recurrence rate of <5% to 10% should be expected if proper TME techniques are employed.

Embryologic and Anatomical Considerations

The belief that the spread of cancer will tend to remain within the embryologic hindgut "envelope" was presumably the basis for a precise mesorectal excision along embryologically/anatomically defined planes. The gastrointestinal tract, or the primitive gut as it is referred to during fetal development, is derived from the endoderm. The primitive gut is divided into the foregut, midgut, and hindgut and are attached to their mesenteries which envelop blood vessels and lymphatics. The hindgut is comprised of the distal third of the transverse colon, descending colon, the rectum, and the anal canal. The primitive gut spends its early fetal existence outside the abdomen. As development continues, the mesentery adheres to the retroperitoneum and in case of the rectum the mesorectum adheres posteriorly into the developing pelvis while retaining its midline integrity and remaining separate from the surrounding parieties. The mesorectum is of crucial importance in rectal cancer as it contains all the blood vessels, nerves, lymphatics, and lymph nodes through which cancer may disseminate. Importantly, the adherence of the mesorectum is by collagenous loose areolar tissue and is an avascular surgical plane. This was referred to as the "*holy plane of rectal surgery*" by R. J. Heald. Cancer spread initially respects this natural embryologic plane and hence precise surgical dissection along this defined plane enables an oncologically sound resection and a low incidence of local recurrence.

The anterior and lateral mesorectum is covered by a layer of visceral peritoneum, above the level of the peritoneal reflection and is fixed and surrounded by a layer of fascia below the peritoneal reflection. The mesorectum is generally of greatest volume posteriorly with significantly less volume anteriorly. Below the level of the peritoneal reflection the mesorectum gradually decreases in size to a point of maximal waisting at the level of the levator ani muscle (Figs. 154a.2 and 154a.3).

In addition to the oncologic advantages of a complete TME which minimizes local recurrences, the functional outcome and quality of life with regard to autonomic nerve preservation and decreased genitourinary

dysfunction is important. The plane of dissection for TME, if carefully followed, reduces chance for injury to both sympathetic and parasympathetic nerve supply to the urogenital system. The sympathetic nerves of the pelvis originate from the T12 to L3 ventral nerve roots, which form the *superior hypogastric plexus*. The superior hypogastric plexus gives rise to the hypogastric nerves distal to the aortic bifurcation, and these may be associated intimately with the visceral fascia of the mesorectum. *Nervi erigentes*, that carry the parasympathetic innervation to the pelvis, arise from the S2 to S4 ventral nerve roots. These join the sympathetic hypogastric nerves on the pelvic sidewall to form the *inferior hypogastric plexus* (Fig. 154a.4).

Injury to the pelvic autonomic nerves can be associated with significant genitourinary dysfunction. Damage to the sympathetic hypogastric nerves can result in increased bladder tone and reduced bladder capacity, as well as with retrograde ejaculation in men. Damage to the parasympathetic system can result in voiding difficulties from increased tone in the bladder neck, as well as with erectile dysfunction in men and impaired vaginal lubrication in women.

Preoperative Evaluation Including Imaging

A thorough *history and physical* is one of the most important aspects of the preoperative evaluation of patients with rectal cancer. A detailed history regarding the patient's symptoms like bleeding; pain; tenesmus; change in bowel habits; incontinence (both fecal and urinary), if any; and sexual dysfunction should be obtained. Any history of perineal trauma (obstetric or otherwise) should be factored into the decision-making process for patients who are candidates for a low pelvic anastomosis. A *digital rectal examination*, paying attention to the distance of the tumor from the anal verge, the location of the tumor (anterior, posterior, or lateral) relationship to the top of the sphincters (anorectal ring) and the tone of the anal sphincters should be made. While assessing the tumor on digital examination, any suspicion of fixation to adjacent structures (e.g., vagina, prostate, sacrum or pelvic sidewall) should also be noted. In women, with tumors in the anterior wall of the rectum, a complete pelvic examination should be performed to assess for invasion of the vaginal wall.

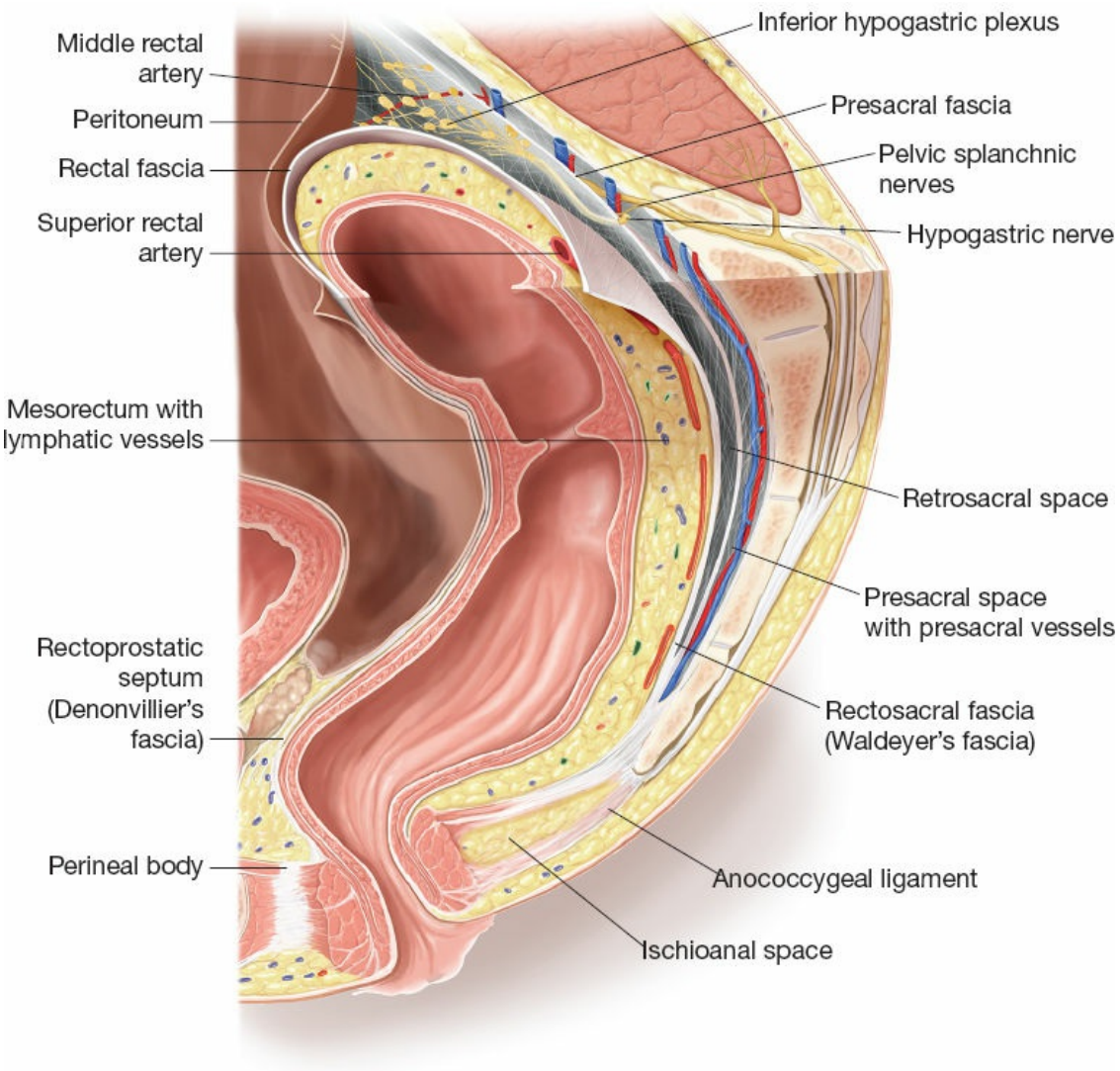

Figure 154a.2. Sagittal section of the pelvis highlighting the mesorectal plane and its relationship to the retrorectal and presacral spaces posteriorly and the Denonvillier fascia anteriorly.

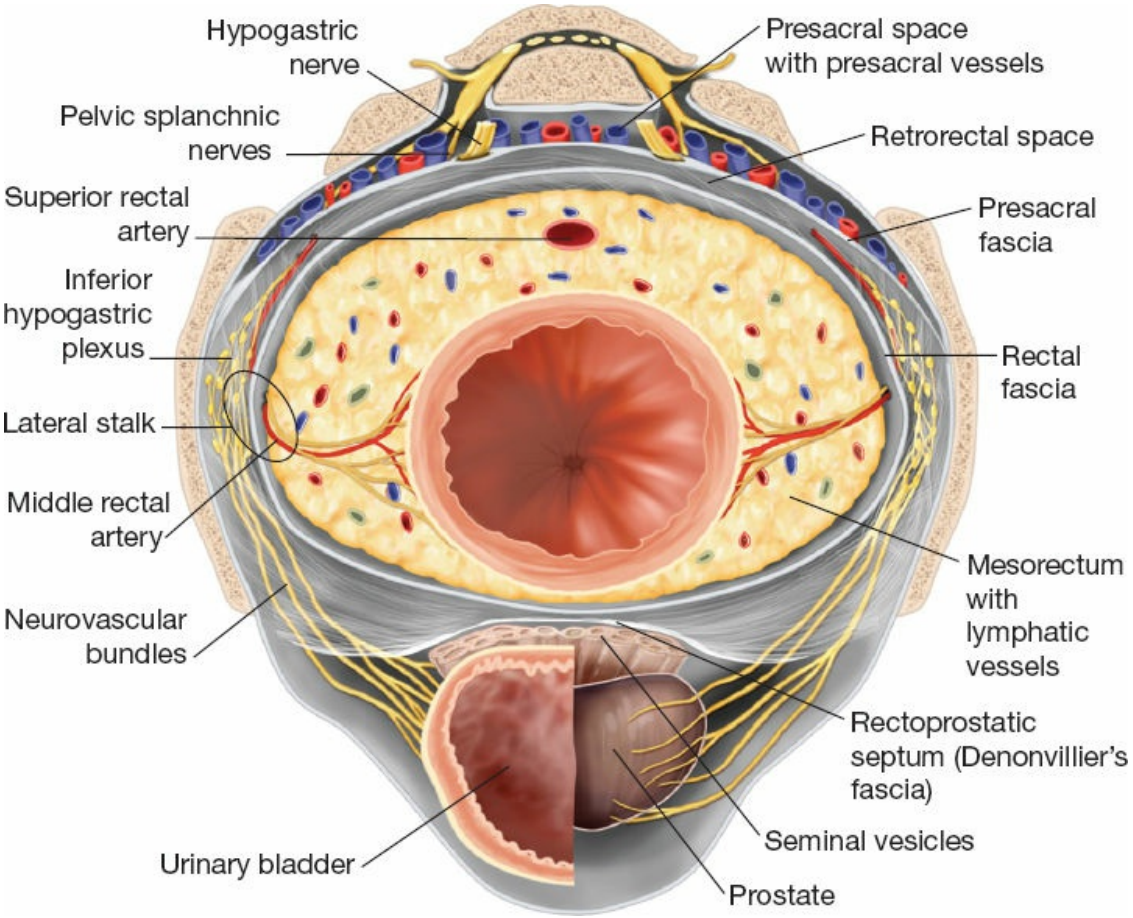

Figure 154a.3. Transverse section through the male pelvis highlighting the relationship of the mesorectum to the pelvic structures. Note the relationship of the middle rectal vessels to the inferior hypogastric plexus.

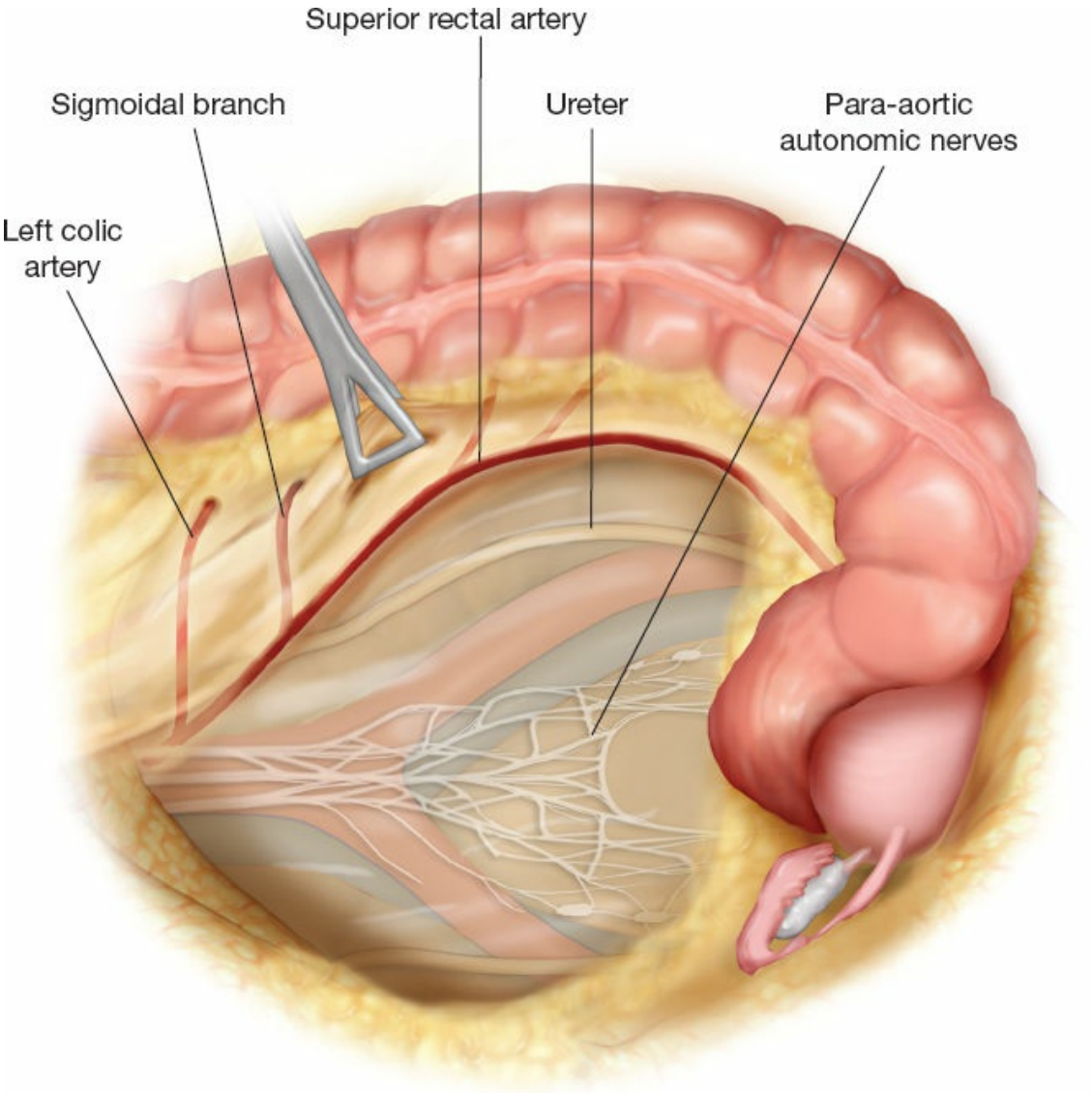

Figure 154a.4. Pelvic autonomic nerves seen after the TME is begun and the sigmoid colon and rectum are retracted anteriorly.

Sigmoidoscopy (flexible/rigid) is often performed during the patient's initial clinic visit by the surgeon to assess tumor location and distance from the sphincter complex. A *colonoscopy* serves two purposes: (1) to ensure that there are no synchronous lesions proximally in the colon and (2) visualize and biopsy the lesion in question to confirm the diagnosis via histopathology. A diagnosis preoperatively is especially important in the present era where locally advanced rectal cancers are treated in a multimodal manner with chemotherapy +/− radiation as an integral part of presurgical treatment.

After a diagnosis is confirmed, a CT scan of the chest, abdomen, and pelvis is useful to rule out distant metastatic disease. CT scans can localize

the tumor in the rectum and can also show extension of the tumor into the surrounding structures but CTs are unable to delineate the depth of invasion through the layers of the rectal wall. To define the pre-therapy T and N stage accurately, endorectal ultrasound (ERUS) and MRI play a very important role. As we know, the risk factors associated with local recurrence are the T and N stage, distance of the tumor to the mesorectal fascia, histologic grade of the tumor, and the presence of extramural lymphovascular and perineural invasion.

Pelvic MRI with high-resolution T2-weighted images provides the best evaluation of the rectal wall and perirectal fat/mesorectum. On T2-weighted images, three layers with alternating signal intensity can be easily identified. The inner mucosa and submucosa appears hyperintense, the middle layer consisting of muscularis propria appears hypointense, and the outer layer of perirectal fat appears hyperintense. Distinguishing a T1 from a T2 lesion on an MRI can be difficult and this is where an ERUS is helpful. This is particularly useful when local excisional procedures using transanal endoscopic microsurgery (TEM) and transanal minimally invasive surgery (TAMIS) platforms are being considered. MRI is more accurate when trying to differentiate between T3 and T4 tumors and the relationship of the tumor to the mesorectal fascia and adjacent pelvic structures. This is particularly important for the surgeon for operative planning. The MERCURY trial was a multicenter study in rectal cancer patients that compared the depth of tumor extramural invasion between preoperative MRI and final pathology in 311 patients undergoing surgery. In this study, MRI could reliably predict involvement of the mesorectum with accuracy to within 0.5 mm in 95% of cases. In their follow-up results after a median follow-up of 62 months, circumferential resection margin (CRM) as predicted by MRI and pathologic margins were found to be equally good predictors for local recurrence, disease–free survival, and overall survival.

However, accuracy of nodal (N) staging with rectal cancer remains comparatively poor. Most imaging modalities use size criteria to determine lymph node involvement and the cut off values are variable across studies. Reported sensitivity and specificity of MRI in predicting lymph node metastases is about 65% to 75%. Alternative criteria like signal heterogeneity and border irregularity are now being considered and we await future studies and changes in technology to help with improvement in pretreatment nodal staging (Figs. 154a.5 to 154a.7).

Key Steps of a Total Mesorectal Excision

After incising the peritoneum lateral to the sigmoid colon on the left side just above the pelvic brim, the underlying left ureter can be seen, distinguishable from the gonadal vessels which are present lateral to it. Once seen, the left ureter should be gently dissected laterally away from mesorectum and the vascular pedicle. After this maneuver, the sigmoid colon is retracted to the left and the peritoneum is incised to the right of the midline and the vascular supply of the rectum can now be approached from either side of the mesentery. Alternatively, if there are significant inflammatory changes or obscuration of tissue planes on the left side of the sigmoid colon, the dissection can commence on the right side a few millimeters anterior to the base of the sigmoid colon mesentery. In fact, many surgeons advocate starting in this location on all patients as dissection is performed just posterior to the superior hemorrhoidal artery and ensuring preservation of the hypogastric nerve plexus. The sigmoid colon is transected in a convenient location prior to pelvic dissection. If there is concern for proximal nodal disease or colon length for a tension-free anastomosis, the inferior mesenteric artery (IMA) should be transected at its origin. Otherwise, after division of the superior hemorrhoidal artery and lateral peritoneal reflection, it is important to find the correct plane of dissection. Mobilization of the splenic flexure and/or transection of the inferior mesenteric vein (IMV) may be required to ensure adequate length for a tension-free anastomosis. While establishing the “holy plane” posteriorly, it is important to stay anterior and medial to the hypogastric nerve plexus. The main trunk tends to be very close to the mesorectum proximally before the branches separate and run along the pelvic side walls.

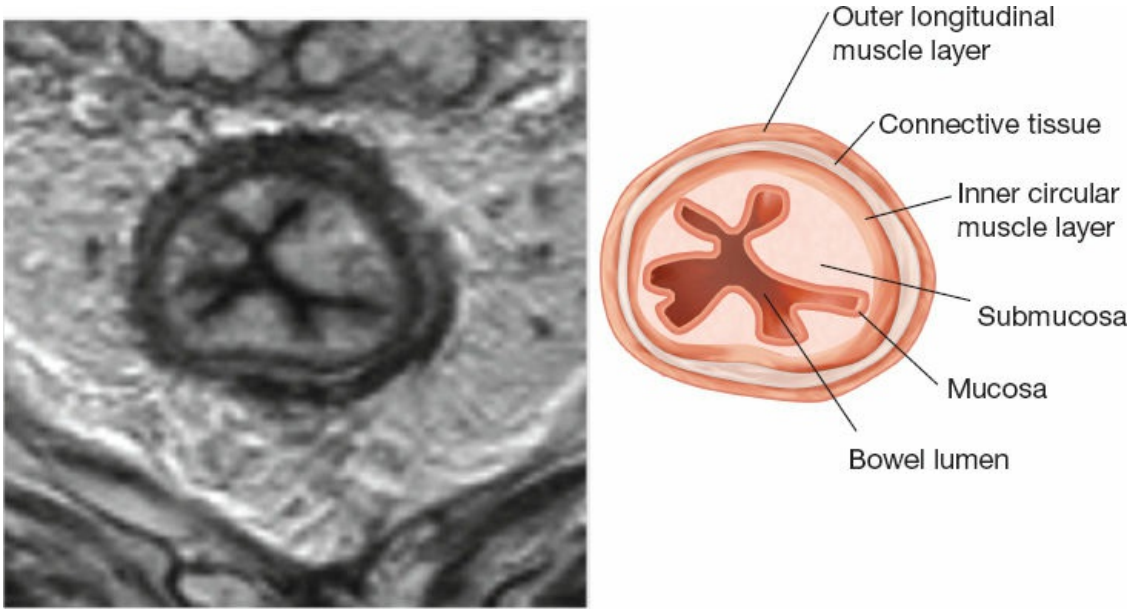

Figure 154a.5. Transaxial view demonstrating the layers of the bowel wall. (This image was acquired after radiotherapy, and hence the exaggeration of the layers due to tissue edema.)

With continuous traction on the rectosigmoid with the nondominant hand or retractor, the posterior dissection plane is established. The key to finding this plane and adhering to it is the anterior traction. This can be facilitated using a St. Mark's retractor in open cases or with an atraumatic bowel grasper in minimally invasive approaches. The posterior dissection should continue downward sharply as far as the coccyx so that the entire mesorectum can be removed with the specimen. Hand dissection should not be performed as injury to the nerves in close proximity to the mesorectum will occur. It is important to complete the posterior rectal dissection under direct vision and with excellent lighting. Care must be taken to follow the curve of the sacrum which necessitates a gentle arc curving slightly anteriorly as the dissection proceeds into the deep pelvis.

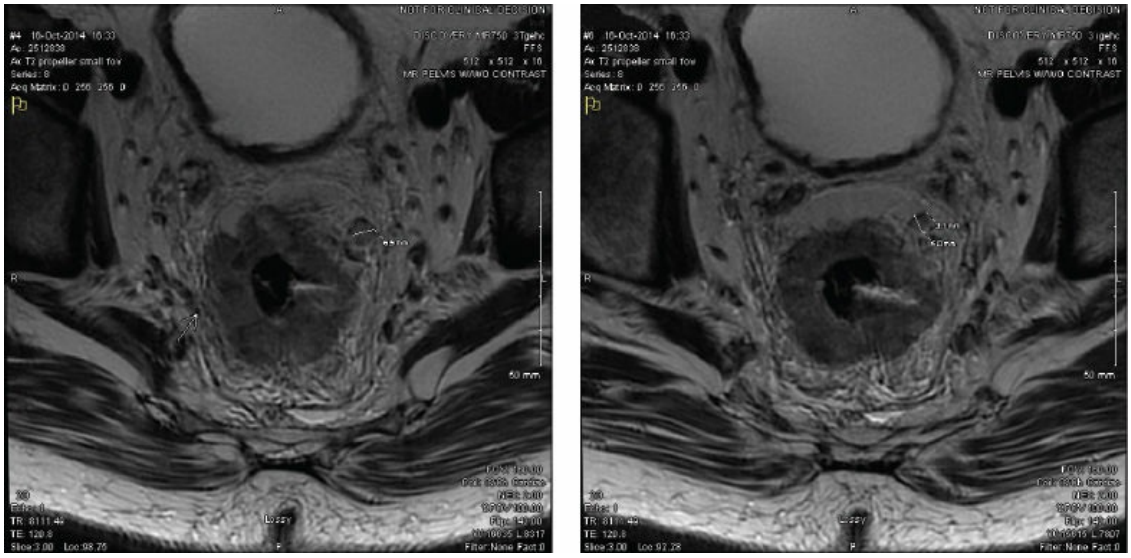

Figure 154a.6. MRI showing the threatened CRM (**left**) and enlarged lymph nodes (**right**) in the mesorectum.

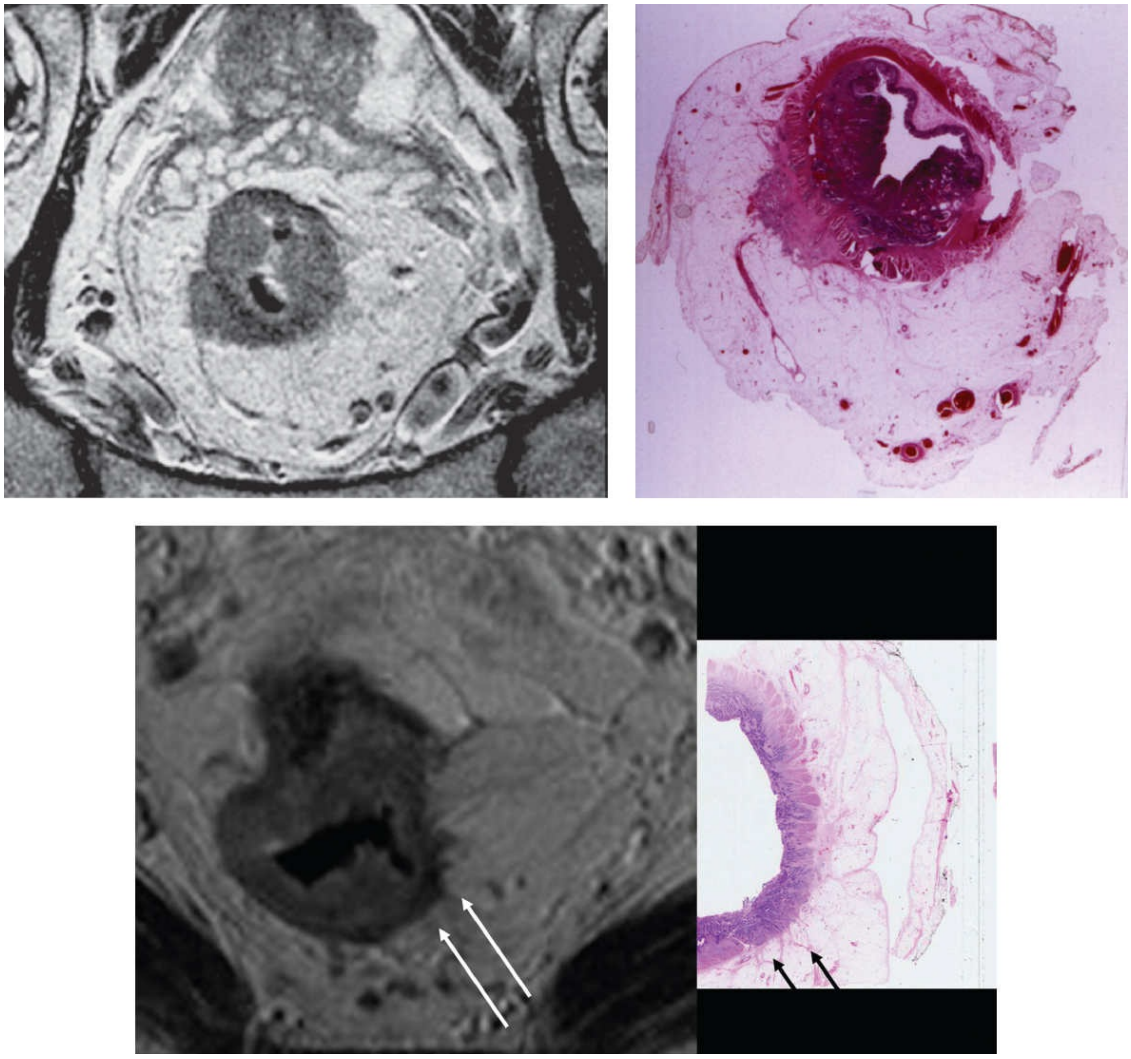

Figure 154a.7. MRI and histopathologic correlation of tumor spread. (Images courtesy of Dr. Gina Brown, Royal Marsden and Imperial College, London, UK.)

One of the risks of posterior deviation from the “holy plane” as dissection proceeds caudally is tearing thin-walled presacral veins, which often have no valves and can bleed vigorously when cut or torn. In addition to completing the posterior dissection, the dissection can proceed partially up the lateral sides of the rectum ensuring the correct mesorectal planes are followed. Once the posterior rectal and some of the lateral dissection is complete, attention is turned toward the anterior dissection (Fig. 154a.8).

For the anterior rectal dissection in women, it is sometimes useful to suture the uterus and fallopian tubes to the abdominal wall. This makes access to the rectum, particularly the anterolateral planes, much easier. The bladder is retracted away from the rectum and the incision on the

peritoneum is then carried down caudally on either side and then joined anteriorly at the level of the rectouterine/rectovesical pouch. Anterior traction with a St. Mark's retractor improves exposure and helps delineate this plane well. The plane is gradually deepened until the base of the bladder and both seminal vesicles or the vaginal wall are reached. Denonvillier fascia lies between the anterior rectal wall and the prostate. We do not routinely include this fascia in our resection unless the patient has an anteriorly based tumor and it is oncologically necessary to achieve negative margins (Fig. 154a.9).

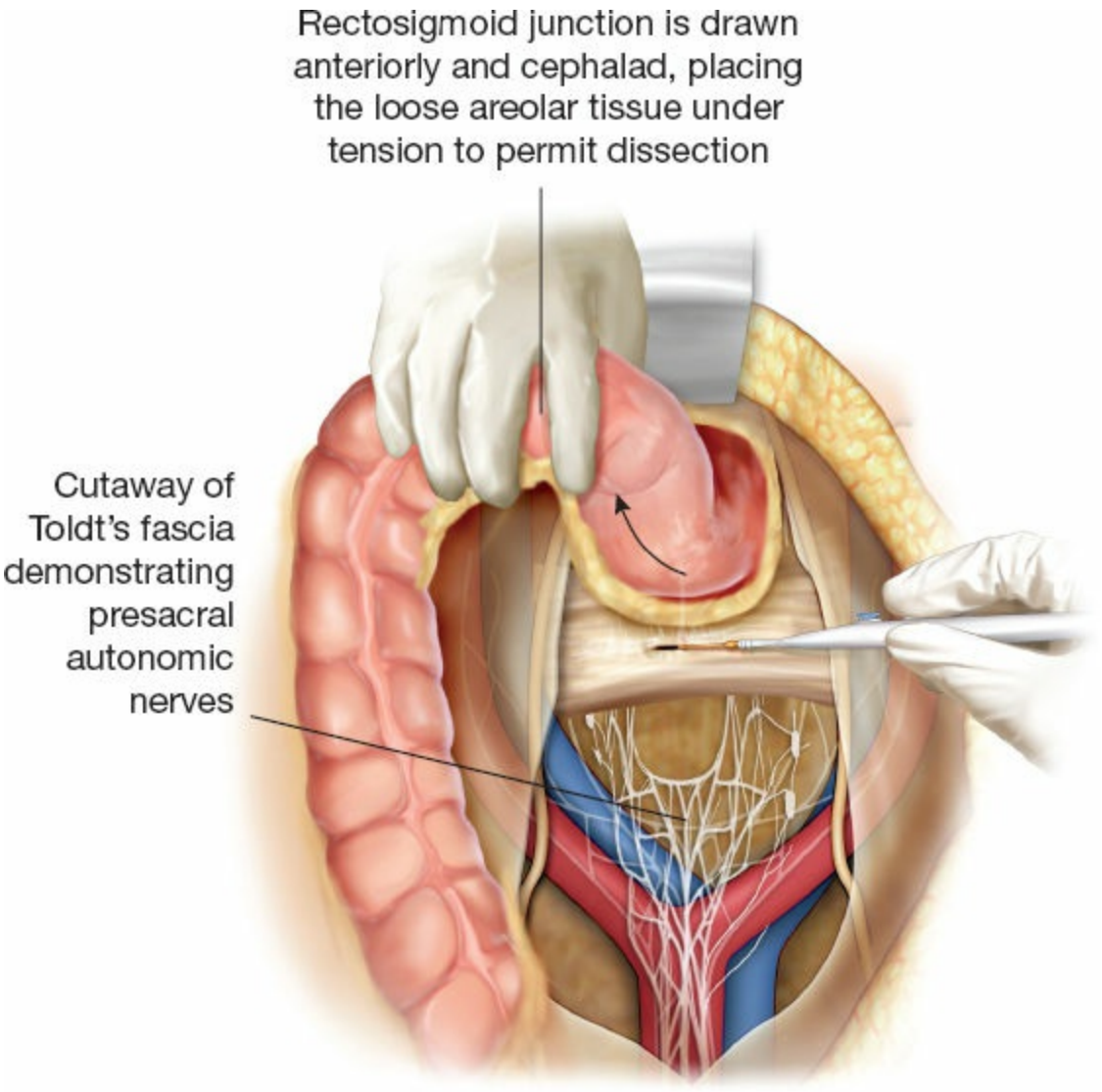

Figure 154a.8. Posterior dissection.

For the lateral dissection, the rectum is retracted superiorly and laterally toward the opposite side so as to put these tissues under tension. We prefer to divide these lateral attachments with an energy device as the middle

rectal artery can be a troublesome source of bleeding here. The dissection at this level should be carried out as close to the mesorectal envelope as possible, so as to avoid the *nervi erigentes.* A rectosacral or anosacral ligament can prevent complete posterior mobilization of the rectum down to the levator muscles. If necessary, this should be divided (Fig. 154a.10).

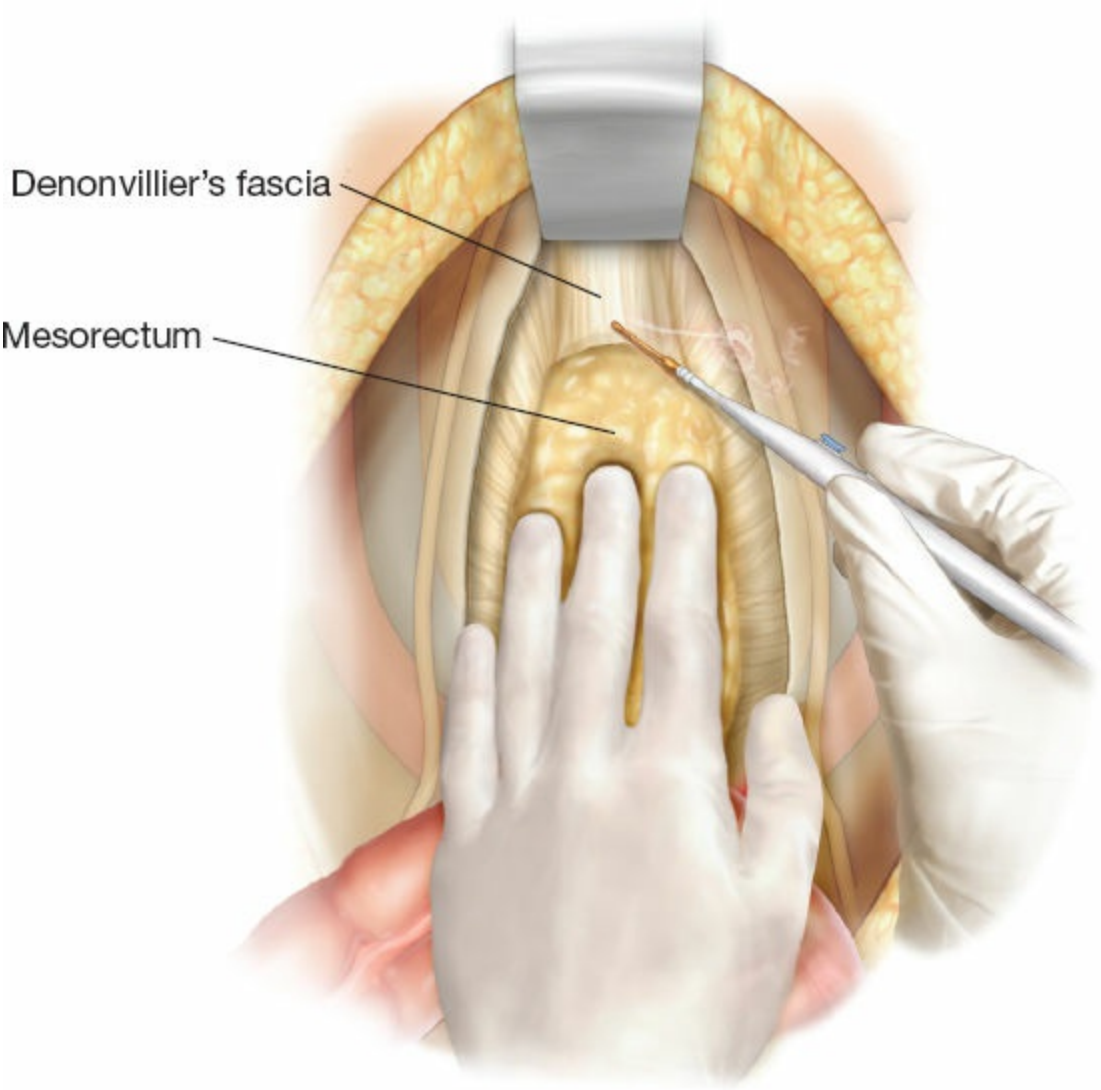

Figure 154a.9. Anterior dissection.

Regardless of which approach is used to perform this operation, open, laparoscopic, or robotic, oncologic clearance with functional preservation should be the goal.

Evidence Regarding Minimally Invasive Approaches to Performing TME

Several randomized trials and other retrospective studies have evaluated a

laparoscopic approach to radical resection of rectal cancer. The *Conventional versus Laparoscopic-Assisted Surgery in Colorectal Cancer (CLASICC) trial* conducted by the United Kingdom Medical Research Council randomized 794 patients between 1996 and 2002 in a 2:1 fashion to laparoscopic or open resection. Of these, 326 were rectal cancer patients: 87 had abdominoperineal resection (APR) and 239 had AR. Surgical resection was undertaken according to every surgeon's current practice. Poorly differentiated, very low rectal lesions (<5 cm from the anal verge) were treated by APR. The trial design required that every surgeon had performed at least 20 laparoscopic-assisted resections. In every center, a gastrointestinal pathologist ensured consistent reporting of resection specimens according to an agreed and established technique that focused on the completeness of resection and extent of the CRM. The trial found that patients undergoing laparoscopic AR were more likely to have a positive radial margin, but long-term survival outcomes were the same. However, local recurrence rate in patients undergoing AR or APR was 9.7% in the laparoscopic group and 10.1% in the open group. Of note, the study also captured a learning curve among participating surgeons; 38% of laparoscopic operations were converted to open in the first year of the trial, but this decreased to 16% by year 6.

The *COlorectal cancer Laparoscopic or Open Resection (COLOR) II Trial* was a multicenter, phase 3 trial that randomized 1,103 rectal cancer patients from 2004 to 2010 to laparoscopic (n = 739) or open (n = 364) surgery. All procedures were required to comply with the principles of TME or partial mesorectal excision if the cancer was localized in the upper part of the rectum. Unedited recordings of five consecutive laparoscopic TMEs were evaluated. The respective pathology reports of these five cases were reviewed to confirm completeness of the specimens. The laparoscopy group had lower median blood loss (200 mL vs. 400 mL), but longer median operative time (240 minutes vs. 188 minutes). This trial found no difference in short-term morbidity or mortality, or pathologic quality of the specimen. At 3 years, the rate of locoregional recurrence was 5% in each of the groups. Long-term follow-up reported by the COLOR II investigators showed no significant difference in either 3-year disease-free survival (74.8% in the laparoscopic group vs. 70.8% in the open group) or overall survival.

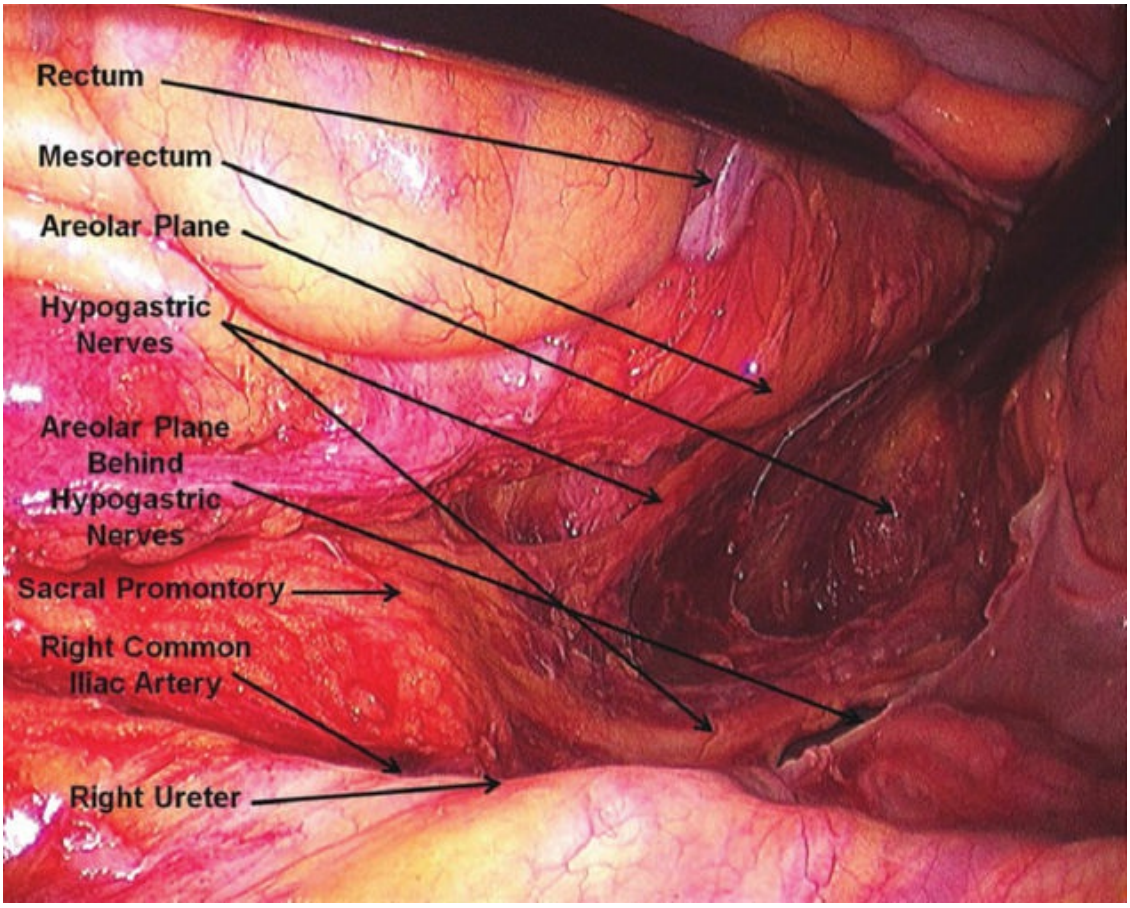

Figure 154a.10. An intraoperative image during a laparoscopic TME highlighting the key structures with the rectum retracted anteriorly toward the abdominal wall.

The *Comparison of Open versus laparoscopic surgery for mid and low REctal cancer After Neoadjuvant chemoradiotherapy (COREAN)* trial randomized 340 patients with mid- and low-rectal cancers after neoadjuvant treatment to open or laparoscopic surgery. Surgery was done 6 to 8 weeks after completion of preoperative chemoradiotherapy, by seven surgeons from three hospitals who had experience with a median number of 75 (range 28 to 150) cases of laparoscopic colorectal resection before the trial. These surgeons were qualified through live demonstrations held by the Korean Laparoscopic Colorectal Surgery Study Group. Each surgeon submitted a videotape of their laparoscopic rectal surgery, which was reviewed by a trial steering committee to assess the surgeon's oncologic technique, including the level of inferior mesenteric vessel ligation, TME quality, and preservation of autonomic nerves. There was no statistical difference in the positive CRM rates between the two groups (4.1% in the open group vs. 2.9% in the laparoscopic group) and the macroscopic quality of the TME specimen was also similar between the

two groups. In addition, there was no difference in the local recurrence rates between the two groups.

The primary end point of 3-year disease free survival was not statistically different between groups (79.2% in the laparoscopic group vs. 72.5% in the open group). A limitation of the study was that there was a statistically significant difference in final staging between patients in the open and laparoscopic arms, with the laparoscopy group having a lower pathologic tumor stage (ypT) and a higher nodal stage (ypN). However, multivariate analysis adjusting for this difference did not suggest an effect on the trial results.

The *American College of Surgeons Oncology Group (ACOSOG) Z6051* trial randomized 486 patients between 2008 and 2013 with rectal cancer within 12 cm of the anal verge, after receiving neoadjuvant treatment, to laparoscopic or open resection. The primary endpoint, unlike previous trials, was a composite of circumferential radial margin greater than 1 mm, distal margin without tumor, and completeness of TME as a composite. A 6% noninferiority difference was chosen between laparoscopic and open resection according to clinical relevance estimation. This composite was higher in the open resection arm (86.9%) versus laparoscopic resection arm (81.7%) and hence favored open resection. Long-term follow-up data regarding oncologic outcomes is awaited.

The *Australasian Laparoscopic Cancer of the Rectum Trial (ALaCaRT)* was another randomized noninferiority trial using a design similar to the ACOSOG Z6051 trial, with the primary endpoint set as a composite of complete TME, circumferential margin of at least 1 mm, and distal margin of at least 1 mm. A total of 475 patients were enrolled between 2010 and 2014; 237 of these had open resection and 238 had laparoscopic resection, with randomization stratified according to level of the rectal tumor. Successful resection was achieved in 82% of the laparoscopic cases and 89% of the open cases; hence, could not prove noninferiority of the laparoscopic approach. Follow-up data regarding recurrence and survival in the longer term are anticipated.

When considering laparoscopic resection for rectal cancer patients, it is important to note that none of the randomized trials included patients with more locally advanced rectal cancers. The trials excluded clinical T4 tumors, or in some cases tumor invasion within 1 to 2 mm of mesorectal fascia or nodal involvement of mesorectal fascia, so conclusions of these trials cannot be clearly extrapolated to these patients in practice.

Based on the results of the current trials summarized above, two studies (ACOSOG Z6051 and ALaCaRT) failed to show comparable quality of resection in the laparoscopic group compared to the open group. Whether this translates into oncologic differences for the patient remains to be seen.

More recently, robotic approach to performing TME has gained popularity. The degree of freedom that the robotic instruments provide in the confines of a narrow pelvis and superior three-dimensional visualization are arguably the strengths of this approach. Collinson et al. reported the design of a large, randomized, international multicenter trial known as the *RObotic versus LAparoscopic Resection for Rectal cancer (ROLARR) trial*. Enrollment began in 2011 and randomized 400 patients to laparoscopic or robotic TME. The primary endpoint was rate of conversion to open surgery, as a surrogate for ease of the robotic-assisted technique. Other endpoints included CRM, morbidity, 30-day mortality, local recurrence, disease-free survival, overall survival, patient reported bladder and sexual function, and other quality of life measures. Preliminary results presented at a national meeting reported CRM positivity rates of 6.3% in the laparoscopic group and 5.1% in the robotic group with an OR of 0.79 (0.35 to 1.76). Formal publication of the results is pending.

As there are more options for the surgical treatment of rectal cancer, the appropriate choice for an individual patient is becoming more difficult. The TME principles remain relevant regardless of the surgical approach selected. At the present time, open surgical resection with careful TME remains the standard of care against which all other techniques must be judged.

Transanal TME

The latest technical iteration for TME is the transanal total mesorectal excision (TaTME). As most commonly described, a combination of laparoscopic and transanal approaches is used, and two teams can work simultaneously. The laparoscopic team performs high ligation of the inferior mesenteric vessels and mobilization of the splenic flexure if needed, and proceeds with dissection of the sigmoid colon and proximal rectum as in a conventional laparoscopic approach. The transanal team begins with placement of a purse–string suture to close the rectal lumen at the level of the distal resection margin (prior to manipulation of the bowel by the laparoscopic team). A transanal surgical platform of the type used for TAMIS is then inserted. Cautery is used to divide the rectum and

mesorectum caudal to the purse–string suture and identify the mesorectal fascia. Sharp dissection in the mesorectal fascial plane is then performed in a "down-to-up" fashion until a "rendezvous" with the laparoscopic team's dissection plane is achieved. The specimen may be removed transanally or transabdominally and an anastomosis may be created with a diverting ileostomy if necessary.

Pathologic Evaluation of TME Specimen

The quality of the excised mesorectum and evaluation of the CRM are the most significant predictors of local recurrence in patients undergoing a TME for rectal cancer. Hence, pathologists play a key role in the evaluation of these specimens as a comprehensive pathologic evaluation not only provides important prognostic information but also provides critical feedback to the surgeon regarding their technical performance and quality assurance.

Gross visual inspection of the TME specimen should demonstrate three clear landmarks:

1. The cut edge of the peritoneal reflection and the whole "cul-de-sac."
2. Smooth shiny anterior surface of the mesorectum of the upper half (rectogenital septum) or middle third (Denonvillier fascia) of the rectum.
3. Anterior aspect of the anorectal muscle in ultralow AR and APR specimens only.

TABLE 154a.1 Assessment of TME Specimen

Mesorectum	
Mesorectal plane (complete)	Intact mesorectum with only minor irregularities No defects deeper than 5 mm No coning toward the distal margin of the resection specimen Smooth CRM on transverse sections
Intramesorectal plane (nearly complete)	Moderate bulk to the mesorectum One or more defects greater than 5 mm deep within the mesorectum Moderate coning No visible muscularis propria Irregular CRM on transverse sections
Muscularis propria plane (incomplete)	Exposed muscularis propria Moderate to marked coning Irregular CRM on transverse sections
Sphincter complex	
Extralevator	Cylindrical specimen with no waist effect Levators removed en bloc
Sphincter plane	Slight waist effect No significant defects or perforations
Intrasphincteric/submucosal plane	Significant waist effect Perforation or missing areas of muscularis propria

The CRM refers to the nonperitonealised bare area of rectum and a positive CRM is defined as direct tumor extension (either contiguous or discontiguous) or the presence of a positive lymph node within 1 mm of the radial, nonperitonealised soft tissue edge.

The CLASSIC study of the Medical Research Council in the United Kingdom and the Dutch TME trial defined a standardized protocol for proper assessment of the quality and completeness of the mesorectum. Table 154a.1 outlines the approach developed by Philip Quirke for the assessment of a TME specimen.

Correlations of MRI findings with gross pathologic findings should preferably be documented in the pathology report and sections submitted accordingly. Transverse slices should be inspected to note the following: (1) extent of tumor and the closest distance of the tumor to the CRM (the closest point is specified as anterior, posterior, right/left lateral); (2) areas suspicious for extramural vascular invasion; (3) any positive lymph nodes and their relationship to the CRM; and (4) other pertinent pathologic findings (diverticula, polyps, adhesions, etc.).

Having a standardized template for pathologic evaluation of a TME specimen should be established as the pathology report contains

information that would risk stratify a patient's chances for local recurrence and help with decision making with regards to surveillance and adjuvant treatment (Fig. 154a.11).

It is clear that TME for rectal cancer can be performed in many patients through open, laparoscopic or robotic approaches. However, the difficulty of performing an adequate margin negative resection with nerve preservation in certain patient populations such as obese males should not be underestimated. As laparoscopic and robotic approaches are improving but remain just tools helpful in reducing the negative impact of surgery on our patients, consideration of the appropriate surgical approach requires much thought and expertise. We await the final results of some current clinical trials (ACOSOG Z6051 and ALaCaRT). In addition, future trials comparing robotic, laparoscopic and open surgical approaches with endpoints including margin negative resections, local recurrence, morbidity and functional outcomes will allow for proper choice of technique.

A critical component to the management of rectal cancer includes a multidisciplinary approach, providing optimal patient care. More recently, the OSTRiCH Consortium (Optimizing the Surgical Treatment of Rectal Cancer) and the Commission on Cancer (CoC) which is a quality program of the American College of Surgeons have formulated plans for a National Accreditation Program for Rectal Cancer (NAPRC), with the goal of ensuring that patients with rectal cancer receive appropriate care using a multidisciplinary team.

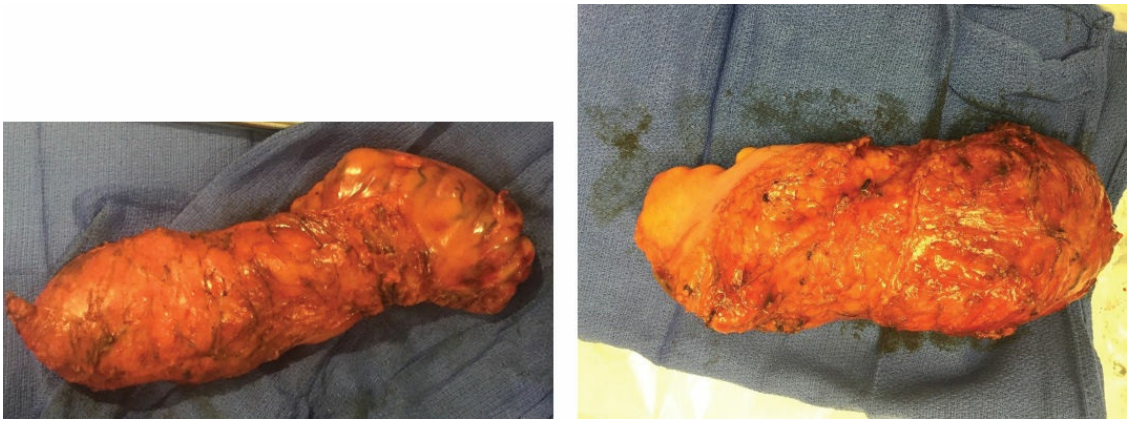

Figure 154a.11. An example of a TME specimen.

ACKNOWLEDGMENTS

We would like to acknowledge the contributions of Prof. Richard J. Heald,

both for the previous version of this chapter and, more importantly, for his pioneering work in the surgical treatment of rectal cancer.

Suggested Readings

Bonjer HJ, Deijen CL, Abis GA, et al. COLOR II Study Group. A randomized trial of laparoscopic versus open surgery for rectal cancer. *N Engl J Med* 2015; 372(14):1324–32.

Fleshman J, Branda M, Sargent DJ, et al. Effect of laparoscopic-assisted resection vs open resection of stage II or III rectal cancer on pathologic outcomes: The ACOSOG Z6051 randomized clinical trial. *JAMA* 2015;314(13):1346–55.

Green BL, Marshall HC, Collinson F, et al. Long-term follow-up of the Medical Research Council CLASICC trial of conventional versus laparoscopically assisted resection in colorectal cancer. *Br J Surg* 2013;100(1):75–82.

Heald RJ, Moran BJ, Ryall RD, et al. Rectal cancer: the Basingstoke experience of total mesorectal excision, 1978–1997. *Arch Surg* 1998;133(8):894–9.

Jayne DG, Guillou PJ, Thorpe H, et al. Randomized trial of laparoscopic-assisted resection of colorectal carcinoma: 3-year results of the UK MRC CLASICC Trial Group. *J Clin Oncol* 2007;25(21):3061–8.

Jeong SY, Park JW, Nam BH, et al. Open versus laparoscopic surgery for mid-rectal or low-rectal cancer after neoadjuvant chemoradiotherapy (COREAN trial): survival outcomes of an open-label, non-inferiority, randomised controlled trial. *Lancet Oncol* 2014;15(7):767–74.

Quirke P, Steele R, Monson J, et al.; MRC CR07/NCIC-CTG CO16 Trial Investigators; Colorectal Cancer Study Group. Effect of the plane of surgery achieved on local recurrence in patients with operable rectal cancer: a prospective study using data from the MRC CR07 and NCIC-CTG CO16 randomised clinical trial. *Lancet* 2009;373(9666):821–8.

Stevenson AR, Solomon MJ, Lumley JW, et al.; ALaCaRT Investigators. Effect of laparoscopic-assisted resection vs open resection on pathological outcomes in rectal cancer the ALaCaRT randomized clinical trial. *JAMA* 2015;314(13):1356–63.

EDITOR'S COMMENT

Before we actually devote ourselves to various pertinent papers that have been recently written, we would like to use this opportunity to congratulate Professor Heald on a magnificent contribution to contemporary surgery as well as to recognize contribution on advances in total mesorectal excision by Professor Hochwald and his group. History has taught us that new innovations do not

come easily and there were probably many times when Professor Heald felt ridiculed and his contribution was minimized. Professor Heald, despite his prominence, stayed at Basingstoke, which is appropriate, that he may have been taken for task for not being in a "major" center. All of that has changed. Total mesorectal excision (TME) is now accepted around the world as the appropriate way to proceed in resection for carcinoma of the rectum in which the long-term survival has been improved by ~15% or perhaps even greater, as well as a decrease in the bladder and sexual dysfunction with a carefully done dissection.

However, all is not well in the world of carcinoma of the rectum, as Mulsow J and Winter D writing in *Arch Surg* (Extralevator abdominoperineal resection for low rectal cancer: new direction or miles behind? 2010;145:811–2) draw attention to the poor results for abdominoperineal resection for low rectal cancer, which has been modified, apparently not appropriately, and thus one does not get a clean resection. The subtitle of the article is "New Direction or Miles Behind?," a clever pun, but in Figure A given in this very brief paper, one can see clearly that the dissections around "Morson's waist" were meant to be a cylinder, that is, for the same reason as Miles resection was originally criticized. That cylinder made the Miles resection, which had to be done in haste given the anesthesia of those days and the absence of blood transfusion, brutal and destructive. The difficulty, as quoted by Marr R et al. (The modern abdominoperineal excision: the next challenge after total mesorectal excision. *Ann Surg* 2005;242:74–82) is that the current oncologic results are simply unacceptable because the circumferential resection margin (CRM) have been positive in up to 40% in some series. This of course "negatively effects" local control and overall survival. Davies M et al. (Management of the asymptomatic primary in the palliative treatment of metastatic colorectal cancer. *Colorectal Dis* 2009;11:845–8) reviewed the incidence of local recurrence in 200 consecutive cases with a diagnosis of rectal cancer of which 139 underwent a curative resection. Of these, 40 underwent Miles resection with curative intent, and two of whom experienced local recurrence (5%) at 1½ and 2 years. Overall recurrence rate for all operations with curative intent was 2.6%. They conclude that, "Tumors at the anorectal junction should not be dissected off the pelvic floor, but radically excised en bloc with the surrounding levator ani, as a cylinder, as originally described by Miles." In a similar vein, Holm T et al. (Extended abdominoperineal resection with gluteus maximus flap reconstruction of the pelvic floor for rectal cancer. *Br J Surg* 2007;94:232–8) propose an extended abdominoperineal resection with a gluteus maximus flap reconstruction of the pelvic floor for rectal cancer. This initiative, supposedly to go external to the levators, would promote a low perforation rate and a lower recurrence rate. The recurrence rate is 7%, that is, 2 patients out of 28, a small number. However, healing postradiation is delayed in ~30% and a flap closure is a problem.

Davies M et al. (Local recurrence after abdomino-perineal resection. *Colorectal Dis* 2009;11:39–43) report good outcomes in abdominoperineal

resections and make the statement that one does not need to resect the iliac nodes (although we are not sure who said that one needs the iliac nodes resected). They state that the closest point to the CRM is anterior and one must teach to do this without perforation, which of course will yield local recurrence. How all of these now stack up against the adage of the late, great Professor John Goligher, "If you haven't made the patient impotent, you have not cured the rectal cancer," we do not know. Professor Heald, who has emphasized postoperative sexual function, has shown very nicely that you do not make the patient impotent if you do the operation correctly. The difference between these various techniques and Professor Heald's results is his insistence that one does not go in the midline cutting the nerves with clamps as shown in Figure 154a.1 and this is not necessary for a good oncologic result. I am certain that this debate will be continued but it is good that people are bringing up matters of technique as against sexual function, which is important even to people in their 70s.

One way of improving the functional results, especially that of sexual function, is to cut down on the delay of patients coming to medical attention following the appearance of the first symptom. Mitchell E et al. (Influences on pre-hospital delay in the diagnosis of colorectal cancer: a systematic review. *Br J Cancer* 2008;98:60–70) point out that especially when there are serious symptoms such as pain that time from the first pain to diagnosis is 7.5 months in cancer of the rectum and only 5 months in colon cancer. This may explain the advanced colorectal disease and the fact that it presents at a more advanced stage than carcinoma of the colon, which is not in such a tight place.

Langenbach M et al. (Delay in treatment of colorectal cancer: multifactorial problem. *World J Surg* 2003;27:304–8) showed that delay from first symptoms correlated with stage of cancer. The delay in rectal cancer was 224 days or 7 months and colon cancer 149 days or 4+ months, similar to MacDonald. Five months or certainly 7.5 months lead to advanced growth of the neoplasm in a bad place and the ability to get to the patient earlier may give them a better functional result as well as an oncologic result.

There is a feeling that one can prevent an anastomotic dehiscence or an anastomotic leak with diversion. This does not appear to be the case, as Tsikitis VL et al., writing from the Mayo Clinic with many well-known colorectal surgeons as coauthor (Postoperative morbidity with diversion after low anterior resection in the era of neoadjuvant therapy: a single institution experience. *J Am Coll Surg* 2009;209:114–8), reviews a retrospective case series including patients who were treated with neoadjuvant therapy and had rectal cancer resection with curative intent from 1996 to 2007. The study comprised 237 patients with a mean age of 59 years receiving 5-flurouracil-based infusion therapy and 45 to 54 Gy of radiation. Of these patients, 43% had coloanal anastomosis and 57 underwent anterior resection. Anastomotic dehiscence occurred in nine patients; seven of the nine were diagnosed as pelvic abscesses (2.1%) and two patients needed re-exploration. There was no mortality and

early overall postoperative morbidity was 26%. For some reason, which is not clear, patients who were not diverted had a lower leak rate at 2.2% than those who did (4.4%). It is possible that the functionality of having the stool go through the area reduces the leak rate. However, in a randomized prospective trial, Matthiessen P et al. (Defunctioning stoma reduces symptomatic anastomotic leakage after low anterior resection of the rectum for cancer: a randomized multicenter trial. *Ann Surg* 2007:246:207–14) also showed that in a randomized controlled trial the functioning loop stomas, while less common, while associated with symptomatic anastomotic leakage after lower anterior resections, nonetheless decreased the number of sequelae of these anastomotic leaks.

An ambitious project was undertaken by Paun BC et al. (Postoperative complications following surgery for rectal cancer. *Ann Surg* 2010;251:807–18) in which the authors attempted to benchmark 53 prospective cohort studies and 45 randomized controlled studies. As many as 36,315 patients were included in the trials, of which 24,845 had an anastomosis. The anastomotic leak rate seemed high (that is 11%), and pelvic sepsis in 29 studies was 12%. In 75 studies, mortality was 2% but continued to improve by years published. Wound infection, studied in 50 papers, was 7%, which seems excessive. To explain the heterogeneity of leak rate, age, median tumor height (in other words, distance from the anus), and method of detection (radiology vs. clinical) were statistically significant. In the paper by Tsikitis (previously quoted), age, ASA class, and cardiovascular disease were significant for the percentage of leaks. They did not mention whether there was a difference between those who were diverted and those who were not, with leak rate.

The possibility that functional flow of stool through an area may result in a lower leak rate or in some other benefit was hypothesized by Kirzin S et al. (Benefits of perineal colostomy on perineal morbidity after abdominoperineal resection. *Dis Colon Rectum* 2010;53:1265–71) in a paper, which compared perineal colostomy on perineal morbidity after abdominal peritoneal resection. Patients between 1993 and 2007 who underwent abdominoperineal resection for rectal adenocarcinoma were compared. Of 110 patients, an iliac colostomy (i.e., a standard colostomy) was carried out in 41 patients and a perineal colostomy group, something which we are not familiar with in this country, in 69. There were fewer instances of pelvic perineal morbidity ($P = 0.008$) and fewer instances of wound dehiscence ($P = 0.02$) in the perineal colostomy group with a shorter healing time of 35.3 versus 45.1 days, $P = 0.04$. As they state in the article, the benefits from perineal colostomy were statistically significant in patients who received radiation in terms of pelviperineal morbidity ($P = 0.01$) and healing time, 50.8 versus 35.9 days, respectively ($P = 0.02$). No differences were found between patients who had not received radiation therapy and indeed it is difficult to know what that signifies.

Row D and Weiser M (An update on laparoscopic resection for rectal cancer. *Cancer Control* 2010;17:16–24) investigated the status of laparoscopy in mid to

low rectal cancer. The principal outcome they looked at was positive CRMs identified in 14% of the patients with open resection and 16% of those with laparoscopic resection, but in the group who underwent anterior resection alone, CRM positivity was 12% in the laparoscopic group versus 6% in the open group ($P = 0.19$). Despite the higher rate of CRM positivity in the laparoscopic group, there was no statistically significant difference in survival rate between groups (68.4% laparoscopic vs. 66.7% in the open group; $P = 0.55$) and no difference in the 3-year overall survival rate in patients undergoing anterior resection (74.6% vs. 66.7%, respectively). Of significance, differences in CRM positivity did not translate into differences in a 3-year local recurrence rate (7.8% for the laparoscopic group vs. 7.0 for the open group; $P = 0.70$).

At the present time, the status of laparoscopy has emerged as a valuable adjunct compared to autonomic nerve-sparing TME. This is evident in the updates provided by Professor Hochwald. As pointed out in Chapter 154a, a robotic approach to performing TME have gained popularity. In addition the transanal TME combined with a laparoscopic approach has emerged as the latest technique to accomplish TME. Regardless of the techniques chosen to the complete TME, the principles as outlined by Professor Heald hold true today. As pointed out by Professor Hochwald, open surgical TME remains the standard against which all other techniques should be compared.

Josef E. Fischer and E. Christopher Ellison

155 Open and Minimally Invasive Sphincter-Preserving Radical Resection for Malignant Disease of the Middle and Lower Thirds of the Rectum

Wolfgang B. Gaertner and Robert D. Madoff

INTRODUCTION

Approximately 40,000 new cases of rectal cancer occurred in 2015, and of these 40% were confined to the rectal wall. Despite a steady decrease in incidence and mortality since 1975, colorectal cancer remains the second leading cause of cancer deaths in the United States.

There have been several key advances in the management of rectal cancer, but none so important as standardization and improvement in surgical resection. There is general agreement that optimal surgical treatment involves total mesorectal excision (TME) with an R0 excision (microscopically negative margins of the excised specimen), regardless of approach (open, laparoscopic, or robotic). The addition of preoperative imaging by computed tomography (CT) of the chest and abdomen to rule out metastatic disease and by magnetic resonance imaging (MRI) of the pelvis to assess local tumor extent, as well as pathologic assessment and audit has also contributed to improved results. The benefits of neoadjuvant chemoradiotherapy for locally advanced tumors are now generally accepted, with good evidence for both downstaging and downsizing, as well as decreased local recurrence. However, no significant differences in survival or sphincter-sparing procedures have been demonstrated.

The complexity of decision making in the management of rectal cancer is undoubtedly best coordinated by a multidisciplinary team, which is crucial for individualized treatment strategies, and must balance between the desired effect on the disease and the short- and long-term side effects associated with treatment. Currently, the goals for treating rectal cancer have broadened to include securing local and distant oncologic control,

minimizing treatment-related morbidity and mortality, optimizing functional outcomes, and promoting rapid recovery after operative treatment with prompt return to normal activities.

ANATOMY

Anatomy is the mother discipline of all surgical interventions, and this holds especially true for rectal cancer surgery. The rectum and the anal canal are the last segments of the gastrointestinal tract responsible for mediating fecal continence and coordinating defecation. The rectoanal segment measures 15 to 20 cm long and extends from the rectosigmoid junction at the sacral promontory to the anal orifice. The rectal wall differs morphologically from the colon by the confluence of taeniae coli to a continuous longitudinal smooth muscle layer, permanent semilunar transverse folds, and the absence of fatty appendices epiploica. Most of the rectum is not covered by peritoneum, with only its upper ventrolateral two thirds related to the peritoneum and reflecting on to the bladder and seminal vesicles in men or uterus and posterior vagina in women (pouch of Douglas).

The rectum narrows at the level of the anorectal ring and becomes the anal canal, which extends down and backward to the anal orifice and measures 2.5 to 4 cm long (Fig. 155.1). The anal canal is divided into an upper and lower segment separated by a transitional zone at the dentate line. The transitional zone exhibits 8–12 vertical anal columns (of Morgagni) containing terminal branches of the superior rectal artery. At the lower end of the anal canal, an intersphincteric groove (anal verge) is palpable between the internal and external anal sphincters. Whereas the “surgical” anal canal is defined as from the anorectal ring to the anal verge, the “anatomical” anal canal is confined from the dentate line to the anal verge.

Perirectal Tissue Planes and Spaces

Comprehensive understanding of the topographic anatomy of the fascia and spaces surrounding the rectum is an essential prerequisite for rectal cancer surgery. Rectal mobilization along the correct planes will achieve oncologically safe margins and preservation of urogenital functions. The inner surface of the pelvic wall and the pelvic muscles (internal obturator, levator ani, coccygeal and piriformis muscles) are covered by the parietal pelvic fascia (Fig. 155.2). The visceral pelvic fascia (endopelvic fascia)

ensheathes the pelvic organs, including the rectum. In contrast to the urogenital pelvic organs, the rectum is enveloped by the rectal (“proper” or mesorectal) fascia. Anteriorly, the mesorectal border is the rectogenital septum (Denonvilliers fascia), and posteriorly it is the presacral fascia. The presacral fascia is part of the parietal pelvic fascia and is separated from the mesorectal fascia by the retrorectal space. Opening the retrorectal space reveals loose areolar connective tissue, also described as “angels hair.” However, at the level of the fourth sacral vertebra, the mesorectal fascia fuses with the presacral fascia. This bridge of connective tissue can be quite thick and is also termed rectosacral or Waldeyer fascia. On both sides, the rectum is loosely connected to the pelvic wall by condensed connective tissue, traditionally described as lateral rectal ligaments. These ligaments do not provide substantial mechanical fixation and serve primarily as vascular and nervous pedicles or stalks, with small branches from the middle rectal arteries and autonomic nerve fiber branches from the hypogastric plexus.

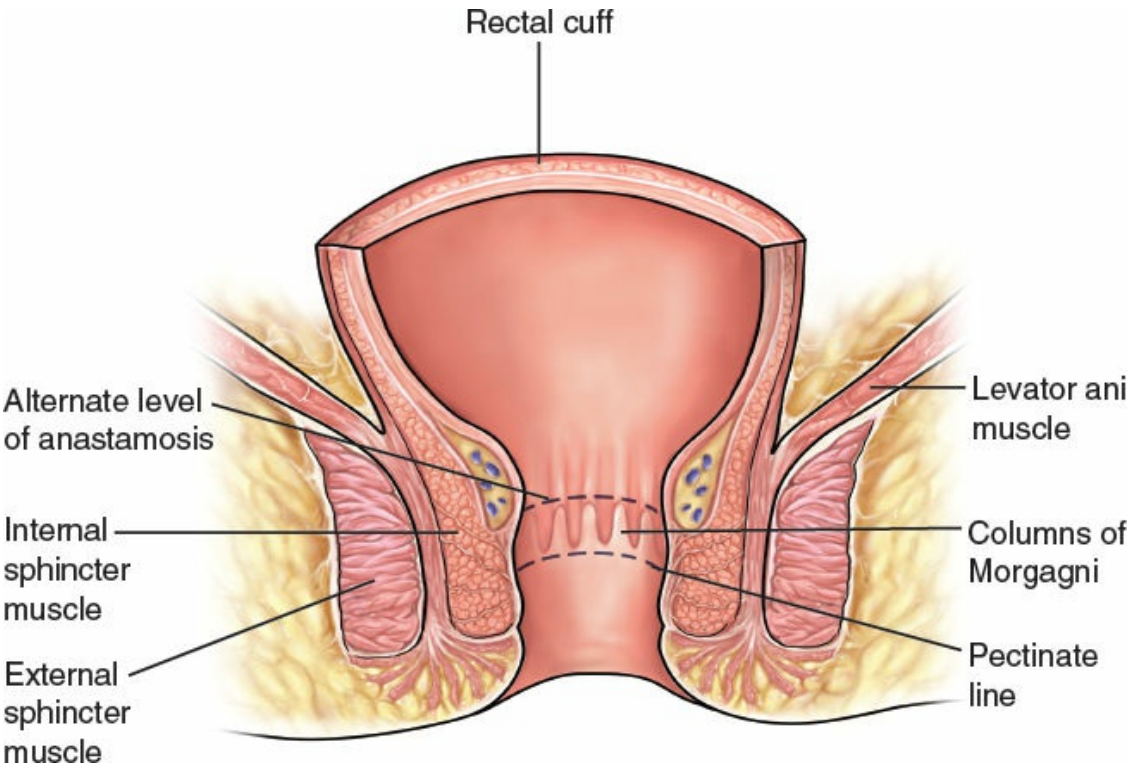

Figure 155.1. Anorectal anatomy.

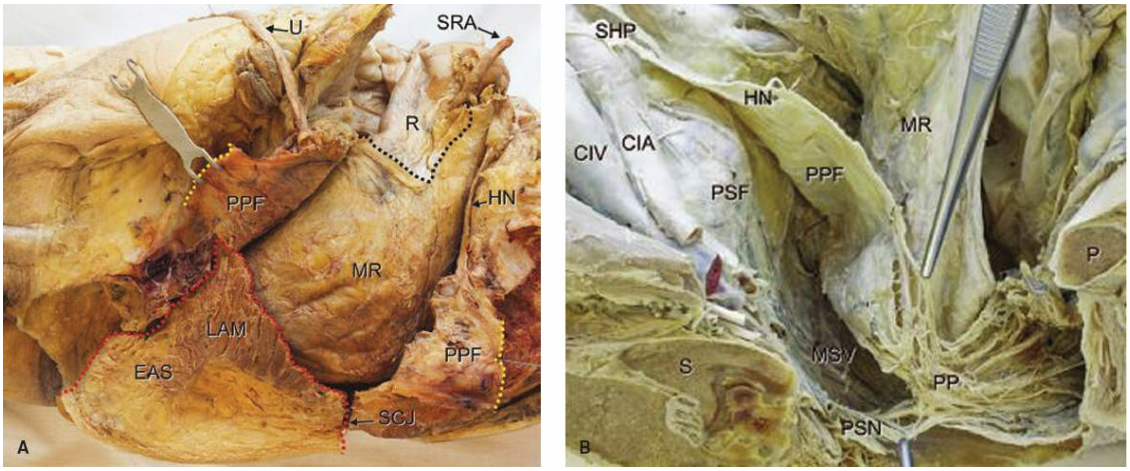

Figure 155.2. **A.** Male pelvis with left hemipelvis removed parasagittally. The left parietal pelvic fascia (PPF) containing the pelvic plexus is divided (*dotted yellow lines* represent the transection line) half-way between the sacrum and the posterior wall of the urinary bladder and prostate. The *dotted black line* shows the peritoneal reflection, and the *dotted red line* delineates excision planes. PPF, parietal pelvic fascia; MR, mesorectal fascia; EAS, external anal sphincter; LAM, levator ani muscle; R, rectum; SRA, superior rectal artery; SCJ, sacrococcygeal junction (divided); HN, hypogastric nerve; U, ureter (reflected). **B.** Female pelvis with right hemipelvis removed parasagittally. The rectum covered by its mesorectum is reflected anteriorly. The parietal pelvic fascia (PPF) is lifted up with the upper forceps to demonstrate the course of the superior hypogastric plexus (SHP). The pelvic splanchnic nerves (PSN) are highlighted with the lower forceps on their course from the sacral roots to the pelvic plexus (PP). HN, hypogastric nerve; PSF, presacral fascia; MSV, median sacral vessels; CIA, common iliac artery; CIV, common iliac vein; P, pubic bone (superior branch); S, sacrum. (Modified from Stelzner S, Holm T, Moran BJ, et al. Deep pelvic anatomy revisited for a description of crucial steps in extralevator abdominoperineal excision for rectal cancer. *Dis Colon Rectum* 2011;54(8):947–57.)

Autonomic Nervous System

The rectum and upper anal canal, including the internal anal sphincter, is controlled by the autonomic nervous system. Sympathetic nerves control urinary bladder filling and mediate ejaculation, while parasympathetic nerves are responsible for controlled micturition, filling of the cavernous bodies (erection in males and swelling of the clitoris in females), and for lubrication of the external genitalia. The lumbar sympathetic nerves form

the inferior mesenteric and superior hypogastric plexuses, which enclose the inferior mesenteric artery (IMA) up to 5 cm from its origin. Therefore, a high arterial ligation without damaging adjacent sympathetic nerve fibers is virtually impossible. The superior hypogastric plexus then enters the pelvis in front of the sacral promontory and divides into the left and right hypogastric nerves (Fig. 155.3). These nerves often appear as intermingling strings and not a single defined nerve. The presacral fascia is intimately associated with the hypogastric nerves, and care must be taken during the posterior rectal dissection to avoid injury to these structures. Gentle cephalad traction on the rectum helps visualize the course of the hypogastric nerves down to the inferior hypogastric plexus.

Parasympathetic innervation of the rectum is provided by the pelvic splanchnic nerves, which derive from the sacral spinal cord (S2 to S4). Because of their function, they are also termed erigent nerves or *nervi erigentes.* The pelvic splanchnic nerves pierce the presacral fascia at the left and right sides and join the inferior hypogastric plexus. The inferior hypogastric plexus or pelvic plexus is an extensive network of sympathetic and parasympathetic nerves that extends anteriorly in a fan-like fashion radiating from the seminal vesicles to the upper aspect of the perineal body in men or along the lower lateral posterior wall of the vagina in women. Terminal branches consist of cavernous nerves that are responsible for erectile functions and innervation of the internal urethral sphincter.

Autonomic innervation of pelvic organs is characterized by a certain functional redundancy, represented by abundant bilateral ramifying nerve plexi with collateral nerve fibers that connect both sides of the pelvis. Thus, the intact contralateral side may compensate unilateral damage. However, the impact of nerve injury after TME should not be underestimated because of this.

Vascular Supply and Lymphatic Drainage

The rectum, including the upper anal canal, receives its blood supply by the IMA via the superior rectal artery. The middle and inferior rectal arteries originate from the internal iliac vessels and contribute to the blood supply of the lower anal canal and minor parts of the rectum via intramural anastomoses. The middle rectal arteries are small and inconsistent (present bilaterally in 10% of individuals), and approach the inferior rectum via the rectal pedicles. The inferior rectal arteries diverge from the internal pudendal arteries located within Alcock’s canal and approach the anal

region via the ischioanal space. The posterior anal canal and internal anal sphincter receive additional blood supply by the median sacral artery, a small vessel that arises from the posterior aspect of the abdominal aorta, superior to its bifurcation.

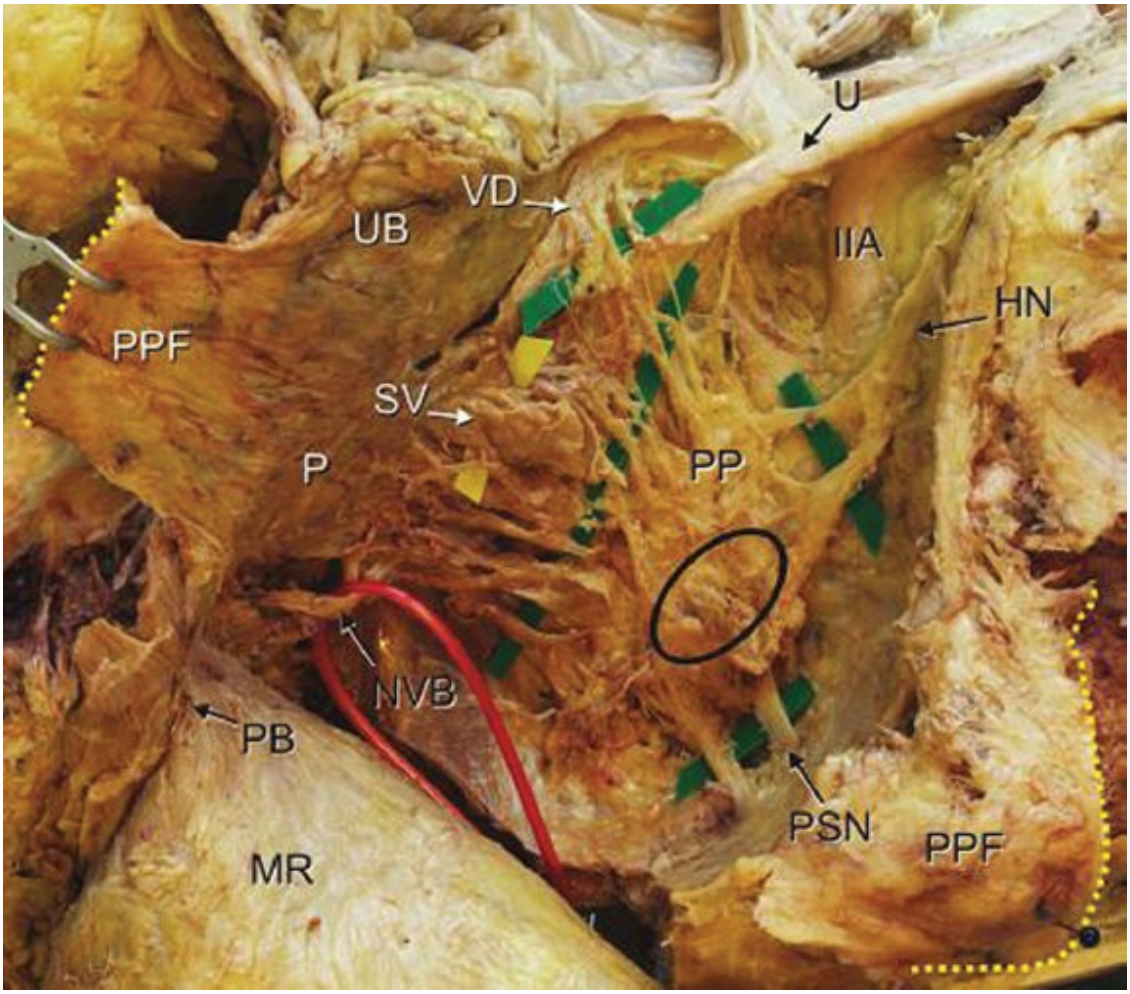

Figure 155.3. Male pelvis with left hemipelvis removed parasagittally. The rectum with the surrounding mesorectum (MR) is pulled out of the pelvis but still attached anteriorly at the region of the perineal body (PB). The left parietal pelvic fascia (PPF) is divided (*dotted yellow lines* show the transection line) and reflected to reveal the autonomic pelvic nerves: the right hypogastric nerve (HN) originating from the superior hypogastric plexus and the pelvic splanchnic nerves (PSN) emerging from the sacral roots join at the pelvic plexus (PP) from which fine branches (*green strips*) diverge in fanlike pattern toward the distal ureter (U), vas deferens (VD), seminal vesicles (SV, *yellow strip*), urinary bladder (UB), and prostate (P). The stumps of the nerves diverging into the rectum (T-junctions) are marked with a *black circle*. The right neurovascular bundle (NVB, *red vessel loop*)

extends toward the apex of the prostate coming into close proximity to the perineal body (PB) and the anterior surgical resection plane. IIA, internal iliac artery. (Modified from Stelzner S, Holm T, Moran BJ, et al. Deep pelvic anatomy revisited for a description of crucial steps in extralevator abdominoperineal excision for rectal cancer. *Dis Colon Rectum* 2011;54(8):947–57.)

The lymphatic drainage from the rectum is analogous to the blood supply, mainly in a cranial direction along the superior rectal and inferior mesenteric vessels, toward the visceral lymph nodes. One anatomical study found a mean of 8.4 lymph nodes in the mesorectum. Lymphatic drainage may also take place via the rectal pedicles toward the internal iliac lymph nodes. Lymphatic spread through this route is commonly seen with locally advanced tumors with pelvic wall invasion. The lower anal canal and perianal region have somatic lymphatic drainage toward the inguinal and external iliac lymph nodes.

CLINICAL PRESENTATION

Patients with rectal cancer may present in three ways: (1) suspicious signs and symptoms; (2) asymptomatic individuals diagnosed by screening; and (3) emergent presentation with intestinal obstruction, peritonitis, or acute gastrointestinal bleed.

Most patients with early-stage rectal cancer have no symptoms and are diagnosed as a result of endoscopic screening. Because of the increasing use of endoscopic colorectal cancer screening, an increasing number of rectal cancers are being diagnosed in asymptomatic patients; however, a majority are still diagnosed after the onset of symptoms.

Symptoms of rectal cancer are typically due to growth of the tumor into the lumen or adjacent structures. Typical signs and symptoms include hematochezia, otherwise unexplained iron deficiency anemia, and a change in bowel habits. Less common presenting symptoms include rectal pain or pressure, tenesmus, diarrhea, fecal seepage, and fecal incontinence. Fecal seepage and incontinence are typically associated with tumors invading the anal sphincter complex, and obstructive symptoms such as abdominal distension, nausea, and vomiting are most commonly associated with obstructing tumors.

Approximately 20% of patients diagnosed with rectal cancer in the United States have distant metastatic disease at the time of presentation. Rectal cancer can spread by lymphatic and hematogenous dissemination,

as well as by contiguous and transperitoneal routes. The most common metastatic sites are regional lymph nodes, liver, lungs, and peritoneum. Signs and symptoms commonly associated with the presence of metastatic disease include right upper quadrant pain, abdominal distention, early satiety, and cervical adenopathy. Tumors arising in the distal rectum may present with inguinal adenopathy and metastasize initially to the lungs because the inferior rectal veins drain into the inferior vena cava rather than into the portal venous system.

Although uncommon, patients with rectal cancer may have atypical presentations. These scenarios typically involve locally advanced tumors and include perianal and rectovaginal fistulas, contained perforation with fistulization to adjacent pelvic organs, rectal prolapse, and fever of unknown origin. *Streptococcus bovis* bacteremia and *Clostridium septicum* sepsis are associated with underlying colorectal malignancies in 10% to 25% of patients. Also, colorectal cancer ultimately proves to be the site of origin of approximately 6% of adenocarcinomas of unknown primary sites.

INDICATIONS AND CONTRAINDICATIONS

Despite advances and refinement in neoadjuvant treatment strategies, the mainstay of rectal cancer management continues to be surgical. While carefully selected early rectal cancers are amenable to transanal excision, the vast majority requires radical resection. Contraindications of radical resection include medically unfit patients, unresectable abdominopelvic disease (unamenable to multivisceral resection with R0 resection margins), and incurable metastatic disease in the absence of complicated factors such as obstruction, impending obstruction, and uncontrollable hemorrhage.

The clinical indications for minimally invasive proctectomy are the same as those for traditional open proctectomy. Postoperative adhesions and obesity can make the laparoscopic approach more difficult; however, the robotic approach has eased these difficulties in our experience because of improved visualization, greater freedom of movement, and the ability to perform fine dissection in confined surgical fields. Furthermore, obese patients have shown greater short-term benefits when the operation is successfully completed laparoscopically. Patients with poor cardiopulmonary function tolerate prolonged pneumoperitoneum poorly and should be monitored closely by an experienced anesthesia team.

With regard to disease-related factors, bulky, locally invasive and perforated tumors often preclude adequate visualization and are better

managed through a laparotomy. Hand-assisted laparoscopic surgery (HALS) is useful in selective patients with bulky tumors. In our experience, patients who require a vertical rectus abdominis myocutaneous flap for pelvic reconstruction are better managed with an open approach as well given that flap harvesting requires a midline laparotomy incision regardless of the approach used for proctectomy.

PREOPERATIVE PLANNING

Patients are routinely staged with full colonoscopy, CT of the chest, abdomen, and pelvis; and MRI of the pelvis; and those with locally advanced tumors or suspicion for metastatic disease undergo interval imaging after neoadjuvant chemoradiotherapy for appropriate staging. The addition of endorectal ultrasound is helpful in selective cases of early rectal cancer with an uncertain degree of rectal wall invasion on MRI. The decision to perform a sphincter-preserving rectal resection largely depends on the quality of preoperative imaging. Diffusion-weighted imaging and dynamic contrast-enhanced MRI have significantly improved the preoperative assessment of patients with rectal cancer by allowing surgeons to accurately evaluate the topography of rectal tumors in the pelvis, assess the degree of invasion of the rectal wall and adjacent structures or organs, and detect lymph node metastases and vascular invasion (Fig. 155.4). Routine discussion with an experienced radiologist is a key factor in our practice to help accurately plan a sphincter-preserving proctectomy with TME and R0 resection.

Operative treatment is typically performed 10 to 12 weeks after completing neoadjuvant chemoradiotherapy, and all cases are discussed at a multidisciplinary session. Repeat flexible or rigid proctoscopy and digital rectal examination are key to assess tumor characteristics and location, anal sphincter function and possible tumor-invasion, as well as response to neoadjuvant therapy. Patients should also have a baseline carcinoembryonic antigen (CEA) level.

Mechanical bowel preparation plus oral antibiotics (metronidazole and neomycin) is given the day before surgery, and patients are allowed a liquid diet up to 2 hours before arrival to the hospital. Consumption of high-carbohydrate supplements is highly recommended 2 to 3 days before surgery. As part of an enhanced recovery after surgery (ERAS) protocol, all patients routinely receive preoperative anti-inflammatory agents, nausea prophylaxis, an opioid antagonist, and appropriate pharmacologic

and mechanical venous thromboembolism (VTE) prophylaxis. All patients are marked preoperatively by an enterostomal nurse in case fecal diversion is intended or required. Both transversus abdominis plane (TAP) blocks with a long-acting anesthetic or epidural anesthesia are strongly encouraged to reduce postoperative narcotic consumption.

In the operating room, patients are placed in the modified lithotomy position with stirrups. Insertion of ureteral catheters is also encouraged in cases that may require extensive pelvic dissection, reoperation, and previous pelvic radiotherapy.

Even with appropriate preoperative planning and despite the location of a given rectal tumor, one must always be aware of the possibility of an abdominoperineal resection. This must be discussed with the patient preoperatively and included in the informed consent document. Patients with moderate to poor anal sphincter function are better served by an abdominoperineal resection, and this should be discussed preoperatively as well. Preparation of the operating room and operative team should include a brief discussion of the operative steps and any potential special requests or needs during the operation. In our experience, it has been helpful to discuss the need for an additional operative set-up for perineal dissection, changes in positioning, intraoperative endoscopy, and frozen-section analysis.

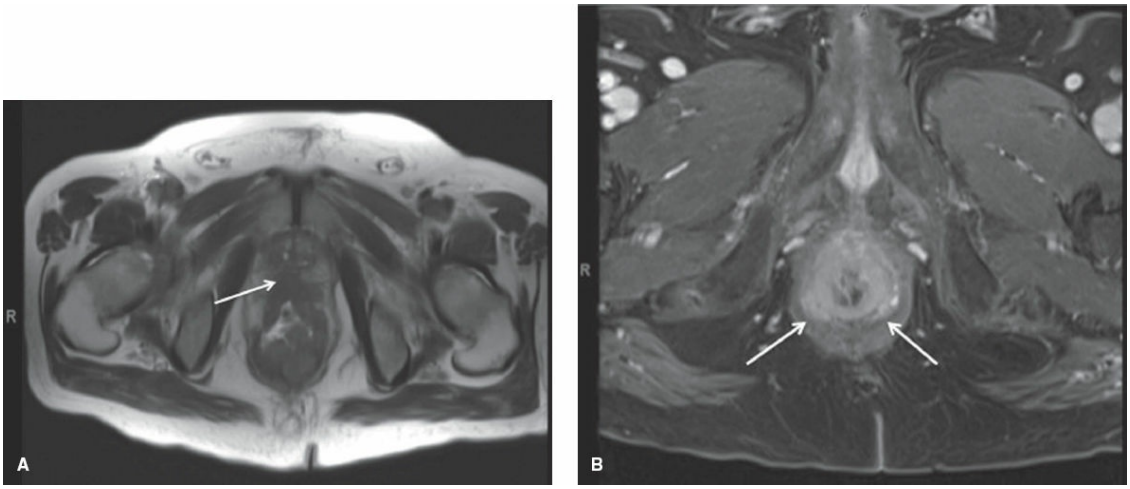

Figure 155.4. Pelvic MRI showing a large bulky rectal cancer with invasion of the prostate (**A**; *arrow*) and bilateral levator ani muscles (**B**; *arrow*).

SURGICAL TECHNIQUE

Regardless of approach (open or minimally invasive), the surgical

technique of proctectomy with TME is the same. For open proctectomy, a lower midline laparotomy incision is preferred and the use of a wound-protector and self-retaining surgical retractor is highly recommended. With a minimally invasive approach (robotic, pure laparoscopy, or hand-assisted laparoscopy), access to the peritoneal cavity varies and options include a hand-assisted incision, open trocar placement (Hassan technique), and closed technique with a Veress needle or an optical viewing trocar. Trocar placement varies according to patient anatomy and surgeon preference. Our preference is shown in Figures 155.5 to 155.7. After entering the peritoneal cavity, the intra-abdominal viscera and peritoneal surfaces should be evaluated to exclude metastatic disease. The presence of ascites should be noted and documented. However, cytology of ascites fluid in the absence of suspicious metastatic disease has little to no impact or benefit. The small bowel is then displaced or packed into the upper abdomen, and the patient is placed in the Trendelenburg position.

Colon Mobilization and Division of Blood Supply

Colon mobilization is then initiated using a medial-to-lateral or lateral-to-medial technique (Figs. 155.8 and 155.9). It is our preference to use the medial-to-lateral technique, especially with a minimally invasive approach as it allows for early identification of the left ureter, dissection of the retroperitoneal attachments from the colon mesentery, and dissection of the vascular pedicle (IMA and inferior mesenteric vein [IMV]). After the medial-to-lateral dissection is complete, the splenic flexure and lateral attachments of the descending colon and sigmoid colon are taken down. In cases where the splenic flexure is high and not easily accessed, mobilization is facilitated by taking down the transverse colon attachments medially first and then continuing laterally to the splenic flexure.

After adequate colon mobilization, the IMA is ligated with sutures, clips, or a stapler with a vascular load (white or gray) (Fig. 155.10). “High ligation” is defined as ligation of the IMA just beyond its origin from the aorta, and “low ligation” is defined as ligation of the IMA just beyond the takeoff of the left colic artery. Consensus does not exist on the optimal level of arterial ligation for rectal cancer operations from an oncologic standpoint. Two systematic reviews have assessed the impact of the level of IMA ligation in rectal and descending colon cancer operations, and one randomized controlled trial has been conducted assessing this topic. Although both reviews found insufficient evidence to support high

ligation, one found increased lymph node retrieval, more accurate tumor staging, and a trend for improved survival with the high ligation technique. The only randomized controlled trial found no significant differences in 12-year survival, anastomotic leak (AL) rates, overall morbidity, and 30-day mortality rates between patients undergoing high IMA ligation or not. It is our practice to perform high ligation of the IMA as well as IMV ligation as required for lengthening the descending colon mesentery but not for additional oncologic benefits.

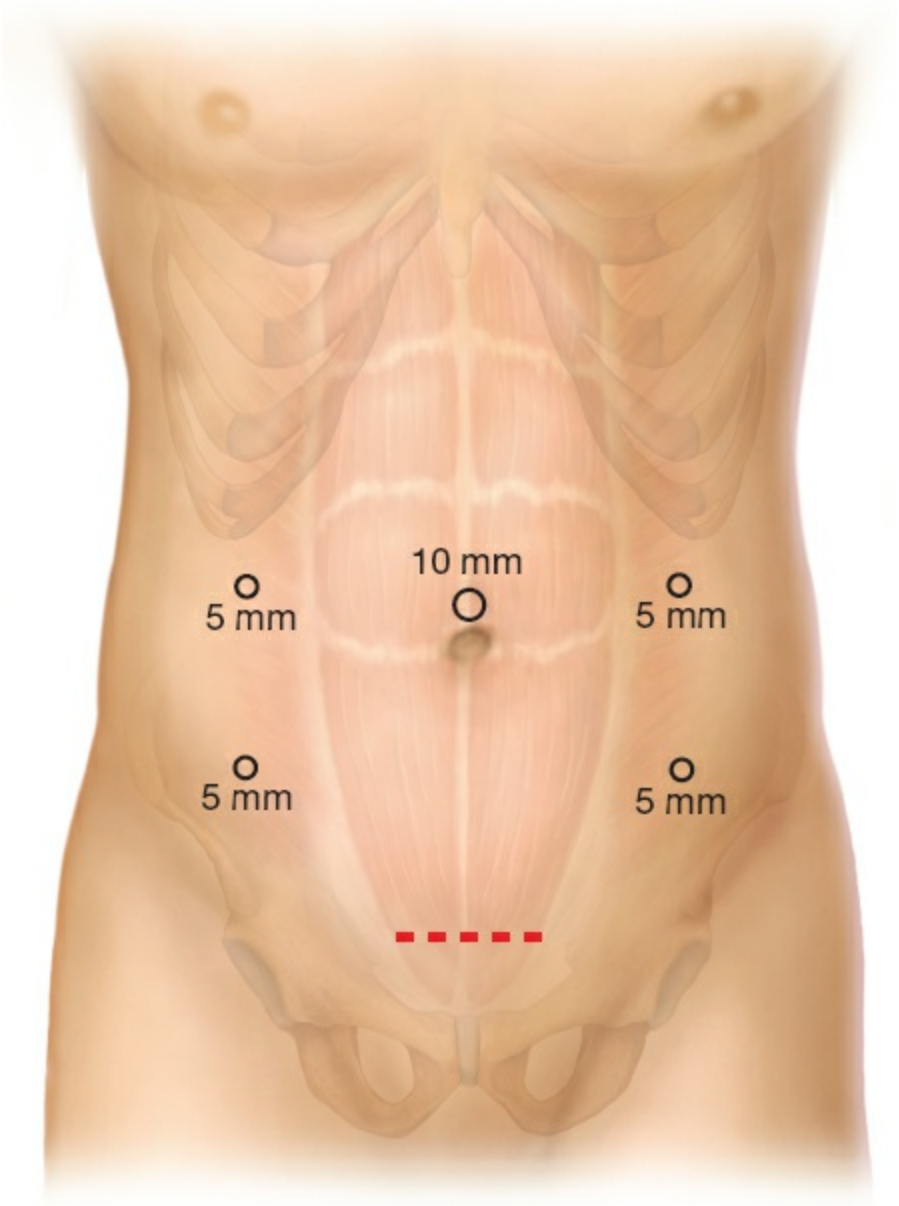

Figure 155.5. Trocar placement for laparoscopic proctectomy. The peritoneal cavity is typically accessed through a left upper quadrant or supraumbilical port. The left-sided ports are optional and are most useful for takedown of the splenic flexure. The right

lower quadrant port should be placed at the pre-marked ileostomy site. A 12-mm port can be placed at the right lower quadrant or mini-Pfannenstiel incision to allow insertion of a laparoscopic stapler. The mini-Pfannenstiel incision allows for anvil placement and specimen extraction. (Figure 15.1 from Laparoscopic Low Anterior Resection with Transanal Anastomosis or Colonic J Pouch Creation [Wexner/Fleshner].)

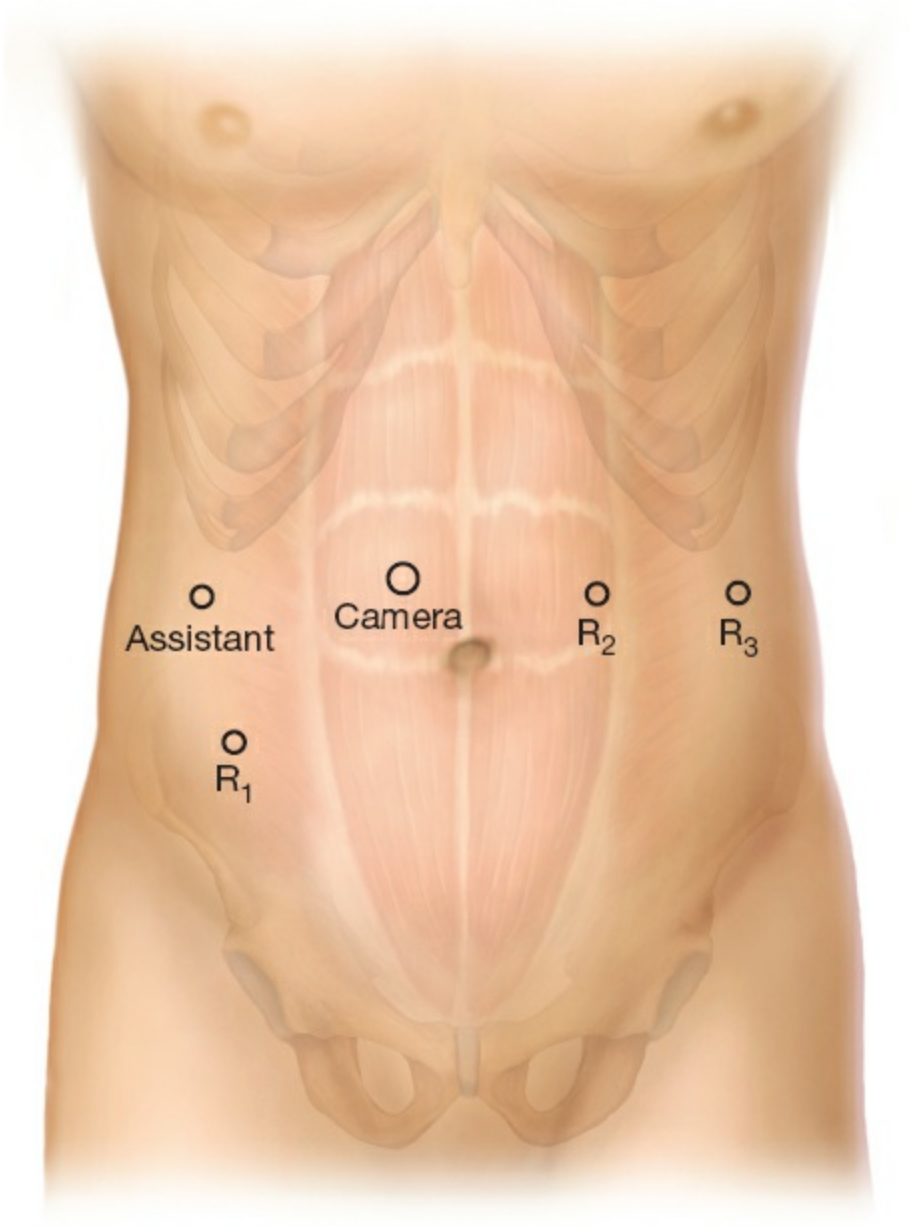

Figure 155.6. Trocar placement for laparoscopic robotic-assisted proctectomy. Access to the peritoneal cavity typically occurs via the left upper quadrant or with an open (Hassan) technique. A 12-mm port will be required at R1 if a robotic stapler is to be used. (Figure 17.5 Hybrid Robotic and Fully Robotic Procedures [Wexner/Fleshner].)

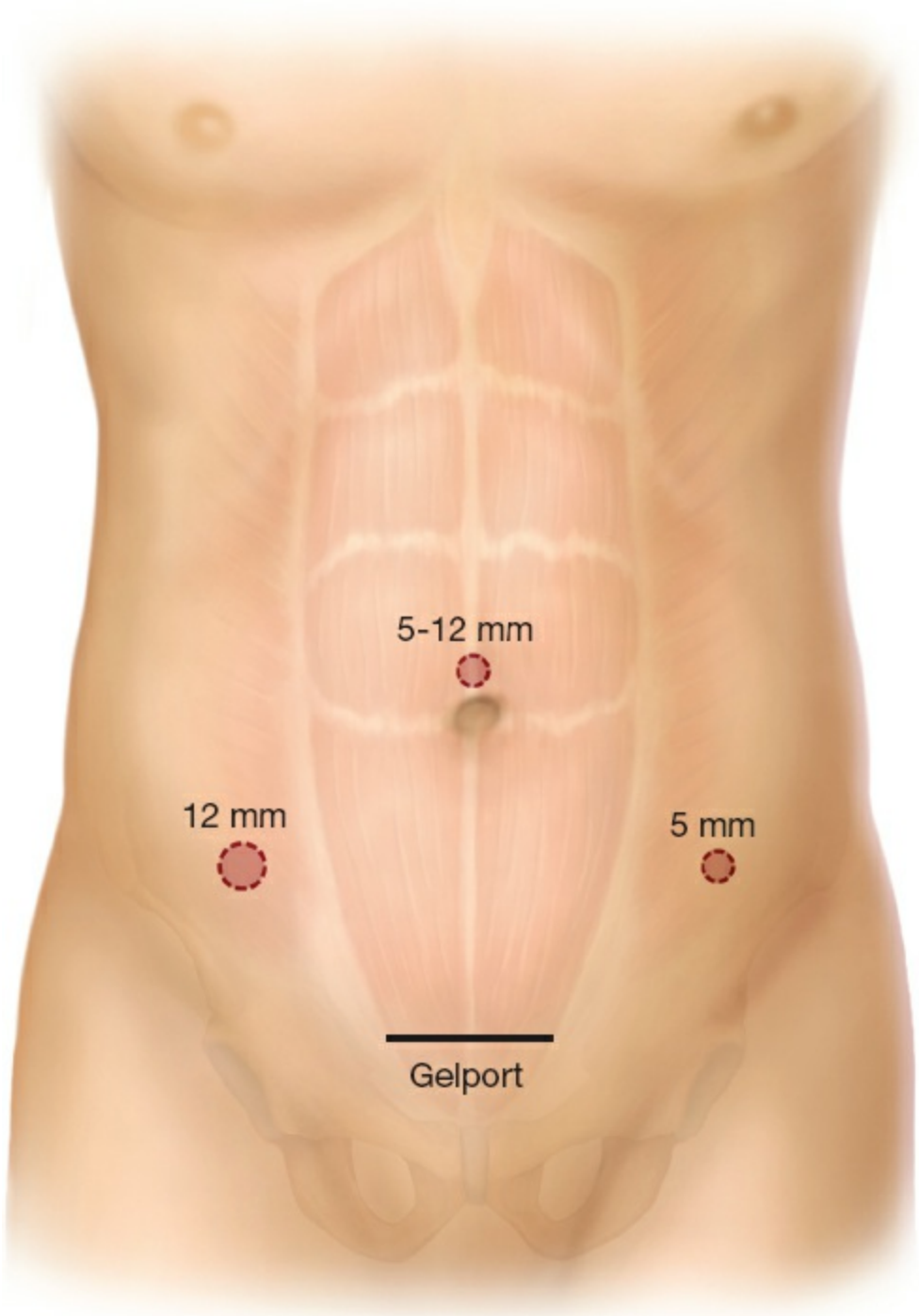

Figure 155.7. Trocar placement for hand-assisted laparoscopic proctectomy. The hand-assisted gelport may be placed at the lower midline or as a Pfannenstiel incision. (Figure 2 from Low Anterior Resection: Hand-Assisted Laparoscopic Surgery Technique [Albo].)

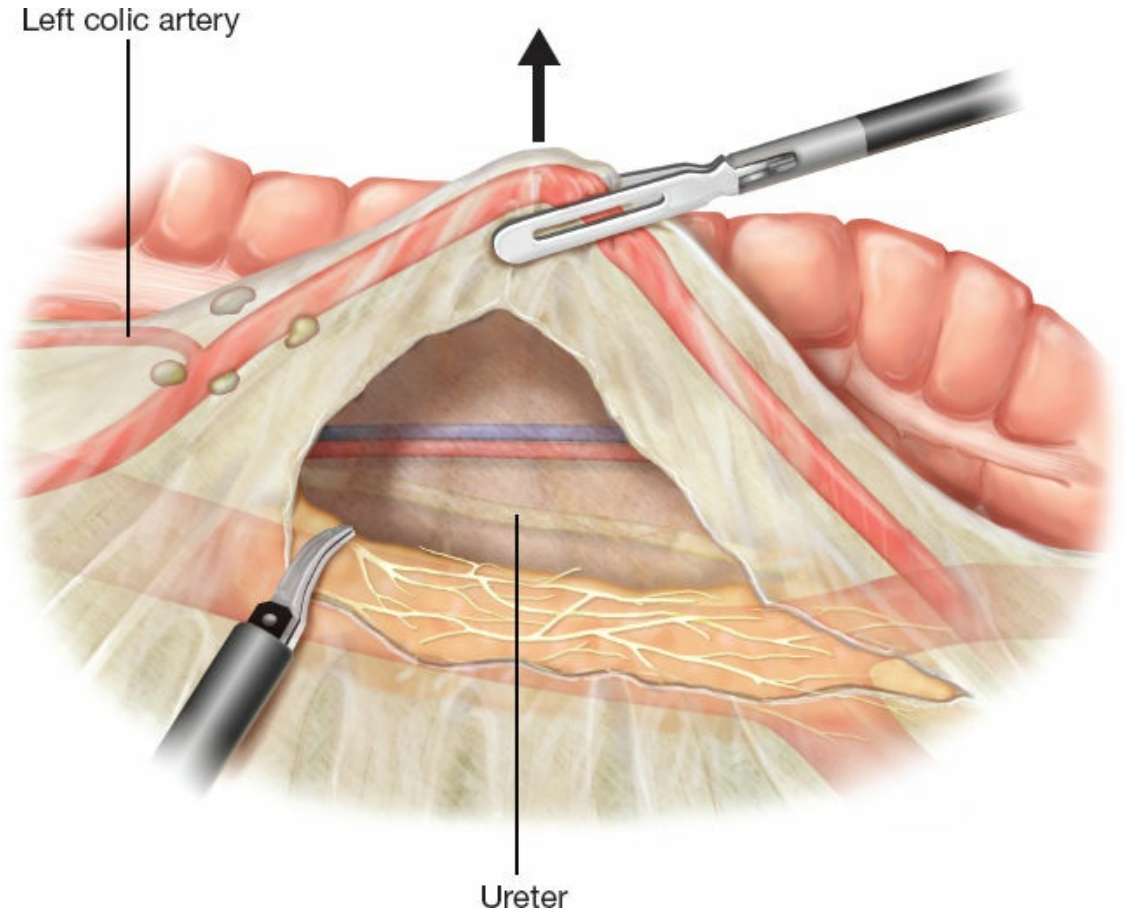

Figure 155.8. Anatomy seen with a medial-to-lateral technique during a laparoscopic low anterior resection. At the level of the sacral promontory, the inferior mesenteric artery is tented anteriorly toward the abdominal wall, allowing for dissection parallel and deep to the artery. Note the left colic artery is preserved. Nerve fibers from the sympathetic plexus lay below the artery, and are swept down and preserved. Prior to transection, identification of the left ureter is vital to ensure it is not inadvertently transected with the vascular bundle. (Figure 15.2 from Laparoscopic Low Anterior Resection with Transanal Anastomosis or Colonic J Pouch Creation [Wexner/Fleshner].)

After vessel ligation, the mesentery is transected and the colon is divided at the descending-sigmoid colon junction with a linear or transverse stapler. This step is especially helpful with the open approach as it facilitates rectal retraction. The descending colon should then be assessed for adequate blood supply and length. To ensure appropriate length for a tension-free anastomosis, the proximal margin should easily reach the pubic symphysis.

Total Mesorectal Excision and Autonomic Nerve Preservation

The fundamental components of TME include the following principles:

- Anatomic dissection under direct vision following the fascia propria of the mesorectum.
- Excision of an intact specimen without tissue tears or involvement of the distal or circumferential margins.
- Intraoperative recognition and preservation of autonomic nerves to reduce postoperative genitourinary dysfunction.
- Personal assessment of the surgical specimen for immediate feedback regarding completeness of resection.

Dissection of the rectum continues into the pelvis, mobilizing the mesorectum off the sacrum along the avascular plane of the endopelvic fascia. TME requires dissection under direct vision along the areolar plane located between the mesorectum at the visceral fascia (fascia propria) and the pelvic parietal (presacral) fascia (Fig. 155.11). As a helpful visual guide to proper dissection, the parietal fascia is usually “whiter” than the visceral fascia. This plane continues laterally with careful dissection around the mesorectum, keeping the integrity of the endopelvic fascia intact. Firm anterior and lateral retraction of the rectosigmoid can facilitate the dissection at the pelvic brim and posteriorly in the retrorectal space. Bilateral hypogastric nerves and ureters should be identified and avoided (Fig. 155.12).

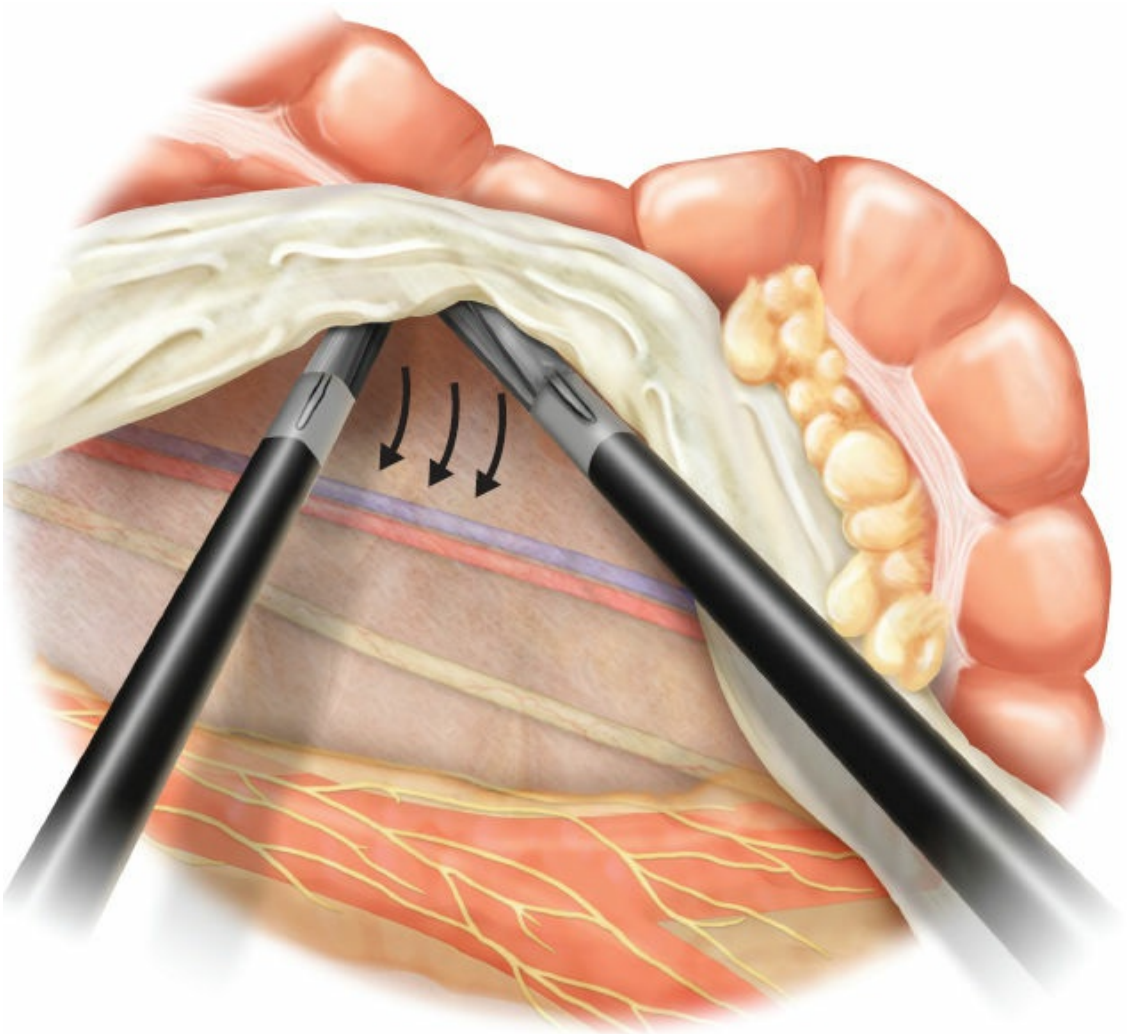

Figure 155.9. The medial-to-lateral dissection is facilitated by reverse Trendelenburg with left side elevated. Retractors are placed under the mesentery to keep tension on the line of Toldt and retroperitoneum. Open bowel graspers elevate the mesentery allowing for a wider line of traction during the dissection. Dissection follows the retroperitoneum to the lateral sidewall, superiorly to the splenic flexure and inferiorly toward the iliac fossa. Care must be taken to ensure that the ureter and retroperitoneal structures remain with the retroperitoneum, and the plane of dissection does not veer under the distal edge of the pancreas. (Figure 15.3 from Laparoscopic Low Anterior Resection with Transanal Anastomosis or Colonic J Pouch Creation [Wexner/Fleshner].)

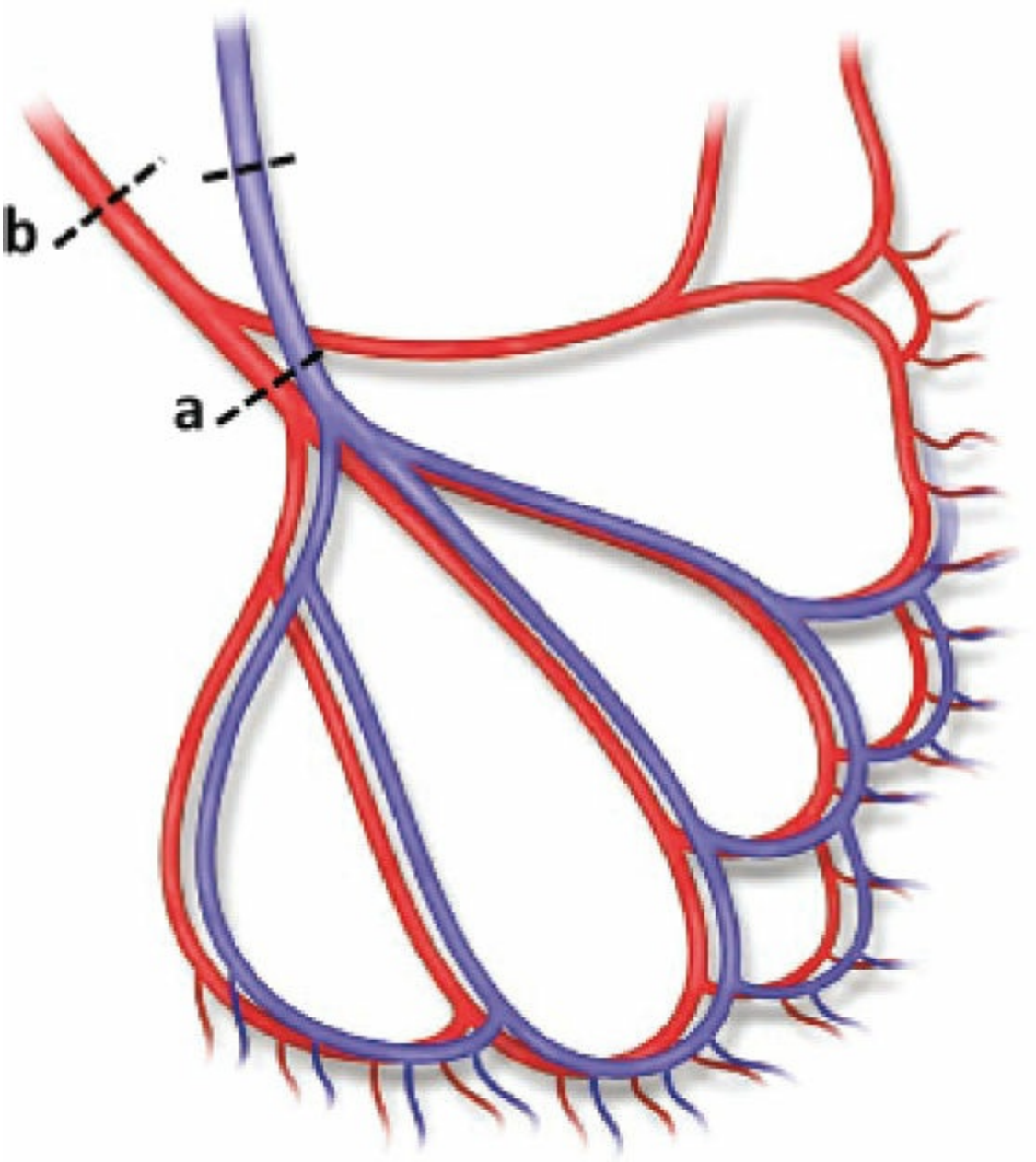

Figure 155.10. Vascular division sites of the inferior mesenteric artery (a. low ligation, b. high ligation), and inferior mesenteric vein. (Figure 17.7 Hybrid Robotic and Fully Robotic Procedures [Wexner/Fleshner].)

After the retrorectal dissection is complete, the peritoneum is incised at the rectouterine or rectovesicle fold at the cul-de-sac starting anteriorly and then extending laterally to connect to the posterior-lateral dissection. Anteriorly, the plane between the rectum and the seminal vesicles and prostate or posterior vaginal wall is dissected under direct vision. We do not routinely excise Denonvilliers fascia unless the tumor involves the anterior rectal wall. Once the dissection is complete, the endopelvic fascia

envelope is maintained resulting in a bilobed mesorectum covered by an intact “shiny” mesorectal fascia (Fig. 155.13).

The autonomic nerves are exposed to trauma at the following locations and operative steps: at the base of the IMA during vessel ligation, at the mesosigmoid colon during mobilization of the sigmoid colon near the sacral promontory, during lateral pelvic sidewall dissection, and just lateral to the seminal vesicles in male patients or the cardinal ligaments in female patients.

Transanal TME

Transanal TME (taTME) is an emerging technique in rectal cancer surgery. Despite significant improvements in operative technique, the laparoscopic and robotic approaches to TME still present a technical challenge, particularly in the case of a low rectal cancer in an obese male patient with a narrow pelvis. Achieving adequate exposure deep in the pelvis and cross-stapling the rectum just above the pelvic floor can be very difficult. Furthermore, an adequate distal rectal margin for distal rectal tumors may be difficult to assess with the laparoscopic approach. Transanal TME has been developed to facilitate dissection in the low pelvis and accurately assess the distal rectal margin approaching the rectum from below (“down to up”) with a combination of laparoscopic and transanal minimal invasive surgery (TAMIS) to perform a full TME (Fig. 155.14). The rectum is divided via a transanal approach without a stapler, leaving an open stump. The surgeon then has the options of performing a stapled anastomosis after closure of the rectal stump with a purse string suture, or a handsewn coloanal anastomosis.

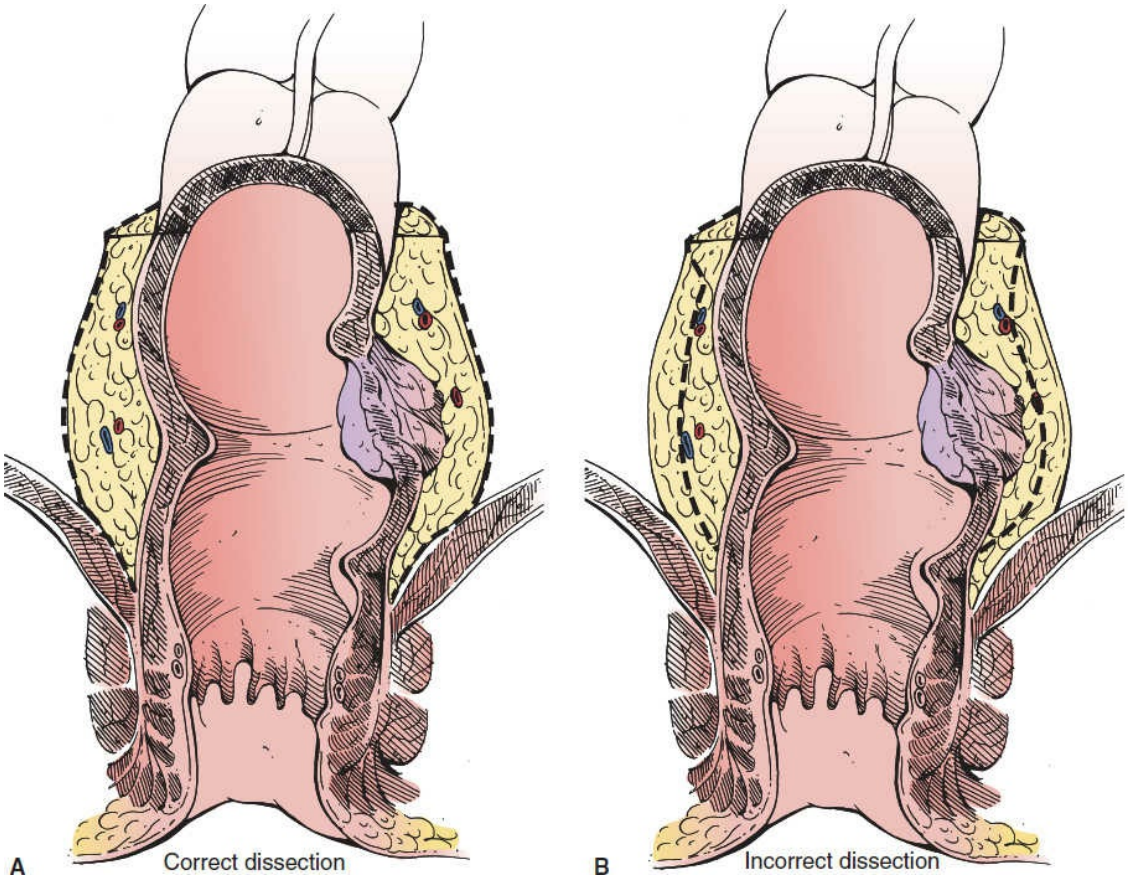

Figure 155.11. Correct total mesorectal excision dissection versus an incorrect dissection. The dissection should proceed between the mesorectal fascia and the pelvic wall fascia.

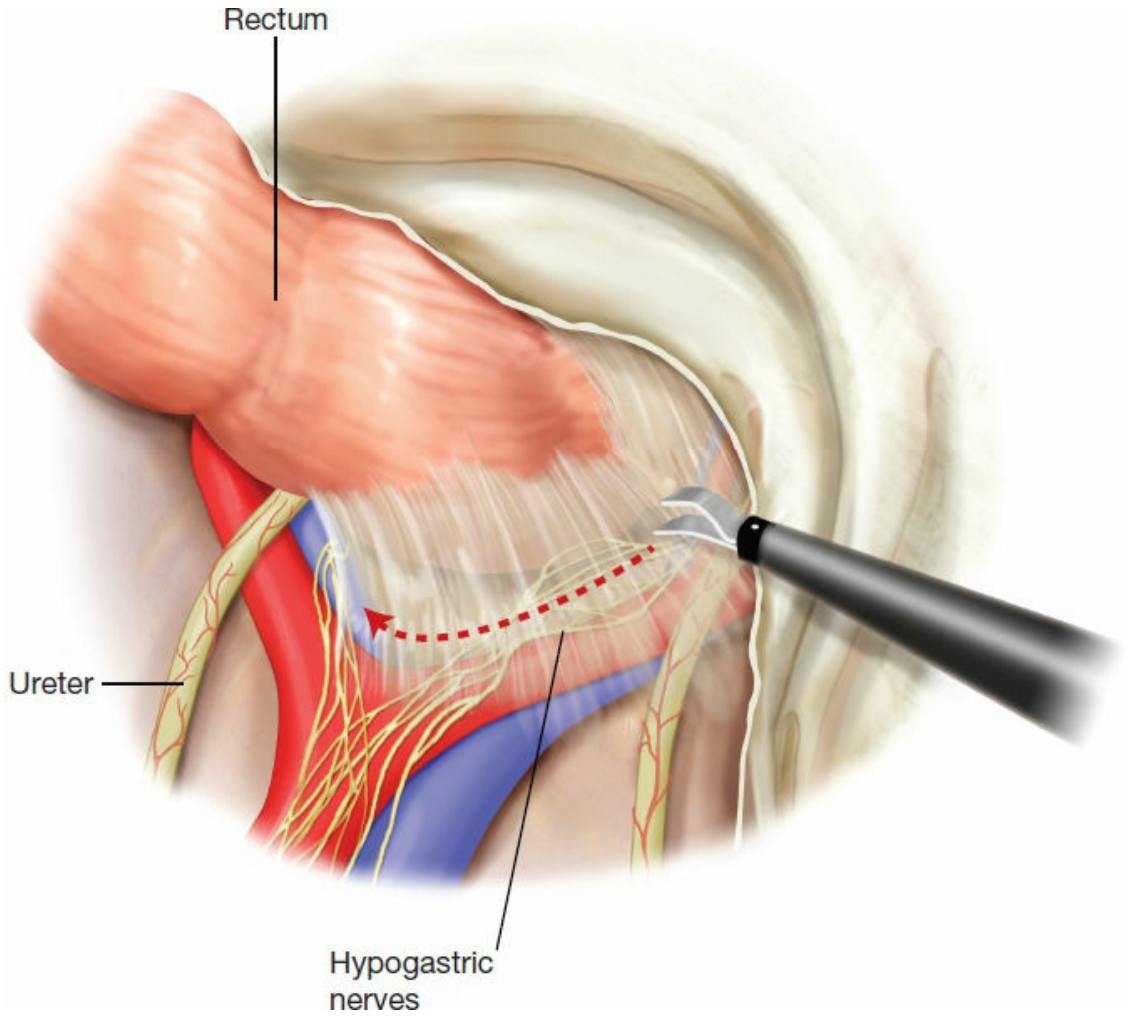

Figure 155.12. Entering the appropriate plane for mesorectal dissection is critical to oncologic resection. By reflecting the rectosigmoid junction anteriorly and superiorly, a plane may be visualized on the right side of the mesorectum. Sharp dissection should be performed in this avascular plane. (Figure 15.5 from Laparoscopic Low Anterior Resection with Transanal Anastomosis or Colonic J Pouch Creation [Wexner/Fleshner].)

Distal Resection

After the rectum distal to the tumor is dissected free, it is then transected with a stapler. With the open approach, a TA or Contour stapler with a green load is used. If a coloanal anastomosis is planned, the distal rectal transection is performed transanally (Fig. 155.15). With the laparoscopic and robotic approaches, it is especially helpful to perform flexible sigmoidoscopy intraoperatively to assure a negative distal margin, as the rectum cannot be palpated and because of the lack of tactile feedback with the robotic approach. In our experience, the articulation provided by the robotic stapler allows for distal rectal transection close to the anorectal

ring, and compares favorably to the laparoscopic staplers. The robotic approach can also facilitate the placement of a purse-string suture on an open rectal stump in preparation for a single-stapled circular colorectal anastomosis.



Figure 155.13. Bilobed mesorectal specimen covered by an intact mesorectal fascia.

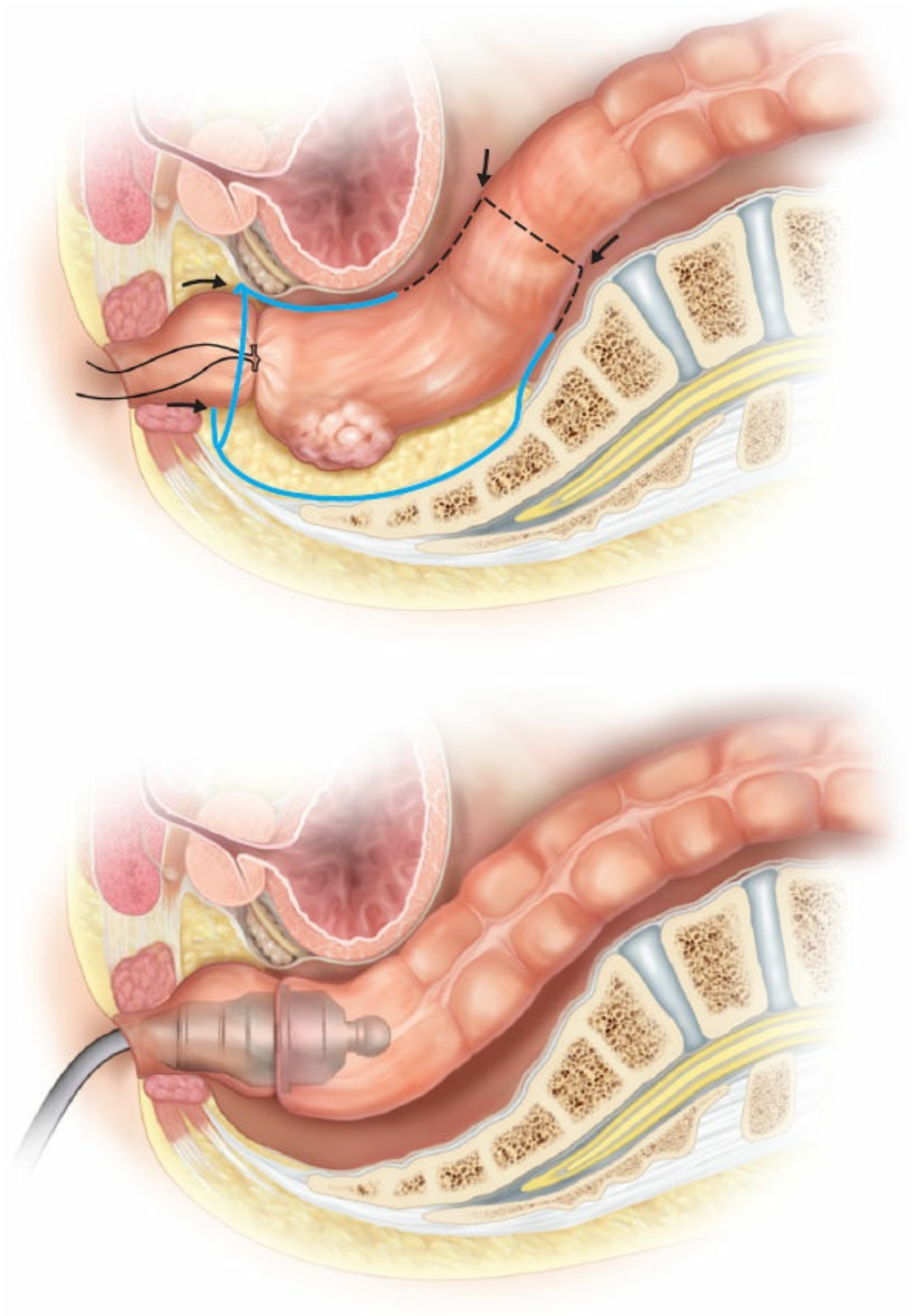

Figure 155.14. Rectal transection and dissection planes for transanal total mesorectal excision (TaTME). The distal rectum is closed from inside and transected below the tumor and the TaTME dissection (*blue lines*) meets the abdominal (open or laparoscopic) dissection (*black lines*).

For high and mid rectal cancers, radical resection with a partial TME 5 cm distal to the tumor and perpendicular to the rectum is performed. For middle to distal rectal cancers, the TME dissection is always taken down to the level of the pelvic floor. In patients with acceptable preoperative anorectal function, ideal body habitus and pelvic anatomy, sphincter preservation is usually possible for rectal tumors that would allow for at least a 1 cm distal margin. Some surgeons will perform an intersphincteric resection with sutured coloanal anastomosis instead of APR. Rullier and colleagues proposed a classification of distal rectal cancers with a standardized surgical approach according to the distance of the tumor from the anorectal ring and degree of invasion of the anal sphincter complex (Fig. 155.16). For an intersphincteric resection, the patient is kept in modified lithotomy, a Lonestar retractor is used to expose the anus, and the distal mucosal margin of resection at the dentate line is accessed through a circular incision. The incision is carried into the intersphincteric plane, preserving the external sphincter and sometimes the distal internal sphincter for continence. The abdominal and perineal dissections are then connected just above the puborectalis muscle. The posterior plane is the safest to initially enter. The anterior dissection is most difficult, and care must be taken to avoid the vagina in females and the prostatic urethra in males. The anterior dissection can be facilitated by placing a finger or sponge-stick into the vagina.

When the specimen is removed, the quality of the specimen is assessed. If there is concern for inadequate negative margins, immediate microscopic analysis should be performed. Pathologists play a key role in the evaluation of the specimen, including the quality assurance of surgical performance, as well as evaluation of the circumferential resection margin (CRM). Since proper pathologic assessment of a TME specimen provides important prognostic information, as well as critical feedback to surgeons regarding technical performance, it is important to have and follow adequate guidelines for the macroscopic handling of these specimens. Complete evaluation involves assessment of the specimen in both its fresh and fixed states, with observations made on both the external appearance and cross-sectional slices. Based on Quirke's grading system, the College of American Pathologists has published guidelines to grade TME specimens (Table 155.1). As an additional quality indicator, the surgical specimen should contain at least 12 lymph nodes but this is rarely achieved

after neoadjuvant chemoradiotherapy.

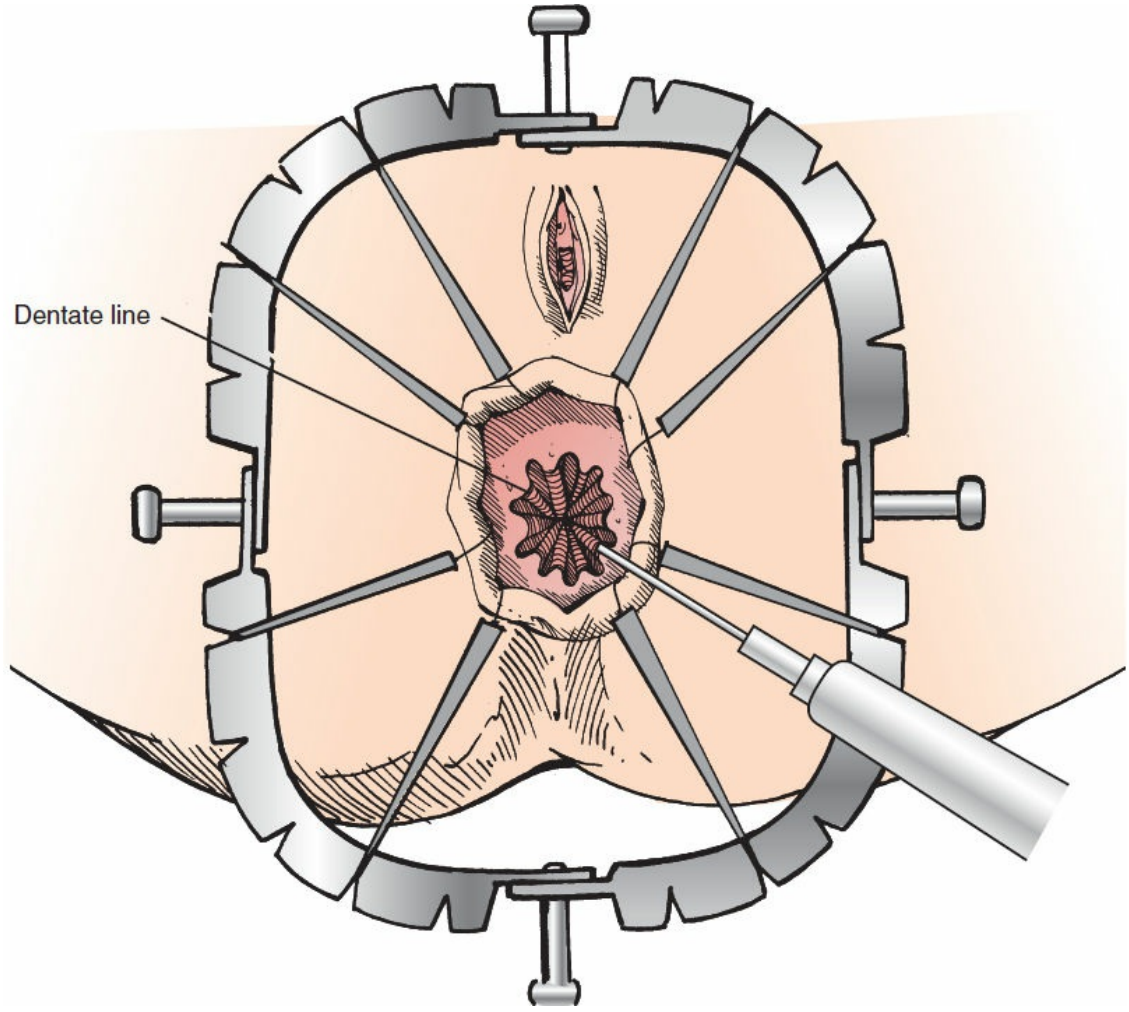

Figure 155.15. Perineal dissection with the patient in lithotomy position. Lidocaine with epinephrine is injected into the submucosa and the dentate line is incised. An intersphincteric dissection is then performed with either partial or complete excision of the internal anal sphincter.

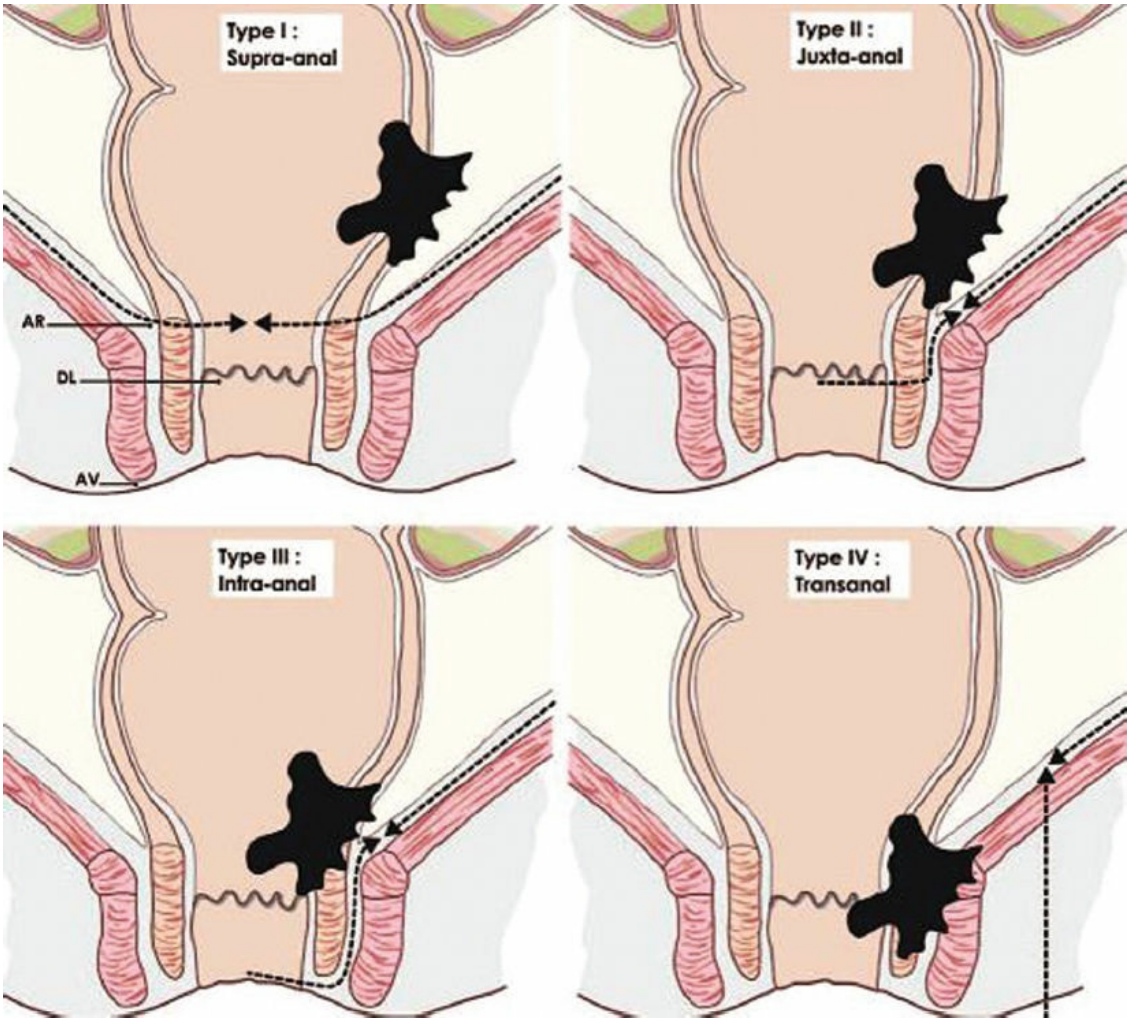

Figure 155.16. Surgical classification of low rectal cancer. Type I are supra-anal tumors (>1 cm from the anal sphincter) and treated by conventional coloanal anastomosis; type II are juxta-anal tumors (<1 cm from the anal sphincter) treated by partial intersphincteric resection; type III are intra-anal tumors (internal sphincter invasion) treated by total intersphincteric resection; and type IV are transanal tumors (external sphincter invasion) treated by APR. AR, anal ring; DL, dentate line; AV, anal verge. The *dotted line* represents the surgical dissection plane. (Modified from Rullier E, Denost Q, Vendrely V, et al. Low rectal cancer: classification and standardization of surgery. *Dis Colon Rectum* 2013;56(5):560–7.)

TABLE 155.1 Guideline for Grading TME Specimens

Incomplete	Nearly Complete	Complete
■ Little bulk to the mesorectum ■ Defects in the mesorectum down to the muscularis propria ■ After transverse sectioning, the circumferential margin appears very irregular	■ Moderate bulk to the mesorectum ■ Irregularity of the mesorectal surface with defects >5 mm, but none extending to the lamina propria ■ No areas of visibility of the muscularis propria except at the insertion site of the levator ani muscles	■ Intact bulky mesorectum with a smooth surface ■ Only minor irregularities of the mesorectal surface ■ No surface defects >5 mm in depth ■ No coning toward the distal margin of the specimen ■ After transverse sectioning the circumferential margin appears smooth

Reconstructive Techniques

There are several methods to reconstruct the rectum. A straight end-to-end anastomosis can be done with hand suturing, stapling, or transanal suturing. Reconstruction after low anterior resection (LAR) for mid and proximal rectal cancers can be performed with a straight end-to-end colorectal anastomosis without significantly sacrificing function. In a retrospective evaluation of patients comparing straight coloanal anastomosis *versus* colonic J-pouch, Hida et al. determined that the functional results are equivalent if the distance from the anal verge to the anastomosis was >8 cm but showed improved functional results with the colonic J-pouch when the distance was <8 cm. A colonic J-pouch should be used for reconstruction when the distance from the anal verge to the anastomosis is between 5 and 8 cm, but is particularly helpful for improved functional outcome when the distance from the anastomosis to the anal verge is ≤4 cm. The colon J-pouch is made using a stapled technique to create a 6-cm reservoir by making an enterotomy at the apex of the pouch (where the colon is folded onto itself) and introducing a linear cutting stapler along the antimesenteric aspect of the colon (Fig. 155.17). Some surgeons place additional sutures along the antimesenteric aspect of the colon to maintain proper configuration of the pouch and to take tension off the end of the staple line.

One disadvantage of the colonic J-pouch is that some patients cannot accommodate a large and somewhat bulky pouch in the pelvis. For this reason, some authors have recommended transverse coloplasty as a means to restore the rectal vault, but this technique has largely fallen in disfavor because of reports demonstrating higher leak rates with transverse

coloplasty (Fig. 155.18).

Anastomotic Techniques

The type of anastomosis depends upon a number of factors, including level of connection, patient body habitus, surgeon experience and preference, and whether or not diversion is planned.

An end-to-end anastomosis can be performed in one of three ways: (1) handsewn, (2) single-stapled, or (3) double-stapled. A handsewn anastomosis is commonly performed with an open approach and when the anastomosis is high in the pelvis. A single-stapled anastomosis can be technically challenging as it involves placing a purse-string suture at the rectal stump deep in the pelvis but, when feasible, it is preferred because there are no crossing staple lines. As suturing in confined surgical fields has become easier with the robotic approach, reports of single-stapled anastomosis have become popular with this minimally invasive approach. The double-stapled anastomosis is technically easier but involves two staple lines—one linear staple line across the distal end of resection at the rectal stump and the other, an end-to-end circular staple line. It is important with a low connection to ensure that the anastomosis does not incorporate the levator muscles or the vaginal wall anteriorly in females. With a double staple technique, there are typically one or two points of staple line intersection.

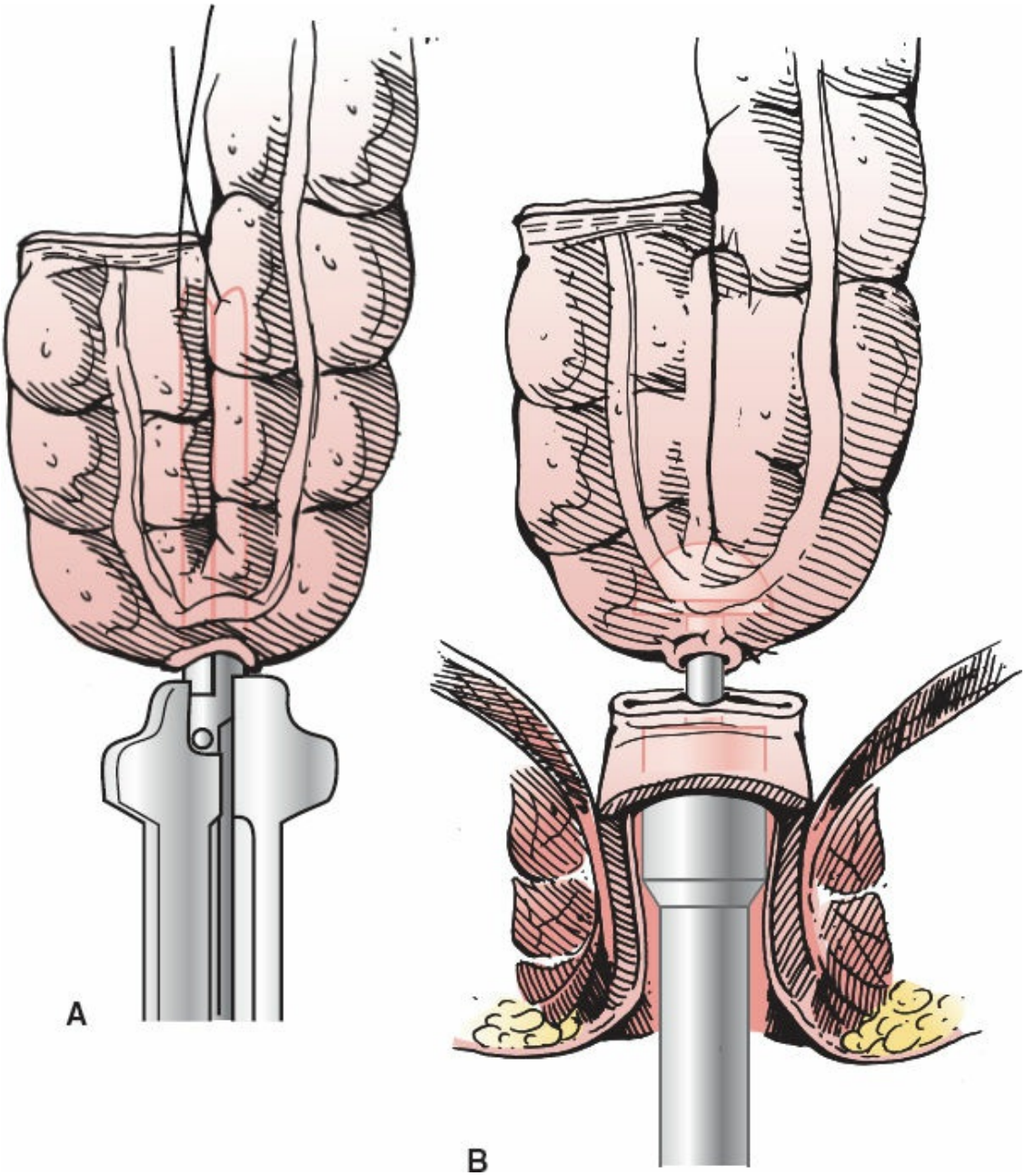

Figure 155.17. Construction of a colonic J-pouch after an ultra low anterior resection. The distal colon is folded back on itself to make a "J" and a 6-cm common channel along the antimesenteric aspect is then created using a stapling device. The J-pouch is then anastomosed to the anus using a circular stapler or in a handsewn manner.

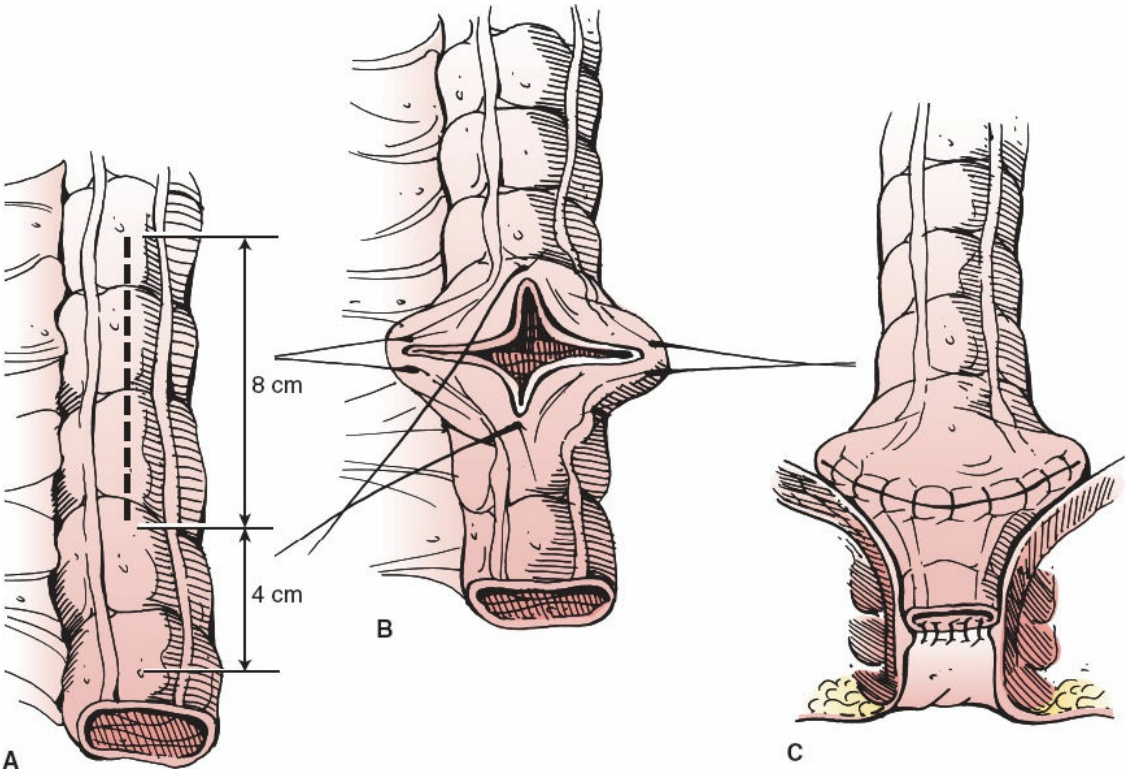

Figure 155.18. Construction of a transverse coloplasty. A longitudinal colotomy approximately 8 to 10 cm in length starting 4 to 6 cm from the distal colon resection margin is closed with a single layer of polyglycolic acid sutures in an interrupted fashion.

The Baker side-to-end anastomosis is preferred by some surgeons (Fig. 155.19). Similar to other reconstruction techniques, the Baker anastomosis is thought to improve postoperative defecatory function by providing a reservoir. It is important to keep the blind end of colon relatively short (2 to 3 cm) in order to avoid fecal stasis.

A handsewn coloanal anastomosis is performed with a perineal approach in cases where an intersphincteric dissection has been performed. This is done with the patient in modified lithotomy position where access is possible to both the abdomen and perineum simultaneously. Prior to delivering the colon through the anus, 2-0 Vicryl sutures are placed at the dentate line, incorporating generous bites of the internal sphincter muscle at the four cardinal aspects (Fig. 155.20). Interrupted sutures are then placed between the four quadrant stitches.

The use of drains in the pelvis is controversial. We do not hesitate to place a closed-suction drain in the pelvis if hemostasis is not perfect. On the other hand, there is little evidence that routine pelvic drain placement reduces the incidence of pelvic sepsis or anastomotic failure.

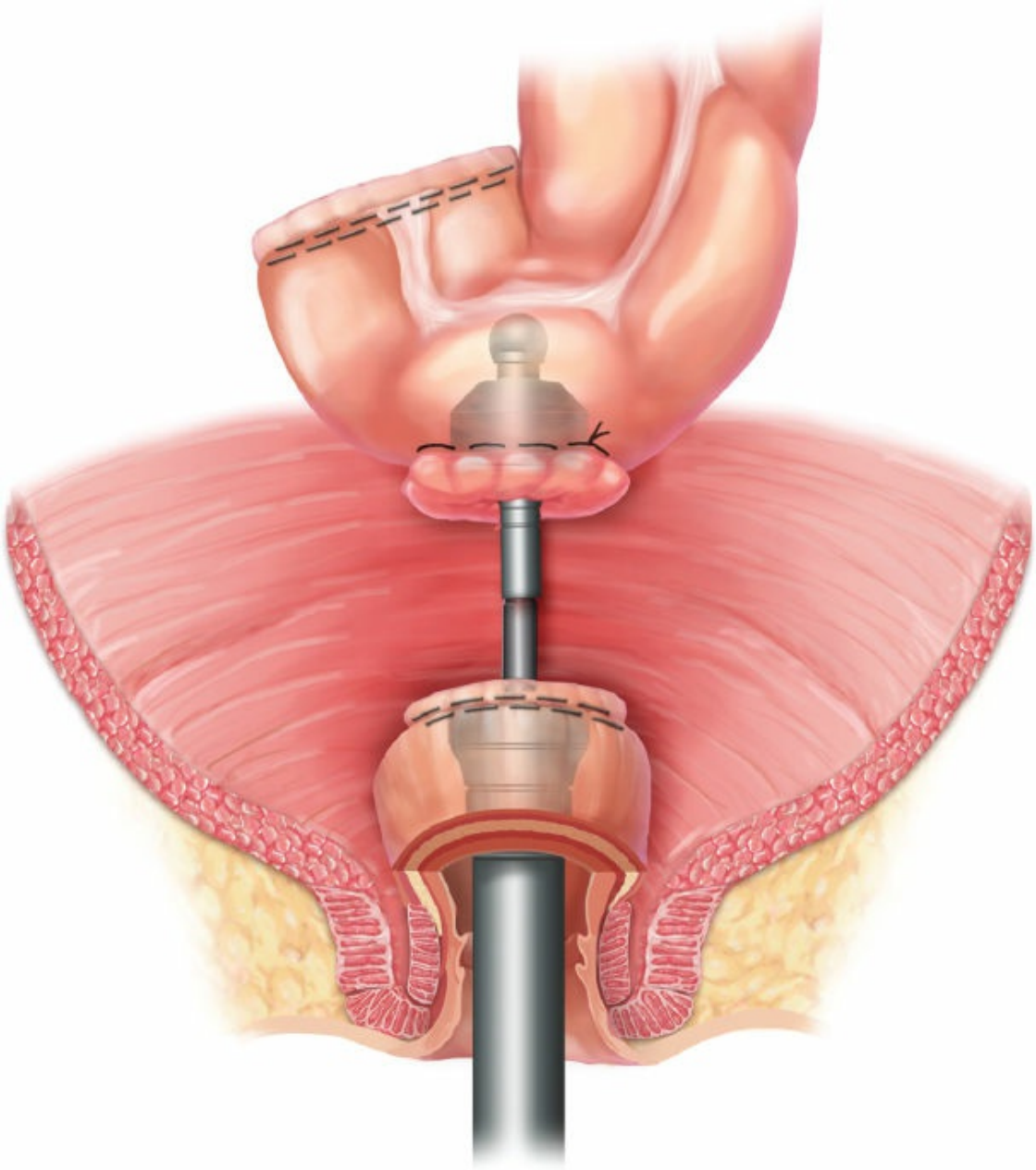

Figure 155.19. An end-to-end circular stapler is introduced through the rectum and the anvil brought out through the side of the colonic wall in order to create a circular side-to-end (Baker) stapled anastomosis. Note the side limb should be approximately 3 cm. (Figure 16.3 from End-to-End, Side-to-End Anastomosis [Wexner/Fleshner].)

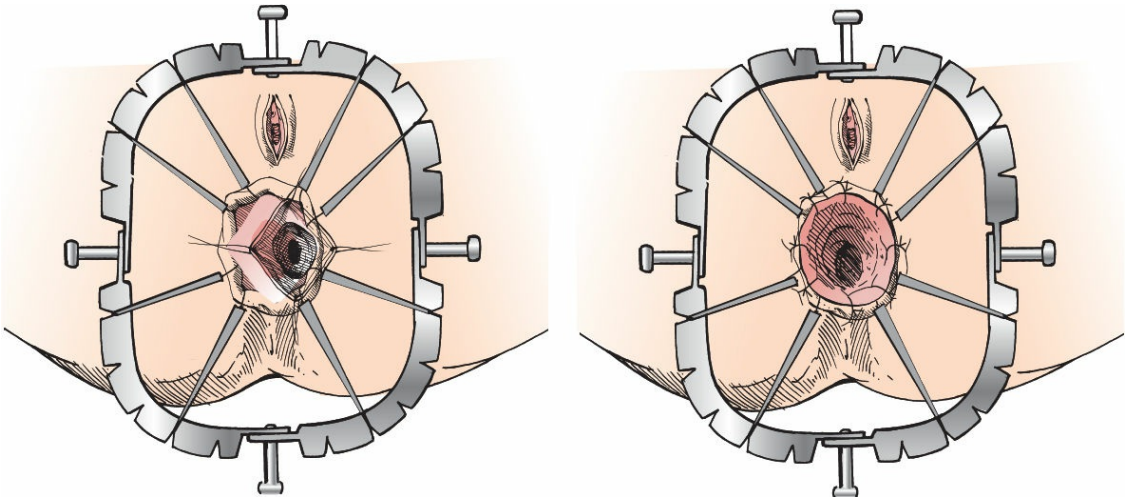

Figure 155.20. Coloanal handsewn anastomosis. This can be straight or a colonic pouch can be created if there is adequate length. Full-thickness bites are taken through the descending colon wall and the transected lower border of the internal sphincter, including the overlying anoderm. Four corner sutures are placed at 12, 3, 6, and 9 o'clock positions and left untied until one or two full-thickness bites have been placed between each corner suture.

Hydro-Pneumatic Testing

All colorectal anastomoses should be tested by gently insufflating the anastomotic site with air while submerged in fluid. Intraoperative anastomotic testing is widely accepted among surgeons, but its role and impact have not been well studied until recently. Ricciardi and colleagues reviewed the outcomes of 998 patients undergoing left-sided colorectal anastomoses without proximal diversion. Intraoperative air leaks were noted in 65 of 825 tested anastomoses (7.9%). A clinical leak developed in 48 patients (4.8%); 7.7% occurring in anastomoses with a positive air leak test compared to 3.8% in anastomoses with negative air leak test. When air leak testing was positive, suture repair alone was associated with the highest rate of postoperative clinical leak (12.2%) compared with diversion (0%) or reanastomosis (0%). In our practice, we divert all patients with mid and low rectal anastomoses. In the setting of a positive hydro-pneumatic test, it is our preference to perform reanastomosis when feasible. However, when a small anastomotic defect is identified and reanastomosis is difficult, primary suture repair (if feasible) with diverting loop ileostomy is preferred. Very low ALs can be repaired transanally, and significant leaks from low rectal stapled anastomoses are usually better-off

by conversion to a sutured coloanal anastomosis.

Diversion

Anastomotic complications are more common with distal rectal anastomoses and include leak and stricture. Complication rates also increase with radiotherapy, tension, or tissue ischemia. Temporary diversion is especially helpful in patients with a low colorectal anastomosis (<5 cm) and in the setting of preoperative radiotherapy. Diversion helps decrease the problems associated with AL and is typically done with a loop ileostomy. In our practice, all patients with a low anastomosis (<6 cm), particularly those with preoperative radiotherapy, undergo diversion.

A loop ileostomy is performed by making a circular skin incision at the preoperative marked site in the right lower quadrant. The subcutaneous tissue and anterior fascia are incised with electrocautery and the anterior rectus muscle is split. The rectus muscle is retracted, and the posterior sheath is exposed and incised. The loop ileostomy is matured without a stoma bridge in an everted Brooke fashion after the abdomen is closed.

POSTOPERATIVE CARE

Nasogastric tube suction is not usually required. Patients are allowed to have a liquid diet the evening of surgery and can be advanced according to return of bowel function. The urinary catheter is kept for 3 to 4 days. Patients are encouraged to ambulate the day after surgery and pneumatic compression stockings are removed once patients are fully ambulatory. Pharmacologic VTE prophylaxis is continued the day after surgery and is continued for up to 30 days in patients who are high risk for VTE (cancer, morbid obesity, and inflammatory bowel disease). Drains, if present, are typically removed before discharge from the hospital. Postoperative enterostomal teaching is essential to all patients with a new stoma.

COMPLICATIONS AND THEIR MANAGEMENT

Anastomotic Leak

AL is the most morbid complication following rectal cancer surgery, with reported incidences ranging between 1% and 19%. Male gender, preoperative radiation, body mass index, smoking, hypoalbuminemia, immunosuppression, American Society of Anesthesiologists score above

II, renal disease, emergency surgery, and extraperitoneal anastomoses have been identified as risk factors in selective studies. Intraoperative risk factors also include blood loss/transfusion and duration of surgery more than 4 hours. Although AL has been reported as an independent risk factor for local recurrence and death from cancer, these results have not been consistently duplicated and remain debatable. Protective stomas have shown to lessen the infectious and functional consequences but not the prevalence of AL.

AL is defined as a breach in the surgical joint between two hollow viscera with or without active leak of luminal contents, but the term involves a spectrum of clinical severity, ranging from a small, contained leak without systemic symptoms to diffuse peritoneal contamination with severe sepsis and multisystem organ failure. Patients typically present with fever, abdominal pain, and elevated inflammatory markers between postoperative day 5 and 7, and CT is the most commonly used diagnostic tool. Abscess adjacent to the anastomosis with or without air or rectal contrast in its interior is the most common radiologic finding. Early AL (24 to 72 hours) is usually related to severe ischemia, mechanical failure from poor technique, or stapler misfiring, and requires prompt reoperation because of the amount of peritoneal contamination. Contained leaks with mild systemic manifestations are commonly managed with percutaneous drainage and intravenous antibiotics with good results. However, if a patient clinically worsens or fails to improve, reoperation with reanastomosis or fecal diversion is warranted. In our experience, only selective patients with AL, minimal peritoneal contamination, and mild systemic manifestations are candidates for reanastomosis with diverting loop ileostomy.

Reanastomosis is not feasible with low rectal anastomoses. Large anastomotic defects with severe abdominopelvic sepsis and irreversible colon ischemia are better managed with abdominal washout, wide drainage, and end colostomy. With low rectal and coloanal ALs without significant pelvic sepsis, we perform transanal drainage with transanal repair, when feasible.

OUTCOMES

Oncologic Outcomes

In most series, local recurrence rates are less than 7% in patients undergoing TME even when no adjuvant therapy is given. The impact of

neoadjuvant treatment including short- and long-course radiotherapy with or without chemotherapy plus TME in two European randomized controlled trials confirmed the local control benefit even in the setting of optimal surgery, with 5-year local recurrence rates of 6% compared to 12% to 13% with TME alone. Despite no significant differences in long-term survival or sphincter-preserving operations, neoadjuvant chemoradiotherapy is currently well accepted in the United States and continues to play a significant role in the management of rectal cancer.

Despite a significant increase in the rate of sphincter-preserving surgery, most radical resections for rectal cancer in the United States result in a colostomy. The determining factor in performing a sphincter-preserving operation is the ability to obtain an adequate distal margin. When distal intramural spread occurs, it is usually within 2 cm of the tumor unless the lesion is poorly differentiated or widely metastatic. A randomized prospective trial conducted by the national surgical adjuvant breast and bowel project did not demonstrate significant differences in survival or local recurrence when comparing distal margins of <2 cm, 2 to 2.9 cm, and >3 cm. Shorter distal margins may be acceptable in patients with very low rectal cancers undergoing a sphincter-preserving operation but should be confirmed by a frozen section as previous reports have outlined the detrimental effect of tumor within 1 mm of the CRM.

Reports supporting acceptable oncologic results with distal margins <1 cm are mainly of retrospective nature, low numbers, limited follow-up, and discrepant survival reporting. These studies have shown local recurrence rates ranging from 6% to 12%, and median survival rates between 3 and 5 years of 70% to 82%, with no significant differences when compared to distal margins >1 cm. Predictive factors of recurrence after ultra-LAR with a distal margin <1 cm have included distance of the tumor from the anal verge, tumor stage (specifically lymph node metastases), and R1 resection (microscopically positive margins).

The decision whether to partially or completely excise the internal anal sphincter and obtain an R0 resection depends on specific location of the rectal cancer and its relation to the anal sphincter complex. Rullier and colleagues proposed a classification of low rectal cancers with standardization of surgery according to the type of tumor (I: supra-anal, II: juxta-anal, III: intra-anal, and IV: trans-anal). Of 404 patients with low rectal cancers, the authors found no difference in local recurrence (5% to 9% vs. 6%), distant recurrence (23% vs. 23%), and disease-free survival

(70% to 73% vs. 68%) at 5 years between ultra-low (types II to III) and conventional (type I) sphincter-preserving surgery.

Outcomes after taTME are being increasingly published. Most reports are single-institution experiences with small numbers and relatively short follow-up. Lacy et al. recently reported their experience with 140 taTME operations and showed a macroscopically complete TME specimen in 97% of patients, with a 2.3% local recurrence rate and a 7.6% rate of systemic recurrence at a mean follow-up of 15 months.

A recent controversy in rectal cancer surgery that deserves discussion is the assessment of the distal margin and feasibility of sphincter-preserving radical resection after neoadjuvant chemoradiotherapy. Distal rectal cancers that are thought to require abdominoperineal resection and have a good clinical response to neoadjuvant therapy may appear to be amenable to a sphincter-preserving radical resection because of tumor downstaging. Complete tumor disappearance on pathologic examination of the surgical specimen (complete pathologic response) is achieved in 10% to 30% of the patients. These results have led to a therapeutic dilemma regarding possible change in the operative strategy in these patients. Madbouly and colleagues evaluated the outcomes of 45 patients with distal T3 rectal carcinoma who were thought to require abdominoperineal resection before long-course neoadjuvant chemoradiotherapy but because of successful downstaging underwent colorectal (n = 9) and coloanal (n = 36) anastomosis. Criteria for changing operative strategy to sphincter preservation were tumor downsizing that would allow for a 1 cm distal safety margin above the anal sphincters with a free potential CRM on pelvic MRI. No positive margins were reported. At a mean follow-up of 57 months, local recurrence occurred in 8.8% of patients and disease-free survival was 87%. Changing operative strategy from abdominoperineal resection to a sphincter-preserving proctectomy after downstaging by neoadjuvant chemoradiotherapy requires further evidence and remains investigational.

Functional Outcomes

Low Anterior Resection Syndrome

Bowel dysfunction following LAR has been well recognized and reported. This so-called ‘‘low anterior resection syndrome’’ or LARS represents a constellation of symptoms that include increased stool frequency, bowel fragmentation, fecal urgency and incontinence, and seriously impacts

patients' quality of life. A variety of studies have reported an incidence of between 25% and 50% of LARS depending on syndrome classification and patient follow-up, but significant variability exists in the reporting of outcomes after anterior resection and the majority of studies do not use a validated assessment tool. This has led to the development of an internationally validated scoring system assessing the severity of LARS, the LARS score (Fig. 155.21).

The aim of this questionnaire is to assess your bowel function. Please tick only one box for each question. It may be difficult to select only one answer, as we know that for some patients symptoms vary from day to day. We would kindly ask you to choose one answer which best describes your daily life. If you have recently had an infection affecting your bowel function, please do not take this into account and focus on answering questions to reflect your usual daily bowel function.	
Q.1: Do you ever have occasions when you cannot control your flatus (wind)?	
No, never	0
Yes, less than once per week	4
Yes, at least once per week	7
Q.2: Do you ever have any accidental leakage of liquid stool?	
No, never	0
Yes, less than once per week	3
Yes, at least once per week	3
Q.3: How often do you open your bowels?	
More than 7 times per day (24 hours)	4
4–7 times per day (24 hours)	2
1–3 times per day (24 hours)	0
Less than once per day (24 hours)	5
Q.4: Do you ever have to open your bowels again within one hour of the last bowel opening?	
No, never	0
Yes, less than once per week	9
Yes, at least once per week	11
Q.5: Do you ever have such a strong urge to open your bowels that you have to rush to the toilet?	
No, never	0
Yes, less than once per week	11
Yes, at least once per week	16
Add the scores from each 5 answers to one final score.	
Interpretation: 0–20: No LARS, 21–29: Minor LARS, 30–42: Major LARS.	

Figure 155.21. Low anterior resection score questionnaire.

Temple and colleagues also developed an assessment tool for LARS, a 41-item bowel function survey that was completed by 129 patients who underwent sphincter-preserving surgery between 1997 and 2001. Patients had a median of 3.5 stools/day and 37% were dissatisfied with their bowel function. The five most common symptoms were incomplete evacuation, clustering, food affecting frequency, unformed stool, and gas incontinence. This instrument also detected significant differences between patients with preoperative radiation versus postoperative radiation versus no radiation; local excision versus LAR versus coloanal anastomosis; and handsewn versus stapled anastomosis.

LARS has been shown to correlate with the manometric disappearance of the rectoanal inhibitory reflex as a measure of internal anal sphincter function and anorectal sampling. This alteration amounts to poor discrimination between liquid or gaseous rectal contents. The most obvious mechanisms potentially responsible for cases of LARS include mechanical tear of the anal sphincter muscles upon stapler insertion, poor

neorectal capacity, a short length of the descending colon, and impaired neo-rectal compliance. Neoadjuvant radiotherapy and autonomic denervation may also be contributing factors to poor functional outcomes. Although early data suggested that the functional outcome for patients undergoing restorative LAR could be improved by the utilization of a neorectal reservoir, long-term studies have shown minimal overall functional differences after 2 years of follow-up.

Current treatment of LARS is fairly inconsistent with no real consensus as to an effective treatment algorithm. Therapies include loperamide, rectal irrigation, the use of pelvic floor physiotherapy (biofeedback), and sacral nerve stimulation (Interstim). Biofeedback has been effective in several small studies, including LARS patients with mild to moderate symptoms. A recent systematic review of seven studies including 43 patients with LARS treated with sacral nerve stimulation showed an overall success rate of 71% at a median follow-up of 15 months, which is comparable to that seen in patients with fecal incontinence from any cause. When intractable fecal incontinence occurs, surgical treatment must be considered. Fecal diversion with end colostomy is often the best option after chronic and progressive fecal incontinence.

Genitourinary Dysfunction

Disturbances to bladder and sexual functions are well-known sequelae of rectal cancer surgery. Bladder dysfunction may consist of difficulty emptying the bladder and incontinence. Sexual dysfunction may include dyspareunia and decreased ability to achieve orgasm in women, and erectile dysfunction, absence of ejaculation, and retrograde ejaculation in men. With careful autonomic nerve preservation, postoperative genitourinary and sexual dysfunction can be reduced from 25% to 75% to as low as 10% to 28%. Bladder dysfunction in particular has been shown to decrease from 9% to 40% to 0% to 11% with TME and autonomic nerve preservation when compared to conventional rectal resection. Additional factors that may influence genitourinary dysfunction after TME include pre- and postoperative radiotherapy and preoperative genitourinary function. A total of 597 patients from the Dutch TME trial were assessed after a median follow-up of 5.1 years, and 39% of patients reported urinary incontinence. No significant differences in urinary function were found in those patients who received short-course preoperative radiotherapy.

Moderate to severe sexual dysfunction after radical rectal cancer

surgery is multifactorial and has been reported in up to 76% of patients, with significantly higher rates in female patients. Data regarding sexual function are difficult to obtain. Plus, impairment of bowel and bladder functions after rectal cancer surgery has a significant influence on sexual function, and this may be interpreted incorrectly when evaluating incontinent patients. Other factors that may contribute to sexual dysfunction such as the patient's psychological response to the cancer, scar or ostomy, and the reaction of the sexual partner have not been examined. Bruheim et al. investigated sexual function in 241 males after long-course radiation therapy for rectal cancer with a median follow-up of 4.5 years after surgery. Patients who received radiotherapy had significantly poorer scores for erectile function, orgasmic function, intercourse satisfaction, and overall satisfaction with sex life when compared with non-irradiated patients. The prevalence of moderate and severe erectile dysfunction was 86% in irradiated patients compared with 55% in the surgery-alone patients. Most studies assessing sexual function after rectal cancer surgery lack information on the preoperative sexual status of patients; therefore, it is reasonable to assume that rates of sexual dysfunction are likely lower than what is reported. Hendren and colleagues reported that 35% of men and 47% of women had sexual problems before treatment.

Patients with mild to moderate sexual dysfunction seldom are treated, mainly because of lack of discussion between patients and practitioners; therefore, data on treatment options are scarce. The use of phosphodiesterase inhibitors has been shown to be safe and effective for the treatment of erectile dysfunction after TME for rectal cancer. Although laparoscopic TME has not shown to significantly decrease the incidence of genitourinary dysfunction compared to open TME, enthusiasts of robotic TME have reported improved visualization of pelvic nerves during TME that may lead to fewer nerve injuries. A small prospective study including 69 patients showed that robotic TME (n = 39) was associated with earlier recovery of normal voiding and sexual function compared to patients who underwent laparoscopic TME (n = 30) up to 12 months after surgery. Long-term functional results after robotic TME are lacking.

Suggested Readings

Chamlou R, Parc Y, Simon T, et al. Long-term results of intersphincteric resection for low rectal cancer. *Ann Surg* 2007;246:916–21.

Holmes Maguire L, Goldberg S, Bordeianou L. Functional problems following

colorectal surgery. In: Steele SR, Maykel JA, Champagne BJ, et al., eds. *Complexities in Colorectal Surgery.* 1st ed. New York: Springer; 2014:435–45.

Juul T, Ahlberg M, Biondo S, et al. International validation of the low anterior resection syndrome score. *Ann Surg* 2014;259:728–34.

Lacy AM, Tasende MM, Delgado S, et al. Transanal total mesorectal excision for rectal cancer: outcomes after 140 patients. *J Am Coll Surg* 2015;221:415–23.

McDermott FD, Heeney A, Kelly ME, et al. Systematic review of preoperative, intraoperative and postoperative risk factors for colorectal anastomotic leaks. *Br J Surg* 2015;102:462–79.

Moran B. Total mesorectal excision for rectal cancer. In: Moran B, Heald RJ, eds. *Manual of Total Mesorectal Excision.* 1st ed. Boca Raton, FL: Taylor & Francis Group; 2013:103–23.

Pigazzi A, Garcia-Aguilar J. Anterior resection—robotic. In: O'Connell PR, Madoff RD, Solomon MJ, eds. *Operative Surgery of the Colon, Rectum and Anus.* 6th ed. Boca Raton, FL: Taylor & Francis Group; 2015:489–98.

Ricciardi R, Roberts PL, Marcello PW, et al. Anastomotic leak testing after colorectal resection: what are the data? *Arch Surg* 2009;144:407–11.

Rullier E, Denost Q, Vendrely V, et al. Low rectal cancer: classification and standardization of surgery. *Dis Colon Rectum* 2013;56:560–7.

Sauer R, Becker H, Hohenberger W, et al. German Rectal Cancer Study Group. Preoperative versus postoperative chemoradiotherapy for rectal cancer. *N Engl J Med* 2004;351:1731–40.

Temple LK, Bacik J, Savatta SG, et al. The development of a validated instrument to evaluate bowel function after sphincter-preserving surgery for rectal cancer. *Dis Colon Rectum* 2005;48:1353–65.

Titu LV, Tweedle E, Rooney PS. High tie of the inferior mesenteric artery in curative surgery for left colonic and rectal cancers: a systematic review. *Dig Surg* 2008;25:148–57.

EDITOR'S COMMENT

Doctors Gaertner and Madoff provide an outstanding review of surgical approaches to malignant disease of the middle and lower thirds of the rectum. Any formal discussion on the current rationale for treatment of rectal cancer is, I believe, incomplete without a historical perspective on the evolution of the surgical management of this entity. France became the epicenter for early attempts at oncologic surgical treatment of rectal cancer in 1739, as Jean Faget is credited for undertaking the first resection of the rectum for a perforated rectal cancer (Craney, 1980), (Corman, 2000), (Lange, 2008). Jacques LisFranc

de St. Martin then performed the first successful perineal excision of a rectal tumor in 1826 (Craney, 1980). His technique was later modified by Aristide Verneuil, who described removing the coccyx to allow for better exposure and a more complete excision (Craney, 1980), (Lange, 2008). Paul Kraske, a professor at the University of Freiburg, presented a lecture at the Fourteenth Congress of the German Society of Surgery on the subject of the transsacral approach to the removal of rectal cancer in 1885 (Craney, 1980), (Kraske, 1984). Although the latter half of the 19th century saw an explosion of new surgical techniques from surgeons including Carl Gussenbauer, J. Hochenegg, and Arthur Norton for removing rectal carcinoma, the mortality of these procedures was reported to be between 11% and 22%, with a recurrence rate of almost 80% (Craney, 1980). Sir William Miles hypothesized that the high recurrence rate could be reduced by extensive mesenteric lymphadenectomy as part of an abdominoperineal resection of the rectum (Miles, 1908), (Zbar, 2007), (Miles, 1910).

Claude Dixon's 1948 presentation to the American Surgical Association, in which he reported on his series of 426 procedures to extirpate lesions from 20 cm to 6 cm above the dentate line in a two-staged procedure, ushered in the concept of sphincter-sparing anterior approaches to rectal cancer. His results, with a 2.6% mortality and 64% 5-year survival, suggested that patients with select rectal cancers could undergo successful sphincter-sparing procedures (Lange, 2008), (Dixon, 1984). Allan Parks subsequently presented his series of 19 patients who underwent anterior resections for lower rectal lesions (Ruo, 1999). Perhaps the most important inflection point in the chronology of sphincter-sparing procedures for rectal cancers was the introduction of the surgical stapler. Mechanical stapling has not only broadened the population of patients who might benefit from sphincter-sparing procedures, but has also improved the safety of anterior resections for cancer (Moran, 1996).

The successful management of patients with middle to lower rectal cancer is predicted on multidisciplinary care that frequently includes radiologists; surgical, medical, and radiation oncologists; and physical therapy specialists who specialize in pelvic floor disease. As highlighted in the chapter, the goals of this team should include oncologic control, minimizing morbidity and mortality, optimizing functional outcomes, and promoting rapid return to preoperative function.

Current discussions around preoperative measures to improve oncologic control center on the use of neoadjuvant chemoradiation for locally advanced tumors. Two randomized trials, the Swedish Rectal Cancer Trial and the Dutch Colorectal Cancer Group Trial, demonstrated improved local control with surgery after neoadjuvant chemoradiation compared to surgery alone (van Gijn, 2011), (Folkesson, 2005). The German Rectal Cancer Study Group Trial (CAO/ARO/AIO-04) established the superiority of preoperative chemoradiation over postoperative therapy, with local recurrence rates of 7.1% and 10.1% in the pre- and postoperative therapy arms, respectively (p = 0.048) (Saur, 2012).

Taken together, these data support the use of neoadjuvant therapy of the treatment of locally advanced rectal cancers. Future work should focus on the optimal radiation dose to be delivered in the preoperative setting. The Swedish and Dutch trials demonstrated good results with a compressed radiation treatment cycle of 25 Gy over 5 fractions, while the German trial employed 50.4 Gy delivered over 28 fractions. A reasonable observer would ask how these treatment schedules impact the conduct of the operation, sphincter preservation, and long-term local control. As we move toward bundled payments for cancer care, it will be important to understand how these treatment modalities affect long- and short-term treatment costs. Another interesting aspect of neoadjuvant chemoradiation is the management of patients who have a complete response to therapy. Given the rate of complete response is reported to be as high as 20%, can we avoid or modify surgical approaches in this very select population of patients?

New surgical techniques have arisen over the past three decades due to the growth of minimally invasive procedures. Approaches to rectal tumors have matured from the aforementioned open procedures to robotic procedures for tumors deep in the pelvis. It has been reported that up to 40% of all rectal resections are performed via a minimally invasive approach (Migaly, 2016). However, the evolution of surgical technique is not without controversy. Doctors Gaertner and Madoff have appropriately suggested that open procedures be applied to individuals with bulky lesions, locally invasive and/or perforated tumors, cardiopulmonary compromise, and those who undergo rectus flap coverage for pelvic reconstruction. On the other hand, the authors clearly advocate for laparoscopic approaches in obese patients in whom complete total mesorectal excision (TME) might be aided by magnification and placement of surgical instruments in the pelvis. Although significant Level 1 data support the use of minimally invasive techniques for colon cancer, a comparable body of evidence does not exist for similar approaches for curable, locally advanced rectal cancer (Fleshman, 2016). The recently reported ACOSOG Z6051 and A La CaRT pathology data demonstrate that the use of laparoscopic resection compared with open resection fails to meet the criteria for noninferiority for pathologic outcomes (Fleshman, 2015), (Stevenson, 2015). On the other hand, the European COLOR II and Korean COREA trials demonstrate comparable pathologic outcomes (Bonjer, 2015), (Jeong, 2014). A meta-analysis of these four trials currently underway might provide clearer direction with respect to the utility of laparoscopic approaches to rectal cancer. The application of robotic TME has sparked considerable controversy among experienced surgeons. Although single institution reports have suggested that robotic TME has comparable operative, perioperative, and oncologic outcomes relative to open and laparoscopic procedures (Shin, 2016), (de Jesus, 2016), this technology has not been evaluated in multi-institution trials in the same manner as laparoscopic procedures.

The authors give an outstanding review of the key technical aspects of low

anterior resections (LAR), including appropriate ligation of the inferior mesenteric artery and the conduct of an appropriate TME. These aspects deserve a brief review. My practice is to perform a high ligation of the inferior mesenteric artery to facilitate enhanced nodal retrieval and adequate tumor staging. A complete TME has been shown to improve outcomes even in with neoadjuvant chemoradiation (Fleishman, 2015). As is appropriately described by the authors, high and midrectal cancers require excision of the mesorectal envelope at least 5 cm distal to the tumor and perpendicular to the mass. Mid to distal cancers necessitate TME to the level of the pelvic floor.

The widespread use of neoadjuvant therapy for locally advanced rectal cancers raises questions on the appropriate timing of operative intervention after the completion of radiation therapy. The authors typically wait 10 to 12 weeks after the completion of neoadjuvant chemoradiation. Interestingly, recent data from the National Cancer Database suggest that an inflection point 56 days after the end of radiotherapy is associated with the highest likelihood of complete resection and pathologic downstaging. Moreover, the risk of margin positivity increases in those who undergo surgery after 8 weeks from the end of radiotherapy (odds ratio [OR] 1.40, 95% CI 1.21 to 1.61, $p < 0.001$) (Sun, 2016).

Sphincter function is perhaps the most important quality of life measure for patients undergoing LAR for rectal cancer. As many as 90% of patients undergoing LAR report fecal incontinence, increased bowel movement frequency, and emptying difficulties (Bryant, 2012). Data from the Dutch TME trial suggest that 39% of patients who had a TME alone and 62% of those treated with surgery and preoperative radiotherapy were incontinent at 5 years (Peeters, 2005). Pelvic floor rehabilitation (PFR), including pelvic floor muscle training, biofeedback training, and rectal balloon training, has been accepted as a standard technique for the treatment of fecal incontinence (Allgayer, 2005), (Lundby, 2011). Visser et al. undertook an outstanding review of five studies in which 286 patients underwent PFT (Visser, 2014). Three studies included patients with anterior resection syndrome after LAR, while the remaining studies included a series of patients after LAR. The authors of this review conclude that PFR is useful for improving the functional outcome after LAR. The data are extracted from studies of limited quality, but the available evidence points to the effectiveness of the procedure. I invite readers to review this excellent meta-analysis and consider incorporating PFR in the management of their patients undergoing LAR.

I commend the authors on an outstanding chapter on sphincter-sparing preserving techniques for the treatment of rectal cancer. Future considerations, including the continuing role of multidisciplinary care of this patient population as well as minimally invasive surgical techniques, will define the role of the surgeon as we continue to make strides in the management of this disease.

John H. Stewart, IV

156 Abdominoperineal Resection for Rectal Cancer

Carrie Y. Peterson and Julio Garcia-Aguilar

HISTORICAL PERSPECTIVE

The treatment of distal rectal cancer has changed dramatically in the last few decades. In order to understand the rationale behind the principles advocated in this chapter, it is worthwhile to briefly describe the historical aspects of surgery for rectal malignancies.

The surgical treatment of rectal tumors did not become feasible until the early 19th century, after the introduction of the colostomy by the French surgeon Jean Amussat. Early surgeons performed two sequential operations: first, a mini-laparotomy to create a colostomy, followed several days later by a distal proctectomy through the perineum. The inability to remove the mesorectum and the high rate of perineal fistulas were significant limitations to this operation. The results were poor, and patients suffered significant morbidity. Those who survived the morbidity eventually succumbed to recurrent disease.

W. Ernest Miles is credited with describing the modern abdominoperineal resection (APR) in 1908. He observed in detailed autopsy studies that most recurrences arose in the mesentery along the superior rectal vessels or the lymph nodes located at the bifurcation of the left common iliac artery. The operation he devised was performed in one stage that included both an abdominal procedure and a perineal procedure. It entailed the creation of an abdominal colostomy and removal of the entire pelvic colon and pelvic mesocolon below the common iliac artery; the lymph nodes at the bifurcation of the common iliac artery; as well as the anus, ischiorectal fat, and levator muscles at their origin. Although this operation was associated with a high mortality rate, the results were an improvement over previous procedures, and APR became the standard treatment of rectal cancer for most of the 20th century. O. V. Lloyd-Davies popularized the synchronous, two-team approach, with the patient in lithotomy position, which is often performed today.

Two crucial aspects of Miles' original operative principles were lost in practice for many decades: the removal of the entire mesorectum and the lateral division of the levator muscles. Most surgeons in the mid-20th century were performing dissection inside the mesorectum, in order to avoid the vascular and neural pelvic structures located laterally. Incomplete excision of the mesorectum leaves behind portions of the lymph node–bearing fat surrounding the rectum, and may even expose the tumor itself, which led to high rates of local recurrence. The need to remove the entire mesorectum via precise, meticulous dissection of the areolar plane outside the fascia propria was reintroduced by Bill Heald in 1982. He and others demonstrated significantly reduced local recurrence rates utilizing this precise surgical technique, and they taught this technique to many surgeons over the decades. For an impeccable description of this operative technique, we refer the reader to Dr. Heald's exceptionally well-written chapter in this volume.

The second important aspect to be re-emphasized was the need to divide the levator muscles laterally, close to their insertion in the pelvic sidewall, to produce a cylindrical specimen. While Miles' original description emphasized the importance of this step, many surgeons divide the levator ani muscles closer to the rectal wall after dissecting down the mesorectum for some distance. This happens when surgeons extend the abdominal dissection progressively closer to the levator muscles along the mesorectal plane, often in hopes of performing a sphincter-sparing procedure. Because the very distal portion of the rectum contains no mesorectum and is in direct contact with the pelvic floor, the dissection gets progressively closer to the bowel wall, and possibly the tumor (Fig. 156.1). This increases the risk of a positive circumferential resection margin and the risk of local recurrence in these "waisted" or "coned-in" specimens, as demonstrated in Figure 156.2.

These deviations from the original procedure described by Miles are thought to be the main reasons why APR for low rectal cancer has been associated with a greater risk of recurrence and reduced overall survival, compared to low anterior resection for higher rectal tumors. The cylindrical, or extralevator, APR is an attempt to avoid these shortcomings by emphasizing complete excision of the mesorectum and lateral division of the levator muscles.

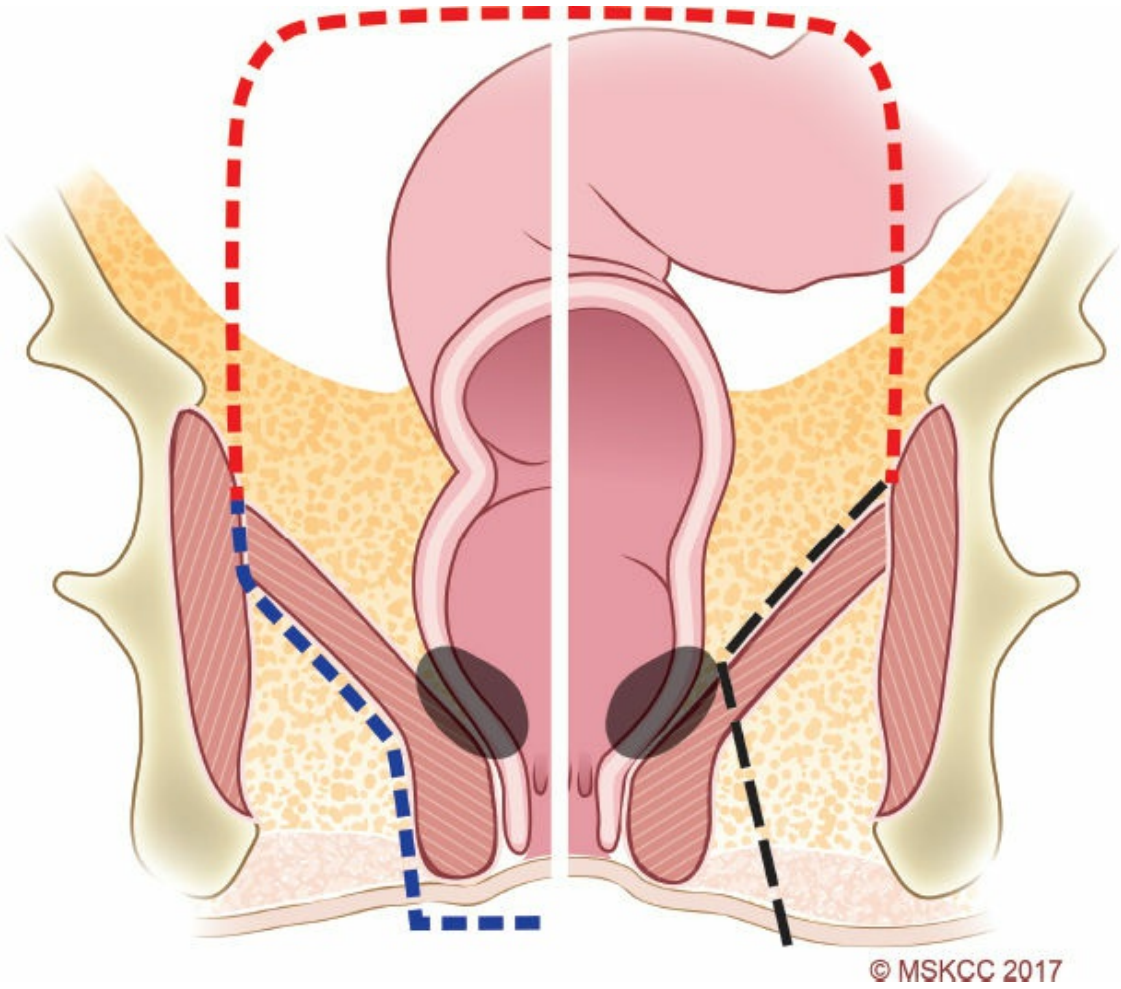

Figure 156.1. Division of the levator muscle in a standard APR (*black line*) and a cylindrical APR (*blue line*). (©2016, Memorial Sloan Kettering Cancer Center.)

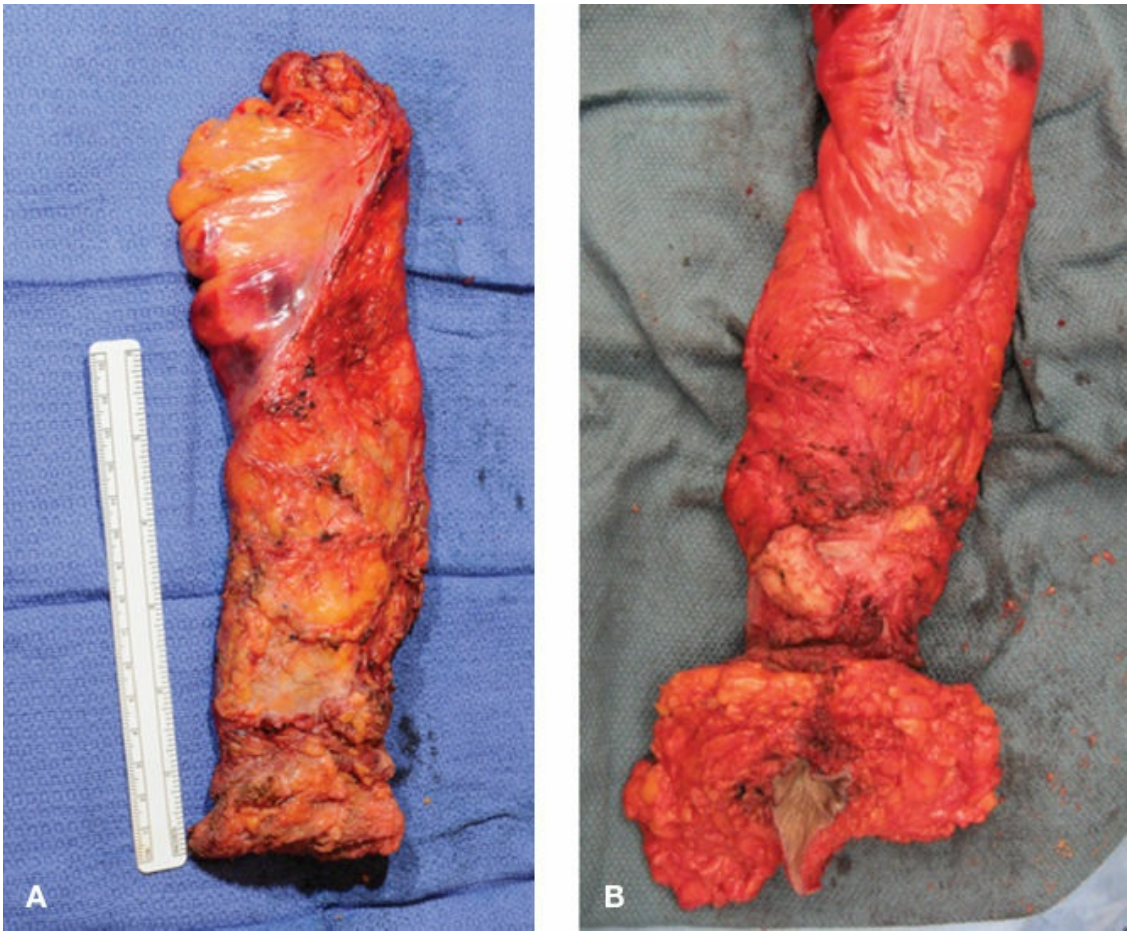

Figure 156.2. Rectal cancer specimens from a standard APR (**A**) and a cylindrical APR (**B**). (©2016, Memorial Sloan Kettering Cancer Center.)

INDICATIONS AND CONTRAINDICATIONS

In most patients with adenocarcinoma located in the lower rectum, the decision for an APR is based on an inability to obtain a negative circumferential resection margin *around* the distal tumor, rather than a negative distal margin *below* the tumor. A digital rectal examination and rigid proctoscopy provide valuable information about the relationship of the tumor to the anal canal. A tumor that lacks clear separation from the anorectal ring or is "fixed" to deeper structures suggests extension laterally beyond the mesorectal plane or bowel wall. Contrast-enhanced magnetic resonance imaging (MRI) of the rectum provides axial, sagittal, and coronal views that can demonstrate the relationship of a tumor to the levator muscles and the external anal sphincter with a high degree of accuracy (Fig. 156.3). Endorectal ultrasound (ERUS) may also be very sensitive in demonstrating invasion of the anal sphincter complex and evaluating the extent of lateral invasion of the tumor. However, the

accuracy of ERUS depends on operator experience and grasp of technique, is susceptible to operator interpretation, and is not as easily reproducible and reviewable.

If the tumor is determined to be amenable to a sphincter-sparing procedure, neoadjuvant chemoradiation therapy may also be considered. This is done in an attempt to downstage the tumor. For further details, we refer the reader to the excellent chapter in this volume on sphincter-preserving surgery. However, in our experience, this rarely changes the surgical plan. The possibility of residual tumor cells being left behind after resection may raise the risk of future recurrences. We suggest that the surgeon determine if sphincter preservation is a possibility at the time of the patient's initial consultation and seriously reconsider any changes to this plan. The temptation to dissect along the mesorectal plane past the level of the tumor in an attempt to save the anus may compromise the oncologic validity of the operation.

Tumor extension beyond the rectum into surrounding organs is not a contraindication for surgery in a patient otherwise fit for a major procedure. There is some long-term survival benefit for patients undergoing extended multivisceral resections (also known as pelvic exenterations), with a 5-year overall survival of 45% or higher. However, resection of retroaortic or pelvic sidewall lymphadenopathy or a palliative APR in the setting of distant metastases is controversial, as these procedures appear to provide minimal long-term benefit. While a digital rectal examination finding of a tumor fixed to deeper structures is indicative of further tumor extension, the best imaging study for evaluating extra-rectal extension is a high-resolution MRI of the pelvis. We review these studies closely with our radiologists to aid preoperative planning.

APR is also the operation of choice for patients with anal squamous cell carcinoma that persists or recurs after chemoradiation therapy, because these tumors usually involve the anal canal and levator muscle. Occasionally, APR is required for less common tumors of the anorectal region, such as anal melanoma, sarcoma, or gastrointestinal stromal tumor, and an extended APR is sometimes required for vulvar, vaginal, or prostate cancers that involve the distal rectum or anal sphincter. An APR can also be performed for benign indications as part of a total proctocolectomy, as in patients with familial adenomatous polyposis syndrome or inflammatory bowel disease. In these cases, a cylindrical dissection is not warranted, given the lack of malignancy. Furthermore, the

perineal wound can be large after extralevator resection, resulting in long-term complications not justified in the setting of benign disease. The dissection plane for a total proctectomy or APR in the setting of benign disease begins in the intersphincteric plane and is carried proximally along the distal rectum into the mesorectal plane, thus preserving as much of the pelvic floor for closure as possible. For further details, we refer the reader to the chapter on sphincter-sparing rectal dissections and the discussion of intersphincteric dissection.

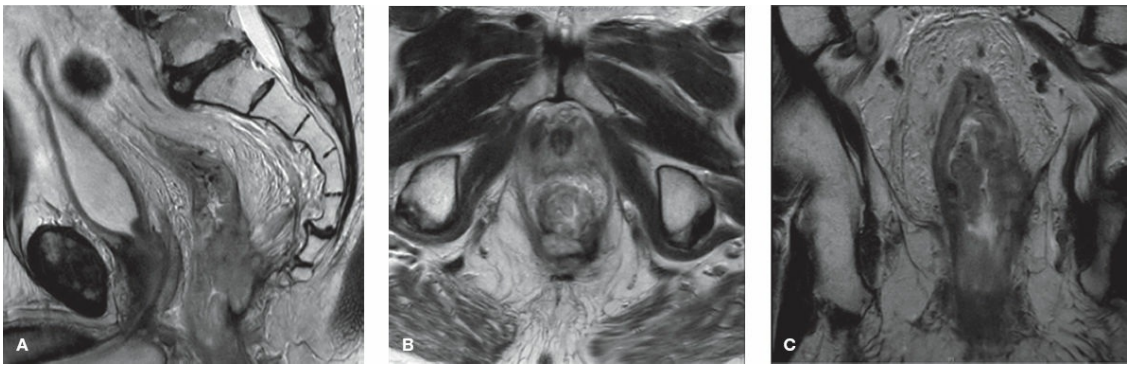

Figure 156.3. MRI images of a locally advanced rectal cancer invading the left and posterior aspect of the levator muscle. T2-weighted sagittal (**A**), axial (**B**), and coronal (**C**) views of the rectum. (©2016, Memorial Sloan Kettering Cancer Center.)

PREOPERATIVE PLANNING

Although APR-associated mortality has decreased dramatically in the last century, APR is still a formidable operation associated with significant morbidity. Patients should undergo medical clearance prior to surgery and should also be marked for a colostomy and counseled by a certified stoma therapist. Patients must be informed about the potential risks and complications of the procedure and possible long-term outcomes, in particular sexual and urinary dysfunction. The necessity of full mechanical bowel cleansing prior to surgery is a subject of some debate, but it is our preference. At the very least, patients should receive an enema to cleanse the rectum of fecal matter.

Extent of Resection

It is paramount to understand the extent of resection needed well before the day of the operation. Close review of imaging and a physical examination can help identify areas of concern. We strongly recommend a

multidisciplinary approach and early involvement of specialists such as gynecologic oncologists, urologists, and orthopedic surgeons when needed. The most commonly involved adjacent structures are the anterior structures: either the prostate in males or the posterior wall of the vagina in females. Posterior vaginal involvement does not pose a significant issue when planning a resection, especially if the patient has already had a hysterectomy. The posterior wall can be removed en bloc with the rectum and the defect closed with the perineal flap. Functionally, however, the patient may develop strictures and have difficulties with intercourse once healed. If prostatic involvement is suspected, the impact can be considerably greater. Generally speaking, the function of the bladder after an extended APR with prostatectomy is very poor, and urinary diversion with an ileal conduit is often needed. Posterior extension of a tumor involving the sacrum can be a significant challenge, and for more information we refer the reader to the chapter by Dr. Solomon discussing extended resections and pelvic exenterations. Another source of potential concern is pelvic sidewall lymphadenopathy. Distal rectal tumors can disseminate in this fashion via the iliac chain, and in this setting, extended pelvic sidewall lymphadenectomy can be of benefit.

Ostomy Marking

All patients who are anticipated to need an ostomy should see a licensed enterostomal therapist prior to surgery. The therapist will identify the optimal site for ostomy placement and educate the patient about ostomy care. This can alleviate many fears and misconceptions, resulting in improved acceptance and coping. Since the end colostomy in an APR is permanent, it is ideal to locate it in a spot that makes appliance application and changing easy for the patient. Proper location can also help minimize the risk of parastomal hernia formation.

Abdominal Dissection—Minimally Invasive versus Open Technique

Consideration should be given to planning the approach for each individual patient. The abdominal portion can be performed through a laparotomy or by using minimally invasive techniques. When a ventral rectus muscle flap is planned for the perineal reconstruction, a large laparotomy incision is needed for flap harvesting. We therefore use an open procedure in such cases. There have been a few reports of rectus flap

harvesting using the robotic platform, but this approach is not widespread. If the surgeon is considering other reconstruction options, or if a flap is not needed, a minimally invasive approach is ideal. Patients derive significant benefit from minimally invasive surgery, including reduced pain and faster recovery. Our preference is to utilize the robotic platform for all pelvic work when possible, as the visualization and dexterity are much improved over traditional laparoscopy. However, this is potentially less important in an APR than in a low anterior resection, where very distal dissection, often below the level of the coccyx, is needed. Robotic techniques above the level of the pelvis can be challenging in obese patients, as achieving exposure and retraction of the intra-abdominal contents is sometimes difficult, and an experienced assistant is extremely helpful. Male patients with a narrow pelvis and large mesorectum can be challenging using any technique, but the laparoscopic approach in these patients may be particularly difficult because of the straight instruments and limited range of motion.

Perineal Dissection—Prone versus Lithotomy

For the perineal portion of the operation, we prefer to place the patient in the prone jackknife position. This allows for maximum exposure, keeps the dissection away from the table edge, and may facilitate lateral division of the levator muscles. Some studies indicate that prone positioning is associated with lower perineal wound infection rates and lower local recurrence rates. This positioning may be challenging for some surgeons, however, as the anatomy appears “upside down” compared to other anorectal surgeries. We encourage all surgeons who make APR part of their regular practice to become comfortable and facile in this position, as there are distinct advantages.

Very obese patients may not tolerate the prone jackknife position well, as their large abdomen may lead to restricted ventilation. An alternate position for very obese patients is a left lateral (Sims) position, with the knees tucked. The right buttock can be taped up and away, allowing exposure without restricting ventilation. We have used this positioning with great success. The high lithotomy, also known as the Lloyd-Davies position, is another alternative. This is ideal when a two-team approach is planned so that perineal dissection and abdominal dissection can take place synchronously. The high lithotomy position can also be helpful in obese patients, or those with complex unstable airways, as anesthesia access to

the airway is unencumbered.

When the perineal portion of the operation is performed in the prone position, a few special considerations should be made in advance. First, an additional operating table should be prepared to shorten turnover time. Second, discussing the order of the specific steps of the operation with the surgical teams beforehand can facilitate timing and coordination. For example, if a ventral rectus abdominis flap is planned, the tissue will need to be dissected, mobilized, and sutured to the proximal rectum prior to closing of the abdomen and maturing of the ostomy—all of which is done before the patient is turned to the prone position. If a urologic procedure is required, as in a pelvic exenteration, this may also need to be performed while the patient is in lithotomy. Careful planning of every aspect of the surgical procedure ahead of time will help synchronize the surgical teams and keep the operation moving forward.

Perineal Reconstruction Options

Primary closure of the perineal wound is associated with a significant risk of wound infection and dehiscence and even perineal hernia. Reconstruction of the perineum using a number of flaps is aimed at reducing the risk of short- and long-term complications, particularly in patients undergoing extended perineal resection. Unfortunately, these reconstructive procedures are associated with specific morbidity. The use of a rectus muscle flap can lead to abdominal wall hernias at the midline incision or parastomal hernias. Another option is gluteal advancement flaps, particularly useful when the perineal portion of the procedure is performed with the patient in the prone position. A gracilis muscle flap is yet another option, but often this approach is less advantageous, as the flap doesn’t contain any skin and is rather small in size. In general, we reconstruct the perineum when the patient has any of the following: large defect with margins well away from the anal sphincter complex, preoperative or previous radiation therapy, poor nutritional status, or other comorbidities that significantly increase the risk of perineal wound infections. Most patients with large distal rectal adenocarcinoma and anal squamous cell cancer will require flaps, while patients with small tumors or nonmalignant conditions may not. The involvement of plastic surgeons in preoperative decision-making regarding reconstruction will be of great benefit.

Pain Management

Pain management is an important issue, and one that should be addressed with patients. When a laparotomy is planned, an epidural to help with postoperative pain control is ideal. Unfortunately, the distribution of anesthesia in an epidural does not make it possible to cover both the midline abdominal wound and the perineal wound. We often choose the abdominal wound, as the pain here can lead to splinting and postoperative reduction in ventilation. Transversus abdominis plane blocks, which are an injection of local anesthetic into the plane where the somatic nerves traverse, can also help with postoperative pain control. These blocks are best utilized in minimally invasive surgery or other limited incisions, as the plane of anesthesia is less predictable and the effect is limited to a maximum of 12 hours.

SURGICAL TECHNIQUE

Anatomical Relationships and Considerations

As we have seen, an APR requires both an abdominal and a perineal approach to completely excise the rectum and anal canal. During the abdominal part of the procedure, the superior rectal vessels are controlled, the rectum and mesorectum are dissected, and a colostomy is created. During the perineal part, the rectum and anus are detached from their surrounding structures and the specimen is removed prior to closure of the wound. The boundary between the abdominal and perineal part of the procedure is delineated by the levator ani—an important landmark in an APR.

The key to a successful APR is a perfect understanding of the anatomy of the rectum and anus, the vessels and nerves of the pelvis, the pelvic floor musculature, and the ischiorectal fossa. The pelvic floor, also known as the pelvic diaphragm, comprises the levator ani and coccygeus muscles. The levator ani muscle is a thin, broad layer composed of several smaller muscles (puborectalis, pubococcygeus, and iliococcygeus) that insert in the inner wall of the pelvis and unite with the muscle of the opposite side to form part of the funnel-shaped pelvic diaphragm. These are the muscles divided during an APR; the coccygeus muscle, located in the same plane as the levator ani muscles but more posterior, is usually not.

The rectum corresponds to the distal 15 cm of the large bowel, but neither its beginning nor its end is sharply defined. The rectum contains

the three internal valves of Houston, which are occasionally used as a reference to locate rectal lesions. However, it is more practical and reproducible to describe the tumor location by measuring the straight distance from the anal verge, the palpable intersphincteric groove at the distal-most aspect of the anal canal. Another important landmark is the anorectal junction, which is palpated at the proximal-most aspect of the anorectal ring, corresponding to the puborectalis and the top of the external sphincter muscle.

The mesorectum is the visceral mesentery containing the terminal branches of the superior rectal vessels and the lymphatic drainage of the rectum. The upper third of the rectum is located above the anterior peritoneal reflection. It is covered with peritoneum in the front and on both sides and has a posterior mesorectum attached to the concavity of the sacrum, which is a continuation of the mesentery of the sigmoid colon. Below the peritoneal reflection, the rectum is completely extraperitoneal. The mesorectum here is thick posteriorly in the middle third of the rectum, where it has a characteristic bilobar appearance. Then it tapers off distally, as the rectum funnels down toward the anorectal ring. At this very distal aspect just above the anorectal ring, there is no appreciable mesorectum. The longitudinal layer of the muscularis propria of the posterolateral rectum is in direct contact with the levator muscles. Anteriorly, the mesorectum is either absent, as in the upper intraperitoneal portion of the rectum, or reduced to a thin layer of areolar tissue in the mid and distal rectum.

The fascia propria of the rectum, a thin, glistening membrane surrounding the mesorectum below the peritoneal reflection, is also thinner anteriorly than posteriorly. Anteriorly, a remnant of the embryologic peritoneal cul-de-sac, known as Denonvilliers fascia, separates the mesorectum from the urogenital structures. The anatomical appearance of Denonvilliers fascia varies, from a barely visible translucent membrane to a distinct, tough, leathery layer of connective tissue. Posteriorly, the fascia propria extends from the promontory to Waldeyer fascia, a condensation of connective tissue spanning the area from the fourth sacral vertebra to the anorectal ring. Here the mesorectum is separated from the presacral fascia by loose, avascular tissue. This is the correct plane, between the fascia propria of the rectum and the presacral fascia, for dissection during a proctectomy.

Below the peritoneal reflection, the mesorectum also intermingles

laterally with the connective tissue of the autonomic nerves that pass from the pelvic plexus to the rectum. These bilateral condensations of the endopelvic fascia, known as lateral ligaments, connect the pelvic sidewall with the mesorectum. In some individuals, the lateral ligaments contain accessory middle rectal vessels. The middle rectal artery usually runs immediately above the levator muscles.

The blood supply of the rectum comes primarily from the superior rectal artery, which is the continuation of the inferior mesenteric artery after it gives off the left colic artery. The superior rectal artery gives several sigmoidal branches before diving into the mesorectum, where it gives multiple branches to the rectum. The lower portion of the rectum also receives blood supply from the internal iliac vessels. The middle rectal artery, an inconsistent branch of the inferior vesicle artery, is usually located deep in the pelvis, running over the levator muscle. The inferior rectal artery is a branch of the pudendal artery and provides blood supply to the anal canal and anal sphincter. The middle and inferior rectal vessels anastomose with the upper rectal vessels to supply enough blood to the entire rectum. The superior rectal vein has a parallel course to its homonymous artery, on its way to join the left colic vein to form the inferior mesenteric vein draining into the splenic vein. As in other locations, the superior, middle, and inferior rectal veins follow the course of their arteries. While the superior rectal vein joins the left colic vein to the inferior mesenteric vein and drains into the portal system, the middle and inferior rectal veins drain into systemic circulation through the internal iliac veins. These anastomoses represent the potential portosystemic communication that becomes relevant in patients with portal hypertension.

The anatomy of the autonomic pelvic nerve system is particularly relevant. The hypogastric plexus, located in front of the aorta, contains preganglionic sympathetic fibers originating from the lumbar sympathetic trunk that converge at the level of the aortic bifurcation into two well-defined hypogastric nerves, which course laterally over the internal iliac vessels toward the lateral pelvic sidewall. There they join the splanchnic pelvic nerves, containing postganglionic parasympathetic fibers from S3 to S4, to form the pelvic plexus. Branches of the pelvic plexus provide innervation to the distal ureter, vas deferens, seminal vesicles, urinary bladder, prostate, and even the distal rectum in some patients. The distal pelvic plexus also forms the urogenital neurovascular bundles that pass anterior to Denonvilliers fascia. The pudendal nerve, originating from the

sacral plexus, contains sensory, motor, and parasympathetic fibers that provide most of the innervation of the perineal region. Damage to any of these nerves during an operation can result in significant urinary, sexual, and sensory dysfunction.

Open Abdominal Dissection

In an open APR, the abdominal portion can be performed through a lower midline or low transverse laparotomy. While the transverse incision causes less pain, is cosmetically more appealing, and has a lower incisional hernia rate, a midline laparotomy is preferred when the rectus muscle is used for reconstruction of the perineal wound.

As in any other colorectal cancer procedure, the operation begins with a thorough examination of the abdomen and pelvis. The sigmoid colon is mobilized by dividing the attachments and adhesions to the lateral abdominal and pelvic sidewall. The incision is carried cephalad toward the splenic flexure and distally toward the pelvis. The mesentery of the sigmoid and descending colon is lifted from the retroperitoneal attachments, exposing the left gonadal vessels and the left ureter (Fig. 156.4). It is important to remain in the retromesocolic plane, as deeper dissection into the retroperitoneal fat can lead to increased bleeding and damage to the gonadal vessels and the left ureter. The sigmoid colon is retracted anteriorly and laterally to expose the root of the sigmoid mesentery. Next, an incision is made in the peritoneum to the right side of the base of the sigmoid mesocolon, proximal to the promontory. A plane is developed underneath the superior rectal vessels in the loose areolar tissue, between the origin of the inferior mesenteric artery and the promontory (Fig. 156.5). Care should be taken to avoid injuring the superior hypogastric plexus, situated between the superior rectal vessels and the bifurcation of the aorta. The hypogastric nerves can be seen as two thick, band-like structures just lateral to the midline, as dissection continues inferior to the sacral promontory.

Once the ureter is identified and kept securely in the retroperitoneum, the superior rectal vessels are isolated between the origin of the left colic vessels and the first sigmoidal vessels and ligated. We do not routinely divide the left colic artery but recommend a careful dissection of any enlarged lymph node around the bifurcation of the inferior mesenteric artery. However, a complete dissection of the origin of the inferior mesenteric artery carries the risk of damaging the hypogastric plexus. The

mesentery of the sigmoid colon is then divided toward the point of the sigmoid colon that has been chosen to create the end sigmoid colostomy. The sigmoid colon itself is divided by using a linear stapler. The proximal end of the divided sigmoid colon and the descending colon should be sufficiently mobilized to ensure a tension-free, well-vascularized colostomy.

The areolar space behind the fascia propria of the rectum is opened by anterior reflection of the stump of the superior rectal vessels and the proximal rectum, away from the promontory. The areolar tissue separating the mesorectal fascia from the parietal pelvic fascia can be easily identified in this view. In the beginning of this dissection, it is important to identify and protect the bilateral hypogastric nerves, which can be seen as two thick bands in the lateral aspects of the areolar space. The dissection is then carried inferiorly along the concavity of the sacrum as far as the sacrococcygeal junction and extended from the midline laterally (Fig. 156.6). Distally, the pelvic splanchnic nerves should be preserved, as they course from the lateral pelvic sidewall near the anterior sacral foramina to join the pelvic plexus.

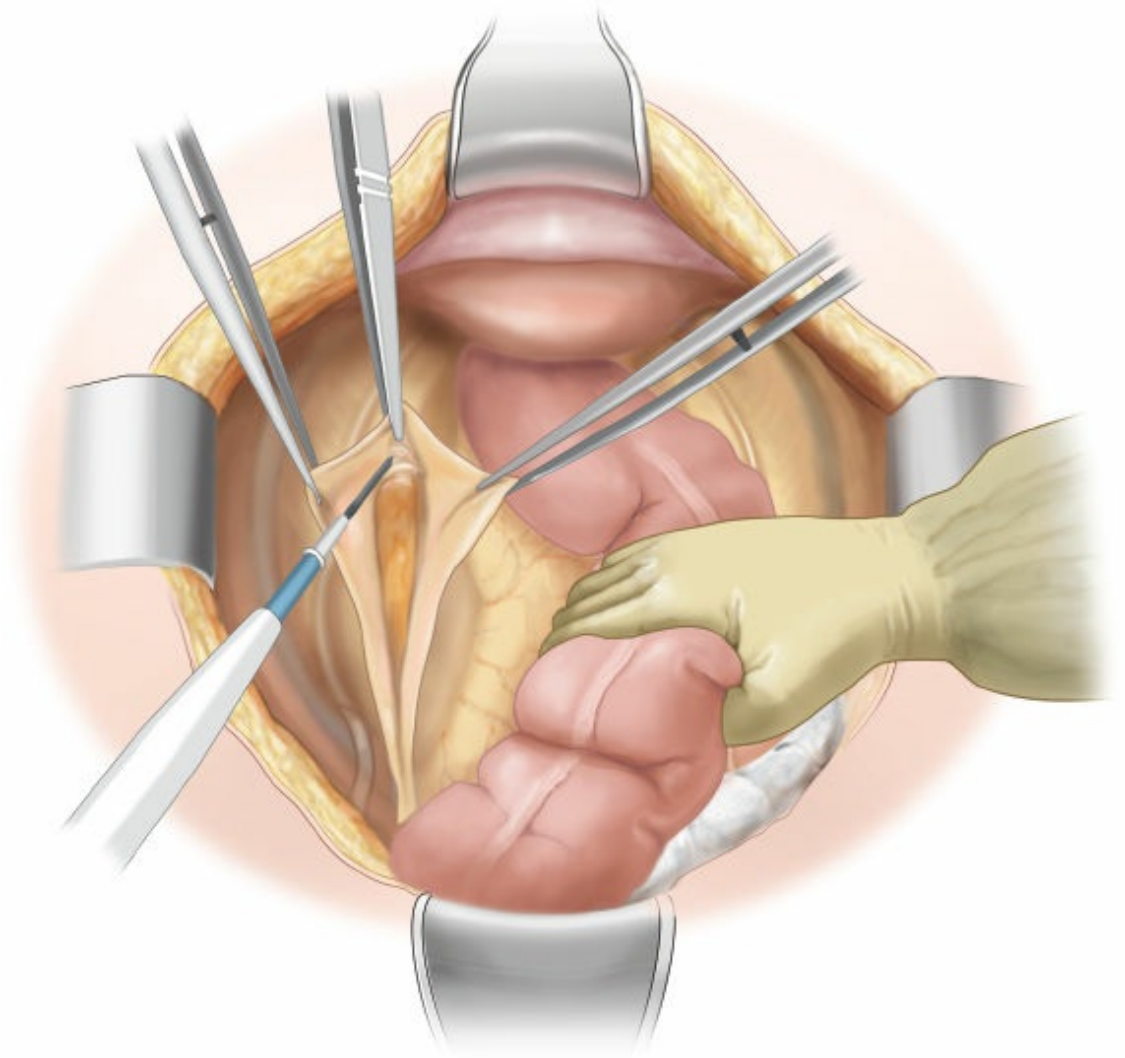

Figure 156.4. Lateral mobilization of the sigmoid colon, exposing the left ureter and gonadal vessels. (©2016, Memorial Sloan Kettering Cancer Center.)

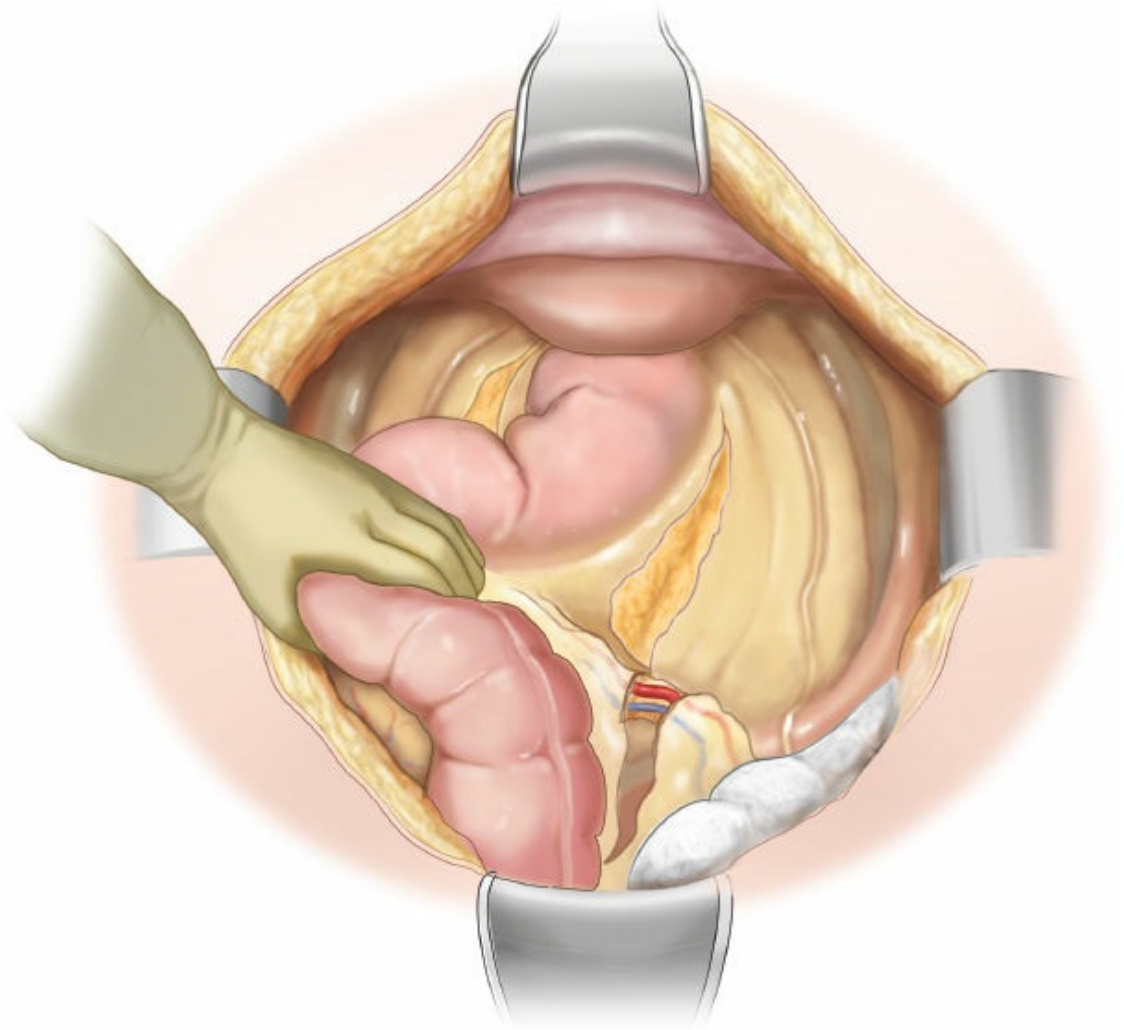

Figure 156.5. Exposure of the superior rectal vessels at the origin. (©2016, Memorial Sloan Kettering Cancer Center.)

We find that a St. Mark's pelvic retractor or a Wiley renal vein retractor —along with strong tension from the surgeon's nondominant hand on the rectum—can help place the areolar plane on tension and expose the proper plane for dissection. Division of the areolar connective tissue should be done using electrocautery or other sharp dissection (Fig. 156.7). Blunt finger dissection is extremely imprecise and can lead to a poor-quality resection plane and thereby compromise the oncologic validity of the operation. In addition, blunt dissection may damage the pelvic nerves and lead to impotence or retrograde ejaculation, as well as severe pelvic bleeding that can be difficult to control.

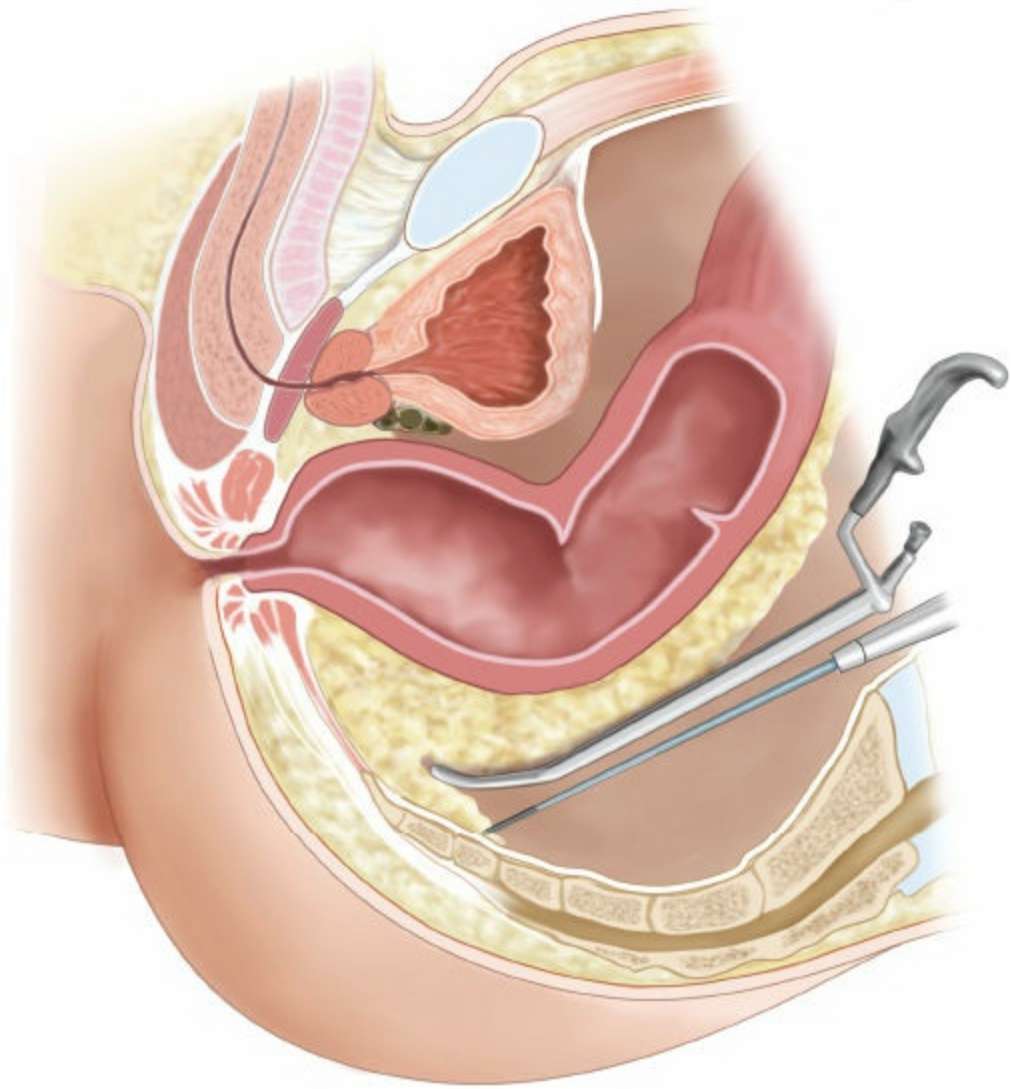

Figure 156.6. Posterior dissection in the areolar space between the mesorectal fascia and the presacral fascia. (©2016, Memorial Sloan Kettering Cancer Center.)

The lateral stalks are then exposed by providing traction on the rectum to the contralateral side of the pelvis and are divided using electrocautery. A forceful retraction can bring the parietal pelvic fascia and the pelvic plexus too far medially and within reach of the electrocautery, resulting in injury. The dissection is continued laterally until the origin of the levator muscle is reached. Finally, the peritoneum is opened anteriorly in the cul-de-sac. Dissection is carried to the level of the prostate in men and halfway down the vagina in women (Fig. 156.8). The anterior dissection can be performed in different planes, depending on the location of the tumor in the circumference of the rectum. For anterior tumors, dissection should proceed in front of Denonvilliers fascia to avoid dissecting into the tumor. For other tumors, dissection can be safely performed behind Denonvilliers

fascia to preserve the nerves of the prostatic plexus. The line along the sacrococcygeal junction, the upper portion of the levator muscles, and the upper prostate/mid-vagina represents the landmark where the perineal dissection will meet the plane dissected from the abdomen.

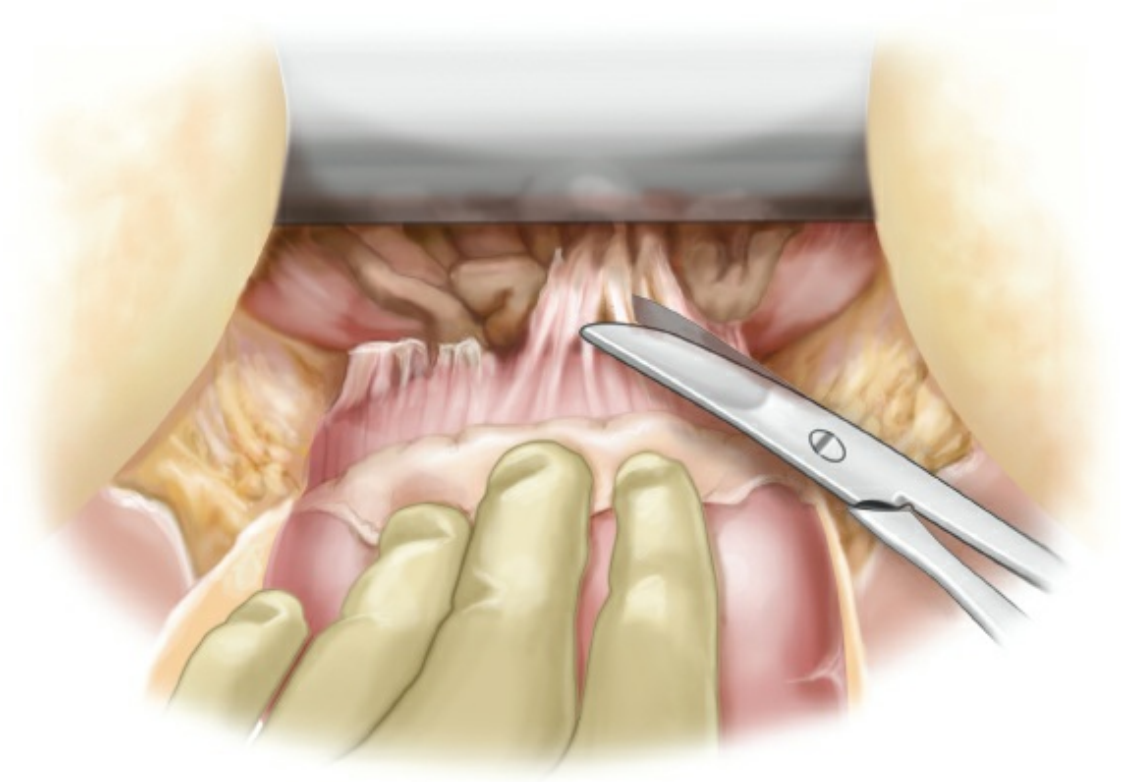

Figure 156.7. Anterior dissection behind the seminal vesicles. (©2016, Memorial Sloan Kettering Cancer Center.)

Minimally Invasive Abdominal Dissection

While the principles and steps are the same as those of the open approach, a minimally invasive approach, whether laparoscopic or robotic, is often facilitated by changing the order of the steps. We have found that, after placement of the ports (Fig. 156.9), the best way to begin the operation is to dissect at the inferior mesenteric artery extending into the retromesocolic plane in a medial-to-lateral fashion. The sigmoid colon is held up and retracted anteriorly. The peritoneum at the base of the sigmoid mesentery over the right iliac artery is incised to enter the areolar space behind the superior rectal vessels. The pneumoperitoneum will facilitate dissection in the areolar plane, and the surgeon, using sharp electrocautery dissection in the areolar tissue, gently opens this plane. The retromesocolic plane is gently opened by using traction and countertraction with the

graspers. The surgeon should be careful not to dissect too posteriorly behind the ureter and gonadal vessels, lifting them from the retroperitoneal position and exposing them to potential injury. Once the ureter is identified and kept out of harm's way, the inferior mesenteric artery can be fully isolated and divided at a location appropriate to the resection.

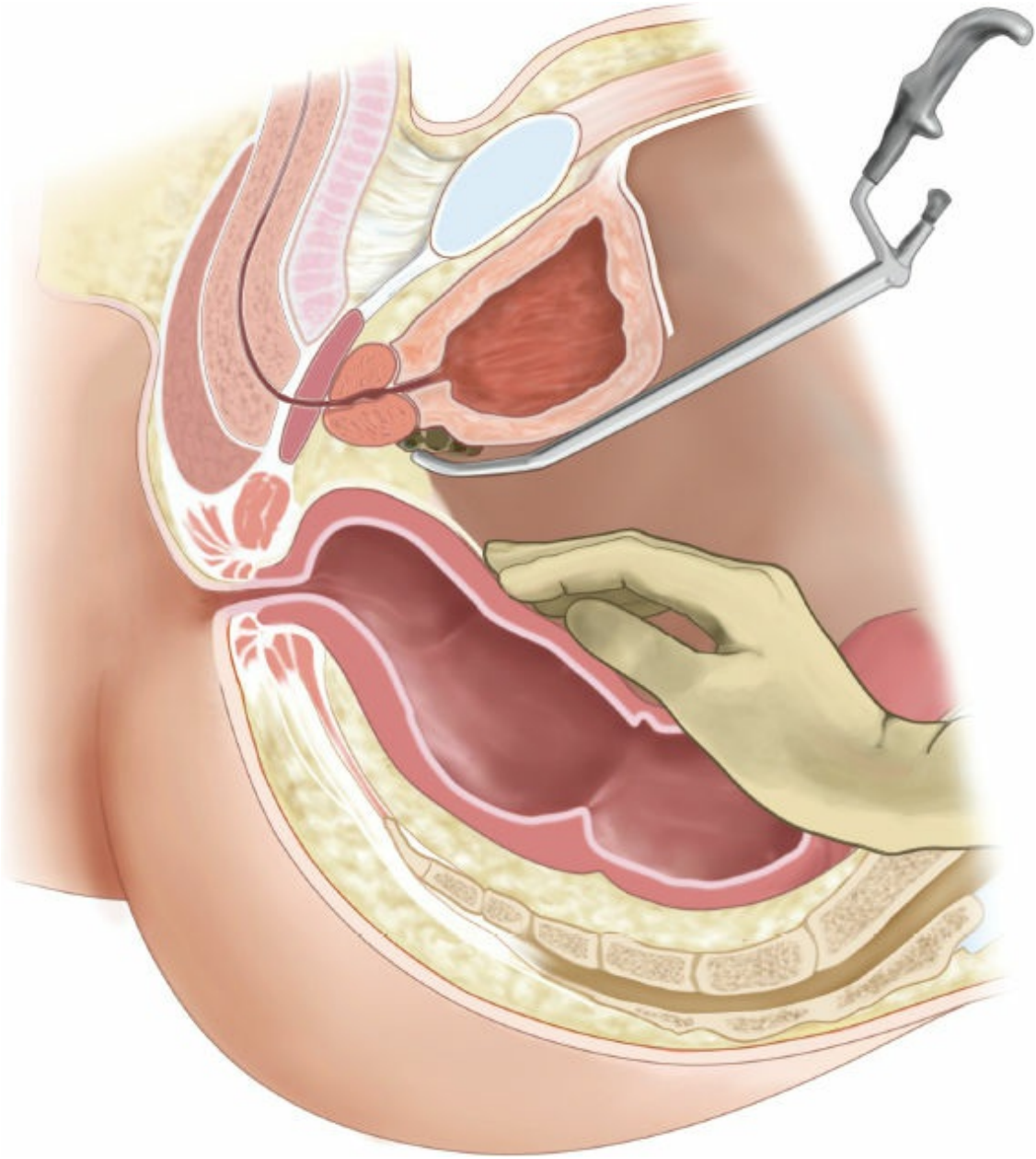

Figure 156.8. Anterior dissection behind the prostate. (©2016, Memorial Sloan Kettering Cancer Center.)

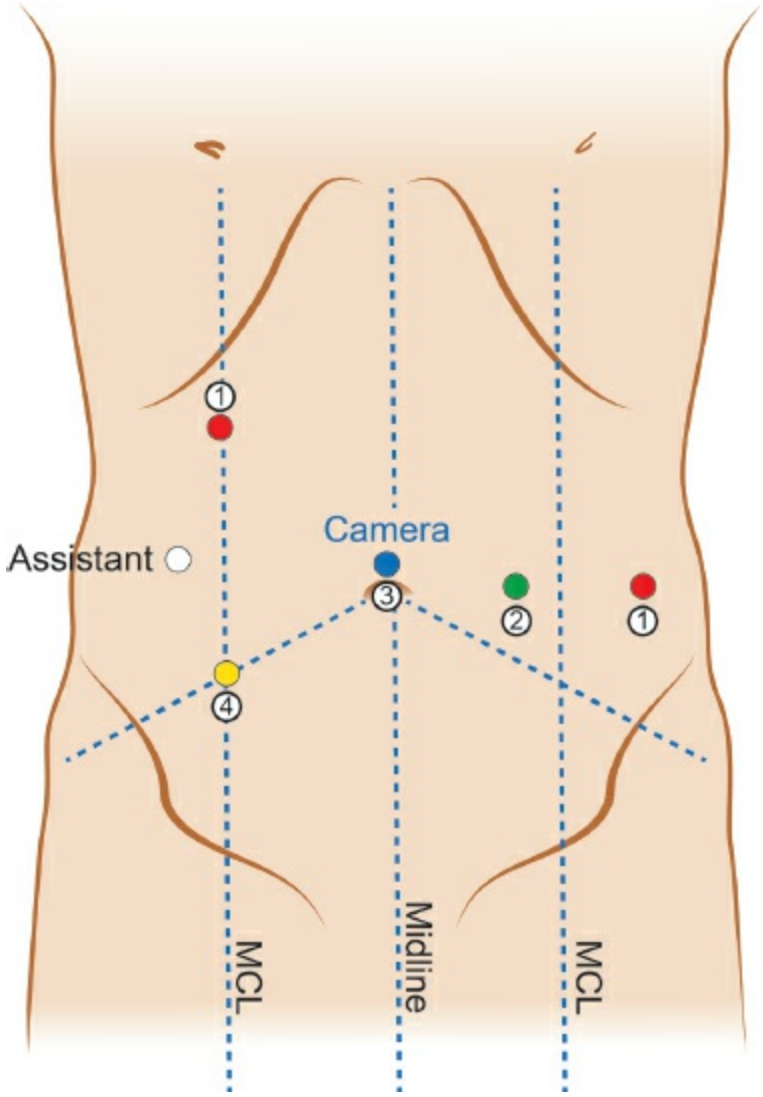

Figure 156.9. Trocar positioning for a robotic APR. The robot is positioned to the left of the patient. Arm 1 can be positioned in the right upper quadrant for the dissection and division of the superior rectal vessels. Arms 4 and 2 are the operating arms for the perineal portion of the procedure, while arm 1, positioned in the left lower quadrant, is used for retraction of the prostate or vagina. Trocar 3 is usually positioned at the site intended for the stoma. (©2016, Memorial Sloan Kettering Cancer Center.)

The retromesocolic dissection then continues laterally, mobilizing some of the descending colon and the sigmoid colon. When this portion of the colon is mobilized sufficiently, the surgeon should then incise the pelvic peritoneum in both sides of the mesorectum and sharply enter the posterior areolar space behind the mesorectal fascia. With the rectum continually on tension, sharp dissection of the areolar tissue in the mesorectal plane begins posteriorly and extends laterally. As in an open APR, care should

be taken to avoid the nerves at the sacral promontory and pelvic sidewall. It is often necessary to switch back and forth with the assistant: first retracting to the left, then to the right, to obtain good exposure and tension on the mesorectum and expose the proper plane. We find it helpful to wrap 15 cm of vaginal packing around the rectum. Using this as a "handle" helps to protect the mesorectum during this part of the dissection. (Vaginal packing is preferable to umbilical tape because it has radiotracers and can be seen on an x-ray if left in the abdomen.) In addition, the division of the proximal colon should be done after the rectal dissection, to facilitate intraoperative retraction of the upper rectum during the pelvic portion of the procedure.

Once the posterior dissection has reached the pelvic floor, we then extend our peritoneal incision anteriorly. When performing this procedure robotically, we have found that using a grasper in the third arm, placing the open blades into the cul-de-sac, and lifting up will help provide good exposure to the plane anterior to the rectum. If a laparoscopic approach is used, this is often a key step for the assistant. Then anterior peritoneum can be incised, and the dissection is extended to just below the cervix or seminal vesicles. Once fully mobilized to the pelvic floor, as described above, the sigmoid mesentery can be divided using a vessel-sealing device, and the proximal colon can be divided using a laparoscopic or robotic stapler. As the specimen will be removed via the perineal wound, no incision in the abdominal wall to extract the specimen is needed. However, we do place a grasper on the end colon in order to identify it easily when creating the ostomy, prior to switching to the prone position.

Perineal Part: Prone Position

When the abdominal part of the procedure is finished, it is advantageous to proceed with placing pelvic drains, closing the incision, and maturing the colostomy, leaving the distal rectum in situ for extraction during the perineal phase. The drains should be secured to the proximal portion of the specimen to facilitate placement into the pelvis when the patient is in the prone position. In addition, if a ventral rectus abdominis muscle flap is the chosen reconstruction technique, this should be performed prior to closing the abdomen and repositioning the patient. The flap should be secured with a small stitch to the proximal specimen, so that it can be located easily when necessary.

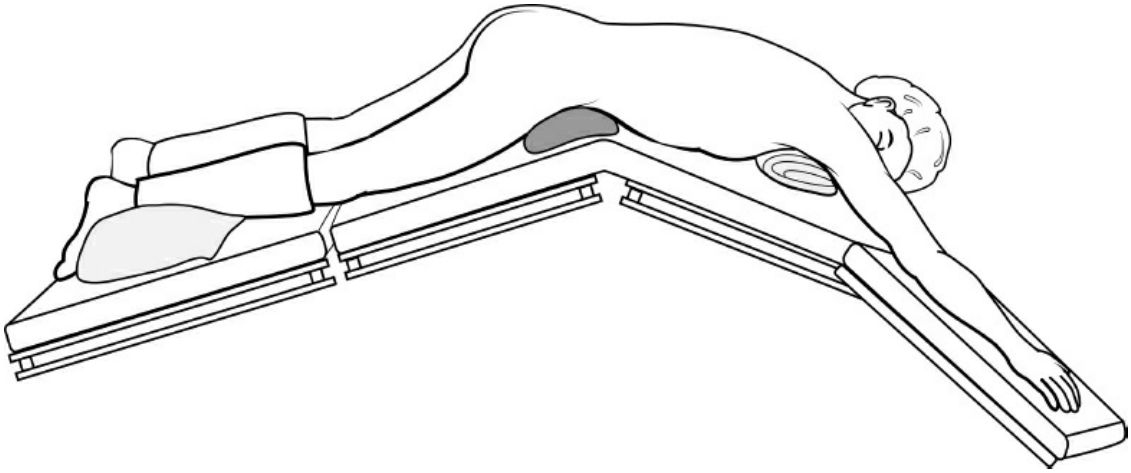

Figure 156.10. Prone jackknife position for perineal dissection, with padding under the chest, hips, knees, and feet. (©2016, Memorial Sloan Kettering Cancer Center.)

When ready to reposition the patient, we have found it best to use a second operation table set up for the prone position (Fig. 156.10). The patient can then be transferred in one step. A large hip roll is placed at the level of the break in the additional table, and a second, smaller roll is placed closer to the head of the table to support the upper portion of the patient's chest. This table is positioned alongside the original table, and the patient is flipped in one turn. The now-vacant lithotomy table is then quickly removed from the room. Armrests should be available and placed parallel to the head of the table to support the patient's arms as they are extended over the head. A soft pillow is used to support the patient's feet and pad the knees. The patient should be secured to the table across the chest as well as the legs. The bed is then moved into a deep flex position to bring the perineal area up, and the buttocks are secured laterally with tape. Rectal washout and closure of the anus with a heavy silk suture are done before prepping and draping. Sometimes a split table is used to separate the legs, allowing the surgeon to stand in the midline with one assistant on each side.

The perineum is then prepped with antiseptic solution and draped. An elliptical incision is made outside the lateral edge of the external sphincter and can be extended posteriorly if further dissection is needed. The incision should be lateral to the external sphincter muscles and medial to the ischial tuberosity. Palpating the tuberosity and placing the incision one to two finger breadths medially facilitates the medial incision. Posteriorly, the incision should be placed midway between the anus and the coccyx and can be extended if needed. Anteriorly, the incision should divide the

perineal body. For tumors that do not penetrate the anal sphincter or the levator musculature, a narrower incision can be utilized, and the dissection can be carried along the external sphincter muscle, thus preserving the ischiorectal fascia for wound closure (Fig. 156.11). A Lone Star Retractor (CooperSurgical, Inc.) works well for superficial exposure once the skin incision is made. If the resection is performed for anal disease such as recurrent anal squamous cell cancer, a wider resection margin can be used. In this setting, it is important to stay in the same plane as the dissection is extended superiorly. The dissection is done using electrocautery, watching for and controlling the perforating vessels as well as the inferior rectal arteries, seen laterally, which may bleed profusely. A number of additional retractors can be helpful in the deeper portions of the operation, such as a Sklar Gelpi Retractor (Sklar Surgical Instruments) or cerebral self-retaining retractors.

It is generally a good approach to palpate the coccyx and aim the posterior dissection toward a just-anterior location, to join with the posterior mesorectal dissection (Figs. 156.12 and 156.13). Some surgeons routinely remove the coccyx, but we do not feel this is routinely necessary unless the coccyx is involved by the tumor or additional exposure is needed. The perineal approach makes it much easier to perform a coccygectomy, or even a limited sacrectomy, as the incision can be extended posteriorly with excellent visualization and without risk of contamination. Dividing the anococcygeal ligament at the tip of the coccyx provides access to the posterior pelvis for joining the mesorectal dissection (Fig. 156.14). Once the two dissection planes (the abdominal mesorectal plane and the perineal plane) have been connected posteriorly, just anterior to the coccyx, the surgeon should divide the levator muscles beginning at the apex of the ischiorectal fossa, close to their insertion on the tendinous arch covering the obturator internus (Figs. 156.15 and 156.16). We find that placing the index of the nondominant hand into the pelvis and “hooking” the levator muscles facilitates this division. The puborectalis should be divided anteriorly before the transverse perineal muscle is reached.

At this point, the rectum, still attached anteriorly to the prostate or vagina, should be delivered through the wound to facilitate exposure for the anterior dissection. The distal portion of the anterior dissection—the separation of the distal rectum and anal canal from the perineal body—is best performed from proximal to distal, following the anterior surface of

the prostate or vagina, and from medial to lateral, rather than from the bottom (Fig. 156.17). The perineal approach affords better visualization of the neurovascular bundle (the distal portion of the pelvic plexus) and can help avoid injury to the urethra. It is important to stay in the correct plane, and palpation can facilitate this. In males, palpating for the urethra and urinary catheter can help avoid injury. In women, placing a finger in the vagina can help to define the plane of the rectovaginal septum.

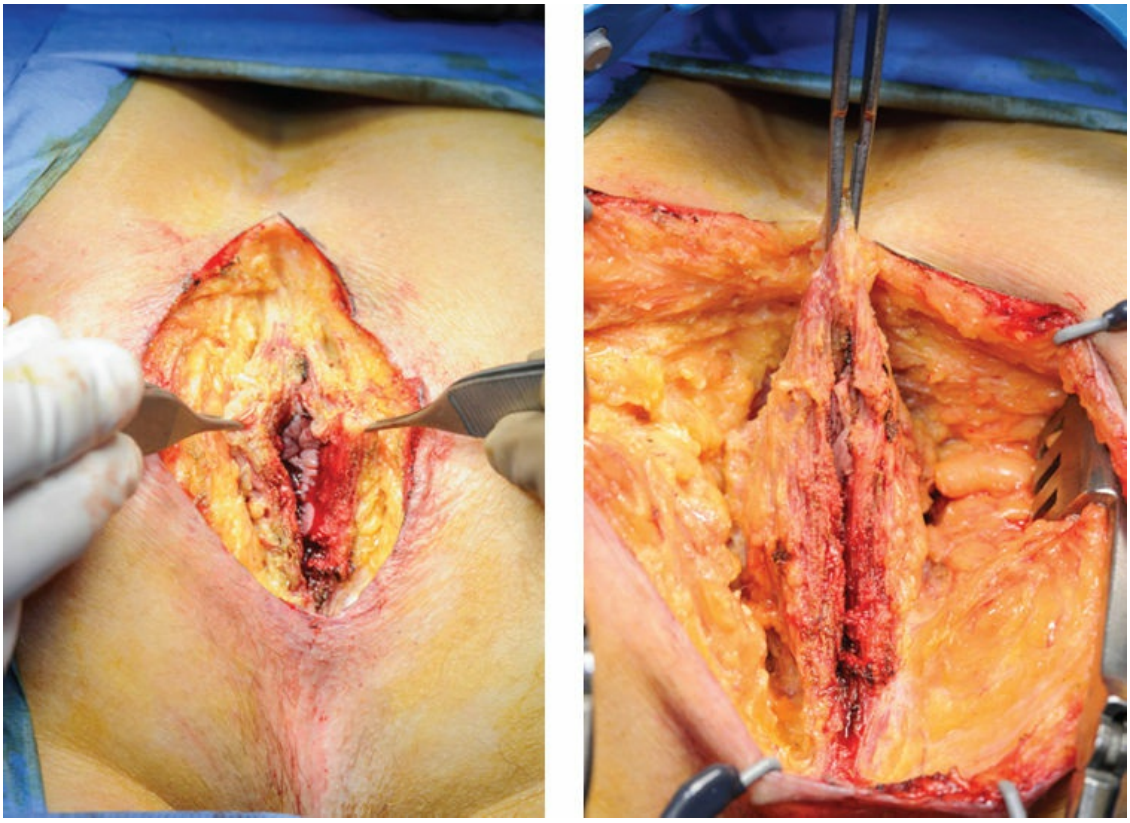

Figure 156.11. Perineal dissection immediately outside the external sphincter, preserving the ischiorectal fat. (©2016, Memorial Sloan Kettering Cancer Center.)

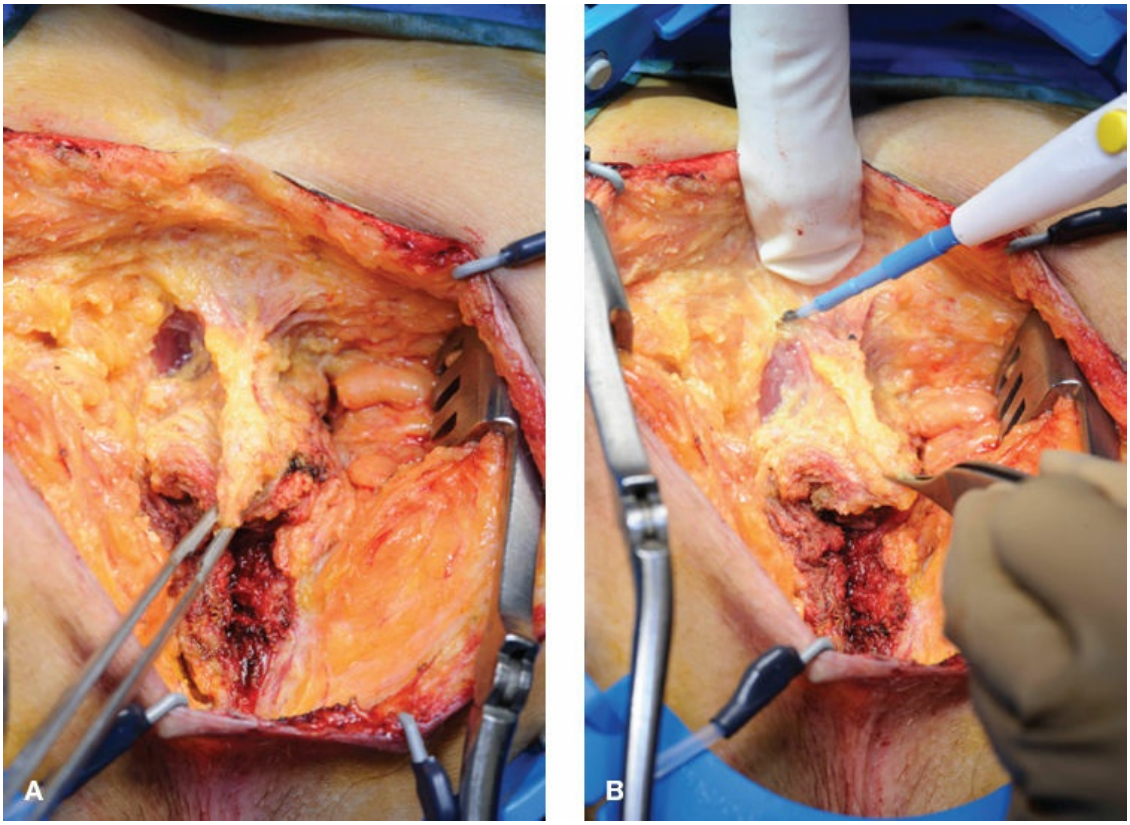

Figure 156.12. Exposure (**A**) and division (**B**) of the anococcygeal ligament. (©2016, Memorial Sloan Kettering Cancer Center.)

Once the specimen is removed, the pelvic cavity is irrigated. Pelvic drains placed previously during the abdominal phase of the procedure are repositioned as needed, and the perineal defect is closed. For primary closure, we prefer a meticulous, multilayered closure with large absorbable sutures, to approximate the ischiorectal fat, and a layer of nylon sutures in a vertical mattress pattern to approximate the skin (Fig. 156.18).

Reinforcing the perineal closure with a biologic absorbable mesh anchored to the coccyx, coccygeus muscles and pelvic side-wall along the insertion of the levator muscles is often used to prevent wound dehiscence and perineal hernias in patients with larger perineal defects. Alternatively, there are a number of reconstructive options using homologous tissue. The ventral rectus abdominis muscle flap is mostly used in open procedures done in the lithotomy position, but it can also be used when the perineal portion is done in the prone position. In this case, the flap is mobilized when the abdomen is open and the patient is in the supine position prior to abdominal wall closure or colostomy maturation. The flap is then tagged with a suture and positioned deep in the pelvis for easy retrieval during the

perineal phase. The bilateral V-Y advancement gluteal flaps are an excellent alternative, especially if there is concern about retaining the integrity of the abdominal wall. These flaps are done in the prone position and allow for excellent tissue coverage, even for posterior vaginal reconstruction. Gracilis muscle flaps have also been described, with good results. No differences in outcomes or morbidity have been noted between different reconstruction options, and the strategy should be individualized based upon each patient's needs and functional limitations.

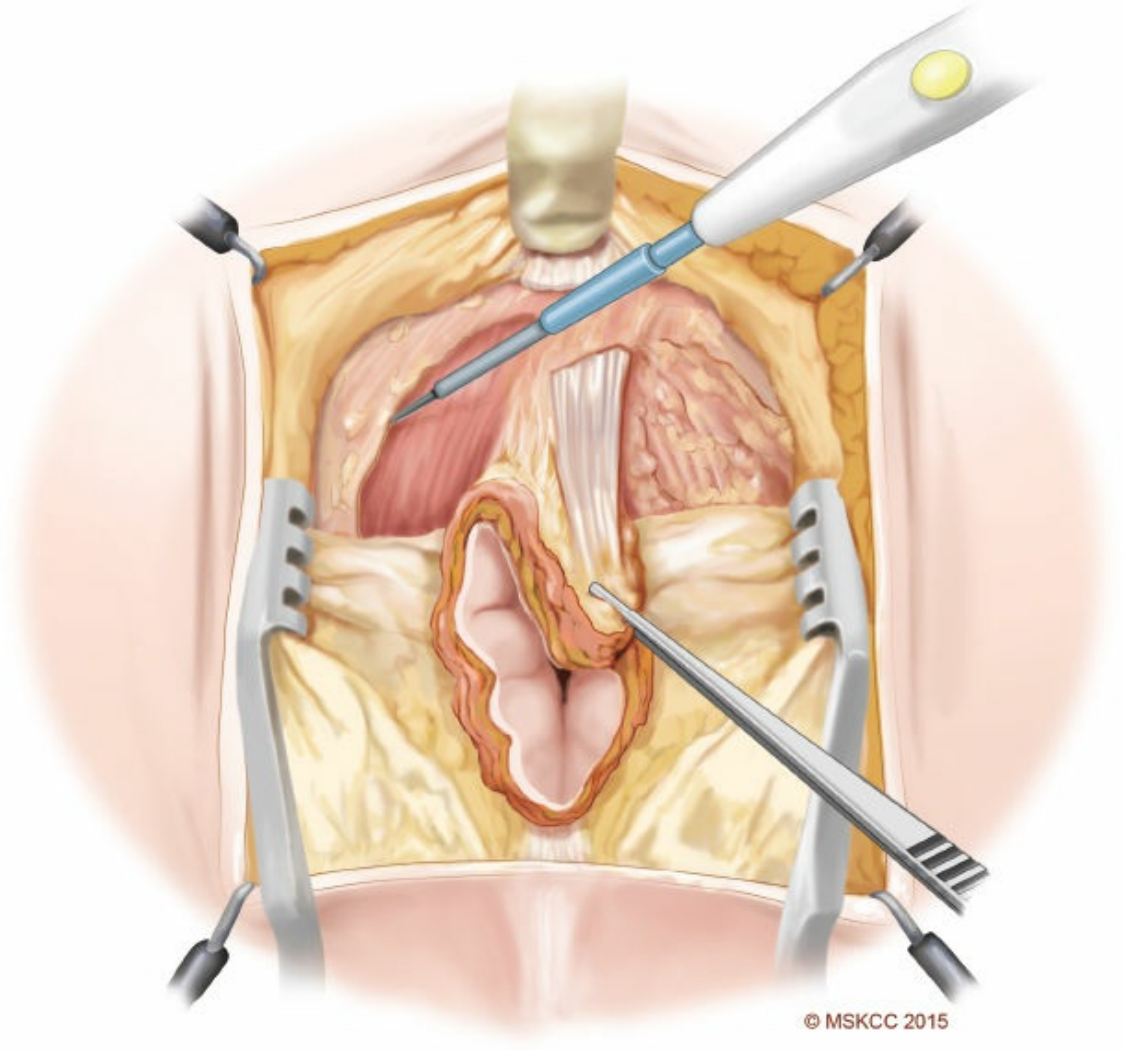

Figure 156.13. Exposure of the levator muscles and the anococcygeal ligament. (©2016, Memorial Sloan Kettering Cancer Center.)

Perineal Part: Lithotomy Position

As discussed above, lithotomy is the most comfortable patient position for most surgeons. The orientation of the anatomy is familiar, and there may

be specific reasons to consider this position for the perineal part of the dissection. We find it helpful to place a large metal or plastic tray across the lap of the operating surgeon, to allow easy access to frequently used instruments. In addition, care should be taken to keep a sterile field under the patients' buttocks. The operation proceeds as described above for the prone position. However, anterior dissection can be more difficult in lithotomy, given the reduced exposure. The surgeon must be in the correct plane, feeling for the urethral catheter in males and the vagina in females.

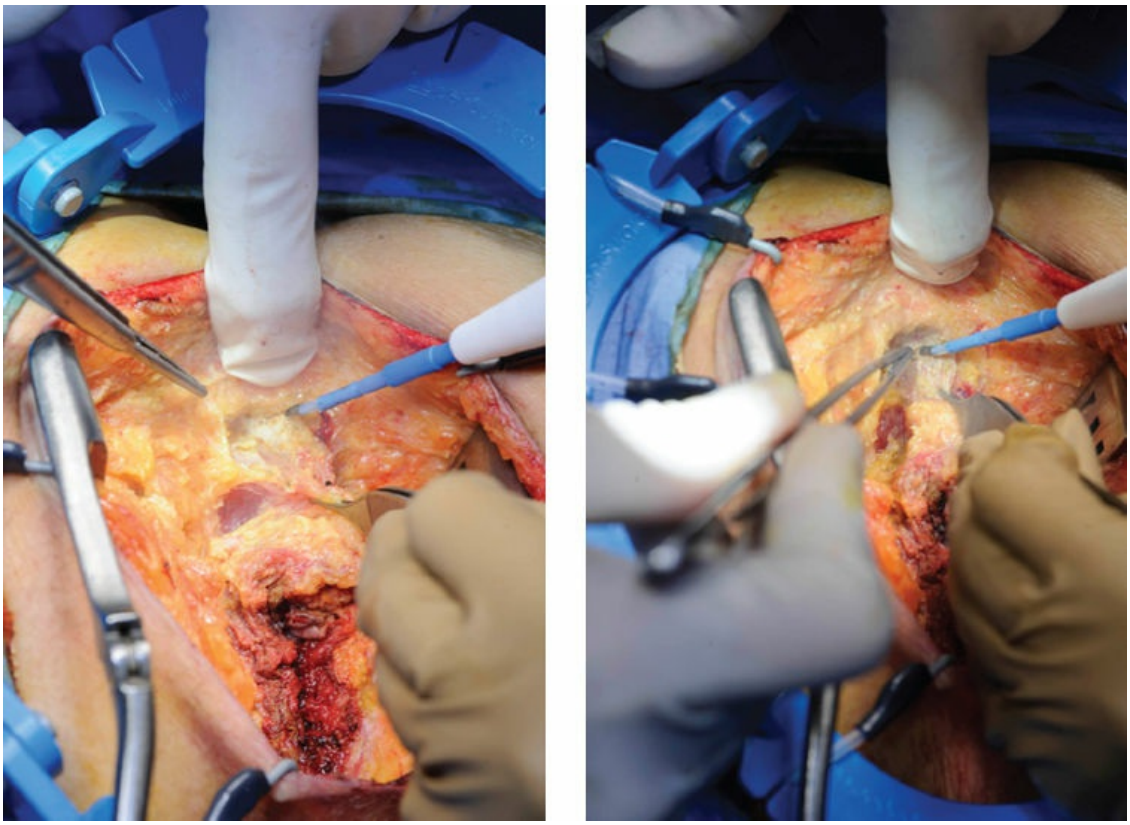

Figure 156.14. Dissection underneath the coccyx and distal sacrum to connect with the pelvic cavity. (©2016, Memorial Sloan Kettering Cancer Center.)

POSTOPERATIVE CARE

Postoperative care after an APR is relatively routine. We advocate an enhanced recovery strategy, permitting early ingestion of clear liquids and advancing to low-residue diet as tolerated, with limited intravenous fluid resuscitation, early ambulation, and a pain control strategy to minimize the use of narcotics. Because of the extensive pelvic dissection and concomitant risk to the nerves, the urinary catheter remains in place until at least the third postoperative day.

Post-APR drain management is a subject of controversy. After a primary closure of the perineum, the pelvic drain is often removed prior to discharge, because the pelvic peritoneum can reabsorb any peritoneal fluid that is secreted. If a rectus flap is used, additional drains are often needed in the abdominal wall, and the pelvic drain remains in place until output has diminished significantly and the wounds are healing well. These drains sometimes remain in place for as long as 2 weeks.

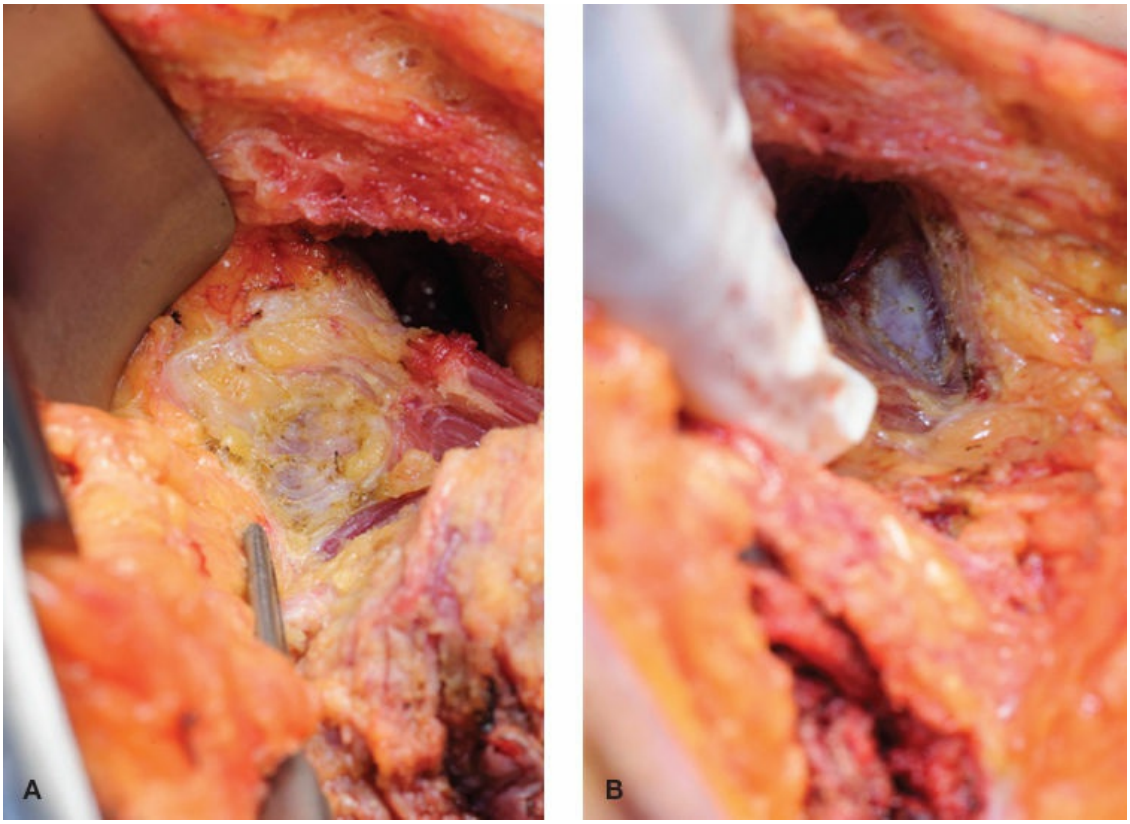

Figure 156.15. Division of the left (**A**) and right (**B**) levator muscles. (©2016, Memorial Sloan Kettering Cancer Center.)

To protect the perineal wound, physical activity is restricted. If the closure was primary, the patient should avoid sitting for 4 to 5 weeks following surgery, to allow the wound to fully heal. Often, the perineal sutures remain in place for 3 to 4 weeks, as this area has a high incidence of wound dehiscence and infection. If short-duration sitting is absolutely necessary, as is usually the case in the car ride home from the hospital, patients should employ a soft pillow. They should avoid using a foam ring, which can lead to increased pressure in the perineum and disrupt blood flow. If the perineum was closed with a flap, the patient should also be instructed to avoid bending at the waist for a similar duration of time, to

prevent placing undue tension on the reconstruction.

MANAGEMENT OF COMPLICATIONS

The most significant source of morbidity following an APR is the perineal wound. The rate of wound infections in the perineum is as high as 40%, often due to the large excision required and the necessity for preoperative radiation. Thus, using healthy autologous tissue can help reduce these complications. Wound infections necessitate opening the wound. Because of the high risk of evisceration—since there may be no fascia or muscle to support the pelvic floor—this procedure must often be done in the operating room. The wound is irrigated, necrotic tissue is removed, additional drains are placed as needed, and the wound is closed if possible. If the wound cannot be closed, a negative-pressure dressing can be employed, with a good rate of success. We have even seen good results using synthetic prosthetic devices (silicone breast implants) to fill the defect. Generally though, we do not recommend using such synthetic materials in contaminated fields.

Genitourinary and sexual dysfunction is prevalent after APR, occurring in up to 50% of patients. Good surgical technique, including identification and protection of the pelvic nerves, goes a long way toward preventing such dysfunction. Fortunately, in some patients the dysfunction is relatively minor, and function often continues to improve for 12 months following surgery. However, a significant minority of patients sustain permanent dysfunction.

Stoma-related complications, particularly parastomal hernias, are a significant long-term consequence of APR. The findings of several well-designed studies support the use of preperitoneal prosthetic mesh for constructing permanent ostomies. The extent of the operation and the risk of mesh-related complications are important considerations, and for these reasons we avoid permanent mesh placement during the initial surgery. However, if a symptomatic parastomal hernia does occur, placement of permanent mesh during the repair operation should be strongly considered.

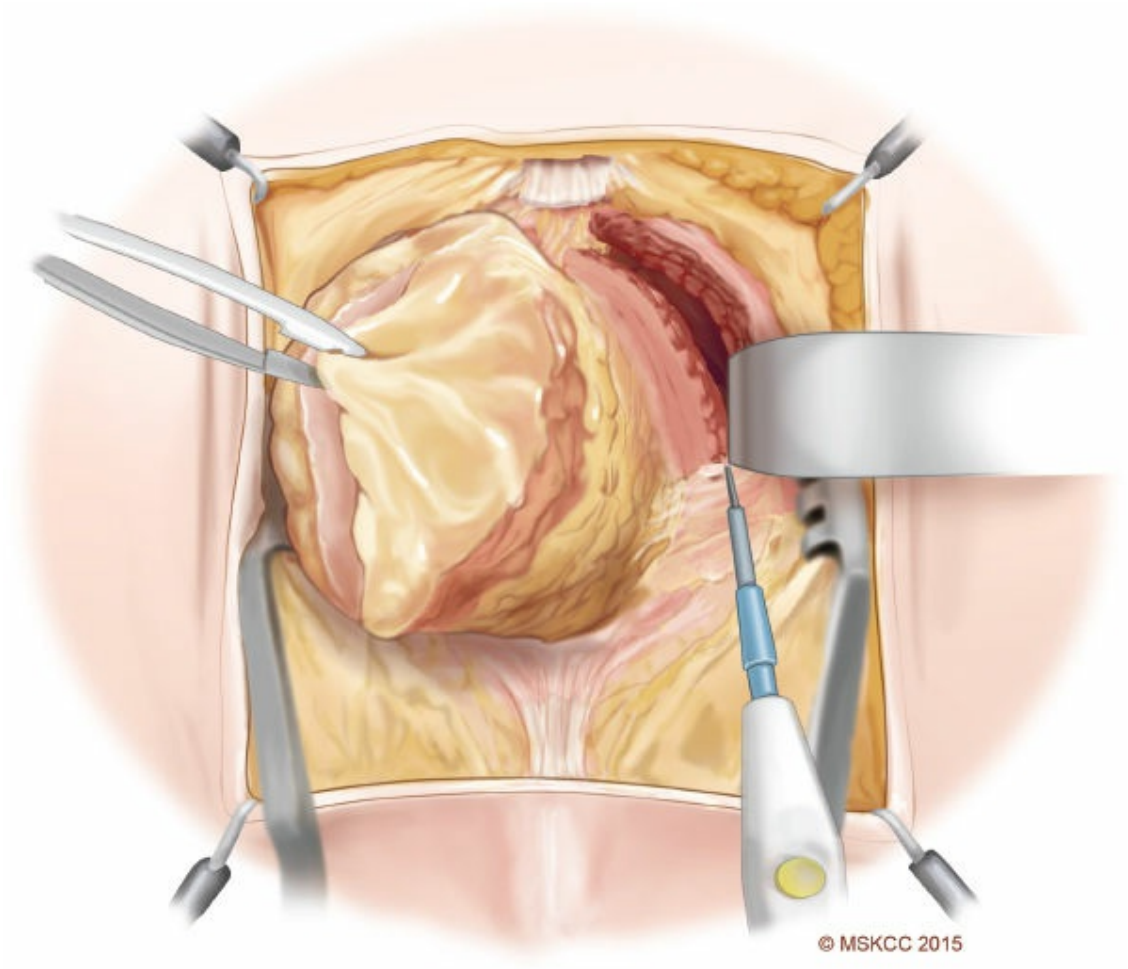

Figure 156.16. Division of the right levator muscle. (©2016, Memorial Sloan Kettering Cancer Center.)

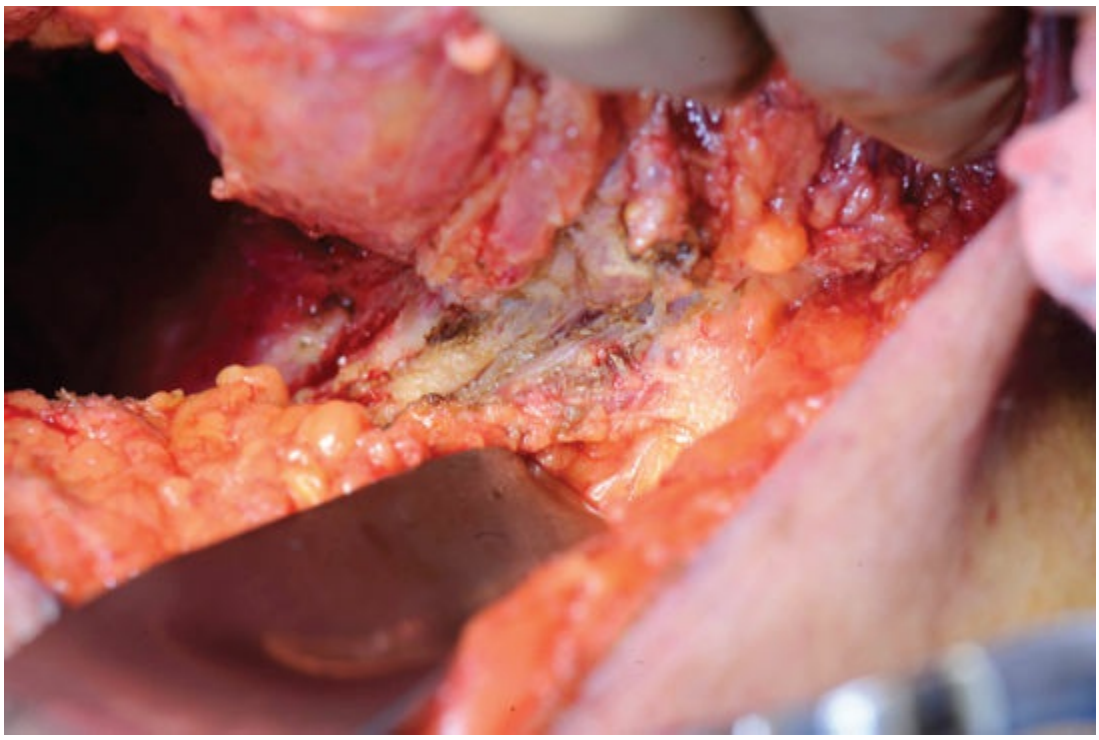

Figure 156.17. Division of the rectourethralis and separation of the distal rectum from the transverse perineal muscle. (©2016, Memorial Sloan Kettering Cancer Center.)

OUTCOMES

APR performed in the lithotomy position is associated with a risk of intraoperative bowel perforation and positive circumferential margins, both of which contribute to higher rates of local recurrence and mortality compared with low anterior resection. Even with neoadjuvant chemoradiation, this trend remains, with the rate of local recurrence as high as 30%. While the etiology is likely multifactorial, intraoperative patient positioning may play an important and influential role.

The evidence regarding the positioning of the patient during the perineal portion of the APR is mixed. In small, single-institution studies, prone positioning for cylindrical APR was associated with reductions in the rates of local recurrence (to 6%) and perineal wound infections (to 11%). A single-institution randomized controlled trial also found decreased rates of circumferential margin involvement and local recurrence for cylindrical APR performed in the prone position, although at the cost of higher rates of chronic perineal pain. In the authors' opinion, the position of the patient during the perineal portion of the APR procedure is a matter of preference, and the surgeon should use the approach he or she feels more comfortable with.

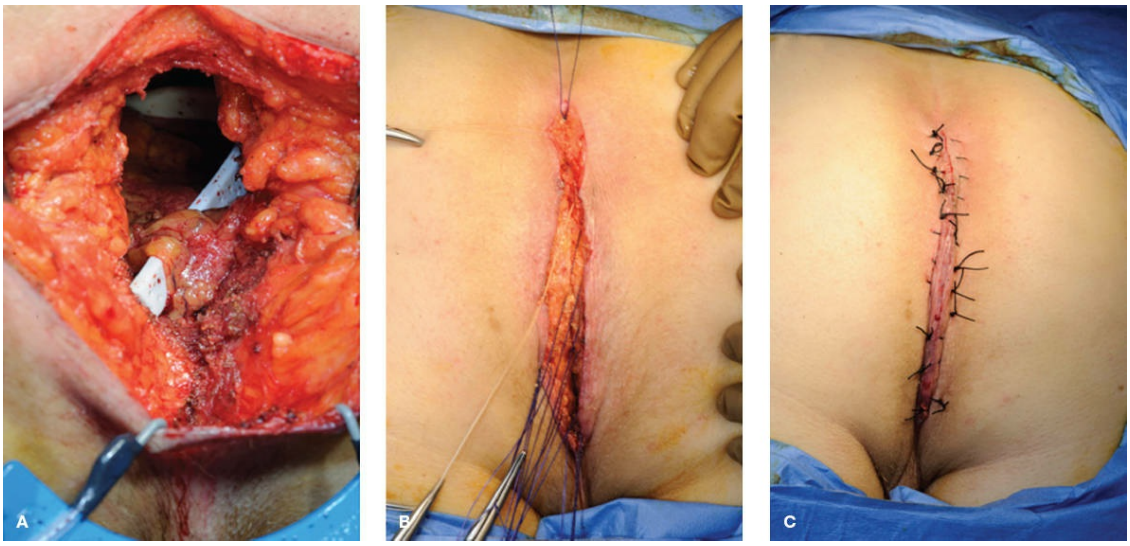

Figure 156.18. **A.** Perineal defect after removal of the specimen. **B.** Approximation of the fat of the ischiorectal fossa with absorbable sutures. **C.** Closure of the skin with nonabsorbable

sutures. (©2016, Memorial Sloan Kettering Cancer Center.)

Overall, oncologic outcomes following an APR for distal rectal cancer are poorer than outcomes following surgery for higher rectal cancers. In patients with clinical stage II or III disease treated with neoadjuvant chemoradiotherapy and optimal surgery, the 5-year survival rate after an APR is close to 70%, compared to 85% after a sphincter-preserving surgery. However, rectal cancer care does not always follow best-practice guidelines and such deviations can increase local recurrence rates and reduce long-term survival.

Suggested Readings

Barker T, Branagan G, Wright E, et al. Vertical rectus abdominis myocutaneous flap reconstruction of the perineal defect after abdominoperineal excision is associated with low morbidity. *Colorectal Disease* 2013;15:1177–83.

Cercek A, Goodman KA, Hajj C, et al. Neoadjuvant chemotherapy first, followed by chemoradiation and then surgery, in the management of locally advanced rectal cancer. *JNCCN* 2014;12:513–19.

Crawshaw BP, Augestad KM, Keller DS, et al. Multivisceral resection for advanced rectal cancer: Outcomes and experience at a single institution. *Am J Surg* 2015;209:526–31.

Han JG, Wang ZJ, Wei GH, et al. Randomized clinical trial of conventional versus cylindrical abdominoperineal resection for locally advanced lower rectal cancer. *Am J Surg* 2012;204:274–82.

Jänes A, Cengiz Y, Israelsson LA. Preventing parastomal hernia with a prosthetic mesh: A 5-year follow-up of a randomized study. *World J Surg* 2009;33:118–21.

Judge BA, Garcia-Aguilar J, Landis GH. Modification of the gluteal perforator-based flap for reconstruction of the posterior vagina. *Dis Colon Rectum* 2000;43:1020–2.

Miles WE. A method of performing abdomino-perineal excision for carcinoma of the rectum and of the terminal portion of the pelvic colon. *Lancet* 1908;172:1812–3.

Quirke P, Durdey P, Dixon MF, et al. Local recurrence of rectal adenocarcinoma due to inadequate surgical resection. Histopathological study of lateral tumour spread and surgical excision. *Lancet* 1986;2:996–9.

Silberfein EJ, Kattepogu KM, Hu CY, et al. Long-term survival and recurrence outcomes following surgery for distal rectal cancer. *Ann Surg Oncol* 2010;17:2863–9.

Wibe A, Syse A, Andersen E, et al. Oncological outcomes after total mesorectal excision for cure for cancer of the lower rectum: anterior vs. abdominoperineal resection. *Dis Colon Rectum* 2004;47:48–58.

EDITOR'S COMMENT

We have two chapters on the same surgery but with differences. I am familiar with them because in my early years at the Massachusetts General Hospital I pursued saving the rectum, at least partially, but saving the rectum was a widely criticized practice at the time, though in my experience I had very few recurrences.

Dr. Garcia-Aguilar is describing the "old-fashioned" abdominoperineal resection which does not very often allow the patient to avoid a colostomy. Both of the techniques, described in the two chapters can be utilized.

Professor Garcia-Aguilar's procedure is the 1908 procedure which Professor Miles described. Its purpose is to "cure the cancer." That is what Dr. Claude Welch did at the Massachusetts General Hospital. Few patients moved their bowels via the rectum. Many patients were cured. Many had recurrences and died while trying to save the rectum. My own view is that in good hands recurrences occurred but not often.

J.E.F.

157 Abdominoperineal Resection for Rectal Cancer

Steven Nurkin, Aaron Saunders, Rupen Shah, and Steven N. Hochwald

INTRODUCTION

Current investigations in rectal adenocarcinoma are developing paradigms of management that emphasize minimally invasive surgery, less radical resections, and even organ preservation—complete omission of any radical resection from the initial treatment plan. However, there undoubtedly remains a population of patients with rectal cancer in whom the best oncologic outcome can be achieved by an abdominoperineal resection (APR, also known as abdominoperineal excision, or APE). Initially described by Sir Ernest Miles at the beginning of the 20th century, this treatment was for decades the standard of care for the surgical management of all rectal cancers. Now, many patients can be managed with restorative proctectomy, often with excellent results. Unfortunately, patients with very low rectal tumors have not achieved the high rates of margin negativity and low rates of local recurrence brought about by total mesorectal excision (TME) in mid- to high-rectal tumors. To address this, the approach to APR in low rectal tumors has been re-evaluated, and variations on the classic operation have been developed, each with different indications and important distinctions in technique. The choice between these techniques is driven by patient and tumor characteristics, and the successful operation is based upon a detailed understanding of the anatomy, with a meticulous approach to dissection.

CLINICAL PRESENTATION

Rectal adenocarcinoma in general will often present with blood per rectum, and possibly anemia, as well as a change in the caliber or character of the stool. Symptoms of rectal fullness or tenesmus may also be present. In the patient destined for an APR, there may be signs of anal sphincter or pelvic floor involvement, such as fecal incontinence and anal pain. Tumor

perforation with perirectal abscess may also occur.

INDICATIONS AND CONTRAINDICATIONS

In general, an APR for malignant disease should be reserved for patients with very low rectal adenocarcinomas in whom sphincter preservation is not possible, or patients with anal squamous cell carcinoma (SCC) that has not been successfully treated with chemoradiation therapy. The options for surgical approach to APR are based upon concentric anatomic tissue planes. The basic concept is that the resection should target the tissue plane outside of the tumor's apparent extent of invasion, in order to achieve a margin-negative resection.

The intersphincteric variation of APR creates the narrowest perineal wound of the APR techniques, and may be appropriate for patients whose rectal tumors have no levator involvement, who suffer from fecal incontinence at baseline, or who are very high risk for an anastomotic leak, either from the standpoint of poor capability for wound healing or of inadequate physiologic reserve to withstand a septic insult. However, these patients might also be treated with a very low Hartmann procedure, avoiding a perineal wound altogether.

The extralevator approach to APR (also known as extralevator abdominoperineal excision, or ELAPE) is a technique in which the levator muscles are not dissected away from the tumor or the mesorectum and are removed en bloc with the specimen (Fig. 157.1). This approach is indicated for patients who have tumors within a centimeter from the dentate line, or low rectal tumors with a threatened circumferential resection margin (CRM) in whom a sphincter saving procedure may not be oncologically possible (Fig. 157.2).

The ischioanal variation of APR entails incising the levator muscles at their lateral insertions and performing dissection along the outside of the fat pad of the ischioanal fossa and along the fascia of the obturator internus muscle. This is the widest of the perineal dissection approaches, and is indicated in patients with tumors that involve the perianal skin, ischioanal fat, or levator muscles with direct tumor invasion, perforation, or formation of abscesses or fistulous tracts.

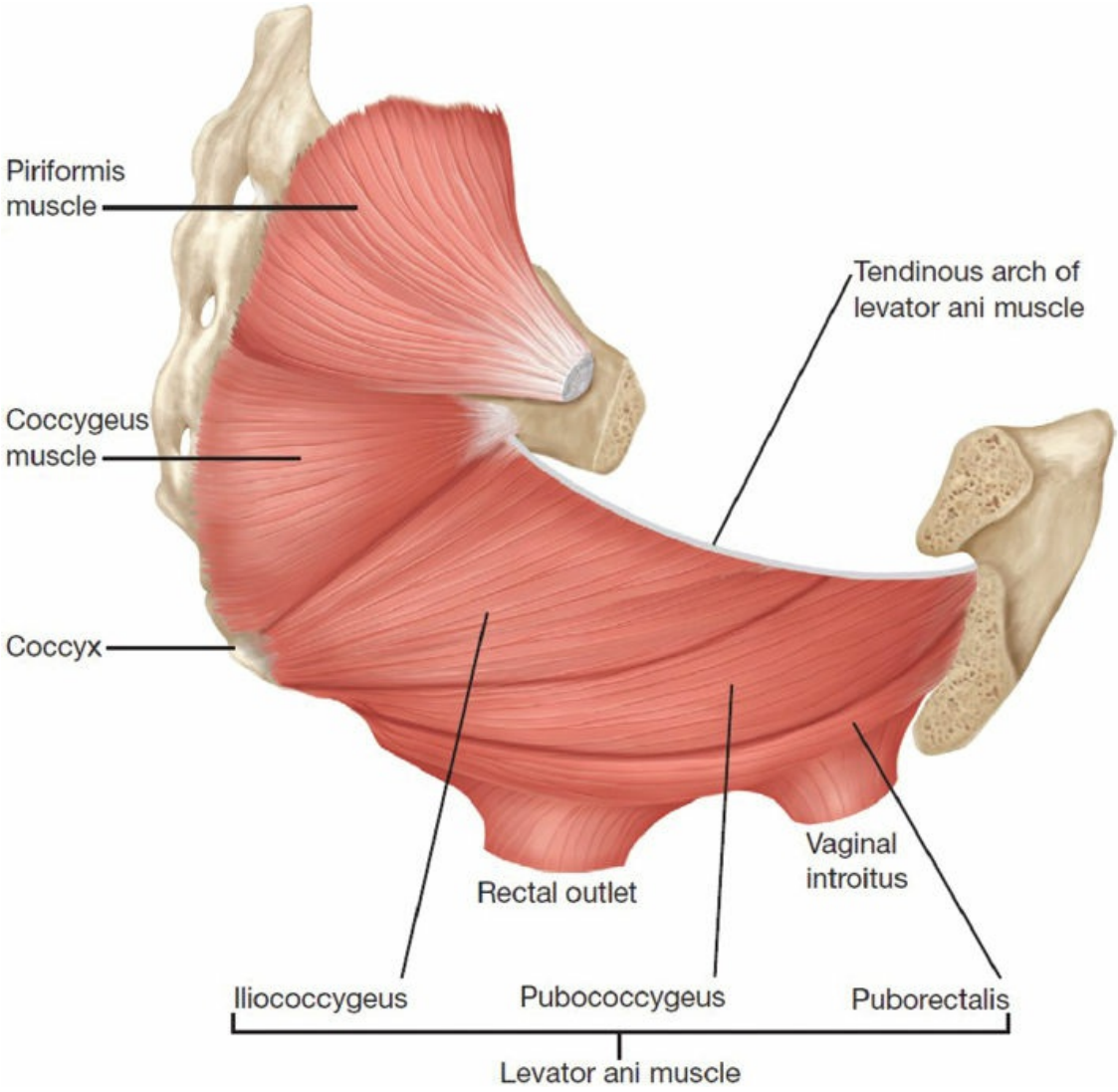

Figure 157.1. Illustration of the levator ani complex with musculoskeletal anatomic relationships. Varying amounts of this pelvic floor are resected with different approaches to APR.

At best, an APR has the potential for significant morbidity. Risks for significant bleeding and injury to adjacent structures such as pelvic nerves, prostate, and vagina, are higher than for low anterior resection. The most frequent complications occur in relation to the perineal wound, including dehiscence and/or infection. For this reason, patients of advanced age and with poor performance status and physiologic reserve should be counseled carefully about the risks and benefits of surgery. It should be considered that for some, the morbidity of this operation may decrease their expected survival relative to palliative chemoradiation. These findings may be considered a relative contraindication to APR.

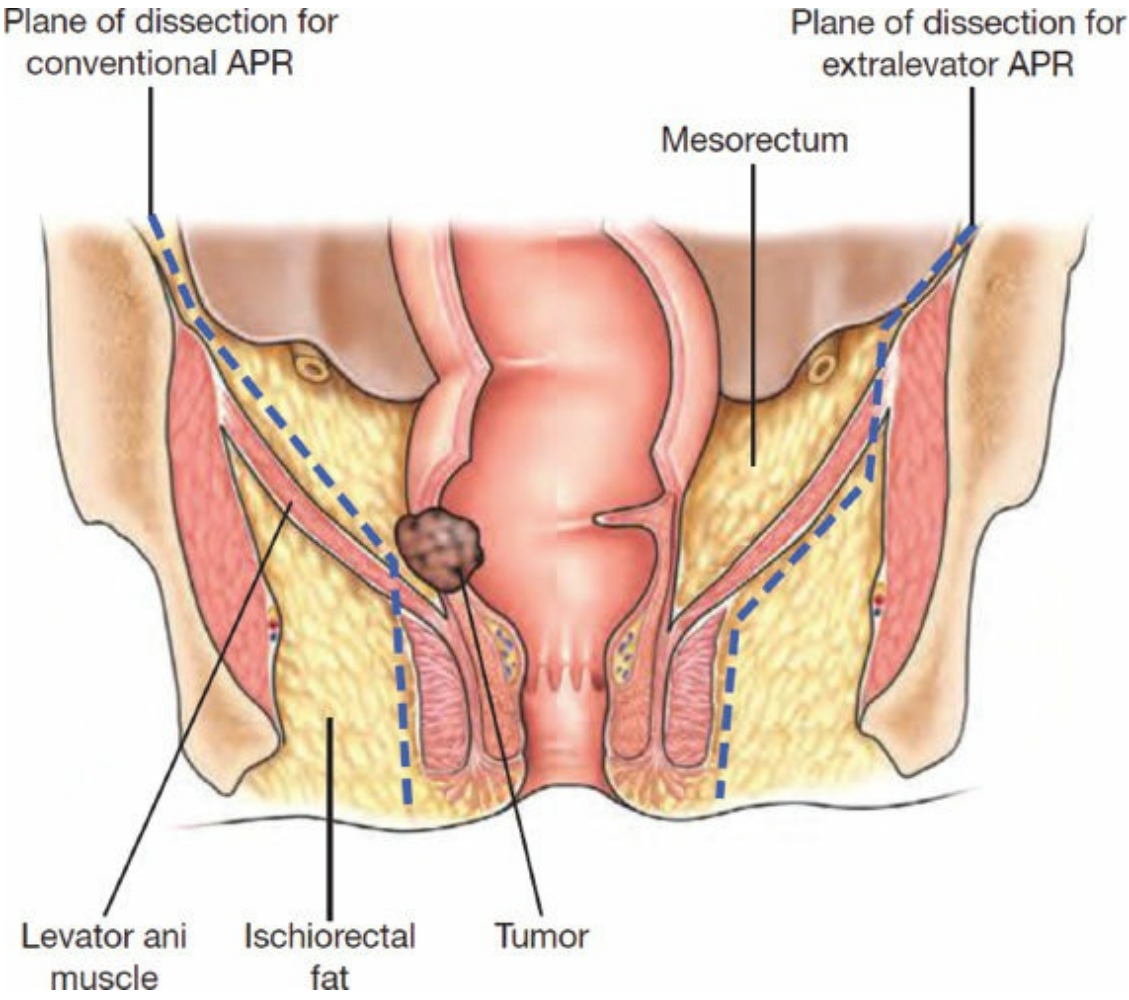

Figure 157.2. Illustration of the distinction between conventional APR, and extralevator APR, highlighting the risk to the surgical margin in the left side of the image.

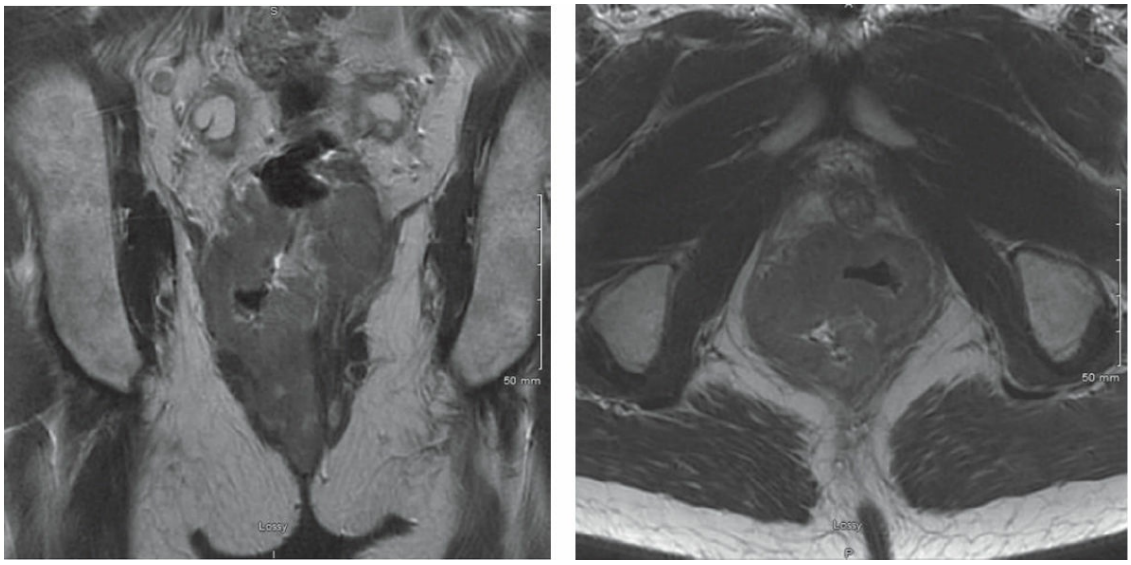

Figure 157.3. Selected images from a pelvic MRI demonstrating a locally advanced rectal tumor with invasion into the sphincter

complex and levator muscles.

WORKUP AND MULTIDISCIPLINARY TREATMENT PLANNING

The initial interview should include a detailed history establishing the baseline urinary and sexual function of the patient, and whether the patient experiences fecal incontinence. A digital rectal examination should be performed, and note should be taken of the relationship of the tumor, including possible fixation or invasion, to the surrounding structures. Staging workup should include computed tomography (CT) scan of the chest, abdomen, and pelvis, as well as a baseline carcinoembryonic antigen (CEA) level. In addition, endorectal ultrasound (ERUS) or, preferably, magnetic resonance imaging (MRI) of the pelvis provides invaluable information about the extent of local tumor invasion and regional lymph node involvement (Fig. 157.3). The MERCURY trial evaluated 408 consecutive rectal cancer patients at several European centers with MRI, and assessed the correlation between the MRI prediction of curative surgery and final margin status. The trial found a 91% accuracy of MRI in predicting a negative resection margin in patients going to primary surgery, and a 77% accuracy rate among patients who had received neoadjuvant treatments.

Review of a rectal MRI should carefully assess for invasion of the levator muscles or the sphincter complex. By definition, any tumor that appears to invade the levator ani complex is at least a clinical T3 (stage II, according to the *AJCC Cancer Staging Manual*, 7th ed.), and standard treatment often includes neoadjuvant chemotherapy and/or radiation therapy followed by surgery. Multiple randomized clinical trials have demonstrated that neoadjuvant chemoradiation therapy in stage II and higher rectal cancer decreases rates of local recurrence following surgery. Furthermore, the Dutch Trial combining neoadjuvant chemoradiation and total mesenteric excision (TME), which has also been shown to be an independent factor in the reduction of local recurrence rates, demonstrated the lowest reported rates of local recurrence, yet. Current multimodal treatment is capable of achieving local recurrence rates of 5% or lower. This has served to emphasize the importance of well-coordinated multidisciplinary treatment of patients with rectal cancer to achieve optimal outcomes.

SHIFTING PARADIGM REGARDING PERINEAL MARGIN

Of note, while outcomes improved for rectal cancer overall, the population requiring APR for curative resection remained a negative outlier, associated with higher rates of positive CRMs and tumor rupture at time of surgery. These findings prompted a renewed interest in wider dissection through the pelvic floor and perineum in order to more consistently achieve margin-negative resections, and the extralevator approach to APR gained increasing support. More recent investigations have not uniformly shown that extralevator dissection leads to better outcomes than conventional APR, with both techniques achieving local recurrence rates approaching those for patients treated with sphincter-preserving TME when margin-negative resection is achieved. These studies have confirmed that CRM involvement or tumor perforation are associated with higher rates of local recurrence, emphasizing the importance of keeping the dissection plane well away from the edge of the tumor. It is clear, then, that successful extirpation of disease involving the distal rectum in particular must begin with a thorough and accurate assessment of the tumor's extent of invasion.

PREOPERATIVE PLANNING

Following neoadjuvant therapy, the patient should be restaged with CT scans of chest, abdomen, and pelvis, and rectal MRI. It is important to recognize that the extent of tumor invasion seen on MRI guides the surgeon in selecting the plane of dissection through the pelvic floor. In some patients with locally advanced disease, MRI may also show tumor invasion into adjacent organs or structures, such as prostate, vagina, bladder, branches of the iliac vessels, sacrum or pelvic sidewall. In such cases, the surgeon plans for a more radical operation involving en bloc resection and reconstruction of adjacent organs; it may be prudent to invite additional surgical specialists to be available to assist in the surgery, as needed.

Sometimes underappreciated in preparation of the patient for an APR is the creation of a permanent end colostomy. It is critical that attention be paid to appropriate selection of a site for this colostomy. The patient should be observed and marked in the preoperative area in the seated, standing, and bending positions, taking care to identify a location for the

stoma that will be surrounded by flat, smooth skin that is free of creases, scars or radiation damage, and is easily visible and accessible to the patient. Ideally, the patient should receive education prior to surgery about the nature and care of a colostomy. A preoperative visit with a trained enterostomal therapist is helpful.

The question of bowel preparation remains controversial. It is our practice to perform a full Nichol's colon preparation, that includes oral antibiotics and mechanical preparation, prior to surgery, with the intent of reducing infectious wound complications in the postoperative period.

SURGICAL TECHNIQUE

In our practice, it is common to perform an APR with a minimally invasive approach, often with robotic assistance for the abdominal dissection. The principles of the operation are the same as in conventional open surgery, with minor variation in the typical order of steps. The selection of the approach should depend primarily on the experience and comfort level of the operating surgeon, as the primary consideration must be safe and oncologically sound surgery, ideally with preservation of autonomic innervation and baseline urogenital function.

Positioning

It is our preference to place the patient in the Lloyd-Davies position, and perform both the abdominal and perineal portions of the operation without repositioning the patient. Some surgeons, however, prefer to begin with the patient supine with legs apart, and complete the abdominal portion of the surgery, including construction of the colostomy and closure of all abdominal wounds. The patient is then repositioned in a prone jack-knife orientation for the perineal dissection. Proponents of this latter approach cite improved visualization of the anterior pelvis, which facilitates dissection of the specimen off of the prostate or vagina, and the pelvic nerves. Still others will start the surgery in the prone jack-knife position and perform the perineal dissection, and then place the patient in the supine position to continue with laparoscopic removal of the specimen and formation of the colostomy. Advantages of maintaining the Lloyd-Davies position throughout, however, are that two teams may work simultaneously, and difficult dissection maneuvers in the deep pelvis can sometimes be facilitated by alternating approaches between the abdomen and perineum.

Abdominal Dissection

The approach to the abdominal dissection for an APR proceeds in much the same fashion as for a low anterior resection. For the minimally invasive approaches, the initial access to the abdomen and creation of pneumoperitoneum is achieved with placement of a Veress needle in the left upper quadrant of the abdomen, confirming intraperitoneal placement with a saline drop test, and beginning abdominal insufflation with a goal pneumoperitoneum pressure of 15 mm Hg. Planning for the location of port sites then depends on the laparoscopic or robotic equipment to be used and the preferences of the surgeon. The key principle is that port placement should facilitate full range of motion and appropriate traction and countertraction during surgery. A diagnostic laparoscopy is performed, inspecting the liver and peritoneal surfaces to evaluate for the possibility of metastases. The small bowel is retracted to the right upper quadrant with the aid of Trendelenburg positioning and placing them left side up. It may be necessary to suspend the uterus by the use of sutures passed through the abdominal wall.

Once access and exposure has been achieved, a minimally invasive operation begins with mobilization of the sigmoid colon, using a medial-to-lateral approach. This dissection begins with an incision of the peritoneum just medial to the right iliac artery. Lifting the peritoneal edge allows pneumodissection to assist in exposure of the target plane, which is then followed cephalad. The sigmoid colon is lifted up, placing the inferior mesenteric artery (IMA) pedicle on tension and allowing more lateral dissection in the alveolar plane between the mesocolon and the retroperitoneum. Retroperitoneal tissues are dissected with care to avoid injury to the hypogastric nerve plexus. Following this dissection cephalad will reveal the origin of the IMA. The superior rectal artery is then isolated and divided with a laparoscopic or robotic vessel sealing device (Fig. 157.4). Conventional descriptions of the operation describe high ligation of the IMA (which, when performed, should be at a location a few centimeters away from the aorta, to avoid injury to hypogastric nerves), but it is our opinion that an adequate oncologic resection for low rectal tumors requiring APR can be performed in cases of clinically negative nodes and low risk for lymphatic metastases, allowing preservation of the IMA trunk and the left colic artery. This serves to maintain better perfusion to the left colon beyond the watershed area and, therefore, to the level of the colostomy. However, when preoperative or intraoperative

findings suggest significant regional lymphadenopathy, the conventional high ligation of the IMA should be performed.

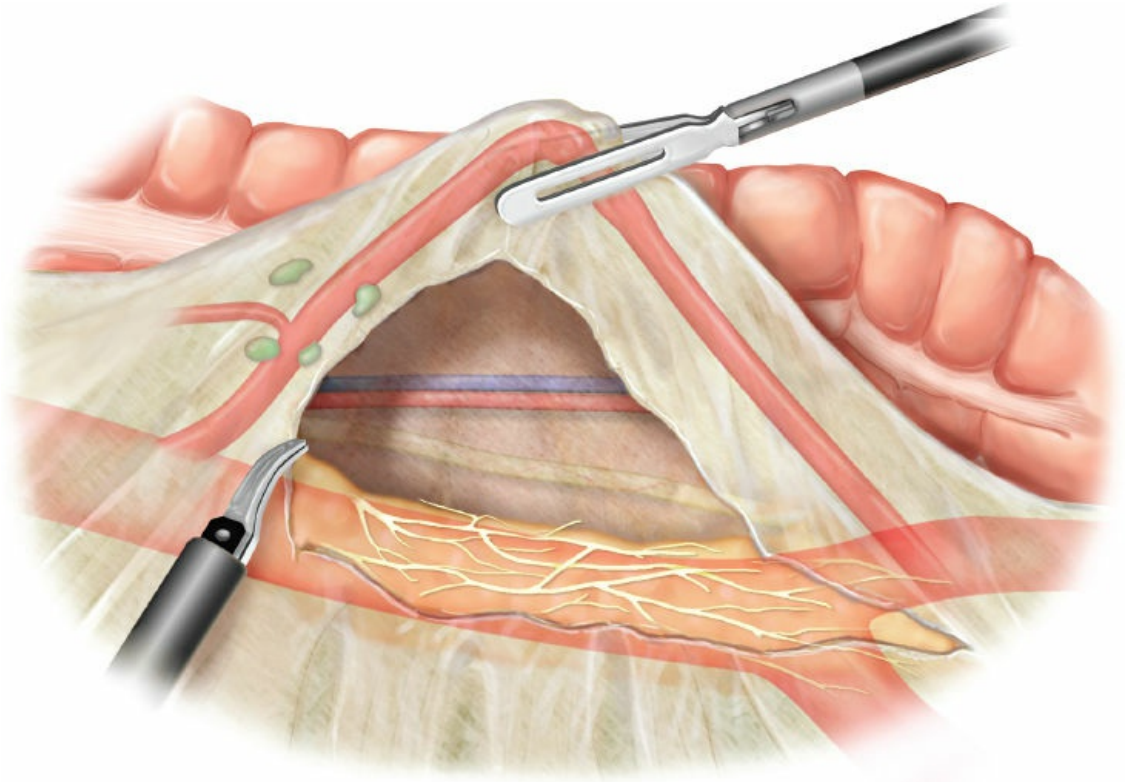

Figure 157.4. The inferior mesenteric artery (IMA), origin of the left colic artery, and superior rectal artery are exposed. The superior rectal artery is isolated and may be divided with a vessel sealer or other mode of ligation, unless clinically positive nodes are encountered, in which case a high ligation of the IMA is performed with care taken to preserve the hypogastric nerve trunks.

Continuing in this plane will expose the hypogastric nerves, gonadal vessels, and ureter. In some cases, the sigmoid colon may be tethered laterally, and it may be necessary to release these attachments before sufficient anterior traction can be placed on the sigmoid to reveal the vascular pedicle and facilitate the medial-to-lateral dissection. In this situation, it is crucial to recognize that the colon must be pulled toward the right upper quadrant and dissection should proceed more medially than posteriorly. It is a common mistake for the operating surgeon to expose and follow the plane just lateral to this, and begin to dissect more posteriorly toward the quadratus lumborum muscle and toward the lateral edge of Gerota fascia. Following this plane at the level of the pelvic brim

would threaten the ureter and iliac vessels, and should be avoided. When there is sufficient mobility of the sigmoid to retract anteriorly, the dissection between the mesocolon and the retroperitoneum continues until the lateral peritoneal leaflet is reached and incised, entering the left paracolic gutter. As this dissection proceeds laterally, it is helpful to place a laparoscopic or robotic instrument behind the dissected mesocolon and lift it anteriorly. This provides the best exposure and tension at the leading edge of the dissection plane.

The apex of the mobilized sigmoid is lifted anteriorly, and should be observed to reach the abdominal wall without tension. The location for transection of the sigmoid is selected such that the cut end can be brought out for colostomy formation without further mobilization. In some cases, this will be not be possible, and division of the remaining line of Toldt superiorly and mobilization of the splenic flexure may be necessary. Once adequate mobilization is achieved, the sigmoid mesocolon is divided at the intended transection site, using an energy device. This controls the remaining sigmoidal vessels. All mesenteric tissue is dissected away from the bowel wall, and the colon is divided with a stapling device.

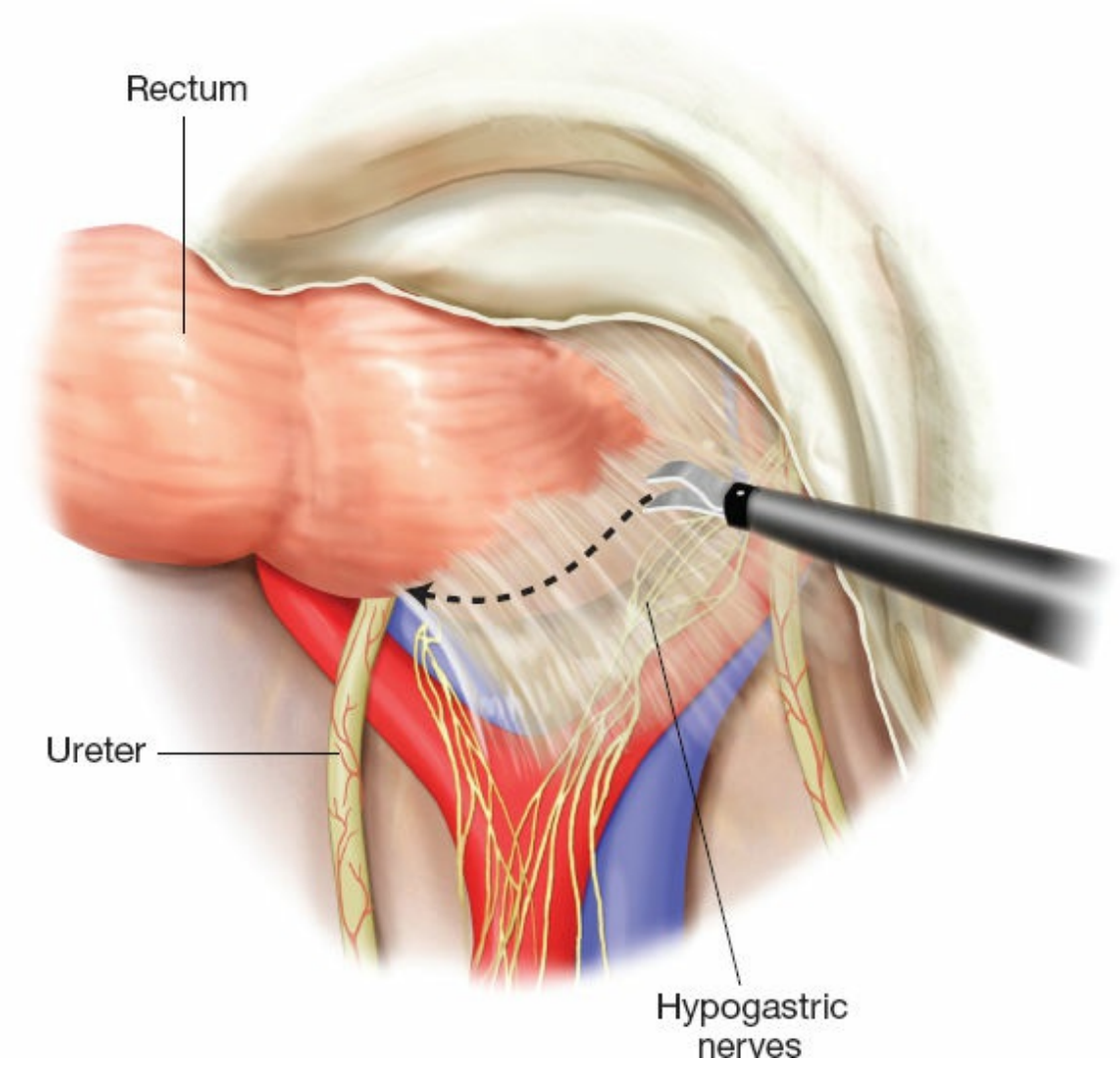

Figure 157.5. Anterior retraction of the rectum provides exposure for the posterior TME dissection. Care is taken to preserve the hypogastric nerves by meticulously following the mesorectal fascia and sweeping the posterior tissues away from the specimen.

Attention is turned to the rectal dissection. Previous maneuvers have already exposed the sacral promontory and the distal sigmoid colon is now retracted anteriorly, exposing the posterior point of entry for dissection along the mesorectal fascia (Fig. 157.5). Dissection from this point proceeds according to the principles of TME, discussed in more detail elsewhere in this volume. Side to side dissection proceeds first posteriorly in the alveolar plane between Waldeyer fascia and the mesorectum, and then anteriorly in the alveolar plane between Denonvillier fascia and either the seminal vesicles and prostate or the vagina (Fig. 157.6). This progressively exposes the middle rectal pedicles laterally, which are

ligated and divided with an energy device. For extralevator and ischioanal approaches to APR, this dissection stops when the superior-most extent of the levator muscles is encountered.

It is important to note that the TME dissection in a conventional APR would have continued inward along the superior surface of the levator muscles, which narrows the diameter of the cylinder that had until this point been preserved by the TME approach, and can create an hourglass shape, or so-called “waist,” at the inferior portion of the final resected specimen (Fig. 157.7). Unless the preoperative evaluation has shown the tumor to be well away from the levator muscles (in which case the patient may have been a candidate for restorative proctectomy, or a very short Hartmann pouch) this maneuver should be expected to compromise the oncologic result of the operation, and must be avoided.

While we have so far described a minimally invasive approach, the principles for the open operation are the same, with the general exception of the technique for colon mobilization. A lower midline laparotomy is used and a self-retaining abdominal wall retractor is placed. The patient is placed in Trendelenburg position, and the small bowel is packed away from the field. Mobilization of the left colon is then typically performed in a lateral to medial fashion (though some surgeons still prefer medial to lateral), beginning with incision of the white line of Toldt in the left paracolic gutter with medial traction on the colon. This exposes the alveolar plane between the mesocolon and the retroperitoneum, and dissection proceeds medially, revealing the ureter, gonadal vessels, and hypogastric nerves. The medial peritoneal leaflet is opened, the superior rectal artery is ligated proximally, and the mesocolon is divided up to the intended colon transection site, where a stapling device is used. The rectal dissection is performed on identical principles, facilitated by frequently adjusted retraction using St. Mark’s or Heald retractors. The middle rectal pedicles are divided as above, and dissection stops at the superior edge of the levators.

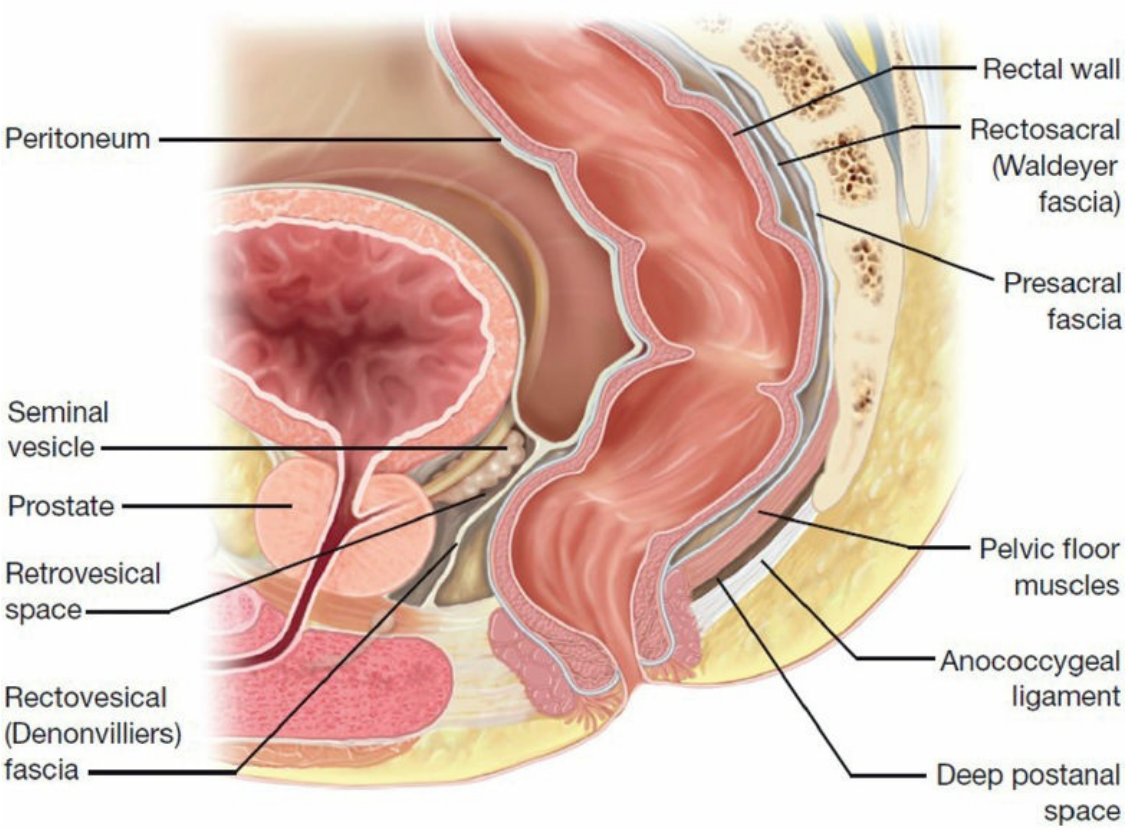

Figure 157.6. Anatomy of the low pelvis and perineum, highlighting important structures for orientation in TME and APR.

Intersphincteric Dissection

The exception in this discussion is the intersphincteric APR. As mentioned above, this approach is reserved for situations in which the tumor does not threaten the levators, but the patient is not a candidate for an anastomosis due to comorbidities or baseline incontinence. In this case, dissection in the abdominal portion of the procedure continues along the pelvic aspect of the levator muscles until the sphincter is reached. The perineal approach to dissection begins with placement of a self-retaining anal retractor (Fig. 157.8). The anoderm is incised just caudal to the intersphincteric groove, and the anal canal can then be occluded with an Allis clamp or suture. Dissection then proceeds circumferentially between the internal and external sphincter muscles in a cephalad direction and into the pelvis to join with the TME dissection plane on the superior edge of the levator muscles (Fig. 157.9). The specimen is then removed and the perineal defect is closed in layers.

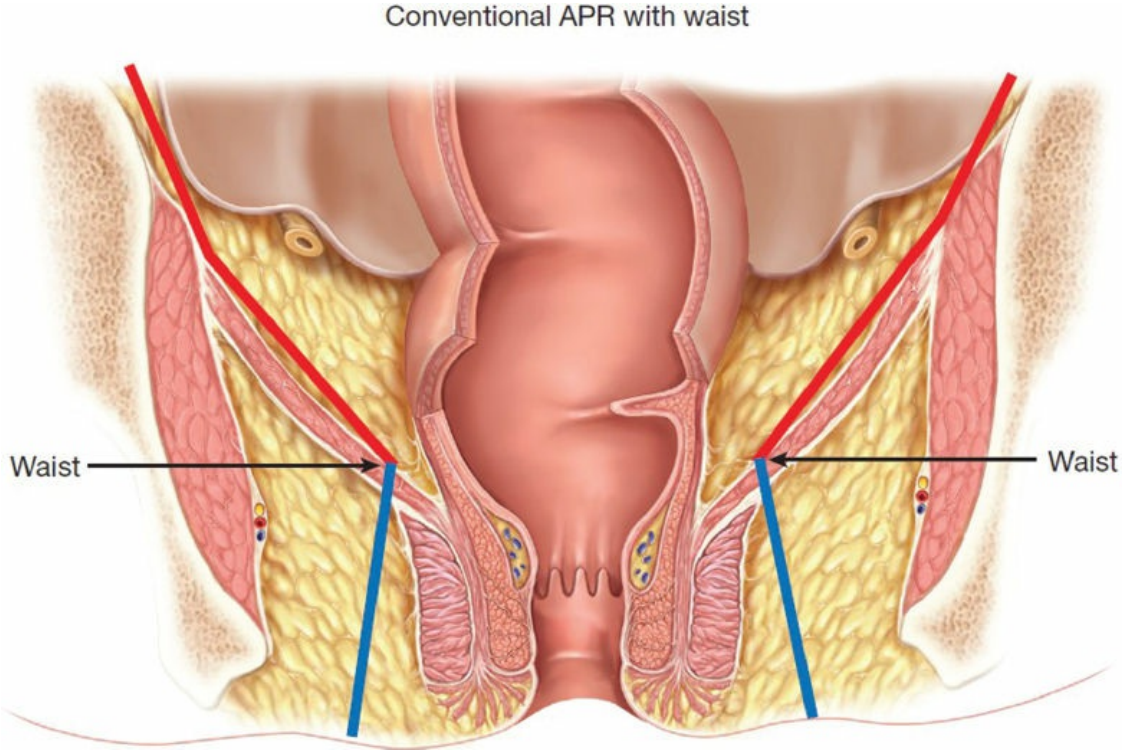

Figure 157.7. Illustration of dissection planes in conventional APR, potentially impinging upon what would be the margin for a low-lying, full thickness rectal tumor.

Extralevator Dissection Versus Conventional APR

The perineal dissection for a conventional APR begins with an elliptical incision around the anal sphincter complex, and includes dissection in a cephalad direction through the levator muscles near their medial insertions to connect with the TME dissection (Fig. 157.10). However, this may compromise the surgical margin of a low-lying rectal tumor. Consequently, an extralevator dissection is sometimes necessary to achieve a margin-negative resection of a tumor that appears on preoperative imaging or examination to threaten invasion into the levator muscles. When extralevator APR is performed, the perineal dissection begins with a circumferential perianal incision, created as an ellipse with the posterior apex over the tip of the coccyx and the anterior apex over the perineal body. The anus is closed with suture and/or Allis clamps. It is helpful to begin with the posterior dissection first, following the outer margin of the sphincter complex in the direction of the coccyx, which will be felt through the intervening fat on palpation. Dissection proceeds through the anococcygeal ligament, the distal Waldeyer fascia, and into the pelvis. Beginning in this relatively hypovascular tissue improves

subsequent exposure for lateral dissection and ultimately maximal mobility for retraction of the distal rectum and sphincter complex when dissecting away from the prostate or vagina. A self-retaining retractor is placed, and frequently adjusted to maintain outward traction on the circumferential edges. Countertraction away from this is provided by the nondominant hand; this places the intended dissection plane on tension laterally and allows dissection on the outer border of the sphincter complex and levator muscles in a cephalad direction until the lateral edges of the levator muscles are reached. The levator muscles are divided at the level corresponding to the distal extent of the pelvic dissection. Once the posterior and lateral dissections are complete, the distal end of the specimen is grasped with the nondominant hand and traction in a cephalad and posterior direction exposes the plane for anterior dissection. It must be noted that the membranous portion of the male urethra can be pulled into the path of dissection at this point, and dissection must proceed with caution until the posterior surface of the prostate is revealed. Cephalad dissection then continues just away from the posterior surface of the prostate, to avoid troublesome bleeding or parasympathetic nerve injury. In the female patient, dissection away from the posterior wall of the vagina is performed, except in the case where the tumor is adherent to the vaginal wall. In this situation, the posterior wall of the vagina is resected en bloc with the specimen, and the vagina is repaired with interrupted sutures. Once the distal specimen has been circumferentially freed, it can then be removed and careful attention paid to hemostasis.

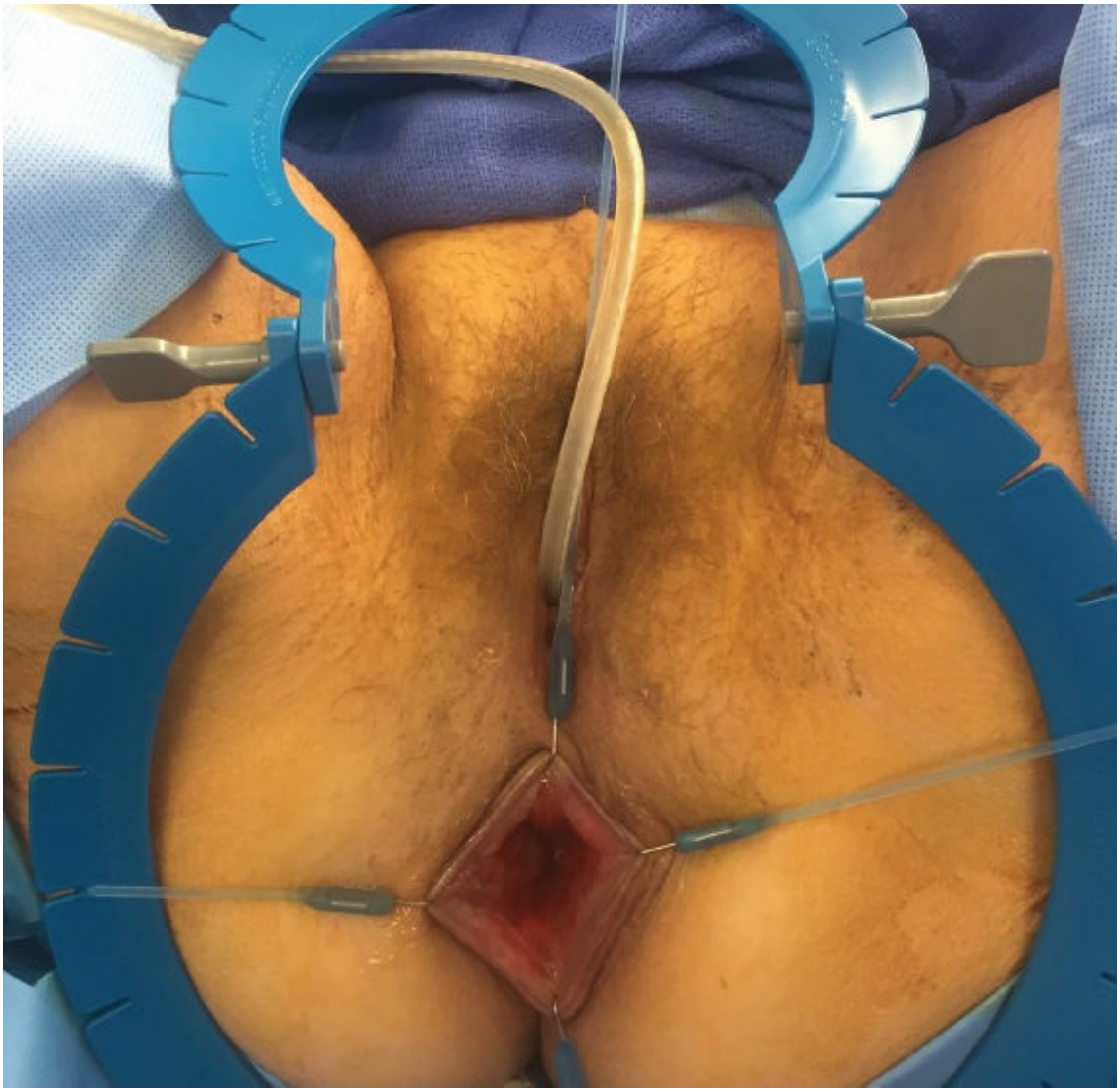

Figure 157.8. A self-retaining retractor (Lone Star®) in place for intersphincteric dissection.

Ischioanal Dissection

Ischioanal dissection entails maximal clearance of the perirectal and perineal tissues, and is similar to the original Miles operation in terms of tissues included in the specimen. The incision created can be similar to that for extralevator dissection, except in cases of perianal fistulas or tumor invasion. In this situation, the incision should include any affected perianal skin with a margin of at least 2 cm. The anus is closed and a self-retaining retractor is placed, with periodic adjustments often necessary to maintain appropriate traction and countertraction on the tissues for dissection. Dissection begins posteriorly toward the coccyx and through the distal Waldeyer fascia into the pelvis, then is directed laterally toward the ischial tuberosities. The fascia of the internal obturator muscle is exposed, and

followed superiorly (Fig. 157.11). Depending on the size, laterality, and local invasiveness of the tumor, an ischioanal dissection may be necessary only on one side, while an extralevator dissection may be performed contralaterally. The anterior dissection is performed in the same fashion as the extralevator approach described above, and the specimen is removed.

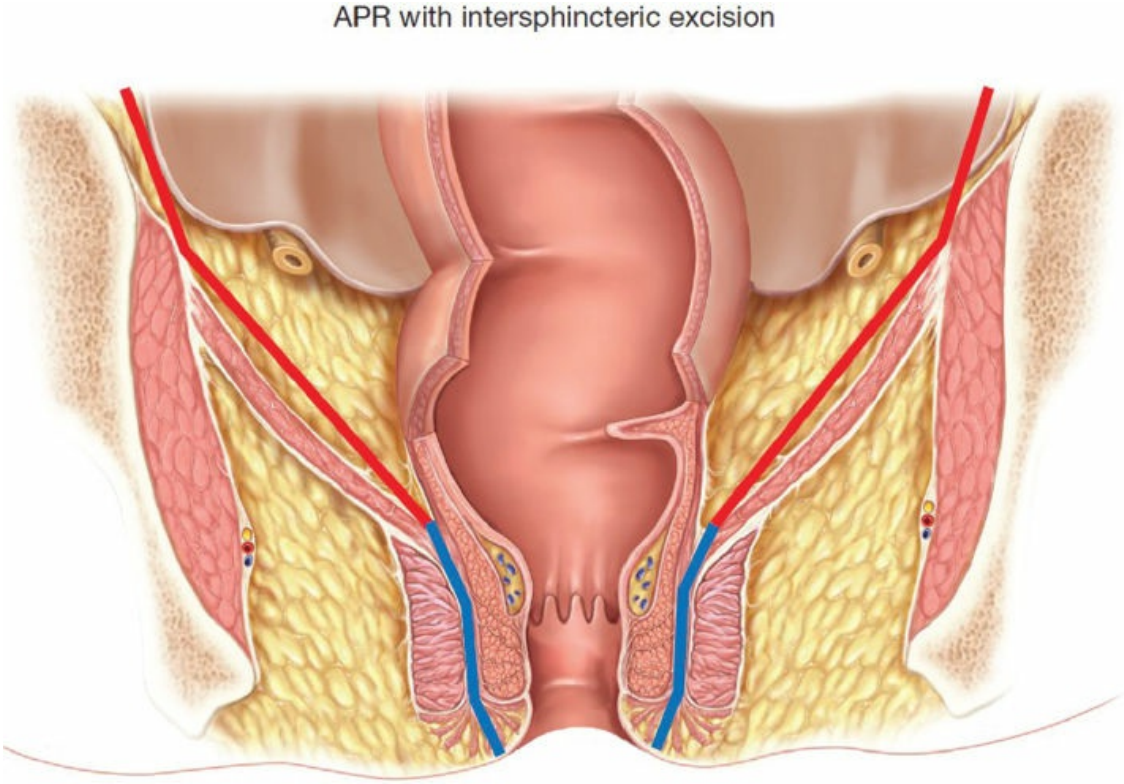

Figure 157.9. Illustration of the planes for intersphincteric dissection in APR.

Management of the Perineal Wound

Reconstruction options depend upon the patient's anatomy and body habitus, preoperative radiation exposure, and the extent of resection. In some cases, a primary repair will be possible, especially in intersphincteric APR or in cases where a tumor is lateral and some of the levator ani complex on the contralateral side can be preserved and used for closure. In many cases, however, a primary closure would result in undue tension on the suture lines, and dehiscence is a common complication. When considering reconstruction for APR patients, it is important to recognize two distinct issues. There is, first of all, the defect through the pelvis and perineum, associated with the problem of a potentially high-tension closure between tissues that are tethered to contralateral bony insertions. This defect predisposes patients to fluid collections, and small bowel may

fall into the dead space, and lead to development of a perineal hernia. In addition, there is the issue of a skin closure that is prone to infection and separation, especially in patients who have undergone pelvic radiation. A well-perfused rotational flap to cover this defect appears to be associated with decreased risk of superficial wound infections. Other considerations in reconstruction include possible mesh placement at the pelvic inlet, to prevent perineal herniation and placement of closed suction drains within the pelvic defect or deep to layered closures when there is concern for postoperative hemostasis or residual or potential dead space that would predispose to fluid collection and abscess formation.

In complex situations, assistance from a plastic and reconstructive surgeon can be helpful, to perform rotational muscle flaps to fill in dead space and provide an alternative to a high-tension closure of the deep tissues and of the skin. These techniques are able to lower rates of wound complications, but carry the potential for morbidity at the donor site. Common options for rotational flaps include rectus abdominis, gracilis, or gluteus muscles. The vertical rectus abdominis myocutaneous (VRAM) flap provides a good amount of tissue bulk for filling the pelvis, and can be performed with the same exposure as that achieved in open APR, obviating the need for additional incisions and closures. In minimally invasive cases, however, the VRAM flap becomes less practical. Gracilis muscle flaps often provide relatively lower volume for filling the pelvis, although bilateral gracilis muscle flaps can be performed. An advantage of this option is the relatively lower functional morbidity of harvesting the gracilis muscles. The gluteus option can provide an adjacent source of muscle bulk for filling the defect.

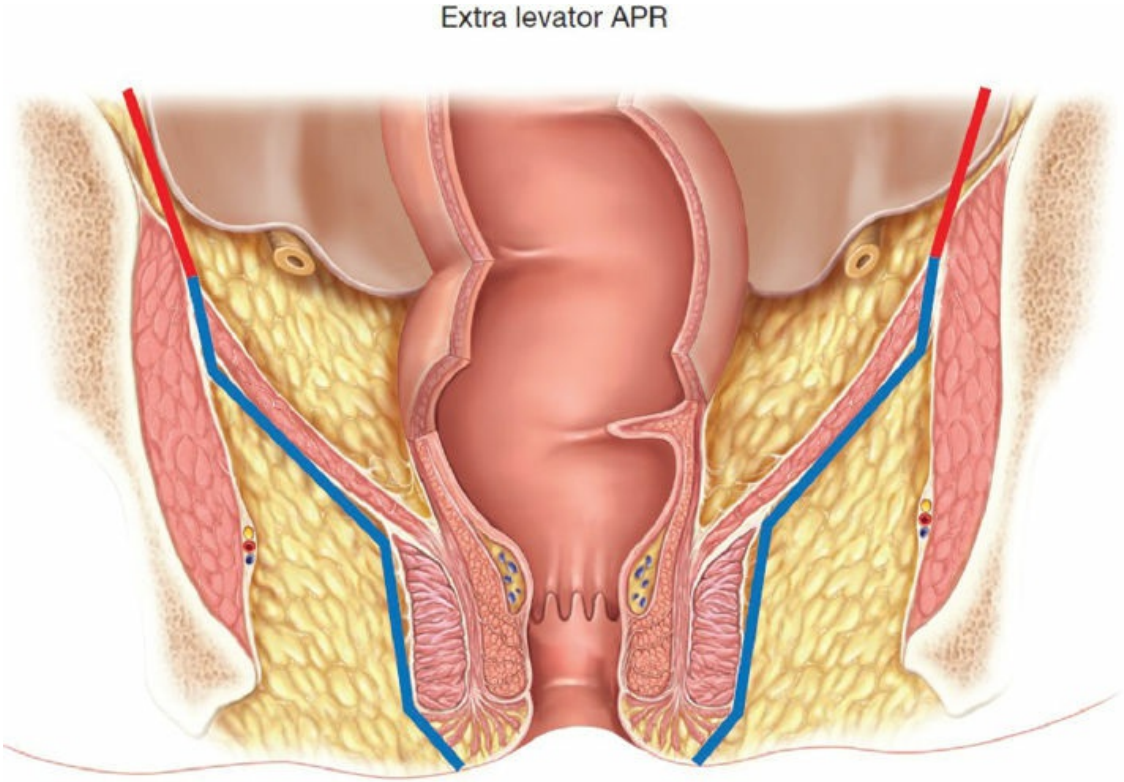

Figure 157.10. Illustration of the planes for extralevator dissection in APR.

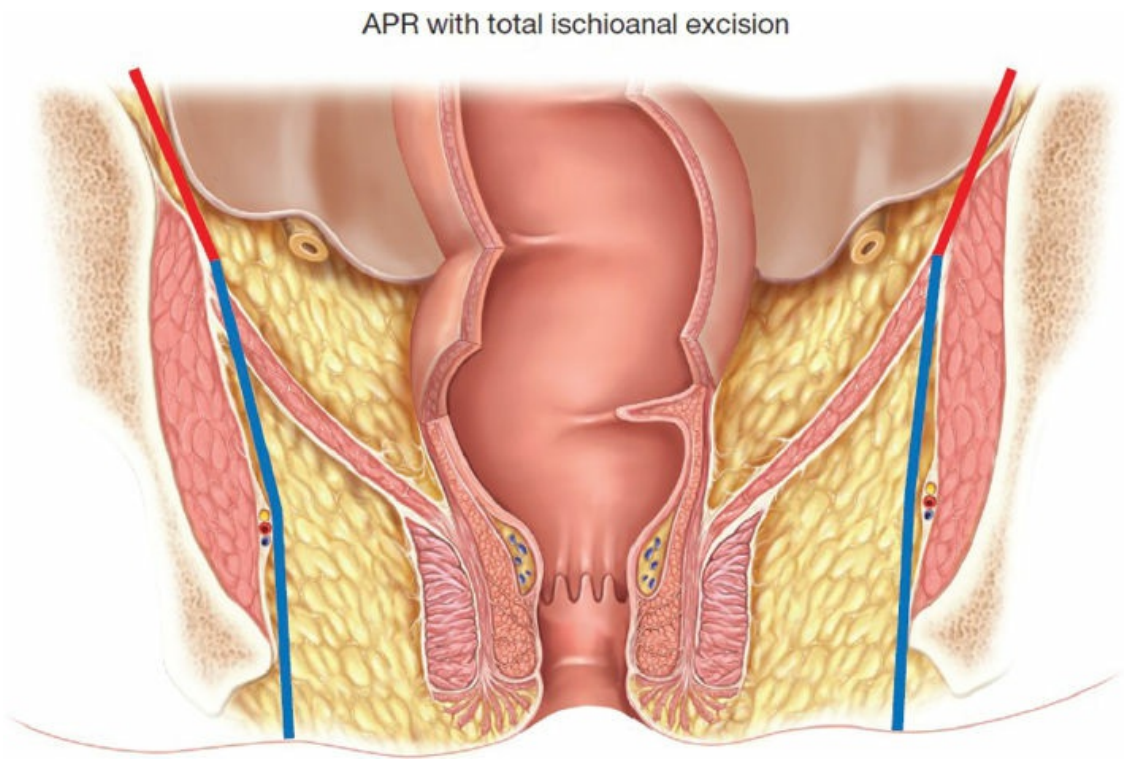

Figure 157.11. Illustration of the planes for ischioanal dissection in APR.



Figure 157.12. Final closure of a V-Y fasciocutaneous gluteal advancement flap. (Courtesy Dr. Steele and Dr. Campbell.)

In the prior edition of this text, the chapter on APR by Dr. Steele and Dr. Campbell described a fasciocutaneous V-Y flap option for closure. A V-shaped incision is made to one side of the perineal wound, carried down through the deep fascia and onto the gluteal muscle. The fascia is mobilized from the gluteus muscle with preservation of the perforators supplying the skin. The medial portion of the resulting flap is de-epithelialized and placed into the perineal defect, where it is sutured to the contralateral levator muscle. The remaining medial edge of epithelium is sutured to the contralateral wound edge, and the rest of the wound is closed with the V-Y technique (Fig. 157.12). In the female patient in whom a posterior vaginal defect has been created, epithelium can be retained on the medial portion of the flap and sutured into the posterior vaginal defect.

When a primary closure is performed, it should be constructed in multiple layers. The lateral edges of the levator muscles are approximated with interrupted or figure-of-eight stitches of 0 Vicryl or PDS. Any remaining ischioanal fat can be approximated with interrupted sutures to minimize dead space. Subcutaneous and deep dermal stitches are placed with 2-0 or 3-0 Vicryl to distribute tension as much as possible, and the skin is closed with mattress stitches, allowing enough space for fluid

drainage, if necessary.

POSTOPERATIVE CARE

Patients recovering from APR can be managed according to principles of enhanced recovery after surgery (ERAS), pioneered in the field of colorectal operations. A clear liquid diet and oral nonnarcotic analgesics are generally safe beginning immediately after recovery from the anesthetic. Early mobility and ambulation is encouraged, except in cases where complex flap reconstruction may require a period of bedrest.

COMPLICATIONS

The most common complication following APR is infection or separation of the perineal closure. Close attention should be paid to the perineum in the immediate postoperative phase to monitor for fluctuance, erythema, drainage, or skin separation. It may be necessary to judiciously remove some of the superficial sutures in cases where there is concern for undrained superficial fluid collections. When infection and dehiscence occur, management commonly includes negative pressure wound therapy in a wound that is sufficiently clean, or frequent gauze dressing changes in cases where the wound needs to be inspected at least once per day or where such dressing changes will facilitate debridement of wound exudate. In the patient with dehiscence of a primary closure, consultation with a plastic and reconstructive surgeon may be appropriate for delayed flap reconstruction of the defect.

Among patients with locally advanced rectal cancer with invasion into adjacent organs, complete or partial pelvic exenteration may be necessary. Patients treated with exenteration and even APR are at increased risk for nerve injury and resulting genitourinary dysfunction. Urinary incontinence or retention may develop, and long-term management with suprapubic catheter drainage may be necessary. Patients may also develop sexual dysfunction, including erectile dysfunction in men and loss of vaginal lubrication in women.

CONCLUSION

The management of rectal cancer is in evolution. Refinements of multimodality therapy are being researched to optimize oncologic outcomes, reduce morbidity and improve quality of life. Suboptimal care

can lead to significant morbidity, and it is therefore critical that an experienced multidisciplinary team treat patients with rectal cancer. With current understanding of the pathophysiology, and improved surgical techniques, most patients can have curative surgery with sphincter preservation. In selective cases, however, this may not achieve optimal oncologic results. While APR is one of the most morbid of operations for rectal cancer, it remains an indispensable tool in managing this disease. We continue to look for ways to reduce the morbidity through minimally invasive techniques, optimal perineal wound management, and preservation of genitourinary function. When performed with meticulous attention to the anatomy and to surgical planning for the achievement of a margin-negative resection, it can be accomplished with both good functional and oncologic outcomes.

Suggested Readings

Chu QD, Sangster GP, Kulaylat MN. Chapter 18, In: Chu QD, ed. Rectal cancer. *Surgical Oncology: A Practical and Comprehensive Approach.* New York: Springer; 2015.

Holm T. Controversies in abdominoperineal excision. *Surg Oncol Clin N Am* 2014;23(1):93–111.

Kapiteijn E, Marijnen CA, Nagtegaal ID, et al. Preoperative radiotherapy combined with total mesorectal excision for resectable rectal cancer. *N Engl J Med* 2001;345(9):638–46.

Salem ME, Hartley M, Unger K, et al. Neoadjuvant combined-modality therapy for locally advanced rectal cancer and its future direction. *Oncology (Williston Park)* 2016;30(6):546–62.

Taylor FG, Quirke P, Heald RJ, et al. Preoperative magnetic resonance imaging assessment of circumferential resection margin predicts disease-free survival and local recurrence: 5-year follow-up results of the MERCURY study. *J Clin Oncol* 2014;32(1):34–43.

EDITOR'S COMMENT

If skin cancer is excluded, colorectal cancer is the third most common cancer diagnosed in both men and women in the United States. The American Cancer Society's estimates for the number of colorectal cancer cases in the United States for 2017 are 95,520 new cases of colon cancer and 39,910 new cases of rectal cancer. Overall, the lifetime risk of developing colorectal cancer is: about 1 in 21 (4.7%) for men and 1 in 23 (4.4%) for women. Colorectal cancer is the

third leading cause of cancer-related deaths in women in the United States and the second leading cause in men. It is expected to cause about 50,260 deaths during 2017. The death rate (the number of deaths per 100,000 people per year) from colorectal cancer has been dropping in both men and women for several decades. This is likely multifactorial and related to increased screening and improved treatment. As a result, there are now more than 1 million survivors of colorectal cancer in the United States.

One of the most interesting parts about AP resection to me is how infrequently it is needed compared to 20 or more years ago given advances in low rectal resection techniques, adjuvant, and neoadjuvant therapy. In general, a 1-cm distal margin is recommended in sphincter-preserving surgery for rectal cancer. A recent systematic review of the literature identified 17 studies showing results in relation to margins of approximately less than 1 cm (948 patients) versus greater than 1 cm (4,626 patients). In most studies, pre- or postoperative radiation therapy was administered. In total, the local recurrence rate was 1.0% higher in the less than 1-cm margin group compared to the greater than 1-cm margin group (95% confidence interval [CI] –0.6 to 2.7; P = 0.175). The local recurrence for less than 5-mm distal resection margin was 1.7% higher (95% CI –1.9 to 5.3; P = 0.375). The authors of this systematic review designed to evaluate the impact of distal resection margin on local recurrence in rectal cancer concluded, “In the selected group of patients, less than 1-cm distal margin did not jeopardize oncologic safety.”

Resection of low rectal cancers is a complex procedure. As outlined in this chapter, higher rates of positive circumferential resection margins and tumor rupture at the time of surgery necessitate a careful and skilled approach to these tumors. The volume–outcome relationship in surgery has been demonstrated for many complex and high-risk procedures such as esophagectomy, pancreatectomy, and abdominal aortic aneurysm repair. It’s no surprise that a volume–outcome relationship is apparent in rectal cancer resection. A retrospective population-based cohort study utilizing the Surveillance, Epidemiology and End Results (SEER)-Medicare linked database identified 2,815 rectal cancer patients aged 65 and older who had surgery for a primary tumor diagnosed in 1992–1996 in a SEER area. Hospital- and surgeon-specific procedure volume was determined as well as mortality at 30 days and 2 years, overall survival, and the rate of abdominoperineal resections. Neither hospital nor surgeon-specific procedure volume was significantly associated with 30-day postoperative mortality or rates of rectal sphincter-sparing operations. Surgeon-specific volume was associated with 2-year mortality and remained an important predictor even after adjustment for hospital volume. Surgeon volume was also better than hospital procedure volume at predicting long-term survival. Another study evaluating more recent data identified 47,000 patients from the Nationwide Inpatient Sample who underwent surgery for rectal cancer from 1988 to 2006. Univariate analysis was used to identify patient and hospital factors associated with sphincter preservation. In this analysis, the overall rates

of sphincter preservation were consistently higher in high-volume and urban hospitals, and among patients who are female, white, and younger. A Cochrane systematic review examined surgeon caseload and specialization on outcomes after colorectal cancer surgery. For rectal cancer, there was a significant association between high-volume hospitals and improved 5-year survival but not with operative mortality. Higher hospital volume was associated with significantly lower rates of permanent stomas and APR.

High-volume surgeons and specialists also achieved lower rates of permanent stoma formation. For low rectal cancers, referral to a high-volume specialist is appropriate.

As discussed toward the end of this chapter, in patients with locally advanced primary or recurrent rectal cancer, pelvic exenteration may be offered. A systematic review on this topic included a total of 23 studies with 1,049 patients. The complication rates for pelvic exenteration ranged from 37% to 100% (median, 57%) and the perioperative mortality rate ranged from 0% to 25% (median, 2.2%). The rate of local recurrence ranged from 4.8% to 61% (median, 22%). The median survival for primary advanced rectal cancers was 14 to 93 months (median, 35.5 months) and 8 to 38 months (median, 24 months) for locally recurrent rectal cancer. Based on this review, the authors conclude "*Although the human costs and risks are significant, the potentially favorable survival outcomes make this acceptable in the absence of other effective treatment modalities that would otherwise result in debilitating symptoms that afflict patients who have advanced pelvic malignancy.*"

The concept of Enhanced Recovery after Surgery (ERAS) pathways in colorectal surgery patients is covered briefly in this chapter. The international, multicenter ERAS registry data were reviewed (2008–2013) to examine the impact of compliance with different parts of an ERAS bundle on outcomes. A total of 1,509 colonic and 843 rectal resections were undertaken in 13 centers from 6 countries. Median length of stay for colorectal resections was 6 days, with readmissions in 9.2%, complications in 40%, and reoperation in 7.1% of patients. Laparoscopic surgery was associated with reduced complications and length of stay. Increasing ERAS compliance was correlated with fewer complications and shorter primary hospital admission. Shorter hospital stay was associated with preoperative carbohydrate and fluid loading, and totally intravenous anesthesia. Longer stay was associated with intraoperative epidural analgesia. Reduced postoperative complications were associated with restrictive perioperative intravenous fluids. We've come a long way from the era when I was a resident 20 years ago when all patients were NPO after midnight, had an epidural placed preoperatively, a nasogastric tube until they passed gas, and a gradual progression from clear liquids, to full liquids, to a general diet over a course of several days.

Dr. Nurkin and colleagues have written an excellent description of the technical details regarding abdominoperineal resection for rectal cancer. The descriptions and accompanying illustrations of the intersphincteric resection,

extralevator, and ischioanal resection techniques are especially informative. This is a great chapter for residents and surgeons who perform rectal resections for cancer.

Jon C. Gould

Suggested Readings

Archampong D, Borowski D, Wille-Jorgensen P, et al. Workload and surgeon's specialty for outcome after colorectal cancer surgery. *Cochrane Database Syst Rev* 2012;(3):CD005391.

Bujko K, Rutkowski A, Chang GJ, et al. Is the 1-cm rule of distal bowel resection margin in rectal cancer based on clinical evidence? A systematic review. *Ann Surg Oncol* 2012;19:801–8.

ERAS Compliance Group. The Impact of enhanced recovery protocol compliance on elective colorectal cancer resection: results from an International Registry. *Ann Surg* 2015;261(6):1153–9.

Schrag D, Panageas KS, Riedel E, et al. Hospital and surgeon procedure volume as predictors of outcome following rectal cancer resection. *Ann Surg* 2002;236(5):583–92.

Yang TX, Morris DL, Chua TC. Pelvic exenteration for rectal cancer: a systematic review. *Dis Colon Rectum.* 2013;56(4):519–31.

158 The Approach to Reoperative Pelvic Surgery in Rectal Cancer

J. Joshua Smith and Jose G. Guillem

ETIOLOGY AND PATHOPHYSIOLOGY

In spite of significant improvement in neoadjuvant and surgical treatment for primary rectal cancer over the past 20 years (e.g., chemotherapy, radiation, and adherence to the surgical principles of total mesorectal excision [TME]), a 5% to 10% rate of local recurrence remains. Local recurrence rates vary by center—ours is <3% over a 5-year period (unpublished data). Possible explanations for local recurrence include inadequate surgical technique in completeness of TME, circumferential margin positivity, and rectal tumors located at <5 cm from the anal verge. Management of a local recurrence in the pelvis is important as it directly impacts patient quality of life and survival. We define local recurrence as tumor in the true pelvis, including the neorectum, associated mesentery, pelvic sidewall, pelvic viscera, neurovasculature, and adjacent bony anatomy (see Fig. 158.1 for examples). We have observed that 50% of the patients who recur are resectable, and are candidates for an R0 resection. This is important as we have noted median disease-free survival (DFS) and disease-specific survival (DSS) following an R0 resection is 31 and 66 months (DFS and DSS respectively) versus 8 and 23 months (DFS and DSS, respectively) for R1 or R2 resections. The Mayo experience demonstrated a 5-year survival of 37% in patients undergoing R0 resection for recurrent rectal cancer compared to 16% in those undergoing an R1 resection. A recent US analysis demonstrates 5-year overall survival of 50% in patients undergoing R0 resection for recurrent rectal tumors versus 18% for those patients undergoing an R1 resection. Recent analyses from Europe show a similar trend in locally recurrent rectal cancer where 3- and 5-year survival rates for R0 resection were 55% and 40% while they were 42% and 16% for R1 resections. These data suggest that inability to achieve an R0 resection is associated with very poor long-term survival.

When the goal is an R0 resection, the patient must be carefully selected

using a combination of factors in the decision-making process to operate including history, symptoms, physical exam, and radiologic images to delineate the anatomy. It is important that rectal MRI is used and that the imaging capture the entire pelvis. Multiple radiographic means have been studied to determine the best method of detection. It is beyond the scope of this chapter to cover this topic in depth, but the basics will be mentioned. Our current approach is to obtain a good quality computed tomography (CT) chest, abdomen, and pelvis followed by a dedicated magnetic resonance imaging (MRI) of the rectum/pelvis for characterizing local anatomy and to determine resectability.

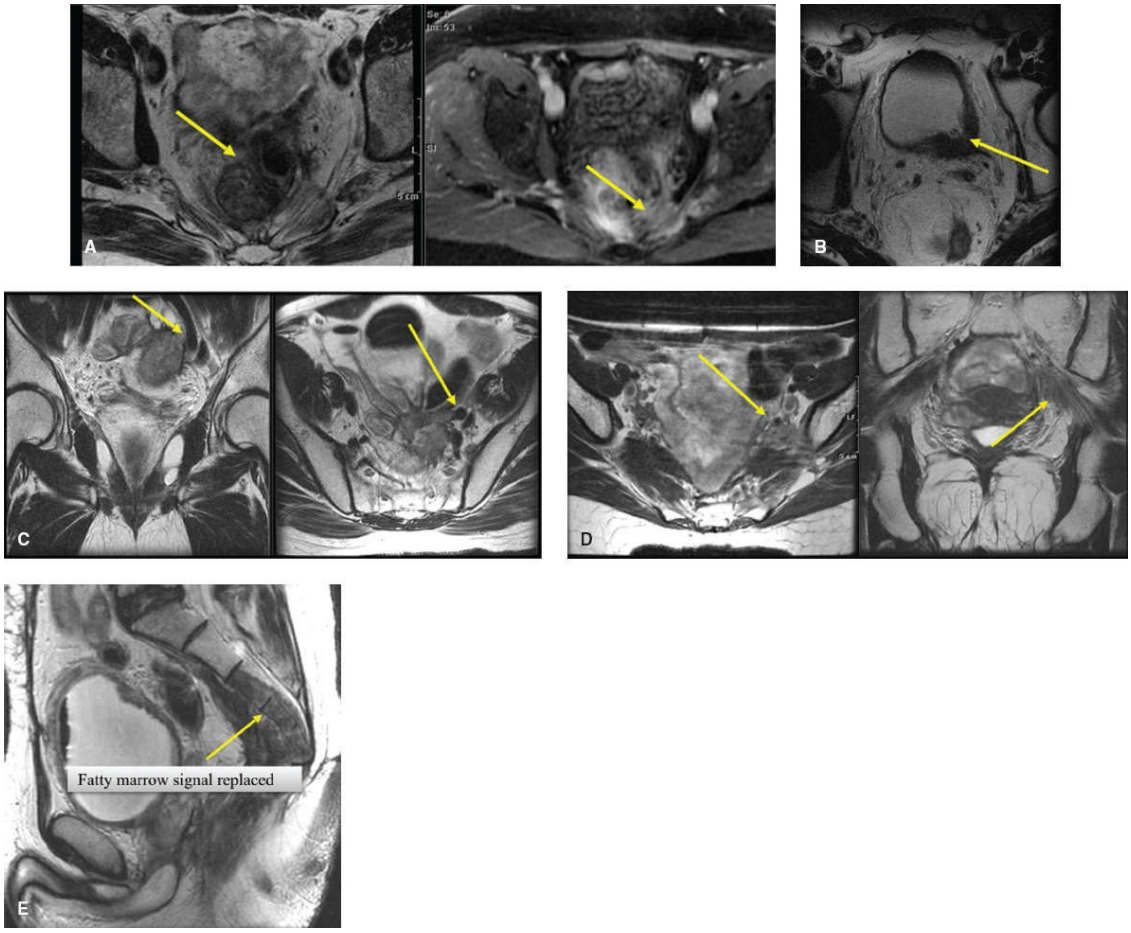

Figure 158.1. MRI examples demonstrating the spectrum of structures that can be implicated in rectal cancer recurrence. Shown are MRI examples of local recurrence involving the (**A**) neorectum, (**B**) the bladder, (**C**) the external iliac artery, (**D**) the sciatic nerve, and (**E**) the sacrum. All views are T2 and axial. (Images courtesy of M. Gollub, MD.)

Considering the clinical outcomes after surgical resection for recurrent rectal cancer, review of a database of 634 patients undergoing resection for recurrent rectal cancer between 1990 and 2000 to determine predictors of survival after surgery and intraoperative radiation therapy (IORT) yielded 111 patients. Of these, 100 patients had substantive follow-up and had undergone surgical resection and IORT. Clinicopathologic variables were assessed and only complete resection with microscopically negative margins and the absence of vascular invasion in the recurrent specimen predicted improved outcomes as indicated above (better DFS, DSS, and local control). In a UK study of 119 patients brought to the operating room for IORT and planned complete resection of locally recurrent colon and rectal cancer between 1994 and 2000, an R0 resection was achieved in 61

patients. These patients were then compared to those who underwent R1, R2, or palliative procedures (*n* = 38, 7, and 13, respectively). Of note, when recurrence was axial only or axial and anterior, then R0 was achieved more often than recurrences in other locations. Especially notable were the lateral recurrences, which were significantly less likely to be associated with an R0 resection. In light of these findings, relative contraindications to surgical resection of rectal cancer recurrence in the pelvis are sciatic pain and/or lateral recurrence versus central recurrence. Palliative resections can be contemplated for symptomatic recurrence even with metastatic disease as long as a safe diversion approach can be planned.

CLINICAL PRESENTATION

It is well known that local recurrence rates have markedly decreased (historical rates of 25% to 30% vs. more recent rates of <10% in randomized trials) due to better multi-modality treatments including TME; however, patients still present with both local and distant recurrences within 2 years of surgical resection of the primary tumor. Patients who present with recurrent disease have a variety of complaints. The most common complaints include pelvic pain, sciatic irritation, bowel and/or bladder dysfunction. The patient should undergo a full work-up led by the surgeon, including complete history and physical examination, restaging via CT chest, abdomen and pelvis in addition to an MRI of the rectum and/or pelvis depending on anatomical region of interest. These studies will help determine the likelihood of an R0 resection. Once all of the data are in hand, we recommend discussion of these cases in a disease-management team (DMT) setting to allow all relevant disciplines an opportunity to optimize the care of the patient.

INDICATIONS AND CONTRAINDICATIONS

Each patient must be willing to undergo an extensive operation that may require prolonged recovery, decrease in functional status, and post-operative complications. Patients with poor baseline function, low motivation, or with significant burden of comorbidities may not be the best candidates for a pelvic recurrence operation. Relative contraindications for surgical salvage include advanced distant metastases, multifocal disease in the pelvis, and upper sacral invasion or vascular encasement in the setting of unresectable distant disease.

PREOPERATIVE CONSIDERATIONS

Given the complexity of clinical presentation, extent of disease, and multimodality therapeutic options, it should be reiterated that the patient with recurrent rectal cancer is best discussed in a multidisciplinary DMT. Regarding radiation therapy, if a patient has been previously radiated, additional preoperative radiation may or may not be advantageous. However, if no prior pelvic radiation, then preoperative chemoradiation is appropriate. Use of IORT is usually reserved in our hands for recurrent disease (e.g., local failure after multimodality treatment and low anterior resection [LAR]) and can be combined with an abdominoperineal resection (APR) or an exenteration if surgical margins are a concern. In unique situations where an R0 resection seems unlikely and external beam radiotherapy is no longer an option, systemic chemotherapy may be considered preoperatively in carefully selected cases.

Preoperative planning aims to assess likelihood of an R0 resection and the need for en bloc resection, involved organs, and need for additional surgical expertise in resection or reconstruction (e.g., urology, gynecology, vascular, orthopedics, neurosurgery, and plastics). For example, in a redo LAR or an APR, the seminal vesicles or the pelvic ureter could be compromised (see Fig. 158.2), and in an anterior exenteration, the bladder or iliac vessels could necessitate sacrifice and need for subsequent reconstruction or revascularization. Recurrence in a woman with a prior hysterectomy usually requires an exenteration as the bladder is typically involved and must be resected en bloc. In terms of total pelvic exenteration (TPE) or need for sacral resection, multiple teams are often required to achieve an en bloc R0 resection, reconstruction, and urinary and fecal diversion. It is important that all teams that are anticipated to be involved have seen the patient preoperatively and are available on the scheduled operative date. These colleagues may include vascular surgery, plastic surgery, orthopedic surgery, urology, and radiation oncology. We recommend that an epidural for pain control be placed in the preoperative holding area. Proper site marking must be done preoperatively with a visit to the enterostomal nurse. The patient must understand that first and foremost the surgeon must adhere to *Primum non nocere* and that there might be a point during the operation where the attending surgeon decides to stop. Lastly, the expectations of all parties involved including the patient, family, and involved healthcare providers must be carefully communicated preoperatively and documented to avoid unnecessary

disappointments or unrealistic outcomes.

Another item of discussion with the patient is quality of life and expected return to activities of daily living after the operation. Most patients with recurrent rectal cancer who require external beam radiation therapy, extensive pelvic dissection, and intraoperative radiation therapy have reported poor functional and quality-of-life outcomes after sphincter preservation especially with coloanal anastomoses. Furthermore, when it comes to reconstruction, usually for cancers at 7 to 8 cm from the anal verge, restoration of continuity can be difficult even with a combined abdominopelvic approach. Therefore, even if sphincter preservation is technically achievable, it may not always be the best option for the patient given the poor functional results and quality of life that follows. As alluded to above, in the setting of unresectable disease, even a palliative diversion is helpful in maintaining some quality of life.

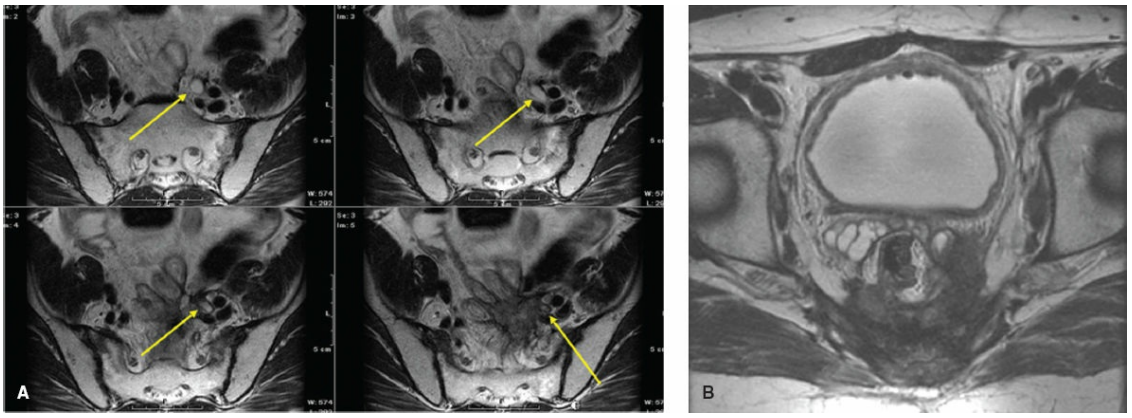

Figure 158.2. Radiographic evidence of pelvic ureter or seminal vesicle involvement by MRI. Shown are MRI examples of local recurrence involving the (**A**) ureter and the (**B**) seminal vesicles. All views are T2 and axial. (Courtesy of M. Gollub, MD.)

SURGICAL TECHNIQUE

The patient is usually placed in the Lloyd-Davis position and then moved to the prone position. In selected cases, especially those with an anteriorly based recurrence where a TPE is not planned, repositioning in the prone position for the perineal portion of the procedure enhances visualization of the anterior plane and helps secure an R0 resection. The general conduct of the operation is outlined generally in Table 158.1. Based on the level of recurrence and need for flaps (e.g., rectus abdominis vs. gracilis or the need for both), the positioning becomes critical to accommodate all teams involved. After all teams have agreed on the positioning and urology has

performed a cystoscopy and placement of bilateral ureteral stents, then the patient is explored and a determination of resectability is made. A small incision is made initially to rule out carcinomatosis, and then further exploration can be pursued. Diversion and restorative options are always on the mind of the experienced surgeon. To further assess resectability, we often proceed with a splenic flexure mobilization in order to get into the posterolateral spaces and to determine if an R0 resection is feasible. An axial location of the recurrence is best for optimal resectability versus a posterior or lateral recurrence or a purely perineal recurrence. An important point to reemphasize is that R0 resection in our hands was much more likely with an axial recurrence versus when a lateral component affecting the pelvic sidewall was present. It is prudent to dissect deep and posterior as far as possible then to proceed anteriorly with urologic support as needed. Movement into the lateral planes is usually reserved for the latter portion of the operation, but space-specific approaches can be tailored according to the recurrence location. Indications for vascular sacrifice may include local tumor invasion and/or dense tumor abutment in the absence of distant metastatic disease. The colorectal surgeon must be prepared to take the external iliac and the common iliac if necessary.

TABLE 158.1 Conduct of the Operation in the Setting of Recurrent Rectal Cancer

1. Positioning of the patient
2. Cystoscope and urethral stent placement
3. Skin preparation
4. Limited exploration to rule out carcinomatosis
5. Extend the incision
6. Mobilize the colon as necessary (e.g., splenic flexure)
7. Determine resectability
8. Determine diversion or restorative options
9. Call in surgical colleagues/ consultants
10. Intraoperative radiation therapy
11. Reconstruction, flap coverage, and closure

The indications for a sacrectomy are institution-dependent due to local expertise and skill. Resection of a part or the entire sacrum is sometimes required in order for the surgeon to obtain clear posterior margins where the tumor is invading or abutting the sacral bone. In many centers, sacral invasion is a contraindication to surgical resection, but there are some data to suggest that pelvic exenteration with sacrectomy in the management of recurrent rectal cancer is increasing with respectable results. S1, S2, and S3 can be sacrificed, but when anticipated preoperatively the sequelae of taking these nerves should be clearly discussed with the patient. To be specific, S1 sacrifice can lead to difficulties in ankle flexion. S2 and S3 are usually taken only unilaterally as bilateral sacrifice can lead to fecal and urinary incontinence and possible sexual dysfunction. In the case of TPE, this is less of an issue as the rectum and bladder are resected with upstream diversion via colostomy and ileal conduit. Bilateral sacrifice of S4 is associated with impotence for males.

A word of caution should be emphasized for the conduct of the operation: do not burn bridges. For example, in the case where a restorative resection is planned and desired by the patient, do not transect the bowel until you are certain that there are ample length and adequate vascular supply to redo an anastomosis. Similarly when a mucus fistula is

planned, ample length of the distal limb is required to avoid rectal stump dehiscence. It is best to remove the seminal vesicles en bloc and to determine the level of ureteral transection if need be with the urologist's input once en bloc resection is thought to be prudent. Another pearl of wisdom is careful attention to prior anastomoses while honoring oncologic principles. For example, do not apply excess traction on anastomotic limbs from prior resections as this may disrupt the anastomosis and result in intraoperative fecal and/or tumor contamination. In addition, try to accomplish as much mobilization as possible from the abdominopelvic region prior to moving toward the perineal portion of the resection. Liberal consultation with the displayed preoperative imaging is encouraged, and continual reassessment of the anatomy is the key to success. As the late, Lahey Clinic Master Colorectal Surgeon, Dr. Malcolm C. Veidenheimer would say, "Do the easy portions first." If the patient underwent an inadequate TME during the initial resection, there might be an opportunity to enter a "virginal plane." Unfortunately, this is not always the case, and the surgeon should review the prior operative reports and discuss the case with the prior surgeon whenever possible.

Use of IORT should be considered when the margins might be close in an area not amenable to safe resection. IORT is thought to help eradicate microscopic tumor cells within a few millimeters of the final resection margin. Clearly the appropriate infrastructure has to be in place for IORT to be administered safely, and we use a specially designed and dedicated operating room suite for this purpose. When a complete resection with negative margins can be achieved along with use of IORT following preoperative external beam radiation therapy, improved outcomes can be expected. These data underscore the importance of approaching the patient with the clear purpose of performing a complete resection and procuring microscopically negative margins.

Following a major pelvic or en bloc resection, there is often the need to fill the space to avoid complications of bowel incarceration and deep space fluid collections with resultant infection and to promote optimal healing conditions. Anatomical structures that can be readily used to fill this space include the uterus, a pedicled omental flap, or a myocutaneous flap. If the patient has received prior pelvic radiation in the distant past with a long interval to the planned surgical intervention (>6 months), the delivery of nonradiated tissue into the field also promotes robust wound healing and decreases the incidence of perineal wound complications without

adversely affecting abdominal incisional hernia rates. If a partial or total vaginectomy is anticipated, this should be discussed preoperatively and reconstruction options reviewed with plastic surgery colleagues. Another population in which to consider a flap would be elderly female patients who are at increased risk for urethral obstruction from posterior contraction, scar, or irregular urethral angulation following a posterior vaginectomy.

When determining optimal wound coverage options, the principle of opposing nonradiated, well-vascularized tissue without tension is central to proper healing and minimizing the risk of a surgical site infection and wound dehiscence. Oftentimes, use of a well-placed myocutaneous flap abides by this principle. In review of the literature, it appears that there is an association with less wound complications and better outcomes when flaps are utilized (see Table 158.2). Although there may be exceptions, in general, rates of wound complications are threefold more common with primary closure versus with myocutaneous flap reconstruction. Review of the literature indicates no level I data, but limited, nonrandomized studies support flap reconstruction instead of primary closure of perineal wounds after APR especially in cases where the pelvis has been previously irradiated in the distant past (>6-month interval). Although studies do not provide definitive evidence favoring one type of flap over the other (e.g., gracilis vs. rectus abdominus vs. V-Y myocutaneous gluteal flap), we and others prefer using a rectus abdominis flap. This is especially the case when filling large surgical defects such as those left behind when performing a TPE.

TABLE 158.2 Primary Versus Myocutaneous Flap Coverage of the Resultant Perineal Defect in APR or TPE Cases

Study	*N*	Patient Groups	Design	Primary Versus Flap Wound Complication Rate	Conclusion; Supports Use of Flap?
Radice, *Br J Surg* 1999 PMID 10201777	57	20 primary + 24 omental + 13 flap	Prospective cohort	15 vs. 21 vs. 0% (n.s.)	Yes (variable time period)
Shibata, *Ann Surg One* 1999 PMID 10030413	40	24 primary + 16 flap (gracilis)	Case-control	46 vs. 12% ($p = 0.03$)	Yes (variable preop XRT)
Chessin, *Ann Surg One* 2005 PMID 15827789	78	59 primary + 19 flap (VRAM), all preop XRT	Prospective cohort	44 vs. 16% ($p = 0.03$)	Yes
Persichetti, *Ann Plast Surg* 2007 PMID 17667411	35	25 primary + 10 flap (gracilis)	Case-control	10 vs. 0% ($p = 0.03$)	Yes
Butler, *JACS* 2008 PMID 18387476	111	76 primary + 35 flap (VRAM), all preop XRT	Case-control	30 vs. 9% ($p = 0.01$)	Yes
Lefevre, *Ann Surg* 2009 PMID 19801930	95	27 primary + 42 flap (VRAM)	Case-control	17 vs. 26% (n.s.); dehiscence 12 vs. 0% ($p = 0.02$)	Equivocal but less dehiscence
Chan, *Colorec Dis* 2010 PMID 19341404	51	21 primary + 30 flap (24 VRAM, 6 gracilis)	Prospective cohort	14 vs. 17% (n.s.)	Equivocal but variable application of RT

The table shows multiple studies indicating the rates of wound infection or dehiscence after either flap or primary closure in APR, TPE, or recurrent rectal cases requiring tissue coverage. References and PubMed Identifiers (PMIDs) are displayed.

POSTOPERATIVE CARE

The care of the patient undergoing major pelvic reoperative surgery and reconstruction of the perineum for a recurrent rectal cancer is complex and requires special and precise planning and attention. First, a special bed should be used to minimize pressure points and to promote comfortable repositioning for the patient and ease of use by the nursing staff. Next, we do not permit sitting for 6 weeks. We employ aggressive physical and occupational therapy from the first postoperative days as long as it does not jeopardize flap reconstruction wound integrity. We liberally use drains and keep them in place until they are nearly dry. Meticulous care of the wounds should be a priority, and we use negative pressure vacuum dressings on the surface of the wound. In diabetic patients and/or those with >3 cm of subcutaneous fat, we generally leave perineal sutures in place for at least 3 to 4 weeks and remove them once the wound is "crusty."

Multidisciplinary care is instituted right away and involves nursing staff, physician staff, enterostomal nurses, physical and occupational therapists and case managers.

COMPLICATIONS, MANAGEMENT, AND OUTCOMES

Mortality after recurrent rectal cancer surgical intervention is <10% in most modern series while rates as high as 30% have been quoted. In our own institutional experience, operative mortality is <1%. Refined surgical technique and enhanced multidisciplinary care improve outcomes.

However, most patients face some sort of morbidity after the operation and a majority of these problems are due to wound issues in the reoperative/radiated pelvis. One of the most feared complications is dehiscence of the perineal wound and/or flap necrosis after a complex tumor resection and reconstruction with a myocutaneous flap. Patients at increased risk have the following characteristics: obesity, diabetes, malnutrition (e.g., hypoalbuminemia, cachexia), active smoking, corticosteroid usage, and history of prior radiation therapy. In our series of 55 patients undergoing TPE, we noted a 40% perineal wound infection rate and 20% rate of grades 3 to 5 abscesses. A series of 90 patients from Denmark with rectal cancer s/p TPE noted a 20% wound infection rate, 7% intra-abdominal abscess rate, and flap necrosis in 5% with <5% "wound rupture" rates. A recent NSQIP review of >7,000 patients noted 303 patients undergoing TPE and noted a 29% wound complication rate and a 3% rate of wound disruption. In addition, predictors of SSI in pelvic exenteration, APR, or LAR included the following: obesity (1.43 adjusted OR [1.23 to 1.67]), diabetes mellitus (1.24 adjusted OR [1.02 to 1.51]), pelvic exenteration versus APR/LAR (1.23 adjusted OR [1.03 to 1.71]), return to the OR (4.99 adjusted OR [4.02 to 6.19]), or OR duration >4 hours (1.34 adjusted OR [1.15 to 1.55]). In addition, other significant factors associated with SSI were male sex, disseminated cancer, pulmonary disease, and serum albumin.

General surgical principles apply and include early recognition of wound breakdown and aggressive treatment in the operating room to obtain the best exposure and to maximize patient comfort. Recently, we have had good experience with early use of negative pressure vacuum therapy. Creative use of wound sponges, topical dressings, and skin protectant agents must be employed. Even the most difficult of wounds (see Fig. 158.3) can be managed and brought to a reasonable end with diligence, patience, and careful attention to patient nutrition, positioning, and comorbidity management (see Fig. 158.3). This patient had a number of the aforementioned risk factors (e.g., obese, diabetic, prior irradiation for cervical cancer), and in spite of the use of a well-vascularized flap, the patient experienced wound dehiscence and the need for wound salvage. Additional potential complications include pelvic DVT, deep space infections amenable to IR drainage or requiring operative washout, postoperative bleeding or excessively poor bowel or bladder function necessitating proximal bowel diversion, or decompression of the urinary

system.

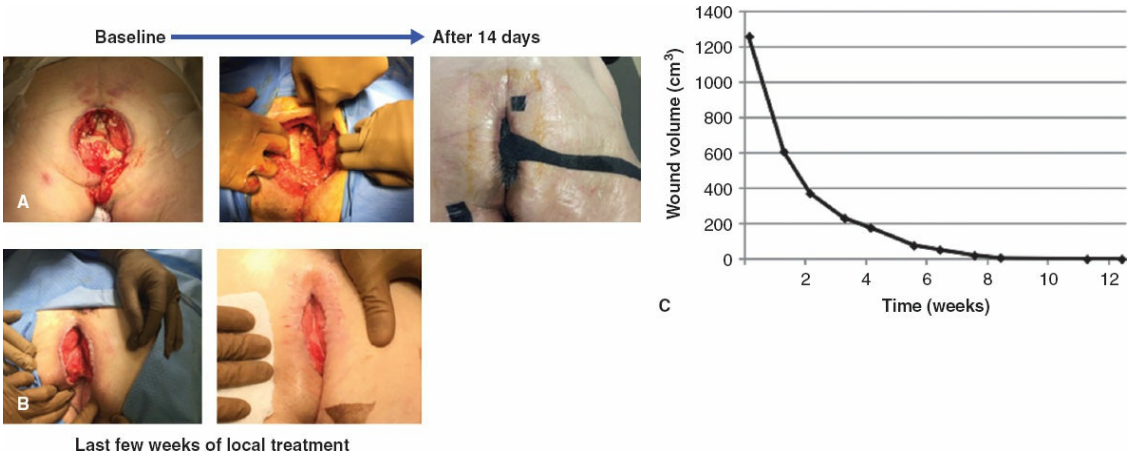

Figure 158.3. Pelvic wound dehiscence and final outcome after judicious multidisciplinary management. **A.** Shown is a patient in the prone position. The patient is s/p TPE with wound dehiscence 2 weeks postdischarge. The patient is an obese, diabetic woman with history of irradiation for cervical cancer prior to diagnosis of rectal cancer. Initial wound status upon diagnosis of dehiscence is shown followed by two photographs of progress over the first 2 weeks with serial debridement, washout, and negative pressure dressing changes. **B.** Wound status is shown after several treatments and at approximately 1 week prior to discharge home with local wound care only. **C.** The wound volume reduction over time is shown with the use of a negative pressure dressing system with irrigation features (used in the early 3- to 4-week phase).

SUMMARY

Reoperative pelvic surgery in rectal cancer is complex; requires seasoned surgical judgment; demands multidisciplinary contributions; and makes exacting demands on the surgeon, hospital, and patient. In a well-equipped center that can provide the necessary preoperative, intraoperative, and postoperative care, salvage surgery for recurrence can be completed safely with good outcomes. In addition, durable survival can be achieved when an R0 resection can be completed. The colorectal surgeon should expect some degree of postoperative complications in the reoperative case for recurrent rectal cancer and must be wary of critical risk factors and respond to early signs of wound infection or flap loss in order to expedite source control and subsequent healing to get the patient back to a functional status.

Suggested Readings

Alektiar KM, Zelefsky MJ, Paty PB, et al. High-dose-rate intraoperative brachytherapy for recurrent colorectal cancer. *Int J Radiat Oncol Biol Phys* 2000;48(1):219–26. http://www.ncbi.nlm.nih.gov/pubmed/10924992. Accessed September 30, 2015.

Arbman G, Nilsson E, Hallböök O, et al. Local recurrence following total mesorectal excision for rectal cancer. *Br J Surg* 1996;83(3):375–9. http://www.ncbi.nlm.nih.gov/pubmed/8665198. Accessed November 4, 2014.

Fisher B, Wolmark N, Rockette H, et al. Postoperative adjuvant chemotherapy or radiation therapy for rectal cancer: results from NSABP protocol R-01. *J Natl Cancer Inst* 1988;80(1):21–9. http://www.ncbi.nlm.nih.gov/pubmed/3276900. Accessed October 12, 2014.

Hahnloser D, Nelson H, Gunderson LL, et al. Curative potential of multimodality therapy for locally recurrent rectal cancer. *Ann Surg* 2003;237(4):502–8.

Heald RJ, Ryall RD. Recurrence and survival after total mesorectal excision for rectal cancer. *Lancet* 1986;1(8496):1479–82. http://www.ncbi.nlm.nih.gov/pubmed/2425199. Accessed October 4, 2014.

Heriot AG, Byrne CM, Lee P, et al. Extended radical resection: the choice for locally recurrent rectal cancer. *Dis Colon Rectum* 2008;51(3):284–91.

Jimenez RE, Shoup M, Cohen AM, et al. Contemporary outcomes of total pelvic exenteration in the treatment of colorectal cancer. *Dis Colon Rectum* 2003;46(12):1619–25.

Lambregts DM, Cappendijk VC, Maas M, et al. Value of MRI and diffusion-weighted MRI for the diagnosis of locally recurrent rectal cancer. *Eur Radiol* 2011;21(6):1250–8.

Milne T, Solomon MJ, Lee P, et al. Sacral resection with pelvic exenteration for advanced primary and recurrent pelvic cancer. *Dis Colon Rectum* 2014;57(10):1153–61.

Moghadamyeghaneh Z, Hwang GS, Hanna MH, et al. Surgical site infection impact of pelvic exenteration procedure. *J Surg Oncol* 2015;112(5):533–7.

Moore HG, Shoup M, Riedel E, et al. Colorectal cancer pelvic recurrences: determinants of resectability. *Dis Colon Rectum* 2004;47(10):1599–606. http://www.ncbi.nlm.nih.gov/pubmed/15540287. Accessed August 1, 2015.

Nagtegaal ID, van de Velde CJ, Marijnen CA, et al. Low rectal cancer: a call for a change of approach in abdominoperineal resection. *J Clin Oncol* 2005;23(36):9257–64.

Nielsen M, Rasmussen P, Pedersen B, et al. Early and late outcomes of surgery for locally recurrent rectal cancer: a prospective 10-year study in the total mesorectal

excision era. *Ann Surg Oncol* 2015;22(8):2677–84.

Nielsen MB, Rasmussen PC, Lindegaard JC, et al. A 10-year experience of total pelvic exenteration for primary advanced and locally recurrent rectal cancer based on a prospective database. *Colorectal Dis* 2012;14(9):1076–83.

Pilipshen SJ, Heilweil M, Quan SH, et al. Patterns of pelvic recurrence following definitive resections of rectal cancer. *Cancer* 1984;53(6):1354–62. http://www.ncbi.nlm.nih.gov/pubmed/6692324. Accessed September 10, 2015.

Rödel C, Graeven U, Fietkau R, et al. Oxaliplatin added to fluorouracil-based preoperative chemoradiotherapy and postoperative chemotherapy of locally advanced rectal cancer (the German CAO/ARO/AIO-04 study): final results of the multicentre, open-label, randomised, phase 3 trial. *Lancet Oncol* 2015;16(8):979–89.

Shibata D, Guillem JG, Lanouette N, et al. Functional and quality-of-life outcomes in patients with rectal cancer after combined modality therapy, intraoperative radiation therapy, and sphincter preservation. *Dis Colon Rectum* 2000;43(6):752–8. http://www.ncbi.nlm.nih.gov/pubmed/10859073. Accessed September 29, 2015.

Shoup M, Guillem JG, Alektiar KM, et al. Predictors of survival in recurrent rectal cancer after resection and intraoperative radiotherapy. *Dis Colon Rectum* 2002;45(5):585–92. http://www.ncbi.nlm.nih.gov/pubmed/12004205. Accessed August 1, 2015.

Terezakis S, Morikawa L, Wu A, et al. Long-term survival after high-dose-rate brachytherapy for locally advanced or recurrent colorectal adenocarcinoma. *Ann Surg Oncol* 2015;22(7):2168–78.

You YN, Skibber JM, Hu CY, et al. Impact of multimodal therapy in locally recurrent rectal cancer. *Br J Surg* 2016;103(6):753–62.

EDITOR'S COMMENT

Drs. Guillem and Smith describe an orderly approach to reoperation in pelvic surgery. The prospect of reoperative pelvic surgery can, however, be a daunting one. As many things with in surgery, this can be made simpler with proper preoperative planning and with an organized approach. If one has the luxury of being able to wait, much as is described in the chapter for surgery for small bowel obstruction, waiting for several months until adhesions become softer is always advisable. This will be possible if one is operating on a patient to reestablish intestinal continuity, that is, if a patient has had a previous Hartmann procedure and one is planning to close a colostomy. However, this will not be possible, if the patient has a recurrent cancer and one is treating a malignancy. One can sometimes "buy time" and facilitate the surgery by giving a patient who has *not* received prior radiation therapy, external beam radiation therapy

with a concomitant radiation sensitizing chemotherapy such as 5-fluorouracil or capecitabine. These will, in some cases, downstage the tumor and facilitate subsequent surgery. Although encountering patients with recurrent rectal cancer who have not had prior radiation therapy is becoming less common, it is always important to determine whether or not the patients have received this type of therapy.

As the authors note, it is always vital to exclude metastatic disease before operating. In cases, elimination of pelvic disease is important even in the presence of metastatic disease. Having uncontrollable pelvic disease in my opinion is not a good option even in the presence of metastatic cancer, simply because pain control in this scenario is *extremely* difficult and surgical eradication of this is preferable. Palliative reoperative surgery may be necessary to treat fistulas or in an attempt to relieve pain, and patients must understand that the pain may or may not be relieved with surgery. It may also be performed to relieve bowel obstruction and is frequently associated with a high morbidity and mortality, and patients must be made aware of this as well. A lengthy and detailed preoperative discussion with the patient is essential (Boostrom SY, Dozois EJ. Recurrent pelvic surgery. *Surg Clin North Am* 2013;93(1):199–215). However, a recent report from a high-volume center questions the utility of performing palliative exenteration in terms of both durable palliation of symptoms and improved quality of life (Quyn AJ, Solomon MJ, Lee PM, et al. Palliative pelvic exenteration: clinical outcomes and quality of life. *Dis Colon Rectum* 2016;59(11):1005–10). This same group has reported on the usefulness of MRI in predicting an R0 resection in such reoperative cases (Brown WE, Koh CE, Badgery-Parker T, et al. Validation of MRI and surgical decision making to predict a complete resection in pelvic exenteration for recurrent rectal cancer. *Dis Colon Rectum* 2017;60(2):144–51). Sadly, the availability of good quality pelvic MRI for rectal cancer staging is something that is still not ubiquitously available in the United States.

The authors propose first making an initial incision to ensure that there is no carcinomatosis and then proceeding on with the formal operation assuming that this is not the case. One aspect the authors have not mentioned is the prospect of what to do if there is difficulty in terms of reestablishing intestinal continuity. As is referred to in the section on anatomy, in cases in which extensive left-sided colon resections have already been performed, a very useful technique is the concept of the retroileal colorectal anastomosis. This can provide for a tension-free colorectal anastomosis by leading the transverse or right colon through a defect in the mesentery adjacent to the ileocolic vessels. Another variation of this is to completely mobilize the right colon and rotate the entire right colon so that a direct end-to-end colorectal anastomosis can be fashioned. Another point, in a difficult pelvis, I have always found it easier to enter the pelvis from posteriorly in patients who have had multiple previous pelvic operations. No matter how daunting the pelvis may appear, *posteriorly* these planes are often much more supple and easier to enter than anteriorly. Also a

point to remember, in patients with very dense pelvic fibrosis, attempts to reestablish intestinal continuity will most likely lead to poor functional results due to decreased compliance of the pelvis.

One of the most important points, if not *the* most important point, in operating on these patients is the utilization of specialists. Because of significant scarring from previous radiation, as well as due to tumor involvement, it is not unusual to have to excise and reimplant ureters or to perform adjacent organ (i.e., bladder) resections, in essence anterior, posterior, or formal pelvic exenteration. With extirpative procedures, the aid of a plastic and reconstructive surgeon is essential in avoiding wound complications. This obviously has to be planned ahead of time. In facilities that do not have access to plastic surgeons, I would very strongly urge for referral of patients to facilities where this is available. The addition of flap coverage to these large wounds greatly aids in postoperative recovery and healing (Devulapalli C, Jia Wei AT, DiBiagio JR, et al. Primary versus flap closure of perineal defects following oncologic resection: a systematic review and meta-analysis. *Plast Reconstr Surg* 2016;137(5):1602–13). In patients who have previously undergone pelvic radiation therapy, there is a high rate of perineal wound breakdown; these wounds heal slowly and the use of vacuum-assisted closure devices is problematic. Such devices can be made to work very effectively. It is difficult finding nurses with the necessary skill to do this so that the vacuum seal is maintained and so that this sponge change process is not unduly painful for the patient.

With the recent increase in the use of laparoscopic surgery for rectal cancer, there also has been an increase in the use of laparoscopy in the reoperative approach to recurrent rectal cancer (Akiyoshi T, Nagata J, Nagasaki T, et al. Laparoscopic salvage lateral pelvic lymph node dissection for locally recurrent rectal cancer. *Colorectal Dis* 2015;17(10):O213–6). One concerning problem is the lack of referral of patients with recurrent pelvic disease to surgeons for timely resection and treating them with chemotherapy until the disease has progressed to an unresectable state. We need to make more of our medical oncologist colleagues aware of the leading role of surgery in the management of these patients.

As with many things in surgery, outcomes for reoperative surgery are better at high-volume centers. It is with reoperative pelvic surgery that a surgeon truly attains the “Mastery of Surgery.”

Susan Galandiuk

159 Sacral Resection for Recurrent Rectal Cancers

Peter J. Lee, Michael Solomon, and Kirk K. S. Austin

INTRODUCTION

Approximately 50% of colorectal cancers recur, but 10% of them recur only locally. Historically, patients who did not have surgery died with poor quality of life. The prognosis for inoperable recurrent rectal cancer is poor with a median survival of 9 months and 5-year survival of less than 5%.

There have been significant advances in surgical techniques allowing successful radical extended resection including sacrectomy with no mortality. The critically important advance has been the lateral pelvic dissection with ligation of the lateral pelvic vasculature, thus permitting high sacrectomies without uncontrollable hemorrhage and intraoperative mortality. The extended radical resections with sacrectomy are necessary in recurrent rectal cancer in order to achieve the principal aim of surgical oncology, clear surgical margins (R0). There is no survival difference between recurrent rectal cancer that invades the sacrum compared to those with no sacral involvement as long as R0 margins are achieved. Therefore, internationally there is increasing interest in performing sacrectomy combined with pelvic exenteration for both recurrent rectal cancer and locally advanced primary rectal cancers, which is evident in the growing number of published case series. The largest series, of 100 sacrectomies, quotes a sacrectomy rate of up to 33% of all pelvic exenterations at the RPAH, Sydney, Australia.

The consequence of radical resection is surgical morbidity. A high morbidity rate is well documented, and increases when the resection includes the sacrum, up to 70% to 80%.

The mortality rate following sacropelvic exenteration of the largest series in the 21st century is up to 3.5% and within the last 5 years (2010 to 2015) zero mortality. Complete resection margins (R0) have also been improving with R0 rates of 68% to 100%, and this translates to improved survival, 5-year survival following sacropelvic exenteration of 34% to

46%.

As a result, there has been growing interest in pelvic exenteration surgery for locally recurrent cancer, and the historic absolute contraindications to resection, such as lateral pelvic bone and high sacral invasion, are no longer contraindications. It is essential to bear in mind that despite these advancements in surgical technique and improved outcomes, pelvic exenteration is complex surgery and thus should be performed in specialized units comprising an experienced team of surgeons, anesthetists, intensive care unit staff, as well as oncologists. At the same time, the benefit and risk of morbidity must be balanced and individualized for each patient with locally recurrent rectal cancer.

ETIOLOGY AND INCIDENCE

Local recurrence can occur due to positive macroscopic and microscopic margins at the primary operation and lateral pelvic lymph node disease. Increased risk for recurrence also includes anastomotic leak and peritoneal deposit following surgery, incomplete total mesorectal excision (TME), and omitting radio-chemotherapy for locally advanced primary rectal cancer.

Ten percent of rectal cancers recur only locally, and thus it is postulated that truly locally recurrent rectal cancers are biologically different to those that disseminate. Wong and colleagues support this theory; there are two types of colonic cancers—locally active and those that have the tendency to metastasize.

It was observed that 75% to 85% of patients with locally recurrent rectal cancer recur within the first 3 years following the primary cancer surgery.

CLINICAL PRESENTATION

The clinical presentation and symptoms are related to the location and organ involvement of the pelvic recurrence. The most common symptoms include pain or referred pain, per rectal bleeding and discharge, altered bowel habit or obstruction, and tenesmus. Pain is the most common presenting symptom that is a result of sacral bone, pelvic floor, lateral pelvic wall invasion and/or neural invasion, notably the sacral nerve roots or the sciatic nerve. The latter will produce referred pain to the buttock, hamstrings, and down to sole of the foot. The recurrence can be extensive to involve organs of the anterior compartment of the pelvis, that is the

genitourinary system. When there is bladder involvement, then the symptoms are reflective of a malignant fistula, such as hematuria, dysuria, and recurrent cystitis. If the vagina is involved, then patients complain of PV discharge, bleeding, and dyspareunia.

There is a smaller group of asymptomatic patients who are diagnosed with recurrence detected by routine cancer monitoring. This includes clinical assessment and examination, an elevation of the carcinoembryonic antigen (CEA), colonoscopy, computed tomography (CT) scan, magnetic resonance imaging (MRI), and positron emission tomography (PET) scan. The latter two imaging modalities are essential prior to sacrectomy with pelvic exenteration.

PREOPERATIVE ASSESSMENT AND INVESTIGATIONS

The majority of patients would present to a pelvic exenteration multidisciplinary team with at least a CT scan and colonoscopy. All locally recurrent rectal cancer patients need to be assessed clinically and radiologically to evaluate the stage of their disease.

It is vital that all patients with locally recurrent rectal cancer are discussed and decisions made in a multidisciplinary setting with surgeons, radiation oncologists, medical oncologists, and radiation oncologists. The surgical team comprises colorectal, plastic, orthopaedic or neurosurgeons, urologists, and gynecologists. The team also includes allied health specialties, including stoma therapy, rehabilitation, nutrition, and psycho-oncology.

CLINICAL ASSESSMENT

It is important to ascertain whether the patients have had chemo-radiation at the time of their primary surgery. All patients prior to pelvic exenteration are recommended for chemo-radiation.

Examination under general anesthesia can be helpful in assessing tumor fixation and involvement of other pelvic organs. Preoperative histologic confirmation is not a prerequisite but is necessary when recurrent rectal cancer cannot be conclusively diagnosed with imaging. Biopsy of tissue, cystoscopy and transanal ultrasound are useful and can all be performed during the examination under general anesthesia.

Tumor Marker—Carcinogenic Embryonic Antigen (CEA)

CEA is commonly used as part of surveillance for recurrence. CEA is not elevated with all colorectal cancers and does not determine the extent of recurrence. Earlier studies claimed that an elevated CEA predicts a worse survival but recent studies contest this, thus CEA as a prognostic tool is not commonly implemented.

Computed Tomography

Chest, abdominal, and pelvic CT scan is the first imaging modality of choice to assess for both local and distant recurrence. With the introduction of the PET/CT scan in recent years, this is preferred and is recommended for all patients with recurrent disease.

Magnetic Resonance Imaging

MRI is vital for preoperative locoregional staging of the recurrent disease and planning for surgery. The MRI is the best imaging modality for anatomical and tumor definition. The MRI outlines accurately the tumor(s) and the extent of invasion of adjacent soft tissue and viscera, lymph nodes, vessels, nerves, muscle, and bone. MRI is well renown for the difficulty in differentiating between tumor recurrence and postoperative and postradiotherapy scar tissue, infective and inflammatory tissue. The addition of a PET/CT can be but, not always is, helpful in differentiating malignant tissue. Tissue confirmation by biopsy is then recommended.

Positron-Emission Tomography

PET scan has a high rate of accuracy in the detection of disseminated disease and thus has shown to alter the course of intervention in up to 40% of patients by demonstrating metastatic disease otherwise undetected on conventional imaging.

Limitations of PET/CT scans include difficulty detecting small-sized peritoneal disease, mucinous adenocarcinoma, and differentiating between malignancy and inflammation.

INDICATIONS AND CONTRAINDICATIONS

There are many published lists for indications and contraindications for pelvic exenteration with sacrectomy. The list of contraindications is diminishing as more series are published. A decade ago, pelvic exenteration was contraindicated for high sacral bone invasion (higher

than S2), lateral recurrence involving bone, nerves, encasement of external iliac vessels, ureteric obstruction, and para-aortic lymph node metastases. Traditionally, lateral pelvic wall recurrence was a poor prognostic indicator due to a low R0 rate, of up to only 22%.

Recently these are no longer the absolute contraindications of pelvic exenteration especially since lateral wall and sacral recurrences have been performed with significant improvement of R0 rates. Austin and Solomon reported an R0 rate of 53% with extended lateral resections, including vessels, nerve, ligaments, and bone.

External iliac vessel tumor invasion can be resected and vascular reconstruction performed to achieve R0 resection. Similarly, lateral recurrences with ureteric invasion can be resected with preoperative preparation for different reconstructive procedures undertaken. Reconstruction includes ureterectomy and reimplanttion or if necessary, radical cystectomy and a conduit. An alternative to conserving the bladder when reimplantation is not possible is performing a unilateral nephrectomy with ureterectomy.

The relative contraindications include patient comorbidities, multiple disseminated disease including peritoneal disease, and bone invasion involving above the first sacral vertebra (S1). Palliative resection is also more contentious due to extensive complications and poor survival. Conversely, if R0 resection is not possible, that is, if the planned surgery is not for curative intent, then surgery should not proceed.

Dozois recently published a small series of high sacretomies including a complete sacrectomy and fibula bone pelvic reconstruction. R0 resection was achieved in all nine patients without any mortality. This demonstrates the surgical advancements over the last decade, thus reducing the absolute contraindications for surgery.

Metastatic disease is considered by some to be a relative contraindication rather than an absolute one. There is some evidence to suggest that patients with limited and resectable metastatic disease can have a survival advantage after surgery, some even beyond 5 years. Importantly, this group of patients is highly selective for surgery and therefore represent the minority of pelvic exenteration patients.

In addition to the contraindications, the surgeon must contemplate and balance the high postoperative morbidity with the quality of life implications and patient’s choice. One in five patients in the authors’ experience will elect not to preceed to pelvic exenteration once fully

informed of the magnitude of the procedure and the expected outcomes.

Wanebo, the pioneer and advocate of pelvic exentertation, believed that the number of contraindications would diminish three decades ago when he commented “the definition of resectability has changed in the management of advanced pelvic malignancy.”

SURGERY

Wanebo, the pioneer and advocate for pelvic exenteration with sacrectomy for recurrent rectal cancer, described a two-stage procedure occurring over 3 days—the first stage in the modified Lloyd Davies position and the second stage, 2 days later, completion in the prone position.

A sacrectomy involves an abdominal and a perineal approach. The sacrectomy is performed in the either the prone or lithotomy position depending on the level of sacral transection. The level of sacrectomy also determines the necessity of myocutaneous flap reconstruction of the pelvic floor, while the extent of the tumor determines the number of pelvic organs resected. The nature of the primary colorectal cancer surgery also influences the extent of radical resection. For example, a recurrence involving the sacrum in a previous abdominoperineal resection in a male often would require sacrectomy with radical cystectomy whereas in a female, the uterus may allow preservation of the bladder. Colorectal surgeons predominantly perform the surgery, with plastic, urologic and orthopaedic or neurosurgical disciplines being involved at the appropriate time. Anesthetists and nursing staff specifically trained and experienced in complex pelvic surgery complete the theatre team. A dedicated unit is required as surgery is physically and mentally challenging and can take up to 20 hours, averaging 12 hours.

The principal goal of sacrectomy and pelvic exenteration for locally recurrent rectal cancer is to achieve an R0 resection. R0 is the single most important prognostic factor for survival. Surgery is difficult and complex as the anatomical planes are no longer the same and there are fibrous adhesions due to previous dissection, radiotherapy, and sepsis. These make identifying the margins of the recurrent tumor very difficult and challenging. Intraoperative frozen section is useful to exclude positive margins. Some units utilize intraoperative radiotherapy when there is doubt or compromise to the surgical margins.

CLASSIFICATION

Sacrectomy is divided into high and low. High sacrectomy involves transection at a level or above the junction of S2 and S3. A sacrectomy distal to this level at the lower border of the sacroiliac joint that is S3 and below is classified as a low sacrectomy. Total sacrectomy with autologous fibula graft reconstruction has been performed with success. Total sacrectomy is rare and the least common type of sacrectomy performed in highly specialized units.

Sacrectomy can be performed without the resection of the other compartments of the pelvis, but this is usually not the case. Localized recurrent rectal cancers are a heterogenous group and usually require surgery in more than one compartment. The compartments of the pelvis have been described by Lee, Austin, and Solomon in previous texts and publications (Fig. 159.1). They include anterior, axial, lateral, and posterior compartments.

Posterior compartment: consists of the rectum, pelvic floor (coccygeus muscle), branches and tributaries of the internal iliac vessels, piriformis muscle, sacral nerves S1 to S4, pelvic bone (sacrum and coccyx), anterior sacrococcygeal ligament, medial sacrotuberous and sacrospinous ligaments.

Lateral compartment: consists of the pelvic side-wall structures, ureter, internal iliac vessels, external iliac vessels, piriformis and obturator internus muscle around the ischial spine, coccygeus muscle, lateral sacrotuberous and sacrospinous ligaments attached to ischium, ischium including tuberosity and spine, lumbosacral trunk and sciatic nerve distal to ischial spine, and obturator nerves and vessels.

Anterior compartment: consists of the bladder, prostate, seminal vesicles, vas deferens, urethra, urogenital diaphragm, dorsal vein complex, obturator internus and externus muscle, anterior half of the vagina, anterior pelvic floor muscle (pubococcygeus and puborectalis part of the levator ani), and pelvic bone (pubic symphysis, superior and inferior pubic rami).

Axial compartment: consists of the posterior half of the vagina, uterus, ovaries, fallopian tubes, broad ligament, round ligament of uterus, rectum, pelvic floor muscle (iliococcygeus part of levator ani), lower sacrum (S4 down), and coccyx.

A sacrectomy includes the posterior compartment but may also include the lateral, axial, combination lateral and axial or all compartments depending on the location, size, and the number of organs or structures involved.

High sacrectomy usually, but not always, requires a total pelvic exenteration due to resection of the sacral nerve roots and compromise to the blood supply of the pelvic organs and or tumor involvement of the organs. The bladder can be preserved with a low sacrectomy with preservation of normal function in the majority, up to 67%, but following a high sacrectomy, when the bladder is preserved it becomes atonic and therefore requires a permanent suprapubic catheter. Alternatively, females can be educated in self-catheterization to avoid a permanent suprapubic catheter.

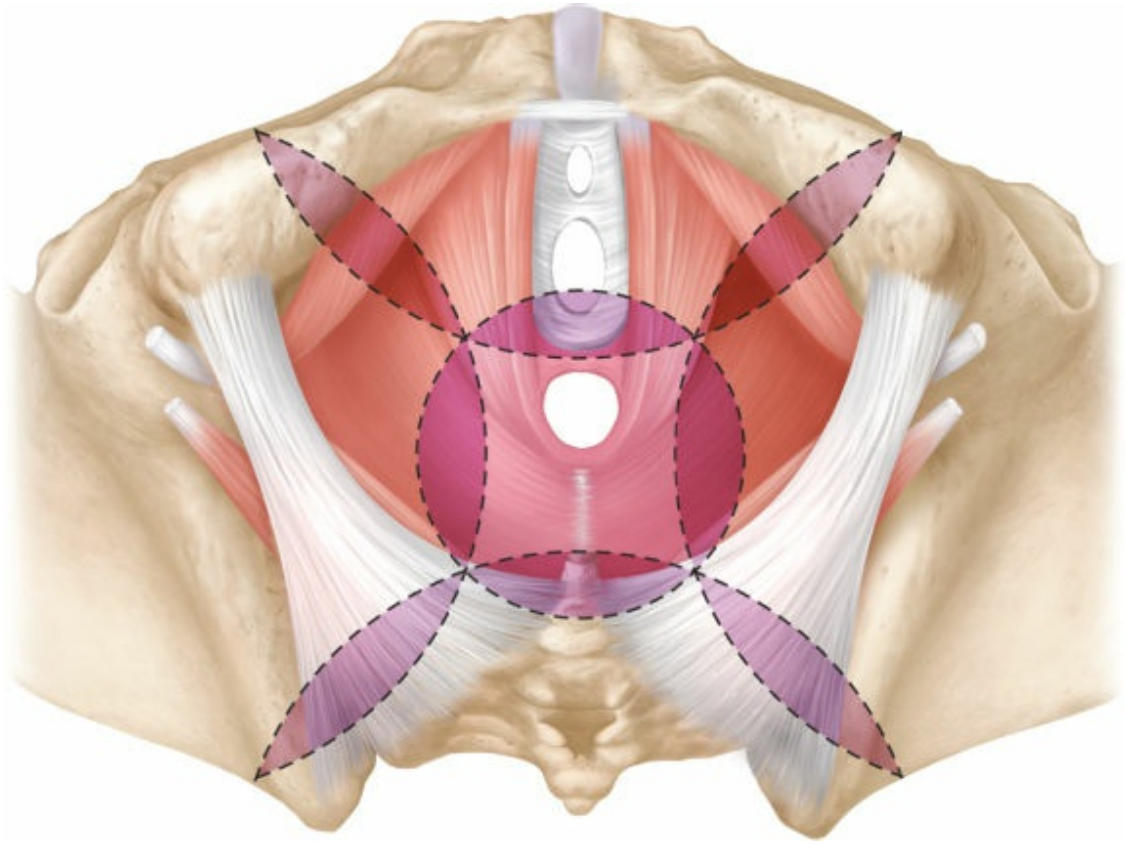

Figure 159.1. The compartments for pelvic exenteration.

SACRECTOMY: THE ABDOMINOPELVIC PHASE

Perioperative Preparations

Patients without a pre-existing stoma should have bowel preparation the day prior to surgery. Skin marker is used to mark stoma sites and, if required, for an elliptical cutaneous vertical rectus abdominis myocutaneous flap (VRAM flap). The use of ureteric stents can be an important aid, especially if the aim is to preserve the bladder.

The anus is sutured to prevent soiling. The vagina is always included in

the skin preparation. Drape the patient so that the thigh and groin are prepared and exposed in anticipation for a vein harvest if an interposition graft or patch is necessary for an iatrogenic vascular injury or vascular resection.

Positioning

The patient is positioned in the modified Lloyd Davies position with the arms secured by the sides. The patient is lying directly on a gel mattress to prevent slippage during steep Trendelenburg position.

During the perineal phase, the surgeon must pay attention to the duration of bilateral leg elevation and allow for repositioning in the neutral position if the operation is becoming prolonged to prevent compartment syndrome of the lower limbs.

High sacrectomy is performed in the prone position. Low sacrectomy (S3 and below) and partial anterior cortical bone sacrectomy can be performed via the transabdominal approach, thus avoiding the prone position.

Laparotomy

The role during laparotomy is to exclude peritoneal disease. MRI and PET/CT scans can miss peritoneal disease, and if confirmed then surgery should be abandoned. If however, it is only localized small volume disease, for example, in the pelvic peritoneum, then pelvic exenteration should continue. During the adhesiolysis, it is important to avoid enterotomies, especially to the irradiated small bowel, to prevent post operative small bowel leak, and the development of enterocutaneous fistulas.

The appendix is removed if present to avoid a potentially extremely hazardous surgery if appendicitis occurred after the complex surgery of an abdominosacrectomy.

Preparing for Sacrectomy

Any involved segments of small bowel in the pelvis and the rectum are disconnected with a liner stapling and cutting device.

The lateral dissection involves mobilizing the ureters with its surrounding vessels and connective tissue, especially the abdominal portion. To maintain good supply to the abdominal portion of the ureter, the gonadal vessels should be ligated distally in the pelvis. The pelvic portion of the ureters have been in the radiation field and thus resected

minimizing the risk of urinary leak when an ileal conduit is created. If the bladder is preserved, then gonadal vessels should also be preserved if possible. The ureter, especially the left, is invariably displaced due to previous dissection.

The internal iliac vessels are ligated, preferably distal to the superior gluteal branches to promote buttock and perineal skin and muscle flap healing. This has been referred to as “pelvic devascularization” and is recommended to avoid catastrophic pelvic bleeding (Figs. 159.2 and 159.3). Profuse brisk hemorrhage occurs when there is inadvertent injury to the internal iliac vasculature and more difficult to control when it is venous bleeding. This can lead to uncontrollable and fatal hemorrhage. This vascular dissection and ligation innately include a lateral pelvic lymph node dissection.

Lymphadenectomy is performed routinely with or without vascular resection. The lateral wall lymph node dissection commences from the bifurcation of the common iliac artery and continued with the internal iliac chain and ends with the removal of the obturator nodes and at the level of the inferior vesicle vessels. The obturator neurovascular bundle can be resected if the obturator nodes are positive on preoperative imaging.

If the recurrent tumor also involves or abuts the lateral bone, then a lateral pelvic exenteration is performed. This involves the excision of the internal iliac vessels and its branches, sacral nerve roots with or without sciatic nerve, piriformis and obturator internus muscle, sacrotuberous and sacrospinous ligaments, and the ischial bone and spine. The bladder may not routinely be excised, but usually a complete exenteration is performed with a high sacrectomy.

The dissection on the presacral fascia is discontinued at least 1 cm from the recurrent tumor. A metallic pin is inserted into the sacrum at this point and is used as the marker for sacral transection with an image intensifier when the patient is in the prone position. The aim is to transect the sacrum with the pin in the specimen.

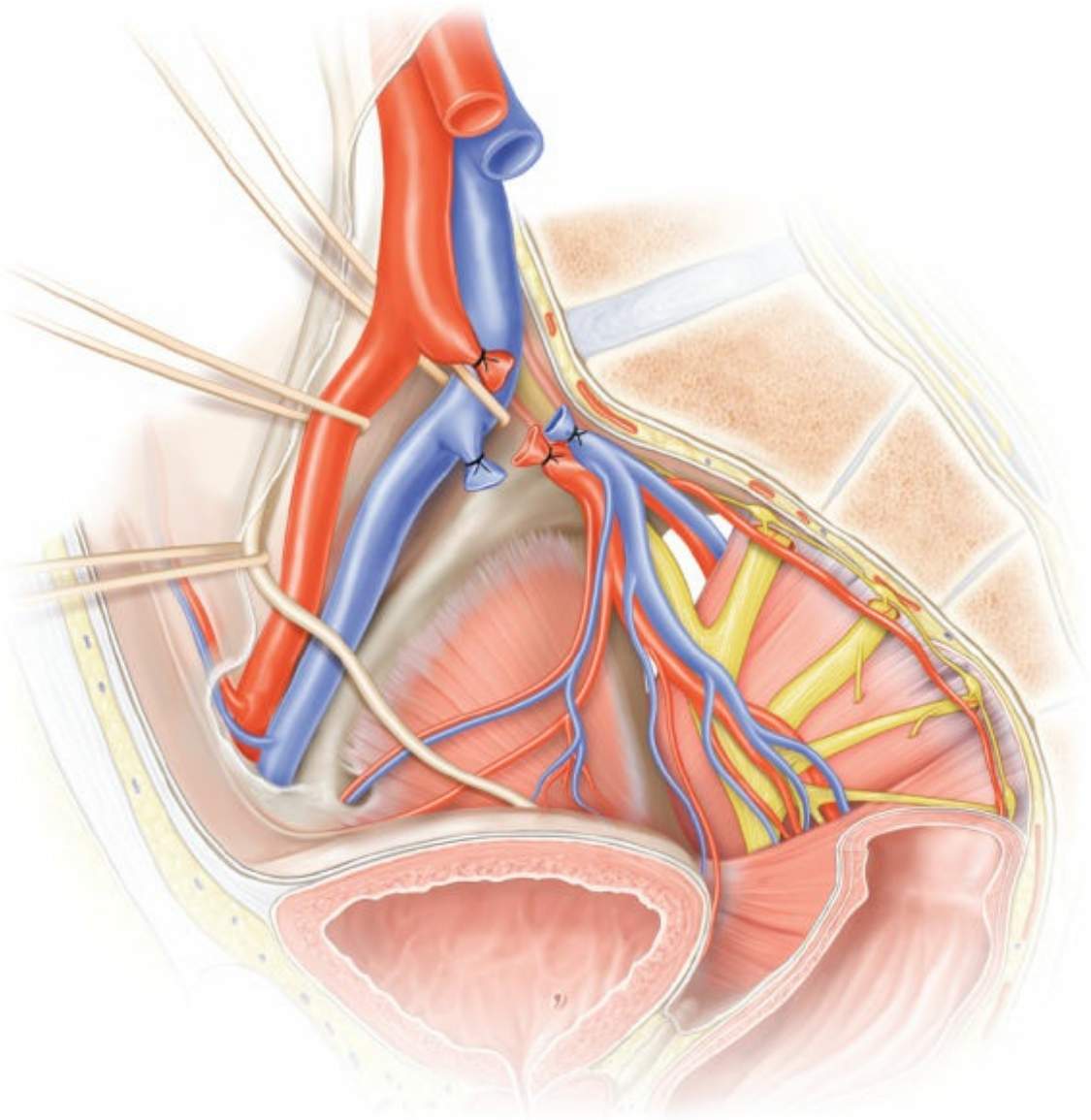

Figure 159.2. Vascular ligation of internal iliac arteries and veins.

High Sacrectomy

A high sacrectomy is performed in the prone position after the abdominopelvic component of the exenteration. The abdominal surgery includes ligation of the internal iliac vessels, mobilization of the pelvic organs, rectum, and possibly the urogentital organs. The sacral nerve roots and sciatic nerve, lateral pelvic bone, the ischial spine, and ischium may need resection if there is extension of the recurrence into the lateral compartment (Figs. 159.2 and 159.3). The stoma and ileal conduit are created and fashioned. The pelvis is packed with surgical sponges to prevent inadvertent damage to pelvic structures during the transection of the sacrum just before closure of the abdominal wall. A pelvic drain is inserted and positioned appropriately. The abdominal wall is closed

primarily, but if a VRAM rectus abdominis flap has been mobilized then polyproprolene mesh reconstruction on the donor side is performed. This is to prevent an incisional hernia.

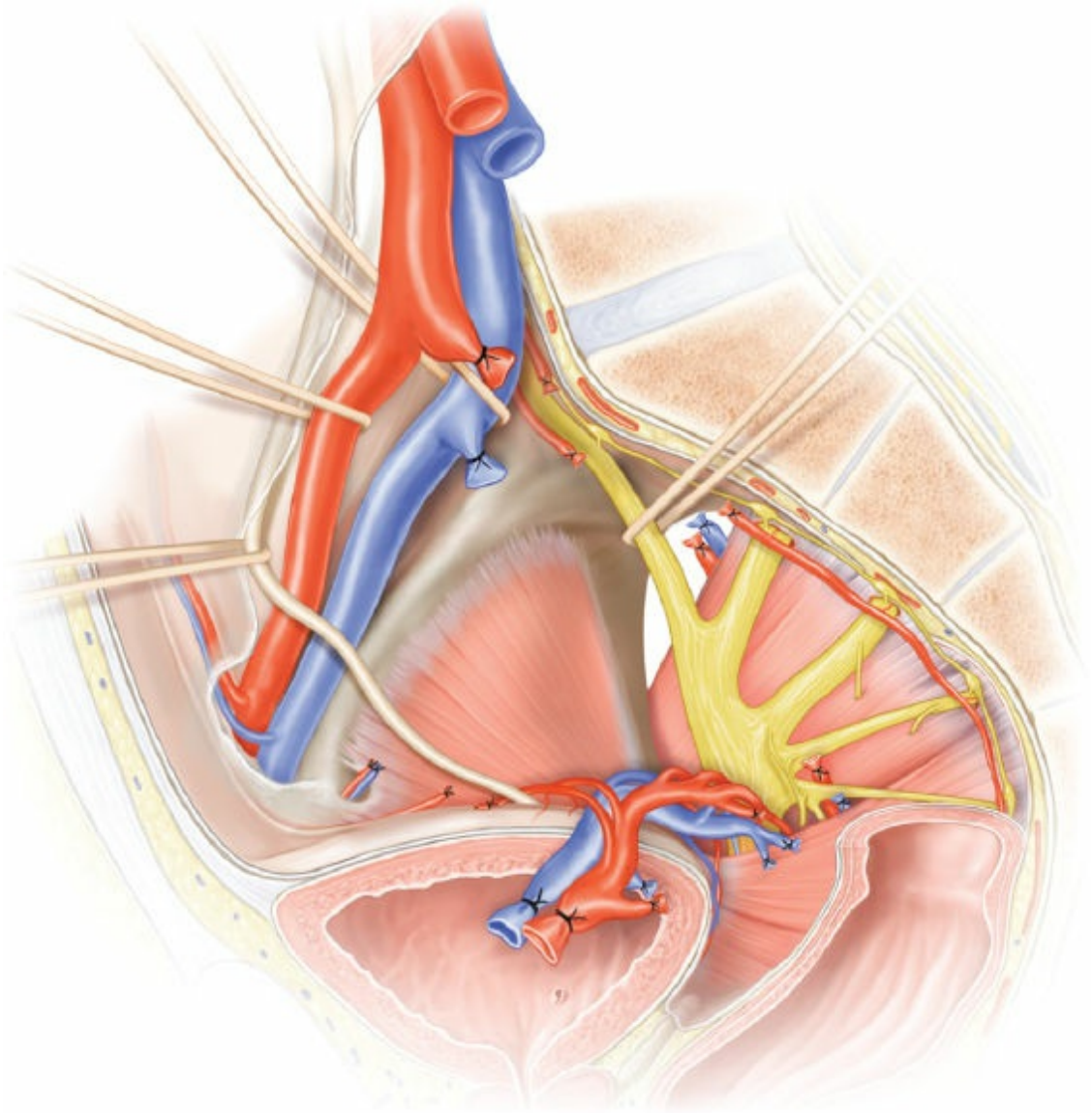

Figure 159.3. Pelvic nerves revealed after internal iliac venous ligation.

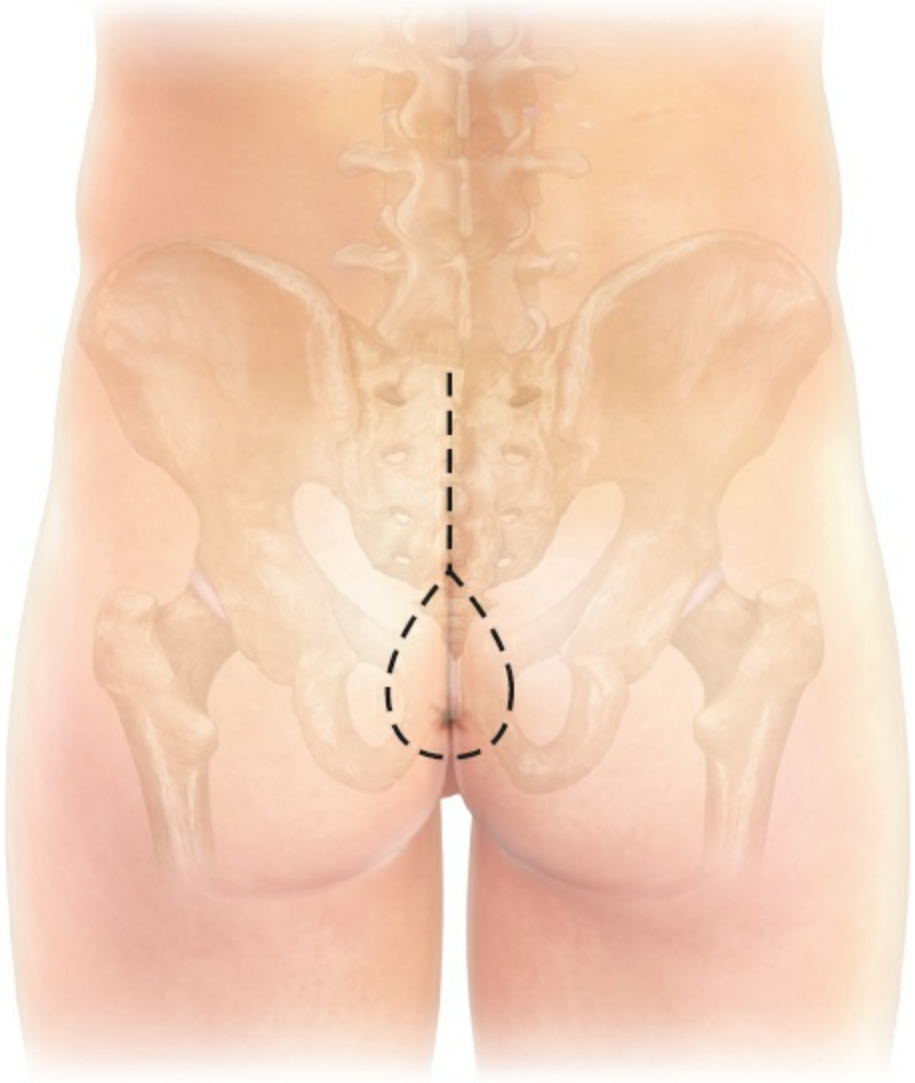

Figure 159.4. Incision for sacrectomy in the prone position (high sacrectomy).

The Perineal Phase

The patient is positioned in the prone jack-knife position, and the surgical site prepared and draped. A racquet-shaped incision is performed, the head of the racquet as the perianal incision (Fig. 159.4). If there is no anus, then a linear incision will suffice. Alternatively, the perineal wound developed during the lithotomy position is continued cephalad to incorporate the sacral wound (Fig. 159.5). The dissection continues until the sacrum is exposed. This involves mobilization and detachment of the gluteus maximus muscles, posterior and lateral sacrococcygeal ligaments, the posterior sacroiliac and sacrotuberous ligaments, and the deepest structure, the sacrospinous ligaments. The detachment of the ligaments exposes the lateral borders of the sacrum and the pelvic muscle deep to it, the

piriformis. Once the piriformis muscle is divided, then the sacrum is ready for transection (Fig. 159.6).

The image intensifier is utilized to locate the previously inserted metal pin. A high sacrectomy requires the ligation of the dura mater prior to transection. The sacrectomy is completed with an oscillating saw (Fig. 159.7). Finally, if not already performed by the perineal surgeon during the lithotomy position, the lateral pelvic dissection is continued caudad to detach the levators from the pelvic bone.

It is vital to preserve lumbosacral and S1 nerve root, and the sciatic nerve to maintain normal motor function of the lower limb. Gait with foot-drop ensues if these nerves are transected; however, patients can still walk. Loss of S2 and lower sacral nerve roots will result in variable sensory loss of lower limb and an atonic bladder but no loss of lower limb motor function.

Low Sacretomy

A low sacrectomy, even as high as the junction of S3 and S4, can be performed in the lithotomy position saving time and effort of repositioning the patient in the prone jack-knife postion and providing dual surgical access for difficult lateral compartment exenteration (Fig. 159.8). The sciatic nerve also lies more laterally in the lithotomy position than in the prone position. In addition, operating in the prone position can be confusing unless the surgeon is familiar with this approach.

Sacrectomy does not always involve the complete transection of the sacrum but rather, the removal of the anterior cortical or partial resection. This is best performed in the abdominolithotomy position.

The main trunk of the internal iliac vasculature is preserved and the distal sacral nerve roots are divided thus organs such as the bladder can be preserved and maintain function.

The perianal surgeon mobilizes the gluteus muscles and the ligamentous attachment from the sacrum. The pelvic floor muscles, and including the obturator internus and piriformis muscles for lateral recurrences, are also mobilized from its lateral bony attachments before sacral transection is performed.

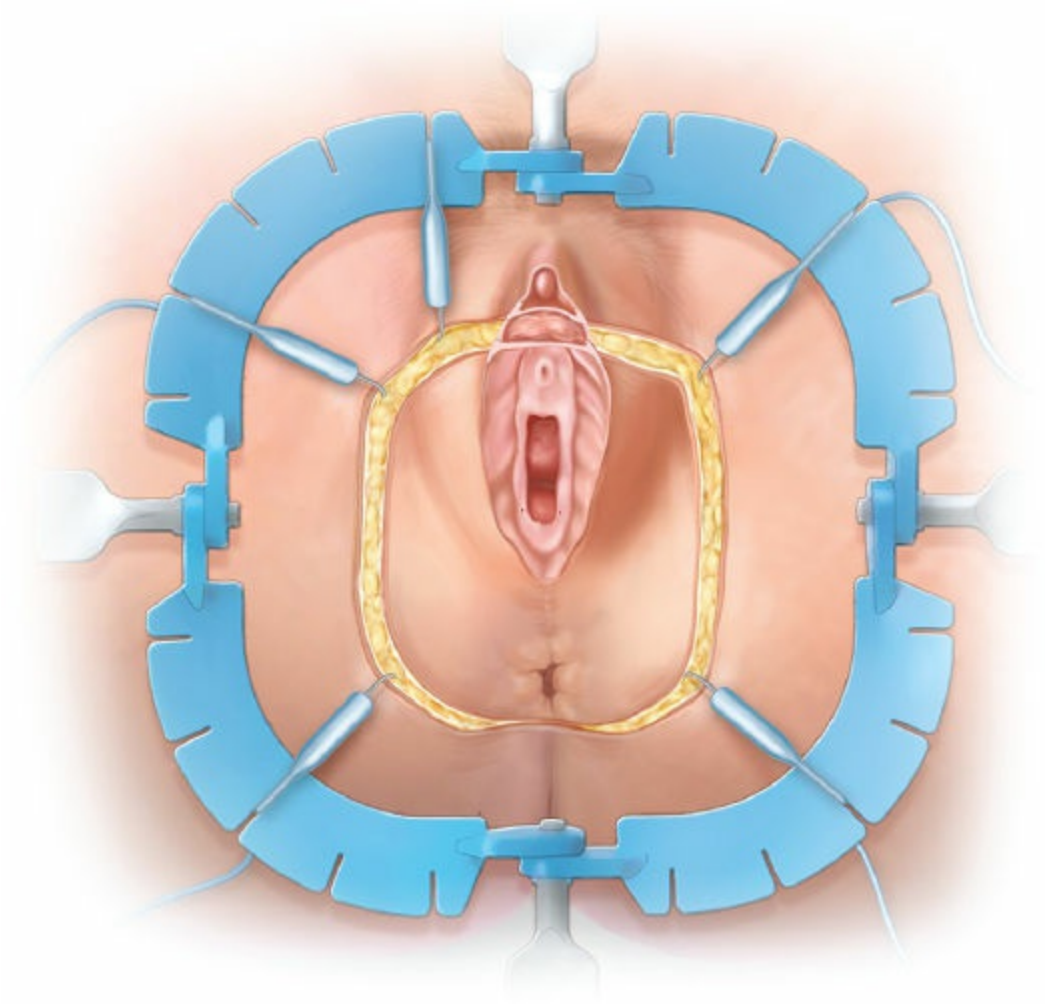

Figure 159.5. Perineal incision during abdomino-lithotomy position (in preparation for the prone position).

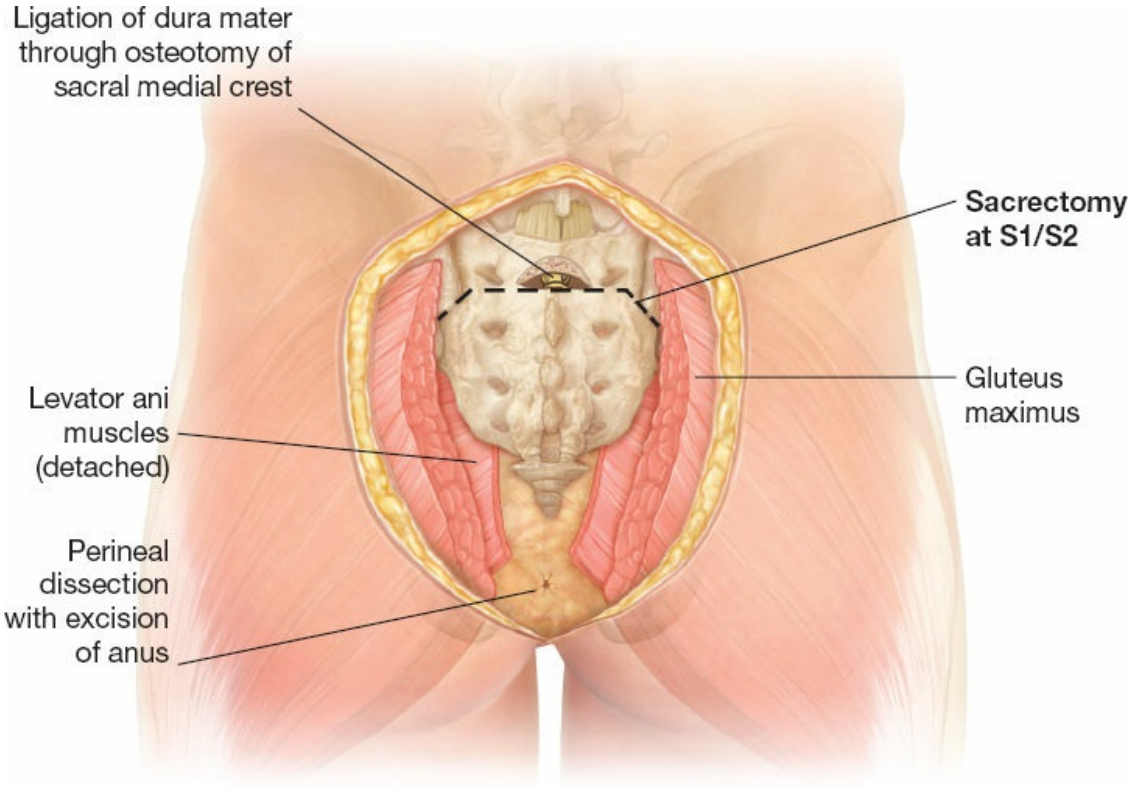

Figure 159.6. Pre-S1/S2 sacrectomy in the prone position.

The presacral fascia is divided at the line of transection to expose the bone. An osteotome is used to transect the sacrum. The perineal surgeon places another osteotome at the posterior surface of the sacrum to protect the skin during the transection.

Hemostasis is achieved more easily once the specimen has been removed simply due to better accessibility.

Perineal wound is closed usually without a musculocutaneus flap unless there is extensive perineal skin involvement with tumor or radiation damage or a complete soft tissue exenteration.

Intraoperative Radiotherapy

Some units have used intraoperative radiotherapy. The median dose of 1,250 cGy has been used and the Mayo Clinic, where 67% (20 of 30 patients) received intraoperative radiotherapy. Doses higher than 1,250 cGy increase the incidence and severity of the neuropathy.

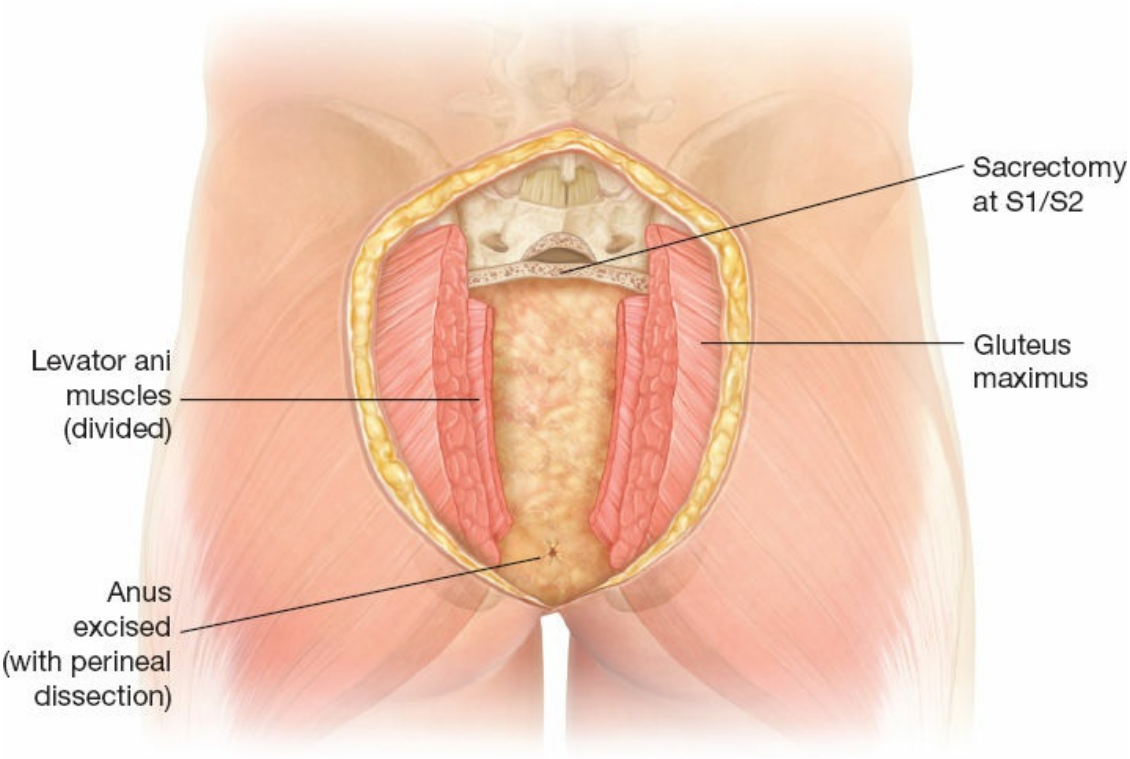

Figure 159.7. Post-S1/S2 sacrectomy.

POSTOPERATIVE CARE

The patient is transferred to the intensive care unit. The patient is usually extubated for pelvic exenteration of duration of less than 10 hours.

Total parental nutrition (TPN) is commenced on the first postoperative day, and nasogastric tube inserted as ileus occurs invariably. Routine postoperative care also includes intravenous antibiotics, analgesia including neuroleptics, deep venous thrombosis prophylaxis with a combination of mechanical calf compressing devices, compression stockings, and subcutaneous anticoagulant.

Patients with VRAM flap reconstruction are initially nursed in a 30 degrees lateral tilt position to avoid prolonged pressure on the flap. After the first postoperative day, depending on the healing of the flap, the patient is allowed to be in the supine position. The patient is encouraged to mobilize on the fifth day.

Usually at day 2 or 3 post surgery, the patient is transferred to the ward with a specialized team of nurses, occupational therapist, physiotherapists, psychologists, dietitian, and cancer care specialist nurse coordinator.

Hospital admission is prolonged and a consequence of the high incidence of morbidity. The mean hospital stay post sacrectomy has decreased from 5 weeks and with more recent studies reporting hospital

admission of 3 weeks. The time to recovery with a stabilized quality of life is at least 3 to 6 months.

COMPLICATIONS AND THEIR MANAGEMENT

Pelvic exenteration with sacrectomy is the most complex pelvic operation for recurrent cancers. Therefore, it is not surprising that complication rates are high, up to 82%. Sacrectomy itself is a predictor of increased morbidity.

Complications are divided into major and minor (Table 159.1), and as high as 40% and 78%, respectively. Interestingly, in the largest series comparing high and low sacrecotmies, there was no difference in major and minor complications rates, but on separate subanalysis, S1 resection showed a significant increased rate of major complications.

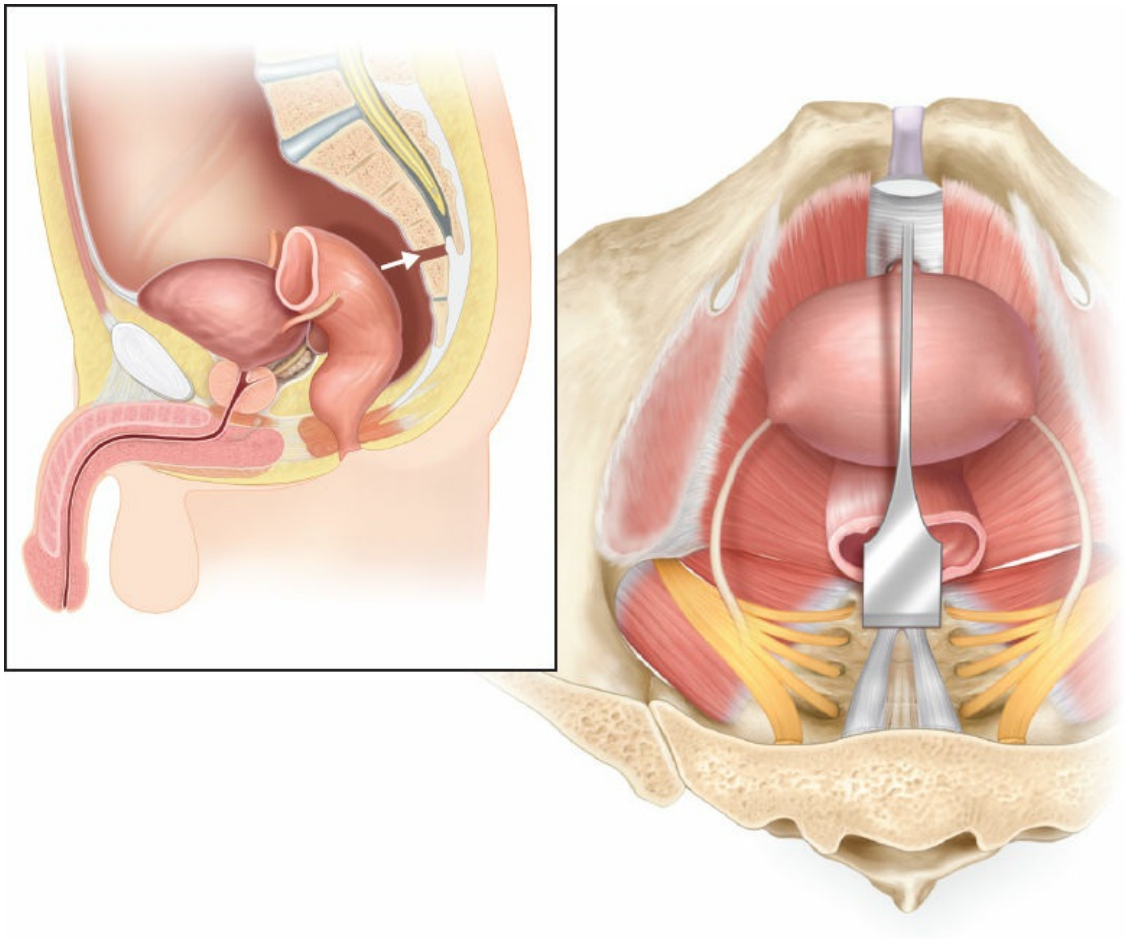

Figure 159.8. Sacrectomy in the abdominolithotomy position.

The most common major complications include sacral wound dehiscence and flap necrosis, pelvic sepsis, and urinary conduit leak.

Reoperations for major complications including percutaneous procedures such as CT-guided pelvic abscess drainage and CT-guided nephrostomies were performed in 38% of sacrectomy patients. Twenty-four percent of patients had reoperations including sacral wound debridement, for small bowel obstruction, repair of enterocutaneous fistulas, and revision of urinary conduit.

Despite the perineal wound and flap being one of the common complications, the selective use of the vertical rectus abdominis myocutaneous flap has not reduced the complication rate.

Prolonged ileus and small bowel obstruction (nonoperative management), neuropathic bladder and urinary incontinence, lower limb neuropathy, deep venous thrombosis, and atrial fibrillation are the most common minor complications.

Most patients develop postoperative ileus, whereas prolonged ileus is less common at 10%. An ileus is the result of a combination of long operative time, prolonged use of narcotic analgesia, radiated bowel and extensive abdominal and peritoneal dissection. Therefore, TPN is recommened for all patients undergoing a sacrectomy.

The level of sacral resection with its respective nerve roots will determine the severity of neurologic complications affecting the bladder and bowel. A high sacrectomy with the resection of S1 to S3 nerve roots will result in bladder and bowel dysfunction. In contrast, low sacrectomies result in lower rates of neurologic dysfunction and comparative to pelvic exenterations without sacrectomy. Interestingly, two more recent studies comparing high and low sacrectomies did not show a significant difference in the rate of a neuropathic bladder. The overall rate of neuropathic bladder was high (47%) and the authors attributed the higher neuropathic bladder rate in low sacrectomies as a combination of loss of lower sacral nerve roots, preoperative radiotherapy, and the nature of tumor invasion.

All sacretomy patients with local recurrent rectal cancer have a colostomy, so bowel function is not an issue. However, when the bladder is preserved, the bladder becomes atonic resulting in urinary retention especially in a patients where S2 vertebra or above is resected.

The Mayo Clinic and the Japanese National Cancer Center have reported significant motor deficit and bladder dysfunction following a high sacrectomy, especially S2 vertebra or above. Neurologic deficit of the lower limbs, where the sciatic nerve was preserved, has been shown to be significantly higher in high sacrectomies. In particular, motor deficit was

higher in high sacrectomies and corresponded to the recurrent tumors abutting the lumbasacral trunk necessitating a partial resection. However, there was no significant difference in the rates of sensory loss and neuropathic bladder when compared with low sacrectomies. Therefore, the cause of an atonic bladder is multifactor and not solely a result of level of sacral transection.

TABLE 159.1 Complications—Major and Minor

Major Complications

Wound/flap

- Deep wound dehiscence
- Deep flap dehiscence
- Flap necrosis partial or full thickness
- Pelvic abscess (CT drainage)
- Sacral osteomyelitis

Cardiovascular

- Myocardial infarct
- Pulmonary embolus
- Middle cerebral artery stroke
- Thrombophlebitis

Gastrointestinal/urologic (reoperation)

- Enteric fistula
- Small-bowel obstruction
- Anastomotic leak
- Urinary conduit leak

Minor Complications

Wound/flap

- Wound infection
- Superficial wound dehiscence
- Minor flap dehiscence

Gastrointestinal (conservative management)

- Prolonged ileus
- Small-bowel obstruction
- Pelvic abscess (no drainage)

Renal/urologic

- Urinary retention
- Urinary incontinence
- Urinary tract infection
- Acute renal failure

Cardiovascular

- Atrial fibrillation
- Deep vein thrombosis

Respiratory

- Atelectasis
- Pneumonia
- Pulmonary oedema
- Pneumothorax

The largest sacrectomy series to date compared the operative outcomes between high and low sacrectomies. High sacrectomies had a significantly longer operation time, greater blood loss but did not translate into an increase hospital length of stay. The level of sacrectomy did not influence the ability to achieve an R0 margin.

TABLE 159.2 Sacretomies for Recurrent Rectal Cancer and Survival Rates

Author	N	HS (%)	R0 (n[%])	5 yr OS (%)	DFS (%)	
					3 yr	5 yr
Moriya *et al.*	57	9 (16)	48 (84)			31
Milne *et al.*	49	21 (43)	36 (74)	38[a]	51[a]	43[a]
Akasu *et al.*	44[b]	25 (57)	24 (54.5)	34	26	24
Uehara *et al.*	32	6[c] (19)	27 (77)		39[a]	
Colibaseanu *et al*	30	17[d] (57)	28[e] (93)	46		43
Melton *et al.*	29	15 (55)	18 (62)			20
Bhangu *et al.*	22	5 (23)	15 (68)			55
Dozois *et al.*	9	9 (100)	9 (100)	30		

HS, high sacrectomy = proximal sacrectomy at S1, S2 vertebra.
[a]Survival rates for R0 margins.
[b]Four patients were for palliative intent (metastatic disease; lung = 2, lung and local = 1, lymph nodes = 1).
[c]19 patients in intermediate sacrectomy but not included as proximal sacrectomy at S2 vertebra was not defined.
[d]Includes proximal transection at L5 (2 patients) and L4 (2 patients).
[e]Three patients were included in R0 after further resection of R1 after frozen section.

Mortality rates have significantly improved over the last 30 years mainly as a result of improved surgical techniques. In the 1990s, Wanebo et al. reported a mortality rate of 5.4% in 63 patients. In the next decade, the mortality rate decreased to 1% to 3.4%. Since 2010, the mortality rate has been zero in all the major reported series for sacrectomies.

PROGNOSIS AND SURVIVAL

Historically, there have been several factors that affected survival. The factors that were shown to have an adverse effect on survival include resection margin status, lateral recurrences, increased number of points of fixity, lymph node status at primary surgery, pain at presentation and sciatic nerve involvement.

Irrefutably, the single most important predictor of survival is R0 resection margins and hence the most important prognostic indicator. Advancements in surgical techniques with extended and radical resection have made the other factors listed above less significant and re-classified as relative indicators. Conversely, if R0 margins are achieved, then the other negative prognostic indicators are no longer as important.

A more recent study published in 2014 by Royal Prince Alfred Hospital, Sydney, Australia reported additional pathologic factors that influenced R0 margins. The involvement of anterior organ, cortical bone invasion, involved local lymph nodes, and lymphovascular and perineural invasion influenced R0 resection margin thus ultimately survival. The authors proposed resecting the pubic bone to achieve an R0 anterior margin and are due to report on their series in the near future. Melton et al., from Memorial Sloan Kettering Cancer Center, also reported anterior organ involvement as a negative prognostic indicator for survival.

The rate of R0 resection margins for sacrectomies has significantly improved in the last decade, ranging from 50% to 93% (Table 159.2). A smaller series from the Mayo Clinic reported R0 rate of 100% in nine patients with high sacretomies including one total sacrectomy and fibula graft bone reconstruction.

Overall 5-year survival rates have been reported in the range of 30% to 46%. Disease-free survival (DFS) rates at 3 years and 5 years are in the range of 26% to 55% and 20% to 43%, respectively. Survival differences have been reported between R0 and R1/R2, ranging from 30% to 58% and 0% to 20%, respectively.

Performing surgery for palliative intent has been shown to be a predictor of both poor disease-free and overall survival. In addition, the inherent high morbidity rates with this type of surgery highlight why palliative pelvic exenteration should not be recommended.

Recurrence after abdominpelvic sacrectomies has been reported as high as 45%. The sites of recurrence include local recurrence only, distant disease alone, and a combination of local and distant disease. The series of nine high sacrectomies from Mayo clinic with 100% R0 margin reported that all patients ultimately died from metastatic disease.

Suggested Readings

Akasu T, Yamaguchi T, Fujimoto Y, et al. Abdominal sacral resection for posterior pelvic recurrence of rectal carcinoma: analyses of prognostic factors and recurrence patterns. *Ann Surg Oncol* 2006;14:74–83.

Arulampalam TH, Loizidou M, Visvikis D, et al. Positron emission tomography and colorectal cancer. *Br J Surg* 2001;88:176–89.

Austin KK, Young JM, Solomon MJ. Quality of life of survivors after pelvic exenteration for rectal cancer. *Dis Colon Rectum* 2010;53:1121–6.

Austin KK, Solomon MJ. Pelvic exenteration with en bloc iliac vessel resection for

lateral pelvic wall involvement. *Dis Colon Rectum* 2009;52(7):1223–33.

Bakx R, van Tinteren H, van Lanschot JJ, et al. Surgical treatment of locally recurrent rectal cancer. *Eur J Surg Oncol* 2004;30:857–63.

Bedrosian I, Giacco G, Pederson L, et al. Outcome after curative resection for locally recurrent rectal cancer. *Dis Colon Rectum* 2006;49:175–82.

Bhangu A, Brown G, Akmal M, et al. Outcomes of abdominosacral resection for locally advanced primary and recurrent rectal cancer. *Br J Surg* 2012;99:1453–61.

Boyle KM, Sagar PM, Chalmers AG, et al. Surgery for locally recurrent rectal cancer. *Dis Colon Rectum* 2005; 48:929–37.

Colibaseanu DT, Dozois EJ, Mathis KL, et al. Extended sacropelvic resection for locally recurrent rectal cancer: can it be done safely and with good oncologic outcomes. *Dis Colon Rectum* 2014;57:47–55.

Delbeke D, Vitola JV, Sandler MP, et al. Staging recurrent colorectal carcinoma with PET. *J Nuclear Med* 1997;38:1196–201.

Desai DC, Arnold MW, Burak WE, et al. Positron emission tomography affects surgical management in recurrent colorectal cancer patients. *Ann Surg Oncol* 2003;10:59–64.

Devin C, Chong PY, Holt GE, et al. Level-adjusted perioperative risk of sacral amputations. *J Surg Oncol* 2006;94:203–11.

Dozois EJ, Privitera A, Holubar SD, et al. High sacrectomy for locally recurrent rectal cancer: can long-term survival be achieved? *J Surg Oncol* 2011;103:105–9.

Ferenschild FT, Vermaas M, Verhoef C, et al. Abdominosacral resection for locally advanced and recurrent rectal cancer. *Br J Surg* 2009;96:1341–7.

Fourney DR, Rhines LD, Hentschel SJ, et al. En bloc resection of primary sacral tumors: classification of surgical approaches and outcome. *J Neurosurg Spine* 2005;3:111–22.

Gagliardi G, Hawley PR, Hershman MJ, et al. Prognostic factors in surgery for local recurrence of rectal cancer. *Br J Surg* 1995;82:1401–5.

Guo Y, Palmer JL, Shen L, et al. Bowel and bladder continence, wound healing, and functional outcomes in patients who underwent sacrectomy. *J Neurosurg Spine* 2005;3:106–10.

Hahnloser D, Nelson H, Gunderson LL, et al. Curative potential of multimodality therapy for locally recurrent rectal cancer. *Ann Surg* 2003;237:502–8.

Hartley JE, Lopez RA, Paty PB, et al. Resection of locally recurrent colorectal cancer in the presence of distant metastases: can it be justified? *Ann Surg Oncol* 2003;10:227–33.

Hashiguchi Y, Sekine T, Kato S, et al. Indicators for surgical resection and

intraoperative radiation therapy for pelvic recurrence of colorectal cancer. *Dis Colon Rectum* 2003;46:31–9.

Heriot AG, Byrne CM, Lee P, et al. Extended radical resection: the choice for locally recurrent rectal cancer. *Dis Colon Rectum* 2008;51:284–91.

Heriot AG, Tekkis PP, Darzi A, et al. Surgery for local recurrence of rectal cancer. *Colorectal Dis* 2006;8:733–47.

Huguier M, Houry S. Treatment of local recurrence of rectal cancer. *Am J Surg* 1998;175:288–92.

Jacombs A, Rome P, Harrison J. Wound outcomes after pelvic exenteration surgery in patients requiring myocutaneous flap reconstruction. *ANZ J Surg* 2012;82:130.

Jeffery M, Hickey BE, Hider PN. Follow up strategies for patients treated for non-metastatic colorectal cancer. *Cochrane Database Syst Rev* 2007(1):CD002200.

Kusters M, Austin KK, Solomon MJ, et al. Survival after pelvic exenteration for T4 cancers. *Br J Surg* 2015;102:125–31.

Lee PJ, Austin KS, Solomon MJ. Assessment and management of recurrence. In: Moran B, Heald RJ, ed. *Manual of Total Mesorectal Excision.* London: Hodder & Arnold; 2013:203–21.

Lopez M, Luna-Perez P. Composite pelvic exenteration: is it worthwhile? *Ann Surg Oncol* 2004;11:27–33.

Mannaerts GH, Rutten HJ, Martijn H, et al. Abdominosacral resection for primary irresectable and locally recurrent rectal cancer. *Dis Colon Rectum* 2001;44:806–14.

McDermott FT, Hughes ES, Pihl E, et al. Local recurrence after potentially curative resection for rectal cancer in a series of 1008 patients. *Br J Surg* 1985;72:34–7.

Melton GB, Paty PB, Boland PJ, et al. Sacral resection for recurrent rectal cancer: analysis of morbidity and treatment results. *Dis Colon Rectum* 2006;49:1099–107.

Messiou C, Chalmers AG, Boyle K, et al. Pre-operative MR assessment of recurrent rectal cancer. *Br J Radiol* 2008;81:468–73.

Milne T, Solomon MJ, Lee P, et al. Assessing the impact of a sacral resection on morbidity and survival after extended radical surgery for locally recurrent rectal cancer. *Ann Surg* 2013;258:1007–13.

Milne T, Solomon MJ, Lee P, et al. Sacral resection with pelvic exenteration for advanced primary and recurrent pelvic cancer: A single-institution experience of 100 sacrectomies. *Dis Colon Rectum* 2014;57:1153–61.

Moore H, Shoup M, Riedel E, et al. Colorectal cancer pelvic recurrences: determinants of respectability. *Dis Colon Rectum* 2004;47:1599–606.

Moriya Y, Akusa T, Fujitu S, et al. Total pelvic exenteration with distal sacrectomy for fixed recurrent rectal cancer in the pelvis. *Dis Colon Rectum* 2004;47:2047–54.

Ogunbiyi OA, McKenna K, Birnbaum EH, et al. Aggressive surgical management of recurrent rectal cancer—is it worthwhile? *Dis Colon Rectum* 1997;40:150–5.

Onodera H, Maetani S, Kawamoto K, et al. Pathologic significance of tumor progression in locally recurrent rectal cancer: different nature from primary cancer. *Dis Colon Rectum* 2000;43:775–81.

Pawlik TM, Skibber JM, Rodriguez-Bigas MA. Pelvic exenteration for advanced pelvic malignancies. *Ann Surg Oncol* 2006;13:612–23.

Sagar PM, Gonsalves S, Heath RM, et al. Composite abdominosacral resection for recurrent rectal cancer. *Br J Surg* 2009;96:191–6.

Schlag P, Strauss LG, Georgi P, et al. Scar or recurrent rectal cancer. Positron emission tomography is more helpful for diagnosis than immunoscintigraphy. *Arch Surg* 1989;124:197–200.

Solomon MJ, Tan KK, Bromilow R, et al. Sacrectomy via the abdominal approach during pelvic exenteration. *Dis Colon Rectum* 2014;57(2):272–7.

Takeuchi O, Koda K, Sarashina H, et al. Clinical assessment of positron emission tomography for the diagnosis of local recurrence in colorectal cancer. *Br J Surg* 1999;86:932–7.

Uehara K, Yoshino Y, Arimoto A, et al. Aggressive surgical treatment with bony pelvic resection for locally recurrent rectal cancer. *EJSO* 2015;41:413–20.

Wanebo H AP, Koness R, Levy A, et al. Pelvic resection of recurrent rectal cancer. Technical considerations and outcomes. *Dis Colon Rectum* 1999;42(11):1438–48.

Wanebo HJ, Marcove RC. Abdominosacral resection of locally recurrent rectal cancer. *Ann Surg* 1981;194:458–71.

Wanebo HJ, Whitehill R, Gaker D, et al. Composite pelvic resection. *Arch Surg* 1987;122:1401–6.

Wells BJ, Stotland P, Ko MA, et al. Results of an aggressive approach to resection of locally recurrent rectal cancer. *Ann Surg Oncol* 2007;14:390–5.

Wiggers T, de Vries MR. Surgery for local recurrence of rectal cancer. *Dis Colon Rectum* 1996;39:23–8.

Wong SKC, Jalaludin BB, Henderson CJ, et al. Direct tumour invasion in colon cancer: correlation with tumour spread and survival. *Dis Colon Rectum* 2008;51:1331–8.

Yamada K. Patterns of pelvic invasion are prognostic in the treatment of locally recurrent rectal cancer. *Br J Surg* 2001;88:988–93.

Zileli M, Hoscoskun C, Brastianos P, et al. Surgical treatment of primary sacral tumors: complications associated with sacrectomy. *Neurosurg Focus* 2003; 15:1–8.

EDITOR'S COMMENT

I would start by commenting the authors on presenting an excellent overview of an exceedingly complex operation. Their elaborate description is a testament to the authors' faculty with this operation. The chapter presents the technical aspects of the operation in an elegant manner with clean, crisp description of operative technique that can be easily followed by the reader.

One of the unintended "side effects" of the authors' exceptional account is the fact that their description almost makes sacrectomy for locally recurrent rectal cancer seem like a relatively straightforward operation. Their description certainly does not do justice to the operative planning, technical complexity, and associated morbidity that this procedure entails. In my opinion, reoperative pelvic surgery for recurrent rectal cancer is one of the most difficult procedures in colorectal surgery. This is particularly true in patients who have received radiation therapy in the past specially if adjuvant radiation was administered after the index operation. Performance of sacrectomy adds yet another layer of complexity to an already challenging operation.

While the authors briefly touch upon the importance of surgeon's experience, I think it is worth to reemphasize the importance of this point. In my opinion, these surgeries should only be performed by surgeons who are highly experienced in reoperative pelvic surgeries. In addition to the surgeon's expertise, a certain level of institutional experience is also mandatory as this procedure requires skilled anesthesia and ICU teams, availability of urology, orthopedic, neurosurgery and plastic surgery support, access to intraoperative radiation and most importantly, a robust postoperative rehab program. Embarking upon these surgeries without the needed experience and institutional support would inevitably result in poor patient outcomes. For those in the early phase of their learning curve, I strongly suggest entailing the help of a senior partner with prior experience in this arena.

Patient selection is of paramount importance for these cases. It makes very little sense to do an exceedingly complex, maximally invasive operation with intentions of accomplishing local control in a patient already harboring metastatic disease. I concur with the authors that a preoperative pelvic MRI to confirm resectability and a PET scan to rule out metastatic disease are essential components of preoperative planning. All patients being evaluated for sacrectomy should be thoroughly discussed in multidisciplinary tumor board to obtain radiology and oncology input before a trip to the operating room is planned.

The authors touch the issue of intraoperative radiation therapy in a very cursory manner, which in my opinion is an integral component of this operation.

As authors have indicated, this operation is marred by a fairly high rate of local failure. It will be truly unfortunate to put a patient through such an extensive operation only to encounter an early recurrence. I think that the gravity and invasiveness of this operation coupled with severe postoperative morbidity and functional limitations that often follow this surgery demand an “all out” approach—one that maximizes the chance of a successful outcome. For this reason, I routinely use intraoperative radiation therapy (IORT) or high-dose radiation (HDR) for almost all recurrent rectal cancer patients requiring a partial sacrectomy or in cases where preoperative MRI imaging indicates threatened surgical margins. While there relative paucity of data evaluating routine use intraoperative radiation with partial sacrectomy, there is plenty of evidence supporting its role in decreasing local recurrence after surgery for recurrent rectal cancer and I feel it is fair to extrapolate these data to partial sacrectomy.

Although not discussed in the chapter, the importance of multidisciplinary team approach cannot be overstated. In my practice, I have always managed these tumors using a multidisciplinary approach entailing help from urology, orthopedics, neurosurgery, and plastic surgery in addition to intraoperative radiation oncology consult. This may just be a reflection of my relative inexperience with this technique compared to the authors. Being a colorectal surgeon, I am not very facile with orthopedic and neurosurgical anatomy and feel out of my domain while operating in those areas. In my experience, having these specialties on board not only improves the quality of operation but also helps in achieving negative margins.

Syed Husain

160 Cytoreductive Surgery and Hyperthermic Intraperitoneal Chemotherapy for Cancers of the Appendix and Colon

Edward A. Levine

INTRODUCTION

Peritoneal metastases complicate the initial diagnosis of colorectal cancer in approximately 10% of cases, and mucinous appendiceal cancer in up to 50% of cases. The peritoneum is the second most common site of metastases (after the liver), found in nearly 50% of recurrent cases, and it is the only site of recurrence in nearly one third of those cases of colorectal carcinoma. Untreated, these patients have an anticipated survival of <1 year. Historically, such patients have been treated exclusively with palliative systemic chemotherapy, and have been approached with therapeutic nihilism. Unfortunately, the efficacy of systemic chemotherapy for peritoneal metastasis lags behind that found for metastatic tumor at other sites, where the 5-year survival rate with “modern” systemic chemotherapy is in the 5% range, with median survival of approximately 20 months.

Isolated peritoneal metastasis is a regional problem. Consequently, the use of an aggressive regional approach, such as cytoreductive surgery (to remove gross disease) along with hyperthermic intraperitoneal chemotherapy (HIPEC), to treat microscopic residual disease, is a promising modality. Clearly, the majority of the benefit is from the resection, and it must be kept in mind that chemo-perfusion will treat to a maximal depth of 5 mm. Therefore, using HIPEC to treat gross residual disease is rarely appropriate.

Complete cytoreduction in the peritoneum is required to achieve a significant survival benefit, similar to surgical therapy for metastatic disease to the liver or lung. Furthermore, it has given rise to a sizable minority of patients who are long-term survivors with good quality of life,

whereas with previous therapies there were essentially none. Despite survival benefits in appropriately selected patients, the procedure can be associated with significant morbidity, particularly for patients with higher volumes of peritoneal metastases, treated at inexperienced centers. This type of case presents a substantial surgical challenge. It is associated with a long learning curve for the surgical teams, and should not be attempted by the occasional operator.

Preoperative Evaluation

Cytoreductive surgery alone or with HIPEC is a substantial operative undertaking, and thorough evaluation is mandatory. The extent of disease in the peritoneal cavity, as well as the lack of extra-abdominal metastatic sites, must be determined with computed tomography (CT) and/or magnetic resonance imaging (MRI) scans. Malignant ascites is a poor prognostic indicator, particularly in patients with high-grade disease. The procedure should be approached with great caution, as complete cytoreduction is not usually possible in this setting. Resection of the primary tumor as well as the metastatic disease must be deemed feasible. Colonoscopy is helpful preoperatively, as there is a significant risk of second primary colonic lesions.

Preparation for the procedure must include evaluation of medical comorbidities, along with cardiopulmonary and nutritional assessments. The best candidates are free of hepatic parenchymal metastases. Peritoneal surface metastases on the capsule of the liver are not a contraindication. Pathologic confirmation of peritoneal disease/dissemination should be obtained.

Frank discussions with the patient regarding the magnitude of the resection's impact on lifestyle, including the possible need for colostomy or ileostomy formation, and the potential loss of mobility and even mortality are required. Patients with preoperative imaging that suggests the need for splenectomy should undergo vaccinations for encapsulated organisms preoperatively. Preoperative consultations by anesthesia, enterostomal therapy nurses (if a stoma is anticipated), and potentially urology (for ureteral stent placement should complex pelvic anatomy from tumor or previous surgery require it) should be obtained.

Preoperative Preparation

Mechanical bowel preparation, with oral antibiotics, is given the day prior

to surgery. Preoperative antibiotics are given intravenously, and deep venous thrombosis prophylaxis using both chemical and mechanical approaches is appropriate. Patients are positioned in the supine position, cushioned as appropriate for the potentially lengthy operative intervention. General anesthesia may be supplemented with epidural catheters for postoperative analgesia. Arterial line monitoring is helpful for most patients. For patients with complex pelvic disease or extensive prior pelvic surgery, placement of externalized ureteral stents by urologic consultants is frequently a time-saving procedure. Patients are typically prepped from the mid chest (should tube thoracostomy be required) to the proximal thigh. Nasogastric and urinary catheters are routinely placed. Core temperature monitoring in the esophagus and/or bladder should be arranged for with the anesthesia team.

Surgical Technique

The goal of cytoreduction is the removal of all grossly apparent disease, while preserving organ function. Although some patients with very low peritoneal disease burden may be approached laparoscopically, most cases are best approached with a generous midline incision. After making the incision, self-retaining retractors are placed. The abdomen must be thoroughly and completely explored at this point, which requires lysis of any pre-existing adhesions. The peritoneal carcinomatosis index is the most commonly utilized descriptor of tumor volume, and should be determined (range of 0 to 39) at this point. An assessment of the extent of visceral involvement must then be undertaken to direct planning for the remainder of the case. Close attention to the extent of small bowel disease is critical. Most low-grade appendiceal cancer cases have relative sparing of the small bowel, which facilitates complete resections. However, the same cannot be said for colonic and high-grade appendiceal carcinoma. Resections that leave the patient with <100-cm small bowel (and attendant permanent short gut syndrome) are rarely if ever warranted. Furthermore, the key assessment is whether the complete cytoreduction is feasible or if a palliative resection is all that can be achieved. The majority of patients (>90%) if properly assessed preoperatively should be able to undergo a complete cytoreduction procedure.

Having evaluated the abdomen and peritoneal disease burden, an operative plan should then be apparent. Clearing the primary tumor (if not resected previously), as well as all gross disease, and determining which

organs must be resected should be thought out carefully. The necessity of peritonectomy procedures should be decided upon so it can be discussed with the operative team at this point.

Some patients will have a significant omental cake that may need to be removed before complete assessment of required resections can be fully evaluated. Since the greater omentum is routinely resected in these cases, there is no need for hesitation. The omentectomy is usually facilitated by entering the lesser sac just outside of the gastroepiploic arcades. If there is disease on the gastroepiploic arteries, it should be resected. However, resection preserving the gastroepiploic vessels can minimize delayed gastric emptying postoperatively. The lesser omentum can be resected off the stomach while preserving the nerves of Latarjet when feasible. The round ligament of the liver should be resected deep into the umbilical fissure of the liver, as it is a common site for metastasis.

The small bowel should be run from the ligament of Treitz to the ileocecal valve, removing nodules from the mesentery as well as the serosa of the bowel. For predominantly mucinous lesions, an ultrasonic surgical aspirator can facilitate resection of small modules particularly on the mesentery. For more sclerotic lesions, an argon beam coagulator or plasma jet dissector can be helpful. Caution must be taken with the serosal implants. If the muscular wall must be resected to clear the implants, they should immediately be repaired with Lembert sutures. If small bowel resection is necessary, measurements *with a ruler* of residual small bowel, beyond the ligament of Treitz, after all resections are completed, should be performed prior to resecting. Rarely should more than two anastomoses be required.

The colon is then run in a similar fashion. For low-grade appendiceal cancers, with peritoneal dissemination, a right colectomy to obtain an adequate lymphadenectomy is rarely required, as the rate of nodal metastasis is quite low. However, for right colonic or high-grade appendiceal cancers, right colectomy is appropriate as part of the cytoreduction. The tenia epiploica is a frequent site of peritoneal metastasis, and these should be resected if diseased. When amputating tenia epiploica, it is important to be cautious not to inadvertently open a colonic diverticulum. Should a colonic diverticulum be encountered, they should be closed with suture and oversewn with 3-0 Lembert sutures. The mesocolon should be cleared in a fashion similar to the mesentery of the small bowel.

The pelvis is dealt with next, and follows clearance of the distal sigmoid colon. The ovary is a common site of metastasis, and should be resected in women with any disease apparent upon the ipsilateral tube or ovary. A hysterectomy is required only if there is disease that cannot be removed from the surface of the uterus. A supracervical hysterectomy is a reasonable choice if disease does not extend beyond the neck of the uterus. If there is disease encroaching upon the neck of the uterus or the cervix, a complete hysterectomy with bilateral salpingo-oophorectomy is appropriate. The pelvic cul-de-sac should be thoroughly inspected as it is a frequent site of “drop metastasis.” This can usually be dissected off the rectum without the need for resection. Should there be significant disease found on the anterior rectum that cannot be removed without resection, proctectomy should be undertaken to remove gross disease. A restorative anastomosis is usually feasible; however, proximal diversion is typically chosen to minimize the risk of anastomotic leak after perfusion. The internal inguinal rings should always be inspected for metastasis and cleared of any grossly apparent disease. This may require resection of the gonadal vessels in some cases.

Pelvic peritonectomy procedures may be required to clear gross disease. They are not required when no disease is apparent. If needed, the stripping of the peritoneum should begin at the superior portion of the bladder and proceed ever deeper into the pelvis. The bladder muscle can be thin at the dome, and care must be taken to avoid cystotomy. However, if tumor is adherent to the bladder, a partial cystectomy can be performed, and closed in two layers with 3-0 absorbable suture. The peritonectomy can be then taken around the cul-de-sac onto either the uterus or the rectum, and laterally onto the pelvic sidewalls if needed.

Attention should then return to the upper quadrants of the abdomen. Involvement of the right diaphragm is much more common than the left in appendiceal cancer cases. If the spleen has disease on its capsule, it should be resected in its entirety, as stripping the splenic capsule is typically associated with prohibitive-loss. The spleen can be resected with the gastrosplenic ligament and omentum as a single unit. The lesser sac is widely exposed at this point and disease should be cleared from it at this time. Should disease be found to be adherent to the stomach, partial gastrectomy is preferred. Total gastrectomy is rarely necessary, and should be undertaken only if it is the limiting site to complete cytoreduction, and in cases where substantial small bowel resection is not necessary, as a

Roux-en-Y reconstruction would be necessary. The lesser omentum should be resected if there is any disease upon it, but need not be done routinely. Lesser omentectomy should spare the vagal branches to the stomach (nerves of Latarjet) if not diseased. If lesser omental disease requires division of both the nerves of Latarjet, a pyloromyotomy should be considered.

The right upper quadrant is then addressed. The porta hepatis should be carefully inspected. Bulk disease on the hepatoduodenal ligament that cannot be cleared is a contraindication to chemotherapy perfusion. The peritoneum on the anterior surface of the hepatoduodenal ligament can be stripped while preserving the vasculature and bile duct. Should disease be found on the gallbladder, a cholecystectomy is indicated. If there is disease on the right diaphragm, mobilization of the right lobe of the liver is required, and should include division of the right triangular ligament. With the liver mobilized to the left, it may be necessary to readjust the self-retaining retractor system to optimize exposure of the diaphragm. A peritonectomy procedure can be performed if required. Frequently, peritoneal disease on the right diaphragm can be stripped entirely as the tumor tends to thicken and stiffen the peritoneum. However, this is not feasible in all cases. Peritonectomy of the right diaphragm should begin just beneath the ribs to proceed more progressively deeper into the abdomen. High-power cautery and good traction/counter-traction facilitate this maneuver. A Cobb dissector can also be quite helpful in stripping the diaphragm (Fig. 160.1). Should disease be apparent in the right gutter, the anterior lamina of Gerota fascia can be resected with the right diaphragm stripping as a single unit. If disease is found on a portion of the diaphragm that cannot be stripped, resection of the diseased diaphragm can be undertaken, with closure with a nonabsorbable suture. A tube thoracostomy can then be placed with fresh gloves and instruments to try to avoid pleural contamination with cancer cells.

Disease on the liver capsule can be stripped as individual metastases if limited in number. If larger areas of disease, or confluent disease is found, the liver capsule can be stripped off by incising the capsule and bluntly removing large areas of capsule. Hemostasis is typically not difficult to obtain after parietal peritoneal stripping, and may be facilitated by high-power cautery or an argon beam coagulator.

Whether to perform restorative anastomoses at this time or after the perfusion is controversial. We have found it advantageous to perform the

anastomosis, prior to perfusion, to allow them to be inspected after the perfusion is complete. While this has the theoretical risk of not perfusing tissue incorporated into the anastomoses, we have not found failure at these sites to be problematic with this approach.

Hyperthermic Intraperitoneal Chemotherapy Administration

The delivery of intraperitoneal chemotherapy can be performed with either an open or closed technique. The open technique requires the abdomen to be open and filled with fluid during the time of perfusion. Since evaporation with chemotherapy vapor will accompany this technique, it may violate occupational and health and safety administration rules. Therefore, most centers use a closed abdominal technique (safety standards vary by state) to avoid this issue. The closed technique requires placement of cannulas for inflow and outflow. Our center uses two inflow and two outflow cannulas, which is a simple system that works well. Inflow cannulas, of 22 French, are placed via small incisions and carried through the subcutaneous tissue into the upper quadrants. The outflow cannulas, of 32 French, are placed in a separate set of incisions, taken through the subcutaneous tissue and positions in the lower quadrants or pelvis. A device to diffuse suction is required on the outflow cannulas to avoid injuries to the bowel. The skin is then temporarily closed with a running suture. Each cannula is also sutured in position. The two inflow and two outflow cannulas are connected with Y-connectors. One-quarter inch tubing is connected to the inflow cannulas, and ⅜-inch tubing is connected to the outflow cannulas.

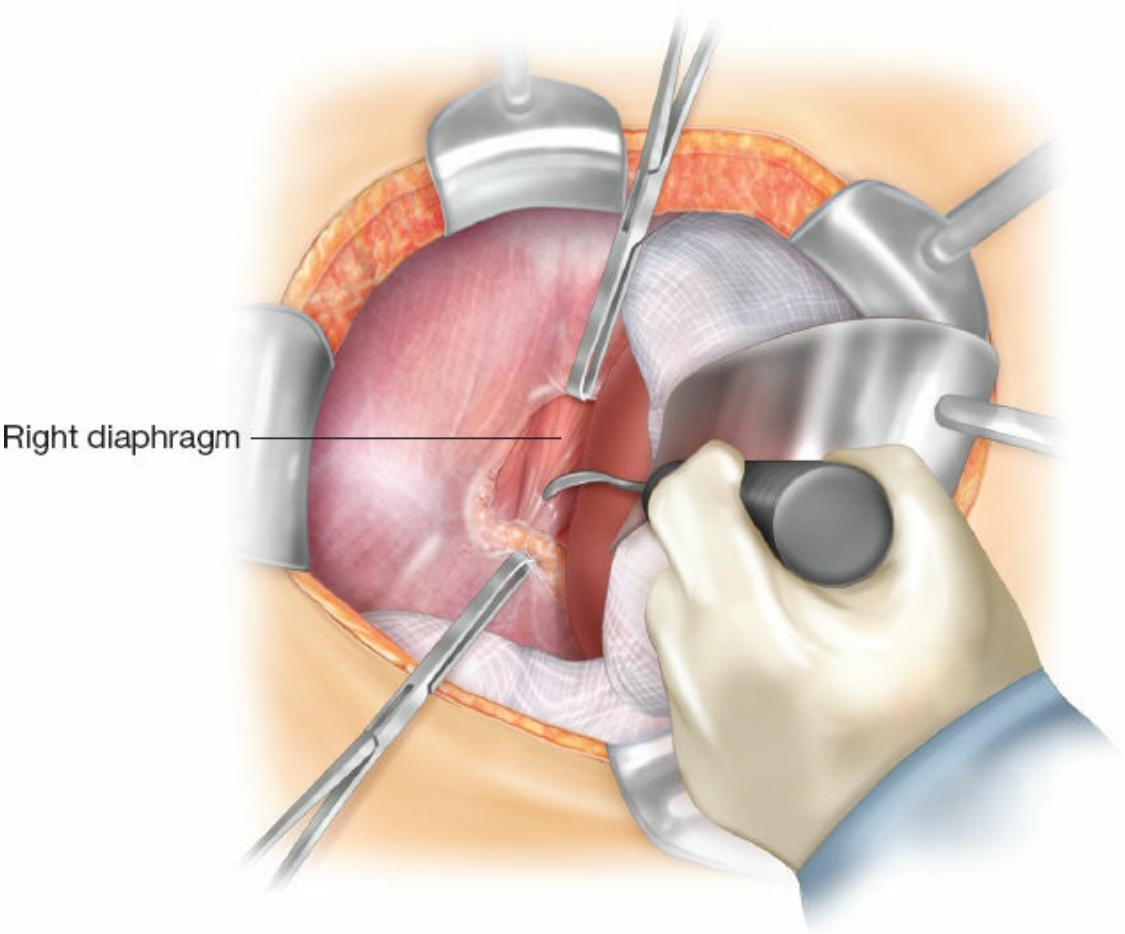

Figure 160.1. Cobb Dissector used for a right peritoniectomy. The peritoneum of the right diaphragm is grasped by Allis clamps and the dissector is dissecting the peritoneum off the muscle of the diaphragm (liver mobilized well to the left).

Thermistors are attached to the inflow and outflow cannulas to monitor temperature. A three liter crystalloid solution is used to prime the circuit. The perfusion pump is associated with a heat exchanger to manipulate the temperature of the perfusate. Gentle manipulation of the abdomen should remove all air from the peritoneal cavity. Toward the end of the extirpative portion of the procedure, communication with the anesthesia service should allow for discontinuation of warning devices to allow the patient to passively cool to approximately 35°C. The perfusate inflow is warmed to 42°C and manipulated to obtain outflow temperatures of 40°C.

With a stable patient and perfusion circuit, the chemotherapy is then introduced. Mitomycin C is the most commonly used chemotherapeutic agent at most centers. Typically 30 mg is given at the initiation of perfusion, with an additional 10 mg dose given into the circuit 1 hour into the perfusion, to maintain drug levels in the circuit. Oxaliplatin is an

alternative agent, more commonly utilized in Europe. We have used a dose of 200 mg/M^2 as a single dose into the HIPEC circuit. Most centers perfuse the peritoneum for 60 to 120 minutes (our protocol is for 120 minutes), at a flow rate of at least 1 L per minute. At the end of the perfusion, the circuit is drained, the abdomen reopened, the retractor repositioned, and the cannulas removed. We usually redose systemic antibiotics at this time as antibiotic levels are washed out with the perfusate.

Re-Exploration and Definitive Closure

After completion of the perfusion, the self-retaining retractor is replaced, all cannulas are removed, and the abdomen is re-explored. Complete hemostasis is then assured. Required anastomoses are inspected or (if not performed prior to perfusion) are then completed. Should a colostomy or ileostomy be required, they are created at this point. The nasogastric tube should be confirmed to be in good position. Typically, a nasojejunal feeding tube is positioned in the proximal jejunum to facilitate early postoperative enteral alimentation. Final counts should then be obtained, and when correct, closure initiated.

Fascial closure is typically performed with absorbable number one suture. The subcutaneous tissue can be approximated if thick and the skin closed. The skin should be closed at the midline, as well as at the cannula sites. If a stoma is required, it is then matured and dressed with an appropriate appliance. After the dressings are placed, patients are typically extubated and taken to the recovery area. Intensive care unit (ICU) monitoring is required for most, but not all, cases. Operative dictation should be completed immediately following the procedure to ensure that all relevant details are crisply recalled. Long-term follow-up is greatly facilitated by notes that include the areas where disease was encountered, the peritoneal carcinomatosis index, and the completeness of resection, as well as the volume and location of residual disease if any.

Postoperative Care

Patients undergoing substantial resection with HIPEC typically stay in the ICU overnight. Antibiotics are discontinued after the day of surgery. Patients are encouraged to be out of bed on the first postoperative day and on their feet the second day. Ureteral stents (if placed) are removed if there are no urinary clots, typically on the first postoperative day, with the

urinary catheter removed on the second day. Patients with nasojejunal feeding tubes have nutrition initiated the day after the procedure. Venous thrombosis prophylaxis is continued with fractionated heparin *and* sequential compression stockings. The sequential compression is discontinued when the patient is fully ambulatory, and the fractionated heparin continued for a few weeks after discharge. Nasogastric tube is maintained on low intermittent suction until motility is confirmed.

Results

Patients with low-grade cancer of the appendix who undergo complete cytoreduction have 10-year survival rates in the 75% range. Those who undergo incomplete cytoreduction have a 5-year survival of approximately 50%. Patients with peritoneal metastases from colon or high-grade appendiceal carcinoma, undergoing cytoreductive surgery with HIPEC, have 5-year survival rates in the 30% range, with a median survival of ~30 months after complete resection. Furthermore, it should be kept in mind that the 30-month survival is typically found after the patients have undergone systemic chemotherapy for months.

There has only been one completed prospective randomized trial evaluating cytoreductive surgery with HIPEC to systemic chemotherapy alone. Reported initially in 2003, the findings from this trial of 105 randomized patients (85% colon, 15% appendix) demonstrated a significantly improved median overall survival with cytoreductive surgery and HIPEC of 22.3 versus 12.6 months in the systemic chemotherapy-alone group. Overall survival was significantly associated with the completeness of resection status ($P < 0.0001$) and the initial volume of disease (PCI) score. This was found despite the 8% perioperative mortality that is two to three times that currently reported at leading centers. Although this study showed impressive and durable results, the findings were tempered by low participation rate, high mortality, and a now obsolete 5-FU/leucovorin chemotherapy regimen. Two other colorectal randomized trials were opened in order to compare cytoreductive surgery followed by EPIC (Europe) or HIPEC (United States), versus cytoreduction with systemic therapy. Unfortunately, both trials were closed due to failure to accrue patients. The utility of the intraperitoneal chemotherapy after cytoreductive surgery is currently being tested in the Protige 7 trial in France, which has completed accrual of 280 patients.

Conclusions

The role of cytoreductive surgery for peritoneal disease is clearly established for appendiceal cancer (as well as ovarian and peritoneal mesothelioma and other primary sites) and is increasing for colon cancer with peritoneal metastases. Long-term survival is possible when complete cytoreduction can be achieved.

Although there are some who have suggested that cytoreductive surgery and intraperitoneal chemotherapy are an alternative to systemic chemotherapy, peritoneal metastasis from colon and high-grade appendiceal cancers may best be approached *with* systemic chemotherapy *and* not in lieu of it. Approaching all patients with peritoneal metastasis with therapeutic nihilism is clearly no longer appropriate. Furthermore, close collaboration between medical oncologists and surgical oncologists experienced in the evaluation of, and operative therapy for, peritoneal disease is important to optimize the survival of patients with metastases from colorectal and appendiceal carcinoma. Based upon currently available data, and unless the results of the Protige 7 trial show otherwise, surgery with intraperitoneal chemotherapy should be considered for patients with isolated peritoneal disease who are otherwise fit.

Suggested Readings

Chu DZ, Lang NP, Thompson C, et al. Peritoneal carcinomatosis in nongynecologic malignancy: a prospective study of prognostic factors. *Cancer* 1989;63:364–7.

Dawson LE, Russell AH, Tong D, et al. Adenocarcinoma of the sigmoid colon: sites of initial dissemination and clinical patterns of recurrence following surgery alone. *J Surg Oncol* 1983;22:95–9.

Elias D, Goéré D, Dumont F, et al. Role of hyperthermic intraoperative peritoneal chemotherapy in the management of peritoneal metastases. *Eur J Cancer* 2014;50:332–40.

Glehen O, Kwiatkowski F, Sugarbaker PH, et al. Cytoreductive surgery combined with perioperative intraperitoneal chemotherapy for the management of peritoneal carcinomatosis from colorectal cancer: a multi-institutional study. *J Clin Oncol* 2004;22:3284–92.

Jacquet P, Sugarbaker PH. Current methodologies for clinical assessment of patients with peritoneal carcinomatosis. *J. Exp Clin Cancer Research* 1996;15:49–58.

Knorr C, Reingruber B, Meyer T, et al. Peritoneal carcinomatosis of colorectal

cancer: incidence, prognosis, and treatment modalities. *Int J Colorectal Dis* 2004;19:181–7.

Levine EA, Stewart JH, Shen P, et al. Intraperitoneal chemotherapy for peritoneal surface malignancy: experience with 1,000 patients. *J Am Coll Surg* 2014;218:573–87.

Sugarbaker PH. Peritonectomy procedures. *Ann Surg* 1995;221:29–42.

Turaga K, Levine E, Barone R, et al. Consensus guidelines from The American Society of Peritoneal Surface Malignancies on standardizing the delivery of hyperthermic intraperitoneal chemotherapy (HIPEC) in colorectal cancer patients in the United States. *Ann Surg Oncol* 2014;21:1501–5.

Verwaal VJ, van Ruth S, de Bree E, et al. Randomized trial of cytoreduction and hyperthermic intraperitoneal chemotherapy versus systemic chemotherapy and palliative surgery in patients with peritoneal carcinomatosis of colorectal cancer. *J Clin Oncol* 2003;21:3737–43.

EDITOR'S COMMENT

Dr. Levine has written an excellent chapter describing the concept of cytoreductive surgery and hyperthermic intraperitoneal chemotherapy (HIPEC) for cancers of the appendix and colon. The concept of tumor debulking surgery for locally advanced abdominal malignancy was first described for ovarian cancer in the 1930s. In the 1960s and 70s, research was beginning to demonstrate that survival in stage II and III ovarian cancer patients was directly related to residual tumor mass after cytoreductive surgery. During about the same time, research was starting to show that hyperthermia as well as intraperitoneal chemotherapy was effective at killing cancer cells. Further studies in the 1980s delivered chemotherapeutic agents at concentrations up to 30 times higher than those safely administered intravenously. As cytoreductive surgery and heated intraperitoneal chemotherapy were combined as a therapeutic approach to intra-abdominal malignancy, it became apparent that the completeness of cytoreduction was associated with survival benefit. In 1995, Dr. Paul Sugarbaker created and described a stepwise approach to cytoreduction in an attempt to standardize and optimize the process.

HIPEC is also known as intraperitoneal hyperthermic chemoperfusion (IPHC) or the Sugarbaker technique/procedure. HIPEC is used most often after tumor debulking for cancers of the appendix, colorectal cancer, ovarian cancer, and gastric cancer. It has also been described for use in mucinous adenocarcinoma of the appendix, mesothelioma, and low-grade sarcoma. Tumor debulking and cytoreduction may include removal of all involved peritoneal areas and even all or parts of involved organs as described in this chapter. These procedures may be 8 to 10 hours long and associated with a significant rate of complications. The volume–outcome relationship has been demonstrated in

many complex procedures, including esophagectomy, pancreas resection, bariatric surgery, and knee replacement, to name a few. At the current time, cytoreductive surgery and HIPEC are performed at a high volume in a small handful of centers across the country. The author of this chapter is from one such center and makes the point that these procedures "present a substantial surgical challenge…associated with a long learning curve for the surgical teams, and should not be attempted by the occasional operator." I would strongly agree that these procedures should be undertaken by only the most highly trained, focused, and collaborative multidisciplinary teams at centers with appropriate resources to manage critically ill patients with potentially significant postsurgical complications.

Minimally invasive surgery has substantially reduced the morbidity of many procedures. Minimal-access cytoreductive surgery with HIPEC has been studied in patients with low tumor burden and with disease of less malignant potential. The PCI score is referenced in this chapter without a clear description. The peritoneal cancer index (PCI) is a scoring system that utilizes tumor size and region of distribution to quantify disease burden. So far, most trials of minimally invasive cytoreductive surgery plus HIPEC have included only patients with low PCI scores. With strict patient selection, laparoscopic cytoreductive surgery and HIPEC have been demonstrated to be a procedure associated with minimal morbidity and mortality and shorter operating times while achieving similar operative and oncologic outcomes to the open procedure. Concerns regarding the ability to complete a thorough examination of the peritoneal cavity have precluded the widespread application of this technique until further evidence is gathered.

The technical descriptions in this chapter include many bits of excellent advice universally applied to almost any surgical procedure. In describing the decision process to proceed with extensive small bowel resection for diffuse disease, the author advises "*measurements with* a ruler *of residual small bowel, beyond the ligament of Treitz, after all resections are completed, should be performed prior to resecting. Rarely should more than two anastomoses be required.*" This is an excellent piece of advice that may also be applied to cases of ischemic bowel and resections in the case of adhesive or inflammatory bowel disease. This falls under the surgical dictum of "measure twice and cut once." When discussing documentation of the procedure performed and operative findings the author advises, "*Operative dictation should be completed immediately following the procedure to ensure that all relevant details are crisply recalled. Long-term follow-up is greatly facilitated by notes that include the areas where disease was encountered, the peritoneal carcinomatosis index, and the completeness of resection, as well as the volume of residual disease if any.*" In the current era of computerized medical records and dictation templates, the necessity of detailed and accurate operative reports has become readily apparent, especially for those of us who perform complex reoperative surgery. An accurate roadmap describing what was encountered and what

exactly was done at the time of an index surgical procedure can be invaluable for patients needing additional surgery or treatment at a later date.

The major controversy surrounding cytoreduction plus HIPEC revolves around the role of hyperthermic intraperitoneal chemotherapy in achieving the observed survival advantage when compared to cytoreduction and systemic chemotherapy. Chemoperfusion has continued to progress since the HIPEC delivery system was first trialed. The potential benefits of the intraperitoneal delivery of antineoplastic drugs are significant. Hyperthermia aids in increased cellular penetration of the drug while synergistically enhancing cytotoxicity. Moreover, vascular stasis of microcirculation occurs in neoplastic cells at temperatures produced by HIPEC, while normal cells experience increased flow. This, combined with the selective accumulation of lactic acid and the resulting lowered level of pH in neoplastic tissue, results in cell death. Drug concentrations achieved through this route cannot be replicated by intravenous chemotherapy and, to some extent, systemic toxicities are avoided.

Potential future directions include improved methods for appropriate patient selection (advanced imaging and possibly genetic tests). Dynamic techniques for accurate intraoperative pathologic diagnosis may prevent unnecessary interventions. Some of these technologies and techniques may enhance the adoption of minimally invasive techniques for addressing peritoneal malignancy. This may include the robotic platform and perhaps telemedicine as a modality for increasing access to surgical expertise for these complex resections. Additional research will define the role of intraperitoneal chemotherapy. Although significant progress has been made in improving survival from intra-abdominal peritoneal malignancy, there is still much work to be done.

Jon C. Gould

Suggested Readings

Neuwirth MG, Alexander RH, Karakousis GG. Then and now: cytoreductive surgery with hyperthermic intraperitoneal chemotherapy (HIPEC), a historical perspective. *J Gastrointest Oncol* 2016;7(1):18–28.

Rajeev R, Turaga KK. Hyperthermic intraperitoneal chemotherapy and cytoreductive surgery in the management of peritoneal carcinomatosis. *Cancer Control* 2016;23(1):36–46.

Sugarbaker PH. Surgical management of peritoneal carcinosis: diagnosis, prevention and treatment. *Langenbecks Arch Chir* 1988;373(3):189–96.

Sugarbaker PH, Van der Speeten K. Surgical technology and pharmacology of hyperthermic perioperative chemotherapy. *J Gastrointest Oncol* 2016;7(1):29–44.

161 Management of Retrorectal Tumors

Cindy Kin and Mark Welton

ETIOLOGY AND PATHOPHYSIOLOGY

The retrorectal space is the continuation of the retroperitoneal plane in the pelvis. It is also called the presacral space. This space is a potential space containing loose areolar tissue, fat, and connective tissues. Its anterior boundary is the fascia propria of the rectum that contains the mesorectum, and its posterior boundary is the sacrum and the overlying presacral fascia. The lateral boundaries are the ureters and internal iliac arteries. The superior boundary is the point at which the upper rectum curves away from the sacrum. The posterior boundary of the retrorectal space is technically the rectosacral (Waldeyer) fascia, although we consider tumors arising in the supralevator space that is inferior to the rectosacral fascia to belong to this category as well.

The classification of the different types of retrorectal tumors is based on the etiology of the tumors: congenital, neurogenic, osseous, and miscellaneous (Table 161.1).

Congenital Tumors

Most cystic retrorectal lesions are congenital. Developmental cysts may be epidermoid, dermoid, or enteric. Enteric cysts may be either tailgut cysts (also known as retrorectal cystic hamartomas) or rectal duplication cysts. Tailgut cysts are the most common benign retrorectal tumor in adults. Women are more likely (15:1) to have retrorectal cysts than men.

Teratomas and teratocarcinomas arise from totipotential cells originating in utero, and are classified as mature (benign); immature, probably benign; immature, possibly malignant; or frankly malignant. However, even mature teratomas have malignant potential. Teratomas are the most common type of retrorectal tumor seen in infants and children. Recurrent teratomas often harbor malignancy. Adult sacrococcygeal teratomas are rare and occur more commonly in female patients. Thirty

percent of sacrococcygeal teratomas harbor malignancy at the time of resection. Teratomas and teratocarcinomas are generally well encapsulated, and even those with malignancy do not tend to invade neighboring structures.

Chordomas are rare neoplasms originating from notochordal remnants. Half of all chordomas occur in the pelvis and retrorectal space, and they represent the most common malignant tumor occurring in the retrorectal space. They occur more commonly in men and have a peak incidence in the sixth and seventh decades. They are locally destructive and tend to recur locally, although they don't tend to metastasize.

Anterior sacral meningoceles are also rare congenital lesions occupying the retrorectal space, and are caused by herniation of the theca through a sacral defect into the pelvis. Neural structures may be present in the herniated sac, and this can ultimately lead to neurologic symptoms.

Neurogenic Tumors

Tumors of neurogenic etiology occurring in the retrorectal space include benign tumors arising from the peripheral nerve sheath such as neurofibromas, schwannomas, ganglioneuromas, and ependymomas; and malignant tumors arising from the peripheral nerve sheath such as malignant schwannomas, neurofibrosarcomas, neuroblastomas, and ganglioneuroblastomas. Benign peripheral nerve sheath tumors such as schwannomas and neurofibromas comprise up to 10% of all retrorectal tumors. Malignant retrorectal tumors of neurogenic origin such as neuroblastoma are rare and occur more in children. Malignant schwannomas of the pelvis occur more in adults.

TABLE 161.1 Classification of Retrorectal Tumors

Congenital

Benign	Malignant
Developmental Cysts	Chordoma
Epidermoid	Teratocarcinoma
Dermoid	
Mucus-secreting	
Teratoma	
Duplication of rectum	
Anterior sacral meningocele	
Adrenal rest tumor	

Neurogenic

Benign	Malignant
Neurofibroma	Neuroblastoma
Ganglioneuroma	Ganglioneuroblastoma
Neurilemoma/Schwannoma	Malignant peripheral sheath tumors (malignant schwannoma, neurofibrosarcoma, neurogenic sarcoma)
Ependymoma	

Osseous

Benign	Malignant
Giant cell tumor	Osteosarcoma
Osteoma	Osteoblastoma
Aneurysmal bone cyst	Ewing sarcoma
	Myeloma
	Chondrosarcoma
	Chondromyxosarcoma

Miscellaneous

Benign	Malignant
Lipoma, myelolipoma	Liposarcoma
Fibroma	Fibrosarcoma/malignant fibrous histiocytoma
Leiomyoma	Leiomyosarcoma
Hemangioma	Hemangiopericytoma
Endothelioma	Metastatic carcinoma
Desmoid	

Other

Ectopic kidney
Hematoma
Abscess

Osseous Tumors

Primary tumors of the sacrum are very rare. Giant cell tumors are rare bone lesions that are benign in the large majority of cases, although 5% of cases may metastasize to the lungs. Aneurysmal bone cysts are neither aneurysms nor cysts, but rather a neoplastic lesion that may arise primarily (two thirds of aneurysmal bone cysts), or secondarily within an existing bone tumor such as a giant cell tumor or osteosarcoma (one third of aneurysmal bone cysts). Twelve percent of aneurysmal bone cysts occur in

the pelvis and sacrum.

Osteoid osteomas and osteoblastomas are innervated bone-forming lesions. They have been historically classified as one or the other based on size. Tumors 1 cm or less in diameter are classified as osteoid osteoma and those 2 cm and greater are classified as osteoblastoma; those 1 to 2 cm in size are classified as osteoma or osteoblastoma according to other features, including anatomic site, presence of a nidus, and presence of peripheral sclerosis. Osteoblastomas are more likely to occur in the sacrum, while osteoid osteomas are more likely to occur in the extremities. Osteosarcomas occurring in younger patients are more likely to be primary tumors, while those occurring in older patients are more likely to be secondary tumors due to Paget disease or prior pelvic radiation. About half of osteoblastomas are associated with metastases at the time of presentation. Prognosis is poor, with 5-year survival of 33% for patients without metastases at the time of diagnosis. Patients with secondary tumors have overall worse outcomes than those with primary tumors. In patients with primary tumors, sacral location, positive surgical margin, and larger tumor size are poor prognostic factors. Ewing sarcoma presents more commonly in males than females, and tends to affect teenagers and young adults. It is the second most common bone tumor in this age group. Chondrosarcomas may present in patients of any age, and occur most commonly in the pelvis and shoulder. Chondromyxosarcoma is a subtype of this tumor.

CLINICAL PRESENTATION

Back or pelvic pain is the most common symptom of a retrorectal tumor, although the clinical presentation is quite variable and can include neurologic symptoms affecting bowel function, bladder function, or lower extremity function, constipation, difficulty evacuating, or abdominal pain.

Tailgut cysts often go unrecognized or misdiagnosed because of their rarity and the wide variability and nonspecificity of their associated symptoms. About half of patients with tailgut cysts present with symptoms, which are highly variable and nonspecific. Patients may have bowel-related complaints such as constipation, diarrhea, change in stool caliber, rectal bleeding, or difficult evacuation. They may present with pain in the abdomen, rectum, anus, pelvis, back, or lower limbs. They may also present with recurrent perianal infections, and many of them have already undergone prior procedures to drain abscesses. Half of patients

with tailgut cysts have no symptoms at all, and their cysts are found incidentally.

Sacral chordomas most commonly present with pain that is worse with sitting (85% of patients), and cauda equina symptoms of saddle anesthesia and bladder or bowel dysfunction (70% of patients). Adults with sacrococcygeal teratomas most commonly present with pelvic pain or a palpable mass. Anterior sacral meningoceles may be asymptomatic and discovered incidentally, but as they grow they cause pressure on neighboring pelvic structures, causing pelvic pain, urinary retention, and chronic constipation. They have been reported to be a rare cause of cauda equina syndrome, or meningitis or perirectal sepsis if they become secondarily infected.

A presacral ganglioneuroma typically becomes symptomatic when the mass becomes so large that it causes abdominal or back pain, constipation, or bowel obstruction (Fig. 161.1). Other retrorectal neurogenic tumors including neurofibromas and schwannomas can cause similar symptoms of pelvic pain or constipation, as well as neurologic symptoms.



Figure 161.1. MRI T1-weighted images of a ganglioneuroma show a hypointense homogeneous mass. This patient is a young woman who was found to have this pelvic mass during her first gynecologic examination, during which her physicians could not locate her cervix due to the sharp anterior angulation as a result of the mass effect.

Osseous tumors of the sacrum may cause radicular pain or neurologic dysfunction affecting bowel and bladder function.

INDICATIONS AND CONTRAINDICATIONS

Traditionally, it has been recommended that retrorectal tumors should be

surgically resected in order to prevent malignant transformation, prevent secondary infection, alleviate symptoms, and obtain a definitive histologic diagnosis. With advancements in imaging modalities, some authors have recommended that cystic lesions that do not have any suspicious radiologic features may be safely followed with serial imaging rather than undergo resection. However, the authors recommend that tailgut cysts be removed when discovered, not only to relieve symptoms but also because of the small risk of malignant degeneration.

Teratomas should be resected along with the coccyx to reduce the risk of recurrence, especially as recurrence of teratomas is often associated with malignant transformation. Anterior sacral meningoceles should also be resected because they will enlarge with time due to their tendency to enlarge and increase pressure on surrounding structures. Untreated anterior sacral meningoceles may cause neurologic deficitis, meningitis, fistulous connections with the rectum, and urinary complications.

Neurogenic tumors range in malignant potential, and surgical management should be tailored accordingly. Neurogenic tumors in the retrorectal space should undergo surgical resection. Ganglioneuromas, while slow-growing and benign, should be resected to establish a definitive diagnosis, and also for therapeutic purposes given their potential to cause symptoms from mass effect.

Management of osseous tumors of the sacrum varies depending on the pathology, proximal extent of the lesion, and preoperative bowel or bladder function. Patients with malignant tumors should undergo wide resection with adequate margins. Patients with benign distal tumors where bilateral S3 preservation is feasible should also undergo wide resection. Benign sacral tumors that involve S3 and above may be treated with serial embolization. Aneurysmal bone cysts may be treated with arterial embolization, avoiding the morbidity of surgical excision. Sacral giant cell tumors may be treated with intralesional resection/curettage rather than sacrectomy, although wide excision or radiation therapy may be used for patients with more extensive or aggressive disease. The optimal management of Ewing sarcoma of the pelvis remains controversial, with some centers treating with local radiation therapy alone, and others advocating for surgical resection with radiation and/or chemotherapy. Treatment of chondrosarcoma depends on tumor grade, but surgical resection is the mainstay of treatment given the resistance of these tumors to radiation and chemotherapy.

PREOPERATIVE PLANNING

Physical examination of the perineum and digital rectal examination aid in determining the location and size of the lesion. Anoscopy and proctoscopy are necessary for determining whether there is any communication with the anus or rectum, especially in patients who have undergone prior procedures.

Cross-sectional imaging with computed tomography (CT) and/or magnetic resonance imaging (MRI) of the pelvis is key for surgical planning and is often diagnostic. MRI is superior to CT imaging in its ability to differentiate benign from malignant tumors. Cystic lesions are less likely to be malignant than solid or heterogeneous tumors. Other radiologic features that raise the suspicion for malignancy include irregular infiltrating borders and enhancement. For the purposes of surgical planning, imaging can identify the extent of the tumor and its involvement of pelvic viscera and pelvic sidewall structures.



Figure 161.2. CT demonstrates a large thin-walled hypoattenuating lesion posterior to the anorectal junction, consistent with a tailgut cyst. This patient presented with difficulty evacuating stool.

In cases of developmental cysts such as tailgut, dermoid, and neurenteric cysts, CT will demonstrate a thin-walled hypoattenuating nonenhancing lesion in the retrorectal space (Figs. 161.2 and 161.3). In the case of secondary infection or fistula, the cyst may have a thicker wall

with inflammatory changes, and may contain air if there is communication with the rectal lumen. Pelvic MRI is also helpful in making the diagnosis and will demonstrate a thin-walled lesion that is hypointense on T1-weighted images and hyperintense on T2-weighted images (Figs. 161.4 and 161.5). Malignant degeneration is suspected if enhancing focal irregular wall thickening on both T1- and T2-weighted images is seen. The pathognomonic sign of an anterior sacral meningocele is the scimitar sign on plain x-ray, and CT or MRI should be obtained for confirmation.



Figure 161.3. CT demonstrates a large thin-walled hypoattenuating lesion posterior to the anorectal junction, consistent with a tailgut cyst. This patient presented with difficulty evacuating stool.

Sacral chordoma is the most common primary sacral lesion. MRI is commonly used for surgical planning purposes, and will demonstrate a heterogeneous mass with destruction of the sacrum (Fig. 161.6). MRI shows a ganglioneuroma to be a hypointense homogeneous mass on T1-weighted images, and a hyperintense heterogeneous mass on T2-weighted images (Fig. 161.7).

Rectal leiomyosarcoma is a very rare tumor arising from smooth muscle, and most commonly occurring in the distal rectum. If it involves the rectal mucosa, anoscopy or proctoscopy may reveal surface ulceration

and bleeding. CT demonstrates an enhancing heterogeneous multilobulated tumor with cystic necrotic areas (Figs. 161.8 and 161.9).



Figure 161.4. Tailgut cyst. MRI demonstrates a thin-walled lesion that is hypointense on T1-weighted images.

Preoperative biopsy is rarely necessary as preoperative imaging usually provides sufficient diagnostic information. Preoperative biopsy carries the risk of tumor seeding with increased recurrence risk, as well as the risk for secondary infection, so it should only be performed if the results will change management. In some series, biopsy of solid retrorectal tumors has been found to be safe and useful for guiding treatment decisions. For example, in the case of a possible presacral ganglioneuroma versus malignant schwannoma, preoperative biopsy or fine needle aspiration can

be helpful in determining the surgical plan—the former is a benign tumor that does not warrant such an extensive resection that would cause morbid neurologic deficits while complete surgical resection for the latter is the recommended treatment. Even with preoperative fine needle aspiration or biopsy, establishing a firm diagnosis of ganglioneuroma preoperatively can be difficult. While neurogenic tumors are typically indistinguishable from one another on radiographic and neuroimaging evaluation, MRI can help distinguish lesions of pelvic origin from those of spinal origin, as chordomas, teratomas, soft tissue sarcomas, Ewing sarcoma, osteosarcomas, chondrosarcomas, and metastases tend to involve bone.

Preoperative counseling regarding expected functional outcomes is paramount, especially if neurologic deficits are expected. A robust shared decision-making process is necessary in order for patients to make high-quality decisions that incorporate their personal values and preferences regarding their quality of life. Patients who are expected to have fecal incontinence should be counseled about having a colostomy for improved bowel management.

As some retrorectal tumors may be hypervascular, preoperative embolization may decrease surgical blood loss. Ensuring availability of blood products for possible transfusion is also important.

The final important aspect of surgical planning is assembling the necessary surgical team members. Interventional radiologists may be needed for preoperative embolization. Urology may be needed to place ureteric stents. General or colorectal surgeons may be needed to mobilize the rectum off the tumor and often work with neurosurgeons or orthopedic surgeons for the tumor resection, especially when sacrectomy is necessary. Plastic surgeons may be required for reconstruction of the resultant soft tissue defect. The operating room staff needs to be aware of the various steps in the case including changes in surgical teams and repositioning needs. These cases often will take many hours, so it is ideal for these complex and high-risk cases to start early in the morning.

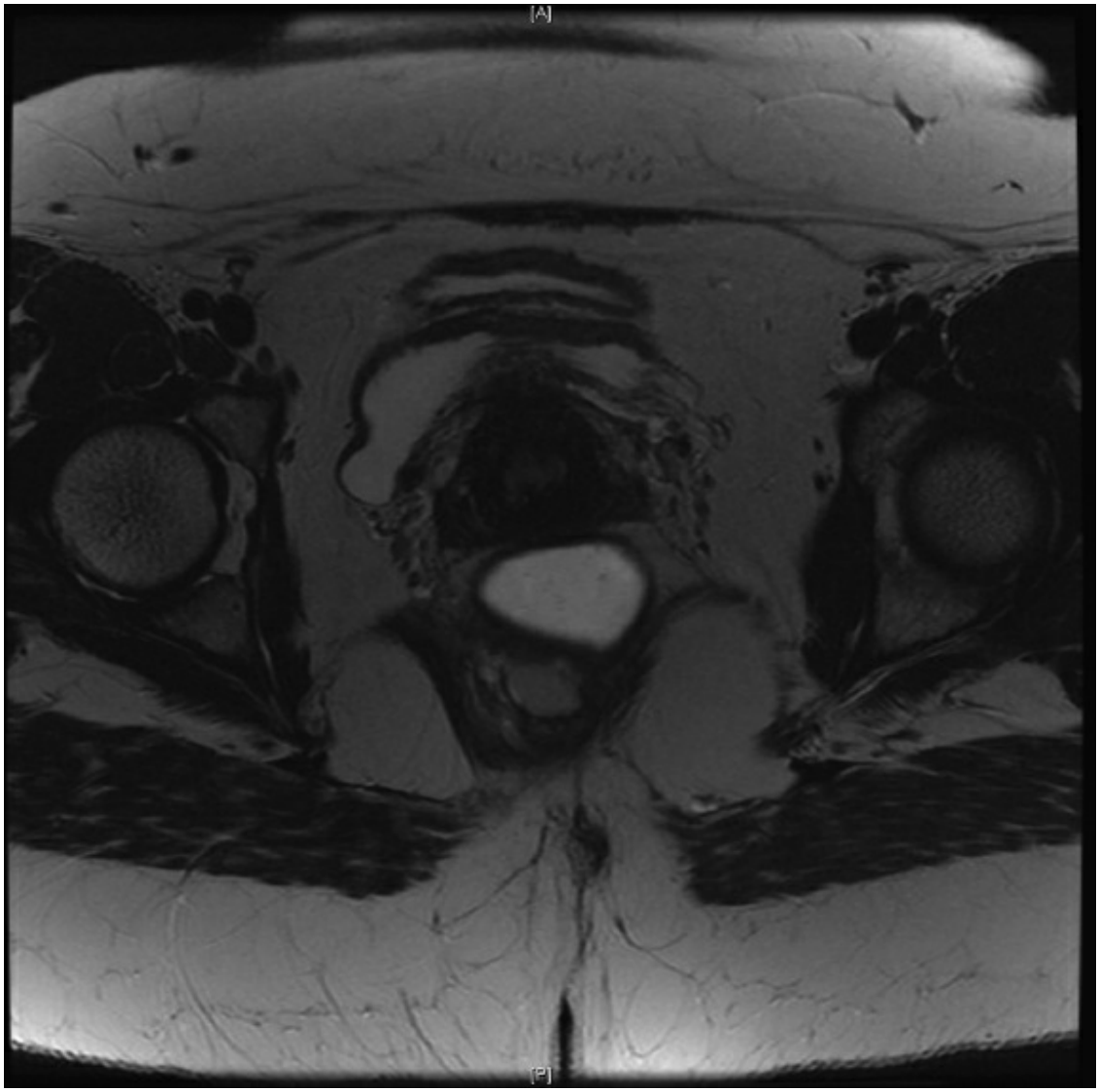

Figure 161.5. Tailgut cyst. MRI demonstrates a thin-walled lesion that is hyperintense on T2-weighted images.

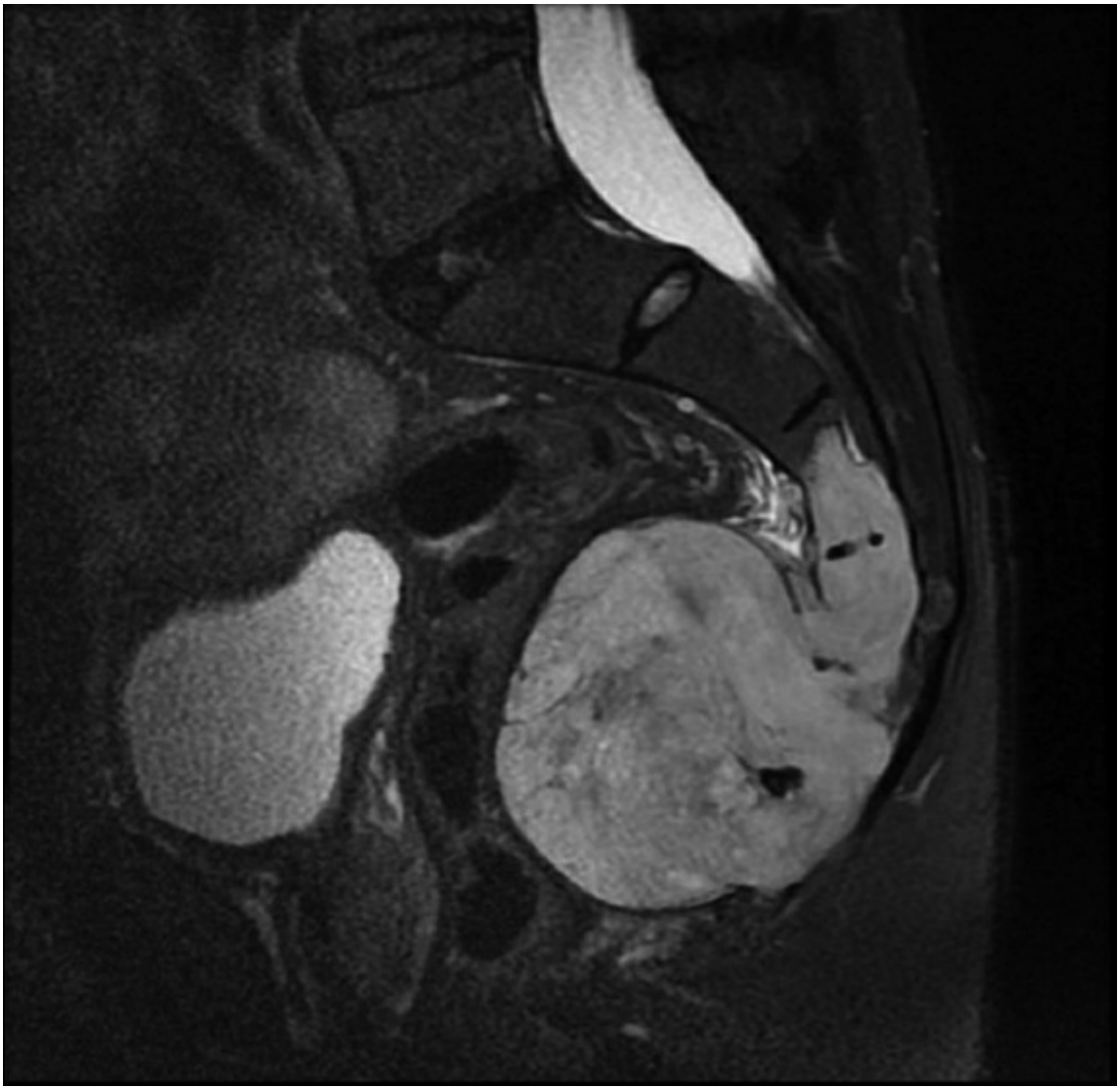

Figure 161.6. Sacral chordoma. MRI is ideal for surgical planning, and demonstrates a heterogeneous mass with destruction of the sacrum.

SURGICAL TECHNIQUE

There are three options for the surgical approach: posterior approach, anterior approach, and combined anterior and posterior approach.

Posterior Approach

The posterior approach can be used for more caudal tumors that are at or inferior to S3 and do not involve the pelvic viscera or pelvic sidewalls. Most tailgut cysts are amenable to this approach, although some are so large that they require a combined anterior and posterior approach. The patient is placed in the prone jack-knife position and the table is flexed. The buttocks are spread using tape. A self-retaining retractor is helpful for

exposure (Fig. 161.10). A vertical midline incision centered over the coccyx or a parasacrococcygeal incision can be used. If a vertical midline skin incision is made, the anococcygeal ligament is divided to gain access to the retrorectal space, taking care not to violate the tumor capsule or cyst wall. Some surgeons prefer a parasacrococcygeal incision, especially if the tumor is larger or extends cranially, to avoid having to divide the anococcygeal ligament. Insertion of the index finger into the anus and rectum may aid in retraction and exposure, as well as identification of the rectal wall. Sterility of the surgical field can be maintained by using sterile adhesive drapes between the anus and the incision site, and changing the surgeon's glove each time a digital exam is performed. Insertion of a sizer into the rectum can also be helpful for identification of the rectal wall. Tailgut cysts should be removed in their entirety to prevent future recurrences and malignant transformation. Complete cyst excision may require distal sacrectomy or coccygectomy; some surgeons routinely perform coccygectomy during tailgut cyst excision because of the possibility that the coccyx is the source of totipotent cells that may lead to recurrence of the cyst if not removed. An associated fistula to the rectum may be present and require rectal wall repair. This is suspected when there have been prior procedures performed for incision and drainage of perianal abscesses, or if the cyst has been secondarily infected (Figs. 161.11 and 161.12).

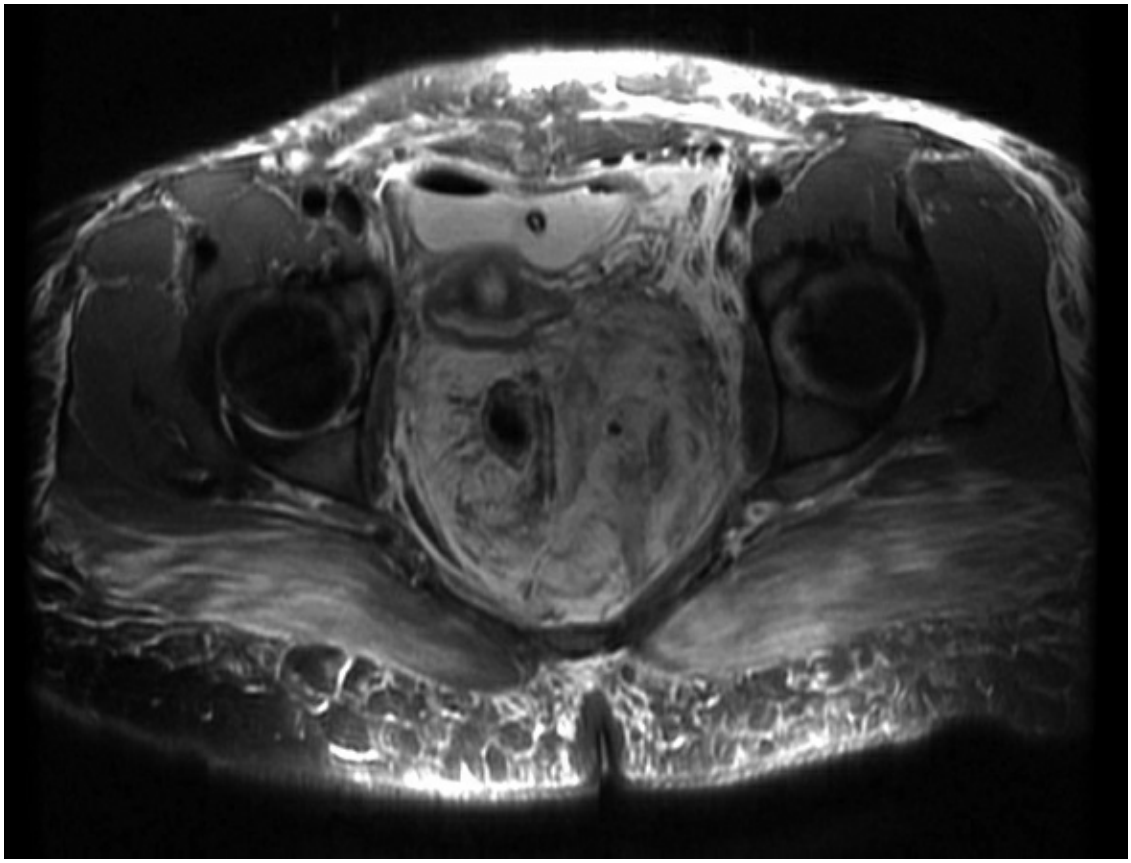

Figure 161.7. T2-weighted images of ganglioneuroma show a hyperintense heterogeneous mass.

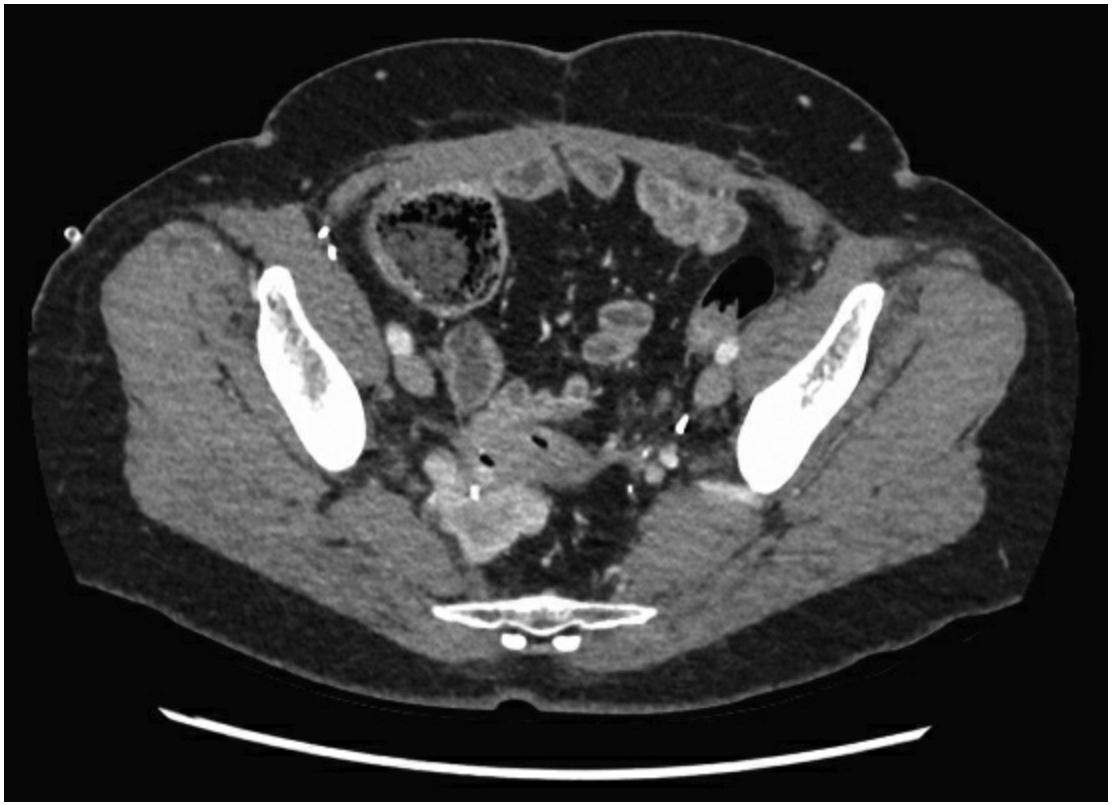

Figure 161.8. This patient had recurrent pelvic leiomyosarcoma

that involved the rectal wall and required redo low anterior resection. CT images demonstrate an enhancing heterogeneous multilobulated tumor with cystic necrotic areas.

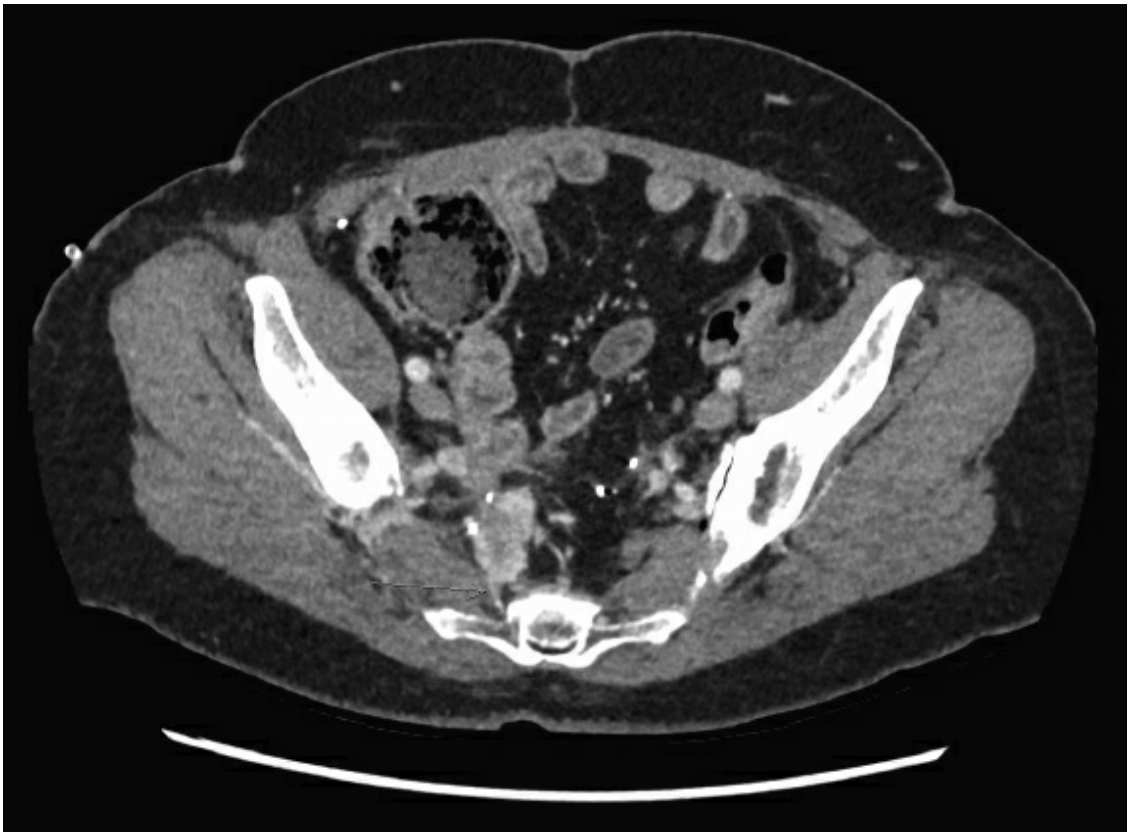

Figure 161.9. This patient had recurrent pelvic leiomyosarcoma that involved the rectal wall and required redo low anterior resection. CT images demonstrate an enhancing heterogeneous multilobulated tumor with cystic necrotic areas.



Figure 161.10. Most tailgut cysts are amenable to resection via a posterior approach.

For distal tumors such as chordomas that directly involve S4 and S5, the origins of the gluteal muscles and sacrotuberous and sacrospinous ligaments will need to be divided to facilitate dissection and division of the sacrum and en bloc resection of the tumor. Dissection around the tumor anteriorly requires recognition of the fascia propria of the rectum anterior to the tumor in order to remain in the right plane. Closure of the posterior defect may require reconstruction with bilateral gluteal flaps, depending on

the extent of sacrectomy.

Anterior Approach

The anterior approach is appropriate for retrorectal tumors that do not require sacrectomy, and which may involve pelvic viscera and the pelvic sidewall structures. The patient is placed in a modified Lloyd-Davies position or a split-leg position (Fig. 161.13). Placement of bilateral ureteric stents may be helpful as the anatomy may be distorted from the tumor. The open anterior approach is performed with a vertical midline incision. The ureters and iliac vessels are identified. One must then determine whether the tumor is involving the rectum or other pelvic organs.

If the tumor is not involving the rectum directly, then the next step is to open the presacral space by incising the peritoneum just posterior to the superior rectal artery. The dissection in the presacral space is continued inferiorly to the pelvic floor, and the peritoneal layer on either side of the rectum is divided to mobilize the rectum completely off the tumor (Figs. 161.14 and 161.15). During this dissection, it is important to remember that the retrorectal tumor distorts the normal contour of the sacrum, and the plane of dissection will be more anterior than usual. Once the rectum is mobilized off the tumor, it is retracted anteriorly and the tumor can then be resected.

The extent of resection depends on which structures are directly involved by the tumor, and whether the tumor is benign or malignant. Nerve-sparing techniques for benign retrorectal neurogenic tumors may preserve function and minimize postoperative morbidity. Intraoperative nerve monitoring decreases the risk of a postoperative motor deficit. In the case of a large presacral ganglioneuroma, complete resection with division of nerve roots causes excessive morbidity for a slow-growing benign tumor. An anterior approach can be employed in which the general or colorectal surgeon mobilizes the rectum away from the tumor, and the neurosurgeons debulk the tumor with the aid of intraoperative neurologic monitoring. Intralesional debulking improves the exposure and allows for identification of nerve roots, so that that capsule may be dissected out as well; however, if the capsule is densely adherent to functional nerve roots, it can be left in place rather than risk neurologic dysfunction (Fig. 161.16). While an anterior intraperitoneal approach via a midline laparotomy is ideal for midline low pelvic tumors, an anterolateral retroperitoneal approach may be used for retrorectal ganglioneuromas that are located

higher and lateral in the pelvis.



Figure 161.11. This patient presented after having undergone incision and drainage of what was thought to be a perianal abscess. She actually had a tailgut cyst that became infected as a result of the first procedure.

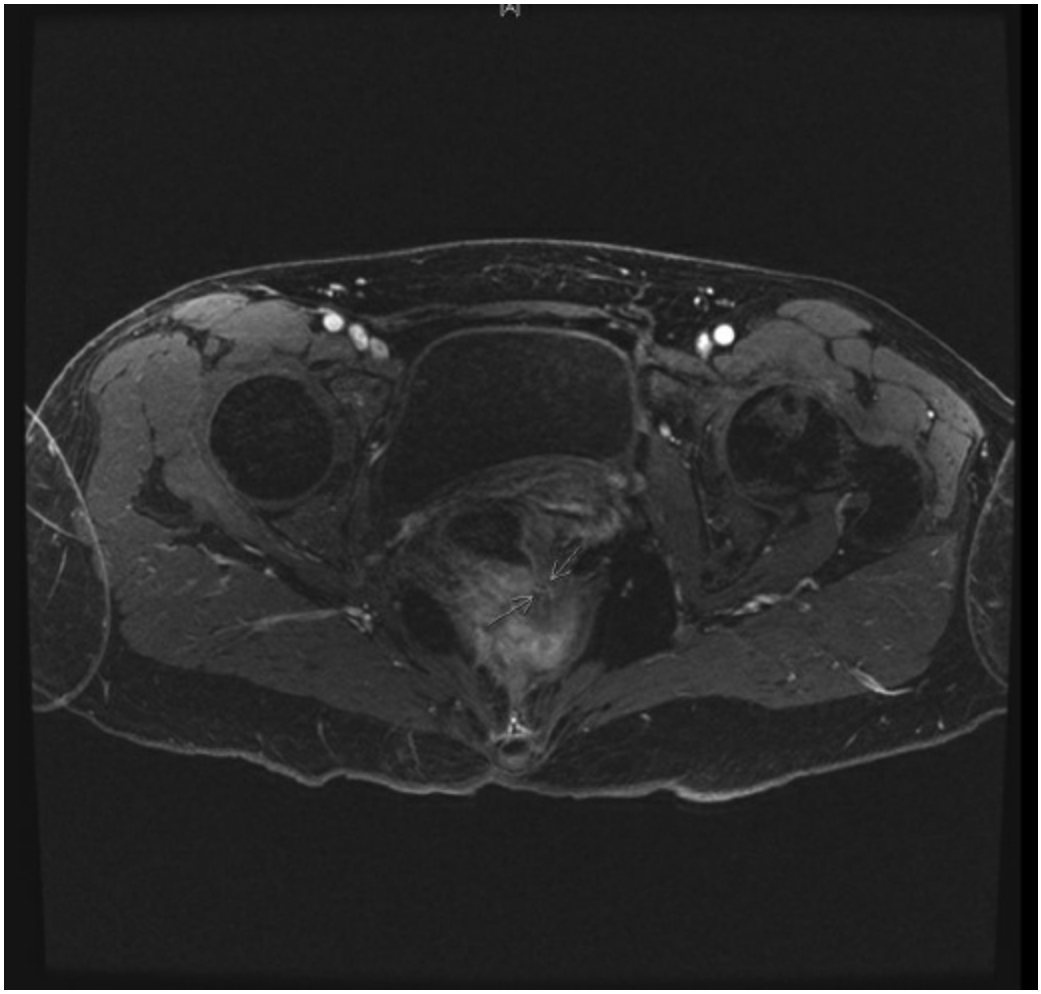

Figure 161.12. This patient underwent drainage of what was thought to be a perianal abscess. The cyst was drained through the rectal wall, resulting in a chronic fistula.

For patients who do not require sacrectomy, but do require rectal resection to remove the retrorectal tumor, often a low pelvic anastomosis is required. Because of the high risk of anastomotic leak associated with these low anastomoses, diverting loop ileostomy is recommended to ameliorate the septic complications in the event of a leak.



Figure 161.13. For the anterior approach, the patient is placed in modified Lloyd-Davies position. This allows for proctoscopic examination of the rectum to ensure no rectal injury during mobilization. This also allows for rectal resection and re-anastomosis or abdominoperineal resection if the tumor directly involves the rectum.

Combined Anterior and Posterior Approach

A combined anterior and posterior approach is necessary if the tumor involves the sacrum and requires sacrectomy, and there is potential involvement of pelvic viscera. Even without direct involvement of the pelvic viscera, tumors that extend proximal to S3 should be managed via a combined approach. The general or colorectal surgeons start with the laparotomy, or via a minimally invasive fashion. Laparoscopic port sites for rectal mobilization include a supraumbilical port and bilateral upper and lower quadrant ports (Fig. 161.17). The authors have found that robotic mobilization offers excellent views of the pelvis, especially in a small space that is largely occupied by an anteriorly bulging tumor. If only rectal mobilization is needed, then the robot should be positioned between the legs so that the arms are targeted toward the pelvis (Fig. 161.18). If proctectomy with mobilization of the left colon and splenic flexure is required, then the robot should be positioned on the patient's left side such that the arms are targeted toward the left lower quadrant (Fig. 161.19). The presacral space is opened by incising the peritoneum just posterior to the superior rectal artery, and continuing that dissection sharply to the pelvic

floor. The lateral peritoneal attachments are incised to mobilize the rectum completely off the tumor. Some surgical teams may elect to place a laparotomy sponge between the rectum and the tumor to serve as a marker for the posterior approach. If only rectal mobilization is performed, a proctoscopy with insufflation is performed to confirm that there is no rectal injury.

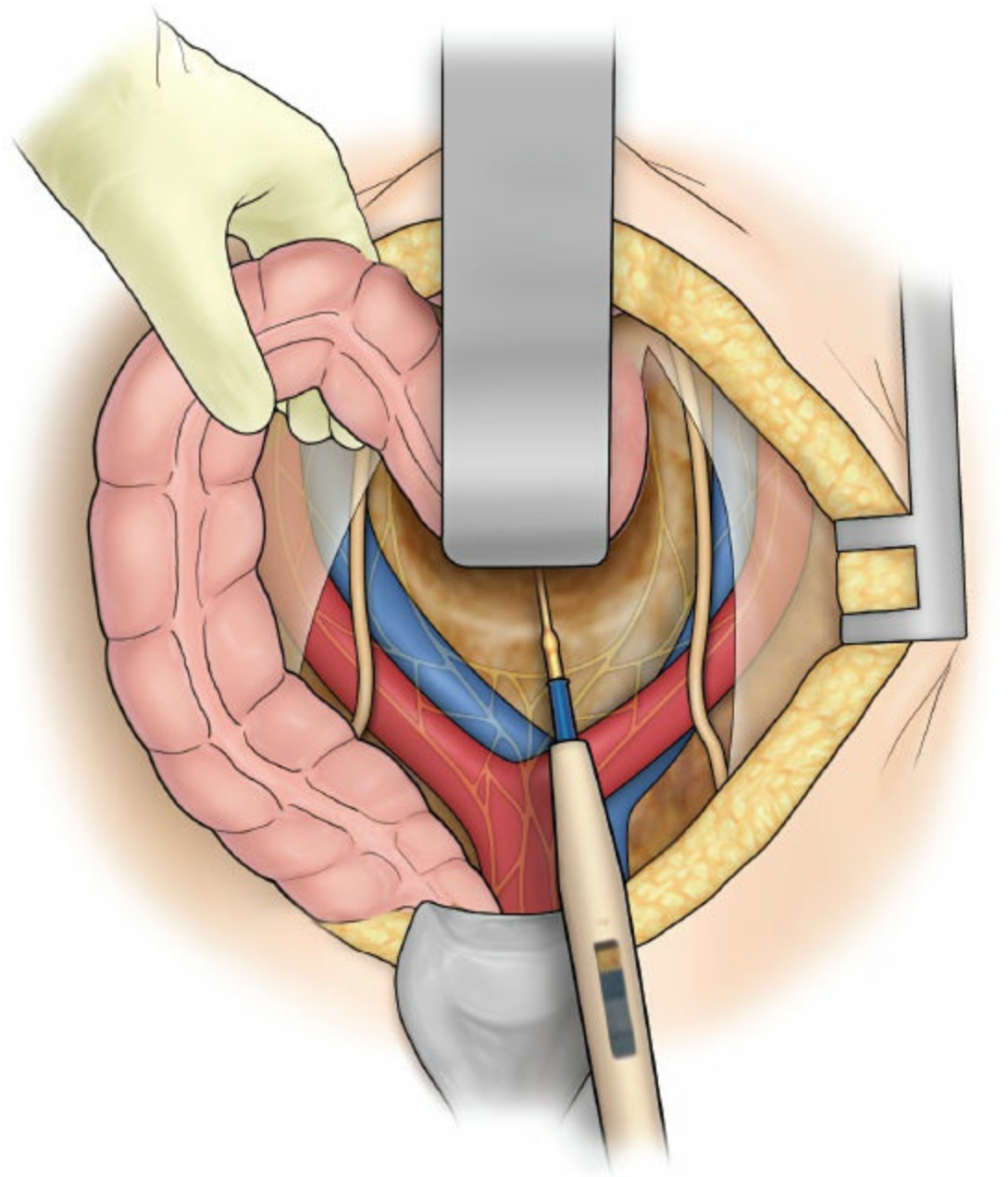

Figure 161.14. Sharp dissection in the avascular plane of the presacral space is performed down to the pelvic floor.

After the rectal mobilization or resection, and closure of the abdominal incision, the patient is then repositioned in prone position and the

sacrococcygectomy with en bloc tumor resection is performed. Intraoperative neurologic monitoring is needed if resection involves dissection around or of the nerve roots. The anesthesiologists need to be aware of this so that they do not administer additional paralytic agents. In cases where a substantial portion of the sacrum is removed, reconstruction with bilateral gluteal muscle flaps may be necessary.

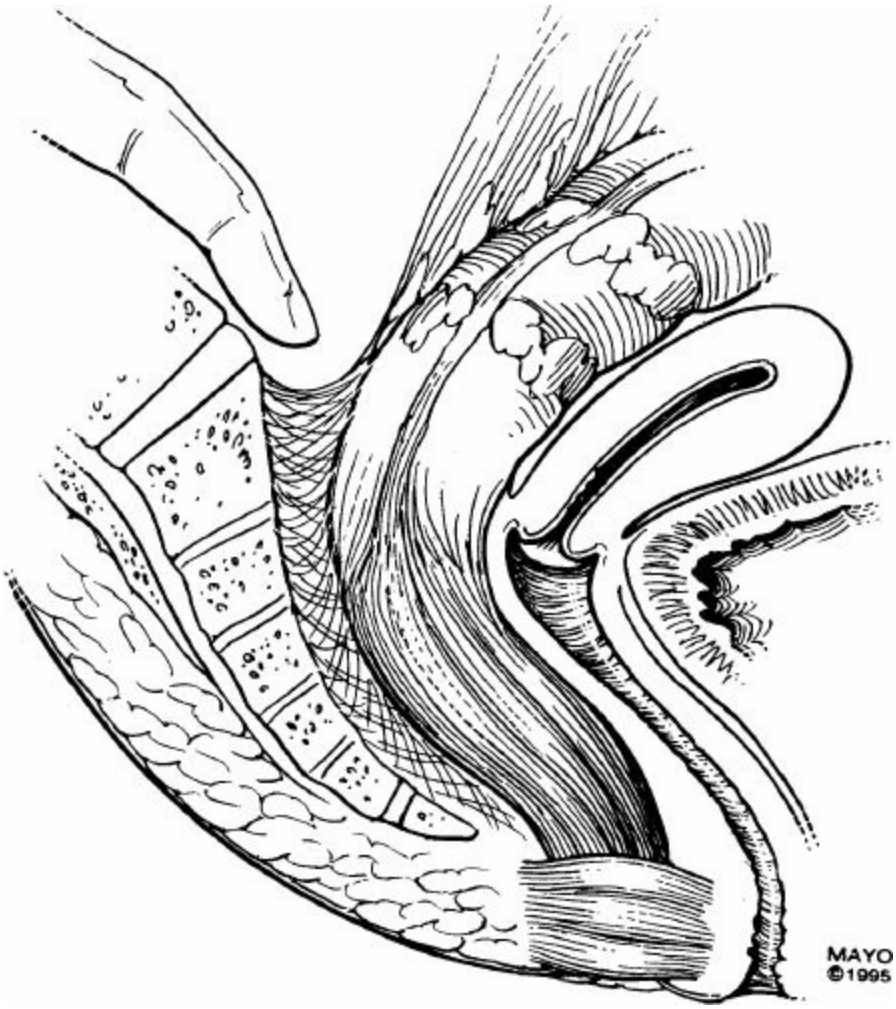

Figure 161.15. The presacral space is entered by retracting the upper rectum anteriorly and incising the peritoneum just posterior to the superior rectal artery.

POSTOPERATIVE CARE

Patients who undergo a posterior surgical approach for tumors like tailgut cysts that do not involve the sacrum have relatively fewer postoperative needs. They can often go home the day of or the day after surgery. Patients who undergo more extensive resections involving sacrectomy have varying postoperative needs depending on the extent of the resection and

any neurologic deficits. Patients who require flaps to cover large defects will often have activity and positional restrictions in order to prevent placing undue pressure on the new myocutaneous flap. Patients who undergo an anterior (laparotomy) approach and mobilization of the rectum off the tumor may experience postoperative ileus.

The need for follow-up imaging and the frequency of follow-up examinations vary depending on the likelihood of recurrence. Tailgut cysts do not warrant follow-up imaging unless malignant degeneration is found. Presacral ganglioneuromas, while benign, should have regular follow-up for at least a year after resection in order to diagnose a potential recurrence, although there are no guidelines for time interval owing to the rarity of this tumor. Malignant tumors require more frequent follow-up to monitor for recurrence.

COMPLICATIONS AND THEIR MANAGEMENT

Complications of tailgut cyst excision include delayed wound healing and pelvic floor dysfunction. Patients who only require a posterior approach for excision are less likely to have postoperative complications than those who require an anterior and posterior approach or those who require sacrectomy.

Patients who undergo sacrectomy are also at risk for wound complications, and also sacral insufficiency fractures. Sacral insufficiency fractures occur in 76% of patients who undergo high-dose radiation for sacral chordomas followed by high sacrectomy, but in no patients who undergo low sacrectomy after high-dose radiation have these fractures. Wound complications including surgical site infection with or without wound dehiscence may occur in up to 30% of patients undergoing sacrectomy for sacral tumors even in highly specialized centers. Risk factors include prior radiation therapy, rectal laceration, larger tumor size, longer operative time, cerebrospinal fluid leakage, history of diabetes, and instrumentation. Other risk factors include prior lumbosacral operations, number of surgeons involved in the case, bowel and bladder dysfunction, and complex soft tissue reconstruction.

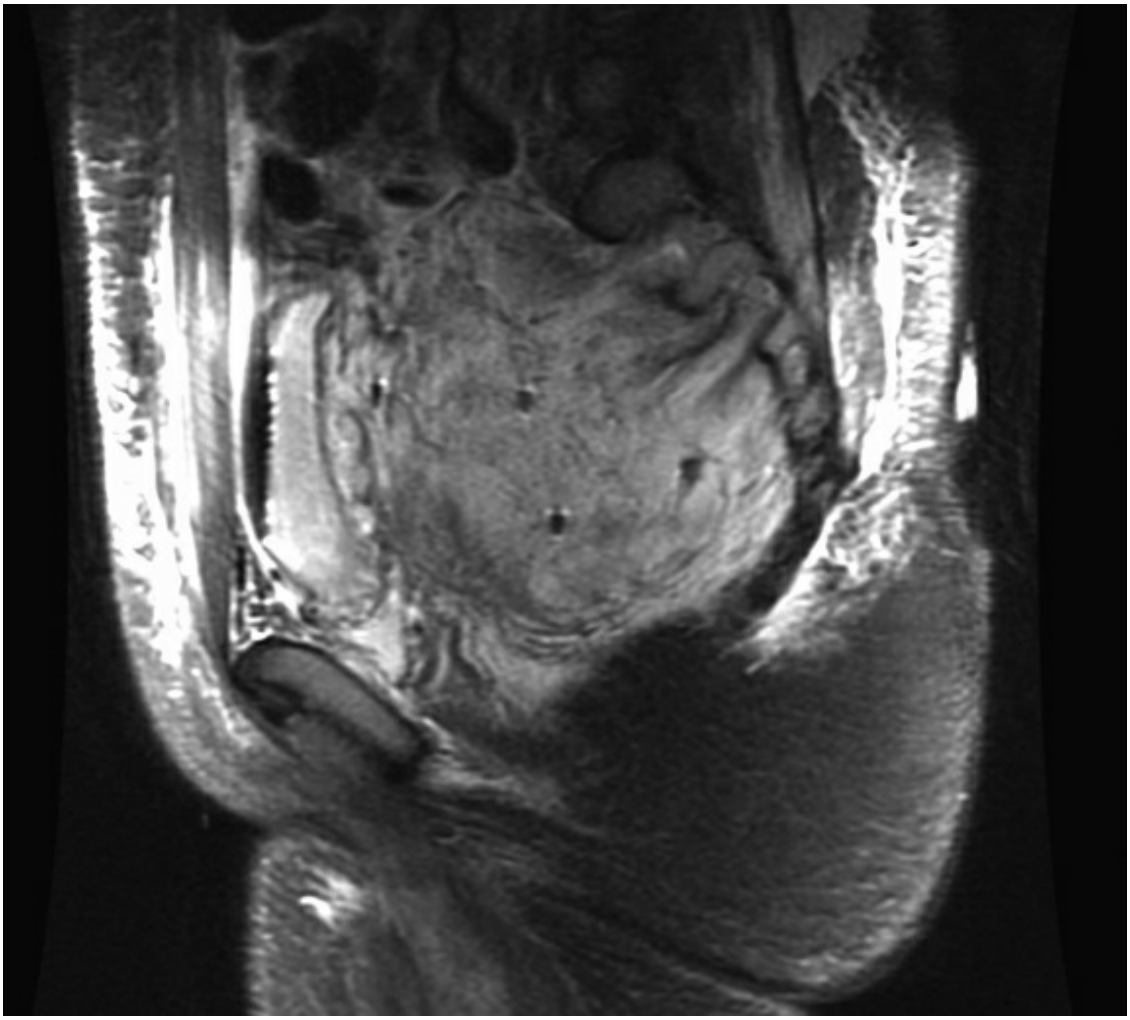

Figure 161.16. Given the benign and slow-growing nature of this ganglioneuroma that involves multiple nerve roots, complete resection of the tumor capsule is not indicated as it would cause significant neurologic deficits.

Anastomotic leak after low anterior resection for retrorectal tumors involving the rectum may occur, and management is dictated by the clinical severity of the anastomotic leak. Minor leaks may be managed with antibiotics and percutaneous drainage, while major leaks may require return to the operating room with proximal diversion or takedown of the anastomosis and creation of an end colostomy.

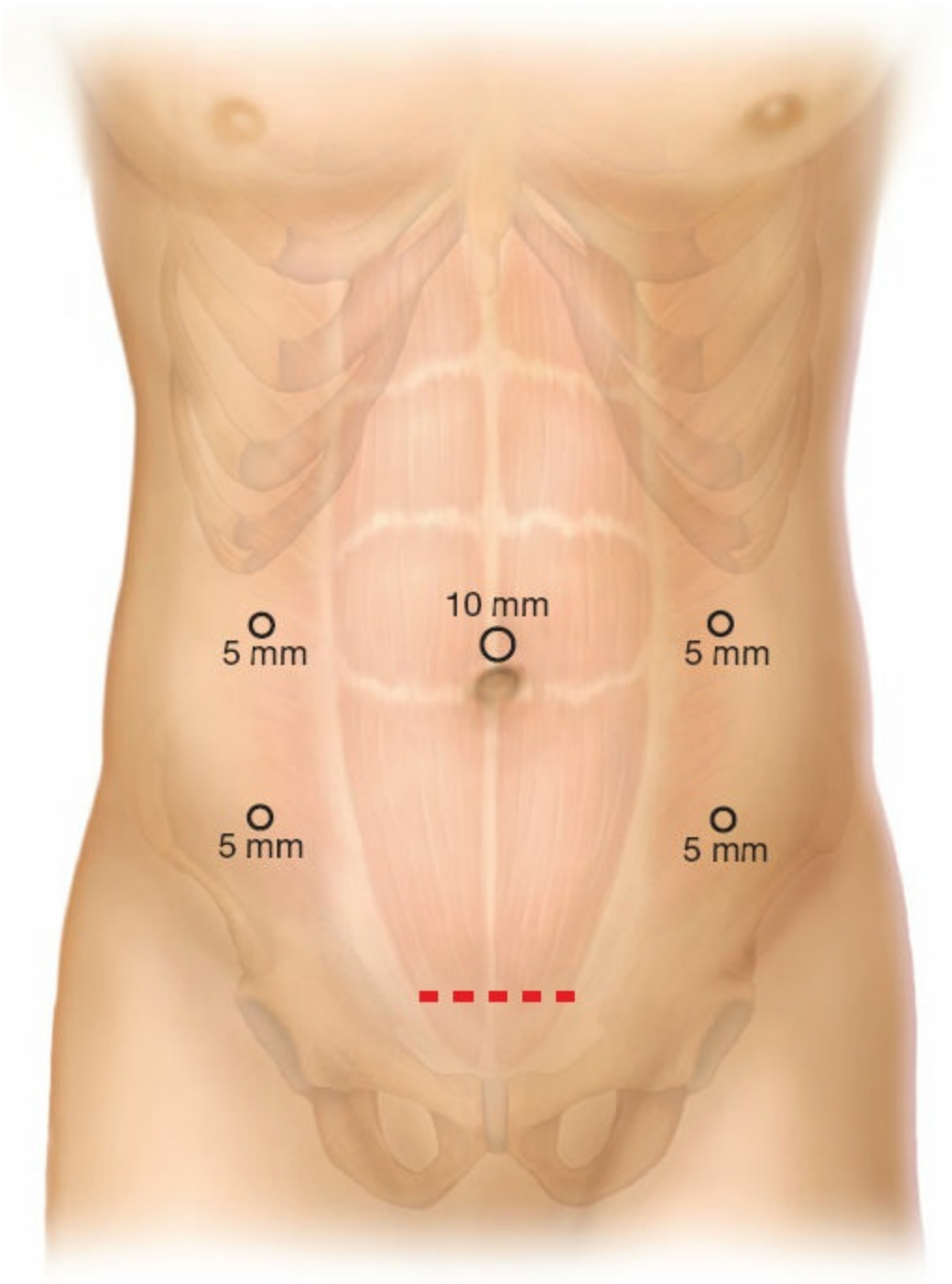

Figure 161.17. Port sites for laparoscopic rectal mobilization or resection.

Chronic pain may occur if there is intraoperative manipulation of the nerve plexuses.

OUTCOMES

The 5-year disease-free survival for benign and malignant retrorectal lesions is 93% and 75%, respectively. The recurrence rate after tailgut cyst

excision ranges from 0% to 16% in multiple small case series.

Overall 5-year survival for all patients with sacral chordoma is 60% based on SEER data, regardless of treatment modality. Patients who undergo surgical resection alone have 82% 5-year overall survival, and those who undergo both surgical resection and radiation have 78% 5-year overall survival. Patients who were treated only with radiation had a 52% 5-year overall survival. This probably reflects the nature of the tumor and resectability; that is, patients with resectable tumors were more likely to undergo surgical intervention and therefore have higher survival rates. Patients with negative surgical margins have a higher 5-year survival than those with a positive surgical margin (86% vs. 67%). Local recurrence occurs in 40% to 46% of patients. Risk factors for tumor recurrence include positive surgical margin and proximal tumor extent.

Patient-reported outcomes among patients undergoing sacrectomy depend on the level of sacral resection. Patients with more caudal resections have better overall physical health, less pain, less interference resulting from pain, better mobility, and better sexual function than those who underwent higher sacrectomies. Postoperative motor, bladder, and bowel function correlates with the level of sacral nerve preservation. Motor function depends on preservation of L5 and S1 nerve roots. Patients with bilateral S1 nerve resection had impaired plantar flexion but were able to walk with support; 56% of patients with bilateral S2 preservation are able to walk normally and 94% of patients with bilateral S3 preservation, and 100% of patients with more distal resections. Patients with bilateral S2 resection had lower scores for bladder function than those with bilateral S3 resection. Normal bladder function occurs in 25% in patients who have preservation of one S2 nerve root, 40% of patients who have preservation of both S2 nerve roots, 73% of patients with preservation of one S3 nerve root, and 83% of patients with preservation of both S3 nerve roots. Patients with bilateral S3 nerve preservation have a lower incidence of urinary leakage and better bladder sensation and lower rates of fecal incontinence compared to those with unilateral S3 nerve preservation. Preservation of both S2 nerve roots results in normal bowel function for 50% of patients, while preserving one S3 nerve root or both S3 nerve roots results in normal bowel function in 70% and 94%, respectively. Finally, preservation of just one S4 nerve root results in normal bladder and bowel function in 100% of patients. Patient-reported outcomes with regard to mental health and physical health were lower in

patients who had preservation of the S2 nerve roots compared with those who had S3 preservation. Patients with preservation of the S2 nerve roots had a better orgasm score than those with preservation of the S1 nerve roots. There are no differences found with regard to mental or physical health or pain between patients who underwent sacrectomy with colostomy or without colostomy.

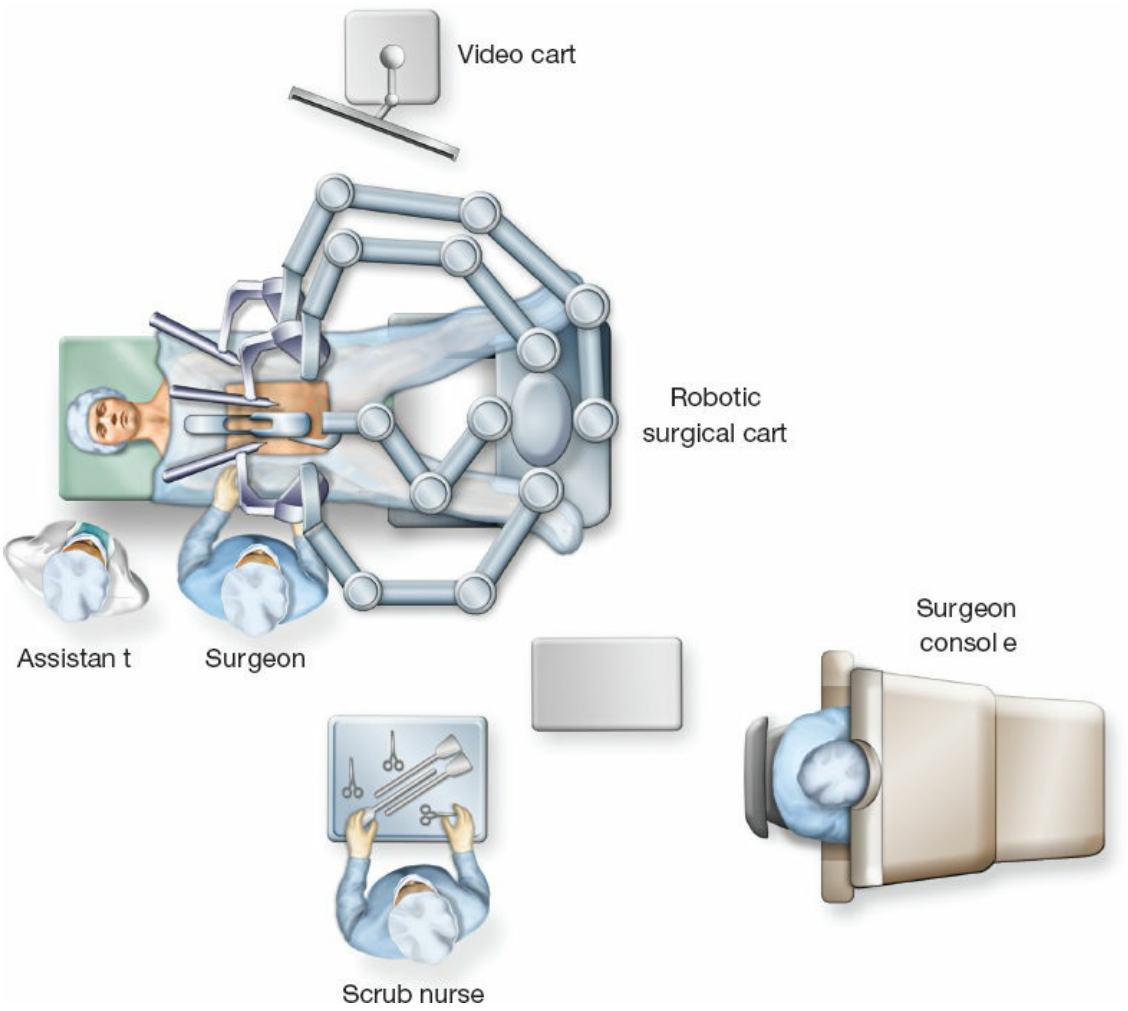

Figure 161.18. Robotic set-up for rectal mobilization.

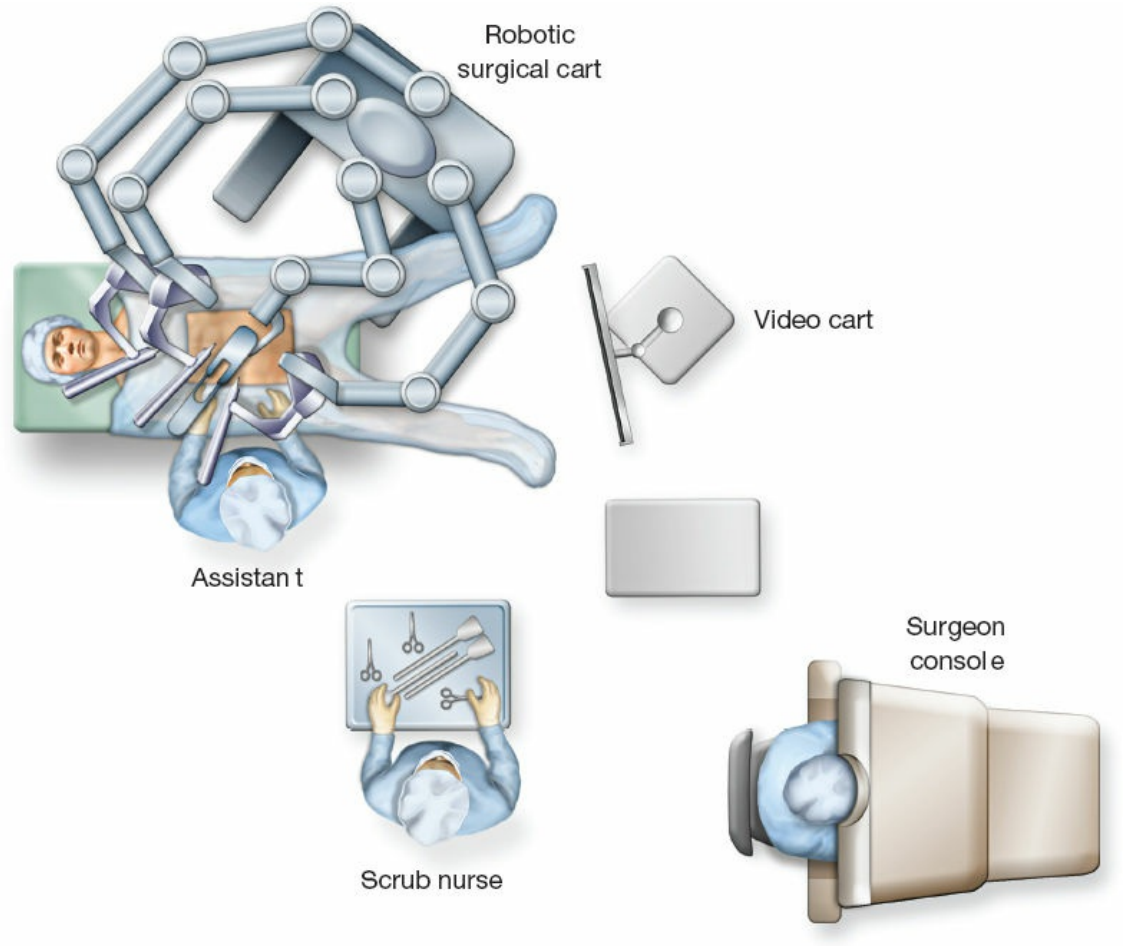

Figure 161.19. Robotic set-up for proctectomy.

SUMMARY

Retrorectal tumors are a heterogeneous group of tumors that require a tailored approach depending on their size, involvement of pelvic structures, malignant potential, and likelihood of recurrence. Preoperative assessment requires high-quality cross-sectional imaging and thorough physical and neurologic examination to assess for anorectal involvement and preoperative neurologic deficits. A thorough discussion of expected outcomes related to quality of life and recurrence risk is necessary. Surgical planning requires attention to the best surgical approach, need for preoperative embolization, involvement of other surgical specialists, and need for intraoperative neuromonitoring.

Suggested Readings

Boscà A, Pous S, Artés MJ, et al. Tumours of the retrorectal space: management and outcome of a heterogeneous group of diseases. *Colorectal Dis* 2012;14(11):1418–23.

Chéreau N, Lefevre JH, Meurette G, et al. Surgical resection of retrorectal tumours in adults: long-term results in 47 patients. *Colorectal Dis* 2013;15(8):e476–82.

Domovitov SV, Chandhanayingyong C, Boland PJ, et al. Conservative surgery in the treatment of giant cell tumor of the sacrum: 35 years' experience. *J Neurosurg Spine* 2015;9(5):1–13.

Hébert-Blouin MN, Sullivan PS, Merchea A, et al. Neurological outcome following resection of benign presacral neurogenic tumors using a nerve-sparing technique. *Dis Colon Rectum* 2013;56(10):1185–93.

Mathis KL, Dozois EJ, Grewal MS, et al. Malignant risk and surgical outcomes of presacral tailgut cysts. *Br J Surg* 2010;97(4):575–9.

Merchea A, Larson DW, Hubner M, et al. The value of preoperative biopsy in the management of solid presacral tumors. *Dis Colon Rectum* 2013;56(6):756–60.

Osler P, Bredella MA, Hess KA, et al. Sacral insufficiency fractures are common after high-dose radiation for sacral chordomas treated with or without surgery. *Clin Orthop Relat Res* 2016;474(3):766–72.

Park HY, Yang SK, Sheppard WL, et al. Current management of aneurysmal bone cysts. *Curr Rev Musculoskelet Med* 2016;9(4):435–44.

Parry MC, Laitinen M, Albergo J, et al. Osteosarcoma of the pelvis. *Bone Joint J* 2016;98-B(4):555–63.

Puri A, Agarwal MG, Shah M, et al. Decision making in primary sacral tumors. *Spine J* 2009;9(5):396–403.

Simpson PJ, Wise KB, Merchea A, et al. Surgical outcomes in adults with benign and malignant sacrococcygeal teratoma: a single-institution experience of 26 cases. *Dis Colon Rectum* 2014;57(7):851–7.

Vardas K, Manganas D, Papadimitriou G, et al. Presacral ganglioneuroma: diagnostic considerations and therapeutic strategy. *Case Rep Oncol* 2013;6(3):561–8.

Yalcinkaya U, Doganavsargil B, Sezak M, et al. Clinical and morphological characteristics of osteoid osteoma and osteoblastoma: a retrospective single-center analysis of 204 patients. *Ann Diagn Pathol* 2014;18(6):319–25.

Yu E, Koffer PP, DiPetrillo TA, et al. Incidence, treatment, and survival patterns for sacral chordoma in the United States, 1974–2011. *Front Oncol* 2016;6:203.

Zoccali C, Skoch J, Patel AS, et al. Residual neurological function after sacral root resection during en-bloc sacrectomy: a systematic review. *Eur Spine J* 2016;25(12):3925–31.



EDITOR'S COMMENT

Drs. Kin and Welton describe the differential diagnosis, evaluation, and treatment of extremely uncommon retrorectal tumors. Knowledge of their symptoms and differential diagnosis is nonetheless important. Presacral space tumors can have a single or multi-tissue origin from osseous, mesenchymal, or neural tissues (Patel N, Maturen KE, Kaza RK, et al. Imaging of presacral masses—a multidisciplinary approach. *Br J Radiol* 2016;89(1061):20150698). While some of these cause symptoms, many are discovered as incidental findings during imaging performed for other conditions. The majority of presacral tumors are benign, and most patients middle-aged women (Toh JW, Morgan M. Management approach and surgical strategies for retrorectal tumours: a systematic review. *Colorectal Dis* 2016;18(4):337–50). Surgery is generally indicated even in benign conditions due to the risk of malignant change and symptom progression.

Preoperative planning is essential and the availability of magnetic resonance imaging has greatly facilitated the identification of bone involvement, as well as facilitating the differentiation between benign, inflammatory, and malignant lesions (Patel N, Maturen KE, Kaza RK, et al. Imaging of presacral masses—a multidisciplinary approach. *Br J Radiol* 2016;89(1061):20150698). I refer readers to the excellent review "MR imaging of the retrorectal-presacral tumors" (Hosseini-Nik H, Hosseinzadeh K, Bhayana R, et al. MR imaging of the retrorectal-presacral tumors: an algorithmic approach. *Abdom Imaging* 2015;40(7):2630–44).

There has been some change in the philosophy regarding biopsy of solid lesions. While this was formerly discouraged, in many series biopsies of solid tumors are now felt to be safe and useful for guiding treatment decisions. This is true particularly for presacral tumors arising from bone where the appearance on imaging is often not specific enough for diagnosis (Patel N, Maturen KE, Kaza RK, et al. Imaging of presacral masses—a multidisciplinary approach. *Br J Radiol* 2016;89(1061):20150698). In addition, lesions such as Ewing sarcoma and osteosarcoma, among others, could benefit from neoadjuvant therapy. The diagnosis is not established without biopsy. More detail can be found in a systematic review on retrorectal tumors by Toh and Morgan (Toh JW, Morgan M. Management approach and surgical strategies for retrorectal tumours: a systematic review. *Colorectal Dis* 2016;18(4):337–50).

As the authors discuss in their chapter, because of the location of these lesions in the presacral area, any discussion of surgery needs to include a frank, honest discussion of complications such as possible fecal or bladder incontinence with the patient. Typically the S3 nerve root must be preserved at least on one side to maintain bladder and bowel continence. The authors very nicely describe different scenarios of nerve root preservation with respect to the likelihood of retaining bowel and bladder function.

With the increasing refinement and skill of minimally invasive surgery and surgeons, minimally invasive procedures to address these lesions have been described (Nedelcu M, Andreica A, Skalli M, et al. Laparoscopic approach for

retrorectal tumors. *Surg Endosc* 2013;27(11):4177–83). In one series describing nine patients with presacral tumors treated laparoscopically, no lesion was below S4 and the one case that was converted to open involved a large (7.5 cm) schwannoma.

Similar to rectal cancer surgery, there is a high risk of local recurrence. In one large multicenter series of 62 patients with retrorectal tumors, which excluded osseous lesions, 9 patients developed recurrence (14.5%) (Buchs NC, Gosselink MP, Scarpa CR, et al. A multicenter experience with peri-rectal tumors: the risk of local recurrence. *Eur J Surg Oncol* 2016;42(6):817–22). Five of the nine recurrences occurred following treatment of malignant lesions. Most of these patients were asymptomatic, but a palpable mass was present on digital rectal examination. Forty-four percent of patients with recurrence had an R1 resection of the initial tumor, while the remainder had an R0 resection.

These operations are typically multidisciplinary efforts often with the aid of an orthopedic or neurosurgeon and, in some cases, plastic surgeon. Sacrectomy can be associated with formidable blood loss, and not every operating room may be equipped to deal with this. Intraoperative changes in patient position from supine to prone can also pose challenges to anesthesia. In areas where adequate support is not available, serious consideration should be given to referring these patients to centers where such expertise and facilities are available as these are not urgent procedures and this is in the patient's best interest.

Susan Galandiuk

162 Rectal Prolapse: The Open Abdominal Approach

Philip H. Gordon

Complete rectal prolapse is a lifestyle-altering disability that commonly affects older people. Rectal prolapse is the protrusion of the full thickness of the rectal wall through the anal sphincter. More than 100 techniques for its repair have been described indicating that none are entirely satisfactory. This chapter presents the current information about the more popularly used techniques in the repair of complete rectal procidentia. Each procedure has advantages and disadvantages. The particular method of repair used by a surgeon depends on his previous training and exposure to a certain technique, which is modified by his own personal experience. The goals of any operation are to control the prolapse, achieve continence, and correct constipation.

ANATOMY AND ETIOLOGY

There are two theories regarding the etiology of rectal procidentia—a sliding hernia through a defect in the pelvic fascia and an intussusception. Cineradiographic studies support the latter belief, that is, that rectal prolapse is the result of intussusception, or infolding of the rectum, usually beginning 6 to 8 cm from the anal verge. However, the factors that cause intussusception are still unknown. Excessive straining at defecation appears to be an important factor in the pathogenesis of rectal prolapse. The anatomic abnormalities commonly found in patients with this condition are the results of prolonged rectal prolapse, and not the cause. Pathological anatomy of patients with rectal procidentia includes a deep cul-de-sac, a redundant sigmoid colon, diastasis of the levator ani muscle, a patulous anal sphincter, and loss of the posterior sacral curve of the rectum and its sacral attachments.

It was once thought that weakness of the pelvic floor muscle was the main cause of rectal prolapse. However, electromyography shows overactive pelvic floor muscle in some patients and weakness in others.

Fecal incontinence in rectal prolapse is the result of neuropathy of the pudendal nerve due to prolonged stretching, and not from mechanical stretching of the external sphincter by the prolapse, as previously believed.

CLINICAL MANIFESTATIONS AND DIAGNOSIS

These patients may present with a wide range of symptoms including mucous leakage into their underwear and around the anus that causes variable degrees of perineal skin irritation. Rectal bleeding is frequently present. Dull perineal pain or pressure and a feeling of incomplete evacuation are common. Difficult defecation is another common feature. By the time the patients seek medical consultation, about 50% of them already have fecal incontinence. In a review of 32 young adults (<30 years), Sun et al. found 41% had chronic psychiatric disease requiring treatment and these patients experienced significantly more constipation than nonpsychiatric patients (83% vs. 50%). All patients in whom rectal prolapse is suspected should be examined while straining on the toilet. The diagnosis of rectal prolapse is easy if the protrusion comes through the anus (Fig. 162.1). Hidden prolapse, in which the intussusception is above the anal canal, can be diagnosed only by defecating proctography (Fig. 162.2). When the prolapse comes to but not through the anus, it can be easily misdiagnosed as mucosal prolapse or prolapsed hemorrhoids, but the latter are characterized by radial folds rather than circular folds.

INDICATIONS FOR OPERATION

Bachoo et al. tried to determine the best choice of operation for rectal procidentia. All randomized or quasirandomized trials of operation in the management of rectal prolapse were sought. The three primary outcome measures were number of patients with recurrent rectal prolapse, and residual mucosal prolapse or fecal incontinence. Eight trials were included with a total of 264 participants. There were no detectable differences in recurrent prolapses between abdominal and perineal approaches, although there was a suggestion that fecal incontinence was less common after abdominal procedures. There were no detectable differences between the methods used for fixation during rectopexy. Division rather than preservation of the lateral ligaments was associated with less recurrent prolapse but more postoperative constipation, although these findings were found in small numbers.

Ideally, the repair should be chosen not only to correct the prolapse but

also to restore defecatory function and improve fecal incontinence. By and large, the major consideration is the patient's general state of health. At present, for the good-risk patient an abdominal approach is still favored. The recommended procedure would be a pelvic fixation in which the rectum is not completely surrounded anteriorly by a synthetic material. However, a resection might be recommended instead of one of the fixation procedures for an individual who has symptomatic diverticular disease or suffers from severe constipation in association with a very redundant colon. Certainly one would hesitate to insert a foreign body in the pelvis in association with the resection.



Figure 162.1. A typical overt rectal prolapse, with circular mucosal folds.

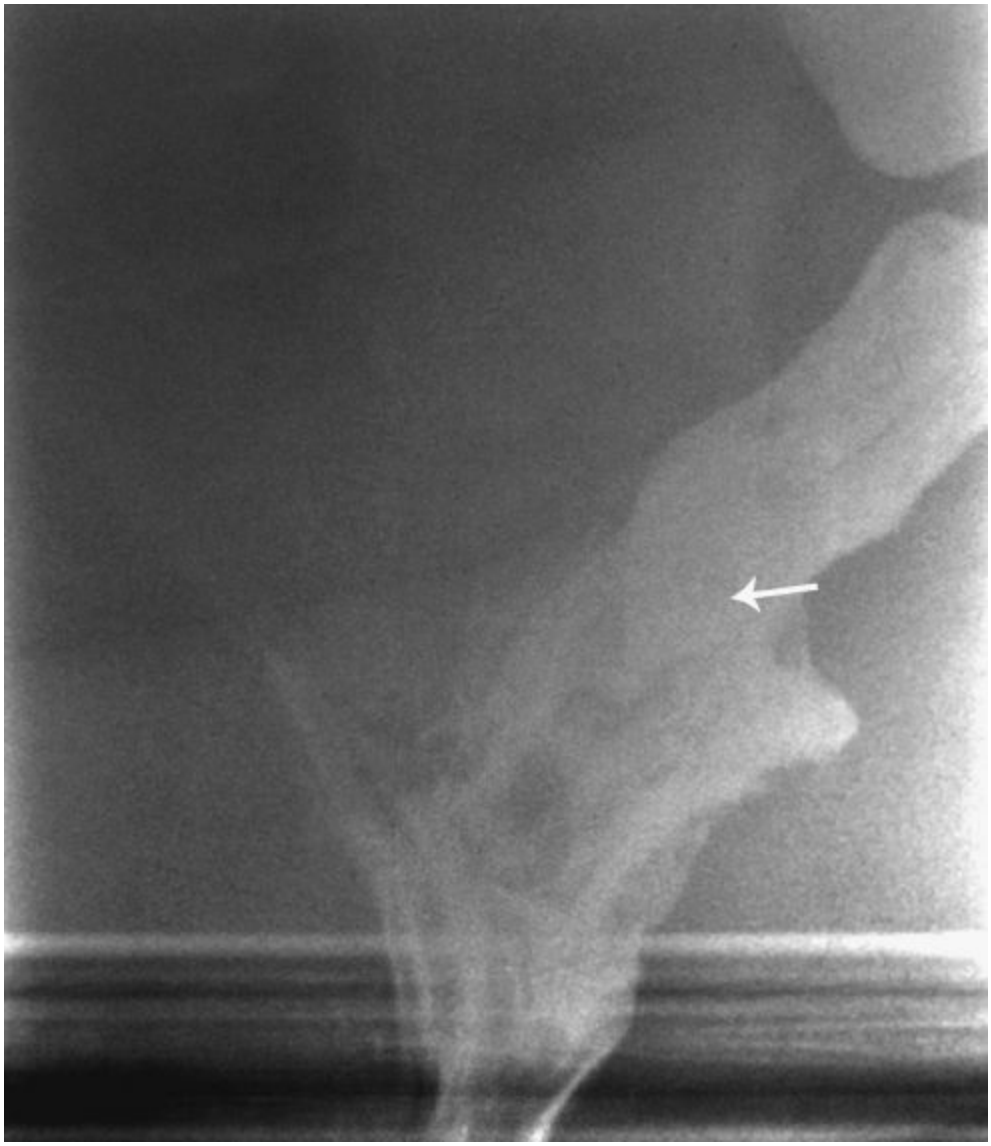

Figure 162.2. Defecating proctogram shows intussusception of the rectum to the upper anal canal (*arrow*).

For poor-risk patients, a perineal approach would be more appropriate, and the Delorme operation or possibly a perineal rectosigmoidectomy (Altemeier procedure) is recommended. For intermediate-risk patients, a perineal rectosigmoidectomy should be considered. For patients confined to a nursing home, amputation of a massive prolapse definitely would facilitate their care.

PREOPERATIVE EVALUATION

All patients with rectal prolapse should at least be examined with a flexible sigmoidoscope to rule out associated abnormalities, especially polyps, cancer, and inflammatory bowel disease. Occasionally, a solitary rectal

ulcer is found. If indicated, a total colonoscopy should be performed. Defecating proctography is indicated if hidden prolapse is suspected.

Anal manometry will not change the surgical approach and is not helpful to predict postoperative functional results. Electromyography and measurement of the pudendal nerve terminal motor latency are useful to confirm the nerve damage to the external anal sphincter and the pelvic floor muscles. Patients with damage to the pudendal nerves usually continue to have fecal incontinence after successful repair of the rectal prolapse.

BOWEL PREPARATION

Despite ongoing controversy, the author continues to prepare patients with a mechanical bowel cleansing. A bowel devoid of stool is easier to handle especially if a resection is anticipated. At present, two sachets of oral Pico-Salex are used the day prior to operation. Antibiotics are also administered preoperatively and our current choice is either cefazolin 2 g intravenous (IV) or piperacillin/tazobactam 4.5 g IV within 1 hour of incision and two postoperative doses q8h. No doubt other options may be equally satisfactory.

WELL'S REPAIR

The anterior mesh sling or Ripstein repair has long been the most popular repair for rectal prolapse in the United States. This technique has been plagued with complications and Ripstein himself abandoned the technique in favor of the posterior sling. The complication rate might be reduced by half if the sling were placed posterior to the rectum leaving the anterior one fourth to one third of the circumference of the rectum free to expand, a principle expounded by Wells.

Ivalon Sponge (Polyvinyl alcohol), a popular material used in the United Kingdom, I understand is not approved by the U.S. Food and Drug Administration. I have successfully used this material for many years. Marlex (polypropylene) and Teflon (polycarbon fluoride) are the most common materials used. Other materials such as Gortex (polytetrafluoroethylene), Prolene (polypropylene, similar to Marlex), and Vicryl (polyglycolic acid) have also been employed. I currently use Parietex—a polyester mesh (Sofradim Production, Trevoux, France).

TECHNIQUE

With the patient in the supine position, after the bladder has been catheterized the skin is prepared with a suitable antiseptic. The abdomen is entered through an infraumbilical transverse incision. With the patient placed in a 20 degree Trendelenburg position, the abdominal viscera are packed away in the upper abdomen with a self-retraining retractor. Dissection is begun by incising the peritoneum on each side of the rectosigmoid, commencing about 5 cm above the pelvic brim (Fig. 162.3). Care is taken to protect the ureters. The presacral space is entered at the level of the sacral promontory, and the rectum is gently mobilized from the sacral hollow (Fig. 162.4). At this point, great care must be taken to ensure that the mesorectum is anterior to the plane of dissection or the intestine may be devascularized and there may be annoying bleeding. At the same time, one should avoid the presacral nerves. Dissection in the presacral plane should be performed with cautery taking care not to injure the rectal wall. Any fibrous bands are cut with scissors or cautery, since tearing will result in troublesome bleeding. Sweeping the hand to each side of the rectum will make the lateral stalks more prominent. The rectum is fully mobilized to the level of the coccyx. Anterior mobilization is begun by continuing the lateral peritoneal incisions distally until they meet in the deepest portion of the cul-de-sac (Fig. 162.5). With the rectum grasped in the left hand, this plane can often be dissected with cautery. Extensive dissection in this plane is not necessary because a deep cul-de-sac is a characteristic anatomic feature in most instances of complete rectal procidentia. The seminal vesicles or vaginal vault is easily reached. The lateral stalks, or at least the upper portion of the lateral stalks on each side, are divided between clamps and ligated. If the rectum is not fully mobilized, redundant rectum remaining below the point of fixation may lead to recurrence of prolapse. Throughout the procedure, meticulous hemostasis is essential since hematoma formation may predispose to infection.

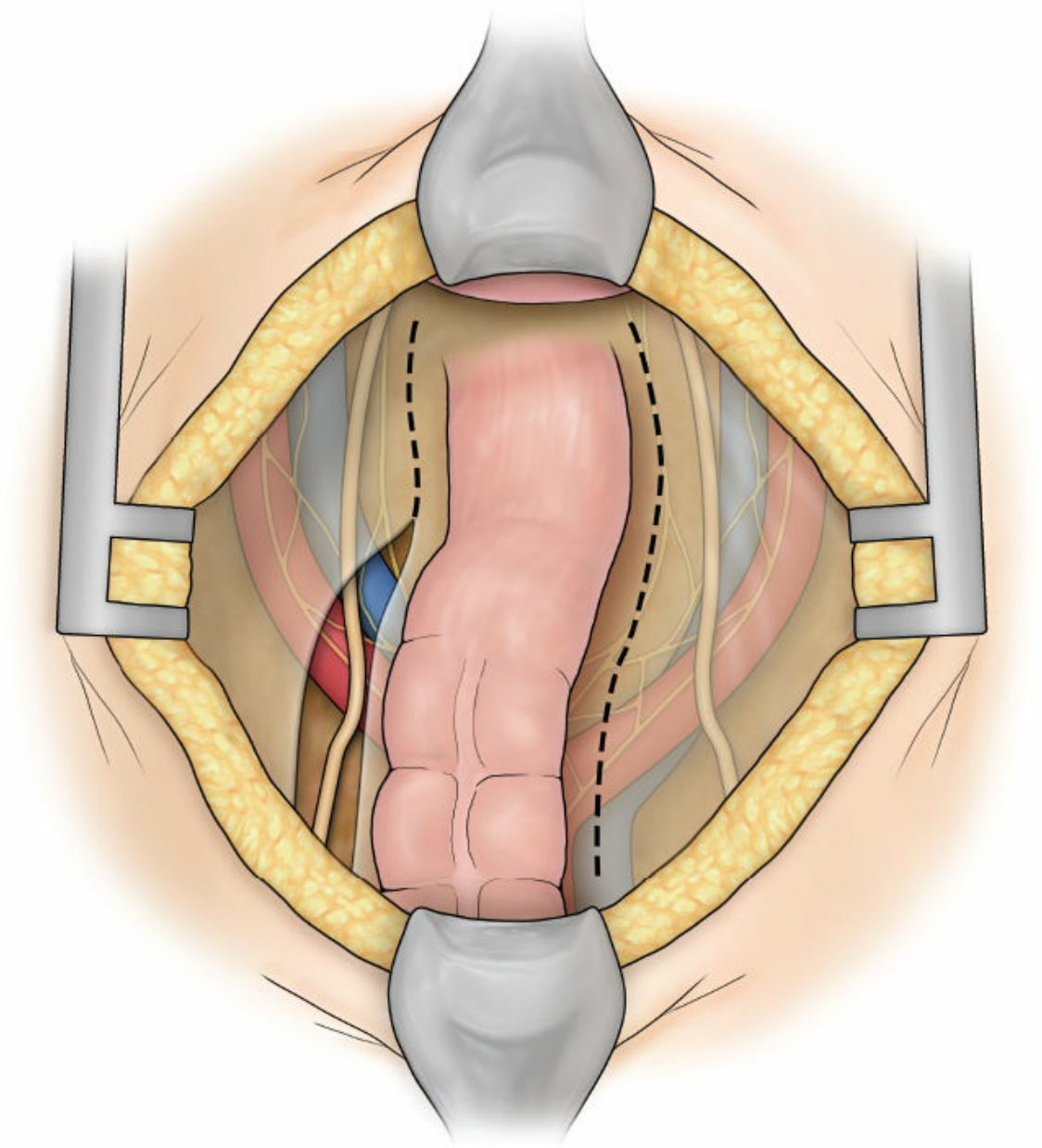

Figure 162.3. Peritoneum incised on both sides of the rectosigmoid, beginning 5 cm above the pelvic brim.

A rectangular sheet of previously sterilized Parietex has three sutures of a nonabsorbable monofilament material such as 00 polypropylene on a noncutting needle pass through the mesh, the presacral fascia, and back through the mesh (Fig. 162.6A). The distal suture should be placed as low as possible deep in the pelvis. The mesh is then "rail-roaded" into the pelvis, and the sutures are tied (Fig. 162.6B).

The mobilized rectum is drawn upward and placed on the front of the mesh sheet, and the lateral extremities of the mesh are folded around to encompass approximately three fourths of the circumference of the rectum.

It is important to leave a portion of the circumference uncovered to prevent constriction of the lumen. Excess mesh is excised. A series of three 000 polypropylene sutures on each side is used to fasten the lateral limbs of the mesh to the anterior aspect of the rectum (Fig. 162.7). Penfold and Hawley point out that care must be taken to ensure that the base of the sigmoid mesocolon is not shortened because this may predispose to sigmoid volvulus. To this end, they recommend the use of a hitch suture. One or two nonabsorbable sutures are inserted between the mesorectum and tissue at the level of the sacral promontory (Fig. 162.8).

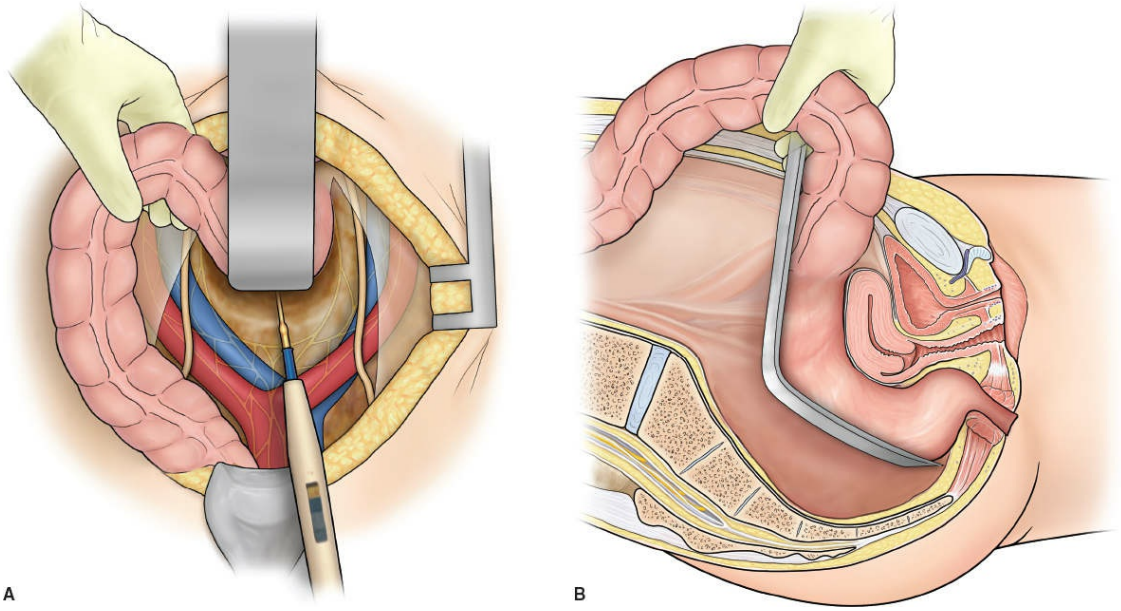

Figure 162.4. A. Mobilization of rectum accomplished by cautery dissection, avoiding presacral plexus of veins. **B.** Sagittal view. Dissection carried down toward tip of coccyx, preserving mesorectum.

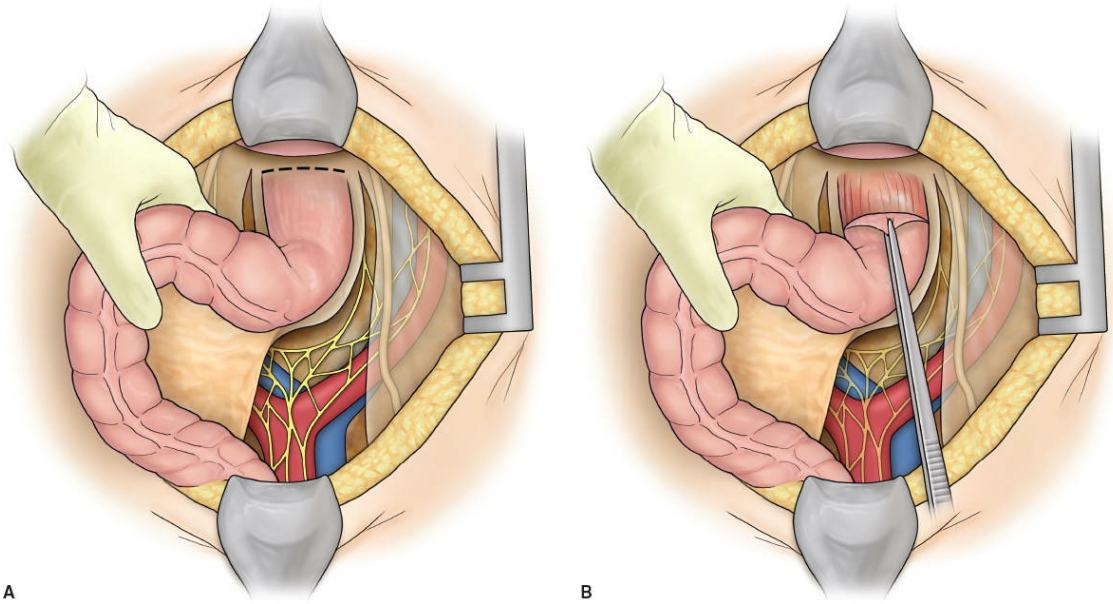

Figure 162.5. **A.** Lateral incisions joined in anterior cul-de-sac. Presacral neural plexus should be left intact. **B.** Sharp dissection frees anterior rectal wall. Peritoneum of anterior cul-de-sac is retracted superiorly.

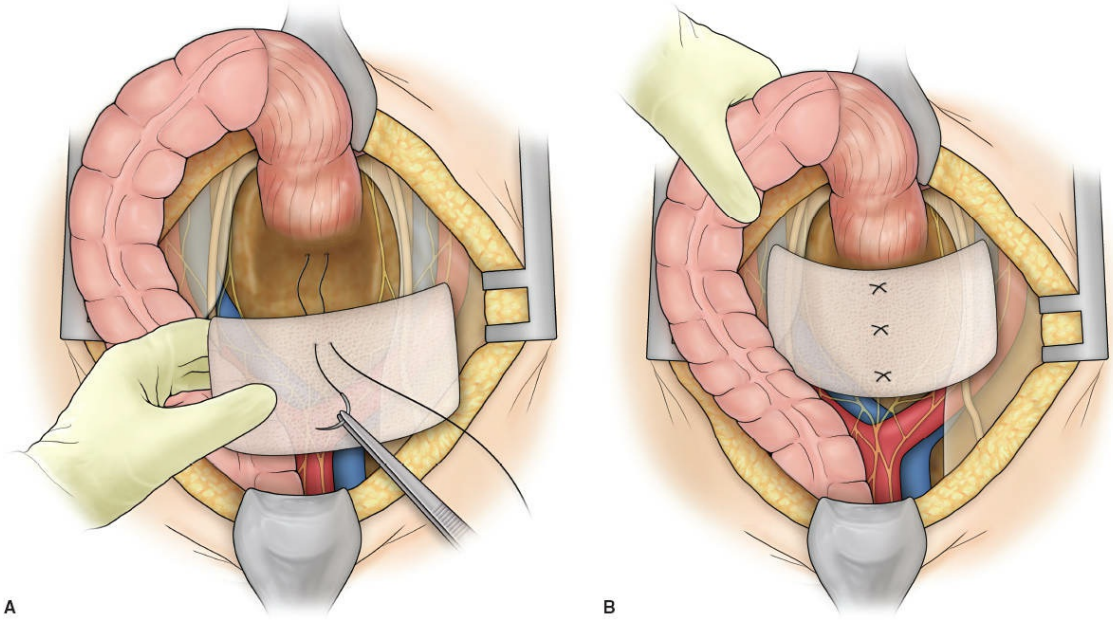

Figure 162.6. **A.** Sheet of Parietex mesh sewn to presacral fascia with interrupted 00 polypropylene suture material on a round needle. Rectum retracted forward, away from sacrum. **B.** Three polypropylene sutures hold the mesh immobile against presacral fascia.

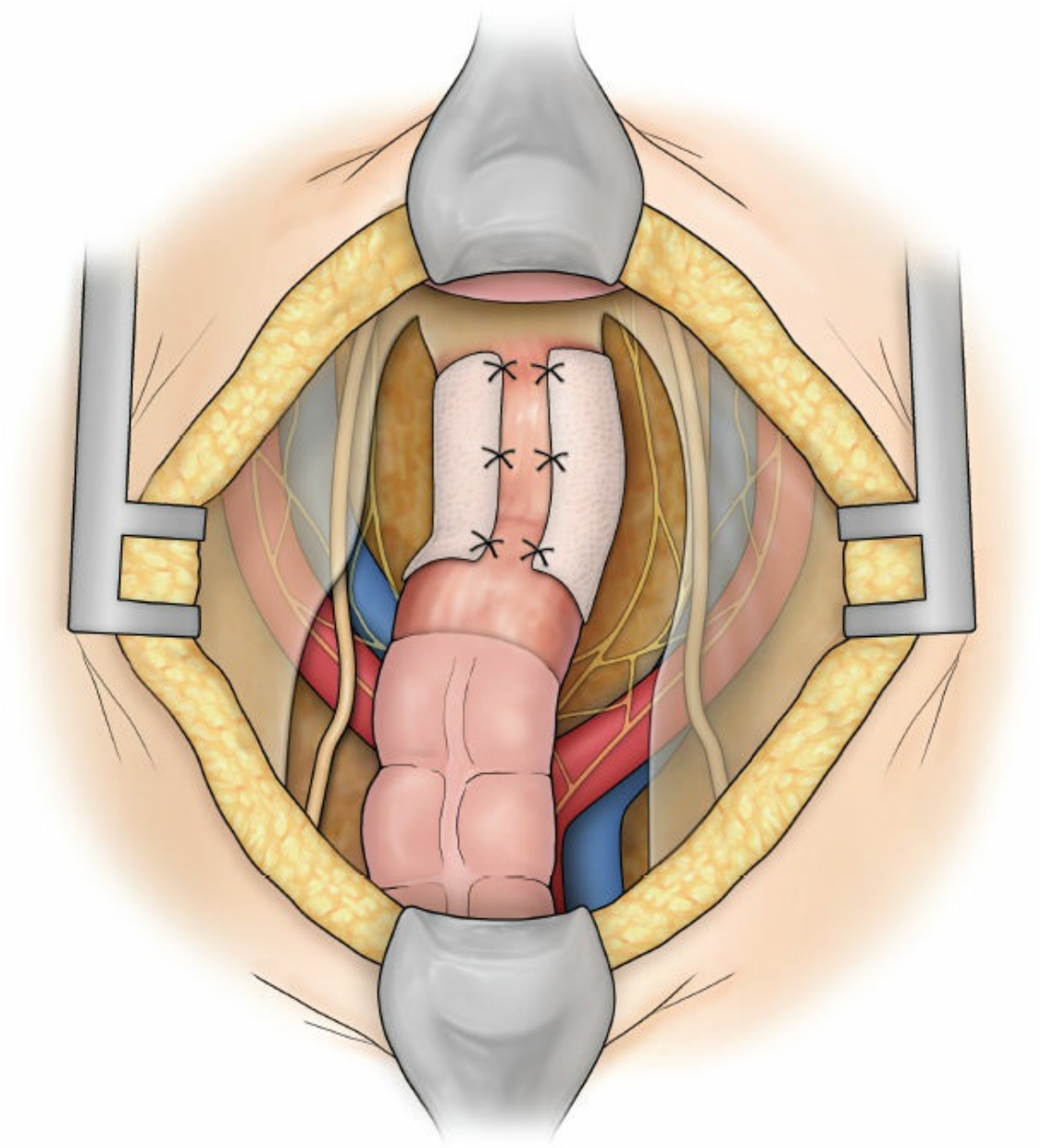

Figure 162.7. Mesh applied to posterior three fourths of circumference and sutured in place with three 000 polypropylene sutures on each side.

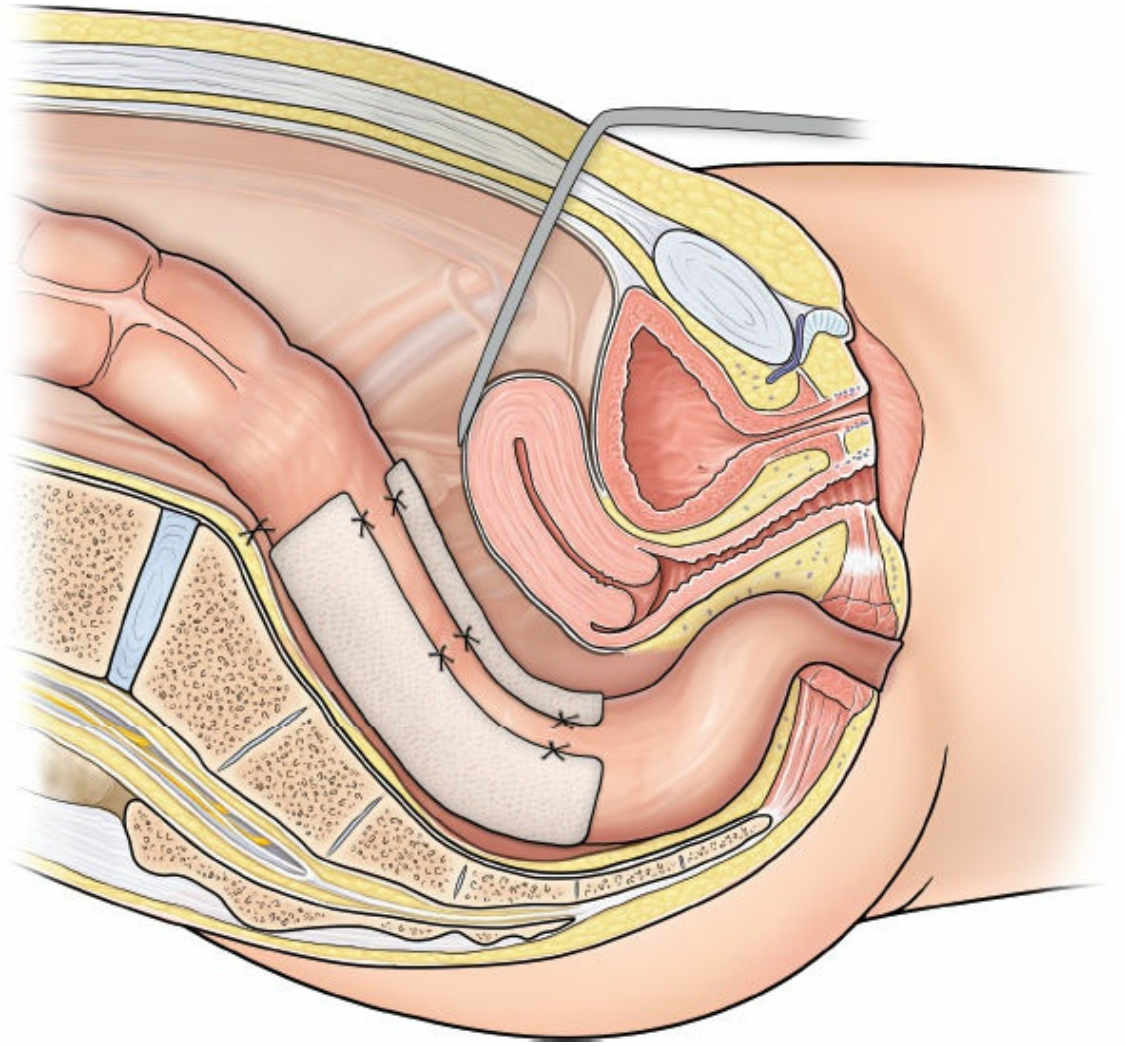

Figure 162.8. One or two additional sutures placed superior to the mesh to hold sigmoid colon and prevent sigmoid volvulus.

The pelvis is copiously irrigated with saline solution. Then the sponge is extraperitonealized by closing the pelvic peritoneum with continuous 000 Vicryl (Fig. 162.9). The abdominal cavity is irrigated with saline solution and closed in layers.

POSTOPERATIVE CARE

IV fluids are given until the postoperative ileus has resolved, usually in 2 or 3 days. Nasogastric suction is ordinarily not necessary. The Foley catheter is removed on the second day.

It is of paramount importance to ensure that the patient does not strain at defecation. To this end, as soon as the patient has begun oral intake, a bulk-forming agent in the form of a psyllium seed preparation is given two or three times a day, depending on how much difficulty the patient

encountered on defecation preoperatively. This preparation may be supplemented by milk of magnesia as necessary. It should be stressed that the incontinence experienced by many of these patients preoperatively may not be improved immediately. Improvement has been noted over a period of many months, and therefore the attending surgeon should be dissuaded from performing any secondary procedure for 6 to 12 months. Minor mucosa prolapse can be treated by the application of rubber band ligatures. For persistent incontinence, the Park's postanal repair should be considered.

OPERATIVE TECHNIQUE OF SIGMOID RESECTION AND SUTURE PROCTOPEXY

This technique was originally described by Frykman and can be performed through a transverse or midline abdominal incision. The patient is placed in the supine position with both legs on Yellowfin stirrups (OR Direct, Acton, MA) or Allen stirrups. A No. 16 Foley catheter is inserted into the urinary bladder. The head of the operating room table is tilted down 30 to 40 degrees, depending on the shape of the pelvis. The entire small bowel is packed to the upper abdomen with moist lap pads.

MOBILIZATION OF SIGMOID COLON AND RECTUM

The lateral peritoneal reflection of the sigmoid colon (white line of Toldt) is incised by electrocautery. The gonadal vessels and the left ureter are identified and swept posteriorly. The peritoneal incision is continued to the left side of the rectum, about 1 cm lateral to the rectal wall, and curves anteriorly to the rectovesical sulcus. Similarly, the peritoneum at the base of the sigmoid mesentery is incised by cautery and continued to the right side of the rectum to unite with the incision on the left side at the sulcus (Fig. 162.10). The sigmoid vessels are taken close to the sigmoid colonic wall to preserve the superior rectal artery. This technique will ensure a good blood supply to the rectum and avoid injury to the presacral nerve.

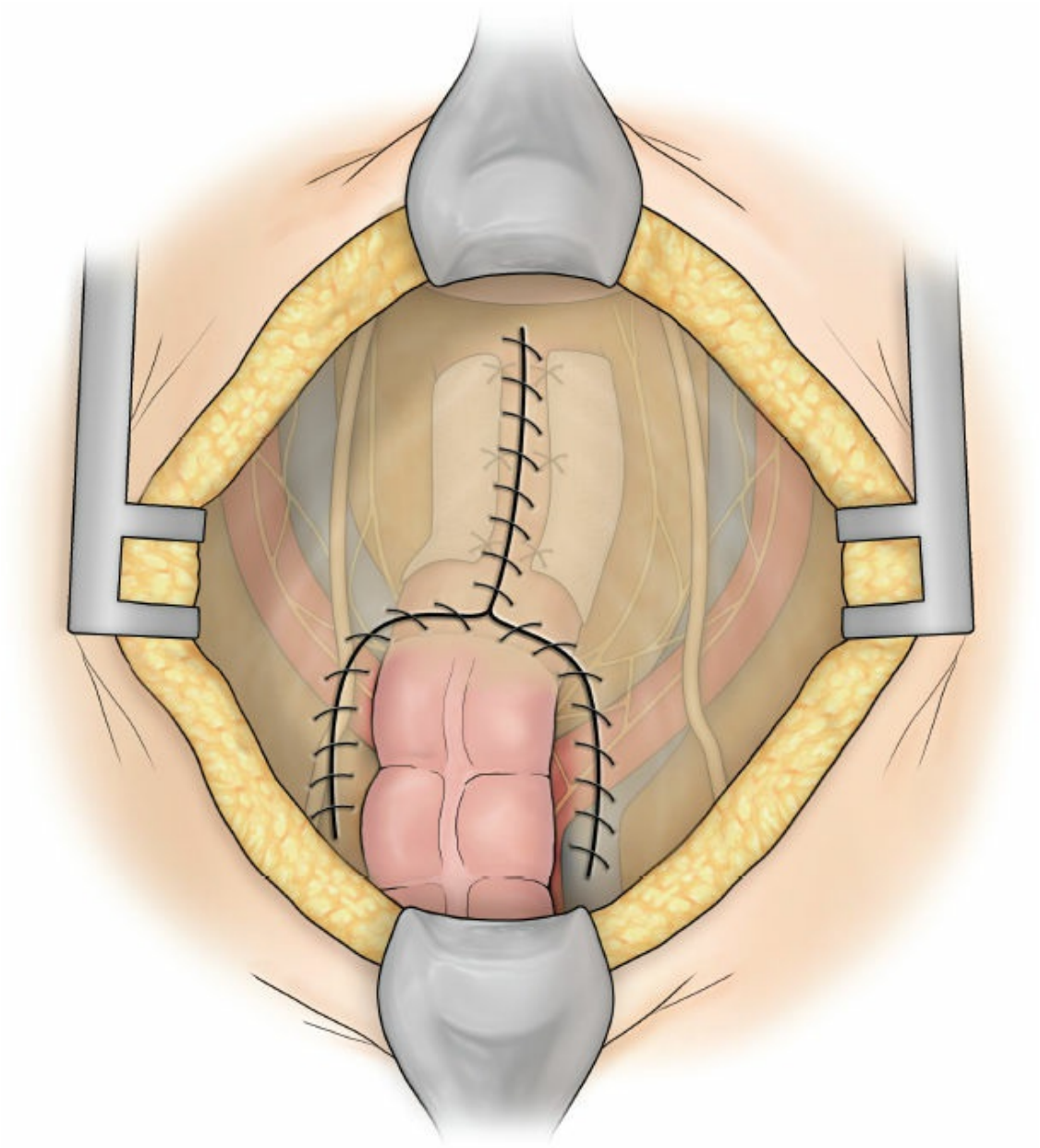

Figure 162.9. Operation completed by closing pelvic peritoneum.

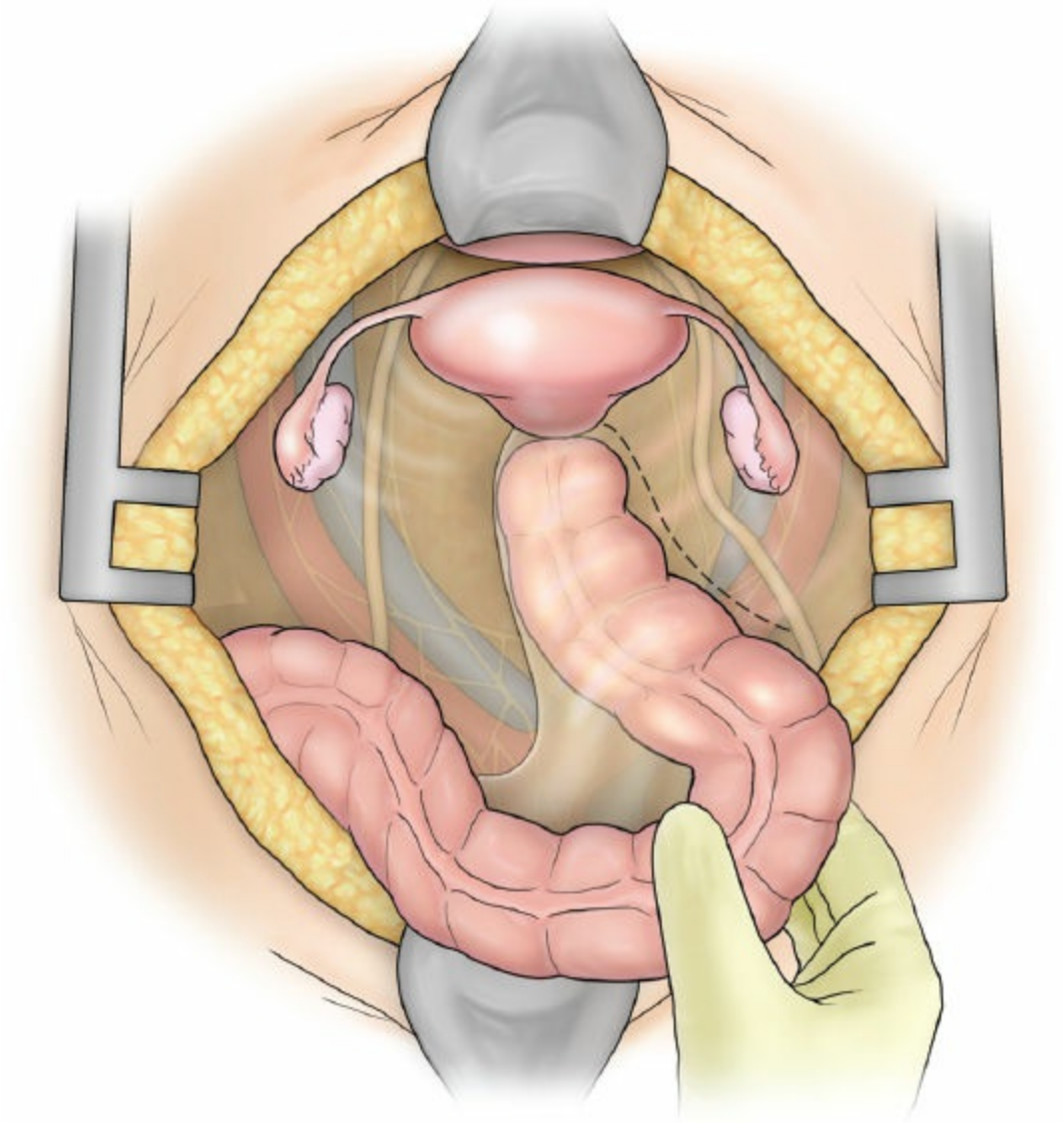

Figure 162.10. Mobilization of sigmoid colon to identify the left ureter. Note the line of incision.

ENTERING THE RETRORECTAL SPACE (POSTERIOR MOBILIZATION)

The surgeon's left hand lifts the sigmoid colon. The right index finger presses firmly on the promontory of the sacrum and the presacral space is entered (Fig. 162.11). A lipped St. Marks retractor is placed behind the rectum and lifted up by the assistant, who stands between the patient's legs. The avascular areolar plane is dissected with electrocautery (Fig. 162.12). This maneuver is continued to the pelvic floor muscles.

SWEEPING THE URETERS AND PELVIC NERVES

With the left hand holding the sigmoid colon, the right hand, with all the

four fingers closed together, is placed behind the posterior rectal wall. The tissues lateral to the right rectal wall are swept away laterally (Fig. 162.13) and then the tissues on the left side are swept away in the same manner. This maneuver should not be taken until the rectum is sharply dissected posteriorly near the pelvic floor muscle. The previous incision of the peritoneum will allow the ureters and nerves to be swept away laterally.

ANTERIOR MOBILIZATION

The assistant, standing between the patient's legs, retracts the uterus and cervix or (in men) the bladder, using the St. Mark retractor. The surgeon's left hand presses on the anterior wall of the rectum over a gauze. The posterior vaginal wall or seminal vesicle will be visualized. With electrocautery, the areolar tissue plane between the anterior wall of the rectum and the vagina or seminal vesicles is entered in the midline. This incision is carried laterally to each side of the rectum. At the lateral edge of the rectum, it is important that the line of incision curve downward to avoid injury to the neurovascular bundles (Fig. 162.14). The dissection is carried about 3 to 4 cm distally. It is advisable that the lateral ligaments that are distal to this level are preserved as preservation is associated with an improvement in continence and reduction in constipation.

RESECTION OF THE REDUNDANT SIGMOID AND ANASTOMOSIS

I prefer a stapled anastomosis with a circular stapler. A point of transaction of the redundant sigmoid colon is selected so that the anastomosis is without too much slack or any tension (Fig. 162.15). A purse-string clamp is applied, a purse-string suture placed, and the bowel transected (Fig. 162.15A). The anvil is inserted into the proximal bowel and the purse-string is tied (Fig. 162.15B). The bowel at the level of the promontory of the sacrum is cleared of fat and blood vessels. The purse-string clamp is again placed at the planned line of resection, the purse-string inserted, and the bowel proximal transected. The circular stapler is inserted through the anus, the anvil engaged in the central shaft, and the anastomosis created (Fig. 162.15C–E).

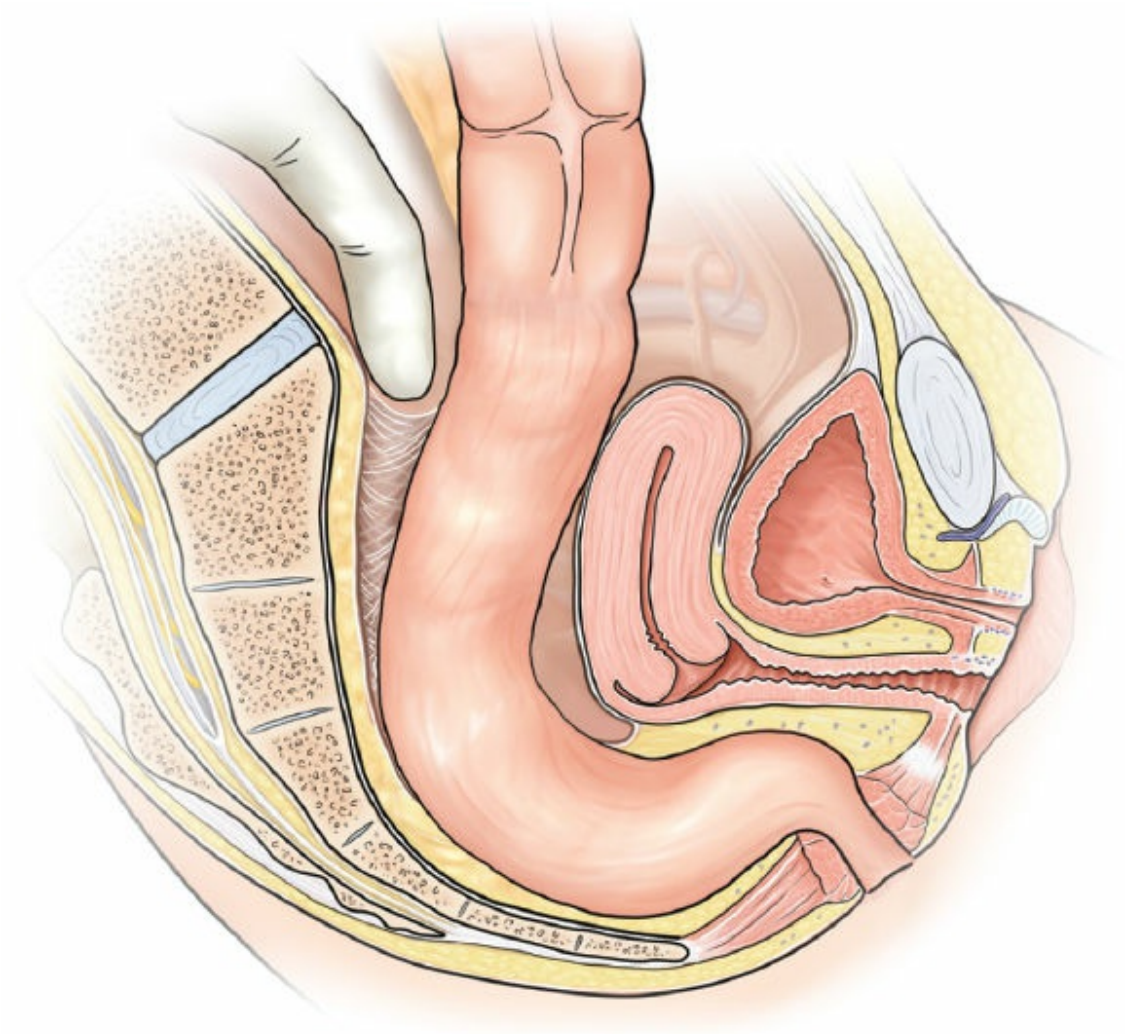

Figure 162.11. Entering the retrorectal space, the right index finger presses firmly on the promontory of sacrum.

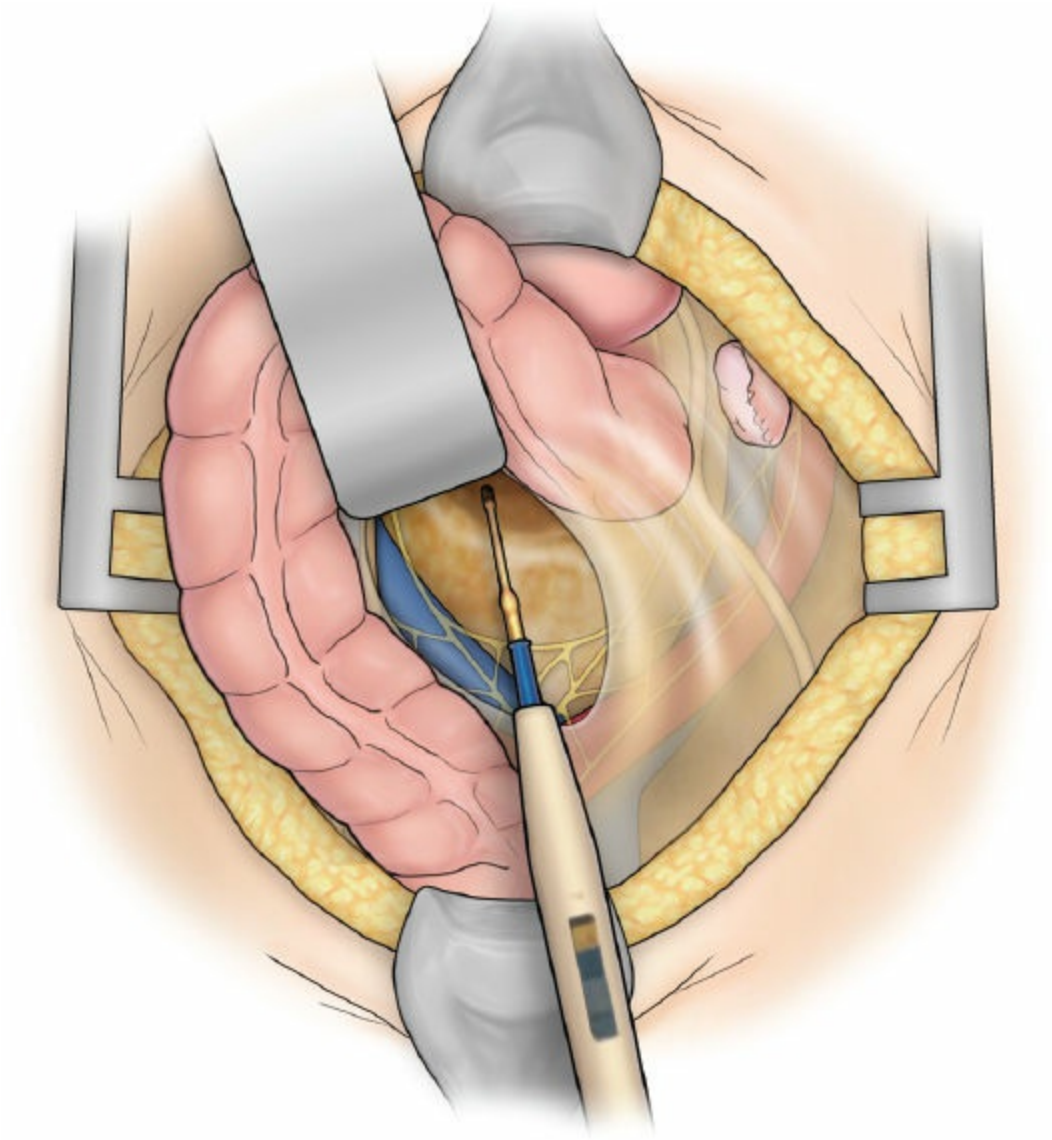

Figure 162.12. Avascular plane dissected with electrocautery.

If a hand-sewn anastomosis is preferred, the anastomosis begins with the posterior wall. Through-and-through full-thickness stitches of 4-0 Vicryl or Dexon are placed at each corner and in the middle, 5 mm from the edges. Two such stitches are placed in between, and the sutures are tied with the knots inside the lumen. Additional stitches are then placed at 5 mm apart. In the anterior wall, full-thickness stitches with only mucosal inversion (Gambee technique) are placed 5 mm from the edges and 5 mm apart (Fig. 162.16). The mesentery and the pelvic peritoneum are not closed.

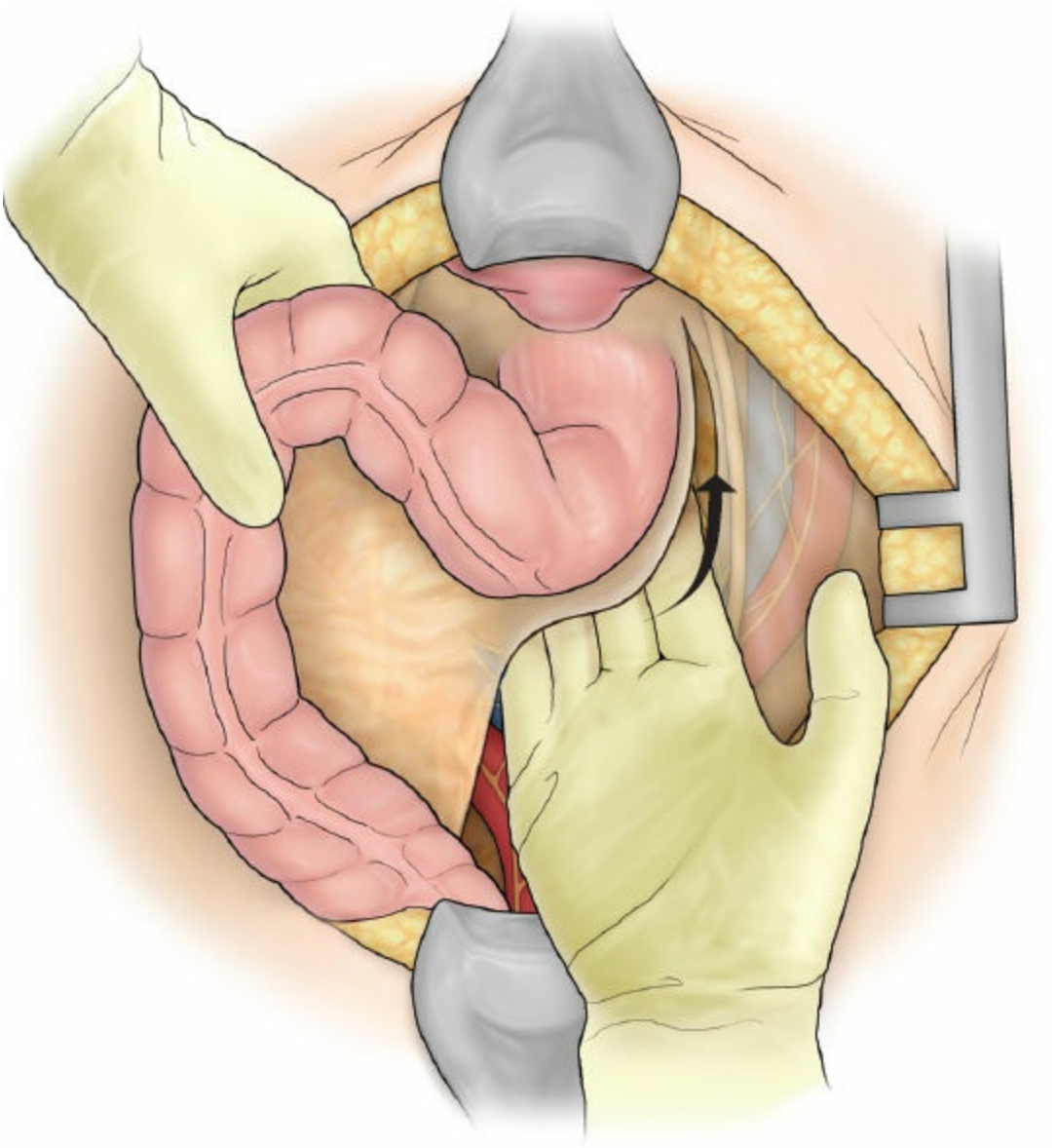

Figure 162.13. Technique of sweeping the ureters and pelvic nerves.

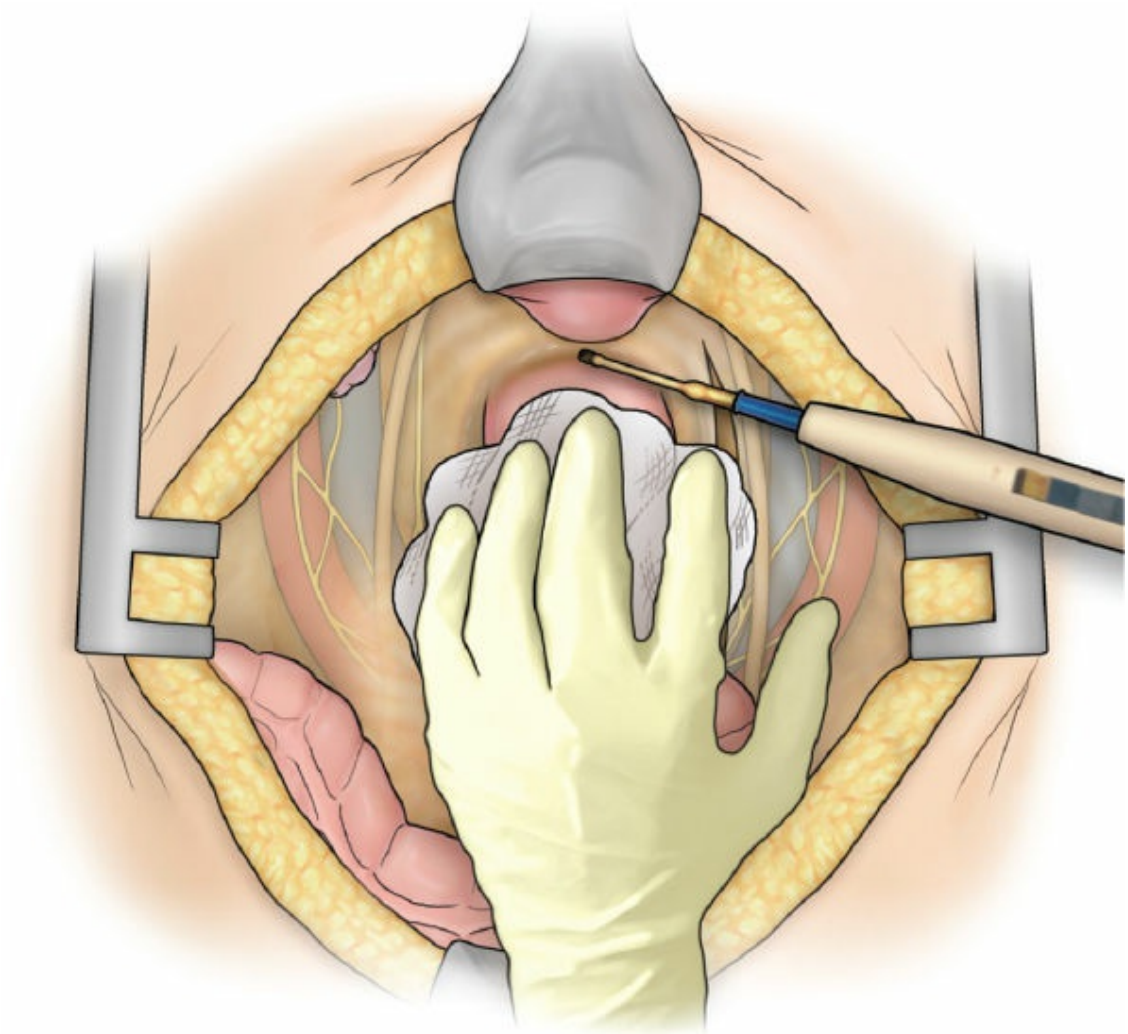

Figure 162.14. Entering the rectovaginal space. The line of incision curves down laterally to avoid injury to the neurovascular bundles.

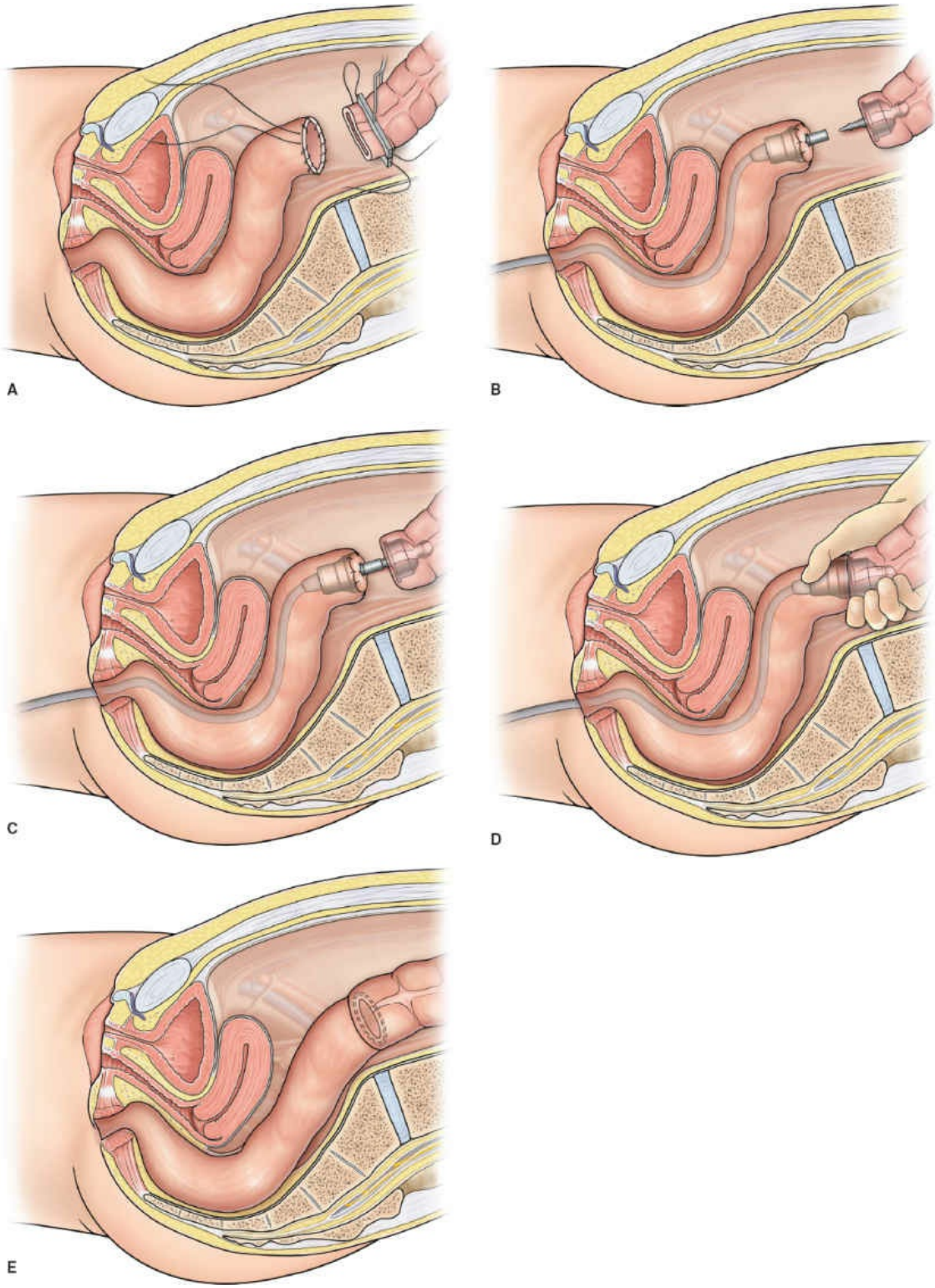

Figure 162.15. Resection of sigmoid colon.

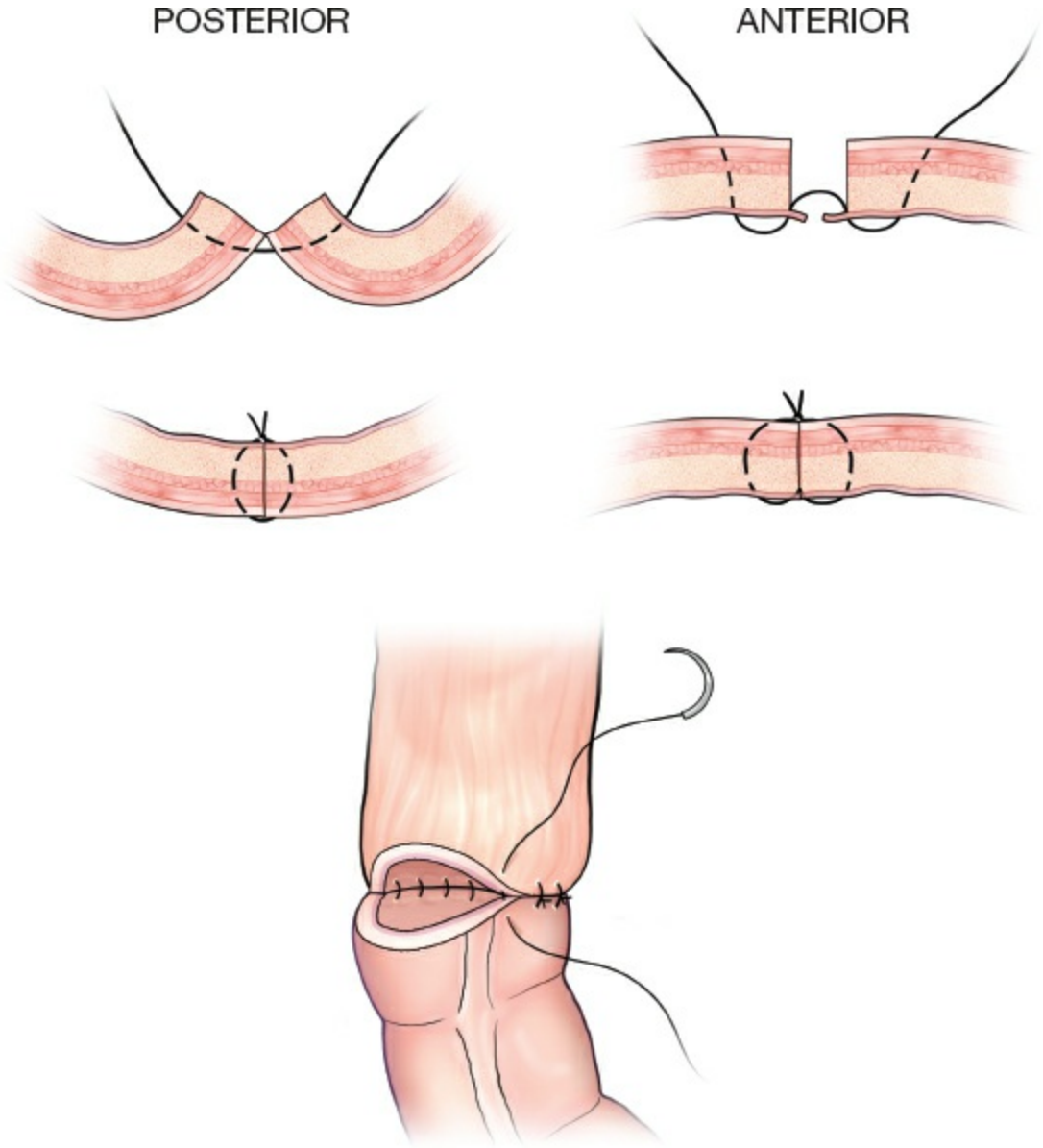

Figure 162.16. Techniques of bowel anastomosis. Insets shows stitches for posterior and anterior walls.

PLACEMENT OF PROCTOPEXY SUTURES

While the rectum is allowed to lie along the curve of the sacrum, sutures of 2-0 Vicryl are placed through the lateral stalks on each side of the rectum and through the presacral fascia in the upper third of the sacrum. Usually one suture on each side can be safely placed. The sutures are tied snugly only after the anastomosis is created (Fig. 162.17).

The abdominal cavity is irrigated with normal saline and aspirated until dry. Unless there is oozing of blood, a pelvic drain is not used. The abdomen is closed in layers.

POSTOPERATIVE MANAGEMENT

IV fluids are instituted. In the absence of nausea and abdominal distention, liquids may be started after the ileus has resolved and the diet is advanced as tolerated. Patients are discharged after their first bowel movement.

COMPLICATIONS: THEIR PREVENTION AND MANAGEMENT

Unfortunately, complications are an inevitable consequence of any operation. Gordon and Hoexter polled the members of the American Society of Colon and Rectal Surgeons, obtaining information on the results of a total of 1111 Ripstein procedures. This review revealed a recurrence rate of 2.3%, and complications directly related to placement of the sling occurred in 16.5% of the patients. The overall reoperation rate was 4.1%. Indications for reoperation included fecal impaction, small bowel obstruction, stricture, pelvic abscess, rectal erosion, and hemorrhage. Reoperations for mucosal prolapses and recurrences were not included in this calculation. Possible reasons for recurrence are intraoperative difficulties that result in failure to secure the mesh adequately to the presacral fascia, failure to secure the mesh to the rectum, or inadequate initial mobilization of the rectum, resulting in the presence of prolapsed rectum distal to the point of fixation. To prevent fecal impaction, considerable care must be exercised to ensure that the sling is not applied too tightly around the rectum.

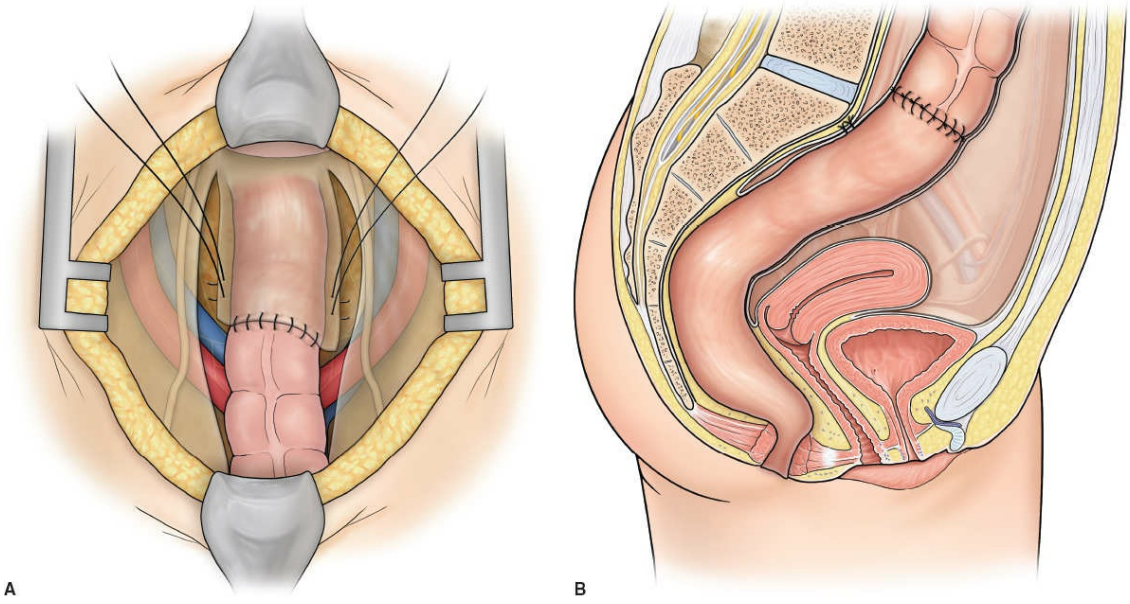

Figure 162.17. **A.** Placement of presacral suture. **B.** Lateral view

of the rectum at completion. Note the rectum lies along the curve of the sacrum.

Presacral bleeding may range from nuisance bleeding to hemorrhages of terrifying proportions. To minimize this complication, care must be exercised during mobilization of the rectum to ensure that the correct plane is developed. Care must be exerted during the placement of sutures into the presacral fascia. If bleeding occurs in this area, the sutures should be tied immediately; failing this, pressure can be used. If this measure also fails, the use of further sutures may control the bleeding.

Strictures were common, but only those that required further operation, either division or removal of the sling or resection of the segment of bowel, were included. The treatment of severe symptomatic strictures includes either division or removal of the sling and in some cases may require resection of this segment of bowel. When the sling requires division, it should be cut laterally because it is fused anteriorly to the rectal wall and injury may be encountered. Prevention consists of avoiding tight application of the sling.

Pelvic abscesses are treated by removal of the sling and drainage, but some may require diverting colostomies. To prevent this complication, care should be taken to avoid placement of sutures through the full thickness of the rectum. Patients should receive a mechanical bowel preparation, and it is probably wise to administer systemic antibiotics.

Small bowel obstruction was described as developing from adhesions of the bowel to the site of the placement of the sling. Treatment is by lysis of adhesions. It may be prevented in part by reperitonealizing the pelvic floor and excluding the sling from the remaining peritoneal cavity.

The exact incidence of impotence was impossible to evaluate, especially since the distribution of men and women was not determined and because many of the patients who underwent the procedure were elderly and experienced the problem preoperatively. The chance of causing impotence can be minimized by careful dissection within the pelvis. However, despite meticulous dissection, young male patients were reported to have become impotent.

Fistulas may arise from piercing the bowel the bowel with a suture or possibly from erosion of the bowel by the sling, perhaps caused by ischemia of the bowel. The late occurrence of this complication may be due to repeated pressure exerted on the bowel wall by stool as it passes

through the sling. Should a fistula arise because of erosion, removal of the sling, closure of the rectum, and a temporary diverting colostomy are required. This complication might be prevented by avoiding excessive tension when placing the sling around the rectum.

An unusual complication is the erosion of the sling into the bladder.

To address the cause of postoperative constipation following rectopexy, division of the lateral ligaments is followed by a higher incidence of constipation than when they are preserved. The complication rate might be reduced by half, if the sling were placed posterior to the rectum, leaving the anterior one fourth to one third of the circumference of the rectum free to expand, a principle expounded by Wells.

Potential complications of the posterior mesh wrap operation are identical to those of the Ripstein procedure with the noted exception that fecal impaction and stricture are not observed postoperatively because of the entire circumference of the rectum is not closed.

A major complication reported with the Wells procedure is the development of pelvic abscesses. This occurrence might be minimized by the use of adequate bowel preparation, by taking care in not transgressing the full thickness of the bowel wall when placing sutures, and by administering prophylactic antibiotics. The treatment of an abscess associated with insertion of a mesh requires removal of the mesh and drainage of the abscess. If the bowel is opened or injured during dissection, a mesh implant should be abandoned.

The intraoperative complications with abdominal proctopexy and sigmoid resection are similar to those of abdominoperineal resection or low anterior resection and are as follows. Bleeding from the venous plexus can be severe and difficult to control. Cutting the rectosacral fascia with long scissors or cautery instead of tearing it reduces the chance to injure these vessels. The needle used to suture the rectum to the presacral fascia may tear the presacral vessels, causing severe bleeding that usually stops when the sutures are tied. Injury to the sympathetic and parasympathetic nerves from mobilization of the rectum is difficult to evaluate. The incidence should be similar to that for total proctocolectomy in patients with inflammatory bowel disease, which is 0% to 17%. Suturing the rectum too close to the wall may cause compression on the anterior wall of the rectum as a result of stretching the visceral peritoneum. Compression must be recognized and corrected by making a vertical incision over the compressed serosa. An alternative method is to place the sutures in the

back of the rectum.

RESULTS OF OPERATIVE TREATMENT OF RECTAL PROCIDENTIA

Varma et al. in their American Society of Colon and Rectal Surgeons Practice Parameters for rectal prolapse noted the perineal approaches result in less perioperative morbidity and pain but recurrence rates are four times higher than those for abdominal operations making the later the preferred treatment of younger and healthier patients. Recurrence rates for suture rectopexy range from 3% to 9%. Rectopexy can produce new-onset or worsening constipation. Recurrence rates for resection rectopexy range from 2% to 5% and major complication rates range from 0% to 20% and relate either to obstruction or anastomotic leaks. Division of lateral stalks during rectal dissection may worsen symptoms of constipation postoperatively but is associated with decreased recurrence rates. Recurrence rates after the Ripstein procedure range from 4% to 10% but complication rates were as high as 50%.

In their review of the literature, Gourgiotis and Boratsis found no reported mortality and recurrence rates ranged from 0% to 27% mostly in the 0% to 3% range for suture rectopexy. For the posterior mesh, rectopexy mortality rates ranged from 0% to 3% and recurrence rates 3%. Improvement in continence occurred in 3% to 40%. Sepsis rates ranged from 2% to 16% with prosthetic rectopexy. For the Ripstien procedure mortality, rates ranged between 0% and 2.5%, recurrence rates between 0% and 13%, and there was a trend toward improvement in continence and a mixed response to constipation. For resection rectopexy, the mortality ranged from 0% to 6.2% with an associated recurrence rate of 0% to 5%. There was an overall reduction in constipation. Continence was improved in most patients.

Russel et al. studied the American College of Surgeons National Surgical Quality Improvement Program and found 1,485 patients who underwent rectal prolapse operations (706 abdominal and 779 perineal). Patients treated with abdominal approaches had significantly higher rates of infectious (9.8% vs. 3.7%) and overall (12.9% vs. 7.6%) complications compared with those treated with perineal operations.

Lee et al. conducted a retrospective study of patients undergoing abdominal (64) and perineal procedures (40). The abdominal group had a lower overall recurrence rate (6.3% vs. 15%). The overall rate of major

complications was similar in both groups (10.9% vs. 6.8%). The patients in the abdominal group complained more frequently of constipation than of incontinence but the opposite was true for the perineal group.

Kosba et al. evaluated the functional outcome of posterior sagittal rectopexy with Prolene mesh for rectal prolapse in 32 young adults. They found fecal incontinence scores reduced from 11.1 to 4.4 and constipation improved in 13 of 15 cases. There was no mortality, a single case of recurrence (3.2%), mucosal prolapse in two patients (6.4%), and mild wound infection in three patients (9.4%).

Riansuwan et al. compared the results of 122 abdominal operations with 55 perineal operations. There were no deaths but the recurrence rates of prolapse were significantly higher for perineal operations (26.5%) versus 5.2% for abdominal operations. They concluded perineal operations were appropriate for the elderly and sick but second-best choice for younger healthier patients.

Karas et al. conducted a randomized controlled trial in 41 tertiary centers in 21 countries to determine the value of rectopexy versus no rectopexy with respect to recurrence rates. There were 252 patients, 116 in the no rectopexy arm compared to 136 in the rectopexy arm. Sigmoid resection was performed more frequently in the no rectopexy arm. There was no significant difference in complication rates (11% vs. 17%). The mortality rate was 0.8%. There was no significant difference in the 5 years recurrence rate (8.6% for no rectopexy vs. 9.5% for rectopexy).

In their Cochrane review, Tou et al. found insufficient data to say which of the abdominal and perineal approaches has a better outcome. Division rather than preservation of the lateral stalks was associated with less recurrent prolapse but more postoperative constipation. Laparoscopic rectopexy was associated with fewer postoperative complications and shorter hospital stay than open rectopexy. Bowel resection during rectopexy was associated with lower rates of constipation.

In a systematic review of the literature on the surgical management of recurrent rectal prolapse, Hotouras et al. found 161 patients who underwent abdominal surgery for their recurrence. With a follow-up ranging from 0 to 23 years, recurrence rates varied from 0% to 15%. Morbidity rates ranged from 0% to 32% with a 4% mortality.

OCCULT (HIDDEN) RECTAL PROLAPSE

Brown et al. conducted a retrospective review comparing the results of

patients undergoing operations for occult (74 patients) versus overt (69 patients) rectal prolapse. Resection rectopexy was the treatment of choice except in patients with fecal incontinence who underwent sutured rectopexy. There were significantly more perineal procedures in overt prolapse compared with occult prolapse (54% vs. 5%). Rectal prolapse surgery reduced the incidence of St Marks grade 4 fecal incontinence from 38% to 19% in the overt prolapse group and from 49% to 22% in the occult prolapse group. The incidence of constipation increased in the occult group from 39% to 50% but decreased in the overt prolapse group from 42% to 35%. They concluded operations for occult prolapse are unlikely to benefit patients whose principle symptom is constipation. Approximately half of those patients whose occult prolapse is associated with fecal incontinence will have their bowel function habit improved by prolapse surgery.

Symptoms associated with internal rectal prolapse include fecal incontinence, incomplete evacuation, straining, and repetitive toilet visits.

Suggested Readings

Bachoo P, Brazzelli M, Grant A. Surgery for complete rectal prolapse in adults. *Cochrane Database Syst Rev* 2000;2:CD001758.

Broden B, Snellman B. Procidentia of the rectum studied with cine-radiography: a contribution to the discussion of causative mechanism. *Dis Colon Rectum* 1968:11:330.

Brown AJ, Anderson JH, McKee RF, et al. Surgery for occult rectal prolapse. *Colorectal Dis* 2004;6:176–9.

Corman ML. Rectal strictures secondary to Teflon sling repair for rectal prolapse. *Dis Colon Rectum* 1974; 17:89–90.

Frykman HM. Abdominal proctopexy and primary sigmoid resection for rectal procidentia. *Am J Surg* 1955;90:780–9.

Goldberg SM, Gordon PH, Nivatvongs S. Complications of surgery after complete rectal procidentia. In: Ferrari BT, Ray JB, Gathright JB, eds. *Complications of Colon and Rectal Surgery, Prevention and Management.* Philadelphia, PA: WB Saunders; 1985:251–66.

Gordon PH. Ivalon sponge wrap and Thiersch operation for prolapse. In: Nyhus LM, Baker RJ, eds. *Mastery of Surgery.* Boston, MA: Little Brown; 1984:1045–50.

Gordon PH. Rectal procidentia. In: Gordon, PH, Nivatvongs S, eds. *Principles and Practices of Surgery for the Colon, Rectum and Anus.* 3rd ed. New York: Informa Healthcare USA Inc; 2007 Chapter 21:415–50.

Gordon PH, Hoexter B. Complications of Ripstein procedure. *Dis Colon Rectum* 1978;21:277–80.

Gourgiotis S, Baratsis S. Rectal prolapse. Review. *Int J Colorectal Dis* 2002;22:231–45.

Hotouras A, Ribas Y, Zakeri S, et al. A systemic review of the literature on the surgical management of recurrent rectal prolapse. *Colorectal Dis* 2015;17(8):657–64.

Karas JR, Uranues S, Altomare DF, et al.; for Rectal Prolapse Recurrence Study Group. No Rectopexy versus Rectopexy following Rectal mobilization for Full-thickness Rectal Prolapse: A randomized Controlled Trial. *Dis Colon Rectum* 2011;54:29–34.

Kosba Y, Elshazly WG, Abd El Maksoud W. Posterior sagittal approach for mesh rectopexy as a management of complete rectal prolapse in adults. *Int J Colorectal Dis* 2010;25:881–6.

Lee JL, Young SS, Park IJ, et al. Comparison of abdominal and perineal procedures for complete rectal prolapse: an analysis of 104 patients. *Ann Surg Treat Res* 2014;86:249–55.

Madiba TE, Baig MK, Wexner SD. Surgical management of rectal prolapse. *Arch Surg* 2005;140:63–73.

McMahan JD, Ripstein CB. Rectal prolapse: an update on rectal sling procedure. *Am Surg* 1987;53:37.

Penfold JC, Hawley PR. Experiences of Ivalon sponge implant for complete rectal prolapse at St. Mark's Hospital 1960–1970. *Br J Surg* 1972;59:846.

Raftopoulos Y, Senagore AJ, Di Giur G, et al. Rectal prolapse recurrence study group. Recurrence rates after abdominal surgery for complete rectal prolapse: a multicenter pooled analysis of 643 individual patient data. *Dis Colon Rectum* 2005;48:1200.

Riansuwan W, Hull TL, Bast J et al. Comparison of perineal operations with abdominal operations for full-thickness rectal prolapse. *World J Surg* 2010;34:1116–22.

Russel M, Read TE, Roberts PL, et al. Complications after rectal prolapse surgery: does approach matter? *Dis Colon Rectum* 2012;55:450–8.

Sun C, Hull T, Ozuner G. Risk factors and clinical characteristics of rectal prolapse in young patients. *J Visc Surg* 2014;15:425–9.

Tou S, Brown SR, Malik AI, et al. Surgery for complete Rectal Prolapse in Adults. *Cochrane Database Syst Rev* 2008;(4):c0001758.

Varma M, Rafferty J, Buie WD. Practice parameters for the management of rectal prolapse. *Dis Colon Rectum* 2011;54:1339–46.

Wells C. New operation for rectal prolapse. *Proc R Soc Med* 1959;52:602–3.

Wijffels NA, James M, Cunningham C, et al. What are the symptoms of internal rectal prolapse? *Colorectal Dis* 2013;15:368–73.

EDITOR'S COMMENT

Few topics are associated with as much controversy as the treatment of rectal prolapse. There are few conditions for which as many different types of procedures have been described as have been for rectal prolapse. In reviewing the literature, one is impressed by the heterogeneity of publications, by the differences in the populations studied, procedures performed, length of follow-up, and number of surgeons performing the procedures. It is not surprising that the average surgeon is at a loss of how to proceed with respect to selection of the best procedure for his/her patient.

Similar to other fields, new technology and modes of access have promoted novel methods of surgical repair, resulting in an avalanche of publications which report "superior" results for these techniques as compared to "conventional" procedures. With the advent of both minimally invasive hiatal hernia repair and the prolapse procedure for hemorrhoids, where there was a plethora of articles flooding the scientific literature with very favorable outcomes and large case series, so much so, that one wondered where are all these patients came from! The same is true in the field of rectal prolapse. Suddenly, there are large series of patients treated with new procedures. One wonders what degree of rectal prolapse these patients had, selection criteria for surgery and other important points to determine study and outcome quality. For example, in one large series of laparoscopic ventral rectopexy, one notes that although 919 patients are reported upon, with a median 34-month follow-up, only 26% had external rectal prolapse (Consten EC, van Iersel JJ, Verheijen PM, et al. Long-term Outcome After Laparoscopic Ventral Mesh Rectopexy: An Observational Study of 919 Consecutive Patients. *Ann Surg* 2015;262(5):742–8). It gives one pause to note conclusions of a recent Cochrane review on complete full-thickness rectal prolapse in which 15 randomized controlled trials including 1007 patients were evaluated (Tou S, Brown SR, Nelson RL. Surgery for complete (full-thickness) rectal prolapse in adults. *Cochrane Database Syst Rev* 2015;11:CD001758). The authors concluded

"The lack of high quality evidence on different techniques, together with the small sample size of included trials and their methodological weaknesses, severely limit the usefulness of this review for guiding practice. It is impossible to identify or refute clinically important differences between the alternative surgical operations. Longer follow-up with current studies and larger rigorous trials are needed to improve the evidence base and to define the optimum surgical treatment for full-thickness rectal prolapse."

One of the determinants by which procedures are chosen is the frailty of a given patient and whether they can withstand a general anesthetic. If the answer to this question is no, one selects a perineal procedure (Altmeier or Delorme procedures described in Chapter 163). If they can undergo a general anesthetic, one it is then left to choose between a perineal procedure or an abdominal procedure as Gordon eloquently describes in the preceding chapter. The choice of whether to do a sigmoid resection or solely a fixation procedure depends upon whether there is associated constipation. Although the connotation "open abdominal approach" makes one envision a large painful incision, open rectal prolapse procedures can be done through a relatively "minimally invasive approach" using a Pfannenstiel incision, since mobilization of the proximal colon is not required. The rectopexy can easily be performed through this incision. Gynecologists have long employed this incision and have favored it due to its rapid relatively painless recovery, avoidance of cutting through muscle, and very low rate of hernia formation.

When choosing between abdominal and perineal procedures, it has been generally been assumed that there are lower recurrence rates with intra-abdominal procedures as opposed to perineal procedures; however, there have been only a few randomized prospective trials evaluating this. The recently published Prolapse Surgery Perineal or Rectopexy (PROSPER) trial was one of the few trials albeit its complex design to randomize patients among the different surgical approaches (Senapati A, Gray RG, Middleton LJ, et al.; PROSPER Collaborative Group. PROSPER: a randomised comparison of surgical treatments for rectal prolapse. *Colorectal Dis* 2013;15(7):858–68). This large 293 patient trial showed higher recurrence rates than anticipated (19% following abdominal procedures, 28% following perineal procedures, $p = 0.2$) with a median follow-up of 36 months. The observed recurrence is higher than I believe most surgeons generally quote to their patients during preoperative counseling. Another recent study of laparoscopic rectopexy with 10-year follow-up data showed a 10-year recurrence rate of 20% (Foppa C, Martinek L, Arnaud JP, et al. Ten-year follow up after laparoscopic suture rectopexy for full-thickness rectal prolapse. *Colorectal Dis* 2014;16(10):809–14).

One of the problems with surgery for rectal prolapse is the fundamental etiology of rectal prolapse. In some cases, there is a weak pelvic floor; in others, there is a physiologic reason this has occurred. Interestingly, there has been something of a change in demographic, and we are seeing more men with rectal prolapse, with the increase in extreme physical exertion and significant Valsalva maneuvers associated with heavy construction work and significant weight lifting of extreme training and bodybuilding. Failure to address this behavior postoperatively will of course lead to recurrence, much as with any other kinds of hernia surgery. Weakness in other components of the pelvic floor can also promote recurrence, that is, failure to adequately provide for vaginal fixation or bladder support in a patient in whom this is an issue. Many surgeons do not have the luxury of urogynecology support in their institutions and many of these

problems are often not discovered at the original preoperative assessment. It is, however, worthwhile to perform a vaginal exam in the upright position to ensure there is not an accompanying vaginal vault prolapse that must be addressed at the time of surgery.

One of the issues that is not clearly addressed in the foregoing chapter is the issue of when to perform a repair for rectal prolapse. In many patients, prolapse has existed for years prior to repair. It is thought that much of the incontinence arising in patients with prolapse is due to stretch injury of the pudendal nerve. The longer a rectal prolapse persists, the more neural damage may occur. It is imperative to counsel patients that there *will* be a period of incontinence following the repair until the anal sphincter regains its tone. There are, however, a portion of patients that will have significant *permanent* impairment in continence. Until recently there were no interventions one could offer them other than biofeedback, dietary modification with fiber and antidiarrheals, or at the extreme, colostomy or artificial anal sphincter. Recently sacral nerve root stimulation appears to be a promising option in this subset of patients. Also not addressed in the decision for operation is the danger of an incarcerated rectal prolapse, which although not frequent is a real concern. This condition frequently occurs in frail, elderly individuals. The only thing worse than performing this surgery in the elective situation, is facing this as an emergent situation with vascular compromise of the rectum in the setting of incarceration. In this scenario, one can even find small bowel in the hernia sac mandating *both* and an abdominal and perineal approach. In this circumstance, laparoscopy may be useful to identify if the abdominal contents are compromised after the prolapse has been reduced.

Few procedures provide as much satisfaction neither as repairing a rectal prolapse nor as much frustration as seeing it recurs.

Susan Galandiuk

163 Rectal Prolapse

Elisa H. Birnbaum

DEFINITIONS

Rectal prolapse is the protrusion of the rectum through the anal canal. Intussusception of the rectum is an occult (or internal) prolapse that occurs when the rectum descends toward but does not pass through the anal canal. A complete rectal prolapse (procidentia) occurs when all layers of the rectum prolapse through the anal canal (Fig. 163.1). A partial (mucosal) prolapse occurs when all layers of the rectum are not involved and only the mucosal layer prolapses (Fig. 163.2).

EPIDEMIOLOGY AND CAUSE

The incidence of rectal prolapse is bimodal, although patients of any age can be affected. One peak occurs in children within the first 3 years of life and the second peak occurs after the seventh decade. Rectal prolapse associated with children occurs equally in both sexes and is often associated with a diarrheal illness. Prolapse in children is typically not a recurring problem and can be self-limited. In the elderly, rectal prolapse is more common in women (80% to 90%), and the prevalence of this abnormality increases with age. Many of these elderly women have concurrent pelvic organ prolapse, defecatory disorders, and may be multiparous. Rectal prolapse may also effect institutionalized patients who have neurologic or psychiatric comorbidities (15%). It is possible that chronic constipation and straining to defecate may be a contributing factor in this group of patients.

The exact cause of rectal prolapse is still unclear. It was initially thought to be a type of perineal hernia or a consequence of a pelvic fascial defect. Many patients are found to have a deep pouch of Douglas and associated enterocele. Constipation and straining are felt to be contributing factors (30% to 60%). A wide pelvic inlet and redundant, nonfixed rectosigmoid are commonly found. Pelvic floor atony and a patulous anus may be a result of chronic straining with denervation or stretch injury to

the anal canal. Cinedefecography shows that the rectum initially intussuscepts before prolapsing. Anal physiology testing frequently shows low resting tone, diminished squeeze efforts, and prolonged pudendal motor nerve terminal latency. Pudendal neuropathy may be a result of chronic stretch injury associated with straining. Vaginal prolapse and enteroceles are commonly seen in studies of patients with long-standing rectal prolapse (50%).

CLINICAL PRESENTATION

Rectal pressure, mucus discharge, rectal bleeding, and fecal incontinence are frequent symptoms of rectal prolapse. Chronic constipation and difficulties defecating are common complaints. Once the prolapse occurs, patients complain more of fecal incontinence and rectal bleeding and they do of constipation. Rectal pain is a complaint in early prolapse and may be due to the protrusion of the rectum with normal anal rectal tone. Pain is less of a complaint in patients with long-standing prolapse (probably due to chronic dilatation of the anal canal), but patients do note the uncomfortable sensation of sitting on a mass within their anal canal. Early in the diagnosis, patients will state that the rectal prolapse occurs primarily during defecation. It is not uncommon for symptoms to be attributed to prolapsing hemorrhoids. There may also be spontaneous reduction of the prolapse after defecation. Over time, however the prolapse occurs during any activity associated with increased abdominal pressure and in some patients occurs every time they stand upright. Manual replacement by the patient or their caretakers is common. Mucus discharge and bleeding are common complaints and may be a result of ulceration at the leading edge of the rectal prolapse. Although rare, the rectal prolapse can become incarcerated or strangulated if there is normal tone to the anal sphincter or the prolapsed rectum has become extremely edematous. These patients require urgent or emergent surgery.

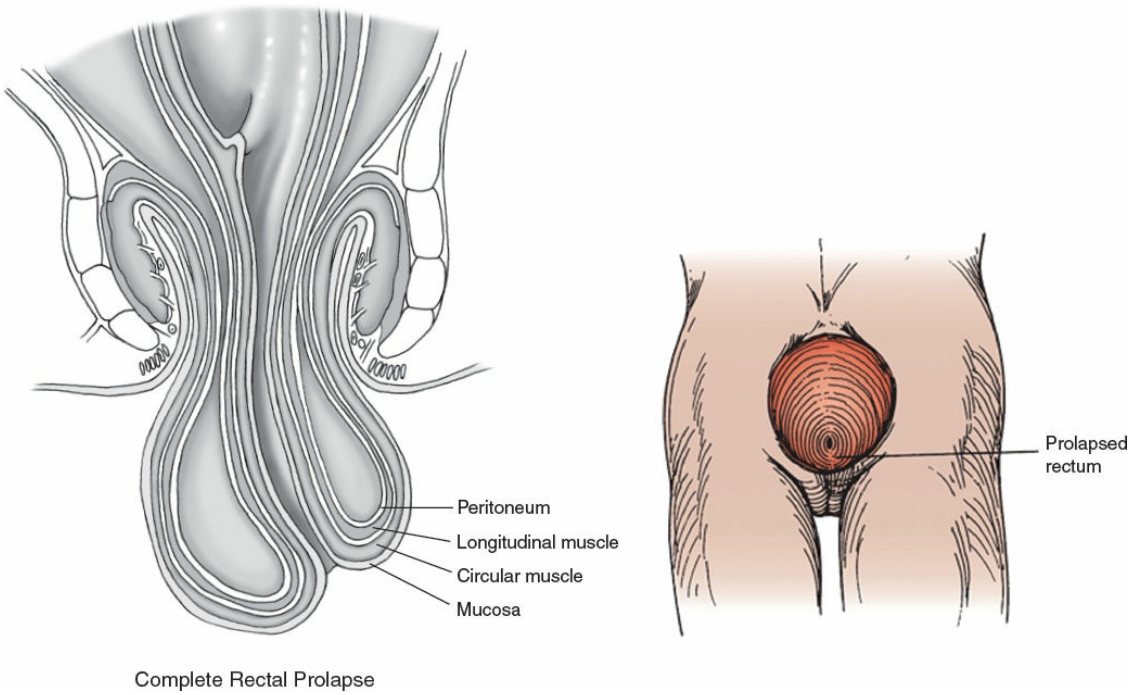

Figure 163.1. Complete prolapse (full-thickness bowel wall). Complete prolapse folds generally circular. (From Lawrence PF. *Essentials of general surgery*. Philadelphia, PA: Wolters Kluwer Health/Lippincott Williams & Wilkins; 2013.)

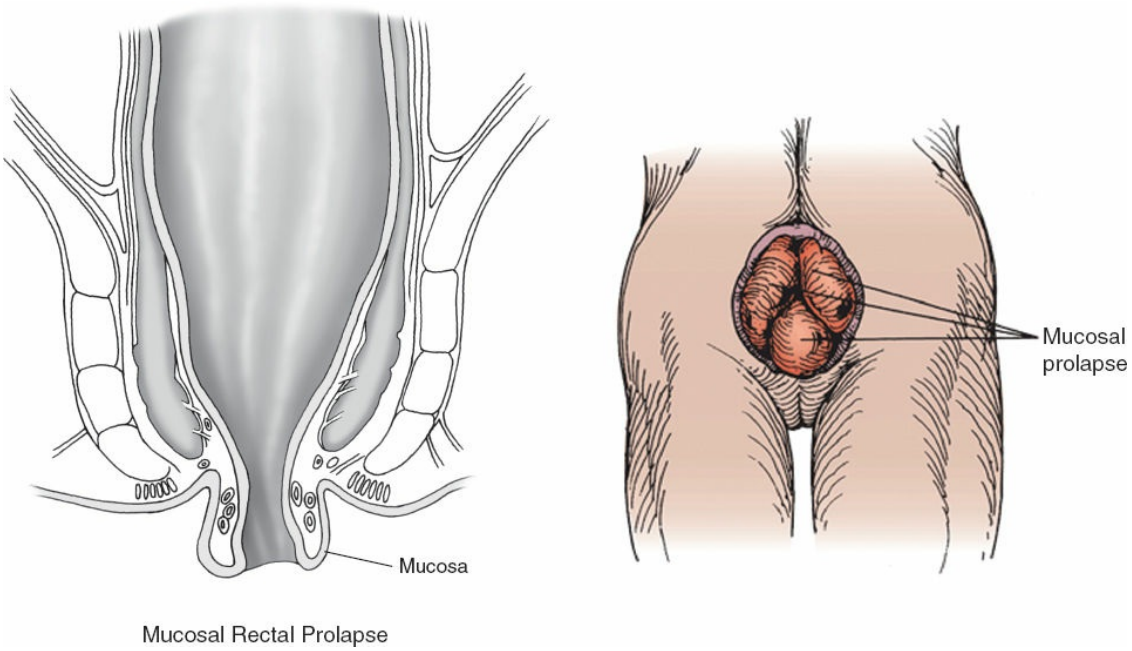

Figure 163.2. Folds in mucosal prolapse usually radial in orientation. Partial prolapse (mucosa only). (From Lawrence PF. *Essentials of general surgery*. Philadelphia, PA: Wolters Kluwer Health/Lippincott Williams & Wilkins; 2013.)

Although the diagnosis is suspected by history, confirmation should be

made during physical examination. The visualization of the prolapse may be as simple as asking the patient to stand and Valsalva while examining the perineum. It is useful to have the patient strain on a commode to demonstrate the extent of the rectal prolapse. Circumferential rings are typical of a full rectal prolapse; radial folds are more typical of equal full prolapse or prolapsing hemorrhoids. A lax anal sphincter and diminished squeeze efforts are frequently found on digital rectal examination. Proctosigmoidoscopy might reveal an erythematous, edematous rectal mucosa, and possibly a solitary rectal ulcer in the mid rectum. The "leading edge" is typically an erythematous ring seen up proximally 5 to 8 cm from the dentate line on proctosigmoidoscopic examination. Solitary rectal ulcers may be confused with rectal tumors, and biopsies should be obtained to get a more definitive diagnosis.

If the prolapse cannot be demonstrated in the office setting, a defecography or dynamic magnetic resonance imaging (MRI) may be done to demonstrate the redundant, prolapsing rectosigmoid. These tests may also be useful to identify other elements of pelvic organ prolapse such as vaginal prolapse, enterocele, and cystoceles. A complete colonic evaluation with colonoscopy or a contrast enema is necessary to rule out a tumor as the lead point of the rectal prolapse and clear the proximal colon. The anal sphincter may be assessed with anal physiology testing, although the results typically show very low rest and low squeeze pressures. Unilateral or bilateral neurogenic injury to the pudendal nerve may result from chronic stretching of the nerve. Preoperative colonic transit studies should be done for patients with complaints of severe constipation and infrequent bowel function to identify patients who may also have colonic inertia.

SURGICAL TREATMENT

It is often said that more than 100 operations have been cited as forms of treatment for rectal prolapse. Elimination of the rectal prolapse and restoration of continence is the goal of most surgical procedures. Surgical therapy must be tailored to the individual patients and their symptoms. The choice of operation is determined by the patient's age, comorbidities, operative risk, and associated anatomic abnormalities. The surgical approach to rectal prolapse is either transabdominal or perineal. Prior surgical treatment of rectal prolapse or colonic surgery will influence and determine the type of operations that can be offered to patients. For

example, doing a perineal proctosigmoidectomy if the patient had a prior rectal resection places the remaining bowel at risk of being devascularized.

Transabdominal approaches include sutured rectopexy, mesh rectopexy, and resection rectopexy. These approaches can be done as an open laparotomy, laparoscopically or robotically. These procedures can be done in conjunction with the urogynecologist's repair of an enterocele and cystocele. Perineal procedures include perineal rectosigmoidectomy (Altmeier procedure), mucosal sleeve resection (Delorme procedure), and anal encirclement (Thiersch procedure).

The abdominal procedures are associated with lower recurrence rates but higher morbidity rates. These procedures are generally reserved for younger patients who can tolerate general anesthesia. Resection rectopexies may improve the bowel habits of patients who complained of preoperative constipation and in whom have a markedly redundant rectosigmoid. Evacuation difficulties may continue to plague patients after suture or mesh rectopexies that may be due to stenosis by the foreign material or angulation of the redundant rectosigmoid.

Perineal procedures can be done under regional anesthesia to minimize the anesthetic risk for the high-risk patient. These procedures have decreased perioperative morbidity rates, shorter hospital stays, and quicker postoperative recoveries. Fecal incontinence rates and recurrence rates remain fairly high with the Altemeier procedure.

PREOPERATIVE PLANNING

It is our practice to get preoperative anesthesia clearance prior to undertaking surgery in these potentially high-risk patients. At that time the decision for epidural or general anesthesia can be discussed with the patient. Preoperative and postoperative care is similar to any patient undergoing a major pelvic operation. A bowel preparation is typically done the day prior to surgery. Since most of these patients have fecal incontinence, patients and their caregivers should be aware of the implications of the bowel preparation and plan accordingly. Oral antibiotics may be done in conjunction with the bowel preparation and prophylactic intravenous antibiotics are given within an hour of operation. Positioning the patient for the perineal procedures is surgeon dependent. A Foley catheter is placed prior to positioning the patients. Lithotomy position allows anesthesia better control of the airway with epidural anesthesia. The prone jackknife position allows greater flexibility for the

surgeon. The perineum and vagina are prepped in standard fashion.

SURGICAL TECHNIQUE

Anal Encirclement (Thiersch Procedure)

The Thiersch procedure was initially described in 1891 using a silver wire. Since that time other material such as nylon, silicone tubing, and Marlex mesh have been described as a means of preventing rectal prolapse by encircling and reinforcing the anal sphincter. This procedure can be done with local anesthesia minimizing the anesthetic risk in high-risk patients. A Thiersch wire or other synthetic material is used to encircle the anal canal preventing rectal prolapse. Two small incisions are made lateral to the external anal sphincter in the perineum (Figs. 163.3, 163.4 and 163.5). A submucosal tunnel is created around the anus. The mesh is placed through one of the incisions and advanced around the anal canal. The length of mesh and calibration of mesh tension are determined by the surgeon by placing an index finger within the anal canal. The mesh should be snug enough to prevent the prolapse while allowing enough room for elimination of stool.

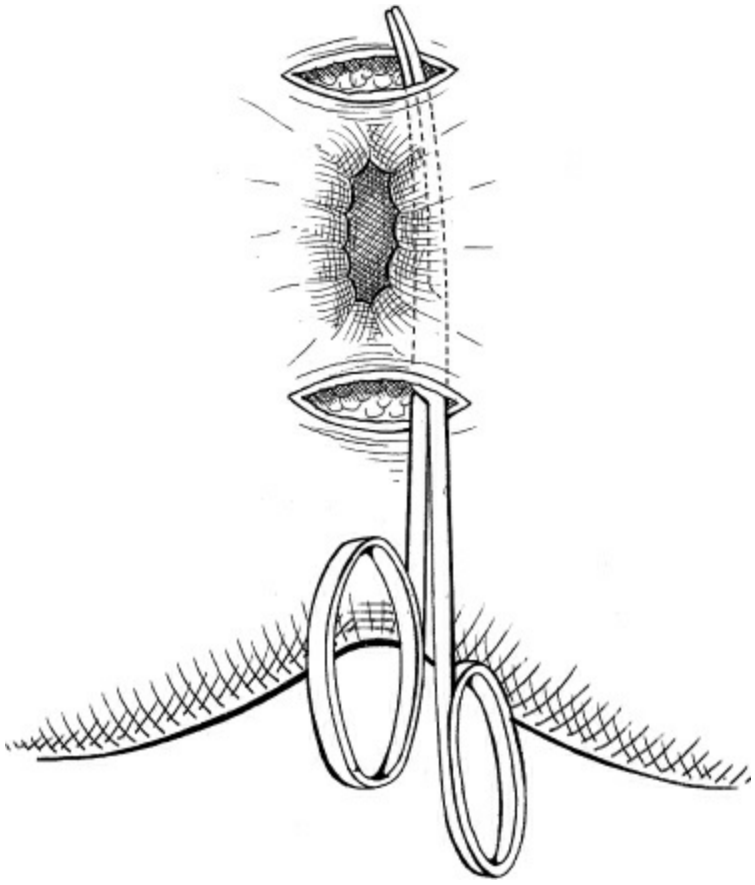

Figure 163.3. Two longitudinal incisions are made and a Kelly clamp is used to create a submucosal tunnel around the anus.

The Thiersch procedure does not eliminate the redundant rectosigmoid nor does it eliminate the rectum from descending into the anal canal. Persistent pressure and recurrent prolapse can occur. In addition, fecal impaction is a common occurrence after this operation (>80%), and stool softeners, laxatives, and enemas are necessary in the postoperative period. Pain is a frequent postoperative complaint, and erosion of the mesh can occur over time. Anal encirclement as a primary treatment for rectal prolapse has fallen into disuse. The only advantage of this operation is that it can be done with local anesthesia. It is generally reserved for moribund patients with limited life expectancies because the septic and mechanical complications are high.

Mucosal Sleeve Resection (Delorme Procedure)

In 1900, Delorme described a way of managing rectal prolapse by excising the rectal mucosal and submucosal layers and plicating the outer muscular layer of the rectum. This procedure avoids a full thickness rectal resection. The muscle plication may aid in improving fecal incontinence by adding bulk to the perineum.

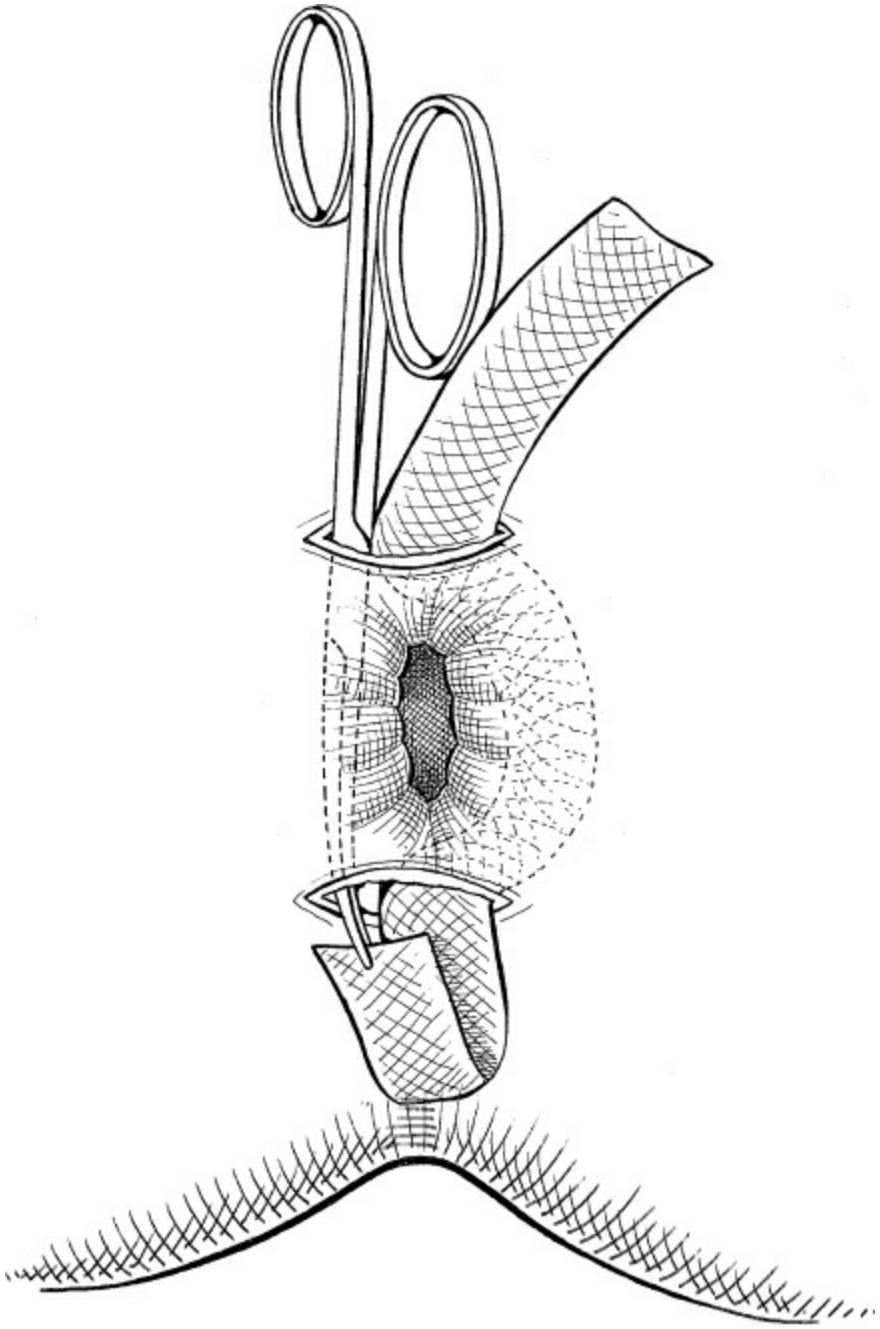

Figure 163.4. A mesh is passed through the submucosal layer to encircle the anus.

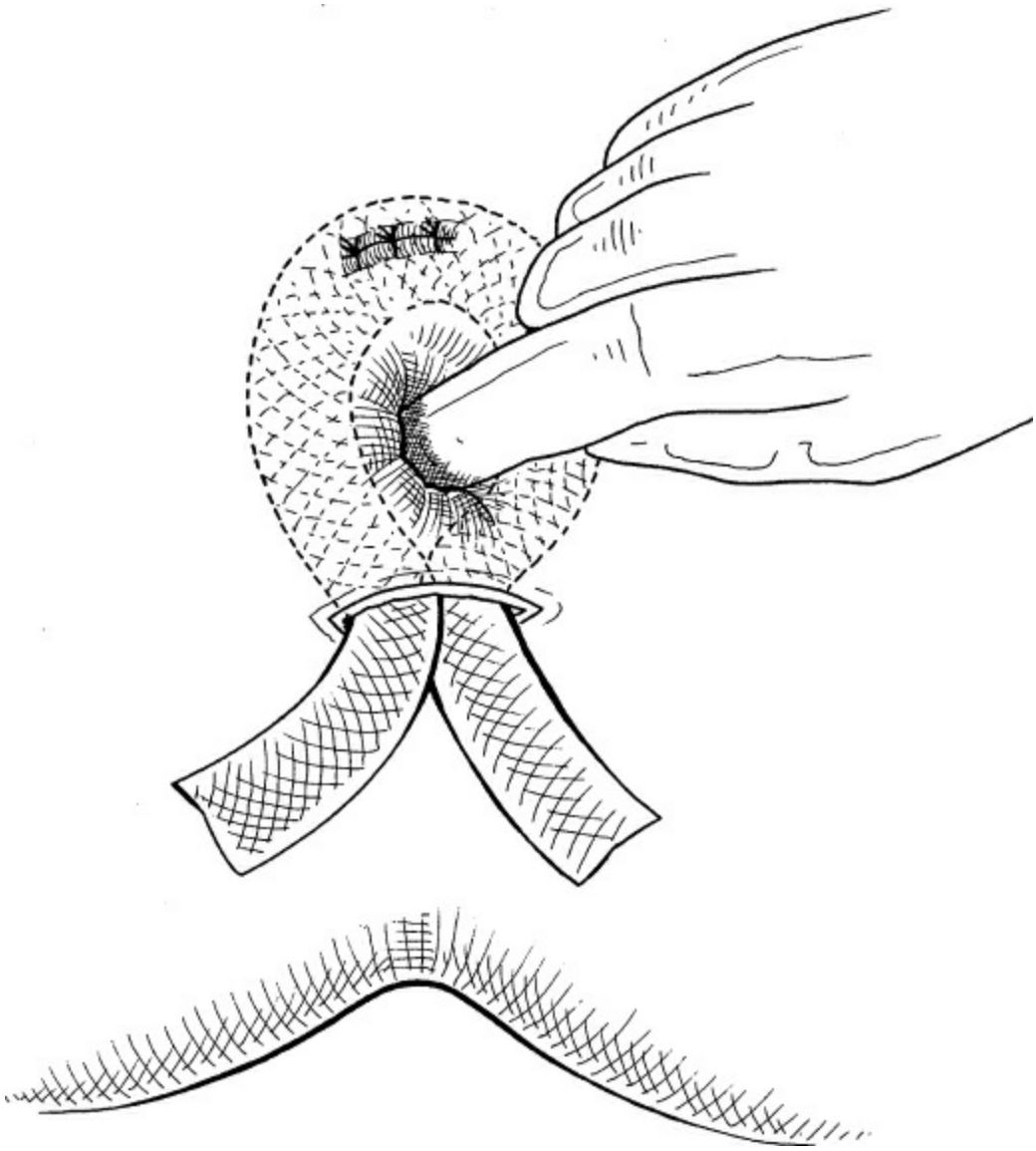

Figure 163.5. Calibration of the mesh tension is performed using a finger inserted into the anal canal.

Once the patient is in position (lithotomy or prone jackknife) and prepped, the rectum is prolapsed through the anal canal using Babcock clamps (Fig. 163.6). The submucosal layer is injected with an epinephrine solution approximately 2 cm above the dentate line to facilitate dissection and decrease bleeding. A circumferential incision is made 2 cm above the dentate line and completed through the mucosal and submucosal layer (Fig. 163.7). Care is taken not to do a full thickness dissection. The electrocautery is used to dissect the submucosal layer circumferentially along the length of the prolapse elevating it off of the underlying muscular layer of the rectum. The extent of dissection is determined by placing traction on the rectum delivering the entire prolapse through the anal canal

until tension is noted. Absorbable sutures are then placed in the muscular layer creating an accordion effect. The sutures are placed longitudinally beginning at the outer edge and ending just above the dentate line (Fig. 163.8). The stripped mucosa is resected after sutures are placed circumferentially around the rectum (Fig. 163.9). The muscular sutures are tied and the mucosal anastomosis is completed with absorbable sutures circumferentially placed around the anal canal (Figs. 163.10 and 163.11).

Although the Delorme procedure can be done with minimal morbidity and a short hospital stay, the recurrence rate is approximately 15% to 30%. The mean time to recurrence is 2 to 3 years. This procedure is not used as widely for treatment of full rectal prolapse because of concerns for recurrence of the prolapse. It is best used for patients with mucosal prolapse or those with short segment full prolapse.

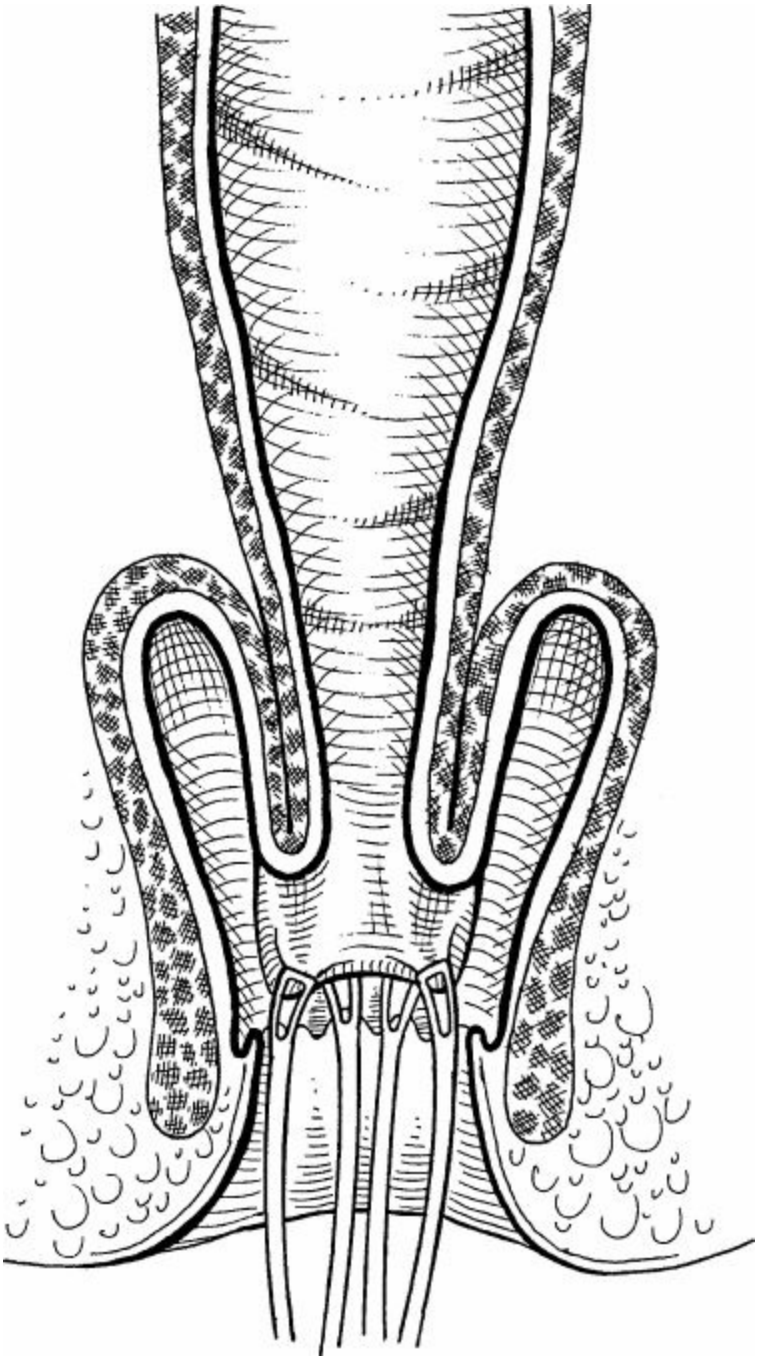

Figure 163.6. Rectal prolapse is delivered through the anus by Babcock clamps.

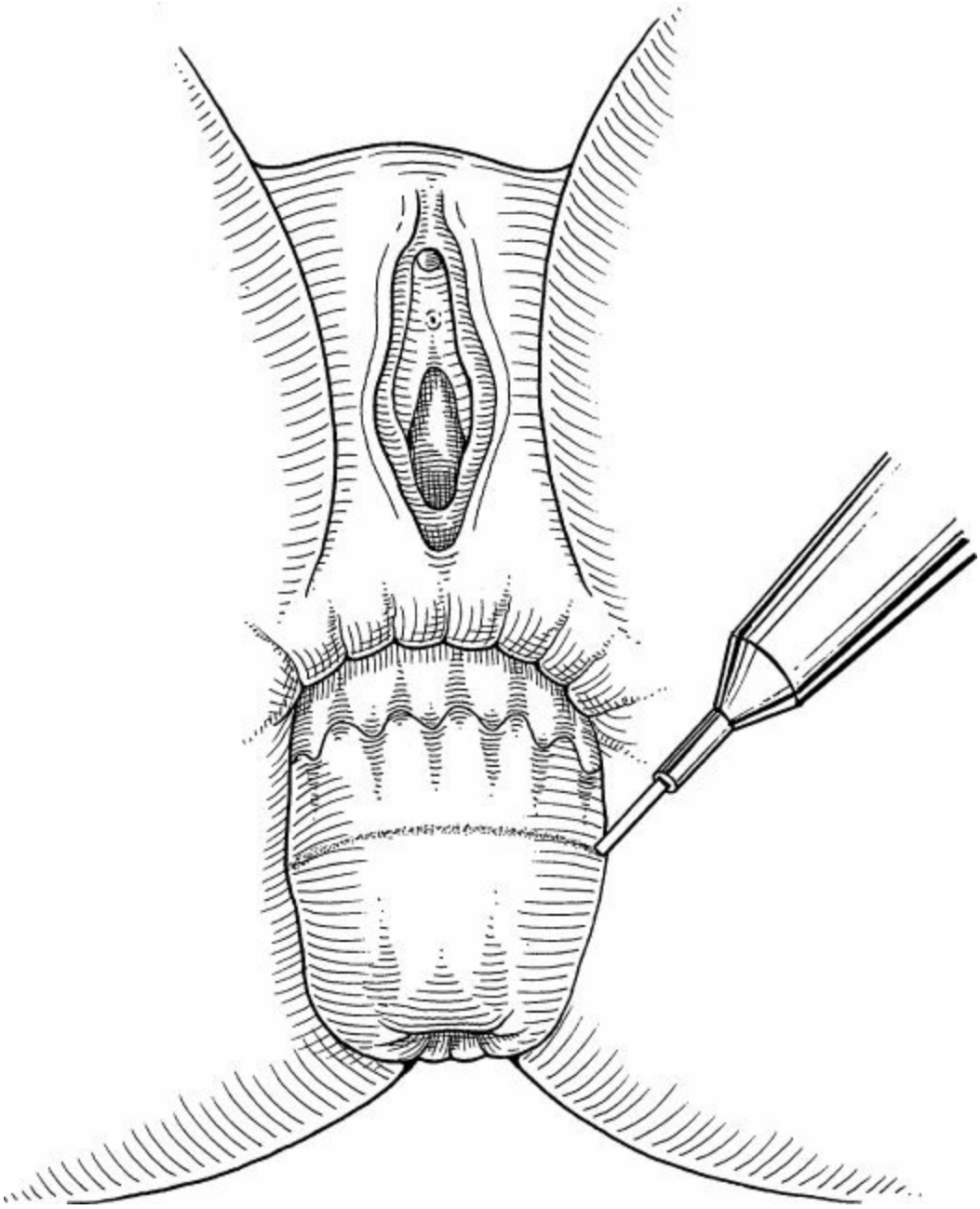

Figure 163.7. Incision is circumferentially marked 2 cm cranially to the dentate line by electrocautery.

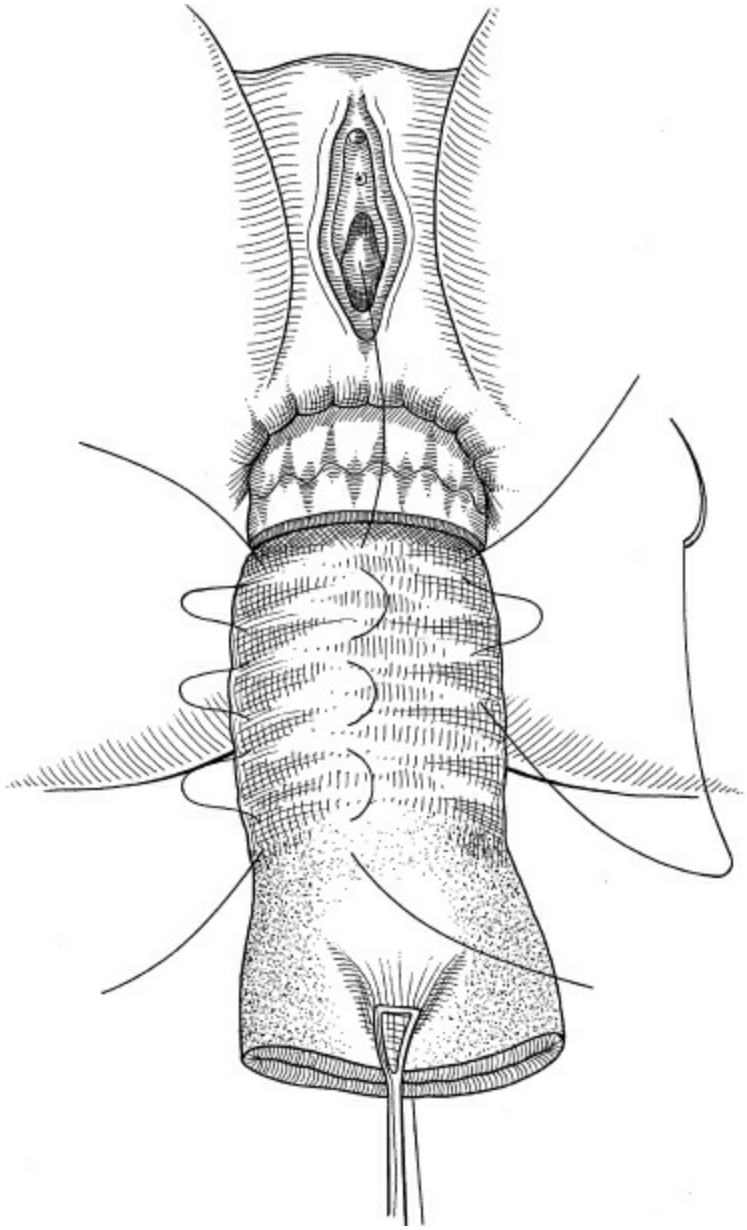

Figure 163.8. After the mucosal sleeve is stripped from the muscularis, plication of this layer is performed using longitudinal sutures.

Perineal Rectosigmoidectomy (Altemeier Procedure)

The perineal rectosigmoidectomy was first described by Mikulicz in 1889 and was the preferred operation for rectal prolapse until the mid-20th century. The variable results may have been secondary to inadequate mobilization of the rectum. In 1952 Altemeier described the perineal rectal sigmoidectomy with anterior levatorplasty. This modification was done to narrow the pelvic floor in an attempt to prevent recurrence and restore fecal continence. Prasad described a modification utilizing a posterior

levatorplasty to recreate the anatomic anal rectal angle in an effort to help patients gain fecal control postoperatively. These procedures can be easily performed under regional or general anesthesia in either the prone jackknife or lithotomy position.

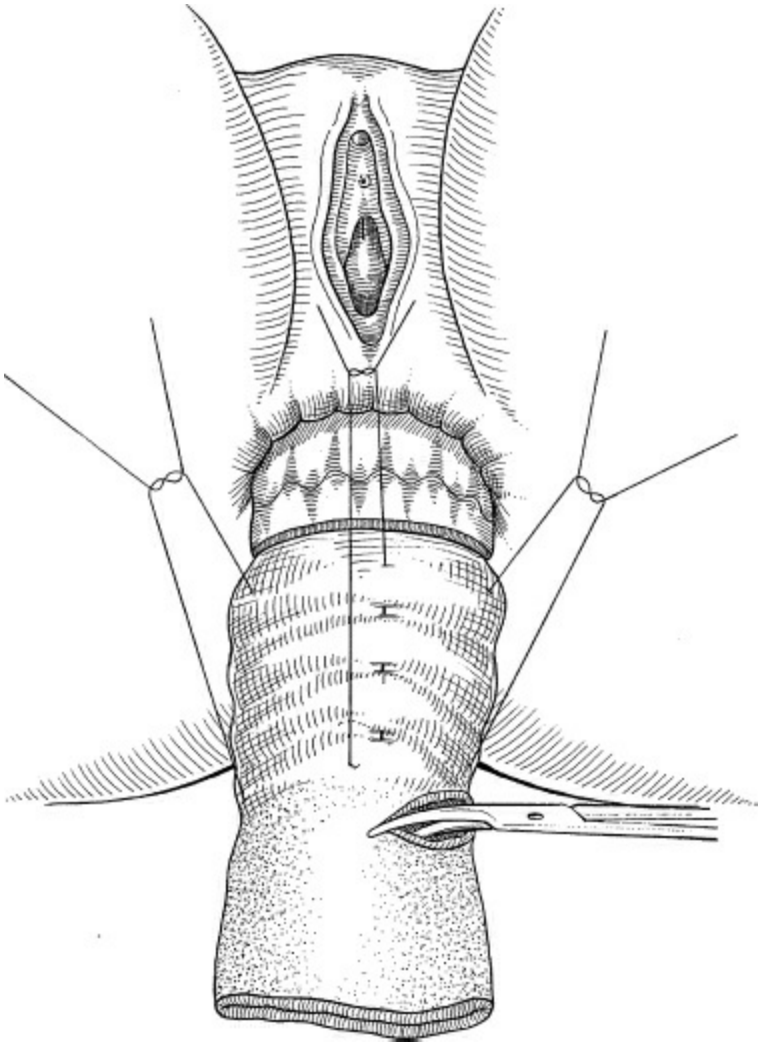

Figure 163.9. Plication of the muscular layer is followed by resection of the excess of stripped mucosa.

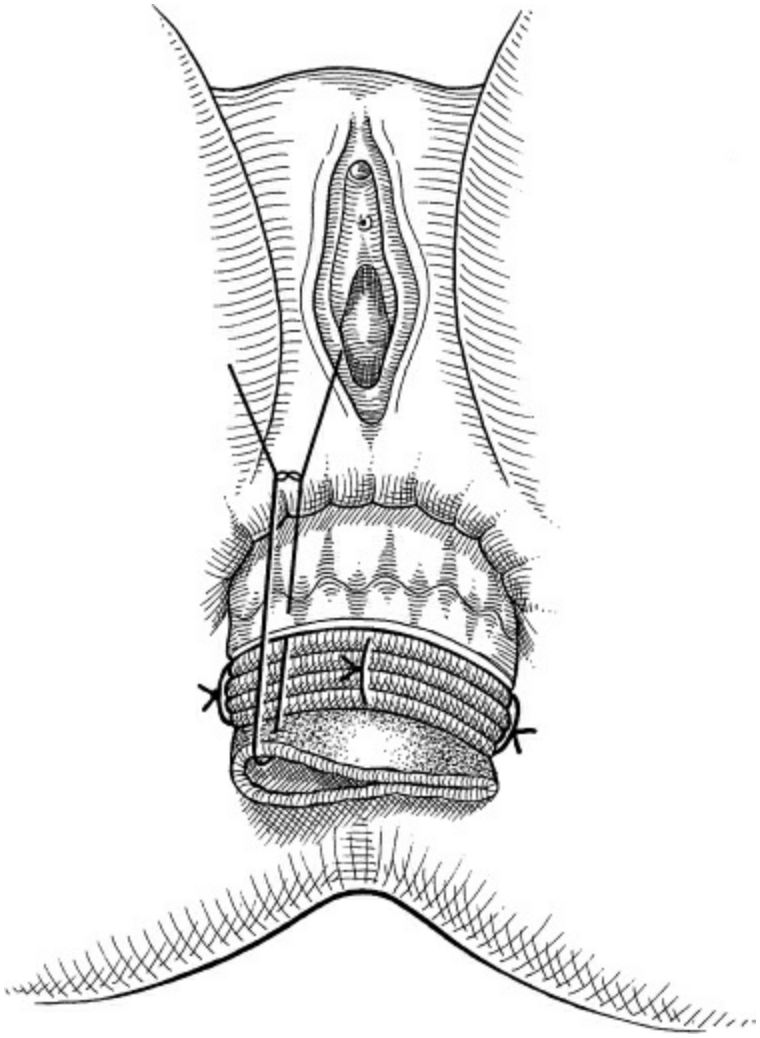

Figure 163.10. Mucosal coloanal anastomosis is performed with interrupted absorbable sutures.

Once the patient is in position and prepped, the rectum is prolapsed through the anal canal using Babcock clamps (Fig. 163.6). The mucosal layer is injected with an epinephrine solution approximately 2 cm above the dentate line to facilitate dissection and decrease bleeding. A Lone Star retractor is useful to evert the anal canal a circumferential incision is made approximately 2 cm above the dentate line (Fig. 163.7). The electrocautery is used to complete the dissection circumferentially. It is helpful to dissect each layer with separate passes of the cautery. After division of the mucosal layer, the dissection of the submucosal layer can be done slowly to minimize bleeding. The blood supply of the rectal wall resides within the submucosal layer. The incision is completed full thickness through the rectal wall. My preference is to then enter the pouch of Douglas between the rectum and vagina and extend the dissection laterally (Fig. 163.12). The posterior mobilization is done after completion of the anterior and

lateral dissection since this is where the redundant mesorectum and mesorectal vessels are found. The rectum is placed under tension, and the redundant mesorectum is divided sequentially (Fig. 163.13). Care must be taken to ensure that these vessels are tied tightly since retraction into the pelvis will occur. Palpation of intraperitoneal contents is feasible through the open pouch of Douglas. Dissection continues posteriorly in the mesorectum to completely mobilize the rectum and occasionally sigmoid colon until all of the redundant bowel has been mobilized. The peritoneum of the pouch of Douglas can be excised and closed with absorbable suture.

A posterior levatorplasty can be done prior to division of the colon (Fig. 163.14). Palpation of the levator ani muscles will ensure correct placement of the sutures. 0 Vicryl or nonabsorbable sutures can be placed. Typically 2 or 3 sutures are necessary to plicate the posterior anal canal. At this time, an anterior plication can also be done using similar sutures. The rectum should fit snugly within the anal canal.

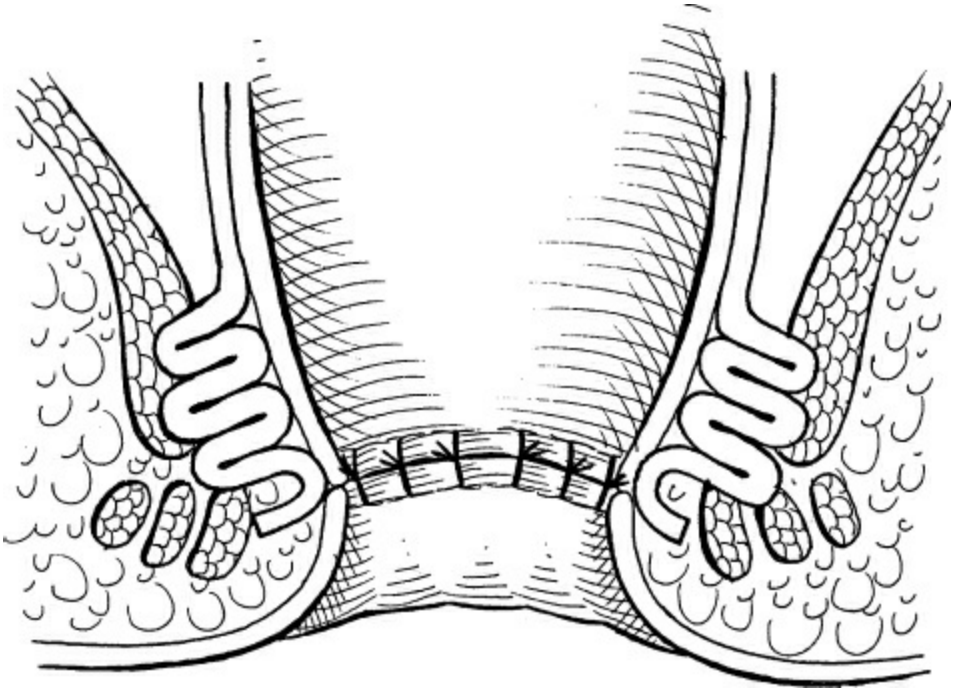

Figure 163.11. Final aspect of the anastomosis and underlying muscular plication.

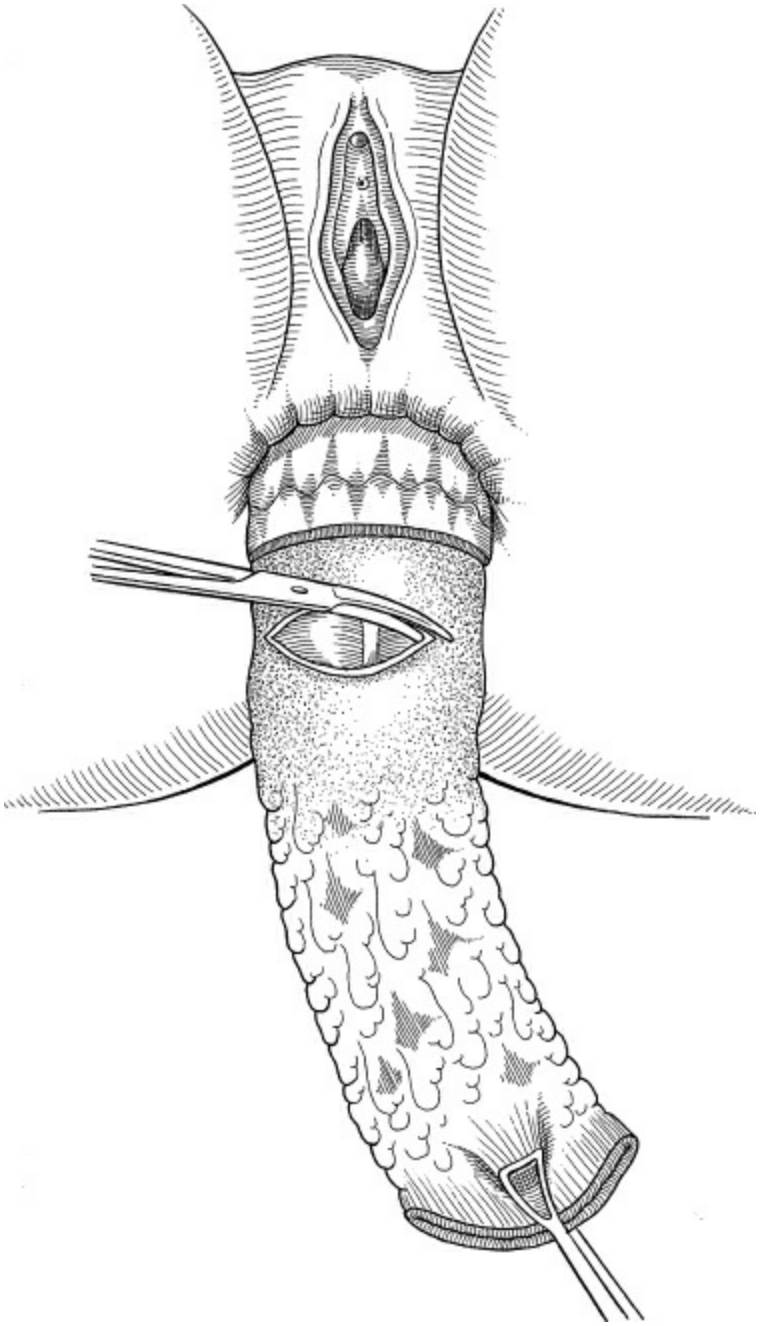

Figure 163.12. After careful mesorectum dissection, the Douglas pouch is opened transversally, facilitating full rectosigmoid mobilization and allowing the intraperitoneal contents to be palpated.

The level of the redundant colon to be transected is identified and marked circumferentially using the electro-cautery (Fig. 163.15). A handsewn or stapled anastomosis can be done at this point. My preference is to do a handsewn anastomosis to control for the size discrepancy between the proximal colon and anal canal. Absorbable anastomotic sutures are placed through the anal mucosa in all four quadrants and

tagged with the needles on. One half of the colon is divided and the anastomotic sutures are placed in their appropriate positions but left untied to prevent tension on the proximal bowel. The second half of the colon is divided and the remaining sutures are placed. It is helpful to tie these sutures after they have all been placed to avoid undue tension on the bowel wall. Placement of the sutures in this manner will ensure proper spacing since there will be a size discrepancy between the proximal colon and anal canal. After the four-quadrant sutures are tied, attention is turned to each quadrant. Sutures are then placed through the anal mucosa and the full thickness bowel wall and tied sequentially. Examination of the anastomosis is done to ensure that there are no defects or tears in the anastomosis.

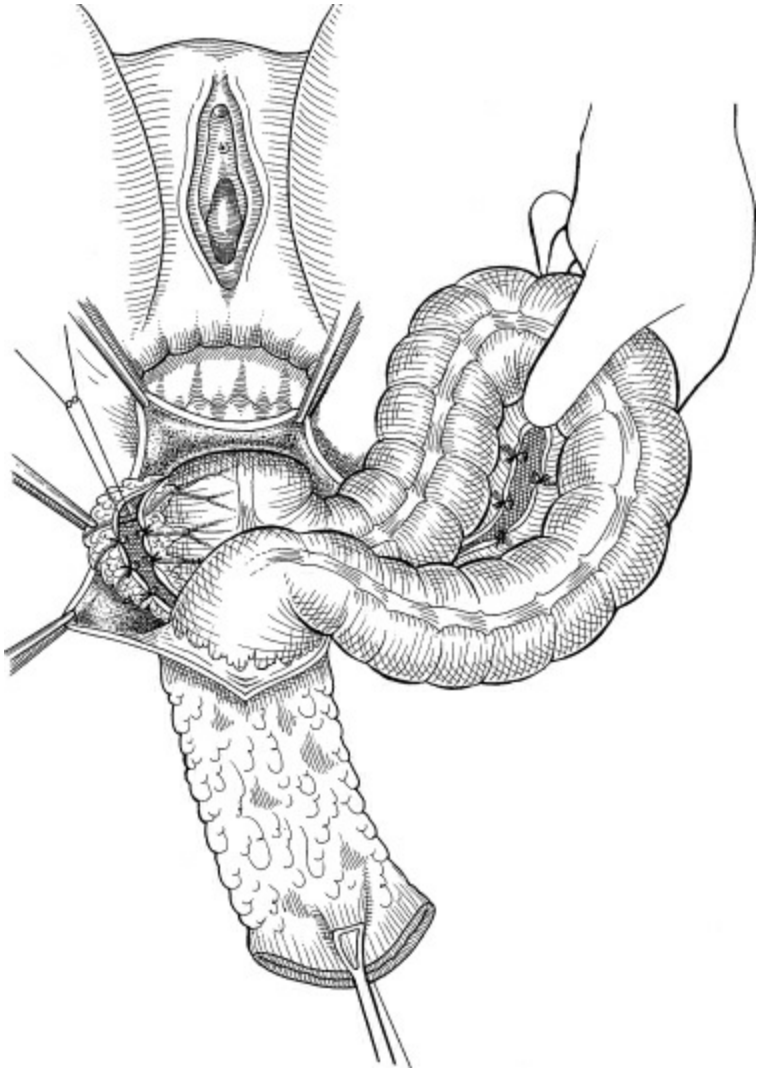

Figure 163.13. Mesocolic vessels are ligated until mobilization of the redundant bowel is complete.

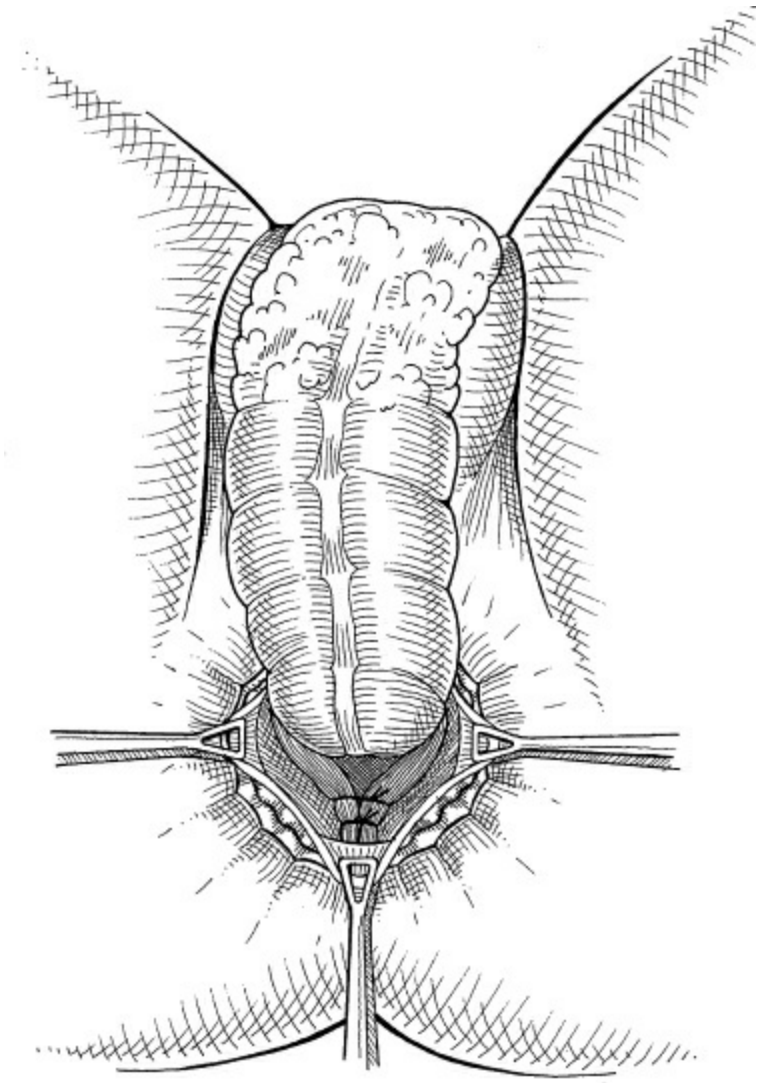

Figure 163.14. Posterior levatorplasty is performed with a 0 Vicryl suture (two to three stitches) until the bowel fits loosely in the opening.

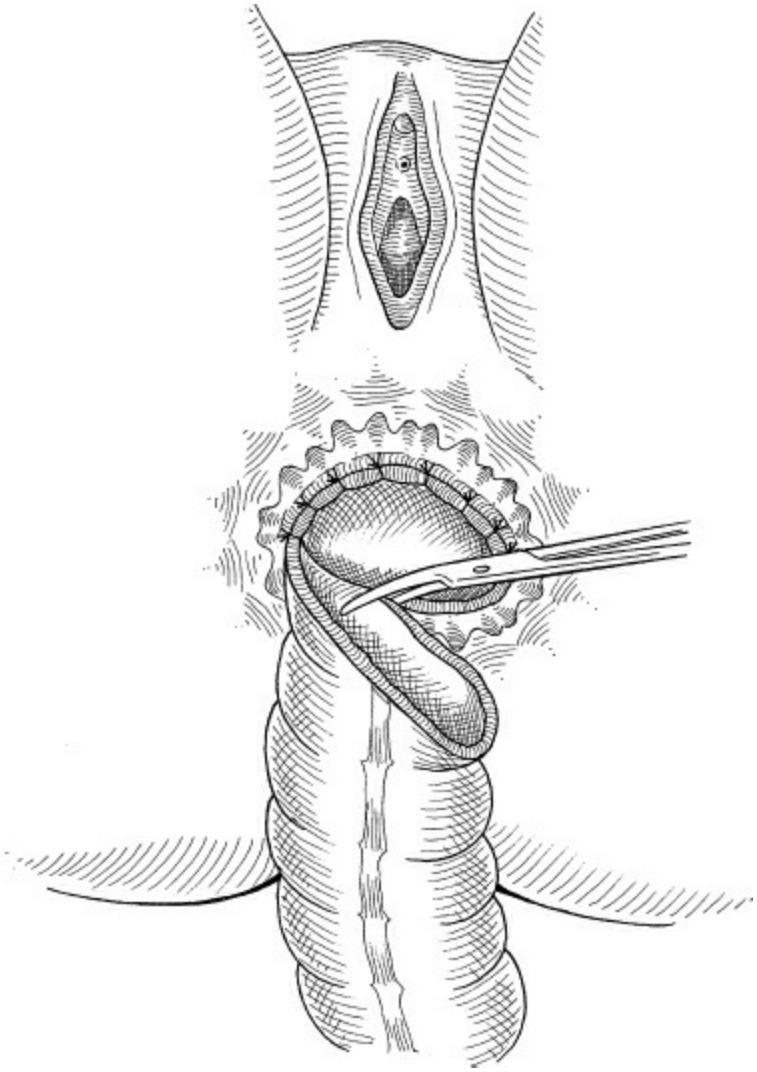

Figure 163.15. Once the anterior half has been cut and sutured, the posterior wall is sectioned and the anastomosis is completed with an interrupted suture.

An end-to-end stapled anastomosis can be performed utilizing a circular stapler (Fig. 163.16). The pursestring is placed on the proximal bowel, and the stapler head is tied in place. A second pursestring is fashioned on the distal bowel around the post of the stapler post. The stapler is then coupled, tightened, and fired making sure that the anastomosis is located above the dentate line (Fig. 163.17).

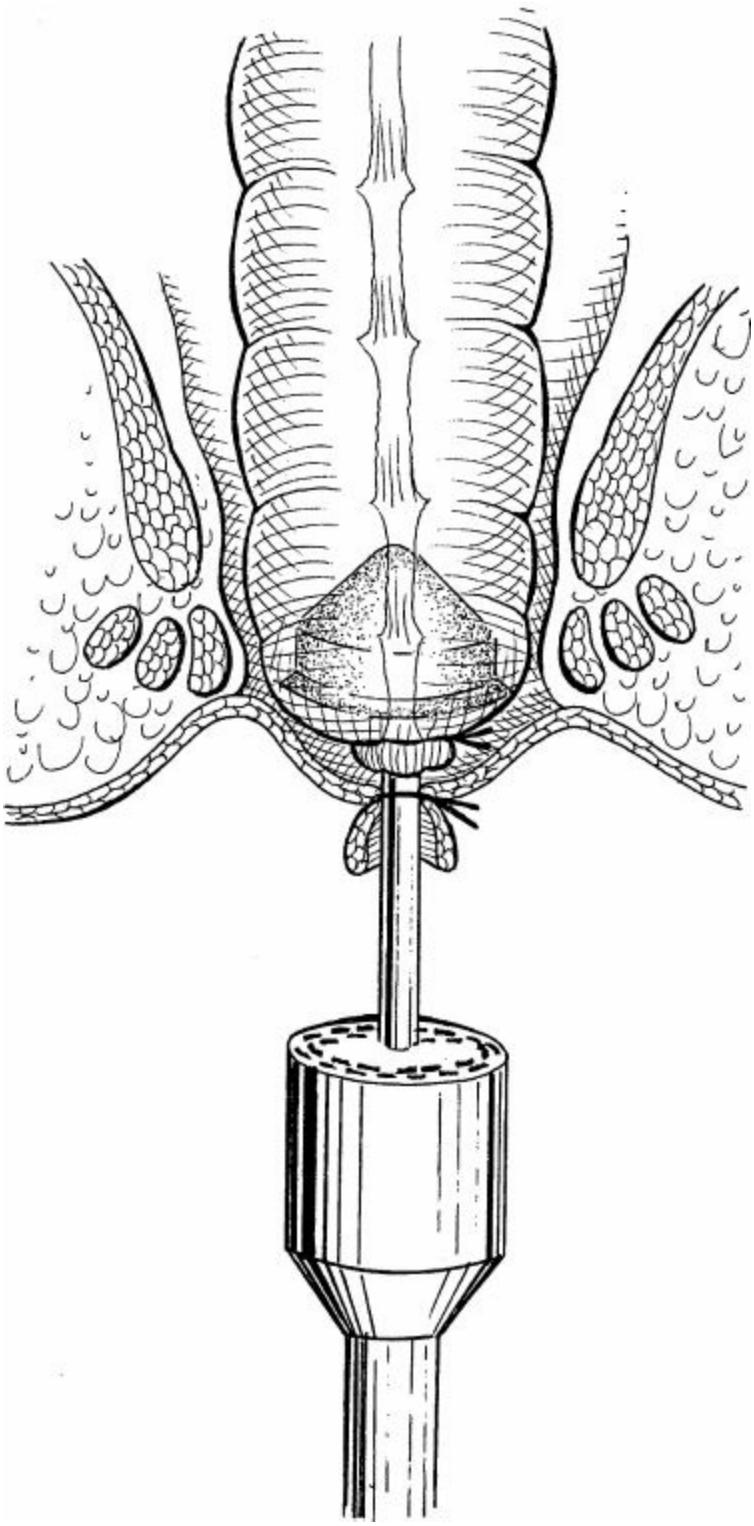

Figure 163.16. Coloanal anastomosis using circular stapling devices.

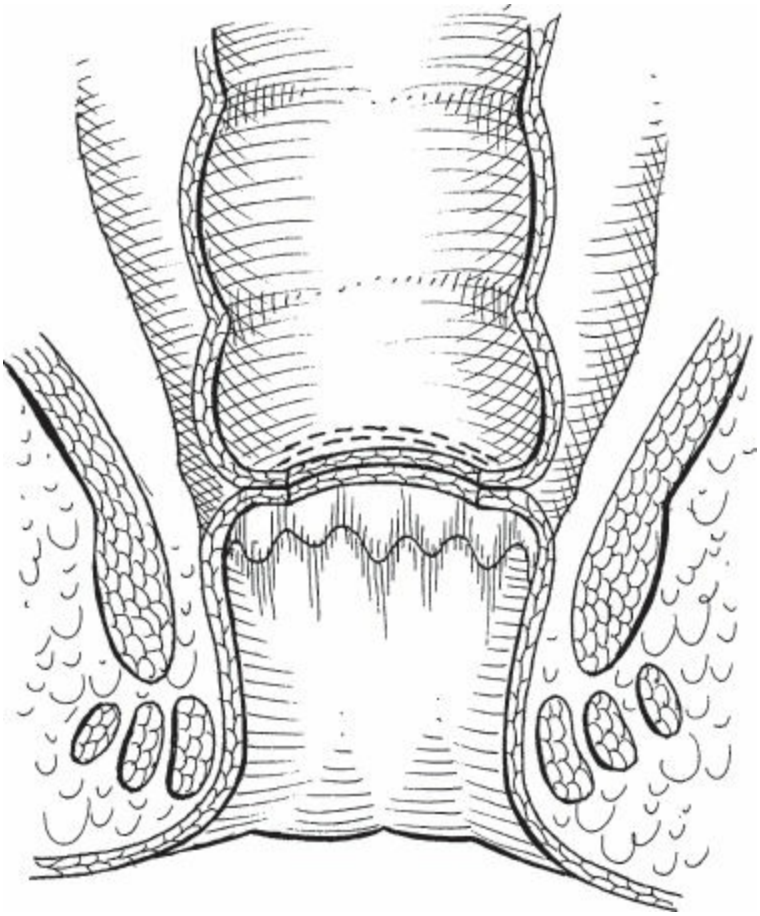

Figure 163.17. Final aspect of a stapled coloanal anastomosis.

POSTOPERATIVE MANAGEMENT

Patients can resume a diet and ambulate as soon as they tolerate it. The Foley catheter is typically removed on the first or second postoperative day. Discharge is done as soon as the patient tolerates a diet, voids, and has some bowel function. Postoperative medications depend on the patient's preoperative bowel function. If the patients have a history of severe constipation, it is our practice to discharge them on stool softeners and laxatives. Laxatives are not generally necessary if the patients have soft stool and incontinence. In general, patients do not complain of excessive pain after these operations. Mild analgesics and warm tub soaks may be useful in controlling the postoperative discomfort. Patients are counseled not to expect the fecal incontinence to improve in the immediate postoperative period. A follow-up appointment is generally scheduled 4 weeks from surgery and at that time a digital rectal examination should be done to ensure anastomotic healing.

COMPLICATIONS

Complications from perineal rectosigmoidectomy range from 0% to 32%. Deaths are rare and may be related to the patient's comorbidities. Pelvic hematomas, abscesses, or anastomotic dehiscence may occur early and require surgical intervention. Several studies have shown that the complication rates for infections and overall morbidity are higher with abdominal operations than for perineal procedures. Age does not seem to be a factor in complications, but there is a significant selection bias for most studies. Late complications include stricturing of the anastomosis that can be treated with digital dilation. Fecal incontinence is the most common postoperative complaint and can be managed with fiber and antidiarrheals, although it is not uncommon for this to be a persistent problem. Recurrent rectal prolapse can occur at variable rates and may be due to an incomplete resection or persistent straining. Studies have shown that recurrences are more common in stapled anastomoses and short specimen lengths. Studies with longer follow-up show higher rates of recurrences and not all patients with recurrences are treated surgically.

Suggested Readings

Altemeier WA, Culbertson WR, Schowengerdt C, et al. Nineteen years' experience with the one-stage perineal repair of rectal prolapse. *Ann Surg* 1971;173:993–1006.

Altemeier WA, Giuseffi J, Hoxworth PI. Treatment of extensive prolapse of rectum in aged and debilitated patients. *Arch Surg* 1952;65:72–80.

Bordeianou L, Hicks CW, Kaiser AM, et al. Rectal Prolapse: an overview of clinical features, diagnosis, and patient-specific management strategies. *J Gastrointest Surg* 2014;18:1059–69.

Chun SW, Pikarsky AJ, You SY, et al. Perineal rectosigmoidectomy for rectal prolapse: role of levatorplasty. *Tech Coloproctol* 2004;8:3–8.

Delorme R. Sur le traitement des prolapses du rectum totaux pour l'excision de la muscueuse rectal ou rectolique. *Bull Mem Soc Chir Paris (Bulletin et Memoires de la Societe des Chirugiens de Paris)* 1900;26:499–518.

Glasgow SC, Birnbaum EH, Kodner IJ, et al. Preoperative anal manometry predicts continence after perineal proctectomy for rectal prolapse. *Dis Colon Rectum* 2006;49:1052–8.

Madoff RD, Mellgren A. One hundred years of rectal prolapse surgery. *Dis Colon Rectum* 1999;42:441–50.

Madsen MA. Perineal approach to rectal prolapse. *Clin Colon Rectal Surg* 2008;21:100–5.

Mikulicz J. Zur operation behandlung des prolapsus recti et cold invaginati. *Arch Klin Chir* 1889;38:74–97.

Prasad ML, Pearl RK, Abcarian H, et al. Perineal proctectomy, posterior rectopexy and postanal levator repair for the treatment of rectal prolapse. *Dis Colon Rectum* 1986;29:547–52.

Ricciardi R, Roberts PL, Read TE, et al. Which operative repair is associated with a higher likelihood of reoperation after rectal prolapse repair? *Am Surg* 2014;80:1128–31.

Tiengtianthum R, Jensen CC, Goldberg SM, et al. Clinical outcomes of perineal proctectomy among patients of advanced age. *Dis Colon Rectum* 2014;57:1298–1303.

EDITOR'S COMMENT

Dr. Birnbaum's chapter on perineal approaches for the treatment of rectal prolapse describes three operations: (1) the Thiersch, (2) Delorme, and (3) Altemeier* (perineal proctectomy) procedures. The Thiersch procedure is rarely performed in adults, as it is associated with significant postoperative complications due to its restrictive encirclement of the anal canal, which can result in problems with subsequent fecal impaction. When utilizing foreign bodies such as mesh bands, this procedure can also be associated with erosion of the device into the rectum or anal canal and/or infection of these foreign bodies.

The Delorme procedure, although anatomically attractive in that it avoids bowel resection and buttresses or plicates the rectal wall, is technically challenging for many surgeons to perform, particularly in a prolapsed rectum, in which the overlying mucosa has become extremely edematous and hyperemic from chronic prolapse. Elagili and colleagues cited the advantages of the Delorme procedure as its shorter hospitalization as compared to a perineal proctectomy and lesser rate of complications (Elagili F, Gurland B, Liu X, et al. Comparing perineal repairs for rectal prolapse: delorme versus Altemeier. *Tech Coloproctol* 2015;19(9):521–5). Although the operation was associated with a higher rate of recurrent prolapse, the authors concluded that if this should occur, the patient can still undergo a repeat transanal Delorme without compromising the vascular supply of the rectum.

In the hands of many surgeons, however, the Altemeier procedure, or perineal proctectomy, is the easiest and most direct approach to treat rectal prolapse, particularly in elderly, frail individuals. Despite the fact that it is in essence a handsewn coloanal anastomosis, and the fact that one enters the peritoneal cavity in almost all cases due to the very low level of the pouch of Douglas in these patients, this procedure has a low morbidity and mortality rate. In a study of over 500 patients undergoing perineal proctectomy over an 8-year

period, Tiengtianthum and colleagues found that both early and late postoperative complication rates were low (5.6% and 3.5%, respectively) and did not differ by age (comparing patients <70 years old, 70 to 79 years of age, 80 to 89 years old and those over 90) (Tiengtianthum R, Jensen CC, Goldberg SM, et al. Clinical outcomes of perineal proctectomy among patients of advanced age. *Dis Colon Rectum* 2014;57(11):1298–303). Dr. Birnbaum describes that this procedure can be done in either the prone or supine position. Because of the very frequent and high number of comorbidities present in these patients, when I perform this procedure it is always done in the supine position with the patient in lithotomy position in “candy cane” stirrups, providing easy airway access for the anesthesiologist. Depending on the frailty of the patient, this procedure can even be performed using only local anesthesia with some accompanying mild intravenous sedation or using a saddle block; however, it is sometimes difficult to find an anesthesiologist who is capable of performing this type of regional anesthesia. Because of their multiple comorbidities, anesthesiologists are frequently leery of administering general anesthesia to these patients. The main portion of the procedure that is associated with discomfort is traction on the mesentery. For this reason, if possible, I prefer to use general anesthesia or local anesthesia with monitored anesthesia care, that is, additional intravenous sedation such as with propofol or midazolam.

Although Dr. Birnbaum describes the use of circular stapled anastomoses, she describes in detail the discrepancy in lumen size between the proximal “pulled-through” colon and the diameter of the very distal rectum/anal canal. This is definitely true and poses a significant risk for a leak even if great care is taken in placing the distal purse string suture. Another variant of a stapled perineal procedure has been described using a combination of linear and curved stapling devices (GIA and Contour staplers, Ethicon Endo-Surgery, Cincinnati, Ohio) (Sehmer D, Marti L, Wolff K, et al. Midterm results after perineal stapled prolapse resection for external rectal prolapse. *Dis Colon Rectum* 2013;56(1):91–6). With this type of approach however, the mesenteric vessels are not ligated. These staple loads are not vascular staplers, many patients undergoing this type of surgery are anticoagulated, and postoperative bleeding from the staple line (and presumably the mesenteric vessels) has been reported despite the authors oversewing their staple lines with absorbable monofilament suture. Although the authors report a short operation time (33 minutes), their operating room time savings are more than offset by consumables in terms of staple loads. I believe that handsewn anastomoses are more reliable. I also prefer, prior to constructing the coloanal anastomosis to perform a posterior levator plication. This sounds complicated, but is easy to do. Several sutures (I use 2-0 polypropylene) are used to bring the right and left levator muscles together posteriorly. This narrows the anal canal, but more importantly helps reestablish a more normal, more acute anorectal angle, which is usually not present in these patients.

There has been a great deal of controversy in the past decade regarding the

possible adverse effects of mechanical bowel preparation on the rate of postoperative complications following colorectal surgery, with sometimes differing outcomes reported for rectal as opposed to colon surgery (Bretagnol F, Panis Y, Rullier E, et al.; French Research Group of Rectal Cancer Surgery [GRECCAR]. Rectal cancer surgery with or without bowel preparation: The French GRECCAR III multicenter single-blinded randomized trial. *Ann Surg* 2010;252(5):863–8; Güenaga KF, Matos D, Wille-Jørgensen P. Mechanical bowel preparation for elective colorectal surgery. *Cochrane Database Syst Rev* 2011;9:CD001544). In this chapter, Dr. Birnbaum describes a preoperative bowel preparation. It is often difficult to give elderly patients preoperative bowel preparation. In many cases, this is associated with significant electrolyte disturbances and dehydration and generally associated with more harm than good. Almost all of these patients are constipated and the rectal prolapse seems to function like a "cork in a bottle." Getting a good bowel prep is difficult! While no one relishes working in a field full of stool, I think it is preferable to have some solid bowel movement in the area, rather than a large amount of liquid diarrhea, as is frequently present when patients have had a mechanical bowel preparation. In many cases, a single preoperative enema can clear the rectum prior to surgery to facilitate the surgeon's work (Pittet O, Nocito A, Balke H, et al. Rectal enema is an alternative to full mechanical bowel preparation for primary rectal cancer surgery. *Colorectal Dis* 2015;17(11):1007–10). This may, however, be difficult as these patients frequently have greatly reduced sphincter tone and often cannot hold enemas well. While we had previously always kept these patients NPO for several days, with the increased use of enhanced recovery pathways we have immediately fed these patients a regular diet and not observed any difference in morbidity, but have noticed a quicker time to bowel function, a happier patient and a shorter hospital stay, all of which are desirable.

Dr. Birnbaum accurately states that incontinence is a frequent problem after these perineal procedures for rectal prolapse. This is definitely true, and is an important part of the preoperative discussion with the patient and family. I typically advise patients that there can be up to a 6-month period of significant incontinence postoperatively. There is typically a chance for continued improvement until the anal sphincter regains its tone. After that, there is less chance for additional functional improvement. The availability of sacral nerve route stimulation (see Chapter 166 Fecal Incontinence by Keighley) may, however, allow for additional improvement in continence in some of these patients.

Because the reservoir function of these patients is lost, that is, the rectum is removed, and the proximal colon is of much narrower caliber, postoperative patients most frequently have multiple smaller bowel movements throughout the day. This is very similar to an anterior resection syndrome and patients must be counseled regarding this. This can be problematic in the older patient who has decreased mobility. Postoperatively, the use of methylcellulose fiber

products (Citrucel), as well as medications such a loperamide, which slows intestinal transit, while at the same time increases internal anal sphincter tone, can help to regulate bowel habits.

There is a high recurrence rate following repair of rectal prolapse. This is due mainly to the pre-existing laxity of the pelvic floor. I typically advise these patients to avoid heavy lifting, that is, anything heavier than 20 lb postoperatively. If a recurrence occurs, this can be treated with a repeat procedure, beginning the rectal transection at the previous anastomosis site.

Susan Galandiuk

---

*Editor's Comment: I must correct something that has bothered me for a long time and that is the unfortunate credit for what was called the "Altemeier" procedure. I was chair at the University of Cincinnati, for 23 years, and during my time Bill Culberston actually did almost all of the procedures, took care of the patients, and got paid next to nothing. Dr. Altemeier received most of the credit, and Bill Culbertson did all the work. After I arrived as chair I doubled Dr. Culbertson's salary. He asked for nothing and was a careful, meticulous surgeon. The procedure should have been called the Culbertson procedure. I am happy to give him the credit that I think he deserves.

164 Anorectal Disorders

Michael R. B. Keighley

Fissure in ANO

CLINICAL PRESENTATION

The principal clinical presentation of fissure in ano is intense anal pain during defecation, often associated with a small amount of bright red bleeding noticed on the toilet paper. There may be perianal swelling from a skin tag and discharge of mucus. There is often a sensation of tearing during defecation, and there may be a dull ache in the perineum 3 to 4 hours after bowel evacuation.

Women are more commonly affected than men, in a ratio of ~58% to 42%, respectively. Most patients are in the third decade of life, but fissure can occur at any age and is well recognized as a cause of pain and constipation in children. Fissure may be exacerbated by a recent episode of constipation and straining. It commonly occurs in women after vaginal delivery. It may occur as a complication of severe diarrhea.

Inspection of the perineum reveals a small, shallow anal ulcer with a sentinel pile and edema, usually in the posterior aspect of the anal margin, particularly in men. Fissures occur anteriorly in 40% of women.

CAUSES

The causes of fissure in ano are unknown. Primary fissure is often associated with alteration in bowel habit, particularly an episode of constipation. Postpartum fissure may be a result of tearing of the anterior aspect of the anal canal during childbirth. Local trauma is believed to be responsible for the initial skin defect that leads to a boat-shaped ulcer, resulting in chronic symptoms.

Primary fissure in ano may be acute. If healing does not occur, the fissure becomes chronic, in which case the ulcer enlarges in size. There is edema around the fissure associated with an anal skin tag. In 10% of chronic fissures, there is a low intersphincteric anal fistula communicating

between the base of the fissure and the dentate line.

Anal fissure is associated with increased resting anal canal pressures. Motility studies reveal ultraslow waves indicative of increased internal anal sphincter activity. Some data suggest that anal fissure is associated with a local reduction in blood flow. Healing of anal fissures is associated with a return to normal anal canal pressures with normal blood flow measurements.

Secondary fissure in ano may occur as a complication of Crohn disease, anal tuberculosis, or acquired immunodeficiency syndrome (AIDS). Occasionally, fissure in ano may complicate a previous operation on the anal canal. Fissures complicating Crohn disease and tuberculosis are often painless. By contrast, anal fissures and ulcers complicating AIDS are often intensely painful and are associated with incontinence and local sepsis.

DIAGNOSIS

Diagnosis of anal fissure can usually be achieved by inspection. Gentle parting of the buttocks reveals an edematous skin tag and a shallow anal ulcer, usually situated posteriorly in men but anteriorly in women. There is puckering of the perianal skin as a result of intense spasm of the anal sphincters. Digital examination is often impossible and should not be attempted in patients with severe pain, because the diagnosis can be made by inspection. In patients with chronic anal fissure, digital examination and proctoscopy are often well tolerated. The fissure has edematous margins and is boat shaped, with the transverse fibers of the internal anal sphincter seen at the base of the fissure.

Sigmoidoscopy should be performed in patients who can tolerate a rectal examination to exclude a primary cause for fissure in ano and any rectal pathology.

TREATMENT: CONSERVATIVE

Nonspecific Medical Therapy

Up to 70% of chronic anal fissures will heal by conservative therapy alone. If patients have a history of chronic constipation, treatment should include a bulk laxative, such as methylcellulose or psyllium hydrophilic mucilloid, with a mild laxative, such as bisacodyl or docusate sodium. Patients should be told to avoid straining and be instructed in basic anal hygiene.

Application of local nonsteroidal preparations to control pain may be

helpful. Local anesthetic agents may be effective, particularly for acute anal fissure. Steroid preparations may be used to reduce inflammation. A wide variety of commercially available ointments and suppositories exist, which consist of local anesthetic and steroid preparations. The cumulative relapse rate after these forms of medical treatment for chronic anal fissure is ~50% at 12 months.

Specific First-Line Therapy: Nitric Oxide Donors or Calcium Channel Blockade

No patient in the United Kingdom today is treated by sphincterotomy for anal fissure unless at least first line, and in some cases, second-line treatment is used because of the fear of bowel incontinence with sphincterotomy.

The most widely used first-line therapy is with nitric oxide donors, usually glyceryl trinitrate cream, but other formulations of topical nitrates give identical results. The cream is applied, where possible, over the fissure after defecation and at night initially, increasing the applications to four times a day if symptoms do not rapidly improve. The principal complication is headache, occurring in 30% to 40%, but if treatment can be tolerated, there is tachyphylaxis in most people such that the headaches do not persist for more than 5 to 6 days. Nitric oxide donors are not tolerated in 20% to 30% because of persistent headache. If patients are able to persist with therapy for 4 weeks, there is complete alleviation of anal pain in 60% to 70%, but in 10% to 20% there may be a relapse of the anal fissure during the next 3 months. Thus, healing is achieved in 45% to 60% of patients in 3 months. For those who relapse a repeat treatment course achieves healing in a further 20% to 30%, overall healing is 60% to 80%.

If patients have a persistent anal fissure and symptoms or cannot tolerate nitric oxide donors the alternative first-line therapy is the use of diltiazem, a calcium channel blocker. Diltiazem cream is used topically over the fissure twice daily initially but up to four applications a day if needed. The preparation is more expensive, but there are virtually no side effects. The outcome in terms of resolution of pain is comparable to those achieved with topical nitrates; pain free at 4 weeks 60% to 70%, with healing at 3 months of 40% to 60%. For those who relapse a repeat course achieves healing in 20% to 30%, overall healing is 60% to 80%.

Specific Second-Line Therapy: Botulinum Toxin

When first-line therapy fails, injection of Botulinum toxin into the intersphincteric plane away from the fissure, usually at 3 and 9 o'clock, with a dose varying from 2.5 to 20 units at each site achieves healing in 40% to 60%. Complications include transient incontinence, hematoma, or sepsis, but these are unusual. For refractory cases, repeat injection can be used. Since transient incontinence is now recognized, patients must be warned about this.

Surgical Principles

Patients with anal fissure can be treated surgically during an office visit or in an outpatient surgical unit, but an operation should not be advised until specific first- or second-line treatment has been vigorously pursued. The purpose of surgical treatment is to reduce excessive activity in the internal anal sphincter. In the past, this was attempted by anal dilatation, but now only sphincterotomy is used and only after very thorough counseling about the risks of impaired continence.

Anal dilation results in disruption of the fibers of the internal and external anal sphincters. Unfortunately, anal dilatation is associated with a variable risk of bowel incontinence depending on risk factors, but incontinence to flatus is common and may be permanent. For this reason, anal dilatation is no longer advised for the treatment of anal fissure and will, therefore, not be described.

The alternative is internal anal sphincterotomy, which results in division of a part of the internal sphincter, but leaves the external sphincter intact. Sphincterotomy may be performed as a subcutaneous, blind technique or may be performed as an open operation. All patients having sphincterotomy must be warned that there is a risk of temporary or even permanent bowel incontinence following treatment. Preoperative bowel preparation with a disposable enema is usually advised. Postoperatively, the patient should be prescribed adequate analgesics and local anesthetic creams, as well as a mild laxative to avoid postoperative constipation. Patients should be warned that there is a 3% risk of postoperative bleeding, and that local pain may continue for 2 to 3 weeks. Flatus incontinence and soiling is usually transient, lasting only 2 to 3 months, but may occur in 20% to 40% of patients. Long-standing incontinence and soiling may complicate internal sphincterotomy and is not confined to patients in whom a part of the external sphincter has been inadvertently divided. It

can occur when the internal anal sphincter alone has been divided.

SURGICAL TECHNIQUE

Closed Lateral Subcutaneous Internal Sphincterotomy

This procedure may be performed with local or general anesthesia. The intersphincteric groove is identified. Twenty milliliters of a local anesthetic with a weak adrenaline solution is infiltrated in the submucosal and the intersphincteric planes. A fine cataract blade is inserted in the intersphincteric groove with the blade lying parallel to the circular fibers of the internal sphincter. The cataract blade is then rotated, so that the blade faces the lumen of the anal canal. With the surgeon's index finger in the anal canal, the cataract blade is advanced toward the index finger so as to divide the internal sphincter, but not the anal mucosa (Fig. 164.1). A small tampon is placed in the anal canal to prevent hematoma.

Open Internal Sphincterotomy

This is the author's preferred surgical procedure. The patient may be placed in the prone jackknife or the lithotomy position, depending on the surgeon's preference. The lateral aspects of the submucosal and intersphincteric planes are infiltrated with a local anesthetic and a weak adrenaline solution. An anal speculum is inserted to expose the lateral aspect of the anal canal. A circumanal incision is made just inside the anal canal and below the dentate line for a length of ~1.0 to 1.5 cm. Scissors are used to develop the submucosal plane so that the anal mucosa can be lifted from the internal sphincter and to develop the intersphincteric plane so that there can be no damage to the external sphincter. Once the lower fibers of the internal sphincter have been clearly separated from other structures, internal sphincterotomy consists of dividing the internal sphincter with scissors for a length of ~2 cm (Fig. 164.2). The results of the closed and open sphincterotomy are comparable. Complete relief of pain and healing of the fissure is recorded in 70% to 90% of patients. It is hardly ever necessary to contemplate a second sphincterotomy for patients with persistent symptoms and in any event this would not be advised on account of the very high risk of permanent incontinence with a second sphincterotomy.

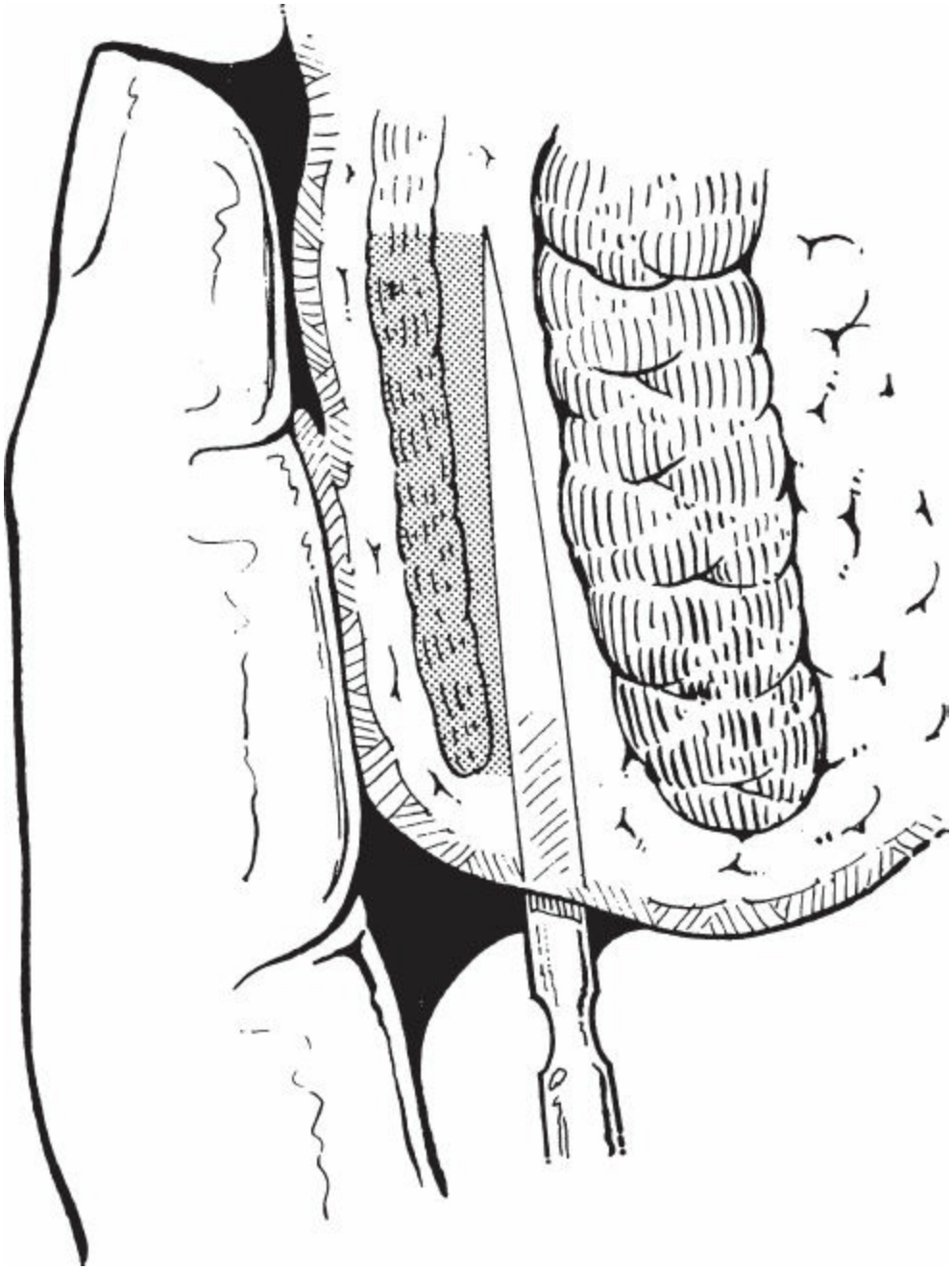

Figure 164.1. Closed lateral subcutaneous sphincterectomy under general anesthetic. (From Keighley MRB, Williams NS. *Surgery of the Anus, Rectum, and Colon*. 3rd ed. Philadelphia, PA: WB Saunders; 2008, Copyright © MRB Keighley MA MS FRCS.)

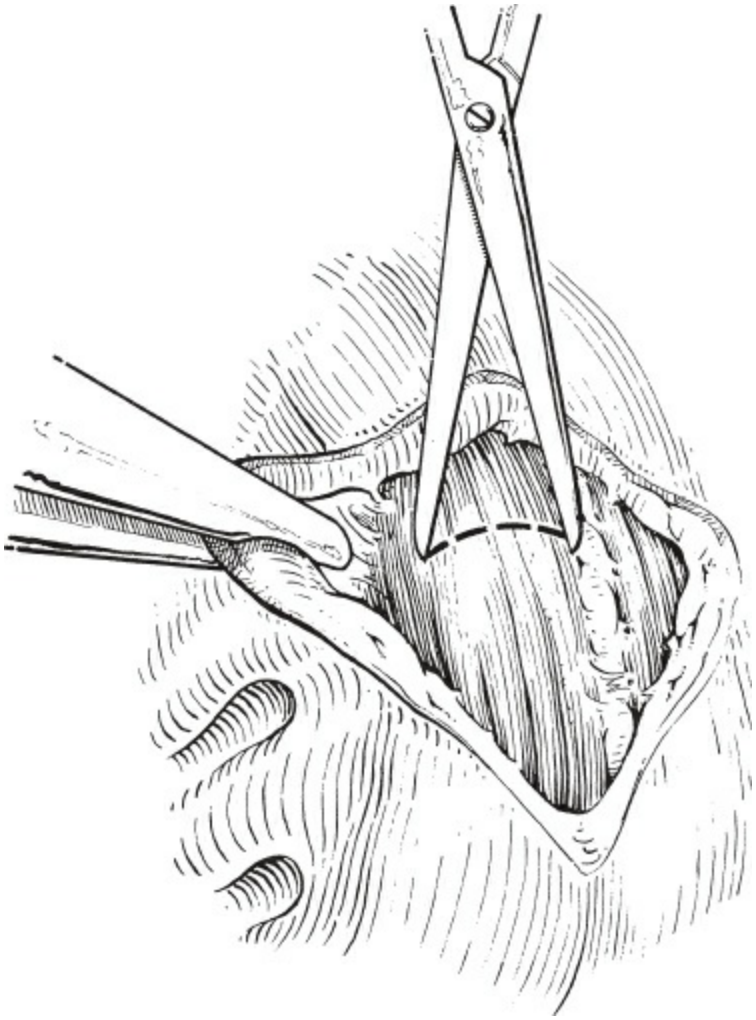

Figure 164.2. Open internal sphincterectomy. (From Keighley MRB, Williams NS. *Surgery of the Anus, Rectum, and Colon*. 3rd ed. Philadelphia, PA: WB Saunders; 2008, Copyright © MRB Keighley MA MS FRCS.)

We never advocate posterior sphincterotomy or excision of the anal fissure, sometimes termed "fissurectomy," because these operations may be complicated by a gutter deformity in the anal canal and thus result in soiling and impaired continence.

Anorectal Abscess

CLINICAL PRESENTATION

Anorectal sepsis usually presents with anal pain, swelling, and fever. There may be associated swelling and discharge around or within the anal canal. Approximately 30% of patients give a history of a previous episode

of anorectal sepsis that has spontaneously discharged or required surgical drainage. Constitutional symptoms are common, and swelling is obvious in patients with ischiorectal abscess, because large volumes of pus under tension give rise to fever, malaise, anorexia, and weight loss. By contrast, swelling may not be evident in patients with intersphincteric and submucous abscesses; similarly, patients with supralevator abscess may have no swelling but have constitutional symptoms. In secondary anorectal sepsis, there may be a history of AIDS, pelvic inflammatory disease, Crohn disease, malignancy, or previous anal surgery.

CAUSES

Anorectal sepsis arises from an infection in an anal gland or as a skin infection. Acute infection of an anal gland results in a chronic intersphincteric collection of pus that spreads upward in the intersphincteric plane causing a supralevator abscess, or downward in the intersphincteric plane causing a perianal abscess. Alternatively, pus may spread through the external sphincter and result in an ischiorectal abscess or may spread through the internal sphincter and result in submucous abscess. Occasionally, as a result of surgical intervention, pus may spread through the levators and cause supralevator collections of pus (Fig. 164.3).

Anorectal sepsis from an infection of an anal gland originates from intestinal organisms; thus, the predominant organisms recovered from culture are *Escherichia coli* and other gram-negative aerobic bacteria or anaerobic organisms from the large bowel, particularly *Bacteroides* species.

Some perianal abscesses arise from an infection in the skin and are merely a manifestation of a boil, furuncle, or carbuncle around the anal canal. True skin infections are almost always staphylococcal in origin and are not associated with an internal communication with the anal canal. Thus, culture of pus is helpful in establishing whether an anorectal abscess may have a coexisting anal fistula. Anorectal abscess with intestinal organisms is associated with an underlying anal fistula in 70% of patients. A fistulous communication with the anal canal virtually never occurs in patients with staphylococcal anorectal sepsis.

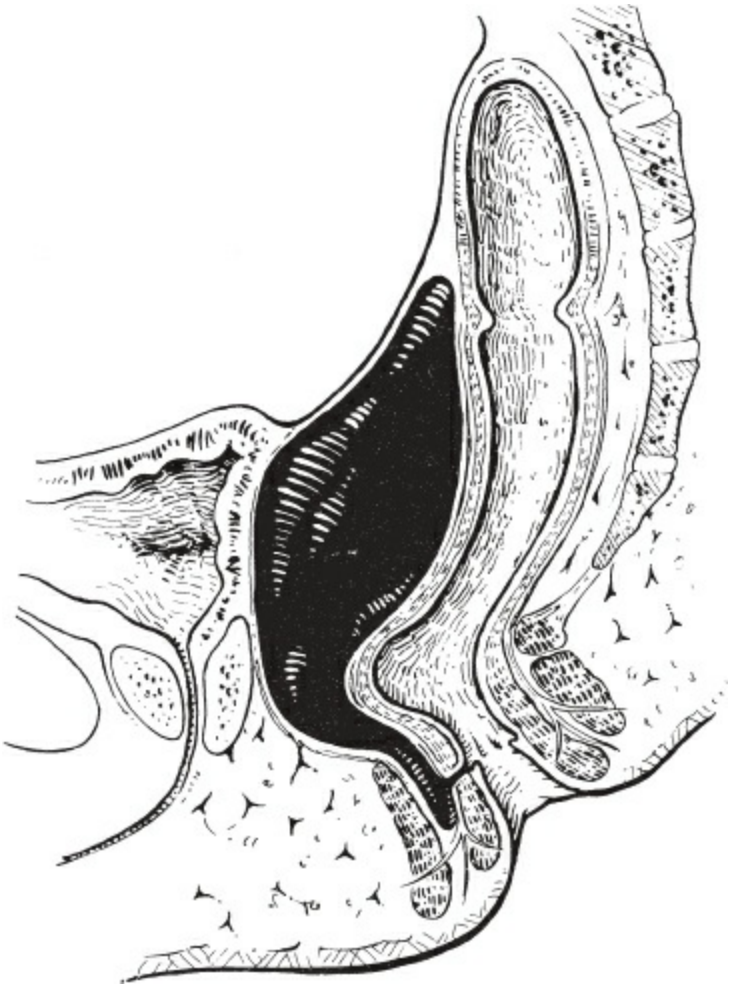

Figure 164.3. Suprasphincteric abscess. (From Keighley MRB, Williams NS. *Surgery of the Anus, Rectum, and Colon*. 3rd ed. Philadelphia, PA: WB Saunders; 2008, Copyright © MRB Keighley MA MS FRCS.)

The five classic sites of anorectal sepsis are (in order of frequency): (a) perianal (60%), (b) ischiorectal (20%), (c) intersphincteric (5%), (d) supralevator (4%), and (e) submucosal (1%) (Fig. 164.4). Supralevator abscesses may occur as a result of upward spread in the intersphincteric space or as a result of overenthusiastic surgical intervention to drain an ischiorectal abscess, creating a track through the levators. Anterior supralevator abscesses are more common in women, and posterior supralevator abscesses are more common in men. Supralevator abscess may occur as a result of disease in the pelvis, such as appendicitis, gynecologic sepsis, colorectal cancer, diverticular disease, or Crohn disease, or as a result of trauma to the large bowel.

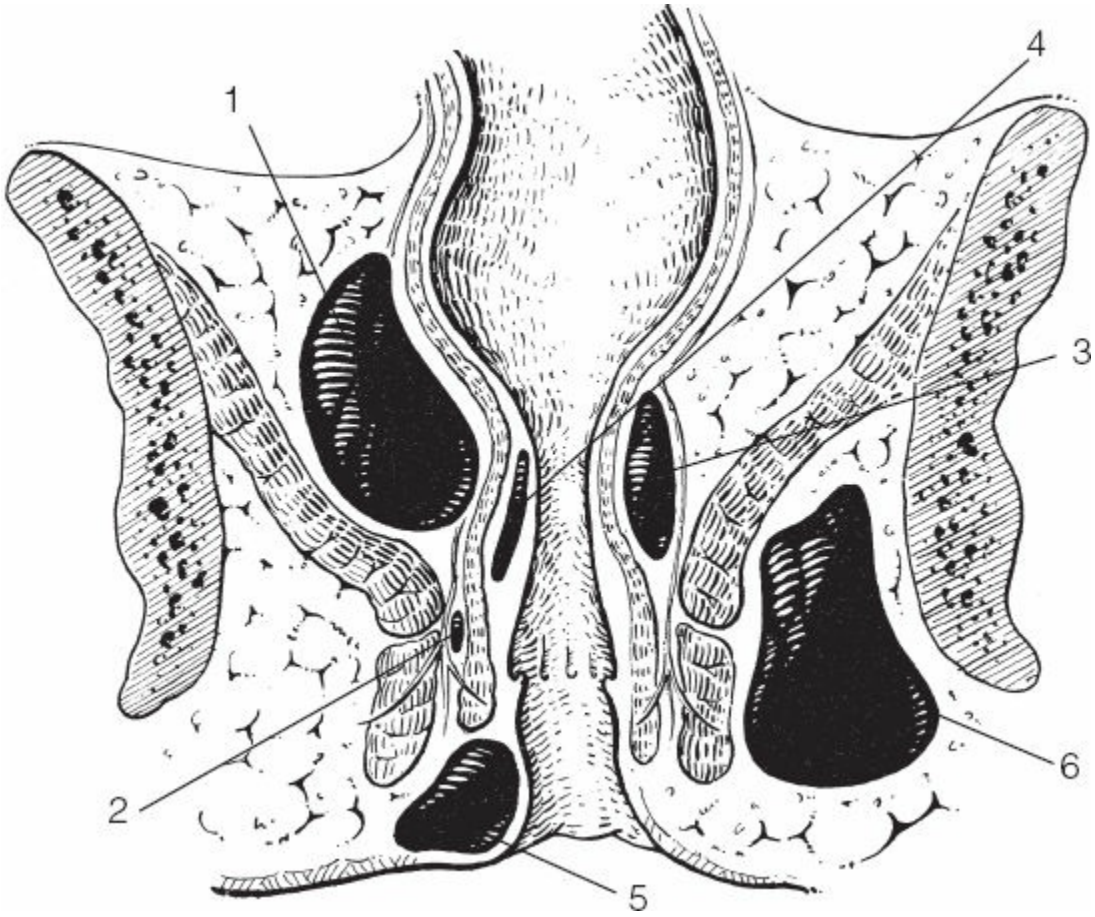

Figure 164.4. Classification of anorectal sepsis. (From Keighley MRB, Williams NS. *Surgery of the Anus, Rectum, and Colon*. 3rd ed. Philadelphia, PA: WB Saunders; 2008, Copyright © MRB Keighley MA MS FRCS.)

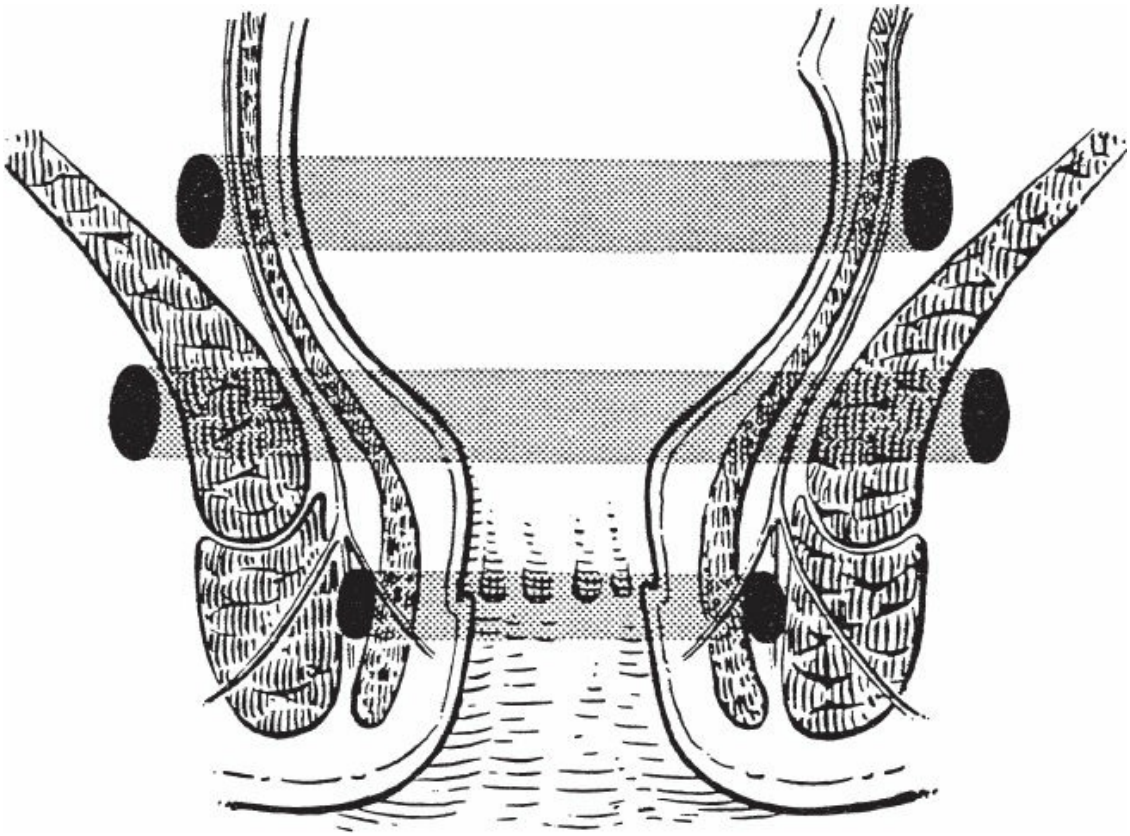

Figure 164.5. Circumferential spread of perianal sepsis. (From Keighley MRB, Williams NS. *Surgery of the Anus, Rectum, and Colon*. 3rd ed. Philadelphia, PA: WB Saunders; 2008, Copyright © MRB Keighley MA MS FRCS.)

Spread of anorectal sepsis may also occur circumferentially in the three spaces surrounding the anal canal: supralevator space, ischiorectal fossa, and intersphincteric space (Fig. 164.5).

DIAGNOSIS

Diagnosis of anorectal sepsis is usually obvious clinically by a large, painful, red swelling over the buttock (ischiorectal abscess) or a small, well-circumscribed, red, tender fluctuant swelling near the anal margin (perianal abscess). Inspection may fail to reveal intersphincteric sepsis or supralevator abscess. The presence of pus may be confirmed by needle aspiration, but in patients who do not have an obvious collection in the ischiorectal fossa or the perianal region, diagnosis may require examination under anesthesia, magnetic resonance imaging (MRI), or anal ultrasonography. In our experience, anal ultrasonography is helpful in identifying intersphincteric and submucous collections, but it is incapable of imaging sepsis in the supralevator space or in the ischiorectal fossa.

MRI has become the investigation of choice for obscure and complex anorectal sepsis.

Proctosigmoidoscopy should be performed to exclude sepsis from a primary cause, such as AIDS, pelvic sepsis, inflammatory bowel disease (particularly Crohn disease), anal malignancy, and sepsis resulting from previous anal surgery.

Conservative Therapy

Conservative treatment is never advised for treatment of anorectal sepsis. The practice of prescribing antimicrobial agents in the hope of resolving infection around the anal canal should be discouraged. Antibiotic therapy simply delays adequate surgical drainage. Delay in drainage results in chronic infection and destruction of tissue, particularly if there is synergistic gangrene and necrotizing fasciitis. Delay is often complicated by extensive fibrosis and long-term impairment of function, with incontinence and stricture.

SURGICAL TECHNIQUE

Our preference is early surgical drainage in almost all instances, except possibly in patients with hematologic disorders associated with neutropenia and thrombocytopenia. The principles of drainage are accurate localization and complete drainage. Careful examination under anesthesia is essential to define the site of infection. Pus is sent for immediate culture, and patients are carefully followed to identify recurrent sepsis or an underlying anal fistula. We do not attempt to identify an underlying anal fistula at the time of primary drainage, because we believe that an attempt to identify and treat the underlying fistula may result in anal destruction and compromise continence. Thus, our policy is careful follow-up and reinvestigation only if there is clinical evidence of underlying fistula. Postoperatively, patients are given analgesics and a mild laxative to prevent postoperative constipation. Careful follow-up is necessary, because there is a 30% risk of recurrence of sepsis and a 40% risk of subsequent anal fistula. In some patients, there may be evidence of underlying inflammatory bowel disease, pelvic sepsis, or sexually transmitted disease, which may become evident only during follow-up.

Drainage of Perianal Abscess

A small perianal abscess is incised using a cruciate or saucer-shaped incision so that pus can be adequately drained. A drainage tube is not inserted. The procedure may be performed in the physician's office under caudal or general anesthesia (Fig. 164.6).

Ischiorectal Abscess

A cruciate incision is made to the site of maximum swelling, pus is allowed to drain, and a finger is gently inserted into the ischiorectal fossa to break down any loculi. It is essential to check that there has been no posterior circumferential spread to the opposite side. A drain is not usually left in situ unless the ischiorectal abscess is bilateral or chronic. These operations are much better performed with the patient under general anesthesia. Great care must be taken not to damage the levator plate, which will convert an ischiorectal abscess into ones with a supralevator extension (Fig. 164.7).

Drainage of Intersphincteric Abscess

These abscesses are difficult to identify and to localize, and examination with the patient anesthetized is essential. A small incision is made transversely just inside the anal canal and below the dentate line. The intersphincteric space is identified and, with scissor dissection, the plane between the internal and external sphincters is exposed. If the intersphincteric abscess is well localized, the internal sphincter is divided and the abscess is drained. A small mushroom catheter is left in situ and sutured into position. Failure to insert a mushroom catheter results in contraction of the sphincter muscles because of postoperative pain and impaired drainage, causing recurrent sepsis.

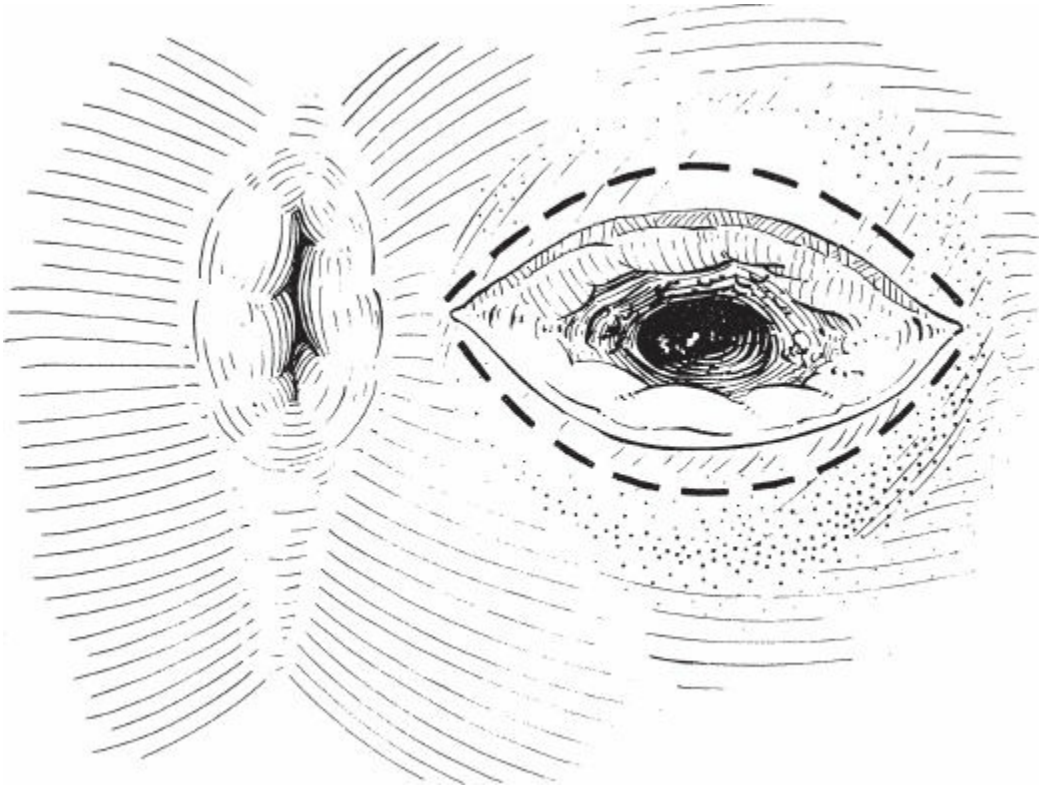

Figure 164.6. Drainage of a perianal abscess. (From Keighley MRB, Williams NS. *Surgery of the Anus, Rectum, and Colon*. 3rd ed. Philadelphia, PA: WB Saunders; 2008, Copyright © MRB Keighley MA MS FRCS.)

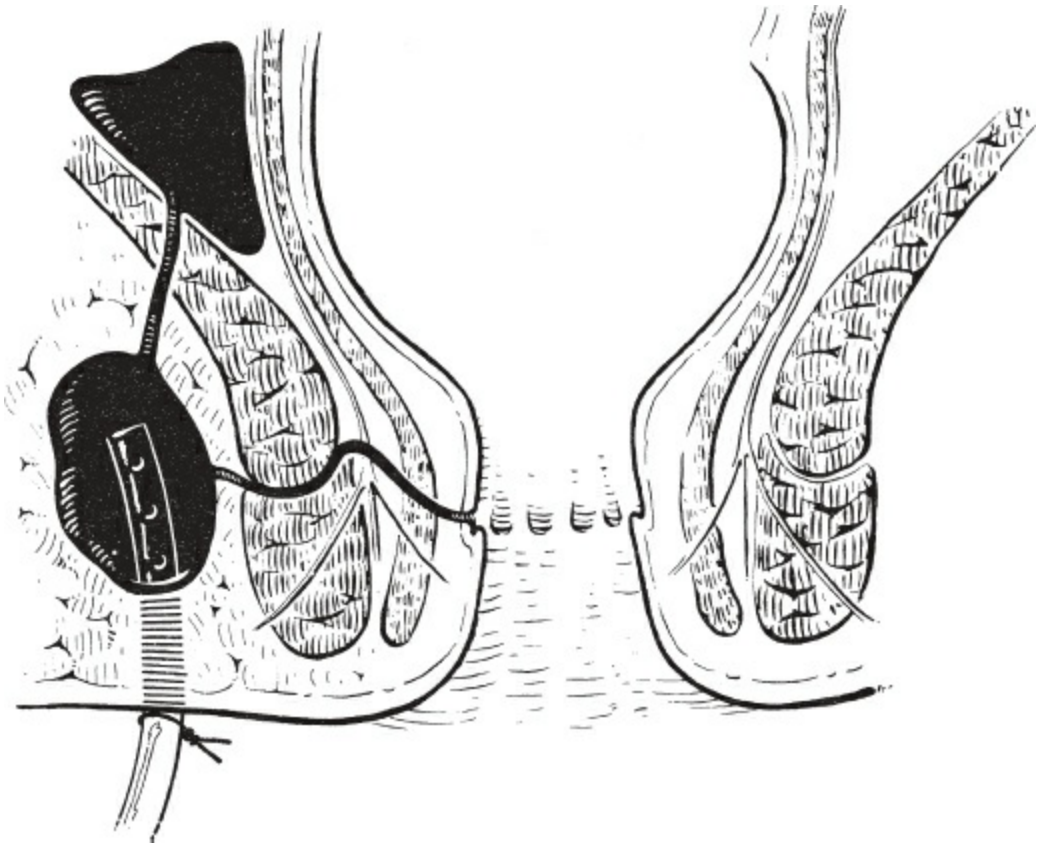

Figure 164.7. Drainage of an ischiorectal abscess and avoidance of suprasphincteric spread. (From Keighley MRB, Williams NS. *Surgery of the Anus, Rectum, and Colon*. 3rd ed. Philadelphia, PA: WB Saunders; 2008, Copyright © MRB Keighley MA MS FRCS.)

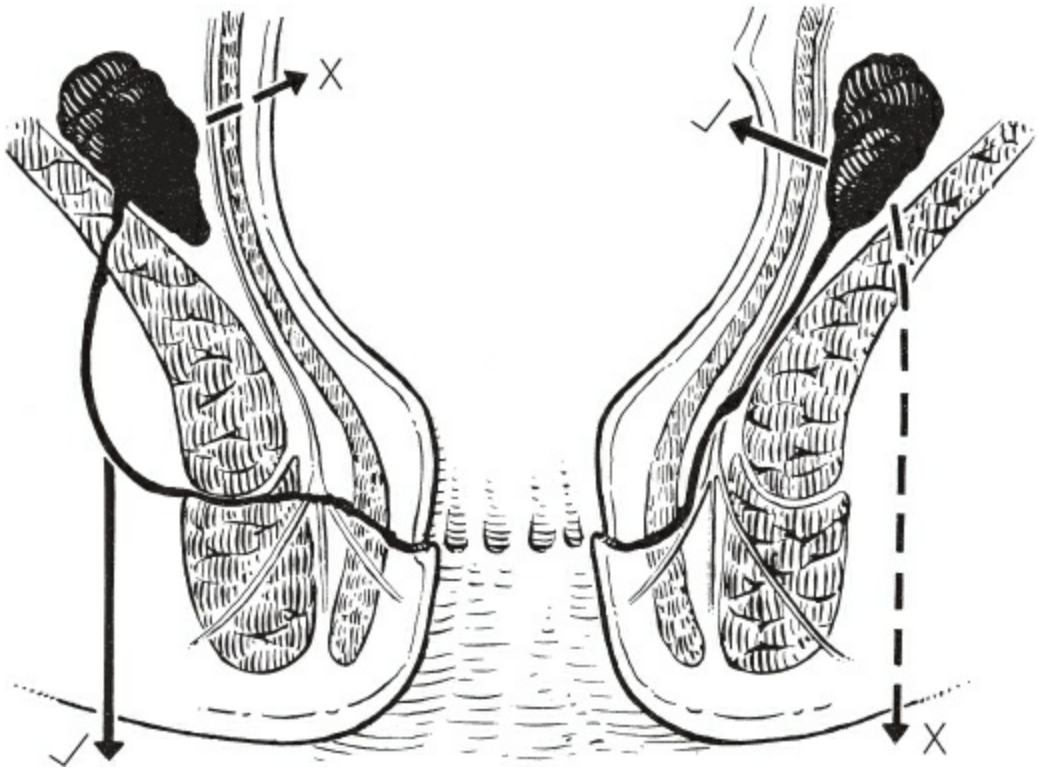

Figure 164.8. Principles of drainage of a supralevator abscess. (From Keighley MRB, Williams NS. *Surgery of the Anus, Rectum, and Colon*. 3rd ed. Philadelphia, PA: WB Saunders; 2008, Copyright © MRB Keighley MA MS FRCS.)

Drainage of Supralevator Abscess

Posterior supralevator abscesses are drained in the manner described for drainage of intersphincteric abscess. The intersphincteric plane is opened posteriorly. It is exposed inside and beyond the puborectalis sling so that the supralevator abscess in the postanal space can be adequately drained. It is essential to suture a mushroom catheter into position. Failure to do so results in recurrent sepsis because of contraction of the puborectalis and sphincters.

Anterior supralevator abscesses are also drained with the patient under general anesthesia using the intersphincteric plane through a transverse anal incision anteriorly. Anterior supralevator abscesses tend to be much more superficial. Again, it is essential to leave a mushroom catheter in

situ. Failure to do so results in a high incidence of recurrent sepsis (Fig. 164.8).

Drainage of Submucous Abscess

With the patient anesthetized, the abscesses are drained using an anal speculum. Drainage involves opening the mucosa above the swelling so that pus can be discharged. It is often wise to combine the operation with internal sphincterotomy to reduce anal spasm postoperatively to facilitate efficient drainage, which might otherwise lead to a high incidence of persistent sepsis.

Anorectal Fistulae

CLINICAL PRESENTATION

Anorectal fistulae present with purulent discharge around the anus and from within the anal canal. Discharge is associated with impaired anal hygiene and soiling. There may be a history of recurrent episodes of anorectal sepsis that have required surgical drainage or that have spontaneously ruptured. In some patients, there may be a history of sexually transmitted disease, inflammatory bowel disease, or malignancy. It is important to exclude rectal malignancy, skin cancer, and a growth complicating long-standing anorectal fistula. Inspection in most cases reveals an external opening around the anal canal but, particularly in patients with intersphincteric fistulae, there may be no apparent external opening.

CAUSES

Most anorectal fistulae are secondary to cryptoglandular infection caused by enteric bacteria. The anal glands lie in the intersphincteric space, and their ducts enter the anal canal to discharge at the dentate line. The acini ramify in the intersphincteric space and some penetrate the internal sphincter muscle and the external sphincter. Pus spreads in the intersphincteric space upward, downward, or laterally and results in an abscess, commonly in the perianal region or in the ischiorectal fossa. These abscesses are treated by drainage or by spontaneous discharge. Once the anorectal sepsis has drained, there is a potential communication from the perianal region to the anal canal at the dentate line. Continued

communication between the two epithelial surfaces results in anorectal fistulae. For many patients, drainage is delayed, or surgical treatment complicates the course of the fistula and results in circumferential spread, if there has been delay, or in high blind tracks if there has been aggressive and inexperienced surgical intervention.

Although most anorectal fistulae are primarily caused by anoglandular infections, a few are secondary to other diseases. Congenital fistulae may occur and may be associated with inclusion dermoids. Chronic pelvic sepsis may result in fistulae if there is an infective process that drains through the levator plate to the perineum from diverticular disease, Crohn disease, large-bowel malignancy, or irradiation injury. Secondary fistulae are common in Crohn disease and are common manifestations, but secondary fistulae should not be regarded as specific, because 7% of patients with ulcerative colitis also develop perianal fistulae. Anorectal fistulae may occasionally complicate tuberculosis, actinomycosis, anal fissure, rectal carcinoma, squamous cell carcinoma, and foreign bodies around the anal canal.

Anorectal fistulae are categorized as primary or secondary. Primary fistulae are further classified by (a) the course of the primary track, which is usually subdivided into intersphincteric, transsphincteric, suprasphincteric, and extrasphincteric; (b) whether there are high blind tracks; and (c) whether there is any evidence of circumferential involvement. Thus, a three-dimensional drawing of the perineum and the anorectum in the coronal and sagittal planes with the smooth and circular muscular sphincter apparatus displayed is necessary to thoroughly identify the course of an anorectal fistula. It must be evident from this complicated classification that treatment of such anorectal fistulae must be directed on an individual basis to the particular anatomic distribution of the track, the presence of high blind extensions, and circumferential spread (Fig. 164.5).

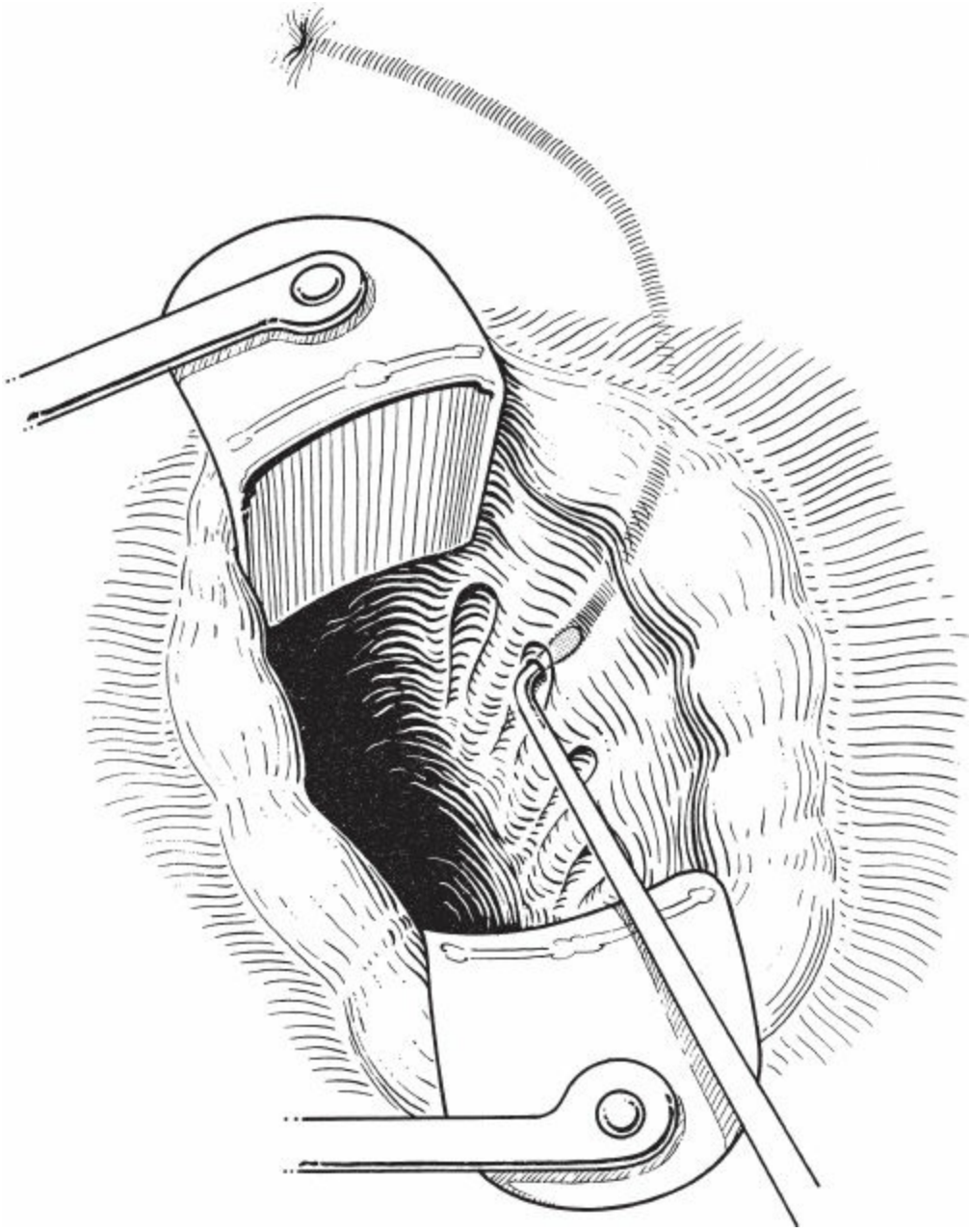

Figure 164.9. Retrograde probing of an anal fistula. (From Keighley MRB, Williams NS. *Surgery of the Anus, Rectum, and Colon*. 3rd ed. Philadelphia, PA: WB Saunders; 2008, Copyright © MRB Keighley MA MS FRCS.)

DIAGNOSIS

Accurate diagnosis of the site, extent, and complexity of the fistula is essential for a successful treatment. Preoperative diagnosis includes careful anal inspection and digital examination, particularly to identify areas of induration and external openings that may discharge pus during rectal examination; proctoscopy to identify the internal opening and any associated anal papillae or skin tags; and proctosigmoidoscopy to exclude

primary colorectal disorders, particularly Crohn disease.

Anorectal ultrasound may be helpful in delineating the course of intersphincteric fistulae, but the focal length of the 7-MHz probe is not sufficiently deep to image beyond the external sphincter or puborectalis. MRI is regarded as the investigation of choice for the delineation of anorectal fistulae, particularly in complex transsphincteric, suprasphincteric, and extrasphincteric fistulae.

It is essential that all patients with anorectal fistulae be examined carefully under anesthesia. The fistula track should be identifiable by a combination of palpation for induration and gentle probing of the fistula track. Often, a combination of external and internal probing is necessary to identify the track (Fig. 164.9). Injection of methyl blue may be helpful but is rather messy, and povidone-iodine is preferred if the technique is to be used. Fistulography may sometimes help delineate the course of a complex anorectal fistula.

TREATMENT

There are a wide variety of techniques for the treatment of anorectal fistulae. We prefer fistulotomy, or “lay open” for low-lying tracks that do not traverse skeletal muscle and seton fistulotomy for almost all other fistula tracks that involve the sphincters or puborectalis. Occasionally, fistulectomy (excision of the fistula track) with an anorectal advancement flap is advised for specialized fistulae, particularly extrasphincteric and rectovaginal fistulae where sphincter function is to be preserved but there is a high rate of recurrent sepsis. Other methods include the fibrin plug, which preserves sphincter function and needs to be sutured into position or otherwise it is likely to migrate and fall out. Early results using the fibrin plug appear to be promising but the same could have been said about methods using glue, thus only time will tell whether the claims made by the manufacturers of the anal plug will prove to be comparable or superior to conventional therapy. Consequently, the results of randomized controlled trials will be needed before the role of the anal plug will be known.

Preoperative bowel preparation with a phosphate enema may be used in complex fistulae. Postoperative management requires the provision of adequate analgesics and laxatives to prevent postoperative constipation. Rigorous follow-up is essential for these patients, as there is a 10% to 20% risk of subsequent anorectal sepsis complicated by recurrent anorectal

fistulae. Follow-up is particularly important for patients with a seton as these frequently require to be changed. Follow-up is also essential to identify any evidence of underlying disease, particularly in patients with complex anorectal fistulae.

Fistulotomy (Lay Open)

The principle of fistulotomy is the identification of the fistula track so that the track can be laid open. Clearly, this method of treatment is inappropriate for patients with extrasphincteric and suprasphincteric fistulae, because the fistula track lies outside the sphincter mechanisms, and any lay-open procedure divides the striated sphincter complex and renders the patient incontinent, usually from a rigid gutter causing soiling. Fistulotomy is thus appropriate only for simple intersphincteric fistulae and low transsphincteric fistulae.

The first and most important maneuver is the demonstration of the primary fistula track. Probing is thus used to define the course of the track and should also identify high blind tracks. If the external opening is located obliquely from the internal opening, there will be some element of circumferential involvement. The course of simple fistulae usually obeys the Goodsall rule (Fig. 164.10). Thus, an external opening lying posterior to the horizontal plane is likely to open into the anal canal at the midline posteriorly, whereas an external opening lying anterior to the horizontal line is more likely to run directly into the anal canal. A malleable fistula probe is gently passed through the fistula track. By use of diathermy, the perianal skin and anal epithelium are divided. The internal sphincter, if involved, is identified and divided. If there is striated muscle superficial to the fistula track, this may be divided provided it consists of only a few fibers. However, if a substantial amount of striated muscle is encountered superficial to the fistula track, division of the muscle is not advisable and a seton is inserted. If a high blind track is found, the track should be loosely curetted and adequately drained through the fistulotomy incision. Provided the fistula track can be safely laid open, any bleeding from the edges should be secured by cautery and gauze dressing applied.

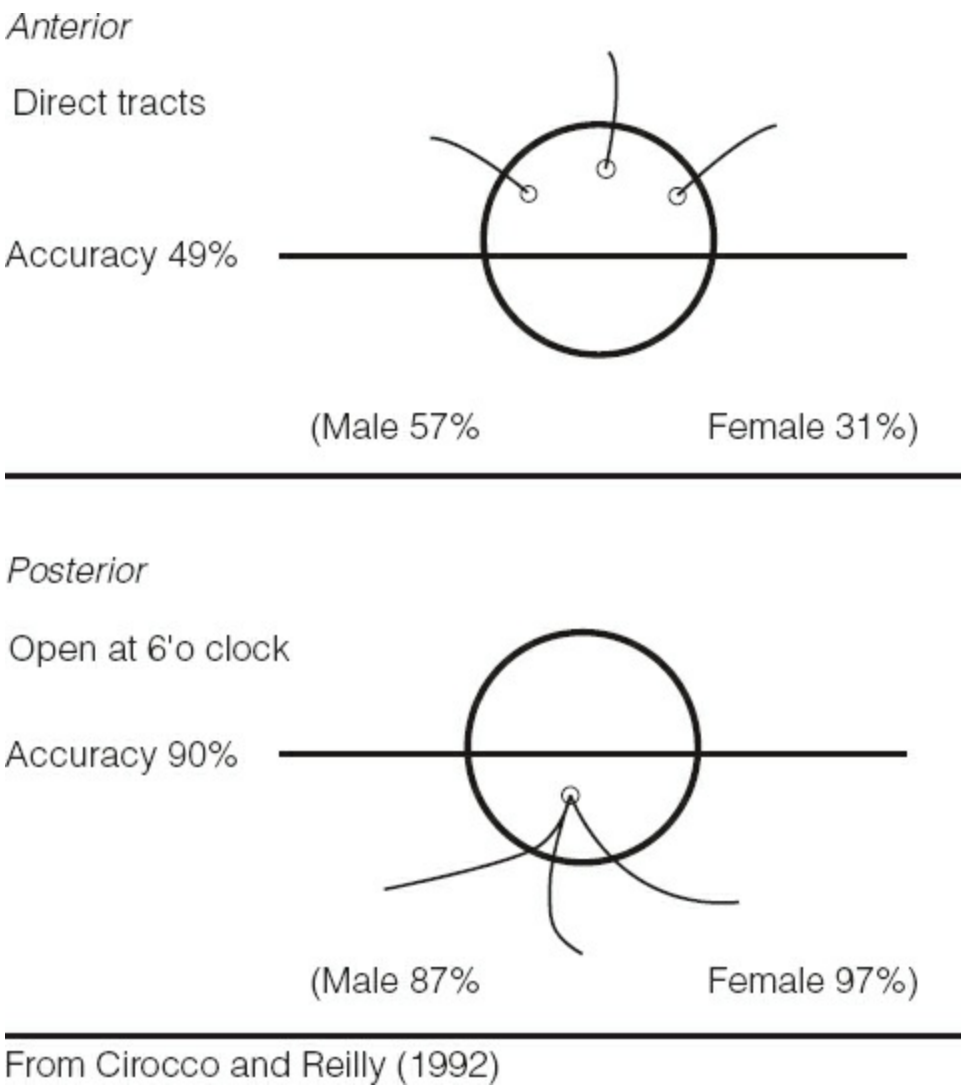

Figure 164.10. Goodsall rule. (From Keighley MRB, Williams NS. *Surgery of the Anus, Rectum, and Colon*. 3rd ed. Philadelphia, PA: WB Saunders; 2008, Copyright © MRB Keighley MA MS FRCS.)

Patients may have more than a single external opening. Multiple anterior openings usually have separate internal openings, which should be dealt with in the same manner by defining all fistula tracks and opening them, provided that this does not involve division of a large amount of striated muscle (Fig. 164.11). For multiple posterior anal fistulae, the tracks usually open at the same site in the midline posteriorly. Furthermore, under these circumstances, there may be a small supralevator collection in the postanal space. Again, each fistula track is opened, provided that this does not involve the division of a large amount of striated muscle. The internal opening is then further explored in the intersphincteric plane to ensure that there is no supralevator component.

Any redundant skin is excised, and an antiseptic dressing is applied.

Seton Fistulotomy

The principle of seton fistulotomy is that any striated muscle lying superficial to the fistula track is encircled by a length of soft rubber or latex tubing, or by using a Prolene or silk tie. The seton is tied loosely and left in situ. Over the following weeks, the striated muscle is slowly divided by the presence of the seton. However, because the process of striated muscle division is relatively slow, the muscle does not therefore spring apart, leaving a defect (gutter), but heals behind the process of division. Consequently, fibrous tissue is laid down in the bed of the fistula as it is slowly divided. This process avoids the gutter deformity, which is usually associated with soiling and minimizes the risks of impaired continence. The problem with this technique is that treatment may take a number of weeks and follow-up is essential. On the other hand, preservation of continence is much better than with fistulotomy, especially for mid or high transsphincteric fistula.

The fistula track is identified by using a probe, as described in the previous section. The perianal skin and the skin of the anal canal are divided. The internal sphincter is also divided, but the striated muscle lying superficial to the fistula track is preserved. Thus, a substantial amount of the fistula is laid open. A vascular rubber sling (sloop) is threaded through the eye of the fistula probe and is delivered around the striated muscle as a seton, but other materials may be used (e.g., latex and Teflon). The seton is tied with multiple knots, and the end is sutured beyond the last knot so that it cannot become untied with patient movement during follow-up (Fig. 164.12). Usually, the patient can be discharged on the same day. Arrangements for follow-up should be made.

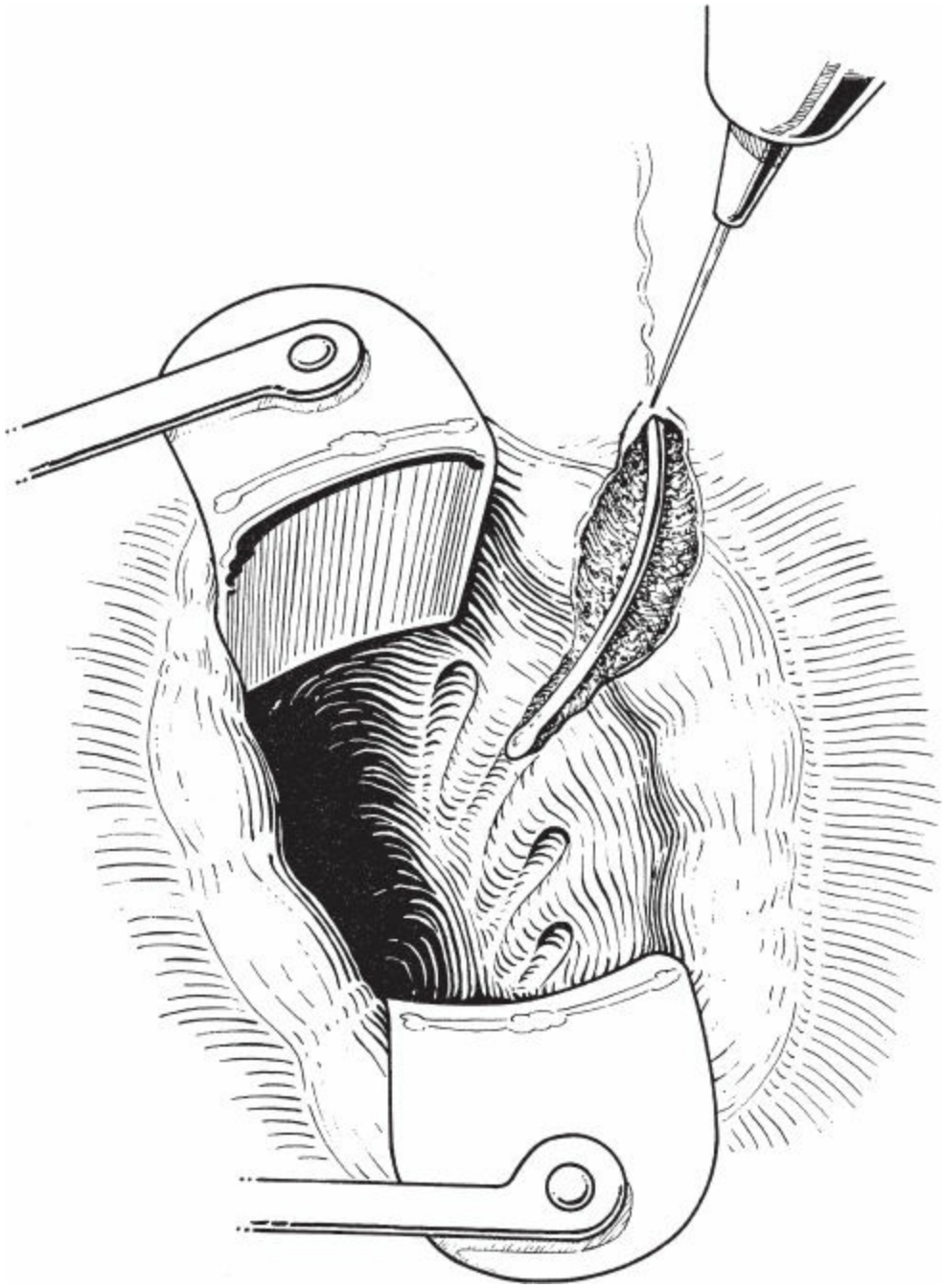

Figure 164.11. Laying open of a low-lying transsphincteric fistula. (From Keighley MRB, Williams NS. *Surgery of the Anus, Rectum, and Colon*. 3rd ed. Philadelphia, PA: WB Saunders; 2008, Copyright © MRB Keighley MA MS FRCS.)

At the first follow-up, the seton usually remains in situ but has already partially divided the striated muscle superficial to the fistula track. A simple method of tightening the seton is by the application of rubber bands beyond the first knot. Commonly, five or six bands should be applied to ensure that the seton snuggly surrounds the residual striated muscle. Alternatively, the seton is replaced and retied. A second follow-up in 1

week should then be scheduled. At the second visit, the seton has usually completely divided the striated muscle and has fallen out. If, on the other hand, it has not fallen out, the seton is replaced and follow-up continues until the track has been divided. Thus, the fistula track is slowly divided during a period of 1 to 6 weeks. The technique is remarkably successful at preserving sphincter function and avoiding the development of a gutter deformity. Careful follow-up is essential to detect recurrent fistula. Careful attention to the wound is also essential to ensure that it does not become infected, and that there is no bridging over the fistulotomy site during healing.

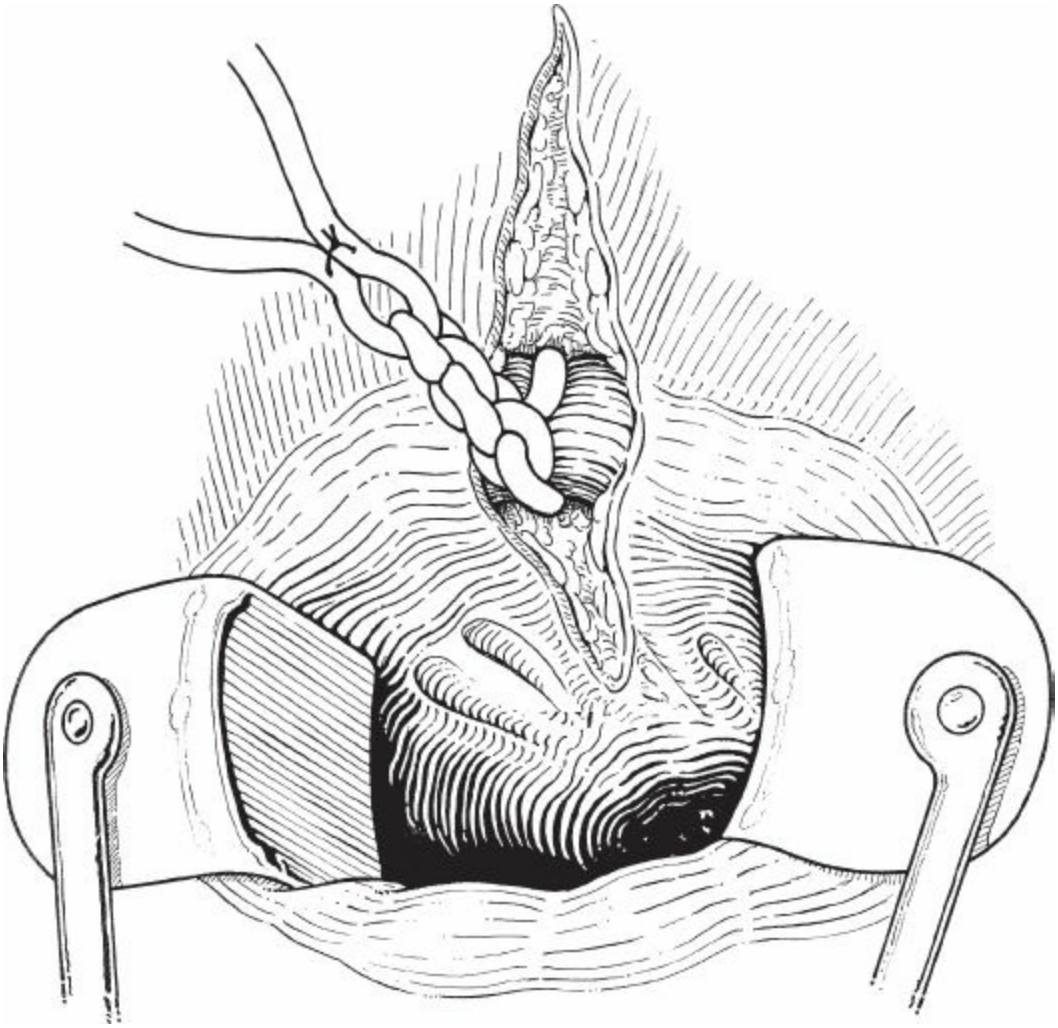

Figure 164.12. Seton fistulotomy. (From Keighley MRB, Williams NS. *Surgery of the Anus, Rectum, and Colon*. 3rd ed. Philadelphia, PA: WB Saunders; 2008, Copyright © MRB Keighley MA MS FRCS.)

Fistulectomy and Anorectal Advancement Flap

Although anorectal advancement with excision of the track should preserve continence and avoid soiling, despite spectacular results reported by some, in this author's experience, sepsis and recurrent fistula are common. In future, the anal plug may replace this technique.

The first part of the operation involves fistulectomy, that is, excision of the fistula track. This can be technically difficult and involves careful dissection using a fine scalpel or diathermy point around the fistula track through to its internal opening. Side tracks must be similarly excised. In complex fistulae, three or four separate fistula tracks will need to be cored out. The defect in the external sphincter may require closure, and some form of drainage procedure is usually needed. The next step is to close the internal opening, usually with an anorectal advancement flap.

The anorectal advancement flap is simply a way of closing the internal opening of the excised transsphincteric fistula. A wide-based curvilinear flap, consisting of mucosa, submucosa, and rectal wall, is advanced from above so as to close the internal component of the fistula without tension, while draining any coexisting sepsis. The technique is fully described and illustrated later in the section on "Rectovaginal Fistula." However, in anorectal fistula, unlike rectovaginal fistula, there is an external perineal orifice that should be thoroughly drained (Fig. 164.13).

Complete Lay Open and Repair

Extrasphincteric and suprasphincteric fistulae may be treated by total fistulotomy (if setons are not used) while ensuring that the divided and striated muscle is marked so that it can be identified at a later date. Once all of the infection has been cleared, a standard sphincter repair is then performed. The alternative is to perform the reconstruction at the time of the primary lay-open procedure. The problem with sphincter repair under these circumstances is that the primary sphincter repair may break down because of coexisting sepsis. We therefore do not advise the technique in the majority of cases and believe that it has been superseded by fistulectomy and advancement flap closure or the anal plug.

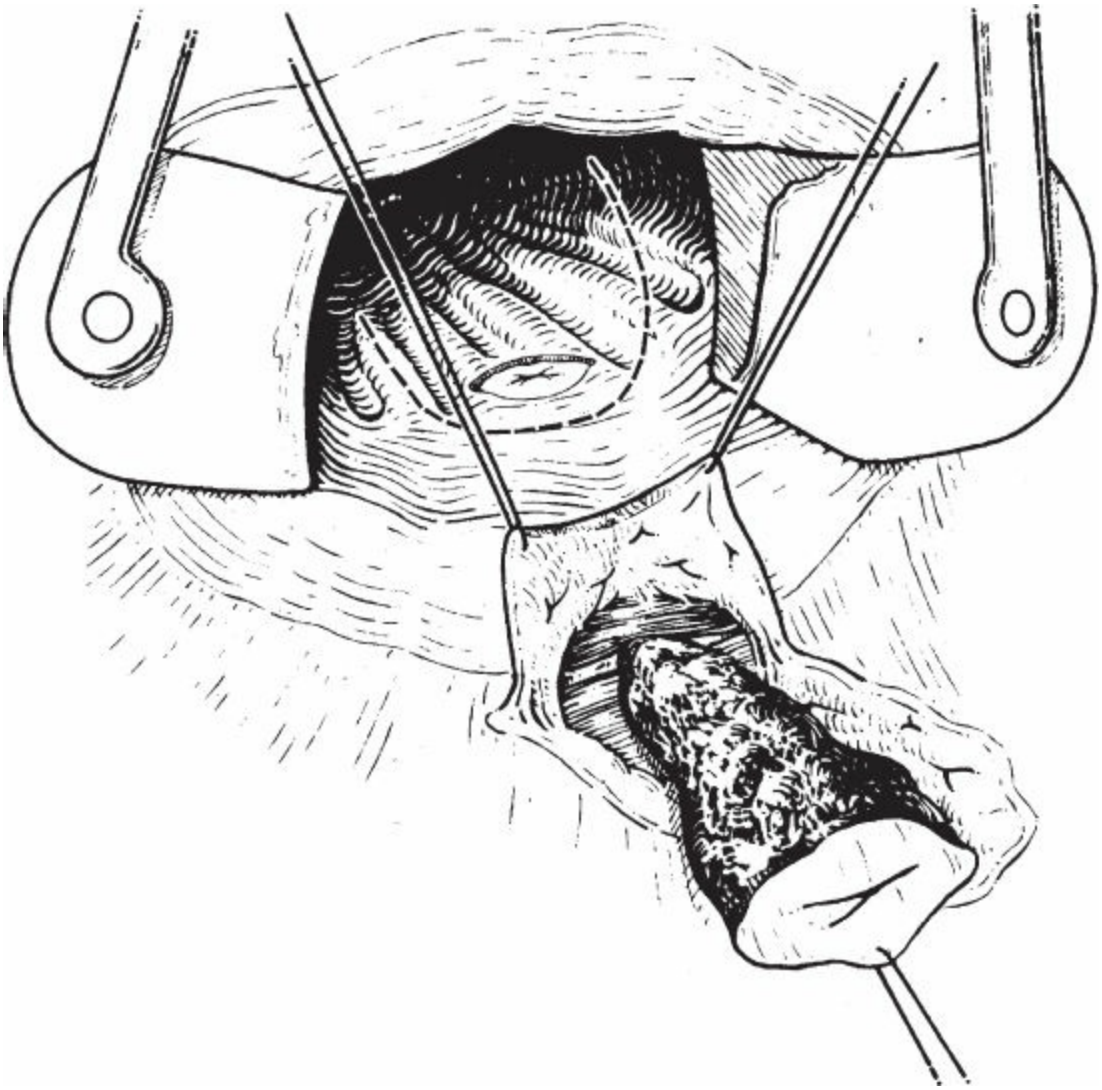

Figure 164.13. Further details of the advancement flap technique. The fistula track is excised from the external opening to the intersphincteric plane. The flap incorporating the internal opening is raised along with full-thickness internal sphincter. The raised flap, with line marking the level of division to excise the internal opening. The advancement flap is sutured to a site distal to the excised internal opening. (From Keighley MRB, Williams NS. *Surgery of the Anus, Rectum, and Colon*. 3rd ed. Philadelphia, PA: WB Saunders; 2008, Copyright © MRB Keighley MA MS FRCS.)

Anal Plug

This attractive method of managing anal fistulae still requires careful evaluation by randomized trails compared with conventional fistulotomy and setons. The principle of this therapy is to preserve anal sphincter function with the avoidance of a gutter by filling the fistula track with a

rod of fibrin, which enhances fibroblastic activity thereby eliminating the fistula track by forming a collagen matrix in the fistula. The disadvantage of this method is that the plug must be held in situ until it becomes incorporated into the healing process. Thus, the usually surgical technique involves identification of the fistula, which is then gently curetted with a fine wire brush or an equivalent bougie to remove the granulation tissue. After irrigation of the fistula, the plug is inserted and sutured into position in the anal canal. Spectacular results have been claimed with avoidance of open wounds, indwelling setons, and preservation of anal continence with avoidance of soiling. Results of trials compared with conventional therapy are awaited.

Hemorrhoids

CLINICAL PRESENTATION

Hemorrhoids usually present with bleeding or prolapse. Patients also frequently complain of discharge of mucus, pruritus, and some discomfort. Symptomatic hemorrhoids are often intermittent. Bleeding is commonly associated with constipation and straining. Similarly, prolapse is more evident during pregnancy or in the puerperium or when the patient is constipated. Hemorrhoids are often associated with skin tags, which may cause irritation and difficulty with anal hygiene. If hemorrhoids prolapse, they may spontaneously return to the anal canal after straining. Further enlargement may require digital replacement; large hemorrhoids may be irreducible. Thus, hemorrhoids may be classified as first degree, piles that never prolapse; second degree, piles that prolapse but spontaneously return; third degree, piles that prolapse and require digital replacement; and fourth degree, piles that are permanently prolapsed.

COMPLICATIONS

Hemorrhoids may be associated with complications, such as massive bleeding, thrombosis, gangrene, and septicemia. Massive bleeding may occur particularly if there is excessive straining or portal hypertension, but such bleeding is rare, and an alternative diagnosis such as bleeding polyps, rectal varices, or anorectal arteriovenous malformations should be sought. Treatment of massive bleeding is by blood transfusion and urgent hemorrhoidectomy.

Thrombosed hemorrhoids present with a history of prolapse complicated by intense pain and swelling. There is an obvious prolapsed internal hemorrhoid with surrounding edema, and the pile itself is hard as a result of venous thrombosis. The condition should be distinguished from external plexus hematoma, which is thrombosis of an external varix and is often unassociated with internal hemorrhoids. External plexus hematoma is a self-limiting condition that resolves during a period of 5 days. It presents with severe anal pain and swelling. Treatment is usually conservative, but for patients in excruciating pain from localized hematoma, evacuation of the hematoma may alleviate pain and result in more rapid resolution. True thrombosed hemorrhoids may resolve over a period of 10 to 14 days, but the process is painful, and the underlying hemorrhoids frequently give rise to more symptoms in the future. Hence, thrombosed hemorrhoids are best treated by emergency hemorrhoidectomy. Evacuation of the hematoma in such cases is often disappointing and does not alleviate long-term symptomatology. Emergency hemorrhoidectomy is infinitely superior to anal dilation because, although dilation controls pain, the thrombosed hemorrhoid persists and subsequently requires treatment.

Strangulated hemorrhoids imply a process of thrombosis and infarction that may be complicated by sepsis or even synergistic gangrene. The history is that of a prolapsed hemorrhoid that becomes painful and tender, subsequently it begins to suppurate, causing a foul-smelling discharge around the prolapse. The hemorrhoid is obvious and is blackish-green, ulcerated, and suppurating. Treatment is by emergency open hemorrhoidectomy. Closed hemorrhoidectomy under these circumstances is dangerous and unsatisfactory, because the wounds invariably become infected and lead to iatrogenic anorectal sepsis and possible sphincter damage. Septicemia is a rare complication of strangulated hemorrhoids. Infected material tracks through the portal venous system causing portal pyemia, and hepatic abscesses if early treatment with antibiotics and local control of the anal sepsis are not established quickly.

Chronic anemia is a further complication of hemorrhoids. It may occur even though the amount of blood loss from the hemorrhoids does not seem to be excessive. Chronic anemia should rarely be presumed to be caused by hemorrhoids, and patients should, therefore, be thoroughly evaluated to ensure that there is no other source of gastrointestinal blood loss. Thus, upper gastrointestinal endoscopy, colonoscopy, and small-bowel radiology

are probably necessary to exclude a primary cause. If no other lesion is identified and the history is compatible with bleeding from hemorrhoids, hemorrhoidectomy is usually advised.

CAUSES

Primary hemorrhoids are present in all individuals. Cross section of the anus in the normal fetus demonstrates some mucosal vascular cushions at the classic hemorrhoidal sites: 3, 7, and 11 o'clock. The vascular cushions correspond with the venous drainage of the anal canal and are distributed in a manner similar to that of the branches of the superior hemorrhoidal artery. There are no valves in the hemorrhoidal veins. Thus, increased intra-abdominal pressure, such as the type that occurs during a Valsalva maneuver or from a space-occupying lesion in the abdomen, is associated with reduced venous return and engorgement of the vascular cushions. Vascular cushions fulfill a normal physiologic function. They lubricate the anal canal and keep the anal canal closed at rest. This mechanism helps to prevent soiling and incontinence of flatus.

Vascular cushions may increase in size under situations in which there is increased intra-abdominal pressure, particularly if there is a history of straining at stool as a result of constipation or a feeling of incomplete rectal evacuation.

Primary hemorrhoids can be subclassified into those associated with anal hypertension and those associated with reduced anal canal tone. High anal canal pressures are recorded, particularly in men younger than 40 years, with first-degree hemorrhoids that present with bleeding. By contrast, significantly lower resting anal canal pressures are found in patients with prolapsing hemorrhoids and are common in women older than 40 years.

Secondary hemorrhoids occur under pathologic situations of increased intra-abdominal pressure, for instance, in patients with chronic obstructive airway disease or in patients who strain from prostatism or urethral stricture. Secondary hemorrhoids may also occur in patients with ascites, during pregnancy, and if there is a space-occupying lesion, such as an ovarian tumor, a large rectosigmoid carcinoma, or a distended bladder. Secondary hemorrhoids may also develop in patients with portal hypertension. Localized impairment of venous return from rectal disease may cause hemorrhoids, for instance, in rectal carcinoma, or from excessive fibrosis resulting from radiation therapy.

DIAGNOSIS

Some hemorrhoids can be diagnosed solely by inspection. There may be skin tags and descent of the hemorrhoids during straining. When hemorrhoids become evident during straining, they appear as two or three circumscribed swellings, as compared to the circumferential appearance of a full-thickness rectal prolapse. Furthermore, most patients with hemorrhoids do not have a patulous anus, as do patients with rectal prolapse. In large hemorrhoids, the columnar epithelium becomes thickened and undergoes squamous metaplasia. Digital examination is important to detect the presence of anal pathology and to assess anal tone. Hemorrhoids are confirmed by proctoscopy at rest and during straining. Proctosigmoidoscopy is important to exclude any rectal pathology, particularly polyps, proctitis, or a neoplasm. In patients with a history suggesting colorectal pathology, full evaluation of the large bowel by colonoscopy or contrast radiology is desirable.

TREATMENT

The principles of treatment are to alleviate symptoms, not necessarily to improve the appearance of the anal canal. Asymptomatic patients with hemorrhoids do not justify treatment, because the therapy could cause more trouble than the underlying disease pathology. Patients with minor, intermittent symptoms and who are constipated or who strain should be taught to defecate only after an urge, and bulk laxatives should be prescribed to increase the volume of stool. Outpatient treatment is suitable for 85% of all patients with hemorrhoids. However, patients should be warned that outpatient therapy is not always a cure, and that there is a recurrence rate of 20% to 25% during a period of 5 years. Hence, repeat consultation and outpatient treatment are often necessary. Despite this, symptoms can often be satisfactorily alleviated by outpatient therapy, which thereby avoids a painful ablative operation. Hemorrhoidectomy is usually reserved for patients with severe prolapsing hemorrhoids or hemorrhoids with complications. Patients should be warned that hemorrhoidectomy is not only painful, but can also be associated with complications, such as minor impairment of continence, anal stenosis, and early postoperative complications, such as bleeding and sepsis. We no longer advise anal dilatation for treatment of patients with hemorrhoids and a tight anal canal because of the fear of iatrogenic bowel incontinence.

Preoperative preparation is unnecessary for outpatient treatment.

Postoperative follow-up and management depend on the type of treatment used. In our practice, we usually discharge patients after outpatient therapy and indicate that if they develop recurrence of symptoms, another appointment can always be scheduled for further evaluation and repeat outpatient therapy. Postoperative management after hemorrhoidectomy includes the prescription of stool softeners and mild laxatives and an explanation of the risks of complications, such as reactionary hemorrhage, secondary hemorrhage, minor transient impairment of continence, postoperative constipation, and anal stenosis. A single check-up appointment is usually arranged to ensure that there is no compromise of continence and no stenosis, and that there have been no complications.

Conservative Therapy

Conservative therapy consists of bulk laxatives, avoidance of straining, topical application of a local anesthetic, or steroid-based suppositories for pain, and the use of glycerin suppositories if there is any impairment of rectal evacuation.

Outpatient Therapy

The principle of outpatient therapy is to fix the mucosa above the prolapsing hemorrhoid. Outpatient therapy is particularly suitable for first-, second-, and some third-degree hemorrhoids. We prefer rubber-band ligation, but we recognize that many clinicians find injection sclerotherapy satisfactory, although invasive and effective, but sclerotherapy may be more difficult to administer in a busy clinic setting. Photocoagulation is less effective than rubber-band ligation and tends to be reserved for first-degree hemorrhoids. Cryotherapy has been discontinued in our clinic, because it is commonly complicated by mucus discharge.

Rubber-Band Ligation

The principle of this technique is to apply a rubber band to the mucosa above each of the principal hemorrhoids (Fig. 164.14). It is absolutely essential that the pile itself is left undisturbed so that treatment is directed to the mucosa above the hemorrhoid. We prefer the suction-band technique, because it can be undertaken without the need for an assistant. Usually only the two principal hemorrhoids are treated, but in some cases it is entirely feasible to apply three rubber bands. The mucosa is sucked

into the cup of the instrument and the rubber band is advanced, which leaves a polypoidal segment of mucosa snared at its base by the rubber band. Subsequently, the band causes ischemic necrosis and an ulcer above the hemorrhoid, which generates an area of fibrosis and thus prevents the hemorrhoids from slipping down into the lower part of the anal canal to cause symptoms. Treatment by rubber-band ligation is extremely effective; in our experience, 70% of patients are rendered asymptomatic after the first treatment and 90% after two or three treatments if needed. Patients should, however, be warned that there is a 5% risk of a significant bleeding in the first week after treatment, and that ~5% of patients suffer anal discomfort in the first 48 hours. Intense pain after treatment indicates that the rubber bands have been applied too low; occasionally, it is necessary under such circumstances to remove the rubber band with the patient under local, caudal, or general anesthesia. In many patients, it is necessary to administer further band ligation on one or two occasions in order to control prolapse and bleeding.

Injection Sclerotherapy

The principle of injection therapy is to place 2 to 5 mL ethanolamine oleate in the submucosal plexus just above the hemorrhoid. The three principal sites of the hemorrhoids are identified, and the mucosa above each lesion is injected with sclerosant (Fig. 164.15). It is most important not to inject too deeply, particularly anteriorly, because of the risk of entering the prostate, the seminal vesicles, or even the base of the bladder causing hematuria, hematospermia, and prostatitis. Sufficient sclerosant should be injected under the mucosa to raise a white wheal, which eventually ulcerates and causes mucosal fixation, thus preventing the hemorrhoid from descending into the lower anal canal.

Complications of injection sclerotherapy include pain, bleeding, hematospermia, hematuria, urethritis, and retention of urine. Complications are rare, occurring in <2% of patients. Ninety percent of patients require no further injection sclerotherapy. When injection sclerotherapy was compared with rubber-band ligation, results were almost equivalent, but, in our experience, there is a marginal advantage with rubber-band ligation.

Photocoagulation

The photocoagulator probe is applied to the mucosa above each

hemorrhoid, and three or four applications are used above each hemorrhoidal site (Fig. 164.16). A white area of burn is identified after completion of treatment. The treatment itself is somewhat more painful than injection or rubber-band ligation, but there are fewer posttreatment side effects. In our experience, only 70% of patients require no further treatment.

Cautery or Laser Hemorrhoidectomy

A limited hemorrhoidectomy is possible as an intra-anal procedure using cautery or laser. The hemorrhoidal tissue is dissected from the internal anal sphincter, and hemostasis is controlled by contact or spray cautery, or by laser. It is a lesser operation than hemorrhoidectomy and is appropriate for small, second-degree hemorrhoids. There is a risk of secondary or reactionary hemorrhage, but the operation can be performed in the physician's office or as an outpatient procedure.

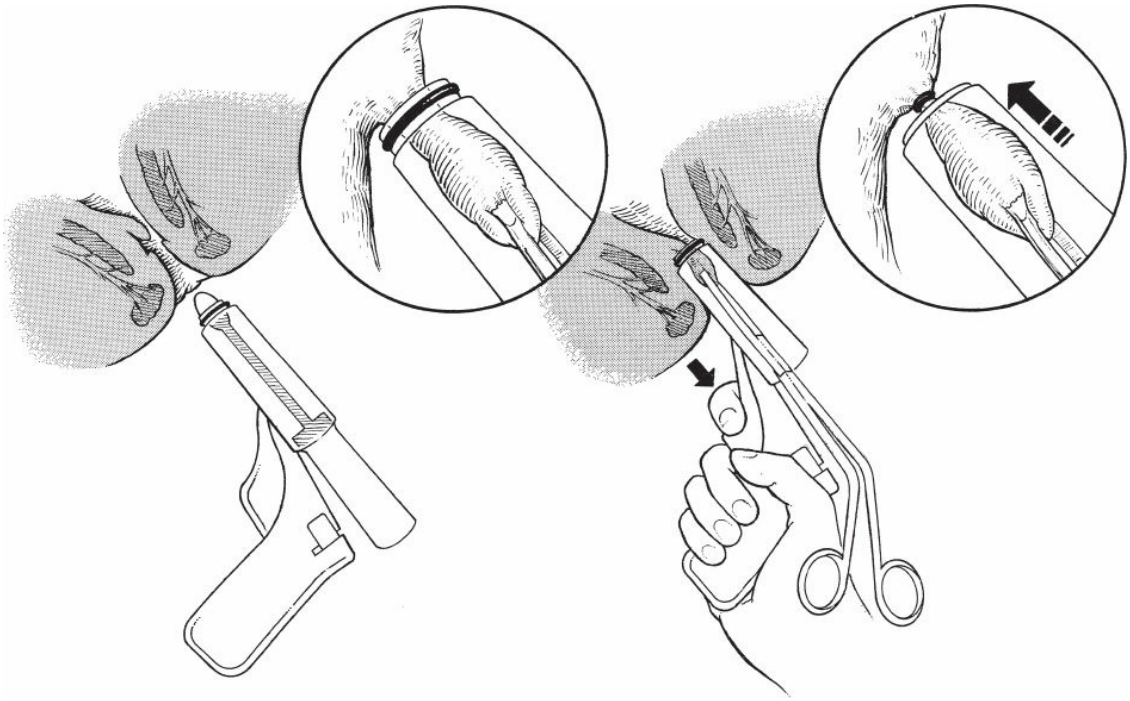

Figure 164.14. Technique of applying bands to the base of the pile using suction banding. (From Keighley MRB, Williams NS. *Surgery of the Anus, Rectum, and Colon*. 3rd ed. Philadelphia, PA: WB Saunders; 2008, Copyright © MRB Keighley MA MS FRCS.)



Figure 164.15. Technique of injecting hemorrhoids. (From Keighley MRB, Williams NS. *Surgery of the Anus, Rectum, and Colon*. 3rd ed. Philadelphia, PA: WB Saunders; 2008, Copyright © MRB Keighley MA MS FRCS.)

Suture Ligation of Hemorrhoids: LigaSure

A technique of intra-anal suture ligation of the hemorrhoid pedicle is practiced by some surgeons using a specific applicator. It is suitable for small, second-degree hemorrhoids, but, in our opinion, recurrent second-degree hemorrhoids are common and we prefer rubber-band ligation.

Hemorrhoidectomy

Hemorrhoidectomy is unfortunately a painful operation, but is usually extremely successful as a means of controlling symptoms from third-degree piles. Patients should be counseled before the operation and informed that postoperative pain is usual. There is also a small risk of reactionary or secondary hemorrhage, scarring from excessive skin loss, and possible impairment of continence from damage to the internal anal sphincter. Rare complications include unhealed open wounds, postoperative fissure, and submucous abscess. In the majority of patients, the operation is extremely successful at controlling prolapse and bleeding.

There are two techniques for conventional hemorrhoidectomy. The operation may be performed as an open procedure so that any discharge of blood, serum, or pus can be drained easily, or a closed hemorrhoidectomy may be performed in which the mucosa and the skin defects are closed, leaving an intact anal canal. By comparing these two techniques, it has

been found that the degree of postoperative pain is identical. Physiologic studies also indicate that internal and external sphincter functions are equally well preserved by the two operations. Thus, the choice of technique is entirely personal. The author has practiced both techniques but tends to favor the open operation, because the risk of postoperative hematoma and sepsis is reduced.

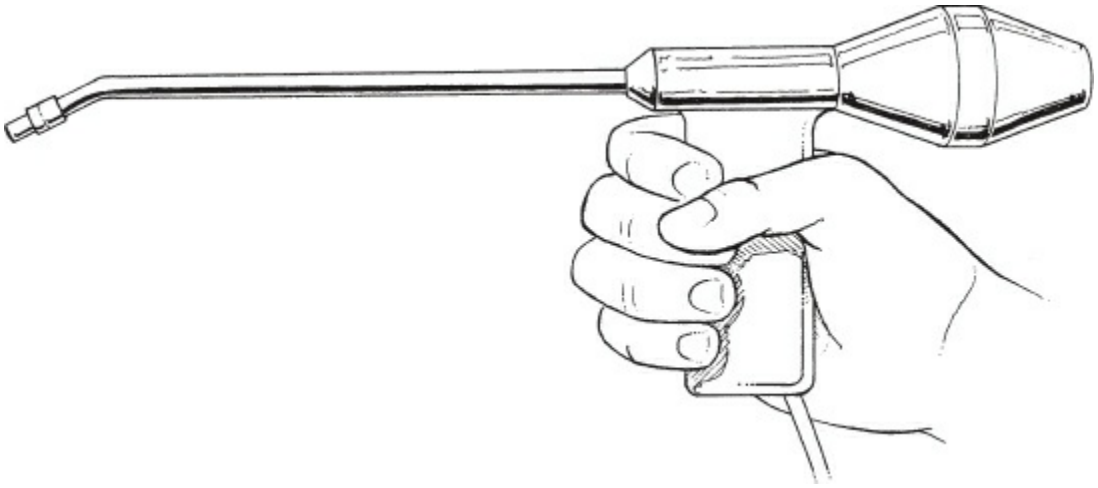

Figure 164.16. Infrared photocoagulation equipment. (From Keighley MRB, Williams NS. *Surgery of the Anus, Rectum, and Colon*. 3rd ed. Philadelphia, PA: WB Saunders; 2008, Copyright © MRB Keighley MA MS FRCS.)

Open Hemorrhoidectomy

The operation may be performed in the lithotomy or prone jackknife position. We prefer lithotomy for open hemorrhoidectomy. We also prefer to use general anesthesia. The patient is placed with the feet in stirrups, and the anal canal is gently dilated. A proctoscope is inserted to identify the site of the three principal hemorrhoids. A weak adrenaline solution (1:200,000) in saline is infiltrated around the skin adjacent to each primary hemorrhoid, and further injection is made in the lower part of the intersphincteric space and in the submucosal plane under the hemorrhoid.

Tissue forceps are then applied to each pile and to the skin adjacent to the hemorrhoid (Fig. 164.17). The author prefers to start with the 7 o'clock hemorrhoid, followed by the 3 o'clock hemorrhoid, and finish with the 11 o'clock hemorrhoid, so that the operation field is not obscured by bleeding. The tissue forceps holding the hemorrhoid and its adjacent skin is grasped in the left hand. A V-shaped incision is made in the surrounding perianal skin with scissors. The cut is deepened toward the anal canal to

reveal the lower fibers of the internal anal sphincter. The sphincter is gently swept away with tissue forceps from the hemorrhoid (Fig. 164.18). The scissors are then used to excise the hemorrhoidal tissue within the anal canal, which leaves the apex of the hemorrhoid with its arterial supply and venous drainage intact for ligature. The pedicle of each hemorrhoid is enclosed in an arterial clip, and the pedicle transfixed using nonabsorbable suture material (Fig. 164.19). Hemostasis is secured from the bed of the hemorrhoid by use of cautery. Only then is the pedicle ligated. The ligature is left long so that if any further bleeding occurs, the pedicle can be easily identified and delivered into the operative field. Each hemorrhoid is dealt with in the same manner. Well-established skin bridges between each V-shaped segment of excised skin must be preserved. At the end of the operation, an anal speculum is inserted to be absolutely certain that there is complete hemostasis. Gauze dressings are then applied to each hemorrhoidal area.

Closed Hemorrhoidectomy

We perform closed hemorrhoidectomy with the patient in the prone jackknife position with the buttocks strapped apart and with 40 degrees of hip flexion. A Fansler proctoscope is crucial to the success of the operation. First, the proctoscope is inserted so that the three sites of the primary hemorrhoidal disease are identified. A maneuver that helps to identify the primary hemorrhoids is the insertion of a soft gauze swab into the anal canal. The swab is withdrawn from the anus after removal of the proctoscope. Removal of the swab usually brings with it the hemorrhoids, which can be readily identified.

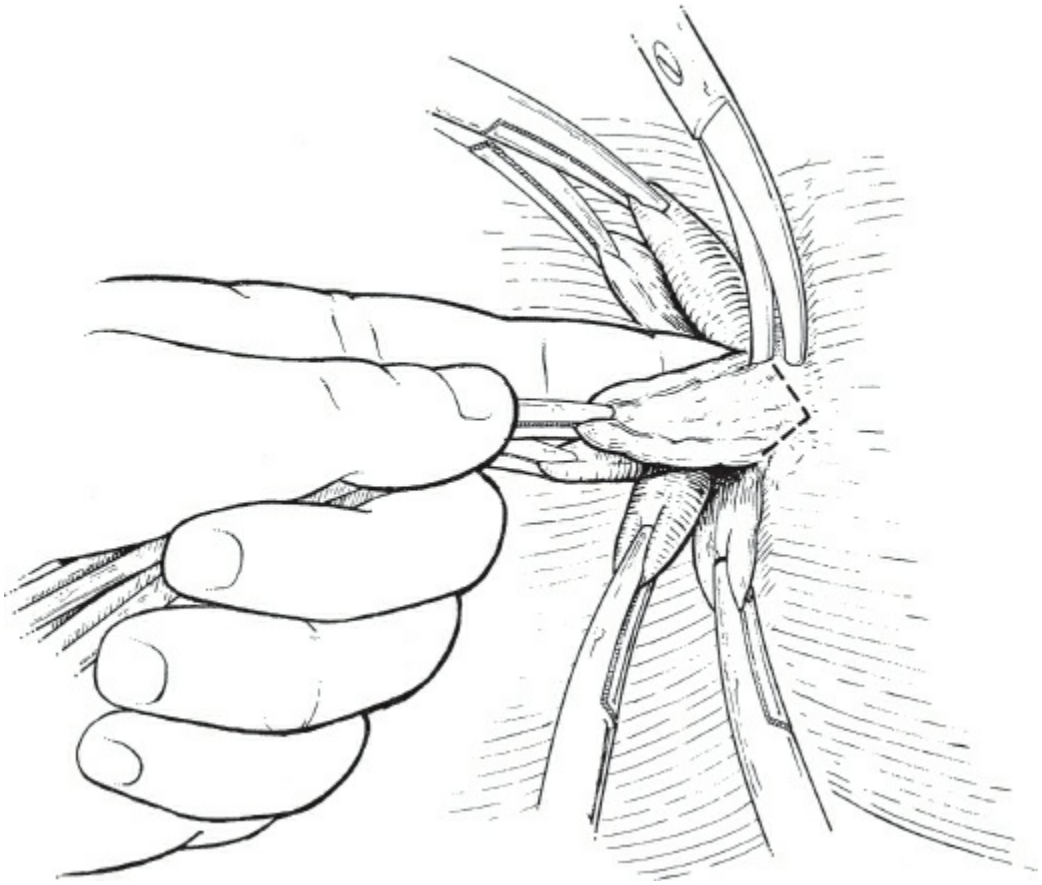

Figure 164.17. A V-shaped incision is made over the anoderm at the base of the hemorrhoid. (From Keighley MRB, Williams NS. *Surgery of the Anus, Rectum, and Colon*. 3rd ed. Philadelphia, PA: WB Saunders; 2008, Copyright © MRB Keighley MA MS FRCS.)

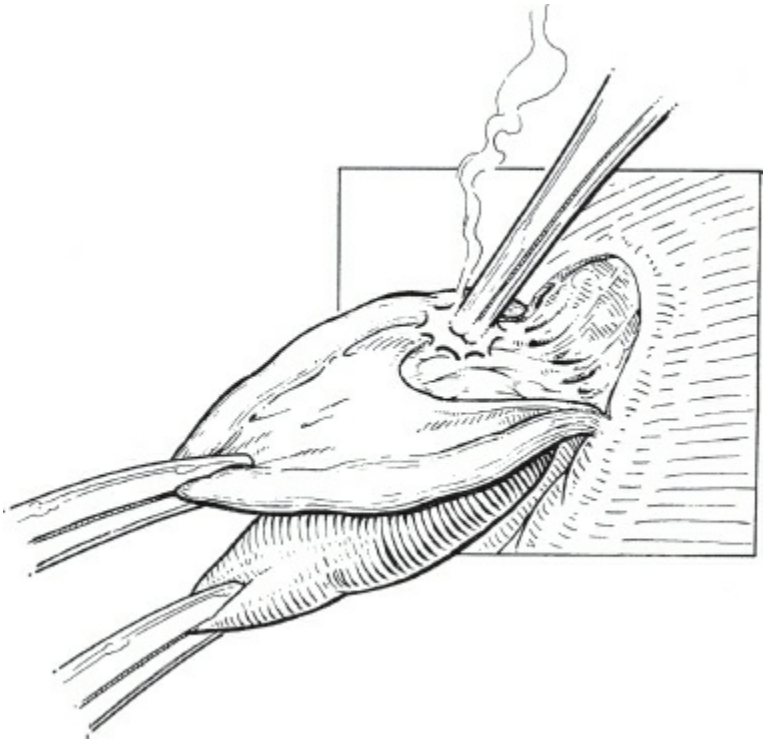

Figure 164.18. Diathermy and dissection of the fibers of the muscularis submucosa ani. (From Keighley MRB, Williams NS. *Surgery of the Anus, Rectum, and Colon*. 3rd ed. Philadelphia, PA: WB Saunders; 2008, Copyright © MRB Keighley MA MS FRCS.)

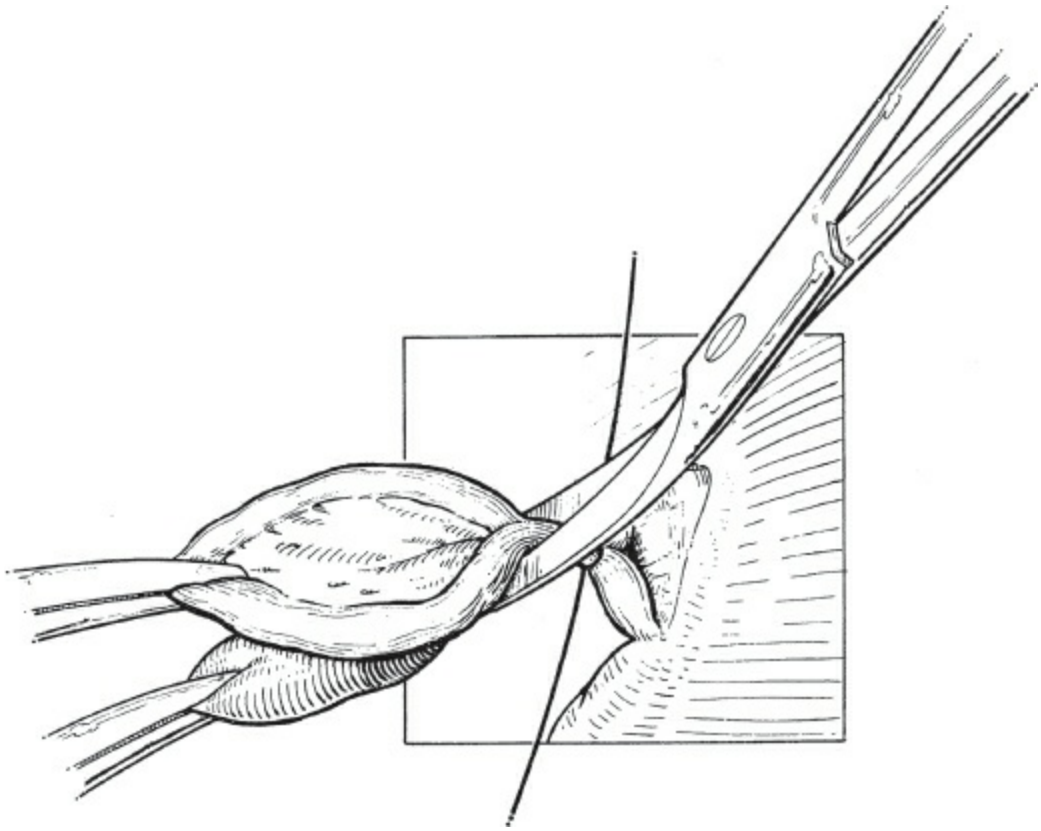

Figure 164.19. Excision of the hemorrhoid after transfixion and ligature of its base. (From Keighley MRB, Williams NS. *Surgery of the Anus, Rectum, and Colon*. 3rd ed. Philadelphia, PA: WB Saunders; 2008, Copyright © MRB Keighley MA MS FRCS.)

In our clinic, we use general anesthesia for this procedure, but some prefer caudal or regional anesthesia. Even when general anesthesia is used, we strongly advise infiltration with a local anesthetic and a weak adrenaline solution, such as bupivacaine with 1:200,000 adrenaline. Ten milliliters of infiltrate is introduced into the submucosal and subcutaneous planes of each hemorrhoid, so that the hemorrhoidal tissue can easily be separated from the fixed fibers of the internal anal sphincter. Short, curved scissors are used for the excision. The anal skin tag is lifted up with tissue forceps and, by use of the heel of the scissors, the skin tag is cut away from the underlying internal anal sphincter. With a second cut of the scissors, the hemorrhoidal tissue is divided from the wall of the anal canal, which leaves the circular fibers of the internal sphincter readily displayed at the base of the wound (Fig. 164.20). With an adrenaline solution, there is minimal bleeding. The next maneuver is to dissect any residual hemorrhoidal tissue from beneath the cut edge of the mucosa on either side of the defect (Fig. 164.21). This also facilitates creating two mucosal flaps for subsequent closure of the defect. Closure is achieved starting at the apex of the mucosal defect in the depth of the anal canal. We use an absorbable suture on a cutting needle. The apex of the mucosal defect is anchored to the internal anal sphincter at the apex, and a running suture is then used to approximate the cut mucosal edges (Fig. 164.22). At the anal verge, a subcuticular technique is used to approximate the skin to avoid leaving a knot at the perianal apex of the wound. The absorbable suture is thus continued backward into the anal canal, and a knot is tied just below the dentate line. The process of closure usually completely controls blood loss. The same technique is used for each of the three hemorrhoidal components. At the completion of the operation, a Pratt operating proctoscope is inserted to ensure that there is complete hemostasis. If not, any residual bleeding must be secured by underrunning the vessel. Meticulous hemostasis is particularly important in this operation because, with the patient in the prone jackknife position, blood readily runs back into the rectum and may not be obvious to the surgeon. Furthermore, infiltration with an adrenaline solution may mask a source of potential reactionary hemorrhage.

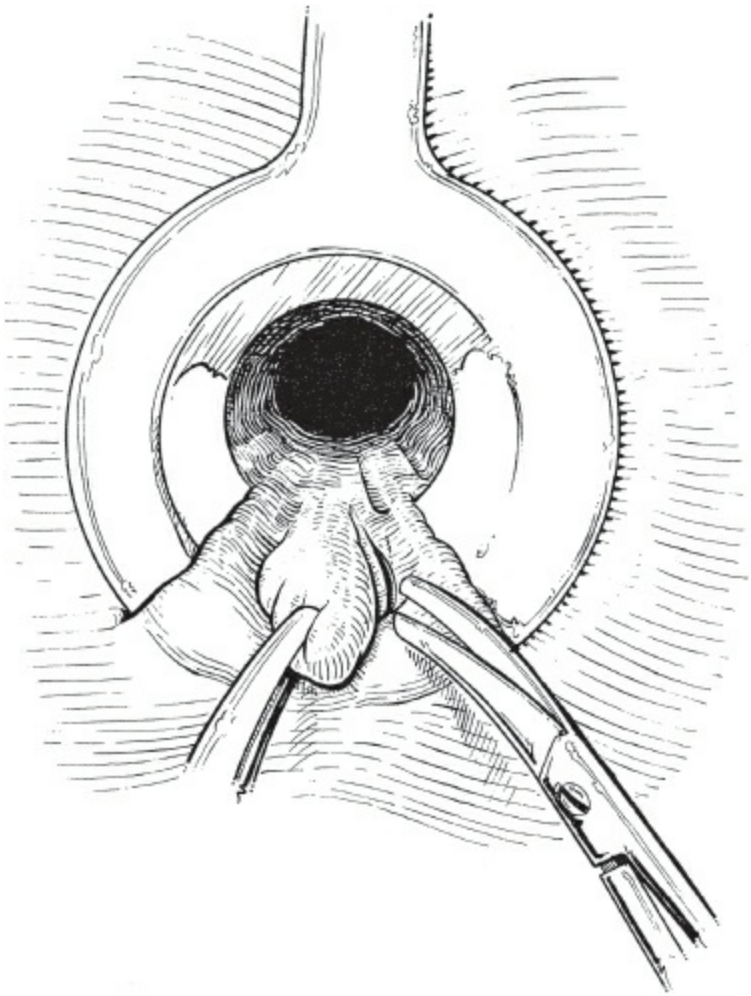

Figure 164.20. Closed hemorrhoidectomy. (From Keighley MRB, Williams NS. *Surgery of the Anus, Rectum, and Colon*. 3rd ed. Philadelphia, PA: WB Saunders; 2008, Copyright © MRB Keighley MA MS FRCS.)

Patients should be warned of the risk of bleeding. They must be given liberal supplies of analgesics and laxatives. If fever develops, patients should return to the doctor as quickly as possible because submucosal and intersphincteric abscesses are a recognized complication of closed hemorrhoidectomy.

COMPLICATIONS OF CONVENTIONAL HEMORRHOIDECTOMY

There are a variety of complications after hemorrhoidectomy, and patients should be warned about them in the consent and counseling process. Reactionary hemorrhage occurs early in the first 24 hours due to restoration of a normal blood pressure causing extensive bleeding from a

vessel that was not secured or where a ligature slipped in the early postoperative recovery phase. Treatment is by emergency relegation of the vessel. Secondary hemorrhage may be major necessitating resuscitation and emergency reoperation. It usually occurs 5 to 8 days postoperatively due to erosion of a vessel from sepsis needing suture ligation and antibiotics. Acute retention of urine is not uncommon in elderly patients. Anal pain postoperatively must be managed appropriately. Where possible, opiates should be avoided altogether. Topical or oral nonsteroidal analgesics are advised and stool softeners with laxatives are essential as patients are immobile and dehydrated. Consequently, fecal impaction is inevitable unless prevented. Impaction only aggravates the pain. Unhealed open wounds or closed wounds that break down should be treated with topical nitrates or Diltiazem creams and regularly assessed. Flatus incontinence and soiling may occur if there has been operative injury to the internal anal sphincter. Anal stenosis should not occur but is a consequence of leaving inadequate skin bridges or, where retained skin bridges slough because the base of the bridges is not wide enough, resulting in ischemic necrosis. Should anal stenosis (the Whitehead deformity) occur after hemorrhoidectomy management can be very difficult? Anal dilatation is usually associated with restenosis requiring repeated anal stretch procedures, which threaten damage to the residual sphincters. Anal skin advancement procedures after excision of a localized stricture might be beneficial. However, in most cases, a complete circumferential defect develops requiring excision with bilateral rotating anoplasty. Anoplasty carries a 20% to 30% risk of sepsis and restenosis.

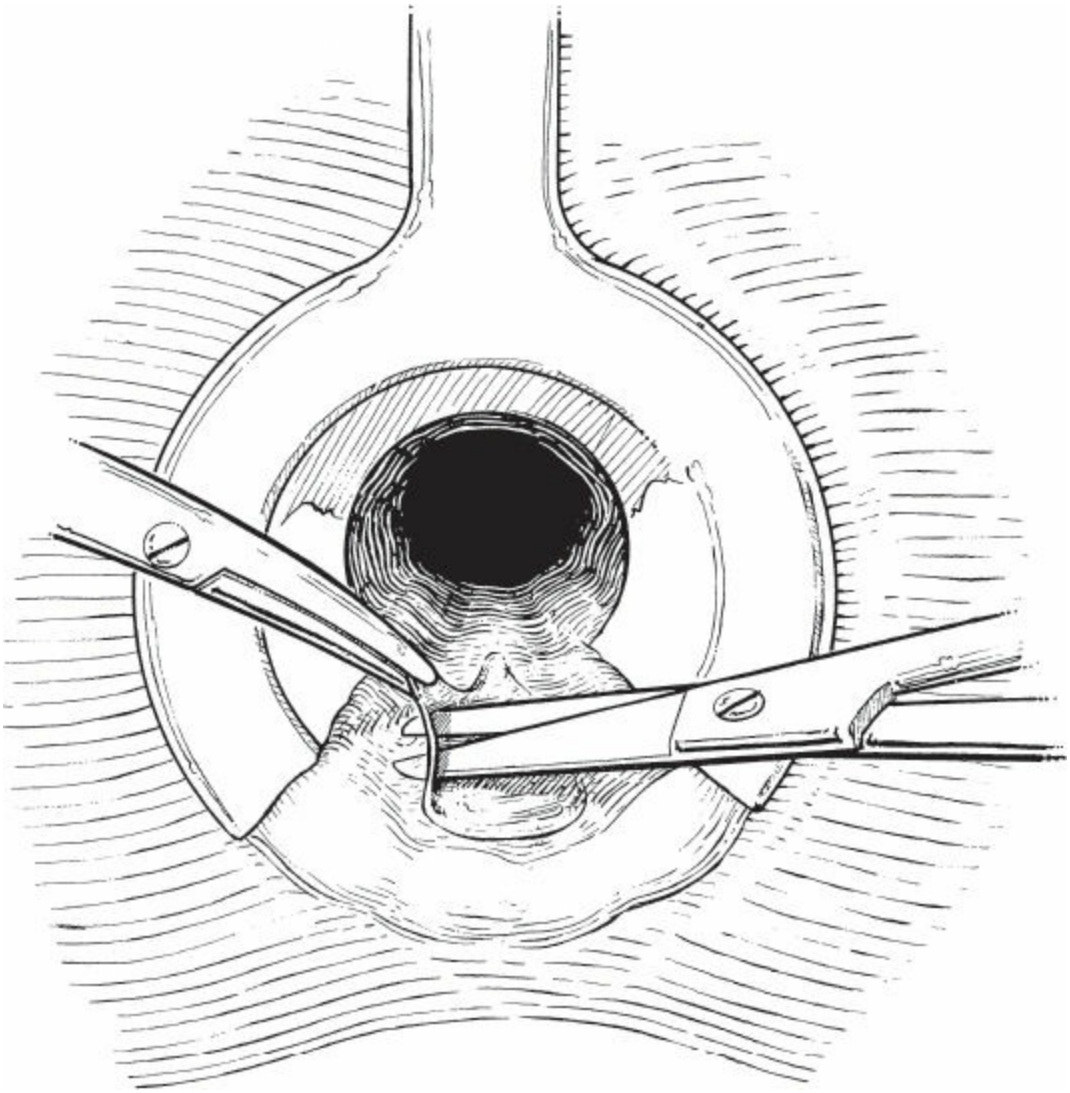

Figure 164.21. Additional vascular tissue beneath the anoderm on either side of the incisions is removed. (From Keighley MRB, Williams NS. *Surgery of the Anus, Rectum, and Colon*. 3rd ed. Philadelphia, PA: WB Saunders; 2008, Copyright © MRB Keighley MA MS FRCS.)

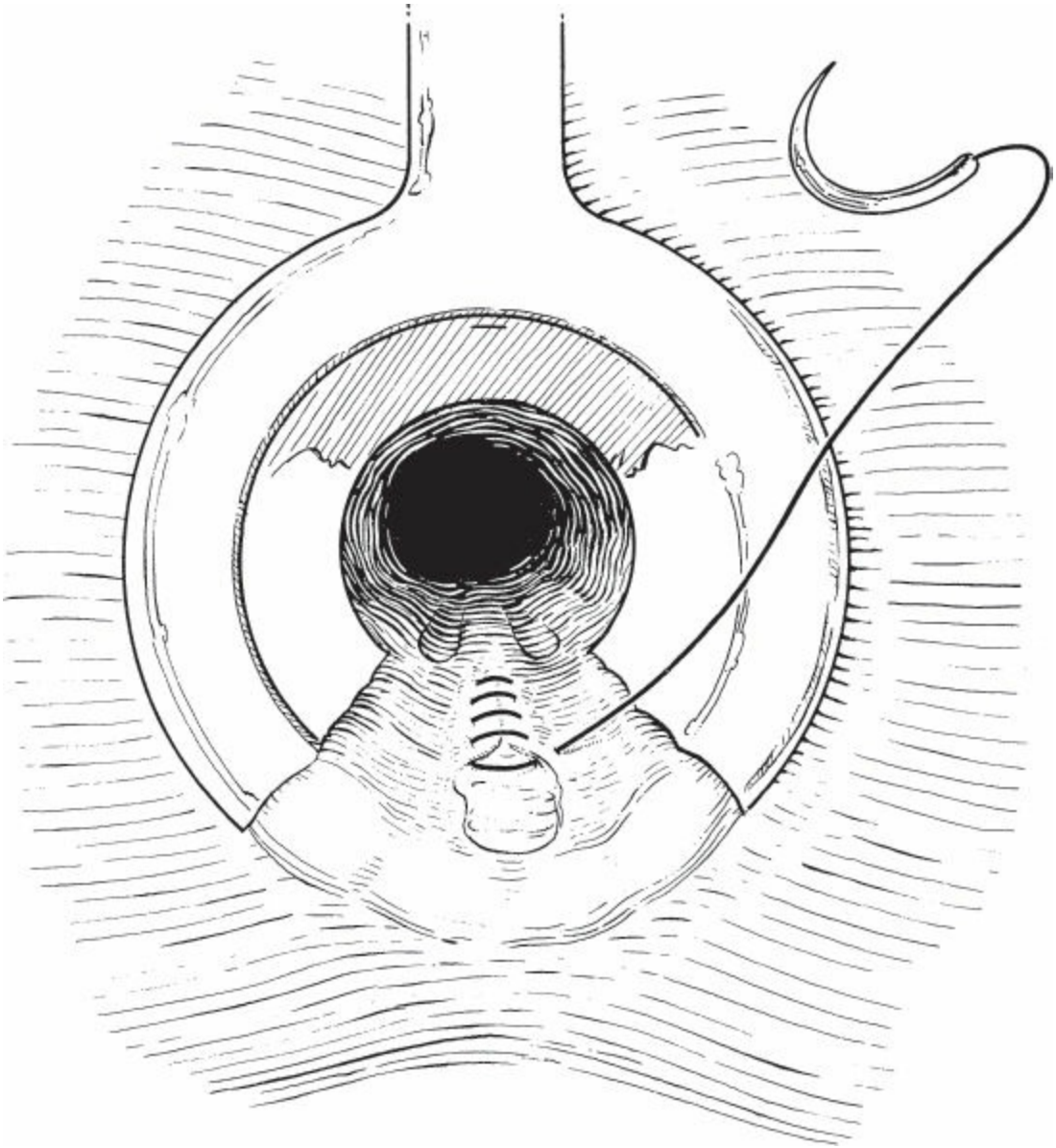

Figure 164.22. The defect in the anal canal mucosa is closed. (From Keighley MRB, Williams NS. *Surgery of the Anus, Rectum, and Colon*. 3rd ed. Philadelphia, PA: WB Saunders; 2008, Copyright © MRB Keighley MA MS FRCS.)

Stapled Hemorrhoidopexy

Stapled hemorrhoidopexy (PPH) has been used for over a decade with both spectacular and disastrous results. The spectacular results reported in 80% to 90% involve an almost painless overnight stay procedure, which is painless and with excellent long-term results. The disasters include rectovaginal fistulae, rectal perforation, sepsis, and chronic symptoms of tenesmus, a feeling of incomplete rectal evacuation and pain (anterior resection syndrome). The reason for this is that the procedure is blind, and

consequently, it is not possible to check that there are no correctable problems during the excision process when the gun is fired.

PPH involves excision of a cylinder of rectal mucosa and submucosa in the top of the anal canal about 2 to 4 cm from the dentate line. Thus, it does not directly deal with skin tags, although skin tags may improve as a result of excision of the anal rectal mucosal cylinder.

In view of the unpredictable results of this operation, patients must be warned that this is a blind procedure and that complications such as rectal (or rectovaginal) injury may occur, there may be bleeding, and that excision of this cylinder of anorectum may cause the anterior resection syndrome. Most informed patients would be wary of consenting to the operation. Thus, it is critical that patients are not pushed into having this new, nearly painless hemorrhoidectomy procedure without careful explanation of the potential complications.

The equipment for the operation (Fig. 164.23) includes an operating proctoscope, which remains sutured in position throughout the operation with an obturator to facilitate the placement of a purse-string suture. The purse-string suture should only include submucosa from the circumference of the anorectum, which must not be too high (Fig. 164.24). Once the purse-string suture has been placed, the stapling gun is introduced, after which the operator cannot be sure what is happening until the gun is fired and the stapling device is withdrawn. Tying of the purse-string suture around the central spindle is facilitated by a hooked probe so that the ends of the purse string can be tightened before the staple gun is closed around the cylinder of tissue, which is then amputated and the residual tissue stapled together (Fig. 164.25). When the circular stapler is removed, the ring of tissue should be inspected to make sure that it is an intact cylinder and it should be sent for histology to ensure that there is no muscle entrapment in the excision. The staple line is then checked for hemostasis and any bleeding vessels should be overrun with a suture. Rectal integrity should also be checked by proctosigmoidoscopy and by bimanual examination in women to ensure that the rectovaginal septum is intact.

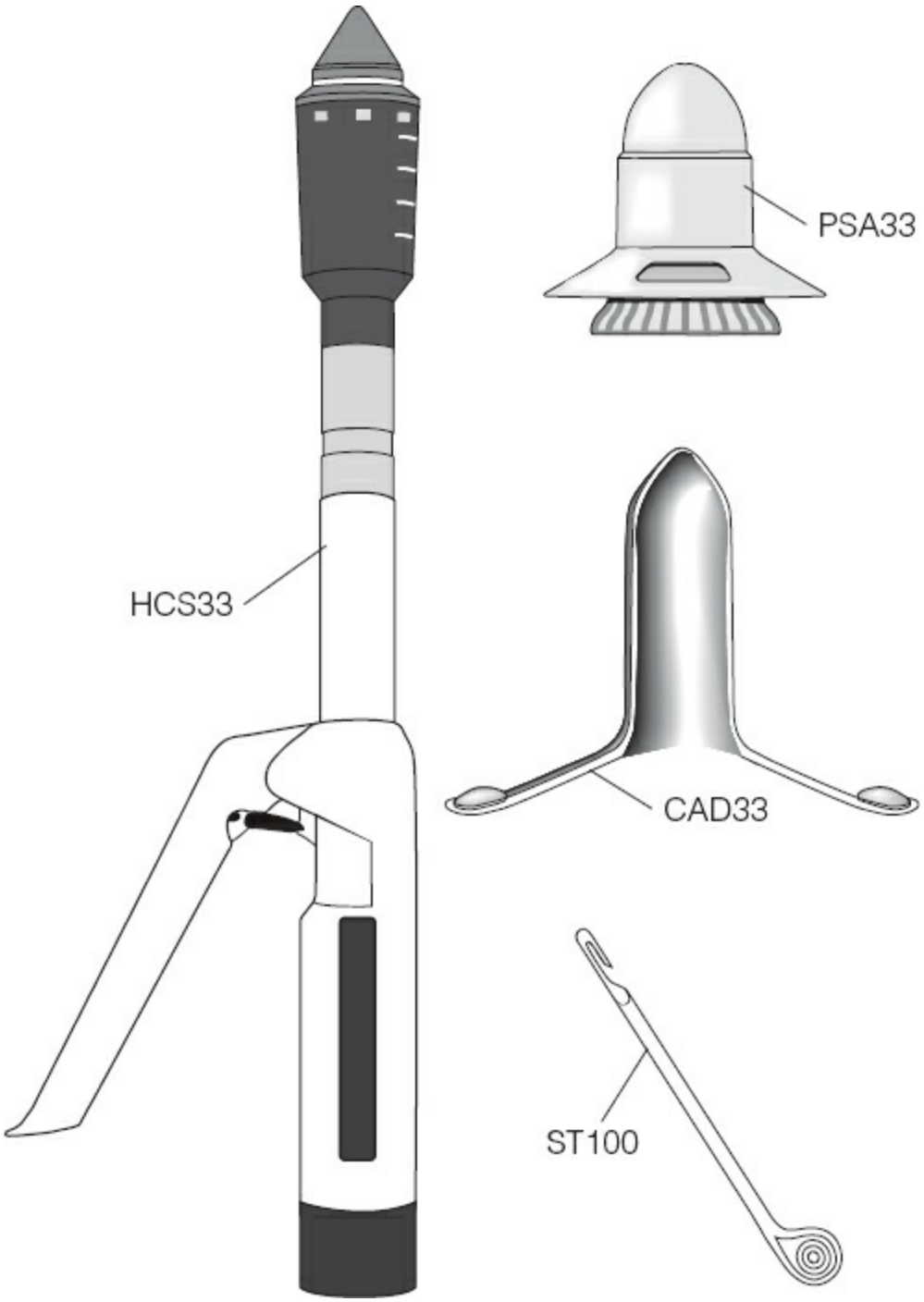

Figure 164.23. Equipment for PPH. (From Keighley MRB, Williams NS. *Surgery of the Anus, Rectum, and Colon*. 3rd ed. Philadelphia, PA: WB Saunders; 2008, Copyright © MRB Keighley MA MS FRCS.)

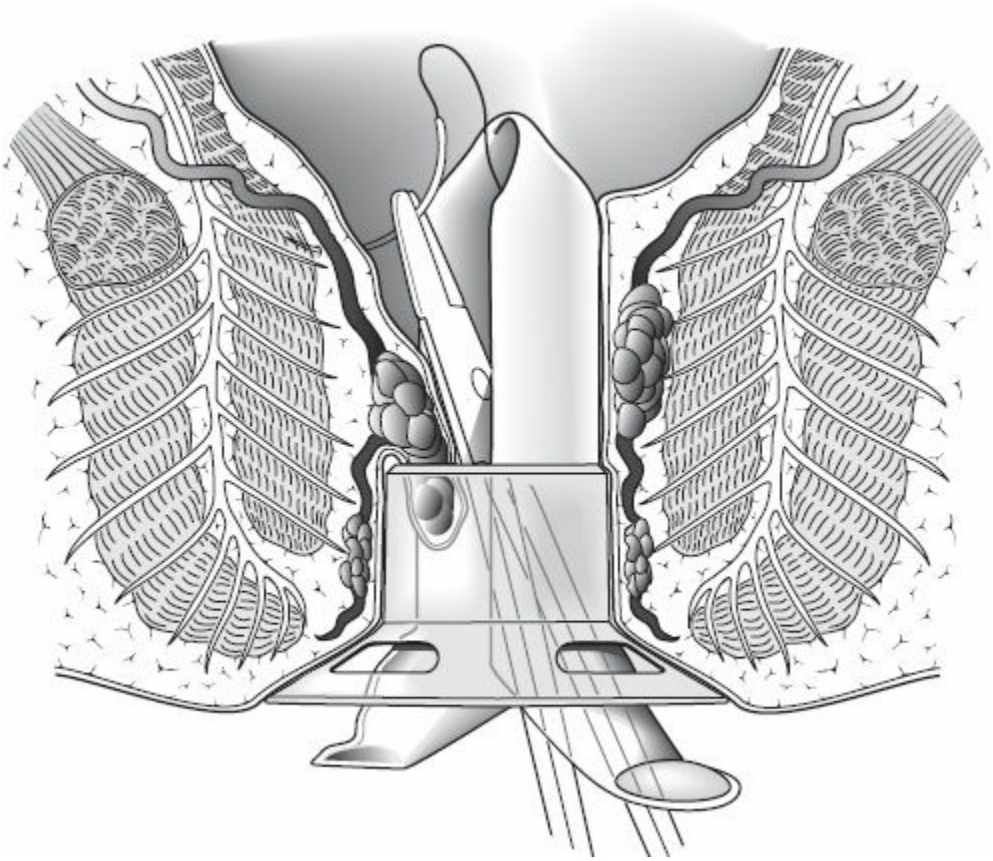

Figure 164.24. Purse string in PPH. (From Keighley MRB, Williams NS. *Surgery of the Anus, Rectum, and Colon*. 3rd ed. Philadelphia, PA: WB Saunders; 2008, Copyright © MRB Keighley MA MS FRCS.)

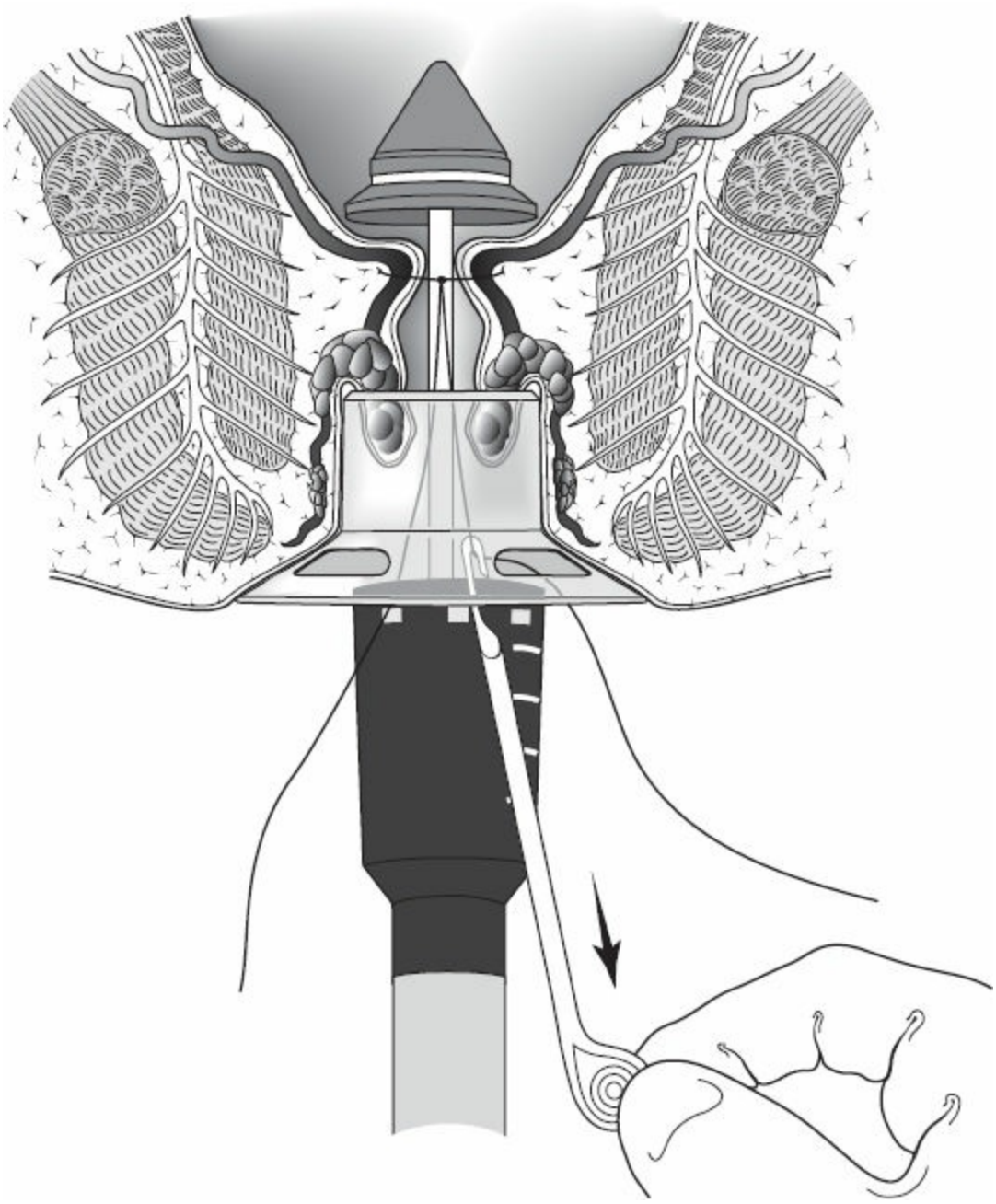

Figure 164.25. Closing the instrument between purse string. (From Keighley MRB, Williams NS. *Surgery of the Anus, Rectum, and Colon*. 3rd ed. Philadelphia, PA: WB Saunders, 2008, Copyright © MRB Keighley MA MS FRCS.)

In the vast majority of patients, the results are spectacular. However, 5% to 10% may develop potentially serious complications or the anterior resection syndrome, which may be permanent.

Anorectal Warts

CLINICAL PRESENTATION

Patients present with small, discrete, papilliferous warts around the perineum or at the anal margin. Some anal condylomata coalesce to form large sessile edematous swellings with hyperkeratinization and discharge of mucus. Anal condylomata may bleed or may give rise to pruritus ani. Associated lesions are common and may occur in the vulva and vagina in women, and on the penis or on the scrotum in men. They may also occur within the urethra and the anal canal, and they may be found on the face and hands.

CAUSES

Anorectal warts are caused by the human papillomavirus. They are usually, but not exclusively, acquired by sexual transmission. Inoculation may occur from the finger or the penis. Homosexual patients may have associated sexually transmitted disease. Thus, many of these patients should be counseled and screened for the human immunodeficiency virus, as well as for gonorrhea, syphilis, chlamydia, hepatitis, *Giardia*, herpes, cytomegalovirus, and lymphogranuloma venereum.

The human papillomavirus is responsible for malignant change; thus, long-standing anal condylomata should be biopsied. The urethra and the anal canal are important sources of reinfection, and so treatment must be directed for the patient or the patient's partner to such potential sources of reinfection.

DIAGNOSIS

Anal warts are obvious on clinical inspection of the perineum. Women should undergo a full speculum examination so as to exclude lesions in the vulva and vagina. All patients should undergo proctoscopy to exclude condylomata within the anal canal. In male patients, the penis, scrotum, and urethra should be inspected.

TREATMENT

Patients with anal condylomata should be screened in a clinic for sexually transmitted diseases for the reasons given previously. The lesions may be treated by topical application of podophyllum resin, by chemo- or immunotherapy, or by surgical excision.

Podophyllum resin is usually applied as a 10% or 20% solution in

benzoin. Long-term studies, however, indicate that only 25% of all patients treated with podophyllum resin achieve complete resolution.

Chemotherapy with colchicine, thiotepa, or fluorouracil (5-FU) has been used. Today, these methods are rarely recommended. There was a vogue for immunotherapy, but long-term studies do not substantiate the early claims of resolution in >80% of patients.

Surgical treatment is by cautery, laser ablation, cryotherapy, or scissor excision. We do not advocate cryotherapy. Laser treatment is highly specific to each lesion and causes less tissue destruction than fine-point high-frequency cautery. However, we prefer scissor excision and recommend the technique of subcutaneous and submucosal infiltration with a weak adrenaline solution, which lifts the condylomata away from the normal skin so that the condylomata themselves can be excised and leave the surrounding skin or mucosa intact (Fig. 164.26). This technique is tedious, but it causes infinitely less tissue destruction than excision by cautery and probably less than that from laser excision. In confluent lesions, it may be necessary to treat patients in more than a single visit. Despite the use of a weak adrenaline solution, bleeding can be quite troublesome after multiple scissor excisions. We do not recommend the use of cauterization to control bleeding, but prefer pressure tamponade. Any lesions in the anal canal must be thoroughly cleared by scissor excision as well as removal of the perianal lesions. Follow-up is absolutely essential, because some patients require treatment more than once, and recurrence is common. The overall recurrence rate is ~40%. Many recurrences are caused by reinfection. Hence, patients must be carefully counseled and their partners screened.

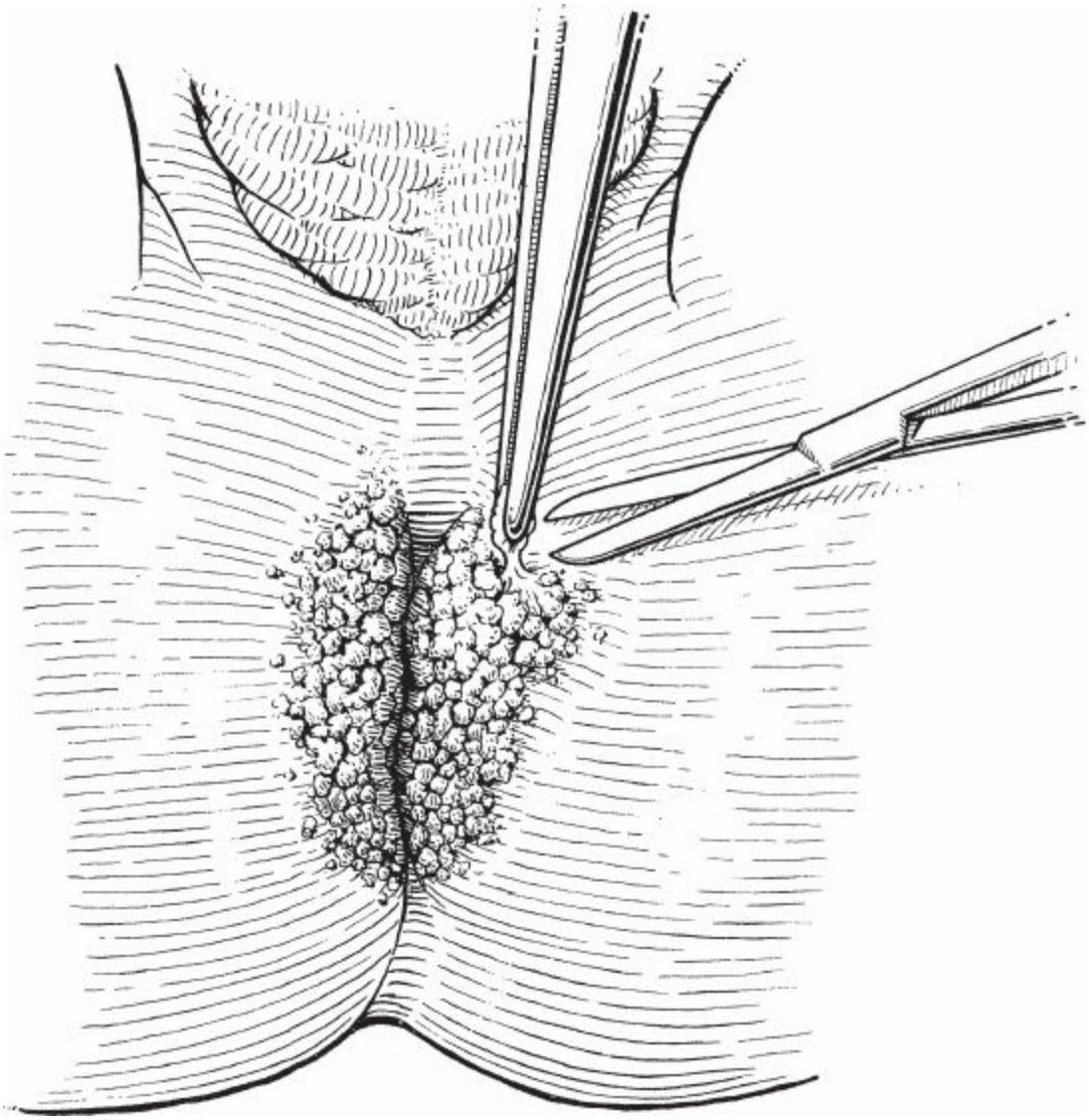

Figure 164.26. Scissor excision of anorectal warts. (From Keighley MRB, Williams NS. *Surgery of the Anus, Rectum, and Colon*. 3rd ed. Philadelphia, PA: WB Saunders; 2008, Copyright © MRB Keighley MA MS FRCS.)

Pilonidal Sinus

CLINICAL PRESENTATION

Pilonidal sinus is associated with small midline pits behind the anal canal over the sacrum and coccyx. There may be lateral openings, particularly if the disease is complicated by sepsis. These sinuses often discharge purulent material that causes poor anal hygiene. Alternatively, the disease may be complicated by acute infection presenting as an abscess. The midline pits often contain hair. The condition principally affects young

people after puberty, is more common in men than in women, principally affects whites, and is rare in Black or Asian patients. The condition may be completely asymptomatic and may disappear with age.

CAUSES

There are two theories about the cause of pilonidal sinus—that the disease is caused by a developmental abnormality and that it is acquired. The developmental theory proposes that there are epidermal rests with hair embedded below the dermis in the midline as a result of failure of fusion. Occasionally, implantation dermoids are seen, but they are quite distinct from pilonidal disease. Most authorities now believe that pilonidal disease is acquired.

The acquired theory suggests that hair is shed from around the perineum or from the head, and that the distal ends of the hair act as drills into small sebaceous or hair follicles. In this manner, hair penetrates or is sucked into the dermis and subcutaneous tissues, which creates minute pits. Subsequently, the pits become infected by skin organisms and give rise to suppuration. The fact that pilonidal disease is more common among barbers, and that it can occur between the web spaces of the fingers, strongly supports the acquired theory.

DIAGNOSIS

Pilonidal disease is easily diagnosed by the typical location of the midline pits behind the anus overlying the sacrum and coccyx. Occasionally, pilonidal disease may form small subcutaneous fistulae around the anal canal, but this is rare. Most sinuses are directed cephalad, and lateral openings are characteristic if previous episodes of sepsis have occurred. Broken hairs can often be seen exuding from the midline pits.

TREATMENT

Management of Pilonidal Abscess

Pilonidal abscess presents as a swelling just lateral to the midline over the sacrum. There is a hot, tender, fluctuant swelling that may exude pus through the midline pit and also may spontaneously discharge at its apex. Treatment in the emergency room is by incision and drainage. Any further treatment is meddlesome at this stage. Thereafter, treatment of the underlying disease is as described in the following sections.

Elective Treatment of Pilonidal Sinus

Elective treatment of pilonidal sinus can be divided into three major categories: (a) minimal surgery, (b) opening of sinus tracks, and (c) excision with or without rotational skin flaps. Before any form of surgical treatment is begun, serious consideration must be given as to whether treatment is likely to cause more morbidity than does the underlying pilonidal disease itself. In many instances, surgical treatment leaves the patient worse, not better. For many patients, treatment involves a chronically discharging open unhealed wound that persists for months or even years and necessitates frequent hospital admission for surgical curettage, as well as repeated office appointments. Furthermore, the natural history of pilonidal disease in untreated patients suggests that, in some, the disease disappears with time.

Minimal Surgery

The principle of minimal surgery is simply to remove hair from midline pits and to keep the buttocks shaved. Many patients with pilonidal disease are not particularly meticulous about personal hygiene. Thus, some form of counseling is necessary to explain the importance of washing the area regularly and to teach how to shave the area. A fine wire brush may be used with local anesthesia to clear the pits and any lateral openings of granulation tissue and hair (Fig. 164.27).

Excision of Pits and Closure of the Presacral Cavity: Bascombe Operation

This is a relatively minor day-case procedure. The midline pits are excised by a fine scalpel blade around each pit down to the presacral cavity and left open. All the pits are drilled out. A lateral incision is then made about 1 cm from the midline so as to expose the presacral cavity deep to the pits. The cavity is opened and the contents are scooped out with a Vulsellum spoon. The incision is then closed primarily (Fig. 164.28).

Fibrin Glue

Spectacular results have been reported with fibrin glue application to the tracks once they have been curetted as described in the preface to this section. “Tisseal” glue (commercially available fibrin plug) is then applied to each of the tracks and any excess wiped away. The healing rates are

comparable to the Bascombe operation, and there is much less postoperative pain.

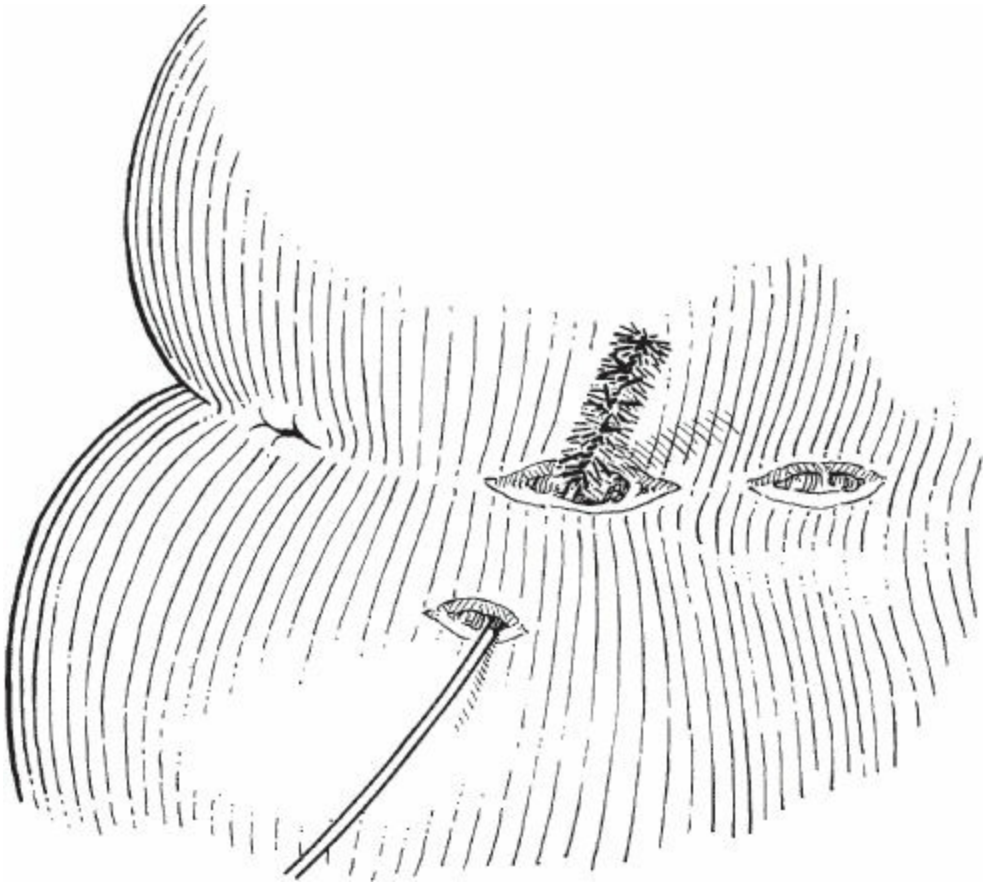

Figure 164.27. Curretting out midline sinuses and their lateral tracks. (From Keighley MRB, Williams NS. *Surgery of the Anus, Rectum, and Colon*. 3rd ed. Philadelphia, PA: WB Saunders, 2008, Copyright © MRB Keighley MA MS FRCS.)

Lay Open of Sinus Tracks

If minimal surgery does not control episodes of suppuration, the sinuses themselves may be opened as in fistulotomy (Fig. 164.29). A probe is passed through the pilonidal sinuses, and the tracks are carefully opened by dividing the skin with a scalpel blade or by cautery. The granulation tissue at the base of the sinuses is curetted. The edges of the skin are excised so that there is an open granulating wound that must be kept meticulously clean and free of hair by the methods described in the previous section. The superficial wounds may heal completely. If they do not, a skin graft or advancement flap may be used to close the defect.

Excision of Sinus Tracks

Wide excision of the pilonidal area, including all affected skin and subcutaneous tissues down to the presacral fascia, may be needed if all other methods of treatments fail. Excision has traditionally been by midline incision to enclose all the disease process. The wound may be left open, allowed to marsupialize, or closed as a primary procedure. There is a high breakdown rate, mainly because of the shearing forces around the buttocks in young, active patients. The shearing forces can be minimized by placing the incision off the midline as in the Karydakis procedure. Avoidance of midline incisions reduces the risk of nonhealing.

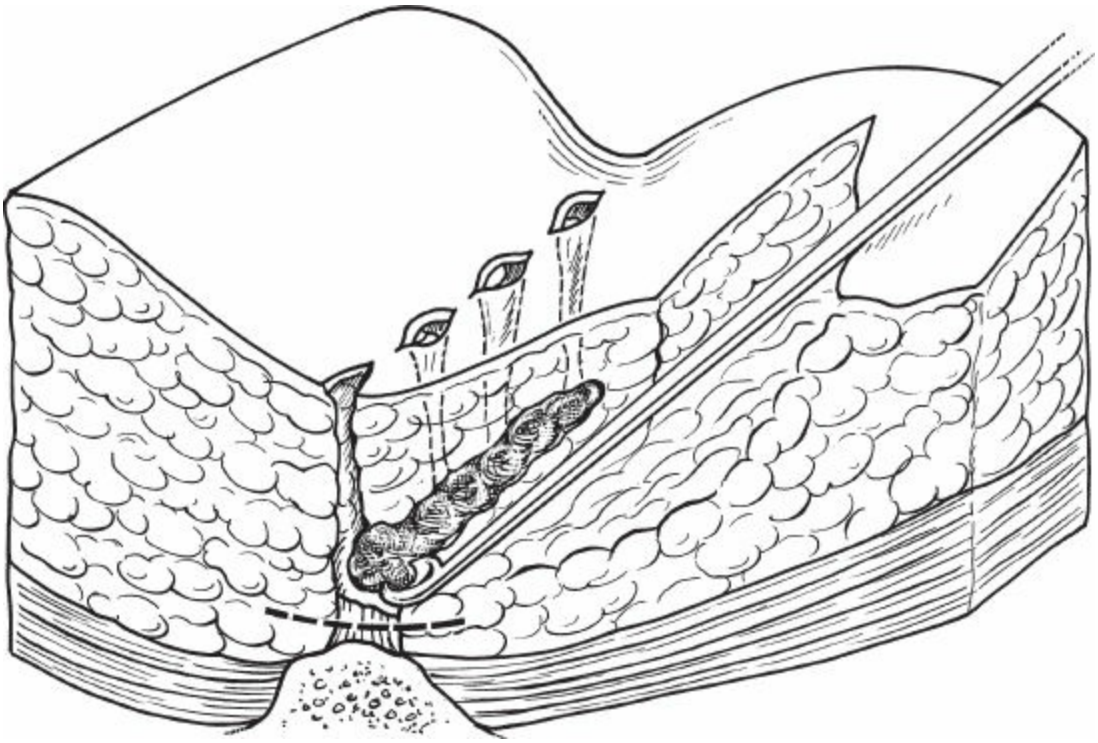

Figure 164.28. The Bascombe operation. (From Keighley MRB, Williams NS. *Surgery of the Anus, Rectum, and Colon*. 3rd ed. Philadelphia, PA: WB Saunders; 2008, Copyright © MRB Keighley MA MS FRCS.)

If the sinus is infected at the time of excision, no attempt should be made to primarily close it. The wound may be left open to granulate and secondary suture may be performed, or a technique of marsupialization may be used, whereby the skin surrounding the defect is sutured down to the presacral fascia.

Primary closure, if it is to be performed, should ensure that there is no dead space and that some form of pressure dressing is used to prevent hematoma that may become secondarily infected. Suction drains may be

used. Alternatively, compression dressings can be applied within the sutures used to close the defect (Fig. 164.30).

Occasionally, there are patients whose primary excision sites have never healed. These postoperative nonhealed ulcers can cause considerable morbidity, and their closure may prove difficult. Techniques that may be used to cover such defects include Z-plasty, the use of the rhomboid flap, or the use of myocutaneous flaps based on the superior gluteal artery and nerve. Under these circumstances, most coloproctologists require the help of a plastic surgeon. However, Z-plasty and rhomboid flap techniques may be used during primary excision and suture.

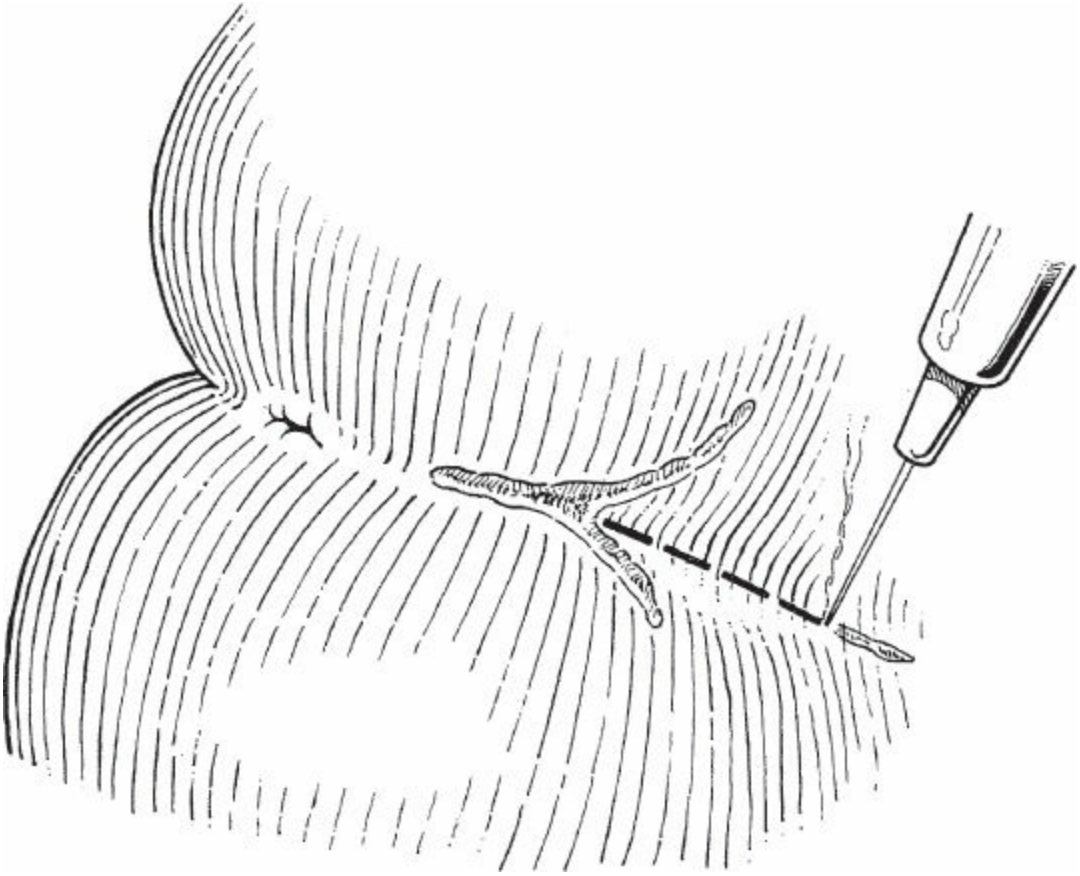

Figure 164.29. Lay open of pilonidal sinus. (From Keighley MRB, Williams NS. *Surgery of the Anus, Rectum, and Colon*. 3rd ed. Philadelphia, PA: WB Saunders; 2008, Copyright © MRB Keighley MA MS FRCS.)

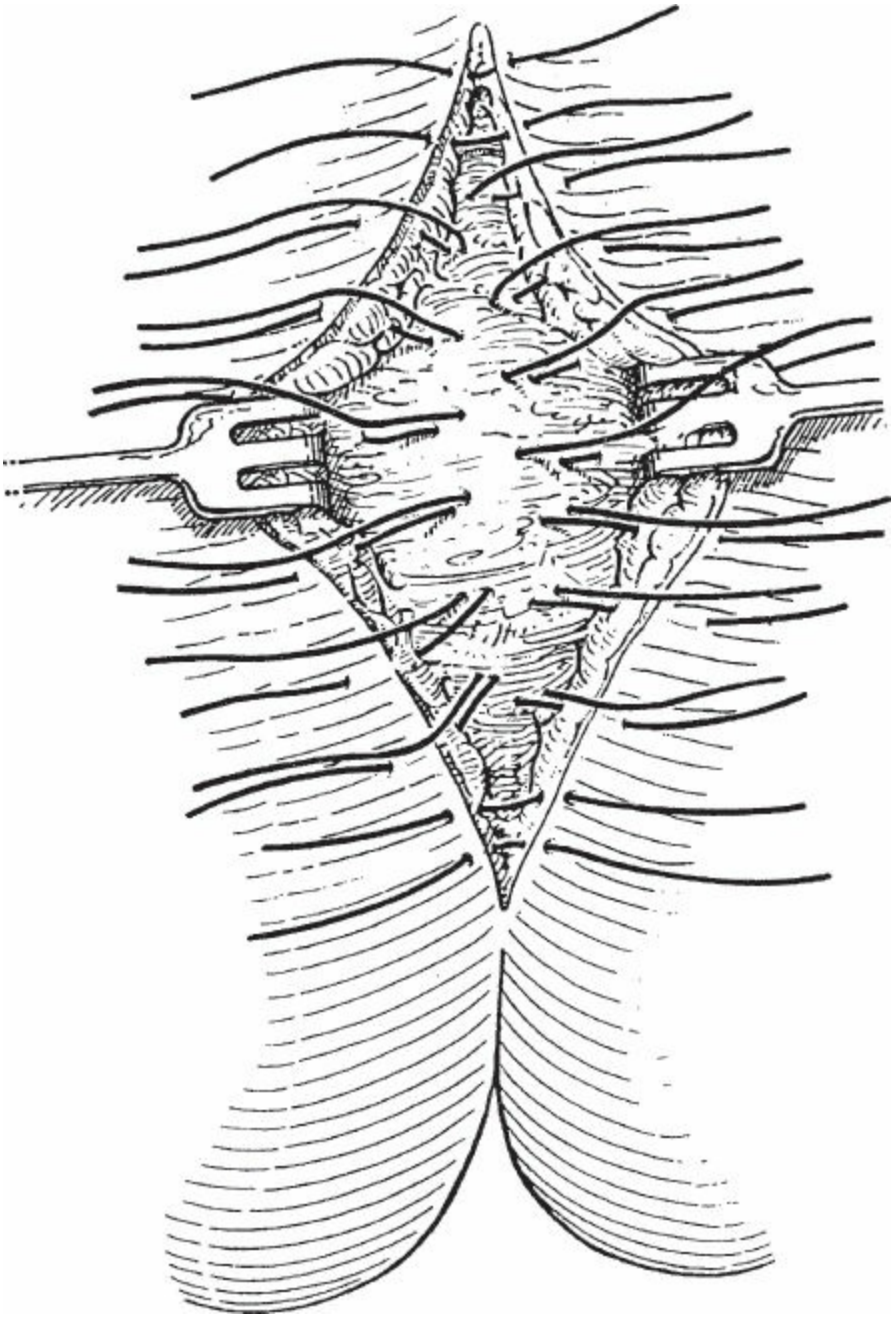

Figure 164.30. Primary excision and closure. (From Keighley MRB, Williams NS. *Surgery of the Anus, Rectum, and Colon*. 3rd ed. Philadelphia, PA: WB Saunders; 2008, Copyright © MRB Keighley MA MS FRCS.)

Karydakis Primary Excision and Closure

The excision is performed using an asymmetrical incision, which deliberately removes much more skin on one side than on the other. The pits in the presacral cavity are excised, and the side of the excision closest to the midline is undermined, so that when the skin is approximated to the other side (the wider skin excision area) the wound lies off center (Fig.

164.31). Antibiotic cover should be used for the procedure and closed suction drainage if hemostasis is other than perfect. Using this technique, achieved primary healing rates of 60% to 90% have been reported.

Hidradenitis Suppurativa

CLINICAL PRESENTATION

Hidradenitis suppurativa never occurs before puberty. Women are affected more commonly than men. The disease presents with skin suppuration and superficial fistulae associated with brawny edema and induration in areas of the body in which there are apocrine glands. One of these areas, the perineum, may give rise to extensive disease that can be difficult to differentiate from perianal Crohn disease, anorectal fistulae, tuberculosis, and anogenital cancer. The typical presentation is of boils, furuncles, induration, and discharging sinuses on the perianal region, the vulva, the groin, or the axilla. The discharge is thin, watery, and offensive. The condition is a form of acne.

CAUSES

It is presumed that there is a hormonal basis for this disease, because it never occurs before puberty. The principal abnormality is the occlusion of apocrine ducts by keratin. Obstruction leads to retention of secretions, and secondary infection resulting in fibrosis, sinus formation, and induration.

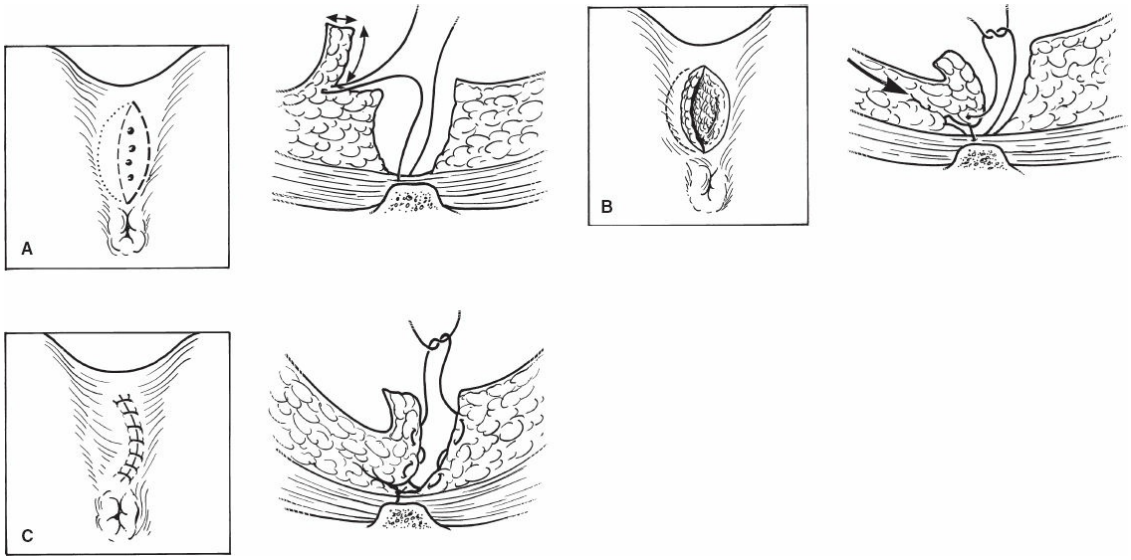

Figure 164.31. Karydakis procedure. **A.** Incision off center. **B.** Lateral mobilization. **C.** Closure off center. (From Keighley MRB,

Williams NS. *Surgery of the Anus, Rectum, and Colon*. 3rd ed. Philadelphia, PA: WB Saunders; 2008, Copyright © MRB Keighley MA MS FRCS.)

DIAGNOSIS

Diagnosis of hidradenitis is made by the typical appearance in association with lesions in the groin or the axilla. If there is difficulty in making a diagnosis, excision biopsy may prove necessary.

TREATMENT

Treatment depends mainly on the severity of disease. Some patients with chronic induration and only occasional discharge prefer to accept the morbidity of the disease rather than the morbidity of surgical treatment. Surgical treatment is often extensive, is not always successful, and may be associated with extensive morbidity and prolonged hospital stay. Low-dose antibiotics may be used for prolonged periods to prevent secondary infection, but under these circumstances there is the inevitable risk of bacterial resistance and superinfection. Alternatively, intermittent courses of antibiotic may be used to treat acute exacerbations of the disease or for secondary infective complications. Localized collections of pus may need drainage. With time, the disease often slowly disappears, leaving fibrosis without infection.

Surgical treatment, to be effective at all, requires total ablation of the apocrine area. Hence, all skin and subcutaneous tissues involved in fibrosis, sinus, and fistulae are excised. For perianal disease, this may involve extensive saucerization, which leaves only perianal skin. The defect may be left to granulate, and VAC dressings have proved extremely helpful, particularly for deep cavitating wounds, and if subsequent skin grafting, should be necessary. Alternatively, myocutaneous flaps may be used to cover the defect. For extensive perianal disease requiring wide excision, a defunctioning stoma is often necessary to keep the area clean, allow healthy granulation tissue to form, and facilitate skin grafting.

Rectovaginal Fistula

CLINICAL PRESENTATION

The principal symptom for a patient with a rectovaginal fistula is of the

passage of pus or feces through the vagina. Symptoms may be intermittent or continuous and may result in impaired vaginal hygiene or lead to frank fecal incontinence. Small fistulae are often associated with intermittent symptoms, amounting to a small amount of vaginal discharge sometimes accompanied by the passage of gas through the vagina. Small, low rectovaginal fistulae can be extremely difficult to diagnose, whereas large rectovaginal fistulae are clinically obvious with perianal soiling, fecal incontinence, and severe pelvic sepsis and necessitate urgent surgical management.

CAUSES

Rectovaginal fistulae are classified into three broad anatomic groups: (a) forniceal fistulae, (b) septal fistulae, and (c) perineal fistulae (Fig. 164.32).

Forniceal Fistulae

Fistulae entering the posterior fornix of the vagina arise from disease in the pouch of Douglas or from the upper rectum. The common causes are diverticular disease, carcinoma of the large bowel, Crohn disease of the ileum or large bowel, postirradiation fistulae after treatment of gynecologic malignancy (particularly after hysterectomy), and postoperative fistulae after an intestinal anastomosis in the pouch of Douglas.

Septal Fistulae

Fistulae running through the rectovaginal septum, that is, within the middle third of the vagina, are often large, are usually direct, and are invariably caused by rectal or gynecologic conditions. The rectal causes include rectal carcinoma, rectal Crohn disease, and postirradiation rectovaginal fistulae. Gynecologic causes include carcinoma of the cervix or vagina and severe postobstetric fistulae resulting from pressure necrosis from the fetal head in obstructed labor. These are suprasphincteric fistulae.

Perineal Fistulae

Perineal fistulae often pursue a tortuous course. They run through a part of the perineum or sphincter mechanisms. The fistulae may be small and cause minimal symptoms. Causes of perineal rectovaginal, rectovulvar, and anovulval fistulae include cryptoglandular infections, as in anorectal

abscess and fistula (see previous sections); postobstetric fistulae from sphincter damage associated with a defect between the two viscera (either third or fourth degree obstetric tears); iatrogenic fistulae caused by previous surgical treatment; and fistulae complicating perianal Crohn disease (often cryptoglandular).

DIAGNOSIS

Identification of large fistulae is often not difficult. By contrast, small, tortuous perineal fistulae may prove exceedingly difficult to positively identify. Large rectovaginal fistulae causing fecal incontinence are associated with intense excoriation of the perianal skin and a red, raw vagina, obvious clinically. Vaginal speculum examination is necessary for smaller fistulae to identify the site of the vaginal opening. Perineal fistulae may be difficult to see, but septal and forniceal fistulae are usually obvious. Examination should also include proctoscopy, particularly for perineal fistulae, to identify whether there is an opening at the dentate line, which is characteristic of a cryptoglandular origin. Proctosigmoidoscopy is necessary to exclude rectal malignancy, Crohn disease, and irradiation damage.

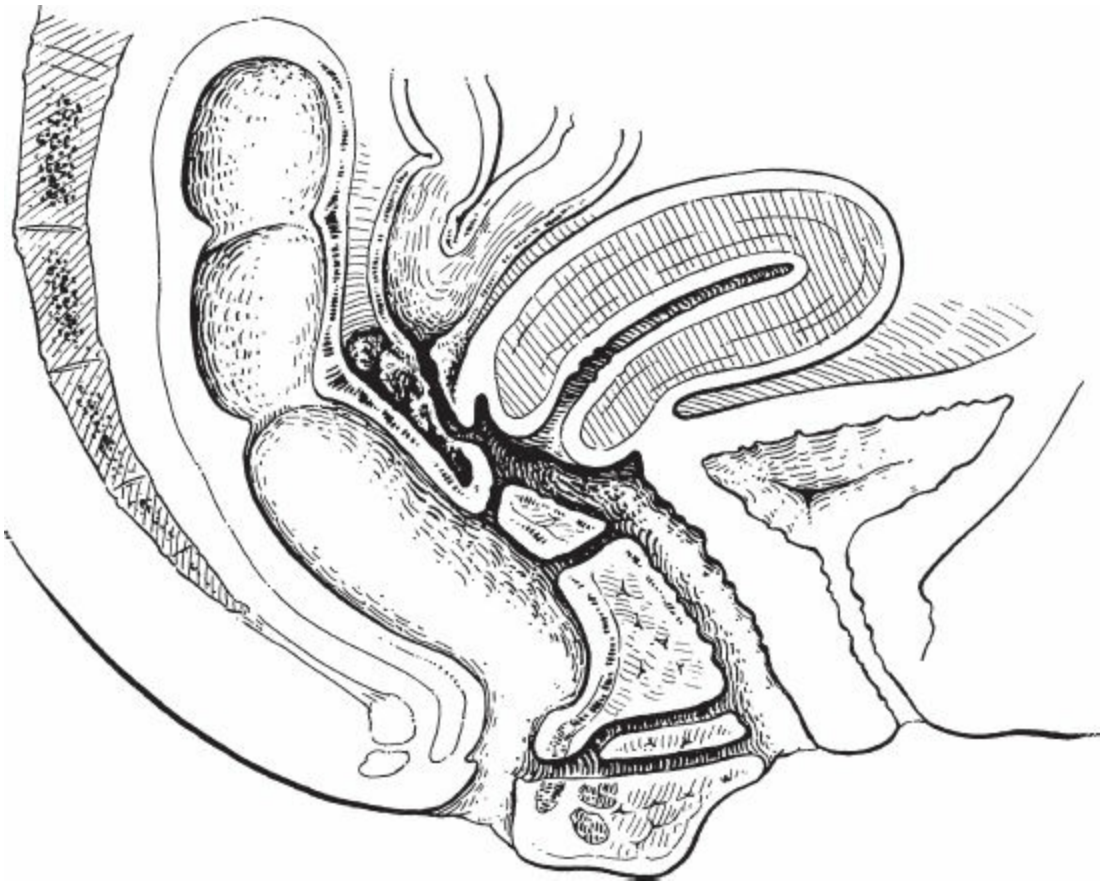

Figure 164.32. Classification of rectovaginal fistulas. (From Keighley MRB, Williams NS. *Surgery of the Anus, Rectum, and Colon*. 3rd ed. Philadelphia, PA: WB Saunders; 2008, Copyright © MRB Keighley MA MS FRCS.)

Special investigations may be helpful in delineating the cause and the course of the fistula. Barium enema examination may be necessary to identify inflammatory bowel disease, but the examination is relatively limited in defining the course of the fistula. Likewise, colonoscopy is useful in identifying inflammatory or malignant disease of the large bowel but rarely demonstrates the internal opening unless it is large. Vaginography may be a helpful method of identifying forniceal fistulae that cannot be demonstrated by speculum examination.

Examination with the patient anesthetized is usually necessary to demonstrate many fistulae, particularly those that are cryptoglandular in origin or that are postoperative. The use of fistula probes and injection of dyes may also facilitate identification. Rectal ultrasound is disappointing in the identification of rectovaginal fistulae except in the septal region, in which they are already obvious clinically. Perineal MRI is particularly helpful in identification of obscure fistulae. Any suspicious fistula should be biopsied to exclude malignancy.

TREATMENT

Preliminary Fecal Diversion

Preliminary fecal diversion is absolutely essential for patients with severe fecal incontinence or where a fistula is complicated by pelvic sepsis.

Definitive Treatment

Disease in the Pouch of Douglas

Disease in the pouch of Douglas causing a fistula through the posterior fornix of the vagina should be treated by resection when possible. Thus, resection is indicated for Crohn disease associated with fistulae, for diverticular disease causing a rectovaginal fistula, and for malignancy, but in these cases radical hysterectomy and partial excision of the vagina may be necessary. Rectal cancer associated with rectovaginal fistulae certainly requires radical resection of the rectum and the uterus and vagina. High postirradiation fistulae should be treated by sleeve coloanal anastomosis and covering loop ileostomy.

Surgical Treatment of Septal Fistulae

A carcinoma of the middle third of the rectum that causes a rectovaginal fistula is usually treated by abdominoperineal excision, hysterectomy, and partial vaginectomy. Occasionally, sphincter-saving procedures are possible with a coloanal anastomosis and covering loop ileostomy. In patients with a rectovaginal fistula complicating severe rectal or perianal Crohn disease, proctocolectomy and end ileostomy are the treatment of choice. Septal fistulae resulting from radiation damage require rectal excision and an end stoma or a sleeve coloanal anastomosis after excision of the fistula with a covering loop ileostomy (Fig. 164.33).

Treatment of Perineal Fistulae

Perineal fistulae can be treated in a number of ways, depending on their location, the patient's condition, and previous surgical procedures undergone by the patient.

Anorectal Advancement

Anorectal advancement and excision of the fistula track is the treatment of choice for postobstetric or cryptoglandular rectovaginal fistulae. The fistula track is first identified by careful probing. The vaginal side of the fistula is completely ignored unless there is sepsis, in which case it is cleared by local excision and curettage. An intra-anal retractor is inserted and, with the patient in the prone jackknife position, excellent exposure of the fistula is obtained. The mucosa surrounding the fistula is infiltrated with a weak adrenaline solution. The anterior aspect of the anal canal is also infiltrated in the submucosal and the intersphincteric plane. A curvilinear incision is made at the level of the fistula or just below it. The internal sphincter at this point is divided transversely, and upward dissection proceeds in the intersphincteric plane for a distance of ~4 to 5 cm. Thus, a flap of mucosa, submucosa, and both internal sphincter and rectal smooth muscle is created, containing opening of the fistula. The fistula is then excised by fine scalpel or diathermy excision through to its origin in the vagina. Any infection in the intersphincteric plane is cleared by curettage. The mucosa and internal sphincter below the transverse incision of the anal canal are dissected free. Once the fistula has been excised, the anal opening is closed with the lower margin of the flap. The lateral margins are then secured with interrupted sutures (Fig. 164.34). It is rarely necessary to defunction anorectal advancement flap unless there is underlying Crohn disease or severe perianal sepsis.

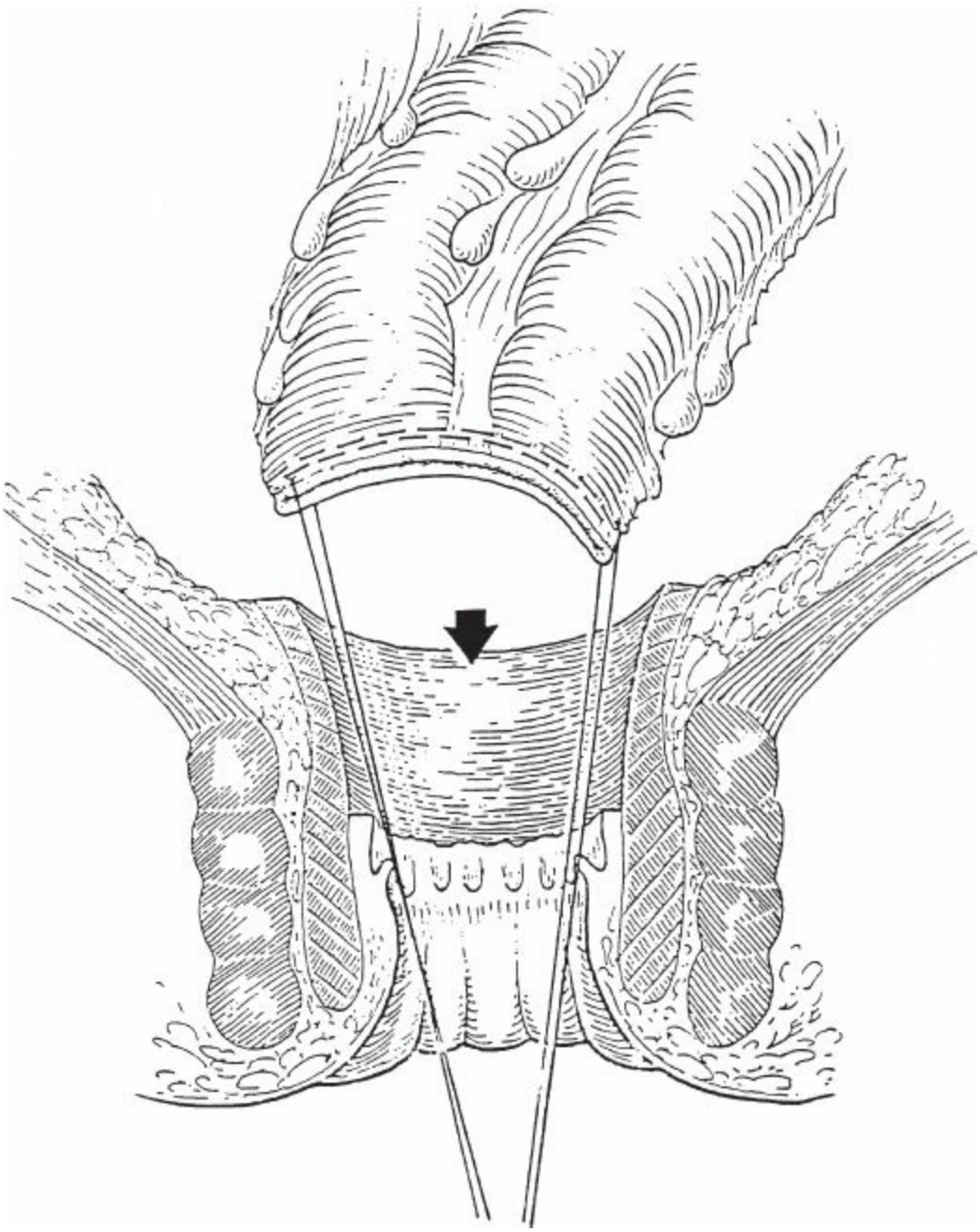

Figure 164.33. Coloanal reconstruction of a high rectovaginal fistula. (From Keighley MRB, Williams NS. *Surgery of the Anus, Rectum, and Colon*. 3rd ed. Philadelphia, PA: WB Saunders; 2008, Copyright © MRB Keighley MA MS FRCS.)

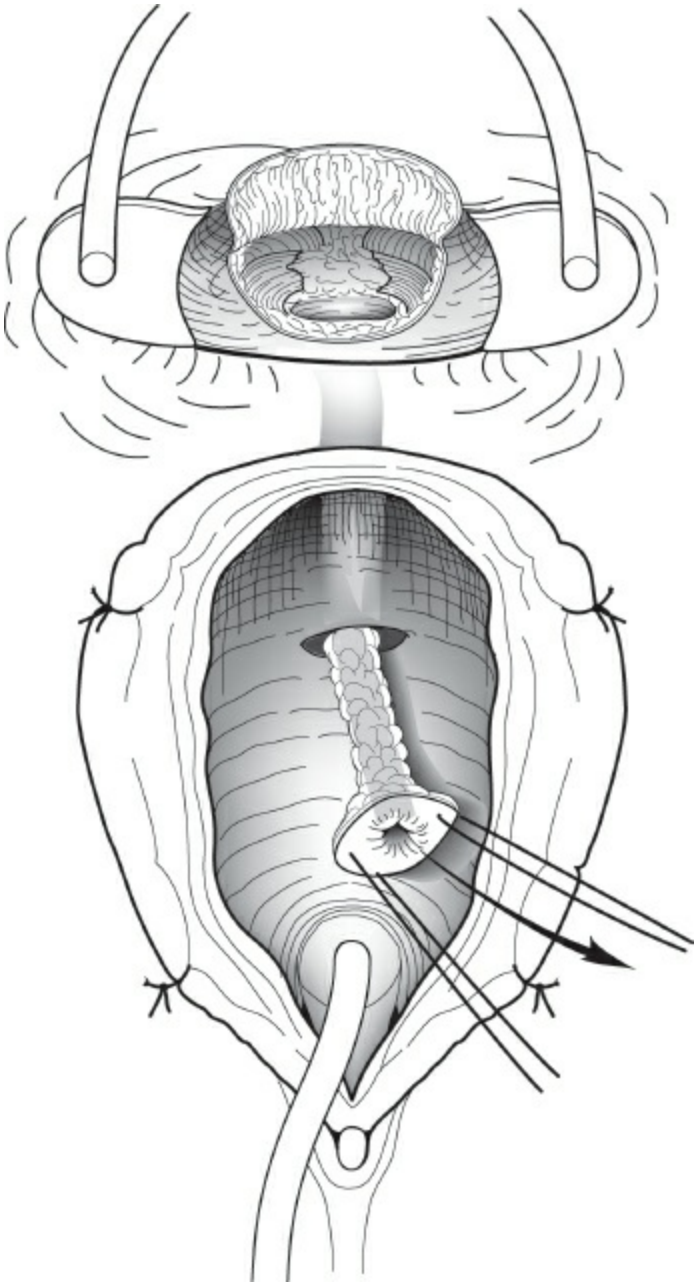

Figure 164.34. Anal advancement flap. (From Keighley MRB, Williams NS. *Surgery of the Anus, Rectum, and Colon*. 3rd ed. Philadelphia, PA: WB Saunders; 2008, Copyright © MRB Keighley MA MS FRCS.)

Transvaginal Advancement Flap

A vaginal advancement flap is a useful alternative to an anorectal flap, especially for recurrent fistulas (Fig. 164.35). The problem with vaginal advancements is that tissues are less lax than tissues in the anal canal, and thus it is technically more difficult to bring down mucosa from above to close the defect. Nevertheless, for some postoperative fistulae, particularly after restorative proctocolectomy or a previous coloanal anastomosis, there

is so much scarring in the anal canal that anorectal advancement is impossible; under these circumstances, a vaginal advancement is a more satisfactory option. The technique is identical to that described for rectal mucosal advancement, and the operation may be performed with the patient in the prone jackknife or the lithotomy position.

Transsphincteric Mucosal Advancement

If the internal opening of the rectal component of a rectovaginal fistula is inaccessible through an anal speculum, access may be obtained using the transsphincteric approach or by a posterior rectotomy without division of the sphincters (Fig. 164.36). A posterior rectotomy is preferred to the transsphincteric approach, because it does not compromise sphincter function, but access is slightly more restricted. The patient is placed in the prone jackknife position, and a longitudinal incision is made slightly off the midline from the buttock down toward the anal margin. The upper part of the incision is deepened and, if necessary, the lower aspect of the coccyx is excised. If the sphincters need to be divided, they are carefully marked with sutures before division so that they can be reconstituted with ease at the close of the operation. The rectum is then opened between stay sutures or, in the case of the transsphincteric approach, the entire anorectum is opened to expose the fistula that is excised. Closure involves a rectal advancement flap, which consists of the entire thickness of the rectal wall. Once the defect has been closed, the anorectotomy is then reapproximated in layers—first, the anorectal mucosa, then the internal sphincter, and, finally, the external sphincter, if divided. Closed-suction drainage is usually advisable.

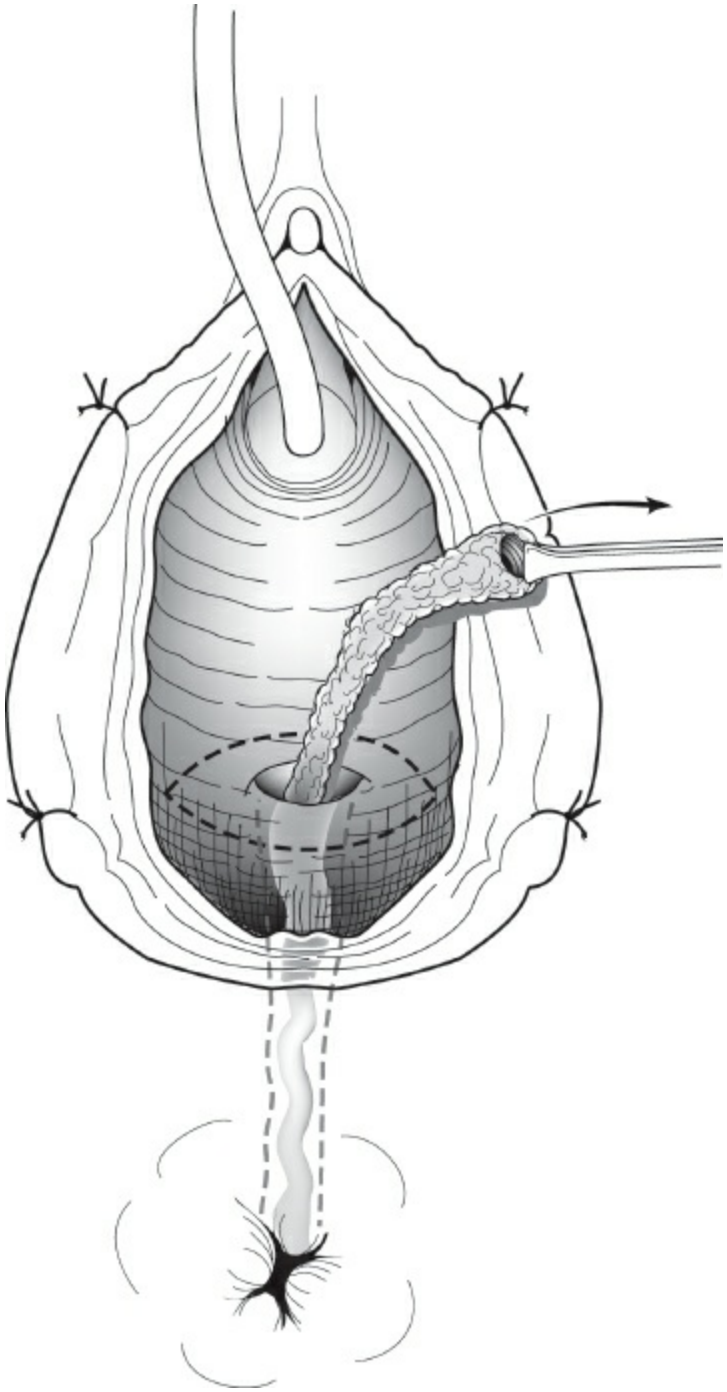

Figure 164.35. Transvaginal repair. (From Keighley MRB, Williams NS. *Surgery of the Anus, Rectum, and Colon*. 3rd ed. Philadelphia, PA: WB Saunders; 2008, Copyright © MRB Keighley MA MS FRCS.)

Seton Fistulotomy

Seton fistulotomy is rarely indicated for the treatment of rectovaginal fistulae unless the fistulae complicate Crohn disease, in which case a loose seton provides an ideal method of draining pus.

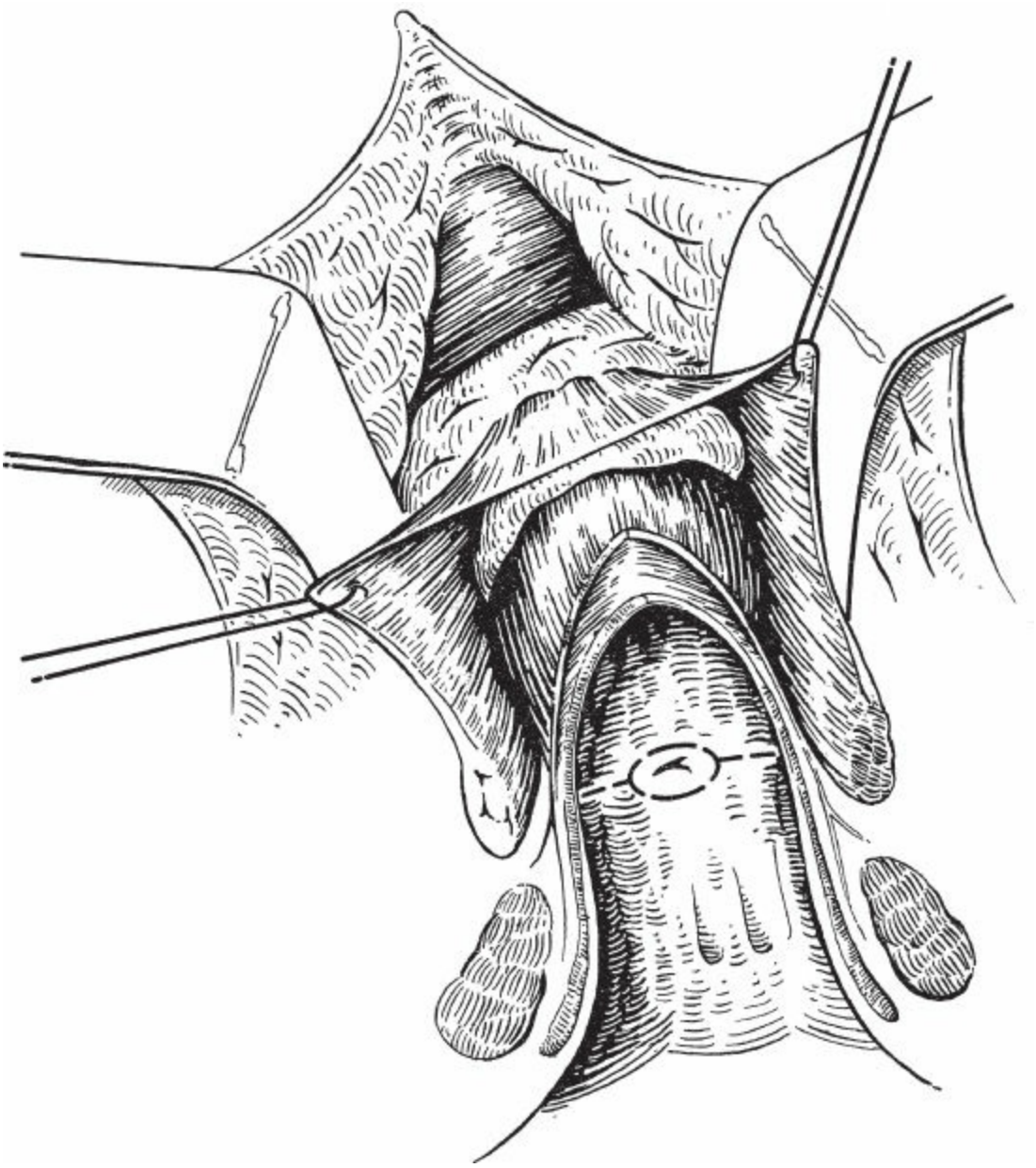

Figure 164.36. Transsphincter repair. (From Keighley MRB, Williams NS. *Surgery of the Anus, Rectum, and Colon*. 3rd ed. Philadelphia, PA: WB Saunders; 2008, Copyright © MRB Keighley MA MS FRCS.)

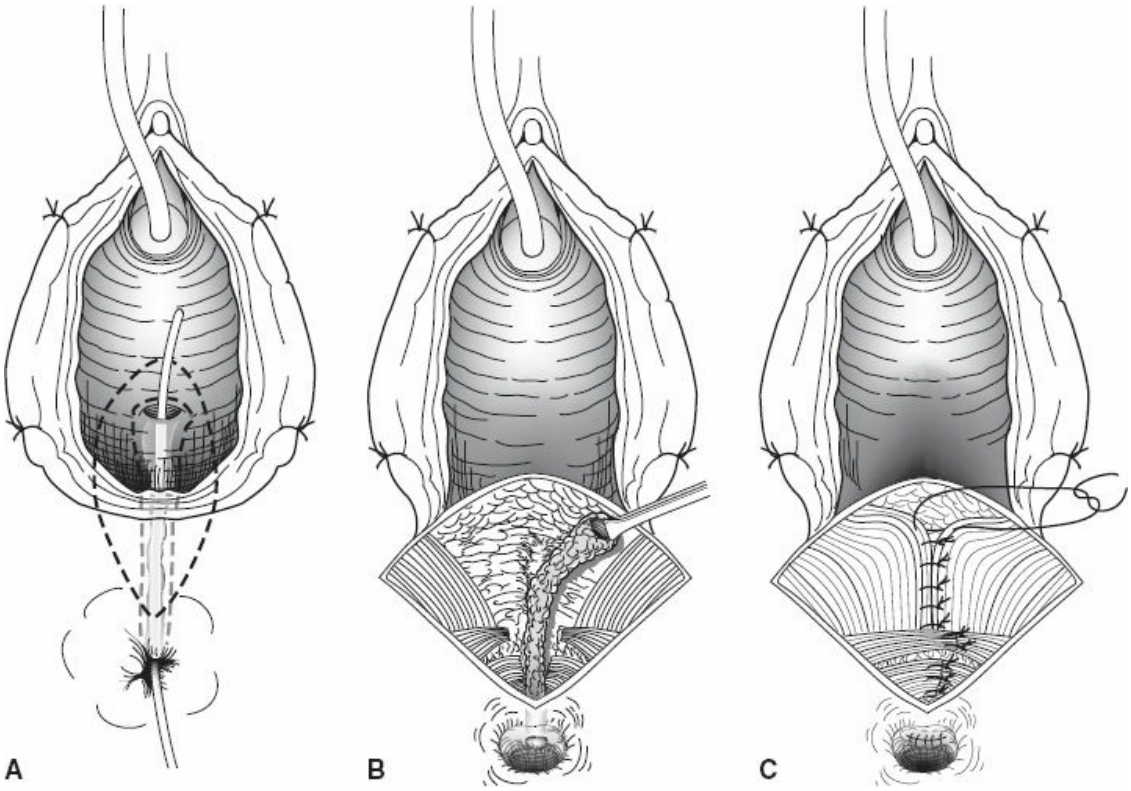

Figure 164.37. Lay open and anatomical reconstruction for repair of a rectovaginal fistula. **A.** Lay open of the fistula. **B.** Excision of the tract. **C.** Reconstruction. (From Keighley MRB, Williams NS. *Surgery of the Anus, Rectum, and Colon*. 3rd ed. Philadelphia, PA: WB Saunders; 2008, Copyright © MRB Keighley MA MS FRCS.)

Lay Open of the Fistula and Complete Anorectal Reconstruction

A few fistulae lie superficial to the sphincters. If this is the case, the fistula can be safely laid open.

Postobstetric fistulae involving the anal sphincters may be treated by opening the fistula track and repairing the underlying defect in the sphincter. This method of treatment is particularly appropriate if a postobstetric rectovaginal fistula is complicated by a traumatic sphincter injury. (The technique of sphincter repair is described in an earlier section.) The principle of the procedure is simply to lay open and excise the entire fistula after which the levators, sphincters, and perineal body are repaired (Fig. 164.37). If there is any evidence of sepsis, a proximal stoma might be advisable. If there is localized sepsis, the skin incisions may be left open to granulate.

Special Considerations for Perianal Crohn Disease

CLINICAL PRESENTATION

The following are the hallmarks of perianal Crohn disease:

1. Edematous skin tags
2. Painless fissures
3. Deep cavitating ulcers
4. Complex anorectal sepsis associated with complex anorectal fistulae
5. Rectal strictures

Approximately one third of the patients with Crohn disease develop perianal disease before the macroscopic and symptomatic appearance of any intestinal disease. Hence, in approximately one third of patients, perianal disease is the first manifestation and predates the label of Crohn disease. In 45% of patients, perianal Crohn disease appears at the same time as intestinal disease. In the remaining 25% of patients, perianal disease occurs subsequent to the established diagnosis.

CAUSES

Perianal Crohn disease is a manifestation of a panmural granulomatous condition. In the anal region, it is particularly prominent as a result of nonspecific cryptoglandular infection, as well as enormous lymphoid aggregates found in the anal region. It is thought that the primary process in the anal canal is a penetrating anal ulcer that causes lymphedema, fibrosis, and activation of cryptoglandular infection.

Perianal Crohn disease can be subclassified into benign or aggressive disease. Benign disease often pursues a low-grade course with remission and relapse. Indeed, complete resolution may occur without any specific treatment. Such remission often occurs after surgical treatment or successful medical treatment of the underlying intestinal disease. Benign anorectal disease consists of skin tags, fissures, simple anorectal sepsis, and fistulae. By contrast, certain manifestations of Crohn disease result in progressive anorectal destruction, sepsis, fibrosis, and eventual rectal excision. Aggressive forms of perianal Crohn disease include: (a) deep penetrating anal ulcers, (b) complex anorectal fistulae, and (c) extensive perirectal fibrosis and stricture. The rectal excision rate in patients with aggressive disease during a period of 5 years exceeds 80%.

DIAGNOSIS

Diagnosis of Crohn disease is by the typical clinical syndrome, in

conjunction with typical radiology demonstrating intestinal ulceration, deep fissure, thickening of bowel wall, segmental disease, longitudinal ulcers, strictures, and cobblestoning of the mucosa. When possible, diagnosis should be supported by histopathologic evidence of noncaseating granulomas and deep fissured ulcers associated with transmural disease.

The typical appearances of perianal Crohn disease with skin tags, anal fissures and ulcers, complex anorectal fistulae, and anorectal strictures should be supported by biopsy, when possible, along with full intestinal radiology. The following conditions should also have been excluded: sexually transmitted disease, anorectal tuberculosis, anorectal and anogenital cancer, hidradenitis suppurativa, Behçet syndrome, and anorectal lymphoma.

TREATMENT

Conservative Therapy

Conservative treatment is recommended for asymptomatic perianal Crohn disease. It is particularly appropriate for patients with minor skin tags, painless anal fissures, and simple anal fistulae (including simple and low rectovaginal fistulae), and in patients with other nonspecific anal disease, such as hemorrhoids. In some patients, attempted surgical treatment may compromise continence. Perianal wounds tend to heal slowly. Hence, surgical treatment should be avoided when disease causes no symptoms or is likely to remit spontaneously.

Drainage of Pus

Perianal Crohn disease is likely to cause progressive fibrosis and anal destruction if sepsis is left without being adequately drained. Anorectal sepsis in Crohn disease is complex and should be carefully defined by MRI and examination under anesthesia. The intersphincteric plane is often a source of occult sepsis, and in patients with infective symptoms and in whom traditional drainage identified little pus, the intersphincteric plane should be explored to ensure that this is not the seat of sepsis. Anorectal sepsis is often associated with fistulae. Recurrent sepsis is common; we recommend the use of soft, loosely tied setons to establish prolonged drainage and subsequent resolution. Mushroom catheters can also be used to drain pus, particularly if irrigation is deemed necessary.

Defunction

In some patients, the progression of anorectal disease can be halted and completely resolve by diverting the fecal stream. This method of treatment is particularly appropriate for severe anorectal sepsis and fistulae and in patients with anorectal strictures. Many patients undergoing loop ileostomy for fecal diversion in perianal disease eventually progress to proctocolectomy because, although fecal diversion switches off active disease, the chances of restoring intestinal continuity are <20%. Some patients, however, prefer to live with a loop ileostomy, especially if they are made aware of the potential complications of proctocolectomy.

Selective Treatment

Certain forms of anorectal Crohn disease deserve specific treatment.

Steroid Injection

Local steroid injection may be useful as a means of healing penetrating ulcers complicating Crohn disease.

Dilation

Anorectal dilation may play a useful part in the management of patients with short diaphragmatic anorectal strictures.

Advancement Flaps With Fibrin Glue

Mucosal advancement may play an important role in selected patients with anorectal and rectovaginal fistulae, but because of the risks of sepsis and the relatively poor healing in perianal Crohn disease, coexisting fecal diversion is often advised. In some cases, healing can be promoted by using fibrin glue or the anal plug.

Seton Fistulotomy

Loose seton drainage may be used in selected cases of anorectal fistulae. Each case must be judged on its own merit. Whenever anorectal fistulae are treated in Crohn disease, coexisting sepsis must be adequately drained, and fecal diversion may be necessary.

Proctocolectomy

Proctocolectomy is eventually required in many patients, particularly those with deep penetrating anal ulcers, complex anorectal fistulae, and progressive anorectal stenosis with sepsis. Proctocolectomy in these

patients is difficult. An intersphincteric excision of the anorectum is impossible, and wide excision is often necessary to clear sepsis. These patients have a high rate of unhealed perineal wounds and persistent perineal sinus. Persistent perineal sinus in these patients may eventually require treatment by myocutaneous rectus abdominis flaps. Nevertheless, the quality of life in patients after proctocolectomy for anorectal Crohn disease is usually greatly improved, once patients have accepted that their lives are better with a permanent ileostomy.

Suggested Readings

Fielding LP, Goldberg SM. *Surgery of the Colon, Rectum, and Anus.* New York: Chapman & Hall; 2003.

Keighley MR, Williams NS. *Surgery of the Anus, Rectum, and Colon.* 3rd ed. Philadelphia, PA: WB Saunders; 2008.

Phillips RKS, Lunniss PJ. *Anal Fistula.* New York: Chapman & Hall; 1996.

Stein E. *Anorectal and Colon Diseases.* New York: Springer; 2002.

Wollff BG, Fleshman JW, Beck DE, et al. *The ACRS Textbook of Colon and Rectal Surgery.* New York: Springer; 2007.

EDITOR'S COMMENT

Anorectal conditions comprise a considerable portion of any colorectal practice and an in-depth understanding of anatomy and physiology, as detailed in this chapter, is cornerstone to successful management of these conditions.

The chapter opens with a discussion on anal fissure. As alluded by the author, acute anal fissure often precludes a detailed physical examination due to the severity of associated tenderness. Fortunately, in most cases anal fissure can be readily elicited with gentle effacement of the anal canal and a detailed examination can be deferred to a later date after the fissure has healed. The author describes treatment with suppositories however my preference is to use topical agents (steroids, anesthetics, smooth muscle relaxing agents) for two reasons: first, most patients report extreme pain during suppository insertion resulting in poor compliance and second, suppositories deliver steroids in the distal rectum rather than the site of the fissure—the anal canal. In terms of surgical treatment, sphincterotomy has been the gold standard for decades. There has been a longstanding argument to determine the optimal extent of internal sphincter division. While most accounts suggest dividing internal sphincter to a point just proximal to dentate line, others have advocated "tailored sphincterotomy" using the length of the fissure as a guide. Needless to say that an inadequate sphincterotomy results in persistent symptoms whereas

an overzealous division of internal sphincter will inevitably lead to passive leakage of stool.

The chapter does not address the issue of the so-called “low-pressure” fissure, a condition where a chronic anal fissure exists sans acute inflammatory changes or pain in the area. This condition is a distinct entity in itself and no specific treatment beyond biopsy is necessary unless the patient is symptomatic. Since the etiology is not sphincter hypertonia, measures directed toward decreasing sphincter tone are best avoided. Treatment, when necessary, involves a cutaneous advancement flap.

Next, the author addresses the topic of anal abscess and recommends routine collection of cultures at the time of abscess drainage. Since most patients do not require antibiotics after drainage, cultures rarely provide clinically actionable information and incur unnecessary costs. My preference is to obtain cultures only in cases where an unusual infection (fungus, mycobacterium, MRSA, etc.) is suspected on clinical grounds or postoperative antibiotic use is anticipated due to significant perianal cellulitis or immunocompromised state of the patient.

I agree with the author that the best treatment for anal fistulae is fistulotomy, where feasible. However, simple fistulotomy can only be employed for the treatment of simple, subcutaneous, or intersphincteric fistulae and in selected cases of transsphincteric fistulae with minimal sphincter involvement. Treatment of complex, transsphincteric or extrasphincteric fistulae is a bit more challenging as simple fistulotomy in these cases would inevitably lead to compromised sphincter function. The author reports encouraging results with the use of cutting seton in this situation. In my experience, cutting setons are associated with significant pain which lasts several days after tightening the seton. I have found that local anesthetic infiltration is often necessary and many patients also require narcotics during the immediate period following the cinching of the seton. Furthermore, the procedure requires repeated office visits and interruptions in work resulting in poor patient satisfaction. For these reasons, I have abandoned this technique in favor of staged fistulotomy. This technique typically involves partial division of the fistula and a draining seton is left encircling the residual fistula tract. The patient is given some time to allow healing of the divided sphincter followed, typically in 2 to 3 months, by division of residual fistula tract.

Long-term data for anal plugs indicated recurrence rates as high as 70% to 85%. It appears that success rates are directly dependent on the length of fistula tract; those longer than 4 cm are likely to heal whereas short tracts, specially rectovaginal fistulae, inevitably experience a recurrence after plug insertion. These disappointing results have led to a significant reduction in interest in this modality.

Perhaps the most significant advancement in the field of anorectal surgery over the last decade is the introduction of LIFT procedure: ligation of intersphincteric fistula tract. This ingenious approach, first described in 2009, involves dissection in the intersphincteric plane, identification and ligation of

fistula tract in the intersphincteric groove, and curettage of distal tract. This approach results in sphincter preservation with excellent functional outcomes, however, a good number of patients require a second operation for treatment of intersphincteric fistula or a blind sinus tract. Regardless, LIFT has become the leading procedure for transsphincteric fistulae given its sphincter preserving ability.

Stapled hemorrhoidopexy, also known as procedure for prolapsed hemorrhoids (PPHs) was initially described by Dr. Longo in 1993. As is the case with many novel surgical techniques, the initial results were very encouraging leading to a rapid, widespread adaptation of this technique. Long-term results however, were not very supportive confirmed by recent publication of eTHoS trial, a large randomized trial comparing PPH to conventional hemorrhoidectomy. Given these findings, the initial interest in PPH has waned dramatically over the last few years.

Although not described in this chapter, transrectal hemorroidal dearterialization (THD) certainly deserves a mention here. This novel technique utilizes a Doppler-enabled anoscope to identify the feeding vessels which are then suture ligated. The results so far are comparable to conventional hemorrhoidectomy, however, there appears to be an increased cost associated with this procedure. Very few studies detailing long-term results are currently available.

The section on anorectal condyloma emphasizes the need for a complete screen due to possible coexistence of other STDs. I typically offer HIV screening to all patients with anogenital condylomas and cervical PAP smear to all females as many patients harbor a concomitant cervical HPV infection.

I feel it is imperative to assess structural integrity of sphincter complex with an endorectal ultrasound in all rectovaginal fistula patients. In my experience, many of these patients have sustained significant sphincter trauma and preforming an advancement flap alone will guarantee postoperative fecal incontinence. Instead, an anterior overlapping sphincteroplasty is the treatment of choice, which not only addresses the fistula but also assures optimal functional outcomes after surgery.

Rectal mucosal advancement technique described by the author differs from the standard approach to this operation in two aspects: first, the author describes creation of a flap utilizing full-thickness rectal wall rather than the mucosa alone and second, the author recommends coverage of the primary sinus opening with the lower (distal) mucosal flap rather than the conventional description of advancing the proximal mucosal flap over the sinus opening.

I concur with the author that conservative, nonoperative management is perhaps the best approach for mild perianal Crohn disease that presents with minimal symptoms. The importance of avoiding surgical intervention in these patients cannot be overstated; surgical intervention in many cases results in very slow healing or nonhealing wounds which may in turn be more symptomatic than patient’s original presentation.

No description of perianal Crohn's is truly complete without the mention of biologics. We now have excellent, level I evidence attesting to the efficacy of Infliximab against fistulizing perianal Crohn disease. My approach is to proceed with fistulotomy if the following conditions are met: the fistula is simple, does not involve sphincter complex, and there is no evidence of active proctitis. However, most fistulae in setting of Crohn disease are branching, complex fistulae often encompassing the sphincter complex thus precluding fistulotomy without risking fecal incontinence. In these cases, I proceed with placement of a seton followed by biologic therapy. Given the long lag period between initiation of biologics and clinical response, I typically keep the seton in place for about 8 weeks after the initiation of biologic therapy. Premature seton removal will result in treatment failure, conversely, leaving the seton in situ for a long period leads to epithelialization of the tract necessitating a complete coring out of the tract. I proceed with inducing "surgical remission" with a diverting stoma in cases where seton placement and biologic therapy fail to control symptoms. The patients are then maintained on biologic therapy for a period of 3 to 6 months before stoma reversal is attempted. However, the risk of recurrent Crohn's after restoration of bowel continuity remains very high and many patients with severe perianal Crohn disease ultimately require proctectomy.

Syed Husain

165 Transanal Excision of Rectal Neoplasms

Sam B. Atallah and John R.T. Monson

HISTORY AND EVOLUTION OF TRANSANAL EXCISION

Transanal excision of rectal neoplasms can be performed for removal of benign rectal neoplasms as well as appropriately selected early-stage rectal cancer. Transanal excision has evolved over the centuries. The first documented report of transanal excision of a rectal neoplasm was performed by Jacques Lisfranc (1790 to 1847) in the early 1800s, and was performed prior to Dr. William Morton's (1819 to 1868) discovery of general anesthesia in 1846. Lisfranc performed the operation on a 45-year-old male with a distal rectal neoplasm. The patient was fully awake, and the technique involved the introduction of a speculum with downward traction of the lesion and then the use of "strong short scissors" to circumferentially excise the lesion. The defect was not closed and significant hemorrhage was described. After 2 months in the hospital, the patient was discharged in good condition.

The modernization of surgery to include safe administration of general anesthesia and more sophisticated instruments has enabled transanal excision to develop from peranal techniques, including the Parks' approach and the transcoccygeal Kraske method, to more sophisticated platforms including transanal endoscopic microsurgery (TEM), transanal endoscopic operation (TEO), and transanal minimally invasive surgery (TAMIS). A comparison of these advanced transanal platforms is delineated in Table 165.1. More recently, robotic TAMIS using the da Vinci Surgical System has also been reported, and as next-generation single-port robotic platforms evolve, the role of robotic transanal surgery may increase further.

During the laparoscopic and minimally invasive era, there had been a trend toward minimizing the radicality of cancer surgery in an effort to create a better balance between risks and functional deficits associated with radical surgery and the potential oncologic inferiority of a local

excision. However, this trade-off is only viable if it results in acceptable oncologic outcomes. Conceptually, there has always been a dichotomy between two surgical approaches for curative-intent cancer surgery. In simple terms, they are (a) local excision (LE) that results in organ preservation and (b) standard oncologic resection (SR) that typically removes the entire organ and the associated lymph node basin. For some types of malignancies, LE is a proven method of therapy and examples include excision of dermal melanoma, anal margin early-stage (T1) squamous cell carcinoma, appropriately selected rectal neuroendocrine tumors, and so forth. Perhaps the closest cancer-paradigm to the management of early-stage rectal cancer is early-stage breast cancer, whereby negative margin excision of a tumor (i.e., breast-conservation surgery) coupled with external beam radiotherapy has been shown to render an overall survival equivalent to modified radical mastectomy.

TABLE 165.1 A Comparative Assessment of Advanced Transanal Platforms

TAMIS	TEM	TEO
Developed 2009	Developed 1984	Developed mid-2000s
Manufacturer Applied Medical/Covidien	Manufacturer Richard Wolf	Manufacturer Karl Storz
Disposable	Reusable	Resusable
Flexible	Rigid	Rigid
Low cost	Requires capital investment	Requires capital investment
Shallow learning curve	Steep learning curve	Steep learning curve
Advanced laparoscopic skill	Specialized TEM training	Specialized TEO training
High-quality local excision	High-quality local excision	High-quality local excision
Access to 15 cm	Access to 15 cm	Access to 15 cm
Applicable for transanal TME	Applicable for transanal TME	Applicable for transanal TME
360-degree view	220-degree view	220-degree view
2D monitor, 3D optional	Binocular (3D) or 2D monitor	Binocular (3D) or 2D monitor
Laparoscopic instruments	Specialized TEM instruments	Specialized TEO instruments
CO_2 laparoscopic or valveless	CO_2 using TEM apparatus	CO_2 using TEO apparatus
3.5–4-cm diameter	4.0-cm dia; 12/20-cm shaft	4.0-cm dia; 7.5/15/20-cm shafts
Patient positioned lithotomy	Patient positioned tumor down	Patient positioned tumor down
No evidence of sphincter injury	Transient sphincter injury reported	Transient sphincter injury reported
Nonbeveled	Beveled or straight	Beveled or straight

Typically, local excision of rectal neoplasia is performed via a transanal approach, but a trans-sacral approach for LE of rectal neoplasia has also been described and, although less frequently performed, is still considered a valid alternative to transanal excision. This technique was pioneered by Paul Kraske (1851 to 1930) in 1884 and hence trans-sacral excision is often referred to as the Kraske procedure. Today, the technique is reserved mostly for excision of presacral tumors and repair of rectourethral fistulae in males.

CLINICAL WORKUP

The extent of the clinical workup depends on the histopathology and endoscopic evaluation of the lesion. Benign neoplasms only require a completion colonoscopy to exclude synchronous lesions and consideration of endorectal ultrasound (ERUS) if there remains question of tumor invasion. Any lesion that is benign and not amenable to simple endoscopic retrieval is considered an appropriate candidate for LE, although lesions in the mid and proximal rectum require an advanced transanal platform as they carry an increased risk of peritoneal entry.

For lesions with proven or suspected invasion, ERUS is performed to determine clinical stage. Pelvic 3-Tesla (3T) magnetic resonance imaging (MRI) is a valid alternative to ERUS and is strongly recommended by many experts. The two modalities are often complementary, as ERUS, when performed by an experienced operator, provides excellent information about depth of invasion (T-stage) while rectal protocol 3T MRI provides a better assessment of nodal disease, although neither can accurately detect lymph node metastasis. Importantly, 3T-MRI can determine the status of the circumferential resection margin (CRM) and is thus preferred over ERUS for instances in which the tumor is locally advanced. Serum carcinoembryonic antigen (CEA) level and staging computed tomography (CT) body imaging are also performed to assess for distant tumor metastasis as recommended by national guidelines.

INDICATIONS AND CONTRAINDICATIONS

The indication for transanal excision includes benign neoplasia (e.g., tubular adenoma, villous adenoma) that is not amenable to simple endoscopic retrieval. This also includes neuroendocrine tumors that are ≤1 cm in diameter, or other neoplasms of unknown histology (such as submucosal lesions). Highly selected early stage I rectal cancers can also be removed via the transanal approach provided they are histologically favorable. Thus, the most appropriate lesion for local excision would be a cT1 sm1 lesion that does not exhibit lymphovascular invasion, poor differentiation, and which does not harbor mucinous features on histology. This is particularly true for invasive neoplasms confined to the distal one third of the rectum, because SR carries considerable morbidity and bowel function is often significantly altered postoperatively. Tumors of the proximal one third—even early-stage tumors otherwise fit for local excision—are best managed by SR in fit patients.

Data from the late 1990s including the Cancer and Leukemia Group B (CALGB) 8984 suggested that more advanced stage I lesions such as T2 lesions (which by definition penetrate the submucosa) could be managed by LE and subsequent external beam radiotherapy. However, in clinical practice, T2N0 lesions that were excised locally and treated with adjuvant radiotherapy resulted in an unacceptable rate of local recurrence suggesting that some form of addition therapy is required for cancers beyond the most favorable T1 lesions. More recently, trials on neoadjuvant chemoradiation followed by local excision have been performed with mixed results. In recent years, numerous trials have been either completed or commenced to assess clinical outcomes of neoadjuvant radiation followed by local excision of T2 cancers. These are the ACOSOG Z6041, UK-TREC (TEM and Radiotherapy in Early Rectal Cancer), and the CARTS study (Chemoradiation Therapy for Rectal Cancer in Distal Rectum Followed by Organ-Sparing TEM). Current guidelines recommend that, except for patients enrolled in a study protocol, T2 lesions should be managed by an SR unless the operation is for palliation and/or the patient is too infirm to undergo major abdominal surgery. Single-center experience led by Lezoche (Rome, Italy) has demonstrated that T2N0 lesions that were randomized to undergo upfront chemoradiation followed by LE using TEM versus upfront chemoradiation followed by SR had no difference in survival or loco-regional recurrence rates.

In general, the LE of malignant neoplasia is generally recommended only for patients with histologically favorable, early-stage malignancy (uTis or uT1uN0M0 cancer). More advanced lesions require SR (APR vs. LAR) except in patients who are not medically fit to undergo major surgery. Patients with stage IV disease or locally advanced lesions are not candidates for LE unless the objective is palliation.

SPECIAL CIRCUMSTANCES AND CONTROVERSIES

Accept for palliation, LE is not typically considered an option for locally advanced rectal cancer. However, in patients who have undergone neoadjuvant chemoradiation and have achieved complete pathologic response (cPR), consideration for LE of the tumor scar for the purpose of confirming mural sterilization (ypT0) has been suggested by some authors who plan to enroll patients in a so-called “watch-and-wait” program. Some experts argue that the morbidity from LE of a radiated scar (which often

results in wound dehiscence) can be avoided, especially since cT0 can be sufficiently determined by endoscopic evaluation and additional imaging such as MRI or positron emission tomography (PET) scanning if necessary. Furthermore, mural sterilization does not imply nodal sterilization and approximately 6% to 8% of ypT0 lesions will have node-positive (ypN1) disease on final pathology after SR.

Other special problems relate to confounding variables. For example, in patients who present with synchronous rectal and sigmoid cancer, the overall approach should be determined by the tumor characteristics, staging, and MRI results. There can be a role for LE under special circumstances. For example, a distal T1N0 sm1 histologically favorable adenocarcinoma with a synchronous mid sigmoid adenocarcinoma can be treated by LE for and anterior resection of the sigmoid cancer. Such an approach would spare the patient from the otherwise significant risk of morbidity from pelvic surgery. Specific treatment should be individualized, and it is recommended that all newly diagnosed rectal cancer be presented at a multidisciplinary tumor board.

Controversy regarding LE for rectal cancer remains, as even favorable pT1 lesions have a higher recurrence rate when they are locally excised compared to SR, probably because of occult nodal disease as current imaging techniques (MRI and ERUS) will not detect one third of nodal metastasis, thus understaging a significant portion of patients who would otherwise be recommended to undergo radical resection or at least adjuvant therapy. There may be other factors as well, including the technique used for excision (discussed later). Ultimately, SR for even early-stage rectal cancer still provides lower rates of local recurrence and possibly survival than LE. Thus, the argument for LE is not that the approach is oncologically equivalent to SR, but rather that spares patients the morbidity of a pelvic dissection.

Controversy also remains concerning proximal rectal cancer LE that intentionally violates the peritoneal cavity. Typically, LE for cancer requires a full-thickness excision and removal of a small portion of the mesorectum that lies deep to the tumor. Conventional therapy argues that, from an oncologic standpoint, violating the peritoneum and a noncomplete excision of the mesorectal envelope defy the basic principles of oncologic surgery. Therefore, most experts believe that proximal invasive lesions (T1 cancers between 10 and 15 cm from the anal verge) should be managed by SR and not LE.

PREOPERATIVE PLANNING

Localization of the tumor is critical in determining the general approach to LE. Rigid proctosigmoidoscopy remains the preferred method of determining the tumor's anatomic position with the two key variables being (a) distance from anal verge (or more precisely anorectal ring) and (b) position of the tumor relative to rectal wall and pelvis (e.g., anterior versus posterior). In general, tumors distal to the mid rectal valve are within 10 cm from the anal verge, and thus lie beneath the peritoneal reflection. Thus, proximal to 10 cm (especially for anterior tumors) the operating surgeons should be prepared to manage the closure of a peritoneal entry. This can be accomplished using an advanced transanal platform, but may require laparoscopic assistance for a layered closure and possible placement of a pelvic drain, which is left to the surgeon's discretion.

As described in the section on surgical technique, the patient positioning is sometimes determined by the transanal technique used to perform the excision, and thus it is important to have knowledge of the tumor's position prior to initiating LE.

Preoperatively, patients undergo a mechanical bowel preparation and the administration of parenteral antibiotics less than 30 minutes prior to surgery (e.g., single-dose ertapenem 1 g intravenously). The operation can be completed under general or rarely spinal anesthesia. Most often, particularly when an advanced transanal platform is used and where pneumorectum is essential, general anesthesia with endotracheal intubation is recommended with full muscle paralysis to avoid collapse of the rectal wall (bellowing), which often occurs with diaphragmatic excursion and which is at least partially offset by positive pressure ventilation.

SURGICAL TECHNIQUE

Parks' Transanal Excision

Sir Alan G Parks (Royal London Hospital and St Mark's Hospital, London) described Parks' transanal excision (TAE) in 1968 with a very brief communication of less than two pages that described the technique of full-thickness excision using a ratcheting transanal retractor made of steel and designed for transanal access and exposure. Nowadays, this is referred to as the Parks' retractor and the conventional transanal excision is referred to as the Parks' TAE. In the same report, Parks described the

sleeve excision used for a circumferential villous adenoma, but in his original description of the sleeve excision, an abdominal approach was also used to mobilize the rectosigmoid colon and deliver it through the denuded segment after excising the entire mucosa (leaving in situ the rectal muscle tube) from the portion of rectum containing the neoplasm. Today, advanced transanal platforms, which offer improved reach, allow surgeons to perform the entire sleeve excision from below and thereby obviate the need for abdominal access. Thus, the Parks' TAE is most typically used for full-thickness excision of rectal neoplasia and is increasingly being replaced by the advanced platforms.

The technique of excision requires obtaining exposure with the self-retaining retractor with three steel blades inserted in the rectal vault transanally. There are secured to a ratcheting device that allows for the incremental separation of the blades, which increased the exposure. Typically, this allows for reach to 6 to 7 cm from the anal verge. With the retractor in position and the patient positioned prone-jackknife for anterior lesions and in high dorsal lithotomy for posterior lesions, the Parks' TAE is carried out under direct vision using monopolar cautery or sharp dissection depending on surgeon preference. The objective is full-thickness excision with 1-cm negative margins (Figs. 165.1 and 165.2). Once excised, the lesion is oriented and pinned out and sent to pathology for margin analysis (Fig. 165.3). The surgical defect is then reapproximated using absorbable suture, although some experts believe that closure is not required for small defects in the subperitoneal rectum (Fig. 165.4).

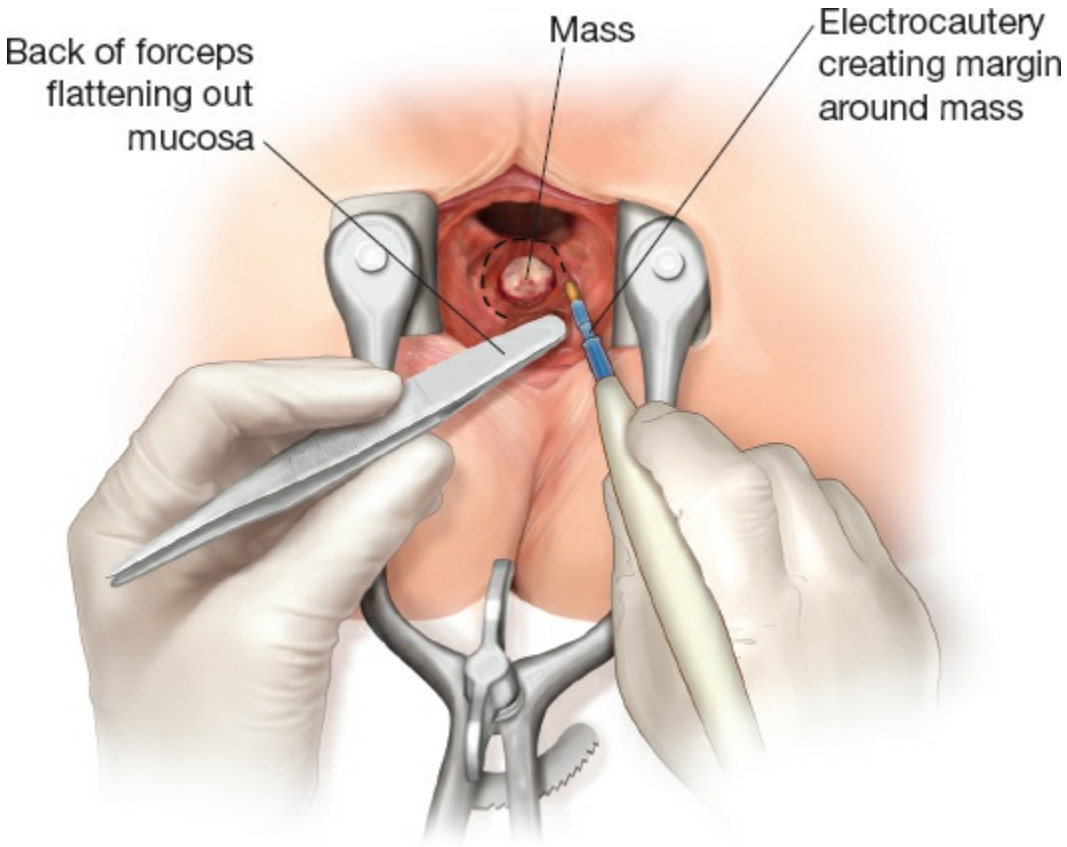

Figure 165.1. Defining the surgical margin. Once adequate exposure is obtained, electrocautery is used to mark out the surgical margin: 1 cm for malignant lesions and 0.3 cm for benign lesions or those of indeterminate pathology. Because mucosal folds can obscure the true margin and lead to a margin that is lesser or greater than intended, using the back of a DeBakey forceps or a handheld retractor such as the Hill-Ferguson retractor can help flatten the mucosal folds, so an appropriate margin can be defined. (Reproduced from Albo D, Mulholland MW. *Operative Techniques in Colon and Rectal Surgery*. Philadelphia, PA: Wolters Kluwer Health; 2015.)

Until the early 1980s, the Parks' TAE was the only method of full thickness excision of rectal neoplasia. Alan Parks (1920 to 1982) died after emergency cardiac surgery and did not live to see the evolution of the TEM era that began shortly after his death.

Transanal Endoscopic Microsurgery (TEM)

Prior to TEM, there was a limited ability to remove benign polyps of the mid and upper rectum using an operating rigid proctosigmoidoscope capable of delivering a snare and allowing for snare polypectomy of benign neoplasia. Gerhard Friederik Buess (Tubingen, Germany; 1948 to

2010), in 1983 and in collaboration with the Richard Wolf Company in Germany, developed a more advanced instrument that melded important principles into one very functional apparatus. TEM was undoubtedly precocious for many reasons. First, TEM utilized instruments very similar to those used for laparoscopy prior to the era of laparoscopic general surgery. Second, the TEM interface was essentially a multichannel single-port, yet this single-port laparoscopy was not developed until decades later in the 2000s. Third, it employed a magnified stereoscopic (three-dimensional [3D]) optical system, which is currently the most advanced vision system employed by laparoscopic systems and is currently the standard vision used on all robotic platforms. Finally, it utilized a sophisticated insufflation system that would allow for the optimal regulation of CO_2 within the rectal lumen and thus provide for stable pneumatics within a small volume. Thus, Gerhard Buess' TEM apparatus unified key technological components into a system that was so durable that it would essentially remain unchanged for three decades and today it is still considered by most the gold standard in allowing for very precise, high-quality LE of rectal neoplasia (Fig. 165.5).

The original indication for TEM was for the local excision of benign neoplasms, and not malignant lesions, with a strong emphasis on using TEM for lesions localized to the mid and upper rectum, as these were out of the range of what could be excised using a conventional Parks' TAE approach. With experience, however, the local excision of early-stage rectal cancer using TEM, particularly for highly selected T1 cancers within the mid and even upper rectum was adapted and during the 1990s this became an acceptable, and perhaps even preferred method of curative-intent surgical treatment. Thus, TEM offered an improved quality for local excision and access to the proximal two thirds of the rectum.

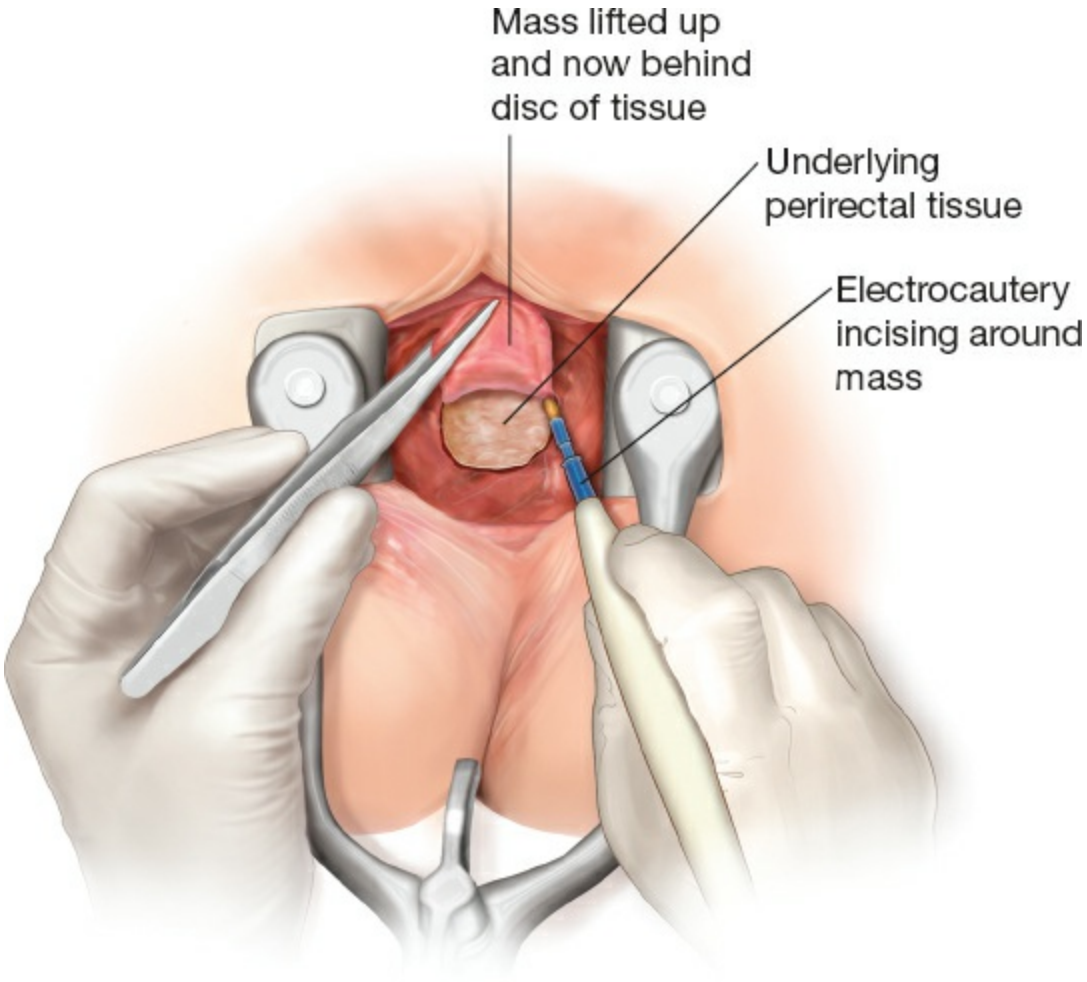

Figure 165.2. Full-thickness excision of the mass. Electrocautery is used to create a full-thickness defect through the rectal wall until the perirectal fat is identified. It is easier to begin at the most distal aspect of the lesion because visualization is better. Once the full-thickness defect is created, the free edge of tissue or a retraction suture is grasped to lift the mass and normal tissue away from the underlying perirectal fat as the excision proceeds proximally along the lateral aspects of the lesion, leaving the most proximal part of excision for last. (Reproduced from Albo D, Mulholland MW. *Operative Techniques in Colon and Rectal Surgery*. Philadelphia, PA: Wolters Kluwer Health; 2015.)

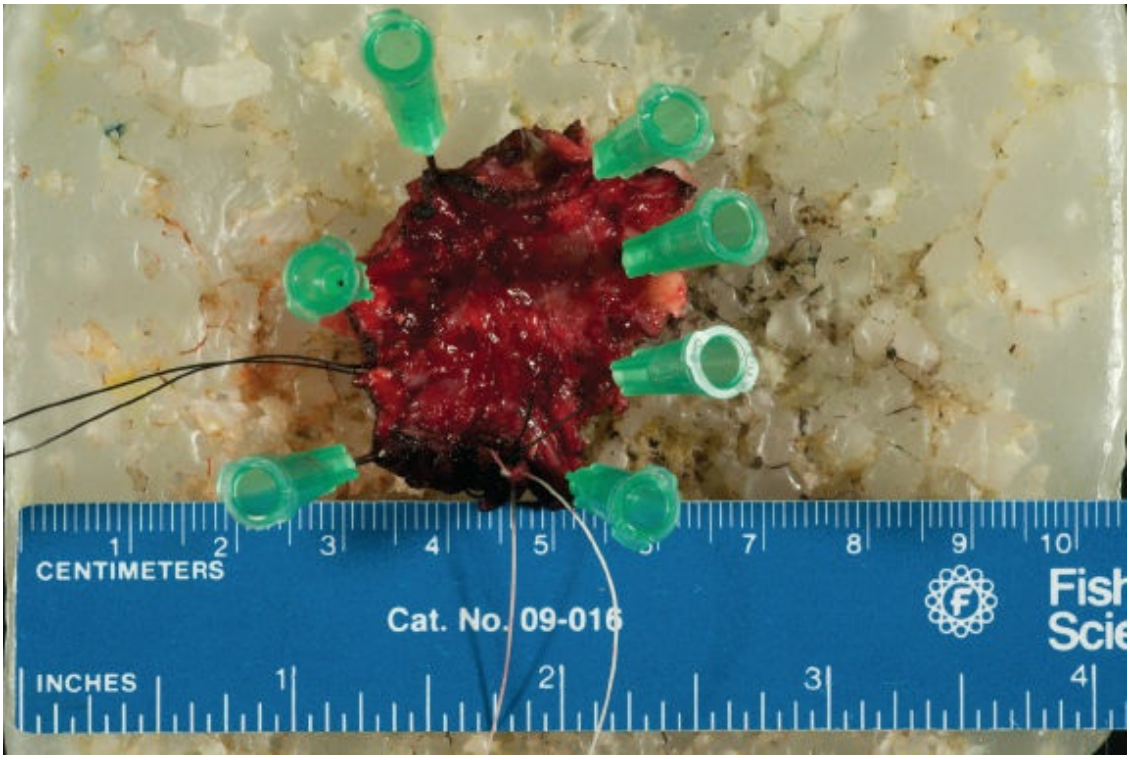

Figure 165.3. Submitting the specimen to pathology. The resected specimen is then secured to a wax board with 22-gauge needles for proper orientation. Because orientation sutures were placed early in the case, there should be no confusion about the specimen orientation. The surgeon then brings the specimen to the pathology suite to confirm orientation with the pathologist and the margins are inked and assessed. If tumor cells are present at any of the margins, additional tissue must be removed. (Reproduced from Albo D, Mulholland MW. *Operative Techniques in Colon and Rectal Surgery*. Philadelphia, PA: Wolters Kluwer Health; 2015.)

While the TEM equipment requires a significant up-front capital investment, the cost-savings argument has been proposed that if lesions could be locally excised with TEM and the need for SR is obviated, then the per-case cost of the operation is significantly lower ($7,775 with TEM vs. $34,018 for low anterior resection based on a study by Cocilovo et al.). More importantly, the significant potential for morbidity from SR—including diminished rectal function due to loss of the rectal reservoir and potentially autonomic nerve injury for the dissection, sexual and bladder dysfunction, possibility of a permanent (and often temporary stoma), and potential for sepsis from anastomotic leak—is negated by the use of TEM.

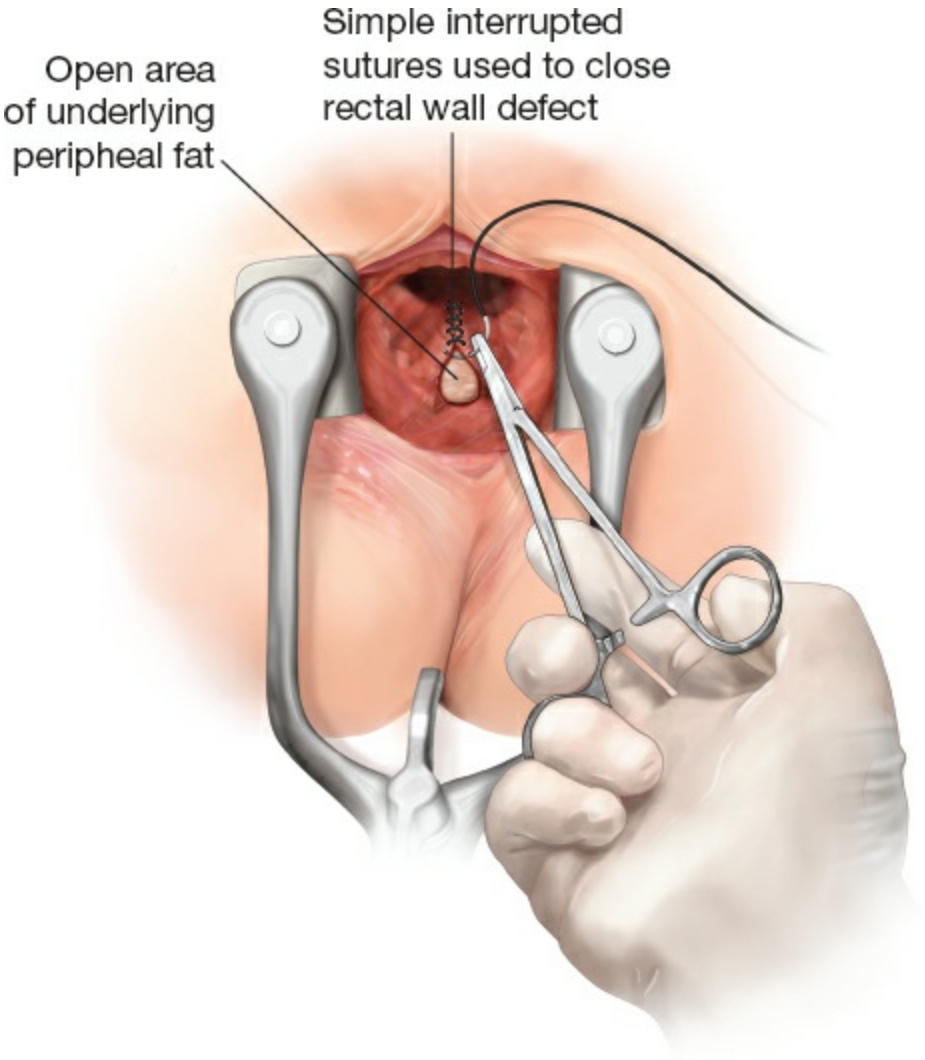

Figure 165.4. Closure of the rectal wall defect. **A.** After appropriate hemostasis is obtained, the rectal wall defect is closed with a 2-0 Vicryl suture. (Reproduced from Albo D, Mulholland MW. *Operative Techniques in Colon and Rectal Surgery*. Philadelphia, PA: Wolters Kluwer Health; 2015.)

TEM Technique and Equipment

The TEM equipment consists of three major components. They are the (1) operating rectoscope (including shaft and faceplate), (2) the optical stereoscope, and (3) the specialized long-shaft instruments that closely resemble laparoscopic instruments, except that the tip has a slight angulation (typically a downward and inward deflection at the instrument's tip making them right or left handed) that facilitates maneuverability within the rectal lumen. Additional components include a stabilizer clamp (Martin's Arm) that attaches to the bed rail and maintains a fixed orientation and a specialized insufflation system designed for

providing pneumorectum and is intended to create gaseous distention within a much smaller volume than the abdominal cavity.

The rectoscope shaft measures 4 cm in diameter and has a beveled end (or optional straight end); the available shaft lengths are 12 cm and 20 cm. An airtight multichannel faceplate allows the admission of four instruments via four sealed and capped rubber sleeves. Through these four ports, the optical lens (6× magnified and stereoscopic), suction device, and two 5-mm long-shafted TEM working instruments are introduced to facilitate LE. The surgeon is able to operate with a 3D view using the stereoscopic eyepiece or with an accessory monocular scope. This optical feed can be transmitted to a standard LCD video monitor. The 5-mm instruments most typically used include right (or left) curved graspers, endoscopic scissors, a needle driver, and a monopolar cautery knife.

As with all transanal excisions, preoperative preparation for TEM includes either full mechanical bowel preparation or alternatively two cathartic enemas on the day of the procedure. Systemic antibiotics should be administered, but a Foley catheter is usually not required. The preoperative planning also requires rigid proctosigmoidoscopy to determine the anatomic position of the lesion to be resected. This is important with TEM, because the patient must be positioned such that the lesion is dependent (at the 6 o’clock position). For example, if the lesion is along the left lateral sidewall at the level of the mid rectum, the patient will be placed in the left lateral position.

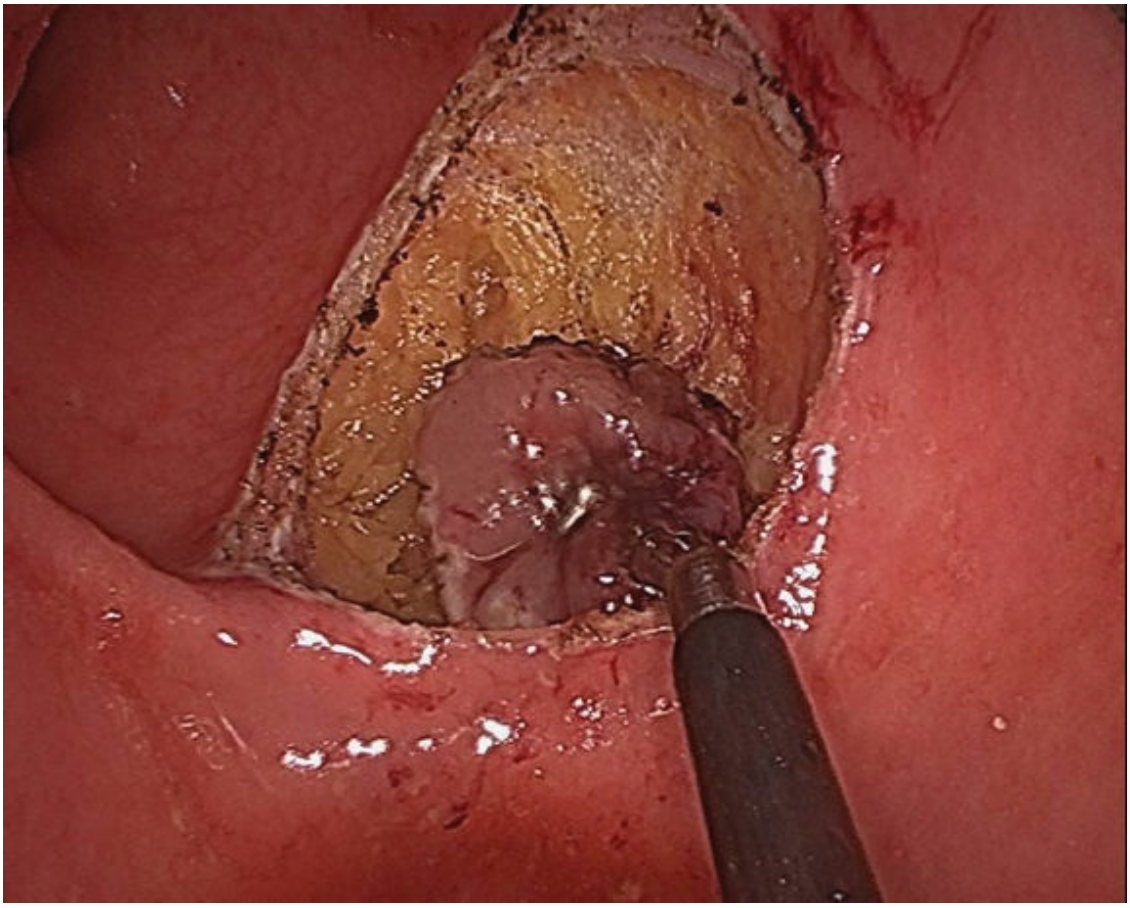

Figure 165.5. The operative picture shows the full thickness circumferential dissection of a malignant lesion with a 1-cm margin all around. Notice that the dissection is carried through the entire rectal bowel until the yellow fat of the perirectal tissues is reached. (Reproduced from Albo D, Mulholland MW. *Operative Techniques in Colon and Rectal Surgery*. Philadelphia, PA: Wolters Kluwer Health; 2015.)

After proper positioning, the rigid rectoscope is gently introduced with the aid of an obturator. The obturator is withdrawn and pneumorectum is established. When the lesion is visualized, the TEM rectoscope is secured via the Martin Arm to the operating table rail. Although this secures the platform, frequent subtle repositioning of the rectoscope is often necessary during local excision with TEM to maintain a clear view of the operative field.

Once the instruments are introduced and the target lesion identified, the operating surgeon works to perform an LE. The first and critical step in TEM local excision is to determine the excision margin by marking with cautery the perimeter of the lesion. An accepted negative margin is 1 cm for malignant lesions, and typically 5 mm for benign neoplasms. However,

most authors will accept any negative margin. Therefore, surgeons will not perform reexcision for lesion resected with a close but negative margin, and further intervention in this scenario is seldom necessary.

Because there can be uncertainty about whether or not a benign neoplasm harbors an invasive component, most experts believe that for lesions within the extra peritoneal rectum, a full thickness excision is required. For benign, typically small lesions that involve the intraperitoneal portion of the rectum whereby the morphologic appearance and preoperative biopsy do not suggest malignancy, then a partial thickness, submucosal excision can be performed to decrease the probability of peritoneal entry. If the peritoneum is inadvertently entered, the defect can be closed using the TEM suturing device. If the patient is appropriately positioned (such that abdominal access is practical), then a laparoscopic-assisted approach can also be performed to reapproximate the defect with a two-layered repair, although this is usually not necessary.

For early-stage T1 lesions in the upper one third of the rectum whereby peritoneal entry is likely and full thickness excision is mandatory, consideration for a low anterior resection rather than local excision with TEM should be given. This is especially true because morbidity from a minimally invasive anterior resection in this segment has significantly less morbidity than for resections of the lower portions of the rectum.

Circumferential adenomas that carpet the rectum are often resected as a mucosal sleeve preserving the underlying rectal muscle tube, utilizing the same technique described by Sir Alan Parks. TEM can be used to perform an anastomosis, but if the excision does not violate the peritoneal cavity and is confined to the subperitoneal rectum, it can be left open to granulate and heal by secondary intention.

The techniques for closure after excision with TEM typically utilize absorbable monofilament suture (such as 3-0 polydioxanone) in combination with silver clips secured to the suture to minimize the need to perform knot tying with TEM, which is arduous for even adept surgeons. Alternatively a self-locking suture can be used. As stated previously, closure of the surgical wound for any partial thickness defect or any subperitoneal full-thickness excision is not mandatory, and some authors do not routinely close these defects after TEM. It is strongly recommended by pathologists that the fresh specimen be pinned out and oriented prior to submission (Fig. 165.3). This greatly facilitates the accuracy of specimen interpretation. For defects that have been closed, and when a margin for a

malignant lesion is found to be positive, then most experts will reexcise the scar or consider rescue radical rectal excision. Thus, the specific margin that was positive is not relevant, as all margins will have become incorporated into the scar itself.

Transanal Endoscopic Operation (TEO)

TEO is a rigid, reusable advanced transanal platform similar to TEM and is indicated for LE of rectal neoplasms, which are 2 cm to 15 cm from the anal verge. This device, manufactured by Karl Storz-Endoskope (Tuttlingen, Germany), is available in three beveled shaft lengths—7.5 cm, 15 cm, and 20 cm. The outer diameter of TEO is the same as outer diameter of TEM and measures 40 mm. The optics for TEO relies on a forward-oblique telescopic 30-degree angled eyepiece, with diameter 5 mm. Like its analogue TEM, the TEO utilizes a stabilization arm, which affixes to the operating tableside rail to firmly secure the TEO scope and prevent movement once it has been inserted transanally. The working instruments (WEXNER Operating Instruments) consist of specialized 5-mm devices with unique distally curved design and specialized effector arm handles that are intended to facilitate operating within the narrow confines of the rectal lumen. The rigid platform is also intended to be used with a specialized CO_2 insufflation system (ENDOFLATOR 40 SCB), which provides a stable pneumorectum.

The technique of TEO is similar to that of TEM, and the two are considered analogues of one another although TEO does not offer true binocular vision or “steady-state” insufflation. An appropriate shaft length for the TEO scope is first selected based on the distance of the lesion from the anal verge, with long shaft (15 cm/20 cm) typically selected for proximal one-third rectal neoplasms. The patient is prepared as described previously, and the tumor is positioned dependently. The anus is gently dilated, and the shaft is then introduced with the aid of an obturator. Once the TEO scope is in place, it is secured to the operating table rail and connected to the video feed so that the image can be transmitted to an LCD monitor for viewing. An eyepiece is also available so that the surgeon can operate under direct vision without videoscopic assistance. The specialized instruments are then used to perform the LE in a manner similar to TEM.

Transanal Minimally Invasive Surgery (TAMIS)

TAMIS was developed in 2009 as a consequence of advancement in

laparoscopic surgery and was based on the need to provide surgeons who did not have access to TEM and TEO with the ability to perform advanced transanal surgery for the LE of rectal neoplasia. In the mid- to late 1990s, both surgeons and industry began looking at methods to improve laparoscopic abdominal access. Among the important refinements in laparoscopy was the ability to decrease instrument size to 5 mm without detracting from function, and thereby decreasing abdominal access trauma. Another important development occurred in 2004 when Anthony Kalloo and colleagues performed the first transgastric peritoneoscopy in a porcine model and soon afterward Rao and Reddy performed the first transgastric appendectomy in a human, heralding a new era in minimally invasive surgery. The advancements would lead to steering committees and working groups that would describe this next-step in minimally invasive surgery as Natural Orifice Trans luminal Endoscopic Surgery, or NOTES. Industry manufactures and surgeons then began to explore abdominal access with a different viewpoint. In particular, the concept of trans-umbilical access as a kind of “embryonic” or E-NOTES was born. In fact, one-wound trans-umbilical laparoscopy for appendectomy had been described as early as 1992 by MA Pelosi et al.; but, now with the impetus of E-NOTES, industry developed multi-channel laparoscopic ports that could essentially combine three or more 5-mm ports into a single platform. Introduced at the umbilicus, a multichannel, disposable port could be used to perform an appendectomy, cholecystectomy, and even colectomy with the specimen retrieved via an embryonic natural orifice. Today, fewer surgeons refer to single-port surgery as E-NOTES, and the same device can be used elsewhere in the abdomen with essentially the same cosmetic outcome. Interestingly, surgeons have not been successful in demonstrating a true advantage to single-port laparoscopy over conventional laparoscopy, and some argue that the rate of hernia formation for general surgical procedures may be higher than with conventional multi-port laparoscopy.

Notwithstanding, the development of the multichannel port and its availability led to colorectal surgeons pioneering its use as a platform for transanal access—an approach now known as TAMIS. Because of its versatility and availability, TAMIS has become an important method for accessing the rectum for LE. The platform does not require an upfront capital investment and relies on ordinary (reusable) laparoscopic equipment and standard CO_2 insufflation machines used in laparoscopy.

TAMIS is perhaps the best application for the multichannel single-port device. Ironically, however, this application was never intended by the original manufacturer design. As TAMIS became a practical and cost-effective alternative to the rigid platforms (TEO and TEM), manufactures have now begun to develop ports specific for this application. In the United States, there is one multichannel port that has been specifically designed and FDA-approved for advanced transanal surgery (GelPOINT Path, Transanal Access Platform, Applied Medical, Rancho Santa Margarita, CA, USA). Currently, the only other FDA-approved device for transanal access is the Single-Incision Laparoscopic Surgery PORT (SILS Port, Covidien, Minneapolis, MN, USA). This port was the original port used to perform the first TAMIS operations, when the technique was pioneered on June 30, 2009.

TAMIS Operating Room Setup

Patient preparation includes mechanical bowel prep and the administration of parenteral antibiotics less than 30 minutes preoperatively (our preference is single-dose ertapenem 1 g intravenously). Patients should be positioned dorsal lithotomy in candy-cane stirrups. This is preferred, regardless of the position of the lesion in the rectal wall. The operating room should be fitted with standard laparoscopic equipment, including light source, video monitor, and CO_2 insufflator. We strongly recommend general anesthesia with muscle paralysis to avoid collapse of the rectal wall, which often occurs with diaphragmatic excursion. Unlike TEM and TEO, which can be completed via a single-surgeon approach, TAMIS does require an experienced assistant to operate the camera and direct the visual field as the TAMIS surgeon operates.

TAMIS Surgical Technique

Either a single-incision laparoscopy surgery port (SILS Port, Covidien) or the GelPOINT Path (Applied Medical, Rancho Santa Margarita, CA, USA) (Fig. 165.6) is deployed into the anal canal with lubricant and gentle maneuvering. These ports are seated with the inner lip just above the anorectal ring. Once in place, three cannulas allow access to the rectum so that TAMIS can be performed. Using a standard laparoscopic tower, pneumorectum with high-flow cycled CO_2 is established with the pressure maximum set to 18 mm Hg. This is achieved via an insufflation-dedicated cannula. Alternatively, a valve less trocar system can be adapted to the

TAMIS platform using a specialized trocar and insufflation system (AirSeal ConMed, Inc. Milford, CT, USA). Such a system helps decrease smoke and keeps the operative field clear. Because the system can regulate pressure and CO_2 insufflation separately, the pneumorectum is more stable with less billowing of the rectal wall during LE.

The current TAMIS platforms allow admission of both 5-mm and 10-mm devices. Once the port is placed, standard laparoscopic instruments, including graspers, thermal energy devices, and needle drives, can be used to perform the procedure. A 5-mm 30- or 45-degree angled camera lens is inserted, and triangulation of the instrument facilitates the surgical dissection.

The first step with TAMIS for LE is to demarcate the perimeter of the lesion (Fig. 165.7), providing an appropriate negative margin. As with TEM and TEO, this is done using electro cautery to circumscribe the lesion. Simple short bursts of suction using a laparoscopic suction irrigator device maintain image clarity quite well. The specimen may be tented gently using a grasper and electro cautery on a spatula tip or needle tip allows for full-thickness excision. As with all advanced transanal platforms, the CO_2 insufflation provides a natural "pneumodissection," thereby clarifying the plan of dissection during LE.

Using this approach, TAMIS permits for margin-negative full-thickness local excision, and allows for a portion of the mesorectum to be removed with the specimen in the majority of cases (Fig. 165.8). Once the excision has been completed, the specimen can be retrieved by removing the SILS port, or by simply removing the lid of the GelPOINT Path platform. Depending on surgeon discretion, the specimen may be sent to pathology intraoperatively, so that clear margins can be established.

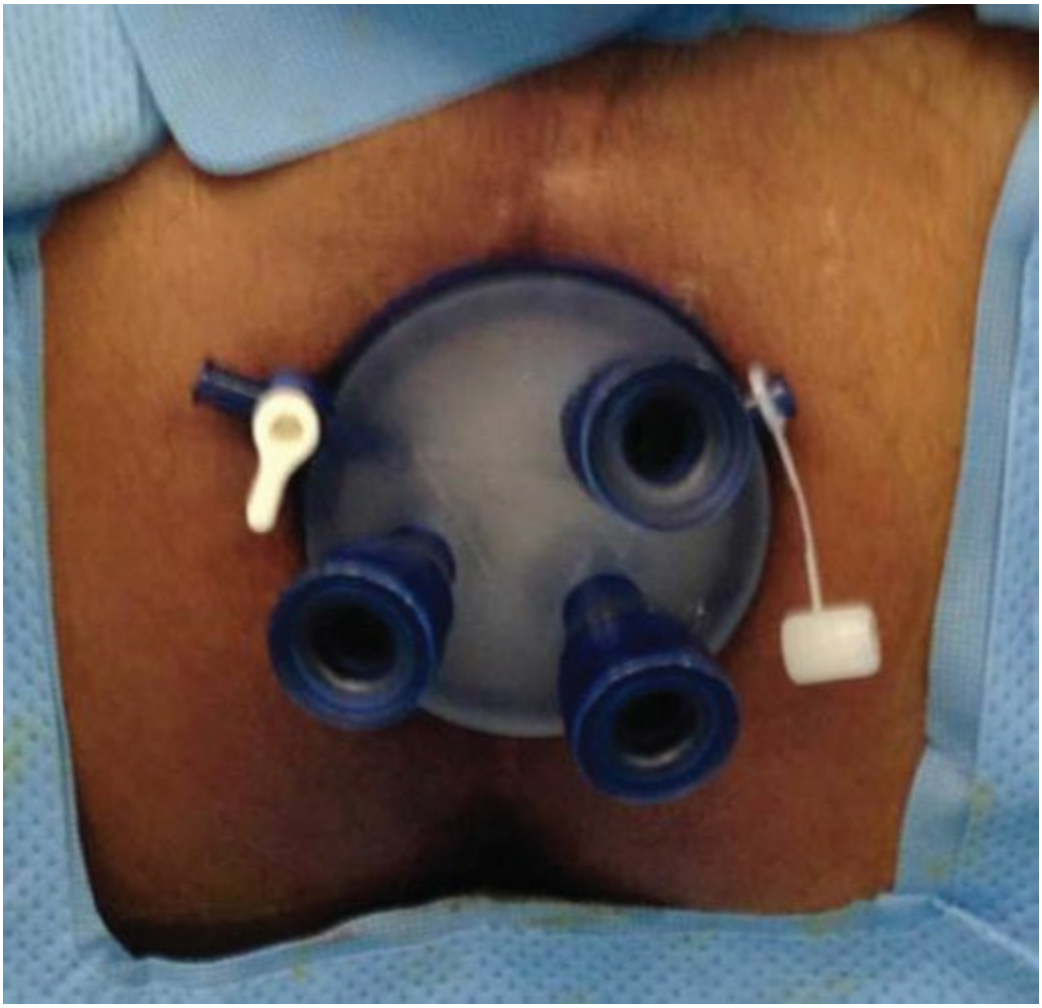

Figure 165.6. Transanal access device with cap and ports inserted into anal canal. (Reproduced from Albo D, Mulholland MW. *Operative Techniques in Colon and Rectal Surgery*. Philadelphia, PA: Wolters Kluwer Health; 2015.)

Next, the TAMIS platform is reintroduced and suturing of the rectal wall defect is performed, typically with absorbable suture. This is facilitated by gently bending a swaged needle to permit admission through one of the 5-mm cannulas or by using an available 10-mm cannula, which does not require skiing of the needle. Securing knots intraluminally is done with the help of standard laparoscopic knot pusher. Alternatively, automated suturing devices such as the EndoStitch (Covidien) or RD 180 (LSI Solutions) can be used to perform endoluminal suturing (Fig. 165.9). When coupled with Lapra-TY (Ethicon) or 5-mm TK (LIS Solutions), the suture can be secured without intraluminal knot tying. Generally, it is preferred to close the rectal wall defects after excision, and this should be done transversely (when feasible) to prevent luminal narrowing.

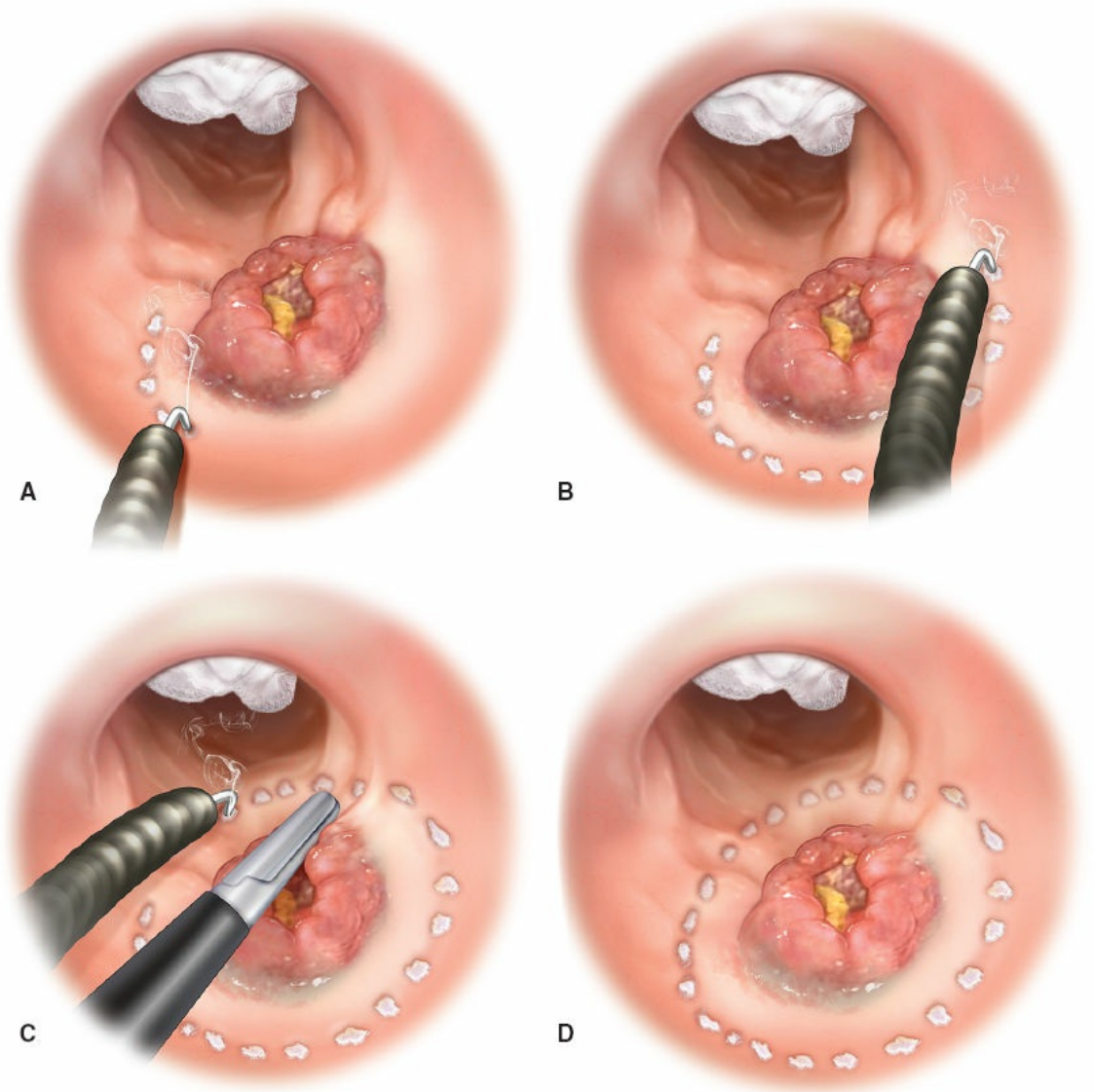

Figure 165.7. Delineation of margins of excision, 1 cm in the majority of cases. (**A–D**) demonstrate progression of circumferential margin delineation. (Reproduced from Albo D, Mulholland MW. *Operative Techniques in Colon and Rectal Surgery*. Philadelphia, PA: Wolters Kluwer Health; 2015.)

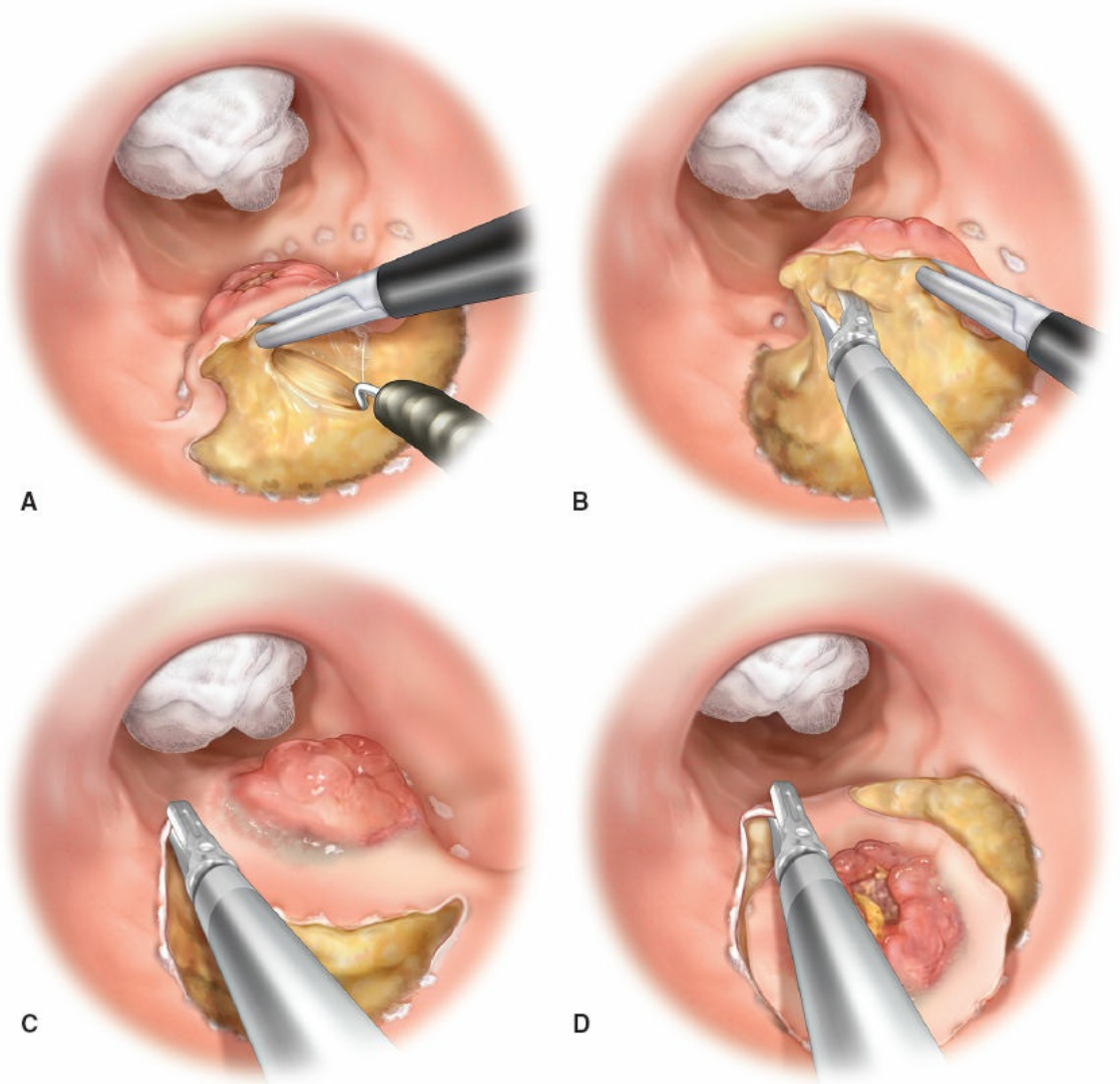

Figure 165.8. Circumferential dissection of the lesion with 1-cm margins. The deep fat is taken with either hook cautery or harmonic scalpel. The rectal wall is then taken also with either cautery or harmonic scalpel. (**A–D**) demonstrate progression of circumferential dissection. (Reproduced from Albo D, Mulholland MW. *Operative Techniques in Colon and Rectal Surgery*. Philadelphia, PA: Wolters Kluwer Health; 2015.)

MANAGEMENT OF COMPLICATIONS

Operative complications of transanal local excision are not common, but have been reported to occur in 6% to 30% of cases. The most significant intraoperative complication of full-thickness LE in the proximal one third of the rectum is peritoneal entry. With TEM and TAMIS, the rate ranges from 0% to 9%, depending on the series. Peritoneal entry rates are biased by the level of the lesion and whether or not a full thickness excision was performed. For TAMIS, the mean peritoneal entry rate has been measured

at 1.025%.

Overall, this is a special complication specific to the use of advanced transanal platform (TEM/TEO/TAMIS) since the intraperitoneal rectum is not accessible by conventional TAE. Inadvertent peritoneal entry can be managed by performing a two-layered sutured repair, either using suturing techniques from below or in combination with laparoscopic assistance. Some authors prefer the abdominal approach to assess the degree of peritoneal entry and rule out collateral damage to surrounding viscera.

Except for instances in which the bowel has been irradiated, dehiscence of the surgical wound after layered repair is quite uncommon, although patients should be admitted and monitored for 24 hours or longer depending on clinical course. The primary symptom reported by patients with dehiscence of the surgical wound after LE is pain at the operative site.

Dehiscence of the rectal wall closure is most likely to result in patients who have received neoadjuvant external beam radiotherapy, for example, for patient who have a cPR after upfront chemoradiation. Under study protocol including ACOSOG Z6041 and the UK-TREC trial, stage I rectal cancer (uT2N0 lesions) was treated with upfront radiotherapy prior to local excision. In these instances, the rate of dehiscence is high, and typically occurs between 5 and 7 days postoperatively.

Some authors have described techniques to decrease the risk of wound dehiscence including postprocedure catheter drainage (using a Foley catheter in the rectum) and applying fibrin glue into the base of the excision site prior to sutured closure in an effort to minimize dead-space. Adjuvant antibiotics have also been used. All together, no proven benefit has been established for these approaches and benefit remains anecdotal. Wound dehiscence is most typically managed expectantly with hospital admission and pain control. Bowel rest, intravenous fluid hydration, and oral or intravenous analgesics are used. Reintervention is reserved for patients who develop systemic signs of infection or sepsis. Rarely, surgical debridement and diversion of the fecal stream are required.

Fistulization to the vagina after local excision of an anterior rectal neoplasm has been described in females. In males, it is difficult to injure the prostatic urethra and this is less of a concern with LE. However, more radical resection such as transanal TME using TAMIS, TEM, or TEO for rectal cancer can lead to injury of the preprostatic urethra when the dissection from below commences in the distal 3 cm of the rectum.

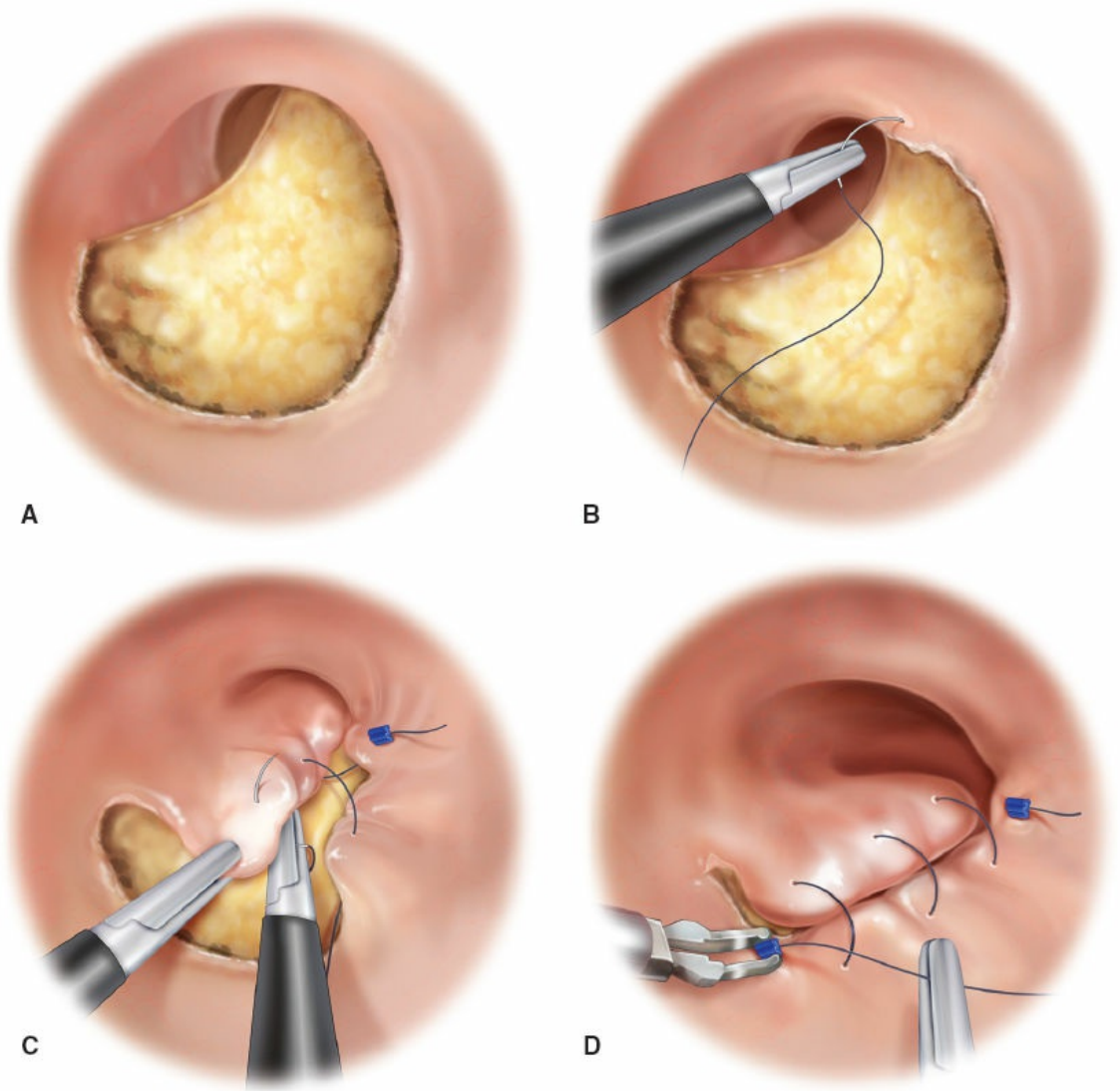

Figure 165.9. Suture repair is completed transversely from right to left (surgeon's dominant to nondominant side). The sutures are secured on both ends with Lapra-Tys. A single running suture or two to three shorter running sutures may be used. (**A–D**) demonstrate progression of suture repair. (Reproduced from Albo D, Mulholland MW. *Operative Techniques in Colon and Rectal Surgery*. Philadelphia, PA: Wolters Kluwer Health; 2015.)

Fistulization to the vagina after local excision is first managed expectantly with tap-water enemas with or without antibiotics (depending on whether or not there is a local septic process). Definitive treatment depends on the level of the fistula, with proximal fistulas approached transabdominally and often the fistula is taken down with an omental interposition placed in the recto-vaginal septum.

Lower-third fistulae are best managed via a local procedure, such as a transvaginal or transperineal flap repair. Patients who have received prior

radiotherapy to the pelvis or who are immunocompromised or otherwise deconditioned will require diversion of the fecal stream prior to planned repair of the fistula regardless of approach.

Other morbidity includes pneumodissection of tissue planes when an advanced transanal platform in utilized. This can lead to subcutaneous emphysema, particularly of scrotum; however, crepitation to the level of the neck has been observed. Patients are usually asymptomatic and no treatment in indicated. The symptoms resolve without further sequelae. Occasionally, pneumatic dissection with TAMIS/TEM/TEO can lead to retroperitoneal air and even “free” intraperitoneal air. If pneumoperitoneum is realized at the time of transanal surgery, diagnostic laparoscopy is indicated to exclude an occult rectal wall injury that violates the peritoneal cavity.

Bleeding can occur after LE regardless of the surgical approach used. Postoperative hemorrhage usually will result from submucosal arterial bleeding and has been reported to occur 1% to 10% of the time. Most often postoperative hemorrhage is managed expectantly; however, persistent hemorrhage mandates evaluation and most authors would recommend evacuation of retained rectal clot to prevent further bleeding.

Infection of the surgical site after local excision is infrequent. Pelvic CT imaging can help determine whether or not there is a drainable abscess, and if so this can be drained percutaneously. Adjuvant antibiotics with gram-negative and anaerobic coverage are indicated. Rarely, in the event of pelvic sepsis, debridement and diversion of the fecal stream can be performed. Other complications include rectal stenosis and long-term functional compromise when the rectum is narrowed from excision of a bulky lesion and whereby rectal compliance is diminished. Overall though, morbidity rates are low and significant complications rare.

CLINICAL OUTCOMES

In general, the clinical outcomes of local excision of rectal neoplasia are determined by the quality of the excision. The key measurable metrics in determining the quality of excision are the (a) completeness of the specimen (i.e., degree of fragmentation) and (b) the margin status. Most of the emphasis on high-quality excision is for invasive cancer and less emphasis is placed on excision quality for benign neoplasms. Overall, the adenoma recurrence rate following TEM ranges from 0% to 16%, and it has been demonstrated that the most likely predictor of adenoma

recurrence is inadequate excision with positive margins. Parks' TAE (in comparative studies with TEM) results in a higher margin positivity rate and increased specimen fragmentation. This is the likely reason for the higher local recurrence rate of adenomas observed with conventional Parks' TAE (32% TAE vs. 3% TEM, $p = 0.003$).

Data on TAMIS are limited as it is a relatively new modality for LE of rectal neoplasia. Pooled data from 390 TAMIS procedures performed during the first 4 years of clinical experience with this platform (2010 to 2013) revealed that the overall margin positivity rate was 4.36% and specimen fragmentation occurred 4.1% of the time, which is similar to results with TEM and TEO. Recurrence rates measured 2.7% with TAMIS (compared to 3% for TEM), although mean follow-up was limited to 7.1 months, and long-term data for TAMIS are not yet available.

There are increasing data to strongly suggest that the excision quality of the specimen is dependent on whether or not an advanced transanal platform is used, and this is most significant when local excision is being performed for rectal cancer with curative-intent. As early as 1996, Winde et al. demonstrated that patients with T1 rectal cancer who were randomized to standard anterior resection versus local excision with TEM had no difference in survival and cure rates. Meanwhile, a 2015 meta-analysis of local treatment for T1N0M0 rectal cancer demonstrated that while oncologic outcomes with TEM were similar to those with standard resection, local excision via conventional TAE demonstrated a significantly lower 5-year survival rate. Importantly, evidence-based medicine demonstrates that patients who undergo curative-intent local excision—via any transanal approach—and who develop a local recurrence have a much lower likelihood of ever being cured as neither reexcision of a luminal recurrence nor salvage anterior resection or even APR will result in an acceptable cure rate in this setting. In fact, not all recurrences are amenable to surgical intervention. Salvage surgery via SR is only feasible if, after LE, the excised lesion is of a more advanced T stage or demonstrates unfavorable histologic features (e.g., lymphovascular invasion, sm3, mucinous features). Patients who undergo immediate salvage surgery in this setting have been shown to have survival patterns predicted for their specific stage without diminished oncologic results.

FUNCTIONAL OUTCOMES

While the conventional, Parks' TAE has not been well studied in terms of functional outcomes, TEM and, more recently, TAMIS have been studied. The data on functional outcome with TEM appear to be conflicting, but most experts agree there is no proven adverse functional compromise after TEM. A series by Allaix ME et al. revealed that there was no adverse functional outcome in quality of life (QoL) after local excision at 12- and 60-month follow-up. The existing data on function after TEM do however reveal transient anal sphincter mechanism impairment; specifically decreased anorectal manometric resting pressures following TEM have been reported and this correlates with TEM operative time. Other measurable parameters such as pudendal nerve terminal motor latency, anorectal sensation, and rectal compliance were not altered by TEM. Continence was shown to be impaired by some, but not all, studies and the effect was noted to be transient. Dafnis et al. demonstrated impaired continence in 37% of patients after TEM, and this was shown to be independent of patient age or gender. This correlated with prolonged operative time. Cataldo et al. demonstrated that there was no significant change in patient anorectal function before and after the procedure based on the fecal incontinence severity index (FISI) and the fecal incontinence quality of life (FIQL) assessment tool.

The functional outcomes after TAMIS have also recently been studied. Schiphorst et al. examined 37 patients who underwent TAMIS for local excision of rectal neoplasia by a single-surgeon. With median 11-month follow-up, the functional outcomes based on the FISI assessment tool demonstrated that the majority of patients (88%) *improved* after TAMIS excision. This can most likely be attributed to the functional effects of a mass in the rectum and because, after excision, function returns to normal. Furthermore, TAMIS is typically performed with a soft, flexible multichannel port, and hence anorectal dysfunction from device insertion is probably nominal.

Verseveld et al. have prospectively studied patients undergoing TAMIS and the FISI and FIQL were used to assess anorectal function postoperatively. The data for $n = 24$ patients in the study revealed that FISI remained unaffected after TAMIS (9.8 vs. 7.3; $p = 0.26$) and FIQL preoperative versus postoperative scores were similar (3.8 vs. 3.9; $p = 0.15$). Overall FISI was either improved or the same after TAMIS in 11 out of 13 patients who had a preoperative abnormal FISI, and the authors concluded that improvement in function is probably attributed to tumor

removal. Data from most series on postoperative function after transanal surgery with TEM show similar results with either no change in functional outcome or improvement after excision.

Risk factors for dysfunction include distance from the anal verge. For example, LE for tumors near the anorectal ring has a relatively decreased incidence of functional impairment and lower postoperative FISI scores as well as incontinence (p = 0.01). In contrast, it has been shown that functional results are decreased when the lesions excised are more proximal (≥8 cm from the anal verge). One explanation for this may be that excision of more proximal lesions typically requires a longer operative time as it is a more challenging and complex operation than when excision is performed in the lower two thirds of the rectum.

Larger tumors—in particular, lesions ≥4 cm in diameter—that undergo LE result in an increased urgency primarily because the rectal volume and compliance are decreased upon excision and closure of the defect.

Suggested Readings

Albert M, Atallah S, Larach S. Minimally invasive anorectal surgery: from Parks local excision to transanal endoscopic microsurgery to transanal minimally invasive surgery. In: *Seminars in Colon and Rectal Surgery* (Vol. 24, No. 1). Philadelphia, PA: WB Saunders; 2013:42–9.

Artinyan Avo. *"Transanal Minimally Invasive Surgery for Rectal Cancer." Surgery for Cancers of the Gastrointestinal Tract.* New York: Springer; 2015:297–307.

Atallah S, Albert M. Robotic transanal surgery. In: *Robotics in General Surgery.* New York: Springer; 2014:261–6.

Atallah S. Robotic transanal minimally invasive surgery for local excision of rectal neoplasms. *Br J Surg* 2014;101(5):578–81.

Friel CM. Local excision of T1 rectal cancer: where are we now? *Dis Colon Rectum* 2010;53(9):1231–3.

Larach SW, Polavarapu HV. Transanal Minimally Invasive Surgery (TAMIS). In: *Advanced Techniques in Minimally Invasive and Robotic Colorectal Surgery.* Boston: Springer; 2015:243–8.

Marks JH, Reynolds H. Local treatment of rectal cancer (TEM versus TAMIS versus transanal excision). In: *Complexities in Colorectal Surgery*. New York: Springer; 2014:219–30.

Nastro P, Beral D, Hartley J. Local excision of rectal cancer: review of literature. *Dig Surg* 2005;22(1–2):6–15.

Platz J, Cataldo P. Functional outcomes following transanal rectal surgery. In: *Seminars in Colon and Rectal Surgery* (Vol. 26, No. 1). Philadelphia, PA: WB Saunders; 2015:41–4.

Quinteros F, Thiruppathy K, Albert MR. Transanal Minimally Invasive Surgery (TAMIS): operative technique, pitfalls, and tips. In: *Minimally Invasive Approaches to Colon and Rectal Disease.* New York: Springer; 2015:283–91.

EDITOR'S COMMENT

The authors present an outstanding account of local excision of rectal tumors. The chapter opens with an elaborate description of history followed by a detailed account of various stages of technical evolution this operation has enjoyed over the last few decades. The authors close the chapter with a detailed technical discussion complemented by excellent descriptions of operative approach.

As described by the authors, transanal resection for rectal tumors has been in clinical practice for a long time. The technique underwent a surge in popularity roughly two decades ago when it transitioned from its steady, low level of clinical application to mainstream use. Perhaps, this sudden popularity and ensuing widespread adaption was attributable to the initial reports suggesting local control rates comparable to proctectomy complemented by the obvious benefits that the technique offered: low operative morbidity coupled with sphincter preservation in patients who would have otherwise received an abdominoperineal resection and a permanent stoma. In addition, the introduction of TEM was truly a game changer. With its enhanced visualization and increased reach, TEM helped to catapult this technique into popular use.

The widespread adaption of this technique lead to expansion of its indications from the treatment of low lying, mostly benign tumors to extirpation of mid, even upper rectal tumors. Not surprisingly, some surgeons went as far as routine employment of this approach for locally advanced rectal cancers. Like many new techniques in surgery, this newfound enthusiasm was soon to be dampened by emergence of multiple reports detailing suboptimal local oncologic control compared to total mesorectal excision, as eloquently described by the authors in this chapter. Consequently, most practices limited the use of transanal resection to benign polyps and selected cases of early T1 cancers. Another area where the technique remains valid is its use as a "full-thickness excisional biopsy" to help determine the need for a radical excision in cases where a large polyp is suspected to harbor a malignant component.

More recently, the interest has been revitalized by the emergence of literature attesting the effectiveness of chemoradiation in combination with local excision. Multiple large retrospective series and a recent prospective trial (Z6041) have indicated that the disadvantage of inferior local control—the major drawback of this technique—can be resolved by the addition of chemoradiation therapy.

These studies are fairly recent and long-term results are keenly awaited. A word of caution to the reader: While the early results of Z6041 trial show comparable local control to total mesorectal excision, the surgical and radiation-related side effects and complications were also observed at a very high rate prompting midstudy radiation dose adjustment. Furthermore, the investigators recently reported the functional outcomes of the trial; while there were no significant changes in Fecal Incontinence Severity Index, there were statistically significant reductions in Fecal Incontinence Quality of Life Scores (Lynn PB, Renfro LA, Carrero XW, et al. Anorectal function and quality of life in patients with early stage rectal cancer treated with chemoradiation and local excision. *Dis Colon Rectum* 2017;60(5):459–68).

The operative technique itself has gone through a remarkable evolution from its early stages entailing utilization of standard anal retractors with a limited reach of 5 to 6 cm from the anal verge to introduction of TEM and finally modern day TAMIS technique. TEM and TAMIS result in much better operative visualization and increase the operative reach allowing the surgeon to approach tumors in mid and upper rectum. Due to its low cost, universal availability and its compatibility with conventional laparoscopic equipment, TAMIS has mostly supplanted older techniques and is my preferred approach for transanal resection of rectal tumors.

As mentioned by the authors, the importance of Airseal insufflation system cannot be overstated. There is no doubt that the Airseal system results in dramatic reduction of the luminal bellowing effect resulting in significantly improved visualization and more importantly, a considerable reduction in operator frustration.

In my practice, conventional transanal resection remains relevant for very distal tumors, those located within 3 to 4 cm from anal verge. In my opinion these tumors are relatively inaccessible to TEM or TAMIS due to their proximity to anal verge making it very difficult to maintain airtight seal around the anus, a prerequisite for successful performance of video-assisted platforms.

I concur with the authors that all patients undergoing local excision, perhaps with the exception of very distal tumors, should undergo bowel prep. It is my practice to use oral antibiotic prep in addition to mechanical prep specially in cases where peritoneal entry is anticipated. I feel that the reduction in colonic bacterial burden with preoperative oral antibiotics assists in minimizing peritoneal contamination in case an inadvertent peritoneal entry during the course of the operation.

In terms of complications, I think it is imperative to mention the risk of luminal compromise and in some cases, complete luminal occlusion during rectal defect closure. This typically occurs during conventional transanal excision and in my opinion, is much less of a concern with video-assisted platforms (TEM and TAMIS). The limited visualization afforded by the standard anal retractors can lead to approximation of mucosal edges across the lumen. I have personally experienced this on two occasions, both of which were

during the early phase of my learning curve and involved extirpation of large tumors occupying substantial portion of rectal circumference. Fortunately, I was able to identify the luminal compromise in both cases as I routinely perform endoscopic evaluation of mucosal closure at the end of these operations. For this reason, I strongly recommend an endoscopic exam at the conclusion of all transanal resections as this complication can have disastrous consequences, assuring a return trip to the operating room.

Next, I would like to touch the topic of inadvertent peritoneal entry during the course of these operations. A breach of peritoneal cavity typically has dramatic appearance on imaging studies due to tracking of large amount of gas in the peritoneal and retroperitoneal spaces. While fairly ominous in its appearance, this outcome can be managed successfully with conservative therapy and reoperation is rarely necessary. My approach is to keep patients with inadvertent peritoneal entry in house for 2 to 3 days for close clinical observation. I also maintain these patients on broad-spectrum antibiotics for 10 to 14 days. While there is no evidence supporting empiric antibiotics therapy in this situation, I feel that it minimizes the risk of a postoperative abscess and provides me with much needed peace of mind.

Finally, in my experience postoperative bleeding is one of the most common complications after this procedure. The bleeding is typically associated with wound dehiscence. In the recent past, I have adapted what I call the “three-point suturing” technique. This technique incorporates a full-thickness edge of rectal wall on one side followed by a deep bite including the base of the defect and a third full-thickness bite through the edge of rectal wall on the opposite side. I feel that this approach results in complete obliteration of dead space minimizing the risk of hematoma formation, which typically leads to suture line dehiscence and resultant bleeding.

As indicated by the authors, sphincter dilation during the performance of TEM can result in poor sphincter function. Much of this sphincter trauma can be mitigated by the use of soft, pliable TAMIS port. Although there are limited data on functional outcomes after TAMIS in comparison to TEM, it is conceivable that the reduced amount of sphincter stretch during TAMIS will result in improved postoperative functional outcomes.

In my opinion, local excision is an optimal approach for benign tumors located in distal rectum; however, the use of this approach in malignant conditions remains controversial. Locally advanced (T3 or more) or lymph node positive tumors should be dealt with neoadjuvant chemoradiation followed by total mesorectal excision; local excision in these cases is not advisable. Early T1 tumors without poor prognostic features can be cautiously treated with local excision with a clear understanding that this approach may result in increased local recurrence rates and decreased survival. These facts underscore the importance of a detailed preoperative discussion with the patient to ensure a complete understanding of these risks on patient’s part. The issue of local excision of T2 tumors in combination with chemoradiation remains unsettled

until long-term data become available. We have to bear in mind that a total mesorectal excision alone is curative for T2 rectal cancers *without* the need for chemotherapy or radiation. The important question we need to ask ourselves is this: Are the benefits of local excision for T2 rectal cancer worth the side effects and reduction in quality of life seen with neoadjuvant chemoradiation therapy. I feel that this will remain an important philosophical question even after long-term data from prospective trials become available.

Syed Husain

166 Functional Bowel Disorders

Michael R. B. Keighley

INCONTINENCE

Incontinence of feces is a demoralizing and psychologically devastating condition for the patient. It is far worse in terms of quality of life than incontinence of urine. So distressing is the condition that many patients afflicted by incontinence of feces never admit their problem to their families or closest medical attendants. Symptoms are therefore concealed, because patients feel ashamed that they are "dirty," with the inevitable consequence that they become social outcasts with loss of self-esteem, demoralization, and loss of confidence.

Fecal incontinence without awareness causing passive incontinence is the most distressing symptom, necessitating protective clothing and diapers. There is loss of anorectal sensation and motor function.

With urge incontinence, patients have to rush to the bathroom. Hence, sensory awareness is retained, but motor control is only capable of preventing involuntary defecation for a short time. These patients fear traveling or moving out of social circumstances in which a bathroom is not available. Urgency is a common symptom in patients with rectal disease, particularly proctitis or a narrowed rectum, as well as after obstetric trauma.

Soiling is caused by the inability of the anal canal to close completely. Sensation is preserved, and there is a gutter defect in the anal canal through which feces may seep.

Overflow incontinence is caused by fecal impaction. Liquid feces leak around a solid bolus of fecal material that occupies the entire lumen of the rectum. Overflow incontinence is often associated with the aging process; megacolon is associated with loss of sensory awareness in the rectum.

Clinical Presentation

Clinical presentation usually identifies the principal cause for incontinence. Women are affected far more commonly than men are,

because obstetric injury is the most common cause of incontinence requiring surgical treatment. Some patients become incontinent after operations on the anal canal or on the rectum and colon. A further group includes patients who sustain trauma to the perineum. Any patient presenting with fecal incontinence should be closely questioned to exclude underlying neurologic disorders, particularly demyelinating disease in the young and cauda equina lesions at all ages. There is also a group of patients with congenital disease who present with incontinence. In such patients, there is usually a history of surgical treatment in the neonatal period for anorectal agenesis, Hirschsprung disease, meningocele, or other congenital lesions affecting the cauda equina or anorectum. Finally, 70% of patients with a rectal prolapse are incontinent; hence, prolapse must be excluded in all patients with symptoms of incontinence.

Causes

Factors Responsible for Normal Continence

Normal continence depends on a number of correlated factors that, in principle, include a reservoir, an anorectal junction that opens and closes at will, and a closed anal canal at rest.

The rectal reservoir may be compromised in patients with inflammatory disease affecting the rectal mucosa and the wall of the rectum, as in ulcerative colitis and Crohn disease. The capacity of the rectal ampulla may be severely compromised in patients who have had previous radiation treatment or may have been surgically reduced in patients having ileoanal or coloanal anastomoses, particularly where no reservoir has been constructed. The voluntary control mechanism for opening and closing the anal canal consists of the pelvic diaphragm and puborectalis sling, particularly, as well as the striated external anal sphincter. These muscles may be damaged from trauma after obstructed vaginal deliveries. They may become neuropathic from prolonged second stage of labor, and they may be traumatized by the fetal head or if an episiotomy extends through the sphincters. The striated muscle may fail to function if there has been severe infection resulting in fibrosis around the sphincters or pelvic floor, or the external sphincters may have been divided during anal operations, particularly fistulotomy, or by perineal trauma.

The anal canal is normally closed at rest. This depends on the involuntary contraction of the circular smooth muscle around the anal canal and the integrity of unscarred anus. The internal sphincter is under

autonomic control mediated through nitric oxide. The smooth muscle itself may be damaged by previous surgery, such as hemorrhoidectomy, anal dilation, or sphincterotomy. It may become neuropathic from operations that interrupt the normal intermyenteric fibers innervating the internal sphincter, and it may be defective in patients in whom normal chemical transmitters no longer function, as, for instance, in Hirschsprung disease.

The anorectum cannot function normally if it does not receive afferent signals. Thus, patients with impairment of rectal or anal sensation have compromised continence. The sensory fibers of the pudendal nerve supply the anorectum, and this nerve may be damaged after obstetric trauma and in cauda equina lesions. Cerebral degeneration from any cause may result in impaired rectal evacuation and incontinence.

Causes of Incontinence

Obstetric trauma may result in disruption of the fibers of the puborectalis and pelvic floor, a neuropathic injury affecting the pudendal nerve, division of the internal or external anal sphincter, or fibrosis encasing the sphincters following sepsis or repeated operations. Patients may have impairment of rectal evacuation urgency, urge incontinence, soiling, and lack of flatus control.

Postoperative incontinence may be a result of damage to the internal or external anal sphincter after operations on the anus, such as hemorrhoidectomy, sphincterotomy, anal dilation, and anorectal fistula surgery. In some cases, the sphincter muscles may be divided. In others, a gutter deformity may develop in the anal canal, which prevents the anal canal from remaining closed at rest. Colorectal operations may also result in incontinence if they cause rectal strictures or fibrosis of the reservoir, which then is no longer compliant and is small in volume capacity. Incontinence may develop after transection of the low rectum or anal canal as a result of interruption of the intermyenteric autonomic nerve plexus. Thus, any operation on the colon and rectum, particularly if it involves a low anastomosis, may result in impaired continence.

Perineal trauma may result in damage to the sphincter, pelvic floor, anal canal, and rectum. There is often associated injury to the urethra, the bony pelvis, and the soft tissues of the buttocks.

Neurologic injury may involve upper motor neurons, which usually results in severe constipation, fecaloma, and soiling, or lower motor neurons, in which the anorectum is completely patulous and there is buttock anesthesia. More localized neurologic injury may involve the

pudendal nerve in patients who strain or in whom there has been a prolonged second stage of labor. Diffuse neurologic abnormality may occur in demyelinating disease and in the neurologic degenerative process seen in the acquired immunodeficiency syndrome.

Sepsis around the anal canal may result in skeletal muscle destruction and fibrosis. This cause of incontinence may occur when inefficient or delayed drainage of anorectal sepsis has occurred and in patients with severe localized inflammatory disease of the anal canal, as may occur in Crohn disease or in deep penetrating ulcers associated with the acquired immunodeficiency syndrome.

Congenital causes of incontinence may be anorectal agenesis, Hirschsprung disease, rectal reduplication, and anorectal dermoids, or the congenital abnormality may affect the neural tube, as in patients with meningomyelocele or its variants.

Diagnosis

Clinical Examination

Clinical examination identifies the principal cause of incontinence in most patients, but in certain instances specialized anorectal physiology is required for diagnosis and as a means of recommending whether surgical treatment is indicated.

Inspection of the perineum can identify scars from previous anal surgery, episiotomy, or obstetric injury. Often, a defect in the sphincter ring is apparent. The site of the anus should be noted. Anterior displacement suggests an ectopic anus (minor variant of anorectal agenesis). The presence of skin tags, fistulae, or the presence of patulous anus should be recorded. Inspection should then include examination during straining to exclude a rectal prolapse and to assess the degree of perineal descent and vaginal descent, cystocele, and rectocele.

Rectal examination should attempt to assess resting tone and the contractile activity of the external anal sphincter and the puborectalis. Rectal examination should also identify any defect in the sphincter and any gutter deformity, in addition to any palpable pathologic abnormality in the rectum.

Proctosigmoidoscopy should be performed to exclude proctitis, polyps, or any other colorectal pathology.

Specialized Diagnostic Techniques

Anal manometry provides data on the maximum resting anal canal pressure and the maximum pressure generated during a maximum squeeze effort (Fig. 166.1). Manometry also helps to identify the length of the high-pressure zone, and vector manometry may be used to clarify areas of reduced anal pressure, signifying localized defects. In some circumstances, ambulatory manometry may be necessary. An inflatable balloon should then be inserted into the rectum and anal manometry performed during balloon distention to determine the presence or absence of the rectoanal inhibitory reflex. This reflex may be absent in Hirschsprung disease and in some patients with incontinence. Distention of a rectal balloon is a simple method of crudely assessing rectal capacity and rectal sensation. However, for compliance measurements of the rectum, integrated changes in intrarectal pressure are recorded with incremental volumes in the rectal balloon. Anal sensation should be measured using the technique of anal mucosal electrosensitivity in the lower, mid, and upper anal canal.

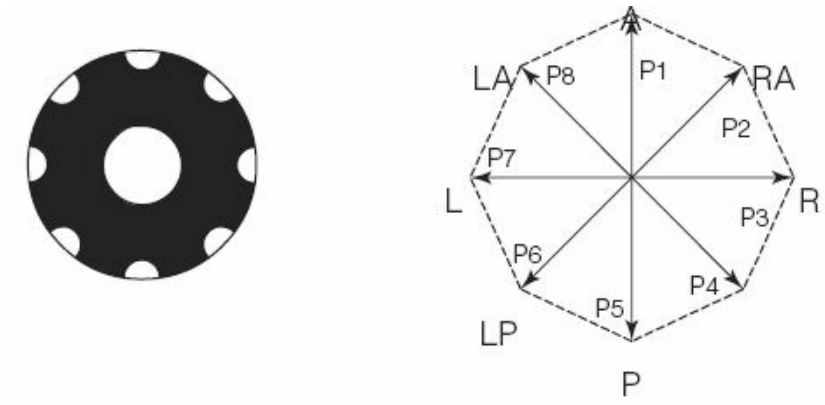

Eight-port catheter

Pressure vector diagram

A

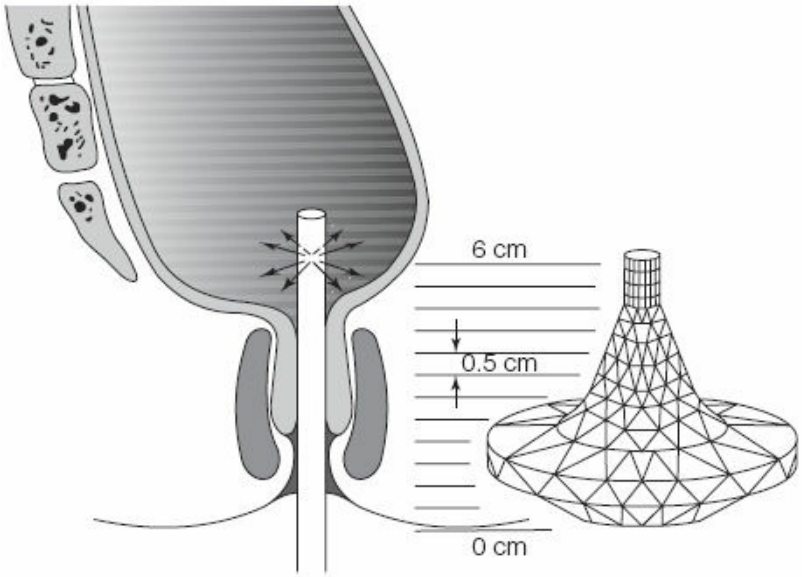

Twelve-station pullout

Composite reconstruction of pressure vectors

B



C

Figure 166.1. Vector manometry. A typical and pressure profile in fecal incontinence. (From Keighley MRB, Williams NS. *Surgery of the Anus, Rectum, and Colon.* 3rd ed. Philadelphia, PA: WB Saunders; 2008. Copyright © MRB Keighley MA MS FRCS.)

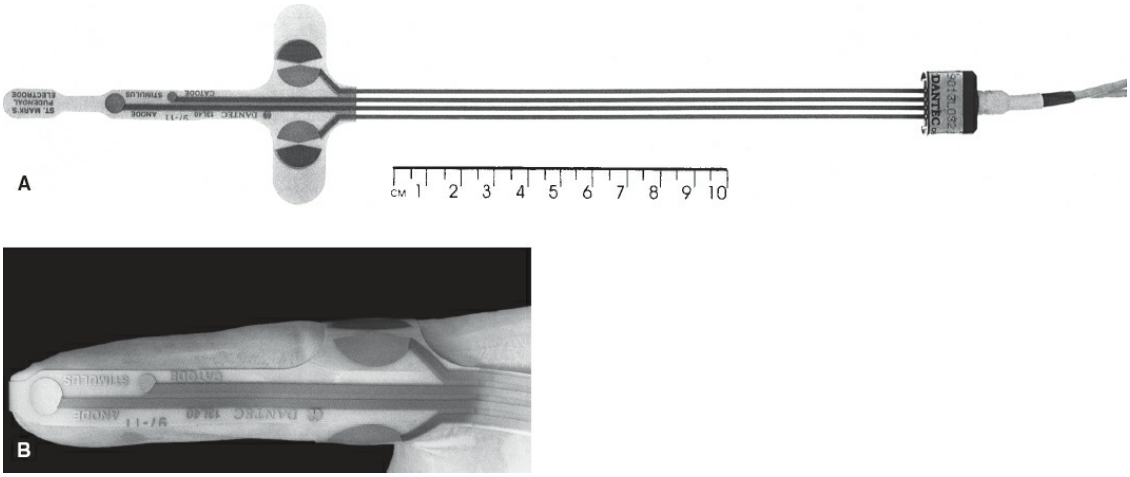

Figure 166.2. The disposable pudendal electrode. (From Keighley MRB, Williams NS. *Surgery of the Anus, Rectum, and Colon.* 3rd ed. Philadelphia, PA: WB Saunders; 2008. Copyright © MRB Keighley MA MS FRCS.)

Electromyography was formerly used for mapping the external anal sphincter in patients with sphincter defects and in assessing ectopic anus. However, the use of needle electrodes is painful and poorly tolerated by patients, particularly if there is scar tissue. Likewise, measurement of fiber density as an assessment of the degree of denervation may be performed by repeated sampling of the external sphincter and puborectalis by the use of concentric needle electrodes. For the same reason, patients find this investigation difficult to tolerate and are not particularly compliant. By contrast, conduction studies are less invasive and give an assessment of pudendal neuropathy. Pudendal nerve terminal motor latency measurements can be made by stimulating the pudendal nerve as it winds around the ischial tuberosity and recording the evoked contraction in the external sphincter after stimulation (Fig. 166.2). Conduction delays are associated with pudendal neuropathy, but there is considerable observer variation with this measurement and most units have abandoned this method of assessment because it is considered unreliable.

Ultrasound examination of the anal canal and rectum has superseded electromyography in the identification of sphincter defects. It is important to assess the length of any injury in the anal canal as well as its

circumferential extent and position. Anal ultrasonography can be used for dynamic assessment of contractility, as well as definition of anatomic defects (Fig. 166.3A,B), morphology, and pathologic conditions (e.g., abscess and fistula). Magnetic resonance imaging (MRI) of the anorectum may provide additional important information, particularly in injuries and disorders affecting the pelvis floor.

Many patients with fecal incontinence have some impairment of rectal evacuation. Thus, assessment of rectal emptying by isotopic techniques or during videoproctography is indicated for some patients. Videoproctography may also be needed to exclude coexisting abnormalities, such as intussusception, perineal descent, and rectocele, as well as to provide playback images to record pelvic floor movements during contraction and attempted defecation.

In general, patients with low resting anal pressures, a short high-pressure zone, gross perineal descent, anal anesthesia, gross prolongation of pudendal nerve terminal motor latency, and those with poor external sphincter contractility do badly after attempted reconstructive surgery. Thus, for such patients, counseling that there are alternative therapies other than conventional surgical reconstructions that are more likely to improve a patient's quality of life is needed.

Treatment

Conservative Therapy

Many patients with fecal incontinence have a history of diarrhea. Under these circumstances, particularly if the incontinence is relatively mild, control of the diarrhea may achieve sufficient improvement and further therapy becomes unnecessary. Use of codeine phosphate and loperamide can be important. In patients with rapid transit times, tablets or capsules may not be absorbed, but an elixir may be.

Diet and Anal Hygiene Methods

Many patients with bowel incontinence find that bowel control is poor on a vegetarian diet. Foods that produce gas, for example, onions, root vegetables, beans, and brassicas, should be avoided if the sufferer has flatus incontinence. Alcohol is generally poorly tolerated in incontinence patients. Diets rich in animal protein and starch often suit patients who suffer with bowel incontinence. Many patients find that the timing of meals is critical for work and social events.

For those whose principal problem is soiling, washing with water, the use of wipes to remove fecal debris when visiting the toilet to micturate avoids perianal excoriation and soreness from fecal staining.

Physiotherapy and Biofeedback

Unquestionably, some patients can no longer contract the sphincter and pelvic floor complex appropriately in response to rectal distention. Others seem incapable of sphincter and pelvic floor contraction on command and tend to strain during attempted voluntary contraction. Another group finds it difficult to contract the sphincter and pelvic floor after recent injury because of pain and psychological trauma. Such patients may be improved dramatically by a series of pelvic floor exercises, faradism, electrical stimulation of the sphincter muscles, and biofeedback retraining. Biofeedback involves an afferent stimulus as a learning process to trigger pelvic floor and sphincter contraction. Biofeedback retraining may produce dramatic improvement in patients who have problems in learning the technique. Biofeedback may also heighten rectal sensory awareness. However, biofeedback is dependent on cooperation by the patient and personality synthesis between the therapist and the patient. For motivated patients, this form of treatment is useful in minor forms of incontinence. It may also be helpful as a preoperative conditioning process so that the discipline can be reinforced postoperatively.

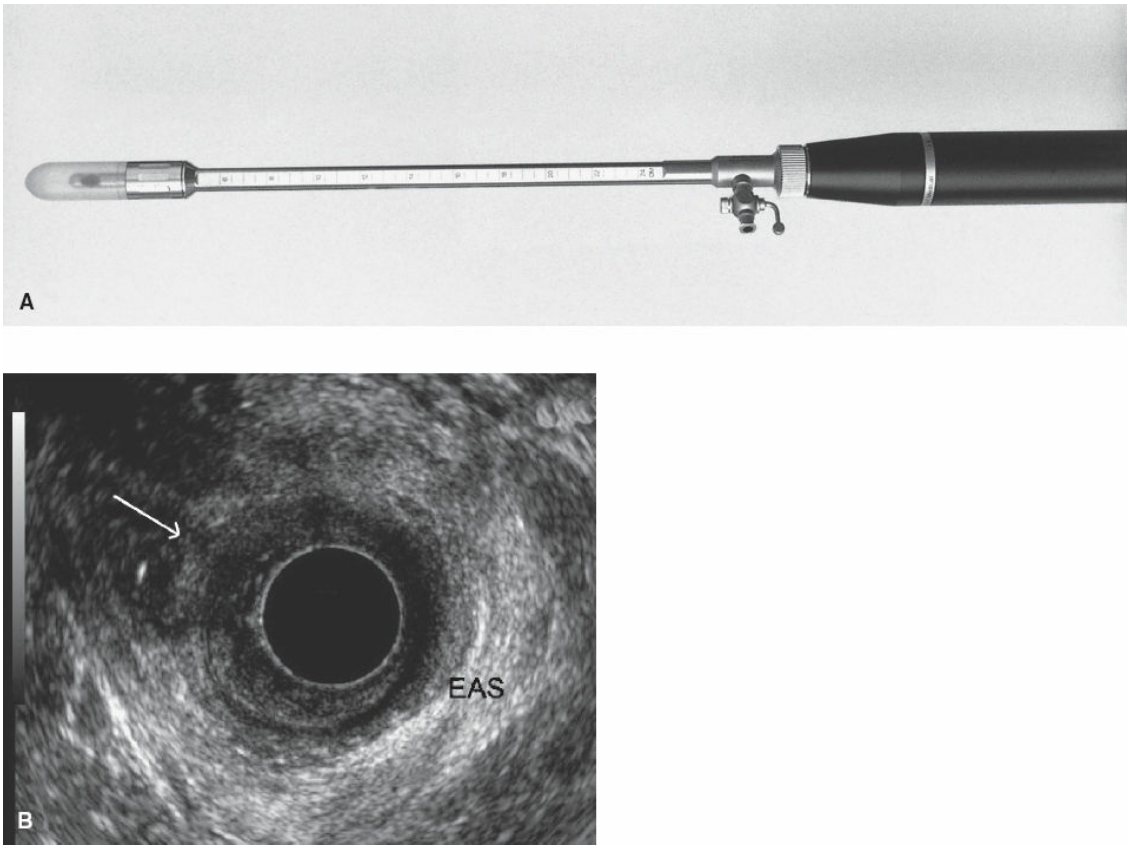

Figure 166.3. A and **B:** Anal ultrasound. (From Keighley MRB, Williams NS. *Surgery of the Anus, Rectum, and Colon.* 3rd ed. Philadelphia, PA: WB Saunders; 2008. Copyright © MRB Keighley MA MS FRCS.)

Keeping the Rectum Empty

Recognition that surgical treatments for bowel incontinence rarely fully control the symptoms of flatus incontinence, soiling, and may result in deterioration of rectal emptying, conservative measures to keep the rectum empty have assumed a much greater role for therapy during the last decade.

The simplest approach is the use of glycerin or bisacodyl suppositories, but these only empty the rectum. Small volume enemas achieve greater compliance than phosphate enema but are less effective in emptying the left colon. Enemas are used by many with a neuropathic anorectum so as to achieve regular evacuation while preventing fecal impaction.

Self-administered rectal washout is the logical extension of colostomy irrigation. It was pioneered in countries where availability and cost of stoma appliances were prohibitively expensive. The technique has now been accepted in colorectal units. Management of incontinence by washouts has become an extension of the role of the stoma therapists or

colorectal nurse specialists. It is curious that this simple measure has taken so long to become accepted as an alternative to a stoma and as an effective method of achieving predictable anal hygiene. Like colostomy irrigation, it requires a motivated patient who is psychologically able to accept the technique as an extension to normal toileting. There are now commercially available kits and nursing staff trained to teach and supervise rectal irrigation.

The principle is to teach patients to infuse a variable volume of fluid through a delivery system with an appropriate anal applicator so as to stimulate a series of mass left side colonic evacuations. As a consequence, the left colon is emptied of gas, liquid, and solid contents. If successful, patients may then feel clean for the rest of the day without the fear of urgency, soiling, or even flatus incontinence. The technique takes between 20 and 40 minutes at the beginning of the day and achieves almost complete continence for the rest of the day in over 80% of patients. Thus, in compliant poor outcome potential surgical patients, this procedure replaces the need for an operation with uncertain results and greatly improves patient's quality of life. Consequently, individuals who master self-administered rectal washouts are largely able to lead independent social lives, allowing a full range of physical exercise and return to the workplace.

Anterior Levatorplasty

Anterior levatorplasty is useful in patients with rectocele and in many patients requiring sphincter repair, in whom, there is also a deficiency of the perineal body and the anterior aspect of the pelvic floor. The patient is placed in the prone jackknife or lithotomy position. Liberal infiltration of the rectovaginal septum with a weak adrenaline solution and a local anesthetic is often advisable. A transverse incision is made across the perineum, between the rectum and the vagina, but in front of the anterior border of the anal sphincters. The external anal sphincter is identified posteriorly, and the entire rectovaginal septum is dissected free to the level of the pelvic peritoneum, where the rectum and the vagina move away from one another at the rectovaginal cul-de-sac. The posterior vaginal wall is then dissected from the levator muscles, so that the anterior limbs of the puborectalis can be easily identified. Repair involves approximating the anterior aspect of the puborectalis in the midline between the rectum and the vagina. In patients with an obstetric sphincter injury, the anterior aspect of the external anal sphincter is also plicated or repaired (Fig.

166.4).

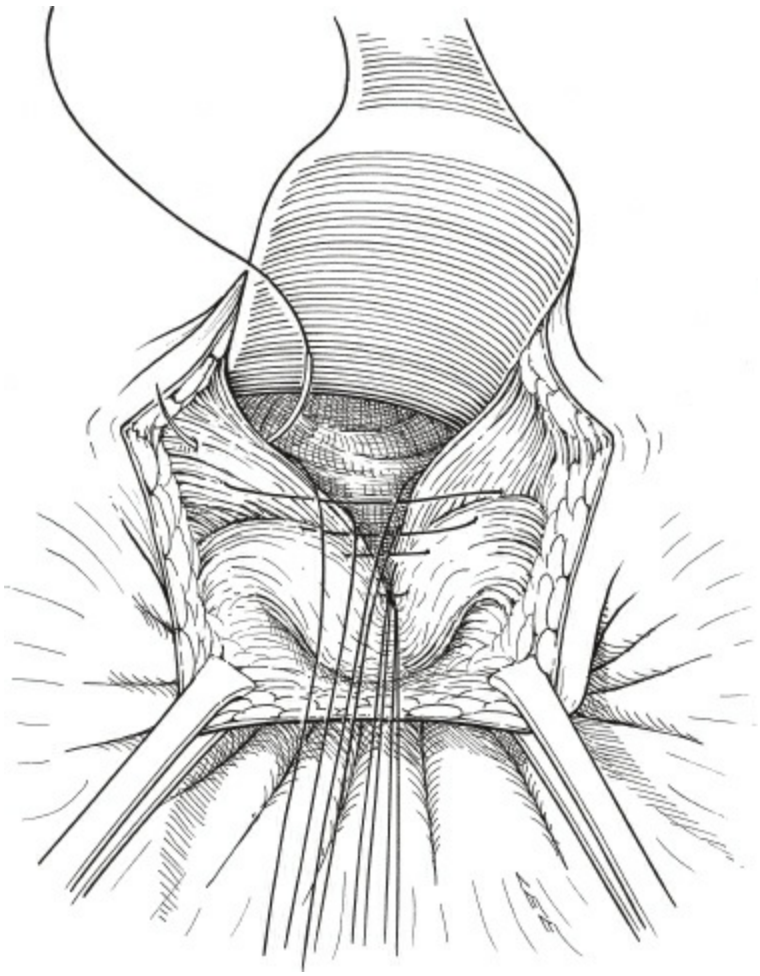

Figure 166.4. Anterior levatorplasty. (From Keighley MRB, Williams NS. *Surgery of the Anus, Rectum, and Colon.* 3rd ed. Philadelphia, PA: WB Saunders; 2008. Copyright © MRB Keighley MA MS FRCS.)

Sphincter Repair

Sphincter repair is indicated for patients with a localized defect in the external anal sphincter, provided the healthy sphincter is capable of vigorous contraction. The operation may be needed for postobstetric injury, division of the sphincter after fistula surgery, or traumatic injuries of the perineum. In each of these three situations, the specific method of repair may have to be modified according to the extent of damage.

The patient may be operated on in the prone jackknife or lithotomy position. Prior infiltration with a weak adrenaline solution and a local anesthetic is always advisable. In postobstetric sphincter injuries, a cruciate incision may be used to provide excellent access to the

rectovaginal septum, the perineal body, and the sphincters. The cruciate incision is usually closed as a Z-plasty, but there is a tendency for wounds to break down. Thus, a circumanal incision is preferred by most surgeons, leaving the center open for drainage (Fig. 166.5). For a defect after previous fistulotomy, a circumanal incision is usually more appropriate (Fig. 166.6). In traumatic perineal injuries, the incision depends on the precise site of the defect. The first task is to dissect the external anal sphincter on either side of the defect and preserve, where possible, the internal anal sphincter. Stay sutures are placed on either side of the sphincter defect, and the scar tissue is divided. In patients with postobstetric injuries, the entire rectovaginal septum is dissected free so that an anterior levatorplasty (Fig. 166.7) can be combined with sphincter repair. However, in the case of traumatic injury and defects after fistula operations, levatorplasty is rarely necessary unless one is dealing with an anterior deficiency. In patients with perineal trauma, it may be necessary to identify any defect that may be present in the anorectum as well as by MRI. In such cases, reconstitution of the anorectum by repair of its circular smooth-muscle fibers and mucosa may have to be combined with sphincter repair.

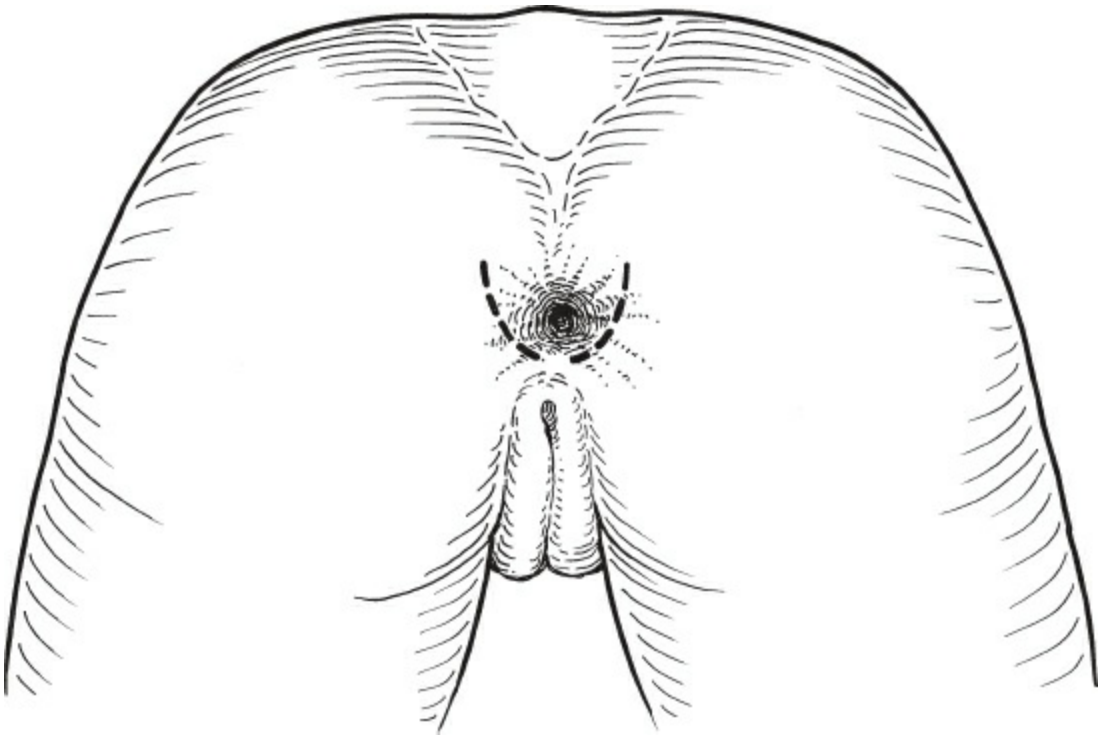

Figure 166.5. The incision for a conventional obstetric injury sphincter repair. (From Keighley MRB, Williams NS. *Surgery of the Anus, Rectum, and Colon.* 3rd ed. Philadelphia, PA: WB

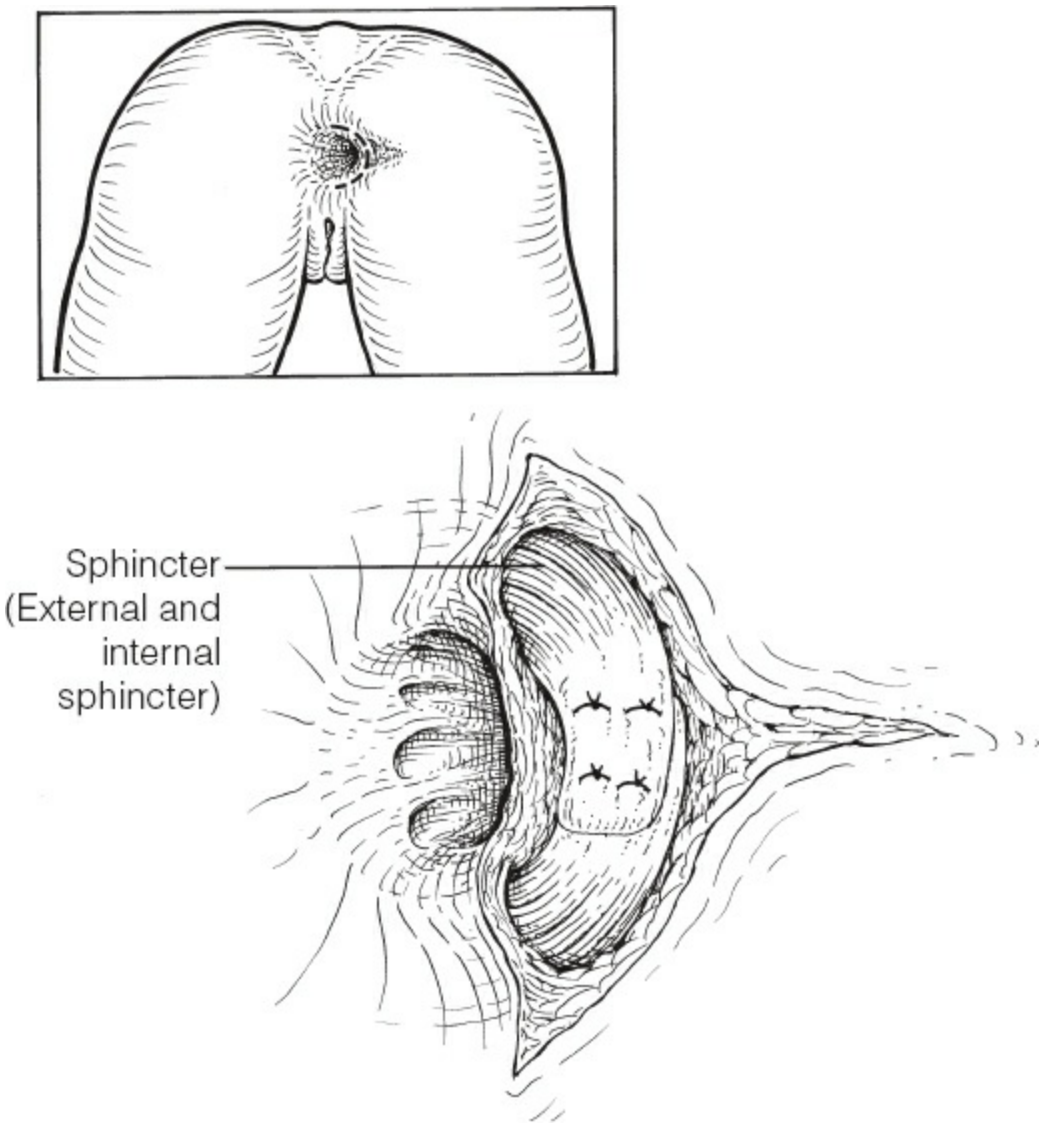

Figure 166.6. The incision for sphincter repair following fistula surgery. (From Keighley MRB, Williams NS. *Surgery of the Anus, Rectum, and Colon.* 3rd ed. Philadelphia, PA: WB Saunders; 2008. Copyright © MRB Keighley MA MS FRCS.)

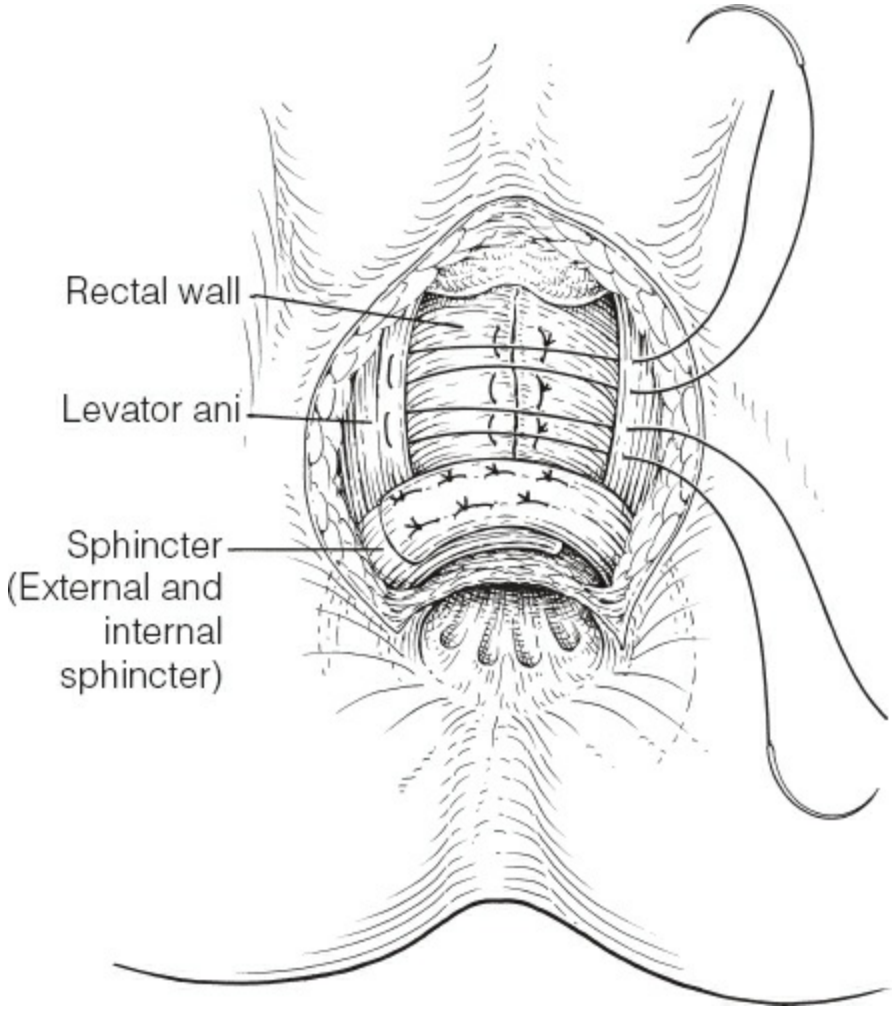

Figure 166.7. Sphincter repair. (From Keighley MRB, Williams NS. *Surgery of the Anus, Rectum, and Colon.* 3rd ed. Philadelphia, PA: WB Saunders; 2008. Copyright © MRB Keighley MA MS FRCS.)

Sphincter repair itself involves a flap-over technique that takes one half of the divided sphincter muscle under the other, which thereby tightens the sphincter and eliminates the defect. It is wise to use a closed suction drain if there has been any difficulty with hemostasis. If the patient has a large sphincter defect or a history of impaired rectal evacuation, or is at risk of sepsis, it would be wise to consider a temporary covering loop colostomy.

Postoperative complications include sepsis, hematoma, stenosis with impairment of rectal emptying, and breakdown of the repair, which can lead to a suprasphincteric fistula. Thus, it is essential that all patients are carefully counseled. It is also important to use perioperative antibiotic cover, mild laxatives, and ensure careful attention to local dressings and hygiene. Fecal impaction must be avoided. The short-term success rate of sphincter repair is ~75%, but there is deterioration in the quality of

continence with time. All the long-term evidences indicate that <50% of patients having a delayed sphincter repair are fully continent at 5 years. Nevertheless, the symptom of urgency is greatly improved and patients are usually more able to cope after a secondary sphincter repair provided there is good contractile activity in the remaining sphincter.

Sacral Nerve Stimulation

This treatment is now established as a successful treatment modality for fecal incontinence and impaired rectal evacuation and the 5 year results indicate that about 50% remain improved. Urgency is greatly reduced but soiling and flatus incontinence often persists despite treatment.

It is unclear how sacral nerve stimulation (SNS) achieves continence. It may also improve impaired rectal evacuation and has been applied for treatment of intractable constipation. It appears therefore to coordinate rectal evacuation and sphincteric contraction. Treatment was first explored in patients with an intact sphincter and pelvic floor who had features of pudendal neuropathy. Since then, it has been assessed in patients with a sphincter deficiency and poorly contracting muscle. Given the potential risks of sphincter repair, particularly sepsis and breakdown, SNS has an important role in patients with an anatomical defect in the sphincter ring.

A careful selection process is essential. Candidates for SNS must be psychologically stable and sufficiently intelligent to cope with programming the implanted stimulator. Patients are only offered treatment if temporary percutaneous SNS has been effective over 4 to 6 weeks. Usually, S4 on one side of the sacral foramina is stimulated. The implantable device is placed in a subcutaneous pocket; either the perineum or in the supra pubic region and connected to the stimulator electrodes, which is programmed according to clinical efficacy and manometry (Fig. 166.8). The implantable device is expensive. There may be battery failure, migration of leads, and problems with electrical connections requiring reoperation and careful surveillance.

So far, the 5-year results indicate that in carefully selected patients, quality of life and quality of continence are greatly improved in 60% to 80%; however, continence to gas and avoidance of soiling are frequently imperfect.

Nerve stimulation is usually switched off at night, which prolongs battery life. The stimulator is often used during physical exercise, which is normally associated with a greater risk of leakage.

Clearly, SNS has the potential for considerable therapeutic benefit and

the long-term results are at least as good as sphincter repair without the risks of anatomical reconstruction.

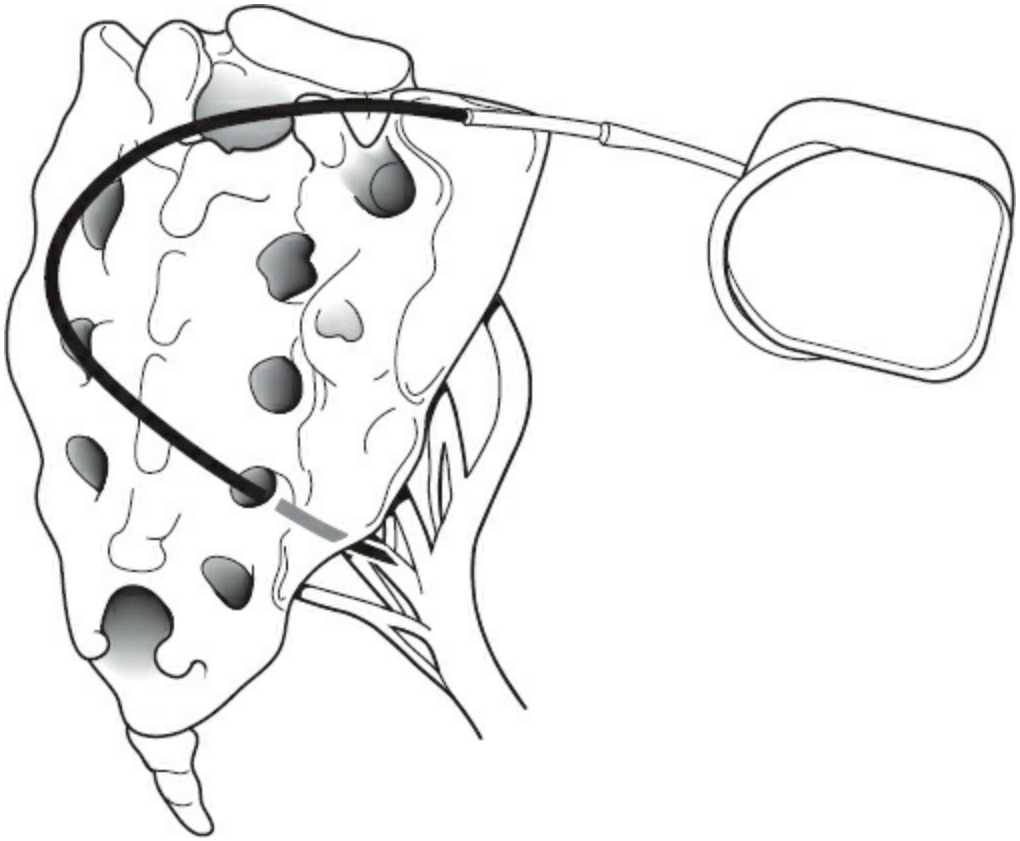

Figure 166.8. Sacral nerve stimulation (SNS). (From Keighley MRB, Williams NS. *Surgery of the Anus, Rectum, and Colon.* 3rd ed. Philadelphia, PA: WB Saunders; 2008. Copyright © MRB Keighley MA MS FRCS.)

Posterior Tibial Nerve Stimulation

This is an alternative method of neuromodulation. It involves transcutaneous needle stimulation or percutaneous stimulation of the posterior tibial nerve. Usually six sessions of electrical stimulation is offered. Short-term improvement is achieved in about 50%, but sustained benefit is disappointing. The great advantage is that this is noninvasive and cheap.

Rerouting of Ectopic Anus

The patient is catheterized and placed in the prone jackknife or the lithotomy position. Previous infiltration with a weak adrenaline solution in a local anesthetic is advised around the ectopic anus. The external anal sphincter should have been identified preoperatively by electromyography

or MRI. A disk of skin is taken from the center of the defined external anal sphincter, and a plane of dissection is developed through the center of the sphincter ring. A gauze swab is placed in the future site of the anal canal.

The ectopic anus is then dissected from the back of the vagina or from the back of the prostate by use of a circumanal incision. The anus must be mobilized for at least 6 or 7 cm from the perineum above the levators before it is rerouted to its correct anatomic site. Stay sutures are placed on the lateral margins of the anus after it has been thoroughly mobilized, particularly anteriorly. The stay sutures are used to draw the anorectum through the center of the external anal sphincters to its correct anatomic position (Fig. 166.9). The mucosa is then sutured to the edges of the skin disk, and an anterior levatorplasty is performed to reconstitute the perineal body. The biggest hazard of rerouting the anal canal is fecal impaction. Many patients have chronic constipation and some impairment of evacuation. Thus, a regimen of postoperative laxatives is essential to achieve a satisfactory long-term outcome.

Gluteus Maximus Transposition

Gluteus maximus transposition may prove extremely useful for a few patients with sphincter failure, particularly if the sphincters and puborectalis are neuropathic. The concept of taking normally innervated muscle, particularly from a muscle that is usually used to assist continence, is an attractive concept. Bilateral oblique gluteal incisions are made to expose the superficial fibers of the gluteus maximus on either side of the anus. The neurovascular bundle to the superficial fibers of the gluteus maximus is identified. The muscle insertion into the femur or its origin from the ileum is detached. We prefer the former. Superficial fibers of the detached gluteus are then split. Subcutaneous tunnels are made anterior and posterior to the anus, so that the split muscle can be taken on either side of the anus and sutured to one another on the opposite side and to the opposite gluteus muscle itself (Fig. 166.10). Postoperative complications are hematoma and infection. Long-term results of this procedure are disappointing and most patients would now be offered SNS as first-line therapy.

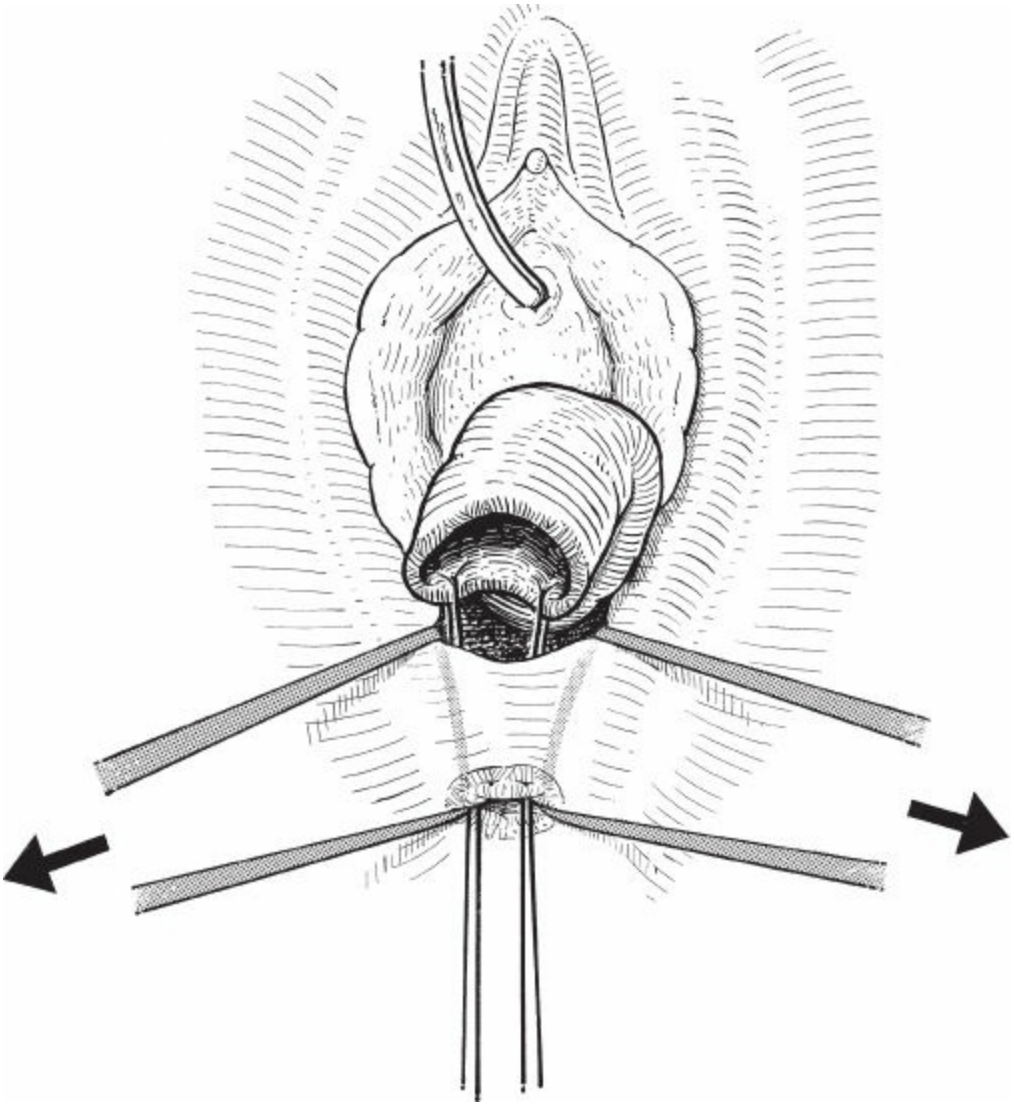

Figure 166.9. Rerouting of the anal canal. (From Keighley MRB, Williams NS. *Surgery of the Anus, Rectum, and Colon.* 3rd ed. Philadelphia, PA: WB Saunders; 2008. Copyright © MRB Keighley MA MS FRCS.)

Gracilis Muscle Transposition

Graciloplasty was introduced as a means of augmenting a damaged sphincter if the defect was too large to perform a sphincter repair. The unique properties of the gracilis muscle are that it is long, has a strong tendinous insertion to the tibia, is not required for locomotor function, and has a proximal neurovascular supply. Hence, by detaching the distal tendon, two thirds of the distal component of the muscle can be rerouted around the anus, and its tendon can be sutured to the opposite ischial tuberosity or to the sphincter if it is used for augmentation. The muscle may be rerouted clockwise or anticlockwise.

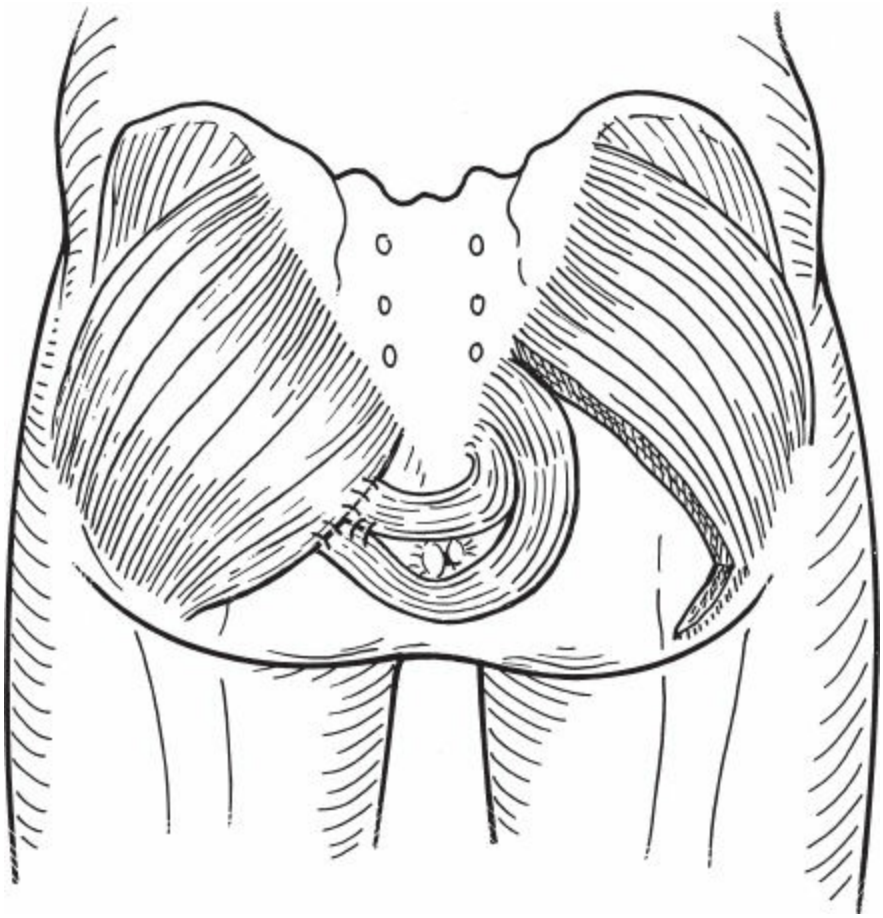

Figure 166.10. Gluteus maximus transposition. (From Keighley MRB, Williams NS. *Surgery of the Anus, Rectum, and Colon.* 3rd ed. Philadelphia, PA: WB Saunders; 2008. Copyright © MRB Keighley MA MS FRCS.)

The patient is placed in the lithotomy position with the legs in stirrups. The gracilis muscle is mobilized through a single longitudinal incision or through multiple small incisions over the muscle or laparoscopically, which improves cosmesis and reduces postoperative pain. We prefer a single longitudinal incision, because identification of the muscle can be difficult, and we do not think that morbidity is reduced by a series of small incisions. Tributaries of the long saphenous vein often require ligation. Great care must be taken to avoid injury to the saphenous nerve. The muscle is easily identified by its longitudinal muscle fibers, rounded belly, and long tendon. The tendon is detached from the medial border of the tibia as close to its insertion as possible. The distal two thirds of the muscle are delivered from its bed, but great care must be taken at the junction between the proximal third and the distal two thirds to identify the neurovascular bundle. The nerve is a branch of the anterior obturator nerve

lying on adductor brevis. The blood supply is more variable, but the principal artery is nearly always just distal to the nerve, which splits into two branches before it reaches the muscle. If separate distal arteries are identified, they must be ligated. An incision is made over the buttocks, and another over the ischial tuberosity on the opposite buttock (Fig. 166.11). It may be possible to develop subcutaneous tunnels around the anus without making further incisions, but sometimes, additional anterior or posterior access is necessary. If this is the case, the anterior and posterior anal raphe should be preserved. After subcutaneous tunnels around the anus are developed and meticulous hemostasis is achieved, gauze swabs are left in each before muscle transposition.

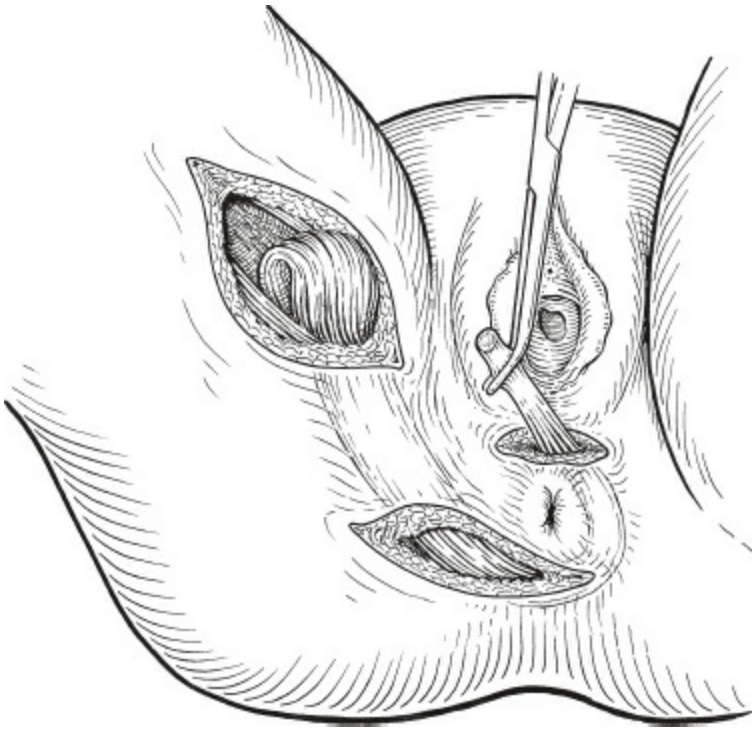

Figure 166.11. Unilateral graciloplasty. (From Keighley MRB, Williams NS. *Surgery of the Anus, Rectum, and Colon.* 3rd ed. Philadelphia, PA: WB Saunders; 2008. Copyright © MRB Keighley MA MS FRCS.)

We prefer to transpose the gracilis muscle by using an alpha loop, taking the muscle initially anterior to the anus around the right lateral margin of the anus underneath the posterior raphe and subsequently over itself, and then under the anterior raphe so that the tendon can be sutured to the opposite ischial tuberosity or in the case of augmentation into healthy sphincter muscle and the scar of the injury. It is crucial to obtain

secure apposition between the periosteum of the ischial tuberosity and the tendon, or the tendon and the sphincteric scar. We use three or four interrupted Prolene sutures on a heavy, round-bodied needle. The sutures are carefully positioned before they are tied. Closed suction drains are needed to evacuate hematoma, and the wounds are closed with Prolene sutures or staples.

A variant of unilateral nonstimulated graciloplasty is bilateral graciloplasty. This is a much more extensive operation, but the advantage is that a complete encircling sling of muscle, rather than tendon, is achieved around the anus, and each tendon is sutured to itself, thereby minimizing the consequences of local sepsis that causes disintegration of the sutures from the tendon to the ischial tuberosity (Fig. 166.12).

Complications of graciloplasty include pain, hematoma, infection, nerve injury, ischemic necrosis of tendon, and synergistic gangrene of the perineum. In view of these risks, some advocate a proximal colostomy until complete healing has been achieved.

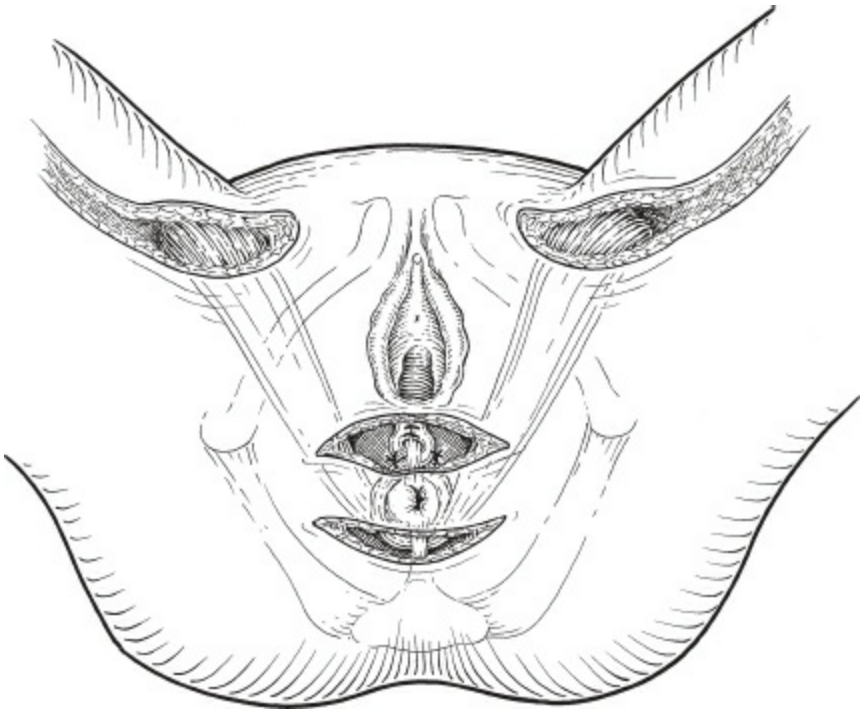

Figure 166.12. Bilateral graciloplasty. (From Keighley MRB, Williams NS. *Surgery of the Anus, Rectum, and Colon.* 3rd ed. Philadelphia, PA: WB Saunders; 2008. Copyright © MRB Keighley MA MS FRCS.)

Graciloplasty seems to be effective for patients who are incontinent from anorectal trauma and in patients with incontinence after previous

surgery for Hirschsprung disease. It has been far less effective for patients with fecal incontinence in whom all other simpler methods of treatment have failed.

Gracilis Neosphincter

The principle of the gracilis neosphincter is to convert the gracilis muscle from a fast-twitch to a slow-twitch, continuously active muscle. Constant electrical stimulation of the nerve to the gracilis or to the muscle fibers themselves can convert the fast-twitch muscle of locomotor function to a slow-twitch, constantly active sphincter. Constant electrical stimulation is achieved by leads placed on the muscle itself or on the nerve to the gracilis muscle after the muscle has been transposed. Electrical stimulation, as in SNS, is delivered through an implantable stimulator box placed in the subcutaneous tissues of the anterior abdominal wall or perineum from which leads deliver the electrical stimulus to one or two gracilis muscles (Fig. 166.13A,B). This operation can successfully replace a sphincter in 60% to 70% of patients but the device is expensive and there is high risk of infection and obstructed defecation. Furthermore, the battery life of the stimulator box is unknown. The operation must be selected only for patients who have a primary sphincter abnormality. Patients with incontinence often have coexisting impairment of rectal evacuation and impairment of anorectal sensation. Such patients are probably unsuitable for gracilis neosphincter unless some form of colonic irrigation is used. Currently, the three possible stages of the procedure are: (a) delivery of a proximal stoma (optional) and mobilization of the gracilis muscle in situ; (b) rerouting of the gracilis muscle and placement of stimulator leads on the nerve or muscle, which is attached to an implantable stimulator box; and (c) reprogramming of muscle over a period of 6 months to convert the muscle from fast to slow twitch. At the end of the 6-month reprogramming period, the stoma is closed (optional). Many surgeons now perform the operation as a single procedure without stoma and continence stimulation after 6 to 8 weeks, provided there are no complications.

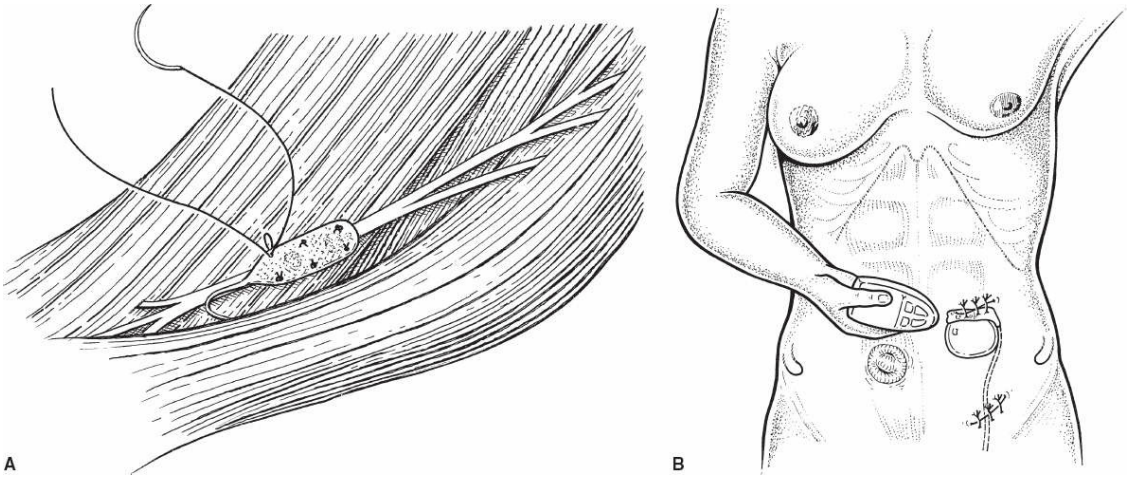

Figure 166.13. Stimulated graciloplasty. **A:** The stimulator is placed on the nerve to gracilis. **B:** The stimulator box being programmed. (From Keighley MRB, Williams NS. *Surgery of the Anus, Rectum, and Colon.* 3rd ed. Philadelphia, PA: WB Saunders; 2008. Copyright © MRB Keighley MA MS FRCS.)

ABS Implantable Artificial Bowel Sphincter

An implantable device has been used for many years for treatment of urinary incontinence. A device using the same principle is available for treatment of anal incontinence (Fig. 166.14). An inflatable cuff is placed around the anorectum through a single perineal or two paraanal incisions. The cuff is connected by a closed, water-filled system to a compliant reservoir placed in the retropubic space and is activated using a pump placed in the scrotum in the man or labia in the woman. Normally, the anorectal cuff is distended with fluid, which achieves continence. When there is a desire to defecate, the patient squeezes the pump that deflates the cuff to allow stool to pass. This device has been implanted under controlled audit in North America and Europe. There is a high risk of sepsis and extrusion of the implant in 20% to 40%. In those who achieve successful implantation continence of solids and liquids is achieved in 50% to 70%, but flatus incontinence and soiling usually persist.

Stoma Construction

For some patients, particularly the elderly and patients with severe neuropathy, the construction of a good stoma may be the best means of improving quality of life and restoring self-esteem to patients with fecal incontinence. However, with self-administered rectal washouts, the need to construct a stoma for bowel incontinence has fallen considerably. The best stoma is an end colostomy, which can be constructed laparoscopically or

through a small trephine in the abdominal wall. This stoma can be subsequently used for colostomy irrigation. Thus, patients are not necessarily committed to wearing a bag. Some patients with an improved quality of life following a colostomy eventually require rectal excision if they become incontinent of mucus from the defunctioned rectum.

For patients who are incontinent after extensive colorectal surgery, a loop ileostomy may be a better option than a colostomy. In a small number of patients, the option of a reservoir ileostomy should not be totally dismissed. Admittedly, this is an extensive operation, but patients do not have to wear an appliance. Furthermore, with stapling of the nipple valve, the proportion of patients requiring revision surgery after Kock reservoir ileostomy is not as high as it used to be. For more information on stoma appliances, see Chapter 141. Finally, in some patients, consideration should also be given to an appendicostomy for antegrade colonic irrigation (ACE) or a continent colostomy irrigation device to facilitate ACE. Such techniques are particularly appropriate when impaired rectal evacuation exists with the incontinence (Figs. 166.15 and 166.16).

RECTAL PROLAPSE

Chapters 145A and B contain an account of the functional considerations of rectal prolapse.

Clinical Presentation

Rectal prolapse is a complete rectal intussusception. The prolapse appears on the perineum as a circumferential swelling that bleeds or becomes ulcerated. In 70% of patients, there is a history of bowel incontinence. In 60% of patients presenting with rectal prolapse who are under 40 years of age, there is associated constipation.

Causes

Rectal prolapse, as a complete intussusception of the rectum, results in attenuation of the lateral ligaments of the rectum. There is often descent of the uterus associated with cystocele or rectocele. There is always a patulous anus and a weak pelvic floor associated with pudendal neuropathy. Rectal sensation is impaired because of the presence of the prolapse. Almost all patients with rectal prolapse give a history of discharge of mucus, which is commonly associated with pruritus ani.

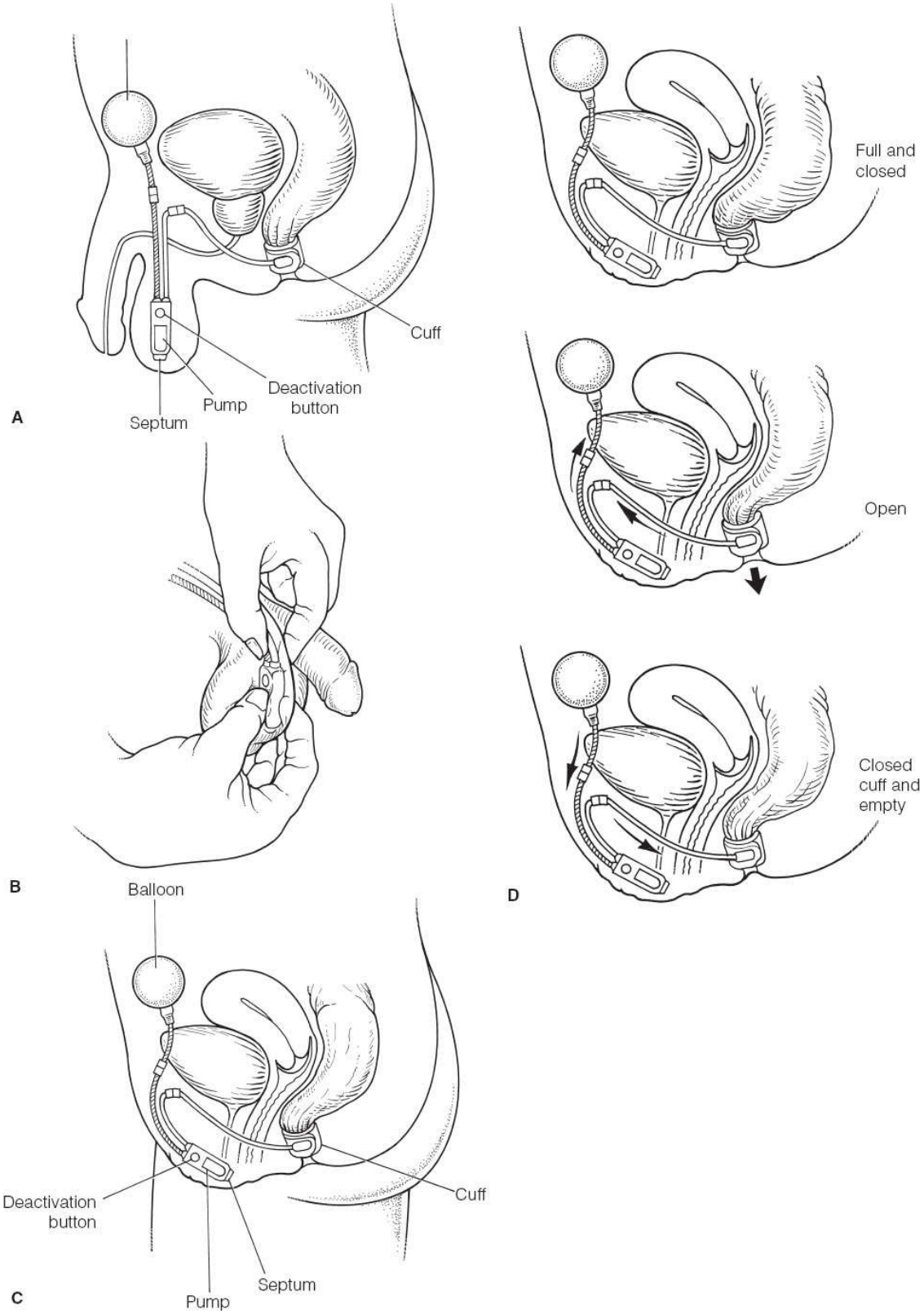

Figure 166.14. Artificial bowel sphincter. **A.** A cuff is placed around the anal canal. An inflatable pump control assembly is placed in the scrotum and the balloon reservoir under the symphysis pubis. **B.** The pump in males is placed in the scrotum. To open the cuff to defecate, the pump must be squeezed and

released several times. **C.** The same arrangement is used in women, but the pump is placed in the labia. **D.** When the cuff is closed, the stool stays in the rectum. When the pump is repeatedly squeezed (in the labia in women), the cuff opens, and the bowel can empty. Fluid then automatically returns to the cuff, which again closes around the anal canal. (From Keighley MRB, Williams NS. *Surgery of the Anus, Rectum, and Colon.* 3rd ed. Philadelphia, PA: WB Saunders; 2008. Copyright © MRB Keighley MA MS FRCS.)

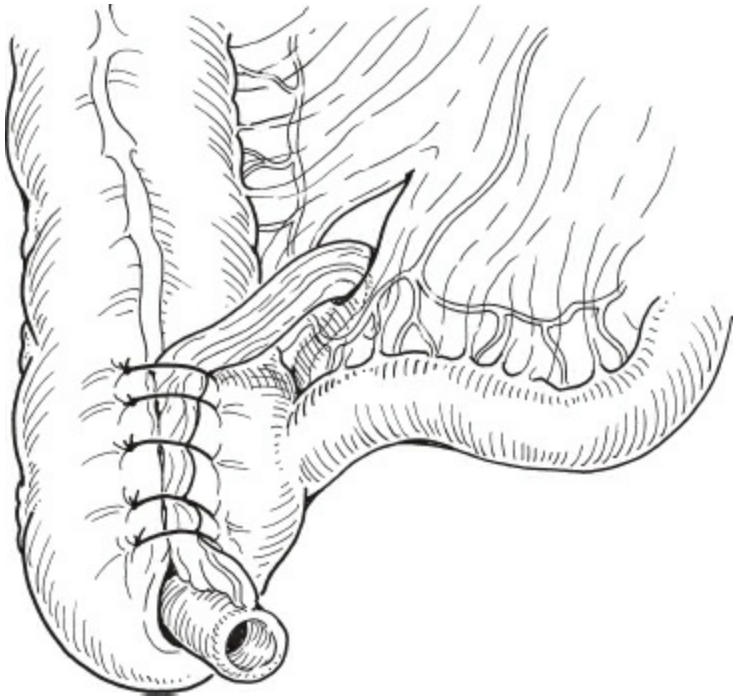

Figure 166.15. Appendicostomy for antegrade colonic enema. **A.** The mesoappendix is preserved. **B.** The appendix is relocated through the mesentery along the cecum in an antiperistaltic fashion. **C.** The appendix is laid within a submucosal space, its distal end is amputated, and this is then anastomosed to the cecum. **D.** The seromuscular layer is closed over the enterocecostomy without compromising the mesenteric vascular pedicle. The proximal end of the appendix is exteriorized. (From Keighley MRB, Williams NS. *Surgery of the Anus, Rectum, and Colon.* 3rd ed. Philadelphia, PA: WB Saunders; 2008. Copyright © MRB Keighley MA MS FRCS.)

Diagnosis

A rectal prolapse is usually obvious on clinical examination during straining, but some patients are too embarrassed to strain and deliver the

prolapse during clinical inspection. A patulous anus is a ubiquitous in prolapse. It is important during clinical examination to assess whether uterine descent, cystocele, enterocele, or rectocele exists and to assess the tone of the anal sphincters at rest and during maximum voluntary contraction. Videoproctography may be helpful, as may inspection of the perineum after defecation.

Treatment

The treatment of rectal prolapse depends on the functional abnormality. In most young patients with rectal prolapse, there is coexisting straining, impaired rectal evacuation, and delayed colonic transit. In such patients, we believe that an abdominal rectopexy is advisable, with a variable colonic resection above the rectopexy (Fig. 166.17). Usually this is performed laparoscopically. If impaired rectal evacuation is a major feature and the prolapse is small, anterior resection might be a better option. By contrast, for elderly patients with rectal prolapse and associated comorbidity, we believe that a perineal procedure is much more appropriate and favor perineal rectosigmoidectomy with synchronous repair of the pelvic floor (Fig. 166.18).

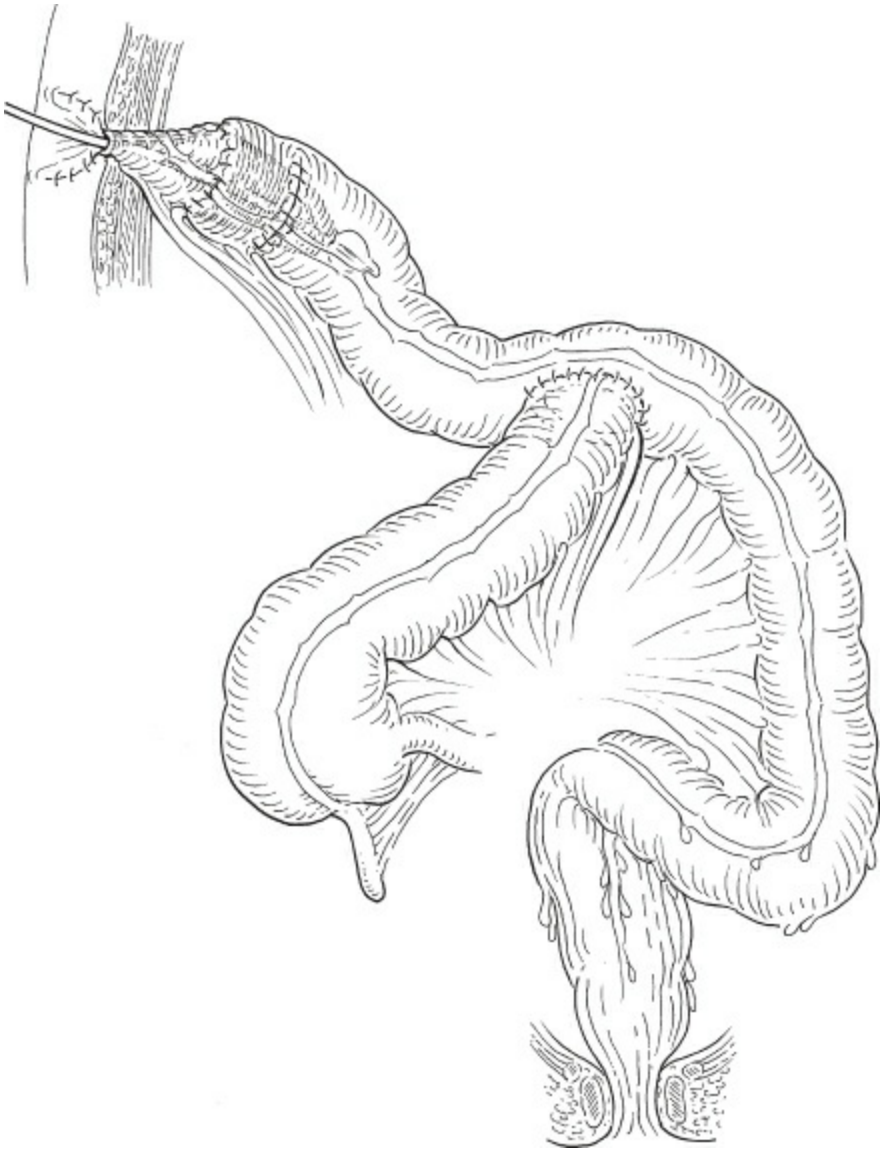

Figure 166.16. Transverse colonic conduit. (From Keighley MRB, Williams NS. *Surgery of the Anus, Rectum, and Colon.* 3rd ed. Philadelphia, PA: WB Saunders; 2008. Copyright © MRB Keighley MA MS FRCS.)

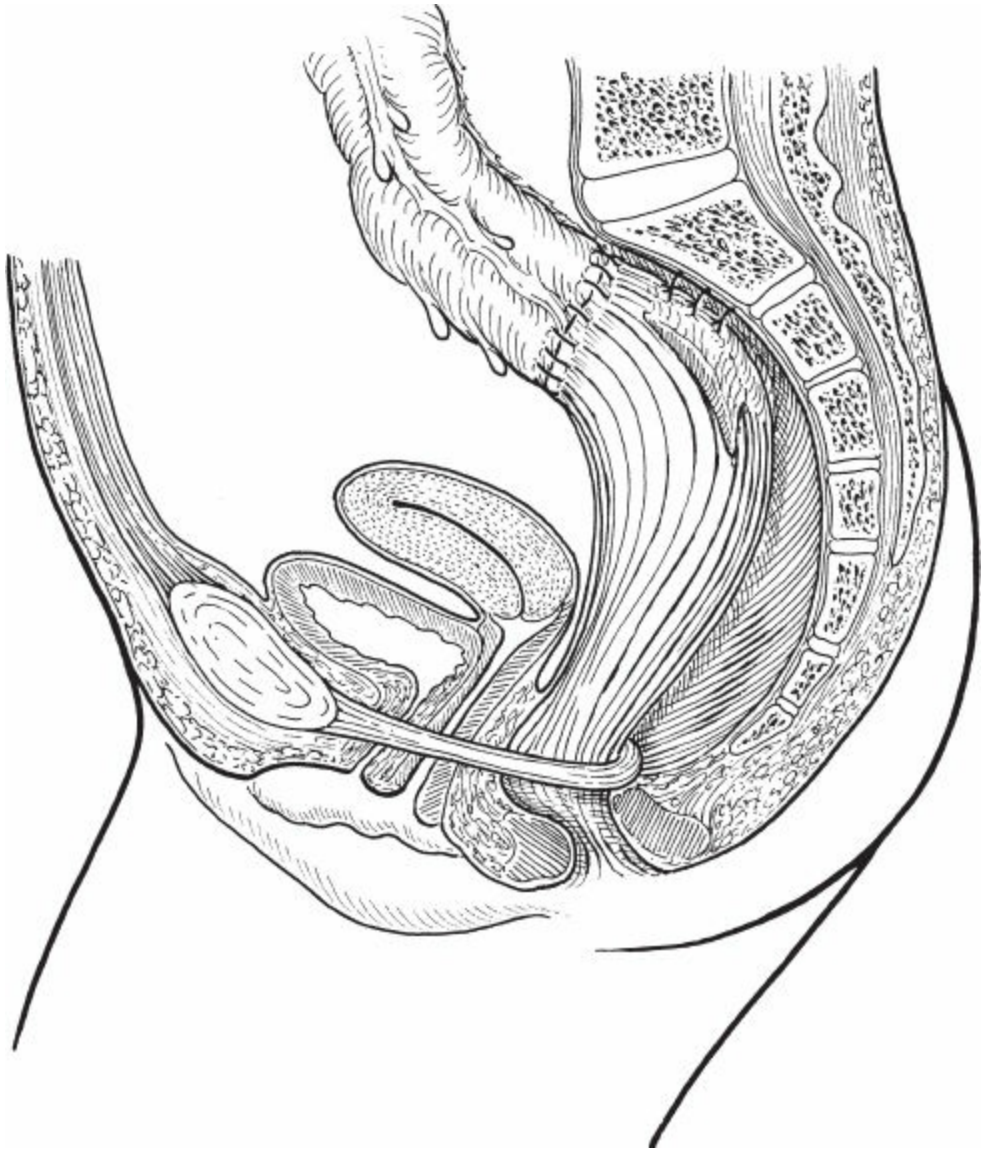

Figure 166.17. Rectopexy (**A**) and sigmoidectomy (**B**). (From Keighley MRB, Williams NS. *Surgery of the Anus, Rectum, and Colon.* 3rd ed. Philadelphia, PA: WB Saunders; 2008. Copyright © MRB Keighley MA MS FRCS.)

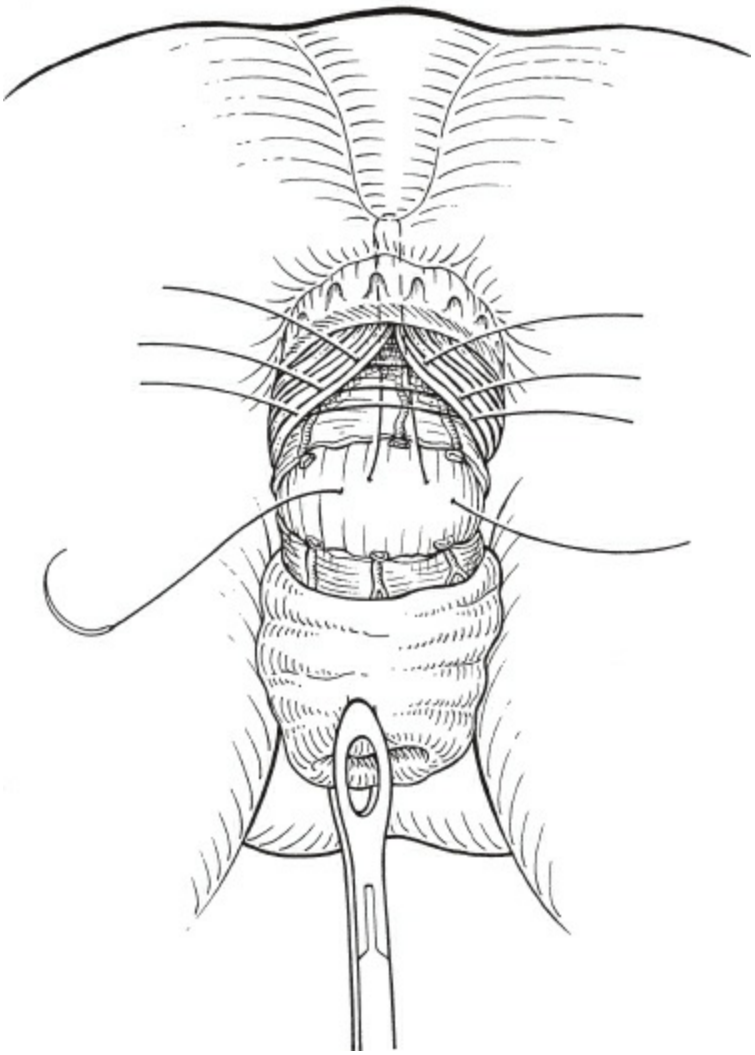

Figure 166.18. Rectosigmoidectomy with levatorplasty. (From Keighley MRB, Williams NS. *Surgery of the Anus, Rectum, and Colon.* 3rd ed. Philadelphia, PA: WB Saunders; 2008. Copyright © MRB Keighley MA MS FRCS.)

MEGABOWEL

Clinical Presentation

Megacolon or megarectum usually presents with severe constipation and soiling caused by a large fecaloma filling the rectum and around which liquid feces seep. Patients also frequently complain of abdominal discomfort and abdominal swelling, which is caused by gross fecal loading of the colon.

Causes

The cause of adult megacolon is not well understood. Some are almost

certainly cases of adult Hirschsprung disease, usually with a short segment of aganglionosis. However, the majority of cases are acquired and associated with long-standing constipation or neurologic disease (e.g., hydrocephalus, epilepsy, or cerebral birth trauma), or result from degenerative disorders affecting the autonomic nervous system, as in Chagas disease.

There are four anatomic varieties: megacolon alone, megarectum alone, megarectum and megasigmoid, and total megacolon with megarectum.

Diagnosis

Megacolon may be suspected solely on clinical grounds. A huge fecal mass may be felt arising from the pelvis. Rectal examination may reveal an enormous fecaloma in a cavernous rectum with a patulous anus.

Plain abdominal radiographs may demonstrate gross dilation of the transverse diameter of the rectum filled with solid fecal material. In other cases, the diagnosis is less obvious, and a barium enema examination may be necessary. However, preparation for barium enema can prove difficult. Sometimes, patients require hospital admission for manual evacuation and repeated enemas to disimpact the fecaloma from the rectosigmoid region.

For the same reasons, anorectal physiology can prove extremely difficult in these patients and is virtually useless unless the fecaloma is disimpacted. If the rectal obstruction can be removed, resting and squeeze anal canal pressures are usually low, and the rectoanal inhibitory reflex is usually absent. Rectal sensation is always impaired. Transit marker studies usually reveal some delay in colonic transit proximal to the dilated segment, but isotopic studies are much more useful in determining whether proximal colonic motility and transit are normal. Despite these theoretic considerations, the extent of resection is largely determined by the macroscopic appearance of the bowel at the time of laparotomy. The presence of normal ganglion cells in the anorectum may be verified by full-thickness rectal biopsy or anorectal myectomy. However, we would not advise anorectal myectomy in these patients, because it might compromise continence, and the histopathologic exclusion of Hirschsprung disease is really academic. In the presence of megarectum, these individuals do not have a normal lower rectum or upper anal canal, and full rectal excision is necessary.

Treatment

Conservative Therapy

There is no doubt that some forms of megarectum may be controlled by keeping the rectum empty. Thus, a manual evacuation and thorough colon catharsis with purgatives and repeated enemas can be justified at first. Thereafter, the aim of conservative treatment is to keep the rectum empty by use of stimulant suppositories, enemas, and mild laxatives. This policy may be satisfactory, provided that anal sphincter function is sufficiently preserved for patients to be able to retain the enema and suppositories. This approach also needs a good deal of compliance by the patient, but sometimes, in mild disease and in patients who understand that surgical treatment is a major undertaking, these measures are successful.

Surgical Treatment

For most patients, surgical treatment is the only way to overcome overflow incontinence. Unlike the surgical treatment for pediatric Hirschsprung disease, the aim of surgical resection in the adult is to remove the dilated, nonfunctioning colonic and rectal segments. In some patients wishing to avoid major surgical resections, loop ileostomy alone may be the best approach to therapy. For megacolon alone, subtotal colectomy and ileorectal anastomosis are indicated (Fig. 166.19). For patients with megarectum or megarectum and megasigmoid, excision of the dilated nonfunctioning segment is undertaken, and the normally innervated normal caliber proximal colon is preserved with coloanal anastomosis (Fig. 166.20). Hence, operations described for the treatment of Hirschsprung disease, such as the Duhamel procedure, are inappropriate for adult megarectum. Also, for technical reasons, the Duhamel procedure is rarely possible in these patients, because the rectum completely fills the pelvis. In the small proportion of patients with gross megarectum and megacolon, total excision of the large bowel and rectum is indicated; if anal sphincter function is adequate, ileopouch–anal anastomosis is indicated. One must admit, however, that there are some patients whose anal sphincter function is so badly compromised that no form of restorative resection is indicated. In such patients, proximal loop ileostomy alone may be used for treatment. If ablative surgery is indicated, conventional resection and a covering proximal stoma are advisable.

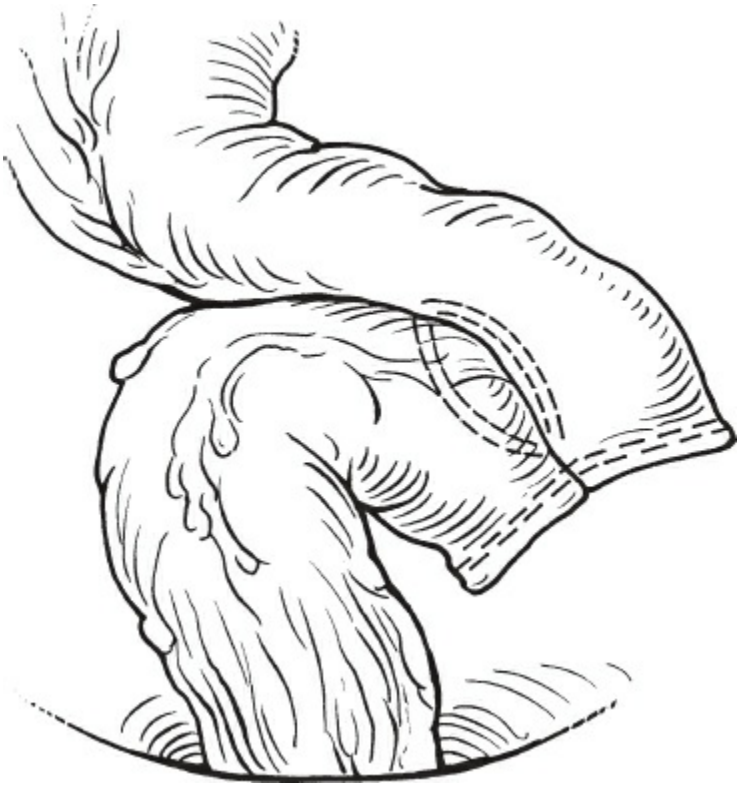

Figure 166.19. Subtotal colectomy and ileorectal anastomosis. (From Keighley MRB, Williams NS. *Surgery of the Anus, Rectum, and Colon.* 3rd ed. Philadelphia, PA: WB Saunders; 2008. Copyright © MRB Keighley MA MS FRCS.)

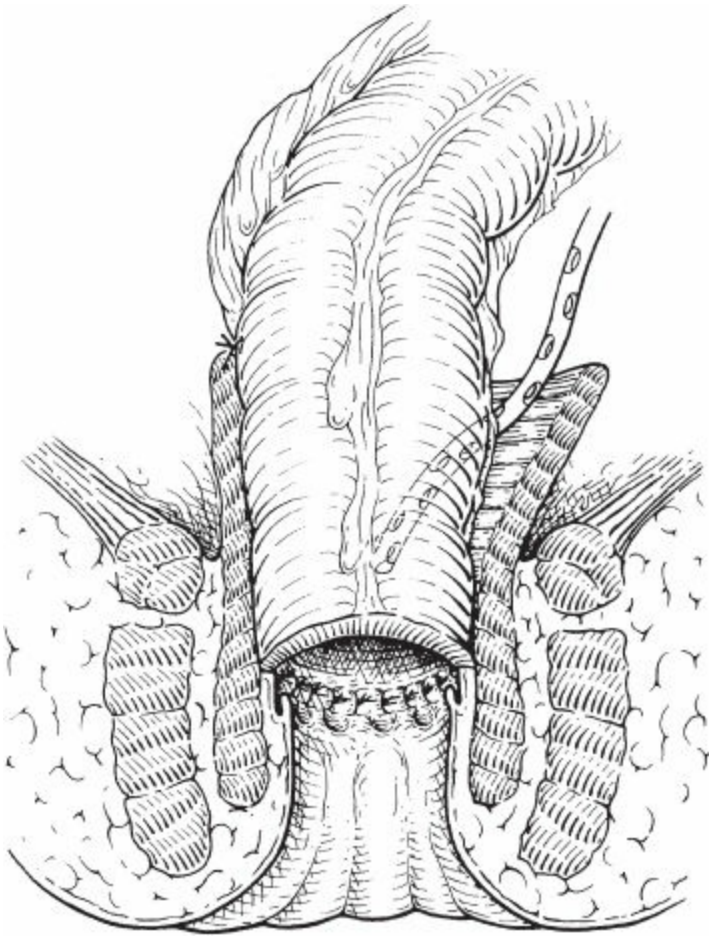

Figure 166.20. Coloanal anastomosis (hand sutured). (From Keighley MRB, Williams NS. *Surgery of the Anus, Rectum, and Colon.* 3rd ed. Philadelphia, PA: WB Saunders; 2008. Copyright © MRB Keighley MA MS FRCS.)

There are certain specific surgical strategies that have to be considered in patients with adult megarectum. These strategies are described below.

1. Preoperative mechanical bowel preparation may not be possible or desirable. Manual evacuation of a huge fecaloma before a reconstructive surgical procedure may cause iatrogenic damage to the sphincter and pelvic floor. Hence, we do not attempt mechanical bowel preparation preoperatively. We milk the fecaloma from the anorectum during operation into the segment of bowel that is being resected.
2. Stapling procedures to perform a coloanal anastomosis are rarely possible in these patients. The dilated rectum imperceptibly continues downward into a dilated anus. Furthermore, the walls of the bowel are extremely thickened, which makes stapling transection almost impossible. Hence, for these patients, hand-sutured straight coloanal or ileoanal anastomosis is the only technique possible for restoring

intestinal continuity. We do not advise constructing a colonic pouch.

3. Hemorrhage is a real problem in these patients. The pararectal veins are enormously enlarged. Hence, meticulous hemostasis is necessary at operation, and intense vigilance is needed postoperatively to detect blood loss and to assess transfusion requirements. In view of the risk of blood loss, it is often wise to retain the lower third of the rectum so that it can be transected at a site that can be easily controlled from above by the abdominal surgeon. In this manner, the proximal colon can be delivered through the anal stump without the necessity of a mucosectomy and a sleeve coloanal anastomosis at the dentate line (see Chapter 154). The same technique may be used for ileoanal anastomosis with pouch construction. In these complex surgical procedures, a covering ileostomy is always desirable unless, of course, the dilated segment is confined to the colon, in which case an unprotected ileorectal anastomosis is an accepted option.

SLOW TRANSIT CONSTIPATION

Clinical Presentation

Slow transit constipation typically occurs in women between the ages of 20 and 35. There are often menstrual irregularities, which suggest abnormal ovulation and coexisting symptoms of nausea, backache, and abdominal distention. Many patients express evidence of psychological instability. Some may have a history of sexual abuse. Many patients are aggressive, and some are on psychotropic drugs for depressive illness. A few of these patients give a history of eating disorders. A few patients also experience intermittent diarrhea and constipation and exhibit features of the irritable bowel syndrome.

Causes

There are a variety of organic disorders that may be associated with slow transit constipation. Endocrine causes include hypothyroidism, glucagonoma, hypercalcemia, pheochromocytoma, hypopituitarism, and pregnancy. Metabolic causes include amyloidosis, diabetes, systemic sclerosis, hypokalemia, porphyria, and uremia.

A variety of underlying neurologic disorders may be associated with slow-transit constipation. They include demyelinating disease; neurologic ischemia; traumatic lesions of the brain and spinal cord, or tumors of the central nervous system; Parkinson disease; tabes dorsalis; autonomic

neuropathy; von Recklinghausen disease; and multiple endocrine tumors.

A number of drugs may be associated with delay in the transit of fecal material through the colon. They include all analgesics (particularly opiates), anticholinergics, compounds formulated with calcium or aluminum, iron compounds, anticonvulsants, antidepressants, antihistamines, barium, bismuth, drugs for the treatment of Parkinson disease, ganglion-blocking drugs, long-standing laxatives, muscle relaxants, and psychotropic drugs.

There is also a large group of psychogenic disorders associated with slow-transit constipation.

Diagnosis

Constipation can be subclassified functionally into delayed colonic transit and impaired rectal evacuation. In practice, many patients exhibit both forms of motility disorder.

The history of prolonged incapacitating constipation given by many patients may be unreliable. Therefore, a variety of simple screening tests are needed to determine whether there is a physical problem and to ascertain whether the problem is one of impaired colonic transit or a disturbance of rectal evacuation. It is also important for clinicians to recognize that many in this group of patients are unhappy, aggressive, and expect instant attention for a long-standing problem. These patients must be counseled and told that a series of investigations is essential to unravel the source of the problem.

First, patients should be given the opportunity to carefully explain their normal dietary habits and their fluid intake. Definition of terms is important, because there is enormous variation in the understanding of the word “constipation.” A careful drug history is essential. Some patients date the onset of symptoms to a previous operation; hysterectomy, oophorectomy, and other pelvic operations are predisposing factors to constipation. It is crucially important to exclude an eating disorder and to ascertain the patient’s normal toilet practice. Many patients spend hours straining.

A plain abdominal radiograph can help determine whether there is gross fecal loading in the colon. An inert marker study is also a useful method of screening for impaired colonic transit. However, it is not a sensitive test, and the results may vary markedly from week to week. Hence, the test may need to be repeated. The distribution of markers also gives some

indication of the possible site of colonic delay. However, therapy should not be based on marker studies alone. Simple assessment of rectal emptying may be achieved by inserting a known volume of a semisolid inert physical substance into the rectum and asking the patient to attempt evacuation under normal circumstances in the bathroom for a specified period. This simple technique may give a rough guide as to whether there is impairment of rectal evacuation. For a more detailed study, colonic transit should be assessed by using an isotopically labeled meal, and rectal evacuation should be studied after inserting an isotopically labeled paste into the rectum. Further important information can be obtained by videoproctography, which can help to define any morphologic abnormality in the anorectum and the degree of pelvic floor movement during attempted contraction and evacuation. Incomplete intussusception can also be demonstrated, along with evidence of rectocele, cystocele, or enterocele. Definition of these abnormalities may involve placing contrast material in the vagina, bladder, peritoneal cavity, or the small bowel. Videoproctography also helps define the efficiency of rectal evacuation and the degree of perineal descent. Electromyography of the puborectalis can indicate whether there is failure of relaxation of the puborectalis during attempted defecation, but the technique is painful and has generally been superseded by other methods. Preoperative assessment is not complete without a detailed psychological evaluation. Previous physical and psychological trauma should be explored. Eating disorders should be identified, and sexual disturbance should be gently investigated.

A few physical disorders must be excluded in the patient with long-standing constipation. These disorders are sigmoid volvulus, cecal volvulus, and pseudo-obstruction. In addition, patients with constipation may have a disturbance of motility affecting the whole of the gastrointestinal tract. Hence, gastric emptying and small bowel transit should also be studied. Surgical treatment should not be undertaken without these investigations.

Treatment

Conservative Measures

Many patients pressure the surgeon to undertake something immediately to relieve pain and distress. However, it is essential to ensure that patients have an adequate fluid intake and a balanced diet. Excessive intake of fiber may be contraindicated in these patients, because it aggravates abdominal

distention. If there is impaired rectal evacuation, simple measures, such as nonstimulant or stimulant suppositories, should be tried. Failing this, disposable enemas may provide a regular regimen of rectal evacuation. Patients should be told that laxatives are not necessarily harmful if they are used judiciously—a variety of prokinetic agents or cathartics should be tried as a way to alleviate symptoms. Patients must be told that symptoms of pain, nausea, abdominal distention, and backache cannot necessarily be relieved by control of constipation.

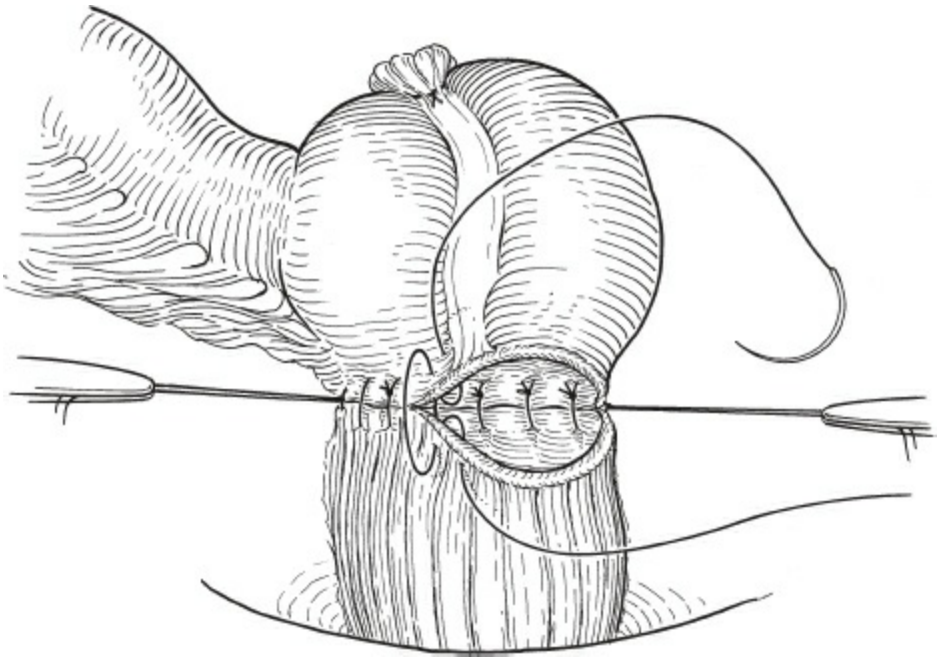

Figure 166.21. Colorectal anastomosis. (From Keighley MRB, Williams NS. *Surgery of the Anus, Rectum, and Colon.* 3rd ed. Philadelphia, PA: WB Saunders; 2008. Copyright © MRB Keighley MA MS FRCS.)

Biofeedback retraining may have a role, but it is usually directed to patients with outlet obstruction. Elderly patients with constipation may have fecal impaction; for these individuals, manual evacuation may be necessary.

Surgical Treatment

Surgical treatment of slow-transit constipation should never be undertaken lightly. Patients must be psychologically stable, and there must be a physical abnormality demonstrated on repeated investigation. All patients should be counseled about the possibility of having a stoma. In some patients, the construction of a stoma is a useful screening technique to see

whether an operation is likely to improve symptoms. They should be warned that the results of resection may be unpredictable and that colic, abdominal bloating, backache, and nausea may not be improved at all.

If surgical resection is contemplated, the optimal type of resection should be tailored according to the results of repeated physiologic studies. Segmental colectomy may have a role in patients with isolated segments of colonic inertia. However, the long-term results of segmental colectomy for slow-transit constipation are generally disappointing, because many patients continue to have infrequent bowel actions. If there is impairment of rectal evacuation and colonic transit, the primary abnormality may lie in the rectum, and for such patients, excision of the rectum and sigmoid with coloanal anastomosis may be the most appropriate treatment. However, for most patients, subtotal colectomy and ileorectal or cecorectal anastomosis (CRA) are the operations most commonly performed (Fig. 166.21). The results of resection are generally poor in patients with coexisting outlet obstruction; they are terrible if there is coexisting psychiatric disease. These operations are described elsewhere. In most patients, constipation is alleviated by either of these operations, but other abdominal symptoms usually persist. Furthermore, in 20% there is troublesome diarrhea, and a few develop incontinence. Subtotal colectomy relieves associated abdominal pain in <50% of patients and rarely influences abdominal distention or nausea. In our view, preoperative psychological assessment is absolutely essential for all these patients. A high index of psychological instability is almost always associated with a poor outcome. Hence, psychological evaluation has a predictive value in defining outcome in this difficult group of patients. There are some patients who would be better served by a stoma, a continent colonic conduit, or antegrade colostomy irrigation through an appendicostomy.

OUTLET OBSTRUCTION

Clinical Presentation

Some patients with constipation recognize that their problems are essentially caused by impairment of rectal evacuation. Many give a history of straining and the feeling that something obstructs the defecation process.

Causes

The onset of outlet obstruction may be precipitated by difficult vaginal delivery, particularly if there has been an assisted delivery or delay in the second stage of labor. Previous pelvic operations may be associated with outlet obstruction, and a long-standing history of straining is often elicited. Outlet obstruction may be secondary to solitary rectal ulcer, incomplete intussusception, enterocele, or rectocele, and may be associated with an anterior mucosal prolapse.

Diagnosis

Classically, diagnosis of outlet obstruction is made by electromyographic evidence of failure of the puborectalis to relax during attempted defecation. In many patients, the syndrome can be assumed from clinical examination, particularly if there is gross perineal descent, an anterior mucosal prolapse, or evidence of an incomplete intussusception on sigmoidoscopy.

Apart from electromyography, simple tests of rectal evacuation by use of physical agents, videoproctography, or isotopic studies help to define the syndrome. In many patients, the impairment of rectal evacuation is associated with secondary stasis of markers in the colon. In some patients, there is impairment of rectal sensation.

Treatment

Conservative Therapy

Simple conservative measures include the regular use of suppositories or enemas and biofeedback. The aim of biofeedback is to retrain the pelvic floor so that relaxation occurs during attempted defecation. The short-term results of biofeedback are often reported to be encouraging in 80% of patients, but long-term results are generally disappointing.

Surgical Treatment

Anorectal myectomy may be used to exclude Hirschsprung disease. It should not be considered a treatment, but in many patients (45% to 50%), improvement occurs afterward. Similarly, improvement has been reported in some patients after gentle anal dilation. However, care must be exercised in advising anorectal myectomy or anal dilation, because in a few patients impairment of continence may result.

Patients with a large rectocele and a history of having to press the vagina to achieve complete rectal evacuation deserve consideration for

repair. Repair of a rectocele may be performed through the perineum, the vagina, or the rectum and performing an anterior levatorplasty, as described in the section on incontinence. However, the results of rectocele repair, if the rectocele involves the entire rectovaginal septum, are often disappointing, with a high recurrence rate, continued symptoms, and dyspareunia. Thus, case selection is critical. An abdominal rectopexy with ventrosuspension of the vagina may be a better alternative. However, great care should be taken in selecting patients for repair of a rectocele and particularly rectopexy when used to treat nonprolapsing functional disease.

There was tremendous enthusiasm a few years ago for attempted correction of rectal intussusception by laparoscopic ventral mesh rectopexy (LVMR). Unquestionably, surgical treatment prevents the intussusception from continuing, but most patients do not report any improvement in their symptoms as a result; indeed, in many patients, symptoms are actually made worse by rectopexy. Similarly, there has been a vogue for correcting enteroceles by LVMR, but most of these patients strain and the habit is generally difficult to correct. Hence, the results of surgery for enterocele like rectocele are often disappointing. LVMR introduced in 2006 gained great popularity in Europe, but case selection was often not particularly rigorous and the long-term results were often very disappointing. The operation has virtually disappeared from the list of therapeutic options for functional disease owing to the lawsuits associated with chronic sepsis and mesh erosion into the rectum, vagina, and small bowel.

In a few patients with solitary rectal ulcer not improved by rectopexy, excision of the rectum and sigmoid with coloanal anastomosis may prove to be worthwhile, but these patients must be carefully selected.

Finally, there are a few patients whose symptoms are so intolerable that life for them is better with a stoma. Hence, there are also some patients in whom a trial of stoma construction alone might be justified.

Suggested Readings

Keighley MR, Williams NS. *Surgery of the Anus, Rectum, and Colon.* 3rd ed. Philadelphia, PA: WB Saunders; 2008.

Wolff BG, Fleshman JW, Beck DE, et al. *The ACRS Textbook of Colon and Rectal Surgery.* New York: Springer; 2007.

EDITOR'S COMMENT

This chapter deals with functional disorders of the elimination of feces: either the inability to control it (incontinence) or having too much control as it were (constipation). Both fecal incontinence and constipation are high expense items in terms of health care dollars. Due to embarrassment, it is estimated that 70% of patients with fecal incontinence problems do not seek help or advice from any treating physician (Whitehead WE, Rao SS, Lowry A, et al. Treatment of fecal incontinence: state of the science summary for the National Institute of Diabetes and Digestive and Kidney Diseases workshop. *Am J Gastroenterol* 2015;110(1):138–46). Incontinence can make patients virtually homebound for fear of having an accident in public. Affected patients carry changes of clothes with them; they are uncomfortable in social situations and lack confidence in performing the most mundane tasks. In contrast, constipation is even more widespread, largely due to our Western diet. There is great variability in what is considered "normal." In the Rome III definition (http://www.romecriteria.org/assets/pdf/19_RomeIII_apA_885–898.pdf. Accessed January 16, 2016), constipation is defined as two or more of six criteria including (a) straining during at least 25% of defecations, (b) lumpy or hard stools in at least 25% of defecations, (c) a sensation of incomplete evacuation for at least 25% of defecations, (d) a sensation of anorectal obstruction/blockage for at least 25% of defecations, (e) facilitating manual maneuvers performed during at least 25% of defecations (e.g., digital evacuation and support of the pelvic floor), and lastly (f) fewer than three defecations per week. In my experience, many patients who have problems with certain types of outlet obstruction constipation (i.e., nonrelaxing puborectalis muscle) have a past history of having been a victim of sexual abuse. One presumes this severe psychological trauma to be a significant contributor to this condition. In evaluating the patient with a fecal incontinence, there is always the debate how much elaborate anorectal physiology testing really is necessary. The "educated finger" can determine a lot. During a digital exam, the physician can assess the resting tone, which roughly corresponds to that of the internal anal sphincter. Asking the patient to squeeze on the examining finger in the anal canal will allow the physician to assess the external anal sphincter tone. In a woman, placing one finger in the vagina and the other finger in the anal canal permits one to assess the thickness of the tissue between these structures (which represents the perineal body). Thinning of this structure suggests loss of external anal sphincter, most frequently seen due to obstetrical injury. In cases of recent traumatic obstetric injury, it is advisable to wait at least 6 months before proceeding with a definitive repair. Digital examination can also reveal the presence of a rectocele anteriorly within the rectum; this is a very common cause of constipation in women. Examination of the patient in the upright position while straining is important to in order to exclude rectal or

hemorrhoidal prolapse that can be a cause of fecal incontinence.

This chapter could easily also been referred to as the "bionic chapter" since it describes implantation of peripheral sacral nerve root stimulators or "pacemakers" to "pace" the S3 nerve root to improve fecal incontinence. It is no accident that Medtronic, the world's largest pacemaker manufacturer produces this device. The cost implication of technology is enormous. Beyond the initial implantation, long-term patient care, including programming and battery replacement can be very costly (McMullin CM, Jadav AM, Hanwell C, et al. Resource implications of running a sacral neuromodulation service: a 10-year experience. *Colorectal Dis* 2014;16(9):719–22; Hetzer FH, Bieler A, Hahnloser D, et al. Outcome and cost analysis of sacral nerve stimulation for faecal incontinence. *Br J Surg* 2006;93:1411–17). Depending on programming, the average battery life ranges from 3 to 5 years. The cost of the stimulator device alone (not including surgical and anesthesia fees, electrode costs, and other charges) is roughly $15,000!

Notwithstanding the above comments, sacral nerve stimulation appears to be a procedure that is almost too good to be true and long-term results seem to be durable (Altomare DF, Giuratrabocchetta S, Knowles CH, et al.; on behalf of the European SNS Outcome Study Group. Long-term outcomes of sacral nerve stimulation for faecal incontinence. *Br J Surg* 2015;102:407–15; Thaha MA, Abukar AA, Thin NN, et al. Sacral nerve stimulation for faecal incontinence and constipation in adults. *Cochrane Database Syst Rev* 2015;8:CD004464). The procedure is minimally invasive, and unlike sphincteroplasty or operations for incontinence, it results in no scarring to the anal sphincters. In addition to benefiting patients with conventional fecal incontinence due to obstetric injury, it appears that patients who have "atypical problems" such as those with fecal incontinence following pelvic radiation, imperforate anus, and perhaps even those who have low anterior resection syndrome may benefit from this procedure (Ramage L, Qiu S, Kontovounisios C, et al. A systematic review of sacral nerve stimulation for low anterior resection syndrome. *Colorectal Dis* 2015;17(9):762–71).

The issue of implantation of mesh prosthetics into the pelvis is one of tremendous debate. In 2008, the U.S. Food and Drug Administration (FDA) posted a public health notification on severe complications associated with transvaginal placement of mesh in the repair of pelvic organ prolapse and urinary incontinence and updated again in 2011 (http://www.fda.gov/MedicalDevices/Safety/AlertsandNotices/ucm262435.htm. Accessed January 16, 2016). The FDA received over 1,000 reports of adverse events from 2005 to 2007 and subsequently received nearly 3,000 additional reports of complications associated with surgical mesh devices used to repair pelvic organ prolapse. It was in this environment that colorectal surgeons increasingly performed laparoscopic anterior ventral mesh rectopexy for rectal prolapse. That debate continues. As is true for many minimal access procedures that are "newly developed," large series rapidly appeared in the literature

reporting outstanding results with often very short follow-up. This technique was used to treat a range of diagnoses from full-thickness rectal prolapse, to internal rectal Intussusception, to rectocele. In longer follow-up, the expected mesh complications are starting to be reported, although still with relatively low infrequency (Evans C, Stevenson AR, Sileri P, et al. A Multicenter Collaboration to Assess the Safety of Laparoscopic Ventral Rectopexy. *Dis Colon Rectum* 2015;58(8):799–807). These reports will undoubtedly increase with increased patient follow-up. In this report of 2,203 patients who had undergone this procedure at five centers in the United Kingdom over a 14-year period, the median length of follow-up for patients with synthetic mesh was 38 months (0 to 162 months) and 26 months (0 to 68 months) for patients with "biologic grafts." Surgeons must be leery of device and product manufacturers when they promote their products. While some of these products are worthy, the surgeon must use common sense and always keep the overall good of the patient foremost. The surgeon must carefully evaluate his or her patient and make sure a given procedure is unequivocally indicated for that patient before proceeding.

One final comment on the future; before one begins buying Medtronic stock, and hiring extra TSA personnel for the airports to help with all the implanted stimulators, there should be brief mention of the stem cell research being done on fecal incontinence (Raghavan S, Miyasaka EA, Gilmont RR, et al. Perianal implantation of bioengineered human internal anal sphincter constructs intrinsically innervated with human neural progenitor cells. *Surgery* 2014;155(4):668–74). There are promising animal experimental data that have been obtained using bioengineered internal anal sphincter constructs innervated with human neural progenitor cells. Obviously, such approaches are far from clinical application; however, "re-growing" an anal sphincter or using such technology to enforce weakened tissues seems likely to be preferable to using synthetic materials and power sources.

Susan Galandiuk

167 Groin Dissection

Kiran K. Turaga and Jonathan S. Zager

Groin dissection is a technique utilized in the management of lymph node metastases to the inguinofemoral and pelvic nodal basins. Involvement of the regional lymph nodes in these basins occurs commonly from lymphatic metastases from cutaneous malignancies such as melanoma, squamous cell, and Merkel cell carcinoma. Pelvic malignancies can also present with inguinal metastases especially when metastases occur along the external pudendal vessels (superficial and deep). The detection of adenocarcinoma in an inguinal lymph node must prompt thorough evaluation of the vaginal canal, the cervix, the endometrium, and the prostate. Squamous cancers and melanomas of the perineum can also present with lymph node metastases.

PATHOPHYSIOLOGY AND ANATOMY

The understanding of the development of lymphatic metastases significantly improved in 2001 after the discovery of tumor lymphangiogenesis that is distinct from angiogenesis. Malignant tumors can generate factors such as VEGF-C, VEGF-D, VEGF-A, and HGF (Hepatocyte growth factor) that foster lymphangiogenesis both on pre-existing lymphatic channels and at the draining "sentinel" lymph node. Remodeling of the lymphatic channels occurs with dilation of the channels, and with changes in the structure of the smooth muscle cells, which then leads to secondary lymph node metastases or distant metastases via the thoracic duct.

The anatomical location of the malignancy dictates its drainage to the corresponding inguinal nodal basin, although it can be quite varied due to extensive collaterals of the lymphatic channels. The development of the sentinel node biopsy technique enhanced the understanding of the anatomical drainage of extremity lesions. The femoral triangle is bounded by the inguinal ligament, the sartorius muscle, and the adductor magnus/pectineus muscles. The contents of the femoral triangle include the "superficial nodal basin," and the technique of removing the nodes in

this anatomical space is called a superficial node dissection or a femoral lymphadenectomy. Inclusion of the lower external oblique and inguinal canal lymph nodes is mandatory during such a dissection, and thus the term is appropriately coined as an inguinofemoral lymphadenectomy. Dissection of the lymph nodes along the external and internal iliac vessels (and obturator) is termed as a pelvic lymphadenectomy.

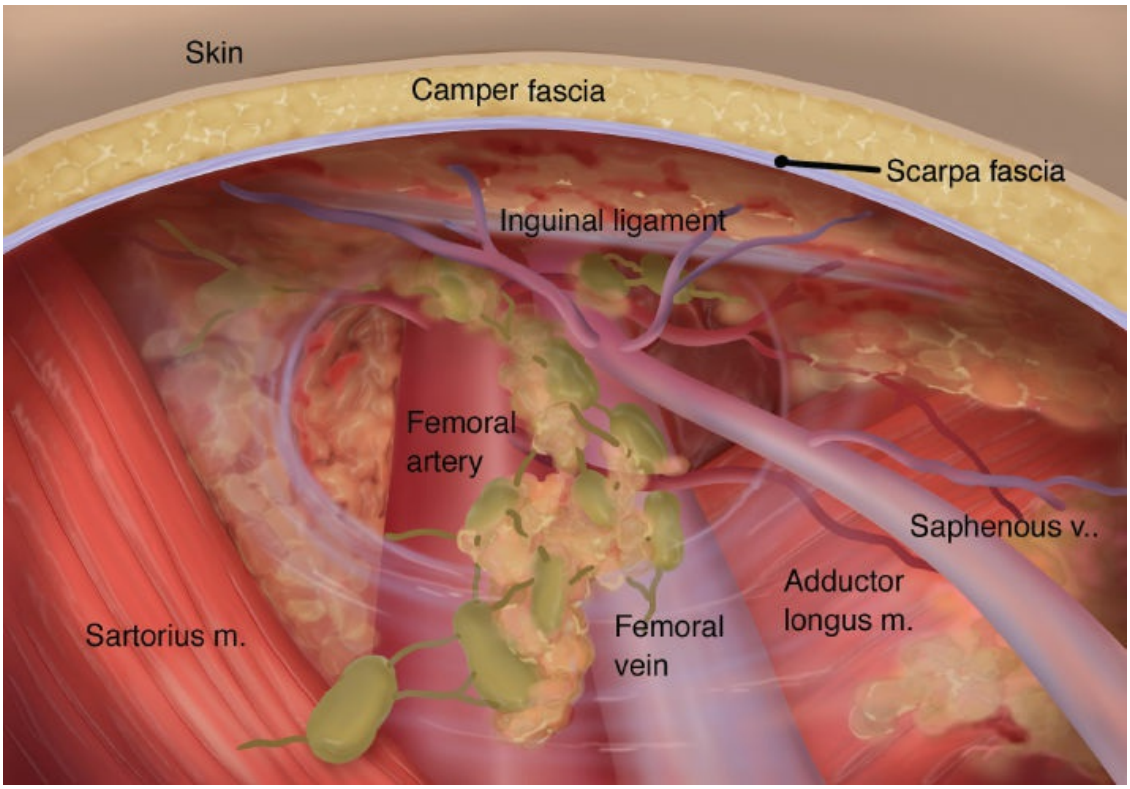

Figure 167.1. Cross-section of upper thigh showing skin, nodes, and saphenous vein.

The apex of the dissection is defined by the saphenous vein, along with the saphenous nerve (Fig. 167.1). Laterally the sartorius muscle defines the constant border as it arises from its origin on the anterior superior iliac spine. It is easy to injure the lateral femoral cutaneous nerve superficially during the lateral dissection. The motor and sensory branches of the femoral nerve are medial to the sartorius. The lateral femoral circumflex artery runs posterior to the femoral nerve and often given branches to the sartorius. Denervation and devascularization of the muscle can occur with an aggressive medial dissection. The femoral artery and vein have fewer anterior branches in the inferior aspect of the femoral triangle. Superiorly, the saphenous vein drains into the femoral vein after piercing through the fascia lata via the fossa ovalis. The superficial branches of the femoral

vessels at this level include the superficial circumflex, the superficial epigastric, and the superficial and deep external pudendal vessels. Posterior to the inguinal ligament as the femoral artery transitions to the external iliac artery, one must be aware of the deep circumflex branch that lies posterior and the inferior epigastric branch that lies medial. The external iliac artery has fewer branches in the true pelvis. The internal iliac artery divides into the anterior and posterior division. Relevant branches of the internal iliac artery that are encountered in the dissection include the obturator vessels from the anterior trunk, and the inferior vesical artery supplying the bladder that can be torn during dissection. The posterior trunk branches such as the superior gluteal artery have particular significance for collateral flow to the lower extremity. The dissection is considered complete as the bifurcation of the aorta common iliac artery is reached and care must be taken to protect the ureter that crosses anterior to the vessels.

CLINICAL PRESENTATION AND INDICATIONS

Nodal metastases can either be palpable or clinically occult, which are usually detected by either imaging or sentinel lymph node biopsy. In advanced cases, nodal disease can present with lymphedema (limb and scrotal), and with local ulceration and excoriation. Large lymph nodes can also predispose to ipsilateral venous thrombosis.

The indications for a radical groin dissection are discussed in Table 167.1. Recent randomized controlled trials in melanoma have failed to show a survival benefit with immediate completion node dissection in patients with intermediate thickness melanoma with SLN positive nodes compared to observation (MSLT-II trial). Similarly, patients with micrometastatic disease in the lymph nodes are also unlikely to draw survival benefit from lymphadenectomies (DECOG trial). The improved control of local recurrences must be balanced with the morbidity of the procedure.

Patients who have uncontrolled metastatic disease are not usually recommended nodal dissection. Palliation of nodal metastases with surgery or radiation may be warranted when patients present with pain, excoriation, or significant enlargement.

PREOPERATIVE PLANNING

Patients who may be considered as candidates for a radical groin

dissection must undergo a thorough tumor staging evaluation (cross-sectional imaging such as computed tomography [CT] scans or CT/Positron emission tomography [CT/PET] fusion scan and magnetic resonance imaging [MRI] or CT of the brain for those with metastatic melanoma) and in case of palpable nodes must include fine needle aspiration to confirm the diagnosis. Occasionally, contrast-enhanced cross-sectional imaging of the groin and pelvis with CT scan or an MRI might be essential to further delineate vascular anatomy (Fig. 167.2).

Once the decision to proceed with surgery has been made, one must optimize the patient for surgery, and the ACS-Risk calculator can be used as a tool to quantify perioperative risk. Preoperative fitting with 20- to 30-mm compression stockings is useful in the preoperative setting before significant lymphedema develops. Planning for resection of the primary site of disease and planning of the skin incision are essential at the preoperative visit.

Surgical Technique

An inguinofemoral node dissection can be performed under general or regional anesthesia. In the event of a pelvic lymphadenectomy, muscle relaxation is helpful and such cases are best done under general anesthetic. Preoperative antibiotics are usually administered, although these cases are clean cases with a low risk of postoperative wound infections, since the wound breakdown rates are high. Foley catheters are placed in patients undergoing pelvic lymphadenectomy to decompress the bladder and in cases that are anticipated to be long. The patient is placed supine, and the leg is usually abducted and externally rotated after supporting the heel with soft padding. Hair clipping of the pubic area is performed. The knee can be supported on a pillow or sterile towels depending on whether the entire extremity is included in the prep. Sequential compression devices are applied to both legs unless specifically precluded. Surgical prep is performed with standard prepping solutions containing chlorhexidine or iodophors. Scrubbing solutions of povidone iodine or chlorhexidine can be used in case of contaminated wounds or in the case of significant debris. Table to table prep is often helpful especially if manipulation of the thigh is necessary and the abdomen is prepped to the umbilicus. U-drapes are useful in maintaining a sterile field.

TABLE 167.1 Indications for Groin Dissection

Inguinofemoral Lymphadenectomy

Melanoma
- Clinically palpable lymph nodes with no extra-nodal metastatic disease
- Positive sentinel node with macrometastatic disease in patients with thick melanomas (not included in MSLT-II)
- Symptomatic nodal disease in the setting of controlled extra-nodal disease

Evolving indications
- Based on MSLT-II trial:
  - Nodal failure on observation of sentinel node positive disease
  - Inability to participate in frequent ultrasound nodal observation
- Incomplete assessment of nodal drainage due to lack of technology, or absence of sentinel node identification in a high-risk melanoma
- Positive SLN with micrometastatic disease do not need immediate completion dissection (DECOG trial)

Merkel cell carcinoma
- Clinically palpable lymph nodes with no extra-nodal metastatic disease
- Positive sentinel node
- Symptomatic nodal disease in the setting of controlled extra-nodal disease

Squamous cell carcinoma (skin and perineum)
- Clinically palpable lymph nodes with no extra-nodal metastatic disease
- Positive sentinel node
- Symptomatic nodal disease in the setting of controlled extra-nodal disease

Pelvic lymphadenectomy

Melanoma
- Enlarged (imaging) or biopsy proven external iliac/obturator lymph nodes without extra-nodal metastatic disease

Relative indications
- Involvement of >3 inguinal nodes, especially with extracapsular extension of disease
- Large (>3 cm) positive superficial inguinal nodes
- Pelvic sentinel lymph nodes (SLNs) identified on lymphoscintigraphy that were not sampled in the setting of positive superficial SLN

Merkel cell carcinoma/squamous cell carcinoma
- Enlarged (imaging) or biopsy proven external iliac/obturator lymph nodes without extra-nodal metastatic disease

Gynecological malignancies/anal cancer
- See associated chapters



Figure 167.2. Patient with enlarged necrotic metastatic melanoma to the left external iliac nodal chain requiring contrasted cross-sectional CT scan to define relationship to external iliac vessels.

The classic skin incision for the lymphadenectomy is planned in a longitudinal fashion incorporating the prior sentinel lymph node biopsy site. In the event of a pelvic lymphadenectomy, the incision is modified into a lazy S incision with termination 2 to 3 cm medial to the anterior superior iliac spine. Variants of the incision include a transverse incision along Langers lines in the suprainguinal crease (or infrainguinal crease, although the latter has been shown to have higher wound infection rates) or two separate incisions to avoid traversing the inguinal ligament. After a skin incision is made, it is carried down to the level of Scarpa fascia in the abdomen and the fascia lata in the thigh. Skin flaps are raised medially until the adductors, laterally until the sartorius, and superiorly about 4 cm above the inguinal ligament. Care must be taken in handling the skin flaps and maintaining a uniform thickness of the flaps. While an elliptical incision could avoid subsequent trimming of skin edges, our preference has been to trim the edges of the skin flaps at the end of the dissection. Self-retaining retractors such as long Adson-Beckman retractors are preferred over Weitlaner retractors. Gelpie’s have also been used by

others. Our preference has been to start laterally to expose the sartorius muscle. While modifications of the technique have been proposed to preserve the sartorius fascia, we routinely include the sartorius fascia in the dissection. The entire node bearing fatty tissue is swept medially. Superiorly above the inguinal ligament, branches of the superficial circumflex vessels are often encountered and must be ligated or appropriately coagulated to maintain hemostasis. At the inferior aspect of the femoral triangle, the saphenous vein is encountered and is a relative constant anatomical landmark during this operation. The saphenous vein is doubly ligated with 2-0 silk ties. Anterior tributaries of the vein and the posteromedial thigh tributary can be encountered and occasionally mistaken for the main saphenous trunk. The dissection is carried out medial to the sartorius muscle, and care is taken to preserve the branches of the femoral nerve. Patients are routinely not paralyzed during this operation in order to detect any twitching if thermal proximity occurs to the nerves. The specimen is elevated up off the adventitia of the femoral artery. At this point, we tend to dissect the medial aspect of the specimen elevating the nodal tissue of the adductor longus and adductor magnus muscles and the pectineus superiorly. The dissection is carried out in the infrainguinal space, and the specimen is made contiguous with the lateral specimen inferiorly. Dissection of the common femoral artery and vein is then undertaken, elevating the specimen off the adventitia of the vessels. Branches that are encountered are usually small and can be safely clipped or ligated. At this point, the superior aspect of the node dissection is performed. In this way, the dissection is performed in from the lateral medial and superior aspects until all dissections meet at the fossa ovalis. The fatty tissue under the skin flaps raised superior to the inguinal ligament is elevated off the external oblique fascia. The inguinal ligament is identified and preserved. Careful dissection can help preserve the ilioinguinal and hypogastric nerves, laterally. The nodal tissue is swept off the superficial ring and is made contiguous with the medial aspect of the specimen. Upon approaching the infrainguinal portion of the fatty nodal tissue, the superficial circumflex iliac, superficial epigastric, and the superficial external pudendal vessels are encountered and must be ligated. The nodal tissue is dissected off the femoral canal where Cloquet node is identified. This node may be sent off separately for evaluation in the event that a pelvic lymphadenectomy is contemplated. At this point, the dissection is centered around the fossa ovalis that is about 4 cm medial and

inferior to the pubic tubercle. The entire node packet is dissected away and is centered around the saphenous vein as it enters the femoral vein. The nodal packet around the junction must be dissected carefully and elevated up until the junction is clearly seen. The saphenous vein is ligated between clamps and is occasionally suture ligated if larger in size. Occasional use of a side biting vascular clamp may be necessary with primary suture closure of the defect with a 4-0 or 5-0 Prolene stitch. The specimen is oriented and handed of for further evaluation.

In the event that the dissection proceeds toward a pelvic lymphadenectomy, one must be prepared to use a self-retaining retractor such as a Bookwalter, Omni, or Thompson retractor system. The decision must be made whether a radical dissection that splits the inguinal ligament should be undertaken or two separate incisions would be used with a dissection of the inguinal ligament. While the former creates excellent exposure, the morbidity of splitting the ligament is not inconsequential with risk for hernias and weakness of the abdominal wall. To split the ligament, an incision is made in the external oblique fascia 4 cm medial to the anterior superior iliac spine and carried down until the ligament is divided medial to the femoral artery. On the other hand, a transverse incision is made 5 to 6 cm above the inguinal ligament and is carried through the external oblique fascia. The muscles are separated and the transversus abdominis muscle and transversalis fascia are carefully opened until the preperitoneal plane is reached. At this point, a blunt dissection of the retroperitoneal space usually affords a clear visualization of the pelvis as the peritoneum is swept away. Care must be taken not to avulse the inferior epigastric vessels and the lateral circumflex iliac vessels. The lateral circumflex vessels lie between the internal oblique and the transversus abdominis muscles and must be ligated. The bladder is the medial aspect of the dissection and this must be visualized and noted to be decompressed. Pelvic retractors are placed and a deep right angle blade is suitable to medially retract the bladder. Cord contents such as testicular vessels and the vas deferens are preserved in males while the round ligament can be divided in females. The inferior epigastrics may be ligated between silk ties if the dissection is restricted by the exposure reached. Cadaveric studies have demonstrated the presence of nodal metastases only in the medial aspect of the external iliac vessels and hence the dissection is started over the anterior aspect of the external iliac artery. The dissection is carried over the external iliac vein, and the space between the

bifurcation of the external and internal iliac artery is clearly dissected out. The obturator nerve is usually encountered in this space as a taut string like structure before it joins the obturator vessels to exit via the obturator foramen. While electrocautery dissection might be necessary, a significant portion of this dissection can be performed even with gentle sweeping motions of the peanut dissector. Clips for small branches might be used, although there are rarely any anterior branches of the vessels in the pelvis. The dissection over the adventitia of the external iliac artery is carried up to the bifurcation of the common iliac artery. The ureter is encountered along the dissection, and it is gently elevated away from the vessels. The internal iliac artery is rarely dissected out, although prominent branches of the anterior trunk including the inferior vesical artery and the obliterated umbilical artery may be encountered. The entire nodal packet is dissected and delivered with careful identification of the obturator and the iliac nodal chains separately. It is critical if a decision to not transect the inguinal ligament is made, that all nodal tissue behind the inguinal ligament be dissected away and made contiguous with the pelvic specimen.

At the completion of the pelvic lymphadenectomy, a drain is usually introduced in the pelvis via the lateral side. A 10/19-French drain is usually appropriate for collection of pelvic fluid in the perioperative phase. The internal oblique muscle is approximated using a 2-0 Vicryl running suture, and the external oblique is also closed with the same suture. In the event that the superficial ring was opened, it is recreated to ensure adequate space for the cord structures. Careful attention is placed to ensure that the drain is not trapped between the sutures that might prevent removal.

In the event that the inguinal ligament is divided, it is our practice to re-approximate it with 0-polyester suture in an interrupted fashion. It is our usual practice to rotate a sartorius flap over the exposed vessels. While this is not always necessary, the significantly high wound complication rate of an inguinal node dissection can lead to significant issues if the vessels are exposed. The sartorius muscle is dissected from its origin and is detached from the anterior superior iliac spine. If significant muscle fibers are present near the origin, we occasionally use a stapler to divide the muscle since it holds sutures more easily. A 4.5-mm leg length stapler is usually necessary for this division. Dissection of the sartorius is performed over the upper third to half of the muscle to ensure mobility to rotate over the

vessels. Care is taken to protect the medial vasculature and nerve fibers so as to prevent atrophy of the muscle. Sutures are then placed between the muscle and the inguinal ligament to close the femoral canal. The femoral canal is approximated with the lacunar ligament with a figure-of-eight stitch. Interrupted sutures are placed to approximate the divided sartorius to the adductors and pectineus medially, the inguinal ligament and femoral canal superiorly. Two 19-French drains are placed in the space and brought out through stab incisions inferiorly taking precautions to avoid skewering the saphenous vein. The skin edges are examined and trimmed back to healthy tissue. The deep dermis is closed with 2-0 or 3-0 Vicryl interrupted deep dermal sutures, and the skin is closed with 4-0 monocryl sutures. The drains are secured with nylon or similar sutures. Skin closures are often reinforced with dermabond- or cyanoacrylate-based adhesive dressings given their remarkable water resistance in a fairly moist area. Alternate dressings are acceptable and no superiority has been seen in any comparative studies.

TECHNICAL MODIFICATIONS

While several technical modifications exist outside of those discussed in the above section, the preservation of the saphenous vein, and/or the adductor and sartorius muscular fascia have been suggested to have lower morbidity. While the dissection is relatively similar, the former requires more bisection of the specimen to clearly examine the saphenofemoral junction. In the case of preservation of the muscular fascia, care must be taken to elevate the fascia lata off the femoral vessels to restore continuity of the specimen.

POSTOPERATIVE COURSE

In the case of the inguinofemoral lymphadenectomy, patients are watched overnight to ensure adequate pain control. The lower limb is elevated and could be wrapped with ACE wrap bandages to minimize swelling. Patients are typically discharged the next morning and brought back for early follow-up to check the wound site. Drains are typically removed when the output is <30 to 50 mL/24-hr period. When a pelvic lymphadenectomy is performed, we routinely remove the pelvic drain the next morning after the operation (12 to 24 hours later). If excessively high outputs (>200 mL) are noted, the drain is left in for an additional 24 hours. Some patients could develop an ileus and resumption of bowel function could take a few days.

For patients with reliable follow-up, early discharge is relatively safe even in the absence of bowel function. Voiding without a catheter needs to be confirmed prior to discharge.

Significant wound complications have been described for patients undergoing this operation. Flap necrosis/dehiscence has been reported in almost 19% to 26% of the patients. A significant wound infection rate has also been described of as high as 9%. Early and meticulous wound care is essential with early debridement of necrotic tissue. Use of vacuum-assisted closure devices may be necessary in some cases. Occasionally, reoperation to place a skin graft or flap assisted closure may be necessary. Prevention of lymphoceles and hematomas with meticulous dissection helps tremendously, although they still occur 5% to 27% of the time. In such a setting, early aspiration may be considered, although repeated aspirations could lead to infection of the lymphocele. In the case of aspiration or drain placement, it is essential to place the puncture site away from the main incision.

Lymphedema has been described in as many as 30% of patients undergoing a radical groin dissection. Early appropriate management with a compression stocking with 20- to 30-mm graded compression is highly effective in managing patients. Elevation of lower extremity during the early postoperative period and regular use of stockings during nonsleep hours for 6 months are generally adequate in managing lymphedema. Massage therapy and other lymphedema management therapy can be used in patients with persistent or long-standing edema. Body garments with compression are also available for those who develop abdominal wall edema. Scrotal edema can be managed with supportive undergarments. Microsurgical therapy for lymphedema has been shown by some proponents to be effective in controlling both scrotal and lower limb lymphedema, although this has been more commonly used in the upper extremity.

MINIMALLY INVASIVE LYMPHADENECTOMY

The technique of a minimally invasive lymphadenectomy has potential advantages in reducing the wound complications associated with a radical groin dissection. The technique is best suited to patients with low burden of disease and favorable anatomy. Below we describe the technique associated with a minimally invasive inguinofemoral and pelvic lymphadenectomy. While both are feasible procedures separately, it can be

logistically arduous to combine both procedures at the same time.

INGUINOFEMORAL LYMPHADENECTOMY

Patients with infrainguinal disease are placed in split leg position (Fig. 167.3). Foley catheter is optional especially if concern for a technically difficult dissection is anticipated. The femoral triangle is marked out including the space 5 cm above the inguinal ligament. The site of the previous sentinel lymph node biopsy site is usually included within the skin flaps of the dissection. The technique is performed using three ports of 10- to 12-mm diameter placed away from the femoral triangle. The inferior most port is placed inferior to the apex of the triangle by 3 to 4 cm, and the other ports are separated by around a hand breadth outside the triangle. The procedure is begun by making an incision to accommodate a balloon Hasson port. Dissection through the fascia lata is performed, and a combination of blunt and cautery dissection is performed to raise flaps for around 5 cm in the direction of the triangle. Teflon tip cautery is essential if flaps are being raised with thermal energy. Insufflation with a higher pressure (20 to 25 mm Hg) is initiated for the first 10 minutes followed by reduction in the pressure to 15 mm to reduce CO_2 crepitus. Using short 12-mm ports in the medial and lateral positions, dissection is carried out using ultrasonic shears and counter traction with a grasper/endoscopic kittner instrument. Skin flaps are raised endoscopically, while maintaining care to not create thermal burns. The pneumatic dissection facilitates dissection that makes this procedure expeditious. The dissection is carried out by identifying the saphenous vein and dissecting along the vein superiorly. After creating dissecting space, the sartorius fascia is incised ensuring that the medial aspect of the dissection is carefully performed. The ultrasonic shears does not lead to nerve stimulation similar to thermal energy and femoral nerve branches must be carefully preserved. The dissection is then carried out medially over the adductor and pectineus muscles and the fascia is elevated up. At the fossa ovalis, we dissect the saphenofemoral junction. The superficial circumflex, superficial external pudendal, and superficial epigastric branches are identified and divided using 10-mm clips. Care must be taken to ensure that subsequent division of the saphenofemoral junction is not impaired by the clips. Dissection above the inguinal ligament is performed later on in the dissection to reduce CO_2 insufflation of the abdominal wall. The saphenofemoral junction is dissected, and Cloquet node is identified and pulled into the specimen. The

junction is divided with a 45-mm vascular staple load. The specimen is then dissected off the femoral artery and vein, carefully re-establishing the subfascial plane with the femoral sheath. The hook electrocautery can be useful along with blunt dissection with the kittner device. Vasavasorum can occasionally lead to nuisance bleeding and must be controlled. Medial branches to the adductors and pectineus are controlled. Posterior dissection of the femoral vessels is not performed. The specimen is rolled inferiorly, and the distal proximal aspect of the saphenous vein is identified and divided with the stapler (Fig. 167.4). A specimen bag is introduced and the contents are placed within the bag and removed. The specimen is oriented and hemostasis is confirmed. One or two drains are placed through the medial and inferior incisions. Patients are discharged home either the same day or the next and are given a regular diet.

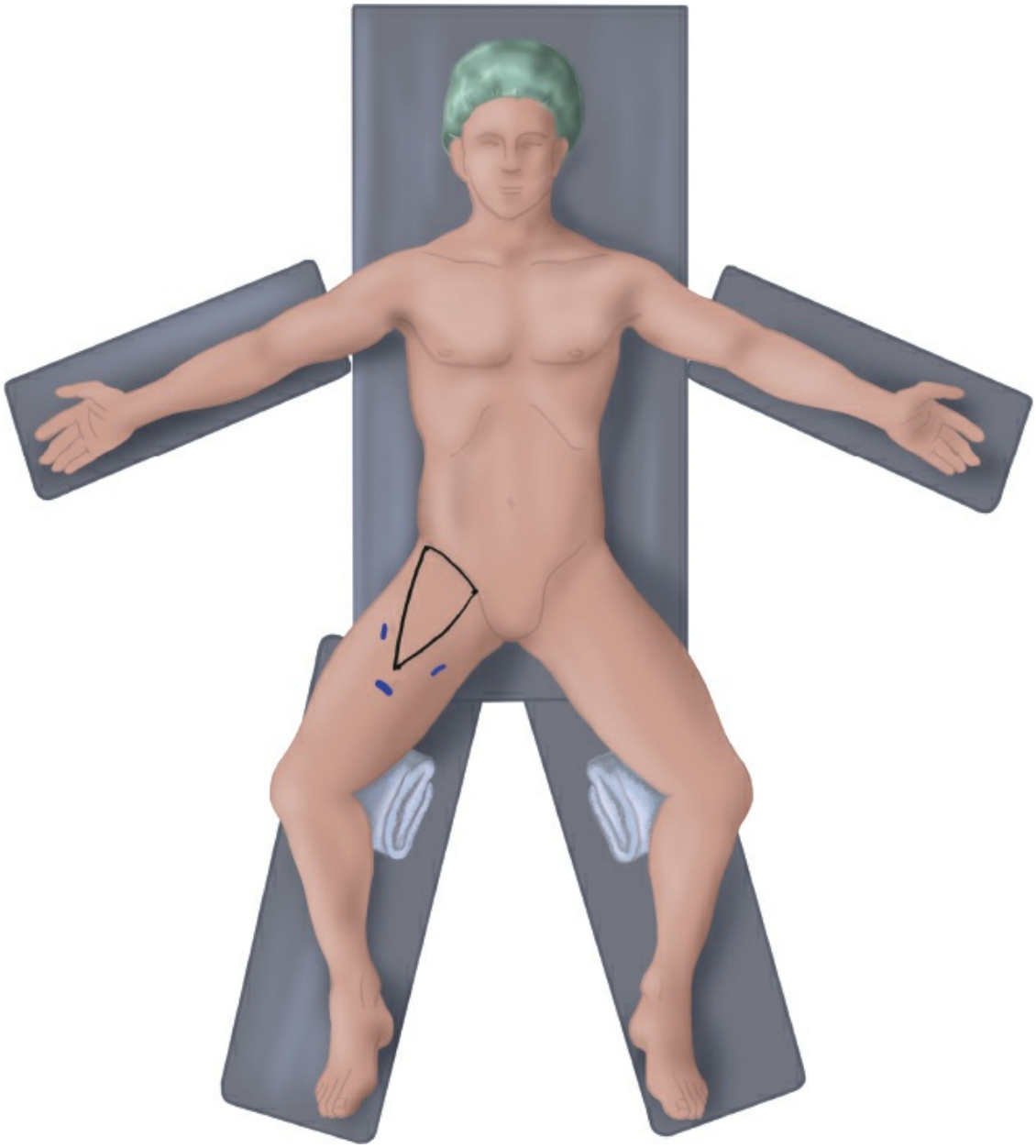

Figure 167.3. Patient is placed in split-leg position and femoral triangle is marked for a inguinofemoral lymphadenectomy.

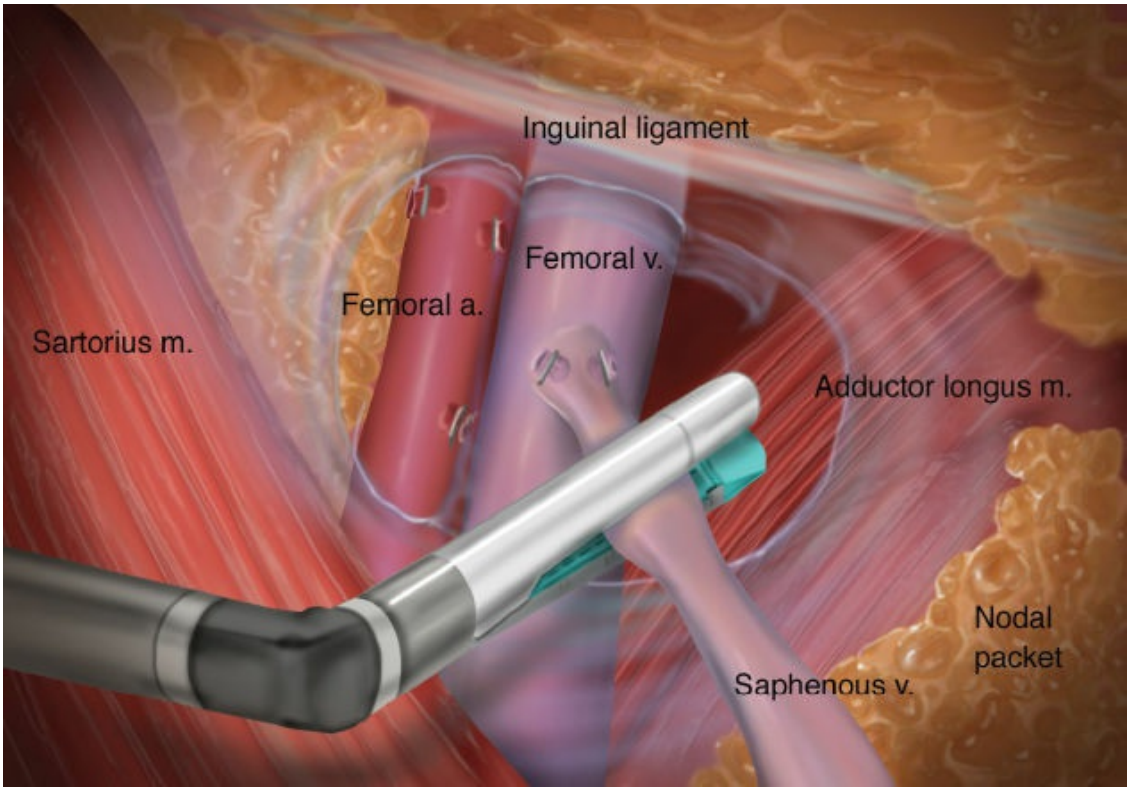

Figure 167.4. The surgical stapler dividing the distal proximal section of the saphenous vein.

ROBOTIC PELVIC LYMPHADENECTOMY

Techniques for a robotic pelvic lymphadenectomy are similar to those described in this book elsewhere (Chapter 163). While the anatomical principles of a laparoscopic and robotic pelvic lymph node dissection are similar, the setup of the patient and the port placement differ significantly. The utility of a minimally invasive pelvic lymphadenectomy is usually in the setting where a pelvic recurrence occurs after a prior inguinofemoral lymphadenectomy. Patients identified as candidates for robotic pelvic lymphadenectomy are adequately staged and imaged as discussed previously. Foley catheters are routinely placed. Patients are placed in split leg position. Pneumoperitoneum is usually created with a supraumbilical 12-mm port. Robotic ports must be spaced at least a hand breadth distance, and the ports are usually placed with two robotic ports on the contralateral side and one robotic and one assistant port on the ipsilateral side. The patient is placed in steep Trendelenburg position before docking the robot. Incising the peritoneum lateral to the medial umbilical ligament is usually accomplished as the first step. The monopolar scissors are usually in the ipsilateral port, and the Maryland bipolar and a grasping forceps such as a Cadiere or Prograsp are appropriate third arm graspers. The Cadiere allows

for potential manipulation of the bowel especially on the left side. The sigmoid colon attachments are taking down, and any adhesions are taken down to ensure a clear field. The peritoneum is incised anterior to the external iliac artery and carried over to the common iliac artery. The ureter is carefully dissected as it crosses the artery. Medially the nodal packet is swept between the external iliac vein and the internal iliac artery. The obturator nerve and vessels are encountered, and care must be taken to dissect with minimal thermal cautery. The nodal packet is usually swept up, and the pneumoperitoneum significantly facilitates dissection. The external iliac artery and vein are dissected carefully, closer to the inguinal ligament. While occasional branches need to be coagulated, it is rare to require significant clips/ties. The inferior epigastric artery is dissected and divided if necessary, and the dissection is made contiguous with the infrainguinal dissection if extensive scar tissue is not present. The node packet is placed in a specimen bag and extracted. The peritoneum can be reperitonealized with an absorbable suture, although this is not necessary. The port sites are closed. Patients are watched overnight for any events, and are typically discharged the next day after the operation.

Management of Complications of a Groin Dissection

Wound complications are the predominant class of complications that require close management. Aggressive debridement of necrotic wounds, early detection and treatment of cellulitis, and close monitoring of lymphoceles are essential in preserving flap integrity. Dusky flaps frequently require reoperative surgery. In the case of an open wound, vacuum-assisted closure devices are safe especially if a sartorius muscle flap transposition was done at the primary operation. If not, reoperative surgery is necessary if exposed vessels are present. Lymphedema must be managed aggressively in patients undergoing groin dissection. Early elevation of the limb is key. Wrapping the leg and ankle with ACE bandages has been utilized by some to reduce edema. Compression stockings and elevation play a key role in the management of edema. Avoiding long travel, excessive salt intake, and optimization of other causes of edema are essential. Lymphedema massage therapy is helpful for patients with intractable edema. Microsurgical options have also been explored for patients with life-limiting edema.

SUMMARY

Radical groin dissection is the standard of care for patients with palpable/clinically involved nodes in patients with melanoma and other cutaneous and perineal malignancies. The overarching goal is disease control, and there is limited evidence to suggest prolongation of length of life with a node dissection in a majority of disease sites. Immediate completion node dissection for patients with positive sentinel lymph nodes for patients with intermediate thickness melanoma or with micrometastatic disease is no longer the only standard of care when careful observation is feasible. The major morbidity of this operation includes lymphedema and wound complications that can be reduced with meticulous surgical technique, aggressive postoperative management of edema, and potentially minimally invasive strategies.

EDITOR'S COMMENT

Although less commonly performed today than in decades past, radical groin dissection remains a very important surgical procedure in the regional control of a number of cutaneous, gynecologic, and urologic malignancies. Indeed, prior to the advent of lymphatic mapping and sentinel lymph node (SLN) biopsy in the 1990s, it was routine for many patients with melanoma to undergo elective lymph node dissections even in the absence of clinically evident regional adenopathy. Of course, routine lymph node dissections only conferred a potential benefit to the 20% of patients who harbored metastatic disease in their nodes, while at the same time exposing all of the patients to the morbidity of the procedure. Don Morton revolutionized the staging of the regional nodal basin(s) with the sentinel lymph node biopsy technique for a whole host of malignancies with a propensity for nodal metastasis. He and his colleagues showed in the prospective Multicenter Selective Lymphadenectomy Trial (MSLT-1), randomizing patients with cutaneous melanoma to either SLN biopsy or nodal observation, that SLN status is the most significant predictor of survival. Although no overall survival benefit was observed for the entire cohort of 1,269 patients, subgroups of patients with intermediate thickness (1.2- to 3.5-mm) and thick (>3.5-mm) melanomas showed improved distant metastasis-free survival and melanoma-specific survival after SLN biopsy and completion lymphadenectomy compared with observation alone (Morton DL, Thompson JF, Cochran AJ, et al. Sentinel-node biopsy or nodal observation in melanoma. *N Engl J Med* 2006;355:1307–17; Morton DL, Thompson JF, Cochran AJ, et al. Final trial report of sentinel-node biopsy versus nodal observation in melanoma. *N Engl J Med* 2014;370:599–609). Even in the absence of an overall survival benefit, most would agree that the SLN biopsy procedure provides important staging information to estimate prognosis and to guide further treatment decisions, as well as to provide regional disease control. The question of greater

debate is the role of completion lymph node dissection in extending survival in patients with positive SLN biopsies and, importantly, in identifying which patients may be safely spared the morbidity of a radical lymph node dissection. This question is of such debate because only 20% or so of patients with one or more positive SLNs will have metastatic disease in one or more of the remaining nonsentinel lymph nodes (Pasquali S, Mocellin S, Mozzillo N, et al. Nonsentinel lymph node status in patients with cutaneous melanoma: results from a multi-institution prognostic study. *J Clin Oncol* 2014;32:935–41), bringing us back to the exact same problem we faced in the 1980s with performing morbid lymph node dissections on a significant percentage (80%, to be exact) of melanoma patients who could not hope to benefit from it. Thus, the MSLT-2 trial was launched to specifically address this question, the results of which were just published. In this trial, patients with sentinel node metastases were randomly assigned to immediate completion lymph node dissection or nodal observation with ultrasonography. Though the findings of this trial confirmed that immediate completion lymph node dissection increased the rate of regional disease control and provided valuable prognostic information, it did not lead to an improvement in survival, and the rate of lymphedema in the dissection group was significant at 24% (Faries MB, Thompson JF, Cochran AJ, et al. Completion dissection or observation for sentinel-node metastasis in melanoma. *N Engl J Med* 2017;376:2211–22). Therefore, the European Organisation for Research and Treatment of Cancer (EORTC) initiated a similar trial (EORTC 1208, or MINITUB), randomizing patients with minimal sentinel lymph node tumor burden to either completion node dissection or observation, but the results of this trial are not expected for at least another 3 to 5 years.

In the meantime, we do have prospective data from the DeCOG-SLT trial, which was organized by the German Dermatologic Cooperative Oncology Group. This was a multicenter, randomized, phase III trial comparing the survival of SLN biopsy positive melanoma patients with and without completion lymph node dissection. Although underpowered, the authors found no difference in any survival outcome in patients treated with completion lymph node dissection compared with those who were simply observed (Leiter U, Stadler R, Mauch C, et al. Complete lymph node dissection versus no dissection in patients with sentinel lymph node biopsy positive melanoma (DeCOG-SLT): a multicentre, randomised, phase 3 trial. *Lancet Oncol* 2016;17:757–67). The majority (66%) of patients in this study had a low tumor burden (micrometastases <1 mm in size) in the SLNs, and so the authors concluded that melanoma patients with micrometastatic disease in their SLNs should not undergo a completion radical lymph node dissection. These findings have been confirmed in many other retrospective cooperative group and single-center studies (van der Ploeg AP, van Akkooi C, Rutkowski R, et al. Prognosis in patients with sentinel node-positive melanoma without immediate completion lymph node dissection. *Br J Surg* 2012;99:1396–405; Satzger I, Meier A, Zapf A, et al. Is there a therapeutic benefit of complete lymph node dissection in

melanoma patients with low tumor burden in the sentinel node? *Melanoma Res* 2014;24:454–61).

Regardless of the potential benefits of radical groin dissection, a major drawback of this procedure is the undeniable fact that it can be quite morbid. Chang et al., in a prospective assessment of postoperative complications following radical groin dissection in 53 melanoma patients, identified a 30-day wound complication rate of 77.4% (Chang SB, Askew RL, Xing Y, et al. Prospective assessment of postoperative complications and associated costs following inguinal lymph node dissection (ILND) in melanoma patients. *Ann Surg Oncol* 2010;17:2764–72), and a body mass index >30 significantly increased the risk of wound complications. Stuiver et al. examined the outcomes of 145 patients undergoing a radical groin dissection for melanoma and found that one or more complications occurred in 72% of cases, including a wound infection in 45%, seroma formation in 37%, and skin flap necrosis and/or dehiscence in 26% (Stuiver MM, Westerduin E, Ter Meulen S, et al. Surgical wound complications after groin dissection in melanoma patients—a historical cohort study and risk factor analysis. *Eur J Surg Oncol* 2014;40:1284–90). These authors identified older age as the only predictor of complications. Notably, neither the type of skin incision (longitudinal vs. transverse vs. two transverse), sparing of the greater saphenous vein, removal of an ellipse of skin with the specimen, nor use of a sartorius muscle transposition flap influenced the risk of complications. In my practice, I prefer the longitudinal, lazy S-shaped incision described by the authors in this chapter, as well as the routine division of the greater saphenous vein and the trimming of the skin edges at the conclusion of the case prior to skin closure. I selectively harvest a sartorius muscle flap in those I deem at highest risk of a major wound complication (e.g., patients with obesity, diabetes, currently smoking), though admittedly, prospective, randomized data demonstrate that use of a sartorius muscle transposition flap does not in fact reduce the wound complication rate after radical groin dissection (Judson PL, Jonson AL, Paley PJ, et al. A prospective, randomized study analyzing sartorius transposition following inguinal-femoral lymphadenectomy. *Gynecol Oncol* 2004;95:226–30).

In order to minimize the significant morbidity associated with a radical groin dissection, many groups (including our own) have adopted minimally invasive techniques. The most common minimally invasive technique is the video endoscopic inguinal lymphadenectomy (VEIL), which the authors of this chapter so nicely describe. One of the first clinical applications of this technique dates back to 2003, when it was proposed for the treatment of inguinal lymph node metastases from squamous cell carcinoma of the penis (Bishoff JT, Basler JW, Teichman JM et al. Endoscopic subcutaneous modified inguinal lymph node dissection (ESMIL) for squamous cell carcinoma of the penis. *J Urology* 2003;169:78). Since then, at least 10 series of this minimally invasive technique have been described, most commonly for the treatment of metastatic melanoma (Sommariva A, Pasquali S, Rossi CR, et al. Video endoscopic inguinal

lymphadenectomy for lymph node metastasis from solid tumors. *Eur J Surg Oncol* 2015;41:274–81). VEIL has been shown to be safe and feasible, is associated with much lower rates of complications than its radical open counterpart, and, at least on short-term follow-up, appears to offer equivalent oncologic outcomes, with lymph node yields ranging between 7 and 16 nodes and locoregional recurrence rates of <10% (Delman KA, Kooby DA, Ogan K, et al. Feasibility of a novel approach to inguinal lymphadenectomy: minimally invasive groin dissection for melanoma. *Ann Surg Oncol* 2010;17:731; Master VA, Jafri SM, Moses KA, et al. Minimally invasive inguinal lymphadenectomy via endoscopic groin dissection: comprehensive assessment of immediate and long-term complications. *J Urol* 2012;188:1176–80; Sommariva A, Pasquali S, Rossi CR, et al. Video endoscopic inguinal lymphadenectomy for lymph node metastasis from solid tumors. *Eur J Surg Oncol* 2015;41:274–81). Not surprisingly, we are also starting to see reports of the salutary benefits of robot-assisted inguinal and pelvic lymph node dissections (Ahlawat R, Rakesh K, Gagan G, et al. Robot-assisted simultaneous bilateral radical inguinal lymphadenectomy along with robotic bilateral pelvic lymphadenectomy: a feasibility study. *J Laparoendosc Adv Surg Tech A* 2016;26:845–9), including one from the authors of this chapter (Dossett LA, Castner NB, Pow-Sang JM, et al. Robotic-assisted transperitoneal pelvic lymphadenectomy for metastatic melanoma: early outcomes compared with open pelvic lymphadenectomy. *J Am Coll Surg* 2016;222:702–9). Despite the higher costs of equipment and operating room time with the robotic approach, I suppose the cost savings conferred by the much lower rate of complications than that seen with the radical, open approach may justify its use.

John Mullen

168 Transanal Pull-Through for Hirschsprung Disease

Jacob C. Langer

ETIOLOGY AND PATHOPHYSIOLOGY

Hirschsprung disease is characterized by the absence of ganglion cells within the submucosal and myenteric plexuses in the distal bowel. The aganglionic bowel lacks peristalsis, which results in functional obstruction. The disease involves the rectum and part of the sigmoid colon in about 85% of cases, although the aganglionosis can extend through the entire colon (10%) and even through some or all of the small bowel in rare cases.

It is unknown why the ganglion cells are absent in the affected bowel, or why the aganglionic segment virtually always starts at the anus and extends to a variable distance proximally. It is known that the ganglion cells arise from the neural crest, and there is evidence that the neural crest cells fail to either complete their migration or fail to survive within the microenvironment of the aganglionic bowel. It is clear that Hirschsprung disease is not a single disease, but in fact is a common phenotype of a variety of genetic mutations and therefore likely a variety of etiologic mechanisms. The most common gene that has been identified is the RET proto-oncogene, but mutations in the endothelin family of genes as well as SOX-10, ZFHX1B, Phox2B, and the Hedgehog/Notch complex have been implicated as contributory to Hirschsprung disease. These mutations may cause early neuronal cell death, early maturation or differentiation of neural crest cells, or a hostile microenvironment for ganglion cell survival.

CLINICAL PRESENTATION

Hirschsprung disease involving the rectum or rectosigmoid is more common in males than females (4:1), but long-segment disease affects males and females with the same frequency. Associated congenital anomalies are seen in a significant number of patients. Hirschsprung disease may also be associated with chromosomal abnormalities (particularly trisomy 21) and a number of other syndromes, including a

number of neurocristopathies, congenital central hypoventilation syndrome, and multiple endocrine neoplasia type 2.

Diagnosis is suspected on clinical grounds in newborns and infants with distal intestinal obstruction or in older children with severe chronic constipation. Contrast enema usually shows a transition zone between the normal and aganglionic bowel (Fig. 168.1), although the contrast enema may be falsely negative in up to 10% of neonates with Hirschsprung disease. The diagnosis is confirmed based on a rectal biopsy showing aganglionosis, usually associated with histologic evidence of hypertrophic nerves and abnormal cholinesterase and calretinin staining. In neonates this is done using a suction device, and in older children a deeper biopsy must be done. In all cases, care must be taken to biopsy at least 1 to 2 cm above the dentate line, since there is a normal hypoganglionic region below that level.

SURGICAL MANAGEMENT

The treatment of Hirschsprung disease is surgical, and the principle of the operation is to remove the aganglionic colon and anastomose normally innervated bowel to the anus, while preserving anal sphincter function. The first such operation, described by Swenson in the late 1940s, involved complete rectal resection and primary end-to-end anastomosis just above the anal sphincter. Two additional operations were subsequently described and popularized. The Soave procedure involves a submucosal dissection with an endorectal pull-through, leaving a rectal muscular cuff, and the Duhamel operation brings the normal bowel through the avascular plane behind the aganglionic rectum, with a stapled anastomosis joining the two lumens.



Figure 168.1. Contrast enema demonstrating a typical transition zone between normal and aganglionic bowel at the rectosigmoid junction. The lateral view is the most effective for seeing the transition zone.

Because these children often presented with severe malnutrition or enterocolitis, a preliminary colostomy was usually done, followed by a pull-through procedure many months later. Earlier recognition and diagnosis of the disease led a number of surgeons in the 1980s to report single-stage pull-through procedures even in small infants. Over the past few decades, one-stage operations have become increasingly popular are considered to be safe, cost-effective, and the approach of choice for most children with Hirschsprung disease. A stoma is still considered to be appropriate in children with severe enterocolitis, very dilated proximal bowel, long-segment aganglionosis, or lack of adequate pathology support.

In the early 1990s, Georgeson described a minimal access approach, consisting of a laparoscopic biopsy to identify the transition zone,

laparoscopic mobilization of the rectum below the peritoneal reflection, a short endorectal mucosal dissection from below, and an anastomosis from below after prolapsing and excising the rectum. Laparoscopic approaches were subsequently described for the Duhamel and Swenson operations. The transanal Soave procedure represented a natural evolution from the laparoscopic operation, and initial series in children with Hirschsprung disease were published by de la Torre and by Langer in the late 1990s. The transanal approach has the principal benefit of avoiding the need for intra-abdominal mobilization of the rectum via either laparotomy or laparoscopy. Both the laparoscopic and transanal approaches are associated with less pain, shorter hospital stay, and a better cosmetic result than open surgery, but there have not been any studies comparing the laparoscopic to the transanal approach. However, the transanal pull-through can be done by any pediatric surgeon, including those without laparoscopic skills, and by pediatric surgeons in parts of the world where access to appropriately miniaturized laparoscopic equipment is limited.

PREOPERATIVE PLANNING AND PREPARATION

Infants with intestinal obstruction or enterocolitis should undergo rapid resuscitation with intravenous fluids, antibiotics, and a nasogastric tube. Early decompression of the colon using digital rectal stimulation and/or irrigations through a rectal tube is important to prevent and treat enterocolitis and to decrease the diameter of the colon. Children with associated abnormalities such as cardiac disease or congenital central hypoventilation syndrome must have these problems investigated and managed prior to definitive surgical repair. Once the child has been stabilized, surgery can be done semi-electively. While waiting for surgery most children can be fed breast milk or an elemental formula, in combination with rectal stimulations or irrigations, although some will require ongoing nasogastric decompression and parenteral nutrition.

The older child who presents with severe constipation and an extremely dilated colon may require weeks or months of irrigations to bring the colon to a more normal size prior to definitive surgery. Some children with particularly dilated or thickened proximal colon may require a colostomy to achieve adequate decompression.

IMPORTANT ANATOMICAL CONSIDERATIONS

There are three important anatomic structures or planes that must be

recognized during the safe and correct performance of a transanal pull-through. Firstly, the anorectal squamocolumnar junction (dentate or pectinate line) must be clearly identified, and the initial mucosal incision must be made high enough that the transitional epithelium is preserved. If this epithelium is damaged, sensation will be abnormal and continence will be impaired. Secondly, the relatively bloodless submucosal plane of the rectum permits the surgeon to avoid injury to the vagina or prostate during the initial dissection. Thirdly, the plane on the serosal surface of the rectum is also relatively bloodless, and the principle of staying in this plane will prevent injury to pelvic structures.

Since the basic principle of the operation is to bring normally innervated bowel to the anus, it is very important to ensure that the proposed pull-through bowel has normal ganglion cells, confirmed by frozen section. We prefer to do this prior to beginning the anal dissection using a small umbilical incision, although some surgeons prefer to use laparoscopy for this purpose. The advantage of the umbilical approach is that it can be done by any surgeon, anywhere in the world, regardless of ability or access to neonatal laparoscopy. The use of a preliminary biopsy does not change the outcome of the transanal pull-through in terms of time to feeds, amount of pain, or hospital stay. If the operation is to be done in one stage, the surgeon must have the assistance of an experienced pediatric pathologist in order to avoid error.

In children with a more proximal transition zone, the normal bowel may not reach the anus. In these cases a number of maneuvers can be done, including dividing the lateral attachments of the descending colon, taking down the splenic flexure, and dividing the mesenteric vessels proximally so that blood supply is maintained via the marginal vessels. These maneuvers can be done through a small umbilical incision or using laparoscopy.

SURGICAL TECHNIQUE

A single-shot caudal block should be placed both prior to beginning the operation and at the end of the procedure. All patients should receive antibiotic prophylaxis to cover gram-negative bacilli and colonic anaerobes. Preoperative bowel preparation usually fails because of the functional obstruction caused by the aganglionic segment, and results in abdominal distension and retention of fluid. Instead, the rectum and distal colon should be washed out on the table after induction of anesthesia. A

Foley catheter is not necessary in infants; the bladder can be emptied intermittently using a Coude maneuver instead.

The patient is placed into lithotomy position, and an umbilical incision is made. This can be either supra- or infraumbilical, and can be extended into an “omega” shape if necessary. A Hager dilator is placed through the anus to push the sigmoid colon toward the umbilical incision (Fig. 168.2A), where it can be easily grasped with a Babcock clamp. A full-thickness biopsy is done in order to optimize the pathologist’s accuracy. While awaiting the frozen section, the mesentery between the biopsy site and the peritoneal reflection is divided from proximal to distal, using bipolar electrocautery along the edge of the colon.

Once the frozen section has documented normal ganglion cells the surgeon moves to the bottom of the table for the perineal portion of the operation. A nasal speculum can be gently used to initially visualize the mucosa and the dentate line, without the need for stretching of the sphincter (Fig. 168.2B). A circumferential mucosal incision is made 0.5 to 1.0 cm above the dentate line, depending on the size of the child, ensuring that the transitional epithelium is protected from injury. Fine silk sutures are placed in the mucosal edge to provide traction, and the mucosa is then stripped from the underlying muscle for approximately 2 cm using a combination of electrocautery with a fine-tipped needle and blunt dissection (Fig. 168.2C). Once the mucosal dissection has been completed, the rectal muscle can be seen prolapsing down through the anus. The muscle is incised circumferentially, starting anteriorly and progressing circumferentially around both sides, permitting the dissection to continue proximally along the outside of the rectal wall (Fig. 168.2D). The vessels must be divided either by electrocautery or with ties just as they enter the bowel wall, to avoid injury to pelvic nerves and vessels, as well as to the prostate or vagina. It is also very important to avoid twisting of the bowel as the dissection progresses proximally. This can be accomplished by holding the rectum with a curved clamp, making sure that the orientation of the clamp does not change. It is also important that most of the dissection be done outside the anus without the need for retraction of the anal sphincter, which can result in long-term continence issues from sphincter injury.

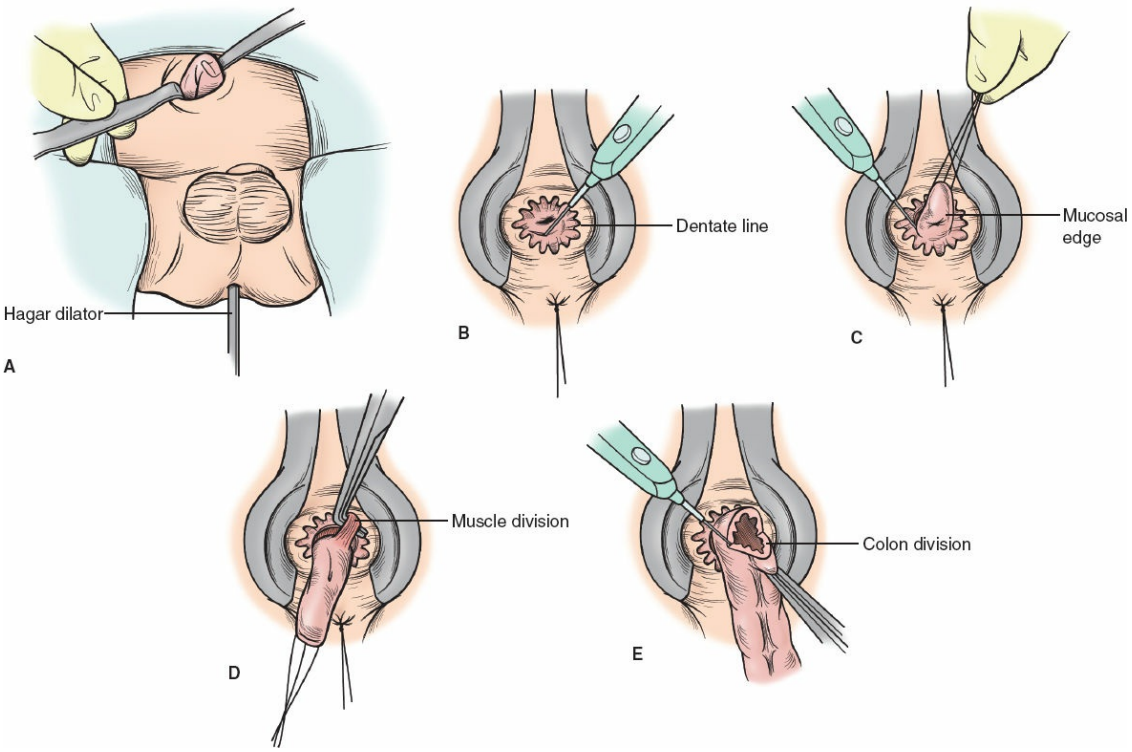

Figure 168.2. **A.** A Hagar dilator is passed through the anus to push the sigmoid colon up toward the incision, and the colon is biopsied until normal ganglion cells are identified on frozen section. **B.** The dentate line is clearly visualized and a mucosal incision is made 0.5 cm above the dentate line. **C.** Fine silk sutures are placed circumferentially along the mucosal edge and the mucosa is dissected off the underlying muscle for approximately 2 cm. **D.** The muscle is divided and the dissection is carried proximally on the rectal wall until the site of the normal biopsy is reached. **E.** The colon is divided and the anastomosis performed.

If the transition zone is proximal to the mid-sigmoid colon, additional mobilization must be done. The first step is division of the lateral attachments of the descending colon, which can be done bluntly using a finger through the umbilical incision. If there is still too much tension, the splenic flexure can be mobilized, and if necessary, the middle colic vessels can be divided, leaving a generous arcade of marginal vessels along the colon. Both maneuvers can be accomplished through the umbilical incision.

When the site of the biopsy that revealed normally innervated bowel has reached the anus, the colon is divided at least 2 cm above the transition zone, and the anastomosis is performed using 4-0 polyglycolic acid sutures (Fig. 168.2E). The stitches should include a generous bite of the pull-

through colon, as well as substantial bite of underlying muscle and a small bite of distal mucosa. As previously mentioned, the transitional epithelium must be spared in order to avoid postoperative pain and preserve normal continence.

When the anastomosis has been completed, the umbilical incision is closed, a second single-shot caudal block is placed, and the patient is awakened.

POSTOPERATIVE CARE

Feeding is started as soon as the child starts to pass stools, which is usually within the first 24 hours. For pain management, oral acetaminophen is usually sufficient, with narcotics reserved for those in whom the caudal block was ineffective. Most children can be discharged 24 to 48 hours after the operation. Because of the high incidence of perianal dermatitis due to frequent bowel movements and liquid discharge during the initial months after a transanal pull-through, immediate application of barrier creams to the perianal skin is imperative. The stool frequency usually decreases to a more normal rate over several months.

The patient is seen 1 to 2 weeks postoperatively, and the anastomosis is calibrated with a dilator or finger, depending on the size of the child. Although most surgeons then teach the parents to do daily dilatations at home, we prefer to see the child weekly for 6 weeks, calibrating the anastomosis each week and only recommending daily dilatations if there is evidence of anastomotic or cuff narrowing.

The most important and dangerous complication following a pull-through is enterocolitis, since it is the most common cause of death in children with Hirschsprung disease. The major signs and symptoms of enterocolitis include fever, abdominal distension, vomiting, diarrhea, and in the later stages, systemic sepsis. In the early stages it can be difficult to differentiate enterocolitis from gastroenteritis, but it is extremely important that both the parents and the community pediatrician who follows the patient be educated to recognize possible enterocolitis, and that the child is brought to medical attention early if any of those clinical features occur. It is better for a child to make an unnecessary trip to the emergency department with gastroenteritis than to delay and develop overwhelming sepsis from rapidly progressive enterocolitis.

COMPLICATIONS AND THEIR MANAGEMENT

Like with any operation on the intestinal tract, surgery for Hirschsprung disease may be complicated by bleeding, infection, injury to other organs or structures, and the risks of anesthesia. Children undergoing a staged repair with a preliminary stoma may experience stoma-specific complication such as stricture, retraction, prolapse, and skin breakdown.

Anastomotic complications, although uncommon, can be seen after any of the pull-through procedures. Anastomotic leaks, or subsequent anastomotic strictures, may occur due to inadequate blood supply or excessive tension of the pulled-through bowel. In addition, the normally innervated bowel may be twisted during the pull-through. Perianal excoriation is seen in up to 50% of children undergoing pull-through surgery, and tends to be more common in children with long-segment disease.

OUTCOMES

Although most children with Hirschsprung disease do well after pull-through surgery, a significant number will have problems that include ongoing obstructive symptoms, soiling, and enterocolitis. In most children these problems improve significantly or resolve by 5 years of age, and every child should therefore be followed on a regular basis until at least school age, or longer if they are continuing to have ongoing problems. It is extremely helpful for these children to have access to a nurse practitioner who is experienced with bowel management, as quality of life is enhanced by ongoing support.

Obstructive symptoms may take the form of abdominal distension, bloating, borborygmi, vomiting, or ongoing severe constipation. There are five major reasons for persistent obstructive symptoms: mechanical obstruction, recurrent or acquired aganglionosis, disordered motility in the proximal colon or small bowel, nonrelaxation of the internal anal sphincter, or stool-holding behavior. Effective management of persistent obstructive symptoms requires careful investigation to identify the underlying cause, followed by targeted intervention and close follow-up with ongoing support (Fig. 168.3).

Soiling after pull-through surgery is present in between 10% and 50% of children, depending on how it is defined. The three major causes of soiling are abnormal sphincter function, abnormal sensation, and “pseudo-incontinence,” which may be caused by severe constipation or hypermotility of the pulled-through proximal colon. Anorectal manometry

may be very helpful in identifying the underlying cause of soiling. Treatment is dependent on a clear understanding of the etiology of the problem, and may include dietary manipulation, stool softeners, stimulant laxatives, enemas, or in severe cases a colostomy.

Enterocolitis may occur both before and after surgical correction of Hirschsprung disease. Estimates of incidence range from 15% to 50%, depending on how it is defined. Most importantly, enterocolitis is the most common cause of death in children with Hirschsprung disease, so early recognition and treatment with bowel rest, colonic irrigation, and systemic antibiotic therapy is imperative.

Long-term outcome for children with Hirschsprung disease is usually excellent, even for those children who have issues with obstructive symptoms, soiling, or enterocolitis in the first few years postoperatively. Children with long-segment disease and those with trisomy 21 are more likely to have ongoing problems, but even these children will ultimately have an excellent quality of life in most cases.

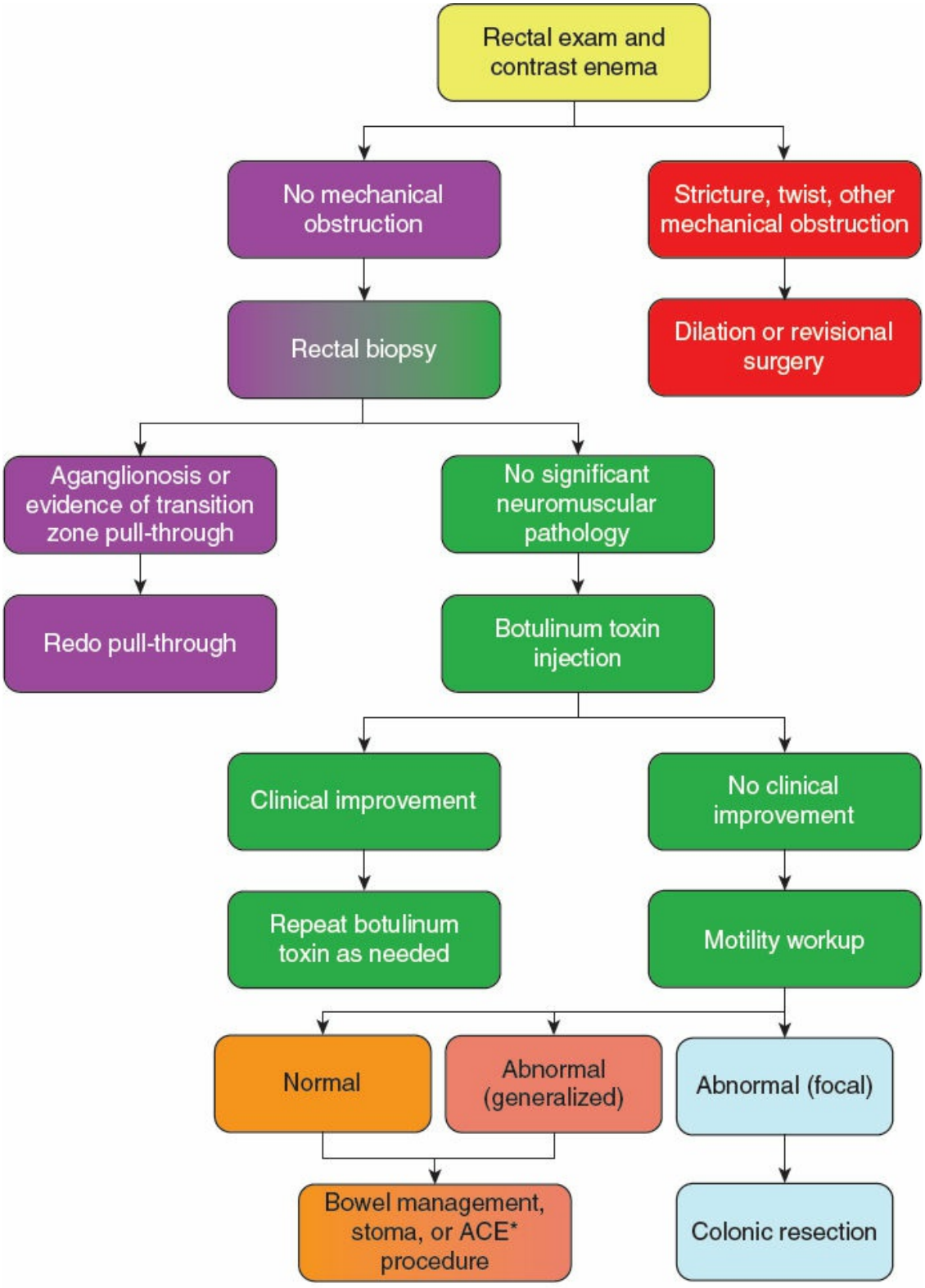

*ACE, antegrade colonic enema

Figure 168.3. Proposed algorithm for managing a child with persistent obstructive symptoms after a pull-through for Hirschsprung disease.

Suggested Readings

Burkhardt DD, Graham JM Jr, Short SS, et al. Advances in Hirschsprung disease genetics and treatment strategies: an update for the primary care pediatrician. *Clin Pediatr (Phila)* 2014;53:71–81.

Dasgupta R, Langer JC. Evaluation and management of the child with persistent problems after surgery for Hirschsprung disease. *J Pediatr Gastroenterol Nutr* 2008;46:13–9.

de la Torre L, Langer JC. Transanal pullthrough for Hirschsprung disease: technique, controversies, pearls, pitfalls, and an organized approach to the management of post-operative obstructive symptoms. *Sem Pediatr Surg* 2010;19:96–106.

Georgeson KE, Cohen RD, Hebra A, et al. Primary laparoscopic-assisted endorectal colon pull-through for Hirschsprung's disease: a new gold standard. *Ann Surg* 1999;229:678–83.

Gosain A, Cowles RA, Frykman PK, et al. on behalf of the American Pediatric Surgical Association Hirschsprung Disease Interest Group. Guidelines for the diagnosis and management of Hirschsprung-associated enterocolitis. *Pediatric Surgery International* 2017;33:517–21.

Langer JC, Caty M, de la Torre-Mondragon L, et al. International Pediatric Endosurgery Group colorectal panel. *J Laparoendosc Adv Surg Tech* 2007;17:77–100.

Langer JC, Durrant AC, de la Torre ML, et al. One-stage transanal Soave pullthrough for Hirschsprung disease: a multicenter experience with 141 children. *Ann Surg* 2003;238:569–76.

Langer JC, Rollins MD, Levitt M, et al. on behalf of the American Pediatric Surgical Association Hirschsprung Disease Interest Group. Guidelines for the management of postoperative obstructive symptoms in children with Hirschsprung disease. *Pediatric Surgery International* 2017;33:523–6.

Nasr A, Langer JC. Evolution of the technique in the transanal pull-through for Hirschsprung disease: effect on outcome. *J Pediatr Surg* 2007;42:36–9.

Sauer CJ, Langer JC, Wales PW. The versatility of the umbilical incision in the management of Hirschsprung's disease. *J Pediatr Surg* 2005;40:385–9.

EDITOR'S COMMENT

Dr. Langer discusses transanal pull-through for Hirschsprung disease in children and while many readers may think that this is only relevant for pediatric surgeons, knowledge of this subject is important for all general and colorectal surgeons.

Virtually every surgeon will in their career see the occasional adult patient with newly diagnosed Hirschsprung disease. These are almost always short-segment Hirschsprung's and are almost invariably patients with proactive parents such as mothers who are nurses, who have regularly given their children enemas or other vigorous bowel regimens to ensure that their children remained asymptomatic.

It is amazing how difficult treating an adult with Hirschsprung disease is with respect to obtaining a proper pathologic evaluation of colon biopsies for ganglia. In many institutions, this is done exclusively by the pediatric pathologists. I have had to send specimens from the "adult" hospital to a "pediatric" hospital pathologists for evaluation!

In the adult, operations that seem so simple in children are far more complicated. Years of disordered bowel function will frequently lead to extreme colonic dilatation, with size discrepancy as well as significant thickening of the colonic wall making handling and suturing of this tissue much more difficult. The colon wall in such patients is so thick and unwieldy that routine suturing and stapling is much more difficult than usual.

Knowledge of this subject is also important for the all abdominal surgeons since patients with Hirschsprung disease, who have undergone surgery when they were young, in many cases will have deteriorating bowel function as they age (Granström AL, Danielson J, Husberg B, et al. Adult outcomes after surgery for Hirschsprung's disease: Evaluation of bowel function and quality of life. *J Pediatr Surg* 2015;50(11):1865–9). This is manifest in multiple different ways including increased problems with fecal soiling, increased complaints of pruritus, and night-time incontinence, leading to increased referrals for evaluations for procedures to improve anal sphincter tone such as sacral nerve root stimulation and evaluations for colostomy construction. Some of these patients may be helped by conservative irrigating techniques such as using daily "colonic washout" therapy with a bulb syringe to cleanse their colons every morning so that they are not incontinent during the day. Other patients may wish to utilize an antegrade continence enema (ACE) procedure, whereby they perform colonic irrigation through a cutaneous appendicostomy in order to prevent fecal incontinence (Dolejs SC, Smith JK Jr, Sheplock J, et al. Contemporary short- and long-term outcomes in patients with unremitting constipation and fecal incontinence treated with an antegrade continence enema. *J Pediatr Surg* 2017;52(1):79–83).

In one report evaluating quality of life in patients who had undergone Hirschsprung surgery during childhood, continence was impaired as compared to controls, with a greater number of patients having continence problems for flatulence, having difficulty with respect to needing to strain, and requiring several defecations in order to completely empty (Granström AL, Danielson J, Husberg B, et al. Adult outcomes after surgery for Hirschsprung's disease: Evaluation of bowel function and quality of life. *J Pediatr Surg* 2015;50(11):1865–9). The general quality of life in patients was; however, said

to be comparable to that of controls. In another study, Rintala and colleagues showed that the functional outcome and quality of life in patients with Hirschsprung disease may deteriorate with increasing age and that constipation and fecal soiling are common late sequelae (Rintala RJ, Pakarinen MP. Long-term outcomes of Hirschsprung's disease. *Semin Pediatr Surg* 2012;21(4):336–43).

In a recent systematic review and meta-analysis, the transanal endorectal pull-through that Dr. Langer describes was found to be superior to the transabdominal approach with respect to time of operation, duration of hospital stay, and rate of postoperative constipation and incontinence (Chen Y, Nah SA, Laksmi NK, et al. Transanal endorectal pull-through versus transabdominal approach for Hirschsprung's disease: A systematic review and meta-analysis. *J Pediatr Surg* 2013;48(3):642–51). It may be that over time we will see fewer such problems as these procedures become more popular.

Managing the adult Hirschsprung patient can be difficult, that is the pediatric patient who has had surgery and has "outgrown" his pediatric health care providers. This class of patient is often "lost" in the transition of care between their pediatrician and an "adult" primary care physician or internist. Problems such as fecal incontinence are embarrassing, they are often not brought up or volunteered on behalf of the patient, and may therefore long go untreated.

Often, modification of the consistency of the bowel movement with something as simple as loperamide, for example, taking ½ tablet every day or every other day (1 mg/day) is all that is needed to improve continence. In other patients, adding an antispasmodic such as hyoscyamine may provide adequate symptom relief. Anecdotally, in selected patients, sacral nerve root stimulation may be useful for improving continence. Use of this technology has already been proposed as an aid in the initial management of such patients (Hasselbeck C, Reingruber B. Sacral nerve stimulation is a valuable diagnostic tool in the management of anorectal and pelvic malformations. *J Pediatr Surg* 2012;47(7):1466–71).

Hirschsprung disease is one of the entities that educated surgeons once upon a time thought they understood, but it has now been shown to be due to a variety of genetic mutations. More progress continues to be made as we learn about this disease and its associated enterocolitis.

Susan Galandiuk

169 Neonatal Enterocolitis and Short Bowel Syndrome

Brad W. Warner and Jacqueline M. Saito

Despite dramatic progress in the overall care of the premature infant, neonatal necrotizing enterocolitis (NEC) remains a significant cause of morbidity and mortality. The underlying cause of NEC has not yet been identified and is likely multifactorial. The pathophysiology of NEC and strategies to prevent development of NEC continue to be actively investigated. For infants who require surgical intervention, research efforts have focused on improving patient survival, minimizing intestinal loss, and assessing neurodevelopmental outcomes. Infants who require massive intestinal resection are at high risk for developing short bowel syndrome (SBS) and long-term dependence on parenteral nutrition (PN). SBS is characterized by insufficient intestinal absorptive capacity to sustain normal growth and development. The underlying cause of SBS may be acquired, as with NEC, or congenital. In conjunction with medical management, surgical intervention has an important role in the prevention and treatment of SBS complications.

NEONATAL NECROTIZING ENTEROCOLITIS

NEC is an acquired condition in which the intestine develops acute inflammation. The inflammation may affect the small intestine and/or colon in a focal, patchy, or extensive distribution, and may progress to necrosis and perforation. Risk factors for NEC include low birth weight and prematurity. Though NEC may affect full-term infants, approximately 90% of cases occur in infants born under 36 weeks' gestation. The estimated incidence of NEC ranges from 0.5 to 5 per 1,000 live births. Up to 7% of very low birth weight (VLBW) infants (birth weight <1,500 g) may develop NEC. Case fatality rates for NEC range from 12% to 30% and are higher among infants who require surgical intervention.

The pathophysiology of NEC has been the subject of intense investigation but remains incompletely understood. In retrospective studies

of NEC, the role of feeding practices (breast milk vs. formula, rate at which feedings are increased) has been examined. An infectious etiology has been suggested by clusters of NEC cases within neonatal intensive care units. Hypotension and hypoxia have been less strongly associated with NEC; however, comorbidities such as congenital heart disease, perinatal asphyxia, and respiratory distress are often present in term neonates who develop NEC. Experimental studies have explored the role of intestinal immaturity, abnormal intestinal microbe colonization, and immature regulation of intestinal circulation (Fig. 169.1). Features of the premature intestine that may confer susceptibility to NEC are abnormal or immature bowel motility, digestive capacity, epithelial barrier function, and immune function.

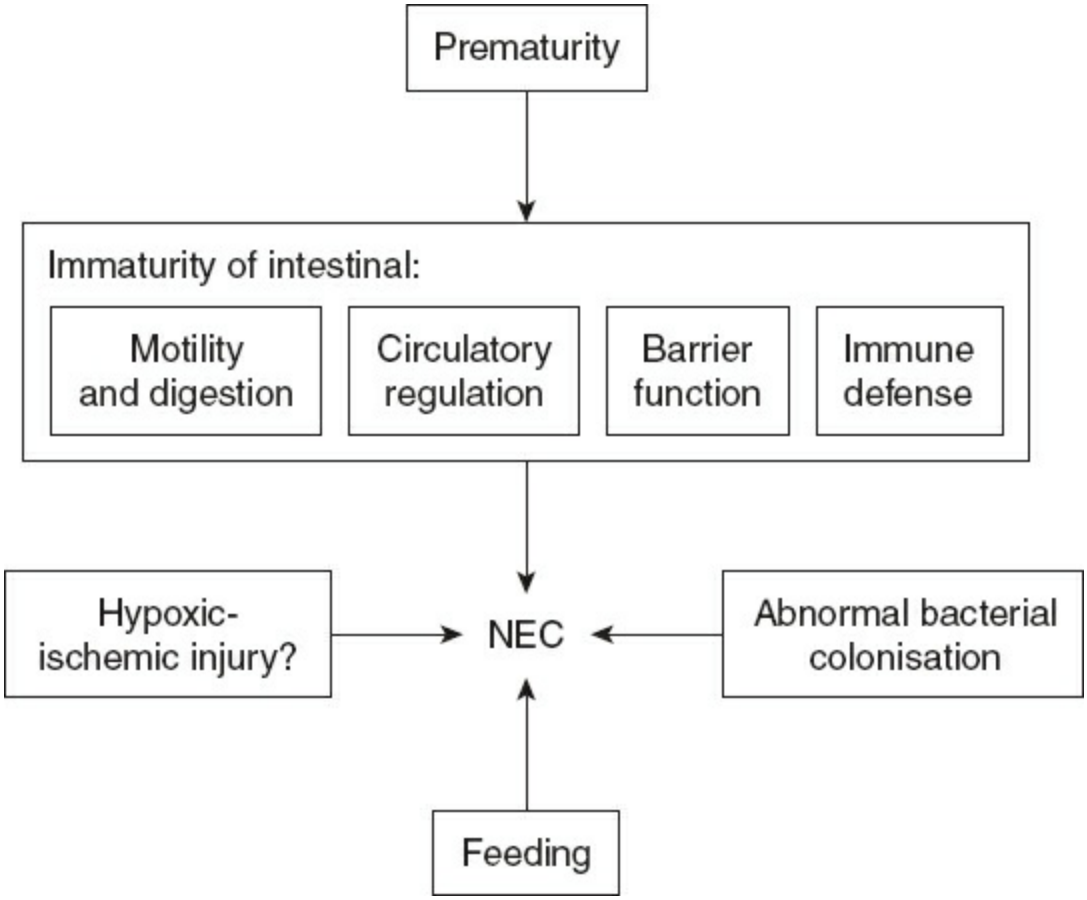

Figure 169.1. Pathophysiology of NEC. (Reprinted from Lin PW, Stoll BJ. Necrotising enterocolitis. *Lancet* 2006;368:1271–83. Copyright © 2006, with permission from Elsevier.)

Clinical Presentation and Diagnosis

The clinical presentation of NEC varies in severity and rapidity of onset.

Bell criteria for NEC categorize the signs and symptoms into suspected, definite, and severe disease (Table 169.1). Infants with NEC may have a combination of symptoms such as hypotension, temperature instability, feeding intolerance with emesis or increased gastric residuals, and bloody stool. Manifestations of NEC on physical examination are mottled skin, reflecting poor peripheral perfusion, abdominal distension, abdominal discoloration, and abdominal wall erythema and edema. Because of the thin abdominal wall in premature infants, dilated, edematous loops of intestine may be visible; leaked stool from intestinal perforation may cause a blue discoloration to the abdomen. Laboratory abnormalities are generally nonspecific and resemble those seen with neonatal sepsis, such as thrombocytopenia, leukocytosis or leukopenia, elevated C-reactive protein, metabolic acidosis, and respiratory acidosis, especially if ventilation is impaired by abdominal distension. The diagnosis of NEC is usually established with plain abdominal radiographs. Pneumatosis intestinalis, or air within the intestinal wall, and portal venous gas can be transient radiographic findings (Fig. 169.2A,B); therefore, intermittent radiographs are typically obtained when NEC is suspected. Other radiographic signs of NEC are persistent dilation of a specific bowel loop ("fixed loop"), and separation of bowel loops due to bowel wall edema. Free intraperitoneal air may be subtle on supine abdominal radiograph and can create a lucency over the liver (Fig. 169.2C), with a central longitudinal line from air adjacent to the falciform ligament; free air is typically more easily seen on left lateral decubitus or cross-table lateral views (Fig. 169.2D). Abdominal ultrasound may reveal complex ascites in the context of intestinal perforation, evidence of gas within the portal vessels, and bowel wall thickening.

TABLE 169.1 Bell Stages of Necrotizing Enterocolitis

	I. Suspected disease	II. Definite disease	III. Advanced disease
Systemic signs	Temperature instability, lethargy, apnea, bradycardia		Deterioration of vital signs, septic shock
Gastrointestinal signs	Poor feeding, ↑ gastric residuals, emesis, mild abdominal distension, occult blood in stools	Persistent occult or gross gastrointestinal bleeding, marked abdominal distension	
Abdominal radiographic findings	Distension with mild ileus	Marked intestinal distension, small bowel separation/edema, persistent bowel loops, pneumatosis intestinalis, portal venous gas	Pneumoperitoneum

Adapted from Bell MJ, Ternberg JL, Feigin RD, et al. Neonatal necrotizing enterocolitis: therapeutic decisions based upon clinical staging. *Ann Surg* 1978;187:1–7. Wolters Kluwer Health, Inc.

Treatment

Treatment of suspected and definite NEC includes bowel rest, nasogastric or orogastric decompression, broad-spectrum intravenous antibiotics, and resuscitation with intravenous fluids (Fig. 169.3). Pressor and ventilatory support is instituted as required by the infant's overall status. Unfortunately, premature infants who have respiratory distress syndrome often require abrupt escalation of ventilatory support with the onset of NEC. The optimal duration of bowel rest and antibiotics for treatment of NEC is not known. For infants who recover from NEC with medical treatment, the role of contrast studies of the intestine prior to feeding is also not well established.

Indications

The clearest indication for surgical intervention in NEC is evidence of intestinal perforation, typically diagnosed with plain abdominal radiograph showing free intraperitoneal air. Relative indications are progressive clinical deterioration, as reflected by worsening hypotension, metabolic acidosis, respiratory acidosis related to abdominal distension, or thrombocytopenia, and evidence of bowel obstruction or necrosis. On physical examination, patients may have focal abdominal wall erythema or abdominal wall discoloration indicative of segmental bowel necrosis or

loculated intestinal perforation. Fixed or persistent intestinal loop on plain abdominal radiographs may be indicative of bowel compromise.

Preoperative Planning

Consideration of patient comorbidities and stability is essential in the preoperative preparation of the infant with NEC. Even in the absence of NEC, the respiratory status of the premature neonate is often tenuous and can rapidly deteriorate. Increased oxygen and ventilatory requirements sometimes precede the clinical recognition of NEC. Tenuous respiratory status may render transport of a neonate to the operating room too risky and necessitate a bedside operation. In the face of massive intraperitoneal air, temporary decompression of the abdomen with a large-bore angiocatheter can significantly improve ventilation. Intravenous fluid resuscitation must be carefully administered, especially if a patent ductus arteriosus is present; overaggressive intravenous fluid administration may lead to worsened hypoxia, because of increased shunting through the pulmonary vascular bed. Anemia, thrombocytopenia, and coagulopathy necessitate the availability of appropriate blood products.

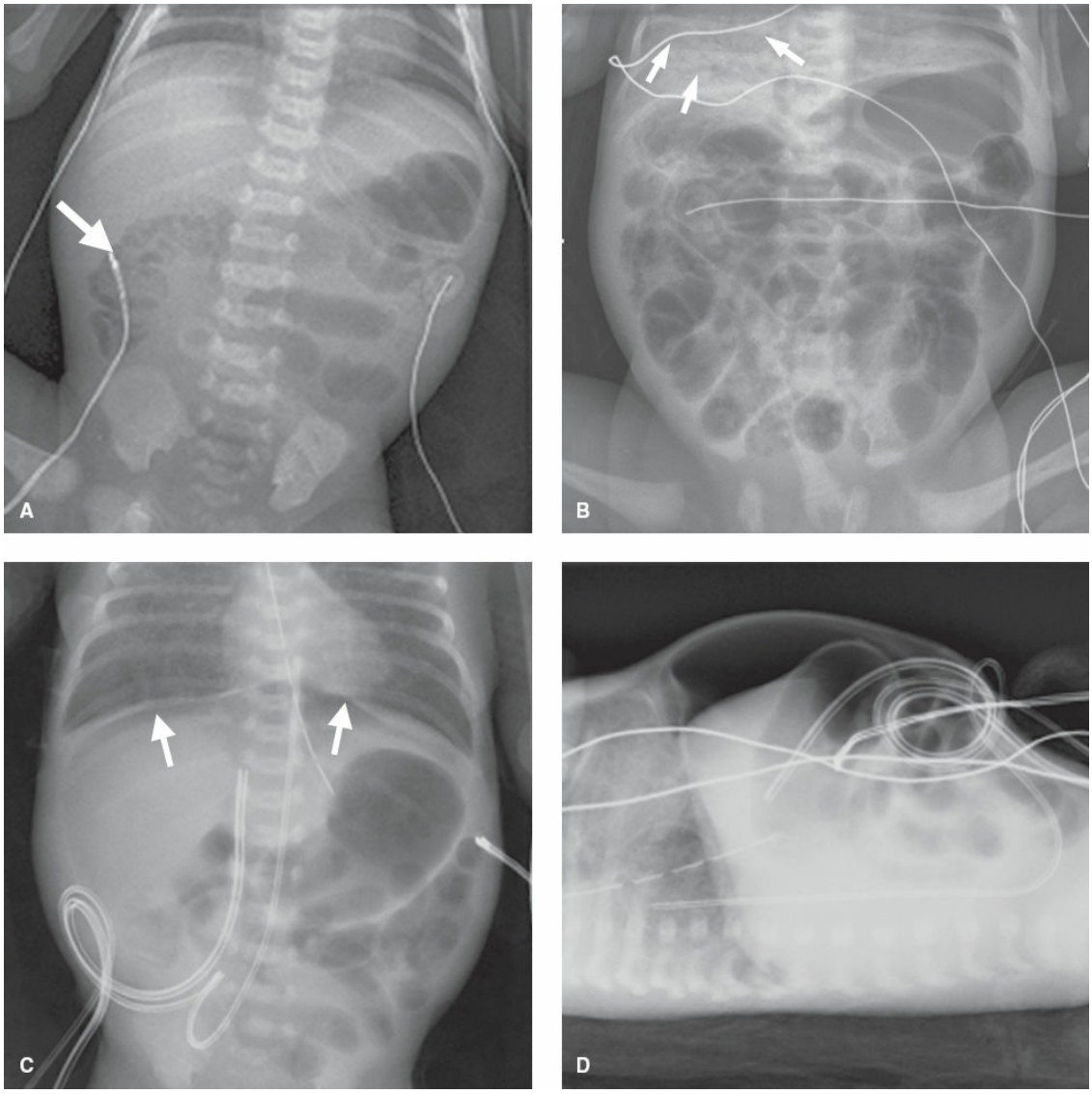

Figure 169.2. Findings associated with neonatal necrotizing enterocolitis on plain abdominal radiographs: (**A**) focal pneumatosis (*arrows*), (**B**) diffuse pneumatosis and portal venous gas (*arrows*), (**C**) free intraperitoneal air (supine) manifested as lucency over liver and under diaphragms (*arrows*), and (**D**) free intraperitoneal air (cross-table lateral view).

Often influenced by the gestational age, size, and stability of a patient, the choice of surgical procedure has been the subject of multiple studies. Laparotomy traditionally has been the mainstay for treatment of neonates with intestinal perforation. Peritoneal drainage was first described by Ein in 1977 in a series of five unstable neonates with intestinal perforation. In a follow-up report in 1980, 46% of patients survived, and 49% never required laparotomy. Over the past 30 years, mixed outcomes following peritoneal drainage or laparotomy have been reported from single

institutions; meta-analysis of these studies has shown that neonates treated with peritoneal drainage tend to be smaller and more premature. A prospective cohort study in 2006 through the National Institute of Child Health and Human Development (NICHD) Neonatal Network of extremely low birth weight (ELBW) infants (401 to 1,000 g) who developed NEC or isolated intestinal perforation reported 50% overall survival to discharge and a high rate of neurodevelopmental impairment at age 18 months (49% of survivors). Infants in the peritoneal drain group tended to have lower birth weight, were more premature, and had greater use of vasopressors, more severe hypotension, and higher ventilatory requirements. In addition, several infants in the peritoneal drain group were “too ill” for laparotomy. Unadjusted mortality was higher in the peritoneal drain group; with adjustment for confounders, the difference in mortality between infants treated with peritoneal drainage and laparotomy was diminished. In an effort to minimize selection bias, randomization to peritoneal drain or laparotomy was used in NECSTEPS, a multicenter trial of infants who developed intestinal perforation and weighed less than 1,500 g at birth; both peritoneal drain and laparotomy groups had similar 90-day mortality (35%), hospital length of stay, and need for total parenteral nutrition (TPN) at 90 days.

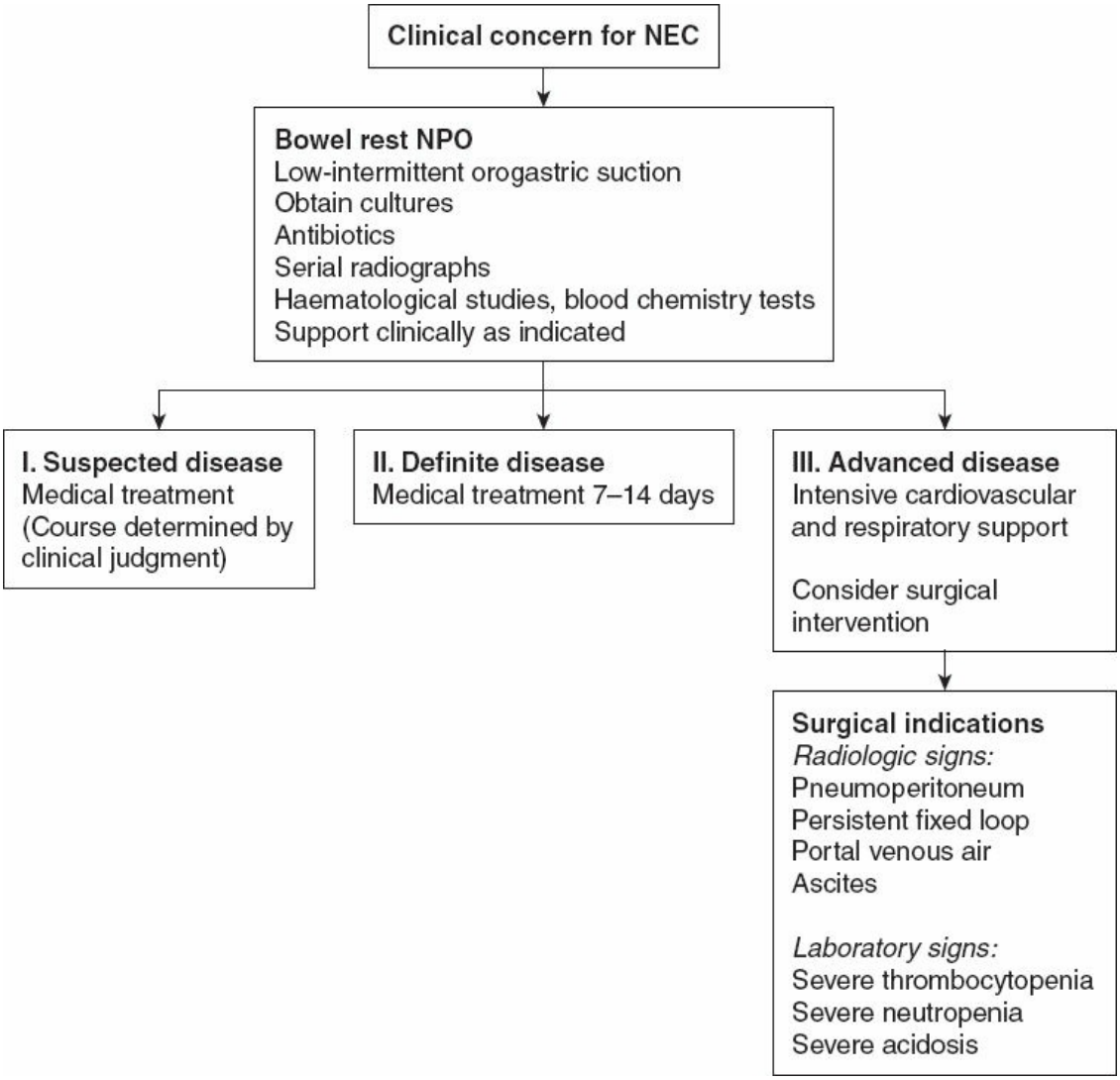

Figure 169.3. Neonatal necrotizing enterocolitis (NEC) management algorithm. (Reprinted from Lin PW, Stoll BJ. Necrotising enterocolitis. *Lancet* 2006;368:1271–83. Copyright © 2006, with permission from Elsevier.)

Surgical Technique

Peritoneal drain placement may be performed rapidly at the patient's bedside (Fig. 169.4). After administration of intravenous sedation, the abdomen is sterilely prepped and draped. Local anesthetic is infiltrated in the right lower abdomen. A small incision is made at a site that avoids the liver edge and bladder. The subcutaneous tissue and abdominal wall muscle are spread with a fine-tipped clamp, and the peritoneal cavity is entered bluntly as confirmed by release of air and feculent ascites. The peritoneal cavity may be lavaged with warmed saline through a large-bore angiocatheter. A quarter-inch plastic drain is advanced into the peritoneal cavity and secured to the skin. A second drain may be placed in the left

lower abdomen. After drainage ceases, the drain is gradually withdrawn. Clinical deterioration, bowel obstruction, and persistent fistula are among the indications for laparotomy following drain placement; up to two-thirds of patients treated with peritoneal drainage require subsequent laparotomy.

For infants undergoing laparotomy, minimizing surgical stress is a priority. Laparotomy, like peritoneal drainage, may be performed at the patient's bedside if transport to the operating room is too hazardous. Anesthetic considerations include availability of pressors and blood products to minimize hypotension, and maintenance of patient warmth. Performance of an expeditious operation to avoid hypothermia, limit blood loss, and avoid injury to the delicate premature liver is a key concern for the surgeon. Generally, a transverse incision is used for laparotomy in neonates, as the width of the abdomen generally exceeds the length. The incision may be placed above the umbilicus to leave room in the lower abdomen for potential ostomies. Because intravascular access may be limited, umbilical catheters may need to remain in place and should be avoided when making an abdominal incision.

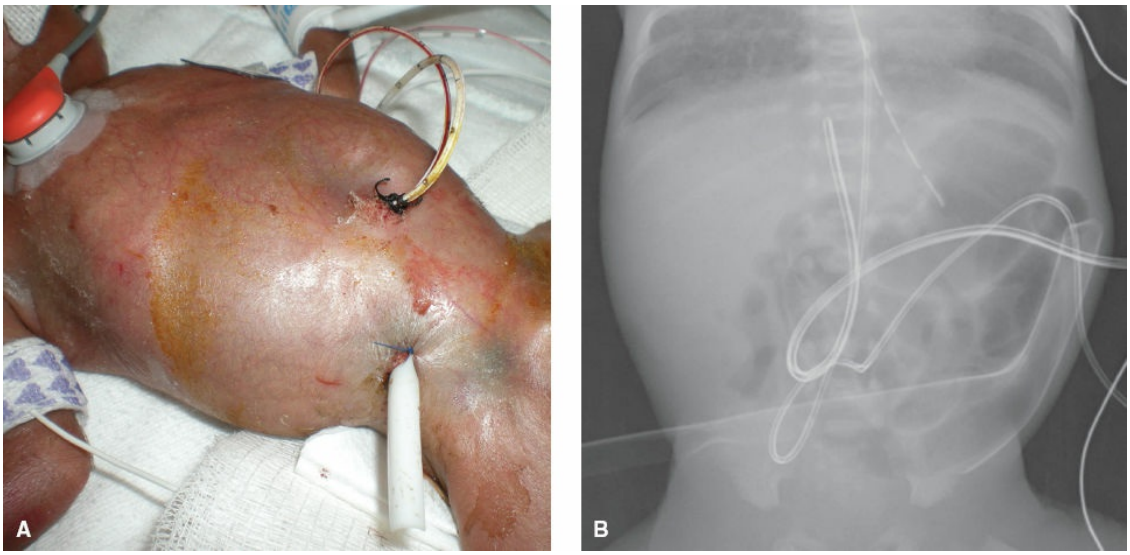

Figure 169.4. Peritoneal drain placement for intestinal perforation: (**A**) ELBW infant following peritoneal drain placement, with prominent bluish discoloration of the abdomen inferior to the drain, (**B**) peritoneal drain crosses the abdomen on abdominal radiograph.

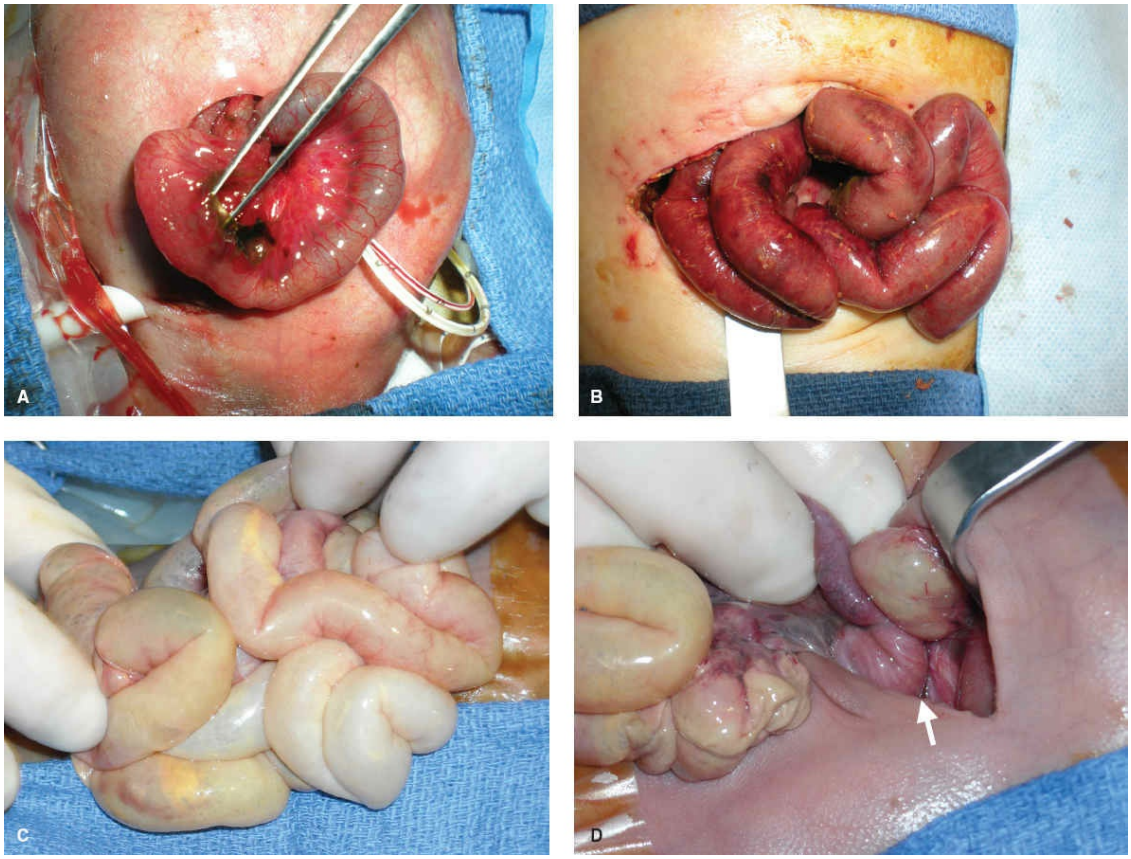

Figure 169.5. Findings during laparotomy for intestinal perforation: (**A**) isolated ileal perforation, (**B**) patchy/diffuse NEC, (**C**) extensive NEC, (**D**) extensive NEC with only viable duodenum (*arrow*).

In contrast to peritoneal drainage, laparotomy enables full assessment of the disease extent. Findings may range from isolated intestinal perforation, which typically occurs in the ileum and may represent a distinct disease process, to pan-intestinal necrosis (Fig. 169.5). For focal disease, options include repair (patch/imbricate), resection with anastomosis, and resection with ostomy. Ostomy creation is often selected because of concern for the additional time required for intestinal anastomosis and inadequate healing postoperatively. In patchy or extensive disease, a key priority is preservation of intestinal length to avoid SBS. Second-look laparotomy may be used for reassessment of intestine with marginal viability at the initial operation. If multiple intestinal resections are performed, anastomoses may be created distal to a protective ostomy and stented with a tube. Ostomy placement can be challenging due to the limited space on the premature infant's abdominal wall. For markedly edematous infants, the laparotomy incision may be left open, closed loosely with prosthetic mesh sewn to fascia, or closed at the

level of the skin only. When the skin is left open, the wound may be covered with a sterile dressing or wound vacuum. Following recovery from NEC, laparotomy may be required for intestinal obstruction from strictures (Fig. 169.6) or adhesions, or persistent drainage of stool from a peritoneal drain site.

Postoperative Management

Immediately following peritoneal drain placement or laparotomy, supportive care includes intravenous antibiotics, pressor support, ventilatory support, and transfusion of blood products as needed to correct anemia, thrombocytopenia, and coagulopathy. Patients are continued on intravenous fluids and PN, with initiation of feedings after recovery of bowel function and as permitted by patient stability. In the face of severe comorbidities associated with prematurity and extensive intestinal necrosis, an ethical discussion regarding continuation of aggressive care may be warranted. Ostomy closure is generally delayed to allow for infant growth, stabilization of hemodynamic and respiratory status, and maturation of intra-abdominal adhesions.

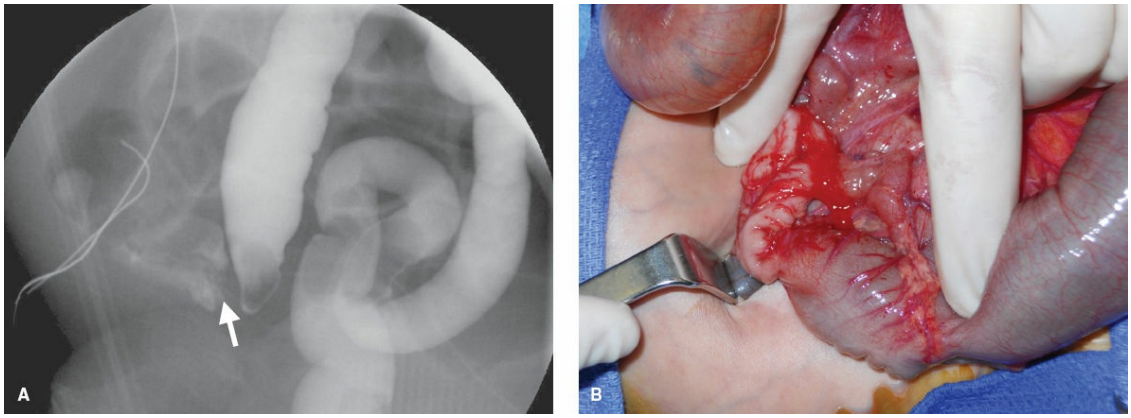

Figure 169.6. Stricture following episode of medically treated neonatal necrotizing enterocolitis: (**A**) contrast enema revealing ascending colon stricture with small amount of contrast within proximal colon (*arrow*), (**B**) intraoperative photograph of ascending colon stricture with proximal dilation of small bowel and colon.

Complications

The most concerning complication in the treatment of NEC is death. Mortality is high among infants with NEC who require surgical

intervention, with only 50% survival to hospital discharge. Early complications, such as intra-abdominal abscess, intestinal stricture formation, and intestinal obstruction, may occur with both peritoneal drain placement and laparotomy. Laparotomy wounds may develop superficial infection and fascial dehiscence. SBS and neurodevelopmental impairment are among the most extensively studied long-term outcomes. The length of residual intestine correlates with survival and ability to wean off of PN. For VLBW (<1,500 g birth weight) infants, meta-analysis has revealed increased risk of neurodevelopmental impairment among infants who had NEC compared with those without NEC, and among infants who had surgically treated NEC compared with those with medically treated NEC.

SHORT BOWEL SYNDROME

SBS occurs when intestinal mass is insufficient for enteral absorption of nutrients necessary to support normal growth and development. The diagnosis of SBS is based on intestinal function rather than absolute intestinal length. Individuals with SBS require support with PN chronically, though the minimum duration of PN administration is not uniformly defined in the SBS literature. The incidence of SBS is estimated as 1,200 per 100,000 live births. Common underlying causes of pediatric SBS are NEC, intestinal atresia (multiple or extensive), complicated gastroschisis (with bowel necrosis or atresia), volvulus associated with intestinal malrotation, and long-segment Hirschsprung disease. In the older child, traumatic injury, Crohn disease, and vascular thrombosis may lead to massive intestinal loss. The distribution of underlying etiologies for SBS varies geographically and may reflect differences in the aggressiveness with which extremely premature infants receive care. With the development of PN over 40 years ago, the survival of children with SBS markedly improved and is currently estimated at 73% to 89%.

Massive intestinal resection results in dramatic changes in intestinal morphology and function, both experimentally and clinically. The remaining intestine undergoes “bowel adaptation,” a process in which the bowel dilates and thickens macroscopically, and has increased villus height and surface area microscopically. In terms of function, the intestinal transit time slows, and enterocyte carrier capacity increases. Clinically, this results in the ability of SBS patients to gradually increase enteral absorption of nutrients and gradually decrease dependence on PN. Overall, small bowel length and patient age affect the ability to wean off of PN; the

presence of the ileocecal valve and underlying cause of SBS may also affect this process. Experimentally, specific nutrients such as long-chain fatty acids may enhance bowel adaptation. Strategies to increase bowel adaptation, such as administration of growth hormone, GLP-2 (glucagon-like peptide 2), and glutamine, have been explored with mixed results.

Treatment

When an infant or child is recognized to have shortened bowel length and potential for development of SBS, the focus of early treatment is bowel preservation and placement of a tunneled silastic central venous catheter in preparation for PN administration. If possible, ligation of major veins should be avoided during central venous catheter placement to preserve sites for future catheters. In the initial weeks to months following massive intestinal resection, the primary goal of medical therapy is to limit gastrointestinal losses of fluid, electrolytes, and nutrients. Treatment is multifaceted and includes proton pump inhibitors to minimize gastric hypersecretion, antimotility agents to slow intestinal transit, bile acid binders to decrease steatorrhea and bile salt diarrhea, and elemental formulas to minimize nutrient malabsorption. Despite its complex composition, breast milk contains growth factors that potentially enhance bowel adaptation and may be favored over elemental formula.

For patients with established SBS, placement of a gastrostomy and closure of ostomies may facilitate enteral tolerance. Tube feedings are often necessary for infants with oral aversion, and may help maximize enteral intake through administration of continuous and nocturnal tube feedings. In addition, infants and children may be adverse to drinking elemental formulas, which are not known for their taste. By maximizing intestinal length, ostomy closure has been associated with increased likelihood of weaning off of PN.

Complications of SBS

Care of the SBS patient must be intensive due to the range of potential complications. Many SBS complications directly result from absence of intestinal length. Early after intestinal resection, SBS patients are prone to fluid–electrolyte abnormalities; as bowel adaptation occurs, malabsorptive diarrhea tends to subside. However, SBS patients remain at risk for profound dehydration and electrolyte disturbances with acute conditions such as viral gastroenteritis and may temporarily require supplemental

intravenous fluids and bowel rest. Due to malabsorption, growth failure in weight and height are often chronic problems for SBS patients. Careful monitoring of growth is imperative, with provision of calories and nutrients in the form of PN and supplemental enteral nutrition when failure to thrive is detected. Depending on the absence of specific regions of intestine, SBS patients are susceptible to vitamin and micronutrient deficiencies, and may require supplementation of vitamin B12, zinc, iron, or fat-soluble vitamins (A, D, E, K). With bowel adaptation, the small intestine tends to progressively dilate and have slower motility. As a consequence, bacteria not normally present in the small intestine may overgrow and lead to inflammation; bacterial overgrowth can lead to decreased fluid and nutrient absorption and gaseous distension, which are manifested by watery diarrhea and cramping. Bacterial overgrowth is often diagnosed by clinical symptoms and treated with cycled oral antibiotics. Caused by fermentation of malabsorbed carbohydrate by colonic bacteria, D-lactic acidosis presents with weakness and mental status changes, such as confusion, slurred speech, and ataxia, and is treated with intravenous hydration and oral antibiotics. Over time, SBS patients may develop osteopenia due to a combination of vitamin D deficiency and calcium malabsorption. Oxaluria may occur when malabsorbed fat is metabolized by colonic bacteria and can lead to nephrolithiasis.

Parenteral nutrition-associated liver disease (PNALD) is a particularly vexing problem for the SBS patient. PNALD can progress from fibrosis to liver failure and has been among the primary causes of death in SBS. The pathophysiology of PNALD is not well established and may be related to patient and PN characteristics. Contributing factors include liver immaturity, as SBS patients born prematurely are at higher risk for PNALD, disruption of enterohepatic circulation of bile acids, the composition of PN, and recurrent sepsis. In terms of PN composition, excessive energy intake, specific amino acids and lipids, and disrupted glucose homeostasis are among the potential causes of PNALD. Recently, lipid composition and dose have been specifically implicated in PNALD development. Current parenteral lipid preparations in the United States are derived from soy and are primarily composed of omega-6 fatty acids that may be pro-inflammatory. Reversal of PNALD has been reported with use of a low dose (0.5 to 1 g/kg/d) of lipid derived from fish oil that is rich in omega-3 fatty acids. It remains unclear whether the beneficial effect seen with low-dose fish-oil lipid is related to reduced hepatic inflammation

from omega-3 fatty acids or lowered lipid dose itself.

While PN administration is required, the SBS patient is at risk for central venous catheter-associated complications. Sepsis, especially with Gram-negative bacteria and yeast, can be recurrent and severe. Like PNALD, catheter-associated sepsis is included among the most common causes of death in SBS patients. The chronic presence of an intravascular foreign body can lead to venous thrombosis, which can pose a challenge when ongoing central venous access is needed. Catheter breakage and occlusion are common complications of chronic central venous catheters; fortunately, central venous catheters can often be salvaged with repair kits and thrombolytic therapy.

Though it may sound trivial in comparison with liver disease and sepsis, skin breakdown can be a significant of source of misery for SBS patients. Skin breakdown often occurs with leakage of fluid around gastrostomy tubes or under ostomy appliances, or with profuse diarrhea. Desquamation can be extensive and painful; though skin breakdown can occur rapidly, healing of the affected skin can be a slow and challenging process. Prevention by monitoring the fit of gastrostomies and ostomy appliances and aggressive treatment of early skin breakdown with thick ointments are imperative; recognition and treatment of yeast rashes with topical ointment or powder are also important.

Bowel Lengthening Procedures

Intestinal dilation that occurs as part of bowel adaptation can be problematic when associated with bacterial overgrowth. Bowel tapering has been used to reduce stasis and enhance motility. However, removal of a portion of the intestine in a SBS patient is unappealing. Bowel lengthening procedures capitalize on the intestinal dilation seen with bowel adaptation to improve motility and preserve absorptive surface area while effectively increasing intestinal length. The primary indication for bowel lengthening procedures is persistent PN requirement despite bowel adaptation and maximal medical therapy. Bowel dilation of a minimum 4- to 5-cm diameter must be present and can be assessed with contrast studies. Two procedures are currently used for bowel lengthening. Longitudinal intestinal lengthening and tailoring (LILT) was described by Bianchi in animals in 1980 and in a series of patients in 1984. Kim reported serial transverse enteroplasty (STEP) in animals and cases in 2003. Both procedures effectively increase the intestinal surface area-to-

volume ratio, which may improve motility and absorption while decreasing bacterial overgrowth.

Surgical Technique

Both LILT and STEP are performed through a laparotomy incision. Because patients have typically undergone prior laparotomies, the operations often begin with extensive lysis of adhesions. Often called the Bianchi procedure, LILT involves longitudinal division of the bowel along a midline intervascular plane, which is made possible by separation of the mesenteric blood vessels into two leaves when entering onto the bowel wall (Fig. 169.7). After bluntly separating the mesenteric blood vessels adjacent to the dilated small intestine, the bowel is divided to form two smaller tubes or “hemi-loops” sewn by hand or using a GIA stapling device. Intestinal continuity is reestablished with isoperistaltic anastomoses in an S-shape or loop.

STEP alters the surface area-to-volume ratio of the dilated bowel by converting one large tube into a narrower zigzag (Fig. 169.8). The antimesenteric surface of the dilated small bowel is marked. The goal is to create a lumen that is uniformly 2 cm in diameter. A small mesenteric window is created adjacent to the small bowel at 2-cm intervals. Oriented perpendicular to the mesentery, a GIA stapler is applied partially across the bowel with 2 cm left uncut. Serial applications of the GIA are fired, separated by 2 cm on alternating sides. A stitch may be placed for reinforcement of the vertex of the staple firings. The increase in effective bowel length correlates with the degree of bowel dilation.

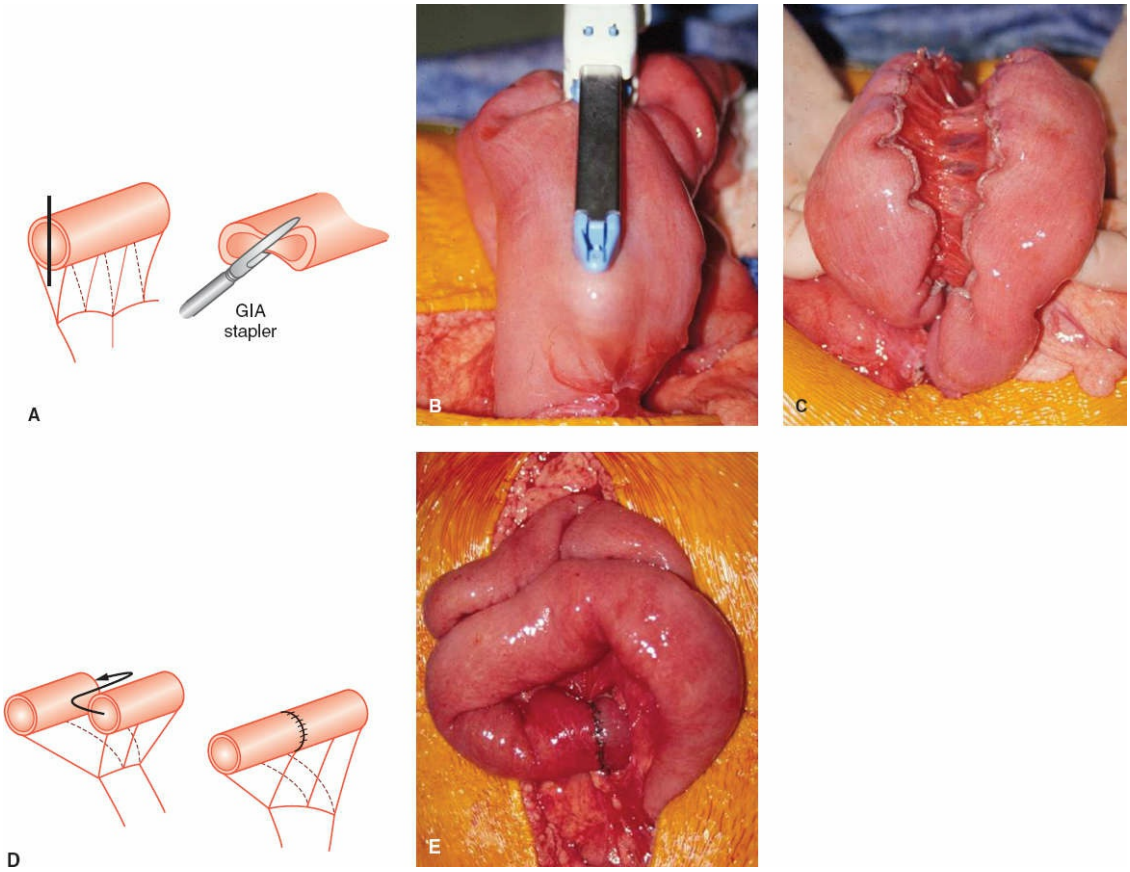

Figure 169.7. Longitudinal intestinal lengthening and tailoring, or Bianchi procedure: (**A**) intramesenteric plane developed adjacent to dilated small intestine; (**B**) GIA stapling device applied to oppose intramesenteric plane and antimesenteric border of dilated small intestine; (**C**) resulting small intestine hemiloops; (**D**) and (**E**) isoperistaltic anastomosis created between hemiloops.

Postoperative Management

Postoperatively, patients are supported with intravenous fluid and PN until bowel function resumes. Contrast studies may be obtained to confirm bowel patency and check for anastomotic or staple line leaks. Enteral feedings are gradually initiated. In terms of functional outcomes following bowel lengthening procedures, a trend toward more rapid weaning of PN following STEP compared with LILT has been reported.

Complications of Intestinal Lengthening

Anastomotic or staple line leak and intestinal obstruction have been reported as early complications for both LILT and STEP. Bowel necrosis may occur after LILT, likely due to damage to the mesentery during dissection prior to longitudinal division of the bowel. Late complications

include adhesive bowel obstruction, stricture, and recurrent bowel dilation. Recurrent bowel dilation may be treated with STEP following LILT or initial STEP. Interloop fistulas have been found following LILT.

Intestinal Transplant

For SBS patients who have severe complications related to dependence on PN, intestinal transplant offers some hope for a future free of PN. Indications for transplant referral include PNALD, thrombosis of major venous access (more than two of subclavian, jugular, or femoral veins), recurrent catheter-associated sepsis, and frequent severe dehydration or electrolyte losses caused by the underlying disease. Intestinal transplant may be performed alone, in combination with liver, or with other abdominal organs (multivisceral). Though refinement of immunosuppression is reducing the incidence of acute and chronic rejection, the current 5-year pediatric patient survival rate is approximately 55%. Survival may be influenced by the underlying cause of intestinal failure and may be better with volvulus as compared with other causes of pediatric SBS. Other complications seen in association with intestinal transplant are infections, posttransplant lymphoproliferative disease, and graft-versus-host disease. Limited availability of donor organs has also led to significant mortality in pediatric SBS patients while awaiting transplant.

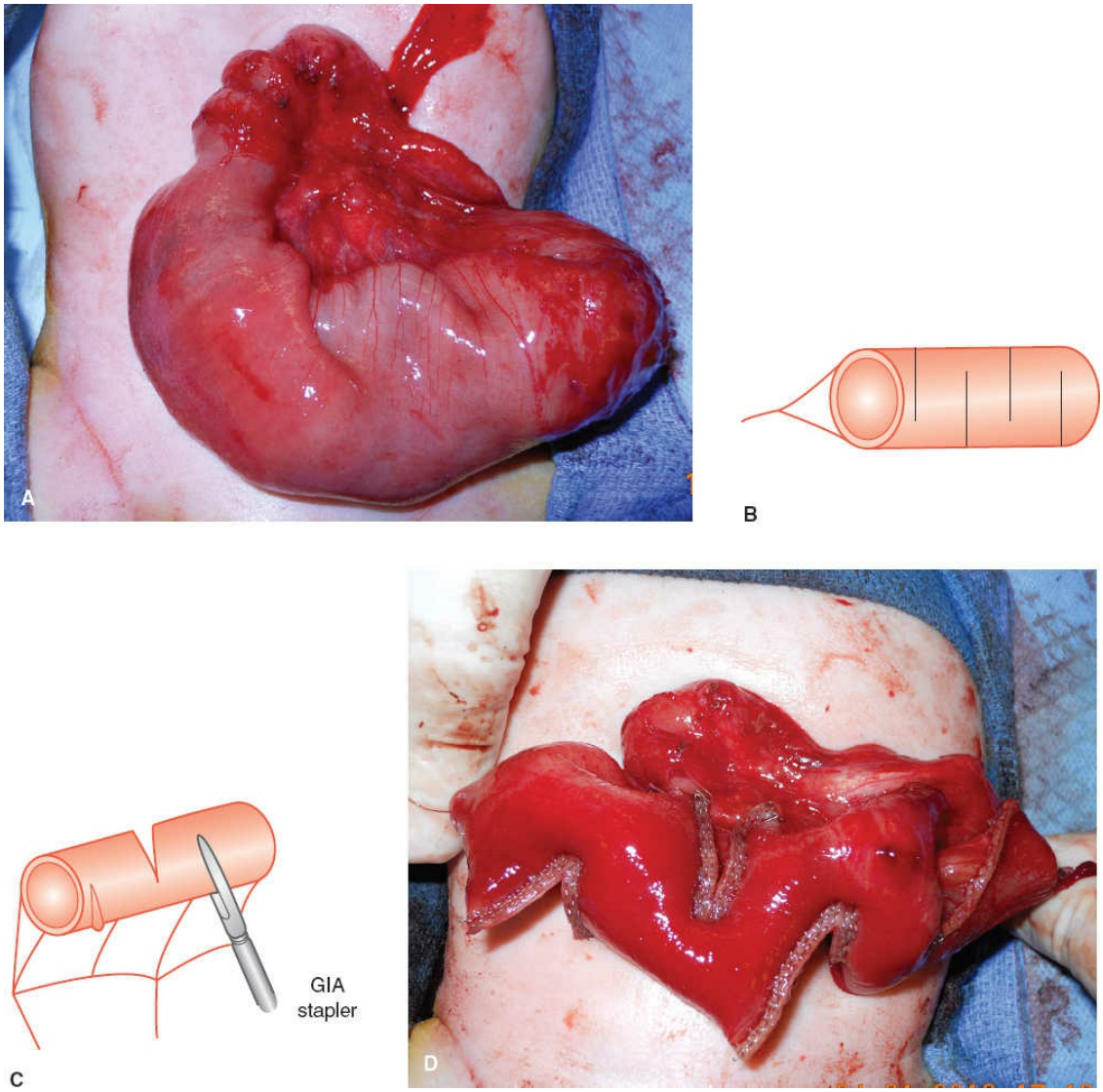

Figure 169.8. Serial transverse enteroplasty (STEP) procedure: (**A**) dilated jejunum in a neonate born with intestinal atresia (**B**) schematic of STEP procedure to create a 2-cm channel (**C**) GIA stapler is applied on alternating sides of the dilated small intestine, oriented perpendicular to the small bowel mesentery (**D**) appearance of small intestine after completion of the STEP procedure. Photographs courtesy of Shawn Larson, MD.

Suggested Readings

Bianchi A. Intestinal lengthening: an experimental and clinical review. *J R Soc Med* 1984;77:35–41.

Duro D, Kamin D, Duggan D. Overview of pediatric short bowel syndrome. *J Pediatr Gastroenterol Nutr* 2008;47:S33–6.

Goulet O, Ruemmele F. Causes and management of intestinal failure in children. *Gastroenterology* 2006; 130:S16–28.

Henry MC, Moss RL. Neonatal necrotizing enterocolitis. *Semin Pediatr Surg* 2008;17:98–109.

Kim HB, Fauza D, Garza J, et al. Serial transverse enteroplasty (STEP): a novel bowel lengthening procedure. *J Pediatr Surg* 2003;38:425–9.

Lao OB, Healey PJ, Perkins JD, et al. Outcomes in children after intestinal transplant. *Pediatrics* 2010;125:e550–8.

Lin PW, Stoll BJ. Necrotising enterocolitis. *Lancet* 2006; 368:1271–83.

Moss RL, Dimmitt RA, Barnhart DB, et al. Laparotomy versus peritoneal drainage for necrotizing enterocolitis and perforation. *N Eng J Med* 2006;354:2225–34.

Petty JK, Ziegler MM. Operative strategies for necrotizing enterocolitis: the prevention and treatment of short-bowel syndrome. *Semin Pediatr Surg* 2005;14:191–8.

Sudan D, Thompson J, Botha J, et al. Comparison of intestinal lengthening procedures for patients with short bowel syndrome. *Ann Surg* 2007;246:593–604.

EDITOR'S COMMENT

One of the most challenging situations in pediatric surgery remains the premature infant with neonatal enterocolitis or other bowel problems. Fortunately, there is now considerable expertise in the care of these tiny infants with a reasonable salvage. Nucci et al. (*J Gastrointest Surg* 2008;12:429–36) described the fate of 389 pediatric patients with a median age of 1 year (range from 1 day to 28.8 years). They described their effort as interdisciplinary, utilizing parenteral and enteral nutrition, surgical lengthening procedures, and finally intestinal transplantation. They found three features that were predictive of weaning from TPN:

1. Increased mean bowel length in patients with gastroschisis: 44 cm versus 23 cm (P <0.05).
2. In those patients with intestinal atresia, increase in bowel length 35 cm versus 20 cm (P <0.01).
3. A decrease in bilirubin to 6.1 versus 12.7 mg/dL in neonatal enterocolitis (P <0.05).

If the patients were able to wean from TPN, the average time of weaning was 2.5 years. Further, 95% of those who were weaned survived 5 years while only 52% of those who did not wean survived. In addition, in 25 patients who underwent bowel lengthening procedures, eight weaned from TPN without intestinal transplantation.

Another center dealing with relatively large numbers of these patients and using a total bilirubin of >2 mg/dL as a marker for liver disease was reported by Cowles et al. (*J Pediatr Surg* 2010;45:84–88). When the patients were admitted,

76 of the 93 reviewed retrospectively had a total bilirubin of >2.0 mg/dL indicating some intestinal failure-associated liver disease. Treatment between 2003 and 2009 consisted of cycling of parenteral nutrition, limiting lipid infusion, enteral stimulation, use of ursodeoxycholic acid, and finally surgical intervention "when necessary." The total bilirubin normalized in 57 of 76 children with elevated total bilirubin at the time of referral, but total bilirubin remained elevated in 19. Normalization of total bilirubin resulted in the mortality of 5.2%. Transplantation was required in 5.2%. When total bilirubin remained elevated, in about 19 children, mortality was 58% and transplantation occurred in 58%. Fish oil was not utilized in this group despite the fact that for at least 3 years in which these children were treated it could have been used as a desperate measure. The response to this paper was remarkably brief in the discussion period and the absence of commentary speaks volumes. In the discussion section of the paper, the question of Omegaven was raised. However, this product was possibly not available in all centers. It is possible but unclear that the 19 patients in this study who did not respond to treatment would have benefited from a fish oil-based lipid emulsion. The obvious question to me is why didn't the patients receive Omegaven? I find it difficult to believe that "Omegaven was too expensive" for the Morgan Stanley Children's Hospital. Transplants were not thought to be very expensive. The only reason I can think of as to why fish oil-based lipid emulsions were not used in the 19 children who did not normalize their bilirubin, most of whom died, is that the authors did not originate the therapy. This in my view, if it is true, is a disgrace and is one of the things in our current situation when attention is focused on the medical profession, which gives us a bad name. I could say more, but this is a book which may be read by polite company.

Gura et al. (*Pediatrics* 2008;121:e678–86) compared 18 patients with reversal of cholestasis who were given Omegavens with 21 historical controls with bilirubin >2.0 mg/dL who had intestinal failure-associated liver disease and had not received Omegaven. In the current group, there were two deaths without any liver transplantation, while in the historical control group, there were seven deaths and two patients requiring transplantation. The obvious question to the authors in what is a series of papers is why not do a randomized prospective trial? The authors state that this type of study would be difficult to conduct, because "some may consider it unethical to perform a study where children with preexistent parenteral nutrition liver injury could potentially be randomly assigned to a treatment group in which they would continue to receive a soybean oil-based parenteral lipid emulsion." I would argue that if this break with past practices is to be fully accepted, then one would have to design a trial in which patients with further deterioration on a soybean oil-based lipid emulsion would be entered provided there was a rescue provision. Failing this, there will still be children dying for all of the reasons given in the Cowles paper previously quoted, and that is not right.

An interesting paper reported by Malcolm et al. (*J Pediatr Surg*

2007;42:1811–5) in which dietary fat was added to 10 neonates with necrotizing enterocolitis or isolated intestinal perforations requiring temporary enterostomies. Paradoxically, administering dietary lipids decreased the excretion of ostomy output from 29.3% to 19.8% of dietary intake, a relative decrease of 32%. Daily weight gain increased from an average of 7.7 to 26.8 g/day (P <0.05). Patients with the greatest ostomy output benefitted the most. They report this result as a paradoxical effect and attribute it to "a jejunal and ileal brake," which has been well described and is associated with decreased bowel motility. Peptide YY has been implicated and follows a neurohormonal pathway. I have an alternative explanation based on some experience in patients who have had denudation of the bowel lining due to an ischemic event and believe that part of the beneficial effect may simply be increased number of calories enabling increased protein synthesis and enterocyte proliferation, resulting in a greater absorptive surface. It is likely that multiple beneficial effects are operant.

Despite the progress in salvaging low birth-weight preterm infants with surgical short bowel syndrome, Cole et al. (*Pediatrics* 2008;122:e573–82) reviewing a huge database of the National Institute of Child Health and Human Development Neonatal Research Network evaluated survivors at 18 to 22 months. Although the incidence of short bowel syndrome is less than 1%, necrotizing enterocolitis was the most common diagnosis associated with a short bowel syndrome. At the time of evaluation between 18 and 22 months, 33% still required tube feedings and 79% had been rehospitalized at some time in the course. Importantly, these infants had growth delay and smaller head circumference than those without neonatal enterocolitis. This is probably an outcome that needs to be examined because of the lifelong necessity for support.

Finally, in very low birth-weight infants with multiple perforations, Blejter et al. (*J Pediatr Surg* 2008;43:1358–60) report on using SILASTIC stents either inserted into perforations both proximally and distally or using an appendectomy site as an exit site, sparing a resection. While only two patients are reported, they are now at 3.5 and 2 years of age, respectively, eating without restriction and with "mild developmental delays." This latter point appears, unfortunately, to be the price paid for salvaging these tiny infants. It remains to be seen what the overall price for society is.

J.E.F.

SECTION VIII

NONGASTROINTESTINAL TRANSABDOMINAL SURGERY

A THE SPLEEN

170 Laparoscopic Splenectomy

Charles E. Lucas and Anna M. Ledgerwood

DANGERS OF THE ASPLENIC STATE

The ancients considered the spleen essential for such diverse functions as laughter, humor, purification of the blood, and the maintenance of life. In contrast, many senior surgeons were taught that the spleen is a vestigial organ without function. These philosophical controversies had no clinical relevance until Riegner, in 1892, introduced the modern era of splenic surgery when he performed a successful splenectomy following a blunt injury. This 14-year-old construction worker fell from a scaffold and sustained a grade V splenic injury (Fig. 170.1) with fragments of the spleen lying free in the peritoneal cavity. This operation helped establish two principles. First, laparotomy with definitive control of bleeding, rather than extra-abdominal compression for refractory bleeding, leads to a better outcome; second, splenectomy is well tolerated, thus, laying to rest the ancient concept that the spleen was essential for life.

Early 20th century authors perpetuated the view that the spleen was without function. Pearce, in 1918, reported that 25% of animals undergoing splenectomy died from either peritonitis or pneumonitis; unfortunately, these deaths were considered unrelated to the asplenic state as reflected in his conclusion that these animals survived splenectomy with "relative impunity." Pearce also noted postsplenectomy eosinophilia and leukocytosis, of unknown significance. Shortly thereafter, Morris and Bullock documented the importance of the spleen as an immune organ. Asplenic rats, subjected to a *Pasteurella* bacterial challenge, did poorly when compared to their eusplenic controls suggesting immune incompetence. The surgical community, however, rejected these findings concluding that fears of infection after splenectomy were "poppycock"; thus, routine splenectomy for even the smallest of injuries became the

norm.

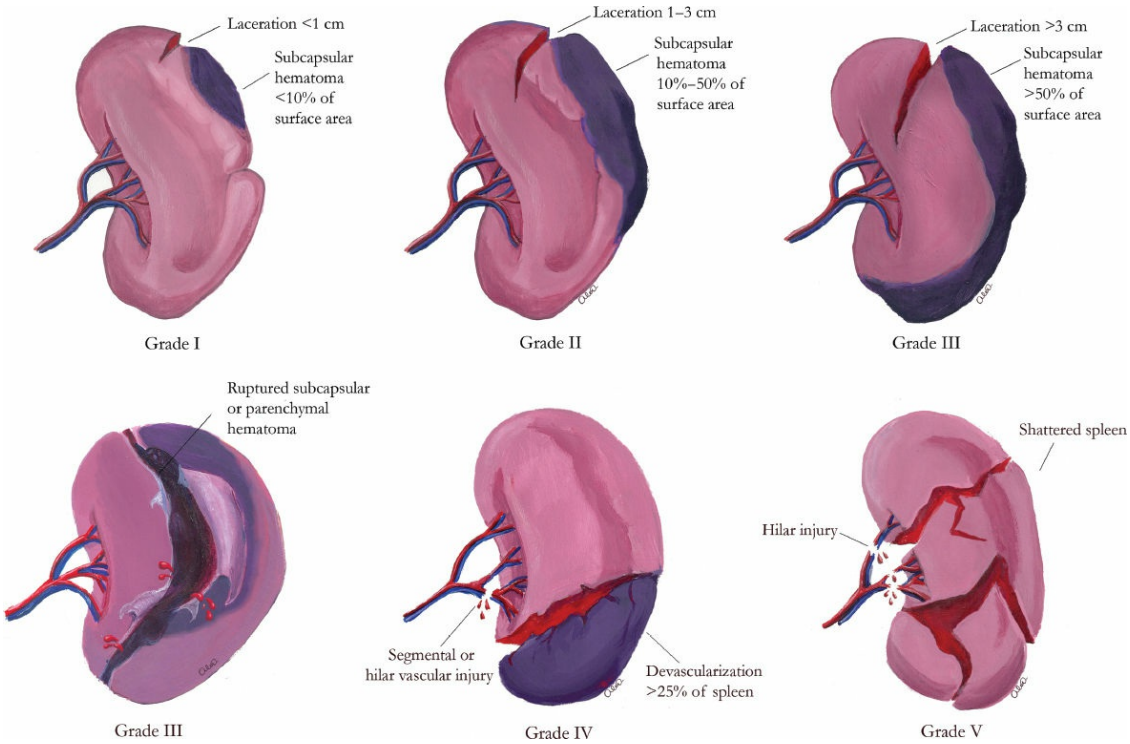

Figure 170.1. AAST grades of splenic injury.

The seed that gave rise to our current appreciation of splenic function was planted when King and Shumacker reported two deaths in five children, who died of an overwhelming postsplenectomy infection (OPSI) after splenectomy for spherocytosis. Smith, in 1957, reported the first death from OPSI following splenectomy in an injured patient without pre-existing comorbidities. Subsequent studies demonstrated that OPSI occurs in about 2% of children and 1% of adults without vaccination and frequently causes death. The common organisms responsible for OPSI are the gram-positive encapsulated bacteria, namely, *Pneumococcus*, *Meningococcus*, *Staphylococcus*, and *Streptococcus;* however, *Escherichia coli*, *Haemophilus influenza*, and other coliform organisms may lead to this syndrome. These findings led to a reassessment of splenic function.

SPLENIC FUNCTION

The spleen at birth is small and remains immature throughout the neonatal period; there are fewer lymphoid follicles and a relative absence of germ centers. Throughout childhood, the spleen slowly increases in size and reaches its maximal weight at puberty when it represents about 25% of the

total body lymphoid mass. Perfusion through the mature spleen facilitates leukocyte sequestration and the production of immunoglobulins, tuftsin, properdin, and antibodies to circulating antigens. This immunologic protection is mediated through the perifollicular lymphoid cells. The result is enhanced opsonization and phagocytosis of bacteria. The resultant enhancement of bacterial clearance is directed primarily toward the encapsulated gram-positive bacteria, but also affects gram-negative bacteria.

Immunologic efficiency correlates with the amount of spleen mass; animals with hemisplenectomy do far better than their asplenic controls, but not as well as eusplenic animals when subjected to a bacterial challenge. Furthermore, the volume of the spleen following partial splenectomy correlates directly with the antigenetic response. Thus, preservation of the maximal splenic tissue affords the best protection against OPSI. The intact spleen participates in the normal response to the polyvalent pneumococcal vaccine. Thus, vaccination is best administered before splenectomy.

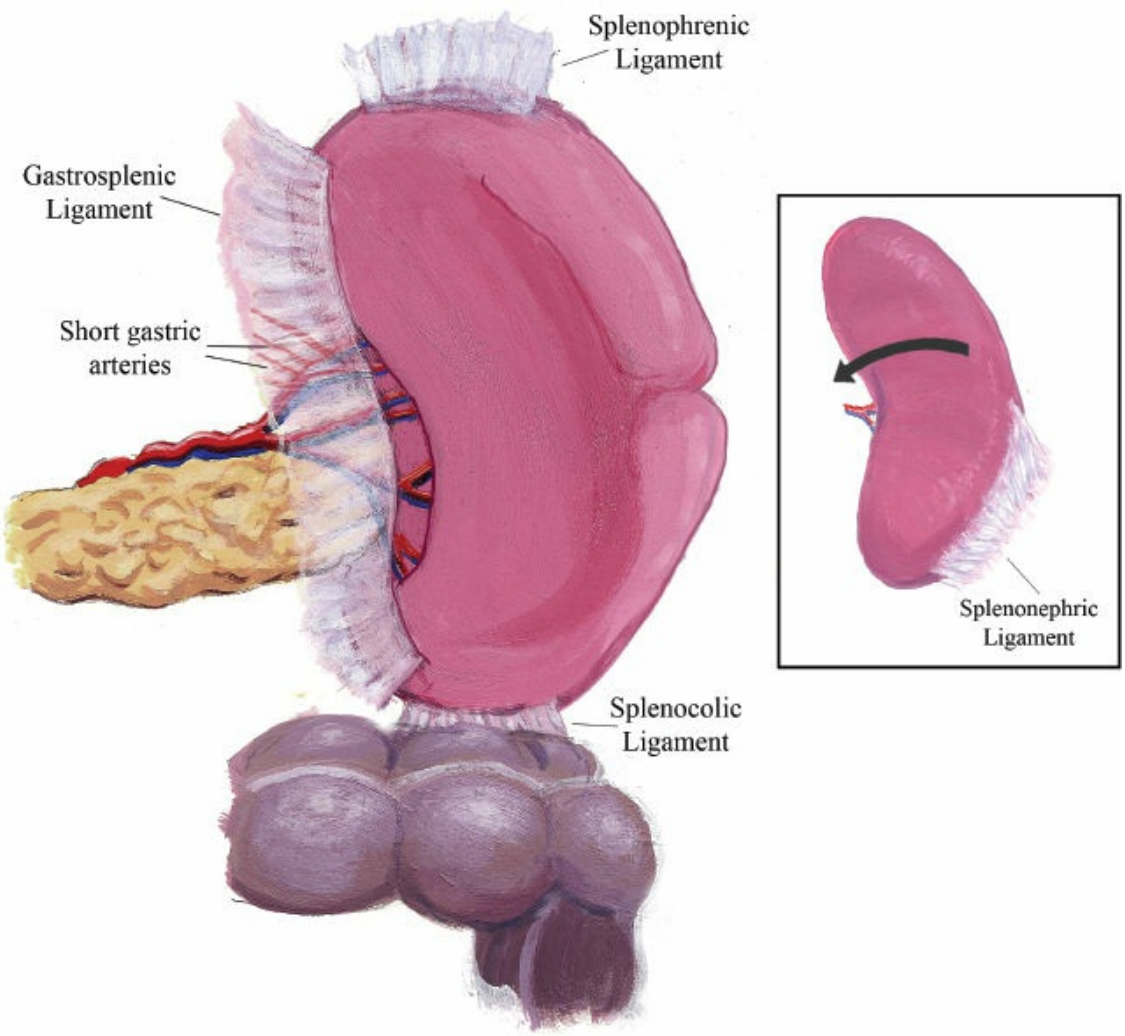

Figure 170.2. Splenic ligaments and attachments along with the splenic blood supply are shown. The gastrosplenic ligament contains the short gastric vessels that extend from the upper pole vessels and also contains the posterior gastric vessels that arise from the splenic vessels approximately 4 cm proximal to the splenic hilum. The splenocolic ligament always contains at least two small vessels, whereas the splenophrenic and splenorenal ligaments have no named vessels.

SPLENIC ANATOMY

The normal spleen is about 8 to 10 cm in longest dimension, weighs about 100 g, and lies high up in the left upper quadrant protected by the lower rib cage. The splenic hilum lies within 2 cm of the pancreatic tail and contains the branching vessels of the splenic artery and splenic vein. The superior branches of these vessels extend superiorly through the gastrosplenic ligament and attach, as the short gastric vessels, to the very proximal greater curvature of the stomach (Fig. 170.2). Other ligamentous

attachments include the superior and posterior splenophrenic ligament, the inferior splenocolic ligament, and the posterior splenonephric ligament (Fig. 170.2).

SURGICAL INCISIONS

Most injured patients undergo laparotomy in the supine position through a midline incision that gives rapid access to the peritoneal cavity and provides good visualization for all organs including the spleen. When operation is done for hemoperitoneum, rapid packing of the left upper quadrant allows one to sequentially identify any associated injuries that have a greater priority than the splenic injury. When patients with a small spleen require elective splenectomy, a left subcostal incision provides excellent exposure.

Infrequently, splenectomy is indicated in patients with myeloproliferative disease with extensive splenomegaly. The largest spleen removed by the authors weighed 26.5 kg. Massive splenomegaly requires wide exposure to all structures since bleeding from enlarged unnamed vessels can be lethal. A thoracoabdominal incision excising the eighth or ninth rib and extending medially to the linea alba allows safe exposure to the mammoth spleen. The diaphragm is divided to the hiatus. The vessels are huge with the splenocolic veins being 5 mm in diameter, the short gastric vessels 5 to 7 mm in diameter, and the splenic vein 3 to 4 cm in diameter. The wide exposure permits bloodless control of all named and unnamed vessels to prevent rapid lethal hemorrhage.

OPEN SPLENECTOMY

Once the peritoneal cavity is entered, typically through a midline incision, the actively bleeding spleen should be packed in order to obtain temporary hemostasis while full splenic exposure is accomplished. The lesser sac is entered through the greater omentum outside the arcades of the gastroepiploic vessels (Fig. 170.3). Using the nasogastric tube as a handle, one can retract the stomach anteriorly and medially, thus identifying the most proximal left gastroepiploic vessels and the short gastric vessels within the gastrosplenic ligament (Fig. 170.2). There usually are two or three short gastric vessels that are most safely controlled by ligature. As this dissection is carried superiorly along the greater curvature of the stomach, the proximal branches of the left gastroepiploic vessels may need to be divided; this facilitates the dissection near the apical fat pad and the

cardiophrenic ligament. Mobilization of the proximal stomach anteriorly and medially allows for one to visualize the short gastric vessels coming from the superior branches of the splenic artery before these branches enter into the superior segment of the spleen. Dissection of the apical fat pad helps expose and control the highest short gastric branches. Once these vessels are divided, one can see the posterior gastric artery that arises from the splenic artery and inserts on the posterior gastric wall about 2 cm medial to the short gastric vessels. Careful dissection of these vessels permits safe division and ligation. The splenic flexure of the colon is then mobilized. Typically, there will be two short vessels extending from the colonic mesentery to the inferior pole of the spleen. These are the same “aberrant” vessels that are notoriously avulsed from the splenic capsule when too much anterior and medial tension is placed on the omentum during gastric mobilization for truncal vagotomy. These vessels are always present; they should be identified and made hemostatic by coagulation or ligation prior to division.

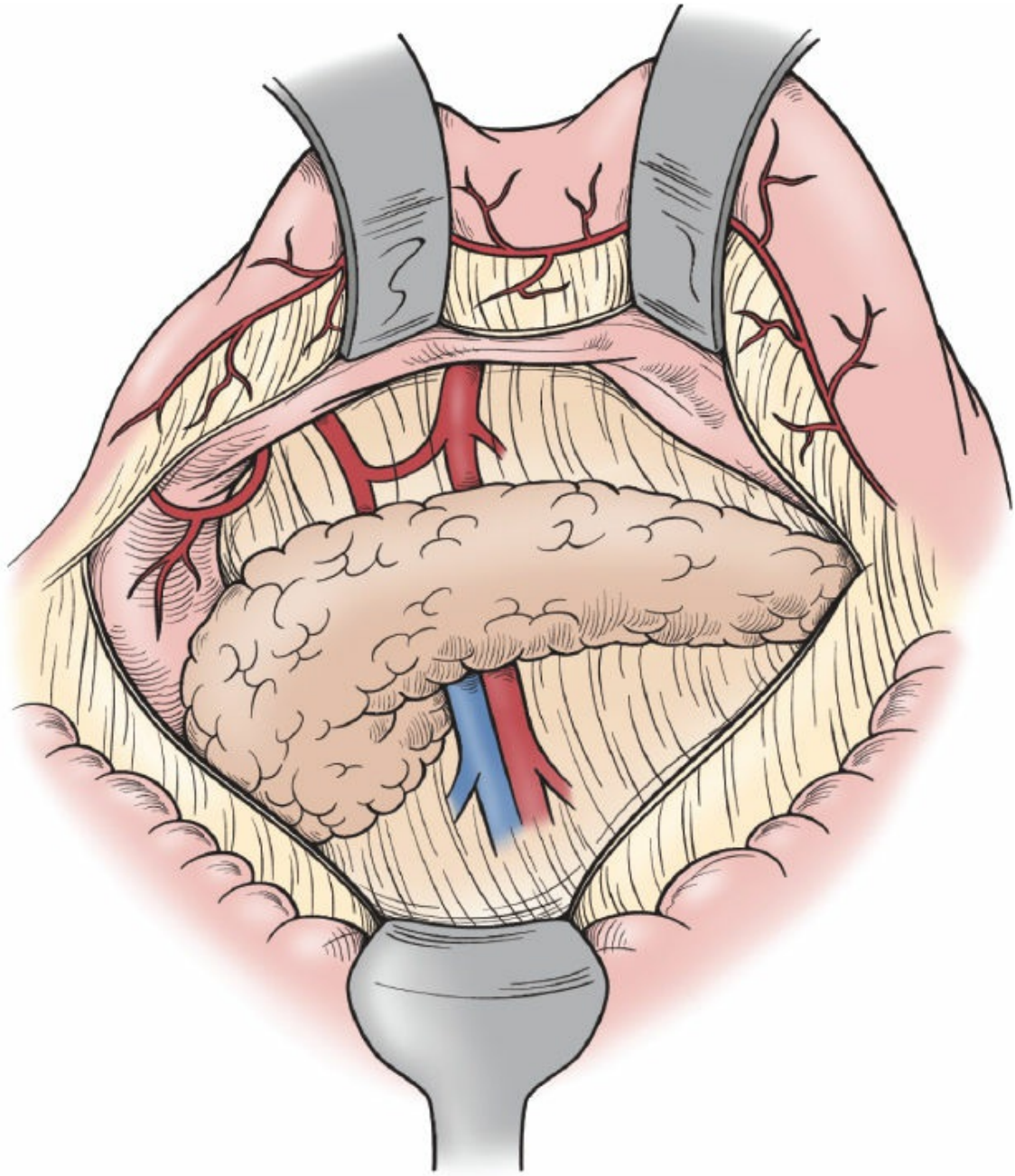

Figure 170.3. When splenic exposure is not hurried, access to the lesser sac is achieved through the greater omentum outside the arcades of the gastroepiploic vessels. Proximal dissection exposes short gastric vessels near the apical fat pad of the stomach, whereas lateral dissection exposes the splenic hilar vessels.

The spleen can then be detached from its “avascular” splenophrenic and splenonephric attachments (Fig. 170.2) remembering that small vessels are often present in these attachments; they can be controlled by electrocoagulation. Patients with portal hypertension may have extensive collaterals in this “avascular” plane, necessitating suture ligation or

ligature control. This can be achieved by dividing the ligamentous attachments approximately 2 cm from the spleen, between clamps and suture ligating each side. The spleen shares in the hyperdynamic portal hypertensive state, thereby making successful splenorrhaphy for trauma unlikely in cirrhotic patients. Such patients are served best by splenectomy. When bleeding occurs from the posterior ligamentous attachments, placement of packs posterior to the area of digital dissection controls bleeding and allows the operation to proceed as the spleen is mobilized. The plane posterior to both the spleen and the body and tail of the pancreas is then bluntly dissected, taking care to remain within this plane and not extend posteriorly, where one might injure the adrenal vessels or renal vessels. The pancreas with spleen is then gently pushed anteriorly and medially; one must never pull on the spleen in an effort to lift the pancreas (Fig. 170.4). When the injured spleen is actively bleeding, control of hemorrhage can be achieved by compressing the splenic hilum with the fingers and thumb of the left hand while the right hand is used to continue the anterior and medial mobilization of both the pancreatic body with tail and the spleen. Again, packs can be placed posteriorly in the plane that was previously occupied by these organs. This holds the spleen anteriorly and medially. When digital pressure does not control splenic bleeding, the operation likely will be hurried; this almost certainly will result in the patient requiring a total splenectomy. Therefore, this tedious and compulsive digital mobilization should be continued until the spleen has been fully delivered to the wound (Fig. 170.4).

One can then approach the branches of the splenic artery and splenic vein. When the pancreas has been fully mobilized anteriorly and medially, these vessels are more easily identified along the posterior aspect of the splenic hilum and can be individually divided and ligated. One should be careful in performing this dissection to avoid inadvertent clamping of the tail of the pancreas, which may result in subsequent pancreatitis or a pancreaticocutaneous fistula.

Prior to closing, one needs to check carefully for hemostasis. Placing a pack in the left upper quadrant allows one to assess the splenic flexure, the greater curvature of the stomach, and, finally, the tail of the pancreas. Once these areas have been confirmed to be hemostatic, the pack is removed and inspection of the posterior surface of the diaphragm is performed; oozing is controlled by electrocoagulation. Drains are not normally placed unless there is concern about refractory oozing or injury

to the tip of the pancreas.

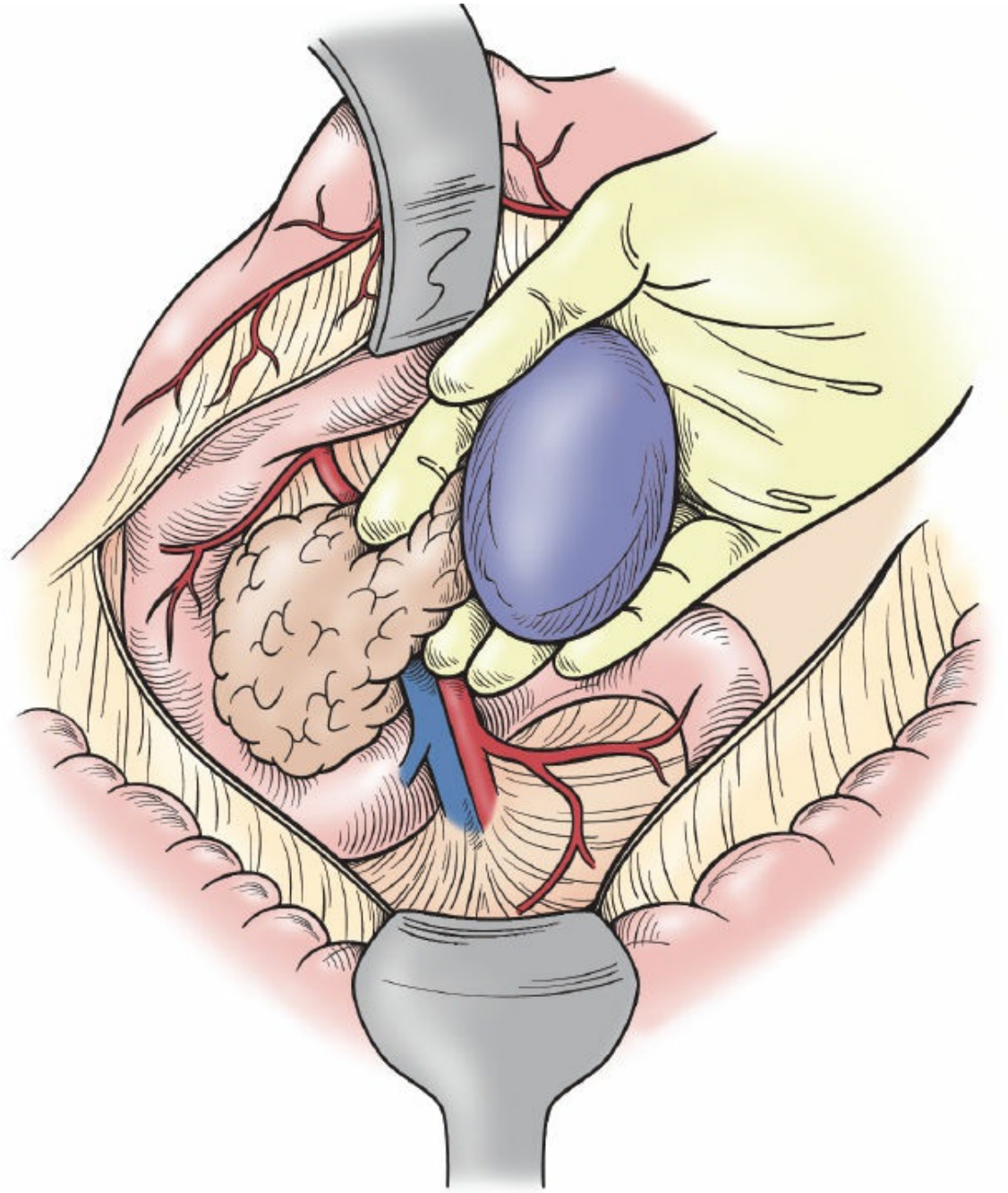

Figure 170.4. After dividing the posterior and lateral splenic attachments to the diaphragm, the plane posterior to the spleen and pancreas is digitally dissected so that the pancreas with spleen can be gently rotated anteriorly and medially. Pulling on the injured spleen will inevitably aggravate the injury, necessitating total splenectomy.

IMMUNE THROMBOCYTOPENIA PURPURA (ITP)

When the procedure is done for ITP, one enters the abdomen through a

midline incision and divides the greater omentum just outside the arcades of the gastroepiploic vessels. This permits access to the pancreas and exposure of the splenic artery as it courses along the superior posterior border of the pancreas. Ligation of this artery is recommended in patients with ITP in order to reduce splenic blood flow and continued platelet destruction. If intraoperative platelet replacement is planned, the transfusion should be delayed until the splenic artery is ligated or the splenic hilar branches are controlled. The remainder of the operation proceeds as above.

POSTOPERATIVE SPLENIC BLEEDING

When the patient has postoperative bleeding, rapid return to the operating room is the procedure of choice. Once the incision is reopened, the clots are removed from the left upper quadrant and packs are placed. One should then sequentially look for bleeding from the small vessels arising from the splenic flexure of the colon, from the gastrosplenic ligament, namely, the short gastric vessels and the posterior gastric vessels, and the left gastroepiploic vessels. Bleeding sites should be suture ligated. Inversion of the greater curvature of the stomach at this point with seromuscular sutures will prevent the development of a gastric fistula. Seldom is the bleeding coming from the branches of the pancreatic vessels that are inspected next. Any bleeding at this site is best controlled by suture ligature. Lastly, the left upper quadrant packs are removed one at a time to look for any oozing from the retroperitoneal tissues and the posterior surface of the diaphragm. Hemostasis here is best achieved by electrocoagulation.

LAPAROSCOPIC SPLENECTOMY

Schwaitzberg provides an excellent summary for the role of laparoscopic splenectomy. This procedure has become the procedure of choice for the performance of elective splenectomy in patients with both benign and malignant conditions. Common indications are ITP, spherocytosis with hemolytic anemia, various types of leukemia, and myeloproliferative disease without massive splenomegaly.

Patient positioning for laparoscopic splenectomy is vital and is surgeon-specific. Delaitre described the “hanged spleen” approach, based upon the same lateral approach advocated for laparoscopic adrenalectomy. The patient is placed in the right lateral decubitis position or semi-lateral

position (Fig. 170.5A,B) and the “kidney bar” of the operating table is raised, thus, flexing the operating table and increasing the distance from the lower rib cage to the iliac crest. When the lateral position is at approximately 80 degrees, there is greater freedom to move the laparoscopic instruments along the left costal margin. Three 12-mm trocars are placed underneath the left costal margin with the most lateral port being just medial and inferior to the tip of the 10th rib where the abdominal musculature is not excessively thick. Once inside the abdomen, the reverse Trendelenburg position allows the intra-abdominal viscera to hang by gravity away from the diaphragm and the spleen. With the patient placed in the lateral position, the stomach is mobilized by dividing the superior gastroepiploic vessels allowing the stomach to pull away from the spleen by gravity as the spleen remains attached to its retroperitoneal ligaments. A fourth more lateral trocar may be added after the splenic flexure has been mobilized. Schwaitzberg describes the sequential ligamentous mobilization using ultrasonic dissection and cautery to divide the splenocolic ligament, the gastrosplenic ligament, and the more proximal short gastric vessels. Division of these structures is made by clips, vascular staples, ultrasonic shears, or bipolar cautery. Once these ligamentous attachments have been divided, the splenic artery may be dissected and ligated prior to the splenic hilum after which the splenic hilar vessels are approached. Extra care is taken when accessing the splenic hilar vessels to avoid the potential hazard of ligating too close to the pancreas resulting in pancreatic injury and pancreaticocutaneous fistula. Adjusting the camera at this critical point of the operation will allow for the splenic hilar vessels to be divided near the splenic hilum, thus avoiding pancreatic injury. Once the spleen is completely freed, it is placed in an endobag and morselized with a crushing clamp prior to removal by way of the endobag.

Some laparoscopic surgeons prefer to have the patient in the supine position with the left chest and abdomen elevated by a folded sheet (Fig. 170.6). This may raise the patient’s left side approximately 35%. Gas insufflation is provided by way of a Veress needle that is placed inferior to the left rib cage in the anterior axillary line where a 12-mm port is inserted. A second 5-mm port is placed directly medial to port no. 1 in the midclavicular line; this port is used for the camera. A third 5-mm port is placed slightly superior in the midline and is used for most of the tissue dissection, tissue mobilization, and hemostasis with the ligature. A fourth

5-mm port is placed underneath the right rib cage at the midclavicular line and is used to grasp tissues that are being dissected. A fifth 5-mm port is placed at the right anterior axillary line and helps retract the liver away from the areas of dissection while the patient is in a reversed Trendelenburg position.

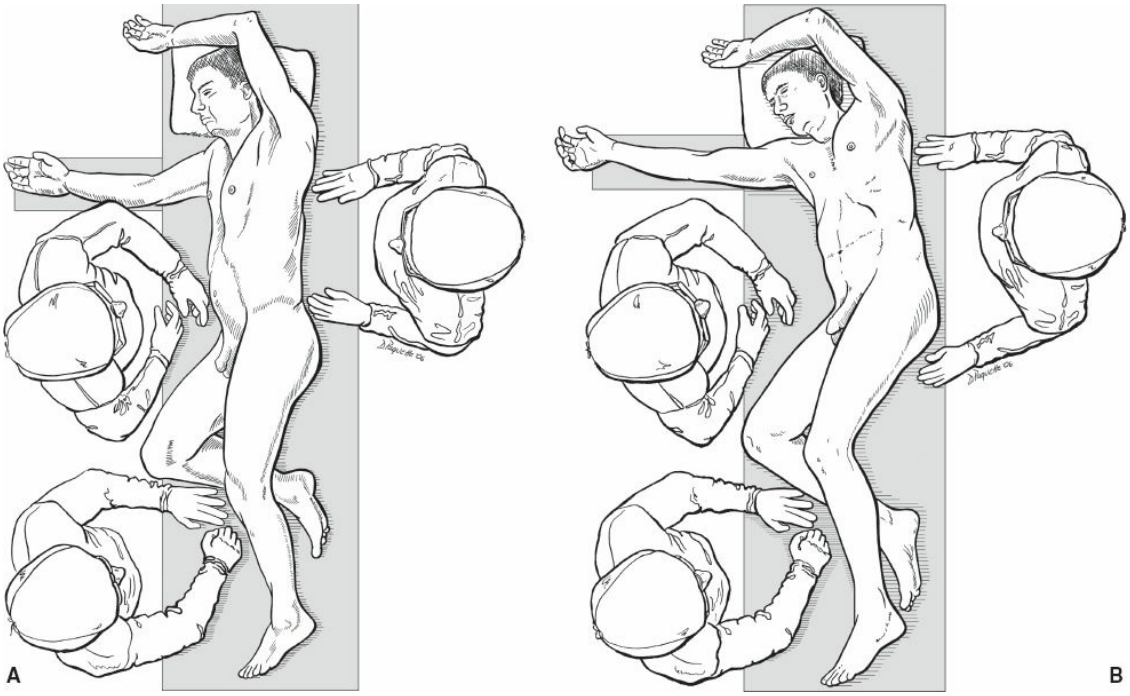

Figure 170.5. A. Demonstration of the lateral decubitus position. **B.** Demonstration of the semilateral decubitus position.

The sequential dissection includes division of the greater omentum peripheral to the gastroepiploic vessels, division of the short gastric vessels and the posterior gastric vessels, and division of phrenocolic ligament; this is typically achieved with electrocoagulation. The division of these vessels may be achieved by clips or vascular staples. Sometimes this may be accomplished by bipolar cautery. At this time, one needs to be sure that there is no accessory spleen and to identify the tail of the pancreas to make sure that there is no iatrogenic injury. The patient is placed in a reverse Trendelenburg position to facilitate division of phrenosplenic ligaments leaving, as the only remaining attachments, the vessels of the splenic hilum. These are taken down with a curved stapler that fires staples of 1-mm thickness in the closed position while the stapler is being gently pushed toward the spleen itself in order to avoid injury to the tail of the pancreas. The spleen is then placed in the endobag for morselization by a crushing clamp so that it can easily be extracted through the port site no. 1.

During the course of the dissection, there may be inadvertent bleeding; the surgeon should always be prepared to convert to an open procedure. The patient should understand, ahead of time that such conversion is potential and should be considered as an extension of a safe operation rather than a complication.

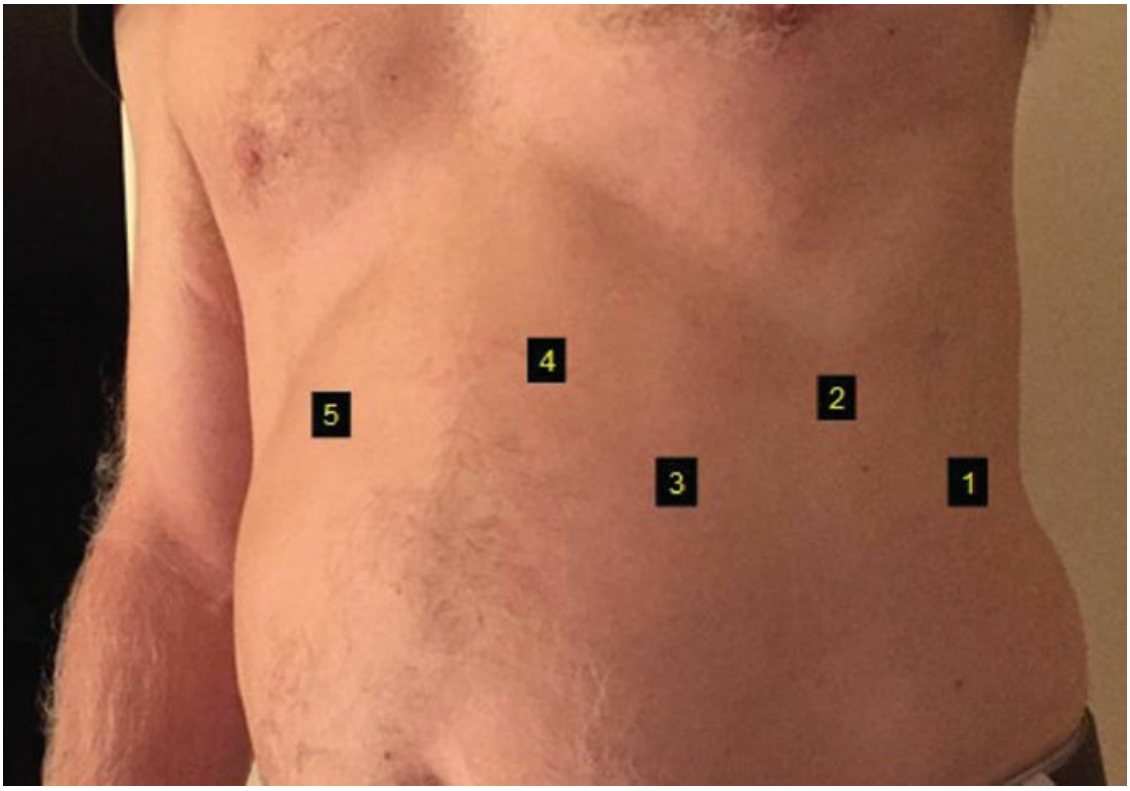

Figure 170.6. Port site 1 is used to insert the Veress needle followed by placement of a 12-mm port. The remaining ports are 5 mm with port site 2 used for the camera; port site 3 used for most of the tissue dissection, mobilization, and hemostasis; port site 4 used to grasp tissues that are being dissected, and port site 5 used to retract the liver away from the area of dissection. (Courtesy Dr. John D. Webber, Chief of MIS, Michael & Marian Ilitch Wayne State University Department of Surgery.)

The role of laparoscopic splenectomy in the injured patient has not been established. Most injured patients who require splenectomy have major injuries and have shown evidence of hemorrhage so that the added time to perform a laparoscopic splenectomy in the presence of active bleeding is potentially dangerous. The decision to convert from laparoscopic to open splenectomy, of course, will be based upon surgical experience. Otherwise, the potential for postoperative complications following laparoscopic splenectomy is similar to those seen following open

splenectomy.

LAPAROSCOPIC SPLENECTOMY WITH PORTAL HYPERTENSION

Portal hypertension due to liver cirrhosis is complicated by upper gastrointestinal bleeding from gastroesophageal varices. Some type of splanchnic devascularization procedure has been effective in controlling such varices. Part of this procedure includes splenectomy with or without devascularization of the gastroepiploic vessels along the greater curvature. Laparoscopic splenectomy in this setting has traditionally been considered contraindicated. With improved results of different treatments for portal hypertension from cirrhosis such as the use of interferon, laparoscopic splenectomy has gained in popularity. Depending upon the grade of cirrhosis and the clinical findings, splenectomy may be indicated with or without associated devascularization of the gastroepiploic vessels and may require a hand-assisted port site for patients with unusual splenomegaly.

Kawanaka recommends that the patient is placed with the left flank elevated about 60 degrees. A 12-mm port that is used for insufflation is placed to the left of the umbilicus following which three additional ports are placed in the epigastric area, the midclavicular line underneath the rib cage, and the left flank. When the spleen extends below the left subcostal margin, two additional ports are placed in the flank immediately below the lower pole of the spleen. When a hand-assisted splenectomy is planned, a 7-cm midline epigastric incision is used. This is routine when the spleen is unusually large. Based upon past experiences, Kawanaka and colleagues plan ahead of time for a hand-assisted laparoscopic splenectomy when the Child-Pugh score exceeds 9 and the preoperative splenic weight is thought to be greater than 1,000 g, or there appear to be large perisplenic collateral vessels on preoperative imaging.

The sequence of the splenic mobilization is similar to that described in patients without portal hypertension, but the increased vascularity of portal hypertension favors the use of a vessel-sealing device. Once all of the ligamentous tissues have been divided, the last step is to divide the hilar attachments from the tip of the pancreas. These attachments are taken down using the endoscopic vascular stapler with a 1-mm thickness in the closed position. Because of the rapid bleeding that may occur in patients with portal hypertension, conversion to open splenectomy is performed much more quickly than would be the case in patients without portal

hypertension.

OPERATIVE SPLENIC SALVAGE AFTER INJURY

Once the spleen became recognized as a vital link in the immune response to infection, operative attempts at splenic salvage became fashionable. A few far-sighted surgeons, however, practiced splenic salvage before their less prescient colleagues. Zikoff, in 1897, may have performed the first splenorrhaphy; Dretzka, in 1930, published the first splenorrhaphy performed on a child. This early report by Dretzka and the subsequent report by Morganstern and Shapiro highlight the technical factors involved with achieving successful splenorrhaphy, including a generous incision, proper exposure, and gentle manipulation.

SURGICAL TECHNIQUE

Splenorrhaphy

Once fully mobilized using the techniques described above, there are a variety of techniques for obtaining splenic hemostasis. For large deep injuries, the authors prefer the placement of 2-0 chronic sutures swedged on a 2-in, blunt tip needle; these are placed about 1 to 2 cm away from the torn margin and passed deep into the wound crevice; the suture exit tract should be a mirror image of the entrance placement (Fig. 170.7). Often, two of these sutures are placed sequentially so that the surgeon can tie one while the other suture is held by the assistant, with the exact tension to achieve gentle compression of the spleen without tearing the parenchyma or causing tissue necrosis. Equal tension on both sides of the crevice is best obtained with two-handed ties, with each hand being close to the splenic surface. Displays of virtuosity by immature residents using fancy one-handed ties should be discouraged; these cause uneven tension, which promotes parenchymal injury with additional bleeding. Once parenchymal apposition is achieved, most bleeding will rapidly subside; minor oozing through the needle holes is best treated by placing a dry sponge over the spleen and returning the spleen to the left upper quadrant for about 10 minutes while other organs are assessed. If hemostasis appears good when the pack or sponge is removed, the “no touch” technique applies; the surgeon should leave it alone.

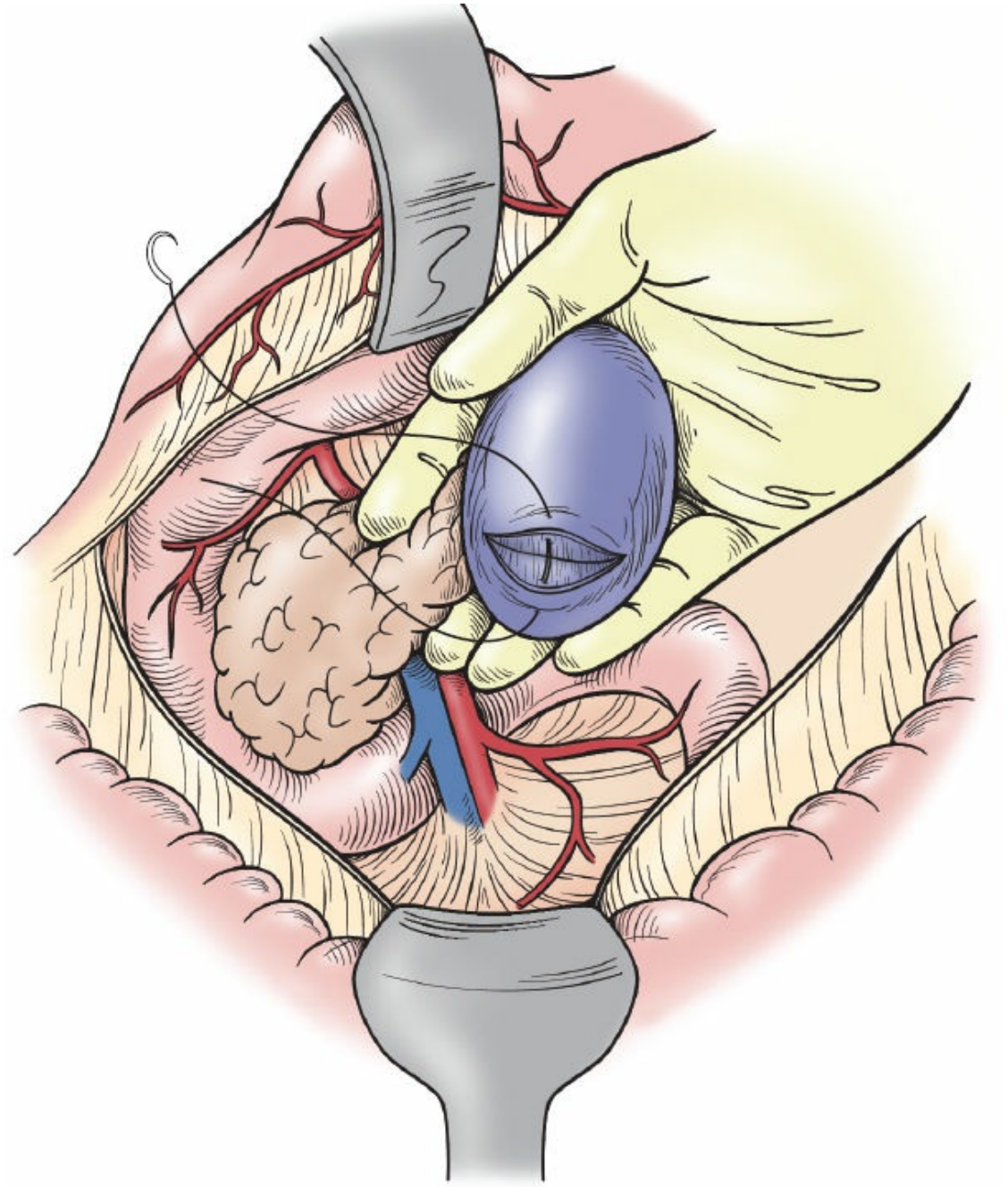

Figure 170.7. Deep splenic lacerations can be sutured with the blunt-tipped, swedged-on, 2-0 chromic (EAD21) suture, which is placed 1 to 2 cm away from the tear and passed deeply into the wound crevice. When two sutures are placed, one can be held at the desired apposition while the other is gently tied.

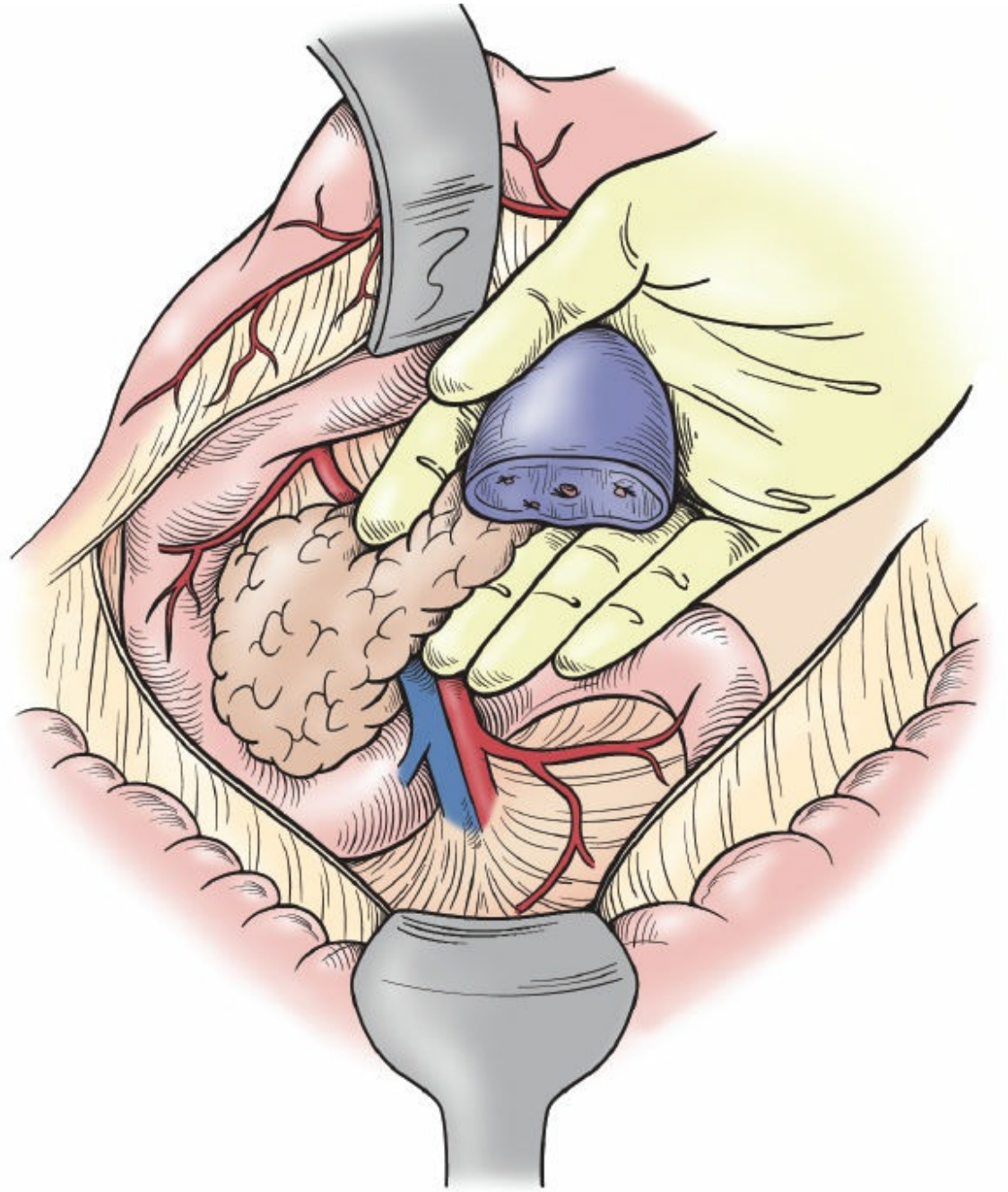

Figure 170.8. When performing partial splenectomy for major laceration or for ischemia caused by hilar segmental vessel disruption, the trabecular vessels may be made hemostatic by electrocoagulation or suture ligation. Carefully placed figure-of-eight sutures followed by gentle tying give good hemostasis without excessive injury to the adjacent parenchyma.

Partial Splenectomy

When performing a partial splenectomy for extensive injury to a splenic segment, or for segmental splenic ischemia distal to transected hilar segmental vessels, transverse intraparenchymal arteries may continue to

bleed. Sometimes these transverse spurting vessels can be made hemostatic by electrocoagulation applied to an occlusive clamp, whereas other bleeding vessels require suture ligatures (Fig. 170.8). The authors prefer to use a 4-0 silk suture placed in a figure-eight manner to best avoid tearing of the adjacent splenic tissue while getting hemostatic occlusion of an arterial pumper (Fig. 170.8). The same principles of gentleness apply when suturing the splenic parenchyma surrounding a spurting vessel; a two-handed tie with equal tension reduces the chance for added parenchymal injury.

Following partial splenectomy, the splenic capsule may be approximated, especially if the splenic crevice angles toward a central valley. This approximation should be done with fine parenchymal sutures, such as 4-0 silk, and they should be tied quite gently. Bleeding through the needle holes is best contained by placing a pack over the repair and returning the spleen to the left upper quadrant, as previously indicated. When the injury causes disruption of the hilar vessels, identification and ligation provide optimal hemostasis, whereas an obviously ischemic splenic segment, distal to the ligation, is best resected using the techniques described previously.

There are many adjuncts to successful splenorrhaphy. These include the use of a variety of hemostatic agents to augment the hemostatic effect afforded by temporary packs; the argon laser may be more effective than simple electrocoagulation for larger splenic tears; the use of stapling devices gives quicker control, but may cause ischemia or tearing; the placement of absorbable meshes around the badly injured spleen, which is then restored to the left upper quadrant and covered, may provide salvage of grade V injuries (Fig. 170.9). In general, the authors advocate simplicity in providing splenic preservation; when complicated techniques must be used, the surgeon must ask the question whether the added efforts are conducive to an enhanced risk-to-benefit ratio in the patient with ongoing bleeding.

Using these techniques, the success of operative splenic salvage is over 50%. The best results have been obtained in patients with blunt injury, although these techniques can be used for penetrating wounds. Attempts at operative splenic salvage are discouraged, however, in the unstable patient with active bleeding from the spleen and/or from other organs; the extra time required for splenic preservation will increase the need for blood transfusion and compromise the patient’s overall well-being.

Splenectomy With Splenic Replantation

Splenosis is a condition whereby patients with shattered spleens will sometimes develop islets of splenic growth following splenectomy when not all of the splenic fragments are identified and removed. Stimulated by this unusual event, the use of splenic preservation, by placing small fragments of splenic tissue within the folded omentum, has been promulgated. This “omental omelet” of multiple splenic fragments, measuring no more than 1 cm in size, may contain 50% of splenic parenchyma. This technique has often been used in patients requiring rapid splenectomy for bleeding after penetrating wounds. Large clinical series have demonstrated that these splenic segments remain viable and, later, will concentrate isotope. The clinical protection against OPSI afforded by this splenic omelet, however, has not lived up to expectations. Likewise, these patients with splenic replantation do not respond in the same way as do patients with splenic salvage in the normal position with maintained splenic blood flow or in patients without splenic injury. Maintenance of normal splenic perfusion is critical to successful clearance of circulating bacteria.

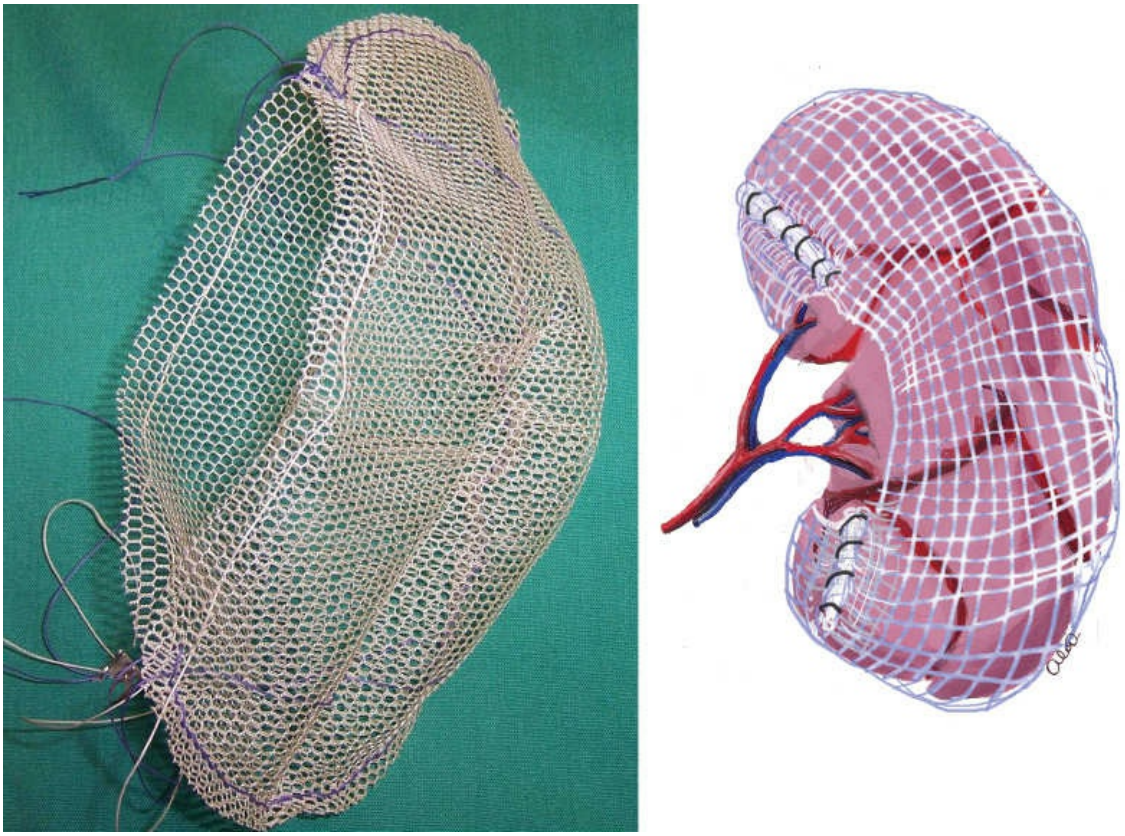

Figure 170.9. Type V splenic injuries may be salvaged by the placement of a custom devised mesh wrap around the injured

spleen, which is then returned to the left upper quadrant. Careful inspection of successful hemostasis is mandatory prior to closure.

The paradox of having a live splenic replant without the expected immunologic protection was studied in a canine model of splenic replantation over 18 months; the results of this study explain why the omental omelet does not provide full immunologic protection. The splenic omelets in this canine model uniformly survive and take up isotope but the histology of these surviving splenic fragments shows that the perifollicular lymphoid tissue is absent. This lymphoid tissue is thought, by most researchers, to be the source of the protective immune response. Based upon these animal studies and upon bad clinical experiences, the authors no longer recommend this technique.

Nonoperative Splenic Preservation After Injury

Billroth, in the 1870s, suggested that the injured spleen could be treated nonoperatively. He reported on a patient who sustained a lethal closed head injury and died on postinjury day 5; the autopsy revealed a splenic rupture, which had completely coagulated. Despite this early prophetic observation, nonoperative treatment of splenic injury, for all practical purposes, was avoided until the 1950s in children and the 1970s in adults. During the past 30 years, nonoperative splenic preservation has become the norm; successful observation in both children and adults approaches 90% after blunt injury. Success with this regimen correlates with a number of factors, with the grade of splenic injury (Table 170.1), and the presence of associated injuries requiring laparotomy being high on the list (Table 170.1). The high success rate of nonoperative treatment, likely, will create a generation of surgeons who are insecure with open splenectomy.

TABLE 170.1 Severity of Splenic Injury

Grade – Injury Description[a]
I. Small subcapsular hematoma (<10% surface area) Small laceration (<1 cm deep)
II. Medium subcapsular hematoma (10%–50% surface area) Intraparenchymal hematoma (<5 cm in diameter) Medium laceration (1–3 cm deep)
III. Large subcapsular hematoma (>50% surface area) Intraparenchymal hematoma (>5 cm in diameter) Expanding hematoma Large laceration (>3 cm deep or involving trabecular vessels)
IV. Laceration involving hilar vessels Devascularized >25% of spleen
V. Shattered spleen involving hilar vessels Total devascularization of spleen

[a]Condensed from Organ Injury Scaling Committee for the American Association for the Surgery of Trauma (1994 revision).

Many important advances in the successful nonoperative splenic preservation have been made in the past few years. The clinical presentation is now recognized as the single most important factor in deciding upon nonoperative therapy; patient age and grade of splenic injury are less important in the clinically stable patient. A vital clinical decision about aborting the nonoperative approach relates to the need for blood transfusion during the period of observation. When the patient requires more blood transfusions than would be predicted on the basis of associated injures, especially to bones, or when the patient with an isolated splenic injury requires any blood transfusion because the hemoglobin has drifted to below a critical range of 8 to 10 g/dL, the authors recommend immediate operative intervention for a recently ruptured spleen. Like any clinical decision, the risk-to-benefit ratio must be assessed and

comorbidities must be taken into consideration. As long as one does not endanger the patient with the risk of multiple blood transfusions, which could be avoided with splenectomy, the main complication of nonoperative therapy for splenic injury is the need to do a delayed exploration.

When nonoperative therapy fails and the patient requires exploration, the same principles of splenic preservation by the techniques described previously apply; the likelihood of successful operative splenic salvage, however, is much lower after unsuccessful observation. In retrospect, it appears that patients, who had injuries that could be successfully treated by splenorrhaphy or partial splenectomy, are now being successfully treated by nonoperative therapy. Thus, the 50% success rate for operative splenorrhaphy falls to about 10% when nonoperative management is used as the primary treatment mode.

One of the important subgroups, for patients being observed nonoperatively for splenic injury, includes those patients who have evidence of a splenic blush on computed tomography or active bleeding into the parasplenic hematoma. The stable patient with a splenic blush may benefit from angiography and embolization of the intrasplenic vessel. Tominaga and coworkers showed that immunologic function, as measured by immunoglobulins, C3 compliment, compliment factor B, and T cell function, was maintained after splenic embolization in comparison to eusplenic patients. In patients with active bleeding, embolization provides prompt cessation of bleeding, thereby precluding emergency operation. Cessation of active bleeding can be achieved in over 60% of patients. Splenic embolization, however, is not without risk. Even when the embolization is performed in one of the segmental branches, splenic infarction with significant and prolonged pain may result. Likewise, the patient with splenic infarction may develop the picture of sepsis and circulating cytokines, which is immediately relieved with splenectomy (Fig. 170.10). Shih and coworkers suggest that splenic embolization dysregulates the immune response and aggravates the cytokine response to peripheral mononuclear cells, which may increase susceptibility to infection.

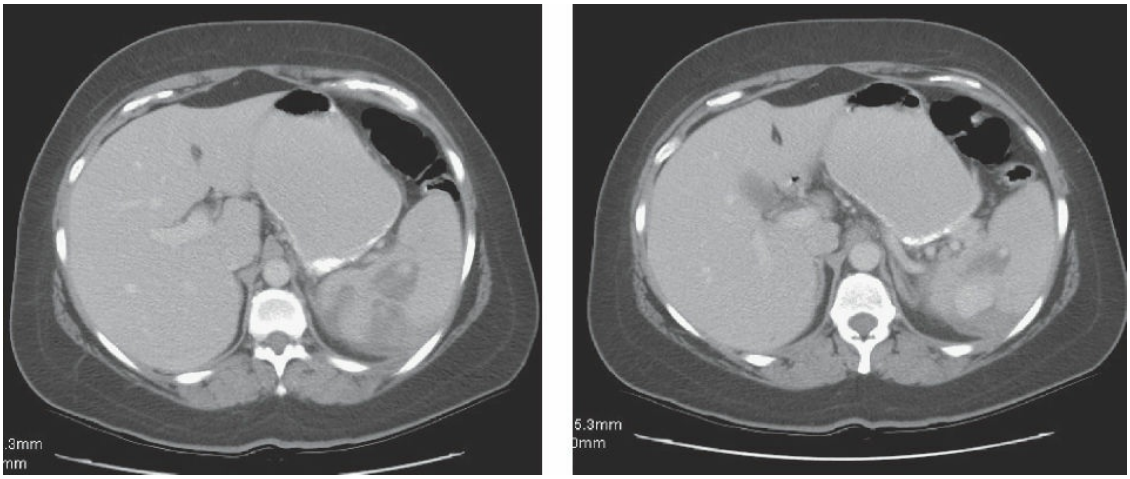

Figure 170.10. This 27-year-old woman driver was T-boned on the left side and presented with a type III splenic injury (**left**) with an intrasplenic pseudoaneurysm (**right**). She was transferred for splenic embolization that was successfully accomplished as an outpatient through a pole lower branch. Within 12 hours, she had diffuse aches and pain, fever, and malaise, which subsided immediately following splenectomy 7 days later. Histology showed necrosis around the false aneurysm. Consequently, the authors recommended observation for asymptomatic patients whose false aneurysm is totally intrasplenic.

Nonoperative Management and Anticoagulation

The pendulum has swung toward the widespread use of pharmacologic anticoagulation for venous thromboembolic (VTE) prophylaxis in all surgical patients, including patients with injury. Patients with defined intraparenchymal bleeds to solid organs such as the liver, spleen, and brain have initially been excluded from any anticoagulation regimen. The emphasis on initiating anticoagulation in all patients, however, has extended to patients with intraparenchymal hemorrhages that have remained stable for 24 to 48 hours; after this interval, VTE prophylaxis has been recommended. The urgency to initiate VTE prophylaxis is even greater in those patients with atrial fibrillation, a prior myocardial infarction, or a mechanical heart valve. The authors have seen rebleeding into solid viscera in patients with brain injury and splenic injury following initiation of VTE prophylaxis after 48 hours (Fig. 170.11). Njaastad and coworkers showed that the likelihood for a thromboembolic event was 0.6% in 3 weeks in patients without VTE prophylaxis in the presence of atrial fibrillation. The authors recommend that no VTE prophylaxis be administered in patients with intraparenchymal hemorrhage for the initial 3

weeks, by which time the hematoma and surrounding tissues will be in the third phase of wound healing.

Distal Pancreatectomy With Splenic Salvage

The use of splenic preservation while performing distal pancreatectomy for grade II or grade III pancreatic injury with ductal disruption to the left of the superior mesenteric vein was promulgated by Pachter (Fig. 170.12). The distal pancreatectomy is performed by ligating each branch of the splenic artery and splenic vein as they enter into the pancreas while, at the same time, protecting their terminal branches at the splenic hilum in order to protect splenic perfusion. This technique has subsequently been applied to localized pancreatic tumors that are benign, cystic in nature, or have low potential for malignancy, such as some of the papillary tumors. Most reports describe the open laparotomy technique.

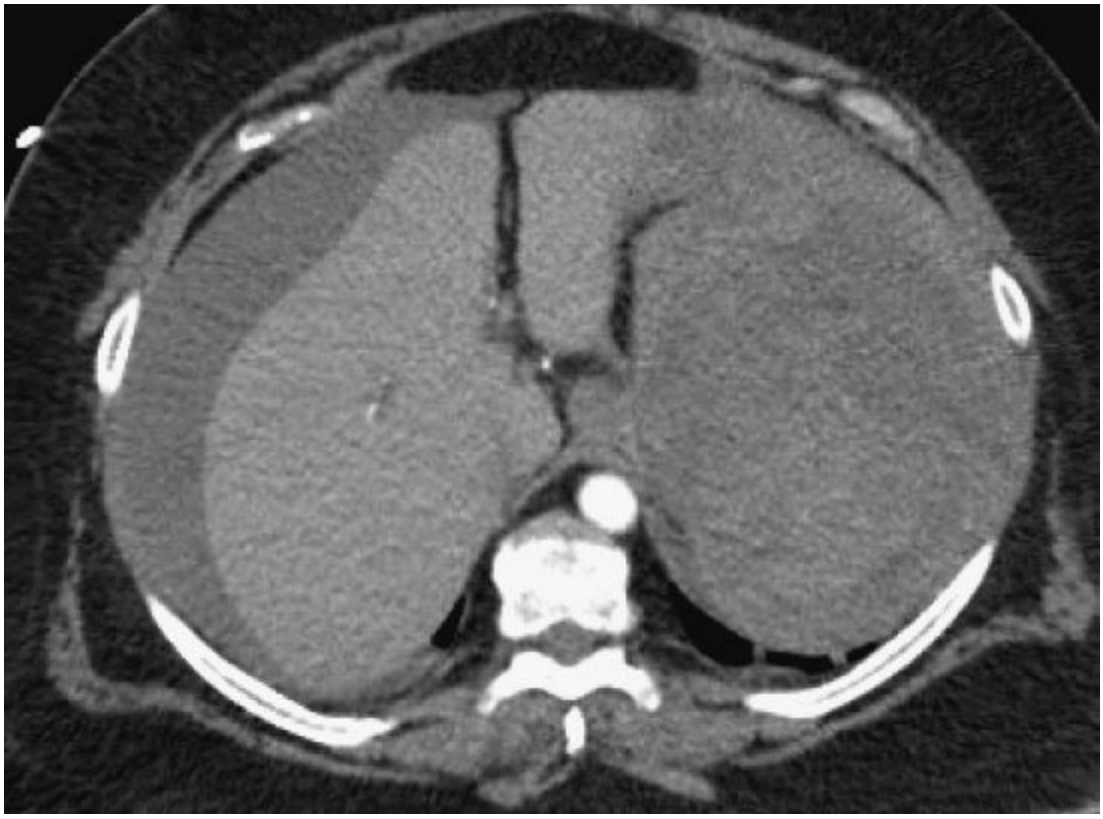

Figure 170.11. This middle-aged woman was restarted on her Coumadin for atrial fibrillation 2 days after sustaining a type II splenic injury. Five days later, she presented with an acute abdomen and hemoperitoneum necessitating emergency splenectomy. The authors recommend that reinstitution of anticoagulation be delayed for 3 weeks with nonoperative treatment of splenic injury.

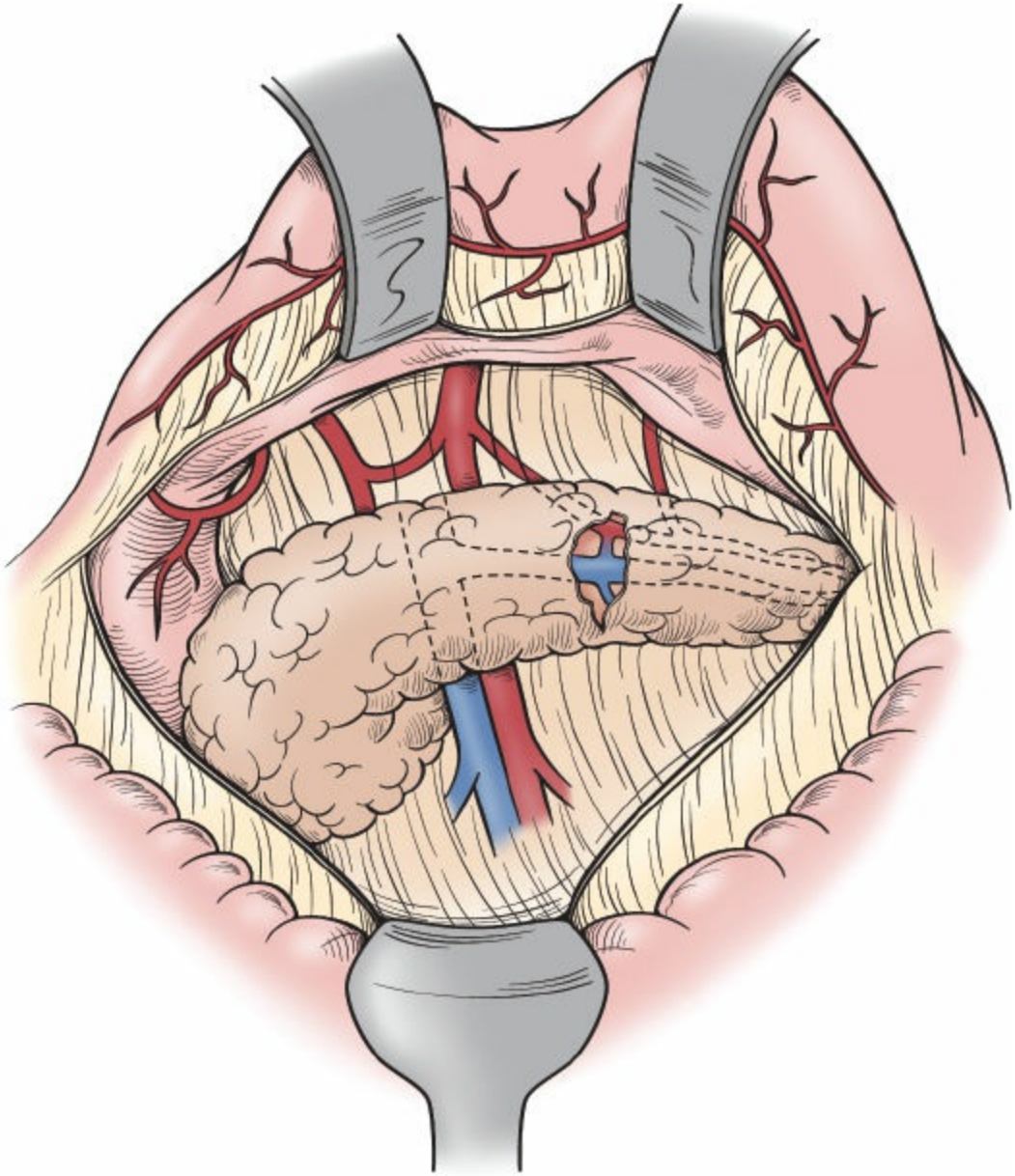

Figure 170.12. A grade II pancreatic injury, typical for what is seen after blunt trauma, is depicted. The pancreatic transection is to the left of the superior mesenteric vein and is associated with ductal disruption. The dot indicates the posterior gastric artery (PGA), which arises from the splenic artery approximately 3 to 4 cm proximal to the splenic hilum, and enters into the stomach posteriorly and slightly inferior to the short gastric vessels.

Access to the pancreas and spleen may be achieved through a midline incision, although the authors prefer a left subcostal incision, which may be extended as needed into the right subcostal area to give good exposure to all of the pancreas and the splenic hilum. The omentum is divided as described above, and the splenic flexure is mobilized to fully expose the

retroperitoneal tissues (Fig. 170.13). The posterior leaf of the lesser omentum attaches to the superior border of the pancreas. The anterior leaf of the transverse colon mesentery attaches to the inferior border of the pancreas. These attachments should be severed through the avascular plane, which is quite close to the pancreas. There will also be some avascular attachments between the posterior greater curvature of the stomach to the tail of the pancreas; these should also be divided close to the pancreas. The above techniques leave the pancreas fully exposed on the anterior, superior, and inferior surfaces.

The splenic vein and its branches should be approached first. This is best achieved by rotating or lifting the inferior border of the pancreas superiorly and anteriorly, thus exposing the posterior surface (Fig. 170.14). Careful dissection in this area will identify the short branches of the splenic vein as they enter into the pancreatic parenchyma (Fig. 170.14). These short veins should be carefully freed, divided, and ligated. Passing sutures around these vessels with the help of small right angle clamps helps minimize bleeding. This ligation can be achieved with fine 4-0 silk ties or with small hemoclips; the authors prefer the fine silk ties, which do not get caught by sponges, as may happen when staples come in proximity to fine mesh gauze. The sequential division of the venous branches is more easily accomplished by moving from the superior mesenteric venous area toward the inferior mesenteric vein and, finally, to the splenic hilum.

Once the hilum is identified, the small terminal arterial branches of the splenic artery can be identified and controlled in the same manner prior to moving from the splenic hilum back to the splenic artery as it descends from the celiac axis. Once all of these branches have been divided, while at the same time preserving the terminal branches of the splenic artery and vein within the hilum, the pancreas can be resected. The division of the pancreas should be at the point of transection in injured patients or to the right of the neoplastic lesion in patients with tumors or cysts (Fig. 170.15). The pancreatic division can be performed by electrocoagulation followed by suture ligation of small parenchymal vessels that exhibit refractory bleeding; the pancreatic duct, if it can be identified, should be suture ligated. The remaining pancreatic stump is then approximated with fine “capsular” sutures to decrease the likelihood of later bleeding or fistulization. Alternatively, the pancreatic resection can be accomplished in a “fish mouth” manner with the “mouth” being closed or apposed with interrupted 4-0 silk sutures. The authors have also been pleased with

resection and stump closure using the GIA stapler. Long-term data on complications of suture closure versus stapler closure of the pancreatic stump have not yet accrued. When this technique of splenic preservation is performed, the spleen does not have to be fully mobilized from its retroperitoneal attachments. When dissection is difficult, however, mobilization is recommended.

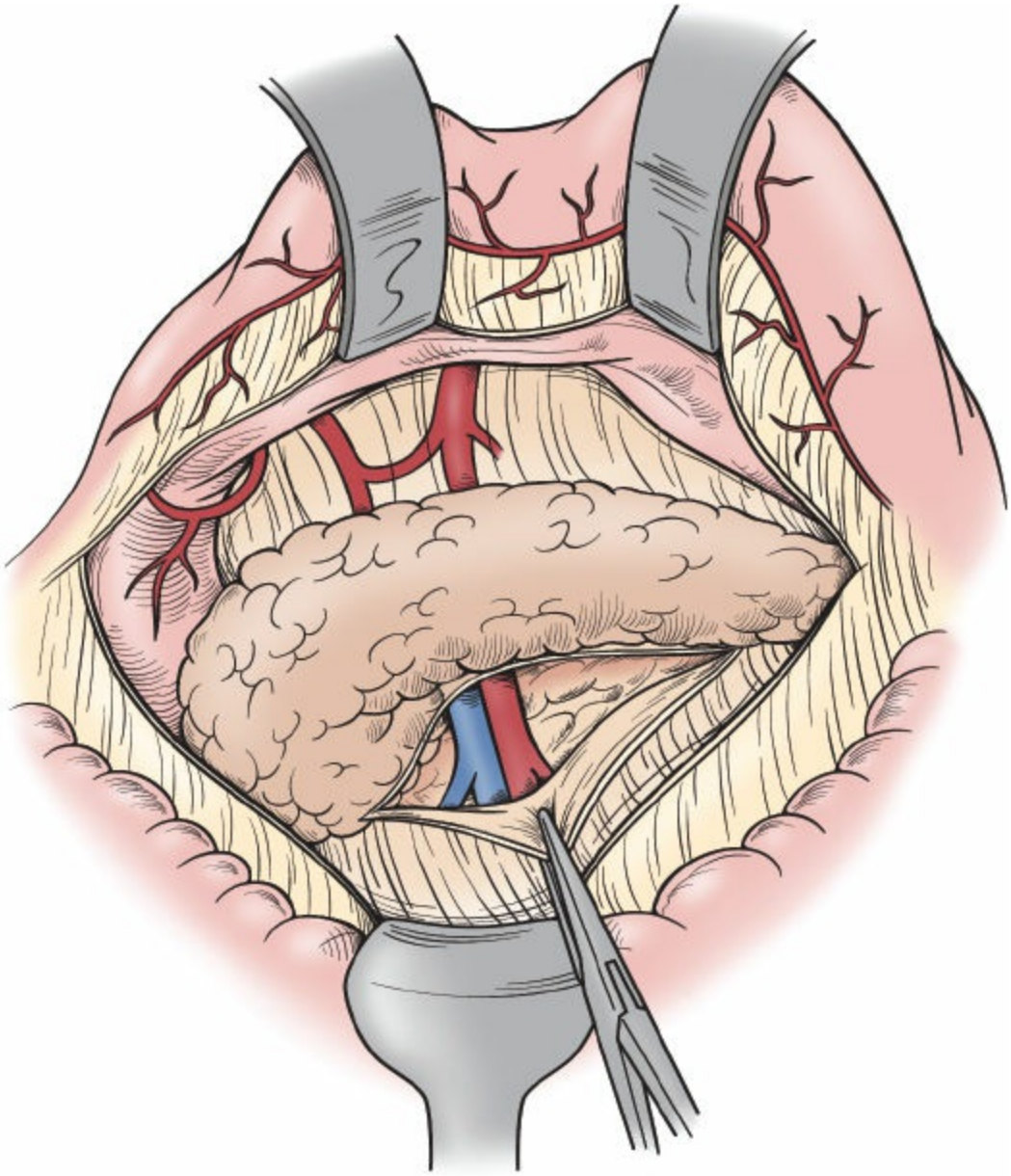

Figure 170.13. The anterior leaf of the transverse mesocolon inserts onto the inferior border of the pancreas. Division of this mesenteric leaf is best performed immediately adjacent to the pancreas, where there are no collateral vessels. This schematic highlights how the underlying mesenteric vessels are exposed after separation of this anterior leaf from the pancreas.

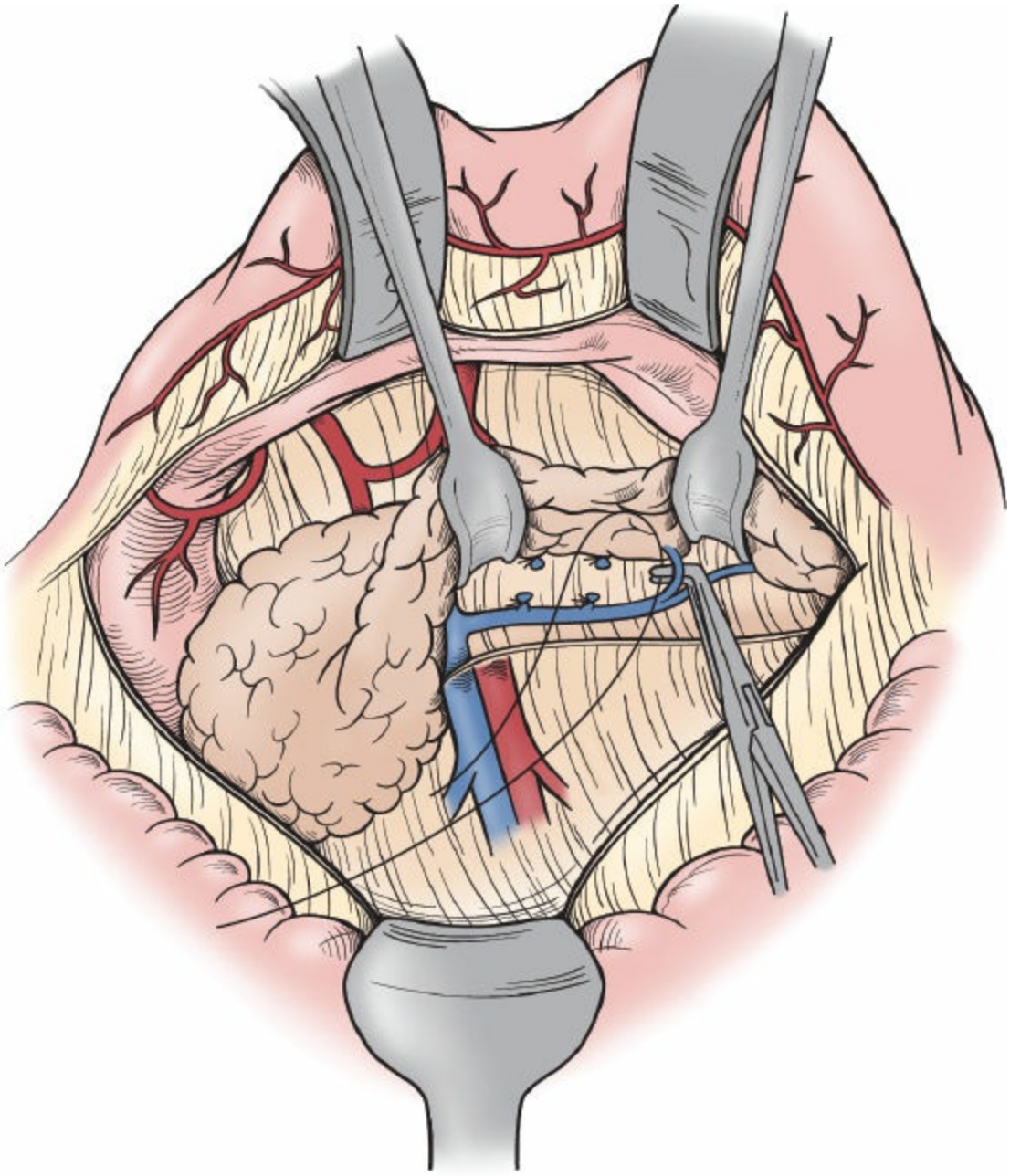

Figure 170.14. By gently rotating the inferior border of the pancreas anteriorly and superiorly, the splenic vein, with its branches into the pancreatic parenchyma, is identified. These branches, which are much shorter than those depicted in this schematic, are individually divided and hemostasis is obtained by means of small clips or ligatures.

Warshaw described an alternate technique for splenic preservation while doing distal pancreatectomy for small, localized neoplasms (Fig. 170.15). This consists of dividing the pancreas with the splenic artery and splenic vein at the site of pancreatic division, but preserving the splenic hilar branches so that perfusion of the spleen is maintained by means of

backflow through the short gastric vessels and the posterior gastric artery (Fig. 170.12). The short gastric vessels arise from the superior segmental branches of the splenic vessels and enter into the greater curvature of the stomach just below the apical fat pad. The posterior gastric artery arises from the splenic artery about 3 or 4 cm proximal to the splenic hilum and enters the posterior wall of the proximal stomach about 2 cm inferior and medial to the short gastric vessels (Fig. 170.12). When using this technique for splenic salvage, one has a better chance for maintaining retrograde flow to the spleen if both the short gastric vessels and the posterior gastric vessels are protected. One of the complications of this technique for splenic preservation is splenic infarction of the inferior pole, which was documented in the Warshaw report of distal pancreatectomy for small tumors and has been observed by the authors following distal pancreatectomy with splenic preservation after injury. When retrograde flow is insufficient, inferior pole splenic ischemia may result and lead to significant pain and possible abscess formation. When seen during operation, splenectomy is recommended.

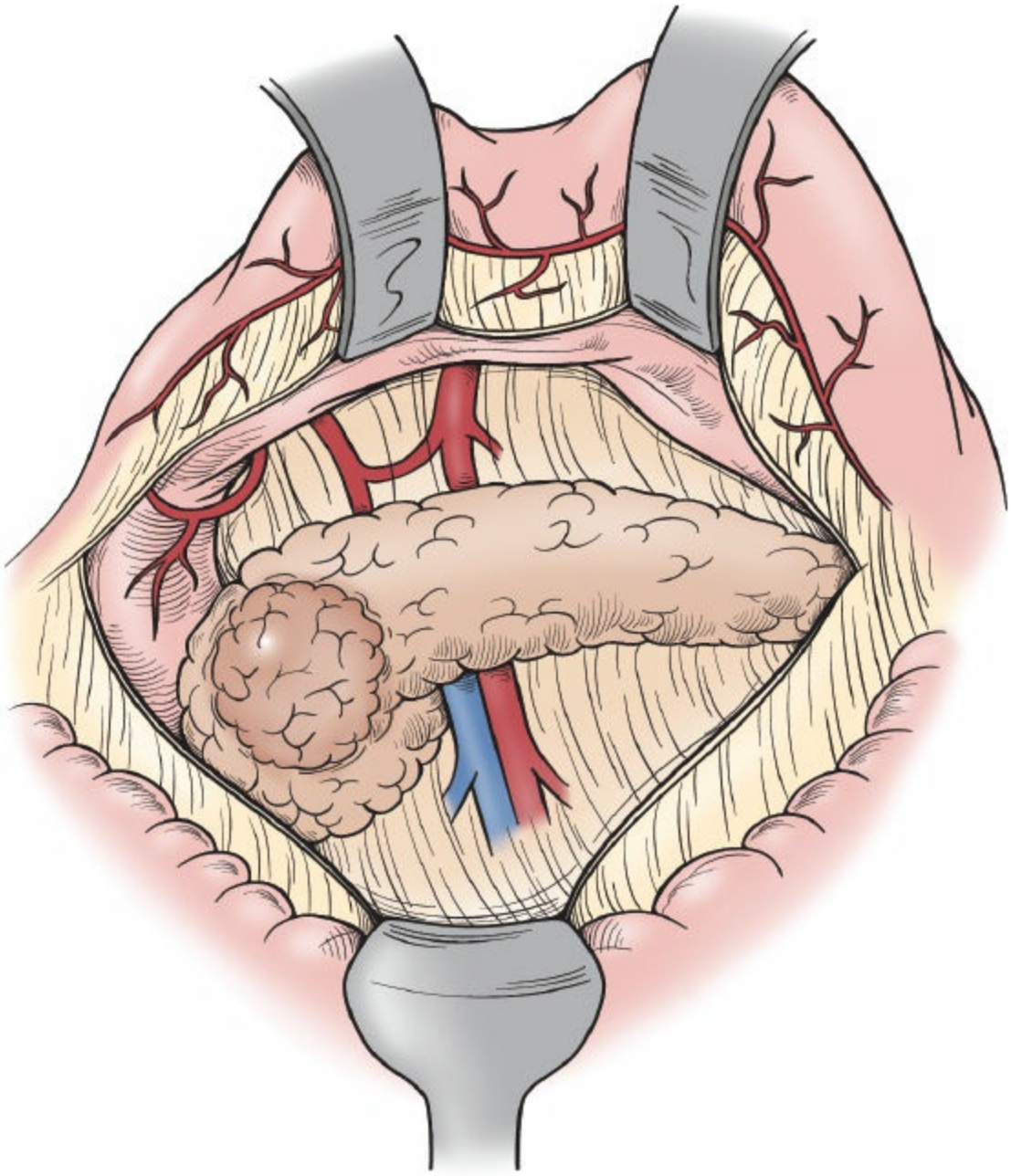

Figure 170.15. Patients with cystic neoplasms or atypical papillary masses at the neck of the pancreas may be treated by local resection of the neoplasm followed by closure of the duodenal segment of remaining pancreas and decompression of the distal pancreas into a Roux-en-Y jejunal limb.

Distal pancreatectomy with splenic preservation in patients with gunshot wounds or stab wounds involving the distal pancreas is more likely to be accomplished by the technique of dividing the splenic artery and splenic vein at the site of pancreatic injury, because ongoing bleeding or significant hematoma following penetrating wounds in this area is more common. Blunt rupture of the pancreas is seldom associated with major

bleeding, which compromises proper exposure. When splenic preservation with distal pancreatectomy is performed after penetrating injury, the surgeon must be sure that the patient is stable and that there is no persistent bleeding from other sites. The risk of spending extra time preserving the spleen in a patient with marginal stability or ongoing bleeding outweighs the risk of OPSI following rapid distal pancreatectomy with splenectomy. When splenectomy is needed, the administration of polyvalent vaccine is indicated; the authors no longer send the patients home on oral antibiotics.

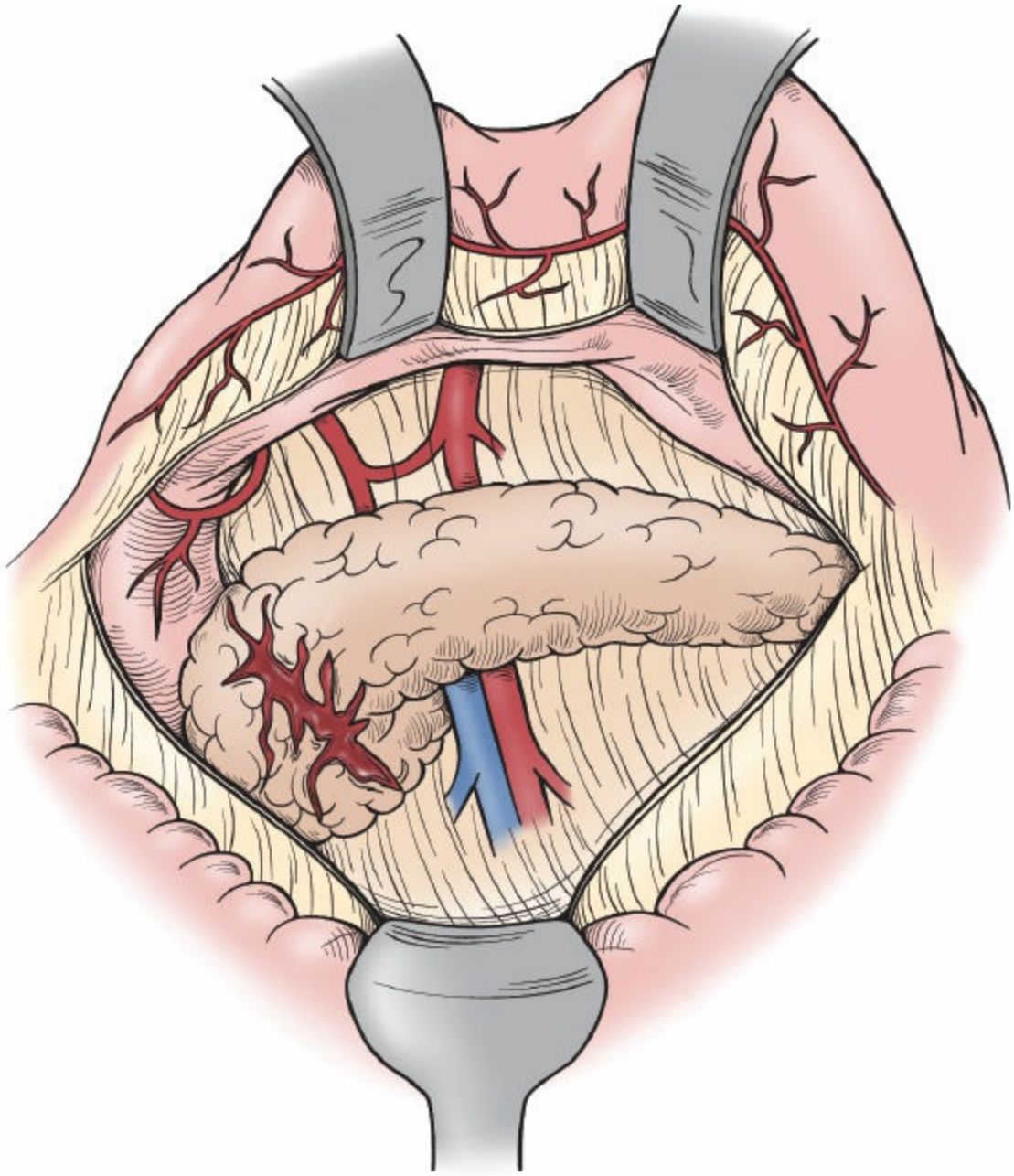

Figure 170.16. Patients with blunt abdominal injury may sustain a stellate fracture of the head of the pancreas in the vicinity of the intrapancreatic portion of the common bile duct. Patients with

large gunshot wounds to this area usually die on the operating table.

Treatment of Pancreatic Head Lesions/Tumors With Splenic Preservation

Some patients with blunt abdominal injury will present with a stellate laceration in the head of the pancreas, anterior to the intrapancreatic portion of the distal common bile duct (Fig. 170.16). Although superficial lacerations in this area after blunt injury can be treated with wide drainage, the deeper lesion requires careful assessment for complete transection and for involvement of the bile duct. When complete transection of the pancreatic head occurs, preservation of the lateral portion of the head of the pancreas, pancreatic neck, and the distal pancreas with spleen preservation can be achieved by creating a Roux-en-Y jejunal limb, which is then anastomosed to the distal pancreas in an end-to-end or, in the author's preference, an end-to-side pancreaticojejunostomy (Fig. 170.17). The residual pancreatic rim along the duodenal sweep is made hemostatic followed by "capsular" approximation (Fig. 170.17). When this injury occurs following a gunshot wound, the associated bleeding from injuries to adjacent vessels usually makes this approach impractical and unsafe. Some cystic tumors or benign pancreatic tumors lying between the superior mesenteric vein and the intrapancreatic portion of the bile duct can be treated in the same manner with local resection of the tumor, closure of the residual pancreas along the duodenal sweep, and Roux-en-Y pancreaticojejunostomy.

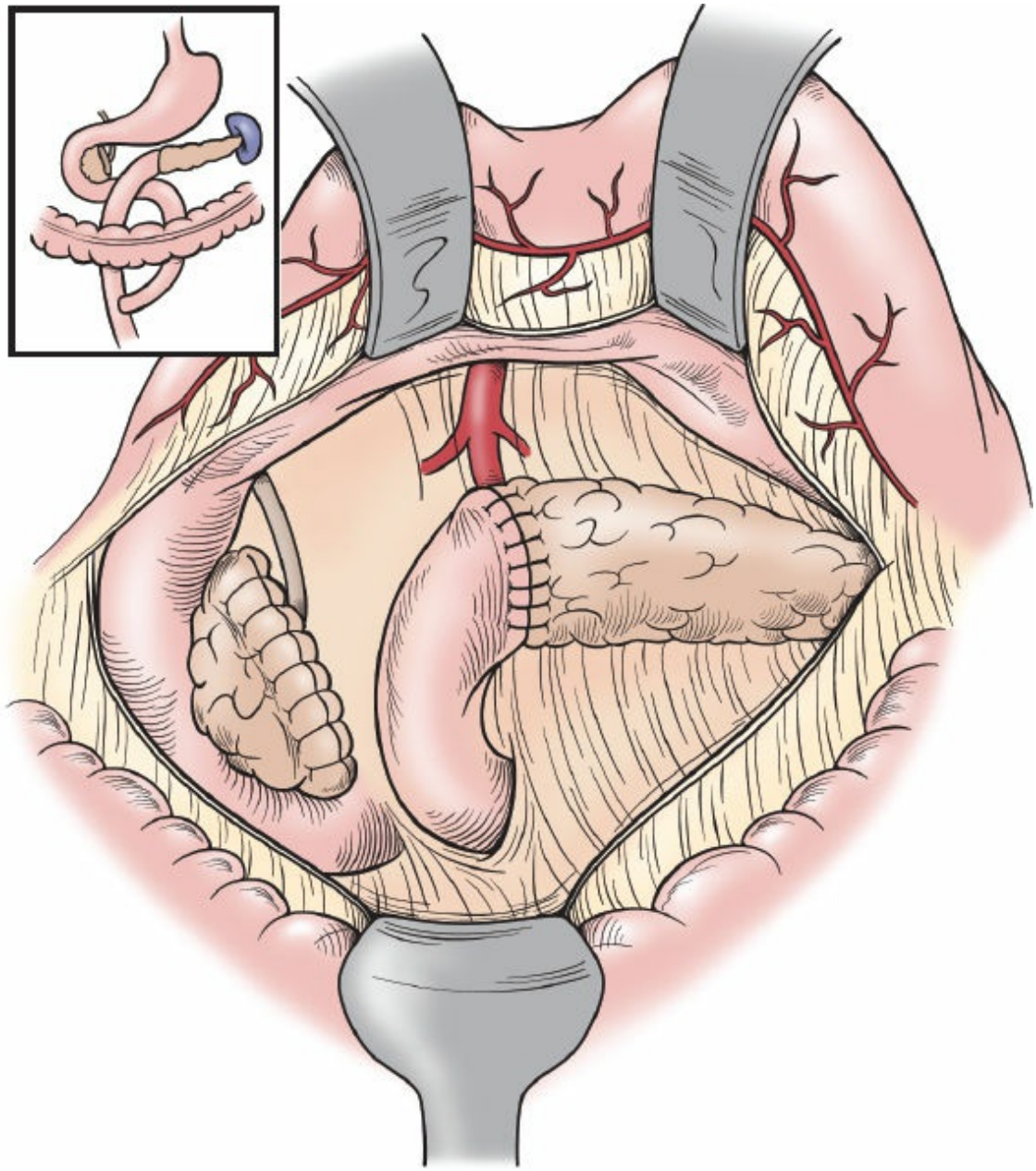

Figure 170.17. When extensive injury to the head of the pancreas occurs anterior and to the left of the intrapancreatic portion of the common bile duct, the transection can be completed and followed by end-to-side Roux-en-Y pancreaticojejunostomy and oversewing of the residual pancreatic remnant adjacent to the duodenum.

Laparoscopic Approach to Splenic Preservation

The rising trend toward laparoscopic surgery has expanded into the domain of splenic preservation. Removal of a benign pancreatic cyst with distal pancreatectomy and splenic preservation has been described utilizing a three-port technique. The laparoscopic approach follows the same steps

summarized previously with the open approach; each step is followed sequentially. The authors have no experience with this technique.

Distal pancreatectomy with splenic preservation has also been described in patients with pancreatitis requiring distal resection for ductal ectasia. This approach, however, must be scrutinized carefully; the authors have had extensive experience with surgery of the inflamed pancreas, which can be quite tedious. Dissection of the severely inflamed pancreas is most difficult using the open approach. The authors question the severity of pancreatitis that would need pancreatectomy in a setting where this could be safely accomplished laparoscopically. Furthermore, most patients with benign pancreatic ductal obstruction are best treated with Roux-en-Y pancreaticojejunostomy rather than distal pancreatectomy, thus preserving both endocrine and exocrine functions.

The use of the laparoscopic approach has also been used for the resection of simple splenic cysts, thus providing for splenic preservation. These are true cysts of the spleen. The results of these studies have not been uniformly good. These techniques can be facilitated by radiofrequency control of bleeding. The true role of such techniques needs to be determined by future experience.

Suggested Readings

Arbuthnot M, Onwubiko C, Mooney D. The lost art of the splenorrhaphy. *J Pediatr Surg* 2016;51(11):1881–4.

Buffet PA, Millon G, Brousse V, et al. Ex vivo perfusion of human spleens maintains clearing and processing functions. *Blood* 2006;107(9):3745–52.

Dai MH, Shi N, Xing C, et al. Splenic preservation in laparoscopic distal pancreatectomy. *Br J Surg* 2017; 104(4):452–62.

Gavriilidis P, Lim C, Menahem B, et al. Robotic versus laparoscopic distal pancreatectomy: the first meta-analysis. *HPB (Oxford)* 2016;18(7):567–74.

Kawanaka H, Akahoshi T, Kinjo N, et al. Laparoscopic splenectomy with technical standardization and selection criteria for standard or hand-assisted approach in 390 patients with liver cirrhosis and portal hypertension. *J Am Coll Surg* 2015;221:354–66.

King H, Schumacker HB Jr. Splenic studies: 1. Susceptibility to infection after splenectomy performed in infancy. *Ann Surg* 1952;136:239–42.

Moore GE, Stevens RE, Moore EE, et al. Failure of splenic implants to protect against fatal postsplenectomy infection. *Am J Surg* 1983;146:413.

Morgenstern L, Skandalakis JE. Anatomy and embryology of the spleen. In Hiatt JR, Phillips EH, Morgenstern L, eds. *Surgical Diseases of the Spleen.* New York: Springer; 1997:15–24.

Morgenstern L, Shapiro ST. Techniques for splenic preservation. *Arch Surg* 1979;114:449–54.

Potoka DA, Schall LC, Rod HR. Risk factors for splenectomy in children with blunt splenic trauma. *J Pediatr Surg* 2002;37(3):294–9.

Resende V, Petroianu A. Functions of the splenic remnant after subtotal splenectomy for treatment of severe splenic injuries. *Am J Surg* 2003;185(4):311–5.

Saxe JM, Hayward SR, Lucas CE, et al. Splenic reimplantation does not affect outcome in chronic canine model. *Am Surg* 1994;60:674–80.

Scarborough JE, Ingraham AM, Liepert AE, et al. Nonoperative management is as effective as immediate splenectomy for adult patients with high-grade blunt splenic injury. *J Am Coll Surg* 2016;223(2):249–58.

Schwaitzberg S. Laparscopic splenectomy. In Fischer JE, ed. *Mastery of Surgery.* 6th ed. Philadelphia, PA: Lippincott Williams & Wilkins; 2012:2859–1868.

Tominaga GT, Simon FJ, Dandan JS, et al. Immunologic function after splenic embolization. Is there a difference? *J Trauma* 2009;67(2):289–95.

EDITOR'S COMMENT

The authors have done a masterful job combining and integrating three previous chapters in the 6th edition of *Mastery of Surgery* that were devoted to splenic preservation and splenectomy. Therefore, the current chapter covers multiple topics including nonoperative management of the spleen for trauma, splenic preservation for traumatic injury to the spleen and pancreas, spleen preserving distal pancreatectomy for neoplasms, as well as open and minimally invasive splenectomy.

Clearly their experience with traumatic injury to the spleen is nearly unparalleled. As the authors point out, clinical presentation remains the single most important factor in deciding upon nonoperative therapy while patient age and grade of splenic injury are less important in the clinically stable patient. Successful nonoperative observation for splenic injury approaches 90% for in both children and adults. As the authors state, it is clear that patients who could be successfully treated by splenorrhapy or partial splenectomy are now being successfully treated by nonoperative therapy. As a consequence, many surgeons, including trauma and pediatric surgeons, will have limited experience and opportunities to practice splenorrhapy. In fact, in those patients failing nonoperative management of the spleen, the success rate of splenorrhapy falls

from about 50% to 10%. Since only the more extensive splenic injuries are requiring operative management, once operative management is embarked upon, only a small minority of patients will be appropriate for splenorrhapy.

Recent articles have commented on the lost art of splenorrhapy (Arbuthnot M, Onwubiko C, Mooney D. The lost art of the splenorrhaphy. *J Pediatr Surg* 2016;51(11):1881–4). Arbuthnot et al. reviewed a large pediatric national database of 9,567 children with splenic injury from 2004 to 2013. The vast majority of children were managed nonoperatively while 2.1% underwent a splenectomy and 0.8% underwent a splenorrhaphy. The average surgeon performed 0.6 splenectomies and 0.2 splenorrhaphies for trauma. It was calculated that if these rates remain constant over time, the average surgeon would perform 1.8 splenectomies and 0.6 splenorrhaphies for trauma over a 30-year surgical career. It was concluded that nonoperative management has resulted in a decrease in the experience level of the pediatric surgeons expected to perform an emergency splenectomy or splenorrhaphy when the unusual occasion arises. It is likely that similar trends have been witnessed for adult trauma patients with splenic injury.

Algorithm-based care for trauma patients including those with splenic injury has become standard practice and should be utilized to help guide trainees. Certainly, angiography for an arterial “blush” visualized on CT scan in the stable patient is approached with embolization in the vast majority of patients. In a review by Scarborough et al. of the American College of Surgeons Trauma Quality Improvement Program (TQIP) Participant Use Data Files from 2013 to 2014, nonoperative management was attempted in 1,489 (52.2%) of 2,746 patients who sustained grade IV or V blunt splenic injury (Scarborough JE, Ingraham AM, Liepert AE, et al. Nonoperative management is as effective as immediate splenectomy for adult patients with high-grade blunt splenic injury. *J Am Coll Surg* 2016;223(2):249–58). Propensity matching techniques resulted in a cohort of 758 immediate splenectomy (IS) and nonoperative management (NOM) patients who were well matched for all known patient- and injury-related variables. In-hospital mortality was not different between the IS and NOM patients (11.5% vs. 10.0%, $p = 0.33$). The rate of NOM failure in the sample was 20.1%. Independent predictors of failed NOM included the presence of a bleeding disorder, early blood transfusion requirement, and grade V injury. Splenic artery embolization was associated with a decreased risk of NOM failure. It was concluded that nonoperative management is as effective as IS for hemodynamically stable adult patients with grade IV or V blunt splenic injury. The delay in operative intervention that results from failed attempts at NOM does not adversely affect the outcomes of patients who ultimately require splenectomy.

Approaches to splenic preservation during distal pancreatectomy have evolved over time. As laparoscopic approaches have become more mainstream and with the improvement in instrumentation, visualization, and tissue sealing techniques, it is much easier to perform complicated dissection with

laparoscopy with excellent accuracy and minimal bleeding. Up to recently, there have been limited series that have described results with splenic preservation during laparoscopic distal pancreatectomy. However, Dal et al. have recently published a single institution series of 108 patients who underwent laparoscopic spleen preserving distal pancreatectomy (Dai MH, Shi N, Xing C, et al. Splenic preservation in laparoscopic distal pancreatectomy. *Br J Surg* 2016 Dec 22. doi: 10.1002/bjs.10434. [Epub ahead of print]). From 2004 to 2016, 126 had a planned laparoscopic spleen preserving distal pancreatectomy for which it was accomplished in 86% of patients. Tumor size was an independent risk factor for splenic vessel resection in planned splenic vessel preservation operations, and a cut-off value of 3 cm provided optimal diagnostic accuracy. After a median follow-up of 35.9 months, there were no clinically significant splenic infarctions and no patient developed gastrointestinal bleeding after laparoscopic spleen preserving distal pancreatectomy. These results emphasize the excellent results that can be achieved with careful surgical technique and patient selection.

Recently, surgeons have increased their experience with major pancreatic resection utilizing a robotic assisted platform. Those surgeons who have embraced the robotic approach to distal pancreatectomy have argued that increased visualization and better angulation of the robotic arms allow for increased opportunity for blood vessel control and spleen preservation. Nevertheless, published results to date are conflicting. Two recent metanalyses have compared laparoscopic spleen preserving distal pancreatectomy with robotic spleen preserving distal pancreatectomy. Zhou et al. reported a literature review of seven nonrandomized studies involving 568 patients (Zhou JY, Xin C, Mou YP, et al. Robotic versus laparoscopic distal pancreatectomy: a meta-analysis of short-term outcomes. *PLoS One* 2016;11(3):e0151189). Robotic-assisted distal pancreatectomy was associated with longer operating time, lower estimated blood loss, and a higher spleen-preservation rate. In contrast, Gavriilidis reported a literature review of nine nonrandomized trials evaluating 637 patients. Although conversion rates were only 9% for robotic spleen preserving distal pancreatectomy as compared to 20% for laparoscopic spleen preserving distal pancreatectomy, they concluded that there was no significant difference in the conversion rate and spleen preservation rate between laparoscopic spleen preserving distal pancreatectomy and robotic spleen preserving distal pancreatectomy (Gavriilidis P, Lim C, Menahem B, et al. Robotic versus laparoscopic distal pancreatectomy: the first meta-analysis. *HPB (Oxford)* 2016;18(7):567–74). There are no randomized controlled studies so far that have compared laparoscopic spleen preserving distal pancreatectomy and robotic spleen preserving distal pancreatectomy; therefore, selection bias is a real problem and these findings have to be interpreted with caution. It is clear that there are now increased options for minimally invasive distal pancreatectomy with spleen preservation and that it can be routinely and safely achieved with proper patient selection.

Drs. Lucas and Ledgerwood briefly describe the approach for laparoscopic

splenectomy advocated by Dr. Schwaitzberg in the 6th edition of *Mastery of Surgery* (Schwaitzberg SD. Laparoscopic splenectomy. In Fischer JE, ed. *Mastery of Surgery*. 6th ed. Philadelphia, PA: Lippincott Williams & Wilkins, Chapter 176) and by colleagues at Wayne State University (Fig. 170.6). Drs. Lucas and Ledgerwood indicate that patient positioning for laparoscopic splenectomy is vital and is surgeon-specific. All the approaches they describe involve some component of elevation of the left side of the patient either via the right lateral decubitis or semilateral position or via the supine position with the left chest and abdomen elevated by a folded sheet.

I have found that a laparoscopic splenectomy (with or without distal pancreatectomy) can be routinely accomplished with no elevation of the left side of the patient. This keeps patient positioning very simple and easily remembered by the trainees, anesthesiologist, and operating room staff. A footboard and a table that can obtain steep reverse Trendelenburg position are needed. The table can also be rotated to allow the spleen to tilt forward as necessary.

In almost all patients undergoing laparoscopic splenectomy, the dissection, blood vessel transection, and detachment of the spleen from the ligaments can be accomplished with one 12-mm and three 5-mm ports. An additional 5-mm incision for the nathanson liver retractor is needed in the subxiphoid location. Port placement is quite different than that demonstrated in Fig. 170.6 and depends on the size of the spleen. The larger the spleen, the better it will be to have the ports away from the left upper abdomen. An optiview direct entry 5-mm port is placed in the left paramedian position approximately at the level of the umbilicus. This is for the camera and will be held by the assistant. The assistant also will be utilizing a 5-mm port in the left mid to lower lateral abdomen. The operating surgeon will have a 12-mm port just to the right of midline and a 5-mm port in the right abdomen. The ports are all placed well away from the epigastrium except for the nathanson port. Following mobilization of the stomach and division of the short gastric vessels, the nathanson blade is utilized to retract the stomach and liver. The posterior gastric artery does not need to be routinely divided.

In large spleens, the splenic artery and vein are clearly identified as separate pedicles feeding the lower and upper poles of the spleen. The dissection of the splenic hilum proceeds from a caudal to cranial direction. The inferior attachments of the spleen are divided, and this helps provide access to the lower pole blood vessels. The lower pole vessels are encircled (a gastric band dissector can assist) and then they are stapled with an articulating stapler. Subsequently, the upper pole vessels are encircled and divided. Alternatively, if desired, the splenic artery can be identified and divided along the superior border of the pancreas in an attempt to reduce spleen size and make the hilum dissection safer. Following division of the hilar blood vessels, the superior and lateral attachments of the spleen are divided. The spleen is typically removed through a pfannenstiel or infraumbilical midline incision. Embolization of the

splenic artery prior to splenectomy in the presence of splenomegaly is not routinely done and typically reserved for massive spleens (i.e., >20 cm in maximal dimension).

Steven N. Hochwald

B THE URINARY TRACT AND BLADDER

171 Anatomy of the Kidneys, Ureter, and Bladder

Jennifer M. McBride and Richard L. Drake

KIDNEYS

The kidneys are located in the retroperitoneal connective tissue of the posterior abdominal wall. They develop as pelvic organs that ascend to their final position in the abdomen. The kidneys are bean-shaped structures with a reddish-brown coloration and are approximately 11 to 12 cm long, 5.0 to 7.5 cm wide, and 2.5 to 3.0 cm thick. The left kidney is usually somewhat longer and narrower than the right kidney. Their location in the posterior abdominal wall is usually between the upper border of T-12 and L-2. However, the right kidney is usually slightly lower than the left kidney because of the presence of the liver.

Relationships and Fascias

The location of the kidneys against the posterior abdominal wall provides development of unique relationships with numerous other structures. Structures anterior to the right kidney are the suprarenal gland, the liver, the second part of the duodenum, the right colic flexure, and the small intestine (Fig. 171.1A). Structures posterior to the right kidney include the diaphragm; the costodiaphragmatic recess; the 12th rib; the psoas major muscle; the quadratus lumborum muscle; the transversus abdominis muscle; and the subcostal, iliohypogastric, and ilioinguinal nerves (Fig. 171.1B). Structures anterior to the left kidney include the suprarenal gland, the spleen, the stomach, the body (or tail) of the pancreas, the left colic flexure, and the small intestine (Fig. 171.1A). The listed structures lie directly against the fascias covering the kidney without any intervening

tissues except for the liver, the stomach, the spleen, and the small intestine, which are covered with peritoneum. The structures listed as posterior to the right kidney are also posterior to the left kidney, with the addition of the 11th rib because of the higher position of the left kidney (Fig. 171.1B). Thus, numerous structures must be considered in any surgical approach to the kidneys.

The fascias covering the kidneys are unique. Enclosing the renal parenchyma is a fibrous tissue called the *renal capsule.* This layer of tissue is lightly bound to the kidneys and can be removed easily except in certain disease processes. Immediately adjacent to the renal capsule is the perinephric (perirenal) layer of fat (Fig. 171.2). This layer covers the kidneys and the ureter and is called the *adipose capsule.* Continuing outward is a membranous condensation of the extraperitoneal connective tissue called the *renal (Gerota) fascia* (Fig. 171.2). This specialized membrane separates the perirenal fat from the adipose tissue covering the posterior abdominal wall and must be incised in any operation, whether an anterior or posterior approach is used. The renal fascia consists of anterior and posterior layers that surround the kidneys and the suprarenal gland, usually sending an intervening septum between the two structures. Moving laterally, the anterior and posterior layers may fuse and become continuous with the transversalis fascia. Medially, the posterior layer fuses with the fascia covering the psoas muscle, and the anterior layer may fuse with the sheaths of the blood vessels in the area or cross to the opposite side and fuse with the anterior layer from that side (Fig. 171.2). Superiorly, the anterior and posterior layers fuse after passing over the suprarenal gland and, inferiorly, the layers also fuse, except where the ureter passes through these tissues. Because of the opening around the ureter, infections around the kidneys may descend into the pelvis and vice versa. Finally, outside the renal fascia is the paranephric (pararenal) fat (Fig. 171.2). This is a layer of adipose tissue on the posterior abdominal wall and is usually in a posterolateral position.

Structure

The renal parenchyma consists of the outer cortex and the inner medulla (Fig. 171.3). The cortex is an outer, pale, continuous broad band of tissue. It is a dense, homogeneous tissue and consists of renal corpuscles and convoluted portions of renal tubules. The medulla is an inner layer of discontinuous tissue caused by the inward projections of cortical tissue

called the *renal columns.* The medulla is a darker brown than the cortex and is composed of the renal pyramids. The renal pyramids appear to have longitudinal striations, which extend into the cortex as medullary rays. Each pyramid contains the descending and ascending limbs of the renal tubules and the collecting tubules. The apex of each pyramid is called a *renal papilla*, and it projects into a minor calyx, which is a subdivision of the renal pelvis.

The medial margin of each kidney is occupied by the hilum. The hilum expands into a central cavity called the *renal sinus* and is the site of entrance or exit for blood vessels, lymphatics, and nerves. It transmits, from anterior to posterior, the renal vein, the anterior branch of the renal artery, the ureter, and the posterior branch of the renal artery. It also contains fat and the renal pelvis. The renal pelvis is the expanded upper end of the ureter. It divides into two or three major calyces that further subdivide into many minor calyces. Each minor calyx is indented by a renal papilla. The renal pelvis continues inferiorly and tapers to a narrow tube that becomes the ureter. The ureteropelvic junction is rather indefinite but is usually referred to as located opposite the lower pole of the kidneys.

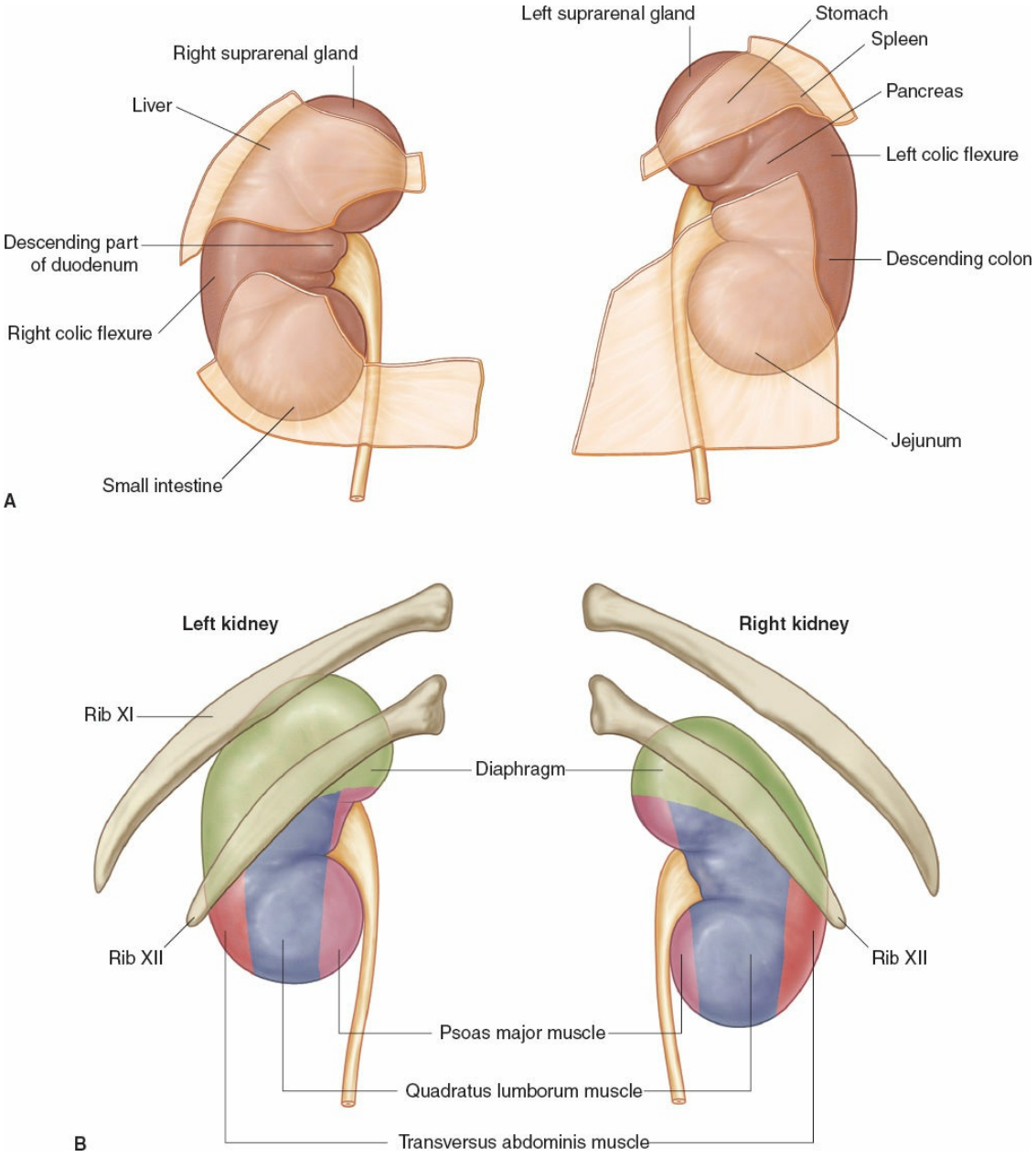

Figure 171.1. A. Anterior relations of the right and left kidneys. All the structures lie against the fascias covering the kidneys, except for the liver and the small intestine on the right and the stomach, the spleen, and the small intestine on the left, which are covered with peritoneum. **B.** Posterior relations of the right and left kidneys. (From Drake RL, Vogl W, Mitchell AWM. *Gray's Anatomy for Students*, 3rd ed. Philadelphia, PA: Churchill Livingstone [Elsevier], 2015, with permission.)

Vascular Supply and Lymphatics

The kidneys are supplied by the renal arteries, which arise from the lateral aspect of the aorta just inferior to the origin of the superior mesenteric

artery (usually between L-1 and L-2). On occasion, the right renal artery may arise a little higher than the left and has a unique pathway to the right kidney in that it passes posterior to the inferior vena cava as it crosses the posterior abdominal wall. As each renal artery approaches the renal pelvis, it divides into anterior and posterior branches that pass on either side of the renal pelvis and major calyces (Fig. 171.3). This provides a somewhat bloodless horizontal plane through the kidney because the anterior branch supplies the anterior half of the organ, and the posterior branch supplies the posterior half of the organ. Additional accessory renal arteries may be found entering the hilum or extrahilar regions. Generally, the accessory arteries do not anastomose with the major renal arteries and may arise from the aorta, the renal artery, or from a different vessel.

The venous drainage of the kidneys consists of anastomosing channels forming a single renal vein that exits at the hilum. Most tributaries of the renal vein pass anterior to the renal pelvis, but on occasion one may pass posterior to this structure. After exiting the hilum, the left renal vein passes anterior to the aorta and posterior to the superior mesenteric artery as it approaches the inferior vena cava. The right renal vein has a short, direct path to the inferior vena cava and enters this vessel at approximately the same level as the left renal vein.

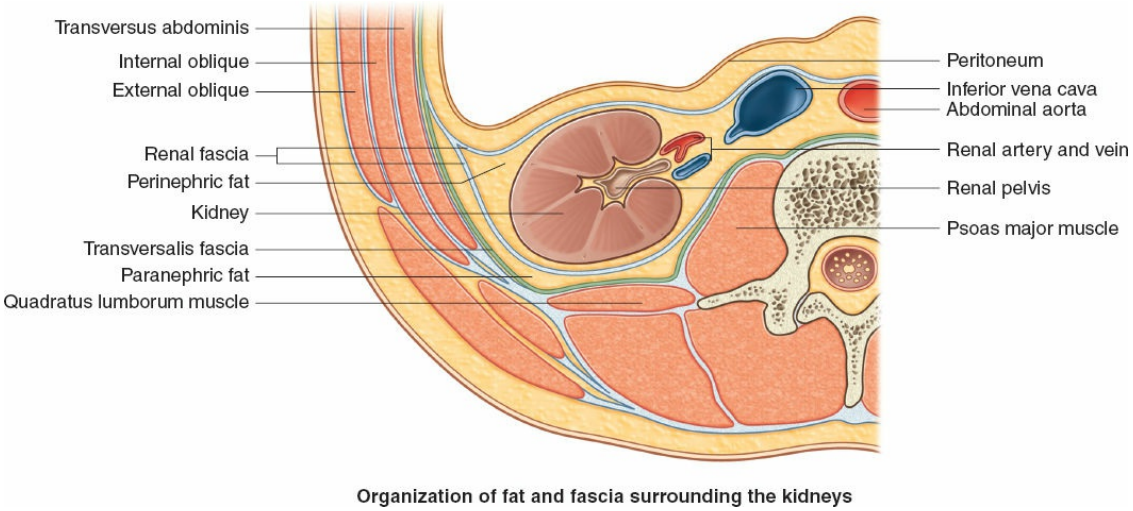

Figure 171.2. Transverse section showing the relation of the renal fascias to the right kidney. (From Drake RL, Vogl W, Mitchell AWM, et al. *Gray's Atlas of Anatomy,* 2nd ed. Philadelphia, PA: Churchill Livingstone [Elsevier], 2015, with permission.)

The lymphatic drainage of each kidney is to the lateral aortic or lumbar

nodes around the origin of the renal artery.

URETER

The ureters are muscular tubes that extend ~25 cm from the kidneys to the posterior surface of the bladder (Fig. 171.4). Each ureter has an upper expanded end called the *renal pelvis.* Of clinical relevance is the fact that three constrictions are present as the ureter descends from the kidney to the bladder. These constrictions occur at the ureteropelvic junction, where the ureter crosses the pelvic brim and where the ureter enters the bladder wall. In addition, obstruction of the ureter may be caused by stenosis of the ureteropelvic junction, compression of the ureter, a urinary calculus lodged anywhere along the ureter, or from abnormalities at the junction of the ureter with the bladder.

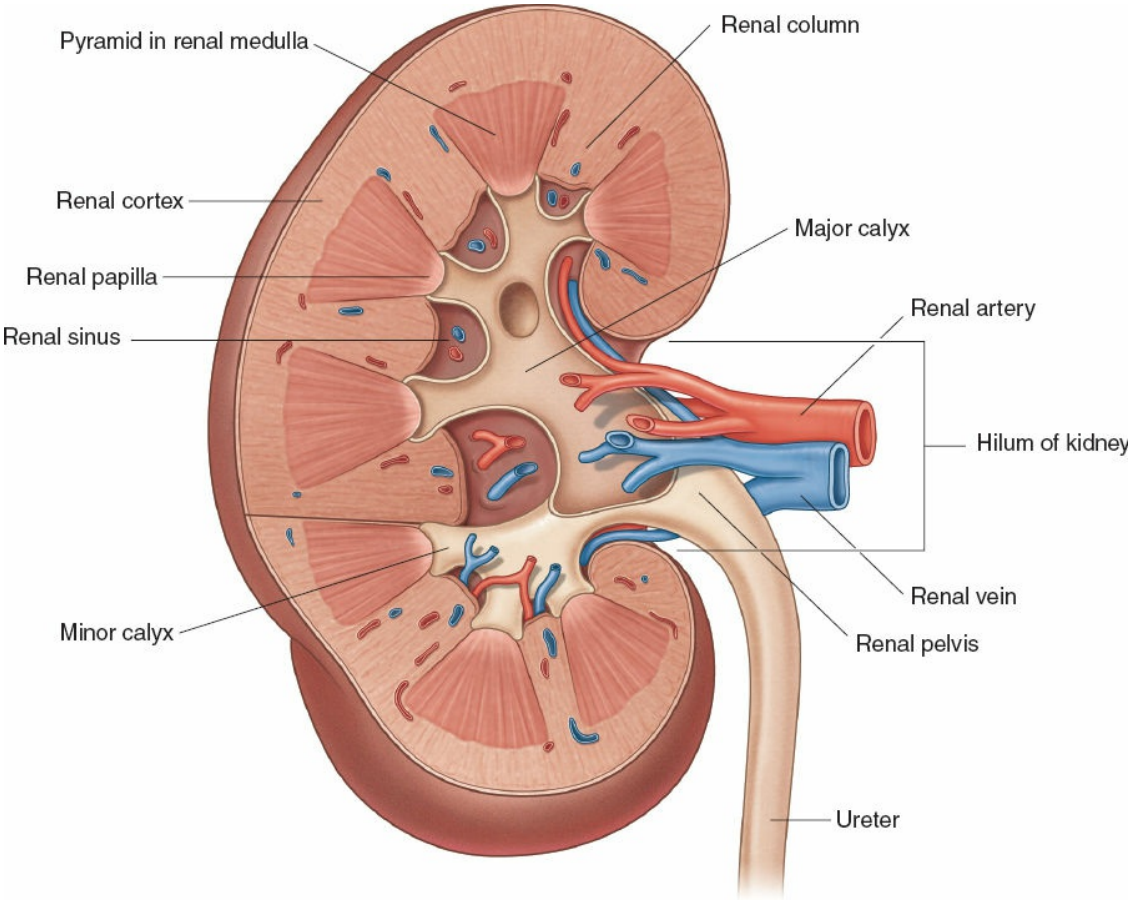

Figure 171.3. Longitudinal section showing the internal structure of the kidney, which consists of an outer cortex and inner medulla. Note that each renal pyramid ends as a renal papilla that projects into a minor calix. (From Drake RL, Vogl W, Mitchell AWM. *Gray's Anatomy for Students*, 3rd ed. Philadelphia, PA: Churchill Livingstone [Elsevier], 2015, with permission.)

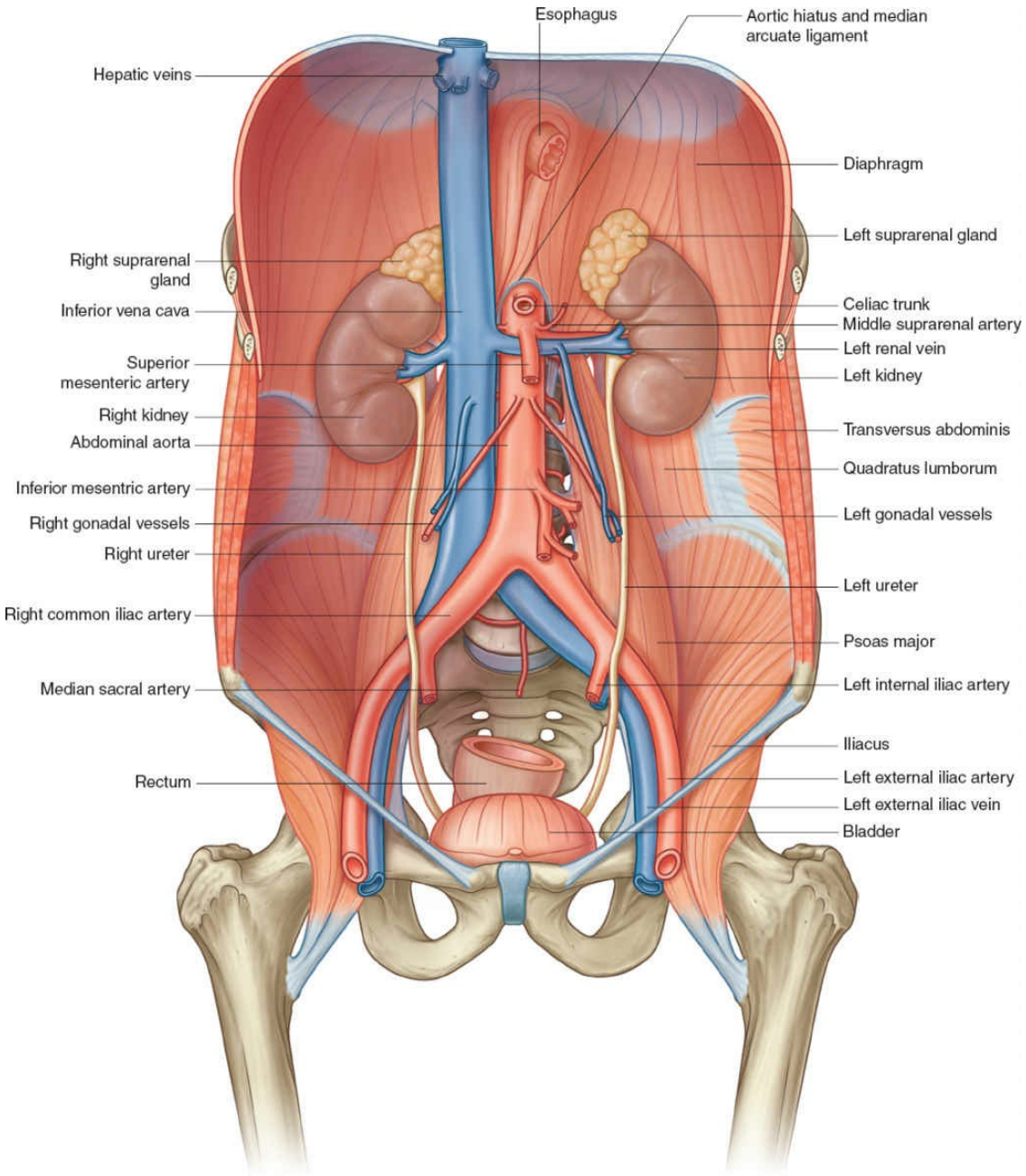

Figure 171.4. The path of the ureter as it passes down the posterior abdominal wall toward the bladder. (From Drake RL, Vogl W, Mitchell AWM, et al. *Gray's Atlas of Anatomy*, 2nd ed. Philadelphia, PA: Churchill Livingstone [Elsevier], 2015, with permission.)

Pathway

Inferior to the ureteropelvic junction, the ureter descends more or less vertically in the extraperitoneal connective tissue of the posterior abdominal wall on the psoas major muscles (Fig. 171.4). In this retroperitoneal position, the proximal portion of each ureter is lateral to the

testicular/ovarian vessels before being crossed by these vessels and continuing distally on their medial side.

The right ureter begins posterior to the descending (second) part of the duodenum and is crossed anteriorly by the right colic and ileocolic vessels. Because of its relationship to the ascending colon as the right ureter continues toward the pelvis, it can be injured when the ascending colon is being "mobilized."

The left ureter is crossed anteriorly by the left colic vessels. In addition, in this retroperitoneal position, the left ureter travels for a considerable distance along the lateral border of the inferior mesenteric vein. It should also be mentioned that as the left ureter nears the common iliac vessels, it lies lateral to the superior rectal (hemorrhoidal) artery. As the left ureter approaches the pelvic brim, it lies posterior to the sigmoid colon in the base of the sigmoid mesocolon. This is a unique relationship that exists only on the left side and is a location where an injury to the ureter can occur during a surgical case involving the sigmoid colon.

At the pelvic brim, the ureters cross the common iliac vessels, usually at the level of the bifurcation of these vessels into the external and internal iliacs (Fig. 171.4). They continue along the posterolateral pelvic wall medial to the internal iliac artery, obturator nerve, and the branches of the artery. From this point to their entrance into the bladder, the pathway is somewhat variable in man and woman. Each one is discussed here separately.

The Female Pathway

At the pelvic brim in the female, the ureters are closely related to the ovarian vessels (Fig. 171.5), a relationship that makes them vulnerable to injury during surgical procedures. The ureters cross the pelvic brim just medial to these vessels. During surgical procedures involving the ovaries, the ureters may be damaged when the ovarian vessels are secured. Continuing inferiorly, the ureters lie deep to the peritoneum and are located near the internal iliac vessels as they pass down the lateral pelvic wall. The ureters pass posterior to the ovaries and enter the uterosacral folds toward the floor of the pelvis. They continue in a medial and anterior direction in these folds along with numerous vessels and nerves. At the base of the broad ligament, the ureters are associated with the lateral cervical or cardinal ligament and pass inferior to the uterine artery as this vessel passes in a transverse direction toward the uterus (Fig. 171.5).

Crossing of the ureters by the uterine artery occurs just lateral to the uterus and is a possible site of surgical injury to the ureter. After crossing inferior to the uterine arteries, the ureters continue in their anterior and medial pathway, passing just lateral to the lateral fornix of the vagina before entering the posterolateral aspect of the bladder. This is another site of possible injury during surgical procedures. Because of these unique relationships to the female pelvic viscera, injuries to the ureter during surgical procedures are more common in females than in males.

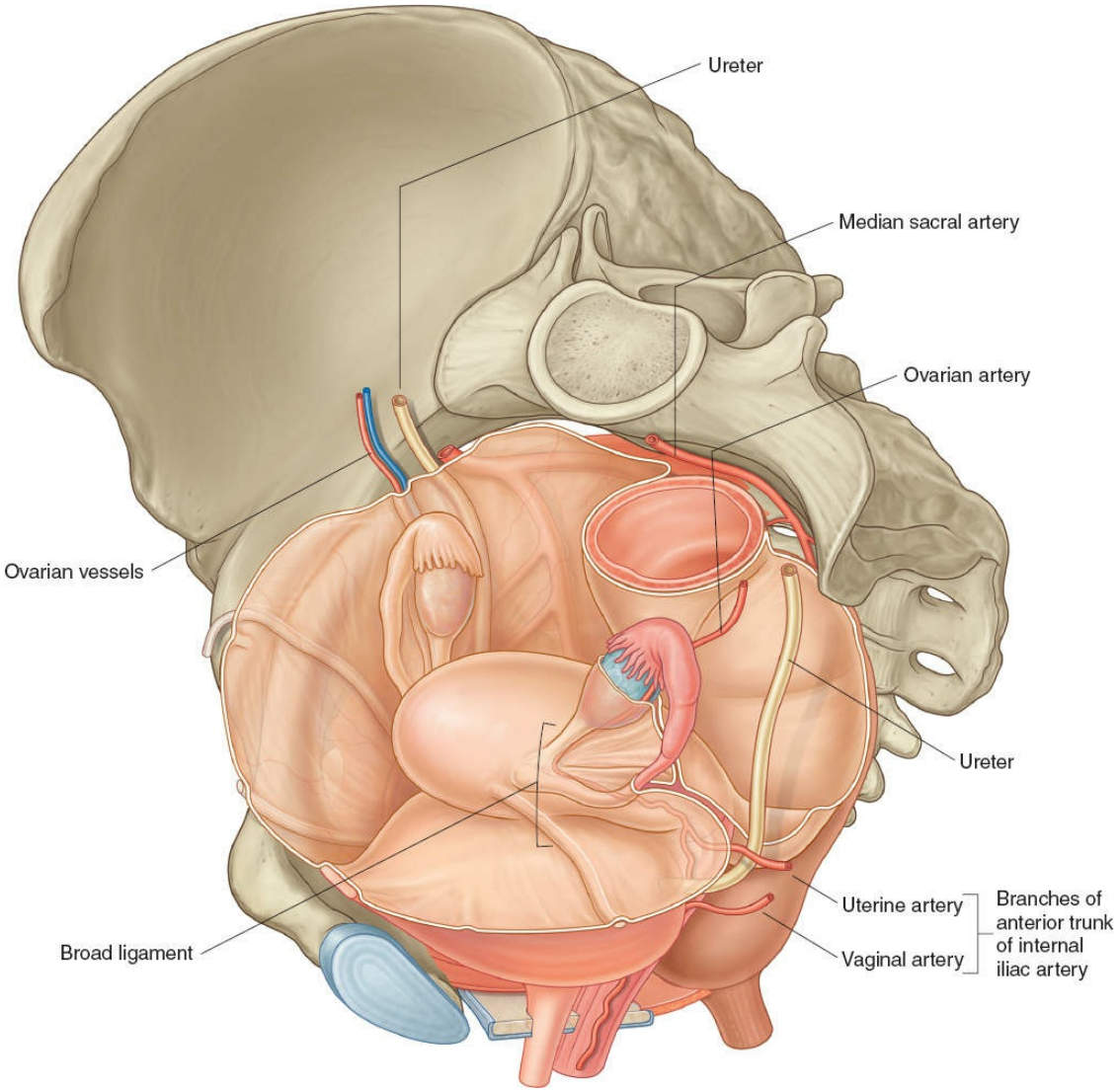

Figure 171.5. Superolateral view looking into the pelvis. As the ureters move toward the bladder, they are located inferior to the uterine artery as this vessel passes in a transverse direction to supply the uterus. (From Drake RL, Vogl W, Mitchell AWM. *Gray's Anatomy for Students*, 3rd ed. Philadelphia, PA: Churchill Livingstone [Elsevier], 2015, with permission.)

The Male Pathway

Near the pelvic brim in the male, the ureters and the testicular vessels separate and the testicular vessels follow the external iliac vessels. The ureters cross the pelvic brim and continue to descend in a slightly medial direction as they continue their intrapelvic course to the bladder (Fig. 171.6). As in the woman, they lie deep to the peritoneum and near the internal iliac arteries as they pass down the lateral pelvic wall. Toward the floor of the pelvis, the ureters enter the sacrogenital folds along with

several vessels and nerves. As they continue anteriorly and medially in these folds, the ureters pass inferior to the ductus deferens and anterior to the seminal vesicles before entering the posterolateral aspect of the bladder (Fig. 171.6). Because of the particular relationships to these two structures, the ureters are vulnerable to injury during surgical procedures in this region.

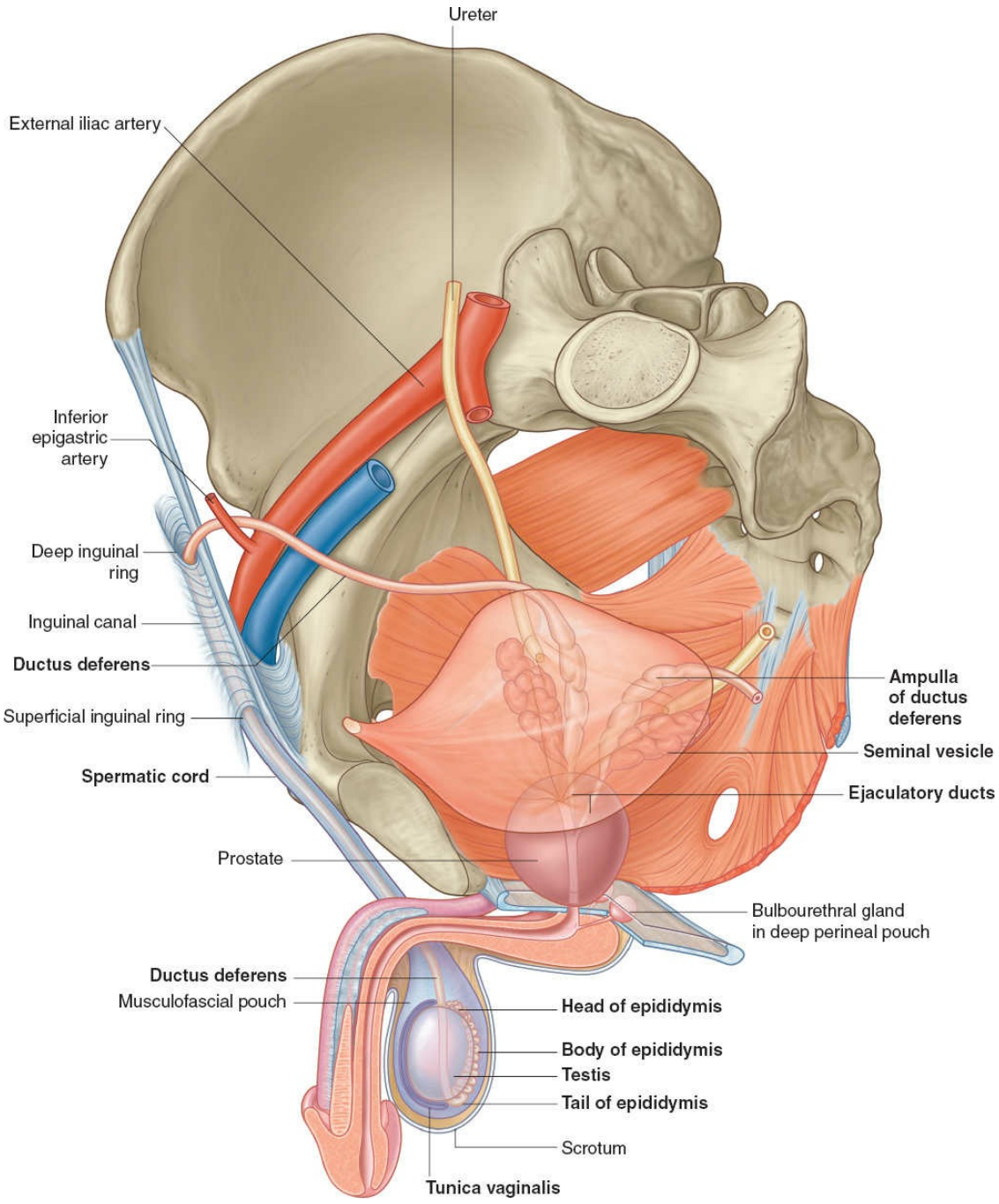

Figure 171.6. Superolateral view looking into the male pelvis showing the ureter passing inferior to the ductus deferens and anterior to the seminal vesicle before entering the posterolateral aspect of the bladder. (From Drake RL, Vogl W, Mitchell AWM. *Gray's Anatomy for Students*, 3rd ed. Philadelphia, PA: Churchill Livingstone [Elsevier], 2015, with permission.)

Vascular Supply and Lymphatics

The ureters receive arterial branches from adjacent vessels as they move toward the bladder (Fig. 171.7). The renal arteries supply the upper end,

and the middle portion may receive branches from the aorta, the testicular or ovarian arteries, and the iliac arteries. In the pelvis, the ureters are supplied by one or more arteries from branches of the internal iliac arteries. In all cases, arteries reaching the ureters divide into ascending and descending branches that form a longitudinal anastomosis.

Lymphatic drainage of the ureters follows a pattern similar to that of the arterial supply. Lymph from the upper portion of each ureter drains to the lateral aortic or lumbar nodes, from the middle portion drains to lymph nodes associated with the common iliac vessels, and from the inferior portion drains to lymph nodes associated with the external and internal iliac vessels.

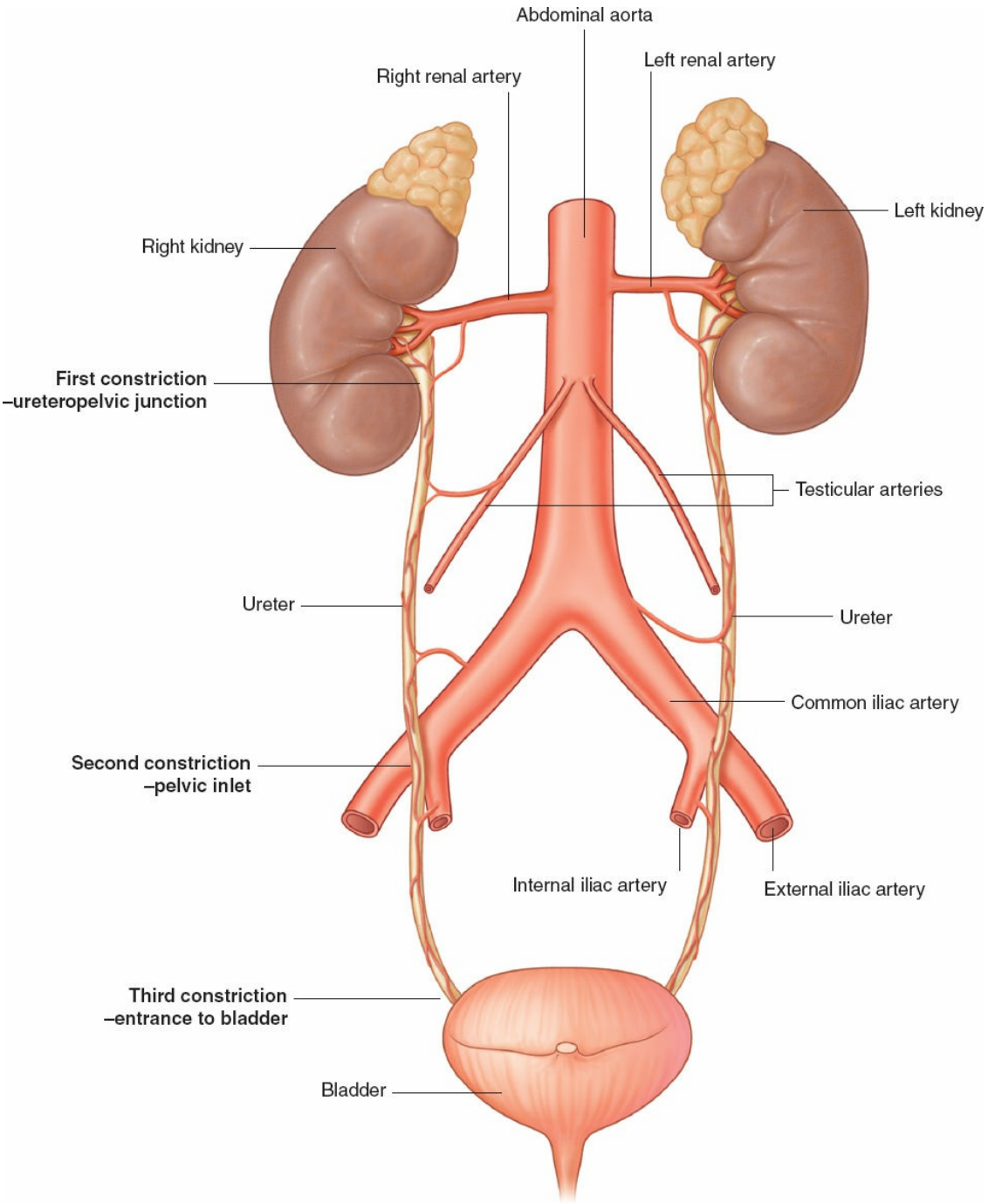

Figure 171.7. The ureter receives arterial branches from the renal, ovarian (testicular), and common iliac arteries. (From Drake RL, Vogl W, Mitchell AWM. *Gray's Anatomy for Students*, 3rd ed. Philadelphia, PA: Churchill Livingstone [Elsevier], 2015, with permission.)

BLADDER

The bladder is a musculomembranous sac located behind the pubic bones and the pubic symphysis. The empty bladder has a pyramidal shape with an apex, a base, and a superior and two inferolateral surfaces (Fig.

171.8A). It also has a neck that extends inferiorly. The empty bladder is within the pelvic cavity. As it fills, it rises above the pelvic brim, contacting the posterior surface of the anterior abdominal wall.

Structure

As mentioned, the bladder, when empty, has a pyramidal shape (Fig. 171.8A). The apex (or vertex) of the bladder points anteriorly and is connected to the umbilicus by the median umbilical ligament (a remnant of the allantois). The base (or fundus) of the bladder is the area between the two ureteric openings and the internal urethral orifice. It is triangular and points posteriorly. Internally, the smooth triangular area outlined by the three openings is called the *trigone* (Fig. 171.8B). This area is smooth compared with the rest of the internal surface of the bladder because here the mucous membrane is firmly bound to the underlying muscular coat.

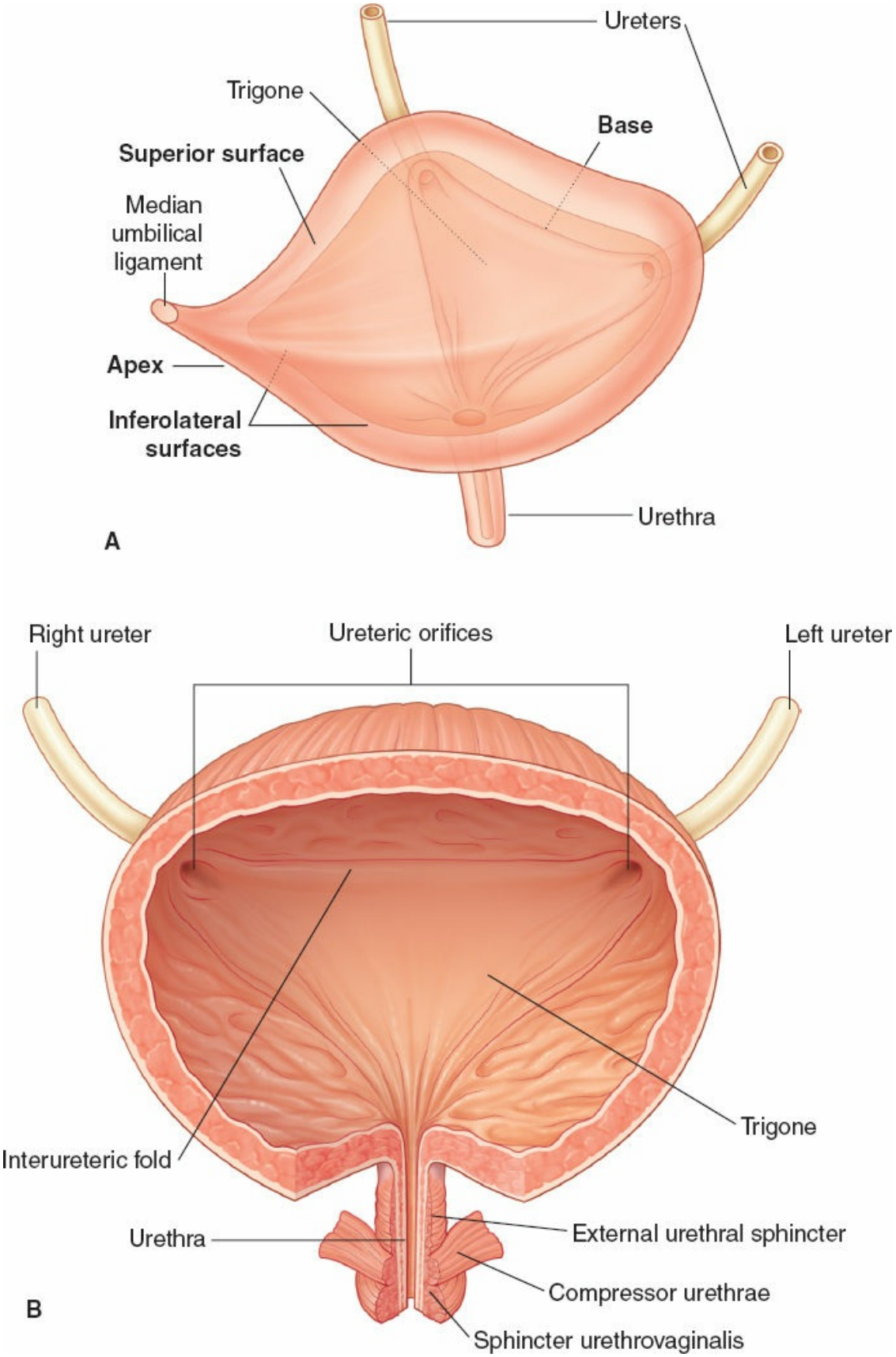

Figure 171.8. A. A superolateral view of the bladder. (From Drake RL, Vogl W, Mitchell AWM. *Gray's Anatomy for Students,* 3rd ed. Philadelphia: Churchill Livingstone [Elsevier], 2015, with

permission.) **B.** Internal view of the bladder. (From Drake RL, Vogl W, Mitchell AWM, et al. *Gray's Atlas of Anatomy*, 2nd ed. Philadelphia, PA: Churchill Livingstone [Elsevier], 2015, with permission.)

There are two additional internal structures. One is found in men and women, and the other is found only in men. In men and women, there is a ridge between the two ureteric openings called the *interureteric crest (fold)* (Fig. 171.8B). The second structure, observed in men only, is the uvula vesicae. This is a small swelling produced by bulging of the prostate's median lobe into the bladder at the inferior corner (apex) of the trigone, just above the internal urethral orifice.

The musculature in the wall of the bladder (tunica muscularis) is called the *detrusor muscle.* It consists of three layers of smooth-muscle fibers arranged as an outer longitudinal layer, a middle circular layer, and an inner longitudinal layer. At the neck of the bladder, the middle circular layer forms the sphincter vesicae muscle.

Relationships and Fascias

Peritoneum covers the bladder on its superior surface and is continuous anteriorly with the median and medial umbilical folds and with the parietal peritoneum of the supravesical fossa. Posteriorly, the peritoneal reflections differ between men and women. In the man, the peritoneum descends to the base of the bladder, lines the rectovesical pouch, and continues posterolaterally as the sacrogenital folds. In the woman, the peritoneum reflects onto the uterus without covering the base of the bladder and lines the shallow vesicouterine pouch.

Numerous structures are directly related to the bladder because of its location in the pelvic cavity. In the man, the neck of the bladder rests on the upper surface of the prostate (Fig. 171.9A). Anterior to the bladder are the pubic symphysis, the retropubic pad of fat, and the anterior abdominal wall. Posterior to the bladder are the rectovesical pouch, ductus deferens, seminal vesicles, rectovesical fascia, and the rectum (Fig. 171.6). Lateral to the bladder are the obturator internus muscle above and the levator ani muscle below. Superior to the bladder are the peritoneal cavity, coils of the ileum, and the sigmoid colon. Inferior to the bladder is the prostate. In the woman, the bladder lies at a lower level than it does in the man, and the neck of the bladder lies directly on the deep perineal pouch (Fig. 171.9B).

Anterior to the bladder are the pubic symphysis, the retropubic pad of fat, and the anterior abdominal wall. Posteriorly, the bladder is separated from the rectum by the vagina. Lateral to the bladder are the obturator internus muscle above and the levator ani muscle below. Superior to the bladder are the vesicouterine pouch of the peritoneal cavity and the body of the uterus. Inferior to the bladder is the deep perineal pouch.

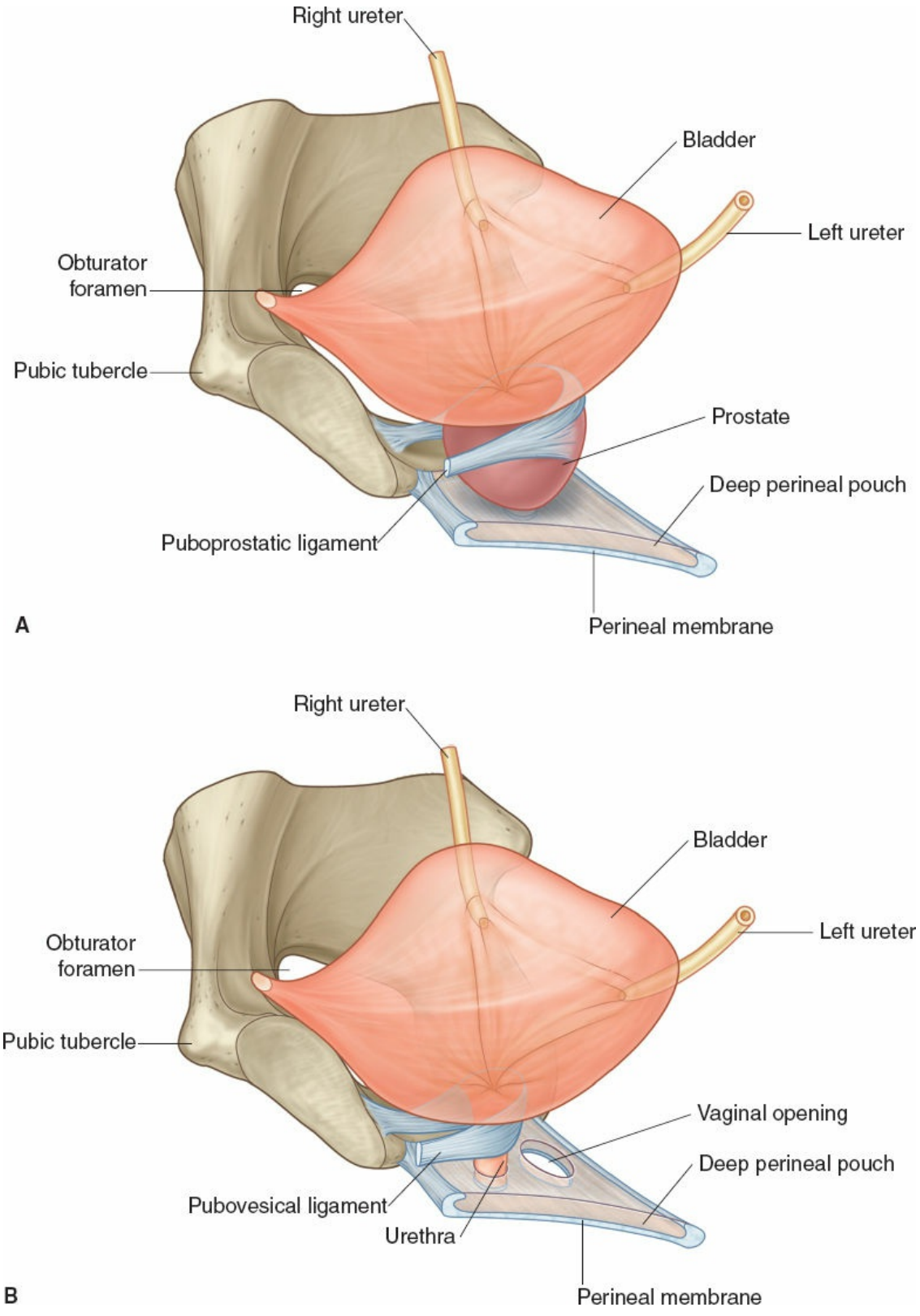

Figure 171.9. A. Puboprostatic ligaments supporting the bladder in the male. **B.** Pubovesical ligaments supporting the bladder in the female. (From Drake RL, Vogl W, Mitchell AWM, et al. *Gray's Atlas of Anatomy*, 2nd ed. Philadelphia, PA: Churchill Livingstone [Elsevier], 2015, with permission.)

The bladder is held in position by ligaments attached to the base of the bladder near the exit of the urethra and the apex of the bladder. In the man, because the prostate is attached to the bladder in this region, the ligaments pass between the prostate and pubic bone. These ligaments are called the *medial* and *lateral puboprostatic ligaments* (Fig. 171.9A). In the woman, the ligaments attach directly between the bladder and the pubic bone. These ligaments are called the *pubovesical ligaments* (Fig. 171.9B). The base of the bladder is also attached posteriorly to the sides of the rectum and the sacrum by the rectovesical ligaments in the man and by the uterovesical and uterosacral ligaments in the woman. Finally, the apex of the bladder is attached anteriorly by the median umbilical ligament, which is a fibrous cord extending from the bladder to the umbilicus.

Vascular Supply and Lymphatics

There are usually two, and sometimes three, arteries that supply the bladder. The superior vesical arteries are present in men and women. They arise from the paired umbilical arteries and are distributed to the apex and body of the bladder. The other constant arterial supply to the bladder is through the inferior vesical arteries. These arteries are variable in their origin and supply the inferolateral region of the anterior surface of the bladder. In the woman, a vaginal artery is usually identified as having a distribution pattern similar to that on the bladder. In men, a third artery has been described as supplying approximately one third of the posterior surface of the bladder. This artery is usually a branch of the artery of the ductus deferens. The venous drainage of the bladder is through a network of veins that drain down toward the neck of the bladder to form the vesical venous plexus. From this point, the plexus receives drainage from other nearby structures before draining laterally to the internal iliac vein. Lymphatic drainage is through lymph nodes associated with the common, internal, and external iliac arteries.

Suggested Readings

Drake RL, Vogl AW, Mitchell AWM. *Gray's Anatomy for Students.* 3rd ed. Philadelphia, PA: Churchill Livingstone (Elsevier); 2015.

Drake, RL, Vogl AW, Mitchell AWM, et al. *Gray's Atlas of Anatomy.* 2nd ed. Philadelphia, PA: Churchill Livingstone (Elsevier); 2015.

Standring S. *Gray's Anatomy.* 41st ed. Edinburgh: Churchill Livingstone (Elsevier); 2016.

EDITOR'S COMMENT

The anatomies of the kidneys, ureter, and bladder are quite important not only because they are vital in urologic surgery, but also because we need to keep in mind that the lower GI tract, especially the sigmoid, retrosigmoid, and certainly the rectum wanders into the area, which is essential to know where you are and where you are not. The kidneys are less of a problem, except that they are retroperitoneal, and sometimes when one is dealing with great vessels or especially the lymph node dissections associated with malignancies of either lymphoma of the testis or the bladder, there is also alongside the great vessels things called kidneys. These have large vessels associated with them, which I think is fair to say that the average general surgical resident does not see much of. The renal vein can bleed, the right adrenal vein which is very short and connected directly to the inferior vena cava can bleed a lot, and some idea of where you are, especially when doing a right adrenalectomy, whether it is open and associated with the other side or laparoscopically, means that it behooves you to avoid injury or disruption of the short right adrenal vein, which goes directly into the vena cava. If you want to see bleeding, injuring that vessel and being careless in that area will show you bleeding.

Another area in which one needs to be careful is at the lateral border of the inferior mesenteric vein, and in other parts of these volumes you will see that there are a number of surgeons who believe that with carcinoma of the colon, the inferior mesenteric vein should be divided and taken near its origin. This is an area where the left ureter lies close to the inferior mesenteric vein as the author points out and needs to be protected. Further down, when one is doing a hysterectomy, the left ureter comes close to the ligaments behind the ureter, and if one gets careless while taking the posterior aspect of the ureter, one may run into the ureter and sever it. The left ureter is close to the base of the sigmoid mesocolon and crosses to the mesocolon on the way to the bladder. In the female, especially the left ureter is medial to the ovarian vessels as the author points out, and again the left ureter comes very close to the uterosacral ligaments while one is taking and dividing the uterosacral ligaments, especially on the left side. On the occasion when one has to take the uterine arteries up front and down near the base of the uterus for a uterine exenteration or else a hysterectomy in which the tumor grows adjacent to the base of the bladder, care must be utilized. The uterine arteries come close to the ureter as they come around and enter the bladder anteriorly. Less common point of injury are the vaginal corners when one is taking out the uterus, in which the ureters are slightly lateral to the lateral fornix, so some care is necessary.

In the male, the seminal vesicles need to be protected, especially when one is doing a total mesenteric excision (TME) of rectosigmoid cancer, which is responsible for the improvement in the survival of cancer of the rectum by ~15%; Professor Heald has been universally recognized for this work. As one

dissects down, it is important to stay within Denonvilliers fascia, which is a demarcation between the border of where the dissection is for carcinoma of the rectum and where one wanders into the area in which the ureters come close to the seminal vesicles and is necessary to protect the seminal vesicles, especially the base of seminal vesicles where they are adjacent to the prostate. The nerves of orgasm and sensation run at the base of seminal vesicles, and if one gets into bleeding in that area, which is not hard to do, suturing blindly or cauterizing blindly at the base of the seminal vesicles near the prostate will render the patient impotent.

It is particularly unfortunate that our medical schools think that it is much more important to learn about leprosy and genetics of some of the rarer diseases than to teach anatomy. It is true that surgery attracts in most schools a minimum of students who want to go into surgery. This does not negate the fact that what used to be a surgical anatomy course is the last time that these medical students and residents will hear anything about some of the things that are going to be important, and that is completely true of this particular chapter in which I suspect that more damage is done to the ureter, and also to seminal vesicles and prostates, resulting in impotence, making the male more miserable and being told that nothing can be done or nothing could be helped about preventing impotence. We now know that this is very important for our freshman surgeons, urologists, and so forth, to learn the anatomy of this area completely because it may help some people who otherwise might be miserable after certain operations.

J.E.F.

172 Surgical Management of Nephrolithiasis

Brian H. Eisner

INTRODUCTION

Nephrolithiasis is a common cause of morbidity, including emergency department evaluation and procedural intervention; the lifetime prevalence of kidney stone disease in the United States is nearly 9%. Over the past 25 years, advances in minimally invasive and endoscopic techniques have significantly changed the management of patients with nephrolithiasis, bringing shockwave lithotripsy (SWL), ureteroscopy, and percutaneous nephrolithotomy (PCNL) to the forefront of management as the standards of care while open, laparoscopic, and robotic approaches are typically reserved for unique situations. Herein we review the current standards of care for minimally invasive treatment of nephrolithiasis.

PREOPERATIVE EVALUATION

Imaging Studies

The mainstays of imaging for renal and ureteral stones include plain abdominal radiography of the kidneys/ureters/bladder (KUB), renal ultrasonography, and computerized tomography (CT) scan. Ultrasonography is not associated with any ionizing radiation exposure to the patient, whereas KUB and CT both expose the patient to some degree of radiation, with CT being greater radiation exposure than KUB. KUB can be useful in the detection of renal and ureteral stones, as well as preoperative planning for intervention. The sensitivity of KUB for detection for nephrolithiasis has been reported to be 45% to 85% as the technique can be limited by bowel gas, extrarenal calcification, and high body mass index (BMI).

Renal ultrasonography is a useful tool to assess for hydronephrosis or ureteral obstruction, and also carries the advantage of not exposing patients to any ionizing radiation. Ultrasonography is highly sensitive for

the detection of hydronephrosis and also useful for the evaluation of renal stones, with sensitivity and specificity for renal stones at 24% to 81% and 82% to 100%, respectively. However, it is noteworthy that in many adult patients, the ureteropelvic junction and ureterovesical junction are visible on ultrasound whereas the proximal and distal ureter are not, so renal ultrasound alone often will not identify a ureteral stone though it will identify hydronephrosis. Studies have also questioned the accuracy of renal ultrasound in accurately estimating the size of renal and ureteral stones, which is of importance in guiding decision for observation versus intervention for renal and ureteral stones. Finally, a recent study noted that in the emergency department setting, ultrasonography is an excellent first-line imaging study for patients with suspected nephrolithiasis and may be comparable with CT in terms of identifying high-risk diagnoses and the risk of return emergency visits.

Noncontrast CT is considered the gold standard for evaluation of nephrolithiasis, with superior sensitivity and specificity to KUB and ultrasound. While CT does expose patients to greater amounts of radiation than KUB and ultrasound, in recent years, efforts to decrease the radiation dose of CT while maintaining its diagnostic accuracy have resulted in a significant reduction in radiation exposure. In addition, CT parameters including stone Hounsfield density, stone-to-skin distance (SSD), and renal infundibular anatomy predict outcomes of SWL and are not available by KUB or renal ultrasound. CT is recommended for all patients in whom PCNL is considered to identify potential for injury to retrorenal organs and risk of thoracic complications, and it is considered an option for clinicians who are deciding between ureteroscopy and SWL for a given patient.

Laboratory Studies and Antibiotic Prophylaxis

For elective management of ureteral or renal stones, demonstration of sterile urine or sterilization of the urine prior to intervention is the standard of care. It is recommended that patients undergo urinalysis prior to planned procedure, and if the urinalysis is suspicious for infection, then a urine culture should be obtained. In the absence of infection, the American Urological Association Best Practice Policy Statement on Urologic Surgery Antimicrobial Prophylaxis recommends the following: no antibiotics for SWL procedures and ≤24 hours of IV antibiotics for ureteroscopy and PCNL. Examples of appropriate antibiotics in these cases include first-/second-generation cephalosporin, ampicillin +

aminoglycoside, ampicillin/sulbactam. Though historically fluoroquinolones were used for antibiotic prophylaxis, issue with selection of resistant organisms and also for tendon rupture have raised concerns about the use of this class of antibiotics. Two recent studies have examined the effects of these antibiotic prophylaxis recommendations on postoperative infection rates after ureteroscopy and PCNL, respectively, and have confirmed the safety of this practice.

In patients who are at higher risk for infection after stone treatment (i.e., those with history of prior recurrent cystitis, pyelonephritis, or positive preoperative urine culture), the exact duration of antimicrobial prophylaxis and postoperative antimicrobial treatment has not been determined. Many clinicians will treat a positive preoperative urine culture for 5 to 7 days both prior to and after stone treatment with SWL, ureteroscopy, or PCNL. No specific guidelines exist on this topic. A previous study reported that 1 week of antibiotics prior to PCNL may be beneficial in patients with a positive urine culture in terms of reducing the risk of postoperative positive urine culture and systemic inflammatory response syndrome (SIRS) where as other studies have failed to confirm this finding.

With regard to laboratory studies, the American Society of Anesthesiologists recommends selective ordering of preoperative laboratory studies. Complete blood count with platelet count is recommended for those undergoing procedures where there is a significant risk of blood loss such (i.e., PCNL) or for patients with symptoms of anemia or thrombocytopenia. Serum electrolytes can be obtained selectively for patients with suspected renal insufficiency.

PATIENT AND TREATMENT SELECTION

Drainage of the Collecting System for Patient With Obstruction and Active/Acute Infection

Though much of stone treatment can be performed on an elective basis, for patients with obstruction of the urinary system due to a ureteral or renal stone and concomitant infection (i.e., fever, signs/symptoms of pyelonephritis, positive urinalysis/culture), emergent decompression of the collecting system is the standard of care. This can be performed either by cystoscopic placement of ureteral stent or by image-guided placement of a nephrostomy tube—each is an equally acceptable treatment. A recent study demonstrated that mortality decreased by over 50% for patients with

infection and obstruction in whom immediate decompression was performed compared to those who were treated with antibiotics and observation (8.8% mortality versus 19.2% mortality). It is also recommended that if purulent urine is encountered during ureteroscopy or PCNL, the procedure should be aborted, the collecting system should be drained with a stent or nephrostomy tube, and then the procedure can be completed in a second-stage several weeks later after treatment with culture-specific antibiotics.

Ureteral Stones

For the patient presenting with an obstructing ureteral stone (in the absence of infection and severe unremitting renal colic), observation can be offered for stones ≤10 mm in diameter. Spontaneous passage rate are largely determined by stone size, with passage rates for stones <10 mm from 30% to 90%; passage rates decrease with increasing stone diameter. The use of alpha blockers for medical expulsive therapy (MET) has been debated. In the early 2000s, MET was recommended and used as the standard of care after multiple reports showed that alpha blockers increased the spontaneous passage rate for ureteral stones, presumably by decreasing peristaltic contractions of the ureter. However, a recent multicenter study, the SUSPEND trial, has called the use of MET into question as this trial failed to show efficacy of this treatment. More recent examinations of data from dozens of trials of MET have demonstrated that MET is most efficacious for larger ureteral stones (i.e., those 5 to 10 mm) and for distal ureteral stones.

Repeat imaging is typically performed 4 to 6 weeks after the initial stone event to assess for interval stone passage, and for those in whom a ureteral stone and ureteral obstruction persists, intervention is recommended using a shared decision-making approach to select either SWL or ureteroscopy. It is also acceptable to perform intervention sooner than 4 to 6 weeks if the patient has recurrent bothersome symptoms such as renal colic and/or nausea/vomiting. It is paramount to ensure the resolution of ureteral obstruction either by visual confirmation of stone passage per urethra or by imaging studies—if the ureteral stone fails to pass (even in the case where colic has resolved), it should be removed using SWL or ureteroscopy due to the potential risks of renal ureteral stricture formation and/or renal damage secondary to long-term obstruction.

For ureteral stones which fail to pass, it is recommended that the patient and clinician participate in a shared decision-making approach to determine the optimal treatment. SWL is the less invasive of the two treatments, but is also associated with a lower stone-free rate for ureteral stones (SWL success rate = 72%, ureteroscopy success rate = 90%). The 2016 joint guidelines publication by the American Urological Association and the Endourological Society for the surgical management of stones advises that for patients who have a distal or mid ureteral stone which fails to pass, clinicians should offer ureteroscopy as first-line therapy due to its higher success rate and reserve SWL for patients who decline ureteroscopy. Of note, this is a significant update and change in recommendation from the previous guidelines published nearly a decade earlier which viewed SWL and ureteroscopy as equivalent first-line treatments for ureteral stones.

Though stone-free status can be accomplished in the majority of patients with ureteral stones by either observation (with or without MET), SWL, or ureteroscopy, there are cases in which these treatments may not be efficacious. These scenarios may include the following: altered genitourinary anatomy which does not allow for retrograde ureteroscopy (e.g., urinary diversion or neobladder, prostatomegaly) or stone impaction within the ureter resulting in a significant inflammatory response and edema of the urothelium which can cause difficulty visualizing the stone during ureteroscopy. For those patients, PCNL with antegrade ureteroscopy can be considered, in addition to laparoscopic or robotic surgery. Laparoscopic/robotic surgery is typically the final consideration if SWL, ureteroscopy, and PCNL have failed, but surgical outcomes with laparoscopic/robotic techniques demonstrate low morbidity and success rates above 90% for ureteral stone removal.

Renal Stones

Standards of care and guideline recommendations for the treatment of renal stones are dependent on several factors, including whether or not the stone is causing symptoms, whether the stone is likely to lead to a future symptomatic event, and stone size and location. Other factors which predict outcomes of surgical procedures (such as stone Hounsfield density, SSD, and renal anatomy) are useful in determining which patients are suitable candidates for SWL versus ureteroscopy or PCNL (covered later in this chapter).

For patients with asymptomatic renal caliceal stones, observation with surveillance may be offered. Periodic follow-up imaging to assess for stone growth is recommended. For patients with an asymptomatic renal stone diagnosed on imaging, 5-, 10-, and 15-year rates of a symptomatic stone episode are 30%, 45%, and 50%, respectively. Clinicians may take these episode rates and stone size into consideration when counseling/informing patients about the risks and benefits of observation for these stones.

Stone location plays a role in the decision for type of intervention for renal stones—in particular, stone location in the lower pole may influence treatment decisions. The lower pole of the kidney lies in a dependent position, which has been shown to decrease the efficacy of SWL—stones may fracture with the treatment but are difficult to expel due to their dependent position in the lower pole. In addition, to treat lower pole stones with ureteroscopy requires anatomy that will allow the ureteroscope to properly deflect to safely fracture the stone or place the stone into a basket and move it to a position in the kidney which is more favorable for treatment. A prospective-randomized study of SWL versus ureteroscopy for lower pole stones demonstrated 3-month stone-free rates of 35% and 50%, respectively, and a similarly designed study comparing SWL to PCNL demonstrated 3-month stone-free rates of 37% and 95%, respectively. It is important to note that with continued improvements in technology of flexible ureteroscopes, stone-free rates for flexible ureteroscopy for lower pole stones have improved significantly in the past 5 years with a recent large multicenter study reporting lower pole stone-free rates of 89% for stones <10 mm, 75% for stones 10 to 20 mm, and 23% for stones >20 mm.

For symptomatic lower pole renal stones, SWL or ureteroscopy may be offered for stones ≤10 mm in diameter. However, for lower pole stones >10 mm, ureteroscopy or PCNL are preferred due to the lower efficacy of SWL for lower pole stones of that size. Ureteroscopy is associated with lower stone-free rates and need for retreatment but also lower morbidity compared with PCNL. For symptomatic nonlower pole renal stones ≤20 mm in diameter, SWL and ureteroscopy are appropriate first-line options. Retreatment rate are lowest for PCNL and greatest for SWL. For symptomatic renal stones >20 mm, PCNL is the standard first-line treatment; ureteroscopy can be offered but patients must be counseled that ureteroscopy may require multiple procedures to render the patients stone

free. SWL is not recommended for symptomatic renal stones >20 mm.

SURGICAL INTERVENTIONS

Shockwave Lithotripsy Background

The first report of SWL by Chaussy and colleagues in 1980 signaled the beginning of the end of the era of open stone surgery. At that time, options for the treatment of ureteral and renal stones were limited to observation, open surgery, and chemolytic agents (for less common stones susceptible to chemolysis); SWL represented a truly minimally invasive technique to treat painful renal colic and/or obstructing stones which threatened the overall health of the kidneys. Over the past 35 years, SWL technology has evolved to include newer-generation and more portable machines, allowing for the widespread use of this technique. Though it competes with other minimally invasive techniques such as ureteroscopy and PCNL in the urologist's armamentarium for the treatment of stone disease, SWL accounted for just over 50% of all procedures in the United States for stone disease in 2005. More recent studies note that as stone-free rates for ureteroscopy improve with improvements in ureteroscope technology that ureteroscopy may overtake SWL as the most common procedure for stone disease in the near future.

Shockwave Lithotripsy Patient Factors

There are multiple patient factors which are associated with success rates for SWL. Stone composition is known to affect outcomes of SWL. From least successful to most successful treatment by SWL, stone composition is ranked as follows: cystine, struvite, brushite, calcium oxalate, uric acid. As stone composition is often unknown at the time of SWL (especially for first-time stone-formers), attention has shifted to imaging characteristics which define stone fragility; Hounsfield density has been shown to correlate with SWL success. Several studies have evaluated this relationship and determined that stones with Hounsfield densities greater than 900 to 1,000 Hounsfield units are associated with lower stone-free rates than those of lower Hounsfield densities. Patient body habitus, and more specifically SSD also predicts the success of SWL. Multiple studies have examined SWL stone-free rates in patients with varying SSD. SSD of ≤8 to 10 cm is associated with higher stone-free rates than higher SSDs.

SWL is contraindicated in patients who are pregnant. Though limited

data exist, concerns regarding the effects of shockwaves on fetal hearing and other fetal organs are largely unknown. Animal studies have demonstrated potential for fetal trauma due to SWL exposure. SWL is also contraindicated in patients taking anticoagulants or with uncorrected bleeding diathesis. Renal hematomas are a known complication of this procedure and occur in 1% of patients without bleeding diathesis—as such, the risk of significant hemorrhage for those with bleeding disorders or taking anticoagulants exceeds the benefits of SWL, especially since ureteroscopy is an alternative procedure which can be safely performed in this group of patients. One study demonstrated a 4-fold increased risk of postoperative perinephric hematoma for SWL patients who were taking aspirin or nonsteroidal anti-inflammatory drugs and use of more potent antiplatelet agents such as clopidogrel has been associated with hemorrhage requiring nephrectomy after SWL. Patients with untreated urinary tract infection or acute cystitis/pyelonephritis should not be treated with SWL until infection has been properly treated.

Shockwave Lithotripsy Technique

Shockwave Rate

SWL fractures stones by creating cavitation bubbles in the urine which fracture the stone upon contact. Several studies have demonstrated that there is an optimal range of shocks per minute to achieve the highest stone-free rates. In this instance, “faster is not always better.” At the highest shock wave rates, it is thought that the increased frequency of cavitation bubbles may actually cause the bubbles to interfere with one another, decreasing their effectiveness at fracturing the stone upon contact. A recent meta-analysis of nine randomized controlled trials (over 1,500 patients) noted that rates of 60 to 90 shocks per minute are equivalent in terms of postoperative stone-free rates, and that these rates are superior to 120 shocks per minute.

Renoprotective Protocols

SWL does cause a small amount of trauma to the kidney. While clinically significant bleeding or hemorrhage after SWL is rare, animal studies have demonstrated that focal kidney injury occurs after this procedure. While the majority of these injuries likely resolve, multiple SWL procedures for a given patient could create renal scarring over time. Several protection protocols which alter treatment parameters of the SWL machines have

been investigated in efforts to determine whether particular settings will decrease renal trauma due to SWL. Early animal studies demonstrated that giving 100 shocks at a lower power (18 kV) followed by a 3-minute pause, and then finishing treatment at the highest power (24 kV) up to 2,000 total shocks resulted in less renal damage than giving 2,000 consecutive shocks at the highest voltage (24 kV). More recent studies have noted that low voltage can be applied continuously for the first several hundred shocks and the pause can be omitted, while maintaining decreases in renal trauma compared with continuous SWL at the highest voltage level—that is, 500 shocks at low voltage followed by the remainder at high voltage without pause resulted in effective renoprotection.

Voltage Escalation

It is hypothesized that initial treatment with lower power shocks may "prime" the stone for more efficient fragmentation with escalation of shockwave power. A randomized controlled trial evaluated the use of escalating voltage doses during SWL versus performing the entire procedure at a higher power. In this study, the control group was treated at a higher power for a total of 3,000 shocks, while the experimental group was treated with a voltage escalation protocol, starting at lower power and increasing the power every 500 shocks for a total of 3,000 shocks. The control group demonstrated 72% stone-free rate compared with the voltage escalation of 96% stone-free rate at 8 weeks follow-up. The authors concluded that voltage escalation protocols result in more efficient stone fragmentation than standard high power protocols.

Strategies to Improve Stone-Free Rates After SWL

Pharmacotherapy is used to improve stone-free rates after SWL. Tamsulosin, a selective alpha blocker also used to facilitate expulsion of ureteral stones, has been evaluated in multiple trials, as have other medications such as calcium channel blockers and corticosteroids. These medications result in reduced expulsion time (i.e., quicker time to stone-free status or decrease in residual fragments) as well as decrease in incidence of postoperative colic and pain medication requirements. In addition to medications to facilitate stone passage, medications to prevent regrowth of stones have also been used successfully. Potassium citrate, which complexes with calcium in the urine to calcium oxalate stone formation has been used to decrease stone recurrence and improve stone-free rates. A randomized trial demonstrated that at 1-year follow-up, SWL

patients treated with potassium citrate demonstrated significantly fewer renal stones (and presumably residual stone fragments) than those treated with placebo—12.5% versus 44.5%. A final class of therapeutics, herbal remedies, has also been used effectively—*Phyllanthus niruri*, also called "chanca piedra," is an extract that comes from a tropical, coastal plant seen commonly in South America. This extract is thought to prevent crystal aggregation and has been associated with improvement in stone-free rates after SWL compared with placebo (93% versus 70.8%).

Percussion, diuresis, and inversion therapy has also been used to improve stone-free rates. This technique involves the patient bending 90 degrees with the waist parallel to the ground and the head directed toward the ground, most often accomplished by the patient lying on a bed or similar furniture. Prior to getting into this position (e.g., 30 to 60 minutes prior), the patient is often advised to drink 1 to 2 large glasses of fluid. Once in the inverted position, percussion (either by machine or by hand percussion by another individual) is applied to the patient's flank on the side of the stone for 5 to 15 minutes. While no universally accepted protocol exists, this is often done for 2 to 4 weeks after SWL treatment. Two randomized-controlled trials of diuresis, inversion, and mechanical percussion have been shown to significantly increase stone-free rates after SWL.

Complications of Shockwave Lithotripsy

Serious complications of SWL are rare, but can occur. Renal subcapsular hematoma occurrence is associated with the following risk factors: hypertension, diabetes, preoperative urinary tract infection, coronary artery disease, obesity, and age. Urinary tract infection occurs in about 2% to 4% of post-SWL cases and sepsis is a rare occurrence. Infection after SWL may be more related to the patient and stone (i.e., patient with history of recurrent cystitis/pyelonephritis; stone colonized with bacteria than the SWL treatment itself). Steinstrasse, from the German for "stone street" occurs 2% to 10% of the time after SWL and is defined as an accumulation of stones within the ureter. Often this can be managed conservatively but for unresolving steinstrasse or in patients who present with concomitant infection, decompression with stent or nephrostomy tube followed by definitive stone treatment is often necessary. The risk of steinstrasse is related to stone size—larger stones carry a far greater risk than smaller stones. Concerns have been raised about the risk of long-term development of diabetes mellitus and hypertension after the publication of a

retrospective review of 20 years' clinical experience with SWL from the Mayo Clinic, which demonstrated that patients undergoing SWL were more likely to develop diabetes and hypertension than those who underwent ureteroscopy for the treatment of stone disease. However, there have been a number of articles which dispute this finding. These potential complications are important to remember and perhaps should be taken into account for those who have undergone many SWL treatments or those who may already carry a diagnosis of diabetes mellitus and/or hypertension.

Ureteroscopy Technique

Gaining Access to the Ureter

Ureteroscopy is performed in the dorsal lithotomy position and with fluoroscopic guidance in the majority of cases. After positioning and sterile preparation of the penis or female introitus, the procedure generally begins with a cystoscopy and the passage of a guidewire into the ureteral orifice and into the renal pelvis or calyces, performed under fluoroscopic guidance. Various types of guidewires exist and generally fit into one of several categories. A standard 0.035- or 0.038- in PTFE-coated guidewire is cost-effective and useful for gaining access to the ureter—straightforward cases without significant ureteral obstruction or tortuous anatomy. Other commonly used guidewires include hybrid guidewires (which include a floppy, hydrophilic tip attached to a stiffer nitinol core), glidewires (entire guidewire is hydrophilic), and "superstiff" or "extra-stiff" which are useful for the introduction of dilators or access sheaths. Advantages of the hybrid wires are that the hydrophilic floppy tip often aids in bypassing ureteral obstruction or tortuous anatomy, but the stiff core still allows this wire to be used for the passage of a ureteroscope and sometimes the passage of ureteral access sheaths. In contrast, the glidewires, which are hydrophilic in their entirety, are excellent for bypassing obstruction or tortuous anatomy but are less commonly used as a "working wire" and more commonly used for difficult anatomy, then exchanged for a more suitable working wire such as a hybrid wire. Many urologists also advocate for placement of a second "safety wire," especially if the ureteroscopy is to treat pathology within the ureter (e.g., stone, tumor, stricture). The safety wire remains in position adjacent to the ureteroscope throughout the procedure—in the event of ureteral abrasion, ureteral trauma, or perforation of the ureter, the safety wire often still

allows for a ureteral stent to be placed at the end of the procedure, decreasing the risk of significant ureteral injury or need for nephrostomy tube placement for extremely difficult cases. If performing flexible ureteroscopy in the renal pelvis or kidney, the safety wire may not be as necessary or useful in preventing injury because the risk of ureteral injury should be decreased in these situations.

If the ureteral orifice is too narrow to accommodate the ureteroscope, a number of techniques exist to dilate the orifice to allow for passage of the ureteroscope. A common technique is balloon dilation—in general, a dilating balloon of short length (e.g., 4 cm) is introduced over the guidewire and inflated to 12 to 15 Fr. Other options for dilation of the ureteral orifice include sequential rigid dilators, dual-lumen catheters, or ureteral access sheaths. Whereas routine balloon dilation of the ureteral orifice was performed in the early experience with ureteroscopy in the 1990s, it is less commonly performed currently—the continued development of smaller and more ergonomic ureteroscopes over the past 2 decades has allowed for more frequent introduction of the ureteroscope into the ureteral orifice without the need for dilation of the ureteral orifice.

Ureteral access sheaths are commonly used for flexible ureteroscopy procedures and are most useful for the following indications: (1) large stone burden which requires basket extraction of multiple stone fragments from the upper ureter or kidney; (2) to decrease renal pelvis pressures and lower the risk of urosepsis for patients at risk for postoperative infection; and (3) for dilation and access to the ureter that is too narrow to accommodate the ureteroscope alone over a guidewire. A recent survey noted that over 50% of flexible ureteroscopy procedures worldwide are performed with a ureteral access sheath by routine. Ureteral access sheaths have been shown to cause trauma to the ureter, though significant long-term complications of ureteral abrasion such as ureteral stricture have not been reported, leading many to feel that these ureteral abrasions heal over ureteral stents placed at the end of the procedure.

Semi-Rigid and Flexible Ureteroscopy

The choice of ureteroscope is determined by the patient's anatomy and the location of the stone or pathology to be treated. Semi-rigid ureteroscopy is commonly performed for the distal ureter in all patients. It can be used for the proximal ureter in males, but sometimes the use of this instrument is limited by the length of the male genitourinary tract and the potential difficulty in advancing the semi-rigid ureteroscope proximal to the

sacroiliac joint where the iliac vessels cross anterior to the ureter in males. In females, however, semi-rigid ureteroscopy can be more regularly performed in the proximal ureter. For patients in whom the semi-rigid ureteroscope cannot be advanced up to the stone (regardless of gender), the flexible ureteroscope can be used.

Semi-rigid ureteroscopes range in size from 4.0 to 7.5 Fr and can be introduced into the ureteral orifice alongside a safety guidewire or over a guidewire with an additional safety wire in position. Of note, this diameter is a significant decrease from the semi-rigid ureteroscopes commonly used in the late 1990s and early 2000s, many of which were as large as 10 Fr and were much more difficult to atraumatically advance into the ureter and up to the target stone. As mentioned previously, if the ureteral orifice is too narrow to accommodate the semi-rigid ureteroscopes, dilation of the ureteral orifice is performed with a balloon or rigid dilator. For extremely narrow ureters, the surgeon may choose to place a ureteral stent to allow for passive dilation of the ureter and return several weeks later to perform ureteroscopy. In general, the ureteroscope is advanced alongside the guidewire up to the stone, and then lithotripsy (most commonly laser lithotripsy) is performed. Stones are either dusted into tiny fragments which are too small to basket and are expected to pass spontaneously or stones are fragmented into larger fragments and basket extracted. The advantages of the semi-rigid ureteroscope are ease of maneuverability (easier than flexible ureteroscopes), large working and irrigation channels which allow for the placement of larger laser fibers or combinations of laser fibers and baskets, durability, and visibility.

Flexible ureteroscopy is performed routinely for stones from the iliac vessels to the renal collecting system. Advances in size (i.e., smaller tip size), optics (digital imaging), and deflection over the past 20 years have revolutionized the practice of flexible ureteroscopy and moved this procedure to the forefront of options for the treatment of upper ureteral and renal stones <2.0 cm. The working channel of flexible ureteroscopes is typically 3.6 Fr and can accommodate a laser fiber for lithotripsy or a basket for stone manipulation or the fragment retrieval. The flexible ureteroscope is commonly passed up to the kidney either over a guidewire through its working channel or through a ureteral access sheath. In a similar fashion to semi-rigid ureteroscopy, the flexible ureteroscope is then advanced to the stone and lithotripsy and/or extraction is performed.

Ureteroscopic lithotripsy is most commonly performed using a

Holmium:YAG laser as the energy source. For semi-rigid ureteroscopes, laser fibers up to 400 μm are frequently used, whereas smaller fibers (i.e., 200 to 270 μm) are used for flexible ureteroscopy. For the flexible ureteroscopes, larger fibers are associated with decreased deflection capability and may also increase the risk of damaging the internal working channel. There are a wide range of potential laser settings and two commonly used techniques are “fragmentation with basketing” and “dusting.” Fragmentation with basket retrieval is typically a higher-power, lower-frequency setting of the laser (e.g., 1 to 2 J, 4 to 10 Hz); this typically results in fracture of the stone into larger fragments which may require basket extraction. In contrast, dusting is predicated on lower-power, high-frequency laser settings (e.g., 0.2 to 0.5 J, 20 to 80 Hz) and typically results in tiny particles which are likely to spontaneously pass and may not require basket retrieval. It is important to note that not all stones fracture in the same manner—some calculi may be more efficiently treated with fragmentation settings while for others, dusting may be preferable. A recent multicenter trial demonstrated similar efficacy in terms of procedure success of these two techniques. A recent survey study noted that the dusting technique is used in up to 65% to 75% of ureteroscopic procedures worldwide.

Postoperative Ureteral Stent

Ureteral stents are commonly placed in ureteroscopy in order to optimize drainage of the kidney and ureter which may be decreased due to ureteral edema after instrumentation. Absolute indications for stent placement include ureteral perforation or injury and infected upper urinary tract, while relative indications for stent placement include large stone burden, solitary kidney, edematous ureter, and bilateral ureteroscopy. Potential advantages of ureteral stent placement include decrease in postureteroscopy admissions for pain and dilation of the ureter which may allow stone fragments to pass easier after the procedure. For procedures in which a ureteral access sheath is used, many surgeons will use a ureteral stent due as ureteral edema is likely after this magnitude of ureteral dilation—in this setting, ureteral stenting has been demonstrated to decrease emergency department visits. However, ureteral stents are also associated with bothersome flank pain and bladder discomfort and have not been shown to decrease risk of ureteral stricture formation after ureteroscopy. Stent-related symptoms of flank discomfort, urinary frequency, and urgency have been successfully treated with alpha

blockers, anticholinergics, and nonsteroidal anti-inflammatory medications. The decision to leave a ureteral stent is surgeon-dependent, and multiple studies, including systematic reviews and meta-analyses have struggled to make firm recommendations due to heterogeneity of prior published studies on the topic.

Complications of Ureteroscopy

One of the more important principles of ureteroscopy and stone treatment in general is that if there is a high risk of injury to the ureter or collecting system associated with complete treatment of a stone, placement of a ureteral stent and return in several weeks for a second-stage procedure is an acceptable and prudent approach. In 2% to 8% of procedures, access to the ureter or the stone is difficult and stent placement with second-stage treatment is necessary. Rates of urinary tract infection and sepsis after ureteroscopy are reported at 2% to 4% each, and rates of ureteral stricture formation (which may require future ureteroscopic dilation/incision or reconstructive surgery) are 1% to 4%. Mucosal abrasion or minor ureteral perforation from the ureteroscope or ureteral access sheath may occur and will often require a stent postoperatively—however, as discussed prior, the association between these abrasions and downstream formation of ureteral stricture has not been established. Selective postoperative imaging with renal ultrasound is recommended for complicated procedures such as those with ureteral perforation or impacted ureteral stone due to risk of stricture in these patients.

Major ureteral injuries such as ureteral avulsion occur at very low rates (~0.2%) and are typically treated either with immediate reconstruction if possible or nephrostomy tube placement and delayed reconstruction.

Treatment of Pregnant Patients With Ureteral Stones

Pregnant patients with ureteral stones and renal colic may present a dilemma to the obstetrician and the urologist. Renal colic is a common cause of nonobstetric abdominal pain in pregnant women and may be associated with preterm labor. The first step in management of the pregnant patient with renal colic and urolithiasis is always conservative management—however, if this fails, drainage with a ureteral stent or nephrostomy versus ureteroscopy with definitive treatment should be considered. Whereas stent or nephrostomy tube placement may be a quicker procedure than ureteroscopy and require lower amounts of regional or general anesthesia, the risk of encrustation of stents or

nephrostomy tubes in the gravid patient is high, due to elevated levels of urine calcium. A recent multicenter study demonstrated the safety and feasibility of ureteroscopy for stone removal in pregnant patients without apparent increased risk of preterm labor compared with renal colic itself.

Percutaneous Nephrolithotomy

PCNL is the gold standard treatment for larger stones—renal stones >2.0 cm, branched/staghorn stones, lower pole renal stones >1.5 cm, as well as for patients in whom ureteroscopy may not be possible due to aberrant anatomy (i.e., urinary diversion, neobladder, significant prostatomegaly). The key to this procedure is percutaneous access to the kidney via needle puncture, using either ultrasound or fluoroscopic guidance. Typically a posterior facing calyx is desired and puncture directly through the "cup" of the calyx will minimize bleeding and also optimize access to the kidney. From its inception to present, PCNL has been commonly performed in the prone position, though over the past 2 decades, many have adopted a supine or modified supine/flank position for this procedure. Advantages of the prone over supine position may include reduced risk of injury to adjacent organs due to greater ability to vary the entry point and position of the puncture needle. Advantages of supine over prone position include elimination of need to reposition the patient, potential increased ability to perform flexible ureteroscopy, and decrease anesthetic risks for obese patients or others with respiratory compromise. No comparative studies have shown a definitive superiority of one position over the other—this is based largely on surgeon preference and experience.

Access to the collecting system is gained via percutaneous puncture, using either ultrasound or fluoroscopic guidance. Proponents of ultrasound guidance note that they have real-time control of the puncture and the ability to change direction guided by the ultrasound image. Ultrasound also allows for identification of retrorenal structures (i.e., spleen, liver, colon, pleura) and avoidance of injury. While retrorenal spleen, liver, or colon are uncommon, the consequences of injury can be great. Ultrasound-guided puncture also avoids exposure of the patient and operating room personnel to ionizing radiation. In contrast, fluoroscopy-guided puncture tends to be technically less challenging—a 2-dimensional image of a retrograde pyelogram (either performed with contrast injection or air injection of the kidney) is visualized on the monitor, various techniques exist to judge the depth of the puncture, and then the needle is advanced

into the kidney. Common techniques for fluoroscopic puncture include “triangulation” and “eye-of-the-needle” techniques. A modification of access techniques which is used by some includes endoscopic-guided access—in which a flexible ureteroscope is advanced to the desired calyx of entry and then the puncture needle is directly visualized entering the kidney; the wire can be grasped with a ureteroscopic basket and brought to the patient’s bladder or urethra with the flexible ureteroscope.

Once access to the collecting system has been achieved with the puncture needle, a variety of techniques exist to establish the percutaneous tract. An example of step-by-step technique is as follows, though significant variation of technique exists among surgeons: (1) puncture desired calyx under imaging +/− endoscopic guidance; (2) advance wire down the ureter into the bladder with assistance of torqueing catheter; (3) use coaxial dilator to dilate tract to 10 to 12 Fr and advance second wire (safety wire) down to the bladder (some may omit the introduction of safety wire); (4) radial dilation of PCNL tract with either sequential rigid dilators or single-step balloon dilator; (5) advance nephrostomy sheath over rigid or balloon dilator to proper position within the collecting system with imaging guidance; (6) remove dilator and leave guidewires and sheath in place; (7) introduce nephroscope into kidney and perform lithotripsy with stone disintegration and/or extraction; (8) survey collecting system and ureter with combination of imaging (ultrasonography, fluoroscopy with antegrade or retrograde pyelography, rigid or flexible nephroscopy and ureteroscopy); (9) consider placement of nephrostomy, stent, or omission of drainage tube.

In recent years, significant variation in nephrostomy tract/sheath sizes has been reported. Standard PCNL is performed via a 30-Fr nephrostomy sheath and typically a 24- to 26-Fr nephroscope. However, significant advances in technology have allowed for the miniaturization of the PCNL technique. Namely, the introduction of higher power lasers, the miniaturization of lithotripters, and improvements in nephroscopes now support mini PCNL, micro PCNL, and super-mini PCNL (with tract sizes ranging from 18 Fr to 5 Fr). Somewhat analogous to the debate of prone versus supine position for PCNL, proponents of each PCNL tract size have debated the merits of each. Smaller tract size may theoretically be less traumatic to the kidney, but also is associated with the necessity to create smaller stone fragments in order to extract through smaller sheaths. Surgeon preference and experience as well as surgeon comfort/ability with

flexible ureteroscopy (during or after PCNL) determines the choice of tract size.

Postoperative Drainage After PCNL

Historically, it was surgical dogma that a nephrostomy tube be left in the percutaneous tract(s) after PCNL to promote drainage and to tamponade the percutaneous tract to decrease the risk of postoperative hemorrhage. In addition, for those considering a "second-look PCNL"—that is, a second percutaneous procedure within 1 to 2 weeks of the first PCNL procedure for complex stones—an indwelling nephrostomy maintains access to the collecting system and may avoid additional punctures and tract dilations. However, within the past decade, many of the perceived advantages of the postoperative nephrostomy tube have been called into question. Multiple systematic reviews and meta-analyses have been performed and have reported that tubeless (i.e., placement of ureteral stent and omission of nephrostomy tube) and even "totally tubeless" (i.e., neither nephrostomy nor stent) are safe, feasible, and equally efficacious to standard PCNL with a postoperative nephrostomy tube in properly selected patients. Some advantages of tubeless approaches include decreased postoperative pain and decreased urinary leakage/extravasation after surgery. Also, studies have failed to demonstrate that leaving a nephrostomy tube in place actually reduces hemorrhage or need for transfusion compared with tubeless approaches. The decision whether to perform PCNL with a nephrostomy, a ureteral stent, or without either drainage device is largely surgeon dependent. However, many surgeons agree that for situations in which there is a large amount of urinary extravasation or renal pelvis injury, placing a nephrostomy tube and a ureteral stent concomitantly optimizes drainage and healing of such injuries.

Complications of PCNL

Though PCNL is the most complex procedure performed for urinary stone disease, major complications are uncommon. A recent multicenter international cooperative study of over 5,800 PCNL cases demonstrated that ~9% of complications were >Clavien class 2. Major complications which are seen after PCNL include the following: infection/sepsis; bleeding requiring transfusion or angioembolization; injury to retrorenal structures including spleen/liver/colon; and pleural injury resulting in pneumothorax, hydrothorax, or hemothorax. Significant postoperative bleeding is reported to occur in 0.5% to 5% of procedures and risk

increases with operative time and multiple punctures. Injury to surrounding organs is quite rare and preoperative evaluation of cross-sectional abdominal imaging may decrease the risk of these types of injuries. Pleural injury can often be managed conservatively, though occasionally a chest tube is required for drainage of fluid or blood or for re-expansion of the lung in situations of pneumothorax. This is most commonly associated with upper pole punctures.

Special Cases—Patients With Uncorrected Bleeding Diathesis

SWL is contraindicated in patients who are taking anticoagulants or those with uncorrected bleeding diathesis due to the increased risk of hemorrhage. On the other hand, ureteroscopy is considered safe and feasible in patients with coagulopathy and is commonly performed under these conditions. A meta-analysis of three studies of ureteroscopy in patients with coagulopathy demonstrated no major complications and a stone-free status of 87%. A more recent publication comparing 272 patients who underwent ureteroscopy and had associated coagulopathy versus >4,400 control patients noted an increased risk of hematuria, emergency visits, and unplanned return to the OR after ureteroscopy and a stone-free rate of 73%. More recently, surgeons have begun to study the safety of continuing aspirin during PCNL. Evaluating a cohort of patients who chronically take aspirin for a history of coronary artery disease, a recent study noted no significant increase in transfusion rates after PCNL for those who continued aspirin therapy compared with those who held aspirin for 1 week prior to PCNL.

TAKE HOME POINTS

The last 3 decades have witnessed the end of open surgery for urolithiasis. SWL, ureteroscopy, and PCNL have become the mainstays of intervention for stone disease. These treatments are safe and effective and with proper patient selection as described above, can be utilized to treat nearly all renal and ureteral calculi.

Suggested Readings

Assimos D, Krambeck A, Miller NL, et al. Surgical management of stones: American urological association/endourological society guideline, PART I. *J Urol* 2016;196(4):1153–60.

Assimos D, Krambeck A, Miller NL, et al. Surgical management of stones: American urological association/endourological society guideline, PART II. *J Urol* 2016;196(4):1161–9.

EDITOR'S COMMENT

In this chapter "*Surgical Management of Nephrolithiasis*," Brian Eisner nicely overviews the current minimally invasive treatment options for renal stones including the primary options of SWL, ureteroscopy (URS) with laser lithotripsy, and PCNL. Indeed, with the tools available today, the role of open surgical stone management has largely been relegated to historic interest.

In recent years, advances in surgical technology have come primarily in the realms of URS and PCNL, with SWL technology remaining stagnant. As Dr. Eisner highlighted in the text, the advances that have occurred with SWL have related to optimizing the outcomes with the current technology while at the same time attempting to reduce complications. The technology used for SWL has changed little in recent years. It is interesting that so many years after the instruction of SWL that it was realized that delivering the maximum number of shocks at the maximum power was not the optimal technique for SWL, but rather a "start low and go slow" approach is superior. Furthermore, by utilizing information from the preoperative CT imaging that is readily available on most patients, such as the density of the stone (measured in Hounsfield units) and the skin to stone distance, that patients can be more appropriately selected and counseled regarding the potential efficacy of the procedure (Bhojani N, Lingeman JE. Shockwave lithotripsy-new concepts and optimizing treatment parameters. *Urol Clin North Am* 2013;40(1):59–66).

An important aspect of SWL that does distinguish it from URS and PCNL to some degree, is that the majority of procedures can be performed without the placement of a ureteral stent. Indeed, the 2016 AUA Guidelines on Surgical Stone Disease do not recommend the placement of a ureteral stent for routine stones <15 mm in maximal diameter (Assimos D, Krambeck A, Miller NL, et al. Surgical management of stones: American urological association/endourological society guideline, PART I. *J Urol* 2016;196(4):1153–60). This can be an important consideration for patients as stent morbidity remains a major factor for both patients and clinicians alike and stent placement after URS remains a common practice (Muslumanoglu AY, Fuglsig S, Frattini A, et al. Risks and benefits of postoperative double-j stent placement after ureteroscopy: results from the clinical research office of endourological society ureteroscopy global study. *J Endourol* 2017;31(5):446–51). Patients who have previously tolerated stents poorly may be more inclined to select SWL over URS, even if the success rate may be slightly lower, knowing that a stent would not be placed. This highlights the importance of a shared decision-making approach with patients to consider all aspects of the

intervention.

Ureteroscopy, specifically flexible URS for the upper ureter and renal collecting system, is the area of surgical stone disease management that has garnered much interest over the past decade. As Dr. Eisner outlined in the chapter, with modern flexible endoscopes the entire renal collecting system can be accessed in most of the cases. With the advent of the holmium:YAG laser, and the small caliber flexible fibers that deliver the laser energy to the target stone, stones of all compositions can be fractured into small pieces. The ability to safely perform the procedure in patients on anticoagulation, as well as in the morbidly obese, gives the urologist a critical tool to treat these challenging patient populations. From a patient perspective, the lack of a surgical incision, the high fragmentation rate, and the outpatient nature of the procedure are highly appealing. However, there remain challenges with URS. The initial purchase cost of the flexible ureteroscopes are high and maintenance of these fragile instruments even higher. The durability of these endoscopes is poor with only 10 to 15 procedures on average performed before repair is needed (Knudsen B, Miyaoka R, Shah K, et al. Durability of the next-generation flexible fiberoptic ureteroscopes: a randomized prospective multi-institutional clinical trial. *Urology* 2010;75(3):534–8). Even with the advent of digital technology has failed to show an improvement in these figures (Shah K, Monga M, Knudsen B. Prospective randomized trial comparing 2 flexible digital ureteroscopes: ACMI/olympus invisio DUR-D and olympus URF-V. *Urology* 2015;85(6):1267–71). In addition to the cost of the endoscopes, the other equipment used during the procedure such as guidewires, stone baskets, laser fibers, and stents are primarily single use, with laser fibers being the exception where both single use and reusable options are available. This disposable equipment adds significantly to the cost of the procedure. Worldwide, health care costs are a growing concern and the high cost of the equipment used for these procedures will be a budgeting challenge in the future. When one factors in payment reform, such as bundled payments, having to justify each tool used will likely become a reality.

While PCNL has been an established treatment modality for many years, the technique has been continually refined to improve the success rate and decrease the morbidity (Duvdevani M, Razvi H, Sofer M, et al. Third prize: contemporary percutaneous nephrolithotripsy: 1585 procedures in 1338 consecutive patients. *J Endourol* 2007;21(8):824–9). It remains the treatment of choice for large stone >2 cm and for smaller stones in the lower pole (Assimos D, Krambeck A, Miller NL, et al. Surgical Management of Stones: American urological association/endourological society guideline, PART I. *J Urol* 2016;196(4):1153–60). This is due to the ability to efficiently clear large volumes of stones through a small incision in a rapid and safe manner. Refinements in percutaneous renal surgery have occurred in recent years. While data are limited, there is a trend toward using smaller tract sizes in an attempt to further reduce surgical morbidity. As Dr. Eisner discussed, there has been a

trend in PCNL to reduce the tract size from 30 Fr to a smaller size (<20 Fr) with the goal to reduce the morbidity of the procedure. However, with a reduction in tract size there are other trade-offs. The size of the fragments that can be removed are limited by the size of the tract. Therefore any reductions in the tract diameter require additional fragmentation of the stone prior to removal, thereby lengthening the procedure. In addition, the instruments used to fragment the stones are all smaller with a reduced tract size; again this can result in a decrease in efficiency and longer operative times. In the coming years it is likely that prospective studies evaluating tract size in a randomized fashion will help to determine which size is truly optimal.

Physicians, especially in the United States, have been actively challenged to reduce length of stay (LOS) for our patients. While SWL and URS are performed primarily as outpatient procedures, PCNL has historically been associated with an inpatient hospital admission. However, the LOS for PCNL has become shorter with many cases in tertiary care centers in the United States taking place as 23-hour observation stays. Others have taken this a step further and are now performing PCNL as a same-day outpatient procedure (Beiko D, Lee L. Outpatient tubeless percutaneous nephrolithotomy: the initial case series. *Can Urol Assoc J* 2010;4(4):E86–90). While these patients must be carefully selected, the feasibility of this approach has been clearly demonstrated and is a trend to observe in the coming decade.

Surgical management of stone disease has been well established in the minimally invasive era for some time now. Future refinements aimed at increasing stone-free rates, limiting morbidity, and reducing lengths of stay are likely to occur over the next decade. These improvements, however, will need to be balanced with cost containment as our health care systems come under increasing budgetary challenges in the years to come.

Bodo E. Knudsen

173 Operations on the Ureteropelvic Junction

Frank Hinman, Jr.



This Chapter can be accessed in the accompanying eBook edition (see inside front cover for access instructions).

As an alternative to open operation, consider endoscopic incision. If open surgery is indicated, the most adaptable technique is the Anderson–Hynes dismembered pyeloplasty. This method not only uniformly provides a funnel, but also allows resection of functionless portions of the pelvis and ureter. For selected cases, the YV-plasty and pelvic flap operations are excellent, whereas intubation techniques are reserved for cases in which more plastic methods are not possible.

ANDERSON–HYNES DISMEMBERED PYELOPLASTY

Expose the kidney through an anterior subcostal incision, taking care to stay out of the peritoneal cavity, or use a flank incision. In infants, the pelvis may be readily approached through a dorsal lumbotomy incision.

Open Gerota's fascia laterally to preserve the dorsal layer; its contained perinephric fat will be used later to cover the repair.

Dissect the ureter starting below the ureteropelvic junction, taking care not to interfere with the segmental blood supply to this area (Fig. 173.1). Place a small Penrose drain or vessel loop around the ureter.

After exposure of the ureteropelvic junction, decide on the type of operation. Ureteropelvic junction obstructions are usually from an anomalous insertion of the ureter, with or without stricture, from a stricture just below the ureteropelvic junction, or, in the upper ureter, from a stricture or a ureteral valve. Ask yourself: Is the ureter long enough to allow dismemberment and excision of the ureteropelvic junction? If so, a modified Anderson–Hynes pyeloplasty is suitable most often, although a Foley Y-plasty can work well with high insertions of the ureter. For a long dependent junction, the Culp or Scardino techniques may solve the

problem of having insufficient ureter for approximation.

Place a stay suture in the ureter at its junction with the pelvis (Fig. 173.2), divide the ureter obliquely, and spatulate it on its (less vascularized) lateral surface for a distance equal to the length of the proposed V-shaped flap.

With the pelvis full, map the proposed diamond-shaped incision with a skin-marking pen, angling the caudal triangle medially to form a V-flap (Fig. 173.3). Place stay sutures of 7-0 catgut at the angles of the diamond. Incise along one of the planned lines for a short distance with a no. 11 hooked blade. With Lahey or Potts scissors, cut the pelvis from the inside of one stay suture to the inside of the next (Fig. 173.4).

Insert an infant feeding tube of suitable size into the ureter to prevent a suture from catching the far wall (Fig. 173.5). Place one 5-0 or 6-0 synthetic absorbable suture adjacent to the apex of the V-shaped flap, inserted first from outside in, then out through the apex of the ureteral slit. Place a second suture 2 mm away from the first. Tie both sutures with four knots and cut the short ends.

Continue the first suture along the far side of the wall to the tip of the ureter as a continuous stitch, locked at every four or five bites (Fig. 173.6A). Do the same for the second suture on the near side. Be sure to irrigate the pelvis and calices free of clots.

Tie the two sutures together, cut one at the knot, and close the pelvic defect with the other (Fig. 173.6B). If the infant feeding tube is to remain as a stent, bring it out through the renal parenchyma.

Inject saline with a fine needle through the pelvic wall to test for watertightness and for patency of the anastomosis.

Insert a Penrose drain and fasten it by the long-suture technique to be sure it is near but not touching the anastomosis or the ureter below it (Fig. 173.7). Nephropexy stitches can be used to hold the kidney in place if it has been mobilized. Tack the two edges of Gerota fascia together around the kidney with fine plain catgut to isolate the kidney from the body wall and close the wound in layers.

FOLEY YV-PLASTY

This technique may be indicated for a high insertion of the ureter, especially when the pelvis has a box shape (Fig. 173.8A).

Draw the ureter cephalad with a Penrose drain and mark a long Y-shaped incision between stay sutures. Incise the pelvis between the stays

with a no. 11 hooked blade, and open it with Potts scissors. This forms a V with arms equal to the length of the ureteral incision (Fig. 173.8B). A nephrostomy tube may be placed, with or without a stent. Suture the apex of the flap to the apex of the ureteric incision with a 7-0 synthetic absorbable suture passed in through the apex of the V and out through the apex of the ureteral incision (Fig. 173.9A). Place interrupted sutures of 4-0 synthetic absorbable suture down both sides of the V to make a watertight anastomosis (Fig. 173.9B).

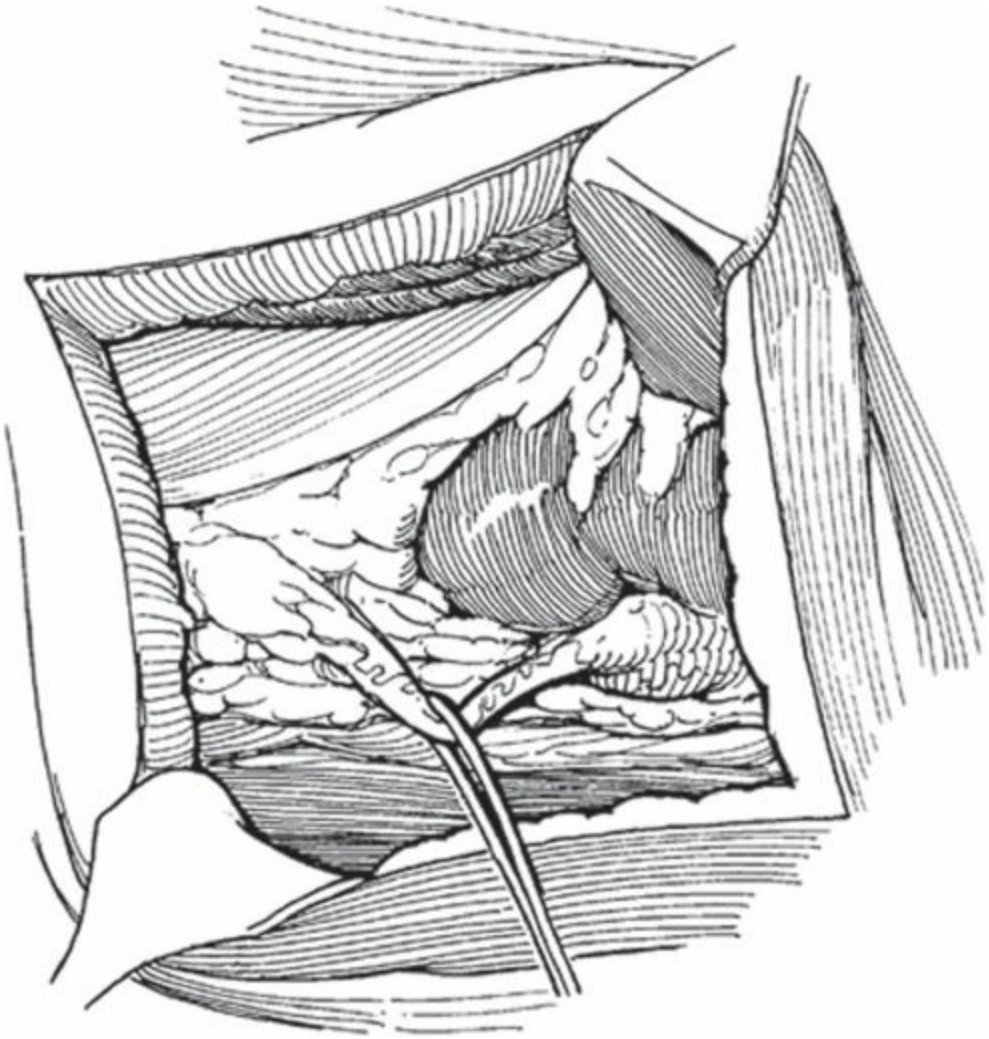

Figure 173.1. Anderson–Hynes dismembered pyeloplasty. Exposure and dissection of the ureteropelvic junction. (Published in Hinman F Jr. *Atlas of Urologic Surgery*. 2nd ed. Philadelphia, PA: WB Saunders, 1998, with permission. Copyright Elsevier.)

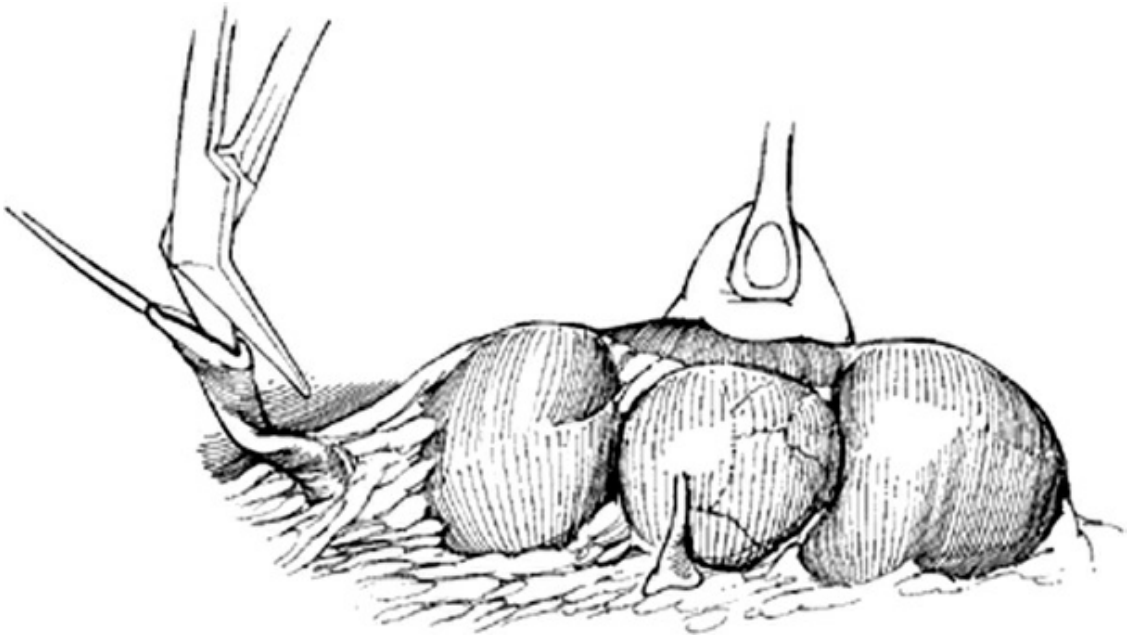

Figure 173.2. Division and spatulation of the ureter. (Published in Hinman F Jr. *Atlas of Urologic Surgery*. 2nd ed. Philadelphia: WB Saunders, 1998, with permission. Copyright Elsevier.)

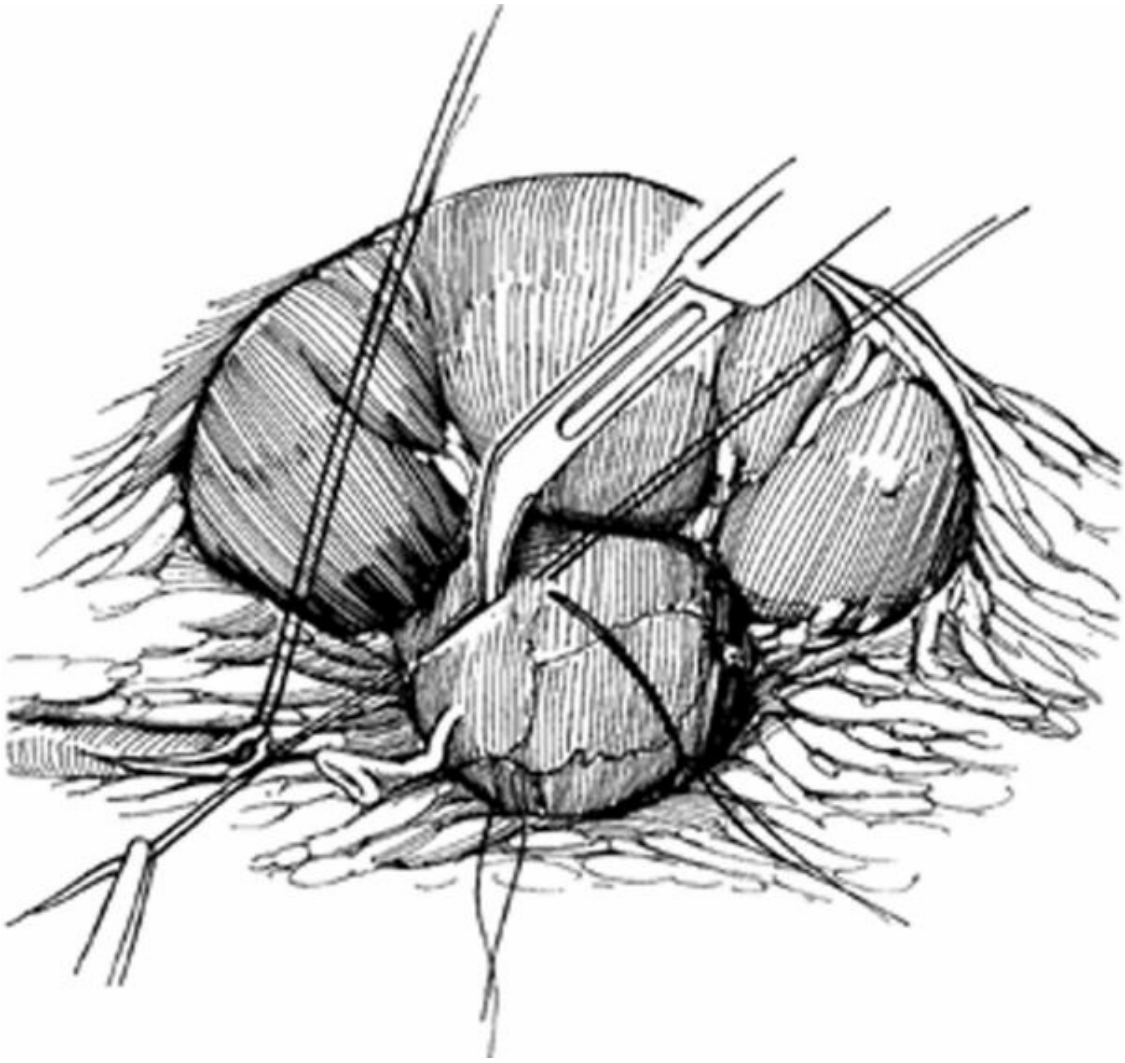

Figure 173.3. Mapping and incising the pelvis. (Published in Hinman F Jr. *Atlas of Urologic Surgery*. 2nd ed. Philadelphia, PA: WB Saunders, 1998, with permission. Copyright Elsevier.)

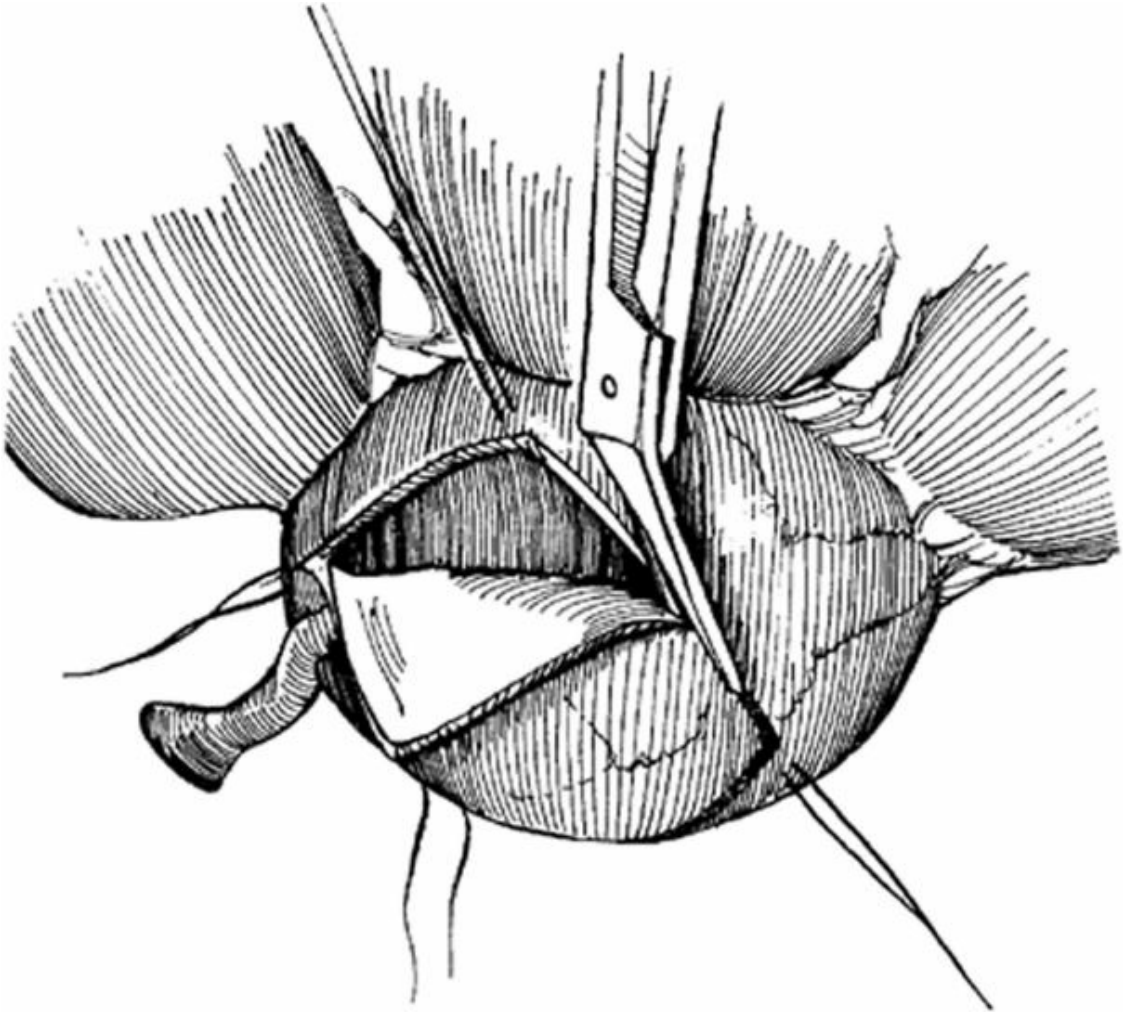

Figure 173.4. Completing the pelvic incision–excision. (Published in Hinman F Jr. *Atlas of Urologic Surgery*. 2nd ed. Philadelphia, PA: WB Saunders, 1998, with permission. Copyright Elsevier.)

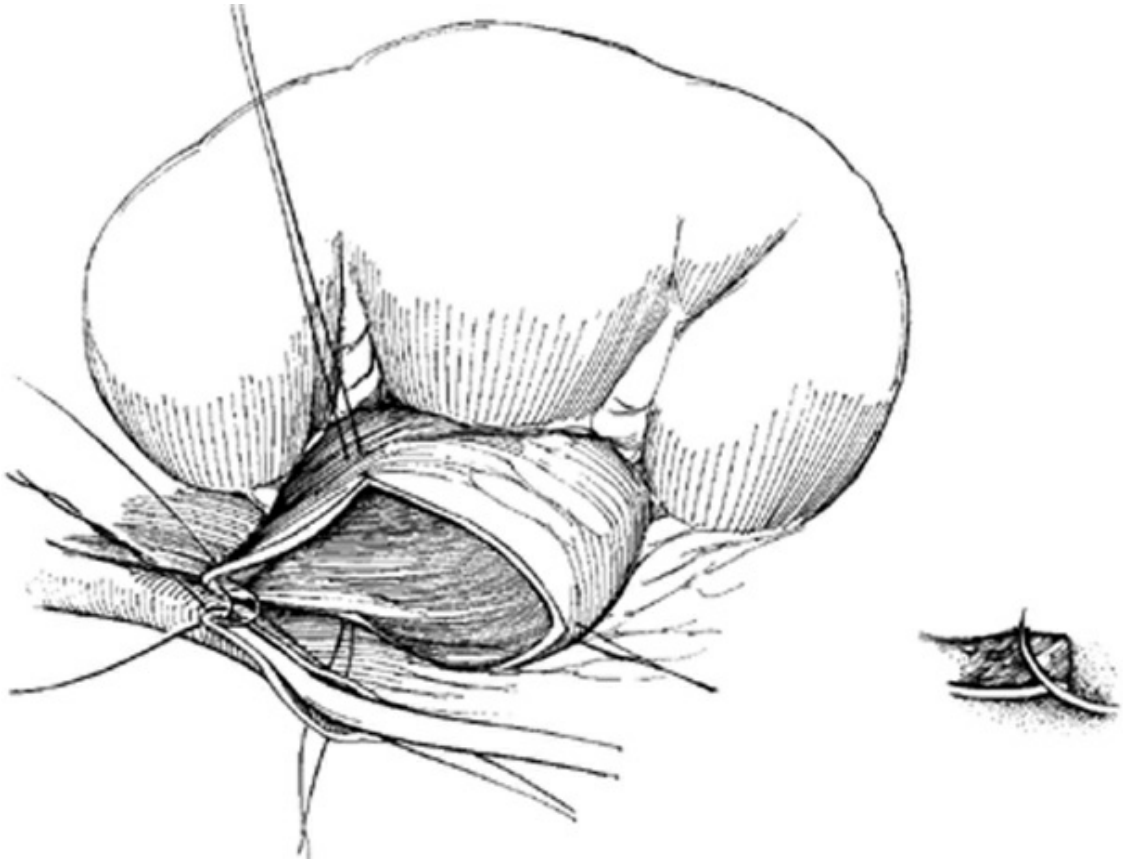

Figure 173.5. Anastomosing the apex of the ureteral incision to the apex of the pelvic flap. (Published in Hinman F Jr. *Atlas of Urologic Surgery*. 2nd ed. Philadelphia: WB Saunders, 1998, with permission. Copyright Elsevier.)

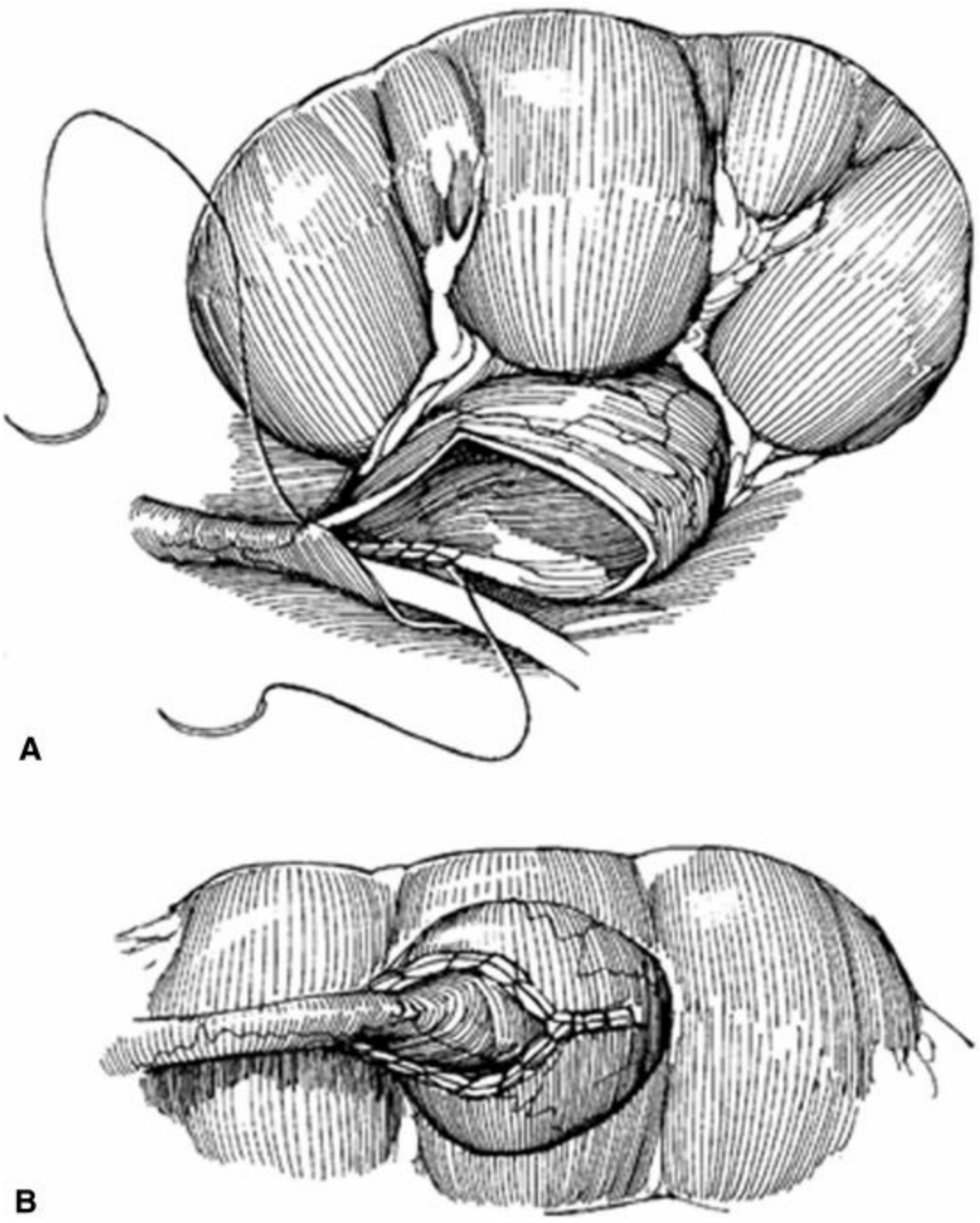

Figure 173.6. **A:** Placing the posterior continuous suture. **B:** Anastomosis completed. (Published in Hinman F Jr. *Atlas of Urologic Surgery*. 2nd ed. Philadelphia, PA: WB Saunders, 1998, with permission. Copyright Elsevier.)

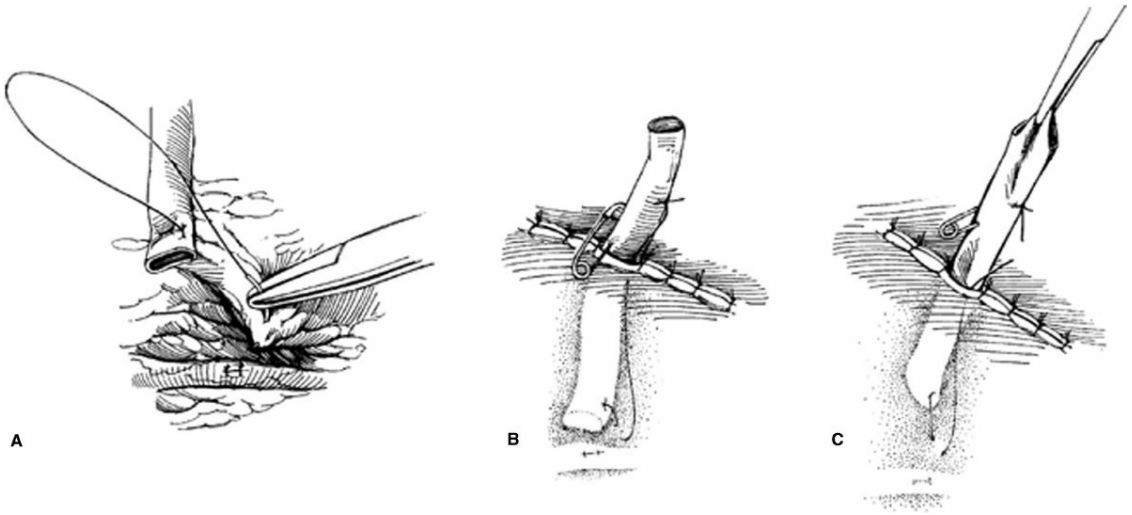

Figure 173.7. Long-suture technique for placement of Penrose drain. **A:** Insert an absorbable suture through the end of the drain and tie it, then pass suture through the body wall tissue adjacent to the repair. **B:** Pass suture through the exterior end of the drain and tie it. **C:** To remove the drain, cut the tethering suture flush with the skin. (Published in Hinman F Jr. *Atlas of Urologic Surgery*. 2nd ed. Philadelphia, PA: WB Saunders, 1998, with permission. Copyright Elsevier.)

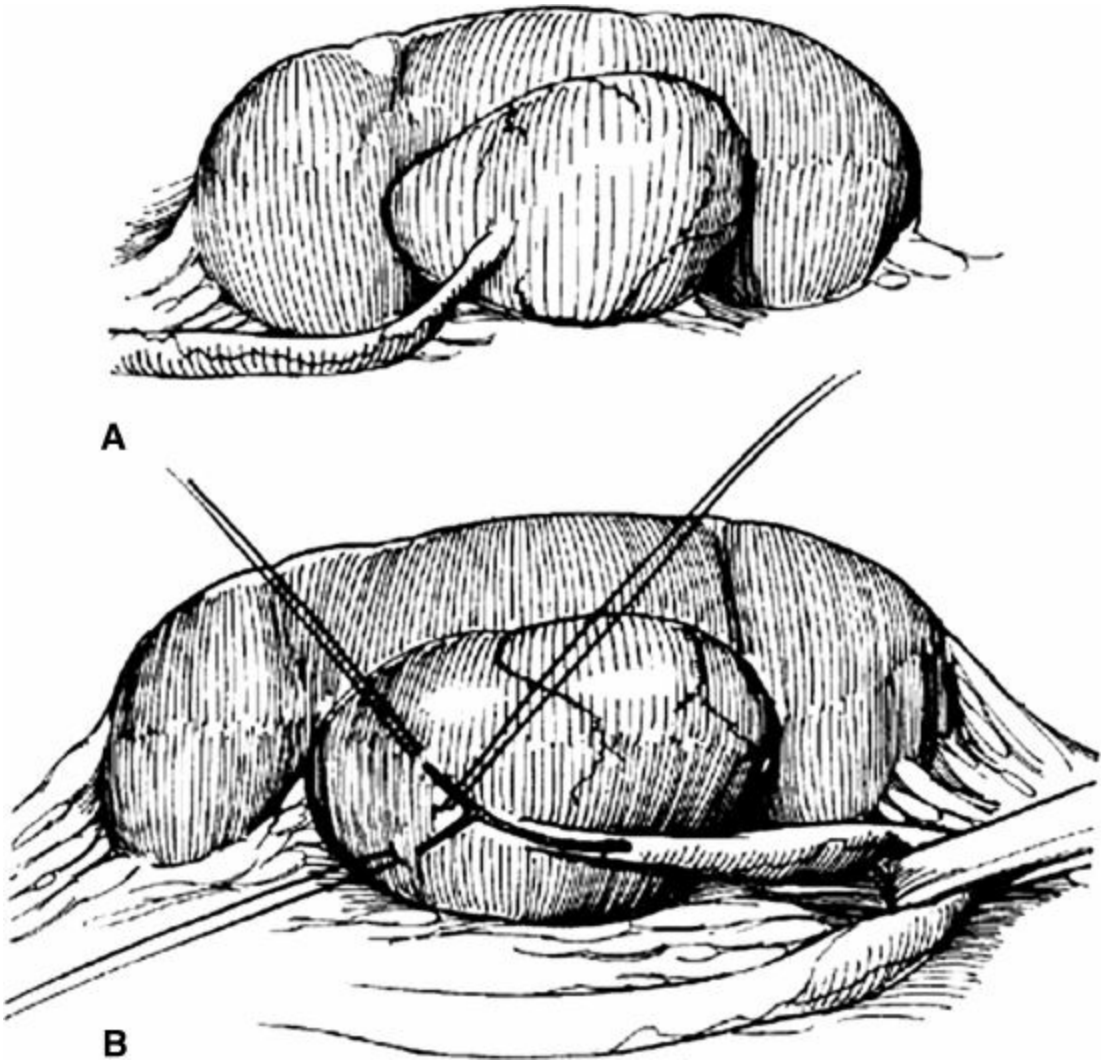

Figure 173.8. Foley YV-plasty. **A:** High insertion of the ureter. **B:** Making Y incision at the ureteropelvic junction. (Published in Hinman F Jr. *Atlas of Urologic Surgery*. 2nd ed. Philadelphia: WB Saunders, 1998, with permission. Copyright Elsevier.)

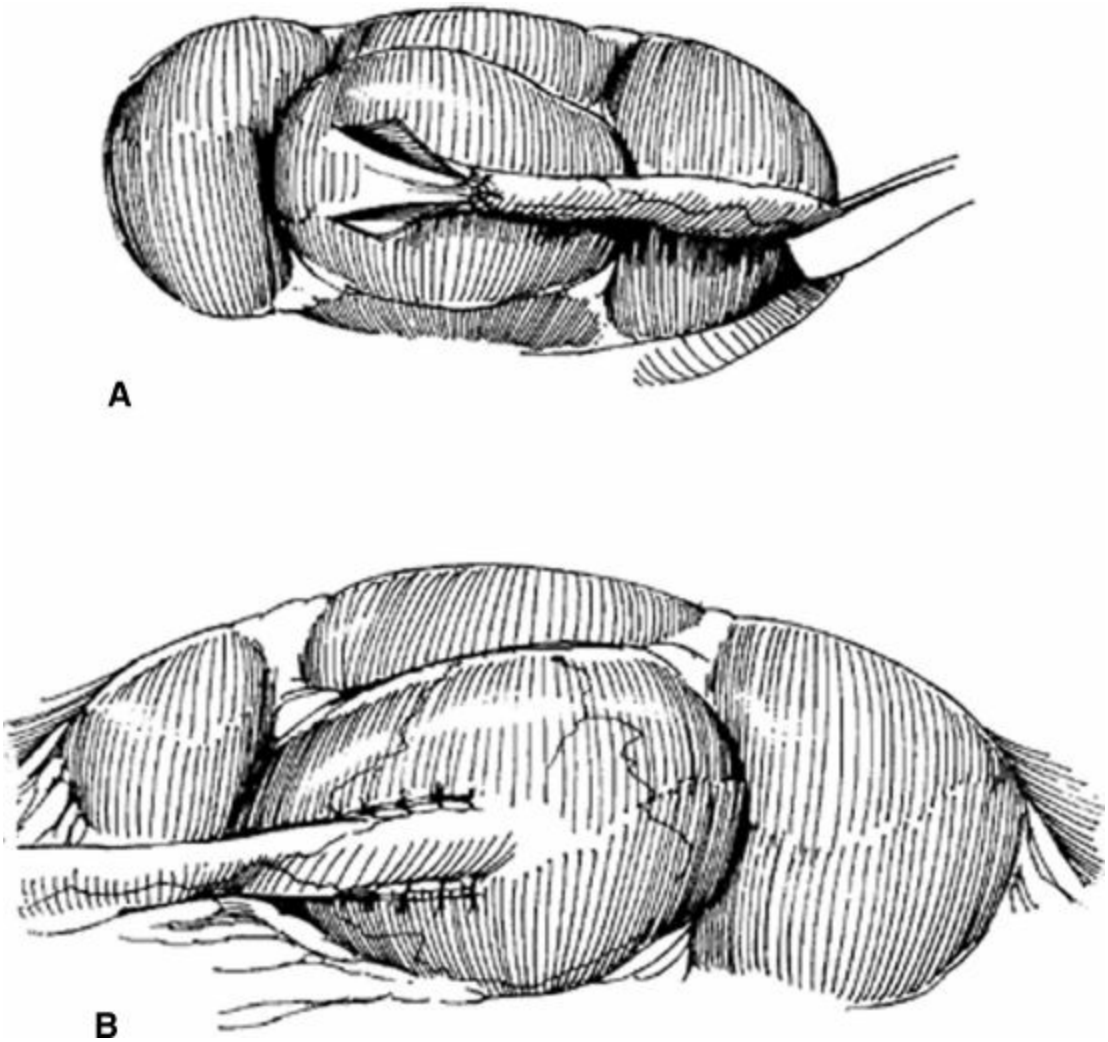

Figure 173.9. A: Sutures are first placed at the apex of the flap. **B:** Sutures are continued down the sides. (Published in Hinman F Jr. *Atlas of Urologic Surgery*. 2nd ed. Philadelphia, PA: WB Saunders, 1998, with permission. Copyright Elsevier.)

CULP-DEWEERD PELVIC FLAP PYELOPLASTY

This procedure may be used for long low defects with a dilated pelvis, for which a dismembered procedure would result in tension.

Make a spiral (Culp) flap running obliquely around the enlarged pelvis, and extend the incision down the ureter for a distance equal to the length of the flap (Fig. 173.10A). For the Scardino variation, run the incision vertically from the ureteropelvic junction.

Incise the flap and deflect it down with a stay suture (Fig. 173.10B). Suture the posterior edge of the flap to the lateral ureteral edge with a running 4-0 or 5-0 synthetic absorbable suture (Fig. 173.10C). Close the anterior edge of the flap and pelvis with similar sutures (Fig. 173.10D).

DAVIS INTUBATED URETEROTOMY

Intubated ureterotomy is reserved for very long scarred defects involving the ureteropelvic junction, but endoscopic incision is usually preferable.

Incise the pelvis with a no. 11 knife blade just above the ureteropelvic junction between two stay sutures. Open the ureter with Potts scissors, until normal caliber is reached (Fig. 173.11A). Insert a No. 8 French silicone double-J stent and a nephrostomy tube. Tack the edges of the defect loosely together with 5-0 synthetic absorbable sutures. Cover with omentum (Fig. 173.11B).

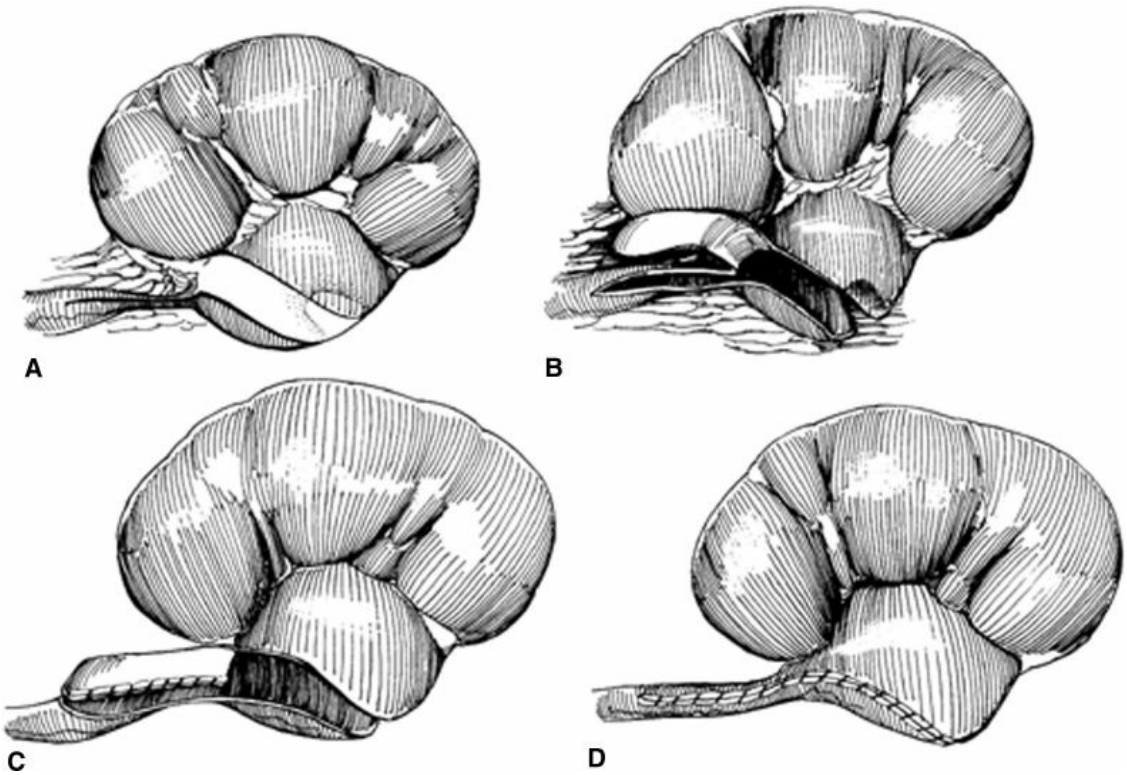

Figure 173.10. Culp–DeWeerd pelvic flap pyeloplasty. **A:** The spiral flap is marked. **B:** The flap is incised. **C:** Sutures are placed to attach the flap to the open ureter. **D:** The defect is closed. (Published in Hinman F Jr. *Atlas of Urologic Surgery*. 2nd ed. Philadelphia, PA: WB Saunders, 1998, with permission. Copyright Elsevier.)

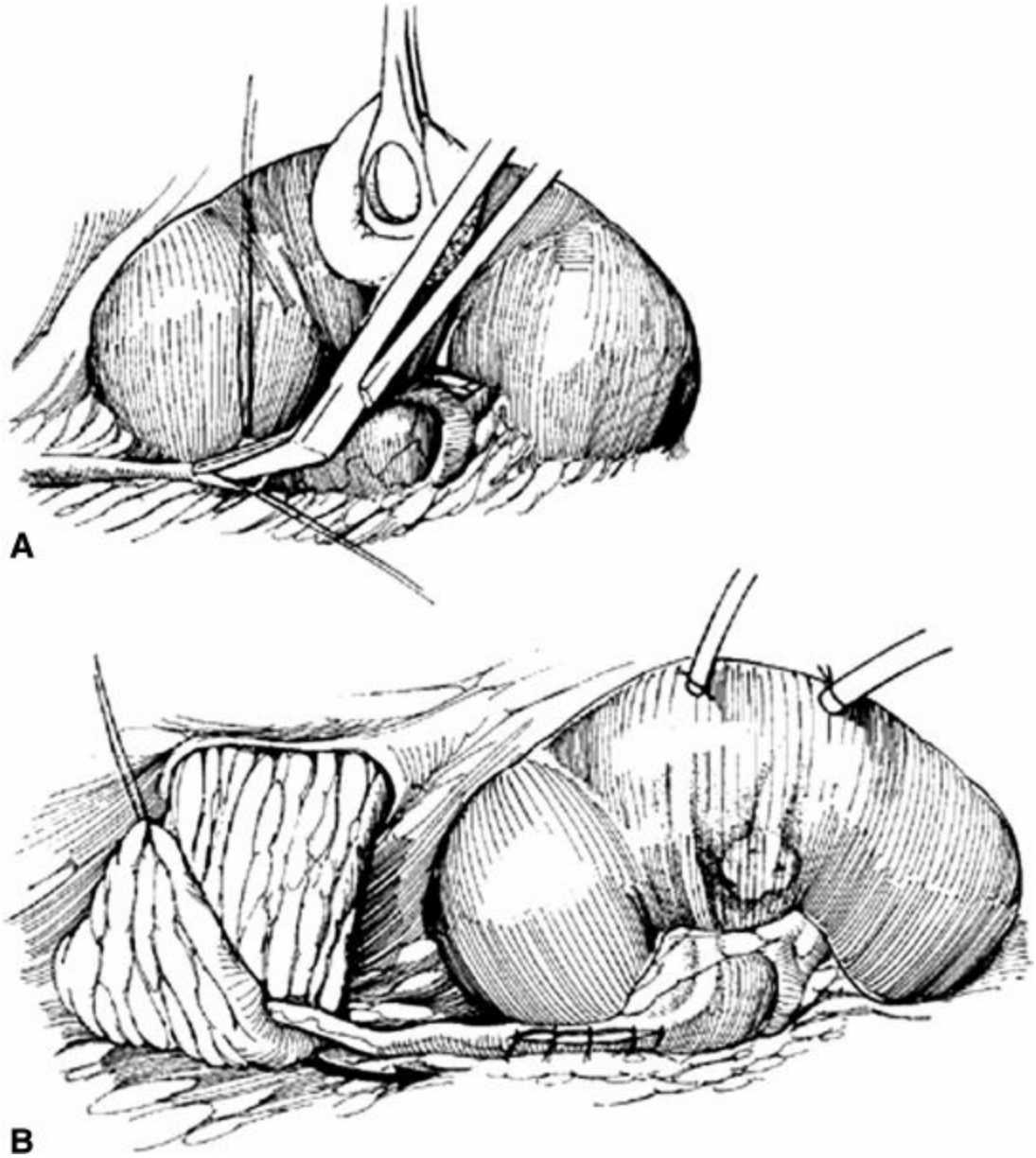

Figure 173.11. Davis intubated ureterotomy. **A:** The strictured segment is incised. **B:** The ureteral walls are brought loosely over a stent and the defect covered with omentum. (Published in Hinman F Jr. *Atlas of Urologic Surgery*. 2nd ed. Philadelphia, PA: WB Saunders, 1998, with permission. Copyright Elsevier.)

Suggested Readings

Abala DM, Grasso M. *Color Atlas of Endourology*. New York: Lippincott-Raven; 1999.

Bauer JJ, Bishoff JT, Moore RG, et al. Laparoscopic versus open pyeloplasty: assessment of objective and subjective outcome. *J Urol* 1999;162:692.

Brooks J, Kavoussi L, Preminger G, et al. Comparison of open and endourologic approaches to the obstructed ureteropelvic junction. *Urology* 1995;46:791.

Cadeddu JA, Kavoussi LR. Laparoscopic pyeloplasty using an automated suturing device. *Curr Tech Urol* 1997;10.

Cadeddu JA, Moore RG. Laparoscopic pyeloplasty. In: *Glenn's Urology* 5th ed. Philadelphia, PA: WB Saunders; 1998.

Capolicchio G, Homsey YL, Houle A-M, et al. Long-term results of percutaneous endopyelotomy in the treatment of children with failed open pyeloplasty. *J Urol* 1997;158:1534.

Chen RN, Moore RG, Kavoussi LR. Laparoscopic pyeloplasty. Indications, technique and long-term outcome. *Urol Clin North Am* 1998;25:323.

Cornford PA, Rickwood AMK. Functional results of pyeloplasty in patients with ante-natally diagnosed pelvi-ureteric junction obstruction. *Br J Urol* 1998;81:152.

Culp OS, DeWeerd JH. A pelvic flap operation for certain types of ureteropelvic obstruction: preliminary report. *Mayo Clin Proc* 1951;26:483.

Danuser H, Ackermann DK, Böhlen D, et al. Endopyelotomy for primary ureteropelvic junction obstruction: risk factors determine the success rate. *J Urol* 1998;159:56.

Davis DM. Intubated ureterotomy: a new operation for ureteral and ureteropelvic stricture. *Surg Gynecol Obstet* 1943;76:513.

Eden CG, Sultana SR, Murray KHA, et al. Extraperitoneal laparoscopic dismembered fibrin-glued pyeloplasty: medium term results. *Br J Urol* 1997;80:382.

Foley FEB. New plastic operation for stricture at ureteropelvic junction: report of 20 operations. *J Urol* 1937;38:643.

Gauer DD. Retroperitoneal laparoscopy: a simple technique of balloon insertion and establishment of the primary port. *Br J Urol* 1996;77:458.

Hamm FC, Weinberg SR. Renal and ureteral surgery without intubation. *J Urol* 1955;73:475.

Hinman F Jr. Dismembered pyeloplasty without urinary diversion. In: Scott R, ed. *Current Controversies in Urologic Management.* Philadelphia, PA: WB Saunders, 1972:253.

Hinman F Jr. Techniques for ureteropyeloplasty. *Arch Surg* 1955;71:790.

Janetschek G, Peschel R, Altarac D, et al. Laparoscopic and retroperitoneoscopic repair of ureteropelvic junction obstruction. *Urology* 1996;47:311.

Karlin GS, Badlani GH, Smith AD. Endopyelotomy versus open pyeloplasty. Comparison in 88 patients. *J Urol* 1988;140:476.

Kavoussi LR, Meretyk SM, Dierks SM. Endopyelotomy for secondary ureteropelvic junction obstruction in children. *J Urol* 1991;145:345.

Lee WJ, Badlani GH, Karlin GS. Treatment of ureteropelvic strictures with percutaneous pyelotomy: experience in 62 patients. *AJR Am J Roentgenol* 1988;151:515.

McLean PA, Gawley WF, Gorey TP. Technical modifications of Anderson–Hynes pyeloplasty for congenital pelviureteric junction obstruction. *Br J Urol* 1985;57:114.

Moore RG, Brooks JD. Ureteropelvic junction obstruction: assessment of minimally invasive therapies. *Contemp Urol* 1995;7:47.

Nakada S, McDougall E, Clayman RV. Laparoscopic pyeloplasty for secondary ureteropelvic junction obstruction: preliminary experience. *Urology* 1995; 46(2):257–60.

Orland SM, Snyder HM, Duckett JW. The dorsal lumbotomy incision in pediatric urological surgery. *J Urol* 1987;138:963.

Perlmutter AD, Kroovand RL, Lai Y-W. Management of ureteropelvic obstruction in the first year of life. *J Urol* 1980;123:535.

Peters C, Schlussel R, Retik A. Pediatric laparoscopic dismembered pyeloplasty. *J Urol* 1995;153:1962.

Rickwood AM, Phadke D. Pyeloplasty in infants and children with particular reference to the method of drainage postoperatively. *Br J Urol* 1978;50:217.

Scardino PL, Prince CL. Vertical flap ureteropelvioplasty: preliminary report. *South Med J* 1953;46:325.

Smith JM, Butler MR. Splinting in pyeloplasty. *Urology* 1976;8:218.

Snyder HM III, Lebowitz RL, Colodny AH, et al. Ureteropelvic junction obstruction in children. *Urol Clin North Am* 1980;7:273.

Tan HL. Laparoscopic Anderson–Hynes dismembered pyeloplasty in children. *J Urol* 1999;162:1045.

Vamvaillie T, Schuessler W, Preminger G. Laparoscopic dismembered pyeloplasty. *J Endourol* 1993;7:117.

Woo HH, Farnsworth RH. Dismembered pyeloplasty in infants under the age of 12 months. *Br J Urol* 1996;77:449.



EDITOR'S COMMENT

Dr. Hinman has presented the classic operation of the Anderson–Hynes dismembered pyeloplasty. This operation appears to be the classic operation from which most of the pyeloplasties for strictures at the ureteropelvic junction are derived. The chapter herein describes the classic open technique. In the intervening interval since this operation was described, attention in urology

since Schuessler's introduction of laparoscopy in a number of urologic operations has increased. Endoscopic pyeloplasties have also been used. The success of the open procedure appears to be 90% or greater (O'Reilly et al., *Br J Urol* 2001;87:287; Brooks et al., *Urology* 1995;46:791). However, rigorous follow-up of endopyelotomy and balloon dilatation, which gained popularity in the early 1990s, have failed to reveal a similar success rate (Knudsen et al., *Urology* 2004;63:230). It is also true in most series that subsequent reconstruction of the ureteropelvic junction for failed primary pyeloplasty results in lower success rates (Inagaki, *Br J Urol Int* 2005;95(suppl 2):102).

Moon et al. (*Urology* 2006;67:932) reported 170 consecutive cases of laparoscopic pyeloplasty using the four-port extraperitoneal approach. The conversion rate was 0.6% with no conversions in the last 161 cases. Mean hospital stay was 3 days, not different than the open pyeloplasty; however, this was a report from the Basingstoke North Hampshire Hospital in the United Kingdom, in which lengths of stay generally tend to be longer. Success rate as measured by diuresis renography obtained 3, 12, 24, and 36 months after surgery and ureteroscopy performed when the renographic findings were equivocal or obstructive resulted in a success rate of 96%, with 12 complications including three major adverse events and one contained urinary leak. A right hemicolectomy for colonic injury was diagnosed 6 days postoperatively; port site bleeding was operated 12 hours postoperatively and one patient had a postoperative subendocardial myocardial infarction. In an earlier review, Inagaki (previously quoted 2005) reported 147 transperitoneal pyeloplasties between 1993 and 2000 in patients whose mean age was 36 years. The Anderson–Hynes dismembered pyeloplasty was performed in the majority (106) of patients, whereas YV-plasties and 28 Fenger pyeloplasties were used. Twenty-five patients had previously undergone a procedure. The success rate in the primary cases was 95% in patients followed for at least 2 years, with the longest being 84 months.

Ost et al. (*Urology* 2005;66(suppl 5A):47) reported 100 consecutive outpatients, of which 50 were operated on endoscopically and 50 laparoscopically and an additional 5 by endopyeloplasty. The average age was approximately 45 ± 16 years and the mean hospital stay was 2.5 days. Postoperative creatinines were unchanged in both groups. The criterion for success was an improvement in the half-life of diuretic renal scintigraphy of less than 12 minutes. Obstruction was a half-life of more than 20 minutes. Success rates were 92% for primary antegrade endopyeloplasty and 58% for secondary percutaneous antegrade endopyelotomy.

Laparoscopic pyeloplasty, using a transperitoneal three-port Anderson–Hynes pyeloplasty, was performed on patients averaging 38 ± 15 years of age. Again, there was no significant change in the postoperative creatinine level (1.1 → 1.0). Success rates included 100% for primary repair and 95%, 20 of 21, for secondary repair. It does seem as if a number of groups have mastered laparoscopic transperitoneal Anderson–Hynes pyeloplasty with excellent

results.

This can also be carried out in an infant younger than 4 months as reported from the Children's Hospital of Philadelphia by Kutikovia et al. (*J Urol* 2006;175:1477). Eight infants with a mean age of 4.5 months underwent transperitoneal laparoscopy pyeloplasty for ureteropelvic junction obstruction. A hospital stay was 1.2 days; the stent was removed 6 weeks postoperatively in all patients except one. Laparoscopic pyeloplasty in this young group resulted in 100% relief of obstruction.

Geavlete et al. (*J Endourol* 2006;20:179) reviewed 2,436 patients between 5 and 87 years of age who underwent retrograde ureteroscopy under video and fluoroscopic procedures. Upper urinary tract lithiasis was present in 2,041 cases. The mean complication rate was 5.9%; 95% of these 95 cases were operated on for ureteropelvic junction stenosis. It is difficult to tell exactly how many patients of the benign ureteropelvic junction stenosis group were successful, but it seems to be in the 80% or more range.

Taken altogether, it does appear as if the laparoscopic Anderson–Hynes dismembered pyeloplasty carried out transperitoneally seems to have evolved as the new ìgold standardî for the treatment for this disease.

J.E.F.

174 Radical Nephrectomy for Renal Cell Cancer

Elias S. Hyams and Mohamad Allaf

INTRODUCTION

Renal cell carcinoma (RCC) constitutes ~3% of adult malignancies and 90% to 95% of renal neoplasms. Rising utilization of abdominal imaging in the past 20 years has increased the rate of incidental diagnosis to >50%. Concurrently, there has been stage migration with a rising frequency of small tumors and localized disease at presentation. As such, nephron-sparing surgery (NSS) has been increasingly performed with the goal of preserving normal renal parenchyma and residual renal function without conceding oncologic outcomes. Although NSS has become the standard of care for treatment of most small renal masses, radical nephrectomy is still the treatment of choice for larger and/or central lesions. RCC overall remains a surgical disease given its resistance to chemotherapy and radiation, although immunotherapies have been shown to have modest survival benefit in the setting of metastatic disease.

In this chapter, we review the pathology, epidemiology, clinical presentation, and surgical management of RCC with a detailed review of the various operative approaches.

PATHOLOGY

RCCs are derived from renal tubular epithelial cells and have variable histologic subtypes. Differentiating between histologies provides useful information regarding prognosis, recurrence risk, familial associations, and possibly response to systemic therapies in the metastatic setting. Clear cell or “conventional” RCC is the most common subtype (70% to 80%) and is associated with loss of chromosome 3p. These tumors have a worse prognosis compared with the other main types of RCC (i.e., papillary, chromophobe). Clear cell RCC is associated with von Hippel Lindau (VHL) disease and hereditary clear cell RCC, but more frequently occurs sporadically. Clear cell disease responds better to immunotherapies should

they be necessary in the adjuvant setting; in particular, IL-2 only addresses clear cell RCC.

Papillary RCC (10% to 15%) is associated with trisomy of chromosomes 7 and 17, c-met gene mutations on chromosome 7, and loss of the Y chromosome. Papillary RCC can occur in hereditary syndromes as well ("hereditary papillary RCC") and is frequently bilateral and multifocal (up to 40%).

Chromophobe RCC (5%) may have a more indolent course than other RCC subtypes, and frequently presents at low stage and low grade. It has a close histologic resemblance to oncocytoma, which is a benign renal neoplasm. There can be difficulty differentiating chromophobe RCC from oncocytoma on percutaneous biopsy.

Additional subtypes of RCC are less common. These include collecting duct carcinoma, which is rare and aggressive and frequently presents with metastasis, and renal medullary carcinoma, which is associated with sickle cell trait and is extremely aggressive with a poor prognosis. Certain histologic characteristics of RCC are associated with more aggressive behavior, including sarcomatoid or spindle cell variants.

Grading of RCC is an important prognostic tool. Fuhrman nuclear grading (I to IV) is based on nuclear characteristics, including size, contour, and nucleoli. Higher grade is associated with a worse prognosis.

ETIOLOGY/GENETICS

Tobacco smoking is the most salient risk factor for RCC with an estimated doubling of risk of cancer. Numerous other potential environmental factors (e.g., phenacetin, heavy metals) have been investigated, but none has been definitively shown to be causative. Obesity and hypertension appear to be associated with the increased risk of RCC. Acquired cystic disease from chronic end-stage renal disease (ESRD) also increases the risk of RCC; the relative risk in ESRD patients may be up to 20 times higher than the general population.

RCC occurs in both sporadic and hereditary forms. Sporadic RCC is typically unilateral and unifocal, with 2% to 4% rate of bilateral disease. Hereditary forms are more commonly bilateral, and occur within several syndromes. VHL disease is an autosomal dominant disorder associated with a deletion of chromosome 3p, the VHL tumor suppressor gene. Renal cancer develops in 30% to 55% of patients with VHL. RCC is typically multifocal and bilateral; thus, there may be a greater imperative to perform

NSS in this population. Major clinical manifestations of VHL include clear cell carcinoma, hemangioblastomas of the central nervous system, retinal angiomas, and pheochromocytoma. Interestingly, deletion of the VHL gene is associated with both sporadic and familial forms of clear cell RCC.

Birt–Hogg–Dube syndrome is a hereditary cutaneous syndrome associated with development of fibrofolliculomas, lung cysts, pneumothorax, as well as bilateral multifocal oncocytoma and chromophobe RCC. This syndrome results from mutation of the BHD1 gene on chromosome 17.

Hereditary papillary RCC is an autosomal dominant disorder in which patients develop bilateral, multifocal papillary RCC; the specific type of tumor is considered Type 1 papillary RCC. Mutations in the c-met proto-oncogene on chromosome 7 are thought to be etiologic.

Familial leiomyomatosis and RCC result from mutation of the fumarate hydratase gene on chromosome 1. This leads to Type 2 papillary RCC as well as cutaneous leiomyomas and uterine leiomyomas. These RCC lesions tend to be more aggressive than other forms of familial RCC.

Tuberous sclerosis appears to be associated with RCC, although the underlying relationship is not well understood. Interestingly, there is not thought to be increased incidence of RCC in autosomal dominant polycystic kidney disease.

CLINICAL PRESENTATION

Symptoms of RCC when present may be related to bleeding, local growth, paraneoplastic syndromes, or metastasis. The classic “triad” of flank pain, gross hematuria, and a palpable flank mass is fortunately uncommon (10%) as it generally represents advanced disease. Findings suggestive of advanced disease include significant weight loss, bone pain, clinical lymphadenopathy, and poor performance status. Patients with local invasion may have pain from invasion of the abdominal wall, nerve roots, or paraspinous muscles.

Up to one third of patients with RCC have metastasis on initial presentation. Metastases usually involve more than one site, and occur by both hematogenous and lymphatic spread. Metastatic sites from most to least frequent include lung, bone, regional lymph nodes, liver, ipsilateral adrenal gland, contralateral kidney, and brain. Systemic abnormalities may represent metastatic disease and include elevated erythrocyte sedimentation rate; hypertension; anemia; cachexia; weight loss; fever;

abnormal liver function; and hypercalcemia, polycythemia, and neuropathy.

Importantly, these abnormalities may also be stigmata of a paraneoplastic syndrome, although metastatic disease should be rigorously excluded. Paraneoplastic syndromes develop in 20% to 30% of patients with RCC and result from ectopic hormone section. Substances that can be secreted include parathyroid-like substance (causing hypercalcemia), erythropoietin (polycythemia), renin (hypertension), gonadotropins, placental lactogen, enteroglucagon, insulin-like substances, prostaglandin A, and prolactin. Syndromes associated with these hormones typically reverse upon removal of the tumor; persistence is compatible with occult metastatic disease.

"Stauffer syndrome" is an idiopathic reversible hepatic dysfunction that occurs in up to 20% of patients with RCC. This syndrome manifests with increased alkaline phosphatase, indirect bilirubin, and altered international normalized ratio (INR). These abnormalities will reverse postoperatively in the setting of localized disease.

Venous insufficiency and thromboembolism may be consistent with tumor thrombus extending into the inferior vena cava (IVC), and may warrant an investigation for RCC. Concerning signs include lower extremity edema, pulmonary embolism, right-sided varicocele or persistent varicocele in the supine position, and dilated superficial abdominal veins.

DIAGNOSIS

Diagnosis of renal neoplasms is typically made on cross-sectional abdominal imaging. The gold standard exams for evaluation of a renal mass are contrast-enhanced computed tomography (CT) or magnetic resonance imaging (MRI). The differential diagnosis for a renal tumor may include RCC, benign neoplasm (e.g., angiomyolipoma [AML], oncocytoma, renal adenoma), abscess, lymphoma, metastasis from a separate primary lesion, pyelonephritis, renal cyst, renal infarction, and sarcoma or Wilms tumor.

Renal masses may be solid, cystic, or mixed. Solid masses may represent benign or malignant disease, thus contrast imaging is needed to detect "enhancement" that is generally compatible with malignancy. An increase in Hounsfield units of >10 to 15 from noncontrast to arterial phase is thought to be consistent with a malignant process. However, although ~80% of enhancing renal masses are histologically malignant

upon removal, 20% will be benign (e.g., oncocytoma, fat-poor AML). Patients should be appropriately counseled regarding this possibility.

Considerations on CT/MRI include the size and position of the tumor, the status of the adrenal glands and contralateral kidney, presence of lymphadenopathy, presence of visceral metastasis, and renal vein or IVC involvement. Nodes ≥2 cm are thought to be more likely malignant, whereas smaller nodes are typically inflammatory. Presence of tumor thrombus can be detected with high sensitivity with both multiplanar CT and MRI.

Cystic renal masses are typically categorized using the Bosniak system that applies to CT appearance. This system reflects the likelihood of malignancy, with increasing complexity (thickness/number of septations, solid and/or enhancing components) increasing the likelihood of RCC. Bosniak III–IV lesions are typically treated as carcinoma, II–IIF lesions are followed radiographically, and Bosniak I or "simple" cysts do not require follow-up. Calcifications are thought to be associated with malignancy but are not pathognomonic.

Renal ultrasound frequently detects incidental masses in the course of evaluation for flank or abdominal pain. Ultrasound may assist in characterizing a mass as solid versus cystic, and a cyst as simple versus complex; however, ultrasound has a poor sensitivity for malignancy compared with cross-sectional imaging. Ultrasound may be used as a screening study in patients with impaired renal function who cannot receive iodinated contrast or gadolinium.

Percutaneous biopsy of renal masses has become more common, particularly at tertiary centers, as pathologic accuracy has improved. Indeed, 20% to 30% of small renal masses will represent benign pathology and may not require treatment. However, while biopsy may be useful and impact clinical decision making, in many cases it will not change management and is not required. For instance, a negative result may not be trusted in a young healthy patient such that surgery will be performed regardless of biopsy result. Conversely, in an elderly, comorbid patient, a biopsy showing malignancy may not lead to surgical intervention based on concerns regarding procedural risks, and the tumor may be observed such that the biopsy was superfluous and potentially harmful. In addition, biopsy is known to underestimate tumor grade in a way that limits risk stratification. Scenarios in which biopsy should be performed include presence of a second malignancy and concern for renal metastasis,

suspicion for infection (abscess/phlegmon), or suspicion of lymphoma based on radiographic appearance of the mass (diffuse and infiltrating rather than encapsulated).

STAGING

The TNM staging system of the American Joint Committee on Cancer is most commonly used for RCC and had been validated to correspond with cancer-specific survival. See Table 174.1 for details of staging. Estimated 5-year disease-specific survival rates are 95% for T1 disease, 88% for T2, 59% for T3, and 20% for T4.

TABLE 174.1 American Joint Committee on Cancer (AJCC) TNM Staging System for RCC

T1a	Organ confined, ≤4 cm
T1b	Organ confined, 4 to 7 cm
T2a	Organ confined, 7 to 10 cm
T2b	Organ confined, >10 cm
T3a	Perinephric tissue, renal sinus, or renal vein
T3b	Vena cava below diaphragm
T3c	Vena cava above diaphragm or into wall of vena cava at any level
T4	Beyond Gerota's fascia or directly into adrenal gland
Nx	Regional lymph nodes cannot be assessed
N0	No regional lymph node metastasis
N1	Metastases in regional lymph node(s)
M0	No distant metastasis
M1	Distant metastasis

Stage	T	N	M
I	T1	N0	M0
II	T2	N0	M0
III	T1 or T2	N1	M0
	T3	N0 or N1	M0
IV	T4	Any N	M0
	Any T	Any N	M1

Adapted from American Joint Committee on Cancer. Kidney. In: Edge SB, Byrd DR, Compton CC, et al., eds. *AJCC Cancer Stagng Manual*. 7th ed. New York: Springer; 2010:479–89, permission conveyed through Copyright Clearance Center, Inc.

PREOPERATIVE EVALUATION

Preoperative evaluation for radical nephrectomy includes a complete history and physical exam. Comorbidities that might affect patient positioning or surgical approach (e.g., severe cardiopulmonary disease, kyphoscoliosis) should be assessed. The presence of chronic kidney disease (CKD) or comorbidities affecting risk of renal dysfunction (e.g., diabetes, hypertension) should be noted and factor into decision-making regarding partial versus radical nephrectomy. Prior abdominal or retroperitoneal surgery should be considered regarding the desired surgical approach. Family history of renal masses or genetic syndromes should be elicited. Assessment of patient performance status is critical if cytoreductive nephrectomy is being considered.

A complete metabolic panel including liver function tests is sent preoperatively. Serum calcium should be assessed to screen for bone metastasis or paraneoplastic syndrome. A complete blood count should be assessed to rule out polycythemia due to erythropoietin-producing tumors or lactoferrin-producing tumors with anemia. Glomerular filtration rate (GFR) should be calculated to stratify for risk of renal dysfunction postoperatively.

Operative planning based on CT or MRI is critical. The size and position of tumor are noted for radical nephrectomy to ensure Gerota's fascia is not violated near the tumor and to anticipate areas of gross inflammation, and for partial nephrectomy to plan the depth/extent of resection. Relationships of the tumor to the collecting system, renal sinus fat, and the renal hilum should be assessed. The number and position of renal arteries and veins should be noted. Involvement of the adrenal gland and other adjacent structures should be assessed, as should the presence and extent of renal vein or caval thrombus. The contralateral kidney should be examined for abnormalities.

Chest imaging is necessary preoperatively to rule out lung metastasis. A chest x-ray is an acceptable first-line test, and a chest CT can be performed if there are equivocal findings. A bone scan can be considered if there is bone pain, fracture, hypercalcemia, or elevated alkaline phosphatase. A head CT can be considered if there is an abnormal neurologic exam.

Preoperative infarction via angioembolization is rarely utilized, but can be useful for large tumors in patients with arterialized caval tumor thrombus or medial extension of the tumor that may prohibit early ligation of the renal artery. Infarction can also be used for palliation in the setting of severe bleeding.

TREATMENT

There are numerous management strategies for RCC, including radical nephrectomy (open vs. laparoscopic), partial nephrectomy (open vs. laparoscopic/robotic), ablation (percutaneous vs. laparoscopic), and active surveillance.

Radical Nephrectomy

Radical nephrectomy is indicated for large and/or complex renal tumors that are not candidates for NSS. This procedure entails removal of Gerota's fascia and its contents including kidney and perirenal fat. The adrenal gland is also present within Gerota's fascia; however, it is generally spared unless there is direct invasion or metastasis. Laparoscopic radical nephrectomy (LRN) is currently the standard of care based on equivalent long-term cancer control compared with open surgery, with hastened convalescence, and decreased postoperative pain. This procedure is typically performed transperitoneally but can be performed retroperitoneally as well. Hand-assisted LRN can be performed to decrease the learning curve of the procedure. There has been recent interest in further minimizing the invasiveness of nephrectomy through single-incision surgery, which has been shown to be safe and feasible in those with appropriately thin body habitus. Open radical nephrectomy (ORN) is rarely performed for localized kidney cancer, although it is the approach of choice in the presence of caval tumor thrombus because of superior exposure to the great vessels and the ability to mobilize the liver as necessary. ORN is performed if there is concern for local invasion, plan to resect visceral metastasis, or significant lymphadenopathy in the setting of cytoreduction.

We advocate sparing the ipsilateral adrenal gland during radical nephrectomy unless there is direct involvement or if there is an abnormality suggestive of metastasis. The adrenal should also be taken for upper pole lesions in which there is concern regarding surgical margins.

We do not routinely perform a regional lymphadenectomy with radical nephrectomy, as studies have shown that it does not appear to influence outcome. Indications for a nodal dissection include suspicious lymphadenopathy on preoperative imaging and/or concerning nodes detected intraoperatively.

Tumor thrombus extending into the renal vein or IVC occurs in 4% to 10% of patients. When there is isolated renal vein involvement, the vein

can be controlled beyond the edge of thrombus and standard radical nephrectomy performed. However, extension into the cava requires opening the cava for extraction of thrombus. Primary repair, patch grafting, or interposition grafting can be employed in conjunction with a vascular surgeon. Extension to the diaphragm and/or chest may require mobilization of the liver, venovenobypass, and/or cardiopulmonary bypass with circulatory arrest in conjunction with a cardiothoracic surgeon. Caval thrombus is associated with high perioperative risks and modest long-term survival rates; however, long-term survival can be achieved with radical surgery in up to 50% of the patients depending on patient selection. Important predictors of survival include tumor stage, grade, lymph node status, presence of distant metastasis, and presence of systemic symptoms at diagnosis.

When RCC presents with a single site of metastasis, radical nephrectomy and metastectomy are recommended for patients with good performance status as resection may provide a cancer-specific survival advantage. Recent reports have suggested that there is a survival advantage with resection of multiple metastases as well when technically feasible. If a metachronous single metastasis occurs, resection of that metastasis is performed. Radical nephrectomy in the setting of advanced and/or metastatic disease is performed for “cytoreduction” to be followed by systemic immunotherapy in conjunction with a medical oncologist. There is thought to be an immunologic benefit to removing the primary tumor; cytoreduction has been shown to confer advantages in terms of delayed progression and overall survival in selected patients with metastasic disease. Eastern Cooperative Oncology Group (ECOG) performance status 0–1 is an important selection criterion for pursuing this treatment approach. There are specific criteria described by Motzer and colleagues that help predict survival in patients with metastatic RCC, and may help with decision making regarding use of systemic therapy. There is active investigation of neoadjuvant immunotherapy in the setting of metastatic RCC, and recent prospective data have suggested a survival benefit of this approach in selected good-risk patients. Importantly, RCC is notoriously resistant to chemotherapy and hormonal therapy. Radiation therapy may be considered for palliation of bone and brain metastasis, but is not effective for treatment of the primary tumor.

Partial Nephrectomy

Partial nephrectomy is currently the standard of care for treatment of most small renal masses. Historically, partial nephrectomy has been used primarily for patients with imperative indications for renal preservation (e.g., solitary kidney, bilateral renal tumors, preexisting CKD, genetic tumor syndromes). However, it is presently recommended for all patients with T1a and T1b disease, when technically feasible, based on equivalent long-term oncologic outcomes of radical nephrectomy and decreased long-term risk of CKD. There is convincing evidence linking radical nephrectomy with CKD, particularly in patients with preexisting medical renal disease, as well as CKD with cardiovascular morbidity and mortality. As such, nephron preservation is highly prioritized in treatment of renal tumors to maximize overall survival. However, there has been an evolving debate on how far to push partial nephrectomy, as it is not appropriate for higher stage masses. The balance between nephron preservation and cancer eradication for more complex tumors, at present, requires a case by case evaluation. There has been one randomized trial (EORTC-GU trial 30904) comparing radical and partial nephrectomy, and unfortunately it underaccrued; however, it did demonstrate decreased overall survival among partial nephrectomy patients, which is counterintuitive. Further high-quality studies are needed to clarify the appropriate line for partial versus radical nephrectomy for larger and more complex tumors.

The desired approach to partial nephrectomy depends on surgeon experience, but in general a minimally invasive approach including laparoscopic and/or robotic surgery is preferred. Laparoscopic partial nephrectomy (LPN) by experienced surgeons has been shown to have long-term oncologic outcomes equivalent to open surgery, with decreased perioperative morbidity and hastened convalescence. Robotic techniques are analogous to traditional laparoscopy, and facilitate the suturing/reconstructive portion of the procedure. Indeed, improved dexterity, magnification, and surgeon ergonomics have applied naturally to tumor resection and renal reconstruction. Ultimately, however, nephron-preservation should be prioritized over a minimally invasive approach, given the long-term benefits of renal preservation that outweigh the short-term and cosmetic benefits of laparoscopy and robotics.

Partial nephrectomy, whether open or minimally invasive, generally requires temporary clamping of the renal artery during resection of the tumor to minimize blood loss and to allow visual assessment of the deep tumor margin. Clamping of the renal vein may also be performed,

although sometimes will cause back-bleeding and require release. Renal ischemia should be minimized to reduce the risk of acute kidney injury postoperatively and to ensure preservation of long-term renal function. Recent evidence has demonstrated that the safe duration of ischemia depends largely on nonmodifiable patient factors like preexisting renal dysfunction. For open partial nephrectomy (OPN), the kidney is cooled via ice slush prior to resection to prolong the safe duration of ischemia by slowing renal metabolism; this is called “cold ischemia.” Minimally invasive partial nephrectomy (MIPN) requires “warm” ischemia as there is not an opportunity to cool the kidney intracorporeally. It is typically thought that 30 minutes of warm ischemia will minimize the likelihood of long-term renal dysfunction, although shorter ischemia times are preferred. Cold ischemia is thought to prolong this safe duration for up to 4 hours. There has been recent debate regarding the importance of ischemia time and the role of selective ischemia or “off-clamp” partial nephrectomy. While it is beneficial as a general concept to limit renal ischemia, thresholds for significant or permanent renal injury are likely to vary by patient based on preexisting renal function and the presence of medical kidney disease. Studies have demonstrated that there may be a short-term benefit of selective artery clamping or off-clamp surgery; however, there are no rigorous intermediate or long-term data supporting this approach, and there is a short-term risk of bleeding that argues rather for an efficient resection during global renal ischemia.

Ablative Treatments

Ablative treatments have also been developed to treat small renal tumors in minimally invasive fashion. Cryotherapy and radiofrequency ablation (RFA) have been employed both percutaneously and laparoscopically to destroy a lesion while minimizing treatment morbidity and enabling preservation of the kidney. These approaches are typically used in older, comorbid patients, as retreatment rates are higher than for extirpative therapy, and long-term efficacy has only been demonstrated in selected patients.

Active Surveillance

Active surveillance has been increasingly utilized as a management strategy for patients with small renal masses and significant comorbidities that might compromise the safety of active intervention. Many small renal

masses (20% to 30%) will be benign, and additional malignant lesions will have indolent biology; in an older, sicker patient, it may be reasonable to observe a mass for growth as a proxy for its aggressiveness, with the thought that the risks of surgical intervention exceed the potential benefits. The typical threshold for “safe” observation of a renal mass is 3 cm. Most small renal neoplasms that are observed have slow growth (0.15 cm/yr), and incidence of metastasis in these observed populations is quite low. Ultimately, the decision to pursue active treatment versus surveillance requires a detailed conversation with the patient regarding the risks and benefits of alternative management strategies.

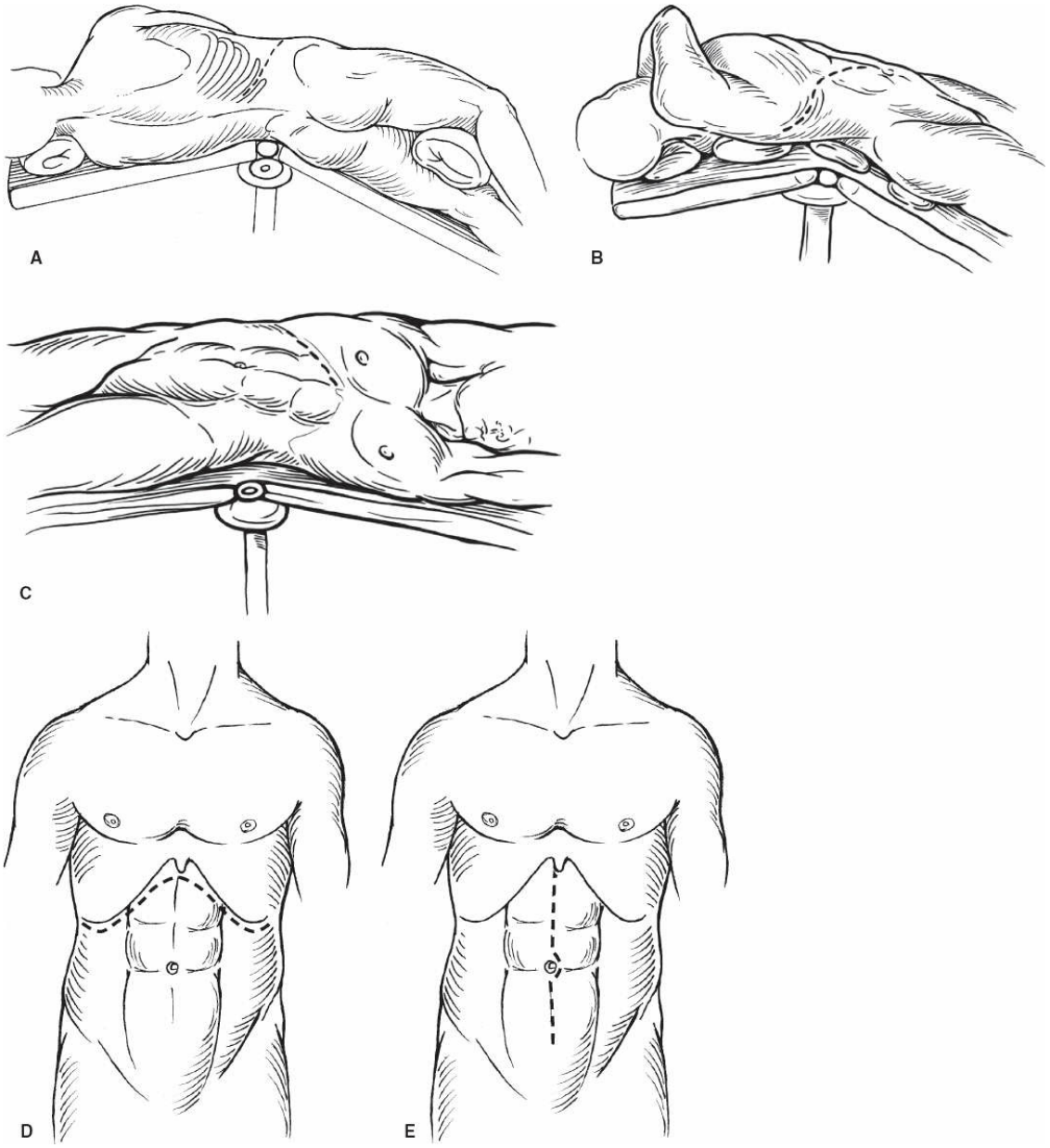

Figure 174.1. Types of incisions used in nephrectomy. **A.** Full flank (thoracoabdominal). **B.** Anterior thoracoabdominal. **C.** Subcostal. **D.** Chevron. **E.** Midline.

INCISIONS

Selection of the appropriate incision is critical to enable optimal exposure during open renal surgery. Factors influencing the type of incision include size and location of the tumor, body habitus of the patient, prior abdominal or retroperitoneal surgery, adjacent organ involvement, and/or the need for bilateral renal operations. The type of incision can globally be divided into the flank approach and the anterior approach (see Fig. 174.1).

Flank/Thoracoabdominal Approach

We favor the flank approach for open surgery as it enables an extraperitoneal dissection that avoids the abdominal viscera. The flank approach may be contraindicated in patients with severe cardiopulmonary disease or scoliosis based on positioning concerns. An incision is made from the interspace between the 10th and 11th ribs, and directed toward an area ~1 cm above the umbilicus (see Fig. 174.2). Incisions below the 11th rib may not enable adequate access to the renal hilum, adrenal gland, and upper pole of the kidney. A traditional flank incision involves positioning the patient perpendicular to the bed. The patient can also be positioned in a modified flank position to improve access to the central abdomen, or depending on surgeon preference. This entails placing the patient with the ipsilateral abdomen tilted up 45 degrees. The patient is carefully strapped to the table, and the table can be tilted in either direction as needed.

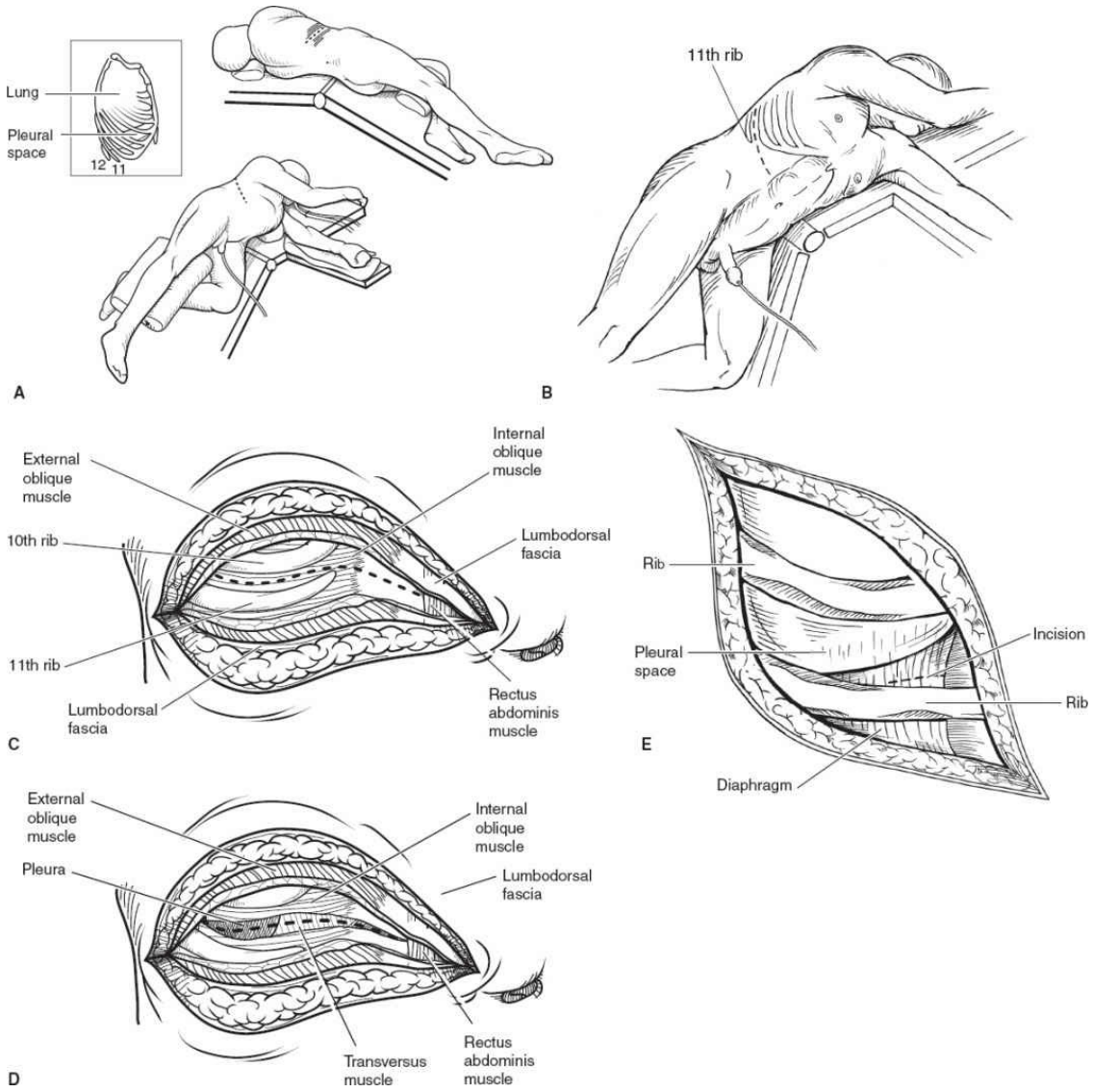

Figure 174.2. Steps for performing flank incision. **A.** Position of the patient for the flank approach. **B.** The incision is lined up between the 11th and 12th ribs, going from the midaxillary line to the edge of the rectus, and aimed at a position 1 cm above the umbilicus. **C,D.** The incision continues through the lumbodorsal fascia. **E.** The peritoneum is incised and the diaphragm cut about 5 to 10 cm with the liver cephalad and the colon covering the retroperitoneal kidney.

A thoracoabdominal incision is utilized for large upper pole masses or management of caval tumor thrombus on the right side. This incision may start as high as the eighth to ninth interspace and is directed toward the umbilicus. This incision enables excellent exposure of the upper pole and adrenal gland, as well as the suprarenal IVC. Frequently, the pleural space will be entered, which can be expeditiously closed at the end of the case with evacuation of pleural air.

For a flank incision, the patient should be positioned with the tip of the 12th rib over the kidney rest. An “axillary roll” is placed under the upper chest, though not in the axilla per se, to avoid direct compression of the axillary nerve and vessels. The legs are positioned with flexion of the lower leg to 90 degrees and straight extension of the upper leg, with careful padding. The contralateral arm can be tucked at the patient’s side, or extended perpendicular to the body on an arm board. The ipsilateral arm can be positioned in padded fashion over the patient’s chest above the xiphoid, or extended over the bed and secured within a padded armrest. The table is generally flexed and kidney rest is utilized to increase the space between the costal margin and iliac crest.

A flank incision is typically made starting in the 10th to 11th rib interspace and extending toward the supraumbilical abdomen to the edge of the rectus muscle. Incision of skin and subcutaneous tissue is performed through the latissimus dorsi and external oblique fascia and muscle, continuing through the internal oblique and transversus abdominus. Transversalis fascia is divided near the tip of the 11th rib with care to avoid entering the pleural cavity, if possible. The retroperitoneal space is then developed by blunt and sharp technique. Resection of the rib is sometimes needed to obtain the desired exposure. Care is made not to injure the intercostal neurovascular bundle that runs typically along the inferior border of the rib.

The pleural reflection typically crosses the ribs at the junction of the anterior and middle third of the ribs. The pleura may be released by incising fascial attachments to the diaphragm, or the lower diaphragmatic fibers can be detached from the posterior 11th and 12th ribs. Frequently, however, the pleural space is entered, which does not present a significant problem. Care should be taken to avoid injuring the lung; however, the diaphragm can generally be expeditiously repaired and air from the chest evacuated at the end of the case. When entering the chest, one should take care to anticipate the eventual closure and leave diaphragmatic tissue adequate for suturing on either side of one’s incision.

A flank incision can be used for either a retroperitoneal or intraperitoneal radical nephrectomy, depending on surgeon preference. The peritoneum may be violated during a retroperitoneal procedure, which is not problematic, as the bowel should just be carefully retracted. If the procedure is performed retroperitoneally, the peritoneal reflection should be identified on the underside of transversus abdominus and bluntly swept

medially, superiorly, and inferiorly with either a sponge stick or Kitner to develop the retroperitoneal space. Once this space is developed, or once the intraperitoneal cavity is entered depending on the approach, a self-retaining retractor is placed. The radical nephrectomy is then performed as discussed below.

At the conclusion of the nephrectomy, the table is taken out of flexion to reduce tension for closure. If the pleural cavity has been entered, the diaphragm can be closed in running fashion using nonabsorbable suture. Air and fluid from the chest can be evacuated using a red rubber catheter that is placed through the closure prior to knot tying. The open end of the catheter can be placed in a basin under water and several deep breaths are administered by anesthesia with the goal of releasing air from the pleural space. When bubbles are no longer seen under water, the catheter can be removed and the knot cinched down. Alternatively, a chest tube can be left in place; this can be inserted through a separate stab incision and attached to suction. The layers of the flank are then closed in stepwise fashion, typically with the transversus abdominus and internal oblique muscle/fascia closed in one layer, then the external oblique fascia closed as a second layer. The external oblique fascia constitutes the strength layer of the closure and should be closed securely with nonabsorbable or heavy absorbable suture to prevent flank hernias. If a partial nephrectomy has been performed, a Jackson-Pratt drain can be placed through a separate stab incision and secured to the skin.

Anterior Transabdominal Approach

Transabdominal approaches to nephrectomy include chevron or subcostal incisions. We do not prefer this approach for most tumors because they provide less optimal exposure to the adrenal gland and upper pole. We use these incisions primarily when a transperitoneal laparoscopic procedure requires conversion to open. A chevron incision can be considered if access to bilateral kidneys and renal hilar structures is desired, or for a left-sided tumor thrombus case. A midline or paramedian approach can be considered in thin patients and/or those with spinal deformities. Transabdominal approaches do enable exploration of the abdominal cavity for metastatic disease if that is a concern. Our preferred subcostal incision is made from the tip of the 11th rib anteriorly toward the xiphoid process, about 2 fingerbreadths below the costal margin (see Fig. 174.3). Dissection is performed through the layers of the anterior abdominal wall to the

peritoneum, which is sharply entered. A self-retaining retractor is placed for the nephrectomy.

OPEN RADICAL NEPHRECTOMY

As discussed above, radical nephrectomy is typically performed for larger and/or deeper renal masses for which NSS is not feasible. ORN is rarely performed as a first-line option, as LRN has become the standard of care based on equivalent cancer control and decreased postoperative morbidity. ORN may be performed if a laparoscopic procedure requires conversion, if there is significant prior abdominal surgery such that an open approach is preferred, if there is concern for involvement of adjacent structures (e.g., colon, pancreas, spleen), and/or in the presence of caval thrombus.

Radical nephrectomy traditionally has included all components within Gerota's fascia, including kidney, perirenal fat, and adrenal gland. As discussed above, however, the adrenal gland can be safely spared if there is no gross or radiographic involvement. Radical nephrectomy, by including perirenal fat, helps optimize cancer control for tumors that are T3 or greater. Performance of lymph node dissection depends on the presence of suspicious adenopathy, as discussed above.

For all patients undergoing nephrectomy, we recommend a bowel preparation that includes clear liquids starting the morning prior to surgery, and one bottle of magnesium citrate the evening prior to surgery. Even when performing a pure retroperitoneal operation, it is helpful to have the bowel decompressed, and there may be a need to work intraperitoneally. We recommend one perioperative dose of prophylactic antibiotics, typically a first-generation cephalosporin administered prior to incision. Use of subcutaneous heparin perioperatively can be considered based on patient habitus or history of thrombosis. Initially, the patient is brought to the operating room and bilateral compression stockings and sequential compression devices are placed on the lower extremities for deep venous thrombosis prophylaxis. General anesthesia is administered, and an endotracheal tube is placed to secure the airway during patient positioning. An orogastric tube is placed to ensure the stomach is completely decompressed. A Foley catheter is placed at the beginning of the case as well. The patient is then positioned on the table.

Retroperitoneal Approach

The retroperitoneal space is entered through a flank incision, and

developed by bluntly releasing the peritoneal reflection from the underside of the transversus abdominus muscle. This is done medially, superiorly, and inferiorly. A self-retaining retractor is placed. Care is taken to gently retract adjacent structures to provide exposure including, on the left side, the bowel and pancreas medially and the spleen superiorly, and on the right side, the bowel medially and the liver superiorly; see Figure 174.4 for anatomical relationships. The kidney is generally palpable at this time. Initially release of the lateral attachments of the kidney is performed using an instrument such as LigaSure (Covidien, Mansfield, MA). The ureter and gonadal vessels are identified running caudally from the kidney within its medial attachments. The plane posterior to the kidney is developed bluntly to separate the posterior surface of Gerota's fascia from the psoas muscle such that the kidney can be elevated (see Fig. 174.5). With advanced tumors, care must be taken during lateral and posterior dissection to avoid inadvertently injuring parasitic vessels, which can be well developed and cause significant bleeding.

The superior attachments of the kidney are taken including lienorenal ligaments on the left and hepatorenal ligaments on the right. The adrenal gland is released from the kidney by identifying a plane between the adrenal and kidney within Gerota's fascia, and releasing with a device like LigaSure or with use of clips (see Fig. 174.5). It is important to be cognizant of vital adjacent structures within the peritoneal cavity including the bowel that is vulnerable to thermal injury. Also the pancreas on the left side should be carefully identified and retracted with care.

We address the hilar structures last once the rest of the kidney has been dissected, in case hilar bleeding occurs such that urgent clamping and removal of the kidney are required. Dissection of the hilum is performed to isolate the vessels for control. It is important to dissect out the artery proximally so that multiple distal branches do not require separate control. Initially, sequential ligation of arterial structures is performed. The renal artery is dissected for sufficient length to accommodate suture ligation or vascular stapling. A posterior approach to the artery may be preferred for visibility. On the left side, extreme care should be taken to ensure the putative renal artery is running directly to the kidney, as the superior mesenteric artery can be inadvertently ligated. For hilar control, a vascular stapler can be used, either an EndoGIA with cutting capability or a TA that requires the surgeon to cut between the staple lines. If there is insufficient length to accommodate a stapler, as per the surgeon's preference, suture

ligation can be performed. Generally, large permanent (e.g., O silk) sutures are passed around the artery proximally and distally, and tied down. The proximal end should be double ligated, with another tie or a suture LigaSure. If the latter is preferred, the proximal end of the artery can be carefully clamped with a right angle clamp; the artery is divided and suture-ligated with 2-0 nonabsorbable suture. After release of the artery, the renal vein is ligated in similar fashion. The right renal vein is shorter, and there may have only modest length to the vena cava. On the left side, care should be taken regarding the takeoff of the adrenal, gonadal, and lumbar veins from the longer left renal vein. It is preferable to spare the adrenal vein if the adrenal is being spared. The gonadal vein can be left intact or ligated without sequelae. In addition, there may be a lumbar vein emanating posteriorly from the left renal vein that may require ligation for exposure of the artery, and that should not be inadvertently avulsed.

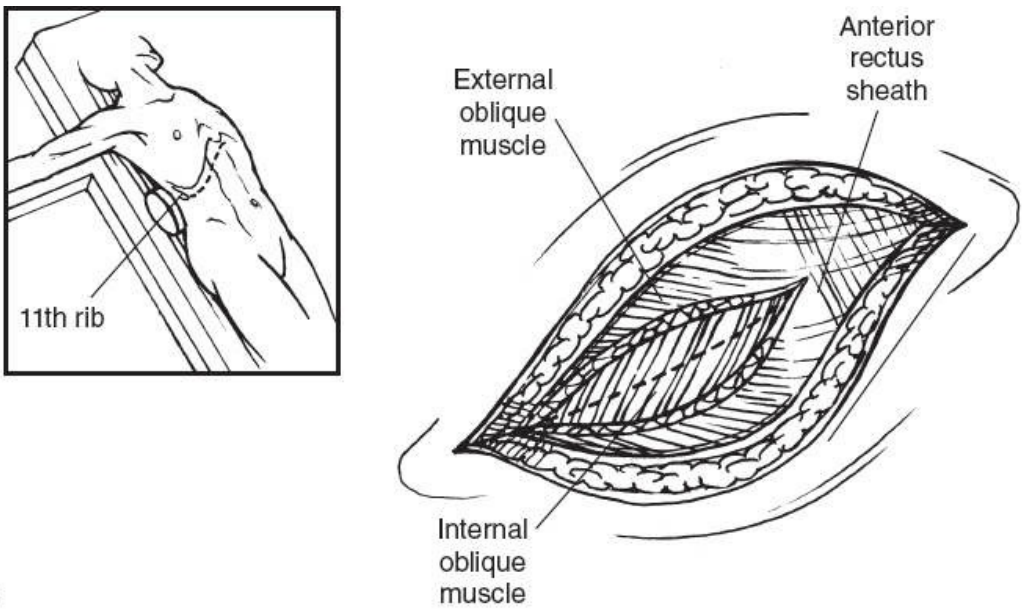
11th rib
External oblique muscle
Anterior rectus sheath
Internal oblique muscle

A-1

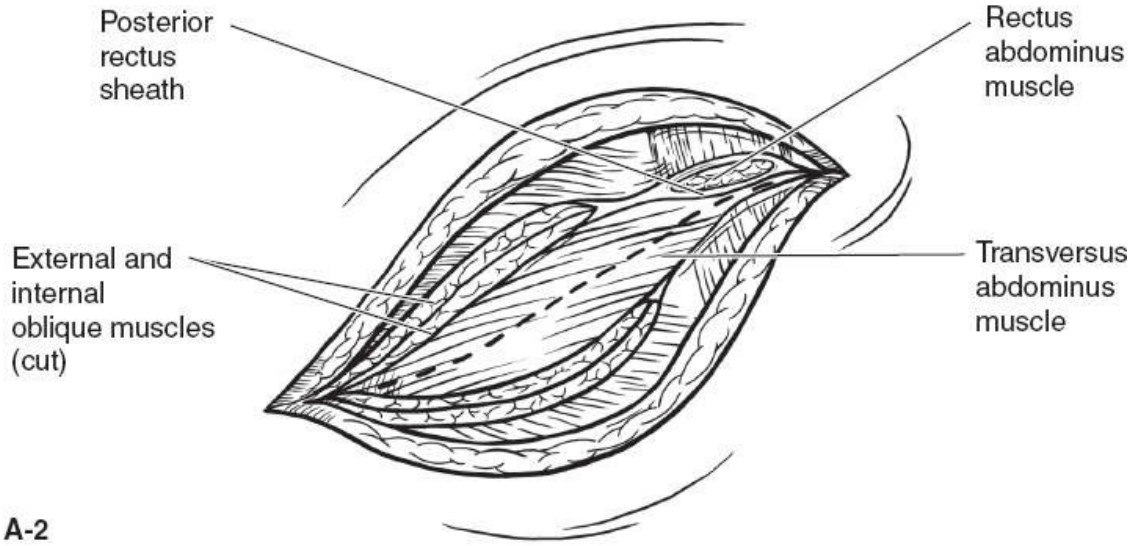
Posterior rectus sheath
Rectus abdominus muscle
External and internal oblique muscles (cut)
Transversus abdominus muscle

A-2

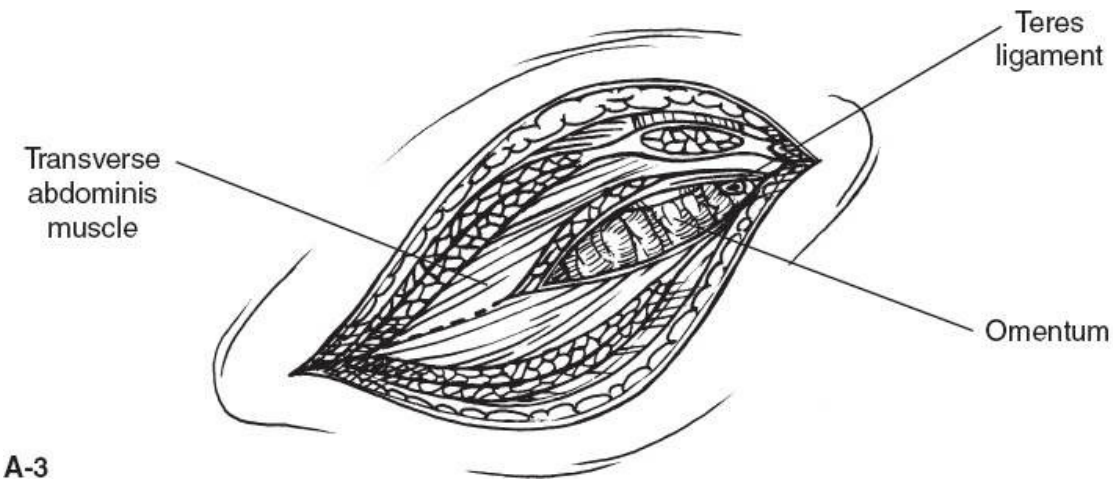
Teres ligament
Transverse abdominis muscle
Omentum

A-3

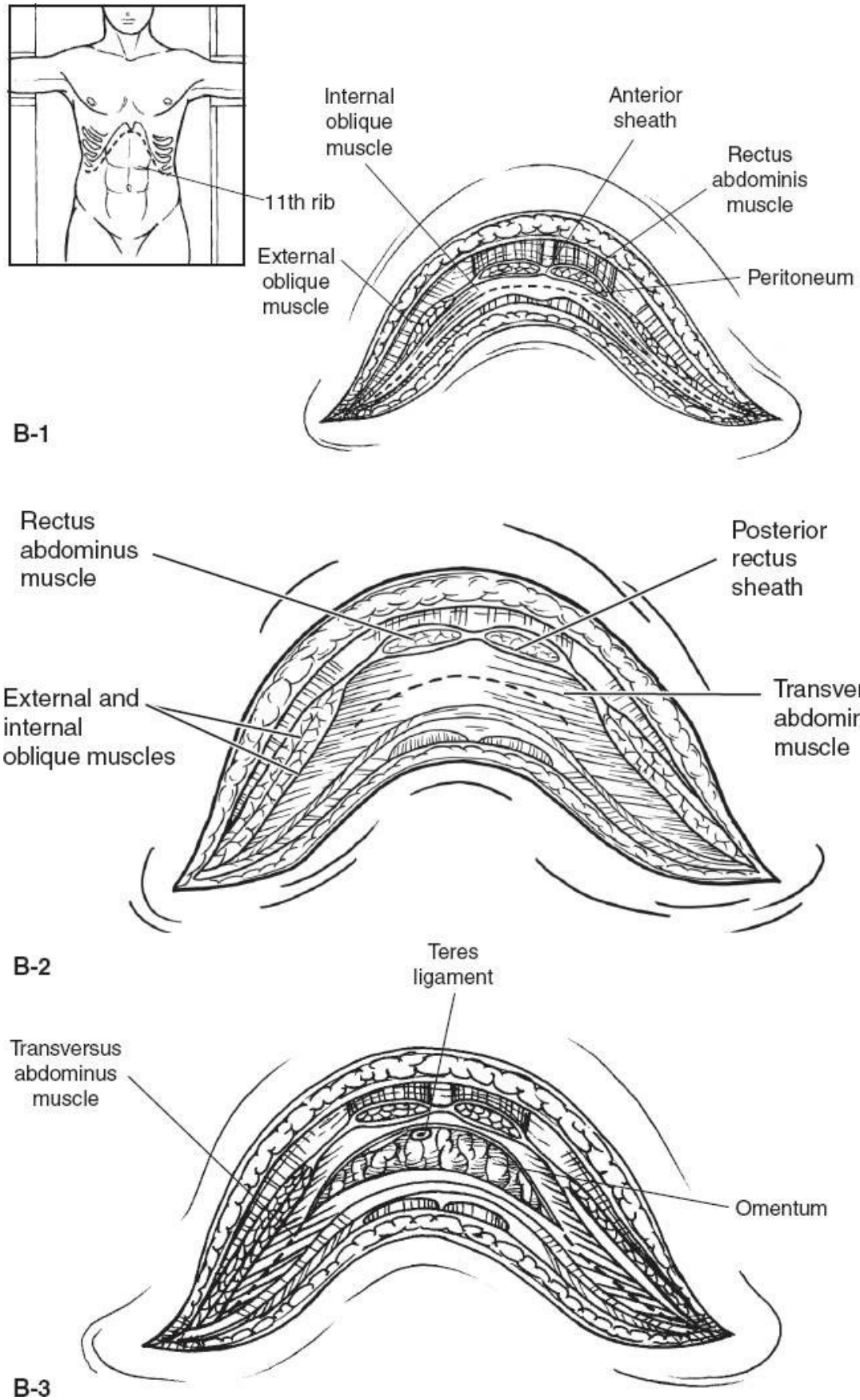

Figure 174.3. Incision using the chevron or subcostal approach. The incision begins at the tip of the ipsilateral 11th rib and

remains 2 fingerbreadths below the costal margin, extending medially to the midline near the xiphoid process.

Once the specimen is completely free, it is removed from the patient and sent as specimen. Lymph node dissection can be performed as indicated. If nodes are removed, it is critical that clipping of lymphatic channels be meticulously performed to minimize the risk of lymphatic leak. Meticulous hemostasis should be obtained. In particular, the integrity of hilar control should be evaluated, and the adrenal gland/bed inspected.

Transabdominal Approach

ORN can also be performed transabdominally or intraperitoneally. The initial steps of this procedure diverge from the retroperitoneal approach, although hilar control is performed with a similar technique. Upon entering the peritoneal cavity, a self-retaining retractor is placed. The white line of Toldt is incised to medialize the ascending or descending colon off of the anterior surface of Gerota's fascia depending on laterality (see Fig. 174.6). On the left side, the splenorenal ligament is incised to mobilize the spleen cephalad and medial from the upper pole. On the right side, the hepatic flexure is mobilized from the right upper pole. The colon mesentery should be carefully preserved. On the right side, the duodenum will typically be encountered overlying the hilum and should be carefully Kocherized. Use of cautery should be stringently avoided in the vicinity of the duodenum to avoid inadvertent thermal injury. On the left side, reflection of the colon should proceed with awareness of the pancreas and splenic vessels, which can ordinarily be avoided. Reflection of these structures should be relatively avascular based on ordinarily good tissue planes between the peritoneum and retroperitoneum. The remainder of the procedure occurs as stated above.

RADICAL NEPHRECTOMY WITH INFRAHEPATIC VENA CAVAL INVOLVEMENT

RCC may have venous extension from the renal vein to various levels in the IVC, and extend as high as the right atrium. Staging of IVC thrombus includes level I (adjacent to the ostium of the renal vein), II (extending to the lower aspect of the liver), III (involving the intrahepatic portion of the IVC but below the diaphragm), and IV (extending above the diaphragm). It is critical that patients have recent staging imaging by CT or MRI to

assess level of thrombus to inform the need for vascular and/or cardiothoracic surgical consultants. Thoracoabdominal incisions are preferred for right-sided tumors, whereas bilateral subcostal or a long midline incision can be utilized for left-sided tumors to enable exposure of the ipsilateral kidney as well as the IVC.

For management of tumor thrombus, ORN is initially performed as discussed above. The specimen is completely mobilized except for the renal vein in continuity with the cava; manipulation of the venous structures is minimized. The cava is widely exposed to provide full vascular control. If the thrombus extends partly into the vein, there may be sufficient margin to control the vein on the cava side with ties or a stapler. If this is not feasible, the cava may need to be side-clamped, and the vein with a cuff of cava resected. If there will be <50% decrease in circumferential diameter of the cava, the cava can be primarily repaired with 4-0 Prolene. If the thrombus extends cephalad into the cava, the cava will have to be opened with proximal and distal control, and a portion of the caval wall may require resection along with the specimen. Primary repair can again be performed if there is not significant narrowing (>50%), or patch graft repair with bovine pericardium or expanded polytetrafluoroethylene (ePTFE) can be performed. If thrombus extends further cephalad to the retrohepatic cava, further maneuvers are required including mobilization of the liver and ligation of retrohepatic venous branches. Venovenous bypass may be needed if test clamping of the cava above the thrombus leads to significant hypotension. Cardiopulmonary bypass and circulatory arrest may be needed for thoracic and intracardiac extension of tumor thrombus.

OPEN PARTIAL NEPHRECTOMY

OPN is performed for resection of renal lesions for which cold ischemia is desired in anticipation of longer clamp times, that is, for larger and/or deeper tumors, and/or in patients with an imperative indication for NSS, for example, solitary kidney, bilateral masses, preexisting renal dysfunction. In addition, OPN is performed when NSS is preferred, but there are not capabilities for a minimally invasive approach. The goal of partial nephrectomy is to remove the mass while sparing normal renal tissue. Unlike radical nephrectomy, in which Gerota’s fascia is left intact, partial nephrectomy requires entering Gerota’s fascia to identify the tumor itself. Typically a resection of tumor with a margin of at least several

millimeters of normal tissue is performed. However, in certain cases of well-circumscribed tumors, particularly deep tumors abutting the renal vessels, or in cases of multiple tumors, enucleation can be performed to minimize damage to vital adjacent structures and enable preservation of uninvolved kidney without obtaining a positive margin.

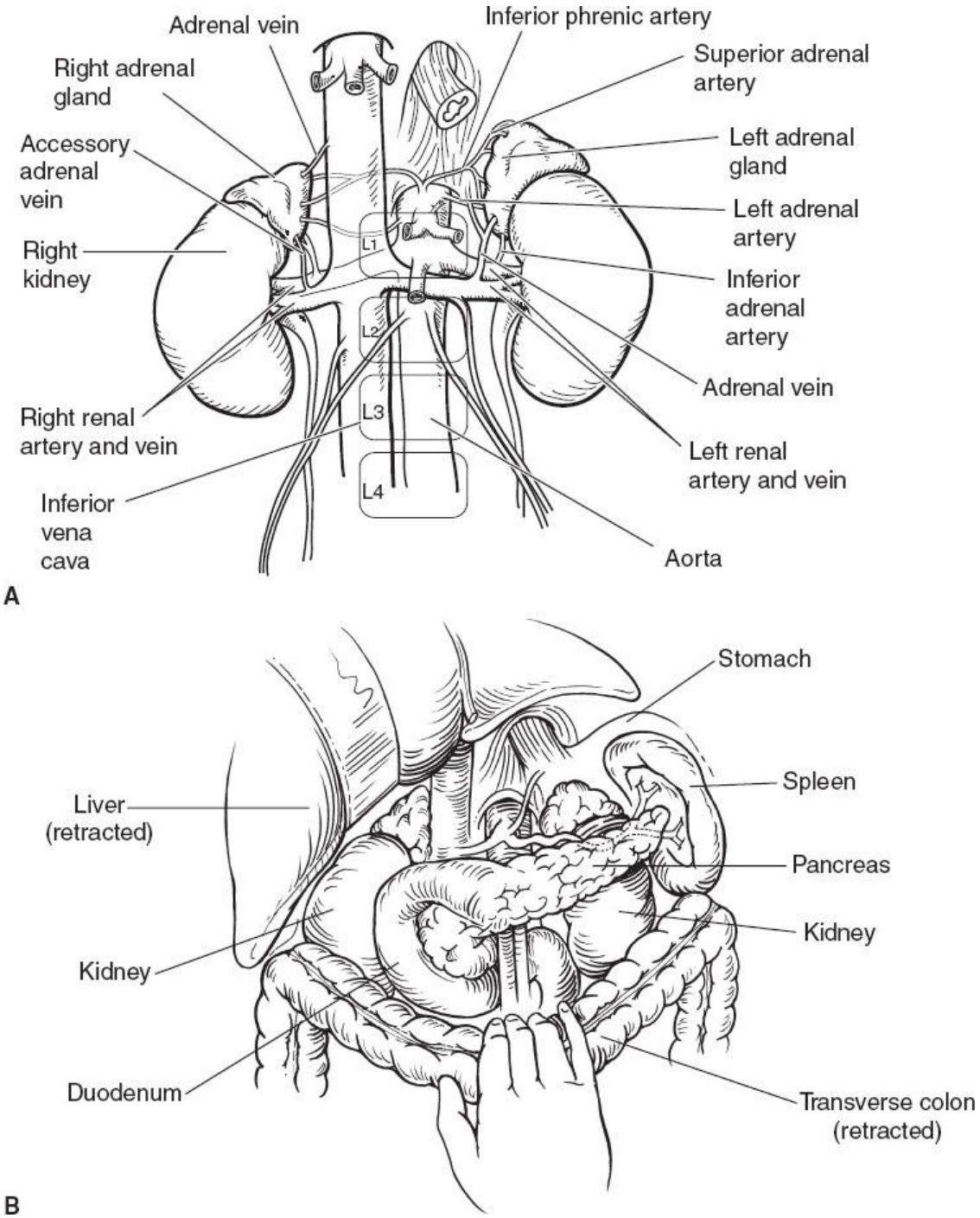

Figure 174.4. Anatomical relationships of kidney, adrenal glands, and associated organs.

For OPN, the kidney should be separated from adjacent structures in all directions to ensure ready access to the renal hilum. Gerota's fascia is entered away from the tumor itself, as perinephric fat overlying the tumor should be preserved to be sent as specimen. Intraoperative ultrasound is used to confirm the location, shape, and depth of tumor; for purely endophytic tumors, this may be the only means of tumor identification. The renal capsule is exposed circumferentially around the tumor leaving adequate space for a resection line and sutures to be used for renorrhaphy. The intended line of resection is superficially marked with cautery. Capsule should be left intact to ensure sutures used to repair the defect are held by strong tissue, as renal parenchyma itself may easily tear. The hilum is fully dissected to enable temporary clamping of the hilum. Accessory vessels should be sought, as a missed artery can cause significant bleeding during tumor resection. The renal vein should be exposed as well, as it can be clamped per surgeon preference. The vessels are marked with color-coded vessel loops, and each is doubly encircled with a loop so that gentle traction can compress the vessel. The ureter is marked with a vessel loop as well as the surgeon should always be keenly aware of the location of this structure to avoid inadvertent injury.

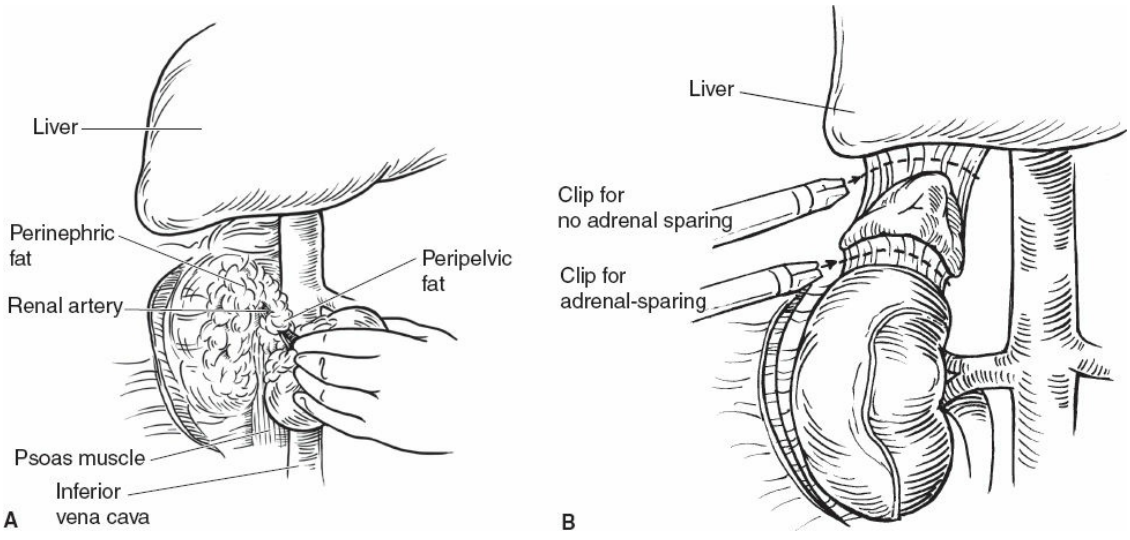

Figure 174.5. **A.** The kidney is lifted off the retroperitoneum; there is a fat plane between the peripelvic and perinephric fat. **B.** The attachments between the kidney and adrenal gland are dissected.

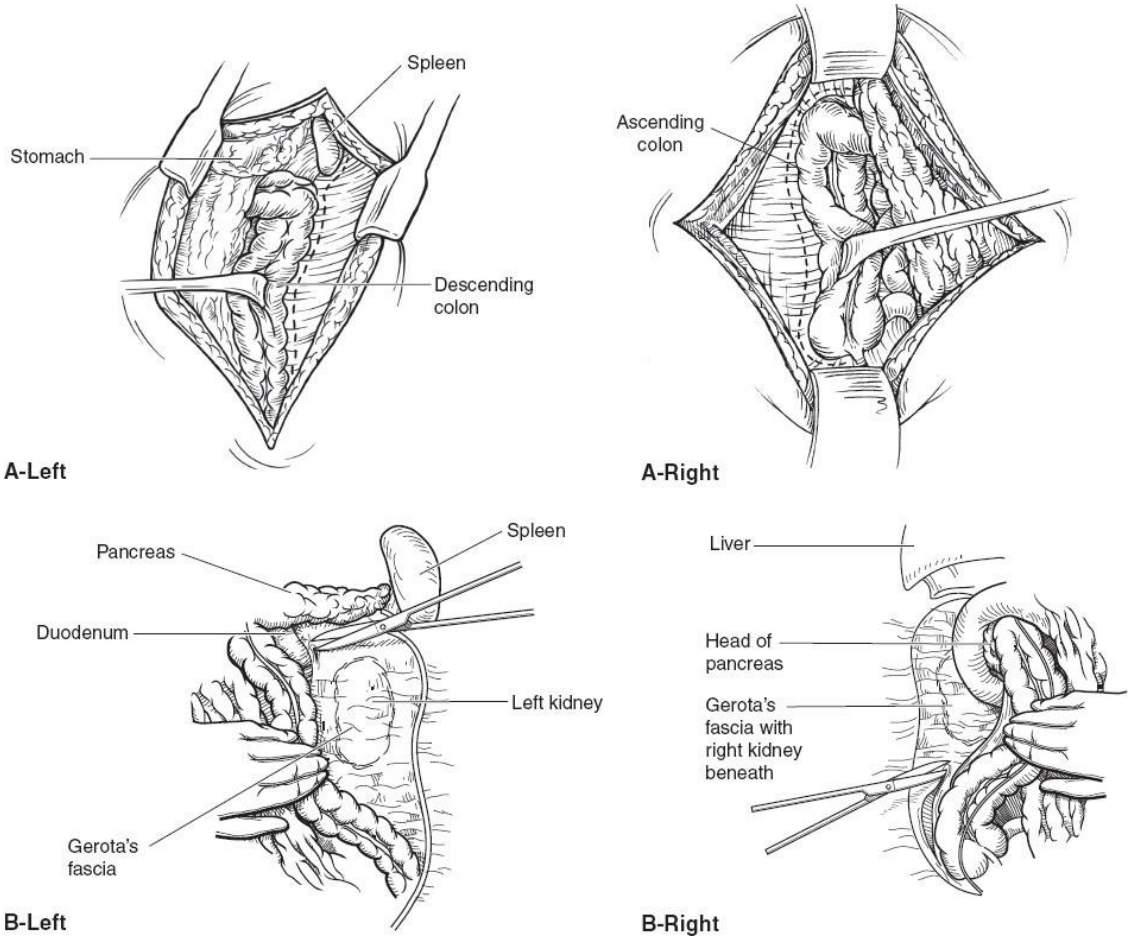

Figure 174.6. The colon is reflected medially to expose the right (**A**) or left (**B**) kidney and great vessels. When approaching the right kidney (**C**), the colon is reflected with the mesentery up off the Gerota's fascia. The colon is held at a right angle to Gerota's fascia and blunt dissection is used to separate the two. When approaching the left kidney (**D**), the mesocolon also separates off Gerota's fascia, leading down to the duodenum.

Prior to initiating renal ischemia, the patient is given 12.5 g of intravenous mannitol and 20 mg intravenous lasix for the purpose of minimizing reperfusion injury. Instruments and sutures for resection and renorrhaphy should be readily available prior to going on clamp. Then, bulldog clamps are placed on the renal artery and vein for occlusion. The kidney is "iced" by placing a bowel bag around the kidney; this is placed upside down, with the draw string pulled around the base, and the bottom cut out to allow exposure to the kidney. Chopped ice is placed in the bag and the kidney is cooled for at least 10 minutes. There are various techniques for tumor resection, but we prefer the use of a Metzenbaum scissors to incise the previously marked line of resection circumferentially.

Resection proceeds with a margin of at least 3 mm from the specimen. Cutting to renal sinus fat and/or collecting system may be necessary to ensure a negative deep margin. A Penfield dissector, or the handle of a scalpel blade, can be used for blunt dissection and/or enucleation per surgeon preference. Frazier tip suction can be used to evacuate backbleeding from the defect. When the specimen is removed, it is inspected to ensure there is a grossly negative margin. If there is concern for residual tumor, further resection and/or biopsy from the base of the defect can be performed. Routine frozen section analysis of a biopsy from the base can be done for patient reassurance but is not necessary.

The base of the defect is then examined, and discrete blood vessels and collecting system are oversewn. This is done in running or figure-of-eight fashion with absorbable suture such as 3-0 vicryl or chromic. High current electrocoagulation such as argon beam can be used along the cut surface to improve hemostasis. Then, closure of the defect is performed. This can be performed with horizontal mattress sutures placed 90 degrees to one another, with or without use of a bolster, typically with 2-0 vicryl suture. Bolsters are typically made from Surgicel (Ethicon, Somerville, NJ), which is oxidized cellulose to promote clotting. Our preferred technique is termed the “Weck sliding technique,” which emulates the laparoscopic approach. Individual sutures (2-0 vicryl) are placed across the defect in simple fashion, ensuring that a healthy bite of capsule is taken on either side for strength. These sutures are pre-made by the scrub nurse to have a Weck clip (Teleflex, Research Triangle Park, NC) on the side opposite the needle, with a knot at the end of the suture to prevent clip dislodgement. After the suture has been placed across the defect, a second Weck clip is placed on the needle side of the suture, and firmly but carefully slid down to the renal capsule, with sufficient tension for dimpling of the kidney but without tearing through. This Weck is secured with another Weck clip or a Lapra-Ty (Ethicon, Somerville, NJ) to prevent dislodgement. We feel that this technique allows for excellent closure of the defect in expeditious fashion.

After closure of the defect, the bulldog clamps are removed from the hilum. The venous clamp if present should be removed first. The arterial clamp is removed and the defect observed. Bleeding from the defect if mild can be observed as venous bleeding may stop from tamponade effect as the kidney fills. However, if there is substantial bleeding, additional bolster sutures can be placed. Repeat clamping should be avoided if

possible to minimize reperfusion injury; however, this can be performed if hemostasis cannot be readily obtained. With significant persistent bleeding, the initial renorrhaphy may need to be taken down and the defect inspected for an arterial vessel.

At this time, the vessel loops are removed and the ureter inspected to ensure its integrity. Perirenal fat can be secured over the defect for tissue coverage, if possible. Closure proceeds as discussed above. We routinely place a 10-mm Jackson-Pratt drain adjacent to the kidney through the skin through a separate stab incision, usually inferior to the wound.

"Clamp-less" partial nephrectomy can be performed as well for small exophytic tumors. Bleeding during resection can be profuse and can obscure the deep margin; thus, patients for clampless procedures should be carefully selected. Patients with preexisting CKD may be candidates for this procedure as the risk of ischemia may outweigh transient operative bleeding.

LAPAROSCOPIC RADICAL NEPHRECTOMY

Laparoscopy is the approach of choice for radical nephrectomy in most patients. LRN is typically performed transperitoneally; thus, the steps of surgery are quite similar to the transabdominal open approach described above. A retroperitoneal approach can also be utilized and will be discussed below. For the transperitoneal approach, the patient is positioned in a modified lateral position at ~30 to 45 degrees. He/she is carefully secured to the table with surgical tape as the table will be tilted for the majority of the operation. A Pfannenstiel or lower vertical midline incision (in men) is premarked on the abdomen for extraction.

Laparoscopic access is achieved by either Veress or Hassan techniques. The abdomen is insufflated to 15 mm Hg. Incisions are marked on the abdomen for camera and working ports. A camera port is placed periumbilically for patients with normal body habitus; however, for obese or large patients, we shift the camera port laterally and superiorly to where the "adjusted" umbilicus would be. Then 10- to 12-mm working ports are placed one hand's breath laterally and superiorly to the camera port. Optical access for the initial port is preferred in the cases of prior abdominal surgery. For right-sided cases, a 5-mm port will be placed subxiphoid for placement of a self-retaining liver retractor. We prefer placement of a locking grasper under the liver for anterior and superior retraction; this is secured superficially to the peritoneum overlying the

diaphragm in the right superolateral abdomen. An additional assistant port can be placed in the lower abdomen within the intended extraction incision. We prefer to use a 15-mm port for this assistant port, as a large specimen bag will be placed here for ultimate extraction. This may be less useful in larger patients for whom reach to the upper abdomen may not be feasible. The table is then maximally rotated toward the contralateral side of surgery to medialize the visceral contents.

A laparoscopic grasper (e.g., DeBakey's) is used in the left hand, and a monopolar shears in the right hand. We will exchange the shears for a simultaneous coagulation/cut device like the Harmonic scalpel (Ethicon, Somerville, NJ) or LigaSure. The line of Toldt is incised to a point just superior to the iliac vessels to release the colon and expose the anterior surface of Gerota's fascia. Importantly, the lateral attachments are preserved to enable lift of the kidney to expose the hilum later in the case. The spleno- or hepatorenal attachments are released to expose the upper pole of the left- and right-sided kidneys, respectively. On the right side, the duodenum is carefully Kocherized using athermal technique to reveal the renal vein; the tail of the pancreas is carefully reflected medially on the left side. The kidney is carefully lifted anteriorly and the medial lower pole attachments are assessed. The plane posterior to the kidney, above the psoas muscle, is bluntly entered. It is important, during this step, to identify the ureter and the gonadal vein to avoid inadvertent injury. The ureter and the gonadal vein on the left side are elevated anteriorly with the kidney to put the medial attachments and renal hilum on "stretch." This stretch is the most important facet of LRN as it allows safe and expeditious dissection of the hilum. The medial attachments are released to the level of the renal vein. On the left side, the insertion of the gonadal vein into the renal vein will be seen. In addition, on the left side there is typically a lumbar vein running posteriorly from the renal vein that prohibits full lift and exposure of the artery. This lumbar vessel requires dissection and control. Once the renal artery is identified, typically posterior to the vein, it is controlled and released with a vascular stapler. Accessory arteries can be sought and controlled depending on preoperative imaging and intraoperative inspection. When the artery has been controlled, the vein is taken with a vascular stapler as well. For adrenal sparing, Gerota's fascia is entered adjacent to the adrenal and it is released from the kidney. The remaining renal attachments are released, and the kidney is placed in a specimen bag. Reassessment of the hilar staple line and adrenal bed is

performed to ensure complete hemostasis.

Retroperitoneal LRN can also be performed, though less commonly. This approach is considered if there has been significant prior transperitoneal surgery, and the patient strongly desires a minimally invasive approach. Advantages of retroperitoneoscopy include rapid access to the renal hilum, as the renal artery can be rapidly identified. The major disadvantage of this approach is limited working space, which can make this procedure more challenging. For this approach, the patient is placed in full flank position. The tip of the 12th rib is identified and a 2- to 3-cm incision made at the tip of the rib. Dissection is performed through initial tissue layers, then a Kelly clamp is used to enter the retroperitoneal space. Finger dissection is performed to release the retroperitoneal fat and peritoneum off of transversus abdominus and quadratus lumborum. The retroperitoneal space is developed using a balloon insufflator. A camera port is placed in this initial access tract. Two additional 10-mm working ports are placed superomedially and superolaterally under vision. The peritoneum is bluntly reflected to increase working space, with care not to enter the peritoneal cavity, as this will result in loss of retroperitoneal insufflation. The psoas is identified as the initial landmark, and the kidney is elevated to expose the posterior hilum. The artery and the vein are controlled and the remainder of the kidney dissected. Extraction can be performed by extension of the initial incision or through a Gibson incision.

MINIMALLY INVASIVE PARTIAL NEPHRECTOMY

MIPN has been increasingly performed in an era in which both minimally invasive techniques and NSS have been prioritized. LPN has been the traditional minimally invasive approach to NSS; however, the technical challenges of intracorporeal suturing have been a major impediment to dissemination of this technique. Robotic assistance using the DaVinci system (Intuitive, Sunnyvale, CA) has recently been applied to LPN, and has provided substantial benefits regarding ergonomics and suturing dexterity.

MIPN is typically performed transperitoneally but can be performed retroperitoneally, akin to LRN as discussed above. The steps of surgery are initially equivalent to LRN, with reflection of the colon, release of adjacent structures, and exposure of Gerota’s fascia. The ureter and gonadal vessels are identified and the kidney lifted anteriorly. The hilum is dissected but preserved for clamping. Warm ischemia is used for MIPN as

there is no reliable method of cooling the kidney intracorporeally. Gerota's fascia is entered away from the tumor, and exposure of the kidney surface circumferentially around the tumor is performed. Laparoscopic ultrasound is used for confirming tumor location and depth, akin to the open approach. The resection line is marked with cautery, and the hilum is clamped using laparoscopic bulldogs. Resection is performed with cold shears. The tumor is placed to the side, and a biopsy can be taken from the base of the defect. Discrete large vessels and collecting system are oversewn laparoscopically or robotically. Suturing can be done in figure-of-eight fashion, or by running a suture through the defect. We use 3-0 vicryl suture for this purpose. Argon beam can be used to cauterize the raw resection edges within the defect. Then, parenchymal sutures are placed in simple fashion across the defect with care to include generous capsule for strength. The Weck sliding technique as described above is utilized. A bolster is optional but may be used for wider defects. After closure of the defect, the hilar clamps are released (vein first) and the renorrhaphy is observed. Mild bleeding will typically cease with tamponade effect, but persistent or brisk bleeding may require additional sutures placed across the defect. Similar to open surgery, the need for reclamping is rare. A drain is placed equivalently to the open procedure.

POSTOPERATIVE MANAGEMENT

Patients are treated on an inpatient basis following nephrectomy. Immediately postoperatively, the orogastric tube is removed. If patients are hemodynamically stable, complete blood count (CBC) and basic metabolic panel (BMP) are checked the morning of postoperative day (POD) 1; bloodwork can be sent postoperatively depending on clinical concern. Early ambulation is encouraged. Use of minimally invasive approaches shortens hospitalization to 1 to 2 days for LRN patients, and ~2 days for MIPN patients. Open surgical patients have variable hospitalization times depending on postoperative pain, but average length of stay is 3 to 4 days. Diet is initiated with sips of clear liquids on the evening of surgery, and is advanced as tolerated. Patients with flank incisions have more postoperative pain and may have issues with splinting and atelectasis. Incentive spirometry, early ambulation, and effective pain management are critical to minimize pulmonary complications in these patients.

For radical nephrectomy patients, the Foley catheter is typically removed on POD 1 and/or when the patient is ambulating well. For

patients undergoing partial nephrectomy, the Foley catheter is generally left in place for 2 days. On the morning of POD 2, the Foley is removed and output from the perirenal drain is observed. If output is low (<30 cc/shift), it may be pulled. However, if the output increases with removal of the Foley and/or there is >30 cc drainage/shift, the fluid should be sent for creatinine assessment. If it is equal to serum creatinine, there is no urinary leak and it may be removed; if fluid creatinine is elevated, it should be left in place until the leak seals.

LONG-TERM FOLLOW-UP

Postoperative surveillance following nephrectomy depends primarily on final pathology, specifically tumor stage. There are variable recommendations for timing of surveillance, but we generally follow the protocol recommended by the National Comprehensive Cancer Network (NCCN Web site). Timing of follow-up exams is based pathologic stage. Patients have interval history and physical exams, abdominal imaging (CT or MRI), chest imaging (chest x-ray), and bloodwork including liver function tests and BMP. Development of CKD warrants referral to a nephrologist for counseling.

COMPLICATIONS

Intraoperative Complications

Bleeding may be encountered during nephrectomy from various sources. Venous bleeding, in particular, generally resolves with manual pressure, even from the renal vein or vena cava. During laparoscopic nephrectomy, increasing the abdominal insufflation pressure to 20 mm Hg and holding manual pressure, often with an intracorporeal “lap pad,” may be effective. The sites prone to venous bleeding include the entry of lumbar veins into the posterolateral vena cava, where the right gonadal vein enters the cava on the anterolateral surface, where a lumbar vein often enters the left renal vein posteriorly, and the short right renal vein from the cava that can avulse without care. Large tumors with parasitic vessels may be at increased risk for bleeding during dissection, and these vessels should be carefully identified and controlled. In addition, the adrenal gland is typically friable and can ooze during dissection; this will typically resolve with pressure as well. Arterial bleeding requires identification of the cut vessel and clip or suture control. If a vascular injury requires suturing, 4-0

or 5-0 Prolene suture can be used. An Allis clamp or Satinsky clamp can be used to oppose edges of the vascular defect to enable suturing. There should be a low threshold to involve a vascular surgeon in larger vessel repair.

Bowel injuries are rare and typically are avoided with constant awareness of the location of the bowel. Athermal technique should always be used for bowel mobilization. Mobilization of the duodenum on the right side, in particular, should be performed carefully as duodenal injuries can be devastating. Sharp injuries to bowel should be repaired via suture imbrications with silk suture. Thermal injuries if recognized should be similarly oversewn.

Injury to the spleen or liver can occur typically from avulsion of renal attachments. Delicate manipulation of these structures during release is critical to avoid injury. Management of these injuries, if minor, includes pressure and coagulation (e.g., argon beam). For more significant splenic injuries, splenectomy may be necessary. Also, the pancreas should be identified and treated with extreme care during nephrectomy; gentle manipulation is needed to avoid postoperative pancreatitis or pancreatic leak.

Diaphragmatic and/or pleural injuries can be encountered during nephrectomy. The chest may be deliberately entered during open surgery, and should be evacuated and closed by the methods described above. This avoids significant postoperative pneumothorax. If a diaphragmatic injury occurs laparoscopically, this can be repaired via laparoscopic suturing. If there is concern for pleural injury and pneumothorax, a small chest tube can be placed, or an angiocatheter is placed in the lateral chest and attached to intravenous tubing that is placed in a basin under water. Deep breaths are delivered by anesthesia and the air evacuated as detected by bubbles in the water. The angiocatheter is subsequently removed.

Postoperative Complications

There are some postoperative complications unique to partial nephrectomy that deserve mention. Delayed bleeding can occur based on pseudoaneurysm or arteriovenous fistula formation. This can occur from several days to several months postoperatively, and can be associated with precipitous bleeding. There is frequent fistulous formation to the connecting system and severe gross hematuria. The gold standard for both diagnosis and treatment of these vascular lesions is angioembolization,

which should be promptly performed if there is a high index of suspicion.

Urine leak can also occur after partial nephrectomy. The perirenal drain will frequently have increased output, and will have an elevated fluid creatinine level. For modest elevations of fluid creatinine, the drain can be left in place for an additional 1 to 2 weeks, then removed if there is resolution of leak based on fluid creatinine levels. An abdominal imaging study (e.g., CT) should be obtained to ensure there is no undrained perirenal urinoma, and as well as no distal obstruction within the ureter from a blood clot. A CT with intravenous contrast and delayed images is diagnostic of ongoing urine leak. More substantial urine leaks require placement of a ureteral stent to maximize antegrade drainage and decrease intrarenal pressure; a Foley catheter should be replaced in these patients as well to avoid vesicoureteral reflux. When healing is confirmed (e.g., via repeat CT w/delayed images, or retrograde pyelogram), the drain and stent can be removed.

If the patient presents at a delayed interval from partial nephrectomy with a symptomatic perirenal collection, urinoma should be considered and a percutaneous drain should be placed. A drain should be placed immediately if there is a suspicion for an infected collection based on clinical signs and symptoms. Collections adjacent to the kidney following nephrectomy may also be hematoma or lymphocele, particularly in the setting of concomitant lymphadenectomy with nephrectomy. Lymphocele is generally managed with percutaneous drainage and a medium chain triglyceride diet.

In addition, patients may have acute elevations of creatinine following radical or partial nephrectomy. In radical nephrectomy patients, this requires careful trending and possibly involvement of a nephrologist. Following partial nephrectomy, a rising creatinine +/− flank pain may be indicative of ureteral obstruction from clot, and a renal ultrasound or CT should be performed to rule out hydronephrosis.

Suggested Readings

Alt AL, Boorjian SA, Lohsa CM, et al. Survival after complete surgical resection of multiple metastases from renal cell carcinoma. *Cancer* 2011;117(13):2873–82.

Bensalah K, Pantuck AJ, Rioux-Leclercq N, et al. Positive surgical margin appears to have negligible impact on survival of renal cell carcinomas treated by nephron-sparing surgery. *Eur Urol* 2010;57(3):466–71.

Berger A, Brandina R, Atalla MA, et al. Laparoscopic radical nephrectomy for

renal cell carcinoma: oncological outcomes at 10 years or more. *J Urol* 2009;182(5):2172–6.

Blom JH, van Poppel H, Marechal JM, et al. Radical nephrectomy with and without lymph-node dissection: final results of European Organization for Research and Treatment of Cancer (EORTC) randomized phase 3 trial 30881. *Eur Urol* 2009;55:28–34.

Dulabon LM, Lowrance WT, Russo P, et al. Trends in renal tumor surgery delivery within the United States. *Cancer* 2010;116:2316–21.

Gill IS, Aron M, Gervais DA, et al. Clinical practice. Small renal mass. *NEJM* 2010;362(7):624–34.

Haramis G, Mues AC, Rosales JC, et al. Natural history of renal cortical neoplasms during active surveillance with follow-up longer than 5 years. *Urol* 2011;77:787–91.

Huang WC, Levey AS, Serio AM, et al. Chronic kidney disease after nephrectomy in patients with renal cortical tumours: a retrospective cohort study. *Lancet Oncol* 2006;7(9):735–40.

Lane BR, Abouassaly R, Gao T, et al. Active treatment of localized renal tumors may not impact overall survival in patients aged 75 years or older. *Cancer* 2010;116(13):3119–26.

Lane BR, Russo P, Uzzo RG, et al. Comparison of cold and warm ischemia during partial nephrectomy in 660 solitary kidneys reveals predominant role of nonmodifiable factors in determining ultimate renal function. *J Urol* 2011;185(2):421–7.

Molina AM, Motzer RJ. Clinical practice guidelines for the treatment of metastatic renal cell carcinoma: today and tomorrow. *Oncologist* 2011;16(2):45–50.

Richard PO, Jewett MA, Bhatt JR, et al. Renal tumor biopsy for small renal masses: a single-center 13-year experience. *Eur Urol* 2015;68(6):1007–13.

Roos FC, Brenner W, Muller M, et al. Oncologic long-term outcome of elective nephron-sparing surgery versus radical nephrectomy in patients with renal cell carcinoma stage pT1b or greater in a matched-pair cohort. *Urology* 2011;77:803–8.

Thompson RH, Siddiqui S, Lohse BC, et al. Partial versus radical nephrectomy for 4 to 7 cm renal cortical tumors. *J Urol* 2009;182(6):2601–6.

Van Poppel H, Da Posso L, Albrecht W, et al. A prospective, randomized EORTC Intergroup Phase 3 study comparing the oncologic outcome of elective nephron-sparing surgery and radical nephrectomy for low-stage renal cell carcinoma. *Eur Urol* 2011;59:543–52.

EDITOR'S COMMENT

Kidney cancer is among the 10 most frequently diagnosed cancers in the United States with an estimated incidence of more than 62,000 new cases in 2016 (Siegel RL, Miller KD, Jemal A. Cancer statistics, 2016. *CA Cancer J Clin* 2016;66(1):7–30). The overall 5-year survival rate for kidney cancer is 74%, decreasing to 53% among patients with locoregional disease and 8% among patients with metastatic disease. Interestingly, this survival demonstrates a temporal trend with survival increasing from 57% in 1987−1989 to 74% in 2006−2012 (Li P, Wong YN, Armstrong K, et al. Survival among patients with advanced renal cell carcinoma in the pretargeted versus targeted therapy eras. *Cancer Med* 2016;5(2):169–181). Many suggest that this improvement in clinical outcomes is attributable in part to a higher proportion of indolent and low-stage tumors identified using enhanced early-detection techniques. The role of surgery in these patients cannot be understated as the evolution of treatment options has accompanied this differing presentation of RCC.

Perhaps the most notable change in the treatment of kidney cancer is the shift from open radical nephrectomy with its attendant morbidities to minimally invasive alternatives shown to reduce or avoid these inherent negative consequences. Drs. Hyams and Allaf have done an outstanding job of reviewing the role of radical nephrectomy in this patient population. I would like to take the opportunity to expound on two key points related to the surgical management of kidney cancer. First, I will evaluate the role of lymphadenectomy in this patient population. I will then discuss the surgical management of metastatic disease.

Although regional lymphadenectomy is a cornerstone of surgical oncology, its role in the management of kidney cancer is limited owing to the disease's potential for hematogenous and lymphatogenous spread. Lymphatic drainage of the kidney tumors can be divided into anterior, posterior, and intravascular drainage relative to their position to the renal vein. Lymphadenectomy is accepted for 4% to 5% of cases with clinically positive disease (Capitanio U, Jeldres C, Patard JJ, et al. Stage-specific effect of nodal metastases on survival in patients with non-metastatic renal cell carcinoma. *BJU Int* 2009;103(1):33–7); however, the advent of imaging technology and the subsequent discovery of smaller tumors have resulted in the investigation of sentinel lymph node biopsy for the identification and removal of microscopic disease. A reasonable extension of this work would include evaluation of the role of sentinel lymph node biopsy in the management of small renal cancers.

Approximately 30% of patients with RCC present with metastatic disease. A recent analysis by the Surveillance, Epidemiology, and End Results Program (SEER) database revealed that only 35% of patients diagnosed with advanced renal cell cancer between 2000 and 2013 underwent nephrectomy as their initial therapy; therefore, the role of surgery on the management of metastatic disease

is of utmost importance. Current factors to be considered prior to cytoreductive nephrectomy include histology, performance status, symptoms form disease, burden of metastatic disease, Memorial Sloan Kettering Cancer Center Risk Criteria, and the risk of surgical complications (Vaishampayan UN. The role of nephrectomy for kidney cancer in the era of targeted and immune therapies. *Am Soc Clin Oncol Educ Book* 2016;35:e16–20).

Hormonal therapy and cytotoxic chemotherapy have little to no activity in metastatic renal cell cancer while immunotherapeutic approaches with interferon-α and high-dose interleukin-2 have response rates of 12% and 23%, respectively. Two randomized trials have shown that patients who underwent cytoreductive nephrectomy followed by interferon-α experienced longer overall survivals relative to patients treated with interferon alone (Flanigan RC, Yonover PM. The role of radical nephrectomy in metastatic renal cell carcinoma. *Semin Urol Oncol* 2001;19(2):98–102; Mickisch GH, Garin A, van Poppel H, et al. Radical nephrectomy plus interferon-alfa-based immunotherapy compared with interferon alfa alone in metastatic renal-cell carcinoma: a randomised trial. *Lancet* 2001;358(9286):966–70). This difference might be attributable to an improvement in host immune reaction as clinically spontaneous regressions have been observed in patients after cytoreductive nephrectomy (Dadian G, Riches PG, Henderson DC, et al. Immunological parameters in peripheral blood of patients with renal cell carcinoma before and after nephrectomy. *Br J Urol* 1994;74(1):15–22; Uzzo RG, Clark PE, Rayman P, et al. Alterations in NFkappaB activation in T lymphocytes of patients with renal cell carcinoma. *J Natl Cancer Inst* 1999;91(8):718–21). The emergence of immune checkpoint inhibitors for the treatment of renal cell cancer invites continued study of cytoreductive nephrectomy prior to the initiation of these potent immunoodulators.

The current era of targeted therapy for metastatic renal cell cancer has raised very interesting issues regarding the role of cytoreductive nephrectomies in this cohort of patients treated with antiangiogenic agents as well as mTor and tyrosine kinase inhibitors. Two retrospective studies reported improved overall survival in patients treated with cytoreductive nephrectomies prior to the initiation of targeted systemic therapy (Choueiri TK, Xie W, Kollmannsberger C, et al. The impact of cytoreductive nephrectomy on survival of patients with metastatic renal cell carcinoma receiving vascular endothelial growth factor targeted therapy. *J Urol* 2011;185(1):60–6; Heng DY, Wells JC, Rini BI, et al. Cytoreductive nephrectomy in patients with synchronous metastases from renal cell carcinoma: results from the international metastatic renal cell carcinoma database consortium. *Eur Urol* 2014;66(4):704–10). However, these trials have well-recognized selection biases favoring systemic therapy alone in poor-risk patients. Two large, prospective trials are underway to consider the role of cytoreductive nephrectomy for patients being treated with targeted therapy. Patients in the CARMENA trial will be randomized to sunitinib versus sunitinib following cytoreductive nephrectomy. The SURTIME trial will evaluate

patients randomized to sunitinib followed by nephrectomy versus sunitinib alone (Vaishampayan UN. The role of nephrectomy for kidney cancer in the era of targeted and Immune therapies. *Am Soc Clin Oncol Educ Book* 2016;35:e16–20). These trials will hopefully provide insight into the potential synergy between cytoreductive nephrectomy and systemic therapy.

John H. Stewart, IV

175 Radical Cystectomy and Orthotopic Urinary Diversion for Bladder Cancer

Eila C. Skinner and Siamak Daneshmand

INTRODUCTION

In the United States, urothelial carcinoma of the bladder is the second most common malignancy of the genitourinary tract, and the second most common cause of death of all genitourinary tumors. In the United States and the European Union, bladder cancer (BCa) accounts for approximately 180,000 new cancer diagnoses and >50,000 deaths annually. Approximately 75% of patients with primary urothelial carcinoma of the bladder present with tumors confined to the superficial mucosa. These tumors carry a high risk of recurrence but low risk of progression to invasive or metastatic disease, especially if low grade. Nonmuscle invasive tumors are initially managed with transurethral endoscopic resection and in some cases administration of intravesical therapy. However, 20% to 40% of all patients will either present with or develop a high-grade, invasive tumor of the bladder. If left untreated, the majority of patients with muscle invasive bladder cancer will die of the disease within 2 years of diagnosis. Radical cystectomy is considered the most effective therapy for patients with high-grade, muscle invasive bladder and patients with nonmuscle invasive cancers at high risk of progression that are not controlled with intravesical therapies.

Invasive bladder tumors tend to progressively invade through muscularis propria into the perivesical fat, and then into contiguous pelvic organs, with an increasing incidence of lymph node involvement at each level. While distant metastases can appear in the absence of deep invasion, in most patients nodal involvement precedes distant metastatic disease, and the latter can be prevented by cystectomy when the tumor is organ-confined.

With improvements over the past several decades in medical, surgical, and anesthetic techniques, the morbidity and mortality associated with

radical cystectomy have dramatically decreased. Prior to 1970, the perioperative mortality rate of cystectomy was nearly 20%. This has significantly diminished to 2% to 3% in contemporary series. However, postoperative complications are still common with this surgery, even in expert hands, and this has not really been impacted by adoption of minimally invasive techniques. Several studies have shown that morbidity, mortality, and cost are all less for both surgeons and hospitals with higher case volumes.

In addition to the potential for cure, a properly performed radical cystectomy with pelvic lymphadenectomy provides optimal local control of the tumor, with <10% pelvic recurrence for patients with node-negative disease. Local symptoms can be extremely debilitating for patients, with bleeding, urinary frequency, pain, and obstruction. These may stimulate consideration of palliative cystectomy even in patients with metastatic disease.

The Bricker ileal conduit (or urostomy) has been the most popular form of urinary diversion since it was described in the 1950s, and today accounts for 85% to 90% of diversions in patients undergoing cystectomy in the United States. However, many patients are unwilling to accept a permanent stoma, and reconstruction with an orthotopic ileal neobladder urinary diversion has provided an attractive alternative. This may allow both patients and surgeons to consider this surgery earlier in the disease process when it has the best chance of cure. Orthotopic reconstruction eliminates the need for a cutaneous stoma or urostomy appliance, and in most cases the need for intermittent catheterization. In our experience, many if not most patients will choose this option when presented with the pros and cons of each type of diversion.

There are two randomized trials underway to try to clarify the relative benefit of a more extended dissection. Based on nonrandomized studies suggesting improved outcomes with a more extended dissection, we have advocated performing a lymph node dissection with the proximal boundary above the aortic bifurcation at the level of the inferior mesenteric artery and extending laterally to the genitofemoral nerve (lateral limits of dissection), and distally to the lymph node of Cloquet, including a thorough dissection of the obturator, internal iliac, and presacral nodes.

This chapter will detail the perioperative management, surgical technique, and clinical results and outcomes of radical cystectomy and orthotopic ileal neobladder.

ANATOMY

The empty bladder is roughly triangular in shape, with only the top covered by peritoneum. It lies within the true pelvis, and the extraperitoneal space around the sides is known as the space of Retzius. The detrusor muscle of the bladder is closely covered by the perivesical fat, which can be removed only with some difficulty. In both males and females, the anterior bladder lies free of any attachments to the abdominal wall except through the urachal remnant (median ligament), which extends up to the umbilical scar in the midline. Deep in the pelvis the endopelvic fascia reflects from the pelvic floor up onto the prostate and bladder. A consolidation of this fascia, the puboprostatic ligament, fixes the prostatic apex to the undersurface of the pubic bone. Levator muscle fibers also attach to the prostatic apex. A similar but less well-developed ligament extends between the proximal urethra and pubic bone in the female. In the male, the bladder and prostate are essentially fused at the bladder neck, with the transitional mucosal lining of the bladder extending into the prostatic and bulbar urethra without interruption. Posteriorly, the peritoneal reflection behind the bladder and prostate (Pouch of Douglas) extends down as a fusion fascia between the prostate and rectum (Denonvillier's fascia). Dissection in the plane behind this fascia (Denonvillier's space) allows safe separation of the seminal vesicles and prostate from the rectum. In the female, the bladder lies on the anterior surface of the uterine cervix, with the peritoneal fold between the two generally not extending all the way down to the vagina. The bladder is quite densely adherent to the anterior vaginal wall, requiring sharp dissection to separate the two structures.

The blood supply to the bladder arises from the internal iliac artery and vein, including the superior and inferior vesicle branches. The superior vesicle artery and vein course over the top of the ureter as it enters the detrusor muscle. The inferior vesicle artery arises more inferiorly off of the internal iliac trunk, and with the superior vesicle vessels forms the lateral pedicle. The anterior trunk of the internal iliac artery terminates in the internal pudendal artery. In the male, the inferior vesicle artery supplies the prostate and bladder neck area. In the female, the uterine artery arises off of the superior vesicle artery and courses over the ureter toward the uterus and cervix. There are additional branches from the middle rectal artery and vein that course around the rectum (and vagina in the female) and supply the bladder neck area and form the posterior pedicle. A major

venous plexus courses along the lateral bladder in both males and females and can be a source of significant bleeding during cystectomy. A second venous plexus courses anteriorly over the urethra (the dorsal venous complex).

The neurovascular bundle in the male carries parasympathetic fibers along with small vessels from the hypogastric plexus toward the penis, coursing along the groove between the posterior prostate and the rectum. Preservation of this bundle during cystectomy is required if erectile function is to be preserved. A similar bundle courses along the lateral vagina in the female, although the role of these nerves in preserving continence or sexual function is somewhat controversial. The main nerve supply to the external urethral sphincter in both males and females appears to course within the levator muscle fibers in the pelvic floor lateral and anterior to the urethra.

The lymphatic drainage of the bladder follows the primary vessels, coursing to the obturator, internal iliac, and common iliac chains. However, additional drainage includes the external iliacs and presacral nodes. The drainage appears to be bilateral in most cases. From the pelvic nodes, drainage continues up along the periaortic and pericaval chains. There is no single identifiable sentinal node for bladder cancer. Node mapping studies have suggested that the primary landing site is in the internal iliac and obturator areas, but solitary positive nodes can often occur in the external iliac chain and occasionally in the presacral and common iliac areas as well and very rarely in the paracaval and para-aortic areas.

There are few congenital anomalies of bladder formation. However, some vascular variations that are important include the presence of accessory obturator arteries and veins arising from the external iliac vessels in up to 40% of patients, and accessory pudendal vessels in males, which may be important in preservation of potency. In addition, conditions such as bladder diverticula and prior pelvic surgery or radiation, or a prior renal transplant can impact the ease of dissection. Renal anomalies such as horseshoe kidney, duplicated ureters, and others must be recognized as well.

CLINICAL PRESENTATION

The vast majority of patients with bladder cancer present with gross painless hematuria. Any patient over age 40 with hematuria should have

evaluation for bladder cancer. Other presenting symptoms may include irritative symptoms (frequency, urgency, incontinence) that are often misdiagnosed as a urinary tract infection, sometimes delaying diagnosis for months. Symptoms of extravesical involvement include flank pain (from upper tract obstruction), bone pain, cough or hemoptysis, or weight loss.

Smoking is the most significant known risk factor for bladder cancer. Often, patients have quit smoking many years before the diagnosis; however, the risk declines only slightly over decades. Up to 30% of men and 50% of women with this disease have never smoked. Other environmental exposures such as industrial chemicals and dyes have also been identified as etiologic agents.

DIAGNOSIS

The evaluation of hematuria is very standardized and should include upper tract imaging (generally a CT scan of the abdomen and pelvis with intravenous [IV] contrast) as well as flexible or rigid cystoscopy. Ultrasound and noncontrast CT scans have poor sensitivity for detection of both bladder cancer and small renal masses. The ideal CT scan evaluation should include a noncontrast scan followed by an IV contrast scan including the delayed excretion phase (often called a CT urogram or CT IVP). In patients with contrast allergy or poor renal function, the upper tracts may be evaluated with ultrasound combined with retrograde pyelography or MRI with gadolinium.

Currently available imaging tests have poor sensitivity for small bladder tumors, so cystoscopy is required, usually performed in the doctor’s office with a flexible or rigid cystoscope under local anesthesia. Papillary tumors are very easily identified on cystoscopy. Carcinoma in situ (CIS) is a flat lesion in the bladder, which has a very aggressive natural history. It may be difficult to identify with cystoscopy, although a patchy, slightly raised erythematous area may be visible. Urinary cytology is nearly always positive in the presence of CIS, and this test is an important adjunct to the initial cystoscopy. However, cytology can be normal in the presence of low-grade and even high-grade bladder cancers, so it is not useful alone as a screening test. A number of other urinary tests are also currently available to diagnose bladder cancer. There are protein-based tests (NMP22 and BTAStat), immunohistochemical tests (UroVysion FISH and Immunocyt), as well as RNA-based tests (CxBladder), and a number of

others are under development. So far no single or combination of urinary markers has been proven to be sensitive and specific enough to replace cystoscopy in the initial evaluation of hematuria or for follow-up of patients with a history of cancer.

Once a bladder tumor is visualized, the next step is transurethral resection of the bladder tumor (TURBT) to establish histology and grade as well as depth of invasion. A bimanual examination should also be performed under anesthesia during that resection since a palpable mass is highly predictive of extravesical extension. This is important for clinical staging (Table 175.1) and for planning the surgical approach for patients with invasive tumors. For patients with low-grade papillary tumors, no further metastatic workup is necessary. However, patients with high-grade or invasive lesions require a full staging evaluation including a CT scan of the chest, abdomen, and pelvis along with a bone scan. Recently, FDG PET/CT scans have been used for staging, with conflicting data regarding any advantage over standard CT. There is considerable increased cost and radiation exposure with PET scans. However, in patients at high risk of metastases there may be a benefit to identifying occult metastases prior to surgery.

TABLE 175.1 AJCC TNM Staging System for Urothelial Carcinoma of the Bladder

a. 2009 AJCC TNM staging (7th edition AJCC Manual)

Ta		Mucosa only
Tis		Carcinoma in situ
T1		Lamina propria invasion
T2		Muscularis propria invasion
	T2a	<0.5 thickness of detrusor muscle
	T2b	>0.5 thickness of detrusor muscle
T3		Into perivesical fat (clinically palpable mass on bimanual exam)
	T3a	Microscopic invasion only
	T3b	Macroscopic invasion
T4		Invading surrounding organs
	T4a	Into prostate, uterus, ovaries
	T4b	Into pelvic sidewall (fixed mass or invasion of sidewall on imaging)
N	Nx	No nodes sampled
	N1	Single positive node in pelvis
	N2	Multiple positive nodes in pelvis
	N3	Positive node above common iliac bifurcation
M	Mx	No metastatic evaluation
	M0	No metastatic disease
	M1	Distant metastases present

TABLE 175.2 Discrepancy Between Clinical and Pathologic Staging in Patients Undergoing Cystectomy by Clinical Stage

Clinical Stage	Pathologic Stage (%)					
	<pT2	pT2	pT3	pT4	Understaged	Overstaged
Ta, Tis	78	11	3	8	na	22%
T1	59	22	13	6	na	41%
T2	25	29	37	8	25%	45%
T3	18	13	46	23	23%	31%
T4	29	9	10	54	48%	na

Despite recent advances in radiographic imaging techniques, inaccuracy in clinical staging of the primary bladder tumor is very common. Patients with hydronephrosis, a palpable mass on bimanual examination, lymphovascular invasion or variant histology such as neuroendocrine, micropapillary or sarcomatoid variants, or with clear extravesical extension on preoperative imaging are highly likely to have disease in the perivesical fat or positive nodes on final pathology. Table 175.2 shows the discrepancy between clinical and final pathologic stages for a contemporary group of patients undergoing cystectomy.

TREATMENT AND INDICATIONS FOR CYSTECTOMY

The treatment of bladder cancer should be adjusted for the risk of the tumor recurrence or progression. In general smaller, low-grade, Ta lesions are treated successfully with endoscopic transurethral resection alone. Guidelines are available from the European Association of Urology (EAU), the American Urological Association (AUA), and the National Comprehensive Cancer Network (NCCN) to guide optimal therapy for each patient situation. A single dose of intravesical chemotherapy (with mitomycin C or other agent) may be instilled immediately following transurethral resection and has been shown to reduce early recurrence of noninvasive tumors. Repeat resection is recommended for patients with lamina propria invasion or high-volume high-grade disease to ensure that muscle invasive tumor has not been missed.

Patients with high-grade tumors, especially with lamina propria invasion or CIS, are at significant risk of recurrence and progression to muscle-invasive disease. Intravesical immunotherapy with BCG (Bacillus Calmette-Guerin, a live attenuated strain of *Mycobacterium tuberculosis*) has been the most effective to reduce both recurrence and progression for these patients. Six weekly instillations are administered, with ongoing maintenance therapy for the highest-risk patients. BCG is contraindicated in most patients on immunosuppression or those with prior severe

reactions to it. Intravesical chemotherapy with mitomycin C, epirubicin, gemcitabine, and other agents has been effective to reduce recurrence (but not progression) for patients with intermediate risk tumors if BCG is contraindicated or has not been effective. Newer agents and delivery technologies are under development to try to enhance effectiveness of intravesical therapy.

The long-term risk of progression to muscle-invasive disease for patients with high-risk tumors treated with intravesical therapy may be as high as 50%. For this reason, cystectomy may be a reasonable option for the younger, healthy patients with high-grade T1 tumors, especially with known risk factors for progression such as large tumors, associated CIS, lymphovascular invasion, variant histology, or deep lamina propria invasion. If a patient has persistent or recurrent disease after intravesical therapy, cystectomy is most effective if applied before the patient develops a muscle-invasive tumor. Delaying cystectomy until muscle invasive disease has developed results in inferior survival when compared to patients undergoing cystectomy for initial high-grade T2 disease.

Any patient with localized muscle-invasive disease should be considered for cystectomy, with or without systemic neoadjuvant chemotherapy. Patients who are not reasonable surgical candidates or who refuse surgery may be treated with external beam radiation therapy with concomitant systemic chemotherapy. Although radiation therapy is popular in many other parts of the world, it has been much less often used in the United States as primary local therapy for bladder cancer. The advantages of cystectomy over radiation therapy include the ability to obtain accurate pathologic staging, better local tumor control, and better long-term disease-free rates. Randomized trials comparing cystectomy to chemoradiation have not been performed, but nonrandomized comparisons suggest similar overall survival rates. Salvage cystectomy is feasible after failure of local radiation therapy, but it is technically challenging, has higher complication rates, and is generally less amenable to efforts for nerve-sparing and orthotopic neobladder reconstruction.

Many patients with aggressive bladder cancers are very elderly with significant comorbidities. These cancers will usually progress to metastasis and death within 2 years of diagnosis, causing significant misery from bleeding, pain, and obstruction from the local bladder tumor if the bladder is not removed. Therefore, an elderly patient who is believed to have at least a 2-year life expectancy and is likely to survive the surgery should be

considered for cystectomy regardless of his or her chronologic age.

Surgery alone achieves long-term cure in approximately 50% to 70% of patients with invasive bladder cancer. Pathologic stage is the strongest predictor for survival. A number of other factors have been shown to be prognostic indicators, including age and gender, the presence of lymphovascular invasion, and genetic markers in the tumor such as p53 tumor suppressor gene mutation. Cystectomy is rarely recommended in the treatment of low-grade disease unless there is extremely bulky disease and a concerted effort at endoscopic management has failed. Cancer-free patients will occasionally require cystectomy because of severe bladder dysfunction resulting from intravesical therapy or pelvic radiation therapy. Patients with metastatic urothelial cancer with an intact bladder occasionally require palliative cystectomy to manage severe bleeding, pain, or urinary obstruction.

There is strong evidence supporting the use of neoadjuvant cisplatin combination chemotherapy prior to cystectomy in patients who have muscle invasive disease and reasonable renal and cardiac function. Studies have shown a 5% overall survival advantage for patients receiving chemotherapy in addition to surgery compared to surgery alone. Probably similar advantage is obtained with postoperative adjuvant therapy, although this is much more difficult to deliver in patients who are recovering from surgery, and randomized studies in adjuvant therapy have been difficult to complete.

Therefore, a consultation with a medical oncologist to discuss neoadjuvant chemotherapy should be strongly considered for any patient with muscle-invasive disease prior to cystectomy. Patients with a palpable pelvic mass on bimanual exam, hydronephrosis, lymphovascular invasion, or apparent extravesical disease on CT scan should nearly always receive cisplatin-based neoadjuvant therapy (if they have adequate renal function) since they are unlikely to have organ-confined disease at surgery. In addition, patients with variant histologic patterns including the presence of neuroendocrine differentiation or micropapillary pattern should also be considered for initial chemotherapy given the high rates of upstaging at cystectomy. Patients who have not received preoperative chemotherapy and have extravesical or node-positive disease on final pathology may be considered for adjuvant chemotherapy, usually begun 6 to 8 weeks following surgery. Perioperative radiation is not routinely used, although the role for postoperative pelvic radiation in patients with high-risk

pathologic features is being evaluated in a cooperative group clinical trial.

CHOICE OF URINARY DIVERSION

There are three primary options for urinary diversion following cystectomy: ileal or colon conduit, orthotopic neobladder, or continent cutaneous diversion. Cutaneous ureterostomy has been advocated in some countries but has been traditionally associated with an unacceptably high rate of stenosis at the skin requiring indwelling catheters. Orthotopic urinary diversion is offered to nearly all patients undergoing cystectomy in our practice unless they have a specific contraindication (Table 175.3), regardless of age. The advantages and disadvantages of each form of diversion are discussed in an attempt to help the patient make a choice that fits his or her own priorities and lifestyle. Every form of diversion has an impact on the patient's quality of life and carries a risk of specific complications, and there is no strong evidence that the overall quality of life is better for patients with one diversion or another. Table 175.4 shows a simplified list of pros and cons of each diversion that is useful in helping patients make decisions about which to choose.

TABLE 175.3 Contraindications for Orthotopic Diversion

Absolute Contraindications:

Renal insufficiency (estimated creatinine clearance of <40)

Cancer invading the anterior vagina and/or proximal urethra in women

Cancer at the prostatic apex or proximal urethra in men

Incompetent external urethral sphincter or severe urethral stricture disease

Inadequate available bowel

Relative Contraindications:

Severe comorbidities requiring very short operative time

Cancer involving the prostatic urethra (especially with stromal invasion)

Significant stress incontinence in women

Locally extensive disease at surgery (stage T4)

Rectal injury at surgery

Prior prostate or bladder radiation

Continent diversion in the hands of an experienced surgical team does not increase hospital stay or early postoperative complications compared to ileal conduit. Orthotopic diversion has the specific advantage of allowing the most “natural” form of voiding without the need for an appliance. Over 80% of patients achieve daytime continence with time, and approximately half of them are consistently dry at night. In men, advanced age appears to delay the achievement of continence but does not otherwise affect outcome. Elderly women do appear to have a higher risk of permanent incontinence compared to younger women. Patients sometimes need to do self-catheterization (more often in women than in men), so any patient considering an orthotopic neobladder should be willing and able to perform this. Late complications such as stones and anastomotic strictures can generally be managed with endoscopic techniques.

Renal Function

One of the most important contraindications for continent neobladder reconstruction is compromised renal function. In patients with compromised renal function, hyperchloremic metabolic acidosis can develop along with worsening dehydration, uremia, nausea, and bone loss due to reabsorption of electrolytes and loss of bicarbonate. There is general consensus that an estimated creatinine clearance (eGFR) of >40 mL/min is recommended for patients considering continent diversion.

There is no evidence that orthotopic diversion leads to progressive renal dysfunction in patients with normal renal function prior to surgery.

Risk of Urethral Recurrence

In men who have undergone cystectomy and orthotopic diversion, the presence of prostatic urethral involvement with urothelial carcinoma increases the risk of late urethral recurrence. In our series of almost 800 male patients, the risk of urethral recurrence at 5 years was 5% for patients without any prostatic involvement compared to 11% with any involvement. The risk went up to 18% for patients with invasion of tumor into the prostatic stroma (stage pT4a). Thus, in a patient with prostatic urethral involvement documented preoperatively, the decision whether or not to perform an orthotopic diversion must be made with this risk in mind. Preoperative biopsy of a normal appearing prostatic urethra is not mandatory as we routinely perform a frozen section of the apical urethral margin at surgery to determine eligibility for orthotopic reconstruction.

TABLE 175.4 Pros and Cons of Each Type of Diversion for Shared Decision-Making

Diversion Type	Advantages	Disadvantages
Ileal conduit	Simple, quick, familiar to all surgeons	Problems with appliance Peristomal hernia Skin problems
Orthotopic neobladder	Allows normal voiding Relatively simple, quick	Incontinence Retention Need to void at night to stay dry
Continent cutaneous diversion	No initial incontinence Usually can sleep through the night	Most difficult to construct Difficulty catheterizing Leakage from stoma
Common to all diversions	Preserve renal function	Risk of infection Stones in kidney or pouch Ureteroileal stricture Metabolic derangements

For women, the risk of urethral involvement is primarily driven by tumor location. Tumors located at the bladder neck or associated with palpable invasion into the anterior vaginal wall are associated with a high risk of urethral involvement. In all cases, we depend on the negative frozen section of the proximal urethral margin at the time of surgery to make a decision to proceed with orthotopic diversion.

Locally Advanced Disease

Many urologists are hesitant to perform continent orthotopic diversion in patients with locally extensive disease. This is based on two factors: (a) concern about the possible impact of local recurrence on the neobladder itself, and (b) a belief that these patients are doomed to suffer distant recurrence and have a shortened life expectancy and will not benefit from the neobladder. However, in our series of over 2,000 patients undergoing cystectomy, <7% of patients suffered a local recurrence with a median follow-up of over 10 years. Patients who do develop a pelvic recurrence rarely have problems with direct tumor invasion into the reservoir causing symptoms. Thus, this form of diversion appears to be an option even with locally extensive disease, especially if one can achieve a grossly negative margin.

Effect of Prior Radiation Therapy

It is not uncommon for patients with invasive bladder cancer to have a history of prior radiation therapy for other pelvic malignancies. We reported on 184 patients who underwent cystectomy following prior

radiation from 1983 to 2008, 48 of whom underwent neobladder reconstruction and 35 a continent cutaneous diversion. Early complications were more common than in nonirradiated patients, and increased by age. Requirement for artificial sphincter and urethral strictures were also both more common in irradiated patients undergoing neobladder reconstruction. Others have reported similar results with small series of patients. These are highly selected patients, and intraoperative assessment is crucial to determine the health of the urethral tissue and the advisability of performing an orthotopic diversion. High-dose prostate irradiation seems to be particularly damaging to the external sphincter compared to other types of radiation.

PREOPERATIVE PLANNING

Patients undergoing cystectomy often have significant comorbidities, especially heart and lung dysfunction related to smoking. Preoperative optimization is crucial in making this a safe operation. Most patients are evaluated by a cardiologist, usually with provocative cardiac testing (stress tests) and pulmonary function testing when indicated to assist in perioperative management.

Education for the patient and family is a key component of preoperative preparation. We are fortunate to have a dedicated enterostomal therapist on our team who meets with each patient preoperatively to go over expectations for the perioperative period. He or she also marks the patient for a possible ileal conduit diversion in case that should become necessary during the surgery. We also have a set of written instructions that patients receive, which describes the usual perioperative course, management of catheters and drains, Kegel exercise techniques, and techniques for self-catheterization.

Enhanced recovery after surgery (ERAS) techniques have been applied to cystectomy patients in recent years to shorten hospital stay and minimize gastrointestinal complications that have been a common problem with this surgery. Six double-blind randomized controlled trials in colorectal surgery and cystectomy patients have shown that a mechanical or antibiotic bowel prep is not necessary and may be detrimental. In addition to avoiding the bowel prep, minimizing fasting periods before surgery and addition of a liquid bolus with high carbohydrate fluid 2 hours before surgery have decreased preoperative dehydration. These techniques along with postoperative management (described below) have resulted in a

significant decrease in gastrointestinal complications and shorter hospital stay.

Minimally Invasive Surgical Approaches to Cystectomy and Ileal Neobladder

In recent years, laparoscopic and robot-assisted laparoscopic techniques have been applied to radical cystectomy, with somewhat mixed results. Completing a thorough extended pelvic lymphadenectomy using these techniques is challenging and can be very time-consuming. Nearly all surgeons doing laparoscopic or robotic cystectomies now perform an extracorporeal ileal conduit or neobladder through a small suprapubic incision to facilitate the bowel work.

Most reports of minimally invasive cystectomies show a decreased blood loss compared to open series, and a few have shown shorter hospital stay. A recent randomized trial showed lower blood loss but significantly longer surgery for robotic approach, with no difference in hospital stay, complications, or recovery. Another group of experienced robotic surgeons who were trained and committed to performing an extended lymphadenectomy found very similar complication rates and hospital stay to our open series. Techniques for intracorporal construction of the diversion have been developed and are being applied but have been limited to a few very experienced surgeons. Thus, the advantage of the extended operative time and increased cost associated with use of the robot is still unclear.

RADICAL CYSTECTOMY AND EXTENDED LYMPHADENECTOMY: SURGICAL TECHNIQUE IN THE MALE AND FEMALE PATIENTS

Patient Positioning

The patient is placed in the supine position with table extended at the patient's waist to open the pelvis (Fig. 175.1). In the female patient, the modified frog leg or lithotomy position is used to allow access to the vagina. All pressure points are well padded. Slight reverse Trendelenburg position levels the abdomen parallel with the floor and helps to keep the small-bowel contents in the epigastrium. In the female patient, the vagina is fully prepped along with the abdomen, and in both genders the Foley catheter is placed after draping to afford surgeon access to it during the

case.

Incision

A vertical midline incision is made extending from the pubic symphysis to the umbilicus or slightly above in an obese patient. After opening into the peritoneum, the urachal remnant (median umbilical ligament) is divided just below the umbilicus, and kept attached to the bladder (Fig. 175.2). This maneuver prevents early entry into a high-riding bladder and ensures complete removal of all bladder tissue. The rectus fascia should be opened all the way down to the pubic bone to afford optimal view of the deep pelvis.

Abdominal Exploration

A careful systematic intra-abdominal exploration is performed to determine the extent of disease and to evaluate for any hepatic metastases or gross retroperitoneal lymphadenopathy. The abdominal viscera are palpated to detect any concomitant unrelated disease. Adhesions should be incised and freed if present.

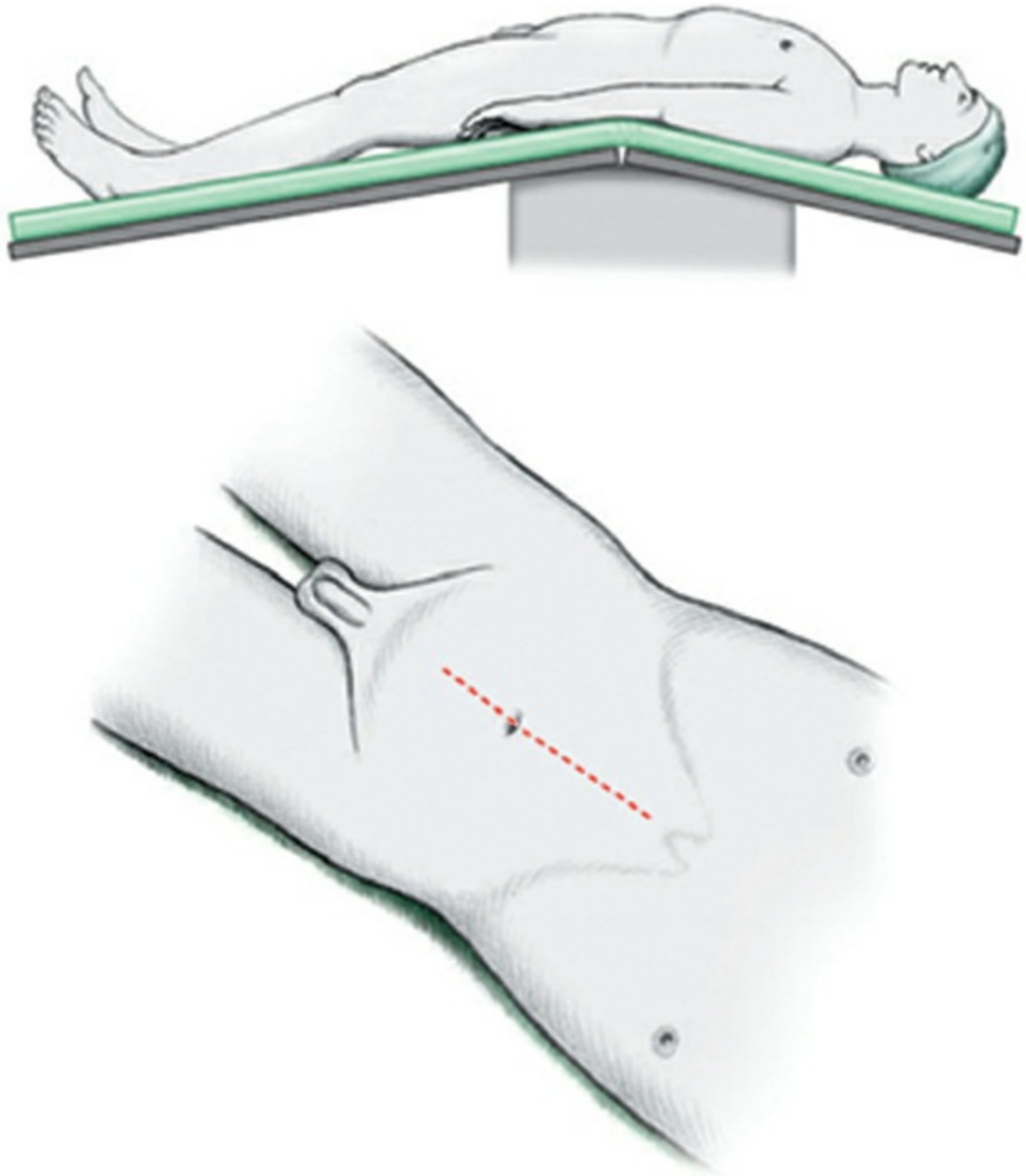

Figure 175.1. Proper patient positioning for cystectomy. Note that the iliac crest is located at the break of the table. Incision usually does not need to extend above the umbilicus except in very obese patients. (From Stein JP, Skinner DG. Surgical atlas-radical cystectomy. *Br J Urol Int* 2004;94:197. Copyright © 2004 by John Wiley & Sons, Inc. Reprinted by permission of John Wiley & Sons, Inc.)

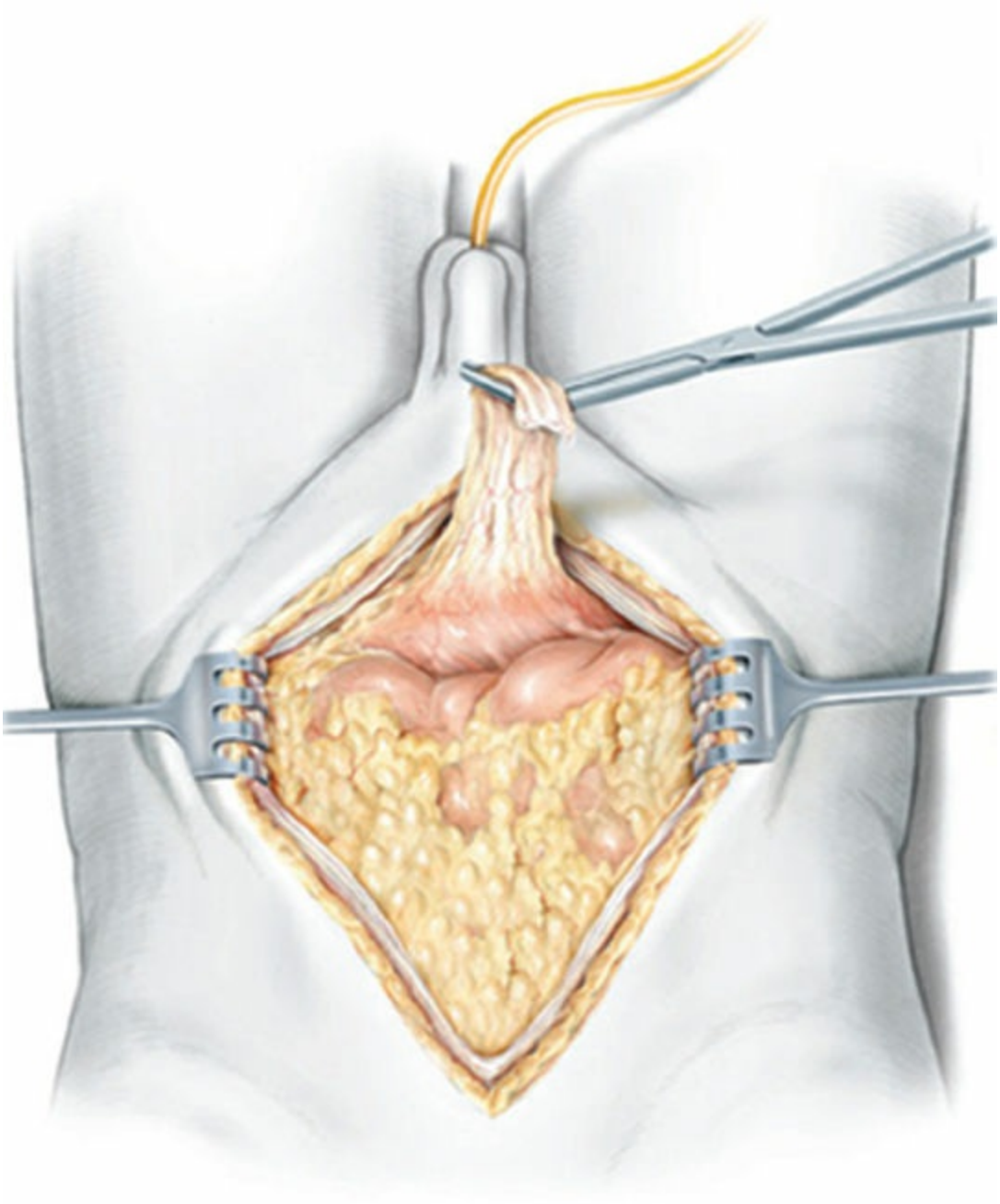

Figure 175.2. Wide excision of the urachal remnant en bloc with the cystectomy specimen. (From Stein JP, Skinner DG. Surgical atlas-radical cystectomy. *Br J Urol Int* 2004;94:197. Copyright © 2004 by John Wiley & Sons, Inc. Reprinted by permission of John Wiley & Sons, Inc.)

Bowel Mobilization

The bowels are mobilized starting with the right (ascending) colon. The posterior peritoneum may be opened along the white line of Toldt lateral to the cecum to facilitate packing. That is carried around the ileocecal area and then across toward the aorta. The cecum and small bowel mesentery

are elevated off of Gerota's fascia to allow access to the proximal portion of the node dissection (Fig. 175.3).

The peritoneum lateral to the sigmoid colon is then incised. The spermatic cord is swept off the side of the colon mesentery and the left ureter identified crossing the common iliac artery. A window is made in the mesentery of the sigmoid colon over the left common iliac vein and is opened up to the level of the inferior mesenteric artery and down behind the rectum. This provides access to the presacral nodes and is later used to bring the left ureter to the right side of the pelvis (Fig. 175.4). Care should be taken to dissect along the base of the mesentery and avoid injury to the inferior mesenteric artery and blood supply to the sigmoid colon.

A self-retaining retractor is placed, and the right colon and small bowel are carefully packed into the epigastrium under moist lap pads. The descending and sigmoid colon are not packed and are left free. The lap pads are used as sheets tucked below and above the bowel contents to keep them out of the pelvis. A wide retractor is placed with gentle traction cephalad. Another retractor is used to keep the sigmoid to the left side, and body wall retractors are used laterally. We use an Omnitrac self-retaining retractor system that gives maximum flexibility without impeding manual access into the pelvis.

Ureteral Dissection

The ureters are most easily identified in the retroperitoneum over the common iliac vessels. They are dissected into the deep pelvis (several centimeters beyond the iliac vessels) and divided between two large hemoclips. A section of the proximal cut ureteral segment (distal to the proximal hemoclip) is then sent for frozen section analysis to ensure the absence of CIS or overt tumor. The ureter is then mobilized cephalad and tucked under Gerota's fascia to prevent inadvertent injury. Alternatively the ureters may be left intact until the node dissection is complete. Leaving the proximal hemoclip on the divided ureter during the exenteration allows for hydrostatic ureteral dilation and facilitates the ureteroenteric anastomosis. In females, the infundibulopelvic ligament is ligated and divided after identification of the ureters.

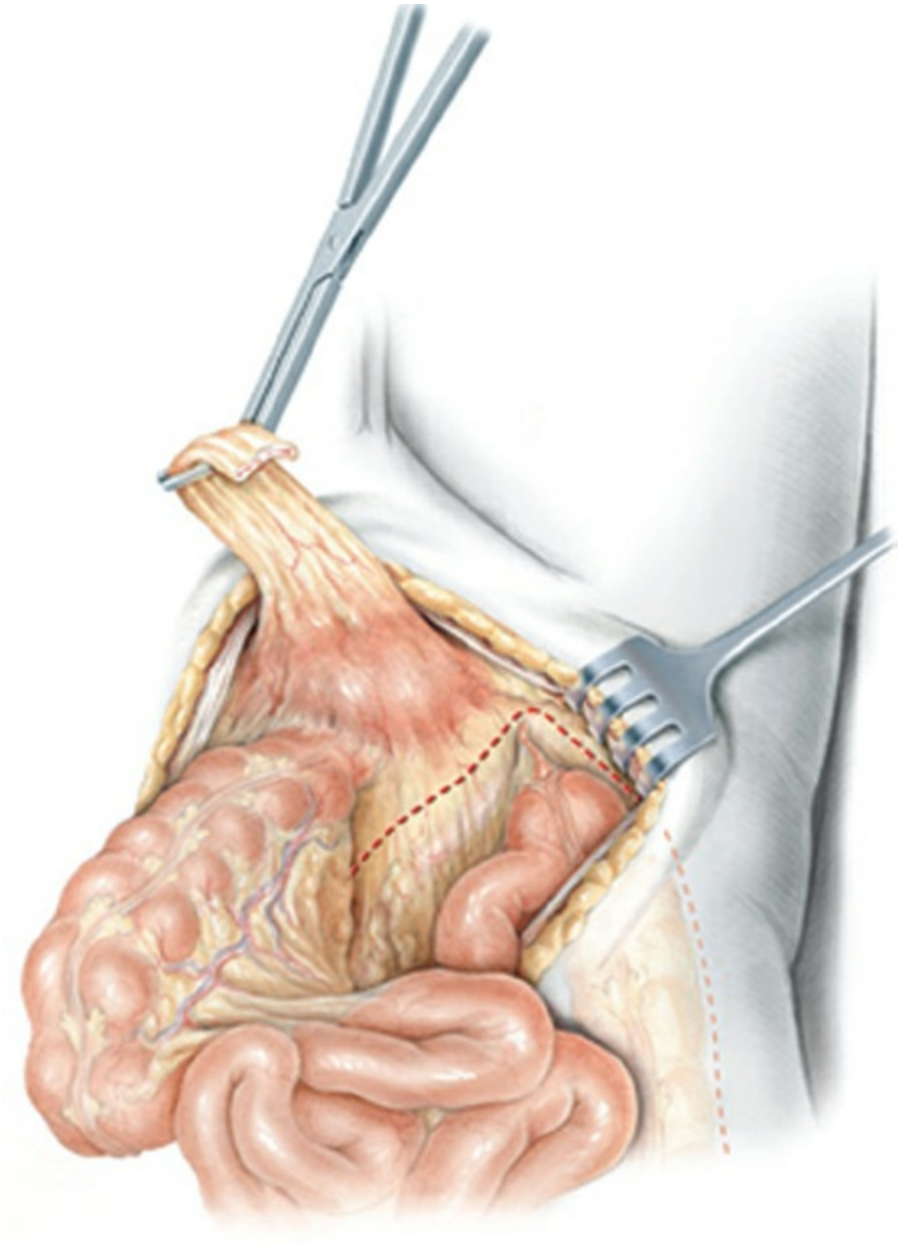

Figure 175.3. View of the pelvis from overhead. Note that the ascending colon and peritoneal attachments of the small-bowel mesentery (*dotted line*) are mobilized up to the level of the duodenum. This lateral mobilization is optional but can allow the bowel to be packed in the epigastrium. The medial dissection exposes the retroperitoneum over the distal aorta and vena cava. (From Stein JP, Skinner DG. Surgical atlas-radical cystectomy. *Br J Urol Int* 2004;94:197. Copyright © 2004 by John Wiley & Sons, Inc. Reprinted by permission of John Wiley & Sons, Inc.)

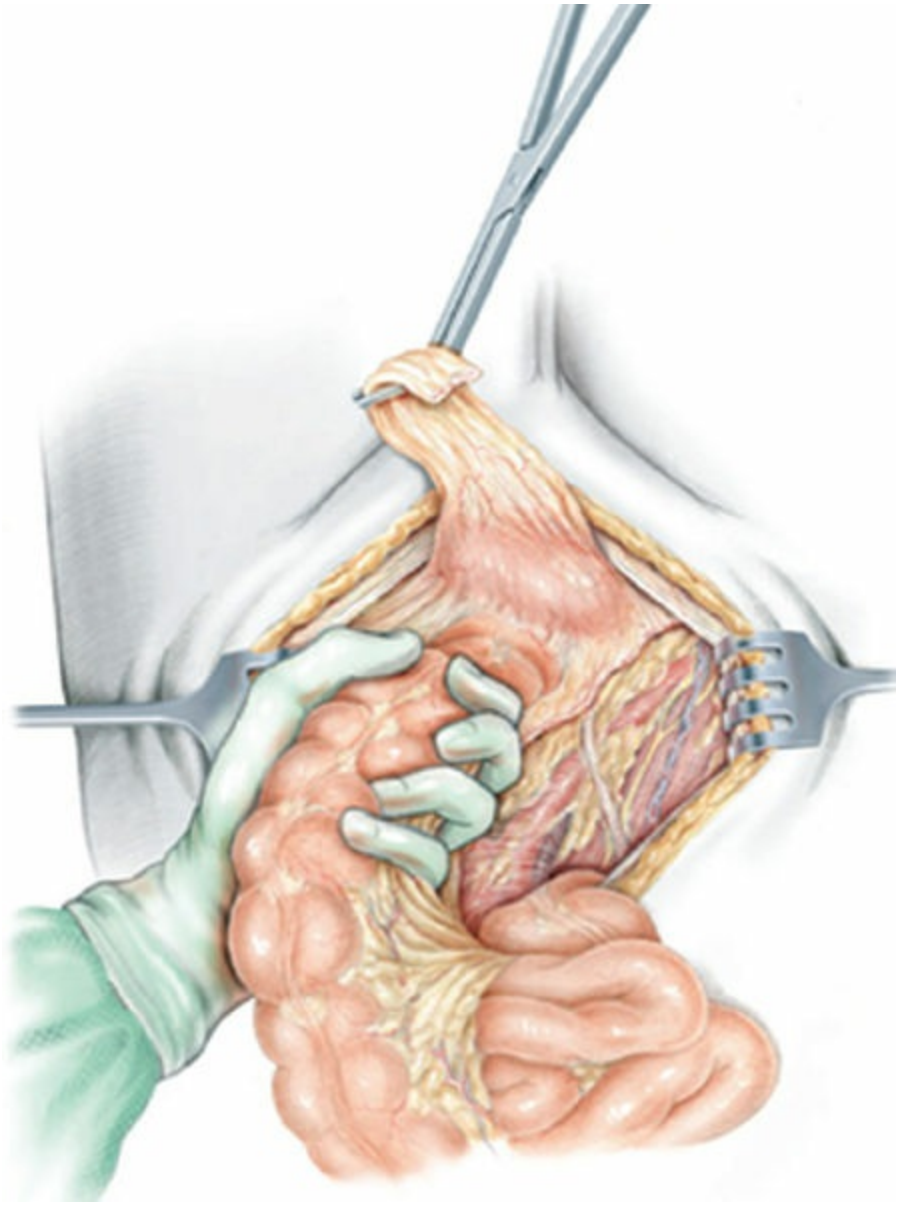

Figure 175.4. View of the pelvis from overhead. The sigmoid mesentery is mobilized off the sacral promontory, common iliac vessels, and distal aorta up to the origin of the inferior mesenteric artery. (From Stein JP, Skinner DG. Surgical atlas-radical cystectomy. *Br J Urol Int* 2004;94:197. Copyright © 2004 by John Wiley & Sons, Inc. Reprinted by permission of John Wiley & Sons, Inc.)

Distal Retroperitoneal and Pelvic Lymphadenectomy

The lymph node dissection is initiated at the inferior mesenteric artery (superior limits of dissection) and extends laterally over the inferior vena cava and aorta to the genitofemoral nerve bilaterally, representing the lateral limits of dissection. Clips are applied distally and proximally to

decrease lymph leak. Distally, the lymph node dissection extends to the lymph node of Cloquet medially (just medial to the external iliac vein on Cooper's ligament) and the circumflex iliac vein crossing the eternal iliac artery. Frequently, small anterior tributary veins originate from the vena cava just above the bifurcation, which should be clipped and divided. We routinely remove the nodes in individual packets identified by location.

All fibroareolar and lymphatic tissues are dissected off the distal aorta and vena cava, and the common iliac vessels are skeletonized. There is often a lateral psoas branch arising from the distal common iliac artery and vein that must be ligated (Fig. 175.5). After cleaning off the left common iliac vein below the aortic bifurcation, the dissection continues over the sacral promontory into the deep pelvis. Care is taken to control small arterial and venous branches coursing along the anterior surface of the sacrum. The tissue is cleaned off the sacral promontory down into the sacral fossa.

Once the proximal portion of the lymph node dissection is completed, the peritoneum is divided lateral to the bladder, dividing the vas deferens (or round ligament in a female). The tissue surrounding the external iliac vessels medial to the genitofemoral nerve is all dissected off, leaving the vessels free of any fat. The genitofemoral nerve is occasionally injured or intentionally taken if involved with adenopathy—the only consequence is some numbness on the anterior thigh. The lymph node of Cloquet is dissected out of the corner medial to the external iliac vein on Cooper's ligament, and the distal lymphatics clipped. An accessory obturator vein or artery is ligated (present in up to 40% of patients). The dissection continues up to the takeoff of the internal iliac artery.

At this point, a finger is passed lateral to the external iliac vein to free it from the sidewall, and a small gauze sponge may be passed lateral to the vessels along the psoas and pelvic sidewall to clean all the tissue off the sidewall of the obturator fossa (Fig. 175.6). This sponge is passed from along the common iliac bifurcation down caudally and posteriorly. Vein retractor is then placed on the medial side of the external iliac vein and the gauze retrieved inferiorly (Fig. 175.7). This maneuver facilitates identification of the obturator nerve deep to the external iliac vein. The obturator nerve is carefully dissected free from all lymphatics (Fig. 175.8). The obturator lymph node packet is then swept medially toward the sidewall of the bladder, ligating small tributary vessels and lymphatics from the pelvic sidewall, and removed.

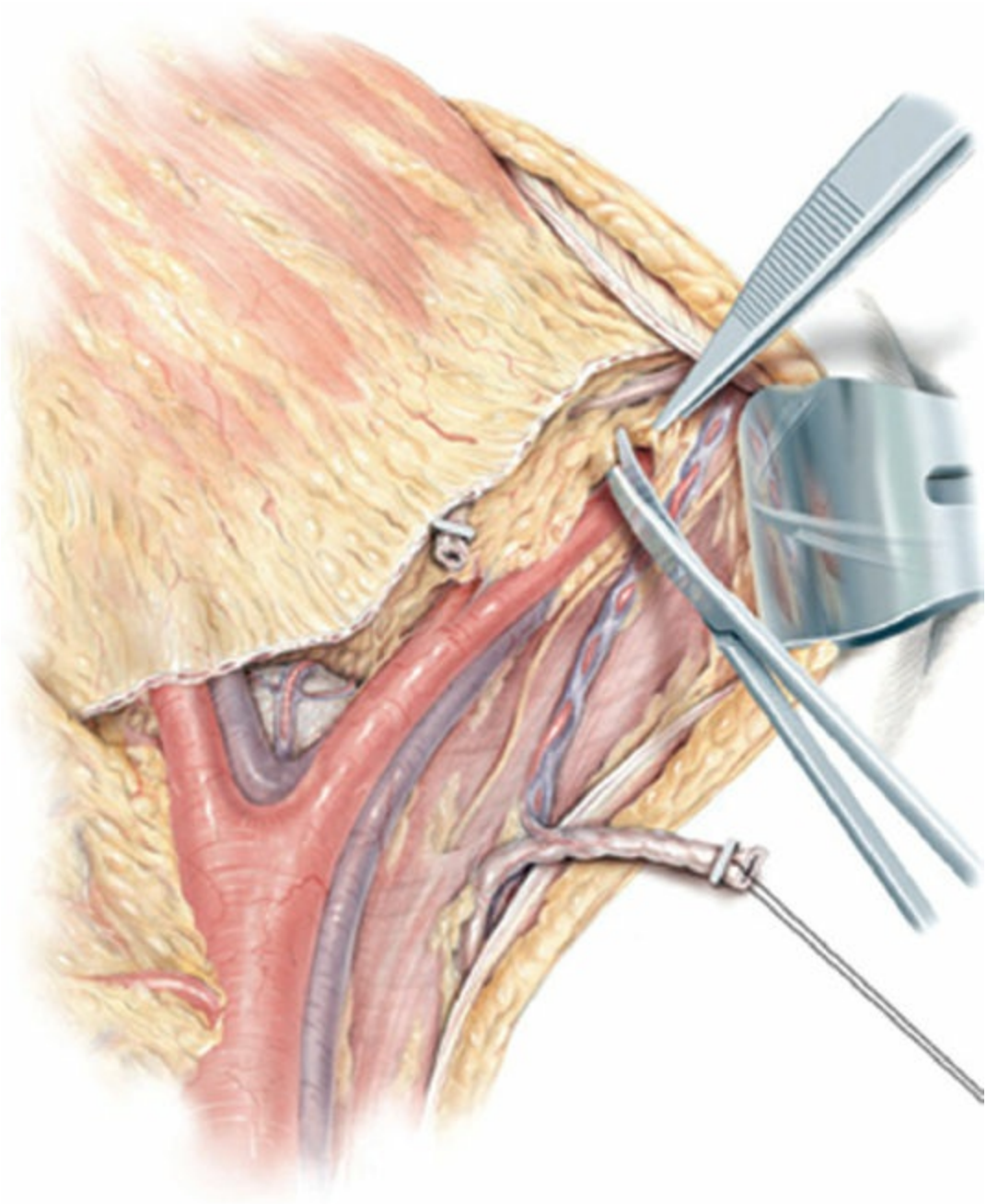

Figure 175.5. Technique of skeletonizing the external iliac artery and vein. (From Stein JP, Skinner DG. Surgical atlas-radical cystectomy. *Br J Urol Int* 2004;94:197. Copyright © 2004 by John Wiley & Sons, Inc. Reprinted by permission of John Wiley & Sons, Inc.)

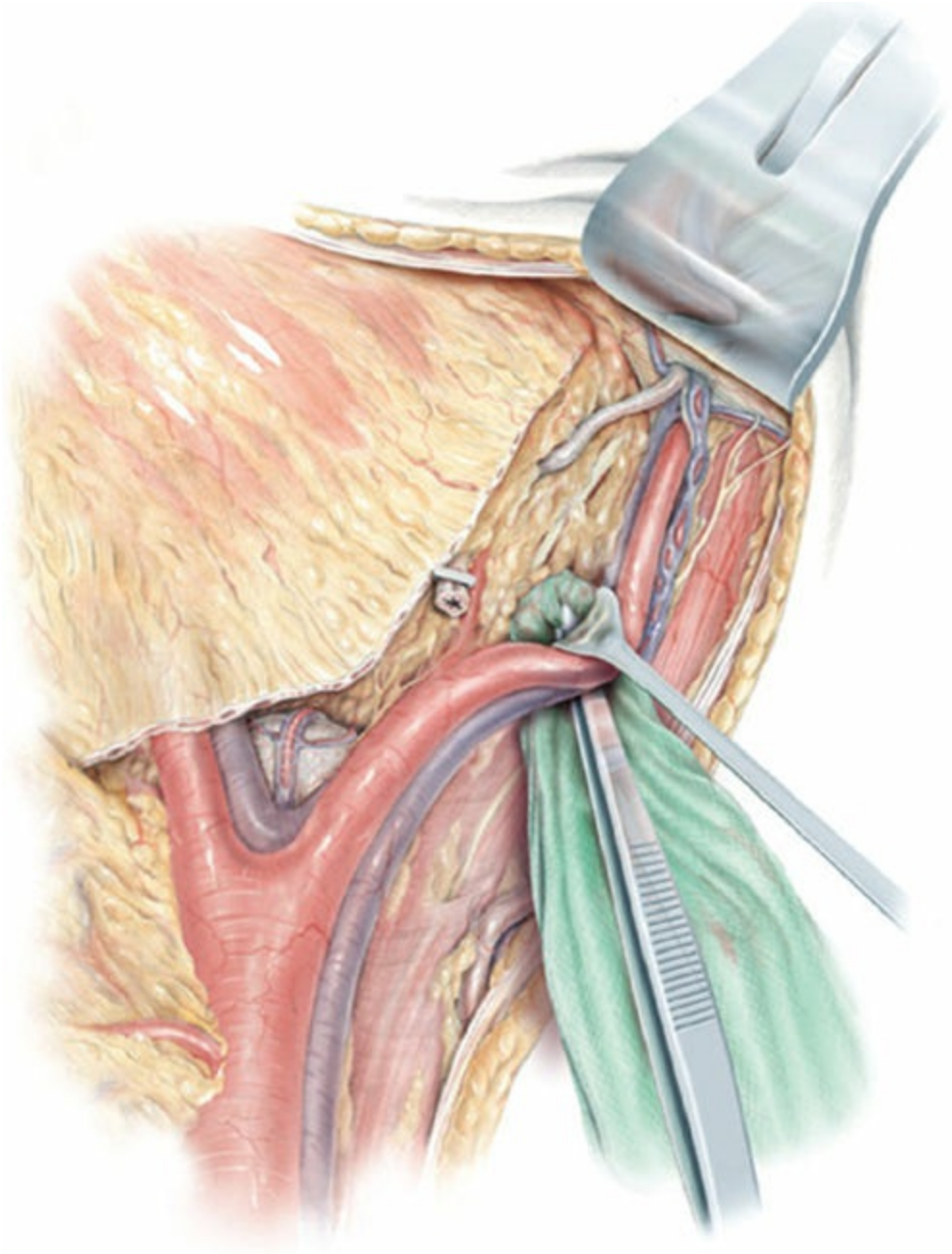

Figure 175.6. Technique of passing a small gauze sponge lateral to the external iliac vessels and medial to the psoas muscle. (From Stein JP, Skinner DG. Surgical atlas-radical cystectomy. *Br J Urol Int* 2004;94:197. Copyright © 2004 by John Wiley & Sons, Inc. Reprinted by permission of John Wiley & Sons, Inc.)

Ligation of the Lateral Vascular Pedicle to the Bladder

Following dissection of the obturator fossa, the lateral vascular pedicle to the bladder is isolated and divided. The ureters may be divided at this point if not done previously, and the proximal ends tucked away. Fingers on the left hand are passed medial and lateral to the internal iliac artery to isolate

the pedicle. The pedicle can be ligated with a tissue sealant device, hemoclips, or suture ties (Fig. 175.9). The superior vesical artery is individually ligated and divided relatively easily. The remaining anterior branches of the lateral pedicle are then isolated and divided. Care is taken to stay anterior to the internal iliac vein, which is just deep to the pedicle.

Male Dissection

Following division of the lateral pedicles, the bladder specimen is retracted anteriorly and the sigmoid retracted superiorly exposing the cul-de-sac (pouch of Douglas). The peritoneum is incised from lateral to the rectum behind the ureteral stump across the cul-de-sac to the contralateral side (Fig. 175.10). The peritoneal incision should be made just to the rectal side of the reflection. This allows dissection posterior to Denonvillier's fascia, which arises as a fusion fascia of anterior and posterior peritoneal reflections, extending caudally to the urogenital diaphragm (Fig. 175.11). This important anatomic boundary in the male separates the prostate and seminal vesicles from the rectum. The plane between the rectum and the posterior sheath of Denonvillier's (Denonvillier space) can usually be developed using primarily blunt dissection down to the apex of the prostate.

Once the plane behind the prostate has been developed, the rectum is swept off laterally to free it from the vessels coursing around the rectum toward the bladder (posterior pedicle). This is best done by sweeping laterally with pressure against the prostate, taking care not to perforate the rectal wall (Fig. 175.12). Incision of the endopelvic fascia on either side of the prostatic apex can facilitate the apical dissection, taking care to avoid injury to the dorsal venous complex anteriorly or the area of the urethral sphincter medially. Once the pedicle is clearly separated from the rectal wall, it may be divided with clips or a tissue sealant device.

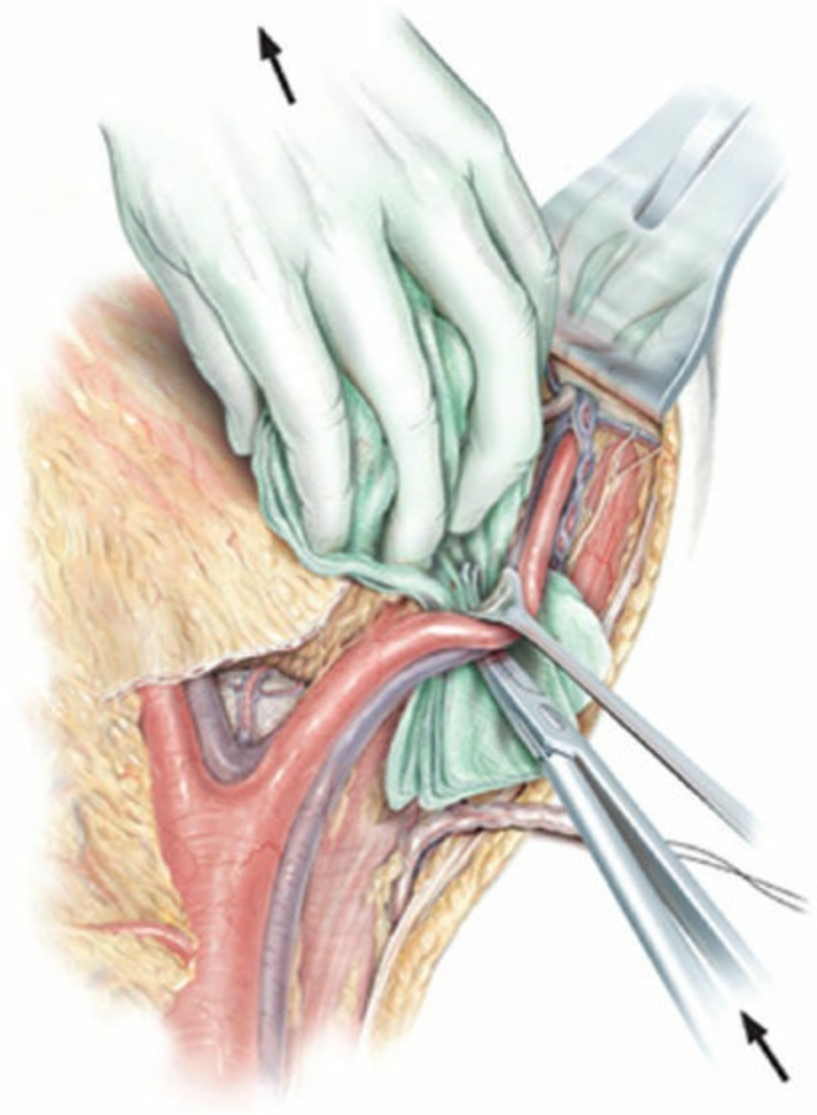

Figure 175.7. Technique of withdrawing the gauze sponge with the left hand. This will clean off the sidewall of the obturator fossa, sweeping all fibroareolar and lymphatic tissue toward the bladder and exposing the obturator nerve. (From Stein JP, Skinner DG. Surgical atlas-radical cystectomy. *Br J Urol Int* 2004;94:197. Copyright © 2004 by John Wiley & Sons, Inc. Reprinted by permission of John Wiley & Sons, Inc.)

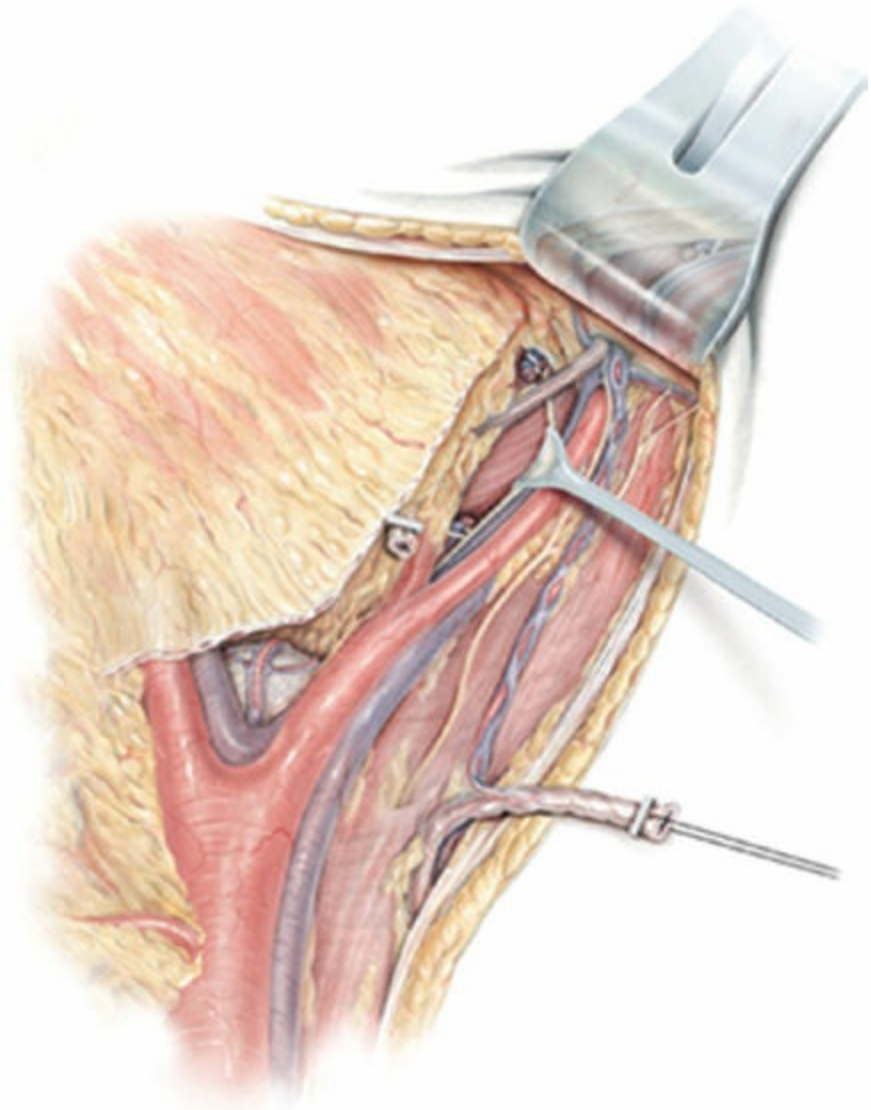

Figure 175.8. The obturator nerve passes deep to the external iliac vein. Here the nerve is retracted with the external iliac vessels. (From Stein JP, Skinner DG. Surgical atlas-radical cystectomy. *Br J Urol Int* 2004;94:197. Copyright © 2004 by John Wiley & Sons, Inc. Reprinted by permission of John Wiley & Sons, Inc.)

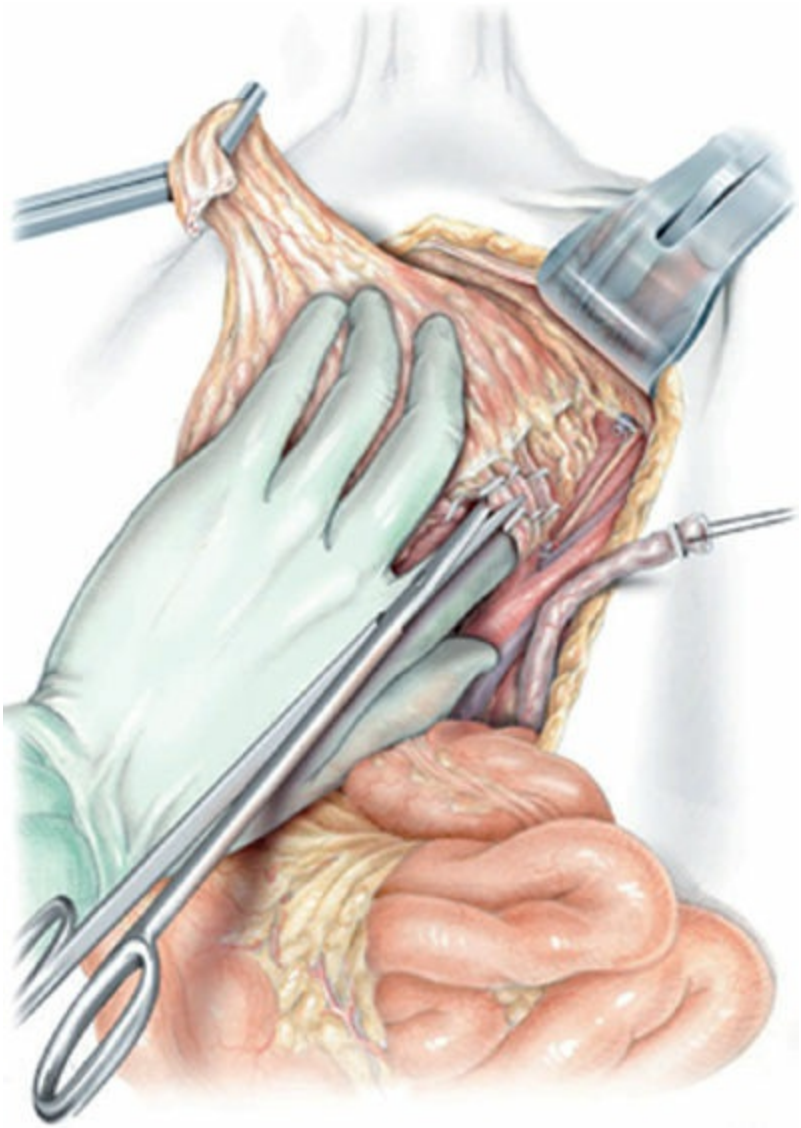

Figure 175.9. The left hand is used to define the right lateral pedicle, extending from the bladder to the hypogastric artery. This vascular pedicle is divided down to the endopelvic fascia. Firm traction with the left hand helps define the vascular pedicle, allows direct visualization, and protects the rectum from injury. (From Stein JP, Skinner DG. Surgical atlas-radical cystectomy. *Br J Urol Int* 2004;94:197. Copyright © 2004 by John Wiley & Sons, Inc. Reprinted by permission of John Wiley & Sons, Inc.)

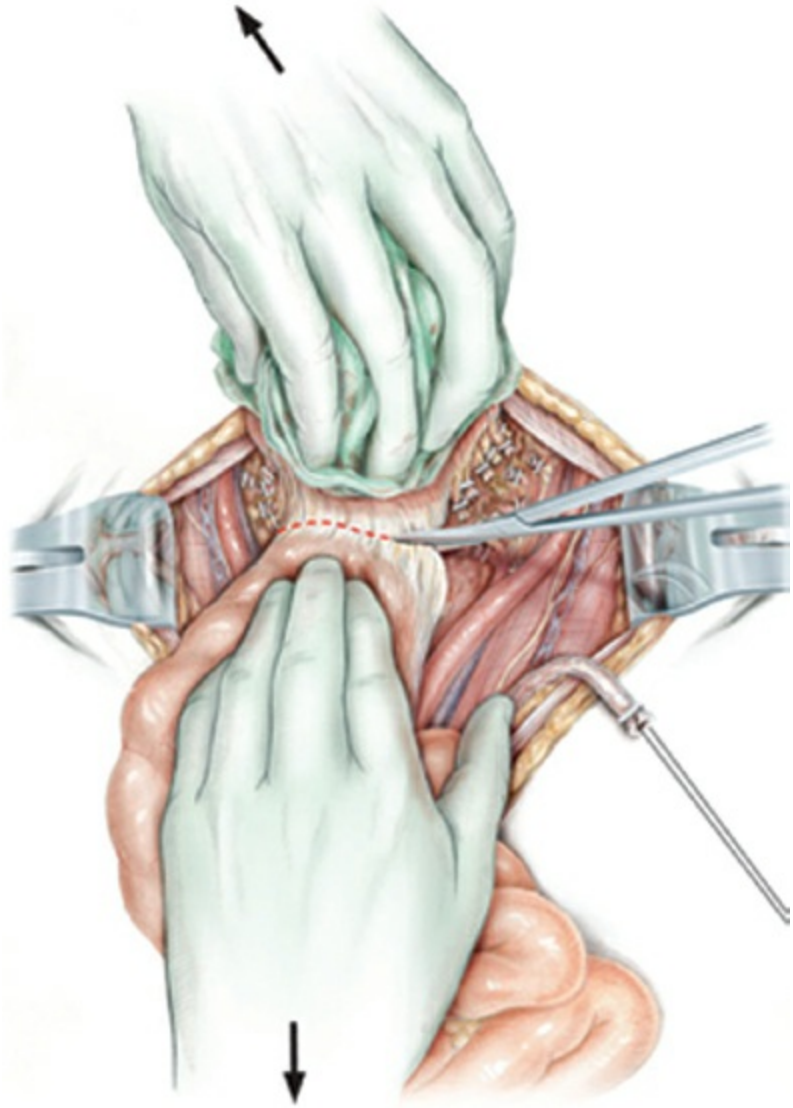

Figure 175.10. The peritoneum is incised across the rectum into the cul-de-sac and carried anteriorly over the rectum to join the opposite side. The incision is made slightly to the rectal side in the center so the plane behind Denonvillier's fascia can be developed safely. (From Stein JP, Skinner DG. Surgical atlas-radical cystectomy. *Br J Urol Int* 2004;94:197. Copyright © 2004 by John Wiley & Sons, Inc. Reprinted by permission of John Wiley & Sons, Inc.)

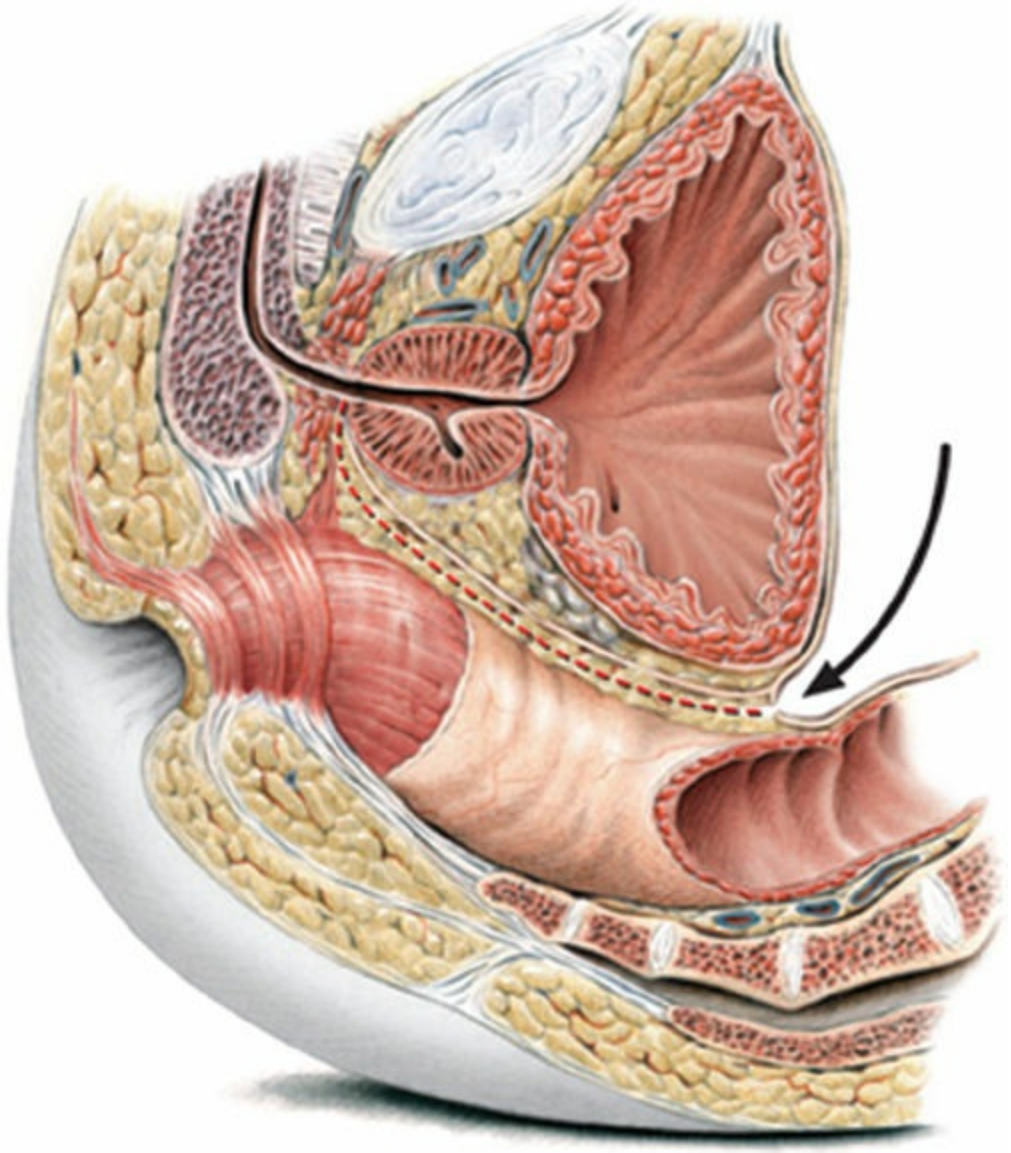

Figure 175.11. The formation of Denonvillier's fascia, derived from a fusion of the anterior and posterior peritoneal reflections. Denonvillier's space lies behind the fascia. (From Stein JP, Skinner DG. Surgical atlas-radical cystectomy. *Br J Urol Int* 2004;94:197. Copyright © 2004 by John Wiley & Sons, Inc. Reprinted by permission of John Wiley & Sons, Inc.)

If the dissection in Denonvillier's space is not easily performed bluntly, it should be taken down with careful sharp dissection under direct vision. This is often required near the prostate apex. In patients with prior high-dose pelvic radiation, sharp dissection is nearly always required. If a rectotomy occurs, a two- or three-layer closure is recommended after removing the specimen. A diverting proximal colostomy is not routinely required unless gross contamination occurs, or if the patient has received previous pelvic radiation therapy. If orthotopic diversion or vaginal

reconstruction is planned, an omental interposition is recommended to prevent fistula.

If a nerve sparing approach is to be used, the neurovascular bundle must be dropped off the side of the prostate before dividing the posterior pedicles. Then care must be taken not to extend the division of this pedicle too far posteriorly. This dissection may be carried out from apex to base of the prostate as in the classic Walsh approach to radical prostatectomy, ultimately connecting up to meet the dissection from above.

Once the cystectomy specimen is completely freed and mobile posteriorly, attention is then directed anteriorly to the urethra. The fat around the anterior prostate apex is teased off and the superficial dorsal vein is identified, ligated, and divided. The incision in the endopelvic fascia is completed and the levator muscle fibers are carefully swept off the lateral and apical portions of the prostate with gentle dissection to preserve the tissue around the urethral sphincter. The puboprostatic ligaments are identified and divided just beneath the pubis. Care should be taken to avoid any extensive dissection in this region. The puboprostatic ligaments need only to be incised enough to allow for a proper apical dissection of the prostate.

There are a number of ways to ligate the dorsal complex. We avoid staples and clips that can work their way into the urethral anastomosis. A suture may be passed on a needle or passer, and the distal DVC is ligated and divided just outside the apex of the prostate. If any bleeding occurs from the transected venous complex, it is oversewn superficially with an absorbable (2-0 polyglycolic acid) suture (Fig. 175.13). Deep suture bites should be avoided because of potential damage to rhabdosphincter.

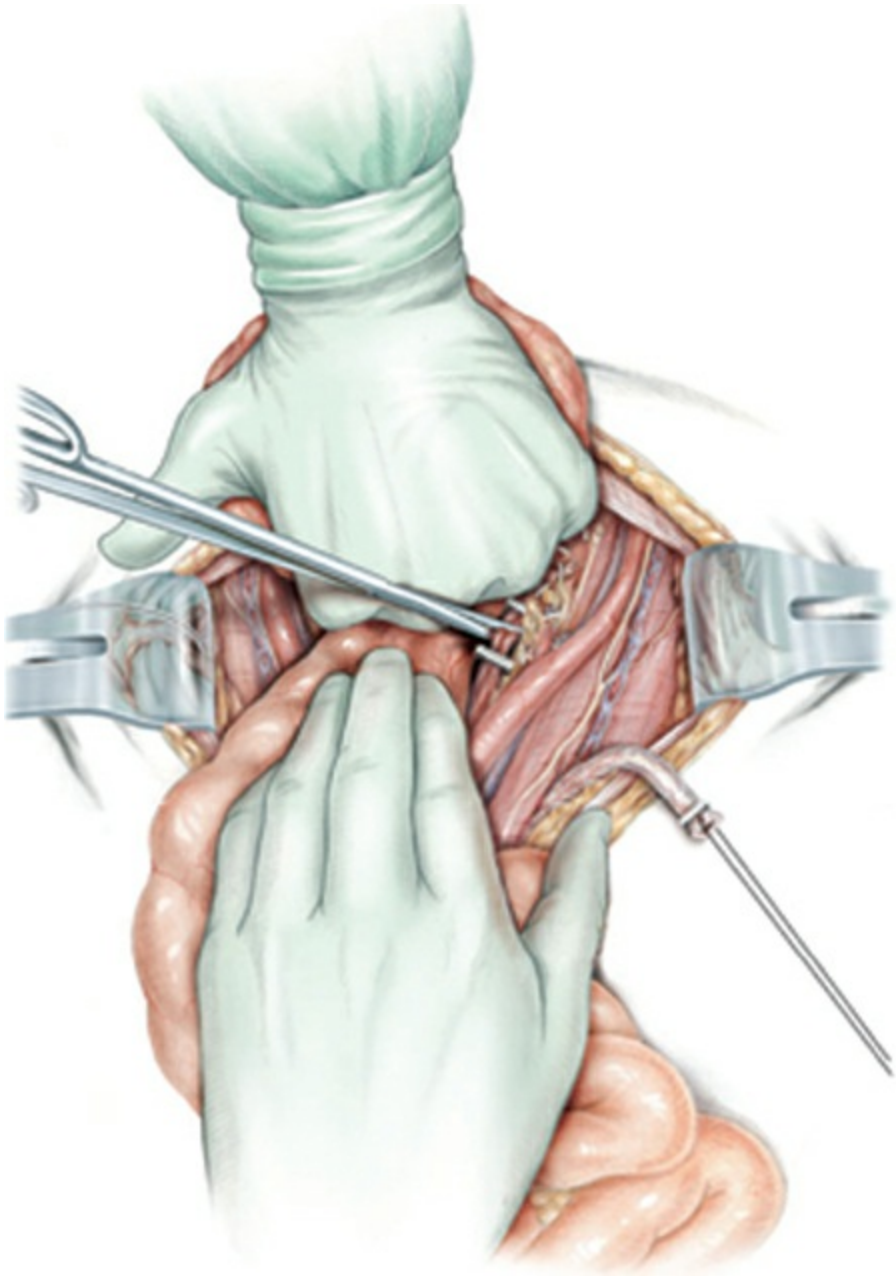

Figure 175.12. After the peritoneum of the cul-de-sac has been incised, the anterior rectal wall can be swept off the posterior surface of the Denonvillier's fascia. This effectively defines the posterior pedicle that extends from the bladder to the lateral aspect of the rectum on either side. (From Stein JP, Skinner DG. Surgical atlas-radical cystectomy. *Br J Urol Int* 2004;94:197. Copyright © 2004 by John Wiley & Sons, Inc. Reprinted by permission of John Wiley & Sons, Inc.)

After the complex has been ligated and divided, the anterior urethra is exposed. The urethra is then incised 270 degrees just beyond the apex of the prostate. Six 2-0 polyglycolic acid sutures are placed in the anterior

urethra, carefully incorporating only the mucosa and submucosa of the striated urethral sphincter muscle anteriorly. Following this, two posterior urethral sutures are placed, incorporating the rectourethralis muscle or the caudal extent of Denonvillier's fascia. The posterior urethra can then be divided and the specimen removed after dividing the Foley catheter between clamps in order to prevent spillage of any bladder contents. Frozen section analysis of the distal urethral margin of the cystectomy specimen is then performed in order to exclude tumor involvement.

Female Dissection

In the female patient when a hysterectomy is planned, the apex of the vagina (posterior fornix) identified and opened behind the cervix. The vagina is then circumscribed anteriorly with the cervix attached to the cystectomy specimen (Fig. 175.14). We prefer to spare the anterior vaginal wall if orthotopic diversion is planned and an adequate margin can be maintained. This decreases the risk of pouch-vaginal fistula and may be important in maintaining the neurovascular bundle that runs along the lateral vaginal wall, which may contribute to continence, sexual function, and efficient emptying.

The plane between the bladder and vagina is carefully developed using sharp dissection right on the anterior vaginal wall. Bleeding is controlled with cautery. The dissection is continued down to the bladder neck, identified by the Foley catheter balloon (Fig. 175.15). The posterior pedicle is mobilized by dissecting along the anterolateral vaginal wall and dividing the pedicle alongside the vagina with the tissue sealing device. There is a complex of veins around the urethra and bladder neck that can cause significant bleeding.

If there is concern about an adequate surgical margin at the posterior or base of the bladder, then a strip of the anterior vaginal wall should be removed en bloc with the bladder specimen. Although neobladder may be considered in this situation, the risk of vesicovaginal fistula is increased. An omental flap is critical in this case after water tight closure of the vagina.

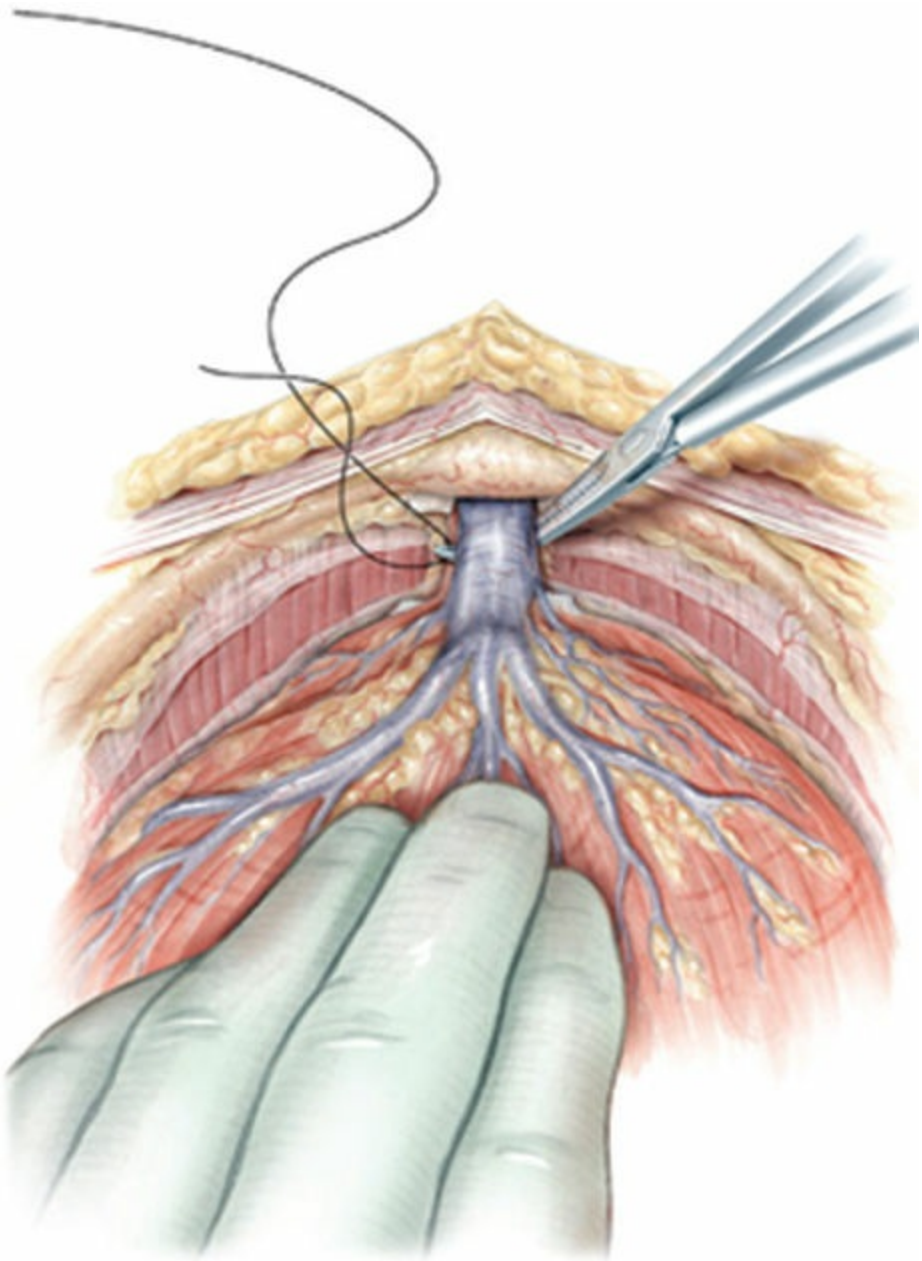

Figure 175.13. Controlling the dorsal venous plexus. One may pass an angled clamp beneath the dorsal vein complex anterior to the urethra to pass a free suture, or alternatively pass a suture on a large needle in the same plane, to ligate venous complex. (From Stein JP, Skinner DG. Surgical atlas-radical cystectomy. *Br J Urol Int* 2004;94:197. Copyright © 2004 by John Wiley & Sons, Inc. Reprinted by permission of John Wiley & Sons, Inc.)

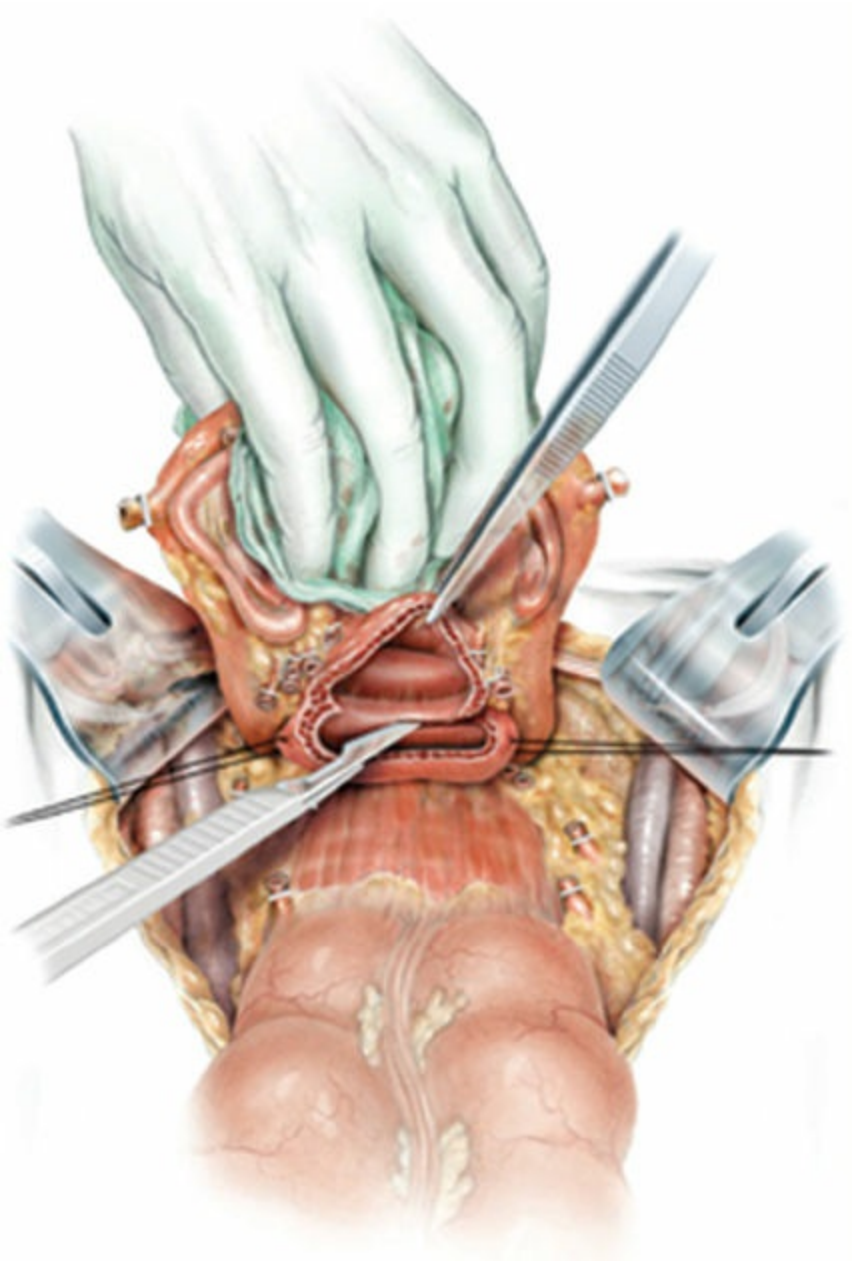

Figure 175.14. Developing the posterior pedicles in women. The posterior vagina is incised at the apex on the posterior fornix behind the cervix. This incision is carried anteriorly along the lateral and anterior vaginal wall, circumferentially around the cervix. (From Stein JP, Skinner DG. Surgical atlas-radical cystectomy. *Br J Urol Int* 2004;94:197. Copyright © 2004 by John Wiley & Sons, Inc. Reprinted by permission of John Wiley & Sons, Inc.)

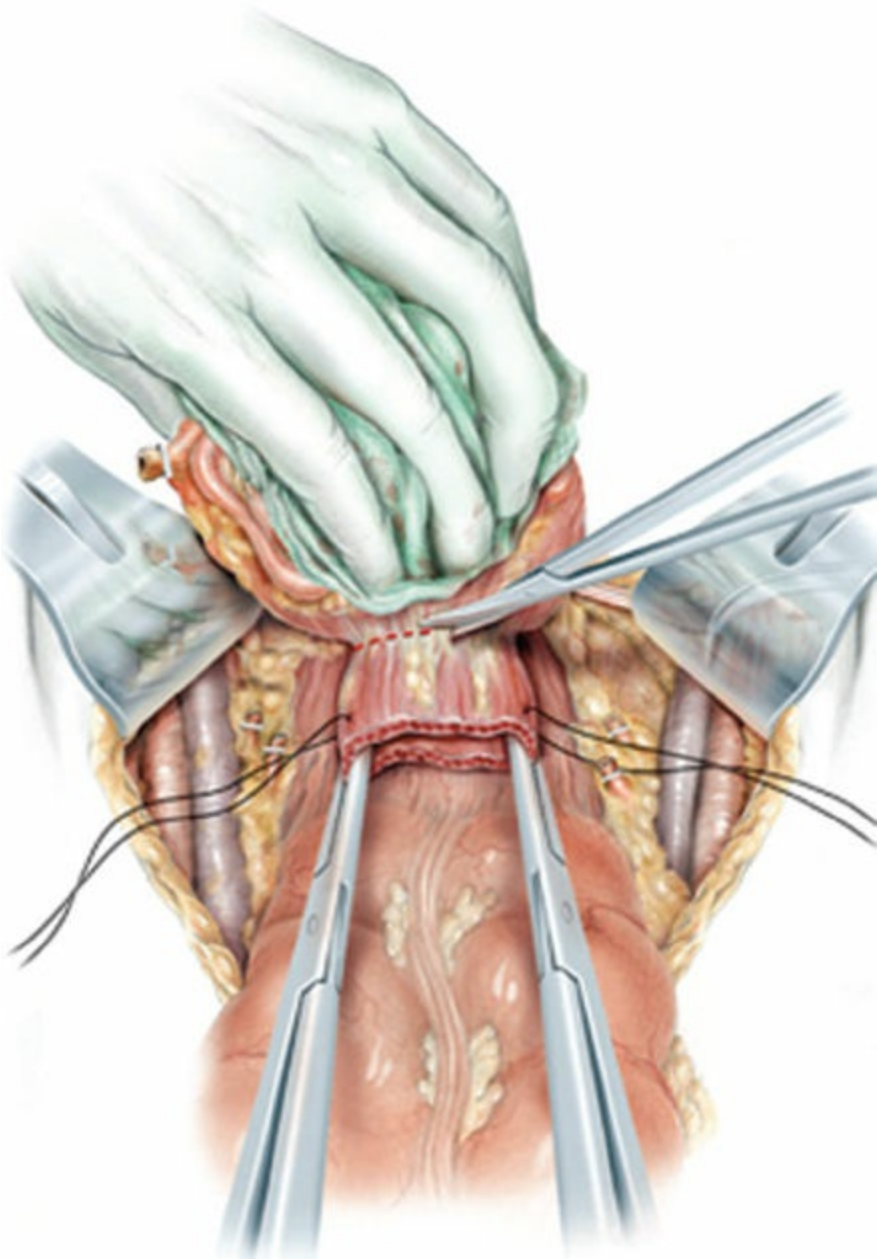

Figure 175.15. The anterolateral vaginal wall is grasped with a curved Kocher clamp, which allows for countertraction, and sharp dissection is used to separate the anterior vaginal wall and the bladder. Care must be taken not to enter the posterior bladder, which may be quite thin. (From Stein JP, Skinner DG. Surgical atlas-radical cystectomy. *Br J Urol Int* 2004;94:197. Copyright © 2004 by John Wiley & Sons, Inc. Reprinted by permission of John Wiley & Sons, Inc.)

There has been recent interest in preserving the uterus in selected women with low-stage bladder cancer away from the posterior wall who are at very low risk of cervical or uterine invasion. In these patients, the infundibulopelvic and round ligaments are preserved. The uterine artery is

isolated and preserved during dissection of the lateral pedicle. An incision in the peritoneum is made anterior to the cervix behind the bladder and the plane between the vagina and bladder developed in an identical manner. Care must be taken to avoid dissecting immediately lateral to the cervix where troublesome bleeding will be encountered. The ureteral stumps must be passed under the uterine artery prior to dividing the posterior pedicles anterolateral to the vagina.

Once the specimen has been dissected down to the bladder neck, the fat above the endopelvic fascia anterior to the bladder is gently cleaned off and the Foley balloon is used as a guide to identify the junction between the bladder and urethra. It may be helpful to put 20 cc into the balloon during this portion. It is important that no dissection be performed below the endopelvic fascia. This prevents injury to the rhabdosphincter region and corresponding innervation, which is critical in maintaining the continence mechanism. The planned incision in the proximal urethra just distal to the bladder neck is marked with a suture or light cautery. The Foley is removed and a clamp placed across the bladder neck to avoid spill. The urethra is divided sharply, avoiding cautery. It is not necessary to place urethral sutures at this time because they are easily placed later once the frozen section is confirmed to be negative.

After careful water-tight closure of the vaginal apex, we routinely mobilize an omental flap and tack it down to the anterior perivaginal tissue on either side of the urethral stump (Figs. 175.16 and 175.17). If a hysterectomy is performed, we also routine do a sacrocolpopexy with mesh attaching the vaginal apex to the sacral promontory to maintain better posterior support of the vagina in the normal anatomic angle.

ORTHOTOPIC LOWER URINARY TRACT RECONSTRUCTION

The Need to Prevent Reflux

Reflux has been recognized as causing renal damage in children, especially in the face of infection. However, it is unclear if the same problems arise in adults. Medium to long-term results with a refluxing type of reservoir such as the Studer pouch show that normal renal function and preserved upper tract anatomy are possible in the majority of patients. Early experience with the Kock ileal neobladder, which included an intussuscepted nipple antireflux valve, showed that the valve mechanism

could be a source of upper tract obstruction, sometimes developing after 10 years or more. The T-pouch was developed by Stein and Skinner in a modification of a pouch designed by Ghoneim to attempt to avoid the risk of late stenosis while maintaining an antireflux system. However, occasional late stenosis of this system has also been observed. A randomized study with over 400 patients comparing the Studer and T-pouch constructions at the University of Southern California (USC) showed no difference in renal function at 3 years but an increased risk of diversion-related procedures in the patients who had a T-pouch.

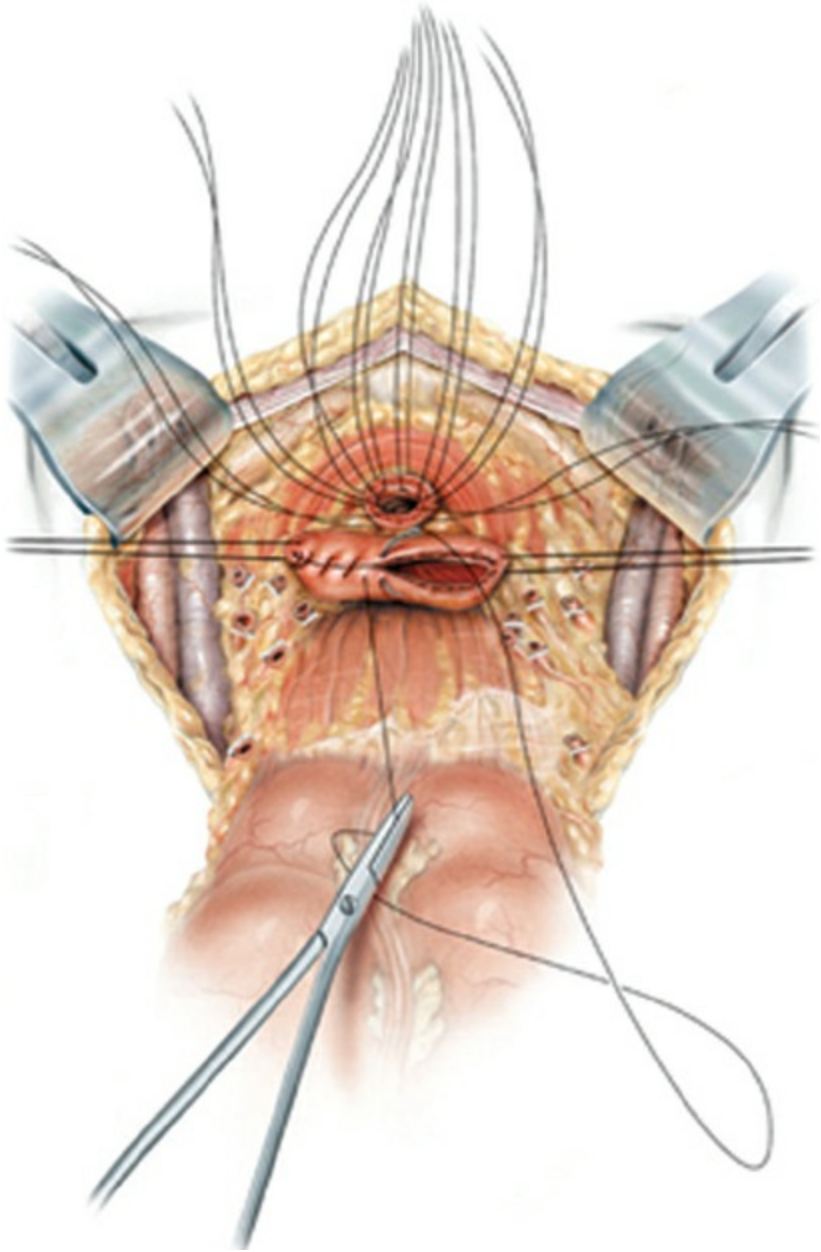

Figure 175.16. The vagina is closed at the apex. Note the urethral sutures placed into the female urethra anterior to the

vaginal cuff after removal of the specimen. (From Stein JP, Skinner DG. Surgical atlas-radical cystectomy. *Br J Urol Int* 2004;94:197. Copyright © 2004 by John Wiley & Sons, Inc. Reprinted by permission of John Wiley & Sons, Inc.)

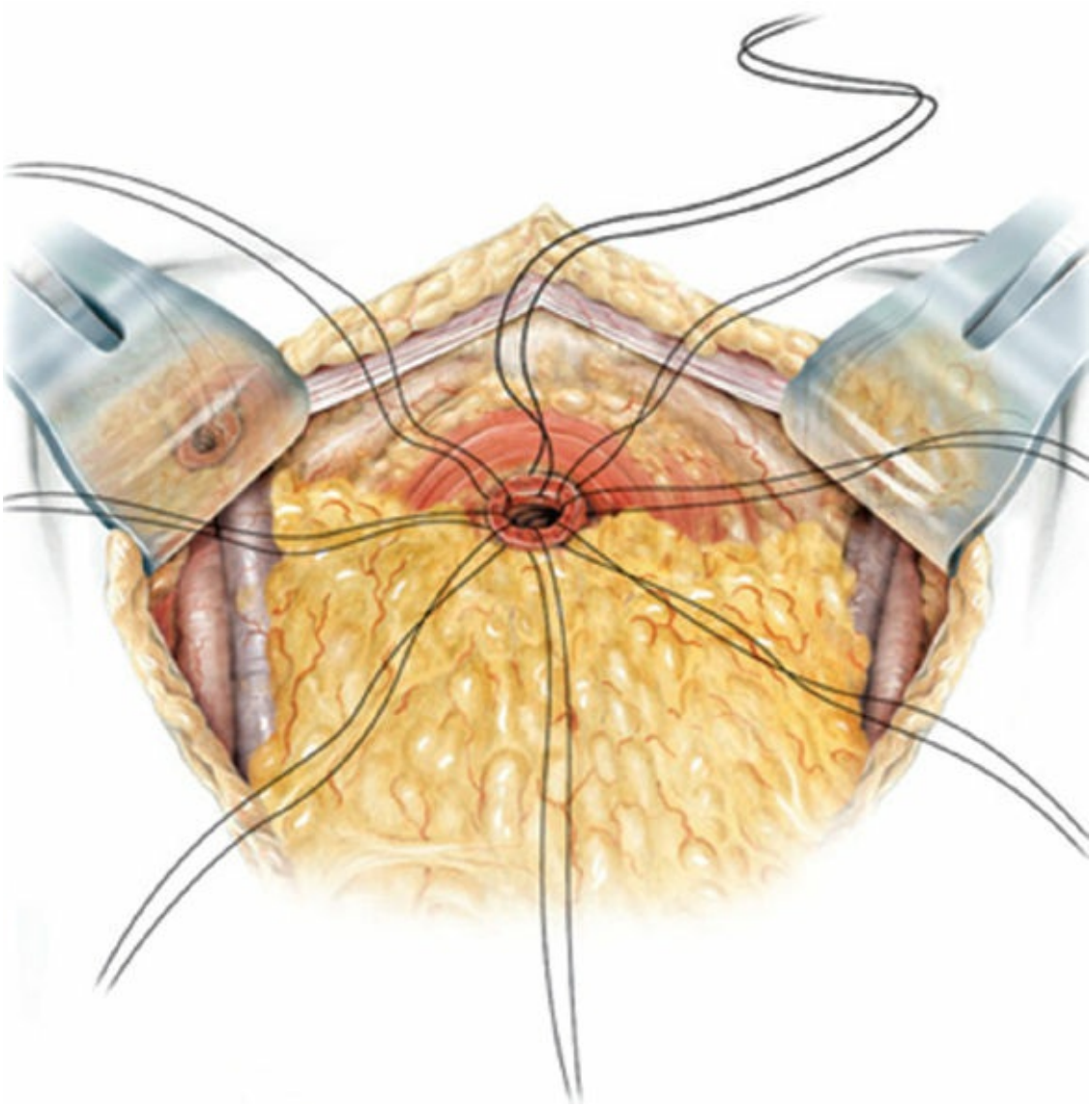

Figure 175.17. A vascularized omental pedicle graft is placed between the reconstructed vagina and neobladder and secured to the levator ani muscles to separate the suture lines and prevent fistula. (From Stein JP, Skinner DG. Surgical atlas-radical cystectomy. *Br J Urol Int* 2004;94:197. Copyright © 2004 by John Wiley & Sons, Inc. Reprinted by permission of John Wiley & Sons, Inc.)

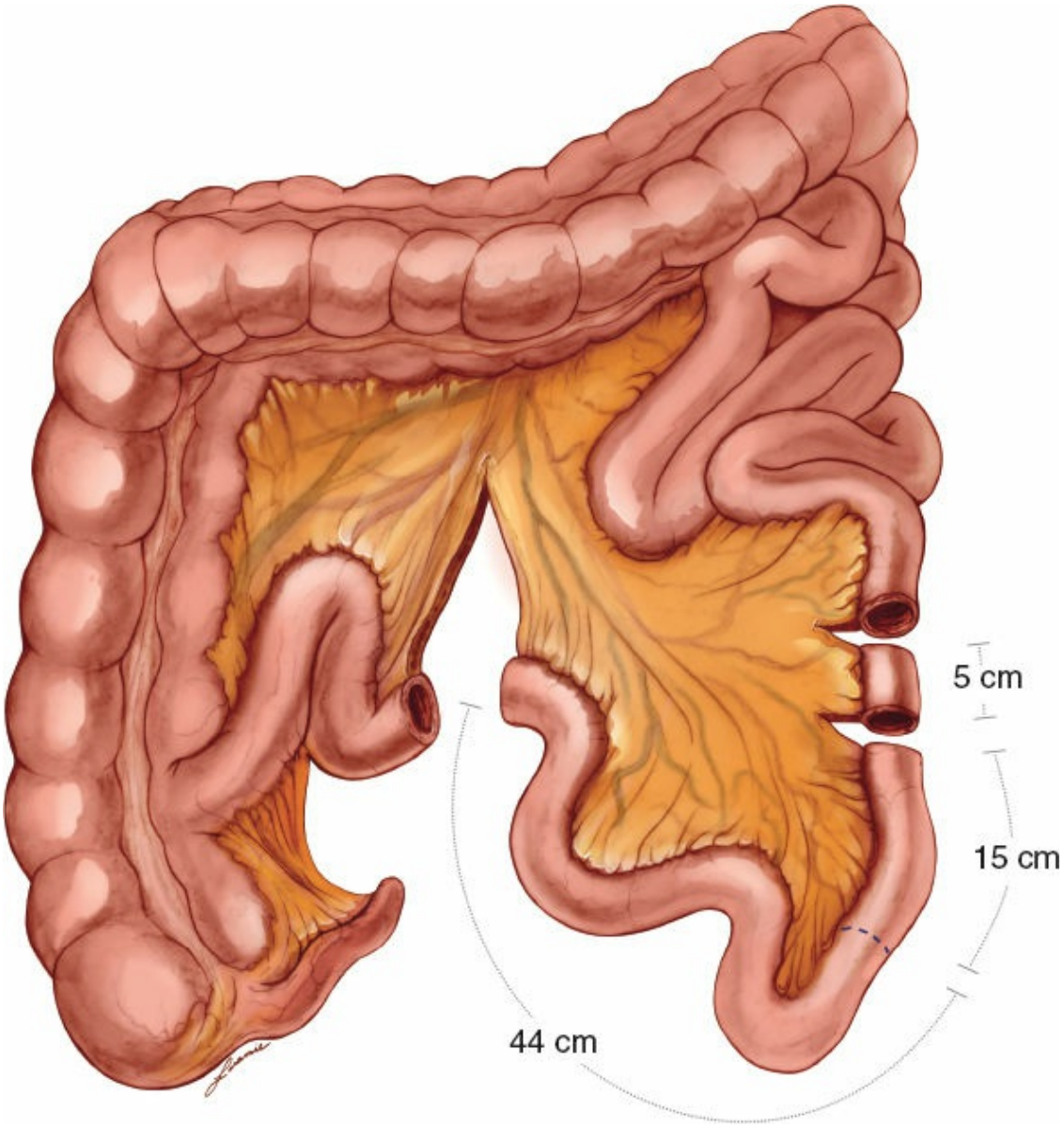

Figure 175.18. Segments of terminal ileum for construction of the orthotopic Studer pouch ileal neobladder. The distal mesenteric division is made between the ileocolic and terminal branches of the superior mesenteric artery, which extends into the avascular plane of the mesentery. In addition, a small window of mesentery and a 5-cm segment of proximal small bowel are discarded to allow mobility to the pouch and small bowel anastomosis. This avoids deep incision into the mesentery proximally, which could compromise the blood supply to the pouch.

We describe here the technique for the modified Studer pouch (without an antireflux mechanism), which is currently the most popular form of ileal neobladder reconstruction in the United States. However, we will also describe how to construct an extra-serosal tunnel antireflux mechanism (T-

pouch) for cases in which prevention of reflux is believed to be beneficial.

SURGICAL TECHNIQUE

The Studer Ileal Neobladder

The terminal portion of the ileum is used to construct the Studer pouch. The distal mesenteric division is made along the avascular plane of Treves between the ileocolic artery and terminal branches of the superior mesenteric artery. This division extends deep into the avascular portion of the mesentery, which is essential for adequate mobility of the reservoir. The proximal mesenteric division, however, is short and provides a broad vascular blood supply to the reservoir. In addition, a small window of mesentery and 5 cm of small bowel proximal to the overall ileal segment are discarded, ensuring mobility to the pouch and small-bowel anastomosis. The bowel segments are divided using the GIA stapler in its most proximal and distal aspect (Fig. 175.18).

The reservoir is created from 44 cm of distal ileum with each limb of the "U" measuring 22 cm, and a proximal 12-cm segment of ileum used as the afferent limb. If ureteral length is short or compromised, a longer afferent ileal segment may be used. The proximal end of the isolated afferent ileal segment is closed with a running Parker-Kerr suture of 3-0 chromic and an imbricating layer of interrupted 3-0 silk sutures. A standard small bowel anastomosis is performed to reestablish bowel continuity, and the mesenteric trap is closed.

The isolated 44-cm ileal segment is then laid out in an inverted "U" configuration, with the apex of the "U" lying caudally and a suture marking a point between the two 22-cm adjacent segments of ileum. It is important to discard the staple line at this point to prevent stone formation in the pouch. Starting at the apex of the "U," the bowel is then opened about 2 cm away from the mesentery using electrocautery and carried upward to the afferent limb (Fig. 175.19). The previously incised ileal mucosa is then oversewn with two layers of a running 3-0 polyglycolic acid suture starting at the apex and running upward to the afferent limb. Once the ostium of the afferent limb is reached, the running suture is tied (Fig. 175.20).

T-Pouch Modification

The technique is modified for construction of an antirefluxing afferent

limb in the T-pouch. The ileum is divided between the proximal afferent ileal segment and the 44-cm segment, and the antireflux mechanism is created by anchoring the distal 3 to 4 cm of the 15-cm afferent ileal segment into the serosal-lined ileal trough formed by the base of the two adjacent 22-cm ileal segments. Mesenteric windows of Deaver are opened between the vascular arcades on the T-limb. A series of 3-0 silk sutures are then used to approximate the serosa of the two adjacent 22-cm ileal segments at the base of the "U" with the sutures being passed through the previously opened windows of Deaver to anchor the afferent limb (Fig. 175.21). The anterior portion of the afferent limb is tapered over a 30-Fr catheter. When the incision in the "U" limb of reservoir reaches the level of the afferent ostium, it is extended directly lateral to the antimesenteric border of the ileum and carried upward (cephalad) to the base of the ileal segment. This incision provides wide flaps of ileum that is brought over the tapered afferent ileal segment and sutured in two layers to create the antireflux mechanism in a flap-valve technique (Fig. 175.22A). An interrupted mucosa-to-mucosa anastomosis is then performed between the ostium of the afferent ileal limb and the incised intestinal ileal flaps with 3-0 polyglycolic acid sutures (Fig. 175.22B). The rest of the neobladder is constructed in the same fashion as the Studer pouch.

For both techniques, the reservoir is closed by folding it in half in the opposite direction to which it was opened (Fig. 175.20). This effectively creates a low-pressure, high-capacity urinary reservoir. The anterior wall is closed with a two-layer 3-0 polyglycolic acid suture that is watertight (Fig. 175.23). This anterior suture line is stopped prior to the end of the (patient) right side to allow insertion of an index finger. This is the most mobile and dependent portion of the reservoir and will later be anastomosed to the urethra (Fig. 175.24). Alternatively, a new hole of 8 to 10 mm can be created in the most caudal part of the reservoir.

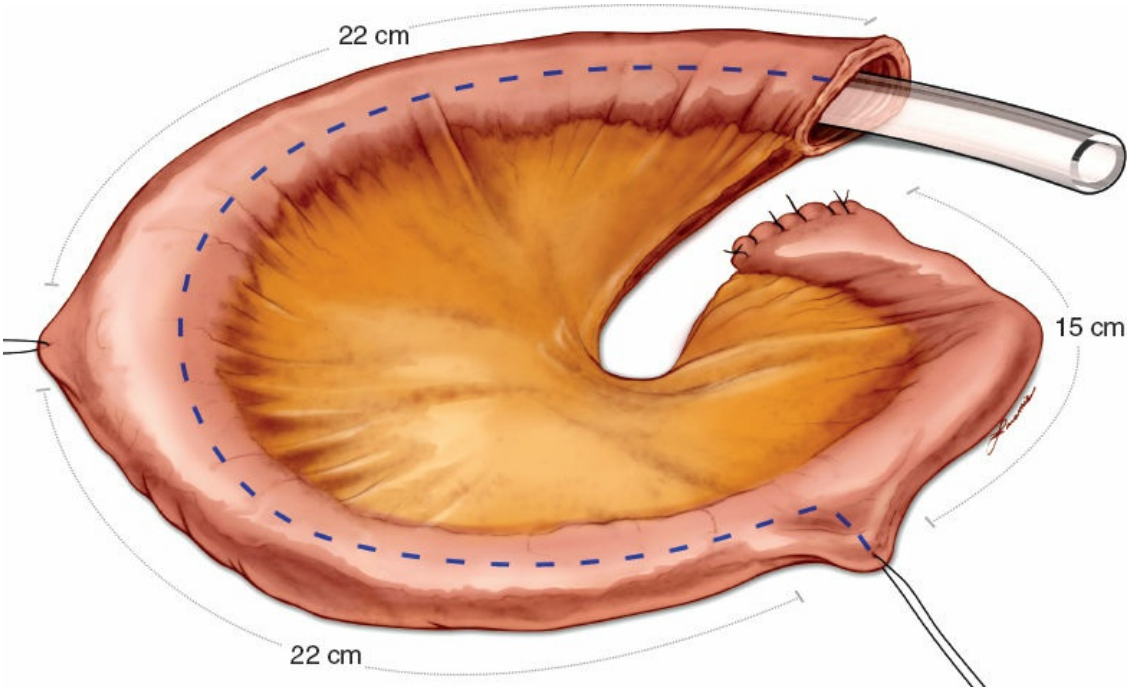

Figure 175.19. The reservoir is constructed from two 22-cm ileal segments (placed in an inverted "U" configuration). A proximal 12- to 15-cm segment of ileum forms the afferent limb. The two 22-cm ileal segments are opened along the medial mesentery.

Once the pouch has been closed, each ureter is spatulated and a standard bilateral end-to-side ureteroileal anastomosis is performed using interrupted 4-0 polyglycolic acid suture (Fig. 175.24, inset). These anastomoses are stented with 8-Fr infant feeding tubes or 7-Fr urinary diversion stents, which are directed from the ipsilateral renal pelvis (kidney) across the ureteroileal anastomosis through the afferent limb into the reservoir. A 24-Fr hematuria catheter is placed per urethra to provide adequate drainage of the reservoir, and the ureteral stents are secured to the end of the urethral catheter with a 3-0 nylon suture. This facilitates removal of the stents at 3 weeks along with the urethral catheter. A tension-free mucosa-to-mucosa urethral anastomosis is performed using the previously placed urethral sutures (Fig. 175.25). Lifting the sigmoid out of the pelvis provides space to bring the pouch down to the urethra. The pouch is irrigated to check that all suture lines are water-tight. A drain is placed and the abdomen is closed.

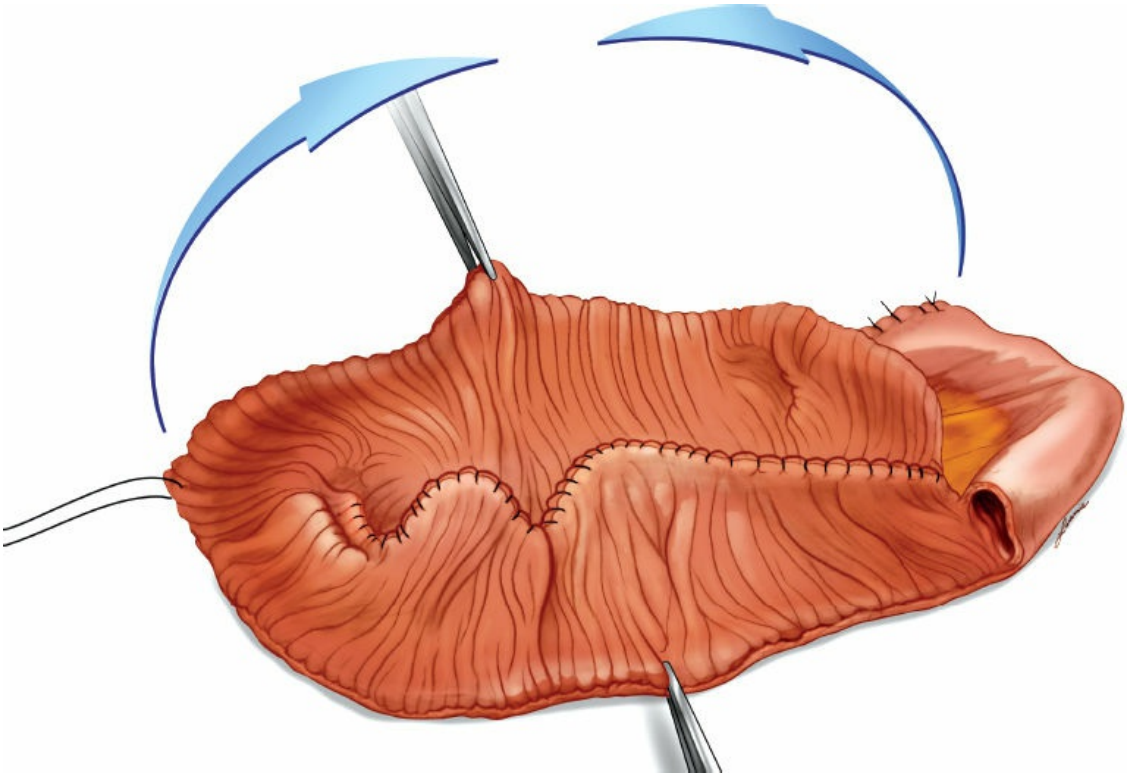

Figure 175.20. The two 22-cm segments are joined with a running 3-0 polyglycolic acid suture starting at the apex and running upward to the afferent limb. A second layer may be used for security. The reservoir is then closed by folding it in half in the opposite direction to which it was opened and that suture line closed in a similar fashion.

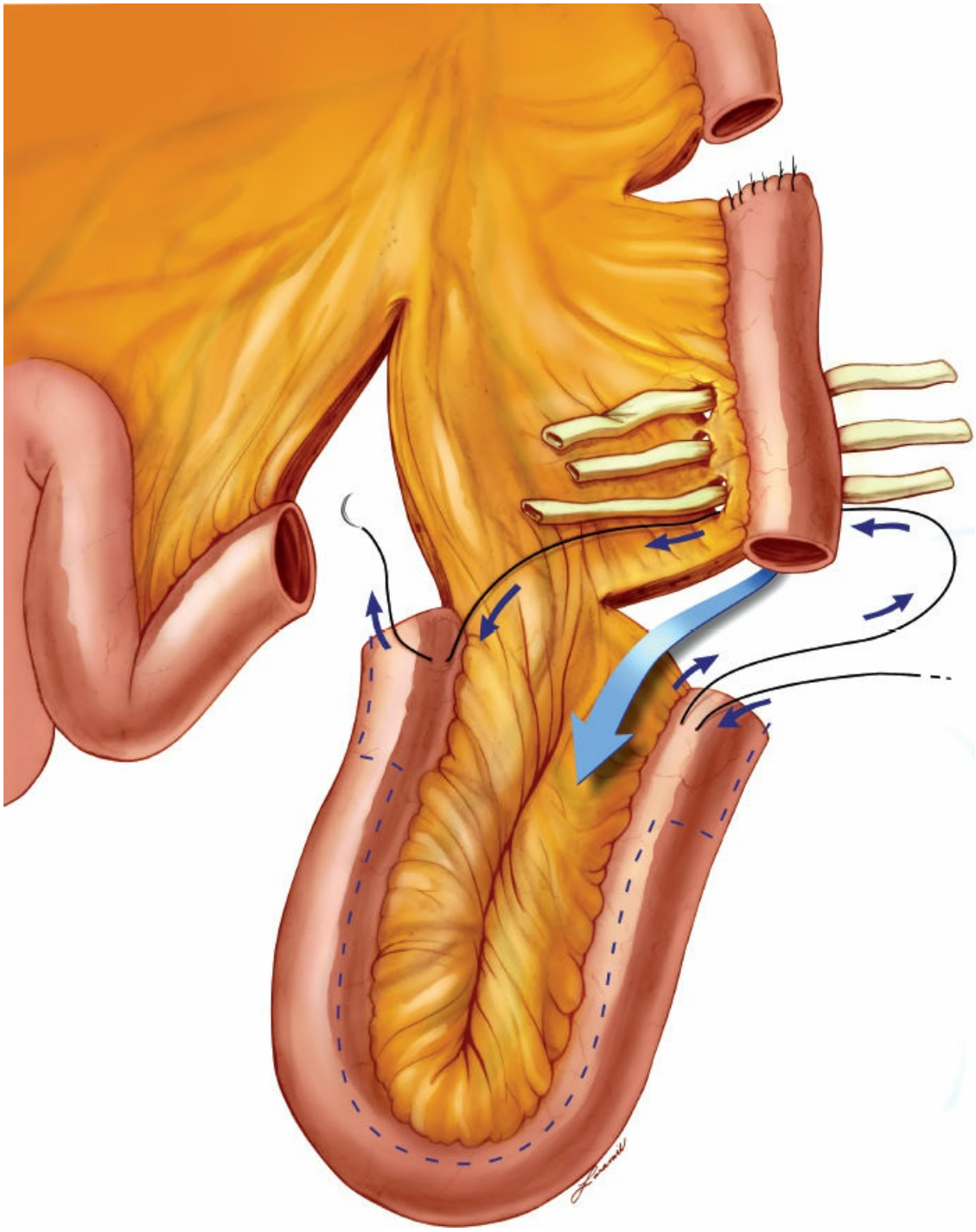

Figure 175.21. Construction of the antireflux mechanism in the T-pouch. The ileum is divided between the proximal afferent ileal segment and the 44-cm segment. The dotted line depicts the incision line on the U limbs. Mesenteric windows of Deaver are opened between the vascular arcades adjacent to the serosa of the separated afferent limb. Placement of small Penrose drains through each mesenteric window helps facilitate passage of sutures. The distal 3 to 4 cm of the afferent ileal segment is anchored into a serosal-lined ileal trough formed by the base of the two adjacent 22-cm ileal segments, using 3-0 silk sutures.

POSTOPERATIVE MANAGEMENT

A clinical care pathway is used to manage these patients postoperatively with a team approach. The ERAS protocol includes patient education, no bowel prep, no postoperative nasogastric (NG) tube, minimization of narcotics, judicial use of perioperative IV fluids, and the use of a μ-opioid antagonist (alvimopan) to decrease ileus related to narcotics. At USC, the ERAS protocol reduced postoperative hospital stay from a median of 8 to 4 days without an increase in readmissions or complications. The primary benefit is from a significant decrease in postoperative ileus and other bowel complications (Table 175.5).

Most patients do not require ICU management unless they have serious cardiac or pulmonary disease. Prophylaxis against deep vein thrombosis is important, using subcutaneous heparin or fractionated heparin compounds as well as leg squeezers. Anticoagulation with low molecular weight heparin should be continued for at least 4 weeks after surgery as supported by large randomized clinical trials of patients undergoing pelvic cancer surgery. Alvimopan is begun on the AM of surgery and continuing for up to 7 days or until discharge. Early feeding has been demonstrated to be safe and to improve recovery of bowel function. Sips of liquids (including high-carbohydrate, high-protein fluids) are started early on the evening of surgery if tolerated. On POD 1, patients are started on a regular diet (tailored for postoperative surgical patients) provided the patient has no nausea, vomiting, or abdominal distention, regardless of gas passage or bowel movement. Laxatives are used as needed. If the patient is not tolerating oral food by POD 6 or 7 and there is no bowel activity, parenteral nutrition is considered.

We manage catheters and drains using a 24-Fr hematuria urethral catheter to which the ureteral stents are secured so that they can all be removed together at 3 weeks from surgery. The drain is also left in the entire 3 weeks to allow for drainage in the event of a urinary leak from the pouch as it heals. We irrigate the Foley catheter every 4 to 6 hours in the hospital to prevent mucous plugs and teach the patient and family to do so at least three to four times daily after discharge. Patients without major complications are generally discharged 4 to 5 days postoperatively.

COMPLICATIONS

Early Complications

Early postoperative complications are common, occurring in >50% of patients, with major complications occurring in ~15%, and postoperative mortality rates of 2% to 4% in most modern series. The most common causes of complications include gastrointestinal problems (although ileus has markedly decreased with current management), cardiovascular and pulmonary complications, hemorrhage, infections, thrombotic events, and problems related to the urinary diversion (Table 175.5). Many studies have shown that the overall incidence of early complications, mortality, and hospital stay are not increased with continent diversion compared to ileal conduit.

Urine leaks are fairly common in continent diversion because of the long suture lines. However, the majority will resolve with observation alone with proper management of catheters and drains. An undrained leak is best treated with an attempt at percutaneous drainage and/or bilateral nephrostomy tube placement rather than open surgical repair, which can be extremely difficult during the first few weeks after the initial surgery. Similarly a pelvic abscess or leak from the bowel anastomosis whenever possible is managed with percutaneous drainage and bowel rest rather than reoperation. In our experience, 5% of patients require some sort of percutaneous drain or nephrostomy tube placement during the early postoperative period to manage these problems. Early operative intervention is rare, primarily used to treat either severe hemorrhage or a dense early bowel obstruction that fails to resolve with conservative management.

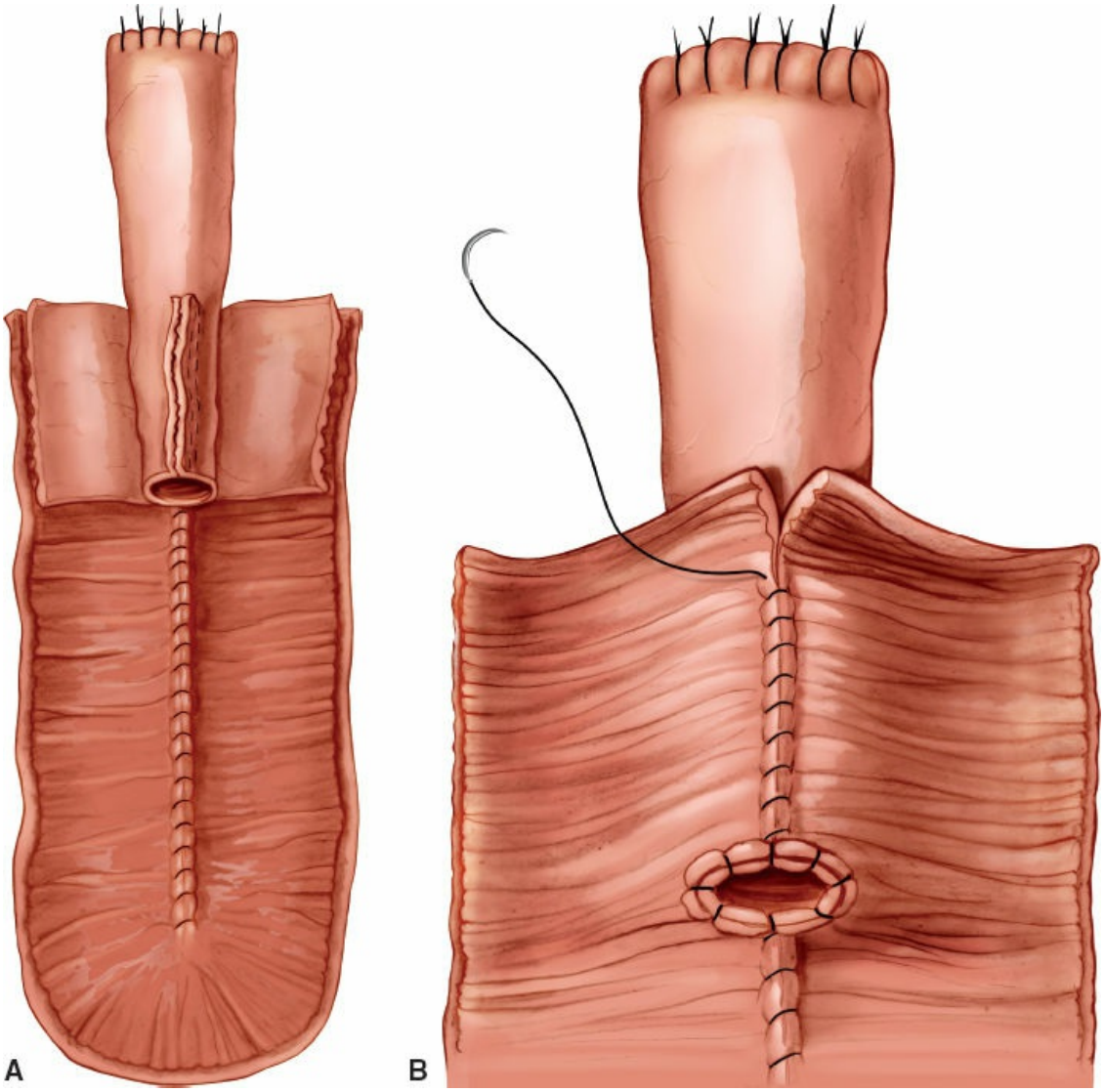

Figure 175.22. Construction of the antireflux mechanism in the T-pouch. **A.** The previously anchored distal 3- to 4-cm afferent ileal segment may be tapered over a 30-Fr catheter or may be left intact. The pouch is then opened creating wide flaps of ileum at the level of the tunnel. The flaps are brought over the tapered distal afferent ileal segment to form the antireflux mechanism in a flap-valve technique. **B.** The ostium of the afferent segment is matured into the reservoir using interrupted 3-0 polyglycolic acid suture.



Figure 175.23. Once the reservoir is folded in half, the anterior wall is closed with a two-layer 3-0 polyglycolic acid suture that is watertight. Note that the anterior suture line is stopped just short of the (patient) right side to allow insertion of an index finger, which will ultimately be attached to the urethra. Alternatively the suture line may be closed completely and a separate small opening made for the urethral anastomosis.

Another common cause of early readmission to the hospital after discharge is dehydration, often associated with the development of nausea or vomiting or diarrhea. The neobladder tends to excrete water and counteract normal urinary concentrating ability in the face of dehydration. This can result in the rapid development of dehydration, especially in elderly patients and those with baseline renal insufficiency. Support with IV fluids in the first few weeks is all that is typically required for this self-limiting problem. Finally, febrile urinary tract infections are also common due to the required prolonged catheter drainage. The ideal method to prevent such infections has not been determined, although long-term antibiotics do not seem to be able to prevent such complications.

Late Complications

The primary late complications of orthotopic neobladders include recurrent urinary tract infections, pouch stones, uretero-ileal stricture, vesico-urethral stricture (rare), metabolic complications, and incontinence. All of these problems except incontinence can be managed initially with endoscopic techniques.

Many neobladder patients will have urine that is chronically colonized with bacteria, especially if they have to self-catheterize regularly. We make an initial attempt to eradicate the bacteria, but long-term antibiotics will only result in resistant organisms. Patients with recurrent febrile urinary tract infections or pyelonephritis should be evaluated to rule out incomplete emptying, ureteral obstruction, or stones.

Pouch perforation is a rare but potentially life-threatening complication. We are aware of at least two deaths due to pouch perforation that was unrecognized when the patient was admitted to an outside hospital. Acute abdominal pain in a patient with any form of continent diversion should be evaluated with a CT cystogram, and a perforation should be generally managed with open exploration and repair.

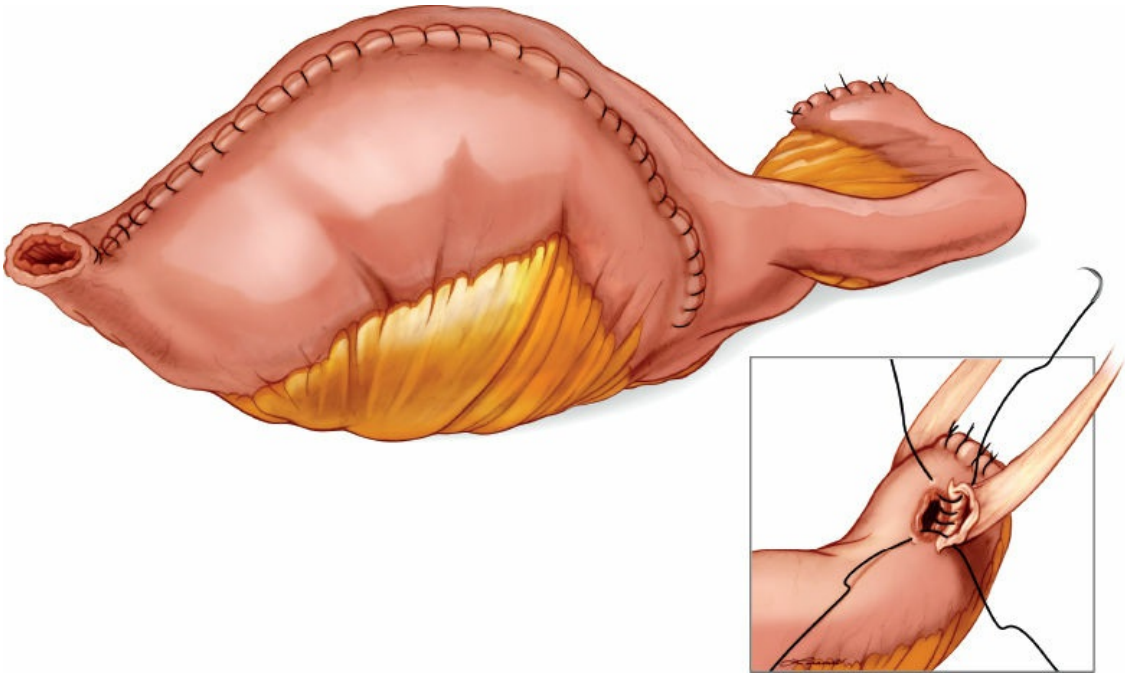

Figure 175.24. Each ureter is spatulated and a standard bilateral end-to-side ureteroileal anastomosis is performed using interrupted 4-0 polyglycolic acid suture. The ureters are stented with either stents that can be tied to the foley catheter or brought out through the pouch to the skin.

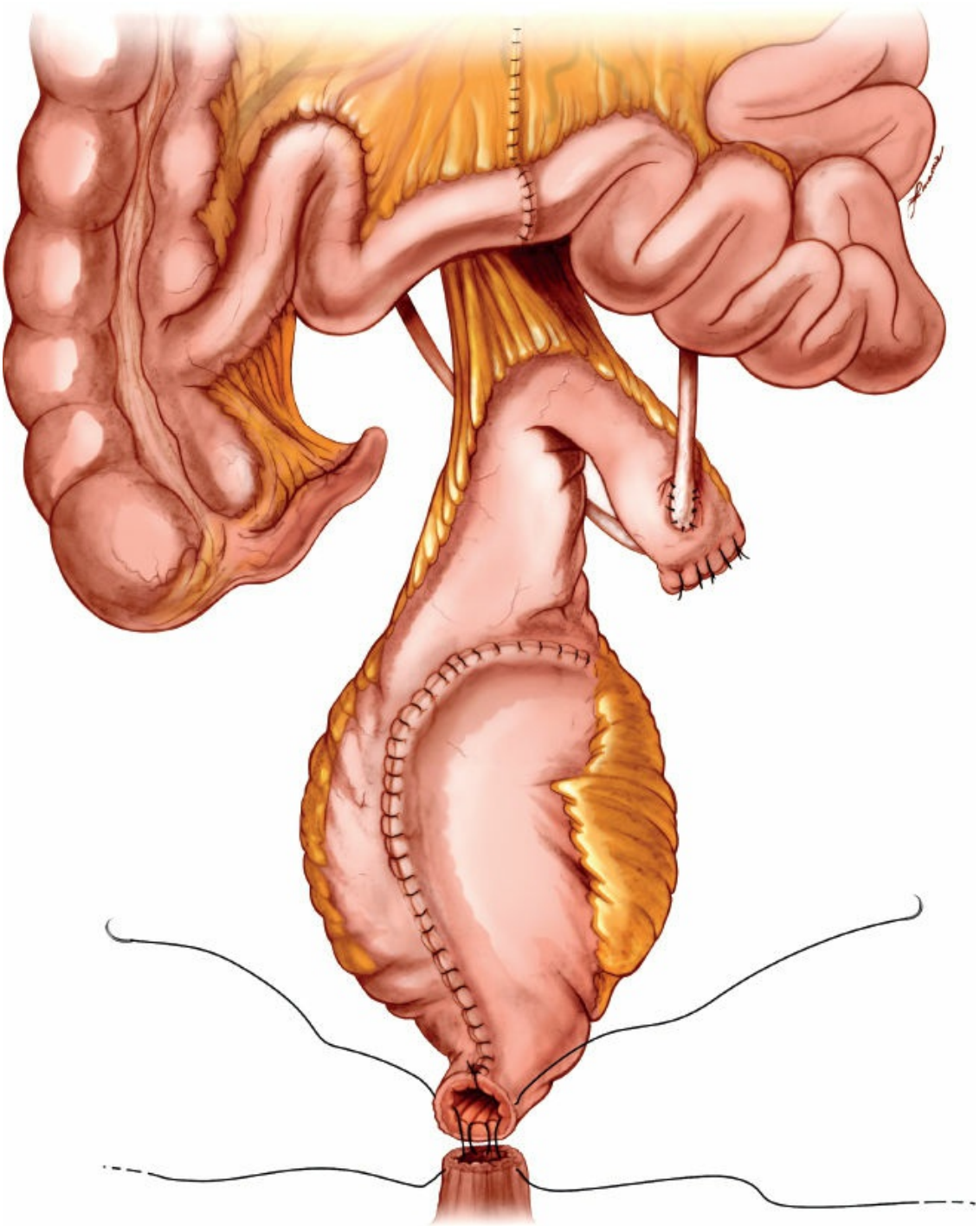

Figure 175.25. The most mobile and dependent portion of the reservoir will be anastomosed to the urethra using the previously placed urethral sutures.

Metabolic problems may develop in patients with continent diversion. The most common is vitamin B_{12} deficiency due to the use of the distal ileal segment. We check serum B_{12} levels annually in all patients and add intramuscular or sublingual supplements when serum levels drop below normal. Diarrhea occasionally may be a long-term problem due to the loss

of bile absorption from the distal ileum. Treatment with oral cholestyramine will usually control this. Patients with chronic renal insufficiency can also lose significant bicarbonate and develop hyperchloremic acidosis. This complication is rarely seen in patients with a creatinine clearance above 40 mL/min. It is treated with chronic sodium bicarbonate or sodium citrate supplementation.

Stones may occur in the neobladder or upper tracts and may be a source of continued infection, obstruction or bleeding. Obstruction of the uretero-ileal anastomosis is usually due to fibrosis and scar, although the possibility of tumor recurrence should be entertained. Urethro-ileal anastomotic strictures are extremely rare probably at least in part due to the excellent blood supply of the pouch and the urethral stump. Endoscopic management is usually possible, although not universally successful. Obstruction of an antireflux valve mechanism may present with silent renal failure with bilateral hydronephrosis. This can also be managed endoscopically in most cases.

Long-term follow-up of patients with continent diversion initially is driven by surveillance for cancer recurrence. After that risk has passed (3 to 5 years), the patient should continue to have periodic upper tract imaging (e.g., annual ultrasound and KUB or CT scans) along with serum chemistries and B_{12} levels. Urinary cytology is also useful to diagnose upper tract or urethral recurrence.

OUTCOME

Cancer Cure

The recurrence-free survival in a series of 1,488 patients treated at USC from 1980 to 2005 was 68% and 66% at 5 and 10 years. Overall survival was 66% and 43% at 5 and 10 years (Table 175.6). Most deaths occurring within the first 3 years following radical cystectomy are due to bladder cancer recurrence. With continued follow-up (after 3 years), most deaths in this elderly group of patients are primarily related to other diseases. Recurrence-free survival has not improved over this time. Although adjuvant chemotherapy was given to patients with extravesical extension, fewer than 50% were able to receive it in this series. In recent years, neoadjuvant chemotherapy has been provided to all patients with muscle-invasive disease who have acceptable renal function, which may provide some improvement over these numbers.

TABLE 175.5 90-Day Complications by Category, ER Visits and Readmissions With ERAS Protocol Compared to Historic Controls

Complication	ERAS%	Control%	p Value
Dehydration	14.2	9.3	0.22
Wound	11.8	20.4	0.05
Thromboembolism	7.7	9.3	0.21
Infection	32.0	41.7	0.10
Cardiovascular	11.8	13.9	0.62
Pulmonary	4.1	4.6	0.85
Gastrointestinal	21.3	33.3	0.03
Renal/metabolic	17.2	21.3	0.22
Neurologic	1.2	1.9	0.65
Hematologic	25.4	17.6	0.13
Other	13.0	7.4	0.14
Death	4.1	4.6	0.85
Total	78.1	79.6	0.76
ER Visits	37.9	35.2	0.65
Readmissions	29.6	26.9	0.62

TABLE 175.6 Recurrence-Free Survival by Pathologic Stage Group by Decade of Treatment

Pathologic Stage (% of Total Group)	Recurrence-Free Survival (%) (n = 1,488)			
	1980–89	**1990–99**	**2000–2005**	**p value**
All patients				0.62
5 years	68	68	66	
10 years	66	63	na	
Organ-confined, N0 (56%)				0.72
5 years	83	85	81	
10 years	80	78	na	
Extravesical, N0 (21%)				0.42
5 years	53	66	53	
10 years	53	69	na	
LN positive (23%)				0.96
5 years	36	33	39	
10 years	33	32	na	

From Zhender P, Studer UE, Skinner EC, et al. Unaltered oncological outcomes of radical cystectomy with extended lymphadenectomy over three decades. *Br J Urol Int* 2013;112(2):e51–8. Copyright © 2013 by John Wiley & Sons, Inc. Reprinted by permission of John Wiley & Sons, Inc.

TABLE 175.7 Percent of Patients With Positive Lymph Nodes by Primary Bladder Pathologic Stage

P Stage of Primary Tumor	Number of Patients (%)	Positive Lymph Nodes (%)
P0, Pis, Pa, P1	421 (40%)	19 (5%)
P2a (superficial muscle)	115 (11%)	21 (18%)
P2b (deep muscle)	133 (13%)	35 (27%)
P3 (extravesical extension)	248 (23%)	113 (45%)
P4	137 (13%)	58 (43%)
Entire group	1,054	246 (24%)

P-stage reflects the 1997 TNM staging system.
From Stein JP, Lieskovsky G, Cote R, et al. Radical cystectomy in the treatment of invasive bladder cancer: long-term results in 1054 patients. *J Clin Oncol* 2001;19(3):666. Reprinted with permission.
© 2001 American Society of Clinical Oncology. All rights reserved.

The median time to any recurrence was 12 months, with 86% of all patients developing their recurrence with the first 3 years postoperatively. Distant recurrence was the most common finding, observed in 75% of those suffering a recurrence. The overall local recurrence rate in our series using this standardized surgical approach with a thorough extended lymphadenectomy was only 7%. Median time to distant recurrence was 12 months and local recurrence 18 months.

The pathologic stage of the primary bladder tumor and the presence of lymph node metastases are the most important survival determinants in patients undergoing cystectomy for bladder cancer (Table 175.6). Patients may be categorized into organ-confined (pT0, pTa to pT2b, N0), extravesical (pT3, pT4, N0), and node-positive subgroups (any T stage, N1-N2) that allow for simplified risk stratification. The incidence of lymph node tumor increases with increasing primary bladder tumor stage (Table 175.7). Other pathologic predictors of recurrence following cystectomy include lymphovascular invasion (in node-negative patients), and a number of genetic alterations and protein tumor markers. Most of these have not been studied in a prospective manner.

Although patients with positive lymph nodes are at very high risk of recurrence, nearly one third of these patients in our series were alive at 5 years, and 23% were alive without recurrence at 10 years. The prognosis in patients with lymph node-positive disease can be stratified by the number of lymph nodes involved (tumor burden), and by the p stage of the primary bladder tumor. Patients with fewer than five positive nodes and with

organ-confined bladder tumors had a significant improved recurrence-free survival compared to those with nonorgan-confined disease or more than five positive nodes. The concept of lymph node density (defined as the total number of positive lymph nodes divided by the total number of lymph nodes removed) accounts for the extent of the lymph node dissection (number of lymph nodes removed) and the tumor burden (number of positive lymph nodes) and was previously shown to have independent prognostic value. In a recent update, submission of the nodes in 13 separate packets significantly increased the total lymph node yield, but did not result in a significant increase in the number of positive nodes or a consecutive nodal stage shift. In this study, lymph node density was not an independent predictor of recurrence. For patients with positive nodes, the level of the highest positive lymph node (above or below the common iliac bifurcation) was a predictor of recurrence, as was receipt of adjuvant chemotherapy.

TABLE 175.8 Day and Nighttime Continence Results With Ileal Neobladders

Author and Pouch Type	Number of Patients	Daytime Continence (%)	Nighttime Continence (%)	Requiring Catheterization (%)
Elmajian 1996 Kock reservoir	295	87	86	8
Hautmann 1999 ileal neobladder	363	96	95	6
Stein 2004 T-pouch	209	87	72	25
Studer 1996 Studer pouch	200	90	80	0.5
Ali-el-Dein 2008 ileal neobladder (females)	192	92	72	16
Stein 2009 (females)		77	66	63% (39% catheterize regularly)

Continence

There is no consensus on the definition of continence or the measures used to describe it in patients undergoing orthotopic reconstruction. Continence can be influenced by a number of factors, including patient age, gender, prior radiation therapy, diabetes, and the segment of bowel used for the reservoir as well as factors such as how often the patient wakes to void at night. However, in spite of this variability, there is remarkable consistency in the rates of continence described in series using ileum for the neobladder (Table 175.8). Most patients undergoing orthotopic diversion experience improving daytime continence over the first 3 to 6 months, with continued improvement out to 12 months and beyond.

From 2000 to 2014, a total of 1,545 patients underwent open radical cystectomy at USC. Orthotopic ileal neobladder was constructed in 1,057

(68%) patients, of whom 892 (84%) were male. A total of 345 pad usage questionnaires have been collected prospectively from 161 male patients from 2012 to 2014 of whom 58% reported daytime continence within 3 months of surgery. By 12 to 18 months postoperatively, daytime continence had increased to 89%. Nighttime continence increased from 25% at 3 months to 52% by 18 to 36 months. Reporting of combined daytime and nighttime continence increased from 25% within 3 months postoperatively to 50% by 18 to 36 months (Fig. 175.26). As the functional capacity of the neobladder increases and mucosal changes occur over time, there is less absorption of electrolytes from the surface and less of a nocturnal diuretic effect caused by the electrolyte shifts. Physical therapy with biofeedback focused on the pelvic floor muscles may help some patients attain initial continence. Patients should be encouraged to wait until the second year to pursue any surgical treatment such as a sling or artificial sphincter device.

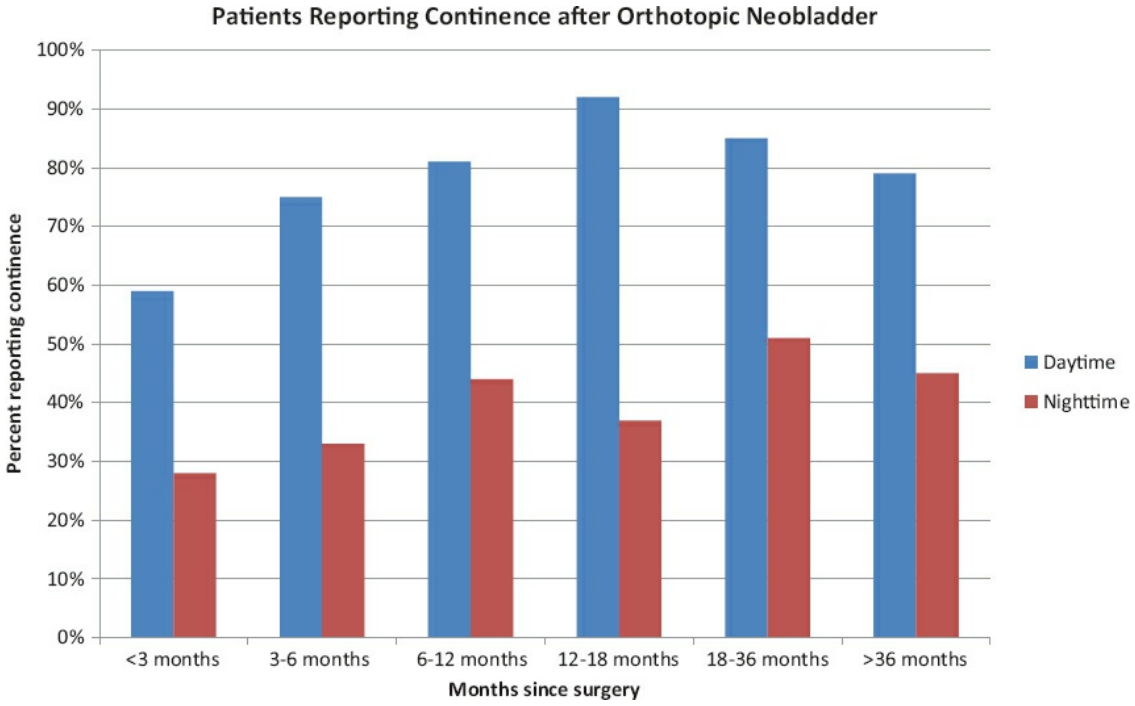

Figure 175.26. Reports of continence on a patient-reported questionnaire filled out prospectively by 161 male patients at various times after undergoing cystectomy and ileal neobladder.

Urinary Retention

Failure to empty or urinary retention has been reported in a wide range of patients undergoing orthotopic reconstruction at various centers, and is

more common in women than in men. Self-catheterization was reported in 13% of men in the 161 patients participating in the questionnaire study described above. Median time from surgery to starting catheterization was 15.8 months (1.2 to 63.7 months). A similar study of 56 female patients using patient-reported questionnaires found similar continence rates as in male patients, but as many as 62% used intermittent catheterization at least occasionally. Patients with incomplete emptying may present with acute retention but more often present with recurrent infections or the new onset of overflow incontinence. The retention may also be discovered on routine follow-up with a distended reservoir on imaging or on postvoid residual check. The development of retention is often a late event, so the reported rates are very much influenced by the length of follow-up of the series.

CONCLUSIONS

The clinical results and outcomes following radical cystectomy and extended pelvic lymph node dissection demonstrate good survival, with excellent local recurrence rates for high-grade, invasive bladder cancer. Details of the surgical technique including surgeon experience, the extent of lymphadenectomy, and the dissection around the proximal urethra have all been shown to impact outcomes of the surgery in terms of both cancer cure and functional outcomes.

These results provide sound data and a standard to which other forms of therapy for invasive bladder cancer can be compared. Furthermore, improvements in orthotopic urinary diversion have allowed us to offer this type of diversion to most men and women undergoing radical cystectomy. Continence rates following orthotopic diversion are good and provide patients a more natural voiding pattern per urethra.

In conclusion, a properly performed radical cystectomy with an extended lymphadenectomy provides the best survival rates, with the lowest reported local recurrence rates for high-grade invasive bladder cancer. The surgical technique is critical to optimize the best clinical and technical outcomes in patients with this procedure. Advances in lower urinary tract reconstruction provide a reasonable alternative for patients undergoing cystectomy.

Suggested Readings

Ali-el-Dein B, Shaaban AA, Abu-Eideh RH, et al. Surgical complications following radical cystectomy and orthotopic neobladder in women. *J Urol*

2008;180:206–10.

Bochner BH, Dalbagni G, Sioberg DD, et al. Open radical cystectomy and robot-assisted laparoscopic radical cystectomy: a randomized clinical trial. *Eur Urol* 2015;67(6):1042–50.

Burger M, Catto JW, Dalbagni G, et al. Epidemiology and risk factors of urothelial bladder cancer. *Eur Urol* 2013;63:234–41.

Daneshmand S, Ahmadi H, Schuckman AK, et al. Enhanced recovery protocol after radical cystectomy for bladder cancer. *J Urol* 2014;192(1):50–5.

Dhar NB, Klein EA, Reuther AM, et al. Outcome after radical cystectomy with limited or extended pelvic lymph node dissection. *J Urol* 2009;179:873.

Dorin RP, Daneshmand S, Eisenberg MS, et al. Lymph node dissection technique is more important than lymph node count in identifying nodal metastases in radical cystectomy patients: a comparative mapping study. *Eur Urol* 2011;60:946–52.

EAU Guidelines on muscle-invasive bladder cancer. https://uroweb.org/guideline/muscle-invasive-bladder-cancer/

Eisenberg MS, Dorin RP, Bartsch G, et al. Early complications of cystectomy after high dose pelvic radiation. *J Urol* 2010;184:2265–9.

Gerharz EW, Mansson A, Hunt S, et al. Quality of life after cystectomy and urinary diversion: an evidence based analysis. *J Urol* 2005;174:1729–36.

Grossman HB, Natale RB, Tangen CM, et al. Neoadjuvant chemotherapy plus cystectomy compared with cystectomy alone for locally advanced bladder cancer. *N Engl J Med* 2003;349:859.

Hall MC, Chang SS, Dalbagni G, et al. Guideline for the management of nonmuscle invasive bladder cancer (stages Ta, T1, and Tis): 2007 update. *J Urol* 2007; 178:2314–30.

Hautmann RE, Abol-Enein H, Davidsson T, et al. International consultation on urologic disease-European association of urology consultation on bladder cancer 2012. *European Urology* 2013;63(1):67–80.

Stein JP, Lieskovsky G, Cote R, et al. Radical cystectomy in the treatment of invasive bladder cancer: long-term results in 1,054 patients. *J Clin Oncol* 2001;19:666.

Studer UE, Burckard FC, Schumacher M, et al. Twenty years experience with an ileal orthotopic low pressure bladder substitute—lessons to be learned. *J Urol* 2006;176:161–6.

Zehnder P, Studer UE, Skinner EC, et al. Unaltered oncological outcomes of radical cystectomy with extended lymphadenectomy over three decades. *BJU Int* 2013;112(2):E51–8.

Zehnder P, Moltzahn F, Mitra AP, et al. Radical cystectomy with super-extended lymphadenectomy: impact of separate vs en bloc lymph node submission on analysis and outcomes. *BJU Int* 2016;117(2):253–9.



EDITOR'S COMMENT

The operation of radical cystectomy and urinary diversion has evolved in many facets over the last two decades leading to a safer and possibly more curative operation with significant improvements in quality of life for some patients. In large part, these improvements in care are the result of a greater understanding of the anatomy of the operation, emphasizing the importance of not only quantity but quality of lymphadenectomy, refinement in continent urinary reservoir design, and postsurgical recovery pathways that shorten hospital stay. The authors of this chapter very nicely outline these points by sharing their extensive experience with this operation. Nevertheless radical cystectomy remains a highly complex surgical procedure and outcomes are influenced by surgical volume, hospital setting, and extent of postresidency training leading to the argument for centralization of radical cystectomy care at centers of experience.

Several recent publications from experienced centers demonstrate that at least 70% of patients experience some form of complication following radical cystectomy, mostly Clavien–Dindo grades 1 and 2, however 15% to 20% of patients experience Clavien–Dindo grades 3 to 5 complications. The negative impact of complications on quality of life, cost to the health care system, and inability to provide adjuvant cancer therapies in a timely manner have all been reported and provide a sobering reminder of the challenges to a patient of undergoing a radical cystectomy. Unfortunately the initial enthusiasm of minimally invasive surgical techniques to reduce complications, including robot-assisted radical cystectomy, has been tempered by several reports, including recently reported randomized clinical trials that demonstrate no improvement in complication rate, length of hospital stay, or hospital readmissions with these techniques.

A recent focus on enhanced recovery after surgery (ERAS) pathways is favorably impacting complication rates after radical cystectomy by reducing bowel-related complications, mostly ileus, leading to earlier hospital discharge. Importantly earlier hospital discharge is not leading to higher readmission rates or number of emergency room visits. Most ERAS protocols focus on precystectomy patient education, (usually with an enterostomal therapist), avoiding a bowel preparation, not placing a postoperative nasogastric tube, early feeding, nonnarcotic pain management, and the use of cholinergic and mu-receptor opioid antagonists. As a result of these changes infectious complications have become the most common complication of radical cystectomy and it is imperative that more attention is focused on how to reduce

this problem.

The chapter provides a very nice detailed description of the operation and important aspects of pelvic anatomy as it pertains to improving oncologic and quality-of-life outcomes following radical cystectomy and orthotopic ileal neobladder. Multiple reports demonstrate that performing a lymphadenectomy at radical cystectomy reduces the rate of positive soft tissue surgical margins and improves overall cure rates from the disease, including curing some patients with metastatic disease to the regional lymph nodes. However, there is a lack of consensus as to how extensive of a lymph node dissection needs to be performed to provide the most oncologic benefit (i.e., bifurcation of the common iliac artery [standard dissection] vs. bifurcation of the aorta [extended dissection]). The authors of the chapter describe a lymph node dissection whose proximal extent is the inferior mesenteric artery (super-extended dissection) and is more extensive than what is done by most surgeons who treat this disease. Fortunately two randomized trials have recently met accrual and closed in the United States and Germany that will provide higher-quality evidence of how different templates of lymphadenectomy affect cancer outcomes and the results of these studies are highly anticipated. Nevertheless it is clear that a lymphadenectomy is an important aspect of the radical cystectomy operation and should be done in all patients.

Preservation of erectile function in a man is challenging for any pelvic operation due to damage to the neurogenic mechanism and possibly the vasculogenic mechanism responsible for erections. The chapter outlines the anatomy of the pelvic plexus and neurovascular bundles responsible for erections that course alongside the tip of the seminal vesicles and in close continuity to the prostate fascia and urethra. Knowing the anatomy of these structures is important for potency-sparing surgery but even with concerted surgical effort to preserve the neurovascular bundles at the time of radical cystectomy the literature is limited both in number and the quality of the studies that measure erectile function after radical cystectomy. Therefore, it is not uncommon that men who desire erectile function after radical cystectomy often require penile injection therapy with vasculogenic agents or surgical placement of an inflatable penile prosthesis. Reports from France suggest that in highly selected younger patients in whom oncologic outcome is unlikely to be compromised that prostate/seminal vesicle–sparing surgery, including preserving only the prostate capsule or the apex of the prostate, leads to high potency rates after radical cystectomy by not disrupting the neurovascular bundles. This approach is somewhat controversial because of cancer recurrence risk but is worthy of discussion in very highly selected individuals.

The number of individuals in the US population who are choosing orthotopic ileal neobladder construction as opposed to an external appliance or urostomy is less than 20% however the number is slowly growing. Quality-of-life studies published to date demonstrate that there is no difference in various health-related domains between patients who choose an ostomy or an orthotopic

neobladder. This may be more a reflection of properly educating and managing patient expectations for a given urinary diversion. Importantly it can take up to 18 months to achieve daytime continence and 36 months to achieve nighttime continence for a neobladder. It is fair to assume that only 50% of men will achieve total day and nighttime continence but up to 85% will remain dry during the day and nighttime leakage is more the norm than the exception. Age and other patient factors, including body mass index, seem to impact neobladder function and continence and this can change over time. The authors of the chapter have a wealth of experience with orthotopic neobladders and have attempted to modify neobladder design to improve functionality and tested the concepts in a clinical trial design. They recently published a randomized trial that demonstrated that creating antireflux mechanisms versus a refluxing orthotopic ileal neobladder does not improve renal function at 3 years follow-up but antireflux mechanisms were associated with more urinary diversion–related procedures to correct problems. Needless to say the outcomes of an orthotopic neobladder are influenced by meticulous attention to detail and surgical experience and this type of procedure should be centralized to centers specializing in bladder cancer care.

Initially orthotopic neobladder construction was limited to male patients because of heightened concern that preserving the urethra in women would increase local cancer recurrence rates as well as increase the risk of urethral cancer recurrences. This has not proven to be the case. There are now multiple reports in the literature of large series of women following radical cystectomy and orthotopic ileal neobladder demonstrating equivalent oncologic efficacy to men with low rates of urethral cancer recurrence. Importantly a frozen section margin of the urethra submitted at the time of surgery to rule out the presence of cancer is the most predictive factor of later developing a urethral recurrence and should be sent on all cases. A urethral margin identifying the presence of cancer on frozen section is a contraindication to neobladder construction in both women and men. Detailed study of the neural innervation of the female urethra has led to modifications of the technique of radical cystectomy in an attempt to improve functional outcomes of an orthotopic neobladder in women and minimize damage to the branches of the pudendal nerve. Unlike men urinary retention or neobladder emptying failure is much more common than incontinence in women resulting in the need to perform clean intermittent catheterization (CIC) to empty the neobladder. Over the short term up to 20% of women develop neobladder emptying failure and require routine CIC but over time this number increases and as many as 60% of women will require some degree of CIC, including once or several times per day. Nevertheless most women when questioned have little regret from their choice of desiring and choosing an orthotopic neobladder. Again this may be a function of properly educating patients when they are making treatment decisions and managing expectations.

176 Laparoscopic Pelvic and Retroperitoneal Lymph Node Dissection

Ornob P. Roy and Louis R. Kavoussi

Regional lymphadenectomy is utilized for staging and treatment in a variety of urologic malignancies. Pelvic lymph node dissection (PLND) is performed in prostate, bladder, penile, and posterior urethral carcinoma. Retroperitoneal lymph node dissection (RPLND) is employed in the management of metastatic germ cell tumors. In an effort to minimize the morbidity of lymph node dissection, laparoscopic and robotic-assisted techniques have been applied to these operations.

LAPAROSCOPIC PELIC LYMPHADENECTOMY

Indications

Prostate cancer is the most common noncutaneous malignancy in men. In 2012, approximately 177,000 men were diagnosed and over 27,000 died from the disease within the United States. Patients with clinically localized disease may undergo active surveillance or primary therapy with either extirpative surgery or radiation treatment. Removal of the prostate gland may be performed via an open (perineal or retropubic) or laparoscopic (conventional or robotic-assisted) approach. Radiation therapy may be delivered by external beam or placement of interstitial implants.

No randomized studies have demonstrated a survival advantage for local therapy in patients with metastatic disease. Unfortunately, no radiologic technique exists to accurately detect lymph node metastases. Both computed tomography (CT) and magnetic resonance imaging (MRI) rely on size-based criteria to diagnose node-positive disease, resulting in sensitivities of approximately 30%. Other diagnostic modalities such as fine needle aspiration and immunoscintigraphy are also unreliable. Pelvic lymphadenectomy remains the most accurate means of detecting lymph node involvement (LNI).

In 1991 Schuessler reported the first series of patients undergoing laparoscopic pelvic lymph node dissection (LPLND) for prostate cancer. Subsequent studies demonstrated the equivalence of LPLND to open node dissection with regard to nodal yield and complication rates. Multiple series found LPLND to be associated with decreased blood loss, analgesic use, length of hospital stay, and duration of convalescence compared with open PLND.

Following its introduction, LPLND became the most commonly performed laparoscopic urologic procedure. However, its role has steadily declined following widespread utilization of prostate-specific antigen (PSA) screening, which resulted in a dramatic stage migration in favor of organ-confined disease. At present, only 5% of individuals are found to have node-positive disease at the time of diagnosis. In addition, multiple nomograms to predict LNI have been developed that are based upon routinely available parameters (clinical stage, PSA level, and histologic Gleason score), which have further obviated the need for staging lymphadenectomy. Based upon these clinical parameters, patients can be classified as having low-risk (clinical stage ≤T2a, PSA <10 ng/mL, and Gleason Score ≤6), moderate-risk (clinical stage T2b, or PSA 10–20 ng/mL, or Gleason Score 7), and high-risk disease (clinical stage ≥T2c, or PSA >20 ng/mL, or Gleason Score ≥8).

Low-risk patients do not require PLND because their risk of metastatic disease is less than 2%. Moderate- and high-risk patients should undergo node dissection at the time of either open or robotic-assisted laparoscopic radical prostatectomy. At present, indications for LPLND (conventional or robotic-assisted) include moderate- and high-risk patients intending to undergo perineal prostatectomy or radiotherapy. In addition, LPLND should be contemplated in high-risk patients being considered for open retropubic prostatectomy in order to spare them the morbidity of a lower midline incision should their nodes prove to be positive.

LPLND has been applied to other genitourinary malignancies. For bladder cancer there is essentially no role for LPLND independent of cystectomy. However, multiple reports of laparoscopic radical cystectomy with extended pelvic lymph node dissection (ePLND) have been published. The majority of these cases were robotic-assisted. Long-term functional and oncologic outcomes are encouraging, and there is evidence for oncologic benefit via increased cancer-specific survival for localized bladder cancer.

Penile squamous cell carcinoma most often metastasizes to the inguinal followed by pelvic lymph nodes. Patients with high-risk disease (tumors invading past the subepithelial connective tissue) should undergo inguinal lymph node dissection for both staging and therapeutic purposes. However, LPLND should be considered in patients with suspicious pelvic lymph nodes on imaging because inguinal lymphadenectomy provides no oncologic benefit to patients with positive pelvic nodes. In this setting, LPLND potentially spares patients the morbidity of radical inguinal node dissection, which includes chronic lymphedema and perioperative wound infections in 25% and 10% of cases, respectively.

Carcinoma of the posterior urethra is a rare, but aggressive urologic malignancy. Treatment involves cystourethrectomy with pelvic node dissection. In women, en bloc removal of the urethra, bladder, uterus, adnexa, and anterior vaginal wall is required. In many instances, resection of the pubic symphysis and inferior pubic rami are also necessary. Patients with node-positive disease have an exceptionally poor prognosis despite aggressive surgical management. Therefore, staging LPLND may spare patients with LNI the considerable morbidity of anterior pelvic exenteration.

Preoperative Planning

For patients at high-risk of lymphatic metastases, radiographic studies, such as CT of the abdomen and pelvis, should be obtained before surgery to detect gross nodal disease. If feasible, percutaneous biopsy in patients with adenopathy should be considered because it may preclude the need for surgical intervention. Bone scans are reserved for patients with prostate cancer who have a PSA ≥20 ng/mL and for individuals with prostate or bladder cancer who have an elevated alkaline phosphatase and/or bone pain suspicious for metastatic disease.

Patients who are scheduled to undergo concurrent prostatectomy or cystectomy should receive a mechanical bowel prep. A full bowel prep may be helpful in patients who are expected to have extensive intra-abdominal adhesions. A type and screen for blood products is appropriate in most cases.

A single dose of a first-generation Cephalosporin or Clindamycin should be given prior to starting the case. If the node dissection is to be done along with a prostatectomy or cystectomy, then either a first- or second-generation Cephalosporin should be used and continued for less

than 24 hours. Alternatively, an Aminoglycoside plus Clindamycin can be used.

Positioning and Setup

General anesthesia is used. Nitrous oxide is avoided given the risk of bowel distention. An orogastric tube and Foley catheter are placed to decompress the stomach and bladder. The genitalia are wrapped with a compressive dressing to prevent tracking of carbon dioxide (CO_2) into the penis and scrotum.

The patient is placed in the supine position with both arms secured at the side (Fig. 176.1). Patients undergoing robotic-assisted LPLND are placed in the low lithotomy position. This position is also utilized for patients undergoing concurrent prostatectomy or cystectomy. All pressure points are adequately padded to prevent compression injury. Extended time in the lithotomy position places the peroneal nerve at increased risk of injury due to its superficial location as it passes around the head of the fibula. Peroneal neuropraxia results in a foot drop.

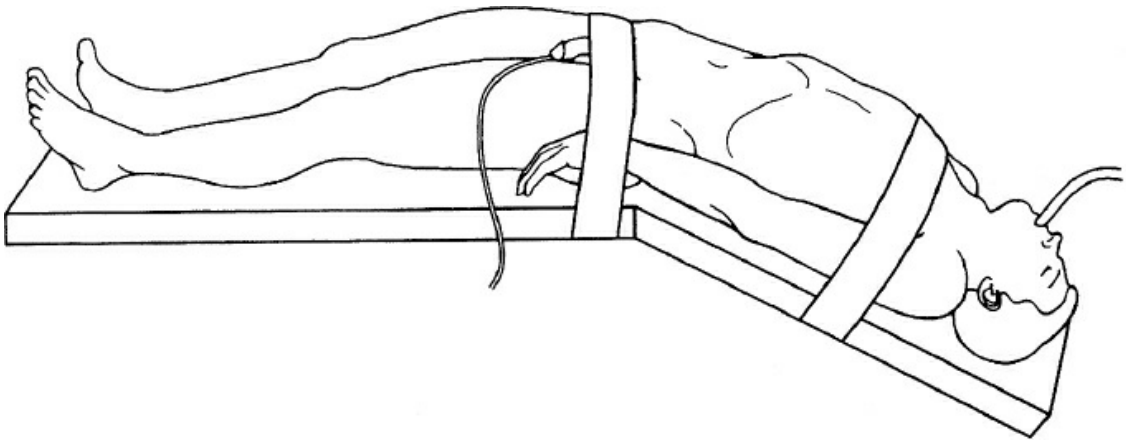

Figure 176.1. The patient is positioned supine, and, after trocar placement, the table is flexed to move the bowel out of the pelvis. A bladder catheter and orogastric tube are placed. The patient is secured to permit maximal table rotation.

The positioning of the surgical team is represented in Figure 176.2. The anesthesiologist is at the head of the table. The operating surgeon is on the contralateral side of the table from the lymph node packet to be excised. The assistant is opposite the surgeon while the scrub nurse and Mayo stand are placed adjacent and superior to the operating surgeon. The video equipment is placed at the foot of the table such that the surgeon is facing

the same direction as he or she is operating. In robotic-assisted cases the Da Vinci patient-side cart (Intuitive Surgical, Sunnyvale, CA) is docked between the patient's legs. The surgeon is located at the console and the assistant at the patient's right side. The ports placed the same except for the suprapubic 12-mm assist port, which is instead placed 2 cm cephalad and medial to the anterior superior iliac spine on the right.

Port Placement

The abdomen is entered using either a Veress needle or the Hasson technique at the base of the umbilicus. If the Veress needle is employed, the surgeon's hand or towel clamps are used to elevate the abdominal wall away from the viscera. Proper needle placement is confirmed by observing a low intra-abdominal pressure during initiation of pneumoperitoneum and by the saline "drop test." Insufflation is continued until an intra-abdominal pressure of 20 mm Hg is achieved, which is decreased to 15 mm Hg once the trocars have been placed.

A 1-cm incision is made at the umbilicus. A hemostat is used to separate the subcutaneous fat down to the fascia. A laparoscope with a 0-degree camera lens is placed within a 10-mm Visiport (U.S. Surgical, Norwalk, CT) or Optiview (Ethicon Endosurgical, Cincinnati, OH) incising visual obturator. The camera is focused on the tip of the obturator. The camera and trocar are advanced into the peritoneal cavity under direct vision. After removal of the obturator, a 30-degree lens is placed through the umbilical trocar. The abdominal cavity is inspected to rule out viscus or vascular injury. The abdominal wall is transilluminated with the laparoscope to identify blood vessels that may be injured, in particular the inferior epigastric vessels, during placement of the remaining ports under direct visualization.

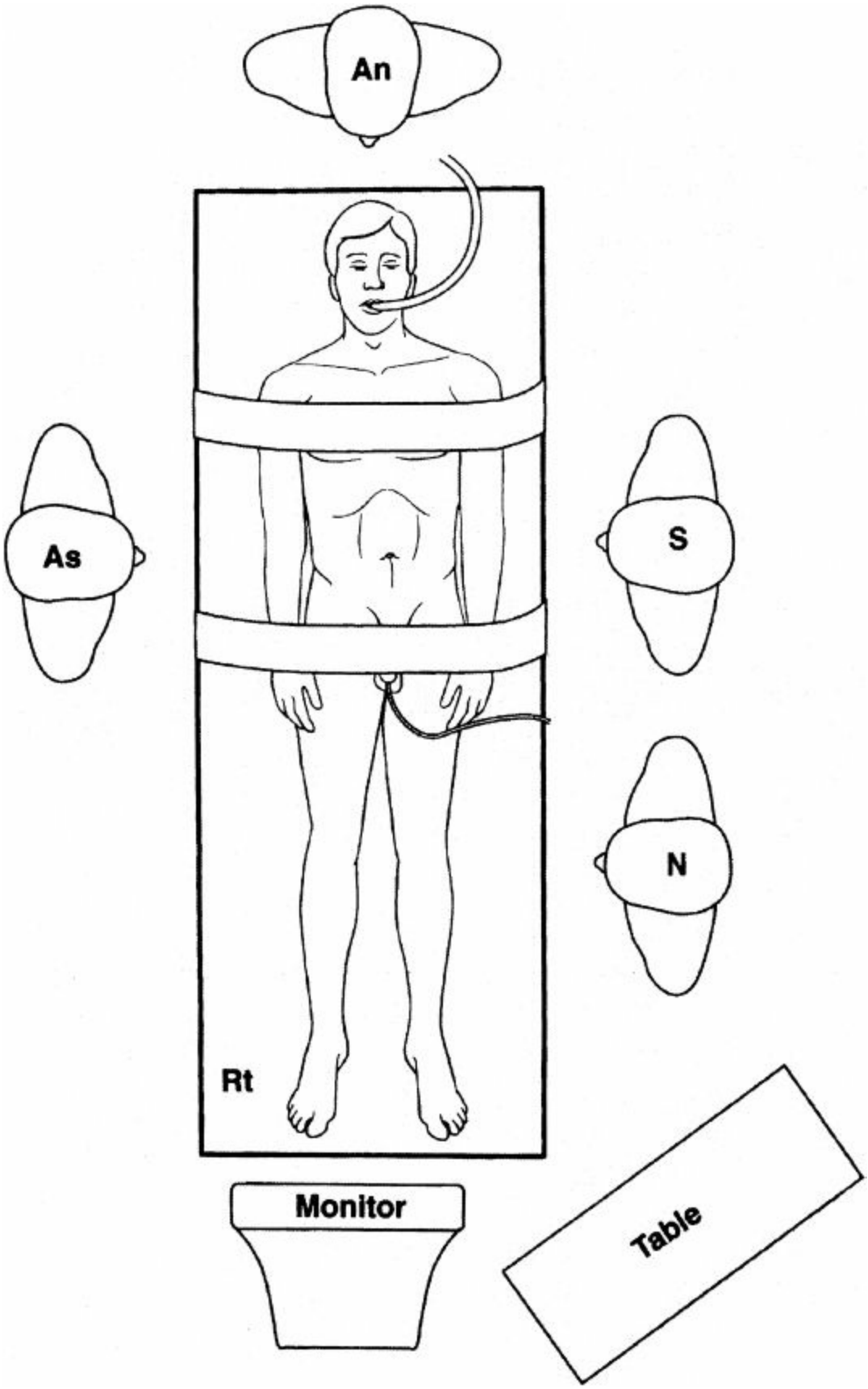

Figure 176.2. Surgical team is positioned as depicted for laparoscopic pelvic lymph node dissection. An, anesthesiologist; As, assistant surgeon; N, scrub technician or nurse; S, surgeon.

The typical port site pattern is illustrated in Figure 176.3A. A "diamond" configuration is most commonly used. The camera is usually situated at the umbilical port. A trocar is placed approximately four fingerbreadths above the pubic bone along the midline. The lateral trocars are placed one third of the way from the umbilicus to the anterior superior iliac spine on each side. In obese patients, a "fan" configuration facilitates retraction and dissection (Fig. 176.3B). For the nonumbilical ports, any combination of 5-mm and 10-mm ports is acceptable, depending on the surgeon's preference. The port site pattern for patients undergoing concurrent radical prostatectomy or cystectomy is typically different and is outside the scope of this chapter. Following port placement, the patient is then placed in the Trendelenburg position, which aides in keeping the intestines out of the pelvis during the dissection.

Surgical Technique

Pertinent anatomic landmarks for pelvic lymphadenectomy are illustrated in Figure 176.4. The node dissection template varies by indication. The anatomical boundaries for patients with moderate- and high-risk prostate cancer undergoing standard template dissection include the pubic bone distally, the bifurcation of the common iliac vessels proximally, the external iliac vein anteriorly, the obturator nerve posteriorly, the medial umbilical ligament medially, and the pelvic sidewall laterally.

Although controversial, several recently published observational series support a potential survival advantage for patients undergoing lymphadenectomy in the setting of limited nodal burden. These data, combined with studies showing up to half of nodal metastases occur within the internal iliac nodes, which would be missed by the standard template dissection, have led some urologists to advocate for an ePLND in patients with high-risk prostate cancer. The limits of the extended lymphadenectomy include the pubic bone distally, the bifurcation of the common iliac vessels proximally, the genitofemoral nerve anterolaterally, the internal iliac artery posteriorly, the medial umbilical ligament medially, and the pelvic sidewall laterally.

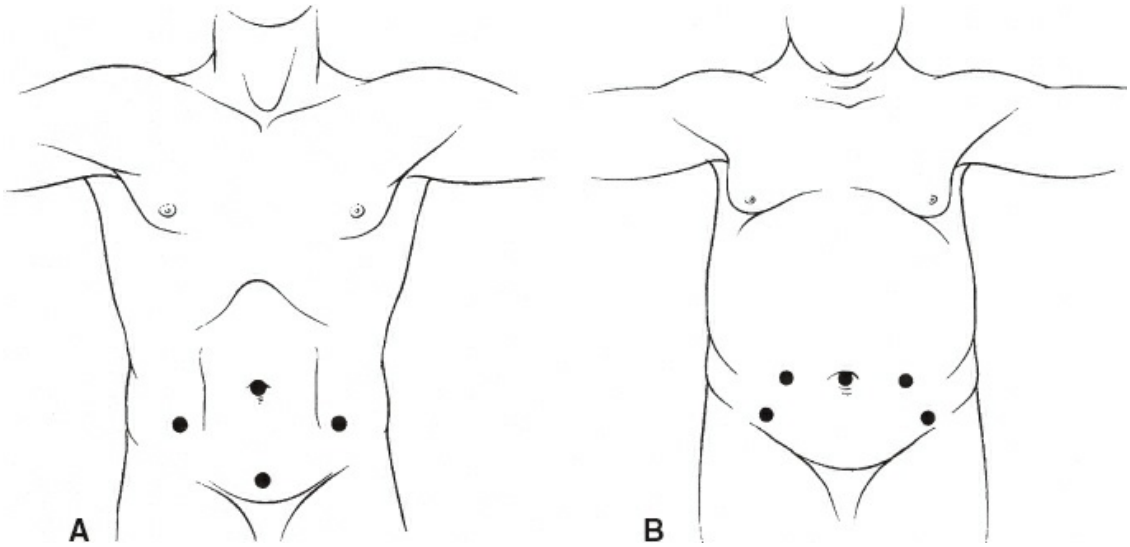

Figure 176.3. A. “Diamond” configuration for laparoscopic pelvic lymph node dissection port placement. **B.** “Fan” configuration for port placement in obese patient.

The importance of an extended node dissection in patients undergoing radical cystectomy for urothelial cell carcinoma (UCC) of the bladder is well established. The limits of the ePLND for bladder cancer are the same as for prostate cancer except the dissection is carried up to the aortic bifurcation cranially. The optimal extent of dissection for patients with penile or posterior urethral carcinoma has not been defined. However, most reports have utilized the standard prostate cancer dissection template.

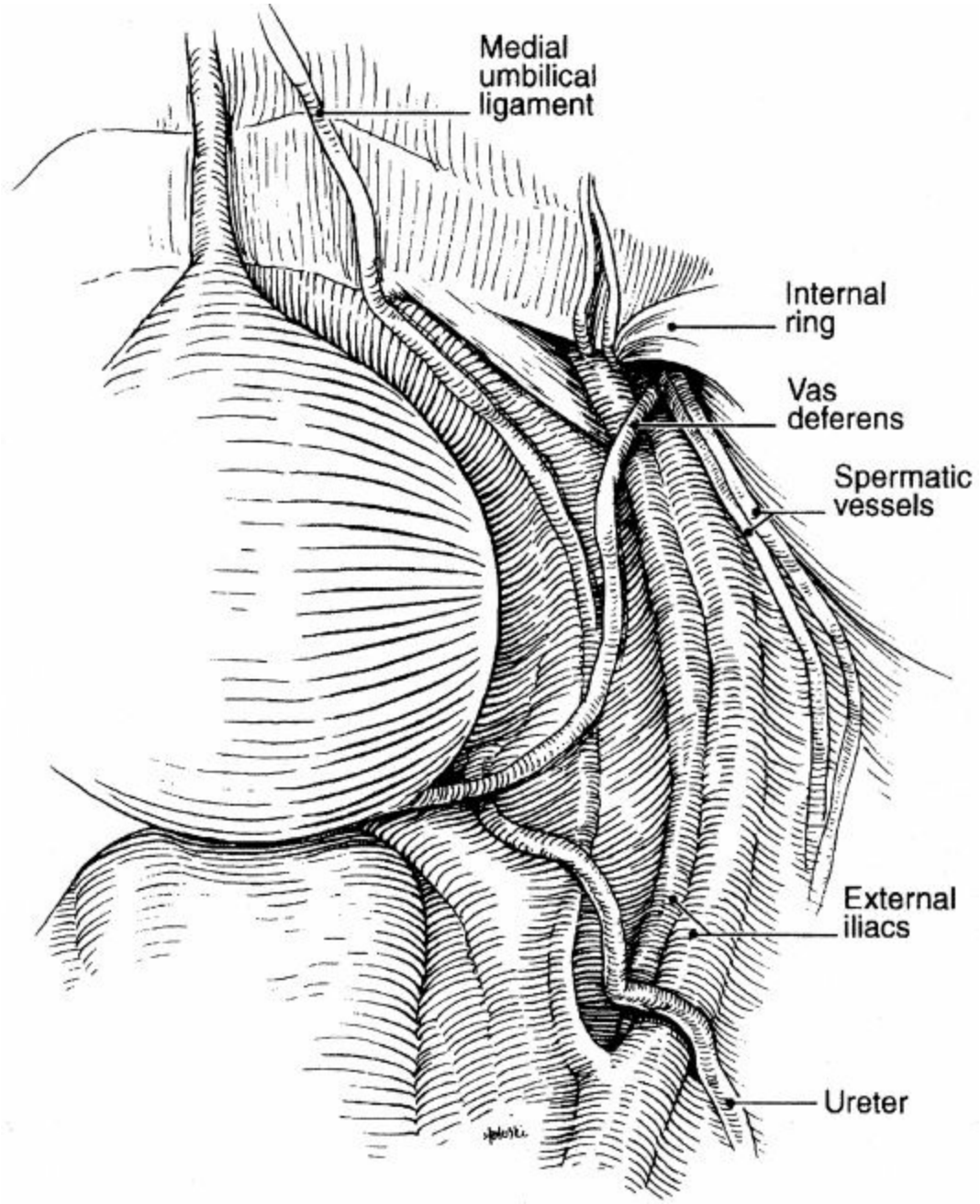

Figure 176.4. Anatomic landmarks for laparoscopic pelvic lymph node dissection.

After placing the trocars, a longitudinal incision is made in the peritoneum lateral to the medial umbilical ligament (Fig. 176.5). This extends from the pubic symphysis to just proximal to the iliac vessels. On the left side, it is quite common to encounter adhesions to the sigmoid colon that need to be incised first. For patients undergoing concurrent prostatectomy or cystectomy, the node dissection may be completed before or after the extirpative portion of the case, depending on surgeon preference.

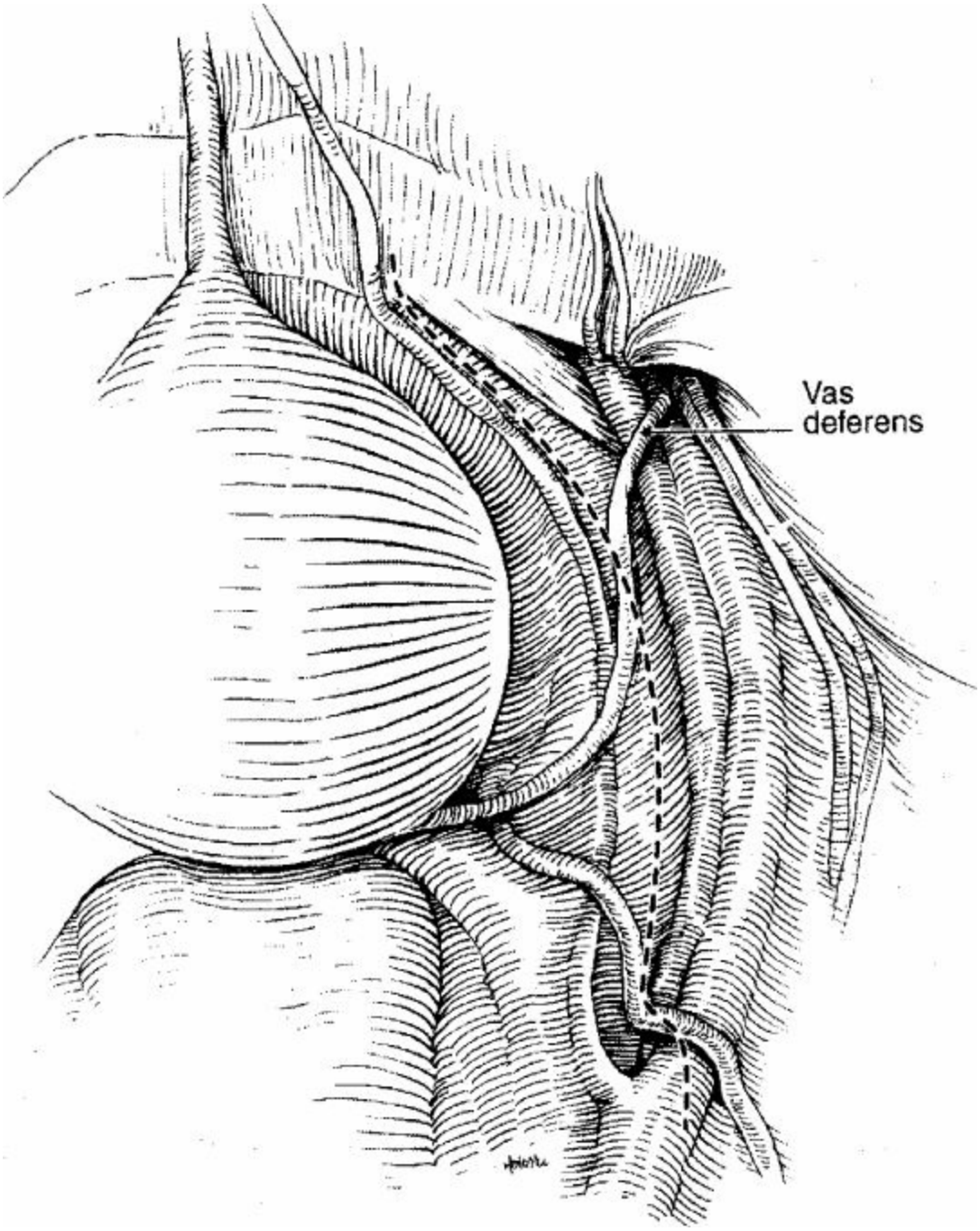

Figure 176.5. An incision is made lateral to the medial umbilical ligament. This is extended from the pubic bone to the bifurcation of the common iliac vessels.

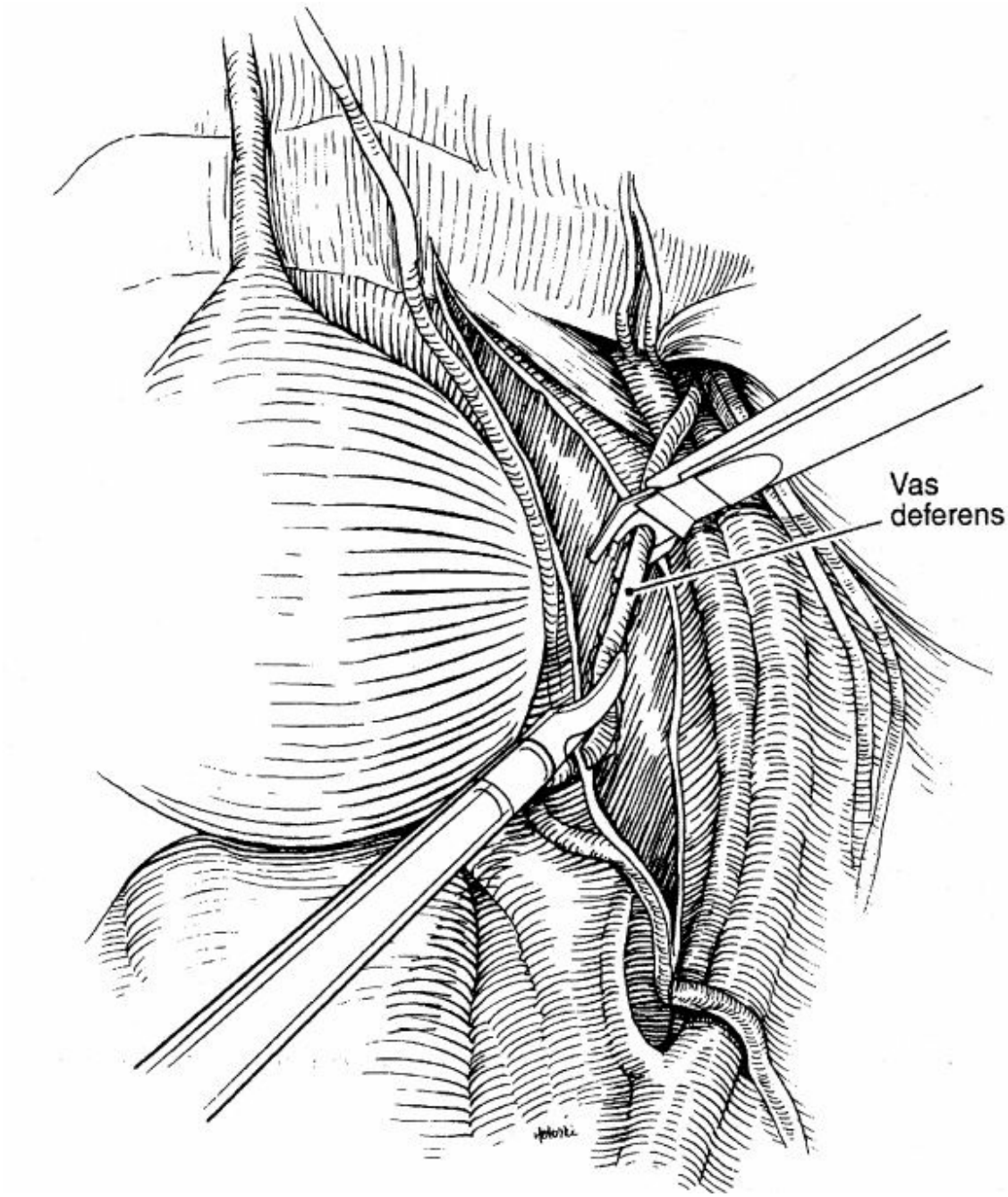

Figure 176.6. The vas deferens is identified, ligated, and divided.

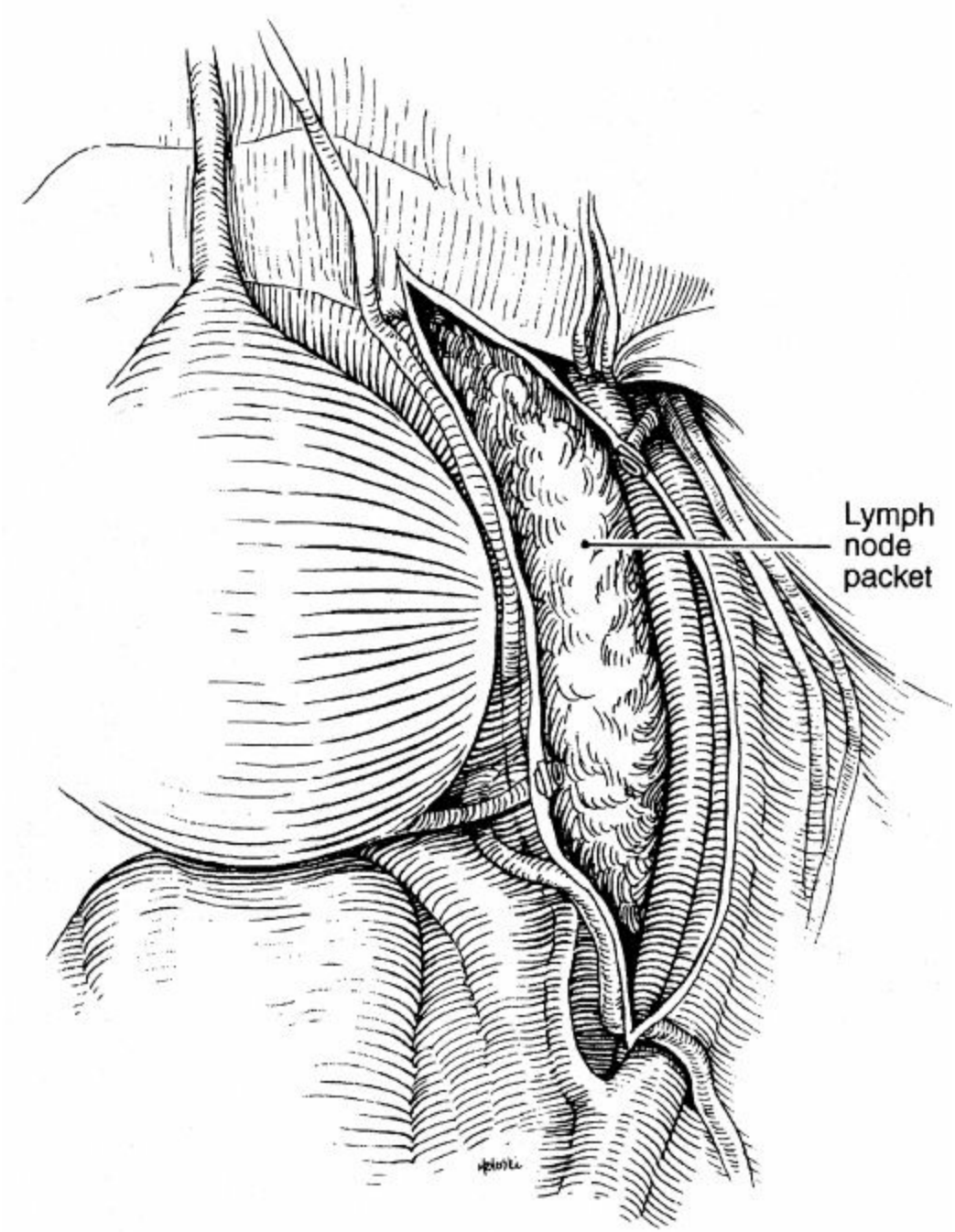

Figure 176.7. The lateral edge of the lymph node packet is developed. The medial edge of the iliac vein and the nodal tissue are identified.

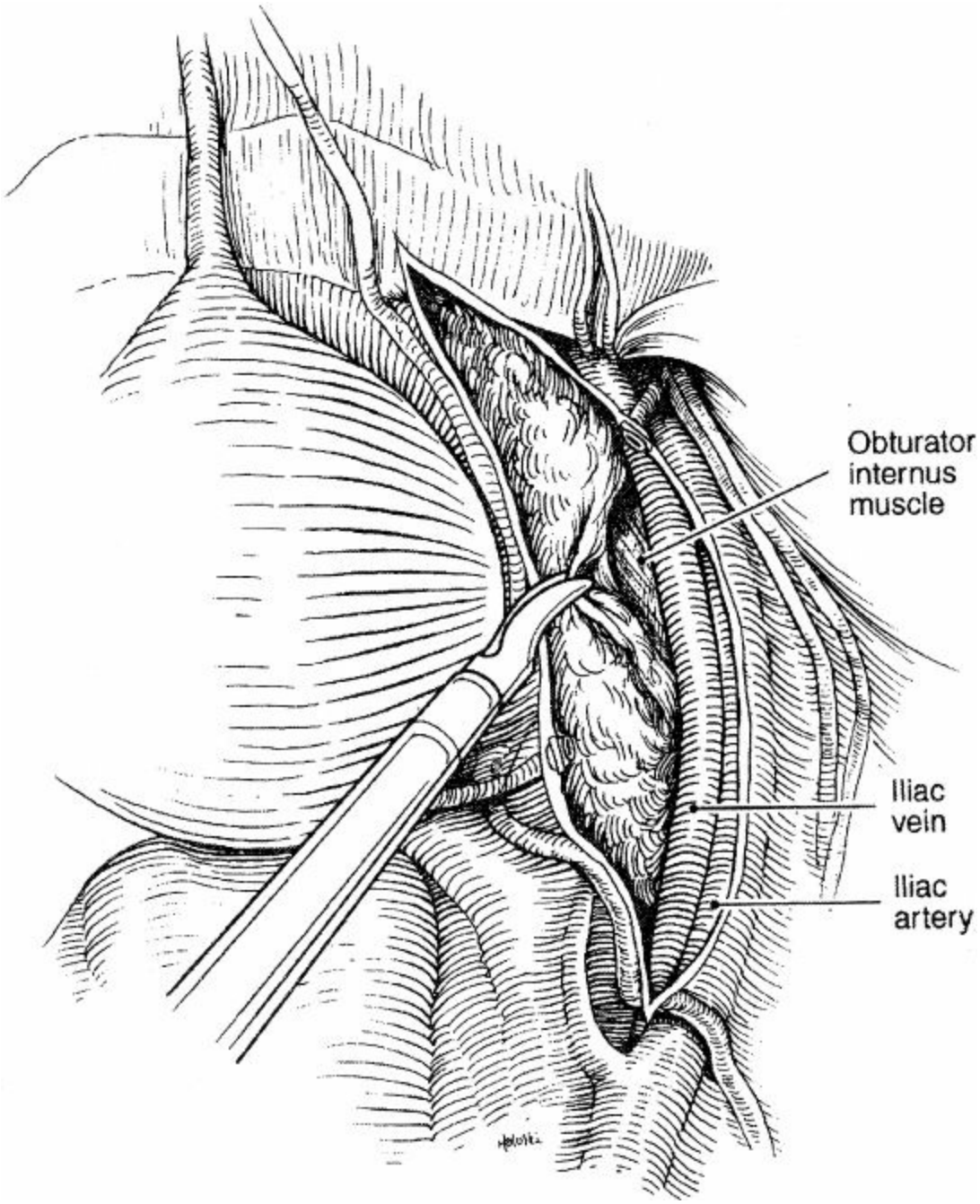

Figure 176.8. The nodal packet is dissected off the obturator internus muscle, and the dissection proceeds proximally toward the junctions of the medial umbilical ligament and the bifurcation of the iliac vessels.

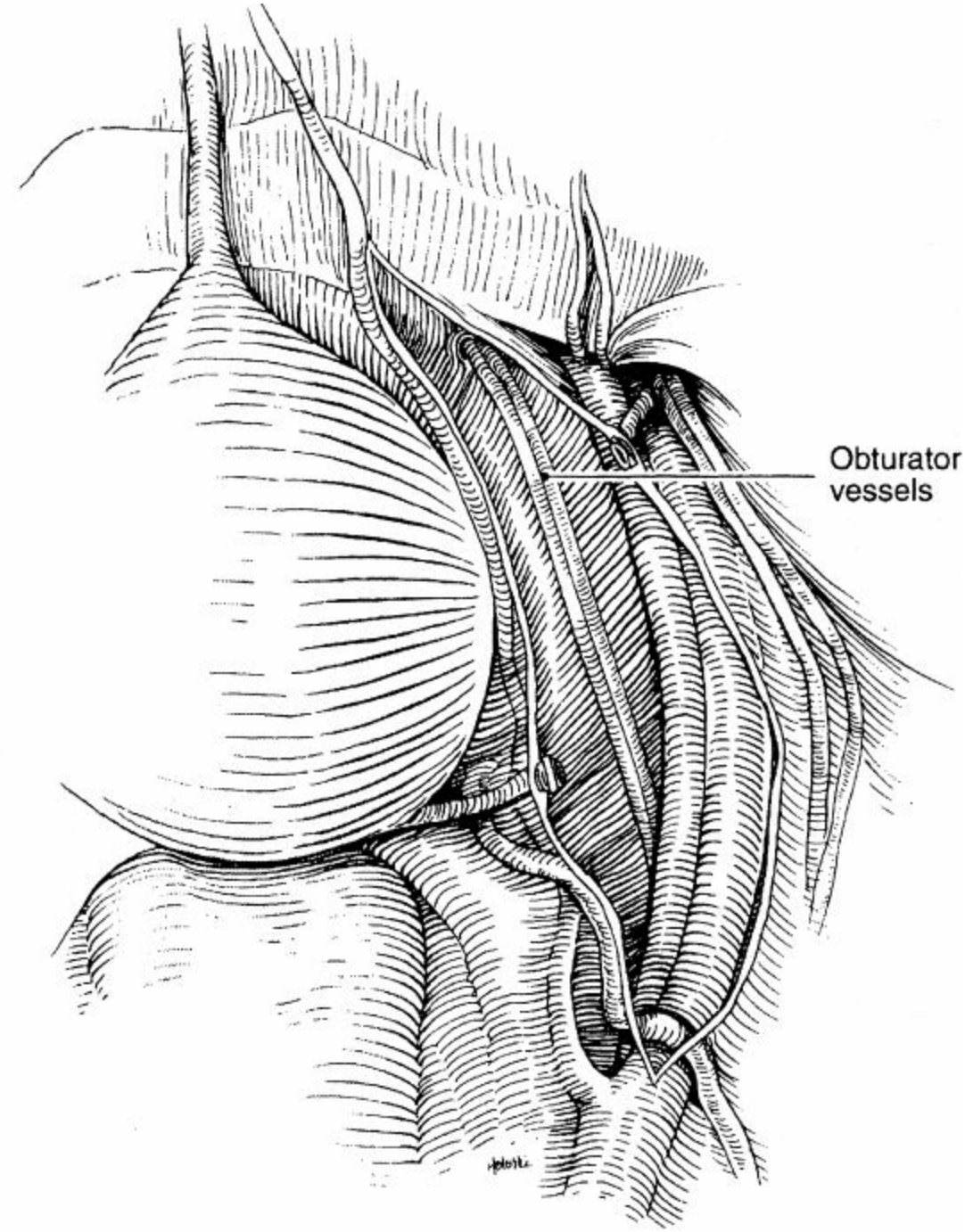

Figure 176.9. With the lymphatic tissue dissected free, the obturator nerve vessels should be visible.

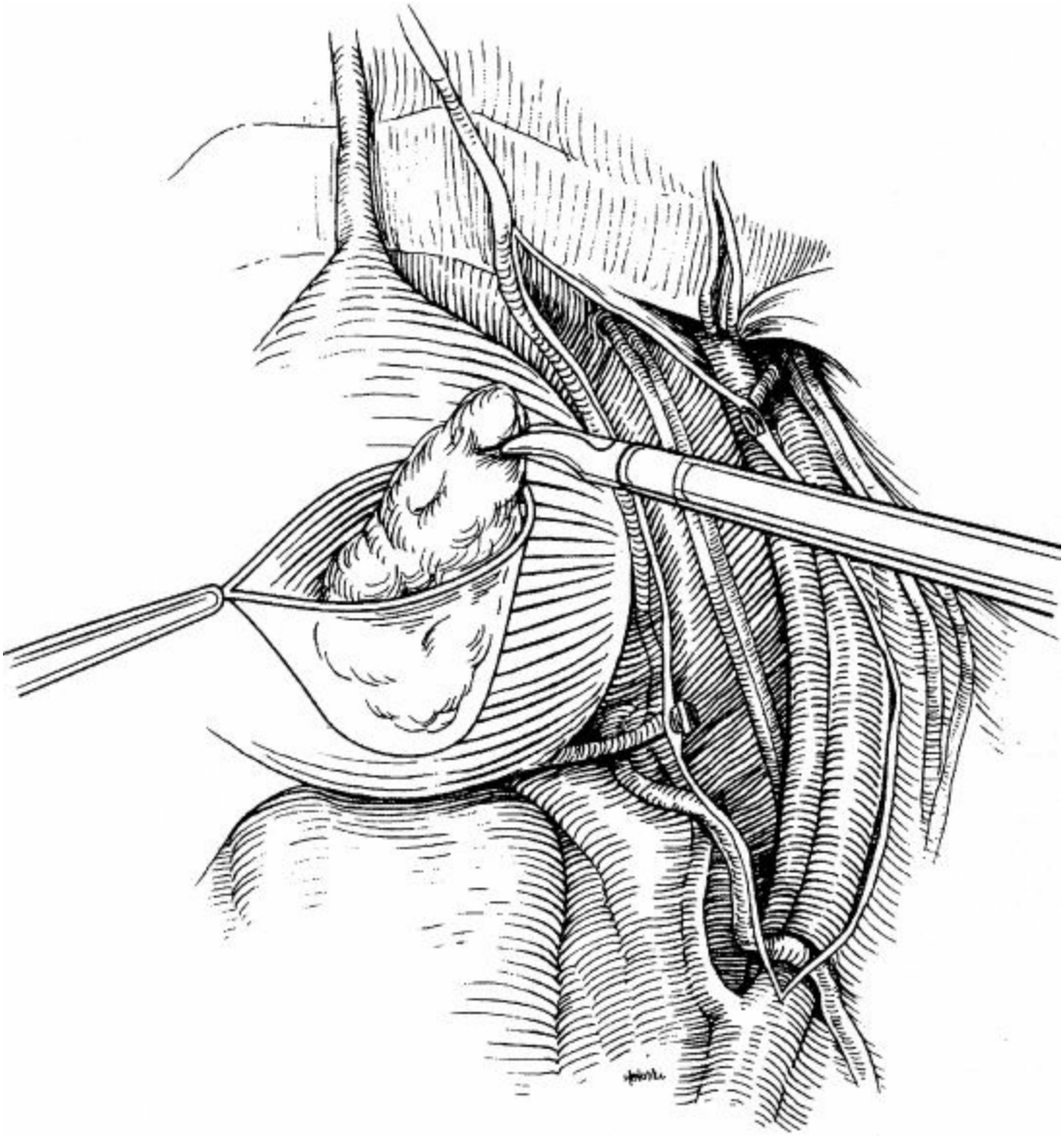

Figure 176.10. The lymphatic tissue is extracted. Depending on specimen size, it can be extracted with an Endocatch bag.

Once the peritoneum is opened, the vas deferens is identified and divided (Fig. 176.6). Next, the medial edge of the external iliac vein is identified and, by retracting the nodal tissue medially, the nodes are freed from the pubic bone to the bifurcation of the common iliac vessels (Fig. 176.7). This defines the lateral border of the nodal packet. The nodal packet is then dissected free posteriorly from the obturator internus muscle. The dissection proceeds proximally toward the junction of the medial umbilical ligament and the bifurcation of the iliac vessels (Fig. 176.8). This maneuver exposes the obturator nerve and vessels (Fig. 176.9). Care must be taken to avoid injury to the ureter, which lies medial at this point.

The medial boundary of dissection is defined by retracting the umbilical ligament medially while pulling the nodal packet laterally. Blunt dissection is usually sufficient to free the nodal tissue along this plane. Distal attachments beneath the pubis are clipped and transected. The entire packet is pulled cranially, and the remaining attachments located at the junction of the medial umbilical ligament and the internal iliac artery are clipped and divided. The specimen can then be extracted using an Endocatch bag (U.S. Surgical, Norwalk, CT) or a laparoscopic spoon forceps (Fig. 176.10). The contralateral side is addressed in a similar fashion.

The extended dissection for prostate cancer begins with the external iliac packet. The adventitia overlying the external iliac vein is divided distally near the superior pubic ramus. The nodal tissue is then retracted medially, and the dissection is carried proximally to the bifurcation of the common iliac vessels. The fibroalveolar tissue just medial to the genitofemoral nerve is divided, and the packet is swept off of the psoas muscle. Clips are usually required along the proximal and distal extents of dissection. The obturator packet is then dissected, as previously described. Dissection of the internal iliac nodal packet is then performed. If not readily apparent after removal of the external iliac and obturator nodal tissue, the origin of the internal iliac artery is identified by tracing the medial umbilical ligament to its origin. The dissection is continued from the origin of the internal iliac vessels down to the floor of the pelvis. Care is taken not to damage the obturator nerve or avulse the obturator vessels. This completes the extended node dissection for patients with prostate cancer (Fig. 176.11). In patients undergoing a radical cystectomy, the dissection is carried up the common iliac vessels to the aortic bifurcation.

The prostatectomy or cystectomy portion of the case is then performed, if indicated, or if not done prior to the node dissection. Upon completion, the pressure within the abdomen is reduced to 5 mm Hg to evaluate for occult sources of bleeding. Hemostasis is achieved using electrocautery, surgical clips (metal or polymer), and hemostatic agents. A final survey of the peritoneal cavity is performed to check for visceral injury. If utilized, the robotic patient-side cart is undocked. The ports are then removed under direct visualization to rule out the onset of abdominal wall bleeding. Closure of the fascia is not required for 5-mm port sites but is for 10/12-mm ports to prevent hernia formation. The fascia may be repaired extracorporeally following evacuation of the pneumoperitoneum or

laparoscopically with the Carter-Thomason (Inlet Medical, Eden Prairie, MN) or Endoclose (U.S. Surgical, Norwalk, CT) devices. Before securing the last trocar site, an effort is made to expel all CO_2 from the peritoneum. The port site skin incisions are closed with absorbable sutures in a subcuticular fashion or with skin glue.

Postoperative Management

For patients undergoing LPLND alone, the orogastric tube is removed at the end of the procedure. The Foley catheter is discontinued when the patient is ambulatory. Oral intake is begun the evening of surgery. The length of hospitalization is usually less than 24 hours. Patients undergoing laparoscopic prostatectomy with PLND are typically discharged on postoperative day 1 with the Foley in place for 7 to 10 days. Laparoscopic cystectomy patients have a longer length of stay primarily due to the urinary diversion portion of the case.

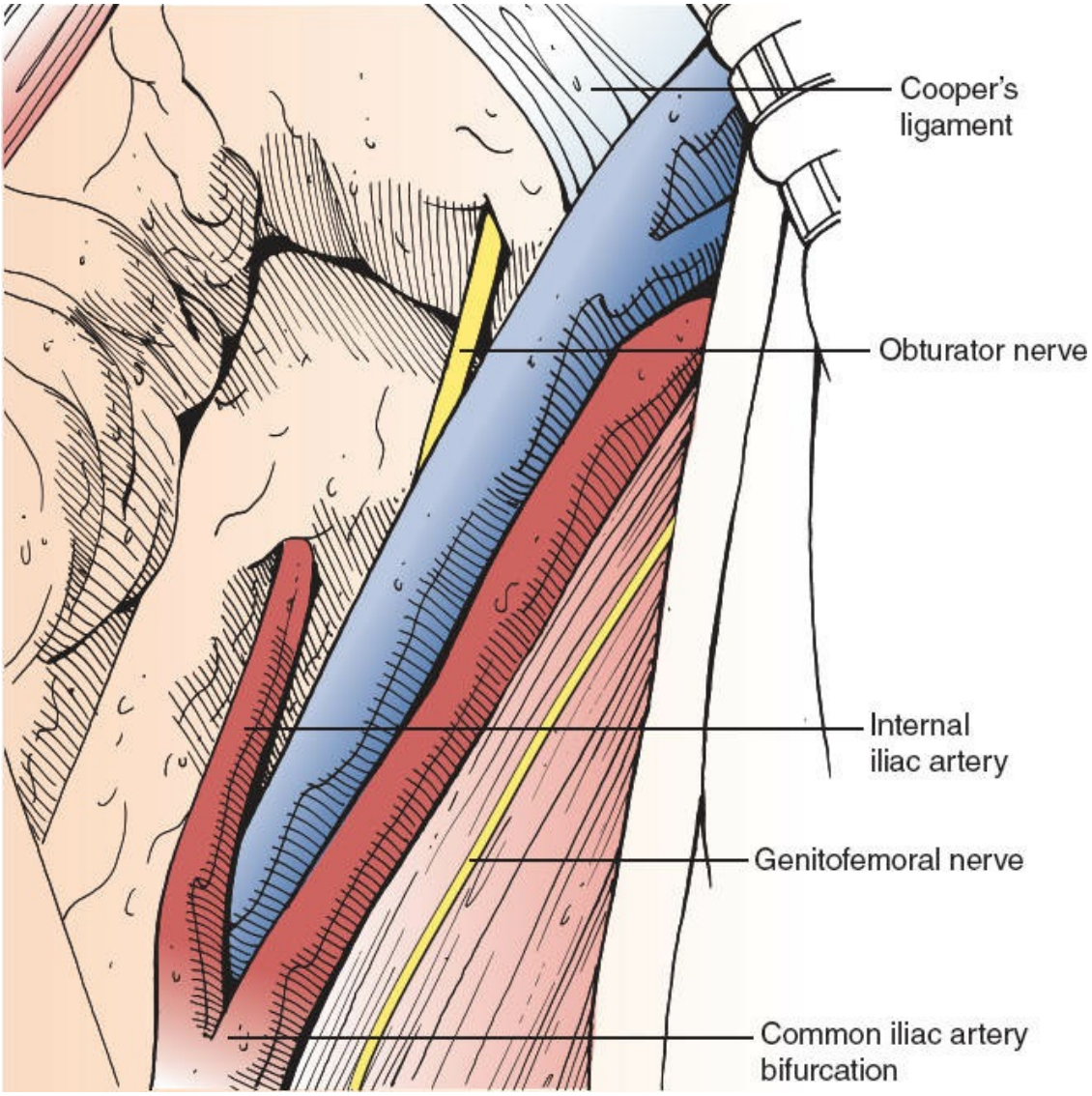

Figure 176.11. Completed extended pelvic lymph node dissection.

Complications

General complications of LPLND are similar to those seen in all laparoscopic cases and include ileus, deep vein thrombosis, and urinary retention. Vascular injuries can occur during trocar placement or nodal dissection. Most commonly, the inferior epigastric vessels are injured during lateral trocar placement. The external iliac and obturator vessels can also be injured during nodal dissection. Despite the close proximity of these vessels, vascular injury is rare, occurring in approximately 2% to 3% of cases.

Care must be taken to identify and avoid clipping or transecting the obturator nerve. Injury results in the inability of the patient to adduct the

thighs. Injury to the ureter, especially during extended dissections, is also possible. Meticulous hemostasis and attention to anatomical relationships help in the identification of these structures, thereby minimizing the risk of injury.

Viscus injuries are also rare; most of these are bowel and bladder injuries. These injuries can occur during trocar placement or dissection. Decompression by orogastric tubes or Foley catheters can minimize the potential for these injuries. Injuries that are recognized intraoperatively should be repaired promptly. Unrecognized bowel injuries often present 2 to 7 days postoperatively with a low-grade fever, persistent ileus with mild distention, possible leukopenia, and notable trocar site pain. A low index of suspicion must be maintained at all times resulting in prompt imaging of the abdomen and pelvis with subsequent surgical repair if a bowel injury is found.

Lymphocele formation is a complication of both open and laparoscopic PLND. Some studies suggest that this complication is more common with extended dissections. The transperitoneal approach may decrease its incidence. Lymphocele management includes open, percutaneous, or laparoscopic drainage.

The overall complication rate for LPLND varies from 3% to 33% depending upon series, with a mean of approximately 15%. This rate is comparable to open series. Reported complications following ePLND have also varied in the literature, ranging from 4% to 36%. An overall complication rate of 20% is not unexpected, which once again is roughly equivalent to open series. The vast majority of complications are minor and require no intervention.

RPLND is utilized in patients with metastatic germ cell tumors, select gynecologic malignancies, and sarcomas of the cord. Retroperitoneal node dissections are also utilized for select patients with transitional cell carcinoma of the upper tract and renal cell carcinoma (RCC). Laparoscopic techniques have been applied to these operations to minimize morbidity.

LAPAROSCOPIC RETROPERITONEAL LYMPHADENECTOMY

The most common application of laparoscopic retroperitoneal lymph node dissection (LRPLND) is in the treatment of select patients with testicular cancer. Testicular cancer is the most common solid malignancy in men

aged 15 to 35. Fortunately, with advances in chemotherapy, radiotherapy, and surgery, significantly improved survival is seen with all stages of this disease. Sensitive biomarkers (e.g., β-human chorionic gonadotropin, α-fetoprotein) and modern axial radiologic imaging have improved staging, allowing for tailored treatment.

Surgery has multiple roles in the treatment of testicular cancer. Radical orchiectomy is the only modality that currently can reliably control the primary growth of the tumor. It also establishes the histologic diagnosis and along with biomarkers, and radiographic imaging, aids in creating individual treatment algorithms.

Testis cancer spreads in a predictable fashion to the retroperitoneal lymph nodes. The patterns of distribution of lymph node metastasis have allowed for the creation of modified templates that preserve the sympathetic nerves that are responsible for normal antegrade ejaculation (Figs. 176.12 and 176.13). RPLND in select patients can give valuable staging information, which dictates further therapy. In addition, RPLND can be therapeutic, particularly those with residual retroperitoneal tissue following chemotherapy.

The classification of testicular cancer can be broadly divided into germ cell or non-germ cell tumors. The germ cell tumors are further subclassified into seminomatous and nonseminomatous germ cell tumors. Further treatment is guided by appropriate staging and the knowledge that most of these tumors initially spread to the retroperitoneal lymph nodes (Figure 176.13). For low-stage disease, strict surveillance protocols, single-agent primary chemotherapy, and primary radiation therapy to the retroperitoneum are widely utilized. Higher-stage seminoma is approached with multi-agent chemotherapy.

The treatment options for stage I nonseminomatous germ cell testicular tumors (NSGCTs) include surveillance, primary chemotherapy, and RPLND. Most patients are cured regardless of which initial option is chosen. Therefore, individual factors, cost, and associated morbidity are important in making individual decisions.

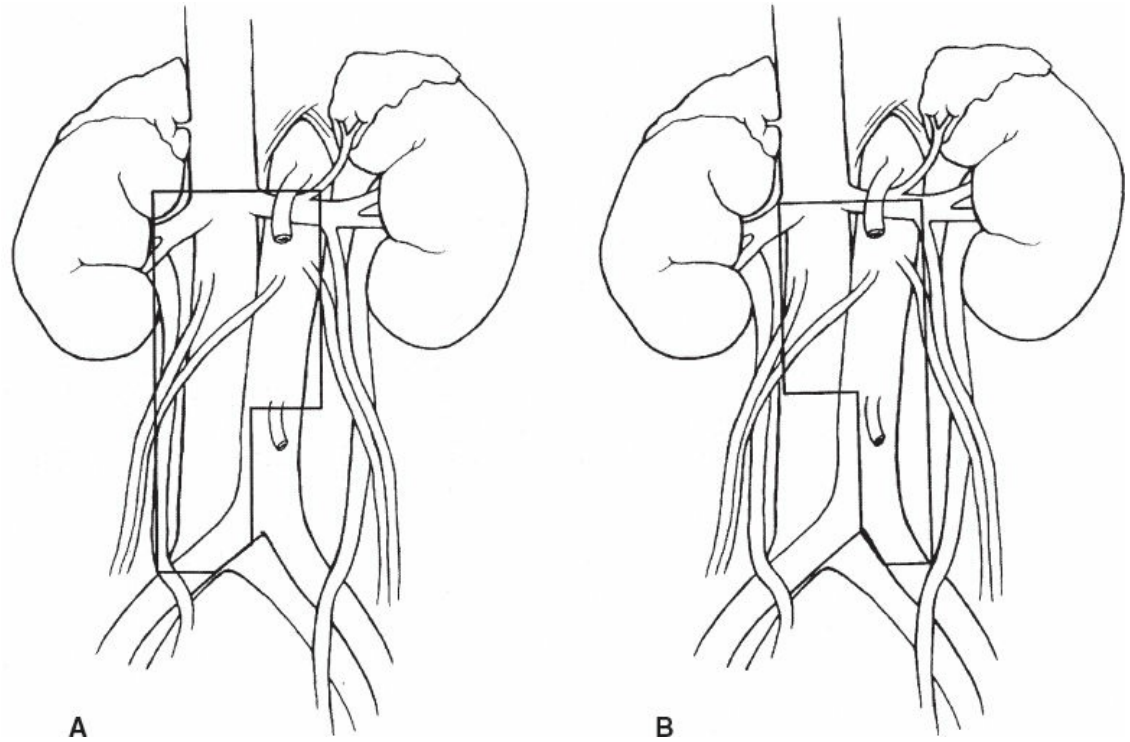

Figure 176.12. **A.** Modified template for right retroperitoneal lymph node dissection. The template is defined by the left renal vein superiorly, the ureter laterally, the bifurcation of the common iliac vessels inferiorly, and the vena cava medially. **B.** Modified template for left retroperitoneal lymph node dissection. The limits of dissection are the left renal vein superiorly, the ureter laterally, the bifurcation of the common iliac vessels inferiorly, and the vena cava medially.

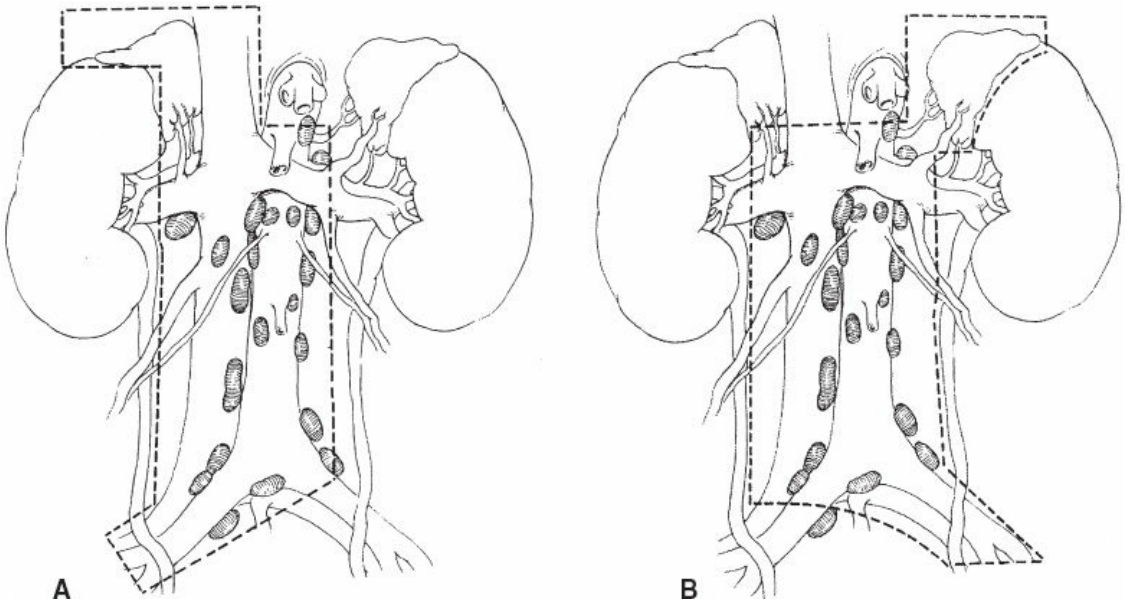

Figure 176.13. **A.** The limit for a bilateral right-sided retroperitoneal lymph node dissection for residual disease after

chemotherapy. **B.** The limit for a bilateral left-sided retroperitoneal lymph node dissection for residual disease after chemotherapy.

RPLND may ultimately overtreat 70% of patients, because these clinical stage I patients have pathologically negative nodes. It is also associated with potential complications as well as a significant incision and postoperative course. However, fertility can be preserved in the majority (75%) of patients. Also, RPLND can be utilized to remove residual retroperitoneal masses following chemotherapy.

In an effort to further decrease the morbidity associated with open RPLND, LRPLND was developed. During laparoscopic surgery, magnification provided by the endoscope can facilitate identification. The application of laparoscopic techniques to this procedure results in a shorter hospital stay, quicker convalescence, less postoperative pain, and improved cosmesis over the traditional open approach. Recent meta-analysis suggests rates of staging accuracy and long-term outcome similar to open RPLND. These meta-analyses also indicate that although operating room times are longer for LRPLND (204 minutes) when compared to open RPLND (186 minutes), length of hospital stay, postoperative analgesic requirements, and complication rates favor LRPLND.

Retroperitoneal lymphadenectomy has more recently been advocated for UCC. RPLND may provide prognostic information in upper tract UCC at the time of nephroureterectomy. Further study is required for RPLND in UCC patients before establishing its utility. The template for lymph node resection in the above scenarios would be similar to that for NSGCT, namely a modified unilateral template for upper tract UCC.

The role of RPLND in RCC is also unclear. Recent literature has suggested that removal of lymph nodes at the time of nephrectomy does not result in a significant increase in complications. Potential benefits include removal of the 10% of clinically undetected local LNI and providing more accurate staging for adjuvant systemic therapies. It does seem that only patients with clinical stage T2 or higher would benefit from RPLND in RCC, because of the very low rates of retroperitoneal lymph node metastasis in patients with lower stage disease. No established template has been agreed upon for lymph node resection due to the variability of renal lymphatic drainage; however, the perihilar nodes would comprise the minimum nodal packet.

Because of the lack of consensus for RPLND in UCC and RCC, in the

following sections we will discuss its role only in testicular cancer.

Indications

RPLND can be used for both staging and treatment of retroperitoneal disease. Suggested utility is most in patients with NSGCT with Stage I and Stage IIa disease and select, low-volume Stage IIb disease. Currently there is no convincing indication to perform RPLND in cases of pure seminoma, although nontemplated resection of residual masses after chemotherapy is supported.

In RPLND, all nodal tissue within the template is excised, including retroaortic and retrocaval tissue. Identification of those patients with pathologically negative nodes avoids the unnecessary morbidity associated with chemotherapy. These individuals still need to be followed, as 10% may develop extraretroperitoneal recurrences. Patients found to have positive nodes at the time of RPLND are subsequently offered observation or chemotherapy. With observation roughly 15% to 30% of individuals with low volume disease will develop recurrent disease, with the most common extraretroperitoneal site in the chest, and require further treatment. If large volume disease is found, more than 80% of individuals will have recurrence, again usually in the chest.

RPLND also has a role in the management of residual disease after chemotherapy. Of resected residual masses after chemotherapy, approximately 50% will have necrosis, 35% will contain teratoma, and 15% will harbor viable tumor. The inability to reliably differentiate tumor from necrosis nonoperatively and the risk of malignant transformation of teratoma to adenocarcinoma or sarcoma usually calls for surgical removal of residual disease. Chemotherapy obliterates the natural tissue planes, increasing the morbidity associated with open and laparoscopic RPLND.

Contraindications for primary RPLND include presence of extranodal metastatic disease or active peritoneal or abdominal wall infection. Patients with excessive bulky adenopathy or bleeding diathesis may best be approached with an open dissection. As mentioned previously, care should also be taken when approaching patients who have had previous chemotherapy. Dense scar tissue that forms in the retroperitoneum after chemotherapy can make dissection difficult. As such, these patients are at increased risk of vascular injury. Conversion to open surgery during a laparoscopic dissection is thus more likely in these cases, and patients should be counseled with respect to this possibility.

Preoperative Planning

Before undergoing RPLND, the patient should have a complete metastatic evaluation, including abdominal CT, chest CT, or chest radiograph; liver function tests; and bone scan as indicated. Serum markers for testis cancer, such as α-fetoprotein, β-human chorionic gonadotropin, and lactate dehydrogenase, should be obtained. Persistent elevation of these markers following orchiectomy indicates the presence of metastatic disease, which usually requires chemotherapy. Preoperative sperm banking should be discussed.

A mechanical bowel preparation is helpful. In postchemotherapy patients and cases where dense adhesions are anticipated (history of multiple abdominal surgeries), a full bowel prep may be indicated. Antibiotic coverage with a first-generation cephalosporin is given.

Blood should be sent for type and screen. Postchemotherapy patients should be typed and cross-matched for at least two units of packed red blood cells owing to the increased risk of vascular injury. For laparoscopic cases, a laparotomy tray should be readily available in the event that open conversion is required.

In patients who have undergone prior chemotherapy, several precautions need to be taken. Bleomycin-induced pulmonary fibrosis puts patients at risk for postoperative adult respiratory distress syndrome (ARDS). As such, screening pulmonary function studies should be obtained along with a baseline arterial blood gas. Patients should be well hydrated preoperatively; however, fluid replacement intraoperatively should be judiciously administered, as large volumes of fluid can increase the risk of developing postoperative ARDS.

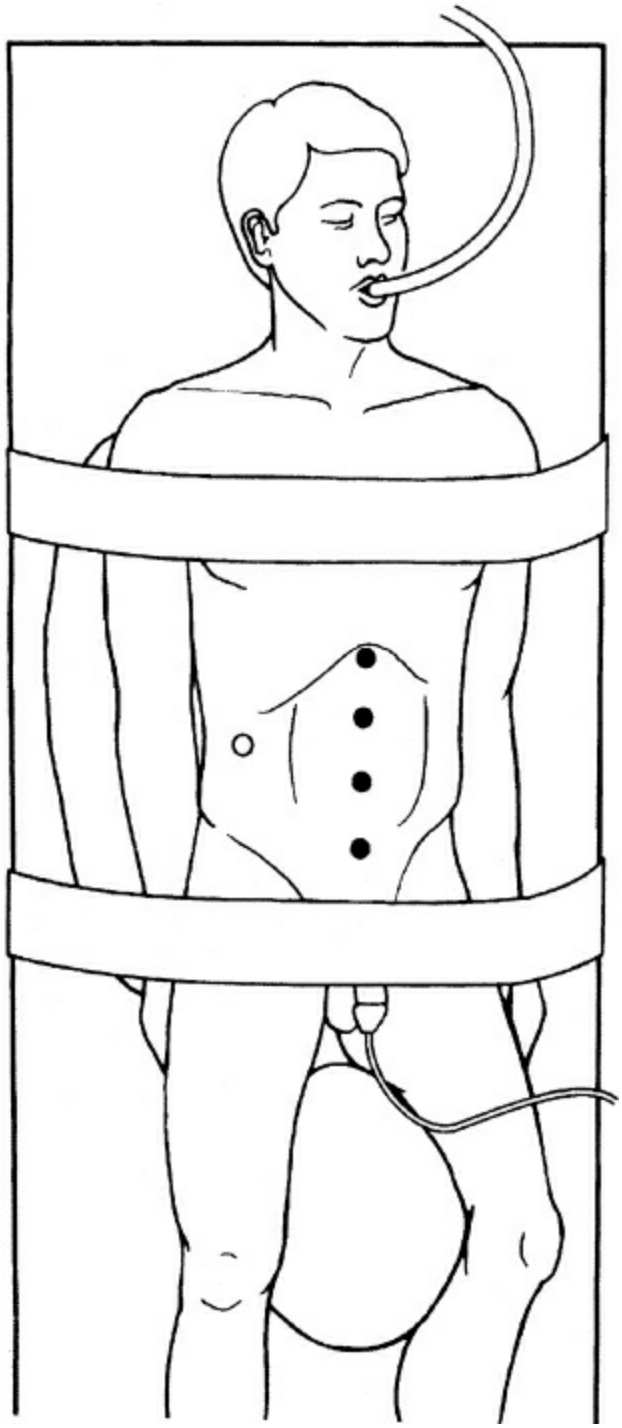

Figure 176.14. Patient and trocar positioning for right laparoscopic retroperitoneal lymph node dissection. The patient is placed in the modified flank position and secured such that the table can be maximally rotated. A bladder catheter and orogastric tube are placed. Four 10-mm ports are placed in the midline (*black circles*). A fifth port is placed in select situations (*open circle*).

Platinum-based regimens can also result in renal toxicity. As such, care

should be taken to avoid additional nephrotoxic agents in the postoperative period. Myelosuppression is also a side effect of chemotherapy regimens. This is self-limited, but adequate time (~5 weeks) should pass after chemotherapy before offering surgical intervention.

Laparoscopic Positioning and Setup

After induction of general anesthesia, an oral gastric tube and Foley catheter are placed. The patient is placed supine with both arms tucked (Fig. 176.14) and sequential compression devices on the lower limbs. The chest, shoulders, and hips are immobilized with heavy cloth tape to permit maximal table rotation during the procedure. For modified template resections, a gel roll or "bump" can be placed underneath the ipsilateral side to facilitate exposure of the retroperitoneum without extreme rolling of the operating table. The patient is prepped from the xyphoid process to the upper thighs bilaterally.

The surgical team is positioned around the operating table, as depicted in Figure 176.15. The surgeon and surgical assistant stand on the contralateral side of the table to the side of pathology. At times, a second assistant is necessary to assist in retraction. This individual would stand across the table from the surgeon with the scrub nurse. A video monitor is placed directly across the operating table from the surgeon and also from the scrub nurse and/or assistant on the contralateral side.

Port Placement

The placement of the Veress needle and initial umbilical trocar is described earlier in this chapter with reference to LPLND. Four 10-mm midline abdominal ports are used. The ports are equally spaced from 2 to 4 cm inferior to the xiphoid process to 4 cm above the pubic symphysis, and as such, the umbilicus may not always be incorporated into one of the port sites. On occasion a 5-mm lateral port is required to help in dissection of the spermatic cord (Fig. 176.14). The table is placed in slight Trendelenburg position and tilted toward the surgeon to allow bowel to fall away from the operative field. For the dissection, a paddle retractor is placed in the lowermost port. This is used to retract the bowel medially for the bulk of the dissection.

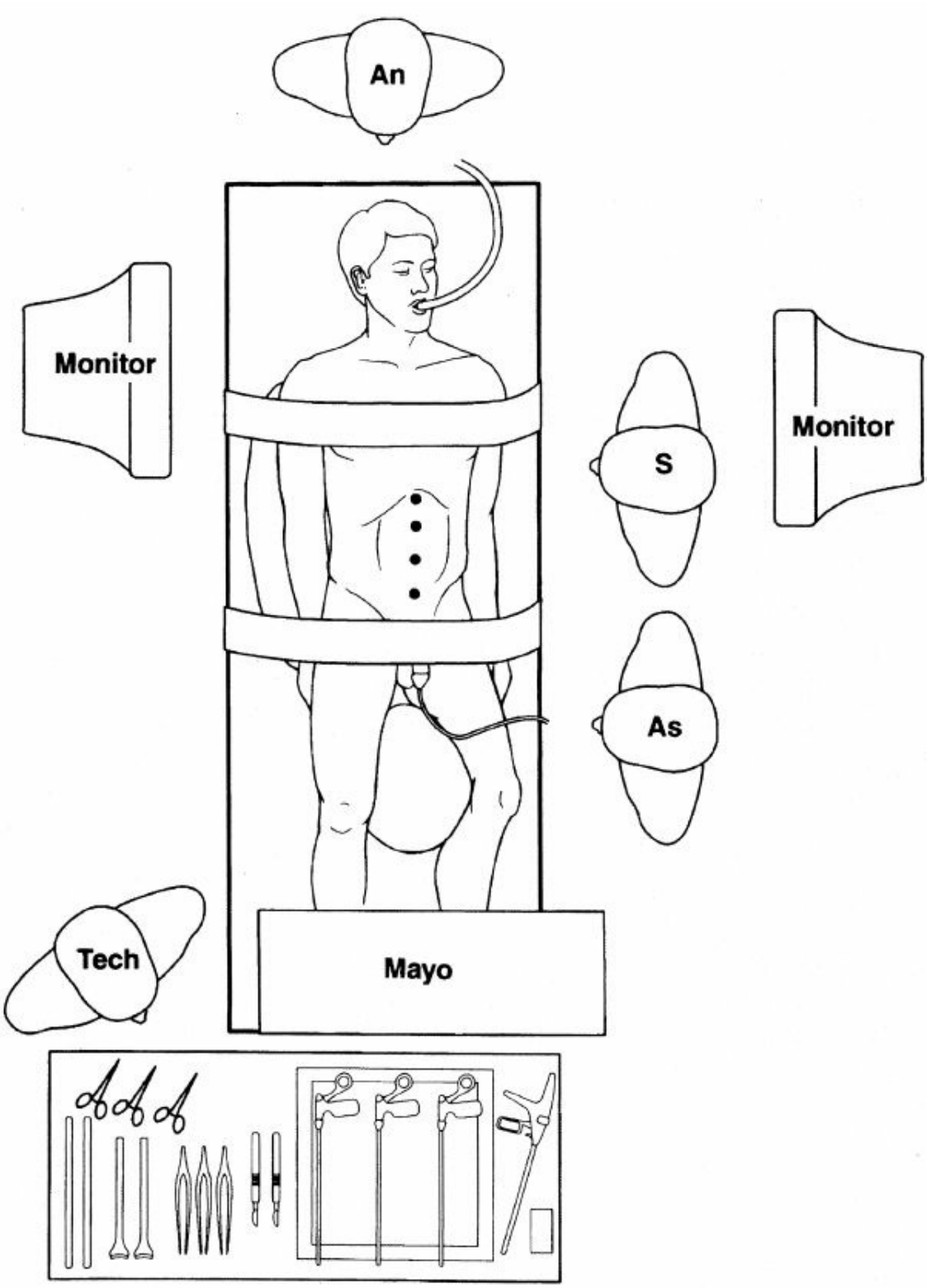

Figure 176.15. The surgical team positioning for right-sided laparoscopic retroperitoneal lymph node dissection is depicted. An, anesthesiologist; As, assistant surgeon; S, surgeon; Tech, scrub nurse or technician.

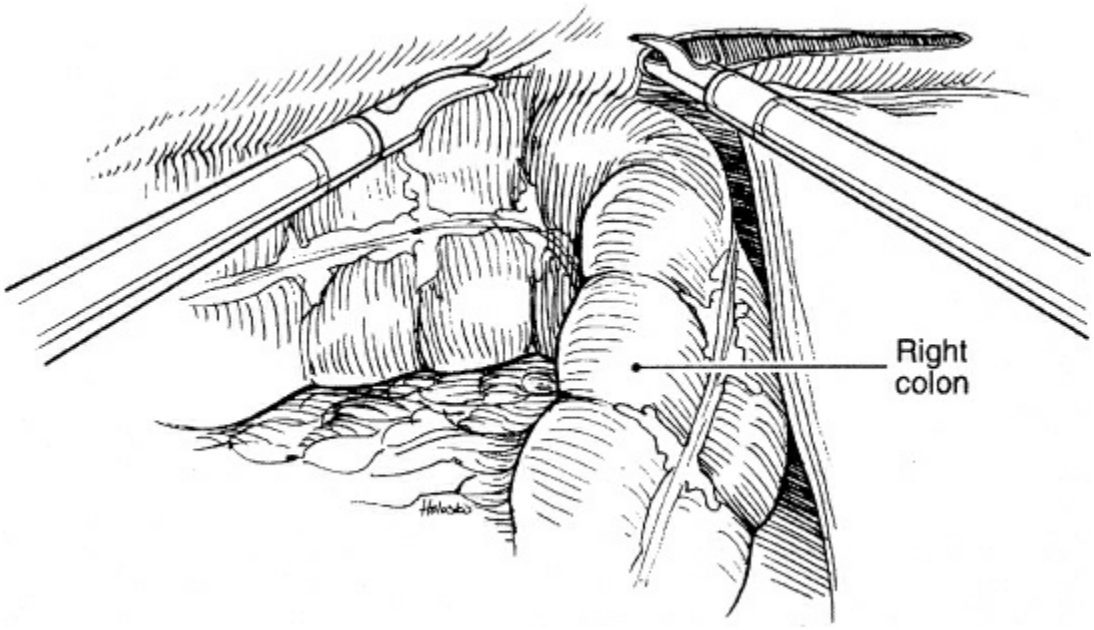

Figure 176.16. Incision of the line of Toldt from the hepatic flexure down to the medial umbilical ligament.

Surgical Technique for Right-Sided Tumor

A modified template is used for dissection. The lateral margin is the right ureter, the superior limit is the level of the renal vein, and the inferior margin is the bifurcation of the right common iliac vessels (Fig. 176.12A). Dissection around the vena cava including intra-aortic tissue is performed superior to the inferior mesenteric artery (IMA). Tissue is taken anterior to the aorta to its left lateral border. Below the IMA, the dissection is limited.

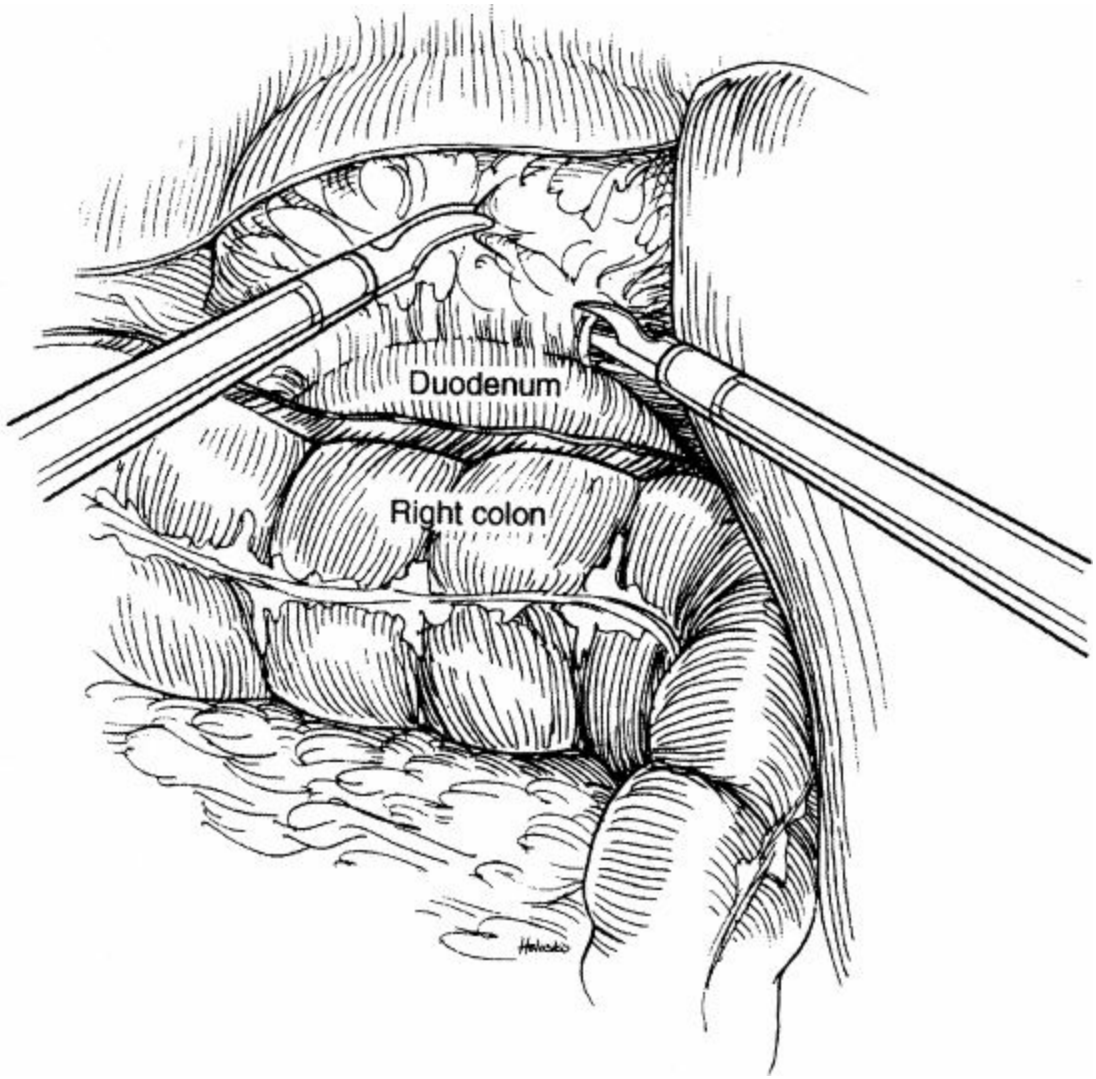

Figure 176.17. With medial retraction of the right colon, the second portion of the duodenum is exposed. The Kocher maneuver is performed to mobilize the duodenum, thereby exposing the great vessels.

The first step is to incise the line of Toldt from the hepatic flexure down to the medial umbilical ligament (Fig. 176.16). This is accomplished by colonic retraction and sharp dissection with the endoscopic scissors or advanced electrosurgical device. Electrocautery can be applied to small vessels as indicated. Lateral to medial sweeping motion with the irrigator aspirator can be used to bluntly dissect the colon medially. Colorenal and hepatorenal ligaments and attachments can be divided sharply to expose the duodenum. The Kocher maneuver is performed to mobilize the duodenum, thereby exposing the great vessels (Fig. 176.17).

After reflecting the colon medially, the spermatic cord and internal inguinal ring are identified. The peritoneum is incised sharply along the

spermatic cord to the level of the common iliac bifurcation, connecting to the peritoneal incision used to reflect the colon. The spermatic cord is dissected free as it crosses over the ureter and followed to the vas deferens, which is clipped and transected. The dissection proceeds distally through the inguinal ring until the permanent ligature placed on the cord at the time of radical orchiectomy is identified (Fig. 176.18). Care must be taken not to injure the external iliac or inferior epigastric vessels at this point.

Once the cord is freed, the dissection proceeds proximally toward the insertion of the gonadal vein into the vena cava and to where the gonadal artery crosses over to the aorta (Fig. 176.19). By placing gentle traction on the cord, it may be dissected off of Gerota's fascia laterally. As one moves cranially, care must be taken not to avulse the origin of the gonadal vessels. The gonadal vein helps identify the vena cava. It is clipped at its origin. The artery is followed medially to identify the aorta, where it is also ligated and divided. The cord is extracted in an entrapment sac bag to prevent loss of specimen or potential port site seeding.

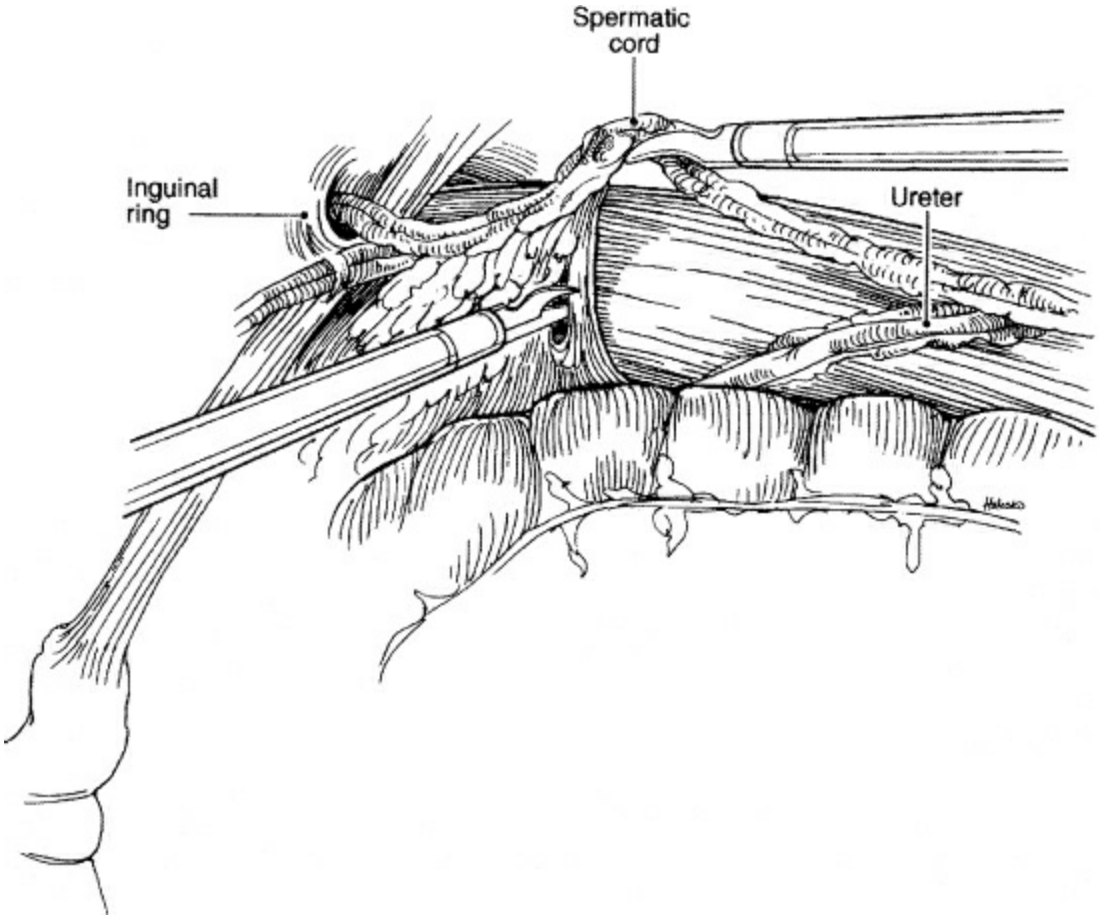

Figure 176.18. The spermatic cord is dissected free as it crosses over the ureter. Distally, the dissection proceeds through the

inguinal ring until the permanent ligature placed on the cord at the time of radical orchiectomy is identified.

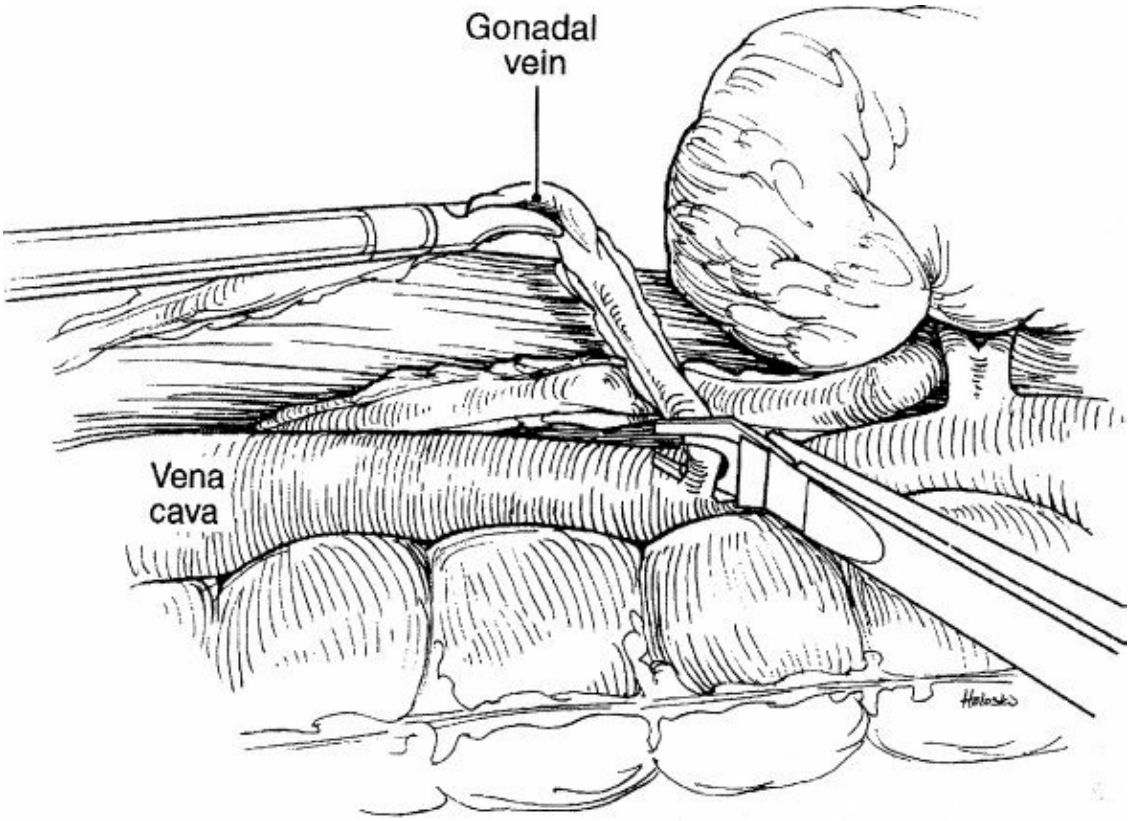

Figure 176.19. Once the cord is freed, dissection proceeds proximally toward the insertion of the gonadal vein into the vena cava and to where the gonadal artery crosses over to the aorta. The gonadal artery and vein are divided.

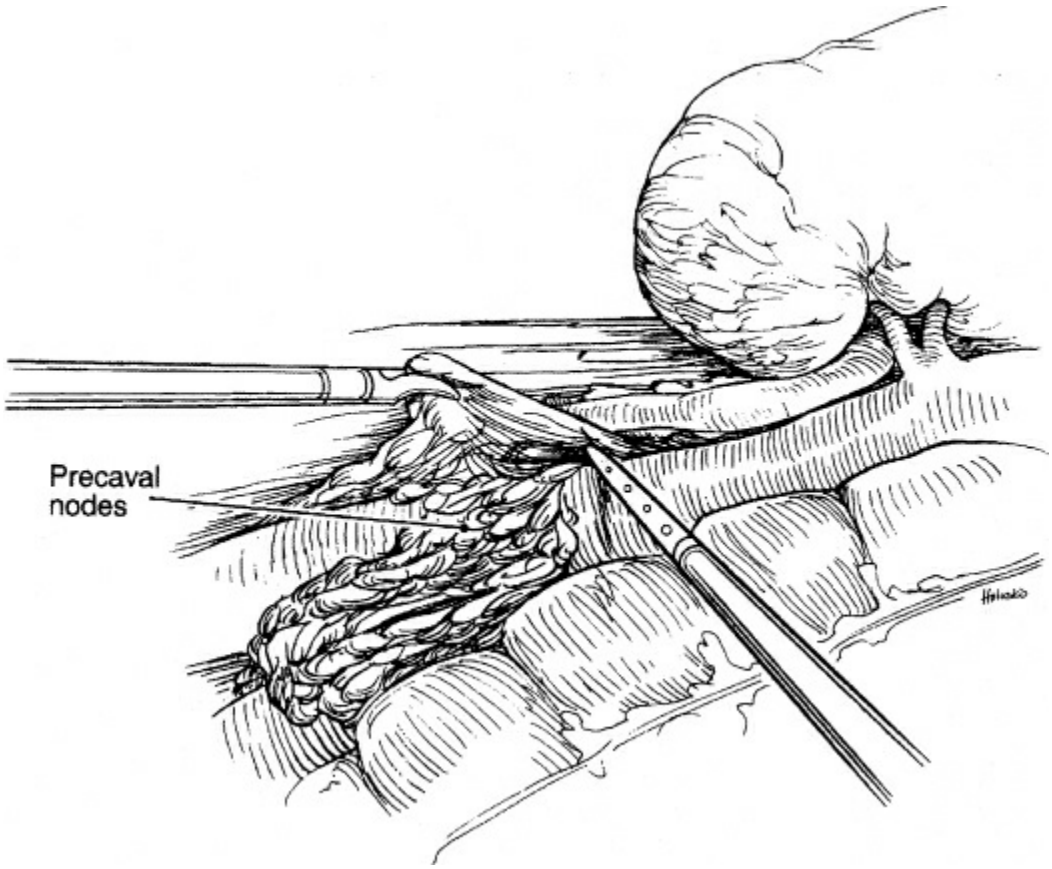

Figure 176.20. The adventitia overlying the vena cava is then divided from the bifurcation of the common iliac vessels to the level of the renal vein. Using blunt and sharp dissection, the lymphatic tissue is reflected laterally toward the ureter.

Beginning at the origin of the gonadal vein, the adventitia overlying the vena cava is then divided to the bifurcation of the common iliac vessels caudally and then cephalad up to the superior level of the renal vein. Using blunt and sharp dissection, the lymphatic tissue is reflected laterally toward the ureter (Fig. 176.20). The ureter is gently retracted laterally as the packet is swept medially. A vessel loop placed around the ureter and closed with a clip is a useful tool to prevent crush injury to the ureter during its retraction. The ureter is traced distally to where it crosses the iliac vessels. At this location, the lymphatic tissue anterior to the artery and vein is clipped and transected. The nodal tissue is swept superiorly. Lateral dissection continues to identify and spare the sympathetic trunk branches, which can be identified lateral and posterior to the vena cava as they course anteromedially toward the hypogastric plexus. Cautery should be avoided during dissection of the sympathetic chain and nerves.

The left border of the iliac aorta is now identified by carefully observing for pulsation and sweeping the sucker onto the lateral surface.

Lymphatic tissue is ligated and the anterior nodal tissue is swept medially. Care is taken to identify branches of the aorta, including the IMA and left renal artery. In some cases, it may be necessary to take the IMA. The medial border of the aorta is identified and tissue continued to be swept medially to join the tissue swept medially from the vena cava. The aorta is followed medially and posteriorly until the fascia of the anterior spinous ligament is identified. Of note, lumbar arteries and veins need to be ligated with clips as they come off the great vessels and again as they enter the vertebral foramen. Care must be taken at the superior aspect of dissection to avoid injuring or inadvertently clipping the right renal artery. In addition, up to 20% of renal units are associated with accessory renal arteries that should be identified and avoided. Beware of retroaortic renal veins and accessory renal arteries, these can be easily confused with lumbar vessels.

The tissue is swept under the vena cava and the vena cava is gently retracted anteriorly. It is important to identify and divide lumbar vessels that tether the vena cava or interfere with the extraction of lymphatic tissue (Fig. 176.21). The tissue is now in continuity with the previously dissected lateral nodal tissue. After dissecting the lateral packet free, final proximal and distal lymphatics are clipped, and the nodal tissue is extracted in an entrapment sac.

Surgical Technique for Left-Sided Tumor

The limits of the dissection are the left renal vein superiorly, the ureter laterally, the bifurcation of the common iliac vessels inferiorly, and the vena cava medially (Fig. 176.12B). The limits of dissection with respect to the IMA are illustrated in Figure 176.12B.

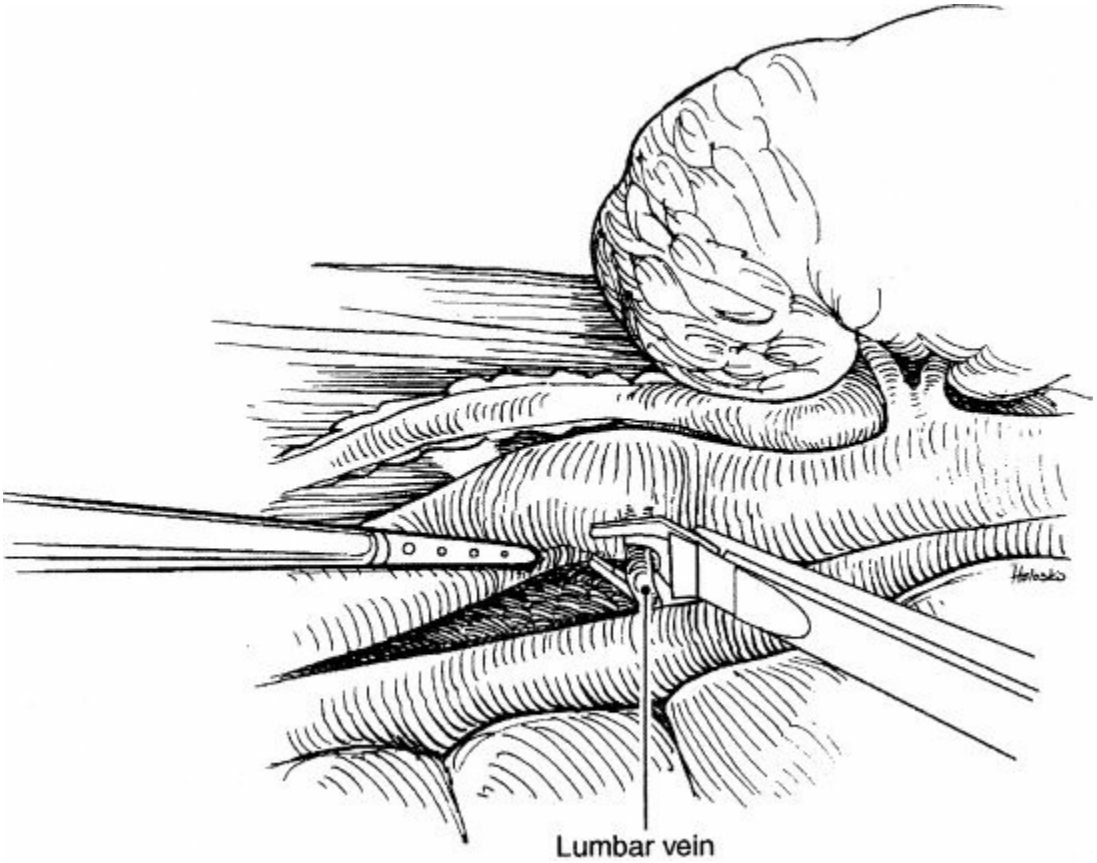

Figure 176.21. It is important to identify and divide lumbar vessels that tether the vena cava or interfere with the extraction of lymphatic tissue.

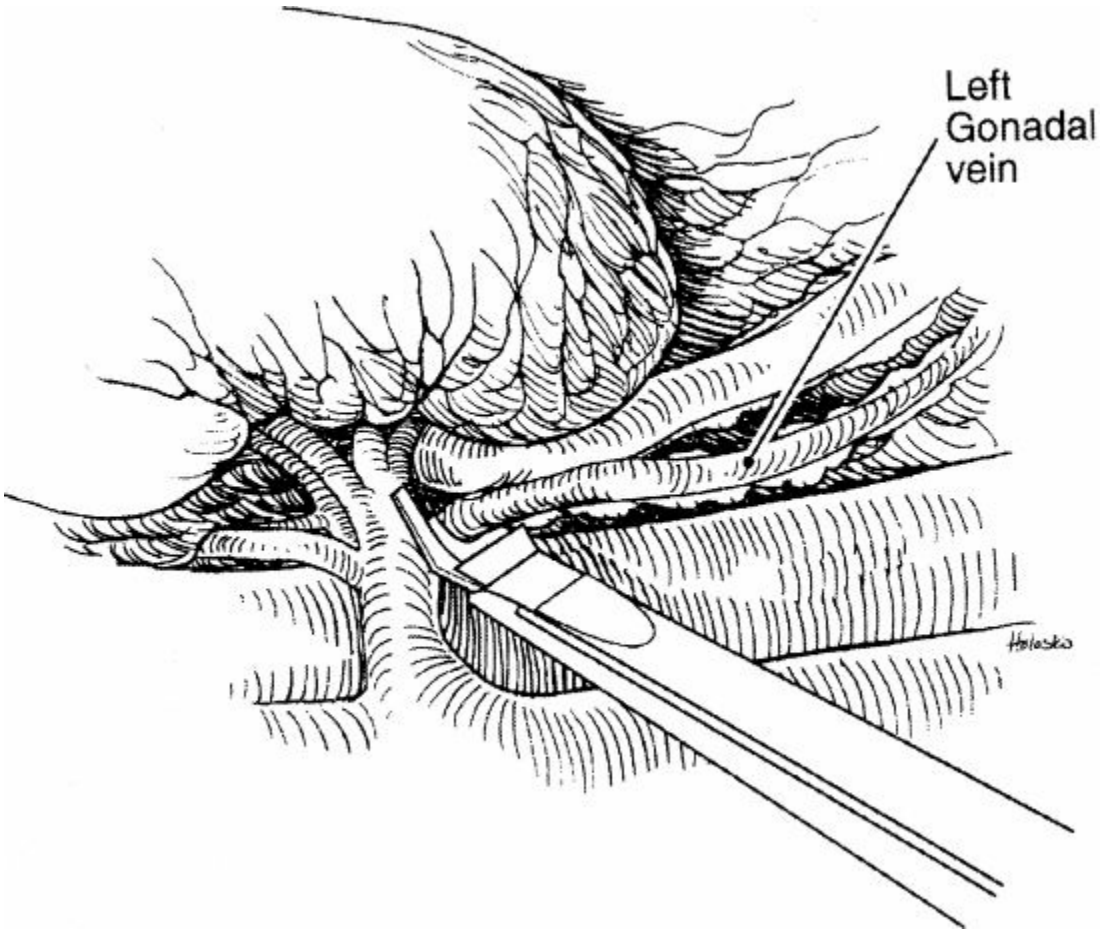

Figure 176.22. The left gonadal vein is dissected up to its origin from the left vein.

Once again, dissection starts with incision of the line of Toldt. Sharp and blunt dissection is used to mobilize the colon medially from the splenic flexure down to the bifurcation of the common iliac vessels. Splenophrenic attachments are divided to assist in exposure of the renal hilum.

After the colon and spleen are mobilized, the internal inguinal ring and spermatic cord are identified, and dissection of the cord proceeds as described previously for right-sided tumor. In this case, however, the gonadal vein is dissected up to its origin in the left renal vein (Fig. 176.22).

With the identification of the ureter and aorta, dissection of the para-aortic lymphatic packet can proceed. The adventitia overlying the aorta is divided, and then the lymphatic tissue is reflected laterally toward the ureter (Fig. 176.23). Dissection proceeds inferiorly to the IMA, where it is shifted to the left side down to where the ureter crosses the iliac vessels. As for the right dissection, branches from the sympathetic chain can be

identified lateral and anterior to the aorta. Sharp and blunt dissection combined with the judicious use of surgical clips is used to free up the nodal tissue (Fig. 176.24). Although advanced surgical sealing devices can be used to divide lymphatics, we prefer the use of metal clips due to the lack of convincing literature on the durability of sealing energy only in prevention of lymphatic leak. The lymphatic tissue in the interaortocaval area is then dissected from the level of the renal vein down to the IMA in the same manner described for right-sided tumor. The tissue overlying the vena cava is split and rolled medially. It is necessary to retract the inferior vena cava to the right and ligate lumbar branches to facilitate total nodal dissection. Lumbar arteries are taken to identify the anterior spinous ligament, and the aorta is gently retracted anteriorly to sweep the interaortal package posteriorly to join the previously freed lateral tissue. Again, it is important to identify and avoid injuring the renal arteries during this dissection.

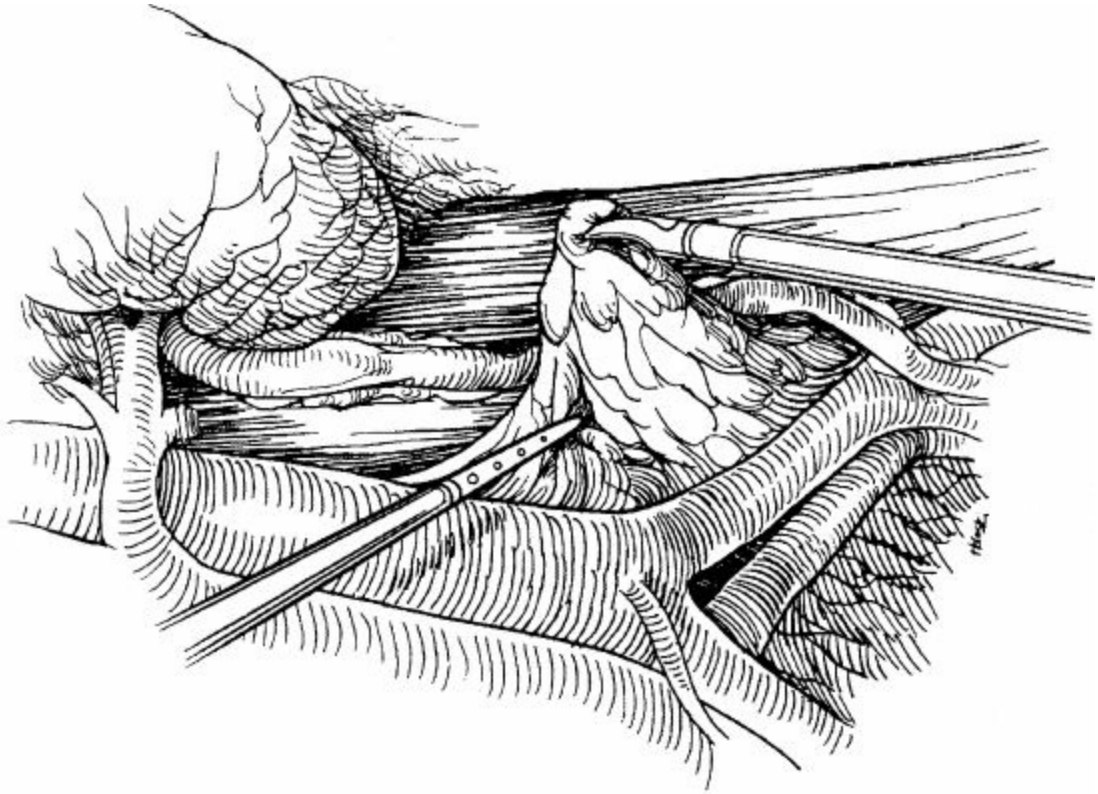

Figure 176.23. The adventitia overlying the aorta is divided, and then the lymphatic tissue is reflected laterally toward the ureter. Dissection proceeds inferiorly to the inferior mesenteric artery. All of the lymphatic tissue between the aorta and ureter is removed.

After completing the dissection, gas pressure is lowered, and the

operative site is inspected for hemostasis. Hemostatic and fibrin-based sealing products can be applied to small areas of venous ooze, but convincing literature does not exist to support improved complication rates. Trocar sites are sequentially closed, as described in the technique section for LPLND.

ROBOTIC-ASSISTED LAPAROSCOPIC RETROPERITONEAL LYMPHADENECTOMY

The indications, pre-operative preparation, post-operative care, and complications are similar to LRPLND. Although surgical literature evaluating feasibility and outcomes of robotic RPLND is currently limited, it has proven the technique to be successfully reproducible across oncologic surgical centers. Operative times with robotic RPLND for surgeons experienced with robotic procedures are similar to an experienced laparoscopist.

For a modified template robotic-assisted LRPLND, the robot is docked from behind the side of the patient in modified ipsilateral flank positioning, similar to LRPLND. Using traditional Hasson or Veress technique with a 12-mm camera port, peritoneal access is obtained with the patient's abdomen flat relative to the floor achieved by rolling the operating table. The bedside assistant is placed on the contralateral side of the template, facing the patient. Figure 176.25 demonstrates the port placement for right-sided modified template robot-assisted LRPLND. The black circles represent the three robotic assistant arm ports (8 mm), the white umbilical port as the robotic camera port (12 mm), and the white right upper quadrant port as a 12-mm assistant port or application of clips and additional retraction. The right upper quadrant robotic port, or "fourth arm port" may be substituted by a second non-robotic 5- or 12-mm port (concentric circles) placed midway between the camera and right-arm robotic ports and 7- to 10-mm laterally toward the contralateral side. Useful robotic instruments include electrosurgical scissors and hook; fine dissecting forceps; and grasping forceps along with traditional laparoscopic retractors, suction irrigator, and clip appliers.

The initial portion of the operation, including the incision of the line of Toldt, mobilization of the colon, and excision of spermatic cord stump may be best performed using traditional laparoscopic instruments prior to docking the robot. This is because of the improved mobility over a large space provided by traditional laparoscopy. For the remainder of the

operation, robotic instruments are used to perform the steps and operative techniques as described above for LRPLND. With more modern surgical robotic systems, improved mobility from decreased arm-clashing may allow the entire procedure to be performed with the robot docked to the patient.

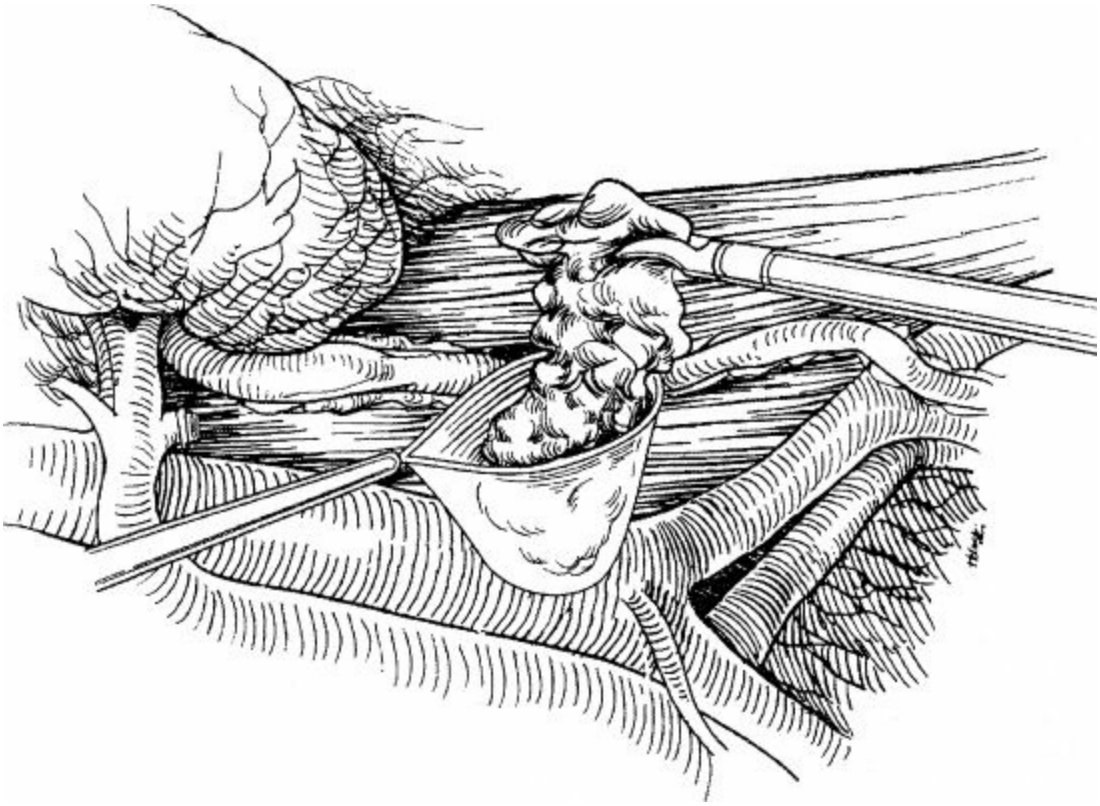

Figure 176.24. The specimen is placed within an Endocatch bag and removed.

Conclusion of Procedure

At the end of the procedure, care is taken to search for hemostasis and any unrecognized injuries. If pooled lymph is seen, an effort needs to be made to locate and occlude the open lymphatic channel. Bowel viability is assessed as it is replaced in the anatomic position. The fascia and skin are closed in a standard fashion.

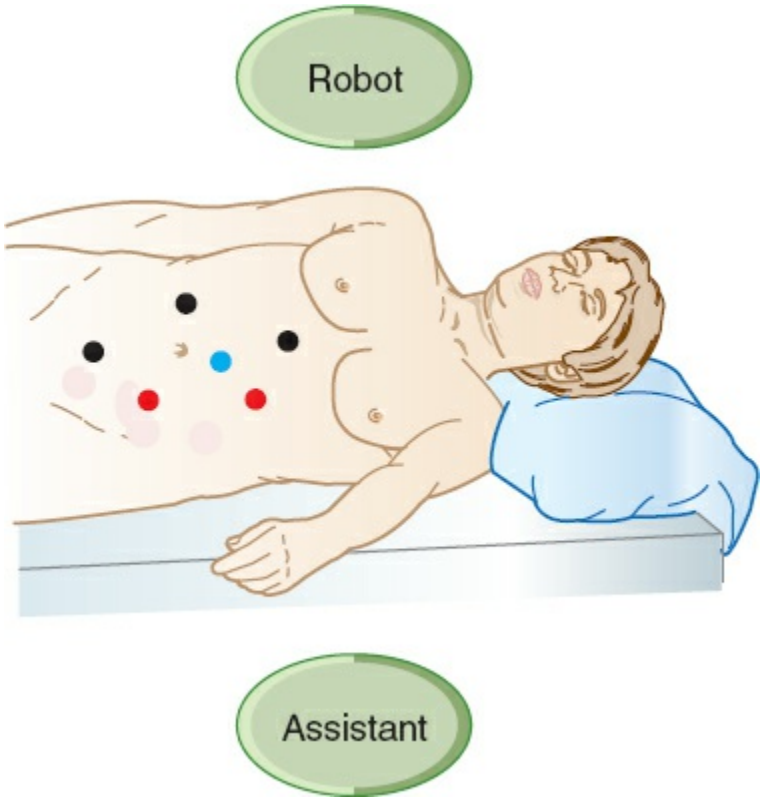

Figure 176.25. Port placement for robotic-assisted modified right template LRPLND in modified flank position. *Black circles* represent robotic ports, *red circles* represent assistant ports, and *blue circle* is camera.

Postoperative Management

The orogastric tube is removed at the end of the procedure. The Foley catheter can be removed when the patient is ambulatory, and diet should be advanced as tolerated. A typical hospital stay is 1 to 2 days with resumption of normal activity as tolerated (usually 2 to 3 weeks).

Complications

Several complications have been reported with LRPLND. The most serious complication reported during LRPLND is hemorrhage. Common areas of potential vascular injury include tributaries of the vena cava and aorta (gonadal branch, lumbar branches, and so on). Minor injuries to the great vessels may be repaired with 5-0 vascular sutures. Major vascular injuries are rare, but may require synthetic grafting and/or removal of a portion of the vessel.

Initial experience with hemorrhage during LRPLND often necessitated open conversion and occasional blood transfusion. More recently

advancements in instrumentation and suturing techniques have decreased the rates of conversion to between 1% and 5%. In cases of venous bleeding, compression with a laparoscopically placed gauze pad for 5 to 10 minutes can abate most bleeding. We have managed bleeding of avulsed lumbar and gonadal veins successfully in this manner. Adjunct hemostatic agents such as gelatin matrix (FloSeal Matrix Hemostatic Sealant, Fusion Medical Technologies, Fremont, CA) or oxidized cellulose (Surgicel, Ethicon, Inc., Piscataway, NJ) should also be available. Large injuries can be sutured or clipped. Torn vessels from the aorta usually require suture ligation as stumps are short for clip placement. Vascular injury is increased in patients who have had chemotherapy.

Lymphocele formation can present postoperatively with persistent flank pain or hydronephrosis from ureteral compression. As with open surgery, this can be avoided with generous clipping of lymphatic channels. Insufficient evidence exists to advocate the use of only advanced bipolar surgical sealing devices in the prevention of lymphatic leak in the setting of RPLND. Lymphocele formation can be managed with percutaneous drainage or laparoscopic marsupialization.

Chylous ascites occurs in 2% to 3% of cases and results from failure to ligate the cisterna chyli. Patients may present in the early postoperative period with abdominal distention, prolonged ileus, pleural effusion, or chylous leakage from the incision. The diagnosis is confirmed with abdominal ultrasound and paracentesis. Patients are initially treated with a low-fat diet, medium-chain triglycerides, diuretics, and, if necessary, hyperalimentation. If conservative management fails, rexploration or lymphangiography may be used to control the leak. When all measures fail, peritoneovenous shunting may be necessary. Asymptomatic lymphoceles may be observed. Aspiration under CT guidance is recommended if there is associated infection, hydronephrosis, or bowel obstruction.

Retrograde ejaculation is less common with nerve-sparing techniques. This complication occurs in less than 5% of patients with nerve-sparing techniques in modern series. Ureteral stricture is another late complication and is also rare (<5%).

Bowel injury can occur during trocar placement or surgical dissection. Unrecognized bowel injuries can result in significant postoperative morbidity or mortality. In suspected patients, CT scan can be used to diagnose these injuries. If bowel injury is identified, prompt surgical

exploration is warranted.

Persistent ileus should raise the suspicion of a retroperitoneal process such as hematoma, pancreatitis, or urinary extravasation. Small bowel obstructions should initially be treated conservatively with nasogastric decompression. Persistent obstruction or associated toxicity may require exploration. Bowel obstruction is rare if the mesentery was carefully closed.

To minimize the risk of atelectasis and pneumonia, all patients should undergo aggressive pulmonary toilet. Pulmonary fibrosis is a potential risk in patients with previous bleomycin chemotherapy. Judicious use of intraoperative fluids and avoiding high concentrations of inspired oxygen help prevent this serious complication.

Other described rare complications include pulmonary embolus, myonecrosis, and leg paresthesia. Port-site metastasis is specific to LRPLND. Fortunately, it is exceedingly rare (0.3%).

SUMMARY

1. Lymphadenectomy has a diagnostic and, in some instances, a therapeutic role in prostate, bladder, penile, urethral, and testicular malignancies.
2. The primary application of lymphadenectomy has been in staging and treatment of patients with low-stage nonseminomatous germ cell tumors of the testis and in the staging of moderate- and high-risk prostate cancer.
3. With the advent of prostate-specific antigen testing, nomograms have been developed to predict nodal status. As such, fewer patients require an isolated pelvic lymphadenectomy.
4. Open RPLND has been the “gold standard” of surgical management of testes cancer. With advances in instrumentation and optics, equivalent dissection has been achieved with the laparoscopic approach by experienced laparoscopists. Robotic-assisted RPLND is feasible, but advantages over traditional laparoscopy have yet to be defined.

Suggested Readings

Bhayani SB, Allaf ME, Kavoussi LR. Laparoscopic RPLND for clinical stage I nonseminomatous germ cell testicular cancer: current status. *Urol Oncol* 2004;22:145–8.

Bhayani SB, Ong A, Oh WK, et al. Laparoscopic retroperitoneal lymph node

dissection for clinical stage I nonseminomatous germ cell testicular cancer: a long-term update. *Urology* 2003;62:324–7.

Briganti A, Blute ML, Eastham JH, et al. Pelvic lymph node dissection in prostate cancer. *Eur Urol* 2009;55:1251–65.

Harris K, Gorin M, Allaf M, et al. A comparative analysis of robotic vs laparoscopic retroperitoneal lymph node dissection for testicular cancer. *BJU International* 2015;116(6):920–3.

Kavoussi LR, Sosa E, Chandhoke P, et al. Complications of laparoscopic pelvic lymph node dissection. *J Urol* 1993;149:322–5.

Kerbl K, Clayman RV, Petros JA. Staging pelvic lymphadenectomy for prostate cancer: a comparison of laparoscopic and open techniques. *J Urol* 1993;150:396–9.

Palese MA, Su LM, Kavoussi LR. Laparoscopic retroperitoneal lymph node dissection after chemotherapy. *Urology* 2002;60:130–4.

Parsons JK, Varkarakis I, Rha V, et al. Complications of abdominal urologic laparoscopy: longitudinal five-year analysis. *Urology* 2004;63:27–32.

Rassweiler JJ, Scheitlin W, Janetschek G, et al. Laparoscopic retroperitoneal lymph node dissection: does it still have a role in the management of clinical stage I nonseminomatous testis cancer? A European perspective. *Eur Urol* 2008;54:1004–15.

Wolf JS. Indications, technique, and results of laparoscopic pelvic lymphadenectomy. *J Endourol* 2001; 15:427–35.

EDITOR'S COMMENT

The staging and management of regional lymph node basins provide the cornerstone for the surgical management of cancer. Regional lymphadenectomy for urologic malignancies has evolved significantly since its original description in the 16th century by Henri Le Dran (Sakorafas GH, Safioleas M. Breast cancer surgery: an historical narrative. Part II. 18th and 19th centuries. *Eur J Cancer Care [Engl]* 2010;19(1):6–29). As with other malignancies, evaluation of regional lymph node basins is based upon Halsted theory that cells from primary tumors spread in an orderly manner along the lymphatic chain to adjacent lymph nodes. Dr. Kavoussi has provided us with an excellent overview of pelvic and retroperitoneal lymphadenectomy, and their work provides the opportunity for robust discussion of the roles of these procedures in the treatment of urologic malignancies.

LeDran first noted that breast cancer that had spread to axillary lymph nodes resulted in much poorer outcomes than localized tumors. Stephen Paget published the definitive article on metastasis, espousing his "seed and soil hypothesis" in 1889 (Sakorafas GH, Safioleas M. Breast cancer surgery: an

historical narrative. Part II. 18th and 19th centuries. *Eur J Cancer Care [Engl]* 2010;19(1):6–29). Isaiah Fidler spent many years studying metastasis, first demonstrating that it is a nonrandom process and later demonstrating the varying metastatic potential of cancer cells. With several decades of research on the genetic basis of cancer, scientists are just beginning to understand the molecular biology of metastasis (Fidler IJ, Kripke ML. The challenge of targeting metastasis. *Cancer Metastasis Rev* 2015;34(4):635–41). It is this understanding of cancer metastases that provides a backdrop for the discussion of lymphadenectomy for urologic malignancies.

The management of the pelvic lymph nodes in patients with prostate cancer has been the topic of significant discussion. Normograms divide patients into low, medium, and high risk for lymph node metastases. Those with low-risk disease should be spared lymphadenectomy, while individuals with medium and high risk should be offered it. Understanding the surgical treatment of prostate cancer relies on clear delineation of lymphatic drainage patterns of the prostate. Lymph from the prostate drains via one of three routes, either draining to internal iliac lymph nodes, to external iliac lymph nodes and thus forming a paravesical plexus, or travelling posteriorly to sacral lymph nodes. The drainage patterns allow for the categorization of pelvic lymph node dissections into standard and extended pelvic lymphadenectomy. An extended pelvic lymph node dissection (ePLND) reaches from the bifurcation of the common iliac artery superiorly to the femoral canal inferiorly; posteriorly, the obturator nerve, obturator vessels, and internal iliac artery are skeletonized. The standard pelvic lymph node dissection does not include removal of the internal iliac artery node. A recent study noted a 14% complication rate with standard PLND compared with a 35% rate in patients who underwent an extended procedure; however, most PLND complications are minor (Rousseau B, Doucet L, Perrouin Verbe MA. Comparison of the morbidity between limited andextended pelvic lymphadenectomy during laparoscopic radical prostatectomy. *Prog Urol.* 2014;24(2):114–20).

Standard PLND has always been preferred to the ePLND in the United States because of the low rates of advanced disease at presentation. Offering an ePLND in low-risk patients is unlikely to slow disease progression or improve cancer-specific survival in this patient population (DiMarco DS, Zincke H, Sebo TJ, et al. The extentof lymphadenectomy for pTXNO prostate cancer does not affect prostate canceroutcome in the prostate specific antigen era. *J Urol* 2005;173(4):1121–5). Proponents of the ePLND contend that there is improved therapeutic benefit to identification and removal of lymph nodes with micrometastatic disease; however, these patients will have improved outcomes compared with clinically node-positive patients and thereby improving the overall outcomes of patients undergoing ePLND. There are no clear data to suggest that ePLND improves survival for all patients with prostate cancer; thus, a prospective randomized trial is required to definitively answer this question. The completion of such a trial is highly unlikely given the decline in

the numbers of PLNDs performed in the United States (Allaf ME, Partin AW, Carter HB. The importance of pelvic lymph node dissectionin men with clinically localized prostate cancer. *Rev Urol* 2006 Summer;8(3):112–9).

The authors did not include a discussion of sentinel lymph node biopsy (SLNB) for urologic cancers. Given that this procedure is increasingly used in the management of penile cancer since its original description by Cabanas nearly 40 years ago, I feel it worthwhile to review the current data on its use. (Cabanas, 1977) Lam et al. recently evaluated 500 inguinal lymph node basins in patients with squamous cell carcinoma of the penis. They found a 94% sensitivity in patients in which SLNB and ultrasound were utilized compared with a 91% sensitivity in patients in whom blue dye and gamma probe guided SLNB (Lam. 2013). Later work by Djajadiningrat et al. found a statistically significant difference in 5-year cancer-specific survival in cohorts before and after the SLNB era (82% vs. 91%, $p = 0.021$) (Djajadiningrant, 2014). These findings suggest that the identification and resection of microscopic disease led to superior outcomes relative to the resection of palpable nodes.

The authors provide an outstanding review of retroperitoneal lymph node dissection (RPLND) with specific attention given to the management of testicular cancer. I believe that a historical perspective will make its consideration complete. Although RPLND was first described by the English surgeon Bland-Sutton in the early 1900s for the treatment of nonseminomatous germ cell tumors, the extent of lymphatic drainage including the suprahilar and contralateral regions was not delineated until the advent of lymphoscintigraphy in the 1960s (Busch FM, Sayegh ES, Chenault OW. Some uses of lymphangiography in the management of testicular tumors. *J Urol* 1965;93:490–5). The ensuing modification of RPLND to include bilateral retroperitoneal dissection combined with suprahilar dissection and division of the lumbar arteries and veins to allow access to the lymphatic tissue dorsal to the great vessels led to numerous complications, including ejaculatory dysfunction. Subsequent improvements in RPLND were focused on targeting the dissection template to avoid injuring the sympathetic plexus, thereby improving ejaculatory function. Richie et al. reported that the primary landing site for regional metastasis for stage I testicular cancer was located well above the aortic bifurcation. They therefore limited their distal dissection to the ipsilateral level of the inferior mesenteric artery, resulting in a relapse rate comparable to that associated with standard bilateral RPLND and an antegrade ejaculation rate of 95% (Richie JP. Clinical stage 1 testicular cancer: the role of modifiedretroperitoneal lymphadenectomy. *J Urol* 1990;144(5):1160–3). Similarly, Donohue et al. dissected only the node-bearing tissue around the postganglionic sympathetic fibers in a procedure that is currently referred to as the nerve-sparing RPLND. This group reported a 98% antegrade ejaculation rate with cure rates comparable to those who underwent classic RPLND (Donohue JP, Thornhill JA, Foster RS, et al. Retroperitoneal lymphadenectomy for clinical stage A testis cancer (1965 to 1989): modifications of technique and

impact on ejaculation. *J Urol* 1993;149(2):237–43).

As with most surgical procedures, minimally invasive approaches to RPLND have undergone numerous refinements. Rukstalis and Chodak presented a case report on laparoscopic retroperitoneal lymph node dissection (L-RPLND) in 1992 (Rukstalis DB, Chodak GW. Laparoscopic retroperitoneal lymph node dissection ina patient with stage 1 testicular carcinoma. *J Urol* 1992;148(6):1907–9; discussion 1909–10). Janetschek et al. consequently reported on 76 patients who underwent L-RPLND for stage I disease in 2000. At a 4-year median follow-up, antegrade ejaculation rate was 99%, while retroperitoneal recurrence rate was very low at 1.3%. We look forward to further refinements, including widespread utilization of robotic RPLND (Janetschek G, Hobisch A, Peschel R, et al. Laparoscopic retroperitoneal lymph node dissection for clinical stage I nonseminomatous testicular carcinoma: long-term outcome. *J Urol* 2000;163(6):1793–6).

John H. Stewart, IV

177 Robot-Assisted Radical Prostatectomy

Ahmed A. Hussein and Khurshid A. Guru

INTRODUCTION

Prostate cancer is the third leading cause of cancer death among American men, and is the commonest non-skin malignancy. Radical prostatectomy is an established treatment modality for localized prostate cancer and is superior to observation in terms of survival. In the past decade, robot-assisted radical prostatectomy (RARP) has gained much popularity among patients and urologists, with more than 80% of all radical prostatectomies performed in the United States are performed with robot assistance. In this chapter, we will shed light on important anatomical and surgical considerations for RARP, with special emphasis on the surgical technique.

ANATOMICAL CONSIDERATIONS

Sound knowledge of the surgical anatomy of the prostate is the key to optimize cancer control and functional outcomes after radical prostatectomy. The main outcomes of radical prostatectomy have been classically reported as "trifecta," comprising the likelihood of urinary continence, potency, and cancer control biochemical recurrence-free survival rates following surgery. Key anatomical considerations to achieve the trifecta will be discussed in this section with special emphasis on the anatomy of the dorsal venous complex (DVC), the location and course of the neurovascular bundles (NVB), and the anatomy of the bladder neck and pelvic floor. With advances in minimally invasive approaches and incorporation of RARP into the surgical armamentarium, the current expectations of patients who desire surgical treatment for prostate cancer are much higher and extend beyond the classic trifecta, and the newer concept of "pentafecta" was introduced. In addition to the factors included in the trifecta, pentafecta also includes negative surgical margin and absence of complications.

The DVC overlies the urethral sphincter covering up to one third of the

cross-sectional urethral sphincter surface area laterally at the apex of the prostate and 5 mm distal to the apex. Therefore, during DVC control especially with transverse en bloc ligation of the DVC extending beyond its lateral limits, a considerable portion of the sphincter tissue might be included, which may adversely affect postoperative continence. To avoid this problem, selective dissection and ligation of the DVC is strongly recommended to minimize sphincter injury as possible.

The most frequent origin of *prostate arteries* is from the internal pudendal artery. The artery then courses obliquely toward the posteroinferior aspect of the bladder and provides several inferior vesical arteries. It terminates in two main pedicles while providing numerous branches to the prostate. The posterior pedicle surrounds the seminal vesicles (SVs) and the vas deferens near the prostate base. The anterior pedicle runs along the lateral border of the prostate to the prostate apex and continues as anterior capsular prostate branch. These arteries may be responsible for ancillary penile blood flow. Therefore, preserving them during radical prostatectomy may help postoperative erectile function and help maintain penile integrity and length. *The inferior hypogastric (pelvic) plexus* is responsible for erection, ejaculation, and urinary continence. It lies within a fibrofatty tissue between the bladder and the rectum. The pelvic plexus and the erectile nerves are at risk during standard pelvic lymph node dissection (pLND) dissection, especially in the area of the internal iliac artery and toward the bladder wall. An inverse relation between erectile function and more extended lymph node dissection and higher lymph node yield has been previously demonstrated.

Several dissection planes have been proposed for *NVB preservation.* One of the most commonly utilized classifications comprise intrafascial, interfascial, and extrafascial dissection planes. Intrafascial dissection follows a plane on the pseudocapsule of the prostate (internal to the prostatic fascia), allowing preservation of the whole NVB. Interfascial dissection occurs within the periprostatic fascia and includes incremental nerve sparing with wider resection. The extrafascial dissection occurs lateral to the levator ani fascia with complete removal of the NVB. Patient selection for NVB preservation on one or both sides depends on patient and cancer site and extent.

Pelvic floor musculature plays an important role in postoperative urinary continence. The anteromedial part of levator ani muscle close to the urethral sphincter, also known as puboperinealis muscle, contracts and

pulls the urethra and prostate forward and upward, resulting in closure of the urethra. The nerve supplying runs on the levator ani surface just lateral to the fascial tendinous arch and may be injured during incision of the endopelvic fascia. Preserving the *bladder neck* is another key component for postoperative urinary continence. It is formed by several structures, including detrusor muscle near the bladder outlet, the internal urethral sphincter in addition to the adjacent proximal prostatic tissue. Although controversial, bladder neck-sparing techniques aim at preserving this area aiming at improving postoperative continence. The external urethral sphincter is located distal to the apex of the prostate, close to the puboperinealis muscle. However, with considerable variation of the shape of the prostate at the apex, parts of the urethral sphincter can be found inside the prostate, making preservation of the entire length of the urethral sphincter difficult. Based on this observation, full-length preservation of the urethral sphincter by dissecting the distinct striated and smooth muscle part of the sphincter from inside the prostate has been proposed for early recovery of postoperative continence.

INDICATIONS AND CONTRAINDICATIONS

Radical prostatectomy may be performed in patients with clinically localized prostate cancer and estimated life expectancy of at least 10 years. It may be also performed in the salvage setting in patients experiencing biochemical recurrence after external beam radiation therapy (EBRT). However, in the salvage setting, the risks of incontinence, bladder neck contracture, and erectile dysfunction are higher and with variable cancer-specific survival. Therefore, salvage prostatectomy should only be performed by highly experienced surgeons.

The decision to proceed with pLND should be guided by the probability of lymph node metastasis. The National Comprehensive Cancer Network Guidelines recommend a cut-off of ≥2% based on the Memorial Sloan Kettering Cancer Center Nomogram. This nomogram utilizes pretreatment PSA, clinical stage, and the Gleason score.

PREOPERATIVE PLANNING

This includes risk stratification and patient counseling about the different available therapeutic strategies, as well as the use of different nomograms to estimate the probabilities of extracapsular extension, SV involvement, lymph node metastasis, positive soft tissue surgical margins, and oncologic

outcomes. A crucial part of preoperative planning is to decide on the possibility and laterality of NVB preservation, as well as to perform pLND or not. The ability of multiparametric magnetic resonance imaging (MRI) to detect extracapsular extension can also guide decision making for nerve-sparing surgery. Patients should be also carefully counseled about the pros and cons of each treatment option and possible consequences on survival and health-related quality-of-life outcomes.

SURGICAL TECHNIQUE

Positioning and Port Placement

The patient is positioned in the Trendelenburg position to provide more working space by displacing the intestinal loops upwards. The abdomen is insufflated using the Veress needle or Hassan technique. After placing the camera port, all ports are placed under direct vision. A standard 6-port transperitoneal approach is used

Complying with the principles of modular training, we recommend deconstructing RARP into seven key steps. The same steps have been developed and validated by a panel of 12 experienced robotic surgeons who created the Prostatectomy Assessment and Competency Evaluation scoring for RARP. This divides the procedure into measurable portions, facilitates learning, and allows structured feedback to trainees that guides training activities.

Bladder Drop and Opening of the Space of Retzius

The bladder is identified and dissected proximally from the anterior abdominal wall lateral to the medial umbilical ligament. Care must be undertaken to avoid injury to the external iliac vein. Dissection of the bladder from the pubic bone distally is then performed opening the prevesical space (of Retzius). Care must be taken to avoid injury of the obturator nerve or vessels, or the lateral pelvic wall.

Defattening of the Prostate

Using the bipolar grasper and the hook monopolar cautery, the periprostatic fat overlying the anterior aspect of the prostate and endopelvic fascia is gently removed till the prostate-vesical junction and the endopelvic fascia are clearly identified. The superficial DVC and puboprostatic ligaments are encountered. We prefer to defer DVC control

with apical dissection to avoid excessive bleeding obscuring the field. The endopelvic fascia is opened and levator muscle fibers are bluntly sweeped laterally and separated from the prostate.

Bladder Neck Dissection

Accurate determination of the correct plane between the bladder neck and the base of the prostate is a key factor to achieve a satisfactory bladder neck. However, this plane is not always obvious. Manipulation of the urethral catheter can help defining the prostato-urethral junction, especially in the presence of a large median lobe. Division of the prostate-urethral junction can be done using the monopolar hook cautery to minimize bleeding. Once the anterior part of prostato-urethral junction is divided and the bladder is opened, the ureteric orifices should be clearly identified. The tip of the urethral catheter can be held up with the fourth arm. Division of the posterior wall of the junction is then ensued. If a median lobe is present, the mucosa along the posterior edge of the lobe is divided and the median lobe mobilized away from the bladder and along with the remainder of the prostate. Adequate and proportionate thickness of the bladder neck should be achieved without entering into the prostate.

Dissection of the Seminal Vesicles and Posterior Anatomical Plane

After complete division of the bladder neck, the SVs can be grasped and dissected. The right SV is grasped with the fourth arm toward the anterior abdominal wall to facilitate exposure and further dissection. The vas is then identified and divided, followed by the SV pedicles. Judicious use of cautery should be exercised to avoid thermal injury of the NVB. The same steps are repeated on the left side. After complete dissection of both SVs, they are both grasped by the fourth arm and retracted toward the anterior abdominal wall. Blunt dissection of the posterior aspect prostate from the anterior layer of Denonvillier fascia is then carried out. Care must be taken to avoid entry into the base of the prostate or into the rectum.

Preservation of the Neurovascular Bundle

Preservation of the NVB should be preoperatively planned depending on the stage, grade, and site of the tumor in the prostate. We use hydrodissection to further define the fascial planes. The NVB is dissected

in a blunt fashion from the anterolateral aspect of the prostate. Care should be exercised to avoid NVB injury or entering the wrong plane. The use of electrocautery should be minimized to avoid thermal injury to the NVB. Once the NVB are dissected, Hem-o lock clips are placed to control the vascular pedicles to the prostate near its base. If nerve sparing was not planned, then a wider dissection of the pedicles is performed to ensure oncologic control and avoid positive soft tissue surgical margins.

Apical Dissection, Control of the Dorsal Venous Complex, and Urethral Transection

The pneumoperitoneum pressure is increased to 15 mm Hg. The DVC is cut with cold scissors and dissection is completed until the urethral is clearly visualized. Maximum urethral length preservation is crucial for adequate urethrovesical anastomosis. Again, manipulation of the Foley catheter can help identifying the prostatic apex. The anterior wall of the urethra is divided with the cold scissors till the Foley is visualized. The Foley is then held up toward the abdominal wall, and cutting the posterior wall is then performed. The pneumoperitoneum is lowered again to 12 mm Hg, and the DVC is then sutured with a 3-0 V-loc suture. The freed prostate is placed in the endobag and moved to the upper abdomen to allow for urethra-vesical anastomosis.

Urethro-Vesical Anastomosis

The “Rocco” stitch (reapproximation of the Denonvilliers fascia) prior to anastomosis of the bladder to the urethral stump has been advocated to improve postoperative continence. One or more figure-of-eight absorbable sutures are placed vertically between the proximal and distal lips of Denonvilliers’ fascia (just posterior to the urethral stump).

The anastomosis starts by constructing the posterior wall first. Two 3-0 v-lock sutures are used, starting at 6 o’clock position with one running to the right and the other to the left. The needle is passed through the posterior bladder wall first (outside-in), then through the urethra (inside-out). The two running sutures are continued anteriorly with mucosa-to-mucosa approximation over a 22-Fr silicone catheter till the 12 o’clock position. The anastomosis should be watertight and not under tension. Irrigation of saline through the Foley can be performed to ensure adequacy of the anastomosis.

Pelvic Lymph Node Dissection

Extended pLND should be performed. It involves dissection of all the lymphatic tissue between the external iliac vein anteriorly, the pelvic side wall laterally, the pelvic floor posteriorly, Cooper ligament caudally, the internal iliac artery cranially, and the bladder wall medially. This template has been associated with better staging, and potentially improved survival due to elimination of micrometastatic foci. Judicious use of cautery is exercised control and seal the lymphatic channels while avoiding vascular injury. The dissected nodal tissue is placed in an endobag and can be extracted through extension of one of the ports incision.

OUTCOMES

Compared with observation, there is level I evidence supporting the benefit of surgery in terms of disease-specific and overall survival, as well as the risk of local progression and metastasis at 13 and 23 years, especially for younger men (65 years or younger). Outcomes also depend on the presence of adverse prognosticators, including PSA >10 ng/mL, cT2b or higher, Gleason score 9 or 10, higher number of positive cores on biopsy, and over 50% of core involvement.

Comparative effectiveness between surgery and irradiation for clinically localized prostate cancer is not straightforward. This may be related to the long natural history of the disease, various definitions of what constitutes recurrence, and the difference in impact and time course of different treatments on cancerous cells (effects on PSA and PSA kinetics, and the definitions of biochemical recurrence). The data suggest that EBRT is comparable to radical prostatectomy, with some benefit for surgery over radiotherapy for higher-risk patients. EBRT avoids complications associated with surgery and anesthesia, including bleeding, blood transfusion, myocardial and pulmonary complications. In contrast to surgery, urinary control and erectile function are better on the short term, but they tend to worsen with time. There is also a low but definite risk of protracted symptoms from radiation proctitis. In cases of recurrence or biochemical failure, salvage prostatectomy is a morbid procedure with high rate of complications and variable success.

RARP offers adequate oncologic control that is equivalent to its open counterpart, and is superior in terms of shorter hospital stay, less blood loss, and fewer blood transfusions. Other studies suggested some benefit in terms of 1-year urinary continence and recovery of erectile function. There

was no significant difference in terms of complications, readmissions, or positive soft tissue surgical margins rates.

Suggested Readings

Bill-Axelson A, Holmberg L, Garmo H, et al. Radical prostatectomy or watchful waiting in early prostate cancer. *N Engl J Med* 2014;370(10):932–42.

Carroll PR, Parsons JK, Andriole G, et al. NCCN guidelines insights: prostate cancer early detection, version 2.2016. *J Natl Compr Canc Netw* 2016;14(5):509–19.

Eastham JA, Scardino PT, Kattan MW. Predicting an optimal outcome after radical prostatectomy: the trifecta nomogram. *J Urol* 2008;179(6):2207–10; discussion 2210–1.

Ficarra V, Novara G, Ahlering TE, et al. Systematic review and meta-analysis of studies reporting potency rates after robot-assisted radical prostatectomy. *Eur Urol* 2012;62(3):418–30.

Ficarra V, Novara G, Rosen RC, et al. Systematic review and meta-analysis of studies reporting urinary continence recovery after robot-assisted radical prostatectomy. *Eur Urol* 2012;62(3):405–17.

Guru KA, Perlmutter AE, Butt ZM, et al. Hydrodissection for preservation of neurovascular bundle during robot-assisted radical prostatectomy. *Can J Urol* 2008;15(2):4000–3.

Hussein AA, Cooperberg MR. Point: surgery is the most cost-effective option for prostate cancer needing treatment. *Brachytherapy* 2015;14(6):753–5.

Hussein AA, Ghani KR, Peabody J, et al. Development and validation of an objective scoring tool for robot-assisted radical prostatectomy: prostatectomy assessment and competency evaluation. *J Urol* 2017;197(5):1237–44.

Mauroy B, Demondion X, Drizenko A, et al. The inferior hypogastric plexus (pelvic plexus): its importance in neural preservation techniques. *Surg Radiol Anat* 2003;25(1):6–15.

Myers RP, Cahill DR, Kay PA, et al. Puboperineales: muscular boundaries of the male urogenital hiatus in 3D from magnetic resonance imaging. *J Urol* 2000;164(4):1412–5.

Patel VR, Sivaraman A, Coelho RF, et al. Pentafecta: a new concept for reporting outcomes of robot-assisted laparoscopic radical prostatectomy. *Eur Urol* 2011;59(5):702–7.

Schlomm T, Heinzer H, Steuber T, et al. Full functional-length urethral sphincter preservation during radical prostatectomy. *Eur Urol* 2011;60(2):320–9.

Song LJ, Lu HK, Wang JP, et al. Cadaveric study of nerves supplying the

membranous urethra. *Neurourol Urodyn* 2010;29(4):592–5.

Walz J, Epstein JI, Ganzer R, et al. A critical analysis of the current knowledge of surgical anatomy of the prostate related to optimisation of cancer control and preservation of continence and erection in candidates for radical prostatectomy: an update. *Eur Urol* 2016;70(2):301–11.

Yaxley JW, Coughlin GD, Chambers SK, et al. Robot-assisted laparoscopic prostatectomy versus open radical retropubic prostatectomy: early outcomes from a randomised controlled phase 3 study. *Lancet* 2016;388(10049):1057–66.

EDITOR'S COMMENT

Radical prostatectomy can be a curative procedure in many cases of prostate cancer. As noted by Dr. Hussein and Dr. Khurshid in their excellent summary of the robotic-assisted radical prostatectomy (RARP) technique, this approach now accounts for over 80% of the cancer-related prostatectomies performed in the United States.

For those new to the robotic approach to radical prostatectomy, the basic intraoperative principles of the surgical removal of the prostate performed using robotic assistance are not new or revolutionary. A robotic prostatectomy replicates the prostate removal of an open radical retropubic prostatectomy. Further, RARP is technically a laparoscopic procedure. RARP can be more formally defined as a robotic-assisted laparoscopic prostatectomy or RALP. These authors and others prefer to use the term robot-assisted radical prostatectomy or RARP.

With the advent of laparoscopic urologic surgery in the early 1990s, the initial focus was on pelvic lymphadenectomy and renal surgery (Gomella LG, Strup SE. History of laparoscopy: urology's perspective. *J Endourol* 1993;7(1):1–5). Interest grew quickly into exploring other potential urologic applications of this minimally invasive technique. While still practiced by a few artisans, the purely laparoscopic approach to the prostate was and remains a challenging procedure due to the location of the prostate, deep within the pelvis, and the technical challenges associated with the suturing necessary for the bladder neck and urethral reconstruction. The ability of the robotic technology introduced around 2000 improved the laparoscopic visualization of the pelvic structures using stereoscopic lens systems, and the articulation of the robotic instrumentation greatly improved the ability to suture using a laparoscopic approach (Menon M, Hemal AK, VIP Team, et al. Vattikuti Institute prostatectomy: a technique of robotic radical prostatectomy: experience in more than 1000 cases. *J Endourol* 2004;18(7):611–9).

The surgical anatomy, physiology of urinary continence, and the principles of nerve sparing have been nicely reviewed by the authors of this chapter. These advances are not directly attributable to the robotic radical prostatectomy but

were refined in association with the renaissance in the open radical prostatectomy that took place in the early 1980s and widely attributed to Dr. Patrick Walsh (Walsh PC. How surgical innovation reduced death and suffering from prostate cancer. *J Craniofac Surg* 2013;24(1):49–50). All of these surgical principles based on the open radical prostatectomy that have evolved over the last 40 years are now being applied to the robotic approach.

As there are alternative approaches to open radical prostatectomy such as the retropubic and perineal techniques, there are also alternative approaches to robotically assisted radical prostatectomy. The authors of this chapter discuss the much more common transperitoneal RARP (tRARP). Also described in the literature is the extraperitoneal robot-assisted radical prostatectomy (eRARP), a less commonly employed robotic prostatectomy technique. Several recent papers have highlighted the outcomes and safety of eRARP in comparison to tRARP (Semerjian A, Pavolvich CP. Extraperitoneal robot-assisted radical prostatectomy: indications, technique and outcomes. *Curr Urol Rep* 2017;18(6):42). The data suggest the two, eRARP and tRARP, are fairly similar in terms of outcomes. In addition, eRARP may be preferred in certain circumstances, such as if concomitant repair of inguinal hernia is being considered.

As noted by Dr. Hussein and Dr. Khurshid, expectations of patients who undergo surgical treatment for prostate cancer may be unrealistically high in our technologically advanced world. Open radical prostatectomy can be associated with increased blood loss and slightly longer hospital stay. The assumptions that a robotic procedure is minimally invasive, allows a more rapid discharge from the hospital are reasonable. However, patients also often assume that RARP is not associated with complications. These men must be counseled in an objective preoperative discussion. Overall, the risks of radical prostatectomy that are most feared, impotence and incontinence, are similar with either the robotic or open approaches (Healy KA, Gomella LG. Retropubic, laparoscopic, or robotic radical prostatectomy: is there any real difference? *Semin Oncol* 2013;40(3):286–96). Selected papers may highlight superior outcomes in favor of one type of procedure over the other; however, the literature is fairly split.

Dr. Hussein and Dr. Khurshid are objective in terms of noting the long-term oncologic control of the robotic versus open radical prostatectomy based on available data. Advocates of the robotic technique also must recognize the increased cost of using robotic technology. It is not appropriate for a low-volume facility to justify the high costs of the robotic operating room technologies now approaching the 2 million-dollar mark for the newest robotic platforms. Further, in addition to annual maintenance contracts, the costs of robotic arm instruments that lock out after typically 10 uses, whether they are still functional or not, also increase the costs of the RARP. These cost increases due to robotic technology vary widely but are generally $2,000 higher for robotic prostatectomy compared with open; when including the fixed cost of the robot, the difference can be increased to $4,800 (Lowrance WT, Parekh DJ. The

rapid uptake of robotic prostatectomy and its collateral effects. *Cancer* 2012;118(1):4–7). The increased cost is often justified by the more rapid hospital discharge and decreased transfusion rate associated with RARP. It should be recognized that all of this cost data may be institution specific.

While RARP has become the most common surgical approach to radical prostatectomy in the United States, the open surgical approach to radical prostatectomy remains a very relevant and important procedure. Some men with localized prostate cancer may not be suitable candidates for a robotically assisted radical prostatectomy. Further, the more specialized and costly robotic technology may not be readily available to patients in all locales.

The patients who may not be ideal candidates for RARP or who do not have access to a robotically trained urologic surgeon or appropriate robotically equipped facility may be better served with an open surgical approach. Although Dr. Hussein and Dr. Khurshid discussed the oncologic indications and contraindications, there are some relative contraindications and limitations of RALP described in the literature and based on the commentators personal experience as an open prostatectomy practitioner (Menon M, Hemal AK, VIP. Vattikuti Institute prostatectomy: a technique of robotic radical prostatectomy: experience in more than 1000 cases. *J Endourol* 2004;18(7):611–9; Huang AC, Kowalczyk KJ, Hevelone ND, et al. The impact of prostate size, median lobe, and prior benign prostatic hyperplasia intervention on robot-assisted laparoscopic prostatectomy: technique and outcomes. *Eur Urol* 2011;59(4):595–603). While some of these may also present challenges to standard open radical prostatectomy surgery, many are more easily managed using open techniques.

- Obesity (BMI >30 kg/m^2): This may distort anatomy and create instrumentation challenges. These men may also present anesthesia-related difficulty tolerating the steep Trendelenburg position required when performing RARP.
- Some patients with pre-existing medical conditions may not be able to tolerate the effects of CO_2 insufflation on hemodynamics, oxygen levels, and acid–base levels.
- Prior abdominal surgery with extensive adhesions or with a history of ruptured viscera or peritonitis.
- Prior mesh hernia repair and orthopedic hip or pelvic surgery can obliterate the prevesical space and make landmarks for lymphadenectomy anatomy difficult to identify.
- Previous pelvic or prostate radiation can be difficult for any radical prostatectomy approach.
- Large volume prostate (>80 to 100 g) with large median or lateral lobes or a very narrow pelvis.

Robotic radical prostatectomy has become the norm for most men undergoing cancer-related prostate removal in the United States. In the not too

distant past, young urologic surgeons who had a keen interest in becoming skilled as robotically assisted surgeons required a post-residency fellowship in order to develop their operative skills. Today, most urology training programs have incorporated robotic surgical exposure into their residency programs and most urologic oncologists employing robotic radical prostatectomy in their armamentarium. However, fewer trainees are leaving residency with the experience needed to operate in the pelvis and perform radical prostatectomy using time-tested open techniques. Robot-assisted radical prostatectomy will continue to evolve and improve as the technology and long-term experience grow. Regardless of these advances, there will continue to be a group of men who should be considered for potentially curative radical prostatectomy but may not be suitable candidates for the robotic approach. These men should be offered alternative standard surgical approaches such as open prostatectomy.

Leonard G. Gomella

178 The Undescended Testis

Courtney Shepard, Kate H. Kraft, and David A. Bloom

ETIOLOGY AND PATHOPHYSIOLOGY

Cryptorchidism is one of the common disorders of pediatric urology, with 1% to 4% of full-term and up to 45% of preterm male neonates having a diagnosis of undescended testis at birth. Testicular descent is now better understood but as a complex part of human development, it requires further investigation.

During the 5th week of gestation, primordial germ cells migrate from the yolk sac and differentiate into gonocytes. In both sexes, the arrival of primordial germ cells in the area of future gonads signals the existing cells of the mesonephros and adjacent coelomic epithelium to proliferate and form a pair of genital ridges medial to the developing mesonephros. In the 6th week, the cells of the genital ridge invade the mesenchyme in the region of future gonads to form the primitive sex cords, which will support the development of germ cells. Under the influence of the SRY (Sex-determining Region of the Y chromosome), cells in the primitive sex cords of males begin to differentiate into Sertoli cells around the 7th week. During the 9th and 10th weeks, Leydig cells differentiate from mesenchymal cells of the genital ridge also in response to SRY. Leydig cells will produce testosterone and Insulin-like 3 ($INSL_3$), thought to be the key hormones required for testicular descent.

Swelling of the gubernaculum is critical in the enlargement of the inguinal canal, allowing testicular passage. The gubernaculum is unattached distally during and following transinguinal passage of the testis, and then it gradually settles into the scrotum, which has formed from the labioscrotal folds. Most testes have situated into a scrotal position after week 27. Studies in rodent models have shown that gubernacular development and testicular descent are most likely driven by $INSL_3$ and androgen signaling pathways. Similar studies have also provided evidence that the genitofemoral nerve may play a role in guiding testicular descent via stimulating development of the gubernaculum (Box 178.1).

CLINICAL PRESENTATION

The definition of an undescended testis is the absence of one or both testes in a normal scrotal position. Most cases are unilateral (60% to 70%). Cryptorchid testes are distinguished by whether they are palpable (75% to 80%) or nonpalpable (20% to 25%) on examination. The patient should be examined in a supine and the inguinal canal compressed manually from the anterior superior iliac spine toward the scrotum, allowing the testis to be palpated by the examiner's opposite hand. If the testis can be brought into the scrotum, it should be released to determine whether it remains in a scrotal position. If not, then this suggests an ectopic or incompletely descended testis. A retractile testis can be manually positioned into the scrotum and will remain there upon release, at least for a few seconds. A palpable undescended testis may lie anywhere within the inguinal canal toward the scrotum along the line of normal descent, or may be found in an ectopic location, such as the superficial inguinal pouch or in a perirenal, femoral, penile, perineal, or contralateral scrotal position.

Box 178.1 Five Major Phases of Testicular Descent in the Human Male

Phase 1: The caudal mesonephros contacts the gubernaculum at the internal inguinal ring (5 weeks).

Phase 2: The genitofemoral nerve becomes associated with the gubernaculum and processus vaginalis (7 weeks). The gubernaculum continues to grow while the processus vaginalis deepens. The cremaster fibers extend into the gubernaculum (8 to 10 weeks gestation).

Phase 3: The testis grows while the müllerian ducts and mesonephros regress (10 to 12 weeks). The testis contacts the gubernaculum, which begins its swelling phase (12 to 14 weeks).

Phase 4: Gubernaculum swelling, development of the cremaster muscle, and migration of the processus vaginalis widen the inguinal canal (14 to 20 weeks).

Phase 5: The subcutaneous attachment of the gubernaculum releases, and the testis begins its passage through the inguinal canal (20 to 28 weeks). Up until the time of birth, the gubernaculum continues to regress while the testis descends caudally into the scrotum (7th month and beyond).

Testes may be nonpalpable due to an intra-abdominal location (25% to 50%); atrophy of the testis before birth, otherwise known as a “vanishing” testis (15% to 40%); or in an extra-abdominal location but difficult to palpate due to obesity, lack of patient cooperation on examination, or small testicular size (10% to 30%). Ultrasonography has proven unreliable in determining testis position, and MRI requires sedation in younger children and is rarely necessary in managing undescended testes. Examination under anesthesia followed by diagnostic laparoscopy for nonpalpable undescended testes is the gold standard according to the American Urological Association Guidelines on Cryptorchidism.

INDICATIONS AND PREOPERATIVE PLANNING

If a patient has a testis that has not descended by 6 months (corrected for gestational age), he should undergo surgical correction by a specialist within the next year. Medical treatment with hormone therapy is not recommended given the lack of evidence for long-term efficacy. Orchiopexy before 18 months of age may maximize future fertility potential as histologic examination of cryptorchid testes has shown that testes that remain undescended are associated with progressive loss of germ cells.

Boys with a history of cryptorchidism are at increased risk of testicular germ cell tumor. The relative risk of malignant transformation in an undescended testis is 2.5 to 8 overall and 2 to 3 in boys undergoing prepubertal orchiopexy. Every attempt should be made to perform orchiopexy as soon as possible given that these data suggest the risk of malignancy increases with deferred orchiopexy. While the overall increased risk of testicular cancer is not eliminated by orchiopexy, bringing the testis into the scrotum facilitates testicular examination, the mainstay of testicular cancer screening.

Undescended testes may be more mobile within the tunical vaginalis, predisposing them to increased risk of testicular torsion. Approximately 70% or more boys with undescended testes will have a patent processus vaginalis (inguinal hernia) on the ipsilateral side, so the surgeon should mobilize and ligate the processus vaginalis to achieve herniorrhaphy. In adolescents or young adults with unilateral cryptorchidism who have not yet undergone orchiopexy, orchiectomy should be considered given the malignancy risk.

Informed consent for orchiopexy should consider the risks including

bleeding, infection, testis atrophy, possibility of a staged procedure, revision if the testis does not remain in a scrotal position, and injury to the vas deferens.

SURGICAL TECHNIQUE

Inguinal Orchiopexy

Inguinal orchiopexy is the standard treatment for undescended testes within or distal to the inguinal canal. After the induction of anesthesia, a scrotal examination should be performed to confirm the location of both testes. A caudal block may be given at this time. A transverse incision is then made approximately one third the distance between the pubic tubercle and anterior superior iliac spine (Fig. 178.1). Dissection is taken down to scarpa's fascia, taking care to avoid injury to an ectopic testis residing beneath it in the superficial inguinal pouch. Blunt dissection is used to expose the three key landmarks of the external oblique fascia, the shelving edge of the inguinal ligament, and the external ring. The external oblique fascia of the inguinal canal is opened sharply, avoiding injury to the ilioinguinal nerve (Fig. 178.2). The spermatic cord is identified within the canal and freed of the cremasteric and spermatic fascial attachments. The cord is further isolated distally to the testis and the gubernaculum is identified. After confirming its identity by visualizing an indentation of the skin of the point of maximal gubernacular fixation when tugging on it, the gubernaculum is transected with electrocautery (Fig. 178.3).



Figure 178.1. Inguinal incision above and lateral to the external inguinal ring one third of the distance from the pubic tubercle to the anterior superior iliac spine. Scrotal incision is made along Langer lines in the mid-scrotum.

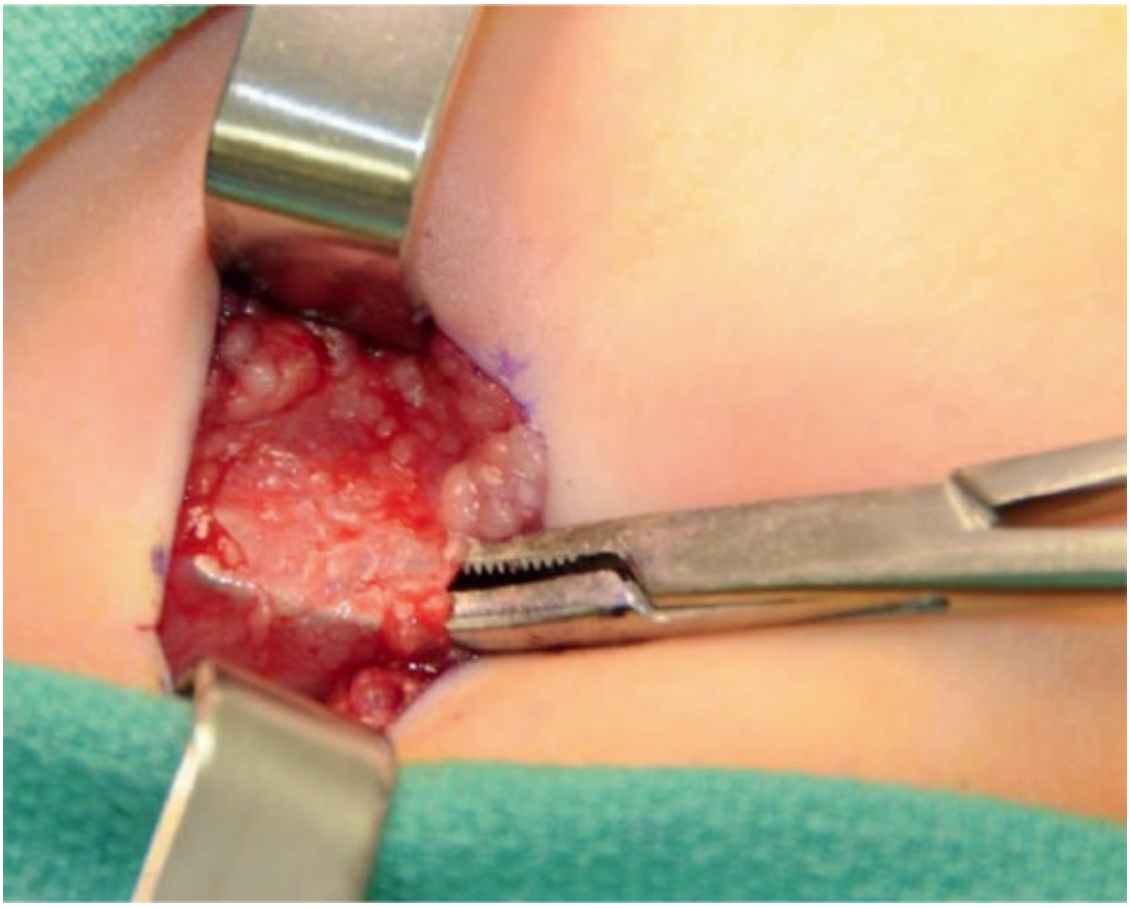

Figure 178.2. The external spermatic ring can be opened in a retrograde or antegrade fashion taking care to avoid injury to the spermatic cord, ilioinguinal nerve, and testis.

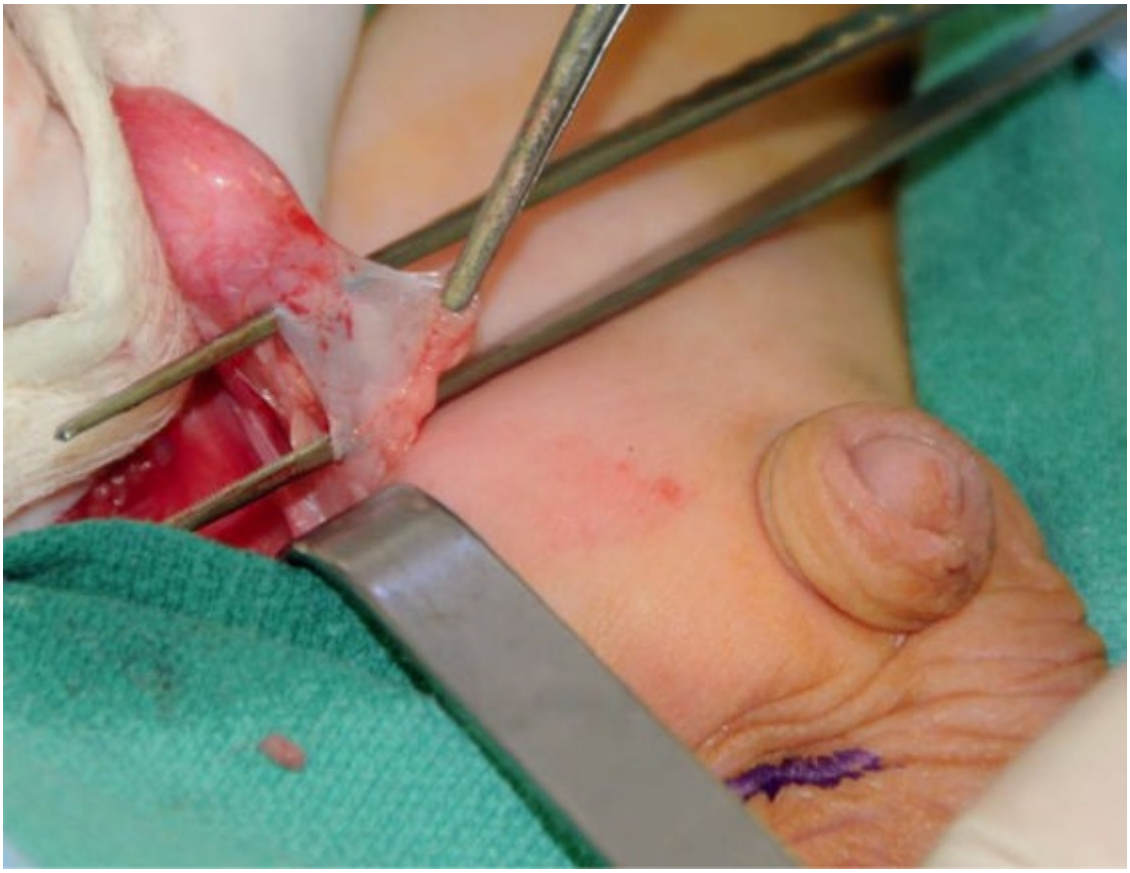

Figure 178.3. The thin white filmy gubernaculum is identified distal to the testis. The superior aspect of the scrotum can be seen tenting inward at the ectopic gubernacular attachment. Care is taken to identify a long looping vas and the ilioinguinal nerve to transection of the gubernaculum.

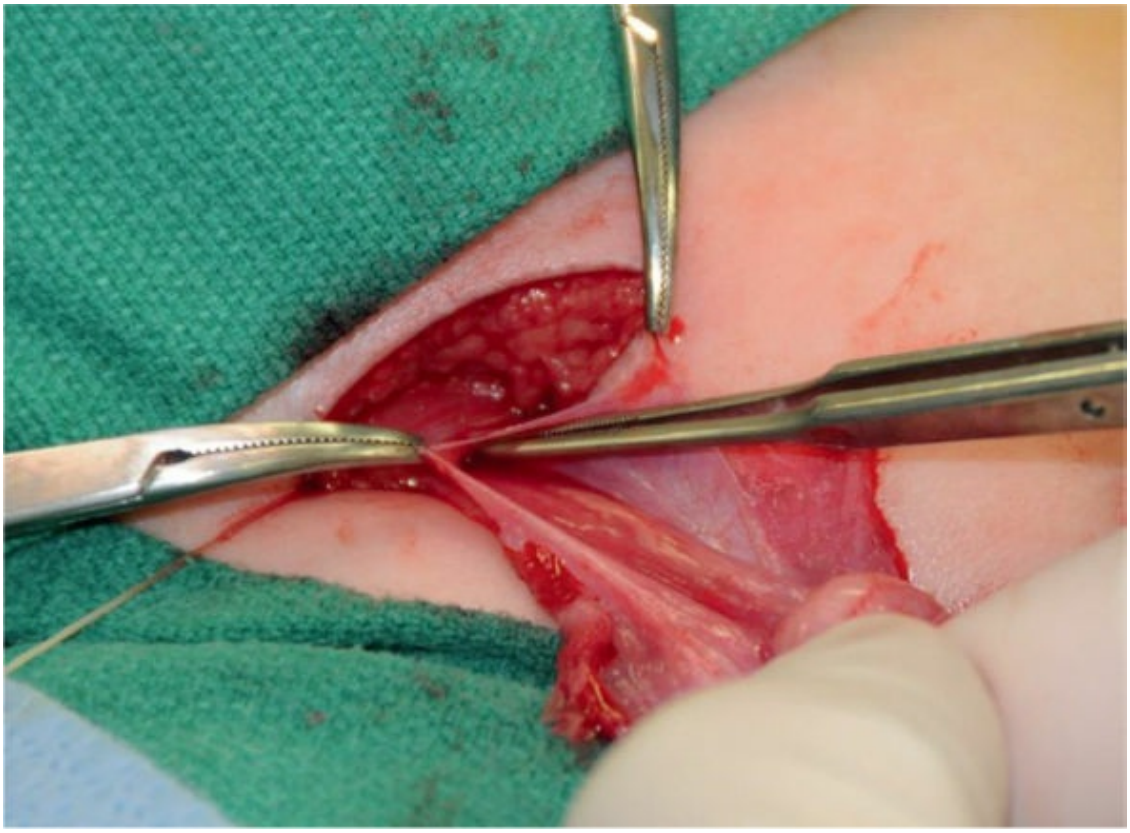

Figure 178.4. The patent processus vaginalis is identified. It may be mobilized away from the spermatic cord by opening the hernia sac and peeling it off the cord or peeling the sac intact off the cord, based on the surgeon's preference. In this example, it is opened.

Most undescended testes are associated with a patent processus vaginalis, so this hernia sac must be carefully freed from the spermatic cord and high ligated. It is helpful to remember that the sac usually forms a "C" or saddle configuration draping over the vas deferens and testicular vessels. The tunica vaginalis surrounding the testis is opened and testicular and epididymal appendages are transected. The tunica vaginalis is then examined to identify a patent processus vaginalis. Based on the patient's anatomy and surgeon's preference, herniorraphy may be performed either by keeping the sac intact while freeing it from the cord or by opening the sac to dissect it off the cord structures (Fig. 178.4). Using either method, the hernia sac is isolated from the spermatic cord to the level of the internal ring where the peritoneal reflection can be identified (Fig. 178.5). The patent processus is divided at this level and the proximal stump double ligated (Fig. 178.6).

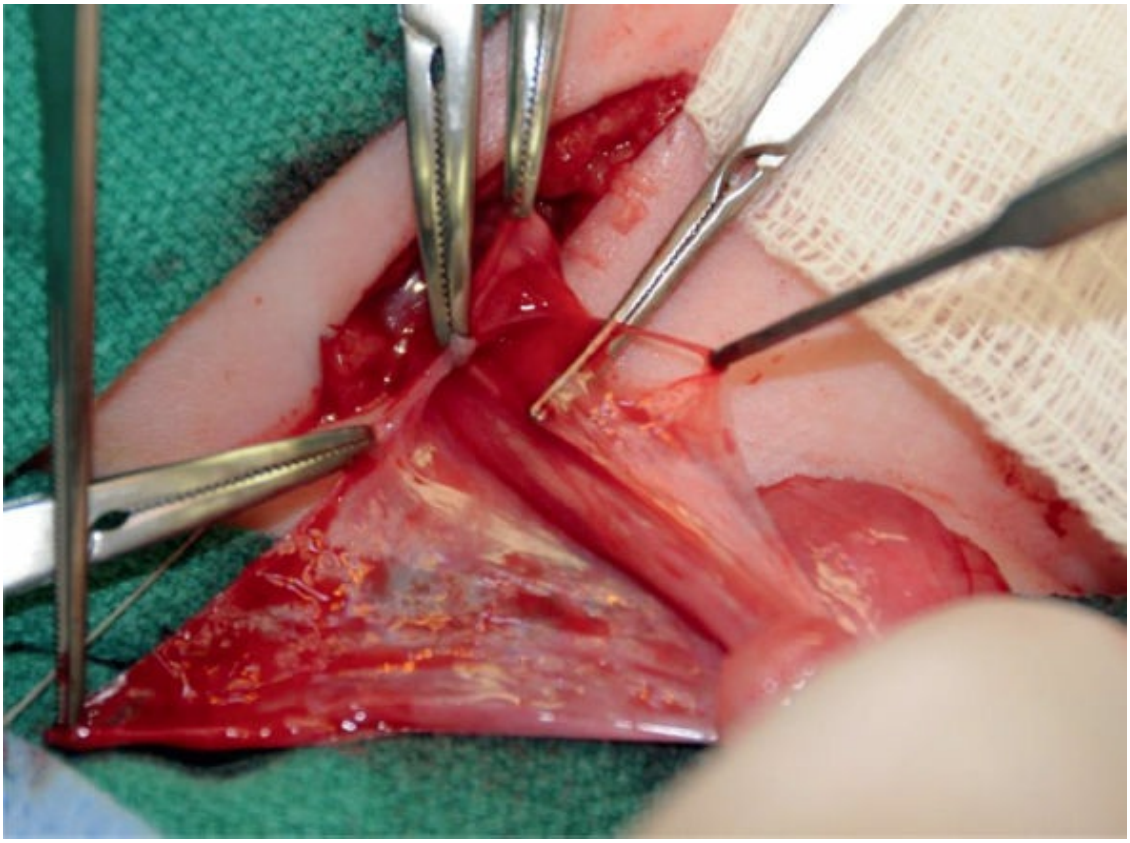

Figure 178.5. The processus vaginalis is carefully separated from the spermatic cord, making sure to mobilize the entire hernia sac while protecting the vas deferens and spermatic vessels.

Next, adequate length on the spermatic cord is established by freeing the cord from any remaining cremasteric fibers and the lateral spermatic fascia. On rare occasions, the above steps fail to achieve adequate length and additional procedures may be required. Prentiss et al. created a more medial pathway by passing the testis under the epigastric vessels. Hutcheson et al. suggested thorough dissection of the internal spermatic fascia from the cord will usually gain necessary length, but the inguinal canal may be further opened to expose the retropeitoneum and the vas deferens and testicular vessels can be freed from the endoabdomial fascia up to their origins. If further length is necessary, the testicular artery can be ligated for a one- or two-stage Fowler–Stephens procedure.

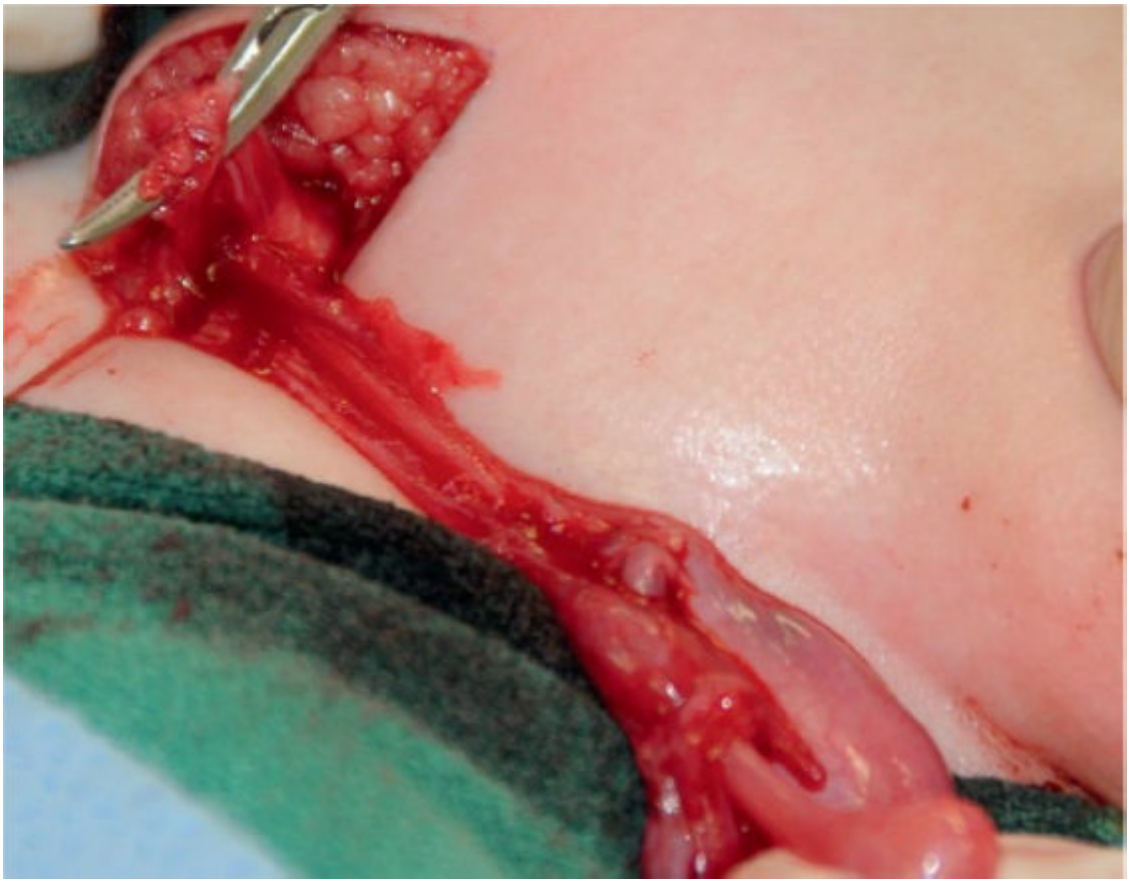

Figure 178.6. The processus vaginalis is mobilized off the cord up to the internal spermatic ring and the peritoneal reflection. It is then suture ligated and allowed to fall back into the retroperitoneal space.



Figure 178.7. The testis is brought down to the scrotum along the path of usual descent, making sure to not cause any iatrogenic twisting of the spermatic vessels. A scrotal pouch is created and the testis secured within it.

Finally, a scrotal pouch is created by passing a finger along the path of testicular descent down into the ipsilateral hemiscrotum where a small incision is made along Langer lines and a subcutaneous pouch is created. The dartos is then opened over a finger, and stay sutures are placed in the dartos aperture and deep in the most dependent portion of the scrotum to act as a pseudo-gubernaculum. A clamp is then passed up from the scrotal incision into the inguinal region over the finger. The testis is grasped by the tunica vaginalis after confirming the correct orientation of the spermatic cord and is brought out through the scrotal incision (Fig. 178.7). The position of the testis and cord is checked again to confirm there is no iatrogenic torsion. The stay sutures are then passed through the paratesticular aspects of the tunica vaginalis of the testis and tied. The testis is dunked into its pouch, and the scrotum is closed with interrupted

buried sutures. Prior to closing the external oblique fascia, a long acting local anethestic can be injected around the ilioinguinal nerve and under the skin if no caudal block was placed. The external oblique fascia is then closed with interrupted sutures taking care not to injure the ilioinguinal nerve or to strangulate the spermatic cord. Scarpa's fascia is reapproximated, and the skin is closed with a running subcuticular suture and skin glue is applied to both the inguinal and scrotal incisions.

Scrotal Orchiopexy

Orchiopexy performed through a single scrotal incision, initially described by Bianchi and Squire, has gained popularity in recent years for its cosmetic appearance, short operative time, and minimal postoperative pain. However, appropriate patient selection is imperative for success.

Once general anesthesia is induced, an examination is performed to determine if the affected testis can be manipulated down into the superior scrotum. If it reaches, an attempt can be made to proceed with a scrotal orchiopexy. Otherwise, inguinal orchiopexy should be performed. The incision is made along the crease between the hemiscrotum and inguinal skin (superior lateral border of the ispilateral hemiscrotum), although an incision along the median raphe has also been described. The testis is grasped and mobilized until it can be brought through the incision. The gubernaculum is usually then transected, although it has been argued that this step is not necessary. The spermatic cord is then mobilized up to the external ring by dividing the attached cremasteric fibers. The use of a Deavor or similar retractor can be helpful at this point for visualization. The processus vaginalis is isolated from the spermatic cord. If it is noted to contain fluid or can be cannulated, this usually implies that it remains patent. It is ligated high in the inguinal canal, similar to the traditional inguinal approach. The remaining lateral spermatic fascial attachments are transected. At this point, the testis should be evaluated for any residual tension. If any tension remains, the external ring and canal may be opened to facilitate further dissection. However, if this still does not gain adequate length, a traditional inguinal incision should be made and inguinal orchiopexy performed. If the testis does reach and remains in the dependent scrotum, it can then be secured in a scrotal pouch and the incision.

Laparoscopic Diagnosis

Laparoscopic evaluation has become the standard approach to a nonpalpable testis, allowing for the identification of an abdominal testis, proof of absence, or facilitation of treatment.

The anesthetized patient should be fully relaxed, and an orogastric tube may empty the stomach. The bladder is drained. A small periumbilical incision is made and the camera port is inserted using the Hasson technique or Veress needle. The abdomen is inflated with care to avoid over-inflation. The camera is then inserted and the abdomen inspected for any entry injury. If needed, the patient may be placed in Trendelenburg position to allow the bowel to fall away from the pelvis. First, the unaffected side is examined to confirm that both the vas deferens and testicular vessels pass through a closed internal ring. The affected side is then examined. The testis usually lies anywhere along its path of embryologic descent between the ipsilateral kidney and inguinal canal. It is imperative to identify the testicular vessels, which may be normal caliber if associated with a testis or atretic if associated with an absent or atrophied testis. However, the vas deferens in rare cases may not unite with the testis, and therefore identification of a blind-ending vas deferens alone is not diagnostic of testicular atresia. Alternatively, the vas deferens may enter the inguinal canal, turn, and exit the canal to meet an abdominal testis in the case of a long-looping vas. The surgeon needs to be cognizant of this possibility during dissection to avoid injury to the vas and its collaterals. If, however, no testicular vessels are identified, the rare circumstance of an ectopic testis and the possibility of an absent kidney should be considered. Ultimately the spermatic vessels are the key to diagnosis: proof of an absent testis are blind-ending spermatic vessels.

Laparoscopic Orchiopexy

Management is based on laparoscopic findings. If testicular vessels and vas deferens enter the inguinal ring, groin exploration is performed and standard orchiopexy is performed if a satisfactory testis is found. If blind-ending vessels are identified, the authors recommend scrotal orchiopexy of the contralateral testis to decrease the risk of torsion in the solitary testis, a catastrophic event. However, because of the very low but nonetheless real potential of injury of the testis during orchiopexy, this is controversial and should be discussed with the parents. In the case of an intra-abdominal testicular nubbin, the authors recommend removal to prevent the risk of malignant transformation, although others argue it can be safely left due to

the low incidence of this.

If a satisfactory intra-abdominal testis is found, it may be brought down into the scrotum in a single or stage procedure depending on the length of the testicular vessels. A 3-mm port is placed in each side of the lower abdomen. In the case of a one-stage laparoscopic procedure, the entire length of the vas deferens is identified so that a long-looping vas is not missed. The gubernaculum is circumferentially dissected and transected using electrocautery. Remaining attachments are used as a handle for manipulating the testis. The peritoneum is incised lateral to the testicular vessels and caudal to the vas deferens. The peritoneum may be carefully freed from the underlying vessels to gain further length, ensuring to preserve a triangle of intact peritoneum distally between the vessels and vas due to the collateral vessels in this area. The cord and testis are also freed from any attachments dorsally. At this point, the surgeon must determine if the testis can be brought down into the scrotum in one or two phases. The gubernaculum is grasped and the testis brought across the midline to the contralateral external ring and inguinal canal. If it reaches this far, it will likely reach the ipsilateral scrotum in one step. An incision is made in the ipsilateral scrotum and a subcutaneous pouch is bluntly developed. A laparoscopic grasper is then advanced from the ipsilateral working port either through the inguinal canal provided adequate spermatic cord length or a new path is created medial to the epigastric vessels (laparoscopic Prentiss maneuver). The grasper is brought out of the scrotal incision and a 3- or 5-mm trocar is backloaded over this. A laparoscopic grasper is then inserted through this scrotal trocar and follows the initial grasper into the abdomen. The testis is then grasped by the gubernacular remnant and pulled out of the scrotum. The cord is inspected laparoscopically and the orientation of the testis is also checked to ensure there is no torsion. The testis is then fixed in the dartos pouch and the scrotal skin closed. After checking for hemostasis, the abdomen is deflated, trocars removed, and fascia and skin closed.

If the testis does not reach into the scrotum, further careful mobilization may be performed or a Fowler–Stephens procedure can be performed. The testicular artery is clipped or suture ligated. In a one-step Fowler–Stephens procedure, the spermatic vessels are occluded for 5 minutes. If the testis seems to remain viable based on the visual appearance, the vessels may then be ligated and transected and the testicle brought down into the scrotum. In the two-step procedure, the spermatic vessels are clipped and

the procedure is terminated. Six months later, after collateral blood supply is better established, the procedure is completed by transecting the testicular artery proximal to the area of ligation, freeing the testicle further from its attachments, and bringing it into the scrotum as described above.

Postoperative Care

Orchiopexy is usually performed as an outpatient procedure unless there are significant comorbidities. Pain is controlled with weight-dosed narcotic pain medication, tylenol, and/or motrin. Caregivers are counseled that the child should avoid any straddle activities such as bike riding for a few weeks, although car seats are safe. Patients are usually seen in 1 to 2 months to ensure adequate recovery and good testicular position. Often patients then follow up again in approximately 1 year to ensure the testis remains orthotopic. Patients return again prior to puberty for counseling on testicular self-exams due to their increased risk of testicular malignancy.

COMPLICATIONS

Complications such as bleeding or scrotal hematoma, hydrocele, or local wound infection are rare, but can usually be managed conservatively unless there is concern for active bleeding or if the hydrocele is large. Division of the vas deferens can be managed with immediate microsurgical repair or delayed repair performed after puberty. Testicular ascent is managed by reoperative orchiopexy.

OUTCOMES

The success of orchiopexy, defined as a normal sized testis in the dependant scrotal position, varies by initial location of the testes and the procedure performed. The lower the testis, the higher the success. Inguinal orchiopexy has a reported 89% to 99% success rate, one-stage Fowler–Stephens orchiopexy has a 63% to 67% success rate, and two-stage Fowler–Stephens orchiopexy has a 67% to 89% success rate.

All patients with cryptorchidism are at increased risk for subfertility, but subfertility is more likely (up to 55%) with bilateral cryptorchidism. Nonetheless, orchiopexy decreases the risk. Later malignancy is possible for both the cryptorchid and the contralateral descended testes in these patients, although the relative risk is substantially less if orchiopexy is performed prior to puberty versus after puberty (2.23 vs. 5.4).

Suggested Readings

Cloutier J, Moore K, Nadeau G, et al. Modified scrotal (Bianchi) mid raphe single incision orchiopexy for low palpable undescended testis: early outcomes. *J Urol* 2011;185:1088–92.

Docimo SG. The results of surgical therapy for cryptorchidism: a literature review and analysis. *J Urol* 1995;154:1148.

Fine RG, Franco I. Laparoscopic orchiopexy and varicocelectomy. *Urol Clin North Am* 2015;42:19–29.

Kollin C, Granholm T, Nordenskjold A, et al. Growth of spontaneously descended and surgically treated testes during early childhood. *Pediatrics* 2013;131:e1174–80.

Kolon TF, Herndon CD, Baker LA, et al. Evaluation and treatment of cryptorchidism: AUA guideline. *J Urol* 2014;192:337–45.

Law GS, Pérez LM, Joseph DB. Two-stage Fowler-Stephens orchiopexy with laparoscopic clipping of the spermatic vessels. *J Urol* 1997;158:1205–7.

Patterson A, Richiardi L, Nordenskjold A, et al. Age at surgery for undescended testis and risk of testicular cancer. *NEJM* 2007;356:1835–41.

Radmayr C, Oswald J, Schwentner C, et al. Long-term outcome of laparoscopically managed nonpalpable testes. *J Urol* 2003;170:2409–11.

Tackett LD, Patel SR, Caldamone AA. A history of cryptorchidism: lessons from the eighteenth century. *J Pediatr Urol* 2007;3:426.

Yucel S, Ziada A, Harrison C, et al. Decision making during laparoscopic orchiopexy for intra-abdominal testes near the internal ring. *J Urol* 2007;178:1447–50.

EDITOR'S COMMENT

As the authors note, the undescended testicle is one of the most common genitourinary anomalies encountered by the pediatric, general, or urologic surgeon. With a better understanding of the physiologic consequences of delayed repair—increased risk for infertility and malignancy—treatment guidelines established by national societies have recommended evaluation by 6 months of age and definitive repair by 18 months (Kolon TF, Herndon, A, Baker LA, et al. Evaluation and treatment of cryptochidism: AUA guideline. *Journal of Urology* 2014;192(2):337–45). Unfortunately, adherence to these guidelines remains inconsistent (Kokorowski PJ, Routh JC, Graham DA, et al. Variations in timing of surgery among boys who underwent orchidopexy for cryptorchidism. *Pediatrics* 2010;126(3):e576–82) and as a result many infants are referred late.

The authors present an excellent summary of how they perform an orchiopexy. One additional step we use to gain additional length on the vas and the blood vessels is blunt dissection of the peritoneum off these retroperitoneal structures. The blunt dissection can be achieved by elevating the hernia sac superiorly with the cord structures on gentle tension inferiorly creating a space into which a corner of a moist unfolded Raytec gauze sponge can be inserted and with gentle packing, bluntly free the peritoneal attachments from the cord structures. We have found that this dissection can result in up to a half centimeter of length allowing the testicle to reach further the scrotum. As the authors note, transposition of the structures under the epigastric vessels is an additional step that can be helpful in patients with a short cord but repair of the inguinal floor will then become necessary.

As the authors nicely describe, laparoscopy for undescended testicle is an integral part of the diagnostic and treatment regimen. If the testicle cannot be palpated in the inguinal canal, laparoscopy is warranted to determine the testicle's location. In some patients no testicle is found and it is presumed that in utero torsion occurred. These patients once they have completed puberty should for cosmetic purposes have a prosthetic testicle placed in the scrotum. When the testicle is found within the abdomen, the key is to determine whether the testicle can be delivered to the scrotum. If using a laparoscopic grasper, the testicle can be delivered through the deep ring into the inguinal canal such that it is palpable, it is likely that a standard orchiopexy can be performed. If this cannot be achieved, we proceed with a Fowler–Stephens two-stage procedure. Of note, one additional approach for an intra-abdominal testicle is testicular autotransplantation. This procedure is done in conjunction with plastic surgeons where the artery and vein of the testicle is carefully dissected from within the retroperitoneum such that adequate length is obtained. The testicle is completely freed and placed in a subdartos pocket with the vessels extending up the inguinal canal where they are then anastomosed to inferior epigastric artery and vein using microsurgery (Bukowski TP, Wacksman J, Billmire DA, et al. Testicular autotransplantation: A 17 year review of an effective approach to the management of the intra-abdominal Testis. *Journal of Urology* 1995;154(2):558–61).

Gregory M. Tiao

179 Surgical Management of Wilms Tumor

Gwen M. Grimsby and Michael L. Ritchey

ETIOLOGY AND PATHOPHYSIOLOGY

Wilms tumor, or nephroblastoma, is an embryonal tumor that develops from remnants of immature kidney. It is the most common renal tumor of childhood constituting approximately 6.3% of all cancers and 95% of all renal cancers in children under the age of 15 in the United States. The average annual age-adjusted incidence is 8.0 per million or approximately 500 new cases in the United States per year. The incidence is highest among children under 2 years of age, in females, and African Americans. Although greater than 80% of cases are diagnosed before 5 years of age, with a median age of 3.5 years, older children and occasionally even adults can be affected. Synchronous bilateral Wilms tumor occurs in 4% to 6% of cases and these patients are diagnosed at a younger age.

Approximately 10% of children with Wilms tumor have a congenital anomaly or an associated overgrowth or nonovergrowth syndrome. Familial cases account for 1% to 12% of Wilms tumor. The overgrowth syndrome Beckwith–Wiedemann (BWS) is characterized by macroglossia, visceromegaly, and an omphalocele. Other overgrowth syndromes include Simpson–Golabi–Behmel syndrome, Perlman syndrome (macrocephaly, macrosomia, visceromegaly, dysmorphic facial features), and Sotos syndrome (cerebral gigantism). Nonovergrowth syndromes include isolated aniridia, trisomy 18, WAGR syndrome (Wilms tumor, aniridia, genitourinary malformations, mental retardation), Bloom syndrome (short stature, micrognathism, café-au-lait spots), and Denys–Drash syndrome (male pseudohermaphroditism, mesangial renal sclerosis). Isolated genitourinary anomalies found in children with Wilms tumor include hypospadias, cryptorchidism, and renal fusion.

Screening with serial renal ultrasounds has been recommended in children at high risk for development of Wilms tumor. Review of most studies suggests 3 to 4 months is the appropriate screening interval.

Tumors detected by screening will generally be a lower stage. Early detection can provide an opportunity for nephron sparing surgery, since these children are at an increased risk for bilateral disease. It is recommended that screening be performed when a condition has a Wilms tumor incidence of greater than 5%. Ultrasound surveillance should continue to 7 years of age in patients with BWS, Simpson–Golabi–Behmel, hemihypertrophy, and familial Wilms. Screening has also been recommended in children in infants under 12 months of age found to have nephrogenic rests (NRs) in the resected kidney.

NRs are foci of primitive metanephric tissue that are found in 1% of postmortem infant kidneys. Because NRs are found in up to 44% of kidneys removed for Wilms tumor and nearly 100% of patients with bilateral Wilms tumors, these tissues are thought to represent precursor lesions in children genetically predisposed to Wilms tumor. NRs are categorized as either perilobar or intralobar based on their anatomical location within the kidney. Perilobar NRs are observed in kidneys harboring Wilms tumors with WT2 deletions, whereas intralobar NRs are more often observed in those with WT1-associated tumors. The presence of multiple NRs in the nontumoral portion of a Wilms tumor kidney has been shown to be a risk factor for development of metachronous tumor in the contralateral kidney.

A number of genes have been identified that play a role in the development of Wilms tumor (Table 179.1). The *WT1* gene is located on chromosome 11p13 and encodes a zinc-finger transcriptional factor that serves both tumor-suppressive and developmental regulatory functions. The incidence of WT1 mutations in patients with nonsyndromal Wilms tumor is 2%. Mutations in the *WT2* gene, located at the chromosome 11p15 locus, have also been associated with Wilms tumor and loss of heterozygosity (LOH) at this locus is associated with BWS. Aniridia, found in 1.1% of Wilms tumor patients, is caused by an abnormality of the *PAX6* gene located adjacent to the *WT1* gene. Another tumor suppressor gene, *WTX*, is targeted by somatic mutations in up to 30% of cases of Wilms tumor. Finally, LOH at chromosome 16q or 1p occurs in up to 20% of Wilms tumors and has been shown to be associated with an increased risk for tumor relapse and mortality. More recently, 1q gain has been identified in up to 30% of Wilms tumors and has been associated with decreased event-free survival (EFS).

TABLE 179.1 Syndromes and Genes Associated With Wilms Tumor

Syndrome	Genes	Locus	Wilms Tumor Risk
WAGR	WT1	11p13	50%
Denys-Drash	WT1	11p13	50%
Frasier	WT1	11p13	5–10%
Beckwith—Wiedemann	WT2	IGF2, H19, p57, Klp2	5–10%
Familial Wilms tumor	FWT1	17q21	30%
	FWT2	19q13	
Perlman	Unknown		>20%
Mosaic variegated aneuploidy	BUB1B	15q15	>20%
Fanconi anemia D1	BRCA2	13q12.3	>20%
Simpson-Golabi-Behmel	GPC3	Xq26	10% (in males)
Li-Fraumeni	p53	17p13	Low
Neurofibromatosis	NF1	17q11	Low
Sotos	NSD1	5q35	Low
Trisomy 18	Unknown	18	Low
Bloom	BLM	15q26	Low

Wilms tumor usually compresses the adjacent normal renal parenchyma to form a pseudocapsule composed of compacted, atrophic renal tissues which can be helpful to distinguish Wilms tumor from NRs and other renal tumors. Most Wilms tumors are unicentric, but 12% are multicentric unilateral tumors. Extrarenal Wilms tumor arising in the retroperitoneum and elsewhere are rare and are thought to arise from displaced metanephric elements or mesonephric remnants. Histologically, “classic” Wilms tumor is characterized by islands of compact undifferentiated blastema and epithelial differentiation in the form of embryonic tubules, rosettes, and glomeruloid structures separated by a significant stromal component. The unfavorable histologic feature of anaplasia is associated with resistance to chemotherapy and has been demonstrated to carry a poor prognosis even when the tumor is confined to the kidney.

CLINICAL PRESENTATION

More than 90% of children with Wilms tumor are diagnosed when an asymptomatic abdominal mass is discovered incidentally by a family member or physician. The mass is usually quite large relative to the size of the child and is not necessarily confined to one side of the abdomen. Approximately 20% of children have hematuria at diagnosis and in these patients it is important to rule out invasion of tumor into the collecting system. Hypertension will be present in 25% of children and may be

secondary to elevated plasma renin levels. Other symptoms may include fever, anorexia, and weight loss in 10% of patients. Rarely children may present with acute abdominal pain from tumor rupture into the peritoneal cavity or bleeding within the tumor.

A firm, palpable mass is usually evident on physical examination. A persistent varicocele in the supine position or hepatomegaly may be reflective of inferior vena caval (IVC) obstruction from tumor thrombus. Atrial thrombus can result in hypertension or congestive heart failure. During the physical examination, it is also important to assess for signs of associated Wilms tumor syndromes such as aniridia, hemihypertrophy, and other genitourinary anomalies.

PREOPERATIVE PLANNING

Emergent operation is not necessary unless there is evidence of active bleeding or tumor rupture. Thus, a thorough preoperative work up with appropriate laboratory and imaging studies is recommended before proceeding with surgical resection. An abdominal ultrasound can differentiate between solid and cystic masses and Doppler ultrasonography of the renal vein and IVC can evaluate for the presence of tumor thrombus. All patients should undergo either CT of the abdomen and pelvis with oral and intravenous contrast or MRI of the abdomen and pelvis with gadolinium. These imaging modalities allow for improved preoperative planning by evaluating for extrarenal spread of disease, the relationship of the tumor to adjacent visceral structures, and the presence of synchronous tumors in the contralateral kidney. Preoperative chest CT with or without contrast is performed to rule out pulmonary disease as the lung is the most common location of distant metastasis. Positron emission tomography (PET) has not been shown to have any advantages over conventional imaging modalities in preoperative assessment of Wilms tumor and is not routinely recommended.

It is important to remember that a precise histologic diagnosis cannot be obtained on preoperative imaging studies and all solid renal tumors of childhood have some common radiographic features including renal cell carcinoma. In the SIOP-9 study, 5.4% of patients who underwent preoperative chemotherapy for Wilms tumor prior to diagnostic biopsy were found to have renal malignancies other than Wilms tumor or a benign renal condition upon nephrectomy.

Preoperative laboratory evaluation should include a complete blood

count, liver enzymes, and serum electrolytes, including blood urea nitrogen, creatinine, and calcium. Acquired von Willebrand disease has been noted in 8% of newly diagnosed patients with Wilms tumor and thus prothrombin time and partial thromboplastin time should be obtained. Patients with prolonged coagulation studies can have this defect corrected preoperatively with the administration of 1-desamino-8-D-arginine-vasopressin (DDAVP).

TREATMENT

Tumor histology and stage have long been recognized as the most important determinants of prognosis in patients with Wilms tumor. Favorable histology tumors have a better prognosis. As noted above, tumors with unfavorable features such as anaplasia, portends a much poorer prognosis. Not all Wilms tumors have a triphasic pattern, but present only biphasic or even monomorphous patterns. Wilms tumors with predominantly epithelial differentiation have a low degree of aggressiveness and the majority are stage I tumors. However, these tumors may be more resistant to therapy if they present as advanced stage disease.

Primary radical nephrectomy is recommended for the majority of children with unilateral Wilms tumor diagnosed in North America. However, many children worldwide are treated with preoperative chemotherapy usually according to protocols developed by the International Society of Pediatric Oncology (SIOP). The relative proportions of histologic subtypes of Wilms tumor differ following preoperative chemotherapy when compared to those reported following primary surgical resection. Stromal and epithelial predominant tumors are found more often after chemotherapy. These histologic subtypes may demonstrate a poor clinical response to therapy but have an excellent prognosis if the tumor is completely excised. The proportion of blastemal predominant tumors is decreased after chemotherapy, indicating some response of this tumor type to the preoperative chemotherapy. However, patients with blastemal predominant tumors after chemotherapy have a high rate of relapse. Tumor progression during therapy occurred in 5% of patients enrolled in SIOP 93–01. These patients were documented to have decreased overall survival. The SIOP group uses the response of the tumor to chemotherapy to stratify patients for treatment.

Staging of Wilms tumor is based on various intraoperative and pathologic findings. The COG staging system is listed in Table 179.2.

Accurate staging of disease allows treatment results to be evaluated and enables universal comparisons of outcomes. Examination for extension through the capsule, residual disease, vascular involvement and lymph node involvement are essential to properly assess the extent of the tumor at presentation. Tumor invasion of the renal sinus is the first sign of spread outside the kidney in stage II tumors. Penetration through the renal capsule is the next most common finding of extrarenal spread. Any tumor spill results in a stage III designation and is associated with an increased risk for local tumor recurrence. It is important to remember that the surgeon has responsibility for complete tumor removal and avoidance of tumor spill. For NWTS-5, the distribution by stage for patients with favorable histology tumors was stage I, 24.9%; stage II, 29.9%; stage III, 30.6%; and stage IV, 14.5%.

TABLE 179.2 Children's Oncology Group Staging System

Stage	Characteristics
I (45%)	The tumor is limited to the kidney and completely excised. The renal capsule is intact and the tumor was not ruptured prior to removal. There is no residual tumor. The vessels of the renal sinus are not involved.
II (20%)	The tumor extends beyond the kidney, but is completely excised. There is regional extension of the tumor (i.e., penetration of the renal capsule, extensive invasion of the renal sinus). Extrarenal vessels may contain tumor thrombus or be infiltrated by tumor. Lymph nodes do not contain cancer.
III (20%)	Residual nonhematogenous tumor confined to the abdomen: lymph node involvement, tumor spillage either before or during surgery, peritoneal implants, tumor beyond surgical margin either grossly or microscopically, or tumor not completely removed.
IV (10%)	Hematogenous metastases (lung, liver, bone, brain, etc.) or lymph node metastases outside the abdominopelvic region are present.
V (5%)	Bilateral renal involvement at diagnosis

For decades, tumor histology and stage were used to guide adjuvant therapies after surgery. All clinical trials for children with Wilms tumor strive to tailor treatment to individual risks for tumor recurrence and reduce the overall morbidity of treatment and reduce treatment related side effects. Recent clinical trials have also incorporated biologic markers (LOH 1p and 16q) into risk stratification. Future trials may also include other markers, for example, gain of 1q. Treatment recommendations for the most recent COG studies are listed in Table 179.3.

The first generation of COG studies (2006 to 2013) grouped patients by risk for recurrence (very low, low, standard, and high). Children with stage I or II FHWT and LOH of 1p and 16q were treated with vincristine (VCR), dactinomycin (AMD), and doxorubicin (DOX) without radiotherapy. Patients with stage III FHWT disease without LOH of 1p and 16q were treated with VCR, AMD, and DOX and irradiation of the flank or abdomen. A response-based approach was explored for management of children with pulmonary metastases. Those with resolution of the pulmonary lesions on chest CT after 6 weeks of chemotherapy were continued on treatment with VCR, AMD, and DOX. Patients who did not have resolution of the pulmonary lesions by week 6 received more intensive chemotherapy and pulmonary irradiation. Children with stage I to III focal anaplastic histology Wilms tumor (AHWT) and stage I diffuse AHWT were treated with AMD, VCR, DOX, and abdominal irradiation. Children less than 2 years of age with stage I FH tumors weighing less than 550 g were defined as very low risk Wilms tumors (VLRWT). These children do not receive chemotherapy after nephrectomy.

TABLE 179.3 Recommended Therapy on Children's Oncology Group Protocols

Stage/Histology	Risk Group	Radiotherapy	Chemotherapy
Stage I FHWT <2 yr, <550 g	Very low	None	None
Stage 1 FHWT, >2 yr or >550g	Low	None	Regimen EE-4A
Stage II FHWT	Low	None	Regimen EE-4A
Stage I or II FHWT and LOH 1p, 16q	Standard	None	Regimen DD-4A
Stage III FHWT, no LOH 1p, 16q	Standard	Yes	Regimen DD-4A
Stage I–III focal AHWT	High	Yes	Regimen DD-4A
Stage I diffuse AHWT	High	Yes	Regimen DD-4A
Stage III or IV FHWT and LOH 1p, 16q	High	Yes	Regimen M
Stage IV FHWT pulmonary metastases			
Lesions resected at diagnosis	High	Yes	Regimen DD-4A
Lesions resolve after 6 weeks chemo	Standard	None	Regimen DD-4A
Lesions persist after 6 weeks chemo	High	Yes	Regimen M
Stage IV FHWT nonpulmonary metastases	High	Yes	Regimen M
Stage II or III diffuse AHWT	High	Yes	Regimen UH-1
Stage IV diffuse AHWT (no measurable disease)	High	Yes	Regimen UH-1
Stage IV focal AHWT	High	Yes	Regimen UH-1
Stage I CCSK	High	None	Regimen I
Stage II or III CCSK	High	Yes	Regimen I
Stage IV CCSK	High	Yes	Regimen UH-1
Stage I–III MRT	High	Yes	Regimen UH-1
Stage IV MRT	High	Yes	Regimen UH-2
Stage IV AHWT (measurable disease)	High	Yes	Regimen UH-2
Stage V FHWT (disease ≤ stage II)	Bilateral	+/–	Regimen EE4A
Stage V FHWT (disease ≥ stage III)	Bilateral	+/–	Regimen DD4a
Stage V AHWT	Bilateral	+/–	Regimen I

Regimen EE-4A: Pulse-intensive AMD plus VCR (18 weeks)
Regimen DD-4A: Pulse-intensive AMD, VCR, and DOX (24 weeks)
Regimen M: VCR, AMD, DOX, alternating with CYCLO and ETOP (24 weeks)
Regimen UH-1: CYCLO, carboplatin, ETOP alternating with VCR, DOX, CYCLO (30 weeks)
Regimen I: VCR, DOX, CYCLO alternating with CYCLO, ETOP (24 weeks)
Regimen UH-2: VCR, DOX, CYCLO alternating with CYCLO, carboplatin, ETOP and VCR, irinotecan (30 weeks)

FHWT, favorable-histology Wilms tumor; LOH, loss of heterozygosity; AHWT, anaplastic-histology Wilms tumor; CCSK, clear cell sarcoma of the kidney; MRT, malignant rhabdoid tumor of the kidney; AMD, dactinomycin; VCR, vincristine; DOX, doxorubicin; CYCLO, cyclophosphamide; ETOP, etoposide.

Children with bilateral Wilms tumors should not undergo initial radical nephrectomy. These patients receive preoperative chemotherapy with the goal of shrinking the tumors and allowing more patients to be treated with renal sparing surgery. The goal is to preserve renal function and decrease the risk of renal failure which approaches 15% at 15 years posttreatment for patients with bilateral tumors. After 6 weeks of VCR, AMD, and DOX, tumor response is evaluated with computed tomography (CT) or magnetic resonance imaging (MRI). Tumors amenable to renal-sparing procedures can proceed with surgery and if there has not been a good response to chemotherapy, biopsy of the tumor(s) is recommended. Open biopsies are recommended because they are more accurate than percutaneous needle biopsies when assessing for anaplasia. Bilateral biopsies are also recommended as anaplasia can be discordant between the two kidneys. Failure to achieve a reduction in tumor volume may be due to tumor

differentiation. Additional chemotherapy is then given, but all patients should undergo surgical resection within 12 weeks of starting therapy.

The SIOP advocates preoperative chemotherapy for patients with Wilms tumor regardless of the extent of disease. The driving force behind this approach is that preoperative chemotherapy can produce dramatic reduction in the size of the primary tumor, thus facilitating surgical excision. SIOP trials have demonstrated that the incidence of tumor rupture is lower after preoperative chemotherapy. There is concern that patients who are staged by imaging studies alone are at risk for understaging. However, the SIOP group has used the response of the tumor to chemotherapy to guide treatment decisions. Overall survival is similar for similarly staged patients treated with COG and SIOP protocols.

COG studies primarily use preoperative chemotherapy for children with bilateral tumors, those with IVC tumor thrombus extending above the hepatic veins and inoperable tumors. The latter decision should not be based on preoperative imaging studies that may overestimate local tumor extension. If the tumor is found to be unresectable at surgery, it is considered stage III. Repeat imaging is performed after 6 weeks of chemotherapy. Experience in SIOP has shown that the majority of reduction in tumor volume occurs in the first 4 weeks of therapy. After there has been adequate shrinkage of the tumor, definitive resection can generally be completed. A clinically good response (by imaging) is usually associated with a pathologically good response in terms of regressive histologic changes. The converse is not always true. Stromal and epithelial predominant tumors are found more often after preoperative chemotherapy. These histologic subtypes may demonstrate a poor clinical response to therapy, but have an excellent prognosis if the tumor is completely excised. Patients with progressive disease during preoperative chemotherapy have a poor prognosis and these patients will require treatment with a more intensive chemotherapeutic regimen.

SURGICAL TECHNIQUE

The initial therapy for most children with Wilms tumor is radical nephrectomy and the surgeon is responsible for determining the extent of tumor. Accurate staging is essential for the subsequent determination of the need for adjuvant radiation and chemotherapy. The recommended surgical approach is through a transperitoneal, transabdominal incision which allows for inspection and exploration of the abdominal cavity. The

peritoneal cavity is inspected to assess for any evidence of tumor rupture of peritoneal implants. Formal exploration of the contralateral kidney is not recommended if preoperative CT or MRI does not demonstrate bilateral lesions. In the case of a contralateral solitary peripheral renal lesion less than 1 cm in diameter, the contralateral lesion can be completely excised at diagnosis followed by a unilateral radical nephrectomy. A margin of normal renal tissue should be removed with the lesion in case the lesion is a Wilms tumor rather than an NR.

The patient should be placed in a supine position with mild flexion of the lumbar spine to facilitate the exposure of retroperitoneal structures. The incision should be made approximately 2 fingerbreadths above the umbilicus beginning in the midaxillary line on the side of the tumor (Fig. 179.1). The incision can be extended across the midline depending on the size of the tumor and amount of exposure needed. The incision may also be extended into a thoracoabdominal approach by continuing through the bed of the 9th or 10th rib, if necessary. The muscle layers are sequentially divided and the peritoneal cavity entered and assessed for evidence of tumor rupture and peritoneal implants. An assessment of tumor extent should be performed by palpation of the IVC and inspection for regional lymphadenopathy, perinephric extension, and tumor mobility.

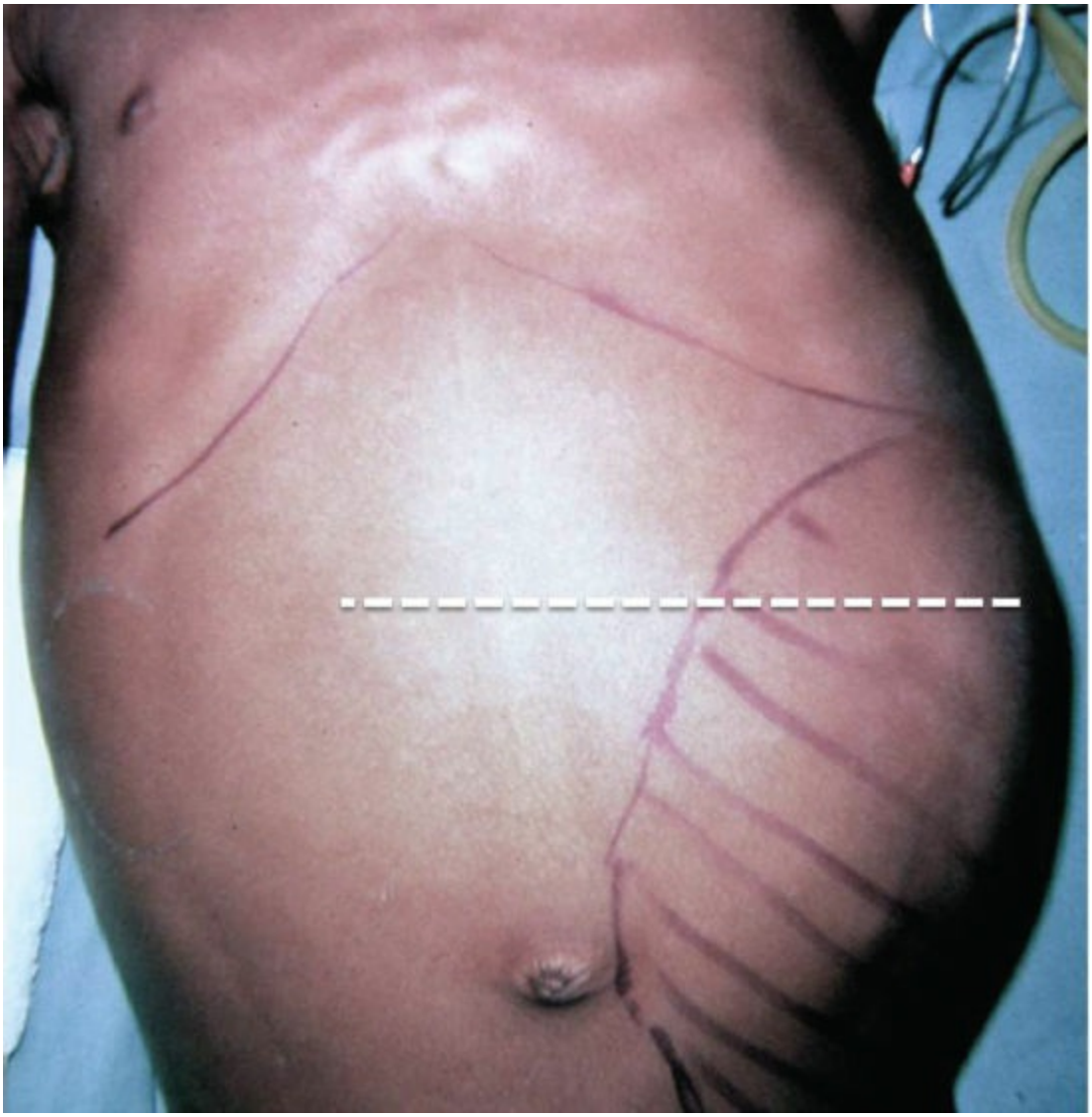

Figure 179.1. Abdominal incision for resection of Wilms tumor.

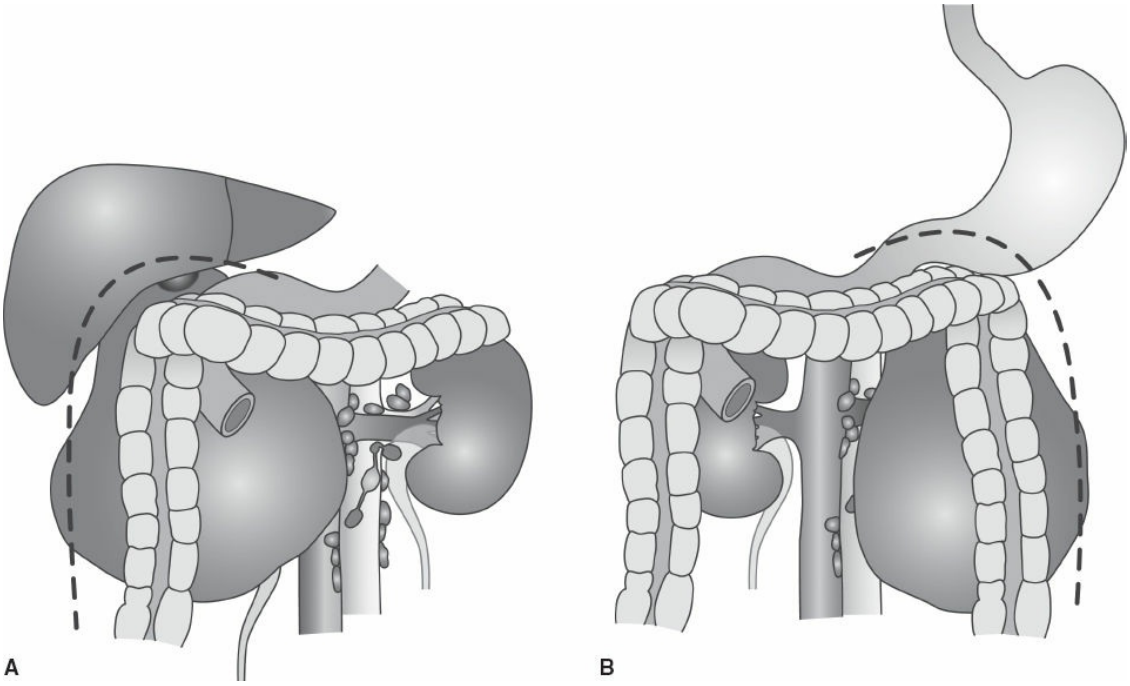

Figure 179.2. Line of dissection for mobilization of the colon to expose the kidney and associated tumor (**A, B**).

Following exploration of the abdominal cavity, the white line of Toldt should be incised and colon reflected medially. The colonic mesentery can then be mobilized, being careful to preserve the colonic vessels that may be draped over the tumor. In some cases, the mesentery may need to be sacrificed to avoid entering the tumor and causing tumor spillage. The colon can then be retracted medially to expose the renal hilum (Fig. 179.2). For right-sided tumors, the posterior peritoneum can be incised up to the base of the mesentery to allow for reflection of the entire colon and small bowel to provide improved exposure of the retroperitoneal vessels.

Early ligation of the renal vessels before manipulation of the tumor is ideal to decrease the theoretical risk of tumor dissemination. After identification, the renal vessels can be individually encircled with vessel loops. Prior to ligation of the renal hilum, the renal vein and IVC should be carefully palpated for the presence of tumor thrombus. However, as large tumors can significantly distort vascular anatomy, it is more important to carefully identify the contralateral renal vessels, superior mesenteric artery or other major vessels prior to ligation of the renal hilum to avoid injury to these structures. The renal vessels can then be doubled ligated and divided, generally taking the renal artery prior to the renal vein in order to avoid distention of the vein, which may dislodge the ligature.

If the renal vein is short or there is tumor extension beyond the renal

vein, a Satinsky clamp can be placed on the IVC just proximal to the insertion of the renal vein. The tumor thrombus should be gently milked back prior to placement of the clamp. The renal vein can then be divided and the venous stump over sewn with continuous 5-0 Prolene in two layers.

If tumor thrombus is present in the IVC, additional surgical exposure is warranted as both proximal and distal vascular control is necessary. For minimal thrombus extension below the level of the hepatic veins, the inferior edge of the liver can be retracted to expose the infrahepatic vena cava. If the tumor thrombus extends more cephalad, mobilization of the liver is required. Division of the triangular and coronary ligaments of the liver allows for rotation and exposure of the retrohepatic vena cava. Additional exposure can also be gained by dividing the lesser hepatic veins. The contralateral renal vein and infrarenal IVC should then be controlled with vessel loops. The IVC is then vertically incised just medial to the entrance of the renal vein. If the thrombus is free floating, it can be manually extracted (Fig. 179.3). If the thrombus is adherent to the wall of the IVC, a Fogarty or Foley balloon catheter can be passed beyond the level of the hepatic veins, inflated, and pulled inferiorly to displace the adherent thrombus into the cavotomy. The IVC should then be allowed to fill by releasing the vessel loops on the distal cava and contralateral renal vein to displace any air from within the IVC prior to closure. The cavotomy can then be clamped with a Satinsky clamp and oversewn with a continuous 5-0 Prolene suture. In rare instances, tumor thrombus invades the wall of the IVC, precluding thrombectomy necessitating partial resection of the IVC.

Patients with IVC extension above the level of the hepatic veins or atrial thrombus remain a difficult surgical challenge. Pretreatment with chemotherapy is recommended in these cases to decrease surgical morbidity. If this fails to shrink the thrombus or if a primary surgical approach is chosen, the procedure may require cardiopulmonary bypass and benefit from a combined abdominothoracic approach with a pediatric cardiothoracic surgeon. Suprahepatic or atrial involvement is best approached through a median sternotomy and performed in conjunction with a subcostal or a midline abdominal incision for nephrectomy.

After the renal vessels are controlled, a dissection plane can be established outside of Gerota fascia with sharp and blunt dissection. Perforating vessels may be quite large and should be ligated individually.

Use of a ligasure can be very helpful for some of these very vascular tumors. Gentle manipulation of the tumor should be emphasized as Wilms tumors are very soft and may easily rupture. Any tumor spill leads to a stage III designation due to the increased risk for local tumor recurrence. It is not necessary to remove the adrenal gland with the specimen if there is no evidence of direct involvement with tumor.

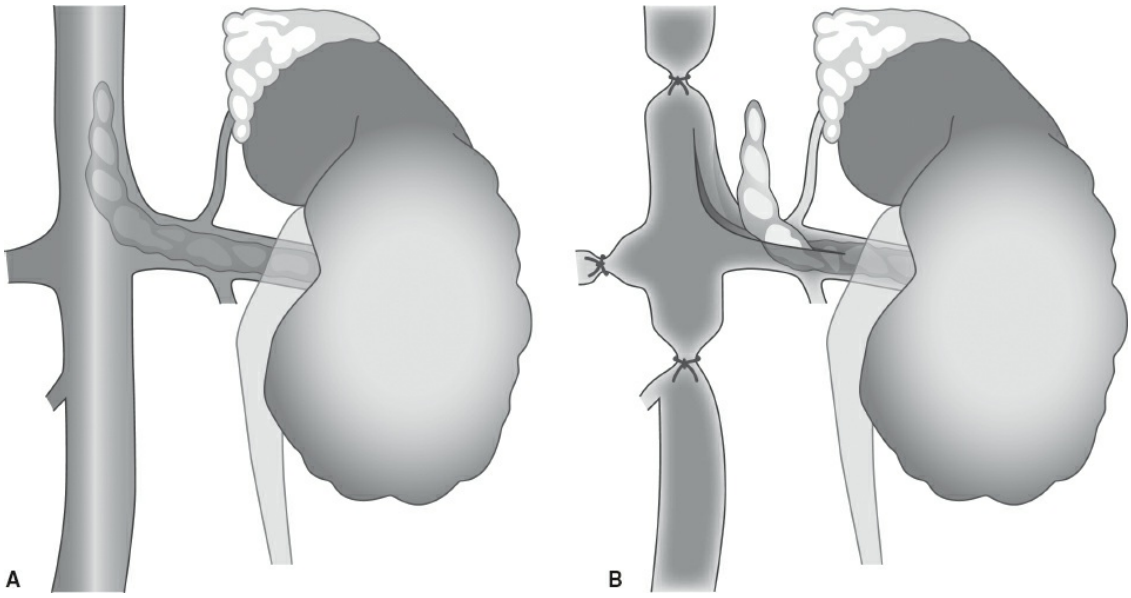

Figure 179.3. Removal of an intravenous tumor thrombus in continuity with the tumor and affected kidney (**A, B**).

Nephroblastomas often compress and adhere to adjacent structures without frank invasion. The gross appearance of the tumor at the time of surgery can be misleading in interpreting tumor extent, and in the majority of cases tumor invasion is not confirmed when adjacent visceral organs are removed. There may be circumstances, however, when removal of other organs is justified. In a patient known to have extracapsular extension, resection of a small portion of liver or tail of the pancreas to avoid leaving residual tumor, for example, may eliminate the need for radiation therapy and allow a reduction in the amount of chemotherapy. Even if the tumor is confined to the kidney, en bloc resection of nonessential structures may also prevent violation of the tumor capsule and obviate tumor rupture or spill. Therefore, it is a tradeoff between the added surgical morbidity of en bloc resection versus a potential reduction in long-term complications of adjuvant treatment if this can be limited by complete tumor removal. In prior reviews, one factor associated with an increased rate of complications was en bloc resection of other visceral organs. If the tumor

is found to be unresectable, biopsy of the tumor can be followed by chemotherapy and/or radiation therapy.

Lymph node sampling is critically important for tumor staging, despite the absence of abnormal nodes on preoperative imaging, or upon gross inspection during operative exploration. Lack of lymph nodes sampling has been identified as a risk factor for local tumor recurrence, likely due to understaging and undertreatment. A prior review of lymph node sampling by the NWTSG demonstrated a false-negative rate of 31% and a false-positive rate of 18% based on preoperative and intraoperative assessment. Unfortunately, there is currently a fairly high incidence of inadequate intraoperative staging, primarily due to failure to sample lymph nodes. In a review of NWTS-4 and -5 patients, 12.5% of patients did not have lymph node sampling performed. The likelihood of having a positive lymph node was greater if more than seven lymph nodes were sampled, but EFS was not improved with removing more lymph nodes. Lymph nodes in the pericaval (right-sided tumors) and periaortic region (left-sided tumors) should be removed and submitted for histologic evaluation. Hilar lymph nodes are often removed with the nephrectomy specimen. However, all suspicious lymph nodes should be biopsied. Failure to sample lymph nodes will mandate increased therapy due to incomplete staging.

The ureter should be palpated to rule out intraureteral tumor extension before it is divided as distally as possible. There is increased suspicion of ureteral extension in children with hematuria and poor visualization of the kidney on preoperative imaging. After extraction of the intact tumor, the wound should be copiously irrigated and hemostasis assessed. Drains are not routinely placed unless a portion of the pancreas or liver has been resected. The displaced colon should be replaced in the tumor bed and abdominal wall closed in the standard fashion.

There have been several reports of laparoscopic nephrectomy for Wilms tumor. This is usually done in conjunction with preoperative chemotherapy and is likely more feasible after the tumor is reduced in size. Experience with open nephrectomy after chemotherapy has shown that these tumors are less prone to tumor spillage. Although prechemotherapy laparoscopic nephrectomy has been reported many more cases will need to be performed to determine if there is an increased risk of tumor spillage, residual disease or surgical complications.

At the time of definitive surgery for bilateral tumors, partial nephrectomy or wedge excision of the tumor is preferred, but only if

complete removal of the tumor can be achieved. The kidney with the lower tumor burden should be addressed first. If complete excision of tumor can be performed leaving a viable functioning kidney, then surgery of the contralateral kidney with more extensive tumor involvement is undertaken. Enucleation of the tumor may be considered in lieu of a formal partial nephrectomy. This may be considered for large centrally located tumors where removal of a margin of renal tissue would compromise the vascular supply to the kidney. Even when very large bilateral masses remain after initial chemotherapy, a high percentage of children can be successfully managed with renal-sparing surgery. As it is easy to underestimate the amount of renal parenchyma that can be salvaged due to compression by the tumor, renal-sparing surgery should be entertained in all patients. Fortunately, bilateral nephrectomies and dialysis are rarely required when the tumors fail to respond to radiation and chemotherapy.

As most Wilms tumors are too large at diagnosis to allow partial nephrectomy, renal sparing surgery has been traditionally used only in patients with bilateral tumors. However, COG is now studying the role of renal sparing surgery for select patients with unilateral tumors. Patients eligible for renal sparing surgery include those with a solitary kidney, a predisposition syndrome where tumors are found at a smaller size, and patients with an increased risk for developing renal failure. After preoperative chemotherapy, partial nephrectomy can be performed in 10% to 15% of patients.

Distant metastases are found in 10% to 12% of patients with Wilms tumor at diagnosis. The lungs are the most common primary site for hematogenous metastases accounting or 80% of cases. Fortunately, the overall survival for patients with favorable histology tumors and metastases at diagnosis is very good. The recent COG study employed a response-based approach for patients with pulmonary metastases. Patients with lung metastases were initially treated with regimen DD-4A. Those children documented to have complete disappearance of the lung metastases (or who had excision of residual nodules that did not contain viable tumor) at the week 6 re-evaluation were considered “rapid responders.” These patients were treated with chemotherapy alone avoiding pulmonary irradiation. Patients that did not have complete resolution of pulmonary nodules were then treated with more intensive chemotherapy and received whole lung irradiation. Patients who had all pulmonary metastases resected at diagnosis (and therefore have no residual

disease available for response monitoring) continued treatment with DD-4A but received whole lung irradiation.

It is strongly recommended that, if there is any doubt about the nature of metastatic lesions, all lesions be biopsied since as many as one third of small (<1 cm) pulmonary lesions may not be metastatic tumor. COG defines pulmonary metastases as detectable lesions of any size which are thought to represent metastases. It is the responsibility of the treating physician to ultimately determine the nature of small metastatic lesions.

Any suspicious site in the abdomen or liver should also be biopsied or resected at exploration to determine the nature of the mass as it will affect tumor stage and therapy. If residual intra-abdominal metastatic disease remains at week 12 of chemotherapy, it should be resected if complete resection is feasible. If complete resection is not feasible, then residual disease should be reassessed for feasibility of resection at the completion of therapy.

POSTOPERATIVE MANAGEMENT

Appropriate postoperative pain management should be obtained with intravenous narcotics, an epidural catheter, or a combination of the two. Intravenous antibiotics are continued for 24 hours postoperatively. A Foley catheter may be left in place until the patient is ambulatory. A nasogastric tube may be used in anticipation of postoperative ileus. Postoperative fluid management is generally routine as the remaining kidney quickly adapts to clear extra fluids.

Approximately 15% to 20% of patients with favorable-histology Wilms tumor and 50% of patients with anaplastic or postchemotherapy blastemal type Wilms tumor develop recurrent tumor. The vast majority of recurrences occur within 2 years of initial diagnosis, with the most frequent sites being pulmonary, tumor bed, and liver. Imaging surveillance after treatment of the primary tumor is recommended to detect tumor recurrence. COG studies advocate for periodic chest CT and either CT or MR of the abdomen. However, some have begun to question the value of these studies and whether they will detect relapse early enough to improve survival. Many patients will present with clinical symptoms related to relapse before imaging detection. Omitting even the pelvic portion of the abdominal CT can significantly reduce the radiation exposure without compromising detection of relapse. Patients with bilateral Wilms tumor need more frequent and longer monitoring after surgery. Local recurrence

can occur many years after the initial renal sparing surgery. These patients are also at greater risk for new renal tumors due to the high prevalence of NRs.

A uniform approach for the treatment of tumor relapse was used in NWTS-5. Patients with relapsed Wilms tumor may be divided into risk groups according to overall survival rates after salvage therapy. Children with nonanaplastic Wilms tumor who relapse after therapy with only VCR and/or AMD are considered standard risk. The survival rates for these patients are in the 70% to 80% range. Patients with nonanaplastic Wilms tumor who relapse after therapy with three or more agents are called high risk and have survival rates in the 40% to 50% range. Patients with unfavorable histology patients who relapse with metastatic disease have a grave prognosis. This very high-risk group includes recurrent anaplastic or blastemal-type Wilms tumor and have survival rates in the 10% range.

The Childhood Cancer Survivor Study group has reported on very late mortality in 5-year survivors of childhood tumor, and found that the leading cause of death was recurrence of the original tumor. The incidence of late tumor recurrence is, however, lower for Wilms tumor patients than for other solid tumors. An international study or more than 13,000 patients found a 0.5% recurrence beyond 5 years. Tumor recurrence in the contralateral kidney was identified in 15 of the 70 patients and 87% of these patients were alive without evidence of disease. This is compared to a 45% survival for those patients with recurrence in other sites.

COMPLICATIONS AND THEIR MANAGEMENT

Removing a large renal tumor in a small child is associated with some morbidity. NWTS-4 patients undergoing primary radical nephrectomy had an 11% incidence of surgical complications. Factors associated with an increased risk for surgical complications include higher tumor stage, tumor size >10 cm, incorrect preoperative diagnosis, thoracoabdominal incision, intracaval tumor extension, and resection of other visceral organs. A mortality rate of 0.5% related to surgical complications was reported from NWTS-3. However, a higher intraoperative mortality rate of 1.5% has been reported from other centers.

The most common intraoperative complication is bleeding. Iatrogenic injury to the aorta and its major vessels may occur as large tumors can distort the anatomy and the great vessels can easily be mistaken for the renal vessels. Mesenteric vessels may also be adherent to the renal hilum.

Vascular injury can be avoided with proper surgical exposure and identification of the aorta, IVC, superior mesenteric artery, celiac axis, and contralateral renal vessels. The renal artery should be carefully traced and seen entering the kidney prior to ligation. Operative repair of significant vascular injury should be undertaken immediately. As tumor thrombus can break off and embolize during the course of nephrectomy, unexplained intraoperative hypotension or cardiac arrest should raise concern for unrecognized vena caval or intracardiac extension of tumor.

Following surgery, the most common complication is small bowel obstruction (SBO) which occurs in 5% of patients. The majority of SBOs occur within the first 100 days after surgery and are usually due to bowel adhesions or intussusception. Factors associated with increased risk of SBO include intravascular tumor extension, resection of other organs, preoperative tumor rupture, residual disease, stage III, and possibly tumor spill. Surgical techniques thought to reduce the incidence of SBO include gentle handling of the bowel, maintaining a moist serosal surface of the bowel, and avoiding foreign materials on the bowel.

Disruption or obstruction of lymphatic drainage can lead to chylous ascites. Increased abdominal girth and poor feeding should lead to the suspicion of chylous ascites. Diagnosis is confirmed by evaluation of the white milky fluid obtained during paracentesis or exploratory laparotomy which will reveal a high triglyceride content 2 to 8 times as great as plasma, specific gravity greater than serum, and protein content >3 g/dL. The initial management should be conservative with total parenteral nutrition or a medium chain triglyceride diet. Small lymphatic leaks usually resolve with conservative management but occasionally chylous ascites may require surgical intervention, such as direct ligation of leaking lymphatic channels or placement of peritoneovenous shunt. Avoiding extended lymphadenectomy may help prevent the formation of chylous ascites and intraoperatively care should be taken to ligate any disrupted lymphatics.

Preoperative chemotherapy may influence surgical complication rates by producing tumor shrinkage. The United Kingdom Children’s Cancer Study Group (UKCCSG) compared the complication rate for patients undergoing immediate nephrectomy versus delayed nephrectomy after 6 weeks of chemotherapy and found significantly fewer complications in those undergoing delayed nephrectomy (1% vs. 5.8%). They also noted a much higher rate of tumor rupture/spill in those undergoing immediate

nephrectomy (14.6% vs. 0%).

Numerous organ systems are subject to the late sequelae of anticancer therapy and clinicians must be aware of the spectrum of problems that face children as they grow into adulthood. Gonadal radiation can produce hypogonadism and temporary azoospermia in boys. The severity of damage is dependent on the radiation dose. Leydig cells are more radio resistant than germ cells, but higher doses of radiation can produce damage resulting in inadequate production of testosterone and delayed sexual maturation. A 12% incidence of ovarian failure was found in girls receiving abdominal XRT. Abdominal XRT also increases the risk for adverse pregnancy outcomes. An increased incidence of second malignant neoplasms has been noted in children treated for Wilms tumor. There is a 1% cumulative incidence at ten years post diagnosis and a rising incidence thereafter. One of the greatest risk factors is prior irradiation, and most tumors occur in the radiation field.

The development of renal failure is of concern for Wilms tumor patients. Fortunately, the incidence of renal failure following nephrectomy for most children with unilateral Wilms tumor is low, 0.6% at 20 years posttreatment. The risk of renal failure is higher for patients with genitourinary anomalies, DDS and WAGR. This is due to mutation of WT1 which is necessary for normal renal development. Patients with bilateral Wilms tumor are also at increased risk for development of renal failure, which approaches 15%, at 15 years posttreatment. The most common cause of renal failure in these children is the need for bilateral nephrectomy for persistent or recurrent tumor in the remaining kidney after initial nephrectomy. For this reason, every effort should be made to perform renal sparing surgery in these children to preserve as much functioning renal tissue as possible.

OUTCOMES

Despite advances in chemotherapy protocols and radiation techniques, a high quality surgical operation remains paramount in the treatment of Wilms tumor. According to the SEER registry, the relative 5-year survival rate for children with Wilms tumor under the age of 15 has improved from 73.1% in 1975 to 93.6% in 2002. This improvement in survival is a testament to the systematic approach from which multimodal therapy has evolved. The overall goal in treatment of Wilms tumor is to maximize outcomes while limiting the intensity of therapy as the late effects of

chemotherapy and radiation can be significant. Clinical trials continue to refine treatment regimens to improve survival, in particular for higher-risk populations with unfavorable histology. Continued support of the pediatric cooperative groups that study Wilms tumor is essential.

NWTS-5 found that children less than two years of age with stage I FHWT weighing less than 550 g (VLRWT) who did not receive chemotherapy after nephrectomy had a 5-year EFS of 84% compared with 97% for those who underwent postoperative AMD and VCR. However, the 5-year OS was equivalent between the two groups at 98% and 99%, respectively ($p = .70$). Thus, there is a tradeoff between more intensive therapy and the potential long-term sequelae required for the 16% of children who relapse versus the avoidance of any postoperative chemotherapy in the majority. NTWS-5 also found that both WT1 and LOH for chromosome 16q and 1p were significantly associated with relapse in VLRWT patients. Finally, NTWS-5 found that stage I patients with anaplastic tumors treated with AMD and VCR had a low 4-year EFS of 69.5% and a new intensified chemotherapy regimen used for patients with Stage II-IV diffuse anaplasia did not result in an improved survival.

SIOP 93–01 evaluated a reduction in postoperative chemotherapy for patients with stage I intermediate risk and anaplastic Wilms tumor. Patients were randomized to receive either 4 or 18 weeks of postoperative AMD and VCR. Two year EFS was 91.4% after 4 weeks and 88.8% after 18 weeks of chemotherapy demonstrating that survival can be maintained while shortening the duration of postnephrectomy therapy. Patients with stage II or III with low or intermediate risk histology received 4 weeks of AMD and VCR before surgery. Postoperative chemotherapy consisted of AMD, VCR and epirubicin/doxorubicin for 27 weeks. Flank or whole abdomen irradiation was given for stage III. With a median follow-up of 8 years, 5-year EFS was 90% and OS 95%. Patients with blastemal type histology had a worse prognosis with 62% EFS at 5 years. These patients comprised only 10% of patients but contributed to one third of the relapses and deaths.

SIOP also found that for stage II or stage III intermediate risk histology Wilms tumor there was no significant disadvantage in removing doxorubicin from postoperative chemotherapy. Thus, SIOP now recommends 6 months only of VCR and AMD rather than a three-drug regimen including doxorubicin which will significantly reduce the number of children receiving this cardiotoxic drug.

Suggested Readings

Davidoff AM, Giel DW, Jones DP, et al. The feasibility and outcome of nephron-sparing surgery for children with bilateral Wilms tumor. The St Jude Children's Research Hospital experience: 1999–2006. *Cancer* 2008;112:1877–8.

deKraker J, Graf N, van Tinteren H, et al. Reduction of postoperative chemotherapy in children with stage I intermediate-risk and anaplastic Wilms' tumour (SIOP 93–01 trial): a randomised controlled trial. *Lancet* 2004;364:1229–35.

Grundy PE, Breslow NE, Li S, et al. Loss of heterozygosity for chromosomes 1p and 16q is an adverse prognostic factor in favorable-histology Wilms tumor: a report from the national Wilms tumor study group. *J Clin Oncol* 2005;23:7312–21.

Hamilton TE, Ritchey ML, Haase GM, et al. The management of synchronous bilateral Wilms tumor: a report from the national Wilms tumor study group. *Ann Surg* 2011;253:1004–10.

Kieran K, Anderson JR, Dome JS, et al. Lymph node involvement in Wilms tumor: results from the National Wilms Tumor Studies 4 and 5. *J Pediatr Surg* 2012;47:700–6.

Lange J, Peterson SM, Takashima JR, et al. Risk factors for end-stage renal disease in non WT-1 syndromic Wilms tumor. *J Urol* 2011;186:378–86.

Scott RH, Walker L, Olsen OE, et al. Surveillance for Wilms tumour in at-risk children: pragmatic recommendations for best practice. *Arch Dis Child* 2006;91:995–9.

Shamberger RC, Anderson JR, Breslow NE, et al. Long-term outcomes of infants with very low risk Wilms tumor treated with surgery alone on national Wilms tumor study-5. *Ann Surg* 2010;251:555–8.

Shamberger RC, Guthrie KA, Ritchey ML, et al. Surgery-related factors and local recurrence of Wilms tumor in national Wilms tumor study 4. *Ann Surg* 1999;229:292–7.

Weirich A, Leuschner I, Harms D, et al. Clinical impact of histologic subtypes in localized non-anaplastic nephroblastoma treated according to the trial and study SIOP-9/GPOH. *Ann Oncol* 2001;12:311–9.

EDITOR'S COMMENT

Renal tumors are among the most common of pediatric cancers. The histologic subtypes of pediatric renal tumors include the benign lesion mesoblastic nephroma and the malignant lesion Wilms tumor, clear-cell sarcoma, malignant rhabdoid and renal cell carcinoma (RCC) with Wilms tumor by far the most common. The treatment strategy for a patient diagnosed with a pediatric renal

tumor requires multidisciplinary coordinated care involving oncologists, pediatric surgeons, and radiation therapists achieving overall outcomes of greater than 90% long-term survival. The authors present an excellent overview of Wilms tumor management.

The current treatment paradigms for pediatric renal tumors were established through a series of cooperative group studies that began over 40 years ago and serve as the template by which a multi-institutional cooperative group can advance pediatric cancer treatment. The National Wilms tumor study group trials (NWTS 1–5) that transitioned to the Children's Oncology Group (COG) driven AREN series prospectively determined how to optimize outcomes while minimizing attendant morbidity (O'Leary M, Krailo M, Anderson JR, et al. Progress in childhood cancer: 50 years of research collaboration, a report from the Children's Oncology Group. *Semin Oncol* 2008;35(5):484–93; Dome JS, Fernandez CV, Mullen EA, et al. Children's Oncology Group's 2013 blueprint for research: renal tumors. *Pediat Blood Cancer* 2013;60(6):994–1000). The approach was to risk adapt treatment reducing therapy intensity in cohorts with good outcomes and intensifying therapy in cohorts with poor outcomes. The first meeting of the Wilms' Tumor Integrated Study Group was held in May 1968 at Babies Hospital in New York with the NWTS-1 study opening soon thereafter. Five NWTS trials were conducted before the study group evolved into the Renal Committee of the Children's Oncology Group which has subsequently conducted multiple AREN studies. In total, over 11,000 pediatric patients with renal tumors have participated in these trials and are captured in the NWTS and COG patient registries. A comprehensive summary of the contributions that these trials accomplished is beyond the scope of this commentary; however, examples of its risk-adapted approach can be summarized in the treatment of stage I Wilms tumor whose outcome is favorable versus those with stage II or III Wilms tumor in which outcomes were more challenging. In children with a stage I tumor, treatment moved from a combination of resection at diagnosis, a long course of chemo, and a moderate dose of radiation to resection at diagnosis, a 4-month course of chemotherapy given in an efficient manner requiring shorter hospitalization and no radiation. In contrast, children with stage II–III tumors, resected at diagnosis saw treatment intensity increases from one-drug to three-drug treatment (vincristine, actinomycin, and doxorubicin) accompanied by radiation therapy of moderate intensity. As the biologic understanding of Wilms tumor pathogenesis evolved, the trials tested that biologic understanding in study questions as demonstrated in NWTS-5, where the molecular markers' loss of heterozygosity on chromosomes 1p and 16q were found to be adverse factors in favorable histology Wilms tumor requiring higher-intensity chemotherapy. The current COG AREN series of studies has established a risk stratification schema in which the risk of relapse (very low, low, intermediate, and high), based on stage and molecular characteristics determine the type and length of therapy. In addition to improving treatment strategies for the varying types of renal tumor

patients, the capture of patients allowed long-term monitoring resulting in late effects studies. Late effects studies determined the impact of nephrectomy, exposure to chemotherapy and abdominal irradiation in Wilms tumor survivors with the knowledge gained altering subsequent studies. Additionally, the paradigms developed in these studies influenced the current late effects follow-up programs integral to the care of every current pediatric oncology patient found at all pediatric oncology programs. Beyond direct clinical treatment regimens, the cooperative group studies had an impact on pathologic definitions as it was during the 40-year effort the concentration of patients allowed study pathologists to review a large number of specimens including the uncommon histologic subtypes clear-cell sarcoma and rhabdoid tumors such that precise definitions of the characteristics of the varying pediatric renal malignancies were established. The NWTS and AREN series of trials have had an immense impact on child health and serve as the template for the development of cooperative group trials that continue to this day.

While the NWTS trials were underway in North America, the Societe Internationale Oncologique de Pediatrique (SIOP) group in Europe developed a markedly different approach. In contrast to the COG approach where resection at diagnosis was favored, the SIOP studies demonstrated the effectiveness in which a child with a renal mass is treated with chemotherapy first with planned resection after several cycles of treatment. The basis by which this approach evolved was the observation of increased surgical morbidity (and in the past mortality) in patients who underwent resection at diagnosis, a factor that could be attenuated by preoperative chemotherapy. The major limitation of the SIOP approach is the potential for misdiagnosis of the uncommon histologic subtypes resulting in overtreatment if the tumor is benign (i.e., mesoblastic nephroma) or under-treatment if the tumor is a more aggressive malignant subtype (i.e., clear-cell sarcoma/rhabdoid tumor). Otherwise, outcomes were similar to those experienced in North America. As a result, in current treatment protocols the two approaches are used in a complimentary fashion.

Wilms tumors are thought to be derived from nephrogenic rests, embryonic remnants from the developing kidney representing microscopic malformations/dysplasias. Although rests are best known as precursor lesion for tumorigenesis, most rests involute and are of no clinical significance. As the authors note, there are two types of rests, peri- and intralobar with differing molecular etiologies. Perilobar rests occur in overgrowth syndromes while intralobar rests are associated with deletions or mutations of the tumor suppressor WT1. The presence of rests dictates the need for close monitoring, especially in high-risk populations (overgrowth syndromes or in the contralateral kidney of an afflicted patient). Here again was a benefit of the NWTS studies as analysis of the registry allowed the generation of evidence-based recommendations for surveillance duration (Beckwith JB. Nephrogenic rests and the pathogenesis of Wilms tumor: developmental and clinical considerations. *Am J Med Genet* 1998;79(4):268–73).

As the authors note, the current COG treatment protocols are risk adapted with treatment regimens shown in Table 179.3. The treatment regimens utilize resection, chemotherapy, and radiation therapy with the intensity of chemotherapy and radiation dosage adjusted according to the risk profile. Complete resection with appropriate staging remains the most critical intervention required to achieve long-term cure. The surgical principles of resection are nicely illustrated in the chapter. As risk profiles for relapse have been better defined, it has become apparent that some children can be cured with surgery alone. Two analyses focused on the very low-risk cohort (resected at diagnosis, small tumor, favorable histology i.e., no anaplasia, negative lymph nodes—NWTS-5 and AREN 0532 trials) have demonstrated the efficacy of surgery alone where over 80% of patients will have event-free survival without adjuvant chemotherapy. In those who relapse, rescue can be achieved with standard intensity chemotherapy achieving 98% overall survival (NWTS-5—Shamberger RC, Anderson JR, Breslow NE, et al. Long-term outcomes for infants with very low risk Wilms tumor treated with surgery alone in National Wilms Tumor Study-5. *Ann Surg* 2010;251(3):555–8; AREN 0532–Fernandez CV, Perlman EJ, Mullen EA, et al. Clinical outcome and biological predictors of relapse after nephrectomy only for very low-risk Wilms tumor: A Report From Children's Oncology Group AREN0532. *Ann Surg* 2017;265(4):835–40). Proper staging is critical as regional lymph nodes must be sampled appropriately to ensure no extrarenal spread which would dictate the need for adjuvant chemotherapy and radiation.

An interesting aspect of the biology of a Wilms tumor can be seen in the management and outcome of tumors that have invaded contiguous organs to the kidney (liver, duodenum on the right, tail of the pancreas on the left) or present with intravascular tumor thrombus. Despite the intuitive assumption that tumors such as these would have more aggressive biologic features therefore require more intense treatment, if local control can be obtained by en bloc resection or complete tumor thrombectomy at the time of diagnosis, intensity of treatment is not escalated. If the treating team elects not to offer resection at diagnosis and perform a biopsy, then the patient is by definition stage III and will be treated with three-drug chemotherapy and abdominal radiation.

Intravascular venous tumor thrombus provides an interesting technical challenge as resection may require complete control of the IVC and its tributaries. Careful analysis of preoperative imaging to determine if tumor thrombus is present is critical for appropriate operative planning (Shamberger RC, Ritchey ML, Haase GM, et al. Intravascular extension of Wilms tumor. *Ann Surg* 2001;234(1):116–21). If by cross-sectional imaging, venous involvement is not clear ultrasound can be helpful. As the authors note, if tumor thrombus remains below the hepatic veins, resection can be completed in the abdomen without the requirement of cardiopulmonary bypass such that resection at diagnosis should be considered. Should the tumor extend into the right atrium, neoadjuvant chemotherapy is warranted as the tumor thrombus

may decrease in size shrinking below the hepatic veins. If right atrial tumor thrombus persists, then cardiopulmonary bypass with hypothermic circulatory arrest is required. In this circumstance, to avoid bleeding during and after the anticoagulation that will be required during bypass and arrest, nearly all of the dissection in the abdomen should be completed (mobilization of the renal tumor, dividing arterial inflow and the retrohepatic IVC dissection) leaving a completely free renal tumor ready to be removed except for its attachment via the vein containing tumor thrombus. The chest can then be opened, the patient heparinized and bypass initiated followed by cooling and circulatory arrest. Both the right atrium and the IVC extending from the renal vein superiorly are opened and the tumor thrombus removed—often in fragments. Once resection is complete, the atriotomy and cavotomy are closed followed by reinstitution of bypass and warming. Postoperatively, careful intensive care unit monitoring is warranted as intravascular volume status will be a complicated combination of post pump physiologic changes altered by a complex abdominal procedure with accompanying fluid shifts. In the Shamberger et al. review of the NWTS registry focused on this population of patients, they found that in the 165 patients who had intravascular extension of disease, neoadjuvant chemotherapy facilitated resection by decreasing the extent of the tumor thrombus including a small subset that went from requiring cardiopulmonary bypass to an abdominal procedure alone. Interestingly, the frequency of complications was similar if resection was attempted at diagnosis when compared to those who received neoadjuvant chemotherapy. Overall survival was similar when comparing those with intravascular extension to no intravascular disease highlighting the counterintuitive observation that vascular involvement does not mandate the need for a more aggressive chemotherapy and radiation treatment.

Patients with stage V, bilateral disease—about 5% of the cohort—provide an interesting treatment challenge as the goal is a high cure rate while maintaining long-term renal function. Renal/nephron sparing is advocated as should bilateral nephrectomy be necessary, renal transplantation with all of the attendant morbidity of life-long immunosuppression will be required. In these patients, biopsy, neoadjuvant chemotherapy followed by partial nephrectomy is the currently recommended treatment paradigm although adherence to that strategy is not uniform. In an analysis of the NWTS-4 experience of 188 patients with bilateral disease, preservation of renal parenchyma was possible in many patients after initial preoperative chemotherapy; however, 87 kidneys in 83 patients were managed with primary resection (encompassing, nephrectomy, partial nephrectomy, and enucleation of the tumor). The incidence of end-stage renal disease was 13%. Relapse or progression of disease occurred in 54 children. The 8-year event-free survival if tumor had favorable histology was 74%, and overall survival was 89%; whereas the event-free survival with unfavorable histology was 40% and overall survival was 45% (Hamilton TE, Ritchey ML, Haase GM, et al. The management of synchronous bilateral Wilms tumor: a report from the National Wilms Tumor Study Group. *Ann Surg*

2011;253(5):1004–109). A more recent single-institution experience reporting on the efficacy of a nephron-sparing approach demonstrated a more favorable outcome (Davidoff AM, Interiano RB, Wynn L, et al. Overall survival and renal function of patients with synchronous bilateral Wilms tumor undergoing surgery at a single institution. *Ann Surg* 2015;262(4):570–6). In the study from St Jude's, overall survival in a 42-patient cohort in which all but three underwent bilateral nephron-sparing surgery was 85.7% (mean follow-up, 4.1 years). Of the 6 patients who died, 5 had diffuse anaplastic histology—a high-risk feature. No patient developed end-stage renal disease. The current AREN 0534 trial focused on bilateral disease and has nearly completed enrollment with study results to be released soon thereafter. Although nephron-sparing surgery is the goal, survival is still paramount as renal transplantation after bilateral nephrectomy is successful.

Clear-cell sarcoma of the kidney is uncommon and in contrast to Wilms tumor is characterized by a distinct pattern of recurrence and metastasis most commonly to the bone. Treatment regimens are when compared stage for stage with Wilms tumor, more intense but as a result have improved survival to reasonable outcomes (Gooskens SL, Furtwängler R, Vujanic GM, et al. Clear cell sarcoma of the kidney: a review. *Eur J Cancer* 2012;48(14):2219–26). In the Gooskens et al. review of the literature, he notes that therapy for CCSK is approaching the maximum tolerated intensity of traditional cytotoxic agents therefore further improvement of outcome will likely depend on more targeted therapy based on specific molecular/genetic aberrations. In this case, the cooperative group construct will need to expand to an international level as the frequency of clear-cell sarcomas are rare enough that current constructs are inadequate. This effort has been initiated by members of the COG Renal committee and their SIOP colleagues.

Rhabdoid tumors of the kidney are even more uncommon but are the most aggressive of the histologic subtypes. As a result, afflicted patients have the worst of outcomes often presenting with metastatic disease to the lung and brain. In the NWTS registry, there were a total of 142 patients who had rhabdoid tumors (Tomlinson GE, Breslow NE, Dome J, et al. Rhabdoid tumor of the kidney in the National Wilms' Tumor Study: age at diagnosis as a prognostic factor. *J Clin Oncol* 2005;23(30):7641–5). Age at diagnosis was a highly significant prognostic factor for survival where infants less than 6 months had a dismal prognosis (9% 4-year OS), while, older children had a slightly better outcomes (40% 4-year OS)—still markedly worse than a Wilms tumor patient. A CNS lesion was also a highly negative predictor as no patient who has brain metastases survived. A better understanding of the molecular basis of these tumors is required such that treatment strategies can be optimized.

RCC is also uncommon in the pediatric population but should it arise, are usually found in the adolescent population. In a recent study by Geller et al. analyzing the cohort enrolled in the COG AREN03B2 bio-repository, the characteristics of adolescent and pediatric RCC was reported (Geller JI, Ehrlich

PF, Cost NG, et al. Characterization of adolescent and pediatric renal cell carcinoma: A report from the Children's Oncology Group study AREN03B2. *Cancer* 2015;121(14):2457–64). There were 120 out of 3,250 patients who had a unilateral RCC with a median age of 12.9 years. Histologic review classified these as translocation morphology (56 patients), papillary (20 patients), renal medullary carcinoma (13 patients), chromophobe (4 patients), oncocytoma (1 patient), conventional clear cell (1 patient), and RCC not otherwise specified (25 patients). Lymph node disease was common and present even when there were small primary tumors. Radical nephrectomy was performed in 73% of the patients with surgical staging including lymph node sampling critical. With current treatment regimens, patients with RCC can be managed effectively as the overall 10-year survival of pediatric RCC patients was 70% (Zhuge Y, Cheung MC, Yang R, et al. Pediatric non-Wilms renal tumors: subtypes, survival, and prognostic indicators. *J Surg Res* 2010;163:257–63).

The surgeon involved in the care of pediatric renal tumors must be well versed in all the histologic subtypes and aware of the nuanced treatment regimens that have evolved for this diverse set of patients. Significant progress in the management of pediatric renal tumors has over the last 40 years been achieved; however, there are still many opportunities to improve outcomes. Future studies are being developed by COG and SIOP that will evaluate therapy adjustments based on novel biomarkers with new treatment regimens that incorporate biologic therapies for the high-risk population (Dome JS, Fernandez CV, Mullen EA, et al. Children's Oncology Group's 2013 blueprint for research: renal tumors. *Pediatr Blood Cancer* 2013;60(6):994–1000).

Gregory Tiao

180 Genitourinary Tract Trauma

Jack W. McAninch and Viraj Master

INTRODUCTION

The genitourinary system, encompassing the kidney, ureter, bladder, urethra, and external genitalia, is commonly injured in both blunt and penetrating trauma. Approximately 10% of all traumatic injuries seen in the emergency department involve some element of the genitourinary tract, from obvious genital skin injuries to subtle renal injuries. Early, thorough assessment allows for accurate staging, which then guides treatment and is essential in preventing serious complications. In this chapter, an evidence-based approach to diagnosis and management has been used. A detailed analysis of all genitourinary trauma articles published worldwide between 1966 and 2002 was conducted by an invited panel of surgeons (and chaired by J.W. McAninch), with subspecialty interests in traumatic and reconstructive urology, which was convened by the World Health Organization at the 2003 Stockholm Société Internationale d'Urologie meeting. Each paper from the primary literature was analyzed according to its numerical level of evidence classification, from randomized prospective clinical trials to case reports. Consensus papers were written on trauma to each genitourinary organ. As the editor of *BJU International* wrote (in a preface to the ureteral trauma consensus paper), "This is quite a unique document, of interest to all urologists, not only as a consensus of how this condition should be managed, but also as a model of how to review publications." The principles embedded in these documents have been codified into a series of guidelines, both from the American Urological Association, presented in 2014, and the European Association of Urology, from 2005. Evidence-supported diagnostic algorithms for adult blunt injury and pediatric blunt injury are shown in Figures 180.1 and 180.2, respectively. Penetrating abdominal trauma, especially gunshot wounds, will certainly be evaluated in the operating room. Treatment and further diagnostic algorithms for injuries to specific areas of the genitourinary tract are presented later in the chapter.

RENAL TRAUMA

The kidney is the genitourinary organ most commonly injured due to external trauma, found in approximately 5% of abdominal trauma cases. Advances in staging techniques resulting from increased use of computed tomography (CT) scanning and increased awareness based on outcomes research of the kidney's capacity for healing have permitted the vast majority of these injuries to be successfully managed nonoperatively by the surgical consultant. Nonetheless, certain severely injured kidneys are best managed by exploration and reconstruction, with nephrectomy reserved for life-threatening hemorrhage or kidneys that have been injured beyond repair. Ultimately, the objective of managing these patients is to prevent significant hemorrhage and retain enough functioning nephron mass to avoid end-stage kidney failure. A secondary goal is to avoid complications specifically attributable to the traumatized kidney.

Staging of Renal Injuries

Approximately 90% of renal injuries result from blunt trauma—usually falls from great heights, motor vehicle accidents, and violent assaults. Most of these injuries are minor and rarely require surgical exploration. At San Francisco General Hospital, only 2% of all bluntly injured kidneys required exploration or repair. Pediatric kidneys as well as congenitally abnormal kidneys (cystic kidneys, hydronephrotic kidneys) are more susceptible to major injury secondary to blunt mechanisms. Although only 10% of renal injuries result from penetrating trauma, up to 55% of these injuries will require exploration or repair. This is usually due to a more severe renal injury, associated intra-abdominal injuries, incomplete preoperative radiographic staging, or a combination of these factors.

The American Association for the Surgery of Trauma (AAST) has created a renal organ injury scale that correlates with patient outcomes and allows appropriate and selective management to be undertaken (Table 180.1). The renal injury classification is one of the few classification schemes that has been prospectively validated and found to correlate directly with need for surgical intervention. Grade 1 injuries include subcapsular hematomas and renal contusions (Fig. 180.3). Grade 2 injuries involve small lacerations into the renal cortex. Grade 3 injuries extend through the corticomedullary junction. Grade 4 injuries consist of either injury into the collecting system or renal vascular injuries such as main renal artery or vein injury with contained hemorrhage, or segmental vessel

injury. Grade 5 injuries include kidneys with pedicle avulsion off the great vessels, as well as completely shattered kidneys.

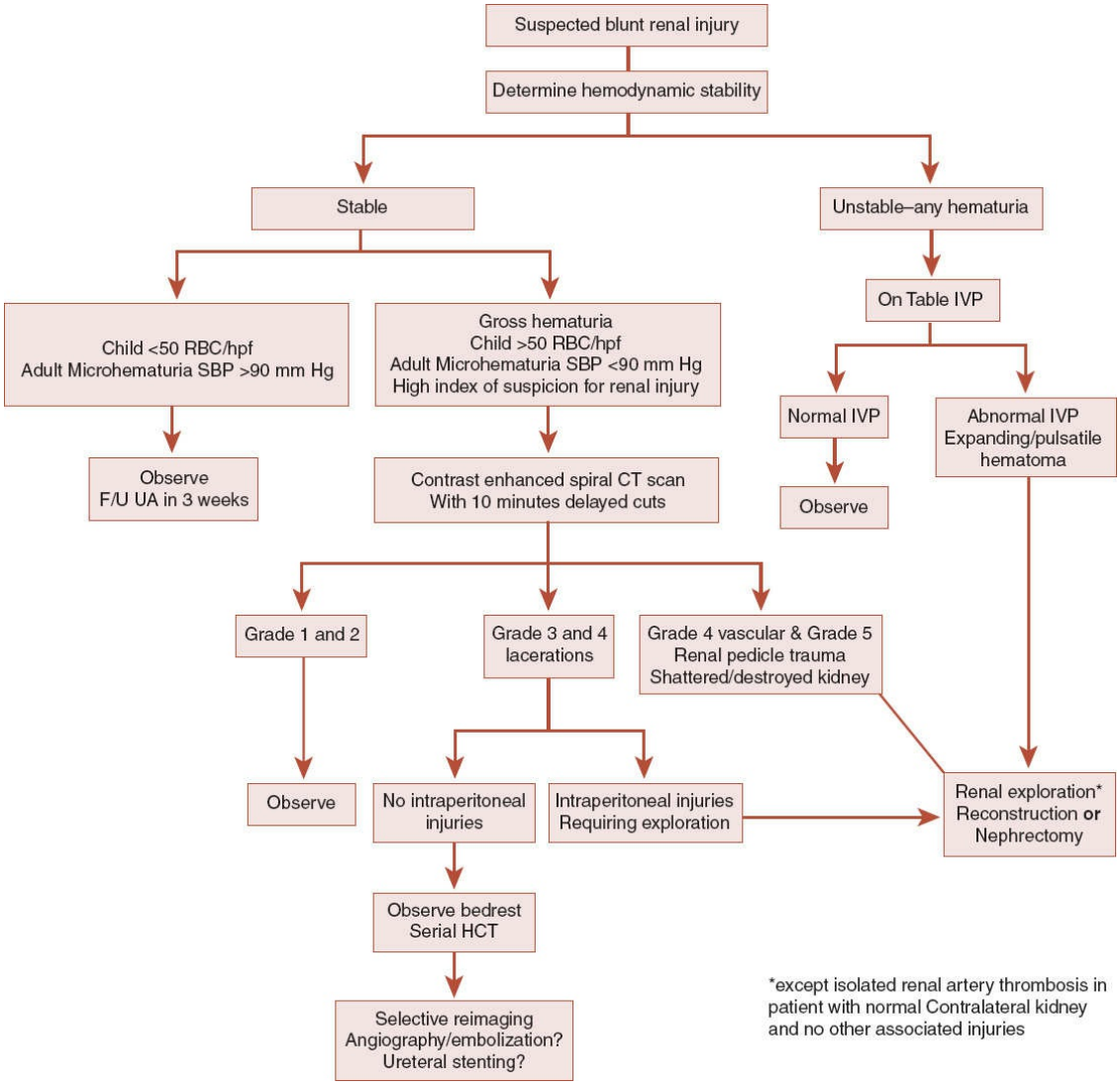

Figure 180.1. Algorithm for staging blunt trauma in adults. CT, computed tomography; HPF, high-power field; IVP, intravenous pyelogram; RBC, red blood cell; SBP, systolic blood pressure. (Adapted from Santucci RA, Wessels H, Bartsch G, et al. Evaluation and management of renal injuries: consensus statement of the Renal Trauma Subcommittee. *BJU Int* 2004;93:937.)

Clinical staging begins with history and physical examination, including the determination of whether the patient has been in shock as well as assessment for presence of hematuria. Based on these criteria, a subset of patients likely to have significant renal injury may be identified. This subset may then undergo radiographic staging in order to completely stage the injury and determine whether operative management is indicated (Figs. 180.4 and 180.5).

History should focus on the mechanism of trauma (blunt [Fig. 180.4] or

penetrating [Fig. 180.5]), as well as presence of significant deceleration, which should raise suspicion for significant renal injury. In penetrating trauma, knowledge of type of bullet (high vs. low velocity) or knife used in the assault may assist in prediction of degree of renal injury. On physical examination, the presence of shock (defined as systolic blood pressure <90 mm Hg) should be recorded. The lowest recorded systolic blood pressure is critical in determining the need for radiographic imaging in adult blunt renal trauma. Clearly, a patient in shock who cannot be resuscitated may require urgent laparotomy, thus bypassing radiographic staging of suspected renal injury, and will require intraoperative staging. The abdomen, flank, and back should be carefully examined. Flank tenderness or ecchymosis as well as lower rib fractures may indicate underlying renal injury. In penetrating trauma, entry and exit wounds may be a helpful indicator that the kidney has been injured.

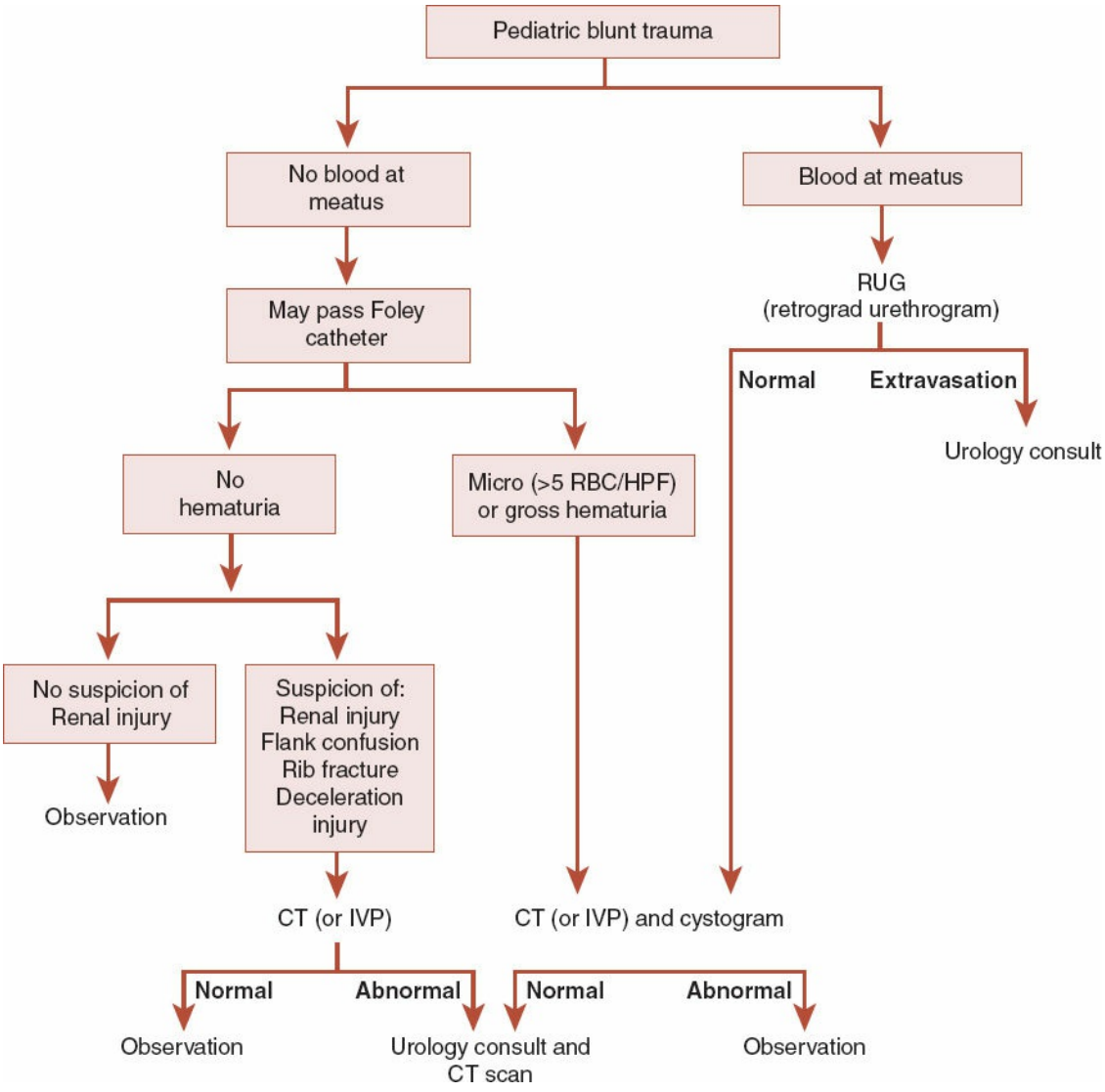

Figure 180.2. Algorithm for staging blunt trauma in pediatric patients. CT, computed tomography; HPF, high-power field; IVP, intravenous pyelogram; RBC, red blood cell.

TABLE 180.1 American Association for the Surgery of Trauma Organ Injury Severity Scale for Renal Trauma

Grade	Injury	Description
I	Contusion	Microscopic or gross hematuria, urologic studies normal
	Hematoma	Subcapsular, nonexpanding without parenchymal laceration
II	Hematoma	Nonexpanding perirenal hematoma confined to renal retroperitoneum
	Laceration	<1 cm parenchymal depth of renal cortex without urinary extravasation
III	Laceration	>1 cm depth of renal cortex without collecting system rupture or urinary extravasation
IV	Laceration	Parenchymal laceration extending through the renal cortex, medulla, and collecting system (meaning extravasation)
	Vascular	Main renal artery or vein injury with contained hemorrhage
V	Laceration	Completely shattered kidney
	Vascular	Avulsion of renal hilum, which devascularizes kidney

Note that the injury scale is advanced one grade for bilateral injuries up to grade III. For more information, go to www.aast.org/injury/injury.html

Hematuria is the most common sign of penetrating and blunt renal trauma. However, importantly, the presence of hematuria and degree of hematuria do not correlate consistently with the degree of renal injury. This is particularly true in penetrating injuries, where a significant percentage of patients with significant renal injuries may have no hematuria. It is imperative that the first voided or catheterized specimen be analyzed, because hematuria may clear rapidly. Either dipstick or microscopic analysis may be performed.

Radiographic Staging

Using the clinical information outlined above, the indications for radiographic imaging may be tailored to detecting patients with a significant chance of having a major renal laceration (AAST Grades 3 to 5). Based on our experience at San Francisco General Hospital, we

recommend imaging the following categories of patients, although it must be emphasized that clinical judgment continues to be paramount:

1. Penetrating trauma: Abdomen, flank, or back injury with ANY degree of hematuria, particularly when the course of the missile appears to involve the kidney or ureter.
2. Blunt trauma with either gross (visible) hematuria or shock (defined as any recorded systolic blood pressure <90 mm Hg): Patients having sustained blunt trauma with microhematuria only can safely avoid renal imaging.
3. Blunt trauma in the setting of significant deceleration injury, for example, falls from heights or motor vehicle accidents: This mechanism of injury has been associated with a higher incidence of ureteropelvic junction disruption as well as renovascular trauma.
4. Pediatric penetrating injury or blunt trauma with microhematuria >20 red blood cells (RBCs) per high-power field (HPF): There is increasing evidence that the adult imaging criteria outlined above will identify the majority of significant renal lacerations in children, but this remains controversial. The surgeon should continue to maintain a low threshold for renal imaging in the pediatric population.

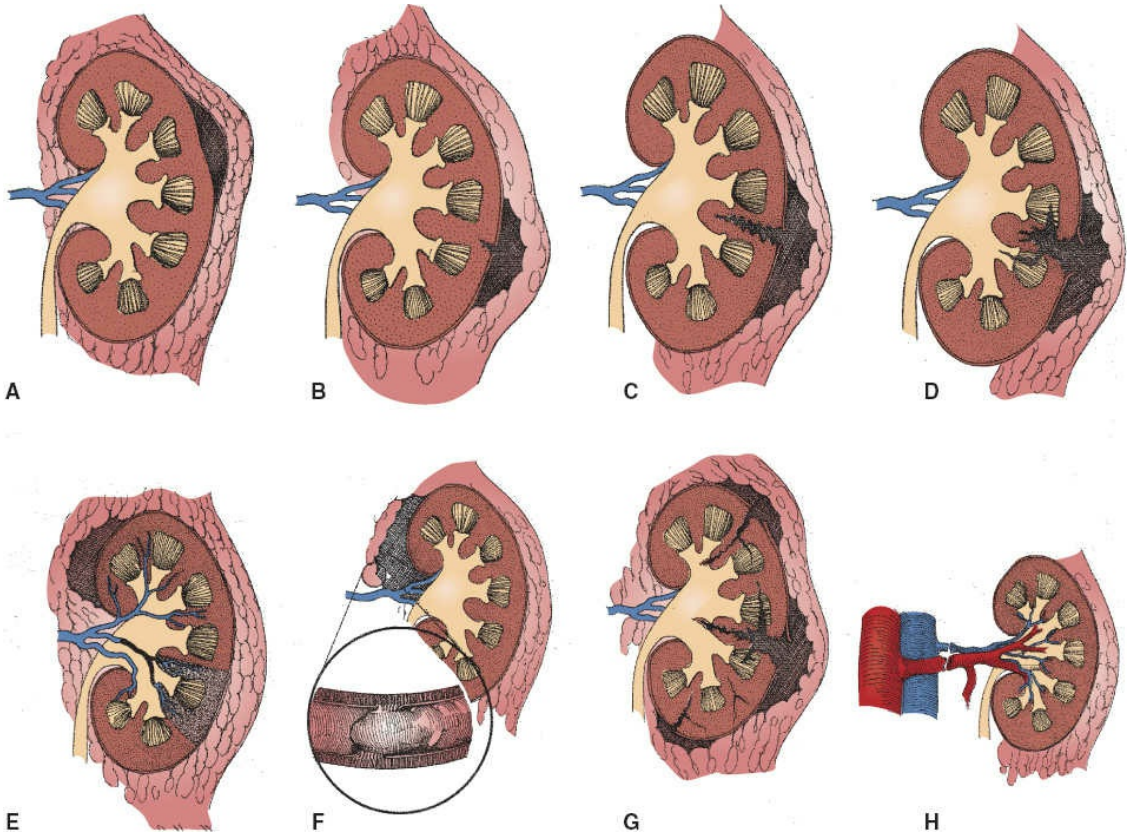

Figure 180.3. Renal injury classification. Renal injuries are

classified by the American Association for the Society of Trauma Organ Injury Scale. Grades 1 and 2 are considered minor renal injuries, only rarely requiring intervention, while grades 3, 4, and 5 are considered major renal injuries. **A.** Grade 1 is contusion or contained subcapsular hematoma without parenchymal laceration. **B.** Grade 2 is a nonexpanding, confined perirenal hematoma or cortical laceration less than 1 cm deep without urinary extravasation. **C.** Grade 3 is a parenchymal laceration extending greater than 1 cm into the cortex, but without urinary extravasation. **D.** Grade 4 can be parenchymal or vascular injury. Parenchymal grade 4 injuries are those with a laceration extending through the corticomedullary junction and into the collecting system. A segmental vessel may also be lacerated. **E.** Grade 4 vascular injury consists of a segmental renal artery thrombosis without a parenchymal laceration. Renal arteries are end-arteries and the area of parenchyma subtended by the injured segmental artery will be ischemic. **F.** Grade 5 injuries are multiple and consist of shattered kidneys, pedicle avulsion, or main renal artery thrombosis. These are life-threatening by nature. Main renal artery thrombosis is generally due to intimal disruption with resultant thrombosis, which can be observed in the close-up of the figure. **G.** Grade 5 injury can also be a "shattered" kidney, consisting of multiple major lacerations. **H.** Avulsion of the main renal artery and/or main renal vein is also a grade 5 injury. (Adapted from Nash PA, Carroll PR. Staging of renal trauma. In: McAninch JW, ed. *Traumatic and Reconstructive Urology*. Philadelphia, PA: WB Saunders; 1996.)

Contrast-enhanced CT scanning has replaced intravenous pyelography (IVP) as the imaging modality of choice in renal trauma patients. CT is noninvasive and offers rapid and accurate detection of renal injuries, as well as associated injuries to other organs. CT defines depth and extent of lacerations, a functioning contralateral kidney, the presence of associated hematoma, and contrast extravasation, which suggests injury through the collecting system, as well as any devitalized renal parenchyma. Consideration must be given to each of these factors when deciding upon a treatment plan.

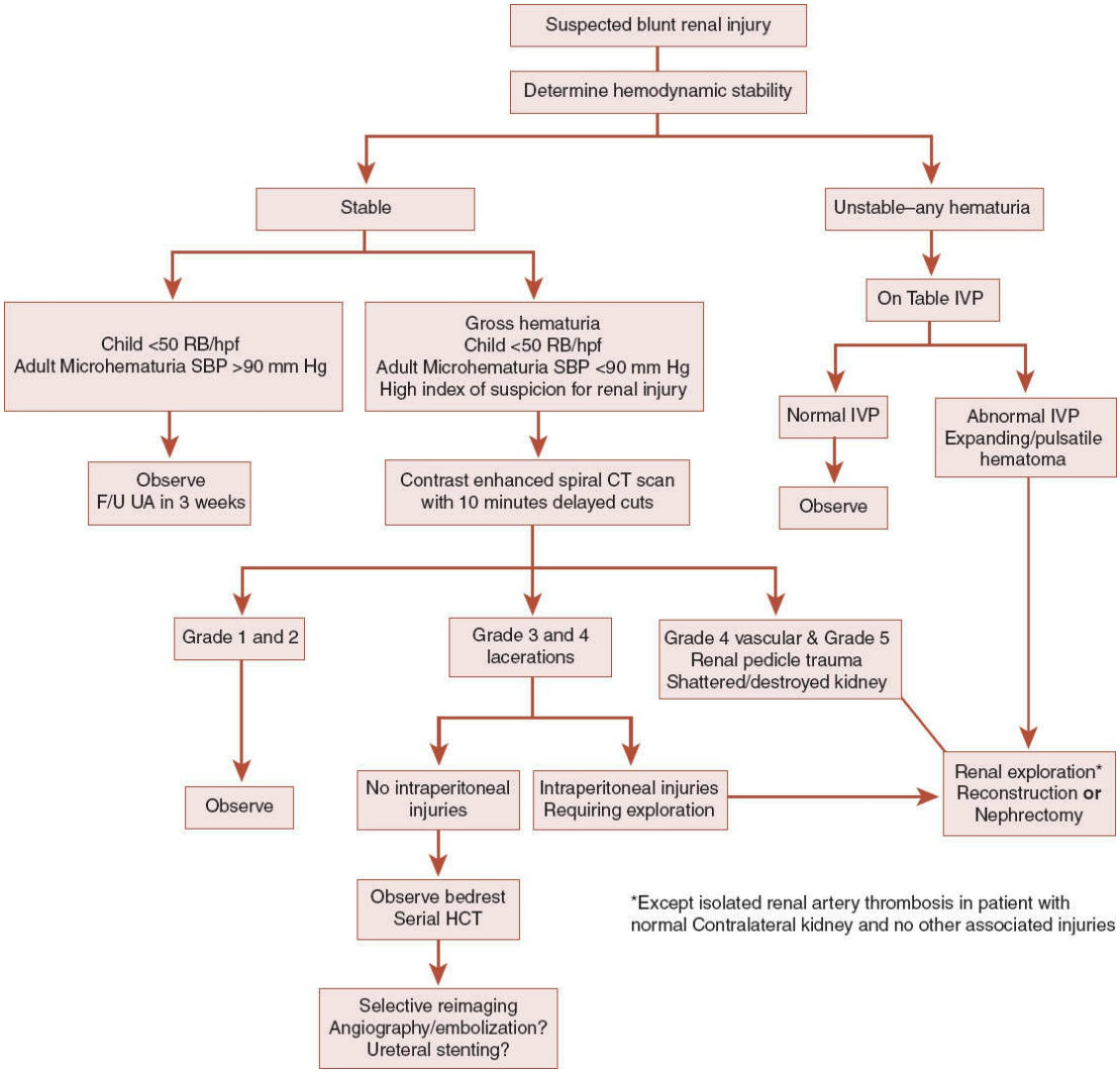

Figure 180.4. Suspected blunt renal trauma algorithm. CT, computed tomography; HCT, hematocrit; HPF, high-power field; IVP, intravenous pyelogram; RBC, red blood cell; SBP, systolic blood pressure. (Adapted from Santucci RA, Wessels H, Bartsch G, et al. Evaluation and management of renal injuries: consensus statement of the Renal Trauma Subcommittee. *BJU Int* 2004;93:937.)

Helical (or spiral) CT scanning has been supplanting traditional CT scanning because of its speed in the trauma setting. The patient may pass through the scanner in a few minutes. This has limited use in fully staging renal injuries, because contrast may not have reached the renal calyces or renal pelvis before the images are obtained. Significant collecting system injuries may thus be missed. We routinely obtain a set of delayed images at 10 minutes in order to visualize the entirety of the collecting system down through the bladder. If this is not possible, a plain abdominal

radiograph (kidney-ureter-bladder [KUB]) at this time may add complementary information to the CT scan. While CT may accurately demonstrate parenchymal lacerations, it has limited use in staging renovascular injuries. A renal vein laceration may be suspected by the finding of hematoma medial to the renal hilum. Adjunctive radiographic imaging techniques include renal ultrasound, nuclear scintigraphy, magnetic resonance imaging (MRI), and retrograde pyelography. None of these is recommended as a first-line study in the acute setting.

INDICATIONS FOR SURGICAL EXPLORATION

The vast majority of renal injuries are contusions or minor lacerations, and may thus be managed nonoperatively if adequately staged. Appropriate radiographic staging has also permitted selective nonoperative management of major lacerations in both blunt and penetrating trauma (Figs. 180.4 and 180.5). In a recent series of grade 4 lacerations at San Francisco General Hospital, 22% were successfully managed nonoperatively. Penetrating injuries more commonly require laparotomy because of associated injuries or hemodynamic instability. In our experience, however, 55% of stab wounds and 24% of gunshot wounds are successfully managed expectantly through the use of careful selection and complete clinical and radiographic staging. If expectant management is selected in the setting of a major renal laceration, close monitoring with serial hematocrit measurements and liberal use of repeat imaging, especially at 36 to 48 hours, is indicated.

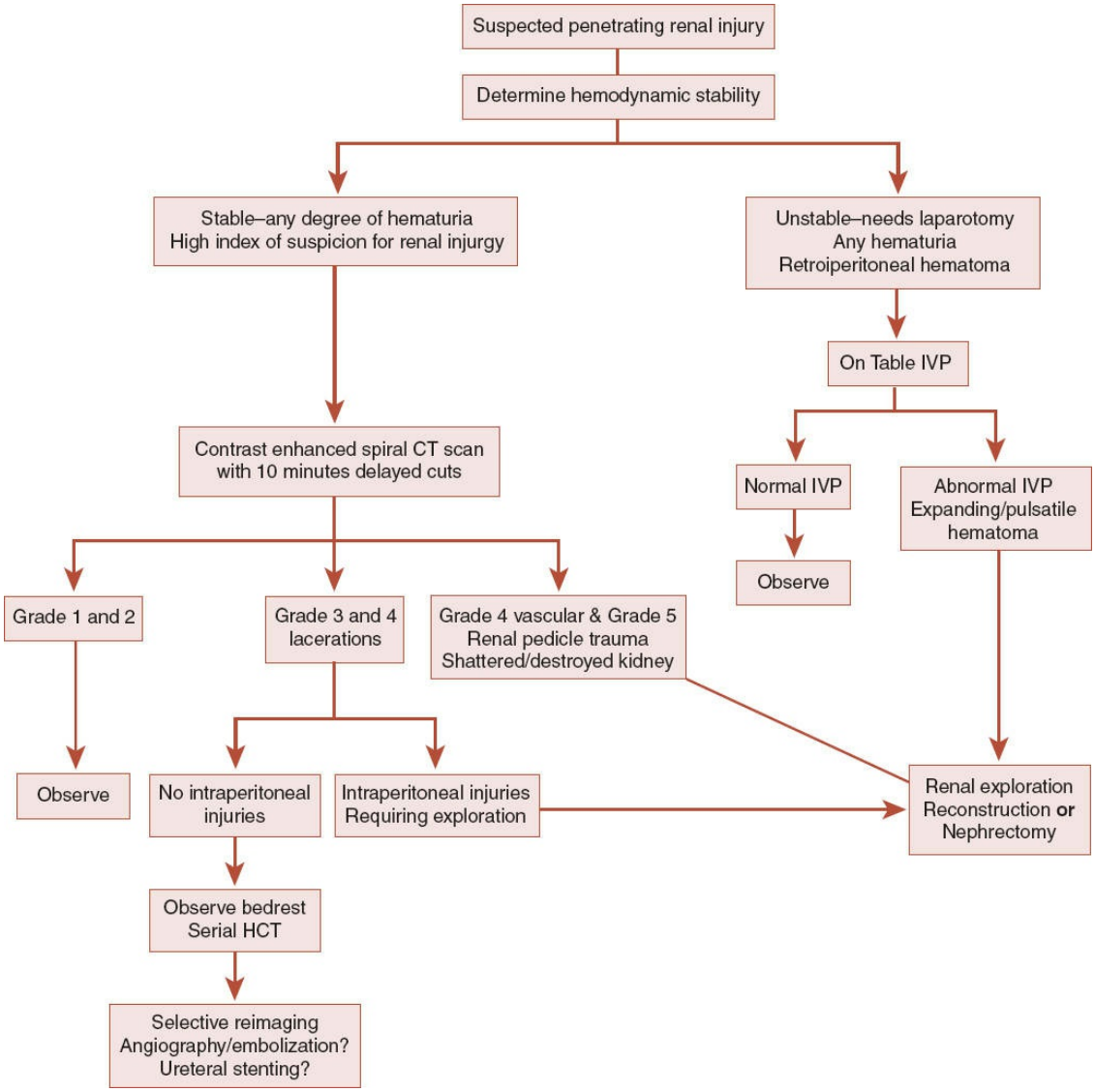

Figure 180.5. Suspected penetrating renal trauma algorithm. CT, computed tomography; HCT, hematocrit; IVP, intravenous pyelogram. (Adapted from Santucci RA, Wessels H, Bartsch G, et al. Evaluation and management of renal injuries: consensus statement of the Renal Trauma Subcommittee. *BJU Int* 2004;93:937.)

The only absolute indications for surgical exploration in renal trauma are persistent, life-threatening hemorrhage believed to be from renal injury, renal pedicle avulsion, and expanding, pulsatile, or uncontained retroperitoneal hematoma. These patients often present in severe shock, and it is thus rare for these patients to have undergone radiographic staging prior to emergency laparotomy. In the setting of renal pedicle avulsion or a severely shattered kidney, reconstruction may be impossible, and nephrectomy may be lifesaving.

Relative indications for renal exploration include incomplete staging, devitalized renal parenchyma, vascular injury, and urinary extravasation. In a hemodynamically unstable patient, radiographic assessment is not possible prior to laparotomy, and there may be an unexpected retroperitoneal hematoma found at the time of laparotomy in the trauma patient. At this time, if the patient's clinical condition permits, a single abdominal plain film taken 10 minutes after the bolus administration of 2 mL/kg of intravenous contrast, delivered as a bolus, in a normotensive patient is quite helpful. This is known as a "one-shot" IVP. This film is most helpful for confirming the presence of a normally functioning contralateral kidney and may possibly help to diagnose the injury in the affected renal unit. In addition, all patients with penetrating trauma and incomplete preoperative staging and a retroperitoneal hematoma require exploration. Although the one-shot IVP may be indeterminate, a recent study found that it successfully obviated renal exploration in 32% of patients in whom it was required. Furthermore, this approach has not been found to increase the rate of unnecessary nephrectomy. The initial laparotomy is the optimal time for any required renal reconstruction. Delayed exploration has resulted in nephrectomy rates as high as 50%.

PARENCHYMAL INJURY

Significant amounts of devitalized renal parenchyma are often best managed by early surgical debridement. Expectant management of patients with devitalized fragments and associated intra-abdominal injury may lead to a higher rate of abscess and infected urinoma formation as well as delayed bleeding. Immediate exploration in this setting reduced the posttrauma complication rate from 82% to 23%. This result suggests that major renal lacerations with devitalized fragments and associated intra-abdominal injuries should be immediately repaired, particularly if a laparotomy is already planned by the trauma surgeon. Additionally, patients with a major devitalized fragment associated with urinary extravasation and a significant hematoma are ultimately best treated by early exploration and reconstruction, even without concomitant intraperitoneal injury. However, the nonoperative approach in this situation may be more prudent for the surgeon who rarely undertakes renal exploration in the trauma setting, as the chance of unnecessary nephrectomy is increased.

Urinary extravasation signifies collecting system violation secondary to

a major renal laceration, but does not specifically mandate surgical repair. The collecting system may be violated at a fornix, at a minor or major calyx, or even through the renal pelvis and ureteropelvic junction (UPJ). While the majority of lacerations into fornices and minor calyces will seal spontaneously, larger degrees of extravasation may leak for a prolonged period and are less likely to resolve spontaneously. Serial CT scans are mandatory in the management of these patients. The first scan should be obtained at approximately 36 to 48 hours postinjury in order to rule out the development of significant new complications. Intervention is indicated in the setting of sepsis, ongoing leakage, or significant urinoma formation. In these cases, placement of an indwelling ureteral stent or even a nephrostomy tube may speed resolution of extravasation. Lacerations of the renal pelvis usually do not resolve spontaneously, and should be surgically repaired. Similarly, UPJ avulsion mandates surgical repair. These unusual injuries are more commonly found in the setting of deceleration injury or in children, but may also take place in adults with an undiagnosed congenital anomaly such as UPJ obstruction. CT findings that suggest UPJ avulsion include nonvisualization of the ipsilateral ureter and medial extravasation of contrast material. When a kidney injured by a gunshot wound shows continued extravasation at the time of the first repeat CT scan, the surgeon should also maintain a low threshold for repair. These injuries are often associated with significant devitalized parenchyma secondary to blast effect, especially when a high-velocity missile has been used, and are unlikely to heal spontaneously.

VASCULAR INJURY

Major injury to the main renal artery or vein usually requires operative management. These patients have higher rates of complications, renal loss, and mortality when compared to those with nonvascular renal injuries. CT findings consistent with main renal artery injury include lack of renal enhancement or abrupt cutoff of an enhancing artery. Segmental arterial injuries typically appear as wedge-shaped infarcts with the apex facing the renal hilum. Injuries to the main renal vein typically appear as central or large hematomas that may displace the kidney anteriorly. Vascular injuries typically occur secondary to deceleration trauma causing the disruption of the inelastic intimal layer with subsequent irreversible parenchymal ischemia and infarction.

Despite the ongoing advances in trauma care, successful renal salvage

after major renovascular injury only occurs in 25% to 35% of cases, at best. Time to reperfusion is the major factor in determining the ultimate outcome. Renal function is significantly impaired following 3 hours of total and 6 hours of partial ischemia. Despite technically successful repair, late hypertension occurs in approximately 50% of renal arterial injuries managed nonoperatively, compared to 57% that were revascularized. Renal arterial repair should be reserved for solitary kidneys, for bilaterally injured kidneys, and in the rare situation of detection within 6 hours of injury. Endovascular stenting may have a limited role, as maintaining patency requires anticoagulation, which is rarely possible in the traumatically injured patient. If detection of renal artery thrombosis is delayed and laparotomy is otherwise indicated, nephrectomy should be performed at that time. Otherwise, the kidney may be allowed to atrophy, with delayed nephrectomy performed if hypertension develops.

RENAL EXPLORATION AND RECONSTRUCTION

Proximal Vascular Control

Primary goals for exploration/reconstruction include control of renal hemorrhage, preservation of maximal parenchyma, and reduction of potential complications attributable to the injured kidney. Historically, renal exploration in the trauma setting usually resulted in total nephrectomy. Using a refined approach to proximal vascular control and a meticulous approach to reconstruction, it is possible to salvage the vast majority of injured kidneys requiring surgical exploration.

The reason behind unplanned nephrectomy in the trauma setting is uncontrolled hemorrhage. We therefore routinely obtain proximal vascular control prior to opening the retroperitoneal hematoma. While temporary vascular occlusion is rarely necessary (approximately 17% of renal explorations at our institution), there is no accurate method of determining which kidneys will require this maneuver during the subsequent reconstruction. Those who have presented series suggesting pedicle control can be safely obtained if necessary following the release of the perinephric hematoma have reported nephrectomy rates approximately three times higher than those with early vascular control.

The traumatized kidney should be explored through a midline transperitoneal incision extending from the xiphoid process to the pubic symphysis. Except in cases of renal pedicle avulsion, all associated intra-abdominal injuries (spleen, liver, pancreas, small and large intestine)

should be addressed before renal exploration, thus allowing Gerota fascia to maintain its natural tamponade effect on the hematoma.

The approach to the injured kidney begins with proximal vascular control. A Bookwalter self-retaining retractor should be used if available. The transverse colon is wrapped in moist laparotomy sponges and placed on the chest (Fig. 180.6A). The small intestine is placed in a bowel bag and retracted superiorly and to the right. This exposes the root of the mesentery and the ligament of Treitz and the underlying great vessels. The retroperitoneal incision is made over the aorta superior to the inferior mesenteric artery and extending up to the ligament of Treitz (Fig. 180.6B). If a large retroperitoneal hematoma obviates easy palpation of the aorta at the level of the ligament of Treitz, the incision may be made medial to the inferior mesenteric vein. This vein is an important guide, running a few centimeters left of the aorta. It is easily identifiable, even in the presence of a large hematoma. Dissection should be carried superiorly along the anterior wall of the aorta until the left renal vein is identified crossing anterior to it. This vessel is encircled but not occluded with a vessel loop, allowing for retraction. The encircled left renal vein serves as a guide to the remaining renal vessels, each of which is then encircled in vessel loops. These vessels are all left unoccluded unless heavy bleeding is encountered during the renal dissection. In our experience, most bleeding is successfully controlled with manual compression alone. Temporary renal vascular occlusion should be kept below 30 minutes to minimize warm ischemic damage. After vascular control has been successfully achieved, the injured kidney may be exposed by mobilizing the ipsilateral colon along the white line of Toldt and reflecting it medially. Gerota fascia is then incised along the lateral aspect of the kidney in order to completely expose the kidney. Care should be taken to maintain the integrity of the renal capsule as the kidney is mobilized in order to decrease hemorrhage and preserve the capsule for later closure.

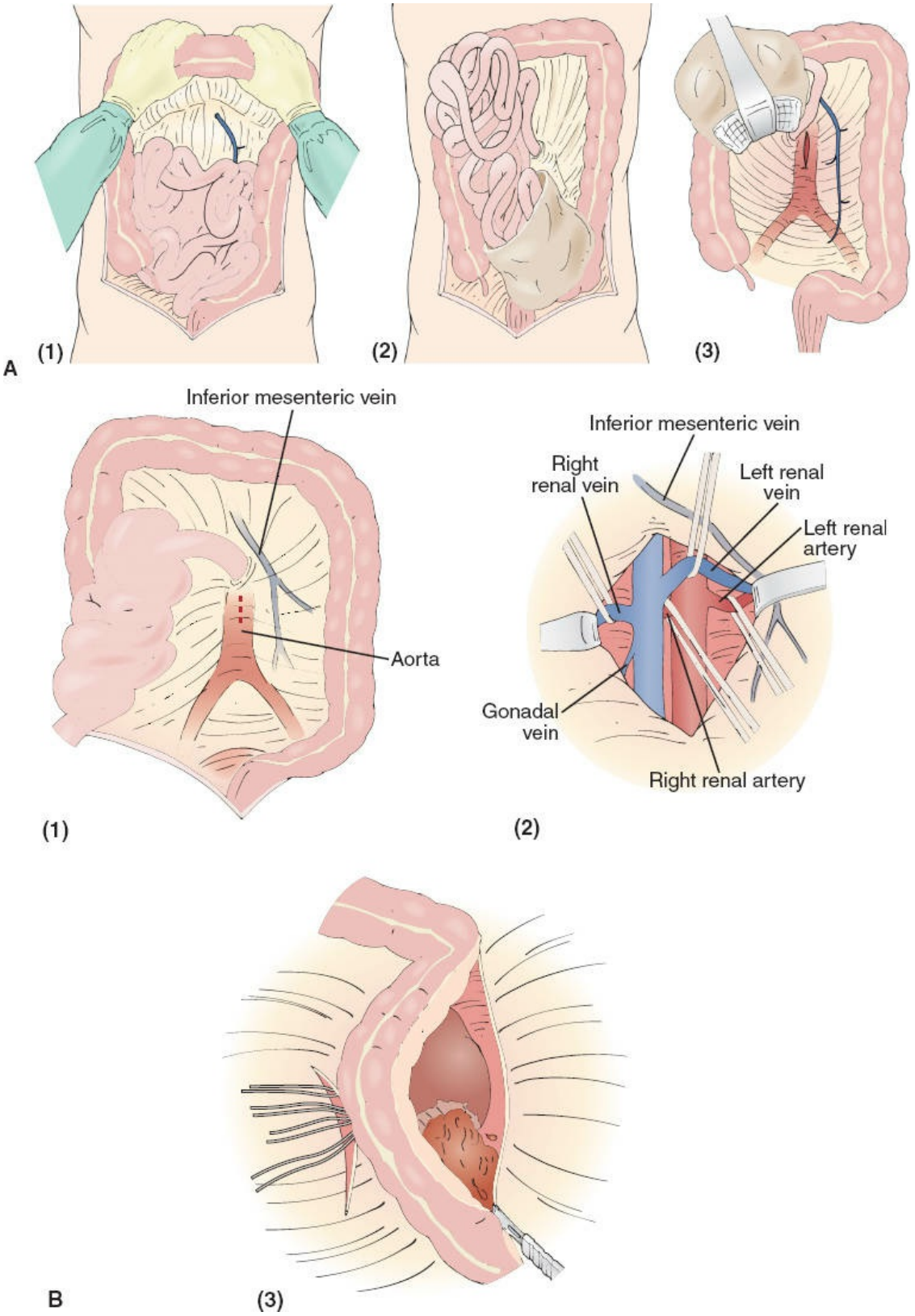

Figure 180.6. A. Optimal exposure for proximal vascular control. **(1)** A midline laparotomy, extending from xiphoid to pubis, should be made, if it has not already been made by the trauma surgeons. It is important to ensure especially that the superior extent of the incision is as high up as possible. The first

maneuver is to place the transverse colon onto the chest. **(2)** The small bowel is reflected out of the body toward the right nipple. **(3)** Small bowel contents are placed into a bowel bag or covered in moist laparotomy pads. The root of the small bowel mesentery should be visible, allowing for excellent visualization of the posterior peritoneal incision overlying the aorta from the ligament of Treitz to the aortic bifurcation. (From Brandes SB, McAninch JW. Surgical exposure and repair of the traumatized kidney. *Atlas Urol Clin North Am* 1998;6(2):32.) **B.** Surgical approach to the renal vessels and kidney. The overlying principle is that of proximal vascular control. **(1)** The posterior peritoneum is incised over the aorta medial to the inferior mesenteric vein. **(2)** The renal vessels are isolated with vessel loops to secure, but not occlude, the vessels. This should be done in the following order: left renal vein, left renal artery, right renal vein, right renal artery. **(3)** After the renal vessels are secured, an incision is made in the posterior peritoneum lateral to the colon, exposing the kidney. (From McAninch JW. Surgery for renal trauma. In: Novick AC, Pontes ES, Streem SB, eds. *Stewart's Operative Urology*. 2nd ed. Baltimore, MD: Williams & Wilkins; 1989:235.)

Principles of Reconstruction

The general principles that are applicable to all renal reconstructions include the following: (a) broad exposure of the entire kidney; (b) temporary vascular occlusion for bleeding not arrested by manual compression of the parenchyma; (c) sharp debridement of nonviable parenchyma; (d) meticulous hemostasis; (e) watertight collecting system closure; (f) primary reapproximation of the parenchymal edges (renorrhaphy) or coverage of the parenchymal defect; (g) omental interposition flap placement to separate reconstructed kidney from surrounding pancreatic, colonic, or vascular injuries; and (h) retroperitoneal drain placement.

The kidney should be débrided sharply back to viable, bleeding parenchyma. Approximately 30% of one normally functioning kidney is required to avoid dialysis, which may serve as a guide in determining whether renal salvage should be undertaken. Major polar injuries are best managed with partial nephrectomy, while lacerations to the midkidney should undergo renorrhaphy. Hemostasis is performed by individually suture-ligating arterial vessels with 4-0 chromic sutures. We then place hemostatic agents such as thrombin-soaked Gelfoam bolsters or FloSeal

between the cut parenchymal edges. The collecting system is then inspected for obvious tears. Injection of 2 to 3 mL of methylene blue into the renal pelvis (using a 27-gauge needle) may demonstrate these openings more clearly. They are then oversewn with running 4-0 chromic suture. A stent is placed only in cases of significant renal pelvis or ureteral injuries, but not in simple calyceal injuries. In a deep, slit-like parenchymal laceration from a knife or sword, the thin parenchymal defect will not permit easy access to the collecting system, and we rely on closure of the overlying parenchyma to seal the collecting system.

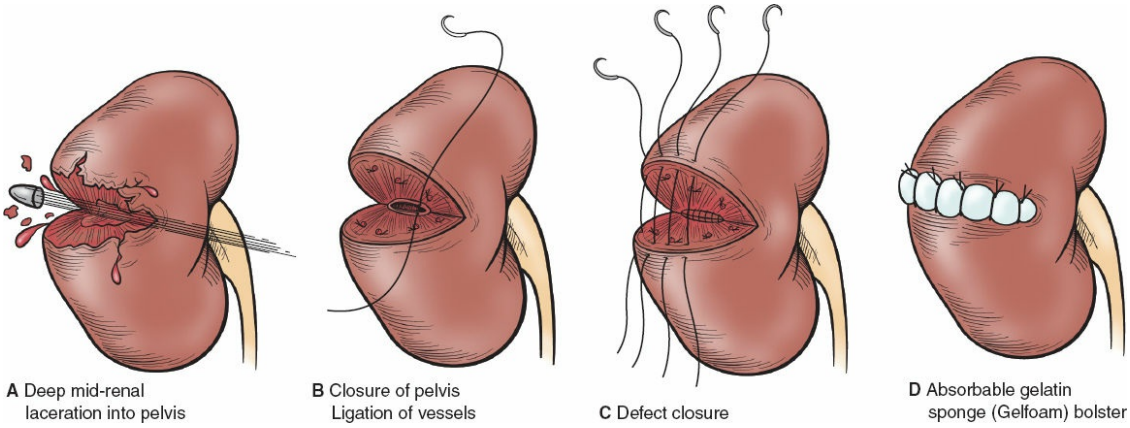

Figure 180.7. Renorrhapy technique. **A.** A deep midrenal laceration is depicted, with collecting system entry. **B.** Sharp debridement is carried out to viable tissue edges. Following this, the collecting system is closed with absorbable suture and discrete end-arteries are suture-ligated. **C.** Interrupted polyglactin (e.g., Vicryl) 2-0 sutures are placed into the renal capsule. After these are placed, thrombin-soaked absorbable gelatin sponges such as Gelfoam are placed as bolsters into the defect. **D.** The parenchyma is approximated by tying the capsular sutures loosely so that they do not rip through the capsule. (From McAninch JW. Surgery for renal trauma. In: Novick AC, Pontes ES, Streem SB, eds. *Stewart's Operative Urology*. 2nd ed. Baltimore, MD: Williams & Wilkins; 1989:238.)

If the renal capsule is intact and viable, it should be used to close the parenchymal defect primarily without tension. If the capsule has been destroyed or the defect is too large to close primarily without causing ischemia, an omental flap can be used. The omentum is guided through the paracolic gutter to reach the kidney, and sutured to the defect. If omentum is not available, the defect may be covered with perinephric fat or a peritoneal free graft; however, these are less desirable options. In the case

of a shattered kidney or multiple deep lacerations, the kidney may be placed in an envelope of Vicryl mesh to stabilize the repair.

Following reconstruction involving the collecting system, a Penrose drain is placed adjacent to the kidney and connected to a urostomy bag to drain any leak if necessary. Alternatively, a closed system drain such as a Jackson-Pratt drain may be used, but the bulb should not be placed on suction, as this negative pressure promotes prolonged urinary drainage. These drains are typically removed after 48 to 72 hours unless output is high, in which case the drainage creatinine should be measured. If the creatinine value suggests a urine leak, the drain is left in place for a more prolonged period. Placement of an indwelling ureteral stent may help to expedite sealing of a persistent urine leak.

Specific Techniques

Renorrhaphy is appropriate for lacerations involving the interpolar aspect of the kidney or polar lacerations with a limited amount of devitalized tissue (Fig. 180.7). This technique employs all the principles outlined above. Following debridement and hemostasis, the collecting system is closed. The residual wedge-shaped defect is then closed over an absorbable thrombin-soaked Gelfoam bolster. Omental flaps are used in cases of large parenchymal defects. In order to identify the site of the repair on subsequent imaging studies, we place titanium surgical clips on the sutures, which approximate the capsular edges.

Extensive damage to the upper or lower renal poles usually requires partial nephrectomy (Fig. 180.8). The capsule should be dissected off the fractured parenchyma for use in defect coverage. Following hemostasis and collecting system closure as outlined above, the defect may be covered by capsule (if available) or alternatively by an omental pedicle flap as shown in the illustration.

VASCULAR INJURY AND REPAIR

Unlike parenchymal lacerations, renovascular injuries are frequently irreparable, and may result in nephrectomy. Proximal vascular control is particularly critical in these cases. Injury to the main renal vein typically results in significant hemorrhage and may require ligation. If reconstruction is feasible, the partially lacerated vein may be repaired with 5-0 Prolene suture following appropriate vascular clamping. Injuries to segmental veins may be safely ligated because of the extensive renal

venous collateral circulation.

As previously mentioned, the ultimate outcome of attempted renal arterial reconstruction is time-dependent. Segmental arterial injuries may be safely ligated, with fewer complications arising from the subsequently devascularized renal parenchyma. Alternatively, a partially lacerated segmental artery may be repaired with 5-0 or 6-0 Prolene suture.

In cases of main renal artery injury, the type of repair indicated relates to the extent and mechanism of injury. Penetrating injuries with incomplete transection may be primarily repaired using 5-0 Prolene sutures. Blunt injuries typically require thrombectomy and debridement of the damaged arterial segment. Ideally, a primary tension-free reanastomosis of the injured artery should be undertaken. If this is not feasible, we recommend an interposition vascular graft. While technically feasible, ex vivo renal reconstruction and autotransplantation into the iliac fossa is rarely indicated in the critically injured patient with multiple associated injuries.

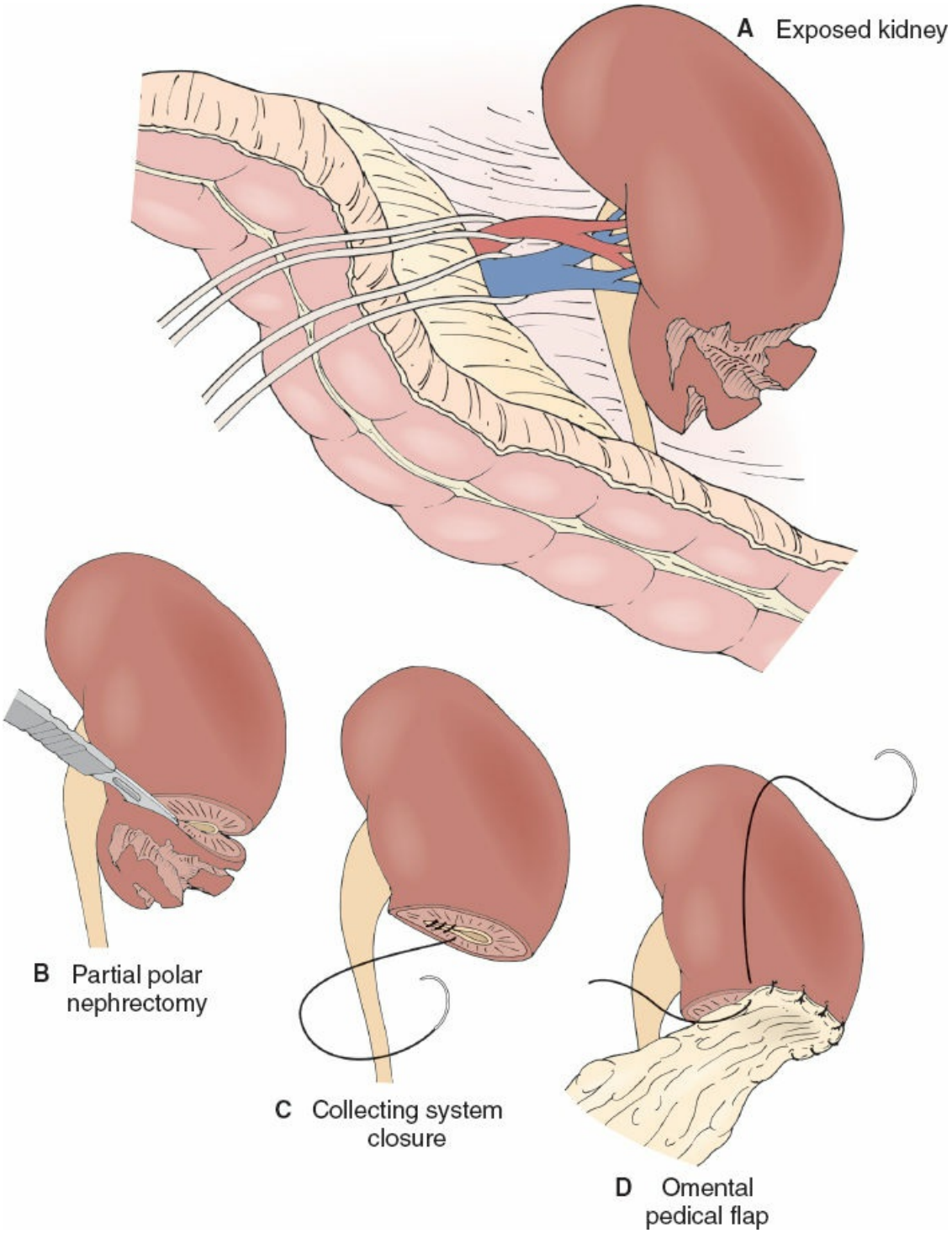

Figure 180.8. Partial nephrectomy technique. **A.** The kidney is totally mobilized to completely assess for injury. The ureter is carefully inspected. **B.** The nonviable renal tissue is sharply removed. Hemostasis is obtained with manual compression of the kidney during this maneuver. **C.** The collecting system is closed with absorbable suture and discrete end-arteries are oversewn. **D.** Defect coverage is done with omentum, or, alternatively, with residual capsule if it was preserved. (From McAninch JW. Surgery for renal trauma. In: Novick AC, Pontes

ES, Streem SB, eds. *Stewart's Operative Urology*. 2nd ed. Baltimore, MD: Williams & Wilkins; 1989:237.)

POSTOPERATIVE CARE AND COMPLICATIONS

A urethral catheter should be maintained until the patient is hemodynamically stable and mobile enough to void. The patient should be kept on bedrest until gross hematuria clears. We recommend obtaining an abdominal CT scan and radionuclide renal scan (DMSA scan) at approximately 3 months to quantify the function of the injured/reconstructed kidney. In our series of traumatically injured and subsequently reconstructed kidneys, the average differential renal function of the repaired kidney was 39%, corresponding to two thirds of one kidney.

The reported complication rate following renal injury ranges from 3% to 20%. Complication rates increase proportionately with increasing grade of injury and appear to be higher in kidneys managed nonoperatively. Our complication rate is approximately 10%. We have observed that the complication rate (attributable specifically to the kidney) for grade 4 injuries was similar for nonoperative and operative management, 5% and 4%, respectively. This is likely due to our higher rate of renal exploration (78% of grade 4 injuries) than other series, as well as our patient selection for nonoperative management. Complications may be divided into early (within 1 month) and late complications. Early complications include urinomas, delayed bleeding, urinary fistulae, abscesses, and hypertension. Late complications include hydronephrosis and renin-mediated hypertension (Fig. 180.9). Urinomas are the most common complication, and are usually successfully managed by endoscopic stenting and/or percutaneous drainage. Delayed bleeding typically occurs within 1 to 2 weeks of injury, and is more commonly associated with stab wounds. Angiography and selective embolization is both diagnostic and therapeutic in this case.

USE OF INTERVENTIONAL RADIOLOGY TECHNIQUES IN RENAL TRAUMA

Angioembolization

There is an increasing utilization of angioembolization in the management of bleeding in the traumatically injured population, but mostly in the form

of case reports and limited case series. This is most commonly done for embolization of pelvic vessel bleeding, rather than solid abdominal organs. The kidney, however, is well suited to angioembolization for bleeding after injury, mostly because the arteries and arterial branches supplying each part of the kidney are end-arteries. Prospective studies are needed to judge the long-term efficacy of this technique.

Endovascular Stents

For renal arterial thrombus without arterial avulsion, it occasionally may be feasible and safe to deploy an endovascular stent to restore arterial inflow, and there have been a few case reports describing this technique. However, many times patients have other visceral injuries such as splenic or hepatic injuries, preventing the use of anticoagulants, which would be required in the case of an endovascular stent. It is possible that new drug-eluting stents that are used in cardiac endovascular stenting may avoid this problem.

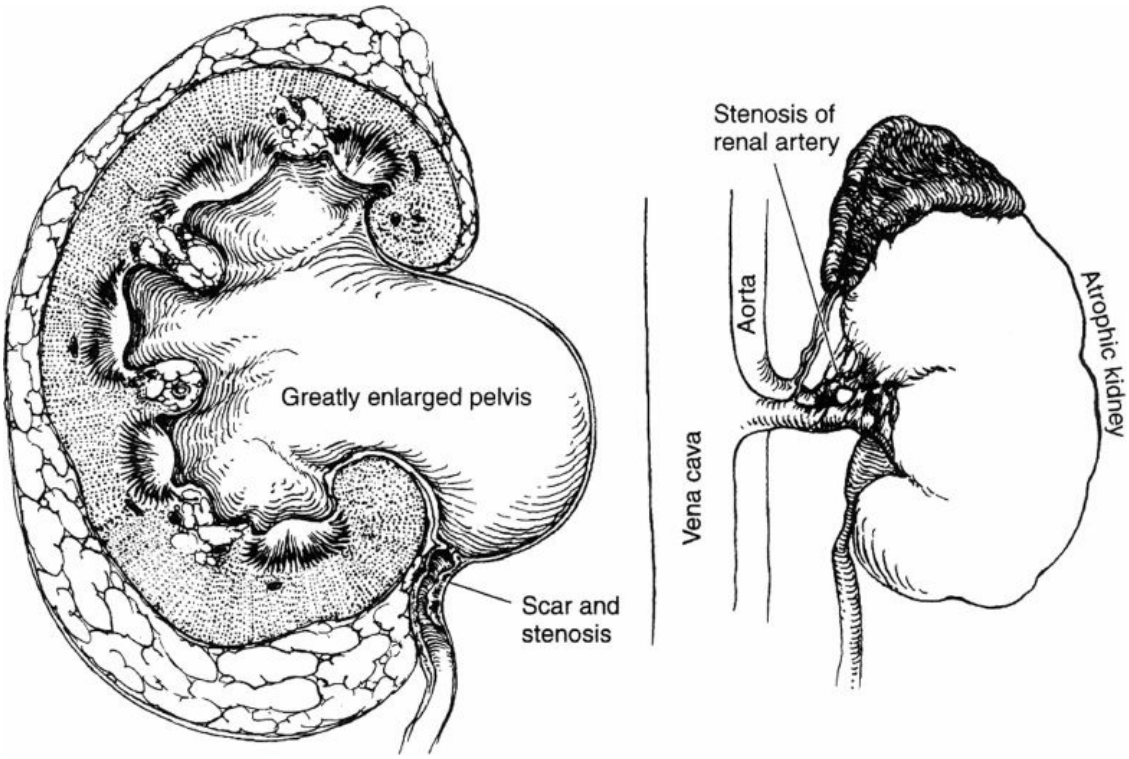

Figure 180.9. Late complications of renal injury. **Left:** Ureteropelvic stenosis with hydronephrosis secondary to fibrosis from extravasation of blood and urine. **Right:** Atrophy of kidney caused by injury (stenosis) of arterial blood supply.

COMPLICATIONS OF RENAL INJURIES

Hypertension may be seen in the setting of untreated arterial thrombosis and devitalized parenchyma. This has been documented in approximately 0.2% of cases. Posttraumatic hypertension is mediated by the renin–angiotensin system, and delayed nephrectomy is indicated in this setting if medical management fails. Arteriovenous fistula may present with hemorrhage, hypertension, or high-outpsut cardiac failure following a stab wound. Arteriography and fistula embolization usually characterize and treat the fistula successfully. Long-term follow-up is critical to check for development of hypertension, which may develop slowly.

URETERAL INJURY

Staging

The physical findings associated with ureteral injuries are nonspecific. Unless the surgeon maintains a high index of suspicion, the diagnosis may go unnoticed, with subsequent renal loss. Any patient who sustains a penetrating injury to the flank or abdomen is at risk for ureteral injury and warrants further evaluation (Fig. 180.10). There is a dearth of prospective data concerning management of ureteral injury. Ureteral trauma accounts for less than 1% of all urologic trauma. Iatrogenic trauma is the leading cause of ureteral injuries. Preoperative stent placement does not prevent injuries, but may assist in the identification of an injury. The vast majority of complications, including renal loss, occur when the diagnosis of ureteral injury is delayed. Diagnostic tests are often specific but not sensitive. The false-negative rate of hematuria is approximately 30%. IVP, but not a “one-shot” (single-view) IVP, is accurate at diagnosing injury. Abnormal IVP findings warrant further investigation (i.e., ureteral dilation or deviation, incomplete visualization of the entire ureter, delayed or no visualization of the renal unit, and urinary extravasation). In the modern era, most patients are imaged with CT scans, which must be performed with the delayed phase, which is at 10 minutes; otherwise, only parenchymal abnormalities will be noted. Thirty to forty-five percent of patients with ureteral injury do not have any degree of hematuria, a consistent finding seen in multiple reports. Most external ureteral injuries occur from gunshot wounds, and if a high-caliber bullet is used, a missile path even close to the ureter can cause significant delayed tissue destruction. Therefore, all periureteral gunshot wounds and associated

retroperitoneal hematomas, if noted during trauma laparotomy, should be explored. Visual ureteral inspection with or without intravenous or intraureteral dye injection is reliable. Ureteral injuries from blunt trauma are rare. They usually occur in children during rapid deceleration, causing excessive hyperextension and disruption at the UPJ. Most traumatically injured patients are usually polytraumatized and have associated multiple organ injuries (liver, spleen, and skeletal system).

Principles of Reconstruction

Prompt treatment of ureteral injuries is required to prevent significant patient morbidity in terms of the development of persistent low-grade fevers, flank and lower quadrant pain, and paralytic ileus, which are all due to urinoma development. Occasionally patients can develop ureterovaginal (usually after gynecologic procedures) or ureterocutaneous fistulae. Proximal urinary drainage via a percutaneous nephrostomy tube may be required if the injury is recognized only in a delayed fashion, or if the injured patient has other significant complications that make immediate reconstruction impossible. The important principles underlying all ureteral repairs are to achieve tissue debridement to viable tissue and a tension-free, spatulated, water-tight repair that is stented and drained via a retroperitoneal drain. If there are simultaneous bowel, pancreatic, or vascular injuries, it may be prudent to isolate the repair with omentum. Stents are important in this repair as they maintain a ureter with a constant caliber during early healing, prevent extravasation, and provide a conduit for urine during healing. They should be left in place for 8 weeks and can be removed using endoscopy and local anesthesia.

Techniques of Reconstruction

The ureter can be conveniently divided into thirds when considering different types of repair: lower, mid, and upper ureter. Injuries to the lower ureter can usually be managed with a reimplantation of the proximal end of the ureter directly into the bladder, as the bladder is mobile enough to be brought to the ureter for lower ureteral injuries. Ureteral reimplantation should be done in an antirefluxing fashion whenever possible (Fig. 180.11) in order to prevent long-term kidney infection and damage. Reimplantation is usually done with the bladder fixed to the psoas muscle, termed a “psoas hitch” (Fig. 180.12), with nonabsorbable sutures in order to prevent tension on the anastomosis. However, if the ureter has been ligated but not

transected during a pelvic surgical procedure, a primary ureteroureterostomy may be performed. Finally, a transureteroureterostomy (Fig. 180.13) can be used in lower ureteral injuries when there is significant scarring and pelvic infection, which may be preferable as the ureteral anastomosis is far from any ongoing pathologic processes.

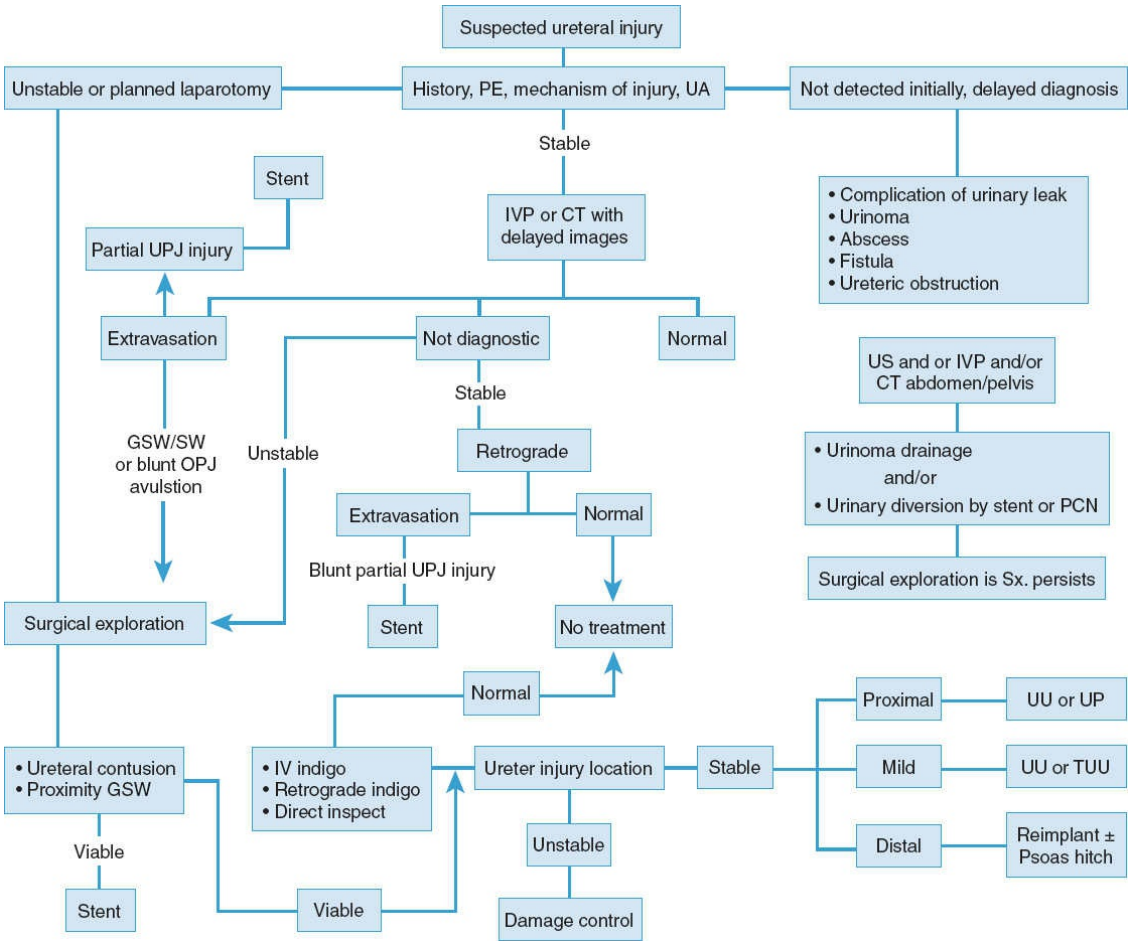

Figure 180.10. Suspected ureteral injury algorithm. CT, computed tomography; GSW, gunshot wound; IVP, intravenous pyelogram; PCN, percutaneous nephrostomy; PE, pulmonary embolism; SW, stab wound; TUU, transuretero-ureterostomy; UA, urine analysis; UP, ureteropyleostomy; UPJ, ureteropelvic junction; US, ultrasound; UU, uretero-ureterostomy. (Adapted from Brandes S, Coburn M, Armenakas N, et al. Diagnosis and management of ureteric injury: an evidence-based analysis. *BJU Int* 2004;94:277.)

Midureteral injuries comprise the majority of injuries from external violence. This injury is best managed with either a primary ureteroureterostomy (Fig. 180.14) or a transureteroureterostomy. The

ureter will usually need to be mobilized distally in order to provide sufficient length. It is critical to avoid devascularizing the ureter, as this will guarantee failure of the repair. Leaving a generous amount of periureteral fat surrounding the ureter may assist in preserving vascularity. Occasionally, the kidney will need to be mobilized downward and fixed with permanent suture to provide ureteral length.

Upper ureteral injuries are best managed with primary ureteroureterostomy. If there is extensive ureteral loss, then a segment of ileum can be harvested to provide a ureteral replacement. Rarely, autotransplantation of the kidney can be performed. This is not advised in the trauma situation as it adds to the length of time on the operating table.

Bladder Trauma

Bladder trauma occurs generally from external forces, but may also be due to iatrogenic/instrumentation-related trauma. A high index of suspicion needs to be maintained in intoxicated individuals with a full bladder who sustain even mild trauma and complain of abdominal pain, as they may have sustained a bladder rupture. Fifteen percent of all pelvic fractures are associated with concomitant bladder or urethral injury, but, conversely, 90% of bladder ruptures are associated with pelvic fractures. Data for management guidelines of bladder trauma are primarily from retrospective analysis (Fig. 180.15). Physical examination is vital, especially a vaginal speculum examination in women, as vaginal lacerations or traumatic communication between the bladder and vagina may occur, which can lead to disastrous results if missed. Gross hematuria is the cardinal sign of a bladder rupture (>95%). Static and CT cystograms are both effective at diagnosing bladder injury, but must be performed with an appropriate amount of contrast (350 to 400 mL). Ultrasound is not effective for diagnosis of rupture. Passive bladder filling is unacceptable and the injury may be missed, even on CT scan. Serious complications, including death, may ensue with a delayed diagnosis. Intraperitoneal lacerations should all be surgically repaired. Extraperitoneal perforations can generally be managed with a catheter providing urinary drainage. However, repair of extraperitoneal perforations should be performed if other surgical services are operating on the patient; if there is a suspicion of bladder neck, vaginal, or rectal injury; if there is a failure of the catheter to provide adequate drainage; or if bleeding is causing catheter malfunction. The catheter can generally be removed on the 10th postoperative day, but a

cystogram should be performed as less than or equal to 15% of bladders may not be healed. With the increasing utilization of laparoscopic technology for more complex surgery, there appears to be a trend of increased iatrogenic bladder injury.

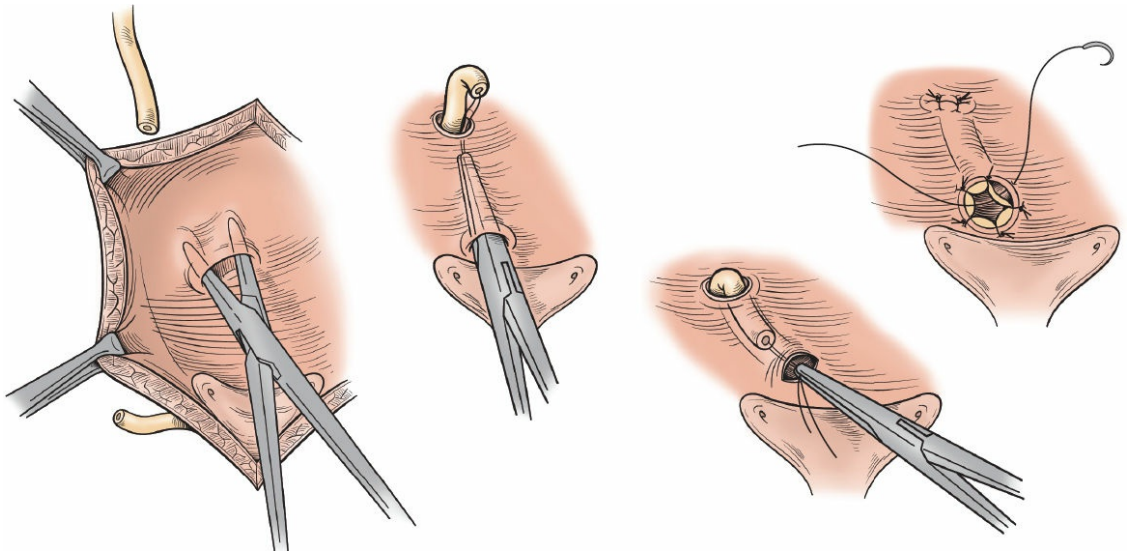

Figure 180.11. Ureteral reimplantation. Ureteroneocystostomy for a distal ureteral injury using the nonrefluxing Politano-Leadbetter ureteral reimplant procedure. (From Presti JC Jr, Carroll PR. Intraoperative management of the injured ureter. In: Schrock TR, ed. *Perspectives in Colon and Rectal Surgery*. St. Louis, MO: Quality Medical Publishing; 1988.)

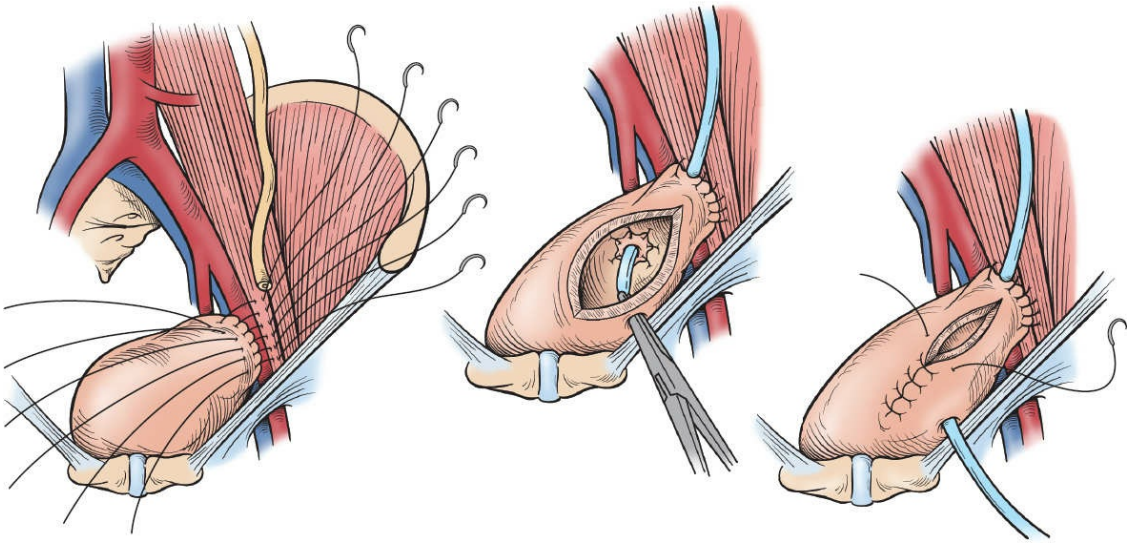

Figure 180.12. Psoas hitch. A ureteroneocystostomy with a bladder psoas hitch is illustrated. (From Presti JC Jr, Carroll PR. Intraoperative management of the injured ureter. In: Schrock TR, ed. *Perspectives in Colon and Rectal Surgery*. St. Louis, MO:

Quality Medical Publishing; 1988.)

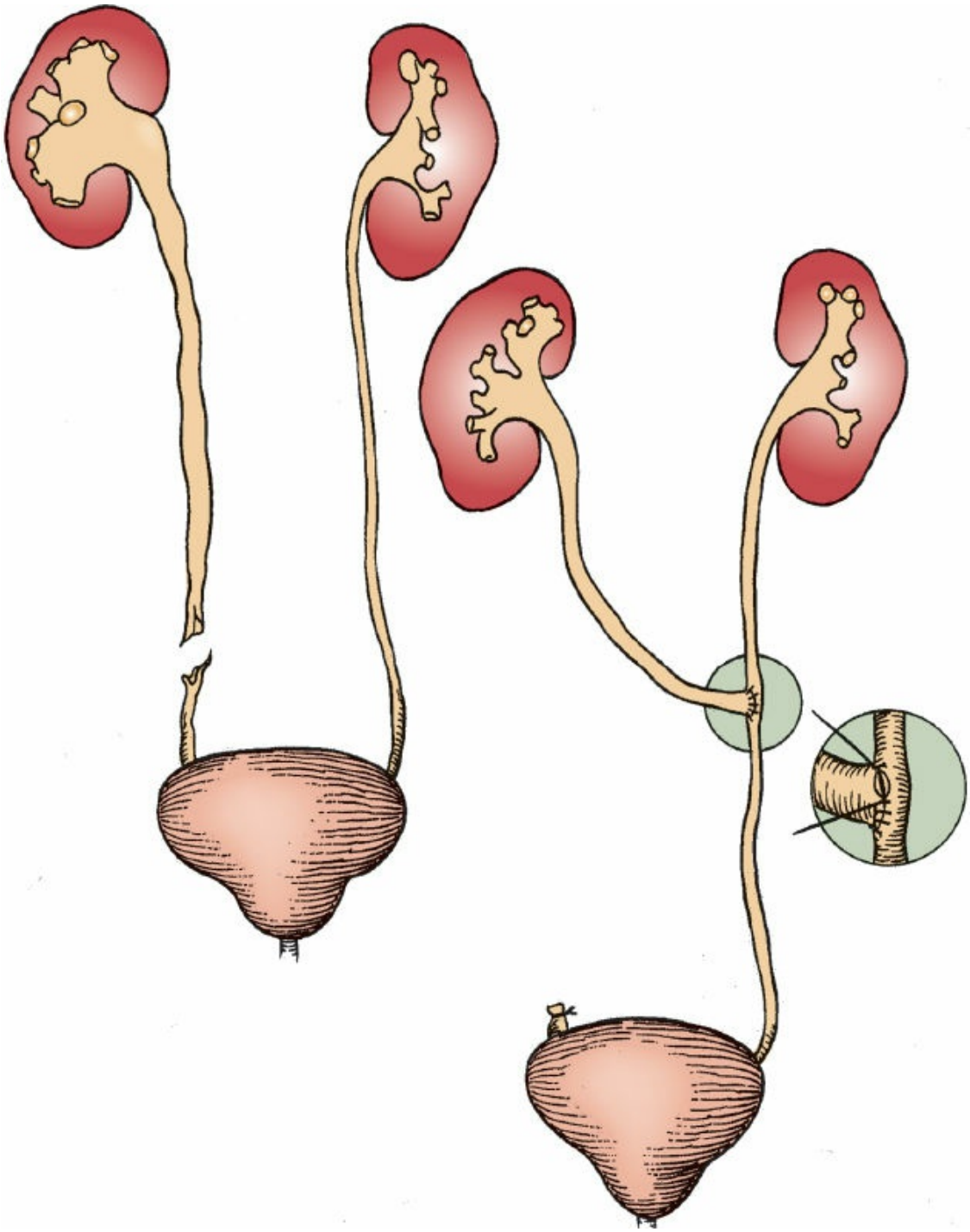

Figure 180.13. Transureteroureterostomy. (From Presti JC Jr, Carroll PR. Ureteral and renal pelvic trauma: diagnosis and management. In: McAninch JW, ed. *Traumatic and Reconstructive Urology*. Philadelphia: WB Saunders; 1996.)

Principles of Reconstruction

If the bladder is the only organ to be repaired, a lower midline abdominal incision should be made. The bladder should be approached in the midline to avoid pelvic hematomas, which are usually lateral. Entering the hematoma is not advisable as release of tamponade can result in significant bleeding and the hematoma itself can then be infected with urine.

For extraperitoneal ruptures, the bladder is opened in the midline and repaired intravesically, usually in two layers with 2-0 and 3-0 chromic or polyglycolic acid sutures. If the bladder neck is lacerated, careful attention should be paid to the repair; the patient will suffer from incontinence if not repaired. In female patients, a careful vaginal exam must be done to examine for the presence of lacerations, which should be repaired. If indicated, a peritoneotomy can be made at the end of the procedure to assess for the presence of bloody intra-abdominal fluid. Drainage via either a suprapubic tube or a urethral catheter is acceptable.

Intraperitoneal bladder ruptures should be repaired via a transperitoneal approach using a lower midline incision. All other bladder sidewall defects should be closed. The peritoneum should be closed over the area of injury, and the wall of the bladder itself should be closed in two or three layers. All urinary fluid should be removed from the peritoneum prior to closure. If a suprapubic tube is used for drainage, care should be taken that the suprapubic cystotomy is in the extraperitoneal position.

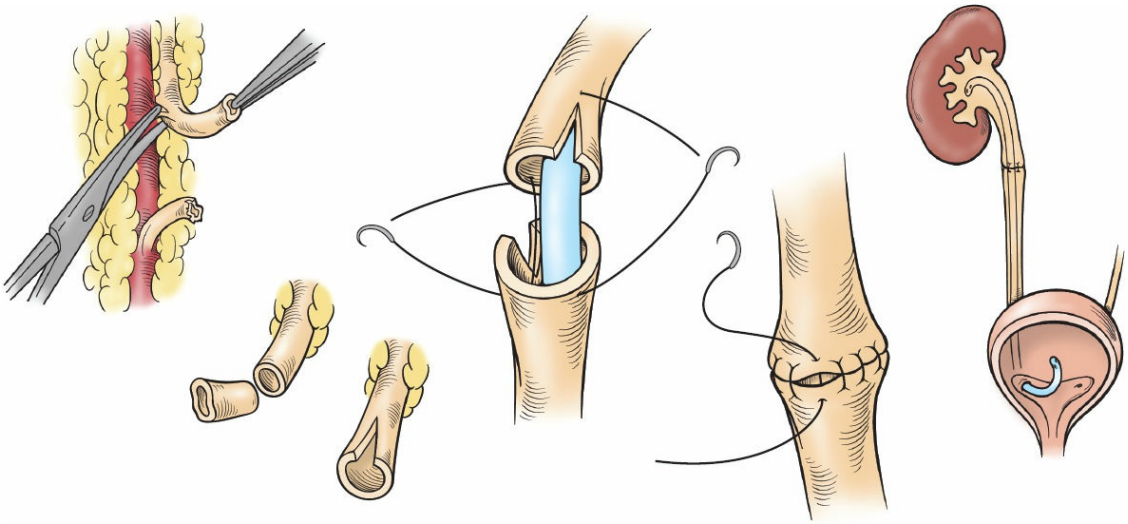

Figure 180.14. Ureteroureterostomy illustrating the surgical principles of debridement, spatulation, and end-to-end repair using interrupted, absorbable, fine sutures over an indwelling stent. (From Presti JC Jr, Carroll PR. Intraoperative management of the injured ureter. In: Schrock TR, ed. *Perspectives in Colon and Rectal Surgery*. St. Louis, MO: Quality Medical Publishing;

1988.)

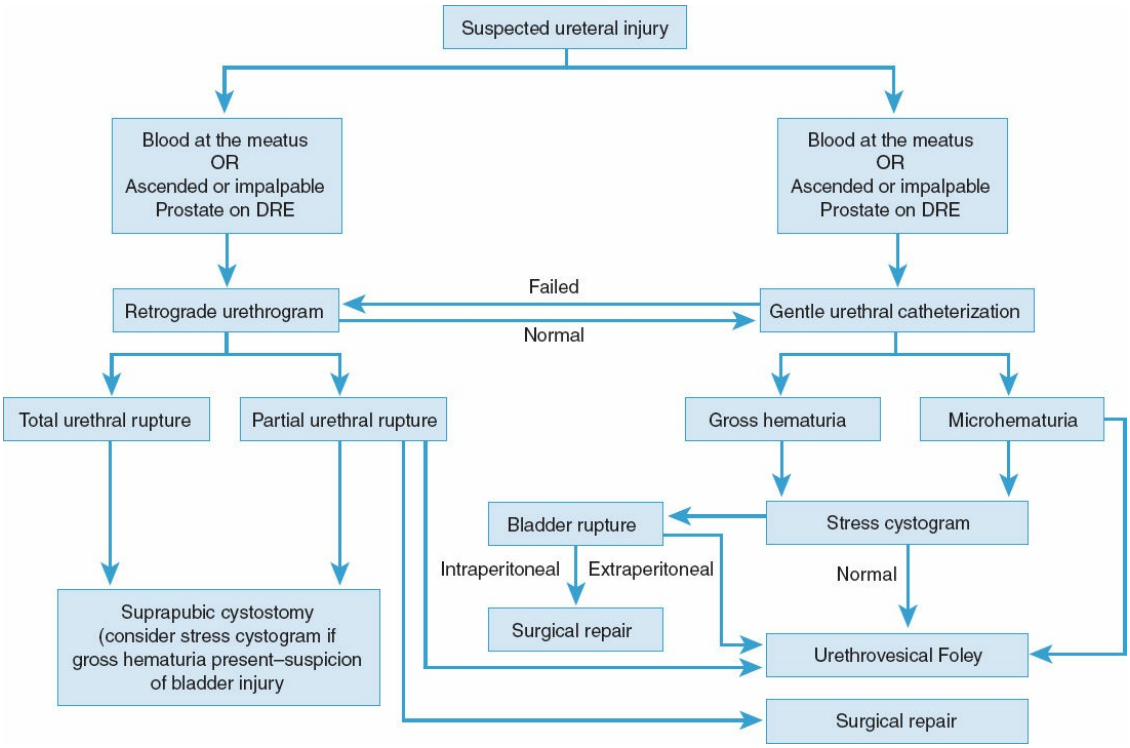

Figure 180.15. Suspected bladder injury algorithm. DRE, digital rectal examination. (Adapted from Gomez RG, Ceballos L, Coburn M, et al. Consensus statement on bladder injuries. *BJU Int* 2004;94:27.)

Urethral Trauma

Injuries to the urethra can be classified as either anterior or posterior urethral injuries. The posterior urethra is the most proximal portion of the urethra and begins at the bladder neck and continues through the prostate. This is referred to as the prostatic urethra, which then continues as the membranous urethra, which passes through the levator muscles and is surrounded only by the striated urethral sphincter. The prostatic and membranous urethras are together termed the posterior urethra. The anterior urethra is the remaining urethra, which continues to the urethral meatus, is surrounded by the corpus spongiosum and glans penis, and consists of the bulbar urethra and the pendulous urethra. Figure 180.16 shows an evidence-based algorithm for diagnosis and treatment of urethral injuries.

Anterior Urethral (Straddle) Injuries

Anterior urethral injuries are distinctly rare, encompassing at most 10% of urethral injuries. These injuries are most commonly caused by a blunt straddle-type injury, where the bulbar urethra is crushed upward against the pubic rami. Penetrating trauma to this region (stab or gunshot injury) is rarely encountered. Patients may present with blood per meatus or inability to void, or an expanding scrotal hematoma, which may contain extravasated urine. Retrograde urethrography is mandatory to diagnose this injury.

Because of the rarity of these injuries, management algorithms have been based upon small series. Most anterior urethral disruptions can be managed with immediate repair consisting of minimal debridement followed by tension-free, spatulated anastomotic repair. Other options include catheter alignment followed by delayed repair, or suprapubic urinary diversion followed by delayed repair. The latter option may lead to the best outcomes in the setting of shotgun blasts or high-velocity projectiles, as the true extent of devitalized tissue injury may only declare itself over time.

Posterior Urethral Injuries

The vast majority of membranous urethral injuries occur in association with a pelvic fracture, and more specifically with bilateral pubic rami fractures. The prostate is anchored behind the pubic rami via the puboprostatic (pubourethral) ligaments. When a deforming force fractures the pubic ramus and distracts the bony fragment superiorly and posteriorly, the resulting displacement will tear through the membranous urethra, typically at the point of departure of the bulbous urethra. The membranous urethra may rarely be injured by bullets or other projectiles. Thus, the physician encountering patients with pelvic trauma must maintain a high index of suspicion for urethral injury.

Appropriate early recognition and treatment of prostatomembranous urethral disruption significantly reduce long-term morbidity. Although these patients have often suffered critical orthopedic, vascular, and visceral injury, it is often the sequelae of the urethral injury (incontinence, erectile dysfunction) that cause the most morbidity after all the other injuries have healed.

Clinically, these patients present with blood at the meatus, inability to void, and a palpably full bladder. The prostate has been described as “high riding,” but this sign is unreliable, as a normal (nondisplaced) prostate may

be impalpable secondary to the surrounding pelvic hematoma. A perineal hematoma may or may not be present. Finding any of these signs warrants a retrograde urethrogram. An attempt at catheter placement in this setting prior to urethrography may have serious consequences if the urethra has been disrupted.

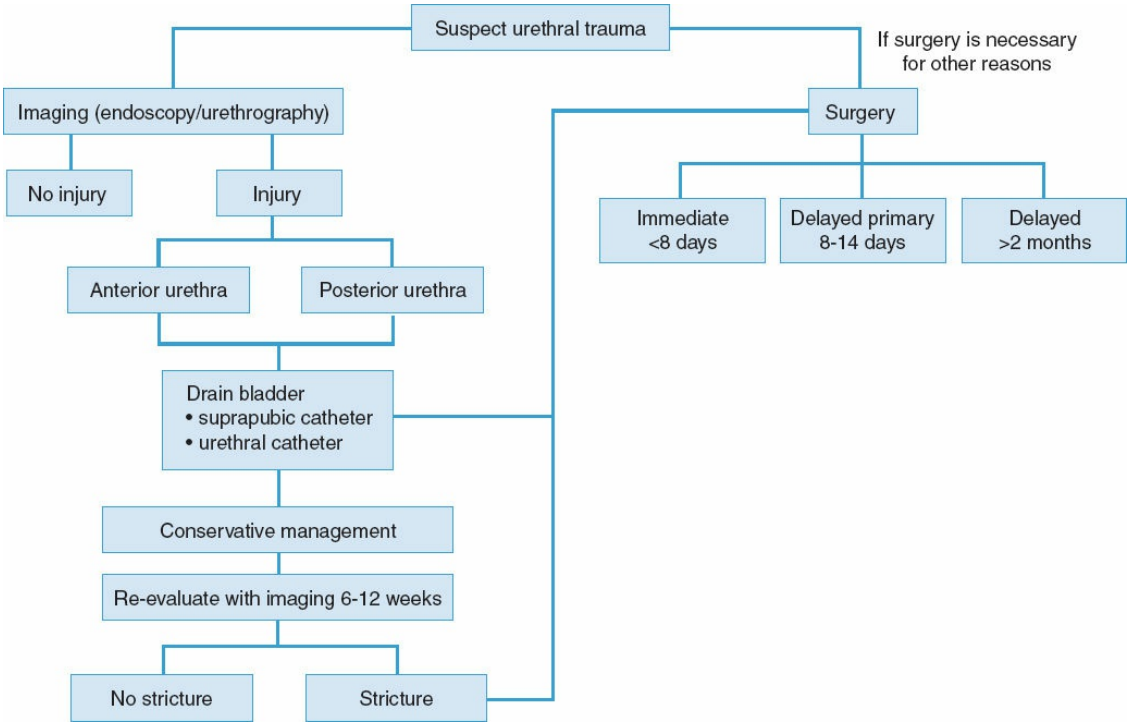

Figure 180.16. Urethral injury algorithm. (Adapted from Chapple C, Barbagli G, Jordan G. Consensus statement on urethral trauma. *BJU Int* 2004;93:1195.)

The findings on retrograde urethrography (RUG) dictate subsequent management steps. It is important to highlight that oblique/lateral decubitus views are necessary to adequately visualize the bulbous and membranous urethra. A normal RUG rules out significant urethral injury, and a Foley may then be placed for urinary drainage. Placement of the catheter in this setting should be immediately followed by a cystogram to rule out an associated bladder or bladder neck laceration.

If the RUG demonstrates extravasation of contrast at the level of the membranous urethra with or without bladder filling, a prostatomembranous urethral disruption is present. Initial and early management of these injuries remains a controversial topic. Current treatment options include suprapubic catheter placement alone followed by delayed reconstruction between 3 and 12 months, suprapubic catheter

placement followed by endoscopic placement of an aligning catheter (to bring the severed ends of the urethra into alignment), and urethral reconstruction in the early postinjury period. We advocate immediate suprapubic cystotomy followed by a delayed urethral reconstruction, as this method of management results in the best long-term success rate of urethral patency. Park and McAninch studied 78 patients with straddle injury–related bulbar urethral injuries. Patients who underwent primary realignment required more complex flap or graft urethroplasties. Success was 95% at a mean follow-up of 25 months. Recurrent strictures occurred in four men who were successfully managed by direct-vision internal urethrotomy.

Regardless of the management option chosen, the first priority is achievement of urinary drainage—typically with a suprapubic catheter. If the patient is stable and the surgeon has adequate expertise and equipment, an attempt to place an aligning catheter may follow. Endoscopic realignment does not appear to increase complications if properly performed, and may simplify a later posterior urethral reconstruction by bringing the urethral ends into alignment. However, most patients managed with aligning catheters will heal with a urethral stricture requiring operation at a later date.

Delayed primary sutured coaptation of the urethra (typically within a few days of the initial injury) is rarely employed in the United States, but this approach has gained enthusiasm in parts of Europe. This approach involves exploration of a maturing pelvic hematoma and placement of sutures into the prostatic apex and severed urethral margins. The long-term results in terms of restricture, continence, and erectile function have yet to be reported, but theoretic concerns exist regarding further injury to cavernous nerves and sphincter muscle fibers in this setting.

Open placement of a suprapubic catheter is indicated in a setting where bladder inspection and repair are planned, for example, in the case of a bladder neck laceration. A suprapubic catheter may also be placed at the time of concomitant orthopedic plating of the anterior pubic arch. Another absolute indication for open suprapubic catheter placement is in the case of simultaneous rectal or vascular injury. In these complicated cases, irrigation and drain placement are warranted, but no attempt to expose or repair the urethral disruption should be made at the time of the acute injury.

Delayed reconstruction may be undertaken between 3 and 12 months,

assuming that the patient has healed from other nonurethral injuries. It is beyond the scope of this chapter to outline technical aspects of posterior urethral reconstruction, but certain key points deserve mention. The vast majority of prostatomembranous urethral disruptions may be successfully repaired via a perineal approach in a single stage. Following excision of all the scar tissue separating the two urethral ends, the urethra is adequately mobilized to allow a tension-free anastomosis. Endoscopic techniques that attempt reconstruction by coring through the scar to bridge the defect ("cut to the light" procedures) between the two ends may have unacceptably high failure rates. Because of the complexity of this type of reconstructive surgery and the relative paucity of patients requiring it, it is best undertaken in referral centers where urologists have developed special expertise in this area.

External Genital Trauma

External genital trauma is relatively uncommon, but may be increasing in terms of proportional incidence, especially due to penetrating injury in war situations, because of the improvements in body armor, which decreases injury to the thorax and abdomen. There are multiple prospective studies concerning genital trauma, and different treatment approaches are described below. It is critical to remember that mismanagement of these injuries may result in significant physical and psychological consequences, which are often difficult to predict at the time of injury.

Testicular Trauma

Traumatic injuries to the testes and scrotum may result from either blunt or penetrating insults. The relative mobility of the testes usually allows it to swing away from crushing forces. The fibrous tunica albuginea usually protects the delicate seminiferous tubules within from further trauma. However, a significant deforming force may cause rupture of the tunica, clinically known as testicular fracture. Scrotal contusions that do not rupture the tunica but nonetheless produce significant hematomas within the wall of the scrotum may be clinically difficult to distinguish from a fractured testicle.

Although once believed to be rare, the risk of testicular rupture following major blunt scrotal trauma may be as high as 50%. The most common causes are assault and sports-related injuries, but testicular trauma may be self-inflicted in the unusual transsexual patient. Penetrating

trauma secondary to gunshot wounds is uncommon, but may rarely be self-inflicted from a loaded firearm misplaced in a pants pocket. Penetrating injury is more likely to require testicular exploration.

Clinical findings are often nonspecific, but usually include significant pain and a swollen, ecchymotic scrotum. Because of rapid expansion of the scrotal hematoma, it is often difficult to appreciate the testicular contour on physical examination. A history of forceful trauma should raise suspicion for testicular rupture. In penetrating trauma, associated injuries to the penis, perineum, and femoral vessels should be considered and ruled out.

While scrotal imaging may serve as a useful adjunct to physical examination in suspected testis trauma, the definitive diagnosis of testis rupture is made surgically. It is thus most appropriate to explore a grossly abnormal scrotum without ultrasonography when the index of suspicion is high. Scrotal ultrasonography is the most sensitive imaging method for detecting intrascrotal injury, with a positive predictive value of 78%. Heterogeneity of the testicle echotexture is diagnostic of a testicular rupture. Discontinuity of the tunica albuginea is insensitive, being visualized only 17% to 20% of the time.

Early scrotal exploration and repair of testicular rupture result in the highest testis salvage rate. Observation of the traumatized testis results in higher orchiectomy rates, and also significantly increases the patient's disability period. Nonoperative management is usually complicated by infection, testicular atrophy, or necrosis and is not advised.

The operative approach via a midline scrotal incision permits full exposure of both testes and spermatic cords, as needed. Large scrotal hematomas are then evacuated. All necrotic testicular parenchyma is débrided, and the tear in the tunica albuginea is closed. Penetrating injury through the spermatic cord is more likely to result in orchiectomy at the time of exploration. Typically, a Penrose drain may be left in place if hemostasis is in question. Testicular salvage is possible in most cases, and spermatogenesis and endocrine function (testosterone production) are thus preserved.

Testicular amputation injuries are fortunately uncommon, and are usually self-inflicted by the psychotic patient. Unlike the penis, the testes do not tolerate prolonged periods of warm ischemia. Testicular replantation is thus reserved for cases of bilateral amputation or amputation of a solitary testis. This involves microsurgical reanastomosis

of the testicular artery, vasovasostomy, and reapproximation of two or three of the spermatic veins. The overlying amputated skin is not vascularized by the deep structures, and thus is usually not replantable. The ideal coverage of the replanted testis is via primary scrotal closure with remaining scrotal skin.

PENILE TRAUMA

Penile Fracture

A fractured penis implies disruption of the tunica albuginea surrounding the corpora cavernosa. Penile fractures are most commonly caused by excessive sudden angulation of the erect penis against the pubic symphysis during vaginal intercourse. This injury may also be self-inflicted by abrupt bending of the erect penis during masturbation. The classic history involves the scenario described above, with patients usually reporting a popping sound as the tunica tears, followed by pain, swelling, and rapid detumescence. The laceration is classically found on the pendulous part of the penis, but more proximal tears have been reported. There is frequently a delay in presentation to the hospital, presumably secondary to patient embarrassment.

Physical examination typically reveals a swollen, ecchymotic penis, classically described as an “eggplant penis,” because of the discoloration and enlargement caused by the hematoma. The fracture line in the tunica is often palpable. There is often a clot lying over or near the fracture site, which corresponds to the cavernosal rupture site. Urethral injury is associated with penile fracture in 20% of cases. Retrograde urethrography should be performed to rule out suspected injury, particularly in the presence of hematuria, inability to void, or blood at the urethral meatus. Physical examination and history are diagnostic and radiologic studies such as cavernosography or ultrasound, which is diagnostic when read by experienced physicians, should be reserved for unclear cases of penile fracture.

Immediate exploration and surgical repair of penile fracture are warranted. Nonoperative management has no place in the management of this injury, as severe penile curvature, abscess, missed urethral injury, and fibrosis will likely ensue. The penis is explored via a circumcising incision, and the entire length of the corporal bodies and urethra are inspected. The corporal laceration is closed with absorbable sutures. If an associated urethral injury is present, it is repaired over a catheter. Patients

who undergo this type of expedient repair have a low complication rate and usually avoid disabling and disfiguring penile curvature in the postoperative period.

Penile Amputation

Penile amputation is a very rare entity, arising largely from self-mutilation in the hands of a psychotic patient. It may also be caused by violent assault or as a devastating complication of circumcision. Most psychotic patients respond well to psychiatric rehabilitation, and the vast majority will not attempt to repeat amputation. Expeditious penile replantation is thus the treatment of choice. Replantation is best accomplished using microvascular techniques, if available.

The penis is remarkably resistant to cold ischemia, and successful replantation has been accomplished up to 24 hours postamputation. The penis should be preserved in a saline-soaked gauze and placed within a sterile plastic bag. This bag is then immersed in ice slush, which increases ischemic tolerance of the amputated segment.

Microsurgical replantation of the amputated penis involves two-layer closure of the urethra over a catheter in order to stabilize the remainder of the repair. The tunica albuginea of the corporal bodies is reapproximated in a watertight fashion. At least one dorsal artery and the dorsal vein should be reapproximated. Dorsal nerve repair through the epineurium is also warranted, if possible. These patients should be diverted with a suprapubic catheter. If microsurgical techniques are not available, the penis may be replanted using macroscopic techniques, whereby only the urethra and the corporal bodies are reapproximated. The incidence of skin loss and urethral stricture is significantly higher using the latter technique. Remarkably, return of partial or complete erectile function has been reported in many cases in the months following replantation.

Penetrating Penile Injury

Penile gunshot and penetrating injuries are uncommon outside of a wartime setting. Eight percent of these patients will have injuries to adjacent organs, which require evaluation. The urethra is injured in approximately 50% of cases, and thus RUG should be performed prior to exploration, if possible. Most of these injuries may be débrided and repaired primarily with a good functional outcome. The exception is in the case of a close-range shotgun injury, where massive and diffuse tissue

destruction is present. These should be débrided and allowed to declare themselves in terms of the extent of injury. They may then be repaired in a staged fashion.

Corporal injuries should be closed with buried absorbable suture. Associated urethral injury should be closed primarily in a watertight fashion over a Foley catheter. A more superficial laceration that is superficial to Buck fascia may be débrided and closed primarily.

Skin Loss to Genitals

Historically, genital skin avulsion resulted from accidental entanglement of clothing and underlying skin in farm or rotary machinery. Currently, these injuries arise more commonly secondary to motorcycle or bicycle deceleration trauma, whereby the genital skin is avulsed as the rider is thrown forward. The most common cause for genital skin loss overall is in the setting of necrotizing genital gangrene (Fournier gangrene), where necrotic genital skin is débrided acutely.

Genital skin usually avulses along a loose, avascular plane, which usually spares the deeper structures. On the penis, it will dissect superficial to Buck fascia, while the scrotal skin usually dissects superficially to the external spermatic fascia. The testes, spermatic cords, urethra, and corporal bodies are thus usually left intact.

Because of the tremendous elasticity of genital skin, the scrotum may usually be closed primarily, even when as much as 60% of the skin surface area has been lost. If primary closure is not possible, the testes and cords are left exposed and dressed during the perioperative period with moist saline gauze dressings. If the wound is clean at this point, split-thickness skin grafts (STSGs) may be applied. If the wounds are contaminated, the testes are placed in subcutaneous thigh pouches for delayed scrotal reconstruction with STSGs or local thigh flaps. Thigh pouches protect the testes well and ease subsequent reconstructive efforts. Testes that are left exposed for a prolonged period develop a thick fibrous peel that impedes graft take. In contrast, thigh pouches prevent the formation of this fibrous covering.

Scrotal reconstruction with meshed STSGs taken from the thigh or buttock usually provides an aesthetically pleasing outcome. The grafts ultimately assume a dependent rugate appearance that mimics the native scrotum. The donor site usually re-epithelializes with minimal complication. Local thigh flaps may also be used, but this may be more

labor-intensive and the ultimate cosmetic outcome is not optimal compared to STSGs.

In the case of avulsed penile shaft skin, STSG reconstruction also provides an excellent result. Meshed grafts should be avoided on the penis because of their tendency toward contracture and a worse cosmetic appearance associated with the meshing. It is important to excise any remaining subcoronal skin prior to grafting, as this residual skin may have impaired lymphatic drainage and lead to circumferential lymphedema.

Genital Burn Injuries

Genital burn injuries may be caused by thermal, electrical, or chemical energy sources. Thermal burns of the genitalia are usually associated with more extensive burns of adjacent tissues. Initial treatment should include aggressive fluid resuscitation and evaluation of depth and extent of the burn. A Foley catheter should be placed early in the resuscitation period unless the urethra is obviously involved in the burn. In this case, suprapubic catheter placement is advised.

Most genital thermal burns are first or second degree, and will usually heal with local wound care and rarely require debridement. Conversely, third-degree genital burns of the penis or scrotum require prompt debridement of nonviable tissue, followed by STSG reconstruction as previously described. This approach may decrease infection rates and ultimately prevent formation of a genital burn scar, which usually results when third-degree burns are managed conservatively. Chemical burns are managed with initial flushing of burned surfaces with copious amounts of sterile water. The injury is then managed as outlined for thermal burns.

Electrical burns to the genitalia may be particularly devastating because tissue destruction is often far deeper and more extensive than the visible surface burn indicates. Evaluation should thus include cystoscopy, vaginal speculum examination, and sigmoidoscopy to rule out associated pelvic organ damage. Electrical burns may cause extensive muscle necrosis and consequent myoglobinuria and hemoglobinuria, both of which lead to renal insufficiency. Electrical burns may require repeat debridement before skin graft or myocutaneous flap reconstruction may be undertaken.

CONCLUSIONS

The genitourinary system is involved in approximately 10% of traumatically injured patients. The recommendations presented in this

review are based on an experience in managing over 3,000 renal trauma patients during more than 30 years at San Francisco General Hospital and, most importantly, on an evidence-based international consensus conference on genitourinary trauma, and incorporated into both 2014 US and 2005 European guidelines for urotrauma. Treatment algorithms presented here are based on this experience; the development and ongoing refinement of these treatment algorithms provide validated guidelines for the surgeon who is called upon to manage urologic trauma.

Suggested Readings

Brandes S, Coburn M, Armenakas N, et al. Diagnosis and management of ureteric injury: an evidence-based analysis. *BJU Int* 2004;94:277.

Chapple C, Barbagli G, Jordan G, et al. Consensus statement on urethral trauma. *BJU Int* 2004;93:1195.

Gomez RG, Ceballos L, Coburn M, et al. Consensus statement on bladder injuries. *BJU Int* 2004;94:27.

Johnsen NV, Dmochowski RR, Mock S, et al. Primary endoscopic realignment of urethral disruption injuries—a double-edged sword? *J Urol* 2015;194(4):1022–6.

Lumen N, Kuehhas FE, Djakovic N, et al. Review of the current management of lower urinary tract injuries by the EAU trauma guidelines panel. *Eur Urol* 2015;67(5):925–9.

McAninch JW. *Traumatic and Reconstructive Urology*. Philadelphia, PA: WB Saunders; 1996.

Morey AF, Brandes S, Dugi DD 3rd, et al.; American Urological Association. Urotrauma: AUA guideline. *J Urol* 2014;192(2):327–35.

Morey AF, Metro MJ, Carney KJ, et al. Consensus on genitourinary trauma: external genitalia. *BJU Int* 2004;94:507.

Santucci RA, Wessells H, Bartsch G, et al. Evaluation and management of renal injuries: consensus statement of the renal trauma subcommittee. *BJU Int* 2004;93:937.

Serafetinides E, Kitrey ND, Djakovic N, et al. Review of the current management of upper urinary tract injuries by the EAU trauma guidelines panel. *Eur Urol* 2015;67(5):930–6.

EDITOR'S COMMENT

The authors provide a concise and comprehensive overview of the key urinary tract injuries requiring immediate evaluation and management. The commentary

is based on evidence-based reviews, including the SIU Consensus Conference on Genitourinary Trauma, and more recently the European Association of Urology, and most recently the American Urological Association (AUA) guidelines. It should be noted that there are differences in recommendations from the different guidelines, and the AUA guidelines from 2014 represent the most up-to-date evidence review. Examples of differences include those around indications for imaging after renal trauma. For example, the question of significant deceleration is raised by the authors. Different guidelines have different suggested algorithms, but whether a deceleration is defined as a fall from a great height or a motor vehicle collision is not specifically clear. Similarly, the authors use the terms shock and systolic blood pressure less than 90 mL of mercury interchangeably; this can create some confusion. Shock is a clinical scenario associated with hypoperfusion of organs that may or may not be present with a systolic blood pressure of 90 mL of mercury. The imaging criteria represent a clinical prediction rule, and the blood pressure less than 90 mL of mercury is used as a point in favor of imaging. The authors appropriately note that a patient in hemodynamic hemorrhagic shock should not undergo radiographic imaging but instead requires some form of operative intervention.

Pediatric natal injuries are difficult because of the lower number of publications and the lower propensity for children to exhibit shock; thus, variable definitions or indications for imaging exist. In blunt trauma cases, the authors point to greater than 20 RBCs per high power field as a criterion. Until we have a definitive consensus statement or guideline, each institution should consistently apply its own criteria. Whether this is 30 or 50 RBCs per high power field or simply following the adult criteria, all of these relate to blunt trauma. For pediatric penetrating injury, the same criteria as for adults are relevant, namely any degree of hematuria. The authors describe a set of 10-minute delayed images in order to visualize the collecting system down through the bladder. This is now part of the AUA guidelines. Of note, sometimes if there is a renal contusion or hypoperfusion for other reasons, the entire upper urinary tract may not be visualized at 10 minutes. In such cases, in the absence of significant perinephric or periureteral low-density fluid, it is reasonable to defer additional attempts at imaging specific segments of the ureter. Certainly, uretopelvic junction injuries should be excluded. This is most commonly done by seeing contrast distal to the UPJ.

The additional pieces of CT that reflect new thinking about imaging include the identification of intravascular contrast extravasation and the distance or thickness of the hematoma. These criteria, which have been validated by a number of series from Japan, Parkland, and Harborview Medical Center, identify high-risk patients at greater likelihood of bleeding.

A trend toward nonoperative management for high-grade renal injuries persists, and the number of patients successfully managed nonoperatively with grade 4 renal lacerations is certainly higher than 22% in most contemporary series. The vast majority of blunt trauma patients, in excess of 90%, require

surgical intervention at most trauma centers. One reason for this is that it is no longer routine practice to explore devitalized renal parenchymal fragments or urinary extravasation. The most expert renal surgeon may be able to preserve and repair such injuries, but in the majority of the country, such injuries may, when explored, lead to nephrectomy.

The authors describe nonoperative management of urinary extravasation. This is the rule with forniceal ruptures and major lacerations. Although no longer mandatory guidelines do recommend a follow-up CT scanning in the post injury period for these patients. Others recommend expectant management and intervention for symptomatic urinoma. Such symptoms may include fever, flank pain, hydronephrosis, and the like.

Renovascular injuries remain challenging because arterial injuries have a high rate of renal loss. Endovascular stenting, described by the authors as having a limited role, should probably be considered experimental and performed under institutional protocols. An important consideration is whether anticoagulation is necessary, and the risks this poses to patients with other solid organ injuries.

Renal reconstruction after injury is well described in this chapter, and following the classic steps of vascular isolation and exploration described can lead to high rates of renal salvage. Increasing use of angioembolization in solid organ injury is an advance that is likely to lead to increased renal salvage rates. However, this important adjunct should not be overused. There is a trend nationally to embolize intravascular contrast extravasation regardless of hemodynamic status. The patient with a small perinephric hematoma and isolated intravascular contrast extravasation (ICE) may not have a significant bleeding event, and embolization may not be necessary. Clinical parameters and injury severity assessment represent opportunities for further enhancement of care pathways.

Ureteral injuries are best repaired in the immediate post-injury period. After several days, urinary extravasation and urinoma formation may lead to significant inflammation that makes reconstruction difficult; thus, when injury identification is delayed, damage control approaches may be appropriate. These include ligation of the ureter, nephrostomy tube drainage, and delayed reconstruction. This is particularly important in the context of delayed presentation of ureteral injury where there may be infection on top of obstruction and urinoma formation. Ureteroureterostomy and ureteroneocystostomy are the mainstay of treatment of upper and lower ureteral injuries, respectively. The transureteroureterostomy puts the contralateral ureter at risk and should be reserved for cases in which the ipsilateral ureteral injuries associated with major vascular or bladder injuries are compromised. In contrast to the authors, this commentator prefers a refluxing ureteral reimplantation. For the vast majority of adults with normal lower urinary tract, such a repair is sufficient and reduces the risk of subsequent obstruction. Lastly, the concept of acutely using ileal ureter or autotransplantation in the setting of a severe ureteral

injury is not advisable. Again, damage control principles are appropriate here. Such more extensive procedures require more additional planning, lengthy operative time, and should not be imposed on the severely injured trauma patient. Bladder injuries should be repaired if there is a potential for adjacent organ injury that would otherwise go unrecognized; very large defects that will not close spontaneously; the presence of contamination, foreign bodies, boney fragments, missiles, or the like; and inability to drain the urinary tract. Thus, penetrating injuries generally require exploration. However, if a penetrating injury could be assessed and all the criteria given above were met, it could be treated in many cases similar to an extraperitoneal bladder rupture.

Bladder ruptures can be managed nonoperatively with great success.

When operative exploration is required, most extraperotineal ruptures are related to pelvic fracture, sit in the anterior bladder wall region, and are easily accessible and visible through a lower abdominal incision. Thus, the bladder does not routinely need to be opened. Instead, the injuries can be identified and closed. Current cystography is generally sufficient to identify additional injuries.

Urethral injury identification relies on retrograde urethrogram, which is clearly recommended in AUA guidelines. As with all injuries of the urethra, in pelvic fracture urethral injury immediate bladder drainage is the top priority. This is generally with a superpubic cystotomy placed either pericutaneously or open. For anterior urethral injuries related to straddle, the crush injury is focal and short and generally a realigning catheter is not required nor will it prevent stricture formation. Conversely, in the posterior urethra, after pelvic fracture urethral injury, an aligning catheter is associated with a lower rate of stricture. A significant minority of patients up to 22% to 35% depending on series will not need subsequent urethroplasty after early urethral realignment. However, heroic attempts at realignment, whether on day 1 or day 5, are to be condemned. If the realignment is attempted, it should be carried out in the environment of the operating room where appropriate equipment, staff support, and patient supervision can be ensured. Attempts at realignment from below with flexible endoscopes retrogradely placed will not be sufficient for many pelvic fracture urethral injuries.

External genitalia trauma can, when repaired surgically in the immediate postoperative period, preserve function and cosmesis with a high degree of success. Ultrasonography is a useful adjunct for both penile and testicular injuries. Its improved accuracy relates to the higher resolution of images, and the ability to visualize the tunic albuginea, the testis, and penis and determine whether there are breaks in its continuity. The sections on genital skin loss and amputation reflect current principles.

Hunter Wessells

181 Supravesical Urinary Diversion

Kristin Chrouser and Badrinath R. Konety

INTRODUCTION

Supravesical diversion involves the external diversion of the urine stream without use of the bladder. While percutaneous nephrostomy offers a short-term alternative to operative diversion, problems with frequent tube changes, dislodged tubes, infection, and external appliances make surgical diversion the preferred method in those needing long-term supravesical diversion. This chapter focuses on surgical supravesical diversion. Except in the case of cutaneous pyelostomy or ureterostomy, supravesical diversion employs intestinal segments to bridge the gap between the ureters and the skin. Types of supravesical diversion may generally be categorized as continent and noncontinent. Noncontinent diversions involve a wide stoma and an external appliance to collect the urine (urostomy bag). Heterotopic continent diversions utilize a catheterizable stoma on the abdominal wall to empty an intraabdominal neobladder or "pouch," whereas orthotopic continent diversions create a pelvic neobladder that is anastomosed to the urethra.

INDICATIONS

The most common indication for supravesical diversion is following radical cystectomy for cancer of the bladder. Other indications include refractory ureteral or urethral obstruction and urinary fistula: these are often less amenable to repair when the etiology is radiation damage. Radiation cystitis, interstitial cystitis, or hemorrhagic cystitis not responsive to more conservative therapy can also be managed with supravesical diversion as a last resort. Additionally, supravesical diversion may be considered in the management of poorly compliant, high-pressure neurogenic bladders when bladder augmentation cystoplasty is not an option.

PREOPERATIVE PLANNING

Patients should be appropriately selected to ensure they are medically fit for major surgery. Coexistent bowel pathology including inflammatory bowel disease, history of abdominal radiation, or previous bowel resection should factor into selection of the appropriate intestinal segment for diversion.

Patient considerations specific to the choice of the type of urinary diversion include visual, cognitive, neuromotor, and renal function as well as the level of available social support. As continent neobladders can lead to electrolyte disturbances, they should be avoided in patients with renal impairment. When considering a continent diversion, one must take into account the patient's neuromotor status and dexterity along with the availability of other caregivers to assist with care of the diversion. Although many patient void spontaneously, some suffer from incomplete emptying or mucous plugging after an orthotopic neobladder, and the ability to catheterize or irrigate the neobladder is important. Patients need to be aware that nighttime leakage is not uncommon after orthotopic neobladder. A heterotopic neobladder (or "pouch") with a catheterizable abdominal stoma also requires the ability to physically catheterize and the cognitive faculties to comply with a regular catheterization schedule. When the ability to catheterize or electrolyte disturbances are a concern, a noncontinent diversion is preferable.

All patients should be seen by a stoma therapist prior to surgery for an upright abdominal examination to determine the optimal placement of the abdominal stoma relative to their pannus. The patient's hand function will also be taken into account in choosing the best location. Even patients who desire a neobladder should be marked for an incontinent stoma as there are rare situations in which the mesentery is too short for the ileum to reach the pelvis without tension, thus preventing construction of an orthotopic diversion.

If a urinary diversion is being contemplated in a patient with a ureteral stricture, it is important to delineate the length and location of the stricture before surgery. As an indwelling stent may mask the true extent of disease, preoperative nephrostomy tube placement and ureteral stent removal are recommended. An antegrade ureterogram several weeks later or in the operating room at the time of reconstruction will best identify the extent of stricture and the appropriate level for ureteral transection. A stent-free period of at least 2 weeks also allows ureteral inflammation associated with the stent to improve prior to reconstruction. In such patients,

intraoperative identification of the ureters is often more difficult due to periureteral scarring from chronic inflammation, so antegrade ureteral catheters may be placed down to the site of obstruction on the day of diversion if needed.

It is always advisable to remove the bladder when performing supravesical diversion, even in the absence of bladder malignancy. Diversion of the urine stream away from an intact bladder too frequently results in pyocystis, a condition of retained mucous and desquamated bladder epithelial cells complicated by infection. Pyocystis is managed by bladder drainage and/or cystectomy. A controversial management alternative in women is to create an iatrogenic fistula into the vagina, which allows for bladder drainage without catheterization. However, removal of the bladder prevents pyocystis altogether and is preferred when performing supravesical diversions. In men, the prostate should also be removed except in rare circumstances where natural fertility is still desired.

SURGICAL TECHNIQUE

Noncontinent Diversions

Cutaneous Ureterostomy

Although cutaneous loop ureterostomy or pyelostomy can be performed as a *temporary* diversion to manage infants with severe hydroureteronephrosis in anticipation of future reimplant, this technique is rarely utilized in adults. Due to the high rate of stomal stenosis, cutaneous end ureterostomy is rarely employed as a *permanent* diversion for adults in the modern era. In adults, the degree of ureteral mobilization that is required in order to bring them to the skin results in devascularization and stenosis in approximately 60%. The small caliber ureter may also be predisposed to stomal stenosis. However, in the rare patient with multiple comorbidities and very dilated ureters, there may still be a role for permanent cutaneous ureterostomy. In order to avoid two stomas, it is customary to perform a “double-barrel” ureterostomy where both ureters exit the skin together. Stomal stenosis may be minimized by eversion of the ureters into a rosebud and by incorporating a V-shaped skin flap into each of the two ureters in the ureterostomy.

Ileal Conduit

Originally pioneered by Bricker in 1950, the ileal conduit is the most

commonly performed type of supravesical urinary diversion. Like other ureterointestinal diversions, ureteral devascularization and the risk of stomal stenosis are minimized because the intestine is brought to the ureters rather than mobilizing the ureters to the skin. Contraindications include short bowel, radiation enteritis, and Crohn disease. After transection, holding sutures are placed on the ureters and a 15- to 20-cm segment of terminal ileum is selected for the conduit. Vitamin B_{12} and folate malabsorption is minimized by selecting a segment 15 to 20 cm proximal to the ileocecal valve. Good blood supply to the ileal segment may be confirmed by palpation or visually with backlighting of the mesentery. After identifying an adequate vascular pedicle, the segment of ileum can be marked with sutures on the bowel. Since the conduit can rotate on its pedicle during the procedure, some choose to tag the proximal and distal ends with different colored suture (e.g., “silk to stoma”). This ensures correct isoperistaltic orientation of the conduit is maintained. The relatively avascular portions of the mesentery adjacent to the proximal and distal ends of the conduit are then divided using ligatures or electrocautery to create windows running at right angles to the selected segment of bowel. The segment of ileum is excised from the rest of the bowel, usually with a gastrointestinal anastomosis (GIA) stapler. The ileal segment is dropped toward the pelvis and the remaining bowel is brought back into continuity above it with either a two-layer sutured end-to-end anastomosis or a stapled side-to-side anastomosis (often using a combination of GIA and straight “TA” staplers). The mesenteric defect is closed with either running or interrupted suture to prevent internal hernias. Due to the risk of urinary stones forming on the staple line, some prefer to exclude the staple line from the proximal (“butt”) end of the conduit using absorbable suture in a horizontal mattress. One can open the distal/cutaneous end of the conduit at this time and irrigate the interior to flush out any remaining enteric contents.

Since most urostomies exit the right side of the abdomen, a window is created either beneath or (carefully) through the sigmoid mesentery to allow passage of the left ureter into the right retroperitoneum in front of the sacral promontory. It is important to do this under direct vision if possible in order to avoid injuring the presacral veins, as controlling bleeding from these veins is difficult. The tunnel should be wide enough to prevent kinking of the ureter and care must be taken to avoid twisting of the ureter. The ureter is brought underneath using the previously placed

holding suture. It cannot be overemphasized that ureteral mobilization should be kept to a minimum and the intestinal segment should be brought to the retroperitoneum rather than bringing the ureters into the peritoneal cavity. When anastomosing the ureters to the intestinal segment, one may elect a tunneled or a refluxing reimplantation. Longitudinal studies have shown the risk of renal dysfunction from obstruction in a tunneled reimplant may outweigh the risk of renal dysfunction from reflux and infection in a nontunneled, refluxing reimplant. Most opt for a refluxing reimplant in the modern era. Refluxing reimplants may be accomplished in the fashion of Bricker or Wallace.

The Bricker ureterointestinal anastomosis involves separately anastomosing the two ureters to the bowel in an end-to-side manner (Fig. 181.1). A small enterotomy is made on the posterior aspect of the proximal end of the ileal conduit. We find it easiest if a seromuscular suture is used to hold up on the intestine and the enterotomy made with scissors just below this. The bleeding from the mucosal edges makes visualization difficult but cautery should be avoided in order to preserve blood supply at the anastomosis site. Some place mucosal eversion stitches, with fine absorbable suture—these control bleeding nicely and make identification of the mucosa during the anastomosis straightforward. Others avoid extra sutures in order to minimize inflammation that may lead to subsequent scarring. Some advocate a shield shaped ileotomy for ease of suturing and to minimize the risk of ureteroileal anastomotic strictures. The ureter is spatulated and a running or interrupted mucosa-to-mucosa anastomosis is performed with fine absorbable monofilament suture such as 5-0 polydioxanone (PDS) (Fig. 181.1). After one side of the ureteroenteric anastomosis is completed, a “single J” ureteral stent is placed. The coiled end of the stent is placed through the open ureter up to the kidney over a guidewire, about 15 to 20 cm. The stent will eventually pass from the renal pelvis, down the ureter, across the anastomosis, through the conduit and out into the appliance. Correct placement can be confirmed with a postoperative plain film of the abdomen. A clear Yankaur suction can be used to negotiate the stent through the conduit or a long Schnidt clamp can be passed from the cutaneous end of the conduit up to the anastomosis to grasp the straight end of the stent and bring it out. A rapidly absorbable suture is used to secure the stent to the distal bowel near the stoma which helps prevent accidental dislodgement. The second half of the ureter is then closed and the same process is repeated on the other side.

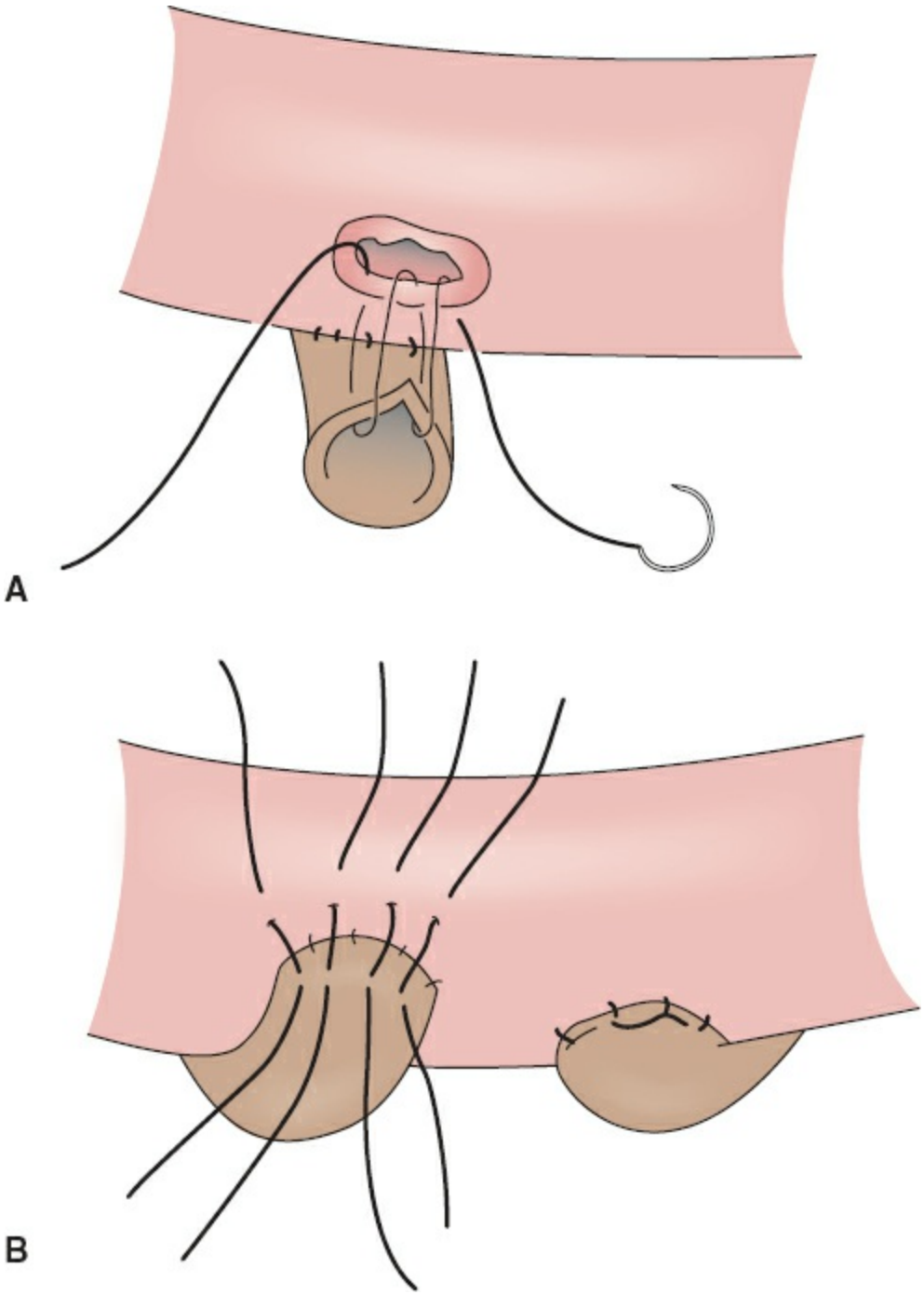

Figure 181.1. Bricker ureterointestinal anastomosis. **A.** An end-to-side mucosa-to-mucosa anastomosis is performed separately between each spatulated ureter and the intestine using fine absorbable suture. **B.** Some elect to further reinforce the anastomosis by creating a second layer closure of serosa to serosa.

In a Wallace ureterointestinal anastomosis, the staple line is trimmed off the proximal end of the conduit and the entire proximal lumen of the conduit is utilized for the anastomosis. The ureters are spatulated and then

sewn together side-to-side in a running or interrupted fashion with fine absorbable suture such as 5-0 PDS (Fig. 181.2). This is followed by an end-to-end anastomosis of the "double-barrel" ureters to the open proximal ("butt") end of a loop of intestine (Fig. 181.2). This can be accomplished using three different orientations as shown in Figure 181.2B–D. We prefer to sew the joined apical ends (proximal spatulation) of the ureters to the bowel first (Fig. 181.2B) as this can be the most difficult portion of the anastomosis. The remaining ureteral walls and distal ends of the joined ureters can then be sewn to the bowel. Ureteral stents are placed before completing the anastomosis, as previously described. The Wallace anastomosis makes it easier to endoscopically access the ureters postoperatively if there is a need for upper tract evaluation or stone removal. The principal concern regarding the Wallace anastomosis is that obstruction of the terminal portion of one ureter, due to stenosis, stone, or recurrent tumor, may obstruct both ureters, resulting in critical renal impairment. In addition, if a ureteric or renal pelvic tumor should develop in one renal moiety, it would be harder to separately dissect out the corresponding ureter at the time of a nephroureterectomy.

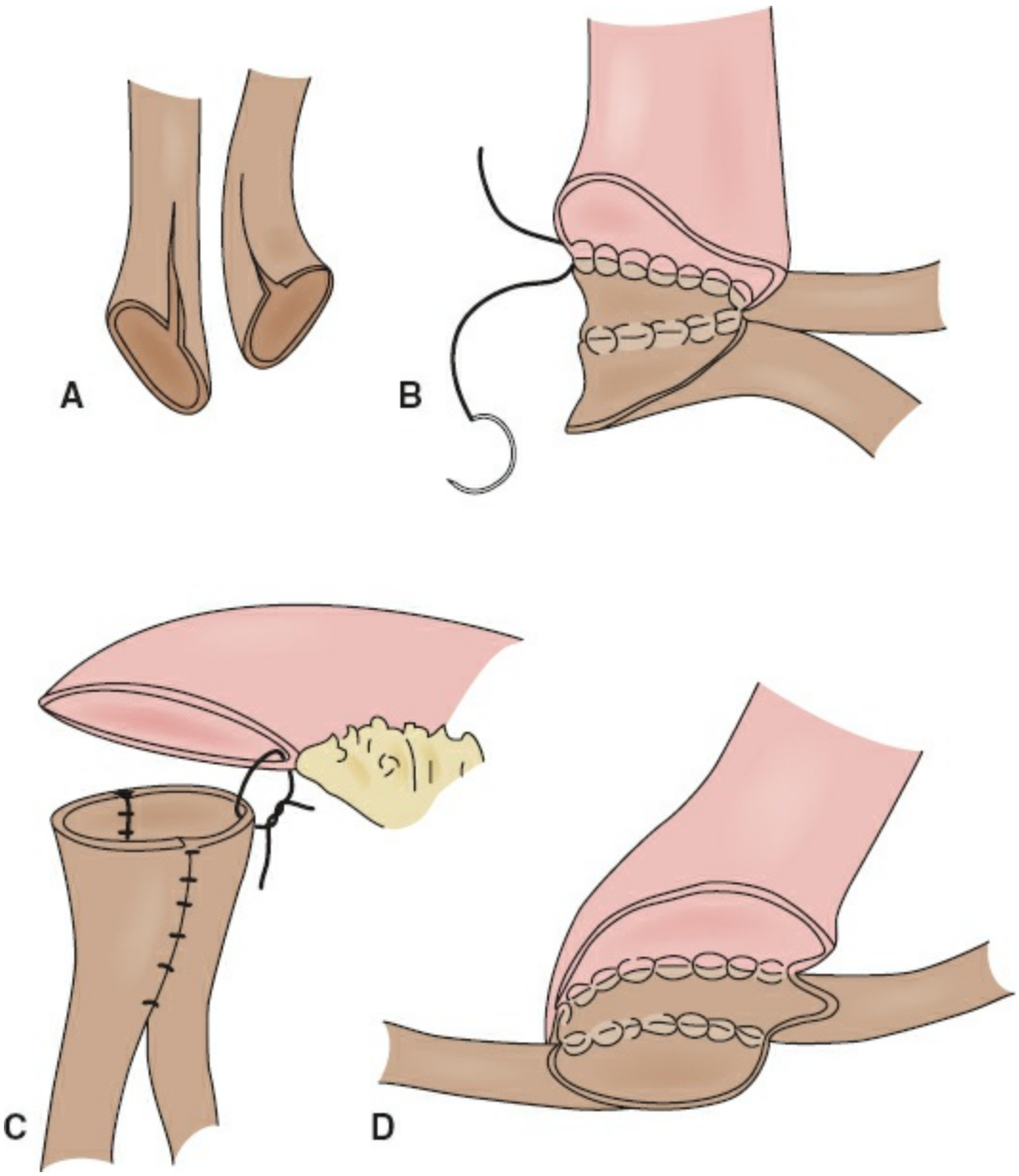

Figure 181.2. A. Common to all techniques is that the ureters are spatulated. There are three methods of Wallace ureterointestinal anastomosis (**B–D**). **B.** Medial walls of ureters are anastomosed in a side-to-side fashion. Then the joined ureters are sewn end-to-side to the bowel. **C.** The medial and lateral walls of ureters are both anastomosed in a side-to-side fashion. Then the joined ureters are sewn end-to-end to the bowel. **D:** The medial wall of one ureter is anastomosed to the lateral wall of the other ureter such that they are side-to-side but directed opposite each other. Then the joined ureters are sewn side to end to the bowel.

A disk of skin is excised from the urostomy site that was marked preoperatively by the stoma therapist. The underlying column of fat is removed down to the rectus fascia. A cruciate incision is made in the

anterior rectus fascia and the rectus muscles separated bluntly with a Kelly clamp. A fasciotomy is then made in the posterior sheath. The fascial defect should accept two fingers. Then, 2-0 or 3-0 absorbable sutures are placed in the outer portions of the cruciate incision with the needles left on. A Babcock clamp is used to grasp the conduit and stents, bringing them gently through the abdominal wall until 5 to 6 cm of bowel is visible. The serosa of the conduit is then anchored to the fascia using the previously placed 2-0 or 3-0 sutures, passing the needles parallel to the ileal blood supply. The conduit should be placed so that the mesentery is oriented superiorly and it should not be under tension. Bricker originally described a stoma that was flush with the skin. Brooke advocated use of the everted “rosebud” stoma, which helps prevent stomal stenosis, urine leaking around the appliance, and minimizes urinary skin irritation by ensuring that the effluent urine drips directly into the bag. This eversion is achieved with three or four 3-0 absorbable sutures passed from the skin to the serosa of the conduit and then through the most distal edge of the conduit (Fig. 181.3), taking care to avoid injury to the mesentery. When tying these down, to encourage eversion, a Babcock clamp can be used to grasp the inner mucosa and pull up from the luminal side or a blunt right angle can be placed on the serosal surface of the conduit near each suture and used to ensure adequate outward intussusception of the bowel circumferentially. The conduit is then matured with interrupted absorbable stitches from the skin to the serosal edge of the conduit. The proximal (internal) end of the conduit is anchored by sewing the cut edge of posterior peritoneum over it with three to five interrupted nonabsorbable sutures. This secures the conduit at both ends and prevents volvulus and internal hernias while retroperitonealizing the conduit which can contain potential urine leaks.

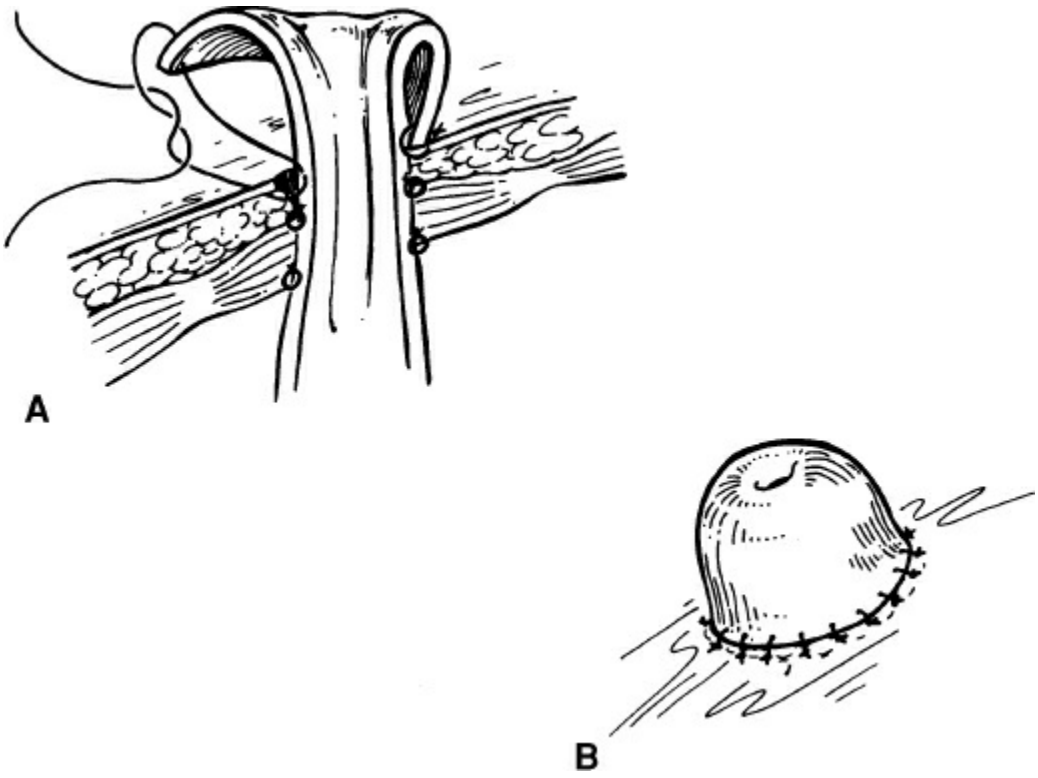

Figure 181.3. Maturation of the urinary conduit in the fashion of Brooke. **A.** The conduit is sutured at the fascia level to prevent parastomal herniation. A separate layer of suture should incorporate the skin, the serosa, and the muscularis of the conduit at the level of the skin and at the edge of the conduit. **B.** Rosebud stoma after maturation.

An alternative to the previously described terminal stomas is a Turnbull loop stoma (Fig. 181.4). This may reduce stomal stenosis because blood supply to the stoma is not compromised as it is with the terminal Bricker stoma. The Turnbull stoma is also advantageous in the obese patient with thick or short mesentery in whom it can be difficult for the distal edge of the conduit to reach the abdominal wall without tension to fashion a Bricker stoma. A shortcoming of the Turnbull stoma is its higher risk of parastomal hernia due to the necessarily larger fascial defect. Both ends of the conduit are left intact and then a loop of the conduit is brought through the fascial defect and secured as in the Bricker technique described previously. The antimesenteric side is opened and the bowel edge is matured to the deep portion of the loop just above the fascia and then to the skin, as for the Brooke modification of the Bricker stoma. One can opt to pass a red rubber catheter or a loop colostomy rod through a window in the mesentery below the loop and suture it to the skin in order to prevent recession of the stoma. If desired, it can be left in place for the immediate

postoperative period. Because the edema that sometimes occurs postoperatively can cause this catheter to erode the skin, an alternative is to simply suture the catheter to itself off the abdominal wall to complete a circle. It can be removed about 2 weeks post operatively.

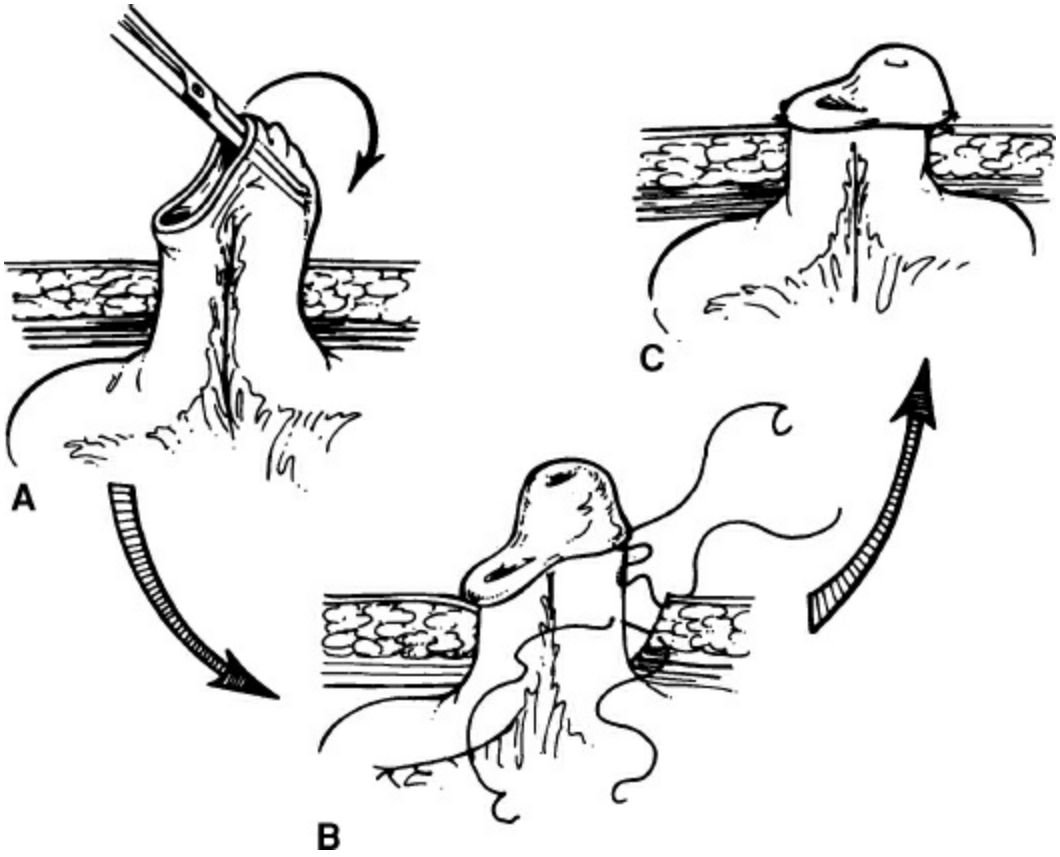

Figure 181.4. Turnbull loop stoma. **A.** The distal end of the conduit is left intact. A loop of conduit is pull above the level of the skin. The loop should protrude 3 to 4 cm and be secured to the fascia. The loop is opened over the antimesenteric side. **B.** The stoma is maturated with interrupted sutures, including the skin, the seromuscular layer of the conduit, and the edge of the mucosa. **C.** Stoma after maturation.

Colon Conduit

The ileal conduit is familiar to most urologists. However, one should be prepared to perform a colon conduit in select patients. When total pelvic exenteration is performed, the sigmoid colon conduit is advantageous since it avoids the potential complications associated with a bowel anastomosis. A transverse colon conduit is essential in cases of long segment ureteral stricture or radiation ureteritis/enteritis.

After identifying an adequate pedicle, the necessary length of sigmoid

colon is selected for the conduit. It should be noted that in some older patients the sigmoid colon can be redundant due to long-standing constipation. Unlike the ileal conduit, it is not necessary to pass the left ureter across to the right side. Once the sigmoid colon mesentery is mobilized, the two ureters can be brought toward the midline or the colon can be stretched across the retroperitoneum. Anastomotic techniques are as described below for the transverse colon conduit. Because the transverse colon and its middle colic artery originate in the upper abdomen, this segment can be anastomosed to the upper one third of the ureter or even directly to the renal pelvis if needed (Fig. 181.5). The transverse colon has the added advantage of being out of the pelvic radiation field whereas the ileum may be affected by radiation enteritis. The combination of unirradiated bowel and unirradiated ureters and the absence of ureteral mobilization optimizes success in the high-risk radiation patient.



Figure 181.5. Loopogram of a transverse colon conduit. X-ray demonstrates the utility of the transverse colon in reaching the upper ureters and renal pelvis. Also shown is how long a segment of transverse colon is required to traverse the retroperitoneum and reach the skin.

When constructing a transverse colon conduit, it is frequently necessary to extend the abdominal incision to the xiphoid in order to adequately mobilize the hepatic and splenic flexures of the colon. The middle colic artery that supplies the transverse colon is easy to identify. The entire transverse colon is isolated and divided as described above for the ileal

conduit. While the segment will seem long, the length is necessary in order to reach both upper ureters, as minimal ureteral mobilization will be performed and the left ureter won't be brought to the right side as for the ileal conduit. Depending on the preference of the surgeon, the transverse colon conduit can be left in an intraperitoneal location or placed on the posterior peritoneum. If intraperitoneal, the colon is brought back into continuity superior to the colon conduit, as described for the ileal conduit. The ureters are brought up through windows in the left and right colonic mesentery, careful to avoid injury to the inferior mesenteric vein on the left side. Small enterotomies are made in the portion of the colon adjacent to each ureter. We avoid the tenia coli when performing refluxing anastomosis, given the thickness of this colonic band of muscle. The ureteroileal anastomoses are then performed, stents are placed, and the stoma is matured as described for the ileal conduit previously.

Because intraperitoneal placement of the transverse colon conduit can be difficult in a patient with (a) very short ureters or a planned anastomosis to the renal pelvis, (b) a thick fatty poorly mobile colonic mesentery, or (c) an edematous mesentery after a long operation, we frequently employ an alternative approach, which involves placing the conduit on the posterior peritoneum. In this case, the bowel is brought back into continuity inferior to the conduit and the conduit is stretched across the posterior peritoneum from kidney to kidney. The upper ureters or renal pelvis can then be anastomosed to the conduit as described above. Regardless of the approach, bringing the stents through the terminal stoma end of the conduit can be difficult due to the long length of the colon conduit, relative to an ileal conduit. This sometimes requires using a flexible cystoscope to pass a wire first or making a small colotomy midway through the conduit to help guide the stents through with a long clamp.

Continent Diversions

Options for continent diversions include rectal diversion, relying on the anal sphincter for continence, orthotopic neobladders, relying on the external urinary sphincter for continence, and heterotopic pouches, relying on a tunneled catheterizable segment for continence.

Continent diversions work best when fashioned as a pouch rather than a tube. Initially, continent diversions used nondetubularized segments of intestine such as the ureterosigmoidostomy or the Camey pouch. However, currently all pouches rely on a detubularized segment of bowel refashioned

in a spherical shape in order to minimize pressure and metabolic complications. Low-pressure reservoirs aid in protecting the kidneys from high pressures as well as maintaining continence. In heterotopic pouches, continence is achieved by creating an antireflux valve as well as by creating a narrow catheterizable segment. The likelihood of leakage through the catheterizable segment is reduced more rapidly by narrowing the tube than by lengthening it. Because long catheterizable segments increase the risk of catheterization problems, a shorter catheterizable segment is preferred (10 to 12 cm). In orthotopic neobladders, continence is aided by preservation of the voluntary sphincter, and in rectal pouches by the anal sphincter. Many of the surgical principles are common to continent and noncontinent diversion, including bowel isolation and reanastomosis as well as refluxing ureterointestinal anastomosis. These have been reviewed in detail in the previous section and are not repeated here. Unique aspects of continent diversion are covered in detail.

Rectal Diversion

Ureterosigmoidostomy

Due to the significant complications associated with this technique it is only briefly described, primarily for historical interest. It is rarely used given concerns regarding increased risk of secondary malignancy (adenocarcinoma), chronic pyelonephritis with renal impairment, and electrolyte disturbances. Some argue, however, that there is still a role for this diversion in the frail or elderly because it can be accomplished quickly and without a bowel anastomosis. This technique essentially combines the urinary and fecal streams, leading to chronic diarrhea that can impact quality of life. It also requires an intact rectal sphincter in order to maintain fecal continence. In summary, the left ureter is brought anteriorly through the sigmoid mesentery and the ureters are anastomosed into the rectum. The anastomosis should always be tunneled; this can be done extracolonically or transcolonically and the techniques parallel those of extra/intravesical reimplant commonly done in pediatric urology for vesicoureteral reflux. The Leadbetter/Clarke technique for extracolonic reimplant involves creating a submucosal tunnel in the anterior colonic tenia and performing a mucosa-to-mucosa anastomosis at the distal end of the tunnel (Fig. 181.6).

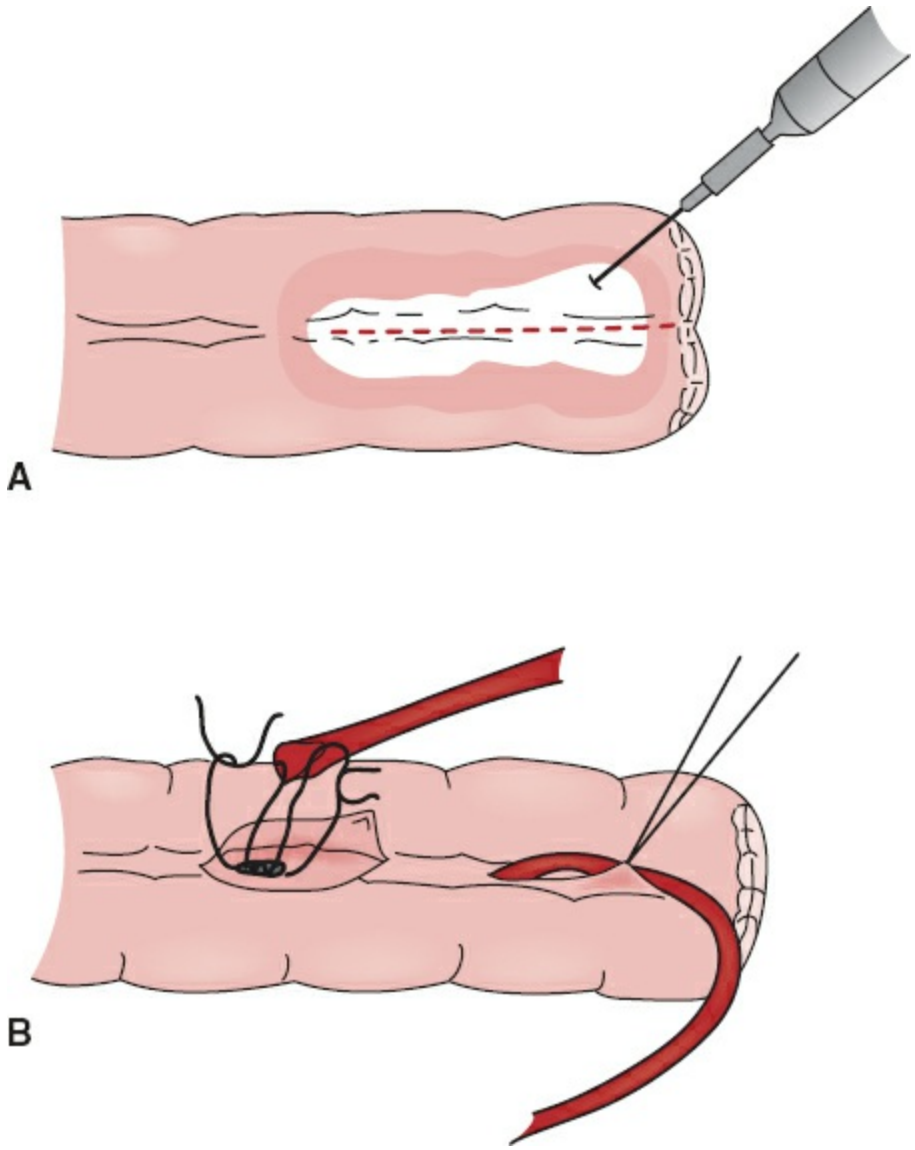

Figure 181.6. Extracolonic ureterocolonic anastomosis in the fashion of Leadbetter and Clarke. **A.** Hydrodissection may aid in the separation of the muscle from the mucosa. The tenia is incised longitudinally. **B.** The muscle is then broadly and meticulously separated from the underlying mucosa. This creates a trough in which one buries the ureters. A mucosal opening is created at one end and the spatulated ureter is anastomosed to the mucosa. The tenia is then closed over the ureter.

Complications including adenocarcinoma and hyperchloremic hypokalemic metabolic acidosis are particularly high with rectal diversions. Metabolic acidosis can be relieved acutely with a rectal tube and managed chronically with oral sodium bicarbonate supplementation.

Rectal Pouches

Rectal pouches were introduced in order to minimize peristaltic pressure in the rectal diversion and thus minimize incontinence, pyelonephritis, and renal stones. Either a U-shaped (Mainz II) or S-shaped pouch can be created by opening and refashioning the rectosigmoid colon. The ureters are tunneled posteriorly and then anastomosed to colonic mucosa via an anterior colotomy (Goodwin technique). Rectal pouches are sometimes utilized in developing countries for urinary diversion after severe obstetric trauma with destruction of the bladder and urinary sphincter. Incontinent diversion in these settings is not only socially unacceptable but external collection appliances are often unavailable or too expensive. Unreliable catheter supplies preclude the use of catheterizable pouches. Given their limited options, many women with severe fistulae are willing to accept the risks associated with a Mainz II pouch in order to achieve continence. However, in the developed world, rectal pouches have generally been abandoned in favor of orthotopic neobladders and heterotopic pouches.

Heterotopic Continent Diversion

Heterotopic pouches utilize a detubularized intestine to create a low-pressure reservoir. Urine is evacuated from the pouch by intermittent catheterization through a continent cutaneous stoma. The various approaches use different segments of intestine for the pouch, different reconfigurations of the intestinal pouch, different segments of intestine for the catheterizable segment, various methods of tapering the catheterizable segment, and a variety of ways of creating a continence valve. The following description of methods is by no means exhaustive.

Right Colon Pouches

Right colon pouches include the Indiana pouch, the Florida pouch, the Miami pouch, and the Penn pouch. The first three utilize tapered ileum for a catheterizable channel whereas the Penn pouch uses an appendiceal Mitrofanoff. The Indiana, Florida, and Miami pouches differ slightly in the amount of colon utilized and in the techniques used for buttressing the ileocecal value to maintain continence. To create an Indiana pouch, the right colon is isolated and divided distally at the junction of the blood supply from the right colic and middle colic arteries. About 10 cm of terminal ileum is isolated (Fig. 181.7). An ileocolonic anastomosis is performed to reestablish continuity of the bowel. If the appendix is present, then an appendectomy is performed. The colon is detubularized over along the antimesenteric border. A refluxing mucosa-to-mucosa

ureterocolonic anastomosis is performed from the inside of the bowel after delivering the ureters through a small posterior colotomy. Alternatively, the ureteral anastomosis can be accomplished in the fashion of Bricker with sutures placed from the serosal side of the bowel (see above). The ileocecal junction is buttressed to maintain continence, using interrupted seromuscular Lembert permanent sutures in two rows (Indiana), opposing Lembert sutures on each side of the terminal ileum (Florida), or two purse-string sutures 1 cm apart placed in the most distal ileum (Miami) (Fig. 181.8A–C). The remaining proximal 6 to 7 cm of ileum is tapered with GIA stapler over 12 to 14F catheter along its antimesenteric border and the excess is excised (Fig. 181.8D). Alternatively, some surgeons use either Lemberts or staples along the entire efferent limb (Fig. 181.7B). We also slightly intussuscept the terminal ileum by burying the final 2 cm inside the cecum with two permanent Lembert sutures in the cecum. It is helpful to perform ileal imbrication with the colon open in order to observe the tightening of the ileocecal valve and confirm easy catheterization. The colon is then closed in a clamshell fashion or the posterior plate is reconstructed in a U-shaped fashion and then the anterior wall is closed. In the end, the two approaches produce a similar final configuration. A large cystostomy catheter and 12F or 14F stomal catheter are left for 3 to 4 weeks and externalized ureteral stents are left for 1 to 3 weeks, at the discretion of the surgeon.

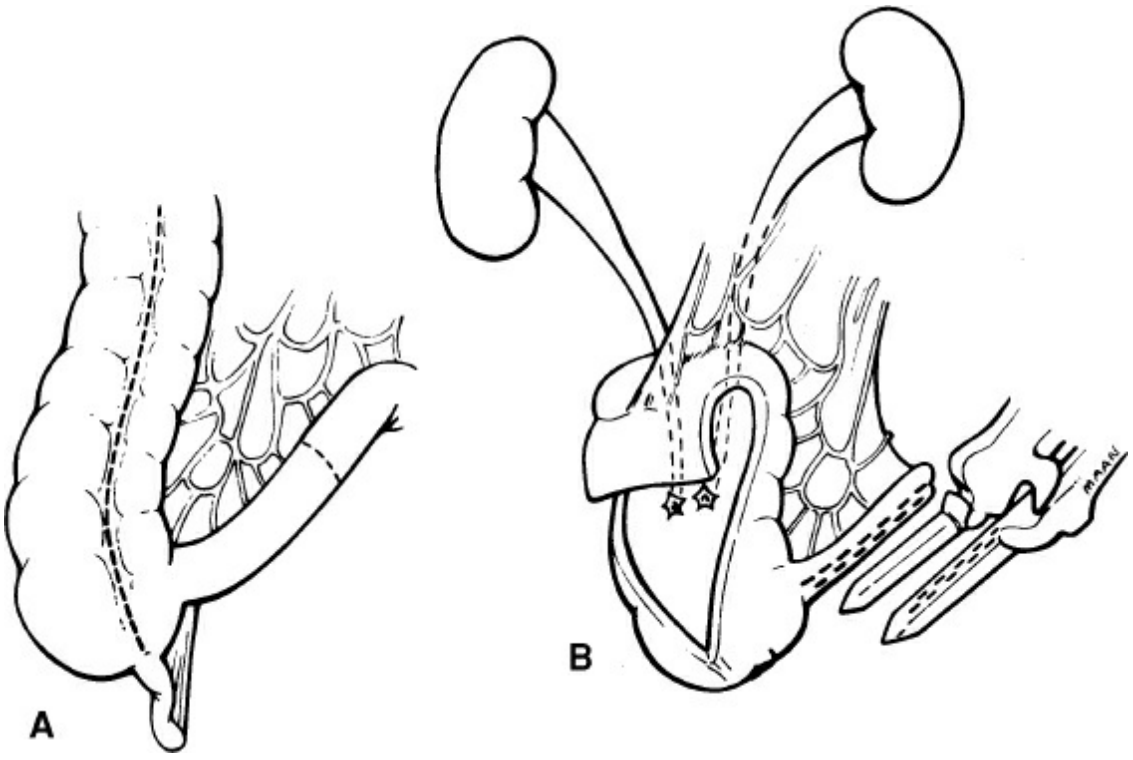

Figure 181.7. Indiana pouch creation. **A.** The right colon is divided at the hepatic flexure. The ileum is divided 10 cm from the ileocecal valve. **B.** The colon is detubularized and closed in a spherical fashion. The ileum is tapered for the efferent limb which can be done with all staples (as shown here) or a combination of Lembert sutures and staples (see Fig. 181.8A).

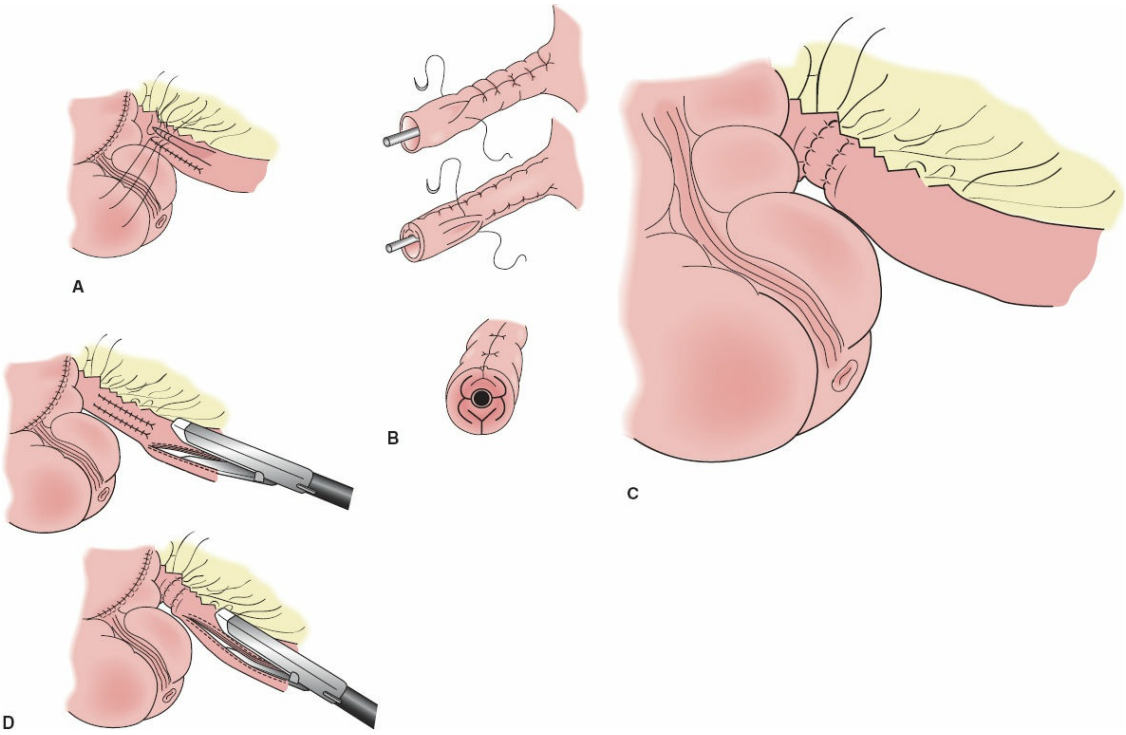

Figure 181.8. Options (A-C) for buttressing distal ileum **A.** Distal ileum can be imbricated using 2 rows of Lembert sutures over a catheter (Indiana). **B.** Opposing Lembert sutures on each side of the terminal ileum (Florida). **C.** Two purse-string sutures 1 cm apart placed in the most distal ileum near the IC valve (Miami). **D.** After buttressing, the proximal 6 to 7 cm of ileum is then tapered over catheter with GIA stapler.

With the Penn pouch, similar techniques are used for right colon isolation and reconfiguration. An ileocolonic anastomosis is performed and the ileocecal valve is closed on the cecal side. A Mitrofanoff procedure is then performed. This can be done by dividing the appendix at its insertion into the colon and by inverting or, more simply, by leaving the appendix in situ and burying it in a 3- to 4-cm tunnel created in the anterior tenia, similar to the technique used in the Malone anterior continence enema procedure (ACE-Malone).

With any of these approaches, the efferent limb is then brought through

a finger-sized defect in the rectus fascia and skin. It can be helpful to anchor the anterior aspect of the pouch to the posterior rectus sheath for two reasons. First, it prevents the pouch from moving, which can alter the catheterization angle. Second, should a percutaneous procedure such as cystostomy tube placement or percutaneous stone removal be necessary, the pouch can be punctured without injury to the intervening bowel. We prefer to perform these fixation sutures on either side of the temporary cystostomy tube that we place intraoperatively.

Ileal Pouches

Three general types of ileal pouches have been described: the Kock pouch, the ileocecal Mainz pouch, and the various orthotopic pouch configurations (described later), which can be used in a heterotopic location with the application of a Monti or Mitrofanoff catheterizable channel. The Kock pouch is rarely performed in the modern era due to its complexity and high rate of complications. It is not described further in this text.

The ileocecal Mainz pouch combines the distal ileum and cecum in a pouch with a separate ileal segment for a catheterizable channel while preserving the ileocecal valve for continence (Fig. 181.9). One isolates 10 to 15 cm of cecum and the right colon, two 10- to 15-cm segments of the distal ileum, and a 20- to 25-cm segment of ileum just proximal to that. The cecal segment and two 10- to 15-cm ileal segments are detubularized and sewn side to side in an “S” configuration to form the posterior plate of the pouch, taking care to preserve the ileocecal valve. The other ileal segment serves as the efferent limb. It is separated from its mesentery for 6 to 8 cm and intussuscepted into the posterior plate of the pouch. The intussusception is stabilized with two passes of a noncutting stapler. The stabilized segment is then passed through the ileocecal valve and stabilized again with the stapler. The pouch is closed and the efferent limb is brought out through the rectus fascia and skin.

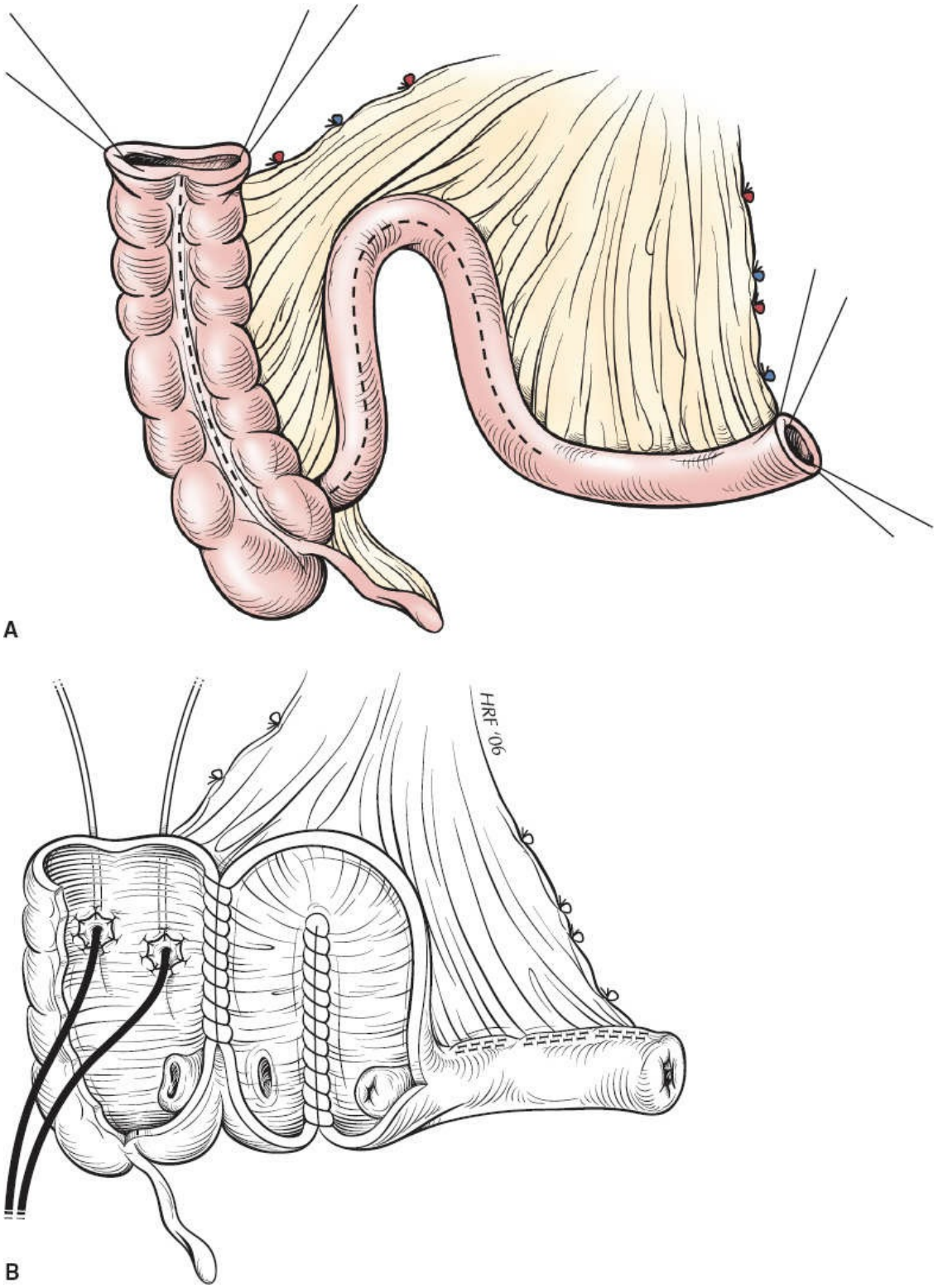

Figure 181.9. Mainz pouch. **A.** The pouch is created from 10 to 15 cm of detubularized ascending colon and 20 to 25 cm of detubularized terminal ileum folded in an S-shape. Another more proximal 10-cm segment of ileum is not detubularized. **B.** The proximal nondetubularized ileum is intussuscepted into the pouch and through the preserved ileocecal valve. This double intussusception is secured with staples.

Any ileal pouch can serve as a heterotopic reservoir, including those originally intended as orthotopic pouches. However, without an ileocecal valve to serve as a continent catheterizable segment, one must rely on a tunneled appendix or ileum. When using the ileum as the catheterizable channel, one minimizes the amount of bowel that must be resected by using the Monti technique rather than by simply tapering a long segment of ileum (Fig. 181.10). In this manner, 2 cm of ileum is harvested and opened lengthwise. The bowel is then closed transversely such that the mucosal folds are oriented along the length of the channel. The closure is done over a 12F or 14F catheter with absorbable sutures. In adults, in order to achieve enough narrowing of the channel over the catheter we often find it necessary to imbricate a second layer of closure in a Lembert fashion. Because this layer will be extraluminal, we use permanent sutures. Because the bowel is opened closer to the mesentery on one side, the mesentery will attach closer to one end of the catheterizable channel. This allows the surgeon some flexibility in putting the shorter end through the pouch and freeing up the longer end to traverse to the skin, or vice versa. Submucosal tunneling into the pouch is done as originally described by Mitrofanoff, which is similar to that described by Leadbetter and Clarke for extracolonic ureteral implantation. The serosa and muscularis are elevated over a distance of 3 cm and the catheterizable segment laid in the trough. A small hole is created in the end of the bowel mucosa and a mucosa-to-mucosa anastomosis performed between the catheterizable segment and the pouch. The Monti technique yields a channel that is about 6 cm in length. When longer segments are required, one can use a spiral Monti or double Monti. In the double Monti, two Monti segments are sewn end to end. In the spiral Monti described by Casale, a 4-cm ileal segment is detubularized on one side of the mesentery for half the length of the bowel, the incision is brought across the bowel to the opposite mesentery, and the remainder of the bowel is opened along that mesentery. When the bowel is closed longitudinally, the reconfiguration is in a spiral (Fig. 181.11).

Orthotopic Neobladders

The original orthotopic diversion was the Camey procedure, using a nondetubularized ileal segment. This has been abandoned due to high rates of incontinence and loss of renal function from high reservoir pressures. Current approaches share the concept of detubularized and reconfigured ileum, with continence achieved by the preserved external urinary sphincter. Some surgeons leave a temporary suprapubic catheter and a

urethral catheter, others just a urethral catheter. In our experience, including the larger suprapubic catheter allows for better irrigation of mucus than the single 16F urethral catheter. However, when no suprapubic catheter was left in place we obtain good results by using a 24F hematuria catheter as the urethral catheter. Regardless which method of postoperative drainage is chosen, scheduled catheter irrigation helps clear mucous and prevent obstruction. Ureters are typically reimplanted in a refluxing manner. Some surgeons externalize “single J” ureteral catheters through the skin and drain them to an external pouch until removal. Others tie “double J” stents to the urethral catheter, allowing them to be removed with the urethral catheter at 3 weeks postoperatively. While “double J” stents may at first appear to minimize morbidity, we have experienced increased pyelonephritis in the postoperative period in the setting of prolonged stenting, potentially due to reflux from bladder irrigation. Thus, we prefer to externalize the stents by passing them out through a stab incision on the pouch and the anterior abdominal wall and allowing them to drain into a stoma bag postoperatively. They can be removed within a week, while the urethral catheter is left for 3 weeks and removed after a cystogram demonstrates no evidence of leak.

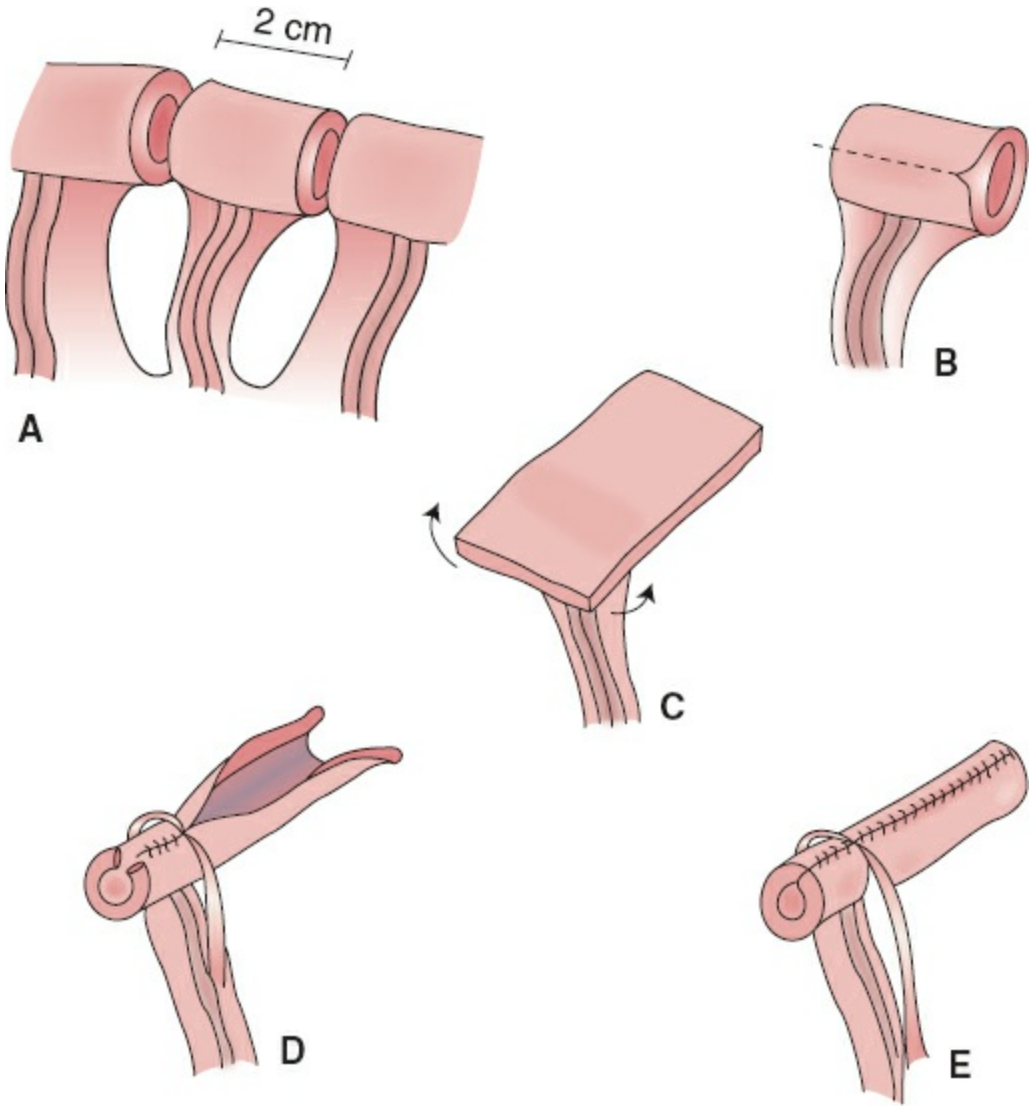

Figure 181.10. Monti catheterizable channel. **A.** A 2-cm segment of ileum is isolated. **B.** The segment is detubularized closer to one side of the mesentery than the other. **C.** The segment is retubularized perpendicular to its original configuration. **D,E.** A mucosa-to-mucosa anastomosis is performed over a 12F to 14F catheter.

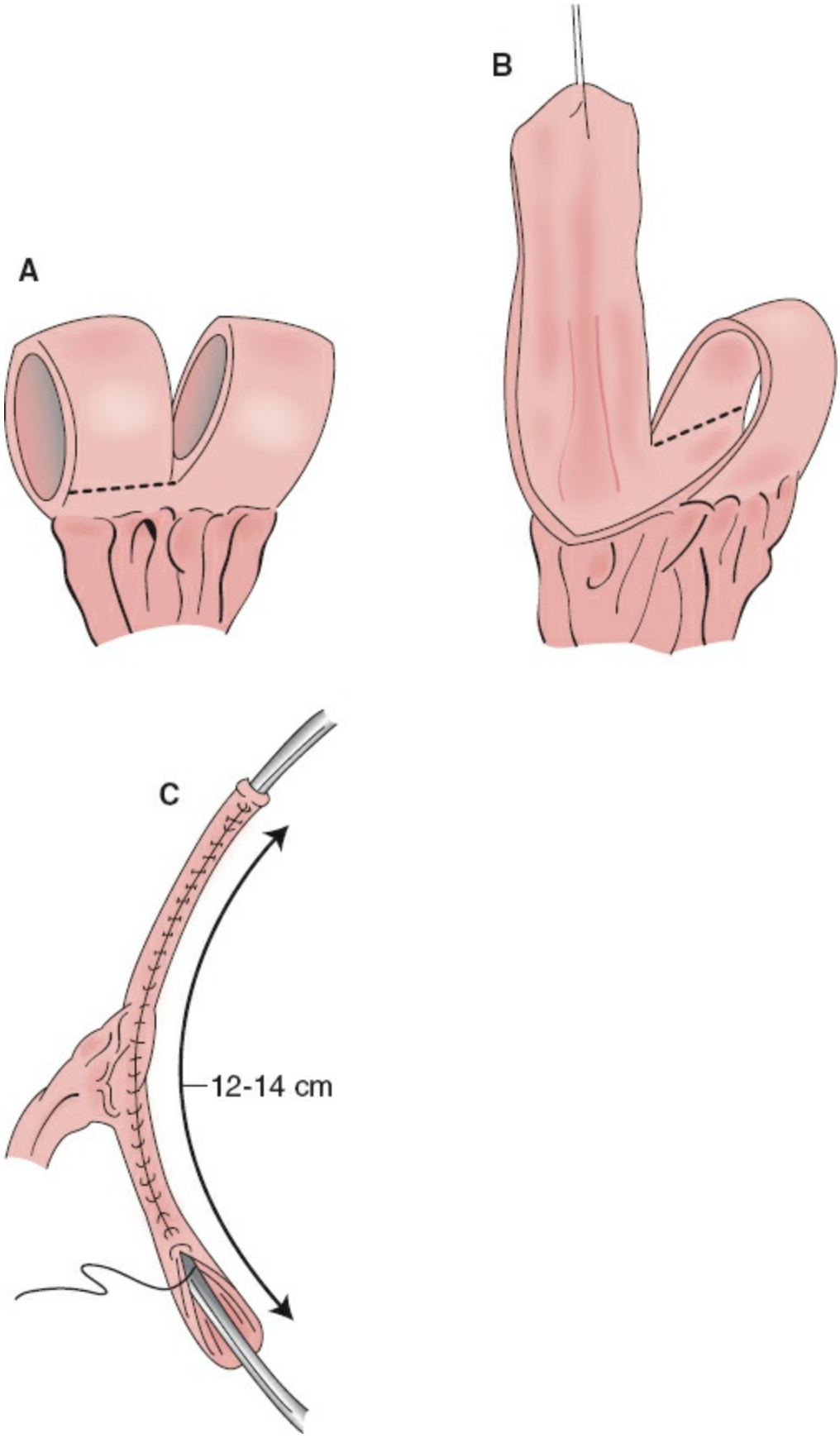

Figure 181.11. Spiral Monti in the fashion of Casale. **A,B.** A 4-cm segment of ileum is isolated and an S-shaped detubularizing

incision is made such that one half of the bowel is opened along one side of the mesentery and the other half is opened along the other side. **C.** The resulting long strip of bowel is then closed over a 12F to 14F catheter.

Voiding is achieved by Valsalva and simultaneous voluntary sphincter relaxation. Daytime continence is better than nighttime continence due to relaxation of the voluntary sphincter during sleep. Both types of incontinence improve over time, with only a minority continuing to experience these issues at 1 year postoperatively. Initial problems with urinary retention, especially in women, have been improved by fixing the pouch to the anterior abdominal wall to avoid kinking of the urethra.

Studer Neobladder

The Studer neobladder is the simplest to perform of the orthotopic diversions. It is essentially a "J" pouch with the upper limb of the "J" serving as the afferent limb for ureteral reimplantation. A 60-cm segment of ileum is isolated 15 to 25 cm from the ileocecal valve (Fig. 181.12). The distal 40 cm is detubularized and the posterior plate reconstructed in a "U" fashion using running absorbable suture (typically 3-0), then the upper and lower halves are closed to each other in a clamshell fashion, forming a sphere. The upper 20 cm is left intact, allowing this segment to reach the mid ureters. The ureters are sewn to the conduit in the fashion of Bricker. This afferent limb may offer several advantages. First, the peristaltic waves help minimize reflux. Second, it allows the surgeon to resect the ureters above the iliac vessels. As the internal iliac blood supply to the ureters is interrupted during cystectomy the distal ureters are relatively devascularized, relying on blood flow from the upper and mid ureter. By anastomosing the mid ureter to the afferent limb, the "chimney" of the Studer neobladder minimizes distal ischemia and may thus minimize ureterointestinal anastomotic strictures. The most dependent portion of the pouch is opened and the mucosa everted for anastomosis to the urethral stump with 2-0 or 3-0 absorbable sutures. Initial pouch volumes are lower than with other pouches—about 150 mL—but this increases over time to about 500 mL.

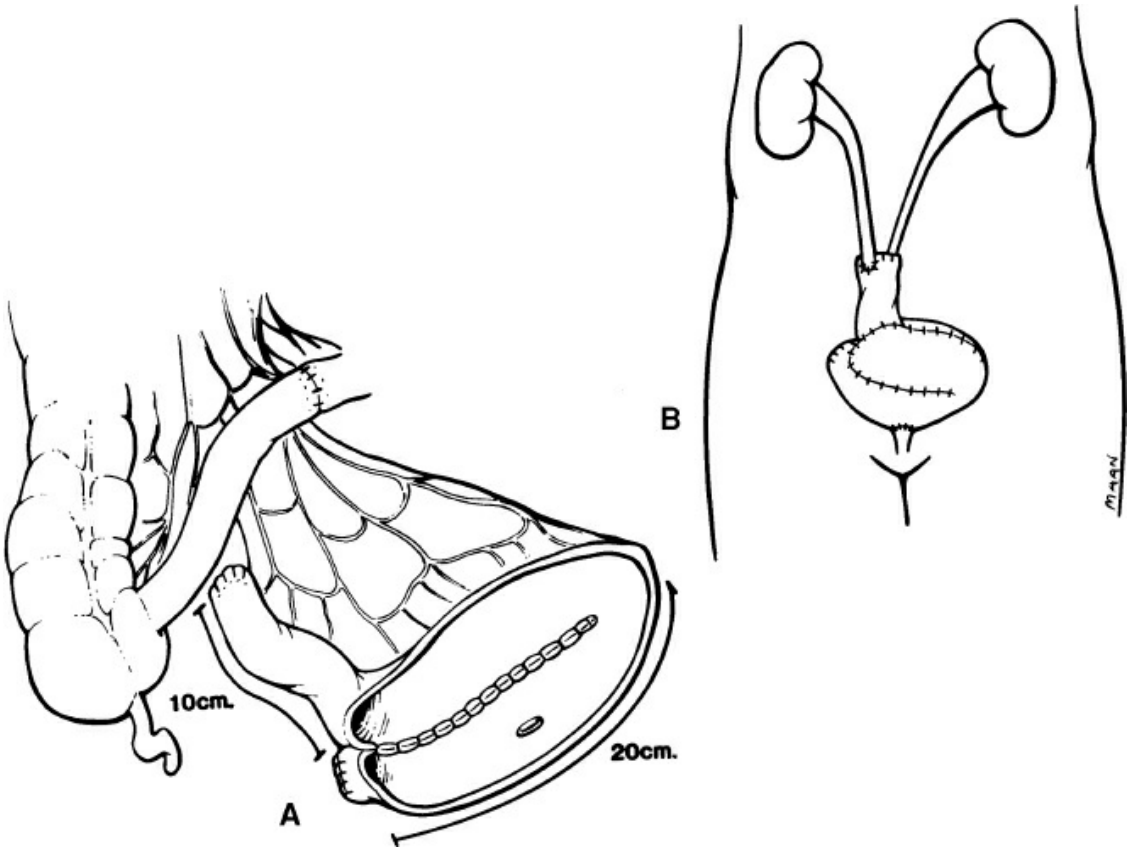

Figure 181.12. Studer neobladder. **A.** A U-shaped pouch is created from 40 cm of ileum while sparing the terminal 15 cm. Another proximal 15-cm segment of ileum acts as the “chimney” into which the ureters are reimplanted. **B.** The bottom of the pouch is closed, but not before the most dependent portion is brought down and anastomosed to the urethra.

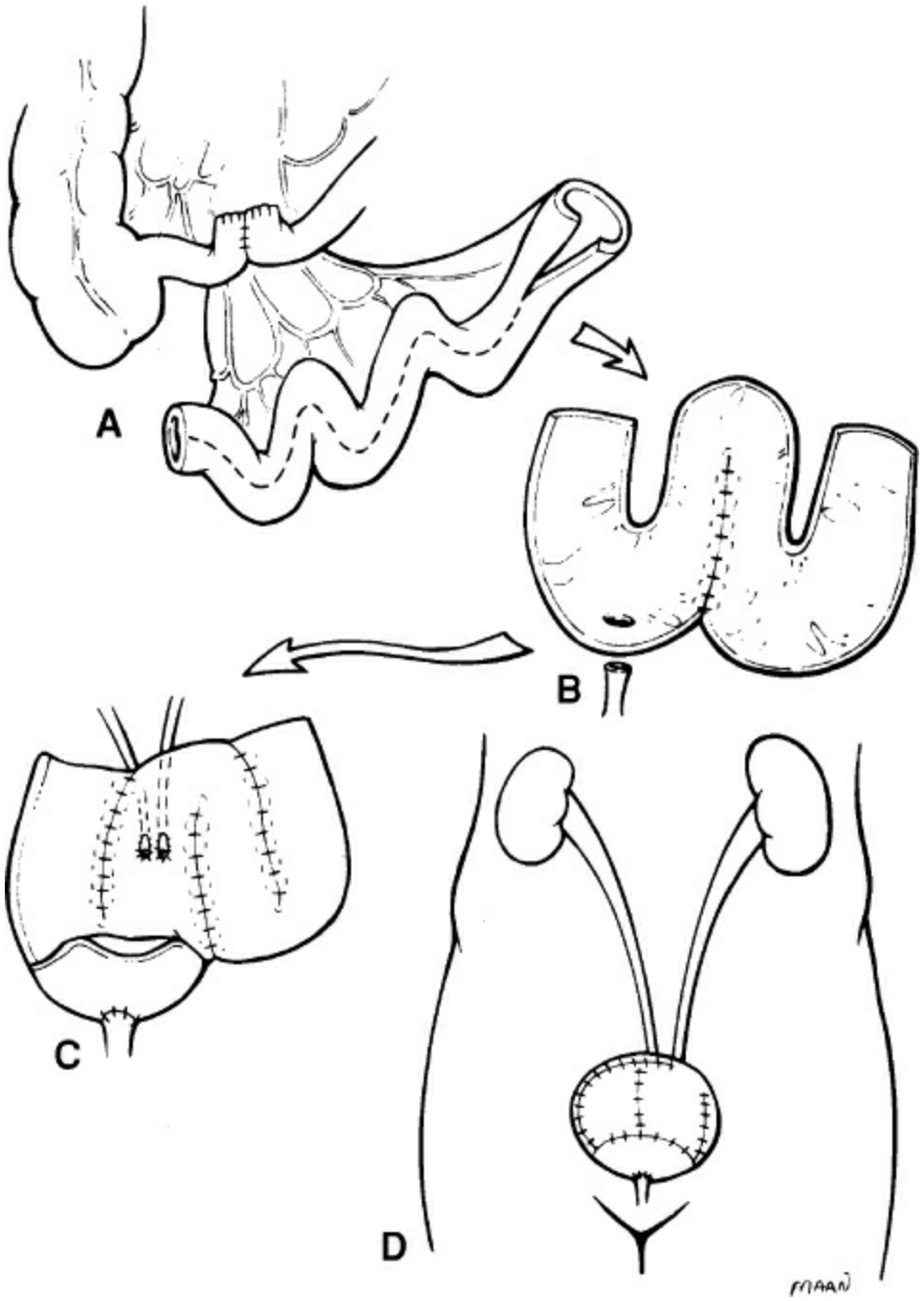

Figure 181.13. Hautmann neobladder. **A.** The pouch is created from a 60- to 80-cm segment of ileum, sparing the terminal 15 cm. **B.** The bowel is detubularized along its antimesenteric border and fashioned into a “W” shape. A larger flap between the first and second limb is allowed to create a wider plate for anastomosis to the urethral stump. **C.** The ureters are reimplanted into the second and third limbs. **D.** The pouch is then folded over to close on itself. A Studer modification includes an afferent nondetubularized limb onto which a Bricker anastomosis of the ureters is performed.

Hautmann Neobladder

The Hautmann neobladder is an ileal reservoir that uses 60 to 80 cm of ileum with the back plate fashioned in a "W" (Fig. 181.13), thus achieving higher initial volumes compared with the Studer pouch. Classically, the ureters were brought through the posterior wall of the neobladder and the anastomosis was done from the inside. Alternatively, a Studer modification can be performed by creating a chimney into which the ureters are anastomosed. This technique also differs from the Studer approach in that the segment to be used for the urethral anastomosis is chosen before opening the bowel. The line one follows when opening the bowel should be deviated away from the antimesenteric line toward the anterior mesentery in the area of the planned urethral anastomosis. This creates a posteriorly based "U" flap, which can be fashioned into a tube and makes the anastomosis easier to perform.

Mainz Neobladder

The Mainz neobladder is created in a fashion similar to the Mainz heterotopic pouch, using 10 to 15 cm of cecum and right colon and two 10- to 15-cm segments of ileum (Fig. 181.14). The posterior plate is constructed in an "S" fashion using the three limbs. The urethral anastomosis is performed and then the anterior wall is closed.

POSTOPERATIVE MANAGEMENT

Cystectomy and urinary diversion are a highly complex operation and operative times may exceed 8 hours in some cases. Blood loss is minimized with current techniques but can still reach 1,000 mL or more. Patients with bladder cancer or radiation cystitis are frequently elderly and may possess multiple comorbidities, increasing their risk of postsurgical complications. For all these reasons, careful postoperative care is essential to a successful outcome. Care pathways have led to earlier discharge and helped minimize complications.

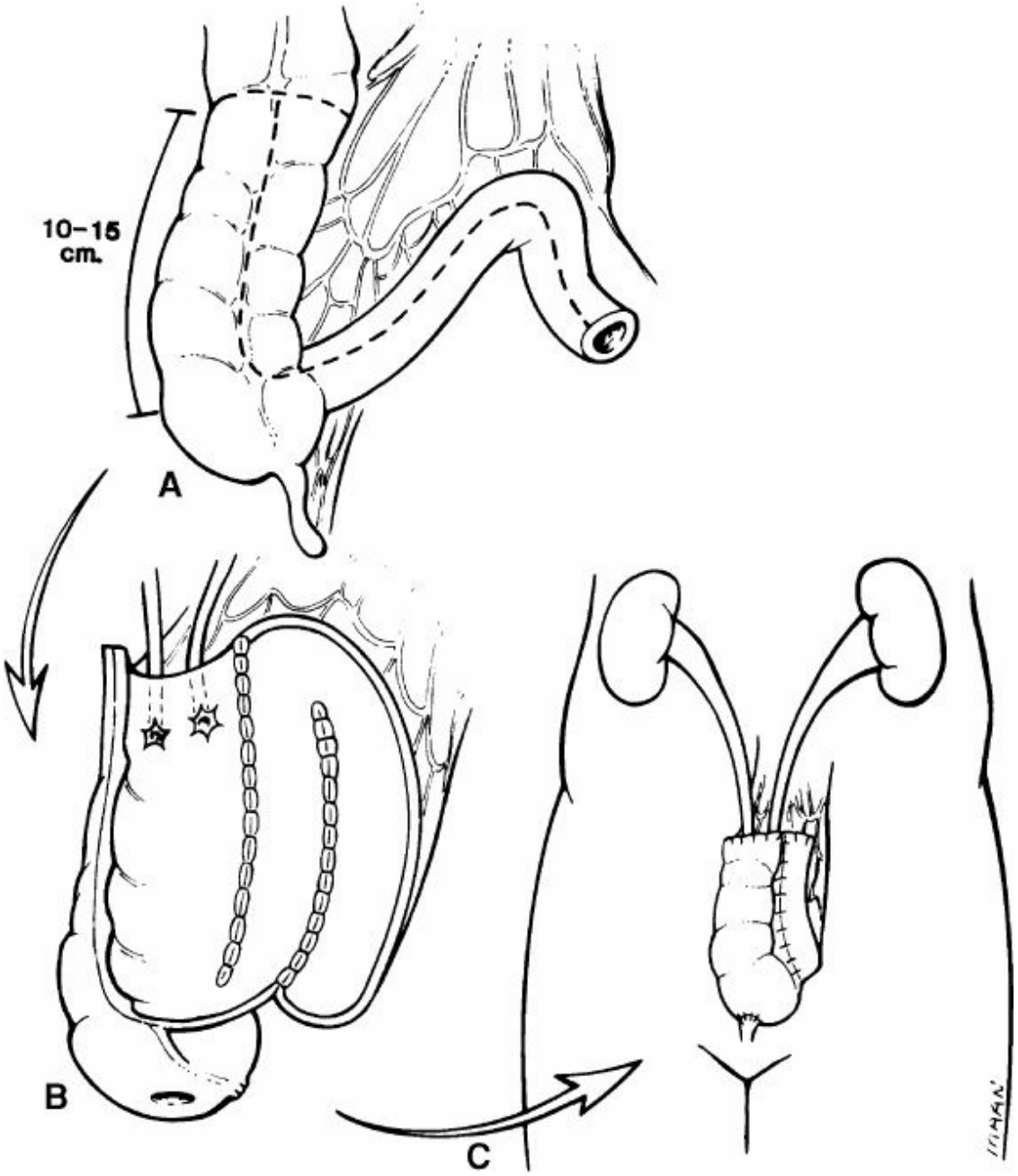

Figure 181.14. Mainz neobladder. **A.** Ten to fifteen centimeters of cecum and ascending colon with 20 to 30 cm of ileum is isolated. **B.** The entire segment is detubularized along its antimesenteric border, and a broad posterior plate is created by suturing the opposing edges to create a W. Tunneled ureterocolonic anastomoses are performed. **C.** A buttonhole incision is created at the base of the cecal portion for the ureterointestinal anastomosis. The neobladder is closed by folding the lateral limbs anteriorly and suturing in a continuous fashion.

If a bowel anastomosis is performed, many opt to leave a nasogastric

tube. Others choose to omit the nasogastric tube based on a meta-analysis of randomized trials that showed no change in return to bowel function but an increase in pulmonary complications with a nasogastric tube. Some surgeons use metoclopramide to help stimulate bowel activity, although evidence of efficacy in the postoperative period is mixed. Ulcer prophylaxis is important. Early feeding may help advance the date of discharge. Deep venous thrombosis prophylaxis is important; many patients undergoing cystectomy are at high risk of thrombosis and anticoagulation therapy in addition to sequential compression devices and frequent ambulation play a role in prevention.

COMPLICATIONS

Perioperative mortality occurs in 2% of cystectomy patients. Over a third to almost 50% of cystectomy patients develop minor complications and about 10% suffer major complications in the acute postoperative period; some of these are related to urinary diversion but most are not. As the focus of this chapter is urinary diversion, not cystectomy, we will focus on complications directly related to urinary diversion. About 5% will develop bowel obstruction and 1% to 2% an enteric anastomotic leak. About 1% to 3% will develop a urine leak from the pouch or ureteroenteric anastomosis and <1% will develop acute stomal problems such as stenosis or necrosis.

In contrast, many of the long-term complications are diversion related. Ureterointestinal anastomotic stricture occurs in 7% to 14%. Minimal mobilization of the ureter and careful mucosa-to-mucosa anastomosis are important. Diarrhea is not uncommon and can impact quality of life. Serious metabolic complications occur rarely and are due to reabsorption of solutes from the urine. Risk is higher in continent than in noncontinent diversions. Almost all reservoirs today utilize the ileum and/or the colon; hyperchloremic metabolic acidosis can result from absorption of ammonium chloride in exchange for excretion of carbonic acid. Most patients have only minor electrolyte abnormalities, but clinically significant changes requiring bicarbonate supplementation occur in about 10% of continent pouches. Upper tract stones can occur in >30% of patients when followed for more than a decade. The risk is related to oxalate malabsorption, serum metabolic acidosis from urine reabsorption, and chronic infection with urea-splitting bacteria. Pouch stones occur due to mucous retention from inadequate emptying or staples/mesh/permanent suture inside the pouch. These can generally be managed transurethrally in

the case of the orthotopic pouch or percutaneously in heterotopic pouches. Revision of the catheterizable channel for stomal stenosis or false passage is required in about one quarter of patients followed long term. Parastomal hernias occur in up to 20% of patients; success rates with repair are disappointing though recent techniques of open transabdominal repair using mesh to buttress the fascial defect have yielded better results. Successful resolution frequently requires contralateral relocation of the stoma.

CONCLUSIONS

Surgical supravesical urinary diversion provides an alternative to a natural bladder function by providing drainage of urine from the kidneys using intestinal segments. Urinary diversion is technically challenging surgery associated with both short- and long-term complications. The variety of approaches, all with different risk/benefit profiles, suggests that there is no "ideal" diversion. Thoughtful patient selection, meticulous attention to intraoperative technique, and careful long-term monitoring are essential for ensuring good outcomes in patients with urinary diversions.

Suggested Readings

Burkhard FC, Kessler TM, Mills R, et al. Continent urinary diversion. *Crit Rev Oncol Hemat* 2006; 57:255–64.

Dahl DM, McDougal WS. Use of intestinal segments in urinary diversion. In: Wein AJ, Kavoussi LR, Novick AC, et al., eds. *Campbell-Walsh Urology*. 10th ed. Philadelphia, PA: Elsevier; 2012:2411–49.

Lawrentschuk N, Colombo R, Hakenberg OW, et al. Prevention and management of complications following radical cystectomy for bladder cancer. *Eur Urol* 2010;57:983–1001.

McKiernan JM, DeCastro GJ, Benson, MC. Cutaneous continent urinary diversion. In: Wein AJ, Kavoussi LR, Novick AC, et al., eds. *Campbell-Walsh Urology*. 10th ed. Philadelphia, PA: Elsevier; 2012;2450–78.

Monti PR, Lara RC, Dutra MA, et al. New techniques for construction of efferent conduits based on the Mitrofanoff principle. *Urology* 1997;49:112–5.

Shaaban AA, Abdel-Latif M, Mosbah A, et al. A randomized study comparing an antireflux system with a direct ureteric anastomosis in patients with orthotopic ileal neobladders. *BJU Int* 2006;97:1057–62.

Skinner E. Continent cutaneous diversion. *Curr Opin Urol* 2015;25:555–61.

Skinner EC, Skinner DG, Stein JP. Orthotopic urinary diversion. In: Wein AJ, Kavoussi LR, Novick AC, et al., eds. *Campbell-Walsh Urology*. 10th ed. Philadelphia, PA: Elsevier; 2012;2479–506.

Studer UE, Varol C, Danuser H. Orthotopic ileal neobladder. *BJU Int* 2004;93(1):183–93.

Wallace DM. Ureteric diversion using a conduit: a simplified technique. *BJU Int* 1966;38:522–7.

EDITOR'S COMMENT

The authors have written an excellent chapter with very detailed diagrams of the operative procedures. Supravesical urinary diversion is employed in patients in the most dire of straits, that is, in patients having bladder cancer, bladder dysfunction, severe congenital abnormalities, major procedures, complications of radical procedures, and often with the causative or complicating factor of radiation field effects. Choosing the right procedure for the right patient depends not only on the causative factor but also coexisting disease, mental faculties, and social support. It seems to me much of what applies for the colorectal surgeon and diversion of the fecal stream applies to urinary diversion. Types of continent pouches include the Kock, J, W and the S pouches including the Mainz pouch and most commonly the Studer pouch. According to the 2007 WHO consensus conference, the frequency of ileal neobladder diversion after radical cystectomy performed in centers of excellence was approximately 50%. Incontinent diversion includes placement of the ostomy as well as maturation of the loop or everted conduit in the fashion of Brooke all being a preoperative consideration. Continent cutaneous diversion is only offered in a few specialized centers in the United States in patients undergoing cystectomy due to the high complication rate and need for revision in 10% to 20% of patients. Many patients are willing to accept this risk in order to avoid wearing an ostomy appliance (Skinner E. Continent cutaneous diversion. *Curr Opin Urol* 2015;25:555–61).

Although not reviewed in this chapter, the number of robotic urinary diversion surgeries is increasing worldwide (Chopra S, Abreu AL, Gill IS. Robotic urinary diversion: the range of options. *Curr Opin Urol* 2016;26(1):107–13). The first robotic case reported was in 2003. However, according to the International Robotic Cystectomy Consortium the percentage of patients undergoing robotic surgery for neobladder reconstruction is less than 10%. Fahmy et al. (Fahmy O, Asri K, Schwentner C, et al. Current status of robotic assisted radical cystectomy with intracorporeal ileal neobladder for bladder cancer. *J Surg Oncol* 2015;112(4):427–9) have systematically reviewed the current status of robotic assisted radical cystectomy with intracorporeal ileal neobladder for bladder cancer. After excluding ineligible studies, they found

three case series and five case reports with a total number of 203 reported cases of which 114 neobladders were intracorporeally fashioned. A majority of complications with the procedure are not with the radical excision of the bladder but with 17.2% of the patients developing diversion-related complications. Although robotic intracorporeal neobladder reconstruction is in its starting phase, initial perioperative results seem to be comparable to open series. The International Robotic Cystectomy Consortium reported with a median follow-up of 9 months that the major complication rate was 20% for robotic-performed intracorporeal diversion compared to 32% with extracorporeal performed diversion. There has been an increasing use of robotics but more so for radical cystectomy than making an intracorporeal neobladder because of the technical difficulty and doubling of the operative time to do so. Some surgeons perform the cystectomy robotically and then form the ileal pouch extracorporeally. Although some advantage is obtained with shortening the length of the operation and decreased nerve damage with this approach, the patient still has the disadvantages of increased postoperative pain, hernias, and ileus from the celiotomy. As always, randomized studies are forthcoming to confirm noninferiority of robotic techniques.

With new approaches come new procedures. Dal Moro and Zattoni have developed a novel robotic intracorporeal orthotopic ileal neobladder, the so-called “Ves.Pa.” procedure and in a systematic manner in a robotic pelvic model confirmed the feasibility of the technique and simplified the technique. In general, developing procedures and working to improve the technical aspects of the procedure is a particular advantage of robotics. Clinical studies are needed to confirm this technique (Perletti G, Magri V. Re: Shoskes et al: The Urinary Microbiome Differs Significantly Between Patients With Chronic Prostatitis/Chronic Pelvic Pain Syndrome and Controls as Well as Between Patients With Different Clinical Phenotypes. *Urology* 2016 Aug;94:315–6.).

Complications with long-term follow-up are detailed in this chapter and as nicely put are best avoided by working with unirradiated bowel and ureters and minimizing ureter mobilization. Something not mentioned that is detailed in a recent study by Raup et al. (Dal Moro F, Zattoni F. Ves.Pa.-Designing a Novel Robotic Intracorporeal Orthotopic Ileal Neobladder. *Urology* 2016 May;91:99–103. doi: 10.1016/j.urology.2016.02.008. Epub 2016 Feb 18.) is use of botulinum toxin type A injection in the treatment of continent catheterizable ileal-colic urinary diversion muscularis overactivity and may be a good option for the long-term treatment of contracted continent catheterizable diversions. Another nice nonoperative procedure detailed using a flexible ureteroscopic treatment and laser lithotripsy for the removal of a frequent complication of pouches—a large urinary stone (Wilhelm K, Frankenschmidt A, Miernik A. Analgesia-free flexible ureteroscopic treatment and laser lithotripsy for removal of a large urinary stone: a case report *J Med Case Rep* 2015;9:225).

Ongoing trials are looking at quality of life issues comparing continent and incontinent diversion. Robotics has little effect on QOL but may assist in the

postoperative management as it is affected by often by the advanced age of the patient and poor functional status as well as the ill-effects of concomitantly administered adjuvant therapies (Ahmadi H, Lee CT. Health-related quality of life with urinary diversion. *Curr Opin Urol* 2015;25(6):562–9). The reduction in ostomies seems the most effective way to improve patients' quality of life.

V. Suzanne Klimberg

C GYNECOLOGIC SURGERY

182 Cesarean Delivery

Thomas R. Moore

BACKGROUND

Definition and History

The origin of the term *cesarean* is unclear, but the legend of Julius Caesar's "cesarean" birth is unlikely to be true. In those ancient times, cesarean delivery was universally fatal, and Caesar's mother was known to have lived for many years after his birth. The term may have derived from the Latin words *caedere* (to cut), and *caesons* (the term for children delivered by cesarean), or from the Roman law known as *Lex Cesare*, which mandated postmortem delivery so the mother and infant could be buried separately. The term "cesarean section" is redundant, derived from the Latin words *caedere* and *secare*, which both mean "to cut."

The evolution of the current surgical technique is of interest. Maternal mortality rates for cesarean birth prior to the 20th century approached 100% owing to the almost universal uterine sepsis that followed. Consequently, very few cesareans were performed. Cesarean delivery was combined with hysterectomy in the late 19th century in an effort to reduce infection and thus prevent maternal death. Although one innovation (the "Porro" technique) involved suturing the edges of the uterine incision to the abdominal wall, allowing the lochia to drain externally significantly reduced postpartum sepsis and death; it was not until well into the 20th century that advances in surgical suture material, aseptic technique, anesthetic advances, the low-transverse incision, and antibiotics improved the safety of cesarean delivery. As a result, cesarean delivery rates in the United States increased from 4.5% of all deliveries in 1965 to 16.5% in 1980 to 24.5% in 1988 to 32% in 2015. Cesarean rates still vary widely with geographic area and type of hospital (i.e., teaching vs. nonteaching). Currently, over 1 million cesarean deliveries are performed annually in the

United States alone, making it the most common surgical procedure performed on women today.

INDICATIONS

Cesarean delivery may be indicated for fetal and/or maternal reasons, such as failure to progress in labor, fetal malpresentation, placenta previa, nonreassuring fetal monitoring (category II or III by the American College of Obstetricians and Gynecologists [ACOG] guidelines), suspected macrosomia (>5,000 g or 4,500 g if diabetic), active infections like herpes simplex virus or high viral load HIV, vertical uterine incisions from previous deliveries, and certain fetal anomalies such as severe fetal hydrocephalus or fetal neck masses. The majority of cesareans are still primary with repeat cesarean as an indication for 37.5% of all cesarean births. A currently controversial topic is the "cesarean-on-demand"—elective, patient-choice cesarean birth. There are data suggesting less urinary incontinence and pelvic organ prolapse after elective cesarean, but the slightly increased morbidity and mortality associated with surgical delivery make the risk/benefit ratio for elective cesarean difficult to quantify. There is currently no standard recommendation regarding patient-choice cesarean. ACOG states, "Given the balance of risks and benefits, the Committee on Obstetric Practice believes that in the absence of maternal or fetal indications for cesarean delivery, a plan for vaginal delivery is safe and appropriate and should be recommended to patients" (ACOG Committee Opinion on Cesarean Delivery on Maternal Request 2013).

RISKS

Currently, cesarean delivery has an overall low maternal mortality and morbidity but is still significantly elevated over vaginal delivery. The current cesarean mortality rate in the risk of death for cesarean sections is 13 per 100,000 and for vaginal birth 3.5 per 100,000 in the developed world. Maternal morbidities associated with cesarean birth depend on the indication for surgical delivery, but include increased risk of endomyometritis (up to 20%); wound infections; increased blood loss; need for transfusion (up to 7%); thromboembolic events; anesthetic complications; and surgical complications with damage to bowel, bladder, and major pelvic blood vessels. Morbidity is highest in emergency cesarean birth, especially after prolonged labor and/or ruptured

membranes.

SUBSEQUENT OUTCOMES

Long-term morbidities commonly attributed to cesarean delivery include uterine scar dehiscence or rupture, fetal demise and expulsion from a uterine scar, placenta previa with or without accreta, increased surgical complications from adhesions, bowel obstruction, bladder injury, and increased blood loss during future surgery. Uterine rupture occurs in subsequent pregnancy <1% if a low-transverse uterine incision was done, and up to 12% if a prior vertical classical uterine incision was performed. Uterine rupture may be an asymptomatic uterine "window" with minimal consequences or may be a catastrophic expulsion of the fetus into the abdomen with subsequent fetal demise. If risk factors such as a previous classical uterine incision, extensive myomectomy, or more than two previous low-transverse uterine incisions are present, repeat cesarean delivery prior to the onset of labor is usually recommended. Alternatively, there is a 70% likelihood of successful vaginal delivery with labor following a single prior cesarean delivery via a low transverse incision. If a vaginal birth after cesarean delivery (VBAC) is considered, an appropriate support team of anesthesiologist, nurse, and pediatrician must be available in case an immediate abdominal delivery during labor is necessary. Women undergoing VBAC must be properly informed about the potential risks/benefits of vaginal versus repeat cesarean delivery, and this should be documented in written consent.

PREOPERATIVE PLANNING

Anesthesia

Choice of anesthesia is determined by the clinical situation and maternal/fetal indications for delivery. The options for anesthesia are spinal, epidural, combined spinal epidural, general anesthesia, and local anesthesia alone (least common). Regional anesthesia is most commonly used for planned cesarean deliveries or nonurgent cases. Epidural anesthesia may be used if already in place for labor analgesia and if time allows for dosing to an adequate level. Slow epidural anesthesia may be indicated in cases where general or spinal anesthesia is contraindicated. One example is a maternal cardiac disorder (i.e., pulmonary or aortic stenosis) where avoiding rapid decreases in systemic vascular resistance is

important. There are significant risks of general anesthesia in the laboring parturient. Gastric emptying is slowed and significant changes in maternal physiology make airways more difficult during gestation. Antacids or histamine-2 blockers are given regardless of gastric contents in all cases prior to surgery. Local anesthesia has been used alone, but should be reserved for the rare case where no anesthesiologist is available, immediate delivery is required, and patient consent has been obtained.

Patient Preparation

The patient is generally positioned supine with leftward uterine displacement (i.e., a wedge under the right hip) to reduce aortocaval compression. Surgical site preparation with betadine or a surgical scrub or paint such as chlorhexidine (CHG) or parachlorometaxylenol (PCMX) is typically recommended. If alcohol-based paints are used, it is important to allow them to dry completely because they are potentially flammable. A Foley catheter is placed in the bladder to allow decompression during surgery and urine measurement for management of intraoperative fluids. Clipping the pubic hair is usually done just prior to surgery in the operating room (OR) because shaving the previous evening may increase the risk of postoperative infection. Prophylactic antibiotics are generally recommended for all cesareans. Common practice in the United States is the use of a cephalosporin (in nonallergic patients) up to 30 minutes before skin incision to reduce the incidence of postpartum endometritis without adversely affecting neonatal outcomes. Ancef, 1 g, or 2 g if the body mass index (BMI) is >30, is a cost-effective choice. There is some evidence that providing extended coverage with azithromycin may further reduce the risk in some patient populations.

SURGICAL TECHNIQUE

Abdominal Incision

Three types of skin incisions are commonly used: Pfannenstiel, Maylard, or midline vertical (Fig. 182.1). In addition, there are three described modifications of the low-transverse incision—Joel–Cohen, Misgav–Ladach, and Pelosi. The choice of incision is based on the urgency of the procedure, presence or knowledge of prior scars/adhesions and presence of other pelvic pathology, and physician preference. The most common is the Pfannenstiel incision, also widely used in gynecologic surgery. The

Pfannenstiel is a transverse incision made in a curvilinear fashion, typically 12 to 15 cm in length (depending on fetal size) beginning 2 cm above the pubic symphysis in the midline and extending toward the iliac crests; the superficial epigastric vessels should be avoided, ligated, or cauterized to prevent excessive bleeding in the subcutaneous space. The fascia is then incised with the knife or cautery and extended laterally as well. Kocher clamps are then used to elevate the fascia and dissect bluntly or sharply the rectus muscles from the undersurface of the fascia. All perforating bleeding vessels should be controlled as this dissection occurs. The underlying rectus muscles are then separated in the midline, and the peritoneum is divided in the midline and retracted laterally. Inspection and palpation of the peritoneum is important at this point, as previous surgery or obstructed labor may affect the bowel or bladder location underlying the peritoneum. Care should be taken to avoid these structures. The peritoneal opening is then extended and the bladder retractor is placed inferiorly. The bladder flap is created by incising the peritoneal reflection over the lower uterine segment usually with Metzenbaum scissors. The vesicouterine space is then created with blunt dissection. The bladder is retracted out of the operating field and an appropriate-sized Richardson retractor is used for exposure in the upper portion of the incision (Fig. 182.2).

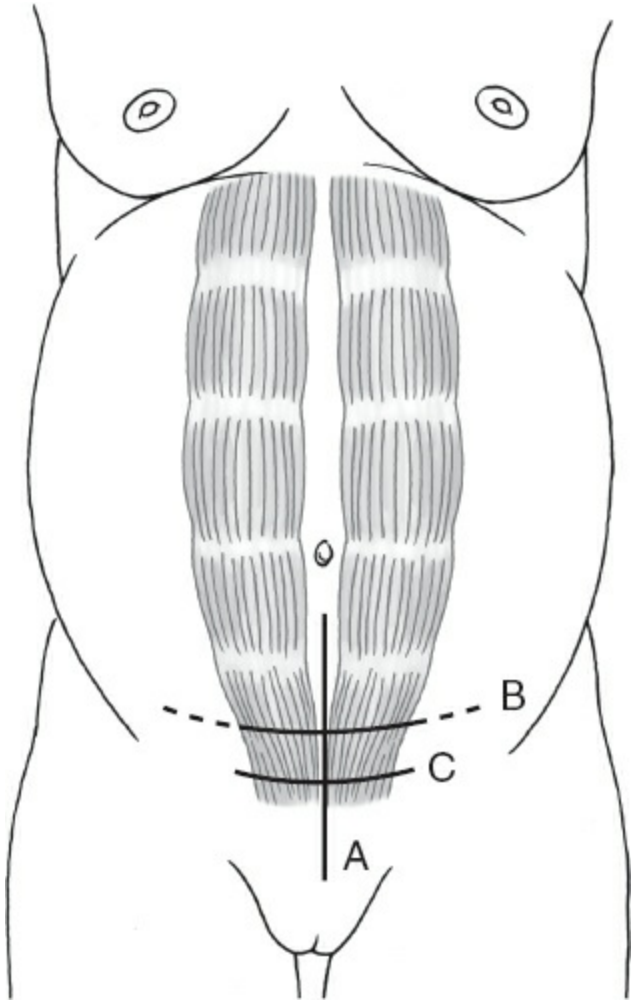

Figure 182.1. The obstetrician most commonly uses one of three abdominal incisions: midline (**A**), Maylard (**B**), and Pfannenstiel (**C**). *Dashed lines* indicate possible extension.

A Maylard incision may be used if significant scarring is suspected, or in a severely obese parturient to avoid making the abdominal incision in or under the panniculus. The Maylard incision is made 3 to 4 cm above the pubic symphysis and is extended in a transverse fashion. The superficial epigastric vessels may need to be ligated and the fascia is extended laterally with scissors or cautery. The rectus muscles are then elevated and incised approximately two thirds on each side with ligation of the deep inferior epigastric vessels located under the outer third of the rectus muscles. The rectus muscles can be incised by cautery (preferred) or sharp dissection.

A vertical skin incision is used if extreme speed is essential for delivery, if pelvic pathology such as ovarian tumor is suspected, if extensive adhesions were noted in a previous operative note, or if a

vertical scar already exists. Other indications include coagulopathies or the need for perioperative anticoagulation in order to reduce the risks of subfascial or wound hematomas. Some authors suspect that vertical incisions are more prone to herniation, poor wound healing, and increased pain postoperatively, but there are multiple confounding factors associated with these observations. The midline vertical incision avoids dissection of the rectus muscles completely. A midline incision is made just above the pubic symphysis and is extended midway to the umbilicus. This is followed by dissection of the subcutaneous layers and then incision of the fascia. Once the midline separation of the rectus muscles is identified, the rectus muscles are separated, the rest of the fascia incision is extended, and the peritoneum is entered sharply. The rest of the delivery proceeds as described below.

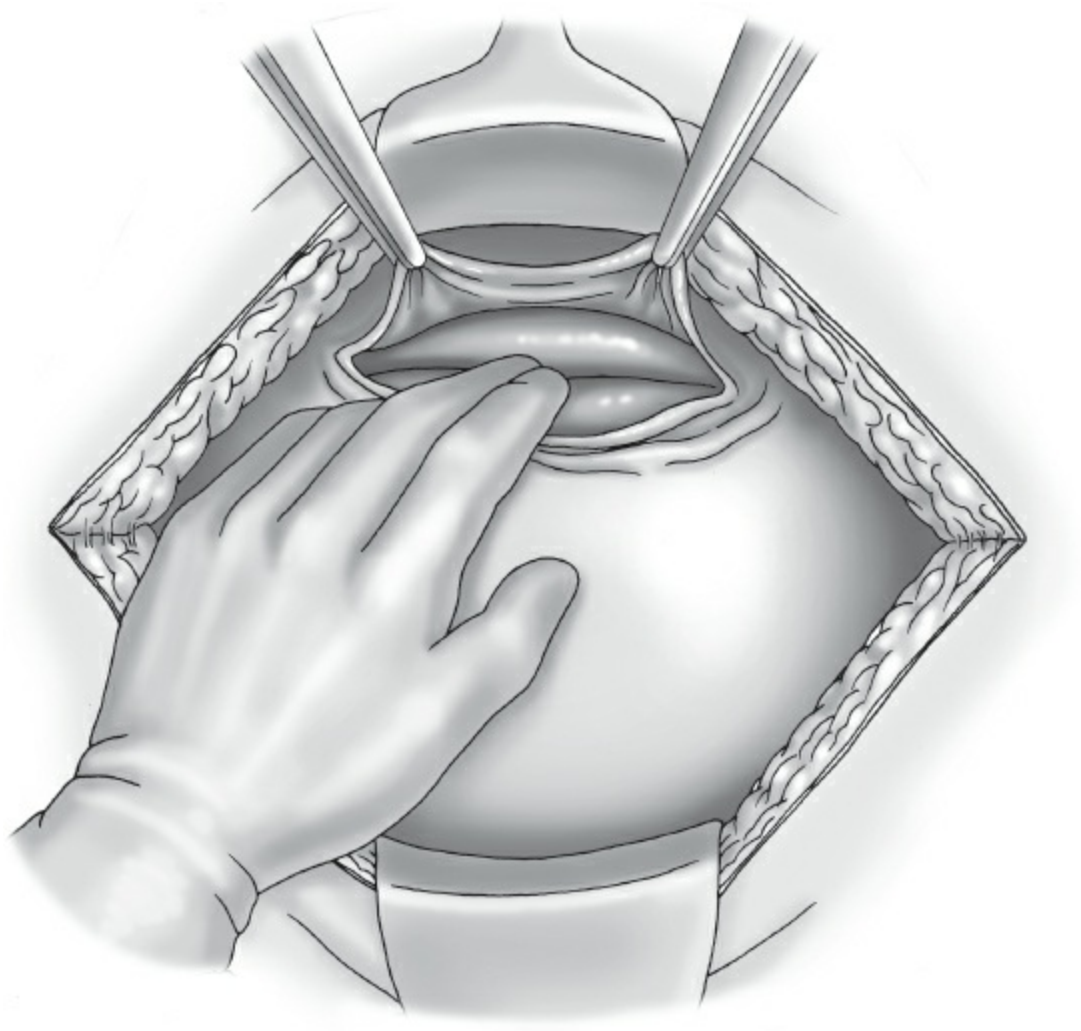

Figure 182.2. The bladder flap is created with the surgeon's index finger and forefinger as the potential space between the bladder and uterus is developed.

There are three described modifications of the low-transverse incision. The Joel–Cohen technique begins with a straight transverse incision slightly higher than a Pfannenstiel, 3 to 4 cm above the symphysis just below the level of the iliac spines. The subcutaneous fat is incised sharply in the middle of the incision and the fascia is also opened to a width of ~3 to 4 cm. The fascial incision is extended either by manual stretch or by inserting scissors into the fascial opening and pushing laterally toward the iliac spines. The rectus muscles are manually separated and the peritoneum entered digitally. The incision is stretched, a bladder flap created, and the myometrium opened in the midline and bluntly extended transversely. The uterus is closed with interrupted sutures. The Misgav–Ladach modification involves abdominal entry using a Joel–Cohen technique; however, the placenta is removed manually, the uterus exteriorized and then closed in a running, locked fashion in one layer. The fascia is closed with a running stitch and the skin with mattress sutures. Peritoneal closure is omitted. In the Pelosi modification, entry is via a Pfannenstiel incision with electrocautery used to divide the subcutaneous and fascial layers. The rectus are separated and the peritoneum entered bluntly with fingers and the incision stretched. No bladder flap is created and the uterus is entered similarly. Oxytocin is administered and the placenta is delivered spontaneously followed by uterine massage. The uterus is closed with a running locked 0-chromic and the peritoneum is not closed. The fascia is closed with a running synthetic absorbable suture and the subcutaneous layer is closed with interrupted 3-0 absorbable sutures if it is deep.

These techniques have been compared in a number of instances to treat randomized trials. These trials have also been subjected to meta-analysis. In general, the Joel–Cohen–based techniques are associated with reduced blood loss and operative times. There also appears to be a reduced time for return of bowel function, less pain, and fever and shorter incision to delivery times. However, these trials do not assess the potential for serious morbidity or long-term outcomes.

Uterine Incision

The uterine incision types are shown in Figure 182.3. The type of uterine incision most commonly used is a Kerr incision (low-transverse), but other choices are Krönig (low-vertical), classical, T, or J incision. Low-transverse incisions are made in the thin area of the lower uterine segment and heal much better than an incision that extends into the contractile or

upper portion of the myometrium. A low-transverse incision is made 1 to 2 cm above the bladder attachment to the uterus. A scalpel should be used to score the uterus in the midline taking care to avoid the fetus, especially if the membranes are ruptured or in emergency deliveries. To avoid fetal injury, one can elevate the myometrium with an Allis clamp or enter bluntly with a Mayo clamp or finger. Extension of the incision can be made with bandage scissors or blunt dissection. If using scissors, the surgeon's fingers should be placed underneath the uterine tissue to prevent unintentional injury to the fetus. Blunt extension is usually preferred because it is associated with less intraoperative blood loss and need for fewer transfusions postoperatively while avoiding the risk of sharp injury to the fetus. Furthermore, blunt manual extension of the low-transverse uterine incision by cephalad–caudad (vertical) stretching has been associated with less uterine vessel injury.

Indications for a classical uterine incision include, but are not limited to, anterior placenta previa, transverse back-down fetal lie, anatomic considerations such as fibroids or extensive vessels in the lower uterine segment, poorly developed lower uterine segment, or previous scarring that limits access to the lower segment. A low-vertical incision can first be made 1 to 2 cm above the bladder and then extended with bandage scissors to allow delivery. If adequate space is not achieved in the lower segment, the incision can be extended superiorly into a classical incision. The J or T incision is an extension when a transverse uterine segment does not allow delivery and must be extended either laterally (J) or in the midline (T) (Fig. 182.3). If any incision extends into the thicker uterine segment, patients should be counseled to avoid labor in the future due to increased risks of uterine rupture in these circumstances.

Delivery of Infant and Placenta

After the uterine incision is made, all retractors should be removed and the table lowered to allow adequate maneuvers for delivery. The surgeon's hand should be placed below the fetal presenting part, and if deeply engaged in the pelvis, the fetal part should be lifted up to the incision. If the vertex is presenting, the head may be flexed and then delivered with gentle external fundal pressure once elevated to the level of the incision. Delivery of the body should occur as usual followed by clamping and cutting of the umbilical cord on the surgical field. Bulb or catheter suctioning of meconium on the surgical field is no longere recommended.

A pediatrician, advanced practice nurse, or anesthesiologist may be present for resuscitation in cases of fetal compromise. A segment of umbilical cord may also be obtained if needed for cord gas analysis. Cord blood collection should only be done after this segment of cord is obtained.

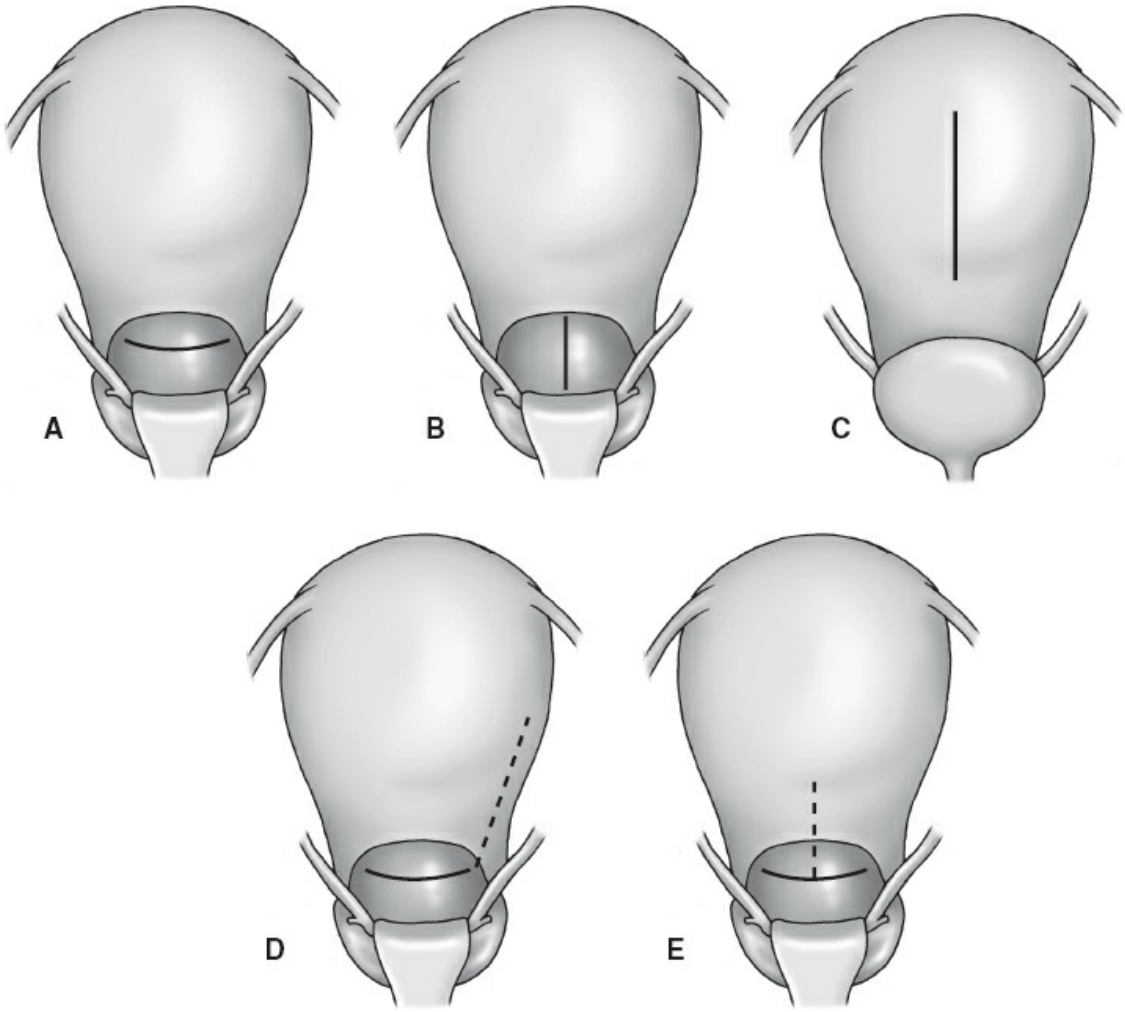

Figure 182.3. Uterine incisions for cesarean delivery. **A.** Low-transverse incision. The bladder is retracted downward, and the incision is made in the lower uterine segment, curving gently upward. If the lower segment is poorly developed, the incision can also curve sharply upward at each end to avoid extending into the ascending branches of the uterine arteries. **B.** Low-vertical incision. The incision is made vertically in the lower uterine segment after reflecting the bladder, avoiding extension into the bladder below. If more room is needed, the incision can be extended upward into the upper uterine segment. **C.** Classic incision. The incision is entirely within the upper uterine segment and can be at the level shown or in the fundus. **D.** J incision. If more room is needed when an initial transverse incision has been made, either end of the incision can be extended upward into the

upper uterine segment and parallel to the ascending branch of the uterine artery. **E.** T incision. More room can be obtained in a transverse incision by an upward midline extension into the upper uterine segment.

Special maneuvers may be necessary for delivery of the preterm infant or multiple gestations. Care should be taken to ensure a large enough uterine incision, especially in the preterm infant. With breech presentation, head entrapment may occur if the incision is too small. This can often be relieved by extending the incision or with uterine relaxation by administering sublingual nitroglycerin. By leaving the membranes intact, en caul delivery of the intact conceptus may reduce trauma in extremely premature infants. The infant in cephalic presentation with occiput posterior (OP) position or deep engagement of the vertex with molding and caput formation can present special difficulties in elevating the fetal head through the uterine incision. With OP positions, it is usually helpful to attempt to rotate the occiput to the anterior and then deliver the head by extension. Alternatively, if the vertex can be maneuvered to a transverse position, forceps can be used to bring the head through the incision. Vacuum devices may also be used, but neither should be used routinely due to the risks of fetal injury. With deep impaction of the vertex, attempts to dislodge the head vaginally before incision can reduce the force needed during surgery and an assistant applying manual pressure from below can also be beneficial. Banking of umbilical cord blood to harvest stem cells has become a common practice, although its efficacy in treatment of pediatric cancers is controversial. Many cord blood storage companies provide patients with kits for collection if notified in advance. The benefits of banked cord blood use for pediatric bone marrow transplantation are not fully known, and the likelihood of use in the routine obstetric patient is low (1:1,000 to 1:200,000).

The placenta should be spontaneously delivered with gentle massage of the uterine fundus and gentle cord traction as this method has been shown to reduce postpartum febrile morbidity. Manual placental removal increases the risk of postpartum endometritis and maternal/fetal hemorrhage. If the placenta cannot be removed spontaneously or if hemorrhage ensues, manual removal may be achieved by the surgeon’s hand creating a plane between the placenta and the uterine wall. After delivery of the placenta, the uterus should be wiped clean of all residual debris using dry surgical gauze. Vigorous curettage should be reserved for

persistently adherent placental cotyledons since this may increase the potential for intrauterine adhesions and theoretically abnormal placentation in the future.

Uterine Closure and Control of Hemorrhage

After delivery of the placenta, there is typically significant blood flow (~1 L/min) from the uterine wound edges as well as the denuded interior uterine surface, which continues until several uterine contractions have reduced uterine dimensions and the cesarean wound edges have been sutured. Hemorrhage should be controlled by rapid surgical closure of the uterine incision as well as stimulation of uterine contractions with intravenous oxytocin infusion. Uterine incision closure can be accomplished by various means, and to date there is substantial variation in technique from hospital to hospital and regions of the world. Most surgeons prefer uterine exteriorization prior to surgical repair to enhance visibility and possibly decreased blood loss, but this may be accompanied by increased patient discomfort. There is no increased risk of infection, and effective anesthesia usually prevents significant discomfort. Occasionally, severe scarring, obesity, or patient discomfort prevents exteriorization. Pennington or Allis clamps can be used to grasp the edges of the incision for control of hemorrhage and identify the hysterotomy during surgical repair. Suture material should be an absorbable material such as Vicryl, polyglycolic dermal suture (PDS), or Maxon (preferably size 0 or 1-0). Blunt needles have been shown to reduce the incidence of glove perforation and presumably needle stick injury (often unrecognized), although this may come at the expense of decreased surgeon satisfaction. If any extensions are identified, these should be closed first with a locking suture working toward the initial incision and then incorporated into the primary closure. The Kerr or Krönig uterine incision closure can be done by a single or double layer starting at one end of the incision and proceeding to the other end with locking sutures ~1 cm apart and 1 cm of tissue on each side. Some surgeons avoid incorporating the endometrium into the incision to theoretically prevent future development of adenomyosis, but little data exist to support this practice and some studies would discourage it. The repair should ensure hemostasis, especially at the edges of the incision as this is the most likely area for bleeding postoperatively. A classical incision should be closed in multiple layers as the uterine wall is much thicker and multiple layers are required to

reapproximate the tissue hemostatically (usually three layers: deep running locked, unlocked imbricating, and superficial unlocked serosal).

The benefit or risk of singleversus double-layer closure of a low-transverse uterine incision is controversial. Many authors feel double layers may decrease the risk of future uterine dehiscence or rupture (and thus theoretically accreta), but the data are confounded by lack of uniformity of suture material, technique, and definition of uterine dehiscence. Uterine dehiscence is also of such rare occurrence that it is difficult to study in a prospective fashion. Despite this, the most recent Cochrane review to address this issue would suggest a two-layer closure in patients who plan future pregnancies or labors. Single-layer closure may cause less necrosis of tissue, decreased surgical time, and fewer sutures to control bleeding. If double-layer closure is done, it may be with a second imbricating suture incorporating 1 cm of tissue above and below the uterine incision in a vertical or horizontal (Lembert) fashion (Fig. 182.4). Most surgeons no longer reattach the bladder flap to the lower uterine segment because theoretically there is less risk of scarring of the bladder high on the uterus (decreasing the risk of bladder injury in future surgery), less risk of hematoma or abscess in the potential closed-off space, and less operative time. Ovaries and fallopian tubes should be inspected prior to return of the uterus to the abdominal space (if exteriorization was done). There may be an exaggerated decidual reaction on the surface of the ovaries, and the fallopian tubes may appear very engorged. If ovarian pathology is suspected preoperatively or intraoperatively, consultation should be expedited so that removal can occur after cesarean delivery. Ovarian corpus luteum cysts need not be excised. Mature teratomas, large hydatid cysts of Morgagni, and suspected ovarian carcinoma should be removed.

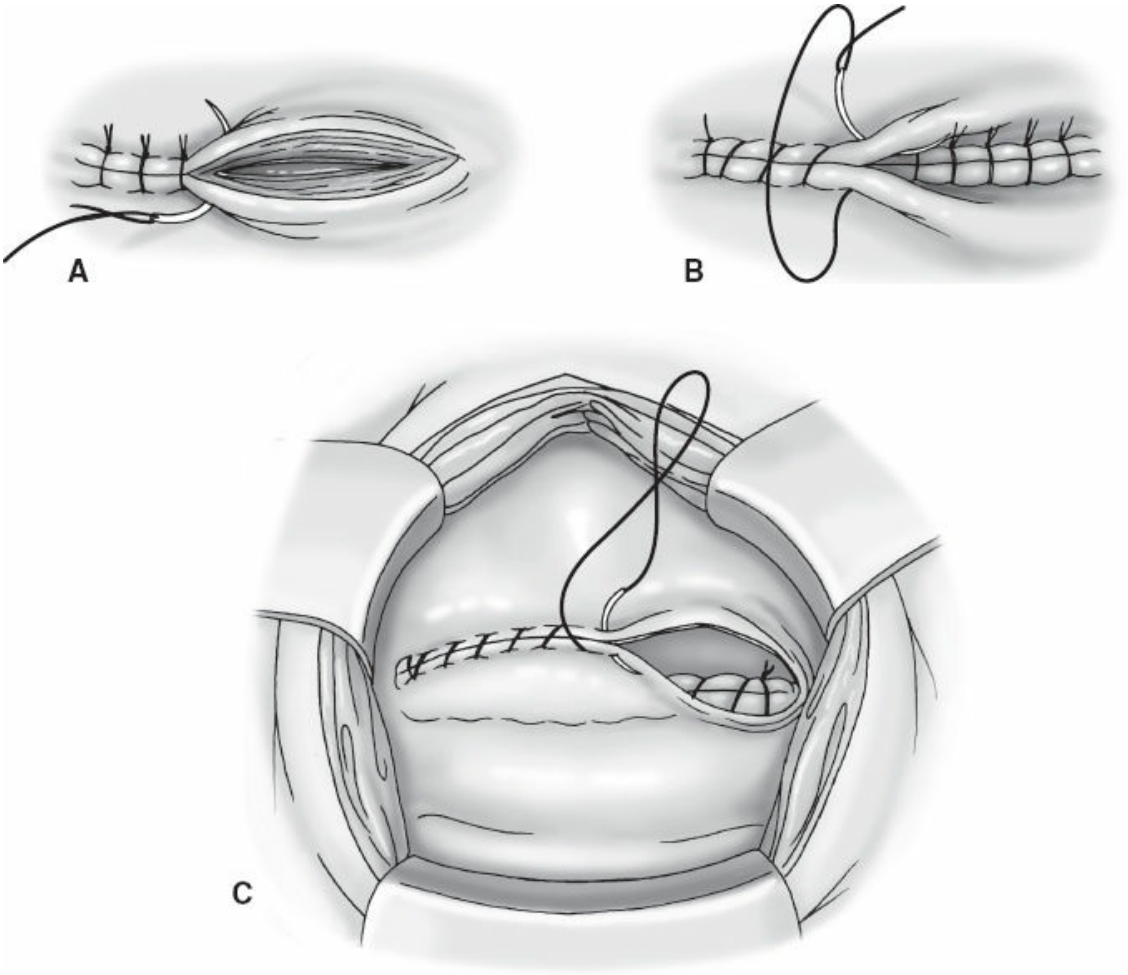

Figure 182.4. Closure of a low-transverse incision. **A.** The first layer can be interrupted or continuous. **B.** A second inverted layer can be created by using a continuous Lembert or Cushing stitch, but is really needed only when apposition is unsatisfactory after application of the first layer. **C.** The bladder peritoneum is reattached to the uterine peritoneum with fine suture.

If a patient has preoperatively consented to permanent sterilization, this may be performed after the uterine incision is closed. A modified Pomeroy method is commonly used. A midisthmic portion of fallopian tube is grasped with a Babcock clamp, a 3-cm portion is doubly ligated with two free ties of 0 or 1-plain catgut, and this segment is removed with Metzenbaum scissors. Alternatively, the Parkland method employs piercing the mesosalpinx, passing two free ties and separately ligating the tube in two places before excising the intervening segment. The removed portions of fallopian tube must be sent to pathology to confirm that a complete cross-section of tube was removed. Sterilization failures due to unintended ligation of the round ligament have been reported. In general,

myomectomy or major uterine surgery should be avoided at the time of cesarean due to the potential for severe blood loss (with the possible exception of a pedunculated fibroid).

The uterus should then be replaced inside the abdomen with care not to disrupt any sutures. If inadequate space is found, the broad ligament vessels should be drained by holding up the uterus in the midline with care to alleviate pressure on the vascular sides and then gently rotating the uterus to allow for easy replacement. Care must be taken to avoid disrupting sutures placed at the site of tubal ligation. Clots of blood and excess amniotic fluid should be removed from the peritoneal gutters prior to abdominal wall closure. Irrigation has not been shown to be of benefit. A careful inspection of all areas, including the bladder, should be done to assess hemostasis. If blood is noted in the Foley catheter, retrograde bladder filling via a three-way catheter can be done with methylene blue or sterile milk to assess for leakage of urine. If a laceration of the dome of the bladder is detected, repair should be performed with a double-layer closure of delayed absorbable suture. Urogynecologic or urologic consultation should be obtained if bladder laceration appears to involve the trigone or ureters.

If hemorrhage is not controlled primarily by uterine incision closure or uterine tone continues to be inadequate with ongoing blood loss during surgery, additional measures must be taken. Increased concentrations of oxytocin may be given intravenously (up to 40 units per liter), but should not be administered as a rapid bolus because hypotension and water intoxication can occur. If uterine tone cannot be achieved by oxytocin, other uterotonics such as Methergine (methylergonovine 0.2 mg IM), Hemabate (15-methyl prostaglandin F2α 250 μg IM), or Cytotec (misoprostol 800 μg per rectum) can be given. The first two are administered intramuscularly *not* intravenously, and Cytotec is given as rectally as suppositories. There are certain contraindications to giving Hemabate, such as asthma, and to giving Methergine, such as hypertension or preeclampsia. Occasionally there is excessive bleeding in the placental bed, and this can be controlled locally with sewing the vessels prior to uterine incision closure. In cases where abnormal placentation or incomplete removal of the placenta is seen or suspected, as in placenta accreta, additional and rapid surgical steps must be taken as peripartum hysterectomy is likely going to be required. In the case where accreta was suspected preoperatively, additional surgical assistance can be requested

from an oncologist or general surgeon.

The mainstay of surgical management for uncontrolled intrapartum hemorrhage remains hysterectomy, but in a gravida with a strong desire for future childbearing the surgeon must try to salvage the uterus. Blood and blood products must be readily available, and the surgeon must be skilled in performing alternative procedures to preserve the uterus. Surgical alternatives to hysterectomy include bilateral vertical uterine artery ligation (O'Leary stitch), bilateral utero-ovarian vessel ligation, B-Lynch suture, or hypogastric artery ligation. The O'Leary stitch is accomplished with a single suture of 0 or 1-0 absorbable material placed in the uterus 2 cm medial to the uterine artery with the needle driven either anterior to posterior or posterior to anterior at the level of the uterine incision (Fig. 182.5). It is often helpful for the surgeon to manually distract the large uterine veins laterally as the needle pierces the broad ligament to avoid tearing the veins as well as to protect posterior structures such as the bowel or the adnexa. It is also important to include at least 1 to 2 cm of myometrium medial to the uterine artery to provide sturdy tissue with which to compress the vessel. Once the stitch has been placed, the posterior broad ligament should be inspected to ensure no adjacent structures have been injured. If this is not successful, then bilateral utero-ovarian vessels may be ligated but with caution that if bleeding continues, each stepwise procedure increases blood loss and the potential for disseminated intravascular coagulation (DIC). Most surgeons would next attempt the B-Lynch suture if atony is the cause of hemorrhage (Fig. 182.6). A large absorbable suture is placed bilaterally in the lower uterine segment and looped over the fundus in an attempt to physically compress the uterus.

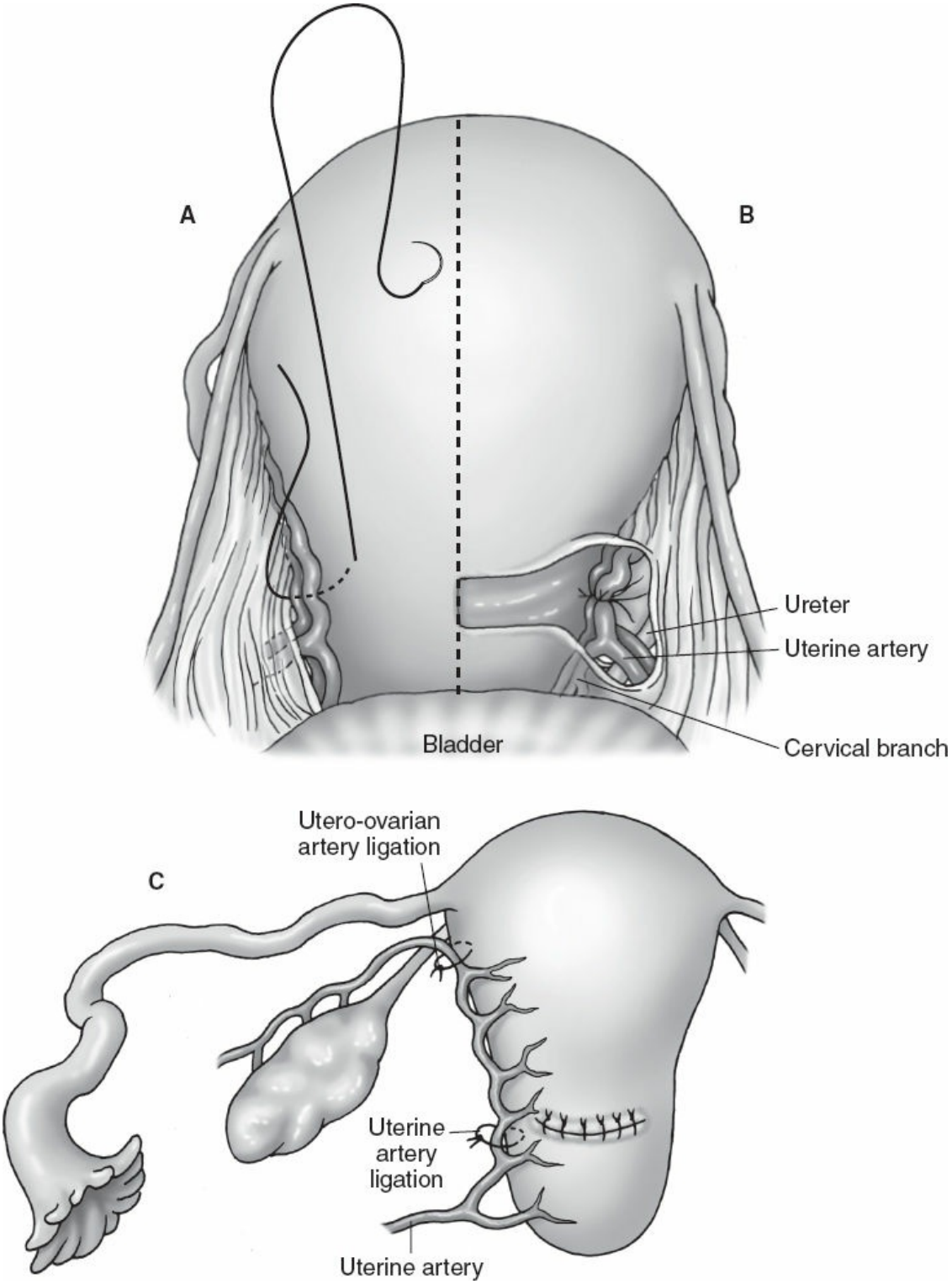

Figure 182.5. Ligation of the uterine artery. **A,B.** This anterior view of the uterus demonstrates the placement of a suture around the ascending branch of the uterine artery and vein. Note that 2 to 3 cm of myometrium medial to the vessels has been included in the ligature. The vessels are not divided. **C.** View of the sutured uterus.

An alternative to the B-Lynch suture is placement of the Bakri Balloon. This device is placed into the lower uterine segment and expanded with 300 to 500 mL saline fluid to provide internal compression of the myometrium and left in place for 24 to 48 hours while monitoring closely for recurrent uterine bleeding that will be evident in the vaginal effluent.

The last resort prior to hysterectomy in a stable but bleeding patient is hypogastric artery ligation. The procedure is begun by pulling the uterus over the symphysis and opening the retroperitoneal space. The iliac bifurcation is identified and the internal iliac traced 2 to 3 cm downstream to avoid the posterior division of the artery. The anterior division of the artery is doubly ligated with a nonabsorbable suture; the vessel is not divided. Between 25% and 60% of patients require additional procedures. Serious morbidities include accidental ligation of the external iliac artery, leading to necrosis of an extremity, laceration of the pelvic vessels, ureteral injury, and retroperitoneal hematomas (Fig. 182.7). Scant evidence exists that this procedure is efficacious, and most practitioners are not familiar enough with the anatomy to perform this quickly or safely.

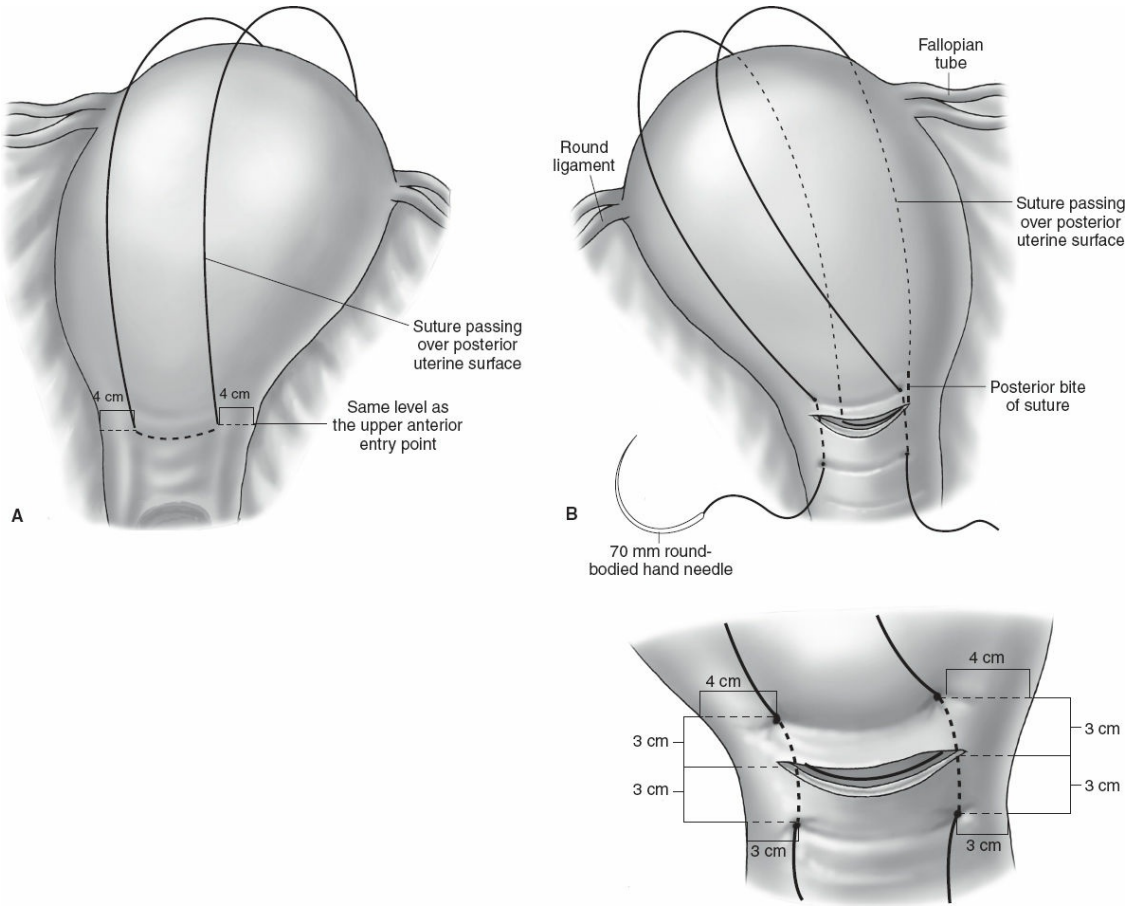

Figure 182.6. A. The B-Lynch technique. **B.** The B-Lynch suture technique for postpartum hemorrhage.

Postpartum or intrapartum hysterectomy is a procedure that must be done in cases of intractable bleeding, hemorrhage, or placenta accreta. The procedure itself is more complicated than the usual hysterectomy as the postpartum uterus is very large, the anatomy and location of routine landmarks (i.e., the ureter, uterine vessels, and the bladder) can be confusing, and the patient may be unstable in many circumstances with ongoing blood loss and DIC. Surgical removal of the uterus must be done with appropriate blood product replacement, adequate anesthesia, and patient consent, if feasible. Supracervical hysterectomy is sufficient to stop the bleeding in most cases. Prior to surgical closure, all efforts must be made to correct coagulation defects and to avoid postoperative bleeding and the need for reexploration.

Abdominal Wall Closure

Multiple studies have failed to demonstrate clear benefit of parietal peritoneal closure. Many studies show decreased operative times, pain and

fever without differences in wound infection, and postpartum endometritis or adhesions. However, other studies have shown decreased adhesions. Some surgeons reapproximate the rectus in the midline with one or two mattress sutures or close the peritoneum to allow more ease in future surgical cases. Because data as to the benefit of these procedures are lacking, the surgeon may individualize technique based on preference or patient anatomy.

All sites should be inspected for bleeding, including the underside of the rectus muscles, the fascia, and the subcutaneous space. The fascia is closed using an absorbable 0 Dexon or 0 Vicryl in a running fashion 1 cm apart and incorporating 1 cm of tissue width starting at the lateral corners and continuing toward the midline in a transverse incision. Hernias are more likely at the corners in Pfannenstiel or Maylard incisions, and therefore care should be taken to incorporate both layers of the fascia. Tissue necrosis occurs more easily here than on the uterus, so care must be taken not to make the sutures too close or too tight. A vertical incision may need to be closed with a delayed absorbable suture such as 0 PDS. A large needle with looped suture allows for extra strength and avoids the need to place knots at the inferior and superior ends of the closure; each strand from the superior suture can be tied to its counterpart from the inferior suture. This continuous layer can be either a full-thickness closure excluding skin and subcutaneous fat or a running Smead–Jones technique consisting of alternating wide full-thickness bites with fascia-only bites.

If the subcutaneous tissue is >2 cm in depth, closure of the subcutaneous tissue with a 2-0 Vicryl or 3-0 plain suture is appropriate. Data suggest a decreased risk of wound disruption and incidence of seroma without differences in hematoma or wound infection. The value of irrigation of this layer has not been proved, and drains have not been shown to be of benefit. The skin may be closed with a subcuticular dermal suture of 4-0 Vicryl/Monocryl or staples. Staples are most commonly used because their use decreases operating time, but the data regarding patient satisfaction and postoperative pain are conflicting. If increased risk of postoperative infection or bleeding is anticipated, a staple closure may be preferable, because it allows easier opening of only a portion of the incision. The patient’s abdomen should be cleaned of the preoperative solution and a sterile bandage applied for 24 hours postoperatively. The uterus should be massaged prior to leaving the OR to ensure that uterine tone is adequate and to prevent further clots from accumulating in the

lower uterine segment as these may distend the uterus and prevent adequate uterine contractility.

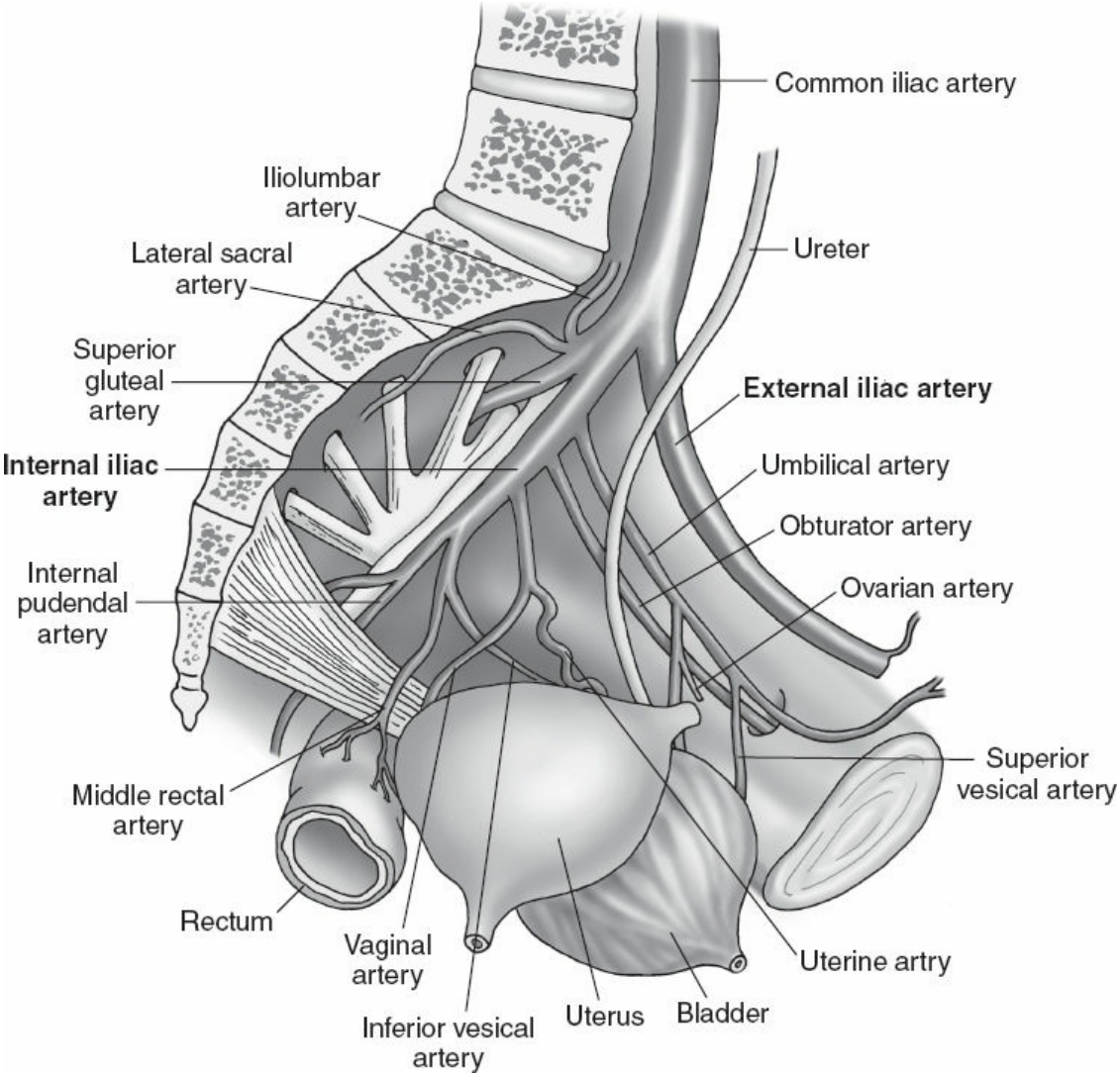

Figure 182.7. The internal iliac (hypogastric artery).

Postoperative pain management should be in the form of continued epidural anesthesia, long-acting morphine given through the epidural or spinal anesthetic, and/or intravenous medications, such as Toradol and/or narcotics.

POSTOPERATIVE MANAGEMENT

Volume Status

Recovery from cesarean delivery is usually uncomplicated as most parturients are healthy preoperatively. Patients may require 125 mL or greater of physiologic intravenous fluids per hour until oral intake is

established. Indications for cesarean delivery must be taken into consideration when assessing fluid status and urine output. Routine hematocrits are not performed unless blood loss was greater than anticipated or medical risk factors are present, such as preeclampsia, fever, low urine output, pulmonary edema, or renal or cardiac disease. However, a hemogram on postoperative day 1 may help identify patients in whom intraoperative losses were greater than expected. The most common cause of fluid imbalance postpartum is an underestimation of blood loss from surgery. As such, it is wise to attempt to quantitate the blood loss in the OR. This can be done by routinely noting the volume of fluid in the suction canister, minus the estimated volume of amniotic fluid and irrigation, plus the estimated volume in saturated lap sponges. Postoperative bleeding and complications can occur in even the most routine cases, and careful evaluation of the postoperative patient should be done if signs of hypovolemia are present. Transfusion of blood is recommended in patients with symptomatic anemia and ongoing blood loss such as postpartum hemorrhage.

Intravenous fluids should be discontinued as soon as oral intake is established, usually within 24 hours postoperatively. There are many studies supporting early feeding after most cesareans without awaiting flatus. If cesarean delivery involved bowel surgery or bowel injury, immediate oral intake is not offered. Ambulation is encouraged within 12 to 24 hours to decrease risk of postoperative thrombosis. Foley catheters are removed in ~12 to 18 hours in most patients without intraoperative bladder complications. Patients who are immobilized in an intensive care unit or who are unable to ambulate postoperatively require deep venous thrombosis prophylaxis in the form of pneumatic boot compression or subcutaneous heparin. Given the increased risk of venous thromboembolism in postoperative pregnant women, it would seem prudent to employ compression stockings routinely after a cesarean and add subcutaneous heparin for patients with additional risk factors such as obesity, history of thrombosis, or thrombophilia

Pain

Many patients receive long-acting morphine in an epidural or spinal catheter at the time of surgery. This allows for excellent pain relief for the first 24 hours in most cases. Additional nonnarcotic medications such as Toradol (ketorolac) can be given to these patients. Care must be taken if

any additional narcotics are used because the delayed absorption of long-acting morphine derivatives is variable and can lead to respiratory suppression. If spinal morphine is not used, patient-controlled analgesia (PCA) or intramuscular narcotics can be used until the patient tolerates oral intake. Pain medication is typically needed for 1 to 2 weeks postoperatively.

Infection

Postpartum febrile morbidity is common after cesarean delivery (3% to 35%), especially if the procedure was performed after rupture of membranes or labor. Ideally, prophylactic antibiotics are given in these cases, but this does not completely eliminate the occurrence of postpartum endometritis or pulmonary complications. The diagnosis of postpartum endometritis is clinical, based on fever above 100.4°F, fundal tenderness, foul-smelling discharge, and absence of alternative infections (i.e., wound infection, mastitis, or pneumonia). Treatment includes broad-spectrum intravenous antibiotics such as clindamycin and gentamicin or Zosyn until the patient is afebrile for 24 to 48 hours. If fever persists 24 to 48 hours after initiation of therapy, imaging studies, pelvic ultrasound, and computed tomography scans are recommended to evaluate for other fever sources such as hematomas, abscess collections, or thrombosis. If wound infection is apparent, wound exploration and culture may be necessary.

Postpartum Follow-Up

It is important to discuss with the patient before discharge her emotions and her understanding of the indication for cesarean delivery. There are wide variations in patient reaction after cesarean birth, including feelings of inadequacy, disappointment, and depression. In addition, if a trial of labor is contraindicated in the future due to a vertical uterine incision, it is prudent to educate the patient about this recommendation for future pregnancy. Patients are usually discharged 3 to 4 days after delivery (third-party payers in the United States will usually pay up to 4 days for uncomplicated care). This time allows for patient recovery while learning how to care for a newborn and ensuring that breast-feeding is well established. Pain medication is usually a combination of narcotic analgesia (oxycodone or codeine) and ibuprofen unless there are allergies or contraindications. Most patients no longer need medications by 2 weeks after delivery. Routine activity is encouraged, although heavy lifting, tub

baths, and vaginal penetration are avoided for at least 6 weeks. Driving is not recommended until the patient is no longer taking pain medications and minimal pain is present, usually about 2 weeks. Bleeding may normally persist for up to 6 weeks, with heavier bleeding noted with increased activity. Breast-feeding may alter this pattern with lighter bleeding but may also decrease vaginal lubrication, and the patient should be counseled that breast-feeding alone is not an adequate birth control option. Birth control should be reviewed and encouraged in all women not intending immediate conception after delivery since the timing of the first ovulation is unpredictable. Fever or incisional drainage should prompt immediate contact with a medical provider. Follow-up appointments may include a 2-week incisional check and 6-week postpartum examination. Additional follow-up may be necessary if any complications arise. Cesarean delivery requires careful postoperative follow-up even though the majority of patients have an uneventful recovery.

SUMMARY OF RECOMMENDATIONS

Suggested by good-quality data:

1. Administer antibiotics before skin incision
2. Bluntly extend the uterine incision
3. Undertake spontaneous delivery of the placenta
4. Close subcutaneous tissue if the depth is >2 cm

Surgeon preference:

1. Exteriorization of the uterus for closure
2. Irrigation of the peritoneal cavity
3. Staples versus suturing for skin closure

Conflict/controversy:

1. Extended spectrum antibiotic prophylaxis (azithromycin)
2. Creation of the bladder flap
3. Singleversus double-layer uterine closure
4. Parietal peritoneal closure

Suggested Readings

Bamigboye AA, Hofmeyr GJ. Closure versus non-closure of the peritoneum at caesarean section: short and long-term outcomes. *Cochrane Database Syst Rev* 2014; 8:CD000163.

Cromi A, Ghezzi F, Di Naro E, et al. Blunt expansion of the low transverse uterine incision at cesarean delivery: a randomized comparison of 2 techniques. *Am J Obstet Gynecol* 2008;199:292.e1–6.

Dodd JM, Anderson ER, Gates S, et al. Surgical techniques for uterine incision and uterine closure at the time of caesarean section. *Cochrane Database Syst Rev* 2014;7:CD004732.

Hohlagschwandtner M, Ruecklinger E, Husslein P, et al. Is the formation of a bladder flap at cesarean section necessary? A randomized trial. *Obstet Gynecol* 2001;98:1089–92.

Mackeen AD, Berghella V, Larsen ML. Techniques and materials for skin closure in caesarean section. *Cochrane Database of Syst Rev* 2012;11:CD003577.

Premkumar G, Metwally M, et al. To close or not to close? A systematic review and a meta-analysis of peritoneal nonclosure and adhesion formation after cesarean section. *Eur J Obstet Gynecol Reprod Biol* 2009;147:3–8.

Rousseau JA, Girard K, Turcot-Lemay L, et al. A randomized study comparing skin closure in cesarean sections: staples vs. subcuticular sutures. *Am J Obstet Gynecol* 2009;200:265e1–e4.

Tita AT, Hauth JC, Grimes A, et al. Decreasing incidence of postcesarean endometritis with extended-spectrum antibiotic prophylaxis. *Obstet Gynecol* 2008;111:51–6.

Wilkenson C, Enkin MW. Manual removal of placenta at cesarean section. *Cochrane Database Syst Rev* 2007; 3:CD000130.

EDITOR'S COMMENT

Childbirth is the most dangerous thing that most women will do in their lifetime. Approximately 50% of maternal deaths are linked to surgery and 16% are associated with surgical site infection. So it is no wonder that both patient and physician are determined to find safer ways to have a good outcome and a healthy live birth. In our very litigious society who can blame anyone for opting for what appears to be the safest surgery. In 1985, a meeting of the World Health Organization (WHO) states that cesarean section (CS) rates higher than 15% were not medically justified (World Health Organization. Appropriate technology for birth. *Lancet* 1986;2:436–7). Despite this "ideal" number of 15% most countries exceed this rate. Souza and colleagues have developed a global reference for projected CS rates at differing health facilities (Souza JP, Betra AP, Dumont A, et al. A global reference for caesarean section rates (C-Model): a multicountry cross-sectional study. *BJOB* 2016;123(3):427–36). The authors used data from over 10 million women giving birth from 43 countries to develop a mathematical model to generate expected CS rates. Using maternal

characteristics their model can give a customized reference rate for CS for individual women and facilities and is available on line. (*www.who.int/reproductivehealth/publications/maternal_perinatal_health/c-model/en/*)

The calculator requires data on parity, previous c-section, multiple pregnancy, provider-initiated childbirth (spontaneous or induced), presentation (cephalic, breech, transverse), maternal age, organ dysfuntion or ICU admission, and complications (placenta praevia, abruption placentae, chronic hypertension, preeclampsia, renal disease, HIV. However, the authors admonish that there is no substitute for clinical judgment. However, note that twinned pregnancies have been shown in randomized trials to have different outcomes whether by CS or vaginal birth (Hutton EK, Hannah ME, Ross S, et al. Maternal outcomes at 3 months after planned caesarean section versus planned vaginal birth for twin pregnancies in the Twin Birth Study: a randomized controlled trial. *BJOG* 2015;122(12):1653–62). More than twin multiple pregnancy may be a different story. Most controversial is cesarean section delivery by maternal request (CDMR). This is performed at the request of the parturient and without any medical contraindication to vaginal delivery. Rates range from 2.6% to 26.8% and as indicated by the authors rates seem to be increasing. The Committee on Obstetric Practice strongly recommends a vaginal delivery in the absence of maternal or fetal indications and especially in women who desire multiple children (American College of Obstetrics and Gynecology: American College of Obstetrics and Gynecology committee opinion no. 559: Cesarean section delivery by maternal request. *Obstet Gynecol* 2013;121(4):904–7). It would seem the only way to stop such practice is for insurance companies not to pay for it.

Once you have had a cesarean section dependent on how the first cesarean section was performed your odds of a vaginal birth are low but as the authors suggest it should be done at full term as an elective repeat CS at 37 weeks has a higher risk of neonatal morbidity and mortality. (Ganchimeg T, Nagata C, Vogel JP, et al. Optimal timing of delivery among low-risk women with prior caesarean section: A secondary analysis of the WHO multicountry survey on maternal and new born health. *PLoS One* 2016;11(2):e014909). About one third of preterm births require special attention (Souza RT, Cecatti JG, Passini R, et al, The burden of provider-initiated preterm birth and associated factors: evidence from the Brazilian multicenter study on preterm birth (EMIP). *PLoS One* 2016;11(2):e0148244).

Perhaps the most interesting and by some controversial is the banking of the baby's cord blood which contains stem cells. Stem cells can be collected at birth and stored. The cells are cryopreserved. Umbilical cord tissue can also be saved and contains different stem cells than that of the cord blood. Stem cells from cord blood are immature (unlike those from a bone marrow harvest) and are easier to match with the recipient and less likely to be rejected. Like many institutions, we have a public cord blood bank and it is available for anyone

who needs stem cells. About one third of minorities (African Americans and Hispanics) have a difficult time finding stem cell matches and receive cord blood stem cells. Method of delivery does not impact this choice.

It would seem that everyone agrees that there are too many cesarean sections but as of yet no one has a plan on how assure diminution of unnecessary cesarean sections and especially cesarean sections by maternal request.

V. Suzanne Klimberg

183 Abdominal Hysterectomy

Mitchel S. Hoffman, Celso Silva, and Aileen Caceres

INTRODUCTION

Hysterectomy is the most common major gynecologic procedure performed in women in the United States; approximately 600,000 women undergo the operation each year. Since hysterectomy is a common surgical procedure among women, its trends and routes become important to evaluate through time. The peak year for hysterectomies for benign indications was in the 1970s, with more than 700,000 procedures performed. New medical technologies and therapies became available to gynecologists and, as a result, hysterectomy rates decreased in the 1980s.

Approximately one third of women 65 years of age have had a hysterectomy with the number of operations varying by year, geographic location, age, and race. The highest hysterectomy rates are in the South and the lowest in the Northeast. This rate difference is 2.5-fold. The highest rate occurs in the 40 to 50 years age group.

There are basically three routes for a hysterectomy: laparotomy, vaginal, and laparoscopic. Even though the American College of Obstetrics and Gynecology (ACOG) and the American Association of Gynecologic Laparoscopists (AAGL) have both published consensus statements regarding the benefits of a minimally invasive approach, the majority of hysterectomies are still performed via laparotomy. Following the introduction of the robotic surgical platform for gynecologic procedures in 2005, the impact of robotic-assisted surgery has also been examined regarding its effect on the mode of access for hysterectomy. For benign cases from 2007 to 2010, the proportion of hysterectomies performed with robotic assistance increased from 0.5% to 9.5%.

The choice of the surgical route of hysterectomy may be complex depending upon the clinical scenario. Clinical factors, a surgeons training and experience, safety, the facility and availability of equipment, and cost-effectiveness are all considerations. Women with very large uteri or complex pelvic pathology generally require a laparotomy. For benign disease, vaginal hysterectomy is the least invasive route and is preferred

whenever anatomic conditions make this feasible. The vaginal and laparoscopic routes for hysterectomy are associated with less postoperative infection, lower estimated blood loss, shorter hospital stay, and faster recovery than abdominal hysterectomy. Although recent data have shown an increase in rates of minimally invasive hysterectomy, in the United States the abdominal route is chosen in over 60% of cases.

Ultimately, the surgeon must decide upon the route of hysterectomy based upon his or her capabilities and the clinical factors associated with the individual patient.

INDICATIONS

About 85% of hysterectomies are performed as treatment of myomata, endometriosis, endometrial hyperplasia, cancer, or prolapse. Hysterectomy is occasionally required (often emergently) for the management of an obstetric complication (such as placenta accreta). Prolapse generally includes loss of support of the vagina and requires concomitant surgical correction. Cancer operations frequently involve extended surgical procedures such as lymph node dissection. Of the above indications, uterine myomata is the most frequent. Myomas are more common in African-American women, who have a higher incidence of having an abdominal hysterectomy. Symptoms usually reported by women with these diseases are abnormal bleeding, chronic pelvic pain, abdominal mass, abnormal Papanicolaou (Pap) test, or pressure in the vagina. Except for the diagnosis or suspicion of cancer, surgery should not generally be the first approach to therapy. Effective medical therapy exists for many of the benign diseases like myomas, endometriosis, and endometrial hyperplasia. Examples of these medical therapeutic agents are gonadotropin-releasing hormone agonists to establish early reversible medical castration for myomas and endometriosis, antiprogestins (RU486) for myomas, androgens (danazol) for endometriosis, and progestins for endometrial hyperplasia. Less extensive surgery is also available for these conditions such as myomectomy, laparoscopic excision and/or ablation of endometriosis, dilation curettage for endometrial hyperplasia, endometrial ablation or progestin-type intrauterine devices for menorrhagia, and pelvic arterial embolization for myomata.

SURGICAL TECHNIQUE

A Foley catheter is inserted into the bladder before surgery. This reduces

the size of the bladder and helps prevents incidental bladder damage when entering the lower abdomen and when taking the bladder off the lower uterine segment and cervix. Entry into the abdomen is usually by either a lower abdominal midline incision or by a transverse (e.g., Pfannenstiel) incision. The Pfannenstiel incision provides more limited exposure and its main advantage is cosmetic. In the presence of complicated pathology, a midline or true transverse incision will provide better exposure.

Once the abdomen has been entered, an exploration is performed. A self-retaining (e.g., Bookwalter) retractor is placed. Assuming the pathology is found to be limited to the pelvis, the bowel is then packed into the upper abdomen. Adhesions need to be divided prior to packing. In many cases, it is helpful to mobilize the sigmoid colon and cecum so that they are packed back as well. The retractor secures the packs and gives good visualization of the pelvic structures. The uterus is grasped and held with long clamps (e.g., Kelley) placed snugly along the lateral sides of the fundus. These clamps are used for traction on the uterus and control of back-bleeding. Traction on the uterus and counter traction on the surrounding soft tissues are important surgical principles to safe and efficient performance of a hysterectomy.

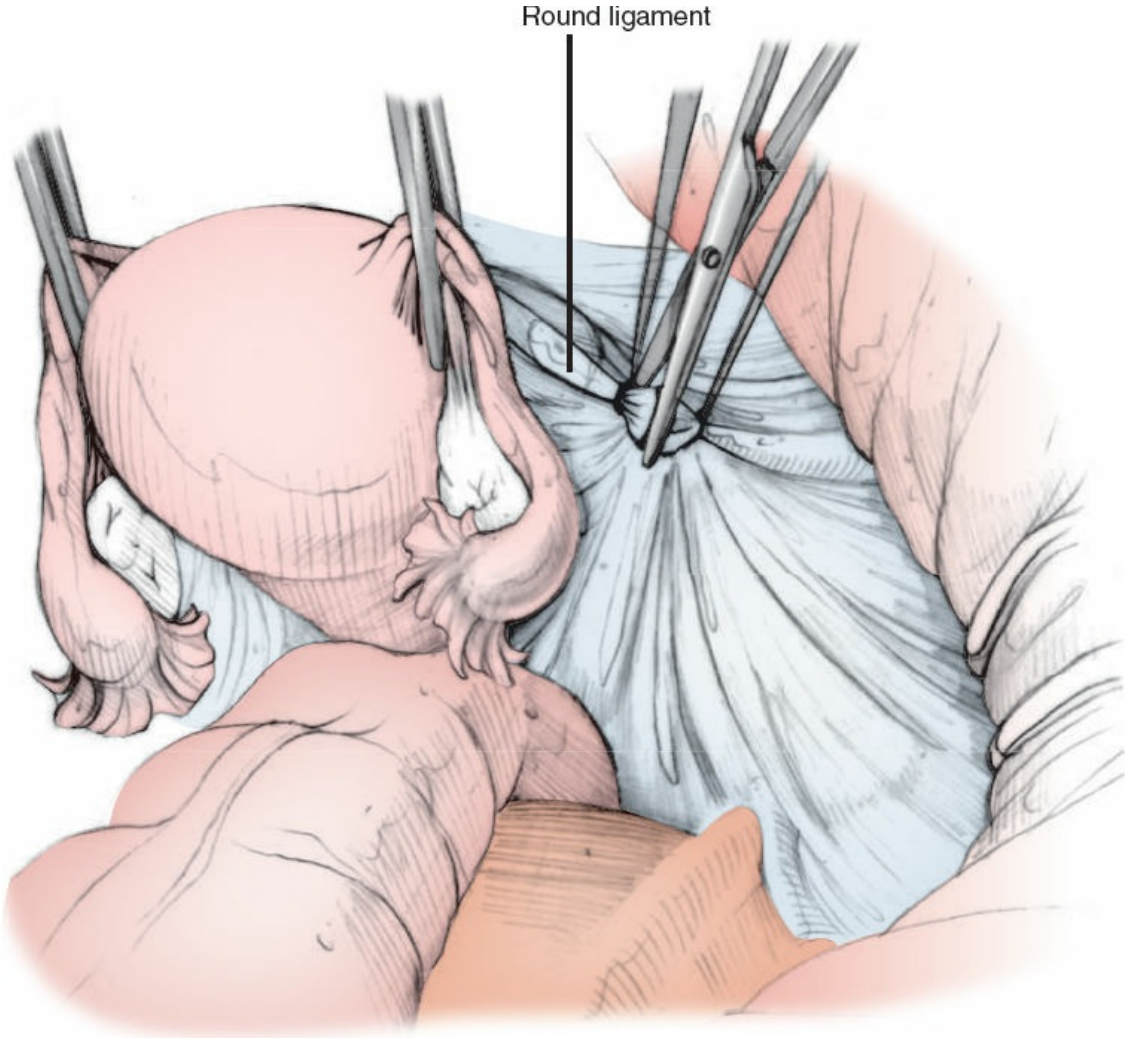

Figure 183.1. Uterus is held and upward traction is exerted with Kocher clamps during the hysterectomy. The right round ligament is doubly ligated and transected as the first step. This opens the retroperitoneal space.

The initial uterine incisions on each slide should begin at the round ligaments. These are elevated and divided hemostatically with cautery lateral to the uteroovarian vascular anastomoses (Fig. 183.1). One small artery (Sampson artery) runs under this ligament. The external iliac vessels are in close proximity. Division of the round ligament lateral to the uteroovarian vascular anastomosis avoids hemorrhage and facilitates isolation of the upper vascular pedicle. The pelvic peritoneum can then be opened laterally, caudal, and cephalad to the round ligament. This peritoneal incision is carried from each side completely across the front of the uterus at the vesicle uterine fold. The surgeon can then partially open the pararectal space. This will allow visualization of the iliac vessels on the lateral pelvic wall and the ureter on the medial peritoneal fold. A

decision about retaining or removing the ovaries should be discussed with the patient prior to surgery. In general, if the ovaries are normal and the woman is premenopausal, it is recommended that they be retained. Removal of ovaries in younger women will reduce their estrogen and androgen hormone levels and is not routinely done unless there is obvious gross ovarian pathology, a strong family history of ovarian cancer (or known genetic predisposition), or a disease process where ovarian hormones either aggravate the disease or may in fact harbor the disease, such as with endometriosis or chronic pelvic infection.

If the ovaries are to be removed, then the infundibulopelvic ligaments are identified safely away from the ureters and hemostatically divided (Fig. 183.2; sutures, staples, or a bipolar energy device). There are many large vessels in these ligaments and particular attention is required. If the ovaries are to be preserved, then the uteroovarian pedicles (uteroovarian ligament, fallopian tube and vascular anastomosis) are hemostatically divided in a similar manner (Fig. 183.3). These ligaments should be divided as close to the uterus as possible to reduce ovarian blood flow disruption.

The bladder is then separated from the cervix, generally in a largely avascular plane. If there are any adherent areas, these must be sharply dissected against or within the stroma of the cervix in order to prevent bladder injury. This is commonly a problem in women who have previously had a cesarean section. If bladder damage is suspected at any time during the operation, the bladder should be back filled with a sterile colored solution, which will quickly identify a cystotomy. Mobilization of the bladder continues just beyond the cervix so that the cervicovaginal junction can be safely transected. Mobilization also exposes the attachments of the paracervical ligaments so that they may also be safely clamped. This creates a “U” shaped region of ***u***rinary tract—containing soft tissue that is to be protected.

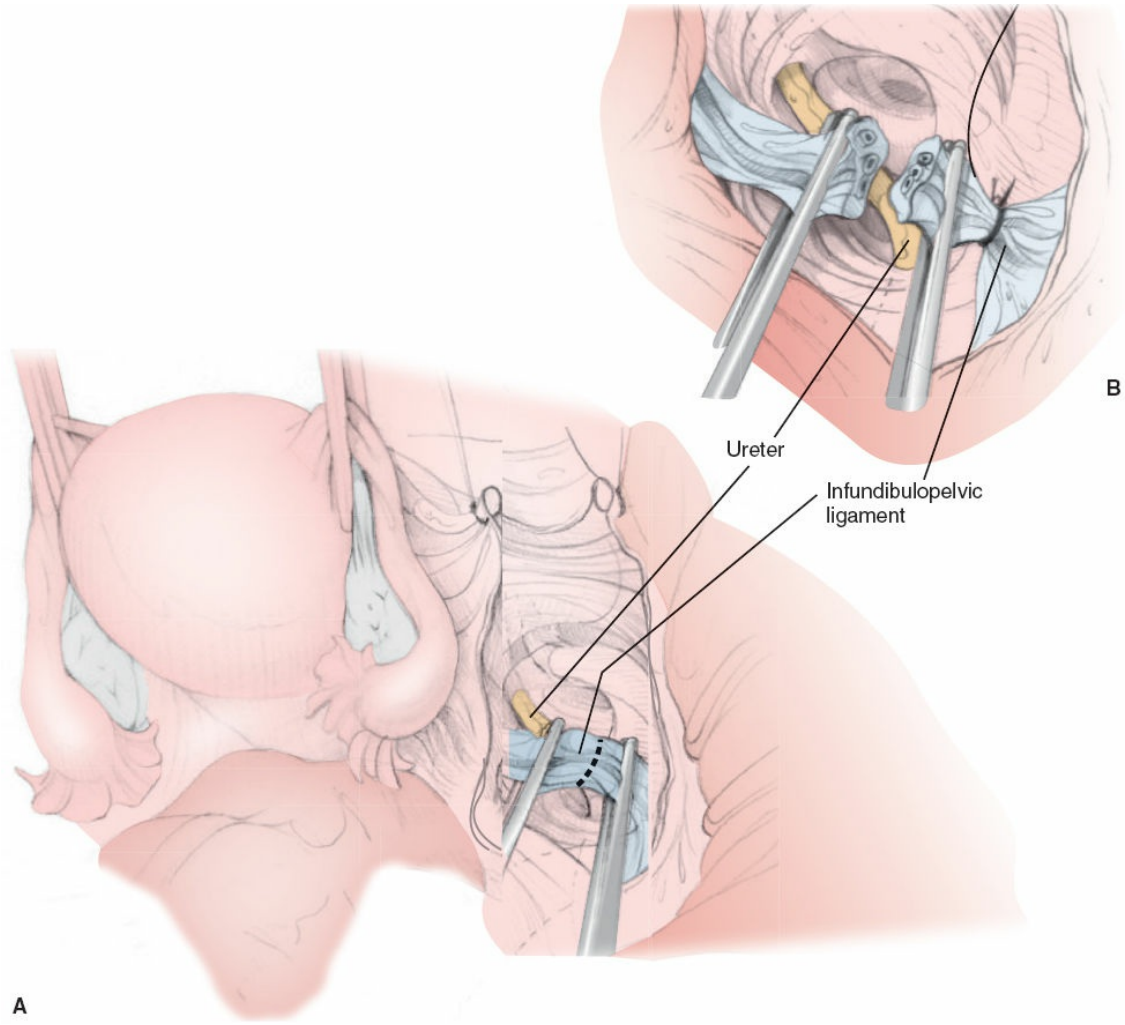

Figure 183.2. The infundibulopelvic ligaments are identified, clamped, cut, and sutured if the ovaries are to be removed. Care is taken to avoid the ureter.

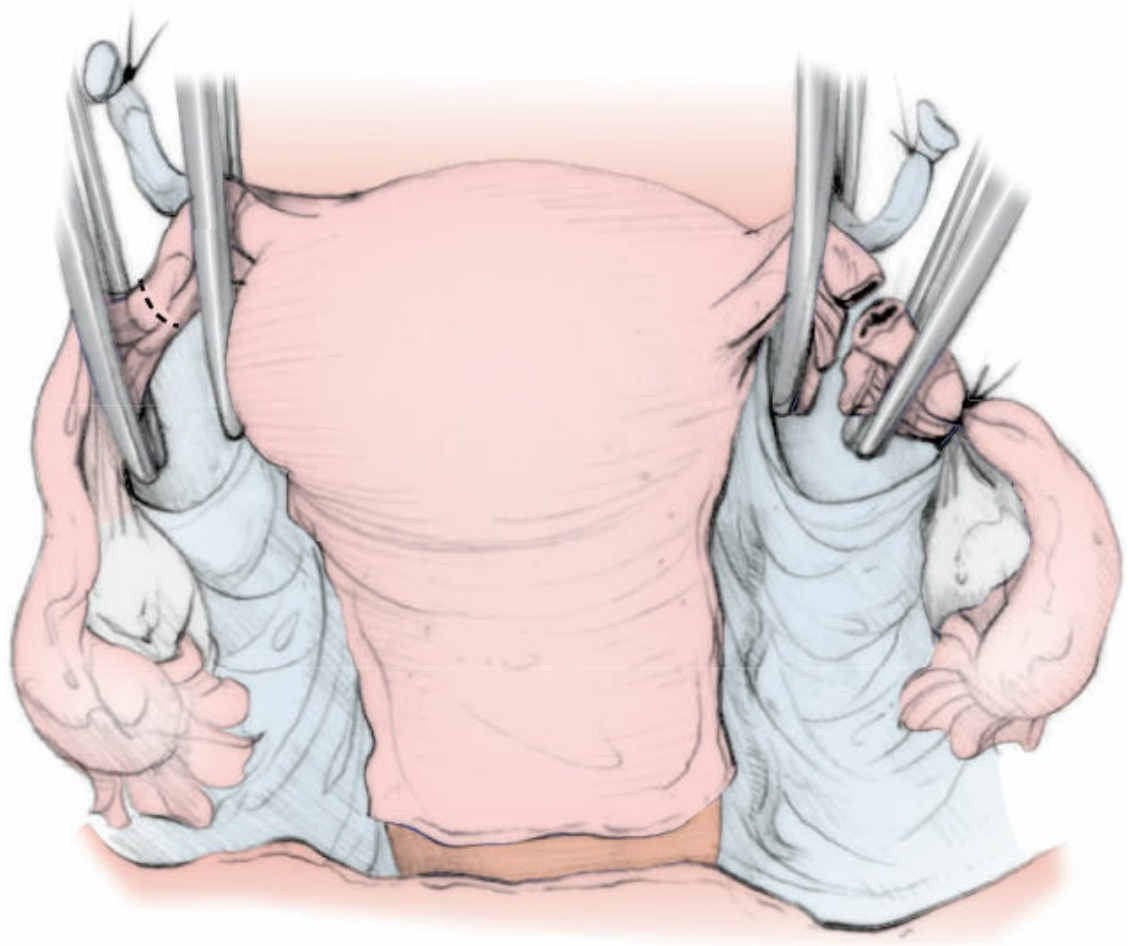

Figure 183.3. The uteroovarian ligaments are clamped, cut, and sutured when the ovaries are to be preserved.

The posterior leaf of the broad ligament is then partially divided toward the posterior cul-de-sac in order to better isolate the ascending uterine arterial branches and move the ureter further from the operative field. Starting with these ascending uterine vessels, hemostatic division then includes the paracervical (cardinal and uterosacral) ligaments (Fig. 183.4). The length of these ligaments varies depending on the uterine size and cervical length. Because the ureter passes approximately 1.5 cm lateral to the uterus and under the uterine artery, it is important to keep the line of dissection applied close to the uterus. When using a clamp-cut-stich method, it is useful to utilize heavy pedicle clamps to manage these somewhat thick fibrovascular tissues (Fig. 183.5).

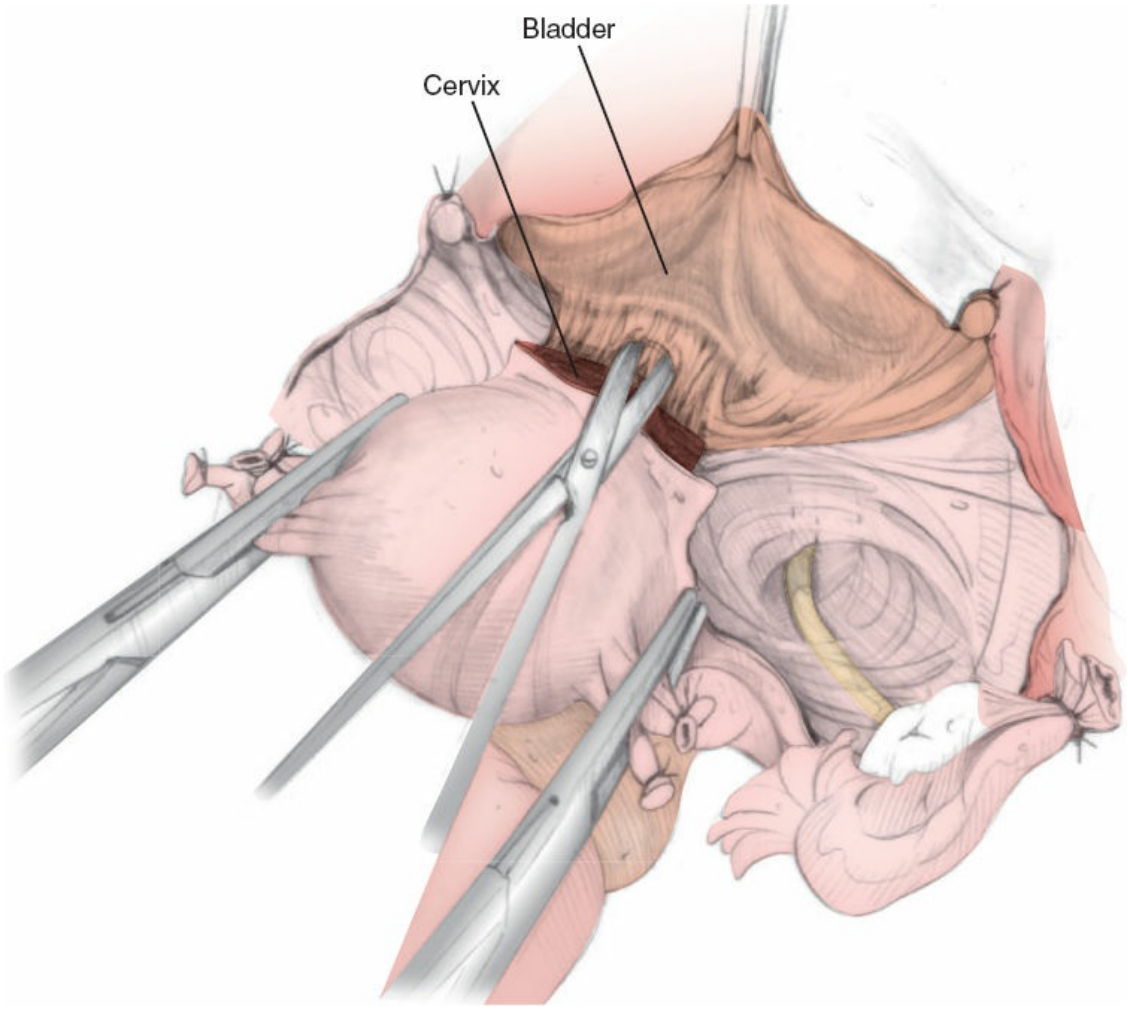

Figure 183.4. The vesicouterine peritoneum is incised and the bladder is dissected away from the cervix.

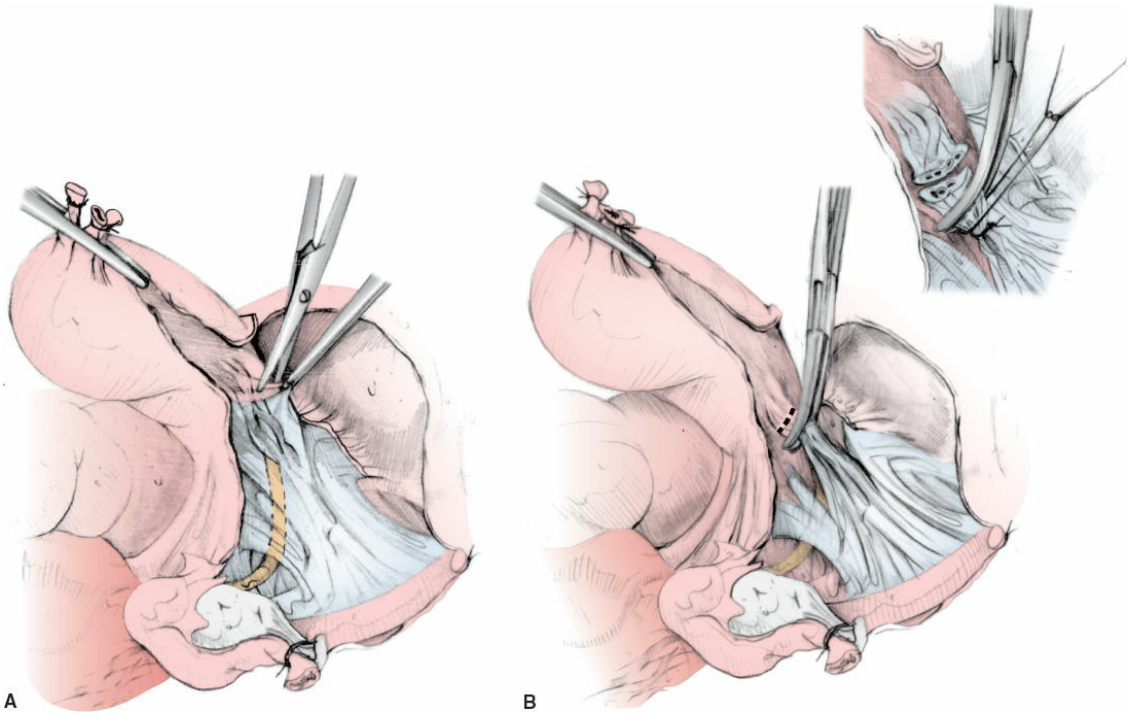

Figure 183.5. The uterine vessels are clamped close to the uterus above the uterine lower segment. These pedicles are clamped, cut, and sutured bilaterally. Staying close to the uterus and well above the cervix avoids damage to the ureters.

The hysterectomy can be done with complete removal of the cervix, which is the usual procedure or the cervix can be left in place (subtotal hysterectomy, Fig. 183.6). If the latter procedure is selected, cervical disease should have been excluded with a normal preoperative pelvic examination and Pap test. Retaining the cervix may be elected in some patients in order to reduce operative time or preclude urinary tract and/or rectal injury in cases of severe adherence. In some cases of advanced ovarian cancer, the cervix is retained to prevent cancer growth into the vagina and/or leakage of ascites. When the cervix is left, the endocervical canal should be excised or cauterized to prevent later bleeding from retained endometrium.

When the cervix is to be removed with the uterus, the end of the cervix can be palpated and a bulge can usually be seen at this area of the vaginal apex. The surgeon should attempt to ensure isolation of the cervicovaginal junction from the lateral vascular attachments. At this point, the vagina may simply be transected from the cervix, clamped and cut at each angle, or stalpled (absorbable). Inspection of the uterus will determine if the entire cervix is in the operative specimen. The vaginal cuff can be grasped with clamps (e.g., Allis, Kocher) including both the vaginal mucosa and submucosa. The cut edge will have small blood vessels, but the main arterial supply is at 3 and 9 o'clock as ascending branches of the internal iliac arteries. These lateral vaginal "angles" require particular attention to hemostasis. The vaginal cuff is usually closed with absorbable suture (Fig. 183.7) but may be left open, with the cut edge made hemostatic by a running locking suture. If the vaginal cuff is left open, the peritoneum should be used to cover the opening in order to prevent bowel herniation into the vagina. An occasional advantage of leaving the cuff open is that pelvic drains can be placed if there has been infection or excessive bleeding, and pelvic collections of fluid postoperatively can be easily drained if they occur. Oncology follow-up may also be facilitated.

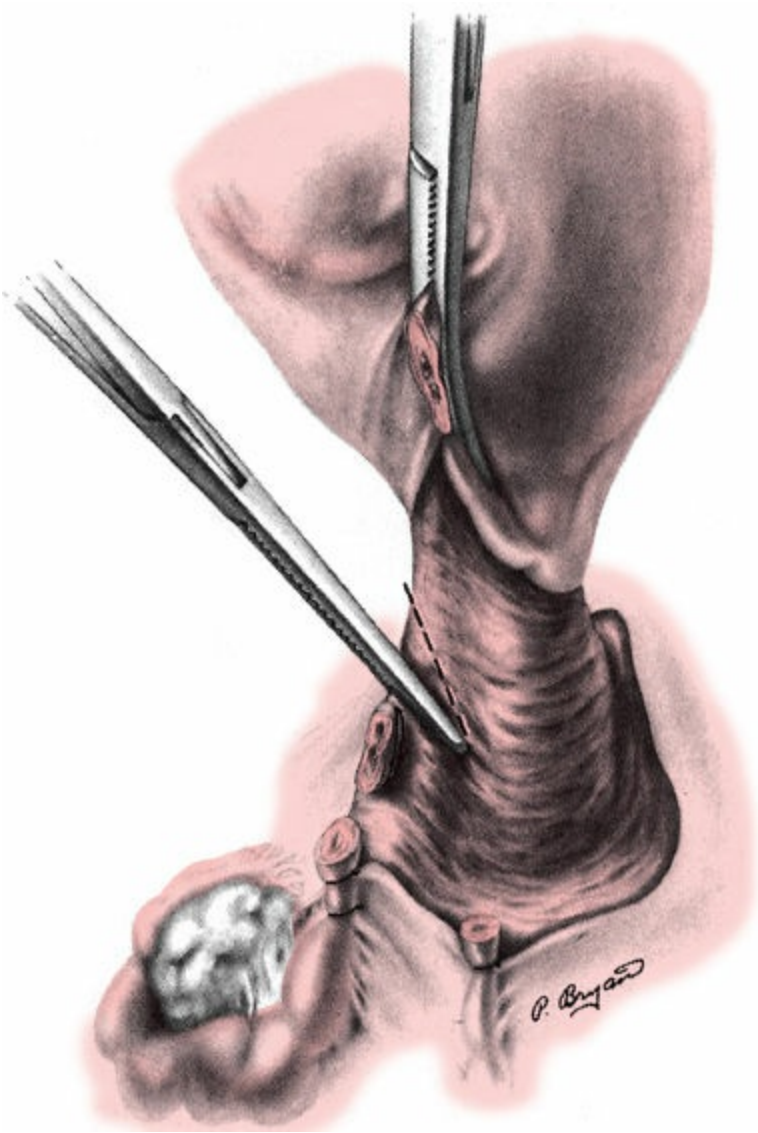

Figure 183.6. Hemostatic division then includes the paracervical (cardinal and uterosacral) ligaments. The clamps are maintained tightly against the cervix and within the “U” shaped region of mobilized soft tissue that contains the urinary tract.

After removal of the specimen, the pelvis should be inspected and hemostasis ensured. If the ovaries are retained, the ovarian ligaments may be sutured to the round ligament stumps to prevent them from falling into the cul-de-sac and producing pain and dyspareunia (Fig. 183.8). This also facilitates later removal if needed. There is no need to reperitonealize the entire pelvic surgical area except if the vaginal cuff is left open.

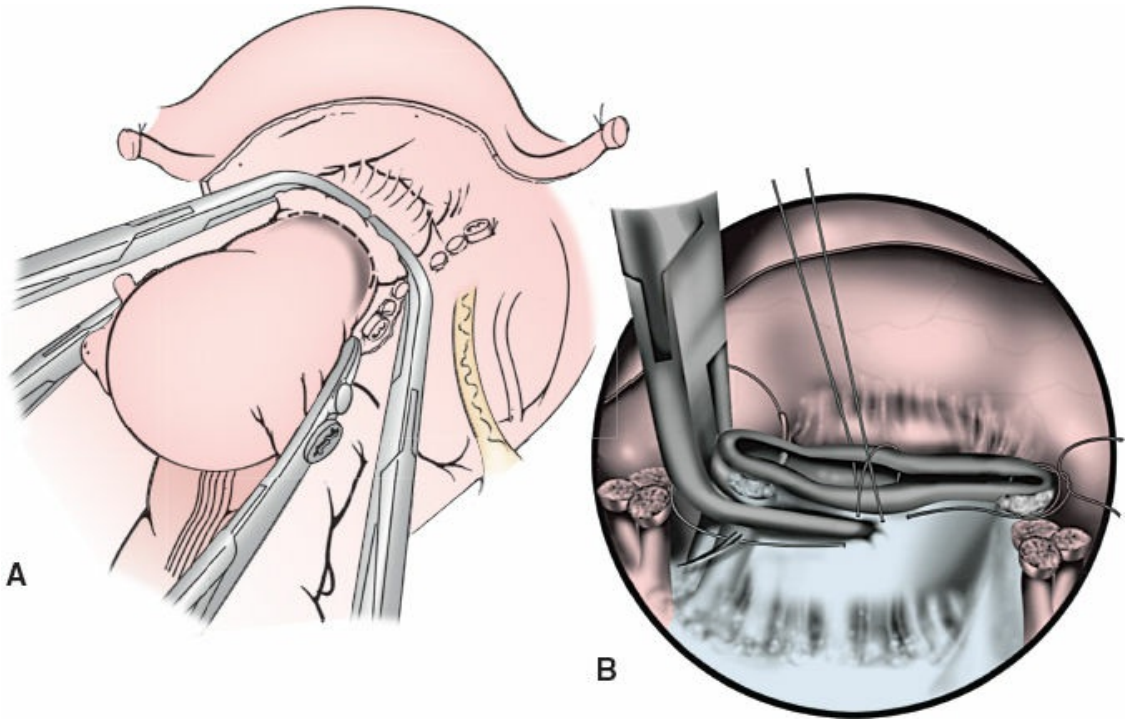

Figure 183.7. In the total hysterectomy the vagina is clamped below the cervix, cut, and sutured.

POSTOPERATIVE CARE

Postoperative care is essentially the same as that for any similar abdominal operation. The vagina and surrounding tissues are past the acute healing process by 6 to 8 weeks. During this time, patients are counseled to avoid immersion in water placement of anything into the vagina (i.e., intercourse, douching). A pelvic exam is done 6 to 8 weeks postoperatively to assess healing and the advisability of returning to sexual activity.

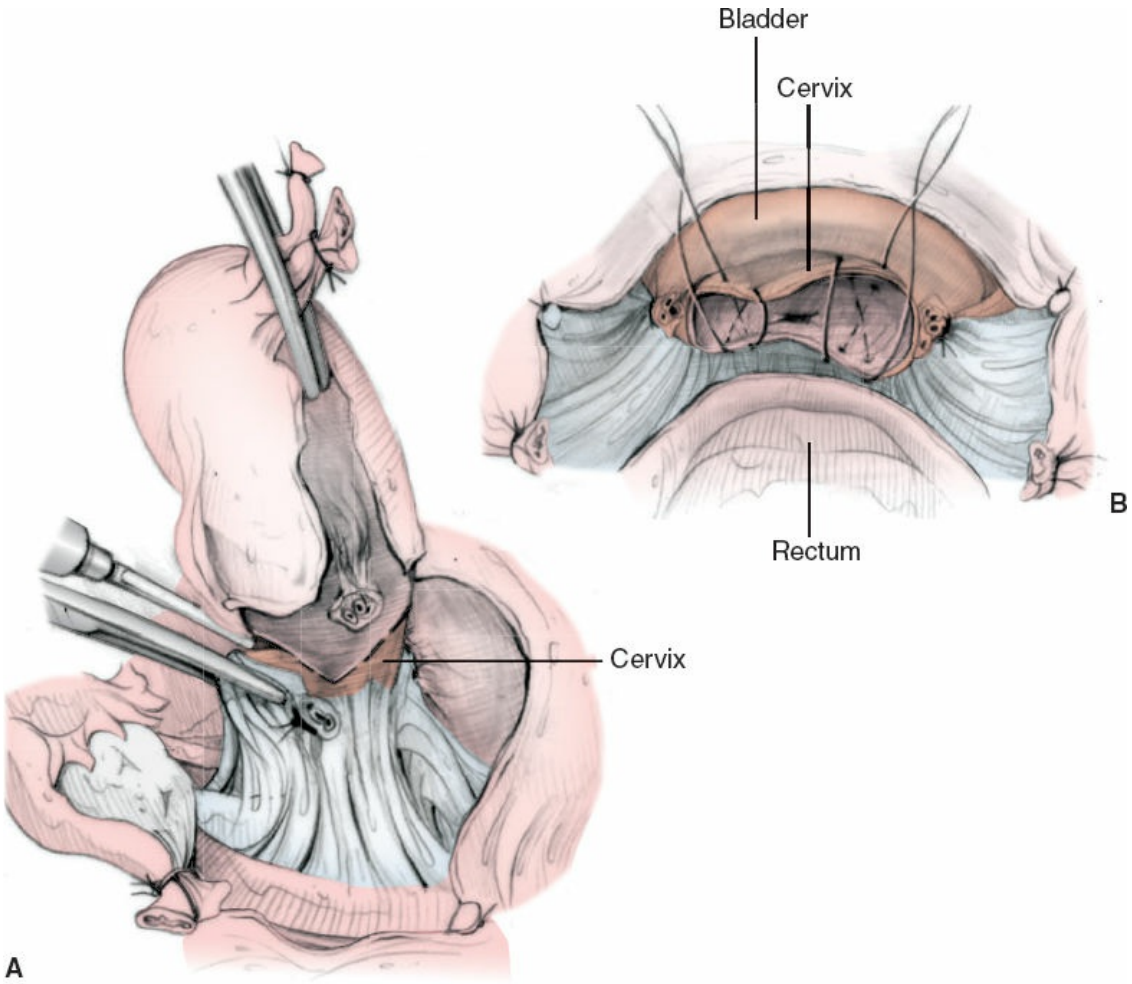

Figure 183.8. In the subtotal hysterectomy the surgeon cuts across the cervix and leaves the cervical stump in place. The cervical stump cut surface is sutured to obtain hemostasis.

When the ovaries have been removed in a premenopausal woman, acute estrogen withdrawal symptoms (vasomotor, mood swings, irritability) may need to be addressed with replacement. Related lifetime health care issues require an acute and long-term plan.

COMPLICATIONS AND THEIR MANAGEMENT

An abdominal hysterectomy has the usual surgical risks of bleeding and infection. For most procedures, the anticipated blood loss should not be excessive, and usually is no more than 500 mL. The major sites for postoperative infection will be the vaginal cuff, the wound, the urinary tract (as a result of the catheter), and the lungs. Total hysterectomy is a clean-contaminated operation and the use of short-term prophylactic antibiotics has been shown to significantly reduce the occurrence of pelvic and abdominal wound infection.

Intraoperative Complications

The majority of complications that occur with abdominal hysterectomy are common to laparotomies in general and especially to pelvic surgery in women. Structures that are occasionally injured during hysterectomy include the bladder, ureter, intestine, and lumbosacral nerves (Table 183.1). In addition, the pelvis is a highly vascular region with significant potential for hemorrhage. Postoperatively, occult injury to a viscus may become evident in the form of a vaginal fistula. Nerve injury is usually noted in the early postoperative period. Care should be taken with self-retaining retractors, especially in thin women where the lateral blades may impinge upon the femoral nerve as it exits from the caudal–lateral aspect of the psoas muscle. Postoperative infection specific to hysterectomy takes the form of a vaginal cuff cellulitis or abscess.

TABLE 183.1 Intraoperative Complications of Hysterectomy

Complication	Incidence (%)
Bladder injury	0.5
Ureteral injury	<0.2
Bowel injury	<0.5
Postoperative hemorrhage	1

The pelvic ureter and the bladder have an intimate anatomic relationship with the uterus. Through knowledge of these relationships, injury is avoided by appropriate traction and counter traction, isolation of the gonadal vessels from the ureters before ligation, careful dissection of the bladder from the cervix and anterior vaginal fornix, and placing clamps and sutures (or energy device) tightly against the cervix to avoid the lateral soft tissue where the ureters course. When there is significant pathologic distortion or inflammation of the pelvic organs, the anatomic relationships are less reliable, predisposing to urologic injury. Other factors that predispose to urologic injury during hysterectomy are intraoperative hemorrhage and poor exposure. Adnexal pathology, especially with fixation in the posterior lateral pelvis and inflammation involving the lateral pelvic peritoneum (especially if also retroperitoneal), makes isolation of the gonadal vessels difficult. Opening the retroperitoneum

above the pathologic process allows the surgeon to identify the ureter and trace it down. Injury of the ureter occasionally occurs at this level and management can be a challenge due to a potentially compromised distal ureteral segment. More commonly, the ureter is injured along its course through the paracervical tissues and is best managed with a ureteroneocystostomy. Less significant ureteral injuries may be managed by simple deligation, with or without stenting. If concern exists about ligating or transecting the ureter, verification of patency can be done with cystoscopy.

The urinary bladder is more likely to be injured during hysterectomy when inflammation or prior surgery (e.g., cesarean section) has obliterated the plane between the bladder and cervix. In such circumstances, leaving some cervical tissue on the bladder is usually the best approach. An inadvertent cystostomy should not be closed until the hysterectomy is completed; this facilitates a more appropriate path of dissection and avoids later tension on the cystotomy closure. When a cystotomy occurs near the vaginal fornix, it is close to the trigone. If there is concern about the integrity of the bladder or unexplained significant hematuria during the operation, then 100 to 200 mL of a dilute dye solution can be backfilled into the bladder to see if peritoneal leakage occurs.

The segment of intestine most commonly injured during the actual hysterectomy is the rectosigmoid colon. Several pathologic conditions (pelvic inflammatory disease, diverticulitis, ovarian cancer, endometriosis) may obliterate the posterior cul-de-sac, resulting in dense adherence of the rectosigmoid colon to the posterior aspect of the uterus. As with the bladder, sharp dissection leaving a small amount of uterus on the colon works well. For women with locally advanced ovarian cancer and in selected cases of severe endometriosis and diverticulitis, en-bloc hysterectomy with rectosigmoid colectomy is indicated.

The uterus, as would be expected from its function, is a highly vascular organ. Along its entire length, anastomosing branches of the gonadal and internal iliac vessels supply and drain the uterus. These numerous vessels run within the lateral uterine attachments, and it is not practical to isolate them. Rather, hemorrhage is avoided by careful attention to clamping, dividing, and ligating these ligaments (or utilizing an appropriate energy device in a similar manor). It is especially important to keep the clamps or energy device tight against the uterus and avoid large spaces between pedicles. This is made more difficult in the presence of significant

pathologic distortion (e.g., large lower uterine segment leiomyomata, adnexa densely adherent to the posterior broad ligament as seen with pelvic inflammatory disease or endometriosis) and with poor exposure (e.g., markedly obese patient). When hemorrhage is encountered, rather than attempting prompt and secure hemostasis, it is usually best to proceed with the hysterectomy in a careful but expeditious manner. Continued bleeding is usually from the more caudal blood supply and hemostasis occurs as this is ligated. When a large myomatous uterus interferes with distal exposure, it is best to ligate the gonadal and uterine vessels and then perform a supracervical hysterectomy. Occasionally, doing myomectomies improves exposure and thus facilitates hysterectomy. With greatly improved exposure, removal of the cervix becomes practical. Clamping or ligating bleeding from divided paracervical tissues endangers the ureter. One can carefully grasp the bleeding site with an Allis clamp, gently apply traction to the midline away from the ureter, and then carefully place a suture ligature. Cystoscopic assessment of ureteral patency is advisable in such cases.

Postoperative Complications

A significant though occult injury of the bladder becomes manifest as urinary leakage through the vaginal cuff. Depending on the mechanism of injury, this may be immediate or delayed, but will usually present within the first 10 days after surgery. The diagnosis is readily made by placing dilute methylene blue solution through a Foley catheter while observing for leakage through the vaginal cuff.

Unrecognized injury of a ureter may also present postoperatively with leakage of urine through the vaginal cuff. However, the patient may develop ureteral obstruction without leakage, and this is frequently asymptomatic. If concern arises immediately after the surgery, a simple test is to measure the blood creatinine level. One ligated ureter will raise the creatinine about 0.8 mg/dL for 2 days. The diagnosis is confirmed with intravenous pyelography.

Postoperatively, serous fluid or blood may accumulate at the operative site (above the vaginal cuff, between the bladder, and rectosigmoid colon). This collection is contaminated by bacteria from the vagina and occasionally develops into an abscess. Important risk factors for postoperative vaginal cuff cellulitis or abscess include prolonged surgery and excessive blood loss. Prophylactic antibiotics have dramatically

reduced the risk of this complication. Patients who develop an abscess present up to several weeks postoperatively with fever and lower pelvic discomfort. Drainage can usually be accomplished through the vaginal cuff although image-guided drainage may be preferred or required.

Absent anticoagulation, significant postoperative bleeding will usually manifest within the first 24 hours. Along with the usual signs of hemorrhage, the patient may develop vaginal bleeding, high drain output, or increasing abdominal distention. The usual source is a branch of the internal iliac system, often from the vaginal cuff itself. Management options include careful observation with transfusion as deemed necessary, reoperation (sometimes transvaginal cuff sutures work), or percutaneous arterial embolization after arteriography.

As with any abdominal operation, postoperative small bowel obstruction may develop. The site of obstruction is usually the ileum adherent to the operative site (pelvis) or abdominal wound. At the completion of hysterectomy, placement of the sigmoid colon and cecum over the raw pelvis and the omentum between the intestines and abdominal wound may help prevent this complication.

During abdominal hysterectomy, a component of the lumbosacral plexus may be damaged. Femoral neuropathy is by far the most common. The usual mechanism is thought to be ischemia or neuropraxia as a result of prolonged compression by a self-retaining retractor. Patients at risk are those who are thin, have poorly developed rectus abdominus muscles, have diabetes, and have a low transverse abdominal incision. The patient reports weakness (usually unilateral) of the leg, often stating that her knee “gives out” upon ambulation. Neurologic examination confirms the diagnosis. Management includes neurologic consultation and physical therapy. It must be emphasized that careful restricted ambulation under the guidance of a physical therapist is important to prevent a fall. Prevention of this injury is based on proper retractor placement to avoid compression of the nerve as it traverses and exits the psoas muscle.

Other postoperative complications may occur, including deep vein thrombosis (DVT), pulmonary embolism, wound dehiscence, and bowel herniation through the vaginal apex. Women who are at high risk for any of these complications may need specific prophylactic measures. For example, women who have had a DVT during pregnancy or during estrogen treatment are at risk of having a congenital coagulation disorder. If any of the thrombophilic tests are positive, then prophylactic

anticoagulation is recommended. Women with a postoperative serosanguineous wound discharge may have occult wound disruption and dehiscence and appropriate wound review is necessary.

SUMMARY

Abdominal hysterectomy is a very common surgical procedure, used as a definitive treatment modality for many gynecologic diseases after more conservative therapies have failed. Preoperatively, decisions about removal of the cervix or ovaries must be made with all concerned. With properly performed techniques, there are few complications expected.

Suggested Readings

AAGL Advancing Minimally Invasive Gynecology Worldwide. AAGL position statement: route of hysterectomy to treat b enign uterine disease. *J Minim Invasive Gynecol* 2011;18(1):1–3.

ACOG Committee Opinion No. 444: choosing the route of hysterectomy for benign disease. *Obstet Gynecol* 2009;114(5):1156–8.

Cardosi RJ, Cox CS, Hoffman MS. Postoperative neuropathies after major pelvic surgery. *Obstet Gynecol* 2002;100:240.

Cohen SL, Vitonis AF, Einarson JI. Updated hysterectomy surveillance and factors associated with minimally invasive hysterectomy. *JSLS* 2014;18(3).

Hoffman MS. How to safeguard the ureter and repair surgical injury. *OBG Management* 2008;20(11):16–28.

Hoffman MS, Zervos E. Intestinal surgery in gynecology. In: Rock JA, Jones HW III, eds. *TeLinde's Operative Gynecology*. 11th ed. Philadelphia, PA: Lippincott Williams & Wilkins; 2015.

Jacoby VL, Autry A, Jacobson G, et al. Nationwide use of laparoscopic hysterectomy compared with abdominal and vaginal approaches. *Obstet Gynecol* 2009; 114(5):1041–8.

Jones HJ III. Abdominal hysterectomy. In: Rock JA, Jones HW III, eds. *Te Linde's Operative Gynecology*. 11th ed. Philadelphia, PA: Lippincott Williams & Wilkins; 2015.

Learman LA, Summitt RL, Varner RE, et al. A randomized comparison of total or supracervical hysterectomy: surgical complications and clinic outcomes. *Obstet Gynecol* 2003;102:453.

Moen, M, Walter A, Harmanli OZ, et al. Considerations to improve the evidence-based use of vaginal hysterectomy in benign gynecology. *Obstet Gynecol*

2014;124:585–8.

Nieboer TE, Johnson N, Lethaby A, et al. *Surgical approach to hysterectomy for benign gynaecological disease (Review). Copyright © 2010* The Cochrane Collaboration. Published by John Wiley & Sons, Ltd.

Turner LC, Shepherd JP, Wang L, et al. Hysterectomy surgery trends: a more accurate depiction of the last decade? *Am J Obstet Gynecol* 2013;208(4):277.e1–277.e7.

Wright JD, Ananth CV, Lewin SN, et al. Robotically assisted vs laparoscopic hysterectomy among women with benign gynecologic disease. *JAMA* 2013;309(7):689–98.

Wright JD, Herzog TJ, Tsui J, et al. Nationwide trends in the performance of inpatient hysterectomy in the United States. *Obstet Gynecol* 2013;122(201):233–41.

Wu JM, Wechter ME, Geller EJ, et al. Hysterectomy rates in the United States, 2003. *Obstet Gynecol* 2007;110(5):1091–5.

EDITOR'S COMMENT

Drs. Hoffman, Silva, and Cecero have written a nice review of the indications, techniques, and potential complications associated with abdominal hysterectomy. As they point out correctly, despite consensus statements from several gynecologic societies regarding the benefits of a minimally invasive approach, the majority of hysterectomies are performed via laparotomy. A multicenter, prospective, randomized clinical trial comparing laparoscopic to open total hysterectomy evaluated 760 women with early stage endometrial cancer. The main study end points for this analysis were surgical adverse events, hospital length of stay, conversion from laparoscopy to laparotomy, including 753 patients who completed at least 6 weeks of follow-up. The incidence of intraoperative adverse events was comparable in either group. The incidence of serious adverse events (14.3% in Total Abdominal Hysterectomy [TAH], 8.2% in Total Laparoscopic Hysterectomy [TLH], $p = 0.007$) was significantly higher in the TAH group compared to the TLH group. Mean operating time was 132 and 107 minutes, and median length of hospital stay was 2 and 5 days in the TLH and TAH group, respectively ($p < 0.0001$). The authors of this trial conclude that compared to TAH, TLH is associated with a significantly decreased risk of major surgical adverse events, and that a laparoscopic surgical approach to early stage endometrial cancer is safe.

A recent Cochrane Database Systematic Review on the surgical approach to hysterectomy for benign gynecologic disease assessed four approaches including abdominal (open) hysterectomy, vaginal hysterectomy, laparoscopic hysterectomy, and robotic-assisted hysterectomy. A total of 47 studies with

more than 5,000 women were included. The authors concluded that among women undergoing hysterectomy for benign disease, vaginal hysterectomy appears to be superior to laparoscopic and abdominal hysterectomy as it is associated with faster return to normal activities. Where vaginal hysterectomy is not possible, the authors found that laparoscopic hysterectomy has some advantages over abdominal hysterectomy (including more rapid recovery, fewer febrile episodes, and fewer wound or abdominal wall infections), but these are offset by a longer operating time. Based on their analysis, the authors felt that robotic hysterectomy should either be abandoned or further evaluated since there is a lack of evidence of any benefit over conventional laparoscopic hysterectomy. The authors of this review do acknowledge that the observed benefits and hazards seem to be dependent on surgical expertise, and this may influence the decision with regard to the optimal approach.

Given the above findings, it is difficult to determine exactly why such a low percentage of overall abdominal hysterectomies are performed with a minimally invasive approach. This likely has something to do with the technical complexity of laparoscopic hysterectomy and the fact that laparoscopic skills are not derivative from open surgical skills. All gynecologists learn how to do an open abdominal hysterectomy in training, yet smaller portions are exposed to laparoscopy to a degree where they are completely comfortable with this approach. The robotic surgical platform may help ease the transition from open to a minimally invasive approach for surgeons who lack extensive laparoscopic experience. A recent review of the Premier Research Database including 289,875 hysterectomies at 156 US hospitals from 2005 to 2010 revealed that open abdominal cases decreased from 60% to 33%, while minimally invasive approaches increased from 40% to 67%. Much of the growth in minimally invasive hysterectomy was using a robotic approach, suggesting that the robotic platform facilitated the conversion of cases from open to minimally invasive—much like was observed in prostatectomy. Interestingly, in this particular study, the authors found that robotic operative times and complication rates decreased with increasing surgeon experience despite increased case complexity.

There is a growing body of literature examining the cost of a robotic approach to hysterectomy when compared to the alternatives. A systematic review and cost analysis on robotic assisted hysterectomy in benign and malignant conditions examined data from two health technology assessments: 1 systematic review and 16 original articles. In malignant conditions, less blood loss, fewer complications, and a shorter hospital stay were considered the main advantages of robot-assisted surgery. There were no significant differences between the techniques regarding oncological outcomes. When compared to laparoscopic hysterectomy, the main benefit of robot-assistance was a shorter learning curve associated with fewer conversions; but the length of robotic operation was often longer. In benign conditions, no clinically significant differences were reported and vaginal hysterectomy was considered the optimal choice when feasible. According to Finnish data, the costs of robot-assisted

hysterectomies were 1.5 to 3 times higher than the costs of conventional techniques. In benign conditions, the difference in cost was highest. Because of expensive disposable supplies, unit costs were high regardless of the annual number of robotic operations, suggesting that economical effectiveness cannot be markedly improved by increasing the volume of robotic surgery. The AAGL released a position statement of robotic surgery in 2013 that concludes "Robotic-assisted laparoscopic surgery should not replace conventional laparoscopic or vaginal procedures for women who could otherwise undergo conventional laparoscopic or vaginal surgery for benign gynecologic diseases." This is based on their findings that robotic-assisted laparoscopic surgery in gynecology is associated with similar clinical outcomes when compared to conventional laparoscopy, but with longer associated operating room time and costs.

Another recent controversy in the domain of minimally invasive hysterectomy revolves around the method of specimen extraction. When the uterus is removed through small incisions and a minimally invasive approach, the specimen usually cannot be retrieved through one of these incisions without significantly enlarging the incision. Devices known as morcellators have been used to facilitate specimen removal. It is difficult to determine if a presumed myoma is actually a uterine sarcoma (0.28%) or a leiomyosarcoma (0.2%) prior to removal. If an electronic morcellator is used during tumor removal and the lesion was actually a sarcoma, intrapelvic and intraabdominal dissemination and a poorer prognosis can result. Because of these concerns, in April of 2014 the Food and Drug Administration (FDA) issued a warning statement with regard to the use of power morcellators in hysterectomy.

"If laparoscopic power morcellation is performed in women with unsuspected uterine sarcoma, there is a risk that the procedure will spread the cancerous tissue within the abdomen and pelvis, significantly worsening the patient's likelihood of long-term survival. For this reason, and because there is no reliable method for predicting whether a woman with fibroids may have a uterine sarcoma, the FDA discourages the use of laparoscopic power morcellation during hysterectomy or myomectomy for uterine fibroids."

There is some controversy about the actual risks of disseminating an unsuspected sarcoma with a minimally invasive hysterectomy, but several studies have clearly demonstrated that following the FDA warning, the proportion of minimally invasive hysterectomies and myomectomies (relative to the total number of open procedures) has significantly decreased.

Overall, this is a very nice review of a topic that many general surgeons know little about. The technical descriptions and discussion with regard to potential complications are of value to anyone who performs pelvic surgery.

Jon C. Gould

Suggested Readings

AAGL position statement: Robotic-assisted laparoscopic surgery in benign gynecology. *J Minim Invasive Gynecol* 2013;20(1):2–9.

Aarta JW, Nieboer TE, Johnson N, et al. Surgical approach to hysterectomy for benign gynaecological disease. *Cochrane Database Syst Rev* 2015;12;8:CD003677.

Bogani G, Chiappa V, Ditto A, et al. Morcellation of undiagnosed uterine sarcoma: A critical review. *Crit Rev Oncol Hematol* 2016;98:302–8.

http://www.fda.gov/medicaldevices/safety/alertsandnotices/ucm393576.htm; Accessed February 6, 2016

Luciano AA, Luciano DE, Gabbert J, et al. The impact of robotics on the mode of benign hysterectomy and clinical outcomes. *Int J Med Robot* 2016;12(1):114–24.

Obermair A, Janda M, Baker J, et al. Improved surgical safety after laparoscopic compared to open surgery for apparent early stage endometrial cancer: results from a randomised controlled trial. *Eur J Cancer* 2012;48(8):1147–53.

Park JY, Kim DY, Kim JH, et al. The impact of tumor morcellation during surgery on the outcomes of patients with apparently early low-grade endometrial stromal sarcoma of the uterus. *Ann Surg Oncol* 2011;18:3453–61.

Tapper AM, Hannola M, Zeitlin R, et al. A systematic review and cost analysis of robot-assisted hysterectomy in malignant and benign conditions. *Eur J Obstet Gynecol Reprod Biol* 2014;177:1–10.

184 Radical Hysterectomy

Jonathan Boone and Warner Huh

INTRODUCTION

Radical hysterectomy with bilateral pelvic lymphadenectomy is considered the standard of care for the surgical management of early-stage cervical cancer. Wertheim developed the modern technique for radical hysterectomy in the early 20th century, and in the 1940s Meigs added routine pelvic lymphadenectomy to the procedure, thereby increasing its curative potential. Radical hysterectomy can now be performed with low rates of complications as modern surgical techniques and advances in anesthesia, transfusion, and antibiotics allow the operation to be performed with morbidity rates approaching 1%. As a result, radical hysterectomy and bilateral pelvic lymphadenectomy are an alternative to radiation for the definitive treatment of patients with FIGO stage IA, IB, and IIA cervical cancer.

A randomized study has shown that radical hysterectomy and radiation both result in 5-year survival rates of 85% in early cervical cancer. Therefore, the choice of treatment for a given patient is based on other considerations. Radical surgery has a number of potential advantages over radiation. It allows preservation of ovarian function. It also allows better preservation of sexual function relative to radiation. It is associated with fewer long-term complications than radiation, particularly with respect to chronic diarrhea and hematuria, tenesmus, small bowel obstruction, and urinary tract and bowel fistulas. Radical hysterectomy does have the disadvantage that it is not as widely applicable as radiation. Poor surgical candidates, such as those with numerous comorbidities or morbid obesity, may be better candidates for radiation therapy. Radical hysterectomy is also associated with more acute complications compared to radiation, such as infection, thromboembolism, and ureteral injury.

Radical hysterectomy differs from an extrafascial (or simple) hysterectomy in that the tissues surrounding the cervix are removed along with the uterus and cervix. This includes the cardinal ligaments, uterosacral ligaments, and upper vagina. While this additionally resected

tissue does not appear very impressive in the final specimen, the additional work necessary to remove them is considerable. During the operation, more time is spent in mobilizing the surrounding structures, namely the bladder, ureters, and rectum, than in removing the specimen. Pelvic lymphadenectomy, while not an essential part of radical hysterectomy, is almost always performed in conjunction with radical hysterectomy when treating cervical cancer. The final result of radical hysterectomy and pelvic lymphadenectomy is a classic Halstedian operation, with radical resection of the primary tumor and resection of the draining lymph nodes.

Early cervical cancer is by far the most common indication for radical hysterectomy and pelvic lymphadenectomy. However, this operation can be considered in patients with stage II endometrial cancers with gross cervical involvement. Small, centrally recurrent cervical cancers occurring after previous treatment with radiation therapy can also be treated with radical hysterectomy, although this is controversial as many surgeons feel these patients have a better chance of long-term survival with pelvic exenteration.

The number of women undergoing traditional radical hysterectomy has declined in recent years. In patients with stage IA1 cervical cancer, the standard operation is now an extrafascial hysterectomy without pelvic lymph node dissection. Studies have shown <1% risk of parametrial involvement or lymph node metastasis with survival rates approaching 99%. By performing an extrafascial hysterectomy in these patients, there is significantly less morbidity with the same curative potential. Patients with stage IB2 and IIA cancer warrant a careful physical examination to determine whether an adequate surgical margin can be achieved. CT, PET/CT and/or MRI imaging is commonly used to assess surgical resectability. Five-year survival rates for women with stage IB and IIA cervical cancer are similar regardless of whether they are treated with radical surgery or primary radiation therapy with radiosensitizing chemotherapy (chemoradiation). A prospective study found that 84% of patients with stage IB disease received postoperative radiation therapy even after radical hysterectomy, and these patients had over twice the morbidity of those who received radiation only. The increased morbidity experienced by patient receiving surgery followed by radiotherapy includes grade 2 and 3 complications like hydroureteronephrosis, chronic neurogenic bladder, cystitis, incontinence, and lower extremity edema. With similar survival rates regardless of treatment, a high likelihood of

receiving postoperative adjuvant radiation, and less morbidity with primary chemoradiation, many surgeons now treat women with stage IB2 and IIA disease with primary chemoradiation.

In an effort to reduce the radicality of this surgery, the modified radical hysterectomy was developed. A randomized clinical trial demonstrated that modified radical hysterectomy is associated with less morbidity and similar rates of cure in patients with stage IB and IIA cervical cancer. One limitation of this study was the high rate of adjuvant radiation, which may have negated the effects of any differences in surgical technique between the treatment arms. While some do not recommend modified radical hysterectomies, it is an accepted surgical treatment for stage IA2 or small (1 to 2 cm tumors) stage IB1 cervical cancers. It can also be performed in patients with cervical cancer who have small volume residual disease after primary chemoradiation or in those with endometrial cancer that have evidence of disease in the lower uterine segment, small volume disease at the level of the cervix, and a positive endocervical curettage.

With advances in surgical technology, minimally invasive traditional and robotic-assisted radical laparoscopic hysterectomies are commonly accepted alternatives to the open, abdominal approach. A systematic review and meta-analysis found a lower estimated blood loss, less febrile morbidity, shorter hospital stays, and fewer wound complications with robotic radical hysterectomies when compared to the open alternative. The traditional laparoscopic radical hysterectomy shows similar intraoperative and short-term postoperative outcomes to robotic radical hysterectomy, so surgeons have a choice between the two minimally invasive approaches. Since the robotic approach is seen by many surgeons as technically less challenging with shorter operative times, it is often the minimally invasive technique of choice.

Although radical hysterectomy is intended to be definitive treatment for early cervical cancer, some patients are at significant risk of recurrence with surgery alone and benefit from adjuvant therapy. Patients with positive pelvic or para-aortic lymph nodes, parametrial involvement, and positive surgical margins should be offered pelvic radiation with concurrent platinum-based chemotherapy. Adjuvant therapy may also be considered for other high-risk patients such as those with large tumors, deep stromal invasion, or lymphovascular space invasion, although the data supporting treatment of these patients are not as definitive. The management of patients with large (stage IB2) cervical tumors continues to

be controversial, with some surgeons favoring a primary surgical approach with or without adjuvant chemoradiation and others favoring chemoradiation alone. This question is currently being addressed by a randomized clinical trial.

Based on the current evidence, radical hysterectomy is indicated for stage IA2, IB1, and select stage 1B2 cervical cancers. In the United States, the procedure is rarely used for stage IIA disease. The purpose of this chapter is to describe the different types of radical hysterectomy and the robotic radical hysterectomy in detail, highlighting important points that allow these inherently difficult operations to be performed with success. Radical trachelectomy is a minimally invasive option for the treatment of stage I cervical cancer intent on sparing fertility without compromising the chance for cure; however, this is beyond the scope of this chapter.

STEPS

General anesthesia is induced. A single dose of antibiotic administered before incision is usually sufficient for prophylaxis, although a repeat dose may be given if the operation exceeds 4 hours or estimated blood loss is greater than 1500 mL. Pneumatic compression stockings (mechanical), a single injection of a prophylactic dose of unfractionated heparin or low molecular weight heparin (chemical), or the combination of both chemical and mechanical prophylaxis may be used for thromboembolism prophylaxis.

The patient is placed in dorsal lithotomy position. Examination under anesthesia is performed to exclude the presence of disease beyond the cervix and upper vagina. Rectal examination is particularly important in order to exclude disease extension into the cardinal ligaments. Cystoscopy and proctosigmoidoscopy may also be performed at the discretion of the surgeon to exclude disease extension into the bladder or rectum; however, with contemporary imaging techniques, this is less frequently utilized. Any findings suspicious for disease extension beyond the cervix and upper vagina should prompt abandonment of the operation in favor of radiation therapy.

A Foley catheter is placed. A vertical midline or low transverse incision may be used. Two transverse incisions, the Maylard and Cherney, provide excellent pelvic exposure. A vertical incision is preferable when the surgeon plans to sample the para-aortic lymph nodes. Once inside the peritoneal cavity, the abdomen and pelvis are thoroughly explored

manually and visually. Any evidence of metastatic disease should prompt abandonment of the procedure if confirmed histologically. Particular attention is paid to the area around the cervix, including the posterior cervix and cul-de-sac. A formal para-aortic lymph node sampling, while favored by some surgeons, is associated with low yield and is therefore not standard.

RADICAL HYSTERECTOMY

A Bookwalter or similar self-retaining retractor may be placed to expose the pelvis. Femoral neuropathy is a risk of using such retractors, but this risk can almost be eliminated by ensuring that there is room between the bottoms of the blades and the psoas muscles. The bowel is displaced cephalad using moist laparotomy packs. The uterus is grasped with Kocher or Kelly clamps on each cornu so that cephalad tension can be placed on the uterus. The round ligaments are suture-ligated and divided. Absorbable suture, commonly 0-Vicryl or no. 1-Chromic, is used throughout the operation. The broad ligaments are opened in a cephalad and caudad direction lateral to the gonadal vessels, and the ureters are identified along the medial leaves of the broad ligament (Fig. 184.1). They are most readily identified as they enter the true pelvis and cross over the bifurcation of the common iliac arteries.

The pararectal and paravesical spaces are then developed. These are avascular potential spaces that allow the peritoneum over the pelvic sidewall to be mobilized safely, thus exposing the pelvic sidewall vessels and the course of the ureters. The pararectal space is bounded by the external and internal iliac vessels laterally, the ureter medially, and the cardinal ligament anteriorly. Using either a single finger or a dissecting instrument, the common iliac artery bifurcation is identified and the space just medial to this is opened, resulting in displacement of the ureter medially. Care is taken to ensure that the dissection remains medial to the internal iliac artery. The dissection follows the hollow of the sacrum caudad and curves slightly medially toward the rectum. The space may be opened to the level of the levator plate.

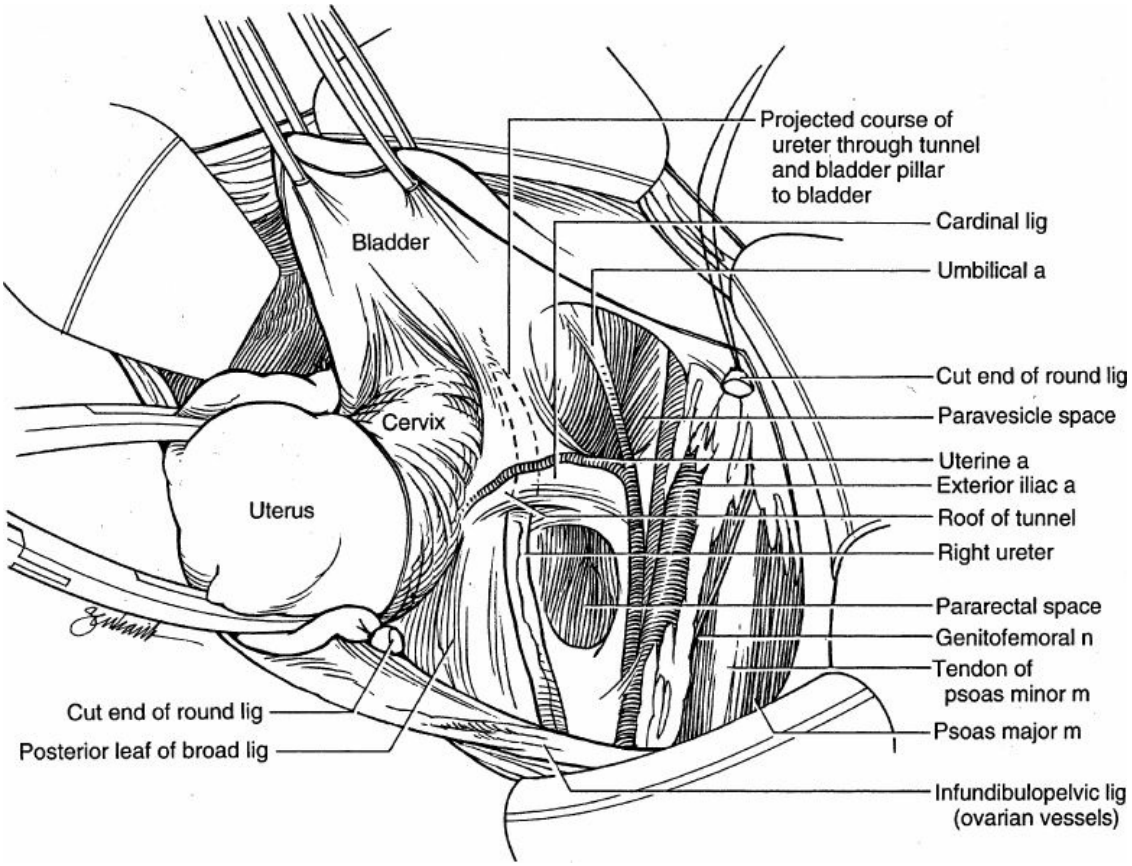

Figure 184.1. The paravesical and pararectal spaces are developed. The cardinal ligaments are assessed for tumor extension. The uterine artery is ligated at its origin from the internal iliac artery.

The paravesical space is bounded by the external iliac vessels laterally, the bladder and superior vesical artery medially, and the cardinal ligament posteriorly. Again using either a finger or a dissecting instrument, the space just medial to the most distal aspect of the external iliac vein is developed, displacing the bladder medially. The space is followed medially and caudad along the pubic symphysis toward the levator plate. Once the space is open, the superior vesical artery is readily apparent as it enters the lateral dome of the bladder. Care must be taken to avoid bleeding in the prevesical space just medial to the paravesical space.

Now the surgeon must make the final assessments for resectability prior to completing the planned operation. The vesicouterine fold of peritoneum is incised and the bladder is dissected down the anterior cervix and upper vagina in an avascular plane. This is best accomplished with sharp dissection or electrocautery to minimize bleeding and trauma to the bladder. Any tumor extension through the anterior cervix will be evident at this point. Such a finding indicates unresectability. The cardinal ligaments

are then palpated with two fingers: one in the paravesical space and another in the pararectal space. This “web” of tissue comprises the condensation of fibrovascular tissue lateral to the cervix constituting the cardinal ligament (the term *parametrium* is often used synonymously). Any palpable disease in the cardinal ligaments also indicates unresectability. Finally, the pelvic lymph nodes are assessed, and any grossly suspicious nodes are sent for frozen section. Most surgeons abandon the radical hysterectomy if grossly positive lymph nodes are encountered. There is evidence that debulking such nodes prior to closing improves the chances for cure so removal of grossly positive nodes should be considered if the surgeon determines resection is feasible.

If the adnexa are to be removed, the gonadal vessels are now isolated above the ureters and ligated. To isolate the gonadal vessels after the broad ligament has been separated, the medial leaf of the broad ligament is transilluminated or two fingers are placed under the gonadal vessels to confirm an avascular plane in that portion of the broad ligament. If the ureter is not visualized in the medial leaf of the broad ligament, it can be palpated by placing the thumb and index finger on either side of that leaf of the broad ligament to palpate for the classic “snap” produced from dragging your fingers across it. An incision is then made in the avascular plane of the broad ligament sharply or with cautery. Clamps are placed across the gonadal vessels that are suture ligated after cutting between the clamps. In order to improve visualization for the remainder of the procedure, removal of the fallopian tubes and ovaries can be performed. Advance the clamp on each uterine cornu across the utero-ovarian pedicle and cut laterally to the clamp so that the fallopian tubes and ovaries can be separated from the uterus.

If the adnexa are to be conserved, the utero-ovarian pedicles are isolated and ligated. The same window is made in an avascular plane of the medial leaf of the broad ligament. The clamp adjacent to the uterus is advanced across the utero-ovarian ligament and a second clamp is placed across the proximal utero-ovarian ligament. Cut between the two clamps and suture ligate the proximal and distal ends of the utero-ovarian ligament.

Some surgeons now proceed with pelvic lymphadenectomy, the rationale being that the finding of microscopically positive pelvic lymph nodes would result in abandonment of the operation. However, the yield is low if the nodes are grossly normal, and the technique of intraoperative

frozen section is inaccurate and cumbersome. Furthermore, many surgeons would complete the radical hysterectomy with microscopically positive pelvic nodes and recommend adjuvant chemoradiation afterwards. This approach may allow for improved sexual function compared with radiation alone, as the latter necessarily includes a very high dose of vaginal brachytherapy. We generally perform the pelvic lymphadenectomy before radical hysterectomy.

Two of the more difficult parts of the procedure are the dissections of the uterine artery and the ureter. The cardinal ligament is dissected down to the uterine artery, which is then ligated at its origin from the internal iliac artery (Fig. 184.2). The uterine artery is reflected above the ureter. The ureteral dissection then commences. The ureter is dissected off the peritoneum near the uterosacral ligament, taking care to preserve its surrounding adventitial blood supply. A small wavy vessel is often seen adjacent to the ureter and should be preserved. The ureter is then freed of its peritoneal attachments. This is facilitated by cephalad traction on the uterus and posterior traction on the ureter's adventitia. The ureter should not be handled directly. The "tunnel," through which the ureter courses lateral and anterior to the cervix, is then dissected, freeing the ureter (Fig. 184.2). It is crucial that the dissecting instrument remain in close proximity to the ureter in order to avoid significant bleeding that can ensue and obscure the field. The instrument is best placed just superolateral to the ureter. Once a pedicle is established, it may be ligated directly or after transection between clamps. The latter method is facilitated by specialized clamps developed by Casey.

The last part of the tunnel is composed of the bladder pillars, which are fibrovascular attachments of the bladder to the lateral aspects of the cervix. The pillars are exposed initially with the bladder dissection. Further anterior dissection of the pillars can facilitate the ureteral dissection, but care must be taken to avoid injuring the numerous small vessels within. The ureteral dissection is completed to the insertion into the bladder (Fig. 184.3). The surgeon must be careful to end the tunnel dissection once the bladder is reached, as the ureterovesical junction is not always obvious. The ureter, having been unroofed from its tunnel, is now dissected out of its cardinal ligament bed completely.

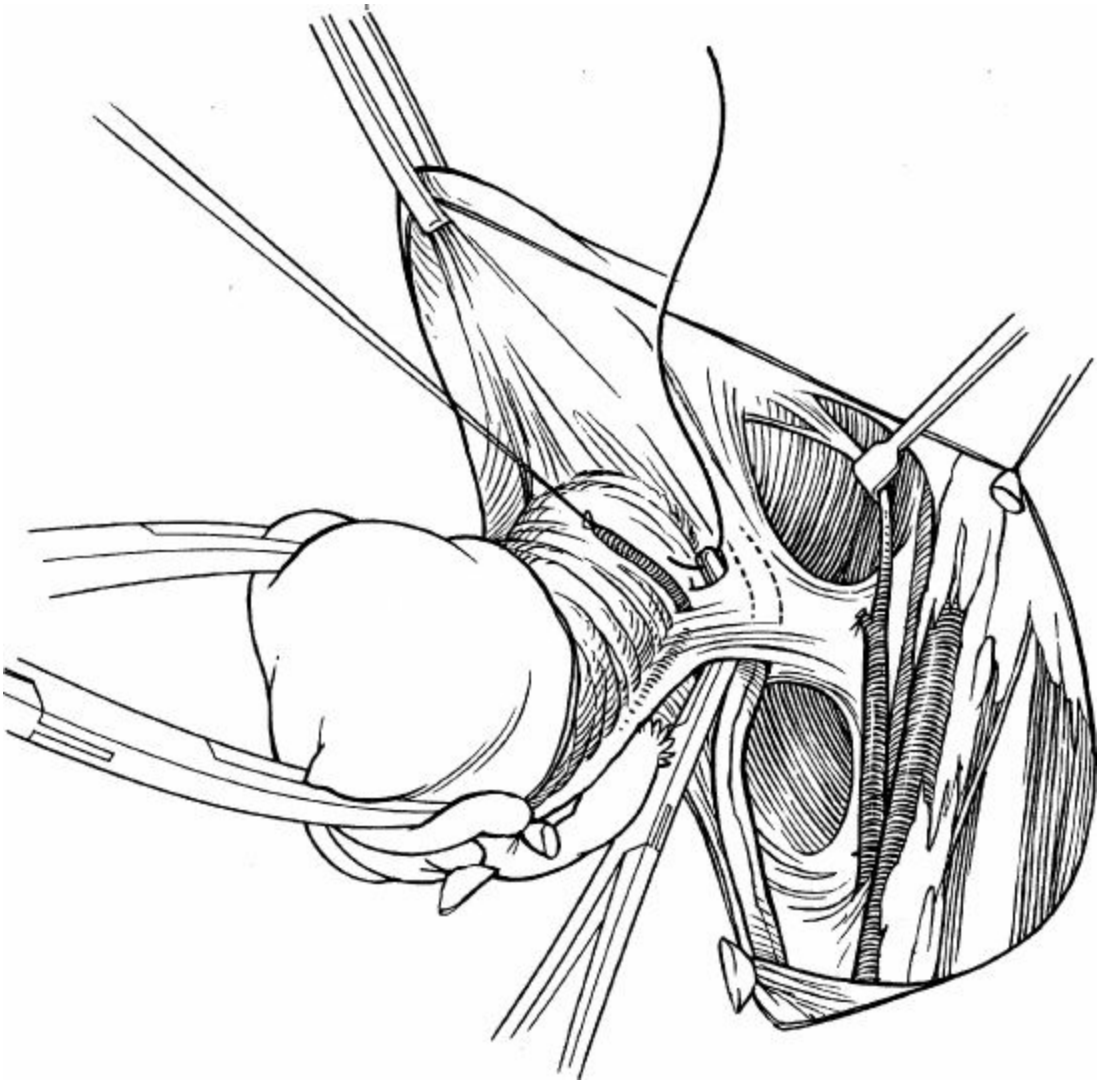

Figure 184.2. The ureteral tunnel is dissected. The ligated uterine artery is reflected above the ureter.

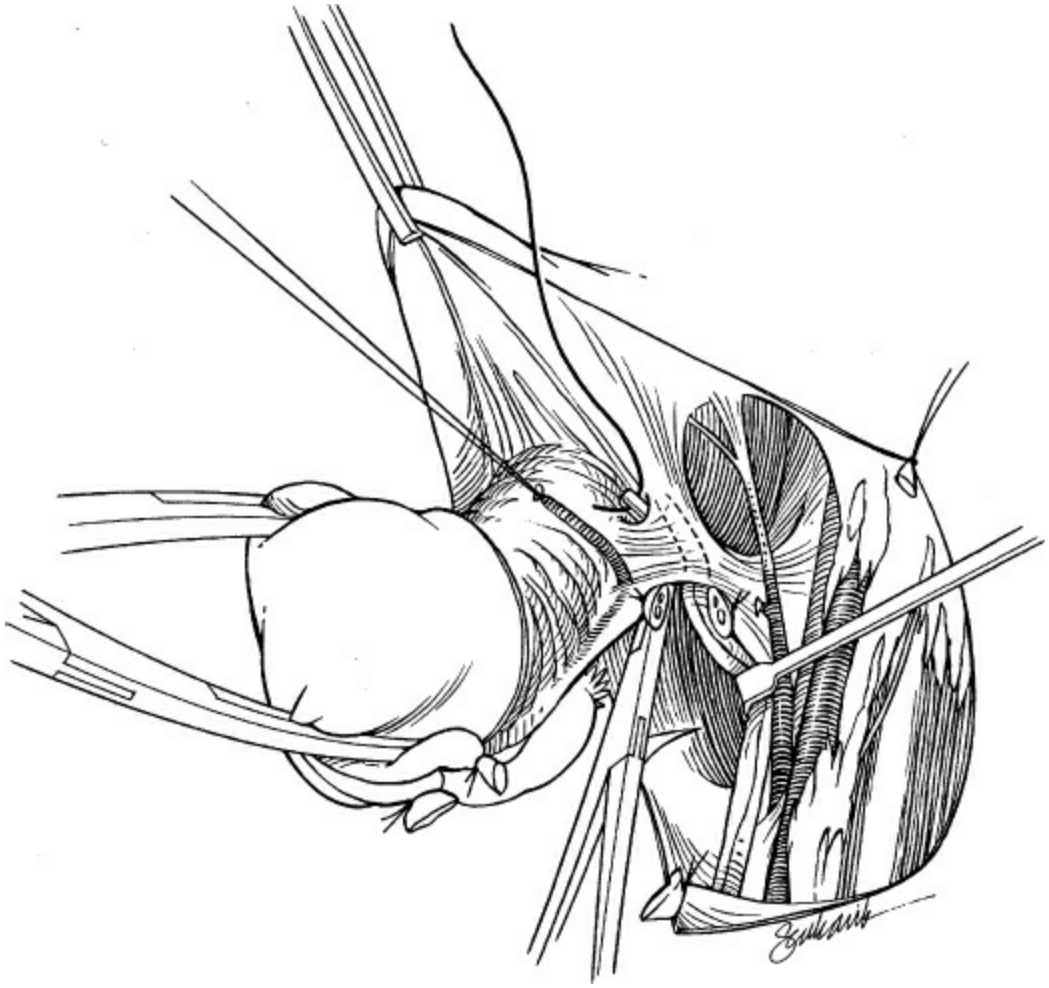

Figure 184.3. The last part of the tunnel is dissected and the ureter is completely freed to its insertion into the bladder.

The posterior dissection is then addressed (Fig. 184.4). The rectovaginal fold of peritoneum is incised, taking care to avoid the ureters. The incision crosses both uterosacral ligaments and the upper cul-de-sac. The rectum is dissected down the posterior vagina in an avascular plane. This can often be accomplished with gentle blunt dissection, with care taken to avoid direct pressure on the rectum. Excessive force can result in unintentional entry into the posterior vaginal wall, which is quite thin. The uterosacral ligaments are cleared of the rectum. Some bleeding from the rectal pillars may ensue, but this is generally not problematic.

The specimen is now removed. It is helpful to palpate the cervix to ensure an adequate margin of vagina. The uterosacral ligaments are taken with clamps, cut, and suture-ligated at roughly their midpoints, taking care to avoid the rectum (Fig. 184.5). The cardinal ligaments are similarly divided near the pelvic sidewalls, taking care to retract the ureters laterally (Figs. 184.6 and 184.7). The vagina is clamped below the cervix and the

specimen is removed. The vaginal margin may now be assessed. A 1 to 2 cm margin of vagina is generally adequate, but a larger margin should be obtained if there is disease extension to the upper vagina. The vaginal margin commonly appears smaller in the removed specimen than it does in vivo. The vaginal cuff is closed with transfixion sutures at the angles and figure-of-eight sutures in between (Fig. 184.8).

If the adnexa have been conserved, they are sometimes transposed out of the pelvis into the lower abdomen in case radiation is necessary postoperatively. This procedure results in preservation of ovarian function in about 50% of patients needing pelvic radiation. The adnexa are mobilized on their vascular pedicles and tacked to the lower paracolic gutter peritoneum with nonabsorbable suture.

At this point, the bladder, rectum, and ureters are inspected for injury. All structures should appear intact and well vascularized. The ureters should be peristalsing freely and of normal caliber. If there is any question of an injury, further evaluation is performed. The bladder may be assessed by distension with methylene blue or sterile milk through the Foley catheter. The ureters may be assessed by intravenous injection of indigo carmine and visualization of urine emanating from the ureteral orifices, preferably via cystoscopy or alternatively via cystotomy at the dome of the bladder. Absence of dye extravasation into the pelvis should also be confirmed. Although rarely necessary, the rectum may be evaluated by insufflation via proctosigmoidoscopy after filling the pelvis with fluid. If an injury is identified, appropriate repairs are performed.

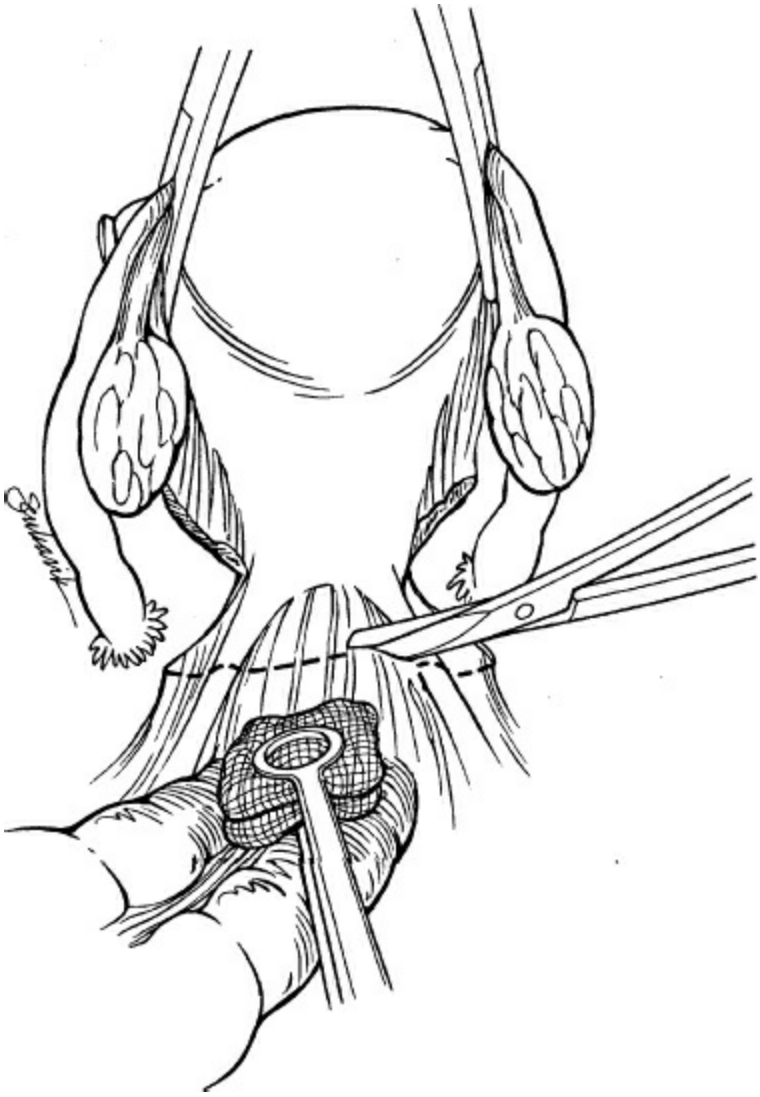

Figure 184.4. The posterior peritoneum is incised and the rectum dissected off the posterior vaginal wall.

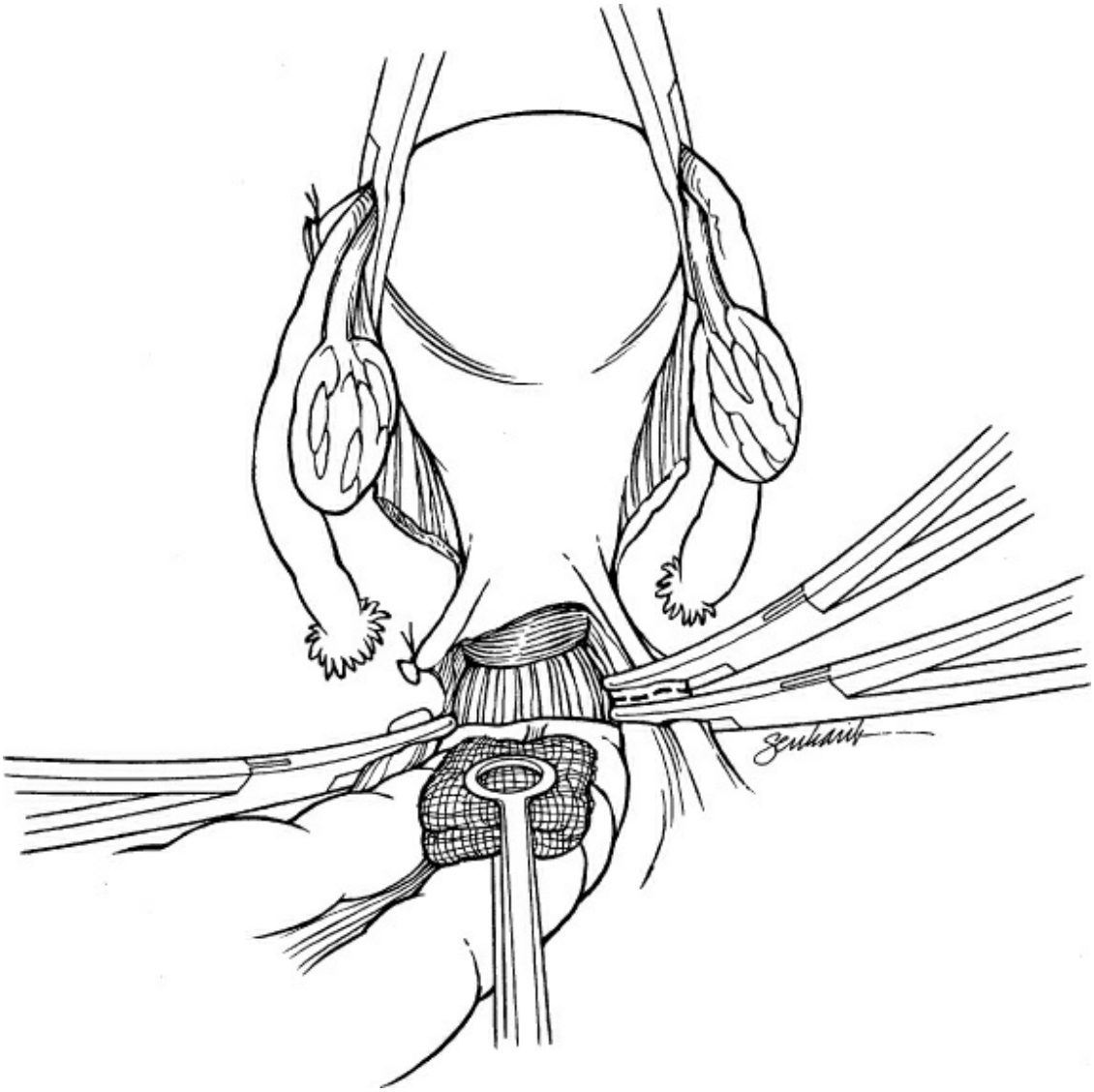

Figure 184.5. The uterosacral ligaments are divided and ligated.

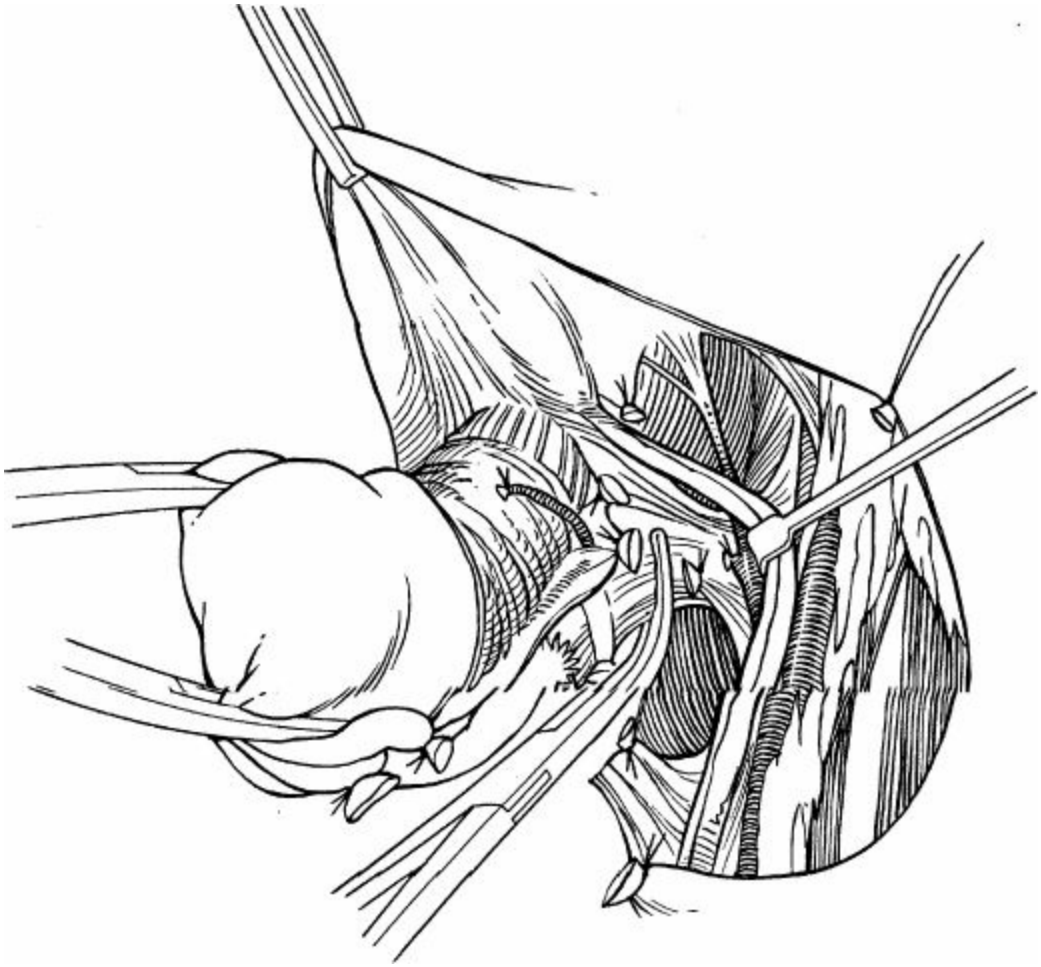

Figure 184.6. The cardinal ligaments are divided and ligated.

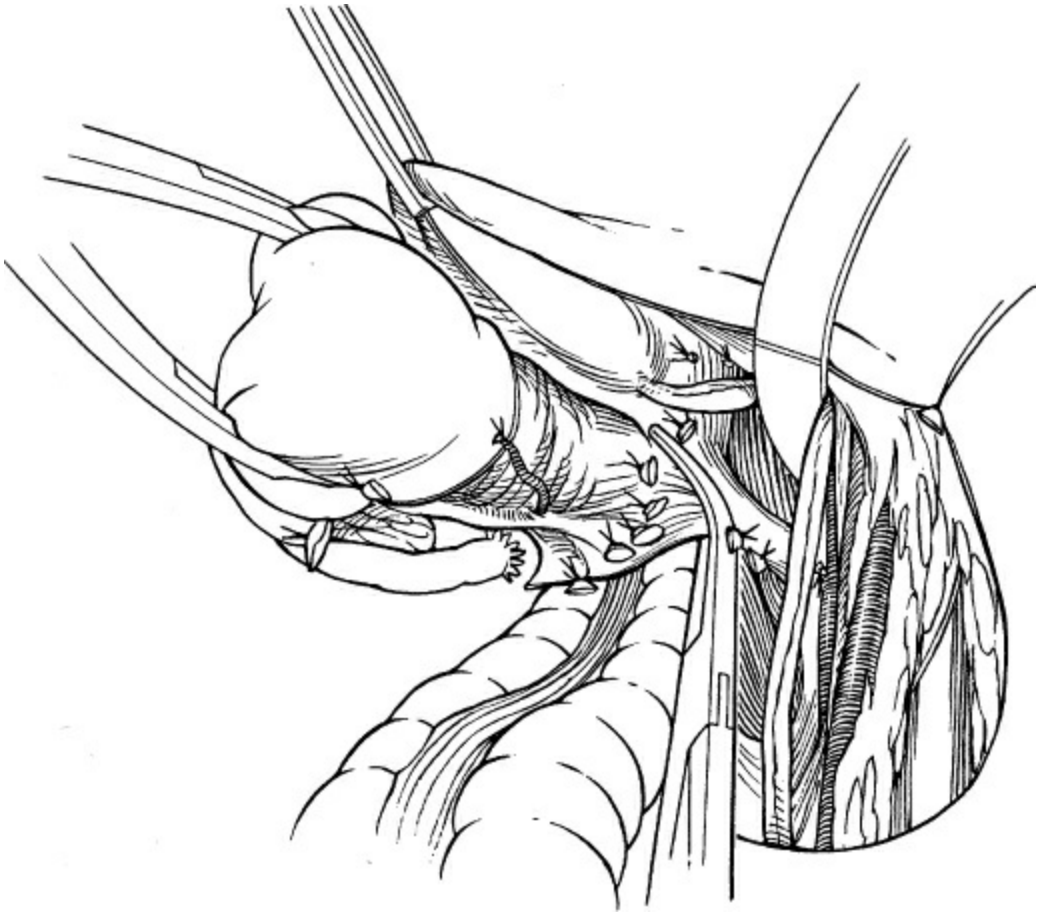

Figure 184.7. The vagina is cross clamped and the specimen is transected just above the clamps and removed.

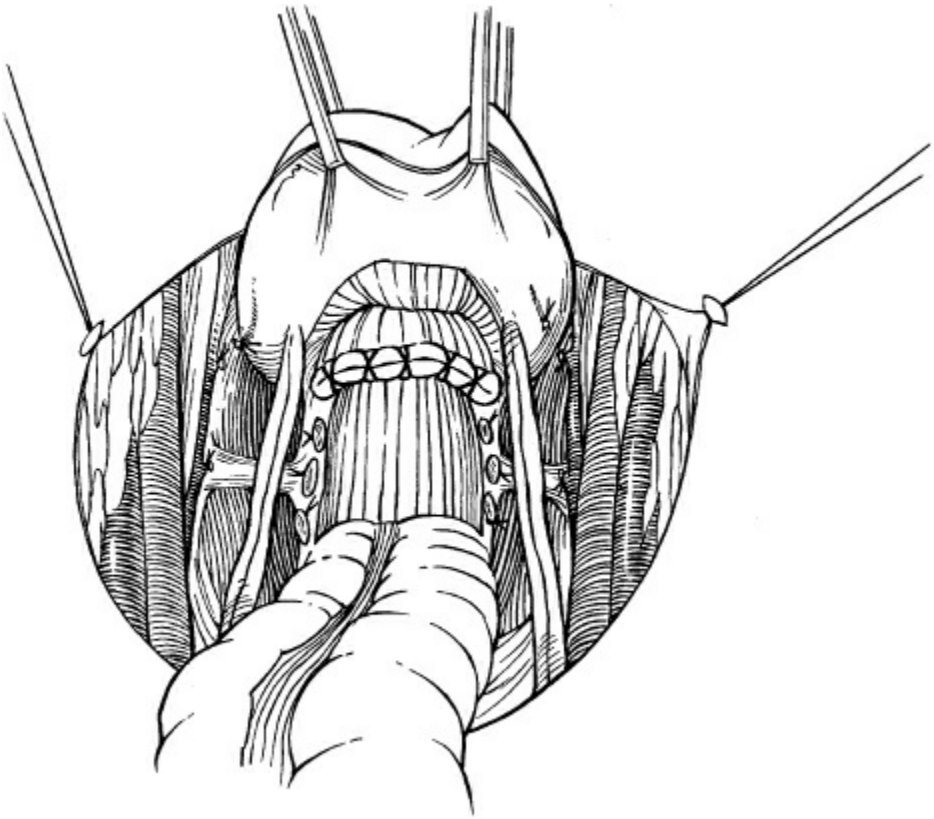

Figure 184.8. The vaginal cuff is closed with suture.

PELVIC LYMPHADENECTOMY

Pelvic lymphadenectomy is almost always performed in conjunction with radical hysterectomy for cervical cancer. Complete removal of the pelvic nodes rather than sampling is the goal. The operation is accomplished with sharp dissection or electrocautery, and hemoclips are often used for hemostasis and possibly to decrease the risk of lymphocysts.

The peritoneum is opened from the mid-common iliac artery to the deep circumflex iliac vein (Fig. 184.9). These landmarks constitute the cephalad and caudad limits of the dissection, respectively. A self-retaining retractor is used to expose the pelvic sidewall and retract the ureter medially. The dissection begins just medial to the genitofemoral nerve, which courses lateral and parallel to the external iliac artery. The lymph node–bearing tissues are mobilized medially off the external iliac artery and vein (Fig. 184.10). The obturator fossa is entered just below the external iliac vein. The surgeon should be aware of a possible accessory obturator vein off the external iliac vein, present in about 10% of patients (Fig. 184.11). This branch may be ligated to facilitate exposure of the obturator fossa. The dissection is carried under the external iliac vein toward the pelvic sidewall to the psoas muscle, separating the node bundle from the vein

completely. A vein retractor may be carefully used to retract the external iliac vein for exposure. The external iliac nodes may be taken separately or in continuity with the obturator nodes. The obturator nodes are then mobilized off the obturator nerve, which courses in the middle of the obturator fossa. It is important to avoid injury to this nerve, as it is vital for adduction of the lower extremity. Care should be taken to remove all lymph nodes above the nerve, including those in the genu between the external and internal iliac vessels and in the most distal aspect of the obturator fossa just proximal to obturator foramen. The lymph node bundle can often be grasped and pulled medially while sweeping it off the obturator nerve and internal iliac vessels with fine scissors. This allows the obturator nodes to be removed, often as a single specimen, without cutting any tissue, thereby minimizing bleeding and the risk of obturator nerve injury. There may be a few obturator lymph nodes below the nerve, but significant bleeding can be encountered in this space so it is generally not recommended to remove this nodal tissue. The distal common iliac nodes are then removed just lateral to the common iliac artery. Particular care is taken on the right, where the right common iliac vein is lateral to the artery. Once the dissection is completed, the genitofemoral nerve, obturator nerve, superior vesical artery, and ureter should all be clearly visible and uninjured. It is not necessary to place drains or close the peritoneum. These steps have not been found to decrease lymphocyst formation. Hemostasis is confirmed. The fascia is closed with a continuous permanent or delayed absorbable suture.

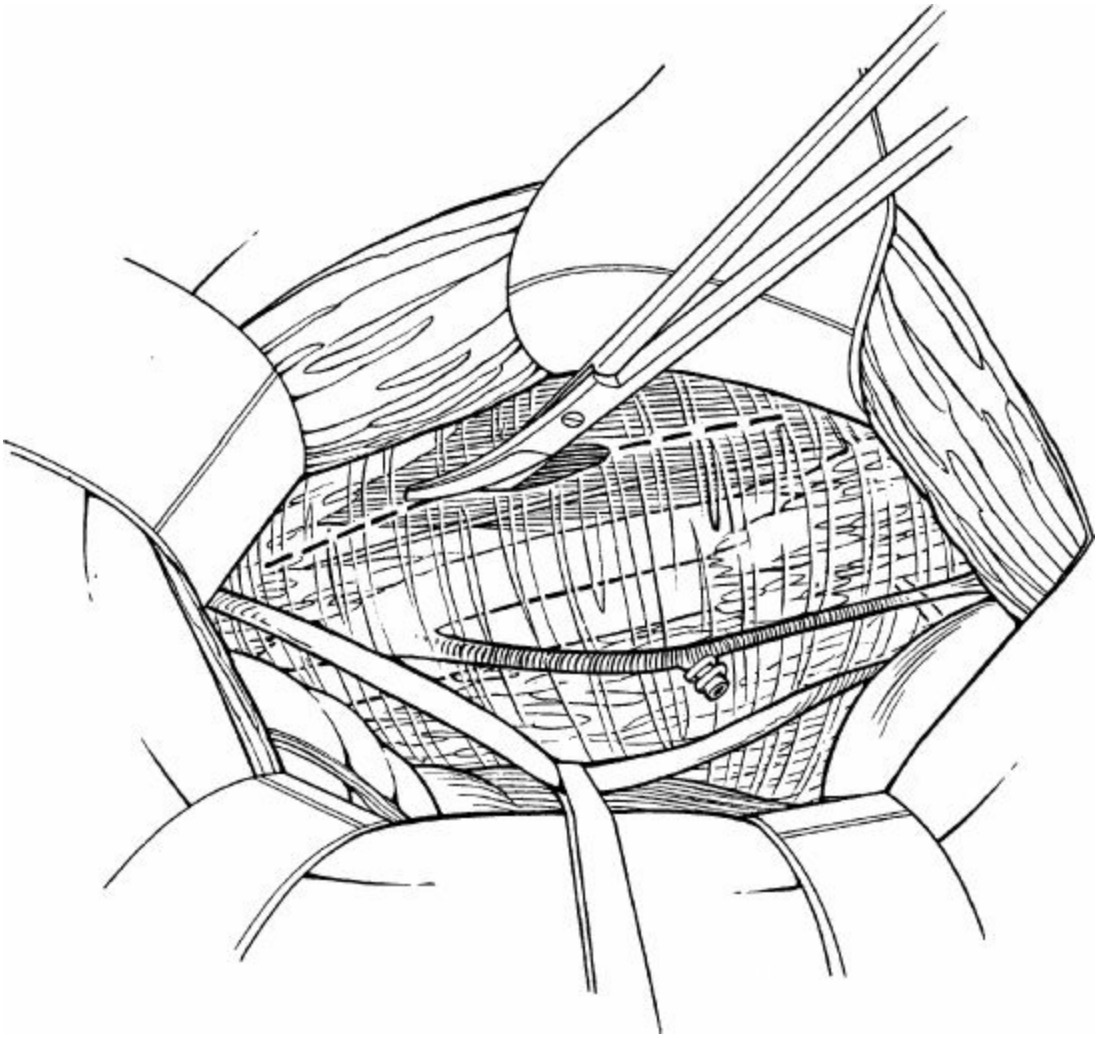

Figure 184.9. The peritoneum over the pelvic sidewall is opened over the external iliac artery.

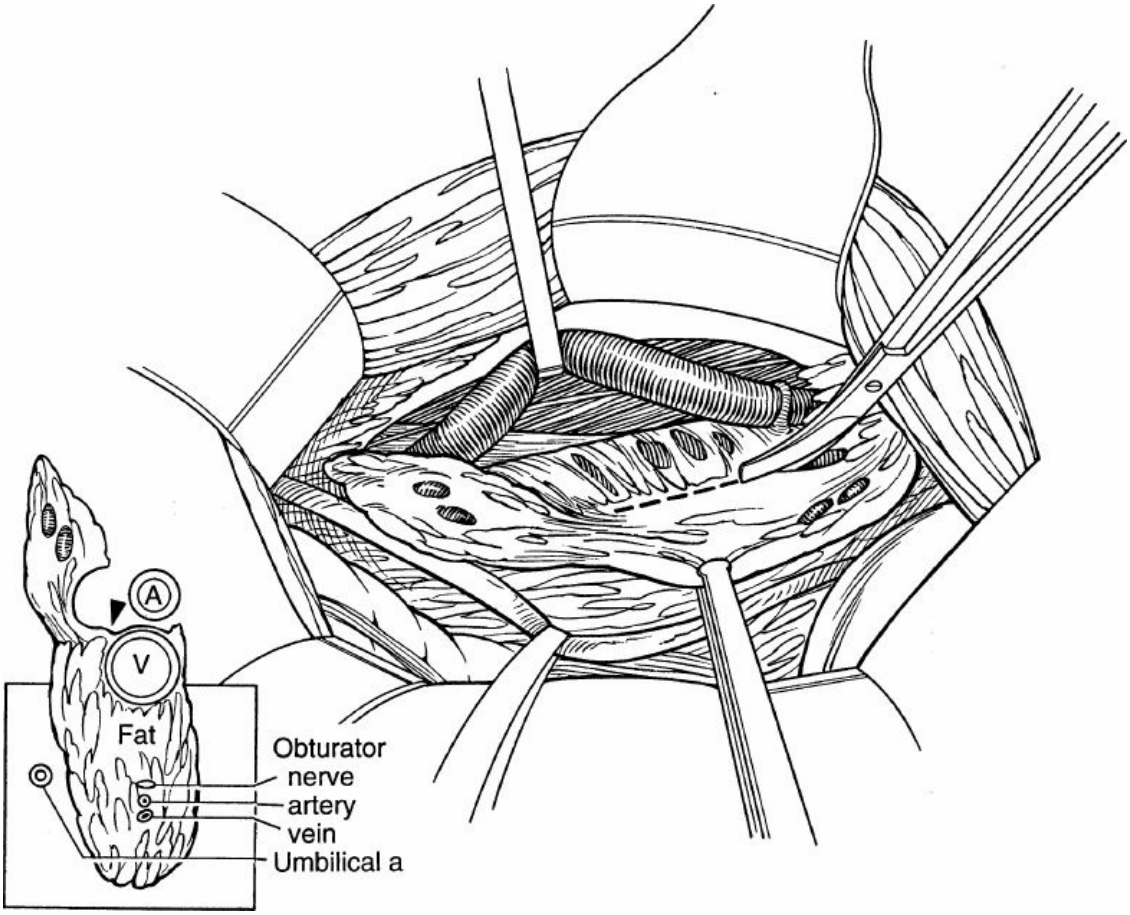

Figure 184.10. The lymph node–bearing tissues are mobilized medially off the external iliac vessels. The obturator space is entered just below the external iliac vein.

CLASSIFICATION OF RADICAL HYSTERECTOMY

The Querleu and Morrow classification of radical hysterectomy was adopted in 2008 in an effort to provide more descriptive, standardize anatomic terminology when defining the different types of radical hysterectomy. There are four different types of radical hysterectomy that differ based on the extent of lateral resection of tissue and to some degree the amount of vaginal tissue removed.

Type A: Extrafascial Hysterectomy

This resection is essentially a simple, extrafascial hysterectomy performed for early, stage IA1 cervical caner. The goal of a type A radical hysterectomy is to remove the cervix in its entirety. It can be performed abdominally, laparoscopically, traditional or robotic-assisted, or vaginally. A complete pelvic lymphadenectomy is generally not performed in conjunction with a type A hysterectomy. The paracervical tissue is

transected between the ureter and the cervix. The vesicouterine and uterosacral ligaments are transected at the cervix, and the vagina is resected at a minimal distance from the cervix, usually <10 mm.

Type B: Modified Radical Hysterectomy

Modified radical hysterectomy differs from radical hysterectomy only in the amount of paracervical tissue that is taken. Although the indications for modified radical hysterectomy are somewhat controversial, many surgeons feel it is the procedure of choice for patients with small tumors (1 to 2 cm) confined to the cervix. Modified radical hysterectomy offers the potential advantages of shorter operating times, less blood loss, and decreased overall morbidity, includin g bladder dysfunction. It can be performed through an abdominal incision or laparoscopically, either traditional or robotic-assisted. As with radical hysterectomy, a complete pelvic lymphadenectomy is almost always performed in conjunction with modified radical hysterectomy.

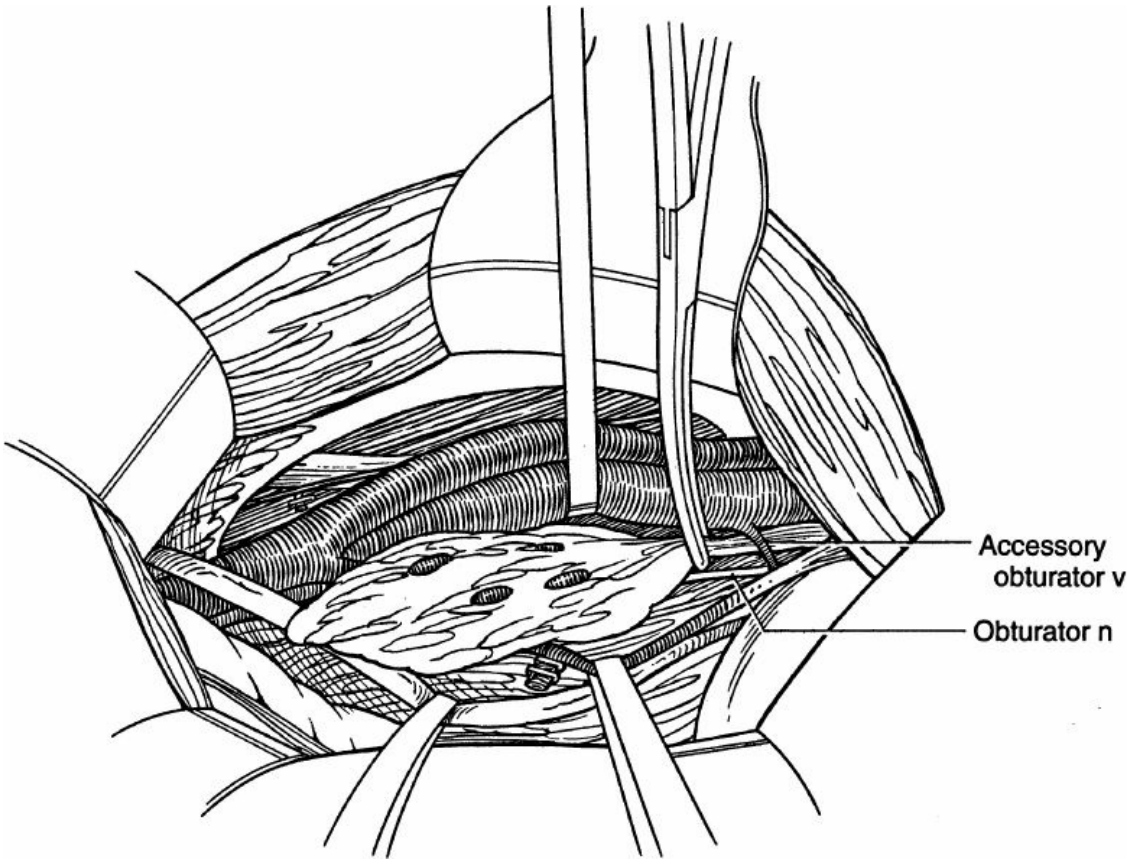

Figure 184.11. The obturator nodes above the obturator nerve are removed.

There are only a few important technical differences compared to radical hysterectomy. The uterine artery is ligated over the ureteral tunnel rather than at its origin (Fig. 184.12). Once the tunnel is unroofed, the ureter is only partially mobilized from its tunnel bed, enough that the paracervical tissue and cardinal ligament medial to the tunnel may be taken with the specimen (Fig. 184.13). The vesicouterine ligament is transected between the bladder and the cervix, and the uterosacral ligaments are ligated between the rectum and the cervix. A small vaginal margin is taken at least 10 mm from the cervix.

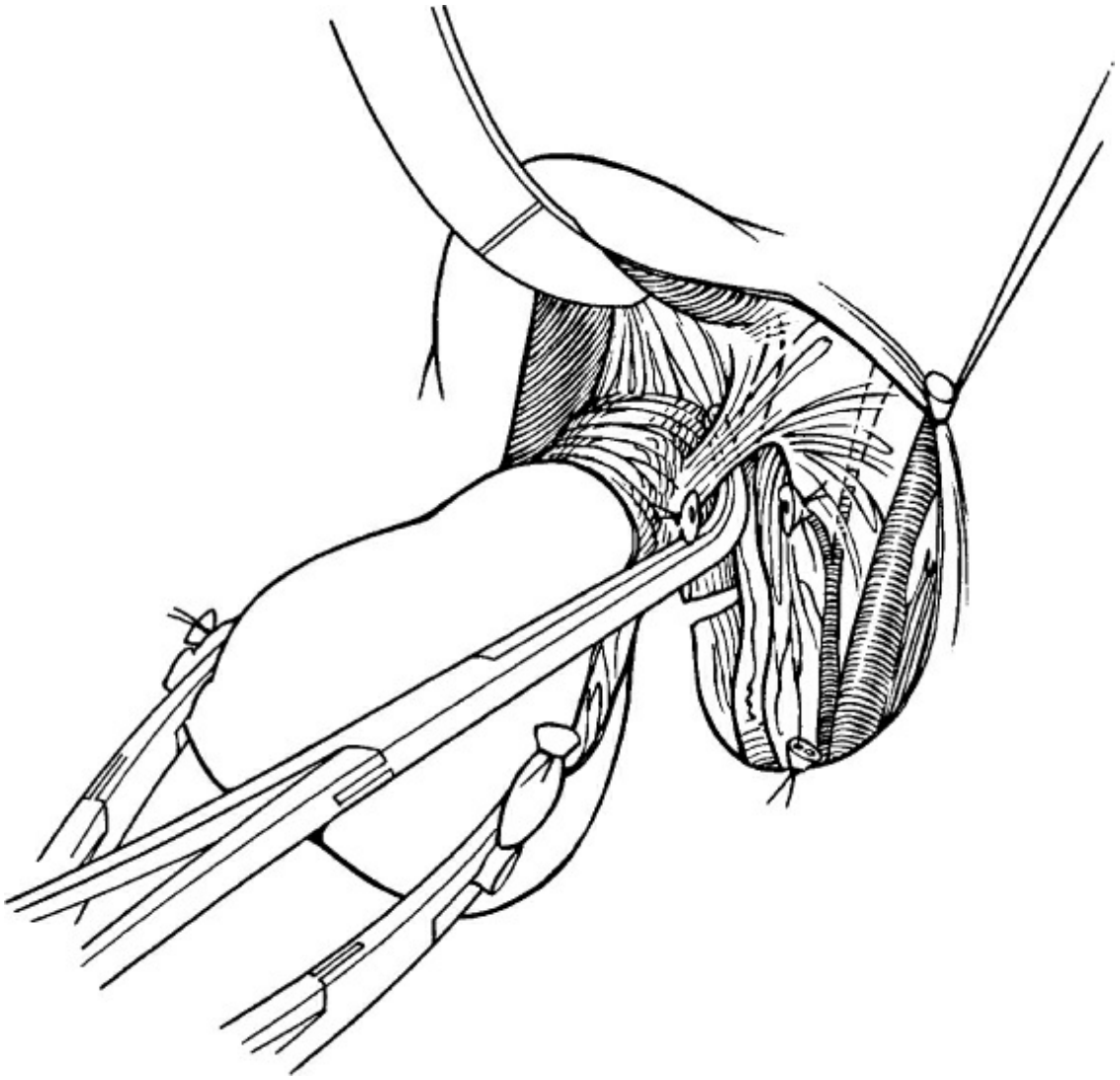

Figure 184.12. The uterine artery is ligated at the level of the ureter.

Type C: Radical Hysterectomy

The type C radical hysterectomy is the traditional radical hysterectomy as

described above in detail. There is a greater degree of tissue removed and, unlike types A and B where the autonomic nerves are not threatened, patients are at risk of autonomic nerve dysfunction. Just as with a modified radical hysterectomy, radical hysterectomy can be performed abdominally or laparoscopically, either traditional or robotic-assisted. If done abdominally, the incision may be altered from a Pfannenstiel to a Maylard of Cherney's incision depending on the patient's body habitus to provide better exposure. The laparoscopic approach does result in less blood loss, less pain, shorter hospital stays, and shorter recovery times.

The ureter is completely mobilized down to the bladder, the paracervical tissue is transected at the junction with the internal iliac artery and vein, the vesicouterine and uterosacral ligaments are transected at the bladder and rectum respectively, and the vaginal is transected 15 to 20 mm from the cervix or the tumor if it extends onto the vagina.

Common postoperative complaints from patients who have undergone a radical hysterectomy include urinary retention, difficulty voiding, and, to a lesser extent, rectal dysfunction. These symptoms are due to the disruption of the hypogastric plexus and splanchnic nerves that contains the sympathetic and parasympathetic nerves supplying the bladder and rectum. Nerve-sparing radical hysterectomies were developed to reduced patients' bladder and rectal dysfunction. While there are no large studies, that clearly show benefit of the nerve-sparing procedure, smaller studies have demonstrated smaller post-void residuals and rates of bladder dysfunction similar to that of the type B modified radical hysterectomy in women undergoing a nerve-sparing type C radical hysterectomy.

In order to perform a nerve-sparing radical hysterectomy, the sacrouterine space must be developed so that the hypogastric nerve can be separated from the uterosacral ligament, the posterior leaf of the broad ligament, and the ureter. The paracervical tissue is isolated down to the deep uterine vein for inclusion into the specimen then dissected away from the hypogastric nerve. The uterine branches of the inferior hypogastric plexus should be isolated and transected in order to be included into the specimen. The uterosacral, rectouterine, and rectovaginal ligaments can then be transected just medial to the inferior hypogastric plexus. Lastly, and most importantly, careful attention should be paid to isolating the bladder branches of the hypogastric plexus in order to avoid including them in transection of the vesicouterine ligament.

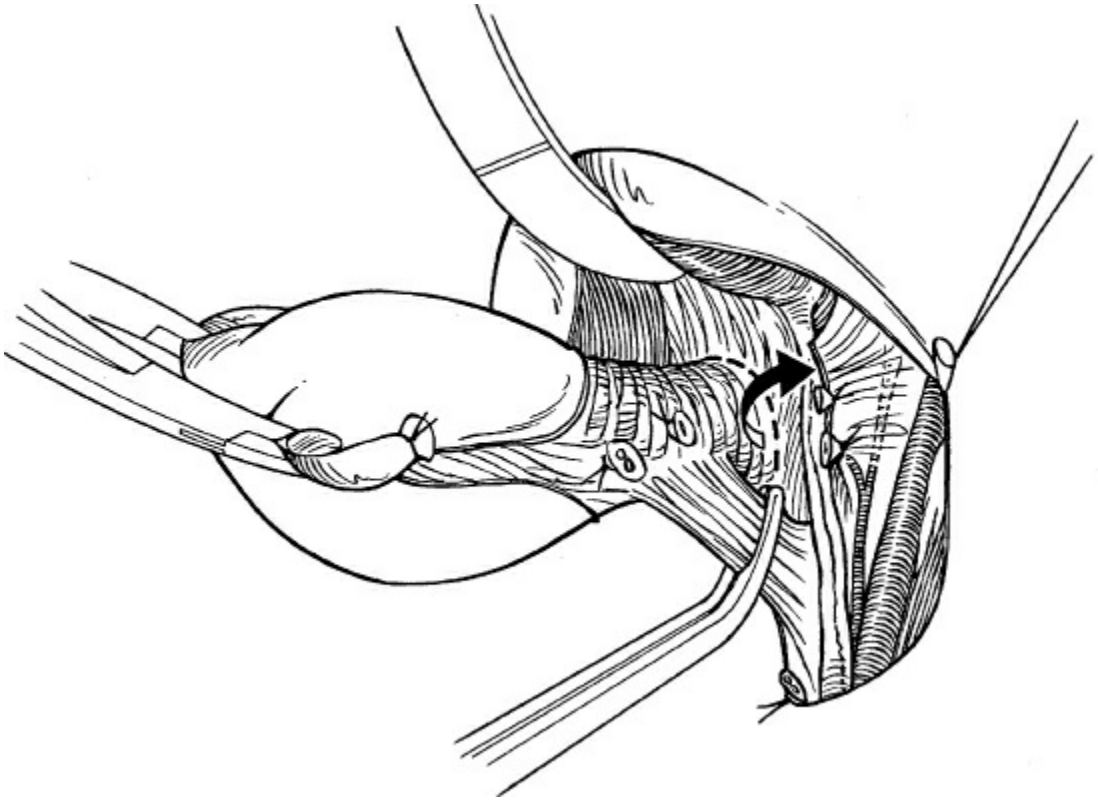

Figure 184.13. The ureter is partially mobilized laterally, enough to take an adequate amount of cardinal ligament.

Type D: Extended Radical Hysterectomy

With advances in chemosensitization and radiation therapy, type D hysterectomies are rarely performed for locally advanced tumors because of the likelihood of needing adjuvant radiation therapy and increased risk of bladder dysfunction and fistula formation compared to types B and C radical hysterectomies. To be considered an extended radical hysterectomy, all of the paracervical tissue extending to the pelvic sidewall, including the hypogastric vessels, is removed with the specimen. Approximately, three fourths of the vagina is also resected.

ROBOTIC-ASSISTED RADICAL HYSTERECTOMY

The patient is placed in dorsal, lithotomy position. Examination under anesthesia is performed to exclude the presence of disease beyond the cervix and upper vagina. A Foley catheter is placed as well as either an orogastric or nasogastric tube to decompress the stomach. The cervix is dilated in order to place a uterine manipulator, the VCare uterine manipulator (CONMED, Utica, NY) for example. Five ports are placed across the abdomen with the midline, camera port being placed roughly 20

cm superior to the pubic symphysis and above the umbilicus. There are different ways to place the remaining ports, but a diamond pattern is commonly used with each port about 8 to 10 cm apart and the lateral ports as far lateral on the patient's abdomen as possible (Fig. 184.14). The patient is then placed in the Trendelenburg position, and the robot is docked.

The procedure begins in the same manner as the abdominal radical hysterectomy with the ligation of the round ligament, separation of the medial and lateral leafs of the broad ligament, and development of pararectal and paravesical spaces with electrocautery after identification of the ureters. This is repeated on the opposite side. The uterine artery and vein are identified and ligated at their origin from the internal iliac vessels. Attention is then paid to developing the bladder flap by incising the peritoneum along the vesicouterine reflection and then dividing the vesicouterine ligament to mobilize the bladder inferiorly enough to ensure an adequate vaginal margin. A window is then made in the medial leaf of the broad ligament superior to the ureter so that the infundibulopelvic ligaments can be transected bilaterally. The rectovaginal septum is opened by incising the peritoneum with electrocautery. The tissue between the rectum and vagina is cut to expose the uterosacral ligaments that are then transected. Monopolar scissors are used to incise the vagina on top of the uterine manipulator removing the upper vagina with an adequate margin. The vaginal cuff is then sutured closed in a running, nonlocking fashion with a 0-Vicryl, 0-PDS, or 0-V-LOC (Medtronic, Minneapolis, MN) stitch.

POSTOPERATIVE MANAGEMENT

Patients are advised to ambulate immediately to minimize pulmonary and thromboembolic complications. Diet may be advanced as tolerated with patients usually tolerating a regular diet on the evening of surgery after a robotic-assisted radical hysterectomy. Evidence of bowel function is not a prerequisite to this. Oral pain medications are started as soon as the patient is tolerating oral intake. The urinary catheter is left in place during the immediate postoperative course due to anticipated voiding dysfunction. Using this approach, most patients may be discharged within 3 days following surgery.



Figure 184.14. Port placement for a robotic radical hysterectomy. C, camera; A, accessory; 1, right arm (monopolar scissors); 2, left arm (fenestrated bipolar forceps); 3, fourth arm (fenestrated ProGrasp forceps).

Traditionally, the Foley catheter was left in place for roughly 7 days; however, Foley removal can be done as early as postoperative day 1 in the case of a robotic radical hysterectomy or on postoperative day 3 or 4 for an open abdominal procedure. If the patient is unable to void, then the Foley catheter is replaced. Some patients require catheter drainage for 3 weeks or more, most require only a week. This will depend to some extent on the radicality of the operation. We typically use a Foley catheter and have a home visiting nurse remove it a week after surgery. We have found that patients rarely need to return for catheter replacement due to voiding difficulties.

INTRAOPERATIVE COMPLICATIONS

The most common intraoperative complication is blood loss. The literature indicates that average blood loss ranges from 500 to 1500 mL and up to two thirds of women receive a transfusion. Blood loss is probably dependent on patient selection and surgeon experience. The most problematic bleeding typically occurs during the ureteral dissection. Surgeons who exercise particular caution here are often rewarded with minimal blood loss and a clear surgical field. The ureter is surrounded by small, easily injured blood vessels as it courses through its tunnel into the bladder trigone. Once bleeding occurs, it can be difficult to control since the ureter is in close proximity. Often the only way to stop the bleeding is to hurriedly complete the ureteral dissection, a circumstance that places the ureter at risk of injury. Transfusion is often necessary, but should be avoided if possible due to concerns, although unproven, that this can adversely affect prognosis.

Operative injury is another major concern, occurring in about 2% of cases. The most common sites of injury are the ureter, bladder, nerves, major vessels, and rectum. Ureteral injuries are slightly more common, although not significantly increased, after robotic radical hysterectomies particularly because of electrocautery injury due to the close proximity of the monopolar scissors to the ureter during dissection of the ureteral tunnel. Sequelae of the most common injuries, to the ureter and bladder, include sepsis, fistula, loss of renal function, and reoperation. Injury can also delay or proscribe adjuvant therapy. Maintenance of a clear surgical field, gentle tissue handling, and careful dissection of surgical planes will minimize, though not eliminate, operative injury. The single most important determinant of outcome after operative injury is whether the injury is detected intraoperatively. Therefore, whenever an injury is suspected, careful evaluation as described above should be performed before closure of the abdomen.

POSTOPERATIVE COMPLICATIONS

Both short- and long-term complications are not uncommon following radical hysterectomy. The most common immediate complications are wound infection, thromboembolism, and ileus. Voiding dysfunction is expected and is therefore arguably not a complication. Likewise, febrile morbidity, although common, is of concern only insofar as it may be indicative of something more serious. In the immediate postoperative

period, the surgeon should be particularly attuned to signs or symptoms suggestive of thromboembolism, and should have a low threshold for evaluating patients with imaging studies. Timely diagnosis of this potentially fatal complication can be lifesaving.

Far less common but perhaps more dreaded, urinary tract fistula should be considered if a patient complains of watery vaginal discharge. Physical examination, testing with dye and tampons, and imaging studies such as contrast-enhanced computed tomography (CT) are diagnostic. A common first step is to instill the bladder with methylene blue after inserting a tampon in the vagina. Absence of dye on the tampon excludes a vesicovaginal fistula. Next, indigo carmine is injected intravenously. Further absence of dye on the tampon excludes a ureterovaginal fistula. It is important to recognize that a positive bladder dye test is diagnostic of vesicovaginal fistula but does not exclude a concomitant ureterovaginal fistula. Further evaluation, usually with cystoscopy and retrograde ureterography or CT urogram, is necessary. Prompt recognition of a fistula can decrease associated morbidity and in some cases even allow immediate reoperation and repair.

Ureteral obstruction after radical hysterectomy may be caused by direct operative injury or adhesions. Potential signs and symptoms include unexplained fever, flank pain, and prolonged ileus. Ureteral obstruction can occasionally be subclinical and come to light only upon discovery of a nonfunctioning kidney. Unilateral ureteral obstruction classically does not cause an elevation in creatinine, but a Mayo Clinic study showed that most patients do in fact experience a modest, transient creatinine elevation in the first 2 postoperative days. Unilateral obstruction is not associated with a change in urine output, but of course bilateral obstruction can result in anuria. Ureteral obstruction can be diagnosed by renal ultrasound or CT. The primary concerns in management are preservation of renal function, control of any urine leak (e.g., urinoma), and ultimately repair. The obstructed ureter may be stented either retrograde or antegrade, or a percutaneous nephrostomy may be placed. Just as with fistula, prompt recognition of ureteral obstruction may allow immediate reoperation if clinically indicated.

Potential delayed complications include lymphocysts, lymphedema, sexual dysfunction, and bowel obstruction. Symptomatic lymphocysts are rare now that most surgeons do not close the pelvic sidewall peritoneum. Chronic lymphedema is surprisingly uncommon after pelvic

lymphadenectomy in unirradiated patients but can be problematic in patients treated with radiation. Patients often experience some change in sexual function after radical hysterectomy, but severe dyspareunia as a result of a shortened vagina is not common with modern surgical techniques. As stated already, a vaginal margin of 1 to 2 cm is all that is necessary in most patients. Certainly patients receiving radiation rather than radical surgery are at higher risk of this complication. In addition, postoperative adjuvant radiation probably increases the risk of sexual dysfunction beyond that of surgery alone. If the ovaries are removed, this can result in dyspareunia from decreased vaginal lubrication, but this problem is readily corrected with estrogen, either topical or systemic. Estrogen use is not associated with cervical cancer risk and is not contraindicated in cervical cancer patients. Small bowel obstruction occurring after radical hysterectomy is usually caused by adhesions, although recurrence must always be considered. The risk of obstruction is increased in irradiated patients.

Suggested Readings

Casey M. A new vascular clamp for radical pelvic dissection. *Am J Surg* 1977;134:434.

Estape R, Angioli R, Wagman F, et al. Significance of intraperitoneal cytology in patients undergoing radical hysterectomy. *Gynecol Oncol* 1998;68:169.

Helmkamp B, Krebs H, Corbett S, et al. Radical hysterectomy: current management guidelines. *Am J Obstet Gynecol* 1997;177:372.

Landoni F, Maneo A, Colombo A, et al. Randomised study of radical surgery versus radiotherapy for stage Ib-IIa cervical cancer. *Lancet* 1997;350:535.

Landoni F, Maneo A, Cormio G, et al. Class II versus class III radical hysterectomy in stage IB-IIA cervical cancer: a prospective randomized study. *Gynecol Oncol* 2001;80:3.

Lopes A, Hall J, Monaghan J. Drainage following radical hysterectomy and pelvic lymphadenectomy: dogma or need? *Obstet Gynecol* 1995;86:960.

Monk B, Tewari K, Gamboa-Vujicic G, et al. Does perioperative blood transfusion affect survival in patients with cervical cancer treated with radical hysterectomy? *Obstet Gynecol* 1995;85:343.

Morrow CP, Curtin JP. *Gynecologic cancer surgery*. Philadelphia, PA: Churchill Livingstone, Harcourt Brace and Co; 1996.

Peters W, Liu P, Barrett R, et al. Concurrent chemotherapy and pelvic radiation

therapy compared with pelvic radiation therapy alone as adjuvant therapy after radical surgery in high-risk early-stage cancer of the cervix. *J Clin Oncol* 2000;18:1606.

Querleu D, Morrow CP. Classification of radical hysterectomy. *Lancet Oncol* 2008;9:297–303.

Rettenmaier M, Casanova D, Micha J, et al. Radical hysterectomy and tailored postoperative radiation therapy in the management of bulky stage 1B cervical cancer. *Cancer* 1989;63:2220.

Sedlis A, Bundy B, Rotman M, et al. A randomized trial of pelvic radiation therapy versus no further therapy in selected patients with stage IB carcinoma of the cervix after radical hysterectomy and pelvic lymphadenectomy: a Gynecologic Oncology Group study. *Gynecol Oncol* 1999;73:177.

Sevin B, Ramos R, Gerhardt R, et al. Comparative efficacy of short-term versus long-term cefoxitin prophylaxis against postoperative infection after radical hysterectomy: a prospective study. *Obstet Gynecol* 1991;77:729.

Shazly S, Murad M, Dowdy S, et al. Robotic radical hysterectomy in early stage cervical cancer: a systematic review and meta-analysis. *Gynecol Oncol* 2015;138:457.

Takeshima N, Yanoh K, Tabata T, et al. Assessment of the revised International Federation of Gynecology and Obstetrics staging for early invasive squamous cell carcinoma. *Gynecol Oncol* 1999;74:165.

Trimbos J, Franchi M, Zanaboni F, et al. “State of the art” of radical hysterectomy; current practice in European oncology centres. *Eur J Cancer* 2004;40:375.

EDITOR’S COMMENT

The incidence of cervical cancer in the United States and the rest of the developed world has dramatically decreased due to the introduction of the Papanicolaou (Pap) smear, and the incidence should decline even further with the recent introduction of vaccines for the human papilloma virus (HPV). In 2016, it is estimated that there will be nearly 13,000 new cases of cervical cancer and an estimated 4,120 deaths due to this disease in the United States, and more than one third of these cases will be diagnosed in women of reproductive age (Siegel RL, Miller KD, Jemal A. Cancer statistics, 2016. *CA Cancer J Clin* 2016;66:7–30). In contrast, the global burden of this disease is much more dramatic, particularly in the developing world, where cervical cancer is the third most common cause of cancer death for women (Torre LA, Siegel RL, Ward EM, et al. Global Cancer Incidence and Mortality Rates and Trends–An Update. *Cancer Epidemiol Biomarkers Prev* 2016;25:16–27). Squamous cell histologies comprise greater than 85% of cervical cancers, with

adenocarcinomas (which are also HPV-related) being the second most common histology. The spread of cervical cancer is predictable, first involving the vagina and parametria, then spreading to the pelvic and para-aortic lymph nodes, and lastly spreading hematogenously to distant sites, at which point the disease is considered incurable.

Cervical cancer is staged clinically, and at its earliest stage (IA1), the vast majority of women are cured with conservative surgical procedures, such as excision of the transformation zone by electrosurgery (LLETZ or LEEP) or laser or cold knife cone excisional biopsy. The rationale for the more radical treatment of stage IA2 disease or greater is the increasing risk of lymph node metastases. For stage IA1 disease, the risk of nodal metastasis is extremely low (<1%), whereas for stage IA2 disease, defined as a depth of tumor invasion of 3 to 5 mm and horizontal spread of <7 mm, the risk of nodal metastasis rises to 5% to 7% (Roque DR, Wysham WZ, Soper JT. The surgical management of cervical cancer: an overview and literature review. *Obstet Gynecol Surv* 2014;69:426–41). For stage IB disease, the risk of regional nodal metastasis ranges from ~5% for tumors <2 cm in size to greater than 35% for tumors >4 cm in size. Thus, for stage IA2 and IB disease, more aggressive treatment with either radical hysterectomy (RH) and bilateral pelvic lymph node dissection (LND) or chemoradiation therapy is offered, and the 5-year survival rates with either of these strategies have exceeded 85%. However, RH with bilateral pelvic LND, as beautifully described and illustrated by Dr. Boone and Dr. Huh in this chapter, may be associated with significant long-term morbidities, such as urinary and bowel dysfunction, sexual dysfunction, and lymphedema, all of which can dramatically affect the quality of life of the many long-term survivors of this disease (Reade CJ, Eiriksson LR, Covens A. Surgery for early stage cervical cancer: how radical should it be? *Gynecol Oncol* 2013;131:222–30). Furthermore, RH obviously renders infertile the many reproductive age women affected by this disease. Therefore, there has been much interest in defining which women with early stage cervical cancer can safely undergo less radical, fertility-sparing surgery.

Radical trachelectomy has been an option for certain women with stage IA2 or IB1 cancers who wish to retain their fertility, though it should not be regarded as a particularly “conservative” option, as long-term morbidity associated with autonomic dysfunction after this procedure can be similar to that seen with RH (Ramirez PT, Pareja R, Rendón GJ, et al. Management of low-risk early-stage cervical cancer: should conization, simple trachelectomy, or simple hysterectomy replace radical surgery as the new standard of care? *Gynecol Oncol* 2014;132:254–9). Furthermore, the nerve-sparing radical hysterectomy (NSRH), increasingly done either laparoscopically or robotically, is felt to reduce long-term morbidity by providing a means to preserve the hypogastric nerves as they course through the uterosacral ligaments as well as the splanchnic nerves as they course through the paracervix. Though NSRH has similar oncologic efficacy, fewer postoperative complications, and a lower

likelihood of bladder dysfunction compared to RH, there are few data to support the assertion that NSRH confers better postoperative anorectal and sexual function than RH (Long Y, Yao DS, Pan XW, et al. Clinical efficacy and safety of nerve-sparing radical hysterectomy for cervical cancer: a systematic review and meta-analysis. *PLOS One* 2014;9:e94116).

Other conservative management strategies for early stage cervical cancer are the subject of three ongoing prospective studies. The Simple Hysterectomy and Pelvic node dissection in Early-stage low risk cervical cancer (SHAPE) trial is an international, multicenter, phase III, randomized trial comparing RH and pelvic LND to simple hysterectomy and pelvic LND (Plante M. The SHAPE Trial 2013;NCT016589309. ClinicalTrials.gov). Women with stage IA2 to IB1 disease are eligible. The study's primary outcome is to determine whether simple hysterectomy is safe and associated with less morbidity than RH and to investigate whether there is a difference in overall survival between the two groups. Secondary outcomes include relapse-free survival rates, rates of parametrial and pelvic lymph node involvement, cost-effectiveness, and patient-related quality of life outcomes. This study opened in 2014 and seeks to enroll more than 700 women.

The second study investigating the safety and feasibility of conservative surgery for stage IA2 and IB1 cervical cancer is the ConCerv trial, which is an international, multicenter trial (Schmeler KM, Frumovitz M, Ramirez PT. Conservative management of early stage cervical cancer: is there a role for less radical surgery? *Gynecol Oncol* 2011;120:321–5). The conservative surgical options in this trial include either cone biopsy or simple hysterectomy with pelvic LND, and the choice is guided by the woman's plans for future fertility. The primary outcome measure of this study is the safety and feasibility of performing cone biopsy or simple hysterectomy with pelvic LND. Secondary outcomes include toxicity and quality of life compared to historically matched patients undergoing RH.

The third study, GOG 278, is a prospective, randomized, phase III trial which seeks to evaluate the physical function and quality of life of patients before and after conservative surgery (either cone biopsy or simple hysterectomy with pelvic LND) for stage IA1 disease with lymphovascular space invasion up to stage IB1 disease, including a tumor size up to 2 cm (NCT01649089. ClinicalTrials.gov). The primary outcomes are to assess bladder, bowel, and sexual function as well as the incidence of lymphedema after conservative surgery.

Another approach to limit the morbidity of RH and pelvic LND for cervical cancer is to try to identify those women at low risk of regional lymph node metastases such that they may avoid unnecessary pelvic LND and its possible sequelae, principally lymphedema. Sentinel lymph node (SLN) mapping and biopsy, which has been successfully used to stage the regional nodal basin in patients with breast cancer or melanoma for more than two decades, is currently being studied prospectively for its feasibility in the surgical management of

early stage cervical cancer. The SENTICOL study evaluated the use of preoperative lymphoscintigraphy and SLN biopsy in women with stage IA1 to IB1 disease, and all patients went on to have bilateral pelvic LND after the SLNs were excised (Lécuru F, Mathevet P, Querleu D, et al. Bilateral negative sentinel nodes accurately predict absence of lymph node metastasis in early cervical cancer: results of the SENTICOL study. *J Clin Oncol* 2011;29:1686–91; Bats AS, Frati A, Mathevet P, et al. Contribution of lymphoscintigraphy to intraoperative sentinel lymph node detection in early cervical cancer: analysis of the prospective multicenter SENTICOL cohort. *Gynecol Oncol* 2015;137:264–9). The SLN detection rate on preoperative lymphoscintigraphy was 87.8%, and the intraoperative detection of the SLN using blue dye in addition to radioactive colloid was 97.8%. Interestingly, lymphoscintigraphy enabled the detection of lymphatic drainage to aberrant lymph nodes, as more than 10% of patients were discovered to have SLNs in the para-aortic region rather than within the pelvis. SLNs were identified in 95% of patients overall and were detected bilaterally in 76% of patients. The sensitivity of SLN biopsy for the detection of lymph node metastasis was 92%, and the negative predictive value of SLN biopsy was 98.2%. This study and others have confirmed that the SLN biopsy technique is feasible for patients with early stage cervical cancer and suggest that less radical surgery is safe in selected patients. Future studies will need to validate these findings in order for SLN biopsy to become the standard of care for the staging of the regional nodal basin in cervical cancer.

Lastly, several groups are investigating the utility of high-quality radiologic imaging to identify regional lymph node metastases preoperatively and to guide treatment in women with cervical cancer. Conventional imaging with CT and magnetic resonance imaging (MRI) scans has a low sensitivity for the detection of lymph node metastases (Choi HJ, Ju W, Myung SK, et al. Diagnostic performance of computer tomography, magnetic resonance imaging, and positron emission tomography or positron emission tomography/computer tomography for detection of metastatic lymph nodes in patients with cervical cancer: meta-analysis. *Cancer Sci* 2010;101:1471–9). Preoperative imaging with positron emission tomography (PET-CT) has been proposed as the optimal method for identifying metastases to the regional nodes, as unlike CT and MRI, PET-CT does not rely on lymph node size to differentiate between normal and metastatic nodes, and it has reasonably good sensitivity (75% to 86%) and specificity (92% to 97%) for the detection of metastatic nodes, at least in patients with more advanced stage cervical cancer (Rose PG, Adler LP, Rodriguez M, et al. Positron emission tomography for evaluating para-aortic nodal metastasis in locally advanced cervical cancer before surgical staging: a surgicopathologic study. *J Clin Oncol* 1999;17:41–5). The sensitivity of PET-CT in patients with earlier stage disease has in general been more variable and not quite as good, such that PET-CT may not be accurate enough to obviate the need for more invasive surgical staging of the regional nodes in many women with cervical cancer.

John T. Mullen

185 Surgical Management of Ovarian Carcinoma

Kara Long Roche, Arlan F. Fuller, Jr., and Dennis S. Chi

INTRODUCTION: THE PATHOGENESIS OF EPITHELIAL OVARIAN TUMORS

In the United States, ovarian cancer is the leading cause of death from a gynecologic malignancy, and its incidence rises steeply with increasing age after menopause. The lethality of this disease is in part due to the fact that the majority of patients present with advanced-stage disease, a result of early peritoneal dissemination and an absence of symptoms associated with early-stage disease. Risk factors include age, early menarche, late menopause, nulliparity, and most importantly, family history.

Only approximately a third of patients will be diagnosed with early-stage disease, and in many of these cases, the finding of an adnexal mass is incidental. It is not uncommon for these women to be asymptomatic; however, symptoms such as pelvic discomfort, bloating, urinary symptoms, dyspareunia, or changes in bowel habits may be subtle indicators of early-stage disease. Unfortunately, most women do not experience symptoms until the disease is advanced. Symptoms of advanced-stage disease can include abdominal distention, discomfort, nausea, vomiting, early satiety, increased abdominal girth, changes in bowel habits (diarrhea, constipation, changes in stool caliber), and/or shortness of breath. Any of these symptoms and/or the presence of a suspicious adnexal mass necessitate prompt evaluation and referral to a gynecologic oncologist, especially if the patient is postmenopausal, has a history of breast cancer, or has a family history of breast or ovarian cancer.

Experts in ovarian cancer pathogenesis have suggested a two-tiered system based on molecular and morphologic determinants. Type I ovarian cancers are generally low grade, indolent, and diagnosed at an early stage. These include endometrioid carcinoma, low-grade serous carcinoma, clear cell carcinoma, and mucinous carcinoma. Mutations in *KRAS*, *BRAF*, *ERBB2*, *PTEN*, *PIK3CA*, *ARID1A*, and microsatellite instability are

common in type I tumors. Type II ovarian cancers, in contrast, are high grade, clinically aggressive, and commonly diagnosed at an advanced stage. High-grade serous carcinoma, carcinosarcoma, and undifferentiated carcinoma are examples of type II tumors. Defects in the homologous recombination repair pathway such as deleterious mutations in *BRCA1* or *BRCA2* are associated with these cancers. Chromosomal disruption and, moreover, mutations in TP53 are extremely common.

Type I Tumors

Endometrioid carcinomas of the ovary commonly present at an early stage and are generally accepted to have their origin in the endometrium or from endometriotic implants. They account for approximately 10% of all invasive ovarian cancers and have an overall favorable prognosis. In addition to loss of mismatch repair proteins (MLS1, MSH2, MSH6, and PMS2), endometrioid ovarian carcinomas may carry other mutations, such as PTEN, ARID1A, CTNNB1, and PP2R1A. In many cases, a concurrent endometrioid carcinoma will be identified in the endometrium, and it remains a challenge for the pathologist to identify the lesion as either a synchronous or metastatic lesion. Synchronous tumors generally occur in young women and are characterized by a low-grade endometrial lesion with no/limited myometrial invasion and no lymphovascular invasion with a concurrent low-grade ovarian lesion. Synchronous tumors are also generally large and unilateral, with an expansile invasion pattern, and associated with endometriosis or an endometrioid borderline tumor.

Clear cell carcinomas are also commonly associated with endometriosis. These tumors also generally present at a low stage and account for approximately 10% of invasive ovarian cancers in the United States. Atypical endometriosis has been identified as a possible precursor lesion to ovarian clear cell carcinoma. They can be associated with loss of expression of mismatch repair proteins (MLS1, MSH2, MSH6, and PMS2) as well as mutations in ARID1A, PIK3CA, and PPP2R1A.

The predisposition for both clear cell carcinomas and endometrioid carcinomas to be multifocal and arising in endometriosis also accounts for the problem of local recurrence in pelvic peritoneum. Presumably, many cases of pelvic recurrence represent a field effect with new cancers arising in residual pelvic endometriosis. The long-term management of epithelial carcinoma arising in endometriosis represents an indication for postoperative pelvic radiation therapy in order to achieve a durable

prolonged remission. It is particularly notable that even after successful primary treatment of endometrioid or clear cell carcinoma arising in endometriosis, second primary tumors may represent a substantial proportion of what is otherwise thought to be “recurrent” carcinoma. This is particularly important for the surgeon to recognize that late recurrence of ovarian carcinoma should be considered as a potential second primary and may well represent isolated disease that can be successfully treated with surgery and potentially adjunctive chemotherapy. Future molecular characterization will better delineate this distinction in the development of second primary lesions.

Low-grade mucinous carcinomas of the ovary account for only 2% to 4% of all invasive ovarian cancers and may arise from one of two origins; as is characteristic of the mucinous borderline tumors, these may be either müllerian or an intestinal subtype. The most commonly encountered mutation is KRAS, which is identified in up to 75% of mucinous ovarian cancers. In non-KRAS mutated tumors, it is common to see overexpression of HER2, although these two mutations have also been found to coexist. It is crucial to rule out metastases from gastrointestinal sources, and as such, part of the abdominal exploration of patients with mucinous ovarian tumors should include the evaluation and removal of the appendix. For reasons yet to be determined, there may be isolated and very bulky metastasis to the contralateral ovary from the appendix without evidence of intervening disease in the ipsilateral ovary or uterus. These low-grade mucinous tumors of the appendix and ovary are often the precursor to the development of pseudomyxoma peritonei.

Low-grade serous ovarian cancers, recently accepted as a distinct entity from high-grade serous ovarian cancer, account for only 2% of all ovarian cancers. While traditionally these tumors are thought to arise in a stepwise fashion (from cystadenoma to borderline serous tumor to micropapillary borderline tumors to invasive low-grade serous carcinoma), recent evidence suggests that they may have a fallopian tube origin related to endosalpingiosis. Unlike the rest of type I tumors, low-grade serous carcinomas tend to present at an advanced stage and respond poorly to cytotoxic chemotherapy. The majority are both estrogen and progesterone receptor positive, and KRAS and BRAF mutations are found in 60% to 70% of cases.

Type II Tumors

High-grade serous carcinomas account for 70% of all ovarian cancers. They are the most common and one of the most lethal ovarian malignancies. Almost all high-grade serous ovarian carcinomas are associated with a TP53 mutation, which leads to the accumulation of DNA damage and chromosomal instability. The most commonly associated germline abnormalities are mutations in BRCA1 and BRCA2; however, mutations in BRIP1, RAD51C, RAD51D, and other mutations, recently have been associated with an increased risk of developing the disease.

In recent decades, the fimbriated end of the fallopian tube has been implicated in the pathogenesis of high-grade serous epithelial ovarian cancer. This is in contrast to the previous theory that epithelial ovarian cancer was derived from the overlying serosal surface of the ovary and related to incessant ovulation. While this theory was accepted for many years, there were major “gaps” to its full acceptability, such as a lack of an identified precursor lesion. Some of the most convincing evidence supporting this theory comes from the identification of serous tubal intraepithelial carcinoma (STIC), thought to be the precursor to high-grade serous cancer. STIC lesions are characterized by noninvasive cytologically malignant tubal epithelium. In women with BRCA mutations undergoing risk-reducing salpingo-oophorectomy, STIC lesions have been identified in approximately 5% to 15% of cases. Moreover, in women with BRCA mutations and high-grade serous carcinoma, STIC lesions are identified in the fallopian tubes in up to 80% of cases. While more is known about the association between BRCA positivity and the risk of STIC lesions, it is important to note that STIC lesions have also been identified in up to 60% to 75% of cases of sporadic high-grade serous carcinoma. Additional evidence comes from the lineage continuity of TP53 mutations in high-grade serous carcinoma and the accompanying STIC lesions. TP53 mutations lead to an overabundance of nonfunctional P53, which when found in the epithelium of fallopian tubes is referred to as a “P53 signature.”

Ovarian carcinosarcoma is a rare, clinically aggressive subtype accounting for only 1% to 4% of all ovarian malignancies. The most commonly accepted theory of pathogenesis is that the carcinomatous and sarcomatous elements represent a single neoplastic process. This is supported by both clonality studies and genomic analysis. P53 overexpression is common and appears to be associated with an overall worse prognosis.

PATTERNS OF METASTATIC DISEASE

While the current staging system (Table 185.1) follows a logical order of progression—from ovarian-confined disease, to pelvic and then abdominal-confined disease, to distant metastases—the natural history of the disease is likely quite different, with transperitoneal dissemination occurring very early in the disease course. This is particularly relevant for high-grade serous carcinomas, in which exfoliated tumor cells, likely from the distal fallopian tube, typically first implant in the paracolic gutters and on the right hemidiaphragm. The negative pressure associated with respiratory movement of the diaphragm over the liver creates a clockwise flow of peritoneal fluid, possibly explaining the predominance of disease in the right upper versus left upper quadrant (LUQ) (Fig. 185.1). Several typical patterns of spread are identified with more advanced disease; some patients may present with disease solely in the omentum, some with "oligo" metastatic disease (bulky metastases, fewer in number, usually in the omentum and on peritoneal surfaces), and some with miliary carcinomatosis.

TABLE 185.1 The FIGO Staging System for Ovarian Carcinoma

IA	Tumor limited to one ovary, capsule intact, no tumor on surface, negative washings
IB	Tumor involves both ovaries, otherwise like IA
IC	Tumor limited to one or both ovaries
IC1	Surgical spill
IC2	Capsule rupture before surgery or tumor on ovarian surface
IC3	Malignant cells in ascites or peritoneal washings
IIA	Extension and/or implant on uterus and/or fallopian tubes
IIB	Extension to other pelvic intraperitoneal tissues
IIIA	Positive retroperitoneal lymph nodes and/or microscopic disease beyond the pelvis
IIIA1	Positive retroperitoneal lymph nodes only
IIIA(i)	*Metastasis ≤ 10 mm*
IIIA(ii)	*Metastasis > 10 mm*
IIIA2	Microscopic, extrapelvic (above the brim), peritoneal involvement ± positive retroperitoneal lymph nodes
IIIB	Macroscopic, extrapelvic, peritoneal metastasis ≤2 cm ± positive retroperitoneal lymph nodes. Includes extension to the capsule of the spleen
IIIC	Macroscopic, extrapelvic, peritoneal metastasis >2 cm ± positive retroperitoneal lymph nodes. Includes extension to the capsule of the spleen
IVA	Pleural effusion with positive cytology
IVB	Hepatic and/or splenic parenchymal metastasis, metastasis to extra-abdominal organs (including inguinal lymph nodes and lymph nodes outside the abdominal cavity

Prat and FIGO Committee on Gynecologic Oncology. FIGO's staging classification for cancer of the ovary, fallopian tube, and peritoneum: abridged republication. *J Gynecol Oncol* 2015;26(2):87–9.

Patients with high-grade primary ovarian tumors clinically confined to the ovary may have evidence of occult regional spread to the pelvic nodes, as well as to para-aortic nodes at the origin of the gonadal arteries. These lymph node metastases may be the only site of metastatic disease. Patients with predominately lymph node metastases in the absence of transperitoneal spread actually have a better prognosis than patients with negative nodes and intraperitoneal disease. The pattern of lymph node metastasis in patients with stage III (abdominal spread) ovarian cancer and any nodal metastasis is such that the majority of patients will have both pelvic and para-aortic nodal disease, while a minority will have either pelvic or para-aortic disease. Patients with peritoneal carcinomatosis with disease not extensively involving the ovary have a lower incidence of nodal metastases for the same extent of intra-abdominal disease.

Each of these patterns has implications for the surgeon as it affects the resectability of disease and intraoperative planning of the sequence of tumor resection. Because stage II disease is relatively uncommon in light of what we understand about peritoneal spread, its occurrence is typically associated with bulky, low-grade tumors and direct rectosigmoid invasion. The association of endometrioid carcinoma and endometriosis accounts for a number of these patients, who, by definition, have local peritoneal involvement, arising in pelvic endometriosis. The locally invasive nature of this tumor is also consistent with the two-tiered approach, with “Type I” lesions less likely to be associated with extrapelvic metastatic disease. This locally advanced disease can be treated successfully with en bloc resection of the ovarian or peritoneal neoplasm, the uterus, pelvic peritoneum, or rectosigmoid colon. In similar manner, as noted above, the pattern of ovarian cancer spread to lymph nodes exclusively appears to carry a better prognosis, as the absence of associated peritoneal metastases seems to reduce the risk of peritoneal recurrence.

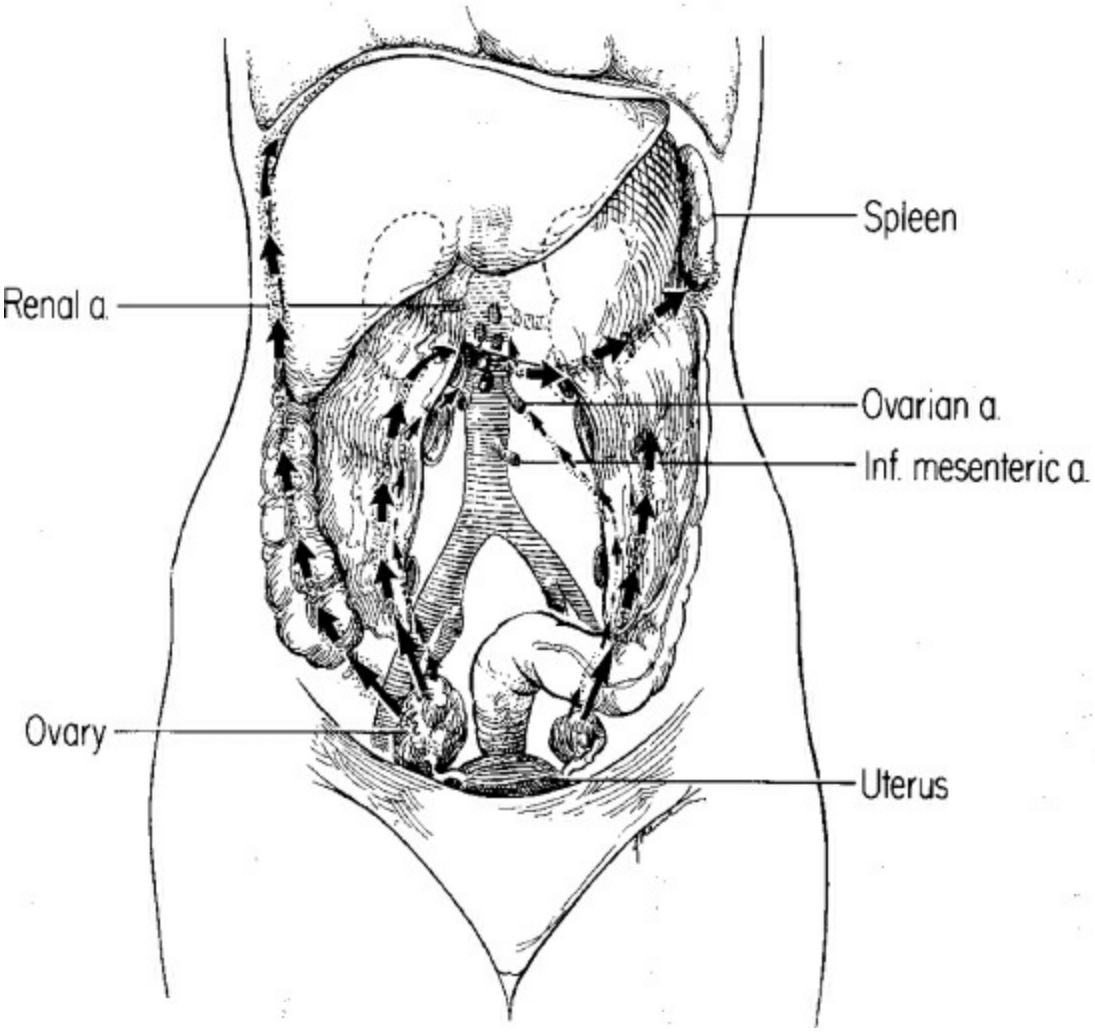

Figure 185.1. The pattern of intraperitoneal dissemination of ovarian cancer (Scully).

The clinical presentation at the time of diagnosis also may reflect the distribution of tumor, the tumor grade, and by inference, the patient's prognosis. Patients presenting with a typical picture of abdominal distention and symptoms of bowel obstruction most commonly have fairly extensive peritoneal carcinomatosis. On the contrary, patients with the largest pelvic masses often have compressive symptoms secondary to tumor bulk without extensive invasion or metastasis; hence, in the absence of invasion, the tumor has sufficient time to grow to a large size. Some patients with surgical stage IV disease actually have an excellent prognosis, if they present solely with distant nodal metastases. The surgeon should not be dissuaded from consideration of a surgical approach to this disease in that setting, although it may be preferable to consider video-assisted thoracoscopic surgery to rule out bulky pleural disease prior to proceeding with laparotomy and debulking.

Screening

There is no effective screening test for ovarian cancer. Various techniques and serologic assays have been evaluated, including review of symptomatology, physical exam, pelvic sonography, and serum tumor markers, without evidence of significant stage shift or decrease in mortality. There is currently no recommendation for routine screening in the average-risk woman. This is in large part related to the relatively high false-positive testing with serum CA125 and pelvic ultrasound, which result in a high rate of potentially unnecessary invasive procedures.

Multiple large prospective studies have not demonstrated a benefit to routine screening for ovarian cancer. In the UK Collaborative Trial of Ovarian Cancer Screening (UKCTOCS) study, more than 200,000 postmenopausal women were randomized to one of three arms: multimodal screening, transvaginal ultrasound screening, or no screening. The multimodal arm, which consisted of serum CA125 testing incorporated into a risk algorithm, was designed to assess change over time. While a reduction in mortality was identified in subgroup analyses of the multimodal arm, this was not significant in the primary analysis, and further evidence supporting a benefit to screening is needed before it can be recommended. In women at increased risk for ovarian cancer, such as

those with a BRCA1 or 2 mutation, screening with twice yearly transvaginal ultrasound and serum CA125 is reasonable; however, studies have failed to show a substantial benefit, even in this cohort.

Risk-Reducing Surgery in High-Risk Women

Family history is the most significant risk factor for the development of ovarian cancer. Hereditary breast and ovarian cancer syndrome (HBOC) is an inherited condition associated with an increased lifetime risk of developing breast and ovarian cancer. HBOC is most commonly associated with mutations in the BRCA1 and BRCA2 genes. The risk of ovarian cancer is 39% to 46% with a BRCA1 mutation and 10% to 27% with a BRCA2 mutation. As there is no effective screening test for ovarian cancer, risk-reducing salpingo-oophorectomy (RRSO) is recommended as the gold standard for prevention. There are strong data supporting this approach, which has been demonstrated to result in a 75% to 96% decrease in ovarian cancer risk, as well as a 50% decrease in breast cancer risk. Despite this dramatic decrease in risk, in women with BRCA mutations, RRSO is recommended by age 40 or when childbearing is complete; however, the timing of surgery can be individualized to an extent considering the patient's specific mutation and goals of care. Other mutations, such as those associated with Lynch syndrome, *MLH1*, *MSH2*, *MSH6*, and *PMS2*, as well as *BRIP1*, *PALB2*, *RAD51C*, *RAD51D*, and *BARD1*, have also been associated with an increased risk of ovarian cancer, and RRSO is recommended after thorough counseling.

Risk-reducing salpingo-oophorectomy is ideally performed in a minimally invasive fashion and should include peritoneal washings, as well as a thorough inspection of the peritoneal cavity. Specimens should be designated as "prophylactic," and pathologic assessment should utilize the SEE-FIM ("sectioning and extensively examining the fimbriated end") technique. As the origin of high-grade serous carcinoma is increasingly understood to be the fallopian tube, bilateral salpingectomy with delayed oophorectomy has been suggested as a risk-reducing option, avoiding the additional morbidity of premature surgical menopause. The efficacy of this technique has not yet been demonstrated, and therefore, it is not recommended outside the setting of a clinical trial.

Approach to the Adnexal Mass

Adnexal masses can generally be classified as physiologic, inflammatory,

or neoplastic. The goal of the clinician should be to address symptoms and assess the risk of malignancy in the setting of the patient's age, menopausal status, and genetic risk. Studies have consistently shown that patients with ovarian cancer who receive their initial surgical care from a gynecologic oncologist have improved outcomes; therefore, a thorough and efficient workup followed by appropriate referral is imperative.

A prompt evaluation is needed when a suspicious adnexal mass is present, or when advanced ovarian cancer is suspected based on patient symptoms or imaging. Workup should include a careful history and physical exam, including breast, gynecologic, and rectal exam. All screening, including colonoscopy, mammography, and cervical cytology, should be up to date. If a pelvic mass is palpated on bimanual exam, the size, mobility, and extent of disease (i.e., sidewall and rectal involvement) should be noted. If a rectal mass is palpated, consider a flexible sigmoidoscopy to evaluate the lesion, even if the patient is up to date on screening colonoscopy. The abdomen should be assessed for the presence of ascites and the lungs examined for the presence of effusions.

Imaging studies may include transvaginal ultrasonography (TVUS), computed tomography (CT) scans of the abdomen and pelvis, pelvic magnetic resonance imaging (MRI), and positron emission tomography (PET) scans. TVUS can evaluate the internal architecture of the ovary, assess the status of the contralateral ovary, and identify any evidence of metastatic disease, including ascites. MRI can serve as an adjunct to TVUS to further characterize a complex lesion, especially with the assistance of a radiologist experienced in gynecologic MRI. Evidence of a large, solid component may indicate occult malignancy, unless the mass has characteristics of an ovarian fibroma. The presence of a complex adnexal mass, pelvic tumor, lymphadenopathy, or peritoneal carcinomatosis suggests the diagnosis of advanced ovarian cancer. If advanced disease is suspected or if the patient has shortness of breath, imaging should also include a chest CT, which can identify pleural disease, effusions, and enlarged mediastinal lymph nodes.

Tests for serum tumor markers, especially CA125, may be helpful in confirming the diagnosis of ovarian cancer or indicating the need for evaluation of other possible primary malignancies. While in the postmenopausal patient, CA125, CEA, and CA19–9 are the most useful, in the young woman with a suspicious mass, LDH, AFP, inhibin, and HCG can be integral in the diagnosis of a nonepithelial ovarian malignancy. In

the setting of carcinomatosis, a CA125 to CEA ratio of 25:1 or greater supports a gynecologic etiology. Routine preoperative testing should also include a basic metabolic panel, complete blood count, coagulation studies, liver function tests, and serum albumin.

Ultimately, surgical pathology is required for the definitive diagnosis of ovarian cancer. If the preoperative suspicion for ovarian malignancy is high, the surgical procedure should be performed by, or in conjunction with, a gynecologic oncologist. Prior to surgical intervention, a thorough preoperative assessment should be performed in order to ensure that the patient is a suitable candidate for a potentially lengthy and extensive surgical procedure. During the preoperative consent discussion, the patient should be informed of the potential need for extensive surgery (laparotomy, if laparoscopy is planned), for blood transfusion, or for the creation of a temporary or permanent ostomy. If there is a question of tumor resectability, it is reasonable to consider a diagnostic laparoscopy as the initial step. In women of childbearing age, it is crucial to discuss the patient's desire for future fertility prior to any surgical intervention and plan accordingly.

There are fewer contraindications to a minimally invasive approach, especially if patients are consented for a possible conversion to laparotomy. In a young woman with apparent benign disease, a laparoscopic ovarian cystectomy with preservation of the integrity of the majority of ovarian tissue would be the appropriate conservative course of action. Ideally, the cyst should be removed and placed intact into a laparoscopic bag for removal. Typically, one will find residual ovarian tissue to be preserved along the ovarian vessels, though occasionally, tumors of very large size do not demonstrate any recognizable residual normal ovarian cortex. In postmenopausal women, in whom the risk of occult malignancy is greater and the value of preservation of one ovary is lesser, the appropriate course of action is to perform an oophorectomy rather than an ovarian cystectomy, particularly if there is any suspicious appearance to the ovarian mass. Generally, any major degree of fixation of the ovarian neoplasm in the absence of obvious endometriosis should both raise the suspicion of malignancy and increase the likelihood of cyst rupture at the time of laparoscopic intervention.

Clinically Early-Stage Disease

An intraoperative frozen section should be performed on any complex adnexal mass to determine the need for further surgical staging. Patients

with apparent early invasive cancer diagnosed at the time of laparoscopy or laparotomy require the same intensive staging procedure (Table 185.1) irrespective of the route of access. In the absence of overt metastatic disease, a minimally invasive approach to surgical staging, either laparoscopically or with a robotic-assisted laparoscopic approach, can be considered. The surgeon should be prepared to carry out a definitive staging and carefully examine (but not necessarily biopsy) the contralateral ovary as well, particularly if fertility-sparing management is warranted.

Intraoperatively, the peritoneal surfaces in all 4 quadrants should be carefully examined. In cases where disease is grossly limited to the ovary, it is important that the specimen be removed intact to avoid spillage of tumor into the abdomen. Frozen section can be utilized to confirm malignancy and gynecologic origin and to assist in planning the remainder of the procedure. Surgical staging of ovarian cancer includes peritoneal cytology, total hysterectomy, bilateral salpingo-oophorectomy, omentectomy, pelvic and para-aortic lymphadenectomy (up to the level of the renal vessels), peritoneal biopsies from anterior/posterior cul-de-sac, pelvic sidewalls, paracolic gutters, and bilateral diaphragms. In the absence of any other sites of extra-ovarian spread, a complete systematic node dissection is necessary to completely evaluate the risk of metastasis, as well as to remove residual disease. If there is histologic evidence of metastatic intraperitoneal disease, then sampling of nodes and only removal of all enlarged nodes may be sufficient, although this is somewhat controversial. The upper abdomen, including the omentum in the LUQ, the liver surface, and both diaphragms, should be carefully examined. It is particularly important to evaluate the posterior aspect of the diaphragm behind the liver, as well as the inferior aspect of the liver at the foramen of Winslow. In select cases, fertility preservation is reasonable, with conservation of the uterus and/or the contralateral ovary.

A systematic and thorough approach should be taken during surgical staging, as incomplete staging can lead to the underestimation of disease and, subsequently, undertreatment. This comprehensive assessment is necessary for the accurate assessment of risk for recurrence and determination of the appropriate adjuvant chemotherapy regimen. Essentially, all patients with high-grade serous ovarian carcinoma, even those confined to the ovary, are candidates for chemotherapy. At the present time, adjuvant chemotherapy has no role in the treatment of well-differentiated early invasive epithelial malignancies confined to the ovary

with no surface involvement. The data regarding grade 2 tumors do not clearly indicate a benefit for adjuvant chemotherapy, and only with grade 3, stage IA tumors, as well as for more advanced lesions, is there a role for adjuvant treatment. As the success with pregnancy following chemotherapy of other malignancies is well supported in the literature, it is reasonable to consider this possibility in carcinoma of the ovary as well. Patients with stage IA, G3, and all with unilateral stage IC disease should receive adjuvant platinum and taxane-based chemotherapy along with the preservation of a normal contralateral ovary. Patients with stage IB disease or more advanced disease with contralateral ovarian involvement may require bilateral oophorectomy. A careful deliberation with the patient and her family and clearly defined informed consent is critical to this course.

Fertility Preserving Surgery

In women of childbearing age who desire future fertility, conservation of the uterus and nonaffected ovary can be considered. In patients with suspicious bilateral lesions or evidence of extraovarian disease, preoperative consultation with a reproductive endocrinologist (REI) to discuss options for oocyte or embryo cryopreservation or other techniques to protect ovarian reserve is recommended. Intraoperatively, if a malignancy is suspected in a young and otherwise healthy woman, it is far more prudent to perform a two-step procedure after a definitive pathologic diagnosis than to proceed with a surgical resection that renders her infertile. One can go back at a later date when the patient is fully informed, has had the opportunity for REI consultation, and better prepared to undergo major surgery. Completion surgery with removal of the adnexa and uterus should be strongly considered when childbearing is no longer desired.

Ovarian Borderline Tumors

In contrast to invasive epithelial carcinomas of the ovary, conservative surgical management of ovarian tumors of borderline malignancy should be considered the rule for young women, rather than the exception. Faced with an ovarian neoplasm with surface excrescences and implants within the peritoneal cavity and omentum, if the histologic diagnosis suggests an ovarian tumor of borderline malignancy, one should still consider preservation of reproductive potential, even if the excision of all of one ovary and part of another might be required for removal of apparent malignant disease. The difficulty in distinguishing between invasive

tumors and tumors of borderline malignancy on frozen section evaluation, particularly with limited sampling of bulky tumors, is the basis for the general recommendation that *one should never ablate reproductive function in a young woman of childbearing age on the basis of frozen section alone.*

Controversial issues related to the surgical care of a patient with a borderline ovarian tumor include:

- Cystectomy versus oophorectomy in the management of the primary tumor, particularly as many tumors will only be definitively diagnosed by histopathology after laparoscopic ovarian cystectomy.
- The need to biopsy the opposite, often normal-appearing, ovary; one must balance the yield from the procedure versus the risk of infertility, which is usually already an issue by that time.
- The need to fulfill the requirements of FIGO staging, with pelvic and para-aortic node dissection in particular, when no definitive therapy is usually recommended for patients with nodal "metastases" that may actually represent mullerian inclusions and not metastases from a noninvasive lesion.

Management of patients with peritoneal implants also presents a difficult problem. Implants may be noninvasive, desmoplastic, or invasive. Each carries a different prognosis and prudent management demands adequate sampling of a substantial proportion, if not all, of the lesions identified. Complete removal of all macroscopic lesions *should* be the goal —both to excise the tumor itself and also to ensure that a more aggressive metastatic lesion is not missed. Only a small proportion of women with borderline tumors will have invasive implants and present a risk of recurrence and death. Monitoring of the typical patient with noninvasive implants requires regular pelvic examinations and CA125 monitoring for the first year. After that time, progressively longer follow-up intervals would be appropriate. Routine CT scans in the absence of symptoms or a rising CA125 level, even for nonserous tumors, would not appear to be indicated.

Chemotherapy for these patients with borderline tumors and advanced or recurrent disease is unlikely to produce any dramatic and sustained responses, because of the low-grade nature of these tumors, their functional similarity to the corresponding normal tissue, and the low growth fraction assayed in vitro.

The Management of Advanced Disease

Standard management of advanced ovarian cancer consists of a combination of debulking surgery and systemic platinum-based chemotherapy. While this combination of modalities has remained the same, the timing of these interventions as well as the radicality with which they are employed has evolved dramatically over the past two decades. The timing of surgical intervention, specifically the role of primary debulking surgery versus the utilization of neoadjuvant chemotherapy followed by an interval debulking procedure, continues to be an area of active research and much controversy. In all of these cases, however, there is little debate regarding the fact that volume of visible residual disease after debulking surgery is one of the strongest prognostic factors in advanced ovarian cancer.

Defining Optimal

At the time of diagnosis, ovarian carcinoma presents with the greatest tumor burden of any solid tumor; a kilogram or more of tumor may be distributed in the pelvis and upper abdomen, along with several liters of ascites. It is distinct from the majority of other solid tumors, in which there is no role for surgery in the setting of advanced disseminated peritoneal disease. Although the epithelial ovarian tumors are considered quite responsive to primary chemotherapy, with response rates in the 80% to 90% range in untreated individuals, the dominant variable predictive of long-term survival is the amount of residual disease present at the conclusion of the initial surgical procedure. The validity of less than total excision in the presence of obvious metastatic disease appears to violate basic tenets of surgical oncology and has often been questioned. Nonetheless, it has been subjected to careful scrutiny over the last three decades and has been consistently documented as the dominant prognostic factor in studies of patient survival, whether treatment involves chemotherapy or radiation therapy. Essentially every clinical study has documented that the extent of residual disease even outweighs surgical stage in its prognostic importance. The theoretical explanation employed to support this observation is that surgical cytoreduction removes bulky tumor that is either constitutively drug-resistant, or one that is resistant because of poor drug penetration into a large tumor mass. In addition to this effect, reduction from a 5-cm tumor mass to a 0.5-mm tumor mass represents a seven log tumor cell reduction, from 10^{11} cells to 10^{4} cells,

decreasing the amount of chemotherapy needed for tumor control based on first-order kinetics of cell kill. This threshold effect may further be explained in theory by the elimination of cells that carry extreme drug resistance.

The concept of maximal cytoreductive effort dates back to work done in the 1970s. Griffiths, in an NCI monograph, demonstrated that patients with bulky intra-abdominal spread of ovarian cancer who underwent extensive cytoreduction to minimal residual disease had the same median survival time as those patients who had the same amount of minimal residual disease but did not require extensive surgical cytoreduction. They demonstrated an inversely proportional relationship between tumor burden after surgery and survival. In this study, 102 patients with stage II and III disease were examined, and results showed that those with no residual disease had the best outcomes compared with those with >1.5-cm residual disease in whom surgery conferred no measurable benefit.

Over time, the concept of "optimal" has evolved. The results of Gynecologic Oncology Group (GOG) study 52, which were published in 1989 by Omura et al., support an "optimal" cut-off of 1-cm residual disease. This definition has become an established standard in many subsequent studies and has been corroborated by many, including Chi et al. in 2001 in a study of prognostic factors in patients with advanced ovarian cancer undergoing upfront surgical debulking. This study, which included 282 women with stage III/IV disease undergoing primary debulking, identified age, ascites, and volume of residual disease as significant prognostic factors.

Since that time, it has been clearly demonstrated in both prospective and retrospective studies that less residual disease after primary surgery continues to be the most important modifiable prognostic factor. A meta-analysis published by Bristow et al. in 2002 included nearly 7,000 patients from 81 studies treated with surgery and chemotherapy during the platinum era. They determined that each incremental decrease in the volume of residual disease below 1 cm translated into improved patient survival. Similar studies from the Mayo Clinic and Memorial Sloan Kettering Cancer Center by Aletti and Chi, respectively, have demonstrated similar results—most notably that the best survival outcomes reliably fall within the cohort of patients with no gross residual disease following primary debulking surgery (Fig. 185.2). Patients who underwent complete cytoreduction had a 5-year survival rate in excess of 75%, while

patients who had macroscopic residual disease of <1 cm in size had an approximate 30% survival rate, and patients with residual disease >1 cm but <2 cm had only a 15% 5-year survival rate. These data all support the concept that complete resection of all visible disease should be the goal of debulking surgery for advanced ovarian cancer.

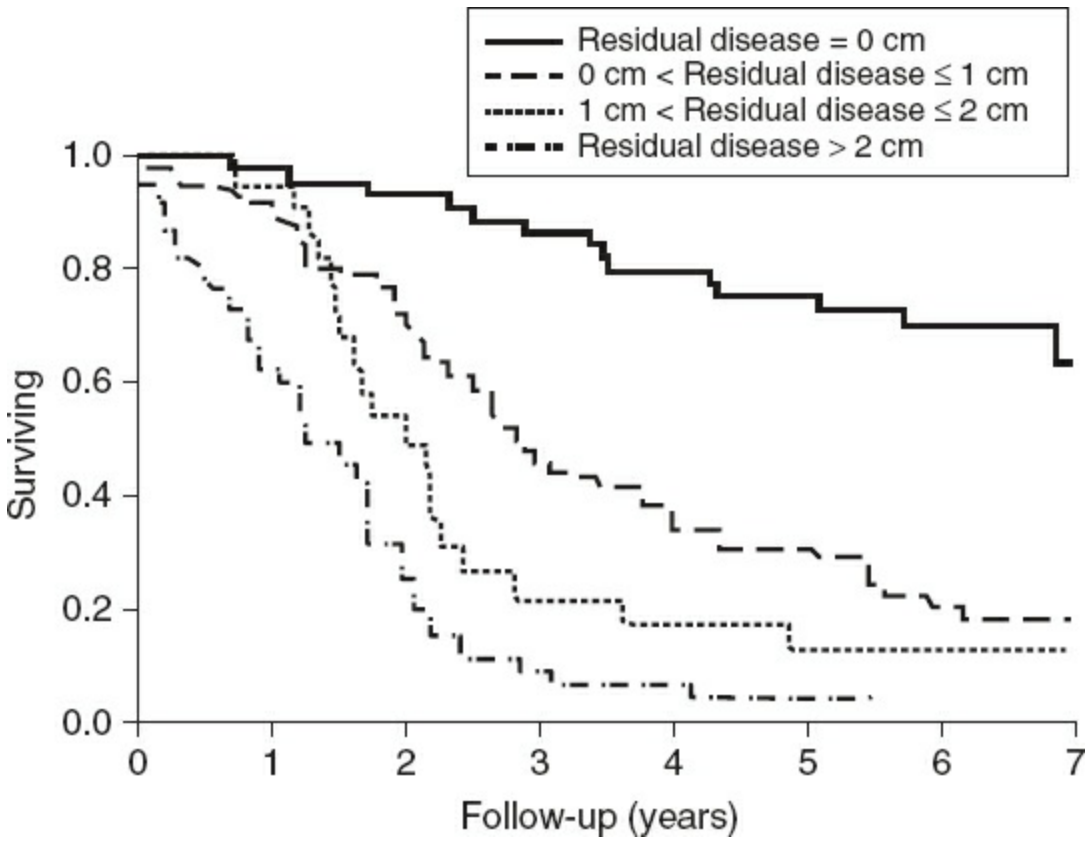

Figure 185.2. Survival curves for patients by the extent of residual disease after primary surgical therapy. (Aletti GD, Dowdy SC, Gostout BS, et al. Aggressive surgical effort and improved survival in advanced-stage ovarian cancer. *Obstet Gynecol* 2006;107:77–85.)

Expanding the Scope of Debulking Surgery

Historically, debulking surgery for ovarian cancer consisted of a hysterectomy, salpingo-oophorectomy, and omentectomy. However, as evidence supporting volume of residual disease as the most influential modifiable prognostic factors accumulated, a change in surgical paradigm occurred, with the routine incorporation of radical upper abdominal and thoracic procedures into debulking surgery. The addition of procedures such as diaphragm resection, liver resections, splenectomy, distal pancreatectomy, cholecystectomy, and portal lymphadenectomy has been

reported in one single institution study to have increased rates of optimal primary debulking from 46% to 80% and complete gross resection rates from 11% to 27%. In this cohort, both progression-free and overall survival were significantly higher than those of similar patients treated in a less-extensive surgical era. While the adoption of more radical and comprehensive debulking surgery results in a higher rate of perioperative morbidity, the survival outcomes remain improved, supporting this approach. In order to facilitate this, there is a clear role for the collaboration of gynecologic oncologists and general surgeons experienced in gastrointestinal and, particularly, hepatobiliary surgery.

In the modern era, ovarian cancer resectability is contingent upon the distribution of disease, the skill of the surgeon, and the patient's ability to undergo a major operation. Rarely is the pelvis the site of residual disease after incomplete cytoreduction. Common sites of surgical failure are the root of the small bowel mesentery, nodal disease above the celiac axis involving the lesser curve of stomach and the left lobe of liver, and perihepatic disease on the right as well as peripancreatic disease involving the C-loop of the duodenum. Although there may be an element of patient selection for surgical exploration, the proportion of patients who undergo "adequate" debulking surgery should be in the 80% to 90% range; approximately half of these patients should have no gross residual disease. Bristow has demonstrated that institutions with a high frequency of optimal cytoreduction also have improved survival when compared with institutions that do not have such a level of surgical success. Further documentation of the positive effect of the aptitude of the gynecologic oncologist also comes from the Mayo Clinic (Table 185.2), where, in another paper, they documented that Mayo surgeons performing radical surgery in >50% of patients had a patient median survival more than double that of their counterparts who performed radical surgery in <50% of patients.

Timing of Surgery

Primary Debulking

Primary debulking surgery, when feasible, should be the first line of treatment for advanced ovarian cancer. In a postmenopausal woman with carcinomatosis and ascites, ovarian cancer should be at the top of the differential diagnosis. If the diagnosis of ovarian cancer is supported by tumor markers, then preoperative biopsy is not necessary prior to

proceeding with debulking surgery. Intraoperative frozen section can be used to confirm a gynecologic origin.

Preoperative evaluation should include a discussion of intraperitoneal therapy. In a randomized prospective trial, the GOG demonstrated a 16-month improvement in median overall survival time (66 vs. 50 months) in patients who had undergone optimal (<1.0-cm residual disease) surgical cytoreduction followed by intraperitoneal chemotherapy with cis-platinum and paclitaxel compared with patients who underwent similar chemotherapy via an intravenous route. This improvement in survival occurred despite both toxic and mechanical complications of intraperitoneal chemotherapy that prevented 58% of patients assigned to this therapy from completing the planned six cycles of treatment. The current clinical challenges are to optimize the delivery of this therapy and, in particular, to minimize catheter complications that prevent completion of treatment.

TABLE 185.2 Impact of the Surgeon

Correlation between two subgroups of surgeons (the ones who perform radical procedures in >50% vs. <50% of patients) and residual disease in patients with IIIC ovarian cancer ($N = 194$) ($P = 0.008$; Pearson χ^2)

Surgeons	RD = 0 Macro	RD < 1 cm	RD = 1–2 cm	RD > 2 cm	Median Survival
Radical surgery in <50% of the patients	23.72	39.10	11.54	25.64	2.53 yrs
Radical surgery in >50% of the patients	23.68	63.16	10.53	2.63	5.9 yrs

RD, residual disease.
The last column represents the median survivals ($P = 0.04$; log rank test).
Aletti GD, Gostout BS, Podratz KC, et al. Ovarian cancer surgical resectability: relative impact of disease, patient status, and surgeon. *Gyn Oncol* 2006;100:33–7.

For patients with advanced ovarian cancer (stages IIIC and IV), National Cancer Database information demonstrates an increased primary surgical rate (vs. neoadjuvant chemotherapy) and an improved overall survival outcome for hospitals with a higher case volume (>21 cases/year) in comparison to hospitals with intermediate (9 to 20) or low (<9) case volumes. This volume effect has also been identified extensively in Europe.

Interval Debulking

In patients medically unfit for surgery or those deemed to have unresectable disease, either based on preoperative imaging or intraoperative assessment at the time of laparoscopy or debulking attempt, neoadjuvant chemotherapy can be utilized and a subsequent interval debulking performed. A retrospective study of 576 women with advanced ovarian cancer from four tertiary care centers identified a "high risk" group of patients in whom the risks of radical debulking appeared to outweigh the benefits. This group, composed of women aged 75 years or older, with poor performance status (American Society of Anesthesiologists score 3 or more) or poor nutritional status (preoperative albumin <3.0 g/dL), and a high tumor dissemination or stage IV disease, should be considered for neoadjuvant chemotherapy.

The role of neoadjuvant chemotherapy versus upfront primary debulking was examined in two recent multicenter randomized trials, both of which showed no significant difference in progression-free or overall survival. Specifically, a noninferiority study conducted by the EORTC of 632 eligible patients with stage IIIC or IV disease showed that neoadjuvant chemotherapy followed by interval debulking was not inferior to primary debulking surgery, with median overall survivals of 30 months and 29 months, respectively. Importantly, complete gross resection of disease at the time of debulking was identified as the single most important prognostic factor.

While these multicenter randomized trials show no significant difference in outcomes between neoadjuvant chemotherapy and primary debulking, the rates of optimal resection achieved in patients undergoing primary debulking were comparably lower than those of other published experiences and are the subject of ongoing critique. More importantly, the median survivals reported in these randomized trials when compared to other single-institution experiences are markedly decreased, and therefore, further studies are needed to validate this approach in other clinical settings.

TABLE 185.3 Recommendations for Secondary Cytoreduction Based on Disease-Free Interval, the Number of Recurrent Sites, and Evidence of Carcinomatosis

DFI	Single Site	Multiple Sites: No Carcinomatosis	Carcinomatosis
6–12 mo	Offer SC	Consider SC	No SC
12–30 mo	Offer SC	Offer SC	Consider SC
>30 mo	Offer SC	Offer SC	Offer SC

DFI, disease-free interval; mo, months; SC, secondary cytoreduction.
Chi DS, McCaughty K, Diaz JP. Guidelines and selection criteria for secondary cytoreductive surgery in patients with recurrent, platinum-sensitive epithelial ovarian carcinoma. *Cancer* 2006;106(9):1933–9.

Surgery for Recurrent Disease

There is convincing evidence that subsequent cytoreduction (secondary, tertiary, etc.) may offer additional survival benefit for a select group of patients. In 2006, Chi et al. published criteria for the consideration of secondary cytoreduction (Table 185.3), specifically disease-free interval, platinum sensitivity, number of sites of disease, and the presence or absence of carcinomatosis. The longer the disease-free interval from prior chemotherapy, the greater the likelihood that complete surgical resection will be associated with prolonged survival, particularly if there has been limited prior exposure to cytotoxic chemotherapy.

Eisenkop and colleagues reported their experience with 106 patients experiencing disease recurrence more than 6 months after completion of chemotherapy. They examined both the probability of successful cytoreduction and the survival after diagnosis of recurrence. In multivariate analysis, the size of the largest residual tumor mass, preoperative chemotherapy with "salvage" chemotherapy, and preoperative performance status influenced the likelihood of success in surgical cytoreduction to minimal residual disease. In univariate analysis, site of disease in the pelvis, a solitary site of recurrence, an asymptomatic state, and the absence of physical findings all influenced cytoreductive success, as might be expected, given that these variables all reflect the preoperative extent of disease. The overall survival was influenced by the disease-free interval prior to surgical resection. With a disease-free interval of 6 to 12 months as the baseline for comparison, the 13- to 36-month interval was associated with a risk ratio for recurrence of 0.16. With a disease-free interval of >3 years, the risk ratio for recurrence dropped to 0.08. It is of note in this study that 83% of patients did not have ascites at the time of recurrence, suggesting a strong selection bias. In further support of this contention, the median survival from the time of recurrence

in the group without preoperative “salvage” chemotherapy was 47 months from the time of diagnosis of recurrence.

In 2011, Bristow et al. published the results of a meta-analysis of 40 studies including 2,019 patients who had undergone surgical treatment for recurrent ovarian cancer (Fig. 185.3). The only significant clinical variable associated with postrecurrence survival was the proportion of patients undergoing complete resection of disease. Specifically, each 10% increase in proportion of patients undergoing complete resection resulted in a 3-month increase in median survival time.

Given the progressive development of drug resistance in this group of ovarian cancer patients treated with chemotherapy, it is not surprising that the outcome of secondary cytoreduction is even more dependent on the surgeon’s ability to completely remove all residual disease, if possible (Fig. 185.4). In patients with a limited number of sites of recurrent disease, the most vigorous attempt at complete cytoreduction is certainly warranted. In patients with multiple sites of “oligo” metastatic disease, again, an aggressive approach to resection of all disease is a prerequisite to success. For patients with recurrent disease, predictive factors for success include limited extent of disease, particularly isolated nodal disease, limited primary surgery, and prolonged time to recurrence (>24 months). In highly select cases with limited sites of disease, a minimally invasive approach is reasonable.

Preoperative Preparation

When the patient is referred with the clinical picture of ascites, abdominal pain, and distention with a palpable pelvic mass, the preoperative diagnosis of ovarian carcinoma is typically one of exclusion. What one seeks to exclude, therefore, are those lesions for which surgical exploration will not be beneficial. Attention to the patient’s history of upper gastrointestinal symptoms may help to exclude those patients with occult gastric cancer. Should there be any question, upper gastrointestinal endoscopy will be a useful adjunct to the abdominal and pelvic CT scan that is part of routine preoperative evaluation. CT scanning has particular value preoperatively in identifying occult liver metastases or extensive retroperitoneal invasion above the celiac axis by tumor that might require collaboration with a hepatobiliary surgeon in the approach to primary debulking surgery. The CT scan may also exclude a clinically occult primary pancreatic neoplasm with intra-abdominal metastases.

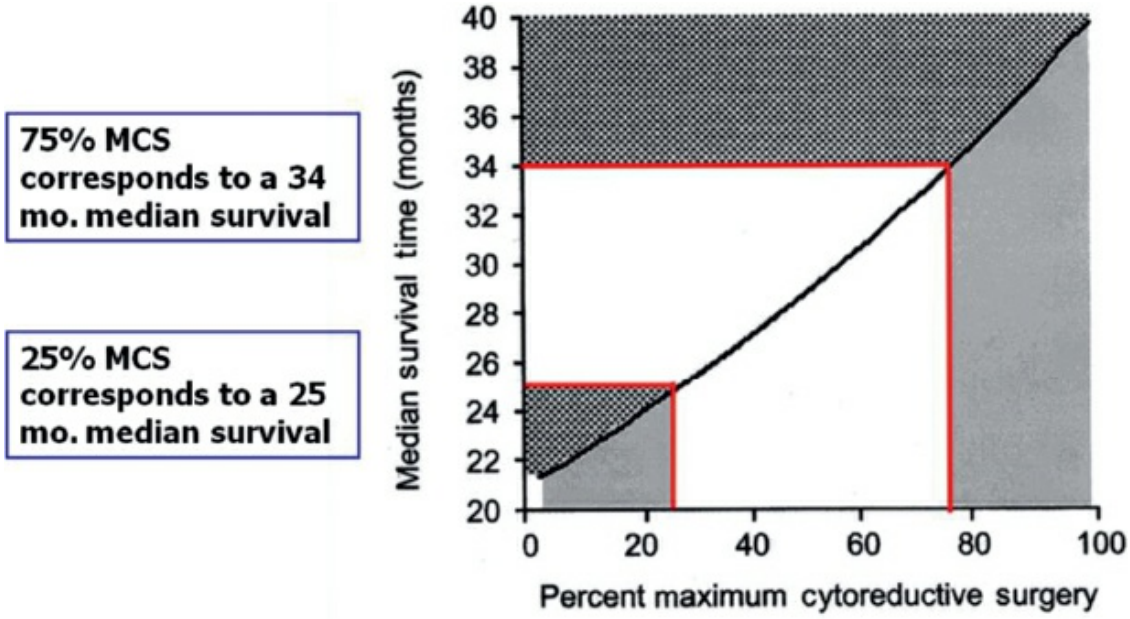

Figure 185.3. Greater success at achieving maximum cytoreductive surgery (MCS) is associated with longer median survival. (Bristow RE, Tomacruz RS, Armstrong DK, et al. Survival effect of maximal cytoreductive surgery for advanced ovarian carcinoma during the platinum era: a meta-analysis. *J Clin Oncol* 2002;20:1248–59.)

Preoperative physical examination is important in the identification of the extent of pelvic disease in so far as one can best identify infiltration of the pelvic sidewall or invasion of the very low rectovaginal septum that may present challenges to primary surgical resection with low anterior anastomosis. Although this extent of disease in the pelvis is not a contraindication to extensive debulking surgery, it certainly requires experience in en bloc resection of the intraperitoneal pelvic viscera, as will be described below. In the event that one encounters a positive stool test for occult blood, colonoscopy will be useful in the identification of a primary colonic tumor; however, surgical intervention with colonic resection is still necessary. On rare occasions when there is a considerable anterior extent of the pelvic tumor and the question of extrinsic bladder involvement, cystoscopy can exclude the rare patient with unresectable disease invading the bladder trigone. Except for overt obstruction of one or both ureters, there is little indication for preoperative ureteral catheterization. The typical lesion associated with ureteral obstruction will be a bulky intraperitoneal tumor with penetration through the peritoneum at the level of the uterine vessels. This is a common presentation of carcinoma arising in endometriosis involving the pelvic peritoneum.

Occasionally, bulky nodal metastases may also cause extrinsic compression; direct invasion of the pelvic ureter is much less common. Preoperative ureteral decompression may reduce the risk of trauma to that dilated ureter. One should not have to rely upon a ureteral catheter for the identification of the pelvic ureter: if the ureter is uninvolved by tumor, it is easily palpable; but if it is encased in tumor, a ureteral catheter provides little reassurance, as it is rarely palpable.

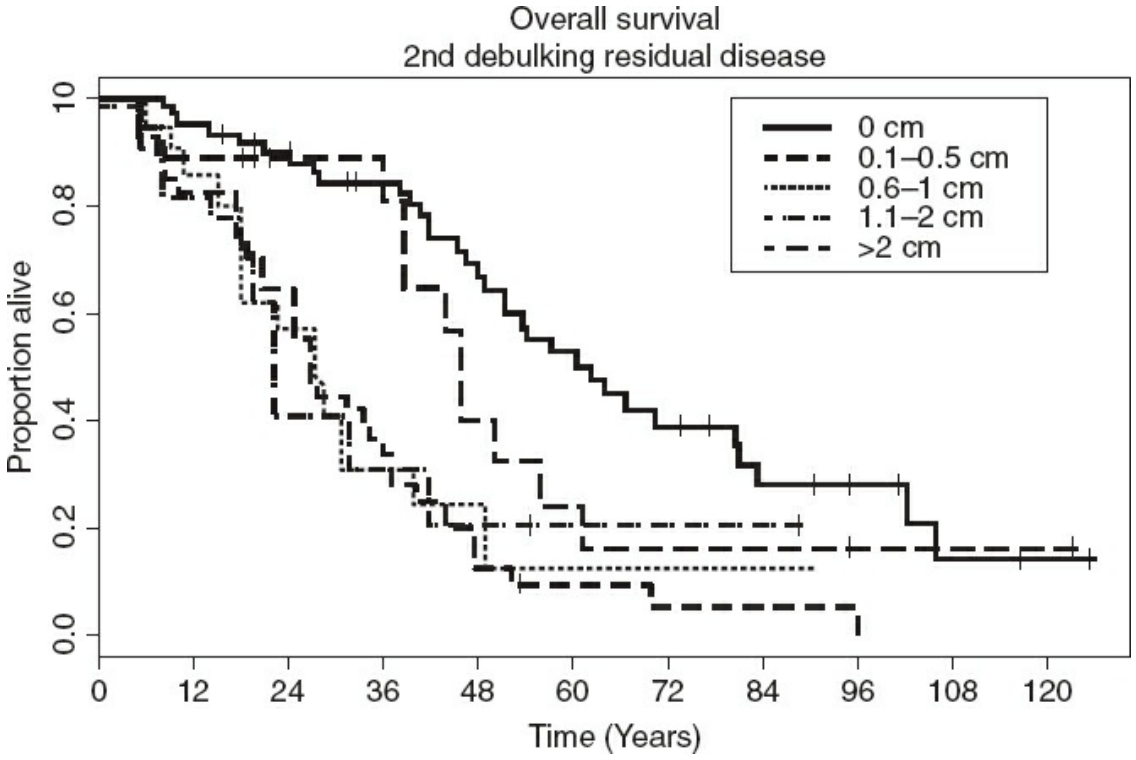

Figure 185.4. Overall Survival based on residual disease after secondary cytoreduction. (Chi DS, McCaughty K, Diaz JP. Guidelines and selection criteria for secondary cytoreductive surgery in patients with recurrent, platinum-sensitive epithelial ovarian carcinoma. *Cancer* 2006;106(9):1933–9.)

The preoperative preparation of the patient should include a forthright discussion of the diagnosis and management, with specific attention to the technique and importance of removing all gross residual tumor. Informed consent should specifically address the importance of complete surgical cytoreduction and the risks associated with this surgical procedure, including those associated with gastrointestinal resection, omentectomy, and retroperitoneal node dissection. As one evaluates the medical status of the patient preoperatively, it is important to identify the occasional patient with ascites secondary to liver disease associated with an elevated portal

venous pressure. Other conditions that can mimic advanced ovarian cancer include severe right heart failure and peritoneal tuberculosis; in both conditions, surgical exploration for a pelvic mass may be relatively contraindicated. Congestive heart failure, severe liver disease, and peritoneal tuberculosis are associated with an elevated CA125 in the absence of malignancy. Such findings may lead to exploration for benign ovarian disease in a patient with substantial medical contraindications to laparotomy.

Clear cell and endometrioid carcinoma of the ovary are associated with a hypercoagulable state; patients with ovarian cancer may present with deep venous thrombosis and pulmonary emboli as the initial sign of their disease. As is true with patients with symptomatic pleural effusions, one or two cycles of neoadjuvant chemotherapy along with anticoagulation using low molecular weight heparin will be beneficial for improvement in cardiopulmonary function with resolution of embolic disease. Typically, the patient will also have an inferior vena cava (IVC) filter placed prior to debulking surgery, unless thrombosis also involved the upper extremities.

The development of enhanced recovery pathways has heightened awareness of the importance of perioperative care and its association with complications. Skin preparation, bowel preparation, perioperative antibiotics, normothermia, euvolemia, and postoperative pain management and pulomonary care are all “bundled” to optimize patient outcomes. Recommendations for routine preoperative bowel prep have been changing and now consist of preoperative antibiotic bowel preparation with or without mechanical bowel preparation. As the extent of incision for the comprehensive surgery involves ultimately the extension of the incision from pubis to xiphoid, the use of preoperative epidural anesthesia is an attractive adjunct and, when properly performed, the source of considerable postoperative comfort for the patient.

Intraoperative Care

The anesthesia team should ensure adequate vascular access and have blood products available for transfusion should they be required. Sequential compression devices should be in place prior to the initiation of anesthesia and preoperative prophylactic heparin administered subcutaneously, unless contraindicated, for venous thromboembolism (VTE) prevention.

The patient should be placed in the dorsal lithotomy position, in which both hips are abducted with knees flexed, allowing for a thorough exam

under anesthesia and optimal access for a rectosigmoid resection and anastomosis, if needed. This position also facilitates improved access to the upper abdomen for an additional surgeon, when needed. A sterile Foley catheter should be placed when the patient is completely prepped and draped. In this manner, one has access to the catheter in order to fill or empty the bladder, as needed, to facilitate the anterior pelvic dissection. Should cystoscopy be necessary intraoperatively, this may be performed quite easily without additional preparation.

Determining Resectability

Assessment of tumor burden and resectability should always be the first step after entry into the abdomen, prior to any organ resections. This can be accomplished via diagnostic laparoscopy or through a reasonable vertical midline incision. After ascites, if present, is drained, all 4 quadrants should be evaluated, with special attention to the serosa and mesentery of the bowel. Once the decision to proceed with debulking is made, a generous vertical midline incision (from pubis to xiphoid) and placement of a fixed, self-retaining retractor (such as a Bookwalter or Omni) are recommended.

The extent of resection required to clear all visible disease is highly dependent on tumor volume and distribution. Other factors, such as patient performance status, patient preferences, surgeon ability, availability of consultants and resources, and judgment, all influence the decision to proceed with debulking. Clear contraindications to debulking include massive involvement of the root of the small bowel mesentery or extensive small bowel serosal disease. While total gastrectomy and total colectomy are technically feasible procedures, the need for these procedures generally represents an indication for neoadjuvant chemotherapy if identified laparoscopically or the need for aborting primary debulking surgery if laparotomy is underway.

Similarly, extensive resection of the small bowel that would compromise long-term bowel function should be avoided, unless of course that bowel appears obstructed or nonfunctioning due to disease infiltration. Ideally, the determination that disease is unresectable will be made prior to any major resections to limit the chance of postoperative morbidity and facilitate the quick initiation of neoadjuvant chemotherapy. As it is frequently the most challenging portion of the case, we recommend starting the resection in the upper abdomen. The following sections review procedures commonly required during extensive cytoreductive surgery

(CRS).

Omentectomy

The omentum is a frequent site of ovarian cancer metastases or tumor "caking." An infracolic omentectomy is occasionally sufficient; however, in cases in which tumor is present in the gastrocolic omentum, a supracolic omentectomy is also required. Mobilization of the hepatic and splenic flexures with resection of adjacent tumor-bearing paracolic peritoneum is necessary when omental disease is extensive (Fig. 185.5). Omental tumor often extends to the splenic hilum and can mimic splenic disease on preoperative imaging. While mobilizing the splenic flexure, care must be taken to avoid excess traction on the omentum, which can cause tears and bleeding from the splenic capsule.

If the transverse colon can be easily mobilized from the underside of the omental mass, that should be done next. If the tumor invades the transverse colon, it usually does so in the midportion of the transverse colon. The most prudent approach is to leave that dissection for last and begin working laterally to medially, freeing up the omentum from the paracolic gutters and mobilizing the ascending and descending colon at the hepatic and splenic flexures, respectively. This allows for the mobilization of both lateral aspects of the omentum from the peritoneal surface to which it may be fixed by tumor. Mobilization and resection of the omentum are ideally performed with a vessel-sealing device, such as the Ligasure, to allow for efficient dissection with excellent hemostasis. The omentum is initially mobilized along the duodenum, and then it is divided from the greater curve of the stomach using the Ligasure, entering the lesser sac just to the left of midline, and dividing the vessels while working toward the previously opened paracolic gutters. Then with the omentum remaining attached only to the transverse colon, one can dissect laterally to medially, mobilizing the omental mass from the mesocolon and from the bowel wall. If there is no plane, it may be necessary to resect the omentum and transverse colon en bloc. At the transverse colon, the mesocolon and middle colic artery should be preserved in order to maintain an adequate blood supply to the colon (Fig. 185.6). One may choose to delay the transection of the bowel until the end of the procedure to broaden options for the reconstruction of the gastrointestinal tract. Resection of a large omental cake may improve exposure to other areas of the abdomen, specifically the small and large bowel centrally, and is therefore a common first step during CRS. One can then proceed by evaluating the paracolic

gutters and subdiaphragmatic spaces, as well as the liver surface, stomach, and splenic capsule.

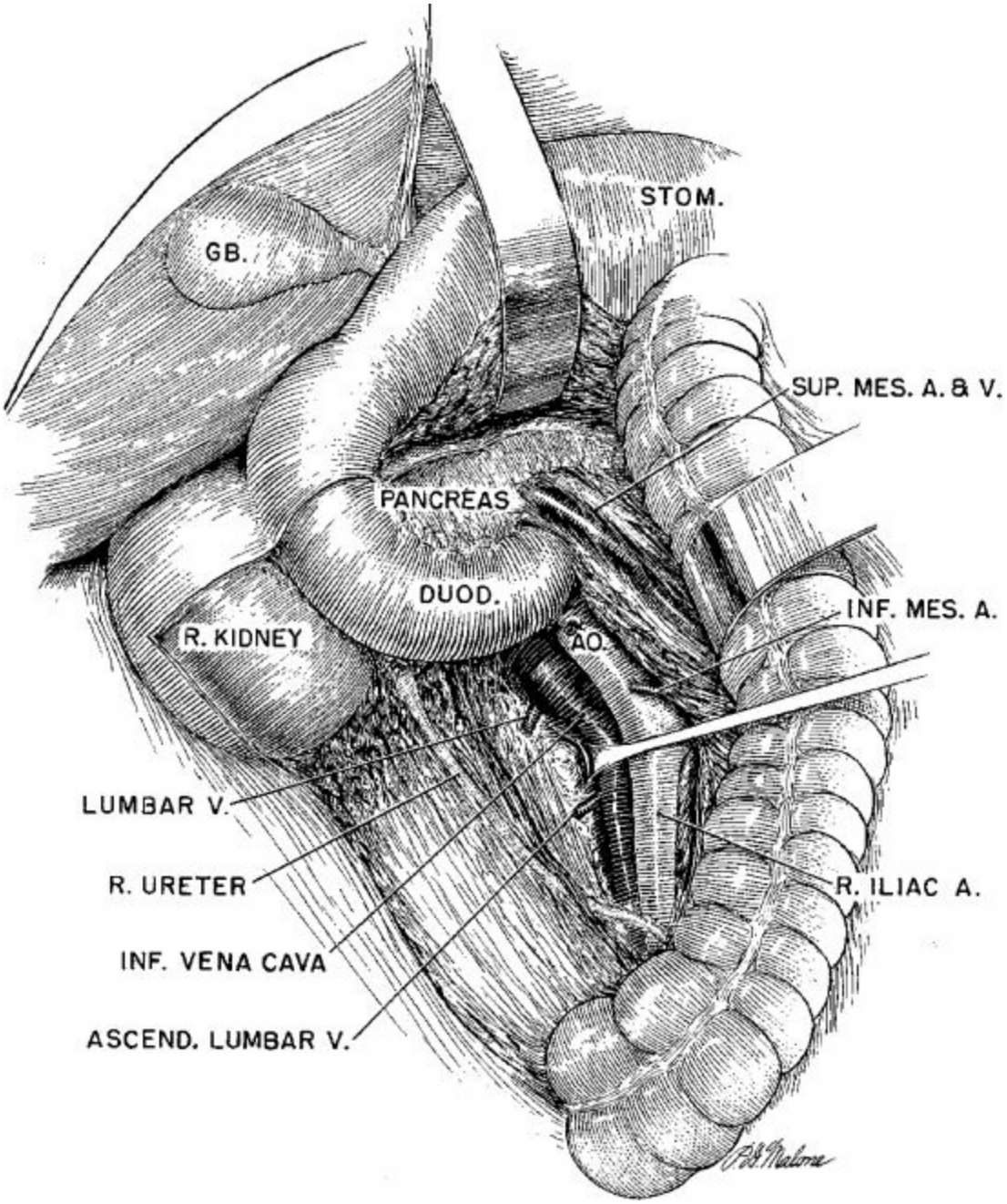

Figure 185.5. Exposure of the right para-aortic nodes by medial mobilization of the hepatic flexure and lesser sac. (From Edwards EA, Malone PD, MacArthur JD. *Operative Anatomy of the Abdomen and Pelvis*. Philadelphia, PA: Lea and Febiger; 1975.)

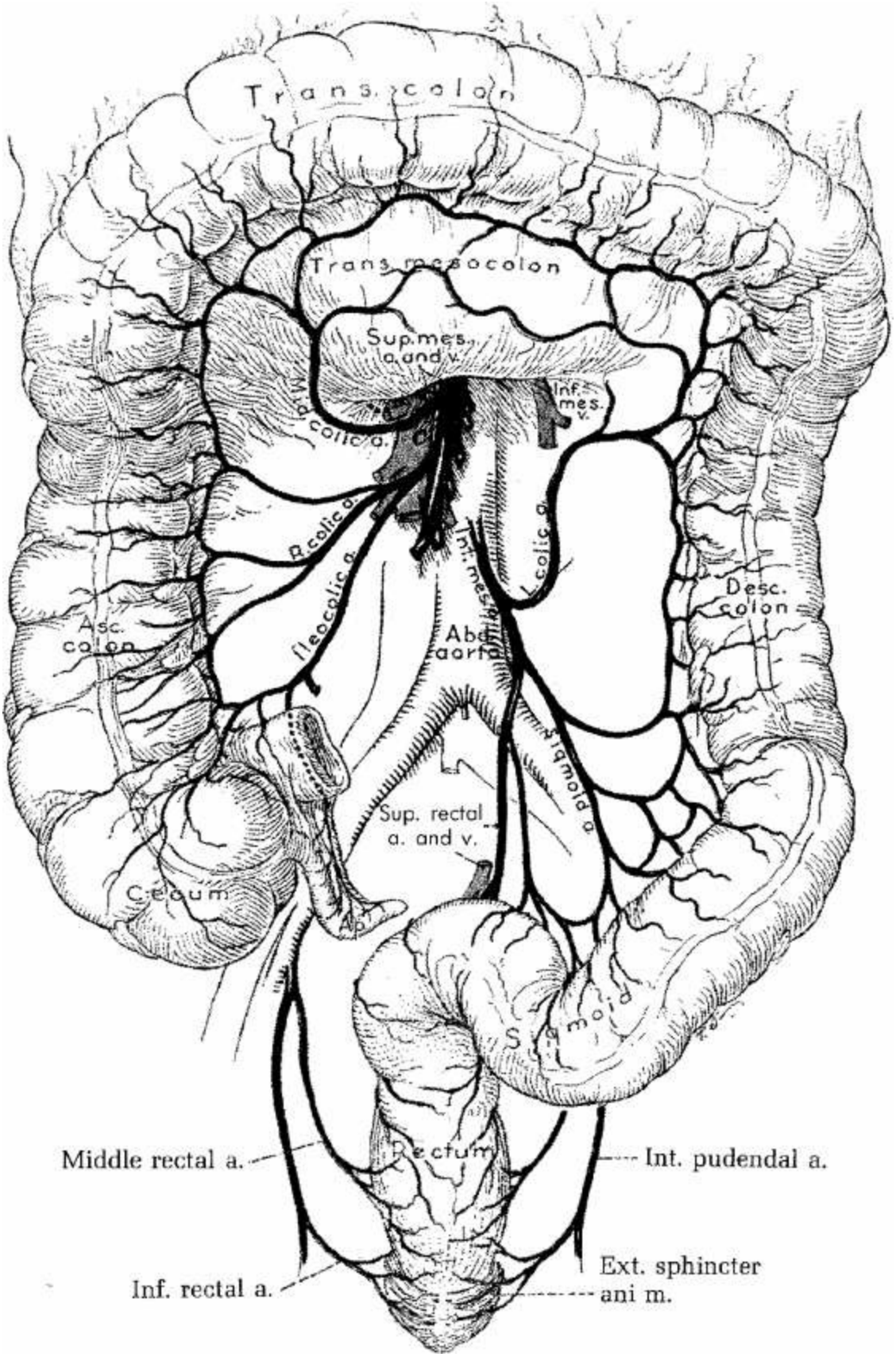

Figure 185.6. Vascular anatomy of the colon. (From Edwards EA, Malone PD, MacArthur JD. *Operative Anatomy of the Abdomen and Pelvis*. Philadelphia, PA: Lea and Febiger; 1975.)

Right Upper Quadrant (RUQ)

The right upper quadrant (RUQ) is a frequent site of metastatic disease in advanced ovarian cancer, partially due to the clockwise flow of peritoneal fluid in the abdominal cavity. The liver (surface and/or parenchyma), the right diaphragm, the peritoneum overlying Gerota fascia and Morrison pouch, the gallbladder, and the porta hepatis are all potential sites of tumor infiltration. While it can present a challenge, tumor involvement of these sites is not a contraindication to optimal or complete CRS (Fig. 185.7).

Liver mobilization is an important first step in adequately evaluating and treating right diaphragm disease, without which the extent of tumor involvement can be significantly underestimated. Tumor not easily visualized on first assessment may be present cephalad to the liver in the subphrenic space, as well as in the subhepatic space. The patient should be positioned in reverse Trendelenburg in the "RUQ up" position. The xiphoid can be resected in order to maximize exposure through the vertical midline incision. The Bookwalter retractor is placed obliquely above the right costal margin, retracting this structure upward. The falciform ligament should be identified and the free edge containing the round ligament (remnant of the umbilical vein) divided and tagged to assist in gentle downward traction on the liver. The falciform's attachment to the anterior abdominal wall should be separated in a cephalad fashion using electrocautery until the layers of the peritoneum split laterally to form the right and left coronary ligaments. During this dissection, we recommend staying adjacent to the liver surface. Dissection should then continue along the right coronary ligament, taking extreme care to identify and avoid the right hepatic vein and inferior vena cava. At this point in the dissection, a combination of medial and lateral approaches is frequently necessary, depending on the disease volume and distribution. The lateral triangular ligament can be divided and the dissection continued medially until the bare posterior surface of the liver is exposed. The liver mobilization will be complete once the right posterior coronary ligament is completely free. Gentle medial traction on the liver will expose the right diaphragm as well as the peritoneum overlying Gerota fascia and Morrison pouch. Metastatic disease typically consists of diffuse peritoneal implants that do not penetrate through and are easily removed with the subjacent peritoneum extending to the foramen of Winslow. With division of the lateral peritoneal attachments of the liver, one can retract the organ medially and excise or fulgurate the posterior peritoneal tumor.

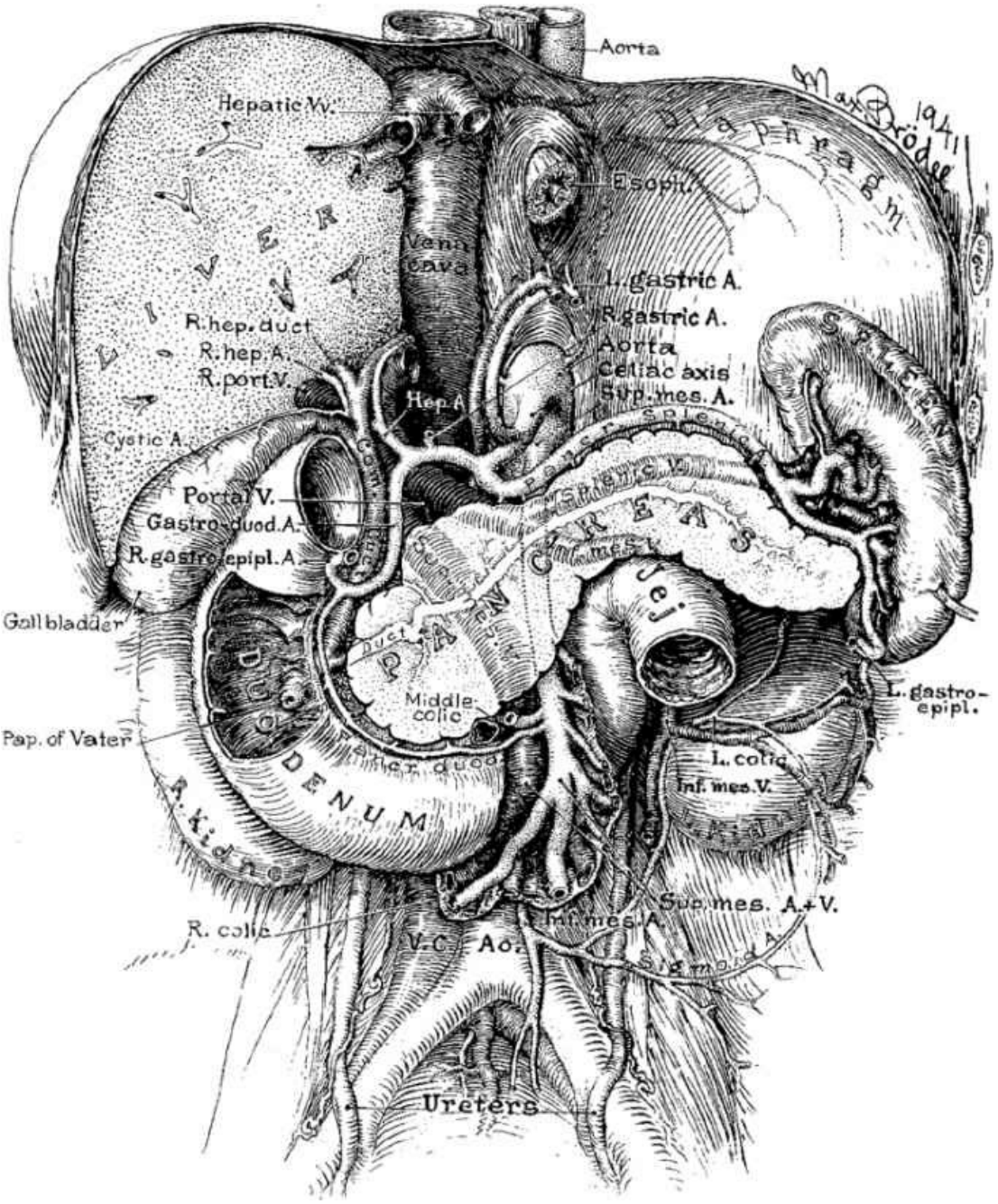

Figure 185.7. Visceral anatomy of the upper lesser sac and foramen of Winslow. In the right upper quadrant, peritoneal disease predominates in the foramen, in the retrohepatic area on the diaphragm, over the right adrenal and in the paracolic gutter. Extensive nodal involvement in the suprarenal area often involves the pancreas and indicates lack of resectability. (From Edwards EA, Malone PD, MacArthur JD. *Operative Anatomy of the Abdomen and Pelvis*. Philadelphia, PA: Lea and Febiger; 1975.)

Right diaphragm peritonectomy and resection. Tumor implants can be

superficially present on the peritoneum of the diaphragm or deeply invasive into the muscle. Once areas of disease are identified, the peritoneum at the level of the costal margin can be incised using electrocautery. The peritoneal edge can be grasped using Allis clamps and the dissection away from the underlying muscle continued posteriorly. Similar to liver mobilization, a combination of a medial and lateral approach is often necessary to achieve optimal results. A combination of blunt dissection (using a sponge stick) and electrocautery can be used as gentle downward traction is placed on the peritoneal edge to free it from the underlying muscle of the diaphragm. While this technique works very well for superficial implants, in areas where the tumor is deeply infiltrative (or at the central tendon of the diaphragm), dissection may become more difficult and may necessitate utilization of more electrocautery, sharp dissection, or ablative techniques such as argon beam coagulation. A vessel-sealing device may also be useful in controlling small bleeding vessels. Once the diaphragm peritoneum is resected, the muscle of the diaphragm should be carefully inspected for defects that can be repaired primarily using delayed-absorbable figure-of-eight sutures. Tumor that has invaded through the peritoneum and into the underlying muscle may require full-thickness resection of the diaphragm. In addition to the right hepatic artery, the right phrenic nerve can be injured if the resection extends medially. Anesthesia personnel should be notified of impending pneumothorax as the pleural cavity is entered. The involved diaphragm can be resected using electrocautery, a vessel-sealing device, or an endo-GIA stapler. Once the disease is resected, often the diaphragm can be closed using permanent sutures (1-0 polypropylene) in either an interrupted, figure-of-eight, or running fashion. A synthetic tissue can be utilized to repair larger defects and secured with a running permanent suture. After closing the diaphragm, air, blood, and fluid should be evacuated from the pleural space using either a red rubber catheter or chest tube placement. In addition to evacuating the acute pneumo/hemothorax, the chest tube can be used to drain postoperative pleural effusions, which are common after extensive diaphragm peritonectomies.

Liver wedge resection is commonly required in the setting of superficial parenchymal liver metastases and is often performed in conjunction with a hepatobiliary surgical consultant. Superficial liver disease frequently can be ablated using the argon beam coagulator (ABC) or other device such as the Cavitron ultrasonic surgical aspirator (CUSA).

Left Upper Quadrant (LUQ)

While metastatic ovarian cancer is less commonly found in the LUQ, a thorough assessment is needed to evaluate for the presence of disease. In order to gain exposure and appropriately identify all disease, entry into the lesser sac (by incising the posterior leaf of the omentum) is recommended. By reflecting the stomach and omentum anteriorly and medially, the spleen, pancreas, celiac axis, and porta hepatis can be accessed (Fig. 185.8).

Left diaphragm peritonectomy and resection. The approach to the left diaphragm is similar to the approach to the right side (as described above). It is best performed after mobilization of the liver. If tumor involvement is excessive, the left diaphragm can be removed en bloc with other structures in the LUQ such as the spleen and distal pancreas.

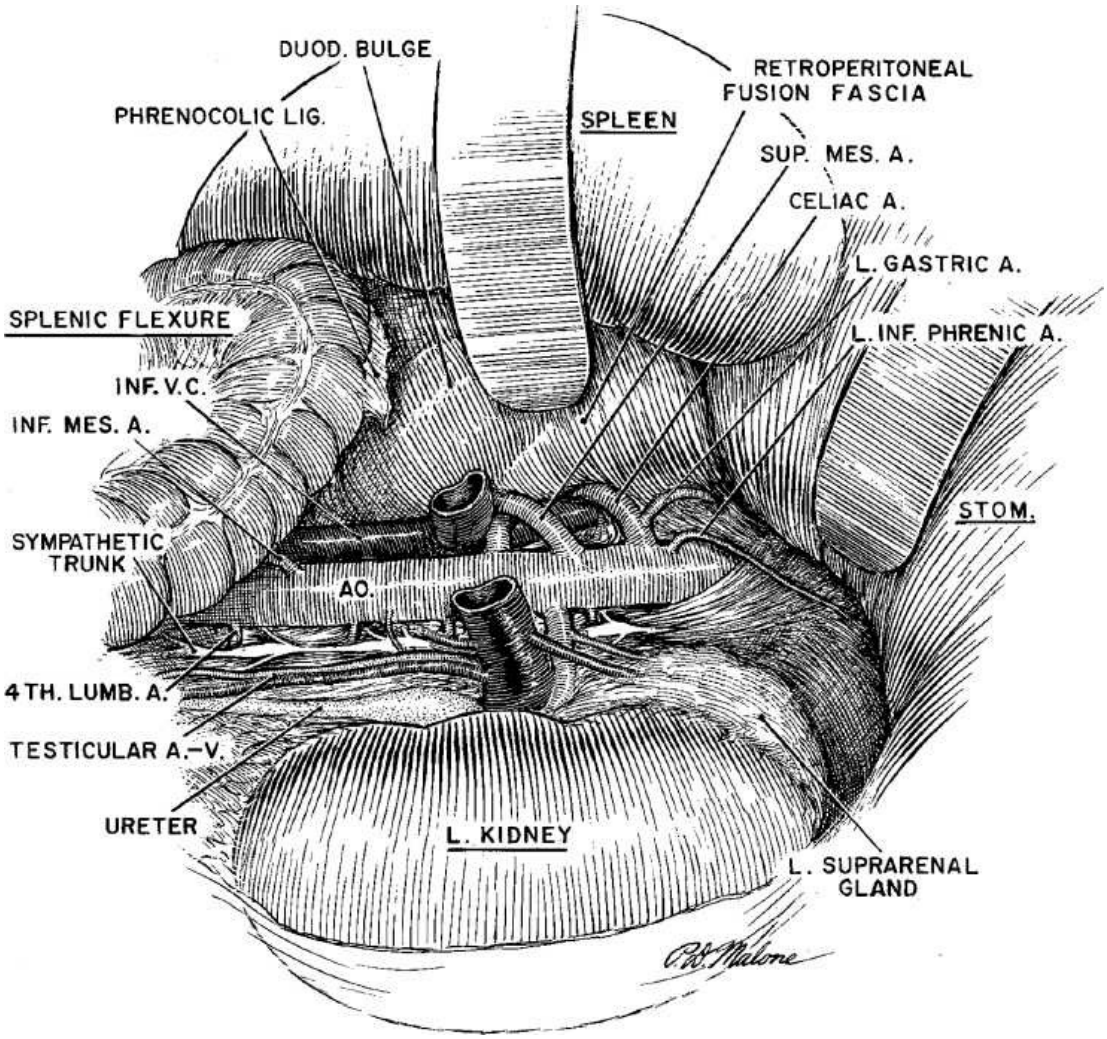

Figure 185.8. Exposure of the celiac axis and left para-aortic nodes by mobilization of the left upper quadrant contents. (From Edwards EA, Malone PD, MacArthur JD. *Operative Anatomy of*

the Abdomen and Pelvis. Philadelphia, PA: Lea and Febiger; 1975.)

Splenectomy is required in approximately 10% of cases due to either superficial or parenchymal tumor involvement. Splenectomy can be performed via an anterior or posterior approach; however, in the presence of tumor, a combination of the two approaches is generally the most efficient and safe. The patient should be placed in the "LUQ up" position, and the retractors should be adjusted accordingly. After entry into the lesser sac and retraction of the stomach medially, the gastrosplenic ligaments and short gastric vessels can be divided (taking care not to injure the posterior wall of the stomach). The spleen can be gently lifted and the distal pancreas examined. After incising the splenorenal ligaments, the splenic artery can be identified, isolated, and doubly ligated using permanent sutures or a surgical stapler with a vascular load. After the vasculature is secured, all remaining attachments, including the inferior splenocolic ligaments, the posterior and lateral lienorenal ligaments, and the splenophrenic ligaments, can be divided. If there is extensive omental tumor infiltration, it may be best to start with the posterior approach (and transection of the lateral attachments). All vascular pedicles should be inspected thoroughly after completion of the procedure, as any unsecured vessel in this region can result in significant postoperative hemorrhaging.

Distal pancreatectomy. Pancreatic involvement by metastatic ovarian cancer usually occurs in the setting of extensive omental involvement (when the disease extends beyond the splenic hilum); in such cases, distal pancreatectomy is generally performed in conjunction with splenectomy. After the gastrosplenic and short gastric vessels are divided, the peritoneum overlying the inferior border of the pancreas is incised proximal to the area of tumor infiltration. After the splenic vessels are secured, the distal pancreas can be transected using a TA or GIA stapler and reinforced using a 2-0 permanent running suture. Similarly, if the pancreatic tail is injured during splenectomy, the defect can be reinforced with a continuous layer of 2-0 or 3-0 sutures. Recognition of injury and proper reinforcement of the transected edge/injured area are crucial to reduce the incidence of postoperative complications, such as pancreatic leak, the development of a pseudocyst, and pancreatitis. During this procedure, it is also important to avoid injury to the underlying inferior mesenteric vein. The placement of a drain in the splenic bed can facilitate monitoring of pancreatic leak and should be continued until minimal

output is noted and the patient can tolerate a regular diet.

Pelvis

While some women require a simple total hysterectomy and bilateral salpingo-oophorectomy to achieve optimal cytoreduction, many will have a large conglomerate mass obliterating the pelvis that will require a more complicated dissection. This frequently can be accomplished by performing a modified posterior exenteration (MPE), which entails an en bloc resection of the uterus, adnexa, rectosigmoid colon, and pelvic peritoneum. This en bloc resection is best accomplished using a retroperitoneal approach, which allows for easier access, exposure, and safer resection of tumor and pelvic viscera (Fig. 185.9A,B).

At the start of the procedure, the pelvic sidewalls should be opened using lateral peritoneal incisions, and the ureters and pelvic vasculature should be identified (Fig. 185.10). The left lateral peritoneal incision can be extended cephalad along the white line of Toldt to mobilize the descending colon. The ureters should be isolated and tagged with vessel loops and the infundibulopelvic ligaments identified and divided high. The pararectal and paravesical spaces should be developed and the ureters skeletonized from the pelvic brim to the tunnel of Wertheim. The peritoneum can be incised anteriorly and the involved bladder peritoneum dissected free from the underlying bladder muscularis. The vesicouterine space can be developed in the standard fashion. Occasionally, this dissection is limited by tumor infiltration into the bladder, which may necessitate full-thickness bladder resection. Bladder defects can be repaired primarily; however, care must be taken to avoid the trigone and bilateral ureteral insertions.

The uterine vessels should be secured and divided laterally at their origin from the hypogastric arteries. After unroofing the ureter from the bladder pillars, the ureters can be reflected laterally away from the specimen using the vessel loops for gentle traction. The bladder is then dissected off of the vagina approximately 2 to 3 cm distal to the cervicovaginal junction. At this point, a vaginal probe or sponge stick can be inserted into the vagina to assist in the anterior colpotomy, which ideally should be 1 to 2 cm distal to the cervicovaginal junction. The colpotomy is then extended laterally with Heaney clamps (or a vessel-sealing device) and the vaginal angles are secured using figure-of-eight sutures. The rectovaginal septum can then be safely entered by incising the posterior vaginal wall **(**Fig. 185.11).

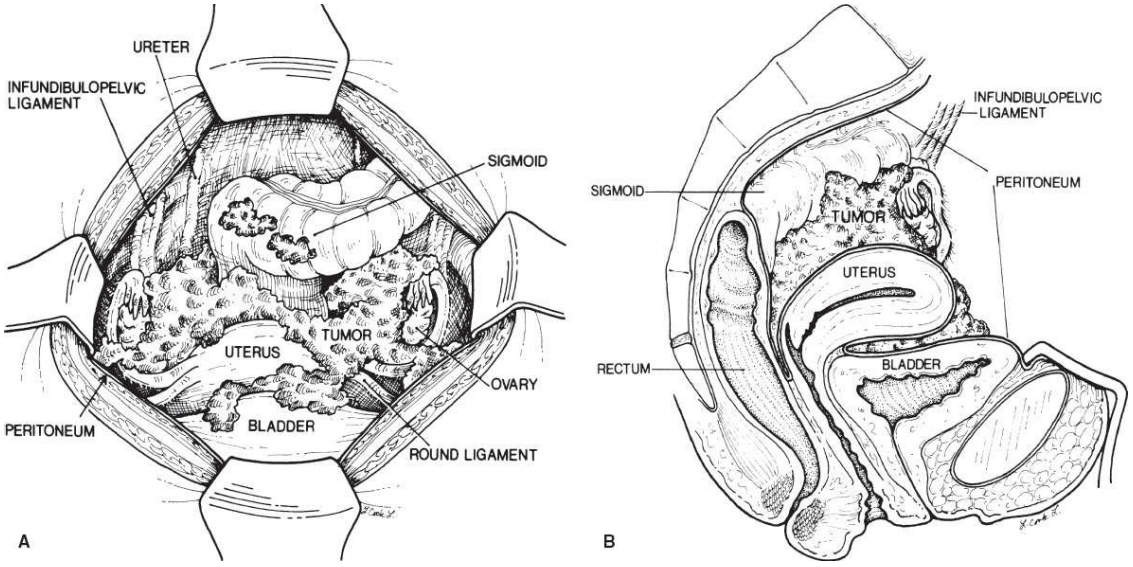

Figure 185.9. A. Anterior view of the pelvis at the time of initial abdominal exploration. **B.** Sagittal view of the pelvic cavity. The tumor obliterates all intraperitoneal tissue planes to the level of the cul-de-sac.

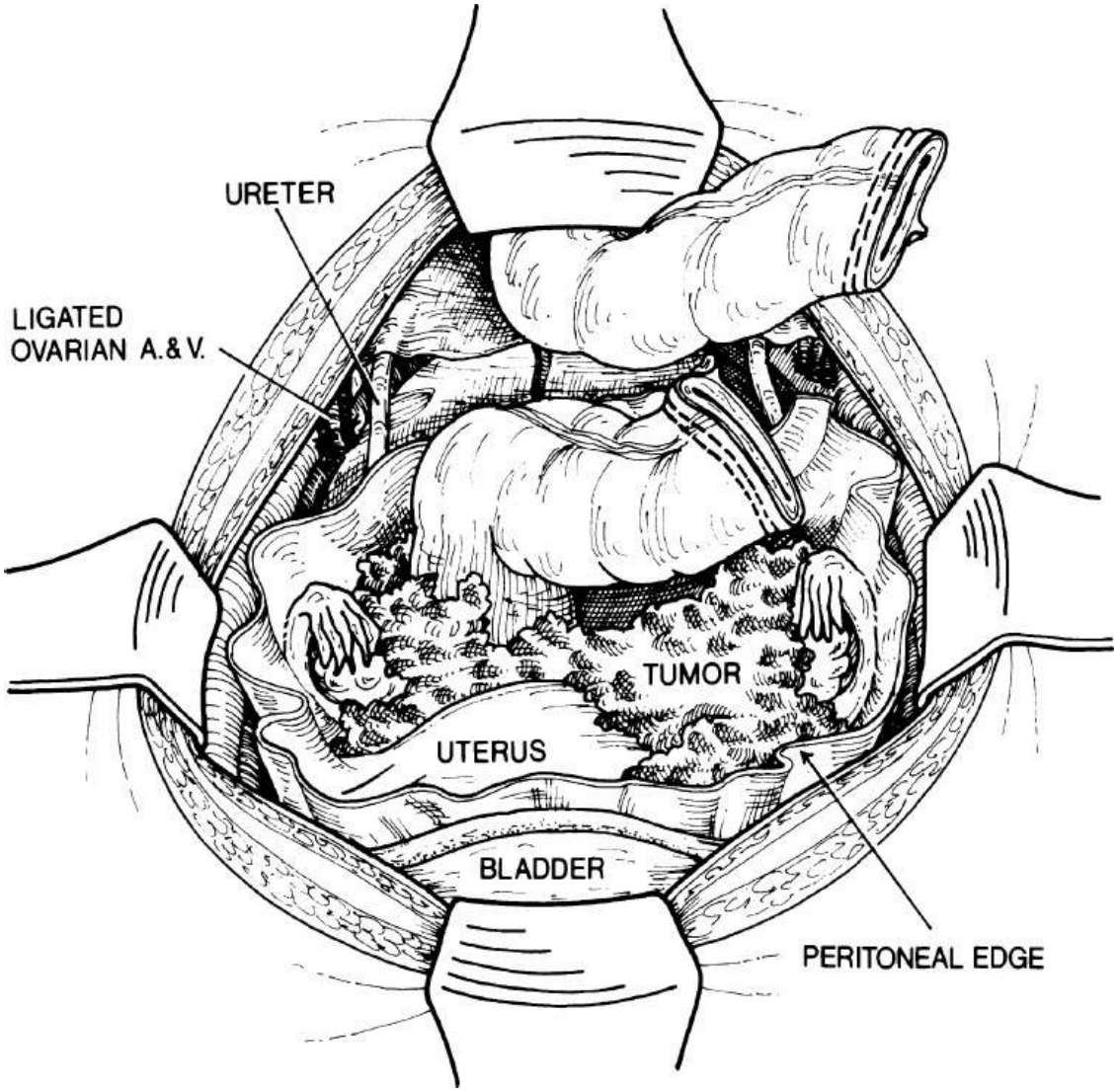

Figure 185.10. The pelvic dissection is started at the pelvic side walls, freeing the ureters laterally and dissecting the peritoneum from the bladder muscularis. The infundibulopelvic ligaments are ligated above the pelvic brand after identification of the ureters.

Depending on the degree of tumor involvement, the decision can be made to proceed with either a type 1 procedure (resection of the pelvic peritoneum including the peritoneum of the posterior cul-de-sac) or a type 2 procedure (resection of the rectosigmoid colon en bloc with the uterus and adnexa). If the decision is made to proceed with a type 2 resection, the rectosigmoid colon can be transected using a GIA stapler 2 to 3 cm proximal to the affected colon. The sigmoid mesentery and presacral peritoneum can then be incised and transected perpendicular to the long axis of the sigmoid and the superior rectal vessels identified, ligated, and divided (Fig. 185.12A,B). During mobilization of the left colon, care should be taken to preserve the left colic artery in order to maintain an

adequate blood supply to the descending colon. The rectum can then be dissected off of the presacral fascia after the development of the pararectal space using a combination of blunt dissection and electrocautery. Once the dissection is carried distal to the area of tumor infiltration, the specimen can be lifted ventrally and the mesorectal fat cleared from the site of transection. After reconfirming the location of the ureters and pelvic vessels, a TA stapler can be used to transect the rectum 2 to 3 cm distal to the area involved by tumor (Fig. 185.13). The rectum then can be anastomosed using an end-to-end stapling technique with a circular EEA stapler, with care to ensure that the anastomotic site is tension free, hemostatic, and secure, and has an adequate lumen and blood supply (Fig. 185.14). The integrity of the staple line is assessed by examination of the two rings of large bowel removed in the stapling device and by insufflating air into the rectum with a bulb syringe after filling the pelvis with warm saline, looking for bubbles issuing from a potential defect in the anastomosis. If there are any concerns regarding the integrity or perfusion of the anastomosis, a diverting loop ileostomy should be considered.

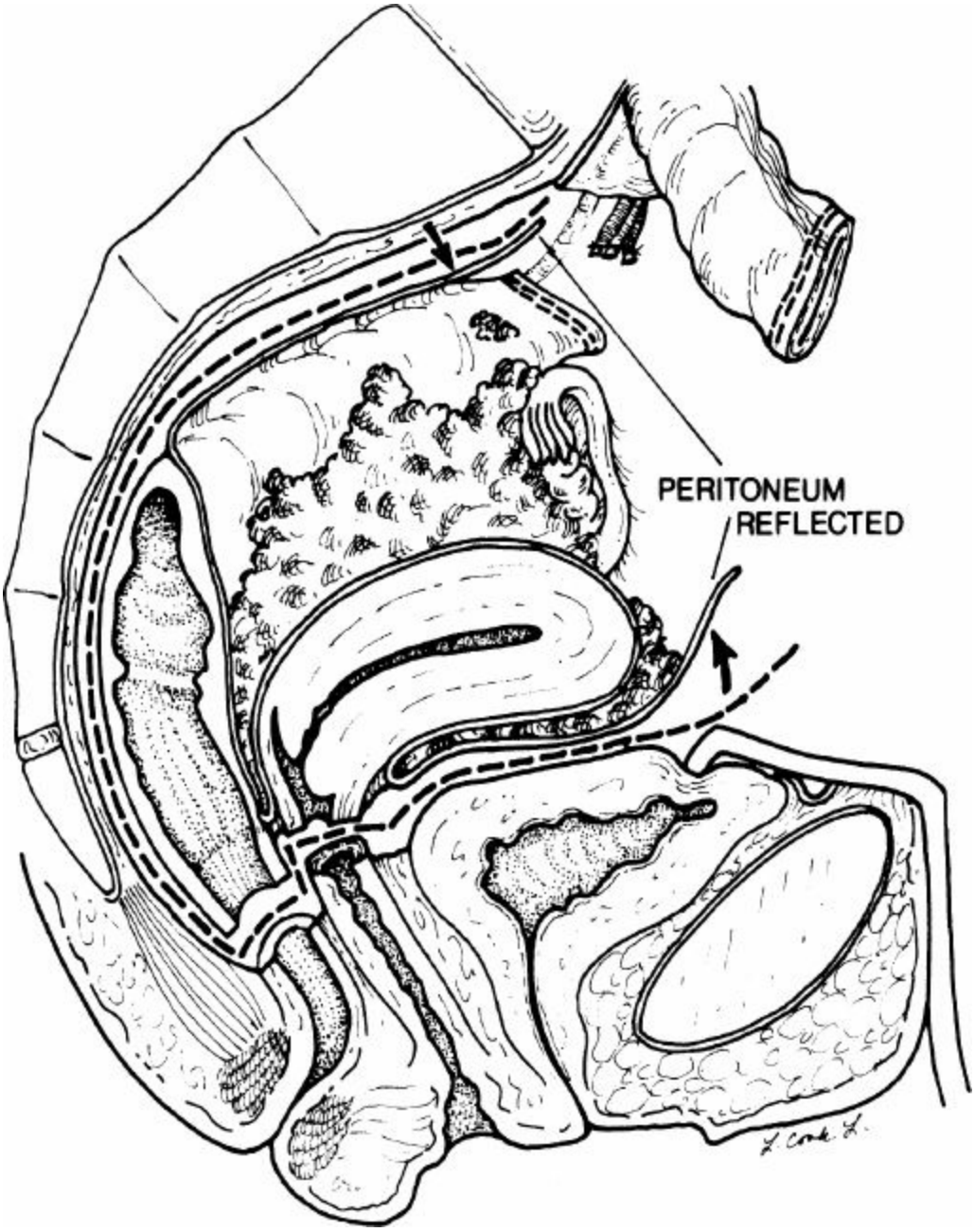

Figure 185.11. The *dashed line* indicates the plane of pelvic dissection. Beginning anteriorly, the peritoneum is dissected from the bladder. The hysterectomy is performed after lateral mobilization of the ureters and prior to its transection from the vagina, the rectovaginal space is bluntly developed.

Bowel Resection

It is important during the course of a debulking procedure to ascertain the degree of bowel resection required to ensure that adequate bowel remains for reconstruction and sufficient function. Approximately 35% of patients will require colon resection and 5% will require small bowel resection to achieve optimal cytoreduction. In addition to the rectosigmoid resection

(described above), patients may require a transverse colectomy, an ileocecal resection, an extended right or left hemicolectomy, or a small bowel resection. Proper mobilization of the colon is a crucial first step of a safe resection. The peritoneum overlying the paracolic gutters should be incised along the white line of Toldt and the colon reflected medially. The splenic flexure, hepatic flexure, and transverse colon can be further mobilized by transecting the gastrocolic ligaments and opening the lesser sac. The inferior mesenteric vein can be ligated and transected inferior to the pancreas to allow for greater descent of the mesentery. In general, the bowel can be transected using a GIA stapler, with care to maintain a adequate blood supply, and a tension-free, stapled, side-to-side or end-to-end anastomosis can be performed.

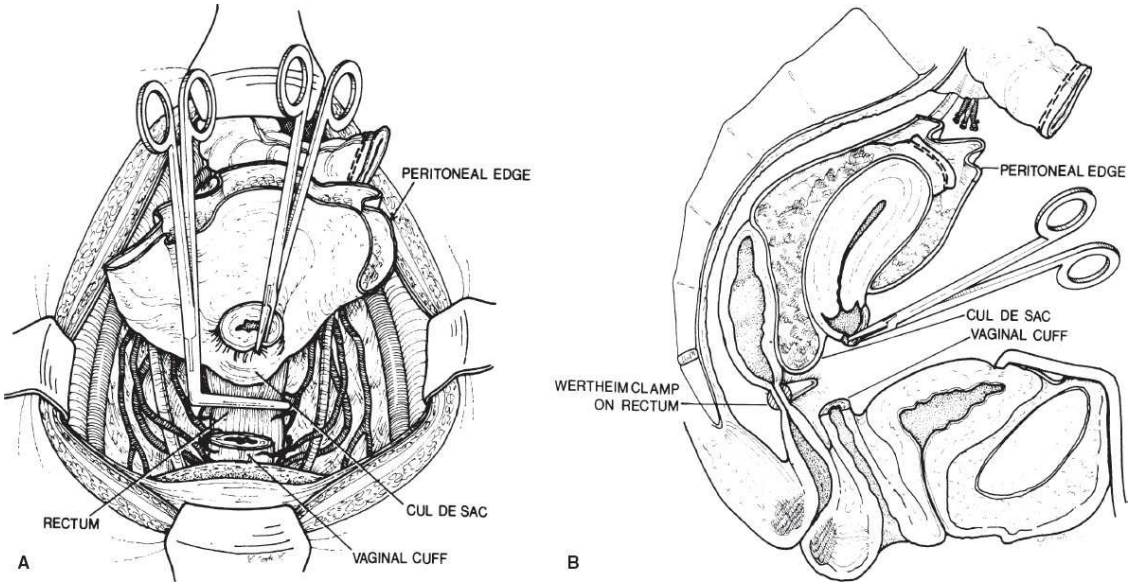

Figure 185.12. A. The entire peritoneal envelope including the anterior and posterior cul-de-sac with the cervix is retracted anteriorly so as to expose and skeletonize the upper rectum. **B.** The lateral view demonstrates the anterior and posterior exposure of the upper rectum levels facilitates transection of the upper rectum and removal of the specimen. Note that the Wertheim clamp is placed above the point of resection.

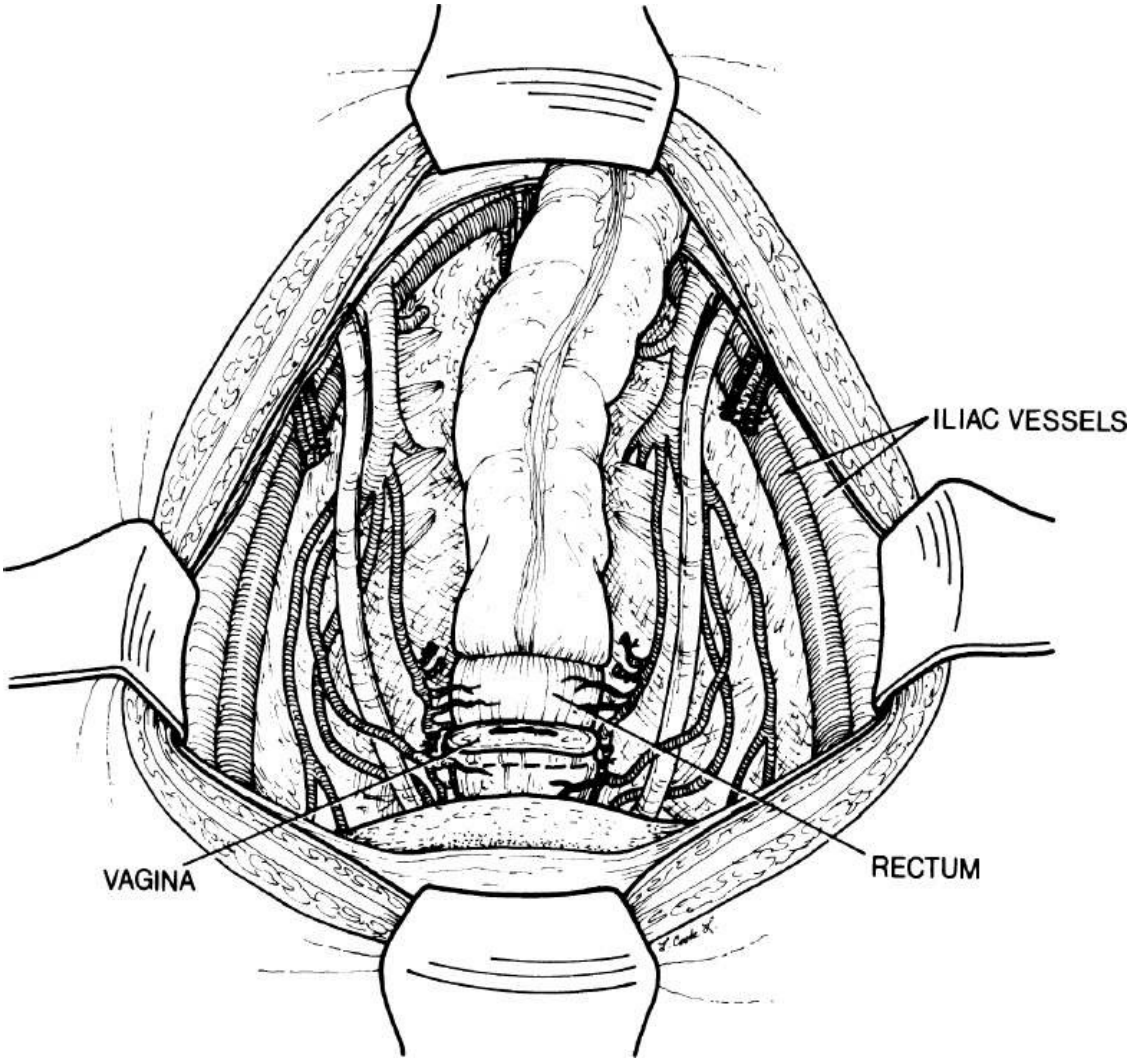

Figure 185.13. Anterior view of the pelvis at the procedures completion. All pelvic peritoneum, associated tumor, lymph nodes, and the intrapelvic peritoneal organs have been removed.

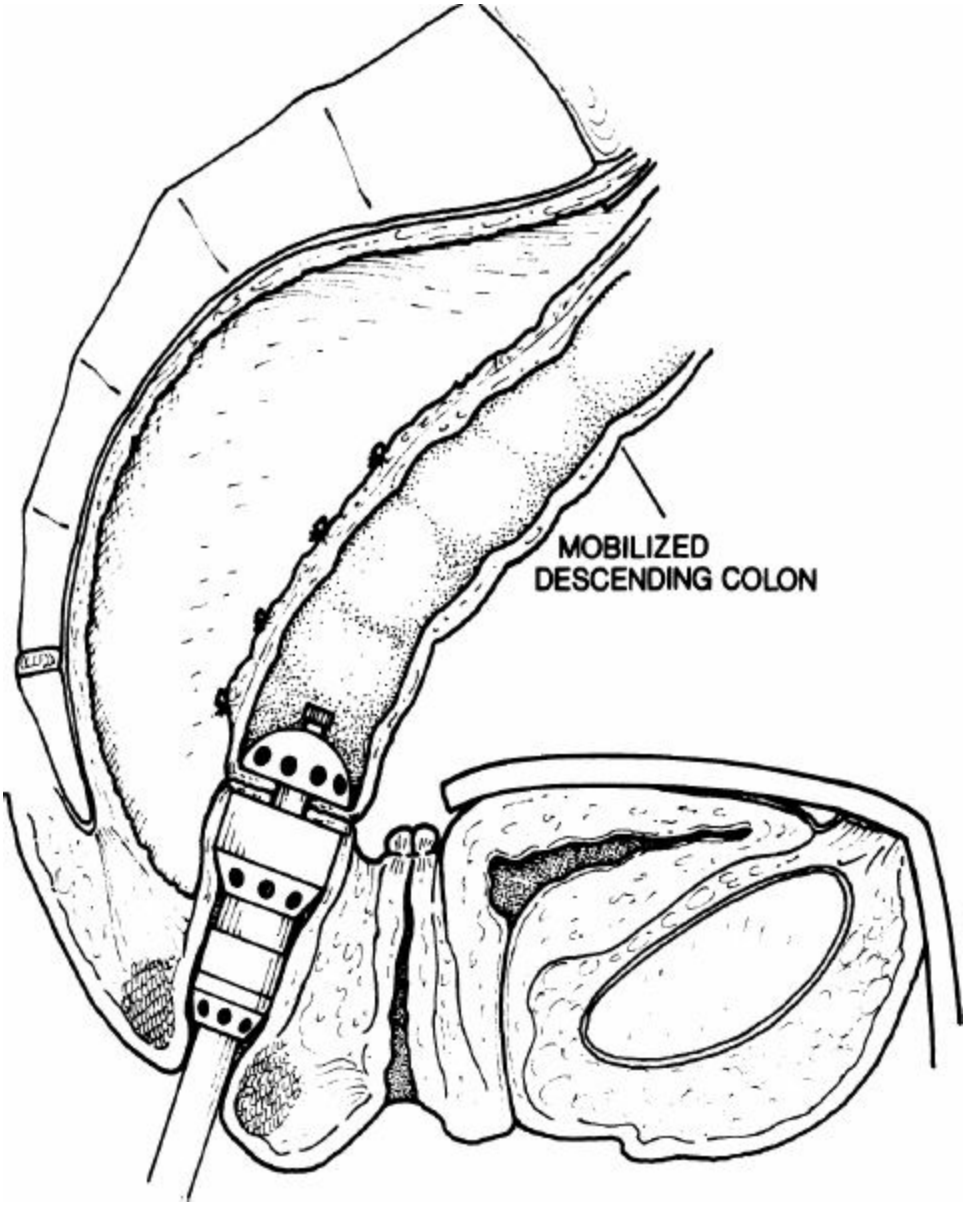

Figure 185.14. The distal end of the rectosigmoid is transected and stapled below the tumor; bowel continuity is restored using an EEA stapling device.

Rarely, one is faced with bulky tumor affecting virtually all of the left colon to the mid portion of the transverse colon. In this case, the appropriate maneuver is to derotate the ascending colon, allow the cecum to move cephalad into the midabdomen, and bring the proximal transverse colon down to a transanal anastomosis with the residual rectosigmoid colon.

Lymphadenectomy

In patients with grossly advanced disease (stage IIIC or IV), we recommend routine removal of any enlarged or grossly abnormal lymph

nodes in the pelvis, abdomen, or chest. If there is extensive adenopathy, then it is prudent to mobilize the root of the small bowel mesentery medially over the aorta and vena cava and reflect the entire small bowel and ascending colon into the upper abdomen. This provides exposure and permits excellent access to the entire infrarenal vasculature. On the right side, it is possible to elevate the cecum and descending colon as well as the root of the distal small bowel in a cephalic direction to expose the vena cava, right side of the aorta, and left renal vein. Again the nodes are dissected from a caudal to cephalic direction to the level of the origin of the right gonadal vessels. In patients with extensive, bulky para-aortic nodal disease, it is not unusual to find nodal metastases in the aortocaval sulcus, posterior to the vena cava, and posterior to the aorta on the left. On the right side, one can first mobilize the hepatic flexure and then perform a Kocher maneuver to improve access to the upper infrahepatic IVC. One can also explore the right side of the aorta through the lesser sac (Fig. 185.15).

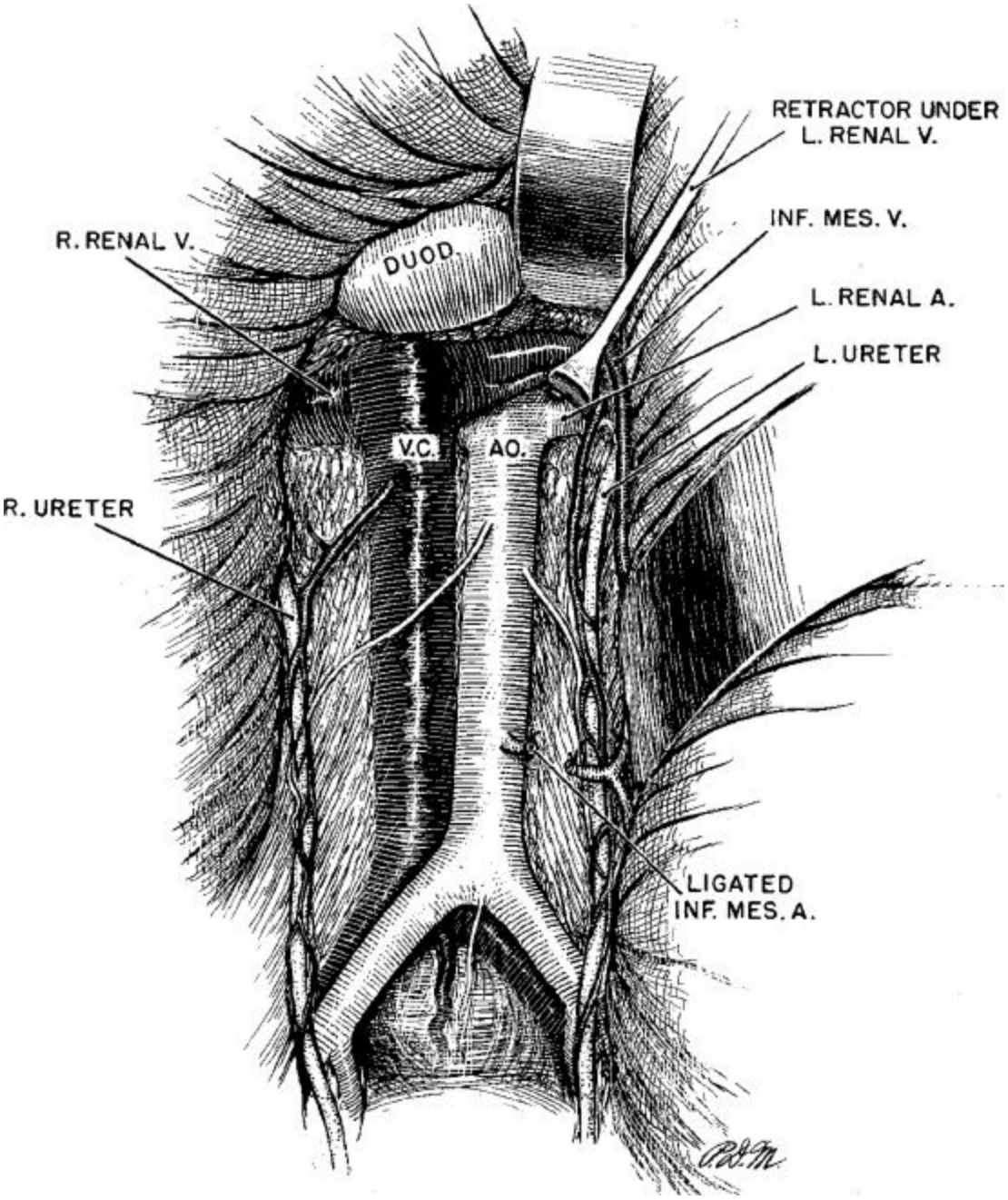

Figure 185.15. Exposure of the right para-aortic area is facilitated by cephalic reflection of the cecum. *Note that the right ureter normally lies immediately adjacent to the inferior vena cava. In this dissection, the sigmoid and descending colon had been resected, along with the inferior mesenteric artery.* (From Edwards EA, Malone PD, MacArthur JD. *Operative Anatomy of the Abdomen and Pelvis*. Philadelphia, PA: Lea and Febiger; 1975.)

Exposure of the left para-aortic nodes is facilitated by medial mobilization of the descending colon and associated left ureter. In patients in whom nodal metastases extend above the left renal vein, medial

reflection of the descending colon from the splenic flexure down may not provide sufficient exposure. In this case, one can mobilize the spleen and pancreas medially to expose the nodes about the celiac axis and superior mesenteric artery on the left (Fig. 185.8). Mobilization of the left kidney on its pedicle will similarly give access to the upper retroaortic area. The dissection of bulky nodes along the left side of aorta from its bifurcation up to the left kidney (and sometimes behind its pedicle) often results in a functional equivalent of a left lumbar sympathectomy. It is not unusual to be told postoperatively of concern for the vascular compromise of a cool right foot when what one is truly seeing is an abnormally well-perfused warm left foot secondary to sympathectomy. If there is more extensive disease in the suprarenal retroperitoneum, reflection of the LUQ contents, including the spleen, will provide optimal access to the celiac axis and posterior left diaphragm.

Mediastinal lymphadenectomy has been shown to be feasible and safe and frequently can be accomplished through the abdominal incision (with the assistance of a cardiothoracic surgeon if needed). In patients without evidence of advanced disease, a full staging lymphadenectomy should be performed up to the level of the renal vessels. The utility of removing normal appearing lymph nodes in the setting of grossly advanced disease is unknown and left to the discretion of the operating surgeon. In a prospective European trial for advanced ovarian cancer, there was no difference in overall survival between patients having selective removal of enlarged pelvic and abdominal lymph nodes and those having complete pelvic and para-aortic lymphadenectomy. Clearly however, it is important to remove any macroscopically enlarged lymph nodes, if they represent the largest site of residual disease.

Placement of an Intraperitoneal Catheter

If optimal cytoreduction is achieved, the placement of an intraperitoneal catheter should be routinely performed for infusion of adjuvant chemotherapy. If there are doubts intraoperatively about the patient’s candidacy for intraperitoneal chemotherapy, we recommend proceeding with placement, as removal can be safely performed under local anesthesia in the clinic. Options include the 9.6-Fr vascular catheter versus a 14-Fr fenestrated catheter and intraperitoneal reservoir.

Ideal placement is in the midclavicular line in the RUQ or LUQ over the distal ribs. A 4-cm transverse incision is made and carried down to the fascia, at which point blunt dissection can be used to make a pocket to

accommodate the reservoir of the port. A long, fine-tipped clamp can be used to create a tunnel from the incision into the mid abdomen (under direct visualization while elevating the abdominal wall). This clamp can be used to grasp the catheter tubing and pull it back through the incision. The tubing should be trimmed, and the reservoir attached as directed by the manufacturer. The port should then be flushed with heparinized saline, and each component examined for patency and leaks. Delayed absorbable sutures can be used to secure the reservoir to the fascia. Finally, the incision can be closed in layers.

Closure

Women with advanced ovarian cancer have been shown to be at high risk for the development of incisional hernias, especially if they go on to receive intraperitoneal chemotherapy. Abdominal closure should be performed with a continuous running delayed absorbable monofilament suture (we recommend No. 1 looped polydioxanone) with a suture length to wound length ratio of at least 4:1. Randomized data suggest that sutures should be placed 5 to 8 mm from the fascial edge to decrease the amount of tissue necrosis. Subcutaneous tissue should be copiously irrigated and closed after hemostasis is assured.

Postoperative Complications

Complications after extensive CRS are extremely common, and the prompt identification of these complications is an important aspect of postoperative care. Single-center data quantified the mortality rate after debulking surgery in advanced ovarian cancer between 1.4% and 2.5%, which compares favorably to population-based studies, with a mean mortality rate of 3.7%. Risk factors for higher mortality in these studies are age, performance status, and comorbidities, as well as emergency treatment compared to patients who were treated electively.

Because of the length and extent of surgical effort, many patients will require intensive care unit (ICU) admission for postoperative fluid management and supportive care. Malnutrition, ascites, and comorbidities should all be considered high-risk features for needing postoperative ICU care. The following list highlights some of the most commonly experienced complications following CRS, in addition to some clinical pearls regarding their diagnosis and management.

Infectious Complications

On physical exam in the first several weeks after surgery, patients should be monitored closely for fever, elevated white blood cell count, and abnormalities in pulse or blood pressure.

Wound infection

- Cellulitis frequently resolves with antibiotic treatment alone; however, we recommend opening surgical wounds to facilitate the drainage of underlying collections in the setting of cellulitis that persists despite appropriate antibiotic therapy, purulent drainage, or fluctuance on exam. Twice daily wet-to-dry dressing changes can be utilized until the infection resolves, at which point a wound vacuum system can be placed to expedite healing.

Hospital-acquired pneumonia

Intra-abdominal or peritoneal abscess

- Should be considered in the setting of unexplained leukocytosis, fever, prolonged ileus, or failure to spontaneously diurese by postoperative day 7. Most abscesses can be managed with intravenous antibiotics and interventional radiology drainage.

Peritonitis/Sepsis

- If peritoneal signs or sepsis is suspected, workup should include CT scan with contrast to identify any possible areas of bowel injury or anastomotic compromise.

Hematologic Complications

Bleeding/Coagulopathy

- Usually occurs within 24 to 48 hours of surgery. Monitoring of vital signs, blood counts, and coagulation profiles should allow for prompt identification. If aggressive transfusion of blood products fails to stabilize the patient and resolve coagulopathy in a timely fashion, prompt reoperation may be necessary. If there are any postoperative concerns about hemodynamic stability, patients should be observed and managed in an ICU setting.

Venous thromboembolism (VTE)

- Patients undergoing surgery for advanced ovarian cancer are at extremely high risk for VTE. Acute shortness of breath, hypoxia, unexplained tachycardia, or lower extremity tenderness/edema (especially if unilateral) should prompt a workup. We recommend that all patients receive postoperative prophylactic anticoagulation therapy after CRS (unless significant concerns exist regarding active bleeding or coagulopathy). Consideration should be given to provide the patient

with an extended course (4 to 6 weeks) of anticoagulants at discharge.

Cardiovascular Complications

Intravascular depletion and third spacing

- Extremely common in women with advanced ovarian cancer, especially in the setting of large-volume ascites. To assess renal perfusion, urine output should be monitored closely with a Foley catheter and serum creatinine tests. Most patients will begin to spontaneously diurese within 3 to 4 days after surgery. In our experience, failure to diurese within 7 days postoperatively may indicate an infectious or other significant intra-abdominal process.

Respiratory Complications

Pneumothorax

- All patients undergoing diaphragm resection/peritonectomy should have a chest x-ray in the recovery room to assess for pneumothorax. If sudden symptoms of dyspnea or hypoxia occur at any time postoperatively, a workup should include a repeat chest x-ray.

Pleural effusions

- The development of pleural effusions after liver mobilization and diaphragm peritonectomy/resection is extremely common, especially in patients with ascites. Routine chest x-ray can be used to diagnose and follow postoperative pleural effusions. If a symptomatic effusion develops, patients may benefit from thoracentesis or the placement of a chest tube or drainage catheter. If a chest tube was placed intraoperatively, the output should be followed closely. We recommend continuing chest tube drainage until output is <200 cc per day on straight drainage alone.

Gastrointestinal Complications

Ileus/Obstruction

- Postoperative ileus is extremely common, especially in patients who require bowel resection or extensive mobilization of the bowel. While we generally encourage early postoperative refeeding, the initial step in the management of postoperative nausea and vomiting should be bowel rest. In the majority of cases, postoperative ileus will resolve with bowel rest and nasogastric decompression. In our experience, limiting narcotics and fluid overload can also decrease the incidence, severity, and duration of ileus. Similarly, small bowel obstruction in the acute

postoperative setting will frequently resolve with conservative management (bowel rest and nasogastric decompression). However, surgical management may be required if these conservative measures fail. Parenteral nutrition should be considered in patients who require >5 to 7 days of bowel rest postoperatively.

Anastomotic leak

- In the setting of peritonitis, sepsis, drainage of enteric contents from surgical drains or incisions, unexplained fever, or persistent leukocytosis, a CT scan should be obtained to evaluate all sites of anastomosis. In unstable or septic patients, prompt reoperation is generally required. In stable patients without evidence of sepsis or peritonitis, anastomotic leaks may be amenable to nonsurgical management with drainage, intravenous antibiotics, and in some cases, endoscopic stent placement or repair.

Pancreatic leak/Pancreatitis

- In patients who underwent splenectomy or distal pancreatectomy, fever, nausea/vomiting, or unexplained leukocytosis may indicate a pancreatic leak. If a surgical drain was left in the LUQ, monitoring of daily output and drain amylase may assist in the early identification of a leak (if drain amylase >3× serum amylase). In addition to bowel rest and drainage, somatostatin can be used to manage a postoperative pancreatic leak.

Suggested Readings

Aletti GD, Dowdy SC, Gostout BS, et al. Aggressive surgical effort and improved survival in advanced-stage ovarian cancer. *Obstet Gynecol* 2006;107(1):77–85.

Aletti GD, Eisenhauer EL, Santillan A, et al. Identification of patient groups at highest risk from traditional approach to ovarian cancer treatment. *Gynecol Oncol* 2011;120:23–8.

Aletti GD, Gostout BS, Podratz KC, et al. Ovarian cancer surgical resectability: relative impact of disease, patient status, and surgeon. *Gynecol Oncol* 2006;100(1):33–7.

Aletti GD, Powless C, Bakkum-Gamez J, et al. Pattern of retroperitoneal dissemination of primary peritoneum cancer: basis for rational use of lymphadenectomy. *Gynecol Oncol* 2009;114(1):32–6.

Ali RH, Kalloger SE, Santos JL, et al. Stage III–IV low-grade serous carcinoma of the ovary is associated with a poor prognosis: a clinicopathologic study of 32 patients from a population based tumor registry. *Int J Gynecol Pathol* 2013;32(6)529–35.

Armstrong DK, Bundy B, Wenzel L, et al. Intraperitoneal cisplatin and paclitaxel in ovarian cancer: A GOG study. *N Engl J Med* 2006;354:34–43.

Bristow RE, Palis BE, Chi DS, et al. The National Cancer Database report on advanced-stage epithelial ovarian cancer: impact of hospital surgical case volume on overall survival and surgical treatment paradigm. *Gynecol Oncol* 2010;118(3):262–7.

Bristow RE, Puri I, Chi DS. Cytoreductive surgery for recurrent ovarian cancer: a meta-analysis. *Am J Obstet Gynecol* 2009;2002(2):182.e1–5.

Bristow RE, Tomacruz RS, Armstrong DK, et al. Survival effect of maximal cytoreductive surgery for advanced ovarian carcinoma during the platinum era: a meta-analysis. *J Clin Oncol* 2002;20(5):1248–59.

Callahan MJ, Crum CP, Medeiros F, et al. Primary fallopian tube malignancies in BRCA-positive women undergoing surgery for ovarian cancer risk reduction. *J Clin Oncol* 2007;25(25):3985–90.

Chan JK, Urban R, Cheung MK, et al. Ovarian cancer in younger versus older women: a population-based analysis. *Br J Cancer* 2006;95:1314–20.

Chi DS, Eisenhauer EL, Lang J, et al. What is the optimal goal of primary cytoreductive surgery for bulky stage IIIC epithelial ovarian carcinoma (EOC)? *Gynecol Oncol* 2006;103:559–64.

Chi DS, Eisenhauer EL, Zivanovic O, et al. Improved progression-free and overall survival in advanced ovarian cancer as a result of a change in surgical paradigm. *Gynecol Oncol* 2009;114:26–31.

Chi DS, Liao JB, Leon LF, et al. Identification of prognostic factors in advanced epithelial ovarian carcinoma. *Gynecol Oncol* 2001;82:532–7.

Chi DS, McCaughty K, Diaz JP. Guidelines and selection criteria for secondary cytoreductive surgery in patients with recurrent, platinum-sensitive epithelial ovarian carcinoma. *Cancer* 2006;106(9):1933–9.

Chi DS, Zivanovic O, Levinson KL, et al. The incidence of major complications after the performance of extensive upper abdominal surgical procedures during primary cytoreduction of advanced ovarian, tubal, and peritoneal carcinomas. *Gynecologic oncology* 2010;119(1):38–42.

Colgan TJ, Murphy J, Cole DE, et al. Occult carcinoma in prophylactic oophorectomy specimens: prevalence and association with BRCA germline mutation status. *Am J Surg Pathol* 2001;25(10):1283–9.

Crum CP, Drapkin R, Miron A, et al. The distal fallopian tube: a new model for pelvic serous carcinogenesis. *Curr Opin Obstet Gynecol* 2007;19(1):3–9.

Deerenberg EB, Harlaar JJ, Steyerberg EW. Small bites versus large bites for closure of abdominal midline incisions (STITCH): a double-blind, multicentre,

randomised controlled trial. *Lancet* 2015;386(10000):1254–60.

Duska LR, Garrett L, Henretta M, et al. When “never-events” occur despite adherence to clinical guidelines: the case of venous thromboembolism in clear cell cancer of the ovary compared with other epithelial histologic subtypes. *Gynecol Oncol* 2010;116(3):374–7.

Eisenhauer EL, Abu-Rustum NR, Sonoda Y, et al. The addition of extensive upper abdominal surgery to achieve optimal cytoreduction improves survival in patients with stages IIIC–IV epithelial ovarian cancer. *Gynecol Oncol* 2006;103:1083–90.

Eisenkop SM, Friedman RL, Spirtos NM. The role of secondary cytoreductive surgery in the treatment of patients with recurrent epithelial ovarian carcinoma. *Cancer* 2000;88(1):144–53.

Elattar A, Bryant A, Winter-Roach BA, et al. Optimal primary surgical treatment for advanced epithelial ovarian cancer. *Cochrane Database Syst Rev* 2011; (8):CD007565.

Finch A, Beiner M, Lubinski J, et al. Salpingo-oophorectomy and the risk of ovarian, fallopian tube, and peritoneal cancers in women with a BRCA1 or BRCA2 Mutation. *JAMA* 2006;296(2):185–92.

Fotopoulou C, Savvatis K, Steinhagen-Thiessen E, et al. Primary radical surgery in elderly patients with epithelial ovarian cancer: analysis of surgical outcome and long-term survival. *Int J Gynecol Cancer* 2010;20(1):34–40.

Fournier M, Stoeckle E, Guyon F, et al. Lymph node involvement in epithelial ovarian cancer: sites and risk factors in a series of 355 patients. *Int J Gynecol Cancer* 2009;19(8):1307–13.

Ghezzi F, Cromi A, Siesto G, et al. Laparoscopy staging of early ovarian cancer: our experience and review of the literature. *Int J Gynecol Cancer* 2009;19(Suppl 2):S7–13.

Giede KC, Kieser K, Dodge J, et al. Who should operate on patients with ovarian cancer? An evidence-based review. *Gynecol Oncol* 2005;99(2):447–61.

Goff BA, Mandel LS, Melancon CH, et al. Frequency of symptoms of ovarian cancer in women presenting to primary care clinics. *JAMA* 2004;291:2705–12.

Griffiths CT. Surgical resection of tumor bulk in the primary treatment of ovarian carcinoma. *Natl Cancer Inst Monogr* 1975;42:101–4.

Griffiths CT, Fuller AF. Intensive surgical and chemotherapeutic management of advanced ovarian cancer. *Surg Clin North Am* 1978;58(1):131–42.

Griffiths CT, Parker LM, Fuller AF Jr. Role of cytoreductive surgical treatment in the management of advanced ovarian cancer. *Cancer Treat Rep* 1979;63(2):235–40.

Gurung A, Hung T, Morin J, et al. Molecular abnormalities in ovarian carcinoma:

clinical, morphological and therapeutic correlates. *Histopathology* 2013;62:59–70.

Harter P, Gershenson D, Lhomme C. Gynecologic Cancer InterGroup (GCIG) consensus review for ovarian tumors of low malignant potential (borderline ovarian tumors). *Int J Gynecol Cancer* 2014;24(9 Suppl 3):S5–8.

Hristov AC, Young RH, Vang R, et al. Ovarian metastases of appendiceal tumors with goblet cell carcinoidlike and signet ring cell patterns: a report of 30 cases. *Am J Surg Pathol* 2007;31(10):1502–11.

Jacobs IJ, Menon U, Ryan A, et al. Ovarian cancer screening and mortality in the UK Collaborative Trial of Ovarian Cancer Screening (UKCTOCS): a randomised controlled trial. *Lancet* 2016;387(10022):945–56.

Jarboe EA, Folkins AK, Crum CP, et al. Pathology of BRCA-associated ovarian cancers, including occult cancers. In: Lu KH, ed. *Hereditary Gynecologic Cancer: Risk, Prevention, and Management.* New York: Informa Healthcare; 2008:29–43.

Jung US, Lee JH, Kyung MS, et al. Feasibility and efficacy of laparoscopic management of ovarian cancer. *J Obstet Gynaecol Res* 2009;35(1):113–8.

Junor EJ, Hole DJ, Gillis CR. Management of ovarian cancer: referral to a multidisciplinary team matters. *Br J Cancer* 1994;70(2):363–70.

Junor EJ, Hole DJ, McNulty L, et al. Specialist gynaecologists and survival outcome in ovarian cancer: a Scottish national study of 1866 patients. *Br J Obstet Gynaecol* 1999;106(11):1130–6.

Kauff ND, Domchek SM, Friebel TM, et al. Risk-reducing salpingo-oophorectomy for the prevention of BRCA1- and BRCA2-associated breast and gynecologic cancer: a multicenter, prospective study. *J Clin Oncol* 2008;26(8):1331–7.

Kauff ND, Satagopan JM, Robson ME, et al. Risk-reducing salpingo-oophorectomy in women with a BRCA1 or BRCA2 mutation. *N Engl J Med* 2002;346(21):1609–15.

Kehoe S, Hook J, Nankivell M, et al. Primary chemotherapy versus primary surgery for newly diagnosed advanced ovarian cancer (CHORUS): an open-label, randomised, controlled, non-inferiority trial. *Lancet* 2015;386(9990):249–57.

Kehoe SM, Eisenhauer EL, Abu-Rustum NR, et al. Incidence and management of pancreatic leaks after splenectomy with distal pancreatectomy performed during primary cytoreductive surgery for advanced ovarian, peritoneal and fallopian tube cancer. *Gynecol Oncol* 2009;112(3):496–500.

Kurman RJ, Shih I. The origin and pathogenesis of epithelial ovarian cancer: a proposed unifying theory. *Am J Surg Pathol* 2010;34(3):433–43.

Lee S, Nelson G, Duan Q, et al. Precursor lesions and prognostic factors in primary peritoneal serous carcinoma. *Int J Gynecol Pathol* 2013;32(6):547–55.

Lee Y, Medeiros F, Kindelberger D, et al. Advances in the recognition of tubal

intraepithelial carcinoma: applications to cancer screening and the pathogenesis of ovarian cancer. *Adv Anat Pathol* 2006;13(1):1–7.

Leeper K, Garcia R, Swisher E, et al. Pathologic findings in prophylactic oophorectomy specimens in high-risk women. *Gynecol Oncol* 2002;87(1):52–6.

Lu KH, Garber JE, Cramer DW, et al. Occult ovarian tumors in women with BRCA1 or BRCA2 mutations undergoing prophylactic oophorectomy. *J Clin Oncol* 2000;18(14):2728–32.

Mayr D, Hirschmann A, Lohrs U, et al. Kras and braf mutations in ovarian tumors: a comprehensive study of invasive carcinomas, borderline tumors, and extraovarian implants. *Gynecol Oncol* 2006;103;883–7.

Medeiros F, Muto MG, Lee Y, et al. The tubal fimbria is a preferred site for early adenocarcinoma in women with familial ovarian cancer syndrome. *Am J Surg Pathol* 2006;30(2):230–6.

Millbourn D, Cengiz Y, Israelsson LA. Effect of stitch length on wound complications after closure of midline incisions: a randomized controlled trial. *Arch Surg* 2009;144(11):1056–9.

Nelson G, Kalogera E, Dowdy SC. Enhanced recovery pathways in gynecologic oncology. *Gynecol Oncol* 2014;135(3):586–94.

Norquist BM, Harrell MI, Brady MF, et al. Inherited mutations in women with ovarian carcinoma. *JAMA Oncol* 2015;2(4):1–9.

Obermair A, Fuller A, Lopez-Varela E, et al. A new prognostic model for FIGO stage 1 epithelial ovarian cancer. *Gynecol Oncol* 2007;104(3):607–11.

Omura GA, Bundy BN, Berek JS, et al. Randomized trial of cyclophosphamide plus cisplatin with or without doxorubicin in ovarian carcinoma: a GOG study. *J Clin Oncol* 1989;7:457–65.

Orezzoli JP, Russell AH, Oliva E, et al. Prognostic implication of endometriosis in clear cell carcinoma of the ovary. *Gynecol Oncol* 2008;110(3):336–44.

Porcel JM, Diaz JP, Chi DS. Clinical implications of pleural effusions in ovarian cancer. *Respirology* 2012;17(7):1060–7.

Powell CB, Kenley E, Chen LM, et al. Risk-reducing salpingo-oophorectomy in BRCA mutation carriers: role of serial sectioning in the detection of occult malignancy. *J Clin Oncol* 2005; 23(1):127–32.

Przybycin CG, Kurman RJ, Ronnett BM, et al. Are all pelvic (nonuterine) serous carcinomas of tubal origin? *Am J Surg Path* 2010;34(10):1407–16.

Rauh-Hain JA, Birrer M, del Carmen MG. Carcinosarcoma of the ovary, fallopian tube, and peritoneum: prognostic factors and treatment modalities. *Gynecol Oncol* 2016; 142(2):248–54.

Rebbeck TR, Lynch HT, Neuhausen SL, et al. Prophylactic oophorectomy in carriers of BRCA1 or BRCA2 mutations. *N Engl J Med* 2002;346(21):1616–22.

Sainz de la Cuesta R, Eichhorn JH, Rice LW, et al. Histologic transformation of benign endometriosis to early epithelial ovarian cancer. *Gynecol Oncol* 1996;60(2):238–44.

Sainz de la Cuesta R, Goff BA, Fuller AF, et al. Prognostic importance of intraoperative rupture of malignant ovarian epithelial neoplasms. *Obstet Gynecol* 1994;84(1):1–7.

Schiavone MB, Herzog TJ, Lewin SN, et al. Natural history and outcome of mucinous carcinoma of the ovary. *Am J Obstet Gynecol* 2011;205:480e.1–8.

Schlaerth AC, Chi DS, Poynor EA, et al. Long-term survival after fertility-sparing surgery for epithelial ovarian cancer. *Int J Gynecol Cancer* 2009;19(7):1199–204.

Shih IeM, Kurman RJ. Ovarian tumorigenesis: a proposed model based on morphological and molecular genetic analysis. *Am J Pathol* 2004;164:1511–8.

Siegel R, Miller KD, Jemal A, et al. Cancer statistics. *CA Cancer J Clin* 2016;66:7–30.

Song T, Choi CH, Park HS, et al. Fertility-sparing surgery for borderline ovarian tumors: oncologic safety and reproductive outcomes. *Int J Gynecol Cancer* 2011;21(4):640–6.

Sørensen SS, Mosgaard BJ. Combination of cancer antigen 125 and carcinoembryonic antigen can improve ovarian cancer diagnosis. *Dan Med Bull* 2011;58(11):A4331.

Soslow RA. Practical issues related to uterine pathology: staging, frozen section, artifacts and Lynch syndrome. *Mod Pathol* 2016;29:S59–77.

Tay EH, Grant PT, Gebski V, et al. Secondary cytoreductive surgery for recurrent epithelial ovarian cancer. *Obstet Gynecol* 2002;99(6):1008–13.

Tebes SJ, Sayer RA, Palmer JM, et al. Cytoreductive surgery for patients with recurrent epithelial ovarian carcinoma. *Gynecol Oncol* 2007;106(3):482–7.

Thrall MM, Goff BA, Symons RG, et al. Thirty-day mortality after primary cytoreductive surgery for advanced ovarian cancer in the elderly. *Obstet Gynecol* 2011;118(3):537–47.

Tian WJ, Jiang R, Cheng X, et al. Surgery in recurrent epithelial ovarian cancer: benefits on survival for patients with residual disease of 0.1–1 cm after secondary cytoreduction. *J Surg Oncol* 2010;101(3):244–50.

Timmers PJ, Zwinderman AH, Coens C, et al. Understanding the problem of inadequately staging early ovarian cancer. *Eur J Cancer* 2010;46(5):880–4.

Timofeev J, Galgano MT, Stoler MH, et al. Appendiceal pathology at the time of

oophorectomy for ovarian neoplasms. *Obstet Gynecol* 2010;116(6):1348–53.

Vang R, Shih I, Kurman RJ. Ovarian low grade and high grade serous carcinomas: pathogenesis, clinicopathologic and molecular biologic features, and diagnostic problems. *Adv Anat Pathol* 2009;16:267–82.

Vang R, Shih I, Kurman RJ. Fallopian tube precursors of ovarian low- and high-grade serous neoplasms. *Histopathology* 2013;62:44–58.

Vasconcelos I, Olschewski J, Braicu I, et al. A meta-analysis on the impact of platinum-based adjuvant treatment on the outcome of borderline ovarian tumors with invasive implants. *Oncologist* 2015;20(2):151–8.

Vergote I, Trope CG, Amant F, et al. Neoadjuvant chemotherapy or primary surgery in stage IIIC or IV ovarian cancer. *N Engl J Med* 2010;363(10):943–53.

Vernooij F, Heintz P, Witteveen E, et al. The outcomes of ovarian cancer treatment are better when provided by gynecologic oncologists and in specialized hospitals: a systematic review. *Gynecol Oncol* 2007;105(3):801–12.

Woelber L, Jung S, Eulenburg C, et al. Perioperative morbidity and outcome of secondary cytoreduction for recurrent epithelial ovarian cancer. *Eur J Surg Oncol* 2010;36(6):583–8.

Wright JD, Shah M, Mathew L, et al. Fertility preservation in young women with epithelial ovarian cancer. *Cancer* 2009;115(18):4118–26.

Yates MS, Meyer LA, Deavers MT, et al. Microscopic and early-stage ovarian cancers in BRCA1/2 mutation carriers: building a model for early BRCA-associated tumorigenesis. *Cancer Prev Res* 2011;4(3):463–70.

EDITOR'S COMMENT

Readers of *Mastery of Surgery* may question the relevance or usefulness of a chapter on ovarian cancer for a general or abdominal surgeon; however, this is an important topic in which to stay current, simply because this is a commonly encountered abdominal cancer and the fifth most common cause of cancer death in women in developed countries (Siegel RL, Miller KD, Jemal A. Cancer statistics, 2017. *CA Cancer J Clin* 2017;67(1):7–30). Metastatic ovarian cancer can also be a source of large bowel obstruction, and as the authors discuss, bowel resection due to direct involvement by ovarian cancer can be necessary in up to 35% of patients (see also Chapter 143 "Large Bowel Obstruction"). Because of its different treatment and sensitivity to chemotherapy, it is important that all abdominal surgeons be aware of this and appropriately treat this cancer when it is incidentally encountered at laparotomy. In addition, the general abdominal or colon and rectal surgeon may be asked to assist the gynecologic or gynecologic oncologic surgeon in operations involving such cancers, and should for this reason also have a basic familiarity with this

cancer's behavior and treatment. In one study, rectosigmoid resections were the most frequently performed colorectal intervention performed during operations for gynecologic malignancy (Bedirli A, Mentes BB, Onan A, et al. Colorectal intervention as part of surgery for patients with gynaecological malignancy. *Colorectal Dis* 20057(3):228–31).

Gynecologic oncology is one of the true remaining "generalist" fields where the surgeon still "does it all." In other words, the gynecologic surgeon evaluates his or her patient preoperatively, performs the staging and surgery, and also administers the systemic or intraperitoneal chemotherapy. This is one of the true bastions for the all-encompassing physician-surgeon who has total charge of his patient! There are many laudable aspects to this type of care in terms of continuity of the doctor–patient relationship—the knowledge of exactly where the cancer was and knowing where a recurrence is likely to occur, and a willingness to reoperate if needed. These facets of care are not always present when surgery and follow-up adjuvant therapy are performed by different physicians, as is often the case with other types of cancers.

Ovarian cancer often has a poor prognosis primarily because only one third of patients have reasonably localized disease when the cancer is diagnosed. Its silent nature has been a clinical problem and recognized for nearly one hundred years. Despite extensive research on this subject, still many false positives exist with CA-125 as well as abdominal ultrasound. Simply stated, presently there are *inadequate* biomarkers for screening for ovarian cancer. The abdominal or colon and rectal surgeon should be alert to family history that may indicate an increased risk of ovarian cancer such as in patients with Lynch syndrome that may be on the order of 10% in MSH2 mutation carriers (Nakamura K, Banno K, Yanokura M, et al. Features of ovarian cancer in Lynch syndrome (Review). *Mol Clin Oncol* 2014;2(6):909–16). In addition, when operating upon postmenopausal women with colorectal cancer, the patient should always be asked regarding the option of oophorectomy. Although the incidence of colorectal metastatic disease to the ovaries is low, one study suggested a survival benefit (Young-Fadok TM, Wolff BG, Nivatvongs S, et al. Prophylactic oophorectomy in colorectal carcinoma: preliminary results of a randomized, prospective trial. *Dis Colon Rectum* 1998;41(3):277–83; discussion 283–5). Elective oophorectomy in such patients is a relatively quick and low-risk procedure.

A classic situation likely to confront a general surgeon who has just discovered unexpected ovarian cancer with limited metastasis at the time of a laparotomy to address suspected appendicitis or diverticulitis, or some other common abdominal illness. Although the operation is one that is conducted for suspected alimentary tract disease, seldom there will have been any preoperative studies except a chest x-ray. The authors in this text stress the importance of considering fertility preserving procedures—here the important item is, of course, whether the general or abdominal surgeon **is aware of them**! Obviously, nothing can be done once the ovaries have been removed. More

often than not, there will *not* be a gynecologic oncologist available for consultation at the time of an often urgent operation. Therefore, one needs to deal thoughtfully and carefully with the family, hopefully including the spouse as to what are the best options. It is always best to note the extent of the disease, obtain a tissue diagnosis if possible (omental or peritoneal implants), peritoneal cytology, and carefully examine the abdomen for any other disease. This should include the pelvis, omentum, upper abdomen, liver surfaces, diaphragms, and both left and right paracolic gutters.

One of the most difficult situations a surgeon will encounter is that of a patient with a recurrent ovarian carcinoma and malignant bowel obstruction. These are often the most challenging patients for which to care. There is currently a paucity of data particularly with respect to quality of life to guide treatment of these patients as to which is the best therapy. Colonic stenting has been shown to be associated with both low technical and clinical success in this particular group of patients (Trompetas V, Saunders M, Gossage J, et al. Shortcomings in colonic stenting to palliate large bowel obstruction from extracolonic malignancies. *Int J Colorectal Dis* 2010;25(7):851–4). A Cochran analysis comparing medical versus surgical palliation for bowel obstruction due to ovarian cancer found low-quality evidence and only one study met inclusion criteria (Kucukmetin A, Naik R, Galaal K, et al. Palliative surgery versus medical management for bowel obstruction in ovarian cancer. *Cochrane Database Syst Rev* 2010;7:CD007792. doi: 10.1002/14651858.CD007792.pub2). Weak evidence supported surgical management. Barton suggested that the absence of an abdominal pelvic mass, ascites, multiple levels obstruction, and weight-loss exceeding 9 kg could be used to help select cases for surgical palliation (Kolomainen DF, Barton DP. Surgical management of bowel obstruction in gynaecological malignancies. *Curr Opin Support Palliat Care* 2011;5(1):55–9). As with many things in surgery, clinical judgment remains the key to selecting which patients benefit most from surgery. Given the limited patient prognosis in this setting, a consult with family and palliative care physicians is indicated, and frank discussions with family regarding the high risk of postoperative complications is warranted.

Susan Galandiuk

186 Anterior and Posterior Colporrhaphy

Dionysios K. Veronikis

CYSTOCELE

The biggest imitator of anterior complex, combined vaginal segment defects is a cystocele. Genital prolapse and especially the anterior vaginal segment remains one of the most challenging aspects of reconstructive pelvic surgery. Anterior segment prolapse, the cystocele, is due to inadequate support and/or insufficient stabilization at rest or during increases in intra-abdominal pressure. Paravaginal defects refer to disturbances in the attachment of the anterior sulcus of the vagina to a connective tissue "bridge" attaching the anterior sulcus to the arcus tendineus fascia pelvis. The paravaginal defect clinically presents as a cystocele due to a lateral separation of the vaginal wall attachments from the lateral pelvic sidewall(s). According to Bayden and Walker, such a detachment should be suspected when the anterior vaginal wall is relaxed. If there is no elevation of the anterior vaginal wall when the patient squeezes the pelvic musculature, the connective tissue and vascular supports of the anterior vaginal wall may have been detached from the arcus tendineus fascia pelvis. The lateral vaginal wall is not attached directly to the arcus tendineus fascia pelvis; instead, the anterior vaginal sulcus is attached to the arcus tendineus fascia pelvis by a meshwork of intervening connective tissue—a connective tissue "bridge." This intervening connective tissue may be subject to various strains and stretching and partial or complete avulsion. This type of strain is more common in parous patients as a consequence of trauma during labor and delivery and perhaps can also be attenuated, stretched, or avulsed with pull of massive genital prolapse, even in the nulliparous woman.

In 1905, Ernest W. Hey Groves published a paper entitled "bridge." He stated in this manuscript that "If we regard the cystocele as a hernia, whose radical cure we have to undertake, it is not surprising that methods which depend for their success upon the fixation of so distensible a structure as

the vaginal wall should lead to failure." He explained that "vaginal cystocele exists under two conditions, that in which it only forms part of a uterine descent, and that in which it forms a distinct hernia or pouch, pushing the vagina before it, but leaving the uterus in a normal position." He further described the levator ani muscle complex, the "bridge" of the pelvis fascia, and its insertion. Although the description of his operative repair is not completely clear, he described the following: "A transverse incision is made from one labium majus to the other, about 3 cm behind the urethral orifice. The incision divides the whole thickness of the vagina…The margins of the levatores ani muscles are then sought for and defined in either angle of the wound. It will be found that they can easily be brought into apposition with little or no tension."

The first description of lateral cystocele repair incorporating the arcus tendineus fascia pelvis into the cystocele repair was by George R. White in 1909. White performed this repair on 19 patients over a 3-year period, as he stated always in connection with some other plastic operation.

White's classic paper described a surgical procedure that was designed to correct cystocele—a radical cure—by attaching the lateral vaginal sulci to the arcus tendineus fascia pelvis. One has to wonder what is meant by the term "bridge" because it could conceivably include as much a displacement cystocele from lateral detachment as a displacement cystocele from an apical prolapse. White's 1909 paper did not receive much attention, and he again reported his views in 1912. Interestingly, based on cadaver dissections, White wrote, "The easiest and simplest way to accomplish this is to incise the peritoneum at the side of the bladder, push the bladder aside until the white line comes into view, and then by the aid of an assistant's finger in the vagina, suture the anterior lateral side of the vagina to the white line of the pelvic fascia." Almost 50 years later, in 1961, John Christopher Burch, in performing a Marshall–Marchetti–Krantz operation, was unable to secure the sutures to the periosteum and concomitantly noticed the intravaginal finger elevating the vaginal wall to the "bridge"—the arcus tendineus fascia pelvis. After seven successful procedures he felt that the Cooper ligament was a stronger attachment point. The paravaginal defect and its repair as we know it today were redescribed by Richardson through an abdominal retropubic exposure instead of the original transvaginal approach used by White.

CYSTOCELE AND THE PARAVAGINAL DEFECT

Cystocele is a consequence of trauma/damage to the vagina, to the apical vaginal supports, to the lateral vaginal attachments, or to the vaginal wall itself. In examining and evaluating the anterior vaginal wall one must have in mind that there are several distinct types of cystoceles and each may contribute partially or totally to anterior segment defects. All of the existing combinations must be recognized and corrected if surgical treatment is to be effective and durable.

Cystocele has been described according to whether it is anterior to the interureteric ridge (anterior cystocele) or posterior to it (posterior cystocele). Anterior cystocele is synonymous with urethrocele, in which straining or Valsalva efforts result in downward bulging or rotational descent of the urethra with or without a demonstrable tendency of the bladder to "bridge" behind the vesicourethral junction. The distal third of the vaginal wall and attachments underlie and support the urethra. This rotational descent of the vesicourethral junction may be of varying degrees and is often associated with urinary incontinence. Pathologic dilation of the midurethra and/or distal urethra (true urethrocele) is quite uncommon. A true cystocele therefore does not include the distal vagina. Similarly, in patients with an intact cervix and uterus, the cervix occupies the upper third or so of the anterior vaginal wall. The length of the anterior vaginal wall plus the length of the cervix roughly equals the length of the posterior vaginal wall. Thus, a distention cystocele is between the bladder neck and cervix. A distention cystocele (Fig. 186.1) is almost without exception the result of an overstretching of the vaginal wall beyond its ability to recover/involute after vaginal delivery, or the consequence of the atrophic changes of aging upon the intrinsic structural components of the vaginal wall with or without earlier damage. Rugal folds once visible on the anterior vaginal epithelium diminish with aging and may disappear as the physiologic/pathologic changes behind the squamous epithelium and within the vaginal wall deep to the squamous epithelium progress. These processes allow the anterior vagina and bladder to "bridge" into the vaginal lumen. In a true distention cystocele the lateral attachments of the vagina are well supported. The transverse topographic length from vaginal sidewall to vaginal sidewall is increased. Therefore, almost without exception the true distention cystocele is the result of attenuation of the anterior vaginal wall. The vagina is an organ that responds to physiologic forces as well as pathologically with the same response, that is, by stretching.

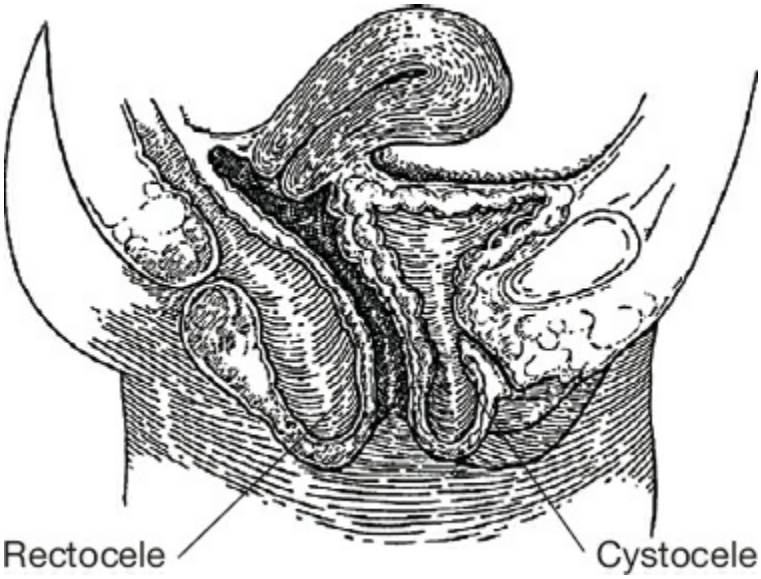

Figure 186.1. Sagittal section showing distention cystocele and rectocele. Note that the vaginal vault and uterus are at a normal position within the pelvis.

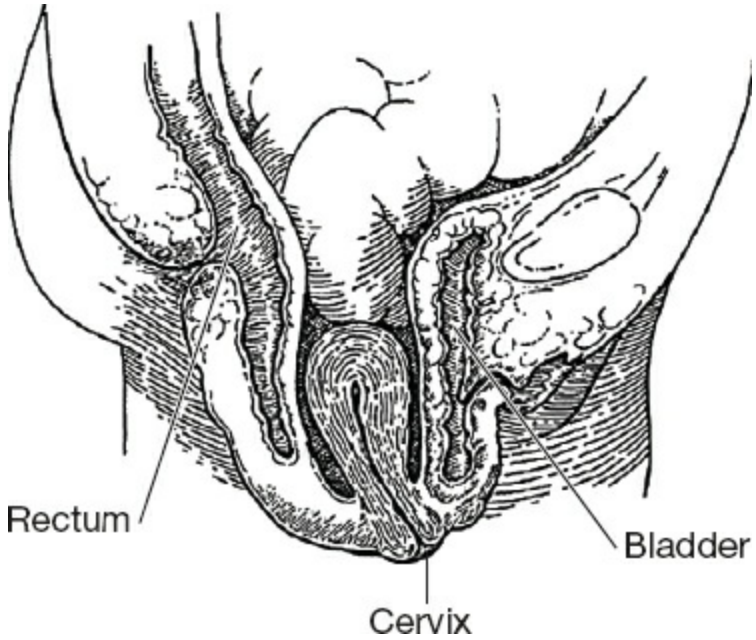

Figure 186.2. Sagittal section showing displacement cystocele, the result of a massive eversion of the vaginal apex and uterus. This represents a procidentia. Note the position of the small bowel entering the pelvic inlet.

Lateral displacement cystocele (Fig. 186.2) is the result of pathologic elongation or detachment of the lateral vaginal attachments and support of the vagina. Etiologically, this is quite different from distention cystocele caused by connective tissue damage to the normal vaginal wall. The

anterior vaginal segment also has superior attachments to the cervix. Thus, the tissues supporting both the vagina and cervix are component parts of the cardinal ligaments and function as an anatomic unit. Displacement of one component is often followed by similar displacement of the other. Posthysterectomy eversion or prolapse of the upper vagina may also present as displacement cystocele by creating a "bridge." If the upper vaginal segment does not descend, there cannot be a telescoping effect or an apical displacement cystocele. In its pure form, the displacement cystocele represents an eversion of the vagina with relatively well-preserved rugal folds. The loss of support of the lateral vaginal attachments can be unilateral or bilateral.

Preserved rugae with descent of the anterior vaginal wall suggests a defect of the connective tissue structures that support the vagina and urethra bilaterally at the lateral pelvic wall along the arcus tendineus fascia pelvis. This type of anterior segment defect is a displacement cystocele as is a cystocele from an upper vaginal vault prolapse. Descent of the upper vagina halfway between the ischial spines and hymen may easily be corrected by a surgical procedure directed only at the vaginal apex. Clinically, when the sulci disappear partially or completely, a paravaginal defect is coexistent. When one is evaluating the anterior segment, it is essential to determine whether the vaginal vault is partially or completely prolapsed, adding to the magnitude of a displacement cystocele. In addition, with the vaginal vault replaced one must consider the extent of distention cystocele as well as the extent of "bridge" displacement cystocele by the vault prolapse. Any coexistent paravaginal defects are then and only then evaluated. To reposition the vaginal vault to the ischial spines with a ring forceps and label it a pure lateral displacement cystocele is an error in diagnosis. Yet, often our residents, referring colleagues, and patients call a posthysterectomy vault prolapse a "bridge" cystocele! Hence, the biggest imitator of a cystocele in a posthysterectomy patient is an apical vaginal segment prolapse.

It is essential that the surgical gynecologist contemplating surgical repair of anterior segment defects take into consideration that "bridge" forms of individual anterior segment defects rarely occur. As a general rule, anticipate a combination, that is, a "bridge" of the above types of defects.

DIFFERENTIAL DIAGNOSIS OF ANTERIOR SEGMENT

DEFECTS

Examination of the patient with genital prolapse is facilitated by forceful Valsalva maneuver, especially in the standing position, in order to delineate defective vaginal sites that manifest themselves better under stress as well as the extent and magnitude of all defects. However, paravaginal defects are best evaluated in the lithotomy position initially at rest and then with forceful Valsalva maneuver to fully visualize descent of the anterior vaginal wall. Subsequent evaluation must analyze the site or sites of defects with repositioning of the sulci, as well as all other pelvic support defects if durable and long-term support of the anterior segment is to be obtained.

The importance of the damage caused by each component of the anterior vaginal segment may be noticeable at different levels within the anterior vaginal depth. Therefore, where are paravaginal defects along the vaginal depth? If we topographically divide the anterior vaginal segment into thirds, the paravaginal defects are in the middle third of the vagina. DeLancey examined vaginal support in cadavers that had previously undergone hysterectomy as well as cadavers with the uterus in place in order to study the relationship of vaginal support to uterine support, and vaginal support following hysterectomy. The structures that supported the vagina were divided into three levels corresponding to different areas of support: levels I, II, and III. Although these three levels of vaginal support are continuous, surgically we repair each of these three areas with different operations. We can almost select a surgical procedure and place it in one of these three levels.

One approach in evaluating patients with genital prolapse is for the initial assessment to be focused on the apical supports of the vagina. Descent of the vaginal apex or cervix suggests loss of connective tissue support between the vagina and the parametria, a level I defect. An undiagnosed partial vault prolapse may be spuriously treated surgically as a cystocele due to the telescoping effect of the anterior vaginal segment (from loss of apical support) in patients who have undergone hysterectomy. This apical defect is very frequently associated with a midline defect of the vaginal wall (distention cystocele).

The literature in reconstructive pelvic surgery has not clearly stated the incidence and coassociation of paravaginal defects in patients with primary and recurrent prolapse. Richardson reported that about 85% of the cystoceles with descent of the anterior vaginal segment in his patients and

more than 95% of the cystourethroceles with stress incontinence were caused by a paravaginal defect. Therefore, 95% of his patients were treated with paravaginal defect repair.

Topographically dividing the anterior vagina into thirds permits evaluation of four distinct areas. This provides a useful paradigm that focuses on the defects and the surgical treatment that can be applied to their repair. As stated by DeLancey, these three levels of vaginal support are continuous with one another and therefore interdependent. The midvagina, level II, relies on a well-supported upper vagina (level I) to prevent an apical displacement cystocele due to a telescoping effect of the anterior vaginal wall. As long as support of the upper vagina (level I) is intact, a “bridge” or anterior segment defect is a support defect at level II. Surgical correction of level I may be performed vaginally by unilateral or bilateral sacrospinous colpopexy—the Mayo-McCall culdoplasty—or an abdominal sacrocolpopexy. On the other hand, level III corresponds to the region of the vagina that extends 2 cm from the introitus to 3 cm above the hymenal ring and is fused with the surrounding structures. This is the area of the bladder neck—the urethrocele. In patients with total prolapse of the anterior vaginal wall and apex, urinary continence may be achieved by a “bridge” effect of the urethra. Reducing the cystocele and restoring the anatomic relationships of the anterior vaginal segment unmasks urinary incontinence.

Thus, the midportion of the anterior vaginal segment, level II, requires careful clinical evaluation because this is the site of both the midline distention cystocele and the lateral displacement cystocele (paravaginal defect). Therefore, a true cystocele develops because of midline damage to the anterior vaginal wall and/or to the lateral connective tissue supports of the bladder and arcus tendineus fascia pelvis. Attenuation and breaks in the connective tissue and/or the muscularis of the anterior vaginal wall within level II results in descent of the anterior vaginal wall into the vaginal canal as a space-occupying mass, that is, the cystocele. Since the distance from the left arcus tendineus fascia pelvis to the right arcus tendineus fascia pelvis is a fixed distance, any increase in the transverse anterior vaginal wall dimension along the length of level II will cause the anterior vaginal wall to bulge into the vaginal canal. Hence, an analogy can be drawn with respect to two fixed points such as clothesline poles and the clothesline between them.

Therefore, the diagnosis of a paravaginal defect requires the vaginal

apex, level I, to be repositioned in its normal anatomic position or at the site where reconstructive surgery will place it; then and only then should level II be evaluated. Preoperatively repositioning the vaginal apex in patients with significant vault prolapse will avoid spuriously diagnosing an apical prolapse as a cystocele or as a paravaginal defect. Repositioning the vaginal apex is the initial step in correctly identifying the cause of level II defects and the complex nature of the pelvic floor defects. Huddleston evaluated patients with magnetic resonance imaging (MRI) preoperatively and then 4 to 30 days postoperatively after surgically correcting the paravaginal defects. This study very effectively identified the paravaginal defects preoperatively and the persistent uncorrected vault prolapse and level I defects postoperatively. The identification of the level I defects in the immediate postoperative MRI scans underscores the need to evaluate level II defects after level I has been repositioned, and if a level I defect exists it ought to be repaired.

Let us consider preoperative evaluation of a patient with an unreduced posthysterectomy vault prolapse to the level of the hymenal ring. The ring forceps may be utilized to reposition the sulci and elevate the vagina to the ischial spines. The vault prolapse and possible paravaginal defect is reduced and disappears as the most dependent portion of the vaginal apex is taken to the level of the ischial spines by the tip of the defect analyzer and as the sulci are elevated in the midvagina to the lateral pelvic sidewall, respectively. These findings may spuriously be diagnosed as a complete bilateral paravaginal defect. Alternatively, if the same patient was evaluated by initially reducing the apex of the prolapse with a disarticulated speculum, a sponge stick, or preferably a Scopette (rectal swab), this would immediately identify the vault prolapse as a level I defect. Then, with the vaginal apex repositioned, a lateral defect at level II may be evaluated by repositioning the sulci with the Baden vaginal defect analyzer or a curved ring forceps at rest and during Valsalva. When the vaginal apex is restored, the displacement cystocele from the apical prolapse is also noted, and any remaining cystocele is due to a midline defect. In clinical practice, the magnitude of pelvic floor genital prolapse will undoubtedly yield variations in the severity of anterior segment defects, that is, cystoceles. Multiple anterior segment site defects, “bridge” with midline distention, paravaginal defect, and apical descent components require meticulous preoperative evaluation.

SYMPTOMS

The most common symptom of a displacement, distention cystocele, and paravaginal defect is an unwanted protruding bulge of anterior vaginal wall that is worse with the effects of gravity when the patient is standing or straining. There is a feeling of pelvic fullness and of "bridge." Urinary incontinence may be a coexistent, troublesome symptom in patients with cystocele. Under normal conditions, the pelvic organs are constantly exposed to increasing intra-abdominal pressure and maintain their anatomic relationships. Increases in intra-abdominal pressure, as from coughing, sneezing, or changing position, and the intrapelvic relationship of the urethra to the posterior aspect of the pubic symphysis cause abnormal rotational descent of the bladder neck and flattening of the posterior urethrovesical angle if a relatively greater portion of the intra-abdominal pressure is transmitted primarily to the bladder, resulting in momentary but troublesome urinary incontinence. This is called *urinary stress incontinence*.

On the other hand, with large cystoceles a "bridge" may occur at the bladder neck, preventing urine loss with coughing and effective evacuation during micturition. When hypotonia of the bladder develops in such instances, normal detrusor tone is compromised, and excess urine from the incompletely emptied bladder may flow over into the urethra, a condition described as *overflow incontinence*. This may also leave a large volume of residual urine that may become stagnant and easily infected, giving rise to chronic cystitis.

In such cases, after colporrhaphy, the "bridge" effect is removed as the bladder base and vagina are repositioned. If there is insufficient urethral sphincter tone to maintain an intraurethral pressure greater than intravesical pressure under these circumstances, occult urinary incontinence may be unmasked, which has also been called *iatrogenic urinary incontinence*. For this reason, if one is performing an anterior colporrhaphy, preoperative testing with the cystocele reduced, provocative coughing with a full bladder, and preoperative urodynamic evaluation are essential, even in the absence of preliminary urinary stress incontinence symptoms.

ANATOMIC SUPPORTS OF THE VAGINA, BLADDER, AND URETHRA

The urethra penetrates the urogenital diaphragm, and condensations of the latter may be found alongside the urethra continuous with the urogenital diaphragm and extending anteriorly to the back of the pubis. These have various names, such as *pubourethral ligament*, *puboprostatic ligaments of the female*, and *triangular ligament.* However, they differ from the standard ligamentous anatomic descriptions in that they include elements of smooth and striated muscle and therefore are capable of expansion and contraction. This constitutes the upper suspensory system that helps to hold the urethra in place. The lateral sulcus of the vagina beneath the urethra and bladder is attached by a connective tissue bridge to the arcus tendineus of the pelvic diaphragm, which runs along the back of the pubis, takes origin from the medial surface of the obturator internus muscle, and is, in fact, the origin of the levator ani muscles. The attachments of the anterior vaginal wall thus support the vagina, urethra, and bladder, which the wall covers. It is clear that the urethra and vesicourethral junction are thus suspended from above by the urogenital diaphragm and supported from below by the anterior vaginal wall and lateral vaginal attachment, anatomic systems that are relatively distinct from one another (Fig. 186.3). It is possible for any of these systems to be damaged with resultant site-specific cystocele. The vesicovaginal space is a natural plane of cleavage between the wall of the vagina and the wall of the bladder and constitutes a potentially useful surgical space (Fig. 186.3). It is avascular in nature and extends from the vaginal vault to the vesicourethral junction and to the bladder pillars laterally. The vesicovaginal space permits independent function of the bladder and vagina. When this space has been lost as a consequence of laceration, fibrosis from infection, or the trauma of an operation, the ability for independent function of bladder and vagina is compromised. Subsequent bladder filling and distention as well as any bladder and vagina movement must thenceforth always occur simultaneously rather than independently. A similarly separate space between the vagina and rectum serving an analogous purpose is known as the *rectovaginal space*, whose dimensions and surgical usefulness as it pertains to posterior colporrhaphy are described later.

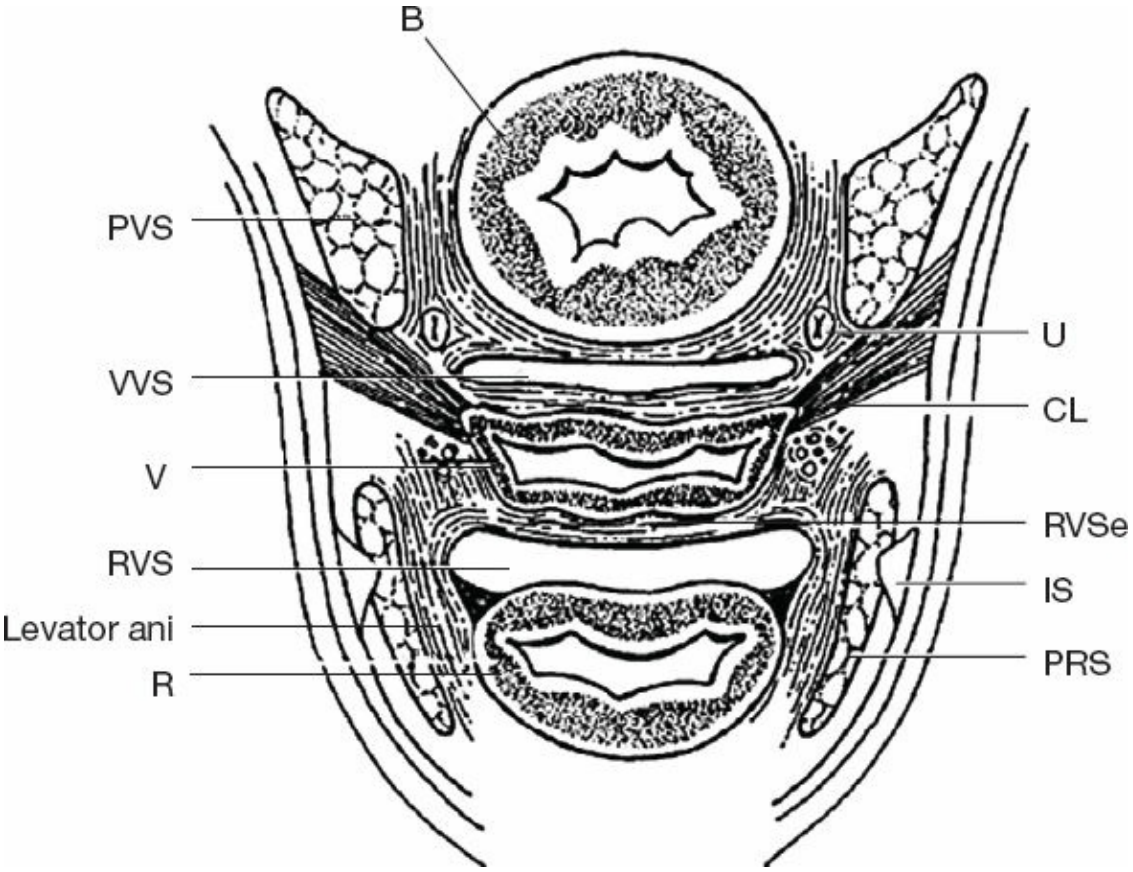

Figure 186.3. Coronal section showing the supports of the vagina and the connective tissue planes and spaces. The bladder (*B*) is separated from the vagina (*V*) by the vesicovaginal space (*VVS*) and is supported from the sidewall of the pelvis by the cardinal ligament (*CL*). This tissue is attached to the levator ani along the pelvic sidewalls as shown. The rectum (*R*) is separated from the vagina by the rectovaginal space (*RVS*) and the rectovaginal septum (*RVSe*). Note the location of the ureter (*U*) in the bladder pillar, the paravesical spaces (*PVS*), and the pararectal spaces (*PRS*). The ischial spine (*IS*) is found in the lateral wall of the paravesical space.

FINDINGS ON PHYSICAL EXAMINATION

The patient should be examined initially while in the lithotomy position, having been instructed not to empty the bladder before pelvic examination. The examination begins with the patient supine and at rest, then voluntarily squeezing the levator ani muscles to determine the extent to which this elevates the anterior sulcus and the bladder, and then voluntarily straining or bearing down. The examiner must evaluate all of the anterior vaginal wall segments for possible defects. While the patient is straining, careful note should be made of any coincident descent of the

vaginal vault with or without the cervix, indicating the presence or absence of any displacement of the vagina and bladder, as described earlier. The rugae and character of the vaginal wall should be carefully noted as an estimate of its estrogen status. If the patient is postmenopausal and no contraindications exist, appropriate oral and vaginal estrogen replacement should be instituted. Any suburethral tenderness should be identified, and nodularity that might suggest a urethral diverticulum should be investigated. The patient should be asked to cough and any spontaneous leakage of urine noted with the structures in the presenting state, and then the patient should be repositioned in the anticipated postsurgical reconstructive position. If no leakage has occurred, the latter is repeated with the patient standing. Additional maneuvers consist of depressing the perineum, thereby stretching the levator ani, after which the patient is asked to cough again. Regardless of the event of urine loss, an estimate of urine volume at that examination time should be obtained by transurethral catheter or by ultrasound, and a concomitant urine specimen should be submitted for culture.

The patient should again be asked to stand, and the previously described examination repeated with specific emphasis on any eversion of the vaginal vault, enterocele, rectocele, and perineal defect.

PLANNING A SURGICAL REPAIR

Because it is impossible to make a patient feel better by operating on something that is asymptomatic to begin with, the goals of surgical therapy must be clear. These are (a) relief of symptoms, (b) restoration of structures to normal, and (c) restoration of function to normal. However, when a patient is to undergo a pelvic reconstructive operation for other indications, such as symptomatic prolapse of the uterus, a rectocele, or an enterocele, any cystocele, even one that is asymptomatic, should be repaired. Other than that, there is no indication for operating on an asymptomatic cystocele, except a demonstrated and sustained progression from year to year with additional areas of developing prolapse and symptoms. Conversely, when a patient demonstrates coincident weakness of the posterior vaginal wall or perineum, or both, a posterior colporrhaphy and perineorrhaphy as needed to help support the anterior vaginal wall and aid the long-term effectiveness of anterior colporrhaphy may be necessary. When there is an obvious coincident prolapse of the vaginal vault or uterus, or both, vaginal hysterectomy and vaginal vault fixation must be

addressed to achieve the best long-term reconstructive result. The surgical reconstructive procedures should embrace techniques that are exacting and meet the specific needs of a particular patient. The hallmark of vaginal surgery is the development of vaginal wall flaps, using avascular planes between organs to reduce blood loss and minimize tissue trauma as well as to gain access to potential pelvic spaces that provide exposure and facilitate the operative procedure. This surgical exposure permits an array of repairs of the underlying structures and organs as well as the vagina, including excision of damaged and overdistended vaginal wall, excision of enterocele, repair of cystocele and rectocele, repositioning of the vagina over the levator plate, and reconstructing the perineum and introitus. It is this exposure and flap generation that bridges plastic surgery with gynecologic reconstructive surgery.

When the vagina is used for surgical exposure during vaginal reconstructive surgery, the goal is to reconstruct a functional, pain-free, pliable, distensible, and well-supported structure. Vaginal reconstructive surgery requires the development of flaps, essentially full-thickness vaginal wall advancement flaps. The anterior and posterior vaginal walls are mobilized by careful dissection within the vesicovaginal and rectovaginal spaces, avoiding splitting the vaginal wall. The amount of full-thickness vaginal wall that is removed from the herniated damaged areas, the overall dimensions of the vaginal caliber and length, and the reconstruction of the perineum and introital aperture are often guided by the indications for surgery and the surgical judgment of the surgeon, which must also take into account repair of all defective vaginal sites. By far, the most frequent defect is that occurring in the midline structures (i.e., the urethra and anterior vaginal wall), so that most of the reconstructive surgical repair is concentrated in the midline. A systematic method for evaluating all the sites of damage is essential to surgical success. The goal of reconstructive surgery is to restore more normal anatomy, restore function, and relieve the symptoms. The massively everted vagina constitutes a completely decompensated vaginal organ with multiple defects in the midline at the vaginal apex/vault of the vagina as well as laterally. It is, in essence, a massive pelvic floor hernia composed of the bladder, small bowel, rectum, vagina, and, at times, the sigmoid colon.

When all of the areas of pelvic floor prolapse and anterior vaginal segment damage have been identified and evaluated, the surgeon must correlate the observations with the patient’s symptoms. Also, any other

laboratory tests that may further explain any additional causes of urinary incontinence, such as detrusor dysfunction or other factors, must be figured into the surgical plan, and attempts must be made to correct these before a surgical repair of cystocele is undertaken.

SURGICAL TECHNIQUE

The surgical technique of full-length anterior colporrhaphy described below presumes that the vaginal vault is located at or has been surgically replaced to a normal depth and that there is no coincident paravaginal defect. If any apical or lateral defects exist, performing only an anterior colporrhaphy will result in a foreshortened and narrow vaginal canal that will create a new symptom during coitus—dyspareunia.

A distention cystocele as seen topographically is shown in Figure 186.4, and a sagittal section of a distention cystocele with rotational descent of the bladder neck is shown in Figure 186.5. Traction on the tenacula applied to the anterior and posterior aspects of the cervix brings the cystocele and cervix to the introitus and just outside the vagina. To avoid splitting the anterior vaginal wall and to facilitate dissection within the vesicovaginal space, Allis clamps are applied to the full thickness of the anterior vaginal wall overlying the cystocele, and the full thickness of the anterior vaginal wall is incised directly into the vesicovaginal space (Fig. 186.6). A depth of dissection away from the vesicovaginal space toward the vaginal epithelium splits the fibromuscular wall of the vagina. The dissection is performed with scissors, and the incision is carried to the anterior margin of the vesicovaginal space. The scissors dissection is continued to the distal urethral segment, creating a plane between the urethra and the vagina, which are normally fused one to another. This incision is continued to within 1 cm of the external urethral meatus (Fig. 186.7). The connective tissue capsule of the bladder is separated from the underside of the full thickness of the vagina with the scissors by sharp and blunt dissection (Fig. 186.8). This dissection mobilizes the bladder and urethra to the full lateral extent of the cystocele, at times as far as the medial margin of the pubis. The pubourethral ligamentous portion of the urogenital diaphragm should be noted and their attachments preserved.

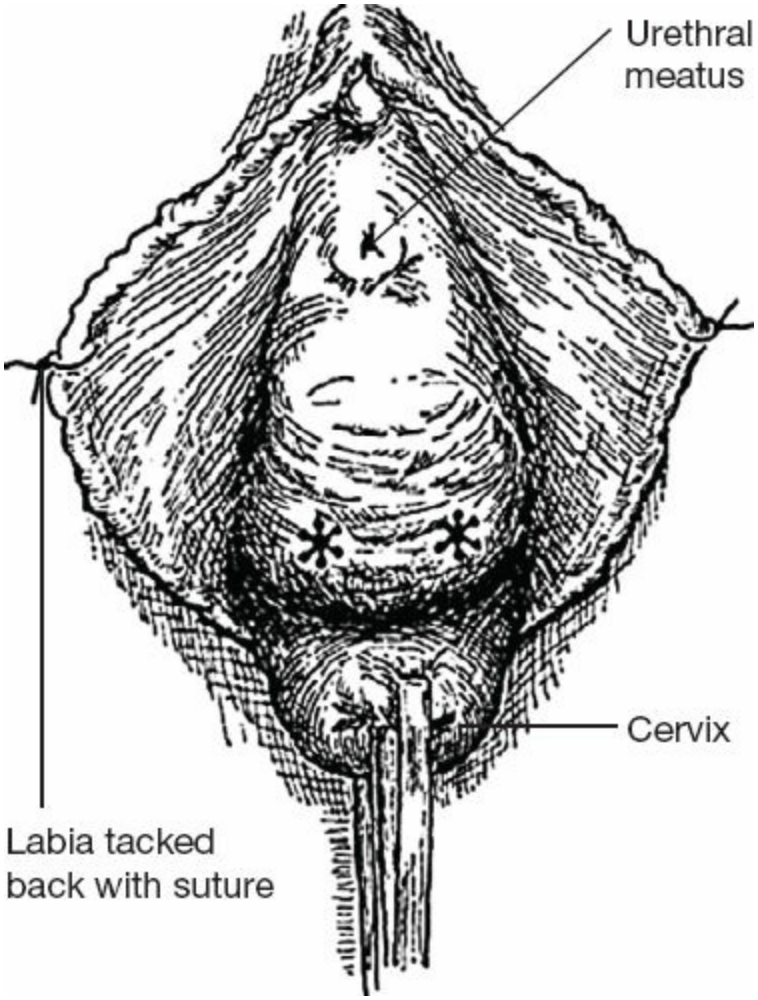

Figure 186.4. A distention cystocele. *Asterisks* identify the site at which Allis clamps are placed before the anterior vaginal wall is opened. (Redrawn from Nichols D, Randall C, eds. *Vaginal Surgery*, 4th ed. Baltimore, MD: Williams & Wilkins, 1996.)

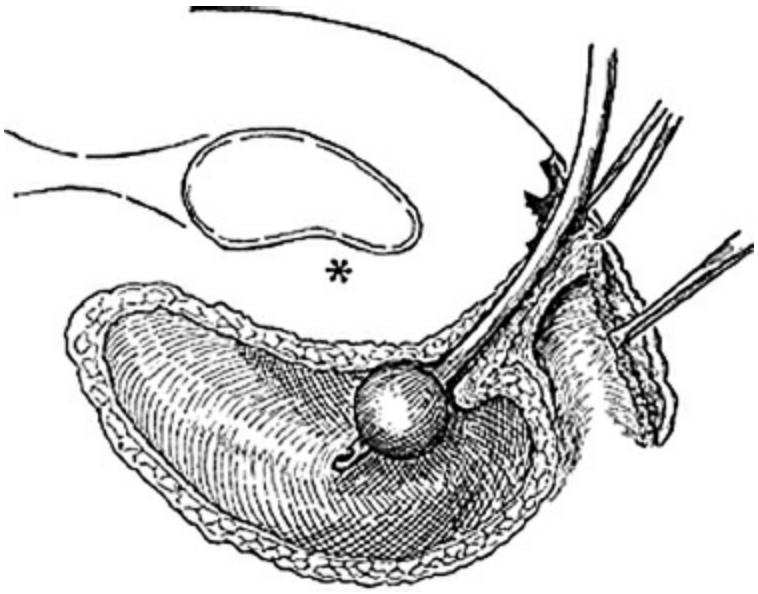

Figure 186.5. Sagittal section of a distention cystocele with rotational descent of the bladder neck in the absence of urethral funneling. Note the relationship of the inflated bulb on the Foley catheter and the *asterisk.* The asterisk is at the position of the normal urethral axis at the junction of the lower third with the upper two thirds of the back of the pubis. (Redrawn from Nichols D, Randall C, eds. *Vaginal Surgery*, 4th ed. Baltimore, MD: Williams & Wilkins, 1996.)

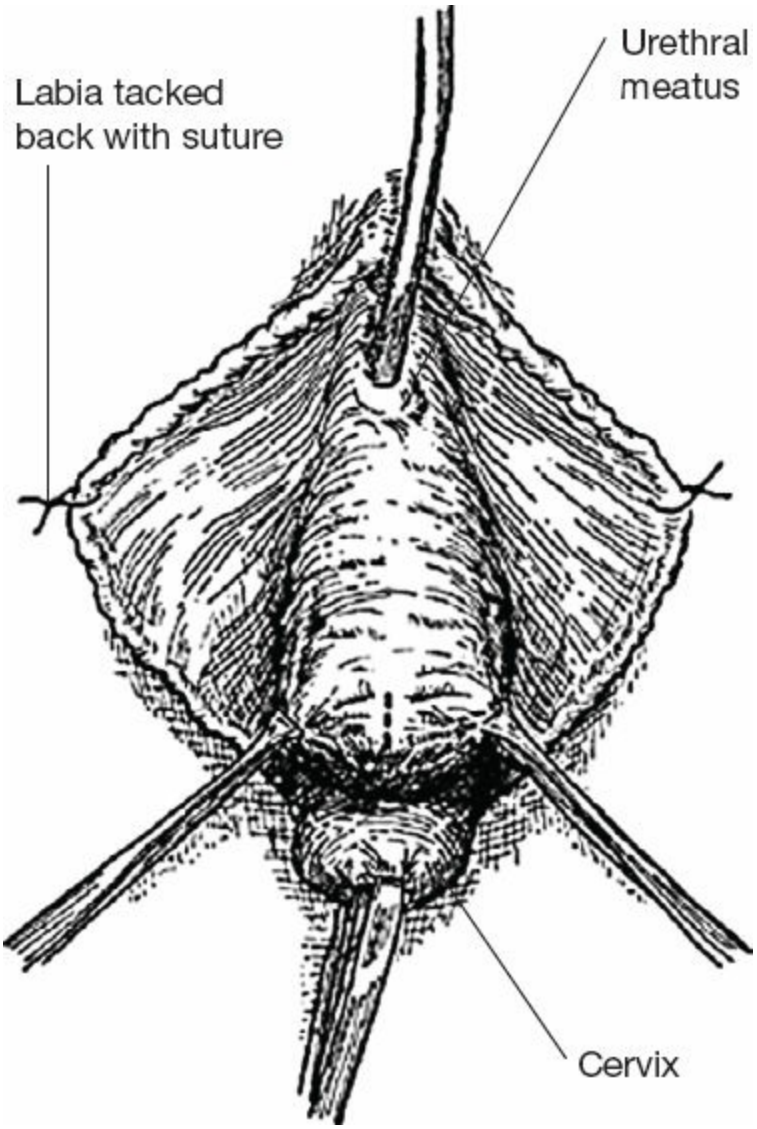

Figure 186.6. Allis clamps grasp the full thickness of the anterior vaginal wall, which is incised at the site of the *dotted line.* (Redrawn from Nichols D, Randall C, eds. *Vaginal Surgery*, 4th ed. Baltimore, MD: Williams & Wilkins, 1996.)

Funneling of the urethra with its consequent vesicalization (Fig. 186.9) should be reduced by one or more Kelly-type sutures of long-lasting

synthetic absorbable or nonabsorbable material. If the patient has urethral funneling as the sole departure from normal, reduction of this funneling by Kelly-type sutures may be all that is required. This may be seen in certain patients with urinary stress incontinence, but without urethral hypermobility.

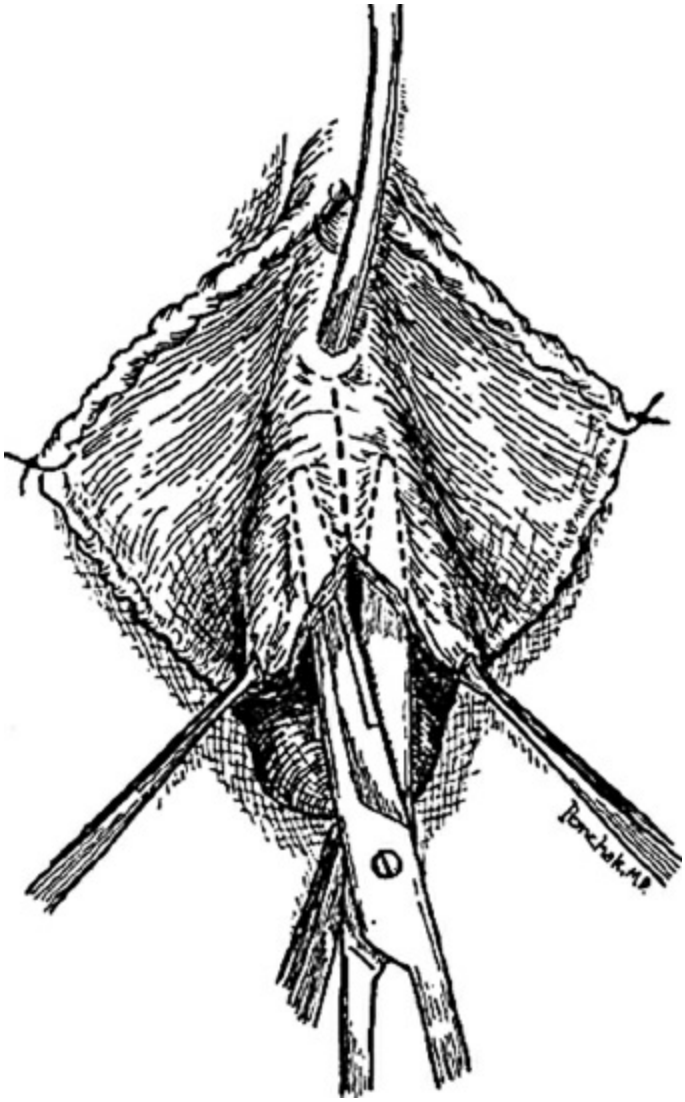

Figure 186.7. The incision in the anterior vaginal wall is carried cranially within the vesicovaginal space as indicated by the dotted line to within 1 cm of the external urethral meatus. (Redrawn from Nichols D, Randall C, eds. *Vaginal Surgery*, 4th ed. Baltimore, MD: Williams & Wilkins, 1996.)

If, on the other hand, there is coincident funneling and rotational descent of the vesicourethral junction, Kelly-type stitches and posterior pubourethral ligament plication can be used as shown (Fig. 186.10). The ultimate goal is that the funneling be reduced and the vesicourethral

junction be restored to its normal position (Fig. 186.11). After the funneling is corrected, the surgeon palpates the inflated bulb of the Foley catheter. This identifies the limits of the urethra and bladder neck. A baby Kocher clamp is applied to the paraurethral connective tissue lateral to the catheter, and the ratchet is closed with only one click. Traction is exerted posteriorly, and if the Kocher clamp has been correctly applied, the tissue condensation of the urogenital diaphragm (i.e., the pubourethral ligament on the patient's right) is captured, and traction actually moves the patient to a minor degree on the table (Fig. 186.12), because the pubourethral ligaments are firmly attached to the posterior aspect of the pubic symphysis (Fig. 186.13). If this movement is not demonstrated, then the clamp has been applied in the wrong place, the pubourethral ligament has been compromised by the dissection, or, possibly, the ligament of this particular patient has no useful surgical integrity.

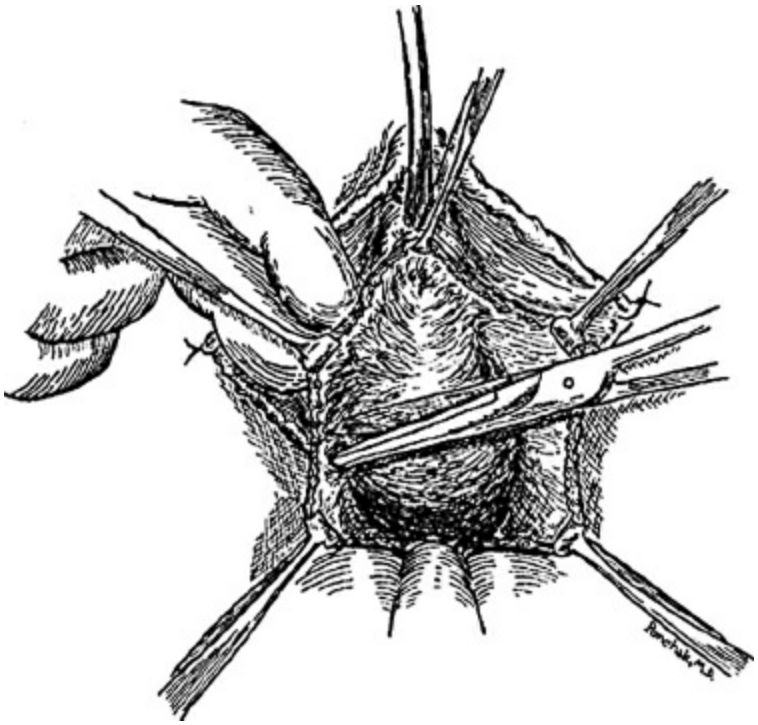

Figure 186.8. The vagina is separated from the bladder by sharp dissection, first on one side and then on the other. (Redrawn from Nichols D, Randall C, eds. *Vaginal Surgery*, 4th ed. Baltimore, MD: Williams & Wilkins, 1996.)

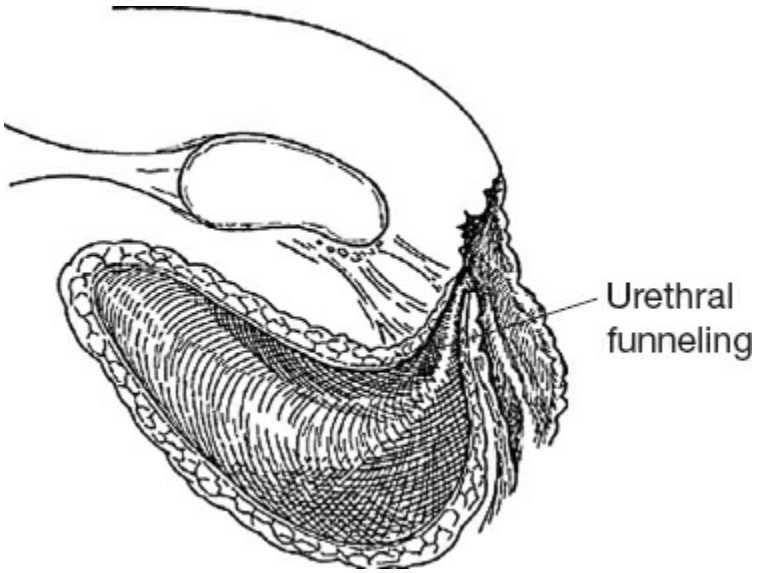

Figure 186.9. Coincident urethral funneling, rotational descent of the vesicourethral junction with elongation of the pubourethral ligament portion of the urogenital diaphragm, and some posterior cystocele. (Redrawn from Nichols D, Randall C, eds. *Vaginal Surgery*, 4th ed. Baltimore, MD: Williams & Wilkins, 1996.)

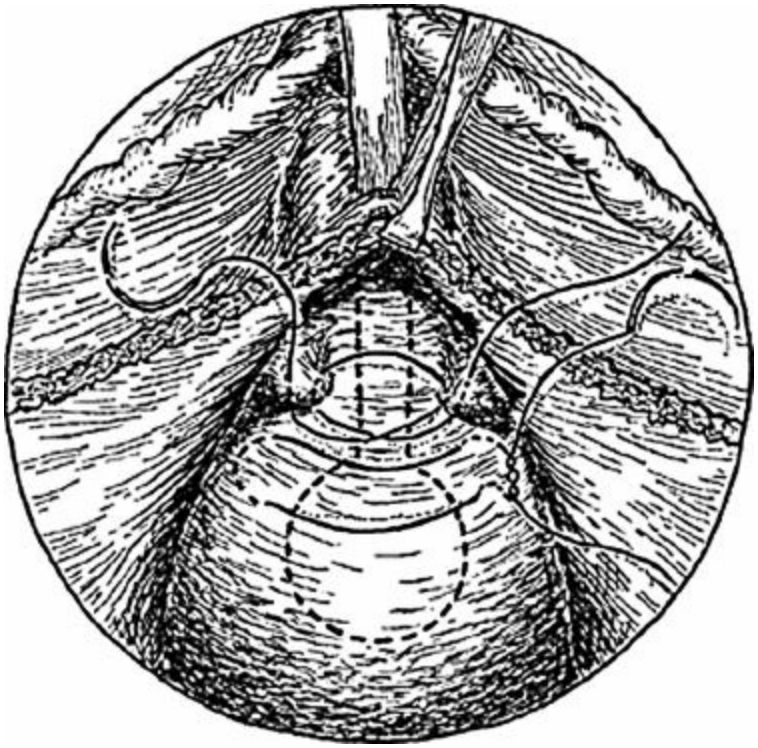

Figure 186.10. At the level of the bladder neck, just above the Foley bulb, a Kelly-type urethral plication stitch has been placed to correct coincident urethral funneling. A posterior pubourethral ligament plication suture has been placed to elevate and correct the urethral hypermobility. (Redrawn from Nichols D, Randall C, eds. *Vaginal Surgery*, 4th ed. Baltimore, MD: Williams & Wilkins,

1996.)

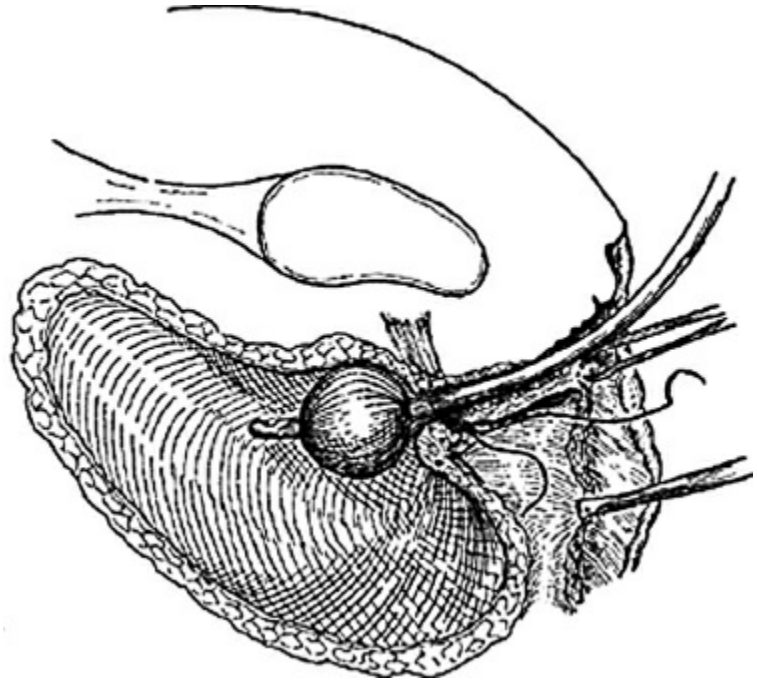

Figure 186.11. Sagittal view showing the effect of plication of the pubourethral ligaments and urogenital diaphragm beneath the vesicourethral junction and the correction of the urethral funneling by a separate Kelly stitch, proximal to the Foley bulb, which has been tied. (Redrawn from Nichols D, Randall C, eds. *Vaginal Surgery*, 4th ed. Baltimore, MD: Williams & Wilkins, 1996.)

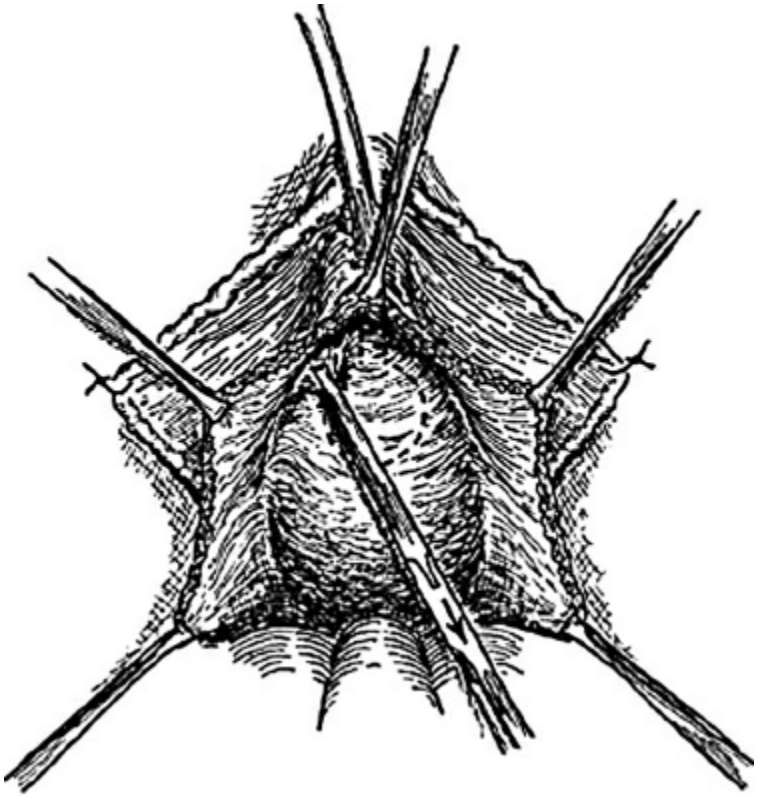

Figure 186.12. The *dotted line* indicates the position of the inflated bulb on a transurethral Foley catheter. The tissues lateral to the bulb are grasped in a Kocher hemostat, and gentle traction is made in the direction indicated by the *arrow* on the Kocher. If this hemostat is properly placed, it should actually move the patient a small bit on the operating table. This tissue represents a condensation of the tissues of the urogenital diaphragm lateral to the point at which it is penetrated by the urethra. These tissues are continuous with those of the pubourethral ligaments. (Redrawn from Nichols D, Randall C, eds. *Vaginal Surgery*, 4th ed. Baltimore, MD: Williams & Wilkins, 1996.)

Another Kocher clamp is applied similarly in the same position on the patient's left, and these tissues are brought together beneath the vesicourethral junction using a synthetic but absorbable suture (e.g., 00 polydioxanone type or polyglycolic acid type). These stitches are placed in such a way that the vaginal ends of these ligaments are plicated beneath the vesicourethral junction (Figs. 186.14 to 186.16). When these sutures have been tied, there is a prompt elevation of the vesicourethral junction, the goal of which is a point marking the junction of the lower third and the upper two thirds of the back of the pubis (Fig. 186.17). The free end of the pubourethral ligament stitch is now sewn to the undersurface of the vagina, re-establishing the fusion between the vagina and urethra that was present

preoperatively. If one suture has not been sufficient to accomplish this goal, a second one may be placed lateral to the first.

The posterior cystocele is then repaired. The connective tissue capsule of the bladder is sewn with one or more layers of interrupted mattress sutures, sufficient to restore it to a normal dimension (Fig. 186.18). If a sling urethropexy is indicated, it is placed before closing the anterior vaginal wall and brought to the skin surface above the pubic symphysis for securing later in the operation.

Similarly, if a coincident distention cystocele and paravaginal defect (Fig. 186.19), lateral detachment of the vagina, is present, then the time to repair this defect is before placing the sling. As described by White, the dissection is carried laterally between the bladder and vagina to the pelvic sidewall on one or both sides as indicated. The intent is to fix with permanent interrupted sutures the lateral vaginal sulcus and the arcus tendineus. Once the dissection is carried sufficiently laterally, the paravaginal space is identified by retracting the bladder medially. This permits palpation of the ischial spine, which serves as the most cephalad point of dissection (Fig. 186.20), and the arcus tendineus is visualized or palpated laterally as it traverses the pelvic sidewall from ischial spine to pubic symphysis. The paravaginal space is developed and enlarged (Fig. 186.21). A series of 00 nonabsorbable braided doubly armed sutures are placed directly into the obturator fascia at the site of the arcus tendineus. The first suture is placed lateral at the level of the ischial spine, and subsequent sutures are placed toward the vesicourethral junction (Figs. 186.22 and 186.23). When all of the sutures (one or both sides) are in place, they are individually sewn to the underside of the full thickness of the vaginal wall at the site of the sulcus (Fig. 186.24) and then tied (Fig. 186.25). The vaginal sulcus is brought to the site of the arcus tendineus on the obturator fascia. Then, all the stitches and the free ends are cut, and the knots are buried beneath the vaginal wall. After these sutures have been tied (Fig. 186.26), any redundant anterior vaginal wall is trimmed (Fig. 186.27), and the remaining vagina is approximated in a running subcuticular suture of polyglycolic acid (Fig. 186.28). The anatomic reconstruction and repair are surveyed to ensure that the desired result has been obtained and that all defects have been corrected (Fig. 186.29).

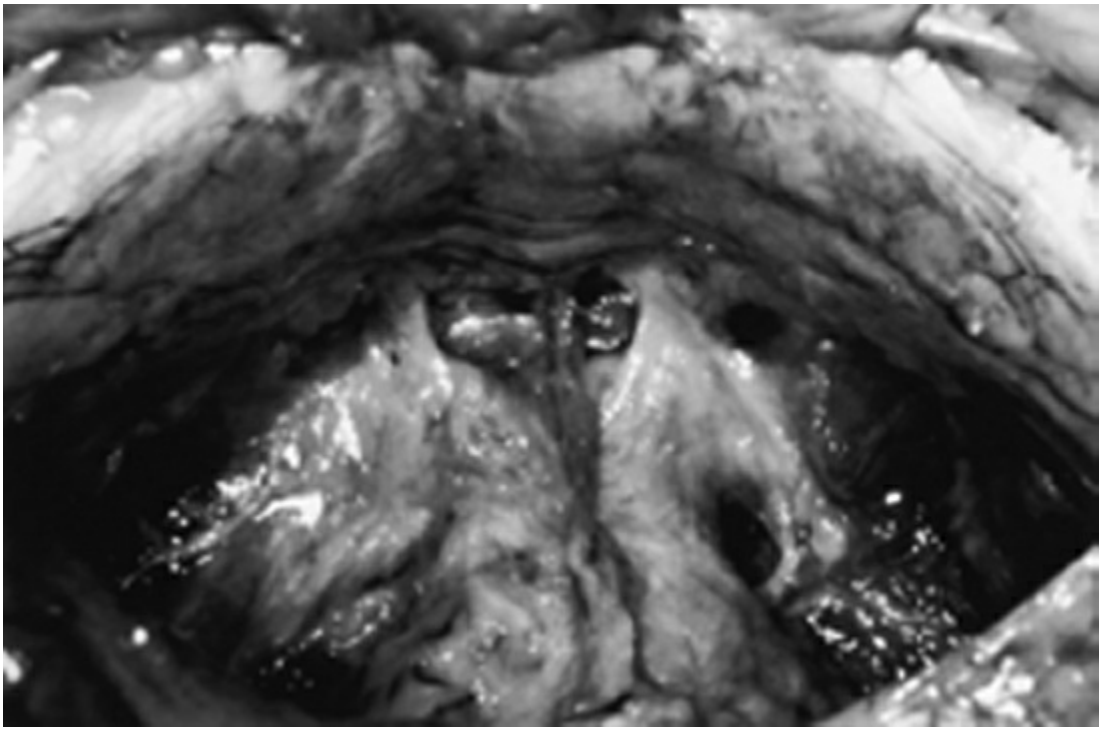

Figure 186.13. The abdominal wall has been opened and the view looking down into the space of Retzius has been developed. Notice the thick, whitish fiber-like condensation of the “bridge” of the urogenital diaphragm along either side of the urethra and extending to the lateral walls of its proximal portion. These are the posterior pubourethral ligaments that are mobilized vaginally and plicated suburethrally. (Photograph courtesy of Dr. Michael Aronson.)

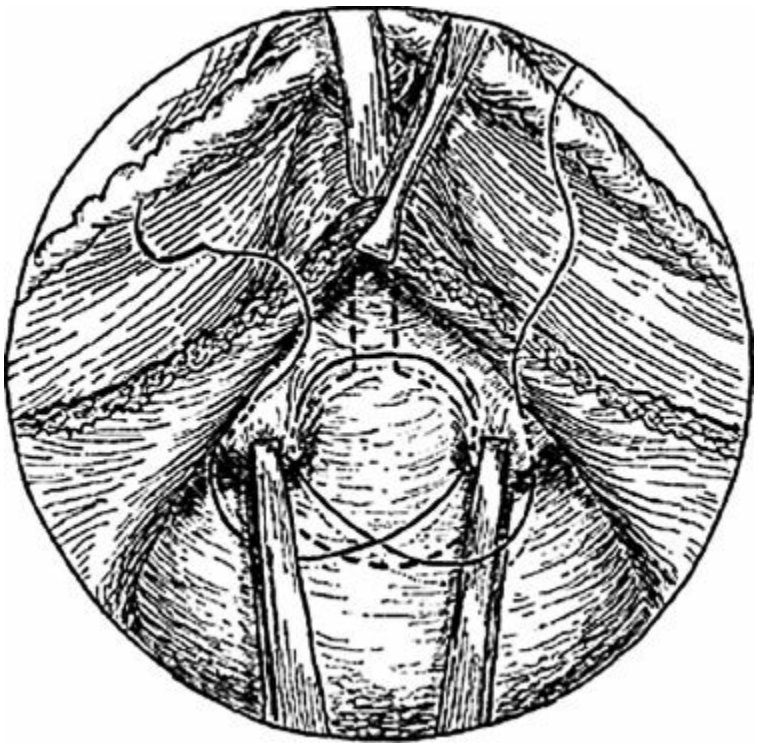

Figure 186.14. A stitch has been placed in a far–near, near–far manner through the tissues of the urogenital diaphragm grasped by the tips of the Kocher hemostats. The *dotted line* indicates the palpable position of the Foley catheter and its bulb. (Redrawn from Nichols D, Randall C, eds. *Vaginal Surgery*, 4th ed. Baltimore, MD: Williams & Wilkins, 1996.)

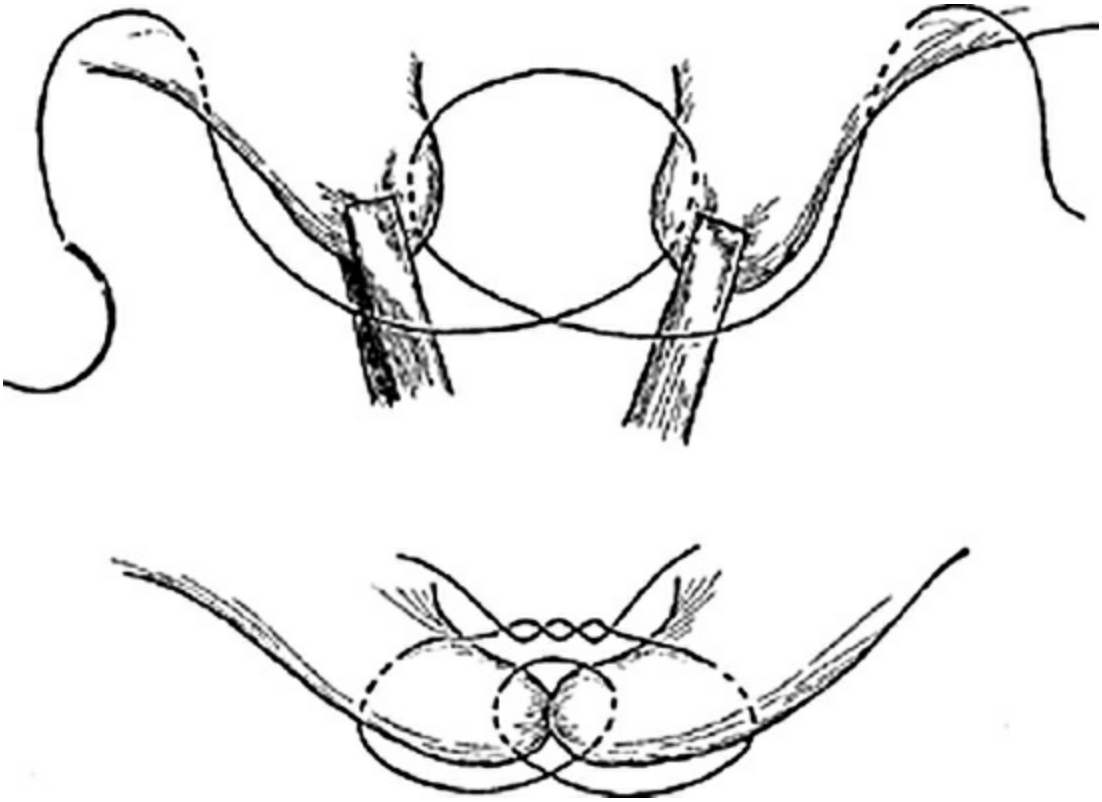

Figure 186.15. Placement of a far–near, near–far suture is shown. The effect of tying this suture (*bottom*) is to bring the tissues of the urogenital diaphragm together beneath the vesicourethral junction. (Redrawn from Nichols D, Randall C, eds. *Vaginal Surgery*, 4th ed. Baltimore, MD: Williams & Wilkins, 1996.)

POSTOPERATIVE MANAGEMENT

Some edema of the tissues is to be expected for several days postoperatively, and for this reason the Foley catheter is left indwelling and is usually removed the morning of the second postoperative day. On this morning, an appropriate antibacterial agent, such as nitrofurantoin or trimethoprim–sulfamethoxazole, is begun, because the mere presence of an indwelling catheter for this length of time predisposes to ascending bacterial colonization. The urethral walls contain many alpha-adrenergic

receptors, stimulation of which by surgical manipulation or by pain induces urethral spasm and, in conjunction with edema, may inhibit the resumption of postoperative voiding. Spasm can usually be blocked in most instances by the administration of a single dose of an alpha-adrenergic receptor blocker such as phenoxybenzamine, a 10-mg dose given by mouth at the time the catheter is removed and repeated as necessary 6 hours later. Prazosin, 1 mg three times a day, is an alternative.

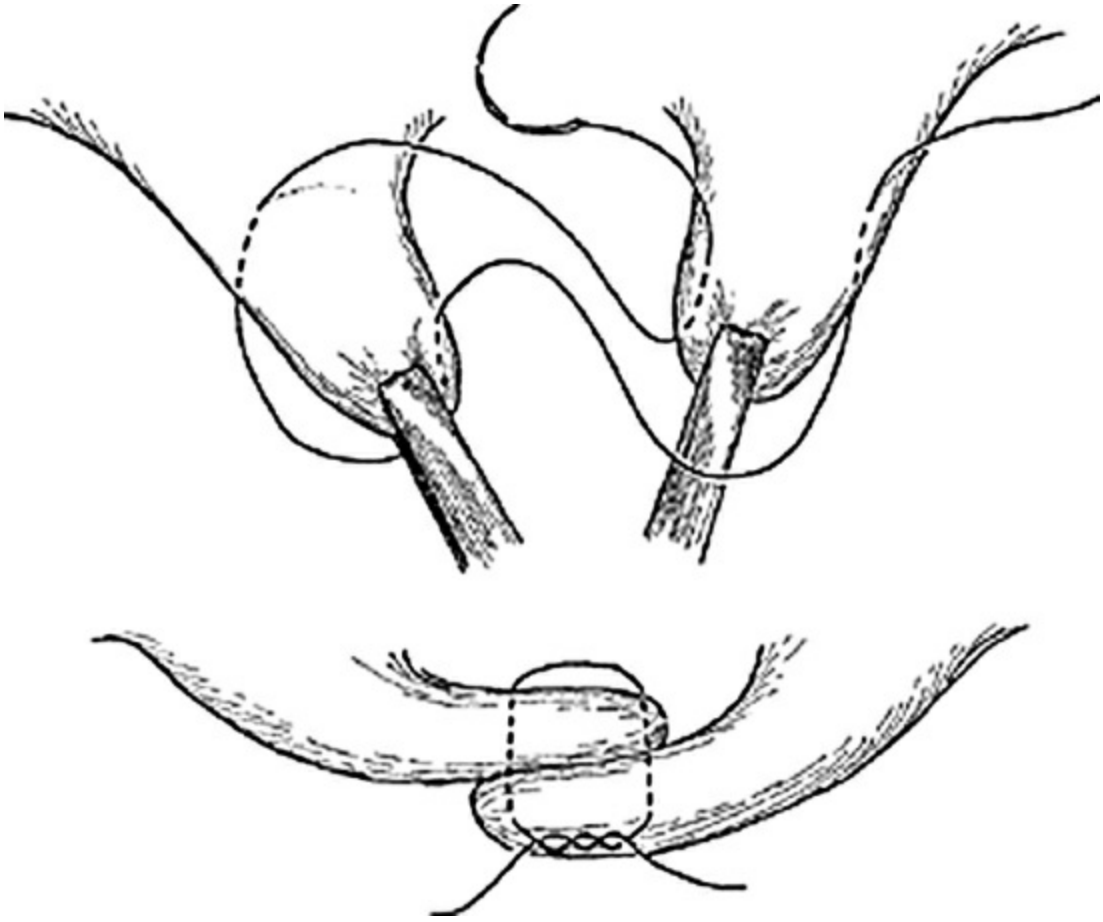

Figure 186.16. Alternative suture placement for bringing together markedly elongated tissues of the urogenital diaphragm. This placement, when tied, overlaps one of the tissue condensations with the other (*bottom*), further shortening this tissue. (Redrawn from Nichols D, Randall C, eds. *Vaginal Surgery*, 4th ed. Baltimore, MD: Williams & Wilkins, 1996.)

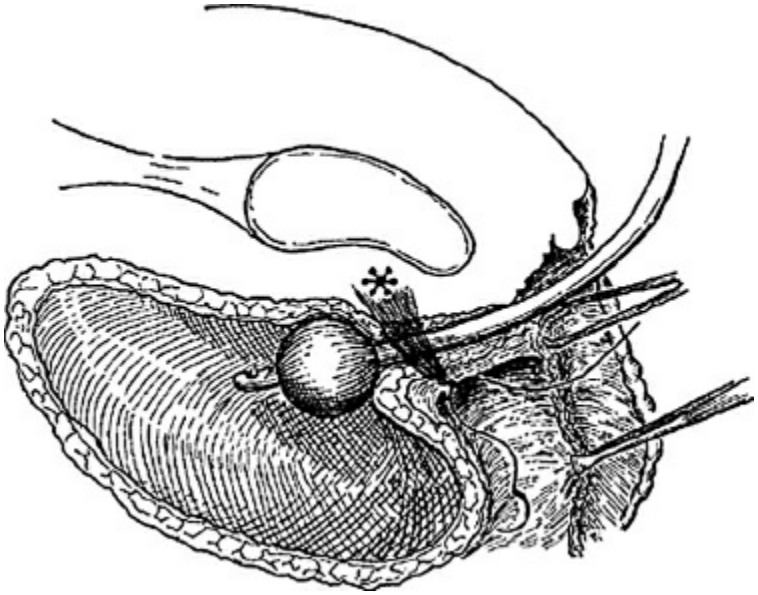

Figure 186.17. The effect of tying the urogenital diaphragm–pubourethral ligament plication stitches. The vesicourethral junction has been restored to its normal position at the junction of the lower third of the upper two thirds of the back of the pubis, the site indicated by the *asterisk.* (Redrawn from Nichols D, Randall C, eds. *Vaginal Surgery*, 4th ed. Baltimore, MD: Williams & Wilkins, 1996.)

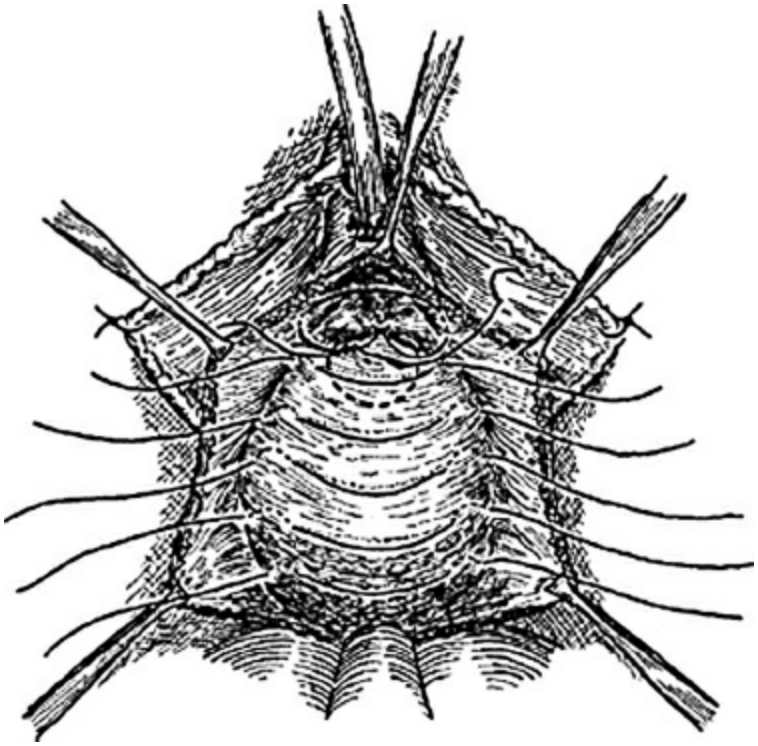

Figure 186.18. The pubourethral plication stitch has been tied, and a second bite is taken to the undersurface of the anterior vaginal wall, which, when tied, re-establishes the fusion that was

initially present in this area. Interrupted mattress sutures are placed in the connective tissue capsule of the bladder to reduce the size of the cystocele. (Redrawn from Nichols D, Randall C, eds. *Vaginal Surgery*, 4th ed. Baltimore, MD: Williams & Wilkins, 1996.)

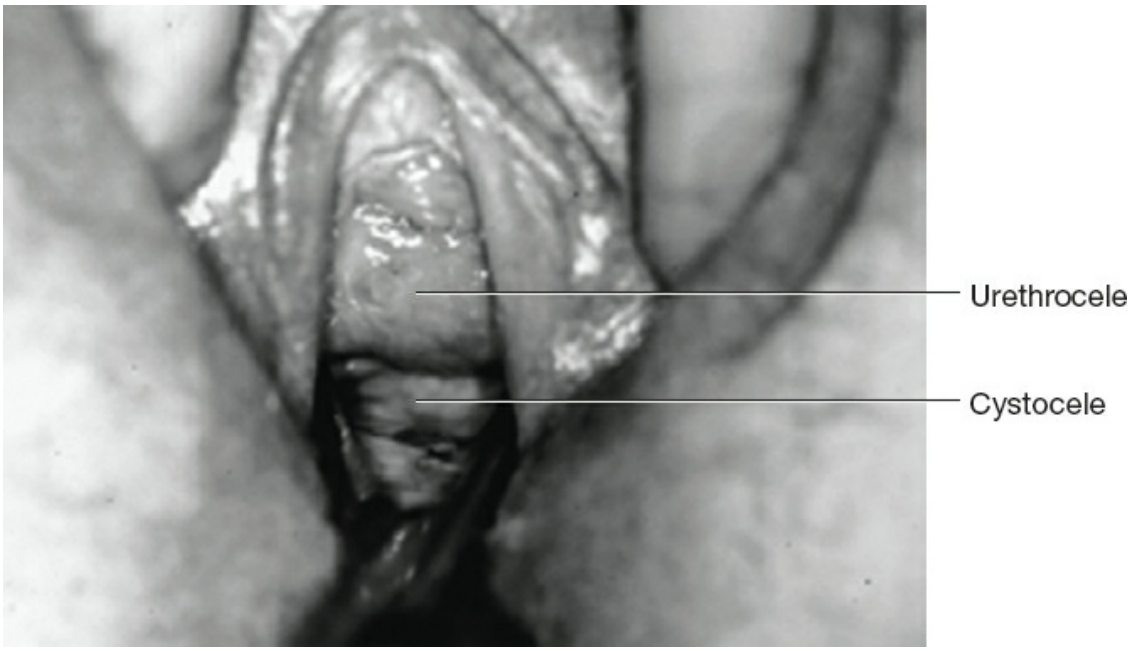

Figure 186.19. Vaginal view of a midline displacement cystocele, urethrocele, and altered urethral axis. Also evident are bilateral paravaginal defects, repositioned with a ring forceps apically to the ischial spines and laterally to the arcus tendineus, in an effort to produce the desired anatomic postsurgical relationships.

Nursing personnel should be instructed to catheterize the patient as necessary if the patient is unable to void and a suprapubic catheter has not been placed. In most instances, the patient voids effectively and comfortably, and can be discharged from the hospital the morning of the third postoperative day. If the patient is unable to void effectively and unable to learn self-catheterization, and if no suprapubic tube has been placed, a 16-Fr silicone-coated Foley catheter can be inserted transurethrally with a terminal plug as used with suprapubic tubes to be released by the patient intermittently. The patient is instructed to release the clamp as necessary to empty the bladder. Once placed, the catheter should be left in place for 7 to 10 days after discharge. The catheter is removed in the office after filling the bladder to a symptomatic volume, and the patient is asked to void. On the rare occasion that the patient is unable to void, the catheter can be reinserted for 1 week or, alternatively,

the patient can be reinstructed in the technique of self-catheterization using flexible plastic and disposable Mentor female urethral catheters. Self-catheterization should be continued as necessary until the bladder is emptying adequately. Some surgeons routinely use suprapubic cystostomy as a means of resting the bladder postoperatively, but we have not found this to be necessary.

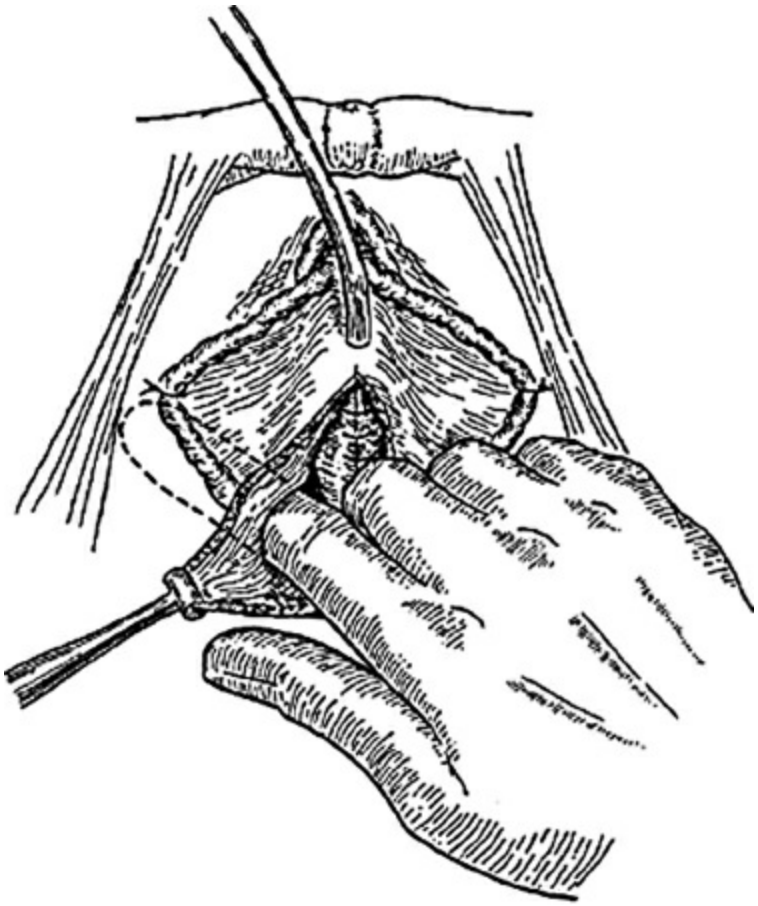

Figure 186.20. The sharp dissection has been carried laterally beneath the vaginal wall and has proceeded to develop the paravaginal space and expose the arcus tendineus fascia of the pelvis on the surface of the obturator internus. The position of the ischial spine and arcus tendineus are confirmed visually and by palpation.



Figure 186.21. Vaginal view of left paravaginal space. The Foley catheter is at the 12 o'clock position, the bladder is being retracted medially, the right paravaginal space is completely developed, and exposure is created for suture placement through the arcus tendineus fascia pelvis. Note the retropubic adipose tissue and the extent to which these spaces can be developed.

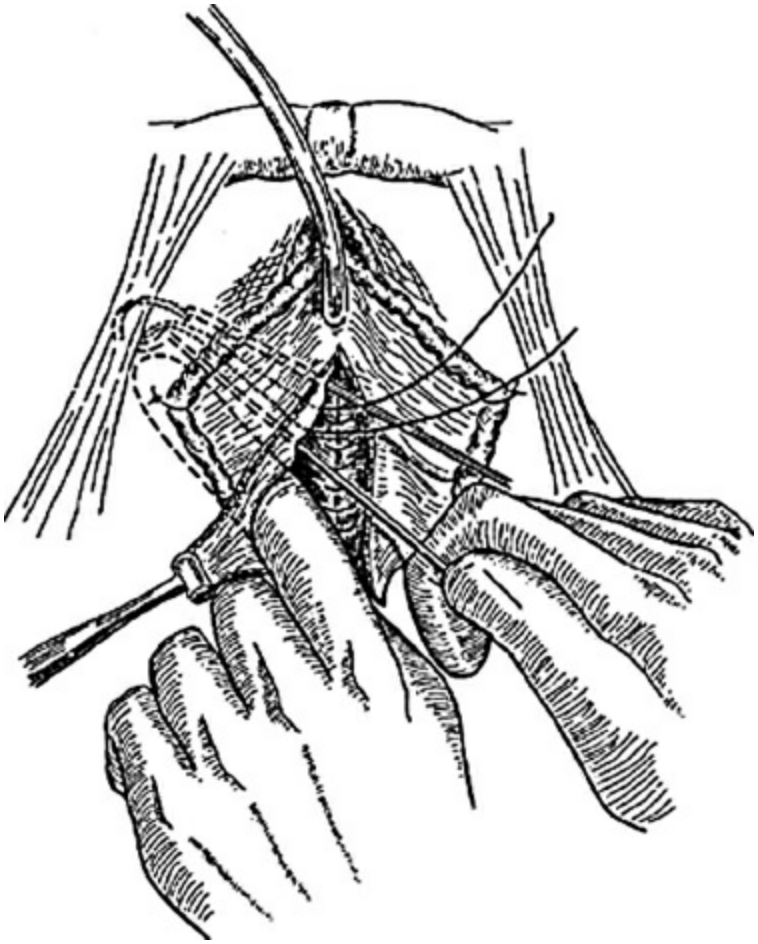

Figure 186.22. A Deschamps ligature carrier, or needle driver with doubly armed sutures, may be used to pass a series of nonabsorbable sutures through the arcus tendineus fascia of the pelvis.



Figure 186.23. Vaginal view of sutures placed through the left arcus tendineus fascia along a trajectory from the ischial spine to the pubic symphysis. The midline cystocele has not yet been repaired. Note thickness of the unsplit anterior vaginal wall.



Figure 186.24. When a Deschamps ligature carrier is used to pass the sutures through the arcus tendineus, a Mayo needle transfers each stitch to the underside of the anterior vaginal wall at the site of the vaginal sulcus. When tied and the freed ends cut, the knots are buried beneath the anterior vaginal wall. Any excess vaginal wall is trimmed, and the vaginal incision is closed from side to side by a running subcuticular suture.

In addition to surgical therapy, one should use certain nonsurgical adjunctive methods of treatment, including not only appropriate estrogen replacement, but also a course of perineal resistive exercises if the patient is able to contract the pelvic floor muscles, as opposed to repeated Valsalva maneuvers. Pelvic floor exercises consist of isometric contractions of the pubococcygeus, 20 repetitions, six times a day. Coincident detrusor hyperactivity related to excess caffeine consumption can be aided by restricting coffee, tea, cola drinks, and chocolate. In addition, bladder drills supplemented by use of anticholinergics such as oxybutynin, 2.5 mg two or three times per day, can be instituted. Newer time-release technology has been applied to oxybutynin, reducing the dry mouth and other anticholinergic side effects, permitting higher relative doses in a once-per-day delivery system.

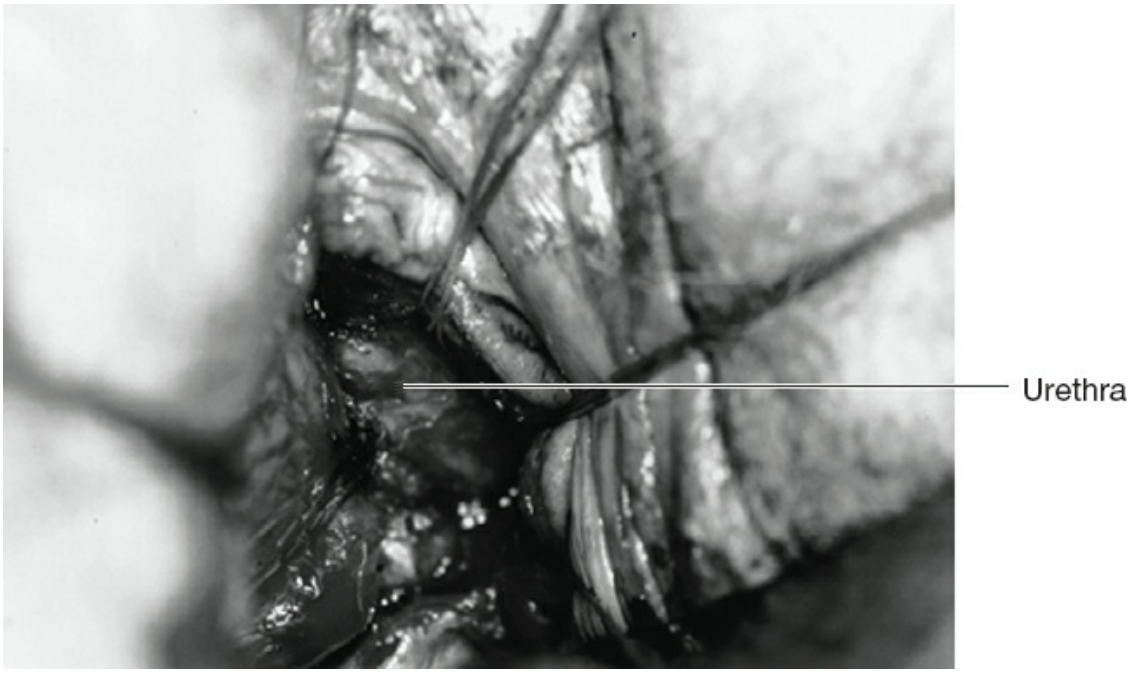

Figure 186.25. Vaginal view of repaired left paravaginal defect and reconstructed left sulcus. Urethra is at the 12 o'clock position.

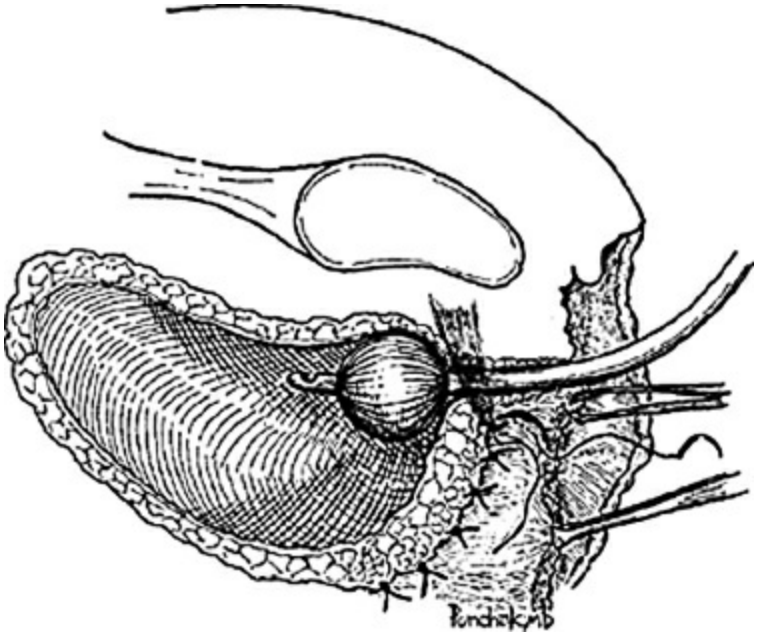

Figure 186.26. Sagittal view showing the effects of pubourethral ligament–urogenital diaphragm plication and anterior colporrhaphy. The urethra is once again in a normal relationship to the back of the pubis, and the cystocele is reduced. Excess anterior vaginal wall has not yet been trimmed. (Redrawn from Nichols D, Randall C, eds. *Vaginal Surgery*, 4th ed. Baltimore, MD: Williams & Wilkins, 1996.)

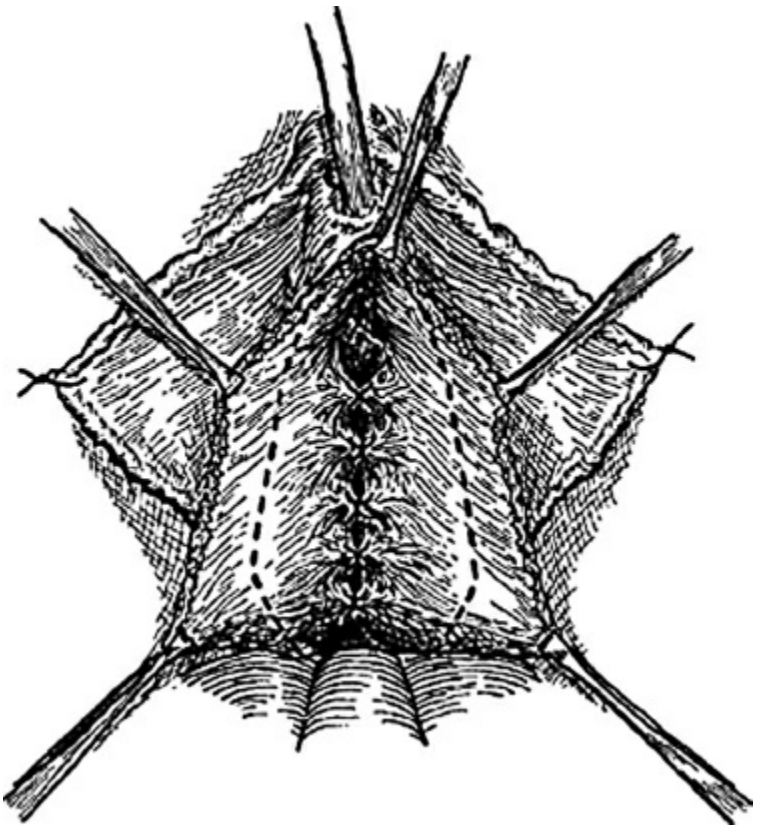

Figure 186.27. Stitches in the connective tissue capsule of the bladder and bladder pillars have been tied. The full thickness of the excess anterior vaginal wall to be excised is indicated by the *dotted lines.* (Redrawn from Nichols D, Randall C, eds. *Vaginal Surgery*, 4th ed. Baltimore, MD: Williams & Wilkins, 1996.)

RECTOCELE ON PERINEAL RELAXATION

Rectocele and perineal defects are separate and distinct lesions occurring in entirely different structures, although frequently these defects coexist. A rectocele is a defect in the posterior vaginal wall that permits the rectum to herniate into the vagina. It may occur with or without a perineal defect and may be seen low within the vagina, at its midpoint, in the upper vagina, or in any combination. Rectocele is more common in multiparous patients, and is, in fact, the most frequent weakness of the pelvis and its supporting tissue. It may be the consequence of various causes, as is a cystocele. It may be caused by damage to the posterior vaginal wall consequent to overdistention during labor and delivery (distention rectocele; see Fig. 186.1), or it may be seen when the posterior vaginal wall follows the descent of the vaginal vault with or without the cervix and uterus (displacement rectocele; see Fig. 186.2). Some women have a combination of distention and displacement, with or without a perineal defect.

Rectocele is often coincident with a widened genital hiatus, with increased distance between the medial borders of the pubococcygeus as a consequence of multiparity.

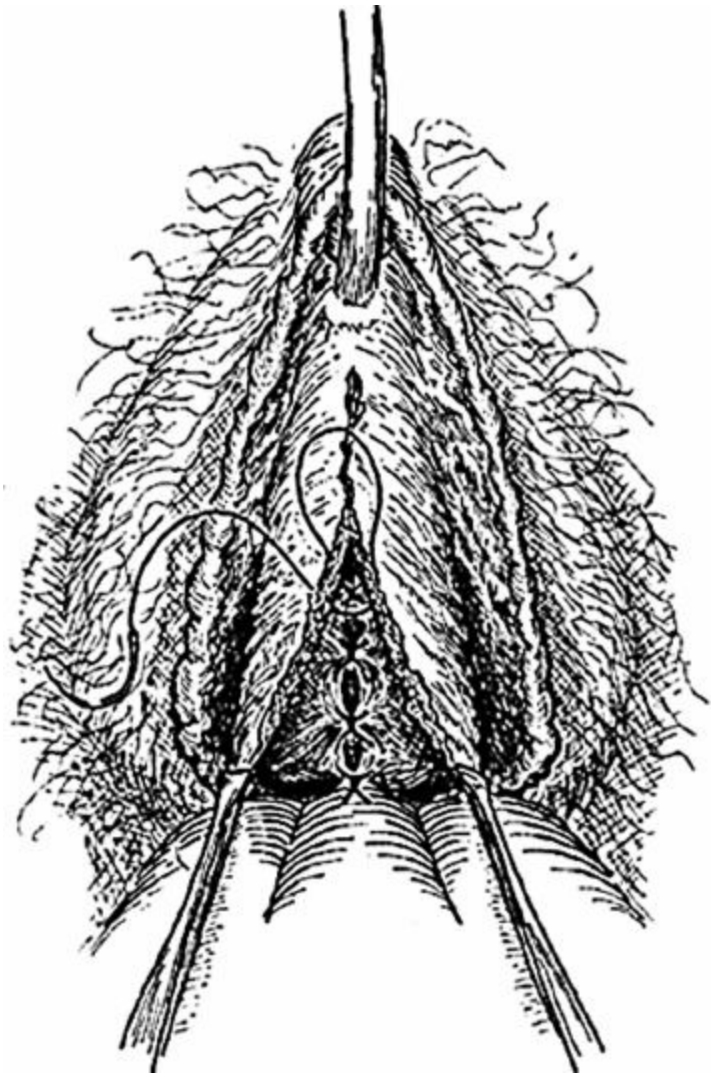

Figure 186.28. Excess anterior vaginal wall has been trimmed and the full thickness of anterior vaginal wall is being approximated from one side to the other with a running subcuticular suture. (Redrawn from Nichols D, Randall C, eds. *Vaginal Surgery*, 4th ed. Baltimore, MD: Williams & Wilkins, 1996.)



Figure 186.29. Vaginal view of reconstructed anterior vaginal wall. The midline distention cystocele and the paravaginal defects have been repaired. The urethral axis has been restored without a sling urethropexy, which, if indicated, could have added to surgical reconstruction.

The perineal body is a pyramidal fibroelastic structure found in the midline between the rectum and the vagina on a line between the ischial tuberosities. Its tone thickness and composition vary in different individuals. It serves as the central attachment point of various muscles, the superficial and deep transverse muscles of the perineum, the bulbocavernosus, the external anal sphincter, and some fibers of the levator ani. Chronic lacerations and relaxation of the perineum cause an enlarged genital hiatus and loss of support to the urethra and anterior vaginal wall.

SYMPTOMS

Many rectoceles are asymptomatic. Symptoms generally related to a rectocele are a feeling of incomplete emptying of the rectum or an aching sensation after bowel movements, or both. Patients quickly learn to “bridge” the herniated rectal area by pushing with several fingers against the posterior vaginal wall during bowel movements to eliminate symptoms

(the need to strain and facilitate bowel movements, often interpreted by the patient as constipation). However, constipation, per se, is not a significant symptom of rectocele but is more the consequence of a disorder of bowel function predicated on poor bowel habits with frequent coexistence of dehydration. Although many women with rectocele experience constipation, many women who are constipated have no rectocele. Repair of a rectocele, therefore, likely only corrects conditions that are associated with a rectocele, and is not curative for constipation in most instances. Symptoms of perineal relaxation are virtually nonexistent, except perhaps shortly after the defect occurs, when the previously asymptomatic patient notices that retaining a tampon for the absorption of menstrual flow is no longer possible.

ANATOMIC CONSIDERATIONS

Depending on the cause of the rectocele, the defect may occur in the lower, middle, or upper vagina, or in any combination of these locations. The rectum bears an intimate relation to the pelvic diaphragm that supports it. The surgeon must always be cognizant that the pubococcygei, in their passage from the back of the pubis to the coccyx, cross the sides of the rectum and fuse effectively posterior to the rectum but not anteriorly. This fusion behind the rectum that extends to the coccyx is termed the *levator plate*, and it is on the integrity of this levator plate that the pelvic support of the internal genitalia is dependent.

During late fetal life, the base of the peritoneal cavity, or posterior *cul-de-sac*, extends all the way to the perineal body. Soon afterward, this deep *cul-de-sac* fuses up to the level of the cervix and to the underside of the layers of the posterior vaginal wall. This fused peritoneum (the fascia of Denonvilliers) forms the anterior margin of the rectovaginal space and is referred to as the *rectovaginal septum.* The rectovaginal septum (fascia of Denonvilliers) is the superior border of the avascular, potential rectovaginal space between the anterior rectal wall and the posterior vaginal wall (Fig. 186.3). The rectovaginal space allows each organ to function with a degree of independence from each other. Recognizing and identifying the rectovaginal space is important for effective reconstruction of the posterior vaginal wall. As mentioned previously with respect to the anterior vaginal wall, splitting the posterior vaginal wall is surgically possible. In addition, if the embryologic fusion of the peritoneal layer is incomplete (the fascia of Denonvilliers), particularly at its cranial end,

there may be a deepening of the *cul-de-sac*, which is the origin of a congenital enterocele—a peritoneum-lined sac separating the vagina from the rectum to various depths. This congenital enterocele weakens the thickness of the upper posterior vaginal wall by its splitting of the peritoneal fusion layer (i.e., the fascia of Denonvilliers), providing one causal basis for a high rectocele. For this reason, a high rectocele is sought coincident with a congenital enterocele, and vice versa. An enterocele suspected preoperatively must incite a surgical search, and it should be deliberately and separately repaired. Almost invariably, when the fascia of Denonvilliers is identified, the enterocele is inferior to the fascia of Denonvilliers and above the rectum. If any doubt exists, or if the enterocele continues to be elusive, cephalad dissection in this space following the fascia of Denonvilliers results in entry into the *cul-de-sac*, and the search for the enterocele can be terminated.

It is important to bear in mind a three-dimensional concept in which the perineal body essentially is considered a pyramid, with its base at the bottom. The base is beneath and parallel to the perineal skin, and the anterior, lateral, and posterior surfaces all converge superiorly to the most inferior limit of the rectovaginal space, at which point they attach to the anterior layer of the fascia of Denonvilliers. The avascular potential space known as the *rectovaginal space* normally permits the rectum and vagina to function independently. When the rectovaginal space has been obliterated due to infection, laceration, trauma, or iatrogenic surgical reconstruction, this important independent function may be lost, with some significant consequences for the patient, such as constipation.

FINDINGS ON PHYSICAL EXAMINATION

Because the pelvic diaphragm (the levator ani and its various divisions) is a voluntary muscle, it is best evaluated when the patient is awake. Because the diaphragm is effectively paralyzed by anesthesia, it is relaxed in the operating room, and therefore any weaknesses, as well as those of a rectocele, are best appreciated by examination of the patient while unanesthetized, retaining the ability to contract the pelvic muscles voluntarily, as described previously.

The physical examination of an unanesthetized patient should be performed initially in the lithotomy position and then standing. In the latter position, the examiner can clearly identify and note for correction of any descent of the vaginal vault, prolapse of the uterus, cystocele, rectocele,

and enterocele. The estrogen effect on the vaginal wall should be noted. The patient should be asked to voluntarily contract the pubococcygei so that their integrity, function, and effectiveness can be adequately assessed. The surgeon should determine the condition of the levator plate posterior to the rectum and whether it is horizontal, remembering that the empty rectum normally rests on the horizontally oriented levator plate. This determines the characteristic horizontal axis of the rectum and the upper vagina. The surgeon should note whether the patient is able to contract the external anal sphincter voluntarily and effectively. With a finger in the rectum and in the vagina, the surgeon should carefully note the integrity of the perineum and perineal body at rest and when the patient is voluntarily contracting the pelvic muscles. The finger in the rectum should carefully identify whether a pocket of rectal wall is herniating into the vagina, into which the examining finger can be introduced. This pocket essentially functions as an effective stool trap and accounts for the patient's inability to completely empty the rectum, thereby necessitating the digital "bridge" and, at times, expression of rectal contents. If constipation is a complaint and hardened stool is noted, a stool softener should be given, along with instruction in proper dietary habits, before surgical correction.

The operator should also note carefully the position of the patient's perineum and anus in relation to the most dependent portion of the buttocks and the ischial tuberosities. A descending perineum or "bridge" in which the anus is the most dependent portion of the patient's perineum, strongly suggests detachment of the external anal sphincter from the perineal body. The same finding may be noted coincident with a defect of the levator ani because of an intrinsic weakness of the muscle or as the result of inadequate innervation. If a defect of the levator ani exists, regardless of the cause, straining during defecation may in effect produce elongation and funneling, the anus descending to an even more dependent position, with resulting constipation and a decrease in the diameter of the stool. As a consequence, the harder the patient strains, the narrower the stool becomes, and it is then more difficult to expel stool and effect a satisfactory bowel movement. The surgical procedure of retrorectal levatorplasty may correct this condition and is performed through an incision posterior to the rectum with attachment of the separated levators to each other posterior to the rectum.

SURGICAL PRINCIPLES

Rectocele repair, posterior colporrhaphy, and perineorrhaphy are separate and distinct operations. Each corrects a specific defect. Some patients require a perineorrhaphy, some require a posterior colporrhaphy, and some require both operations.

The goals of posterior colporrhaphy and perineorrhaphy are relief of symptoms, restoration of anatomy to normal, and restoration of function to normal. Indicated estrogen replacement therapy contributes to the success of the surgical procedure, as does correction of dietary causes of constipation. It is axiomatic in posterior colporrhaphy that the dissection and repair extend to a point cranial to the upper limit of the rectocele. It is therefore essential that the latter be determined preoperatively during examination of the unanesthetized patient.

It is important for the surgeon to remember that the pubococcygei come together behind the rectum and not between the rectum and the vagina. Thus, the so-called bridges, which deliberately interposed the bellies of the pubococcygei between the vagina and rectum, are not anatomic, and, when tightly tied, may form a bridge of tender fibrous tissue between the vagina and rectum that may be the source of future pain with resultant dyspareunia and apareunia, as well as chronic pain in the levator ani. More properly placed side-to-side stitches that reconstitute the perineal body draw the fascia of the pubococcygei, and, thus, the lateral muscles to which the fascia is attached, to the upper lateral sides of the long perineal body, and in doing so effectively restore a normal genital hiatus.

TECHNIQUE OF POSTERIOR COLPORRHAPHY AND PERINEORRHAPHY

In the following technical section, we describe a surgical procedure suited to a patient who would benefit from posterior colporrhaphy and perineorrhaphy. Although a rectocele may be the symptomatic defect, and the perineal defect is asymptomatic, the following techniques are useful in correcting these defects as well as in providing additional support to the anterior vaginal wall, thereby improving the long-term results of the anterior colporrhaphy.

The standard transverse incision for perineorrhaphy provides limited and incomplete exposure of the inferior surface of the base of the perineal body. Closure of the incision runs the risk of creating the formation of a ridge-like “bridge” with the possibility of associated dyspareunia. Rectocele and associated perineal widening are shown in Figure 186.30. A

V-shaped incision made through the skin of the perineum overlying the inferior margin of the perineal body and carried to the hymenal margin provides exposure and permits closure in the longitudinal axis. The width of the incision is determined by the degree to which the diameter of the subsequent vaginal outlet will be narrowed; that is, the incision is wider in a patient in whom there is to be considerable narrowing and is narrower in a patient, usually an older woman, in whom the degree of narrowing is to be considerably less.

The incisions are carried into the full thickness of the wall of the posterior vagina. The perineal skin is carefully dissected from the perineum and the rectum (Fig. 186.31) through the scar tissue from the patient's previous deliveries until the operator has identified the lower margin of the rectovaginal space. This is the upper margin of the perineal body, and the dissection is continued to the weakened fibromuscular wall of the vagina, which is carefully separated from the surrounding scar tissue searching for the fascia of Denonvilliers. Continued sharp dissection using the scissors extends the limits of the dissection laterally to the margins of the rectovaginal space (Fig. 186.32). The limit of dissection should be carried as high as necessary cranial to the highest point of the rectocele (Fig. 186.33). Any enterocele sac should be identified, opened, and, after high ligation of its neck with permanent suture, excised. Any necessary colpopexy should be accomplished to restore the depth and position of the vaginal vault.

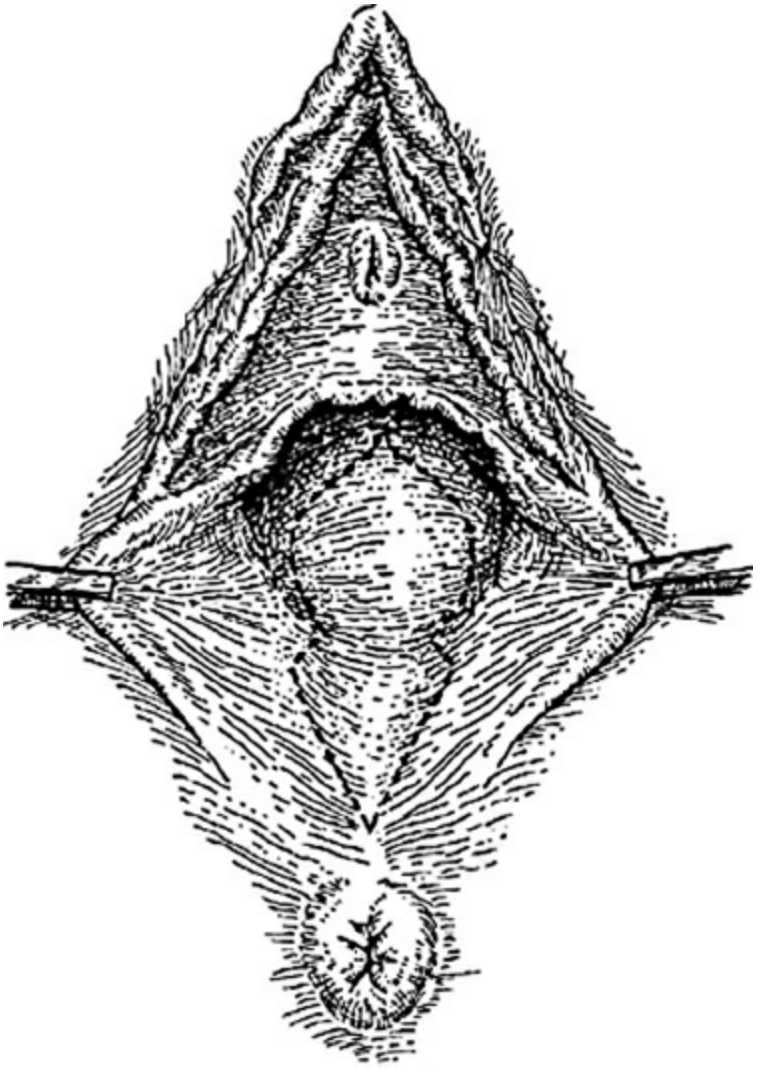

Figure 186.30. A rectocele and perineal defect. The site of the V-shaped incision in the perineum is noted by the *dotted line*, as is the site of incision in the posterior vaginal wall.

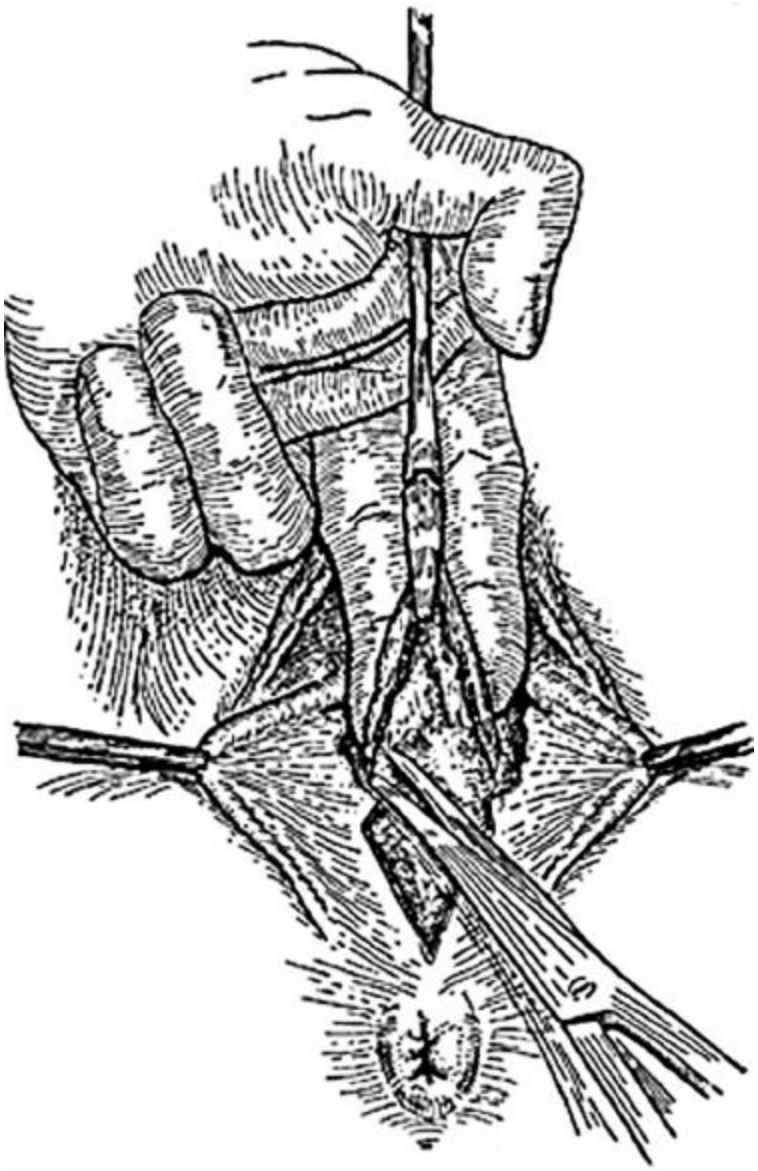

Figure 186.31. The incision has been made, and the skin of the perineum and of the posterior vaginal wall is being separated from the underlying connective tissue.

Ballooning of the anterior rectal wall can be reduced by plication with a running polyglycolic acid. A series of horizontal mattress sutures of polyglycolic acid suture (Fig. 186.34) that includes fibers of the deep transverse perineal muscles as well as perirectal fascia are placed but not tied. After each stitch is placed, the ends are crossed before they are tied, and the operator should check carefully for any bridge or ridge that may be present. If a bridge or ridge is found, the stitch is removed before it is tied and replaced with one positioned closer to the rectum, lessening the chance for postoperative dyspareunia. The posterior vaginal wall is then approximated by a running subcuticular suture embracing the full

thickness of the fibromuscular layer and the fascia of Denonvilliers, which is fused to the undersurface of the posterior vaginal wall (Fig. 186.35). Every effort is made to reconstruct the perineal body with the normal anatomic components. However, if no other usable tissues to reconstruct the perineum are found, stitches are placed in the levator muscles (Fig. 186.36). Detachment of the perineal body from the capsule of the external anal sphincter can be repaired by a figure-of-eight stitch (Fig. 186.37).

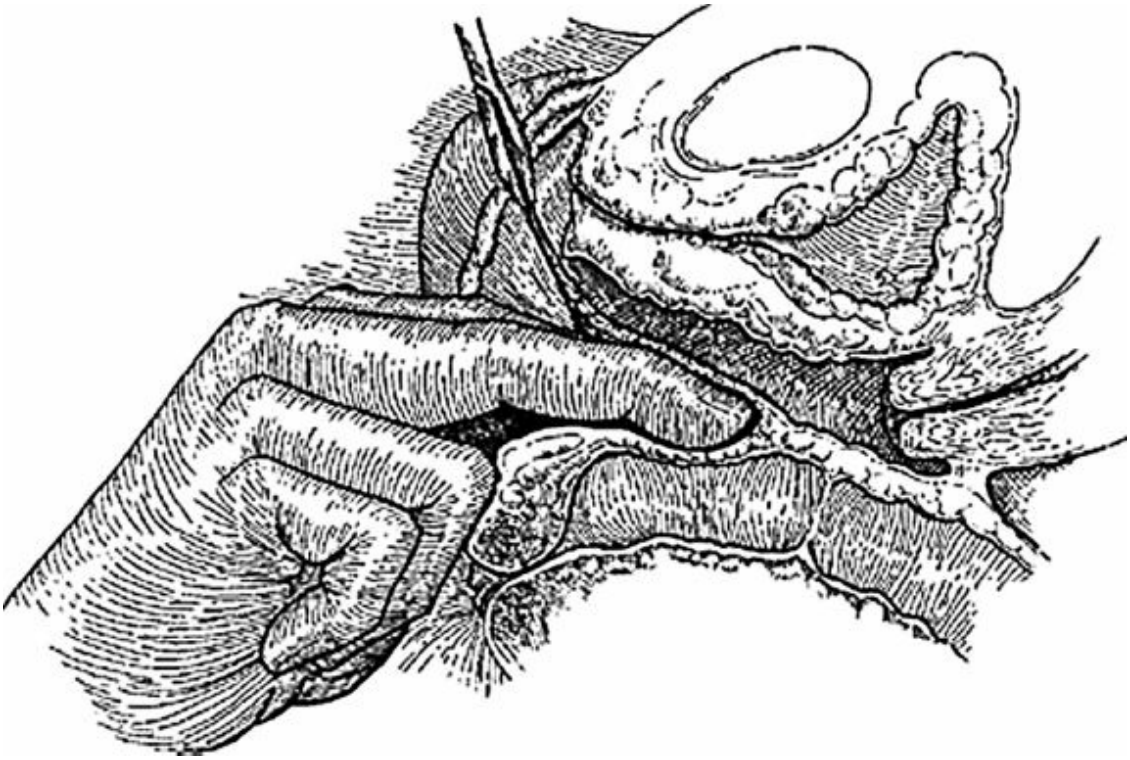

Figure 186.32. Entry has been gained into the rectovaginal space. The surgeon's finger identifies the most cranial point of the rectocele, and the dissection is taken to a point cranial to the defect.

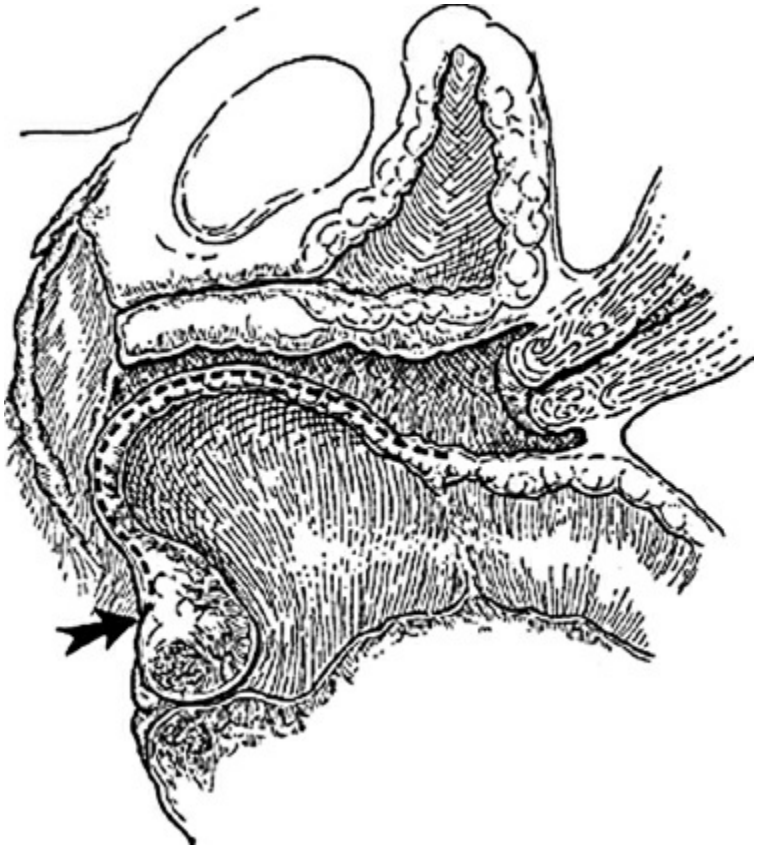

Figure 186.33. The incision is begun at the site indicated by the *arrow*; the extent of dissection is noted by the *dotted line.* The dissection must extend to a point cranial to the rectocele, which may at times extend along the entire length of the posterior vaginal wall.

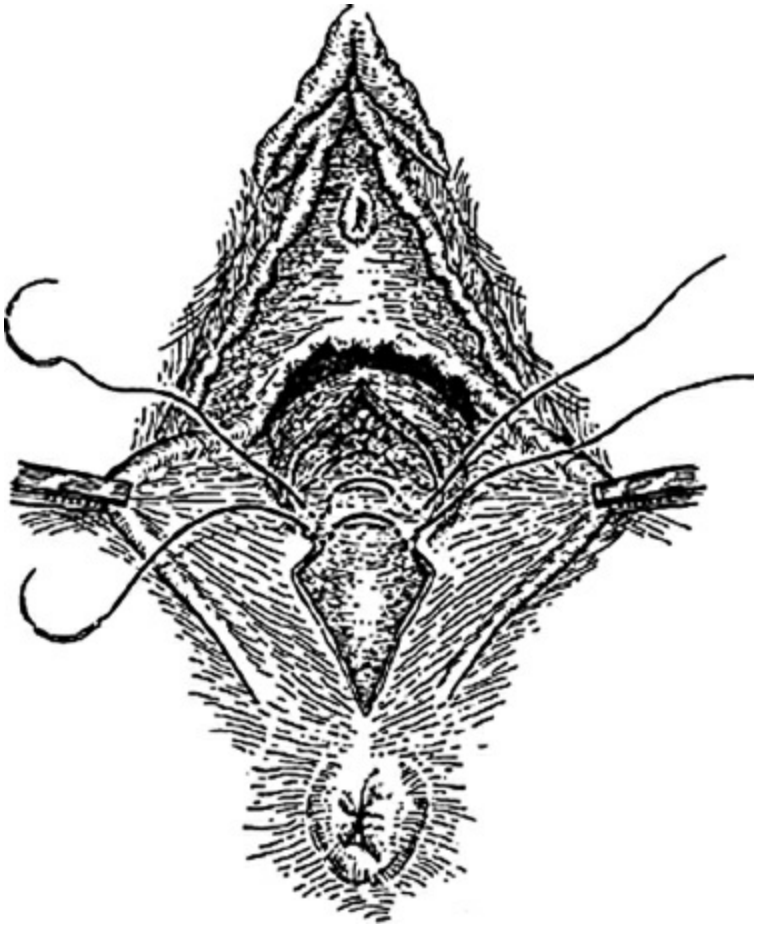

Figure 186.34. The perineum is reconstructed by plicating the transverse perineal muscles and pararectal connective tissues with interrupted mattress sutures in the midline.

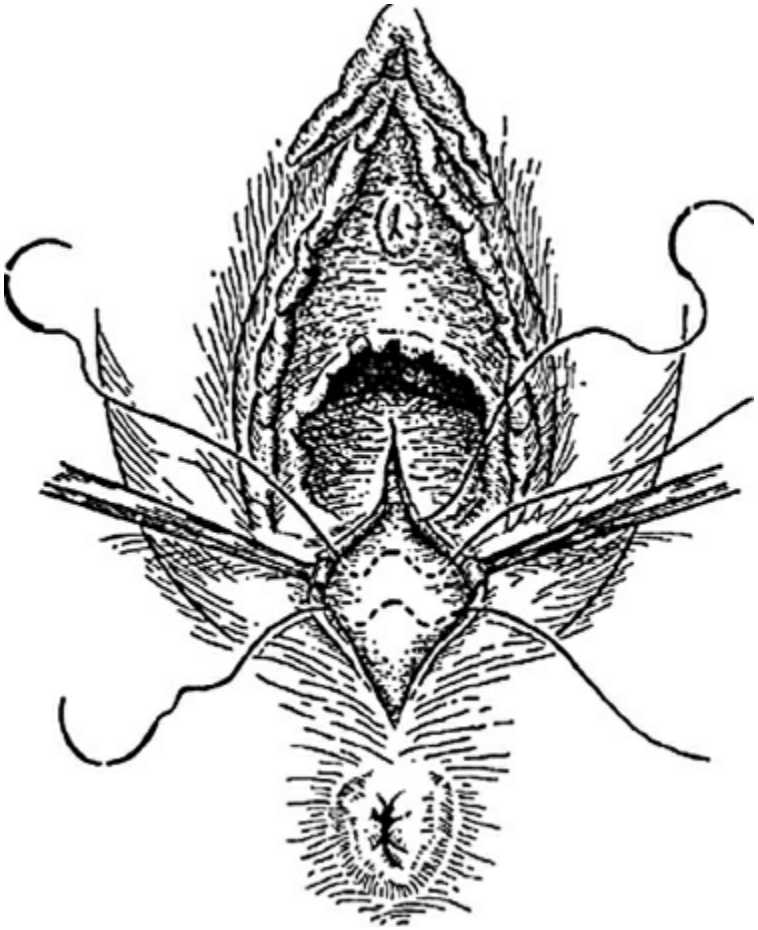

Figure 186.35. The posterior vaginal wall is reapproximated by a running subcuticular suture, and the perineal body is re-formed by placing interrupted mattress sutures.

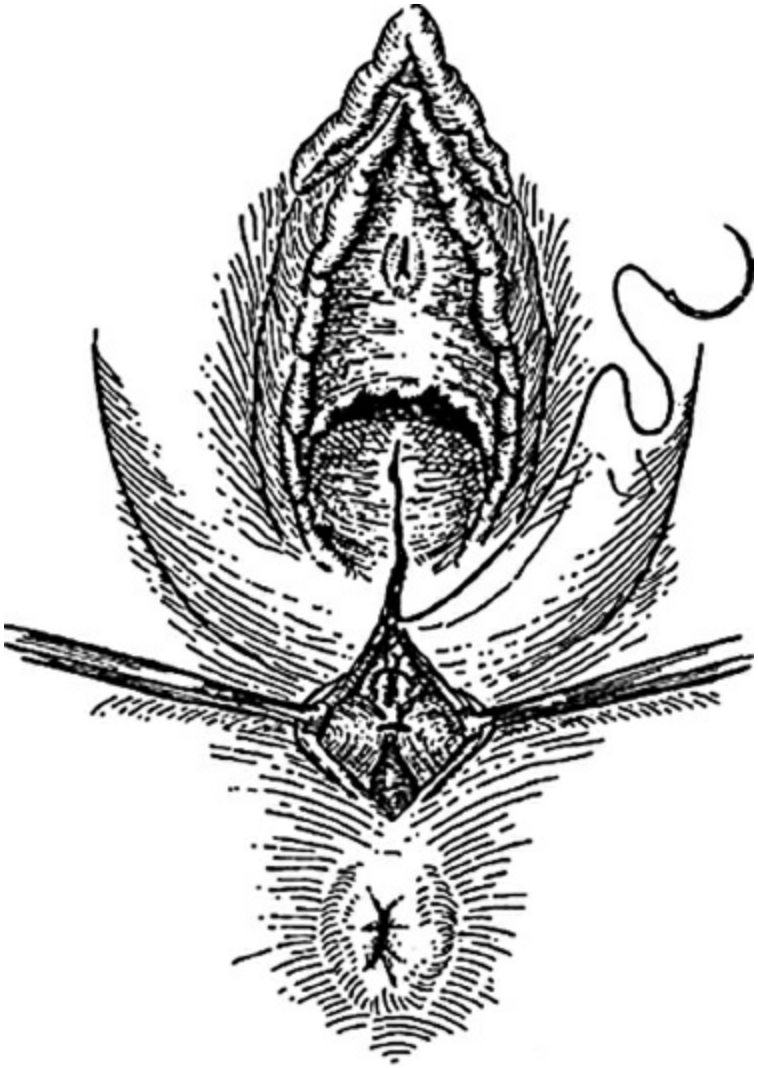

Figure 186.36. If perineal soft tissue is absent, the perineal body can be built up from stitches taken in the fascia of the pubococcygeus.

Horizontal mattress stitches of long-lasting absorbable suture are used to approximate the fascia and connective tissue medial to the levator muscles (Fig. 186.38). Direct levator stitches are unnecessary in most instances and are unanatomic, because the vaginal and perineal closure stitches bring the tissues to which they are attached closer together, appropriately restoring the narrowness of the genital hiatus (Fig. 186.39). The restorative stitches of the perineal body are now tied and the perineal skin closed with a continuation of the running subcuticular suture in much the way one might close a midline episiotomy.

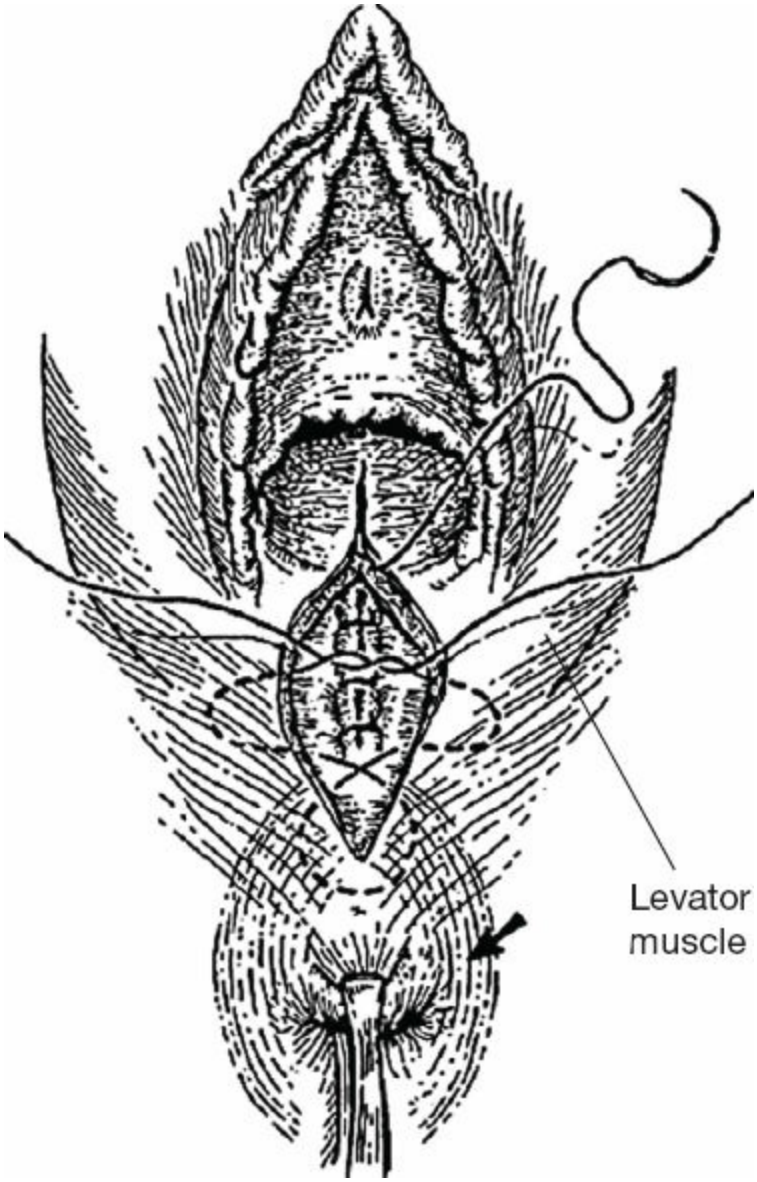

Figure 186.37. Attachment of the perineal body to the connective tissue capsule of the external anal sphincter (*arrow*) can be restored by a figure-of-eight stitch.

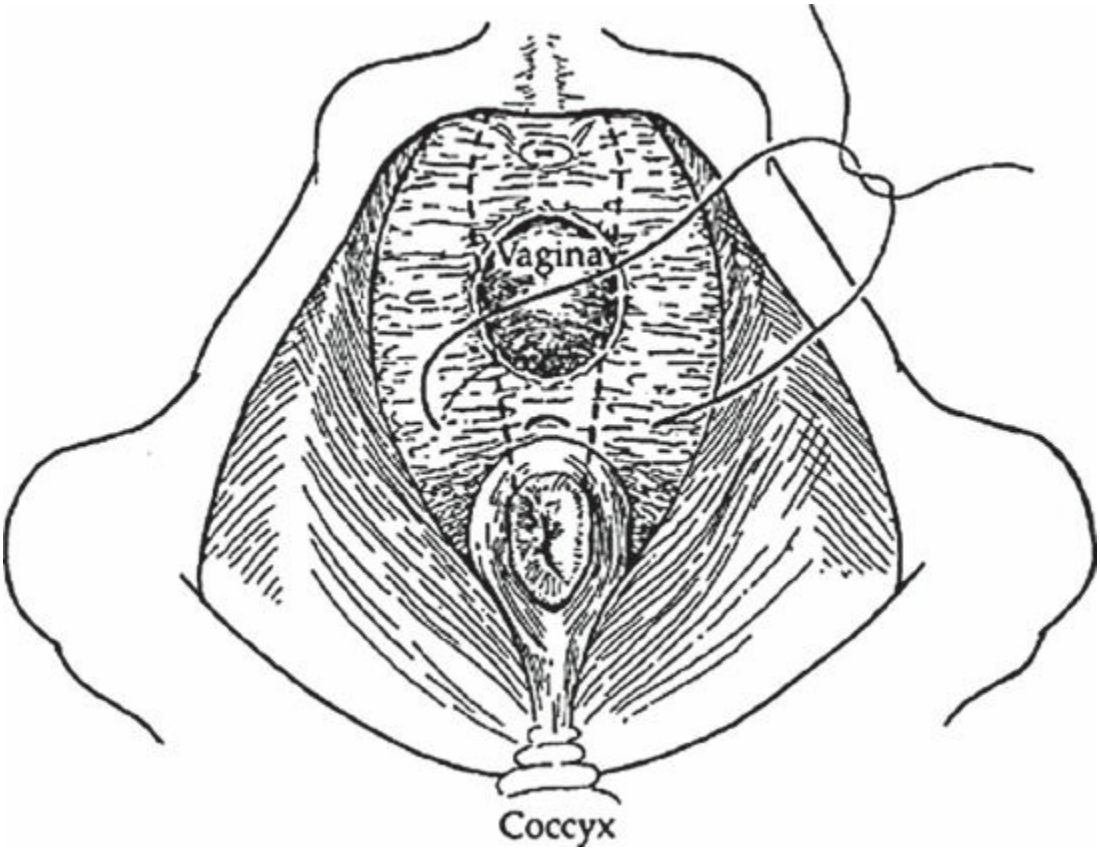

Figure 186.38. Schematic showing the widened genital hiatus between the bellies of the pubococcygei. The normal position of the medial border of the pubococcygei is indicated by the *dotted line.* A perineal body plication stitch has been placed in the connective tissue medial to the pubococcygei.

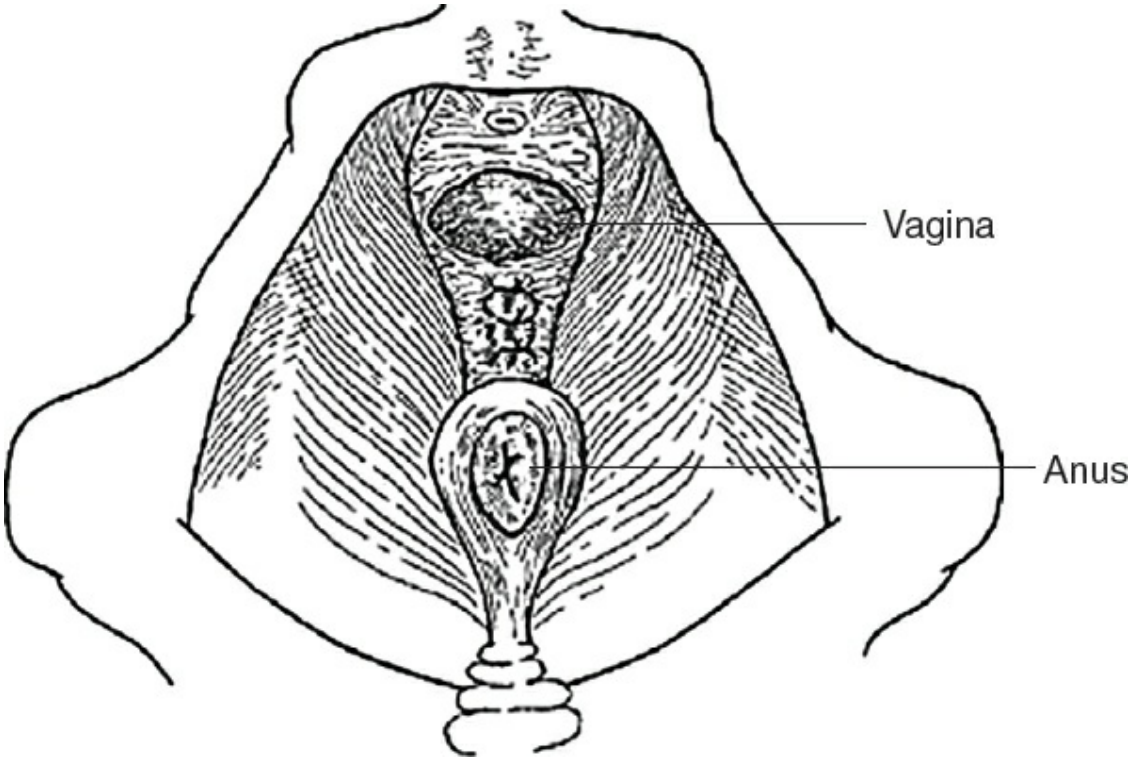

Figure 186.39. Several perineal plication stitches have been placed and tied. Note the narrowing effect on the genital hiatus to a more normal relationship with the vagina.

At the conclusion of the procedure, a gentle rectal examination is performed to confirm the integrity of the rectum and the absence of any suture penetration, as well as to correct the defect that had been determined preoperatively. If, at the conclusion of the procedure, it is evident that the desired goals of surgical treatment have not been met or that the vagina or introitus has been made overly constrictive, narrow, or stenotic, these observations should be addressed by appropriate additional surgical steps while the patient remains anesthetized. These may range from the placement of vaginal relaxing incisions at the 3 and 9 o'clock positions of the vagina to appropriate perineotomy, or to removal of any previously unidentified ridges or bridges in the subepithelial tissue. These conditions are far more easily corrected at this time than postoperatively.

POSTOPERATIVE MANAGEMENT

The rectum is a much more sensitive organ than the bladder. The perirectal tissues are tender postoperatively until the edema and swelling have dissipated and healing is complete. It is important that the patient take stool softeners for 2 months, with laxatives as necessary, to avoid

unnecessary straining at stool. Inquiries should be made as to the patient's bowel habits, appropriate dietary hydration, and restoration of normal bowel function.

Suggested Readings

Baden WF, Walker TA. Evaluation of uterovaginal support. In: *Surgical Repair of Vaginal Defects.* Philadelphia, PA: Lippincott; 1992.

DeLancey JOL. Anatomic aspects of vaginal eversion after hysterectomy. *Am J Obstet Gynecol* 1992;166:1717.

Groves WHE. A new operation for the cure of vaginal cystocele. *Lons Obstet Soc Trans* 1905;17:65.

Henry M, Swash M. *Coloproctology and the Pelvic Floor*, 2nd ed. London: Butterworth-Heinemann; 1992.

Hirsch HA, Käser O, Iklé HA, eds. *Atlas of Gynecological Surgery*, 3rd ed. Stuttgart: Thieme; 1997.

Nichols DH. Retrorectal levatorplasty for anal and perineal prolapse. *Surg Gynecol Obstet* 1982;154:251.

Nichols DH, Clarke-Pearson DL, eds. *Gynecologic, Obstetric and Related surgery*, 2nd ed. St. Louis, MO: Mosby; 1999.

Nichols DH, Randal CL. *Vaginal Surgery*, 4th ed. Baltimore, MD: Williams & Wilkins; 1996.

Reiffenstuhl G. The clinical significance of the connective tissue planes and spaces. *Clin Obstet Gynecol* 1982;25:811.

Richardson AC, Lyon JB, Williams NL. A new look at pelvic relaxation. *Am J Obstet Gynecol* 1976;126:568.

Rock J, Thompson J. *TeLinde's Operative Gynecology*, 9th ed. Philadelphia, PA: Lippincott; 2003.

Symmonds R, Jordan L. Iatrogenic stress incontinence of urine. *Am J Obstet Gynecol* 1961;82:1231.

EDITOR'S COMMENT

Dr. Veronikis has masterfully described the techniques of anterior and posterior colporrhaphy. The clinical entities repaired by these procedures are often not recognized by the general surgeon. Due to the increasing age of our population, all physicians are likely to encounter women with symptoms due to such disorders. Prompt recognition of these problems will earn the physician the

patient's gratitude.

Rectoceles are a common cause of constipation in women, frequently leading to an extensive and negative workup by gastroenterologists and other physicians. A careful history and simple physical examination can often lead to a rapid diagnosis. Rectoceles are often the consequence of vaginal delivery and increasing age. The most common presentation, as is brought out in the chapter, is often a feeling of incomplete evacuation, that is, the patient feels as if they need to defecate; however, they feel as if they cannot completely expel their bowel movement.

Within this chapter, the author carefully outlines the techniques of both anterior and posterior colporrhaphy. General surgeons, particularly those practicing in the United States, should be aware of the significant legal actions that have taken place following some of these procedures. The United States Food and Drug Administration issued a warning regarding the significant complications experienced by patients following use of surgical mesh following transvaginal repair of pelvic organ prolapse, stating that serious complications were "not rare" (https://www.fda.gov/MedicalDevices/Safety/AlertsandNotices/ucm262435.htm). As with all surgery, with attention to detail, careful diagnosis, proper patient selection, and selection of the proper operation, good results are achieved. A recent American College of Surgeons National Surgical Quality Improvement database study examining 6,849 patients undergoing transvaginal cystocele repair found that over 82.5% of patients underwent native tissue repair (Theofanides MC, Onyeji I, Matulay J, et al. Safety of mesh for vaginal cystocele repair: analysis of national patient characteristics and complications. *J Urol* 2017;198(3):632–7). A higher postoperative morbidity was seen in the remaining patients who underwent mesh repair, but this was low in both groups. A recent systematic review aimed at identifying risk factors for mesh erosion after female reconstructive surgery found that patients who were younger, those who had greater parity, those who were smokers, those who were diabetics, those in whom a concomitant hysterectomy was performed, those who were premenopausal or receiving estrogen replacement therapy, and those who had their surgery performed by a junior as opposed to a senior surgeon were at higher risk for mesh erosion (Deng T, Liao B, Luo D, et al. Risk factors for mesh erosion after female pelvic floor reconstructive surgery: a systematic review and meta-analysis. *BJU Int* 2016;117(2):323–43). In yet another 2016 systematic review comparing the use of biologic graft and synthetic mesh in transvaginal prolapse repair, the authors found that synthetic mesh repair of anterior wall prolapse improved outcomes compared with native tissue repair (Schimpf MO, Abed H, Sanses T, et al.; Society of Gynecologic Surgeons Systematic Review Group. Graft and mesh use in transvaginal prolapse repair: a systematic review. *Obstet Gynecol* 2016;128(1):81–91). In this study, however, up to 36% mesh erosion was observed. The rate of reoperation for this was however low. In the 2016 Cochrane review of "Surgery for Women with

Anterior Compartment Prolapse," there is a more guarded recommendation stating that "current evidence does not support the use of mesh repair compared with native tissue repair for anterior compartment prolapse owing to increased morbidity" (Maher C, Feiner B, Baessler K, et al. Surgery for women with anterior compartment prolapse. *Cochrane Database Syst Rev* 2016;11:CD004014). The authors cite the availability of newer lightweight meshes which have not, however, been assessed in randomized controlled trials.

In my community, fewer and fewer general gynecologists are willing to undertake anterior and posterior colporrhaphy and more of these patients are being referred to pelvic floor specialists. Rectoceles can also be treated in a transrectal manner (often performed by colon and rectal surgeons) with an anterior rectal mucosectomy and suture plication of the anterior rectal wall. This accomplishes a similar repair, as the gynecologist is performing from the transvaginal route. It is, however, very important to obtain a detailed history of symptoms from patients, as pelvic floor problems often do not occur in isolation, that is, women who have problems with defecation also may have problems with urinary incontinence. In a woman with an associated cystocele, it makes sense to repair both the anterior and posterior problems at the same time, that is, by a transvaginal approach.

Susan Galandiuk

D SURGERY OF THE HERNIA

187 Surgical Anatomy of the Hernial Rings

Petros Mirilas and Lee J. Skandalakis

Hernia, in general, is defined as the proptosis of tissue or viscus through an opening (ring). It follows that the surgeon must understand the boundaries of the ring, the content of the hernia, and at which surgico-anatomical layer this hernia occurs and the other implicated surgico-anatomical layers. Therefore, mastery of the layers of the abdominal wall, anterolateral and posterolateral, is a prerequisite for understanding and repairing hernias.

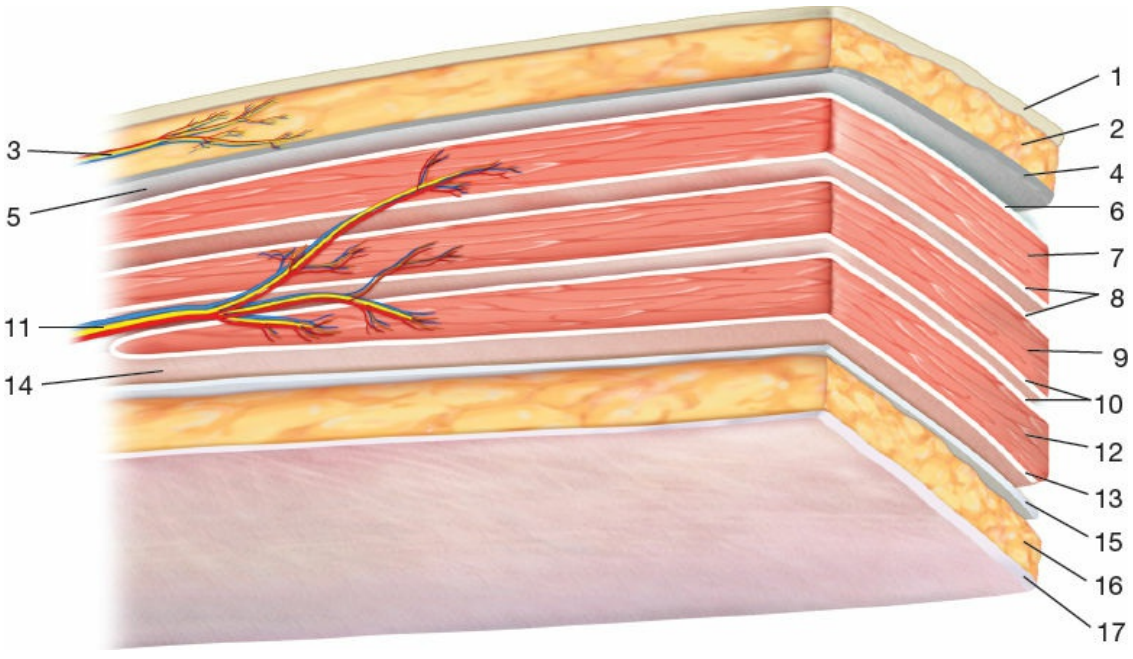

Figure 187.1. Schematic representation of the layers of the anterolateral abdominal wall. 1, skin; 2, fatty layer of superficial fascia (Camper fascia); 3, neurovascular supply of superficial fascia; 4, membranous layer of superficial fascia (Scarpa fascia); 5, space with areolar tissue; 6, deep fascia (outer investing fascia of external oblique muscle); 7, external oblique muscle; 8, inner

investing fascia of external oblique muscle and outer investing fascia of internal oblique muscle (they fuse; here presented separately for didactic reasons); 9, internal oblique muscle; 10, inner investing fascia of internal oblique muscle and outer investing fascia of trnasversus abdominis muscle (they fuse; here presented separately); 11, neurovascular bundle of abdominal muscles (between internal oblique and transversus abdominis muscles); 12, transversus abdominis muscle; 13, transversalis fascia (the inner investing fascia of the transversus muscle); 14, parietal compartment of preperitoneal space; 15, membranous layer of preperitoneal tissue; 16, preperitoneal fat in the visceral compartment of preperitoneal tissue; 17, peritonmeum.

LAYERS OF THE ANTEROLATERAL ABDOMINAL WALL

The structure of the anterolateral abdominal wall is diagrammatically presented in Figure 187.1. Under the skin, the superficial fascia comprises a fatty layer (Camper fascia) and a membranous layer (Scarpa fascia). In the upper abdominal wall, above the umbilicus, the Scarpa fascia is not easily discriminated and separated from the deep fascia, which invests the muscles. Advancing toward the inguinal region, the deeper part of the fatty layer becomes more membranous. Some report that Scarpa fascia becomes multilayered; however, Scarpa fascia is a single, dense, strong layer, distinct from the more superficial fatty layer. Scarpa fascia is always identified during opening of the abdominal wall and always sutured independently during closure. Scarpa fascia is attached on the inguinal ligament, and is fastened to the fascia lata of the thigh at a distance of one finger breadth below the inguinal ligament. Scarpa fascia is attached to the linea alba, and continues in the perineum as the membranous layer of the superficial perineal fascia. It continues in the scrotum, where it is replaced by the dartos (enriched by muscle).

The superficial fascia harbors its neurovascular supply in the fatty layer. Lateral and anterior cutaneous branches of thorocoabdominal and subcostal nerves supply the superficial fascia. The arteries are cutaneous branches of the superficial epigastric and superficial circumflex artery. The superficial veins (superficial epigastric, etc.) below the umbilicus empty in the saphenous vein, while cephalad into the lateral thoracic vein that goes into the axillary vein.

Between Scarpa fascia and muscles, there is an areolar layer, which permits the movement of the whole superficial fascia, fatty, and

membranous layers. The muscles are arranged in three layers—the external oblique, internal oblique, and transversus abdominis muscles. Each muscle is enveloped by an investing fascia. Thus, in the outer surface there is an investing fascia of the external oblique, called deep fascia. The investing fasciae between muscle layers fuse, while the internal surface of the transversus muscle is covered by the investing fascia that takes its name, the transversalis fascia.

The transversalis fascia has been the subject of misunderstanding. Classically, it is described to be continuous with the diaphragmatic, parietal pelvic, and with the transversalis fascia of the contralateral side. Thus, the transversalis fascia, although in truth is the inner investing fascia of the transversalis muscle, is asked to continue behind the rectus sheath where the transversalis muscle is absent or to stay behind as the posterior wall of the inguinal canal at the moment the transversalis muscle arches over the spermatic cord to find the conjoined tendon (together with the internal oblique). In order to solve this inaccuracy, in the past, writers including us suggested that the transversalis fascia has two layers—an anterior lamina and a posterior lamina. The anterior layer was said to be attached to the muscle as should an investing fascia do. The posterior (inner) was deeper, in the extraperitoneal tissue. The truth, however, is that the inner layer of the transversalis fascia is a condensation fascia, part of the extraperitoneal tissue.

The three layers of muscles are fed by the thoracoabdominal vessels and nerves. The neurovascular bundles, which merit attention during operation, are found between the second and third muscular layer, i.e., between the internal oblique and the transversus muscle (Fig. 187.1).

Deep to the investing fascia of the transversus muscle (transversalis fascia), and exterior to the peritoneum is the extraperitoneal space, which is named preperitoneal when referring to the anteriolateral abdominal wall. The structure of this space is almost a mirror image of the superficial fascia: there is a membranous layer of the preperitoneal space and an inner fatty layer (Fig. 187.1). This structure is most evident in the lower abdominal wall pelvic wall; in order to accommodate movement and expansion of extraperitoneal organs (e.g., urinary bladder), there is an aggregation of extraperitoneal fascia to fill in spaces and to ensheath and support these organs. The membranous layer of the extraperitoneal tissue is considered to be a condensation fascia and divides the extraperitoneal space into two planes—a parietal and a visceral. The contents of these

planes are discussed in association with the secondary internal inguinal ring in the inguinal hernia section.

EPIGASTRIC HERNIA

Epigastric hernia is known also as hernia of the linea alba. It is also referred to as a ventral hernia, but this term describes any hernia that can develop in the abdominal wall, even incisional hernias. In the epigastric hernia, the hernial ring is composed entirely of fibers of the linea alba. It may lie anywhere between the xiphoid process and the umbilicus (Fig. 187.2). It is likely that herniation is the result of enlargement of the spaces existing between decussating tendinous fibers of the rectus sheath at the linea alba, especially at sites of passage of neurovascular bundles.

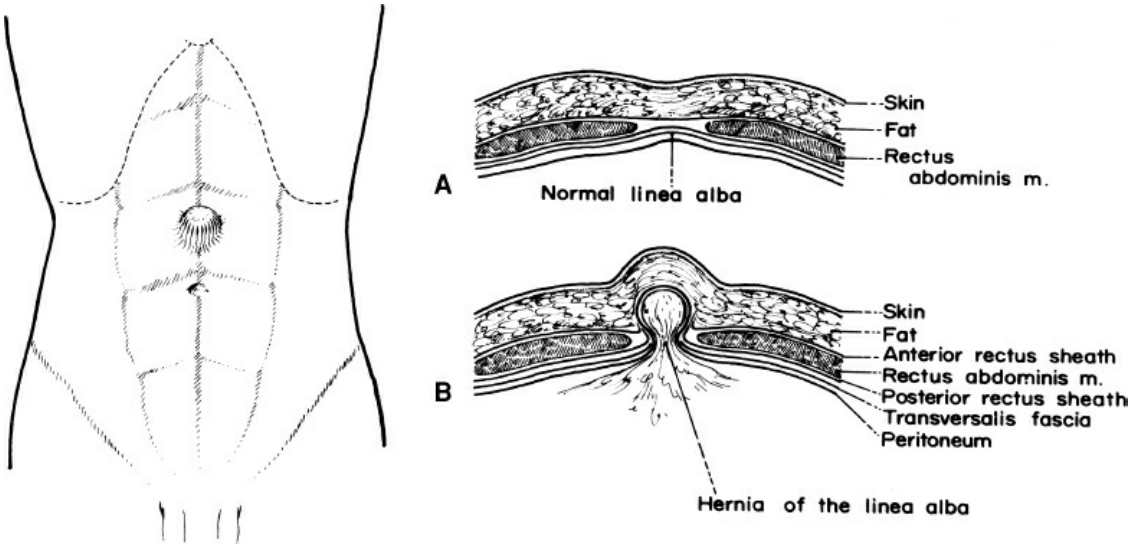

Figure 187.2. Epigastric hernia. **A.** Transverse section of the normal body wall above the umbilicus. **B.** Herniation through the linea alba above the umbilicus. (From Skandalakis JE, Gray SW, Akin JT Jr. The surgical anatomy of hernial rings. *Surg Clin North Am* 1974;54:1227, with permission.)

The medial edge of one or both rectus muscles may form the lateral border of the hernial ring. If the defect is >1.5 cm, the lateral border of the hernial ring may be formed not only by the anterior and posterior laminae of the rectus sheath, but also by the lateral edge of the muscle between.

A sac may be present at the site of weakness, or there may be a protrusion of preperitoneal fat without a sac. When incarceration occurs, the ring may be enlarged surgically by superior or inferior incision of the linea alba. Occasionally, but rarely, a lateral incision of the anterior lamina

of the rectus sheath may be necessary.

The epigastric hernia should be distinguished from the diastasis recti, i.e., the separation of the recti muscles (>2 fingertips), which is due to stretching of the linea alba. This condition usually affects infants, children, and pregnant women. This is not a true hernia and there is no ring, but can lead to epigastric or umbilical hernia as a complication.

UMBILICAL HERNIA

At the umbilicus, the layers of the abdominal wall fuse. Thus, in the mature organism the skin remains attached to the deep fascia despite the accumulation of subcutaneous fat and produces the depressed scar.

In the embryon, the umbilical ring is the exit and entrance point of the major vessels connecting to the maternal circulation (umbilical arteries and umbilical vein) and the entrance for the urachus. At the opening of the umbilicus attaches the umbilical cord that carries the two umbilical arteries and the umbilical vein; the covering of the umbilical cord is continuous with the skin. The round ligament of the liver is the continuation of the umbilical vein that becomes obliterated. This ligament arises from the inferior margin of the umbilical ring and passes superiorly to continue in the falciform ligament of the liver. At the umbilical ring there are more structures-remnants of embryonic entities: the two medial umbilical ligaments representing the two obliterated umbilical arteries, and the median umbilical ligament, which is the obliterated urachus (Fig. 187.3).

Often, in the preperitoneal tissue, between the peritoneum and the umbilical vessels, develops a fibrous lamina, the umbilical fascia (Fig. 187.4). The fibers of this fascia run transversally, and its upper and lower borders are not very distinct. The umbilical fascia is at the same layer with the membranous layer of the preperitoneal tissue and most likely is a condensation of the latter. Some authors consider the umbilical fascia as a thickening of the transversalis fascia (the inner layer), which is here renamed as membranous fascia of the extraperitoneal tissue. The round ligament of the liver is found external to the umbilical fascia (Fig. 187.5).

In most cases, the round ligament of the liver crosses over the umbilical ring (Fig. 187.6A). There are cases where the round ligament splits and attaches to the superior margin of the umbilical ring (Fig. 187.6B). Beneath the umbilical ring, the “floor” consists of umbilical fascia and peritoneum; preperitoneal tissue is minimal at the umbilicus. The umbilical fascia may undercover the floor of the umbilical ring entirely (Fig.

187.6C) or partially, i.e., in the superior portion (Fig. 187.6D) or the inferior portion (Fig. 187.6E); or the umbilical fascia may exist but does not lie under the ring (Fig. 187.6E).

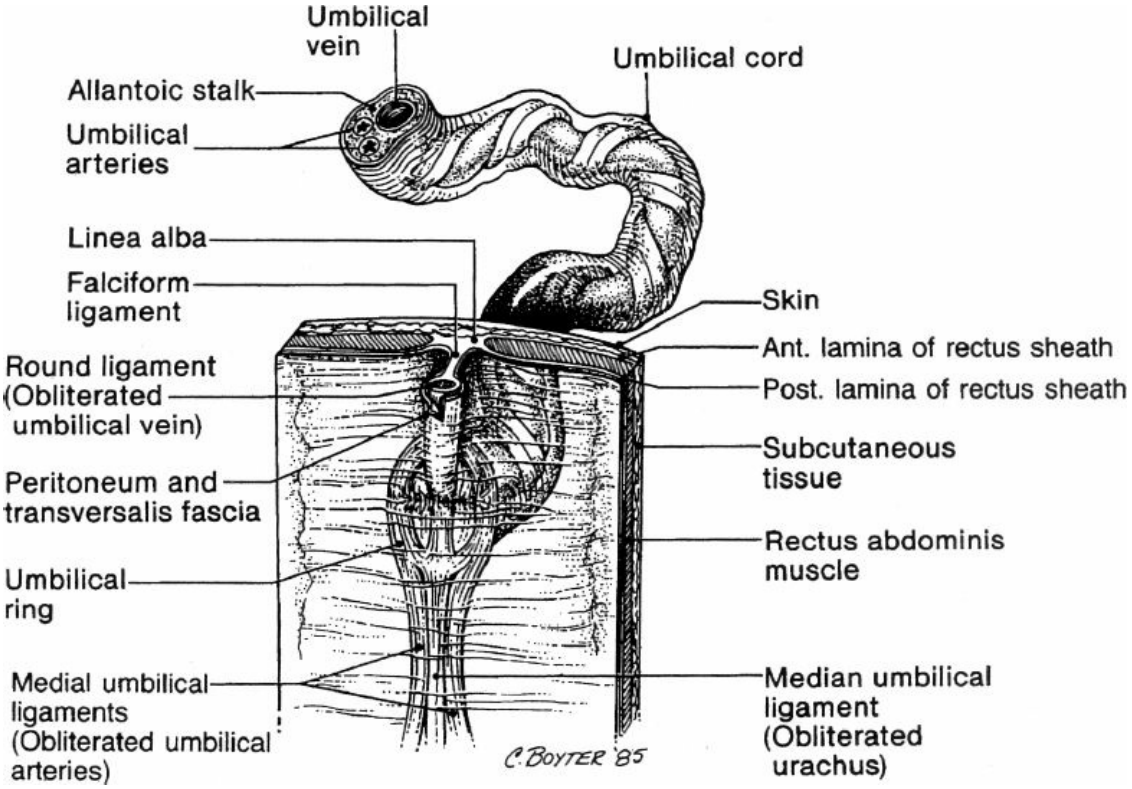

Figure 187.3. Posterior surface of the anterior abdominal wall of a newborn infant. The umbilical cord is still attached. The medial umbilical ligaments (obliterated umbilical arteries) and the median umbilical ligament (obliterated urachus) participate in the formation of the umbilical ring. The round ligament (obliterated umbilical vein) arises from the inferior margin of the ring and passes into the falciform ligament. (From Skandalakis JE, Gray SW, Mansberger AR Jr, et al. *Hernia: Surgical Anatomy and Technique.* New York: McGraw-Hill; 1989.)

The round ligament and the umbilical fascia offer support to the umbilical area. In case the round ligament bifurcates and is not attached to the lower semicircle of the umbilical ring, herniation is easier. If, in addition the umbilical fascia is absent, then the umbilical region is unsupported, and a “direct” hernia may occur through the ring (see arrow in Fig. 187.6B,F). If the umbilical fascia covers only partially the ring, then an “indirect” hernia may descend or ascend into the ring (see arrow in Fig. 187.6D,E). If the umbilical fascia is absent, the umbilical ring is unsupported and prone to hernia (see arrow in Fig. 187.6F,G).

The umbilical hernia is the minor of the congenital anomalies of the umbilical ring. The anomaly is essentially an enlarged umbilical ring, and the sac is covered by all layers, i.e., peritoneum, membranous layer of preperitoneal tissue (the previously called transversalis fascia) (Fig. 187.7). The umbilical fascia is not a covering of the sac; this fascia is considered to belong only to the floor of the umbilical ring and the absence of the fascia or the partial covering of the ring as a reason for the hernia. The hernial sac is usually tightly adherent to the umbilical skin.

The infantile umbilical hernia should be distinguished from more serious congenital anomalies, such as omphalocele and gastroschisis. Omphalocele (exomphalos) is the herniation through the umbilical ring into the base of the umbilical cord. There is no skin covering the hernia as in umbilical hernia, but the sac consists of peritoneum internally and amnion externally (Fig. 187.8). In gastroschisis, the defect (cleft) of the abdominal wall is lateral to the umbilicus, usually on the left. There is no sac, and the contents are usually intestines (Fig. 187.9).

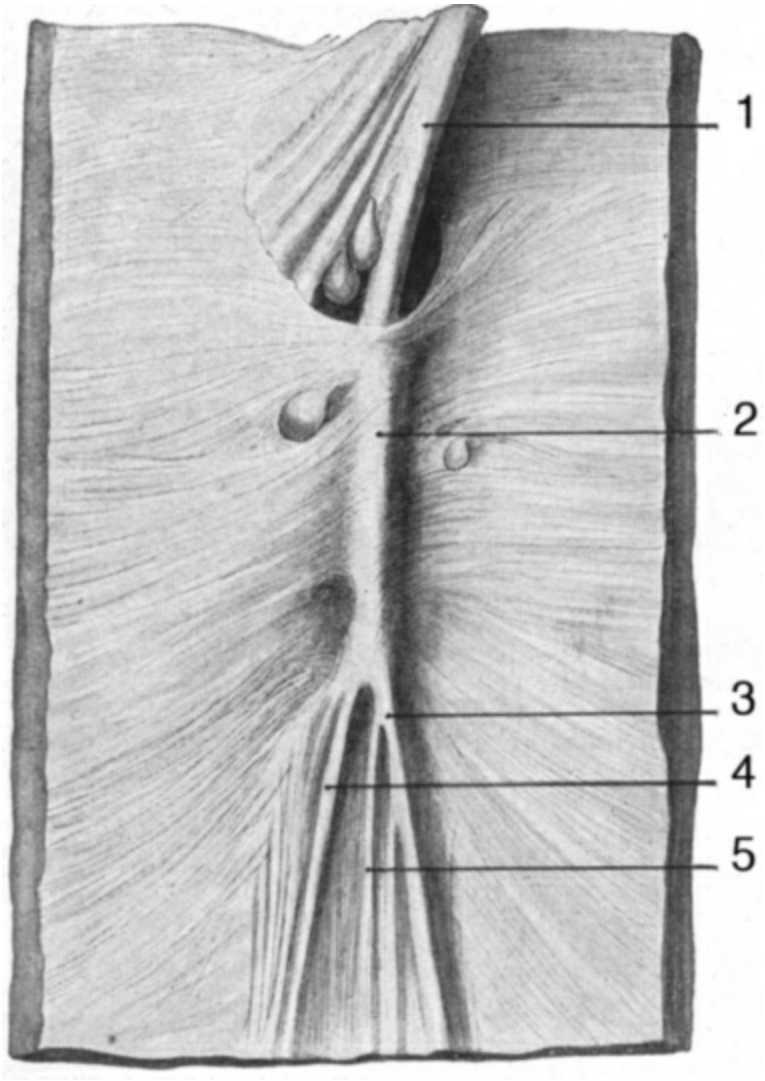

Figure 187.4. Umbilical region: umbilical fascia. 1, umbilical vein; 2, umbilical fascia; 3, right umbilical artery; 4, left umbilical vein; 5, urachus. (Modified from Rouviere H. *Anatomie Humaine. Descriptive et Topographique.* 5me edition. Tome I, Fasciule II. Paris: Masson et Cie; 1943.)

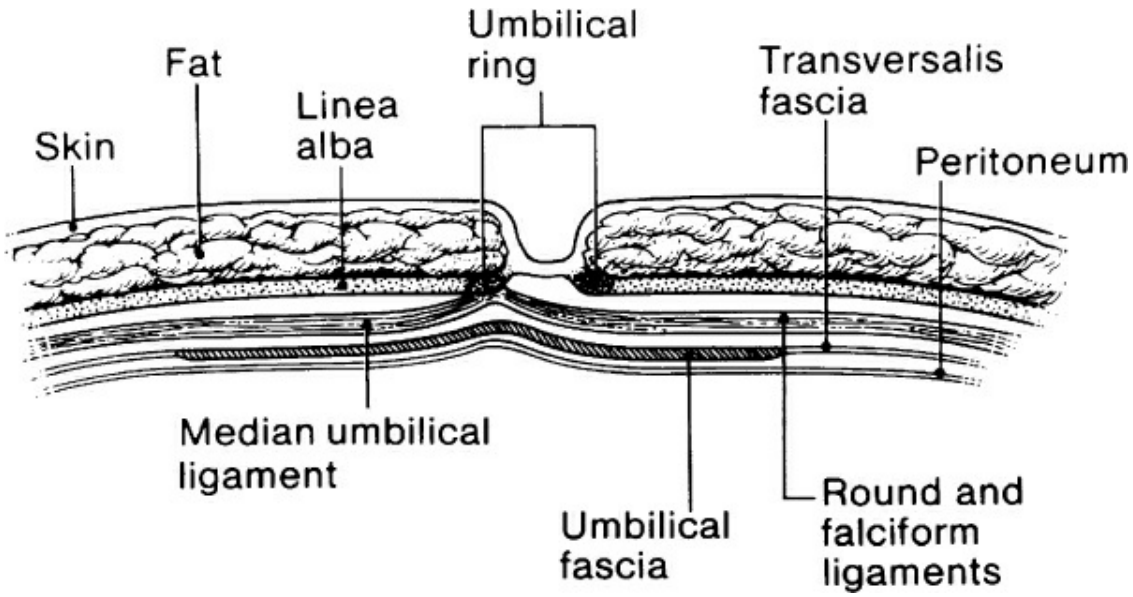

Figure 187.5. Diagrammatic sagittal section through a normal umbilicus showing the relation of the umbilical ring to the linea alba, the round ligament, the median umbilical ligament (urachus), and the umbilical fascia. The umbilical fascia is shown here as a thickening of the transversalis fascia; the latter is chapter revised and called membranous layer of the preperitoneal tissue. Observe the absence of subcutaneous fat over the umbilical ring. (From Skandalakis LJ, Gadacz TR, Mansberger AR Jr., et al. *Modern Hernia Repair.* Pearl River, NY: Parthenon; 1996, with permission.)

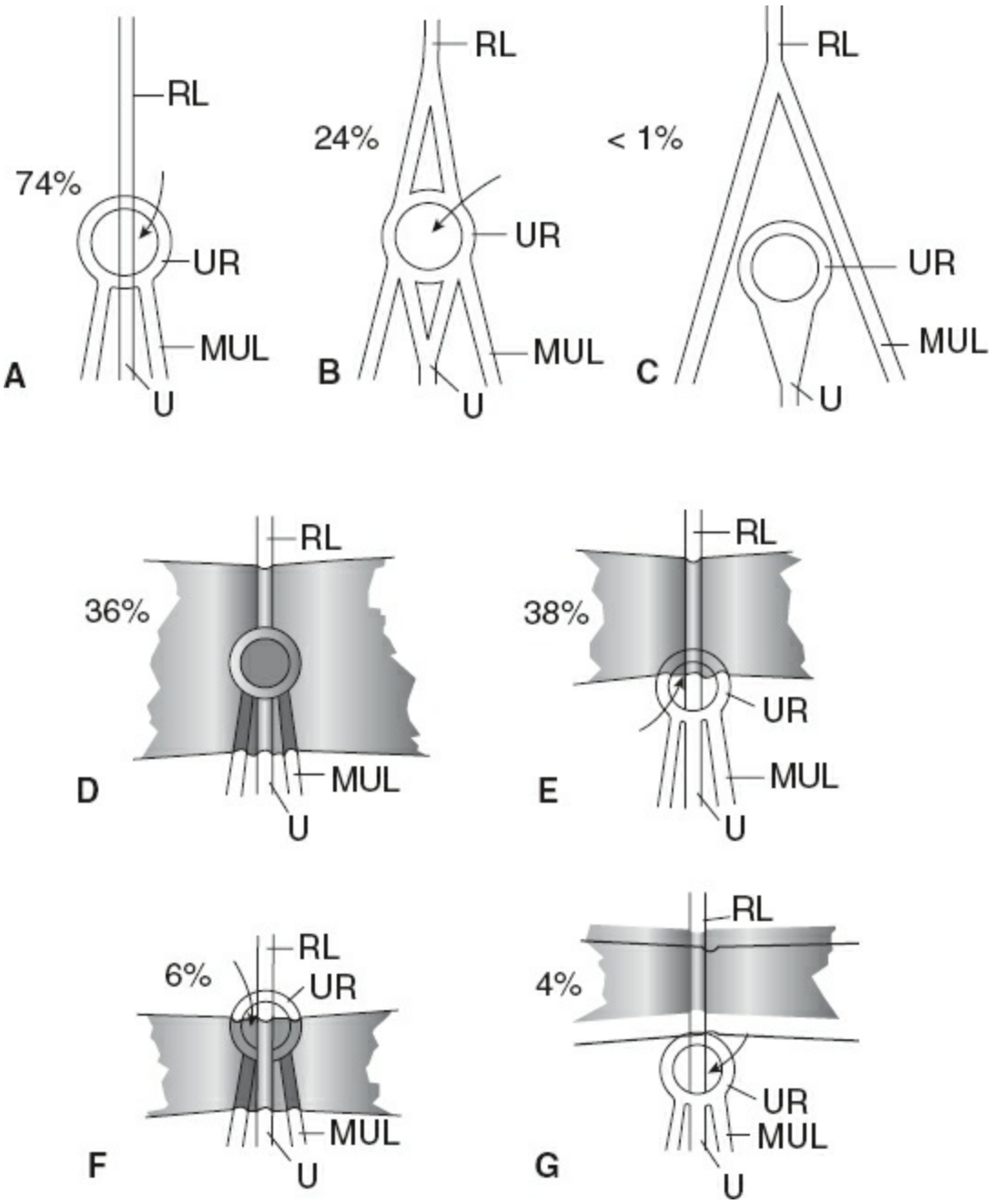

Figure 187.6. Variations in umbilical ring (UR) and umbilical fascia seen from posterior (peritoneal) surface of body wall. **A–C.** Variations in disposition of umbilical ligaments. *Arrows* indicate path of hernia. **A.** Usual relations (74%) of UR, round ligament (RL), urachus (U), and medial umbilical ligaments (MUL). RL crosses UR to insert on its inferior margin. **B.** Less common configuration (24%). RL splits and attaches to superior margin of UR. **C.** Rare configuration (>1%). RL branches before reaching UR. Each branch continues with the medial umbilical ligament without attaching to UR. **D–G.** Variations in presence and form of insertion of umbilical fascia. **D.** Thickened transversalis fascia forms umbilical fascia covering UR (36%). **E.** Umbilical fascia

covers only superior portion of UR (38%). **F.** Umbilical fascia covers only inferior portion of UR (6%). **G.** Although present, umbilical fascia does not underlie UR (4%). Fascia is entirely absent in 16% of cases (not shown). (From Orda R, Nathan H. Surgical anatomy of umbilical structures. *Int Surg* 1973;58:454, with permission.)

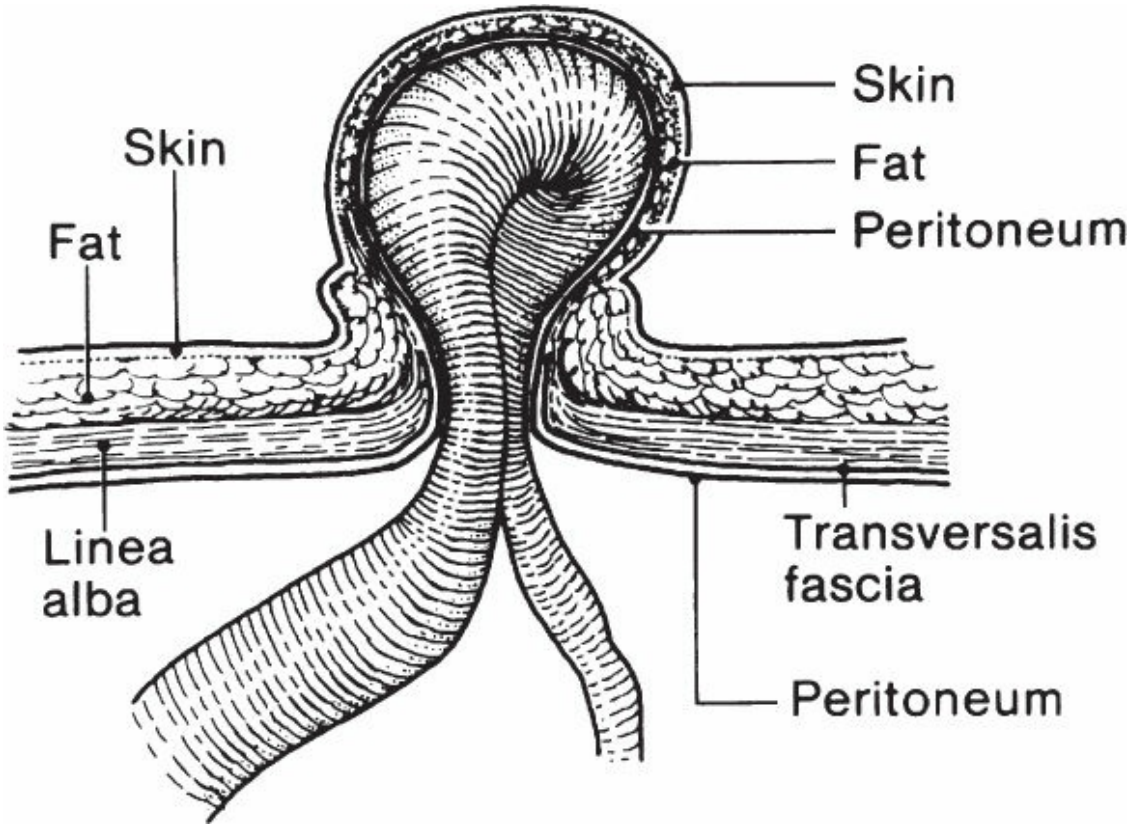

Figure 187.7. Diagrammatic sagittal section through a small umbilical hernia. The transversalis fascia shown here is in truth the membranous layer of preperitoneal tissue. (From Skandalakis LJ, Gadacz TR, Mansberger AR Jr., et al. *Modern Hernia Repair.* Pearl River, NY: Parthenon; 1996, with permission.)

SPIGELIAN HERNIA

Although named after Adriaan van der Spieghel, he only described the semilunar line (linea Spigeli) in 1645. Josef Klinkosch in 1764 first defined the spigelian hernia as a defect in the semilunar line. The latter is produced by and marks the site of transition from the aponeurotic part to the muscular part of the transverse abdominal muscle.

It is more exact to define the spigelian hernia in regard to the spigelian aponeurosis. Protrusion of a peritoneal sac, an organ, or preperitoneal fat through a congenital or acquired defect in the spigelian aponeurosis is

referred to as a spigelian hernia (hernia Spigeli). The spigelian aponeurosis is the aponeurosis of the transverse abdominal muscle limited by the linea semilunaris laterally and the lateral edge of the rectus muscle medially. Evidently, the spigelian aponeurosis is rather a zone than a line, as initially called.

The spigelian zone differs above and below the semicircular line (Fig. 187.10A). Above the semicircular line, the aponeurosis of the internal oblique splits and contributes to both anterior and posterior lamina. Below it, all aponeuroses pass in front (the external oblique has a somewhat more medial insertion toward the linea alba), and the posterior lamina of the rectus sheath consists only of the membranous fascia of the preperitoneal space (previously called transversalis fascia).

The majority (90%) of spigelian hernias lie in a 6-cm zone located above the interspinal plane (spigelian hernia belt). In this zone, the weakest point is at the intersection between the semilunar and semicircular line. The latter, known as arcuate line or line of Douglas, marks the caudal end of the posterior lamina of the aponeurotic rectus sheath and is found in the infraumbilical area. The deep inferior epigastric vessels enter the rectus sheath at or about this edge in the majority of cases (Fig. 187.10B).

A spigelian hernia must be conceived of first as a protrusion through an opening of the transversalis aponeurosis. The opening also includes the transversalis fascia, which is the inner investing fascia of the transverse muscle and aponeurosis. Then, the hernia protrudes toward the aponeurosis of the internal oblique. This aponeurosis may also rupture, but usually the aponeurosis of the external oblique is too strong to be penetrated by the hernia. This partial abdominal wall hernia presents anatomical challenges that cause difficulties in diagnosis. The space between the two oblique muscles is loose; thus, the sac usually expands in the space and adopts a T-shape or mushroom-like appearance. Possible locations of the sac are shown in Figure 187.10.

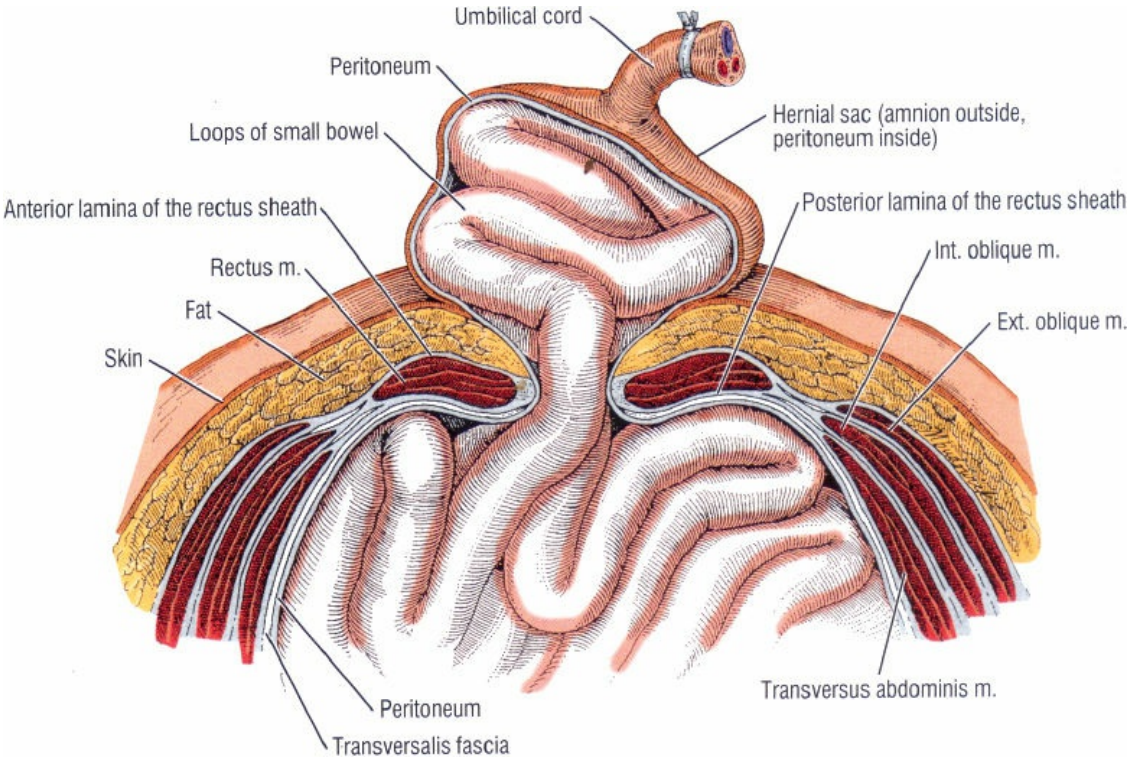

Figure 187.8. Sagittal section through a small omphalocele. (From Skandalakis LJ, Gadacz TR, Mansberger AR Jr., et al. *Modern Hernia Repair.* Pearl River, NY: Parthenon; 1996, with permission.)

GROIN HERNIA

The inguinal region (or groin) in man is the area behind and above the inguinal ligament. Because of the erect position of man, the groin is a weak area, prone to inguinal herniae, direct or indirect; to these are added the supravesical herniae. All of them originate from the fossae of the anterolateral abdominal wall. Adjacent, below the inguinal ligament, are encountered the femoral herniae (Fig. 187.11). To understand these herniae and the formation of the rings, knowledge of the anatomy of the groin and inguinal canal is essential.

The Inguinal Canal

The inguinal canal is an oblique passage through the abdominal wall that contains the spermatic cord or the round ligament of the uterus; embryologically, however, the canal develops before the descent of these entities. The inguinal canal has two openings, the deep and the superficial rings, an anterior and posterior wall, a roof and a floor. A progressing dissection of the inguinal canal, layer by layer, is offered in Figure 187.12.

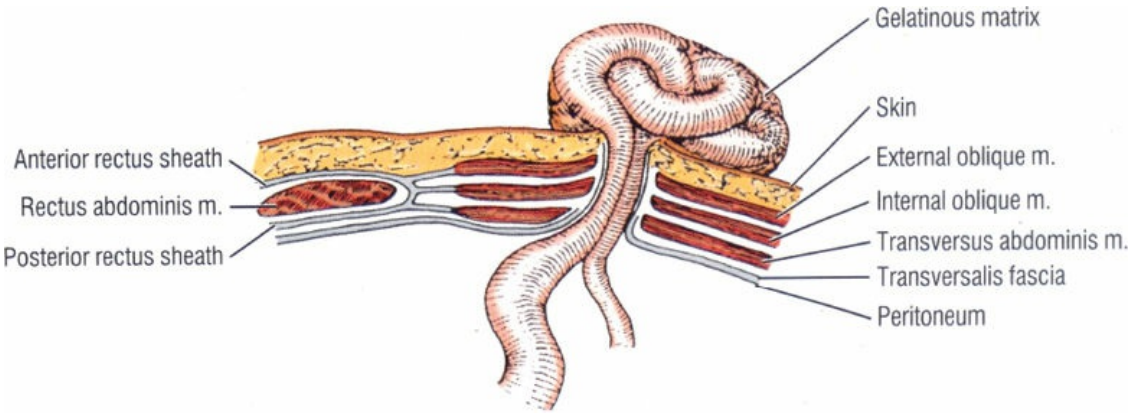

Figure 187.9. Gastroschisis. The herniation is lateral to the umbilicus, through a congenital muscular defect. A gelatinous matrix, but no sac, surrounds the herniated intestines. (Modified from Skandalakis JE, Gray SW, Akin JT Jr. The surgical anatomy of hernial rings. *Surg Clin North Am* 1974;54:1227, with permission.)

Boundaries of the Inguinal Canal

The anterior wall of the canal is formed by the aponeurosis of the external oblique. The external oblique muscle caudally ends in a thickening, the inguinal ligament (Poupart ligament), which extends from the anterior superior iliac spine laterally to the superior ramus of the pubis. This ligament is not cord-like, but the lower edge of the external oblique aponeurosis.

The posterior wall is given by the fascia transversalis and the transversus abdominis aponeurosis.

The roof of the canal is formed by the arched fibers of the lower edge of the internal oblique muscle and by the transversus abdominis muscle and aponeurosis. The internal oblique and the transversalis muscle attach to the lateral two thirds or one-half of the inguinal ligament and then arch over the spermatic cord to reach the pubic tubercle (and also the pectinate line). Close to the deep ring, the arch of the internal oblique muscle is more muscular, while that of the transversus more aponeurotic. Sometimes the lower fibers of these muscles fuse to be inserted together to the pubic tubercle, and thus form the so-called “conjointed tendon.” A true fusion is, however, rare (5%), and maybe the term “conjoined area” should be more exact to describe this mass of aponeuroses inserting together to the tubercle (Fig. 187.13). Many times the “conjoined tendon” has been confused with the falx inguinalis (ligament of Henle), which is the lateral, vertical expansion of the rectus sheath that inserts on the pectin of the

pubis (present in 30% to 50%) and fuses with the transversus abdominis aponeurosis.

The floor of the inguinal canal is formed by the shelving lower border of the inguinal ligament and the lacunar ligament (Gimbernat ligament). The lacunar ligament is in fact the extension of the inguinal ligament backward and laterally to attach to the pectineal line and form a triangular ligament with apex the pubic tubercle (Fig. 187.14). Occasionally, it forms the medial border of the femoral canal. A lateral periosteal extension of the lacunar ligament along the pectineal line forms the pectineal ligament (Cooper ligament). According to O'Rahilly, the pectineal ligament provides a firm anchor for the attachment of muscular, tendinous, and fascial layers of the groin, and thereof is used in the surgical repair of inguinal herniae.

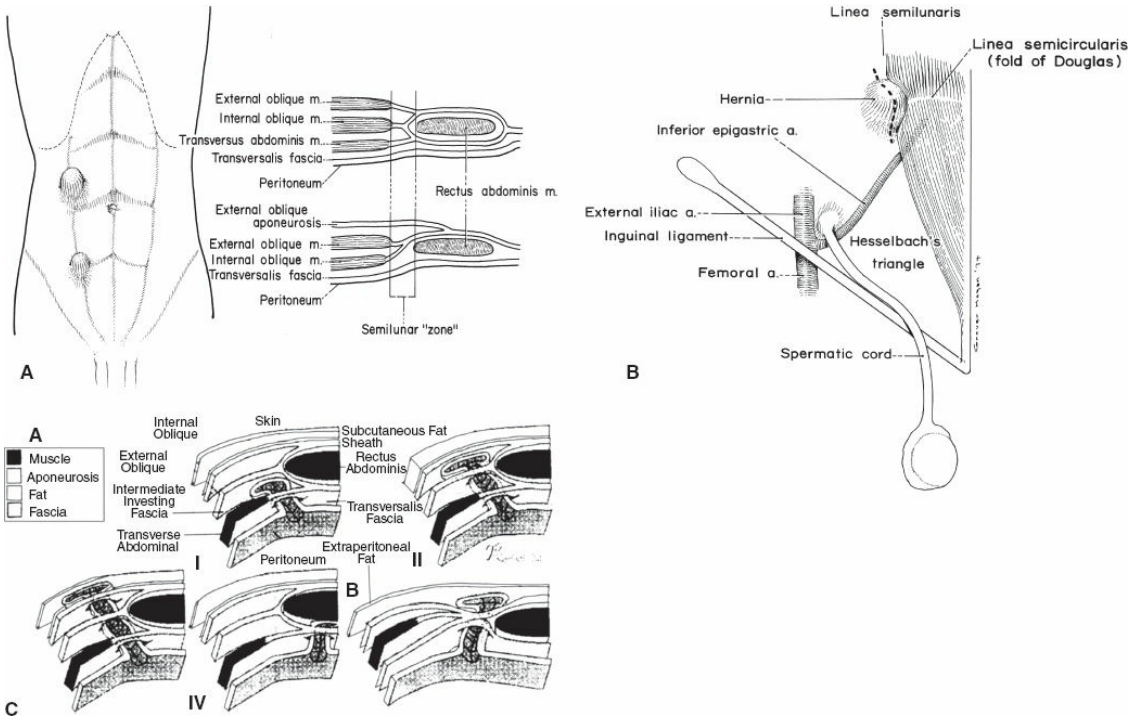

Figure 187.10. Spigelian hernia. **A.** Sites of spigelian herniae and sections through the normal body wall above and below the arcuate line, showing the semilunar "zone" of Spieghel. M, muscle. **B.** Spigelian hernia at the intersection of semilunar and semircerular line, in the infraumbilical area. The deep inferior epigastric vessels enter the rectus sheath at or about the semicircular line. a, artery. (Reprinted from Skandalakis JE, Gray SW, Akin JT Jr. The surgical anatomy of hernial rings. *Surg Clin North Am* 1974;54(6):1227–46, with permission from Elsevier.) **C.** Three-dimensional schematic presentation of cross-section of the abdominal wall in vicinity of the left border of the sheath of the

rectus abdominis muscle, posterior view. Spigelian hernia sac is shown at various surgical levels: A. Above the semicercular line (of Douglas). I. Superficial to the aponeurosis of the transverse abdominal muscle; II. Superticial to the aponeurosis of the internal oblique: III. Superficial to the aponeurosis of the internal oblique muscle: IV. Penetrating the posterior lamina of the rectus sheath. B. Below the semicircular line (of Douglas). (From Skandalakis PN, Zoras O, Skandalakis JE, et al. Spigelian hernia: surgical anatomy, embryology and technique of repair. *Am Surg* 2006;72(1):42–8, with permission.)

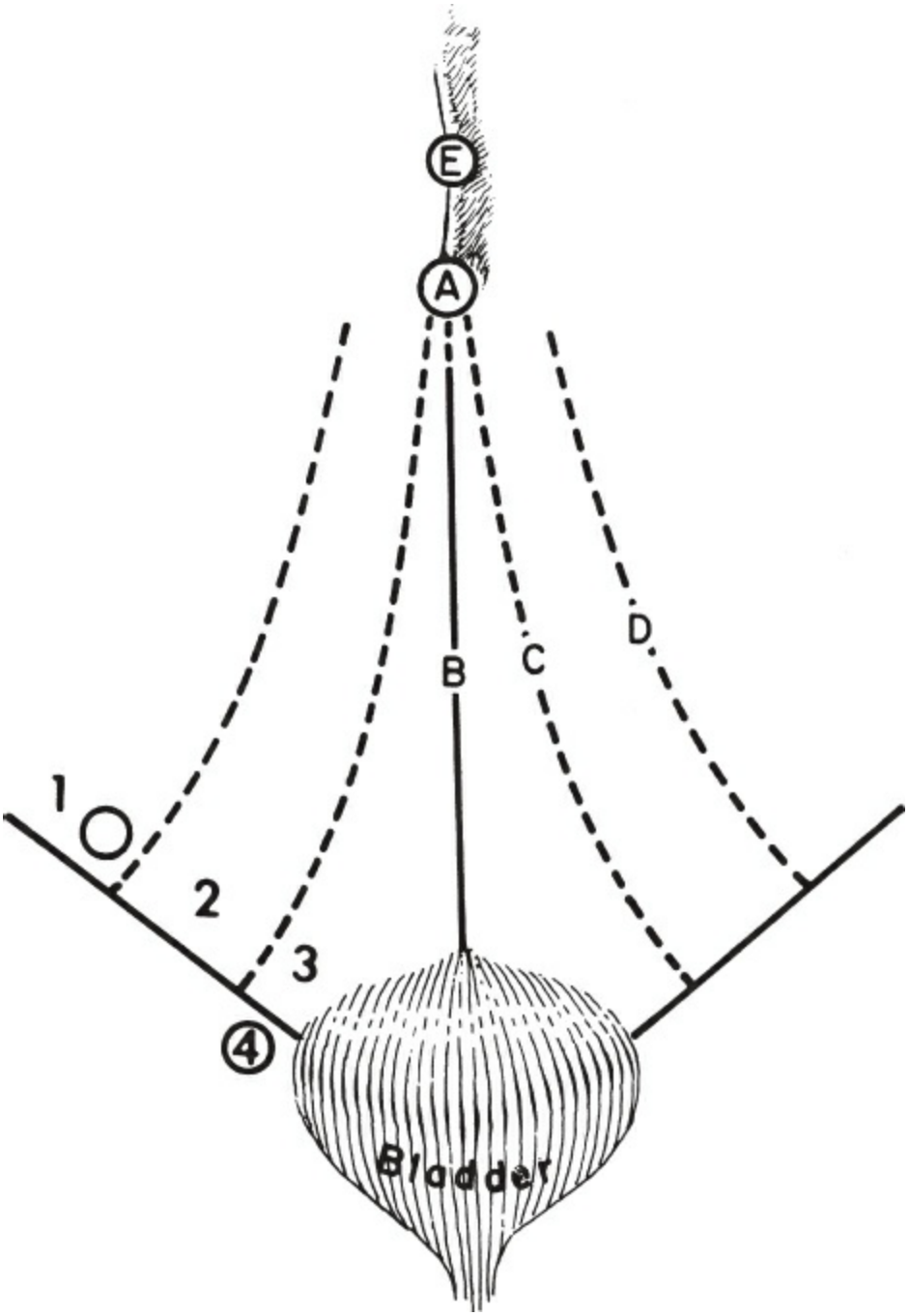

Figure 187.11. Diagram of the fossae of the anterolateral abdominal wall and their relation to the sites of groin herniae. A, umbilicus; B, median umbilical ligament (obliterated urachus); C, medial umbilical ligament (obliterated umbilical arteries); D, lateral umbilical ligament containing inferior (deep) epigastric arteries; E, falciform ligament. Sites of possible herniae: 1, lateral fossa (indirect inguinal hernia); 2, medial fossa (direct inguinal hernia); 3, supravesical fossa (supravesical hernia); 4, femoral ring (femoral hernia). (Reprinted from Skandalakis JE, Gray SW, Akin JT Jr. The surgical anatomy of hernial rings. *Surg Clin North Am* 1974;54(6):1227–46, with permission from Elsevier.)

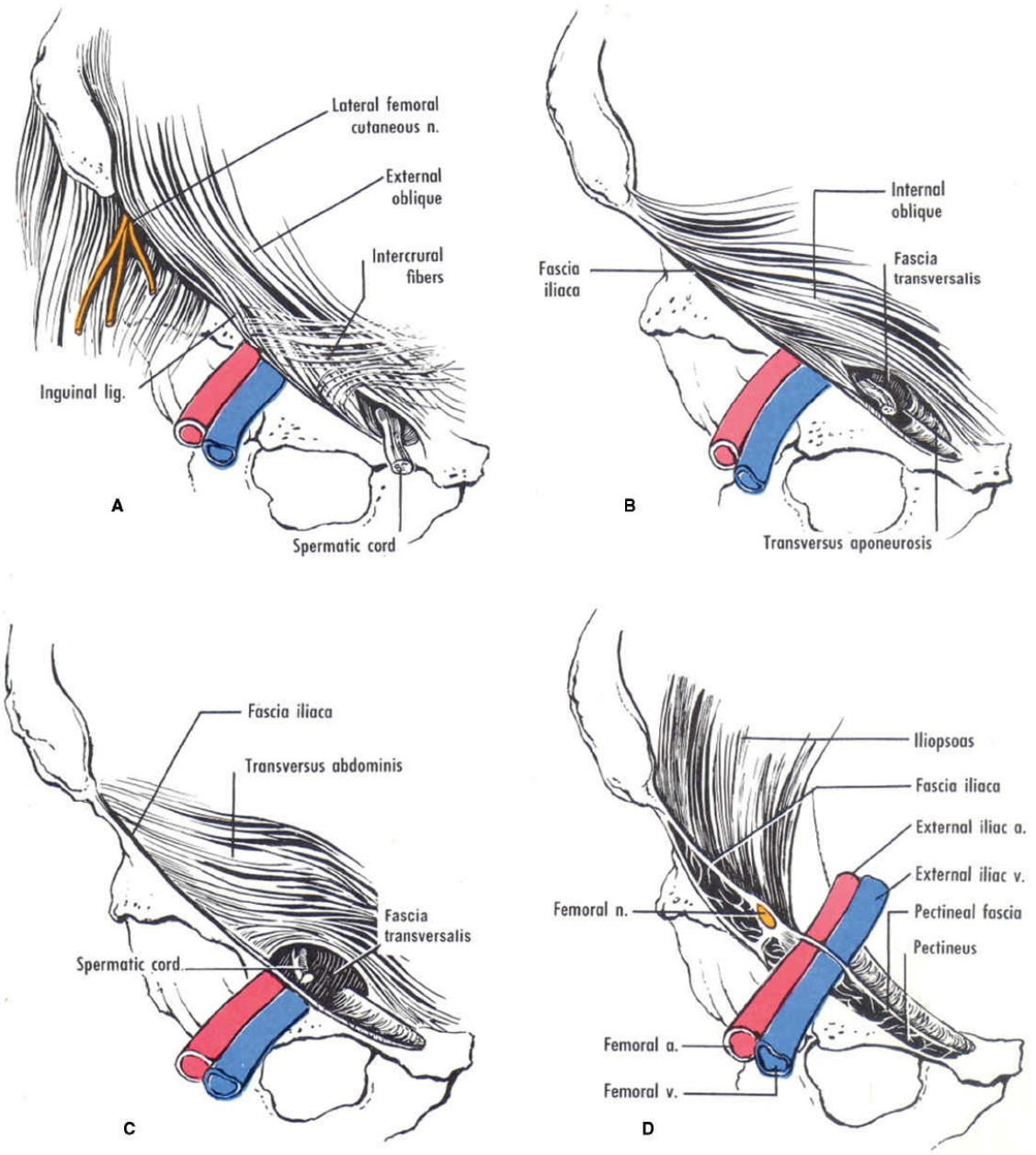

Figure 187.12. Anterior aspect of the inguinal region, progressing from the outside inward, layer by layer. **A.** External oblique muscle and superficial inguinal ring. **B.** Internal oblique muscle extending medially to reach pubis. **C.** Transverse abdominis and fascia transversalis. **D.** Iliopsoas and fascia iliaca, pectineus and pectineal facia. (From O'Rahilly R. *Gardner-Gray-O'Rahilly Anatomy: A Regional Study of the Human Structure.* 5th ed. Philadelphia, PA: WB Saunders Co; 1986, Fig. 33-8, p. 364.)

Beneath the inguinal ligament is found a collagenous band, the iliopubic tract, extending from close to anterior inferior iliac spine to the pubic tubercle (Figs. 187.14 and 187.15). It is said to be a thickening of the transversalis fascia below the inguinal ligament, or a band between the

transversalis fascia and the ligament, or even to disappear when the transversalis fascia is freed from the adjacent preperitoneal tissue (McVay and Anson). It arches over the femoral vessels and contributes to the medial margin of the femoral canal. In any case, the iliopubic tract is found in a deeper layer and should not be confused with the inguinal ligament.

The Deep (Internal) Inguinal Ring

The deep inguinal ring is an opening of the transversalis fascia. It resembles a funnel directed downward and medially. There is no opening of the transversalis aponeurosis for the passage of the spermatic cord—it courses under the arch of the transversus abdominis muscle (and aponeurosis). The iliopubic tract lies under the deep ring and is said to reinforce it (or contribute to it, according to others). These relations are evident when the peritoneum is removed and the deep ring is seen from within the abdomen: the deep ring is found laterally to the inferior epigastric vessels, delineated by the transverse abdominus arch supero-laterally and the iliopubic tract coursing inferolaterally. The vas deferens courses from the pelvis and is found medially; the gonadal vessels descend from the abdomen and are found laterally. Between the two descending resides the genital branch of the genitofemoral nerve (Fig. 187.15). After the internal ring, this nerve is not included in the part of the spermatic cord surrounded by the internal spermatic fascia (given from the internal oblique), but external to it, in companion with the cremasteric vessels.

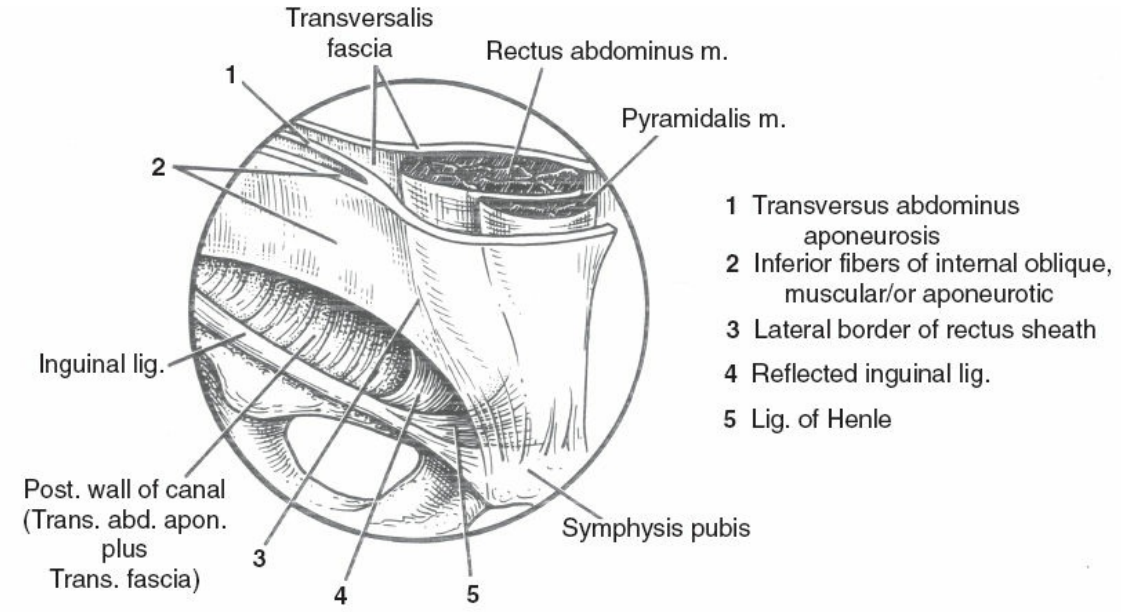

Figure 187.13. The “conjoined area.” (From Gray SW,

Skandalakis JE, McClusky DA. *Atlas of Surgical Anatomy for General Surgeons.* Baltimore, MD: Williams & Wilkins; 1985, with permission.)

The Secondary Internal Inguinal Ring

The secondary internal inguinal was first noted by Lytle in 1945, and later defined correctly in 1975 by Fowler. Our team has brought this ring back in focus (see Mirilas et al. *J Am Col Surg* 2008). The secondary internal inguinal ring arises from the membranous layer of the extraperitoneal fascia located immediately deep to the transversalis fascia. In males, the vas deferens hooks around the inferomedial lip of the secondary internal inguinal ring in order to enter the inguinal canal. The gonadal vessels, which lie lateral to the vas deferens in the extraperitoneal fat and deep to the membranous layer, also traverse the secondary internal inguinal ring in order to become incorporated in the cord. This is readily appreciated when viewing the deep ring from a preperitoneal exposure and is sometimes mistaken for the transversalis fascia during anterior exposure of the groin.

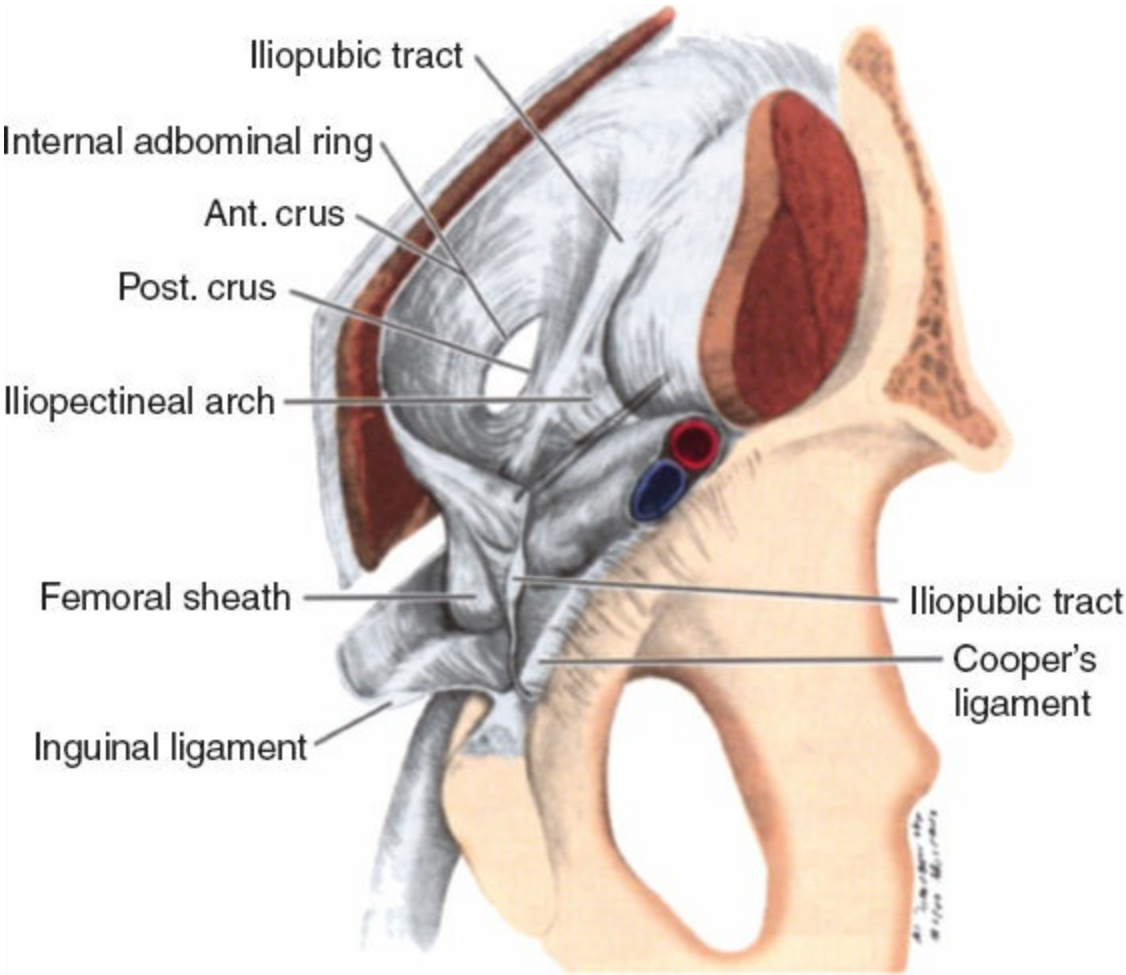

Figure 187.14. Ligamentous attachments of the deep inguinal region. (From Gray SW, Skandalakis JE, McClusky DA. *Atlas of Surgical Anatomy for General Surgeons.* Baltimore, MD: Williams & Wilkins; 1985, with permission.)

As said above, the membranous layer of the extraperitoneal fascia divides the extraperitoneal space into a parietal and a visceral plane. The parietal plane, between the transverasalis fascia and the membranous layer of the extraperitoneal fascia, contains the deep inferior epigastric vessels, the cremasteric vessels, and the genital branch of the genitofemoral nerve. The visceral plane, between the membranous layer of the extraperitoneal fascia and the peritoneum, contains the median and medial umbilical ligaments, the vas deferens/round ligament, the gonadal vessels, and the ureter (Fig. 187.16). This plane is equivalent to the space of Retzius, defined between the peritoneum and the "posterior lamina of the transversalis fascia," here redefined as membranous layer of the extraperitoneal tissue.

The secondary internal inguinal ring has important applications to surgery of the inguinal canal. During the repair of an indirect inguinal hernia, the correct site of sac ligation lies at the level of the secondary internal inguinal ring. Either using the inguinal or the preperitoneal open approach, the internal spermatic fascia should be incised to allow for exposure of the secondary internal ring. At this level, the membranous layer is incised in its thicker area, the peritoneum is detached from the cord structures, and a truly high ligation or inversion of the sac is performed.

The Superficial (External) Inguinal Ring

The superficial ring is an opening in the aponeurosis of the external oblique muscle found 2.5 cm above and laterally to the pubic tubercle in the adult. Although called "ring," it is somehow triangular, with a superolateral border (superior crus), an inferomedial border (inferior crus), and an open base related to the pubic crest. The superior crus is formed by the aponeurosis of the external oblique. The inferior crus is largely formed by the inguinal ligament, which also inserts in the pubic tubercle (Fig. 187.17). Usually, there are superficial transverse fibers superior at the beginning of the diversion of the crura. Superficially to these, there is a fascia that continues from the aponeurosis of the external oblique muscle on to the spermatic cord; this is the outer investing fascia of the muscle that gives the external spermatic fascia extending between the crura of the

ring (thereof also called “intercrural” fascia). After removal of the superficial fascia, the thin intercrural fascia is opened during surgical dissection, and the thick aponeurotic semicircle of the external ring is easily found.

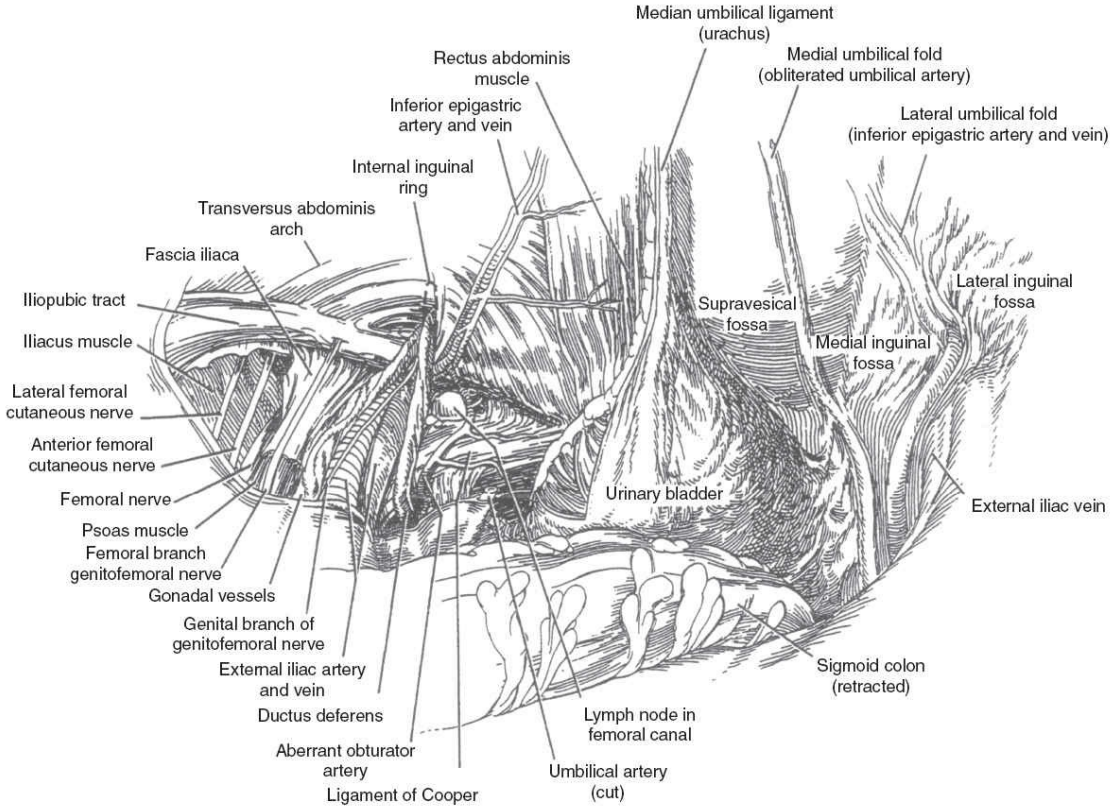

Figure 187.15. Panoramic extraperitoneal view of the anatomical entities of the inguinal area. (From Colborn GL, Skandalakis JE. Laparoscopic cadaveric anatomy of the inguinal area. *Prob Gen Surg* 1995;12:13, with permission.)

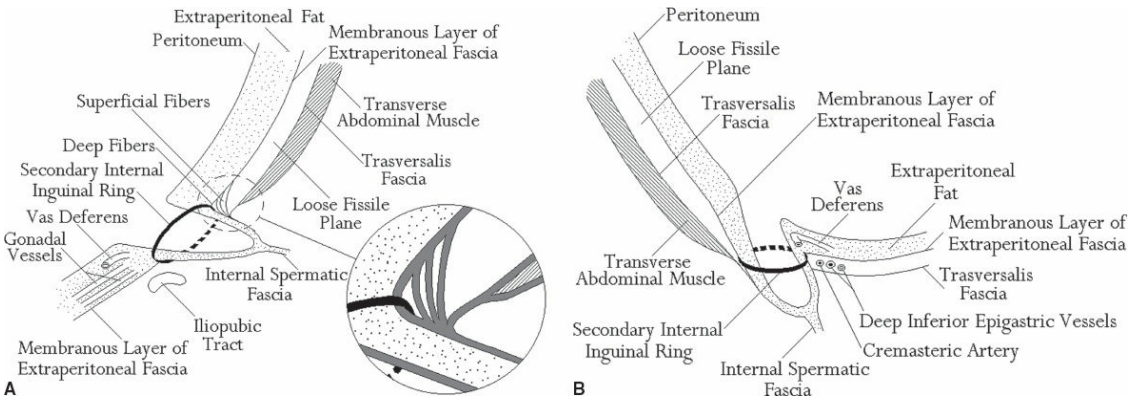

Figure 187.16. Diagrammatic representation of a parasagittal (**A**) and horizontal (**B**) section of the anterior abdominal wall through the area of the secondary internal inguinal ring. The term “loose fissile plane” stands for the areolar extraperitoneal tissue. (From

Mirilas P, Mentessidou A, Skandalakis JE. Secondary internal inguinal ring and associated surgical planes: surgical anatomy, embryology, applications. *J Am Coll Surg* 2008;206[3]:561–70. Copyright © 2008 American College of Surgeons, with permission.)

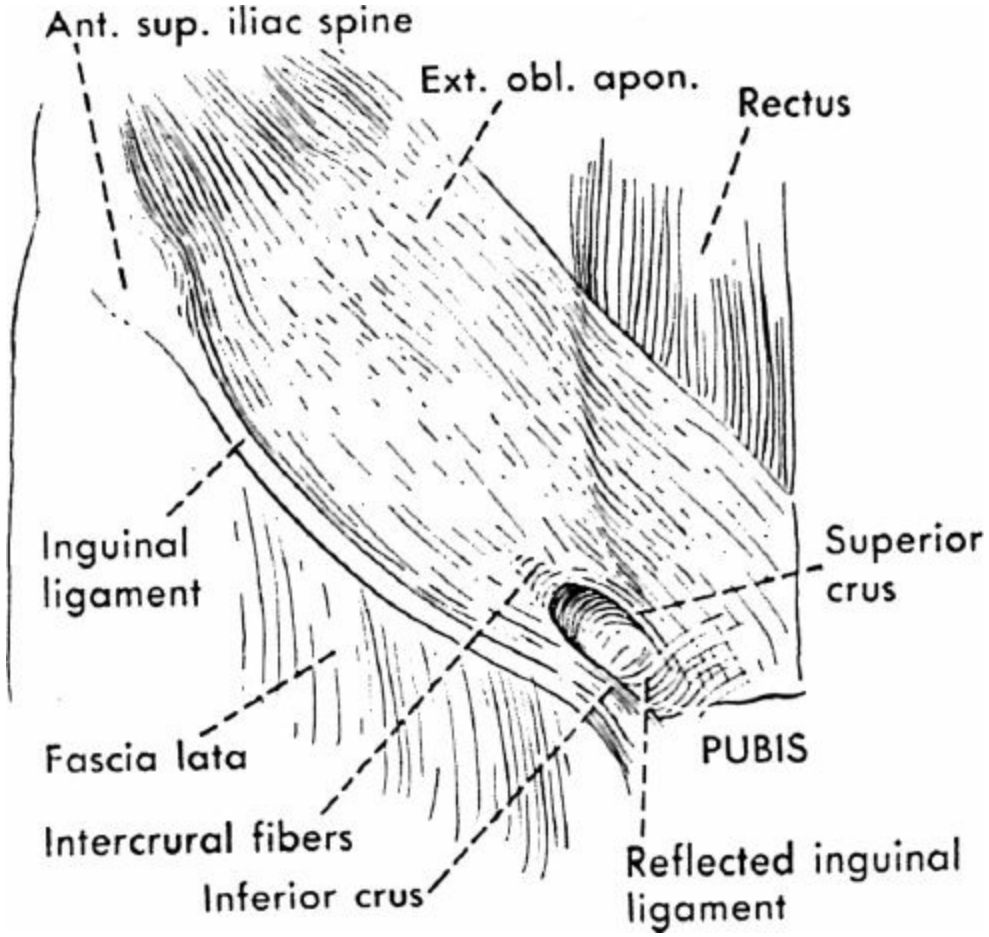

Figure 187.17. The external inguinal ring. (From Hollinshead WH. *Anatomy for Surgeons, vol. 2.* New York: Hoeber-Harper; 1956.)

The Secondary External Inguinal Ring

In our dissections we have rediscovered the secondary external inguinal ring, discovered by McGregor (1929) and described by Martin (1984)—forgotten thereafter (see Mirilas & Mentessidou, *Hernia* 2013). The secondary external inguinal ring arises from the membranous layer of the superficial fascia of the anterior abdominal wall below the classic superficial ring. It is tube-like arrangement of Scarpa fascia, which constitutes the entrance into the scrotum (Fig. 187.18). An examining finger can be easily inserted in the secondary external ring at the root of

the scrotum and follows the spermatic cord until the external inguinal ring. A similar ring-like arrangement of Scarpa fascia has been also noted around the round ligament in female cadavers.

The secondary external inguinal ring is implicated in several disorders of the inguinoscrotal area. Adhesive obstruction, underdevelopment, or congenital absence of the secondary external ring has been considered responsible for some cases of incomplete testicular descent or testicular ectopy. The secondary external ring usually constitutes an anatomical obstacle for hernia sacs to enter the scrotum. In the case that a hernia passes the secondary external ring, the hernia becomes scrotal.

Indirect Inguinal Hernia

An indirect hernia enters the inguinal canal and can be congenital or acquired. Characteristically the hernia starts laterally to the inferior epigastric vessels, in the lateral inguinal fossa (Figs. 187.10 and 187.19). Herniation may take place through all four inguinal rings, when the sac reaches the scrotum. The sac is a peritoneal projection made by the nonclosed (congenital hernia) or reopened processus vaginalis. The sac enters the secondary internal ring (membranous layer of the preperitoneal fascia) and the internal inguinal ring, and progresses in the inguinal canal, where it is covered by the covering layers of the endocanal spermatic cord (internal spermatic fascia, cremaster muscle and fascia—from internal oblique and transversus muscle). The sac exits the external ring and gains another covering from the investing fascia of the external oblique, the external spermatic fascia. When reaching the neck of the scrotum, it enters the secondary external inguinal ring (Scarpa fascia). The reader is invited to study the concept of the new secondary internal and external rings and their implication in indirect inguinal hernia in Figure 187.20.

The sac of the indirect inguinal hernia lies on the vessels and vas deferens, and encloses them like an Ω (omega). This can be designated as the visceral compartment of the spermatic cord. On an outer layer are the cremasteric muscle and vessels, accompanied by the (also parietal) genital branch of the genitofemoral nerve that supplies the scrotum. The ilioinguinal nerve also enters the inguinal canal, found on the cord, under the aponeurosis of the internal oblique muscle, to finally exit the external inguinal ring. Because of their importance, the nerves of the groin will be discussed further below.

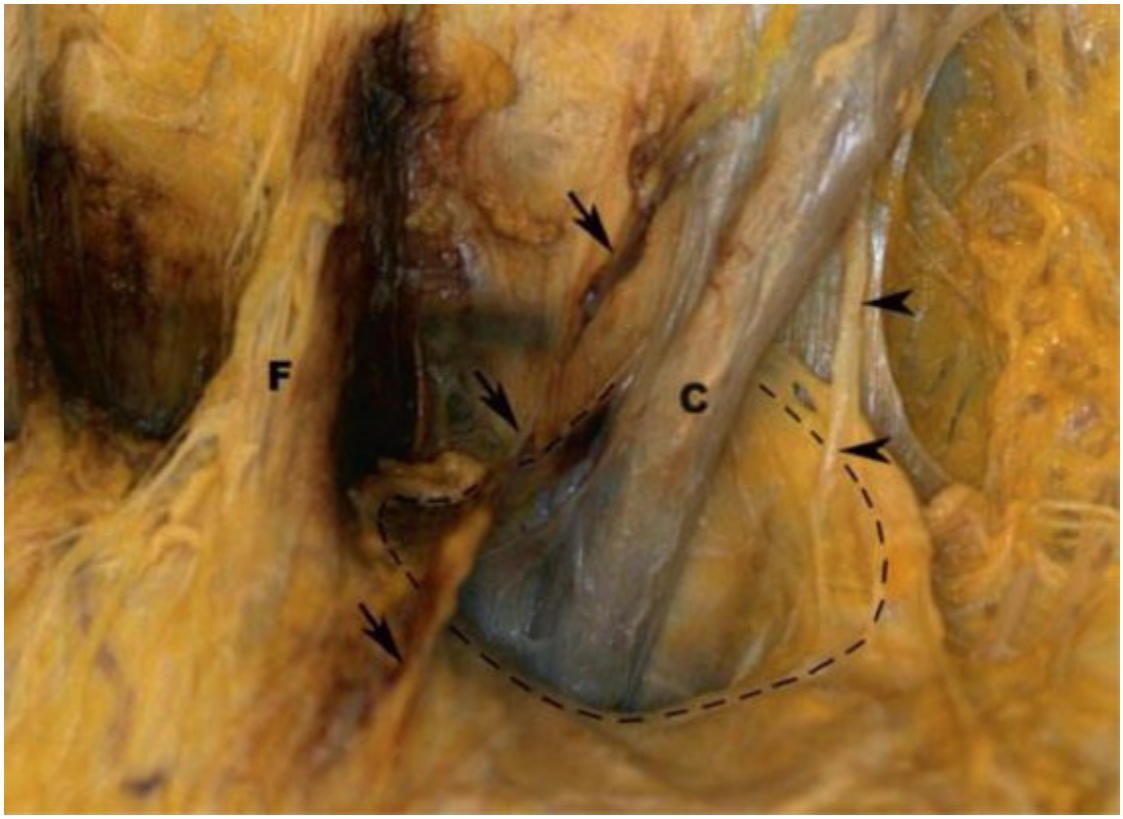

Figure 187.18. Photograph of the secondary external inguinal ring in an adult male cadaver, left side. After a wide transversal incision on the lowest anterior abdominal wall, the membranous layer of the superficial fascia was detached and reflected anteriorly, together with the superficial fat and skin. The ring can be immediately seen, without any further dissection (outlined by a *dashed line* here). Scarpa fascia forms the anterior border of the ring and gives off a lateral-posterior reflection and a medial-posterior reflection. The spermatic cord (C) and the ilioinguinal nerve (*arrowheads*) pass through the ring; here, the nerve can be seen distant from the cord, due to displacement resulting from opening and reflection of Scarpa fascia. The superficial inferior epigastric vessels (*arrows*) course outside the ring, aside to the fundiform ligament (F). (From Mirilas P, Mentessidou A. The secondary external inguinal ring and associated surgical planes: surgical anatomy, embryology, applications. *Hernia* 2013;17(3):379–89. Copyright © 2013 Springer-Verlag France, with permission from Springer.)

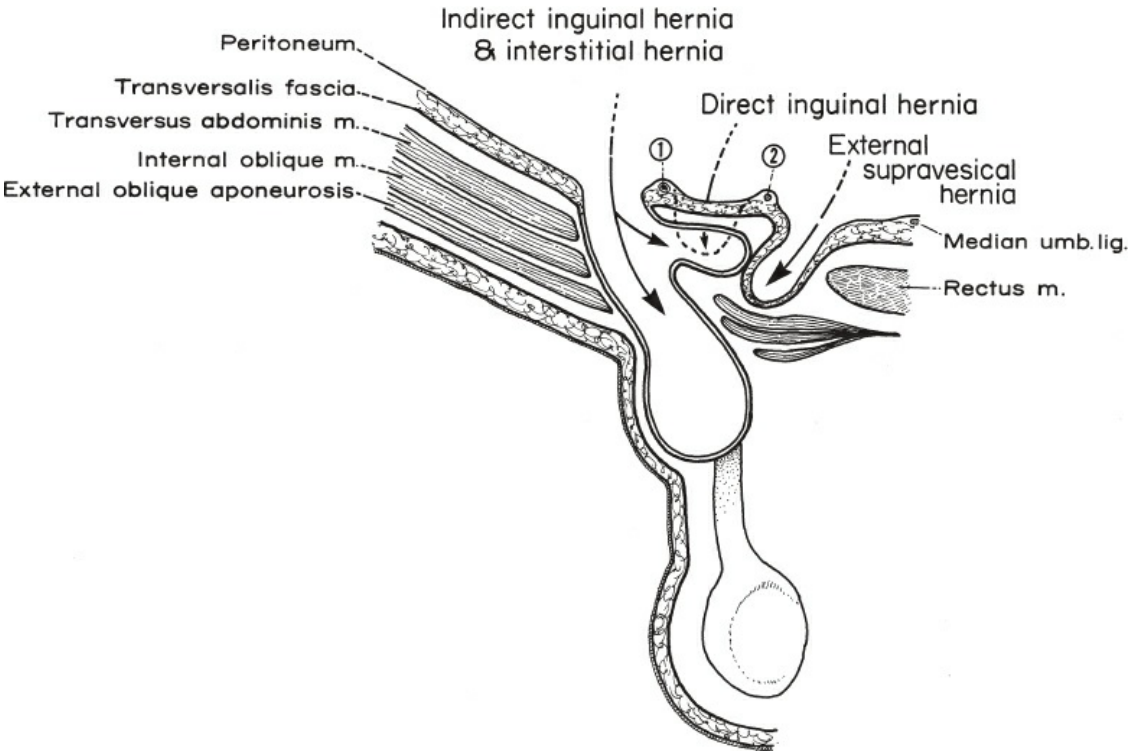

Figure 187.19. Diagram of the relations of the four groin herniae existing in the same patient. An indirect hernia with an intraparietal diverticulum, as well as a direct hernia and an external supravesical hernia, was present. 1, lateral umbilical ligament; 2, medial umbilical ligament. *Arrows* indicate different sites of origin of each hernia. m, muscle; umb. lig., umbilical ligament. Observe that here the transversalis fascia is shown apart from the transversalis muscle; in truth, it is the membranous layer of the preperitoneal tissue. (Republished with permission of Southeastern Surgical Congress from Skandalakis JE, Gray SW, Burns WB, et al. Internal and external supravesical hernia. *Am Surg* 1976;42:142, permission conveyed through Copyright Clearance Center, Inc.)

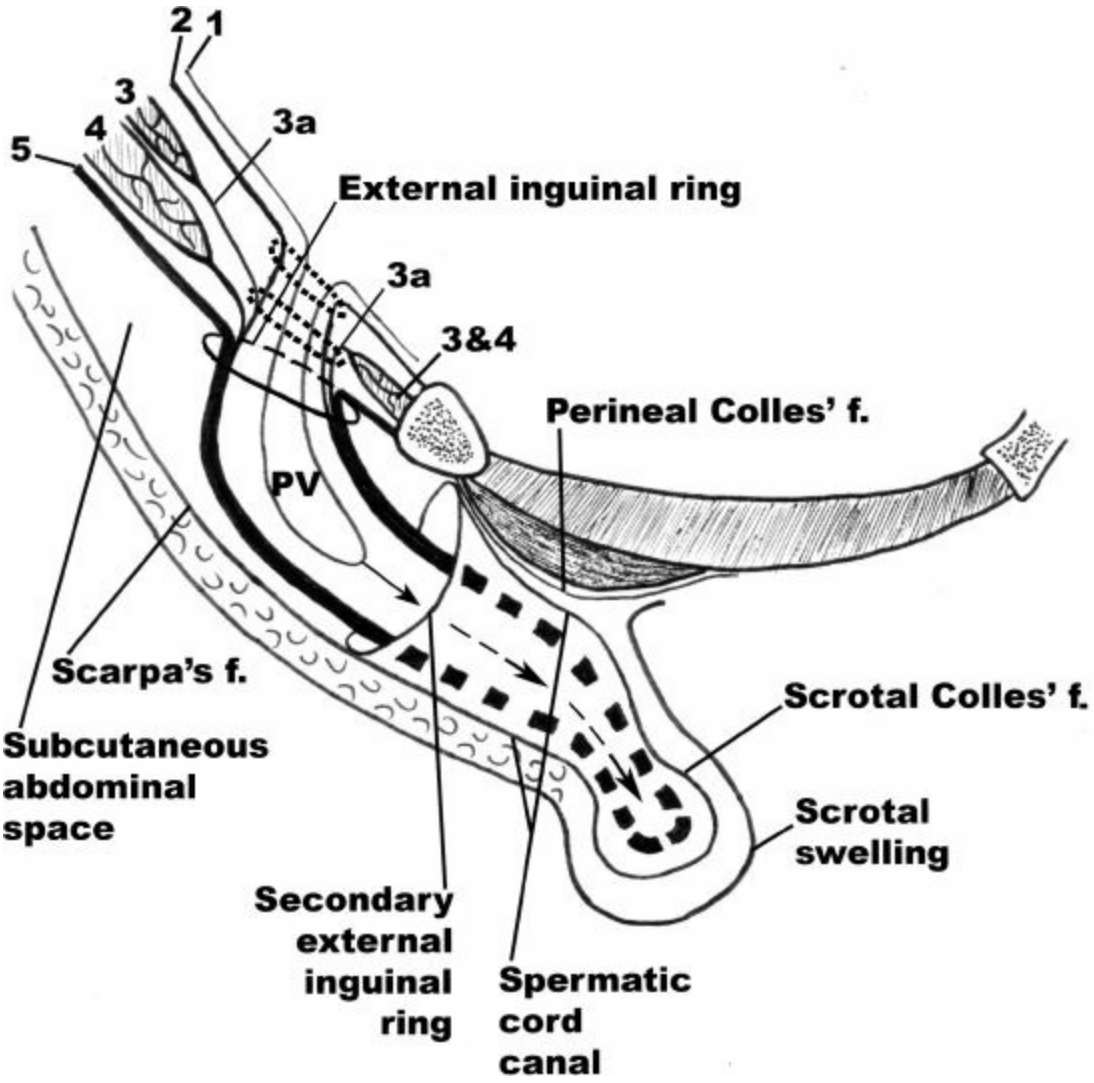

Figure 187.20. Diagrammatic representation of the course of an indirect inguinal hernia through the four inguinal rings: the secondary internal ring is formed by the membranous layer of the preperitoneal tissue, the internal inguinal ring by an opening of the transversalis fascia, the external inguinal ring by an opening in the aponeurosis of the external oblique muscle, the secondary external inguinal ring by Scarpa fascia at the entrance of the scrotum. The *arrows* indicate the course of the sac, that is, the processus vaginalis. 1, peritoneum; 2, membranous layer of the preperitoneal fascia; 3, transverse muscle; 3a, transversalis fascia; 4, internal oblique muscle; 3 and 4, conjoint tendon; 5, external oblique muscle aponeurosis. PV, processus vaginalis; f, fascia. (Modified from Mirilas P, Mentessidou A. The secondary external inguinal ring and associated surgical planes: surgical anatomy, embryology, applications. *Hernia* 2013;17(3):379–89. Copyright © 2013 Springer-Verlag France, with permission from Springer.)

Direct Inguinal Hernia

The ring of the direct hernia is located in the medial inguinal fossa within the “triangle of Hesselbach.” This triangle is topographically delineated by the deep inferior epigastric artery laterally, the lateral border of the rectus muscle medially, and the inguinal ligament as base; the base was originally defined to be the pubis and pectineal ligament, but this has been revised (Fig. 187.21). The base of the triangle is found immediately behind the external inguinal ring, from which according to Hollinshead (see references) is “separated by the transversalis fascia and fascio-aponeurotic derivatives of the transversus or internal oblique muscle.” Evidently, by “transversalis fascia” the membranous layer of the preperitoneal tissue is meant according to our view. The “conjoined tendon” or separately the apoeneuroses of the transversus and internal oblique muscles play a role in this area. This weak area is the site of direct inguinal hernias that may protrude through the external inguinal ring. The hernial ring is medial to the deep inferior epigastric vessels (lateral umbilical ligament) and lateral to the obliterated umbilical artery (medial umbilical ligament); the sac passes through the floor of the inguinal canal (Fig. 187.19).

External (Anterior) Supravesical Hernia

Supravesical hernias start in the supravesical fossa. The fossa is bounded between the median umbilical ligament (obliterated urachus), the medial umbilical ligament (obliterated umbilical artery), and the peritoneal reflection on the urinary bladder inferiorly (Fig. 187.15). The external hernias (as opposed to internal) extend directly through the anterior abdominal wall or through the inguinal, femoral, or obturator canals.

The external supravesical hernia can pass through the floor of the inguinal canal. It is our opinion that it is a form of direct hernia occupying the medial part of the Hesselbach triangle. The hernial ring may be small or large, partially or totally occupying the supravesical fossa. The defect may be small or it may involve into the triangle of Hesselbach extending to the median fold.

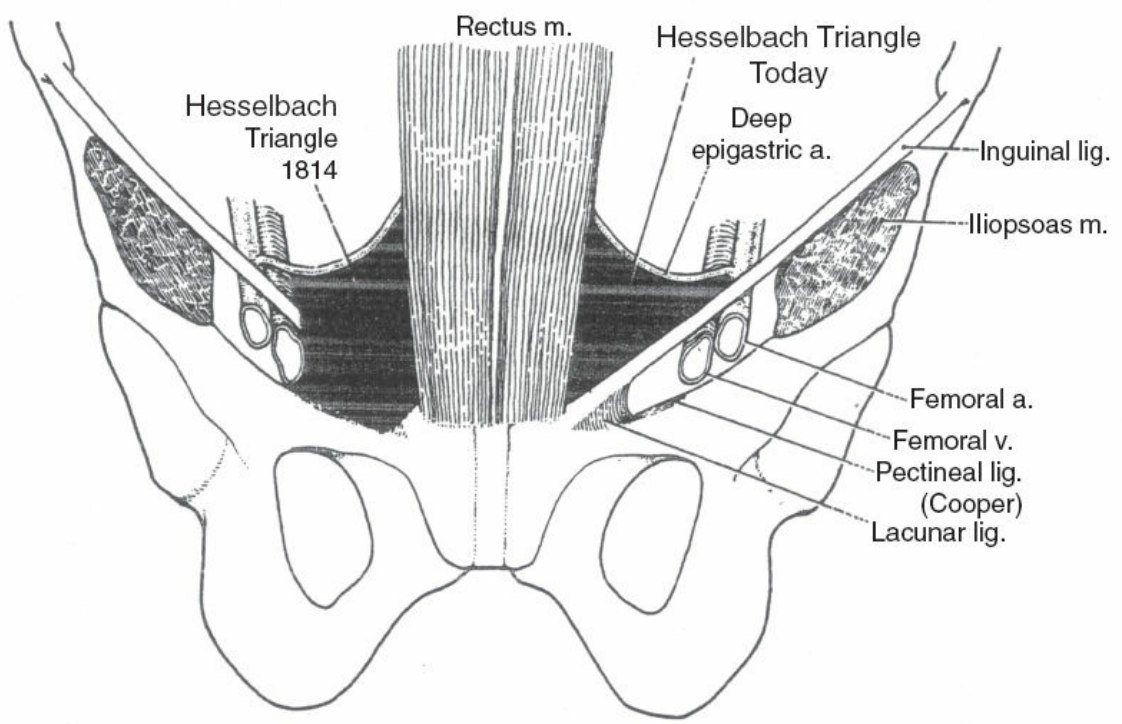

Figure 187.21. Hesselbach triangle. (From Skandalakis JE, Gray SW, Rowe JR. *Anatomical Complications in General Surgery.* New York: McGraw-Hill; 1983, with permission.)

The hernial sac of the external supravesical hernia or of the direct hernia rarely travels through the external ring. If such pathology is present and incarceration occurs, the subcutaneous hernial ring should be treated as in indirect hernia.

Femoral Hernia

A femoral hernia is a protrusion of preperitoneal fat or viscus through the femoral canal. The sac has to pass through the femoral ring that normally exists and a new opening (orifice) at the lower end of the femoral canal.

The femoral ring is bounded medially by the lacunar ligament (Fig. 187.22). Some authorities (McVay and Anson, Hollisnhead) suggest that it is really the transversus edge that forms the medial edge of the ring. Anteriorly the ring is bounded by the inguinal ligament and the iliopubic tract, posteriorly by the pectineal ligament (Cooper's) and laterally by connective tissue between it and the femoral (or iliac) vein. The femoral ring is prone to hernia because the "transversalis fascia" (in truth the membranous layer of the preperitoneal fascia) does not protect it, but passes downward to form the femoral sheath.

After entering the femoral ring, the hernial sac enters the femoral canal.

The boundaries of the femoral canal are the following:

Anterior: Iliopubic tract or the inguinal ligament (or both)
Posterior: Pectineal ligament (Cooper) and fascia iliaca
Lateral: A connective tissue septum and the femoral vein
Medial: The aponeurotic insertion of the transversus abdominis muscle and transversalis fascia or, rarely, the lacunar ligament

The femoral hernia sac passes behind or deep to the inguinal ligament. Thus, the exit orifice is found behind the fascia lata and in front of the fascia on the pectineus muscle. If the hernia is more pronounced, the sac will find an exit at a weak point of the fascia lata, which is the saphenous opening (fossa ovalis). The medial border of the hernia is the lacunar ligament. Laterally, it is the sheath of the femoral vessels. The orifice of a femoral hernia sac is found below the inguinal ligament, about 3 cm lateral to the pubic tubercle in the adult.

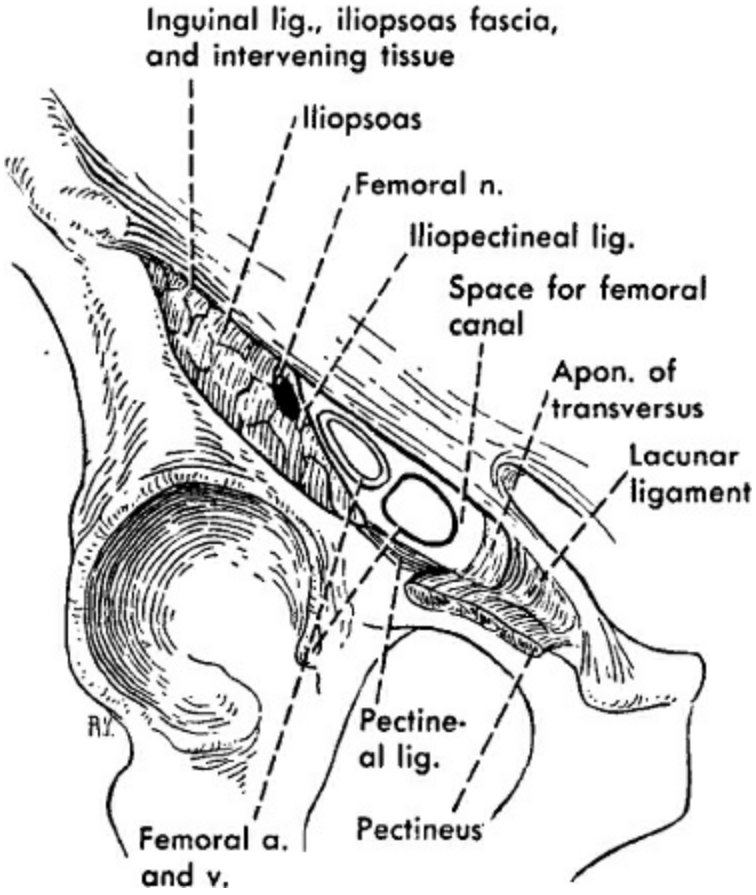

Figure 187.22. Schema of the region of the femoral canal, seen from below. The inguinal ligament is pulled upward so that the lacunar ligament can be seen. (From Hollinshead WH. *Anatomy for Surgeons, vol. 2.* New York: Hoeber-Harper; 1956.)

If there is incarceration, a small incision should be made to divide the inguinal ligament anteriorly or to divide the lacunar ligament medially. The incision of the inguinal ligament is preferred because the lacunar ligament is only 0.5 to 1.0 cm in length; division of the lacunar ligament may not enlarge the ring sufficiently.

We prefer the division of the inguinal ligament also because an aberrant obturator artery, found in >30% of cases and arising from the inferior epigastric artery, or, even more frequently, an aberrant vein, may pass across or medial to the femoral ring in the edge of the lacunar ligament rather than lateral to the ring. If the approach is made from above the inguinal ligament, and thus through the floor of the inguinal canal, the aberrant obturator can be seen clearly, and the lacunar ligament can be cut safely.

Nerves of the Inguinal Region

Anterior Exposure

Amid and colleagues stretched that the ilioinguinal, iliohypogastric, and the genital branch of the genitofemoral nerve must be identified during the anterior access for indirect inguinal hernia, in order to avoid postherniorrhaphy neuropathic pain. These nerves are responsible for the sensory innervation of the inguinal region.

Ilioinguinal nerve: Arises from the 12th thoracic and the first lumbar nerves. Lateral entry into the groin is via a path that courses through the transversus abdominis muscle medial to the anterior superior iliac spine. Normally, it follows the spermatic cord below the external oblique aponeurosis until it exits the deep ring. In 35% of cases, it can be found anterior to the spermatic cord within the cremasteric fibers. It can also be found to course through the external oblique aponeurosis anywhere between the deep and superficial rings.

Iliohypogastric: Arises from the 12th thoracic and first lumbar nerves. Its path courses through the transversus abdominis muscle superior to the ilioinguinal nerve to cross the groin in the plane between the external and internal oblique aponeuroses medial to the spermatic cord. It can be found during identification and dissection of the conjoined area. In some cases, the ilioinguinal and iliohypogastric nerves join prior to entry into the groin. Occasional absence of either the iliohypogastric or ilioinguinal nerves has also been reported.

Genital branch of the genitofemoral: Arises from the first and second

lumbar nerves. This follows the gonadal vessels as it enters the inguinal canal deep to the lateral crus of the deep ring. An aberrant ilioinguinal nerve may accompany the genital branch of the genitofemoral nerve in select cases.

Extraperitoneal Exposure

The iliohypogastric and ilioinguinal nerves, branches of the genitofemoral nerve, and the anterior and lateral femoral cutaneous nerves are found in the parietal compartment of the extraperitoneal (preperitoneal) space between the transversalis fascia and the membranous layer of the extraperitoneal fascia.

Ilioinguinal and Iliohypogastric: Both can be found along the upper lateral edge of the psoas entering the transversalis fascia above the iliac crest. These are rarely exposed during extraperitoneal exposure.

Branches of the genitofemoral: In contrast, the genital branch of the genitofemoral nerve is readily encountered as it travels with the gonadal vessels toward the deep inguinal ring. Inferolaterally, the femoral branch of the genitofemoral nerve can be found coursing over the fascia iliaca up toward the iliopubic tract.

Femoral cutaneous nerves: These nerves arise from the second and third lumbar nerves. Both the anterior and lateral femoral cutaneous nerves are located lateral to the fascia iliaca as they pass over the iliacus muscle and under the iliopubic tract. Because of the presence of these nerves lateral to the spermatic cord, the area beneath the ilopubic tract spanning from the gonadal vessels to the lateral pelvic wall toward the anterior superior iliac spine has been referred to as the “triangle of pain.” Nerve injury or entrapment here can cause neuralgia.

POSTEROLATERAL ABDOMINAL WALL (LUMBAR AREA)

Surgically, the lumbar area is defined as the area between the lower edge of the 12th rib superiorly, the iliac crest inferiorly, the erector spinae muscle medially, and the posterior border of the external oblique muscle laterally. Topographically, it is the area lateral to the midclavicular line and between the subcostal plane and transtubercular plane (which joins the tubercles of the iliac crests).

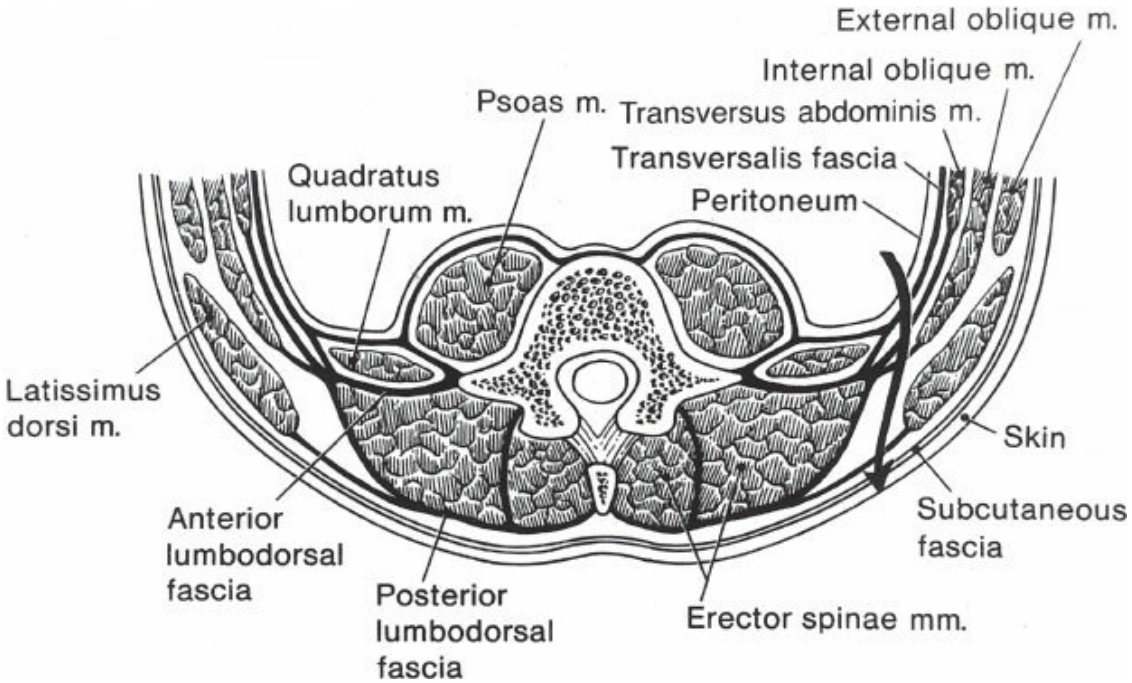

Figure 187.23. A diagrammatic cross-section through the posterior body wall in the lumbar region. *Arrow* indicates the pathway of a superior lumbar hernia. m, muscle. (Copyright (© 1996) From Skandalakis LJ, Gadacz TR, Mansberger AR Jr, et al. *Modern Hernia Repair: The embryological and anatomical basis of surgery.* Pearl River, NY: Parthenon; 1996. Reproduced by permission of Taylor and Francis Group, LLC, a division of Informa plc.)

The lumbar wall comprises the following anatomic entities: (1) extraperitoneal tissue with fatty and membranous layer; the membranous layer is continuous with the renal fascia; (2) transversalis fascia: this is the inner investing fascia of the transversous muscle; (3) deep muscular layer consisting of quadratus lumborum muscle and psoas muscle; (4) middle muscular layer consisting of sacrospinalis muscle, internal oblique muscle, and serratus posterior inferior muscle; (5) thoracolumbar (lumbodorsal) fascia, which is the union of aponeuroses and of all muscles; the innermost layer is continuous with the transversalis fascia; (6) superficial muscular layer consisting of latissimus dorsi muscle posterolaterally and external oblique muscle anterolaterally; (7) superficial fascia, formed by two layers: membranous and fatty; and (8) skin (Fig. 187.23).

Formation and Boundaries of the Lumbar Triangles

Hernial Ring of the Superior Triangle (of Grynfeltt) (Lesshaft Space)

The superior lumbar triangle is an inverted triangular space, with base the

12th rib and serratus posterior inferior muscle (Fig. 187.24, **right**). Anteriorly the triangle is bounded by the posterior border of the internal oblique muscle, and posteriorly by the anterior border of the sacrospinalis muscle. The roof is formed by the latissimus dorsi muscle. The floor is formed by the aponeurosis of the transversus abdominis muscle.

The superior lumbar triangle is related to the 12th thoracic and 1st lumbar nerves. The area of the fascial penetration of the 12th intercostal neurovascular pedicle is a very common site of herniation.

If incarceration occurs in a lumbar hernia, the ring of the superior triangle can be enlarged by medial or lateral incision midway between the 12th rib and the iliac crest.

Hernial Ring of the Inferior Triangle (of Petit)

The inferior lumbar triangle is an upright triangular space (Fig. 187.24, **left**). Its boundaries are the posterior border of the external oblique muscle anteriorly, the anterior border of the latissimus dorsi muscle posteriorly, and the iliac crest inferiorly, which forms the base of the triangle. Its roof is the superficial fascia. Its floor is the internal oblique muscle, with contributions from the transversus abdominis muscle and the posterior lamina of the lumbodorsal fascia.

If incarceration occurs, the ring of the inferior triangle can be enlarged by medial or lateral incision of the thoracolumbar fascia.

INCISIONAL HERNIA

It is not possible to provide a generalized description of the ring in an incisional hernia because each case is different. The ring may be small or large, the result of any incision of the anterolateral or posterolateral abdominal wall.

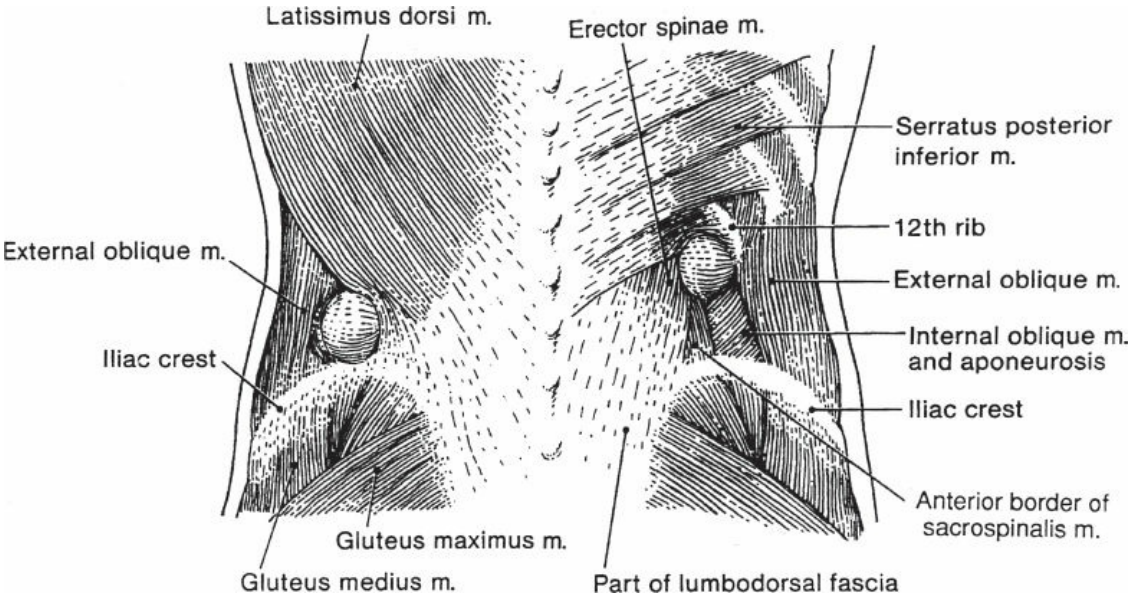

Figure 187.24. Left: An inferior hernia through Petit triangle. The base of the triangle is formed by the iliac crest. **Right:** A superior hernia through the Grynfeltt triangle. The base of the inverted triangle is formed by the 12th rib. m, muscle. (Reprinted from Skandalakis JE, Gray SW, Akin JT Jr. The surgical anatomy of hernial rings. *Surg Clin North Am* 1974;54(6):1227–46. Copyright © 1974 Elsevier, with permission.)

PELVIC WALLS

The pelvic walls are formed by four walls—anterior, posterior, right lateral, left lateral—and by a floor.

Anterior Wall

The anterior wall is formed by the pubic bones and the pubic symphysis.

Posterior Wall

The posterior wall is formed by the sacrum and coccyx, sacroiliac joints, piriformis muscles, part of the pelvic diaphragm, and several ligaments.

Lateral Walls

The hip bones and the obturator foramen, with its membrane, form the lateral pelvic walls. The majority of the surface of the lateral pelvic walls is covered by the obturator internus muscles. The following anatomic entities are located medial to the obturator internus muscle: obturator nerve, obturator vessels, and branches of the internal iliac arteries and

veins.

The obturator internus extends posteriorly from the lesser pelvis, through the lesser sciatic foramen, and then laterally toward the greater trochanter of the femur.

Pelvic Floor

The pelvic floor is simply the pelvic diaphragm (Fig. 187.25), which is formed by the levator ani muscles, the coccygeus muscles, and the superior and inferior fascial layer that covers the muscles. The levator ani is formed by three muscles: pubococcygeus, puborectalis, and iliococcygeus.

SCIATIC HERNIA RINGS

There are three potential rings associated with the at-large sciatic hernia (Fig. 187.26). The suprapiriformic and infrapiriformic rings are associated with the greater sciatic foramen, above or below the piriformis muscle. The subspinous ring is associated with the lesser sciatic foramen.

Boundaries of the Sciatic Hernia Rings

Suprapiriformic Ring

Anterior: Sacroiliac ligament
Inferior: Upper border of piriformis muscle
Lateral: Ilium
Medial: Sacrotuberous ligament and upper part of sacrum

If incarceration occurs, the piriformis muscle should be transected by a posterior and inferior incision (downward and outward). Remember that the greater sciatic foramen is the “Monemvassia” (only gate) of the gluteal area. The surgeon must exercise care to avoid damaging any of the structures that lie in or pass through the foramen:

Piriformis muscle
Superior gluteal nerve and vessels
Inferior gluteal nerve and vessels
Pudendal nerve and internal pudendal vessels
Posterior femoral cutaneous nerve
Nerve to the internal obturator muscle
Nerve to the quadratus femoris muscle

Sciatic nerve

Infrapiriformic Ring

Above: Lower border of piriformis muscle
Below: Sacrospinous ligament
Posterior: Sacrotuberous ligament
Anterior: Ilium

With incarceration, the piriformis muscle should be transected by upward and inward incision. Keep in mind the proximity of the vessels and nerves passing through the greater sciatic foramen (see the previous section).

Subspinous Ring

Anterior: Ischial tuberosity
Superior: Sacrospinous ligament and ischial spine
Posterior: Sacrotuberous ligament

If incarceration occurs, incise the obturator internus and gemellus muscles, as necessary.

OBTURATOR HERNIA RING

An obturator hernia is the protrusion of either intraperitoneal or extraperitoneal organ or tissue through the obturator canal.

The obturator (or adductor) region lies in the medial portion of the upper thigh, between the flexor muscles of the thigh in front and the extensor muscles behind. It includes the origins of the adductor muscles from the circumference of the obturator foramen and the obturator membrane, and the obturator canal.

The obturator foramen is formed anteriorly and inferiorly by the rami of the ischium and pubis. It is closed by the obturator membrane, except for a small area, the obturator canal.

The obturator membrane is a continuation of the periosteum of the surrounding bones and of the internal and external obturator muscle tendons.

The obturator canal is a 2 to 3 cm long, 1 cm wide tunnel. It starts in the pelvis and follows an oblique downward course, exits the pelvis, and ends in the obturator region of the thigh. The obturator canal is bounded by the obturator groove of the pubic bone superolateraly, and by the free edge

of the obturator membrane and the internal and external obturator muscles inferiorly. The pelvic orifice of the obturator canal can be conceived as an opening of the obturator fascia, which is the continuation of the transversalis fascia, forming a general investing layer for the pelvic muscles. The external (superficial) opening of the obturator canal that also can be conceived of is found under the pectineus muscle, medially to the femoral vein.

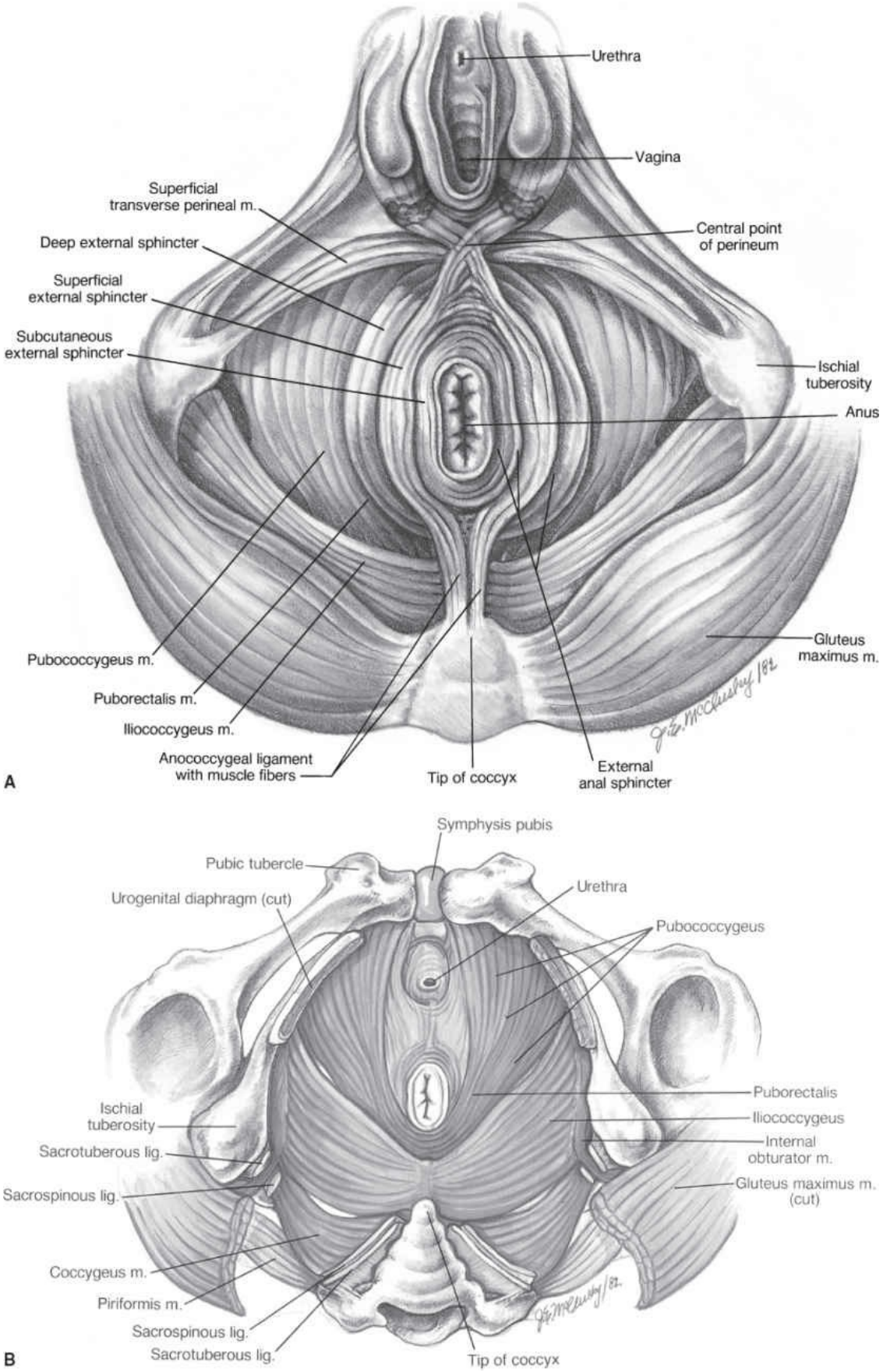

Figure 187.25. A. Female pelvic diaphragm, seen from below. m, muscle. **B.** Male pelvic diaphragm, seen from below. lig,

ligament; m, muscle. (From Gray SW, Skandalakis JE, McClusky DA. *Atlas of Surgical Anatomy for General Surgeons.* Baltimore, MD: Williams & Wilkins; 1985, with permission.)

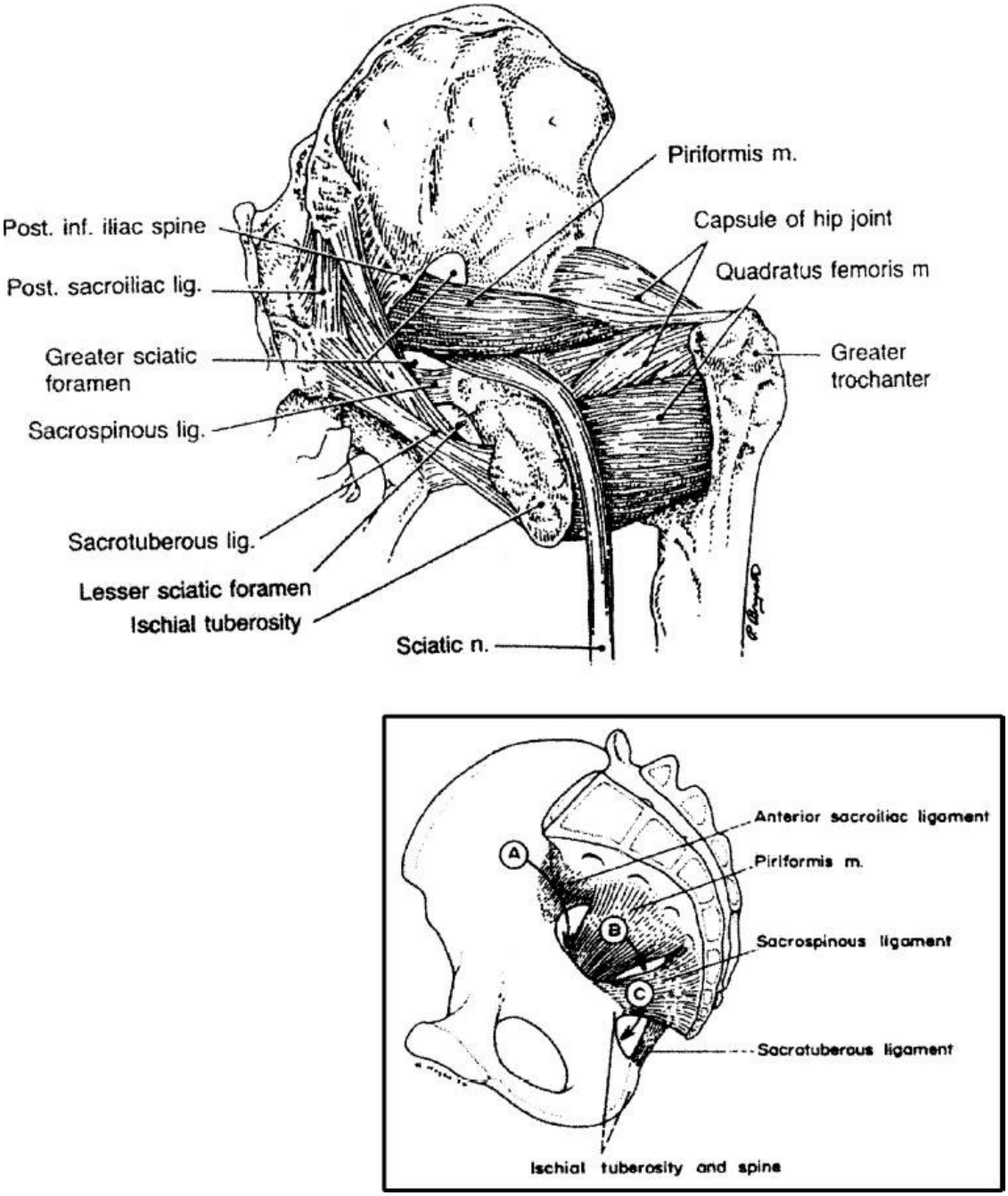

Figure 187.26. Right lateral external view of pelvis. The greater sciatic foramen transmits the piriformis muscle and sciatic nerve. **Inset:** Sites of potential herniae through the sciatic foramina. A, suprapiriformic sciatic hernia; B, infrapiriformic sciatic hernia; C, subspinous sciatic hernia through the lesser sciatic foramen. (Copyright (©1996) From Skandalakis LJ, Gadacz TR, Mansberger AR Jr, et al. *Modern Hernia Repair: The*

embryological and anatomical basis of surgery. Pearl River, NY: Parthenon; 1996. Reproduced by permission of Taylor and Francis Group, LLC, a division of Informa plc.)

Contents of obturator canal include the obturator nerve, artery, and vein (Fig. 187.27). They run in a bed of areolo-adipose tissue, which is the continuation of the extraperitoneal tissue of the pelvis toward the corresponding tissue of the thigh. This tissue is the "fat body" of the obturator canal.

PERINEUM

The perineum is defined as the region of the body lying below the pelvic diaphragm, between the inner aspects of the thighs and anterior to the sacrum and coccyx. The perineum is a diamond-shaped region. A transverse line between the right and left ischial tuberosities divides the diamond into an anterior urogenital triangle and a posterior anal triangle. More correctly the urogenital triangle is delineated posteriorly by the transverse perineal muscles.

The **urogenital triangle** comprises the following layers (superficial to deep): (1) skin; (2) adipose layer of superficial perineal fascia; (3) membranous layer of superficial perineal fascia; (4) deep perineal fascia, i.e., the investing fascia of the superficial muscles of the perineum; (5) the superficial muscles of the perineum (bulbocavernosus, ischiocavernosus, superficial transversus); (6) perineal membrane, consisting of strong fibrous tissue, which extends between the pubic arch and the ischiopubic rami; and (7) deep muscles of the perineum (deep transversus, sphincter urethrae) (Figs. 187.28 and 187.29). These are better understood when placed in spaces (compartments), as follows.

The *spaces of the urogenital triangle* as revised by our team (see Mirilas & Skandalakis, *J Am Col Surg* 2004) are: (1) subcutaneous perineal space, a potential space between the membranous layer of the superficial perineal fascia and the deep perineal fascia; (2) superficial perineal space (Fig. 187.29), between the deep perineal fascia and the perineal membrane, which contains the paired superficial transverse perineal muscles, the corpus spongiosum (male), the bulb of vestibule (female), the corpora cavernosa, the bulbospongiosus and ischiocavernosus muscles, and branches of the internal pudendal vessels and nerves; and (3) deep perineal space (Fig. 187.29), which extends from

the perineal membrane upward into the pelvic cavity. It contains the paired deep transverse perineal muscles, the sphincter urethralis (urethrovaginalis in the female), the bulbourethral (Cowper's) glands (in the male), and the internal pudendal artery and veins.

The **anal triangle** comprises the ischioanal fossae, one on either side, defined as the space between the skin below and the pelvic diaphragm above (Fig. 187.30). These fossae are filled with fat, but also in there pass the inferior rectal vessels and nerves.

PERINEAL HERNIA RING

A primary perineal hernia may occur anterior or posterior to the superficial transverse perineal muscle (Fig. 187.29).

Anterior Perineal Hernia Ring

An anterior perineal hernia passes through the pelvic diaphragm, lateral to the urinary bladder and vagina and anterior to the urethra, and enters the deep perineal space. It then penetrates the perineal membrane and is found in the superficial perineal space (Fig. 187.29).

The ring is located anterior to the superficial transverse perineal muscle through the urogenital diaphragm into a triangle formed by the bulbospongiosus muscle medially, the ischiocavernous muscle laterally, and the transverse perineal muscle posteriorly. The sac passes between the ischiopubic bone and the vagina, producing a swelling in the posterior half of the labium majus.

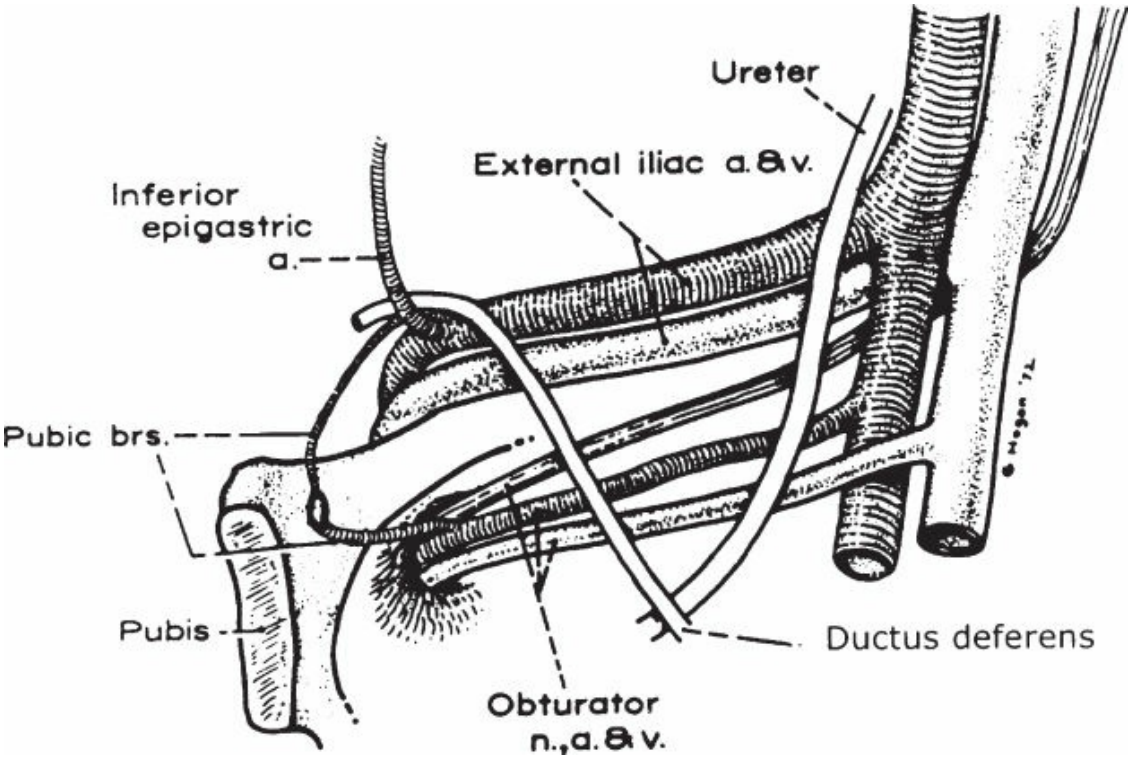

Figure 187.27. View of the medial wall of the male pelvis. The structures that pass through the obturator canal are shown. The obturator nerve lies superior to the obturator artery. The obturator artery lies superior to the obturator vein. An anastomosis between the obturator artery and the inferior epigastric artery is noted. (Reprinted from Gray SW, Skandalakis JE, Soria RE, et al. Strangulated obturator hernia. *Surgery* 1974;75:20–7. Copyright © 1974 Elsevier, with permission.)

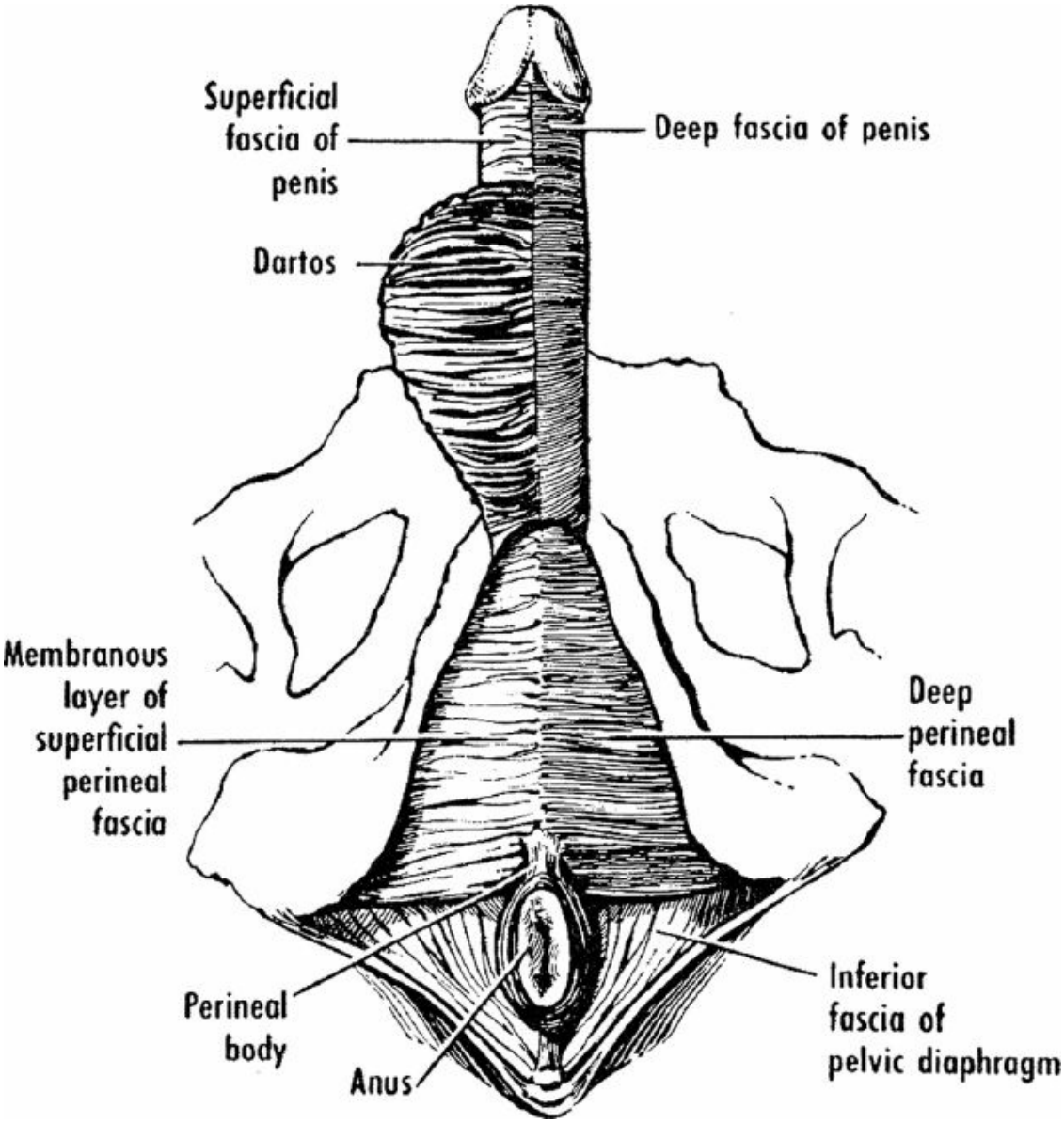

Figure 187.28. Schematic drawing of the male perineum, inferior view. The superficial fascia has been removed at the right. (From O'Rahilly R. *Gardner-Gray-O'Rahilly Anatomy: A Regional Study of Human Structure.* 5th ed. Philadelphia, PA: WB Saunders Co; 1986, with permission.)

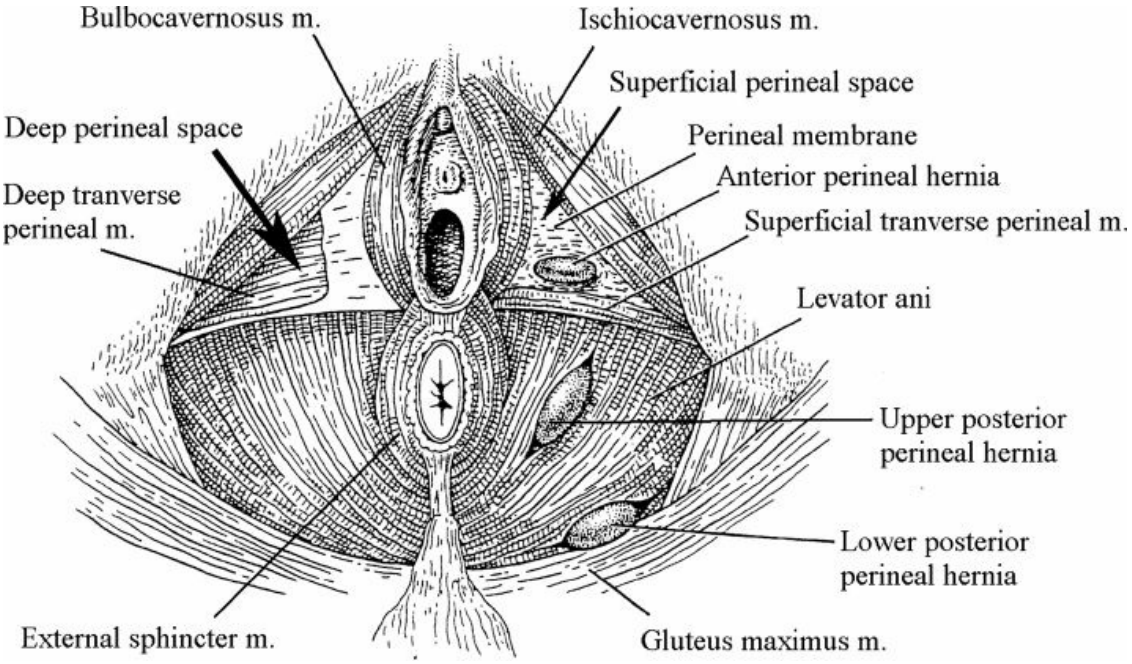

Figure 187.29. The perineum of the female, as seen from below. In this drawing, the investing fascia of muscles has been removed. The superficial perineal space can be seen exteriorly to the perineal membrane. The deep perineal space (containing the deep transverse perineal muscle) is seen interiorly to the perineal membrane. Sites of perineal herniation are shown. An anterior perineal hernia occurs anterior to the superficial transverse perineal muscles. It protrudes through the perineal membrane, into the superficial perineal space. A posterior perineal hernia occurs posterior to the superficial transverse perineal muscles. It protrudes through the pelvic floor. It may emerge either between components of the levator ani muscle or between the levator ani and coccygeus muscles. (Republished with permission of Taylor and Francis Group LLC Books, from Skandalakis LJ, Gadacz TR, Mansberger AR, et al., eds. *Modern Hernia Repair: The Embryological and Anatomical Basis of Surgery.* New York: Parthenon Publishing Group; 1996, permission conveyed through Copyright Clearance Center, Inc.)

If incarceration is present, the deep transverse perineal muscle, including the urogenital diaphragm, should be incised.

Posterior Perineal Hernia Ring

A posterior perineal hernia may pass either between muscles of the pelvic diaphragm (Fig. 187.29), or through a defect resulting from the nonunion of the obturator internus and the iliococcygeus muscles, known as the

hiatus of Schwalbe (Fig. 187.30, ***inset***). Posterior perineal hernias that pass between the pubococcygeus and iliococcygeus muscles are called upper posterior perineal hernias (Fig. 187.29). Those passing between the iliococcygeus and coccygeus muscles are named lower posterior perineal hernias (Fig. 187.30). After passing through the pelvic floor, a posterior perineal hernia enters the ischioanal fossa and presents as a lump below the lower margin of the gluteus maximus muscle or as a swelling between the anus and the ischial tuberosity.

Division of the levator ani muscle by a small incision is sufficient to release an incarcerated viscus. Care must be taken, however, to avoid the pudendal nerve, which lies in the perineum just deep to the levator ani.

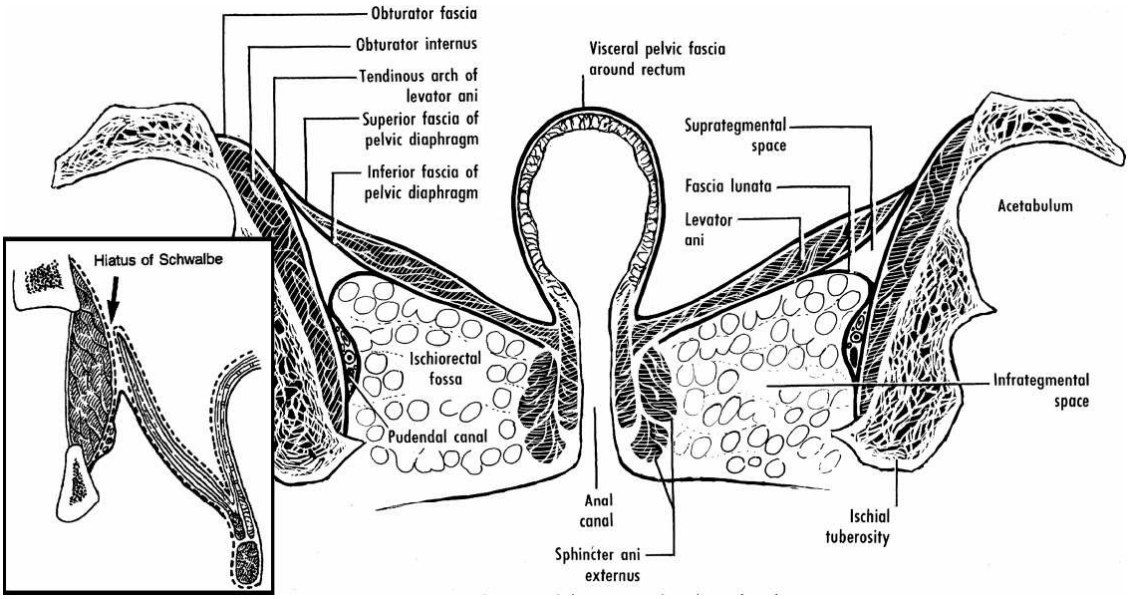

Figure 187.30. Ischioanal (ischiorectal) fossae. (From O'Rahilly R. *Gardner-Gray-O'Rahilly Anatomy. A Regional Study of Human Structure.* 5th ed. Philadelphia, PA: WB Saunders Co; 1986, with permission.) **Inset:** The hiatus of Schwalbe is produced by the nonunion of the investing fasciae (*dashed lines*) of the obturator internus and the iliococcygeus muscles. (From Skandalakis LJ, Gadacz TR, Mansberger AR, et al. eds. Modern Hernia Repair. *The Embryological and Anatomical Basis of Surgery.* New York: Parthenon Publishing Group; 1996, with permission.)

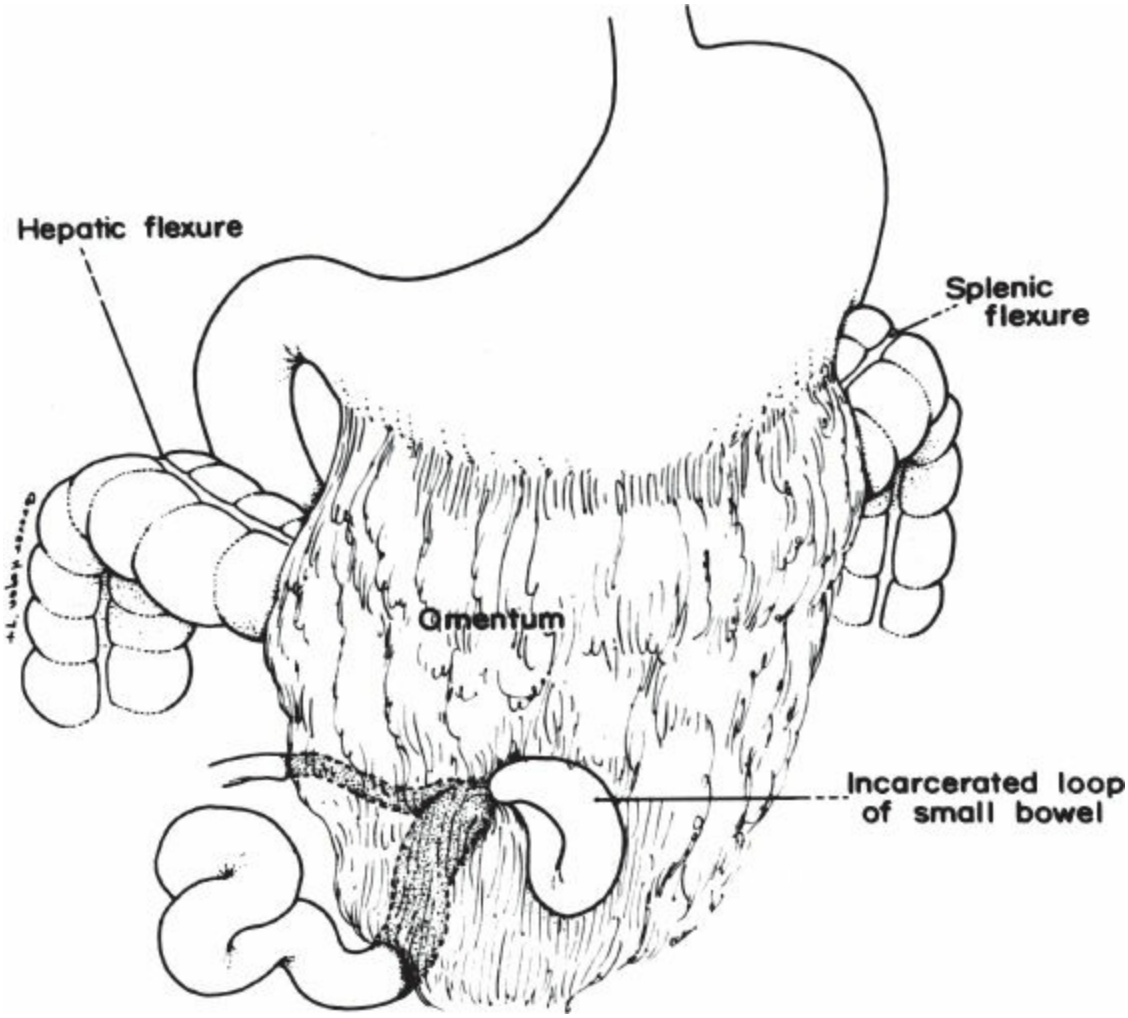

Figure 187.31. Transomental hernia. (Reprinted from Skandalakis JE, Gray SW, Akin JT Jr. The surgical anatomy of hernial rings. *Surg Clin North Am* 1974;54(6):1227–46. Copyright © 1974 Elsevier, with permission.)

DIAPHRAGM

The following hernias are encountered:

Hiatal esophageal hernia (sliding hiatal and paraesophageal)
Congenital diaphragmatic rings

- Bochdalek (Posterolateral) ring
- Morgagni (Retrosternal) ring
- Pericardial ring

These hernias and the surgical anatomy of the respective rings are discussed in Chapter 63 “Surgical Anatomy of the Diaphragm.” They are briefly presented in Table 187.1.

PERITONEAL CAVITY

Hernias Through Mesenteries

Transomental Hernia

The transomental hernia passes through the greater omentum. The surgical anatomy of the ring appears in Figure 187.31. The ring is formed entirely by omentum. A vessel usually lies in one edge of the ring. Incise the omentum between clamps.

Transmesenteric Hernia

A transmesenteric hernia may pass through the mesentery of the small bowel, the transverse mesocolon, the pelvic (sigmoid) mesocolon, or the falciform ligament. The mesenteric ring may be located in the mesentery of the small intestine, the transverse mesocolon, or the sigmoid mesocolon (Fig. 187.32). At least one free edge of the ring is usually formed by a branch of the superior mesenteric or inferior mesenteric artery. Because there is no sac and the obstructed loop is invisible, decompress the dilated loop only and do not incise the neck. Vascular injury must be avoided.

Hernias Through Foramina and Fossae

Hernia Through the Epiploic Foramen of Winslow

The boundaries of the foramen of Winslow (Fig. 187.33) are:

Superior: Caudate process of liver and inferior layer of coronary ligament

Anterior: Hepatoduodenal ligament containing portal vein, hepatic artery, and common bile duct (cystic duct is also present in free edge of lesser omentum)

Posterior: Inferior vena cava

Inferior: First part of duodenum and transverse part of hepatic artery

For the incision, after clamping and decompressing the proximal intestinal loop, open the hepatogastric omentum. The hepatic artery should not be ligated. Remember that there is no excuse for dividing the neck of the sac. As J. E. Fischer commented in the edition (5th) of *Mastery of Surgery*: “It is difficult to conceive a situation in which one might divide the hepatic artery in order to decompress the bowel. Far better to clamp off the bowel, decompress it with a tube, and then extract the herniated bowel.”

Hernia Through the Paraduodenal Fossae (Paraduodenal Hernia Rings)

Right Paraduodenal Hernia

The hernial ring lies behind the superior mesenteric artery and vein or the ileocolic artery at the base of the mesentery of the small intestine (mesentericoparietal fossa of Waldeyer) (Fig. 187.34). The mouth of the sac opens to the left. The sac is directed to the right and usually lies in the retroperitoneal space behind the right mesocolon or transverse mesocolon. Typically the mouth of the sac lies behind the superior mesenteric artery or at its more posterior continuation, the ileocolic artery. The boundaries are:

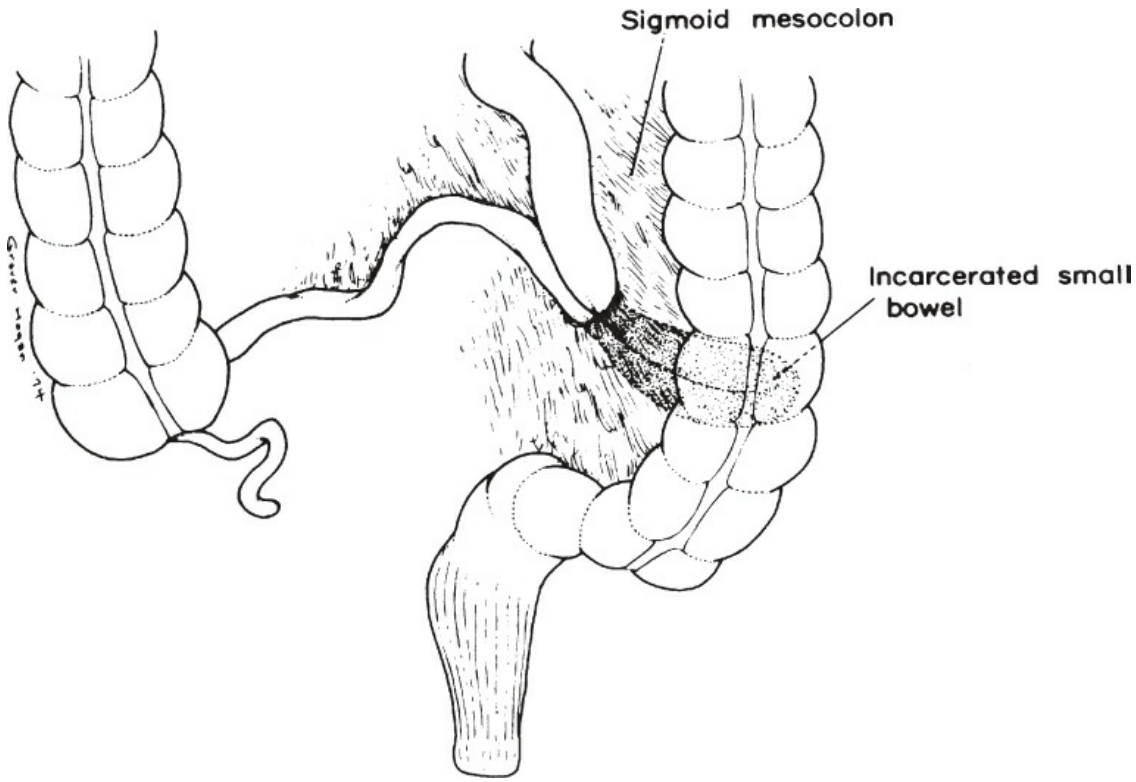

Figure 187.32. Transmesenteric hernia. (Reprinted from Skandalakis JE, Gray SW, Akin JT Jr. The surgical anatomy of hernial rings. *Surg Clin North Am* 1974;54(6):1227–46. Copyright © 1974 Elsevier, with permission.)

TABLE 187.1 Surgical Anatomy of Hernial Rings

Hernia	Definition	Boundaries	If Incarcerated
Anterolateral Abdominal Wall			
Epigastric (ventral)	Defect of linea alba anywhere from xiphoid to umbilicus	Medial edge of right or left rectus sheath (anterior and posterior laminae as well as lateral edge of muscle between) may form lateral border	Superior or inferior incision of linea alba; rarely lateral incision of anterior lamina of rectus sheath
Umbilical	Incomplete closure of early natural umbilical defect; absence of umbilical fascia	Superior and inferior—linea alba Lateral—rectus abdominis muscle	Isolate sac; ligate through superior or inferior incision of linea alba
Omphalocele	Herniation of intraperitoneal viscera into open umbilical ring	Umbilical cord; hernial sac covered by double layer of membranes (amniotic outside, peritoneum inside, Wharton jelly in between)	Right or left horizontal incision
Gastroschisis	Defect of anterior abdominal wall to right or left of the midline	Layers of the abdominal wall	May need to incise the lower edge of the ring
Spigelian	Herniation along the linea semilunaris of Spieghel (line of transition between the muscular fibers and the aponeurosis of the transversus abdominis muscle) anywhere above level of umbilicus lateral to the symphysis pubis	*If at intersection of linea semilunaris (Spieghel) and linea semicircularis (Douglas), or above the linea semicircularis but below and lateral to the umbilicus:* aponeurosis of internal oblique muscle and the aponeurosis of the transversus abdominis muscle *If above the level of the umbilicus:* ring is formed by tear in the transversus abdominus muscle and a defect of the aponeurosis of the internal oblique muscle	Transverse incision above swelling; oblique incision of aponeurosis of the external oblique muscle following the direction of the fibers
Groin—indirect	Herniation through the deep (internal) inguinal ring following the spermatic cord in male patients and the round ligament in female patients; may herniate through superficial (external) ring	*Boundaries of deep ring:* anterior and posterior—thickening of transversalis fascia "sling" inferior—iliopubic tract *Boundaries of superficial ring:* triangular opening of aponeurosis of external oblique composed of superior (medial) and inferior (lateral) crura; base of triangle is pubic crest	If at deep ring: internal oblique retracted medially by upward incision; open sac and release incarceration
Groin—direct	Herniation through floor of inguinal canal—covered by transversalis fascia and aponeurosis of the transversus abdominis muscle	Located at medial fossa	Rarely, through external ring; treat as indirect hernia incarceration
Groin—external supravesical	Herniation between midline and lateral umbilical ligament	Partially or totally occupying the supravesical fossa	Treat as indirect hernia incarceration
Femoral	Herniation through femoral canal (consisting of proximal ring and distal ring)	*Proximal ring:* anterior—iliopubic tract, inguinal ligament, or rarely, both Posterior—ligament of Cooper (pectineal ligament) Lateral—femoral vein Medial—insertion of iliopubic tract *Distal ring:* anterior—fascia lata Posterior—pectineal fascia Lateral—femoral sheath Medial—iliopubic tract or lacunar ligament	Small incision to divide inguinal ligament anteriorly; alternatively, divide the lacunar ligament medially; in the latter case, be aware of an aberrant obturator artery (30%) passing medial to the femoral ring in the edge of the lacunar ligament

Posterolateral Abdominal Wall (Lumbar)			
	Herniation through superior and inferior lumbar triangles	*Superior triangle:* base—12th rib and serratus posterior inferior muscle Anterior—posterior border of the internal oblique muscle Posterior—anterior border of sacrospinalis muscle Floor—aponeurosis of transversus abdominis muscle	Enlarge ring of the superior triangle by medial or lateral incision midway between the 12th rib and the iliac crest
		Roof—external oblique and latissimus dorsi muscle *Inferior triangle:* base—iliac crest Anterior—posterior border of external oblique muscle Posterior—anterior border of latissimus dorsi muscle Floor—internal oblique with transversus abdominis muscle and posterior lamina of thoracolumbar fascia of internal oblique	Enlarge ring of the inferior triangle by medial or lateral incision of the thoracolumbar fascia
Incisions	Varies according to the incision	Various	Incision of the ring is determined by topography
Pelvic Walls and Perineum			
Sciatic—suprapiriformic	Herniation through greater sciatic foramen above piriformis muscle	Anterior—sacroiliac ligament Inferior—upper border of piriformis muscle Lateral—ilium Medial—sacrotuberous ligament and upper part of sacrum	Posterior and inferior (downward and outward) incision of piriformis muscle; be aware of other structures in greater sciatic foramen
Sciatic—infrapiriformic	Herniation through greater sciatic foramen below piriformis muscle	Above—lower border of piriformis muscle Below—sacrospinous ligament Posterior—sacrotuberous ligament Anterior—ilium	Anterior and superior (upward and inward) incision of piriformis; be aware of other structures in greater sciatic foramen
Sciatic—subspinous	Herniation through lesser sciatic foramen	Anterior—ischial tuberosity Superior—sacrospinous ligament and ischial spine Posterior—sacrotuberous ligament	Incise obturator internus muscle
Obturator	Herniation through the obturator canal	Superior and lateral—obturator groove of the pubis Inferior—free edge of obturator membrane and the internal and external obturator muscles	Incision at lower margin of ring; be aware of obturator artery, vein, and nerve as they pass through the canal; inspect for aberrant obturator vessel(s)
Perineal—anterior	Herniation anterior to the superficial transverse perineal muscle	Medial—bulbospongiosus muscle Lateral—ischiocavernous muscle Posterior—transverse perineal muscle	Incise deep transverse perined muscle, including both layers of the urogenital diaphragm; sac passes between ischiopubic bone and the vagina; in male patients, very rare
Perineal—posterior	Herniation posterior to the superficial transverse perineal muscle	Ring formed through levator ani, or between the levator ani and coccygeus muscles	Small incision to divide the levator ani muscle
Diaphragm			
Hiatal esophageal (sliding or paraesophageal)	Herniation through diaphragmatic crura	In 50%, right and left limbs or the right crus; in remainder, both right and left crura are involved	Left lateral incision toward the central tendon (avoid injury to the phrenic nerve); hernial sac is always present

Diaphragmatic Rings			
Congenital—Bochdalek (posterolateral)	Herniation through the lumbocostal trigone (above and lateral to left lateral lumbocostal arch)	Located at the posterior portion of the diaphragm close to 10th and 11th ribs; if large, the central tendon is involved	Incise diaphragm laterally from margin of ring toward periphery (avoid branches of phrenic nerve)
Congenital—Morgagni (retrosternal)	Herniation through the sternocostal triangles (foramina of Morgagni)	Anterior—costal cartilage and xiphoid process Lateral and posterior—diaphragm Medial—diaphragm Ring located at fusion of central tendon and pericardium	Lateral incision to enlarge the ring (avoid phrenic nerve)
Pericardial ring	Herniation through the central tendon of the diaphragm and the pericardium	Various	Incision of the ring is determined by topography
Peritoneal Cavity and Anatomical Entities within			
Transomental	Herniation through greater omentum	Bordered entirely by omental tissues	Incise omentum between clamps since a vessel will usually lie in one edge of the ring
Transmesenteric	Herniation through mesentery of small bowel, transverse mesocolon, pelvic mesocolon, or the falciform ligament	Ring may be located in mesentery of small bowel, the transverse mesocolon, or the sigmoid mesocolon; at least one free edge of the ring is usually formed by a branch of the superior mesenteric or inferior mesenteric artery	Decompress dilated loop; do not incise the neck
Foramina or Fossae			
Epiploic foramen of Winslow	Herniation through the foramen	Superior—caudate process of liver and inferior layer of coronary ligament Anterior—hepatoduodenal ligament Posterior—inferior vena cava Inferior—first part of duodenum and transverse part of hepatic artery	After clamping and decompressing the proximal loop, open the hepatogastric omentum; do not incise the neck
Right paraduodenal	Herniation through right paraduodenal fossa	Superior—duodenum Anterior—superior mesenteric artery or ileocolic artery Posterior—lumbar vertebrae	Incise lower part of the mouth of the sac (sac lies behind the superior mesenteric artery or ileocolic artery at the base of the mesentery of the small intestine)
Left paraduodenal	Herniation through left paraduodenal fossa	Superior—duodenojejunal flexure or the beginning of the jejunum, pancreas, and renal vessels Anterior—inferior mesenteric vein and left colic artery Right—aorta Left—left kidney	Incise lower part of the mouth of the sac in downward fashion (sac lies behind the inferior mesenteric vein and the left colic artery to the left of the fourth part of the duodenum)
Superior ileocecal	Sac under right mesocolon or descending colon	Ileocolic (ileocecal) fold: formed by an anteriorly located semilunar elevation of the ileocolic mesentery by the anterior branch of the ileocecal artery	Avoid the right ileocolic and right colic arteries
Inferior ileocecal	Sac under cecum	Anterior ileoappendicular fold	Avoid the ileoappendicular artery present in the fold; avoid injury to ascending colon
Paracolic	Sac under proximal ascending colon	Paracolic fold located in the right gutter	

Internal Supravesical			
Anterior supravesical	Herniation of the supravesical fossa in front of the bladder	Superior—the upward continuation of the vesical fascia and its fusion with the transversalis fascia and the peritoneum Inferior—fold of vesical fascia and peritoneum Lateral—lateral umbilical ligament and peritoneum Medial—medial umbilical ligament and peritoneum	Incise the posterior margins upward
Retrovesical (posterior supravesical)	Herniation of the supravesical fossa behind the bladder	Superior and anterior—vesical fascia and peritoneum of posterior bladder wall Inferior and posterior—transverse vesical fold	Treat as anterior supravesical
Postsurgery			
After retrocolic gastrojejunostomy	Two potential spaces are created; upper: above the mesocolon; lower: posterior to the gastric remnant	Anterior—gastrojejunostomy and efferent or afferent jejunal loop Posterior—posterior parietal peritoneum Superior—transverse mesocolon and posterior wall of the gastric remnant Inferior—ligament of Treitz and duodenojejunal peritoneal fold	No incision should be made; perform an enterostomy to facilitate reduction and closure of the ring
Postsurgery			
After antecolic gastrojejunostomy (when afferent loop is attached to the lesser curvature of the stomach)	Rare, but more common than herniation of loop to greater curvature	Anterior—afferent jejunal loop with its mesentery Posterior—omentum, transverse colon, and mesoduodenojejunal peritoneal fold Inferior—jejunum with its mesentery	
After antecolic gastrojejunostomy (when afferent loop is attached to the greater curvature of the stomach)	Information is scant because the herniation is so rare	Anterior—gastrojejunostomy and afferent jejunal loop Posterior—omentum and mesocolon Superior—transverse colon and mesocolon Inferior—ligament of Treitz and duodenojejunal peritoneal fold	No incision should be made; perform an enterostomy to facilitate reduction

Superior: Duodenum
Anterior: Superior mesenteric vessels or ileocolic vessels
Posterior: Lumbar vertebrae

When incarceration occurs, the incision must be in the lower part of the mouth of the sac to avoid vascular injury. If vascular damage appears inevitable, the surgeon should open the mesentery and decompress the proximal intestinal loop before attempting reduction.

Left Paraduodenal Hernia

A left paraduodenal hernia is a hernia into the descending mesocolon. The mouth opens to the right. The mouth usually lies behind the inferior mesenteric vein and the left colic artery at the left of the fourth part of the duodenum at the duodenojejunal flexure, so that the first part of the duodenum enters the sac, which contains all the jejunum and ileum, except for the terminal ileum (Fig. 187.35). The sac is directed to the left and usually lies in the retroperitoneal space behind the left mesocolon. The

anterior lip of the sac contains the inferior mesenteric vein, and usually an accompanying branch of the left colic (inferior mesenteric) artery. The boundaries are:

Superior: Duodenojejunal flexure or the beginning of the jejunum, pancreas, and renal vessels
Anterior: Inferior mesenteric vein and left colic artery
Right: Aorta
Left: Left kidney

The inferior mesenteric vein is very likely to be at or very close to the mouth of the sac, mostly anteriorly. Anteriorly, the sac is also crossed by branches of the left colic artery. Thus, the incision should be made in the lower part of the mouth. McNair advised division of the inferior mesenteric vein. A downward incision of the mouth avoids this sacrifice.

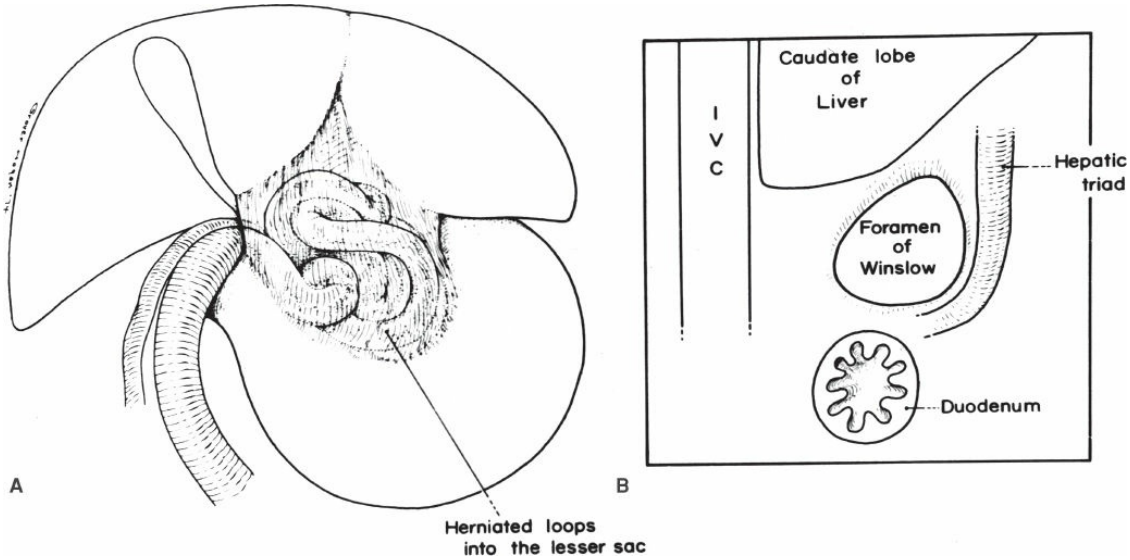

Figure 187.33. Hernia through the epiploic foramen of Winslow. **A.** The intestines have passed through the foramen into the lesser peritoneal sac (omental bursa). **B.** Diagram of the structures surrounding the foramen of Winslow. IVC, inferior vena cava. (Reprinted from Skandalakis JE, Gray SW, Akin JT Jr. The surgical anatomy of hernial rings. *Surg Clin North Am* 1974;54(6):1227–46. Copyright © 1974 Elsevier, with permission.)

Hernia Through the Pericecal Fossae

The pericecal fossa is the most important boundary of the superior

ileocecal fossae in the presence of the ileocolic (ileocecal) fold. This fold is formed by an anteriorly located semilunar elevation of the ileocolic mesentery that contains the anterior branch of the ileocolic artery. The hernial sac travels under the right mesocolon or under the descending colon (Fig. 187.36). The surgeon must avoid the ileocolic and right colic arteries when incising the hernial ring. Aspiration of the proximal loop may be prudent.

The inferior ileocecal fossa has a prominent anterior ileoappendicular fold. This fold occasionally contains the ileoappendicular artery. The hernial sac is found under the cecum.

The paracolic fossa is located at the right gutter, resulting from nonfusion of the layers of the mesocolon of the lateral and posterior walls of the ascending colon. The hernial sac is formed by these mesentery layers, and the sac travels under the proximal ascending colon.

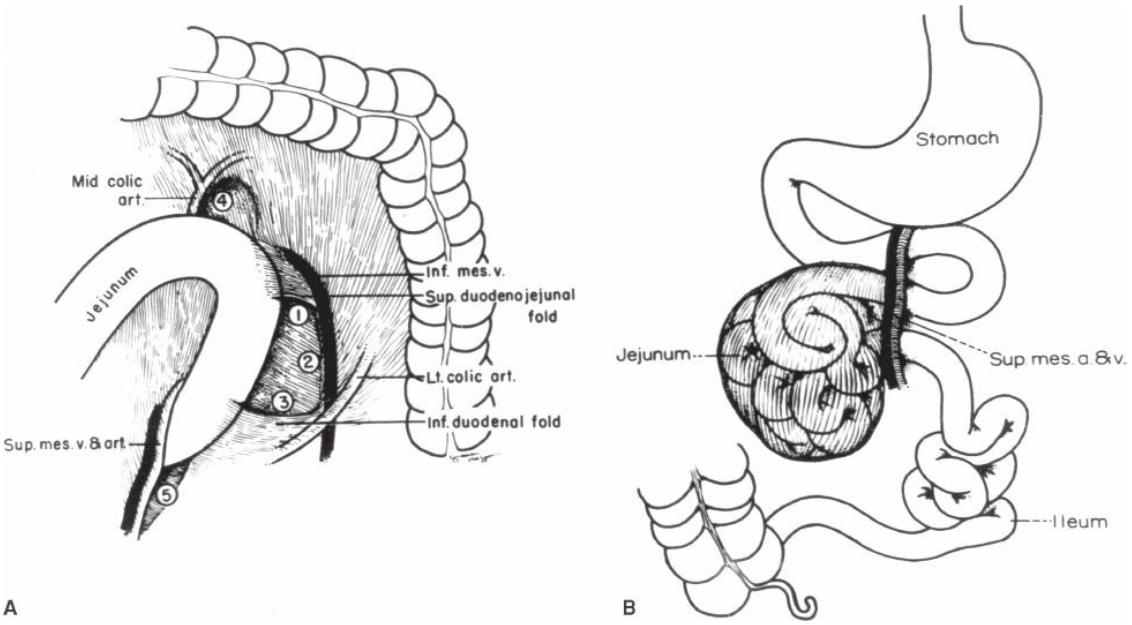

Figure 187.34. A right paraduodenal hernia into the (mesentericoparietal) fossa of Waldeyer. (Reprinted from Skandalakis JE, Gray SW, Akin JT Jr. The surgical anatomy of hernial rings. *Surg Clin North Am* 1974;54(6):1227–46. Copyright © 1974 Elsevier, with permission.)

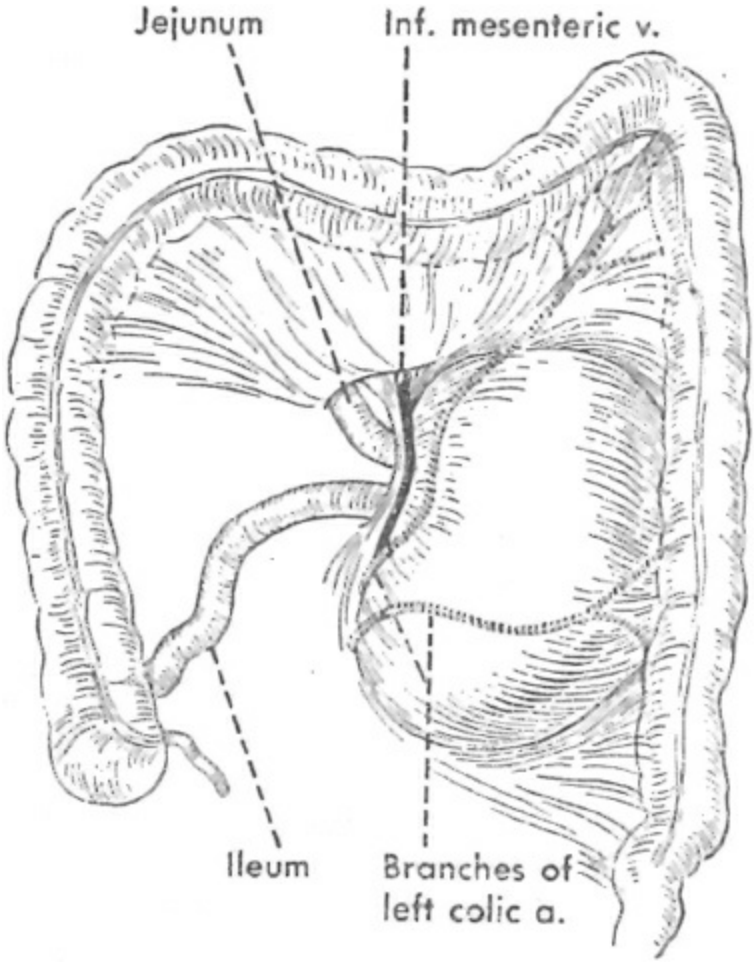

Figure 187.35. Drawing of a left paraduodenal hernia. Note the close relation of the inferior mesenteric vein, and, in this case, of and ascending branch of the left colic artery, to the mouth of the hernial sac. (From Hollinshead WH. *Anatomy for Surgeons, vol. 2.* New York: Hoeber-Harper; 1956.)

Internal Supravesical Hernia

Internal supravesical hernias are the hernias that do not exit through the abdominal wall, inguinal, femoral, obturator canal (these are called external, see specific section in groin hernia, above), but remain internal. There are several sites of internal herniation in the supravesical fossa. The hernia sac may pass in front of, beside, or behind the bladder, and accordingly the hernia is called prevesical, paravesical, or retrovesical (Fig. 187.37).

An anterior supravesical hernia may be retropubic or invaginating. The retropubic hernia is the herniation of the supravesical hernia in front of the bladder, into the space of Retzius (between the membranous layer of the preperitoneal fascia—the old posterior lamina of the transversalis fascia

and—and the peritoneum. Our opinion is that the sac passes through a defect of the umbilicovesical fascia (Fig. 187.38).

The boundaries of the ring of a retropubic hernia can be described as follows:

Superior: The upward continuation of the vesicoumbilical fascia and its fusion with the transversalis fascia and the peritoneum

Inferior: Fold of vesical fascia and peritoneum

Lateral: Lateral umbilical ligament and peritoneum

Medial: Medial umbilical ligament and peritoneum

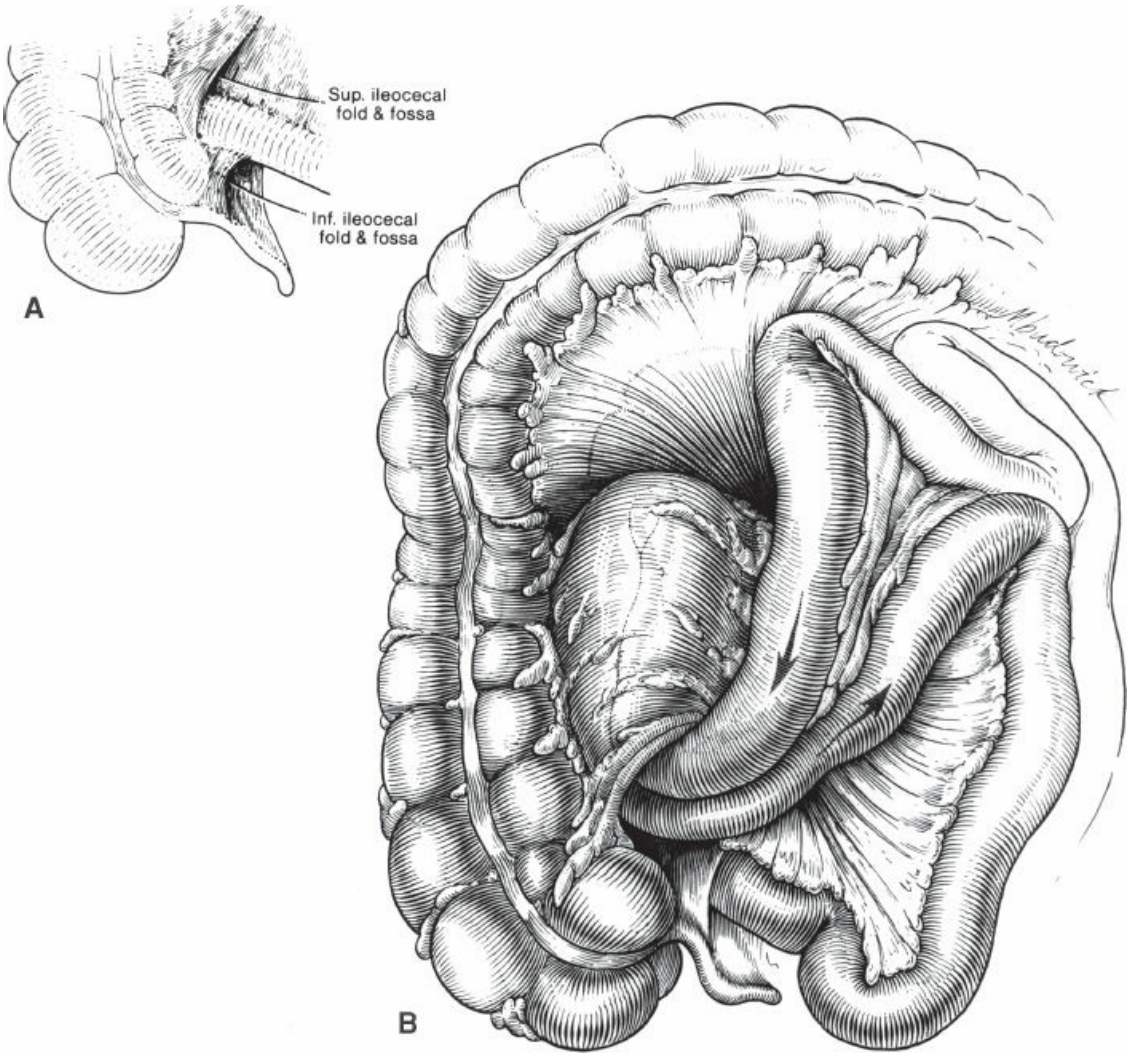

Figure 187.36. Hernia into the superior ileocecal fossa. **A.** Superior and inferior ileocecal folds forming fossae. (From Skandalakis JE, Gray SW, Rowe JS. *Anatomical Complications in General Surgery.* New York: McGraw-Hill; 1983, with permission.) **B.** An intestinal loop trapped by the right mesocolon during fusion with the peritoneum of the body wall. (B. Copyright

(©1996) From Skandalakis LJ, Gadacz TR, Mansberger AR Jr, et al. *Modern Hernia Repair: The embryological and anatomical basis of surgery.* Pearl River, NY: Parthenon; 1996. Reproduced by permission of Taylor and Francis Group, LLC, a division of Informa plc.)

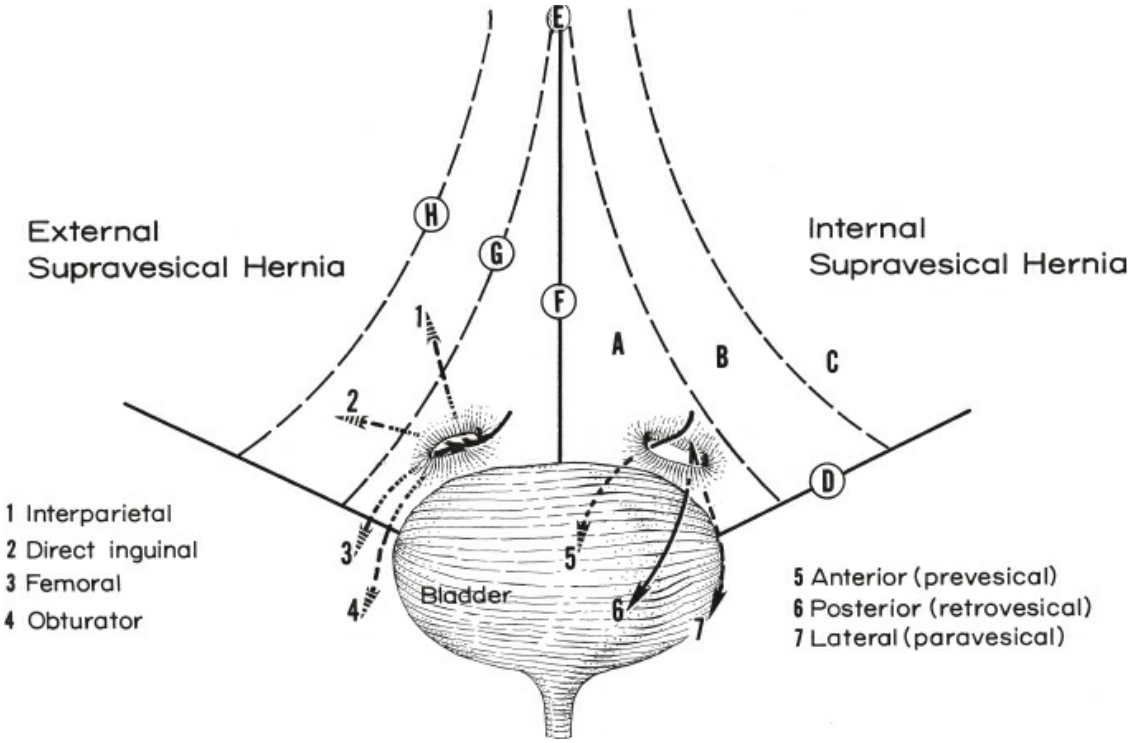

Figure 187.37. The bladder and anterolateral abdominal wall viewed posteriorly. **Left:** Possible pathways of external supravesical herniae. **Right:** Possible pathways of internal supravesical herniae. A, supravesical fossa with mouth of supravesical hernia; B, medial fossa; C, lateral fossa; D, inguinal ligament; E, umbilicus; F, middle umbilical ligament (obliterated urachus); G, medial umbilical ligament (obliterated umbilical artery); H, lateral umbilical ligament (inferior [deep] epigastric artery). (From Skandalakis PN, Skandalakis LJ, Gray SW, et al. Supravesical hernia. In: Nyhus LM, Condon RE, eds. *Hernia.* 4th ed. Philadelphia, PA: JB Lippincott; 1995;400, with permission.)

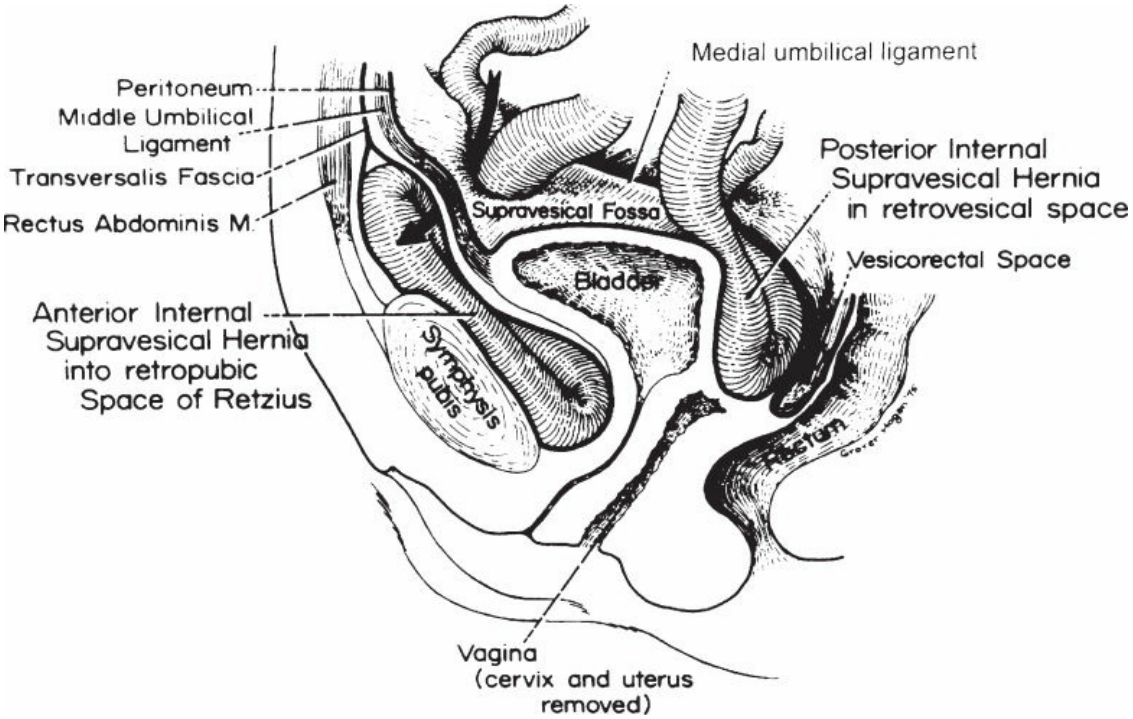

Figure 187.38. Composition of anterior and posterior internal supravesical herniae. Most are of the anterior type. *Arrow* shows path of posterior hernia in a patient who previously had undergone a hysterectomy. (Republished with permission of Southeastern Surgical Congress from Skandalakis JE, Gray SW, Burns WB, et al. Internal and external supravesical hernia. *Am Surg* 1976;42:142, permission conveyed through Copyright Clearance Center, Inc.)

The invaginating anterior supravesical (prevesical) hernia invaginates into the wall of the fundus of the bladder without protruding through the umbilicovesical fascia. This hernia does not enter the space of Retzius (Fig. 187.39).

The hernia may protrude laterally, into the paravesical space (right or left), and hence, by extension to a lateral pelvic position (see No. 2 in Fig. 187.40).

Last, the hernia may be retrovesical (see No. 3 in Fig. 187.40). The ring is at the transverse vesical fold of the bladder, between the latter and the vesical fascia and the peritoneum of the posterior wall of the bladder. The retrovesical hernia can also protrude in the rectovesical peritoneal pouch in men (Fig. 187.41) or in the vesicovaginal pouch in women (Fig. 187.42). A true retrovesical hernia is found in front of Denonvillier fascia (see No.1 in Fig. 187.41); in some occasions, however, the hernia may be found behind Denonvillier fascia, and the sac may be found protruding in the

mesorectum (see Nos. 2 and 3 in Fig. 187.41).

In all internal supravesical herniae, if enlargement of the ring is necessary, we recommend incising the posterior margins upward because of the anatomy of the area.

Postoperative Herniae

Retroanastomotic Herniae

Markowitz, an authority on iatrogenic retroanastomotic herniae, stated: "Construction of each gastrojejunostomy, either as a procedure by itself or as a step in the performance of a partial gastrectomy, results in the formation of an internal hernial ring which may be the cause of severe difficulties in the immediate or distant postoperative period."

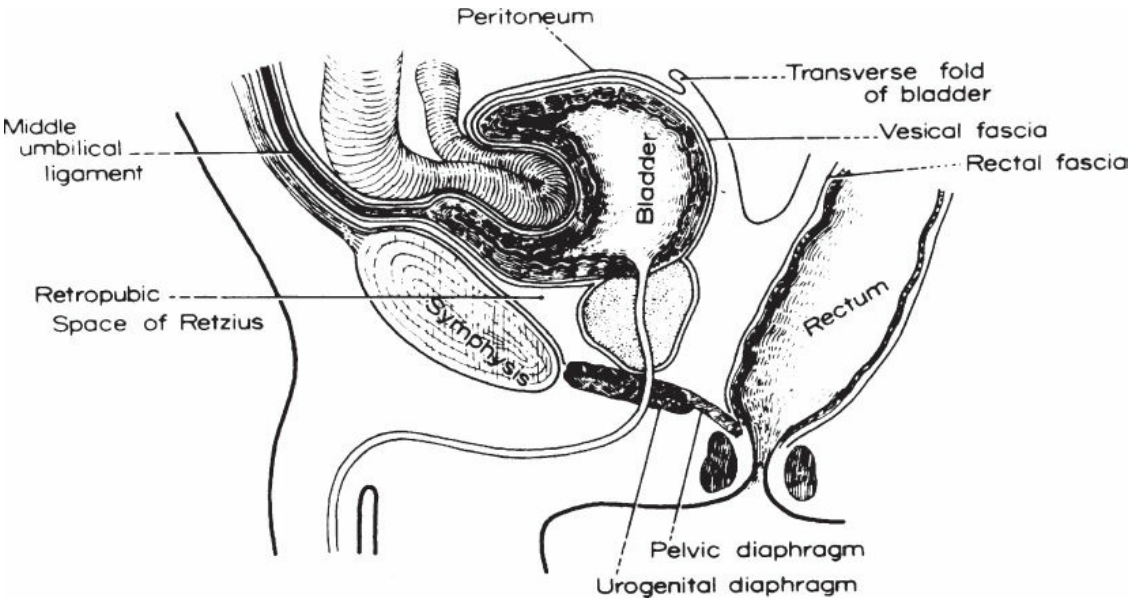

Figure 187.39. Invaginating type of anterior internal supravesical hernia. (From Skandalakis PN, Skandalakis LJ, Gray SW, et al. Supravesical hernia. In: Nyhus LM, Condon RE, eds. *Hernia.* 4th ed. Philadelphia, PA: JB Lippincott; 1995:400, with permission.)

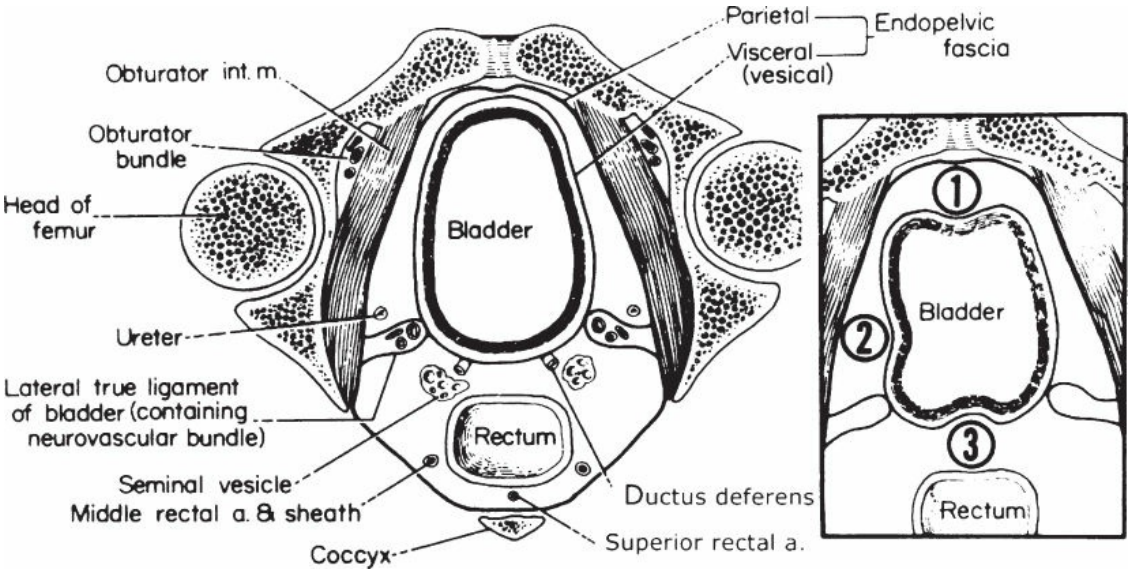

Figure 187.40. Highly diagrammatic section of the body at the level of the acetabulum showing some of the landmarks of the spaces around the bladder. **Inset:** 1, location of sac in anterior internal (int.) supravesical hernia; 2, location of sac in lateral internal supravesical hernia; 3, location of sac in posterior internal supravesical hernia. (From Skandalakis PN, Skandalakis LJ, Gray SW, et al. Supravesical hernia. In: Nyhus LM, Condon RE, eds. *Hernia.* 4th ed. Philadelphia, PA: JB Lippincott; 1995:400, with permission.)

A. Hernia After Retrocolic Gastrojejunostomy

The surgical anatomy of the hernial ring after retrocolic gastrojejunostomy is seen in Figure 187.43. The boundaries of the ring are:

Anterior: Gastrojejunostomy and efferent or afferent jejunal loop (depending on whether the afferent loop is attached to the lesser or the greater curvature of the stomach)

Posterior: Posterior parietal peritoneum

Superior: Transverse mesocolon and posterior wall of the gastric remnant

Inferior: Ligament of Treitz and duodenojejunal peritoneal fold

In case of incarceration, no incision should be made. An enterostomy should be performed to facilitate reduction of the loop. Recurrence is prevented by closure of the ring.

B. Hernia After Antecolic Gastrojejunostomy

When the afferent loop is attached to the greater curvature of the stomach (Fig. 187.36B), the boundaries of the ring are:

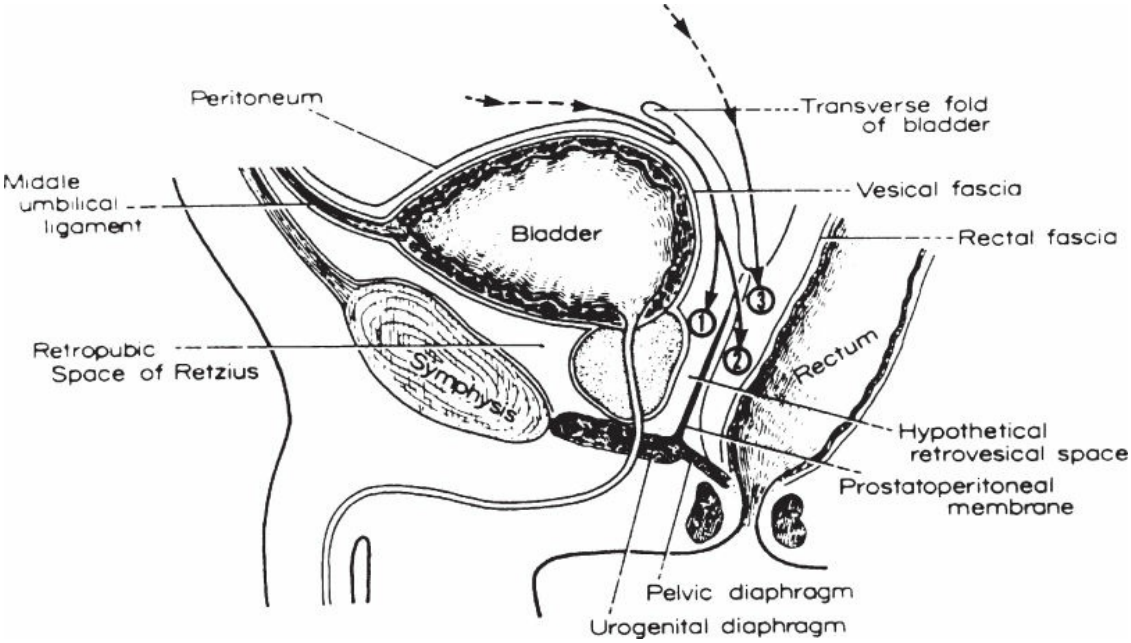

Figure 187.41. Three possible pathways of posterior internal supravesical herniae in men (*arrows*). **1**, path of true retrovesical hernia; **2**, path of retrovesical hernia; **3**, path of hernia through rectovesical pouch. (From Skandalakis PN, Skandalakis LJ, Gray SW, et al. Supravesical hernia. In: Nyhus LM, Condon RE, eds. *Hernia.* 4th ed. Philadelphia, PA: JB Lippincott; 1995:400, with permission.)

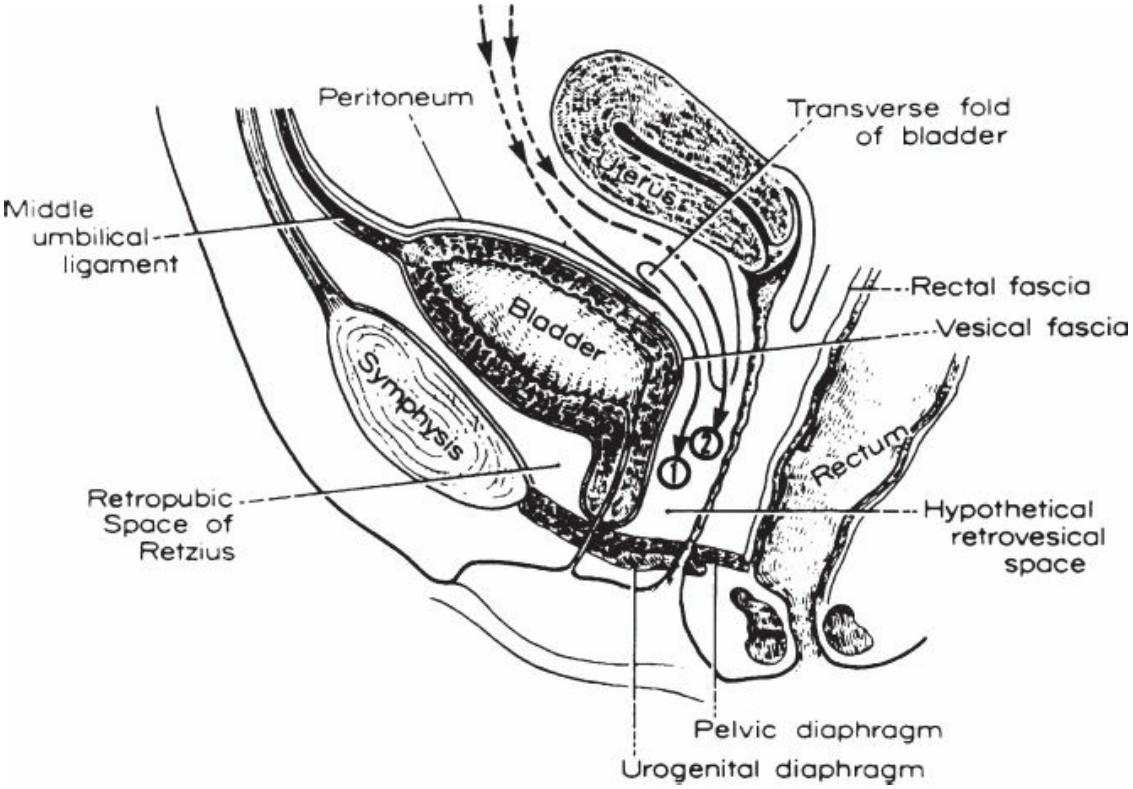

Figure 187.42. Two possible pathways of posterior internal supravesical herniae in women (*arrows*). **1**, path of true retrovesical hernia; **2**, path of hernia through vesicovaginal pouch. (From Skandalakis PN, Skandalakis LJ, Gray SW, et al. Supravesical hernia. In: Nyhus LM, Condon RE, eds. *Hernia.* 4th ed. Philadelphia, PA: JB Lippincott; 1995:400, with permission.)

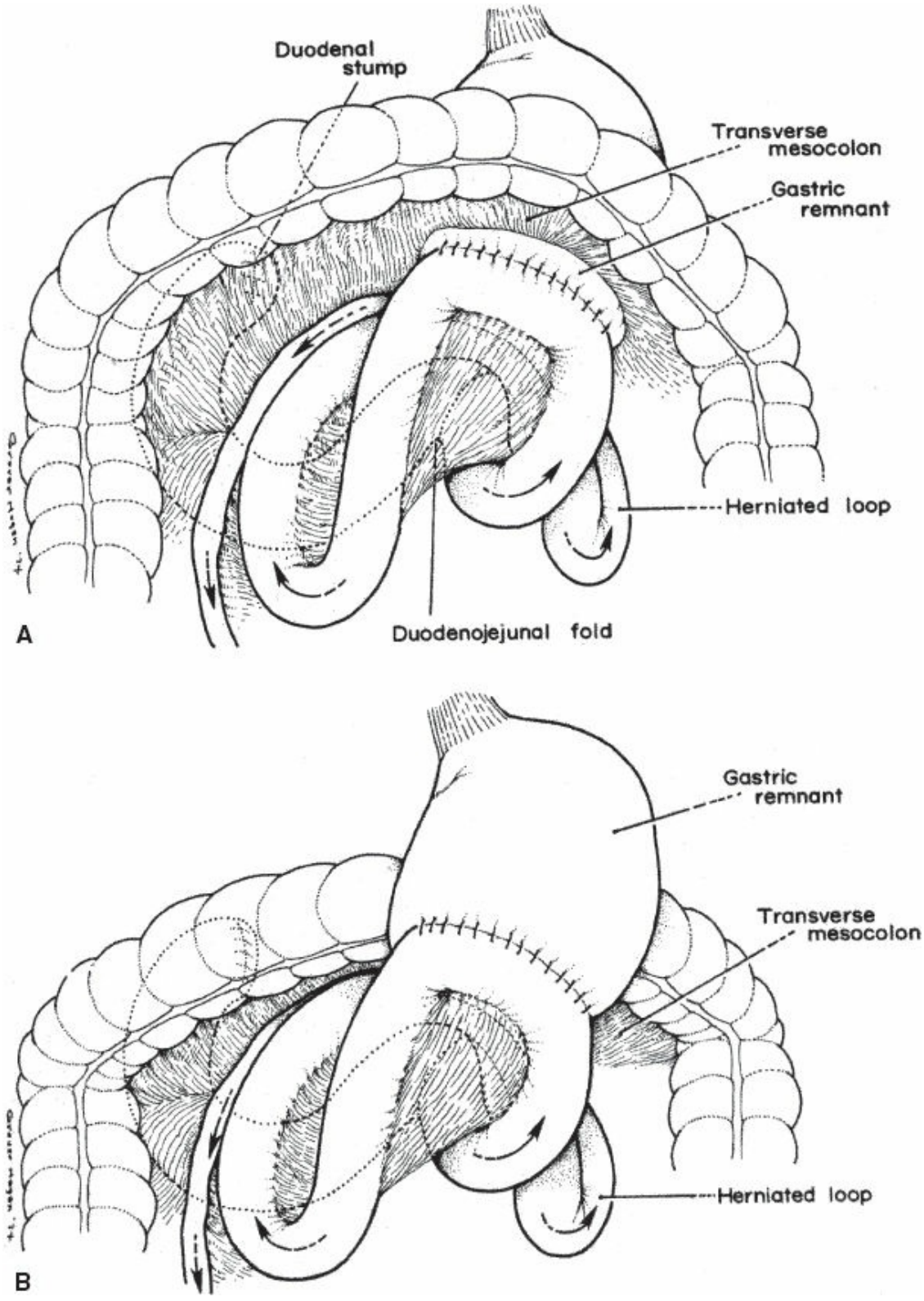

Figure 187.43. Retroanastomotic herniae. **A.** Hernia after retrocolic gastrojejunostomy. **B.** Hernia after antecolic gastrojejunostomy. (Reprinted from Skandalakis JE, Gray SW, Akin JT Jr. The surgical anatomy of hernial rings. *Surg Clin North Am* 1974;54(6):1227–46. Copyright © 1974 Elsevier, with permission.)

Anterior: Gastrojejunostomy and afferent jejunal loop
Posterior: Greater omentum and meso-colon
Superior: Transverse colon and meso-colon
Inferior: Ligament of Treitz and duodenojejunal peritoneal fold

When the afferent loop is attached to the lesser curvature of the stomach, the boundaries of the ring are:

Anterior: Afferent jejunal loop with its mesentery
Posterior: Omentum, transverse colon, and mesoduodenojejunal peritoneal fold
Inferior: Jejunum with its mesentery

With incarceration, no incision of the ring is required. Enterostomy facilitates reduction.

Table 187.1 gives a summary of the surgical anatomy of hernial rings as presented in this chapter.

Suggested Readings

Fitzgibbons RJ Jr, Greenburg AG, eds. *Nyhus and Condon's Hernia*. 5th ed. Philadelphia, PA: Lippincott Williams & Wilkins; 2001.

Hollinshead WH. *Anatomy for Surgeons, vol. 2*. New York: Hoeber-Harper; 1956:239.

Koontz A. Perineal hernia. In: Nyhus LM, Harkins HN, eds. *Hernia*. Philadelphia, PA: JB Lippincott; 1964:655.

Markowitz AM. Retroanastomotic hernia. In: Nyhus LM, Harkins HN, eds. *Hernia*. Philadelphia, PA: JB Lippincott; 1964:607.

McGregor AL, DuPlessis DJ. *A Synopsis of Surgical Anatomy*. 10th ed. Baltimore, MD: Williams & Wilkins; 1969.

McNair TJ. *Hamilton Bailey's Emergency Surgery*. 2nd ed. Baltimore, MD: Williams & Wilkins; 1972.

McVay CB. *Anson & McVay Surgical Anatomy*. 6th ed. Philadelphia, PA: WB Saunders; 1984:484.

Mirilas P, Skandalakis JE. Surgical anatomy of the retroperitoneal spaces. Part II: The architecture of retroperitoneal space. *Am Surgeon* 2010;76(1):33–42.

Mirilas P, Mentessidou A, Skandalakis JE. Secondary internal inguinal ring and associated surgical planes: surgical anatomy, embryology, applications. *J Am Coll Surg* 2008;206:561.

Mirilas P, Mentessidou A. The secondary external inguinal ring and associated fascial planes: surgical anatomy, embryology, applications. *Hernia* 2013;17(3):379–89.

Orda R, Nathan N. Surgical anatomy of the umbilical structures. *Int Surg* 1973;58:454.

Skandalakis JE, Colborn GL, Gray SW, et al. The surgical anatomy of the inguinal area. *Contemp Surg* 1991;38:20.

Skandalakis JE, Colborn GL, Weidman TA, et al. *Skandalakis' Surgical Anatomy: The Embryologic and Anatomic Basis of Modern Surgery*. Athens, Greece: Paschalidis Medical Publications; 2004:393,553,1618.

Skandalakis PN, Zoras O, Skandalakis JE, et al. Spigelian hernia: surgical anatomy, embryology, and technique of repair. *Am Surg* 2006;72(1):42–8.

Stamatiou D, Skandalakis JE, Skandalakis, LJ, et al. Lumbar hernia: surgical anatomy, embryology, and technique of repair. *Am Surg* 2009;75(3):202–7.

Stamatiou D, Skandalakis JE, Skandalakis, LJ, et al. Perineal hernia: surgical anatomy, embryology, and technique of repair. *Am Surg* 2010;76(5):474–9.

Stamatiou D, Skandalakis JE, Skandalakis LJ, et al. Obturator hernia revisited: surgical anatomy, embryology, diagnosis and technique of repair. *Am Surg* 2011;77(9):1147–57.

Standring S, ed. *Gray's Anatomy: The Anatomical Basis of Clinical Practice.* 39th ed. Edinburgh: Elsevier Churchill Livingstone; 2005:1365.

EDITOR'S COMMENT

The authors of this masterful chapter, Lee J. Skandalakis and Petros Mirilas have with their usual meticulous attention to detail, given us a chapter concerning all of the hernia rings and every conceivable type of hernia which could occur. Lee Skadalakis learned his love of the topic from his father the late John E. Skandalakis. Dr. "Skan" as he was affectionately known in and out of medical circles was the late Chris Carlos Distinguished Professor and Director for the Centers for Surgical Anatomy and Technique at the Emory University School of Medicine. He has been immortalized for his contributions to the understanding of applied human anatomy.

The surgeon must know the precise surgical anatomy of the hernial rings to incise without any injury, and more care should be taken, when inserting a mesh in the abdomen, since the mesh becomes embroiled with some of the nerves that transit through these various spaces. Patients who undergo this surgery, I can tell you, caring for some of these patients, face many complications such as inability to walk, sit, go to work, and for certain types of mesh, although I have not been able to Figure out, they can barely sleep. Whether the surgeon employs

mesh or not it is essential to understand the anatomy of the abdominal well and the hernia rings.

History of Hernia Repair

Two excellent reviews of the history of various hernias have appeared recently. Awad and Fagan come down on the side of mesh (Awad SS, Fagan SP. Current approaches to inguinal hernia repair. *Am J Surg* 2004;188:9S–16S). The other by Banks and Cotlar come down on the side of classical repair, if only to remind us that many of us are in the business of training surgical residents. Given the fact that in most of the training programs, the tension-free repairs are the most taught, many residents and young surgeons will not even begin to think about doing a complicated repair such as a LaRoque Repair (Banks SB, Cotlar AM. Classic groin hernia repair…lest we forget. *Curr Surg* 2005;62:249–52).

There are approximately 800,000 cases per year of hernia repair done in the United States (Rutgow IM. Demographic and socioeconomic aspects of hernia repair in the United States in 2003. *Surg Clin North Am* 2003;83:1045–51). The male to female ratio was 12 to 1. The recurrence rate involving primary tissue repairs has varied from 1% to 15% and in some reviews, between 10% and 30% in primary repairs and greater than 35% in recurrent hernia repairs (Abrahamson. *Maingot's Abdominal Operations.* Vol 1. 9th ed. East Norwalk, CT: Appleton & Lang; 1990; Lichtenstein. *Hernia Repair Without Disability.* 2nd ed. St. Louis, MO: Ishiyaku Euroamerica, Inc.; 1986). However, as the authors state after realizing that this is an issue, the Shouldice repair is the only one in which a 2.2% recurrence rate has been published (Shouldice EB. The Shouldice repair for groin hernias. *Surg Clin North Am* 2003;83:1163–87). Whether this is because of the running, nonabsorbable suture or the emphasis on the transversalis fascia repair to reconstruct in an anatomically correct fashion the posterior wall of the inguinal canal and to reconstruct the internal ring is not clear. Mind you, what one is addressing is the overlay patch done openly.

While the Lichtenstein tension-free repair has been the standard for some years, other open mesh repairs, such as the Kugel technique, which utilizes a bilayer of polypropylene patch with a self-retaining outer memory recoil ring that is placed through a muscle-splitting incision. The mesh allegedly ends up in the same place as a properitoneal repair by the laparoscopic approach. Kugel reports 1468 repairs from 1994 to 2003 with a 0.4% recurrence rate (Kugel RD. The Kugel repair for groin hernias. *Surg Clin North Am* 2003;83:1119–39). However, as Awad and Fagan state, others have not been able to reproduce these results (Awad SS, Fagan SP. Current approaches to inguinal hernia repair. *Am J Surg* 2004;188:9S–16S). There is a steep learning curve, and the repair has been described as a touch-and-feel repair with up to 27.8% rate of recurrence in recurrent hernias (Schroeder DM, Lloyd LR, Boccaccio JE, et al. Inguinal hernia recurrence following preperitoneal Kugel patch repair. *Am Surg* 2004;70:132–6). My only comment regarding this is that while one should expect a lower recurrence, it is somewhat unfair to quote the recurrence rate for

recurrent hernias when comparing the data to first-time hernias.

Finally, Banks and Cotlar make the plea for teaching residents how to do classic groin hernia repairs (Banks SB, Cotlar AM. Classic groin hernia repair…lest we forget. *Curr Surg* 2005;62:249–52). They reproduce a number of the original drawings, which have been brought up to date and redone in contemporary techniques (Koontz AR. *Hernia.* New York: Appleton-Century-Crofts; 1963). They also make the point in Figures 187.3 and 187.4 that Halstead used a fourth layer of reinforcing fascia with the external oblique beneath the cord in his original article (Halstead WS. *Bull Johns Hopkins Hosp.* 1890;1:12–13). Later Halstead forswore the transplantation of the cord, since this is symptomatic in some patients, and buried it under the external oblique (Halstead WS. *Bull Johns Hopkins Hosp* 1903;14:208–14).

As for the Cooper ligament repair, I find the most difficult part of this repair (Anson/McVay) is the transition from Cooper ligament to Poupart ligament utilizing Thomson fascia over the femoral vein, a structure which in my experience, having grown up on the Anson/McVay repair, is frequently nonexistent. In addition, there remains a very substantial possibility of injuring the femoral vein in the McVay repair.

The Shouldice repair is well illustrated and is reproduced by Nyhus and Condon's book, *Hernia,* as is pictured by Bendavid and his rendering of the Shouldice repair (Nyhus LM, Condon RE. *Hernia.* 3rd ed. Philadelphia, PA: JB Lippincott; 1989).

Umbilicus and Umbilical Hernias

A number of pediatric surgeons are concerned about the cosmetic effects of an umbilical hernia repair. Kajikawa attempted what seems to be a fairly complicated umbilicoplasty in children in order to create a deep umbilical depression for the umbilicus (Kajikawa A, Ueda K, Suzuki Y, et al. A new umbilicoplasty for children: creating a longitudinal deep umbilical depression. *Br J Plast Surg* 2004;57:741–8). Personally, I had no idea that this was a cosmetic problem for children as my own technique for repairing an umbilical hernia in adults is simply to take one or two fine, nonabsorbable sutures in the overlay of the skin inferiorly and attach it to anterior fascia. After closing, I place a cottonoid dipped in mineral oil in the umbilicus and close the skin.

And it is only a matter of time that someone came up with a mesh plug repair for paraumbilical hernia. Sinha and Keith discuss such a mesh plug repair as an alternative to the Mayo technique as a standard method of repair of a paraumbilical hernia (Sinha SN, Keith T. *Surg J R Coll Surg Edinb Irel* 2004;2:99–102). The Mayo technique utilizes a double-breasted flap of rectus sheath. The authors have adopted the use of a mesh plug as consistent with the excellent repair techniques of femoral and inguinal hernia (more about this later). They undertook the review of hospital records and conducted telephone interviews of 34 patients who had paraumbilical hernias with mesh plug repairs over a period of 4 years. As is often the case, 76% of the patients were obese.

Out of the 32 patients, one had seroma postoperatively, and there was a single-wound infection with recurrence. Ninety-seven percent (32 out of 34) were satisfied with the procedure. A number of these patients, despite their obesity, were done under local anesthesia, thus this procedure could become the standard.

Spigelian Hernia

In my practice, spigelian hernia is a very rare occurrence and requires a great deal of diligence in order to make the diagnosis and repair it. Indeed, the anatomy chapter has cast a great light on what constitutes a spigelian hernia and the definitions of the various lines in the intersection of the linea semilunaris and linea semicircularis. In the *British Journal of Surgery,* Vos and Scheltinga concluded that a spigelian hernia is commonly encountered (Vos DI, Scheltinga MR. Incidence and outcome of surgical repair of spigelian hernia. *Br J Surg* 2004;91:640–4). As stated in his correspondence in response to the article, Mr. Ng surveyed 10 experienced clinicians in Hong Kong who had been in practice for over 25 years (Ng WT. *Br J Surg* 2004;91:1203). None had ever seen a spigelian hernia. The computerized database of the Hong Kong Hospital Authority with 40 hospitals serving a population of 6.8 million people revealed from 1998 to 2003, the incidence of spigelian hernia was 2, 2, 4, 3, 1, and 2 in each respective year. Mr. Ng also adds that there has only been a single case report from this part of the world in the English literature (Ng WT, et al. Facilitation of open Spigelian hernia repair by laparoscopic location of the hernial defect. *Surg Endosc* 2004;18:561–2). I would tend to agree with Mr. Ng that this is a rare occurrence.

My final advice for the surgeon is to know your anatomy!

J.E.F.

188 Overview of Inguinal and Femoral Hernia Repairs

Robert J. Fitzgibbons, Jr. and Michel Wagner

Groin hernia is one of the most common diseases known to mankind, and its repair has been referenced in medical writings as far back as 1500 BC in the Edwin Smith Surgical Papyrus. Nonoperative treatment in patients with minimal symptoms has been shown to be safe but is not curative. Surgery is the only definitive treatment for this condition, and hundreds of repairs have been described in the literature. Most are minor variants of three basic types of repairs: (1) tissue repair, (2) open prosthetic repair, and (3) laparoscopic prosthetic repair. In this chapter, after describing the pertinent anatomy, seven operations felt to be representative of the various types will be discussed in detail. These will include:

For the tissue repairs: Bassini, Cooper ligament, and Shouldice.

For the open prosthetic repairs: Lichtenstein tension-free herniorrhaphy (TFR) for the conventional anterior space and Stoppa's giant prosthetic reinforcement of the visceral sac for the preperitoneal space.

For the laparoscopic prosthetic repair: transabdominal preperitoneal (TAPP) and the totally extraperitoneal (TEP).

ETIOLOGY AND PATHOPHYSIOLOGY

The lifetime risk of developing a groin hernia is approximately 25% in males and 5% in females. Inguinal hernias are more common on the right than the left and are 10 times more likely in males than in females. In men, indirect inguinal hernias outnumber direct by about 2:1, with femoral hernias making up a much smaller proportion. For females, indirect inguinal hernias are most common and are 5 times more common than femoral hernias, with direct hernias occurring rarely. Overall, femoral hernias account for fewer than 10% of all groin hernias but are especially dangerous as 40% present as emergencies, with incarceration or strangulation and need emergency repair that is associated with higher morbidity. Femoral hernias are more common in older patients and in

those who have previously undergone inguinal hernia repair. Femoral recurrences are particularly common in women, in whom the diagnosis at the time of the primary repair was a direct inguinal hernia, strongly suggesting a missed femoral hernia at the original procedure since direct hernias are very rare in women.

The prevalence of inguinal hernia at any given age varies widely in the literature primarily due to a lack of a consistent reporting mechanism, for example, questioner versus actual physical examination. The most reliable data use hernia repair as a surrogate for the prevalence. After an initial surge to 1.4% in infancy, the percentage of persons in the population who are operated for a groin hernia decreases and then steadily increases through life to reach a peak percentage of 4.2% for males aged 75 to 80 years, falling off after that. The pattern is similar for females except that the peak percentage of woman aged 75 to 80 only reaches about 0.4%.

ANATOMY

The external abdominal oblique muscle takes its origin from the posterior aspects of the lower eight ribs and interdigitates with the serratus anterior and latissimus dorsi muscles. Its direction is nearly horizontal in its upper portion and oblique in its lower portion. The muscle fibers become tendons before inserting into the linea alba in the midline and inferiorly onto the anterior superior iliac spine, and the pubic tubercle results in important anatomical landmarks. The obliquely arranged anterior-inferior fibers of these insertions fold on themselves to form the inguinal ligament commonly called Poupart ligament (Fig. 188.1). The more medial fibers of the aponeurosis of the external oblique divide into a medial and lateral crus to form the external or superficial inguinal ring (Fig. 188.2). The spermatic cord (or round ligament) and branches of the ilioinguinal and genitofemoral nerves pass through this opening. The insertion on the pubic tubercle is fan-shaped spanning the space between the pubic tubercle and the pectineal line of the superior pubic ramus forming the lacunar ligament. It blends laterally with the pectineal (Cooper) ligament.

The internal abdominal oblique muscle fans out from the iliac crest obliquely upward toward its insertion on the lower ribs—upper and medially to its insertion on the linea alba and the pubis. It is mainly muscular in the groin region making up the cranial inferior border of the inguinal canal. The transversus abdominis muscle arises from the iliac crest and the lower six ribs and interdigitates with diaphragmatic fibers. Its

direction is mainly horizontal inserting on the linea alba. However, the lower fibers are arranged in a more inferior-medial course toward their site of insertion on the pubic tubercle and the pubic symphysis to form the falx inguinalis (Fig. 188.3). These fibers infrequently are joined by a portion of the internal oblique aponeurosis; only then is a true conjoined tendon formed. The fibers of the transversus abdominis terminate at a variable distance above the inguinal ligament, which results in the formation of the transversus aponeurotic arch. The space between this arch and the inguinal ligament lacks the protection provided by the muscle and, especially when high, may predispose to the development of a direct inguinal hernia. However, contraction of the transversus abdominis in response to increased pressure causes the arch to move down toward the inguinal ligament, which reinforces this weak area and prevents a hernia in most.

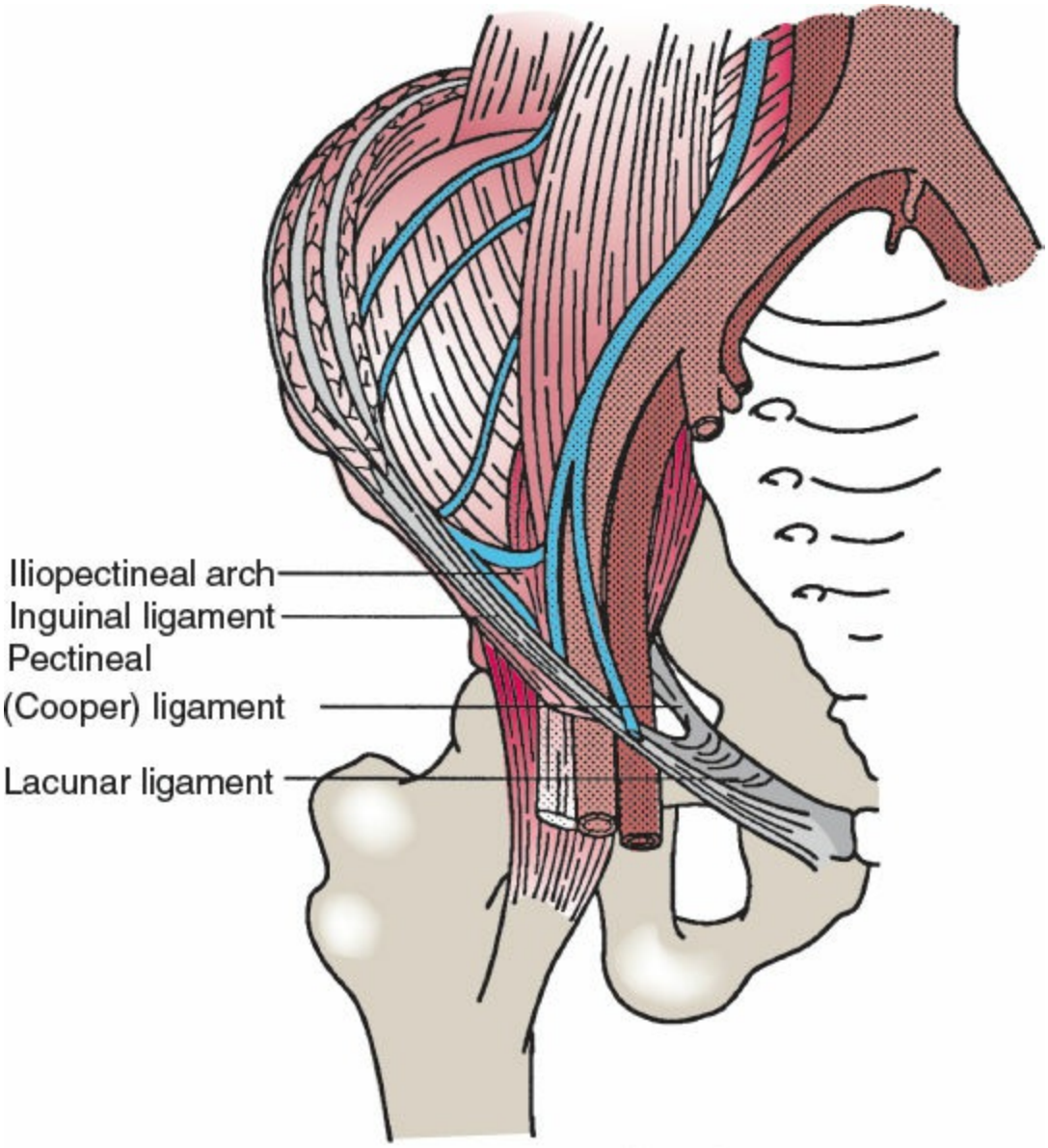

Figure 188.1. Ligaments formed by the lower insertion of the aponeurosis of the external oblique muscle.

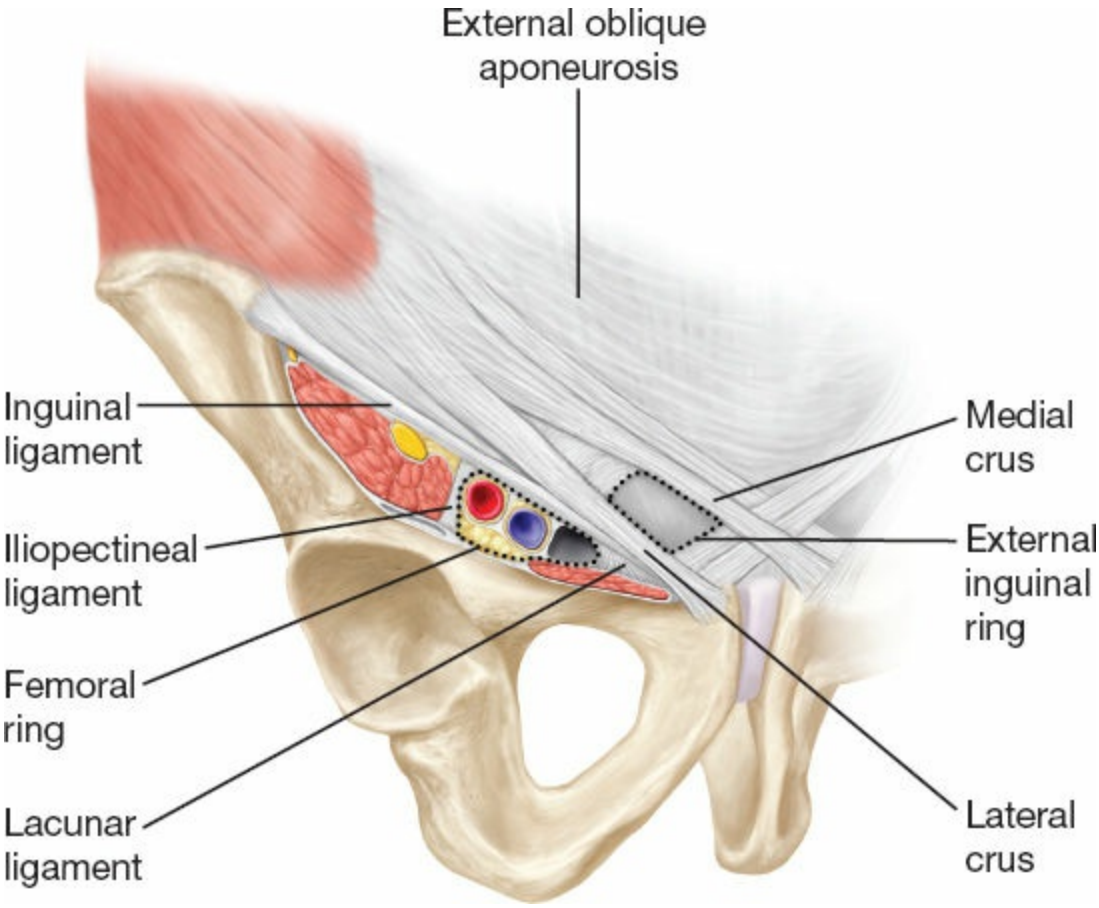

Figure 188.2. Fibers of the aponeurosis of the external oblique divide into a medial and lateral crus to form the external or superficial inguinal ring.

The inguinal canal is bounded by four walls and two rings on either end (internal and external rings). The definition of these four walls is highly variable in anatomical texts. For the purpose of this chapter, the definition in Table 188.1 will be used.

Hesselbach triangle is of historical interest in modern groin surgery classically depicting the site of direct inguinal hernias. Its boundaries are most commonly defined as the inguinal ligament for the base, the rectus abdominis on its medial side, and the inferior epigastric vessels superior-laterally (Fig. 188.4). When considering a preperitoneal perspective, Cooper ligament as originally described by Hesselbach is the base because the inguinal ligament cannot be seen from an abdominal vantage.

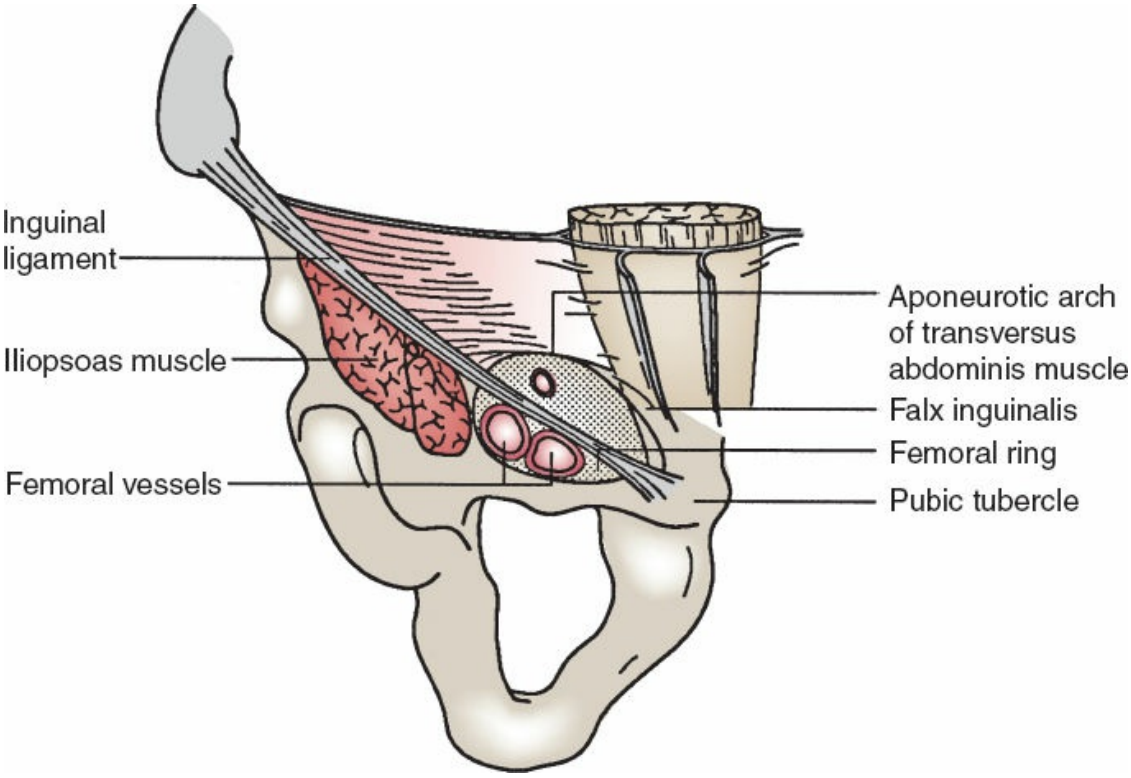

Figure 188.3. The aponeurotic arch and the myopectineal orifice.

TABLE 188.1 The Four Walls which Make Up the Boundaries of the Inguinal Canal

Superior (roof): Medial crus of the aponeurosis of the external oblique muscle, the musculoaponeurotic arches of internal oblique muscle, the transverse abdominal muscle
Anterior: Aponeurosis of external oblique reinforced by the fleshy part of internal oblique muscle laterally
Inferior (floor): Inguinal ligament, lacunar ligament and the iliopubic tract
Posterior: Transversalis fascia and the falx inguinalis

Many of the complications seen with the early laparoscopic repairs were directly related to a lack of appreciation of the anatomy of the

inguinal region from a preperitoneal perspective. In order to safely perform a preperitoneal herniorrhaphy, the anatomy must be learned in a reverse manner than is conventionally taught, that is, starting from the innermost layers. Initial inspection of the peritoneal surface of the inguinal region reveals several consistent landmarks (Fig. 188.5). The umbilical ligaments in most patients are quite prominent and easily identified. The unpaired median umbilical ligament covers the urachus, the fibrous remnant of the fetal allantois, and extends from the urinary bladder to the umbilicus. The urachus may be patent for a variable length along its course, usually close to the urinary bladder in adults and close to the umbilicus in children. The paired medial umbilical ligaments are created by the obliterated fetal umbilical arteries. The artery, like the urachus, may be patent in its proximal course and may contribute to the superior vesical artery. The paired lateral umbilical ligaments are created by the peritoneal coverings over the inferior epigastric vessels. The vas deferens and internal spermatic vessels can commonly be seen through the peritoneum especially in thin individuals.

Once the peritoneum and transversalis fascia are stripped away, important anatomical landmarks in the preperitoneal space can be further defined. These include the inferior epigastric vessels, Cooper's pectineal ligament, internal spermatic vessels, and vas deferens. The inferior epigastric vessels run superomedially along the medial margin of the internal ring toward the rectus sheath and give rise to two branches in the inguinal region: the external spermatic (cremasteric) vessels and the pubic branch that can arch over Cooper ligament and anastomose with the obturator circulation forming what is known as the "corona mortis." The presence of a corona mortis is highly variable and can be arterial or venous or both. It is important because of the significant bleeding that can occur if it is damaged when stapling or suturing around Cooper ligament or dissecting medially to reduce an incarcerated femoral hernia. Similarly, the iliopubic artery and vein track along the iliopubic tract toward the pubic symphysis and are susceptible to damage.

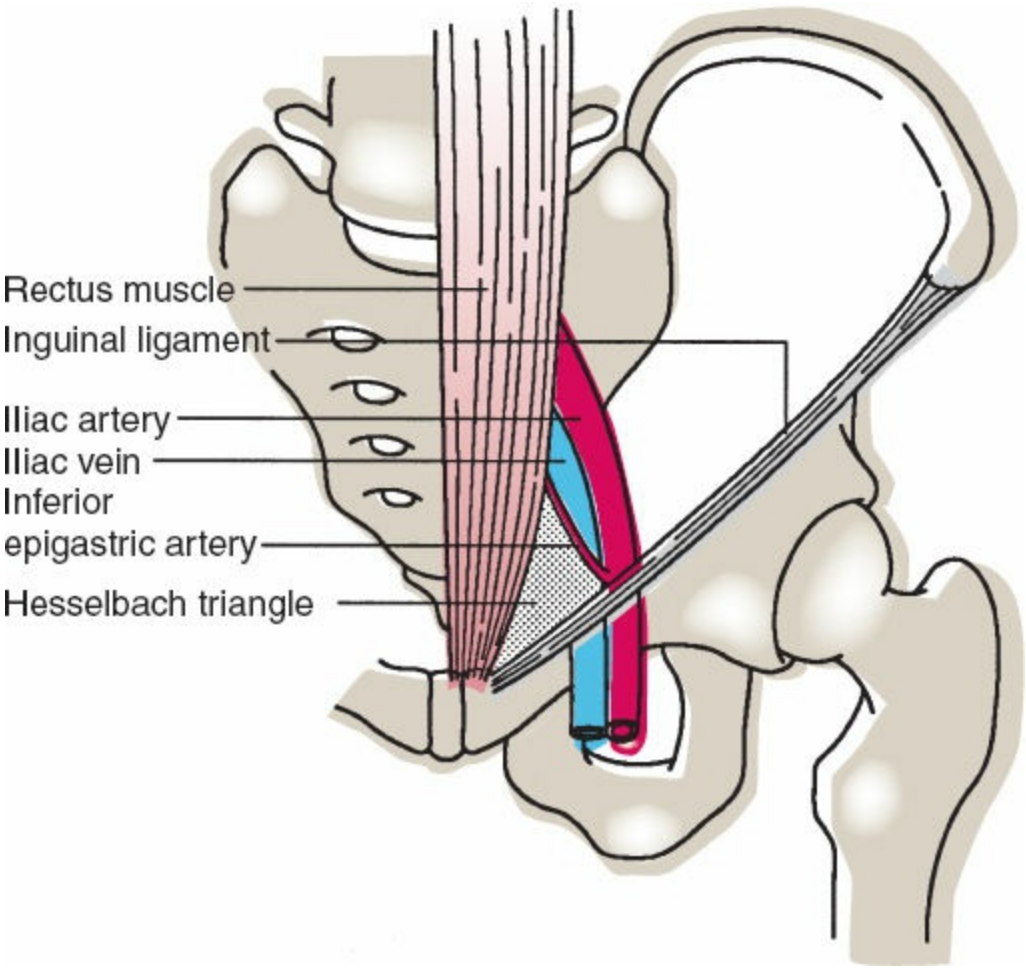

Figure 188.4. Hesselbach triangle as viewed from an anterior perspective.

The course of the nerves in this area needs to be appreciated by the surgeon working in the preperitoneal space so that damage to them can be avoided (Fig. 188.6). The genitofemoral and the lateral femoral cutaneous nerve are at greatest risk for injury. The ilioinguinal and iliohypogastric nerves exit the abdominal cavity above the iliac crest and are not within the normal field of dissection for a hernia repair in the preperitoneal space. However, it is possible to injure them if staples or tacks are placed deeply especially with a vigorous bimanual technique. Two triangular anatomical areas in this space have considerable importance when performing a preperitoneal groin hernia repair. The first is bounded by the spermatic vessels laterally, the vas deferens medially, and the inferior flap of the peritoneal dissection, inferiorly. This area has been referred to as the "triangle of doom" in that the external iliac vessels lie hidden beneath. It has been advised that stapling be done only medial to the vas deferens. The second triangle referred to as the "triangle of pain" is bounded by the

spermatic vessels medially, the iliopubic tract superiorly, and the lateral pelvic wall. In it lie the genital and femoral branches of the genitofemoral nerve, the femoral nerve, and the lateral femoral cutaneous nerve of the thigh. Sutures, staples, or tacks placed caudal to the iliopubic tract and lateral to the internal spermatic vessels can result in neuralgias.

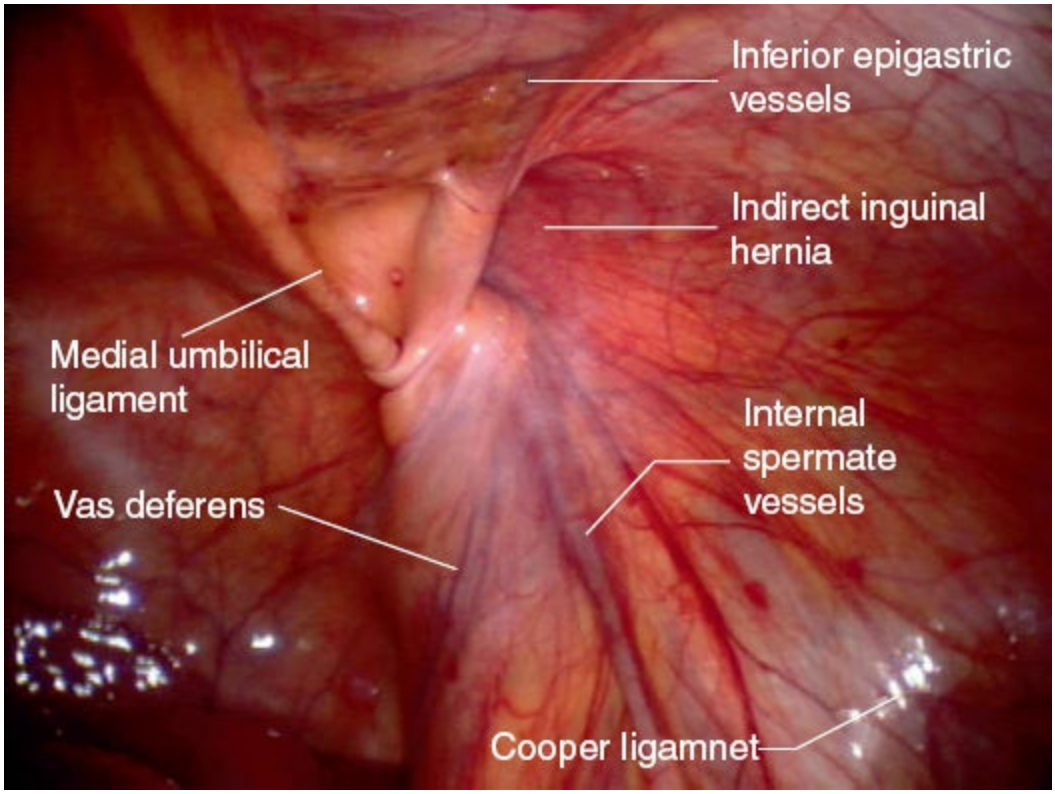

Figure 188.5. Important anatomical landmarks on initial inspection of the lower abdomen from a laparoscopic prospective.

Finally, the myopectineal orifice (sometimes called the musculopectineal orifice) of Fruchaud is important for surgeons performing conventional preperitoneal procedures. Although the exact definition varies as is so common in anatomical texts, for the purposes of this chapter, it is bounded medially by the lateral border of the rectus abdominus, laterally by the iliopsoas muscle, superiorly by the transversus abdominus and internal oblique muscles, and inferiorly by Cooper ligament and the pubis (Fig. 188.7).

CLINICAL PRESENTATION

The three classical groin hernias are direct (commonly referred to as “medial” outside of the United States) indirect (or “lateral”) and femoral.

The nomenclature can be confusing because some studies use the words inguinal and groin interchangeably. For the purposes of this review, direct and indirect hernias are considered inguinal and femoral stands alone.

INDICATIONS AND CONTRAINDICATIONS

In the past, it has been felt that all inguinal hernias should be repaired unless specific contraindications are present. This is because of a perception that there would be significant rates of complications of bowel obstruction and/or strangulation if left untreated. However, several recent randomized controlled trials have provided convincing evidence that watchful waiting is safe for the approximately one third of the total inguinal hernia population who have minimal or no symptoms. Coupled with the increasing awareness of the problem of debilitating postherniorrhaphy groin pain in a small but significant number of patients, watchful waiting has clearly become an acceptable treatment strategy. However, patients should be informed that although safe, long-term follow-up has shown that the vast majority of patients will eventually crossover to surgery because of increasing symptoms. Contraindications include intra-abdominal or groin infection and coagulopathy. Relative contraindications include severe underlying medical illness and ascites. For the laparoscopic procedures, all adult patients with inguinal hernias who are candidates for general anesthesia can be considered candidates for the repair. But relative contraindications also include significant intra-abdominal adhesions from previous surgery and previous “Space of Retzius” surgery because of the increased risk of bladder injury. Severe underlying medical illness is a more significant relative contraindication because of the added risk of a general anesthesia. These patients are better suited for a conventional operation under local anesthesia.

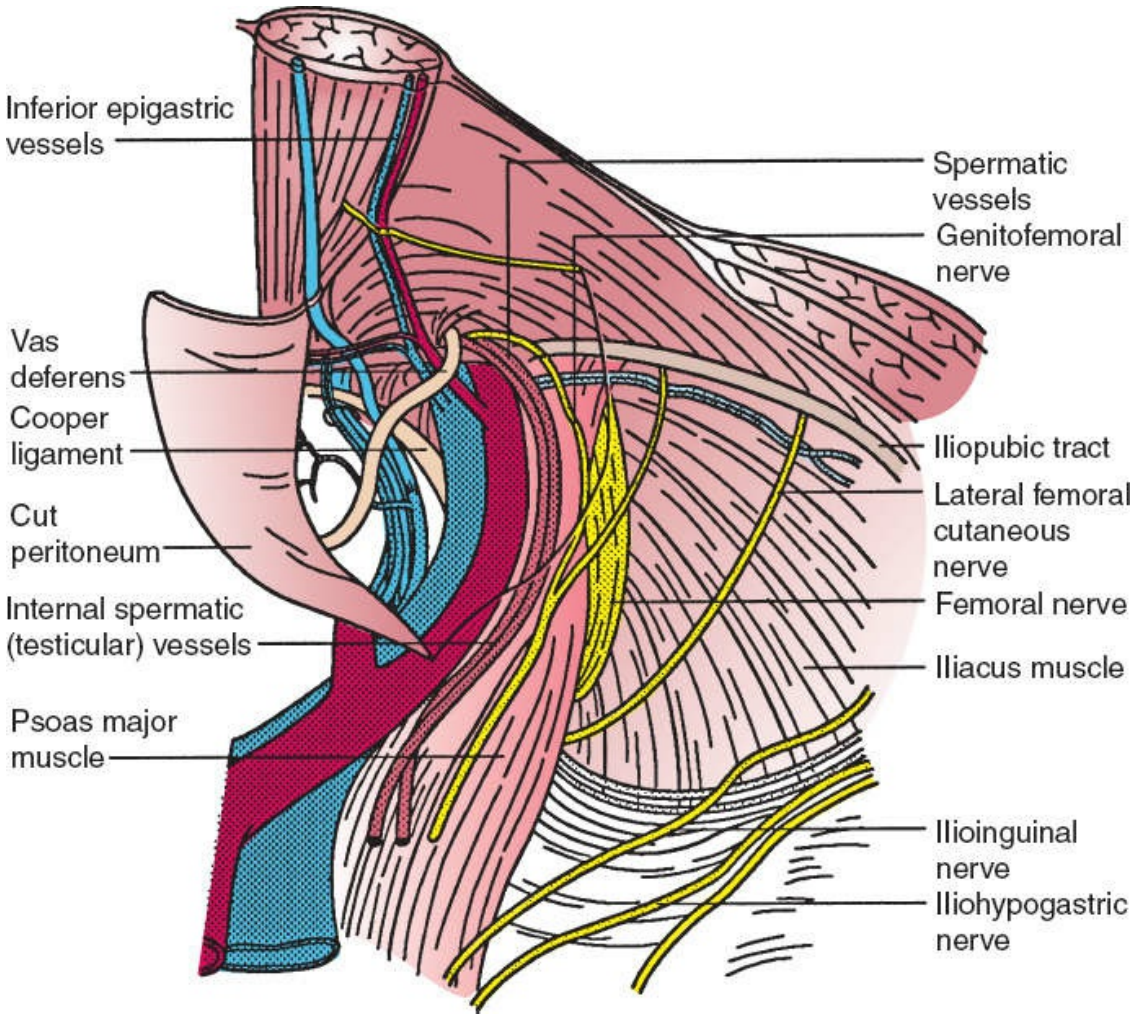

Figure 188.6. Key landmarks in the preperitoneal space as observed from a laparoscopic perspective after the peritoneum has been opened.

PREOPERATIVE PLANNING

Preoperative care should be guided by the patient's underlying physiologic status. The patient should have a detailed history and physical examination taken with concern toward the patient's anesthetic risks. This includes cardiac, pulmonary, and endocrine status. Concern about the ability of the patient to tolerate a general anesthesia mandates consultation with the anesthesia department. If the patient is not a candidate for a general anesthesia, local regional anesthesia should be considered and laparoscopy avoided. Optimization of the diabetic patient's blood sugar should be obtained resulting in an acceptable hemoglobin A_1C. Antiplatelet medication as well as anticoagulant medications should be stopped if possible. Preoperative acetaminophen and neuroleptic agents such as gabapentin can be considered to help with the postoperative pain

management.

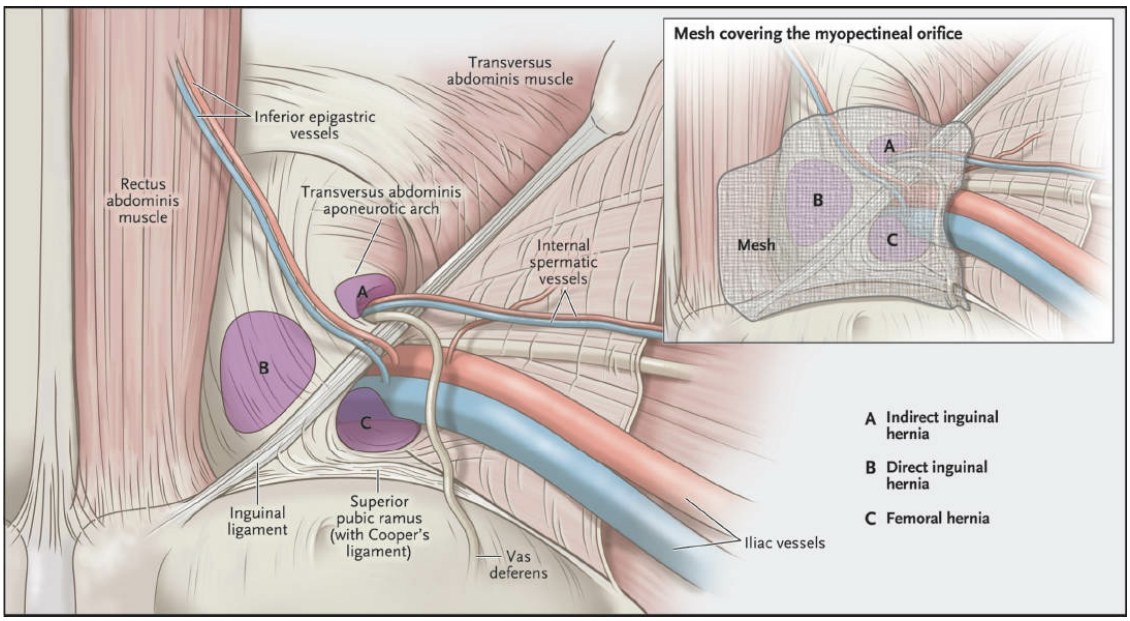

Figure 188.7. The myopectineal orifice of Fruchard is bordered by the arch formed by the termination of the aponeurotic fibers of the transversus abdominis muscle superiorly, the rectus abdominis muscle medially, the iliopsoas muscle laterally, and the superior pubic ramus with attached Cooper ligament inferiorly.

SURGICAL TECHNIQUE

The Tissue Repairs

Bassini

Edoardo Bassini (1844–1924) was born in Pavia, Italy, and received his doctorate in medicine from the University of Pavia at the age of 22. He joined the liberation forces of Garibaldi in the crusade for unification of Italy and in combat suffered a bayonet wound to the right lower quadrant of his abdomen, which was complicated by a fecal fistula. He was eventually transferred back to Pavia under the care of Professor Porta who supervised his recovery. During that time, he developed a close relationship with the Professor who convinced him that surgery was the best career path for him. He joined the staff at the University of Pavia where he commenced intense study of anatomy and surgical pathology of the groin. Bassini's radical cure of a groin hernia resulted from his studies as he was able to appreciate the importance of functional restoration of the inguinal canal to properly treat an inguinal hernia. The operation

revolutionized the field with a recurrence rate that was one fifth of what was accepted at the time and became the gold standard for inguinal hernia repair for most of the 20th century. The procedure was based on the development of several distinct steps that he felt were essential. These included:

1. Complete division of the external oblique aponeurosis and the transversalis fascia,
2. Differentiation between indirect and direct defects,
3. Isolation of the spermatic cord,
4. Ligation and removal of the sac at the deep inguinal ring flush with the peritoneum,
5. Oblique reconstruction of the inguinal canal with an anterior and posterior wall with an internal and external opening (ring).

Technique

Cutaneous Incision

The important landmarks to be identified prior to incising the skin are the anterior superior iliac spine, the symphysis pubis, and the pubic tubercle. In obese individuals, palpating through the base of the scrotum with a finger best identifies the latter two. A 6- to 7-cm skin incision is made 2 cm medial and parallel to a line between the pubic tubercle and the anterior superior iliac spine, which corresponds to the course of the inguinal ligament. Alternatively, in the interest of cosmesis, a more transverse incision can be used (Fig. 188.8).

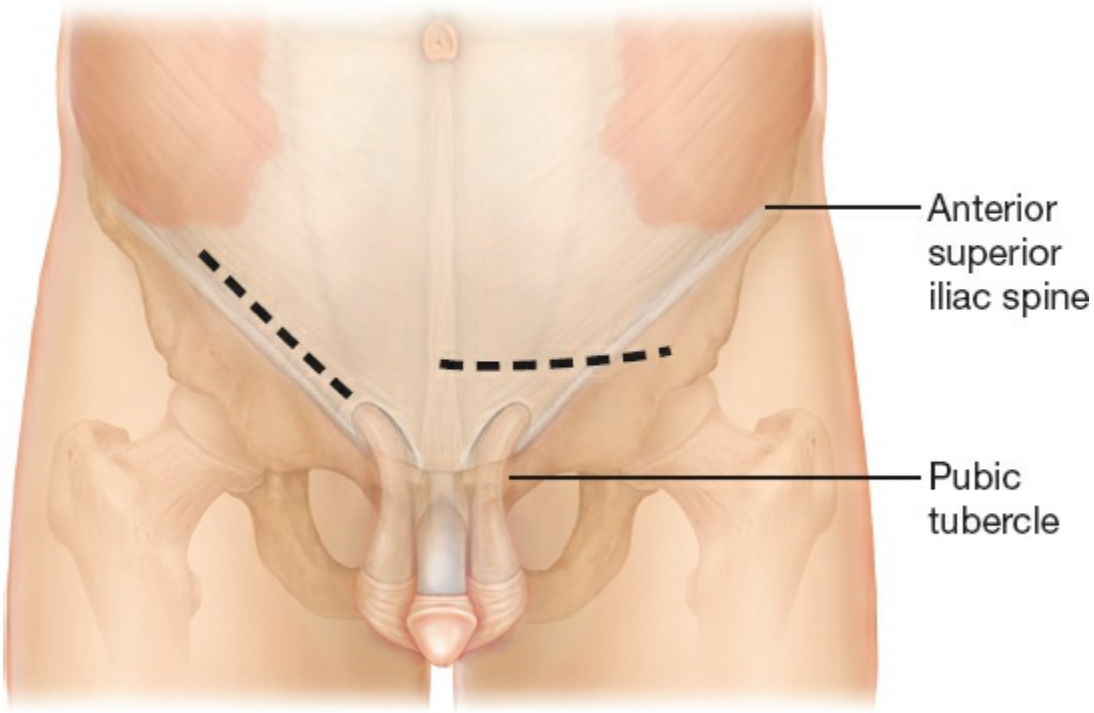

Figure 188.8. Possible skin incisions for the Bassini operation and other anterior inguinal herniorrhaphies.

Incision of External Oblique

The skin incision is extended through the Camper and Scarpa fascia, and the external oblique aponeurosis is identified. The superficial ring of the inguinal canal is located and the external oblique aponeurosis is incised at the upper margin of the superficial ring. When reapproximated, the suture line will not overlap the deep sutures (Fig. 188.9).

Isolating the Cord Structures

The upper flap of the external oblique aponeurosis is separated from the deeper internal oblique muscle and the lateral margin of the rectus muscle using blunt finger dissection or the handle of the scalpel. The ilioinguinal nerve is identified at this time and gently freed from the surrounding tissue. Care must be taken to avoid crushing the nerve with an instrument. A hemostat is used to keep it out of the field of surgery by passing the hemostat under the nerve and grasping the lower flap of the external oblique aponeurosis. This avoids injury to the nerve during surgery. The cord structures are then lifted en-masse with the fingers of one hand exactly at the pubic tubercle so that the index finger of the hand can be passed gently underneath to meet the fingers of the other hand. Once this is done, a finger is slid all the way to the deep inguinal ring completely

isolating the cord structures and a Penrose drain or rubber loop is used to hold them out of the way (Fig. 188.10).

Separation of the Cremaster Muscle and Other Coverings From the Sac

The cord structures are lifted with the help of the Penrose drain, and the cremaster muscle and spermatic cord with its vessels are gently separated. Extreme care must be taken to avoid injury to the vas deferens and the vessels. The cremaster muscle is incised longitudinally for the length of the cord structure in the inguinal canal beginning as close to the deep inguinal ring as possible. This in effect creates a lateral and medial flap. These flaps can be divided to provide more mobility of the cord. Traditionally the medial flap would be divided between hemostats and tied because of the likely presence of the cremasteric artery. Electrocautery is usually sufficient for the lateral flap. Bassini and Shouldice (as will be discussed later) considered division of the cremasteric muscle an essential step in their respective operations. However, today this is not universally agreed upon. Lipomas of the cord are removed at this stage (Fig. 188.11).

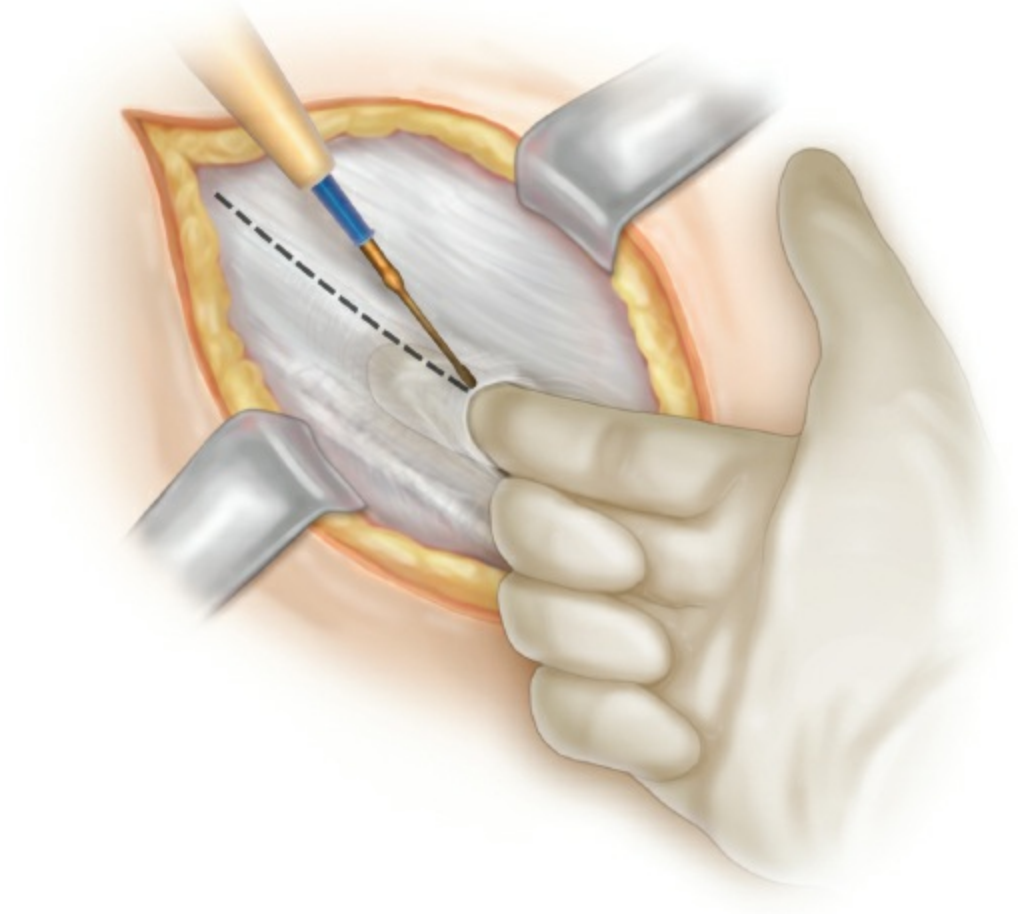

Figure 188.9. The extremal oblique aponeurosis is incised

through the external ring.

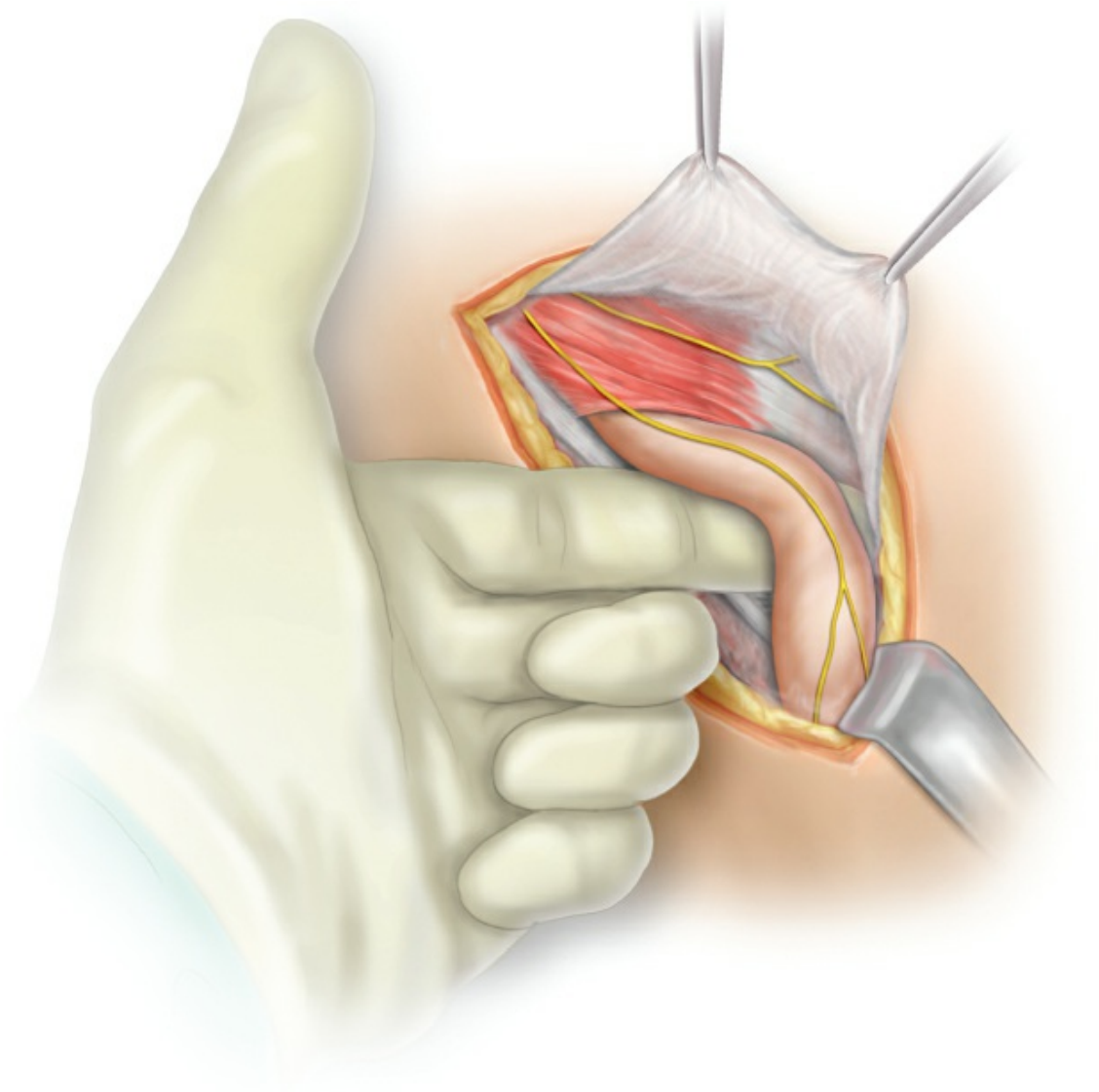

Figure 188.10. Cord structures are freed from the inguinal floor.

Isolation of the Spermatic Cord From the Sac

At this point, the cord should be dissected to determine if there is an indirect sac even if there is an obvious direct inguinal hernia. Even in the absence of an indirect hernia, there is always a tongue of peritoneum that protrudes at the anteromedial aspect of the cord and should be looked for to provide reassurance that an indirect hernia sac has not been missed. When a true indirect sac is found, the internal spermatic fascia is incised and the indirect sac is carefully separated from the spermatic cord dissecting as close to the sac as possible to avoid damaging the cord, especially its vascular elements. Once the sac is free from the cord structures and the vas deferens has been identified, the sac should be

divided and the proximal end ligated. It is imperative to make sure that there are no peritoneal contents in the sac. If necessary, the sac can be opened and the contents reduced back into the abdominal cavity before ligating it. For a large indirect inguinal scrotal hernia where complete removal of the sac might result in testicular complications due to vascular compromise because of the extensive dissection required to mobilize it, the sac is sometimes best transected at the midpoint of the cord structures leaving the distal sac in situ. The distal sac may be left alone or may be slit in its entirety, exposing the inner surface. Some surgeons will go so far as to invert the edges around the cord and suture behind it in an attempt to prevent a hydrocele when the distal sac is left in place. This is probably unnecessary as the experience with laparoscopic inguinal herniorrhaphy where the distal sac is not accessible has not revealed an excessive rate of hydrocele formation. For the usual indirect sac that is completely mobilized, many surgeons now prefer to simply reduce the sac back into the preperitoneal space feeling that either opening or excising the sac is unnecessary. Bassini probably would have considered this heresy, but experience has shown it to be as effective as excision. Proponents point out that simple reduction eliminates any possibility of damage to an incarcerated structure and there may be decreased pain because the richly innervated peritoneum is not incised.

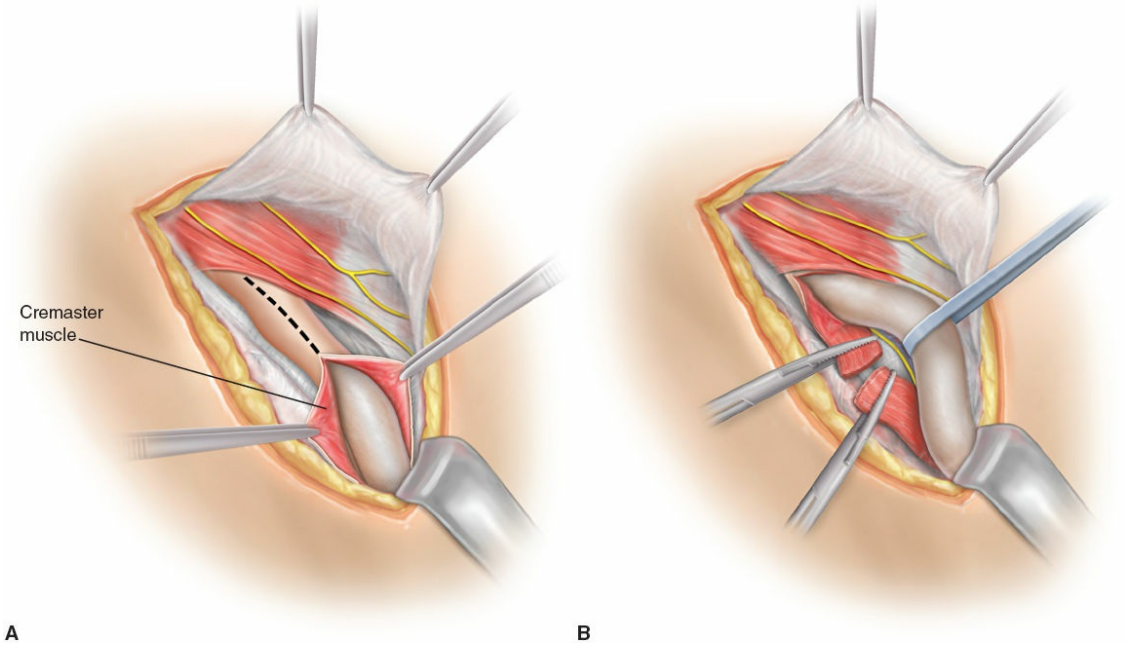

Figure 188.11. **A.** Cremasteric muscle is incised longitudinally. **B.** The caudal flap is divided between clamps.

Direct hernia sacs are almost never removed but instead are dissected from surrounding structures and reduced into the preperitoneal space. Dividing the transversalis fascia circumferentially at the neck (base) of the sac will aid in this reduction in some cases. The defect may be closed primarily at this point to maintain the reduction while a formal reconstruction is being performed. The latter is considered a matter of convenience and adds nothing to the strength of the final repair.

Division of the or Posterior Wall of the Inguinal Canal Over Its Full Length

The cord is retracted laterally and the transversalis fascia is divided from the internal ring to the symphysis pubis (Fig. 188.12A,B). This method of opening the inguinal floor by incising the transversalis fascia completes the creation of Bassini's famous "triple layer" that includes the edges of the transversalis fascia, transversus abdominis muscle, and the internal oblique muscle. Full mobilization is achieved by separating by blunt dissection the lateral margin of the rectus muscle and the triple layer from the aponeurosis of the external oblique above and from the preperitoneal fat below so that the triple layer can be approximated to the isolated posterior border of the inguinal ligament without tension on the suture line. The common modification of not opening the transversalis in favor of using "good stuff" grasped blindly with an Allis clamp underneath the internal oblique muscle is likely the reason for the poorer results when this operation was imported to North America. Once the transversalis fascia has been divided, the femoral ring is exposed from a preperitoneal perspective to make sure that a femoral hernia is not missed.

Suturing the Deep Layer and Closure the Incision

The first stitch includes the cut edge of the transversalis fascia, the transversus abdominis muscle, and internal oblique muscle with the medial side of the pubic tubercle and the rectus sheath. Most surgeons now try to avoid the periosteum of the pubic tubercle to decrease the incidence of osteitis pubis. The second stitch includes the rectus muscle that is approximated to both Cooper ligament and the inguinal ligament. The repair is then continued laterally using interrupted sutures securing the triple layer to the reflected inguinal ligament (Poupart ligament). These sutures are continued until the internal ring has been substantially narrowed on its medial side (Fig. 188.13). The cord is then repositioned resting on the newly reconstructed posterior wall, and the two flaps of the external oblique aponeurosis are sutured over the cord with a running

stitch, reconstructing the external ring. The subcutaneous tissue is closed, and the skin may be stapled or closed with a running subcuticular stitch.

Cooper Ligament Repair

These initial steps in the operation are identical to the Bassini. The key difference is that when the floor is reconstructed, Cooper ligament instead of the inguinal ligament is used for the medial portion of the repair (Fig. 188.14A–C). Classically it is the conjoined tendon that is actually sutured to Cooper ligament. However, as noted previously anatomists disagree about the exact definition of the conjoined making a precise description of this operation difficult. Some surgeons use the triple layer of Bassini, while others simply use the "good stuff" to Cooper ligament approach, perhaps accounting for the poorer results in some reported series with this method. Interrupted sutures beginning at the pubic tubercle and continuing laterally along Cooper ligament progressively narrow the femoral ring, and this constitutes its most common application, that is, treatment of a femoral hernia. The last stitch to Cooper ligament is known as a transition stitch and includes the inguinal ligament. The stitch has two purposes; the first is to complete the narrowing of the femoral ring by approximating the inguinal ligament to Cooper ligament as well as the medial tissue, and second it provides a smooth transition or step-up to the inguinal ligament over the femoral vessel so that the repair can be continued laterally identical to the Bassini. A relaxing incision should always be used given the considerable tension required to span such a large gap. This consists of incision in the lateral side of the rectus aponeurosis after the medial flap of the external oblique aponeurosis is reflected medially beginning just above the symphysis pubis and extending cranially for 5 to 10 cm (Fig. 188.15). Although this does serve to relieve some of the tension, it is still significant enough that it is felt by many to result in more pain than other herniorrhaphies and predisposes to recurrence. For this reason, the operation is rarely chosen with the notable exception of a femoral hernia in a patient with specific contraindications to mesh, for example, infection.

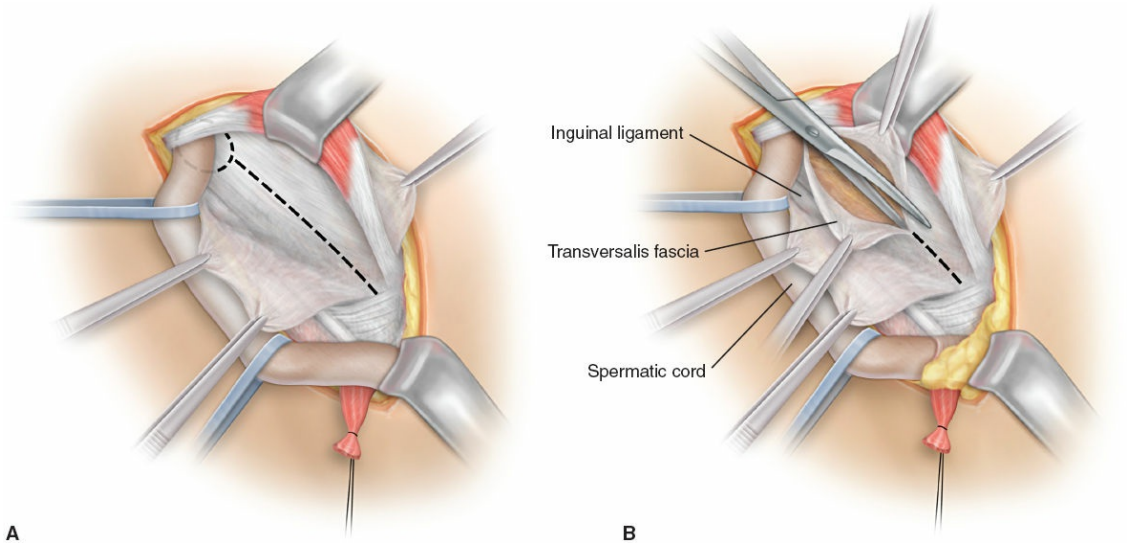

Figure 188.12. A,B. The transversalis fascia is opened from the internal ring to the symphysis pubis.

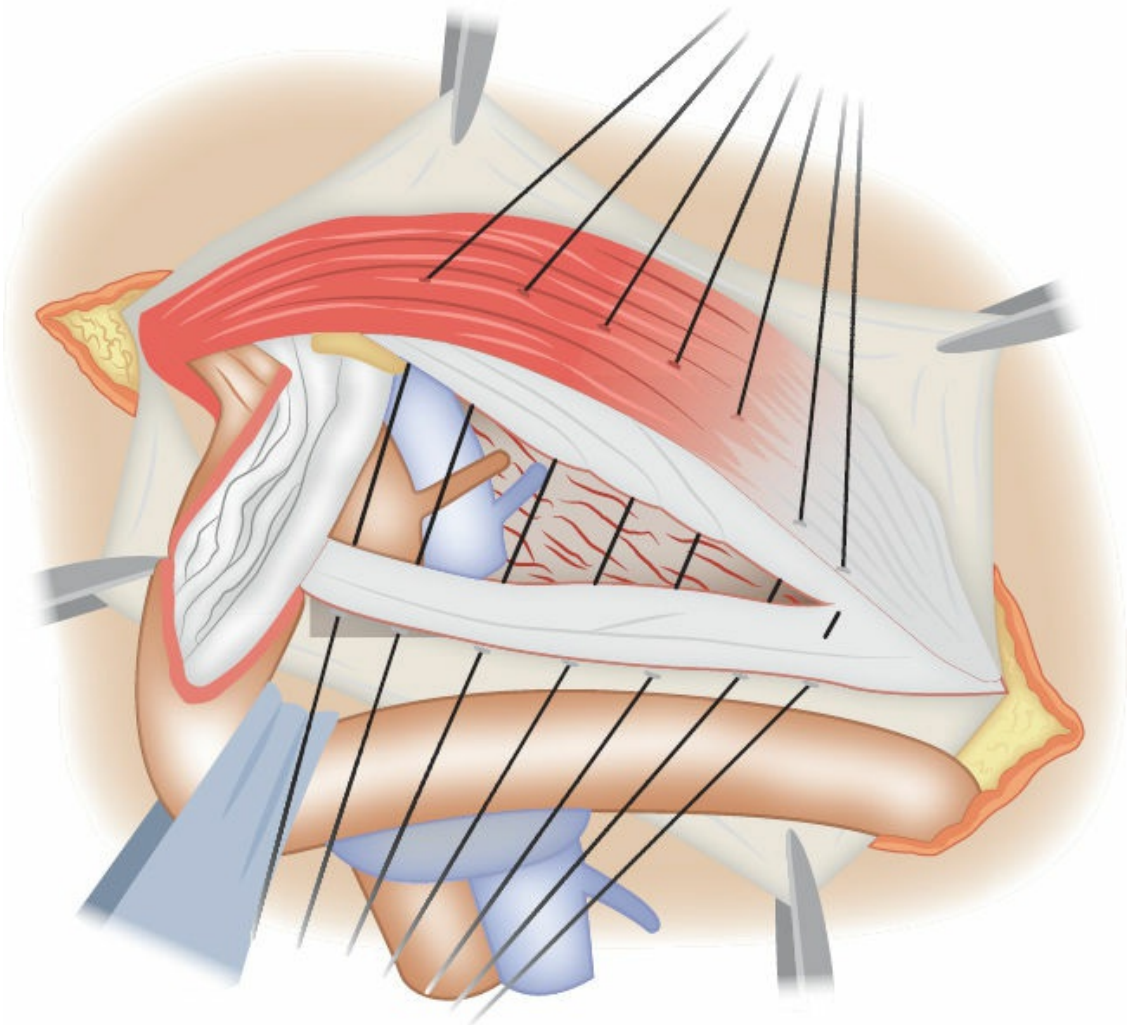

Figure 188.13. The triple layer is sutured to the shelving edge of the inguinal ligament beginning just medial to the pubic tubercle and continuing laterally until the internal ring is narrowed on its

medial side.

Shouldice

Perhaps the most important Bassini modification was popularized by the Canadian surgeon Earle Shouldice in 1945. His hospital stressed the importance of perioperative care of inguinal hernia patients including early mobilization, resuming normal activities as soon as possible, and short hospital stay at a time when such stays were 2 to 3 weeks. The recurrence rate decreased impressively to 1% in experienced hands and specialized clinics. In general practice, long-term results are less satisfying and show a recurrence rate of 1.7% to 15%. Nevertheless, the Shouldice technique is considered by most to be the best pure tissue repair for a primary inguinal hernia. Particular importance is placed on freeing the cord from its surrounding adhesions, resection of the cremaster muscle, high dissection of the hernia sac, and division of the transversalis fascia during the initial steps of the procedure similar to what has been described above with the Bassini operation. The major modification is the method of reconstruction of the posterior wall of the inguinal canal by a four-layer method instead of a single one. A continuous nonabsorbable suture (Shouldice preferred monofilament stainless steel wire) is used to repair the posterior wall. The Shouldice surgeons believe that a continuous suture distributes tension evenly and prevents potential defects between interrupted sutures that could lead to recurrence. Eventually, four continuous suture lines are developed between the iliopubic tract and external oblique aponeurosis laterally to the triple layer and internal oblique muscle medially.

The repair is started at the pubic tubercle by approximating the iliopubic tract laterally to the undersurface of the lateral edge of the rectus abdominis and the triple layer. The suture is continued laterally, approximating the iliopubic tract to the triple layer made up of the internal oblique muscle, the transversus abdominis muscle, and the transversalis fascia. The continuous suture is extended to the internal ring, where the lateral stump of the cremaster muscle is picked up to form a new internal ring (Fig. 188.16). Next, the direction of the suture is reversed back toward the pubic tubercle, approximating the medial edges of the internal oblique muscle and the transversus abdominis to Poupart ligament as far as the crest of the pubis where the wire is tied to itself as the first knot. Thus, two parallel lines are formed by the first suture.

A second suture is started near the internal ring, approximating the

internal oblique muscle and the transversus abdominis to a band of external oblique aponeurosis superficial and parallel to Poupart ligament—in effect, creating a second, artificial shelving edge of inguinal ligament. This third suture line continues to the pubic crest (Fig. 188.17). The suture is then reversed as a fourth suture line is constructed in a similar manner, superficial to the third line. At the Shouldice clinic, the cribriform fascia (the superficial fascia of the thigh that covers the saphenous opening) is always incised in the thigh, parallel to and just beneath the inguinal ligament, to make the inner side of the lower flap of the external oblique aponeurosis more mobile for these multiple layers and to check for a femoral hernia (Fig. 188.18). In general practice, however, this step is commonly omitted.

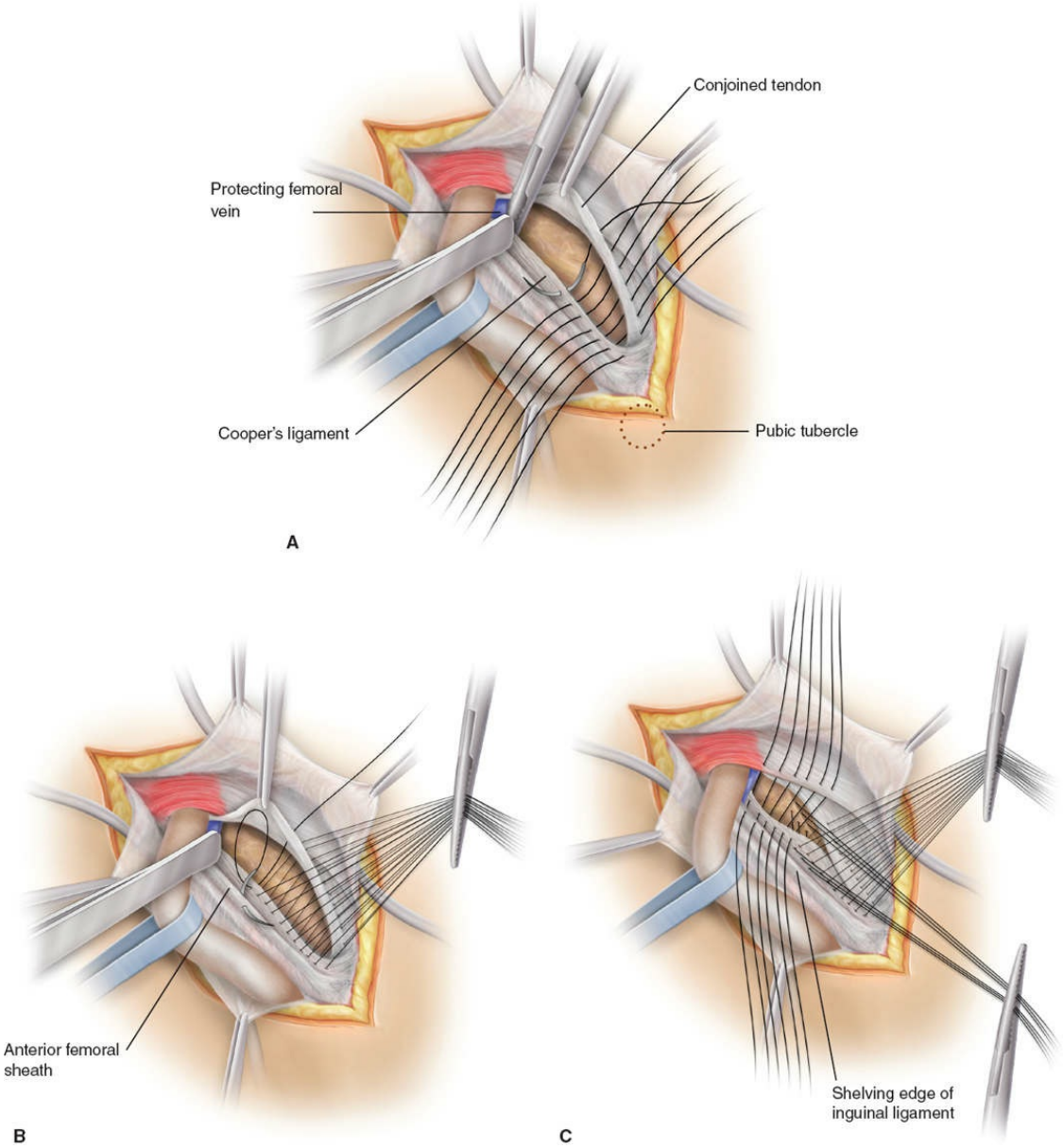

Figure 188.14. **A.** The medial elements of the inguinal canal are sutured to Cooper ligament beginning at the pubic tubercle. **B.** A transition stitch between the medial elements, Cooper ligament, and the shelving edge of the inguinal ligament. **C.** The repair is continued laterally to the inguinal ligament.

The results at the Shouldice clinic have been truly outstanding and continue to be so today. For a time, the Shouldice repair was the gold standard against which all newer procedures were compared. The major criticism of this operation is that it is difficult to teach because surgeons have problems understanding what is really being sewn to what. Unless one is specifically trained at the Shouldice clinic and has the opportunity to work with the surgeons there, one may find it hard to identify the various

layers in the medial flap reliably and reproducibly—a step that is crucial for developing the multiple suture lines. To compound the difficulty, modifications developed outside the Shouldice clinic have given rise to different versions of the procedure.

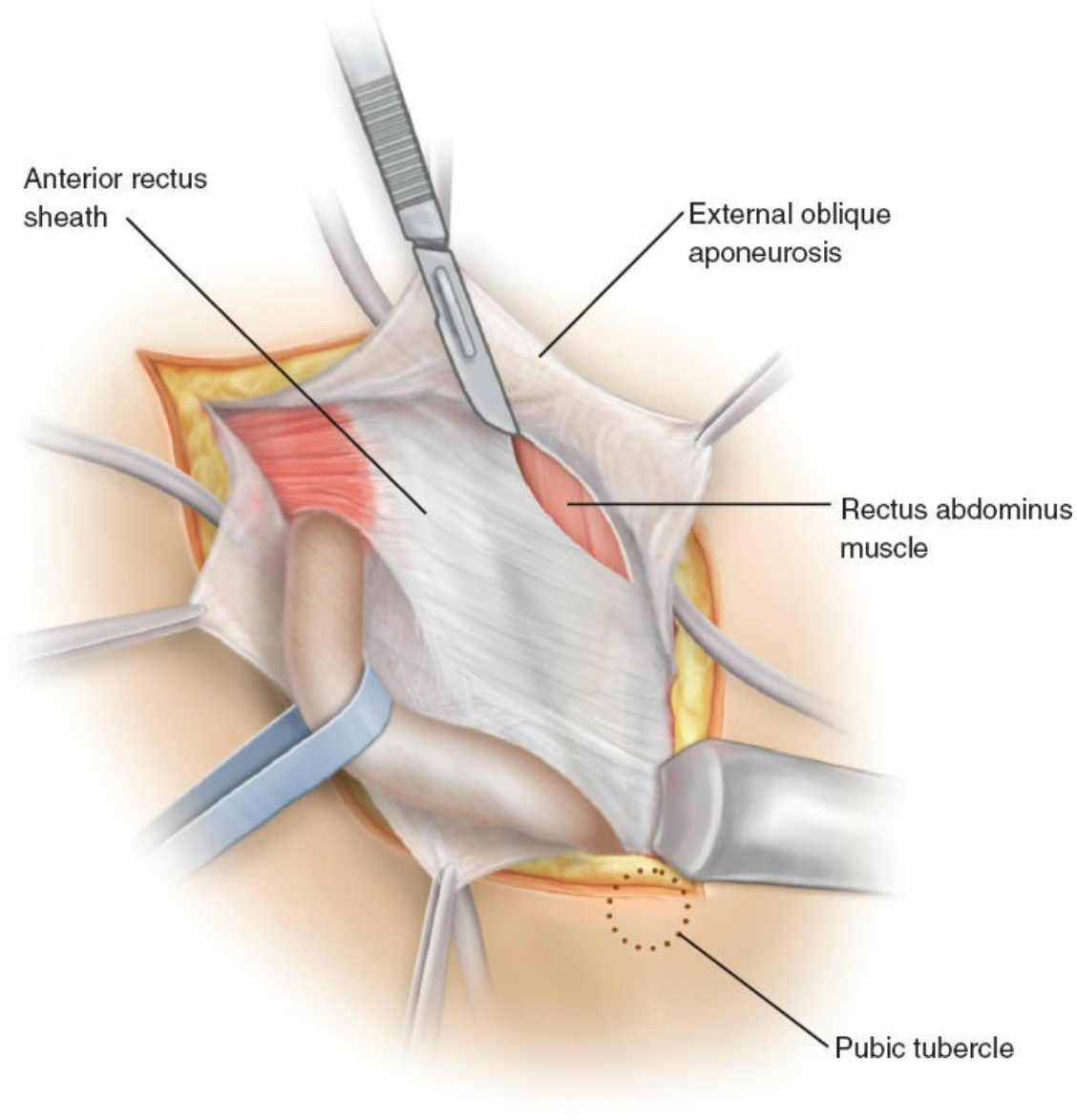

Figure 188.15. A relaxing incision is made in the anterior rectus sheath after the external oblique aponeurosis is reflected medially that begins just above the symphysis pubis and extends cranially for 5 to 10 cm.

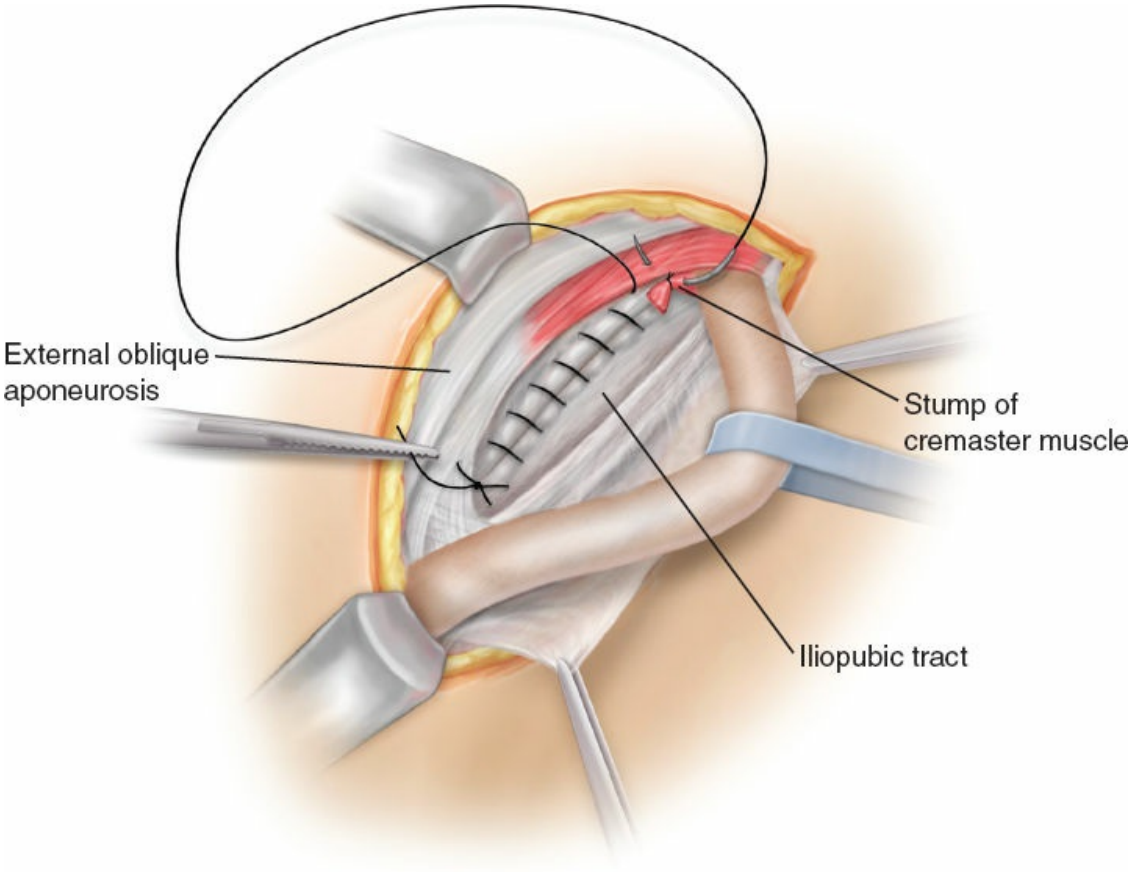

Figure 188.16. The repair begins near the pubic tubercle. The iliopubic tract is sutured to the posterior rectus sheath and then continued laterally to the triple layer until the stump of the divided crematerіc is incorporated.

OPEN PROSTHETIC REPAIR

Lichtenstein Tension-Free Herniorrhaphy (TFR)

Critics of the tissue repairs point out that by definition structures that are not normally in apposition are sutured together under some degree of tension. It is felt that this contributes to the long-term 10% to 15% recurrence rate reported in population-based studies, which is more reflective of general practice. By using a prosthesis to reconstruct the inguinal floor, this tension can be avoided. In 1958 Francis Usher introduced the first tension-free mesh inguinal hernia repair using polyethylene mesh. Anatomical reconstruction of the posterior wall was not performed in favor of reinforcing the inguinal floor with his mesh. In 1962 he introduced the polypropylene mesh that is still the mesh of choice today, especially in the United States.

The surgical technique proposed by Usher never became widely used

until Irving Lichtenstein in 1964 introduced the idea of performing the repair under local anesthesia and promoted its tension-free nature. Lichtenstein and colleges at the Lichtenstein clinic strongly promoted the approach so much so that the anterior tension-free mesh repair is now known as the “Lichtenstein tension-free repair” or TFR. By the 1990s, it had become the most common surgical repair for an inguinal hernia in the Unites States and many other parts of the world. The recurrence rate dropped significantly with this technique even in general practice, and it is still today considered the gold standard for an anterior inguinal hernia repair.

At the Lichtenstein clinic, the procedure is performed under local anesthesia with sedation using 50 cc or less of a 50:50 mixture of 1% lidocaine (Xylocaine) and 0.5% bupivacaine (Marcaine), with 1/200,000 epinephrine. General or regional anesthesia can also be used. The initial steps are similar to the Bassini operation.

Once the external oblique aponeurosis has been opened, the upper leaf is freed from the underlying internal oblique muscle and aponeurosis in an avascular plane beginning at least 2 cm medial to the pubic tubercle. This separation of the external oblique aponeurosis from the internal oblique muscle is continued laterally beneath the nonincised portion of the external oblique aponeurosis to the anterior superior iliac spine. Dissection is continued in this avascular plane from lateral to medial along the shelving edge of the inguinal ligament and iliopubic tract to the pubic tubercle. The purpose is to create a large space for the eventual placement of a prosthesis. The cord structures with their cremaster covering are swept off the pubic tubercle and separated from the inguinal canal. The ilioinguinal nerve, external spermatic vessels, and the genital branch of the genitofemoral nerve all remain with the cord structures.

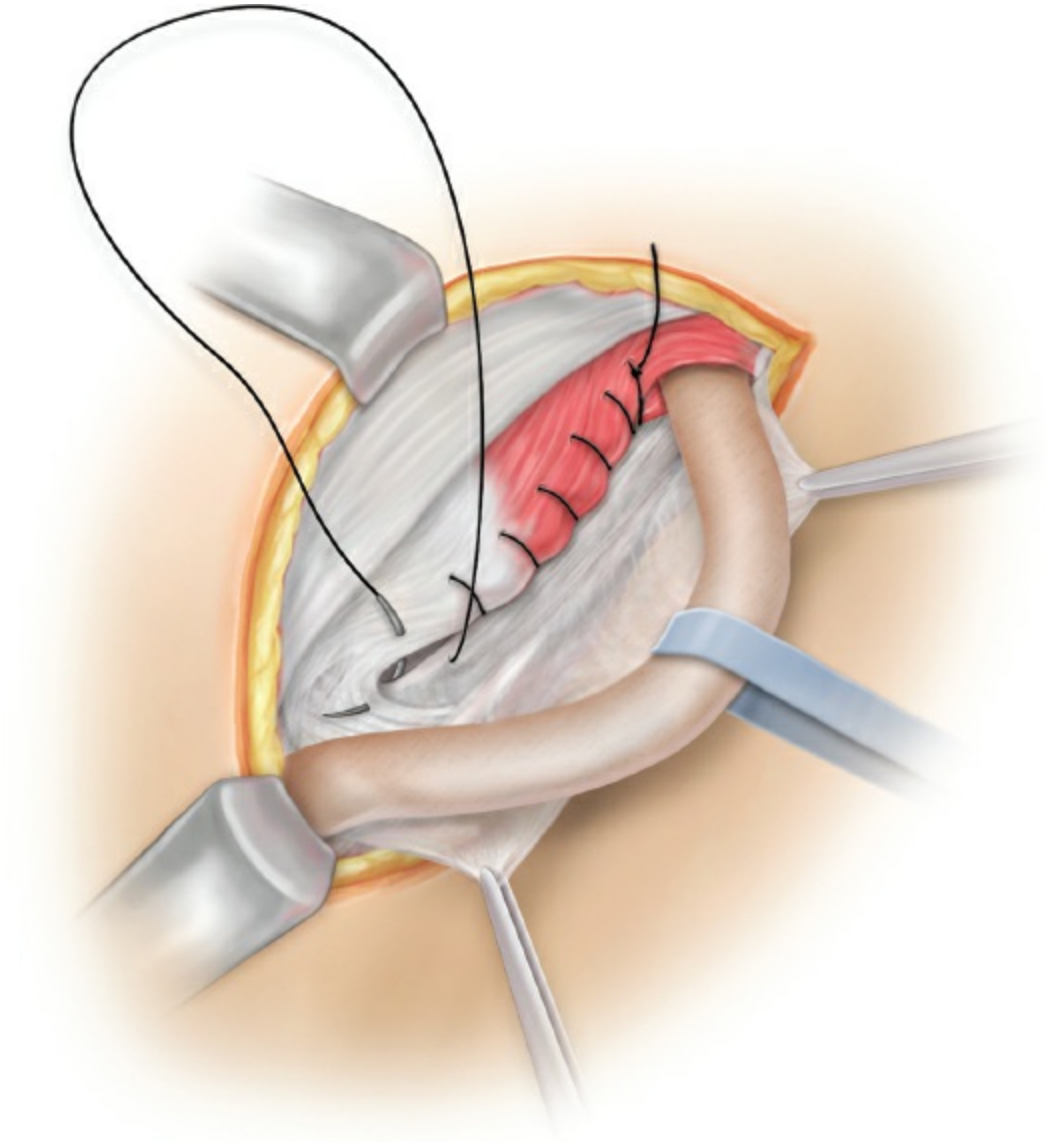

Figure 188.17. A second suture (third row in the repair) is begun at the internal ring approximating the internal oblique muscle to the external oblique aponeurosis along a line parallel and more superficial to the inguinal ligament, in effect creating a pseudo inguinal ligament. The suture is revesed at the pubic tubercle and another pseud inguinal ligament created.

For indirect hernias, the cremasteric muscle is incised longitudinally and the sac dissected free and reduced into the preperitoneal space. A theoretical criticism of this operation is that unless the inguinal floor is opened, an occult femoral hernia may be overlooked. However, an excessive incidence of missed femoral hernias has not been reported except in females with direct hernia. Direct hernias are separated from the cord and other surrounding structures and reduced back into the preperitoneal space. Dividing the superficial layers of the neck of the sac

circumferentially, which in effect opens the inguinal floor, usually facilitates reduction and aids in maintaining it while the prosthesis is being placed. This opening in the inguinal floor can also be used to palpate for a femoral hernia. Suture can be used to invert the sac but its purpose is simply to reduce it to allow the repair to proceed unencumbered by the sac continually extruding into the field especially when the patient strains

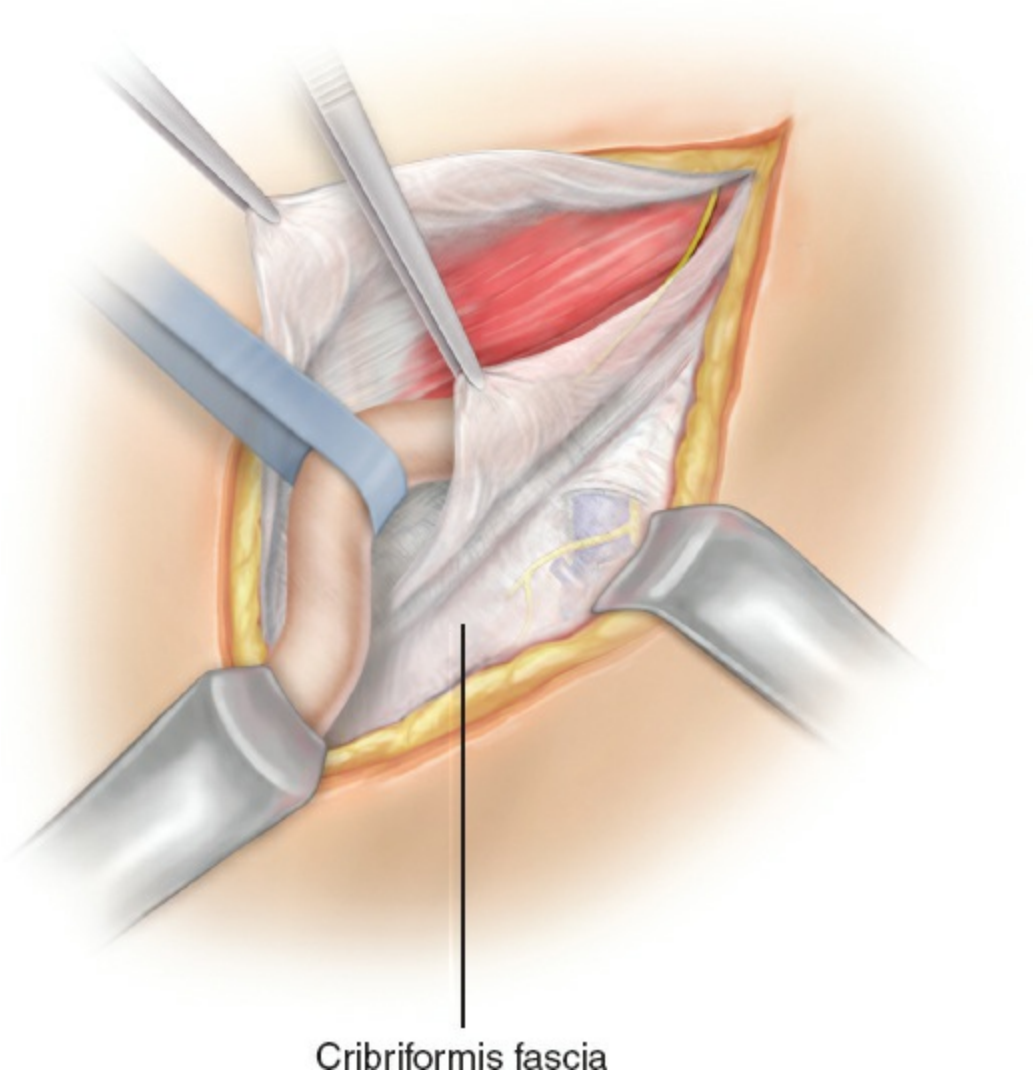

Figure 188.18. At the Shouldice clinic, the cribriform fascia is incised in the thigh, parallel to the inguinal ligament, to make the inner side of the lower flap of the external oblique aponeurosis more mobile for these multiple layers and to check for a femoral hernia.

A mesh prosthesis with a minimum size of 15 by 8 cm for an adult is positioned in the inguinal canal (Fig. 188.19A). The medial end is rounded to correspond to the patient's particular anatomy and secured to the

anterior rectus sheath a minimum of 2 cm medial to the pubic tubercle. Either nonabsorbable or long acting absorbable suture should be used. The wide overlap of the pubic tubercle is important to avoid the all too common pubic tubercle recurrences seen with other operations. The suture is continued in a running locking fashion laterally securing the prosthesis to either side of the pubic tubercle (not into it!) and then the shelving edge of the inguinal ligament. The suture is tied at the internal ring.

A slit is made at the lateral end of the mesh creating two tails—a wide one (two thirds) above and a narrower (one third) below. The tails are positioned around the cord structures and placed beneath the external oblique aponeurosis laterally to about the anterior superior iliac spine with the upper tail being placed on top of the lower. A single interrupted suture is used to secure the inferior surface of the superior tail to the inferior surface of the inferior tail and the shelving edge of the inguinal ligament in effect creating a shutter valve Fig. 188.19B. This later step is considered crucial for the prevention of the indirect recurrence that is occasionally seen when simple re-approximation of the tails is performed. It also serves to wrinkle the mesh somewhat medially, which may decrease any tendency for tension when the patient assumes an upright position. A few interrupted sutures are used to secure the superior and medial aspects of the prosthesis to the underlying internal oblique muscle and rectus fascia. If the iliohypogastric nerve crosses through the external oblique aponeurosis on the medial side, the prosthesis should be slit to accommodate it. The prosthesis can be trimmed in situ, but care should be taken to maintain sufficient laxity to account for a difference between the supine and upright positions as well as the fact that mesh shrinkage is probably a reality.

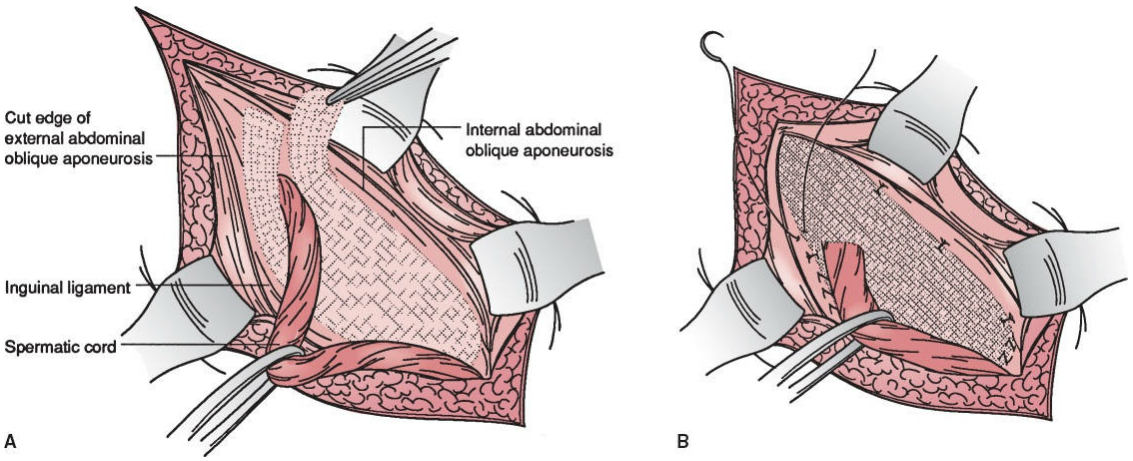

Figure 188.19. The Lichtenstein TFR. **A.** A prosthesis is placed

over the inguinal floor with a slit laterally to accommodate the cord structures. **B.** A continuous suture approximates the prosthesis to the inguinal ligament beginning 2 cm medial to the pubic tubercle. The slit is repaired around the cord laterally incorporating the inferior edge of the superior tail, the inferior edge of the inferior tail, and the inguinal ligament. The repair is completed with interrupted sutures medially and cranially.

If a femoral hernia is present, the posterior surface of the mesh is sutured to Cooper ligament after the inferior edge has been attached to the inguinal ligament. This closes the femoral canal. The wound is closed in layers.

Stoppa's Giant Prosthetic Reinforcement of the Visceral Sac for the Preperitoneal Space

In 1975 Dr. René Stoppa introduced a more invasive technique for repairing an inguinal hernia that was based on the placement of a nonabsorbable mesh in the plane in the preperitoneal space on the abdominal side of the defective myopectineal orifice. He developed the procedure, named the giant prosthetic reinforcement of the visceral sac or GPRVS, largely because of the influence of his teacher and mentor Henry Fruchaud who in 1956 described the myopectineal orifice (sometimes called the musculopectineal orifice) that bears his name. Fruchaud theorized that all groin hernias have a common etiology, which is failure of the transversals fascia to retain the peritoneum from penetrating his myopectineal orifice. Thus, subdividing hernias into direct, indirect, and femoral becomes less important. This concept led Stoppa to develop GPRVS, which reestablishes the containment of the peritoneal sac by inserting a large permanent prosthesis that entirely replaces the transversalis fascia over the myopectineal orifice, separating the internal "os" of a hernia from the peritoneum as opposed to the anterior approaches that address the problem at the external "os" (Fig. 188.7). Stoppa felt this approach would provide an unyielding tissue replacement that would use the intra-abdominal pressure to press a prosthesis against the orifices that he sought to protect from passage of the peritoneum and intra-abdominal contents.

Surgical Technique

GPRVS, also referred to colloquially as the Stoppa repair, is more involved than the anterior approaches previously described. A midline incision is classically made from the umbilicus to the pubis, although inguinal or Pfannenstiel incisions have also been described. The fascia overlying the space of Retzius is opened without entering the peritoneum. The hernia is reduced taking care that there are no structures that may remain at risk for strangulation in the reduced sac. Dissection is continued laterally posterior to the rectus abdominis and the inferior epigastric vessels to the iliopsoas muscle. The symphysis pubis, Cooper ligament, and the iliopubic tract are identified. Inferiorly, the peritoneum is generously dissected away from the spermatic cord structures and the iliac vessels with care to avoid injury to them. This dissection will create a large space that will eventually accommodate a prosthesis without the possibility of rollup. Stoppa emphasized the importance of completely mobilizing or "parietalizing" the spermatic cord to allow the vas deferens and internal spermatic vessels to be displaced laterally so that it will not necessary to split or keyhole the giant prosthesis that will eventually be placed.

Once the dissection is completed, a chevron-shaped mesh (Stoppa preferred Dacron) measuring on average 26 by 15 cm is placed in the preperitoneal space laterally to the borders of the psoas muscle using a sequential technique determined by eight strategically placed clamps (Fig. 188.20). The repair is completed by placing a single stitch at the apex of the mesh to the inferior aspect of the umbilicus. Once the peritoneum is released, the mesh will be held in place by the pressure of the peritoneal contents against the posterior aspect of the anterior abdominal wall. A unilateral variant of this procedure was popularized by Wantz.

LAPAROSCOPIC PROSTHETIC REPAIR

Laparoscopic inguinal hernia repair (LIHR) has several theoretical advantages consistent with its minimally invasive character, which include less postoperative discomfort/pain, reduced recovery time allowing earlier return to full activity, easier repair of a recurrent hernia that had been performed conventionally because the repair is performed in tissue that has not been previously dissected, less morbid treatment of bilateral hernias, the avoidance of a groin incision/ improved cosmesis, and the highest possible control of the hernia sac. These potential advantages of laparoscopic herniorrhaphy must be interpreted in the light of the

disadvantages of a laparoscopic approach. These include complications related to laparoscopy such as bowel perforation or major vascular injury, potential adhesive complications at sites where the peritoneum has been breached or prosthetic material has been placed, the need for a general anesthetic, increased cost because of the expensive equipment required and a steep learning curve. On the other hand, the conventional operation can be performed under local anesthesia on an outpatient basis with minimal risk of intra-abdominal injury, and the cost is less. The result is that widespread adoption in contrast to other minimally invasive operations has not been observed. The adoption rate varies dramatically from country to country. It is estimated that between 15% and 20% of inguinal hernias in the United States are repaired laparoscopically, but this number seems to be gradually increasing as newly trained surgeons enter the workforce.

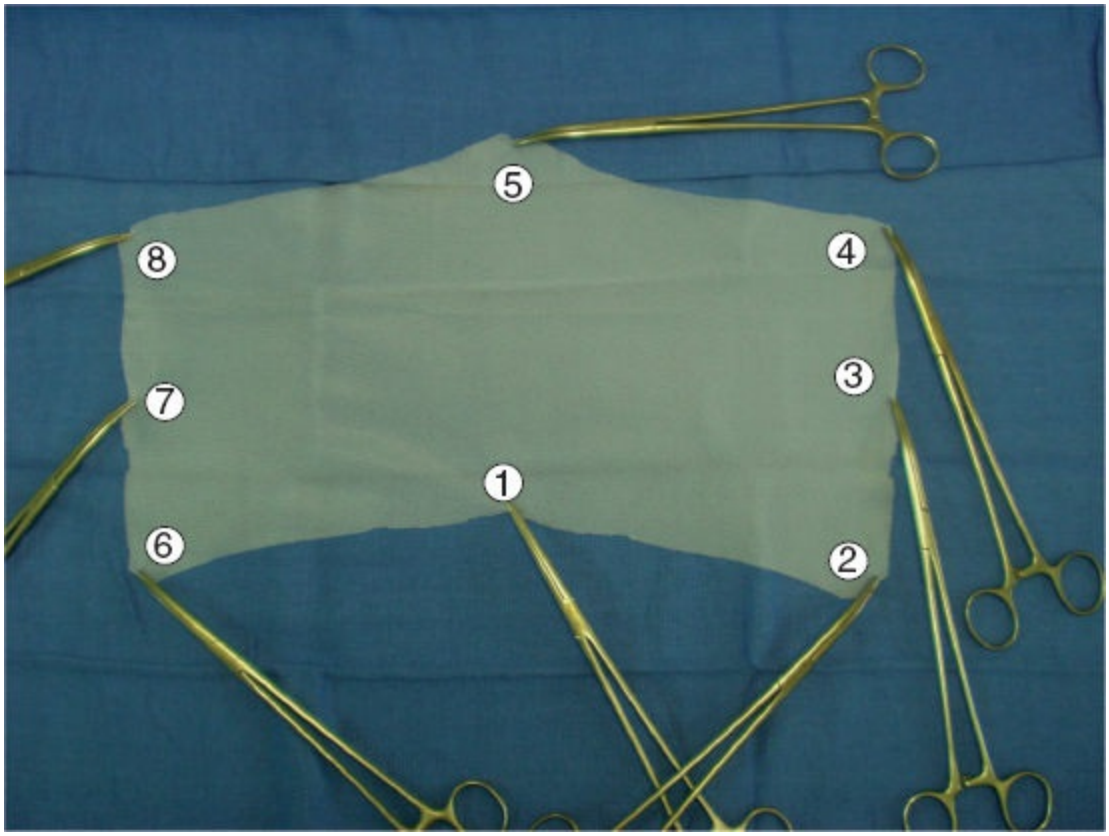

Figure 188.20. Photograph of the chevron-shaped prosthesis grasped by eight long Kelly forceps for their notouch handling and easy correct placement. The numbers 1 to 8 indicate the order of placement of the clamps, beginning on the right side of the patient.

The two most commonly performed laparoscopic herniorrhaphies are

the transabdominal preperitoneal (TAPP) and the totally extraperitoneal (TEP). The essential steps in the preperitoneal space are identical; only the access to the space as their names imply is different. An intraperitoneal onlay mesh (IPOM) procedure has also been described but has never gained popularity, which is somewhat surprising because of the frequent use of the procedure for ventral hernias. IPOM for inguinal hernias is considered by most to be a salvage procedure only. Variations in the two commonly performed laparoscopic repairs include the use of the robot and single port surgery, but these will not be discussed in detail.

TAPP

The TAPP procedure provides the best exposure to the preperitoneal space and is therefore easier to learn. The disadvantage is that the peritoneal cavity is entered, and therefore laparoscopic complications can occur such as visceral injury, adhesive complication, trocar site hernias, etc. In addition, the peritoneum has to be closed that adds time to the procedure.

Figure 188.21 depicts the operating room setup. The operation is performed under general anesthesia with the patient supine. Arms should be tucked at the side of the patient as outstretched arms may compromise the ability of the surgeon to obtain an optimum angle for fixing the prosthesis. A Foley catheter is placed to establish bladder decompression only if the patient does not void immediately prior to entering the operating room. A single video monitor is placed at the foot of the operating table. An angled laparoscope is essential to provide adequate visualization of the inguinal region because it is somewhat anterior. The surgeon stands on the opposite side of the table from the hernia. The first assistant stands opposite the surgeon. The first assistant usually acts as the camera operator as there is not enough room for a third person between the two primary surgeons and the head of the table. This assumes the primary surgeon will use a two-handed technique. Alternatively, some surgeons prefer to use a one-handed approach so that they can control the optics themselves since proper visualization is so critical to a successful laparoscopic herniorrhaphy. This is strictly a matter of personal preference.

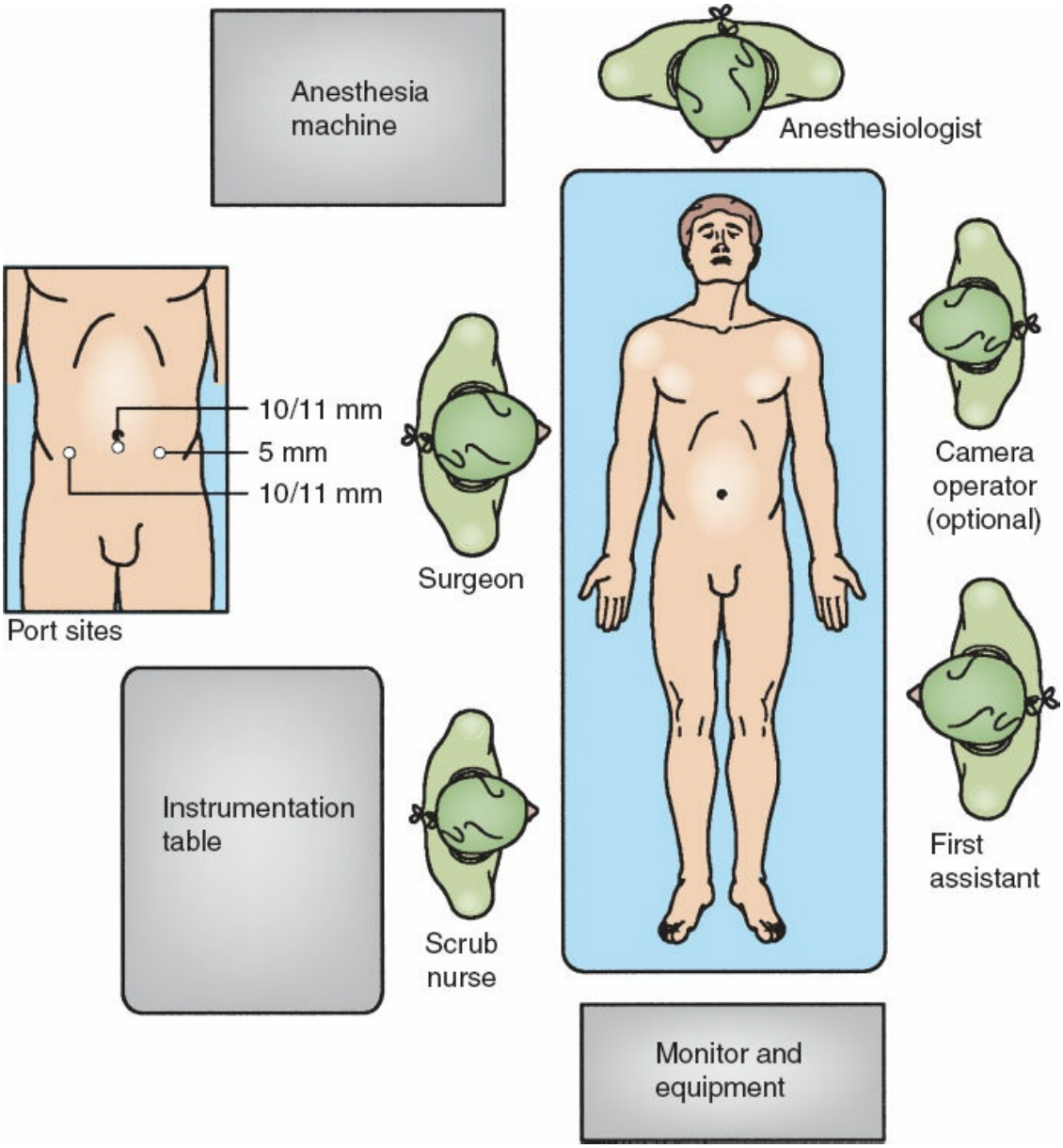

Figure 188.21. Typical operating room setup for laparoscopic inguinal herniorrhaphy.

The laparoscopy is begun by placing an 11-mm cannula at the umbilicus using an open Hasson technique. Alternatively, a Veress needle can be used. Two additional 5-mm cannulas are placed on either side of the midline at the level of the umbilicus, near the lateral edge of the rectus sheath. After a laparoscopic inspection of the entire abdominal cavity, the patient is placed in the Trendelenburg position that allows visualization of important anatomical landmarks through the peritoneum (Fig. 188.5). The peritoneum is incised using scissors approximately 2 cm above the superior edge of the hernia defect, and the space between the peritoneum and the transversalis fascia (spaces of Retzius and Bogros) is entered.

Occasionally the median umbilical ligament is divided if it appears to compromise exposure (Fig. 188.22). A radical dissection of the preperitoneal space is then performed. The key structures that must be identified are the ipsilateral and contralateral pubic tubercles, inferior epigastric vessels, Cooper ligament, and the iliopubic tract (Fig. 188.6). Dissection below the iliopubic tract must be careful to avoid the femoral branch of the genitofemoral and lateral femoral cutaneous nerves, which enter the lower extremity just below the Iliopubic tract. Skeletonizing the cord structures from the peritoneum completes the initial dissection. Direct hernias are much easier to deal with than indirect. The sac and preperitoneal fat are reduced from the hernia orifice by gentle traction separating the peritoneal sac from the thinned out transversalis fascia, which lines the abdominal wall portion of the hernia defect and is easily visualized as a white tongue of tissue that can be teased back into the defect in the abdominal wall. This characteristic layer is sometimes referred to as the “pseudosac.” For indirect hernias, there are two options. A small sac can be mobilized from the cord structures and reduced back into the peritoneal cavity. A large sac may be difficult to mobilize because of dense adhesions between the sac and the cord structures due to chronicity of the hernia. In this circumstance, it is prudent to divide the sac at a convenient point distal to the internal ring and only mobilize the proximal portion which is then closed with sutures of an endoloop. Once the hernia sac has been dealt with, the dissection is completed by mobilizing the inferior flap for a significant distance past the bifurcation of the vas deferens and the internal spermatic vessels. This step is considered essential to prevent rollup of the prosthesis that will be placed in the space leading to recurrence. By gently elevating the internal spermatic vessels, the peritoneum can be stripped off by counter traction. A similar maneuver can be accomplished with the vas deferens.

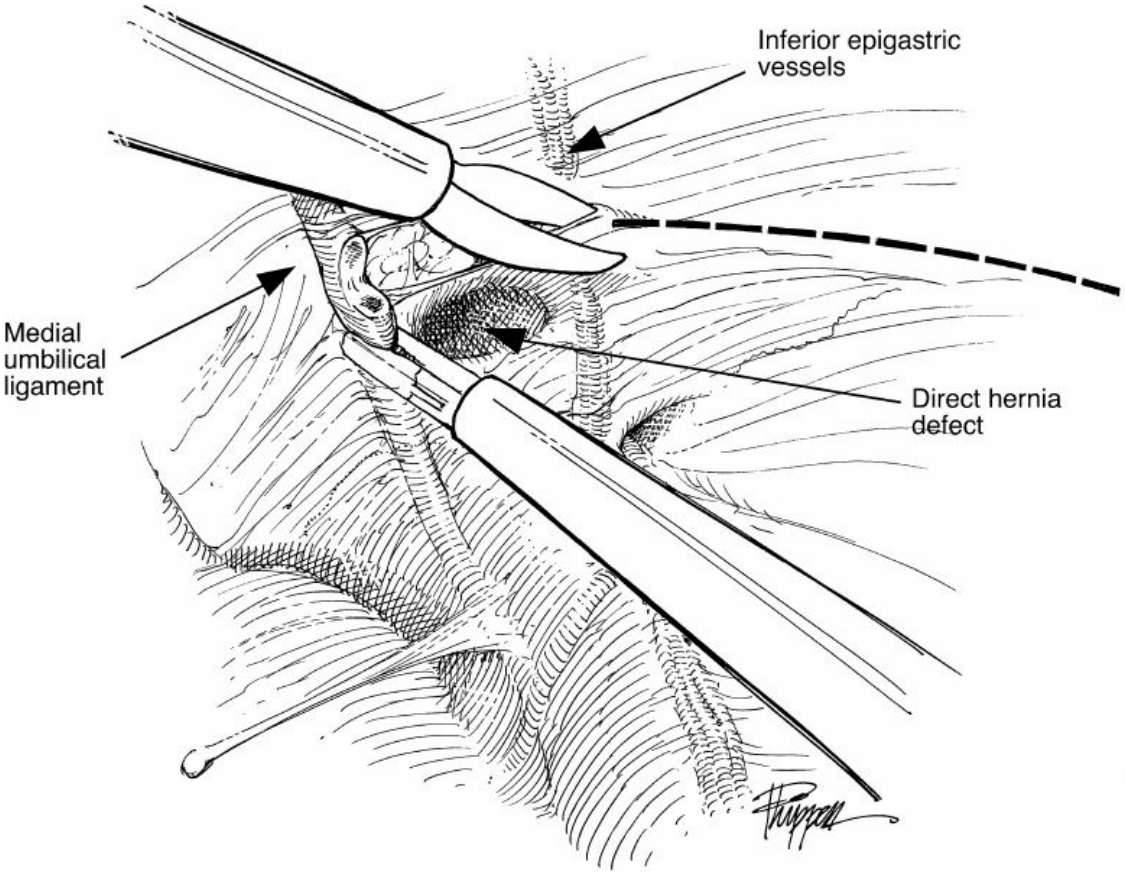

Figure 188.22. The peritoneum is incised beginning on the lateral side of the medial umbilical ligament, beginning about 2 cm above the hernia defect and extending toward the anterior superior iliac spine. Rarely is it necessary to actually divide the medial umbilical ligament.

Next a large prosthesis, at least 11 by 6 cm, is placed over the myopectineal orifice so that it completely covers the direct, indirect, and femoral spaces (Fig. 188.23). The prosthesis can either be simply laid over the cord structures or a slit can be made in the mesh to wrap around the cord structures (Fig. 188.24). Most surgeons now avoid the slit in the prosthesis because recurrences have been noted through these slits even when they have been repaired around the cord. The prosthesis can now be secured with staples, tacks, or glue. The medial edge is stapled or tacked to the soft tissue around the contralateral pubic tubercle and the symphysis pubis. The medial, inferior border is secured just above Cooper ligament. Next the prosthesis is secured along the superior border to the posterior rectus sheath and transversalis fascia, at least 2 cm above the hernia defect. If the prosthesis is large enough, no fixation is necessary. Staples or tacks are never placed below the iliopubic tract when lateral to the internal spermatic vessel because of the danger of damage to the important nerves

in this area. The last step is to cover the prosthesis by closing the peritoneum with sutures, tacks, staples, or glue. This step is aided by decreasing the pneumoperitoneum pressure.

For bilateral inguinal hernias, the same peritoneal incision and preperitoneal dissections are used. One can then either use individual prosthesis on either side or completely expose the symphysis pubis so that both preperitoneal dissections communicate with each other. This exposure allows the placement of one large prosthesis (at least 25 × 8 cm) that essentially covers the entire lower pelvis.

TEP

Because the peritoneal cavity is not intentionally entered, this technically is not a laparoscopic operation. However, since laparoscopic instrumentation is used, it is always grouped with the TAPP. The essential difference is that the preperitoneal space is entered by establishing a plane of dissection outside of the peritoneal cavity between the posterior surface of the rectus muscle and the posterior rectus sheath and peritoneum. An incision is made at the umbilicus as if one were planning to perform open laparoscopy. The rectus sheath is opened on one side and the rectus muscle is retracted laterally. The space is enlarged by placing a blunt instrument blindly or an operating laparoscope (a rigid laparoscope with a working channel). Once the surgeon is below the arcuate ligament, the preperitoneal space is entered and the dissection completed under direct vision. Two additional cannulas are placed in the midline, one approximately 5 cm above the symphysis pubis and the other midway between the umbilicus and the symphysis pubis. The operation then proceeds in an identical fashion to the TAPP procedure described above. A popular alternative is to use a water- or air-filled balloon dissector to perform the preperitoneal dissection (Fig. 188.25). Also the two accessory cannulas can be placed on either side of the umbilicus, similar to the TAPP procedure, instead of in the midline.

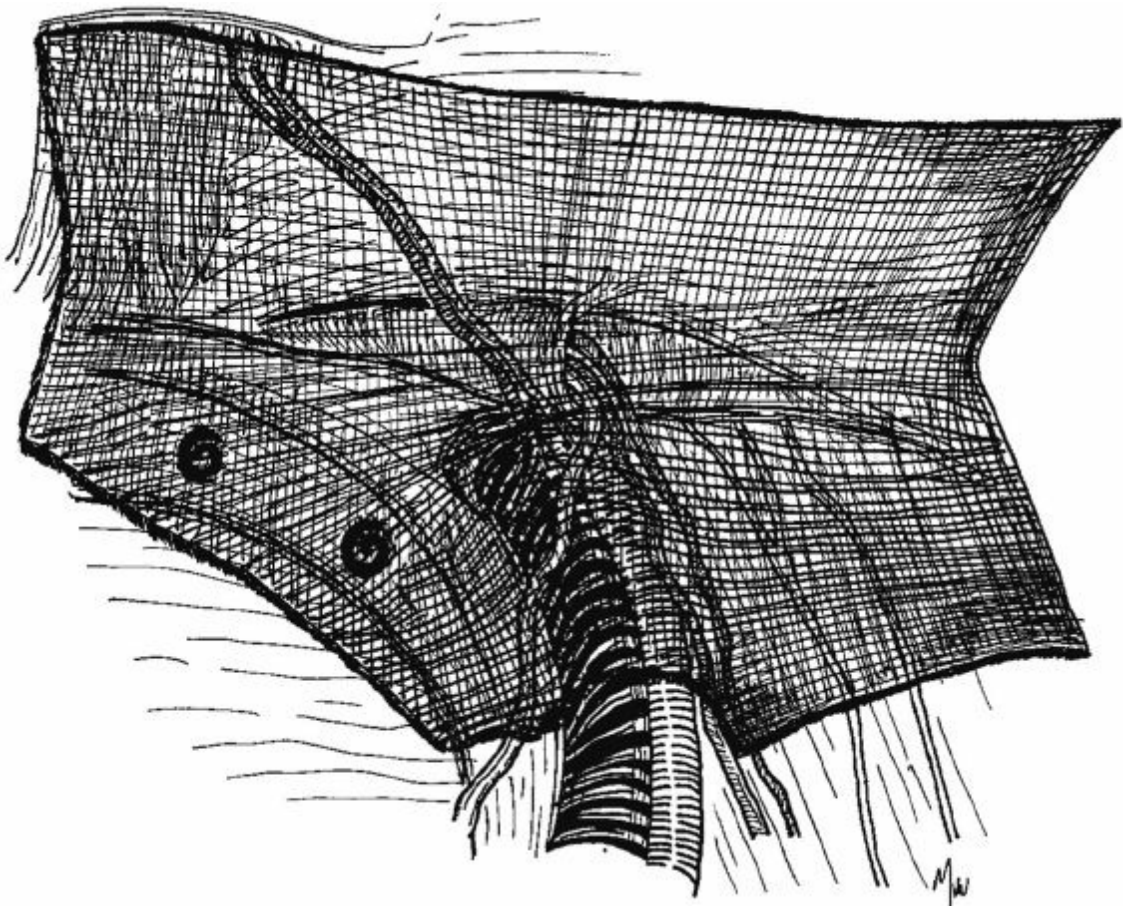

Figure 188.23. A large prosthesis is placed widely overlapping the entire myopectineal orifice. Many surgeons now prefer not to place tacks directly into Cooper ligament shown in illustration.

Postoperative Care

Most patients are discharged home the day of the operation. Those who have urinary retention or persistent nausea, vomiting, or pain that is not well controlled with oral medication are admitted for overnight observation. Empirically, a 15-lb weight restriction is suggested for 1 week. After this, patients are allowed to return to work and normal activity as dictated by pain tolerance. No specific restrictions are made after 2 weeks. Patients return for follow-up at 1 week, 6 weeks, and then as needed.

Complications

In the past, the recurrence rate has been the exclusive measure for determining the value of an individual hernia repair. However, two factors have surfaced that have served to decrease the importance of recurrence. The first is the incidence of postherniorrhaphy sequelae such as chronic

groin pain that occurs more frequently than had been appreciated in the past. Just how “successful” is a hernia repair that is not associated with a recurrence, yet the patient sustains a chronic postoperative syndrome that alters lifestyle? The second factor decreasing the importance of the recurrence rate is the development of the newer tension-free approaches that have brought the recurrence rate down to an essentially irreducible number (i.e., less than 1%) in experienced hands even outside of specialty clinic such as Shouldice.

Complications related to the cord and testicle include bleeding that produces a scrotal or groin hematoma that usually is managed by conservative treatment such as reassurance. Evacuation is rarely required. Ischemic orchitis is an inflammatory process of the testicle occurring within 1 to 5 days after surgery. It occurs in about 1% of primary hernioplasties, but is much more common with operations performed for recurrent hernias. The patient develops enlargement of the testicle that can be excruciatingly painful. A low-grade fever is common and examination discloses an enlarged, hard mass associated with the testicle. The etiology of this complication is not completely understood, but most authorities feel it is caused by thrombosis of the veins draining the testicle secondary to extensive dissection of the spermatic cord. Management consists of supportive care only, with scrotal support and anti-inflammatory agents, as the condition is usually self-limiting. Testicular atrophy can occur after an inguinal herniorrhaphy especially when the procedure is performed for a recurrent hernia. The development of this complication is unpredictable as most patients do not have a history of testicular problems associated with the index herniorrhaphy, for example, orchitis. Indeed, most patients who develop ischemic orchitis after a herniorrhaphy, or any other testicular complication for that matter, go on to recover without testicular atrophy.

Testicular descent can occur with division of the cremasteric muscle. In some patients, the testicle descends into the scrotum. Because of the elasticity of the scrotum, with time, gravity causes the scrotum to elongate. Patients complain their testicle “drops into the toilet.” It is felt that this can be prevented by suturing the distal stump of the divided cremasteric muscle to the tissue around the pubic tubercle. Complete division of the cremasteric muscle is not required with many of the newer procedures, so its incidence should decrease. The dysejaculation syndrome is characterized by searing, burning, painful sensations throughout the groin around the time of ejaculation. It is a rare complication (approximately

0.04%), which is fortunate because it is very hard to treat. It appears to be more common with mesh repairs than pure tissue.

Bladder injury can occur during a herniorrhaphy especially for preperitoneal repairs when there has been previous surgery in the space of Retzius. It is rare with hernia repairs in the anterior space. Bladder injuries are best treated by two-layer repair with absorbable suture, followed by extended indwelling Foley catheter drainage until a cystogram confirms bladder integrity (i.e., 10 to 14 days). Urinary retention can occur after an inguinal herniorrhaphy. It is felt to be related to the choice of anesthetic agent (highest with general and lowest with local), postoperative pain, use of opiates for analgesia, preexisting bladder outlet obstruction, and intraoperative overhydration leading to bladder distension. The treatment is indwelling Foley or repeated catheterizations with or without the use of oral alpha-blockers such as Tamsulosin or Alfuzosin. Voiding trials with ultrasound assessment of residual are begun in a few days usually as an outpatient.

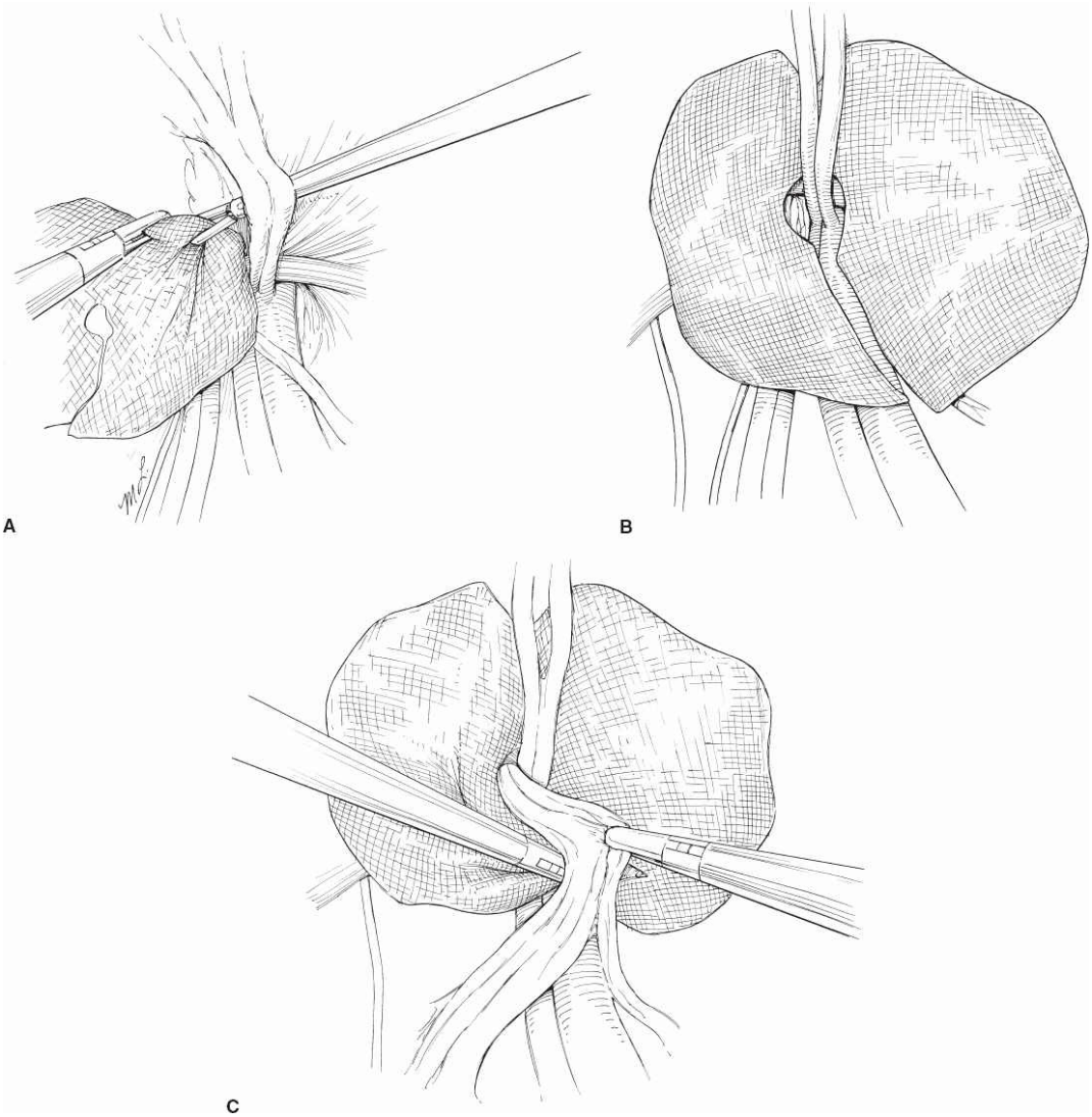

Figure 188.24. A mesh has been slit and a keyhole made and is being positioned beneath the inferior epigastric vessels. TAPP 4 B the mesh is deployed widely overlapping the entire myopectineal orifice TAAP 4C slit is then repaired beneath the cord structures.

Wound infection is surprisingly rare after groin hernia repair. The reason why the groin is apparently a protected area is unclear. When infections do occur in the groin, mesh prosthesis such as polypropylene can commonly be salvaged with drainage alone and this should be the initial treatment for all with removal being reserved for refractory cases. On the other hand, prosthesis made up of nonmesh material such as ePTFE can never be sterilized and virtually always has to be removed. Rejection of the prosthesis because of an allergic response is possible but extremely rare. What patients call rejection in their histories is usually the result of

infection. Seromas can occur especially with the use of synthetic mesh. The finding is most often seen with the laparoscopic hernia repairs. The problem is usual self-limiting as the fluid eventually resorbs spontaneously. Aspiration should be performed for symptomatic relief only as the procedure may result in secondary infection.

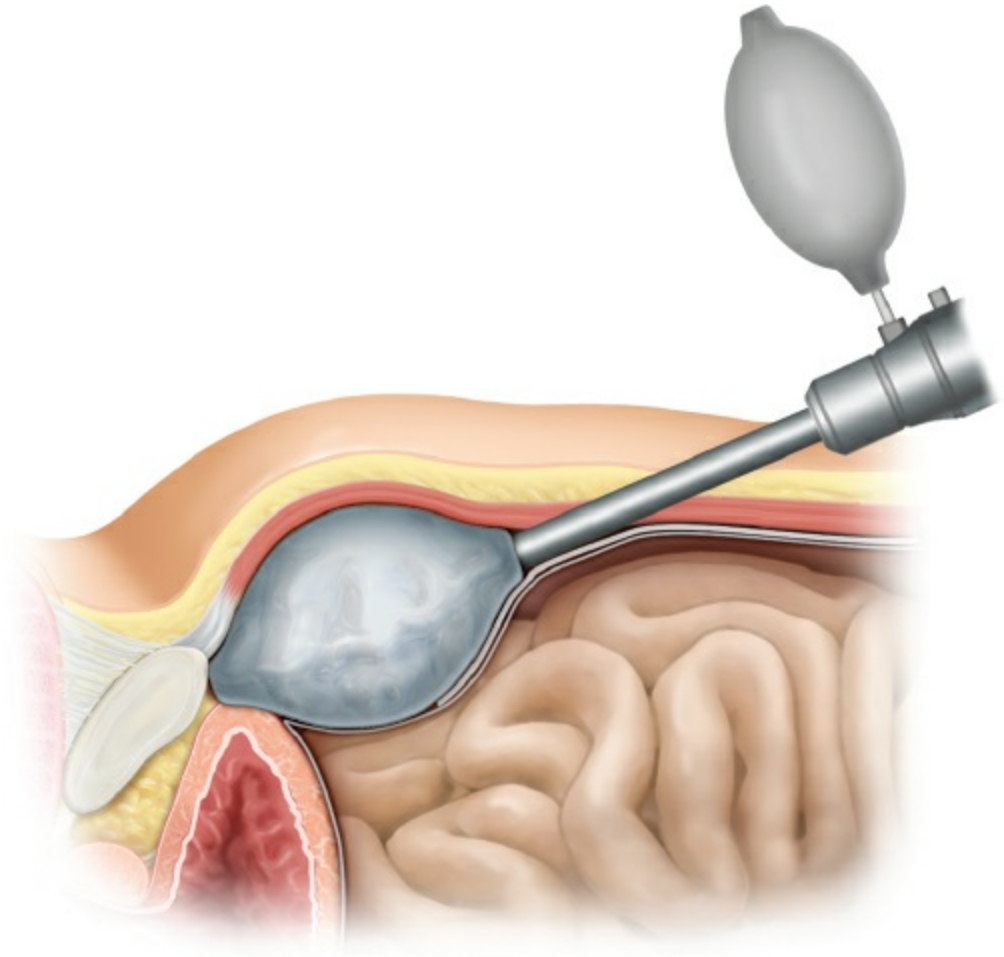

Figure 188.25. The extraperitoneal space is being developed with the aid of a dissecting balloon passed over the posterior rectus sheath into the preperitoneal space.

Osteitis pubis, a noninfectious inflammation of the pubis symphysis, is a known complication of opening the repairs. It is thought to be caused by sutures being placed in the periosteum. Thus, it can be prevented by not placing sutures in that structure. Treatment is largely supportive with heat or ice and anti-inflammatory medication. Rarely does the offending suture have to be removed.

Prosthetic complications include infection (covered above), shrinkage, and erosion into surrounding structures. An overlap in anticipation of an

average 20% contracture with polypropylene as well as other prosthetic materials should be planned. Erosion into the cord structures resulting in vasal obstruction and infertility has been described. Ironically, one of the major arguments for the routine use of mesh in inguinal hernia surgery is to preserve fertility. The theory is that by decreasing the generally accepted recurrence rate in the general population from 10% to 15% seen with Bassini and its variants to less than 5% with the mesh tension-free approach, reoperative surgery with its heavy toll of testicular loss is avoided.

Finally, a host of complications related not to the herniorrhaphy but to the laparoscopy have to be appreciated with the laparoscopic herniorrhaphies. These include laparoscopic accidents resulting in vascular or visceral injury that can be life-threatening, trocar site hernia, and adhesive complications.

Suggested Readings

Amid PK. Groin hernia repair: open techniques. *World J Surg* 2005;29(8):1046–51.

Amid PK, Lichtenstein IL. Long term result and current status of the Lichtenstein open tension-free hernioplasty. *Hernia* 1998;2:89–94.

Bassini E. Nuovo metodo perative per la cura radicale dell'ernia inguinale. Padova, Italy: Prosperini; 1889.

Fitzgibbons RJ Jr, Ramanan B, Arya S, et al. Long-term results of a randomized controlled trial of a nonoperative strategy (watchful waiting) for men with minimally symptomatic inguinal hernias. *Ann Surg* 2013;258:508–15.

Koch A, Edwards A, Haapaniemi S, et al. Prospective evaluation of 6895 groin hernia repairs in women. *Br J Surg* 2005;92:1553–8.

Malik A, Bell CM, Stukel TA, et al. Recurrence of inguinal hernias repaired in a large hernia surgical specialty hospital and general hospitals in Ontario, Canada. *Can J Surg* 2016;59(1):19–25.

Simons MP, Aufenacker T, Bay-Nielsen M, et al. European Hernia Society guidelines on the treatment of inguinal hernia in adult patients. *Hernia* 2009;13:343–403.

Treadwell J, Tipton K, Oyesanmi O, et al. *Surgical Options for Inguinal Hernia: Comparative Effectiveness Review*. Rockville, MD: Agency for Healthcare Research and Quality; 2012 Aug. Report No.: 12-EHC091-EF (http://www.ncbi.nlm.nih.gov/books/NBK100633).

Wantz GE. Giant prosthetic reinforcement of the visceral sac. The Stoppa groin

hernia repair. *Surg Clin North Am* 1998;78(6):1075–87. Review.

EDITOR'S COMMENT

To me the most important aspect of doing a good herniorraphy is knowing the anatomy. Fitzgibbons and Wagner have provided figures with clear anatomical detail. For the novice recognizing landmarks intraoperatively can be difficult, but hernia repair has a steep learning curve. With laparoscopic anatomy, the surgeon must learn the anatomy in reverse and with confidence and a different set of landmarks to avoid injury to important structures.

The authors discuss little about preoperative work-up. As in preparation for any operation, a good history and physical is extremely important to the ultimate outcome. The surgeon needs to fix what he or she can fix prior to embarking on an operation. Any ailment of a patient that creates undue intra-abdominal pressure can be the cause of a failed hernia repair. In the male, a history of a poor urinary stream, urinary tract infection, or an enlarged prostate should be taken care of with a consult to the urology team, with medication and/or prostate surgery prior to hernia repair. Patients with chronic constipation or other bowel symptoms should have a colonoscopy. I would even go far as to say all patients, especially those over 50, should have a colonoscopy as studies have shown that nearly a quarter of these patients will have an abnormality that can be treated. On physical exam if the patient presents with a left indirect hernia even without symptoms of a right hernia, a thorough exam should be made for one on the opposite side, as the left testicle descends first. This is especially true in the pediatric population.

Patients who are smokers should undergo at least a trial of smoking cessation to decrease their risk of recurrence as well as postoperative morbidity. The risk of complications in a smoker is sevenfold that of a nonsmoker. Today, risk assessment and an estimate of the success of any elective operation should play a part in the decision as to whether a patient ultimately even gets an operation. If the patient is not willing to do their part to decrease their own risk of complications, is it incumbent on the surgeon to operate on them and incur the risk of a complication of which ultimately the hospital and surgeon will bear the cost? The American College of Surgeons National Surgical Quality Improvement Program (ACS-NSQIP) database was used to evaluate the effect of tobacco use on outcomes of open versus laparoscopic inguinal hernia repairs. During the time period of the study, 90,162 patients underwent inguinal hernia repair (76% were open compared to 24% by laparoscopic repair). A third of patients were smokers. Failure to quit smoking prior to surgical repair was significantly associated with the complications of pneumonia and reoperation no matter what type of hernia repair was performed.

Most don't realize that the risk of complications of the morbidly obese is as much as that of the smoker. Attempts at weight reduction prior to any

nonemergent operation should be made. Today with the availability of permanent as well as temporary weight control measures such as gastric balloons and endoscopic gastroduodenal sleeves, real weight loss can be obtained prior to hernia surgery. Willoughby and colleagues queried the NSQIP database to examine 65,501 patients undergoing single-sided nonrecurrent hernias to determine if there was an ideal body weight at which the more expensive laparoscopic hernia repair would have less operating time, shorter hospital stay, and less complications than an open repair. There were 17,919 laparoscopic repairs and 46,582 open repairs. The overall morbidity was statistically greater in the open repair group when compared to the laparoscopic group ($p = 0.03$) for all complications across all BMIs. However, laparoscopic repair is significant and different complications not associated with open repair: bowel or major vascular perforation, adhesive complications and secondary hernias, as well as increased cost, need for general anesthesia, and increased length of operation.

Of course, with emergency hernia repairs none of the risk reduction measures can be implemented. However, the ACS-NSQIP database queried and found 4,298 cases of emergent anterior abdominal wall hernia surgery (within 2 days of hospitalization) of which 25.3% were inguinal hernias that were incarcerated, obstructed, strangulated, or gangrenous. The authors derived a risk model that had excellent discrimination for risk of death, which included in descending order of importance congestive heart failure (8.24-fold), age (5.52-fold), history of peripheral vascular disease (4.98-fold), presence of ascites (3.16-fold), preoperative BUN (1.35-fold), and WBC (1.22-fold).

Some of the morbidity of hernia repair can be avoided by the use of local anesthesia. A recent systematic review and meta-analysis by Prakash and colleagues studied a group of 1,379 patients from 10 randomized controlled trials and patients undergoing hernia repair who were anesthetized with local versus spinal anesthesia suffered significantly less pain, urinary retention, and anesthetic failure. In dealing with high-risk patients especially, one should consider utilizing local anesthesia.

One very important advantage of laparoscopic repair is in repair of bilateral hernias in the adult where a bilateral open repair may create too much tension. Along those same lines one may ask what is the long-term incidence and risk factors for contralateral hernia repair after a unilateral repair. Zheng R et al., using the New York Statewide Planning and Research Collaborative administrative data, examined the fate of 32,384 adults who had undergone initial inguinal hernia repair and who had 10-year follow-up. This group had a contralateral repair rate of 10.8%. Based on these data, one could pose an advantage in a bilateral laparoscopic primary hernia repair.

In regard to recurrent hernias, the European Hernia Society made specific recommendations for laparoscopic recurrent hernia repair following a previous open inguinal hernia repair. For recurrent hernias, after a failed laparoscopic repair an open repair is recommended. These recommendations were based on

six meta-analyses. In an attempt to determine compliance with these guidelines as well as a prospective comparison of outcomes, Kockerling and colleagues established the Herniamed Registry. A total of 4,812 men with unilateral recurrent inguinal hernia repair and 1-year follow-up were included in the study. Approximately half of the cohort had laparoscopic repair and the other half open repair of their primary hernia. Ninety percent of the recurrences after laparoscopic repair underwent secondary open repair, but only 38.5% of the recurrent open repairs underwent secondary laparoscopic repairs in accordance with the guidelines. This demonstrates a clear bias of those who do open repairs to keep doing open repairs. This despite the study showing a significantly higher incidence of perioperative complication and re-recurrence for repairs that did not follow the recommended guidelines.

V. Suzanne Klimberg

Suggested Readings

Chung PJ, Lee JS, Tam S, et al. Predicting 30-day postoperative mortality for emergent anterior abdominal wall hernia repairs using the American College of Surgeons National Surgical Quality Improvement Program database. *Hernia* 2017;21(3):323–33.

Köckerling F, Bittner R, Kuthe A, et al. Laparo-endoscopic versus open recurrent inguinal hernia repair: should we follow the guidelines? *Surg Endosc* 2017;31(8):3168–85.

Landin M, Kubasiak JC, Schimpke S, et al. The effect of tobacco use on outcomes of laparoscopic and open inguinal hernia repairs: a review of the NSQIP dataset. *Surg Endosc* 2017;31(2):917–21.

Prakash D, Heskin L, Doherty S, et al. Local anaesthesia versus spinal anaesthesia in inguinal hernia repair: a systematic review and meta-analysis. *Surgeon* 2017;15(1):47–57.

Willoughby AD, Lim RB, Lustik MB. Open versus laparoscopic unilateral inguinal hernia repairs: defining the ideal BMI to reduce complications. *Surg Endosc* 2017;31(1):206–14.

Zheng R, Altieri MS, Yang J, et al. Long-term incidence of contralateral primary hernia repair following unilateral inguinal hernia repair in a cohort of 32,834 patients. *Surg Endosc* 2017;31(2):817–22.

189 The Shouldice Method of Inguinal Herniorrhaphy

Robert Bendavid



This Chapter can be accessed in the accompanying eBook edition (see inside front cover for access instructions).

In an Atlas of Hernia Surgery, all roads lead to Bassini.

—R. Bendavid (2005)

The treatment of inguinal hernias can truly be said to be following an orderly process of evolution. Much credit goes to the anatomists who described the important structures: Poupart, Hesselbach, Cooper, Thomson, Gimbernat, and Fruchaud, to name a few. The next step in this evolution was contributed by the surgeons: Bassini, Ruggi, Narath, Lotheissen, Halsted, and McVay, to name a few. From the late 1940s to the early 1950s, the introduction of synthetics provided the surgeon with a weapon that promised a certain cure and among the pioneers one must recall Acquaviva, Zagdoun and Sordinas, Newman, Lichtenstein, Rives, and Stoppa. From the early 1990s we have seen the introduction of laparoscopy and the emergence of a controversy that is far from settled in terms of safety, cost, learning curve, and complications. Experience reveals that, despite the advances made in the field of hernia surgery where prostheses and laparoscopy have made significant contributions, the need to know anatomy and to be able to perform a pure tissue repair has become indispensable and imperative. Recurrences are still common and often the result of inadequate dissection, failure to recognize a hernia, repair under tension, or an inappropriate use of a prosthesis, the latter being often, blindly, and erroneously considered a panacea for any and all hernias. Each of the above factors can be addressed effectively when one is familiar with anatomy. The anatomy of the groin is, by no means, the easiest to understand, incorporate, or retain!

As anatomy became clearer, early progress was achieved by the introduction of steps that would in some way improve pure tissue hernia

repair. Among these steps, the following stand out:

- Division of the posterior inguinal wall (Bassini, McVay, Fruchaud)
- Ligation of the hernia sac (Championniere, Marcy, Bassini, Fruchaud)
- Resection of the cremaster (Bassini)
- Use of the iliopectineal ligament (Narath, Lotheissen, McVay, Ruggi)
- Appreciation of the iliopubic tract or bandelette of Thomson (Fruchaud, Condon, Nyhus)
- Reconstruction of the posterior inguinal wall (Bassini, Halsted, McVay)

This process of evolution remains manifest as surgeons attempt and evaluate newer techniques. Among the controversial points, one is the value of resection of the hernial sac. Many surgeons believe that an adequate posterior inguinal wall reconstruction would be sufficient to contain the sac and, hence, a hernia. Others consider the resection of the cremaster unnecessary, particularly if a prosthetic repair is considered as an alternative for reconstruction of the posterior inguinal wall. Others still never split the posterior wall of the inguinal canal, under the pretext that this maneuver only promotes the formation of a recurrent hernia. An important aspect of this ongoing evolution in hernia surgery is the introduction of various mesh prostheses through open techniques or laparoscopy and their acceptance as part of the modern treatment of primary as well as the more difficult recurrent inguinal hernias.

The contribution of the Shouldice philosophy in this evolution is simply that it has chosen and implemented the specific steps that have been introduced over the past 120 years. More exactly, in the early 1950s, it was the well-informed staff surgeon Ernie Ryan, a recent addition to the Shouldice Hospital staff, who incorporated all the specific steps of the Bassini repair, which had been known since 1886. Bassini himself had brought together the pieces of this puzzle by acknowledging and implementing the observations of all the previously named surgeons. Bassini had, in a sense, gleaned the fertile fields of the past to produce an operation that was unique, original, and effective, and that would be emulated by at least a 100 techniques of pure tissue repairs to date. The Shouldice repair remains the most faithful reflection of the Bassini technique and therefore its success.

HISTORICAL BACKGROUND

E. E. Shouldice became interested in the treatment of inguinal hernias in

the 1930s. Operative results were then notoriously poor. In addition to attempts at perfecting his surgical technique, Shouldice looked on each patient as an individual who was to be cared for preoperatively as well as postoperatively.

Obesity, the bane of all surgery, was a factor that had to be brought under control before an operation. To that end, a clinic was set up where patients were to be evaluated while on a weight-reducing diet until their ideal weight was reached. Early ambulation was to be instituted postoperatively in a manner that was then considered heretical, namely, the patient walked away from the operating table, bed rest was minimal, and all activities were to be resumed as soon as possible without restriction. Only the patient's discomfort was a limiting factor. Such an approach had been emphasized by Leithauser in a voluminous publication, which he dedicated strictly to the subject of early ambulation. Shouldice, as evidenced by the correspondence he kept, was in contact with Leithauser and became an enthusiastic, adept, and firm believer in the postulates and advantages of early mobilization following all surgical operations.

Local anesthesia was of paramount importance and, to that end, procaine was retained. The basis for this choice of anesthesia was the actual safety of the technique as had been reported convincingly by Halsted, Bloodgood, and Cushing of Johns Hopkins who had published two series of inguinal hernia repairs carried out under local cocaine anesthesia. Cushing at that time provided the most accurate and unparalleled mapping of the innervation of the groin.

Perhaps the most critical contribution was to be the institution of a follow-up system. Unfortunately, the original follow-up and publication of a large series by Iles was flawed and statistics have followed in the same manner, where one is overwhelmed by staggering numbers, but without a closer scrutiny by a professional statistician. Two excellent studies from the Shouldice Hospital would subsequently confirm the serious flaw about the accuracy of their follow-up (Obney and Chan, Bendavid) and provide a more realistic assessment of their results.

The need for a center specializing in external hernias of the abdominal wall was fulfilled in 1945 when the Shouldice Hospital was established. With 10 full-time surgeons, about 7,500 operations are performed every year.

GENERAL PRINCIPLES

Anatomy

The inguinal region is arguably one of the most complex anatomic areas of the human body. One obvious obstacle is the nomenclature, a nomenclature that is academically correct and in place but whose irreverent usage has been corrupted and turned into a vocabulary reminiscent of a bad weed that has been difficult to eradicate. Cooper and Fruchaud are the two authors whose books have contributed most to the clarity and understanding of the groin. Unfortunately, those books have become extremely rare and, when found, unaffordable. For a necessary understanding of the groin, it is imperative that we clarify certain terms and that we adhere to them. It is crucial at all times to remember that anatomy is described with the subject in the standing position. The posterior inguinal wall must never be referred to as the “floor of the canal” as is done too frequently because of the supine position of a subject during surgery, when the posterior inguinal wall presents itself as the floor of the canal simply because it is parallel to the ground!

The transversalis fascia is part of the endoabdominal fascia and is the deepest part of the posterior inguinal wall. It is a thin layer that has no bearing on the genesis of a hernia though it may precede the peritoneum, and this is best seen with direct inguinal hernias. The true posterior inguinal wall is formed by the aponeurosis of the transversus abdominis. It is this layer, when it is weak and degenerated, that is seen to bulge and appear as a direct hernia, followed by the true transversalis fascia and peritoneum. What constitutes the true defect leading up to a direct inguinal hernia is a weakness of a layer of connective tissue situated between the transversus aponeurosis and the transversalis fascia and that Fruchaud has described as the vascular lamina. Posteriorly, in the retroinguinal space of Bogros this is referred to as the inferior epigastric lamina, which extends medial to but not lateral to the inferior epigastric vessels. It is a connective tissue layer that degenerates as a result of the metabolic defects that lead to hernias. These metabolic defects are beginning to be understood and account for the genesis of all hernias, regardless of their site.

Weight Control

Every effort is made to obtain the patient’s cooperation in shedding excess weight. This may require months, but the dividends are obvious and are reflected in an easier operation technically, in less tension during approximation of tissue layers, in early ambulation, and in a lesser

incidence of thrombophlebitis and pulmonary complications. Ironically, with inguinal hernias, there does not seem to be a convincing correlation between obesity and recurrences. The same cannot be said of incisional hernias. Still, the benefits of a lean patient are evident from both the patient's and surgeon's point of view.

Sedation

On the evening before the operation, all patients are given a sedative (diazepam, 5 to 10 mg) orally. On the day of operation, diazepam (10 to 25 mg) is given orally 90 minutes preoperatively, and meperidine (25 to 100 mg) is given intramuscularly 45 minutes preoperatively. These sedatives and analgesics can be varied and often are.

Anesthesia

Local anesthesia is used in 95% of operations. At the Shouldice Hospital, procaine hydrochloride has been used since 1945. It is an excellent drug; it takes effect within minutes, and this effect lasts as long as 2 hours. The effective concentration for the duration of the procedure is a 1% solution, with a maximum volume of 200 mL.

The desirability of local anesthesia may be appreciated when analyzing the patient population. A study at the Shouldice Hospital subsequently published revealed that 52.1% of all patients coming to surgery were older than 50 years (Table 189.1). Significant associated cardiac problems range from 15% to 50% (Table 189.2). The safety of local anesthesia increases the pool of patients who may undergo surgery. An added advantage is the lesser need for extensive consultations and investigations to assess the fitness of a patient to undergo surgery. This, in turn, drives down the cost of health care.

TABLE 189.1 Patient Population Older than Age 50[a]

Age Group (y)	Number of Patients	Number of Operations	Percent
50 to 59	1,116	1,369	19.1
60 to 69	1,330	1,533	21.4
70 to 79	603	689	9.6
80 to 91	124	144	2.0

[a]Data from 7,159 operations in 1990.

TABLE 189.2 Incidence of Associated Conditions in Patients Older than Age 50

Condition	Percent
Cardiac arrhythmias	50
Hypertension	20
Congestive heart failure therapy	17
History of myocardial infarction	15
History of angina	15
Anticoagulation (from warfarin, aspirin, sulfinpyrazone)	12

SURGICAL PRINCIPLES

The surgical aspect of the Shouldice Hospital repair can be broken down into two components: dissection and reconstruction. Before discussing each phase in detail, it would be of interest to emphasize some aspects of the procedure and to justify their importance. It must be stated that, at the Shouldice Hospital, though the technique is generally the same, all surgeons vary to a certain extent. These variations usually have to do with the degree of tension on sutures, the size of tissue bites incorporated, the extent of the dissection, full or partial division of the posterior wall of the canal, and time taken to perform a procedure.

Incision

The incision is lower than is described in most textbooks. It is made along a line joining the anterosuperior iliac spine and the pubic crest. This incision, once made, brings the inguinal area into full view without a strenuous retraction. The latter can be a source of discomfort under local anesthesia. The exposure, about the inguinal ligament, becomes ideal, and so does the pubic crest area.

External Oblique Muscle and Aponeurosis

The incision into the external oblique aponeurosis is extended from the

superficial inguinal ring to a point 2 to 4 cm lateral to the deep inguinal ring. This allows a thorough dissection of the deep ring and examination of the substance and quality of the fibers of the internal oblique and transversus abdominis muscles. Often, fatty infiltration of these muscles is seen near the deep ring, usually laterally and superolaterally, providing poor tissue for repair. One may also find preperitoneal fat protruding through this area, setting the stage for an interstitial hernia, a recurrent inguinal hernia, or an overlooked hernia. If need be, the deep ring is relocated by incising laterally the internal oblique and transversus abdominis fibers over a length of 1 to 3 cm.

Resection of the Cremaster

This important step seems to have been entirely forgotten. Few students have seen it performed, and fewer surgeons practice it. This step was clearly described and emphasized by Bassini, repeated by Catterina, and perpetuated by Shouldice. The resection of the cremaster and lateral retraction of the cord bring into view the posterior inguinal wall in a manner that can best be described as a "revelation." It becomes impossible, then, to overlook a direct or indirect inguinal hernia. The transversus abdominis aponeurosis (i.e., the posterior inguinal wall) is now in full view. Whenever possible, the cremasteric vessels should be doubly ligated separately from the cremasteric muscle.

Incision of the Posterior Wall of the Inguinal Canal

Division of the transversus abdominis aponeurosis and transversalis fascia (the true transversalis fascia, which is part of the endopelvic fascia and which lines the deep aspect of the groin) from the internal ring to the pubic crest is of paramount importance. It serves the purpose of identifying all hernial defects, however small. Redundant and weak transversus abdominis aponeurosis and transversalis fascias medial and lateral to the incision can be excised; this excision then defines the new edges, which will be sutured into the new posterior wall of the inguinal area.

In women, division of the posterior wall of the inguinal canal is not as crucial. Nevertheless, the lateral third of this wall must be incised to allow proper examination of the entire posterior wall and to verify the absence of a femoral hernia from the preperitoneal space, above the inguinal ligament. This attitude with regard to female patients was confirmed by a study carried out by Glassow. Between 1945 and 1959, 27,870 abdominal wall

herniorrhaphies were performed, 676 of them on women. Of these 676 inguinal hernias, 605 were indirect inguinal hernias (592 primary and 13 recurrences) and 71 were direct inguinal hernias (50 primary and 21 recurrences). Of the 50 primary direct inguinal hernias, 40 were accurately documented. The defect was located in the lateral half of the floor in 32 patients and in the medial half of the floor in eight patients. The solidity of the posterior inguinal floor in women is a fact easily observed in practice. The aforementioned figures place the incidence of a direct inguinal hernia in a woman at 0.2% of all abdominal wall hernias.

Search for a Peritoneal Protrusion

The search for a peritoneal protrusion must become a ritual. The experience of the Shouldice Hospital reveals that of all patients with recurrent inguinal hernias referred to that institution, 37% prove to have indirect inguinal hernias. It becomes imperative, then, during all inguinal herniorrhaphies to look for a peritoneal protrusion if an indirect sac is not identified. This protrusion is found on the medial aspect of the spermatic cord within the internal ring and deeper, closely adherent to the vas, from which it must be freed and allowed to retract back into the preperitoneal space. The presence of a peritoneal protrusion confirms the absence of an indirect inguinal hernia. Very rarely, two indirect sacs can be present.

Ligation of the Sac

The ligation and resection of a hernia sac can be likened to a symbolic gesture representing victory of surgery over disease. Most surgeons have resected this sac in the past, understandably so if it is elongated, tubular, or scarred or if strictures are present. Is “high” proximal or even simple resection necessary? Experience relating to sliding inguinal hernias reveals that once a sac and its contents are freed from the spermatic cord, the entire sac, regardless of its size, can simply and reliably be returned into the abdominal cavity. This fact emphasizes the importance and necessity of a good posterior inguinal wall and of its reconstruction as a barrier against recurrent herniation. It has been shown by Ryan and Welsh that the incidence of recurrence after repair of sliding indirect inguinal hernias is less than 1%. What is important, therefore, is that the dissection of an indirect sac be carried out as far as possible deep to the already enlarged internal ring. Once the sac is ligated (“high” or “low”) or even if it remains intact, it should easily be replaced and made to disappear in the

preperitoneal space.

Sliding Hernias

Sliding hernias need not present a problem. A surgeon about to enter practice generally anticipates with trepidation the first encounter with a "slider." So many procedures, often difficult to illustrate, abound in many texts and always prove to be confusing at best. In a report of 2,300 operations from the Shouldice Hospital analyzed by Welsh, only 11 recurrences were recorded. Of these 11, only one was a true recurrent sliding inguinal hernia; the other recurrences were five femoral hernias and five direct inguinal hernias. The standard Shouldice Hospital repair was used in each of the 2,300 operations. The emphasis here is on resection of the cremaster muscle; the proper dissection of the internal ring, which is already and usually enlarged, and resection of a peritoneal sac if such can be carried out safely. I generally prefer to leave the sac intact and simply reduce it. "High" ligation must never be the aim. If the least doubt emerges as to whether the sac can be safely incised, the sac must be left alone and returned to the preperitoneal space intact. This never presents a problem, because 90% of sliding hernias are easily reducible and do so spontaneously before surgical intervention.

Release of the Cribriform Fascia (Thigh Fascia)

After incision of the external oblique aponeurosis along the direction of its fibers, its lateral flap is held taut anteriorly and the fascia cribriforms, beneath the inguinal ligament, is incised from the level of the femoral vein to the medial aspect of the pectineus muscle. This maneuver frees the external oblique aponeurosis to an extent that makes it widely available for the inguinal repair. This step can be compared with the creation of a flap or a "plasty" or relaxing incision. This maneuver also allows examination of infrainguinal, femoral herniation.

Search for Multiple Hernias

Statistics show that a second, simultaneous, ipsilateral hernia was found, if adequately searched for, in 12.8% of the patients who underwent operation. This search in all instances must rule out an indirect hernia, a direct hernia, a femoral hernia, an interstitial hernia, a prevascular hernia, a Laugier hernia (through the lacunar ligament), a prevesicular hernia

(anterior to the bladder), and, lastly, lipomas, which on occasion perforate through the internal oblique and transversus muscles at the deep inguinal ring. The search must be established as a routine.

Relocation of the Superficial Ring

During reconstruction of the posterior inguinal wall, as we shall see, the fourth line of suture tacks down the medial 2 to 3 cm of the external oblique aponeurosis (the lateral flap) in such a manner as to cover the medial portion of the floor of the canal. This is the site of recurrence of most direct inguinal hernias (69.2% of recurrent direct inguinal hernias as reported by Obney and Chan). As a result, the superficial ring becomes relocated in a position slightly lateral from its original site.

Continuous, Nonabsorbable Suture

The continuous suture is considered to be significant, because it allows an even distribution of tension throughout the repair of the inguinal canal. Another important asset of the continuous suture is the elimination of any defect along the suture line, a defect that could otherwise enlarge with interrupted sutures and set the stage for a recurrence, perhaps.

Relaxing Incision

Relaxing incisions were introduced by Wölfler in 1892 and by Berger in 1902 and should be part of all inguinal herniorrhaphies in which tension is believed to be present along the suture line. The relaxing incision must be generous and extend from the level of the pubis to the level of the internal ring, on the anterior rectus sheath. To what extent tension is relieved has yet to be accurately measured. Yet, when the relaxing incision is made, whether a long single incision or several small (“pie-crusting”) incisions, an elliptical shape is immediately assumed. There is no need to cover the newly bare area caused by the relaxing incision since a new fascia develops to cover the denuded muscle, a fact recognized and reported by Koontz.

In a personal series of more than 15,000 operations, I have used a relaxing incision on more than 1,500 occasions without reservation or regret.

TECHNICAL ASPECTS OF THE SHOULDICE REPAIR

Local Anesthesia

The skin is infiltrated with 1% procaine hydrochloride from a level 2 to 3 cm away from the anterosuperior iliac spine, along a line directed toward the pubic spine. A wheal approximately 4 cm wide is raised. A volume of 60 to 90 mL of 1% procaine is required for this purpose (Fig. 189.1).

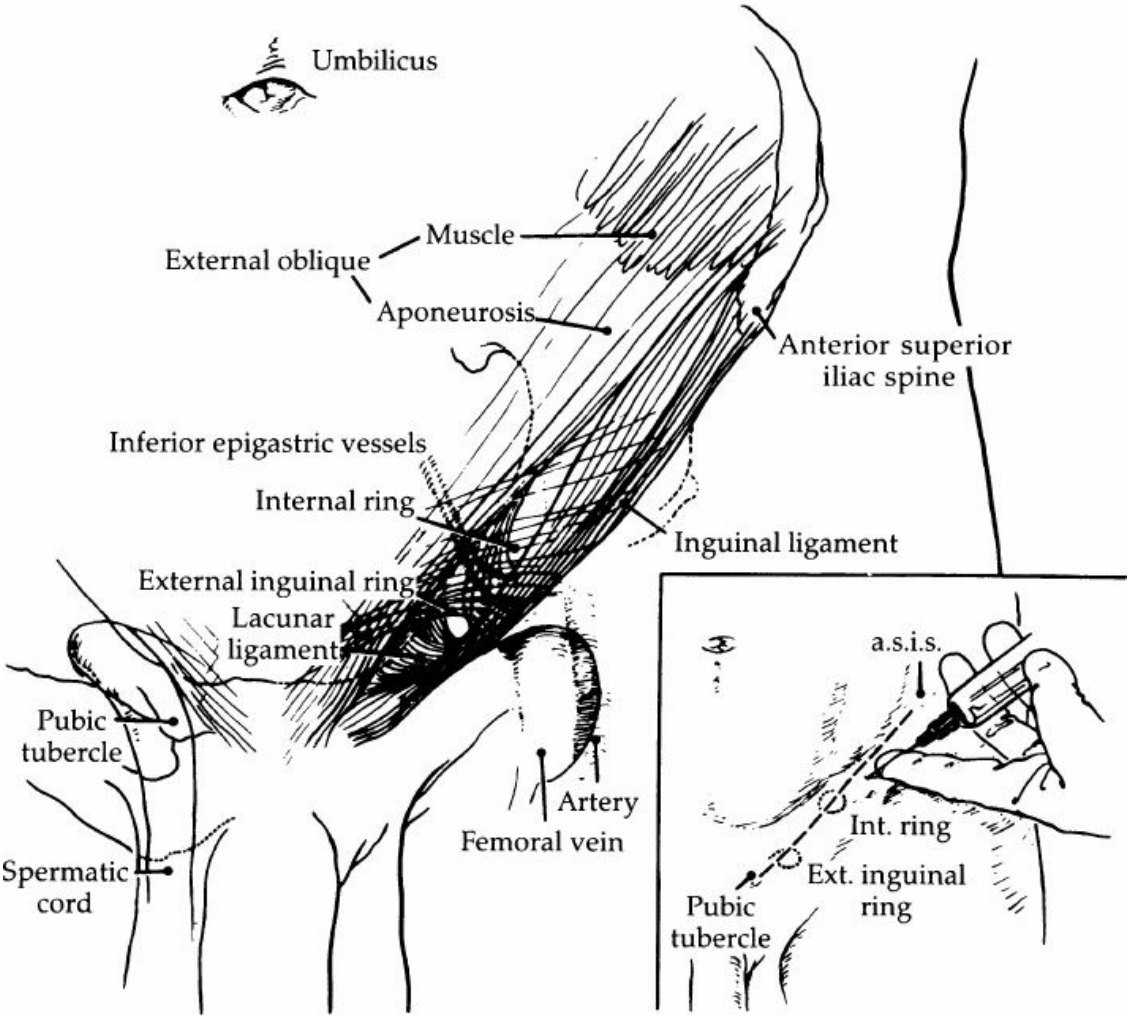

Figure 189.1. Local anesthesia along a line from the anterosuperior iliac spine to the pubic crest. Incision also follows that line; a.s.i.s., anterosuperior iliac spine.

Dissection

An incision is made over the medial two-thirds of a line joining the anterior superior iliac spine to the pubic spine. All subcutaneous bleeders are tied with polyglactin sutures. The external oblique aponeurosis now comes into view. Another 20 to 30 mL of procaine is injected deep to this aponeurosis (Fig. 189.2). Near the internal ring, the procaine is injected

deep enough to allow infiltration between the internal oblique and transversus muscles. This is the plane in which the ilioinguinal and iliohypogastric nerves emerge. More medially, these nerves are deep to the external oblique aponeurosis. The genital branch of the genitofemoral nerve, emerging at the internal ring, is more laterally placed, inferior and lateral to the spermatic cord, often within the substance of the cremaster.

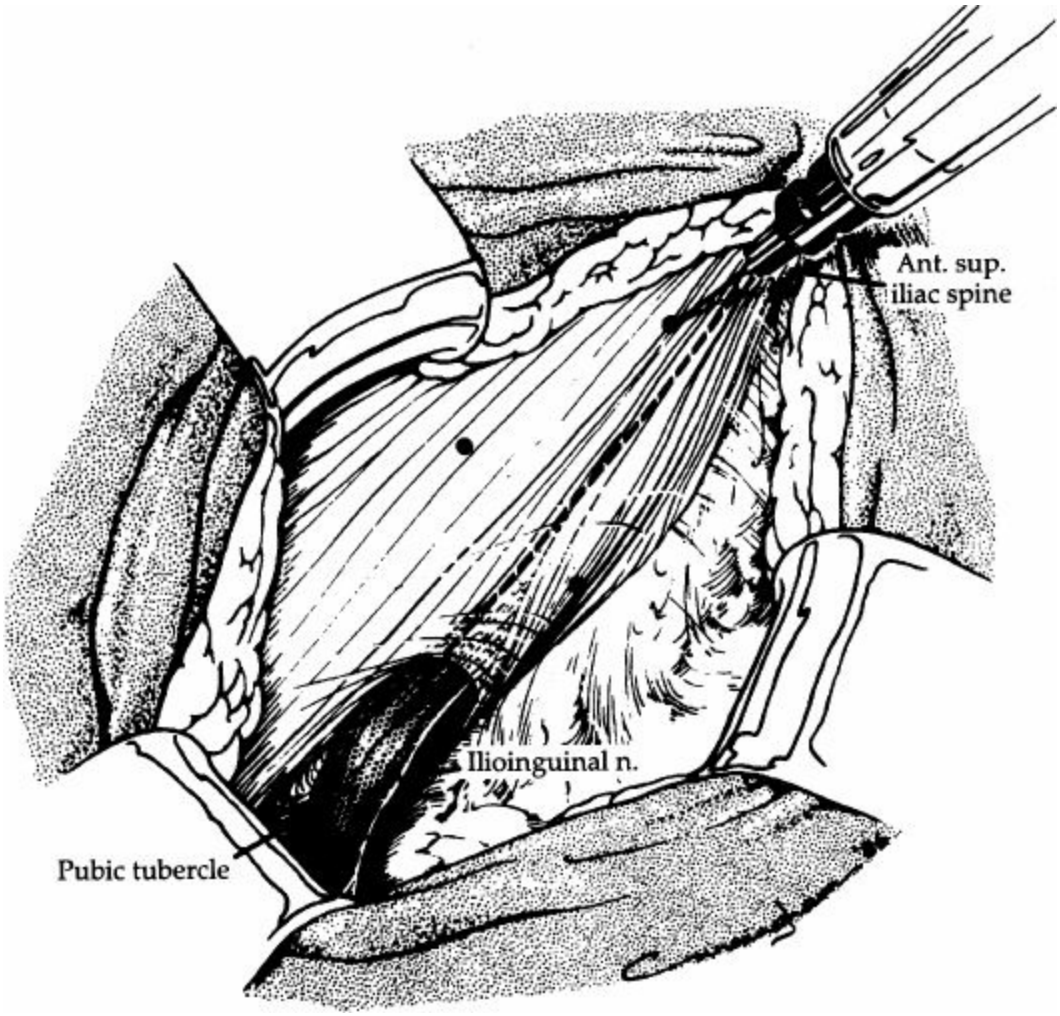

Figure 189.2. Local anesthetic should be generously injected deep to the external oblique aponeurosis.

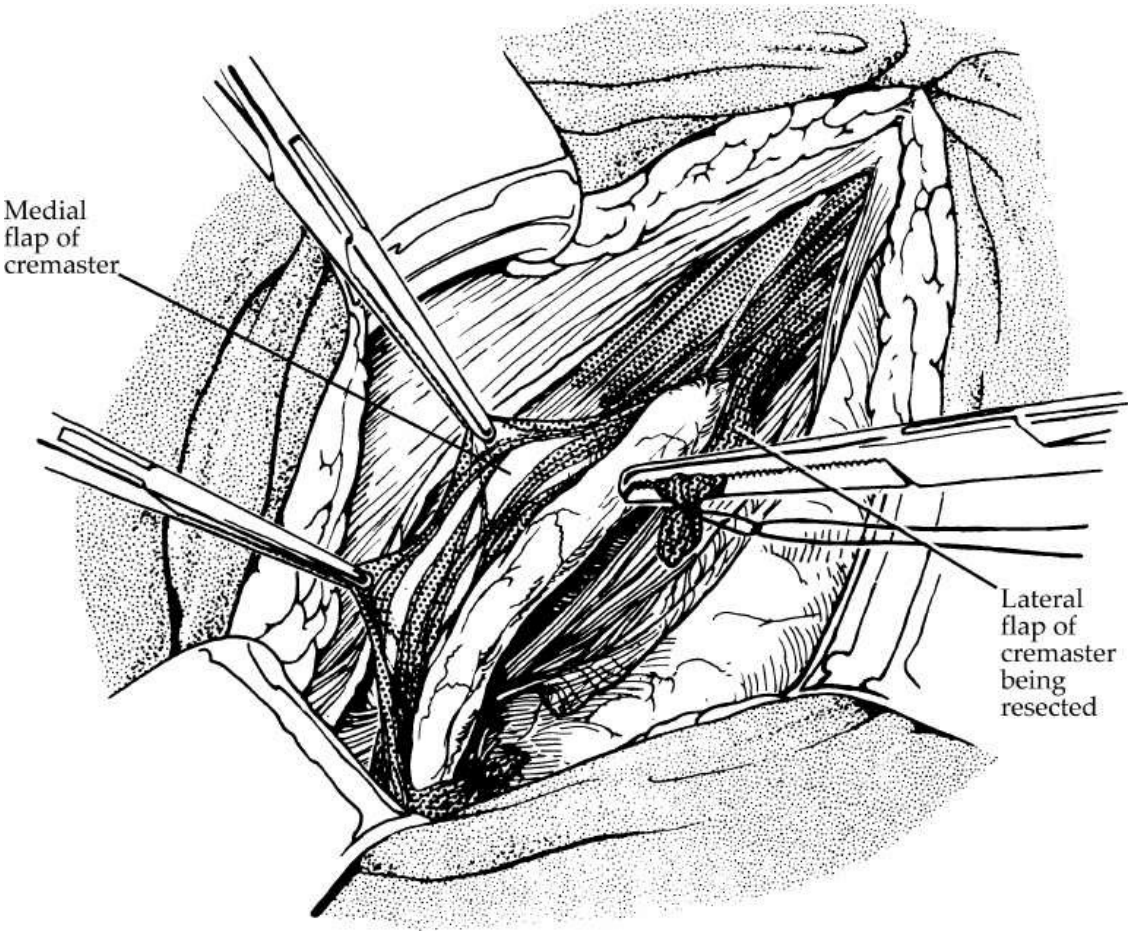

Figure 189.3. The cremaster muscle is divided longitudinally from pubic crest to internal ring.

The external oblique aponeurosis is now incised from the superficial ring to a point 2 to 3 cm lateral to the deep inguinal ring (Fig. 189.3). Each flap of the aponeurosis is widely undermined and freed. Each of the three nerves now becomes distinct and can again be infiltrated individually with 1 to 2 mL of procaine. Another 5 to 10 mL of procaine is injected within the loose areolar tissue around the spermatic cord at the deep inguinal ring and within the external spermatic fascia to block the conduction of the sympathetic pain fibers within this cord.

The cremaster muscle is now in full view and is incised on its anterior aspect, in the direction of its fibers. This incision is extended from the level of the pubic crest to the deep inguinal ring (Fig. 189.4). The vas deferens and accompanying vessels within and about the deep spermatic fascia are freed, leaving a thin flap of cremaster muscle medially and the other flap of cremaster with its cremasteric vessels and genital nerve laterally. This nerve is resected separately. The medial flap of the cremaster muscle is resected entirely. It often contains a small cremasteric

artery, which one must be careful to ligate. The lateral flap of the cremaster is doubly clamped and then divided, leaving two stumps, one medial and one lateral. Each stump is doubly ligated since it will contain cremasteric vessels that are substantial in size and could become a source of postoperative bleed. The double ligature of each stump will allow the insertion of a suture between the ligature, as we shall see later.

At this stage, another 10 to 15 mL of procaine is injected deep to the transversalis fascia. This anesthetizes smaller branches from the ilioinguinal and iliohypogastric nerves that perforate along the margin of the lateral edge of the rectus with the internal oblique–transversus muscle layer.

With the cremasteric muscle resected, it becomes impossible to miss an indirect sac. If no such sac is present, one must then dissect on the medial aspect of the cord along the vas deferens at the level of the internal ring to demonstrate a peritoneal protrusion. The protrusion is infiltrated with 2 to 3 mL of procaine, dissected free, and allowed to retract into the preperitoneal space.

If an indirect sac is found, the dissection is then carried out as deeply beneath the internal ring as feasible. The sac is resected, and the ligated stump of peritoneum retracts and disappears into the preperitoneal space. This ligation of the sac need not be as “high” as possible.

With the cremaster muscle out of the way and the spermatic cord retracted laterally, the posterior inguinal wall of the canal is in full view. The next step is an important one. It consists of dividing the posterior wall of the inguinal canal. This is performed by incising the transversus aponeurosis–transversalis fascia at the deep ring on its superomedial aspect to avoid injury to the inferior epigastric vessels (Fig. 189.5). This incision is extended to the pubic bone. Any direct inguinal herniation would be identified by separating the peritoneum from the transversus abdominis–transversalis fascia. A direct sac is rarely resected, unless a narrow or scarred neck is present. Once the transversus aponeurosis–transversalis fascia is divided, its two edges are trimmed. The lateral border is left 1 cm wide and is partly made up by the iliopubic tract (the bandelette of Thomson); the medial border is trimmed along the muscular edges of the internal oblique–transversus abdominis muscles.

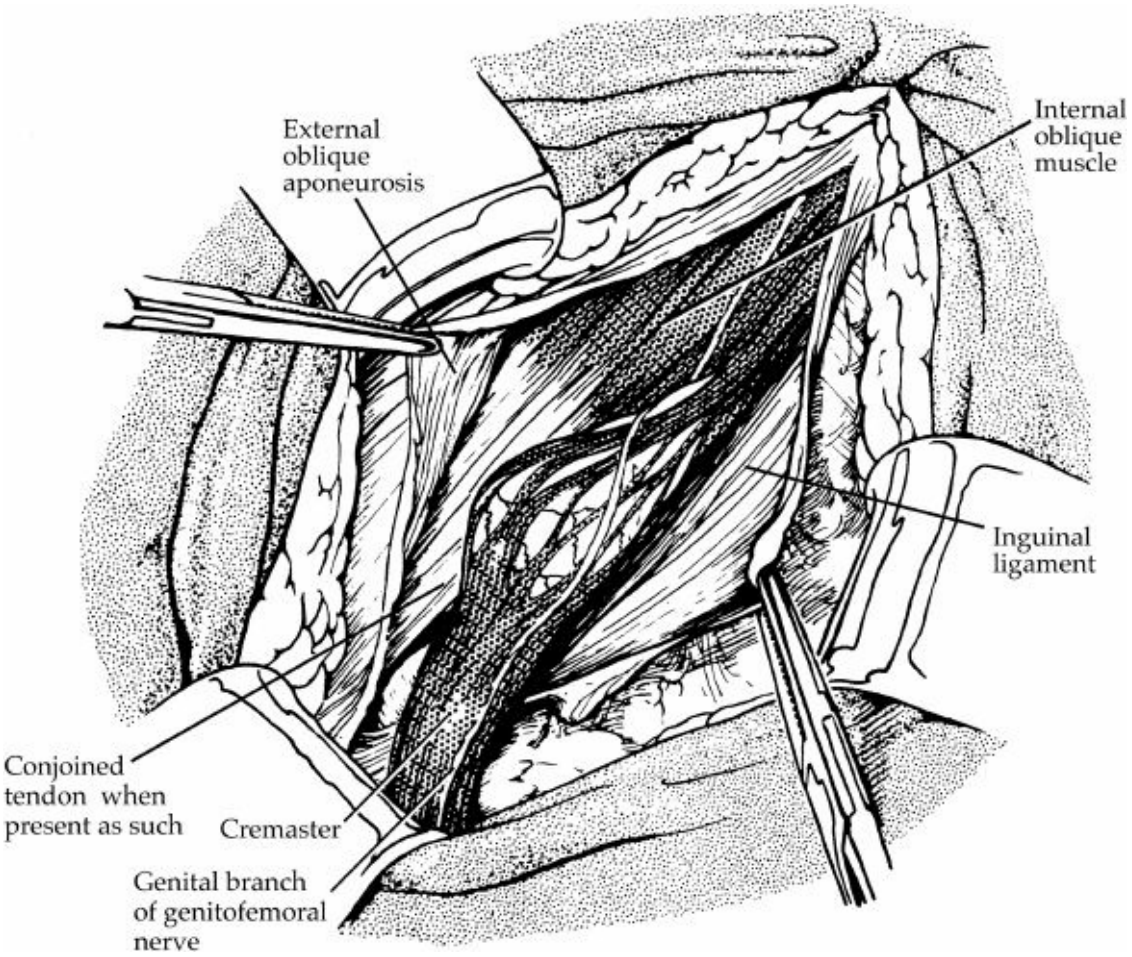

Figure 189.4. Exposure of the spermatic cord. An indirect inguinal hernia is identified.

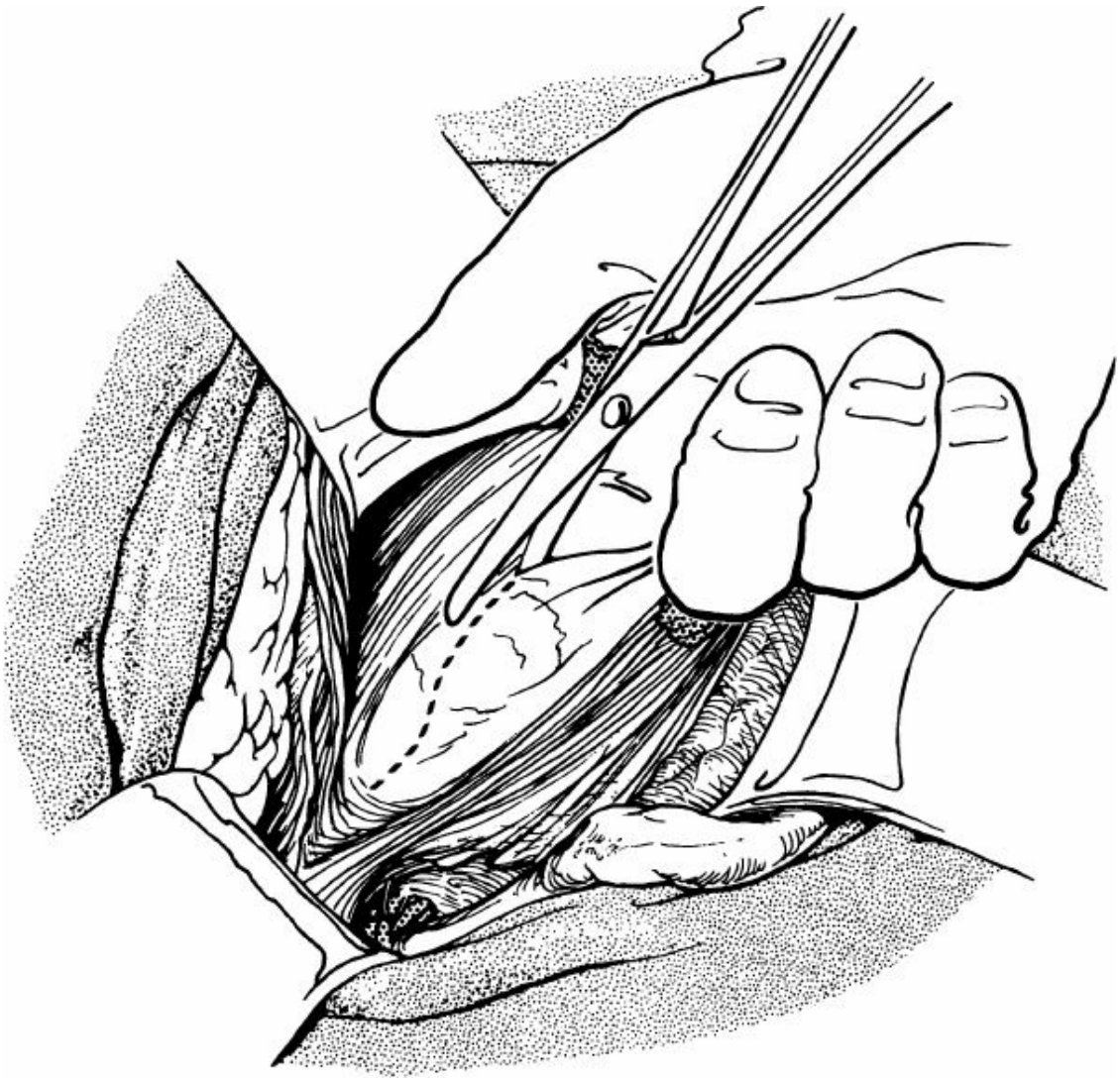

Figure 189.5. Splitting of transversalis fascia from the internal ring to the pubic crest (in all operations).

The dissection (Fig. 189.6) now reveals distinctly, on the medial side, from outside in, the edges of the internal oblique, transversus abdominis muscle to its aponeurosis, rectus abdominis, and, on occasion, the pyramidalis muscles, and deepest of all the true transversalis fascia, which is the inguinal portion of the endoabdominal fascia. Although the transversalis fascia is evident at this level, one can never rely on its solidity as a single layer. Laterally, however, the transversalis fascia thickens and becomes a part of the iliopubic tract. On the deep surface of this iliopubic tract, the superior pubic vein is identified, and care must be exercised to avoid injuring it. This vein can be the source of an important retropubic hematoma. The thigh fascia (cribriforms fascia) is now incised (Fig. 189.7) just beneath the inguinal ligament, from the level of the femoral vein to the pectineus and its overlying fascia. This maneuver frees the external aspect

of the lateral flap of the external oblique aponeurosis. It also allows examination of the inferior femoral opening. The superior femoral ring can be examined as well, because the division of the posterior inguinal allows access to the preperitoneal space of Bogros. The latter space is a lateral extension of the space of Retzius. The dissection is now complete.

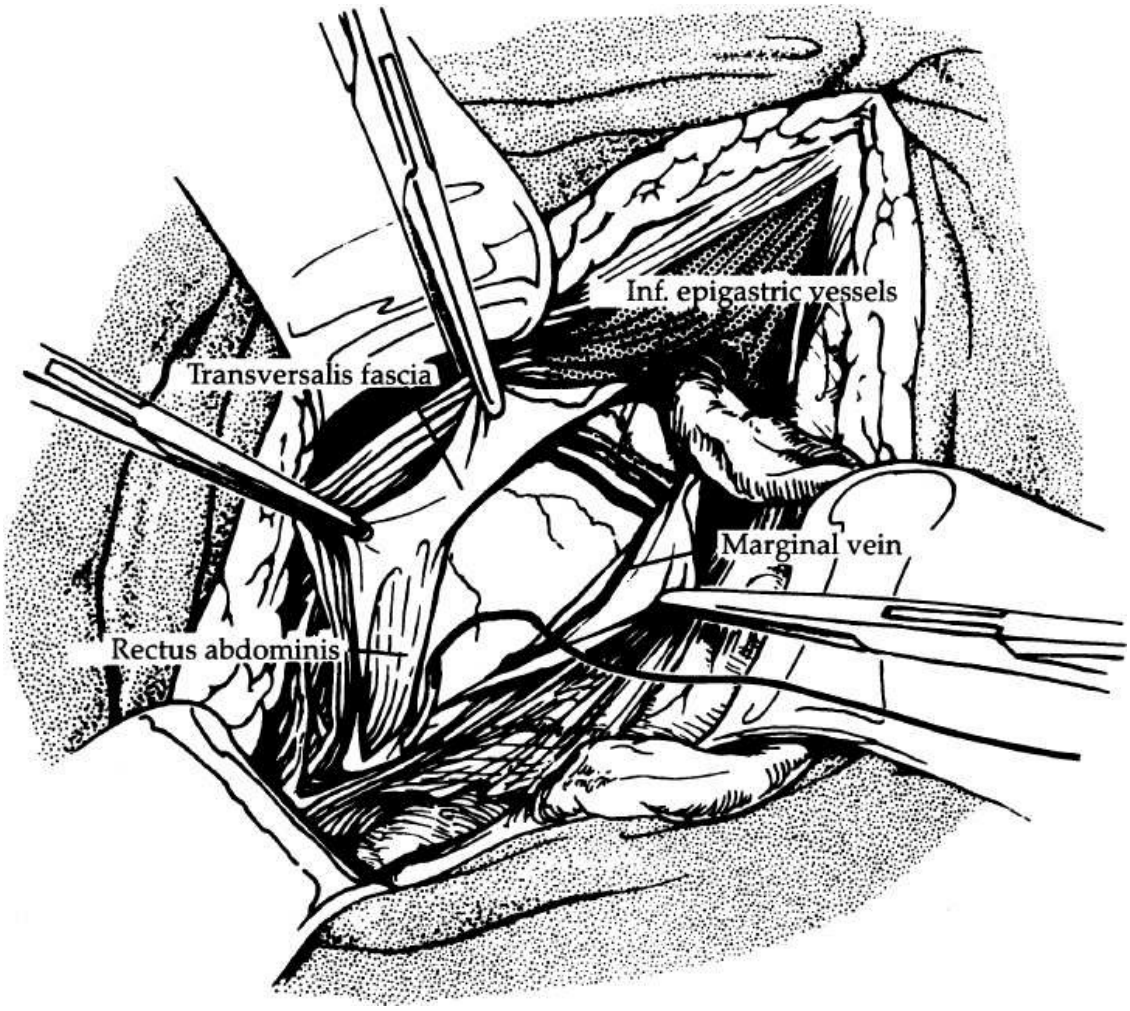

Figure 189.6. Appearance after completed dissection. Note the marginal iliopubic vein and the first line of suture.

Reconstruction

The repair can now begin, and the important objective becomes the construction of a solid posterior wall of the inguinal canal. Monofilament stainless-steel wire (32 or 34 gauge) has been used for many years, but this does not imply inadequacy of other suture materials, especially polypropylene.

The repair begins near the pubic spine (Figs. 189.6 and 189.8) by approximating the iliopubic tract laterally to the medial flap (which is

made up of the lateral edges of the rectus, the internal oblique and transversus abdominis muscles and/or aponeurosis, and the deepest layer, the transversalis fascia). The running suture is continued toward the internal ring. Halfway between the pubic spine and the internal ring, the lateral edge of the rectus abdominis becomes too distant and too medially placed and is no longer included in the running suture. Near the internal ring, the running suture picks up the lateral stump, between its two ligatures (Fig. 189.9), and then crosses over to the medial side to pierce through the transversalis fascia, transversus abdominis muscle, and internal oblique muscle, in that order, thus making the stump of the cremaster a deeper structure than the transversalis fascia. A new internal ring is thus recreated. The suture now reverses its course toward the pubic spine (Fig. 189.10). On its way, it approximates the medial edge (internal oblique and transversus muscles) to the shelving edge of the Poupart ligament. The two wire ends are knotted near the pubic spine. Two lines are thus made by the first wire.

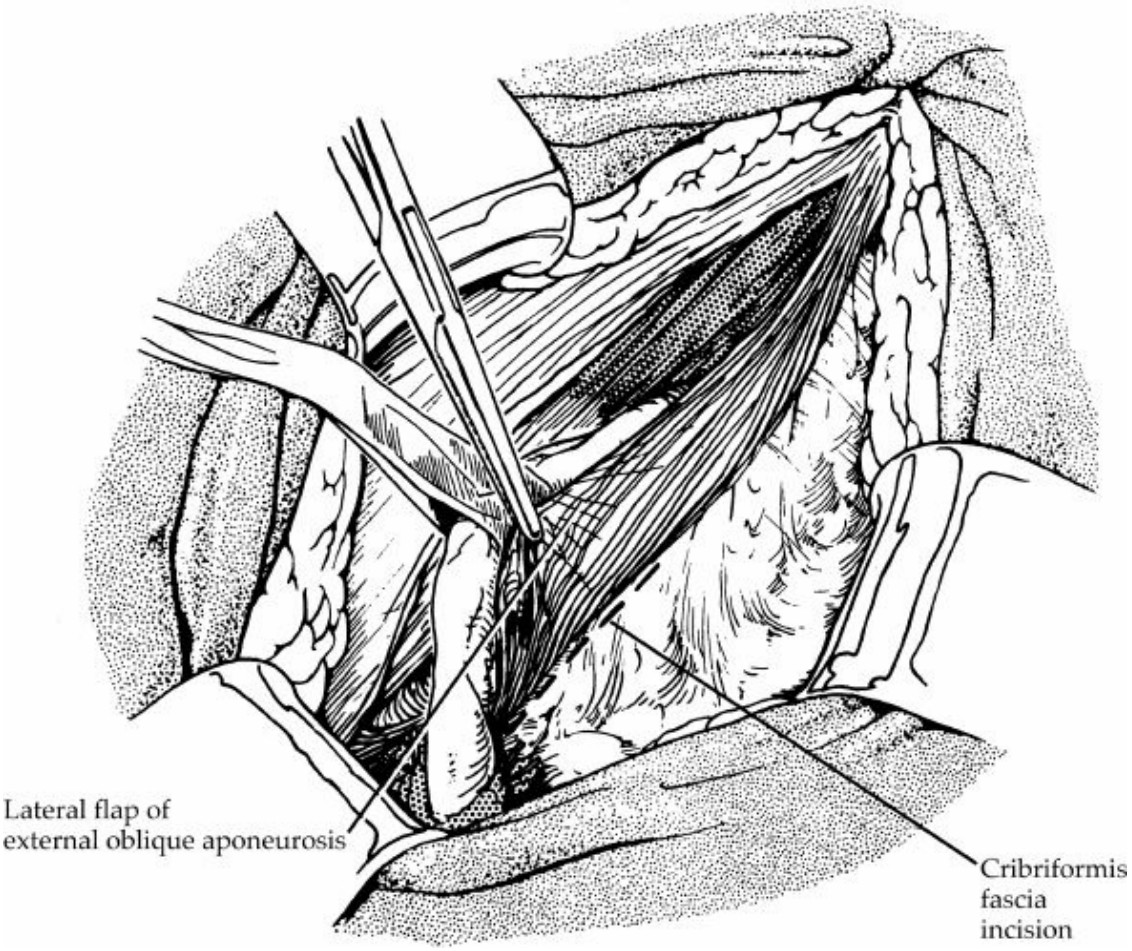

Figure 189.7. The undersurface of the inguinal ligament, medial to the femoral artery and vein, is freed from the thigh fascia to

rule out femoral hernias or femoral fat tabs.

Another two lines are now made by a second wire. The latter is started near the internal ring, picking up a full thickness of muscles medially (again, internal oblique and transversus) and approximating this layer to a band of external oblique aponeurosis (slightly superficial and parallel to the Poupart ligament) (Figs. 189.11 and 189.12). The third line is directed toward the pubic spine, where it then reverses its course back to the internal ring as a fourth line of wire suture. The fourth line again includes a full thickness medially (internal oblique and transversus muscles) to join the external oblique aponeurosis along a line yet more superficial and parallel to the inguinal ligament. The medial 2 to 3 cm of the external oblique aponeurosis, however, is made to lie completely flat on the medial aspect of the posterior wall of the inguinal canal (Fig. 189.13), reinforcing what is a common site for recurrences. This results in a lateral displacement (2 to 3 cm) of the superficial inguinal ring.

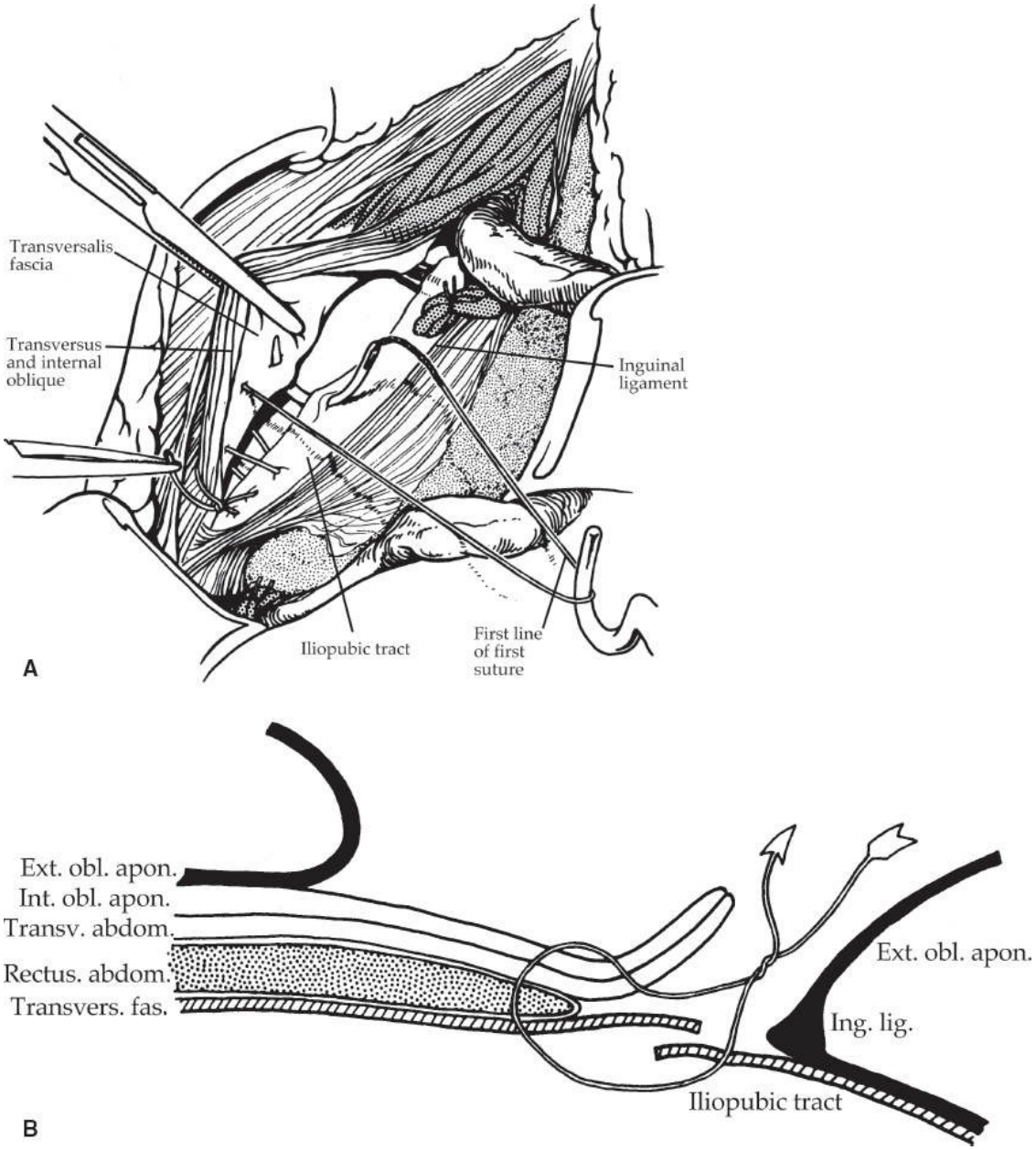

Figure 189.8. A: First line of suture continued. **B:** Cross section of (**A**).

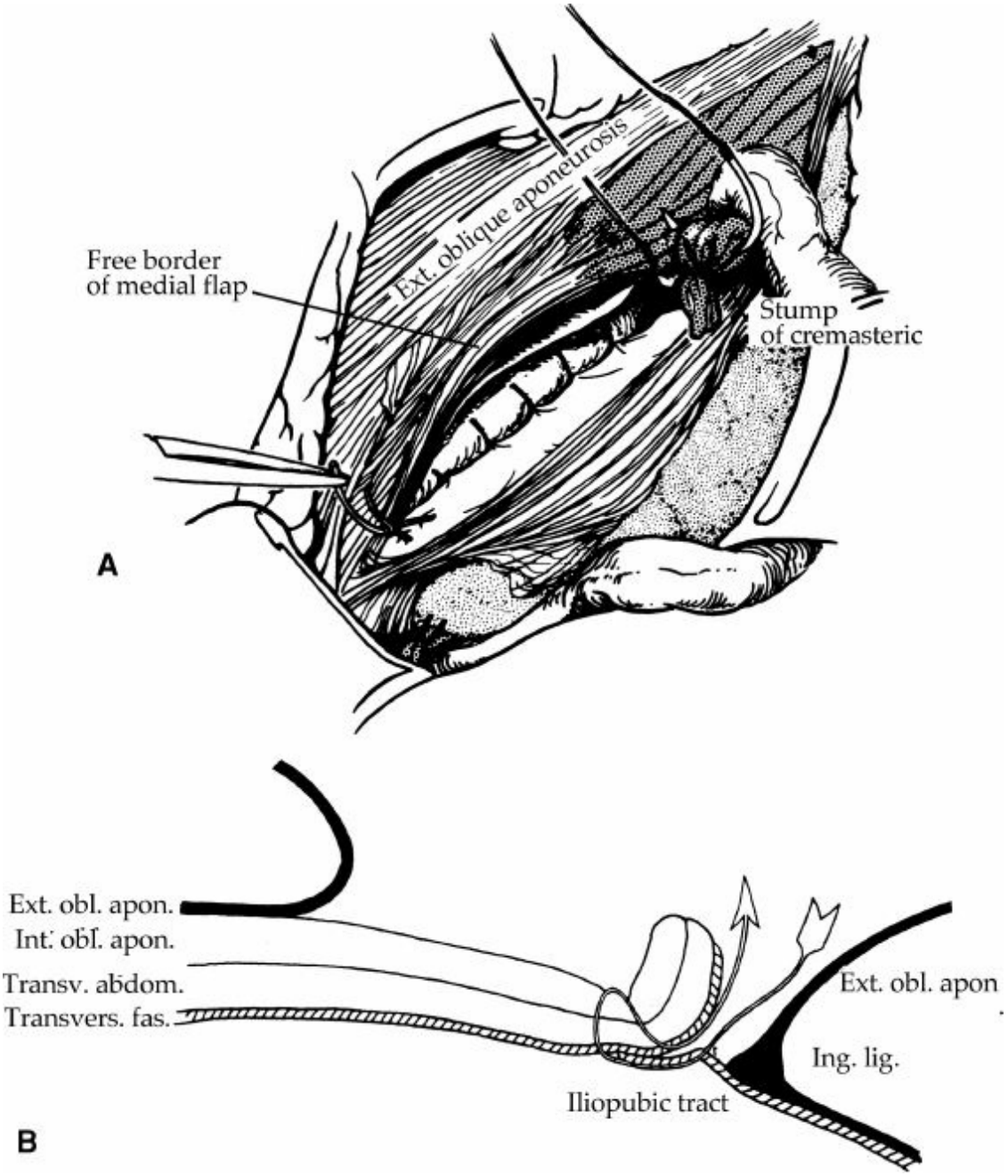

Figure 189.9. A: End of first line of suture and incorporation of the cremasteric stump. **B:** Cross section of (**A**).

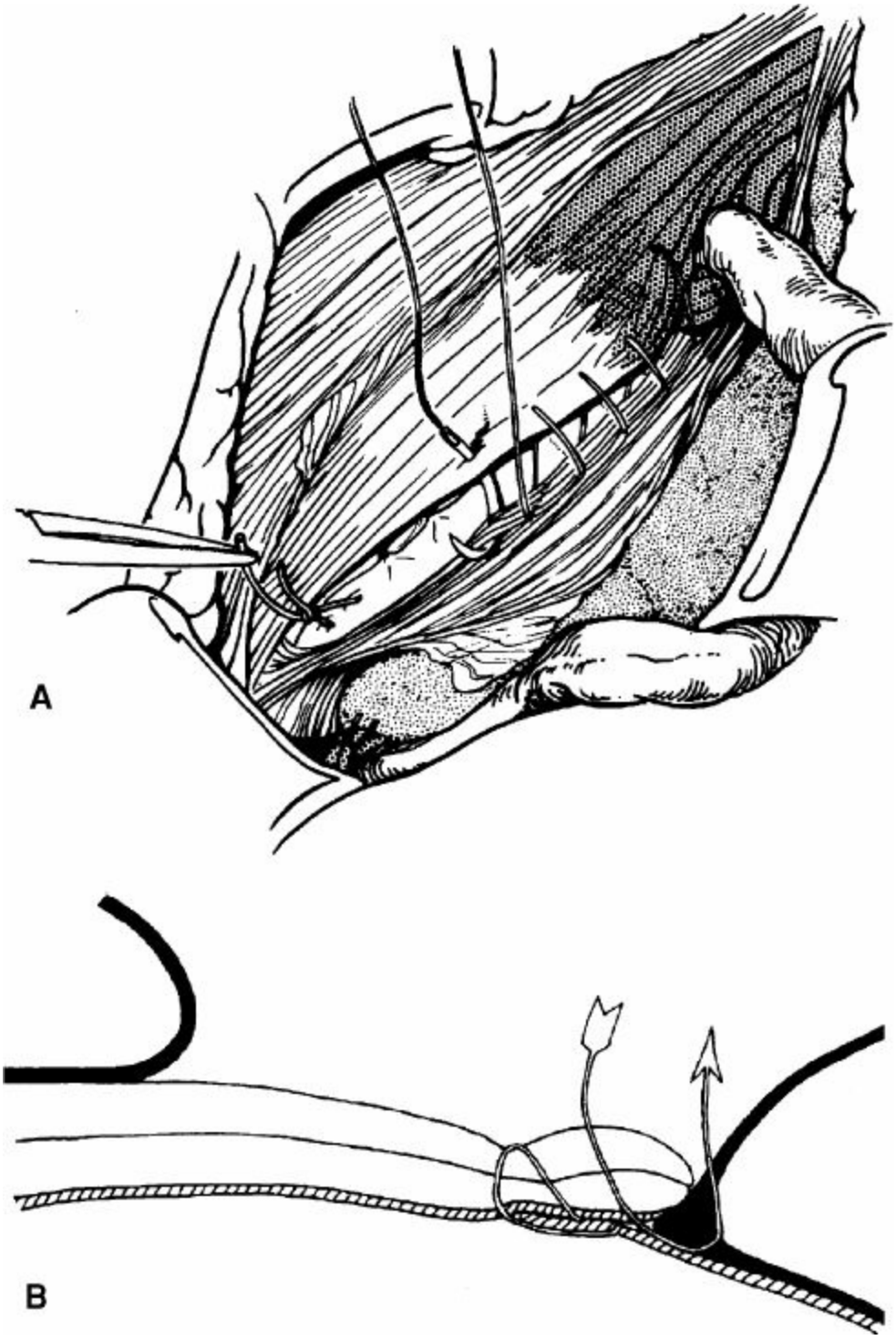

Figure 189.10. A: Second line of suture. This is really the first line of suture returning to the pubic crest to be tied. **B:** Cross section of (**A**).



Figure 189.11. **A:** Third line of suture. This is a different wire, which begins at the internal ring, goes toward the pubic crest, and returns as the fourth line to be tied at the internal ring. The running suture was left loose for the purpose of illustration. **B:** Cross section of (**A**).

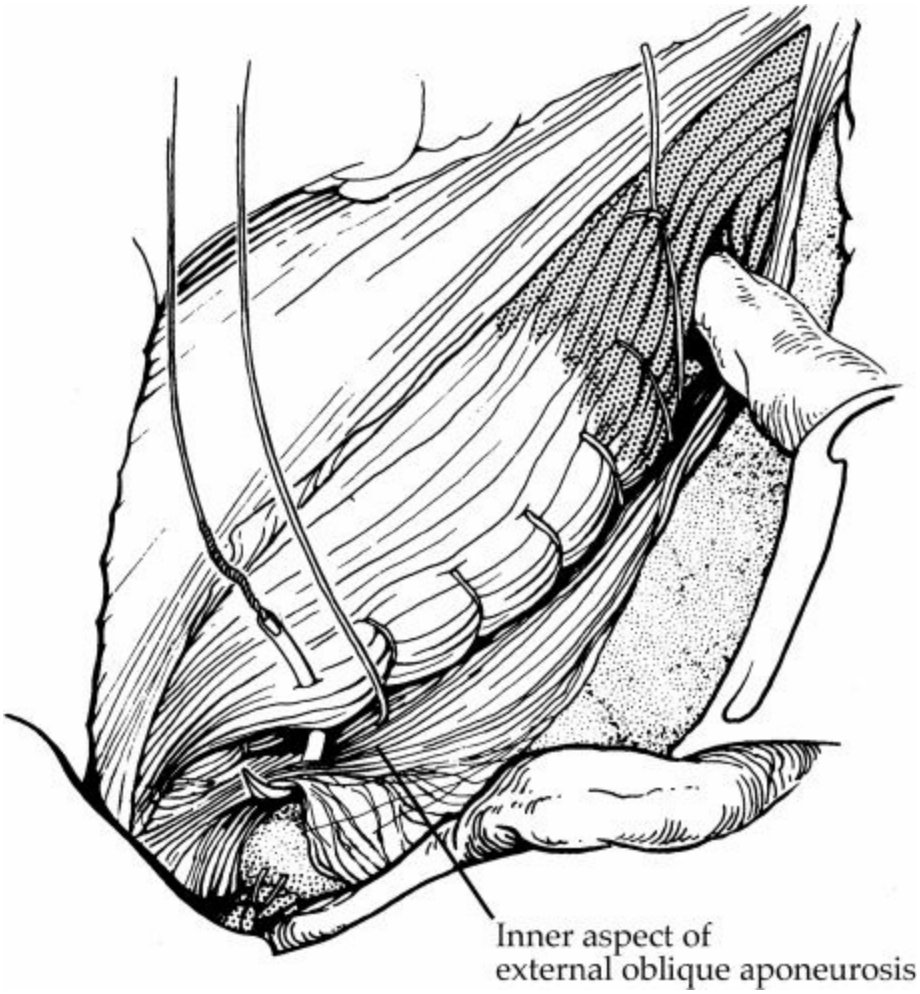

Figure 189.12. Continuation of third line.

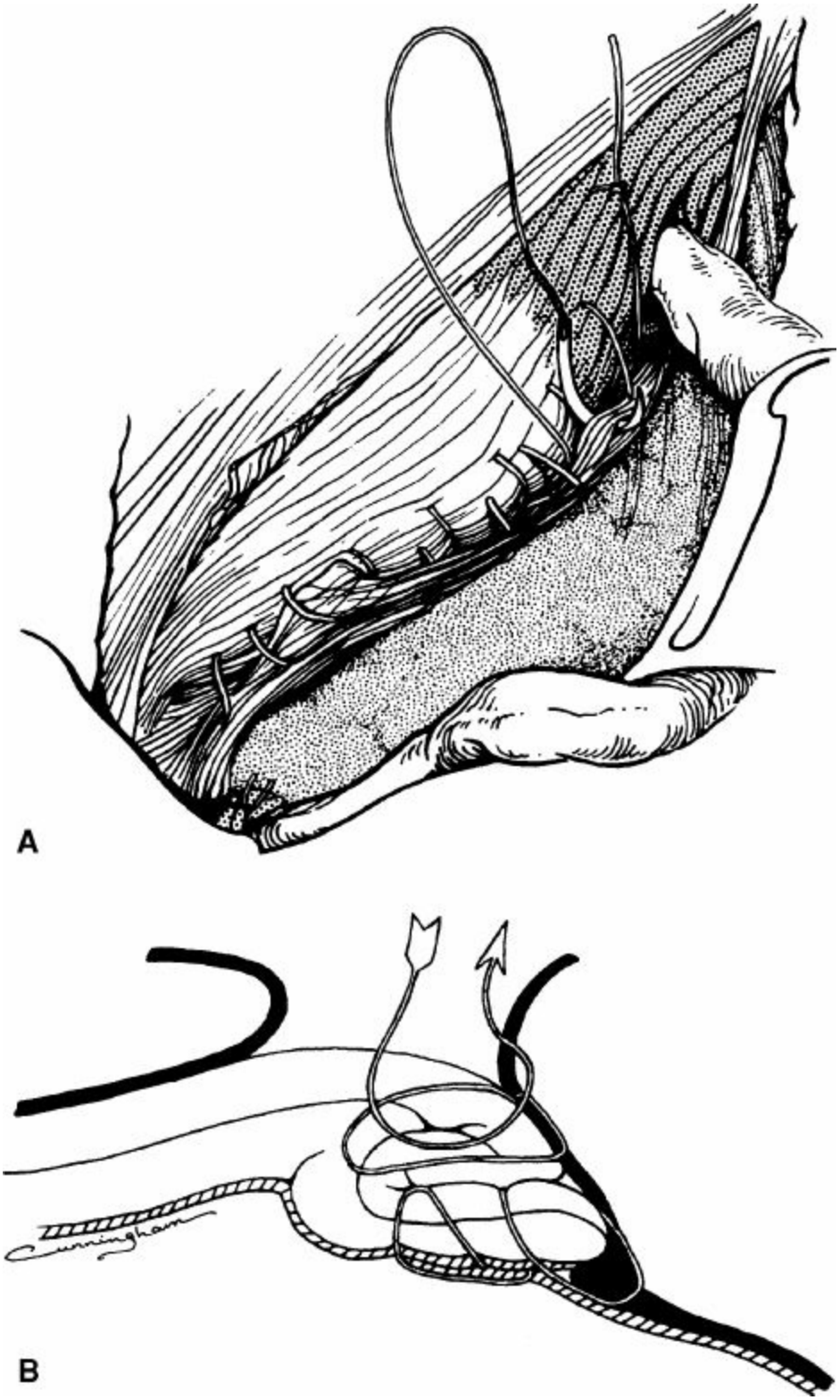

Figure 189.13. **A:** Fourth line of suture. **B:** Cross section of (**A**).

The medial stump of the cremaster muscle is now anchored to the most medial portion of the inguinal ligament or near the pubis–pubic ramus angle to prevent eventual drooping of the testicle. This drooping is a common complaint and is due to the resection of the cremaster and the

subsequent loss of its suspensory and retractile function. The spermatic cord is then replaced in its normal anatomic position, and the external oblique aponeurosis is approximated superficially to the cord (Fig. 189.14). The wound is closed with polyglactin sutures (subcutaneous tissues) and Michel clips (skin).

POSTOPERATIVE PERIOD

At the end of the operation, the patient stands and walks away from the operating table. Ambulation and activities are encouraged on the same day. Half of the Michel skin clips are removed 24 hours postoperatively, and the remaining clips are removed 48 hours postoperatively. I personally remove all clips the following day and apply Steri-Strips.

RESULTS AND FOLLOW-UP DATA

Since 1945, more than 300,000 herniorrhaphies have been performed. Although in 1945 the recurrence rate was 17.8%, the results have been improving: 3.2% in 1950, 1.4% in 1955, and 0.3% by 1980. The improvement was attributed to two factors: The implementation at the Shouldice Hospital (1952) by Ernest Ryan, to a large extent, of the revolutionary technical steps introduced by Bassini (1886) and, undoubtedly, the expertise of the surgeons who made hernia repairs their life's work, doing as many as 600 to a 1,000 cases a year! In an average year, approximately 7,500 operations are performed (Table 189.3).

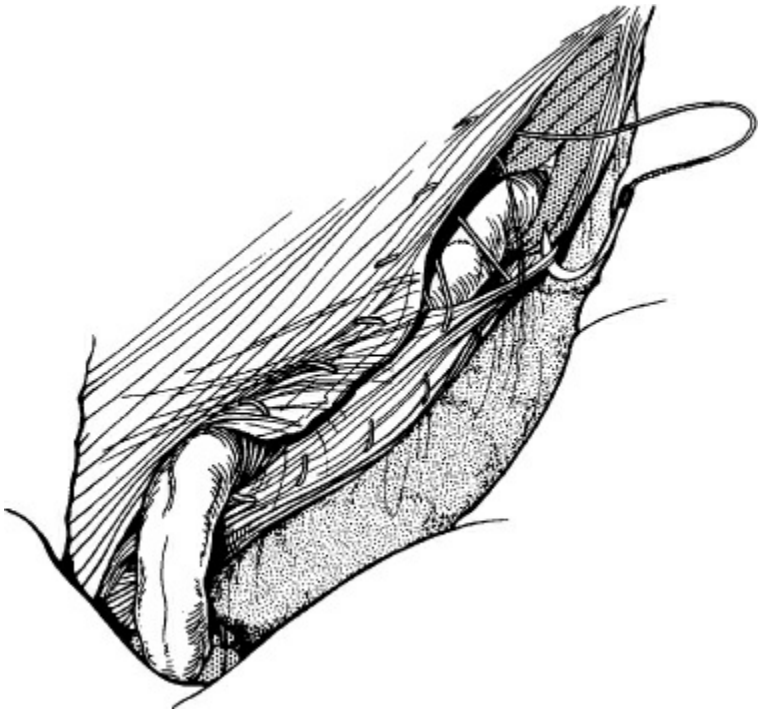

Figure 189.14. Fifth line of suture.

TABLE 189.3 Principal Hernias in 7,273 Operations in 1997

Hernia	Number of Hernias	Percent of Total
Indirect inguinal	4,057	55.8
Direct inguinal	2,460	33.8
Femoral	130	1.8
Umbilical	282	3.9
Epigastric	105	1.4
Incisional	131	1.8
Inguinofemoral	6	0.08
Others	102	1.4

Secondary hernias were seen in 12.8% of patients, a constant figure with little variation between 13% and 15%. A secondary hernia is defined as a second simultaneous hernia, lesser in size and importance, but, nevertheless, one that would have required surgical therapy. Such a hernia is usually discovered during an operation. The good results of the Shouldice repair have been reproduced in many centers, as shown in Table

189.4.

COMPLICATIONS

Complications of relative importance are recurrences, infections, hematomas, dysejaculation, hydroceles, and testicular atrophy.

Recurrences

The follow-up study is the most important critical index of the success of an operation. Follow-up findings were reviewed by Iles, and the same follow-up remains in use today. The data on 2,270 patients operated on in 1955 are presented in Table 189.5. Given the massive numbers, however, the follow-ups have not been statistically accurate and one can easily be overwhelmed and intimidated by those numbers. In a 10-year follow-up (in 1994) of 400 randomly selected patients who had their surgery in 1984, I was able to identify only 10% who had been followed up at least once or more times in that period, either by direct examination or by mail. A curve showing frequency of response reveals that patients are cooperative during the first year, less so after 2 years. The curve drops dramatically afterward. Though the follow-up may consist of 100,000 letters sent to patients, I was never too certain of the accuracy of a patient's own evaluation.

TABLE 189.4 Results of Shouldice Repairs at Other Centers

Author	Number of Cases	Follow-up (%)	Number of Years of Follow-up	Recurrence (%)
Shearburn	550	100	13	0.2
Volpe	415	50	3	0.2
Wantz (1)[a]	2,087		5	0.3
Bocchi	1,640	84	5	0.6
Myers	953	100	18	0.7
Devlin	350		6	0.8
Flament	134		6	0.9
Wantz (2)[a]	3,454		120	1.0
Moran	121		6	2.0
Berliner	591		25	2.7

[a]1 and 2 represent two different series published by G. Wantz.

Infections

More than 7,000 operations are performed yearly with an incidence of

infection of less than 1% and as low as 0.27%. All superficial abscesses were simply drained. I have never seen a deep abscess, that is, deep to the inguinal repair, within the preperitoneal space. If cellulitis was also evident, antibiotic coverage was added. In no instance was it necessary to take down the repair. The low incidence of infection reflects simply the fact that inguinal herniorrhaphies are "clean" operations performed in a "clean" environment. If a patient has any evidence, preoperatively, of any sepsis (e.g., in the genitourinary tract or lungs, or on the skin), the operation is deferred.

TABLE 189.5 Follow-up for 2,270 Patients (2,748 Repairs) Operated on at Shouldice Hospital, 1955

Year	Number of Recurrences
1955	3
1956	4
1957	1
1958	3
1959	3
1960	2
1961 to 1965	8
1966 to 1975	7
1976 to 1990	9
Cumulative total	40

Hematomas

A hematoma is a minor complication, but it may require taking the patient back to the operating room. In a personal series of 5,762 patients, there were 18 instances of hematoma formation (0.3%). All were subcutaneous, and all were recognized and treated within hours. Accurate knowledge of the circulation within the space of Bogros is essential as a preperitoneal bleed can be significant. I have been aware of three cases that have required blood transfusions at the Shouldice Hospital!

Hydroceles

Hydroceles after inguinal herniorrhaphies are a well-known complication.

Obney, from the Shouldice Hospital, reported an incidence of 0.7% after 14,442 inguinal repairs. He also pointed out that ligatures along the spermatic cord should be avoided, and that superficial and deep inguinal rings should be snug but not constrictive.

Testicular Atrophy

Testicular atrophy can be seen after the repair of recurrent inguinal hernias as well as primary hernias. Among 5,762 patients operated on from 1977 to 1984, there were five testicular atrophies after 4,782 repairs of primary inguinal hernias (0.1%) and nine testicular atrophies after 980 repairs of recurrent inguinal hernias (0.9%). The postoperative orchitis, which occurs more frequently, must not be mistaken for a threatening testicular atrophy, though it will mimic the clinical picture quite closely. The picture is one of pain, often excruciating, beginning anytime during the first 3 postoperative days, and swelling of the testicle with induration. This swelling may reach two to five times the size of a normal testis. The overlying skin is hot and stretched and shiny. A color Doppler examination will reveal the absence of circulation. Despite this clinical picture, a color Doppler will, in half the cases, reveal an intact circulation and those patients may be reassured that the testicle will survive the surgical trauma.

Dysejaculation

Dysejaculation is a clinical entity characterized by a burning and searing sensation just before, during, or after ejaculation. Although the condition was first reported at the Shouldice Hospital, there is no reason to believe that it is a complication of the Shouldice repair, but rather of all hernia repairs, with or without mesh. The mechanism is not clear and may be caused by strictures of the vas deferens with obstruction to the flow of ejaculate. Although the condition may at times be extremely painful, the prognosis is excellent. The patients identified numbered 26, with symptoms beginning 2 to 3 weeks after surgery and clearing in 1 to 5 years. By 1998, more than 200 cases had been identified.

TABLE 189.6 Postoperative Complications

Infection rate	0.3%
Recurrence rate	0.5% following primary repair 1.49% on 35-year follow-up
Testicular atrophy	0.1% after primary repair 1% after multiple repairs
Dysejaculation	0.25%
Pneumonia	Nearly nonexistent as a result of early ambulation
Phlebitis	
Atelectasis	
Pulmonary embolism	2
Renal failure	1
Stroke	7
Coronary thrombosis	20
Intestinal obstruction	4
Acute mesenteric thrombosis	1
Perforated duodenal ulcer	1
Spontaneous rupture of gallbladder	1
Necrotizing fasciitis	1
Mortality (of 229,000 operations, none direct result of surgery)	37 (0.0106%)

MAJOR COMPLICATIONS

Table 189.6 reports the list of major complications. There were 14 deaths in the hospital or within 30 days after the operation among 150,000 patients, a mortality of 1 in 10,000. In one case only was the mortality due to a femoral vein laceration and, therefore, was a direct result of the surgery.

Suggested Readings

Bendavid R. *La Chirurgia Dell'Ernia Inguinale. Acts of Congress, International Congress in the Honor of E.* Bassini: Padua; 1986.

Bendavid R. L'Opération de shouldice. Encyclopédie Mé dico Chirurgicale (Paris). *Tech Chir Appareil Dig* 40112, 4.11.12, 1986:5.

Bendavid R. "Dysejaculation": an unusual complication of inguinal herniorrhaphy. *Postgrad Gen Surg* 1992;4:139.

Bendavid R, ed. *Prostheses and Abdominal Wall Hernias.* Austin, TX: RG Landes; 1994.

Bendavid R, Andrews DF, Gilbert AI. Testicular atrophy: incidence and relationship to the type of hernia and to multiple recurrent hernia. *Probl Gen Surg* 1995;12(2):225.

Catterina A. *Bassini's Operation.* London: HK Lewis; 1934.

Glassow F. Inguinal hernia in the female. *Surg Gynecol Obstet* 1963;116:701.

Glassow F. High ligation of the sac in indirect inguinal hernia. *Ann Surg* 1965;109:460.

Iles JDH. Specialization in elective herniorrhaphy. *Lancet* 1965;1:751.

Maykut MD. A reliable colorimetric method for the quantitative determination of procaine in human whole blood. *Can Anaesth Soc J* 1959;6:159.

Maykut MD, Kalow W. Experiments with animals on the combined action of procaine and barbiturates. *Can Anaesth Soc J* 1955;2:109.

Obney N. Hydroceles of the testicle complicating inguinal hernias. *Can Med Assoc J* 1956;75:733.

Obney N, Chan CK. Repair of multiple time recurrent inguinal hernias with references to common causes of recurrence. *Contemp Surg* 1984;25:24.

Ryan EA. An analysis of 313 cases of indirect sliding inguinal hernias. *Surg Gynecol Obstet* 1956;102:45.

Wantz GE. *Atlas of Hernia Surgery.* New York: Raven; 1991:60.

Welsh RJ. Sliding inguinal hernia. *J Abdom Surg* 1964;6:41.

EDITOR'S COMMENT

This is an excellent chapter on one of the classic methods of open hernia repair. Dr. Bendavid, a highly respected expert on hernia surgery, does an excellent job at the exposition of a repair, which has influenced hernia surgery around the world. After briefly reviewing the history of hernia surgery, starting with Bassini and his landmark contribution, which, as Dr. Bendavid says (and I agree), is basically the cornerstone on which all other hernia surgery is built; moving on to Fruchaud, with the myopectineal opening concept, which actually is the basis of many approaches, particularly the laparoscopic approaches and the extraperitoneal approaches; and then discussing work by Rives and Stoppa, who directly followed Fruchaud, this contribution is a landmark in its own right.

Dr. Bendavid emphasizes the dissection of the inguinal canal and its anatomy, which enables an excellent repair such as described. It is clear that this repair, which has influenced hernia surgery around the world, has become less common with the advent of the various meshes and not so much laparoscopic repair, which has not had a great deal of market penetration, at least in this country, and with the small incision patch or plus or what have you with artificial material. That is particularly unfortunate, since we are raising a generation of surgeons who have no understanding of the anatomy of the inguinal canal, which used to be a lot of fun in training residents. I personally do a modified Shouldice repair, or transversalis fascia repair, and I think in my

hands the recurrence rate is rather low and I donít have much in the way of inguinodynia to follow the repair. Just last week, a new chief resident asked if he could scrub in on one of the elective hernias that I was doing because he had never seen the anatomy of the inguinal canal after 7 years (two in research) in our program. He correctly stated that the reason he was scrubbing in was because there may be a time “when one needs to dissect out the inguinal canal.” Nonetheless, I think this is an enlightened attitude and one would rarely find it throughout most training programs in which the tension-free Lichtenstein repair or the Kugel plug or variations of the Gilbert plug and patch are utilized. I think this is most unfortunate because, at least in my practice, which generally consists of reoperative surgery, there is a need to know the inguinal canal, if only to correct the unfortunate situation of nerve entrapment by the mesh and inguinodynia, in which I have a thriving practice. It is probably fair to say that the knowledge of the inguinal canal by the average general surgeon who is confronted with a difficult situation will have to be referred to someone who for some reason has learned the anatomy of the inguinal canal, just like difficult right upper quadrants will have to be referred to a hepatobiliary or liver transplant surgeon because the average general surgeon will have so little exposure to the difficult right upper quadrant in which reoperation is required that it would be dangerous for that person to undertake it. I believe both of these situations are most unfortunate.

As I said in the introduction to this entire section, in the past 5 or 6 years, attention of the general surgical public has been turned from issues of recurrence to issues of postoperative pain or inguinodynia, and indeed this is largely the case. As I also have said previously, it is remarkable that the incidence of inguinodynia was substantial and yet no one seemed to recognize it. Nonetheless, recurrences and pain have been compared by three studies recently in which the Shouldice repair was compared with other approaches. Leibl et al. (*Br J Surg* 2000;87:780) started a randomized, prospective trial of transabdominal preperitoneal (TAPP) endoscopic technique versus the Shouldice repair. The end points were rates of recurrence, late complications, complaints, and patient satisfaction. This is a small study with only 48 patients in the TAPP group and 43 in the Shouldice group, and one wonders what the randomization was. There was one recurrence in the TAPP group and two recurrences in the Shouldice group. Five patients in the Shouldice group and three in the TAPP group reported slight discomfort in the inguinal region at the 6-year follow-up. The chronic pain syndrome was not observed. Of the 48 patients in the TAPP group, 96% (or 46), and of the Shouldice group, 81% (35 of 43) had complete satisfaction with the hernia report, the result not being statistically significant, but two patients in the laparoscopic group and eight in the Shouldice group were less than 100% satisfied, and this is statistically significant (P <0.05). In addition, the time to mobilization and the intake of postoperative analgesia was statistically significant between the two groups, favoring the laparoscopic group.

Fleming et al. (*Br J Surg* 2001;88:1183) in a somewhat larger study compared 117 total extraperitoneal endoscopic (TEP) and 115 Shouldice repairs. While the mean operating time was longer (70 vs. 56 min, $P = 0.0001$), patients were discharged earlier (68% vs. 48% within 1 d, $P = 0.00065$), returned to work quicker (14 vs. 30 d, $P = 0.01$), and had quicker lifestyle recovery (21 vs. 35 d, $P = 0.0001$). Open repair, however, was 40% cheaper. In an 86% follow-up after slightly over 1 year, the TEP repair had fewer complications (9% vs. 21%, $P = 0.05$) and had a better quality of life, work performance and satisfaction, physical symptoms, and well-being.

In a study that is probably more representative of the current surgery in the United States, Nordin et al. (*Br J Surg* 2002;89:45) compared a randomized clinical trial of the Shouldice procedure versus the Lichtenstein tension-free repair. Three hundred patients were randomized; however, in a novel addition five participating surgeons were taught to perform the two techniques in the standard fashion. The longest follow-up was 3 years, and it was done by a blinded assessor.

The Lichtenstein repair was considerably shorter. Seven recurrences were found in the Shouldice group and one in the mesh group, which was statistically significant, and chronic groin pain was reported at 4.2% in the Shouldice group and 5.6% in the Lichtenstein group. This was mild to moderate except in two patients who had the Shouldice operation. They concluded that the Lichtenstein repair was easier to learn, took less time, and resulted in fewer recurrences. Chronic pain syndrome was present in approximately 4% to 5% in both groups, with 2 patients out of the 300 having severe pain, both in the Shouldice groups.

Huang (*J Formosa Med Assoc* 1999;98[2]:122) reported on 212 patients with recurrent inguinal hernias who underwent surgical repair within a 10-year period. This is a complex paper that separates out unilateral first-time recurrent hernias, and they were treated by a modified Shouldice technique using the inguinal approach. Bilateral or multiple recurrent patients ($n = 125$) were treated with a Rives–Stoppa type of approach with a giant prosthesis reinforcement of the visceral sac, utilizing a midline preperitoneal approach. In the 87 patients who had the first-time recurrence there was testicular atrophy in three and femoral vein thrombosis in one. In the Stoppa-type repair in which the mesh was shortened by 2 cm from the classic description by Rives and Stoppa, scrotal fluid accumulation (nine patients), myocardial infarction (one patient) and failure of the peritoneum to grow over the mesh (one patient) were the principal complications. Interestingly, the average hospital stay was 3 days in the single recurrence and 6 days in the multiple recurrences, which probably reflects the social mores of Taiwan rather than medical necessity such as in the United States. Follow-up of up to 9 years revealed a 6% recurrence rate in the single recurrence group and a 2% recurrence rate in the Rives–Stoppa group, although in the summary of the article it is given as the UR group.

Thus, it appears as if the Shouldice repair can be performed in the hands of experts with quite a low recurrence rate, but perhaps is not as easily adaptable to

the general population. If one focuses on recurrence, it would appear that either a laparoscopic repair or a tension-free repair is most efficacious. Whatever the approach, it appears as if a 5% to 6% incidence of chronic pain of mild to moderate severity is a feature of inguinal hernia repair, although some contemporary series have reported up to 22%, which I find difficult to believe.

J.E.F.

190 Iliopubic Tract Repair of Inguinal Hernia: The Anterior (Inguinal Canal) Approach

Robert E. Condon

*This Chapter can be accessed in the accompanying eBook edition (see inside front cover for access instructions).*

The fundamental defect in the structure of the anterior abdominal wall that allows the development of direct and indirect inguinal hernias lies in the deep—or transversus abdominis—musculoaponeurotic layer of the groin. Anatomic reconstruction of these hernias, therefore, involves closure of tissues within the transversus abdominis layer. Closure of the transversus abdominal layer is the only way of anatomically repairing the internal ring. The method of hernial repair described in this chapter—in which the hernia is repaired by the traditional anterior approach through the inguinal canal and the iliopubic tract is used as the anchor for the repair—evolved from an appreciation of groin anatomy gained by dissections in the anatomy laboratory, autopsy room, and operating room. In developing this method, I have emphasized the importance of reconstruction of relatively normal anatomy insofar as the individual situation allows. A thorough understanding of groin anatomy is absolutely essential to success in hernial repair.

The elements of successful construction of a sound primary repair of an inguinal hernia are as follows:

1. Know the anatomy, especially the structure of the transversus abdominis layer.
2. Remember that the anatomic relationships in the groin are relatively constant, although variation is the norm.
3. Identify the hernial defect intraoperatively by sharp dissection.
4. Excise the weak and redundant tissues overlying and surrounding the hernia.
5. Clear the borders of the hernial defect to strong tissue.

6. Test the tissue borders to ensure that they will retain sutures.
7. Close the defect by suture, avoiding tension by means of a relaxing incision when needed.
8. Insert a prosthesis whenever loss of tissue or the size of the hernia indicates that primary repair may not succeed.

In this chapter, techniques are described for the repair of typical indirect and direct inguinal hernias. Repair of a complete hernia—the variety of large indirect inguinal hernia that has destroyed the posterior wall of the inguinal canal—combines features of both indirect and direct repairs and is also discussed.

INDICATIONS

The anterior iliopubic tract repair is suitable for all varieties of indirect and direct inguinal hernias in adults. To avoid incision through the posterior inguinal wall, an area itself subject to herniation, femoral hernias should not be approached anteriorly; the posterior approach is preferred.

This method should not be used for repair of the small indirect inguinal hernia usually found in infants; such hernias do not greatly enlarge the deep inguinal ring and require only excision of the sac and, in some instances, one or two stitches to close the deep ring. Recurrence after previous repair of an indirect inguinal hernia typically occurs at the lateral aspect of the deep inguinal ring and can be repaired through an anterior approach; however, I prefer the posterior, or preperitoneal, approach through fresh tissue for repair of recurrent direct hernias under most circumstances. I also prefer a posterior approach for repair of suspected sliding hernias.

PREPARATION, INCISION, AND EXPOSURE OF THE HERNIA

Shave only the area around the proposed incision that will be covered by the dressing and adhesive tape postoperatively. It is not necessary to shave the entire perineum. Shaving should be done in the operating room immediately before skin preparation. Scrub the lower abdomen, perineum, scrotum, and upper thighs with an iodophor solution or chlorhexidine solution. Do not use alcohol-based solutions for skin preparation because they can cause painful scrotitis. In draping, place a sterile towel under the scrotum and a second one over it to permit aseptic access to the scrotum as

needed intraoperatively.

The deep inguinal ring, through which an indirect inguinal hernia obtrudes, is situated halfway between the pubic tubercle and the anterior superior iliac spine. The incision for repair of an indirect inguinal hernia is centered directly over the projected location of the deep inguinal ring and is made more or less transversely, following a natural skin crease or tension line (Fig. 190.1). In large or complete indirect inguinal hernias that involve the posterior wall of the inguinal canal, the incision is extended medially to provide additional access. In a direct inguinal hernia, the defect is situated between the deep inguinal ring and the pubic tubercle. The upper border of the hernial defect should be identified by palpation, and the incision should be placed just below the level of the superior margin of the direct inguinal hernial defect, centered on the hernial bulge, and made transversely, following a skin crease (Fig. 190.1). Incisions for repair of a direct hernia are located somewhat more medial and inferior to those used for repair of an indirect inguinal hernia.

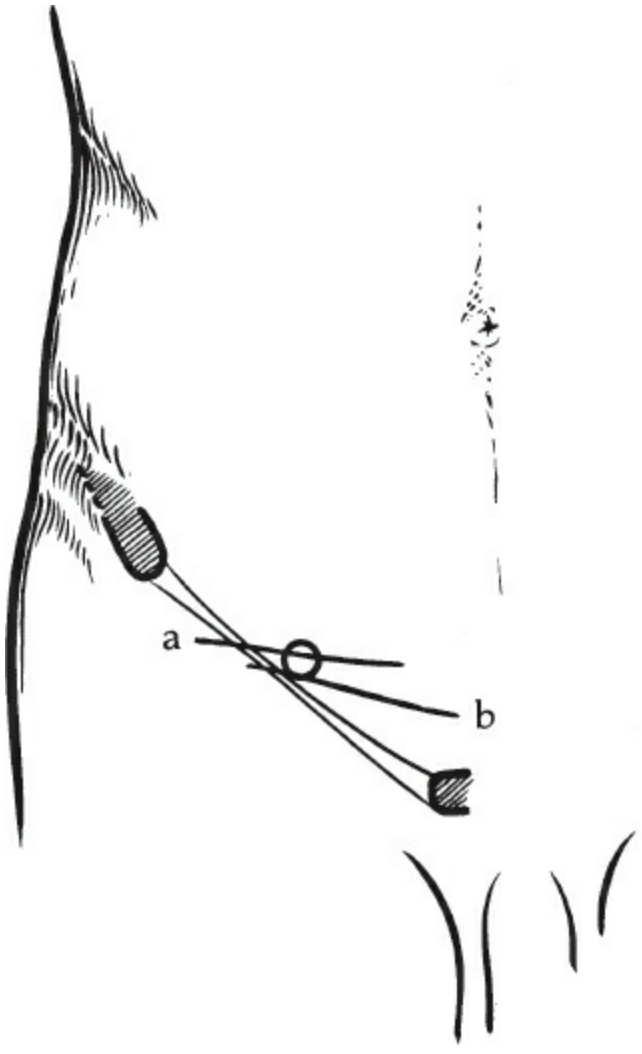

Figure 190.1. The incision for repair of an indirect hernia *(a)* is made transversely in a skin crease, centered on the projected location of the deep inguinal ring. The incision for repair of a direct inguinal hernia *(b)* is made transversely in a skin crease, centered on the hernial bulge and placed just below the palpable superior border of the hernial defect. (From Condon RE. Anterior iliopubic tract repair. In: Nyhus LM, Condon RE, eds. *Hernia.* 4th ed. Philadelphia, PA: Lippincott, 1995, with permission.)

The skin and most of the subcutaneous fat are incised in one sweep to expose the external oblique aponeurosis with its overlying investing (innominate) fascia. Branches of the superficial epigastric vessels are encountered in the medial half of the incision and of the superficial circumflex iliac vessels in the lateral half. The Scarpa fascia can sometimes be identified within the subcutaneous fat as an opaque layer; it does not need to be sutured during wound closure.

The skin and subcutaneous fat are retracted sufficiently to expose the upper portion of the superficial inguinal ring. It is not necessary to clean the external surface of the external oblique aponeurosis thoroughly. A small incision, approximately 1 cm long, is made with the knife between fibers of the external oblique aponeurosis in the middle portion of the main incision, placed so that, if extended, it carries into the apex of the superficial inguinal ring. The lower border of the external oblique incision is picked up with a Cushing forceps, and the closed points of a pair of Metzenbaum scissors are inserted and gently passed laterally on the deep aspect of the external oblique aponeurosis, separating the underlying internal oblique musculature and the iliohypogastric and ilioinguinal nerves from the external oblique aponeurosis.

One blade of the scissors is now inserted deep into the aponeurosis and the other blade is maintained superficial to it; the scissors, in a slightly open position, are pushed laterally between contiguous fibers of the external oblique aponeurosis to open the lateral aspect of this layer. Fine hemostats are applied to the edges of the incision in the external oblique aponeurosis to provide traction. The closed scissors tip is now directed medially beneath the external oblique aponeurosis, separating the underlying nerves and musculature, and the aponeurosis is split in a similar manner down to the superficial inguinal ring.

If dealing with an indirect inguinal hernia that has passed through the superficial ring into the scrotum, it may be necessary to open the

superficial ring; certainly, it is not necessary to do so on a routine basis. A self-retaining retractor is placed deep into the external oblique lamina at either end of the incision to maintain exposure of the deeper tissues. Care needs to be taken throughout this portion of the dissection to protect both the iliohypogastric and ilioinguinal nerves. Usually the ilioinguinal nerve has to be picked up gently and dissected free from the internal oblique muscle so that the nerve can be carried superiorly or inferiorly out of the surgical field and held behind a hemostat placed on the edge of the external oblique aponeurosis.

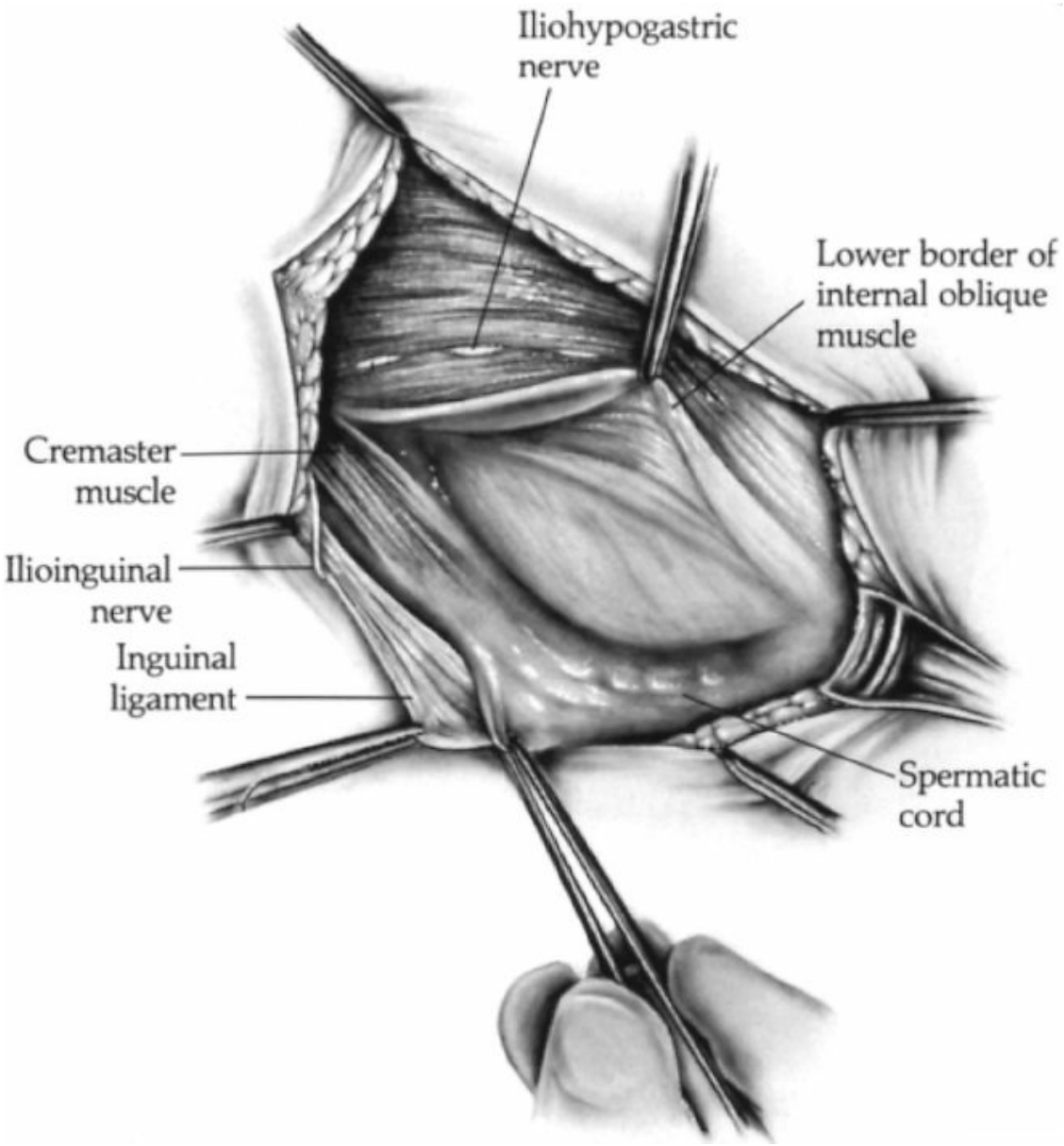

Figure 190.2. The plane between the internal oblique and cremaster muscles is completely opened between the pubic tubercle and the deep inguinal ring to begin mobilization of the

spermatic cord. (From Condon RE. Anterior iliopubic tract repair. In: Nyhus LM, Condon RE, eds. *Hernia*. 4th ed. Philadelphia, PA: Lippincott, 1995, with permission.)

The lower leaf of the external oblique aponeurosis is grasped in its middle portion and retracted inferiorly. The spermatic cord is grasped gently and retracted anteriorly and superiorly. The areolar attachments of the cremasteric fascia to the deep surface of the external oblique aponeurosis and the inguinal ligament are separated bluntly, the dissection continuing posteriorly until the deepest aspect (shelving border) of the inguinal ligament has been exposed from the pubic tubercle through the insertion of the cremaster muscle.

The spermatic cord is then gently retracted inferiorly. The lower border of the internal oblique muscle is found by identifying those muscle bundles that attach to the rectus sheath. The bundles of the cremaster muscle are identified by following them from their lateral attachment and noting that they continue with the spermatic cord. The lower border of the internal oblique muscle is retracted superiorly, the spermatic cord is retracted inferiorly, and the dissection is continued in the plane between the internal oblique and cremaster muscles on the superior and then the posterior aspect of the cord (Fig. 190.2), separating the cord from the posterior inguinal wall over the entire distance between the pubic tubercle and the medial border of the deep inguinal ring.

As mobilization of the spermatic cord proceeds, a small mesentery of cremasteric fascia on the deep aspect of the cord is developed. When the cord is sufficiently mobilized, the mesentery is transected or broken through bluntly, thrusting a finger from above to below and carefully avoiding the posterior wall of the inguinal canal. The cord is encircled with a small Penrose drain (Fig. 190.3A). The dissection is continued on the undersurface of the cord, progressing medially to the pubic tubercle and laterally beneath the deep inguinal ring to the origin of the cremaster muscle.

An indirect inguinal hernia can now be visualized as a bulging sac contained within the cremasteric fascia and the internal spermatic fascia and emerging through the deep inguinal ring on the superior aspect of the cord. A direct inguinal hernia presents as a diffuse bulge or redundancy of the posterior wall of the inguinal canal. A few fibers of transversus abdominis aponeurosis may be spread widely over the surface of a direct hernia, but for the most part, the hernial sac is composed of stretched

transversalis fascia and peritoneum.

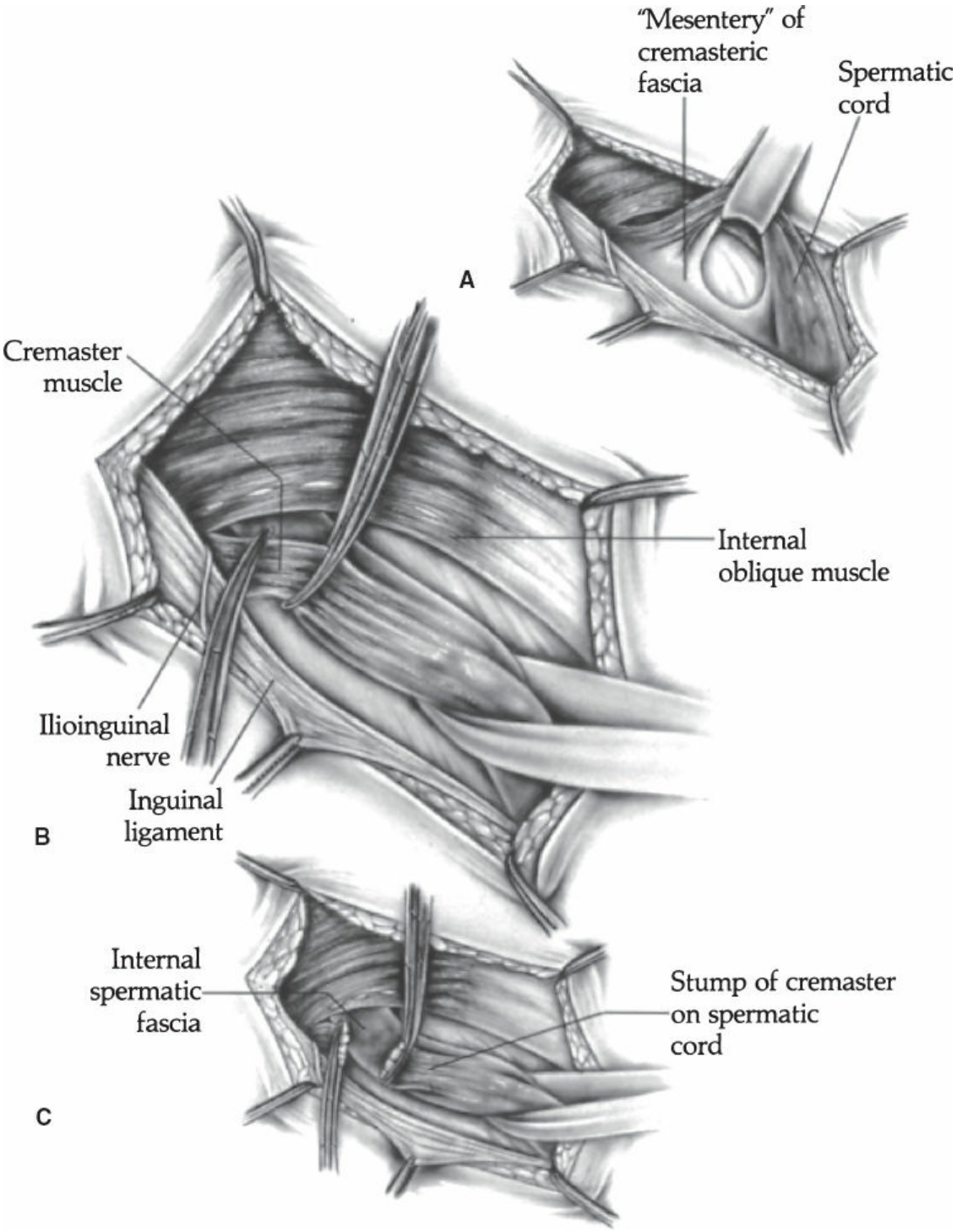

Figure 190.3. A: The mesentery of cremasteric fascia is opened bluntly and the cord retracted with a Penrose drain. **B:** The cremaster muscle is elevated near its origin and cross-clamped. **C:** The cremaster muscle is transected to expose the lateral side of the deep inguinal ring. (From Condon RE. Anterior iliopubic tract repair. In: Nyhus LM, Condon RE, eds. *Hernia.* 4th ed. Philadelphia, PA: Lippincott, 1995, with permission.)

The transversalis fascia is often opaque and may appear thick and

strong; the appearance, however, is illusory. Transversus aponeurosis, rather than transversalis fascia, must be identified and used for the repair. A complete inguinal hernia, the variety that begins as an indirect hernia but progressively enlarges medially to break down the posterior wall of the inguinal canal, has features of both indirect and direct hernias. At some point the displaced inferior epigastric vessels restrict the protrusion of peritoneum in a complete inguinal hernia, so that some "pantaloon effect" is usually present.

REPAIR OF AN INDIRECT INGUINAL HERNIA

In a typical indirect inguinal hernia, the sac is confined within the structures of the spermatic cord, and the posterior inguinal wall remains intact. It is essential that the entire circumference of the deep inguinal ring be exposed by dissection in the course of the hernial repair. This can be accomplished only by mobilization of the cremaster muscle to expose the lateral side of the deep inguinal ring, usually by transecting the cremaster muscle at its origin (Fig. 190.3B), although retracting the muscle is sufficient in some instances to provide the needed exposure.

At the lateral aspect of the deep inguinal ring, the tip of a hemostat is inserted bluntly from above downward, beneath the cremaster muscle but superficial to the iliopubic tract and the inguinal ligament. The ilioinguinal nerve is identified once again to be sure that it has been retracted and is protected. The cremaster muscle is mobilized and retracted to expose the lateral and inferior margins of the deep inguinal ring. Sometimes, to gain adequate exposure, it is necessary to transect the cremaster muscle. Paired hemostats are applied across the origin of the cremaster muscle, and the muscle is cut between the clamps (Fig. 190.3C). The proximal stump of cremaster muscle is suture-ligated to control the cremasteric artery; a simple ligature is sufficient to manage the distal stump.

Any remaining fascicular or areolar attachments of cremasteric fascia at the deep inguinal ring are transected about the entire circumference of the spermatic cord. Distal traction on the cord now makes the internal spermatic fascia (continuous with the transversalis fascia) stand out. The internal spermatic fascia is transected circumferentially around the hernial sac and cord approximately 1 cm distal to the deep inguinal ring. As this dissection proceeds at the inferior aspect of the deep inguinal ring, a small arterial branch, the external spermatic artery, may be noted perforating the transversalis fascia or the adjacent iliopubic tract to join the spermatic

cord; this vessel can be preserved or transected and ligated.

The peritoneal hernial sac, the margins of the deep inguinal ring, the iliopubic tract, and the transversus abdominis arch should now be identified. The iliopubic tract is present immediately adjacent to the inguinal ligament at the inferior aspect of the deep inguinal ring. The transversus abdominis arch can be palpated at the superior aspect of the deep inguinal ring after retracting the overlying lip of internal oblique muscle.

In most instances, the peritoneal sac protrudes through the superior aspect of the deep inguinal ring and is found along the anterior aspect of the cord. In unusual instances, the sac protrudes at the medial aspect of the deep ring between the spermatic cord and the inferior epigastric vessels. In recurrent hernias, the sac usually protrudes at the lateral aspect of the ring. Tendency to recurrence at the lateral aspect of the ring is dictated by the fact that this aspect of the ring usually has not been sutured by the surgeon performing the previous hernial repair.

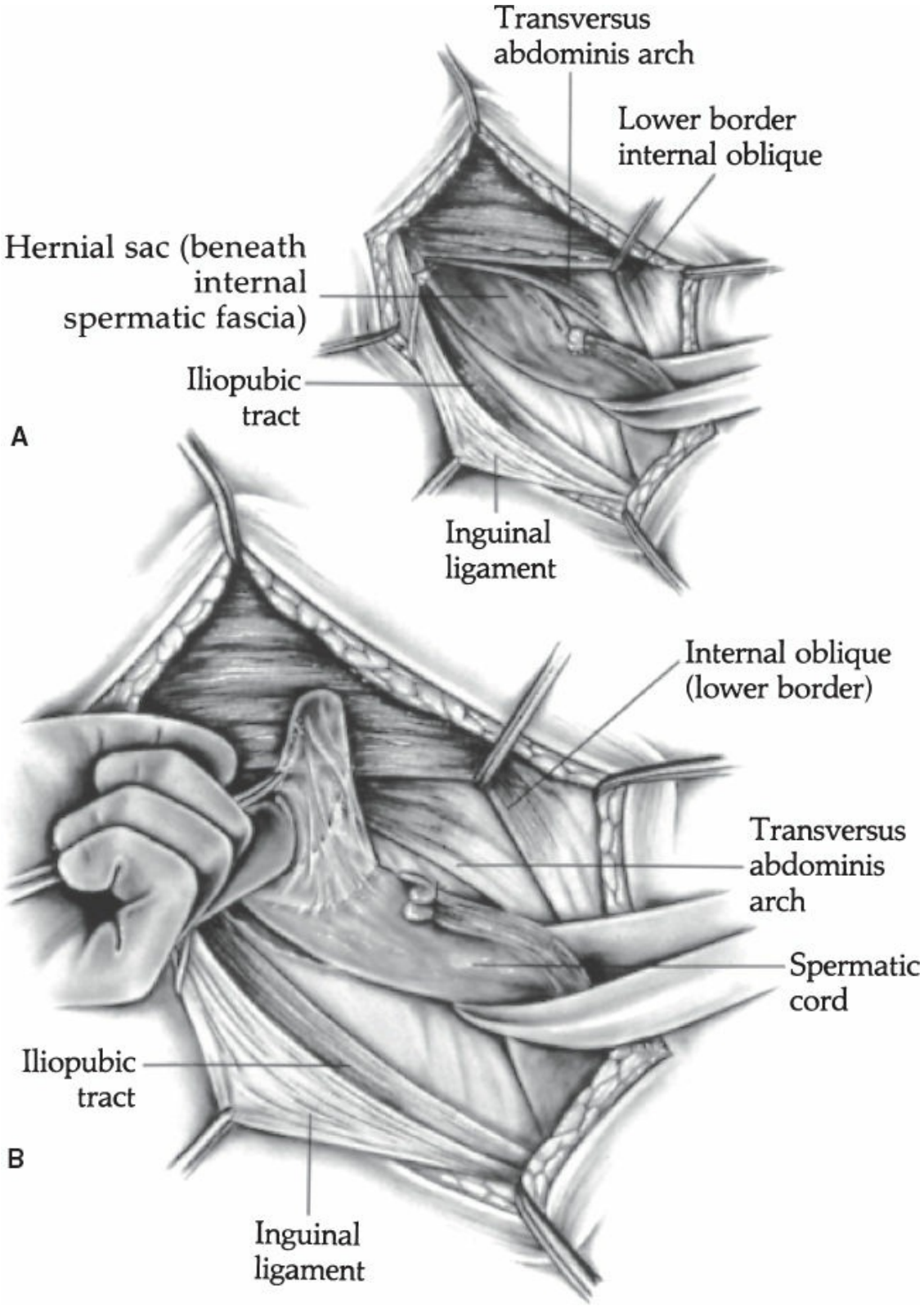

Figure 190.4. **A:** The peritoneal sac on the superoanterior aspect of the cord is incised just distal to the deep inguinal ring. **B:** The peritoneal sac is mobilized from the spermatic cord. (From Condon RE. Anterior iliopubic tract repair. In: Nyhus LM, Condon RE, eds. *Hernia*. 4th ed. Philadelphia, PA: Lippincott, 1995, with permission.)

The tissues covering the hernial sac within the cord—the cremasteric and internal spermatic fasciae—should be cleared from the sac by sharp dissection sufficiently to allow the surgeon to grasp the peritoneal sac directly. A small incision is made into the sac, 2 cm distal to the deep inguinal ring (Fig. 190.4A). The forefinger is inserted and directed distally through the incision. A fine hemostat is applied to the distal apex of the sac incision and held on traction in the palm of the operator's hand to facilitate subsequent dissection.

The sac is removed from the spermatic cord by upward and proximal traction maintained by flexing the forefinger within the sac while the cremasteric and internal spermatic fascia are cleared away, chiefly by sharp dissection (Fig. 190.4B). Sharp dissection is emphasized because blunt dissection increases the risk of injury to the blood vessels of the spermatic cord, which are spread out on the surface of the hernial sac. Clearing of the fascia from the hernial sac is facilitated by maintaining traction on the margins of the cremasteric and internal spermatic fasciae as the dissection proceeds. The dissection is made in the plane between the sac and fasciae, initially clearing the superior and anterior two-thirds of the circumference of the sac. As the initial segment is cleared, the incision in the sac is extended distally, the hemostat is replaced at the apex of the incision, the finger is thrust farther distally, and the dissection is continued until the apex of the sac is reached and mobilized. When the most distal end of the peritoneal sac is reached, the tip of the finger within the sac is flexed anteriorly, and dissection on the posterior aspect of the sac is continued back to the level of the deep inguinal ring.

Before excision and closure of the sac, a finger is inserted into the peritoneal cavity and the areas of femoral and direct inguinal herniation are palpated to ensure the absence of these hernias. In palpating the posterior wall of the inguinal canal from its internal aspect, sufficient pressure should be applied to the tissues to allow judgment as to whether the area is vulnerable to future direct herniation. If these tissues are relatively weak, the hernia should be managed as described later for a complete indirect inguinal hernia.

The finger is removed and the interior of the sac is inspected for the more or less continuous ring of peritoneal thickening and the scar that identifies the level of the deep inguinal ring. The sac can be either twisted and its apex transfixed with a suture ligature or closed with an external or internal purse-string suture placed at or above the level of the peritoneal

scar. The redundant peritoneal protrusion is then excised. Finally, the margins of the deep inguinal ring are cleared of any remaining bits of fatty or areolar tissue so that the entire circumference of the deep inguinal ring is clearly delineated.

The margin of the internal oblique muscle at the superior aspect of the deep inguinal ring is retracted superiorly. The underlying transversus abdominis arch is identified. The transversus abdominis arch is aponeurotic medially, becoming muscular laterally; aponeurotic fibers tend to run farther laterally on the deep aspect of this layer. It is important to be certain that the tissues of the transversus abdominis arch at the superior margin of the deep inguinal ring are sufficiently strong for sutures to be retained.

The iliopubic tract is visible along the inferior margin of the deep inguinal ring. Its full extent can be appreciated by grasping its upper margin with a forceps or hemostat and retracting superiorly while the inguinal ligament is retracted inferiorly. This maneuver also makes the line of demarcation between the iliopubic tract and the inguinal ligament quite clear.

A braided 00 nylon or polyester suture, swaged to a half-circle taper-point needle, is used for the repair. The spermatic cord is retracted to the lateral aspect of the deep ring. The first suture is placed through the transversus abdominis aponeurotic arch superior and medial to the deep inguinal ring, adjacent to the inferior epigastric vessels. The needle point is inserted from without to within the preperitoneal space and directed outward through the open deep inguinal ring.

After the needle is placed in the tissues, outward traction is applied to it to test the ability of the tissues grasped to hold the needle and, subsequently, the suture. As each bite of tissue is taken on each margin of the deep inguinal ring, the tissue is tested by tugging on the needle before its passage is completed to ensure that the tissues encompassed are sufficiently strong to retain the suture against moderate stress.

After the first suture is placed through the transversus abdominis arch, the needle is passed back through the deep ring into the preperitoneal space. It is directed just beneath the iliopubic tract and distally in a flat path anterior to the femoral vein for 1 cm or more before the point of the needle is rotated back through the iliopubic tract into the inguinal canal.

Occasionally, as the needle point turns back into the inguinal canal, it catches one or two fibers of the inguinal ligament. Although it is

unnecessary to include the inguinal ligament within the suture in most instances, I make no particular effort to replace the suture should a few fibers of the inguinal ligament happen to be caught within it. In those occasional instances in which the iliopubic tract is not sufficiently strong, it may be necessary to include a portion of the inguinal ligament deliberately to secure a sufficiently strong repair.

The ends of the initial suture are held and placed on moderate traction. A second suture is placed 5 to 7 mm lateral to the first, again encompassing a tested strong bite of transversus abdominis aponeurosis and muscle superiorly and iliopubic tract inferiorly. In passing the needle beneath the iliopubic tract, one must be aware that the deep circumflex iliac vessels are immediately subjacent; they are avoided by passing the needle tip flatly just beneath the iliopubic tract, encompassing a shallow amount of tissue in the anatomic anteroposterior plane but a substantial bite of tissue in the anatomic superoinferior plane.

Sufficient additional sutures are placed, spaced 5 to 7 mm apart, to accomplish closure of the medial portion of the deep inguinal ring. The objective is to place the exit of the spermatic cord through the reconstructed deep inguinal ring immediately superior and just lateral to the subjacent external iliac artery.

When all the medial sutures have been placed, the spermatic cord is retracted medially to expose the lateral aspect of the deep inguinal ring. Sutures are now inserted lateral to the spermatic cord, encompassing the transversus abdominis muscle above and the iliopubic tract and origin of the cremaster muscle below. In the lateral portion of the groin, the transversus abdominis arch may be almost entirely muscular; nonetheless, it must be tested by applying traction to ensure that the bite of tissue will hold the suture in place. Usually one to three sutures are used laterally to close the deep ring about the cord. The reconstructed deep ring should not be so tight as to cause undue swelling. In an occasional patient, the lateral margin of the deep ring is sufficiently strong and well defined so that suture closure is unnecessary; in such instances, the entire repair is conducted in the medial aspect of the ring. In the typical situation, however, both the medial and lateral aspects of the deep inguinal ring require reconstruction by suture if recurrence is to be prevented.

Sutures at the lateral aspect of the deep ring are tied after their placement. The cord is once again retracted laterally and the sutures in the medial portion of the repair are tied, beginning with the most medial suture

and progressing laterally. At the completion of reconstruction of the deep inguinal ring, it should be possible to pass the tip of a large, blunt hemostat alongside the cord.

REPAIR OF A DIRECT INGUINAL HERNIA

Although it is not necessary to excise the peritoneal sac of a typical direct inguinal hernia, it is necessary to incise the transversalis fascia and gain access to the preperitoneal space to facilitate identification and dissection of the fascial margins of the direct hernial defect. Redundant, stretched-out transversalis fascia is excised. In those rare instances in which there is also a great excess of peritoneum, the redundant peritoneum can be opened and the excess excised, followed by running closure with absorbable suture.

In the typical situation, a small incision is made through the transversalis fascia (posterior wall of the inguinal canal) approximately 1.0 to 1.5 cm above the superior ramus of the pubis. The lower margin of the transversalis fascia is grasped with a hemostat and retracted inferiorly. Blunt dissection with a “peanut” or smaller dissector is used to begin mobilization of the preperitoneal tissues from the overlying transversalis fascia. The underlying peritoneum and preperitoneal fat are pushed away from the internal aspect of the transversalis fascia all along the superior ramus of the pubis. This dissection should be carried out with care not to damage the arterial and venous blood vessels, or “corona mortis,” which are found lying on or near the Cooper ligament. The pubic tubercle, Cooper ligament, and adjacent portions of the iliopubic tract should be identified and cleared.

In dissecting along the medial aspect of a direct hernial defect, one must take care not to injure the urinary bladder, which may have become incorporated in a large direct inguinal hernia. Care also needs to be exercised to avoid entering the prevesical space or damaging the many blood vessels situated there.

The inferior epigastric vessels are identified along the lateral margin of the direct hernial defect and gently mobilized with the preperitoneal tissues and away from the overlying transversus abdominis aponeurosis and muscle. Finally, a finger is inserted into the developing preperitoneal dissection plane and is swept superiorly to identify the arch of the transversus abdominis aponeurosis along the superior margin of the direct hernial defect. Redundant and weakened transversalis fascia can now be excised to expose cleanly all the fascial margins about the direct hernia

defect.

If the patient is managed with a general anesthetic, the typical direct hernial defect can be closed primarily before a relaxing incision is made. A relaxing incision must be made, however, in all primary repairs of direct hernias. If the repair is conducted under a local anesthetic, a relaxing incision must be made before suture closure of the hernial defect is attempted. If there is any question about undue tension in the repair, a mesh prosthesis should be inserted.

Nonabsorbable 00 braided nylon or polyester sutures swaged to sturdy half-round taper-point needles are used for the repair. I prefer interrupted sutures, although running sutures are acceptable for repair of a direct hernia.

The initial suture is placed through the transversus abdominis aponeurosis immediately superior to the pubic tubercle, carried from without to within the preperitoneal space. Quite often this suture also grasps a portion of the rectus sheath, but the tendon of the rectus abdominis muscle must be avoided. As the needle is passed through the transversus abdominis aponeurosis, the strength of tissue encompassed is tested by placing the needle on traction.

The initial suture is extracted through the hernial defect, regrasped, passed back into the preperitoneal space, and carried through the periosteum and ligaments overlying the internal aspect of the pubic tubercle, testing for solid placement as described.

Sutures are placed successively (Fig. 190.5), approximately 7 to 8 mm apart, through the arch of the transversus abdominis aponeurosis, which forms the superior border of the direct hernial defect, and in turn through the Cooper ligament and the iliopubic tract along the inferior border of the direct hernial defect. In general, two or three sutures are placed through the Cooper ligament and the remainder through the iliopubic tract overlying the femoral canal. All the sutures are placed before being tied. The size of the femoral canal should be checked by palpation before the sutures are tied. If the canal seems particularly wide, an additional one or two sutures may be needed to close its medial aspect. The sutures are then tied, progressing from either medial to lateral or vice versa as convenient.

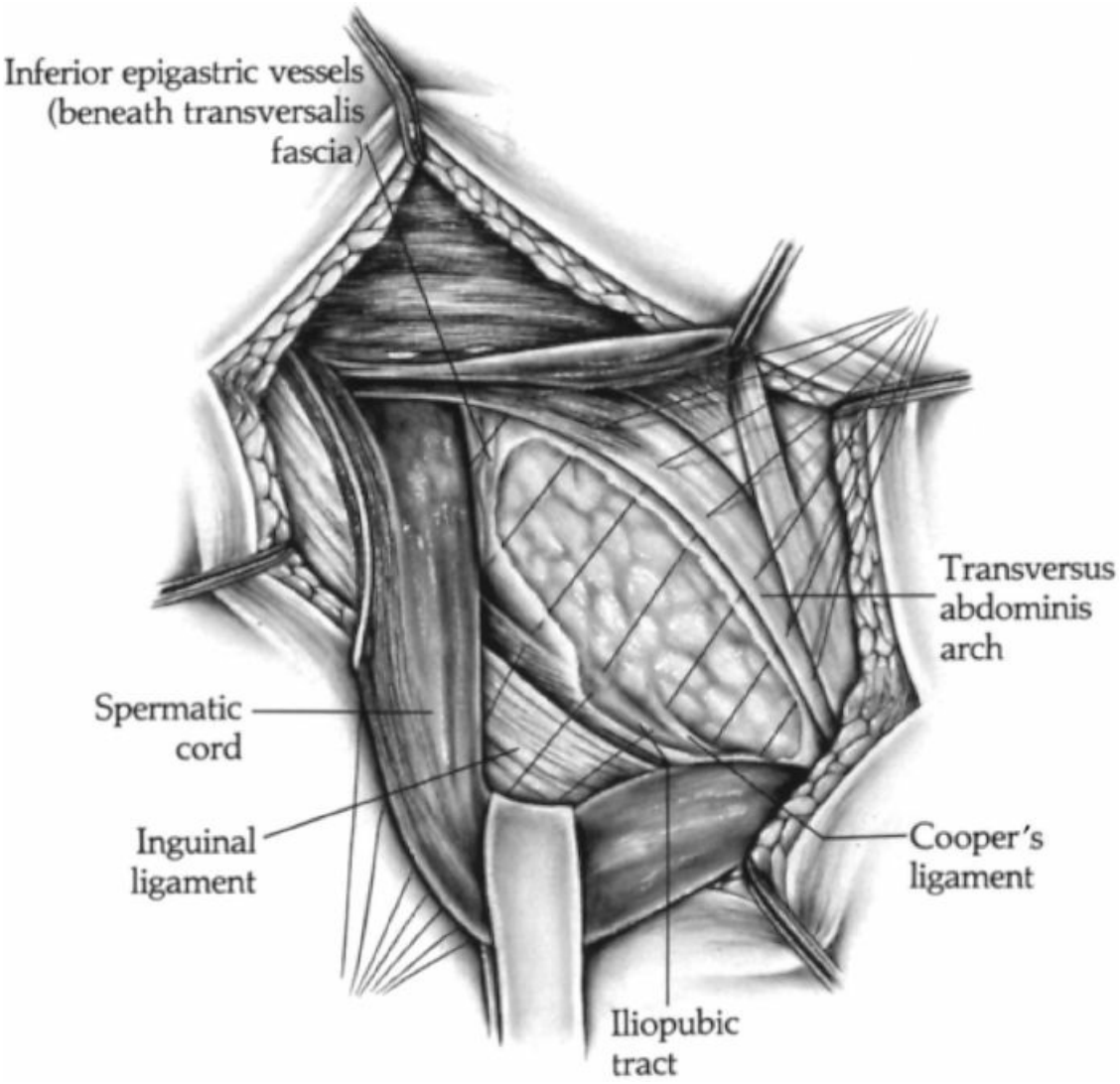

Figure 190.5. Redundant transversalis fascia has been excised and sutures have been placed in the transversus abdominis arch above and Cooper ligament and iliopubic tract below for repair of a direct inguinal hernia. (From Condon RE. Anterior iliopubic tract repair. In: Nyhus LM, Condon RE, eds. *Hernia*. 4th ed. Philadelphia, PA: Lippincott, 1995, with permission.)

RELAXING INCISION

A relaxing incision is used in every primary repair of a direct hernia, except for the smallest diverticular direct hernias, and in every repair of an indirect hernia that requires more than three or four stitches to complete reconstruction of the deep inguinal ring. A relaxing incision is essential in most hernial repairs if tension and consequent recurrence are to be avoided.

The superior flap of the external oblique aponeurosis is dissected bluntly back toward the linea alba in the area immediately above the pubic

symphysis. This plane of dissection is developed superiorly and laterally to a depth of approximately 10 cm. In effect, this dissection mobilizes the superficial lamina of the lower fourth of the rectus sheath.

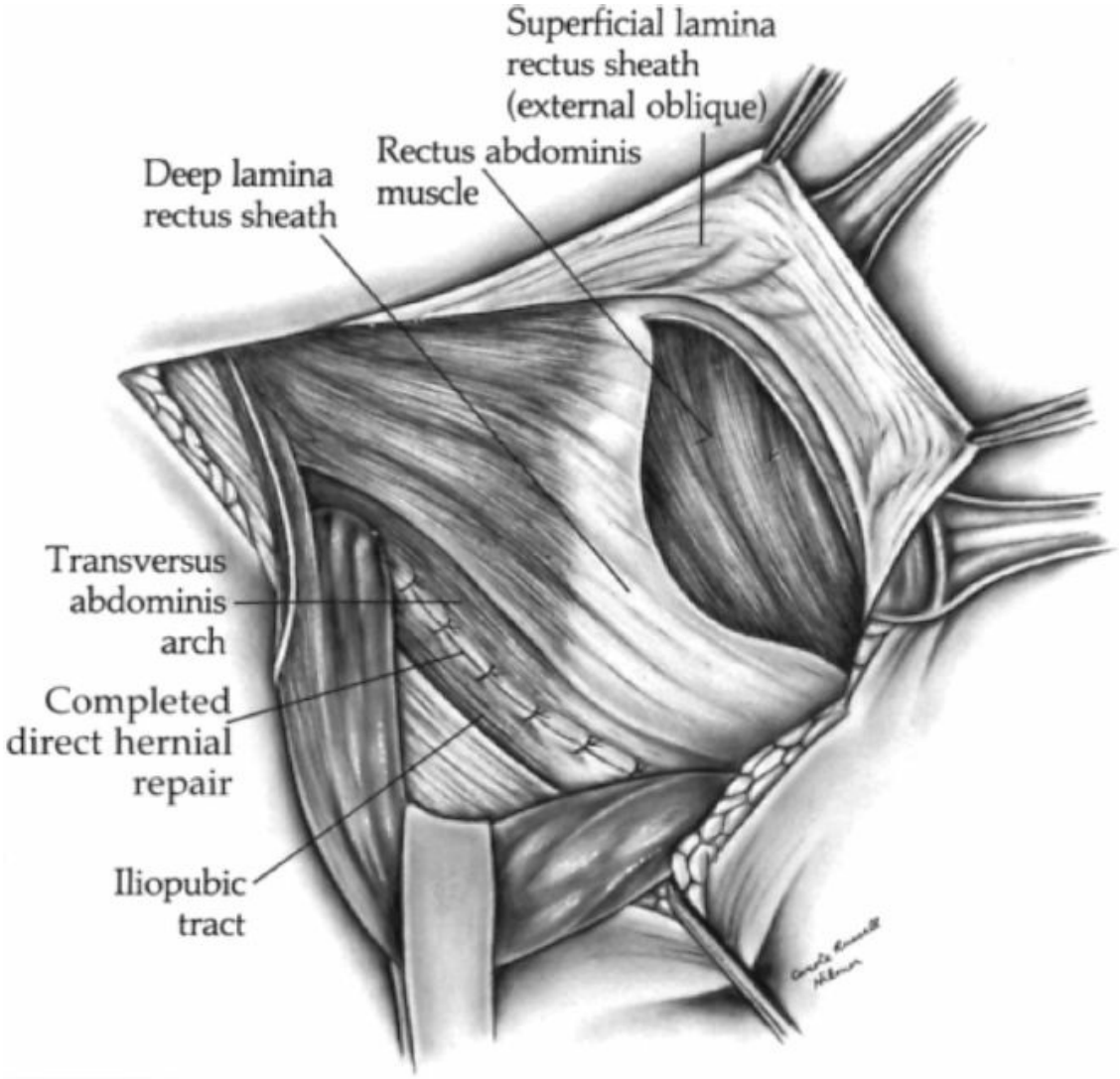

Figure 190.6. A relaxing incision allows the transversus abdominis aponeurosis to slide inferiorly as a bipedicle flap, reducing tension in the hernial repair. (From Condon RE. Anterior iliopubic tract repair. In: Nyhus LM, Condon RE, eds. *Hernia*. 4th ed. Philadelphia, PA: Lippincott, 1995, with permission.)

An incision is made through the deep lamina of the anterior rectus sheath to expose the underlying rectus abdominis muscle. The incision begins 2 to 3 cm above the symphysis pubis and immediately adjacent to the line of fusion of the superficial and deep laminae. It continues superiorly, following the line of laminar fusion, and then curves gently laterally toward the border of the rectus sheath. It is not necessary to

transect blood vessels and nerves that perforate the rectus sheath. The incision usually can be carried medial to (behind) the neurovascular bundles. Traction inferiorly on the transversus abdominis arch slides the resulting bipedicled musculoaponeurotic flap inferiorly and releases tension in the hernial repair (Fig. 190.6). If the deep lamina of the rectus sheath does not slide easily, its internal surface should be cleared by sharp dissection, again taking care not to injure branches of the inferior epigastric vessels.

COMPLETE INGUINAL HERNIA

In this variety of indirect inguinal hernia, the hernia has enlarged sufficiently medially to involve completely or nearly completely the posterior wall of the inguinal canal. Repair of this hernia combines features of the repair of an indirect hernia of more ordinary size with features of direct inguinal hernial repair, both described previously. Because the hernia is so large, the sac is often in the scrotum. The skin incision is made as for a typical indirect inguinal hernia but is carried farther medially. The inguinal canal is opened by splitting the external oblique aponeurosis. The cord is mobilized; the hernial sac and its contents often greatly enlarge the circumference of the cord. Nonetheless, the principles of mobilization are the same as for a more normal-sized spermatic cord.

After mobilization of the cord, the cremaster muscle may be transected at its origin as described for repair of a typical indirect inguinal hernia. Dissection of the peritoneal sac from the cord is occasionally a tedious process, but it follows the principles outlined for an indirect inguinal hernia. The initial incision in the sac is made approximately 2 cm distal to the deep inguinal ring. A finger is inserted distally, a hemostat is placed at the apex of the incision and used for traction, and the overlying cremasteric and internal spermatic fasciae are dissected away from the peritoneal sac by sharp dissection. The incision in the sac is extended distally as needed, and the dissection is continued successively until the tip of the sac is reached.

Sometimes, when mobilization of the hernial sac is completed, the scrotum is found to be inverted and the testicle is in the inguinal canal. In such instances, after excision of the peritoneal sac and its closure, the testicle should be replaced within the scrotum and normal relations of scrotum, testicle, and spermatic cord restored by gentle distal traction. It is

not necessary to anchor the testicle within the scrotum by suture unless the entire circumference of the testicle has been mobilized by sharp dissection. Ordinarily, this extent of mobilization is to be avoided. If the sac envelops the testicle as a hydrocele, that portion of the peritoneum adherent to the testicle should be left *in situ* and hemostasis along the cut margins achieved with a running locking stitch of absorbable suture material.

When the peritoneal sac has been mobilized from the cord, it is usually found to have a broad base. The redundant peritoneum in the area of the posterior wall of the inguinal canal should be reduced by traction on the peritoneal sac, after which the sac is closed, either by twisting and ligation or by a running suture, and the redundant peritoneal sac is excised.

Weakened and redundant transversalis fascia in the area of the hernia needs to be excised, leaving the transversus abdominis arch along the superior border of this large hernial defect cleanly dissected. Similarly, the lower border of the hernial defect must be cleared of areolar tissue and redundant transversalis fascia, beginning at the pubic tubercle and progressing along the Cooper ligament and the iliopubic tract to the lateral aspect of the deep inguinal ring. In this dissection, the external spermatic and cremasteric vessels may need to be ligated. Care is taken to avoid injury to the inferior epigastric vessels and their branches within the preperitoneal space.

Suture repair of this large defect is begun medially at the pubic tubercle. As in the closure of less extensive hernias, the strength of the tissue is tested by traction to ensure that the suture will hold as each needle is passed through the borders of the hernial defect. The initial suture is placed from the superficial to the deep aspect through the transversus abdominis arch just above the pubic tubercle; the needle is extracted through the hernial defect, regrasped, and passed from within to without through the periosteum of the pubis immediately internal and adjacent to the pubic tubercle. Sutures are placed every 5 to 7 mm along each border until the spermatic cord lies immediately superficial to the external iliac artery (Fig. 190.7A). The most medial sutures encompass the transversus abdominis arch above and the Cooper ligament below; usually, two or three such sutures are placed. The remaining sutures encompass the transversus abdominis arch above and the iliopubic tract below.

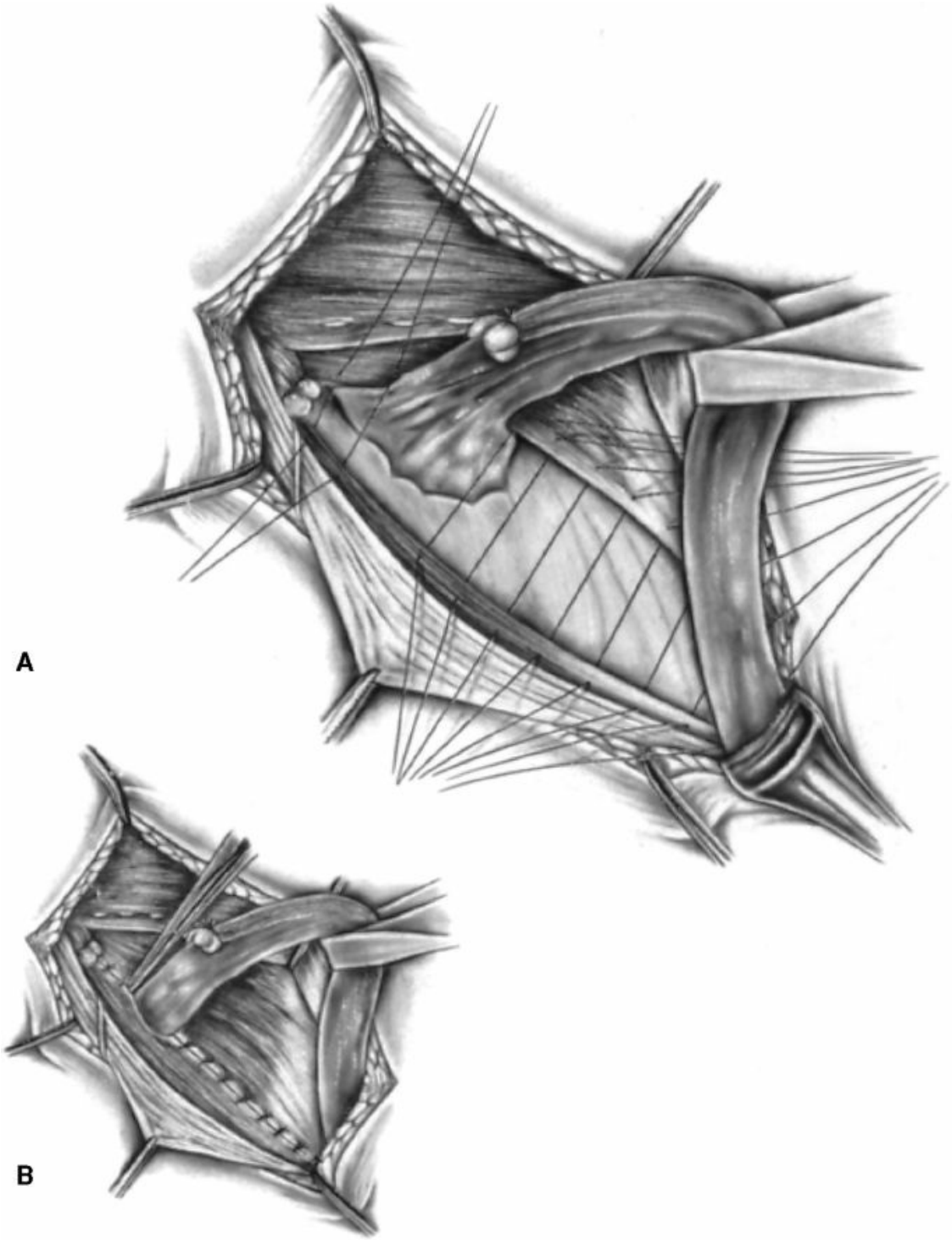

Figure 190.7. A: Sutures have been placed both medially and laterally for repair of a complete, combined indirect and direct hernia. **B:** The reconstructed deep ring should be snug but loose enough to admit the tip of a hemostat. (From Condon RE. Anterior iliopubic tract repair. In: Nyhus LM, Condon RE, eds. *Hernia* 4th ed. Philadelphia, PA: Lippincott, 1995, with permission.)

When sutures for the repair have been placed from the pubic tubercle to the medial aspect of the deep inguinal ring, the cord is retracted medially and the repair is completed on the lateral aspect of the deep inguinal ring with one to three additional sutures (Fig. 190.7B). A large relaxing incision is an essential feature of repair of an extensive hernia of this type. If there is any question of tension in the repair, then primary repair should not be done; a prosthesis should be placed.

WOUND CLOSURE

The wound is irrigated with saline or saline–antibiotic solution (kanamycin, 500 mg, and bacitracin, 50,000 units, in 500 mL normal saline solution). The retractors are removed, and hemostasis is ensured. The position of the testicle in the scrotum should be checked by having the assistant grasp it and exert gentle distal traction. This maneuver usually also accomplishes replacement of the spermatic cord neatly within the inguinal canal. No attempt is made to reattach the cremaster muscle to its origin. It becomes adherent to tissues within the inguinal canal and, surprisingly, appears to function reasonably well in a number of patients postoperatively.

The margins of the external oblique aponeurosis are reapproximated with interrupted or running sutures of 000 braided nylon. If the superficial inguinal ring has been widely dilated by passage of a scrotal hernia, it may be necessary to close the apical portion of the superficial ring by suture approximation of its crura. At completion of the closure of the external oblique lamina, it should be possible to insert the fingertip, but not more, into the superficial inguinal ring beside the spermatic cord.

Bupivacaine solution, 0.25%, is injected beneath the external oblique aponeurosis, into the areolar tissue laterally around the ilioinguinal nerve, and into the dermis of the skin incision.

The subcutaneous fat is not sutured. If the patient is excessively obese, dead space can be managed by placement of a few deep, locked mattress sutures or by use of a closed-suction catheter. The skin is closed with an interrupted or running fine monofilament nylon suture, and a dressing is applied.

CONVALESCENCE

Urinary retention may occur during the first postoperative evening. If the patient is unable to void 12 hours postoperatively, a Foley catheter should

be passed using an aseptic technique. If more than 300 mL of urine is contained in the bladder, the catheter should be connected to straight drainage overnight and removed the next morning.

Requirements for pain relief vary considerably after repair of a hernia. Patients who are very uncomfortable should receive adequate doses of anodynes, including morphine if necessary, in the early postoperative period. Some patients experience little discomfort and require practically no medication for pain relief. My impression has been that the extent of the hernia, the dissection of nerves, the use of a prosthesis, and the anesthetic technique bear only a tenuous relationship to the degree of pain experienced postoperatively.

Ambulation and resumption of normal activities of daily living should be encouraged immediately after recovery from the anesthetic. Of course, activity may be somewhat limited by discomfort in the area of the operation, but activity need not otherwise be restricted. A well-constructed hernial repair should be able to tolerate the usual daily activities of most patients, including going up and down the stairs and walking outdoors.

I have never been excited by the modern practice of early exposure of wounds. The dressing applied in the operating room is usually left in place until the sutures are removed on the fifth or sixth postoperative day. Of course, the dressing should be changed if it becomes stained with blood or serum, and it should be removed for inspection of the wound if there is any suspicion of a developing wound infection or other complication. Sutures are removed on the fifth or sixth postoperative day and replaced with sterile adhesive strips.

Male patients should avoid intercourse in the “missionary” position for a week postoperatively; the “woman-superior” position can be substituted during this period. Patients should also not engage in sudden maximal muscular effort—such as a “panic stop” while driving a car—or lift more than 25 lb during the initial 6 postoperative weeks. Most patients are rarely required to lift as much as 25 lb, even in the course of a job that entails manual labor.

Patients can return to work as soon as they feel ready. Many patients are back to work in less than 1 week postoperatively. Most patients should be back to work by the third or fourth postoperative week. Patients are seen in the office on the sixth postoperative day for suture removal and are monitored at biweekly intervals for a month. Follow-up thereafter at yearly intervals is primarily intended to detect recurrence; approximately half of

all recurrences occur within 3 years postoperatively.

Suggested Readings

Condon RE. Locked vertical mattress suture. *Surg Gynecol Obstet* 1968;127:839.

Condon RE. *Anatomic Repair of Scrotal (Indirect) Inguinal Hernia. Surgery Illustrated.* New Scotland, NY: Learning Technobiology Inc. (Upjohn); 1984.

Condon RE. The anatomy of the inguinal region and its relationship to groin hernia. In: Nyhus LM, Condon RE, eds. *Hernia.* 4th ed. Philadelphia, PA: Lippincott; 1995:16.

EDITOR'S COMMENT

It has been 161 years since Alexander Thomson (*J Comm Ed Pract* 1836;4:137) described the iliopubic tract, a structure that has become such an integral part of hernial repair (*Surg Gynecol Obstet* 1965;121:601). It has been 37 years since Robert Condon, Henry Harkins, and I presented to the Pacific Coast Surgical Association a paper that emphasized, for the first time in the English-American anatomic–surgical literature, the value of the fascial structure (*Am J Surg* 1960;100:234). The observations on groin anatomy were based on fresh dissections in the autopsy laboratory by Dr. Condon (in Nyhus LM, Harkins HN, eds. *Hernia.* Philadelphia, PA: Lippincott, 1964:14).

There is still confusion regarding when to use the anterior or the posterior approach to the repair. Dr. Condon touches on this point, and I wish to reinforce his comments.

The anterior–inguinal canal–iliopubic tract approach serves best the repair of uncomplicated indirect (type II and type IIIB) and direct hernias (type IIIA) in adults. The posterior–preperitoneal–iliopubic tract approach is indicated for femoral hernias (type IIIC), large indirect hernias (e.g., sliding inguinal hernias), large direct hernias (when transversalis fascia in Hesselbach triangle is destroyed), and recurrent groin hernias of any type. A prosthetic mesh is placed as an inlay buttress after the defect has been sutured in all these complex hernial defects. The key to the repair of groin hernias is a thorough knowledge of the complex groin anatomy. The proper approach is only facilitative.

The iliopubic tract is key to both the anterior and the posterior approaches. The iliopubic tract repair as performed by the anterior approach is in certain respects similar to Cooper ligament repair. First, the medial stitches of an anterior iliopubic tract repair are placed into the Cooper ligament because the Cooper ligament and iliopubic tract insert together into the superior ramus of the pubis. Proceeding laterally, successive sutures are then placed from the transversus abdominis aponeurotic arch to the iliopubic tract below. As stressed by Condon, the anterior repair is not complete without a relaxing incision. Because of the routine use of the inlay prosthetic buttress, a relaxing incision

when operating from the posterior approach is not routinely recommended.

Although the iliopubic tract is not as readily apparent by the anterior approach because it is covered by the more superficial overlying edge of the inguinal ligament, I believe it has several advantages over Cooper ligament repair:

1. The distance that must be traversed in pulling down the "curtain" (shutter mechanism) of the transversus abdominis aponeurosis to the iliopubic tract is not as great as the distance in bringing down the aponeurosis to the Cooper ligament. Therefore, there is less tension on the suture line.
2. An integral part of the Cooper ligament repair, the transition suture into the anterior femoral sheath–iliopubic tract, is not necessary because all the sutures are placed into the length of the iliopubic tract from medial to lateral.
3. In small indirect hernias (types I and II), best treated by a plastic closure of the internal ring, incision of the intact posterior inguinal wall is not necessary. The crura of the transversalis fascia are seen directly and are easily sutured.
4. The iliopubic tract repair, both anterior and posterior approaches, restores the laminar structure and maintains synchronous movement at the deep ring to preserve the sphincter mechanism.

As a surgeon-anatomist, Dr. Condon must be credited with clarifying the fine anatomic nuances of hernial repair as performed by the anterior approach. Although the use of eponyms is discouraged, it seems correct to name the anterior approach and iliopubic tract repair that he described so well as the Condon operation.

L.M.N.

EDITOR'S COMMENT

We have kept the comment of Dr. Nyhus from the third edition on this excellent chapter. There are a few other comments I believe need to be added.

In my opinion, it is not necessary to shave the patient. In a study carried out with Dr. J. Wesley Alexander (*Arch Surg* 1983;118:347), clipping has by far the lowest incidence of wound infection except for use of a depilatory, which is messy, difficult to control, and may result in skin reaction to it. Clipping should be carried out in the operating room immediately before surgery.

I was delighted to see the transverse skin incisions, which are much more comfortable for the patient, emphasized by Dr. Condon. A skin crease is an excellent place to carry out the skin incision. There are usually three vessels in a transverse, slightly curved skin incision. Two are medial and are branches of the superficial epigastric; the third is at the lateral edge of the wound and is a

branch of the superficial circumflex iliac vessel.

The comment of using a posterior approach to repair the femoral hernia is well taken. It makes little sense to destroy the transversalis fascia to reach the Cooper ligament, the use of which is necessary to properly repair a femoral hernia.

Dr. Condon's description of repair of an indirect inguinal hernia is classic. The meticulous identification of the anatomic structures is essential if one is to achieve a low recurrence rate.

I agree with almost all of the technical details, particularly the necessity for repairing the lateral aspect of the deep inguinal ring. One cannot emphasize too much that in placing these sutures, the ileoanal nerve must be retracted out of harm's way; otherwise, it is incorporated in these sutures.

I tend to close Scarpia's fascia. I also use a mixture of 1% Xylocaine and 0.5% bivucaine, as this gives adequate pain relief for 6 to 8 hours. Some patients do not require analgesics other than Tylenol or Bufferin.

The failure to void is a vexing problem, particularly in the ambulatory surgical setting. This complication can be almost completely avoided by the use of 10 mg of phenoxybenzamine orally immediately after the close of operation. It may need to be repeated once. Patients usually void after this and may be discharged home in the ambulatory setting, or in the case of the elderly, kept for a 23-hour admission.

J.E.F.

EDITOR'S COMMENT

In carrying out the reproduction of this excellent chapter by Dr. Condon, with minor edits, we have also kept the comments from Dr. Nyhus from the third edition. There are, however, a few comments that I think should be added.

Dr. Condon is responsible for the reidentification of the iliopubic tract 45 years ago, and 170 years since Alexander Thomson first identified the iliopubic tract. This repair is anatomically correct, that is, restoring the posterior wall of the inguinal canal, and as he has correctly emphasized, narrowing the deep internal ring, especially reinforcing the lateral border. I always put at least one suture in the lateral border of the internal ring, and Dr. Condon emphasizes that the area must be clearly exposed in order to obtain adequate visualization of the ring. The ilioinguinal nerve is very close to the deep internal ring and therefore must be protected or else it is either speared with the suture or incorporated. Both may result in postoperative pain.

Since this and many other "tension" repairs result in a 10% to 15% recurrence rate, the question that may be appropriately asked is, why is there a high recurrence rate despite the sound principles and the anatomic restoration of the structures that were originally intended to be together? Dr. Condon has

described many 2-0 nonabsorbable sutures placed at 5- to 7-mm intervals. Taking a cue from other studies on hernia repairs or abdominal wound repairs, especially those of Golligher, running monofilament sutures seem to be preferred (Golligher used stainless steel, which is not available in this country, in the supple manner of English wire). Perhaps this, as well as the use of several other layers, is the secret to the Shouldice repair, which is carried out with at least three and perhaps four layers, but using continual sutures, which then transmit the tension more evenly throughout the wound. The alleged recurrence rate of the Shouldice repair (very low, 0.3%) has been previously dealt with in several commentaries as well as Chapter 189 on Shouldice repair.

With respect to the repair of the femoral hernia, it makes little sense to me to destroy the transversalis fascia in order to carry out the Anson McVay repair, and I reserve this for femoral hernias. I do not like the posterior approach. To me, the weak point of the Anson McVay repair is the transitional suture above the femoral vein, supposedly incorporating Thomson's fascia, which, quite honestly, I have difficulty in identifying.

A few comments on technique. First, shaving. Although Dr. Condon does state that shaving should be limited to the area immediately around the incision and where one puts the dressing, J. Wesley Alexander and I (*Arch Surg* 1983;118:314) showed definitively in a randomized, prospective, four-arm trial that clipping in the operating room yielded by far the lowest incidence of infection. Anything that damages the skin, regardless of whether it is done in the operating room or not, seems to increase the incidence of infection. Depilatories probably have the lowest incidence of infection, but these are messy.

As for the incision, I'm delighted to see a transverse incision advocated because this is more comfortable for the patient, and certainly anatomically correct, and also has decreased pain. There are three vessels in the transverse, slightly curved incision; two are medial and are branches of the superficial epigastric and the third is the lateral edge of the wound, and is a branch of the superficial circumflex iliac vessel. A single swipe of the knife, which appeals to some of the various surgeons' swashbuckling tendencies, may be satisfying, but I believe that these three vessels should be clamped with hemostats and individually ligated with 4-0 absorbable ties. After opening the external oblique, in which care must be taken to identify the iliofemoral and hypogastric nerves, stay sutures should be placed in the edge of the external oblique aponeurosis and clipped to wound towels and drapes, thereby avoiding someone hauling on a retractor for the duration of the operation. I also use vessel loops around the nerves to get them out of harm's way.

In dealing with the cord, about midway through the posterior inguinal canal there is usually a vessel, the external spermatic artery, that may keep the testicle alive if for some reason there is a misadventure with the testicular artery and vein. It should be preserved if possible.

In dealing with the cord, I am surprised that Dr. Condon does not thin the

cord, as this allows one to narrow the deep inguinal ring alongside a hemostat with the thinnest possible cord. It is usually possible to salvage the vessels and the vas while taking off what is sometimes a very large cord lipoma. I do tend to reapproximate the cremaster around the cord with a 4-0 absorbable suture as it looks nicer and may keep the cord slightly buffered from various misadventures involving blows to the inguinal area.

With respect to the closure of the hernia sac, I usually carry this out with a purse-string suture started inside, and then drive this out laterally underneath the iliopubic tract in order to redirect the direction, as it were, of the peritoneal bulge in an indirect hernia. A free needle is used to get to the other end of the purse-string suture used. One must make certain to close the lateral edge of the iliopubic tract and the transversus abdominal arch after placing the suture.

The relaxing incision is described exactly as Dr. Halstead described it, and I agree with the practice of starting it 2 to 3 cm above the symphysis to avoid the rare complication of suprapubic hernia. I violently disagree with the practice of taking the first suture in the periosteum of the pubis, as all of us who have had ample opportunity to take these sutures out for patients who have “osteitis pubis.”

Skin closure continues with closing Scarpa’s fascia, adding more local anesthetic (most of the time, I do the hernias under field block) and large amounts of dilute Xylocaine and Marcaine, giving 5 to 8 hours of analgesia postoperatively. The analgesia is supplemented by injecting the edges of the wound in the subcutaneous tissue before closure. I use subcuticular absorbable sutures reinforced with Steri-Strips or Xeroform over the incision and a water-permeable dressing such as Tegaderm. That way, patients can shower when they go home, as almost all of these procedures, except in the elderly, are carried out on an outpatient basis. Each patient gets 10 mg of phenoxybenzamine or 1 mg of Hytrin so that the patient will void postoperatively (and not require an overnight stay).

I feel privileged to be able to comment on this classic of American surgical anatomic history, which is extraordinarily important.

J.E.F.

191 Iliopubic Tract Repair of Inguinal and Femoral Hernia: The Posterior (Preperitoneal) Approach

Lloyd M. Nyhus



This Chapter can be accessed in the accompanying eBook edition (see inside front cover for access instructions).

The posterior (preperitoneal, properitoneal, or extraperitoneal) approach to the repair of inguinal and femoral hernia had its origin with Annandale in 1876. Since then, interest in its use has waxed and waned, primarily because of a lack of understanding of the groin anatomy as seen posteriorly. The anatomic dissections of Condon first reported in 1960 presented with clarity the long-forgotten analogue of the transversalis fascia: the iliopubic tract. The intimate relation between the iliopubic tract and the abdominal wall defect was apparent, and the use of a strong band of fascia at the edge of each defect—the iliopubic tract—became the cornerstone of the repair. It soon became clear that the approach was mainly facilitative and that the iliopubic tract repair was the key to either an anterior or a posterior approach. In 1966, C. Thomas Bombeck and I presented both approaches and emphasized the iliopubic tract repair. The anterior approach and iliopubic tract repair are presented by Condon in Chapter 190.

SURGICAL ANATOMY

General and detailed concepts of groin anatomy are presented throughout this section. Although greater exposition would be redundant, a few anatomic considerations that relate to the iliopubic tract repair must be reiterated.

LAMINAR STRUCTURE OF THE INGUINAL REGION

The abdominal wall is composed of musculoaponeurotic layers protected externally by skin and subcutaneous fat and covered internally by preperitoneal fat and peritoneum. An anatomic hernial repair should restore the continuity and integrity of each disrupted musculoaponeurotic lamina. In uncomplicated groin hernias, only the transversalis fascia lamina is disrupted; other structures are merely displaced. In the repair of groin hernias, the essential task is the repair and restoration of the transversalis fascial layer.

The inguinal region is separated into two laminar structures. The spermatic cord is contained between these layers within a cleft or space: the inguinal canal. The group of structures that lies anterior to the spermatic cord constitutes the anterior inguinal wall, or the superficial musculoaponeurotic lamina, and is composed of the Scarpa fascia and the external oblique aponeurosis and its lowermost fibers, the inguinal (Poupart) ligament. The spermatic cord exits from the medial end of the inguinal canal by passing through the anterior wall at the external inguinal ring. The structures posterior to the spermatic cord constitute the posterior inguinal wall, or the deep musculoaponeurotic lamina, and are composed of transversalis fascia and the transversalis fascial analogues: the iliopubic tract, crura and sling of the internal abdominal ring, the transversus abdominis aponeurosis, the anterior femoral sheath, and the Cooper ligament. The spermatic cord enters the lateral end of the inguinal canal by passing through the posterior inguinal wall at the internal abdominal ring. The floor of the inguinal canal is formed primarily by the bony superior ramus of the pubis and its closely associated structures: the pectineus muscle, the pectineus fascia, and the more distal portion of the anterior femoral sheath.

TRANSVERSALIS FASCIA

A groin hernia results anatomically from a weakening and relaxation of the transversalis fascia. This concept is fundamental to understanding the anatomy of all repairs of groin hernias. If surgical cure of the hernia is expected, the anatomic integrity of the transversalis fascia must be restored, no matter what technique of repair is used. If the defect in the transversalis fascia is not repaired, a high rate of recurrence follows. In the usual anterior approach to hernial repair, the exposure of the transversalis fascia is less than ideal, which may account in part for continuing relatively high recurrence rates with the anterior approach.

Adherence to the principle of restoration of the anatomic integrity of the transversalis fascia in groin herniorrhaphy does not imply an unalterable commitment to use only transversalis fascia in the repair. It does imply, however, that all the structures used for repair must lie within the transversalis lamina of the inguinal region—in the posterior inguinal wall. This layer still forms the essential guide to repair because it defines the lamina within which repair should be carried out. This statement applies to femoral hernias as well as to direct and indirect hernias. Often used in the hernioplasty are a group of ligamentous and aponeurotic structures closely associated with the transversalis fascia. These are capable of retaining heavy sutures and provide the strength required for the reapproximation and restoration of continuity of the transversalis fascia.

ILIOPUBIC TRACT

The iliopubic tract (ligamentum iliopubicum thomsonii, *bandelette iliopubienne* of the French) is a strong fascial band that begins laterally along the crest of the ilium and at the anterosuperior iliac spine. In this area, it gives origin to the iliacus muscle and the lowermost fibers of the transversus abdominis muscle. The iliopubic tract arches over the psoas muscle and femoral vessels, where it forms an integral part of the anterior femoral sheath (Fig. 191.1). In its midportion, it lies immediately subjacent to the inguinal ligament. It is, however, completely separated from the inguinal ligament, and the relation is one of proximity only. Continuing medially, the iliopubic tract inserts fan-wise into the superior ramus of the pubis and into the Cooper ligament (Fig. 191.2). The most inferior fibers of the iliopubic tract—those that insert most laterally into the Cooper ligament—are sharply recurved in the normal groin. It is this recurved portion of the iliopubic tract that defines the medial border of the femoral canal, rather than the lacunar (Gimbernat) ligament of classic description.

The fundamental importance of the iliopubic tract in understanding the anatomy of groin hernias is that it forms one of the margins of the hernial defect in each of the common groin hernias. Direct and indirect inguinal hernial defects are limited on their posterior aspects by the fibers of the iliopubic tract; femoral hernial defects are similarly limited on their medial and anterior aspects in the transversalis lamina of the inguinal region.

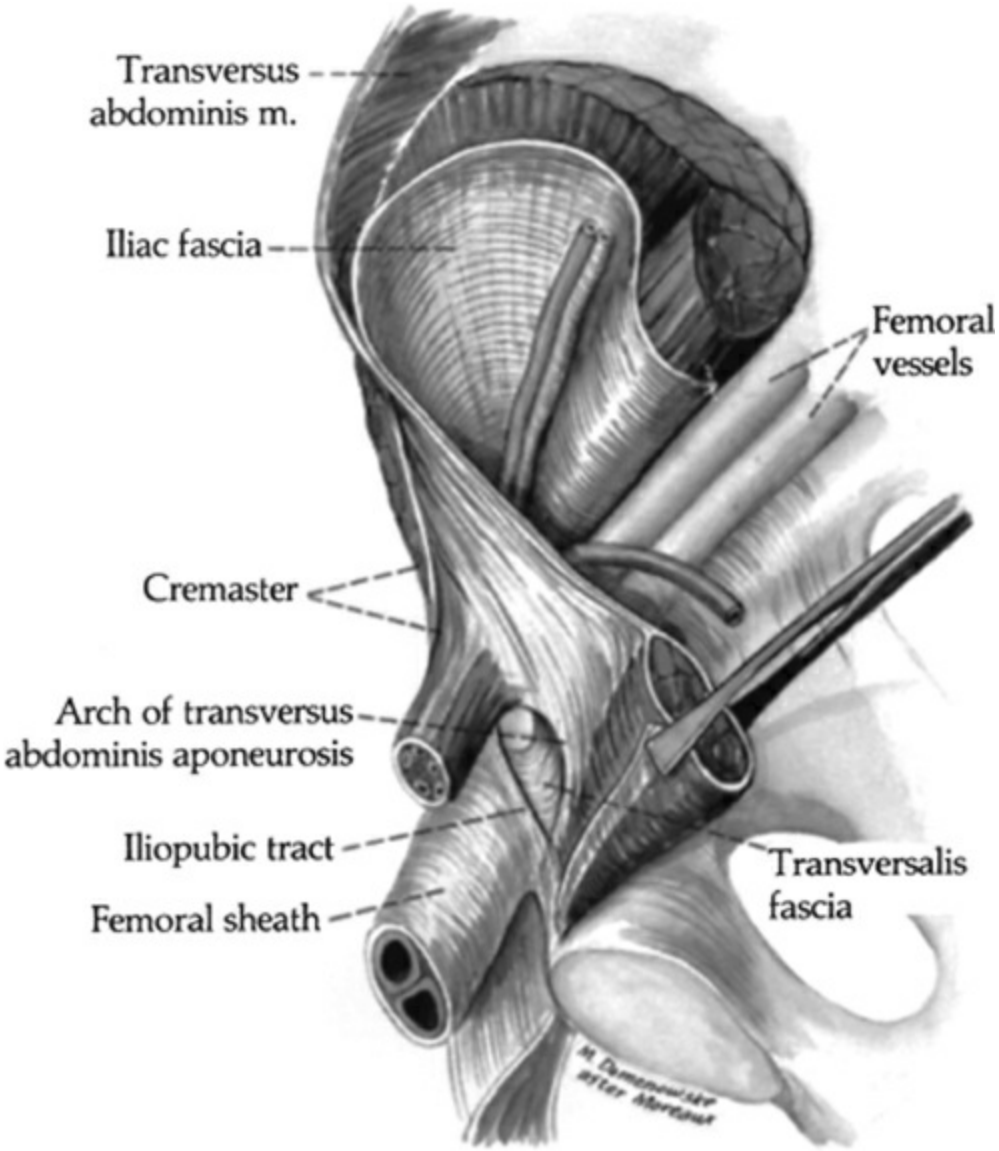

Figure 191.1. Continuity of transversalis fascia and transversus abdominis aponeurosis with iliac fascia, femoral sheath, and iliopubic tract. Inside–outside view of right posterior inguinal wall. The cremaster muscle and fascia originate from the internal oblique muscle and interparietal fasciae. (Reprinted from Nyhus LM. An anatomic reappraisal of the posterior inguinal wall. *Surg Clin North Am* 1964;44:1305. Copyright © 1964 Elsevier, with permission.)

TRANSVERSALIS CRURA AND SLING OF THE INTERNAL (ABDOMINAL) INGUINAL RING

The internal ring is given an elliptic shape by the presence on its anterior and posterior aspects of a double fold of transversalis fascia that cradles and supports the spermatic cord in this region. This sling, however,

appears to be open laterally. As is implied by the name *internal inguinal ring*, transversalis fascia can be delineated on all sides of the defect. The posterior crus, or arm, of this sling consists of fibers that parallel the iliopubic tract and finally fuse with it. The anterior crus is a more dense band that has an extensive origin in the transversalis fascia above the internal ring. The two crura are, of course, continuous with each other on the medial aspect of the internal ring and spermatic cord; because they are more prominent at this level, a sling effect is given, which gives rise to the term *transversalis fascial* sling of the internal inguinal ring. Lateral movement of this sling when straining closes the fascial ring around the spermatic cord. This natural protective mechanism (sphincter) should be enhanced during hernioplasty by placement of sutures only into the posterior lamina, avoiding cross-laminar sutures between the anterior crus and the inguinal ligament.

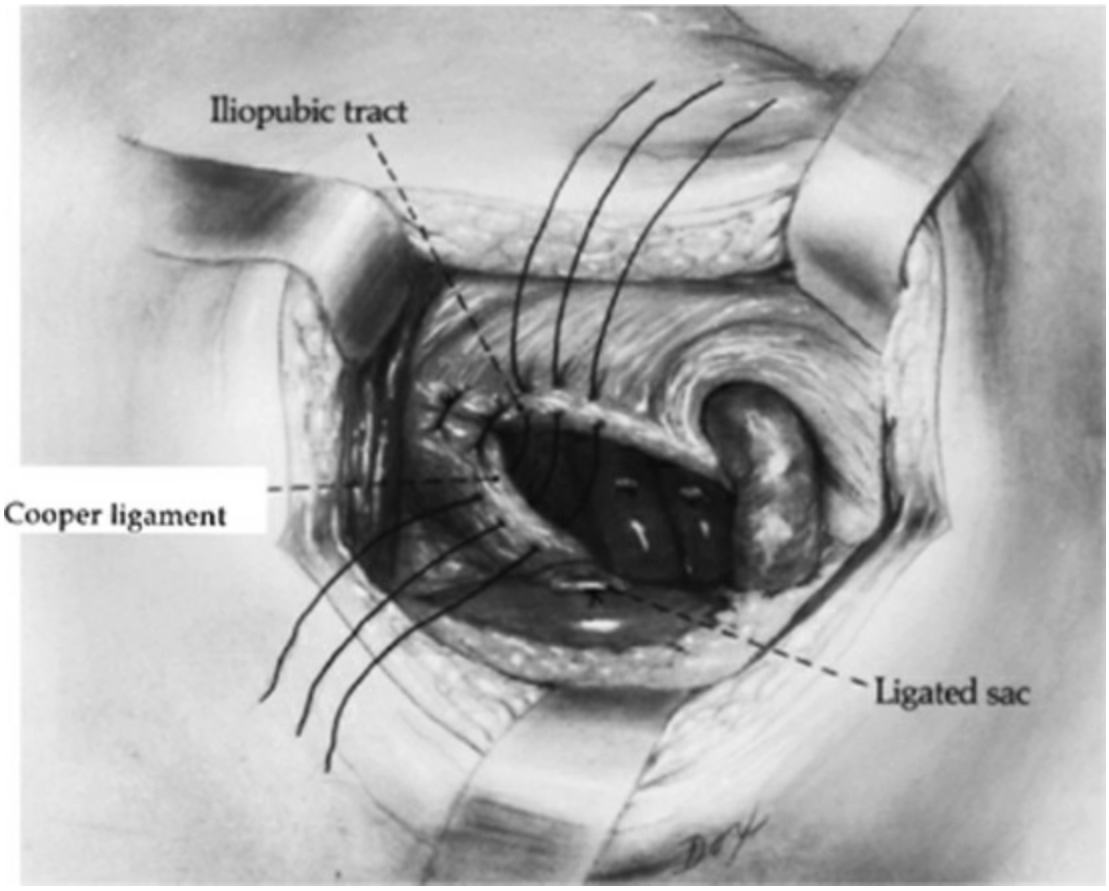

Figure 191.2. Relation of the iliopubic tract to the femoral vessels and to the ligament of Gimbernat. Medial cross section of right lower abdominal wall, viewed medially to laterally. (Reprinted from Nyhus LM. An anatomic reappraisal of the posterior inguinal wall. *Surg Clin North Am* 1964;44:1305. Copyright © 1964

Elsevier, with permission.)

LAYERS IN THE HESSELBACH TRIANGLE

Two layers of fascia cover the Hesselbach triangle: the transversalis fascia and fibers of the transversus abdominis aponeurosis. The adherence of these tissues to one another is also apparent at and above the heavy curved arch of the transversus abdominis aponeurosis. Thus, these structures are not isolated but are sutured as one layer in the repair.

The relevant structures contained within the posterior inguinal wall are illustrated in Figure 191.3.

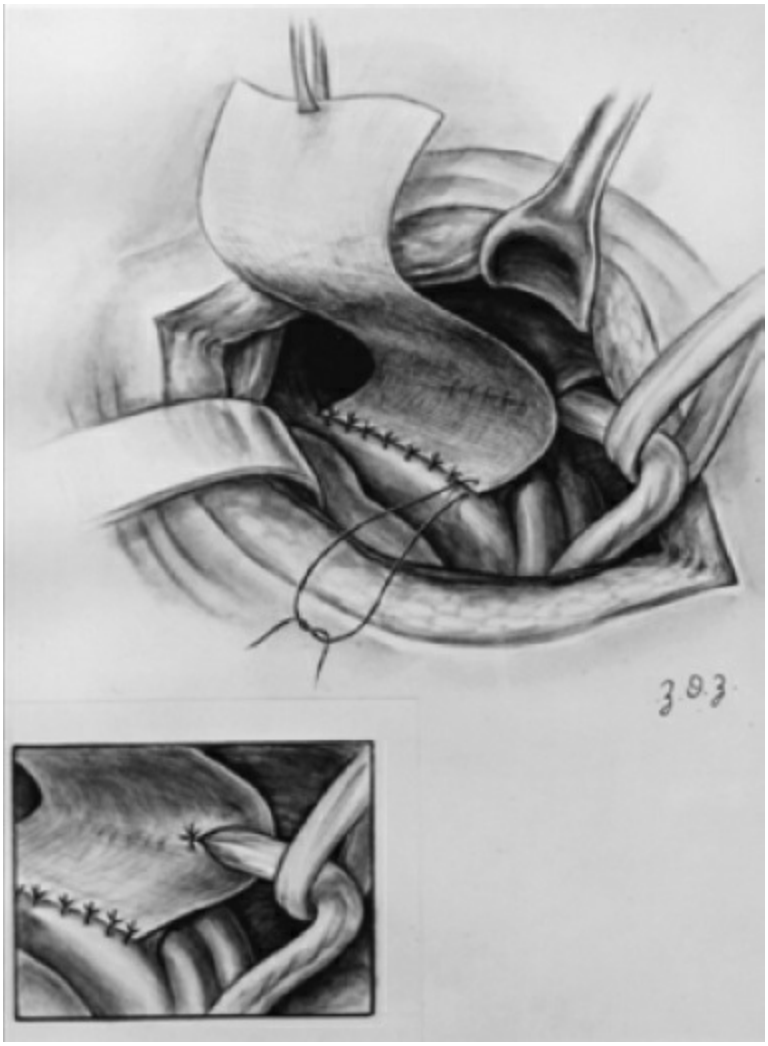

Figure 191.3. Fasciomusculoaponeurotic components of the lower abdominal wall. The spermatic cord has been removed and the iliopubic tract is reflected to demonstrate fascial continuity with the femoral sheath. The posterior inguinal wall (transversus abdominis—transversalis fascia lamina) is firmly “rooted” to the thigh at this point. The crura of the internal abdominal ring are

also shown clearly. (Reprinted from Nyhus LM. An anatomic reappraisal of the posterior inguinal wall. *Surg Clin North Am* 1964;44:1305. Copyright © 1964 Elsevier, with permission.)

TABLE 191.1 Classification of Groin Hernias

Type	Example
I: Indirect inguinal hernia	Internal inguinal ring normal (e.g., pediatric hernia)
II: Indirect inguinal hernia	Internal inguinal ring dilated but posterior inguinal wall intact
	Inferior deep epigastric vessels not displaced
III: Posterior wall defects	Direct inguinal hernia
	Indirect inguinal hernia (internal inguinal ring dilated, medially encroaching on and destroying effectiveness of transversalis fascia of Hesselbach triangle [e.g., massive scrotal, sliding, or pantaloon hernias])
	Femoral hernia
IV: Recurrent hernia	Direct
	Indirect
	Femoral
	Combination

A CLASSIFICATION OF GROIN HERNIA

The classification of groin hernia (Table 191.1) includes primary inguinal and femoral hernias (types I, II, and III) as well as recurrent groin hernias (type IV). Primary inguinal hernias are classified according to the severity of the damage to the underlying internal abdominal ring or the defect in the Hesselbach triangle. Small to massive (e.g., scrotal or sliding) indirect hernias can be viewed as a continuum of disease. Initially, they are confined to the internal abdominal ring (type I); then they enlarge medially (type II). In the final stages, they alter the posterior inguinal wall (type III). All direct hernias (small and large without involvement of the internal abdominal ring) are in the transversalis fascial layer and therefore are considered type III.

The classification of groin hernias is based on anatomic criteria. The challenge in devising a classification of this nature lies in formulating descriptions that are clear and specific. The recommended operative approaches to the various types of hernias are given in Table 191.2.

Type I

Type I hernias are indirect inguinal hernias (usually in infants, children, or

young adults) in which the internal abdominal ring is of normal size, configuration, and structure. The boundaries are well delineated and the Hesselbach triangle is normal. There is an indirect hernial sac, which extends variably from just distal to the internal abdominal ring to the midinguinal canal.

TABLE 191.2 Repair Individualized to Type of Hernia

Type of Hernia	Repair
I. Indirect with normal internal abdominal ring	High ligation of sac[a] No repair
II. Indirect with internal abdominal ring dilated, posterior abdominal wall intact	High ligation of sac Transversalis fascial repair of internal abdominal ring; no crura mesh
III. Posterior wall defects	
A. Direct	Anterior approach
B. Large indirect	IPTR without mesh (Condon) Shouldice repair Cooper's ligament repair Posterior approach IPTR with inlay buttress of prosthetic mesh Stoppa giant prosthetic reinforcement of the visceral sac with Mersilene
C. Femoral	Posterior approach IPTR without mesh
IV. Recurrent	Posterior approach IPTR with inlay buttress of prosthetic mesh

IPTR, iliopubic tract repair.
[a]Excision and ligation of hernial sac performed in all indirect and femoral hernias. A direct sac is usually not opened, excised, or ligated.

Type II

Type II hernias are indirect inguinal hernias in patients in whom the internal ring is enlarged medially and distorted without impinging on the floor of the inguinal canal. The Hesselbach triangle (floor of canal) is normal as palpated through the opened peritoneal sac. The hernial sac is not scrotal but may occupy the entire inguinal canal.

Type III

Type III classifies defects in the posterior inguinal wall (floor) into three subtypes: direct, indirect, and femoral. In direct inguinal hernias (type IIIA), the protrusion does not herniate through the internal abdominal

(inguinal) ring. The weakened transversalis fascia (posterior inguinal wall medial to the inferior epigastric vessels) bulges outward in front of the hernial mass. Again, all direct hernias, small or large, are type IIIA.

Type IIIB hernias are indirect inguinal hernias with a large, dilated ring that has expanded medially and encroaches on the posterior inguinal wall (floor) to a greater or lesser degree. Type IIIB hernias frequently have a scrotal position. Occasionally, the cecum on the right or the sigmoid colon on the left makes up a portion of the sac wall. These sliding hernias always destroy a portion of the inguinal floor (types IIIA and IIIB).

The internal abdominal ring may be dilated without displacement of the inferior epigastric vessels. Direct and indirect components of the hernial sac may straddle those vessels to form a pantaloon hernia (types IIIA and IIIB). Type IIIC are femoral hernias, a specialized form of posterior wall defect.

Type IV

Type IV hernias are recurrent hernias. They cause intricate management problems and carry a higher morbidity than other hernias.

POSTERIOR APPROACH AND ILIOPUBIC TRACT REPAIR INDICATIONS

The posterior approach is ideal for circumventing the scar tissue in operations for recurrent hernias. In addition, the posterior inguinal wall is usually not touched during previous operations, making iliopubic tract repair feasible in every instance. An inlay polypropylene mesh buttress over the posterior repair has become routine in this approach to all recurrent hernias.

Sliding hernias (type IIIB), so often the cause of consternation, are readily recognized and repaired. All incarcerated and strangulated hernias of the groin can be released with relative ease. The constricting ring can be cut with minimal danger to vital blood vessels and nerves.

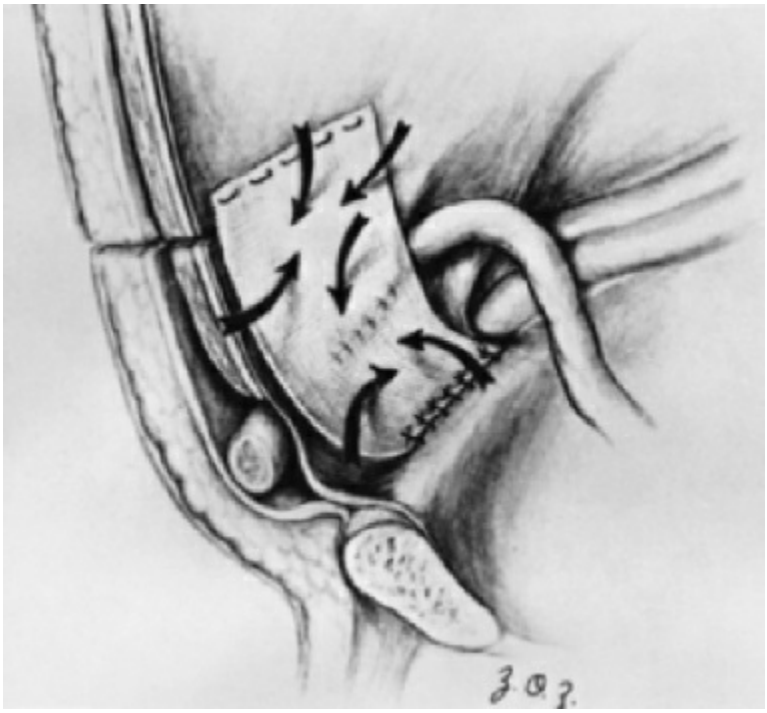

Figure 191.4. Use of the iliopubic tract in the repair of a direct or femoral hernia.

If it is necessary to resect necrotic intestine, the peritoneum can be opened and the appropriate resection and anastomosis undertaken. This approach is ideal for the correction of cryptorchidism.

Femoral hernias (type IIIC) are best approached posteriorly. In fact, as the technique evolved, my associates and I became convinced that it was good for all complicated groin hernias (Fig. 191.4).

CONTRAINDICATIONS

Poor Anesthesia

The lower abdominal wall must be relaxed to facilitate visualization of the posterior inguinal wall. The operation can be performed successfully with only one assistant, provided good abdominal wall relaxation is achieved by general or regional anesthesia (epidural).

Infants

There is general agreement that the technique of excision and high ligation of the hernial sac is sufficient for cure of the ordinary infant hernia (type I). Because repair of the posterior inguinal wall is unnecessary, and the hernial sac can be ligated readily by the anterior approach, the posterior

approach seems to be superfluous in infants. I do not use the posterior approach in children younger than 10 years.

Obesity

Extreme obesity complicates any hernial repair. Because of the necessity of dealing with an anterior abdominal wall flap during exposure of the posterior inguinal wall, the natural difficulties encountered in obesity are multiplied considerably by this approach. However, many of my colleagues do not agree that there is a disadvantage to the posterior approach in obese patients and persist in using it for all patients, lean or fat.

Direct Hernia (Type IIIA)

I do not consider a direct hernia a contraindication to the posterior approach. Recognition that the judicious use of an inlay polypropylene mesh to buttress the repair of large defects should regularly give good long-term results.

TECHNIQUE

Approach to the Preperitoneal Space

A preperitoneal space is entered through a transverse lower abdominal incision placed 3 cm above the inguinal ligament. The incision is approximately two fingerbreadths above the symphysis pubis and slightly above the inguinal incision usually used in conventional anterior hernial repair (Fig. 191.5).

The dissection is carried successively through the skin, subcutaneous tissue, and anterior rectus sheath. Before incision of the rectus sheath, exposure of the external inguinal ring may be helpful as a basic landmark for accurate estimation of the position of the internal abdominal ring. The incision through the anterior abdominal wall must be placed so that it is above (cephalad to) the internal abdominal ring. The initial incision is placed over the rectus muscle. The rectus muscle is retracted slightly toward the midline, and the transverse incision is extended laterally a few centimeters through the full thickness of the musculoaponeurotic layers formed by the external oblique aponeurosis and internal oblique and transversus abdominis muscles.

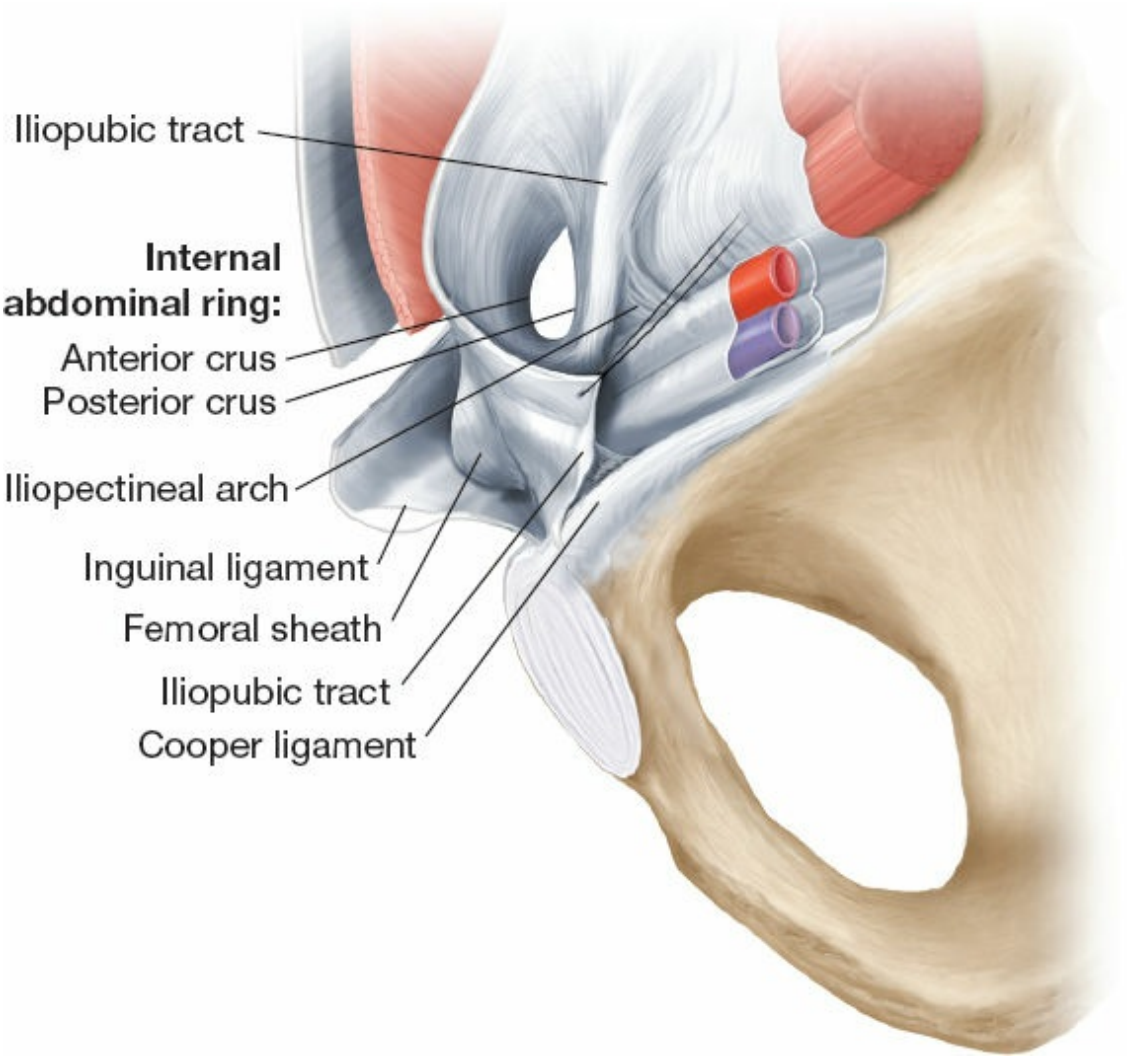

Figure 191.5. Incisions used in the anterior and posterior approaches. The preperitoneal space is approached through the transverse incision. The direct anterior approach is achieved through the longer incision in the lines of skin tension. (Redrawn after Nyhus LM, Bombeck CT. Anatomic and physiologic repair of groin hernia. *Am Fam Physician/GP* 1966;33:114.)

The transversalis fascia is now exposed. It is incised transversely, with special care taken not to enter the underlying peritoneum. The preperitoneal space has been entered. Slight retraction of the lower margin of the incision exposes the posterior inguinal wall and the area of herniation. The pelvic peritoneum and the preperitoneal fat are reflected by blunt dissection, and any peritoneal projections through the posterior inguinal wall are readily visualized.

Repair of a Direct Inguinal Hernia

A direct hernial sac is easily reduced by gentle traction and dissection. As the sac is reduced, the tissues should be carefully watched. The attenuated transversalis fascia at the apex of the sac everts along with the peritoneal sac and can be noted as a prominent fold or “white line.” This fascia can be grasped, and the margins of the hernial defect can be defined rapidly.

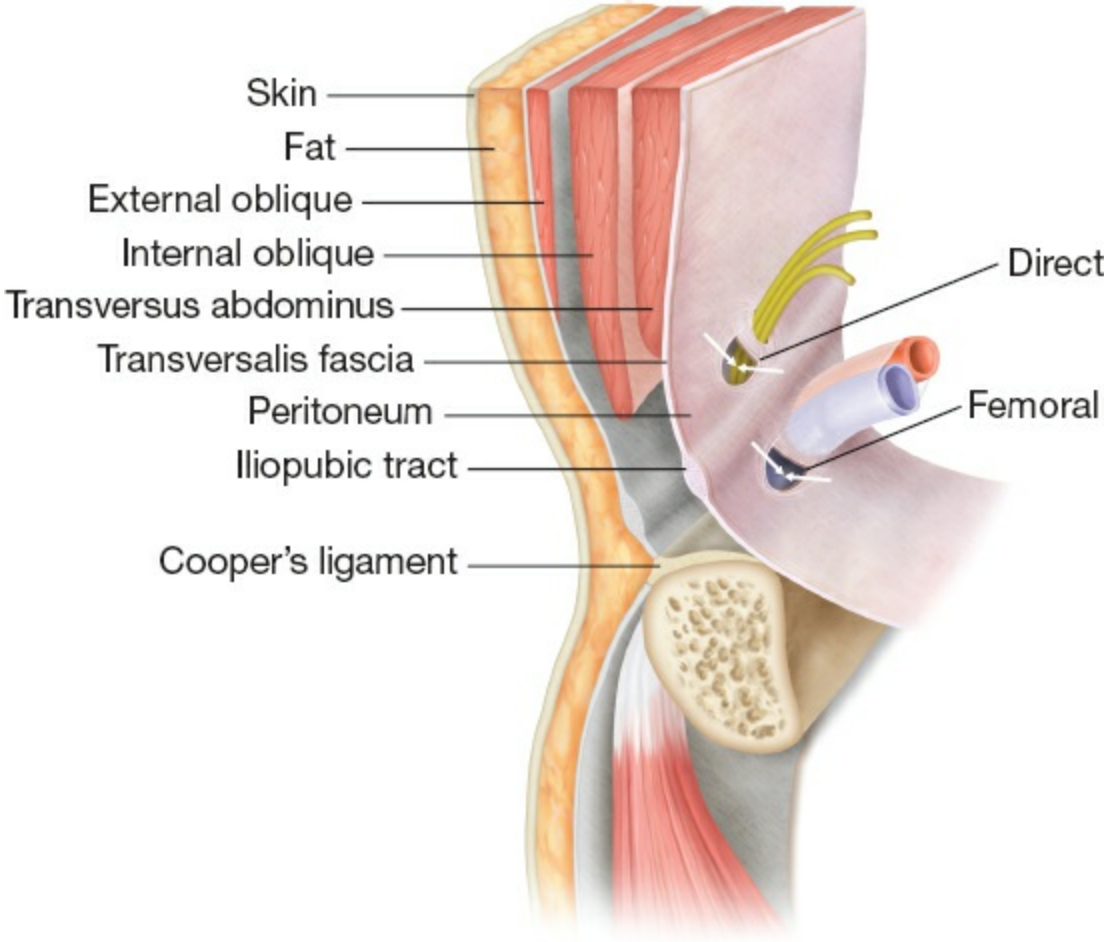

Figure 191.6. Direct hernial repair by the posterior approach. The direct sac has to be extracted and inverted, but not excised. The sutures are placed between the arch of the transversus abdominis aponeurosis above and iliopubic tract below. (Redrawn after Nyhus LM, Bombeck CT. Anatomic and physiologic repair of groin hernia. *Am Fam Physician/GP* 1966;33:114.)

The usual peritoneal sac associated with a direct hernia need not be removed; however, the sac can be invaginated into a purse-string suture. The proximity of the bladder in a direct hernia must be considered if a peritoneal sac is excised, and care must be taken to prevent damage to the bladder wall.

The direct hernial defect is repaired with interrupted sutures to approximate its upper and lower borders. The upper border of the defect is thickened transversalis fascia and arch of the transversus abdominis aponeurosis. The inferior margin of the direct defect is the iliopubic tract, which can be identified visually, by palpation, or by both methods. It is not unusual for the first and second medial sutures to be placed through both the iliopubic tract and the Cooper ligament. The more lateral sutures are placed into the iliopubic tract (Fig. 191.6). If the iliopubic tract has been attenuated by the pressure of a large direct hernia, all the lower sutures can be placed into the Cooper ligament.

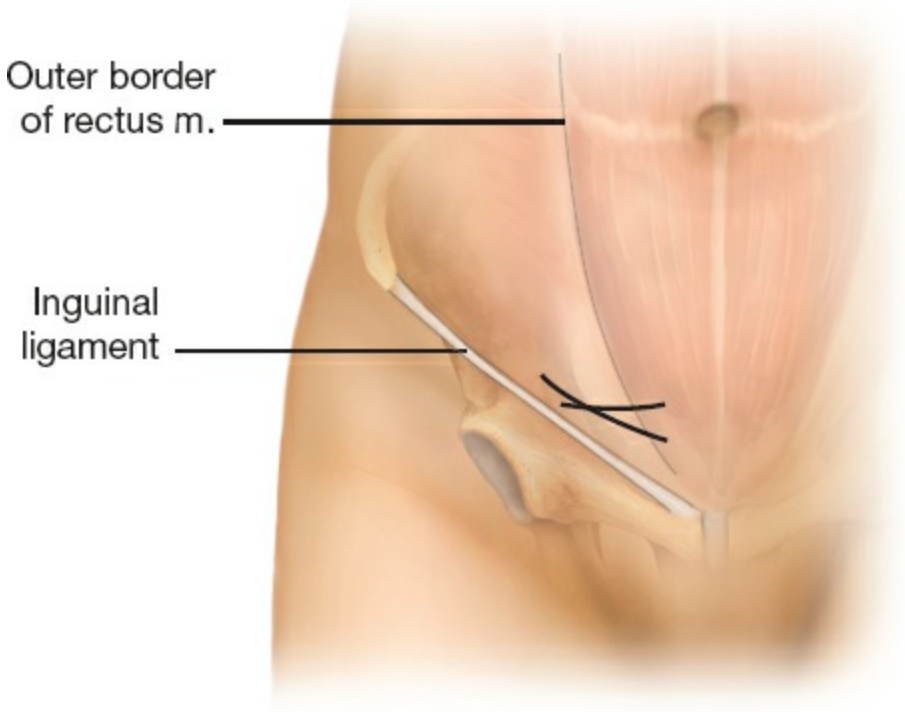

Figure 191.7. Indirect hernia, the posterior approach. The view is from above looking downward. All layers of the abdominal wall except the peritoneum and preperitoneal fat are elevated by the retractors, revealing the floor of the inguinal canal from above and within. Note the indirect sac protruding into the inguinal canal at the superolateral aspect of the internal ring. (Redrawn after Nyhus LM, Bombeck CT. Anatomic and physiologic repair of groin hernia. *Am Fam Physician/GP* 1966;33:114.)

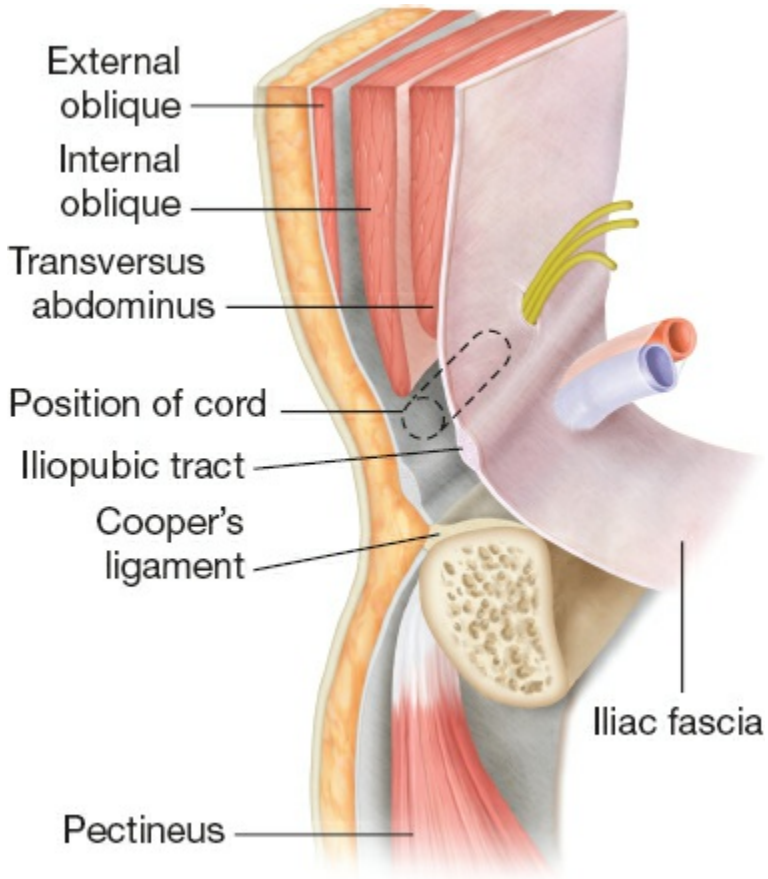

Figure 191.8. The indirect sac has been ligated and removed, and sutures are in place in the superior and inferior crura of the internal ring. The inferior crus blends into the iliopubic tract at varying distances from the medial margin of the internal ring. The sutures at this point are placed into the iliopubic tract. (Redrawn after Nyhus LM, Bombeck CT. Anatomic and physiologic repair of groin hernia. *Am Fam Physician/GP* 1966;33:114.)

Repair of an Indirect Inguinal Hernia

An indirect hernial sac is reduced by traction, a purse-string suture is placed about its neck, the excess sac is excised, and the purse-string suture is tied. An optimum high ligation is performed (Fig. 191.7). Alternatively, the sac can be left *in situ*, the contents reduced, the neck transected, and the peritoneum closed; the distal sac is left open. Although I usually reduce and excise indirect hernial sacs, it is preferable to leave them *in situ* if extensive dissection is needed for their mobilization. I have not encountered hydrocele formation when the distal sac is left *in situ*. Formation of an occasional hydrocele is preferable to the damage to the spermatic cord, vessels, and testicle that accompanies the difficult and extensive dissection needed to remove a scarred indirect sac. This

principle applies also to the conventional anterior approach to indirect inguinal hernias; it is not unique to the posterior approach.

After high ligation of the neck of the hernial sac, the hernial defect is repaired. For the smallest indirect hernias, a few sutures placed medial or lateral to the spermatic cord suffice, approximating fibers of the anterior crus of the internal ring to the posterior crus and iliopubic tract (Fig. 191.8). For larger indirect hernias, the cord is first gently retracted laterally, and sutures are placed between the anterior crus of the transversalis fascial sling and the iliopubic tract medial to the cord. Sufficient sutures—one or two in the usual hernia, more with extensive defects—are placed so that the internal ring and associated spermatic cord are restored to their normal anatomic position above and slightly lateral to the femoral artery. The cord is retracted medially, and the repair of the hernial defect is continued laterally. Two or three sutures usually suffice for the lateral closure. In massive indirect hernias with associated medial displacement of the inferior epigastric vessels and destruction of the posterior inguinal wall in the area of the Hesselbach triangle (types IIIA and IIIB), the principles of repair in both direct and indirect hernioplasty are used. The medial portion of the hernial defect is repaired as a direct hernia; the repair is continued laterally, and a new internal abdominal ring is made at the level of the femoral vessels. An inlay buttress of prosthetic mesh should always be used after repair of these large, complex defects.

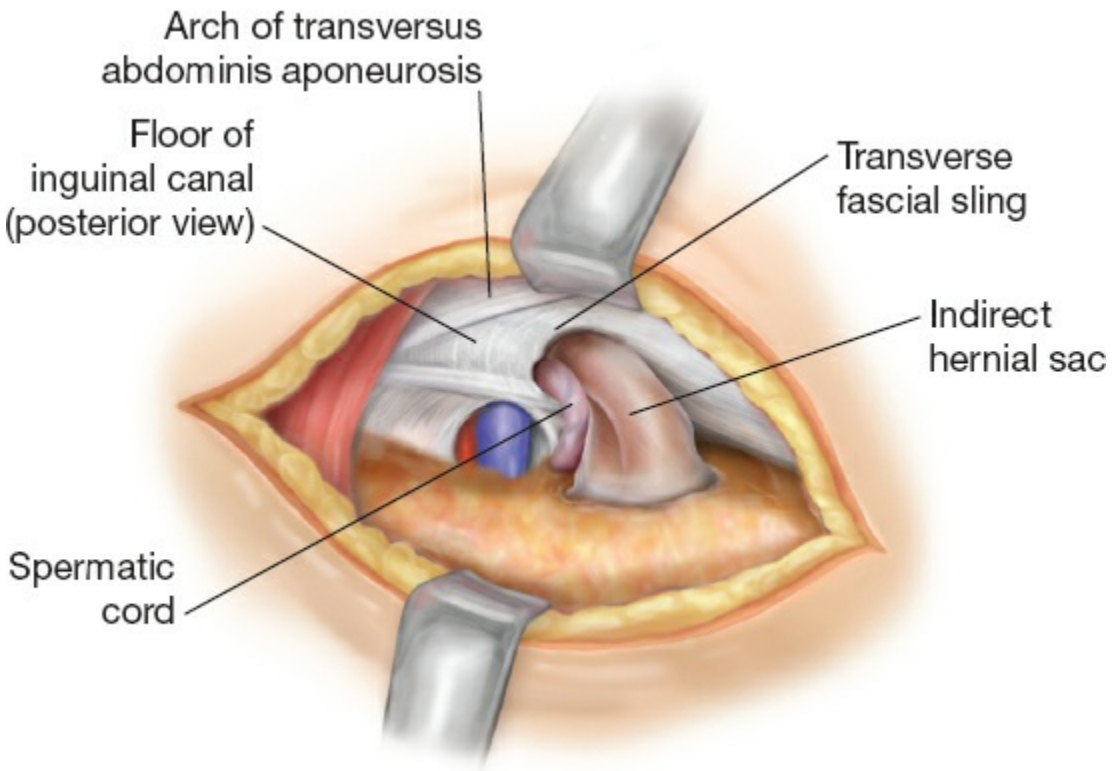

Figure 191.9. Femoral hernia, the posterior approach. The femoral sac protrudes into the femoral canal medial to the femoral vein, inferior to the iliopubic tract, above the Cooper ligament, and lateral to the reflected fibers of the iliopubic tract. The lacunar ligament is external to these structures and does not form one of the boundaries of the femoral defect in the posterior lamina of the transversalis fascia. (Redrawn after Nyhus LM, Bombeck CT. Anatomic and physiologic repair of groin hernia. *Am Fam Physician/GP* 1966;33:114.)

Repair of a Femoral Hernia

A femoral hernial sac is reduced by traction (Fig. 191.9). If the hernia is incarcerated, the sac is released by carefully incising the insertion of the iliopubic tract into the Cooper ligament at the medial margin of the femoral ring. The sac should be opened for inspection of its contents. Hernial repair is initiated with high ligation of the sac. The anterior margin of the hernial defect is formed by the iliopubic tract, and the posterior margin is formed by the Cooper ligament. The hernioplasty is completed by suturing these two structures together, thereby obliterating the femoral canal medial to the femoral vein (Fig. 191.10). In the posterior approach, there is no problem regarding visualization of the external iliac–femoral vein; it is easily seen and easily protected, and the correct degree of

closure of the canal medial to it without compressing it is more readily obtained. The aberrant obturator artery (corona mortis) crossing the Cooper ligament is seen and protected when present.

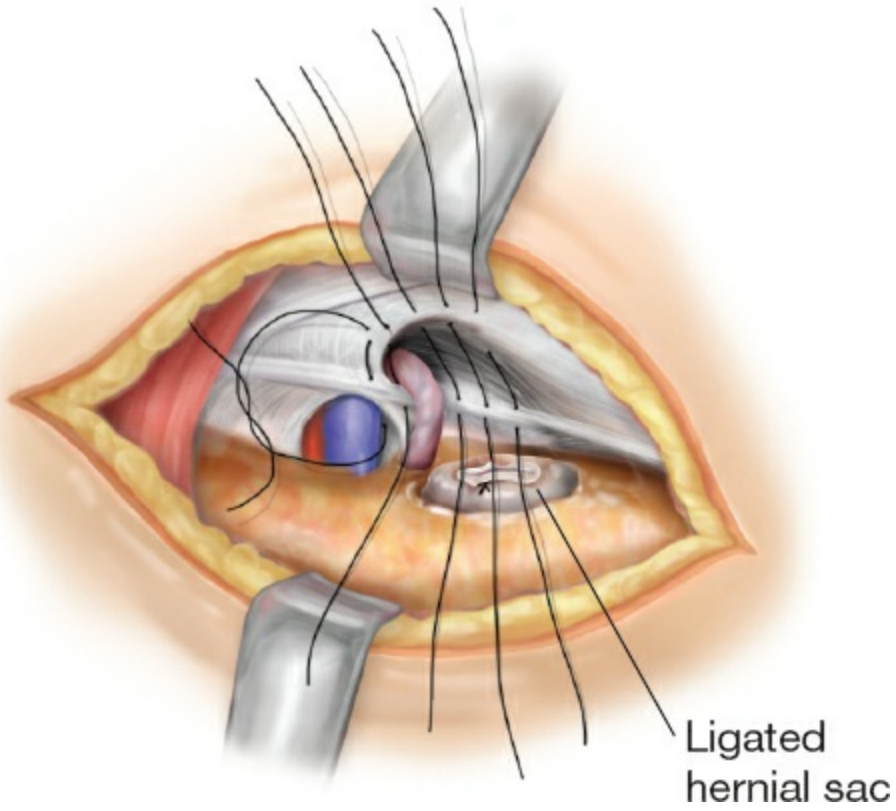

Figure 191.10. The femoral sac has been removed, and sutures are in place for the closure of the defect. The ease of exposure of the femoral defect makes this approach the procedure of choice for the repair of femoral hernias. (Redrawn after Nyhus LM, Bombeck CT. Anatomic and physiologic repair of groin hernia. *Am Fam Physician/GP* 1966;33:114.)

If the restraining fascia is distal in the femoral canal (Gimbernat ligament), release can be attained from above. There is, however, the rare possibility of performing a counterincision in the upper thigh over the femoral hernial mass for release of this restricting fascia. I have never found this necessary. Use of relaxing incisions or polypropylene mesh has not been necessary for the iliopubic tract repair of femoral hernias.

Closure of the Wound

After the hernial repair is completed, the remainder of the groin must be carefully searched for other hernias or areas of weakness. If such a

“missed” hernia is not discovered and repaired, it may appear postoperatively as a “recurrent” hernia.

Meticulous care must be taken to secure complete hemostasis before closure of the wound. The preperitoneal space is well irrigated with saline solution. The thin layer of transversalis fascia entered below the semicircular line of Douglas is usually not closed. The anterior rectus sheath and lateral muscle aponeuroses are sutured in layers with interrupted medium polypropylene followed by closure of the subcutaneous tissue and skin.

GENERAL REMARKS

In early experience, ligation of the inferior epigastric artery and vein was routine. As experience broadened, it was found that this maneuver was not necessary routinely for adequate exposure.

An Allis clamp is placed on the iliopubic tract at the level of the anterior femoral sheath and pulled laterally. This maneuver helps immeasurably to delineate the medial projection of the iliopubic tract. Similarly, lateral traction on an Allis clamp placed on the anterior sling of the internal inguinal ring—including transversalis fascia and transversus abdominis aponeurosis—helps to delineate the superior edge of direct hernial defects and the superior edge of large indirect hernial defects. The fascial bands and thickening may occasionally be easier to palpate than to visualize.

The iliopubic tract should be lifted in an anterior direction when placing sutures into it at the level of the femoral artery and vein. Unless this precaution is taken, the vessels may be traumatized.

I have vacillated in my choice of suture material. The standard suture material used in the fascial layer of the iliopubic tract repair is 0 polypropylene.

USE OF PROSTHETIC MATERIAL FOR RECURRENT HERNIA

The repair of recurrent hernias is technically intricate and is associated with a high incidence of secondary recurrence. I have adopted the preperitoneal approach to the inguinal region for all recurrent hernias repaired since 1978. Evidence that recurrences may result from a localized collagen metabolic defect has confirmed my belief that more than direct

reapproximation of the weakened posterior lamina is necessary if further recurrences are to be avoided. In this context, therefore, incorporation of the prosthetic mesh buttress to strengthen the repair is an important addition to the preperitoneal approach to the management of all recurrent groin hernias.

The posterior approach is expected to serve the following purposes:

1. Avoid dissection through nuisance scar tissue.
2. Allow thorough assessment of the hernial sac and hernial defects.
3. Allow confident exclusion of multiple hernial defects.
4. Facilitate the approach to repair by easy visualization of the Cooper ligament, iliopubic tract, and femoral sheath.
5. Apply the principle of intra-abdominal pressure to the inlay buttress (Pascal law), evenly fortifying its protection.

My 24-year experience suggests that this approach to the management of recurrent groin hernias is associated with minimal morbidity and few secondary recurrences.

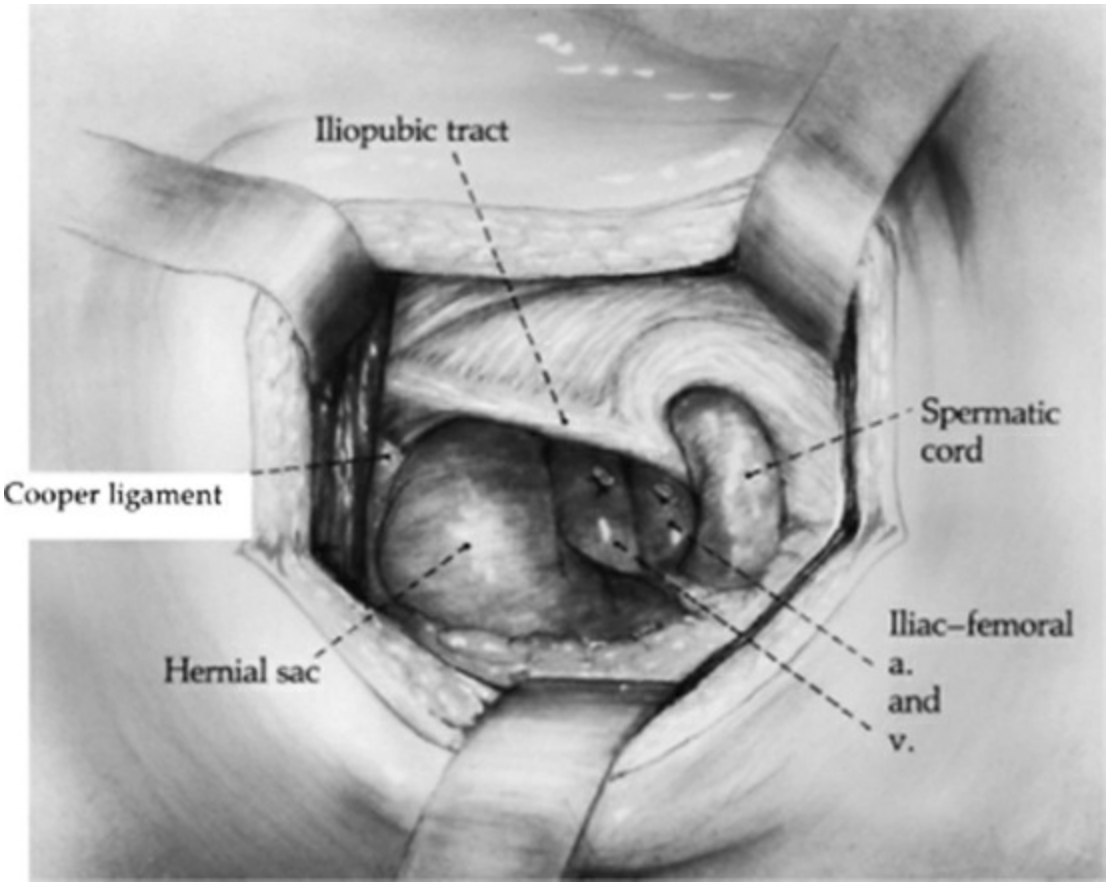

Figure 191.11. A polypropylene mesh buttress is attached posteriorly to the Cooper ligament (after repair of the recurrent defect in the wall) with 0 polypropylene suture material. If there is

concern about closure of the internal abdominal ring (indirect recurrence), the mesh can be folded around the spermatic cord (*inset*).

The steps to gaining access to the proper planes of dissection have been described. Fascial margins of the defects are approximated without excessive tension before the polypropylene mesh is applied to the posterior wall.

After the hernial defect is closed, a piece of polypropylene mesh, usually 10 × 5 cm, is cut. The Cooper ligament is visualized, and the mesh is sutured to it (Fig. 191.11). When a recurrent indirect hernia is being repaired, the spermatic cord should be incorporated into the mesh. The mesh is simply folded over the fascial repair and tacked to the posterior inguinal wall with 000 polypropylene. The polypropylene mesh can be tailored to fit the area that is to be covered. Finally, the mesh is sutured beneath the abdominal wound of entry to buttress the abdominal wall (Fig. 191.12).

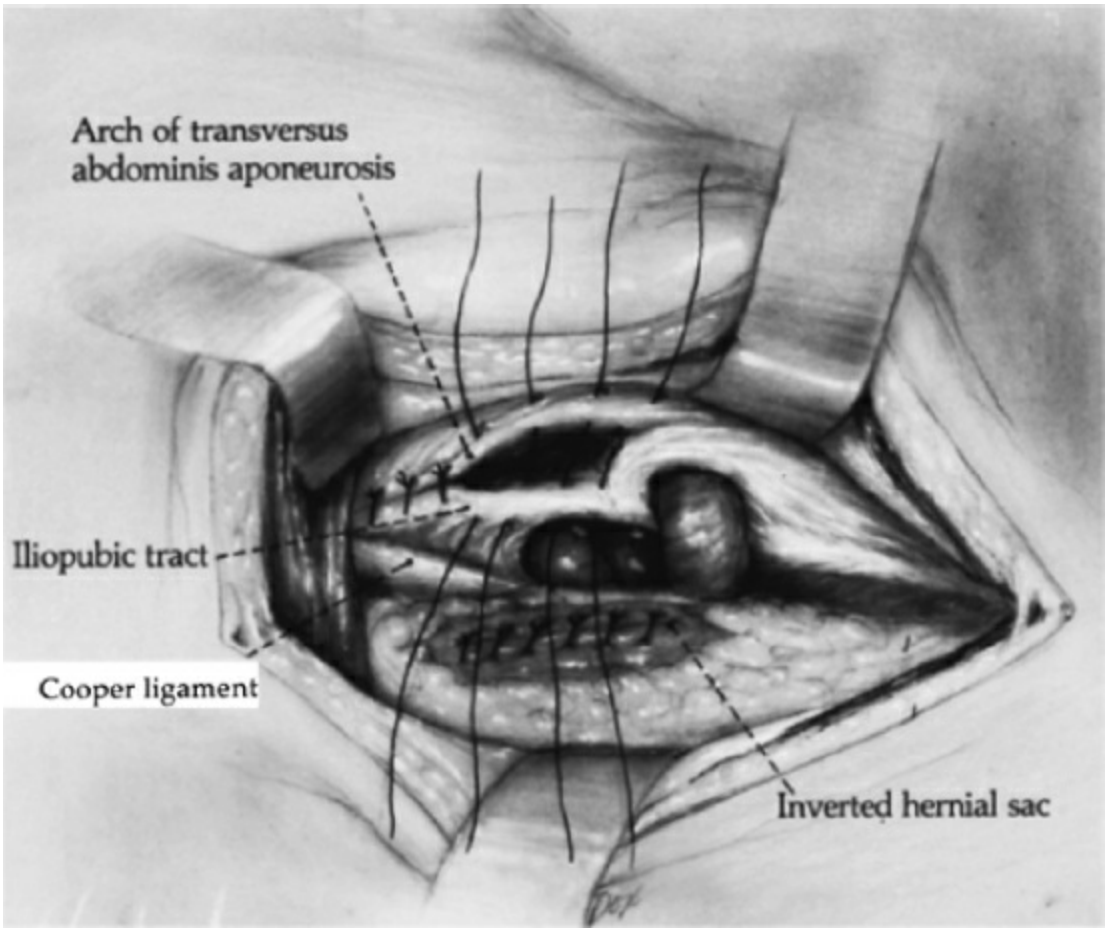

Figure 191.12. Inlay prosthetic mesh. *Arrows* show the Pascal

principle of even pressure applied to the prosthetic mesh. The suture line of the hernial defect remains intact and well protected. (From Nyhus LM. The recurrent groin hernia: therapeutic solutions. *World J Surg* 1989;13(5):541–4. Copyright © 1989 Société Internationale de Chirurgie, with permission from Springer.)

RESULTS OF TREATMENT

It has been shown that the posterior approach can give satisfactory results in the repair of all types of groin hernias. A specific method of repair, however, cannot be recommended unless surgeons understand the fine points of the method. For those who are insecure in the posterior technique, I advise an anterior approach and the repair described by Condon (Chapter 172).

INDIVIDUALIZING THE APPROACH

In 43 years of study of hernias, I have learned much about individualization of approach and repair (Table 191.2). The posterior approach and iliopubic tract repair is excellent for femoral hernias. Small indirect hernias (types I and II) are best treated from the anterior approach by high ligation of the sac alone or with plastic closure of the transversalis fascia at the internal ring. Large indirect hernias (e.g., sliding hernias), recurrent hernias, and incarcerated or strangulated hernias are ideally approached posteriorly. All direct hernias are best approached posteriorly. The larger complex hernial repairs should routinely be buttressed with an inlay of polypropylene mesh.

Suggested Readings

Annandale T. Case in which a reducible oblique and direct inguinal and femoral hernia existed on the same side and were successfully treated by operation. *Edinburgh Med J* 1876;21:1087.

Bendavid R. The Shouldice repair. In: Nyhus LM, Condon RE, eds. *Hernia* 4th ed. Philadelphia, PA: Lippincott; 1995.

Fruchaud H. *Anatomie Chirurgicale Des Hernies de l'aine.* Paris: Doin; 1956.

Fruchaud H. *Le Traitement Chirurgicale Des Hernies De l'aine chez l'adulte.* Paris: Doin; 1956.

Halverson K, McVay CB. Inguinal and femoral hernioplasty. *Arch Surg* 1970;101:127.

Himpens J, Cadiere GB, Bruyns J. Laparoscopic inguinal hernia repair: new policies. *Dig Surg* 1997;14:433.

Lobo E, Sanjuanbenito A, Fernandez-Merino J, et al. The preperitoneal (posterior) approach to the repair of recurrent inguinal hernias. *Hernia* 1999;3:65.

Nyhus LM. An anatomic reappraisal of the posterior inguinal wall. *Surg Clin North Am* 1964;44:1305.

Nyhus LM. Recurrent groin hernia. *World J Surg* 1989;13:541.

Nyhus LM. Individualization of hernia repair: a new era. *Surgery* 1993;114:1.

Nyhus LM, Bombeck CT. Anatomic and physiologic repair of groin hernia. *Am Fam Physician GP* 1966;33:115.

Nyhus LM, Condon RE, eds. *Hernia*. 4th ed. Philadelphia, PA: Lippincott; 1995.

Nyhus LM, Stevenson JK, Listerud MB, et al. Preperitoneal herniorrhaphy: a preliminary report in fifty patients. *West J Surg* 1959;67:48.

Nyhus LM, Condon RE, Harkins HN. Clinical experiences with preperitoneal hernial repair for all types of hernia of the groin. *Am J Surg* 1960;100:234.

Nyhus LM, Pollak R, Bombeck CT. The preperitoneal approach and prosthetic buttress repair for recurrent hernia: the evolution of a technique. *Ann Surg* 1988;208:733.

Nyhus LM, Klein MS, Rogers FB. Inguinal hernia. *Curr Probl Surg* 1991;28:403.

Patino JF, Garcia-Herreros LG, Zundel N. Inguinal hernia repair: the nyhus posterior preperitoneal operation. *Surg Clin North Am* 1998;78:1063.

Renzulli P, Frei E, Schafer M, et al. Preoperative nyhus classification of inguinal hernias and type-related individual hernia repair: a case for diagnostic laparoscopy. *Surg Laparosc Endosc* 1997;7:373.

Stoppa R, Wantz GE, Munegato G, et al. *Hernia Healers: An Illustrated History.* Velizy: Arnette; 1998.

EDITOR'S COMMENT

This chapter by Dr. Nyhus is one of the classic articles in the hernia literature. It should be pointed out that not many surgeons use the preperitoneal approach in the sense of a suture repair. The approach theoretically is derived from Fruchaud's work, as mentioned in the introductory sections to these chapters, in which the myopectinate diaphragm is seen as the origin of all of the problems in the lower quadrants, with hernias presenting either through the internal or deep inguinal ring or through the femoral canal. As such, theoretically, one should interpose something between the myopectinate diaphragm and the site of increased intra-abdominal pressure, that is, the intraperitoneal organs and

contents. Indeed, as pictured elsewhere in this section, Stoppa and Rives used the concept of the myopectinate diaphragm to use a giant prosthesis, which theoretically would, if properly placed, prevent the emergence of hernias from posteriorly to anteriorly. Dr. Nyhus' chapter is somewhat different. In this chapter he is proposing suture repair, but using a buttressing synthetic material or mesh in an attempt to reinforce large or complex hernias and to prevent future herniation.

This repair is not often done. The concept, however, is ever-present whether one is talking about Stoppa's giant prosthetic patch or modifications such as the Kugel or the Gilbert repair, both presented in this section. The underlying hypothesis is that because increased intra-abdominal pressure results in hernias and recurrent hernias, the prosthesis belongs not anterior to the transversalis fascia but posterior to it. The problem that most people have is that it is an unfamiliar approach and they have difficulty in deciphering the anatomy.

I have found this approach useful at times when doing a sigmoid resection and there is a symptomatic hernia in the area; after changing gloves and gowns and instruments, I would then dissect off the peritoneum from the posterior structures and attempt to do a repair through the preperitoneal approach. Mind you, it is somewhat difficult to do and the anatomy is confusing to those of us who have not done this a great deal, but it is probably better than attempting a separate incision to repair a hernia.

This chapter was included because, in a sense, it is the forerunner of all of the preperitoneal repairs and is parallel to Fruchaud's concept of the myopectinate diaphragm, which increasingly is looked to as the anatomic basis for everything that happens in repairs.

J.E.F.

192 Kugel Technique of Groin Hernia Repair

Robert D. Kugel and John T. Moore



This Chapter can be accessed in the accompanying eBook edition (see inside front cover for access instructions).

INTRODUCTION

Hernia repair constitutes a major part of the typical general surgical practice. Expansive literature has been produced demonstrating benefits associated with a large number of repairs. Most of these repairs have focused on tension-free techniques. Tension-free repairs, when performed properly, reduce the risk of recurrence to low levels. These repairs also reduce postoperative pain and accelerate return to normal activity. Surgeons have been exposed to many mesh-designed tension-free repairs. In order to achieve the published results of these repairs, proper performance of the technique selected is the key element. These techniques require a thorough understanding of the procedures used as well as groin anatomy.

INDICATIONS

The Kugel technique for groin hernia repair is a tension-free, minimally invasive, yet open, preperitoneal or posterior abdominal wall groin hernia repair. It is applicable to the treatment of indirect and direct inguinal hernias as well as femoral hernias. It is particularly useful for the treatment of recurrent groin hernias after previously failed anterior repair. It can be used selectively in the patients having undergone prior radical prostatectomy or pelvic radiation, but should be avoided in the patients with recurrence after a failed laparoscopic groin hernia repair. This technique allows for rapid return to regular work and other activities without restriction. It further minimizes the risk of nerve injury and associated burdensome chronic pain syndromes because the inherent

nature of this repair is to avoid direct nerve injury and avoid exposure of the groin nerves to the mesh.

PATIENT'S SELECTION

The key elements in successful hernia surgery are proper patient selection and proper performance of the repair. However, not all patients with hernias need to be repaired. Elderly, debilitated, and inactive patients with asymptomatic hernias where the hernia is easily reduced may be best left alone with rare exceptions. Symptomatic patients should all be repaired promptly. Even here, postponement of the repair may be considered if the symptoms are minimal and the hernia is easily reduced. Factors to consider are cost (immediate and delayed), age, patient health, and type of work. There is no question delaying a repair may create a much more different repair later with more complications. Incarceration also is a rare threat.

Not every patient with groin pain needs surgery. The groin area is particularly susceptible to injury. Muscle and ligamentous tears and strains can cause groin pain and even result in chronic pain, which will not improve with the hernia operation. Very small and occult hernias exist and can be particularly difficult to diagnose, especially femoral hernias. These can cause pain in patients, but in the absence of clear physical findings for a hernia, observation seems to be the best initial course. Special caution in patients is also warranted with a very short history of symptoms or a very long history of symptoms, who do not demonstrate positive physical findings of a hernia. Ultrasound in these patients is sometimes helpful, but frequently overstates the presence of a hernia. The ultrasound also does not correlate well with the symptomatology. A wait-and-see approach is advised in these patients if the surgeon is to avoid the not uncommon patient complaint after surgery that "the pain is worse now than before the surgery" or even "the mesh must be causing the pain."

Though the bias of this presentation is that the Kugel technique is useful for the majority of groin hernias, there are incidences where it would be inappropriate (see indications) and even might not be the best technique. Although Kugel technique is great for bilateral hernias and for obese patients, it might be easier to treat the morbidly obese patient with a different technique.

THE MESH PATCH

The Bard Kugel patch (Davol, Cranston, Rhode Island) was developed to

facilitate performance of the Kugel hernia repair. Although it is started out as a simple single-layer mesh, it became progressively more intricate in order to make the performance of the procedure easier and the repair more secure.

The patch is composed of two overlapping layers of knitted monofilament polypropylene mesh material that are ultrasonically welded together (Fig. 192.1). A pocket of polypropylene is constructed on the outer edge of the patch which contains a single polyester fiber spring or stiffener that helps the patch unfold after placement and maintain its configuration. One centimeter of mesh material extends beyond the outermost welds into which have been cut multiple radial slits. This outer fringe allows the patch to conform and fill more perfectly in the preperitoneal space, particularly when the patch folds back over the iliac vessels. A transverse slit is made in the center anterior patch, which is utilized for insertion of a finger which helps in positioning the patch in the preperitoneal space. Just beyond the anterior slit and inside of the mesh ring are multiple 3 mm holes through both layers of the patch. These serve to allow tissue-to-tissue contact through the patch to prevent movement of the patch after placement. This movement prevention is further augmented by several small V-shaped cuts associated with all of these holes in the anterior layer only. These cuts create a triangle of mesh which tends to pop-up when the patch is placed, and these act as sutureless anchors for the patch.

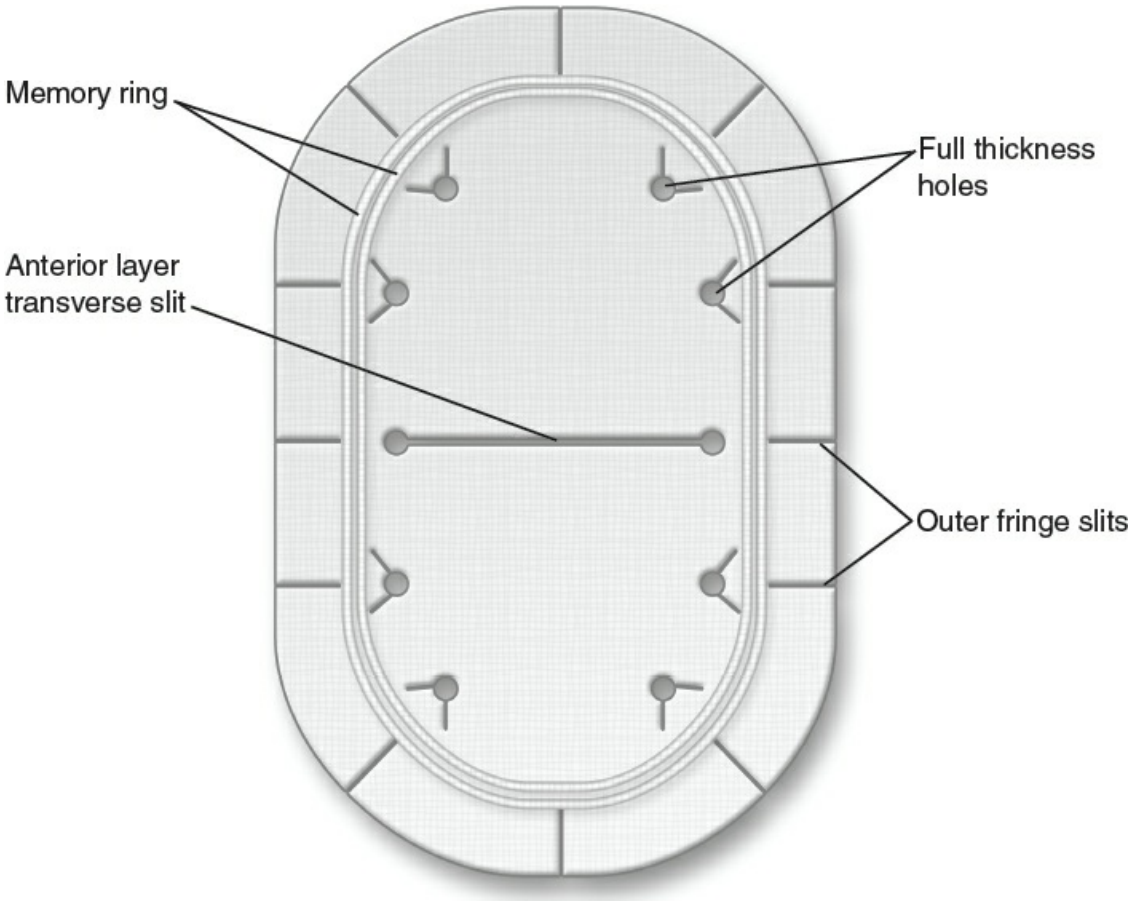

Figure 192.1. Memory ring, anterior layer transverse slit, outer fringe slits, and full thickness holes are illustrated.

There are two mesh sizes used for groin hernias. The small patch is 8 × 12 cm and the medium patch is 11 × 14 cm. The small patch is adequate in most patients; however, the medium patch does provide greater margin for error and is preferred in very large hernias. It is up to the surgeon to decide the appropriate size of the mesh patch to be used, recognizing that the greater amount of underlay will probably result in fewer recurrences.

OPERATIVE PROCEDURE

Anesthesia

1. **General Anesthesia:** This is the author's anesthetic of choice for this operation. The primary disadvantage of a general anesthesia is the limitation of the ability to test the repair at the completion of the operation.
2. **Regional Anesthesia:** This is the preferred choice for some patients with epidural anesthesia being preferred over spinal anesthesia. The epidural anesthetic has the advantage for re-dosing when the catheter is

left in place during the procedure. This not only allows for minimal initial dose, but also for the administration of additional doses as needed if the operation takes longer, which may happen with bilateral hernias. Furthermore, epidural anesthesia results in less muscle paralysis, enabling the patient to respond more forcefully when testing the repair following the operation.

3. **Local Anesthesia:** The author has preformed this procedure using local anesthesia and has monitored anesthesia care provided by an anesthesiologist, but maintenance of a relaxed patient is imperative to be able to enter and maintain appropriate visualization of the preperitoneal space through the incision. If the patient experiences pain and begins to bear down in response, it can make the procedure very difficult. Very obese patients with recurrent hernias or the patients who do not tolerate monitored anesthesia care should not be done under local anesthesia because of the loss of visualization associated with muscle contraction and discomfort.

PATIENT PREPARATION

Appropriate laboratory and radiographic evaluation of patients preoperatively depends on the surgeon and the policies and procedures of the facilities in which they practice. Because of the risk of bleeding into the preperitoneal space, it is recommended that Coumadin be stopped 3 to 5 days prior to the surgery. Use of prophylactic antibiotics is recommended due to the implantation of the foreign body into the wound. Although infection reduction is not clearly substantiated in controlled studies, antibiotics add little risk and may reduce graft infections.

Clipping of hair in the operative area is recommended over shaving at the time of the procedure, followed by an appropriate skin preparation.

The patient is positioned in a supine manner. During the operation, exposure is improved by placing the patient in a Trendelenburg position with slight rotation away from the site of the procedure.

SURGICAL TECHNIQUE

Regardless of the type of the hernia to be repaired, the mesh patch is placed in the same fashion into the preperitoneal space in every patient. The repair can be more difficult to achieve because of the lack of familiarity with the anatomy in the posterior space and the angle in which the repair is approached. Understanding the unique approach is the key to

the successful performance of this procedure. Ideal first patients are of average size or thin where the anatomy should be clearly visible. Avoid recurrent hernias or large scrotal hernias initially. One of the advantages of this repair is the ease with which it can be converted into an anterior repair. The surgeon needs to back out of the preperitoneal space, allow the internal oblique muscle to re-approximate, and extend the skin and external oblique incision through the external ring and perform an anterior repair.

INCISION

The author thinks it is critical to utilize a headlight during the performance of this operation. Because of the angle in which the repair is approached, the headlight helps illuminate extremely well the area of the preperitoneal space and allows for accurate placement and deployment of the mesh patch. In addition, use of a dedicated assistant is also extremely helpful. The operation can be performed with the surgical scrub functioning as the assistant. A dedicated assistant, particularly in larger patients, allows for continued visualization of the preperitoneal space through continuous retraction.

Incision placement is important and can have a bearing on how easy it is to perform the operation (Fig. 192.2). The most important thing is to avoid making the incision too low. The ideal is to pass directly through the skin, muscle, and fascia into the preperitoneal space. This approach is superior to the internal ring and lateral to the inferior epigastric vessels. It avoids the inguinal canal. Marking the anatomic landmarks on the surface of the patient will insure the correct placement of the incision. Identify the anterior superior iliac crest and the pubic tubercle. Measure the distance between these two points and mark the halfway point. This identifies the location of the internal ring. Measure directly superior to this point identified as the internal ring 2 cm and mark the site of the incision. This appropriately positions the incision in the high position to avoid entering into the inguinal canal. A 4-cm oblique incision is made with two-thirds of the incision being made medial to the point marked on the skin and one-third of the incision lateral. Four centimeters is an arbitrary measurement. In the initial performance of this operation, the surgeon may want to make a slightly larger incision as it does not affect the overall outcomes of this operation and may give better visualization.

The skin incisions can be made either transversely or obliquely, but

oblique incisions enable the surgeon to move into a more conventional anterior repair, if needed, with less difficulty. The author prefers to make an oblique incision. The incision is made straight down through the skin and subcutaneous tissue on to the external oblique fascia. The external oblique fascia is then opened a short distance in the direction of its fibers, but not through the external ring. This exposes the underlying internal oblique muscle. Frequently, the ilioinguinal and iliohypogastric nerves can be visualized on the surface of the internal oblique muscle when the external oblique fascia is split. Great care should be taken to avoid traumatizing a sensory nerve when splitting the internal oblique muscle, otherwise there is no need to directly visualize the ilioinguinal or the iliohypogastric nerves at this point. The internal oblique muscle is bluntly split in the direction of its fibers to expose the transversalis fascia. The muscle splitting of the internal oblique musculature when placed in the proper position frequently lies inferior to the iliohypogastric nerve and medial to the ilioinguinal nerve. Transversus abdominis muscles fibers that are occasionally encountered superficial to the transversalis fascia may need to be split as well. The transversalis fascia at this level is frequently a very thin and fragile structure. It can usually be penetrated by gentle blunt dissection. On occasion when it is more tenacious, a cutting of the fascia may be necessary. It is recommended that this is done in a vertical manner to avoid injury to the inferior epigastric vessels which lie in the medial aspect of the incision. Identification of the preperitoneal space is made by the characteristic appearance of the fat of the preperitoneal space and the identification of the inferior epigastric vessels in the medial aspect of the incision. A crucial aspect of the operation is to ensure that the surgeon dissects within the preperitoneal space. Identification of the inferior epigastric vessels, which lie in the medial portion of the incision within the preperitoneal fat keeping the dissection posterior to these vessels, will assure the surgeon will complete the operation in the correct compartment.

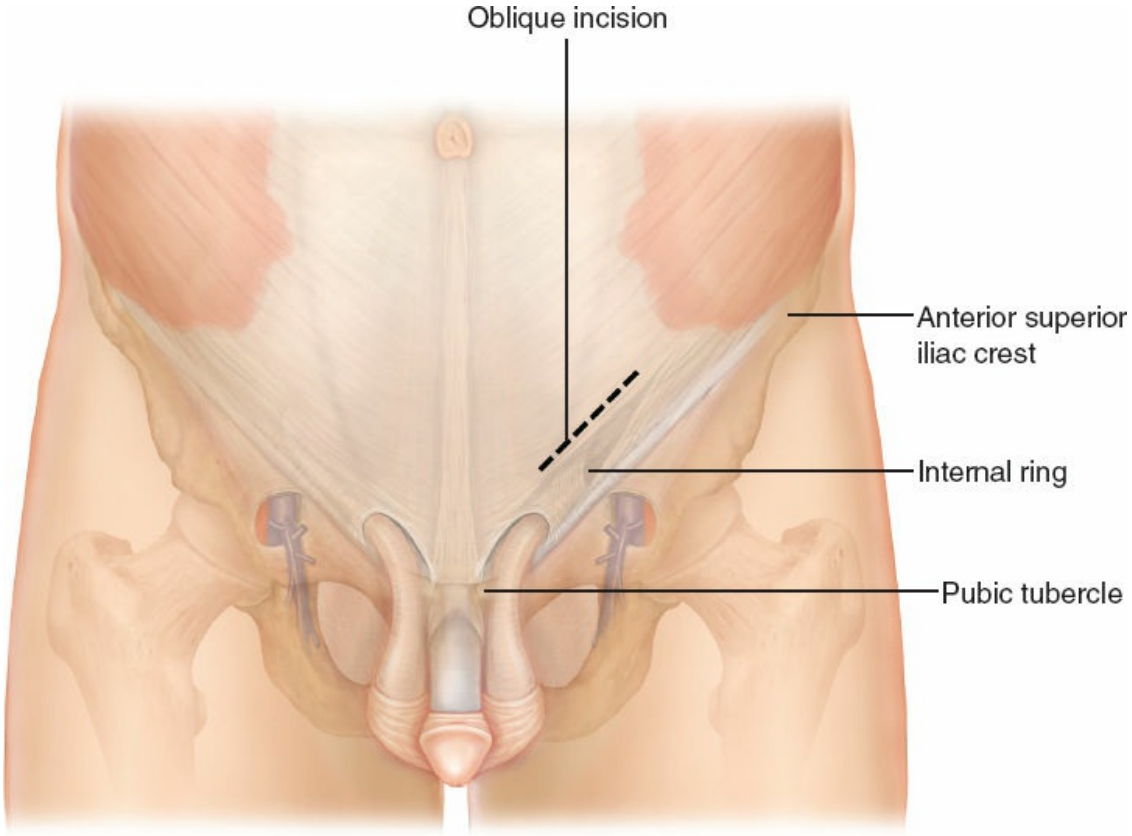

Figure 192.2. Incision.

PREPERITONEAL DISSECTION

Once the preperitoneal space is entered, it is important to become oriented to the anatomy. The internal ring will lie immediately inferior to your incision, with the cord structures lying anterior and lateral as they prepare to exit the preperitoneal space through the internal ring. Hesselbach's triangle will lie just inferior and medial to the inferior epigastric vessels. It is best to approach the dissection as consisting of two compartments: medial and lateral. In the medial compartment will be direct and femoral hernias. Indirect hernias will lie in the lateral compartment. The order of approaching the compartments depends on the surgeon's preference. My preference is to perform the medial dissection first unless there is such a large indirect hernia present that would prohibit entering into the medial compartment. This would require doing the lateral compartment dissection first. The principle in the medial compartment dissection that needs to be maintained is complete reduction of the preperitoneal contents from the attachments to the transversalis fascia. Clear visualization of cooper's ligament from the pubic tubercle to the external iliac vessel is essential. In so doing, the direct hernias will be reduced and femoral hernias, if present,

will be identified. This dissection is carried out using blunt dissection with the finger of the surgeon sweeping the preperitoneal contents posteriorly and superiorly. This medial compartment dissection should be carried out to a point just medial to the pubic tubercle and superior to the incision in the transversalis fascia, which will create the space for the mesh. The headlight and the retraction provided by the dedicated assistant greatly help the visualization.

Attention is then turned to the lateral compartment. The first step in the lateral compartment dissection is identification of the cord structures. The goal to be achieved is skeletonization of the cord, thereby identifying a potential indirect hernia. The peritoneal reflection should be reduced ~3 cm above the internal ring or to a point above the diversion of the vas deferens from the cord vessels. Once reduced, the indirect hernia sac can be left alone or ligated and amputated. Inspection should also be carried out to the area lateral and superior to the cord structures, creating space by freeing the preperitoneal contents, which will allow for free deployment of the mesh (Fig. 192.3). Again the headlight and the dedicated assistant greatly help the visualization.

The space is now ready for mesh insertion (Fig. 192.4). A useful technique is to use a narrow malleable retractor placed on the peritoneum, retracting it superiorly as the mesh is slid into position over the surface of the retractor. The Kugel inguinal mesh is specifically designed for this application. The transverse slit is designed into the mesh to allow for the surgeon to place the mesh over the index finger of the hand of the surgeon opposite to the patient's side upon which they are operating, that is, left-sided hernia right-handed insertion. The mesh is gently folded over the finger of the surgeon into their palm in the form of a taco to allow for this placement. The mesh is slid into the position with the extensor surface of the surgeon's hand sliding along the malleable retractor until the surgeon can easily palpate the pubic tubercle with the tip of the index finger that has been inserted into the mesh slit. The surgeon's hand is then withdrawn and replaced by the malleable retractor into the slit to stabilize and hold the mesh in position as the mesh is unfolded into its proper deployment. The mesh is then deployed back over onto the peritoneum in a curved but unbuckled profile covering all potential defects in the groin. The mesh chosen ought to be large enough to cover the opening in the transversalis fascia extending 2 to 3 cm above the opening that was made for the incision. Two sizes of mesh are available for insertion as previously

described. In our experience, ~75% of hernias have been repaired with the smaller patch. The mesh is secured to the transversalis fascia in the medial portion of the transversalis incision with one absorbable suture. The transversalis fascia is then closed over the surface of the mesh with a running suture. The internal oblique musculature is allowed to recompose itself without suture, thereby avoiding possible nerve entrapment. The external oblique and skin can be closed as per the surgeon's preference, again taking care not to entrap any underlying nerves.

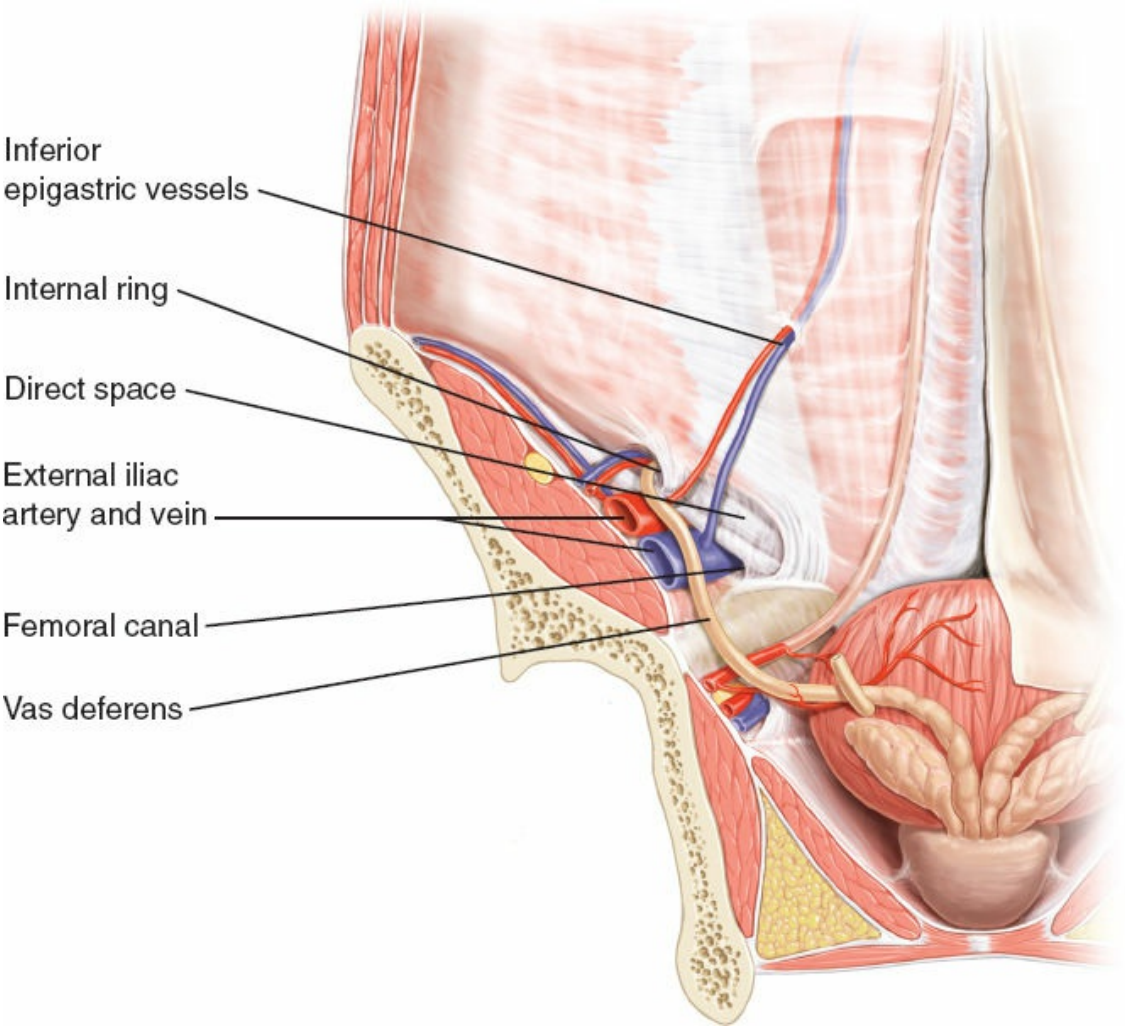

Figure 192.3. Inferior epigastric vessels, internal ring, direct space, pubic symphysis, femoral canal, external iliac artery, external iliac vein, and vas deferens are illustrated.

RECURRENT HERNIA

Repair of recurrent hernias following this repair or previous laparoscopic repair is best avoided using a Kugel approach. Recurrent hernias following prior anterior repair, however, are ideal candidates for this approach. The

majority of scar tissue from the original repair is avoided and the repair is generally not much more difficult than a primary repair. This approach allows for a more thorough evaluation of the posterior space and should reduce the risk of a missed second defect. The most common difficulty encountered with these repairs is scar tissue at the internal ring associated with a prior high ligation of the sac.

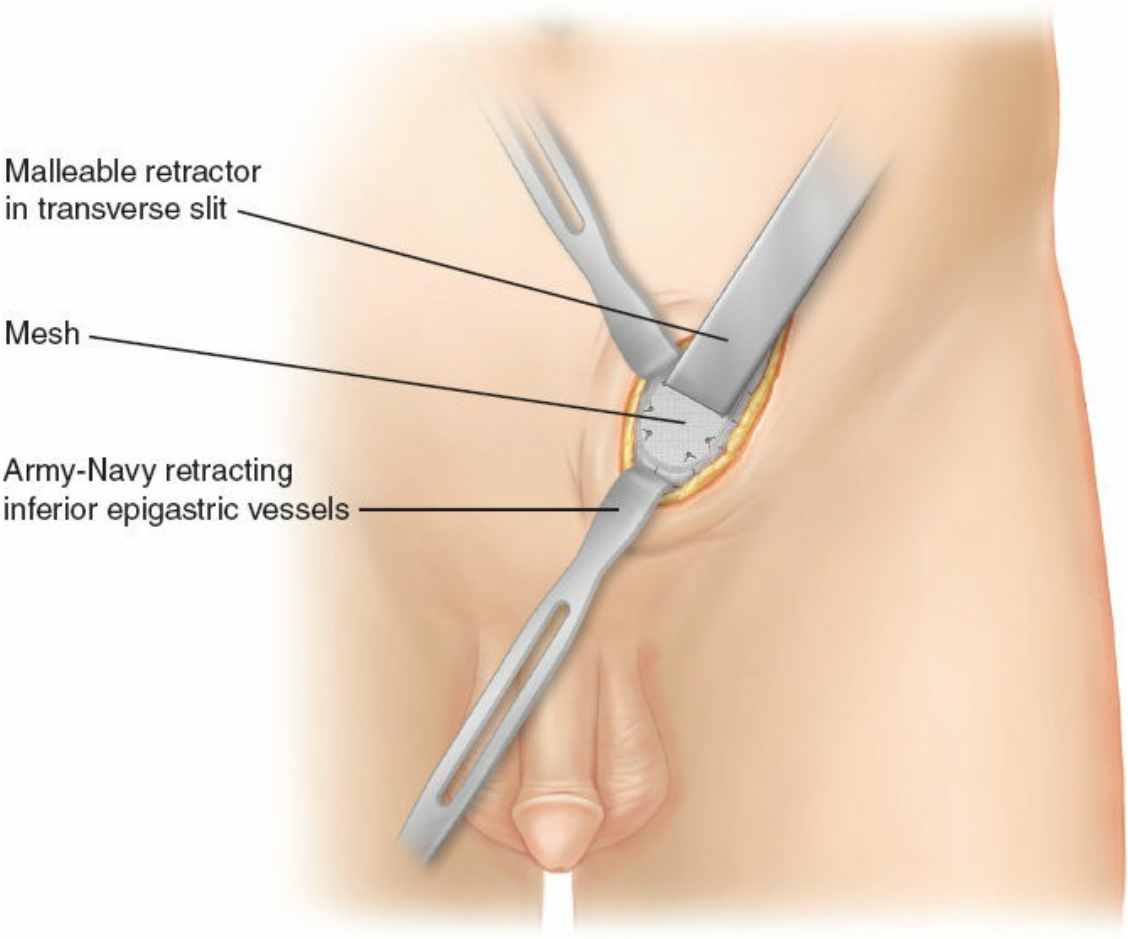

Figure 192.4. Mesh insertion.

FEMORAL HERNIAS

Experiences with this technique and with laparoscopic hernia repair suggest greater prevalence of femoral hernias than previously believed. These will sometimes be encountered unexpectedly during the surgery for an indirect or direct inguinal hernia. The hallmark of the femoral hernia from within the preperitoneal space is an obstructing mass just medial to the external iliac vein which extends into the femoral canal. This will prevent proper deployment of the preperitoneal pocket for the mesh patch until the mass is reduced.

POSTOPERATIVE MANAGEMENT

A majority of patients are discharged from the recovery area when appropriate. No specific restrictions are placed on them regarding all activity including lifting. The patient is cautioned that their greatest discomfort can be expected during the first 2 to 3 days and this should taper off rapidly thereafter. Patients are asked to increase their activities a little everyday until returning to normal. Most patients are usually able to resume most regular activities within a few days to a week. Most patients will require approximately three to ten mild narcotic pain relievers over the first few days following the operation, but generally these can be replaced with either nonsteroidal anti-inflammatory medications or other over-the-counter pain relievers. Most patients are seen in 1 to 2 weeks following surgery and then discharged.

RESULTS

In a previous edition of this text book, Dr. Robert Kugel reported 1662 groin hernia repairs. Of these, there were 803 primary right inguinal hernia repairs and 725 primary left inguinal repairs. There were 85 repairs performed for recurrent right inguinal hernias and 49 repairs performed for recurrent left inguinal hernias. In the 10 years following that initial report, there had been a total of seven recurrences. All of those recurrences were in the primary repairs with an overall recurrence rate of 0.42%.

My group reported the results in 2005. We did 1072 repairs with an overall recurrence rate of 0.47% with a mean followup of 23 months. We demonstrated rapid operating times, minimal postoperative pain, expeditious return to work, and no reports of chronic pain. Multiple other studies have been published since that time and with similar results.

COMPLICATIONS

Complications are infection, bleeding, recurrence, or chronic pain. These issues will be addressed individually.

1. **Infections:** Infections are early or late. Early infections occur within the first couple of weeks following the hernia procedure and should be treated as skin and subcutaneous infections. Aggressive local wound care and antibiotics are advised. I think the initial approach should be one with the idea of salvaging the mesh. CT scan imaging can be helpful to determine the depth of the infection. If the infection does not

penetrate into the preperitoneal space, the wound can be opened for good drainage. With antibiotics, salvaging the mesh is usually successful. If, however, there is clear evidence of infection extending into the preperitoneal space, I believe the most prudent course is to remove the mesh and handle the infection appropriately. It would be ill-advised to immediately place another synthetic mesh material into the wound. The use of biological meshes or tissue repair in this setting would be up to the discretion of the operating surgeon. Late infections usually occur well past the initial operation. It generally means a mesh infection is present. Prolonged antibiotics can be attempted, but they generally are not effective and in most cases the mesh will need to be removed. Early removal of the mesh results in a more rapid resolution of the problem rather than prolonging the problem with unsuccessful therapy.

2. **Recurrences:** There are few recurrences in the published reports. Causes and mechanisms of recurrences have not been clearly defined. One of the primary concerns involves the extent of mesh shrinkage secondary to the ongoing inflammatory reaction through the polypropylene in the mesh. This shrinkage has been estimated in multiple published reports to range between 5% and 30%. As long as an adequate-sized mesh is utilized and the mesh is deployed in the proper position, this should allow for the estimated shrinkage and prohibit recurrence from that point of view. In our experience of operating on our own recurrences as well as other recurrences, the most common cause was a missed indirect hernia. This probably resulted from the failure to completely skeletonize the cord structures at the time of the initial operation and recognize the presences of an indirect hernia. This resulted in a persistent indirect hernia rather than a recurrence.
3. **Bleeding:** Bleeding is not a common problem as the dissection is generally performed in a bloodless plane. A preperitoneal repair should be avoided or approached with caution in the patients who require aggressive preoperative anticoagulation secondary to other underlying hypercoagulable or thromboembolic conditions (i.e., mechanical cardiac valves). The preperitoneal space is very susceptible to ongoing hemorrhage secondary to the induced hypocoagulable situation. This ongoing hemorrhage can be extremely difficult to recognize in the preperitoneal space and significant hemorrhage can occur before it is picked up. It is therefore advisable that an anterior repair be carried out in these patients so that if bleeding does occur, it is obvious and can be

addressed immediately.

4. **Seromas:** Seromas commonly occur, particularly in direct hernia repairs. The patient will usually present at the initial postoperative visit complaining of persistence of the hernia. On exam, a smooth slightly tender mass, which is nonreducible and does not change with Valsalva, will be identified in the inguinal canal. If obtained, an ultrasound will demonstrate the presence of the seroma and we will reassure the surgeon as well as the patient. Unless there are clear signs of infection, no other intervention needs to be or should be taken in regards to the presence of the seroma. They will resolve spontaneously if left alone.
5. **Chronic groin pain:** Chronic groin pain or inguinodynia is defined as pain within the groin. General surgeons see this condition most often following inguinal hernia repair. The most common etiology for this chronic pain is suspected to be related to either direct injury or entrapment of one of the four nerves within the inguinal region. These nerves are the iliohypogastric, ilioinguinal, genitofemoral, and lateral femoral cutaneous nerves. Because of the performance of the Kugel hernia repair in regards to its muscle splitting technique and avoidance of sutures within the internal oblique, nerve injury and subsequent entrapment is rare. In addition, in the Kugel approach, there is no need for fixation within the preperitoneal space that could entrap the lateral femoral cutaneous nerve. The surgeon needs to be very aware of the anatomical course of these nerves and keep the dissection in the planes as described and avoid placement of sutures into the external oblique at the completion of the operation, which could entrap the ilioinguinal nerve.

MISCELLANEOUS COMPLICATIONS

There have been concerns about the direct exposure of the mesh to the iliac vessels. The mesh is specifically flanged on its peripheral 1 cm to prevent direct pressure onto the vessels as it is deployed over the surface of the peritoneum in the preperitoneal space. In addition, it is not necessary or recommended to skeletonize the external iliac vein, the most medial structure within the vascular bundle. Dissection only needs to be carried out at the level of the lacunar ligament to assure that no femoral hernia exists. Avoidance of this excessive dissection will protect the vessels from direct exposure with a surface layer of undisturbed tissue.

There have been intense medical and legal discussions in regards to fractured rings within the Kugel patches resulting in bowel injury. This

problem has only been reported in Extra Large Composix Kugel products utilized in ventral hernia repairs and never truly verified. No reports of such injuries have been reported in a Kugel inguinal repair with the Kugel hernia patch.

DISCUSSION

The preperitoneal mesh patch prosthesis utilizes those forces only available to a posterior repair. Intra-abdominal pressure works in securing the patch in position. A fully expended and appropriately sized patch, with its semi-rigid ring, is difficult to displace through any hernia defect encountered in the groin. Because the patch is placed without fixation sutures, hydrostatic tissue forces also come into play in securing the patch into position. The patch is allowed to more perfectly conform to the patient's unique anatomy, and the two wet surfaces on either side of the patch sandwich it in place and resist patch movement. This method of repair provides protection for the entire groin including the femoral canal and the surgical incision itself. It is an ideal approach following prior anterior hernia repair as it avoids most of the associated scar tissue from the prior repair.

The disadvantages of this repair are related to obtaining the appropriate visualization of the preperitoneal space, assurance of dissection within the correct preperitoneal space, and confidence on the part of the surgeon in regards to the proper deployment of the mesh into the appropriate space. Use of a headlight and a dedicated assistant reduces the disadvantages.

Working with an experienced surgeon on several cases before attempting the repair solo allows for the surgeon to gain the confidence in regards to being able to clearly identify the preperitoneal space and its anatomy as well as to recognize when proper deployment of the mesh is achieved.

SUMMARY

As incidence of recurrence, safety, ease of performance, and shortened disability periods are considered in selection of a hernia repair, the Kugel inguinal hernia repair demonstrates its attractive advantages. Accumulated experience has demonstrated it to be an effective repair.

Suggested Readings

Amid PK, Shulman AG, Lichenstein IL, et al. Biomaterials for abdominal wall hernia surgery and principles of their application. *Langenbecks Arch Chir* 1994;379:168–71.

Fenoglio ME, Bermas HR, Haun WE, et al. Inguinal hernia repair: results using an open preperitoneal approach. *Hernia* 2005;9:160.

Fitzgibbons RJ, Jonasson O, Gibbs J, et al. The development of a clinical trial to determine if watchful waiting is an acceptable alternative to routine herniorrhaphy for patients with minimal of no hernia symptoms. *J Am Coll Surg* 2003;196:732.

Hompes R, Vansteenkiste F, Pottel H, et al. Chronic pain after Kugel inguinal hernia repair. *Hernia* 2008; 12(2):127–32.

Kugel RD. Groin hernia repair: Kugel technique. In *Mastery of Surgery*. 5th ed. Lippincott Williams & Wilkins; 2007:1912–23.

Kugel RD. Minimally invasive repair of groin and ventral hernias using a self expanding mesh patch. *Surg Technol Int* 2002;10:81.

Kugel RD. The Kugel hernia repair for groin hernias. *Surg Clin North Am* 2003;83:1119.

Nieuwenhove Y, Vansteenkiste F, Vierendeels T, et al. Open, preperitoneal hernia repair with the Kugel patch: a prospective, multicentre study of 450 repairs. *Hernia* 2007;11(1):9–13.

EDITOR'S COMMENT

The Kugel hernia patch is supposed to do two things: the first is to prevent the emergence of a hernia through the internal inguinal canal and the second is to bring about a patch on the interior of the transversalis and to provide a remedy against any openings in the myopectineal shield. The Kugel repair has become a very popular procedure because there is not much in the way of dissection and there is a one suture fixation technique, which is to prevent the hernia from recurring. Make no mistake about it, the Kugel repair as well as many of the other contemporaneous repairs function to prevent recurrence. The individuals who have originated the Kugel repair did think about the risk of nerve injury and the chronic pain syndromes. They state that they avoid chronic pain syndromes by avoiding direct injury and/or exposures of the groin nerves to the mesh. They do not believe that this is useful for a younger pediatric population, but it may be used for older teenagers. They also add that the hernias, which appear in the younger population do not often need any change in the configuration of the various ligaments in the groin because although it is usually unnecessary, and all that is needed is a high ligation of the sac. I am not certain that this has been subjected to a true follow-up.

One of the refreshing things about this chapter is that somebody has finally

asked the question, “Do all patients with the hernia require surgery?” I think that is a very good question. It is a question that has become more eventful as we start to think about not recurrence, which is that various herniotomists think about whether or not people should have a mesh repair or not, but does the hernia need to run the chance of having a very painful result if mesh is placed? Indeed, there is a good discussion here about whether to do the repair or not. Very small and occult hernias, to quote the author, “do exist and can be particularly difficult to diagnose especially with femoral hernias.” A short history of symptoms is probably best observed because I think that patients may be better off not getting the hernia repair rather than getting inguinodynia. The mesh will cause pain on occasion as we will see in several of the papers, but hopefully it will be minimal. I do believe that patients who undergo mesh repairs do run a greater chance of having a chronic long-term pain of inguinodynia than the old-fashioned seeming type of repair, which in my hands the transversalis layer is added. This Kugel technique depends on “two concentric walls near the outer edge of the patch serve to contain a single polyester fiber spring or stiffener….” The 1 cm of mesh material extends beyond the outermost weld so that this has been cut into radial slits. I am not certain that this repair really deals with the entire myopectineal shield, but it at least tries. Dr. Moore does under “Incision” state that the incision should not be too low so that the mesh can pass comfortably through the skin, muscle, and fascia into the preperitoneal space superior to the internal ring and just lateral to the inferior epigastric vessel. Thus, it is out of the inguinal canal. In any event, as the author states, the best thing about a repair like this is hopefully not to entrap the nerves and yet prevent a recurrence. I am not certain that “the muscle splitting component when placed in the proper position frequently lies just inferior to the iliohypogastric nerve and just superior to the ilioinguinal nerve.” There are branches between the two nerves and if they are entrapped, my guess is they are as painful as if you trapped the main nerve. The author does say that the patch will end up “sandwiched between the peritoneum and its posterior aspect and tranversalis fascia on the other side.” The cord structures should be out of the way and Cooper’s ligament will be on the inferior aspect of the mesh. One hopes that with all of this description of the mesh and how we have avoided the inguinodynia or the entrapment of the nerves against the patch is minimal. I still get concerned about the focus being on recurrence and not on the groin pain. From the patients with groin pain that I see, I think that recurrence would be an easier thing to experience rather than what they currently have.

A number of people have been interested in some of the aspects of the Kugel repair, including the degree of inflammation. Bender et al. (*Surg Endosc* 2009;23:2657–61) have tried to see whether or not there is more inflammation after the Kugel repair as compared with the totally extraperitoneal (TEP) laparoscopic repair. They measured serum cortisol, high-sensitivity C-reactive protein, and interleukin concentrations before surgery and 1 and 24 hours after

surgery. They did not differ significantly between the two groups. They did say that the cost per patient was 546 dollars lower in the Kugel group, and therefore they do not think that this is a procedure, which is neither very expensive nor one that causes pain and inflammation. Of course pain is where it is at.

Another way of approaching this is by Fujii, T of the Graduate School of Medicine at Gunma University in Gunma, Japan (*Am Surgeon* 2011;77:243–4), in which he observed how the operation is actually done with a laparoscopic approach to see where the mesh actually ends up. This sounds like a reasonable idea and they point to the fact that they can get a Kugel repair or bilateral obturator hernia repair in only 43 minutes. They state that no symptoms have been observed with the diagnosis of the obturator hernia, and therefore this is a valid repair.

Having said all of this, a number of surgeons focus on the amount of pain the patients have with Kugel patches as opposed to other repairs. Van Nieuwenhove et al. (*Hernia* 2007;11:9–13) in a multicenter case series of 450 consecutive Kugel patch repairs reviewed at 1 year and short-term outcomes decided that eight recurrences were present after 18 months (1.9%) and that there was persistent inguinal pain in 15 patients (3.5%). Analgesics were used for 3 ± 2 days and paracetamol was the only painkiller that was used. Thirteen percent did not take any painkiller at all. Half of the patients returned to their daily activities after 9 days and half of the employed patients returned to work after 14 days. The authors concluded that this operation has a low recurrence rate and not too much in the way of pain.

Dasari et al. (*Ulster Med J* 2009;78:115–8) tried to compare the Lichtenstein tension-free repair to the Kugel tension-free repair of inguinal hernia. A total of 219 consecutive patients underwent inguinal hernia repair—92 using a standard Lichtenstein repair and 127 using a Kugel patch. It is likely that these patients were not randomly chosen. They actually summarized the usual characteristics —length of hospital stay, complication rates, and so on, and the endpoints were recurrence and chronic groin pain. There were 214 men and 5 women and they ranged in age from 18 to 87 years with a mean age of 54 years. Unfortunately, only 72% of postal questionnaires were returned. They actually tried to increase response rate by phone and finally got up to 80%. The bottom line is that immediate complications were similar in both groups and recurrence rate was 1.1% with the Lichtenstein repair and 6.3% for the Kugel patch. This difference was not statistically significant ($P = 0.09$). Severe chronic pain was not present in the Lichtenstein group but 1.6% of the patients in the Kugel patch group complained of severe chronic pain in the inguinal region. Thus, the recurrence rate and chronic pain were worse in the Kugel group but not significantly so.

Hompes et al. (*Hernia* 2008;12:127–32) investigated the area of chronic pain after a Kugel inguinal hernia repair. The endpoint in this study was chronic pain 1 year after the Kugel herniorrhaphy and to see whether they could identify the risk factors. All patients in this teaching hospital at the Catholic University in Leuven, Belgium underwent inguinal hernia repair between January 2002 and

June 2005. Analgesia consumption, postoperative function, and impairment and postoperative complications were recorded in all of these patients. One year after the repair, 57 of 377 patients (15.1%) complained of mild to moderate pain. The incidence of mild and moderate chronic pain was 14.3% and .8%, respectively and none of the patients had severe chronic pain. One patient reported numbness in the groin area. They did say that after, the difference was not significant; female patients seemed more prone to develop chronic pain. As their conclusion, they believe that the Kugel inguinal hernia repair is associated with a low rate of postoperative chronic pain. They think that the reason for this is that the minimally invasive preperitoneal approach to the Kugel technique probably causes less nerve damage and subsequently less neuropathic pain. I have no way of knowing one way or the other whether this is the case and it does seem that in the two studies that there were not a lot of patients who really had chronic pain. As I have said earlier in these commentaries, in this group of patients, I wonder whether or not one should take a recurrence rather than a nerve entrapment—a severely painful outcome. Time will tell I am afraid.

J.E.F.

193 Generations of the Plug-and-Patch Repair: Its Development and Lessons From History

Jerrold Young and Arthur I. Gilbert

INTRODUCTION

The principle of hernia repair using an open approach for placing mesh in the properitoneal retromuscular space of Bogros is based on protecting the myopectineal orifice (MPO) from behind. This has been the theory behind the development of many techniques of hernia repair including those of Nyhus, Stoppa, Kugel, and more recently, laparoscopic techniques. Furthermore, the concept of protecting an opening from inside the defect has resulted in modification of the technique of repair of other hernias, including ventral, umbilical, and particularly, incisional hernias.

In 1985, Gilbert borrowed Lichtenstein's idea of creating a rolled plug and used it to repair indirect inguinal hernias. The intact indirect sac was dissected and invaginated. A hand-rolled mesh plug was placed into the internal ring and two permanent sutures were used to fix it to the crura of the ring (Fig. 193.1). To complement this, a flat mesh patch was used to reinforce the floor of the inguinal canal over Hesselbach's triangle. This worked well, but the plug was annoyingly palpable in some thin patients, a problem that was solved by altering the shape of the plug. Gilbert then changed to a hand-rolled plug which he placed through the internal ring into the properitoneal space, allowing it to unravel there—it became seated against the anterior abdominal wall. It literally blocked the peritoneal sac and its contents from protruding through the internal ring. Although no sutures were used, that technique proved satisfactory, providing a lasting repair for small- and medium-sized indirect hernias.

Gilbert soon recognized certain problems uniquely related to the rolled plug. These included its inability to consistently unravel enough to be anything but a wad of mesh, thus limiting its area of protection, and some patients still reported feeling it. Rarely, when a plug became infected, surgical drainage and antibiotics were insufficient to sterilize its multiple

layers, compelling its removal. To avoid these problems, and to protect a wider area, the mesh shape was changed from a rolled plug to an opened patch. The flat mesh was cut, folded to the shape of a closed umbrella, and passed through the internal ring into the properitoneal space. There it was allowed to open and regain its flat contour, avoiding a palpable plug, and providing wider protection (Fig. 193.2). Gilbert originated the procedure of using mesh within the internal ring to repair indirect inguinal hernias, and subsequently used the internal ring as the passageway to place mesh behind the anterior abdominal wall for the repair of all types of indirect hernias.

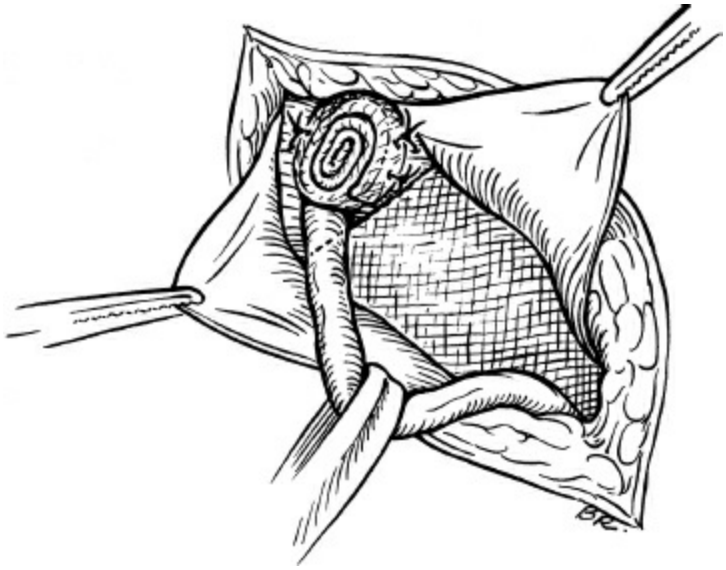

Figure 193.1. Original rolled plug sutured in internal ring and onlay patch.

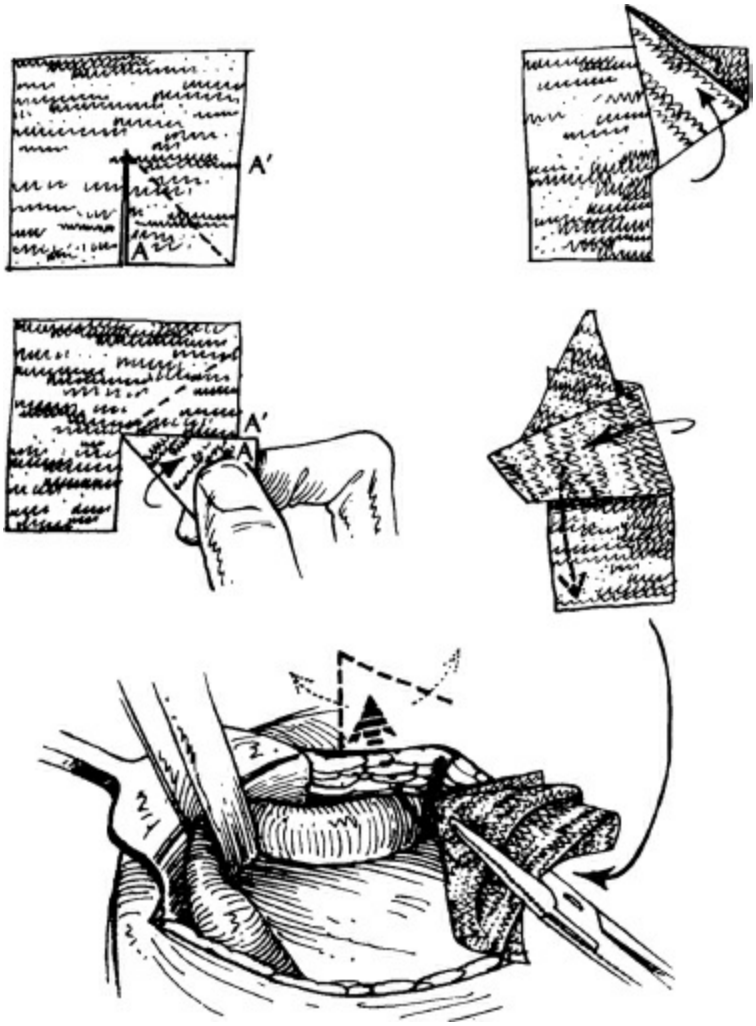

Figure 193.2. Creation and insertion of umbrella plug.

LESSONS FROM HISTORY—SUTURE REPAIRS

Gilbert's approach developed from the work of earlier surgeons interested in herniology. Bassini of Padua is credited with beginning the modern era of hernia surgery. Through an anterior open approach in the groin, he divided the posterior wall of the inguinal canal, ligated the peritoneal sac, and constructed a sutured, three-layered tissue repair in 262 patients, with a failure rate of <3%. A simplification of his technique avoided opening the posterior wall, but approximated the transversus arch, or so-called conjoined tendon, to the shelving edge of the inguinal ligament with interrupted sutures. This became known as the modified (North American) Bassini repair. Lotheissen of Austria and later Anson and McVay of South Dakota, popularized an anatomic repair that approximated the transversus arch to the pectineal ligament (Cooper's ligament), which also required opening the floor. The "McVay" repair became the preferred procedure for

treatment of femoral hernias and many direct inguinal hernias. In 1946, Shouldice of Toronto reincarnated Bassini's original operation, and equally important, popularized the use of local anesthesia. The technically difficult Shouldice operation requires a "thinning" of the cord by dividing the lesser cord, including the genital branch of the genitofemoral nerve, and a multilayered closure of the floor with stainless steel wire. However, suturing the transversus arch to the inguinal ligament creates tension at the suture line. This feature of the Bassini operation, and other sutured repairs, is most disadvantageous. Even with relaxing incisions to reduce suture line tension, patients still experienced a high level of postoperative pain, prolonged disability, and unacceptable failure rates because of the tension.

TENSION-FREE MESH REPAIRS

Usher of Texas, in 1960, reported suturing a polyethylene mesh inlay patch deep to the transversalis fascia to do a "tension-eliminating" inguinal hernia repair. Newman of New Jersey developed a tension-free technique for inguinal hernia using a polypropylene mesh onlay patch that he sutured over the floor. Lichtenstein and Amid popularized Newman's mesh technique, which has become a frequently used open, tension-free procedure for groin hernias worldwide. From 1958 to 1976, Gilbert used the modified Bassini technique with general or spinal anesthesia to repair all inguinal hernias, a technique that was estimated to have failed in 15% of primary hernias and 25% (or more) of recurrent hernias. After a visit to the Shouldice Hospital in Toronto in 1976, he began to perform the Shouldice repair under local anesthesia using 3-0 Prolene suture instead of wire. Failure rates of primary repairs dropped to <2% and of recurrent hernias to 8%. In 1984, to supplement the repair, Gilbert began placing a swatch of polypropylene mesh beneath the transversalis fascia, deep to the first suture line of the Shouldice operation. The failure rate was reduced to <0.5% for primary hernias and to 3% for recurrent hernias. Even before the open tension-free anterior repair of inguinal hernias became popular, open posterior repairs attracted surgeons' interest through the works of Nyhus of Chicago and Condon of Milwaukee. They described musculo-aponeurotic sutured repairs, sometimes adding mesh. Stoppa and Rives of France repaired bilateral groin hernias by widely wrapping the peritoneal base with large mesh netting (giant reinforcement of the visceral sac), thereby blocking the viscera from entering any defect through either MPO. After visiting and operating with Rene Stoppa in Amiens, Gilbert was

further convinced that the ideal place to position mesh is in the properitoneal space, between the force of the hernia and the defect in the abdominal wall.

ANATOMICAL AND FUNCTIONAL CONSIDERATIONS

All groin hernias protrude through the MPO, a window in the lower abdominal wall surrounded by musculo-aponeurotic structures described by Fruchaud in 1956 (Fig. 193.3). The MPO is bounded medially by the lateral edge of the rectus muscle and its fascia, superiorly by the transversus abdominis muscle, laterally by the iliopsoas muscle, and inferiorly by the pectineal (Cooper's) ligament. It is divided into smaller inguinal and femoral windows by the inguinal ligament anteriorly and the iliopubic tract posteriorly. The boundaries of the lateral triangle are the deep epigastric vessels, the middle third of the inguinal ligament, and a line from the junction of the upper and middle thirds of the inguinal ligament to where the deep epigastric vessels cross the lateral edge of the rectus muscle. Groin hernias occur because of poor collagen content in the MPO. The hernia that presents clinically is in that part of the MPO that initially gives way to intra-abdominal pressure. When performing any repair, one should consider the plasticity of the canal's posterior wall and the deformation effect on vulnerable tissues that surround that defect. Appreciation of these factors is important to the long-term success of any repair in which a prosthetic device is used.

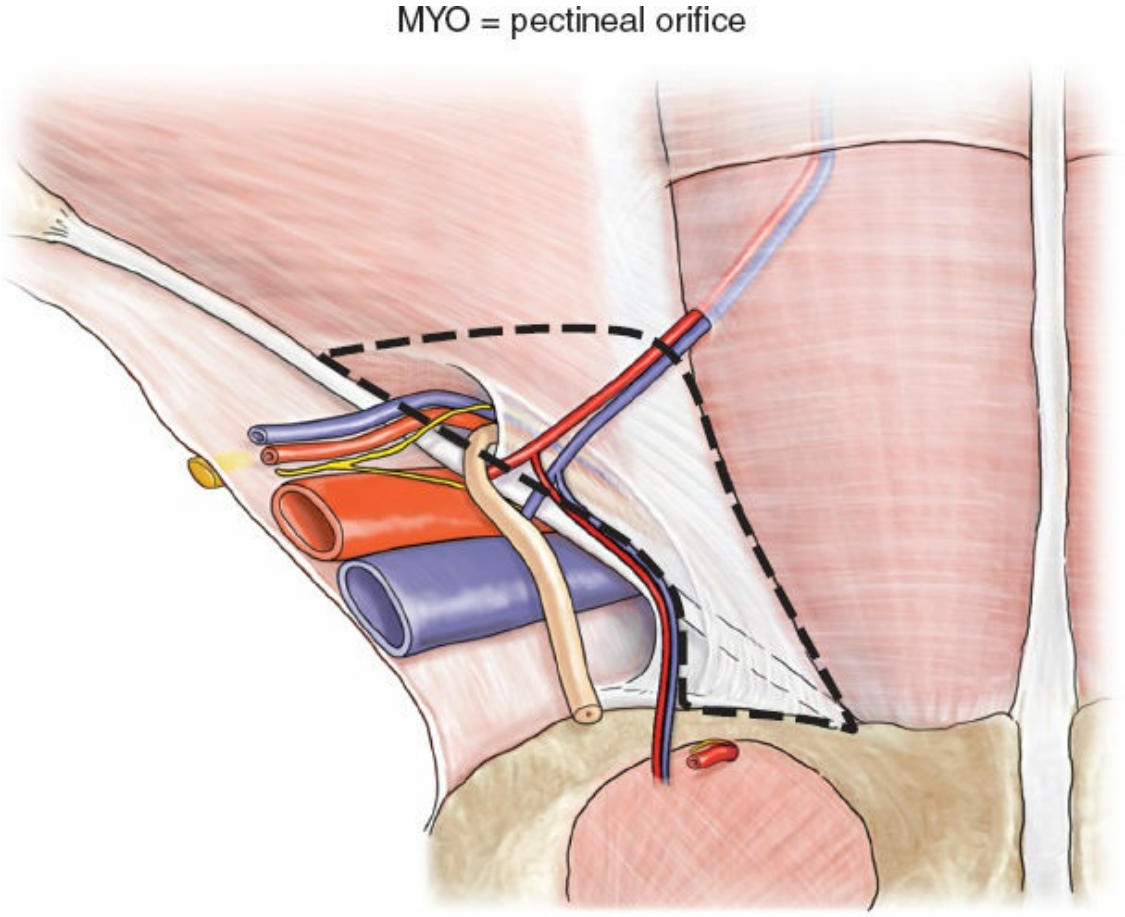

Figure 193.3. Myopectineal orifice.

Cadaver studies indicate that the mean MPO is 7.8 cm wide and 6.5 cm high. Coverage of the MPO can be accomplished from an open or laparoscopic posterior approach, an anterior patch, or a combination of anterior and posterior coverage. Preformed or handmade mesh plugs can be placed in the internal ring of indirect hernias or in the defect of direct hernias. The problem with using a plug without a patch in any primary hernia repair is that the remainder of the canal's unprotected posterior wall, medial and lateral to the plug, becomes subjected to an imbalance of plasticity. It is thereby rendered to have greater risk of herniation. It has been our observation that the majority of recurrences following pure tissue repairs presented in the medial triangle just above the pubic tubercle. Although half of tissue repairs that failed occurred within 5 years, other failures happened much later, some presenting decades after the original repair. On the other hand, failures following prior mesh repairs presented more commonly in the lateral triangle and became clinically evident within 2 years following the initial repair (Fig. 193.4). The reason for failure following mesh repair is that the mesh used initially did not cover the

entire MPO, leaving the unprotected area vulnerable. On occasion, a recurrent hernia may also penetrate the floor and remain under the mesh that was placed anteriorly. It is clear that an anterior patch acts as a lid, not as a stopper.

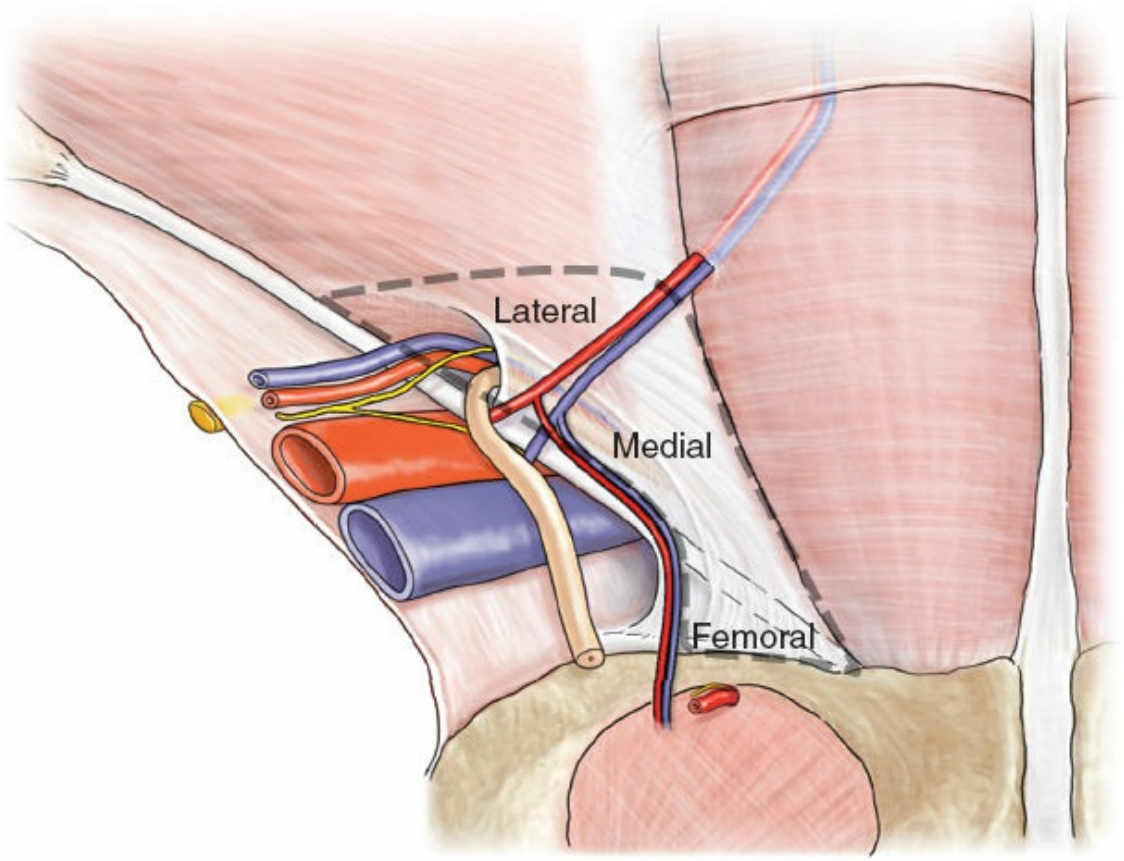

Figure 193.4. Triple triangles of the groin.

PRINCIPLES OF HERNIA REPAIR

The basic principle of every type of inguinal hernia repair is the reduction of the hernia contents and the prevention of passage of any intra-abdominal or properitoneal contents to outside the musculo-aponeurotic plane of the abdominal wall. Indirect inguinal hernia repair requires protection of the internal ring. Regardless of how the distal portion of the sac is treated, the peritoneal sac that resides within the deep inguinal ring of an indirect inguinal hernia must be carefully dissected from the cord and from the investing fibers of the transversalis fascia at the musculofascial threshold of the deep ring. A longer peritoneal sac or one densely adherent to the spermatic cord outside the internal ring should be divided, leaving its distal portion undisturbed, minimizing dissection near the spermatic cord. Further, the “shoulders” of the sac must be separated from the

transversalis fascia to actualize the potential space for the prosthesis (Fig. 193.5). For direct hernias, the floor must be opened to allow the mesh to be placed behind the transversalis fascia.

In Gilbert's original technique, and its two later generations, the mesh was interposed between the peritoneum and the transversalis fascia (the properitoneal space of Bogros) (Fig. 193.6). The principle of those repairs is that when the patient's intra-abdominal force is applied against the mesh, it will hold the patch in place to fortify the area covered. Each generation of technique incorporates the same three features: (a) the deep (internal) inguinal ring is an available and convenient passageway to be used to get to the properitoneal retromuscular space, (b) polypropylene mesh is an excellent permanent barrier to protect the deep inguinal ring, and (c) the body's intra-abdominal pressure is sufficient to permanently fix the mesh in its properitoneal position (Pascal's principle). Until April 1998, Gilbert used a tension-free polypropylene umbrella patch technique to repair all indirect inguinal hernias, and the Shouldice repair with a reinforcing underlay mesh patch (not tension-free) to repair all direct hernias. In doing so, the plug covered the primary defect from behind and the patch functions as an overlay on the full MPO.

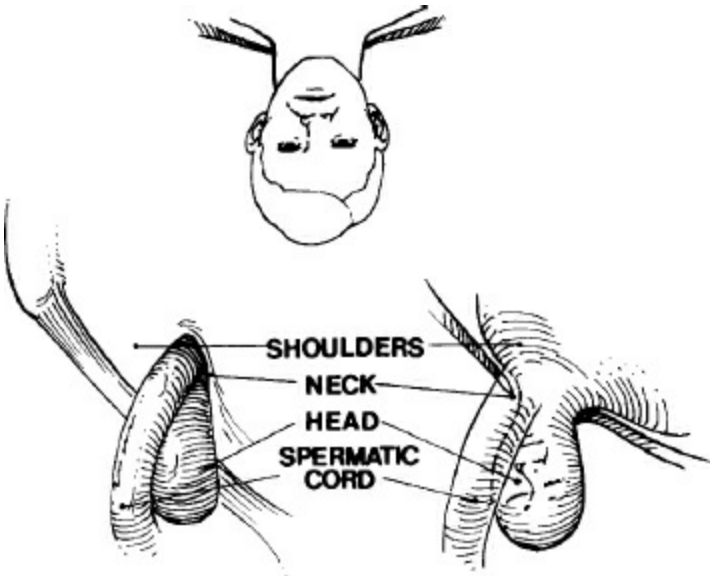

Figure 193.5. Head, neck, and shoulders of the peritoneal sac.



Figure 193.6. Prolene Hernia System device (polypropylene).

Primarily because of the complexity of the anatomy, over the years, there have been many different techniques described for inguinal hernia repair. The ideal hernia repair would be performed as an out-patient procedure under local anesthesia, with a short operative time, minimal post-op and long-term discomfort and disability, at low cost, with low risk for other side effects and complications, and have very few recurrences. The technique should have a short learning curve, with excellent reproducible results when performed by all general surgeons as well as experts. There is no single repair that has all of these desired outcomes—hence the continued investigation and analysis of new concepts and techniques. In 1997, Gilbert, with a personal experience of over 20,000 hernia repairs, designed the Prolene hernia system (PHS) (Fig. 193.7)—a polypropylene bilayer connected mesh device used to repair all types of direct and indirect inguinal hernias through an open anterior approach. The system has three components: a flat round underlay, an elongated overlay (oval shaped with flat edges), and a 1.5-cm round connector that joins these in the center. Three sizes—medium, large, and extra large—are available. The PHS is symmetrical in the longitudinal axis, and can be used on either the right or left side.

QUALITY-OF-LIFE ISSUES

As a result of the use of mesh and improved surgical technique, recurrence rates after hernia surgery have been reduced. Increased attention has been directed to quality-of-life issues, particularly the problem of chronic pain —a common consequence occurring in up to 10% of patients after hernia surgery. These symptoms of somatic, visceral, and neuropathic pain, as well as testicular pain, dysejaculation, and claims of sterility have been enough to warrant discussion at surgical meetings and in the literature. Post-op pain problems are in part related to the scarring, which occurs in both non-mesh and mesh repairs. The incidence of post-op chronic pain is greater in patients with suture repairs than in those with tension-free mesh repairs. Placement of mesh results in immediate strength of the repair. In addition, the mesh induces an inflammatory reaction and scarring, making the repair stronger as the scar creates a plate of tissue. This inflammatory reaction may affect structures, which are in direct apposition to the mesh, a situation that is present in all types of hernia repairs. Lateral to the internal ring, the mesh is placed on top of the internal oblique, and unavoidably comes into contact with the ilioinguinal and iliohypogastric nerves, which may result in inflammation and scarring involving these structures. In routine hernia repairs, nerves, muscle, the spermatic cord, and all structures in the inguinal canal may come in contact with the mesh. This is true in open anterior or properitoneal repairs, as well as in laparoscopic repairs.



Figure 193.7. Creating the anterior space between the internal and external oblique muscles.

There have been suggestions on how some of these post-op

consequences may be reduced by modifying the surgical technique. These include avoiding nerve trauma by blunt dissection, traction, and electrocautery; limiting dissection close to the spermatic cord to reduce scarring that may result in cord dysfunction, obstruction, and possible injury to the nerves and vessels that are present in the adventitia of the vas; avoiding placement of mesh in direct opposition to the vas when possible; using absorbable sutures with air knots and placing sutures in the internal oblique away from visible nerves; dividing a long indirect sac near the internal ring and avoid dissecting near the spermatic cord distally; and avoiding placement of sutures into the periosteum of the pubic tubercle. New products such as lightweight mesh, omega-3 fatty acid-coated mesh (C-Cur Lite®), and tissue glue instead of sutures are being investigated in an attempt to reduce inflammatory reaction and scarring, and possibly improve results. Further evidence-based studies are needed to document the efficacy of these concepts and products. However, preliminary reports indicate that many of these suggestions have sufficient basis to begin implementing them. As a result of this information, we have modified our surgical technique to attempt to limit dissection in the area of the nerves and the spermatic cord to attempt to reduce the incidence of these problems. In time, we will learn if some of the experimental data will hold up in the clinical setting. In addition, “watchful waiting”—conservative management of asymptomatic hernias—is an acceptable course of management in the appropriate patient (Table 193.1).

CURRENT TECHNIQUE

Preoperative Planning

When indicated, medical evaluation and clearance is requested. Groin and testicular ultrasound examination is often done in patients who have recurrent hernias or patients with testicular complaints, to document the location of the hernia, to check for multiple hernias, and to document testicular anatomy and blood flow. Appropriate informed consent is obtained—we have patients sign a “hernia-specific” informed consent, which is sent to the surgery center to become a part of the record. Although we have rarely seen bleeding problems related to Aspirin® and non-steroidal anti-inflammatory drugs, these drugs as well as Plavix® are stopped 7 to 10 days before surgery. If the patient takes Coumadin®, it is stopped 5 days before surgery. Depending on the indication for the anticoagulation, some patients require a short-acting subcutaneous

anticoagulant (Lovenox® or heparin) for the immediate pre-op and post-op period. Our current approach is to discuss this with the medical consultant familiar with the patient, who then will order these medicines. Clotting studies are done on the day of the operation. All other medications are continued up until midnight before surgery. The patient is advised to shower the morning of surgery using a parachlorometaxylenol-impregnated sponge to bathe the abdominal and groin areas, but not to shave the surgical site. In the pre-op suite, the patient is identified and the surgical site is confirmed and marked prior to administration of any sedative. Any hair at the operative site is clipped just prior to the surgery. A single dose of 1 g of cefazolin (or 600 mg of clindamycin for penicillin- or cephalosporin-allergic patients) is administered within 30 minutes of incision time (Table 193.2).

TABLE 193.1 Patient Demographics by Time Period

	Male	Female	Patients	Bilateral	Repairs	Recurrent	Inguinal	Femoral
1998-2005	5630	385	6015	820	6835	789	6727	108
2005-2008	1618	104	1722	334	1956	197	1916	40
Total	**7248**	**489**	**7737**	**1154**	**8791**	**986**	**8643**	**148**

Anesthesia and Preparation

Our preferred approach, used in almost all patients, is intravenous sedation and local anesthesia, in an ambulatory surgery setting. We prefer not to use epidural or spinal, or general anesthesia, in hopes of avoiding prolonged stay in the out-patient department, and an increased incidence of post-op urinary retention. Versed® and other anesthetic agents are administered by an anesthesiologist before patients are brought to the operating room. The local anesthetic mixture of 97 mL contains 60 mL of 0.25% Sensorcaine (Marcaine®), 30 mL of 3% chloroprocaine (Nescaine®), and 7 mL of 8.4% sodium bicarbonate. The bicarbonate neutralizes the acid pH of the local anesthetic and decreases the pain of injection. The skin of the lower abdomen is prepared with Betadine® solution. A “time-out” to identify the patient and the marked operative site is done with the attention of all personnel in the room prior to commencing (Table 193.3).

TABLE 193.2 Size of PHS Device Used

Size	Percent
Medium	1
Large	9
Extended	90

Preparation of the Anterior Space

There are four parts to a hernia repair with the PHS: preparation of the anterior space, dissection of the posterior space, deploying the underlay in the posterior space, and application of the overlay or patch.

The technique for preparation of the anterior space and application of the overlay patch is very similar to the technique that we use when we perform a Lichtenstein procedure. A 3- to 5-cm transverse incision extending laterally from the pubic tubercle is marked. Approximately 60 mL of the anesthetic solution is injected into the skin and subcutaneous layers. No attempt is made to block the nerves in the area by direct injection, which may cause nerve injury that can lead to neuropathy. The skin is incised and the subcutaneous layer is opened. The superficial epigastric vessels are retracted, or ligated and divided, and Scarpa's fascia opened. As soon as the external oblique aponeurosis (EOA) is exposed, 20 to 25 mL of anesthetic solution is infiltrated just beneath it—we use two or three puncture sites to flood the area, avoiding direct injection into the nerves. The subcutaneous tissues are cleared from the EOA, exposing the external ring. Care is taken not to stretch or otherwise damage the ilioinguinal nerve as it exits the external ring with the cord structures. At this time, examination is performed to rule out the presence of a femoral hernia by incising the cribriform fascia at the junction of the thigh. The EOA is opened in the direction of its fibers through the external ring. Its medial flap is elevated and separated from the internal oblique muscle and aponeurosis. The ilioinguinal and iliohypogastric nerves are identified and left undisturbed within the investing fascia on top of the muscle. The nerves are not dissected or retracted outside the EOA to "protect" them. We do not hesitate to sacrifice the nerve or a branch if its location interferes with the repair or if it will be under tension by the mesh. If a nerve is divided, it is ligated with Vicryl, and implanted into the muscle. The anterior space dissection is carried out laterally 3 to 5 cm beyond the internal ring (Fig. 193.8). The lateral flap of the external oblique is then elevated with careful dissection inferomedially toward Gimbernat's

ligament and the pubic tubercle. In patients with large hernias, reduction of the hernia contents at this juncture may facilitate this part of the procedure.

TABLE 193.3 Anesthesia Type by Time Period

	Number of patients		
Anesthesia	1998–2005	2005–2008	Total
IV sedation, local	4207	1662	5869
Spinal, epidural	1803	20	1823
General	5	40	45
Total	**6015**	**1722**	**7737**

Elevation of the cord structures and creation of an arch for the mesh can be done in one of two ways. Our current preferred technique is to elevate the entire cord structures and cremasteric muscle from the floor of the inguinal canal near the pubic tubercle, and encircle them with a Penrose drain. Careful dissection is used to separate the cremasterics from the floor and the reflected edge of the inguinal ligament, limiting trauma to the genital branch of the genitofemoral nerve and the cremasteric vessels, which are left undisturbed as they lay within the lateral cremasterics. An arch is created to accommodate the overlay of the mesh. The cremasteric muscle is opened 2 cm from the internal ring for inspection for an indirect sac or lipoma. The cremasteric opening can be closed with a fine absorbable suture, avoiding the ilioinguinal nerve. This method of elevating the cord structures favors limiting dissection of the vas deferens within the internal spermatic fascia.

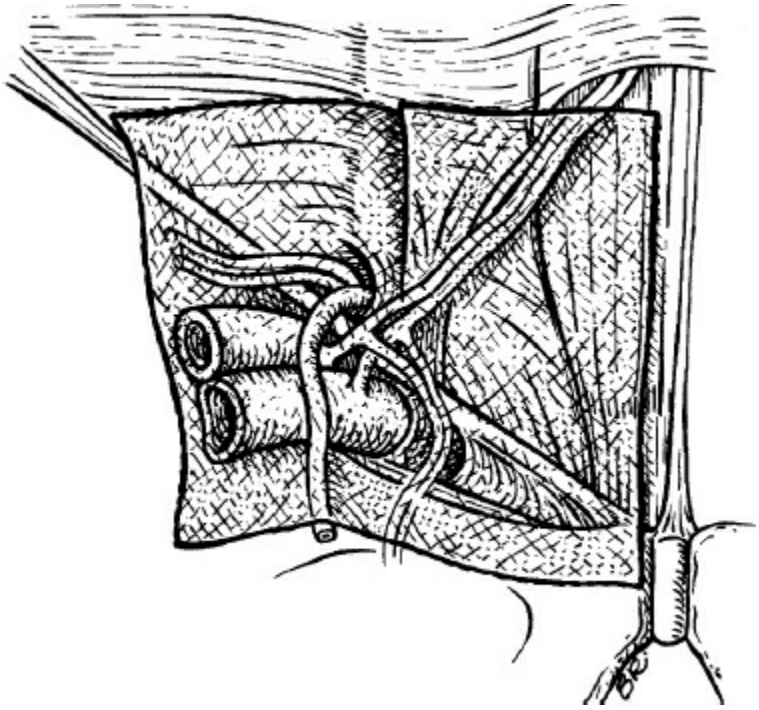

Figure 193.8. Posterior view of mesh covering entire myopectineal orifice.

An alternative approach is to open the entire cremasteric muscle, allowing direct visualization of the transparent, relatively avascular internal spermatic fascia that surrounds the spermatic cord. The spermatic cord and the testicular vessels are elevated with a Penrose and the arch is opened between these structures and the lesser cord, leaving the lateral cremasterics and the genital nerve branch and cremasteric and vessels attached to the floor, while the medial cremasterics are excised. This method allows easy access to the contents of the cord, including a true hernia sac and any lipomas, which may be found within the internal spermatic fascia, but requires more dissection near the vas deferens.

With either method, inspection for a patent processus vaginalis, or frank indirect hernia, is done up to the level of the true internal ring. If an indirect sac is identified and its distal part (head) is not firmly adherent to the cord, the sac is left intact and it is dissected up to its true neck. If the head of the sac is attached or scarred to or near the internal spermatic fascia vessels, its midportion is elevated and divided, leaving its distal portion in place, thereby limiting dissection close to the vas and vessels. Its proximal portion is dissected up to its true neck and ligated with 2-0 Vicryl ligature. The posterior wall, over the medial (Hesselbach) triangle, is inspected for any direct hernia or weakness.

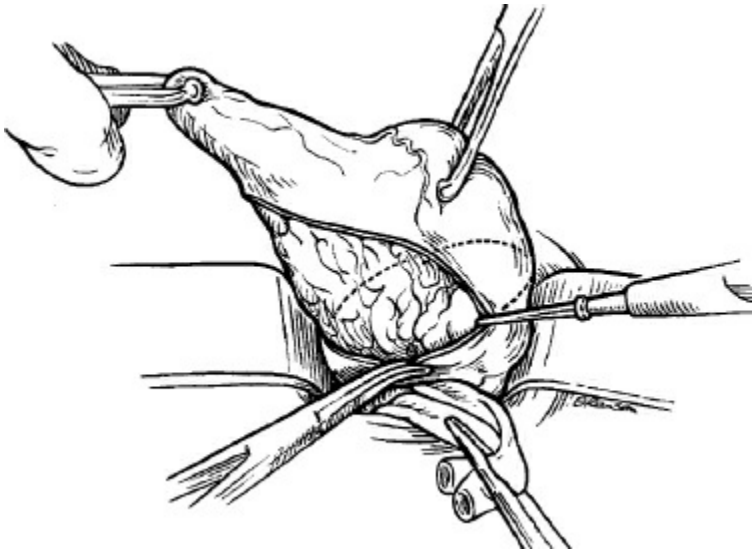

Figure 193.9. Opening a type 4 hernia into true yellow fat.

Posterior Space Dissection

The properitoneal space must be generously opened to allow the mesh to be fully deployed, no different than is properly done for other open mesh or laparoscopic mesh repairs. The space of Bogros behind the MPO is, in fact, more conical than flat in nature, so the underlay should not be expected to lie flat, but more like a cone. The space is relatively flat behind the transversalis fascia in the upper portion. However, inferiorly, below the inguinal ligament, it turns posterior to pass behind the iliopubic tract and Cooper's ligament medially, the femoral lymphatics, vein and artery in the center portion, and the spermatic cord and testicular vessels laterally. *For direct hernias,* the floor of the medial triangle is opened (Fig. 193.9), grasped with four hemostats, and its protruding contents are dissected from behind the transversalis fascia with a sponge to actualize the properitoneal space. The sponge's traction on the fat helps separate the properitoneal fat from the transversalis fascia superficial to it (Fig. 193.10). This dissection goes medially behind the pubic tubercle, inferiorly behind Cooper's ligament, superiorly behind the transversus abdominis muscle, and laterally behind the deep epigastric vessels. If the patient has no indirect defect, we limit this lateral dissection behind the epigastrics at this point, and use the overlay portion to protect the floor lateral to the internal ring. If a lipoma is present it is resected.

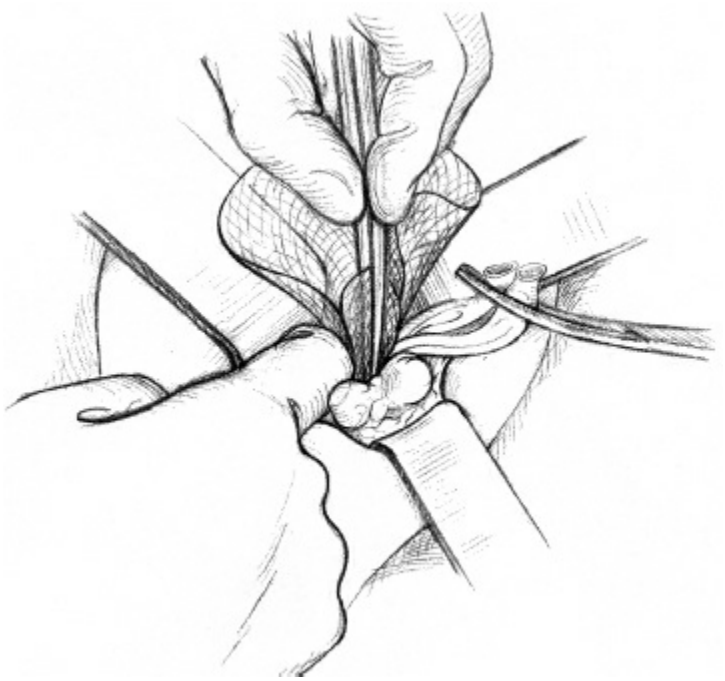

Figure 193.10. Sponge dissection of posterior space.

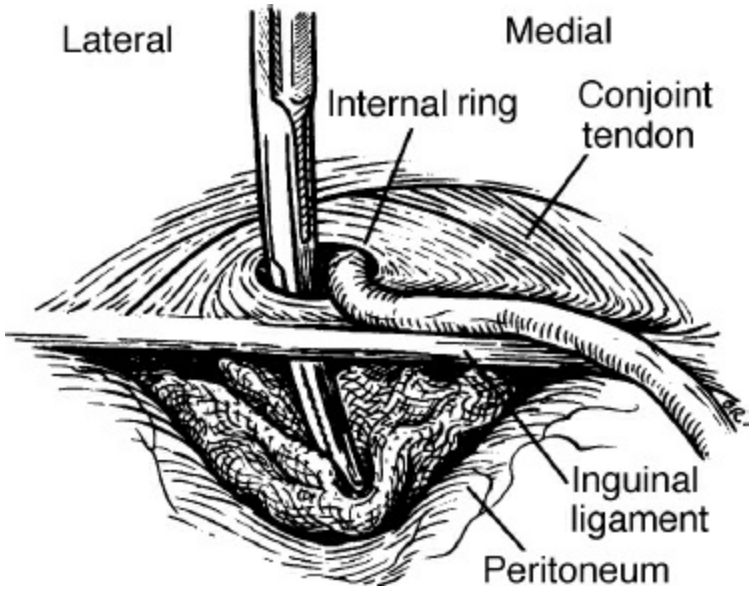

Figure 193.11. Dissecting properitoneal space with sponge.

For indirect hernias, after the head and neck of the entire sac (or ligated sac) have been fully dissected, the sac is grasped with a forceps and invaginated through the internal ring. The surgeon's forefinger is inserted through the internal ring adjacent to the forceps. The forceps are extracted, leaving the forefinger in place. The forefinger palpates the iliac artery, pulsating lateral to it. An opened dry 4 × 4 sponge is passed on the medial side of the forefinger to develop the properitoneal space (Fig. 193.11) and helps separate the hernia contents from the elements of the cord. The

dissection through the internal ring is done superiorly and laterally behind the transversus abdominis muscle. Medially, we go behind the deep epigastric vessels and dissect under the floor of Hesselbach's triangle to behind pubic tubercle and inferiorly behind Cooper's ligament. An army-navy retractor placed behind the epigastric vessels facilitates this dissection. We prefer creating this space with the opened 4 × 4 sponge, but it is also possible to do it with the index finger alone, or forceps and cautery. The sponge is temporarily left in place to maintain the passageway and facilitate continuing the insertion maneuver. *For small indirect hernias*, the mesh can be inserted through an opening in the floor just medial to the epigastric vessels, and the indirect space can be covered by the overlay.

In some cases of *pantaloon hernias*, the transversalis fascia is opened both medial and lateral to the epigastrics, a Penrose drain is placed around the epigastric vessels (or the vessels can be divided), and the two spaces are joined. In no case is it possible to successfully create the space using the device as a ramrod without a careful dissection. Such attempts leave the mesh as a wad rather than a fully expanded patch as it is intended to be.

Insertion and Deployment of the PHS Underlay

The PHS overlay is triple folded on itself longitudinally, and the tails are pulled up and grasped with a sponge stick near the connector, creating an appearance of a "taco" in the underlay. The sponge stick is rotated before insertion so that the lateral flap will align with the inguinal ligament. The device is inserted until the perimeter of the underlay is under the floor. The technical goal of deployment is to spread the edge of the underlay patch circumferentially to be seated at maximum distraction from its connector. By doing so, the underlay patch covers the majority of the MPO—the overlay will complete the coverage. For inguinal hernias, sutures are not necessary in the underlay—the intra-abdominal pressure pushes the mesh against the floor and holds it in place.

For a direct hernia, the device is inserted straight down (posteriorly), at a right angle to the opening. Using a long forceps or the forefinger, the edge of the circular underlay patch is deployed by separating the perimeter of the mesh from its connector (Fig. 193.12) as the onlay component is gently extracted. The perimeter of the underlay is placed behind the previously dissected structures—medially behind the pubic tubercle,

inferiorly behind Cooper's ligament, superiorly behind the transversus abdominis muscle, and laterally behind the deep epigastric vessels. The underlay will have some radial folds to accommodate the conical shape of the space—it will not be flat. The underlay can be trimmed laterally where it will be placed behind the epigastric vessels. The opening in the floor of the medial triangle is closed snugly around the connector with one or two figure-of-eight absorbable sutures, leaving it comfortably seated. If there is a femoral hernia, prior to inserting the device, a single 2-0 Prolene suture can be placed to secure the underlay to Cooper's ligament.



Figure 193.12. Triple fold of overlay.

For indirect hernias, the surgeon's forefinger is placed in the lateral aspect of the dissected internal ring, and the device is slid down the medial side of the finger into the properitoneal space—the direction of insertion is medial and superior, aiming just beneath the umbilicus. The underlay perimeter is placed behind the transversus abdominis muscle superiorly and laterally, where it lies in the horizontal plane, while medially it is deployed behind the epigastric vessels and the pubic tubercle. Inferiorly, the perimeter is directed more posterior, covering the femoral canal and the tissues behind Cooper's ligament, and it separates the hernia contents from the cord contents. Typically, when repairing an indirect hernia, unless it is a large type III defect, the internal ring is not tightened around

the connector—the obliqueness of the internal ring offers additional protection to the underlay patch. Effectiveness of the underlay patch alone can be evaluated by having the patient cough and perform the Valsalva maneuver before any sutures are placed in the onlay patch. After the operation, when the patient stands, intra-abdominal pressure flattens the underlay is against the abdominal wall between the peritoneum and the transversalis fascia.

Application of the PHS Overlay

The sponge stick is used to extract the onlay component to the level of the internal oblique, released, and the tips of the overlay are simultaneously pulled apart to a flat shape (Fig. 193.13). Once extracted, the surgeon inserts the lateral flap beneath the external oblique into the anterior space. The medial part of the onlay patch is then flattened against the transversus arch with the medial end positioned 2 cm over the pubic tubercle. Very early in our series, a suture-less technique was attempted. Two patients with large type III hernias developed almost immediate recurrences by "popping" out the mesh, prompting us to use at least one suture medially. We suggest that the onlay patch be sutured with absorbable sutures (2-0 Vicryl) in three places: one to the soft tissues (not into the periosteum) supero-medial to the pubic tubercle, one at the middle of the transversus arch (using an air knot and avoiding the iliohypogastric nerve), and one at the middle of the inguinal ligament (Fig. 193.14). To accommodate the spermatic cord through the onlay patch, either a central or lateral slit is made (Fig. 193.15). In most indirect hernias, a slit with a "T" is made in the inferior edge of the overlay, close to the connector, adjacent to the midportion of the internal ring. The cord structures are passed through the slit, and the edges of the slit are then sutured to the reflected edge of the inguinal ligament (Fig. 193.16). This opening should be large enough to comfortably accommodate the spermatic cord and its contents without compression. The underlay component is there to prevent herniation in this area. For most direct hernias, a slit in the lateral flap of the onlay patch (Fig. 193.17) serves well. The tails of the lateral flap are crossed and fixed with a single suture to prevent herniation through the slit, similar to a Lichtenstein repair. It is not necessary to suture the lateral flap that lies flat in the anterior space and is well covered by the EOA. The overlay should be trimmed if any excess is noted where the mesh folds on itself, usually on the inferior edge of the lateral and medial flaps. The spermatic cord and

ilioinguinal nerve are replaced over the onlay patch. All layers are irrigated with Bacitracin®—Polymyxin® solution. The external oblique is closed with 3-0 continuous Vicryl® suture, re-creating the external ring, being careful not to make it too tight, anticipating that some swelling of the cord structures will occur. The subcutaneous layer is closed with 3-0 Vicryl® sutures, and the skin with a sub-cuticular 3-0 Vicryl Rapide® suture. The skin is covered with Dermabond® or Steri-strips®.

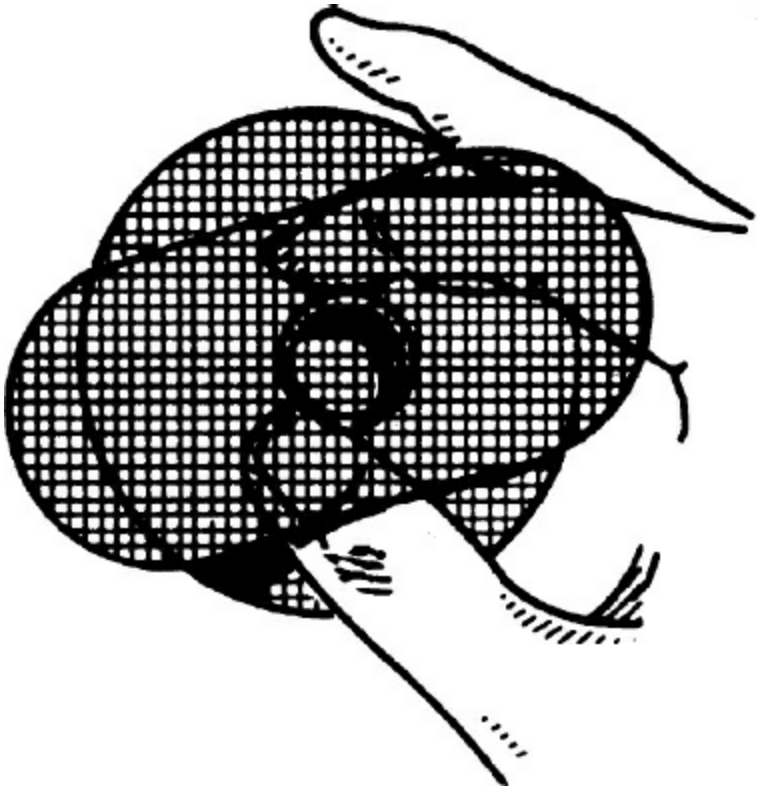

Figure 193.13. Deployment of underlay patch.

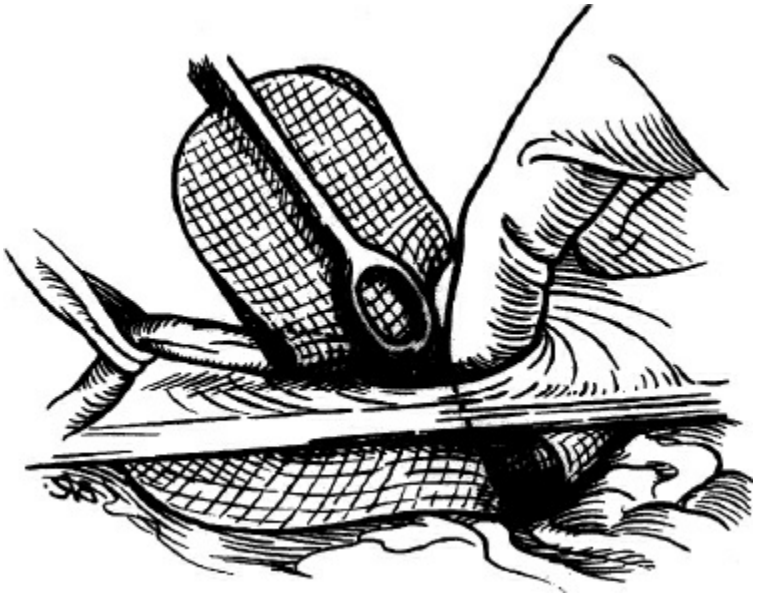

Figure 193.14. Onlay patch extracted with finger in connector.

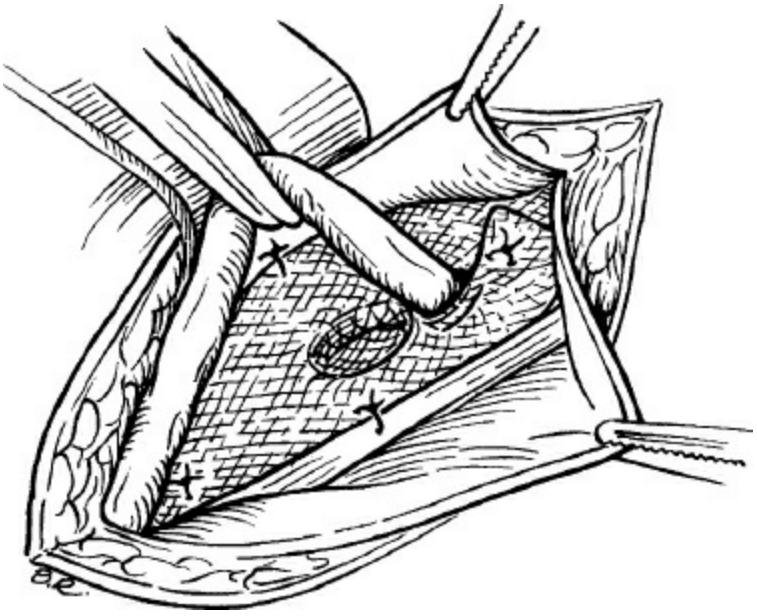

Figure 193.15. Slit in lateral flap of onlay patch for direct hernia.

Most patients go directly to the outpatient discharge area, or to the recovery room if they are too sleepy or need monitoring. An ice bag is applied immediately, and is used for 2 days. After a light meal and being able to urinate, the patient leaves the ambulatory center, 45 minutes to 1 hour after the operation. The patient is encouraged to ambulate often (if not light-headed) and to resume all activities that are not uncomfortable. Milk of magnesia is recommended if the patient has not had a bowel movement by the next day. Patients are told that they will have some ecchymosis around the incision and into the scrotum, and often some

testicular swelling that will last for several days. Swelling in the wound forms a firm wound healing ridge that lasts 6 to 8 weeks. As the healing ridge becomes more prominent, it narrows and rises before it flattens. Patients are told to expect mild to moderate pain, sometimes going down to the testicle, for 1 to 2 days, after which the pain diminishes significantly. All patients are given a prescription for a narcotic analgesic such as oxycodone and acetaminophen. Patients who live geographically close to the surgery center are encouraged to return in 7 to 14 days for a wound check. For those who live farther away, we have a toll-free telephone number and encourage patients to stay in contact regarding their progress.

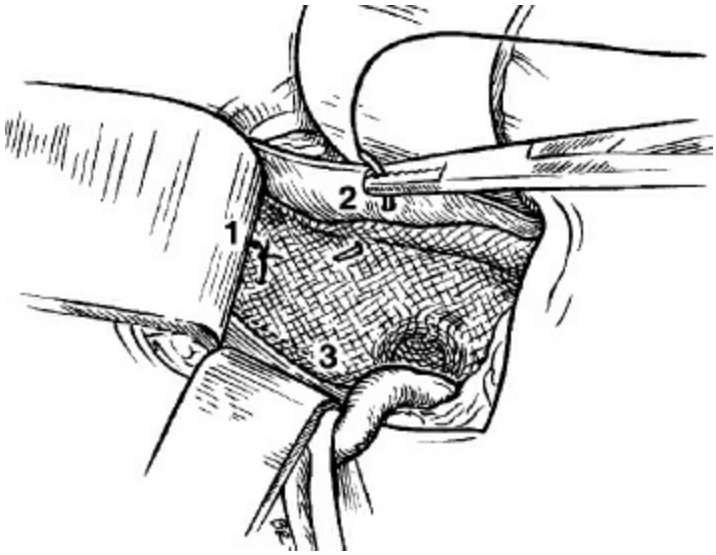

Figure 193.16. Onlay patch flattened against posterior wall and sutured in place.

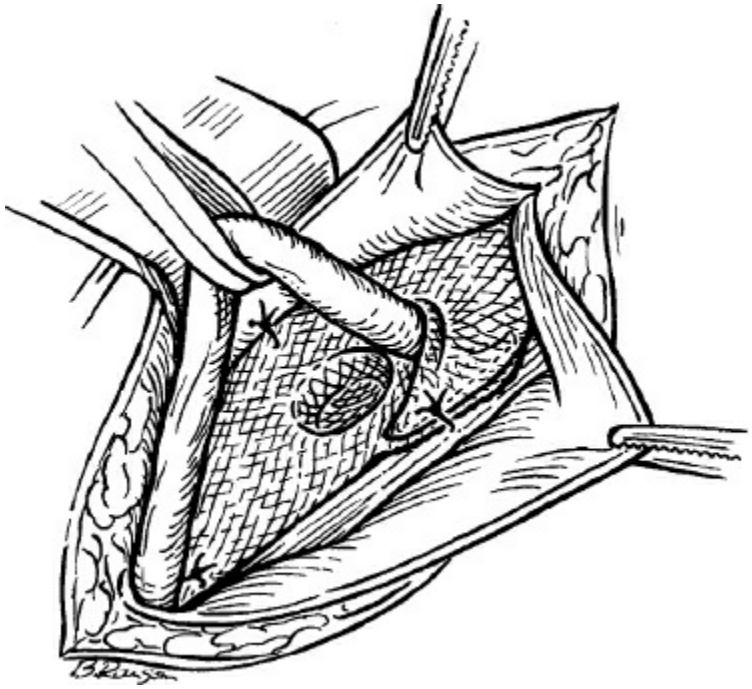

Figure 193.17. Central slit for cord of indirect hernia.

RESULTS

From April 1998 to December 2008, four surgeons used the PHS to repair 8,791 groin hernias in 7,737 patients at the Hernia Institute of Florida. Male patients outnumbered female patients 7,248 to 489. Simultaneous bilateral repairs were done in 1,054 patients; 986 repairs were for recurrences of one to six times. Inguinal hernias outnumbered femoral hernias 8,643 to 148. All sizes of PHS were used, although our preference in 90% of adult male patients was the EPHS (extended size). All patients not covered by workers' compensation were recalled annually by postcard for cost-free follow-up examination. Twenty percent of the patients complied; many others called and related that their hernia repairs were fine but they did not want to take time to come for a checkup. All patients, including those covered under workers' compensation, were emphatically instructed to return if they suspected a recurrence or were bothered by unrelenting discomfort.

To the best of our knowledge, the total number of recurrences in our series since April 1998 is 12. Even if we assume that there are two or three times as many recurrences that we are not aware of, our percentage is well below one-half percent. Early in the series, two patients with large type III hernias, in whom the mesh overlay was not secured, developed immediate recurrences. Two recurrences were in the medial triangle. There were three

femoral recurrences, one that was missed and two that developed following repair of type II indirect hernias. Four recurrences were at the internal ring—all after indirect hernia repairs. Two were in patients who did heavy labor and one in a weight-lifter. One patient who had a repair of a large type III recurrent hernia developed severe bronchitis that lasted for 6 weeks 4 months after surgery and re-recurred. He was referred for a laparoscopic repair of the recurrence. Infection or drainage, that required opening the wound, occurred in 41 patients between 1998 and 2005 and in four patients from 2006 to 2009. In one case, suspicious of containing a gas-forming organism, the mesh was removed. In another, infection presented 3 weeks after surgery in a patient who had a history of lymphoma treated with chemotherapy. Cultures grew out a rare *Mycobacterium fortuitum* organism. The prosthesis was removed and a suture repair was done with a monofilament absorbable suture. After 2 years of follow-up there has been no recurrence of the hernia or the infection. In all the other cases, the mesh did not have to be removed to get complete wound healing. None of the repairs that involved infection failed. There were 35 hematomas that required drainage, 90 seromas, of which 15 required aspiration, and one patient who developed an atrophic testicle following repair for a second-time recurrent hernia.

Thirty percent of patients used only acetaminophen for pain. The remainder used the prescribed narcotic, on the average taking four tablets over 2 days. Ninety-five percent used no analgesics after the first 2 days. Most patients with ongoing discomfort were given naproxen. Ten percent of workers had ongoing pain that lasted between 3 and 6 months. Four patients, including two workers, who had significant chronic postoperative pain lasting longer than 6 months were referred for pain management. One patient had his mesh removed for pain by a surgeon elsewhere. Patients who experienced some degree of testicular pain from epididymitis were treated with sitz baths, naproxen, and Cipro®—all reported that the pain subsided in 3 to 8 weeks.

General surgeons trained in the PHS technique by instructors have been able to reproduce our own results. In 2005, in a report of 21,791 PHS repairs by 42 trained general surgeons, there were only 28 recurrences, for a failure rate of 0.0013.

The PHS has been used successfully by surgeons to do various other hernia repairs. We have used PHS to repair umbilical hernias in 75 obese patients with a mean BMI of 33 without a recurrence. In these patients,

with a high risk for recurrence, we use a sandwich technique with "bilayer" sutures passed through both the mesh layers and the fascia in between. Polat reported benefit using PHS for umbilical hernia repairs. Del Pozo used the PHS for ambulatory surgery in 32 patients to repair trocar site hernias, umbilical hernias, spigelian hernias, epigastric hernias, and small incisional hernias. Mayagoita compared the PHS repair with the Lichtenstein technique in 250 patients with inguinal hernias and found the results comparable; however, the patients who received the Lichtenstein repair had more complications. Huang compared the PHS repair with the mesh-plug repair and found that the mesh-plug repair took less time than the PHS repair, but the mesh-plug repair was associated with three times the number of patients with groin pain. Kingsnorth compared the PHS repair with the Lichtenstein technique and noted that patients with PHS repair returned to work sooner, and that it took slightly less operating time to do the PHS repair.

To perform lasting groin hernia repairs, surgeons must have a stronger appreciation for the need to protect the entire vulnerable area. Only by complete protection of the entire MPO can disparity of resistance and deformation of the remainder of the posterior wall be avoided. This can be accomplished from inside, or from outside, or by a combination of both. Patients have different anatomy, and their hernia problems differ by size and location. Some patients may be more susceptible to recurrence because of age, occupation, activities, body habitus, collagen disorders, and smoking. Although a single technique can be used to repair all different types and sizes of inguinal hernias, the choice of procedure for an individual patient should be based on the anatomical findings and the type of defect, and the expertise of the surgeon with the technique being used. Some techniques are easier to perform, but may not offer good results. The success of the procedure will ultimately depend on the skill of the surgeon —both in choosing the correct procedure and in performing it (Table 193.4).

TABLE 193.4 Complications in 7737 Patients

Complication	Number of patients	Percent
Infection	45	0.58
Infected mesh removal	4	0.05
Hematoma	42	0.54
Seroma	100	1.29
Testicular atrophy	1	0.01
Chronic pain	90	1.16
Pain management referral	10	0.13
Mesh removal for pain	3	0.04
Recurrence	12	0.16

Recently, new products with the underlying concept of the plug and patch have been introduced. The ProLoop® mesh plug is a lightweight, preformed, three-dimensional plug constructed of knitted rows of monofilament polypropylene with multiple protruding monofilament loops (Fig. 193.18). This design offers the benefit of flexibility and pliability—it has a self-forming characteristic that accommodates to the size and shape of the insertion site, and resists "mesh hardening" compared to a solid plug (Fig. 193.19). In a blinded randomized study, Sanders compared the ProLoop® to the Lichtenstein and PerFix® plug repairs. They found it to be a safe, effective, alternative technique compared to the other repairs. It is easy to use, and can be combined with a lightweight patch of ProLite® or omega-3 fatty acid coated C-Cur Lite®. The principle of the omega-3 fatty acid coating is to reduce inflammation in the anterior space, and perhaps reduce pain. The offshoot of the PHS is the bilayer Ultrapro® hernia system (UHS). This has an overlay of a soft lightweight product with a component that is absorbed. The underlay is "stiffened" by an absorbable element that dissolves over several days, but we found the stiff underlay difficult to deploy in comparison to the PHS. In addition, several manufacturers have developed partially or completely absorbable plugs to try to reduce the bulk of the permanent component, to reduce scarring and hopefully, the amount of postoperative pain. The underlying principles of these devices seem clear, but more studies with evidence-based data are needed before a final determination can be made as to the efficacy of these products.

The low failure rate of the plug-and-patch devices is due to complete coverage of the MPO. The plug or underlay component covers the existing defect and a portion of the MPO from behind, while the overlay adds the protection of the remainder of the area to prevent other hernias from

forming. In the case of the PHS, the connector stabilizes the other two components and adds to its strength. With its high success rate and ease of use for all surgeons, the plug-and-patch method using the PHS and some of the newer lightweight materials such as the ProLoop® plug, and partially absorbable plugs, will remain a prime hernia repair technique in the armamentarium of future generations of surgeons.



Figure 193.18. Proloop plug.



Figure 193.19. Proloop plug pliability.

Suggested Readings

del Pozo M. Three-dimensional mesh for ventral hernias: a new technique for an old problem. *Hernia* 2003; 7(4):197.

Ferzli GS. *Chronic pain after inguinal herniorrhaphy*. *JACS* 2007;205:333.

Gilbert AI. An anatomic and functional classification for the diagnosis and treatment of inguinal hernias. *Am J Surg* 1989;157:331.

Gilbert AI. Inguinal hernia repair: biomaterials and sutureless repair. *Perspect Gen Surg* 1991;2:113.

Gilbert AI. Combined anterior and posterior inguinal hernia repair: intermediate recurrence rates with three groups of surgeons. *Hernia* 2004;8(3):203.

Huang CS. Prolene hernia system compared with mesh plug technique: a prospective study of short to mid-term outcomes in primary groin hernia repair. *Hernia* 2005;9(2):167.

Lichtenstein IL. The tension-free herniaplasty. *Am J Surg* 1989;157:188.

Mayagoita JC. Inguinal herniaplasty with Prolene hernia system. *Hernia* 2004;8(1):64.

Nienhuijs S. Chronic pain after mesh repair of inguinal hernia: a systematic review. *Am J Surg* 2007;194:394.

Polat C. Umbilical hernia repair with the Prolene hernia system. *Am J Surg* 2005;190:61.

Rutkow IM. The perfix® plug repair for groin hernias. *Surg Clin North Am* 2003;83(5):1079.

Sanders DL. A two-center blinded randomized control study comparing the Lichtenstein patch, Perfix® plug, and ProLoop® plug in the repair of primary inguinal hernia. *Hernia* 2009;13(5):499.

Stevenson BM. Complications of open groin hernia repair. *Surg Clin North Am* 2003;83(5):1255.

Stoppa RE. The use of Dacron in the repair of hernias of the groin. *Surg Clin North Am* 1984;64:269.

Wolloschek T. Dimensions of the myopectineal orifice: a human cadaver study. *Hernia* 2009;13(6):639.

EDITOR'S COMMENT

This section provides a good review of the plug and patch technique, one of the principal techniques now carried out in the United States and throughout the world, which has evolved from the original idea of Arthur Gilbert who is the head of the Hernia Institute of Florida, and Jerrold Young, his successor. At one time, and perhaps still now, Delta Airlines would fly all its employees with hernia to the Hernia Institute in Miami for repair. As Dr. Young recalls the evolution of the technique, Dr. Gilbert, who I know well, evolved the technique from the Lichtenstein repair. He had in mind to prevent the hernia sac from reoccurring through the internal inguinal canal, as well as protecting the myopectineal orifice. The evolution of inguinal hernia repair over the past two decades has been from the open repair, which while it did not result in long-term inguinodynia, or if it did, certainly not in the 10% range, which now is what is commonly accepted for mesh repairs has a very low incidence of

recurrence. The hernia repair world has moved in the direction of mesh almost 100%, certainly over 90%, as recurrence seemed to be the principal focus. I do wonder about this, because the incidence of inguinodynia is significant, whatever it is, whether it is 3%, 5%, or 10%, the figure of 10% is generally accepted. As I see a lot of these patients with inguinodynia, I can tell you that their lives may be ruined and the pain may be excruciating, and although one can cut all three nerves, resect, and bury them and also deal with the crural nerve or the genital branch of the genitofemoral nerve, laparoscopically in the retroperitoneum, the repair is only successful in about 80% and in the remaining it is a life of suffering indeed. I do wonder why the focus is on recurrence, when avoidance of pain is such a huge problem.

In discussions with Dr. Young as he was writing the chapter, two things emerged. First, the incidence of pain and the suffering that Dr. Young has seen has changed his approach to patients with relatively small hernias. He said that in the past when he first started doing the plug and patch repair, he would fix anyone who would appear on his doorstep with a small hernia. However, as he became aware of the not insignificant incidence, whatever it was, of mesh entrapment of nerves, he did leave the fascia over the nerve intact as Professor Amid advocated, but more important, he was more selective in the patients that he chose to repair, and that is, if patients who did not have very many symptoms but had a hernia that appeared and really did not bother them, then he did not repair them immediately. He told me that he estimated that of the patients he saw, he operated on 20% and observed 80%, which was a real difference from the original numbers. In keeping with this, there is an entire study as I will detail in the chapters that I have had the opportunity to review as to the incidence of recurrence, which now does not seem to be as great a problem in what exactly happens to these patients postoperatively, and what is the incidence of pain?

There are a number of randomized prospective trials that have taken place in many countries, which give us some idea of what the incidence of recurrence is and what the incidence of discomfort or pain is. The first study is from the Beijing Shijitan Hospital (Gong K, et al., *Surg Endosc* 2011;25:234–9), which compared an open tension-free mesh-plug, a transabdominal preperitoneal (TAPP), and a totally extraperitoneal (TEP) laparoscopic technique for unilateral inguinal hernia repair. This is a randomized prospective trial, which was meant to compare the open Lichtenstein type of technique with two laparoscopic techniques that are commonly used in China. The authors state that the choice of the proper technique is still controversial in China and therefore this study was undertaken. There were 164 male patients with a primary unilateral inguinal hernia who were randomized, apparently correctly, to undergo an open operation with a mesh-plug and patch, very similar to the technique described by Dr. Young and Dr. Gilbert, or the laparoscopic technique (TAPP) with 50 and 52 had TEP. The follow-up was for 16 months. The usual parameters for operating time were analyzed, and the open repair was

shorter in duration, significantly so that given the relatively short operating times, that does not seem to be of tremendous significance. I take the authors at their word that the randomization is correct, although seeing these slight differences for the open technique. The open tension-free mesh-plug repair took 66 minutes, the TAPP group took 76 minutes, and the TEP group took 79 minutes; both of the laparoscopic groups took significantly longer than the open group. Pain scores, however, in the open-mesh group, which is what they were interested in, were significantly higher than in the other two groups ($P < 0.01$). Recovery time was significantly longer in the open repair group than in the other two groups. None of the groups demonstrated any recurrence. Reviewing the data in Table 193.3, it does appear as if wound healing problems were 3 of 62 or 4.8% in the open mesh-plug group, infection was 3.2% or 2, whereas there was no infection in the other group. I am not sure what to make of the pain scores. The pain was measured at 24 hours and 1 week, and there was no significant difference between the TAPP and the TEP. At 1 week, the score was 1.5 ± 0.9 versus 0.3 ± 0.5 in the TAPP and the TEP. They state that the result is statistically significant, but it must be a slightly different series of statistics than I am accustomed to. They are entitled to use whatever repair they want, but I do not see the data here, which indicates that postoperative pain of a longer duration is present. They do say in their last paragraph of the discussion that although open mesh-plug hernia repair resulted in significantly more postoperative pain than the two laparoscopic techniques, it had less postoperative pain than traditional surgical procedures and others have used a new type of patch and plug system.

I am left somewhat confused about the data as to randomization and to why they make the statement of postoperative pain unless they are talking about 1 week postoperatively because I see no sign of long-term follow-up.

A longer follow-up on patients with a modified plug and patch inguinal herniorrhaphy was reported from the Royal Gwent Hospital in Newport, South Wales. Bhattarcharjee et al. (*Hernia*, 2010;14:171–4) operated on 200 consecutive unselected men who underwent a hernia repair in 2002 ($n = 89$) and 2004 ($n = 111$). They were followed up by a questionnaire of which 57% and 78%, respectively, replied. They were neither called back nor examined in this study. The questionnaire was allegedly “patient friendly,” which evaluated the frequency and severity of groin “discomfort” and “pain.” Significant groin discomfort, which was not evaluated for frequency, was described by three (6%) and four (5%), respectively, in 2002 and 2004. Overall, only four patients (3%) said that their symptoms restricted their daily activities. Thirteen patients had inguinal surgery on the other side, and 99% (105 out 106) of respondents would undergo a similar future procedure on the opposite side. Interestingly enough, this included all but one of the patients who had pain after their hernioplasty. The authors conclude that a “modified” plug and patch with a well-dissected procedure is associated with minimal chronic groin symptoms 5 to 7 years later in patients willing to undergo a procedure on the opposite side,

indicating satisfaction.

Yet another prospective randomized control trial compared a Prolene Hernia System (PHS), Lichtenstein mesh, and a plug and patch for primary inguinal hernia repair from Gothenberg (Dalenbäck J, et al., *Hernia* 2009;13:121–9). This was a randomized control trial of a total of 472 male patients between 30 and 75 years of age, with primary inguinal hernia. They were randomized to Lichtenstein mesh, PerFix Plug, or to the PHS procedure. All patients were seen and followed up on; data was collected after 2 weeks, 3 months, 1 year, and 3 years. The follow-up rates were between 95% and 100%, the 95% being in the PHS procedure. The usual statistics as far as operative time is normally meaningless, but it was 40.4 minutes for the Lichtenstein repair, 35.5 for the PerFix Plug, and 37.4 for the PHS. More than 85% of the procedures were performed under local anesthesia, and there were no statistically significant differences between the groups concerning early or late complications, return to full function, early pain response, analgesic consumption, and the late-outcome parameters after 3 years of observation. Seven patients (1.5%) with recurrences were varied between the groups and did not accumulate in any single group. The authors conclude that the operating times were significant, but to me they are meaningless. Early and late outcomes are comparable and so there is nothing to choose between these three mesh types of procedures.

In another procedure in another study, this time from two hospital centers, in which there was at least a blinded randomized control study comparing the Lichtenstein patch to the PerFix plug and the ProLoop plug in a new type of procedure for a new type of prosthesis in the repair of primary inguinal hernia. It was reported by Sanders et al., from the Department of Surgery at Derriford Hospital, Plymouth as well as the Department of Surgery at Lake Forest Hospital, Illinois (*Hernia* 2009;13:499–503). The patients who were randomized were over the age of 18, with a single, primary unilateral hernia; they were randomized between the three groups: Lichtenstein tension-free mesh repair, PerFix plug, and the ProLoop plug. Follow-up was at 2 weeks, 6 months, and 12 months, which is short. The endpoints were operative time, pain scores, return to daily activity, complications, and length of hospital stay. There were 295 consecutive patients randomized to the study—93 to the ProLoop plug, 101 to the PerFix plug, and 101 to the Lichtenstein tension-free mesh repair. There was no significant difference among the three groups in terms of age, sex, or importantly, BMI. Operative time was essentially the same, bodily pain scores were no different, and there were no statistical differences in complication rates or in returns to daily activity. The purpose of this study was apparently to show that the ProLoop plug made by Atrium is a safe and effective method in repairing primary inguinal hernias. It is apparently lighter than the thicker mesh plugs, and “it may offer benefit in terms of long-term patient comfort.” And now a word from our sponsor, “the ProLoop plug (Atrium) represents a new effective alternative to the established mesh repairs.” It is of interest that the authors did not report any conflicts of interest.

J.E.F.

194 Postherniorrhaphy Inguinodynia: Causes, Prevention, and Surgical Treatment: Triple Neurectomy

Parviz K. Amid and David C. Chen

BACKGROUND

While the recurrence rate of inguinal hernia repairs maybe significantly reduced in some hands by use of mesh and perhaps other tension-free techniques, postherniorrhaphy chronic pain remains the concern of hernia surgeons around the globe with an incidence ranging from 4% to 20%. Based on the classification of pain by the International Association for the Study of Pain (IASP), postherniorrhaphy inguinodynia can be broadly divided into nociceptive and neuropathic pain. There is no sharp line between the nociceptive and neuropathic pain, and the gray zone is further complicated by social, genetic, patient, and psychological factors.

Nociceptive pain is caused by activation of nociceptors by nociceptive molecules due to tissue injury or inflammatory reaction, and transmitted to the brain via A-delta and C-fibers. Nociceptive pain can be reduced by gentle tissue handling, using local anesthesia to reduce production of nociceptive molecules, and avoiding forceful tissue retraction.

Neuropathic pain is caused by direct nerve injury and characterized by inguinodynia with radiation to the scrotum/femoral triangle, paresthesia, allodynia, hyperpathia, hyperalgesia, hyperesthesia, hypoesthesia, and positive Tinel sign. Neuropathic pain can be reduced from the universally reported rate of 5% to 8% to a fraction of 1% by identification of nerves and their protection from direct contact with mesh that can lead to structural changes of nerve fibers. In-depth groin neuroanatomy knowledge is of paramount importance if postherniorrhaphy chronic pain is to be avoided.

GROIN NEUROANATOMY WITHIN THE INGUINAL CANAL

The ilioinguinal nerve is located over the spermatic cord, covered and protected from the mesh by the investing fascia of the internal oblique muscle (Fig. 194.1). This protective fascia should not be damaged by removing the nerve from its natural bed. Dissecting the ilioinguinal nerve from the cord and placing it below the inguinal ligament, which was the teaching of a prior era, destroys the protecting fascia of the nerve and risks perineural scaring and direct contact of the nerve with mesh.

The genital branch of the genitofemoral nerve is located under the cord, covered and protected from direct contact with mesh by the deep cremasteric fascia. Although small and difficult to see, its location can be determined by the easily visible “blue line” of the external spermatic vein that is always adjacent to the nerve (Fig. 194.2). To ensure safety of the nerve it must be kept with the cord while the cord is separated from the inguinal floor under direct vision. Grasping the cord with the thumb and index fingers and pulling it off the floor also should be avoided as this technique damages the deep cremasteric fascia, which can also lead to perineural scaring and direct contact of the genital nerve with the implanted mesh.

The iliohypogastric nerve is located between the external and internal oblique layers covered and protected from mesh, if one must use it, by the investing fascia of the internal oblique muscle (Fig. 194.3). The key step to expose the iliohypogastric nerve is opening the anatomic cleavage between the internal and external oblique layers high enough to expose the internal oblique aponeurosis. This step, that takes only a few seconds, easily and automatically exposes the iliohypogastric nerve. The iliohypogastric nerve has an easily visible part over the internal oblique aponeurosis; however, below the point marked by the arrow in Figure 194.4, the nerve has a hidden segment that runs inferiorly and laterally within the internal oblique muscle (Figs. 194.4 and 194.5). This segment of the iliohypogastric nerve is the most vulnerable neural structure of the inguinal area because it is not visible within the operative field. Passing suture through the internal oblique muscle, or the so-called conjoined tendon, for its fixation to the inguinal ligament, flat mesh, or plug has the potential risk of injuring the intramuscular segment of the nerve with the needle, or entrapping it by the suture. In less than 5% of patients, the iliohypogastric nerve runs under the internal oblique aponeurosis in a subaponeurotic location. In these cases the location of the nerve must be determined by noting the point of its simultaneous exit from the external and internal oblique layers (Fig.

194.6). Furthermore, in these instances, no suture or fixating device should be inserted into the internal oblique aponeurosis below the area marked by the “xs” in Figure 194.6 to avoid injuring the nerve that runs inferiorly and laterally underneath the internal oblique aponeurosis (Fig. 194.5).

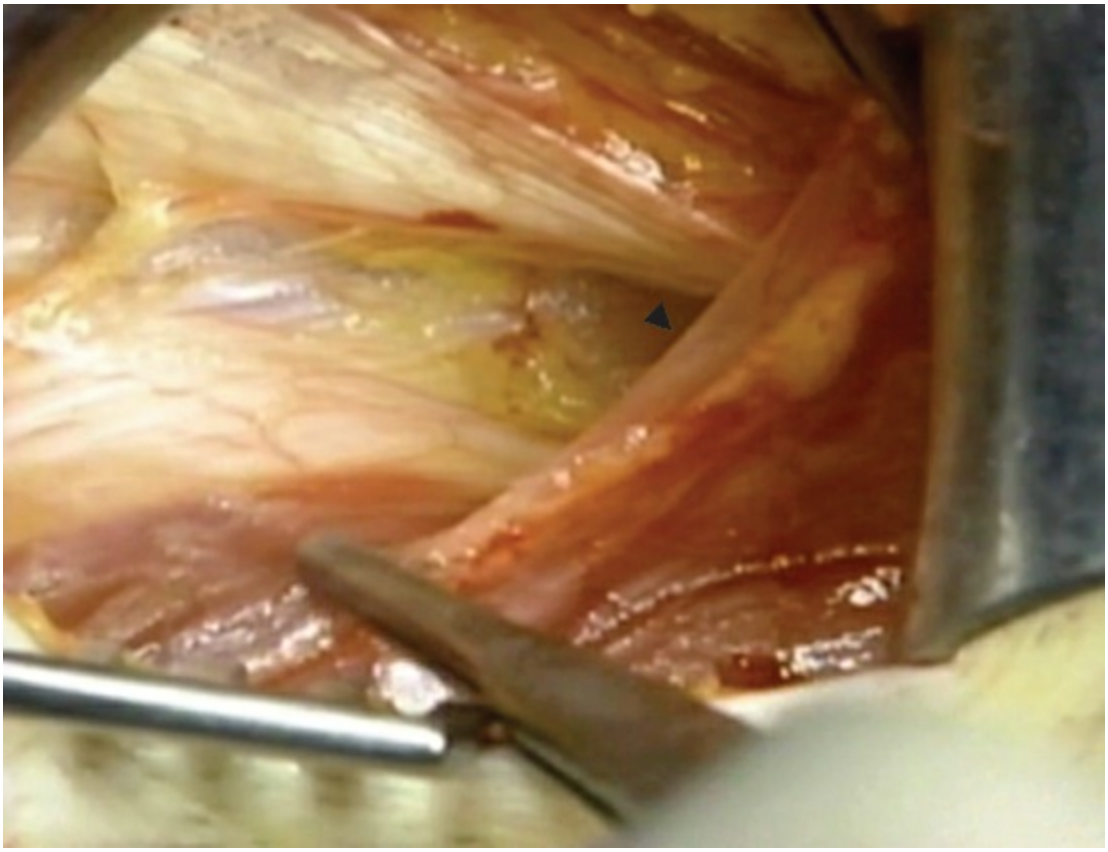

Figure 194.1. Ilioinguinal nerve is located over the cord, covered and protected by the investing fascia of the internal oblique fascia (pointed to by the *arrow*).

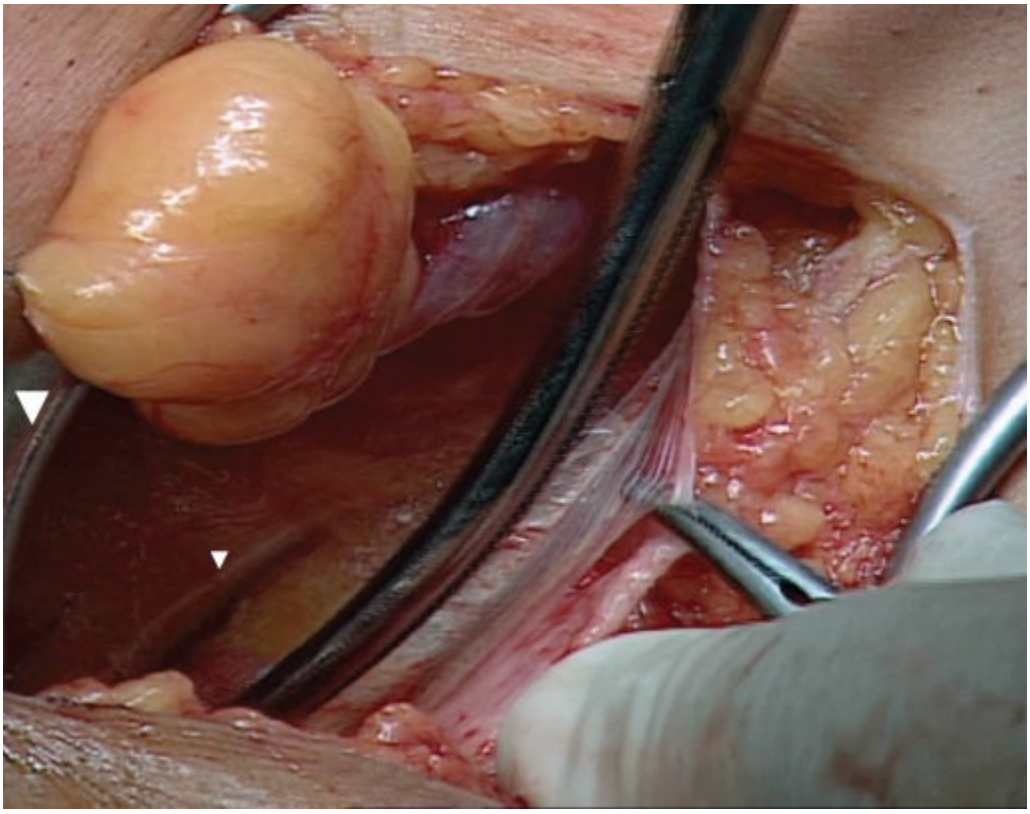

Figure 194.2. Inguinal segment of the genital branch of the genitofemoral nerve is located under the cord (pointed to by the *arrow*), covered and protected by the deep cremasteric fascia.

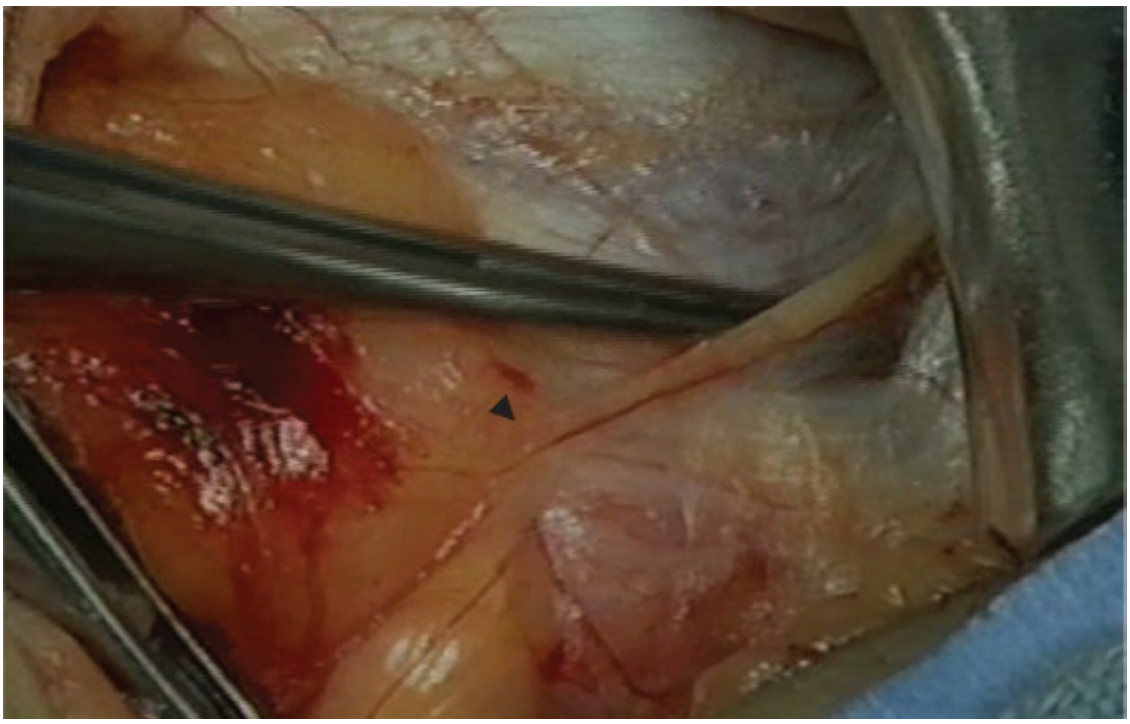

Figure 194.3. Iliohypogastric nerve is located between the external and internal oblique layers, covered and protected by the investing fascia of the internal oblique muscle. The *arrow* shows

the junction of the visible and hidden (intramuscular) segment of the nerve.

CAUSES OF NEUROPATHIC PAIN

Neuropathic pain can be caused by (a) structural injuries such as axonotmesis (disruption of axon and myelin sheath with preservation of the connective tissue covering of the nerve), neurotmesis (partial or complete severance of a nerve, with disruption of the axon and its myelin sheath and the connective tissue elements) due to cutting, thermal, or traction injuries leading to traumatic neuroma formation, and myelin degeneration and separation, axon crystallization due to direct contact of nerves with mesh; (b) entrapment injuries by suture, fixating devices, or wrinkled mesh or meshoma.

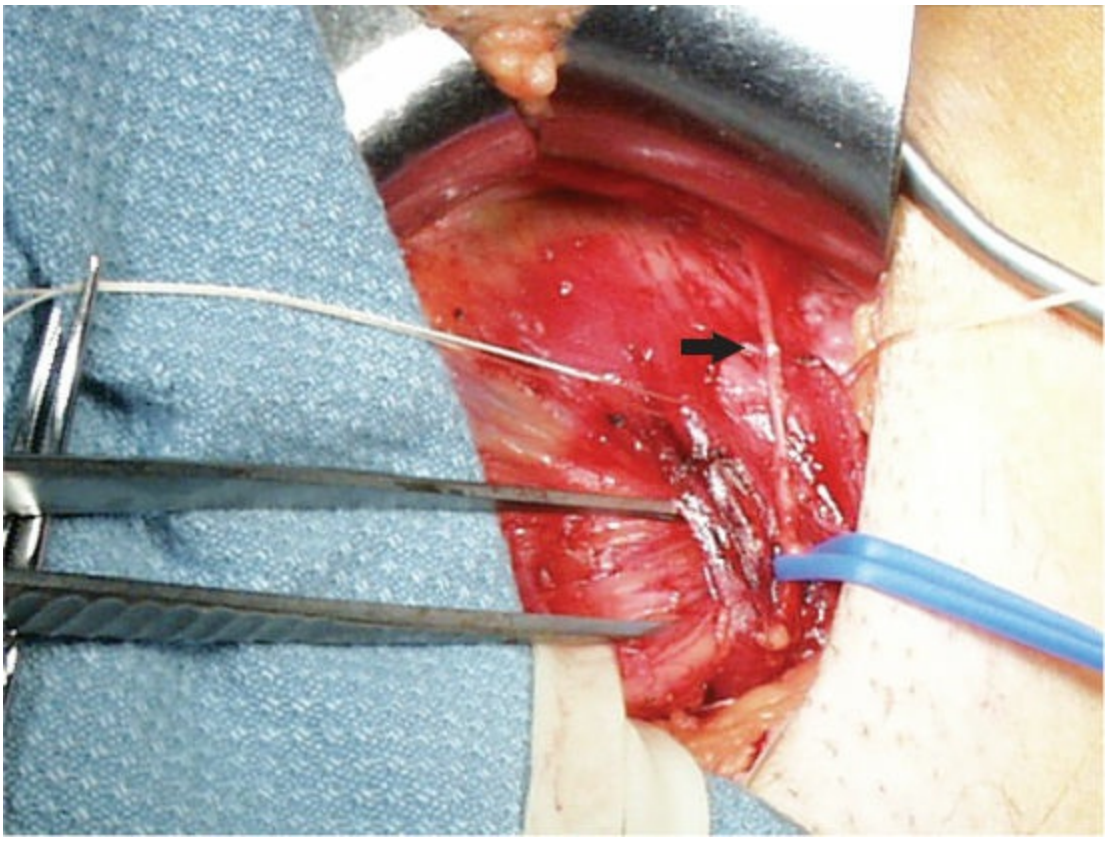

Figure 194.4. Intramuscular segment of the iliohypogastric nerve (below the *arrow*) exposed by the white sutures retracting the edges of a slit made in the internal oblique muscle to visualize the intramuscular segment of the nerve. Tip of the forceps is inside the internal ring.

SURGICAL TREATMENT OF NEUROPATHIC PAIN

Triple neurectomy, advocated by us in 1995, is currently a universally accepted surgical treatment for neuropathic pain refractory to nonsurgical modalities. Neurolysis, which does not address ultrastructural changes of nerve fibers, is no longer recommended. Also, removal of entrapping sutures or fixating devices that leave the injured crushed nerves behind is not recommended. Moreover, we do not recommend single or double neurectomy, as it does not address structural changes of the nerves that are not visible by naked eyes. The nerves should be resected proximal to the field of original hernia repair and as distally as possible. Although there are no data available, we recommend *ligation of the cut ends of the nerves to avoid neuroma* formation, and inserting the proximal cut end into the muscle to keep the nerve stump away from the future scarring of the operative field. The ilioinguinal nerve can be identified lateral to the internal ring, between the ring and the anterior superior iliac spine. If the nerve cannot be easily seen, it could be found underneath the fat-covered grooves in the internal oblique muscle fibers. The iliohypogastric nerve can be easily found within the anatomic cleavage between the external and internal oblique aponeurosis. After visualization, the nerve should be traced proximally within the fibers of the internal oblique muscle to a point lateral to the field of the original hernia repair. Failure to do so may leave the injured intramuscular segment of the nerve behind. It is important to know that in those instances where the iliohypogastric nerve has a subaponeurotic course, the internal oblique aponeurosis is split below the point of its simultaneous exit from the internal and external oblique aponeurosis to visualize the hidden nerve (Fig. 194.5). The inguinal segment of the genital branch of the genitofemoral nerve can be identified between the cord and the inguinal ligament and traced laterally to the internal ring where it is severed. An easier alternative is to visualize the nerve within the internal ring through the lateral cruse of the ring.

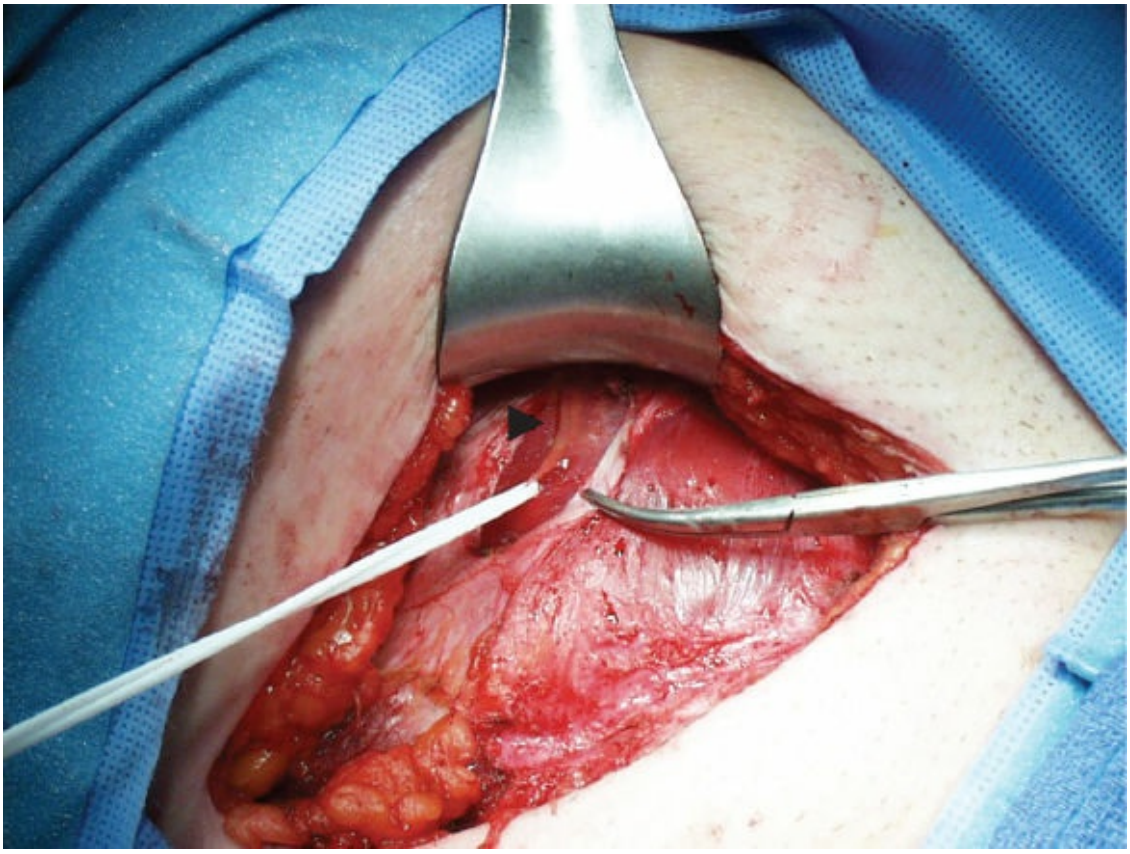

Figure 194.5. Internal oblique aponeurosis below the point of its exit is slit to visualize the inferior and lateral course of the iliohypogastric nerve (pointed to by the *arrow*) underneath the internal oblique aponeurosis.

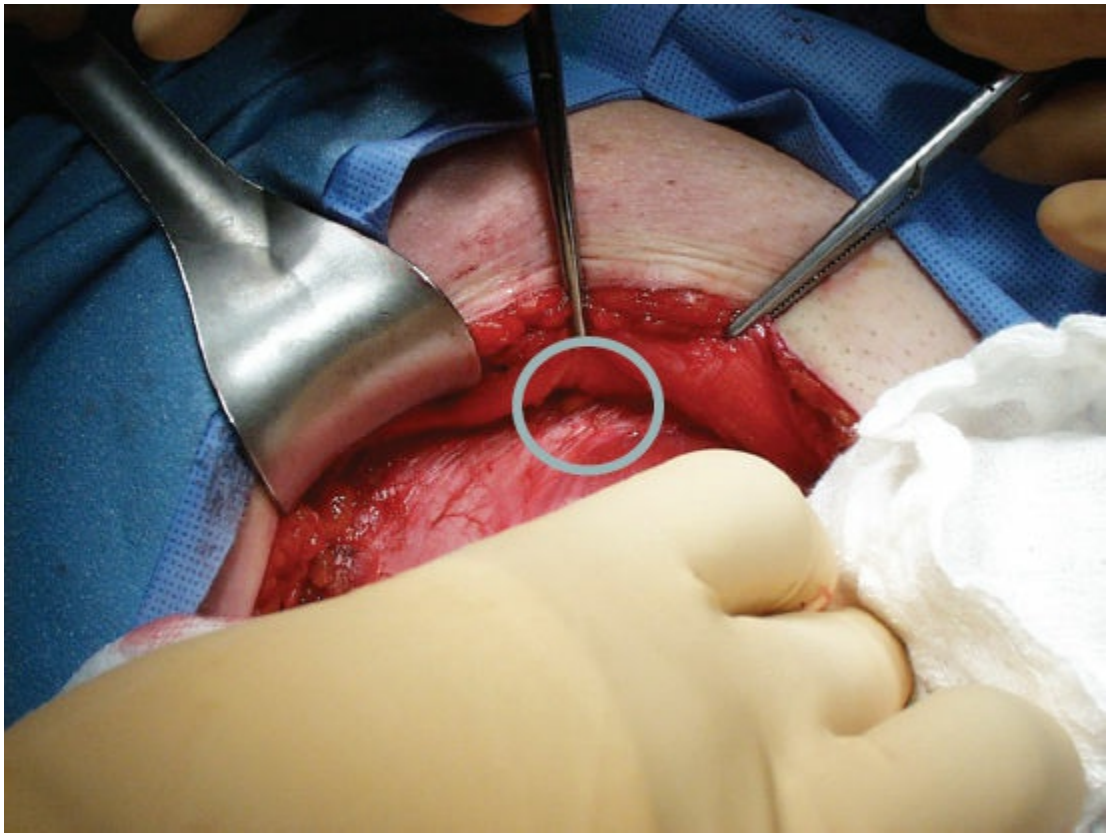

Figure 194.6. Point of simultaneous exit of a subaponeurotically located iliohypogastric nerve (inside the *circle*) from the internal and external oblique aponeurosis.

INDICATION FOR TRIPLE NEURECTOMY AND RESULTS

Recommended timing for surgical treatment of chronic postherniorrhaphy pain, not responding to nonsurgical treatment, is 6 months to 1 year after the original hernia repair. It is important to ask, and document, if the patient had groin pain prior to the original hernia repair and whether the postoperative pain is different from the preoperative pain. Best candidates for the operation are those patients who have no mesh material in their preperitoneal space. This is because “triple neurectomy” does not address neuropathic pain caused by neuropathy of the preperitoneal nerves, unless the operation is extended to include segmental resection of the main trunk of the genitofemoral nerve over the psoas muscle through the same split made in the internal oblique muscle for resection of the intramuscular segment of the iliohypogastric nerve (also see “Chronic Pain After Open and Laparoscopic Preperitoneal Hernia Repairs”). Our series now stand at 500 patients. Prior to including the intramuscular segment of the

iliohypogastric nerve, 85% of our patients in whom the original hernia operation was limited to the front of transversalis fascia had satisfactory results. After extending the procedure to include the intramuscular segment of the iliohypogastric nerve, 95% of our patients had satisfactory results. Triple neurectomy in women leads to numbness on the corresponding labia and sexual dysfunction. This issue requires serious consideration and should be discussed with the patient and adequately recorded.

POSTHERNIORRHAPHY ORCHIALGIA

Based on our limited observation of 17 patients, neuropathy of the nerve fibers within the lamina propria of the vas deferens, referred to as “paravasal nerves” and originating from the deep pelvic plexus, may be responsible for postherniorrhaphy orchialgia. In 17 patients with groin pain associated with orchialgia, segmental resection of the lamina propria of the vas together with triple neurectomy eliminated the testicular pain. Although our experience with paravasal neurectomy for postherniorrhaphy orchialgia is limited, it seems promising and deserving of additional study.

CHRONIC PAIN AFTER OPEN AND LAPAROSCOPIC PREPERITONEAL HERNIA REPAIRS

Pain after preperitoneal herniorrhaphy (both open and laparoscopic) presents special problems. The preperitoneal nerves, including the main trunk of the genitofemoral, its femoral branch, and the preperitoneal segment of its genital branch, are particularly vulnerable to neuropathy from direct contact with mesh. Because contrary to the nerve within the inguinal canal that are covered and protected by a layer of fascia, nerves in the preperitoneal space have no protecting fascia against the mesh. An additional problem related to laparoscopic preperitoneal hernia repair using fixating devices is penetration of fixating devices through the transversalis fascia and abdominal muscles and entrapment of the nerves within the inguinal canal (Fig. 194.7).

CONCLUSION

According to the Swedish Hernia Registry, at this point in time the incidence of postherniorrhaphy chronic pain is greater than that of its recurrence, and ranges between 6% and 8%.

Based on level A evidence from the Netherlands, Denmark, and Italy, nerve identification and protection during inguinal hernia repair reduces the rate of chronic pain to a fraction of 1%.

There is no sharp demarcation between nociceptive and neuropathic pain, and the gray zone is further complicated by genetic, social, psychological, and patient factors. Furthermore, our collaborative study with a group of investigators from Germany suggests that there may also be some biochemical factors at work. These factors include higher-level collagen-3 in the harvested nerves from the patients with neuropathic pain. In addition, chronic inguinodynia is a problem for which there is no universally accepted definition, etiology, classification, and surgical treatment except for triple neurectomy where there is no mesh material in the preperitoneal space. Therefore, at this point in time, the best we can do for our patients is preventing this debilitating complication of hernia surgery. The latter requires in-depth knowledge of pathophysiology of pain and groin neuroanatomy. A number of investigators have shown that failure to identify the nerves is a risk factor for development of chronic pain: some have gone so far to advocate prophylactic neurectomy to avoid chronic pain, a maneuver that we and others believe is an inferior alternative to careful nerve handling. At any time if a nerve is in the way of the repair or suspected of being injured, its resection is universally recommended. In summary, chronic pain can be significantly reduced by not damaging the protective fascia of the ilioinguinal nerve by removing the nerve from its natural bed, by not passing suture through the internal oblique muscle to avoid injuring its intramuscular segment, and by not damaging the deep cremasteric fascia, the protective fascia of the genital nerve, by careful dissection of the cord from the inguinal floor.

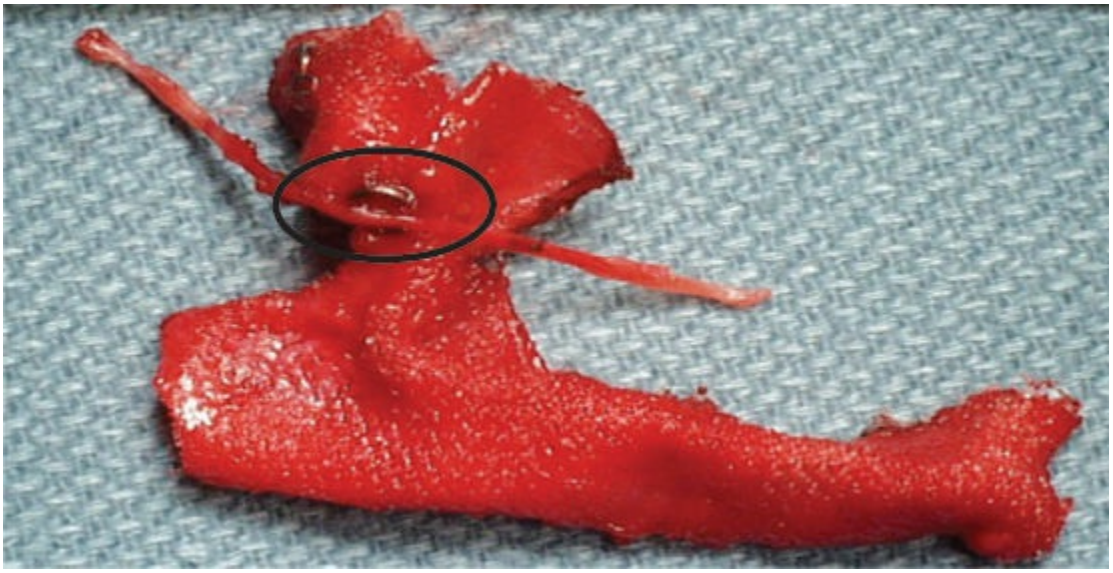

Figure 194.7. Entrapment of the iliohypogastric nerve by a tack used for mesh fixation during a laparoscopic inguinal hernia repair. The mesh is also in the process of forming a meshoma.

Suggested Readings

Aasvang E, Kehlet H. Surgical management of chronic pain after inguinal hernia repair. *Br J Surg* 2005;92:795–801.

Aasvang E, Kehlet H. The effect of mesh removal and selective neurectomy on postherniorrhaphy persistent pain. *Ann Surg* 2009;171:217–20.

Alfieri S, Rotondi F, Di Giorgio A, et al. Influence of preservation versus division of inguinal, iliohypogastric, and genital nerves during mesh hernioplasty: prospective multicenter study of chronic pain. *Ann Surg* 2006;243:553–8.

Amid PK. Causes, prevention, and surgical treatment of postherniorrhaphy inguinodynia: triple neurectomy with proximal end implantation. *Hernia* 2004;8:343–9.

Amid PK. Radiological images of meshoma: a new phenomenon after prosthetic repair of abdominal wall hernia. *Arch Surg* 2004;139:1297–8.

Amid PK. New understanding of the causes and surgical treatment of postherniorrhaphy inguinodynia and orchalgia. *J Am Coll Surg* 2007;205:381–5.

Kingsnorth AN, Bowley DM, Porter C. A prospective study of 1000 hernias; results of the plymouth hernia service. *Ann R Coll Surg Engl* 2003;85:18–22.

Wijsmuller AR, Lang JF, Kleinrensink GJ, et al. Nerve-identifying inguinal hernia repair: a surgical anatomical study. *World J Surg* 2007;31:214–20.

Wijsmuller AR, Lange JF, Geldere D, et al. Surgical technique preventing chronic pain after Lichtenstein hernia repair: state-of-the-art vs. daily practice in the Netherlands. *Hernia* 2007;11:147–51.

EDITOR'S COMMENT

This is an important chapter in this book. It is interesting to note that there seems to be a great deal of denial, inconsistent follow-up, or else the results in various series are so different that there are a large group or series in which there is no postherniorrhaphy incisional pain. However, it does seem to me that there are an awful lot of papers that deal with either prophylactic neurectomy or neurectomy following inguinal herniorrhaphy. By employing mesh have we have traded off the absence of recurrence or minimal recurrence for a fairly large group of patients who had posthernia pain, some of which may be severe? Despite technologic advances with light with polypropylene, postherniorrhaphy continues to be a problem many patients. A recent series reported pain at 1 year in 13% and 25% at 2 years. Is polypropylene as inert as we all think? Nerves become adherent to it. In addition a recent study documented oxidative stress related to polypropylene mesh that was proportionate to the amount of material used (Donati M, Brancato G, Grosso G, et al. Immunological reaction and oxidative stress after light or heavy polypropylene mesh implantation in inguinal hernioplasty: A CONSORT-prospective, randomized, clinical trial. *Medicine* 2016;95(24):e3791). Today patients are now asking for mesh-free hernia repairs. In the paragraphs below we review methods of reducing pain by nerve excision but perhaps we should do more repairs without mesh.

All of this is concerning. There seems to be a trend as some in the surgical community would rather remove nerve tissue at the time of hernia repair rather than doing a mesh-free repair. Johner et al. report in a systemic literature search (Johner A, Faulds J, Wiseman SM. Planned ilioinguinal nerve excision for prevention of chronic pain after inguinal hernia repair: a meta analysis. *Surgery* 2011;150(3):534–41) that during an operation for hernia that has no postoperative pain, it does seem that there is increasing literature activity concerning excision of ilioinguinal or iliohypogastric and genitofemoral nerves for an operation, which has been reported as having no postoperative pain. Chronic postherniorrhaphy pain has reached the point that is truly a public health problem. At least 5% of the population (mostly males) will develop a groin hernia in their lifetime, making groin hernia repair one of the most common operations performed by general surgeons. With more recent attention paid to patient outcomes, apparently "chronic postoperative pain is now considered the most frequent and disabling complication of hernia repair" (Nienhuijs S, Staal E, Strobbe L, et al. Chronic pain after mesh repair of inguinal hernia: a systematic review. *Am J Surg* 2007;194(3):394–400). There seem to be an awful lot of prophylactic studies on excising various nerves, including ilioinguinal, iliohypogastric, and genitofemoral for a problem that does not exist. To do their review, Johner et al. underwent a systematic literature review to identify studies investigating the influence of ilioinguinal nerve excision on the development of chronic pain after inguinal hernia repair.

Once the studies were identified, an analysis of the pool of data was carried out. A total of 6,023 abstracts were reviewed of this supposedly nonexistent problem. Four high-quality randomized controlled trials were identified, and the endpoint is the pooled mean difference in degree of pain at 6 months postoperatively on a 10-point scale. The evidence favored neurectomy to decrease the chance of developing chronic pain. As the authors state in their abstract, "not surprisingly, those individuals undergoing neurectomy were also more likely to develop altered sensation at the same time point." This was statistically significant. The authors concluded that the planned neurectomy seemed to decrease the incidence of chronic postoperative pain.

This controversy is not new. In the past, Lichtenstein and his successor Amid, who is the author of this chapter, recommended preservation of the ilioinguinal, iliohypogastric, and genitofemoral nerves (Lichtenstein IL, Shulman AG, Amid PK, et al. Cause and prevention of postherniorrhaphy neuralgia: a proposed protocol for treatment. *Am J Surg* 1988;155(6):786–90 and Amid PK. Lichtenstein tension-free hernioplasty: its inception, evolution, and principles. *Hernia* 2004;8(1):1–7), whereas Wantz of Cornell (Wantz GE. Complications of inguinal hernia repair. *Surg Clin North Am* 1984;64(2):287–98) recommended intentional nerve division. It is of interest that George Wantz, a very well-known herniorrhaphy specialist recommended inguinal nerve division, whereas in my experience, simple inguinal nerve division is not satisfactory and one must do a resection of all the three nerves since they communicate. It does appear that if in this study as if the ilioinguinal neurectomy there was a significant amount of altered sensation at 6 months after surgery, with decreased touch sensation at 6 months following herniorrhaphy. The authors do conclude on the basis of this data that inguinal neurectomy does prevent chronic pain, which may very well be troublesome—a conclusion also supported by Wijsmuller AR et al., from Holland (Wijsmuller AR, van Veen RN, Bosch JL, et al. Nerve management during open hernia repair. *Br J Surg* 2007;94(1):17–22).

Another paper, "Ilioinguinal nerve excision in open mesh repair of inguinal hernia—results of a randomized clinical trial: simple solution or a difficult problem?," which proposes a solution to this nonexistent problem comes from the Department of Community Medicine in Tehran by Malekpour F, et al. (Ilioinguinal nerve excision in open mesh repair of inguinal hernia—results of a randomized clinical trial: simple solution for a difficult problem? *Am J Surg* 2008;195:735–40). In this study, the authors carried out a double-blind randomized clinical trial performed on 121 patients undergoing open anterior mesh repair of inguinal hernia in one center from April 2005 to June 2006. In half of the patients, the ilioinguinal nerve was excised (but not buried) and in the other half, it was preserved. Pain and hypesthesia on postoperative day 1, and 1 and 6 months after surgery, and 1 year after surgery were evaluated in both groups using a visual analog scale. Of the 121 patients, who were aged between 18 and 86 years, 115 (95%) were male. There were 61 in the nerve-

excision group and 60 in the nerve-preservation group. Follow-up was performed on 100 patients at the end of the first year. The mean scores of the nerve-excision group were 2.2 ± 0.8 versus 2.8 ± 0.7 in the nerve-preservation group ($P < 0.01$). Between 6 months and a year after surgery, median scores of zero were detected in both groups. After postsurgical day 1, the median score of hypesthesia was near zero in both groups, and 13 patients, interestingly enough, developed chronic inguinodynia—10 of whom were in the nerve-preservation group, and presumably three were in the nerve-excision group. Chronic postsurgical inguinodynia was seen in 6% of patients in the ilioinguinal nerve-excision group and in 21% of the patients in which the ilioinguinal nerve-preservation group was preserved. To me this is not surprising. Inguinodynia is a curious phenomenon, but it cannot be completely obviated by excision of the nerve unless I believe one takes the nerve all the way back to its most lateral extent, splits the muscle, ties off the nerve with 6-0 Prolene, touches the nerve with phenol and alcohol, and then buries the nerve in the muscle. It does not appear as if this was done. In addition, if one just takes one of the nerves, in this case the ilioinguinal nerve but not the iliohypogastric and the genitofemoral, then I believe that the incidence of inguinodynia is increased and that is the reason why inguinodynia is 21%.

In another two papers, this time from Veldhoven, the Netherlands, a randomized control trial of injection therapy versus neurectomy for postherniorrhaphy neuralgia was first described as to its design (Loos MJ, Verhagen T, Scheltinga MR, et al. A randomized controlled trial of injection therapy versus neurectomy for post-herniorrhaphy inguinal neuralgia: rationale and study design. *Hernia* 2010;14(6):593–7) and then in follow-up by Loos and his colleagues (Tailored neurectomy for treatment of postherniorrhaphy inguinal neuralgia. *Surgery*, 2010;147(2):275–81). In this study, the registry of patients for postherniorrhaphy groin pain treated by a neurectomy, a study that was designed in the previously mentioned paper, is analyzed. They received a questionnaire evaluating the current pain intensity, overall treatment results, and specifically the effect of sexual intercourse–related pain. The risk factors for failure, and not surprisingly, I think a very good one, the presence of a learning curve is identified. There were 54 patients who underwent a neurectomy over a 5-year period. Of the 54, 49 (91%) responded, 52% claimed to be almost free of pain (good to excellent), 24% reported some relief (they still felt pain on a regular interval), and 24% did not benefit. Sexual intercourse–related pain apparently responded favorably to neurectomy in two thirds of patients. There seemed to be a steep learning curve in performing the procedure and poor treatment results also depended on previously received pain regimens ($P = 0.021$). The authors concluded, and I do not agree, that a selective operative neurectomy for postherniorrhaphy groin neuralgia provides good long-term pain relief in most patients, which I do not believe is true. They and the abstract state as follows: hernia surgeons who are responsible for this iatrogenic complication should consider incorporating selective neurectomy in their surgical

armamentarium. I am not sure that I agree with this conclusion. As I take on a number of these patients, and there are many surgeons who are not particularly interested in dealing with their patients—whether they are their own patients who develop postoperative neural pain or whether they are someone else's, there is a steep learning curve in learning how to deal with these patients. One must resect all three nerves and enter into the internal inguinal canal to resect the crural nerve. If the resection of the genitofemoral nerve either fails or it cannot be found, it is necessary to do a follow-up of a laparoscopy entrance into the retroperitoneum and separate the genitofemoral nerve's origin from that of the lateral femoral cutaneous nerve. The ilioinguinal and iliohypogastric nerves need to be dissected completely, taken back as far laterally, tied off, touched with phenol alcohol, in my humble opinion to prevent the nerve from being alive even as one cohort is buried. Even so, this is not a procedure which works 100% of the time; it is successful closer to 80% of the time. The cavalier way in which some of the authors refer to this procedure is out of place. Many of these patients' lives are ruined.

Finally, the inguinal incision and nerve excision is not only for inguinodynia. This pain also occurs following a Pfannstiel incision, which I like to use for certain operations, and if one wanders off how one does during a Pfannstiel incision, it is entirely possible to entrap the ilioinguinal lump and iliohypogastric nerve. Loos et al., the same group from the Netherlands, have identified 27 women with Pfannstiel-related neuralgia between 2000 and 2007. They say that a single diagnostic nerve block provided long-term pain relief in five patients, which occasionally is true, especially if triamcinolone is included. The remaining 22 underwent neurectomy of which 22 had good to excellent results in 73%, moderate in 14%, and poor in 13% after a median follow-up of 2 years. In particular, successful treatment improved intercourse-related pain in most patients. Lumbosacral radicular syndrome was apparently eliminated as best that the authors could in an effort to identify those patients who had significant pain. That was likely to be from the lumbosacral joint.

This is an important chapter. Given the number of hernias that are done, the fact that mesh is utilized in almost all and the fact that the preventive methods, which have been identified in this chapter by Dr. Amid, which is leaving the nerves within their fascial envelope, is not universally carried out; there are a large number of people who have inguinodynia. Since I have treated them, several have had their lives ruined and one particular patient committed suicide not so much because of his inguinodynia, which was well treated, but because of congestive heart failure. He had had enough. Dr. Amid has experienced more than 500 patients with inguinodynia; he hopes that surgeons will pay attention to the nerves and leave them within their fascial envelope, which I suspect they do not. Once the syndrome is identified, it behooves one to try injections for the trigger point using xylocaine, marcaine, and triamcinolone and if there is no relief, then the patients ought to undergo triple neurectomy as is proposed in this group and in this chapter. The admonition that triple neurectomy does not

address neuropathic pain “caused by neuropathy of the preperitoneal nerves, unless the operation is extended to include segmental resection of main trunk of the genitofemoral nerve over the psoas muscle” prior to the split; this can only be entered retroperitoneally, though more easily laparoscopically, is a statement that I agree with entirely. To get the trunk of the genitofemoral nerve it will also be necessary to render the area of the lateral femoral anterior cutaneous nerve anesthetic, which may be a sensation the patients do not like. Dr. Amid is an expert in this area, and there will be more and more people who will be carrying out triple neurectomies and nerve dissections in order to rid patients of this complication. Since 5% of patients have inguinal hernias and with mesh repairs, probably about 10% will have some sort of neuropathic pain postoperatively, there is enough work to go around. Perhaps we have come full circle and mesh-free hernia repair will see a recrudescence. We predict consumerism will drive mesh-free hernia repair.

J.E.F. and E. Christopher Ellison

SECTION IX

VASCULAR SURGERY

A CEREBROVASCULAR DISEASE

195 Carotid Bifurcation Disease: Carotid Endarterectomy and Stenting

Sapan S. Desai

ETIOLOGY AND PATHOPHYSIOLOGY

Epidemiology

Stroke is the result of a focal disruption of the intracranial blood supply leading to a discrete neurologic deficit that lasts for over 24 hours. There are two types of stroke: ischemic stroke is the result of arterial occlusion, while hemorrhagic stroke occurs due to vessel rupture. Approximately 87% of the more than 600,000 new strokes annually within the United States are ischemic. Ischemic stroke can be due to cerebrovascular disease (17%), cardioembolism (30%), lacunar infarcts (16%), and unknown etiology (37%).

While the overall rate of stroke has decreased over the past 20 years, potentially due to the use of statins, antihypertensives, and better control of risk factors, such as smoking and diabetes, stroke still remains the fourth leading cause of death within the United States and leads to almost $80 billion in direct costs. Only about 10% of patients with stroke return to their baseline function, and this lost productivity leads to an additional $35 billion in indirect costs.

Etiology

Stroke due to cerebrovascular disease is primarily from stenosis of the internal carotid artery (ICA), and most commonly presents as thromboembolism within the distribution of the anterior cerebral arteries

(ACAs) or middle cerebral arteries (MCAs). The risk of stroke increases according to the severity of the atherosclerotic stenosis. In asymptomatic patients with less than 50% ICA stenosis, the annual risk of stroke is <1%; between 50% and 80%, the annual risk of stroke is 0.8% to 2.4%; and over 80% is associated with a 1% to 5% annual risk of stroke. Carotid artery thrombosis and low-flow states are rare causes of cerebral ischemia.

Pathophysiology

Atherosclerotic carotid artery disease leads to plaque formation at areas of low shear stress and flow stagnation, which primarily occurs at the posterolateral portion of the carotid bifurcation. Most plaques are characterized by a fibrous cap, areas of focal calcification, lipid accumulation, and neovascularization. Unstable plaques may become ulcerated, are more prone to atheroembolization, and are characterized by rupture, large lipid cores, hemorrhage within the plaque, and inflammation. Plaques that lead to progressive stenosis over time are also associated with an increased stroke risk; however, they are much more significant indicator of overall cardiovascular disease burden and subsequent risk of myocardial infarction (MI).

Risk Factors

Risk factors for cerebrovascular disease include advanced age, male gender, African American race, hypertension, smoking, hyperlipidemia, diabetes, and renal failure. Atherosclerotic carotid artery disease is present in about 2.5% of all patients, and increases to 5.5% of women and 10.5% of men over the age of 60. Transient ischemic attacks (TIAs) are focal neurologic deficits that resolve within 24 hours, and are a strong risk factor for future stroke.

Anatomy

Aortic Arch

Mastery of the cerebrovascular anatomy is essential to surgical success. The blood supply to the brain originates from branches of the aortic arch. In the normal configuration (found 75% of the time), the three great vessels from the arch include the brachiocephalic artery, left common carotid artery (CCA), and the left subclavian artery. The brachiocephalic artery, sometimes referred to as the innominate artery, divides into the

right subclavian and right CCAs. Each CCA travels within a carotid sheath, along with the internal jugular vein and vagus nerve. The CCA bifurcates into the external carotid arteries (ECAs) and ICAs at the level of the fourth cervical vertebra. The ICA then travels directly into the skull through the carotid canal.

External Carotid Artery

The ECA is differentiated from the ICA near the bifurcation by having a branch that comes off within the first centimeter of the vessel's origination. The superior thyroid artery is the first branch of this vessel before the ECA travels toward the face. The remaining branches of the ECA include the ascending pharyngeal artery, lingual artery, facial artery, occipital artery, and posterior auricular artery. The two terminal branches of the ECA are the maxillary artery and superficial temporal artery.

There are over a dozen connections between the extracranial and intracranial (EC and IC) circulation. While not large enough to prevent major stroke if there is sudden occlusion of the ICA, these anastomoses can be the source of collateral blood flow, but also potentially are associated with thromboembolism to the brain. The most important of these collateral pathways include branches of the internal maxillary artery and superficial temporal artery (ECA branch) to the ophthalmic artery (ICA branch). Branches of the ascending pharyngeal artery (ECA branch) can connect to the caroticotympanic artery (ICA branch). Due to their proximity, a surgical bypass between the superficial temporal artery (ECA branch) and MCA, known as an EC–IC bypass, can be performed in some situations.

TABLE 195.1 Major Segments of the Internal Carotid Artery

Segment	Name	Description
C1	Cervical segment	Extends from carotid bifurcation to carotid canal No branches for extracranial ICA
C2	Petrous segment	Extends from temporal bone to foramen lacerum First branch is caroticotympanic artery
C3	Lacerum segment	Extends from foramen lacerum to periosteal portion of the sphenoid bone
C4	Cavernous segment	Surrounded by cavernous sinus Risk of carotid artery to cavernous sinus fistula
C5	Clinoid segment	Extends from cavernous sinus to subarachnoid space
C6	Ophthalmic segment	Major branch is ophthalmic artery
C7	Communicating segment	Terminal branches of the ICA (ACA and MCA)

Internal Carotid Artery

The ICA is divided into seven distinct segments, which are described in Table 195.1.

Vertebral Artery

The vertebral artery is the first branch off the first part of the subclavian artery on each side. The vertebral artery is divided into four parts. The first part emanates from the subclavian artery, travels to the transverse process of the C6 vertebra, and is accessible for surgical bypass or transposition. The second part travels within the foramina of the transverse processes between C2 and C6 and is generally inaccessible. The third part travels from the C2 transverse process foramen to the vertebral canal, and is accessible for surgical bypass. The fourth part is primarily intracranial and joins together with the contralateral vertebral artery to form the basilar artery. The basilar artery is the chief blood supplier to the posterior portion of the circle of Willis.

Circle of Willis

The circle of Willis is a major cerebral circulatory anastomosis that provides redundant blood supply between the right and left brain, and anterior and posterior brain. The right and left ACAs have a small communicating branch known as the anterior communicating artery. Emanating from the MCA, the posterior communicating arteries connect to the basilar artery.

The five segments of the ACA supply the anterior midline of the brain, including the frontal and superomedial parietal lobes, the caudate nucleus, and the anterior limb of the internal capsule. The four segments of the MCA supply the lateral cerebral cortex, including the frontal, parietal, and temporal lobes, the basal ganglia, and the insula.

The posterior communicating artery connects the circle of Willis to the posterior circulation, including the posterior cerebral artery (PCA) and branches of the basilar artery. This communicating artery is usually small; thus, occipital lobe and cerebellar strokes are a rare manifestation of carotid artery disease.

Management

Treatments of clinically significant atherosclerotic carotid artery disease include medical management, carotid endarterectomy (CEA), carotid artery stenting (CAS), and carotid artery bypass. Carotid artery bypass options include EC-IC bypass, and a CCA to ICA bypass. EC-IC bypass for carotid artery stenosis is associated with poor outcomes and is typically reserved for obliterative diseases, such as Moyamoya disease. CCA to ICA bypass is an uncommon procedure reserved for cases where endarterectomy or stenting cannot be completed. CEA and CAS are discussed below.

Best medical therapy includes amelioration of key risk factors and stabilization of the plaque. The blood pressure should be normalized as close to 120/80 mm Hg as possible for hypertensive patients. The goal HgbA1c should be less than seven for diabetics. Absolute smoking cessation and alcohol consumption reduced to less than two drinks per day are urged. Hyperlipidemia should be corrected to obtain low-density lipoprotein (LDL) levels below 70 mg/dL and high-density lipoprotein (HDL) levels above 40 mg/dL. While statins are typically the first-line therapy for the treatment of hyperlipidemia, they should be initiated in all patients with vascular disease due to their plaque-stabilization, antithrombotic, and anti-inflammatory properties. Finally, patients should also be on one or more antiplatelet agents, such as 81 mg of aspirin daily and/or 75 mg of clopidogrel daily. Dual antiplatelet therapy is most commonly indicated for patients undergoing CAS.

CLINICAL PRESENTATION

TIA/Stroke

TIAs are the result of ischemia to a specific portion of the brain due to hypoperfusion secondary to stenosis or thromboembolism. TIAs have no sequelae beyond 24 hours and the patient returns to their baseline status by this time. Any defect beyond 24 hours is a stroke. Almost 30% of patients who develop a TIA will have a stroke within 5 years.

Stroke is a neurologic deficit lasting more than 24 hours. While acute symptoms can be devastating, the permanent deficit tends to be less as the ischemic portion of the brain improves. Loss of cerebral matter leads to permanent deficits, but loss of function can sometimes be improved with rehabilitation and surgery.

The neurologic deficit following TIA or stroke depends upon the vessel affected. Disruption of the ACA leads to motor and sensory loss of the contralateral lower extremities and changes to the personality. In the acute phase, urinary incontinence can be present, particularly with large strokes that cause bilateral ischemia. Disruption of the MCA can present as motor and sensory loss of the contralateral upper extremities and the face. A left hemispheric stroke can lead to Broca or Wernicke aphasia in left hemisphere dominant (i.e., right-handed) people and neglect of the contralateral side. Motor deficits can range from minor loss of motion to total hemiparalysis. Sensory deficits have a similar gamut ranging from mild numbness to total paresthesia.

Thromboembolism to the ophthalmic branch of the ICA can affect the retinal artery and lead to temporary blindness, known as *amaurosis fugax*. Stereotypical deficits from multiple TIAs or stroke indicate a high likelihood of carotid artery disease, whereas a mixed picture of right and left-sided deficits over time is more typical of cardiac emboli.

PCA-distribution deficits are rare with carotid artery disease and should prompt an exploration of vertebral artery disease. Patients who present with vestibular deficits such as dizziness, vertigo, or abnormalities of gaze, tonic/clonic deficits, loss of consciousness, new onset migraine headaches, amnesia, and confusion are more likely to have disease affecting their vertebrobasilar vascular system. Stroke leading to loss of pain and temperature, visual field defects, Horner syndrome, and facial nerve palsies of the lower face are also uncommonly related to carotid artery disease.

Hypoperfusion Syndrome

Hypoperfusion syndromes leading to global ischemia are rare. These

patients present with syncope or unconsciousness and most cases are due to severe cardiovascular compromise. Severe flow-limiting lesions affecting the carotid arteries do occur occasionally and necessitate treatment of the cerebrovascular blood supply. In rare circumstances, patients with severe disease of the vertebrobasilar system who rely upon the collateral anterior circulation system may develop progressive posterior circulation symptoms due to worsening ICA disease. These patients have a flow-limiting syndrome that may improve with the treatment of the carotid artery disease.

Lacunar Infarct

Lacunar infarcts occur with thrombosis of small vessels within the brain and not usually related to carotid artery disease, due to the larger deficits that tend to occur from atheroembolic sources.

INDICATIONS AND CONTRAINDICATIONS

All patients with cerebrovascular disease should have risk factor modification. Antiplatelet agents and statins are indicated in virtually all patients with an atherosclerotic disease burden. A subset of patients with more clinically significant disease may be candidates for carotid revascularization, such as CEA or CAS. The American Heart Association (AHA), European Society of Cardiology (ESC), and Society for Vascular Surgery (SVS) have published guidelines describing the indications and contraindications to surgery for these patients.

Asymptomatic Carotid Artery Disease

Asymptomatic patients with at least 60% ICA stenosis who are expected to have a 3- to 5-year survival and are likely to survive an intervention and therefore are candidates for surgery. Due to the higher stroke rate associated with CAS, most of these patients should undergo CEA. CAS can be considered in these patients if the interventionalist has a <3% risk of complications or it is being done as part of a clinical trial. High-risk patients or those with poor likelihood of long-term survival should undergo best medial therapy. Due to the improvement in medical management of risk factors and increased use of statins, most clinicians will wait until at least 70% ICA stenosis before proceeding with CEA in asymptomatic patients (Table 195.2).

TABLE 195.2 Indications for Carotid Revascularization

Asymptomatic Disease	Symptomatic Disease
>70% carotid artery stenosis	>50% carotid artery stenosis
>50% carotid artery stenosis and ulcerated plaque	Symptoms within 3 months
<3% risk of complications by surgeon	<6% risk of complications by surgeon
Life span at least 3–5 years	Able to survive intervention

Symptomatic Carotid Artery Disease

Symptomatic patients with at least 50% carotid artery stenosis are candidates for an intervention, according to the AHA and SVS guidelines. The ESC guidelines indicate intervention for patients with at least 70% stenosis. For most clinicians within the United States, low-risk symptomatic patients with at least 50% carotid artery stenosis will undergo CEA. Patients with major cardiac risk factors, hostile necks, or other high-risk situations may undergo CAS. Symptomatic patients should undergo surgery within 2 weeks whenever possible, as most of the risk of recurrent stroke occurs within that 2-week period. Presently, CAS is generally indicated only in symptomatic patients and only when the risk associated with CEA is too high (Table 195.3).

Timing of Surgery

A subgroup analysis of the North American Symptomatic Carotid Endarterectomy Trial (NASCET) found that symptomatic patients with carotid artery disease have a high likelihood of having a recurrent TIA or stroke. The risk is highest within the first 2 weeks of the initial episode; therefore, early operation in appropriate patients is likely to confer the greatest long-term benefit of CEA for these patients. For example, the absolute risk reduction is as high as 30.2% in patients with over 70%

carotid artery stenosis if they are operated on within 2 weeks. This drops to 8.9% if there is a more than 3-month delay, and there is no benefit to surgery in patients with 50% to 69% stenosis.

TABLE 195.3 Indications for CAS and CEA

Indications for CEA	Indications for CAS
Meets criteria for asymptomatic or symptomatic disease	Meets criteria for symptomatic disease and not a candidate for CEA
Severe or unstable plaque (relative indication)	Consider CAS if prohibitive cardiac risk factors (relative indication)
Renal disease (relative indication)	
Age >80 (relative indication)	

Crescendo TIA and Stroke in Evolution

Indications for urgent surgery include crescendo TIA and stroke in evolution. Crescendo TIA occurs when there are multiple TIAs within a few days or weeks and is associated with a high-risk plaque. Stroke in evolution leads to worsening neurologic deficits after the initial event, indicating promulgation of the initial injury and clinically significant ischemia along the penumbra. Both of these classes of patients benefit from early surgery to help limit the area of ischemia and forestall additional injury.

Internal Carotid Artery Occlusion

A small subset of patients may be found to have occlusion of the ICA. While acute occlusion of the ICA is associated with up to a 40% rate of major stroke, chronic occlusion only rarely leads to stroke in a condition, known as *ICA stump syndrome*. Endarterectomy or thrombectomy is not

indicated for occlusion due to the high risk of thromboembolism and the complications associated with retrieving major clot within the intracranial circulation. Stump syndrome occurs when ipsilateral hemispheric defects occur despite thrombosis of the ICA, and is thought to be due to microemboli from within the stump of the occluded ICA passing into the ECA distribution and subsequently into the EC–IC collateral pathways. Patients with stump syndrome are treated with endarterectomy of the ECA and ligation of the ICA stump.

CEA Versus CAS

CEA is generally preferred to CAS in most patients with clinically significant carotid artery disease. However, there are situations where CAS may be utilized due to a higher than normal risk of harm to the patient from CEA. Patients with prior major neck surgery such as a modified radical neck dissection have obliteration of the normal planes of dissection. Identifying cranial nerves (CNs), particularly the hypoglossal (CN XII), vagus (CN X), glossopharyngeal (CN IX), spinal accessory (CN XI), recurrent laryngeal nerve, and superior laryngeal nerve become significantly more complex in repeat neck operations. In a study completed by the Vascular Study Group of New England using a quality improvement registry, the risk of CN injury in redo CEA is not significantly greater (OR 1.0, $p = 0.90$). However, results from the European Carotid Surgery Trial (ECST), redo neck operations are associated with longer operating time, and operation over 2 hours is associated with an increase in risk of CN injury (OR 1.6, $p < 0.05$). A similar obliteration of normal planes occurs with neck radiation. As a result of this potential increase in risk, prior neck surgery (including prior CEA) and radiation exposure are relative indications for CAS in patients with symptomatic carotid artery disease.

CEA is also associated with a higher risk of cardiac complications compared to CAS. The Carotid Revascularization Endarterectomy vs. Stenting Trial (CREST) compared CEA to CAS and was published in 2010. While there was no difference between these two groups when using a composite end point of MI, stroke, and death, patients who underwent CEA were more likely to develop an MI (2.3% vs. 1.1%, $p = 0.03$) but less likely to develop a stroke (2.3% vs. 4.1%, $p = 0.01$ for minor stroke; equivalent rates for major stroke). MI in the CREST study was defined using biochemical markers and a subsequent quality of life survey revealed

no significant differences between CEA and CAS for MI. Despite these findings, many practitioners will favor CAS over CEA in a patient with major cardiac risk factors. As a result, major cardiac risk factors are a relative indication for CAS in patients with symptomatic carotid artery disease.

While there are some relative indications for CAS, there are also strong indications for CEA over CAS. As discussed earlier, asymptomatic patients with clinically significant stenosis should undergo CEA. Based off a post hoc analysis of the Stent-Protected Angioplasty vs. Carotid Endarterectomy (SPACE) trial, patients over the age of 80 have been found to have a higher risk of stroke following CAS. This is likely due to the increase in atherosclerotic disease burden within the aortic arch, leading to an increase in atheroembolic complications secondary to wire and catheter manipulation. Patients with severe or unstable plaques are also poor candidates for CAS due to the risk of causing embolism. Finally, patients with severe renal disease are not candidates for CAS as the IV contrast dye may precipitate renal failure. Some of the indications and contraindications discussed in this section continue to evolve in response to advances in best medical therapy and findings from ongoing clinical trials.

PREOPERATIVE PLANNING

History and Physical Examination

The management of patients with carotid artery disease begins with the completion of a relevant history and physical examination. Any symptoms should be documented with an emphasis on their onset, specific deficit(s), associated symptoms, duration, and probable causes. A distinction between right and left hemisphere symptoms should be made. Specific motor, sensory, speech, visual, and behavioral changes should be noted. Posterior circulation symptoms should also be noted. Recent symptoms should be noted, particularly the most recent time they occurred. Symptomatic patients benefit the most from surgery completed within 2 weeks.

Past medical history should be evaluated for all pertinent risk factors, including hypertension, diabetes, hyperlipidemia, smoking, and alcohol use. The cardiac history should be documented, including the presence of atrial fibrillation, other arrhythmias, prior MI, and congestive heart failure. The renal status should be evaluated with a particular note made for severe

renal disease. Past surgical history is relevant especially for any prior neck surgeries and radiation exposure to the neck. If CAS is being considered, any groin procedures should also be noted. Risk factor management is indicated in all patients and can help reduce the risk of recurrent disease or forestall contralateral disease.

Medication history is especially relevant for anticoagulants, antiplatelet agents, and antiarrhythmics. All current medications and allergies should be documented. Anticoagulation should be held prior to surgery, but most vascular surgeons will proceed with antiplatelet drugs. In fact, aspirin and clopidogrel are indicated for patients who require CAS.

Physical examination should include an examination of all key systems, a complete neurologic assessment, head and neck evaluation, and cardiovascular evaluation. Vital signs should be assessed with blood pressures taken in both arms. If CAS is being considered, a thorough pulse examination should be documented.

Basic laboratory studies should be completed in patients undergoing carotid surgery. Studies include a complete blood count, basic metabolic profile, lipid profile, HgbA1c for diabetics, and a type and screen.

Imaging

Duplex Ultrasound

The severity of carotid artery stenosis is determined by imaging studies. Options include duplex ultrasound (US, Fig. 195.1), computed tomographic angiogram (CTA), magnetic resonance angiography (MRA), and digital subtraction angiography (DSA). While DSA has the highest sensitivity and specificity of all of these tests, it is an invasive test that is associated with a 0.6% periprocedural stroke rate. As a result, its use as a diagnostic test has been supplanted by the other noninvasive tests. Of the three remaining tests, CTA and MRA have the highest overall sensitivity and specificity for carotid artery disease. However, these tests are expensive, time-intensive, and require the use of intravenous (IV) contrast dye (for CTA and gadolinium-enhanced MRA). US rivals CTA and MRA in sensitivity and specificity, especially for patients with ≥70% stenosis (Fig. 195.1D), <50% stenosis, or ICA occlusion. US also provides valuable information about flow dynamics and can help to identify subclavian and innominate artery disease. Due to its low expense and high availability, US is also an ideal screening test, especially in patients with carotid bruit, major cardiac disease, and prior TIA/stroke. Unlike CTA and

MRA, US results may vary by sonographer. Vascular labs with low intersonographer variability and high accuracy (such as those certified by the Intersocietal Accreditation Commission) can generate results that are sufficient for surgical planning.

CTA and MRA

Diagnostic imaging with CTA or MRA provides more robust information about the vascular anatomy. Variations in the aortic arch, calcification of the great vessels, unstable plaques, coils and kinks of the ICA, intracranial disease, circle of Willis variations, and anatomic malformations are more readily identified on CTA and MRA. Unclear or suspicious findings on US should prompt additional imaging. Patients with atypical symptoms, posterior circulation deficits, or other clinical suspicion for issues such as proximal lesions of the innominate or subclavian steal syndrome may also benefit from CTA/MRA. CTA/MRA may also be helpful for symptomatic patients with 50% to 69% stenosis on US due to the low sensitivity of US for these lesions. Complex patients with prior neck surgery may also benefit from CTA/MRA to assist with surgical planning through the creation of detailed 3D reconstructions and multiplanar views (Fig. 195.2). The major limitation associated with MRA is that this study overestimates the extent of stenosis and is susceptible to motion artifacts; both of these issues can be corrected with the use of contrast-enhanced MRA with gadolinium or by completing a CTA. Gadolinium contrast is contraindicated in patients with severe renal disease due to the risk of nephrogenic systemic fibrosis. IV contrast dye used with CTA is also contraindicated in these patients due to the risk of precipitating renal failure. There is no information on flow dynamics with CTA or MRA.

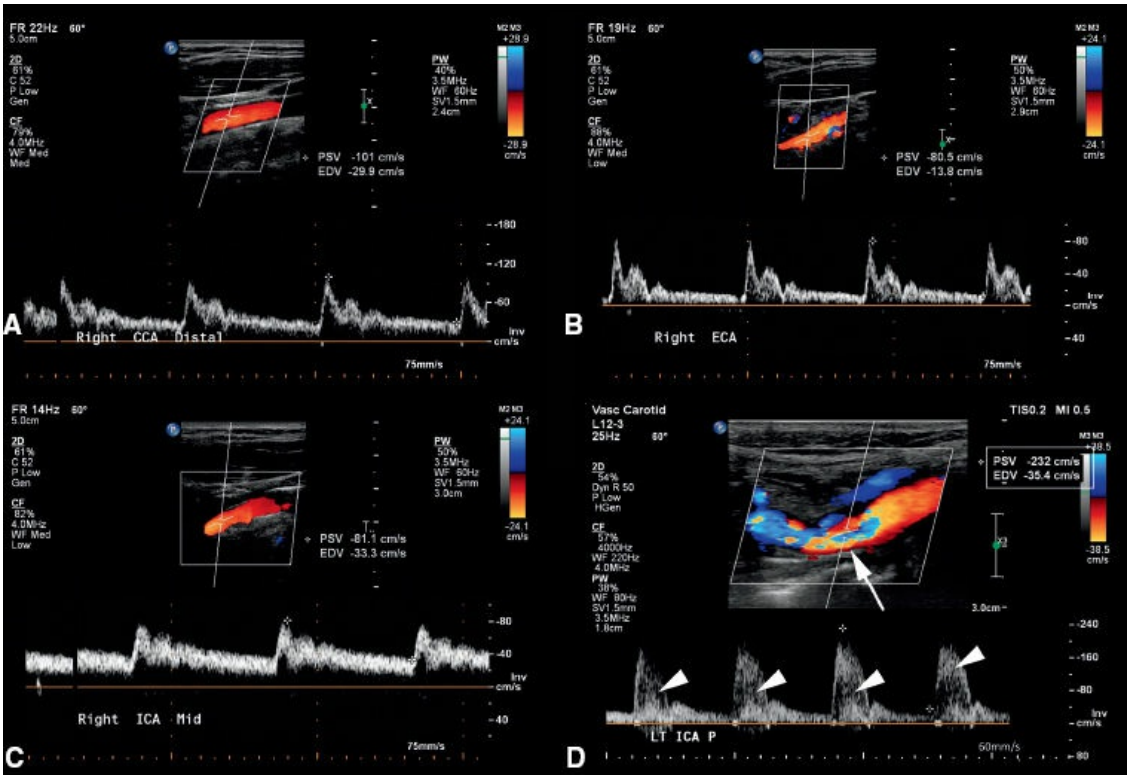

Figure 195.1. Carotid duplex ultrasound. **A.** Color flow and duplex imaging of the right common carotid artery in a healthy patient with no evidence of carotid artery stenosis. **B.** Color flow and duplex imaging of the right external carotid artery in the same patient showing no evidence of stenosis. The waveform here indicates high resistance flow, as noted by the sharp peaks. **C.** Ultrasound of the right internal carotid artery in the same patient showing no evidence of stenosis. There is more spectral broadening and a duller peak noted, which indicates low resistance flow to the brain. Despite this increase in "noise," the color flow remains orange-red and there remains a window underneath the waveform. **D.** A patient with 50% to 79% left internal carotid artery stenosis showing spectral broadening and low of the window (*arrowheads*). Note the mixed color flow (*arrow*), showing turbulent flow within this vessel.

PET scans have a limited diagnostic role for patients with carotid artery disease due to their expense and inaccessibility. The use of specific biomarkers attached to PET-sensitive tracers may help to identify unstable plaques in the future, but this remains investigational for now.

Medical Management

Appropriate preoperative medical management reduces the risk of postoperative complications following this intermediate risk operation.

Cardiac evaluation involves in competing a 12-lead ECG with stress testing indicated only for significant ECG abnormalities or major cardiac risk factors such as recent MI, CHF, or angina. Interventional cardiac procedures may be indicated prior to carotid surgery for patients with three vessel disease, severe left anterior descending (LAD) artery disease, and unstable angina. Clinically significant CAD severe enough to warrant treatment is found in up to 20% of patients who are candidates for CEA.

Patients who are acceptable risk following cardiac evaluation should be on an antiplatelet agent (such as aspirin or clopidogrel) and statin. Aspirin has been associated with a 25% decrease in stroke risk, while statins are associated with a significantly lower 30-day risk of stroke after CEA. Beta blockers should be continued if the patient is already on them, but initiating perioperative beta blockade in the absence of specific indications is associated with a higher risk of cardiac complications.

Laryngoscopy

Patients who have previously had CEA on the contralateral side should be evaluated by an otolaryngologist to ensure that there is no vocal cord paralysis from disruption of the recurrent laryngeal nerve. Cord medialization may be necessary prior to operating on the ipsilateral side to prevent an inability to protect the airway if there is inadvertent injury to the ipsilateral recurrent laryngeal nerve.

Special Considerations for CAS

Patients undergoing CAS should receive a 325 mg aspirin and a loading dose of 300 mg of clopidogrel at least 6 hours prior to the procedure. An alternative regimen is 325 mg of aspirin and 75 mg of clopidogrel daily for at least 4 days prior to CAS. Dual antiplatelet therapy minimizes the risk of intrastent thrombosis. Both the Management of Athero Thrombosis with Clopidogrel in High-risk patients with recent TIA or ischemic stroke (MATCH) trial and Clopidogrel for High Atherothrombotic Risk and Ischemic Stabilization, Management and Avoidance (CHARISMA) trial found a reduction in stroke, MI, and mortality risk in high-risk patients, but with a concomitant rise in bleeding complications. Dual antiplatelet therapy should continue for at least 30 days after CAS.

SURGICAL TECHNIQUE

Carotid Endarterectomy

Informed Consent

The informed consent for patients undergoing CEA should include a discussion of all of the risks, benefits, and alternatives to surgery. A discussion of the surgery, length of hospitalization, time for recovery, and potential complications should also be done with the patient and family. CEA does not "cure" stroke, nor does it prevent cardiac emboli or contralateral atheroemboli. Setting proper expectations with patients will help with management should there be unexpected events postoperatively.

The specific risks of CEA include a risk of perioperative stroke or death (<3% if asymptomatic, based on ACAS; <6% if symptomatic, based on NASCET), CN injury (~1% permanent, 5% to 20% temporary, most commonly the hypoglossal), cardiac complications (1%), infection (<1%), and bleeding requiring reoperation (~1%). Improvement in cognitive deficits and reversal of deficits from stroke are possible but the extent to which CEA leads to these improvements is controversial.

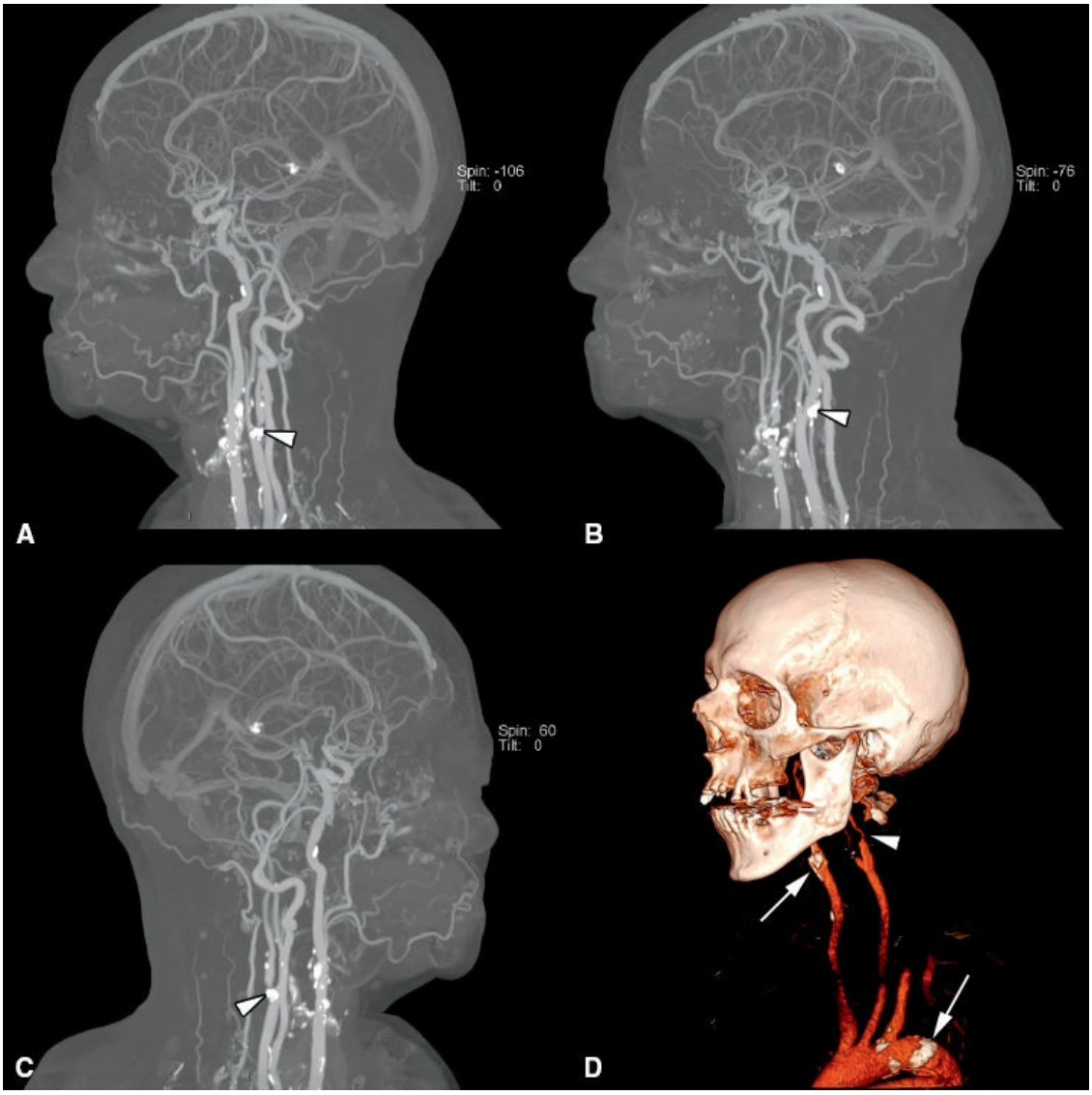

Figure 195.2. CT angiogram with reconstruction. **A**–**C.** CT of the head and neck with IV contrast showing the relationship of the carotid arteries. Calcium is prominently shown near the bifurcation of the carotid artery (*arrowheads*). **D.** 3D vessel reconstruction with subtraction of the bones showing an area of approximately 90% stenosis of the left internal carotid artery (*arrowhead*). Calcium is also noted throughout the aortic arch and the right common carotid artery (*arrows*).

Anesthesia

A variety of choices are available for anesthesia when completing a CEA, including local anesthesia, monitored anesthesia care with a regional block, and general anesthesia. There is no advantage of one approach over another with regard to stroke, death, MI, and length of stay. The primary benefit of using local anesthesia for completing a CEA is to serve as an

indication to shunt. Neurologic monitoring while completing an awake CEA is the gold standard indicator of cerebral ischemia and can prompt shunting with a higher degree of sensitivity and specificity than other modalities that are used during general anesthesia. This theoretical advantage has not been borne out by clinical studies. Nasotracheal intubation should be completed if subluxation of the mandible will be necessary for more cephalic exposure of the ICA.

Routine invasive blood pressure monitoring for CEA is helpful due to the blood pressure changes that can occur during surgery. Working around the carotid bifurcation can stimulate the carotid body and decrease the heart rate abruptly. There is a risk of cerebral hyperperfusion syndrome following revascularization and maintaining the blood pressure near normal after surgery is essential to preventing complications. Artificially raising the blood pressure when clamped may also help minimize cerebral ischemia.

Suitable antecubital IV access can usually be obtained. Central venous access is not necessary in most cases. Urinary catheterization is also not necessary in most cases unless the operation is expected to be more involved, such as in patients with prior neck surgery.

Patient Positioning

The patient should be positioned supine with a shoulder roll to hyperextend the neck. A ring pillow is placed for support of the head. The head should be turned away from the side of the operation and if general anesthesia is being used, the endotracheal tube should be positioned away from the side of the incision. The patient should be placed as close to the lateral and top edge of the operating table as safely possible to permit easy access by the surgeon. Safety straps should be used to secure the patient. The ipsilateral arm is secured next to the patient, while the contralateral arm can be left out to permit access by anesthesia. Drapes at the head of the bed should be left down on the surgical side to permit access by the surgeon. If the patient is awake, raising the contralateral drape can help prevent claustrophobia and allow some air movement for patient comfort.

Time Out

A comprehensive time out should be completed and identify the patient, operation, side of surgery, plan, and any safety concerns. Shunts, patches, sutures, and neurologic monitoring should all be confirmed and available at this time.

Incision and Exposure

The standard CEA incision is made on the anterior border of the sternocleidomastoid and turned posterior to the auricle (Fig. 195.3). An alternate incision can be made in the skin crease of the neck located 2 cm inferior to the angle of the jaw, and the resulting scar can be nearly invisible if closed with meticulous technique. The incision can be perfectly centered over the bifurcation and its size minimized through the use of preoperative imaging.

Following incision, the platysma muscle is divided and hemostasis of numerous skin edge bleeders secured. The external jugular vein should be identified and protected. Injury to the greater auricular nerve in the superior portion of the incision should be avoided to prevent numbness to the earlobe. The dissection continues until the medial border of the sternocleidomastoid muscle is identified.

The medial border of the sternocleidomastoid muscle is mobilized and the carotid sheath entered. Early identification of the internal jugular vein and CCA helps to identify the proper surgical plane. The CCA should be dissected free of surrounding tissue and a proximal clamp site identified. Care should be taken to avoid damage to the vagus nerve, which usually runs immediately posteriorly between the internal jugular vein and CCA. Rarely, the vagus nerve can run more superficially and may be susceptible to injury. The *ansa hypoglossi* is a fine branch of the hypoglossal nerve and usually runs on the anterior surface of the CCA. Mobilization of this plexus can usually be achieved but transection may be necessary of this mostly sensory nerve in order to obtain adequate access to the bifurcation. A vessel loop should be looped twice around the CCA (Pott’s tie).

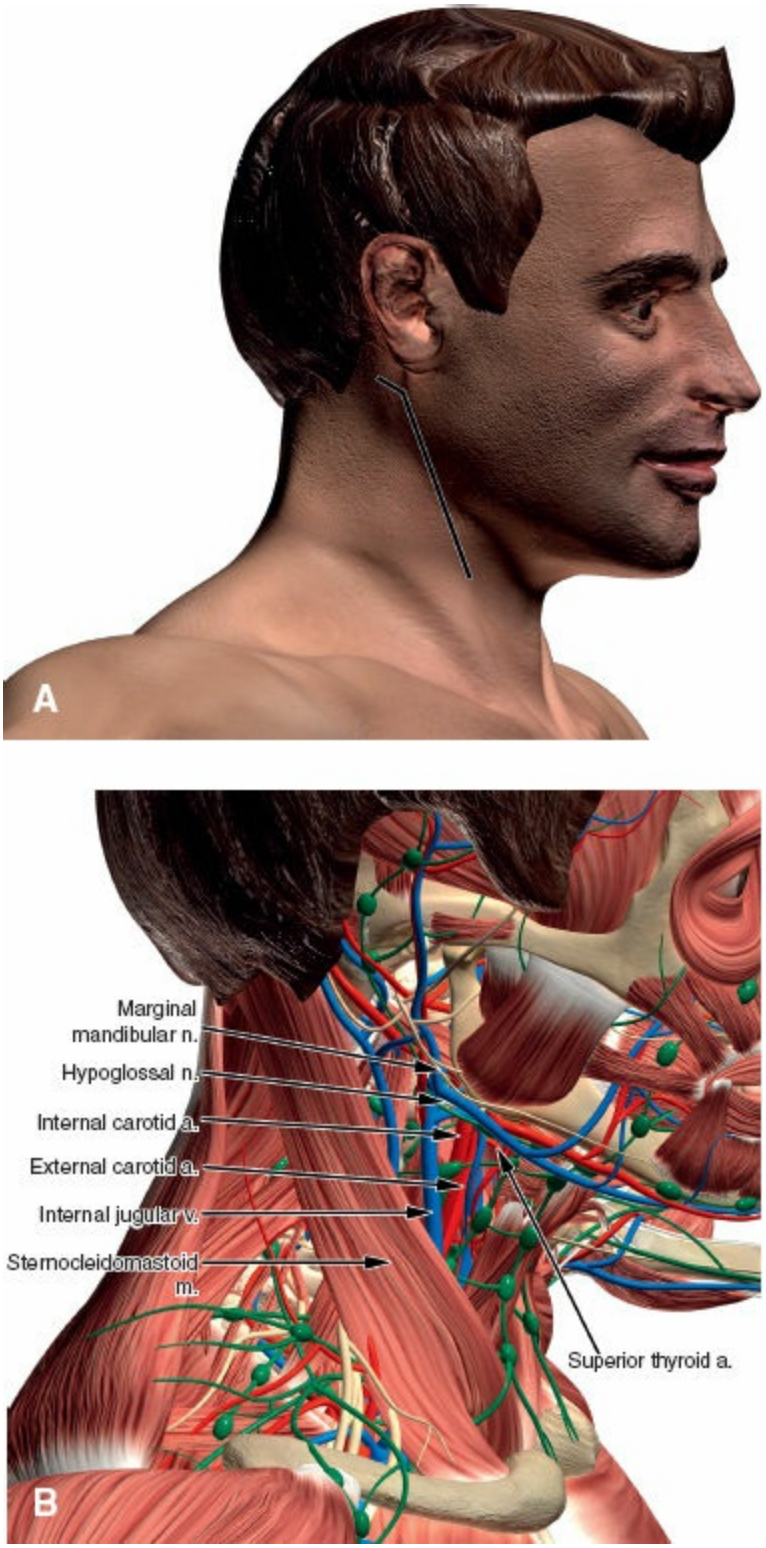

Figure 195.3. Carotid endarterectomy. **A.** Incision for carotid endarterectomy. **B.** Exposure of the carotid arteries.

The dissection proceeds from inferior to superior. The facial vein branch of the internal jugular vein will be encountered and may be safely ligated. At this point, the jugular vein and sternocleidomastoid can be

safely retracted posteriorly to bring the carotid bifurcation into view. Dissection beyond the bifurcation should be done only under direct visualization and by staying as close to the ICA as possible. From inferior to superior, the first major CN that will be encountered is the hypoglossal nerve. This nerve is usually anchored by a small sling and travels with a small arterial branch. Mobilization of the hypoglossal nerve should be done without directly touching any portion of it and by avoiding any tension. Dissecting along the posterior border minimizes the risk of injury to this nerve. Mobilization is not always required and should be done only if access to a more cephalad portion of the ICA is necessary (Fig. 195.3).

In rare circumstances, further cephalad exposure is necessary. The next CN to be encountered is the glossopharyngeal nerve and travels directly inferior to the styloglossus muscle and parallel to the vagus nerve for the first 2 to 3 cm. More posterior exposures may expose the spinal accessory nerve but this is more commonly done for ECA to vertebral artery bypasses. Medially, dissection around the ECA should be done with care to avoid trauma to branches of the superior laryngeal nerve, particularly as they pass perpendicular to the ECA. The recurrent laryngeal nerve passes medial to the CCA and injury to this nerve is uncommon when the dissection is done directly on top of the artery.

Dissection around the carotid body can stimulate the baroreceptors in this area and lead to profound bradycardia. Injection of 1% lidocaine can help minimize this effect. IV atropine may be necessary if there is hemodynamic instability.

The ECA should be isolated next. This is commonly done just distal to the first branch, the superior thyroid artery. A small temporary clip or 4-0 silk tie twice looped around the superior thyroid artery is sufficient for vascular control. A vessel loop is twice looped around the ECA. Dissection of this artery should be done as close to the vessel as possible, especially on the posterior portion, to avoid injury to the superior laryngeal nerve branches.

Attention is then diverted to the ICA. This vessel is dissected free at least 1 to 2 cm distal to the plaque to a region that is soft and amenable to clamping. Sometimes, more extensive cephalad exposure is necessary to reach a safe region. To facilitate exposure, the neck incision can be extended posteriorly below the auricle. Care should be taken not to enter the parotid gland due to the risk of fistula formation and inadvertent injury to the facial nerve. Further cephalad exposure can be obtained through

division of the posterior belly of the digastric muscle. Great care should be taken in dividing this muscle as it is immediately deep to the hypoglossal nerve, and the glossopharyngeal nerve is immediately deep to the muscle. The spinal accessory nerve is just posterior to this muscle near the upper portion of it. Division of this muscle can usually help the surgeon obtain another centimeter of exposure of the ICA.

Further exposure can be obtained through resection of the styloid process along with the styloglossus, stylohyoid, and stylopharyngeus muscles. The occipital artery is usually sacrificed due to its proximity to the muscles and styloid process. Note that the styloid process is a landmark used to identify the facial nerve, and great care must be exercised to avoid trauma to this CN. An additional centimeter of exposure can be obtained through this maneuver.

If knowledge of a high bifurcation is available prior to surgery, nasotracheal intubation can be completed to facilitate anterior subluxation of the mandible. This procedure can be done when there is ICA disease within 2 cm of the skull base. Subluxation, also known as a partial, self-reducing dislocation, is done by placing a wire from the ipsilateral mandibular bicuspid to the contralateral maxillary bicuspid. An alternative technique is to place a wire around the ipsilateral mandible through the anterior nasal spine. Subluxation can provide an additional 1 to 2 cm of exposure and may be critical to exposing the ICA near the skull base. If further exposure is necessary, a small portion of the mandibular ramus may be resected. Reconstruction with a small plate can be completed prior to closure.

Once adequate ICA exposure is obtained, a small vessel loop is twice looped around the artery at least 1 to 2 cm distal to the plaque. During dissection of the carotid arteries, a no-touch technique should be utilized and movement of the vessels should be kept to a minimum to avoid disrupting the plaque. Careful dissection, minimal vessel trauma, and adherence to safe operating principles will help prevent neurovascular injury and iatrogenic stroke.

Shunting

The question of shunting should be answered before proceeding to endarterectomy. There are three strategies for shunting: always placing a shunt, selectively placing a shunt, and never using a shunt. Proponents for always shunting highlight that shunting is relatively safe, provides continuous flow to the brain, and minimizes the risk of propagating

ischemic damage, particularly in symptomatic patients with recent stroke. Routine shunting in all patients is associated with a nonzero rate of iatrogenic thromboembolism and vessel damage, but many cases may be due to poor technique. Proponents for never shunting commonly do eversion endarterectomy, where shunting is more difficult and may disrupt the end point of the endarterectomy. This is associated with a nonzero risk of ischemic stroke and propagation of injury to the penumbra in symptomatic patients.

Selective shunting requires decision making based off intraoperative cerebral monitoring. Using this strategy, shunting is indicated whenever there is significant risk of cerebral ischemia. For the awake patient, this is simply a change in the neurologic status. For patients under general anesthesia, the gold standard is electroencephalographic (EEG) and somatosensory evoked potential (SSEP) monitoring. Although associated with numerous false positives, EEG and SSEPs are the most sensitive marker for cerebral ischemia.

Transcranial Doppler ultrasonography is another mechanism to detect cerebral ischemia and has the added benefit of identifying microemboli during surgery. Its true sensitivity and specificity are controversial and there may be numerous false negatives with this method.

Stump pressures are a relatively crude method to gauge cerebral pressures. A stump pressure of less than 40 mm Hg is thought to be associated with poor collateral cerebral circulation and an indication to shunt. However, pressures greater than 50 mm Hg are not associated with satisfactory perfusion throughout all portions of the brain when compared with EEG findings. These false negatives may lead to propagation of injury or iatrogenic stroke due to cerebral ischemia. An alternative is to monitor cerebral oximetry levels, but results appear to be similar to monitoring stump pressures.

In response to some of these limitations, proponents of selective shunting may opt to shunt patients with prior stroke and contralateral carotid occlusion in addition to anyone who meets criteria based off the aforementioned cerebral monitoring tools. Many surgeons may also artificially increase the blood pressure above 120/80 mm Hg during clamping to ensure sufficient collateral circulation. The best overall shunt strategy remains controversial.

Prior to clamping, 100 U/kg of IV heparin should be given as a bolus and allowed to circulate for 3 minutes. A satisfactory level of

anticoagulation may be confirmed using activated clotting times (ACT) over 250 seconds. Using ACT to monitor the level of anticoagulation can also help estimate the dose of protamine to reverse the anticoagulation at the end of the case, if this strategy is used. The vessel loops themselves can be used to clamp, two angled Debakey (CCA and ECA) and one profunda clamp (ICA) can be placed, or a combination of the two approaches used. Repeated clamping and unclamping should be avoided. Clamping should be done under direct visualization to avoid trauma to CNs, especially to the vagus nerve under the CCA, the superior laryngeal nerve under the ECA, and the hypoglossal and glossopharyngeal nerves near the ICA. Clamps are placed in sequence starting with the ICA, CCA, and ECA. This particular sequence prevents debris from washing into the intracranial circulation.

Standard Endarterectomy

The endarterectomy can be done in one of two ways. Standard endarterectomy involves making a longitudinal incision starting on the CCA and extending onto the ICA. The incision is made on the anterior surface but lateral to the flow divider at the bifurcation. If shunting, the ICA end is placed first, allowed to backbleed, then inserted into the CCA. The incision should extend beyond the endarterectomy site on the ICA in order to allow clear visualization of end points and permit tacking of any loose intima/media.

The endarterectomy is started at the CCA where a Freer elevator and fine mosquito clamp is used to create as thin an endarterectomy plan as safely possible. The plaque is neatly trimmed at the CCA to permit a clean plane free of debris. The plaque is then circumferentially dissected along the CCA and into the ECA. A complete endarterectomy of the ECA is completed to prevent any backwash of debris into the ICA. Back bleeding of the ECA is done after the endarterectomy to ensure that any loose debris is washed out. Attention is then turned to the endarterectomy of the ICA. Care is taken to create a smooth, tapered plane into the ICA to prevent a dissection flap and subsequent thrombosis of the artery. If a perfect endpoint cannot be created, sharply dissecting the plaque and placing 7-0 Prolene sutures to tack the intima/media to the artery should be placed. Tacking sutures should be used sparingly due to their association with perioperative stroke.

Completing a standard endarterectomy with primary closure is associated with a higher rate of perioperative stroke compared to

endarterectomy with patch angioplasty (4% vs. 0%) due to vessel thrombosis, and an increase in recurrent stenosis at 5 years (14% vs. 1%). Options for patching include autologous vein derived from the external jugular or great saphenous vein, bovine pericardium, Dacron, and polytetrafluoroethylene (PTFE). Of these choices, only autologous vein patches are resistant to infection. Patch rupture can occur with autologous vein. To prevent this complication, great saphenous vein with a diameter larger than 3.5 mm should be used, which is more likely to be found in the thigh instead of the ankle. The patch is sewn using 6-0 Prolene suture with care taken to tack down the end points under direct visualization to prevent artificial narrowing and dissection flaps.

If a shunt was used, it is removed once the patch is mostly sewn in. The clamps are released in the reverse order in which they were placed. The ECA clamp is removed first and the endarterectomy site flushed to ensure that any remaining debris is removed. This process is repeated for the CCA and ICA. The remaining patch is sewn in and the ECA clamp released. Hemostasis is confirmed, and the CCA, then ICA clamps released.

Eversion Endarterectomy

Eversion endarterectomy is an alternative to standard endarterectomy. This approach involves sharply transecting the ICA from the bifurcation, carefully everting the artery around the plaque, and gently pulling the plaque out. Any remaining plaque within the ECA and CCA is removed using the Freer elevator. The ICA is then sewn back onto the bifurcation using 6-0 Prolene suture. No patch is necessary. Shunting is possible with this technique, but can be difficult to do, and some proponents of eversion endarterectomy advocate no shunting due to the rapidity in which this procedure can be performed. This technique is particularly well suited for ICA coils and kinks. The vessel can be truncated to reduce redundancy and sewn back to the bifurcation.

Eversion endarterectomy was compared with the standard technique as part of the EVEREST study. No significant differences in outcomes were found between the two approaches with regard to restenosis, stroke, or death. However, eversion endarterectomy was associated with a lower long-term rate of restenosis.

Completion Imaging

Completion imaging remains controversial, with some centers advocating

mandatory completion imaging and others recommending a simple neurologic assessment at the end of the case. Options include continuous wave Doppler, duplex US, and intraoperative angiography. Continuous wave Doppler has the advantage of being simple to use, but does not allow visualization of the lumen. As such, it cannot identify dissection flaps, areas of stenosis, or other technical errors. Duplex US allows B-mode imaging of the lumen and color flow evaluation. The latter permits measurement of velocities and gives immediate anatomic and physiologic data regarding the patch angioplasty. Dissection flaps, areas of stenosis, and other technical defects can be identified. Finally, completion angiography with a needle in the CCA provides excellent information on the quality of the closure. Completion imaging is associated with a lower long-term rate of restenosis, but has no discernable impact on 30-day stroke or death rates. As a result, completion imaging is most strongly indicated when there is doubt about the end point.

Closure

The anticoagulation can be reversed at this point using protamine. Protamine reversal is associated with a small rate of stroke, but failure to reverse is associated with a risk of postoperative hemorrhage. Protamine itself should be given slowly as a bolus dose is associated with profound systemic hypotension.

In order to maximize closure of dead space, we advocate reapproximating the sternocleidomastoid muscle to the soft tissue. This also provides some muscle coverage over the patch. A drain can be left over this layer if there is concern for postoperative hemorrhage. The purpose of this drain is to serve as an early warning indicator for bleeding and allow some drainage of blood while the patient is being taken back to the operating room for a washout and repeat closure. This approach may help to minimize airway compromise from hematoma, but there are no definitive studies that have evaluated this.

The platysma is reapproximated using 3-0 Vicryl suture, followed by deep dermal sutures using 3-0 Vicryl suture. The skin is closed using 4-0 Monocryl suture. Dermabond is placed over the incision. The surgeon stays with the patient during extubation, if general anesthesia was used during the case. Light pressure over the surgery site can be held to minimize pressures at the patch site if the patient coughs. Deep extubation is advocated if experienced anesthesia staff are available to minimize coughing. A full neurologic assessment is done.

Carotid Artery Stenting

Informed Consent

Similar to CEA, patients undergoing CAS should have a discussion of all of the risks, benefits, and alternatives to the procedure. Expectations for management and a discussion of common complications should be had with the patient and family. The specific risk of CAS varies by clinician and there is some evidence that clinicians who do not do CAS very often may have a higher rate of stroke compared to those who work at high-volume centers. The risk of stroke, death, or MI is approximately 5% at 30-day based off the results of the CREST study. The risk of CN injury is minimal, and the risk of groin hematoma is 1% to 3%.

Anesthesia

Local anesthesia using 1% lidocaine is sufficient for the puncture site. Mild conscious sedation is recommended for patient comfort and can be achieved with 25 to 50 μg IV fentanyl and 1 to 2 mg of midazolam. The patient should be awake enough to respond to commands and demonstrate intact motor function (such as squeezing a rubber ducky). Invasive arterial monitoring is recommended and dedicated personnel should be available to care for the patient while the procedure is ongoing.

Patient Positioning

The patient is positioned in a supine manner and a small pillow used for comfort. The arms are strapped to the sides and the patient secured in position. Both groins should be prepped for access, if proceeding with the femoral approach. Some patients with a diseased aortic arch who are not candidates for CEA may require a cervical approach. Occasionally a brachial approach may be used in selected patients.

Time Out

The time out process should confirm that all wires, catheters, sheaths, stents, balloons, embolic protection devices, and other essential equipment are ready and available.

Access

CAS involves precise placement of a stent across a stenotic lesion in an artery that goes directly to the brain, and success is contingent upon having fine control over all aspects of this technique. Access via the femoral or brachial sites requires that the wires, catheters, and stent travel some

distance in order to reach the ICA. Two methods help ensure stability and control during this process. One is to use a long 90-cm sheath placed directly into the distal CCA 3 cm below the bifurcation. A 6F sheath is necessary to permit the use of 5F catheters. An alternative method is to place a short sheath for percutaneous access, but to then do all exchanges and the stent placement using a long 6F guiding catheter. Orienting the sheath or catheter properly within the CCA requires navigating the aortic arch, making one or more turns, and reaching the vessel without causing any embolization. This process can be aided through the use of special, precurved catheters such as a Simmons 1, Headhunter, or Vitek catheter. More complex anatomy such as a type II or III arch in which the innominate and/or left CCA come off the aorta below the apex typically requires a sharper curvature to the catheter. The patient should be heparinized to an ACT of at least 250 seconds.

DSA with multiple views of the carotid and intracranial circulation should be completed to confirm the lesion and ensure that safe access is possible. Confirmation of the ICA should be made at this point and splaying open the bifurcation through left or right anterior oblique imaging is helpful. 3D imaging using rotational angiography can also be useful in complex patients (Fig. 195.4A).

Embolic Protection

Once the patient is confirmed to be a suitable candidate for CAS, an embolic protection device is deployed. Embolic protection devices were found to significantly decrease the risk of iatrogenic stroke due to embolism that can occur during wire manipulation and stent deployment during the EVA-3S trial (7.9% vs. 25% at 30 days). There are several options available, including flow reversal devices, distal occlusion balloons, and distal filters. Flow reversal devices use an occlusion balloon within the CCA and another within the ECA with aspiration of the CCA/ICA done on a regular basis to capture any back-flowing debris. A variation in this device uses a temporary arteriovenous fistula to ensure continuous backward flow. Flow reversal devices have the advantage of not having to cross the lesion, but may not be tolerated by patients who depend on forward flow of their ICA. Distal occlusion balloons function by occluding the distal ICA and require aspiration prior to removal. They are not well-tolerated by patients and the balloon can cause a secondary spasm of the distal ICA. This embolic protection device is thus rarely used today. The most commonly used device is the distal filter. This device is a

small wire basket that crosses the lesion using a 0.014-inch guide wire and opens to capture any particles larger than 100 μm. Its major disadvantage is having to cross the lesion, which increases the risk of embolism.

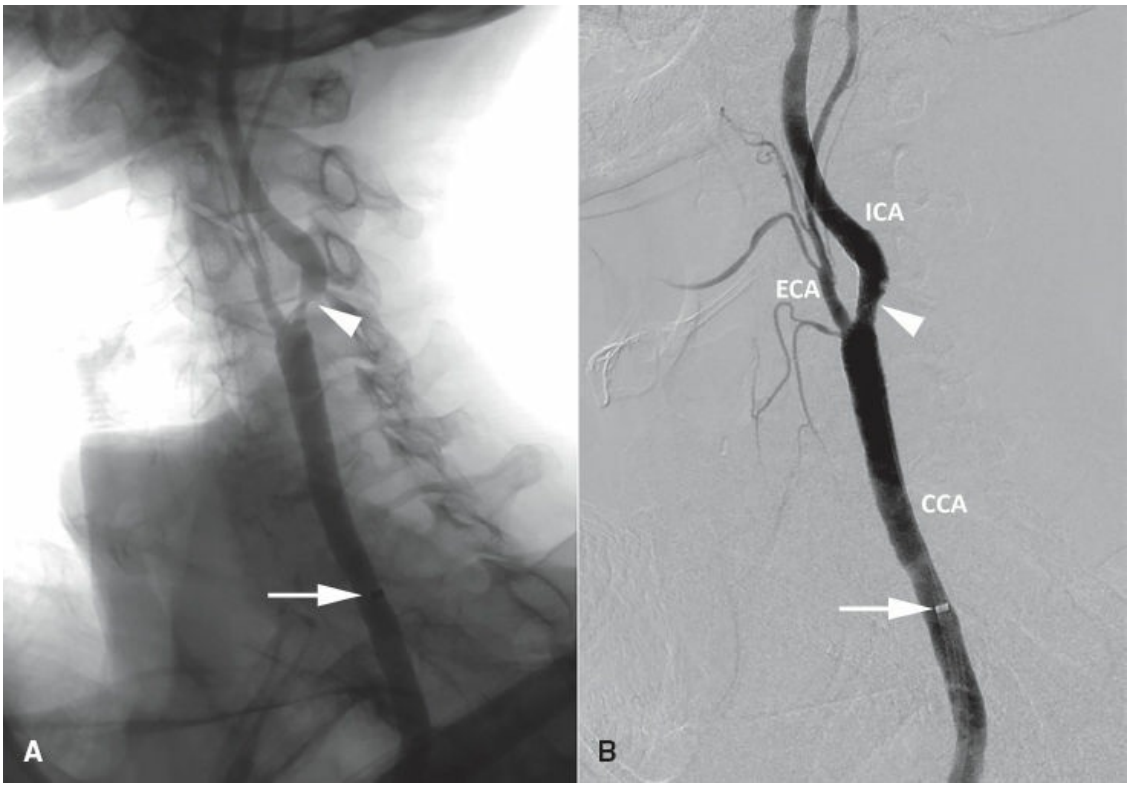

Figure 195.4. Carotid angiogram with stent. **A.** A carotid angiogram of the left common carotid artery is shown. The catheter (*arrow*) is shown within the common carotid artery, and the area of stenosis is indicated (*arrowhead*). **B.** Deployment of a stent across the internal carotid artery and into the common carotid artery resolved the stenosis.

Angioplasty and Stent

Once successful placement of the embolic protection device has been achieved, attention is turned to successfully crossing the lesion with a stent and deploying it. Some severe lesions will not tolerate crossing by the stent and require predilation with a 4.0 mm balloon at low pressure. A self-expanding stent sized to the distal CCA (usually 7 to 10 mm) is then placed across the bifurcation. Most lesions can successfully be treated with a 3 to 4 cm long stent. Balloon angioplasty of the stent is sometimes completed to ensure satisfactory apposition. The balloon is sized to the diameter of the ICA. Following successful stent placement, a completion angiogram is performed and the embolic protection device removed (Fig.

195.4B).

POSTOPERATIVE CARE

Patients without any intraoperative issues following CEA or CAS should be recovered in a postanesthesia care unit. Absent any hemodynamic instability or severe hypertension, invasive arterial monitoring can be removed. Patients should be admitted overnight to an intermediate care unit with telemetry. A routine postoperative check should ensure that the incision site is clean, dry, and intact, that there is no evidence of a hematoma or tracheal deviation, and that the postoperative neurologic assessment continues to be normal or at baseline. The blood pressure and heart rate should be normal. If a drain is present, it should be evaluated to ensure no active collection of bright red blood is present. The patient should be comfortable, relatively pain free, mentating normally, and without any complaints of significant headache, the latter of which could be a precursor to cerebral hyperperfusion syndrome.

The patient may be discharged the following day if there were no significant events overnight. The drain is typically removed the morning of discharge if there is minimal collection. The patient should follow up in clinic and have a duplex US of the carotid done at that visit. The standard of care is to presently obtain a follow-up US at 6 months, then annually thereafter.

If elevated velocities were initially detected on the contralateral side, a repeat duplex becomes critical for proper decision making. Following carotid revascularization, the contralateral velocities often decrease and may place the patient at a degree of stenosis that no longer requires intervention. If a contralateral intervention is indicated, laryngoscopy should be done prior to surgery to ensure normal functioning of the vocal cords and confirm no trauma to the recurrent laryngeal nerves.

COMPLICATIONS

Perioperative Stroke

Perioperative stroke may be due to arterial thrombosis, thromboembolism, ischemia during clamping, dissection due to vessel trauma or an intimal flap, and embolism of debris due to clamp injury. A patient who wakes up with a deficit, or develops one in the recovery room, should be immediately evaluated. Duplex ultrasonography should be used to image

the artery. If no flow is detected, or there is a technical defect such as an intimal flap or stenosis, immediate re-exploration is necessary. Correction of the technical defect is mandatory to prevent recurrence of the problem. If there is thrombosis of the ICA, a distal clamp is not placed. Instead, a Fogarty balloon can be gently inserted and used to complete a mechanical thrombectomy. Care must be taken not to blow the balloon up too large or insert it too far into the ICA, as this can lead to a carotid-cavernous fistula. In rare circumstances, bypass of the ICA to a healthier portion of the vessel may be necessary if the technical defect cannot be easily corrected.

If flow is detected on US, the next step is to complete an arteriogram to evaluate the intracranial circulation. If a thromboembolism is identified, mechanical thrombectomy or catheter-directed thrombolysis can be attempted with angiographic guidance. Complex intracranial maneuvers may require the assistance of a neurointerventional radiologist.

If no technical defects are identified, and angiography demonstrates no evidence of an intracranial pathology, the patient may be awakened from anesthesia and allowed to recover. If signs of stroke continue when the patient is fully awake, a CTA should be completed.

Cranial Nerve Injury

The rate of CN injury varies between 5% and 20%, depending on how the evaluation is completed. The risk of permanent nerve injury is about 1%. The most commonly injured nerve is the hypoglossal, which presents as deviation of the tongue ipsilateral to the side of injury. Injury to the recurrent laryngeal nerve is next, and can lead to ipsilateral vocal cord paralysis. Unilateral injury is often asymptomatic, but bilateral injury can lead to inability to protect the airway. Injury to the superior laryngeal nerve leads to inability to produce high-pitched sounds and can also lead to weakness of the voice. The marginal mandibular nerve, a branch of the facial nerve, can be injured from exuberant retraction during surgery and leads to a drooping lip and paresthesia over the side of the mouth. Injury to the glossopharyngeal nerve is uncommon and presents with dysphasia and aspiration. Injury to the spinal accessory nerve is rare and presents with a drooping shoulder (Table 195.4). Injury to cutaneous nerves can lead to paresthesia along the ear and side of the neck. Most temporary nerve injuries typically resolve within 6 to 12 months.

TABLE 195.4 Cranial Nerve Injuries (Listed From Highest to Lowest

Risk) and Symptoms

Nerve	Symptoms of Injury
Hypoglossal nerve (CN XII)	Ipsilateral tongue deviation
Vagus nerve (CN X)	Variable
Superior laryngeal nerve	Lack of high-pitched sounds, weak voice
Recurrent laryngeal nerve	Asymptomatic if unilateral; inability to protect airway if bilateral
Marginal mandibular nerve	Drooping of the ipsilateral lower lip
Glosospharyngeal nerve (CN IX)	Dysphasia, aspiration
Spinal accessory nerve (CN XI)	Drooping shoulder

Cerebral Hyperperfusion Syndrome

The brain has the capacity to autoregulate intracerebral flow across a wide range of blood pressures. Patients who have severe bilateral carotid artery stenosis have significant vasodilation to decrease the poststenosis resistance and try to improve the blood flow to the brain. Following endarterectomy, there is a sudden increase in the flow volume to the brain, and some patients may not be able to compensate for this increase in flow due to a diminished autoregulatory response. Combined with hypertension, this increased flow rate and pressure can lead to a severe headache. Left uncorrected, seizures, and a severe hemorrhagic stroke can occur and lead to death.

Patients who complain of a headache after carotid revascularization should be treated with strict blood pressure control with a goal of less than 140/80 mm Hg. If symptoms continue, a CTA of the head is urgently indicated to ensure that there is no hemorrhagic stroke. Aggressive blood pressure control to even lower levels may be necessary until the autoregulatory response returns to normal.

Cardiac Complications

The most common cause of death after carotid revascularization is MI. However, the overall 30-day rate of MI after CEA is about 1%. Postoperative cardiac complications can be reduced through aggressive preoperative risk factor control. Cardiac revascularization may be necessary in patients with ST elevation MI or significant cardiogenic shock.

Patients with major cardiac risk factors who also require carotid revascularization should ideally undergo staged intervention due to the

higher risk of stroke in the simultaneous procedure. Ideally, the symptomatic lesion should be treated first whenever possible. If simultaneous surgery is necessary in patients with high-grade, symptomatic carotid and coronary lesions, CAS may have an advantage if there is favorable anatomy. If CAS is not an option, CEA should be done first before the CABG. CABG followed by CEA is associated with a significantly higher stroke rate compared to either simultaneous surgery or CEA followed by CABG.

Hemodynamic Instability

Hypotension after CEA or CAS can occur due to disruption of the baroreceptor reflex and subsequent bradycardia. Severe bradycardia is best treated with atropine, but pressor support may be necessary to maintain an adequate cerebral perfusion pressure. Common causes of hypotension should be sought and conditions such as hypovolemia and cardiogenic failure should be immediately corrected. Most patients have correction of their hypotension within 24 hours. Patients with perioperative or immediate postoperative hemodynamic instability should be kept in an intensive care unit with invasive monitoring.

Recurrent Stenosis

The etiology of recurrent stenosis is dependent upon the time course in which it happens. “Recurrent” stenosis identified within 30 days can be due to technical error or a missed lesion, and is most commonly detected on routine postoperative duplex imaging. Stenosis that occurs within 2 years is commonly secondary to intimal hyperplasia. Many of these cases may regress with time. Repeat endarterectomy is challenging in these cases due to the nature of the intimal hyperplasia, and cases where intervention is indicated may best be served with CAS.

Stenosis that occurs after this time period, usually at 3 years and beyond, is often due to recurrent atherosclerotic disease. This occurs in about 4% of patients and risk factors include female gender, diabetes, hyperlipidemia, hypertension, and smokers. Clamp injury and tacking sutures also contribute to an increased risk of recurrent stenosis. Restenosis due to progression of atherosclerotic disease should be managed by either CEA or CAS, depending on the patient’s risk factors and symptoms. The use of antiplatelet agents, statins, and aggressive risk factor control may decrease the incidence of recurrent atherosclerosis-

mediated stenosis.

Repeat CEA is a safe but challenging procedure in many patients. While there is a theoretical increased risk of CN damage and other complications, studies using the vascular quality initiative database have found only a slight increase in hematoma and no increase in the risk of CN injury, stroke, MI, or death.

Infection

Infection after CEA is uncommon and occurs in fewer than 1 in 1,000 cases, even with the use of a synthetic patch. The risk of infection increases in patients who require re-exploration or develop a neck hematoma. Some difficulty with healing is also seen in patients with prior neck radiation. Patch infections can lead to pseudoaneurysm formation with a high risk of mortality in the event of a blow out. Urgent exploration and replacement with autologous vein patch are indicated in this situation.

Bleeding

Postoperative hemorrhage necessitating a return to the operating room occurs in about 1% of cases. Risk factors include dual antiplatelet therapy and heparinization without reversal with protamine. The accumulation of bright red blood in a drain is an indication for immediate re-exploration due to potential disruption of the patch. Any hematoma that causes compression upon the airway also requires urgent re-exploration and drainage to prevent loss of the airway.

OUTCOMES

ACAS, ACST, and the REACH Registry

The Asymptomatic Carotid Atherosclerosis Study (ACAS) tracked 1,662 patients with asymptomatic ≥60% ICA stenosis over a 5-year period. It found an 11% 5-year risk of stroke with best medical therapy, which was reduced to 5.1% over a 5-year period with best medical therapy and CEA (p = 0.004). The conclusion of this study was that CEA is indicated for asymptomatic patients with ≥60% stenosis. The findings of this trial were confirmed by the Asymptomatic Carotid Surgery Trial (ACST), which similarly found a reduction from 11.8% to 6.4% for ≥60% stenosis treated with best medical therapy and CEA. Both the ACAS and ACST studies found that the risk reduction was disproportionately greater for men than

women, and that the perioperative stroke risk was larger for women. Overall, CEA was associated with a perioperative stroke risk of about 2.3% to 2.8% (Table 195.5).

TABLE 195.5 Landmark Studies for Carotid Artery Disease

ACAS	CEA and best medical management is associated with fewer strokes compared to just best medical management for asymptomatic carotid artery stenosis ≥60%
ACST	CEA and best medical management is associated with fewer strokes compared to just best medical management for asymptomatic carotid artery stenosis ≥60%
REACH	CEA and best medical management (including statins) is most effective for asymptomatic carotid artery stenosis ≥70%
NASCET	Symptomatic patients ≥50% carotid artery stenosis benefit from CEA
ECST	Symptomatic patients ≥50% carotid artery stenosis benefit from CEA (when measured using the NASCET method)
SAPPHIRE	No significant difference in death, stroke, or MI between CAS with distal embolic protection and CEA for patients at high surgical risk
EVA-3S	CAS is inferior to CEA with regard to stroke or death at 4 years
EVEREST	Eversion and standard endarterectomy are similar with regard to patency
CREST	CAS is associated with more strokes than CEA, and CEA is associated with more MIs than CAS

While the ACAS and ACST studies demonstrated a significant decrease in stroke with CEA and best medical therapy, neither study included statins as part of their medical management. Statins have significantly reduced the risk and extent of stroke, thereby reducing the effectiveness of surgery for asymptomatic patients. Effective risk factor management may further increase the number needed to treat, potentially reaching a point where the risk of stroke from surgery outweighs the 5-year risk of stroke from best medical management. Despite advances in medical management, the risk of stroke with current best medical management remains at least twofold higher than best medical therapy and CEA for patients with ≥70% asymptomatic carotid artery stenosis. This was the conclusion of the Reduction of Atherothrombosis for Continued Health (REACH) Registry. In response to evolving medical management and these recent studies, most practitioners continue to recommend CEA for patients with ≥70% asymptomatic carotid artery stenosis. High-risk plaque characteristics may prompt some clinicians to operate sooner, but even in these situations most surgeons will still look for >50% stenosis.

NASCET and ECST

The NASCET was published in 1991 and demonstrated the beneficial effect of CEA in patients with symptomatic carotid artery disease. The intent of the study was to compare outcomes in patients with best medical therapy to those who underwent best medical therapy and CEA over a 5-year period. Patients with over 70% stenosis were found to have a disproportionate benefit for surgery over just a 2-year period (26% rate of events in the medical group vs. 9% in the surgery group). Patients with 50% to 69% stenosis were found to have a reduction in events from 22.2% to 15.7% with surgery over a 5-year period. NASCET also identified fewer recurrent strokes if surgery was completed within 2 weeks of the initial event. NASCET measured ICA stenosis as the ratio between the point of maximal stenosis and a normal ICA diameter distally. ECST had conclusions similar to NASCET but measured stenosis differently. ECST measured ICA stenosis as the ratio between the diameter at maximal stenosis and the carotid bulb.

CREST

The CREST compared these two procedures with regard to stroke, MI, and mortality. When using this composite end point, no differences between either technique were found. A subgroup analysis evaluating individual end points found that MI, as diagnosed by an elevation in cardiac enzymes plus chest pain or ECG changes consistent with ischemia, was more common following CEA; stroke was more common after CAS. Unlike many of the preceding trials, CREST required investigators to use a distal embolic protection device when doing CAS, and preferentially selected high-volume CAS centers. CREST confirmed results from other studies that CAS in older patients is associated with an increased risk of thromboembolism, likely related to the increased atherosclerotic disease burden in these patients.

Despite these positive results, CREST has several limitations and some criticisms. Quality of life surveys for patients revealed that those who suffered from stroke had an inferior quality of life compared to those who had an MI. Use of a composite end point masks the differences in patient impact and makes CAS appear safer than it truly may be. Further, the high volume of CAS by individual practitioners minimizes the risk associated with doing few of these procedures, and may make some of the findings difficult to interpret.

CONCLUSION

Carotid revascularization is indicated for symptomatic patients with over 50% ICA stenosis, and asymptomatic patients with over 70% ICA stenosis. CEA remains the preferred modality for treatment, unless the patient has prohibitive risk factors for surgery. CEA for asymptomatic disease is a prophylactic operation with a relatively safe risk profile, but there remains no substitute for sound clinical judgment and excellent technical skill in the conduct of these procedures.

Suggested Readings

Brott TG, Halperin JL, Abbara S, et al. 2011 ASA/ACCF/AHA/AANN/AANS/ACR/ASNR/CNS/SAIP/SCAI/SIR/SNIS/SVM/S guideline on the management of patients with extracranial carotid and vertebral artery disease. *Stroke* 2011;42(8):e464–540.

Cao P, Giordano G, De Rango P, et al. Eversion versus conventional carotid endarterectomy: late results of a prospective multicenter randomized trial. *J Vasc Surg* 2000;31(1 Pt 1):19–30.

CREST Investigators. The Carotid Revascularization Endarterectomy versus Stenting Trial (CREST): stenting versus carotid endarterectomy for carotid disease. *Stroke* 2010;41(10 Suppl):S31–4.

Endarterectomy for asymptomatic carotid artery stenosis. Executive Committee for the Asymptomatic Carotid Atherosclerosis Study. *JAMA* 1995;273(18):1421–8.

EVA-3S Investigators. Endarterectomy vs. Angioplasty in Patients with Symptomatic Severe Carotid Stenosis (EVA-3S) Trial. *Cerebrovasc Dis* 2004;18(1):62–5.

North American Symptomatic Carotid Endarterectomy Trial Collaborators. Beneficial effect of carotid endarterectomy in symptomatic patients with high-grade carotid stenosis. *N Engl J Med* 1991;325(7):445–53.

Randomised trial of endarterectomy for recently symptomatic carotid stenosis: final results of the MRC European Carotid Surgery Trial (ECST). *Lancet* 1998; 351(9113):1379–87.

EDITOR'S COMMENT

Carotid endarterectomy (CEA) remains under siege. Developed as a surgical treatment to prevent stroke from internal carotid artery (ICA) stenosis, and holding up in randomized trial after randomized trial (Endarterectomy for asymptomatic carotid artery stenosis. Executive Committee for the

Asymptomatic Carotid Atherosclerosis Study. *JAMA* 1995;273(18):1421–8; North American Symptomatic Carotid Endarterectomy Trial Collaborators. Beneficial effect of carotid endarterectomy in symptomatic patients with high-grade carotid stenosis. *N Engl J Med* 1991;325(7):445–53), it is now believed that we are performing too many asymptomatic CEAs. Add to this the overwhelming push by industry and carotid artery stenting enthusiasts to force the government to pay for stenting of asymptomatic high-grade internal carotid stenosis, it is little surprise that both caregivers and patients are confused about how to manage carotid artery stenosis.

The rationale for treating carotid stenosis is to remove the inciting plaque at the carotid bifurcation, thereby reducing the risk of plaque embolization to the brain and subsequent stroke. While I am not sure if this is still true given our burgeoning practice in dialysis access from our ever increasing obese and renal failure population, at one point, CEA was the most common vascular procedure performed in the United States. Management of carotid artery stenosis is something all surgeons should have contemporary knowledge about.

In this outstanding chapter by Desai, he very nicely describes both the pros and cons of CEA and CAS. While the chapter leans a little in favor of CEA, I think it realistically provides a nice balance of the two approaches in managing significant ICA stenosis. The chapter concludes with a review of many of the randomized clinical trials comparing CEA and CAS (CREST Investigators. The carotid revascularization endarterectomy versus stenting trial (CREST): stenting versus carotid endarterectomy for carotid disease. *Stroke* 2010;41(10 Suppl):S31–4). The data in my own mind is pretty clear and is based on many of the cited trials. CEA is associated with fewer strokes, while CAS is associated with few myocardial infarctions (MIs). This is especially true in elderly patients who appear not to tolerate CAS very well. I would also note that this chapter also documents that patient satisfaction data strongly suggests that patients would rather have an MI than a stroke.

I do not want to seem like a zealot favoring CEA over CAS, as I think there is a role for CAS for sure. Patients with radiated necks and recurrent or difficult to access distal ICA lesions should likely undergo CAS. There have been amazing advances in the technology leading to improved outcomes with CAS. I remember as a trainee reading about a trial in Europe that had to be stopped because of the high stroke rate in the CAS group. I am also pretty sure that embolic protection devices could be improved upon and am not completely convinced they prevent stroke (even though no one will perform a CAS without an embolic protection device!). I am a big fan of flow reversal systems which remove the aortic arch from play and can be performed in a very short period under local anesthesia (Kwolek CJ, Jaff MR, Leal JI, et al. Results of the ROADSTER multicenter trial of transcarotid stenting with dynamic flow reversal. *J Vasc Surg* 2015;62(5):1227–34). I hope this technology is advanced and believe that we may likely end up with some sort of hybrid technology to treat both asymptomatic and symptomatic ICA stenosis.

Finally, I would be remiss if I did not mention the ongoing CREST II trial (Lal BK, Meschia JF, Brott TG. CREST-2: Guiding treatments for asymptomatic carotid disease. *Endovascular Today* 2013:73–6). This randomized, controlled trial compares CEA versus best medical therapy, as well as CAS versus best medical therapy. There is little doubt that medical therapy with statins is better than it was when ACAS1 and NASCET2 were performed. However, as my friend and carotid expert Dr. Bruce Perler is quick to point out, we are doing better with our results following CEA as well. Let us not throw out the baby with the bath water, but continue to assess the pros and cons of CEA and CAS as complementary rather than competitive. Let us do what is best for the patient and clearly having more options/tools in our tool bag is likely a good thing for the patient.

Gilbert R. Upchurch Jr.

196 Brachiocephalic Reconstruction: Open and Endovascular

Joseph-Vincent V. Blas and John F. Eidt

ETIOLOGY AND PATHOPHYSIOLOGY

The supra-aortic trunks (SAT) are defined as the vessels arising from the aortic arch and terminating at the carotid bifurcation or the vertebral artery origin. Common anatomic variants include the so-called “bovine arch” (left common carotid originating from the innominate artery) (15% to 25%), a left vertebral artery originating from the aortic arch (2% to 6%), or an aberrant right subclavian artery originating distal to the left subclavian artery (～1%) that passes posterior to the esophagus.

Atherosclerosis is, by far, the most common cause of occlusive disease affecting the aortic arch branches. Distribution of atherosclerosis-related occlusive disease is determined by local hemodynamics, including shear stress, turbulent blood flow, and flow separation dynamics. Other, less common causes of arch vessel occlusive disease include Takayasu’s arteritis and radiation injury. Atherosclerotic occlusive disease in the SAT can produce symptoms due to thromboembolism or low-flow states, either alone or in combination. In comparison to occlusive disease, aneurysmal disease is much less frequent.

The number of open surgical procedures for SAT pathology has declined dramatically in the past 15 years due to the rarity of the underlying pathology and the appeal of endovascular alternatives. This trend has resulted in reduced operative experience for surgical trainees. Nevertheless, open surgical reconstruction remains an effective and durable option for selected patients. This chapter will review both endovascular and open reconstructive options for vascular conditions affecting the SAT.

CLINICAL PRESENTATION

Occlusive lesions in the SAT are often asymptomatic, found incidentally on imaging or identified by asymmetrical arm blood pressures. When

symptomatic, these lesions produce either thromboembolic symptoms or symptoms from low-flow states. In general, thromboembolic symptoms are more common.

The subclavian artery is the most commonly affected of the supra-aortic vessels. Atherosclerotic obstruction is typically localized to the first few centimeters of the subclavian artery. It should be suspected in a patient with asymmetric upper extremity pulses or a difference between brachial artery systolic blood pressures (typically a difference of 15 to 20 mm Hg is clinically relevant). One of three clinical presentations usually predominates: upper extremity exercise-induced pain (incorrectly referred to as “claudication,” which is derived from the root “to limp”), atheroembolic disease to the hands and fingers, or least commonly, vertebrobasilar symptoms. Patients with extremity symptoms may have easy fatigueability or a sensation of heaviness. Less frequently, patients present with evidence of microembolism to the hand or fingers. Neurologic symptoms are characteristically vague, and include dizziness, vertigo, unsteadiness, drop attacks, visual disturbances, or hemisensory abnormalities. The “textbook” presentation of the onset of vertebrobasilar symptoms with arm exercise is exceedingly uncommon. Asymptomatic subclavian steal, or the isolated finding of reversed flow in the vertebral artery ipsilateral to a proximal subclavian stenosis or occlusion, is usually not clinically relevant. It represents a stable and physiologically appropriate collateral pattern of blood flow, and does not usually warrant treatment.

Coronary subclavian steal may result in angina due to subclavian stenosis or occlusion proximal to the origin of an internal mammary coronary artery bypass graft and is now one of the most frequent indications for intervention.

Innominate artery occlusive disease may affect the two vascular territories that it supplies: the right arm and the right brain. Cerebral symptoms may be focal and reproducible due to atheroembolic events, or may be vague and nonspecific due to global hypoperfusion. Furthermore, tandem disease in the right carotid or vertebral arteries may make it difficult to identify the culprit lesion with certainty. Right upper extremity symptoms may include arm fatigue, pain with exertion, paresthesia, or sensation of a cool extremity. Atheroembolic disease to the right upper extremity may manifest as subungal splinter hemorrhages, discolored fingertips, or finger ulceration.

Aneurysmal disease of the SAT is uncommon. The subclavian artery is the most common artery affected. As with aneurysms elsewhere, aneurysms of the SAT may cause thromboembolic symptoms, compressive symptoms, or rupture. The aberrant right subclavian artery presents a unique challenge for vascular specialists. The aberrant right subclavian artery originates distal to the left subclavian origin off the aorta, and most frequently passes posterior to the esophagus. A Kommerell diverticulum is an aneurysmal origin that may occur in up to 60% of aberrant right subclavian arteries. Most patients with nonaneurysmal aberrant right subclavian artery aneurysms are asymptomatic. When present, symptoms include dysphagia (due to the compression of the esophagus with pulsations), odynophagia, or hoarseness.

DIAGNOSIS

Asymmetrical arm pressures at rest indicate a hemodynamically significant stenosis (e.g., >50% luminal diameter stenosis). Less severe stenoses may be detected by increasing flow across a site of stenosis (e.g., arm exercise or suprasystolic cuff inflation). Microembolism may be detected by reduced amplitude of finger plethysmographic waveforms or blood pressures. Finally, subclavian steal can be demonstrated on arterial duplex with evidence of reversal of flow through the ipsilateral vertebral artery.

Computed tomography angiography (CTA) has replaced catheter-based angiography in many institutions as the primary diagnostic test of choice. It avoids the small, but measurable, risk of embolism associated with catheter-based angiography (～1% risk of embolism). Despite reported accuracy equivalent to CTA, magnetic resonance angiography (MRA) has, for a variety of reasons related predominately to availability, not gained widespread adoption as the primary imaging modality.

PATIENT SELECTION FOR INTERVENTION

In general, treatment of aortic arch branch vessels should be considered for: (1) all arterial lesions that are the source of atheroembolism to the arm or cerebral circulation, (2) lesions that are symptomatic by virtue of global reduction in cerebral or extremity blood flow, or (3) selected asymptomatic patients who are believed to be at elevated risk of future adverse events. Although generally unnecessary, intervention for asymptomatic disease may be appropriate prior to, or in conjunction with, internal mammary coronary artery bypass, or aortic arch branch

reconstruction prior to extra-anatomic bypass. Of special note, coexistent coronary artery disease, which has been reported in 25% of patients with significant SAT disease, should be identified prior to planned open surgical procedures to avoid the need for re-operative sternotomy.

OPEN SURGICAL RECONSTRUCTION

Open brachiocephalic reconstruction may be accomplished by a direct (i.e., trans-sternal) or an extra-anatomic approach. The choice of operation is based on several important factors, including patient frailty, number of arteries requiring intervention, and a history of previous procedures. In general, direct reconstruction of the aortic arch branches should be considered in younger patients with good cardiopulmonary function who have not had a previous sternotomy.

Approaches to the Aortic Arch

The median sternotomy is the most common approach to the aortic arch. Some prefer to use a so-called mini-sternotomy that provides limited exposure to the upper mediastinum. Finally, the ascending aorta can be accessed through a limited right thoracotomy through the third intercostal space.

Median Sternotomy

The patient is supine with arms tucked. Techniques to prevent hypothermia (warming blankets, blood warmers, increased room temperature) should be employed. Intravenous prophylactic antibiotics are administered. A radial arterial line and adequate large-bore peripheral intravenous catheters are placed. Iodine-impregnated adhesive plastic skin drapes are used to reduce the risk of skin contaminants. The incision extends from the sternal notch to the xiphoid (Fig. 196.1). The incision may be extended to the base of the right neck to facilitate exposure of the innominate artery bifurcation (Fig. 196.2). Electrocautery is used to expose the sternum and can be used to mark a target line for the sternal saw in the middle of the sternum. Blunt finger dissection beneath the sternum at the cranial and caudal ends helps to protect any large veins from injury with the sternal saw. Ventilation should be suspended during the sternotomy. After dividing the sternum, a lap pad is placed in the wound and the cut edges of the periosteum are cauterized, and bone wax or other hemostatic agents may be applied to the bone marrow. A self-retaining retractor (e.g.,

Finochietto retractor/rib spreader) is placed. The thymus and upper mediastinal fat pads are mobilized. The innominate vein is completely mobilized. Routine division of the left innominate vein is not necessary, but this can be done to improve exposure as necessary. The innominate artery is easily exposed through a complete median sternotomy, although some experienced surgeons may prefer a partial or mini-sternotomy. The origins of the innominate artery and left common carotid artery are exposed, and the pericardium is opened to expose the proximal aortic arch.

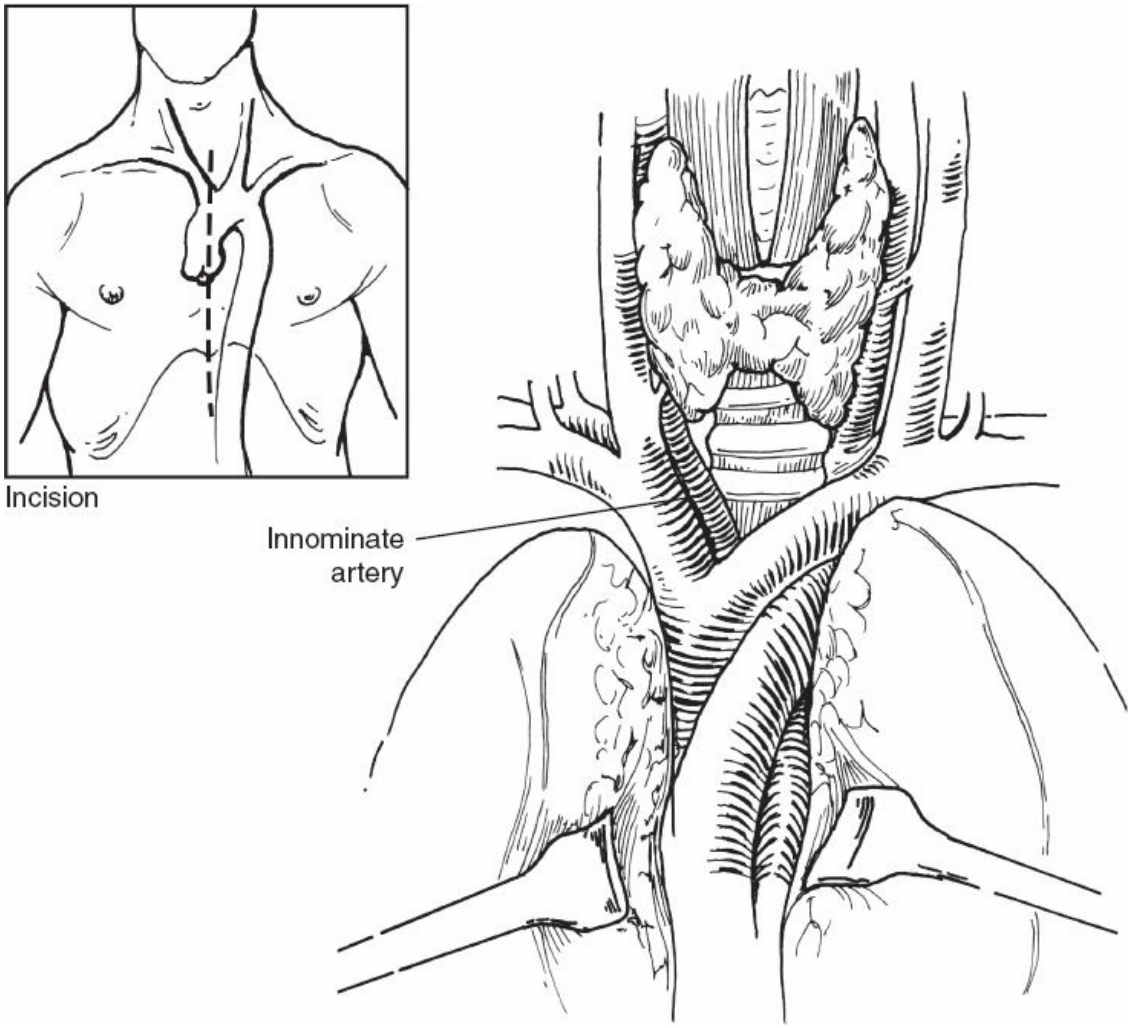

Figure 196.1. Median sternotomy.

Mini-Sternotomy

Preparation for the mini-sternotomy is identical to that for complete sternotomy. The sternum is partially divided longitudinally, with a reciprocating saw, to the inferior border of the third rib. The sternum is divided transversely at this level taking care to avoid injury to the internal mammary arteries, which lie just beyond the lateral borders of the sternum.

Again, a self-retaining retractor is used to separate the sternum sufficiently to provide access to the ascending aorta.

Right Thoracotomy

The ascending aorta and the aortic root may also be approached via a right anterior thoracotomy and segmental resection of the third rib (Fig. 196.3). Use of a wound spreader and avoidance of rib fractures reduces postoperative pain.

INNOMINATE ARTERY RECONSTRUCTION

The origins of the right subclavian and right common carotid arteries are controlled. Care is taken to identify the right vagus nerve and recurrent laryngeal nerve, which wraps around the right subclavian artery just beyond its origin. The phrenic nerve takes a slightly more lateral course between the subclavian artery and vein and is usually not in jeopardy. While the pleura can usually be bluntly dissected without perforation, a pneumothorax should be suspected if inspiratory pressures suddenly rise.

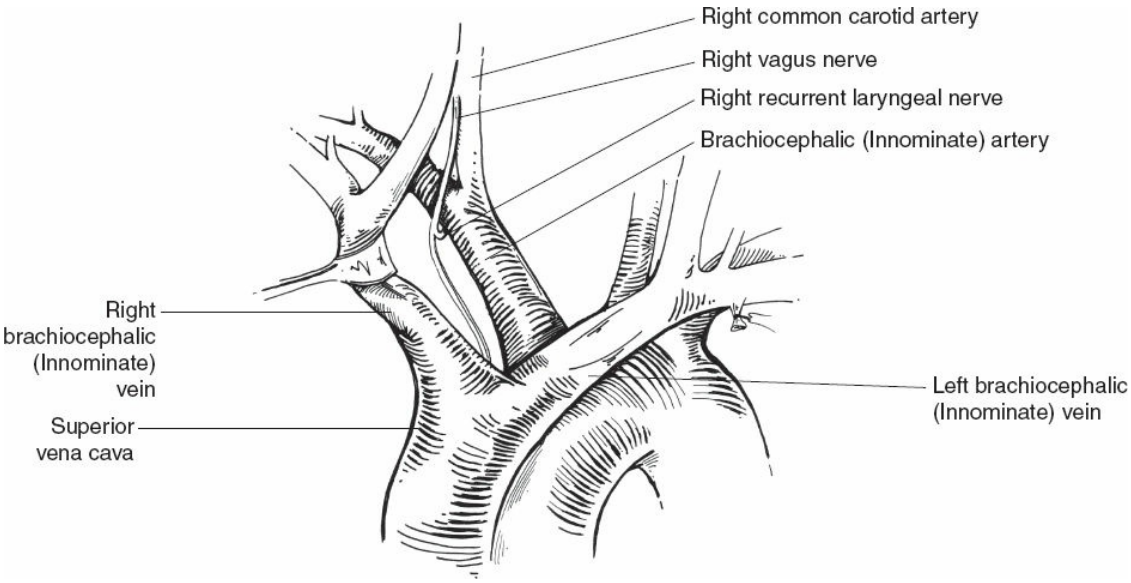

Figure 196.2. Approach to the innominate artery.

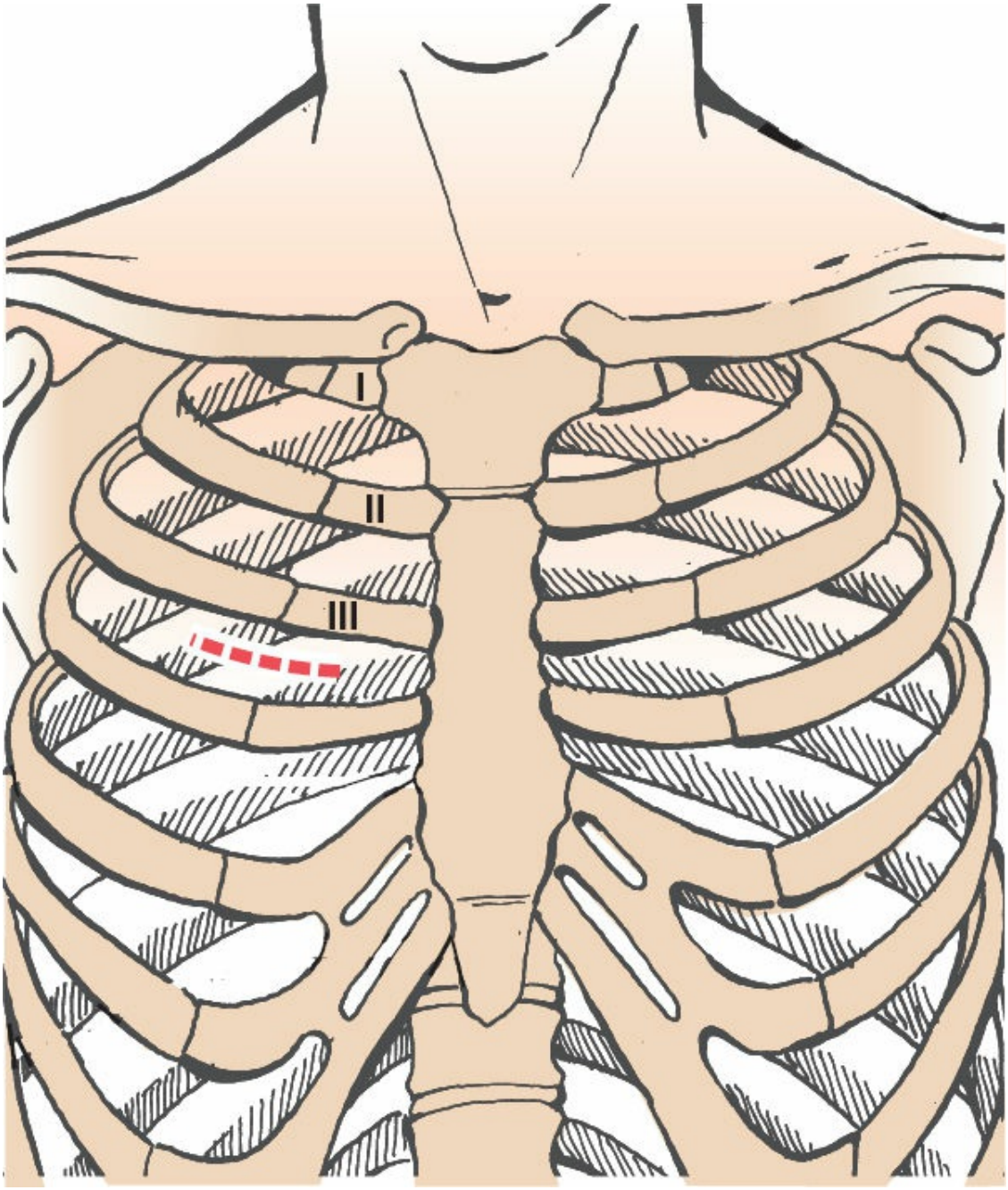

Figure 196.3. Right anterior third space thoracotomy.

At this point, the extent of the arterial lesions must be determined. The aortic arch should be gently palpated to determine suitability for clamping. Areas of heavy calcification should be avoided. Intraoperative ultrasound can be helpful to visualize potential embolic sources in the aortic arch. Endarterectomy or bypass is reasonable for occlusive lesions of the innominate artery. In general, bypass is preferred if the lesion extends to, or beyond, the innominate bifurcation, if the lesion arises from a large aortic plaque that extends into the innominate artery, if there is insufficient

distance between the innominate artery and the left common carotid artery to allow for clamping, if there is significant inflammation or adhesions due to radiation or arteritis, or if there is recurrence after prior endarterectomy.

INNOMINATE ENDARTERECTOMY

Intravenous heparin is administered (100 U/kg). The right common carotid artery is controlled before clamping the aorta to reduce the risk of cerebral embolism during manipulation of the arch (Fig. 196.4). The systemic pressure is maintained at or below a mean pressure (MAP) of 65 to 70 mm Hg. An appropriate-shaped C-clamp, such as the Lambert–Kay or Lemole–Strong clamp, is placed on the aorta at the base of the innominate artery. Aortic pulsations may cause the C-clamp to migrate during the procedure leading to sudden, unexpected hemorrhage. The distal innominate artery or right subclavian and common carotid arteries are controlled. Shunting is not usually required during reconstruction of the innominate artery.

A longitudinal arteriotomy is made in the innominate artery to accommodate the endarterectomy. Traction sutures may be used to evert the arterial edges. The endarterectomy is carried out in the standard fashion. Tacking sutures should be avoided unless absolutely necessary to avoid a distal intimal flap. The arteriotomy is closed with a running 4-0 or 5-0 polypropylene suture. Patch angioplasty is not usually necessary. Prior to closure of the arteriotomy, the common carotid and subclavian arteries are back-bled and the innominate artery is forward flushed to expel any debris or air. Trendelenburg position facilitates the elimination of arterial air. Flow should be restored to the subclavian artery prior to restoring flow to the carotid to reduce the risk of cerebral embolism. When removing the C-clamp, it is necessary to maintain slight downward pressure toward the aorta to prevent the clamp from inadvertently disrupting the suture line. A closed suction drain is placed in the mediastinum for 24 hours. The sternotomy is closed in the usual manner. A postoperative chest x-ray should be obtained to detect occult pneumothorax.

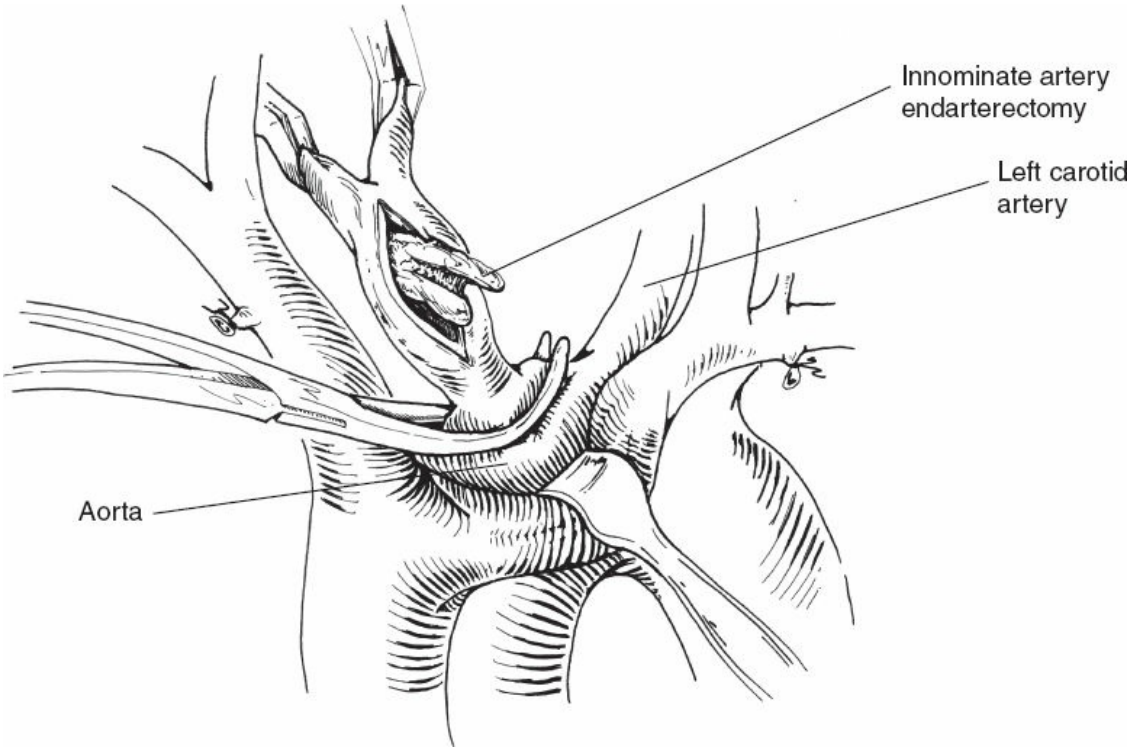

Figure 196.4. Innominate artery endarterectomy.

INNOMINATE ARTERY BYPASS

The innominate artery is exposed for bypass in the same manner as for endarterectomy (Fig. 196.5). The aorta is usually selected for inflow unless the proximal innominate artery is completely free from disease. A soft location on the intrapericardial ascending aorta that is free of disease is selected for the proximal anastomosis. A side-biting C-clamp is applied to the ascending aorta. A sufficient bite of aorta should be taken to accommodate separating the edges of the arteriotomy during suturing. An aortotomy is made along the right anterolateral side of the aorta and extended with a cardiac punch. An 8- or 10-mm low-porosity knitted polyester graft is usually selected for innominate reconstruction. Polytetrafluoroethylene (PTFE) grafts are not typically used in this location due to needle hole bleeding that can be troublesome. The graft is beveled appropriately to avoid a right angle at the origin and sutured in place with a running 4-0 polypropylene suture. The graft is flushed by briefly releasing the aortic clamp to remove any air or debris from the aorta. The clamp is then applied to the graft, and the aortic clamp removed.

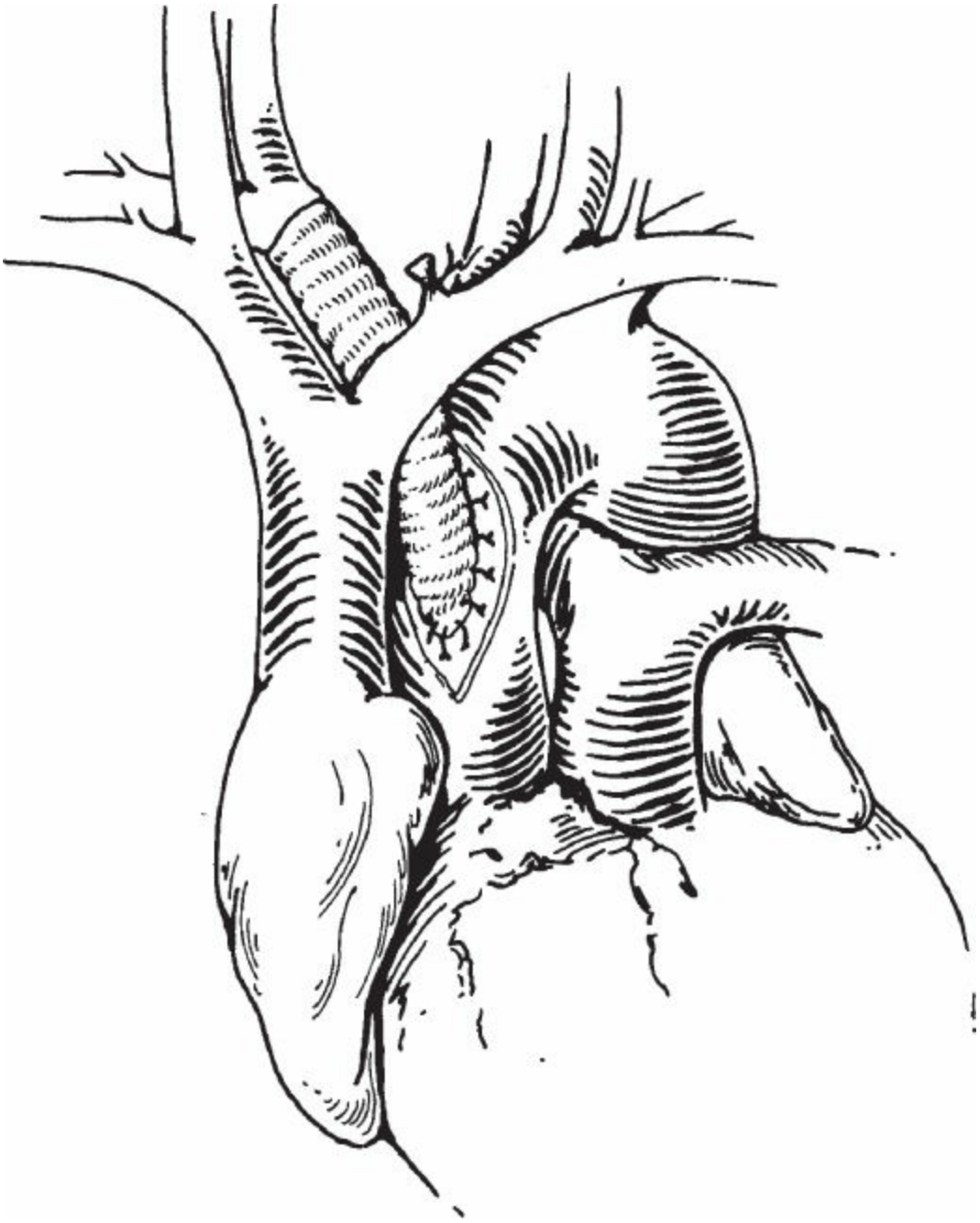

Figure 196.5. Innominate artery bypass.

After obtaining distal control, the innominate artery is transected beyond the lesion. The origins of the subclavian and common carotid arteries are inspected for extension of plaque into their orifices. An end-to-end anastomosis is constructed with a 4-0 or 5-0 polypropylene suture. The graft is irrigated with heparinized saline to remove any particulate debris. Again, the distal vessels are back-bled and the graft forward flushed before restoring flow first to the subclavian artery and then to the carotid.

RIGHT SUBCLAVIAN BYPASS

If the occlusive lesion extends into the proximal subclavian or common carotid arteries, the graft must be extended beyond the bifurcation of the innominate artery. If both the right subclavian and right common carotid artery must be revascularized separately, a bifurcated polyester graft is selected based on the diameter of the outflow vessels, typically 14 mm × 7 mm or 16 mm × 8 mm graft. Larger-diameter grafts are usually avoided due to the excessive arteriotomy that must be made in the aorta. The body of the bifurcated graft should arise the right lateral side of the proximal ascending aorta to avoid kinking, particularly during closure of the sternotomy. Reul et al. have emphasized the importance of leaving a long body on bifurcated grafts and creating an oblique aortic anastomosis to reduce the risk of kinking. Some prefer to use branched custom-made grafts with diameters ranging from 7 to 10 mm in diameter.

DIRECT RECONSTRUCTION OF INNOMINATE OR SUBCLAVIAN ANEURYSM

Exposure for reconstruction of innominate or subclavian aneurysms is the same as for occlusive disease; however, additional distal exposure may be necessary (Fig. 196.6). The position and location of the vagus and recurrent laryngeal nerves may be obscured by the aneurysm. Circumferential dissection of the aneurysm is not recommended, but this may leave intact branch vessels (e.g., internal mammary artery) that must be ligated once the aneurysm is opened. Aneurysm of the proximal subclavian artery often involves the origins of the internal mammary artery and the vertebral artery. If the contralateral vertebral artery is patent, ipsilateral vertebral artery ligation is well tolerated. Reimplantation may be considered otherwise. It is uncommon to reimplant the mammary artery unless coronary bypass is anticipated.

DIRECT RECONSTRUCTION OF MULTIPLE AORTIC ARCH VESSELS

Direct reconstruction of multiple arch vessels is limited only by the surgeon’s imagination and creativity. In the setting of bilateral common carotid artery occlusion, a bifurcated graft arising from the proximal aortic arch can be used to supply both carotid arteries. Side branches to one or both subclavian arteries can be added as needed. Exposure and visualization of the left subclavian are severely limited through a median

sternotomy. Consequently, direct reconstruction of the origin of the left subclavian artery is best approached through a formal left thoracotomy.

CAROTID SUBCLAVIAN BYPASS

A transverse incision is made 1 to 2 cm above the medial third of the clavicle (Fig. 196.7). The platysma and clavicular head of the sternocleidomastoid are divided. The prescalene fat pad is retracted laterally. The phrenic nerve is identified on the surface of the anterior scalene muscle coursing diagonally from lateral (cephalad) to medial (caudad). The anterior scalene muscle is divided, with care to avoid injury to the nerve. On the left side, the thoracic duct should be identified as it enters the junction of the internal jugular and subclavian veins, and protected or ligated. The subclavian artery lies just deep to the anterior scalene muscle. The thyrocervical trunk, internal mammary artery, and vertebral artery are encircled with vessel loops. The vertebral vein may be divided if needed. The lower cords of the brachial plexus are located posterolateral at this level. The jugular vein is retracted medially, and the common carotid artery is controlled, with care to avoid injury to the vagus nerve.

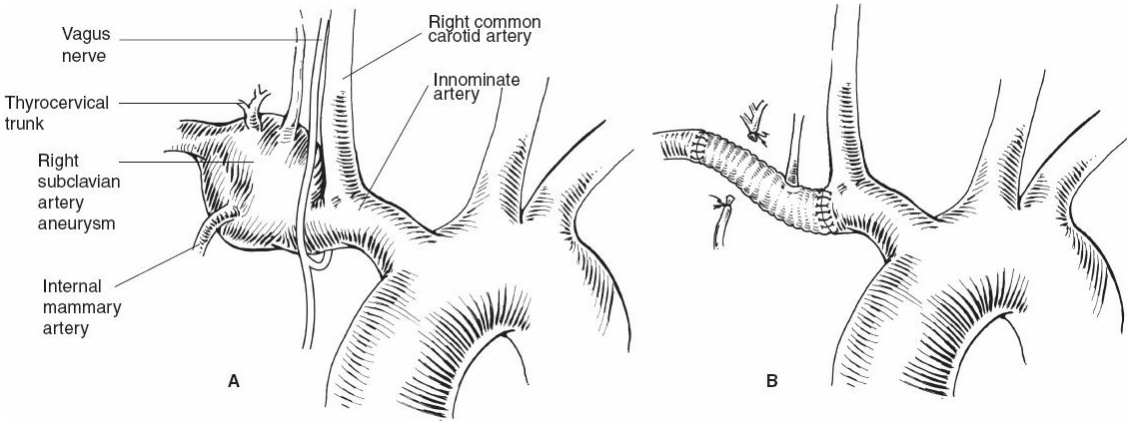

Figure 196.6. Right subclavian aneurysm. **A.** Preoperative view. **B.** Postoperative view.

A site on the lateral wall of the common carotid artery should be marked with ink prior to clamping. It is important to avoid an anastomosis on the anterior surface of the common carotid artery because this may kink the graft. The clamps can be used to rotate the artery to facilitate the anastomosis. Following heparinization, a small arteriotomy is made in the lateral wall of the common carotid and enlarged with a coronary punch.

The arteriotomy is made low in the neck so that the graft lies almost parallel to the apex of the subclavian artery and is as short as possible (2 to 4 cm). An 8-mm polyester graft is typically used, but the size should be chosen to match the subclavian outflow. An end-to-side anastomosis is made between the end of the graft and the side of the carotid artery with a 5-0 polypropylene monofilament suture. The graft is routed posterior to the internal jugular vein. The anastomosis to the subclavian artery is usually placed distal to the origin of the vertebral artery. The thyrocervical trunk may be ligated to facilitate placement of the anastomosis. The relationship of the phrenic nerve to the graft should be recorded in the operative note in the event of reoperation. There is no evidence that carotid subclavian bypass steals blood from the internal carotid artery in the absence of occlusive disease in the common carotid artery proximal to the origin of the bypass.

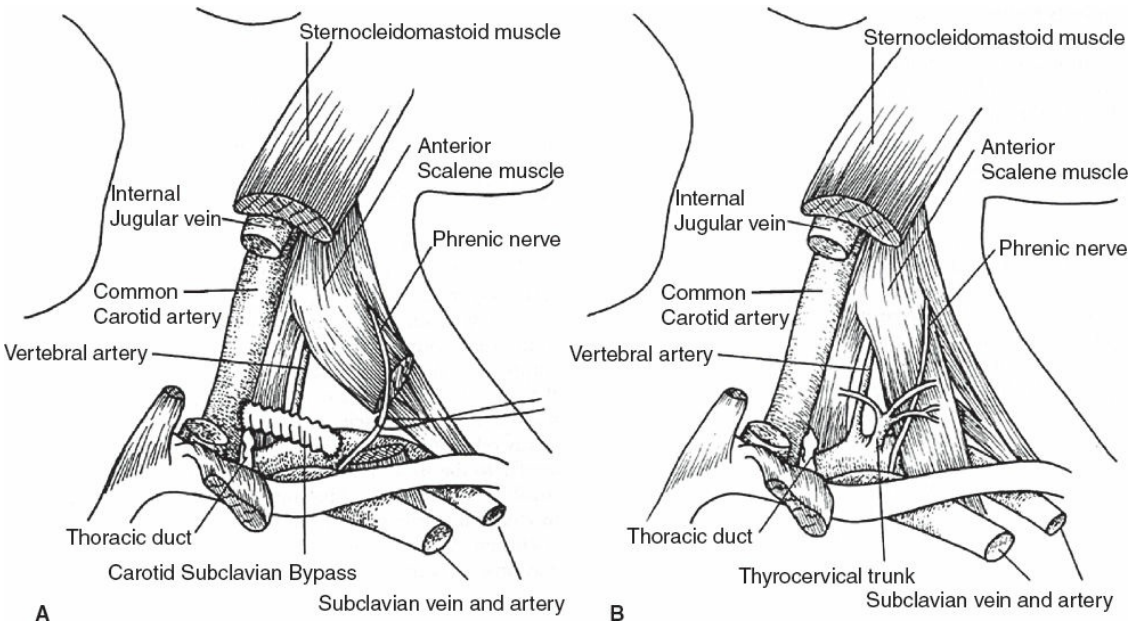

Figure 196.7. A. Synthetic carotid–subclavian bypass graft. **B.** Surgical exposure of the left subclavian artery and common carotid artery through a supraclavicular incision.

SUBCLAVIAN ARTERY TRANSPOSITION

As an alternative to bypass, the subclavian artery can be directly anastomosed to the ipsilateral common carotid. The common carotid artery is approached in the same manner as described for bypass. Again, care is taken to avoid injury to the thoracic duct and phrenic nerves. The subclavian artery must be transected close to the origin to have sufficient

length to reach the common carotid artery. Care must be taken to avoid loss of control of the proximal subclavian stump as it will retract into the thorax and will be challenging to control. If the distance is too great, a short synthetic interposition graft may be interposed between the common carotid artery and the subclavian artery. The anastomosis with the carotid artery is constructed as low in the neck as possible to create an oblique anastomosis rather than a right angle. A low anastomosis between the subclavian artery and the carotid artery also reduces the risk of kinking the origin of the vertebral artery.

ENDOVASCULAR RECONSTRUCTION

Patients are generally pretreated with aspirin (325 mg) and clopidogrel (75 mg) prior to intervention. Both groins are prepared in a sterile fashion; the left and the right antecubital fossae may also be prepped if anticipation of a retrograde brachial approach is anticipated. Retrograde access to proximal arch-branch disease through direct surgical exposure of the carotid arteries is particularly appealing for complex, high-grade lesions in types II and III arches. Use of a long sheath fastened to the drapes (e.g., 8-F 25 cm) greatly simplifies the retrograde carotid approach and reduces radiation to the operators' hands. An arch aortogram is performed prior to intervention in a left anterior oblique (LAO) projection to define the origins of the SAT and to identify any anomalies. Prior to any further intervention, heparin is administered to achieve an activated clotting time (ACT) between 250 and 300 seconds. Distal protection is not usually employed because the filter may be dislodged during the introduction of relatively stiff, large diameter devices. If distal protection is desired, use of an .014 in buddy wire may be useful to provide sufficient support for the devices. The devices can be delivered over both the filter wire and the buddy wire simultaneously.

LEFT SUBCLAVIAN INTERVENTION

Following arch aortogram, a selective view of the left subclavian artery is performed with a simple angled 5-F selective catheter. Lesion length, character, and location of the vertebral and internal mammary arteries are carefully determined. With high-grade stenoses or occlusions, retrograde flow in these branch vessels may preclude adequate visualization until the lesion is crossed. A soft-tipped 0.035-in guidewire (e.g., Glidewire, Glidewire Advantage, or Wooley) is used to cross the lesion, and is

advanced into the axillary artery. For chronic occlusions, a hydrophilic glidewire may be necessary to cross the lesion. In some instances, the lesion cannot be traversed in an antegrade fashion, and access from the brachial artery will be necessary to complete the procedure (Fig. 196.8). Once the lesion is traversed, a 7-French sheath (with dilator) is advanced across the lesion. A balloon-expandable stent (typically 6 to 8 mm diameter) is then advanced into the sheath. As the sheath is withdrawn into the aortic arch and the stent exposed, contrast is injected through the sheath sidearm to visualize the origins of the vertebral and internal mammary arteries and the subclavian–arch junction. The stent can be carefully repositioned as necessary to ensure that it does not cover the origins of these important branch vessels distally and that its proximal portion is 1 to 2 mm into the arch (for ostial lesions). Vertebral protection is not typically employed.

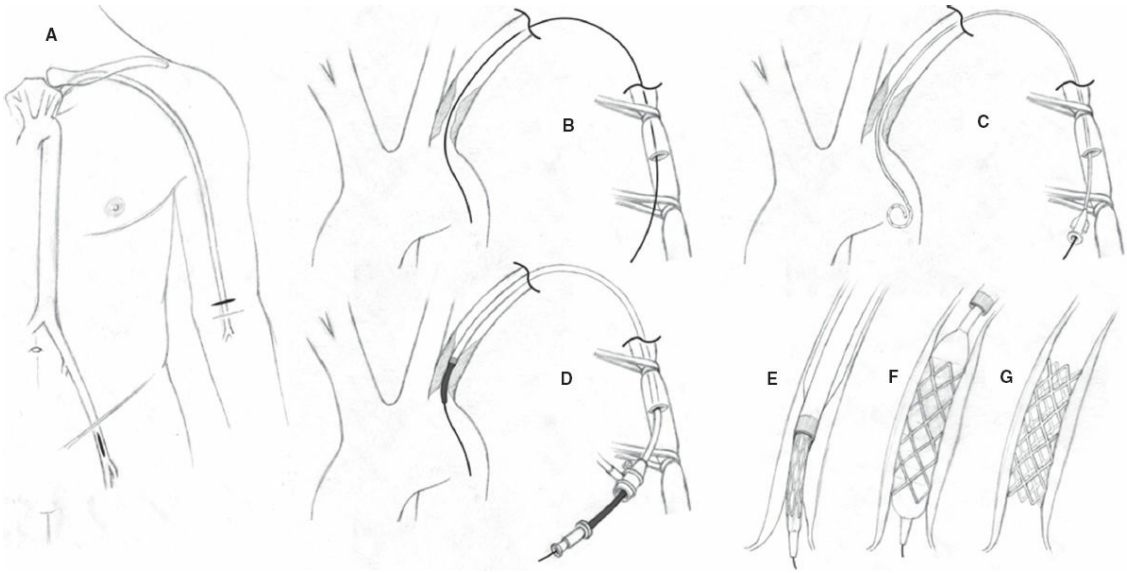

Figure 196.8. Angioplasty and primary stenting of the left subclavian artery via left brachial approach.

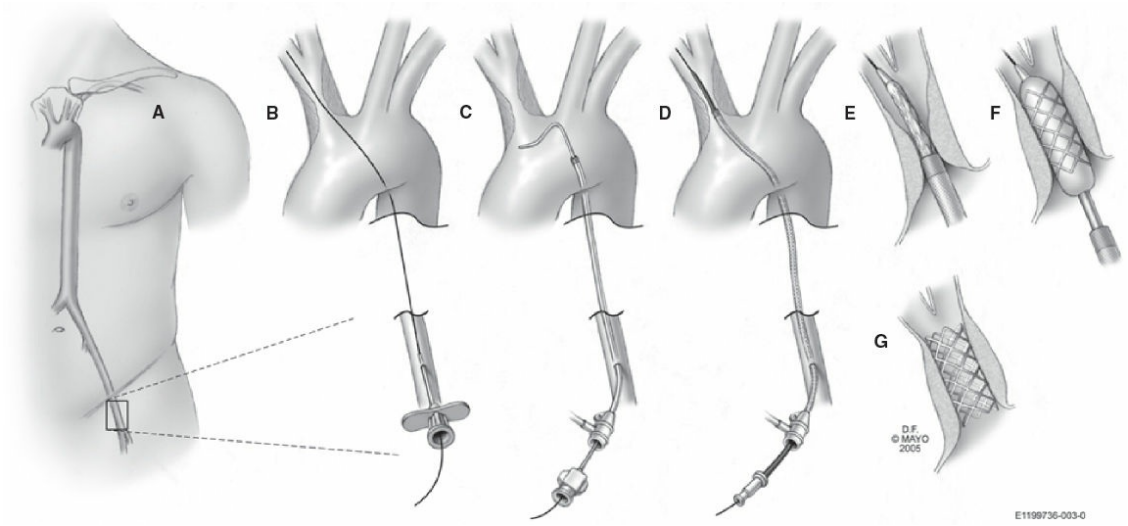

Figure 196.9. Angioplasty of the innominate artery via femoral approach. (D.F. © Mayo 2005.)

INNOMINATE ARTERY INTERVENTION

The innominate artery can be approached from either the right brachial or femoral access (Fig. 196.9). For difficult aortic arch anatomy (type II or III aortic arches), innominate artery lesions may be more easily traversed via a right brachial approach. The same basic techniques of angioplasty and stenting apply as for subclavian artery intervention, including advancing the sheath with dilator, delivery of a balloon-expandable stent to the lesion under protection of the sheath, and deployment after careful adjustment of stent position. For high-grade stenosis in a large diameter innominate artery (e.g., >12 mm), it may be appropriate to use as smaller diameter stent (e.g., 6 to 8 mm) initially and post-dilate to an optimal diameter. This technique avoids extending the shoulder of a large diameter balloon into the origin of the common carotid or subclavian arteries.

POSTOPERATIVE CARE AFTER ENDOVASCULAR INTERVENTION

Patients are maintained on clopidogrel (75 mg/day) for 30 days following intervention, and on aspirin for life. Follow-up studies include an annual physical examination (with evaluation of upper extremity pulses and blood pressure) and a duplex ultrasound. There is a 15% to 25% risk for recurrent stenosis within 3 to 5 years, with half of them being symptomatic. There are no standardized velocity criteria for recurrent stenoses of these lesions. For patients with symptomatic recurrence or

severely elevated velocities by duplex, reintervention or surgical reconstruction can be considered.

OUTCOMES

Open surgical revascularization has shown durable results in large studies. Patency rates for direct innominate artery reconstruction at 5 and 10 years of 80% to 98.4% and 88% to 96%, respectively, have been reported in large studies. They are associated with a 2.9% to 8% risk of stroke, 1.5 to 3% risk of myocardial infarction, and a 3% to 8% mortality rate. Carotid-subclavian bypass is associated with a mortality rate of 1%, stroke risk of 2.1%, and risk of myocardial infarction of approximately 2%. Patency rates at 5 and 10 years are 94 and 89%, respectively. Similarly, subclavian transposition is associated a 1% mortality rate, and a 99% patency rate.

Endovascular reconstruction appears to be associated with decreased patency compared to open reconstruction. One-year primary patency rates vary from 88.5% to 97%, and 5-year primary patency rates vary from 77% to 89%. Secondary patency rates, however, appear comparable to open surgical results (90% patency at 36 months).

EDITOR'S COMMENT

If one ever pines for the "good old days" in terms of open surgical operations, then reconstruction of the brachiocephalic trunks is one of those operations that older surgeons remember fondly while many surgeons finishing today may never actually perform, at least for primary occlusive disease. I used to perform about two to four of these a year, whereas now I will go entire years without performing one. Well described in this chapter by Eidt and his coauthor, open brachiocephalic operations are one of the most elegant and durable operations performed by cardiovascular surgeons. Primarily using the ascending aorta as an inflow source, these operations typically use large diameter bypass grafts and are sewn end to end to the innominate, carotid, or subclavian artery. The patency rates of these bypasses, as described at the end of this chapter, are superb. However, much like most of vascular surgery, the endovascular revolution has made the stenting of most brachiocephalic lesions relatively simple without a stenotomy and obviating the need to clamp the ascending aorta.

One of the issues that I always struggled with when deciding to perform open brachiocephalic reconstruction is what to do to determine the presence of coronary disease. With open aortic aneurysm repair, we are happy to perform noninvasive cardiac imaging to determine a patient's cardiac risk as low,

moderate, or high. However, open brachiocephalic reconstruction required a median sternotomy, and therefore I always felt like it was in the patient's best interest to get a cardiac catherization prior to the operation. Granted one might find an asymptomatic occluded right coronary artery, but I always thought that it was important to know and consult with a cardiologists or cardiac surgeon prior to proceeding. There are really no data on what the right answer is to this, and I am sure that it partially depends on the age and other risk factors for coronary artery disease the patients have.

It seems like stenting of brachiocephalic lesions has rapidly taken over as the primary mode by which to treat these occlusive lesions. The technical success rate of these brachiocephalic stents is high with fewer posteroperative strokes or death (Ben Ahmed S, Benezit M, Hazart J, et al. Outcomes of the endovascular treatment for the supra-aortic trunks occlusive disease: a 14-year monocentric experience. *Ann Vasc Surg* 2016;33:55–66). However, the long-term patency of this approach is somewhat lacking, and there appears to be a relatively high (16.4%) incidence of restenosis. It is unclear to me whether a covered or uncovered stent is better, but I prefer covered, balloon expandable stents.

Often one is called upon to perform a carotid endartectomy (CEA) and a retrograde stent of the innominate or left common artery. Some have even suggested that this can be done under regional block, even though I much prefer doing these combined cases under general anesthesia (Heyn J, Rosch F, Treitl M, et al. Carotid endarterectomy and retrograde stenting of the supra-aortic trunk: does cervical block offer advantages? *Ann Vasc Surg* 2016;34:193–9). Others have suggested that combined CEA and brachiocephalic stenting increases the risk of stroke, and therefore caution was urged when performing this combination operation, especially in asymptomatic patients (Clouse WD, Ergul EA, Cambria RP, et al. Retrograde stenting of proximal lesions with carotid endarterectomy increases risk. *J Vasc Surg* 2016;63[6]:1517–23).

Honestly, I much prefer to perform all brachiocephalic stents under general anesthesia and through a small cervical incision to expose the proximal common carotid artery. The cerebral vessel is only clamped for a very short time, and almost all patients can tolerate it. It also affords one the ability to flush all the debris out the common carotid artery with a clamp distal to the arteriotomy. I typically also, when stenting the innominate artery, use a small sheath in the brachial artery to place a balloon in the proximal subclavian artery to protect the vertebral arteries as the stent is being deployed. I know others who put filter wires up the carotid and vertebral arteries from below, and this is likely done more commonly than what I do. However, the vertebral artery loves to dissect, and I have seen that as well when someone placed a filter wire in it.

Finally, we are about to experience an explosion in the use of extra-anatomic bypasses of the brachiocephalic arteries, as well as stenting of brachiocephalic arteries, as all aortic arch pathology will soon be managed in the United States (and is already managed in many areas of the world) primarily by endovascular stent grafts. This will likely be true for both the treatment of occlusive and

aneurysm disease, as well as with aortic dissections (Alberta HB, Takayama T, Smits TC, et al. Aortic arch morphology and aortic length in patients with dissection, traumatic, and aneurysmal disease. *Eur J Vasc Endovasc Surg* 2015;50[6]:754–60). Presently, we are resigned to chimney's and homemade fenestrations of these complex aortic arch lesions (Liu H, Shu C, Li X, et al. Endovascular aortic repair combined with chimney technique in the treatment of stanford type B aortic dissection involving aortic arch. *Ann Vasc Surg* 2015;29[4]:758–63; Redlinger RE Jr, Ahanchi SS, Panneton JM. In situ laser fenestration during emergent thoracic endovascular aortic repair is an effective method for left subclavian artery revascularization. J Vasc Surg 2013;58[5]:1171–7), but the trials are beginning to be performed, and by the next edition of *Mastery of Surgery*, we will likely have a new chapter entitled "Aortic Arch Stent Grafting!"

Gilbert R. Upchurch

197 Carotid Body Tumors

Wesley S. Moore

The only known pathologic condition associated with the carotid body is a carotid body tumor. The carotid body was first described by Von Haller in 1743, and Heller coined the term *glomus tumor* in 1762. In spite of the long history, these lesions, even today, remain a topic surrounded by considerable misunderstanding and confusion. Much of this misconception can undoubtedly be traced to the lack of established data related to the histologic origin, biologic behavior, and incidence of malignancy associated with carotid body tumors. As one might predict, this situation has generated considerable controversy regarding the appropriate management of these lesions.

Carotid body tumors are uncommon neoplasms. Their exact incidence remains unknown. In 1971, approximately 500 cases had been recorded in the world literature, and by the early 1980s this figure had doubled to just more than 1,000. Like most other types of benign and malignant neoplasms, the precise cause of carotid body tumors is not known. Also, as is frequently the case with other tumors that have the potential for endocrine activity, these lesions are recognized to occur in three distinct forms: sporadic, familial, and hyperplastic. The sporadic form is more common, although the familial pattern has been recognized in as many as 10% of cases by some authors. A review of familial cases of cervical paragangliomas suggests an autosomal dominant inheritance pattern. Hyperplastic lesions are associated with hypoxia and include patients with chronic obstructive pulmonary disease (COPD), congenital heart disease, and those living at high altitude. It has long been appreciated that chronic hypoxia is associated with enlargement of the carotid body in some patients. Although these changes are usually not classified as tumors, histologic examination of carotid body tissue from these patients frequently reveals marked cellular hyperplasia. This observation, combined with epidemiologic data that suggest an increased incidence of carotid body neoplasms occurring in individuals who live at high elevations, has led some investigators to implicate prolonged hypoxemia

as a possible causal factor related to the development of these uncommon tumors.

This chapter reviews my current practice for the treatment of patients who have carotid body tumors. Because many of these management principles are based on an understanding of the pathology and biologic behavior of these lesions, I have included a summary of the current understanding of these important topics. With an appreciation of these principles and the use of operative techniques developed from them, one should be able to safely manage even the most challenging carotid body lesions. Alternatively, inadequately planned neck explorations in improperly prepared patients or biopsies of seemingly unimpressive neck masses often result in disastrous consequences. Even when the presence of a carotid bifurcation paraganglioma is correctly diagnosed preoperatively, resection of this lesion can be a humbling experience even for the most experienced surgeons.

PATHOLOGY

The normal carotid body is an ovoid nodule, measuring approximately 0.5 cm × 0.5 cm, located along the posterior surface of the carotid bifurcation. This structure represents the largest mass of chemoreceptive tissue found anywhere in the body. The blood supply to the carotid body is usually derived from branches of the external carotid artery, and the venous return occurs through tributaries of the lingual and laryngopharyngeal veins. The innervation is exclusively sensory. Small nerve fibers arising from the carotid body join the larger glossopharyngeal nerve before entering the cranium through the jugular foramen. Stimuli that evoke a response by the chemoreceptor cells include increases in the plasma carbon dioxide tension or blood temperature, or a decrease in the plasma pH or arterial oxygen tension. Once activated, the stimulation of carotid body chemoreceptors causes several physiologic responses, including increased minute volume ventilation, increased pulse rate, and an elevation of the mean systemic blood pressure. Embryologically, the carotid body derives elements from both neural crest ectoderm and mesodermal tissue originating from the third branchial arch. The neural crest ectoderm differentiates into chemoreceptor cells that migrate in close association with the autonomic ganglion cells, and are therefore frequently referred to as *paraganglioma cells.* The mesodermal tissue develops into a highly vascular fibrous stroma that supports and nurtures these clusters of chemoreceptor cells.

Carotid body tumors are neoplastic growths that arise from these chemoreceptive structures. The morphologic appearance of carotid body tumors closely resembles that of normal carotid body tissue. Grossly, the tumor is reddish brown and highly vascular. Microscopically, one sees chemoreceptor cells embedded in a fibrous stroma situated adjacent to abundant capillaries. Overall, the lesions have a very well-differentiated benign appearance. Degenerative malignant characteristics, such as unusual nuclear forms, increased mitotic activity, and vascular invasion, are only very rarely seen. Historically, there has been considerable confusion regarding the terminology and classification of these tumors. The term *glomus tumor* is a misnomer and was introduced based on the mistaken impression that these highly vascular tumors were in fact a form of neurovascular arteriovenous malformation. Mulligan introduced the term *chemodectoma* to describe these lesions in 1950 because these tumors are composed of cells with both chemoreceptor and secretory function. Advanced immunohistochemical studies have subsequently suggested that carotid body tumors are capable of synthesizing numerous different neuroendocrine substances. Secretory granules containing a wide variety of neuropeptides and several enzymes involved in the cytoplasmic synthesis of catecholamines have all been demonstrated. For unclear reasons, however, patients who have carotid body tumors almost never manifest any clinical evidence of excessive endocrine hormone secretion. Sporadic case reports have noted secretory activity of norepinephrine and dopamine, but these are the exceptions. Because it is believed that these tumors arise embryologically from epithelioid cells of the neural crest that have migrated with neural tissue adjacent to the autonomic ganglion, they have also been referred to as *paragangliomas.* Paragangliomas actually comprise a family of neoplastic tumors that can occur anywhere along the autonomic ganglion chain, from the organ of Zuckerkandl to the glomus intravagale. Classically, paragangliomas arising in the adrenal medulla secrete high levels of catecholamines and usually stain positive for chromaffin. Despite having been found to contain granules rich in catecholamines within their cytoplasm, carotid body tumors are most commonly nonfunctional and classically stain negative for chromaffin.

Grossly, these tumors are highly vascular and often invade the adventitia of the adjacent carotid vessels. The tumors grow slowly, beginning along the posterior aspect of the carotid bifurcation. As they enlarge, they typically gradually widen the angle between the internal and

external carotid arteries. Frequently, when carotid body tumors grow very large, they encase the main trunk and proximal tributaries of the external carotid artery. Without explanation, however, they only rarely do the same to the internal carotid vessel. This phenomenon may be related to the origin of the blood supply to the tumor from branches of the external carotid artery. Nonetheless, it is a consistent feature found in large carotid body tumors and has important ramifications related to the strategy for resection, which is discussed in more detail later in Resection of the Tumor.

Although most carotid body tumors are considered benign lesions, malignancy does occur. It is generally accepted that the biologic behavior of a given carotid body tumor cannot be predicted based solely on the histologic appearance of the resected specimen. Benign-appearing tumors are capable of both locally aggressive growth and nodal and distant metastatic spread. Adherence to vascular and neurologic structures is well known, and even extension through the base of the skull into the cranium has been described. Therefore, as is the case with many other neuroendocrine tumors, malignancy is determined by how the lesion behaves clinically. This is quite different from most other types of cancers, in which histologic appearance remains the primary criterion for identification of malignancy. If enlarged lymph nodes are encountered during dissection, they should be removed for biopsy. The presence of carotid body cells within an adjacent lymph node is diagnostic of malignancy.

CLINICAL PRESENTATION

By far, the most common presentation of a carotid body tumor is that of an incidentally noted asymptomatic neck mass. The lesion typically causes no pain and is located just below the angle of the mandible. Usually the tumors grow slowly over several years; however, more rapidly growing lesions are occasionally encountered. In a review by Patetsios et al. from Baylor University in Dallas, they found that 62% of their cases presented with a painless neck mass; 10% with a painful mass, and a few with cranial nerve deficits. Most carotid body tumors are diagnosed in the third or fourth decade of life, but they have been reported in younger and older patients. No gender predominance has yet been established. When the tumor occurs in a familial pattern of inheritance, there is up to a 30% incidence of bilateral tumors, as opposed to 2% to 20% in nonfamilial

cases.

Occasionally when a carotid body tumor becomes very large, compression or local invasion of adjacent structures can lead to a variety of different symptoms. Local discomfort such as pain, fullness, and numbness is not uncommon. In this situation, some patients may complain of difficulty in swallowing, hoarseness, and chronic cough due to compression of the airway or involvement of adjacent cranial nerves.

Despite the fact that carotid body tumors are frequently classified as neuroendocrine neoplasms, clinical evidence of any endocrine imbalance resulting from secretory function of these lesions is almost never encountered. Interestingly, however, the histologic machinery to do so is apparently present. As was mentioned previously in the Pathology section, careful ultrastructural and immunohistochemical examination of these tumors has revealed that carotid body tumors are capable of producing secretory granules containing a large variety of catecholamines. Nevertheless, “functional” cervical paragangliomas are exceedingly rare. Only very rarely is a case reported describing a patient who has both hypertension and a concomitant neck mass and in whom the hypertension resolves after resection of the associated carotid body tumor. The assumption, although not proven, is that the hypertension in these cases occurs on the basis of excessive “tumor related” catecholamine secretion.

On examination, these lesions are often described as painless fixed masses located at the angle of the jaw. In fact, more careful examination usually demonstrates that, although movement is limited longitudinally, the tumor can readily be moved in a lateral direction. This is an important feature of the physical examination and helps to establish an association of the mass with the longitudinally running neurovascular structures. Typically, the mass is firm, smooth, and lobulated. Frequently, transmission of the carotid pulsation is appreciated during palpation. Furthermore, in approximately 30% to 40% of patients, an audible bruit is present over the tumor, giving testimony to the highly vascular nature of the tumor. Locally aggressive tumors may invade or compress adjacent cranial nerves. In fact, careful examination yields clinical evidence of nerve dysfunction in approximately 10% of patients who present with carotid body tumors. Most commonly the hypoglossal or vagal nerves are affected, but laryngeal nerve involvement and Horner syndrome have also occasionally been reported. Large tumors can extend into the base of the skull or present as a bulge in the lateral wall of the oropharynx with

deviation of the soft palate. Ischemic cerebrovascular symptoms rarely, if ever, occur. Patients who have carotid body tumors who also present with transient or permanent ischemic events are usually found to have concomitant carotid bifurcation atheroma or another unrelated cause to account for the cerebrovascular systems.

The differential diagnosis of a patient who presents with an enlarging neck mass is extensive. Congenital lesions, such as branchial cleft abnormalities, hygromas, and vascular malformations, should all be considered. Chronic lymphadenitis, reactive lymphadenopathy, and other inflammatory reactions must also be excluded. Many other benign and malignant neoplastic processes, such as lipomas, neurofibromas, salivary gland and parotid tumors, metastatic head and neck cancers, leukemias, and lymphomas, can also present in this way. It should also be remembered that other cervical paragangliomas exist. These include the glomus vagale, and the glomus jugulare. It is beyond the scope of this chapter to describe their management other than to mention that it may be quite different from the management of carotid body tumors. Vascular abnormalities, such as carotid aneurysms, coils, and kinks, should also not be overlooked. A thorough history and physical examination combined with carefully selected diagnostic studies can usually distinguish these other pathologies and successfully identify most cervical paragangliomas. Clearly, however, this orderly workup is critical, as the appropriate treatment for many of these lesions varies greatly.

NATURAL HISTORY AND INDICATIONS FOR SURGERY

Once identified, all carotid body tumors should be removed. Although these lesions are slow-growing neoplasms with a relatively low risk of malignancy, small tumors are easier to excise, and eventually most, if not all, will progress and become locally invasive. These tumors continue to grow and, in time, extension to the base of the skull or involvement of cranial nerves may complicate their management. In addition, the threat of distant metastases, although low, is real. Despite being categorized as generally benign, malignant transformation of carotid body tumors has been reported. The exact incidence of malignancy is difficult to quantitate and depends on the definition of the term used. The biologic behavior and malignant potential of a given carotid body tumor cannot be predicted by histologic examination. Rather, malignant potential is identified by clinical behavior. If strict criteria of regional lymph node or distant metastatic

spread were used, the incidence of metastatic spread from carotid body tumors would be quite low, although it is definitely not zero. Some reports have suggested that the true incidence of distant metastases in untreated lesions approaches 10%. However, locally aggressive growth patterns of carotid body tumors are not at all uncommon, and certainly lesions that invade adjacent structures can be considered at least potentially malignant. Consequently, most authorities consider all cervical paragangliomas capable of malignant behavior. Death from carotid body tumors does occur, and not always from metastatic disease. Relentless local growth of these lesions can cause death by airway compression, cranial neuropathies, or intracranial extension. Also, regional lymph node and distant metastases, which are exceedingly rare at presentation, can occur years after the primary tumor has been resected. It should also be mentioned that, because of this low risk of malignancy, a case could be made against operative treatment in the high-risk or elderly surgical patient who presents with a small, asymptomatic carotid body tumor. In most cases, however, in view of the natural history of progressive enlargement, frequent local invasion, and small but unpredictable risk of distant metastases, most surgeons recommend surgical resection once the diagnosis of a carotid body tumor has been established.

PREOPERATIVE PLANNING

The preoperative evaluation of patients being considered for resection of a carotid body tumor is important and should be directed to address several questions:

- What is the overall general medical condition of the patient?
- Are other cervical paragangliomas present?
- What is the anatomic extent of the lesion under investigation?
- Is there any cranial nerve involvement detectable preoperatively?
- Is there any evidence of endocrine dysfunction or hormonal imbalance?

Each patient should undergo a thorough history, and important risk factors should be identified. Likewise, the physical examination should be complete, with particular emphasis on the neurologic and cerebrovascular systems. Clearly, an asymptomatic elderly patient who is considered to be a poor operative risk may not be well served by a potentially hazardous resection of what is most commonly a benign neoplasm. Likewise, the presence of multiple lesions or extension of a tumor into the base of the

skull would obviously influence the operative approach. Involvement of cranial nerves suggests at least a locally aggressive tumor, and documentation of these deficits preoperatively is obviously very important. Several imaging techniques are now available to diagnose and characterize carotid body tumors. As is frequently the case, each of these modalities has specific strengths and weaknesses that should be carefully considered.

The preoperative evaluation of patients who have carotid body tumors has traditionally relied on the results of selective carotid angiography. This is largely due to the unmatched demonstration of anatomic detail in a familiar format that is easily interpreted by most clinicians. The carotid bifurcation is particularly easy to demonstrate with this examination. Information regarding the overall size, proximal and distal extent, and degree of vascularity of the lesion can usually be easily assessed (Fig. 197.1).

Information regarding the major arterial blood supply to the tumor is also obtained. Infrequently, an unusual tumor blood supply from an aberrant ascending cervical or vertebral artery branch is identified, which can be very important preoperatively. Another advantage of angiography is its ability to evaluate the entire distribution of the brachiocephalic and cerebrovascular tree, including the origin of the vessels as they arise from the aortic arch and the intracranial portion of the branch vessels. This is important because angiography is an extremely sensitive method of identifying cervical paragangliomas and allows the surgeon to easily detect occult nonpalpable synchronous or contra lateral tumors. Also, angiography can occasionally suggest malignancy by demonstrating encasement of the carotid vessels. Rarely, this may alert the surgeon to the presence of extensive internal carotid involvement and allow preoperative planning for the possible need for a vascular reconstruction. Last, by imaging the lumen of the carotid vessels, any atheromatous plaques or significant ulcerations can be documented. Kinks, coils, aneurysms, and any other unsuspected anatomic variations are also all easily identified with this technique. Intracranial pathology that may influence management decisions includes arteriovenous malformations, cerebral aneurysms, and significant siphon stenoses. Finally, some authors have reported the use of preoperative embolization as an adjunct before the resection of particularly large or highly vascular carotid body tumors. As such, although I have not found this necessary (and consider it potentially hazardous), one might qualify the ability to consider this treatment option as another potential

advantage to support the use of angiography during the preoperative evaluation of these patients.

The risks associated with cerebral angiography are numerous. First, this technique is an invasive procedure that requires arterial access, and wound complications are therefore not infrequent. Hematoma formation, acute arterial dissection, false aneurysms, and distal embolization have all been reported. The incidence of these complications has not been documented consistently; however, they probably occur in between 1% and 2% of cases. Second, catheter manipulation within the carotid artery can lead to serious complications as a result of dissection or embolization. In one review of over 5,000 cerebral angiographic procedures, the overall risk of neurologic sequelae was 0.9%, with 0.06% of patients experiencing a permanent stroke. Others have placed the risk of neurologic events and stroke at 2.6% and 0.6%, respectively. Although most of these reviews include patients being evaluated for atherosclerotic vascular disease and not carotid body tumors, it is probably accurate to estimate that, during cerebral angiography, the risk of a neurologic event is approximately 1%. Finally, the contrast injected during angiography can induce allergic reactions, renal failure, and alterations in the coagulation system. Allergic reactions range from mild rashes and gastrointestinal upset to life-threatening hypotension, bronchospasm, pulmonary edema, and cardiac arrhythmias. The risk of contrast reactions in all types of angiographic studies varies between 2% and 8%. For cerebral examinations, risk is in the lower range, with a rate of approximately 2%. In high-risk patients who have antecedent renal disease, the risk of acute renal failure after the administration of contrast can be as high as 40%, with more than 8% of patients requiring permanent dialysis. Finally, depending on the institution, the cost of angiography is as high as $5,000 per procedure.

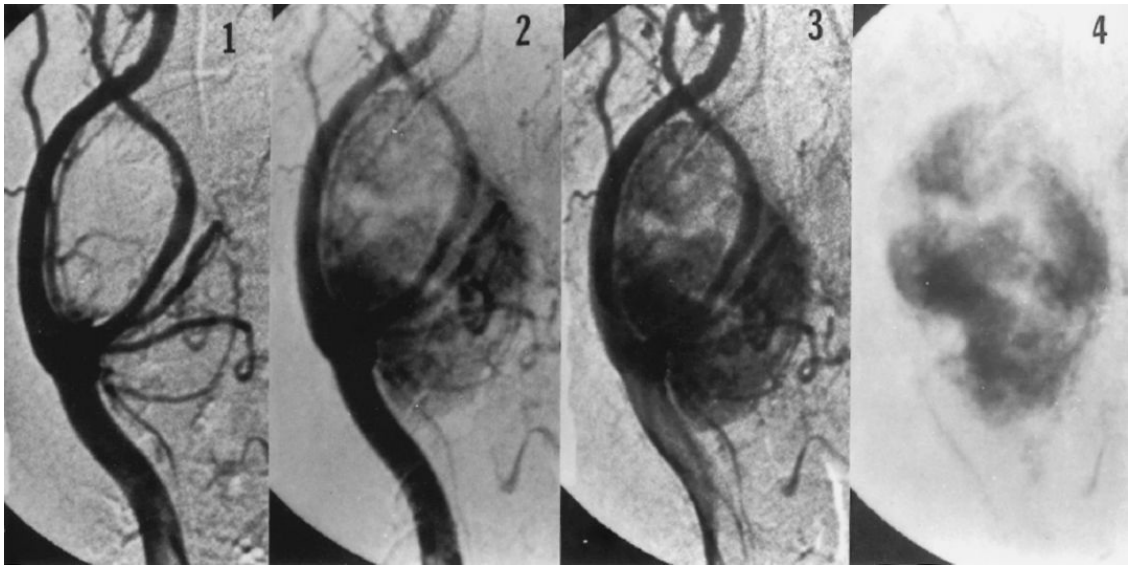

Figure 197.1. Typical angiographic appearance of a carotid body tumor. Initial injection view (1) demonstrates the characteristic "splaying" of the carotid bifurcation. Subsequent delayed views (2–4) show the anatomic extent of lesion and the degree of vascularity.

In summary, angiography has long been considered the "gold standard" for the evaluation of patients who have carotid body tumors. Indeed, some surgeons consider this examination mandatory before performing a resection of this neoplasm. However, as described, this imaging technique is not without risk, and with the emergence of newer, noninvasive imaging modalities, others have questioned whether this study is really necessary in all cases. Also, because the morbidity of any preoperative examination must be added to the overall risk associated with the surgical intervention, methods of safely treating these generally benign tumors without routine angiography are even more desirable. These forces have led several investigators to attempt to gain experience managing these lesions without the benefit of angiographic data.

Duplex scanning has emerged as an accurate noninvasive method of evaluating patients who have carotid body tumors. In terms of technical performance, it clearly has several advantages over angiography. The examination is noninvasive and involves little or no patient discomfort. In contrast to the multiple wound and contrast-related problems associated with angiography, duplex scanning is essentially without risk. The anatomic detail, although not as good as with angiography, is quite satisfactory. The tumor can be localized to the carotid bifurcation and, with the addition of color-flow technology, an estimate of the vascularity

of the lesion can be obtained. Also, as with angiography, tumor size can be estimated and the bifurcation screened for evidence of tumor encasement or concomitant atherosclerotic disease. Finally, most hospitals charge approximately $300 to $400 for a duplex scan, or roughly one-tenth the cost of a cerebral angiogram.

The major limitation of duplex scanning is its inability to clearly image either the proximal or very distal areas within the neck. Proximal and distal extensions of very large lesions are poorly visualized. Also, any significant intracranial component to a tumor invariably goes unrecognized. In addition, this study is not as sensitive for very small lesions, and, when compared to angiography, small occult tumors may not be readily identified. Likewise, potentially helpful detail, such as the presence of an important aberrant blood vessel, is unlikely to be obtained during duplex scanning. Last, and perhaps most important, the reliability of any duplex study depends on the individual performing the examination, and results obtained by different operators vary greatly.

When more information is required, computed tomography (CT) and magnetic resonance (MR) scanning are useful techniques. Both tests can be extremely helpful, particularly in large tumors or when multiple lesions are suspected (Figs. 197.2 and 197.3).

Unlike with duplex scanning, large lesions can be defined even in the proximal or distal portions of the neck. Also, both studies can reveal tumor encasement of the vascular structures or invasion of an aggressive lesion into the base of the skull. MR images have the additional advantage of being able to be analyzed by software that reconstructs angiographic detail. These MR angiograms have gained popularity by virtue of their ability to noninvasively depict the cerebral vessels in a format similar to that of conventional arteriography. Whether these images possess enough accuracy to safely plan carotid body resections and replace conventional angiography remains unproved.

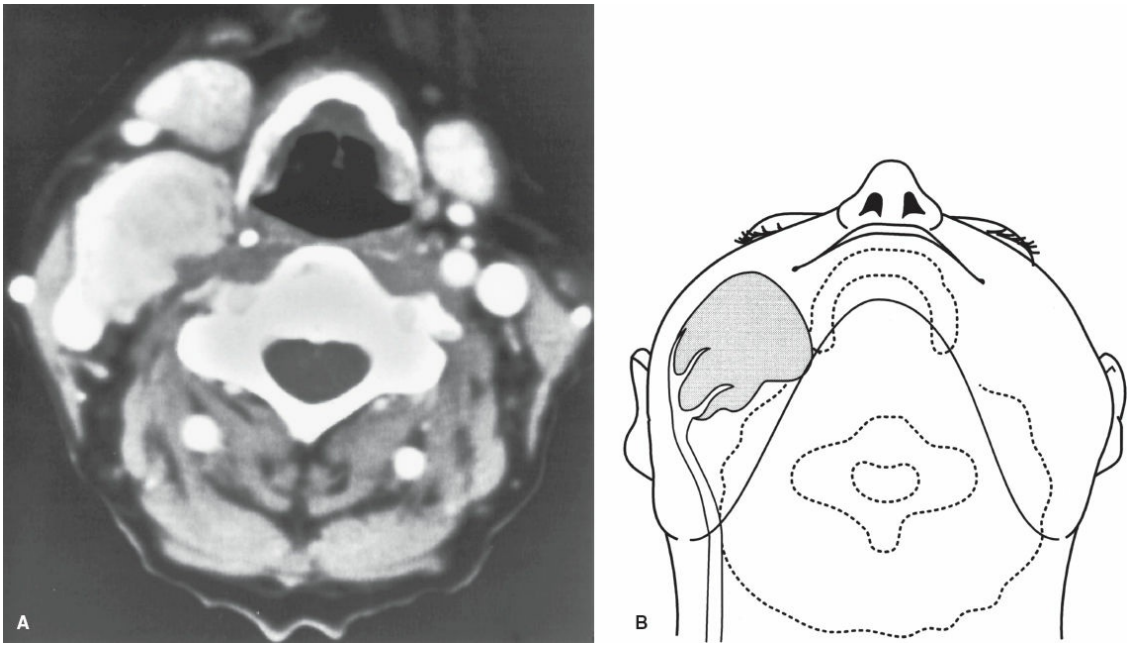

Figure 197.2. **A.** Computed tomographic scan demonstrating large carotid body tumor with probable encasement of the external carotid artery. **B.** This is the artist's concept of the relationship of the carotid body tumor to the carotid artery, as seen in (**A**).

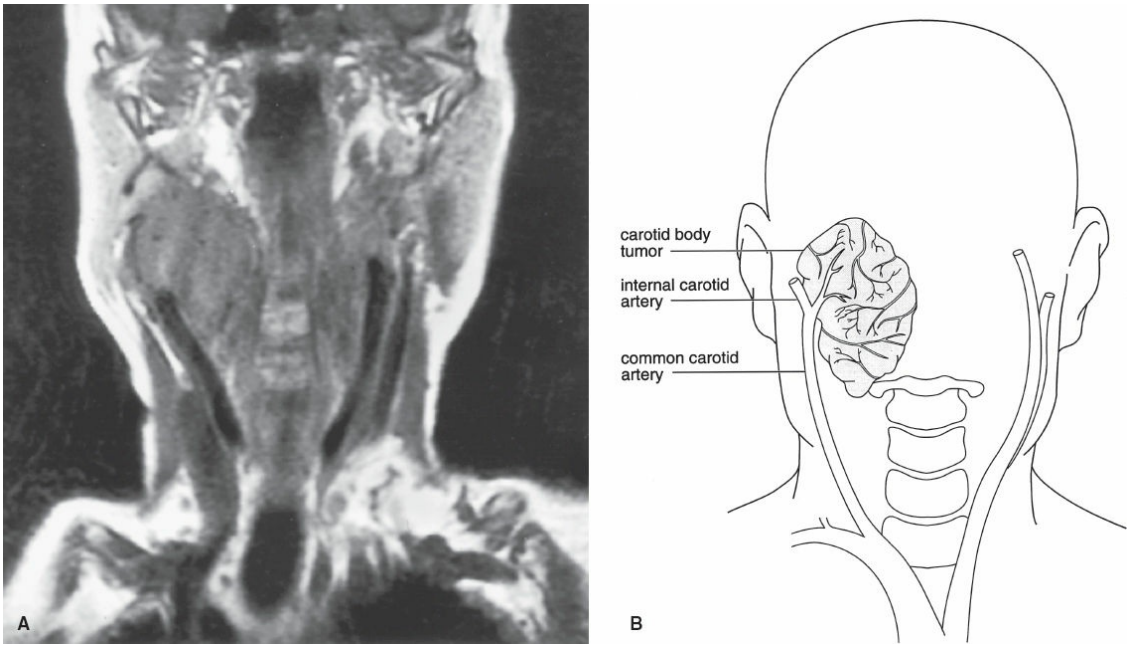

Figure 197.3. **A.** Magnetic resonance image showing large right-sided carotid body tumor. **B.** This artist's concept clarifies the magnetic resonance image, showing the relationship of the carotid body tumor to the common carotid artery and carotid bifurcation.

In 1971, Shamblin and colleagues, from the Mayo Clinic, described their overall experience with 101 patients who were treated at the Mayo Clinic from 1931 through 1967. In reviewing the operative reports, they developed a classification based upon tumor extent and neurovascular involvement. Group I tumors could be freely dissected away from the wall of the carotid artery. Group II tumors partially surrounded the circumference of the carotid artery. Group III tumors had intimate adherence to the entire circumference of the carotid bifurcation. With today's modern imaging, it is now possible to use the Shamblin classification, preoperatively in order to anticipate the degree of difficulty with planned surgical resection. Some surgeons routinely carry out preoperative tumor embolization in patients with Shamblin II and III lesions in hopes of facilitating operation and reducing blood loss. In a 2012 publication, Power and colleagues reported on 144 carotid body tumors treated at the Mayo Clinic between January 1985 and December 2010. They carried out a retrospective comparison of patients with Shamblin II and III lesions who underwent preoperative embolization with those patients who had surgery without preoperative embolization. They found that those patients who underwent preoperative embolization required less extensive procedures. However, there was no difference in operative time, cranial nerve palsy, or postoperative length of stay. They did find that preoperative embolization added significantly to the overall cost of patient care. In my own experience, I have never used preoperative embolization and therefore have no basis for comparison.

To summarize, the duplex scan is an accurate, noninvasive imaging technique that is useful for screening patients who have neck masses. It can most often establish an association between the mass and the carotid bifurcation, but it frequently cannot provide enough anatomic detail to establish the diagnosis of a carotid body tumor or safely plan for its resection. Traditionally, most surgeons have used cerebral angiography to accomplish these goals; however, there is no question that arteriography exposes patients to an increased risk that must be added to the operative morbidity when calculating the overall risk of surgical therapy. Experience with CT and MR scanning has grown and has largely replaced the need for catheter-based angiography when information from carotid duplex scanning, alone, is not sufficient for diagnosis or preoperative planning.

SURGICAL TECHNIQUE

In experienced hands, the removal of a carotid body tumor can be accomplished with very low morbidity and mortality. However, several important operative principles must be appreciated to consistently achieve these results. It cannot be overemphasized that carotid body tumors are, as a rule, extremely vascular lesions. In fact, one can safely say that an inexperienced surgeon who does not appreciate this characteristic and fails to plan his or her operative approach accordingly will not soon forget the operative experience.

My technique for safe resection of even very large carotid body tumors is based on several observations. First, the majority of the blood supply to carotid body tumors arises from a rich matrix of small vessels that surround the bifurcation in a periadventitial plane and originate mostly from small branches of the external carotid artery. Second, perhaps because of this blood supply pattern, very large carotid body tumors frequently completely encase the external carotid artery but only rarely do the same to the internal. Third, all but the very smallest tumors frequently distort the normal anatomy, and often displace important cranial nerves from their usual location. Last, it is critical to bear in mind the relative importance of the internal carotid circulation compared to the external and its branches.

Together, these observations have influenced an operative approach that combines isolation and protection of the internal carotid system with the safe and bloodless resection of these highly vascular lesions. To avoid several unnecessary complications during the resection, it is extremely important to minimize bleeding during the dissection. Excessive hemorrhage may persuade a less experienced surgeon to attempt ill-advised maneuvers to control the bleeding. These maneuvers are commonly the cause of postoperative cranial nerve injuries and strokes. Also, excessive bleeding can occasionally lead to unnecessary transfusions along with their well-known associated complications. Using the operative approach described later, I have not had to administer blood products to a patient undergoing resection of even the largest of carotid body tumors.

Preoperative Embolization

One technique that can aid in the management of very large and hypervascular carotid body tumors is preoperative selective arterial embolization. Using a percutaneous catheter technique, the external carotid artery is selectively catheterized. Thrombogenic particles, such as Gelfoam

(Pharmacia & Upjohn, Kalamazoo, MI) or coils, are introduced into the large nutrient vessels that feed the tumor. This technique has been shown to be effective and can greatly facilitate the resection of very vascular tumors that would otherwise have been difficult to approach safely. However, embolization only reduces tumor vascularity to a small extent—use of preoperative embolization may lead to a false sense of security for the less experienced surgeon. Reported series that include cases with and without embolization have failed to demonstrate any difference in operative blood loss. As mentioned previously, I have not found this technique to be necessary in the majority of patients and have serious concerns about its safety. There are case reports of stroke related to inadvertent embolization of the internal carotid artery. However, it is an available treatment adjunct and can be performed with relatively low morbidity by a sufficiently experienced individual.

Anesthesia

Local or general anesthesia can be used for this type of surgery. Local techniques usually include a regional cervical block in combination with direct skin infiltration of anesthetic agents. Regional cervical block is easily accomplished by infiltrating the cervical plexus with a mixture of 1% lidocaine (Xylocaine) and 0.5% bupivacaine hydrochloride (Marcaine). Rapid skin anesthesia with a prolonged duration can also be obtained by this combination. Subcutaneous injections, as well as deep injections along the posterior border of the sternocleidomastoid muscle to anesthetize the superficial nerves of the cervical plexus, complete the local block. Occasionally, additional injections within the carotid sheath may be required.

The advantages of local anesthesia are related to the avoidance of the cerebral and myocardial depressant effects of general anesthesia. The improved tolerance of the elderly or cardiac-impaired patient to local anesthesia allows for a safer operation in these high-risk individuals. Most surgeons, however, prefer general anesthesia for patients undergoing resection of carotid body tumors. It provides a more controlled operative setting, including excellent airway control and less movement in the operative field.

Cerebral Monitoring and Protection

Because reconstruction, or at least temporary occlusion, of the internal

carotid artery is occasionally necessary during resection of a carotid body tumor, I believe that some method of cerebral monitoring and protection should always be used during resection of these lesions. Several techniques are available to monitor cerebral perfusion during carotid surgery. These include measurement of distal internal carotid artery back pressure, continuous scalp-recorded electroencephalographic (EEG) monitoring, and direct observation and continuous assessment of the awake patient. In general, although a conscious patient is a sensitive intraoperative indicator of adequate cerebral blood flow, as was already mentioned, I prefer general anesthesia for operations on the carotid artery. At the University of California at Los Angeles, my practice has been to use brain-mapping technology in conjunction with continuous scalp-recorded EEG in all patients undergoing carotid surgery. This technique uses several scalp electrodes, normally placed over the distribution of the middle cerebral artery. The EEG is recorded continuously throughout the operation and represents the summation of cortical neuron postsynaptic potentials located beneath each electrode. The newer-generation machines equipped with brain-mapping capabilities use multiple electrodes and color output displays to divide each hemisphere into smaller monitoring parcels and therefore detect more focal abnormalities. Changes in the recorded EEG strongly correlate with alterations in cerebral blood flow. Cortical ischemia is detected by a reduction in the recorded wave amplitude or frequency. In those instances when carotid clamping produces measured cerebral ischemic changes, cerebral protection (using an internal carotid artery shunt) can then be used.

As was mentioned previously, an alternative method of determining when cerebral protection is necessary is the internal carotid artery back pressure measurement. Using this technique, the adequacy of collateral blood flow to the ipsilateral hemisphere during proximal artery occlusion is determined by measurement of the back pressure. A 22-gauge needle is bent 2 cm from the tip, to an angle of 45 degrees, and connected to an arterial pressure transducer. The needle is inserted into the common carotid artery, with the angulated tip lying longitudinally in the lumen and directed toward the bifurcation. First, an open carotid artery pressure is measured, and it should be compared to the peripheral radial artery catheter or cuff pressure to ensure that the carotid pressure transducer is functioning correctly. Then, with the external and proximal common carotid arteries temporarily occluded, the internal carotid artery back

pressure is recorded. Although no precise consensus has been reached, most authorities define the range of 30 to 50 mm Hg as the pressure below which cerebral protection is mandatory. If this is the case, the clamps on the external and proximal common carotid arteries are removed and preparations are made for use of an internal bypass shunt.

Whichever method of cerebral monitoring is used, once it is determined that cerebral perfusion is inadequate during carotid cross-clamping, the ipsilateral cerebral cortex must be protected by insertion of a temporary internal bypass shunt. Safe placement of a carotid artery shunt requires an appreciation of several principles. Most important, full exposure of all three major carotid vessels is mandatory. This allows complete proximal common carotid control and full appreciation of the distal extent of any concomitant atherosclerotic disease in the internal and external carotid arteries. With the internal and external carotid arteries controlled, the common carotid is occluded proximally with a soft clamp. The arteriotomy in the common carotid vessel should be placed comfortably away from the proximal extent of the tumor. The distal internal carotid is allowed to back bleed, and an internal shunt with an appropriate diameter is gently inserted. I prefer to use the Javid shunt; however, other types are available. The shunt is flushed, clamped, and subsequently inserted into the common carotid artery proximally. Snares (Rumel tourniquets) are used to secure the shunt, and the occluding clamp on the common carotid is removed. Thus, in the final configuration, the shunt is in place with only a single occluding clamp in its midportion. One should remove this clamp slowly, watching carefully for air or debris that may be visible through the proximal portion of the shunt. Once the shunt is in place and cerebral protection accomplished, attention can be directed toward resection of the tumor. If reconstruction of the internal carotid becomes necessary, it is possible to maintain cerebral perfusion at all times by interposing a graft over the shunt while it remains in situ. After completion of the procedure, the shunt is always clamped and removed, and the carotid vessels are flushed, beginning distally. The arteriotomy closure is then completed, with the vessels temporarily occluded. This technique is used for vascular operations on the carotid artery, but has limited application to patients with carotid body tumors since early control of the external carotid artery is not possible since the external carotid artery is usually surrounded by the tumor mass. An alternative technique involves the use of an internal shunt that uses inflatable balloons, proximally and distally, as an alternative to

external control with Rumel tourniquets. The shunt is first inserted into the common carotid artery that has been controlled proximal to the carotid bifurcation and the tumor mass. Using digital control of the distal common carotid artery, the shunt is first advanced into the internal carotid artery. The distal balloon is then inflated and the shunt is back-bled and clamped. The proximal shunt is then passed retrograde into the common carotid artery, the proximal balloon is inflated, and the clamp on the shunt is removed. This technique not only restores flow to the internal carotid artery, but effectively obstructs inflow to the external carotid artery. This technique can also be used to reduce the blood supply to the tumor since it effectively occludes the proximal external carotid artery.

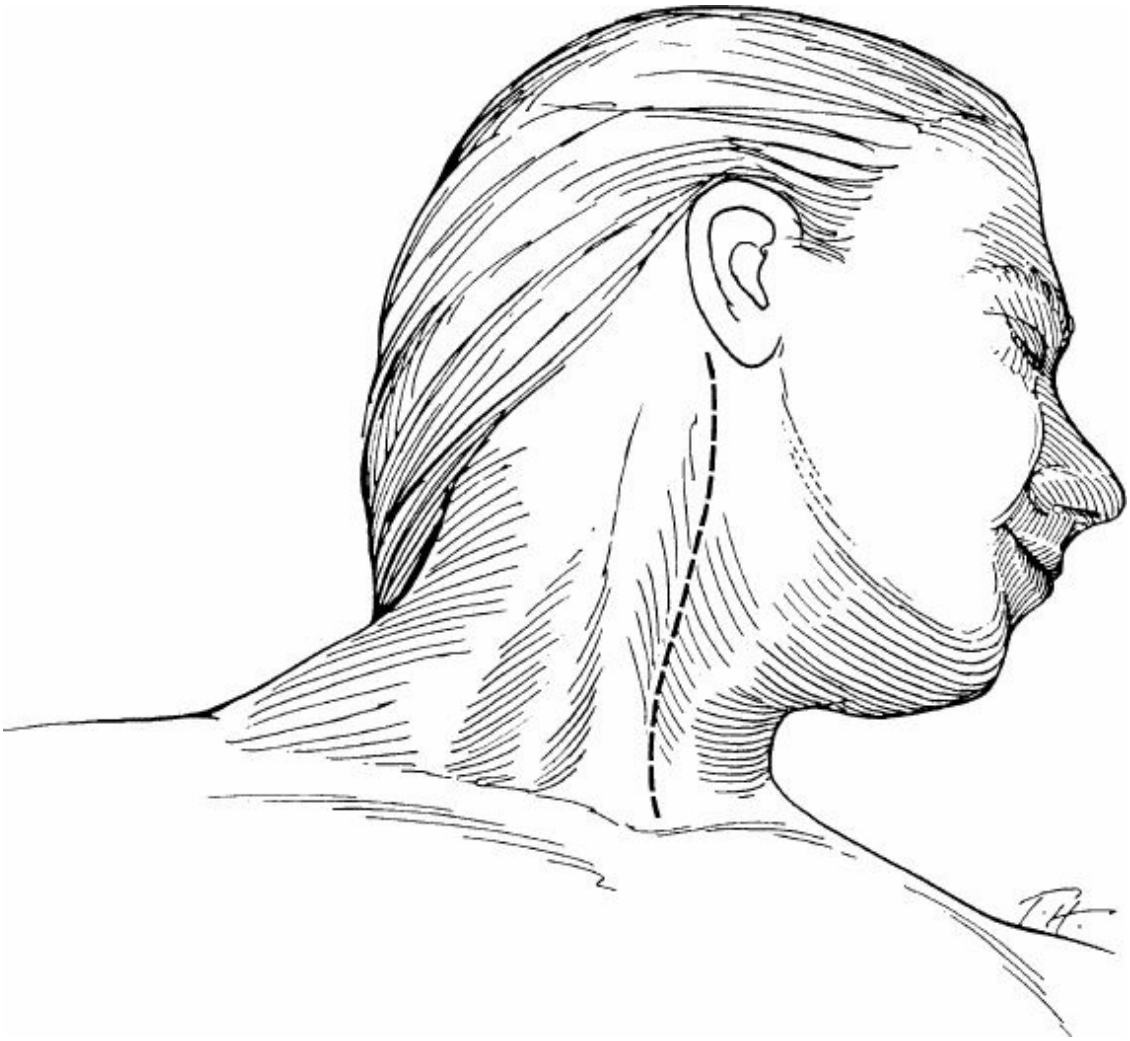

Figure 197.4. Location of the incision along the anterior border of the sternocleidomastoid muscle with the head rotated away from the operative side. For additional cephalad exposure, the incision can be curved posteriorly and extended across the mastoid process behind the ear.

Exposure

The patient should be positioned supine on the operating table and the head rotated away from the operative side. The head of the table is raised 10 to 15 degrees, which reduces venous pressure and minimizes incisional blood loss. Depending on individual differences in body habitus, the neck can be extended by the placement of a small towel roll beneath the shoulders.

A longitudinal incision is made that follows the anterior border of the sternocleidomastoid muscle (Fig. 197.4).

The approximate position of the carotid bifurcation can often be determined by palpation of the lesion or from preoperative diagnostic studies. Ideally, the incision should be centered longitudinally so that the bifurcation is below the midpoint. When necessary for additional exposure, this incision can be continued down to the sternal notch and cephalad to the mastoid process. The plane of dissection remains along the anterior border of the sternocleidomastoid until the belly of this muscle can be reflected off the carotid sheath. Often, the posterior tail of the parotid gland is encountered at this level, and further dissection is required. The gland should be mobilized and reflected anteriorly, rather than divided. Transecting the gland can cause excessive bleeding and occasionally lead to a salivary fistula. Once the carotid sheath is visualized, it should be opened along the anterior border of the jugular vein, which can usually be easily identified through the sheath. The jugular vein is mobilized completely and any large branches identified. The common facial vein is a broad-based tributary that commonly joins the jugular vein just above the carotid bifurcation. This vein provides a useful marker for the location of the carotid bifurcation and, once identified, should be divided between ligatures. Particularly in high bifurcations, the hypoglossal nerve can also be located deep to the facial vein, and care must be taken to avoid inadvertent injury to this structure.

After the facial vein is divided, the jugular vein can be reflected laterally, providing exposure of the carotid vessels (Fig. 197.5).

The vagus nerve, which is ordinarily posterior, can be located anywhere within the carotid sheath. Therefore, in each case, its course must be identified and protected to avoid injury. The laryngeal nerves, which are usually recurrent and therefore in the tracheoesophageal groove, may come off the vagus directly and cross anterior to the carotid artery near the bifurcation, where it enters the vocal musculature. When not recognized,

division of this nerve will lead to vocal cord paralysis. It should also be mentioned that, although this anomaly is more common on the left side, its presence has also been described on the right.

Once the sheath has been entered and all pertinent structures identified and protected, the common carotid artery is sufficiently mobilized proximally to allow complete delineation of the extent of disease and to provide sufficient length in case a bypass shunt is required. Once the common carotid artery is circumferentially mobilized in the perivascular plane of Leriche, dissection is continued on the lateral aspect of the internal carotid artery within that plane until the top of the tumor mass is reached at which point the distal internal carotid artery can be circumferentially mobilized. Dissection can then be continued on the medial aspect of the internal carotid artery in the same perivascular plane. This plane is often erroneously referred to as a subabvential plane in the literature. This incorrect reference has often led to inexperienced surgeons attempting to enter the plane between the adventitia and the media with disastrous arterial injury. Dissection continues down toward the bifurcation at which point the external carotid artery can be identified. In the case of small tumors, the external carotid artery can often be salvaged. In the case of large tumors, the external carotid artery should be divided and the proximal stump over sewn. By leaving a clamp on the tumor side of the external carotid artery, this will provide an excellent handle to begin to lift and dissect the tumor circumferentially from the surrounding tissues. The dissection should stay on the capsule of the tumor, and branches of the external carotid artery should be divided and ligated as the surgeon progresses distally. The 12th cranial nerve should be carefully identified and separated from the anterior surface of the tumor mass as it courses superficial to and oblique to the internal carotid artery. Once the posterior, lateral, and medial aspects of the tumor are freed from surrounding tissues, the superior extent is divided between ligature and the mass removed. Reflex bradycardia can occur during manipulation of the carotid bulb as a result of stimulation of the carotid body. This can be prevented, or reversed when necessary, by a local injection of an anesthetic agent to block the nerves that arise from the carotid body.

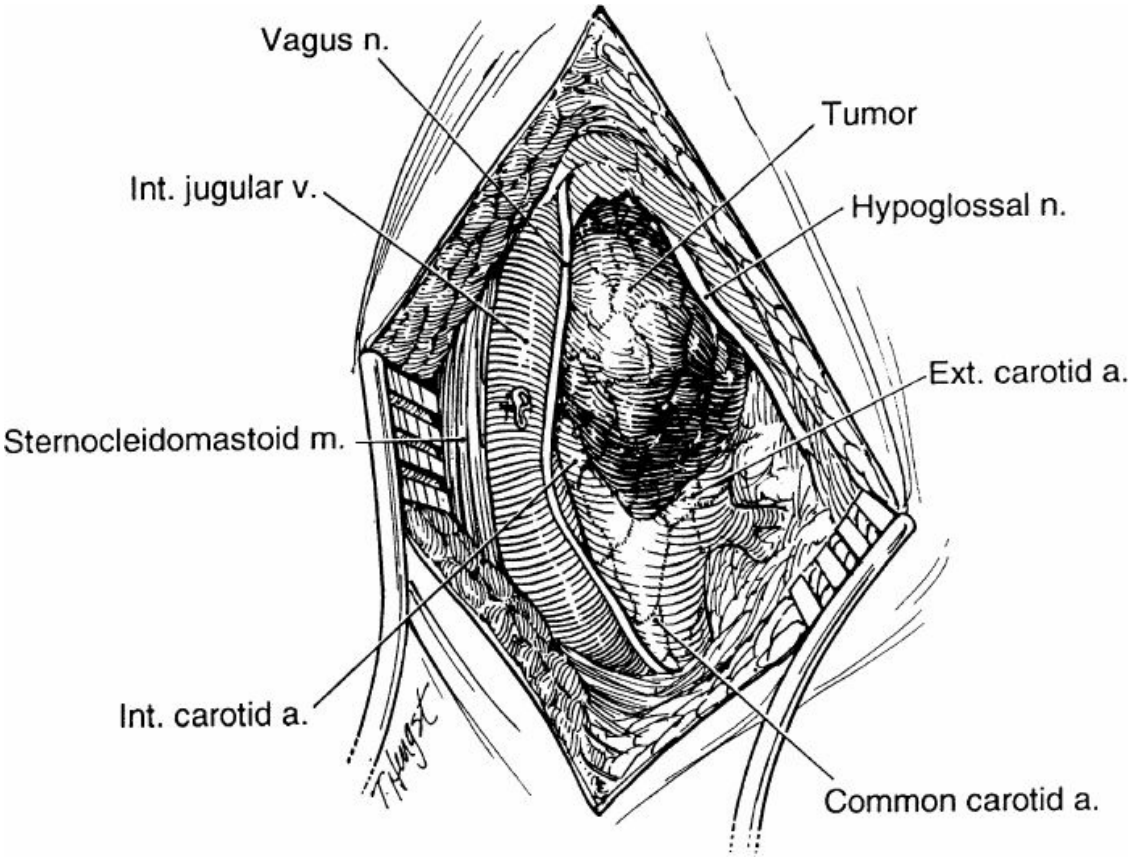

Figure 197.5. Diagram showing typical exposure after ligation and division of the common facial vein and lateral retraction of the sternocleidomastoid muscle and jugular vein.

Extended Exposure Techniques

When one encounters a very large tumor that extends up toward the base of the skull, or when a particular patient's carotid artery bifurcates high in the neck, it may be necessary to obtain additional exposure in the superior aspect of the incision. Several techniques have been described to increase exposure in this area, and surgeons performing carotid surgery should be familiar with these maneuvers. The simplest and most important technique is to extend the skin incision completely across the mastoid process behind the ear. This allows additional mobilization of the sternocleidomastoid muscle up to its tendinous insertion. The spinal accessory nerve enters the muscle at this level and must be preserved. When additional exposure is necessary, the posterior belly of the digastric muscle can be detached from its origin or divided. The digastric muscle consists of two muscle bellies united by a rounded tendon. The posterior belly arises from the mastoid process, and the anterior portion inserts on the mandibular symphysis. It is helpful to appreciate the superficial anatomic position of the posterior

digastric muscle when dissecting in this area. All important neurovascular structures lie deep to the digastric at this level. Only the external jugular vein and branches of the facial and great auricular nerves pass superficial to the posterior belly of the digastric. Below the muscle, particular care must be taken to avoid injury to the hypoglossal and spinal accessory nerves, as well as the facial branch of the external carotid artery. In addition, it should be mentioned that the stylohyoid muscle can also be divided. This muscle stretches between the styloid process and the hyoid bone, and its removal, along with that of the styloid process, can provide additional exposure of the distal internal carotid artery at the base of the skull. When the tumor extends very high, it is possible to gain additional exposure by anteriorly subluxating the condylar process of the mandible. The displaced mandible can be secured in place with inter-dental wires. This maneuver alters the geometry at the base of the skull by turning a triangular space into a rectangle, thereby enlarging the operative field. Lastly, techniques by which the ramus of the mandible is divided have also been described. This is an involved procedure that greatly complicates the postoperative course of these patients. In my experience, I have never found this maneuver necessary.

Resection of the Tumor

After completion of the exposure, the initial dissection is directed toward the proximal common and distal carotid branches, staying away initially from the area of the carotid bifurcation (Fig. 197.6). Control of the common and internal carotid arteries should be obtained before dissection of the tumor. Small tumors can be approached directly, and a periadventitial dissection plane can usually be developed. However, as was mentioned earlier, these lesions are typically extremely vascular and, especially in large adherent tumors, the correct plane for safe dissection is often difficult to locate adjacent to the bifurcation. Therefore, I suggest placing a vessel loop on the proximal common carotid artery, as well as on both the internal and external carotid vessels distal to the tumor, before beginning the resection. My first concern during the dissection is to resect the tumor away from the internal branch of the carotid artery and preserve normal intracranial perfusion. Thus, after control has been achieved with vessel loops, the extensive periadventitial matrix of small vessels is ligated with fine suture, beginning at a convenient spot along the common carotid proximal to the lesion.

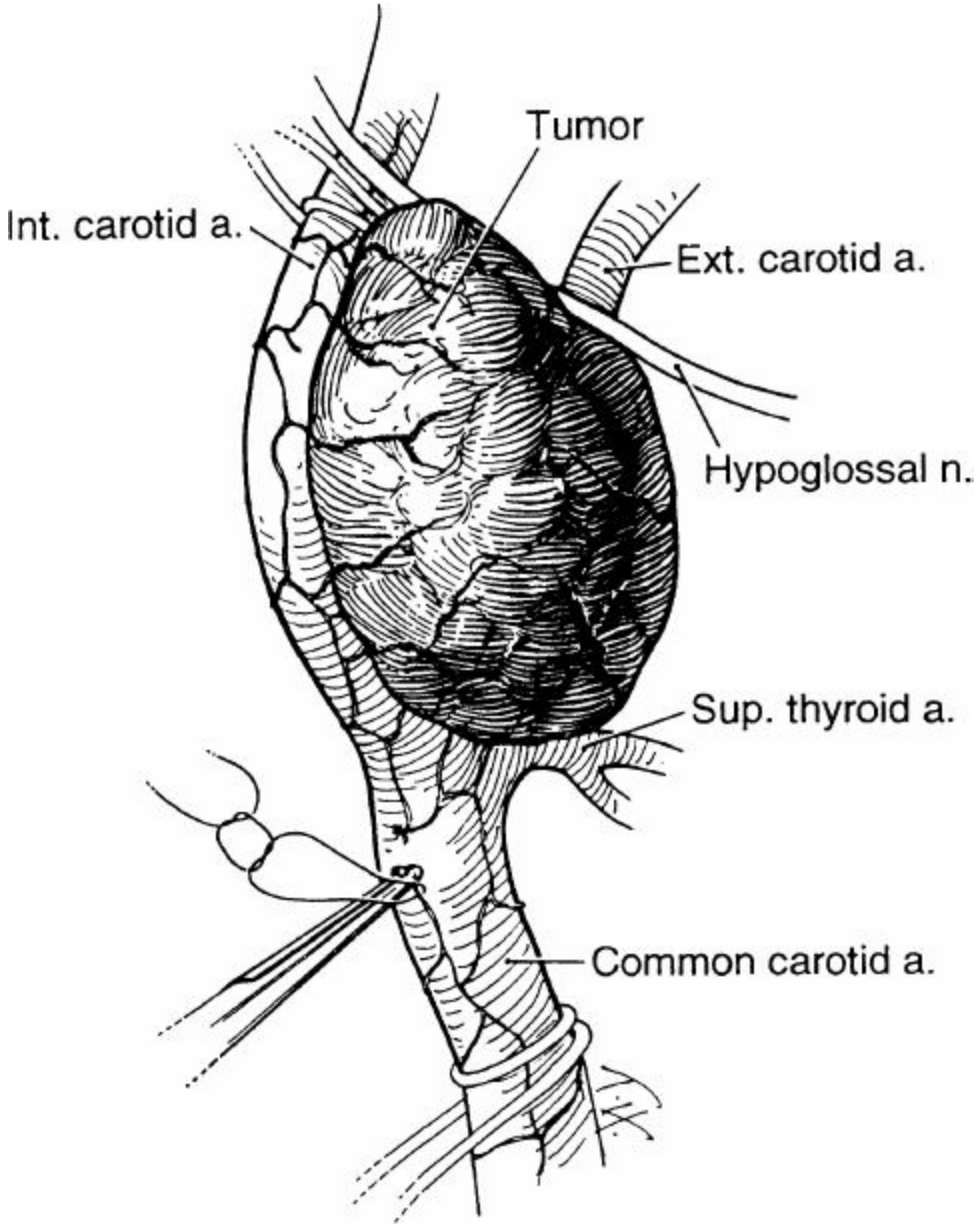

Figure 197.6. After obtaining proximal and distal control with vessel loops, the extensive periadventitial matrix of small tumor feeding vessels is ligated with fine suture, beginning along the proximal common carotid artery in an area located 180 degrees opposite the takeoff of the external carotid.

This dissection is continued distally, following the course of the internal carotid artery along a longitudinal plane located 180 degrees opposite the takeoff of the external carotid branch (Fig. 197.7).

Because carotid body tumors frequently grow around the external carotid while pushing away the internal, beginning the dissection in a plane opposite the origin of the external is the safest technique for isolating and separating the tumor from the cerebral circulation. Once the

periadventitial vessels have all been divided to a point beyond the distal extent of the tumor, the dissection is directed proximally toward the bifurcation along the inner surface of the internal carotid (Fig. 197.8). At this point, the tumor is carefully separated from the bifurcation. Nutrient vessels supplying the tumor are often encountered in this location and should be ligated. When the tumor is large or particularly adherent, division of the origin of the external carotid artery can be a useful maneuver. This allows rotational mobilization of the lesion and, because feeding vessels often arise from branches of the external carotid, can reduce blood loss (Fig. 197.9). Otherwise, it is usually possible to meticulously dissect the carotid body tumor away from the external carotid and its branches, ligating each nutrient tumor vessel as it is encountered (Fig. 197.10). Rarely, resection of the tumor cannot be accomplished without complete removal of the carotid bifurcation. This situation is almost always indicative of malignancy. When necessary, vascular reconstruction can be accomplished by the placement of an interposition graft. I prefer to repair the carotid using a prosthetic PTFE interposition graft. Others have advocated the use of autologous vein for the repair.

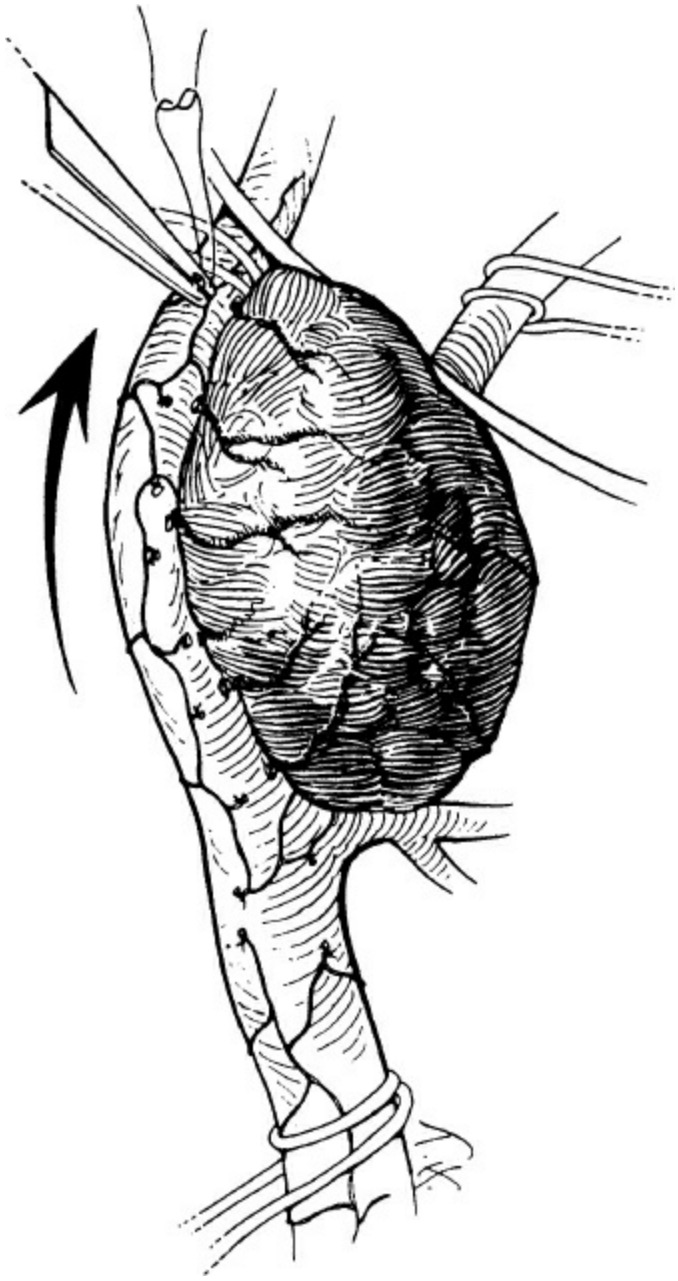

Figure 197.7. The dissection is continued cephalad, following the course of the internal carotid artery (*arrow*), again staying in a periadventitial longitudinal plane located 180 degrees opposite the origin of the external carotid artery.

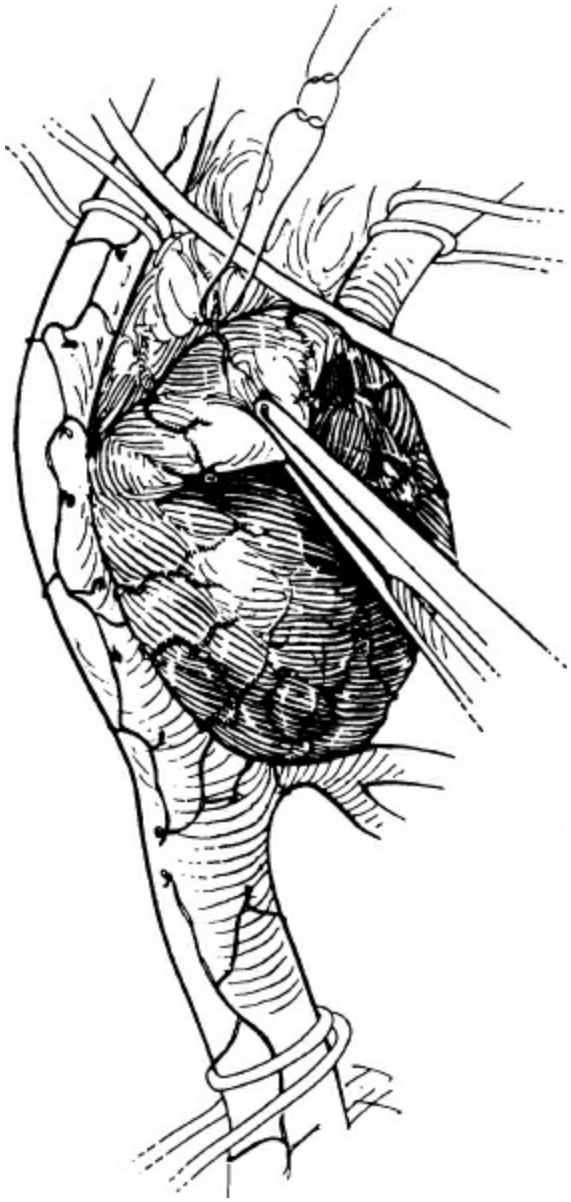

Figure 197.8. Once the tumor feeding vessels located along the internal carotid have been divided to a point beyond the distal extent of the tumor, the dissection is continued proximally toward the bifurcation along the inner surface of the internal carotid.

On occasion, the vagus nerve can be surrounded by or pass through the tumor mass. In the past, I felt obliged to divide the nerve in order maintain the integrity of the tumor mass. This will lead to vocal cord palsy usually requiring collagen injection of the cord to improve phonation. More recently, and in recognition of the benign nature of the tumor, I have been able to split the tumor to allow freeing and preservation of vagus nerve integrity. It is best to delay this maneuver until the tumor mass is fully mobilized and all branches of the external carotid artery are divided in order to minimize bleeding. Sometimes it is necessary to carry out this

maneuver in order to proceed with tumor mobilization. In this instance, the use of bipolar forceps to incise the tumor is helpful in reducing blood loss.

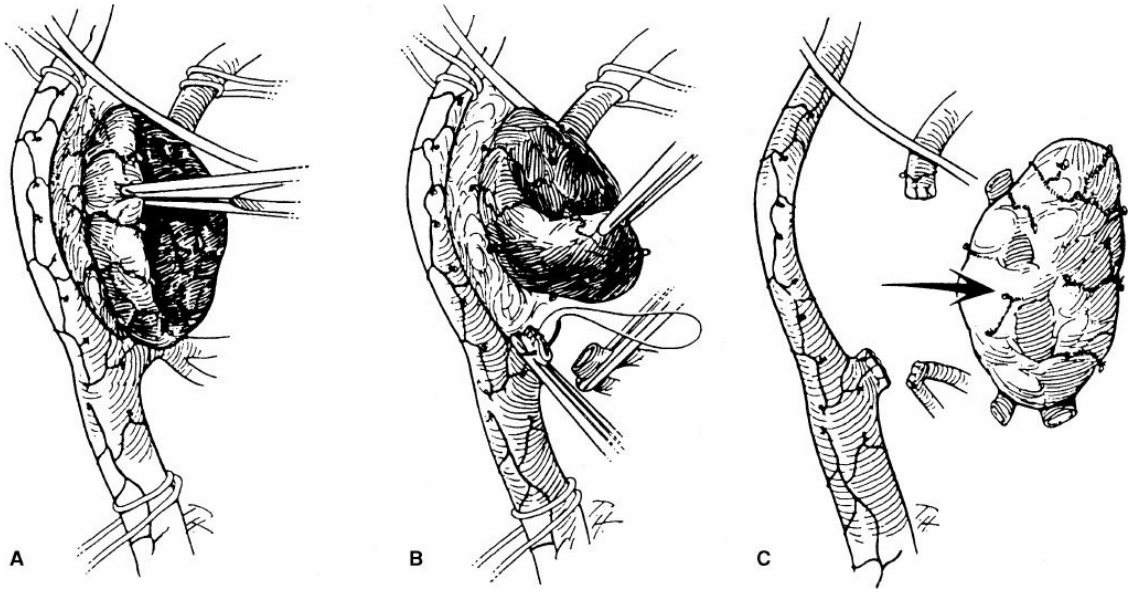

Figure 197.9. When the tumor is very large or particularly adherent, division of the origin of the external carotid artery can be a useful maneuver. After detachment of the tumor from the internal carotid artery, the tumor is carefully separated from the bifurcation (**A**). Next, the origin of the external carotid is clamped and divided (**B**). This allows rotational mobilization of the lesion and ligation of nutrient tumor vessels, which are often encountered posteriorly in this location. Finally, division of the superior thyroid and distal external carotid artery (or its branches) allows for the safe removal of the carotid body lesion (**C**). *Arrow* indicates tumor.

Wound Closure

Closure of the incision after a carotid body tumor resection should be meticulous and should adhere to all of the basic principles of surgery. The wound should be irrigated generously with warm saline solution and perfect hemostasis ensured. The platysma is reapproximated with a running suture, and the skin is closed with either subcuticular sutures or stainless steel staples. I only rarely place a drain, but, should this option be selected, it should be a closed suction drain system that is placed beneath the platysmal layer and brought out through a separate stab wound. Last, a sterile dressing is applied and the patient observed carefully while awakening from anesthesia.

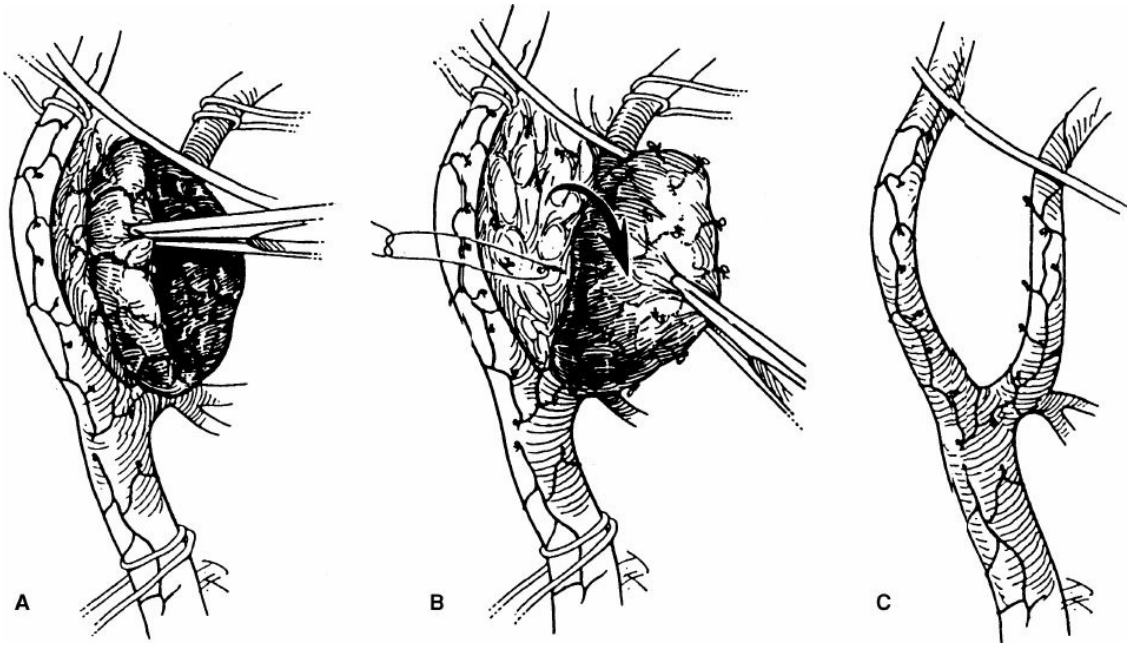

Figure 197.10. Alternatively, with careful dissection, it is frequently possible to remove the carotid body tumor without sacrificing the external carotid artery or any of its main branches. Once again, the tumor is carefully separated from the bifurcation (**A**). Again, by rotating the lesion along the axis of the external carotid, nutrient vessels supplying the tumor posteriorly can usually be ligated easily (**B**). Finally, the carotid body tumor is meticulously dissected free, leaving the carotid bifurcation intact (**C**).

POSTOPERATIVE MANAGEMENT

Immediately after the patient awakens from anesthesia, a preliminary neurologic assessment should be made. Subsequently, the patient is transferred to the recovery room. Particular attention should be made to frequently assess the systemic blood pressure and neurologic function during this period. In addition, careful wound observation is essential to detect the formation of a hematoma, which can threaten the patient's airway. I seldom find it necessary to use an intensive care unit for these patients. After 24 hours, the closed suction drain, if placed, can be removed and the patient considered for hospital discharge. Most patients undergoing carotid surgery are admitted to the hospital the morning of operation and are discharged home on the first or second postoperative day.

RADIATION THERAPY

For completeness, a comment regarding the use of radiation therapy, either as an adjunct or as a primary therapeutic option in the treatment of carotid body tumors, is appropriate. Traditionally, the statement has been made that cervical paragangliomas are not radiosensitive lesions. Very few clinicians have acquired sufficient experience to make sound conclusions regarding the efficacy of this treatment modality in this setting. Most often, radiation is reserved for bulky, inoperable, or recurrent tumors, which may account for the disappointing reported results. There are, in fact, a number of sporadic reports indicating successful control of carotid body tumors by radiotherapy. Long-term follow-up for most of these anecdotal cases is currently not available. I admit little experience with this method of treating these tumors and prefer surgical excision due to its safety and excellent documented long-term success. I acknowledge, however, that in poor surgical candidates with aggressive symptomatic lesions, radiotherapy may have a role in the management of carotid body tumors. This form of treatment requires further investigation.

COMPLICATIONS

An uncomplicated resection of a carotid body tumor is an extremely well-tolerated operation. The tissue trauma and operative blood loss are normally minimal, and patients are routinely discharged from the hospital on the second or third postoperative day. For this reason, perioperative complications are particularly discouraging and must be avoided at all costs. Operative intervention, particularly in the setting of a histologically benign neoplasm, continues to be justified only by keeping the operative morbidity and mortality of the procedure to a minimum.

Technical errors that occur during any operative procedure are preventable. As mentioned earlier, one major cause of technical complications occurring during the resection of carotid body tumors is inadequate hemostasis. Clamping of incompletely identified structures or the temporary occlusion of major cerebrovascular vessels can lead to cranial nerve or neurologic injuries.

As described previously in the Exposure and Extended Exposure Techniques sections, several peripheral nerves must be identified and protected during exposure of the carotid bifurcation. The frequency of injury to these structures is difficult to quantitate, but it is probably in the range of 1% to 15%. This difference is due at least in part to the variable expertise of the individual making the assessment. It must also be

remembered that many cranial nerve deficits are related to tumor involvement and not caused intraoperatively. Once again, the importance of carefully examining the function of these structures preoperatively cannot be overemphasized. Nonetheless, at least half of all postoperative cranial nerve injuries go unnoticed by the surgeon and the patient. The remainder of injuries is usually either very obvious or otherwise identified only after a detailed examination. Most of these injuries are not permanent. It should be acknowledged, however, that all cranial nerve injuries that occur during carotid surgery could be prevented if surgeons became familiar with the normal and possible abnormal anatomic neurovascular relationships and carefully protected these structures during the procedure.

RESULTS

Results after resections for carotid body tumors are excellent. However, this has not always been the case. Early series from the 1950s consistently reported a mortality of 5% to 15% of patients, cranial nerve injuries in 30% to 40% of patients, and significant cerebrovascular complications in as many as 10% to 20% of patients. Advances in preoperative diagnosis and localization, intraoperative anesthetic and surgical management, and postoperative care have all contributed to a significant decrease in these complication rates. Today, in experienced hands, a perioperative mortality of less than 0.5%, essentially no significant cerebrovascular sequelae, and a cranial nerve injury or other minor complication rate of no higher than 5% can be expected.

Suggested Readings

Gardner T, Dalsing M, Weisberger E, et al. Carotid body tumors, inheritance, and high incidence of associated cervical paragangliomas. *Am J Surg* 1996;172:196.

Grufferman S, Gillamn MW, Pasternak RL, et al. Familial carotid body tumors. Case report and epidemiologic review. *Cancer* 1980;46:2116.

Hallett JW, Nora JD, Hollier LH, et al. Trends in neurovascular complications of surgical management for carotid body and cervical paragangliomas: a fifty-year experience with 153 tumors. *J Vasc Surg* 1988;7:284.

Hinerman RW, Amdur RJ, Morris CG, et al. Definitive radiotherapy in the management of paragangliomas arising in the head and neck: a 35-year experience. *Head Neck* 2008;30:1431–8.

LaMuraglia GM, Fabian RL, Brewster DC, et al. The current surgical management of carotid body paragangliomas. *J Vasc Surg* 1992;15:1038.

Nora JD, Hallett JW, O'Brien PC, et al. Surgical resection of carotid body tumors: long-term survival, recurrence, and metastasis. *Mayo Clin Proc* 1988;63:348.

Power AH, Bower TC, Kasperbauer J, et al. Impact of preoperative embolization on outcomes of carotid body tumor resections. *J Vasc Surg* 2012;56:979–89.

Rabl H, Friehs, I, Gutschi S, et al. Diagnosis and treatment of carotid body tumors. *Thorac Cardiovasc Surg* 1993;41:340.

Rodriguez-Cuevas S, Lopez-Garza J, Labastida-Almendaro S. Carotid body tumors in inhabitants of altitudes higher than 2000 meters above sea leval. *Head Neck* 1998; 20:374–78.

Shamblin WR, Remine WH, Sheps SG, et al. Carotid body tumor (chemodectoma): clinicalpathologic analysis of ninty cases. *Am J Surg* 1971;122:732–39.

Smith LL, Ajalat GM. Tumors of the carotid body: diagnosis, prognosis, and surgical management. In: Moore WS, ed. *Surgery for Cerebrovascular Disease.* New York: Churchill Livingstone; 1987:579.

Smith JJ, Passman MA, Dattilo JB, et al. Carotid body tumor resection: does the need for vascular reconstruction worsen outcome? *Ann Vasc Surg* 2006;20:435–9.

Snitzer JL, Sheeler LR, Bravo EL, et al. A carotid body and glomus jugulare paraganglioma secreting norepinephrine. *Endocr Pract* 1995;1(2):82–5.

Wax MK, Briant TD. Carotid body tumors: a review. *J Otolaryngol* 1992;21:277.

Westerband A, Hunter GC, Cintora I, et al. Current trends in the detection and management of carotid body tumors. *J Vasc Surg* 1998;28:84.

Worsey MJ, Laborde AL, Bower T, et al. An evaluation of color duplex scanning in the primary diagnosis and management of carotid body tumors. *Ann Vasc Surg* 1992;6:90.

EDITOR'S COMMENT

This chapter on carotid body tumor (CBT) resection by Dr. Moore remains rather timeless as we have not yet found a way to manage this disease process less invasively. While in general we have moved away from large incisions to smaller incisions, one of the remaining principles in dealing with CBTs is wide exposure. Most vascular surgeons will see one or two CBTs a year and treating them can be very satisfying when the resection goes well.

There are a couple of points to make specifically about technically managing CBTs. First, I learned the utility and necessity of a bipolar cautery from Drs. Jim Stanley and Ramon Berguer. This instrument alone as far as I can tell has helped to revolutionize the resection of these tumors and has really sped up resection times. Using the bipolar cautery also likely has helped to decrease the

blood loss during resection. While I have had to divide the external carotid artery before to get one of these out, I have never had to resect the internal carotid artery. Yet, I still as Dr. Moore suggests always use some sort of cerebral monitoring on these cases. Finally, just specifically in terms of anesthetic techniques, I would personally never do one of these under regional anesthesia unless the patient was a pulmonary or cardiac cripple (and then I would consider radiation). Given the complexity of the surgery, I prefer to put the patients to sleep and nasotracheally intubate them.

There is literature out there on whether these tumors should be embolized preoperatively or not. A recent meta-analysis using the Medline database from 1967 to 2013 used 60 studies to attempt to answer the question of whether embolizing these tumors preoperatively was necessary or better (Economopoulous KP, Tzani A, Reifsnyder T. Adjunct endovascular interventions in carotid body tumors. *J Vasc Surg* 2015;61:1081–91). The authors found no randomized, controlled trials examining the subject, but reported on 465 patients with a mean age of 39.8 years. Their review concluded that preoperative selective endovascular embolization in Shamblin II and III tumors "may be beneficial." For the most part, I agree with Dr. Moore that large tumors get embolized, while small ones do not. Dr. Moore suggests the use of Gel foam slurries or coils when these tumors are embolized preoperatively and that has been our practice. Some have performed embolization of these tumors with Onyx (ethylene vinyl alcohol), a material often used to treat endoleaks in patients with endovascular aortic aneurysm repairs, either preoperative or palliatively. This would seem to be attractive as Onyx seeks blood before hardening and might provide a more radical embolization of these tumors. However, in one case series this resulted in a more difficult surgical resection in 50% of cases and the authors concluded that "preoperative Onyx embolization of CBPs is not recommended" (Michelozzi C, Januel AC, Cuvinciuc V, et al. Arterial embolization with Onyx of head and neck paragangliomas. *J Neurointervent Surg* 2015; May 2 [Epub ahead of print]).

The link between the role of the carotid body and its function in elevating blood pressure, especially in patients with essential hypertension, has been examined and is intriguing. Fudim and coauthors performed a retrospective analysis of 20 hypertensive patients who had undergone CBT resection. Their results documented that both short- and long-term blood pressure was significantly lower following CBT resection (Fudim M, Groom KL, Laffer CL, et al. Effects of carotid body tumor resection on the blood pressure of essential hypertensive patients. *J Am Soc Hypertens* 2015;9(6):435–42). This observation lends some credence to the idea of using carotid body stimulators (and obliteration!) to control blood pressure in patients with essential hypertension, even though this is by no means direct evidence or an endorsement for carotid body stimulation techniques.

Finally, many of these tumors are found in families and are clearly associated with genetic mutations. Some may even be secretory. A recent review of the

literature suggests that approximately 30% of all CBTs are associated with various tumor syndromes. Three syndromes have been described as PGL1, 3, and 4. They are all related to mutations in the succinate dehydrogenase (SDH) gene. Importantly, based on the data on these rare genetic cohorts, SDHD and SDHB account for over 70% of head and neck paragangliomas with a positive family history, but also less than 8% without a positive family history. A certain percentage of these tumors can also secrete catecholamines. This suggests that there is a role, yet undefined, for having these patients seen by an endocrinologist when hypertensive or by a genetics counselor when familial.

Gilbert Upchurch

Suggested Reading

Peterson LA, Mitzenforf M, Ringel MD, et al. SDHB gene mutation in a carotid body tumor paraganglioma: case report and review of the paraganglioma syndromes. *Ann Vasc Surg* 2014;28[5]:e9–e12.

B ANEURYSMAL DISEASE

198 Open Thoracoabdominal Aortic Aneurysm Repair

Mark F. Conrad and Richard P. Cambria

INTRODUCTION

Aneurysms that simultaneously involve the thoracic and abdominal aorta, and/or those aneurysms including the visceral aortic segment are referred to as thoracoabdominal aortic aneurysms (TAA). Such aneurysms are uncommon when compared to isolated infrarenal aneurysms and comprise no more than 2% to 5% of the total spectrum of degenerative aortic aneurysms. The most recent natural history studies looking at patients with TAA show that up to 30% of said patients will also have an abdominal aortic aneurysm (AAA) in their lifetime. The modern era in the surgical management of TAA began with the pioneering work of E. Stanley Crawford who described a simplified operative approach to these lesions that involved the reconstruction of the aneurysmal aorta with direct anastomoses of the aortic origin of visceral and intercostal vessels to the main Dacron graft. This approach inherently leads to some degree of ischemia to the spinal cord, visceral vessels, and lower extremities with the potential for significant morbidity from end organ damage. Indeed, a number of surgical and nonsurgical adjuncts (many discussed herein) intended to minimize distal ischemia and improve outcomes have been investigated, and our approach to these complex aneurysms has evolved over time. Despite improvements in operative strategies, open repair of TAA still carries a 5% to 10% risk of perioperative morbidity and mortality in the form of renal, respiratory, and spinal cord ischemic complications. Endovascular repair of TAA using modular grafts with branched and fenestrated technologies is continuing to gain favor especially in patients who are high risk for open repair but issues of long-term durability and a high rate of spinal cord ischemia need to be

addressed before it will supplant open repair as the standard of care.

ETIOLOGY

Aneurysms of the descending thoracic aorta develop through a complex process involving a combination of genetic and environmental factors. The majority of thoracic aortic aneurysms are degenerative in nature, and indistinguishable on either gross or microscopic pathology from the more typically encountered AAA. However, genetic predisposition remains an important etiologic factor as 20% to 30% of aortic aneurysm patients have a first-order relative with the disease. While there continues to be debate over whether aneurysmal degeneration is a sequela of atherosclerosis or a primary connective tissue weakness, recent studies have shown that although there is significant overlap between the two populations, the propensity to develop weakening of the adventitia and media seen with aneurysmal disease is certainly different from the intimal proliferative process associated with atherosclerosis. Indeed, both processes can diminish aortic compliance and wall tensile strength resulting in aneurysm formation such that the terms “atherosclerotic” and “degenerative” are used interchangeably when applied to aortic aneurysms.

The second most common etiology of TAA (around 20% in most series) is as a late complication of chronic aortic dissection. Of patients experiencing acute aortic dissection, 25% to 40% will develop chronic aneurysmal dilatation of the outer wall of the false lumen that renders them susceptible to late aneurysm rupture and death. Other causes of TAA are less common. Aneurysms secondary to the sequelae of giant cell arteritis are typically seen in women and can result from either Takayasu disease, the nonspecific variety of giant cell aortitis, or there may be no known prior diagnosis of collagen vascular disease. A TAA secondary to an infectious process presents challenging management issues because the dual goals of eradication of sepsis and arterial reconstruction typically demand an in situ type of reconstruction, i.e., placement of a prosthetic graft in a contaminated field. In contemporary practice, the pathogenesis of these lesions is usually hematogenous seeding of atherosclerotic plaque that leads to the development of focal aortitis and dissolution of the aortic wall resulting in the formation of a false aneurysm. Such aneurysms are, in fact, contained aortic ruptures.

Patients with Marfan syndrome may have true cystic medial necrosis, a rare pathology that predisposes the thoracic aorta to aneurysmal

degeneration and dissection. Marfan syndrome is an autosomal dominant, inherited mutation of the fibrillin-1 gene, a structural protein that is the major component of the microfibrils that form elastin. Such mutations lead to a decrease in the amount of elastin in the aortic wall and the deposition of disarrayed microfibrillar connective tissue precipitating subsequent aortic degeneration. The frequency of the various etiologies of TAA is as follows: 80% are degenerative, 15% to 20% the sequelae of chronic dissection (including 5% of patients with Marfan syndrome), 2% related to infection, and 1% to 2% are the sequelae of previous aortitis.

CLASSIFICATION AND NATURAL HISTORY

Anatomy

TAA are classified according to the scheme originally devised by Crawford, which in the most basic terms considers whether the lesion is primarily a caudal extension of a descending thoracic aneurysm or a cephalad extension of a total AAA (Fig. 198.1). This classification is especially useful in patients requiring operative repair since it has direct implications for both the technical conduct of operation and the incidence of operative complications; in particular, ischemic spinal cord injury (SCI). There is considerable variation in the operative approach required to manage different TAA lesions. For example, a type IV TAA can be repaired with the clamp-and-sew approach and should be accomplished with an expected morbidity and mortality that is similar to that of an open AAA repair. But, the same cannot be said for the more extensive type II TAA lesions where the entire descending thoracic aorta is involved and repair is accomplished using distal aortic perfusion with atrial femoral bypass.

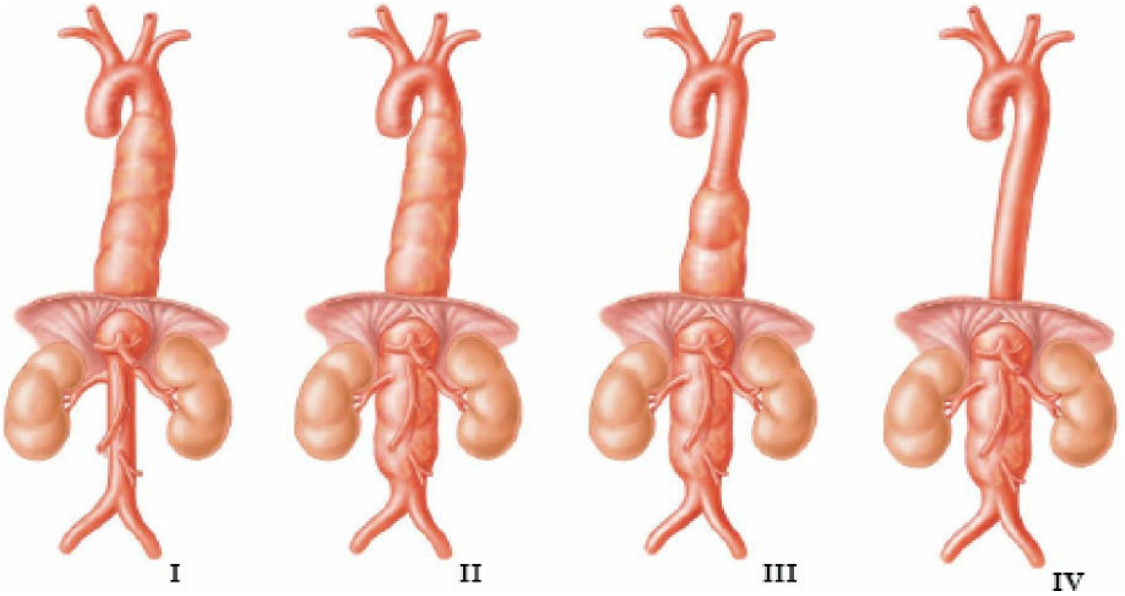

Figure 198.1. Crawford classification of the extent of thoracoabdominal aortic aneurysms.

Natural History

The expected natural history of TAA is progressive enlargement and eventual rupture regardless of etiology or location. Since thoracic aneurysms are uncommon when compared to AAA, fewer natural history studies are available. A recent longitudinal study found that the mean rate of growth for TAA is 0.2 cm per year. This is accelerated in patients with dissections and connective tissue disorders such as Marfan syndrome. The size of the aorta at initial diagnosis has been shown to be an important predictor of future dilation, but there still remains substantial variation in individual aneurysm growth rates making prediction of future aortic size difficult. Population-based studies place the incidence of TAA at 5 to 6 per 100,000 people with a 5-year actuarial survival of 13% if left untreated and aneurysm rupture identified as the cause of death in nearly 75% of untreated patients. Factors associated with increased risk of rupture include increasing aneurysm diameter, an increased rate of expansion, the presence of chronic obstructive pulmonary disease (COPD), steroid use, female gender, advanced age, and the presence of renal insufficiency. Contemporary series indicate that the rupture risk is negligible in TAA <5 cm, equivalent to the risk of surgical morbidity in the 5- to 6-cm range, and increases substantially at aneurysm diameters larger than 6 cm and/or growth rates of ≥10 mm per year. To wit, 6 cm is the surgical threshold for consideration of intervention in patients with degenerative TAA. For patients with TAA secondary to chronic dissection and/or those with

Marfan syndrome, a 5-cm threshold is often used.

CLINICAL PRESENTATION AND PREOPERATIVE EVALUATION

Clinical Presentation

Although patients commonly present in an asymptomatic fashion with incidental detection during radiologic surveillance for other causes, symptoms referable to TAA do occur and should be evaluated in a timely manner. In addition to the acute onset of severe pain, which may be associated with aneurysm expansion, rupture, and/or acute dissection, large thoracic aneurysms may produce symptoms of back, epigastric, or flank pain related either to compression of local structures or chronic inflammatory changes of the mediastinal pleura. Unlike AAA where back pain usually indicates an acute event, the pain associated with thoracic aneurysms may be atypical or chronic in nature and the presence of even uncharacteristic pain is an independent risk factor of rupture and should be taken seriously. When the aneurysm erodes into the thoracolumbar spine or chest wall, complaints of chest and back pain can be prominent and again may be present for weeks or even months. In severe cases, such complaints are often related to a chronic state of contained aneurysm rupture. The new onset of hoarseness can be related to a left recurrent laryngeal nerve palsy, while compression or erosion of the tracheobronchial tree or pulmonary parenchyma will produce a chronic cough, hemoptysis, dyspnea, or dysphasia lusoria. Perhaps related to reluctance to recommend operation because of the threat of surgical morbidity, up to 40% of thoracic aortic aneurysm patients will present with symptoms. This explains the higher incidence of patients treated for rupture when compared to AAA series. Our results are consistent with those available from a review of the literature indicating that some 25% of patients will be treated under urgent or emergent circumstances with approximately half of these presenting with a frank rupture. Unfortunately, we and others have demonstrated that such nonelective operations are associated with a significant increase in morbidity.

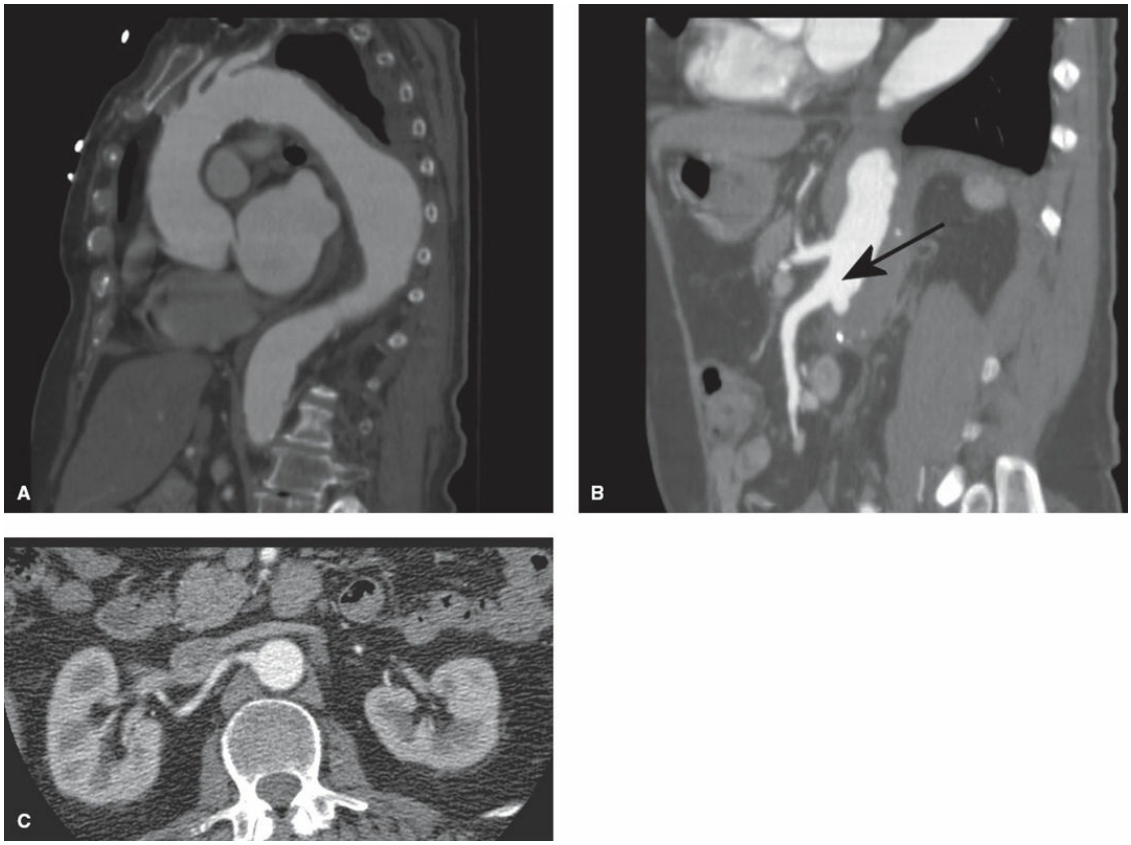

Figure 198.2. Helical CT with reconstruction is the only imaging study required in the majority of cases. It provides evaluation of aortic quality, luminal thrombus (**A**), aortic and branch topography (**B**, *arrow* pointing to patent SMA), renovisceral patency (**C**), and aortic cross-clamp site or proximal and distal seal zones depending on the planned method of repair.

Diagnostic Imaging

Several characteristic findings of thoracic aneurysmal disease seen on a plain chest x-ray include widening of the mediastinal silhouette, enlargement of the aortic knob, and tracheal deviation. Although thoracic aortic aneurysms are often evident on chest x-ray, it is difficult to differentiate between normal thoracic aortic tortuosity associated with advancing age (usually identified as an “ectatic aorta” by radiologists) and actual aneurysmal dilatation. Consequently, it is important to have a low threshold for obtaining more detailed imaging when findings associated with aortic pathology are encountered on plain film.

Accurate and complete radiographic evaluation is essential for precise operative planning with no equivocation in the surgeon’s mind as to the proximal and distal extent of aortic resection. In contemporary practice, a dynamic, fine-cut, contrast-enhanced computed tomography (CT)

angiogram with or without helical reconstruction (Fig. 198.2) provides the physician with the following information:

1. The proposed location of and a qualitative assessment of the aorta in the region of the proximal cross-clamp.
2. The assessment of patency of the visceral vessels.
3. The topography and location of the renal artery origins as well as kidney size and adequacy of perfusion.
4. The distal extent of the resection.
5. Aneurysmal status of the iliac vessels and possible occlusive disease in the pelvis (important if retrograde transfemoral aortic perfusion is to be used).

Accurate assessment of the size of thoracic aortic aneurysms is contingent upon measurement in the appropriate perpendicular plane. When imaging a tortuous aorta or evaluating sections through the aortic arch or lower descending aorta, it is important to understand that individual axial images may section the aorta in a plane that is off axis (Fig. 198.3). Such measurements result in an erroneous overestimation of aortic diameter, and underscore the importance of personally viewing CT scans prior to initiation of therapy. One way to avoid this error is through three-dimensional reconstruction of the thoracic aorta with determination of the centerline of axis that ensures that any cross-sectional measurement will be perpendicular to the aortic axis. The quality of current CT scanners with three-dimensional reconstruction is exceptional, and in our practice, this has become the image modality of choice for the evaluation and treatment of thoracic aortic aneurysms.

PATIENT SELECTION AND PREOPERATIVE EVALUATION

Since the majority of patients seen in consideration for TAA resection are those with degenerative aneurysms, demographic and clinical features typical of a patient population with diffuse atherosclerosis are the rule. Patients treated for degenerative aneurysms average 70 years in age, and a history of hypertension is nearly universal. Cigarette smoking and/or significant COPD are frequently encountered with 25% of patients having significant COPD with an FEV_1 of <50% predicted. Cerebrovascular disease, prior stroke, and symptomatic manifestations of lower extremity arterial occlusive disease occur in 15% of patients. Associated visceral

and/or renovascular occlusive disease occur to some degree in 30% of patients. Such lesions have direct implications for the technical conduct of the operation and the risk of postoperative renal insufficiency. The coexistence of renovascular disease and some degree of renal insufficiency is commonplace in TAA patients and has important implications for accurate assessment of perioperative risk and long-term preservation of renal function. Because the majority of TAA present with involvement of the entire visceral aortic segment, occlusive lesions of the mesenteric and renal arteries or total ostial occlusion of one or more of these vessels frequently accompanies aneurysmal dilation of this region of the aorta. Accordingly, we believe extreme levels of preoperative azotemia (serum creatinine >2.5 cm/dL) constitute a relative contraindication to elective operation unless preoperative studies indicate some potential for salvage or retrieval of renal function with renal artery reconstruction. In many series, the presence of an abnormal preoperative serum creatinine is at least a univariate correlate of perioperative mortality. Indeed, assessment of renal function and associated renovascular disease is an important component of patient evaluation and choice of therapy.

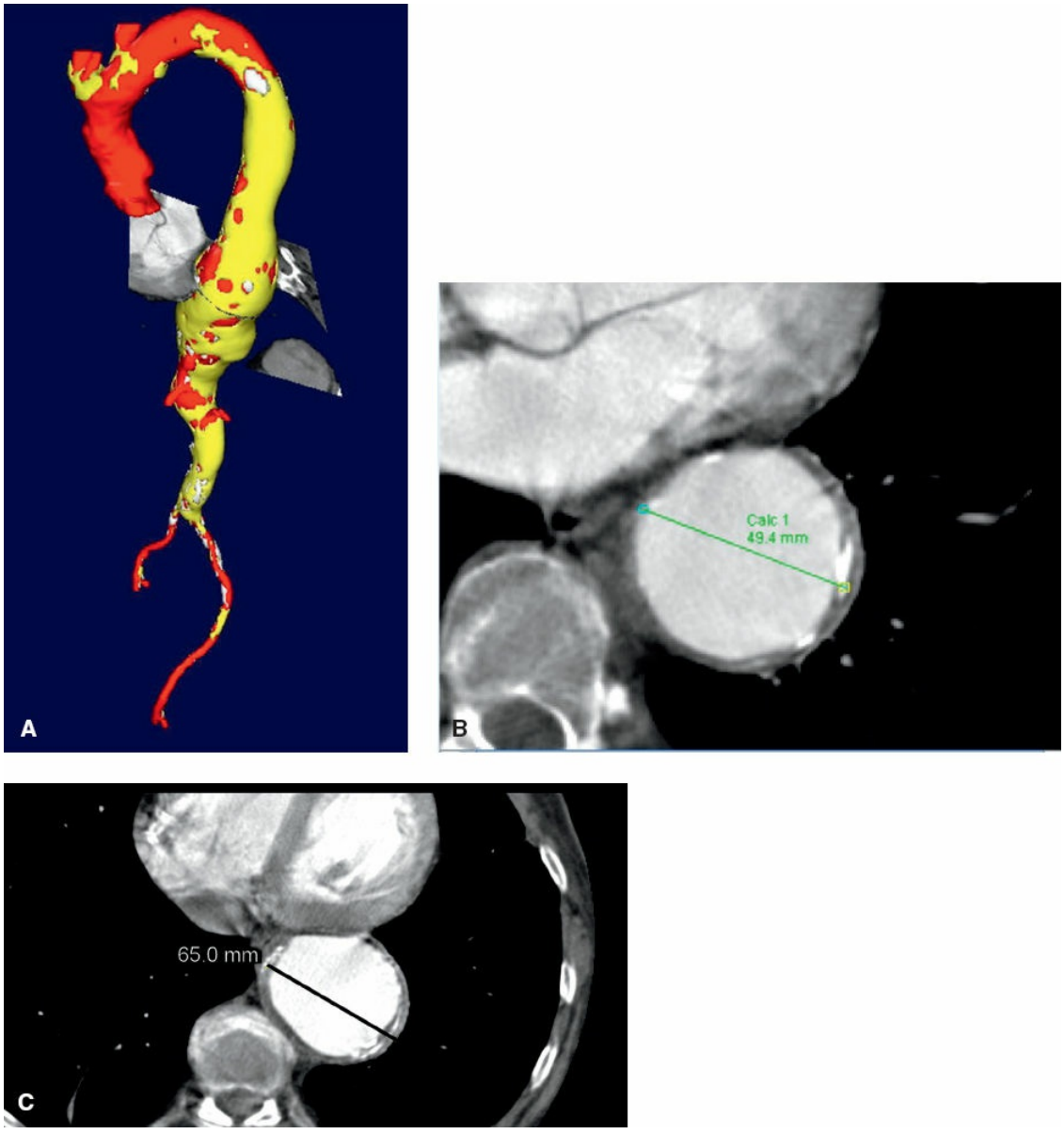

Figure 198.3. Helical CT with reconstruction showing the variation of aortic measurement with changes in axial plane. **A.** 3D reconstruction showing adjusted axial plane to ensure diameter measurement along the centerline axis. **B.** Axial image along plane in 5A yields diameter of 4.9 cm. **C.** Axial image at same level with traditional CT plane overestimates aortic diameter by 1.6 cm.

CARDIAC AND PULMONARY RISK STRATIFICATION

Despite the firm literature base against routine preoperative cardiac testing, all patients should be evaluated with physiologic testing to assess perioperative myocardial ischemic potential. In addition, patients with a history or symptoms suggestive of heart failure should have an assessment of left ventricular function. While patients with significant impairments of

pulmonary reserve can usually be detected on a historical basis alone, we routinely obtain preoperative pulmonary function studies. Preoperative consultation with a pulmonologist for optimization of bronchodilator therapy and pulmonary toilet is an important component in the management of patients with significant COPD. However, institution of preoperative steroid therapy with the intent of improving respiratory function is contraindicated since we have observed this maneuver to precipitate aneurysm rupture. Advanced age is an important component only in as much as it is accompanied by overall fragility and impaired functional status.

SURGICAL TREATMENT

Treatment Options

Graft replacement by direct surgical approach is the current standard of care for TAA. Total endovascular repair continues to evolve but remains limited by a lack of commercial availability of branched/fenestrated grafts and unacceptable early morbidity with several centers reporting SCI rates of >30%. The hybrid approach that combines visceral artery debranching with endovascular exclusion of the TAA has allowed surgeons who lack the resources to perform distal perfusion to offer TAA repair to their complex patients but the reported results compare poorly with open repair at high-volume centers. Medical therapy is appropriate in patients who are frail, have prohibitive associated comorbid conditions or small aneurysms. This consists of aggressive blood pressure control with beta-blockade, which has been shown to decrease the rate of aortic dilation. The goal of anti-hypertensive therapy is to keep the systolic pressure at a low-normal range of 105 to 120 mm Hg, and this often requires additional medications to maintain. Risk factor modification is another important aspect of patient education regarding TAA. Patients should be counseled regarding smoking cessation and given appropriate support to achieve this goal.

Renal and Spinal Cord Protection

Outcomes of TAA repair are closely correlated with renal and spinal cord complications; accordingly, operative adjuncts to minimize these complications have been principal drivers of the technical conduct of the operation. Consistent with a firm literature base supporting regional hypothermic protection of the kidneys, our approach involves direct

installation of renal preservation fluid (lactated Ringers with 25 g of mannitol/L and 1 g/L methyl prednisolone at 4°C) into the renal ostium during ischemia. In type IV TAA, the left renal artery is transected prior to placing the proximal aortic clamp and 250 mL of the renal cold solution is instilled into the artery followed by a continuous drip through a 6-Fr perfusion balloon-tipped catheter. Once the aorta is opened, renal cold is infused in the right renal artery through the ostium, which should be coursing down and away from the surgeon. In more complex TAA (types I to III), where distal perfusion is used, renal cold is given prior to the start of the visceral reconstruction. Experience has shown that such an infusion will result in a rapid decline of renal parenchymal temperature to 15°C after the bolus infusion. During the continuous infusion, renal core temperatures remain in the 25°C range as monitored by direct temperature probes in the renal cortex.

It is evident that most of the nuances that drive the technical conduct of TAA repair are directed toward the prevention of SCI; to wit, is the abundance of adjuncts that have been championed to minimize this dreaded complication. To date, only cerebrospinal fluid drainage is appropriately evidence-based and used by most surgeons. Other adjuncts aimed at preserving spinal cord blood flow such as intercostal vessel reconstruction (IC) have been championed and/or routinely practiced despite its empiric nature and evidence base limited to retrospective studies including our own. The alternative position with specific respect to IC vessel reconstruction is that it is unnecessary (related to the collateral network), and expends cross-clamp time and blood turnover. Distal aortic perfusion via left atrial femoral bypass used in conjunction with intraoperative motor evoked potential (MEP) monitoring to dynamically assess spinal cord ischemia during the operation has replaced epidural cooling as our principal cord protective strategy in patients with more extensive TAA (types I to III). This is based upon a series of studies that used magnetic resonance imaging combined with intraoperative MEP to show that individual intercostal vessels were typically not critical for cord preservation and most collaterals that support the cord originated from the pelvis (i.e., hypogastric arteries); thus, preservation of continuous perfusion of the pelvis is logical and prudent. The addition of MEP monitoring affords the surgeon objective criteria to direct selective IC reconstruction and thus replaces the subjective application of or routine posture toward intercostal vessel reimplantation. The use of MEP

monitoring does mandate a departure from anesthetic techniques typically used in North America, and the technical requirements of such monitoring can only be satisfied by a dedicated team specialized in neurophysiology.

TECHNICAL COMPONENTS

Operative Exposure

Irrespective of individual preferences concerning the technical components of the operation, the key to operative success remains the provision of broad, continuous exposure of the entire left posterolateral aspect of the thoracoabdominal aorta (Fig. 198.4). The patient is positioned on the table in the right lateral decubitus position. The location and extent of the thoracic portion of the incision are determined by the proximal extent of the aneurysm as the posterior portion of a standard posterolateral thoracotomy incision is only necessary for type I and type II aneurysms. We keep the thoracic portion of the incision low and have found that the fifth or sixth interspace with posterior division of the sixth or seventh rib provides adequate exposure for even the more proximal aneurysms. The costal margin is divided at the level of the sixth interspace, and a self-retaining retractor system is placed in order to ensure continuous exposure of the entire operative field. A thoracoabdominal incision at the eighth interspace will usually provide adequate exposure for a type IV TAA, and a double lumen tube for deflation of the left lung is generally not necessary in these cases. The abdominal portion of the incision is not extended to the midline; rather, it is kept well lateral on the abdominal wall along the edge of the rectus. The advantage of this approach is that it allows the visceral contents to lie within the abdominal cavity, thus decreasing evaporative fluid and heat losses. The abdominal portion of the incision is transperitoneal, allowing direct inspection and assessment of the visceral circulation when the case is completed.

Exposure of the left posterolateral aspect of the abdominal aorta is obtained by entering the plane posterior to the spleen, left kidney, and left colon. The abdominal contents are then reflected to the patient's right and the left ureter is identified and preserved under laparotomy pads (Fig. 198.4). The retroperitoneal fatty and lymphatic tissues overlying the aorta are transected with electrocautery, and the renal-lumbar vein that courses across the aorta is identified and divided. Located topographically close to this vein is the left renal artery. Once identified, the left renal artery is dissected toward its origin on the aorta. This serves as a suitable point to

initiate the cephalad and caudal division of the retroperitoneal tissues over the aorta inferiorly and division of the median arcuate ligament and diaphragmatic crura superiorly.

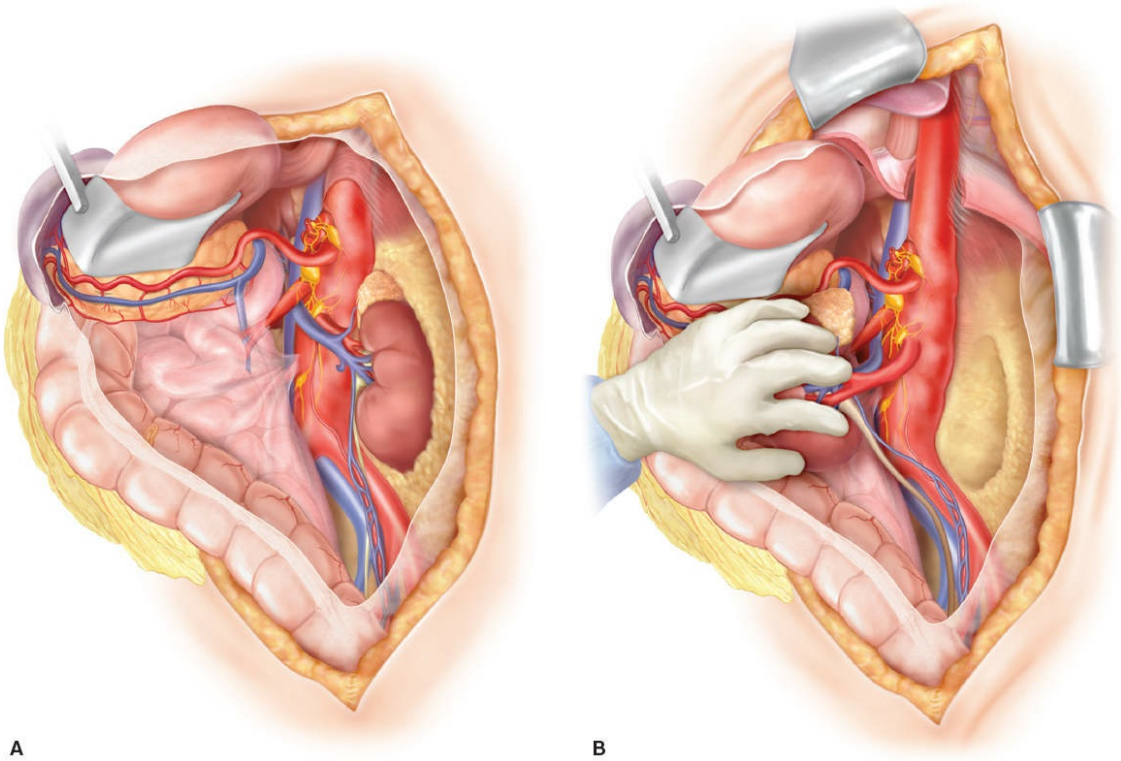

Figure 198.4. Schematic of exposure for TAA repair. **A.** Exposure of the left chest and abdomen through a thoracoabdominal incision with the spleen, pancreas, and left colon reflected up. Note, the left kidney lies in situ and certain situations (such as single functioning left kidney) are best approached in this manner. **B.** Thoracoabdominal exposure of the aorta with the kidney up. This exposes the entire left posterolateral aspect of the TAA.

There are several methods by which the incision in the diaphragm may be managed. The quickest and simplest method that affords excellent exposure is direct radial division of the diaphragm from underneath the costal margin to the aortic hiatus. This approach, however, will irrevocably paralyze the left hemidiaphragm and ultimately contribute to postoperative respiratory embarrassment. A second approach involves the circumferential division of the diaphragm through its muscular portion leaving a few centimeters attached laterally to the chest wall. There is benefit to preserving the phrenic innervation to the left hemidiaphragm by dividing only a portion lateral to the phrenic nerve insertion and then

taking down the muscular fibers of the aortic hiatus. A large Penrose drain can be passed around the diaphragm pedicle and used to retract superiorly and inferiorly as needed during the reconstruction. We have applied this method liberally, particularly in patients with evidence of preoperative pulmonary compromise.

Dissection of Left Pleural Space

After deflation of the left lung, the thoracic component of the dissection is typically straightforward. Electrocautery is used to divide the mediastinal pleura over the aneurysm and proximal aorta. For type I and II aneurysms, proximal control of the aorta in the region of the left subclavian artery origin is necessary. Further mobility of the vagus nerve is gained by dividing it distal to the origin of the left recurrent nerve, which should be identified and preserved. Should more proximal control be necessary, the ligamentum arteriosum is divided on the underside of the aortic arch. Care must be taken to keep the dissection directly on the aortic arch in order to avoid injuring the left main pulmonary artery. When degenerative aneurysm is the underlying pathology, dissection in this area is usually straightforward. However, in patients with chronic dissection, the prior inflammation from the dissecting process makes exposure more difficult. The aorta is surrounded with a vessel tape on either side of the left subclavian artery depending on the proximal extent of the aneurysm. Blunt dissection on the posterior aspect of the aorta is used to clear sufficient normal aorta to allow placement of the cross-clamp while maintaining adequate length of aorta for an accurate proximal aortic anastomosis. External control of the left subclavian artery is desirable but not mandatory as intraluminal balloon control can be obtained if the aortic clamp is placed proximal to the left subclavian artery. During the thoracic portion of the dissection, the left inferior pulmonary vein is isolated in cases where atrial femoral bypass is used; a 4-0 prolene purse-string suture is used to introduce the venous cannula, which in our experience need not be larger than 19 Fr.

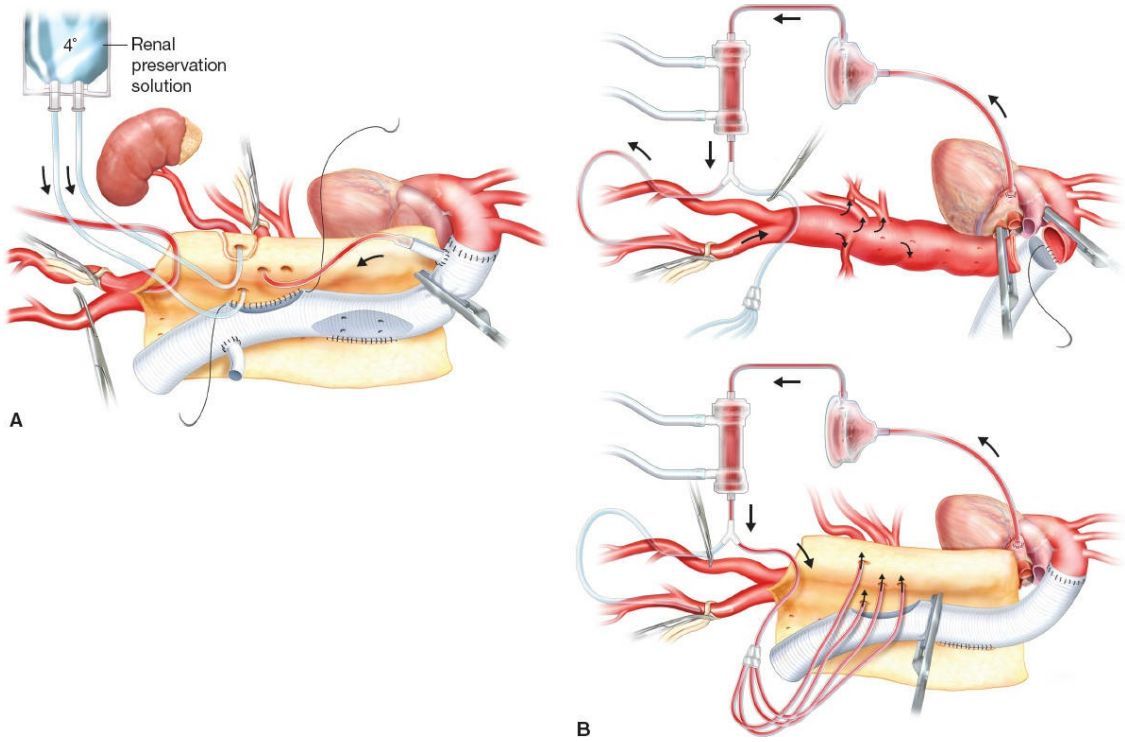

Figure 198.5. Approaches to operative conduct of thoracoabdominal aneurysm repair. **A.** Clamp-and-sew technique with associated adjuncts of mesenteric shunting, renal cold perfusion, and epidural cooling (not shown). **B.** Distal perfusion (left heart bypass) using the heparin-impregnated Bio-Medicus pump where perfusion distal to the proximal cross-clamp is initially maintained via the femoral artery and then by multiple perfusion catheters once reconstruction proceeds distally.

Clamp-and-Sew Versus Atrial-Femoral Bypass

In contemporary practice, the clamp-and-sew technique with adjuncts to minimize warm ischemic time is the best way to approach type IV TAA. The technique of distal perfusion through atrial femoral bypass via a centripetal, motorized pump is the simplest form of distal perfusion and requires no or low doses of systemic heparin to function. Conversely, cardiopulmonary bypass using a femoral vein to femoral artery technique requires an in-line oxygenator and full pump doses of heparin, making it less desirable given the extensive dissection required to complete TAA repair. Most surgeons have adopted the liberal use of atrial femoral bypass for extent I to III TAA. This is again based largely on the concept of the spinal cord collateral network, which has emphasized the importance of the pelvic/hypogastric vessels and the ability to apply a selective rather than routine approach toward intercostal vessel reconstruction based upon

intraoperative MEP monitoring. We prefer to continuously perfuse the mesenteric circulation during reconstruction of the visceral aortic segment. This can be accomplished with either a Y-connection from the atrial-femoral bypass circuit or with in-line mesenteric shunting from the proximal graft after completion of the proximal anastomosis (Fig. 198.5).

Clamping Sequence and Proximal Anastomosis

Next, the aortic prosthesis is prepared by attaching a 6-mm polytetrafluoroethylene (PTFE) side-arm graft that will serve as the conduit for left renal artery reconstruction. An additional side-arm graft of 10-mm PTFE may be placed proximally to provide inflow for the in-line mesenteric shunt. For most aneurysms, a Dacron prosthesis is the preferred conduit. However, a PTFE conduit is used to repair mycotic aneurysms because of its decreased susceptibility to infection.

Atrial femoral bypass is initiated by cannulation of the left atrium through the left inferior pulmonary vein and the arterial return is via the left common femoral artery. Flows are initially adjusted to maintain distal mean perfusion pressures of at least 60 to 70 mm Hg; any deterioration in MEP should prompt either an increase in the stimulus intensity or an increase in distal perfusion pressures. A sudden drop in MEP amplitude (occurring within 2 to 10 minutes) or a sustained progressive drop (within 10 to 40 minutes) of >75% from baseline is considered significant and should be addressed. The clamping sequence is begun in close cooperation with the anesthesia team. Efforts are made to place the first sequential clamp so as to allow lower intercostal and visceral retrograde perfusion.

In cases where the entire descending thoracic aorta is resected, proximal intercostal vessel orifices between T_4 and T_8 typically vigorously back-bleed and those are rapidly oversewn. Intercostal vessels in the critical T_9 to L_1 aortic segment are evaluated for potential reimplantation, usually guided by changes in MEP signals. These vessels are controlled with balloon occlusion catheters to prevent ongoing back-bleeding and also to prevent the negative “sump” effect on net spinal cord perfusion that can result from these vessel orifices when exposed only to atmospheric pressure. Unless there are prompt, significant changes in MEP, we defer any intercostal reconstruction to later stages of the operation. Next, the proximal aortic neck is prepared for reconstruction. Circumferential division of the aorta avoids the late complication of suture line esophageal erosion, and permits the use of circumferential Teflon felt wrap if the aorta

is particularly fragile and/or dissected. After completion of the proximal anastomosis, a clamp is placed on the main aortic graft distal to the mesenteric shunt sidearm (if present). The clamp is moved to the distal sequential clamp position and the visceral aortic segment is opened.

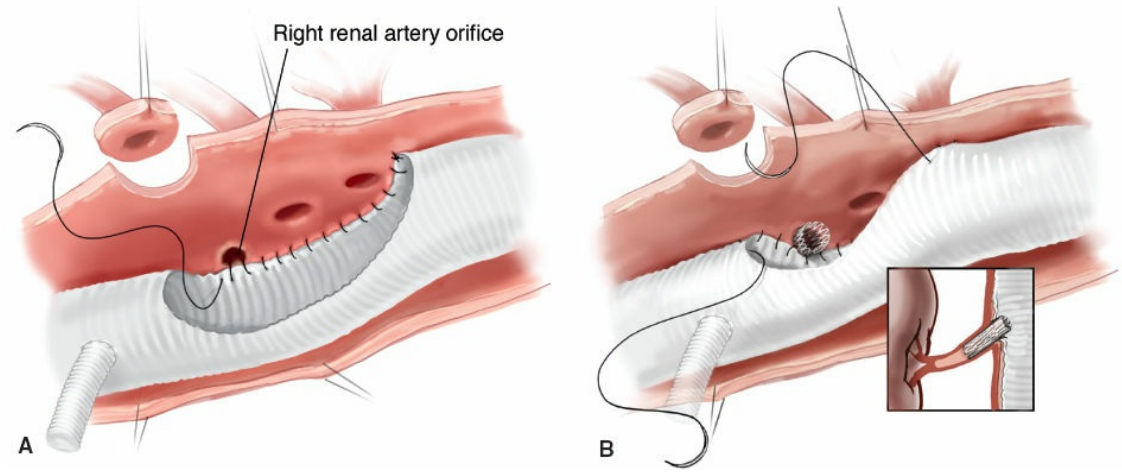

Figure 198.6. **A.** Creation of visceral button inclusion anastomosis of the celiac axis, SMA, and right renal artery and 6-mm PTFE sidearm bypass for left renal artery reconstruction. When performing this, we use a 12-Fr perfusion catheter as a stent of sorts in the right renal artery to prevent compromise of its orifice as the anastomosis is carried around these arterial origins. **B.** Deployment of balloon-expandable stent into the right renal orifice to either treat occlusive lesions or prevent encroachment by the suture line, which should be placed immediately at or into the vessel ostia.

Renal/Visceral Artery Reconstruction

Visceral and renal artery reconstruction is carried out next. Orificial endarterectomy should be performed when significant occlusive lesions of the right renal and superior mesenteric arteries exist. This involves incising the diseased intima and media and developing a proper endarterectomy plane that can be verified by noting the pinkish color of the inner adventitia. In cases where aortic endarterectomy is required, the superior mesenteric and celiac arteries should be dissected sufficiently to facilitate countertraction from the external side of the vessel if necessary. This, however, is not possible with the right renal artery. In the event that the calcified end of the obstructing plaque doses not feather nicely, sharp excision under direct vision is the best way to end the endarterectomy plane.

The most common method of visceral and renal artery reconstruction that has been employed in the majority of our cases is a single inclusion button that encompasses the origins of the celiac, superior mesenteric, and right renal arteries (Fig. 198.6). If the aneurysm is excessively large in the visceral aortic segment, the wide separation of the visceral/renal ostia may necessitate individual inclusion button anastomoses for each vessel. Alternatively, the superior mesenteric artery and right renal artery can be reimplanted as a single inclusion while reconstruction of the celiac trunk is deferred until later. The aortic graft is placed under tension and an elliptical side island is excised from the main aortic graft. This ellipse usually begins on the lateral aspect of the graft and spirals posteriorly in the region of the right renal artery reconstruction. With the graft under tension, it is possible to complete the posterior portion of the anastomosis using single bites of the suture passing through both the aorta and the Dacron graft. Suture bites are taken close to the origin of the visceral vessels in order to avoid leaving excess aneurysmal aortic wall. As the posterior aspect of this suture line continues around the inferior border of the right renal artery, we exchange the 6-Fr perfusion catheter for a 12-Fr perfusion catheter to temporarily stent the origin of the right renal artery. The catheter is gently agitated up and down as the suture line moves around the renal artery orifice to ensure that it is not compromised by generous suture bites as they pass outside of the aorta. It is important to identify the course of the right renal artery with this indwelling catheter in order to avoid renal artery occlusion in circumstances where the right renal artery drapes over a large infrarenal component of the aneurysm. Recently, we have used a 6 × 15 or 6 × 18 balloon expandable stent to ensure that the suture line does not compromise right renal artery flow. The stent is placed under direct vision after the proximal suture line is beyond the orifice of the artery (Fig. 198.6). Just prior to completion of this suture line, backbleeding and patency of the celiac, superior mesenteric and right renal arteries are verified and the in-line mesenteric shunt is clamped and removed. A single flush of the proximal aortic cross-clamp is performed in order to ensure that no clot or debris has built up in the graft.

In extent IV TAA, 90% of the proximal reconstructions are carried out with a single beveled anastomosis incorporating the right renal, superior mesenteric and celiac arteries in the proximal descending aorta. A similar reconstruction often suffices for the distal anastomosis in type I TAA (Fig. 198.7).

Reconstruction of the left renal artery is now accomplished with a separate side-arm graft of 6-mm PTFE. This provides a direct deliberate anastomosis in end-to-end fashion while allowing flexibility to deal with the spectrum of occlusive lesions, multiple renal arteries, and other wrinkles that may be encountered. It is important to orient this side-arm graft so that it will not kink when the left renal artery is returned to its anatomic position (Fig. 198.6). Some surgeons advocate the use of a single inclusion button that contains the renal arteries and the visceral vessels. This often requires the inclusion of too great an area of the native, aneurysmal aorta unless the aneurysm is small in the visceral artery segment. A single, pristine left renal artery and orifice may be directly reimplanted and the clamp is then advanced to a position inferior to the origin of the left renal artery graft prior to completing the distal aortic anastomosis.

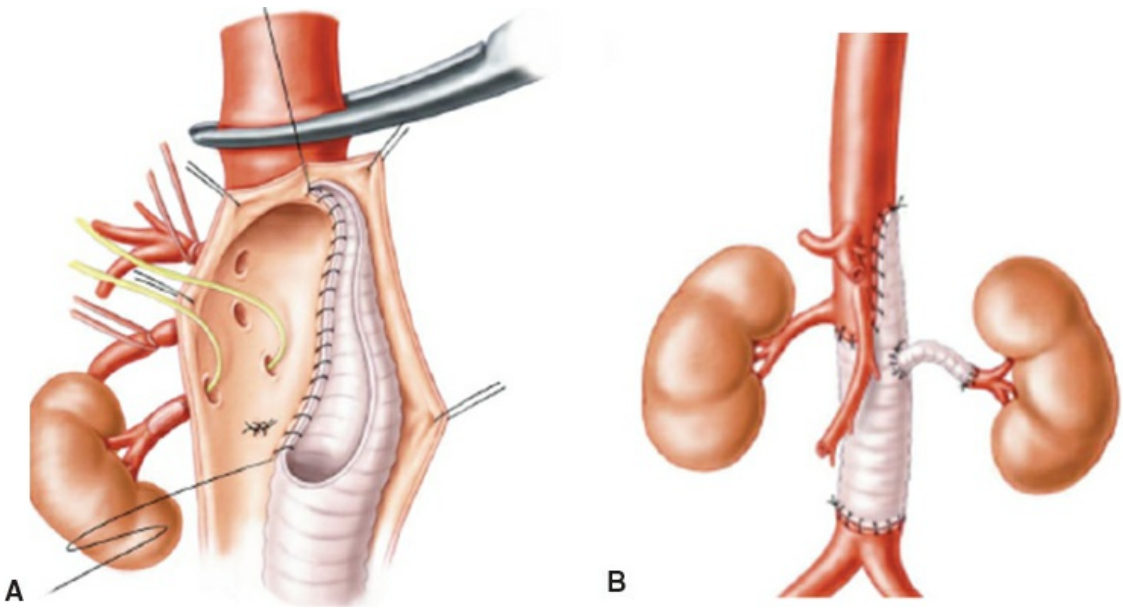

Figure 198.7. Visceral branch management in (**A**) type IV and (**B**) type I TAA. Beveled anastomosis is used for both repairs. Also shown is the reconstructed left renal artery bypass used routinely in type II to IV repairs.

Reconstruction of Intercostal Vessels

The next step in the operation involves reconstruction or oversewing of the intercostal vessels in the T_9 to L_1 segment. If there have been no changes in the MEP during the operation, the occlusion balloons are removed and the remaining intercostals are oversewn with silk sutures. If, however,

reconstruction is desired, it can usually be accomplished through an inclusion button anastomosis. Intercostal arteries in the region of a proximal or distal aortic anastomosis can be reconstructed using a long beveled suture line. Other methods of intercostal vessel revascularization include the attachment of additional short side-arm grafts to the main aortic graft or, in cases where the vessel origin is rotated superiorly and to the patient's left side, implantation to the main aortic graft using Carrel patches of aorta that contain the intercostal vessels may be feasible (Fig. 198.8). Depending on the topography of the origins of the intercostal vessels and/or data from MEP monitoring, it is usually possible to defer reconstruction until after completion of the visceral vessel anastomosis by utilizing partial occluding clamps on the main aortic graft. The intercostal vessels in the T_9 to L_1 segment are crucial to spinal cord perfusion and reconstruction with the inclusion button often overlaps (on the opposite side of the aorta) the inclusion button for reconstruction of the visceral vessels. Accordingly, attempts to clamp the aortic graft distal to the intercostal inclusion button can interfere with reconstruction of the visceral vessels.

Distal Anastomosis

We make every effort to perform tube type of reconstructions to the aortic bifurcation unless there is gross aneurysmal disease of the proximal common iliac arteries. Extending the reconstruction to separate iliac artery reconstructions or, indeed, tunneling to an aortofemoral graft configuration is only performed when no other technical alternative exists. After reestablishment of flow to the lower extremities and verification of adequate lower extremity perfusion by intraoperative pulse volume recordings, Doppler signals in the left renal, celiac, and superior mesenteric vessels are checked in addition to palpation of the superior mesenteric artery pulse in the root of the mesentery.

Hemostasis will usually be adequate upon completion of the distal anastomosis, but infusions of platelets and fresh frozen plasma are typically increased at this point in the operation when a final check for surgical hemorrhage is made. Indeed, careful attention to hemostasis from the beginning of the operation combined with minimal heparin use is an important component of care; we previously identified total blood turnover as an independent correlate of operative mortality. Careful inspection of the inferior aspect of the aneurysm sac in both the chest and abdomen is

necessary to detect back-bleeding lumbar and/or intercostal vessels, which can be a source of significant postoperative hemorrhage. The redundant aneurysm sac is then sutured securely over the aortic prosthesis in the abdomen and the chest. Prior to closure, renal artery reconstructions are interrogated one final time. Occasionally, in patients with modest-size aneurysms, chronic dissections, or prior proximal aortic grafts, there is insufficient aneurysm wall to totally cover the proximal suture line and aortic graft. In select cases, we have used a PTFE or bovine pericardial patch to exclude the aortic prosthesis from the left lung. As the left kidney is returned to its anatomic position, the perinephric fat usually suffices to provide adequate coverage of the aortic graft in the region of the visceral aortic segment. A single pleural tube is placed, and a closed suction drain may be left in the retroperitoneum if hemostasis is in question. Closure of extensive incisions typically takes close to an hour, and two teams are often utilized. Clamp times, blood turnover, and blood component replacement will vary as a function of aneurysm extent, but overall operative time can be kept in the 5 to 6 hours range for most patients.

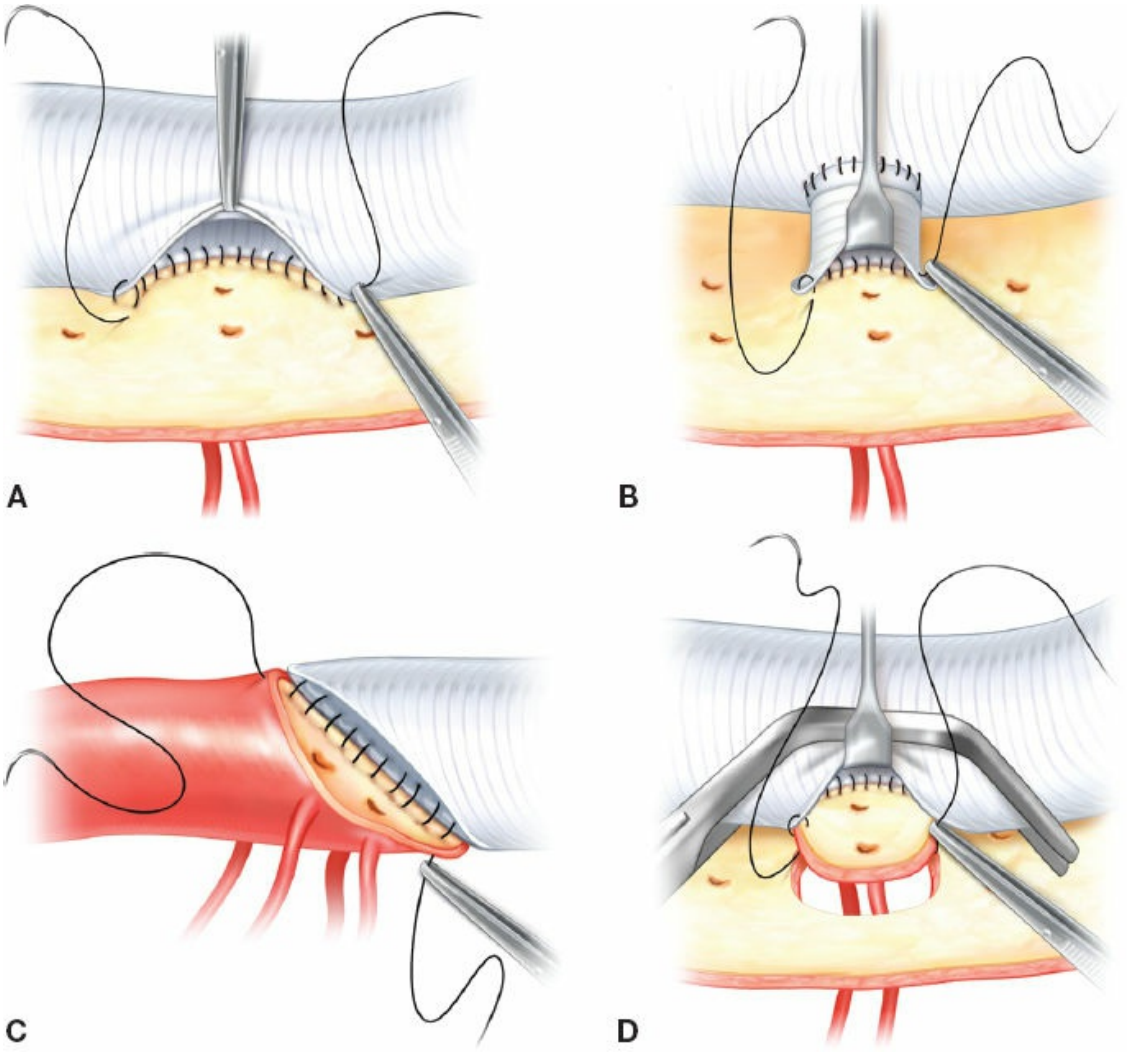

Figure 198.8. Methods of management of critical intercostal arteries. **A.** Inclusion button anastomosis. **B.** Separate sidearm graft. **C.** Beveled anastomosis preservation when possible. **D.** Carrell patch mobilization and direct reimplantation into the graft.

Postoperative Care

Postoperatively, patients should be monitored in an intensive care unit (ICU) setting. It is important to limit hemodynamic shifts as these can contribute to complications such as renal failure and spinal cord ischemia. Blood pressure parameters should be tailored to the patient with the goal of maintaining adequate perfusion to preserve urine output, cardiac function, and spinal cord perfusion. Oxygen delivery is important in the early phase of recovery, and we rarely extubate patients in the early postoperative period. If they have stabilized overnight, we will pull the tube in the morning. It is important to monitor the hematocrit for signs of ongoing bleeding, and all coagulation disorders should be aggressively corrected

with the appropriate products. We typically support intravascular volume with fresh frozen plasma infusions for the initial 12 hours after the operation. Cerebrospinal fluid drainage is arbitrarily continued for 48 hours postoperatively, and the drain is then capped for 24 hours of observation prior to removal. Discontinuation of some preoperative antihypertensive medications may be necessary to maintain the relative hypertension necessary to avoid delayed SCI.

RESULTS OF TREATMENT AND COMPLICATIONS

Operative Mortality

The operative mortality after TAA ranges from 8% to 16% in large clinical series. Preoperative patient characteristics influence the patient's outcome regardless of the conduct of the operation. In a recent update of our experience with type I to III TAA, 30-day mortality was 4.4% for elective TAA repaired with atrial femoral bypass and MEP monitoring. As the number of comorbid conditions increases so does the overall operative risk, and individual series have reported that preoperative coronary artery disease, COPD, and renal insufficiency contribute to postoperative organ-specific complications and increased mortality. The influence of TAA extent is often (and appropriately) emphasized as having a dominant effect on, in particular, spinal cord ischemia. In particular, perioperative death after type IV TAA repair should mirror that of infra-renal repair. To wit, in our recent published experience, the 30-day mortality for type IV TAA repaired with the clamp-and-sew method was 2.8%.

Renal Failure

We have traditionally defined postoperative renal failure as a doubling of the baseline serum creatinine level or an absolute postoperative creatinine level of >3.0 mg/dL. Minimizing renal ischemic times, the use of cold perfusate, avoidance of intraoperative hypotension, and a posture of aggressive treatment of stenotic lesions with either bypass or open stent placement are all strategies used to avoid postoperative renal insufficiency. Most cases are self-limited. We reserve dialysis for patients who need it for specific clinic indications, such as volume overload, hyperkalemia, or acidosis. When needed, continuous venovenous hemodialysis is our preferred method as it provides for a smoother hemodynamic course than conventional hemodialysis. For those patients who continue to require

dialysis, conventional hemodialysis is instituted once the patient is out of the intensive care unit, and out of the window of risk for spinal cord ischemia. In our experience, and that of others, preoperative renal insufficiency is the most powerful predictor for the development of postoperative renal failure, and postoperative renal dysfunction remains independently associated with short- and long-term survival.

Respiratory Complications

Although most clinical series emphasize spinal cord and renal complications, respiratory failure is the single most common complication after TAA repair. Indeed, if strict criteria are used, up to 40% of patients suffer some type of respiratory complication. Contributing factors include paralysis of the left hemi-diaphragm and the pain associated with an extensive chest wall incision that impedes pulmonary toilet. Accordingly, a diaphragm sparing technique is applied when possible in contemporary practice. For patients who fail extubation, we favor early placement of a tracheostomy, although this procedure has been needed in <10% of patients. A slow wean from ventilatory support, often planned to proceed over several days, is appropriate management in patients with extensive TAA resection, particularly those with baseline pulmonary insufficiency. The variables that have been shown to be predictive of postoperative respiratory failure include: active cigarette smoking, baseline COPD (especially those with significant reductions in FEV_1) and cardiac, renal, or bleeding complications.

Spinal Cord Ischemia

Since the first descriptions of TAA repair, SCI has been the most feared and devastating nonfatal complication associated with TAA reconstruction. Although, advances such as epidural cooling, distal perfusion, and the intraoperative monitoring of MEP have improved outcomes, this remains an unsolved problem. The pathogenesis of SCI after aortic replacement is likely multifactorial, but ultimately results from an ischemic insult caused by temporary or permanent interruption of the spinal cord blood supply. SCI manifests along a clinical spectrum from complete flaccid paraplegia to varying degrees of temporary or permanent paraparesis and the degree of SCI directly predicts long-term survival after TAA repair (Table 198.1). Patients with incomplete deficits typically made a reasonable or complete functional outcome and have a long-term

survival that is similar to those without SCI. However, patients with an SCID I score (flaccid paralysis) rarely live beyond the first year. The most common predictors of SCI after TAA repair include extent I and II aneurysms and urgency of operation. While the majority of cases of SCI are detected in the immediate postoperative period, there is a trend toward an increase in delayed paralysis in recent series.

TABLE 198.1 Short- and Long-Term Survival of 576 Patients Undergoing Open TAA Repair at the Massachusetts General Hospital Stratified by Spinal Cord Ischemic Deficit (SCID)

SCID Category	30-Day Survival (%)	1-yr Survival (%)	5-yr Survival (%)
SCID 0: No SCI	92	73	51
SCID I: Flaccid paralysis	54	21	0
SCID II: Average neurologic muscle Grade <50% function	87	70	41
SCID III: Average neurologic muscle Grade >50% function	100	73	45

Late Outcomes

While some studies report significant continued mortality throughout the first year after operation (up to 30%), these reports include centers where the perioperative mortality approached 19%. It is therefore difficult to put these data into context with data from centers where the perioperative mortality is 5% to 8%. We found late survival in our patients was identical to that from a population-based study of patients who underwent elective AAA. In addition, late aortic events occur in about 10% of patients but few of these are graft related. Graft-related complications include occlusion of visceral vessel reconstructions, graft infections (including aortoesophageal fistulas), and the appearance of inclusion patch aneurysms and are rare in our experience. Most late aortic events are the result of native aneurysmal disease in remote (or noncontiguous) aortic segments. These data indicate that the substantial resource investment required to bring these patients through successful operation and recovery is an appropriate expenditure of such resources. With improvement of perioperative outcomes, the focus of long-term follow-up has shifted to examination of the impact of TAA repair on functional outcome. Several reports have emerged validating that

the majority of operative survivors return to their preoperative independent living status.

Suggested Readings

Acher CW, Wynn M. A modern theory of paraplegia in the treatment of aneurysms of the thoracoabdominal aorta: an analysis of technique specific observed/expected ratios for paralysis. *J Vasc Surg* 2009;49:1117–24.

Bicknell CD, Cowan AR, Kerle MI, et al. Renal dysfunction and prolonged visceral ischemia increase mortality rate after suprarenal aneurysm repair. *Br J Surg* 2001;88:1142–6.

Bischoff MS, Di Luozzo G, Griepp EB, et al. Spinal cord preservation in thoracoabdominal aneurysm repair. Perspect Vasc Surg Endovasc Ther 2011;23(3):214–22.

Conrad MF, Ergul E, Patel VI, et al. Evolution of operative strategies in open thoracoabdominal aneurysm repair (TAA). *J Vasc Surg* 2011;53:1195–201.

Conrad MF, Ye JY, Chung TK, et al. Spinal cord complications after thoracic aortic surgery: long-term survival and functional status varies with deficit severity. *J Vasc Surg* 2008;48:47–53.

Coselli JS, Bozinowski J, LeMaire SA. Open surgical repair of 2286 thoracoabdominal aortic aneurysms. *Ann Thorac Surg* 2007;83:S862–4.

Crawford RS, Pedraza JD, Chung TK, et al. Functional outcome after thoracoabdominal aneurysm repair. *J Vasc Surg* 2008;48:828–35.

Lancaster RT, Conrad MF, Patel VI, et al. Further experience with distal aortic perfusion and motor-evoked potential monitoring in the management of extent I–III thoracoabdominal aortic aneurysms. *J Vasc Surg* 2013;58:283–90.

Patel VI, Ergul E, Conrad MF et al. Continued favorable results with open surgical repair of type IV thoracoabdominal aortic aneurysms. *J Vasc Surg* 2011;53:1492–8.

EDITOR'S COMMENT

There are fewer operations performed compared with thoracoabdominal aortic aneurysm (TAAA) repair where the patient is placed at a high risk for not only mortality, but also the devastating complications of renal failure requiring dialysis and paraplegia (Cowan JA Jr, Dimick JB, Henke PK, et al. Surgical treatment of intact thoracoabdominal aortic aneurysms in the United States: hospital and surgeon volume-related outcomes. *J Vasc Surg* 2003;37(6):1169–74). Clearly, there have been tremendous strides made in the operative and critical care of these patients. In this chapter by Conrad and colleagues, the

state-of-the-art care of these patients is well-described.

The evolution of the treatment of repair of TAAAs is well-documented and likely one of the real success stories in surgery. There are multiple examples of significant strides made in the care of these patients. For the most part, the old "clamp and sew" technique has been largely abandoned in favor of more sophisticated techniques aimed at avoiding the significant ischemia reperfusion that occurs to the spinal cord, intestines, kidneys, and lower extremities following TAAA repair. The use of spinal drains has been studied extensively in open TAAA repair and been shown to significantly decrease the risk of paraplegia (Khan NR, Smalley Z, Nesvick CL, et al. The use of lumbar drains in preventing spinal cord injury following thoracoabdominal aortic aneurysm repair: an updated systematic review and meta-analysis. *J Neurosurg Spine* 2016;8:1–11). The use of spinal drains has also been implemented in patients undergoing thoracic endovascular aneurysm repair (TEVAR) and also decreases the incidence of paraplegia in this operation as well (Arnaoutakis DJ, Arnaoutakis GJ, Beaulieu RJ, et al. Results of adjunctive spinal drainage and/or left subclavian artery bypass in thoracic endovascular aortic repair. *Ann Vasc Surg* 2014;28(1):65–73).

One wonders whether a "zero paraplegia risk" will ever be attained, regardless of whether an open or endovascular approach is used. For open TAAA repair, the use of motor and sensory evoked potentials has been studied in detail (Keyhani K, Miller CC 3rd, Estrera AL, et al. Analysis of motor and somatosensory evoked potentials during thoracic and thoracoabdominal aortic aneurysm repair. *J Vasc Surg* 2009;49(1):36–41). Others have used various pharmacologic therapies to decrease the risks of spinal cord injury (Acher CW, Wynn MM, Hoch JR, et al. Combined use of cerebral spinal fluid drainage and naloxone reduces the risk of paraplegia in thoracoabdominal aneurysm repair. *J Vasc Surg* 1994;19(2):236–46; discussion 247–8). With a purely endovascular approach, people have moved to fixing the thoracic portion first, followed by some interval time before taking on the complex abdominal portion of the TAAA (O'Callaghan A, Mastracci TM, Eagleton MJ. Staged endovascular repair of thoracoabdominal aortic aneurysms limits incidence and severity of spinal cord ischemia. *J Vasc Surg* 2015;61(2):347–54). This is not really practical with open TAAA repair, but using a staged hybrid approach (see below) seems like a nice merger of open and endovascular approach (Jain A, Flohr TF, Johnston WF, et al. Staged hybrid repair of extensive thoracoabdominal aortic aneurysms secondary to chronic aortic dissection. *J Vasc Surg* 2016;63(1):62–9).

The continued evolution in the treatment of patients with TAAAs will likely come from the extension of endovascular techniques into the thoracoabdominal aorta, bridging the aorta between the isolated thoracic and isolated abdominal aorta. At present, complicated fenestrated and branched endografts are widely available in Australia and Europe, as well as in clinical trial in the United States. I suspect there will likely never be an endovascular solution for all TAAAs,

especially those associated with dissections. We have moved to repairing these patients with a combined TEVAR and subsequent open distal TAAA repair, the so-called hybrid TAAA repair. The results from this combined approach have been encouraging so far (Jain A, Flohr TF, Johnston WF, et al. Staged hybrid repair of extensive thoracoabdominal aortic aneurysms secondary to chronic aortic dissection. *J Vasc Surg* 2016;63(1):62–9).

Finally, our understanding of the genetics of aneurysms of the thoracic and thoracoabdominal aorta is growing exponentially (Milewicz D, Hostetler E, Wallace S, et al. Precision medical and surgical management for thoracic aortic aneurysms and acute aortic dissections based on the causative mutant gene. *J Cardiovasc Surg (Torino)* 2016;57(2):172–7). From syndromes to single gene mutations, we are now using our knowledge about the genetics of the aorta to help guide us making clinical decisions. There are still a number of questions to be answered especially in patients with connective tissue disorders, including whether TEVAR should ever be used in these patients and how one technically performs surgery in these patients. We have moved to routinely doing end-to-end anastamoses for all bypasses. Others prefer to only do end-to-end anastamoses in patients with connective tissue disorders or in TAAAs secondary to dissections. Likely before the next edition of *Mastery of Surgery*, these questions will be answered.

Gilbert R. Upchurch

199 Open Infrarenal and Pararenal Aortic Aneurysm Repair

Gregorio A. Sicard and Jeffrey Jim

INFRARENAL AND PARARENAL AORTIC ANEURYSMS: OPEN

INTRODUCTION

The surgical treatment of abdominal aortic aneurysms (AAAs) was initially described in 1952 when Dr. Charles Dubost reported resection of an aneurysm and replacement with a preserved human arterial graft. In 1967, the development of a synthetic graft by DeBakey led to improved patient outcomes and since then, the techniques of open surgical repair of AAAs remain largely unchanged. In 1991, Parodi described the first endovascular aortic aneurysm repair (EVAR) with endovascular stent grafts. Even though EVAR is now the preferred treatment modality, there remains a subset of patients that require open repair.

ETIOLOGY AND PATHOPHYSIOLOGY

An aneurysm is defined as segmental, full-thickness dilation of a blood vessel to 50% greater than its normal diameter. As the normal adult human aorta is estimated to be 2 cm in diameter, an aorta that measures greater than 3 cm is considered to be aneurysmal. AAAs are classified based on their extent relative to the involvement of the renal and visceral arteries. The major classification as recommended by the Society for Vascular Surgery include:

1. *"Infrarenal":* The proximal extent of the aneurysm is below the renal arteries; that is, with an adequate aortic neck for placement of a clamp below the renal arteries during surgical repair.
2. *"Juxtarenal"* or *"pararenal":* The proximal extent is at the level of the renal arteries with no normal aorta between upper extent of aneurysm and renal arteries; that is, surgical repair will require

placement of the clamp above one or both renal arteries.

3. *"Suprarenal":* The aneurysm originates above the level of the renal arteries and may have splanchnic and renal arterial involvement; that is, requires splanchnic or renal revascularization (bypass or implantation).

The incidence of juxtarenal/pararenal aneurysms have been estimated to be between 8% and 15% in large intra-abdominal aneurysm series. With the introduction of EVAR, there has been a need to clarify the definition of juxtarenal aneurysms. Many practitioners mistakenly consider patients that cannot be treated with standard EVAR as having a juxtarenal aneurysm. In patients with infrarenal aneurysms, where the distance between the renal arteries and the beginning of the aneurysms is less than 15 cm, the anatomy falls outside of the instructions for use of standard EVAR devices but these are still infrarenal aneurysms where an open repair can be performed with placement of the clamp in the infrarenal location. The development of fenestrated endovascular aneurysm repair (FEVAR) has placed true juxtarenal aneurysms into the realm of potential endovascular repair depending on the characteristics of the juxtarenal area anatomy. Based on the current nomenclature, a juxtarenal aneurysm means that there is *no* measurable neck below the lowest level of the renal artery and the beginning of the aneurysm. By definition, aortic cross-clamping will occur, either above the renal arteries or in the supramesenteric or supraceliac portion of the infradiaphragmatic aorta for control and repair. The aortic clamp location is a crucial and critical aspect, not only due to the technical aspects of the surgical repair but also it is a strong predictor of mortality and morbidity. Aortic cross-clamping for suprarenal or supraceliac control significantly increases the risk of splanchnic and renal ischemia. A direct correlation between duration and location of cross-clamping has been demonstrated to affect postoperative renal dysfunction and coagulopathic complications.

The exact pathophysiology of aneurysmal degeneration remains unclear. It is felt that this is a degenerative disease process and standard atherosclerotic risk factors (such as hypertension, tobacco use, and hypercholesterolemia) are associated with aneurysm development, expansion, and rupture. Molecular studies have demonstrated the role of degradation of structural proteins and smooth muscle cells in aneurysm formation. The role of matrix metalloproteinases (MMPs) have been implicated as part of the pathophysiologic process.

CLINICAL PRESENTATION

Most aneurysms are asymptomatic and most often diagnosed incidentally during a physical examination or with abdominal imaging (e.g., computed tomography [CT] scan or magnetic resonance [MR] imaging). Detection of an AAA by abdominal palpation is most likely when an aneurysm is large or in patients with a thin body habitus. The sensitivity of abdominal palpation in large studies was 29% for AAA 3.0 to 3.9 cm in diameter, 50% for AAA 4.0 to 4.9 cm, and 76% for AAA 5.0 cm or greater. The abdominal circumference also affects the sensitivity of detection. There is an overall sensitivity of 91% for patients with waistline <40 in (100 cm) versus 53% for >40 in (100 cm). For a waistline of <40 in, abdominal palpation had a 100% sensitivity for detecting an aneurysm >5.0 cm. When the presence of an aneurysm is suspected during physical examination, the diagnosis should be confirmed with additional imaging. In instances where patients present with symptoms, this is related to aneurysm expansion or compression of adjacent structures.

A ruptured aneurysm can present with pain (abdominal, flank, or back), abdominal distention, and hypotension. A patient that presents with abdominal pain in the setting of a known aneurysm must undergo emergent additional testing to rule out a rupture.

INDICATIONS AND CONTRAINDICATIONS

As most aneurysms are asymptomatic, treatment is considered to prevent future rupture. As the mortality of ruptured aneurysms approach 90%, surgical intervention is considered in those that are fit for surgery. A careful consideration of the patient's aneurysm rupture risk, operative risk, and life expectancy is necessary. The best predictor for aneurysm rupture is maximal transverse diameter. The annual rupture risk for aneurysms can be seen in Table 199.1. At the current time, the size threshold of elective repair is 5.5 cm for asymptomatic infrarenal AAAs. Two large randomized clinical trials (United Kingdom Small Aneurysm Trial and Aneurysm Detection and Management Trial) demonstrated the safety of surveillance for patients with small aneurysms and no benefit for early surgery for patients with 4.0 to 5.4 cm aneurysms. However, more recent data suggest that a lower size threshold for women (5.0 cm) may be appropriate.

TABLE 199.1 Estimated Annual Aneurysm Rupture Risk

AAA Diameter (cm)	Rupture Risk (%/yr)
<4	0
4–5	0.5–5
5–6	3–15
6–7	10–20
7–8	20–40
>8	30–50

Adapted from Brewster DC, Cronenwett JL, Hallett JW Jr, et al. Guidelines for the treatment of abdominal aortic aneurysms. Report of a subcommittee of the Joint Council of the American Association for Vascular Surgery and Society of Vascular Surgery. *J Vasc Surg* 2003;37(5):1106–17; with permission from Elsevier.

PREOPERATIVE PLANNING

Prior to proceeding with operative intervention, all patients should undergo a thorough preoperative evaluation. This should include a thorough history including particular attention to cardiovascular risk factors as cardiac complication remains the most significant comorbidity related to open aneurysm repair. The availability of multislice thin cut computed tomography angiography (CTA) and three-dimensional (3D) reconstruction has allowed for very precise preoperative planning in terms of the aortic clamp location for open repair of juxta and pararenal aneurysms (Fig. 199.1A,B). The predicted location of the aortic cross-clamp site helps the surgeon predict the risk factors that would impact the intraoperative and postoperative outcomes. Any cross-clamp above the renal arteries for ≥30 minutes significantly increases the risk of renal ischemia and postoperative renal dysfunction. This has been clearly demonstrated in the multiple recently reported series (Table 199.2). Occasionally, the space between the superior mesenteric artery and the renal arteries permits for aortic cross-clamping for repair of a true juxtarenal aneurysm, and if the warm ischemia is maintained below 30 to 45 minutes, usually renal insufficiency will be temporary and the risk of hemodialysis, either temporary or permanent, decreases significantly. On

the other hand, the need for aortic cross-clamping at the supraceliac artery with reconstruction of the celiac, superior mesenteric artery, and renal arteries portends a longer cross-clamp and revascularization time and an increase in the incidence of postoperative renal dysfunction as well as hemorrhagic complications. The current imaging modalities with thin cut CTA and 3D reconstruction does permit preoperative assessment to indicate the exact location where the aortic cross-clamp will take place and to plan the reconstruction of the visceral and renal vessels in an expeditious manner to minimize liver, bowel, and renal ischemia. Techniques to decrease the effect of renal ischemia by surface or intra-arterial cold perfusion will be addressed in the technical consideration section. In addition to aortic neck evaluation, the presence of other intra-abdominal pathology (e.g., malignancy) or anatomic variants (such as retroaortic renal vein, pelvis kidney) should be clearly delineated prior to surgery repair.

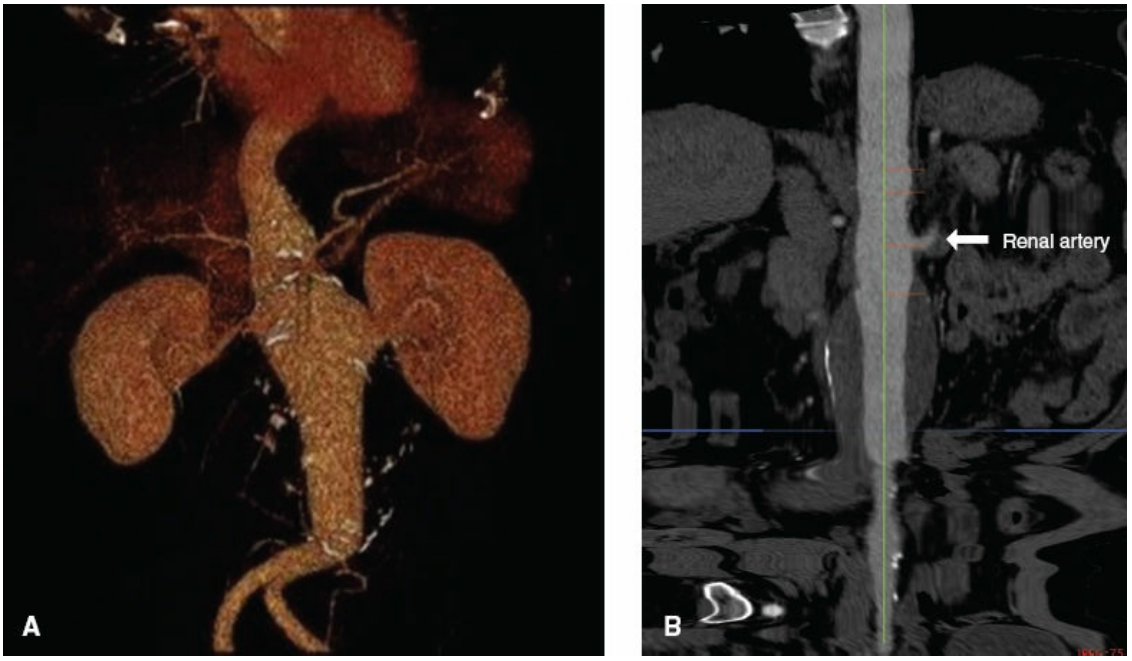

Figure 199.1. **A.** Three-dimensional reconstruction of a suprarenal aortic aneurysm. **B.** Centerline reconstruction of aneurysm for accurate measurements and mesenteric-renal vessel locations.

TABLE 199.2 Recent Series Juxtarenal and Pararenal Open Aneurysm Repair

Author Name	Year of Publication	Number of Patients	Post Op Renal Dysfunction (%)	New Onset Dialysis (%)	Mortality (%)
Chiesa et al.	2006	81	22	6.20	1.20
Pearce et al.	2007	134	14	4.50	3
Knott et al.	2008	126	18	4	0.80
Chong et al.	2009	171	17	0.60	1.80
Tallarita et al.	2011	520	14	5	3
Kabbani et al.	2014	195	28	4	3
Wartman et al.	2014	69	24.6	5.80	4.50

SURGICAL TECHNIQUE (INCLUDING DIAGRAMS)

The patient's body habitus, preoperative CTA assessment of cross-clamp location, presence of previous procedures, and surgeon's experience usually dictate the best technical aortic exposure indicated for a specific patient. There are two preferred approaches to repair of AAAs: transperitoneal and retroperitoneal (Fig. 199.2). Other techniques (laparoscopic or minilaparotomy) have been described but have not been widely adopted. Most practitioners are more familiar with the transperitoneal approach but this requires an experienced surgeon to be able to obtain enough length of normal aorta to cross-clamp for repair in a juxtarenal aneurysm. Transabdominal techniques including enhancement of the proximal neck by left renal vein mobilization or division have been well described, with minimal renal impairment. It does create some difficulties should intraoperative mishaps require higher cross-clamping. The use of the left medial visceral rotation (Fig. 199.3) is a transabdominal technique that allows for full visualization and repair of the infradiaphragmatic aorta. This does require extensive medial visceral mobilization of the left colon, as well as the spleen and pancreas, and the division of the left crux of the diaphragm to allow for cross-clamping up to just below the diaphragm and above the celiac axis. This technique is mostly indicated for surgeons that do not have experience with the retroperitoneal approach and/or primarily in cases with emergency (trauma) situations in which quick and immediate access to the supraceliac aorta is necessary. The retroperitoneal approach is ideal for pararenal and suprarenal aneurysms. The retroperitoneal (and thoraco-retroperitoneal) approach allows clear exposure of the more proximal aorta necessary for these repairs and is also utilized in order to avoid a hostile abdomen (prior operations, presence of ostomies); in treatment of inflammatory aneurysm, or in patients with a pelvic kidney.

Transabdominal Approach

The patient is commonly placed in the supine position and the abdomen is entered through a generous midline or transverse laparotomy incision (Fig. 199.2). There should be a careful inspection of the abdominal cavity and the viscera to evaluate for the presence of any other pathologic processes. The transverse colon and omentum is then elevated and retracted superiorly and the small bowel is eviscerated and packed to the left of the patient. A self-retaining retractor is then placed with care. A longitudinal incision is then made in the posterior peritoneum overlying the aneurysm which can usually be easily palpated. The incision is extended caudally to the entire extent of the aneurysm. Exposure of the bilateral common or external iliac arteries may be necessary if there are concomitant iliac aneurysms. The ureters should be identified and carefully preserved during the entire procedure. In cases of anticipated difficult exposure (e.g., reoperative intervention or significant inflammation), placement of ureteral stents preoperatively may assist in identification of the ureters. Care should be taken to minimize dissection around the left common iliac artery as the autonomic plexus courses in this location and extensive dissection can lead to postoperative complications of sexual dysfunction (retrograde ejaculation) in men. The inferior mesenteric artery (IMA) should be clearly identified during the dissection (Fig. 199.4). The proximal extent of the aortic exposure is dictated by the extent of the aneurysm. For an infrarenal aneurysm, the left renal vein should be identified and dissected from the surrounding tissues to allow cephalad retraction during clamp placement. The presence of a retroaortic left renal vein needs to be identified in the preoperative imaging studies. It is important to identify any significant tributaries to the renal vein (e.g., descending lumbar vein) and these may have to be ligated to allow full mobilization. The left adrenal and gonadal veins may be divided in order to obtain adequate mobilization of the renal vein if necessary for juxtarenal aortic cross-clamping. These branches should be preserved in cases where division of the main left renal vein is anticipated. In cases where the renal vein is dilated, reanastomosis is often not necessary unless there is renal vein engorgement suggestive of inadequate collateral drainage. The extent of the dissection requires exposure of healthy (i.e., nonaneurysmal segments free of significant calcification and thrombus) aorta and iliac arteries for placement of the proximal and distal clamps.

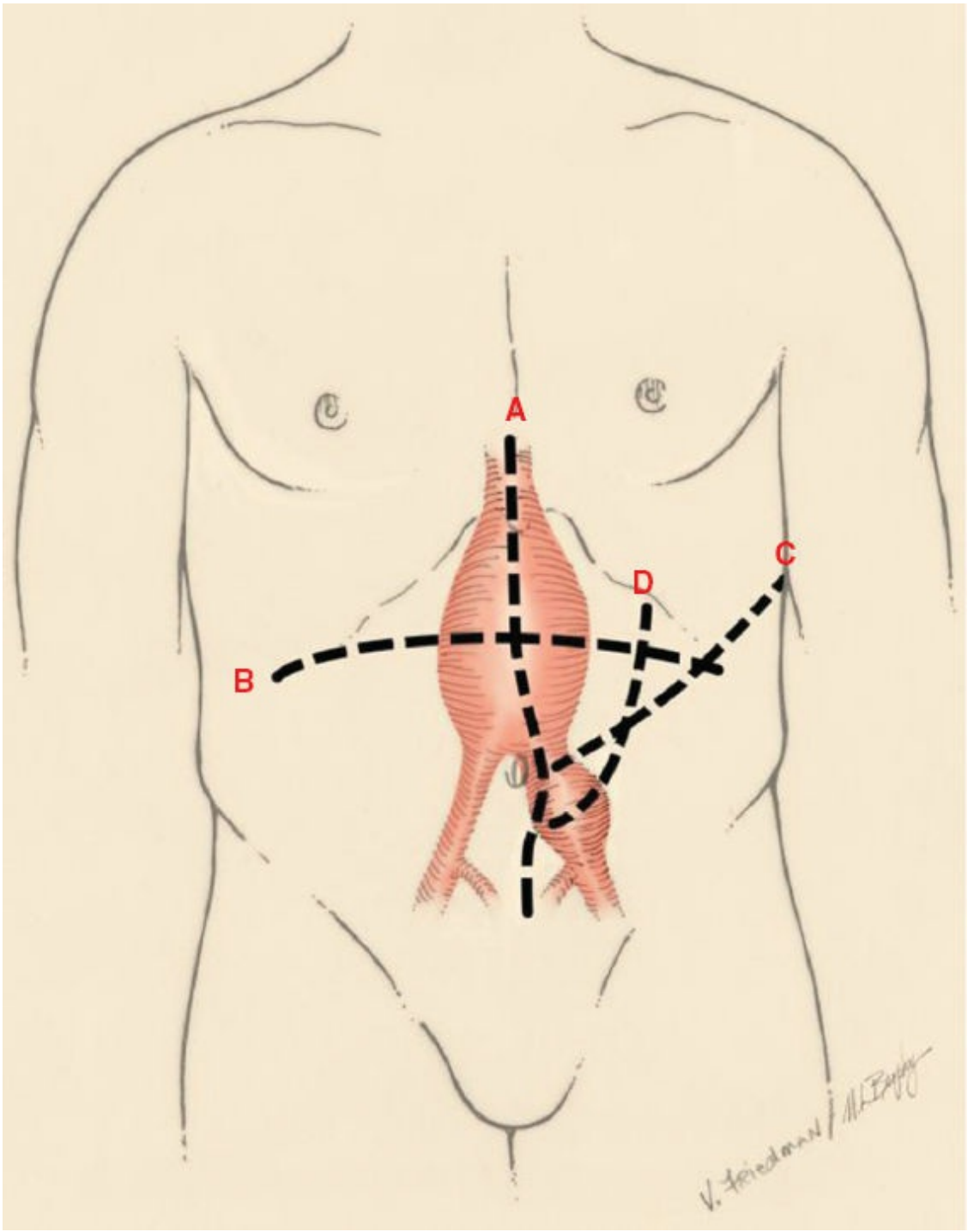

Figure 199.2. Most frequent surgical approaches for infrarenal aneurysm repair. *A,* midline; *B,* transverse; *C* and *D,* retroperitoneal approach depending on body habitus and extent of aneurysm.

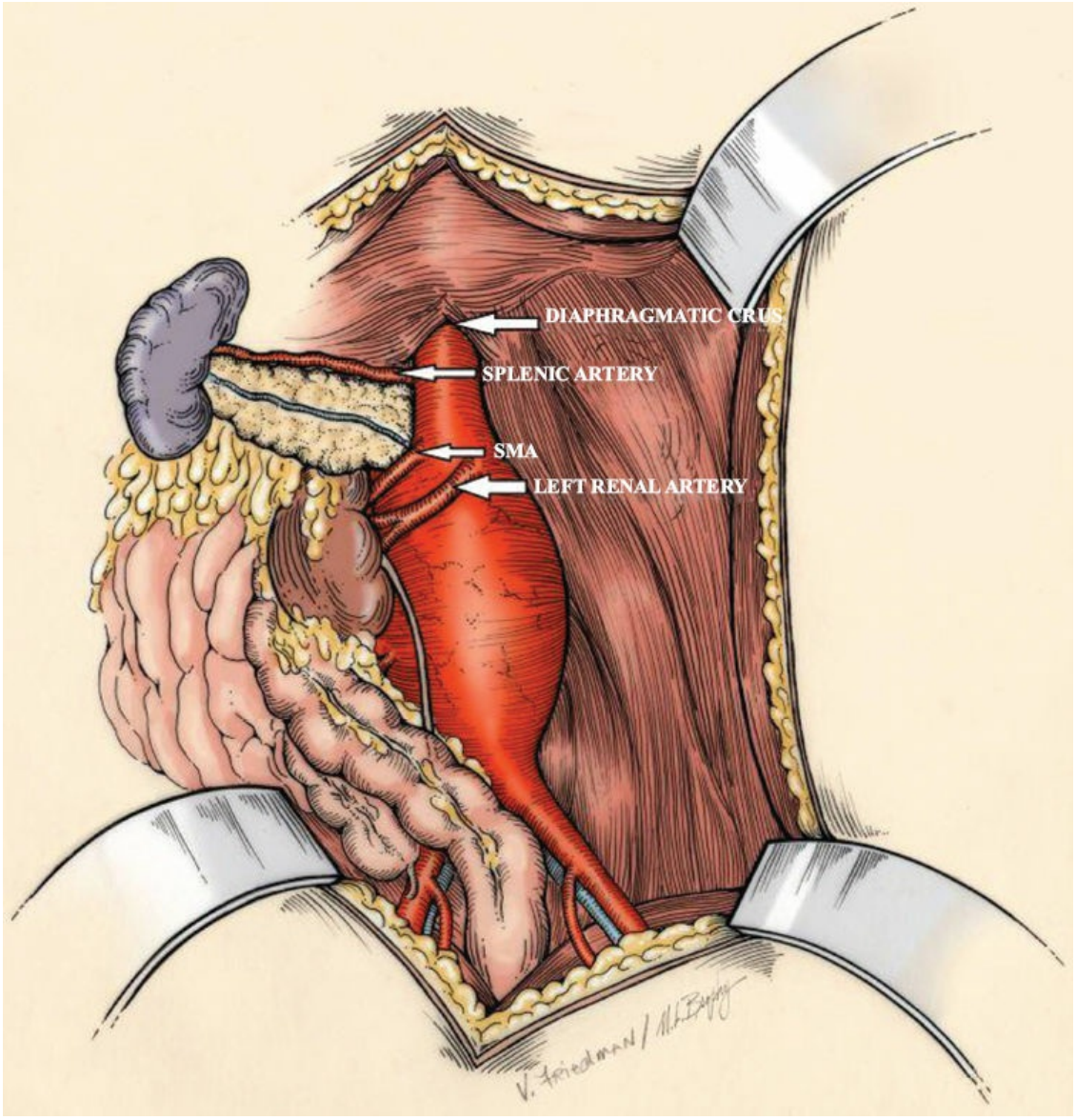

Figure 199.3. Left medial visceral rotation for exposure of entire infradiaphragmatic aorta and iliac vessels.

In cases of pararenal aortic aneurysms, more extensive proximal dissection may be necessary in order to expose an adequate site for proximal clamp placement. The clamp can be placed above one or both renal arteries. For more proximal exposure, a retroperitoneal exposure is ideal for this situation. However, a medial visceral rotation also allows adequate exposure of the proximal aorta with a transabdominal approach. Alternatively, exposure of the supraceliac aorta can be obtained by first mobilizing the left lobe of the liver and dividing the triangular ligament. With the liver gently retracted laterally, the gastrohepatic ligament can be divided along with the left diaphragmatic crural fibers to expose the aorta at this location for clamp placement.

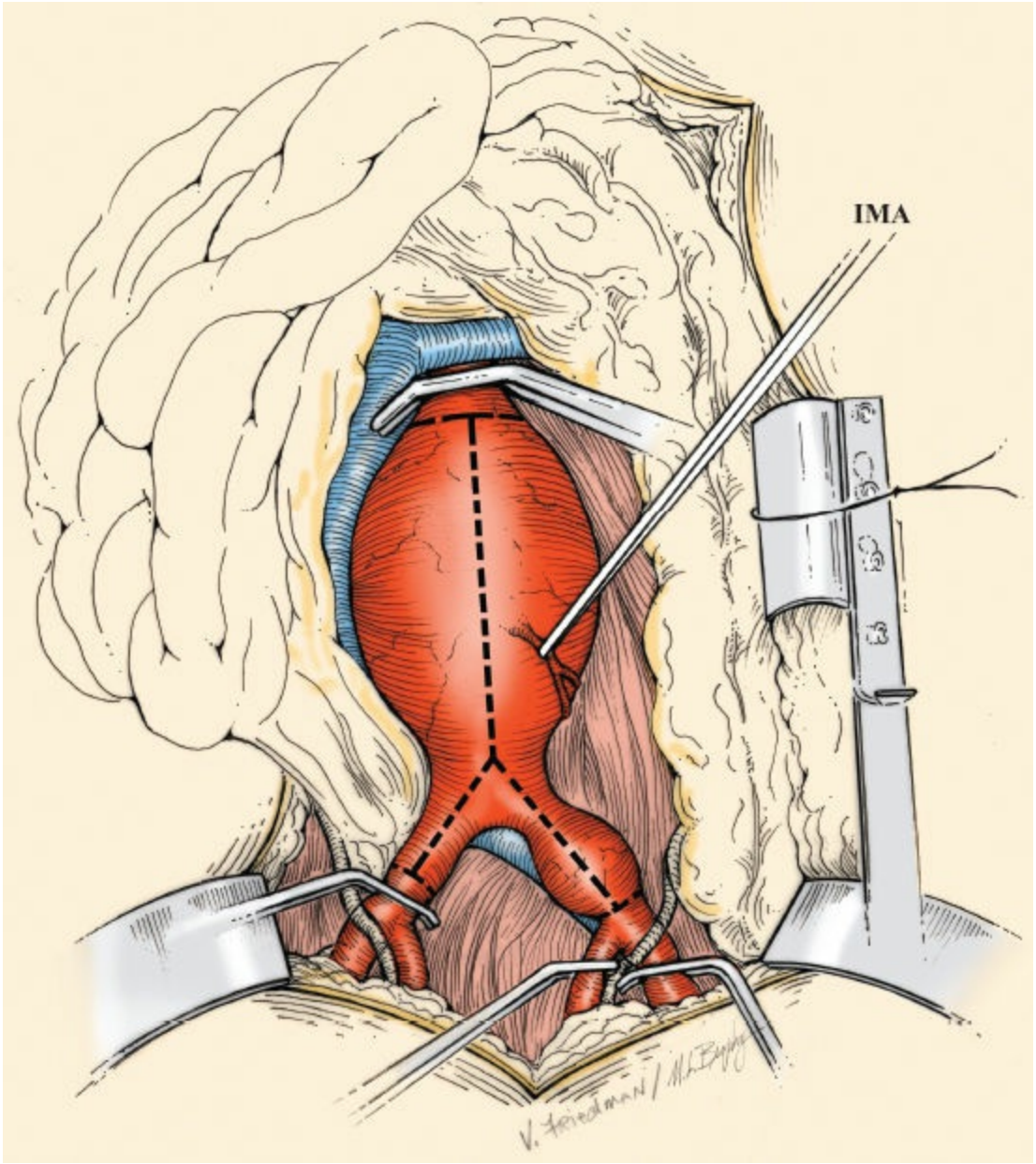

Figure 199.4. Infrarenal aortic and iliac arteries cross-clamped. Notice aneurysm and incision to the right of the inferior mesenteric artery (IMA).

Once adequate exposure is obtained, the proximal and distal clamp positions are identified. As noted above, careful assessment of available preoperative imaging helps guide identification of the location within the arterial vasculature for clamp placement. A disease-free area should be identified to minimize the potential for clamp injury as well as potential embolization of arterial debris. There are instances when the iliac arteries are so severely calcified that safe clamp placement is deemed as not feasible. In these instances, temporary balloon occlusion should be

planned.

The extent of the arterial replacement and graft configuration is balanced between removing all aneurysm tissue and performing an expeditious repair. The proximal extent of aortic replacement should include all aneurysm tissue. In cases of infrarenal aneurysm, the proximal extent of the repair should be just at the level of the renal arteries in order to avoid the future sequelae of continued aneurysm degeneration in the remaining native infrarenal aorta. A straight “tube” graft configuration can be utilized in just under half of infrarenal repairs when there is no aneurysmal degeneration of the iliac arteries. This configuration is the most expeditious repair as there is only one distal anastomosis required. In the remaining cases, a “bifurcated” graft is required with separate distal anastomoses done on the right and left side. This is required if there is aneurysm degeneration of one or both iliac arteries or if the distal aorta is so severely calcified that an anastomosis cannot be performed safely. Different conduits (such as polyester/Dacron or polytetrafluoroethylene) have all been utilized with no clear evidence to support the superiority of one type over another.

Prior to placement of the vascular clamps, the patient should be systemically anticoagulated with intravenous heparin (80 units/kg). Activated clotting times (ACT) can be measured to determine if additional boluses are necessary. We prefer to keep ACT greater than 250 during aortic cross-clamping. The sequence of clamp placement is determined by first placing clamps at locations with the least atherosclerotic burden (typically the distal clamps at the iliac arteries) to prevent embolization. After all proximal and distal clamps have been placed, the aneurysm sac is palpated to ensure the loss of pulsatility. The anterior wall of the aneurysm sac is then opened longitudinally away from the orifice of the IMA. The thrombus within the aneurysm sac is then manually removed and back-bleeding from lumbar arteries can be controlled with suture ligation. If the IMA is patent, then it should be controlled (in most cases) by suture ligation from within the aneurysmal sac (Fig. 199.5).

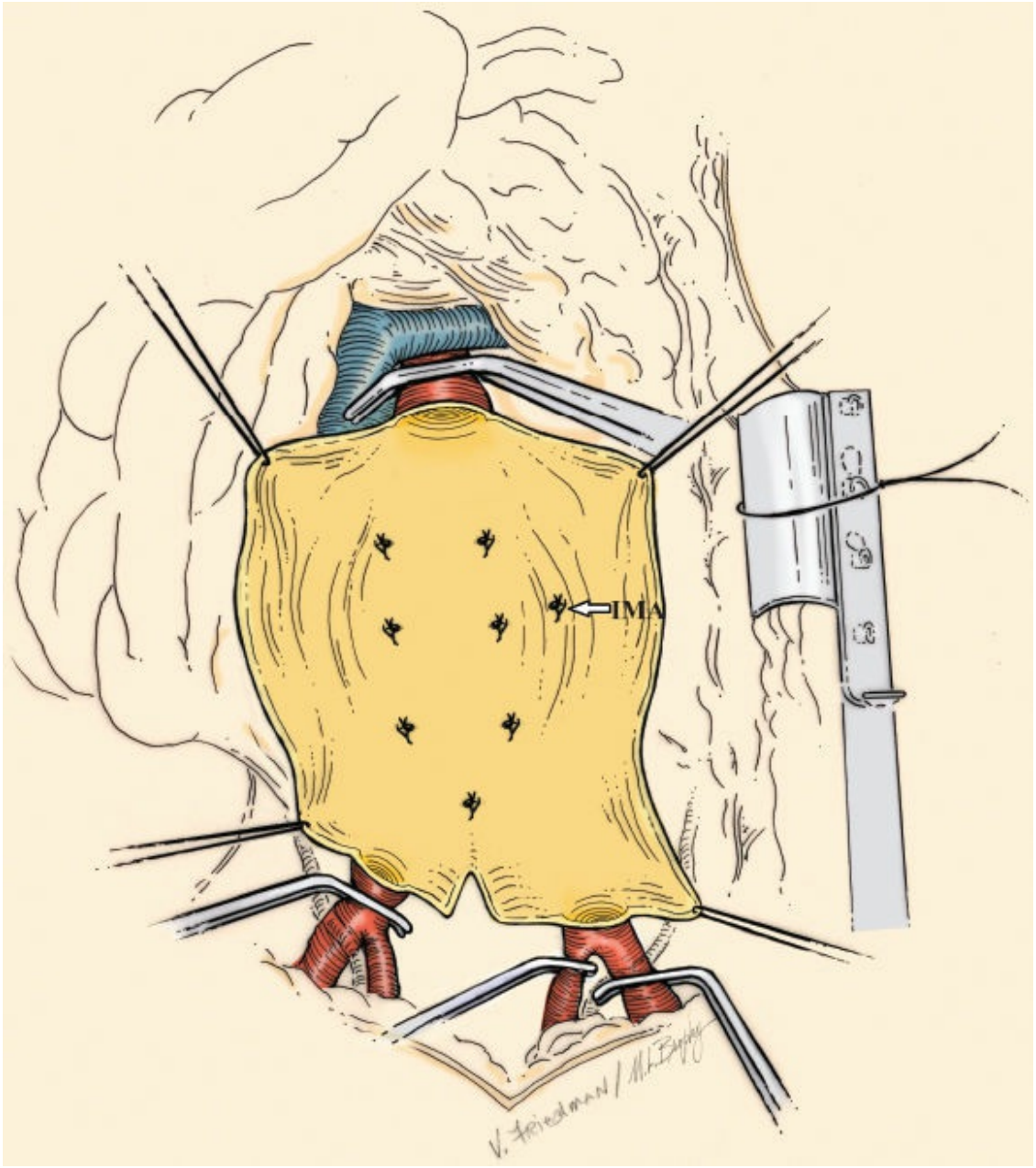

Figure 199.5. Opening of aneurysm sac and suture ligation of lumbar arteries and IMA.

Once hemostasis is achieved, the remainder of the aortic thrombus is removed. The aortotomy is then extended in a cephalad fashion and the aorta is then transverse divided at the level of the proximal neck. While circumferential division may facilitate visualization, this is not necessary and often the posterior aspect of the aorta is left intact. A graft with the appropriate proximal diameter is chosen and an end-to-end anastomosis is created with polypropylene sutures. Care should be taken to ensure that adequate “bites” of native aortic wall is taken to ensure stability of the anastomosis. In cases of friable aortic tissue, a strip of pledget can be

utilized to reinforce the anastomosis. After completion of the anastomosis, heparinized saline can be forcibly infused with a bulb syringe into the distal aspect of graft to test the proximal anastomosis. If this appears to be hemostatic, a separate clamp is placed on the proximal aspect of the graft and the proximal aortic clamp is released. For “tube” graft configurations, the distal anastomosis is created in a similar fashion and encompasses both orifices of the common iliac arteries. If the distal anastomoses are created to the iliac arteries (“bifurcated” configuration), then the anterior wall of the iliac arteries are longitudinally divided to allow visualization and end-to-end anastomoses are created to healthy iliac arteries. In cases where there is aneurysmal dilatation of the distal common iliac artery, the distal anastomosis will be created to the bifurcation of the internal and external iliac artery. The proximal tube component of a bifurcated graft should be kept short and the limbs stretched to avoid redundancy that may lead to future kinking once flow is re-established. The fate of the internal iliac artery is determined by the status of pelvic circulation. If the contralateral internal iliac artery is patent, then the ipsilateral internal iliac artery can simply be ligated and oversewn. If the contralateral internal iliac is either occluded or has a severe stenosis, then considerations should be made to either reimplant the internal iliac or perform a separate bypass graft to it to maintain adequate antegrade perfusion of the pelvic organs. In a bifurcated repair, distal flow should be restored when one anastomosis is completed prior to working on the contralateral anastomosis. There should be aggressive flushing maneuvers to ensure that any debris or thrombus is not allowed to embolize distally. Once the extremity and pelvic circulation is restored, the bowel is carefully assessed to determine if a patent IMA should be reimplanted. The IMA can be ligated if was identified to be occluded preoperative (on imaging) or have strong pulsatile back-bleeding (suggestive of adequate collateral flow from the superior mesenteric artery branches). If there is poor back-bleeding from a patent IMA, presence of SMA stenosis, or if the sigmoid or pelvis perfusion appears to be inadequate, a circular patch of aortic wall encompassing the IMA orifice is then re-implanted onto the prosthetic graft as a Carrel patch. Once adequate perfusion is ensured, the patient may receive protamine sulfate (and additional blood products as necessary) to aggressively reverse the anticoagulation. The native aortic wall is then reapproximated over the prosthetic graft and the retroperitoneum is closed to separate the graft from the adjacent small bowel to prevent future development of an aortoenteric

erosion or fistula. A piece of omentum can also be utilized to create a barrier anterior to the prosthetic graft. A careful inspection of the abdominal contents is then performed again and returned to the normal anatomic location prior to abdominal wall closure.

Retroperitoneal Approach to Juxtarenal Aneurysms

The patient is placed in the right lateral decubitus position with the use of a bean bag to maintain the position of the patient throughout the operation. For most supraceliac exposure using a retroperitoneal approach, the patient is usually placed in a 45-degree angle with appropriate cushioning of pressure points (Fig. 199.6A,B) to avoid iatrogenic pressure injuries. Depending on the proximal extent of the aneurysm and the previously planned aortic cross-clamping site, the incision is then selected. For the retroperitoneal exposure of juxtarenal aneurysm, a curvilinear incision from the lateral border of the left anterior rectus muscle to the tip of the 12th rib or the space between the 11th and 12th ribs is preferred. In very thin patients, just going to the tip of the 12th rib provides enough exposure for juxtarenal cross-clamping.

After the incision is made, the subcutaneous tissue is divided with electrocautery. The left lateral border of the anterior rectus sheath is then incised and the external oblique muscle is divided. It is at this junction between the lateral border of the anterior rectus sheath and the lateral abdominal wall muscles that the dissection is carried out to enter the retroperitoneal space. Once the posterior transverse fascia is incised, the peritoneum is swept medially and superiorly, allowing for the division of the lateral abdominal wall muscle. The division of intercostal muscles should be avoided if at all possible. Once the retroperitoneum is entered, identification of the left ureter is made and a vessel loop is placed around it, with enough tissue surrounding it to avoid ureteral devascularization. The ureter is then mobilized down to the iliac vessels inferiorly and superiorly to the renal pelvis. The space between Gerota fascia and the peritoneum is then bluntly entered and the kidney is allowed to fall backward in its fossa as the peritoneum is swept medially and the left renal vein is easily identified (Fig. 199.7). It is of note that for juxtarenal aortic cross-clamping, the kidney can be safely maintained in its renal fossa, although in obese patients with a very short neck, between the superior mesenteric artery and the renal arteries; then, the mobilization of Gerota fascia to allow the kidney to be elevated and fully mobilized provides a

retrorenal exposure to the juxtarenal aorta when indicated.

The gonadal vein is then identified and ligated right at the junction with the left renal vein. Medial mobilization of the peritoneum and the perirenal vein tissue will then expose the juxtarenal neck of the aorta. After placing the appropriate retractors, the neck of the juxtarenal aorta is mobilized. Because of poor visualization of the right renal artery, careful mobilization of the left renal vein should be made as far to the right as safely possible. If a suprarenal but inframesenteric cross-clamp is needed, then the lower aspect of the left crux of the diaphragm would have to be mobilized to allow the space between the superior mesenteric artery and the left renal artery to be exposed. If cross-clamping is going to be performed just above the renal arteries, every attempt should be made to at least digitally palpate the right renal artery to avoid, if possible, any injuries during aortic cross-clamping. Once the neck has been appropriately dissected, the mobilization of the peritoneum distally to, if possible, expose the right common iliac artery should be attempted. In thin patients this is easily performed, but in obese patients the best option is to cross-clamp the left common iliac artery and the right will be controlled by an intraluminal occlusion balloon after proximal aortic clamping and opening the aneurysmal sac.

After adequate exposure of the proximal and distal clamping sites, the patient is systemically anticoagulated as described above. The iliac arteries are initially clamped and then the aortic cross-clamp is applied, either just below the renal arteries or immediately above the renal arteries with an aortic cross-clamp. If intraluminal control of the right common iliac artery is necessary, this is done after the aneurysm sac is opened and the clot removed. There should be a careful attempt to avoid sweeping the clot down toward the aortic bifurcation. The clot should be removed superiorly to avoid impaction of thrombus in the proximal right common iliac artery. As soon as clear visualization of the ostium of the right common iliac artery is made, an intraluminal occlusion balloon is inserted to control back-bleeding. Once this is performed, the appropriate retractors are placed in the aortic sac to allow for full exposure of the proximal and distal anastomotic sites. If the IMA has retrograde bleeding, this can be easily controlled with suture ligatures from within the aneurysm sac. Any retrograde bleeding lumbar arteries are similarly controlled with suture ligatures. At this point, an end-to-end anastomosis is performed to the proximal aortic neck as well as end-to-end anastomosis (-es) either to the

distal aorta or to the common iliac arteries as needed.

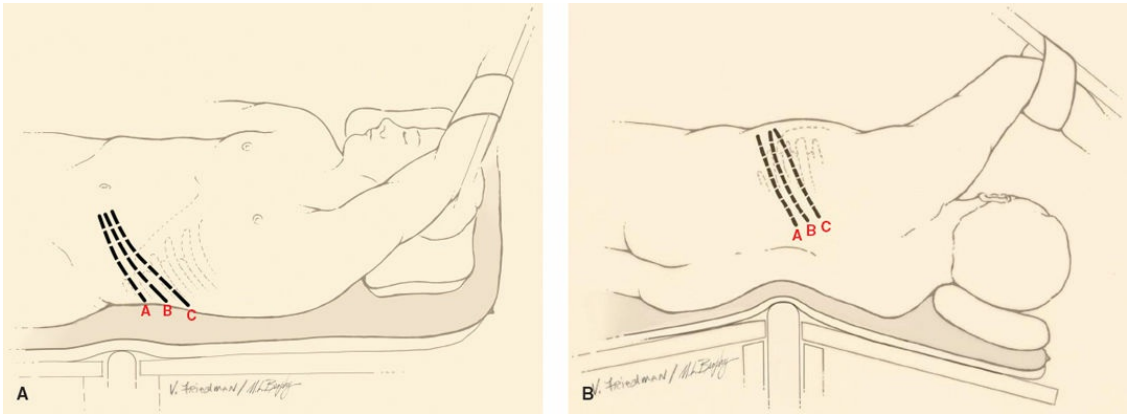

Figure 199.6. Anterior (**A**) and posterior (**B**) views of patient position for retroperitoneal approach to the aorta. Incisions *A* and *B* for infrarenal and juxtarenal, and *C* for suprarenal exposure.

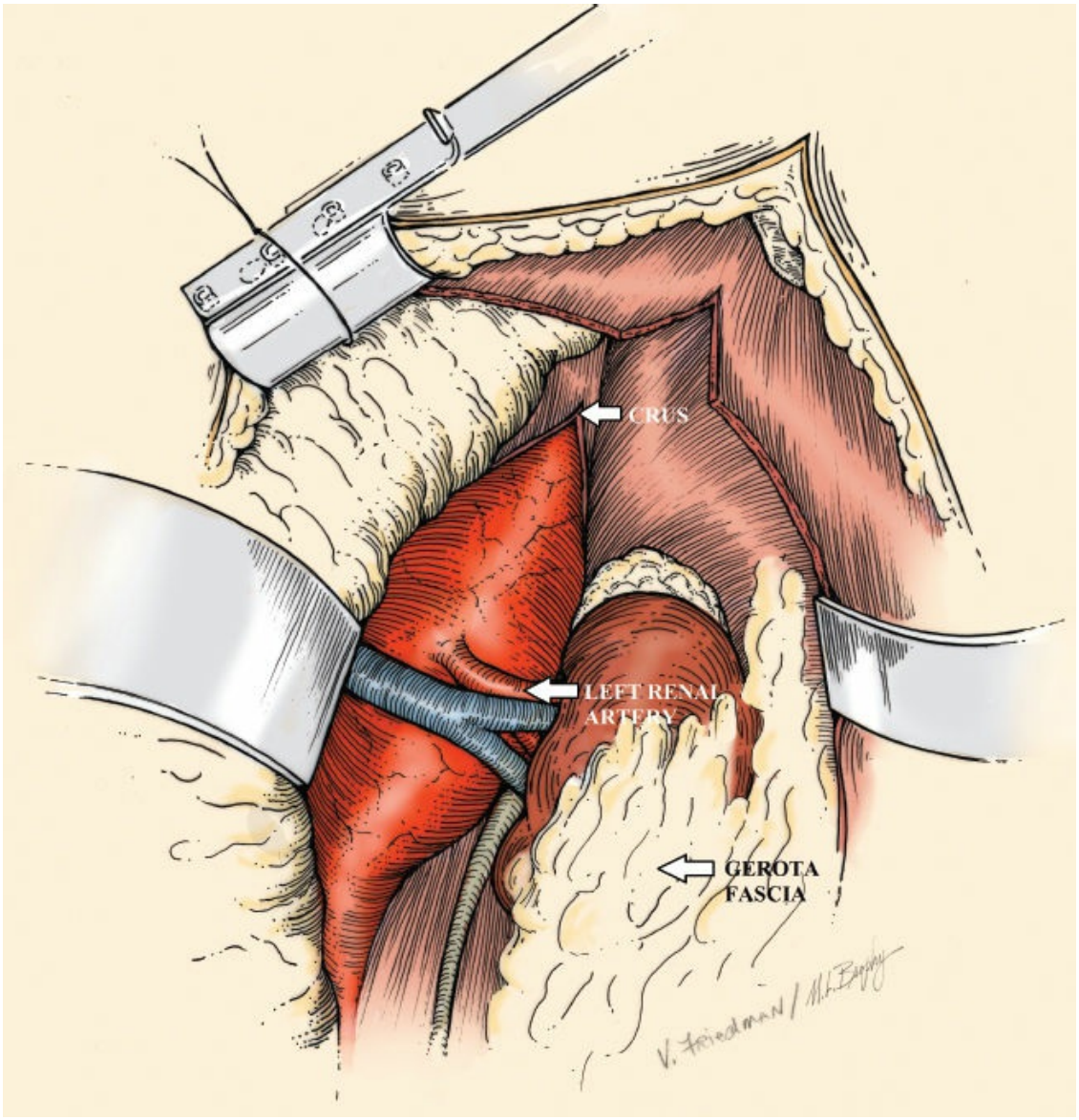

Figure 199.7. Retroperitoneal exposure of suprarenal aorta after mobilization of Gerota fascia. Note crus of diaphragm.

Retroperitoneal Approach to Suprarenal Aneurysms

If the aneurysm extends above the renal arteries but below the celiac axis, then exposure of the suprarenal aorta up to the celiac axis and above may be indicated. The incisions in terms of where they would be carried out on the chest wall are delineated. In these cases, the space in between the ribs will go from the tenth to the eighth space depending on the body habitus of the patient and how high up the aortic cross-clamp will be applied. Following the same maneuvers that were described for the juxtarenal aorta, Gerota fascia should be fully mobilized as to allow exposure to the aorta from a retrorenal approach rather than from the anterior aspect of the renal vessels. Once the left kidney is completely mobilized from Gerota

fascia, the kidney with its vessels are then mobilized to the right and superiorly, allowing for exposure of the left crux of the diaphragm. This is divided up to the diaphragmatic hiatus, allowing for exposure of the entire infradiaphragmatic aorta (Fig. 199.8). It must be remembered that when the left kidney is superomedially mobilized, a large lumbar vein is frequently encountered that drains into the posterior wall of the left renal vein and this must be ligated to avoid any venous injury. After the crux of the diaphragm is divided, the infrarenal exposure is performed in a similar manner as the description for juxtarenal aneurysm repair.

When the proximal aortic cross-clamp site will be at the supramesenteric or supraceliac level, exposure of this space requires the anterior division of the diaphragm in a radial fashion for 3 to 5 cm, so that when the retractors are placed, neither the ribs fracture nor the diaphragm tears. This diaphragmatic division will be appropriately repaired during the closure. Once the appropriate retractors are placed, if the supraceliac aorta is clamped, it is best that the revascularization of the mesenteric and renal vessels are accomplished by either an end-to-end anastomosis of the supraceliac aorta as a Carrel patch to incorporate the right renal artery, superior mesenteric artery, and celiac axis and allowing blood flow to these vessels initially as a side branch that has been previously sutured to the graft is used to revascularize in an end-to-end fashion the left renal artery (Fig. 199.9). In our experience, because the warm ischemia time of the left kidney in this type of reconstruction usually approaches or exceeds 30 minutes, we prefer to maintain the left kidney covered by a laparotomy sponge with ice slush. If more complex reconstruction is required (duration more than 40 minutes), then cold renal perfusion with lactated Ringer’s is performed to the left renal artery to protect it while performing the reconstruction.

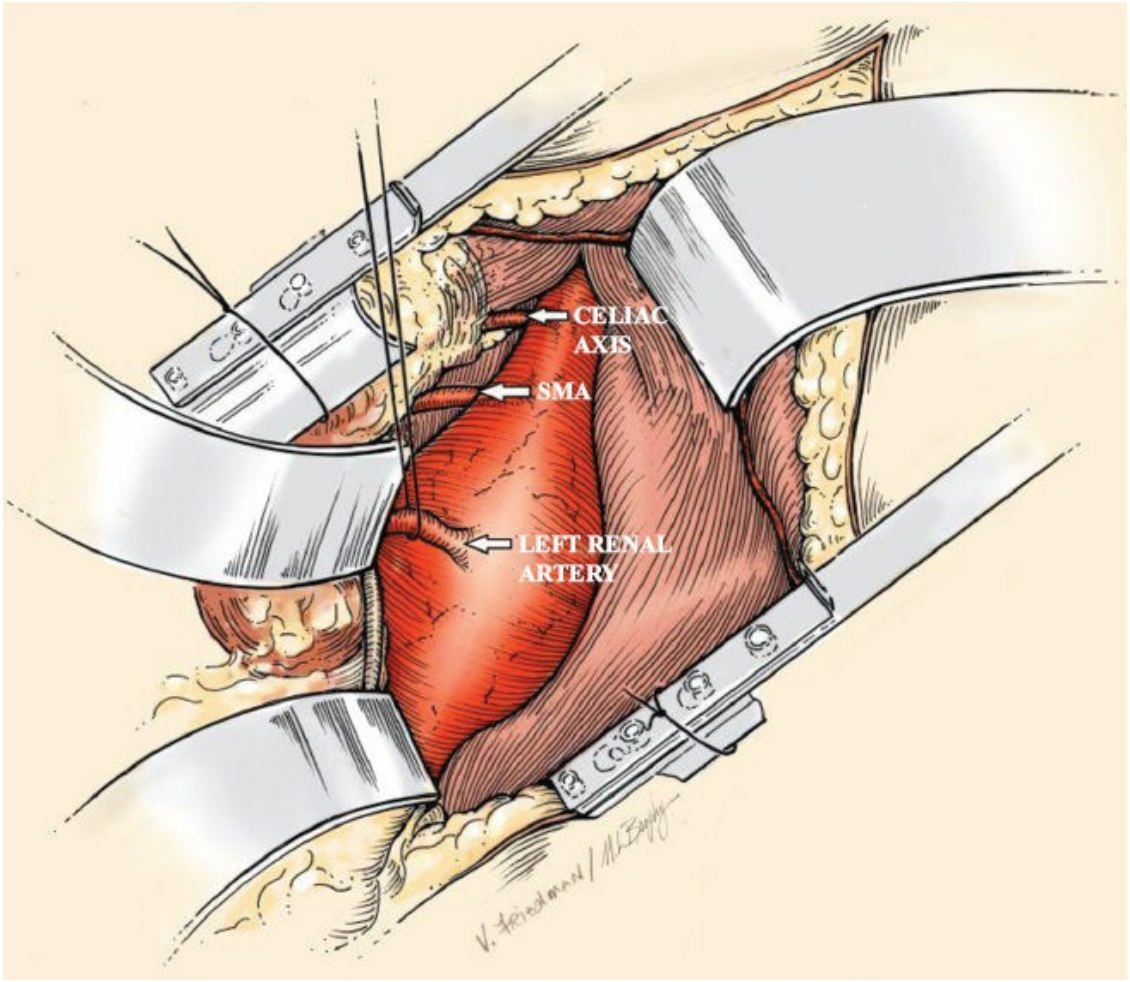

Figure 199.8. Exposure of infradiaphragmatic aorta after dissection of left diaphragmatic crus. Notice exposure with kidney mobilized anteriorly.

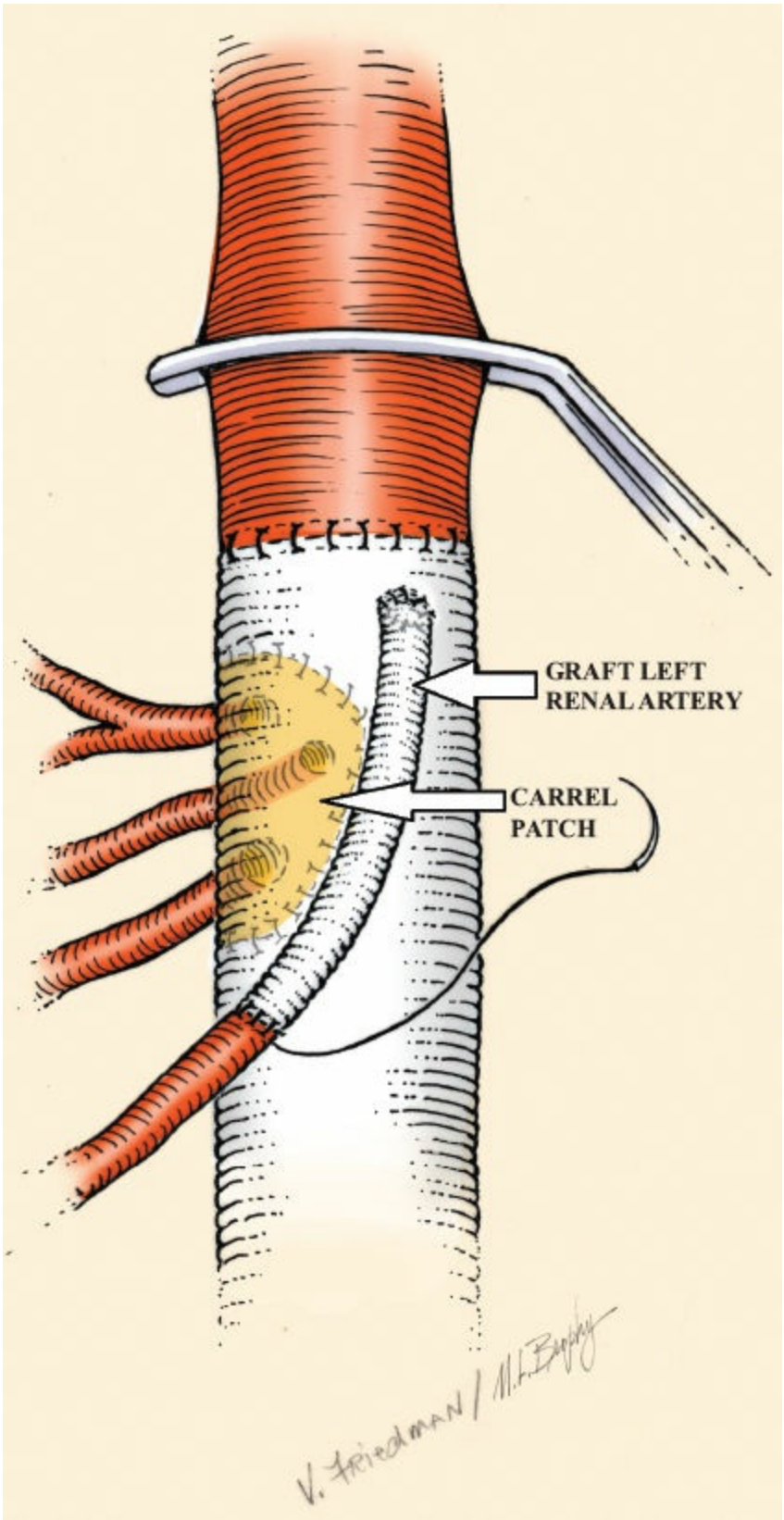

Figure 199.9. Reconstruction of suprarenal aneurysm with Carrel patch to include celiac axis, superior mesenteric artery, and right renal artery. Separate graft for left renal artery.

POSTOPERATIVE CARE AND COMPLICATIONS

Perioperative complications are not uncommon after open aortic aneurysm repair. After completion of the surgical repair, the patient is admitted to the intensive care unit and should be aggressively rewarmed and any postoperative coagulopathy reversed. Despite the increasing case complexity for open aneurysm repair in the endovascular era, the mortality rates have in fact remained the same or decreased with advances in critical care medicine, between 3% and 5% in large reported series. Myocardial infarction remains the leading cause of death. However, postoperative complications include pulmonary dysfunction, myocardial infarction, renal failure, need for dialysis, bleeding complications, colonic ischemia, limb ischemia, and venous thrombosis. Colonic ischemia should be suspected in a patient with acidosis, abdominal distention, or guaiac positive stools. There should be high index of clinical suspicion and bedside flexible sigmoidoscopy is performed to document the extent of ischemia. Aggressive resuscitation with intravenous hydration and broad spectrum antibiotics may suffice to treat limited cases, but colectomy and creation of an end colostomy is needed in case of transmural necrosis. Late complications of open aneurysm repair include anastomotic pseudoaneurysm, incisional hernia and bulges, bowel obstruction, graft infection, and aortoenteric fistula. For long-term follow-up, a CTA of the chest, abdomen, and pelvis is obtained every 5 years to evaluate aneurysm degeneration of the remaining native arterial vasculature.

OUTCOMES OF JUXTA AND PARARENAL OPEN ANEURYSM REPAIR

Recent series have reported acceptable 30 day postoperative mortality with juxtarenal and pararenal aneurysm repair (Table 199.2). Postoperative renal dysfunction and need for dialysis remains a common postoperative morbidity that affects short- and long-term survival. Similar observations have been reported for fenestrated juxtarenal and pararenal aneurysm repair. Perioperative and intraoperative maneuvers to diminish this significant complication rate remains an important area of clinical research.

ACKNOWLEDGMENT

We would like to express our gratitude to nurse practitioner, Dawn Sander,

for her assistance with the editorial completion of this chapter.

Suggested Readings

Chaikof EL, Blankensteijn JD, Harris PL, et al. Reporting standard for endovascular aortic aneurysm repair. *J Vasc Surg* 2002;35(5):1048–60.

Chiesa R, Marone EM, Brioschi C, et al. Open repair of pararenal aortic aneurysms: Operative management, early results, and risk factor analysis. *Ann Vasc Surg* 2006:20:739–46.

Chong T, Nguyen L, Owens CD, et al. Suprarenal aortic cross-clamp position: A reappraisal of its effects on outcomes for open abdominal aortic aneurysm repair. *J Vasc Surg* 2009;49(4):873–80.

Kabbani LS, West CA, Viau D, et al. Survival after repair of pararenal and paravisceral abdominal aortic aneurysms. *J Vasc Surg* 2014;59(6):1488–94.

Knott AW, Kalra M, Duncan AA, et al. Open repair of juxtarenal aortic aneurysms (JAA) remains a safe option in the era of fenestrated endografts. *J Vasc Surg* 2008; 47(4):695–701.

Pearce JD, Edwards MS, Stafford JM, et al. Open repair of aortic aneurysms involving the renal vessels. *Ann Vasc Surg* 2007;21(6):676–86.

Tallarita T, Sobreira ML, Iderich GS. Results of open pararenal abdominal aortic aneurysm repair: Tabular review of the literature. *Ann Vasc Surg* 2011;25(1):143–9.

Wartman SM, Woo K, Yaeger A, et al. Outcomes after abdominal aortic aneurysm repair requiring a suprarenal cross-clamp. *J Vasc Surg* 2014;60(4):893–9.

EDITOR'S COMMENT

Open aortic aneurysm repair is quite honestly the reason I became a vascular surgeon. When I trained open AAA repair was really the only method for repair and it was a massive, but beautiful, insult which parallel the ischemia reperfusion injury we often created in the laboratory. Where I trained, we would admit these patients to the intensive care unit, place a PA catheter, and then do a fluid challenge to determine that their heart could handle the fluid challenge. We would then go to the operating room the next day with the patient already fluid overloaded, perform open aneurysm repair, and then continue to flood the patient with crystalloid for another 48 hours. This is in contrast to what is performed today in which patients are almost never admitted the night before, undergo operations often without a blood transfusion, are extubated on the operating room table, then go to intermediate care floors that are not intensive care units (Vandy FC, Campbell D, Eliassen A, et al. Specialized vascular floors

after open aortic surgery: cost containment while preserving quality outcomes. *Ann Vasc Surg* 2013;27(1):45–52). Wow have we come a long way!!!

In this chapter by Dr.'s Sicard and Jim, they have done an excellent job of describing the technical details of open AAA repair. Dr Sicard in particular has a long-standing history of an academic interest in this subject. In particular, he performed one of the only randomized trials to examine the transabdominal (TAI) versus retroperitoneal (RPI) open aortic repair. In this landmark study in which 145 patients with both aortic aneurysm and occlusive disease were randomized and there were no differences in mortality between the two groups (overall postoperative mortality rate [two deaths] was 1.4%, with both occurring in the TAI group, $p = 0.507$). However, after surgery, the incidence of prolonged ileus ($p = 0.013$) and small bowel obstruction ($p = 0.05$) was higher in the TAI group. Overall, the RPI group had significantly fewer complications ($p < 0.0001$). The RPI group also had significantly shorter stays in the intensive care unit ($p = 0.006$), a trend toward shorter hospitalization ($p = 0.10$), lower total hospital charges ($p = 0.019$), and lower total hospital costs ($p = 0.017$). The authors concluded that the RPI approach for abdominal aortic surgery was associated with fewer postoperative complications, shorter hospital and intensive care unit stay, and lower cost. I believe this is still the best study examining these two operative approaches, even though I view these approaches as complementary and usually tailor my approach to repair based on patient (obesity, redo nature, etc.) and aortic characteristics.

There is no doubt this is a beautiful and elegant operation that we have made significant improvements on. In a recent snapshot of open versus endovascular repairs across the United States, while the number of open AAA repairs has decreased over the last decade, the mortality of open AAA repair has also decreased and is now only 4% (Dua A, Kuy S, Lee CJ, et al. Epidemiology of aortic aneurysm repair in the United States from 2000 to 2010. *J Vasc Surg* 2014;59(6):1512–7). This is remarkable given the observation that most of the patients are not endograft candidates which suggests that their aortic anatomy is even more complex.

While some have suggested that regionalization of endovascular care be performed, there is also a notion that perhaps open aneurysm repair might be even better for regionalization. This has occurred as vascular surgery training programs have performed a higher and higher percentage of their aortic cases endovascularly. It is highly likely that the finishing vascular surgery fellows may have performed less than 10 open AAA repairs in their entire fellowship (Dua A, Upchurch GR Jr, Lee JT, et al. Predicted shortfall in open aneurysm experience for vascular surgery trainees. *J Vasc Surg* 2014;60(4):945–9; Dua A, Koprowski S, Upchurch G, et al. Progressive shortfall in open aneurysm experience for vascular surgery trainees with the impact of fenestrated and branched endovascular technology. *J Vasc Surg* 2017;65(1):257–61). It is almost predictable with so few open AAA repairs, perhaps some form of regionalization is already occurring. I personally noticed a shift in my own

practice as I was an early adopter of endovascular AAA repair (EVAR). However, over time as EVAR became the new standard and matriculated into community hospitals, now patients with poor anatomy are often referred to tertiary referral centers. Thank goodness for this pattern as I love open aortic surgery!!!

Gilbert R. Upchurch Jr.

Suggested Reading

Sicard GA, Reilly JM, Rubin BG, et al. Transabdominal versus retroperitoneal incision for abdominal aortic surgery: report of a prospective randomized trial. *J Vasc Surg* 1995;21(2):174–81; discussion 181–3.

200 Endovascular Repair of Abdominal Aortic Aneurysms

Gregorio A. Sicard and Dawn Sander

Endovascular aneurysm repair (EVAR) has become a consequential less invasive alternative to the treatment of infrarenal abdominal aortic aneurysms (AAAs). Initially reported by Dr. Juan Parodi and collaborators in Buenos Aires in 1991 as an attractive alternative for patients with AAA deemed unfit for open aneurysm repair due to significant comorbidities. Although the initial experience in the 1990s and early 2000s were limited to high-risk patients, the initial good results from randomized clinical trials (RCTs) along with patient preferences for a less invasive approach significantly expanded its use to most elect AAA repair. Industry along with clinical investigators have played a critical role in introducing various devices that have been carefully scrutinized by FDA-approved clinical trials. This relationship between industry, FDA, and surgical investigators has led to various generations and impactful modifications of endografts. Currently there are six FDA-approved and commercially available devices (Table 200.1) each with its structural characteristics and specific Instructions for Use (IFUs).

In the United States, approximately 45,000 patients undergo AAA repair annually. Based on 2010 Medicare data, EVAR was the method used in 74% of beneficiaries. This number is actually higher (>80%) for large centers with significant experience where endovascular alternatives are being utilized even for complex infrarenal and juxtarenal AAA repair. This dramatic increase in the use of EVAR over the last 20 years has created challenges for vascular training programs to provide sufficient, meaningful experience in open AAA repair for trainees. This challenge has further increased with the more frequent use of fenestrated/branch devices for juxta-, suprarenal, and even thoracoabdominal AAA repair. Similar challenges have occurred in laparoscopic versus open intra-abdominal surgery (i.e., cholecystectomy, colon resection, hernia repair etc.).

TABLE 200.1 Commercially FDA Approved Infrarenal Endograft Devices

Company	Commercial Device Name	Endoprothesis Diameter (mm)	Attachment and Sealing
W. L. Gore	Excluder	23–35	Barbs
Medtronic	Endurant	23–36	Suprarenal bare stent with hooks
	Talent	22–36	Bare stent—suprarenal
Cook	Zenith-Flex	22–36	Suprarenal stent with hooks
Endologix	AFXs	25–34	Suprarenal stent with hooks
	Ovation	16–30	Suprarenal stent and neck rings for polymer injection

TECHNICAL CONSIDERATIONS

Different from open aneurysm repair, strict anatomical requirements must be met prior to considering a patient to be a suitable candidate for EVAR. A number of requirements for each device have been established and recommended by the FDA and industrial partner and termed IFUs. Amongst these requirements are included: a proximal aortic neck diameter below the lowest renal artery of equal to or less than 32 mm and equal to or greater than 15-mm aortic neck length. Suitable iliac artery diameters to allow insertion of the device is also important. The neck dimensions and characteristic of the aortic neck remain the primary restrictions for the use of EVAR. Despite these limitations, 80% of patients are candidates for EVAR with current devices. Lower profile devices, as well as techniques to create iliac conduits, have been described to resolve anatomical restrictions of the iliac arteries which are frequently encountered in women. In order to follow the “strict” anatomical requirements, accurate preoperative imaging with CT scan with IV contrast (CTA) and 3D reconstruction are required. The 3D reconstruction and centerline measurements allow for accurate measurements of the diameter and length of the aortic neck from the level of the lowest renal arteries to the common femoral arteries. Due to the frequently seen tortuosity of the infrarenal aortic neck and iliac arteries, precise diameter measurements is best accomplished with 3D reconstruction of thin sliced CT images (1 to 3 mm) and centerline measurement at the appropriate anatomical sites. Contrast CT scan can also identify the presence or absence of thrombus, calcium, or significant atheromatous disease in the aortic neck or in the iliac arteries that may interfere with the delivery of the endograft and the seal at attachment sites. Enhanced images with CTA can also identify polar artery (ies) that affects the true aortic neck (≥15 mm). The use of preoperative thin sliced contrast CT scan and 3D reconstruction with centerline measurement has become the norm for preoperative EVAR evaluation and has practically eliminated the need for preoperative arteriography except

for rare selected cases. In patients with abnormal renal function (serum creatinine equal to or greater than 1.6 mg/dL), magnetic resonance arteriography (MRA) with gadolinium can be useful in providing all the anatomical information required. The use of gadolinium is restricted for patients that have markedly abnormal renal function but the technique of time-of-flight MRA can be useful and avoid the use of gadolinium.

Endograft selection is based on the anatomical characteristics of the specific patient's anatomy, specifically as it related to aortic neck size, aortic neck type (straight vs. tapered), supra- and infrarenal aortic neck angulation, absence/presence of iliac artery aneurysms, and size of the external iliac arteries. Many new devices have been introduced to expand the patient population that can be offered EVAR. Neck angulations of equal to or more than 60 degrees has clinically been associated with graft migration and Type I endoleaks in association with an increased incidence of aneurysm rupture. Because of this, patients that have significant angulation (equal or more than 60 degrees) require devices that are flexible in the proximal portion and have been specifically designed for that type of anatomical variant. Recently, an endostaple has been introduced (Aptus Endosystem) which in reverse tapered aortic necks or in patients with persistent Type I endoleaks can be used to secure the endograft to the aortic wall providing a fixation and seal in this portion of the repair.

OPERATIVE TECHNIQUE

The most common approach for the insertion of the device is through open groin incisions and insertion of the main body and either percutaneous or open insertion of the contralateral limb (Fig. 200.1A,B).

Another important clinical advancement has been the development of arterial closure devices, which permits the use of percutaneous endoluminal repair of aneurysms using devices such as a Perclose or Prostar. The percutaneous approach to EVAR has decreased operative time and groin wound complications, as well as decreased hospital length of stay. Using this approach (percutaneous EVAR), many vascular groups have performed, in selected patients, this procedure as outpatient or as a short stay.

Each endograft has a different construction in terms of the type of stent (nickel titanium alloy, cobalt chromium alloy, or stainless steel), the type and thickness of the graft material used (Dacron, ePTFE), as well as different attachment mechanisms at the proximal and/or distal landing

zones. Even though all the devices rely on the radial force of the stent for attachment (Powerlink), some devices have added hooks (Excluder) or a suprarenal bare stent extension with or without hooks for proximal fixation (Zenith, Endurant, Talent, Ovation) and/or proximal sealing rings filled with a polymer (Ovation). In order to accomplish maximal expansion and appropriate sealing at the landing zones, the diameter of the endograft selected must be 10% to 20% larger at full expansion than the diameter of the proximal (infrarenal aortic) neck and distal iliac arteries. The surgeon must become familiar with the construction of the device, sheath size (profile), delivery system characteristics, configuration and the various diameters, as well as the limbs and extension diameters and lengths. In addition, the surgeon must follow the recommendations by the manufacturer in the IFUs regarding maximal aortic neck diameter and length, as well as neck angulation. Deviation from the IFU has been clearly demonstrated to be associated with higher peri- and postoperative complications (migration, Type I endoleak etc.). Most commercially available devices used (i.e., Zenith, Excluder, etc.) have a modular design, with the main body and ipsilateral limb as one component and the contralateral limb inserted from the contralateral femoral artery which connects to the “cage” of the main body component, thus creating a bifurcated aortoiliac bypass (see Technique for Endograft Insertion below). The only single body device commercially available is the AFX from Endologix. In this device a proximal extension is frequently necessary in the region of the aortic neck. Aortouniiliac configuration devices are currently available from various manufacturers and used for specific anatomic situations. When an aortouniiliac device is used, a contralateral common iliac occluder must be inserted and a femorofemoral bypass constructed (Fig. 200.2).

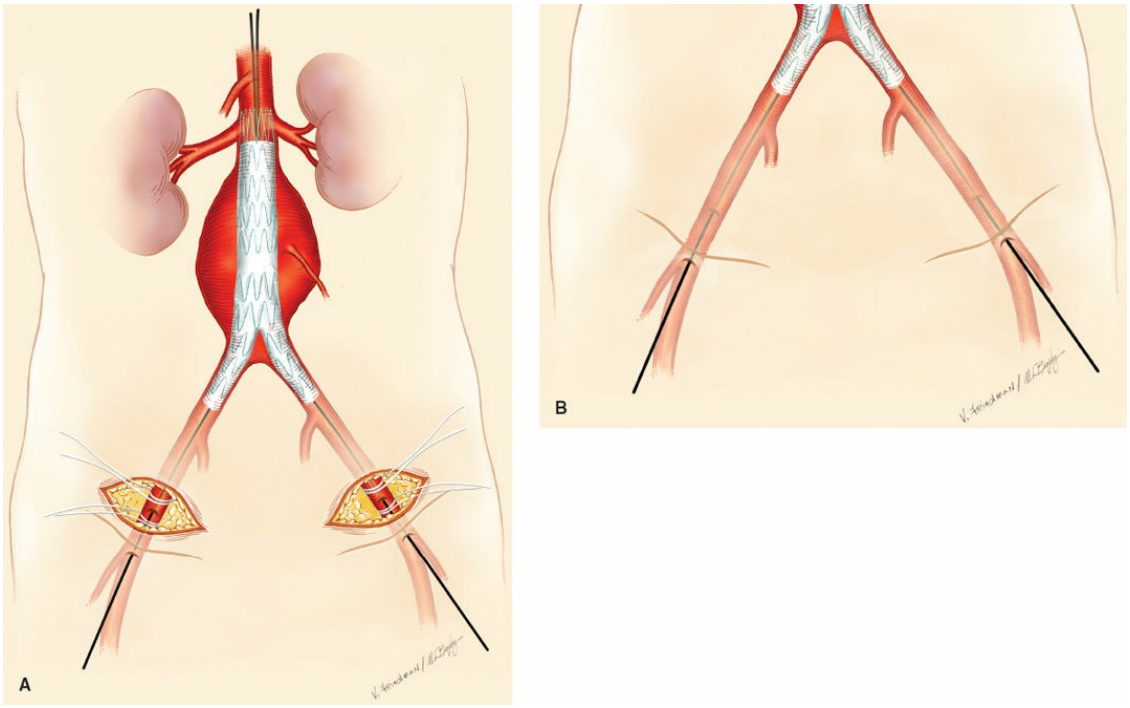

Figure 200.1. A. Endoluminal aneurysm repair by open femoral access. Device depicted has suprarenal stents with hooks for anchors. **B.** Drawing showing percutaneous femoral access for EVAR.

When IFUs are followed, all commercially available devices have demonstrated significantly reduced perioperative mortality, hospital length of stay, and the need for postoperative rehabilitation when compared to open AAA repair. In terms of total hospital costs different studies have demonstrated slightly increased costs with the endovascular repair technique and with the need for further interventions (either endovascular or open) the total long-term cost is significantly higher for endovascular techniques. Long-term results of all of these devices are similar in terms of long-term patient survival.

POSTOPERATIVE SURVEILLANCE

Postoperative imaging at 1, 6, 12 months, and yearly thereafter is of importance to provide early detection of complications associated with the endovascular technique (Type I or III endoleaks, migration and fabric and/or stent integrity). Although most investigators use CTA for follow up, in stable patients, over time, the follow-up can be limited to every 6 to 12 months abdominal aortic ultrasound which will detect expansion of the old aneurysm sac and or any new flow within the aneurysm sac (endoleak). If

any interval abnormality is detected then obviously a confirmatory contrast CT scan is necessary to better define the abnormality.

Clinical Outcomes

RCTs performed in Europe, the United Kingdom, and the United States (Dutch EVAR trial, EVAR 1, EVAR 2, and OVER Trial) have all demonstrated similar significant advantages of EVAR when compared to open aneurysm repair in terms of perioperative mortality, hospital length of stay, and need for rehabilitation.

The most contemporary RCT comparing EVAR to open AAA repair was the OVER Trial. This multicenter aneurysm Veterans Administration trial randomized 881 open versus EVAR using second generation endografts. The 30-day mortality was significantly lower for EVAR when compared to open repair (0.5% vs. 3.0%, $p < 0.004$). Similarly, EVAR had a statistically shorter length of stay compared to open repair (3 vs. 7 days).

All RCTs and nonrandomized trials have demonstrated a higher number of long-term complications after EVAR when compared to open AAA repair. Most of these complications (migration, Type I, II, and III endoleaks) can be resolved by endovascular means. With the continued increase and success of EVAR further expansion of the technology to include juxta- and supra-renal endoluminal repair was to be expected.

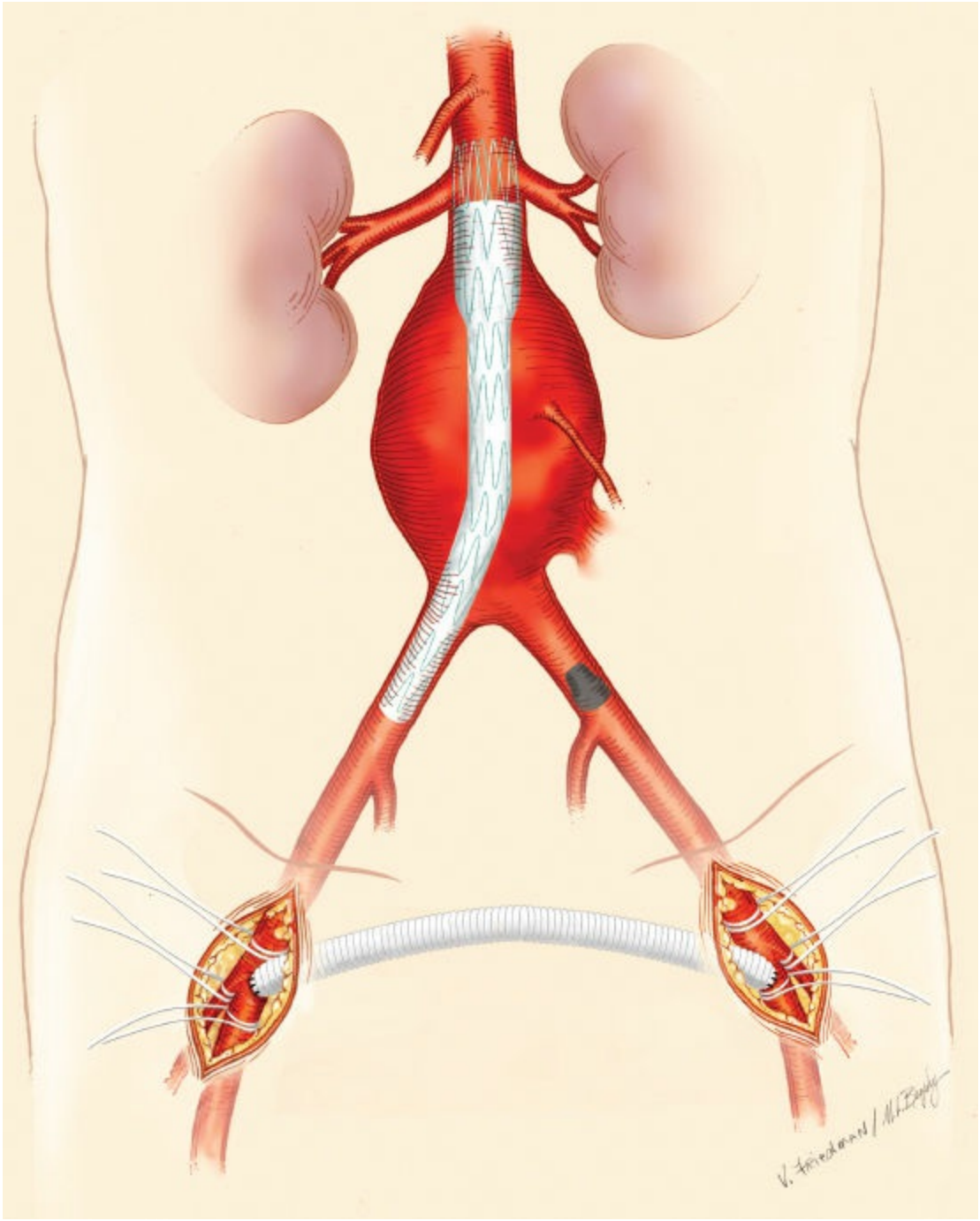

Figure 200.2. Aortouniiliac endograft with left common iliac occlude; notice right to left femoral to femoral prosthetic bypass graft.

New Devices

Currently a Phase II trial in the United States is being conducted for a new concept of EVAR. The Nellix Device by Endologix is two stents which are surrounded by a sealing bag that is inflated with polymer after the two stents are positioned in the juxtarenal aorta. The filling of the bags with

polymer seals the neck and fills the aneurysm sac with a polymer filled bag whose intent is not only to stabilize the two stents, but also eliminate or diminish Type II endoleaks. Early results from Europe are encouraging and a Phase II trial is currently being performed in this country.

ENDOLUMINAL REPAIR OF JUXTA- AND SUPRARENAL AORTIC ANEURYSM

Throughout the mid 1990s and early 2000s various centers nationally and internationally expanded the use of endoluminal aneurysm repair to endoluminal repair of juxtarenal and suprarenal aortic aneurysms. Over the last decade, the use of fenestrated devices (FEVAR) has increased throughout the world. The device with the largest clinical experience has been the Zenith Fenestrated device (Z Fen). This device has demonstrated outstanding results in terms of decreasing perioperative mortality and morbidity, as well as hospital length of stay and patency of target vessels (renals, SMA, etc.) when compared to open repair.

Technical Considerations

The technical aspects of FEVAR is similar in terms of the preoperative preparation and intraoperative technical aspects. Currently, fenestrated devices are custom made based on the specific location of the renal arteries and SMA determined by thin slice CTA with centerline reconstruction. The current delay in construction of the fenestrated device is 3 to 6 weeks. A clinical trial is underway for an off–the-shelf device (P-Branch) for selected patients with anatomy of the location of the renal arteries and SMA that can be used in approximately 70% of patients. Commercial availability of “off-the-shelf” device awaits completion of the trial, although it has obtained CE approval and the results in Europe have been encouraging.

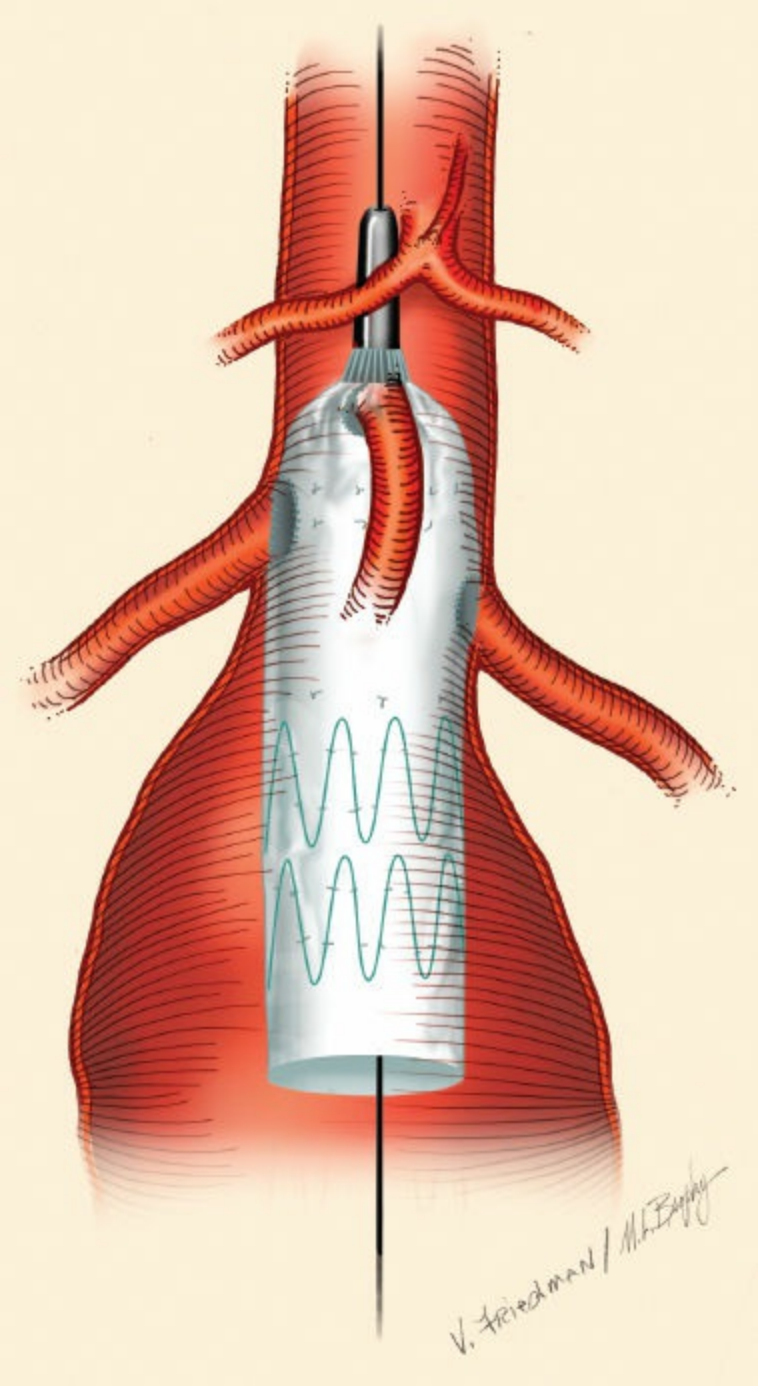

Figure 200.3. Open fenestrated endograft with alignment of fenestrations to renal ostia and scallop to SMA artery. Notice restrained suprarenal attachment which allows rotation of device for proper renal and SMA alignment of fenestration/scallop.

The devices are usually performed either open or percutaneously through the femoral arteries and the fenestrated main body is delivered to the juxtarenal aorta.

The preoperative precise identification of the location of the renal

arteries becomes an important component of the actual construction of the device to ascertain appropriate alignment for the specific patient. Intraoperative after deploying the device with the proximal portion still constrained allows for movement of the main body to make certain the fenestrations align properly with the ostium of the renal arteries (Figs. 200.3 and 200.4).

Once the deployment and ballooning of the renal stents is completed proximal attachment hooks are deployed which will open the scallop that accommodates the superior mesenteric artery (Fig. 200.5). After this portion is completed, a bifurcated Zenith device is placed inside of the tubular fenestrated main body with iliac limbs to ascertain a complete endovascular repair of the entire juxta- and infrarenal aorta.

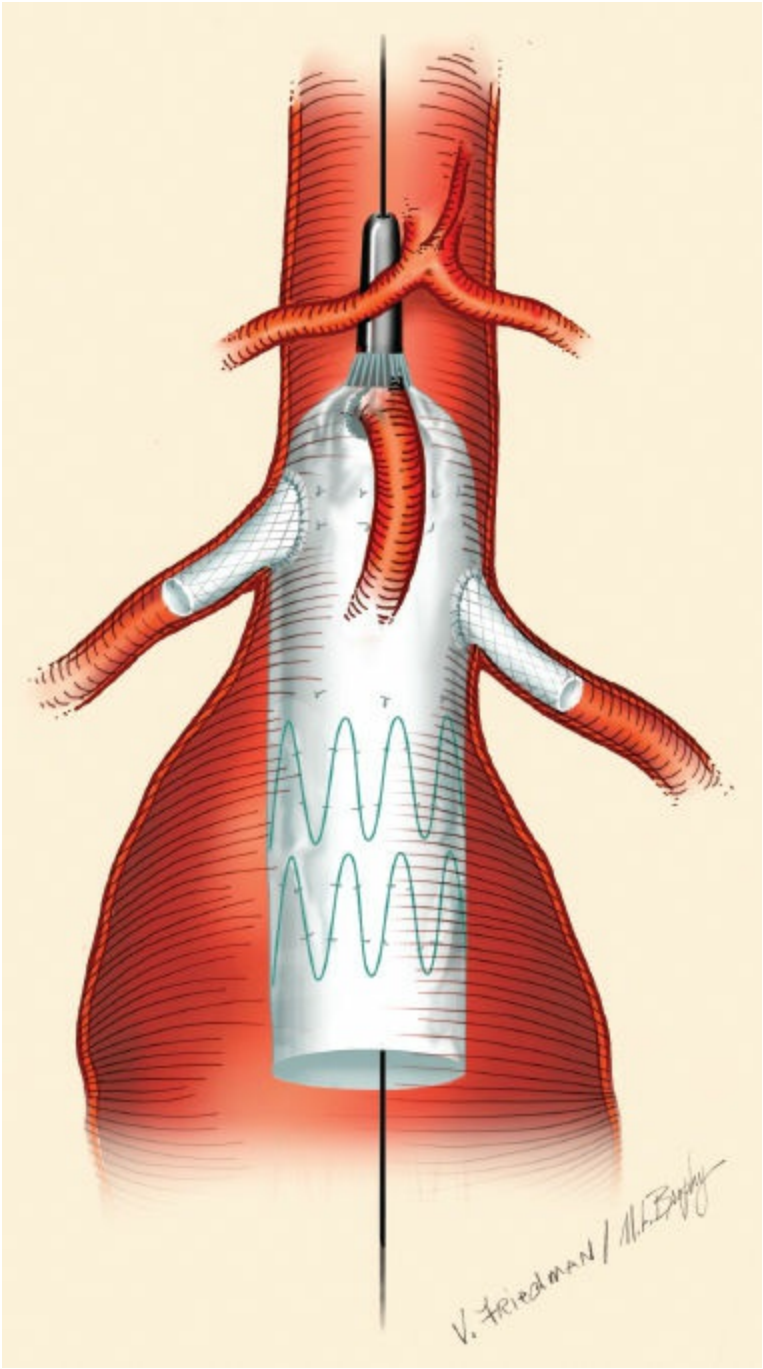

Figure 200.4. Depicts bilateral renal covered stents deployed prior to release of proximal bare stent/hook deployment.

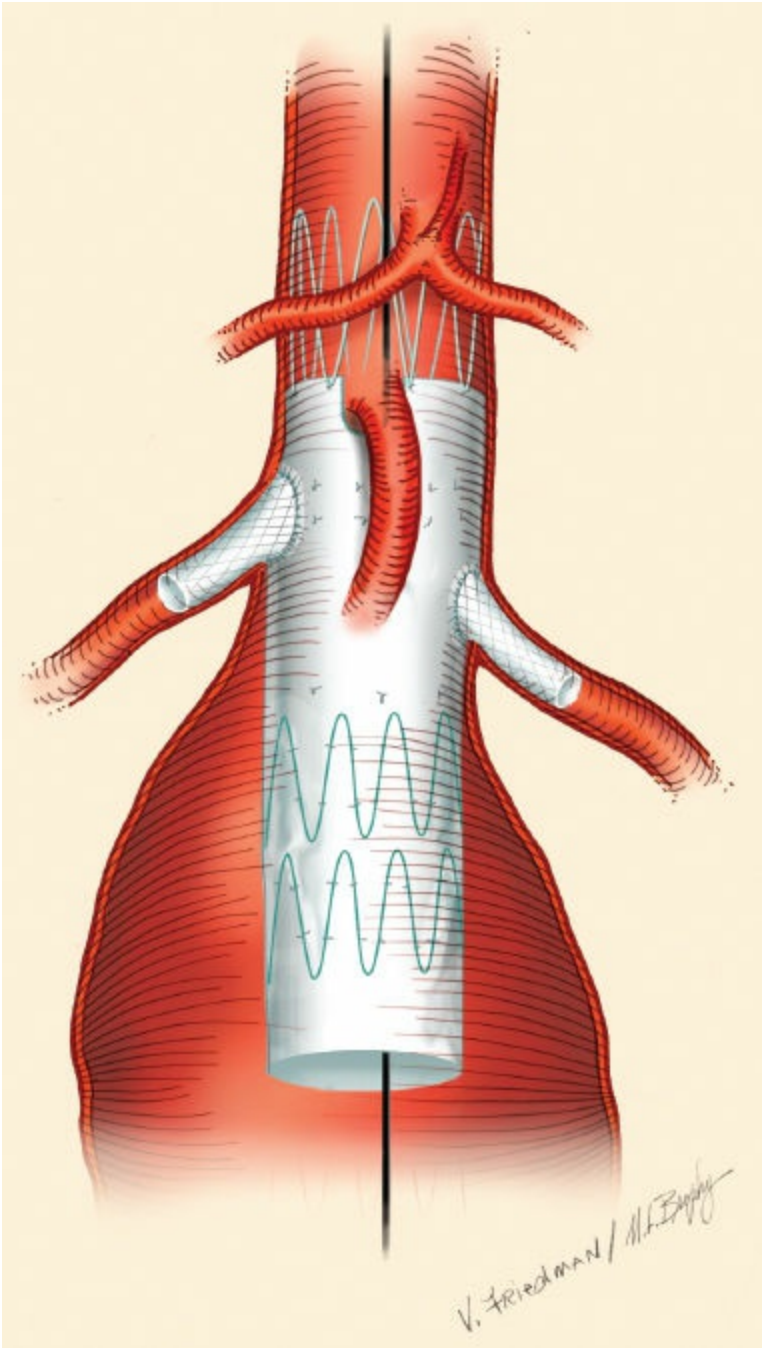

Figure 200.5. Complete deployment of proximal device with bilateral renal stents, scallop SMA, and supra SMA attachment. Bifurcated endograft device will be overlapped to this fenestrated device.

In aneurysms that reach the SMA, a third fenestration for the SMA is incorporated in the main body device and two covered stents are deployed in the renal arteries. In this particular situation, below the celiac artery is as proximal as the aortic endograft can go. Aneurysms that include the celiac artery (Type IV TAA) are being repaired using fenestrated/branch

investigational devices more frequently.

In summary, the introduction of endovascular aortic aneurysm repair in the last 25 years has revolutionized the treatment of this condition. The manufacturing and success of multiple devices that fit different anatomic characteristics in patients with infrarenal AAAs has allowed for the continued expansion of this technology for elective and ruptured aneurysm repair. Further advancements in technology has allowed for expansion of endografts to treat patients with juxta- and suprarenal and aortic aneurysms. Continued technologic advances, introduction of new devices, and carefully designed studies allow for further refinements of these techniques, thus helping most patients to avoid major open surgical repair.

ACKNOWLEDGMENT

We would like to express our gratitude to nurse practitioner, Dawn Sander, for her assistance with the editorial completion of this chapter.

Suggested Readings

Lederle FA, Freischlad JA, Kyriakides TC, et al. Outcomes following endovascular vs open repair of abdominal aortic aneurysm, a randomized trial. *JAMA* 2009;302(14):1535–42.

Mastracci TM, Eagleton MJ, Kuramochi Y, et al. Twelve-year results of fenestrated endografts for juxtarenal and group IV thoracoabdominal aneurysms. *J Vasc Surg* 2015;61(2):355–64.

EDITOR'S COMMENT

As an aspiring general surgery resident, I was attracted to vascular surgery in particular by the complex and technically challenging operations performed to repair aortic aneurysms. I remember one distinct day as a resident that we performed three open abdominal aortic aneurysm (AAA) repairs and feeling like I wanted to spend the rest of my life dedicated to performing that operation. While where I trained was not an early adapter of EVAR, it was clear when I was a fellow that EVAR was here to stay and that even early with first-generation devices patients really benefited from EVAR in terms of decreased mortality, decreased hospital and intensive care unit (ICU) length, fewer transfusions, and earlier return to functions associated with daily living.

It has been almost 20 years since the first EVAR in humans and now what was once a cottage industry has turned into a burgeoning multimillion dollar business with endovascular approaches soon to be available to treat the entirety of the aorta and all of its branches (Parodi JC, Palmaz JC, Barone HD.

Transfemoral intraluminal graft implantation for AAAs. *Ann Vasc Surg* 1991;5(6):491–9). In this chapter by Sicard and Jim, the basics of how to perform an EVAR are well-described and illustrated. Functionally, using almost a purely percutaneous approach the concept is really simple: a reinforced stent graft is placed inside the aneurysm to, in the best scenario, exclude the aneurysm and decrease/eliminate the pressure on the aortic wall thus eliminating aortic rupture. While the aneurysm is not removed or eliminated, the concept is that we functionally convert the aneurysm to a chronic problem that allows the patients, who are typically older with multiple comorbidities, to die from some disease.

Unfortunately, as with almost all surgical therapies that we provide patients, there are a few "Achilles heels" associated with this technology. First, somewhere close to 30% of patients will end up with an endoleak, which represent continued blood flow into the aneurysm sac and can result in increased risk of aortic rupture (Schanzer A, Greenberg RK, Hevelone N, et al. Predictors of AAA sac enlargement after endovascular repair. *Circulation* 2011;123(24):2848–55; Lal BK, Zhou W, Li Z, et al.; OVER Veterans Affairs Cooperative Study Group. Predictors and outcomes of endoleaks in the Veterans Affairs Open Versus Endovascular Repair (OVER) Trial of Abdominal Aortic Aneurysms. *J Vasc Surg* 2015;62(6):1394–404). Some of these endoleaks are considered benign, especially in the setting of decreased aneurysm size over time, while others are not (endoleaks caused by failure of attachments or disconnects of the modular components of an endograft). These latter types of endoleaks are associated with increased rupture risk and the patients unfortunately are unknowing that there is a problem associated with their endograft.

Second, unlike what typically happened when we performed open AAA repair, patients who have endografts inserted are subjected to long-term radiographic surveillance. The good news about this is that we have realized that the natural history of patients who have AAAs who undergo repair have a fairly high incidence of a metachronous aneurysm over time, likely somewhere close to 5%. That is approximately 5% of patients will develop an aneurysm remote from their original EVAR repair site. I suspect this has served to further emphasize to those of us that study the pathogenesis of aortic aneurysm that it is a systemic disease! Unfortunately, this has translated into lifelong imaging that originally was primarily CT angiography based. Patients were getting as many as four CT scans per year with all of the associated radiation and iodinated contrast. I think most of us have moved to, especially for EVAR, trying to use ultrasound as much as possible for follow-up imaging (David E, Cantisani V, Grazhdani H, et al. What is the role of contrast-enhanced ultrasound in the evaluation of the endoleak of aortic endoprostheses? A comparison between CEUS and CT on a widespread scale. *J Ultrasound* 2016 23;19(4):281–87). I would say we are also really heightened to the amount of radiation vascular surgeons who insert endografts are exposed to (Ruz R, Lee K, Power AH, et al.

Anatomic and procedural determinants of fluoroscopy time during elective endovascular aortic aneurysm repair. *Vascular*. 2016;24(1):19–24). Now that this has been brought to light, new imaging systems with programs aimed at reducing radiation exposure are being employed.

Finally, the cost of the actual endograft remains a problem in that in typically is approximately two thirds of the total hospitalization cost when patients undergo EVAR. We performed an interesting study a few years ago which showed that while the contribution margin of EVAR on a per cases basis was surely less than open AAA, the deceased contribution margin was offset by a decreased hospital and ICU length of stay making EVAR overall a margin positive operation (Rosenberg BL, Comstock MC, Butz DA, et al. Endovascular abdominal aortic aneurysm repair is more profitable than open repair based on contribution margin per day. *Surgery* 2005;137(3):285–92). I suspect this ultimately depends on local contracts for endograft prices and whether patients have complications or not, which clearly drives up the cost of both open and endovascular AAA repair. I still cannot figure out with as many as six different endografts available, why the price of endografts has not come down. Endograft pricing has really not followed the law of supply and demand. It will be interesting to see if the same thing happens in TAVR pricing as well.

Gilbert R. Upchurch, Jr.

201 Ruptured Abdominal Aortic Aneurysms

Manish Mehta, Philip S. K. Paty, and Mehdi J. Teymouri

Ruptured abdominal aortic aneurysm (AAA) treatment strategies have witnessed a paradigm shift over the past decade. From 1950s to 1990s, there were marginal improvements in ruptured AAA patient survival, and mortality remained around 50%. In the 1990s, endovascular technology entered the vascular domain and revolutionized ruptured AAA treatment strategies that became more catheter directed, and for the first time had a significant reduction in ruptured AAA mortality to approximately 20%. This chapter will focus attention to historical perspectives, epidemiology, clinical presentation, initial management and triage, operative strategies for endovascular and open surgical repair, associated complications, and outcomes.

HISTORICAL PERSPECTIVES

The first reported operation for ruptured aorto-iliac aneurysm was by Astley Cooper in 1817 when he ligated the aorta for hemorrhage control. The patient survived the operation, and died on the second postoperative day. It was not until 1923 when Rudolph Matas successfully ligated the aorta of a 28 year old with a ruptured syphilitic aortic aneurysm who survived for 28 months; finally succumbing to tuberculosis. Not much changed in the management of ruptured AAA until 1954, when Cooley and DeBakey had treated six patients with surgical reconstruction beyond just aortic ligation and reported a 50% survival rate. Over the next 40 years, centers across the United States and globe adopted open surgical repair and reconstruction as the primary treatment for ruptured AAA with an acceptable mortality of 50%. In the 1990s endovascular technology was evolving and entering the vascular world and shortly after the first reported elective endovascular AAA repair by Juan Parodi in 1991, Yusuf et al. first reported endovascular repair of a ruptured AAA. Over the past two decades we have seen unprecedented acceptance of endovascular

technology for managing elective and reputed aortic aneurysms with significant reductions in patient mortality.

PATHOPHYSIOLOGY

Several risk factors portend rupture. The first is aortic diameter. In the only population-based US study, Nevitt reviewed the outcomes for 370 residents of Rochester, Minnesota followed from 1951 to 1984 and reported no rupture during 5-year follow-up for AAAs <5 cm, but a 5% annual rupture risk for AAA >5 cm at initial presentation. In the most recent analysis of these data, Reed estimated annual rupture risk (with 95% confidence intervals) to be 0% (0% to 5%) for AAA <4 cm, 1% (0% to 5%) per year for 4.0 to 4.9 cm AAAs, 11% (1% to 21%) per year for 5.0 to 5.9 cm AAAs and 26% (7% to 46%) per year for 6.0 to 6.9 cm AAAs. These estimates mirror the findings of the UK Small Aneurysm Trial, which randomized 1,090 patients to surgery or follow-up. The annual rupture rate was calculated as 0.3% for AAAs <4 cm diameter, 1.5% for 4.0 to 4.9 cm AAAs, and 6.5% for 5.0 to 5.9 cm AAAs. It is possible that both these studies underestimated rupture risk since some AAAs underwent elective repair for rapid expansion or symptoms.

Aneurysm rupture represents failure of the aortic wall to bear the load or tension to which it is exposed. When the force of the blood pressure exceeds the ability of the aortic wall to bear that load, the aneurysm wall ruptures and blood extravagates. In vitro testing has demonstrated that the failure strength of human aneurysmal aortic wall is 65 N/cm^2 versus 121 N/cm^2 for nonaneurysmal human aortic wall. This indicates that the aneurysmal aortic wall is weaker. Laplace law (tension is proportional to radius times pressure) relates wall tension to pressure, thus emphasizing the importance of size. Although this method may be satisfactory for symmetric structures, it does not take into account the complex geometry of individual AAAs.

The engineering technique of finite element analysis has been applied to AAAs to estimate regional variations in peak wall stress throughout the entire aneurysm wall. Initial studies assumed that AAAs had uniform wall thickness and material isotropy (uniform strength in all orientations), but several studies show this is not the case and that there are localized “hot spots” of matrix metalloproteinases activity that are variable and depending on wall thickness, stiffness, and regional heterogeneity could cause focal weakening of the aneurysm and rupture at relatively low levels

of intraluminal pressure. Matrix metalloproteinases (MMPs) are a family of 28 endopeptidases that comprise collagenases, gelatinases and stromelysins. They degrade extracellular tissues, cleave cell surface receptors and are involved in tissue remodeling. They are inhibited by four endogenous tissue proteins called Tissue Inhibitors of Metalloproteinases (TIMPs). ILT contains high levels of matrix metalloproteinase 2 and 9 and trapped neutrophils rich in matrix metalloproteinase-9 and Neutrophils Gelatinase Associated Lipocalin, which neutralizes the defensive actions of tissue inhibitor metalloproteinases. An autopsy study of 78 patients who died from ruptured infrarenal AAAs showed 80% of ruptures occurred at the site of mural thrombus.

CLINICAL PRESENTATION

The “classic” presentation for a patient with a ruptured AAA is a male patient over the age of 60 years complaining of acute onset abdominal and back pain. Back pain is severe and unremitting and caused by rupture of the aneurysm into the retroperitoneal space. Patients may describe pain to be nonspecific and present anywhere in the torso with our without radiation to the flank or testes. On examination, the patient is usually pale, diaphoretic and hypotensive with a tender, pulsatile abdominal mass. A patient with a known history of AAA that presents with hypotension and abdominal and/or back pain should be considered to have a ruptured AAA until proven otherwise. A rapid, accurate history and examination are critical. The differential diagnosis may include renal colic, diverticulitis, pancreatitis, gastrointestinal hemorrhage, inferior myocardial infarction, and perforated ulcer. Although the signs and symptoms of ruptured AAA can be clear-cut, in the early stages it may be difficult to recognize. Many patients will initially have relatively normal blood pressure on arrival into the Emergency Room, following fluid resuscitation en route. Some may give a history of pain extending over the course of 3 to 4 days, as the ruptured AAA has bled, sealed, and then bled again. In the affected age group, chronic back problems are common, so the physician may be tempted to ascribe symptoms to an exacerbation of a long-standing problem. The other misdiagnosis is to confuse the presentation with ureteral colic. Symptoms may be incorrectly attributed to acute diverticulitis or a perforated duodenal ulcer, particularly in presence of leukocytosis.

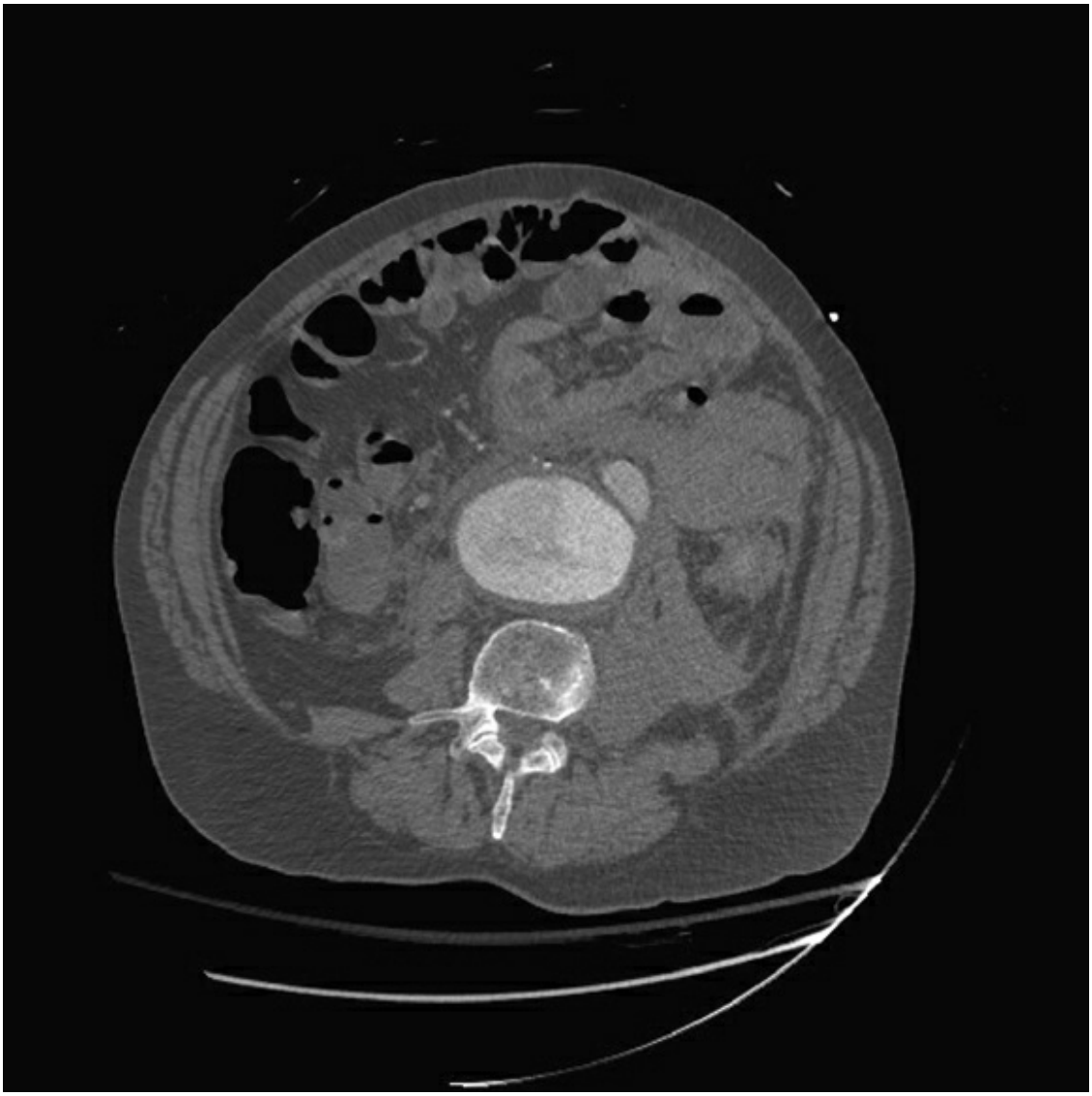

Figure 201.1. Ruptured AAA with extravasation outside aneurysm sac.

Plain radiography is now less frequently performed than ultrasound or CT in patients with abdominal pain. However, if the aortic wall is sufficiently calcified, an aneurysm not otherwise suspected can be identified on radiographs. The introduction of bedside ultrasound in the emergency department and training of emergency physicians in its application for trauma have led to its use for imaging of the abdominal aorta in cases of suspected rupture. Focused assessment with sonography in trauma (FAST) ultrasound protocols can rapidly identify fluid collections, evaluate aortic diameter, and diagnose ruptured AAA, FAST, however, has a limitation in that it cannot be used to exclude ruptured AAA, and further computed tomography imaging is often necessary.

The most accurate method of diagnosing ruptured AAA is CT, which

also provides important information about associated abnormalities and conditions. A non–contrast-enhanced CT scan can identify retroperitoneal hemorrhage associated with a ruptured AAA and can also provide important anatomic information (Fig. 201.1). CT scanning with contrast enhancement is required for ideal planning of ruptured AAA repair with commercially available stent-graft devices for the same reasons that it is required for elective repair. Pre-existing renal insufficiency or contrast allergy might pose limitations in obtaining an appropriate CT and these factors need to be considered on an individual basis for optimum patient care.

INITIAL MANAGEMENT AND TRIAGE

Patients with ruptured AAA are at imminent for death and require immediate vascular surgery evaluation. Hospitals that lack vascular surgery expertise and cannot offer definitive treatments should consider establishing networks with larger institutions that have vascular surgery services and can offer repair by endovascular or open surgical means, as needed. The impact of transferring ruptured AAA patients to regional centers where repair can be carried out by experienced vascular teams has been studied. Rural hospitals without vascular surgery expertise tend to face a higher burden of ruptured AAA patients and national trends suggest they are more likely to transfer patient to regional centers. Although patient transfer might increase the time of arrival from the initial hospital to the operating room, the vast majority of studies suggest that high volume regional centers significantly lower the mortality for ruptured AAA patients. Furthermore, as US nationwide trends suggest increased utilization of EVAR for ruptured AAA, it is likely that regionalization of patient care will significantly impact management of ruptured AAA patients.

Preoperative resuscitation of ruptured AAA patients with hypotension must be judicious. Aggressive resuscitation with large volumes of intravenous fluids, and the resultant elevation in blood pressure can lead to further hemorrhage by overcoming the tamponade that stabilized the initial rupture. It further results in hemodilution, coagulopathy, hypothermia, and acidosis; all factors having a further deleterious cascade. Similar to transfusion protocols that restrict aggressive fluid resuscitation in hypotensive trauma patients with hemorrhagic shock, permissive hypotension for ruptured AAA patients in which resuscitation is

minimized to maintain consciousness, prevent ST depression, and usually keep the systolic pressures of 70 to 80 mm Hg are recommended. A balance should be achieved between organ ischemia from inadequate resuscitation versus the risk of rebleeding from overaggressive resuscitation. Currently, evidence regarding resuscitation with blood versus crystalloids is limited, and if blood is available, without delays in patient transfer, it should accompany the patient and can be given instead of crystalloids solutions to maintain consciousness.

ENDOVASCULAR REPAIR OF RUPTURED AAA

The evolution of endovascular aneurysm repair (EVAR) has led to improvements in our ability to treat AAAs in elective as well as in emergent circumstances when patients present with rupture. The implications of improvements in our technical ability to offer EVAR to patients presenting emergently with ruptured AAA are significant: to date, no other therapy has offered such a survival advantage to these high-risk patients presenting with ruptured AAA. When considering these endovascular techniques for treating ruptured AAA, one has to prepare for the challenges of streamlining patient care from the emergency room to the operating room and the subsequent endovascular procedure that often requires a multidisciplinary approach and a change in paradigm and local cultures. This article will focus on a comprehensive and standardized technical approach for treating ruptured AAA by endovascular means that can maximize our ability to offer this treatment of ruptured AAA to most patients.

The metamorphosis of ruptured AAA treatment from open surgical repair to EVAR has evolved significantly over the past two decades. Since its first report by Yusuf in 1994, ruptured EVAR has evolved from being performed selectively by a few centers in hemodynamically stable patients only to being performed by most endovascular specialists in many centers in patients with varying degrees of hemodynamic instability. Collectively, worldwide experience demonstrates that an increasing number of ruptured AAA are being treated by EVAR. The endovascular approach is less invasive, eliminates laparotomy, eliminates aortic cross clamping, decreases surgical bleeding, and possibly general anesthesia, and has been shown to decrease the mortality of ruptured AAA repair with fewer complications, shorter hospital length of stay, and more patients being able to return home rather than going to institutional care after these emergent

procedures. It is of critical importance when evaluating the evidence in favor of or against of ruptured EVAR is an understanding of the context in which the ruptured AAA patients were treated; the underlying patient selection, and the local, regional, and national influences in offering endovascular treatments to ruptured AAA patients.

Data on 4,972 patients with ruptured aneurysms from 1994 to 2010 were reviewed and showed a decline in mortality from 38% to 28%, which was credited to the introduction of EVAR. The most ambitious review of population data was by Mani et al. using the Vascunet database. In 2011, they collated outcomes for ruptured AAA repair in 7,040 patients from national and regional registries in nine countries (Australia, Denmark, Finland, Hungary, Italy, Norway, Sweden, Switzerland, and the United Kingdom). The overall mortality rate was 31.6%, but it declined by 4.2% between 2005 and 2009. This was again attributed to more liberal use of EVAR. The high postoperative mortality rates after aortic rupture are secondary to a high incidence of myocardial infarction, renal failure, and multiple organ failure. Aortic rupture and open surgical repair result in a combination of ischemia–reperfusion injuries, hemorrhagic shock, and lower torso ischemia. The synergistic effect of the total-body ischemia caused by hemorrhagic shock and the lower torso ischemia that occurs during repair, followed by reperfusion secondary to resuscitation and aortic unclamping, has been proposed to explain the high incidence of multiple organ failure and mortality after repair. This hypothesis is supported by data from both animal experimentation and human clinical studies. The application of ruptured EVAR reduces the operative and ischemic insult in two ways. First, it avoids a laparotomy, thus reducing the potential for iatrogenic arterial and venous operative injuries and their associated blood loss. Second, it minimizes the duration and severity of the lower torso ischemic insult. Recent data from large administrative databases in the United States have demonstrated increased application of EVAR to ruptured AAA.

THE FUNDAMENTALS OF RUPTURE EVAR

Introduction of EVAR for ruptured AAA has forced us to reevaluate protocols that facilitate expeditious patient transfer to the operating rooms for EVAR or open surgical repair. Today, the question is not whether patients with ruptured AAA should undergo EVAR, rather how to develop systems that allow for broader utilization of these complex procedures that

have shown great benefit in high risk patients with aneurysm rupture. There remain several fundamental concerns regarding EVAR for ruptured AAA that include anatomical suitability for EVAR, the availability of dedicated staff and equipment to perform emergent EVAR at all hours, feasibility of treating hemodynamically stable and unstable patients by EVAR, and the surgeon/interventionists ability to manage unexpected scenarios under emergent circumstances. Many of the high-volume institutions have adopted a standardized protocol-based approach that includes a heightened awareness among the ER staff to suspect the diagnosis of ruptured AAA and notify the on-call vascular surgeon and the operating room staff. In the emergency room, hemodynamically stable patients undergo expeditious CT scan and are subsequently transferred to the operating room, and hemodynamically unstable patients are directly transferred to the operating room without a preoperative CT scan for endovascular-first approach and conversion to open surgical repair as needed. Thin-slice CT with contrast enhancement can be accomplished with lower volumes of contrast agent to assess neck diameter, angulation, and iliac size.

Operating Room Setup: Since not all patients with ruptured AAA can undergo ruptured EVAR, all operating room/hybrid endovascular-operating room suits should be setup to facilitate ruptured EVAR as well as open surgical repair. Depending on the size of the room and the fluoroscopic equipment which can be fixed or portable with viewing screens and power injectors, one has to customize the layout of the operating room suite that is conducive for ruptured EVAR and ruptured open surgical repair; it is best to setup the room for endovascular repair with standard needles, wires, catheters, and sheaths open on a sterile table, have the surgical instruments in the room if needed, situate the patient on the operating room table, and as the anesthesiology team prepares the patient setup the fluoroscopic equipment and supplies.

ENDOVASCULAR SETUP AND TECHNIQUES

Adequate resuscitation of patients with ruptured AAA is vital to a successful outcome. As long as the patients maintain a measurable blood pressure, the techniques of “permissive hypotension” by limiting the resuscitation to maintain a detectable blood pressure can help minimize ongoing hemorrhage. The patient is prepped and draped in supine position and via a percutaneous (preferable) or femoral artery cut-down ipsilateral

access is obtained using a needle, floppy guidewire, and a guiding catheter. The floppy guidewire is exchanged for a super-stiff wire that can be used to place a large sheath (12 to 14 Fr × 45 cm length) in the ipsilateral femoral artery and the sheath advanced up to the juxtarenal abdominal aorta so it is ready to be used to deliver and support the aortic occlusion balloon if needed. A compliant occlusion balloon should always be available in these procedures, and in hemodynamically unstable patients, the occlusion balloon is advanced through the ipsilateral sheath over the super-stiff wire into the supraceliac abdominal aorta under fluoroscopic guidance, and the balloon is inflated as needed. Contralateral femoral access is subsequently obtained via percutaneous (preferable) or cut-down approach in a similar fashion, and a “marker flush-catheter” advanced to the juxtarenal aorta for an arteriogram.

The placement of the stent graft main body is planned based on the aortoiliac morphology that is best suited for EVAR. Unless prohibitive, in hemodynamically stable patients, following the initial arteriogram, the aortic occlusion balloon is removed from the initial ipsilateral side and the stent graft main body advanced under fluoroscopic guidance; this limits the number of catheter exchanges. In hemodynamically unstable patients that require inflation of the aortic occlusion balloon, the “marker flush-catheter” is exchanged for the stent graft main body, which is delivered up to the aortic neck. An arteriogram is done via the sheath that is used to support the aortic occlusion balloon, the tip of the stent graft main body is aligned with the lowermost renal artery, the occlusion balloon is subsequently deflated and withdrawn back with the delivery sheath into the ruptured AAA, and the stent graft main body deployed. The remainder of the ruptured EVAR procedure is performed similar to as in elective circumstances: (1) the tip of the stent graft main body aligned with the lowermost renal artery; (2) the contralateral gate aligned to facilitate expeditious “gate-cannulation”; (3) and the ipsilateral and contralateral iliac extensions planned and deployed as needed.

There are several important technical aspects that merit discussion, including: (1) availability of preoperative CT, (2) anatomic suitability for EVAR, (3) choice of anesthesia and percutaneous versus femoral cut-down approach, (4) aortic occlusion balloons, (5) bifurcated versus aorto-uni-iliac stentgrafts, (6) abdominal compartment syndrome, (7) and conversion to open surgical repair.

Availability of Preoperative CT Scan

The hemodynamic status of the ruptured AAA patient generally dictates the need for a preoperative CT scan, and although while planning for this emergent open surgical repair a preoperative CT is not considered a necessity, while planning an emergent ruptured EVAR, most would agree that we would like to have a CT scan for evaluating the feasibility of ruptured EVAR as well as for stent graft sizing. Therefore, the question is whether one has the time to get an emergent CT scan prior to ruptured EVAR, and if not are there other tools available that might help us manage these hemodynamically unstable patients by endovascular means? Published data on the feasibility of preoperative CT in patient with ruptured AAA would indicated that 88% (49 of 56) patients died >2 hours after admission with the diagnosis of ruptured AAA, the median time interval from the onset of symptoms to admission to the hospital was 2.5 hours, and the interval between hospital admission with the diagnosis of ruptured AAA and death was 10.5 hours. This data would clearly suggest that majority of patients with ruptured AAA have the time to undergo an emergent CT scan, particularly if there is an established protocol that facilitates early diagnosis and transfer of patient from the emergency room to the operating room.

Anatomic Suitability for EVAR

The proportion of ruptured AAA patients that are suitable for ruptured EVAR is variable and on the basis of two meta-analysis ranges from 47% to 67%. It has also been reported is that when compared to elective AAA, ruptured AAA patients have larger infrarenal aortic diameters and shorter aortic neck lengths. These differences in AAA morphology likely have an affect the ability to perform EVAR, and it is likely that institutions that treat a higher proportion of ruptured AAA by EVAR expand on the stent grafts indications for use of these high-risk patients. Several institutions including ours have tried to identify the impact of ruptured EVAR in patients with favorable versus unfavorable aortic neck morphology. Mehta and colleagues analyzed aortic neck morphology via CT scans in 180 consecutive patients with ruptured AAA that underwent ruptured EVAR (74, 41%) or ruptured open surgical repair (106, 59%). Based on EVAR device specific favorable versus hostile aortic neck morphology, we identified that only 34% of patients with ruptured AAA had neck morphology that would meet the “indication for use” for available stent

grafts. The ruptured EVAR patients with hostile aortic necks had a significantly higher incidence of female gender (32% vs. 19%, $p < 0.01$), mean maximum AAA diameter (7.4 cm vs. 5.5 cm, $p < 0.01$), abdominal compartment syndrome (20% vs. 4%, $p < 0.01$), Type I endoleaks (16% vs. 4%), and the need for all secondary interventions (77% vs. 40%, $p < 0.01$) during long term follow-up. The 30-day mortality was the lowest in ruptured EVAR patients with favorable aortic necks and the highest in the open surgical repair patients (favorable 8%; hostile 23%; ruptured open surgical repair 43.4%; $p < 0.01$), and both favorable and hostile ruptured EVAR patients had a better cumulative 3-year survival than ruptured open surgical repair (favorable 64%, hostile 67%, ruptured surgical repair 44%, $p < 0.01$).

Choice of Anesthesia and Approach

Depending on one's comfort level and the logistics, ruptured EVAR can be performed under local anesthesia via percutaneous approach to general anesthesia and femoral artery cut-down. The potential benefits of local anesthesia/conscious sedation and percutaneous approach is that it might avoid the loss of "sympathetic-tone" in the compromised ruptured AAA patients. One has to be comfortable with obtaining percutaneous access and using closure devices in patients that might be hemodynamic unstable with difficult to palpate femoral pulses. Although the advantage may be significant, it must be balanced by the potential difficulties encountered during these emergent procedures, as the patient might not be coherent and co-operative enough to lie still. Furthermore, to optimize time management, particularly in hemodynamically unstable patients, some have suggested to start the procedure under local anesthesia, obtain percutaneous access, position the aortic occlusion balloon as needed, perform ruptured EVAR, and following ruptured AAA exclusion induce general anesthesia and remove femoral sheaths via femoral cut-down. Others have recommended total percutaneous approach with local anesthesia and conscious sedation.

Aortic Occlusion Balloon

The appropriate use of aortic occlusion balloons is hemodynamically unstable patients is vital to the success of ruptured EVAR. Access for aortic occlusion balloons can be obtained via the brachial or the femoral artery. There are several advantages of the femoral approach: (1) it allows

the anesthesia team to have access to both upper extremities for arterial and venous access, (2) the patients who require the aortic occlusion balloon are often hypotensive and, in these patients, percutaneous brachial access can be more cumbersome and time consuming than femoral cut-down, and (3) the currently available aortic occlusion balloons require at least a 12- to 14-Fr sheath, which requires a brachial artery cut-down and repair, and stiff wires and catheters across the aortic arch without prior imaging under emergent circumstances might lead to other arterial injuries and/or embolization causing stroke. Occlusion balloons are composed of compliant materials such as polyurethane latex, or silicone, and have low burst pressures of <5 atm. Their primary function if not angioplasty, but molding to the surrounding with gentle inflation and function in capacity of obtaining proximal aortic occlusion during ruptured EVAR.

Several important points should be considered during placement of the aortic occlusion balloon. The sheath supporting the balloon should be advanced and supported fully into the aortic neck prior to inflation of the occlusion balloon, as this will prevent downward displacement and prolapse of the occlusion balloon into the AAA (Fig. 201.2). Inability to fully engage the sheath into the aortic neck due to the presence of significant aortoiliac stenosis, calcifications, or tortuosity might result in downward displacement of the inflated occlusion balloon; this often required forward traction on the inflated balloon catheter to maintain adequate position at the suprarenal/supraceliac aorta. If inflation of the aortic balloon is required to maintain a viable blood pressure, just prior to deployment of the stent graft main body, the aortic occlusion balloon should be deflated from the suprarenal level and withdrawn. The stent graft main body is subsequently deployed; this will avoid trapping the compliant aortic occlusion balloon between the aortic neck and the stent graft. This temporary deflation of the aortic occlusion balloon rarely results in hemodynamic collapse and usually is of little consequence. In hemodynamically unstable patients, the occlusion balloon can be redirected into the aortic neck from the side ipsilateral to the stent graft main body and reinflated at the infrarenal aortic neck within the stent graft main body; this allows for aortic occlusion and does not interfere with the remainder of the endovascular procedure (Fig. 201.3A–E).

Bifurcated versus Aorto-Uni-Iliac Stent Grafts for Ruptured AAA

The decision to use a particular stent graft type is determined by the

patient’s aorto-iliac morphology, and there are several factors to consider regarding the use bifurcated versus aorto-uni-iliac stent grafts for ruptured AAA: (1) inability to access the contralateral gate expeditiously, and (2) inability to access the contralateral iliac artery due to significant occlusive disease and/or tortuosity. The use of aorto-uni-iliac devices during elective or emergent EVAR does require interruption of flow from the contralateral common iliac artery into the AAA via a placement of an occluder device, and a femoral–femoral bypass. Several studies have documented the use of aorto-uni-iliac devices for ruptured EVAR with outcomes similar to the use of bifurcated stent grafts. It is likely that use of aorto-uni-iliac devices might expand on the applicability for ruptured EVAR.

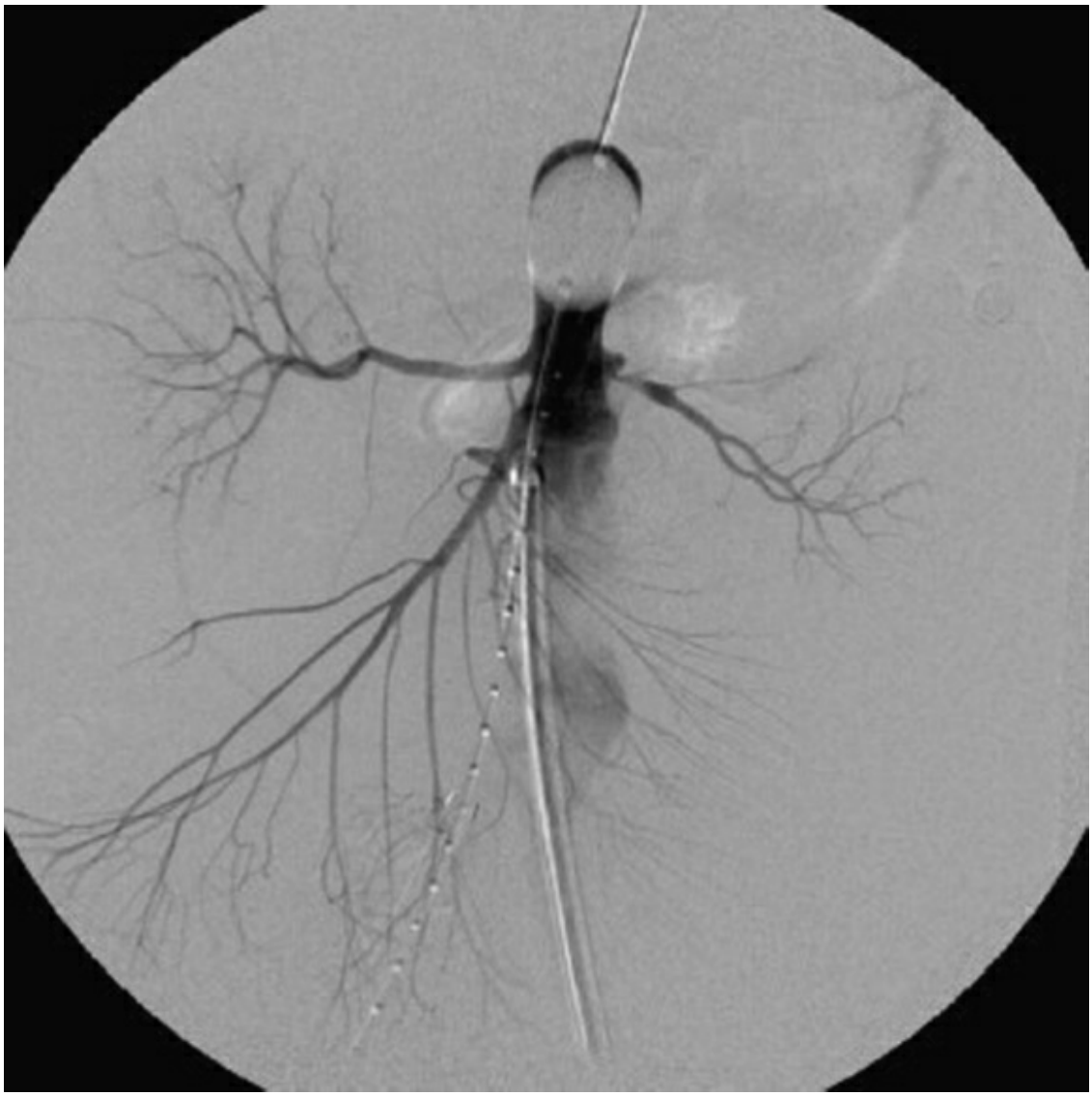

Figure 201.2. The sheath supporting the aortic occlusion balloon should be advanced and supported fully into the aortic neck to prevent downward displacement and prolapse of the occlusion

balloon into the abdominal aortic aneurysm. (From Mehta M. Endovascular aneurysm repair for ruptured abdominal aortic aneurysm: the Albany Vascular Group approach. *J Vasc Surg* 2010;52(6):1706–12; with permission from Elsevier.)

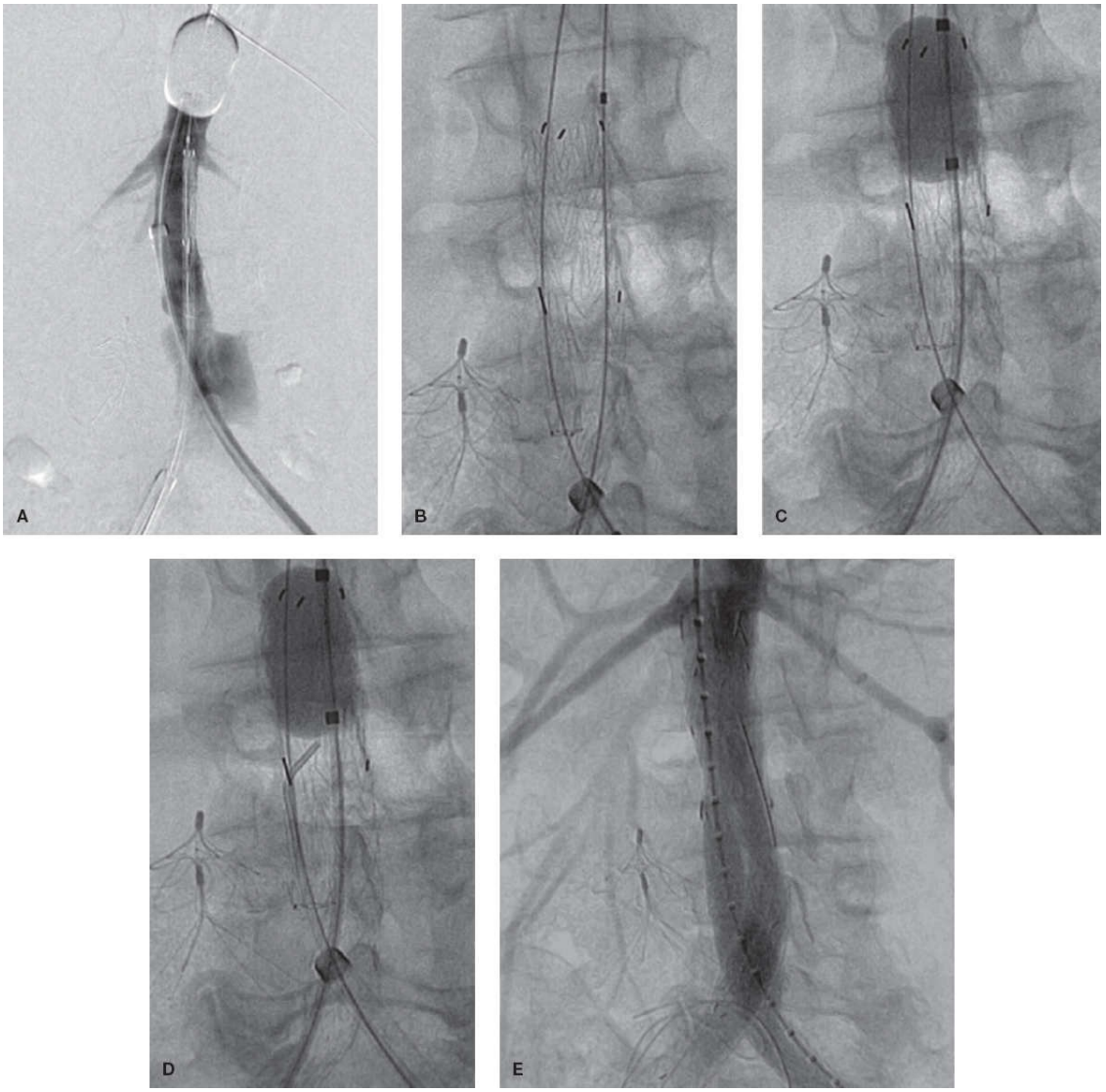

Figure 201.3. A–E. Managing the aortic occlusion balloon during stent graft deployment. **A.** The inflated suprarenal aortic occlusion balloon is advanced through the left femoral approach, the stent graft main body is advanced through the right femoral approach, and the arteriogram is done through the left femoral sheath supporting the occlusion balloon. **B.** The aortic occlusion balloon is deflated and retracted back from the aortic neck, and the stent graft main body is subsequently deployed. This avoids trapping of the compliant aortic occlusion balloon between the aortic neck and the stent graft. **C.** In hemodynamically unstable patients, the occlusion balloon can be redirected into the aortic neck from the side ipsilateral to the stent graft main body and reinflated at the infrarenal aortic neck within the stent graft main body before contralateral gate cannulation. **D.** After the occlusion balloon is reinflated in the stent graft main body in hemodynamically unstable patients, the contralateral stent graft gate can be cannulated and contralateral stent graft extensions

are placed as needed. **E.** After contralateral iliac extension and ruptured abdominal aortic aneurysm exclusion, the occlusion balloon can be removed, as shown in the completion arteriogram. (From Mehta M. Endovascular aneurysm repair for ruptured abdominal aortic aneurysm: the Albany Vascular Group approach. *J Vasc Surg* 2010;52(6):1706–12; with permission from Elsevier.)

Assessing for Abdominal Compartment Syndrome

With increasing use of endovascular techniques for treating ruptured AAA, there is an increased recognition of new complications, such as intra-abdominal hypertension and abdominal compartment syndrome. Intra-abdominal hypertension is graded on the basis of bladder pressures; Grade I (10 to 15 mm Hg), Grade II (16 to 25 mm Hg), Grade III (26 to 35 mm Hg), and Grade IV (>35 mm Hg). Abdominal compartment syndrome is defined as an acute and rapid elevation in intra-abdominal pressure of greater than 20 mm Hg that is associated with cardiovascular, pulmonary, renal, and splanchnic organ dysfunction. Decompression laparotomy and resuscitation is recommended for Grade III and IV intra-abdominal hypertension. Bladder pressure is reflective of intra-abdominal pressure when the bladder volume is between 50 and 100 mL. To measure this pressure, the bladder is drained and then filled with 50 to 100 mL of sterile saline. The drainage tubing is clamped beyond the aspiration port, and a needle is inserted to the aspiration port and connected to the pressure transducer. The transducer is zeroed at the pubic symphysis.

The presenting signs and symptoms include tense distended abdomen, respiratory failure (elevated peek inspiratory pressures, decreased tidal volume, and elevated Pco_2), diminished cardiac output, and oliguria. The pathophysiology of abdominal compartment syndrome after ruptured EVAR is multifactorial: (1) the retroperitoneal hematoma is a space-occupying lesion and a significant factor contributing to intra-abdominal hypertension, (2) ongoing bleeding from lumbar and inferior mesenteric arteries into the disrupted aneurysm sac in the setting of severe coagulopathy might be a contributing factor, and (3) the shock state associated with ruptured AAA is associated with alterations in microvascular permeability that can lead to visceral and soft tissue edema. Patients with abdominal compartment syndrome following ruptured EVAR have increased mortality of >50%, and factors such as the need for aortic occlusion balloon, need for massive blood transfusions,

coagulopathy, and hemodynamic instability have been implicated with increased risk for abdominal compartment syndrome following ruptured EVAR. Abdominal compartment syndrome requires prompt recognition and treatment, which includes decompression laparotomy.

Conversion to Open Surgical Repair

Regardless of all the improvements in endovascular techniques there are times when on-table conversion to open surgical repair is needed and this approach should be in the armamentarium of all surgeons involved in treating ruptured AAA patients. When on-table surgical conversion is needed, the use of aortic occlusion balloon can be extremely valuable in maintaining hemodynamic stability; the techniques of aortic occlusion balloon have been discussed above. In addition, during the time of laparotomy and open surgical conversion it is crucial to maintain the position of the aortic occlusion balloon and its delivery sheath; failure to do so might result in aortic occlusion balloon prolapse into the ruptured AAA and loss of aortic occlusion. If open surgical conversion is needed subsequent to stent graft deployment, the exact approach should be tailored to the type of stentgraft, the type of proximal and distal fixation including suprarenal versus infrarenal stents and barbs.

EVIDENCE FOR RUPTURED EVAR

Worldwide, more ruptured AAA are now treated by ruptured EVAR. The endovascular approach is less invasive and, in some reports, decreases mortality. The following studies summarize the results of ruptured EVAR compared with ruptured open surgical repair in the management of ruptured AAA.

Mehta et al. have documented the largest single-center experience in comparing ruptured EVAR with ruptured open surgical repair for ruptured AAA. In this prospectively collected data set on an intention-to-treat basis, 283 patients with ruptured AAA underwent EVAR (120, 42%) or open surgical repair (163, 58%); outcomes were evaluated by a logistic regression multivariable model and Kaplan-Meier analysis. The ruptured EVAR patients had a significantly lower 30-day mortality than that of the ruptured open surgical repair patients (24% vs. 44%; $P < 0.005$) and better cumulative 5-year survival (37% vs. 26%; $P < 0.005$). Men benefited more from ruptured EVAR (mortality: 21% for EVAR vs. 44% for open surgical repair; $P < 0.001$) than did women (mortality: 32% vs. 44%; $P = 0.39$). Age

older than 80 years was a significant predictor of death for ruptured EVAR (odds ratio [OR], 1.07; $P = 0.003$) but not for ruptured open surgical repair (OR, 1.04; $P = 0.056$). The odds for 30-day mortality in the ruptured open surgical repair patients were 2.48 times the odds in the ruptured EVAR group (95% CI, 1.48–4.18; $P = 0.001$). A multivariate logistic regression analysis indicated that ruptured open surgical repair; age, aneurysm size, and hypertension significantly increased the 30-day mortality. During long-term follow-up, we found that 23% of ruptured EVAR patients required further intervention; 57% of secondary procedures were performed for type II endoleaks, and 3.3% were emergent conversion to ruptured open surgical repair. Last, Kaplan–Meier life-table analysis of survival showed that the overall cumulative survival curves were significantly better in the ruptured EVAR group at 5 years.

Many centers have developed a standardized protocol for ruptured AAA patients, which emphasize use of ruptured EVAR. This has been demonstrated to improve outcomes compared with open surgical repair. Today, many centers have developed protocols for rapid transfer of a ruptured AAA patient from the emergency department to the operating room for ruptured EVAR. Although procedures vary from one institution to another, the fundamentals are simple: early diagnosis of ruptured AAA, an expeditious CT scan to evaluate the aortoiliac morphology, and rapid transfer to an operating room that is equipped to perform ruptured EVAR as well as ruptured open surgical repair. This allows patients who are hemodynamically unstable to be offered ruptured EVAR. The patient's hemodynamic status has been shown to affect the outcomes of ruptured EVAR and ruptured open surgical repair of ruptured AAA. A study from Mehta et al. comparing hemodynamically stable versus unstable ruptured EVAR patients reported notable differences between the groups; hemodynamically unstable patients needed an aortic occlusion balloon more often (41% vs. 5%), lost more blood (744 mL vs. 363 mL), developed compartment syndrome more frequently (29% vs. 4%), and had higher mortality (33% vs. 18%).

An Italian study reported similar findings in comparing hemodynamically stable versus unstable patients with ruptured AAA; the 30-day mortality for hemodynamically stable patients was significantly lower for ruptured EVAR than for ruptured open surgical repair (EVAR, 11% vs. 53%; open surgical repair, 21% vs. 61%). A meta-analysis of observational studies also indicated that the use of standardized algorithms

for managing ruptured EVAR patients was a surrogate marker for improved outcomes; mortality was significantly lower in studies reporting a standardized algorithm compared with those without (18% vs. 32%).

In a multicenter study, authors from the University Hospital of Zurich and Örebro reported their combined 14-year experience of ruptured EVAR and ruptured open surgical repair to address the impact of complete replacement of ruptured open surgical repair for ruptured AAA by ruptured EVAR. Mayer et al. retrospectively evaluated their data during two time periods: during the initial period (1998 to 2009), all ruptured AAA patients were offered ruptured EVAR and ruptured open surgical repair; during the later period (2009 to 2011), all patients were offered ruptured EVAR only. Their overall results indicated a significantly lower 30-day mortality for ruptured EVAR compared with ruptured open surgical repair (17.9% vs. 37.4%; OR, 3.3; 95% CI, 1.4–7.5; $P = 0.004$). Similar 30-day mortality was observed during the period when ruptured EVAR and ruptured open surgical repair were offered (25.5%) and in the later period when only ruptured EVAR was offered (24.3%). However, with the transition to the ruptured EVAR-only period, the overall 30-day mortality of ruptured EVAR increased at both institutions from 10.8% to 24.3% as during this time there was increased use of ruptured EVAR for challenging cases, increased use of adjunctive procedures, and decreased turndown rate from 10% to 4%. The study limitations were that the authors did not analyze outcomes in the 24.3% of ruptured EVAR patients who required secondary procedures, which might have resulted in a higher mortality. Therefore, the ruptured EVAR-only approach for all ruptured AAA will require more secondary procedures and increase the ruptured EVAR mortality, and surgeons need to offer both ruptured EVAR and ruptured open surgical repair to optimize patient outcomes.

Large administrative databases such as the U.S. Nationwide Inpatient Sample and the U.S. Centers for Medicare and Medicaid have the advantage of examining large patient populations over time. Data from the Nationwide Inpatient Sample show EVAR use has significantly increased over time (5.9% in 2001 to 18.9% in 2006). Independent predictors for the use of ruptured EVAR in managing ruptured AAA patients include high institution elective ruptured EVAR volume, treatment at a teaching institution, and advanced age of the patient. More recent data published on U.S. Medicare beneficiaries in 2014 indicated that by 2008, the proportion of ruptured AAA treated by ruptured EVAR had increased to 31%.

A report on the U.S. National Surgical Quality Improvement Program database that collectively evaluated 427 ruptured AAA patients from 2005 to 2007 who underwent either ruptured EVAR (23%) or ruptured open surgical repair (77%) indicated that ruptured open surgical repair was associated with a significantly higher 30-day mortality (OR, 1.9; P = 0.006) compared with ruptured EVAR. Furthermore, in a recent population outcome analysis in England, ruptured EVAR was performed in 7.6% of 4,414 ruptured AAA repairs; a propensity scored analysis indicated that ruptured EVAR was associated with a significant reduction in mortality and offered a survival advantage compared with ruptured open surgical repair (OR, 0.527; $P < 0.001$).

Several meta-analyses and a Cochrane review have been published on ruptured EVAR to determine whether this therapy reduces mortality of ruptured AAA. A meta-analysis of 23 published studies on ruptured EVAR versus ruptured open surgical repair analyzed outcomes in 7,040 patients who underwent ruptured EVAR (N = 730, 10%) or ruptured open surgical repair (N = 6,310, 90%). The findings indicated that ruptured EVAR was associated with a significant reduction in 30-day mortality and operative duration; mean intensive care unit length of stay was lowered by 4 days and mean hospital length of stay by 9 days.

Several randomized trials have evaluated the efficacy of ruptured EVAR have been completed to date. The Dutch multicenter randomized trial, which evaluated death and severe complications as its primary endpoints. The Dutch trial findings indicate that death and severe complications occur in 42% of patients after ruptured EVAR and in 47% after ruptured open surgical repair, which was not significantly different. The Dutch trial was conceived in 2003 and randomized 116 patients during a nearly 8-year period. In this period, 520 patients were enrolled in the trial. Of the 520 patients, 395 (76%) were evaluated by CT scan, of which 240 (61%) were found to have unfavorable anatomy for ruptured EVAR and were excluded. Another 39 (10%) patients were excluded for a variety of reasons. The remaining 116 (22%) patients were randomized to ruptured EVAR or open surgical repair. For a prospective randomized multicenter trial, this trial had a significant patient selection bias, rendering its outcomes questionable in the real-world scenario. The Dutch trial also reported ruptured EVAR mortality of 21% versus ruptured open surgical repair mortality of only 25%. Although this ruptured EVAR mortality was comparable to what is reported in the literature, the ruptured open surgical

repair mortality was remarkably lower than what has historically been reported.

The latest randomized trials, IMPROVE (Immediate Management of the Patient with Rupture: Open Versus Endovascular Repair), compares ruptured EVAR versus ruptured open surgical repair in a heterogeneous group of patients with a primary focus on comparing endovascular-first to open surgical–first strategies; the investigators randomized 613 ruptured AAA patients to ruptured EVAR (n = 316) and ruptured open surgical repair (n = 297) over a 4-year period. The study indicated that overall ruptured EVAR mortality was 35%, and ruptured open surgical repair mortality was 37%, and hence ruptured EVAR first strategy is comparable to ruptured open surgical repair first strategy. This was further interpreted as if the 2 therapies were comparable in managing ruptured AAA patients. The problem with IMPROVE's trial design was that it did not answer the fundamental question of how ruptured EVAR compare to ruptured open surgical repair in patients with ruptured AAA when ruptured EVAR is possible? A detailed data analysis indicated that of the 316 ruptured AAA patients that were randomized for ruptured EVAR, only 59% received ruptured EVAR and 41% were crossed-over and received ruptured open surgical repair; regardless of the treatment received, the overall mortality of 35% was assigned to ruptured EVAR cohort. Similarly of the 297 ruptured AAA patients that were randomized for ruptured open surgical repair, 84% had ruptured open surgical repair and 16% were crossed-over and received ruptured EVAR; regardless of the treatment received, the overall mortality of 37% was assigned to ruptured open surgical repair cohort and hence no difference was noted in the two groups. If the data were evaluated on the basis of the treatment received, and not which arm the patients initially randomized to, the ruptured EVAR mortality would be significantly lower at 26%, when compared to the ruptured open surgical repair mortality of 43%. The IMPROVE trial confirmed that ruptured EVAR offers survival advantage to ruptured AAA patients that are considered suitable for endovascular therapy.

SECONDARY INTERVENTIONS

Late reinterventions occur after both ruptured EVAR and ruptured open surgical repair. In recent series reporting concurrent ruptured open surgical repair and ruptured EVAR, rates of surgical reintervention ranged from 10% to 28% for ruptured open surgical repair cases versus 19% to 23% for

ruptured EVAR cases. After ruptured EVAR, reinterventions were required for endoleaks, stent-graft migration, limb thrombosis, infection, and rupture; those following ruptured open surgical repair included exploration for bleeding, bowel obstruction, ischemia, and hernia repair. To date, the only report on long-term follow-up after ruptured EVAR in 120 patients indicates that among 91 survivors, late interventions for graft-related complications were performed in 21 patients (23%). Of all secondary interventions collectively, the etiology included type I endoleaks (14.3%), type II endoleaks (57.1%), proximal stent-graft extensions for migration (9.5%), femoral–femoral bypass for limb thrombosis (9.5%), and stent-graft explant for infection (9.5%) during a mean follow-up of 34 months.

RUPTURE AFTER EVAR

The goal of ruptured AAA repair is to reduce the risks for aneurysm rupture and death. However, none of the currently available stent-grafts is completely effective in preventing aneurysm rupture after ruptured EVAR, and lifelong surveillance is needed. We evaluated our experience of delayed AAA rupture after EVAR and found that the most common risk factors contributing to rupture included type I endoleaks with stent-graft migration (63%), type I endoleaks without stent-graft migration (11%), type II endoleaks (19%), and undetermined etiology (7%). In this series, 41% of patients with ruptured AAA after EVAR underwent another secondary EVAR procedure with an operative mortality of 9%, whereas 55% required conversion to open surgical repair with an operative mortality of 20%. Data from 1,442 EVAR 1 and 2 trial patients indicate that after EVAR, complications of type I endoleaks, type II endoleaks with aneurysm sac expansion, type II endoleaks, and stent-graft migration significantly increase the risks for aneurysm rupture (adjusted hazard ratio, 8.8 [95% CI, 3.76–20.76]; $P < 0.0001$). Interestingly, several studies have suggested that an existing stent-graft might provide hemodynamic stability when aneurysms rupture after an elective EVAR due to endoleaks, which might be responsible for reduced mortality in patients with ruptured aneurysm with prior EVAR.

Open Surgical Repair of Ruptured AAA

The first priority in the management of ruptured AAA regardless of approach is proximal aortic control. The two choices for open surgical

exposure are retroperitoneal and transperitoneal. The authors' preference for open repair of ruptured abdominal aneurysm is the extended left retroperitoneal approach. The rationale is as follows. First, the aorta is a retroperitoneal structure. There is therefore no need to directly manipulate or avoid bowel or other intraperitoneal structures in order to expose the aorta. Second, exposure of the entire abdominal aorta from the level of the diaphragm to the iliac bifurcation is easily obtained. The surgeon has facile exposure of the paravisceral aortic segment for supra celiac aortic control, clamp placement and visceral branch reconstruction if necessary. It is also the author's opinion that the physiologic insult to the patient with this exposure is less and the ability to treat patients with prior endovascular aortic replacement who present with secondary rupture is improved. We do recognize that some surgeons may be more comfortable with a transperitoneal and have therefore described both techniques.

Extended Left Retroperitoneal Approach

A suction bean bag (Olympic Vac-Pac) is placed on the operating table before the patient is brought into the operating suite. The patient is initially placed supine on the bean bag to facilitate central venous and arterial line placement if the patient is hemodynamically stable. After the induction of general anesthesia, the patient is rotated into a modified right lateral decubitus position (left flank up). The patient is positioned with the table break approximately 10 cm cephalad to the left iliac crest with the torso shifted toward the right and rotated until the left shoulder is elevated 45 to 60 degrees from the horizontal position while the pelvis is rotated 15 to 30 degrees to the right to allow access to both groins (Fig. 201.4). The left upper extremity is brought across the chest and supported by blankets or a stand. The left thigh is elevated above the horizontal plane to relax the iliopsoas muscle. This maneuver improves access to the distal aorta and left iliac arteries. To open the space between the iliac crest and the costal margin the table is flexed at the table break. At this point, the operating table should be tilted in a slight reverse Trendelenburg position so that the plane of the planned retroperitoneal incision is level with the horizontal plane.

The patient is prepped and draped from the mid chest to the mid thighs bilaterally. Ideally, a self-retaining abdominal wall retractor like the Buchwalter is anchored to the left rail of the operating table. The incision is made sharply from the lateral edge of the left rectus muscle between the umbilicus and pubic symphysis in an oblique fashion directed posteriorly

and superiorly through the 10th interspace to the posterior axillary line. The use of this higher incision allows exposure of the paravisceral and supra celiac portions of the aorta.

The muscle layers of the lateral abdominal wall are divided in line with the skin incision. The deepest layer, the transversus abdominis, is divided from a lateral to medial direction to aid the separation of the anterior abdominal wall from the peritoneum, which is usually thicker and more defined laterally. The intercostal muscles are divided on the superior margin of the underlying 10th rib. Any entrance into the pleural cavity is repaired at the end of the procedure.

In the setting of rupture, the hematoma may have already created the retroperitoneal dissection plane, but in general initial exposure is performed laterally and posterior superior to the left kidney so as to avoid disturbing the hematoma that may have tamponaded the bleeding resulting in hemodynamic collapse. The surgeon should place his left palm on the surface of the left psoas muscle and direct it cephalad to the posteromedial diaphragm and crus in order to elevate the peritoneum gently off the posterior dome of the diaphragm. The surgeon should be careful to not go deep to the fascia overlying or into the crevice lateral to the psoas major muscle to minimize dissection related bleeding and genitofemoral nerve injury. The blunt medial cephalad dissection is complete when the supra celiac aorta is palpable beneath the diaphragmatic crus directly on the distal thoracic vertebral column.

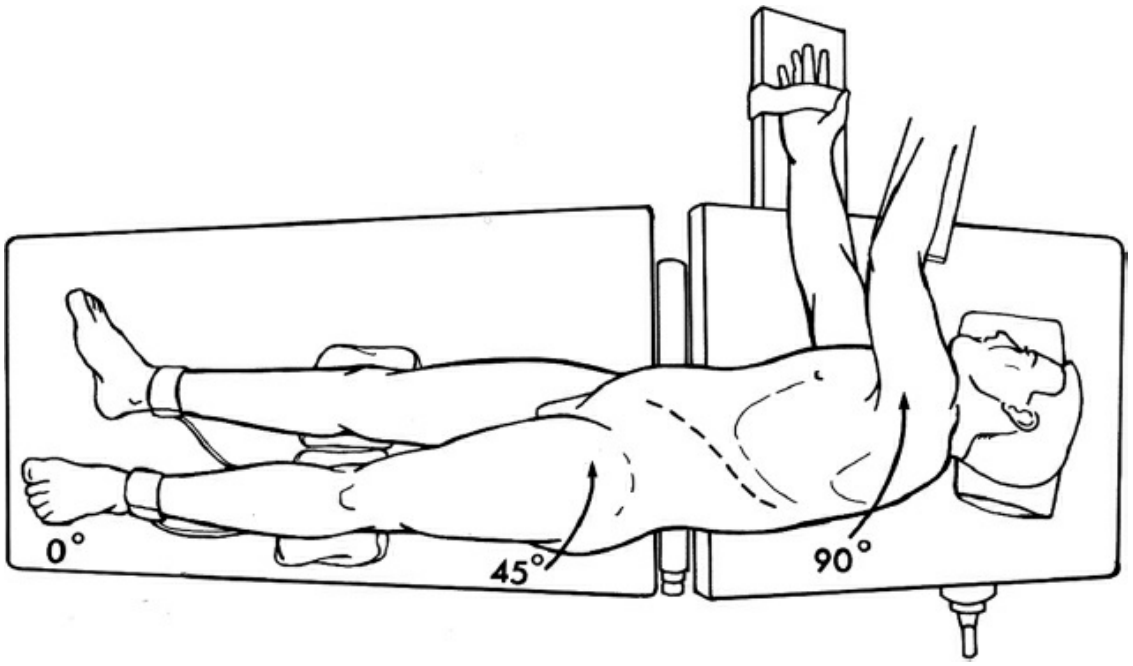

Figure 201.4. Positioning for left retroperitoneal approach.

At this point, the prime consideration is placement of the proximal supra celiac aortic clamp. An assistant should be positioned on the right side of the table and using a large deep handheld Dever retractor medially retract the peritoneum and its contents to allow the surgeon to visualize the crus overlying the supraceliac aorta Vigorous retraction of the anterior and cephalad margin of the incision should be avoided as this may result in splenic or renal injury

Initially, the supra celiac aorta is compressed posteriorly with the tips of the fingers of the left hand against the anterior portion of the thoracic vertebrae. The crural fibers are then snipped transversely with a scissors to expose and directly visualize the supraceliac aorta for clamp placement. The authors' preference is to use a padded type clamp such as a long Fogarty Clamp as we believe it is less traumatic. Our preference is not to systemically heparinize the patient.

The retroperitoneum is widely exposed at this point, and the left kidney is retracted medially and cephalad. This is the key aspect of the extended left retroperitoneal approach that allows the surgeon to exposure the entire abdominal aorta. The blades of the self-retaining retractor are padded to minimize the risk of traction injuries to underlying organs. In addition, dissection is maintained posteriorly to identify and avoid any injury to the left ureter.

As most AAAs rupture infrarenally, the next step is to define the immediate infrarenal aorta. The landmarks for this portion of the aorta are the origin of the left crus of the diaphragm, the lumbar branch of the left renal vein, and the left renal artery. Once the lumbar branch of the left renal vein (which crosses the aorta in a posterior and perpendicular fashion and caudad to the left renal artery) is securely ligated and the lympho-areolar tissue is dissected, the infrarenal aorta is dissected free on its lateral anterior and posterior surfaces. The clamp is then released sequentially and moved down from the supraceliac to the infrarenal location. This will allow any stasis clot proximal to the supraceliac clamp to flush distally and not into the renal and visceral arteries. If there is no infrarenal aortic neck, the authors' preference is to leave the supra celiac clamp in place and control the celiac, superior mesenteric and renal arteries separately.

The next priority is distal arterial control. The distal aorta, proximal right common iliac artery and entire left iliac system can be exposed and clamped through the left extended retroperitoneal exposure. If there is

significant distal involvement of the distal right common or external iliac arteries then a small suprainguinal counter incision can be made in the right lower quadrant by a second surgeon to obtain extra peritoneal exposure of the external iliac artery. Alternatively, right common iliac artery control can also be obtained with a balloon occlusion catheter through the left flank incision at the time the aneurysm is opened. If there is extensive pelvic aneurysmal or occlusive disease, vertical groin incisions are made to expose the femoral arteries for distal arterial control and anastomosis. As the patient is not systemically heparinized, flushing the outflow arteries with local heparin prior to clamp placement may prevent distal arterial thrombosis due to stasis. The sac is then opened with electro cautery; lumbar arteries and the inferior mesenteric artery can be suture ligated within or clipped from outside the opened AAA sac with clips. The aneurysm neck may be transected completely or partially with the posterior medial wall remaining intact. The authors' preference is to completely transect the aorta to allow precise suture placement through the full aortic wall thickness, thus minimizing later development of pseudoaneurysm.

The proximal graft anastomosis is performed using a parachuted anastomotic technique with a continuous 3-0 polypropylene suture. The anastomosis starts medially at the 9 o'clock position and is parachuted anteriorly to the 12 o'clock position. At this point the graft is loosely retracted up anteriorly to allow visualization of the medial and posterior aspect of the aorta to which the graft is sewn next to the 6 o'clock position. The anastomosis is the tightened and the remainder of the anastomosis is completed. Once the suture line is tested, the graft is bled to rid the aorta of any stasis clot and the clamp is replace on the proximal graft, which is then flushed with heparinized saline.

In the setting of a ruptured pararenal aneurysm, an infrarenal anastomosis may not be possible. In this setting, the left extended left retroperitoneal approach allows other variations such as a beveled proximal anastomosis with branch grafts to the involved renal vessels similar to a Type IV thoracoabdominal aortic aneurysm repair. Though this approach, the entire left renal artery may be visualized. With further division of the left crus, the lateral pararenal/visceral aorta is well visualized. The right renal artery is best exposed once the aorta has been divided. The right renal artery can be exposed up to its transverse portion beneath the inferior vena.

Next the distal aortic, iliac, or femoral anastomoses are completed. The distal graft limbs of the graft are tunneled anatomically along the axis of the iliac vessels. On occasion, it may not be possible for limbs to be tunneled anatomically due to inflammation or prior surgery. In this situation, the right limb graft limb can be tunneled through the space of Retzius. Prior to performing distal anastomoses, embolectomy catheters should be passed distally to retrieve any stasis thrombus, 4 Fr for iliac and 3 Fr for femoral arteries. Distal anastomoses are performed end to end to common iliac and end to side to external iliac and femoral arteries with 5-0 or 6-0 Prolene continuous sutures. Hand held Doppler is used to assess distal flow after release of clamps.

If there is any concern regarding intestinal viability or traction injury to the spleen, the peritoneum can be purposefully incised to allow for direct inspection of the intra-abdominal contents. At this point, any defects in the peritoneum are repaired. If entrance into the pleural cavity does occur, it is fixed directly upon incision closure by sewing the cut diaphragmatic edge to the next highest rib while catheter suction is maintained in the pleural cavity. Alternatively, tube thoracostomy can be placed. The abdominal wall musculature is closed in layers followed by closure of the subcutaneous tissue and skin. Closure of the wound is made easier by taking the flex out of the table, which allows a tension free repair.

Transperitoneal Approach

The patient is brought to the procedure table and placed in a supine position. As general anesthesia is induced, the patient is prepped from the nipples to the mid-thigh area. If the patient is in extremis, percutaneous femoral artery access may be obtained and a 7-Fr sheath placed for placement of an intra-aortic balloon occlusion catheter. Alternatively control can be gained by clamp placement after a midline laparotomy incision is made or through a small left thoracotomy incision to clamp the distal thoracic aorta as is done during a trauma arrest situation.

A midline incision is made from the xiphoid process to the pubic symphysis. A self-retaining abdominal wall retractor such as a Buchwalter retractor is very helpful to aid exposure and reliable retraction. Depending on the patient’s hemodynamic status and the location hematoma and extent of hemorrhage, placement of a supraceliac aortic clamp may be necessary. The most expeditious way to accomplish this is through the lesser omental sac. The triangular ligament of the left lobe of the liver is divided and retracted to the patient’s right as necessary and the esophagus with a

nasogastric tube in place is retracted to the patient's left to expose the diaphragmatic crural fibers overlying the supraceliac aorta. Blunt dissection with the surgeon's fingers or sharp scissor dissection is used to divide the crus and expose the aorta, which is then clamped. If the hematoma is mainly distal and the patient stable, the aorta can be approached initially infrarenally for clamp placement.

Alternatively, the entire abdominal aorta can be exposed by incising the left posterior peritoneal attachments lateral to the left colon and solid abdominal visceral and reflecting them medially. This medial visceral rotation (Maddox Maneuver) allows exposure of the entire abdominal aorta from the supraceliac level to the aortic bifurcation. This is similar to the extent and breadth of exposure possible with the extended left retroperitoneal approach.

At this point, the transverse colon is retracted cephalad and the small intestines either retracted and packed into the right lower quadrant or eviscerated and placed into bowel bag or warm saline soaked gauze. The ligament of Treitz is incised allowing retraction of the duodenum and exposure of the retroperitoneal tissue overlying the aorta. If possible, the surgeon should avoid entering the hematoma until the aorta is clamped or the infra renal neck of the aorta is exposed. In general, dissection is limited to the anterior and lateral aortic walls. Exposure and aortic clamp placement is facilitated by exposure and cephalad retraction of the left renal vein which is usually anterior to the aorta. Limiting circumferential aortic dissection also avoids potential venous injuries especially in the setting of a retro-aortic left renal vein. If necessary, the left renal vein can be divided, but this should be done as close to the inferior vena cava as possible to preserve collateral venous drainage from the adrenal and lumbar branches. If there is a segment of nonaneurysmal aorta infrarenally, the aorta should be clamped in this location and supraceliac clamp placement released. At this point communication with the anesthesia team is required to anticipate declamping hypotension from liver and intestinal reperfusion. If the anatomy is obscured or distorted by the hematoma, it may be necessary after supraceliac clamping to enter the aortic sac, define the aortic neck and then place the proximal clamp as distally as possible in order to perfuse the renal and visceral outflow.

After placement of the proximal aortic clamp, a dose of heparin can be given intravenously. It is the authors' preference is not to give systemic Heparin and thereby minimize the exacerbation of coagulopathy. At this

point, the iliac or femoral arteries should be controlled. Ideally, the iliac arteries should be clamped but if the anatomy is difficult to define, the aortic sac can be opened and 14-Fr Foley or large caliber Fogarty catheters placed into the iliac arteries with balloon inflation for control. These catheters can then be irrigated distally with heparinized saline. Within the aortic sac, the lumbar and inferior mesenteric arteries are controlled with 3-0 Prolene suture ligatures.

Whenever possible, aortic reconstruction should be performed with a tube graft prosthesis to expedite getting the patient off the operating table. If there is extensive aneurysmal or occlusive disease then a bifurcated prosthesis should be placed. The proximal anastomosis should be started on the posterior aortic wall. The author's preference is with a continuous monofilament suture such as 3-0 Prolene. As this part of the aorta has not been circumferentially dissected, the surgeon should use a "Creech" type endoaneurysmorraphy. In order to assure incorporating the adventitial layer, the surgeon should aim the needle directly posteriorly and may include the anterior longitudinal spinal ligament in the posterior anastomotic suture line. The anastomosis should be accomplished using a parachuted technique in order to assure appropriate spacing of the needle bites. Once the posterior suture line is completed, the suture line is tightened, the graft brought down and the remaining lateral and anterior aspects are completed. A clamp is the placed on the proximal graft and the suture line is tested. Any significant bleeding is controlled with pledgeted sutures, as the aortic wall may be friable.

If a tube graft is placed, the distal aortic anastomosis is performed similarly. In this situation, flow is restored to the iliac arteries sequentially to limit significant declamping hypotension. This should be coordinated with the anesthesia staff to allow appropriate predeclamping intravenous fluid resuscitation. With bifurcated distal reconstruction, anastomosis is generally performed end to end to the common iliac arteries and end to side to the external iliac and femoral arteries.

The graft is separated from interaction with bowel by approximating the retroperitoneal layer and decompressed aortic sac over the graft prosthesis with a suture closure. Closure of the fascial incision is performed with a continuous or interrupted monofilament suture. In cases of shock with massive fluid resuscitation, it may not be possible to close the incision; and in this situation, the abdomen can be packed with saline soaked laparotomy pads, the patient kept under deep anesthesia with planned

return to the operating suite in 48 to 72 hours for reassessment and closure.

Treatment of AAA Sac Rupture After EVAR

Treatment of AAA sac rupture after prior EVAR can be a technically challenging endeavor. Ideally, this is treated with a secondary endovascular repair. When this is not possible open repair may be required. Although either transperitoneal or retroperitoneal approach can be used, the authors' preference is the extended left retroperitoneal approach as described above for endograft explant and reconstruction. A surgeon's familiarity with the retroperitoneal exposure in elective situations involving infrarenal, juxtarenal and pararenal AAAs lends itself to the use of this approach to more complex clinical scenarios. The same attributes of the left retroperitoneal exposure that facilitate repair in ruptured aneurysm, such as the ability to control the entire abdominal aorta from the distal thoracic segment to the iliac bifurcation, apply to open repair in patients with rupture after failed endovascular repair. The positioning, incision and exposure are identical to the technique for repair of ruptured AAA previously described.

The paramount concern for any type of open repair for AAA rupture is proximal control and stable dissection. Depending on the type of endograft deployed, there is often a varying degree of inflammation present in the retroperitoneum due to several factors including infra versus suprarenal fixation, endostapling and/or translumbar coiling of prior endoleak. The ability to minimize dissection related injury to adjacent structures such as the duodenum and renal veins is easier with a retroperitoneal exposure. Maneuvers such as maintaining the dissection as posterior as possible within the retroperitoneum and identifying the ureter early with or without the use of preoperatively placed stents confer safety. The supraceliac aortic dissection is usually free of inflammation as compared to the infra and juxtarenal portions which are often significantly inflamed and the dissection hazardous. The safest method to avoid mishap is to approach the lateral and posterior aspect of the infrarenal aortic segment after initial clamp placement. One alternative measure mentioned previously is to obtain control with an intra-aortic balloon directed from one of the femoral arteries and inflated at the supra celiac aortic level.

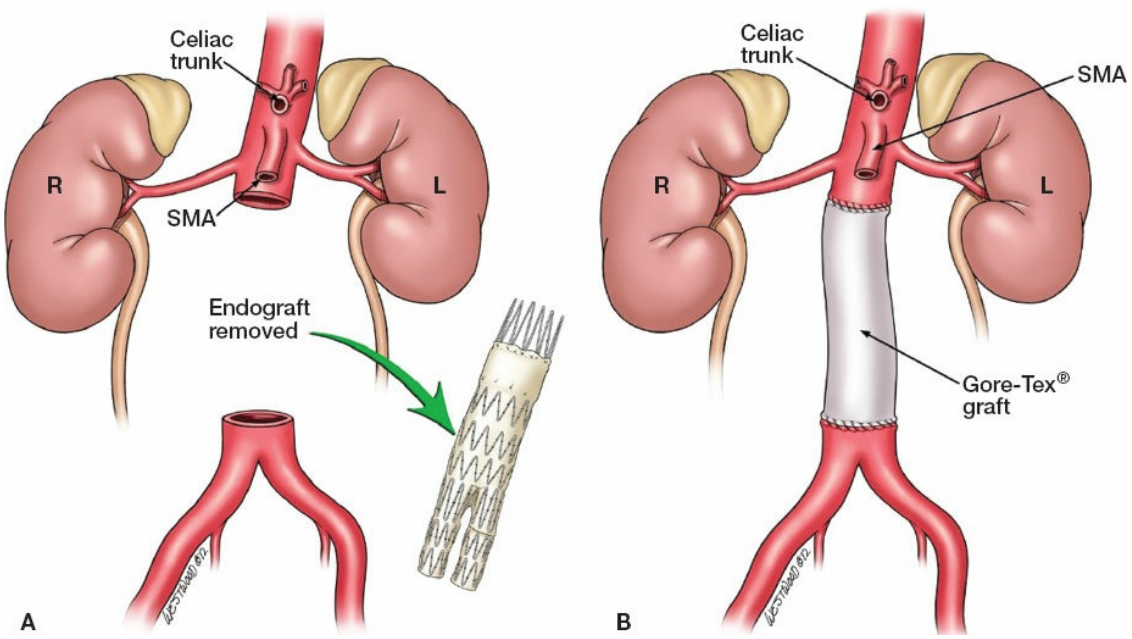

Figure 201.5. A. Complete explant of aortic endograft. **B.** Tube graft aortic replacement after complete explant.

If further dissection of the infra or juxtarenal aortic neck cannot be safely performed, the supraceliac aortic clamp is left in place, renal/visceral arteries are controlled, distal clamp(s) are placed and the aneurysm sac is opened. If information is available regarding the previously deployed endograft in terms of suprarenal versus infra renal fixation, this may help plan subsequent control and clamping of the distal aorta. In patients with a known suprarenal fixation, it is often preferable to leave the aortic cross clamp in place but unclamped on the supraceliac aorta. With a known infrarenal device, assuming the aorta can be accurately dissected, is minimally diseased and has no significant aneurysmal component, the cross clamp can be moved to the infra renal aorta.

The surgeon needs to remember that the goal is to control bleeding and reconstruct in line flow as expeditiously as possible. Ideally, one should try to completely explant the endograft but not at the expense of compromising an expeditious procedure. The single most important factor in deciding between partial or complete stent graft explant is whether the endograft can be completely removed without destroying the aortic wall. Other considerations include the type of stent graft fixation (suprarenal versus infra renal, and active with hooks/barbs versus passive with self-expanding stent only), as this may influence the site of aortic clamping and the possible adjunctive need for visceral endarterectomy and/or

revascularization with complete stent graft explant. Infra renal aortic clamping with partial stent graft explant might be a significantly less morbid procedure when compared with supra celiac aortic clamp and complete stent graft explant, with possible visceral reconstructions, particularly in the patient with aneurysm rupture. In cases of rupture secondary to a Type IA endoleak, the proximal endograft may slide out easily. Lastly, some endografts with suprarenal fixation can be "recaptured" with a cut syringe, thereby facilitating explant.

In AAA rupture patients with infra renal stent grafts, the proximal aortic clamp is placed at the supra-renal level, the aneurysm sac opened, the entire infra renal stent graft is explanted including the iliac limbs, and aorto iliac reconstruction performed as needed (Fig. 201.5A,B). In AAA rupture patients with suprarenal self-expanding stents for fixation, aortic control is obtained by placing a supra celiac aortic clamp. In these cases, if the graft cannot be recaptured as mentioned previously, partial stent graft explant with transaction of the stent graft within the proximal aortic neck is performed. A bone cutter may be necessary to cut the wire scaffold of the prior endograft. In AAA rupture patients with stent grafts that have placement of proximal Palmaz stents, aortic control is obtained via a supra celiac aortic clamp, or an aortic occlusion balloon, with partial or complete stent graft explant. When the proximal aortic stent graft is partially explanted, the proximal graft is sewn to the composite endograft/proximal aorta with or without pledgets depending on the friability of the aortic wall (Fig. 201.6). Renal arterial reconstruction may be necessary as previously detailed depending upon the wall integrity and extent of the proximal aortic aneurysm (Fig. 201.7A,B).

If the entire distal portion of the endograft can be removed, the aortic graft is sewn to the distal aorta, iliac or femoral arteries depending on the extent of aneurysmal and occlusive disease. In instances when the iliac limbs cannot be explanted due to scarring, either the distal anastomosis is constructed beyond the iliac stent grafts and the aortic bifurcation is then over sewn (Fig. 201.8), or the limbs are transected at the aortic bifurcation and aortic tube grafts is sutured directly to the distal aortic bifurcation, and the stent graft limbs are incorporated within the anastomosis. Alternatively, the limbs of a bifurcated graft can be sewn individually to the remaining endograft limbs or the distal body of the endograft (Fig. 201.9). Interrupted 5-0 polypropylene sutures are then used to secure the native distal iliac arteries to the distal portion of the remaining EVAR

limbs.

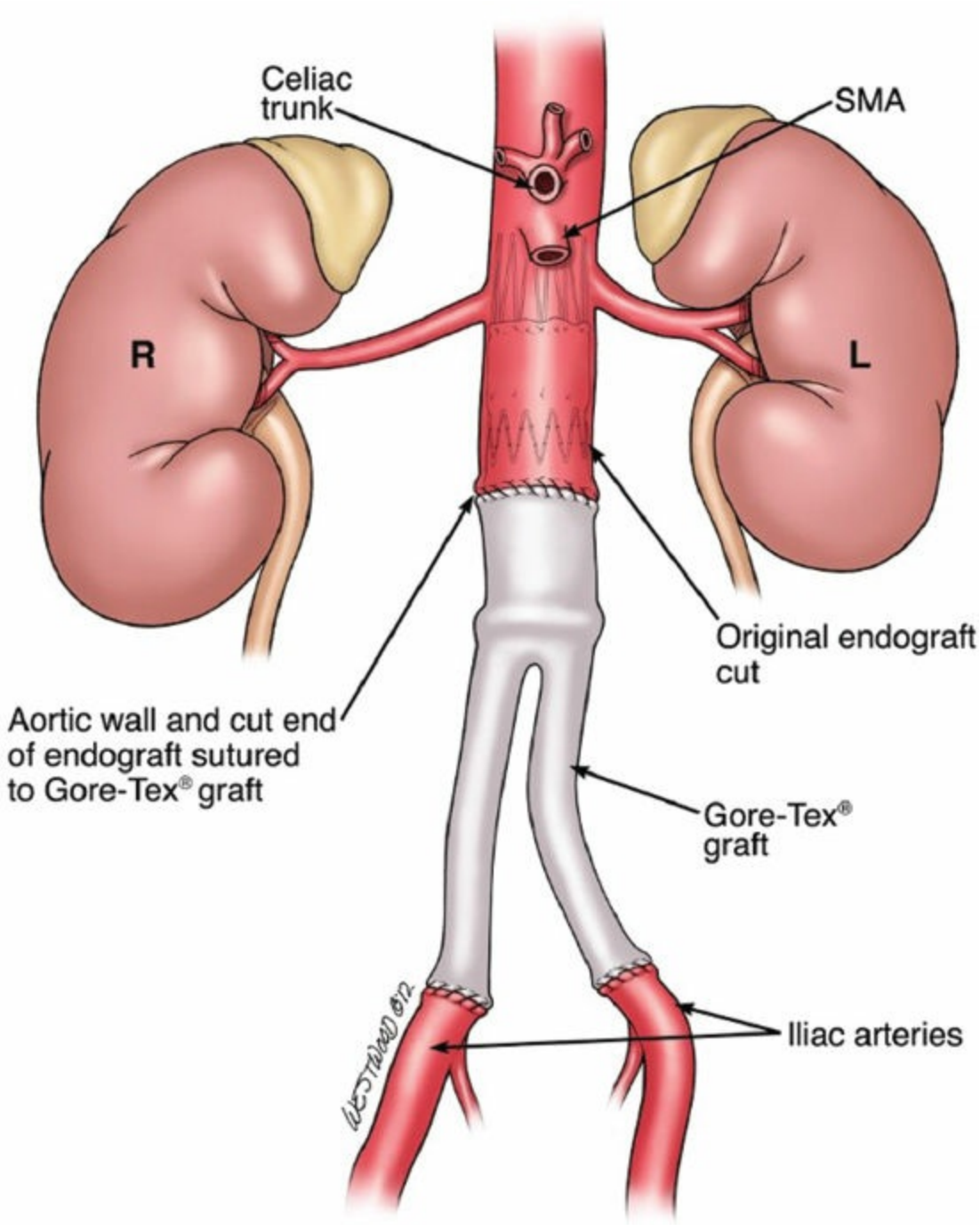

Figure 201.6. Partial proximal and complete distal endograft explant with bifurcated graft reconstruction.

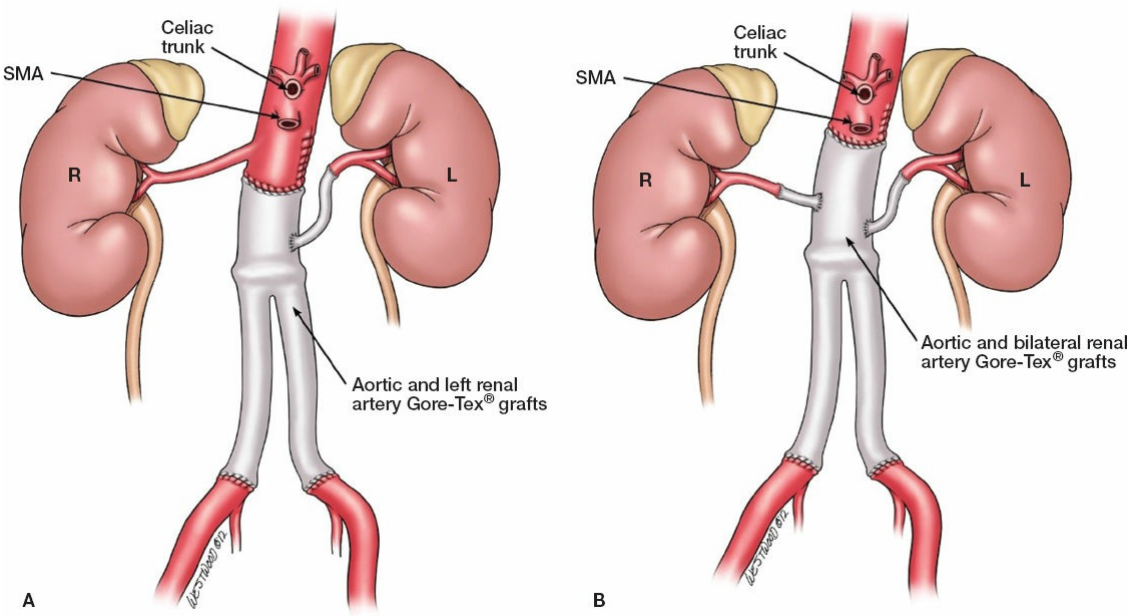

Figure 201.7. **A.** Complete explant of endograft with suprarenal fixation and subsequent aortic reconstruction with left renal bypass. **B.** Complete explant of endograft with suprarenal fixation and subsequent aortic reconstruction with bilateral renal artery bypass.

COMPLICATIONS OF RUPTURED ABDOMINAL AORTIC ANEURYSM REPAIR

Local Complications

Following open surgical repair, postoperative bleeding can occur in as many as 12% to 14% of patients. The incidence is related to the presence of coagulopathy in patients with shock and hypothermia. Limb ischemia can be related to in-situ graft limb thrombosis or distal thromboembolism. With ruptured EVAR, most local complications are access related and dependent on percutaneous approach versus femoral artery cut-down. Local complication of bleeding and clotting are generally in the range of 7% to 10% following ruptured EVAR.

Colonic Ischemia

Colonic ischemia is a lethal consequence of any AAA repair, particularly when it occurs following ruptured AAA repair. The most recent prospective data using sigmoidoscopy noted an ischemic colitis incidence of 38% with open ruptured AAA repair, and 23% following ruptured EVAR. In a prospective analysis of ruptured AAA, patients who survived 24 hours postoperatively, a 26% incidence of grades I & II ischemia was

detected with colonoscopy, with 10% having grade III changes. Of those with grade I, or II changes, 11% progressed to grade III within 48 hours. Those with grade III changes were found at surgery to have extensive sigmoid and frequently rectal necrosis and even with surgical management had a mortality rate of 55%. At the conclusion of open surgical repair, careful examination of the bowels and Doppler evaluation of the mesentery should be routinely performed. When in doubt, reimplantation of the inferior mesenteric artery should be considered.

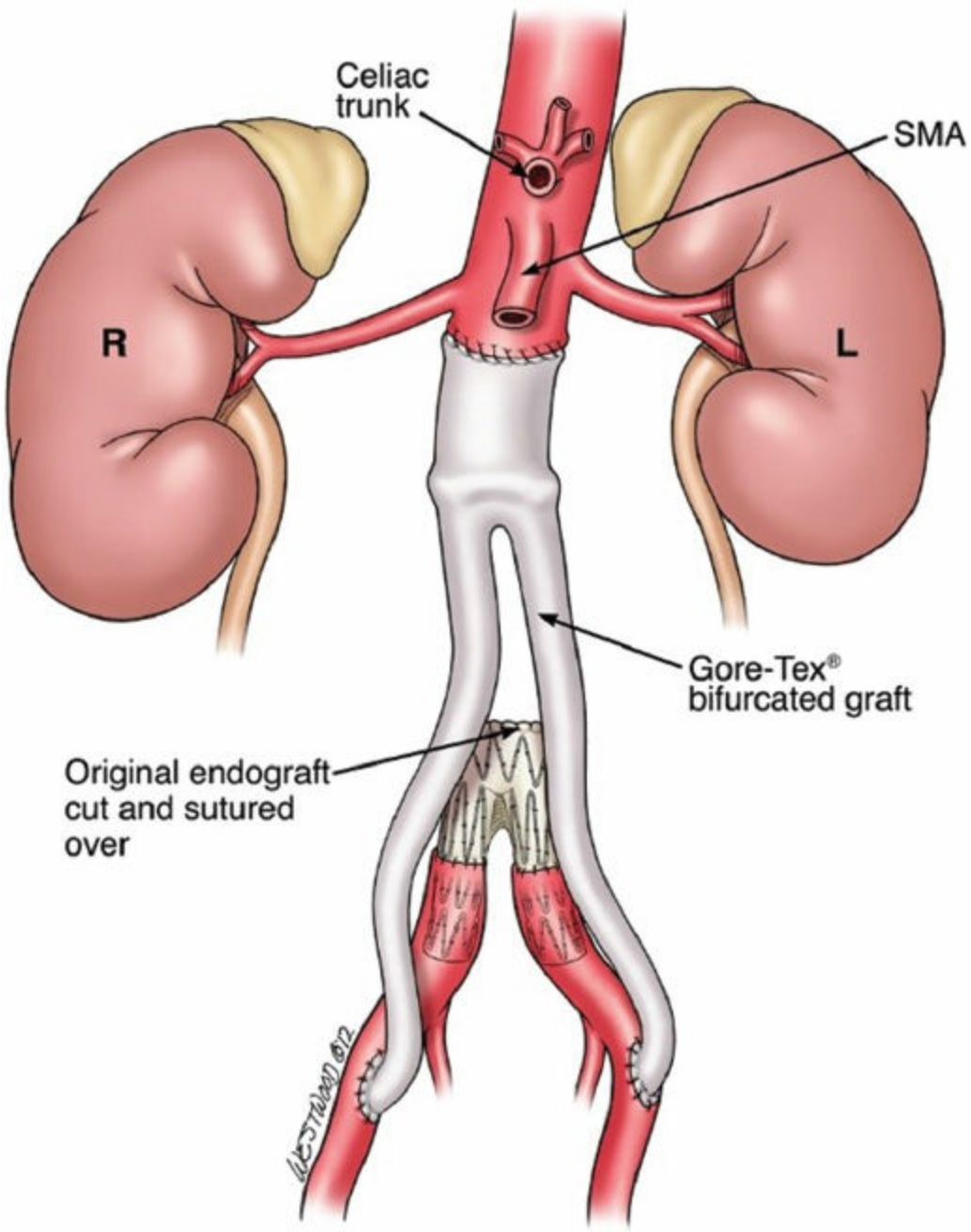

Figure 201.8. Complete proximal and partial distal endograft explant with bifurcated aortic reconstruction to native distal iliac

arteries.

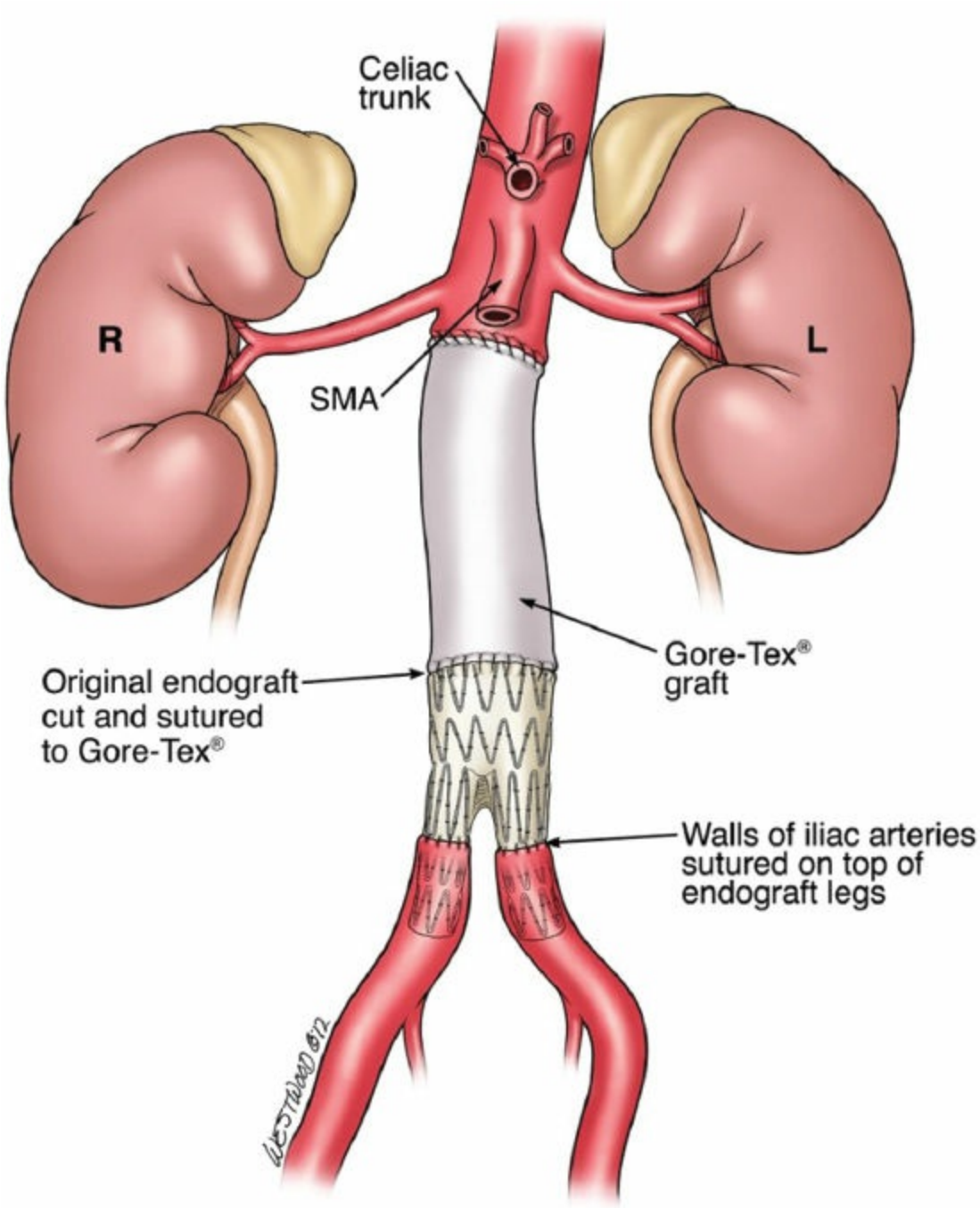

Figure 201.9. Complete proximal and partial distal endograft explant with tube graft reconstruction to remaining endograft body. Remaining endograft iliac limbs are secured to native iliac arteries with interrupted 5-0 Prolene sutures.

Cardiac Complications

Pre-existing coronary artery disease has been shown to increase the risk for myocardial infarction and death after open surgical and endovascular

ruptured AAA repair. Myocardial infarction develops secondary to the increased demand placed on the heart to compensate for the blood loss, resuscitation, aortic clamping and declamping, particularly in the setting of pre-existing coronary artery disease. Myocardial infarction after ruptured EVAR is occurs in 5% to 10% of patients and is associated with a far lower mortality than after open surgical repair. After open surgical repair of ruptured AAA, myocardial infarction develops in 10% to 25% of patients and is associated with a mortality rate of 17% to 66%, while arrhythmias and congestive heart failure develops in nearly 20% of patients and are associated with a mortality of nearly 40%.

Respiratory Failure

Respiratory failure develops in 26% to 47% of patients after open ruptured AAA repair and is dependent on pre-existing chronic obstructive pulmonary disease, and is associated with a mortality of 34% to 68%. It is characterized by high oxygen requirements, increased lung permeability, and a decrease in lung compliance. Administration of large volumes of fluid and blood products, as well as preexisting pulmonary dysfunction and long cross-clamp times, predisposes to the development of respiratory failure. Respiratory complications following ruptured EVAR are as expected noted less frequently and occur in approximately 20% of patients.

Renal Dysfunction

Renal dysfunction in ruptured AAA patients has long been recognized to have a significant deleterious impact on mortality and can range from 26% to 42%. Furthermore, in patients that require dialysis (11% to 40%) the mortality rate is between 76% and 89%. Renal dysfunction has been found to be increased in those with suprarenal cross clamping, longer duration of cross clamping, pre-existing renal insufficiency, shock, and increased age. The incidence of renal dysfunction is significantly reduced after ruptured EVAR (14.8%) when compared to open surgical repair (24.8%).

Multisystem Organ Failure

Multisystem organ failure following ruptured AAA repair tends to occur more frequently after ruptured open surgical repair than ruptured EVAR, and is associated with elevated mortality rates. The incidence of death in patients with postoperative multisystem organ failure has been reported to range from 64% to 93%. The risk factors for the development of

multisystem organ failure center on the magnitude, number, and timing of the inducing inflammatory insults. Evidence from clinical ruptured AAA data suggests that suprarenal location as well as duration of clamping, and development of abdominal compartment syndrome is associated with higher rates of postoperative complications and death. The incidence of multisystem organ failure was noted to be 3.8% after elective AAA repair, 38% after urgent AAA repair, and 64% after ruptured AAA open surgical repair. In this series, the mortality rate of ruptured AAA patients with multisystem organ failure was 69% versus 0% in those who did not have multisystem organ failure.

It is likely that the "Two-Hit" hypothesis of multisystem organ failure accounts for the extensive complications and the persistent high and unchanging mortality in the patients undergoing ruptured AAA repair; the first hit is the hemorrhagic shock that results in total body ischemic event primes the inflammatory response and the aortic cross-clamping leads to ischemia and is the second hit. Reperfusion occurs as a result of resuscitation and the removal of aortic clamp or the aortic occlusion balloon. When the events were combined, a synergistic effect resulted in the rapid onset of systemic organ injury that resembled the clinical situation. Animal studies of hemorrhagic shock have demonstrated that cardiac contractile dysfunction develops after resuscitation and may further reduce tissue perfusion, thereby contributing to a higher incidence of cardiac events after ruptured AAA.

Suggested Readings

Edwards ST, Schermerhorn ML, O'Malley AJ, et al. Comparative effectiveness of endovascular versus open repair of ruptured abdominal aortic aneurysm in the Medicare population. *J Vasc Surg* 2014;59:575–82.

Holt PJ, Karthikesalingam A, Poloniecki JD, et al. Propensity scored analysis of outcomes after ruptured abdominal aortic aneurysm. *Br J Surg* 2010;97:496–503.

Lindsay TF, Luo XP, Lehotay DC, et al. Ruptured abdominal aortic aneurysm, a "two-hit" ischemia/reperfusion injury: evidence from an analysis of oxidative products. *J Vasc Surg* 1999;30:219–28.

Mastracci TM, Garrido-Olivares L, Cina CS, et al. Endovascular repair of ruptured abdominal aortic aneurysms: a systematic review and meta-analysis. *J Vasc Surg* 2008;47:214–21.

Mehta M, Byrne J, Darling RC 3rd, et al. Endovascular repair of ruptured infrarenal abdominal aortic aneurysm is associated with lower 30-day mortality

and better 5-year survival rates than open surgical repair. *J Vasc Surg* 2013;57:368–75.

Mehta M, Burton B, Byrne J, et al. The impact of favorable and hostile aortic neck morphology on the outcomes of endovascular repair of ruptured abdominal aortic aneurysms. *J Vasc Surg* 2013;57(5):88S–9S.

Mehta M, Darling RC 3rd, Roddy SP, et al. Factors associated with abdominal compartment syndrome complicating endovascular repair of ruptured abdominal aortic aneurysms. *J Vasc Surg* 2005;42:1047–51.

Mehta M, Paty PS, Byrne J, et al. Hemodynamic status impacts outcomes of endovascular aneurysm repair for rupture. *J Vasc Surg* 2013;57:1255–60.

Mehta M, Taggert J, Darling RC 3rd, et al. Establishing a protocol for endovascular treatment of ruptured abdominal aortic aneurysms: outcomes of a prospective analysis. *J Vasc Surg* 2006;44:1–8.

Mehta M, Paty PS, Roddy SP, et al. Treatment options for delayed AAA rupture following endovascular repair. *J Vasc Surg* 2011;53:14–20.

Nedeau AE, Pomposelli FB, Hamdan AD, et al. Endovascular vs open repair for ruptured abdominal aortic aneurysm. *J Vasc Surg* 2012;56(1):15–20.

Powell JT, Sweeting MJ, Thompson MM, et al.; IMPROVE trial investigators. Endovascular or open repair strategy for ruptured abdominal aortic aneurysm: 30-day outcomes from the IMPROVE randomised trial. *BMJ* 2014;348:f6771.

Reimerink JJ, Hoornweg LL, Vahl AC, et al.; Amsterdam Acute Aneurysm Trial Collaborators. Endovascular repair versus open repair of ruptured abdominal aortic aneurysms: a multicenter randomized controlled trial. *Ann Surg* 2013;258(2):248–56.

Vallabhaneni SR, Gilling-Smith GL, How TV, et al. Heterogeneity of tensile strength and matrix metalloproteinase activity in the wall of abdominal aortic aneurysms. *J Endovasc Ther* 2004;11:494–502.

Wyss TR, Brown LC, Powell JT, et al. Rate and predictability of graft rupture after endovascular and open abdominal aortic aneurysm repair: data from the EVAR trials. *Ann Surg* 2010;252:805–82.

EDITOR'S COMMENT

In this outstanding chapter by Mehta and coauthors describing both endovascular and open RAAA repair, I am at first reminded of the futility we felt for the longest period of time regarding the management of ruptured AAAs. Despite improvements in blood banking and critical care, including the realization that keeping the patients warm is important, mortality following RAAA only decreased approximately 3% per decade. As described in this

chapter, the onset of elective endovascular aneurysm repair (EVAR) in the early 1990s with improved short-term mortality relatively quickly led to the adoption of EVAR for RAAA (Wainess RM, Dimick JB, Cowan JA Jr, et al. Epidemiology of surgically treated abdominal aortic aneurysms in the United States, 1988 to 2000. *Vascular* 2004;12(4):218–24; Dua A, Kuy S, Lee CJ, et al. Epidemiology of aortic aneurysm repair in the United States from 2000 to 2010. *J Vasc Surg* 2014;59(6):1512–7). As more and more endografts became FDA approved, the ability to treat a wider range of aortic anatomies was realized. While likely we will never be able to treat all RAAAs with EVAR, today as many as 70% to 80% of RAAAs are treated with EVAR (McPhee J, Eslami MH, Arous EJ, et al. Endovascular treatment of ruptured abdominal aortic aneurysms in the United States (2001–2006): a significant survival benefit over open repair is independently associated with increased institutional volume. *J Vasc Surg* 2009;49(4):817–26). There are certain aortic characteristics, including a large diameter aorta and a short aortic neck at the level of the renal arteries, which both portend poor outcomes following EVAR for RAAA. People have used “snorkel” or paragraft techniques are well described to extend the seal zone proximally. Others have intentionally covered or sacrificed renal arteries or the superior mesenteric by covering them with stent graft (Weinberger JB, Long GW, Bove PG, et al. Intentional coverage of a main renal artery during endovascular juxtarenal aortic aneurysm repair in symptomatic high-risk patients. *J Endovasc Ther* 2006;13(5):681–6). There are most certainly surgeons in practice who will not offer patients open AAA repair. It is really hard to know whether this really represents progress as it probably does not, as I have operated on many a patient with a RAAA and open repair who have survived and done well.

One of my favorite sayings I use with patients is to say, the best way to fix a ruptured AAA is to fix it before it ruptures (i.e., tell the patient they need an elective repair). Imaging with thin slice CT angiography, which is used with computer programs that allow for creation of three-dimensional images that are then used for accurate and timely anatomic measurements, removed much of the guess work out of sizing the endografts even in the RAAA setting. The authors describe the unsettling situation of what to do with the RAAA, who when you are finished still may have an endoleak. Clearly, this is a very controversial area and I am not sure people have really written much about this. My practice is always to get a CTA on patients in the near perioperative period. I think if there are type 1 or 3 endoleaks seen, they should be treated before the patient is discharged from the hospital. The data is pretty convincing that patients who are treated with EVAR for RAAA are more prone to rerupture. Therefore, my bias is to make these endografts as good as they can be, especially in the setting of a rupture.

While it was touched upon in this chapter, I think it really needs to be highlighted that there are real differences in the presentation and outcomes for males and females when it comes to RAAAs (Katz DJ, Stanley JC, Zelenock

GB. Gender differences in abdominal aortic aneurysm prevalence, treatment, and outcome. *J Vasc Surg* 1997;25(3):561–8). Female patients present more often with RAAA than males. It is really hard to Figure out what part of this is social (i.e., physicians do not think about AAAs in females as it is primarily a disease of males and screening is not widely recommended) and which part is biologic (i.e., females have more inflammation in the aortic wall) (Rasmussen TE, Hallett JW Jr, Tazelaar HD, et al. Human leukocyte antigen class II immune response genes, female gender, and cigarette smoking as risk and modulating factors in abdominal aortic aneurysms. *J Vasc Surg* 2002;35(5):988–93). This observation suggests that we should be electively repairing AAAs in females when their aortas are between 4.5 and 5 cm, instead of waiting until their aortas are 5.5 cm. In addition, females are less likely to anatomically be candidates for EVAR for RAAA. As endografts continue to become low profile, hopefully this bias will go away.

Finally, I think there is ample data to suggest that most patients with RAAA can safely undergo transfer to a center of excellence for repair of their aorta (Warner CJ, Roddy SP, Chang BB, et al. Regionalization of emergent vascular surgery for patients with ruptured AAA improves outcomes. *Ann Surg* 2016;264(3):538–43). The group from Albany as well as Dr. Mehta has really been a thought/action leader in this area and his data is convincing. My bias of course is that RAAA repair is similar to most operations, that is, the more we perform, the better we are at them. The group from Pittsburgh has written extensively on this and suggests that both elective EVAR and open AAA repair volumes impact outcomes for EVAR for RAAA (Zettervall SL, Schermerhorn ML, Soden PA, et al. The effect of surgeon and hospital volume on mortality after open and endovascular repair of abdominal aortic aneurysms. *J Vasc Surg* 2017;65(3):626–34). I for one do not believe we need a randomized, clinical trial to prove the obvious; namely, that if the anatomy is suitable, EVAR saves lives in the setting of RAAA!

Gilbert R. Upchurch Jr.

202 Femoral and Popliteal Artery Aneurysms

Mohammad H. Eslami

Peripheral artery aneurysms involve aneurysmal dilatation of the arteries in the upper and lower extremities. Traumatic injury to these vessels (e.g., femoral artery injuries after peripheral interventions), infection, or true aneurysmal degeneration may lead to aneurysm formation. Unlike abdominal or thoracic aorta aneurysms, peripheral artery aneurysms can often be detected by physical examination. The focus of this chapter is on the most common type of peripheral artery aneurysms: femoral and popliteal artery aneurysms (PAAs). It is important to distinguish true degenerative aneurysms, where all three layers of artery are involved, from false aneurysms (pseudoaneurysms), where weakness of the arterial layer leads to out-pouching of the vessel. This distinction has significant therapeutic implications.

FEMORAL ARTERY ANEURYSMS

The prevalence of femoral artery aneurysms is on the rise owing to a significant increase in the number of peripheral interventions via the femoral vessels for both peripheral and coronary interventions. Although true femoral artery aneurysms are rare (5 patients per 100,000), the combination of pseudoaneurysms and true aneurysms makes this the most commonly operated peripheral artery aneurysm. The clinical significance of femoral artery aneurysms is that they can thrombose and lead to limb loss. In addition, femoral artery pseudoaneurysms can rupture. True aneurysms are most commonly secondary to atherosclerotic degeneration of the femoral artery, whereas pseudoaneurysms can result from infection (mycotic aneurysms), trauma (e.g., peripheral intervention), or anastomotic degeneration.

Normal Femoral Artery Anatomy and Size

The femoral artery is the artery that begins distal to the inguinal ligament

and is continuation of the external iliac artery. The artery passes over the superior ramus of the pubis and the anterior superior iliac spine. It then passes distally along the medial aspect of the thigh. The proximal portion of the artery is called the common femoral artery, and it is usually 2 to 5 cm in length. This artery then divides into two arteries—the superficial and deep (profunda) femoral arteries. The common femoral artery is a subcutaneous structure and is easily palpated. Because of the ease of palpation and the artery's size, the femoral artery is the most common artery used for cardiac or peripheral interventions. It is important to have an appreciation of the normal size of the femoral artery. Femoral artery diameter measures about 0.78 to 0.85 cm in women and 0.78 to 1.12 cm in men. Aneurysm formation is defined when the artery diameter is increased by >50% compared to the expected normal diameter.

Degenerative (Atherosclerotic Femoral Artery Aneurysm)

Incidence and Risk Factors

Isolated degenerative femoral artery aneurysm is rare occurring in 5 patients per 100,000 hospitalized patients. The incidence is significantly higher among patients already diagnosed with aneurysm disease. For example, these aneurysms are reported in about 6.8% of patients with abdominal aortic aneurysms (AAA). Conversely, the presence of femoral artery aneurysm is a significant predictor of the presence of AAA as 85% of patients with femoral artery aneurysm have AAA.

The majority (72%) of patients with a diagnosis of a true degenerative femoral artery aneurysm have bilateral femoral aneurysmal disease, and 44% of these patients also have PAAs. Patients diagnosed with common femoral artery aneurysm, therefore, must undergo surveillance for the presence of other aneurysms.

These aneurysms are commonly seen among elderly patients (>70 years old) with a male to female ratio of 16:1. In addition to male gender, history of smoking and hypertension are the most significant risk factors among these patients. The most common etiology of common femoral artery aneurysm is degenerative and is caused by atherosclerosis, but other pathology, such as Behçet syndrome, acromegaly, and arteriomegaly, may also cause femoral artery aneurysms.

Anatomy and Natural History

Aneurysm degeneration of femoral artery can involve the common,

profunda, or superficial femoral arteries. The most common type of isolated femoral artery aneurysm involves only the common femoral artery. These occurred in more than 80% of cases in a recent series of isolated femoral artery aneurysms. Isolated aneurysms of superficial femoral artery (14.4%) and profunda (4.6%) are less common. Among patients with common femoral artery aneurysms, if the aneurysm only involves the proximal common femoral artery, this is classified as *type I*. If the aneurysm extends to the orifice of profunda femoral artery, this is classified as *type II*. This classification, introduced by Cutler and Darling, is important, as the reconstruction of type II aneurysm is more complex than type I.

The exact natural history of true degenerative femoral artery aneurysm is unknown due to rarity of these aneurysms, and it is perhaps less benign that was initially reported. Femoral artery aneurysms are commonly asymptomatic in more contemporary series. It is possible that these aneurysms are currently being diagnosed earlier due to the use of more diagnostic studies for other clinical concerns.

Untreated, common femoral artery aneurysms may thrombose or cause distal embolization. These aneurysms rarely rupture. The nature of any symptoms is related to the specific location of these aneurysms. Thrombosis of these aneurysms can lead to limb loss and has been reported in up to 15% of older studies. However in a more recent case series, thrombosis rate was noted to be present in only 1% of patients. Femoral aneurysms at other locations can present with thrombosis or rupture. About 50% of aneurysms in the profunda femoral artery and one third of superficial femoral artery aneurysms rupture. The higher propensity of rupture is perhaps related to deeper location of these aneurysms that may delay diagnosis until these deeper aneurysms are larger and therefore perhaps more prone to rupture.

Clinical Manifestations

The clinical manifestations of femoral artery aneurysms have changed over the past few decades. In the most contemporary series, about 60% of the aneurysms repaired on asymptomatic patients were detected by physical examination or by unrelated diagnostic studies. This is in contradistinction to older studies, some of which found only 40% of the cases were performed on asymptomatic patients with 42% of cases operated on patients with severe ischemic consequences of femoral artery aneurysms. In contemporary series, the most common symptom was the

presence of a palpable mass. Local pain due to the enlarging aneurysm was seen in 10% of patients. In large contemporary series, ischemic symptoms ranged from mild (e.g., claudication, 22%) to severe (e.g., rest pain, 1%). In older series, 42% of femoral artery aneurysm repair was performed for severe ischemic complications of these aneurysms. Embolization (10%) is reported among patients with femoral artery aneurysms and should be in the differential diagnosis among patients with spotty discoloration of their toes in the presence of palpable distal pulses. The rate of thrombosis and rupture for isolated common femoral artery aneurysm is 1% to 6% in multiple series. Leg edema secondary to venous obstruction due to the aneurysm dilation of the adjacent artery is a very rare clinical manifestation of these aneurysms.

Diagnosis

The physical examination finding of a pulsatile mass in the groin may increase the suspicion of femoral artery aneurysm. Physical examination can be misleading if a patient is morbidly obese, the examiner is unfamiliar with the vascular exam, the aneurysm is small or thrombosed or in presence of groin lymphadenopathy.

Radiographic studies such as duplex ultrasound, computed tomography angiography (CTA), or magnetic resonance angiography (MRA) can reliably confirm the diagnosis and the diameter of the aneurysm when there is clinical suspicion. In contemporary series, patients were often diagnosed with femoral artery aneurysm while they are undergoing diagnostic tests for unrelated pathology. Conventional angiography is not very precise in detecting aneurysms or for size measurements and provides only limited size information due to the presence of lumen in the dilated artery. Conventional angiography and CTA are helpful in the operative plan by defining the vascular anatomy particularly if complex reconstruction is required.

Indication for Treatment

Symptomatic femoral artery aneurysms are treated operatively regardless of the size of the aneurysm. In symptomatic cases, repair is indicated to alleviate the antecedent limb-threatening ischemia, local pain, or to remove the source of distal embolization. The current recommendation for treatment of asymptomatic femoral artery aneurysm is repair of the aneurysm when it reaches a diameter of 2.5 cm in patients of acceptable risk. Aneurysms <2.5 cm can be observed by routine ultrasound performed

at regular intervals. The size was chosen because the rate of complications of aneurysms <2.5 cm is reported to be only 1% to 2% annually. Special consideration is also given to smaller aneurysms if they are filled by thrombus.

Most practitioners perform a careful examination for occult symptoms (e.g., embolization) and obtain a Duplex every 6 months to follow patients with these smaller aneurysms (<2.5 cm). The development of symptoms, change in the distal pulse examination, or aneurysmal enlargement is also an indication for operative treatment. Recent studies challenge these size recommendations among asymptomatic patients. In a recent large case-series study, aneurysms >4 cm were associated with increased risks of developing symptoms. This study may, therefore, challenge the current size indication for repair, but further studies are warranted and at the current time, asymptomatic common femoral artery aneurysm >2.5 cm should be electively repaired.

Surgical Therapy and Preoperative Planning

The basic principal behind surgical therapy is resection of the aneurysm and re-establishment of the flow to the lower extremity. In the setting of patients with multiple aneurysms, repair should be staged. Aneurysm surgery for aorta and popliteal artery takes precedent over femoral artery aneurysm in cases of patients with multiple aneurysms unless the femoral artery repair is planned as part of the aorta or PAA repair.

In the patients undergoing endovascular abdominal aorta repair (EVAR), formal exposure of the aneurysmal femoral artery for the introduction of aortic stent and interposition of the aneurysmal femoral artery is indicated at the conclusion of successful EVAR. If open aortic surgery is contemplated and aortofemoral bypass is required, the femoral anastomosis must be performed to an interposition graft after the replacement of the aneurysmal femoral artery. A similar principal applies if the aneurysmal femoral artery is the inflow vessel for a femoropoliteal or femorotibial bypass graft performed for ischemia. No anastomosis should be performed to an aneurysmal femoral artery, as this anastomosis will degenerate. As part of the surgical planning, the arterial anatomy of patient’s circulation must be delineated prior to surgical intervention. This often requires a lower extremity angiogram or CT angiogram.

Surgical Technique

As noted above, the principal basis is resection of aneurysm and

establishment of blood flow to the lower extremity. The surgical techniques and options, therefore, depend on the location of the femoral artery aneurysm. The femoral artery exposure is performed by making a vertical groin incision. If the proximal extent of the aneurysm involves the very proximal common femoral artery, retroperitoneal exposure of the external iliac artery may be required for proximal arterial control. Endovascular control of the distal external iliac artery is possible using percutaneous placement of a balloon through a contralateral femoral artery approach.

For isolated type I common femoral artery aneurysms, distal control may involve controlling the distal common femoral artery or the proximal superficial femoral and profunda femoris arteries. After systemic heparinization and proximal and distal arterial control, the aneurysm is entered. After removing the thrombus, end-to-end reconstruction of the artery is performed using Dacron or expanded polytetrafluroethylene (ePTFE). This graft is sewn to the proximal normal common femoral artery and distally to normal distal common femoral artery or the femoral bifurcation. Smaller aneurysms may be resected, whereas large aneurysms resection may be difficult and they are often left in place. They can be wrapped around the graft to avoid serous fluid collection.

For type II common femoral artery aneurysms, the repair depends on the extent to which the aneurysm involves profunda or superficial femoral arteries. If the profunda and common femoral arteries are involved, an interposition graft between the normal common femoral and profunda is created and the superficial femoral artery is implanted on the side of this graft. Similarly, if the superficial femoral artery is aneurysmal, the interposition graft between normal common and superficial femoral artery is created and the profunda femoris is implanted on the side of this graft.

In patients with lower extremity symptoms or thrombosis of the common and superficial artery, bypass operations and thrombectomy may also be required. In selected symptomatic cases, infusion of catheter-directed thrombolytic agents or endovascular mechanical thrombectomy may be tried prior to open operative technique. Given the ease of femoral artery exposure, this is rarely needed.

Endovascular repair of the common femoral artery has been reported. Endovascular repair may include coil embolization of the artery or use of covered stent grafts. Endovascular intervention should be performed very cautiously and only in selected cases. This is due to the location of the

common femoral artery aneurysm and its proximity to the inguinal ligament, hip flexor, and profunda femoral artery. Stent graft coverage of common femoral artery aneurysm may lead to blockage of the profunda and stent fracture. Profunda femoral artery aneurysm can be treated by coil embolization of feeding arteries and occlusion of the aneurysm provided there is adequate collateral circulation. Covered stents can also be used in the proximal superficial femoral artery or the profunda femoral artery, but as this will lead to a change in the collateral flow, it should be performed cautiously and only in selected cases, such as in patients with many comorbidities who may not be able to tolerate open surgical intervention.

Results

Long-term results are dependent on the quality of distal circulation. In asymptomatic femoral artery aneurysms, 85% 5-year patency results are reported. In symptomatic patients with lower extremity ischemia, the 5-year patency is lower with about 70% of cases achieving good long-term results. The overall postoperative mortality rate for open common femoral artery aneurysm is low (2% to 5%).

Femoral Artery Pseudoaneurysms

In contradistinction to true aneurysms, false aneurysms or pseudoaneurysms are caused by an arterial defect. Blood exits the artery through this defect and swirls in a space composed of surrounding soft tissue and thrombus instead of the three layers that compose the arterial wall and are present in any true aneurysm. Arterial defects can be caused due to injury (e.g., iatrogenic such as postinstrumentation) (Fig. 202.1), infection (mycotic femoral aneurysm), or anastomotic disruption (Fig. 202.2).

Post-Instrumentation Femoral Artery Pseudoaneurysms

Incidence and Risk Factors

The incidence of iatrogenic pseudoaneurysm of femoral artery has risen significantly due to the increased number of peripheral vascular interventions. The common femoral artery is the most common artery used for peripheral interventions, and pseduoaneurysm occurs in 0.6% to 6% of femoral interventions. The incidence increases with the use of postprocedure antiplatelet or anticoagulation medications. Other risk factors are female gender, use of larger sheaths for peripheral interventions

(>7 French), combined artery and vein access, obesity, faulty puncture technique (“high stick”), poor manual compression or failure of the arterial closure device, presence of calcified vessels, hypertension, and patients with chronic renal failure who are on hemodialysis. Use of vascular ultrasound during arterial access has significantly decreased the rate of femoral artery pseudoaneurysm formation. Percutaneous closure devices have also been shown to decrease the rate of arterial injuries by a factor of 10 during interventional procedure where larger sheaths are used.

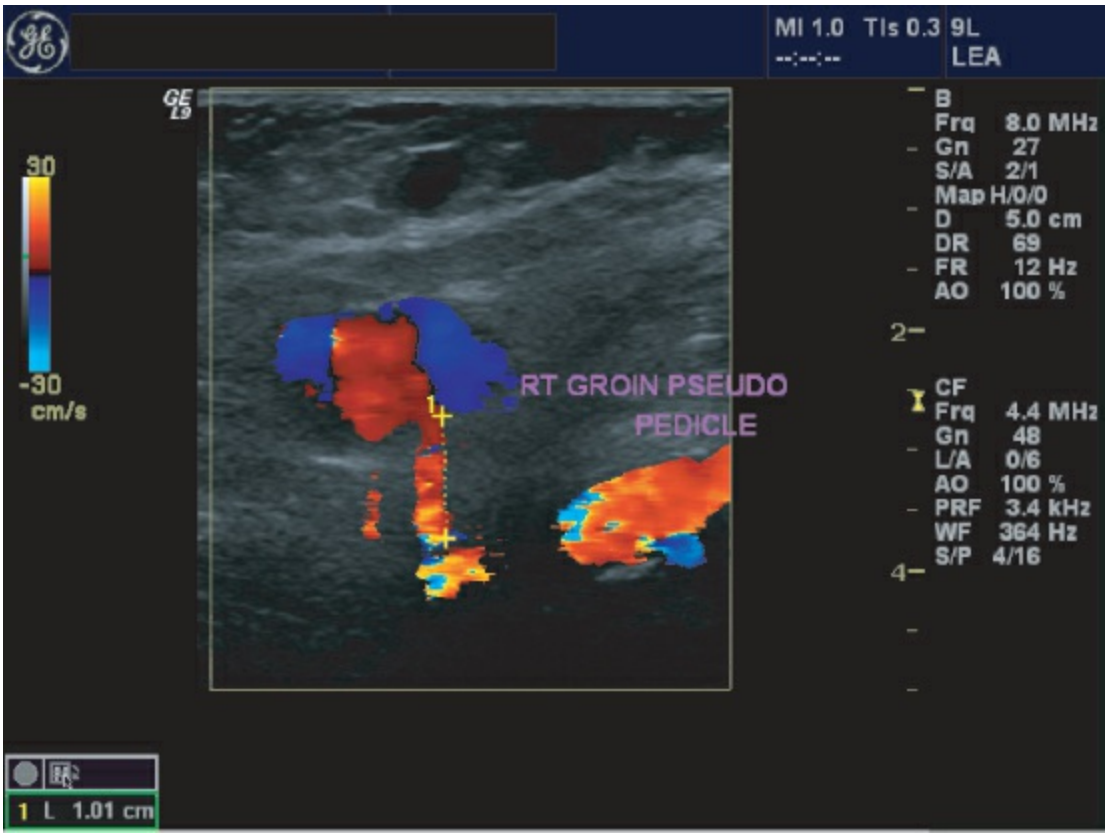

Figure 202.1. Duplex of femoral pseudoaneurysm after arterial catheterization.

Natural History

Many femoral pseduoaneurysms resolve spontaneously, and this is directly related to the size of the false aneurysms and patient’s anticoagulation status. In one series, 90% of aneurysms <3 cm were thrombosed by 23 days, but this rate decreased to 56% in another series in the presence of anticoagulation. Current guidelines suggest that pseudoaneurysms <2 cm can be safely observed with routine ultrasound examination to evaluate for thrombosis. The aneurysms that do not thrombose may enlarge, which may lead to rupture and distal embolization, as well as necrosis of the skin

overlying larger aneurysms. Aneurysm >2 cm or those that do not thrombose require repair.

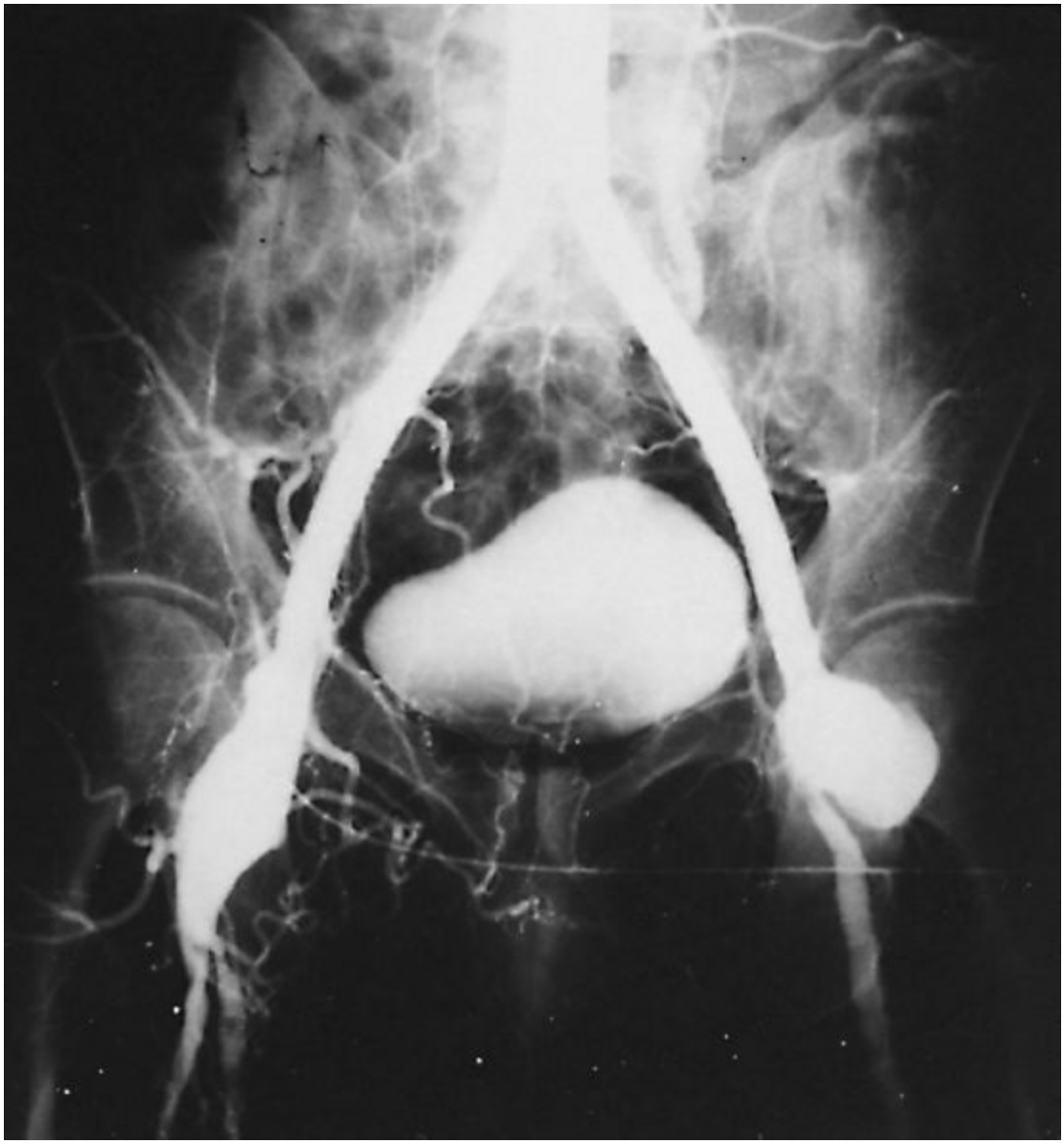

Figure 202.2. Angiogram demonstrating anastomotic femoral pseudoaneurysms after aortobifemoral bypass.

Clinical Manifestations

Patients may present with a pulsatile mass, pain over the femoral access, femoral thrill or bruit, neuralgia from nerve compression, or edema from common femoral vein compression. If the psedoaneurysm is large, patients may also present with skin ischemia and necrosis. Large psedoaneurysms may also present with arterial thrombosis or distal embolization resulting in lower extremity ischemia.

Diagnosis

In addition to physical examination, duplex ultrasound is the most common radiographic study used to confirm the diagnosis of femoral artery pseuduoaneurysm. This study has 94% sensitivity and 97% specificity (Fig. 202.3). In addition, duplex provides information about the size, location, and degree of thrombosis of pseduoaneurysm. Duplex also provides information about the presence of arteriovenous fistula and the size of pseduoaneurysm's neck (diameter and length; Fig. 202.3) CT scan with contrast can also be used for diagnosis, but this is more costly and incurs radiation exposure.

Treatment

The three modalities used to treat femoral artery pseduoaneurysm are ultrasound-guided compression, ultrasound-guided thrombin injection, and surgery. Endovascular interventions have been attempted, and these include direct coil embolization or fibrin glue injection and placement of covered stents across the injured femoral artery. Pseuduoaneurysms that are <2 cm may be observed with repeat ultrasound; and if they become larger, they may need treatment.

Ultrasound-Guided Compression

Ultrasound-guided compression can be used to treat femoral artery pseuduoaneurysms. This technique was introduced in 1991 and is effective for smaller aneurysms (<3 cm) that have a neck visible by ultrasound. The neck is identified by ultrasound and pressure is applied directly to the neck of the psedoaneurysm by the ultrasound probe to cause cessation of flow into the pseduoaneurysm sac on Doppler imaging. Pressure is held in cycles of 10 to 20 minutes. The sac is evaluated for thrombosis; and if no thrombosis is noted, then another cycle is repeated. After the second cycle, if the sac is still patent, patients should receive another treatment. If sac has thrombosed, the patient is placed on bed rest and duplex is repeated in 24 to 48 hours to ensure continued pseduoanaeurysm thrombosis.

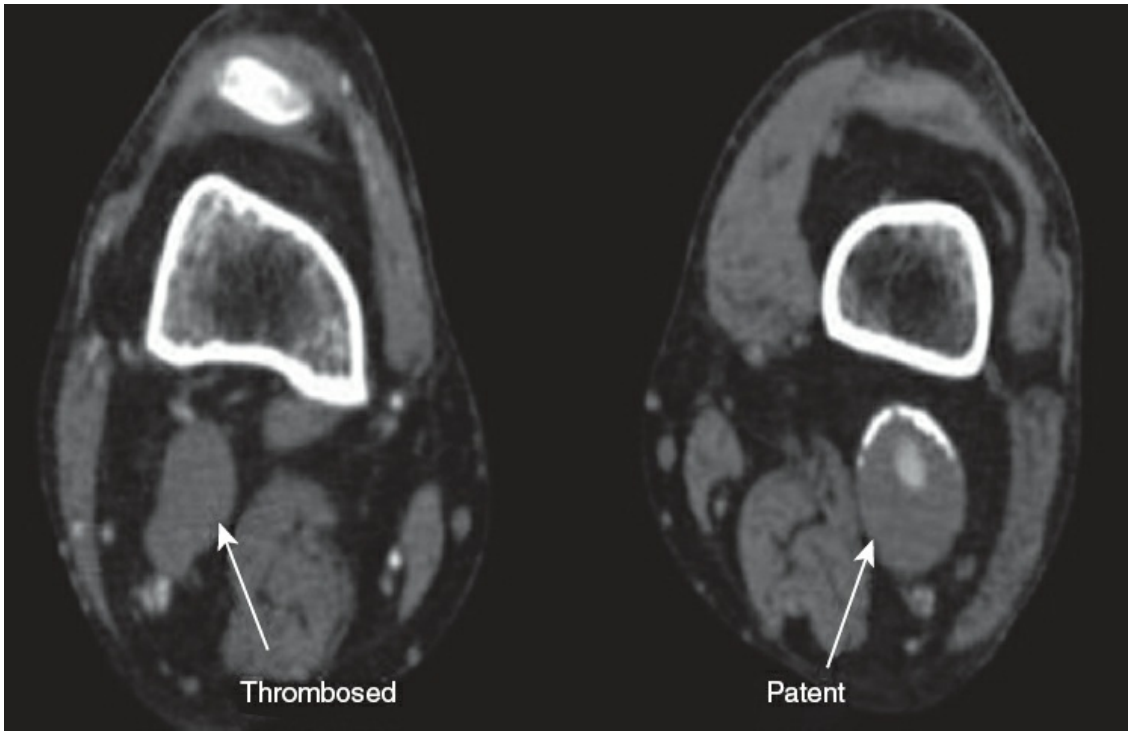

Figure 202.3. A patient with bilateral PAA presented with ischemic symptoms related to thrombosed right PAA and asymptomatic left PAA.

Success rates using this technique are reported to be 66% to 86% with 30 to 44 minutes of compression, but this decreases to 44% when the patient is on anticoagulation. This technique is not well tolerated by most patients secondary to the application of pressure in a traumatized and sensitive area, which often requires sedation and pain control. Another drawback is that there is a 4% risk of recurrence in addition to complications related to the procedure, such as sac rupture, femoral artery occlusion and lower extremity ischemia, and hypotension (vasovagal during compression or due to sedation). Factors that lead to failure, in addition to anticoagulation, include large body habitus and the larger-sized pseudoaneurysms. Given these drawbacks, this technique has been largely replaced by ultrasound-guided thrombin injection as the nonoperative procedure of choice in most instances.

Ultrasound-Guided Thrombin Injection

This technique is a more reliable and better-tolerated nonoperative choice of treatment for most femoral artery pseudoaneurysms. Since thrombin directly converts fibrinogen to fibrin and is not affected by heparin or warfarin, patient's anticoagulation status does not affect the success of this

intervention. In this technique, the pseduoaneurysm is identified by duplex (Fig. 202.3) and is directly punctured under ultrasound guidance by a needle directed away from the pseduoaneurysmal neck after the application of local anesthesia. Then 0.1 to 0.2 mL of 1,000 units/mL of thrombin is slowly injected over 10 to 15 seconds. If thrombosis does not occur, a second injection may be needed. As soon as thrombosis is noted, the injection is stopped to avoid propagation of thrombosis into the femoral artery. After thrombosis, patient is placed on bed rest and the pesduoaneurysm is evaluated by Duplex to assure persistent thrombosis. Additional injections may be required. In cases in which the neck is large, and patient is a poor surgical candidate, an angioplasty balloon may be placed at the neck of the pseduoaneurysm and dilated while thrombin injection is applied. This helps to avoid thrombin propagation in the femoral artery or distal embolization.

The success rates of ultrasound-guided thrombin injection are reported to be 90% to 100% with a recurrence rate of 3%. Complication rates of 0% to 4% are reported and include distal embolization, groin abscess, femoral artery thrombosis, and anaphylaxis in patients previously treated with thrombin injection. Distal embolization should be treated initially by institution of intravenous heparin. If symptoms do not resolve quickly, catheter-directed thrombolysis is added. Pseduoaneurysms with short (<2 mm) or wide (>5 mm) necks should not be treated by this technique, and these patients should be treated with open surgical repair. Other contraindications to ultrasound-guided thrombin injection are skin necrosis or patients with infection, allergy to bovine thrombin or history of thrombin injection, presence of arteriovenous fistula, lower extremity ischemia, and pregnancy.

Surgical Management

The indications for open surgical repair of femoral pseduoaneurysms are large pseduoaneurysms, those with large and short neck, presence of skin necrosis and infection, pseudoaneurysm rupture and expansion, lower extremity ischemia, and when nonoperative therapies fail. Surgical technique involves proximal and distal control of the pseudoaneurysm, which is achieved by a vertical groin incision positioned over femoral artery. Proximal control may require open retroperitoneal exposure of the external iliac artery or balloon control via a contralateral femoral access. Distal control may require individual control of the superficial and profunda femoral arteries. In a stable patient, the sac should not be entered

without proximal and distal control as this may cause significant bleeding in patients who often have other comorbidities. In the presence of rupture, the sac may be entered and manual compression is applied while arterial control is achieved. Once proximal and distal control is achieved, the patient is heparinized, vessels are controlled, and the sac is entered. After evacuation of sac contents, the femoral artery should be repaired. This often may require simple suture closure with one or two stitches using 5-0 or 6-0 prolene sutures. If the femoral artery defect is larger, the wall may be repaired using a vein patch or prosthetic patches, such as bovine pericardium. In rare cases, an interposition graft may be required if artery is badly damaged. Every effort should be made to use autogenous vein when patch angioplasty or interposition graft is required.

Anastomotic Pseudoaneurysms of Femoral Artery (APFA)

Incidence and Risk Factors

Disruption of the arterial anastomosis may cause separation of the graft from the host artery and leads to pseduoaneurysm formation. Since the femoral artery is the most common inflow or outflow vessel, this is the most common site of anastomotic pseduoaneurysm accounting for 80% of these pseduoaneurysms. This is often a late complication of vascular bypass and is seen on average 6 years after bypass procedure. Femoral artery pseduoaneurysm affects 3% of all femoral anastomoses and 6% of the aortobifemoral procedures. Among patients with infrainguinal bypass procedures, the highest incidence is seen among patients with prosthetic conduits. This is observed in 6% of the cases with PTFE conduits and 0.9% of cases with Dacron conduits. In addition to the conduit choice, other risk factors for creation of anastomotic pseudoaneurysm are patients with chronic obstructive pulmonary disease, patients who are current smokers, and those with a postoperative groin infection.

Natural History

These aneurysms should be repaired once they are diagnosed as they enlarge and may lead to rupture and loss of graft and possible significant lower extremity ischemia.

Clinical Manifestations and Diagnosis

The majority of these aneurysms are painless, and patients may notice them during examination as a painless pulsatile mass in the groin incision. Any evidence of infection must be investigated by ruling out any overt

sign and symptoms of infection. Symptoms suggestive of infection include fever, chills, night sweats, and pain. Signs of infection include erythema, sinus tract formation, drainage and tenderness of the pulsatile mass, elevated white blood cell count, and positive blood cultures.

To further rule out infection, CTA is performed of the entire graft to rule out any evidence of air or fluid surrounding the graft. Other tests to rule out infection, such as white blood cell scan, can be used if CTA is not diagnostic, but many false positives make this test difficult to interpret. Angiographic studies may be helpful in operative planning and can show anastomatic pseudoaneurysms (Fig. 202.4).

Treatment

Treatment depends on the presence or absence of infection. If no infection is documented, simple resection of the pseduoaneurysm with reconstruction of the anastomosis is warranted. This may be performed safely with prosthetic material. If the pseudoaneurysm is infected, the repair is more complicated. The principal is resection of the infected material, and revascularization must be performed using autologous vein or prosthetic material through noninfected tissue planes. Treatment of the infected anastomotic pseudoaneurysm depends on the extent of infection. For example, if infection is localized to the distal segment of a limb of aortobifemoral bypass graft, the pseudoaneurysm is resected. If the proximal portion of the limb is well incorporated, this can be chosen for inflow and distally the graft is tunneled through the obturator foramen to a distal location. If the proximal portion of aortobifemoral bypass graft is also infected, resection of the entire graft is necessary. Options to perform in-line revascularization or extranatomic revascularization are often performed in two stages. Overt femoral artery infection may necessitate bilateral axillo-profunda or axillo-popliteal bypass grafts prior to aortic graft removal. After closure of the wounds, the infected aortobifemoral bypass graft is removed and the aortic stump is oversewn. Often this is performed in two stages 24 to 48 hours apart. In-line flow can also be achieved performing neo-aortoiliac system (NAIS) using superficial and deep femoral veins bilaterally. This operation, which is championed by Clagett and his colleagues at UT Southwestern, requires the exposure of bilateral superficial and deep femoral veins, which are then resected and sewn together to create an NAIS. Other authors have used cadaveric artery homografts or rifampin-soaked bifurcated Dacron grafts for in-line revascularization after resection of the infected graft. In both cases,

patients need to be on long-term antibiotics and closely observed for aneurysm degeneration and reinfection of the graft.



Figure 202.4. A patient with “blue toe” syndrome from PAA.

In the case of infected femoral-distal bypass grafts, graft resection and repair of femoral artery is the most common mode of initial therapy. If revascularization is indicated, use of vein bypass graft should be the primary choice with the extra-anatomic bypass revascularization with alternative conduit when no autologous vein is available. When there is no sign of infection during preoperative evaluation, the treatment is resection

of the pseudoaneurysm after proximal and distal control and reconstruction of the femoral artery anastomosis, which may require interposition graft repair of damaged common femoral artery.

Even with no signs of infection, the graft may appear to be unincorporated upon exploration indicating graft infection; the most common causative organism is *Staphylococcus epidermidis.* This is a nonvirulent, slime-producing organism. The graft infection can often be managed with resection of the graft to well-incorporated material, debridement of infected arterial wall and soft tissue, and interposition grafting with ePTFE that is generally thought to be more resistant to infection than Dacron. Authors have recommended using a sartorius flap to wrap the graft. This sartorial rotation flap is created by mobilizing the sartorius and dividing it from its attachment on the iliac spine, and then rotating it over the femoral graft and tacking it in place with absorbable sutures.

If frank pus is found on exploration, or if the infection is secondary to a Gram- negative organism, such as *Pseudomonas*, then complete resection of infected material and revascularization through noninfected field is required. In this situation, a sartorial flap is still used to help protect the oversewn femoral vessels from blowout.

Mycotic Femoral Aneurysms

The term “mycotic aneurysm” is currently used to refer to any infected aneurysm. Mycotic aneurysms today are often a complication of parental drug abuse, but can follow arterial trauma of any form, including invasive diagnostic and therapeutic procedures. In the past, septic emboli from bacterial endocarditis were the major cause of mycotic aneurysm degeneration, but this is less common today. With the advent of antibiotics, aneurysms secondary to syphilis or tuberculosis are rare. With this shift in etiology, the location of mycotic aneurysms has shifted from central to peripheral arteries with the femoral artery being the most common site. The importance of mycotic aneurysms is based on their propensity to rupture.

Pathogenesis

The pathogenesis of mycotic aneurysms can be divided into four major categories, although other less common causes also exist. First, septic emboli from bacterial endocarditis may lodge in normal arteries, causing infection that weakens the arterial wall, resulting in aneurysm formation.

These lesions are often multiple. Second, during an episode of bacteremia, microorganisms may lodge in a preexisting atherosclerotic plaque or aneurysm and begin to multiply with the same result. Third, mycotic aneurysms are caused by contiguous spread of bacteria from a local abscess. The inflammatory process destroys the arterial wall, causing pseudoaneurysm formation. Finally, trauma to the artery with concomitant contamination may result in formation of an infected pseudoaneurysm. Mycotic aneurysms are currently being seen more frequently, coincident with the increased use of catheter-based procedures. Bacteria may be introduced concomitantly with needle puncture or by migration during prolonged arterial catheterization, for example, in patients who may require indwelling catheters for thrombolysis. Mycotic aneurysms accompanying drug abuse may be secondary to direct contamination of the arterial wall, or they may result from destruction of the vessel wall by a local abscess.

The bacteriology of arterial infections depends upon the cause of the lesion. Aneurysms secondary to bacterial endocarditis grew *Pneumococcus*, *Streptococcus*, and *Enterococcus* species most frequently in the past, but recently, organisms such as *Staphylococci*, *Salmonella*, *Escherichia coli*, and *Proteus* have also been cultured. *Staphylococcus aureus* is the most common pathogen in mycotic femoral artery aneurysm secondary to trauma and drug abuse, occurring in >65% of cases. In this population, at least 50% of the *S. aureus* organisms are resistant to methicillin.

Clinical Manifestations

The typical patient with a mycotic femoral aneurysm presents with a history of chills and fever, and a tender, enlarging, pulsatile groin mass. The patient may have a history of intravenous drug use, recent arterial catheterization, penetrating trauma, or bacterial endocarditis. Local signs of infection, including tenderness, erythema, and warmth are noted on physical examination. Lower extremity edema may occur secondary to venous or lymphatic obstruction. Petechial skin lesions, splinter hemorrhages, cutaneous abscesses, and septic arthritis may occur as a result of emboli originating from a mycotic aneurysm. A “sentinel bleed” may occur and indicates risk of impending rupture and life-threatening hemorrhage. Emergency surgery is indicated.

Diagnosis

The diagnosis of a mycotic aneurysm is usually straightforward, but distinguishing an abscess adjacent to the femoral artery from a femoral mycotic aneurysm may be difficult. In the patient with a pulsatile groin mass, laboratory findings including leukocytosis, elevated erythrocyte sedimentation rate, while positive blood cultures are suggestive, but not specific, for a mycotic aneurysm. Multiple blood cultures or downstream arterial blood cultures may be necessary to yield positive results. Ultrasonography and CT angiography are helpful in establishing the diagnosis of an aneurysm, but lack precision in distinguishing infected from bland aneurysms. The diagnosis of a mycotic aneurysm is confirmed at operation by the demonstration of organisms on Gram stain or by positive cultures of the aneurysm wall.

Treatment

Mycotic aneurysms represent a serious life- and limb-threatening disease because their natural history is one of expansion and rupture. Therefore, mycottic aneurysms must be addressed surgically. First, the goal of treatment is eradication of the infection by excision of the aneurysm and debridement of adjacent infected tissue as well as by long-term antibiotic therapy. Second, adequate distal circulation must be restored. Before operative intervention is performed, the patient is started on antibiotics that are modified based on sensitivity testing of intraoperative cultures. Stent grafts have been used in selected cases of mycotic aneurysms when other approaches were not feasible; however, concern about latent infection of the stent graft often renders this as a bridging technique rather than a long-term solution.

The complexity of the operative procedure varies with the location and extent of the mycotic aneurysm. Although a direct approach to the femoral artery may be taken, retroperitoneal exposure of the distal external iliac artery for proximal control is sometimes preferred for large or proximal femoral lesions to avoid excessive hemorrhage. As noted above, with large pseudoaneurysms of the femoral artery, proximal control can be achieved using an angioplasty balloon. When an infected femoral artery aneurysm is confined to only one arterial segment (common, superficial, or deep femoral artery), the aneurysm is excised and the proximal and distal arteries are ligated in emergent situations. In those cases in which an isolated arterial segment is ligated, severe ischemia resulting in amputation is unusual. In >50% of cases, however, the mycotic aneurysm involves the femoral artery bifurcation, and treatment requires resection of the femoral

bifurcation and debridement to healthy arterial wall. The distal external iliac or proximal common femoral artery, as well as the superficial and deep femoral arteries, is oversewn with nonabsorbable monofilament suture. This results in significant ischemia in most patients, but with the patient heparinized, symptoms gradually improve as collateral circulation increases. The majority of patients will not need revascularization for limb salvage, but up to one third of patients may have limb-threatening ischemia. In patients in whom sepsis can be adequately controlled at the initial procedure, aggressive debridement may be followed by immediate revascularization using autogenous saphenous vein graft as the conduit and covering the graft with a sartorius muscle flap. Another option is to observe patients for 24 hours after arterial ligation and selectively revascularize only those patients in whom limb-threatening ischemia persists. Use of prosthetic material is avoided because of the high incidence of early and late septic complications, although they can occasionally be necessary through uninfected tissue planes, such as the obturator or lateral femoral route. Antibiotics are begun preoperatively and are continued for at least 6 weeks postoperatively. Endovascular interventions have no role in the treatment of mycotic aneurysms, except for possibly obtaining proximal control when the aneurysm is too large.

Popliteal Artery Aneurysm

PAAs are the most common peripheral artery aneurysms accounting for 85% of all peripheral artery aneurysms. Although the initial reports of the treatment for PAAs were for syphilitic PAAs, contemporary PAAs are true degenerative aneurysms.

Normal Anatomy and Size

The distal extension of the superficial femoral artery is called the popliteal artery as the artery exits the opening in the adductor magnus distally and enters the popliteal fossa. The artery courses lateral to the intercondylar fossa of femur, and then distally travels behind the knee and between the two heads of gastrocnemius and popliteus muscle. It is a relatively short artery, and most of the branches are in the supra-geniculate portion of the artery. The artery can be approached both medially and laterally. At the lower border of the popliteus muscle, it divides into the tibial arteries.

The popliteal artery is slightly smaller than the femoral artery and is considered aneurysmal when it is 2 cm or 1.5 times the normal caliber.

Incidence and Risk Factors

PAA is the most common peripheral artery aneurysm and is reported in 1% of men aged 65 to 80 years and is often associated with other aneurysms. In >50% of cases, these aneurysms are bilateral and are associated with AAA (40% to 50% of cases) or femoral artery aneurysms (40% of cases). Conversely, PAA is observed in 6% to 14% of patients who present with abdominal aorta aneurysm.

The most common cause of PAA is atherosclerotic degeneration, but other causes including Marfan syndrome, Behçet disease, and mycotic degeneration may also lead to aneurysm changes of popliteal artery. The typical patient with a popliteal aneurysm is a male in his 60s or 70s with the usual risk factors for atherosclerosis. Of patients with popliteal aneurysms, 50% to 75% are smokers, 40% to 60% have hypertension, and about 15% have diabetes mellitus. Other manifestations of cardiovascular disease are also common, with 10% of patients having manifestations of cerebrovascular disease and >40% having evidence of significant cardiac disease.

Natural History

The natural history of popliteal aneurysms is not well delineated. These aneurysms show a differential annual rate of enlargement that depends on the diameter of the PAA at the time of diagnosis. Although many of these aneurysms do not enlarge, those <2 cm enlarge at a rate of 0.7 to 1.5 mm/yr whereas those >2 cm enlarge at higher rate (1.5 to 3.7 mm/yr). In asymptomatic patients with PAA >2 cm, about 25% develop complications related to embolic or thrombotic events within the 1st year of diagnosis. Left untreated at 5 years, about 70% of these patients develop ischemic symptoms ranging from embolic episodes to thrombotic limb-threatening events. Given these observations, current treatment recommendation is for aneurysms >2.0 cm. This may be challenged given that a large population-based study shows the median diameter of PAA when symptoms developed was when these aneurysms were 3 cm (range of 1.4 to 4.6 cm). In addition to popliteal artery aneurysm size, since the presence of thrombus within popliteal aneurysm is a significant risk factor for developing ischemic symptoms, has led some authors to suggest repairing smaller aneurysms if there is significant thrombus burden in the PAA (Fig. 202.5) particularly when the arterial outflow is poor.

Clinical Manifestation

The clinical manifestations of PAAs range from an asymptomatic pulsatile mass to severe lower-extremity ischemia. The majority of patients are symptomatic with patients presenting with symptoms of limb ischemia, usually claudication, but the ischemia may be more advanced and manifest as rest pain or gangrene. Local symptoms, including sensation of a posterior knee mass, local pain, and leg swelling or phlebitis secondary to compression of the adjacent vein, account for the remainder of symptoms. A PAA may be complicated by thrombosis, embolization, or rarely rupture. Thrombosis is reported in 40% of patients, and embolization occurs in about 25% of cases. Some patients present with classic "blue toe syndrome (Fig. 202.4)," but more commonly, repeated episodes of embolization occlude the outflow vessels and result in thrombosis of the aneurysm. Rupture occurs in <5% of popliteal aneurysms, and in these cases the hemorrhage is usually confined to the popliteal space, thus permitting surgical intervention and arterial reconstruction in a timely fashion. Rupture or thrombosis of PAA, however, is a limb-threatening event with amputation rates of 50% to 70% in some series. The asymptomatic cases are often diagnosed during screening of patients for other aneurysm disease.

Diagnosis

The diagnosis of PAA is usually first suspected on physical examination. Palpation of the popliteal space with the knee flexed reveals a pulsatile mass in approximately two thirds of patients. Small aneurysms may not be palpable on physical examination, and if thrombosis has occurred the mass may not be palpable. Radiographs of the knee demonstrating a calcified arterial wall occasionally suggest the diagnosis of a PAA, but duplex ultrasonography, CT, or magnetic resonance imaging (MRI) must confirm it. These diagnostic modalities can establish the diagnosis of PAAs and exclude other entities that could be responsible for a nonpulsatile popliteal fossa mass (tumor or Baker cyst). Ultrasonography, CT, or MRI is also useful in the detection of associated aneurysms, particularly abdominal aortic and femoral artery aneurysms. Angiography can be misleading in the diagnosis of aneurysms because intraluminal thrombus may obscure the true size of the vessel; however, it is essential for visualization of the inflow and outflow vessels necessary for revascularization, and it is a reasonable option if thrombolytic options are contemplated for a thrombosed PAA. CT angiography can be a noninvasive way to provide this information (Fig. 202.5).



Figure 202.5. CT angiography of popliteal artery aneurysm in right lower extremity.

Treatment

The choice of treatment depends on the size and presence of symptoms. Asymptomatic PAA <2.0 cm are managed conservatively with duplex every 6 months until these become >2.0 cm or develop symptoms. For those asymptomatic aneurysms >2.0 cm, the aneurysm can be repaired by open surgical repair (Fig. 202.6) or endovascularly using covered stents (Fig. 202.7).

Most PAAs are easily approached through standard medial thigh and calf incisions for exposure of the distal superficial femoral artery and the distal popliteal artery, respectively (Fig. 202.6A). The proximal

anastomosis will need to originate from normal proximal popliteal artery or distal superficial femoral artery. The distal anastomosis is to the normal distal popliteal artery. The artery intervening is ligated. The choice of conduit is greater saphenous vein, in reversed configuration, which is tunneled anatomically. The disadvantage of this approach is that the feeding branches may not be ligated and the aneurysm continues to receive collateral flow and enlarge. For this reason, authors have suggested a prone or posterior approach to these aneurysms (Fig. 202.6B) that allows direct oversewing of the feeding branches after the aneurysm sac is entered. In this approach, the patient is placed in prone position and an S-shaped incision is used behind the knee with the superior longitudinal portion on the posteromedial aspect of the lower thigh, horizontal portion across the flexion crease and the inferior portion laterally. The deep fascia is then divided vertically and anteromedially, and the popliteal vein is identified with popliteal artery as its immediate lateral structure. The artery is controlled and the aneurysm sac is entered, and all the feeding vessels are oversewn. Because of the size mismatch between the popliteal artery and the greater saphenous vein, an interposition graft with ePTFE or Dacron is often used. Overall open surgical repair results are excellent with 5-year graft patency rates in excess of 85%.

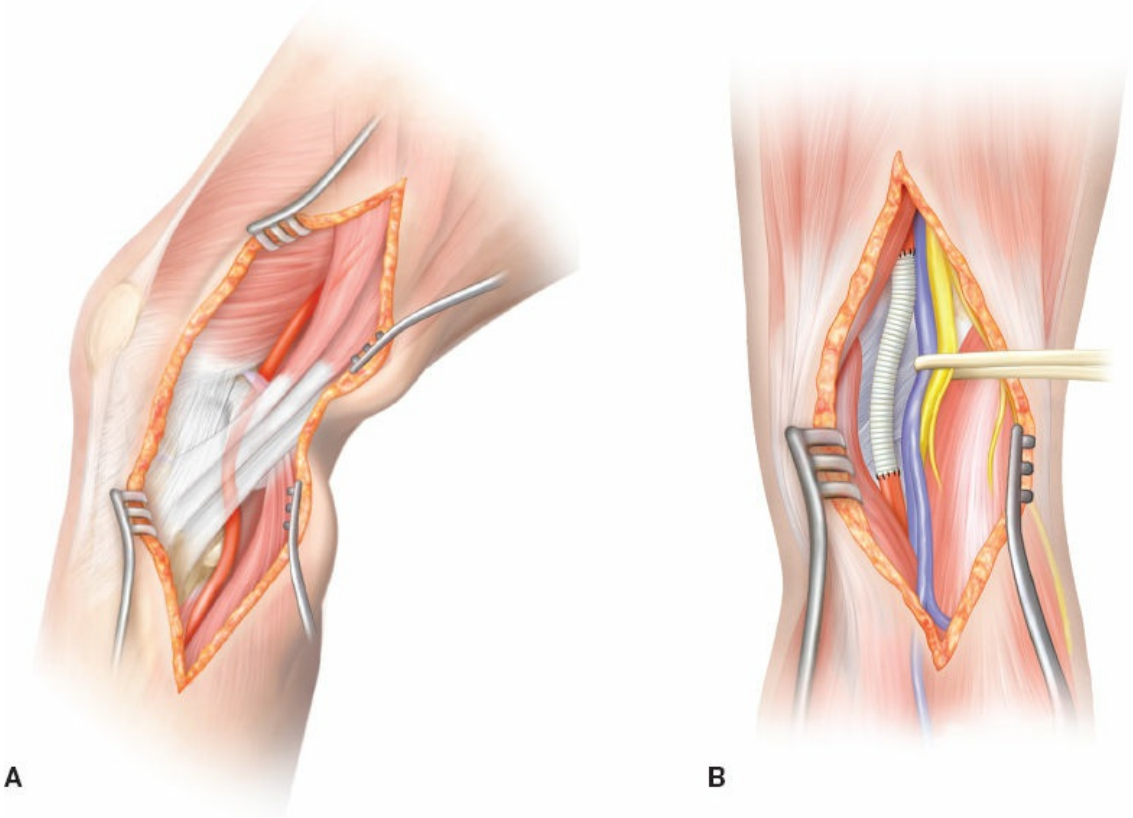

Figure 202.6. Open popliteal artery aneurysm repair. **A.** Supine approach to PAA repair. **B.** Prone approach to PAA repair.

An alternative to open surgical repair is the use of a covered stent graft and exclusion of the aneurysm endovascularly (Fig. 202.7). This is a less invasive procedure and can be performed in antegrade or retrograde fashion with local anesthesia. The artery is crossed and covered stent(s) proximally from normal artery to distal artery excludes the aneurysm sac. Similarly excellent results are reported in both single center analyses and metanalyses with complications being stent fracture, thrombosis, and endoleak. A prospective randomized trial is ongoing to address if one modality is better than the other. In a retrospective analysis of the largest series of asymptomatic PAAs, however, we should note that open repair outcomes were better than endovascular options. Ultimately the role of endovascular repair will be better defined in the future.

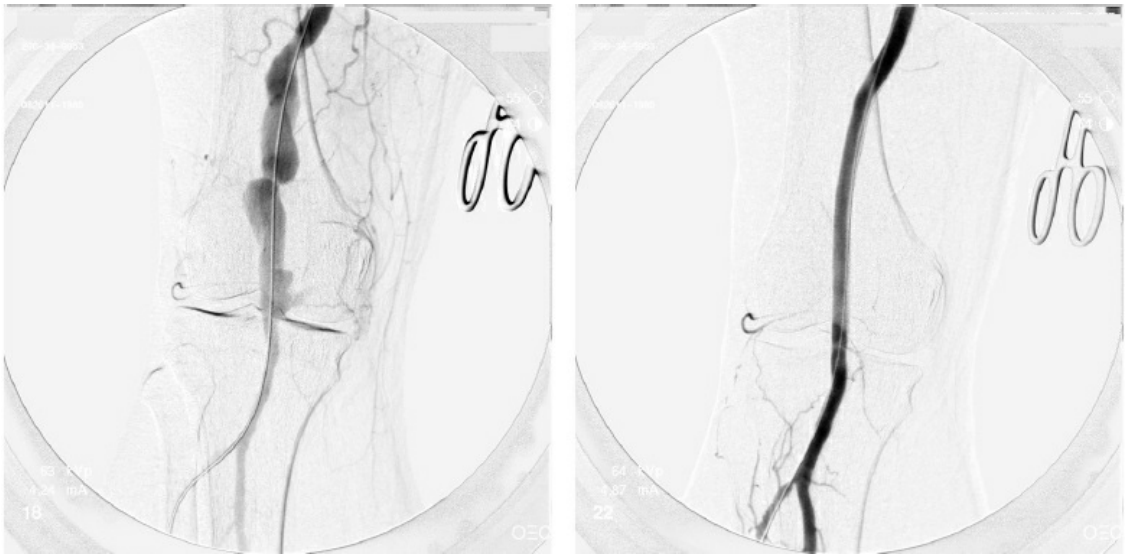

Figure 202.7. Endovascular repair of a large asymptomatic PAA. (Courtesy of Dr. Andres Fajardo from Indiana University.)

For thrombosed PAA, the initial therapy consists of infusion of catheter-directed thrombolysis or open surgical embolectomy and surgical revascularization. Successful catheter-directed thrombolysis is then followed with urgent operative repair. The success of surgical repair and limb salvage depends on the degree of ischemia and the status of the outflow vessels. For patients with Rutherford class I or IIa, excellent graft patency rates of 68% to 100% and limb salvage rates of 73% to 100% are reported. In patients who present with more severe ischemic symptoms,

the amputation rate is significantly higher.

Suggested Readings

Aulivola B, Hamdan AD, Hile CN, et al. Popliteal artery aneurysms: a comparison of outcomes in elective versus emergent repair. *J Vasc Surg* 2004;39:1171–7.

Clagett GP, Bowers BL, Lopez-Viego MA, et al. Creation of a neo-aortoiliac system from lower extremity deep and superficial veins. *Ann Surg* 1993;218:239–49.

Eslami MH, Doros G, Goodney PP, et al. Using vascular quality initiative (VQI) as a platform for organizing multicenter, prospective, randomized clinical trials: OVERPAR trial. *Ann Vasc Surg* 2015;29(2):278–85.

Eslami MH, Rybin D, Doros G, et al. Open repair of asymptomatic popliteal artery aneurysm is associated with better outcomes than endovascular repair. *J Vasc Surg* 2015;61:663–9.

Galland RB. Popliteal aneurysms: from John Hunter to the 21st century. *Ann R Coll Surg Engl* 2007;89:466–71.

Hall HA, Minc S, Babrowski T. Peripheral artery aneurysm. *Surg Clin North Am* 2013;93:911–23.

Johnson ON 3rd, Slidell MB, Macsata RA, et al. Outcomes of surgical management for popliteal artery aneurysms: an analysis of 583 cases. *J Vasc Surg* 2008; 48:845–51.

Kalish J, Eslami M, Gillespie D, et al. Routine use of ultrasound guidance in femoral arterial access for peripheral vascular intervention decreases groin hematoma rates. *J Vasc Surg* 2015;61:1231–8.

Lawrence PF, Harlander-Locke MP, Oderich GS, et al. The current management of isolated degenerative femoral artery aneurysms is too aggressive for their natural history. *J Vasc Surg* 2014;59:343–9.

Levi N, Schroeder TV. Arteriosclerotic femoral artery aneurysms. A short review. *J Cardiovasc Surg (Torino)* 1997;38:335–8.

Lovegrove RE, Javid M, Magee TR, Galland RB. Endovascular and open approaches to non-thrombosed popliteal aneurysm repair: a meta-analysis. *Euro J Vasc Endovasc Surg* 2008;36:96–100.

Magee R, Quigley F, McCann M, et al. Growth and risk factors for expansion of dilated popliteal arteries. *Euro J Vasc Endovas Surg* 2010;39:606–11.

Ravn H, Bergqvist D, Bjorck M, et al. Nationwide study of the outcome of popliteal artery aneurysms treated surgically. *Br J Surg* 2007;94:970–7.

EDITOR'S COMMENT

The management of popliteal artery aneurysms has evolved much like the management of all vascular disease, especially the treatment of aneurysm pathology. Unlike aortic aneurysms that are more prone to rupture, I always tell patients popliteal artery aneurysms won't kill you. Instead they will leave you with an above knee amputation when the popliteal artery aneurysm clots off, after chronically embolizing to your outflow tibial vessels insidiously over time. Unlike aortic aneurysms that tend to rupture as they get larger, popliteal artery aneurysm can embolize and thrombose even when they are small (Mousa AY, Beauford RB, Henderson P, et al. Update on the diagnosis and management of poplitealaneurysm and literature review. *Vascular* 2006;14[2]:103–8). They almost always occur in men with hypertension, and are common in patients with abdominal aortic aneurysms (AAA). Ultrasound of the femorals and popliteal arteries likely should be part of the standard preoperative workup of any male patient with an AAA, as the incidence of femoral and popliteal artery aneurysms is 14% in patients with AAA (Diwan A, Sarkar R, Stanley JC, et al. Incidence of femoral and popliteal artery aneurysms in patients with abdominal aortic aneurysms. *J Vasc Surg* 2000;31[5]:863–9). It should be noted that a popliteal artery aneurysm on one side is also predictive of one in the other leg and aortoiliac artery aneurysms (Whitehouse WM Jr, Wakefield TW, Graham LM, et al. Limb-threatening potential of arteriosclerotic popliteal artery aneurysms. *Surgery* 1983;93[5]:694–9). This is the fodder by which many in service and board questions are made.

I have classically approached popliteal artery aneurysms from a medial approach. The medial approach makes the harvest of the greater saphenous vein easier, and usually these patients can have a short above knee to below knee popliteal artery bypass. Patency rates for these bypasses approach 90% at 5 years, assuming that the conduit and outflow are good and you can sew to the below knee popliteal artery (Upchurch GR Jr, Gerhard-Herman MD, Sebastian MW, et al. Improved graft patency and altered remodeling in infrainguinal vein graft reconstruction for aneurysmal versus occlusive disease. *J Vasc Surg* 1999;29[6]:1022–30). We examined a large series of these bypasses a number of years ago, and there is clearly something different about the veins in these patients (Upchurch GR Jr, Gerhard-Herman MD, Sebastian MW, et al. Improved graft patency and altered remodeling in infrainguinal vein graft reconstruction for aneurysmal versus occlusive disease. *J Vasc Surg* 1999;29[6]:1022–30). Much like the dilated arteries, the veins tend to be large when harvested and continue to dilate over time, leading to a patency advantage over time compared with bypasses done for peripheral arterial disease.

There are reports of using a medial approach to the popliteal artery for bypass with proximal and distal ligation, where the aneurysm continues to enlarge and can cause compressive symptoms on the nerve or the vein (Ebaugh

JL, Morasch MD, Matsumura JS, et al. Fate of excluded popliteal artery aneurysms. *J Vasc Surg* 2003;37[5]:954–9). I have had to go in posteriorly and open an excluded popliteal artery aneurysm and oversew geniculate arteries from inside the aneurysm sac. This actually does not happen that often and it is sort of fun to do, so I would not even hardly consider this a disadvantage in using the medial approach.

Others swear by repairing popliteal artery aneurysms from a posterior approach. The operation is eloquent for sure, but harvesting the saphenous vein from a medial approach and then flipping the patient prone and doing a posterior approach to the popliteal artery are honestly sort of painful. I also rarely find patients with such a small segment of popliteal artery that is aneurysmal where this is effective. The one place where I do like this approach is when the patient has poor or no autogenous venous conduit. A posterior approach with an in-line replacement is a good operation. I have not had patients complain of increased pain with this approach, even though historically people have said this was a more painful approach.

Finally, the issue about whether an endovascular approach is as good as an open approach was the attempted subject of a randomized trial by Dr Eslami (Eslami MH, Rybin D, Doros G, et al. Open repair of asymptomatic popliteal artery aneurysm is associated with better outcomes than endovascular repair. *J Vasc Surg* 2015;61[3]:663–9; Eslami MH, Doros G, Goodney PP, et al. Using vascular quality initiative as a platform for organizing multicenter, prospective, randomized clinical trials: OVERPAR trial. *Ann Vasc Surg* 2015;29[2]:278–85). I have placed plenty of stent grafts behind the knee for popliteal artery aneurysms, and I am sure that the long-term patency is not as good as a vein graft. However, they are likely to be useful in a subset of patients who are elderly and have good outflow. The use of Plavix postintervention seems to be associated with better patency (Tielliu IF, Verhoeven EL, Zeebregts CJ, et al. Endovascular treatment of popliteal artery aneurysms: results of a prospective cohort study. *J Vasc Surg* 2005;41[4]:561–7).

Gilbert R Upchurch Jr.

203 Treatment of Splenic Artery Aneurysms: Open and Endovascular

Dawn M. Coleman and Gilbert R. Upchurch, Jr.

ETIOLOGY AND PATHOPHYSIOLOGY

While rare, splenic artery aneurysms (SAAs) are the most common of splanchnic artery aneurysms, accounting for approximately 60% of such, and the third most common intra-abdominal arterial aneurysm (Fig. 203.1). The prevalence of these aneurysms among the general population is estimated as 0.16% to 0.8%. Women are affected two to four times more often than men with multiparity being a well-recognized risk factor.

Hormonal and local hemodynamic events likely contribute to the evolution of SAAs, as illustrated by the etiologic classification system proposed by Stanley et al. that implicates arterial dysplasia, portal hypertension, local inflammation, and hormonal and hemodynamic events in their pathogenesis.

More than half of patients with SAAs are also afflicted with hypertension. Approximately 20% will demonstrate concurrent aneurysms affecting alternate arterial beds. Additional risk factors for true aneurysms include septic emboli, polyarteritis nodosa, systemic lupus erythematosus, and connective tissue disorders; splenic pseudoaneurysms are typically attributed to chronic pancreatitis, pseudocyst, and trauma.

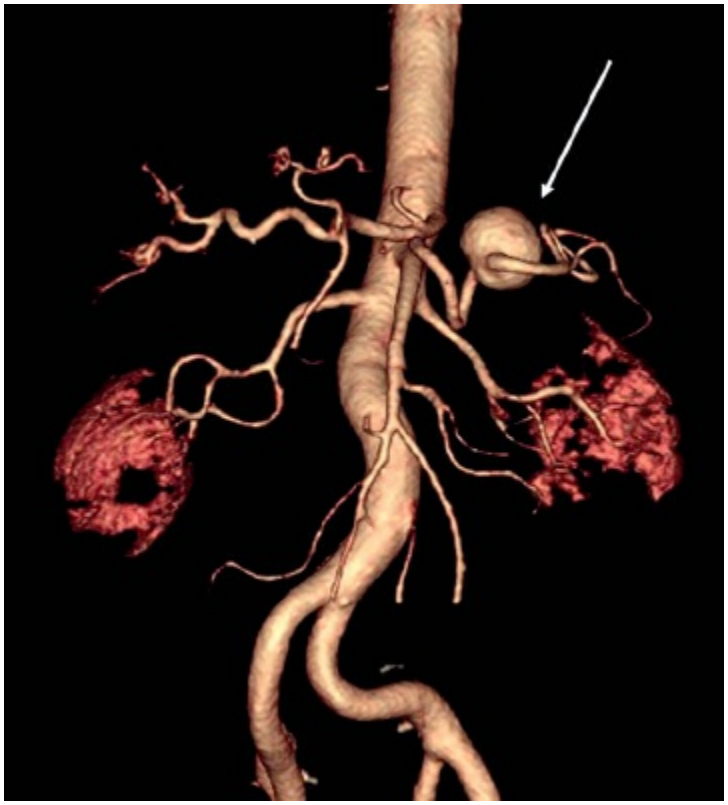

Figure 203.1. CT-angiogram with three-dimemsional reconstruction demonstrating a >3-cm aneurysm affecting the mid-splenic artery.

The majority (80%) of splenic aneurysms are solitary and saccular. Aneurysm location is typically at a distal branch point of the main splenic artery, tortuosity of which is common. These aneurysms are often calcified and may contain mural thrombus; the calcification is felt to reflect a secondary event.

CLINICAL PRESENTATION AND NATURAL HISTORY

Like most splanchnic aneurysms, SAAs rarely produce symptoms. These aneurysms are most often detected as an incidental finding by cross-sectional imaging for unrelated disease. In addition, a curvilinear, signet ring-like calcification in the left upper quadrant by roentgenography may prompt the diagnosis. When symptoms are described, vague epigastric or left upper quadrant discomfort is most commonly described.

Rupture complicates approximately 2% to 5% of SAAs, and the risk of such appears unrelated to age, blood pressure, and aneurysm calcification. Splenic aneurysms typically rupture into the lesser sac with limited self-containment and tamponade; later hemorrhage into the peritoneal cavity

through the foramen of Winslow results in cardiovascular collapse (i.e., “double rupture” presentation). Contemporary aneurysm growth rates are estimated 0.2 mm/year and while increased levels of aneurysmal peripheral calcification are associated with smaller aneurysm size at the time of diagnosis, like rupture risk calcification appears to have no impact on aneurysm growth. Historic rupture-associated mortality rates approached 25% to 70%; more contemporary series suggest mortality rates <25%, likely reflecting improvements in peri-operative care and the increasing utility of endovascular techniques. In comparison, rupture-associated mortality dramatically increases (up to 75%) in the peri-partum with fetal mortality rates that approach 100%. Gestational rupture occurs mainly during the third trimester. While historically a strong association between pregnancy and splenic aneurysm rupture has been reported, a contemporary series reporting on >67,000 consecutive live births over 5 years identified no cases of SAA rupture. Rupture risk is also increased twofold by liver transplantation, the mortality following which is 50%.

INDICATIONS FOR INTERVENTION

Indications for treatment include rupture, symptoms, size >2.0 to 2.5 cm, and any size asymptomatic aneurysm at the time of liver transplantation or in women of childbearing age. Endovascular therapy has become the standard of care for the elective management of SAAs and for cases offering decreased early morbidity, mortality, and hospital length of stay. Open surgical techniques are reserved primarily for pregnant patients (to avoid irradiation) and those who have failed efforts at percutaneous endovascular embolization.

PREOPERATIVE PLANNING

Cross-sectional imaging, mainly in the form of computed tomography angiography (CTA), is invaluable for procedural planning (Fig. 203.2). Axial imaging will identify the angle of the celiac artery origin, tortuosity of the splenic artery, and aneurysm number and location. These factors may influence the complexity of the procedure, the vascular access site (i.e., femoral vs. brachial artery), and available equipment for percutaneous embolization. Those patients with an iodinated contrast allergy require appropriate pretreatment, typically with anti-histamine and steroid therapy; alternative contrast agents may be considered (i.e., carbon dioxide).



Figure 203.2. Reformatted CT-angiogram of a single splenic artery aneurysm.

In cases of elective and planned splenectomy, vaccinations against the encapsulated bacteria *Streptococcus pneumonia*, *Haemophilus influenza*, and *Neisseria meningitides* (i.e., *Meningococcus*) should be administered preoperatively. Patients should be counseled accordingly on the <0.5% per year risk of overwhelming postsplenectomy infection (OPSI) (lifetime risk of 5%) and its associated 50% mortality rate.

OPEN SURGICAL TECHNIQUE

Aneurysm location should dictate surgical approach (Fig. 203.3). While a vertical midline laparotomy incision will yield exposure for most aneurysms, an extended right subcostal incision facilitates exposure of the proximal splenic artery and a left subcostal incision facilitates exposure of the distal splenic artery and hilum for the intent of splenic mobilization and splenectomy. Arterial ligation and aneurysm excision are preferable when technically feasible as this facilitates splenic preservation and host immunity. Arterial reconstruction is not required because splenic viability is maintained through short gastric arterial collaterals. Proximal SAAs are best exposed through the lesser sac following mobilization of the left lateral hepatic lobe and division of the gastroheptic ligament along the

lesser curve of the stomach. Arterial in-flow and out-flow branches are ligated, and the aneurysm should be excised if not embedded within pancreatic tissue. For aneurysms of the mid-splenic artery that are embedded within pancreatic tissue, the aneurysm should at a minimum be opened to ensure that all branches are ligated; alternatively the mid-splenic artery may be exposed from a retroperitoneal approach that includes pancreatic mobilization and anteromedial elevation. Distal SAAs and those affecting the splenic hilum are best visualized with splenic mobilization. While simple suture obliteration of small distal and hilar SAAs when technically feasible facilitates splenic preservation at the cost of downstream segmental splenic infarction, those patients with multiple and peri-hilar aneurysms may in fact require splenectomy.

Laparoscopic and robotic techniques at ligation, aneurysm resection, and splenectomy have become commonplace alternatives to open surgery offering negligible risk of open conversion, need for reoperation, and mortality.

ENDOVASCULAR SURGICAL TECHNIQUE

After percutaneous femoral access is obtained, the celiac artery can often be cannulated without formal aortography. In cases of a severe celiac angulation or extensive femoral artery disease burden, brachial artery access may be considered. Celiac arteriogram will identify the splenic artery with any associated tortuosity or coils along with aneurysm location; these factors will govern the mode of aneurysm exclusion (Fig. 203.4). Embolization with coils, gelfoam, glue, thrombin, and vascular plugs has been advocated for saccular aneurysms with narrow necks, while larger vessels with complex wide-neck aneurysms may be better approached with covered stents or stent-assisted coil embolization.

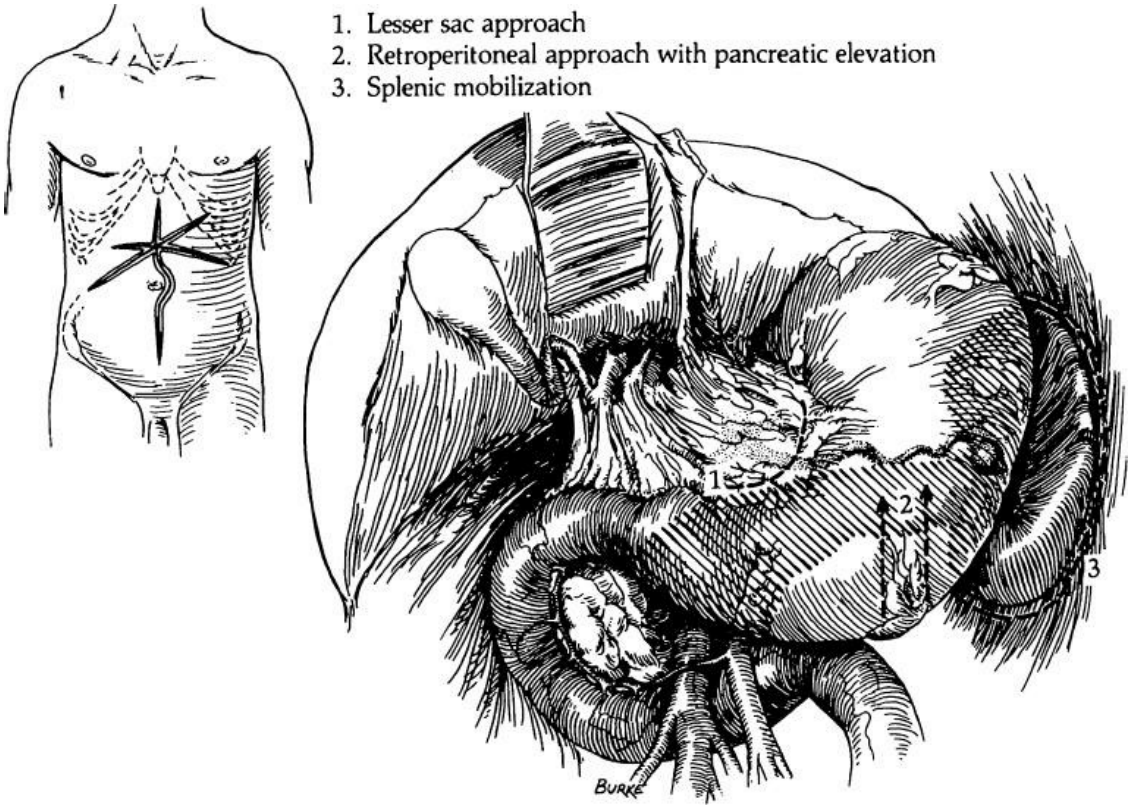

Figure 203.3. Surgical approaches in patients with splenic artery aneurysms include extended right subcostal, left subcostal or transverse epigastric, and vertical midline incisions. Specific intra-abdominal exposure depends on the location of the splenic artery aneurysm.



Figure 203.4. Splenic arteriogram demonstrating a mid-splenic artery aneurysm with mild vascular tortuosity.

For those proximal aneurysms without associated excessive splenic

artery tortuosity, the artery distal to the aneurysm is selected; to secure this platform, a long sheath is typically positioned into the celiac artery or proximal splenic artery when possible. Vascular plugs or a covered stent may be deployed for aneurysm exclusion. Given the size and stiffness of these current devices, their use is limited in those patients with splenic arterial tortuosity and distal or hilar aneurysms. It is far more common to build a more advanced platform for highly tortuous splenic arteries and for those aneurysms affecting the distal splenic artery. With a sheath positioned in the celiac axis and a catheter positioned within the proximal splenic artery (Fig. 203.5), a microcatheter is used to select the outflow branches of such aneurysms (Fig. 203.6). These outflow branches are embolized sequentially (Fig. 203.7); thereafter, the aneurysm sac is commonly packed with coils followed by the main splenic arterial inflow (Fig. 203.8). Care should be taken when employing glue (i.e., n-butyl-cyanoacrylate) for embolization to prevent reflux into the celiac axis. Technical success for endovascular treatment is 93% to 98%, limited primarily by vessel tortuosity that may be overcome with newer, steerable catheters and sheaths. Conversion to open surgery is rarely necessary to accomplish successful aneurysm exclusion.

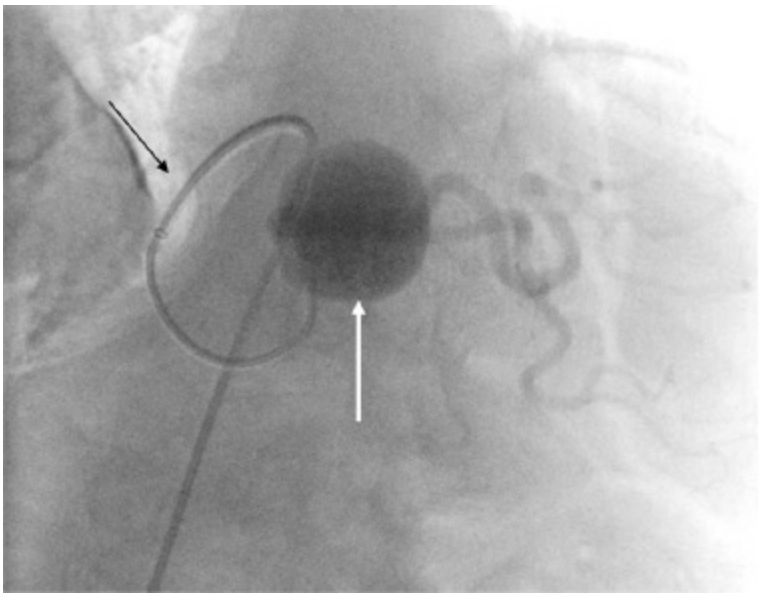

Figure 203.5. Selective catheterization of the splenic artery through sheath positioned in the celiac artery (*black arrow*); splenic arteriogram reveals a mid-splenic artery aneurysm (*white arrow*).

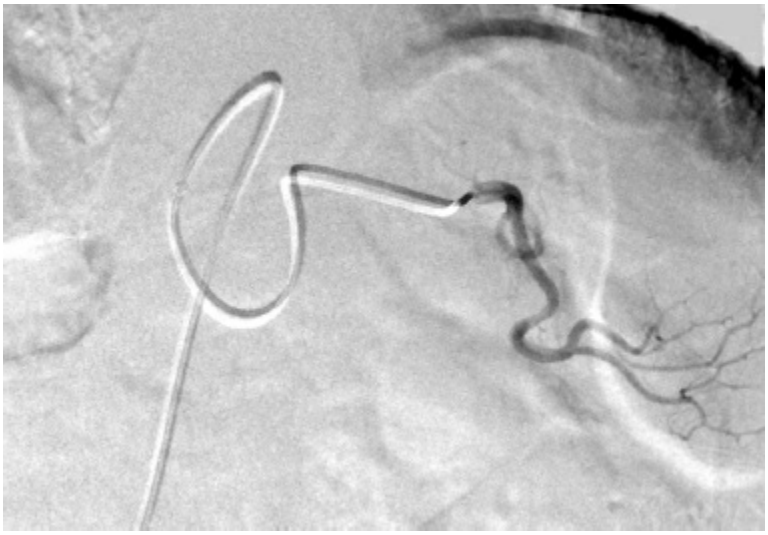

Figure 203.6. Outflow branch selection distal to a mid-splenic artery aneurysm.

COMPLICATIONS AND THEIR MANAGEMENT

Postembolization syndrome (PES) complicates up to 30% of cases and may result in left upper quadrant pain, fever, ileus, platelet dysfunction, leukocytosis, and pancreatitis. Imaging may or may not reveal radiographic evidence of splenic infarction. Up to 20% of patients will demonstrate major splenic infarct and may even require reintervention for splenic abscess by way of percutaneous drainage or splenectomy. This risk is increased in cases of portal hypertension.

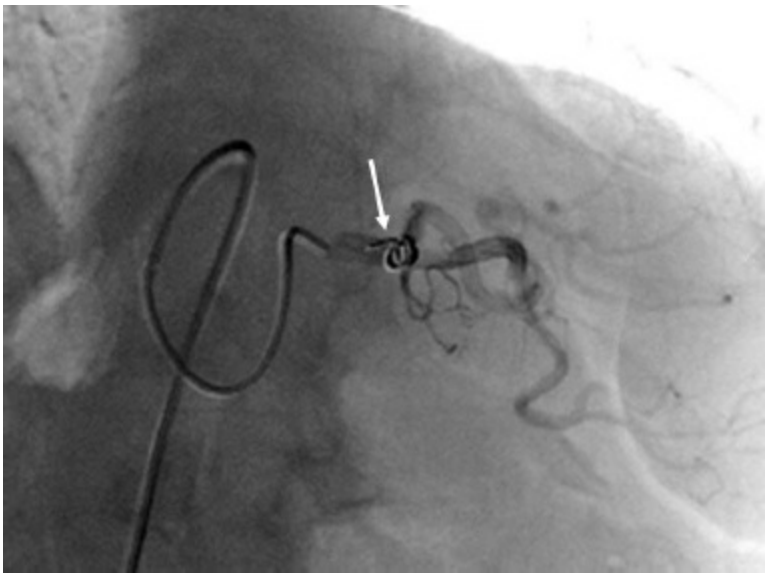

Figure 203.7. Coil embolization (*arrow*) of the main splenic artery outflow tract distal to the aneurysm.

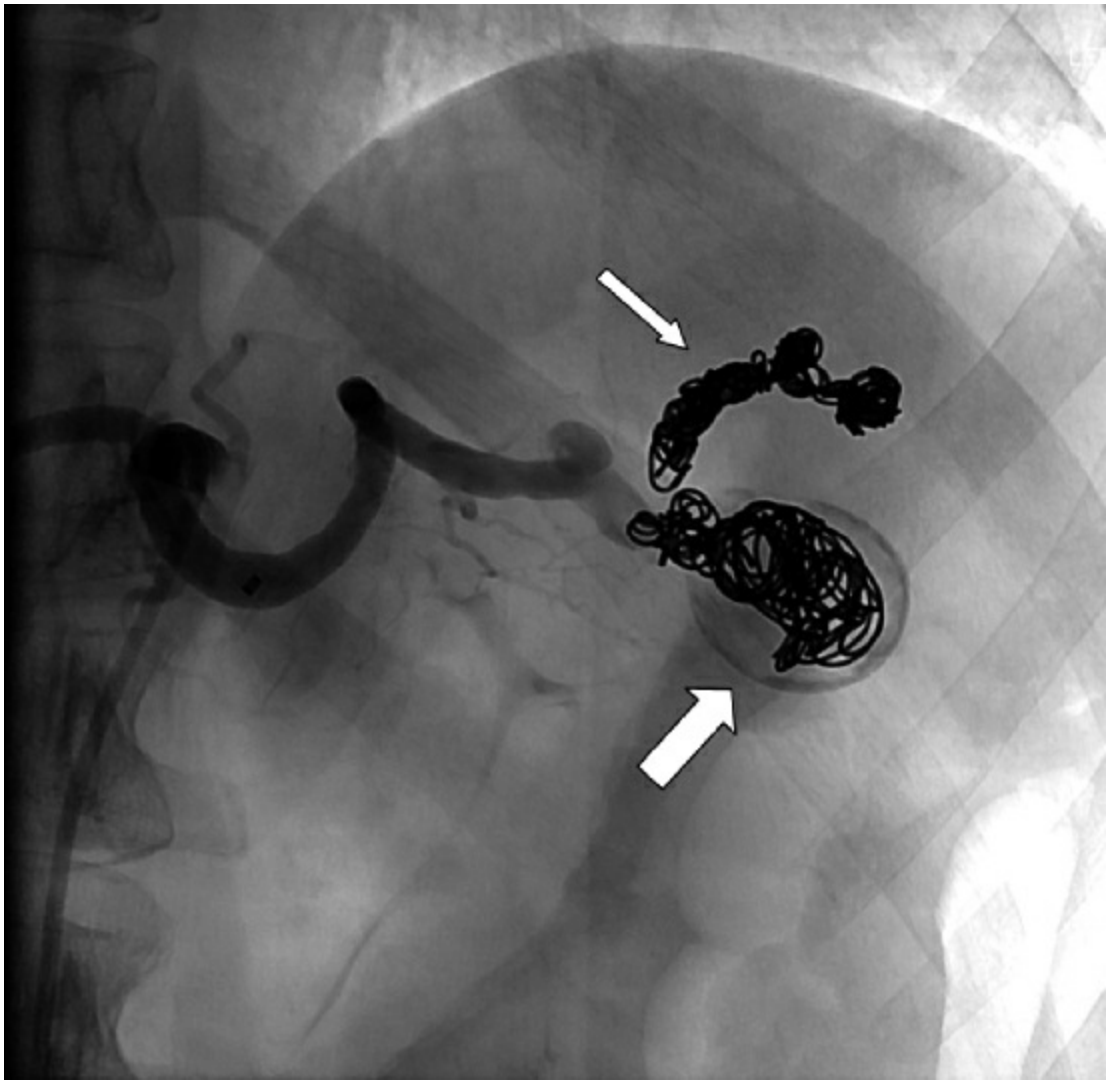

Figure 203.8. Calcified splenic artery aneurysm embolized by packing coils in the aneurysm and inflow tract (*large arrow*); coils in the outflow tract (*small arrow*).

OUTCOMES

Patients with splenic aneurysms have long-term survival rates that approach 90% at 10 years following aneurysm-directed treatments, and the ultimate cause of death is typically unrelated to the aneurysm. This point emphasizes the importance of durability in aneurysm treatment. Perioperative morbidity and mortality following open surgery are estimated as 9% to 25% and 1% to 5% respectively across series. Notably, a recent meta-analysis of splenic aneurysm treatments identified significantly greater technical success and greater 30-day mortality following open repair in comparison to endovascular aneurysm exclusion, which offered higher rates of acute minor complications, late

complications, and need for reinterventions. Long-term postembolization imaging is warranted to assess for aneurysm recanalization with cross-sectional imaging, although follow-up imaging is complicated by artifact produced by radiopaque embolization material (Fig. 203.9). Following successful embolization, an average aneurysm size regression rate of 1.5 mm/year has been demonstrated. The incidence of late complication following embolization is <4%, but this is associated with a 3% rate of reintervention per year.



Figure 203.9. Follow-up CT scan of a splenic artery aneurysm after coil embolization. Note the streaking artifact that complicates vascular interpretation.

Suggested Readings

Giulianotti PC, Buchs NC, Coratti A, et al. Robot-assisted treatment of splenic artery aneurysms. *Ann Vasc Surg* 2011;25:377–83.

Heestand G, Sher L, Lightfoote J, et al. Characteristics and management of splenic artery aneurysm in liver transplant candidates and recipients. *Am Surg* 2003;69:933–40.

Hogendoorn W, Lavida A, Hunink MG, et al. Open repair, endovascular repair,

and conservative management of true splenic artery aneurysms. *J Vasc Surg* 2014;60:1667–76.

Lakin RO, Bena JF, Sarac TP, et al. The contemporary management of splenic artery aneurysms. *J Vasc Surg* 2011;53:958–64; discussion 65.

Nanez L, Knowles M, Modrall JG, et al. Ruptured splenic artery aneurysms are exceedingly rare in pregnant women. *J Vasc Surg* 2014;60:1520–3.

Pasha SF, Gloviczki P, Stanson AW, et al. Splanchnic artery aneurysms. *Mayo Clin Proc* 2007;82:472–9.

Patel A, Weintraub JL, Nowakowski FS, et al. Single-center experience with elective transcatheter coil embolization of splenic artery aneurysms: technique and midterm follow-up. *J Vasc Interv Radiol* 2012;23:893–9.

Pietrabissa A, Ferrari M, Berchiolli R, et al. Laparoscopic treatment of splenic artery aneurysms. *J Vasc Surg* 2009;50:275–9.

Piffaretti G, Tozzi M, Lomazzi C, et al. Splenic artery aneurysms: postembolization syndrome and surgical complications. *Am J Surg* 2007;193:166–70.

Sadat U, Dar O, Walsh S, et al. Splenic artery aneurysms in pregnancy—a systematic review. *Int J Surg* 2008;6:261–5.

Shukla AJ, Eid R, Fish L, et al. Contemporary outcomes of intact and ruptured visceral artery aneurysms. *J Vasc Surg* 2015;61:1442–7.

Stanley JC, Fry WJ. Pathogenesis and clinical significance of splenic artery aneurysms. *Surgery* 1974;76:898–909.

Stanley JC, Wakefield TW, Graham LM, et al. Clinical importance and management of splanchnic artery aneurysms. *J Vasc Surg* 1986;3:836–40.

EDITOR'S COMMENT

Splenic artery aneurysms (SAAs) remain the most common true visceral artery aneurysm. The standard teaching regarding the treatment of these aneurysms has been that they should be treated regardless of size in females of childbearing age. I think that is likely true as the downside to treatment in the elective setting is really negligible compared with the disastrous outcomes of pregnant women presenting with SAA rupture. In contrast, the much more common clinical scenario is to see a patient in the clinical setting with an SAA 1.8 cm in diameter with vague abdominal pain. While I recognize that there is a relatively low risk of aneurysm exclusion, I still believe that we treat too many SAAs because the majority of them are now treated endovascularly. I would suggest that we have likely lowered our threshold for therapy, given the lower short-term mortality and morbidity associated with coiling of SAA.

Part of my bias about how we manage SAAs is that the vascular low frequency disease consortium (VLFDC) has begun to study a number of these so-called rare vascular diseases, which we often use large, single center series with fewer ruptures to dictate global therapy. For example, recently the VLFDC has recently examined both renal artery aneurysms and femoral artery aneurysms, and the conclusion from both of these studies is that we are too aggressive based on a more extensive, multi-institutional natural history in that few of these rupture below 3 cm (Klausner JQ, Lawrence PF, Harlander-Locke MP, et al.; Vascular Low-Frequency Disease Consortium. The contemporary management of renal artery aneurysms. *J Vasc Surg* 2015;61(4):978–84; Klausner JQ, Harlander-Locke MP, Plotnik AN, et al. Current treatment of renal artery aneurysms may be too aggressive. *J Vasc Surg* 2014;59(5):1356–61; Lawrence PF, Harlander-Locke MP, Oderich GS, et al.; Vascular Low-Frequency Disease Consortium. The current management of isolated degenerative femoral artery aneurysms is too aggressive for their natural history. *J Vasc Surg* 2014;59(2):343–9).

It is difficult to find head-to-head comparisons of open versus endovascular therapy. Some series have compared open and endovascular therapy with conservative management of SAAs (Hogendoorn W, Lavida A, Hunink MG, et al. Open repair, endovascular repair, and conservative management of true splenic artery aneurysms. *J Vasc Surg* 2014;60(6):1667–76). As one might expect, more patients who present with rupture undergo open aneurysm repair/ligation and thus there is higher mortality associated with open repair. These series are often filled with institutional biases that often change temporally (i.e., open surgery in days past and endovascular therapy in present).

While not addressed in detail in this chapter, a recent report has heralded the laparoscopic approach as a potential new and preferred method to treat SAAs. In this study of 11 patients, laparoscopic aneurysmectomy of SAAs was described as a safe treatment method with good short- and long-term results (Małczak P, Wysocki M, Major P, et al. Laparoscopic approach to splenic aneurysms. *Vascular* 2016 Jan 1. doi: 10.1177/1708538116682164. [Epub ahead of print]). The authors also importantly highlight the observation that laparoscopy in most settings allows for permanent treatment of SAA, while maintaining splenic function. However, to the authors's credit they suggest that a complete evaluation of lapaoscopic SAA repair/treatment requires further research on a larger study group.

Finally, when I perform a search based on the terms follow-up and splenic artery and embolization, I note there are functionally no papers. Part of the issue is that there is no "gold standard" for coil materials used for these aneurysms as discussed in this chapter by Coleman. In addition, especially in the setting of postcoiling or embolization, it is really difficult to get good cross-sectional or ultrasound imaging of splenic artery aneurysms in terms of determining aneurysm diameter. I also believe that patients honestly think their aneurysm is "fixed" even when merely embolized. We know from the way we manage

cerebral artery aneurysms and how they are saccular and are primarily treated via embolization (just like SAAs) that a certain number of these aneurysms are incompletely coiled and can functionally reperfuse. The risk of course is that patients who believe they have had an SAA “treated” will present catastrophically with rupture (Kingma KD, van der Linden AN, Roumen RM. Rebleeding of a splenic artery aneurysm after coil embolisation. *Case Rep Surg* 2016;2016:1858461. Oct 31, 2016 [Epub ahead of print]).

Gilbert R. Upchurch, Jr.

C CHRONIC LOWER EXTREMITY OCCLUSIVE DISEASE

204 Aortofemoral Bypass

David C. Brewster

INTRODUCTION

The infrarenal abdominal aorta and iliac arteries are among the most common sites of occlusive atherosclerotic disease responsible for symptomatic arterial insufficiency of the lower extremities. Because atherosclerosis is a systemic process, patients with aortoiliac disease frequently have coexistent disease below the inguinal ligament. Nonetheless, the disease is usually segmental in distribution and therefore amenable to effective surgical treatment. Even in patients with significant concomitant infrainguinal disease, successful revascularization of the aortoiliac segment frequently leads to adequate improvement of ischemic symptoms.

Since the introduction of the initial methods of aortoiliac reconstruction more than 50 years ago, improvements in surgical techniques, graft materials, and perioperative care have all contributed to significant reduction of perioperative morbidity/mortality and excellent long-term results in terms of both graft patency and symptom relief.

INDICATIONS

The most common indications for aortoiliac revascularization are severe intermittent claudication and limb-threatening ischemia secondary to atherosclerotic occlusive disease involving the infrarenal aorta and both iliac systems. Almost all patients with severe ischemia manifested by rest pain or tissue loss are found to have multilevel disease involving the aortoiliac and infrainguinal arterial segments. In such patients, initial correction of inflow disease by aortoiliac revascularization is appropriate.

Establishing adequate flow to the profunda femoris affords satisfactory clinical relief of the ischemic symptoms in 75% to 80% of patients despite the uncorrected infrainguinal disease.

A less frequent but well-recognized indication is peripheral atheromatous embolization (blue toe syndrome) from proximal ulcerated atherosclerotic plaques in the aortoiliac system. If a likely source of such events can be identified by arteriographic evaluation, aortobifemoral bypass with exclusion of the native aortoiliac segment is often advisable, even if the lesions are not hemodynamically significant.

PREOPERATIVE ASSESSMENT

There are numerous options for revascularization in patients with aortoiliac disease. Selection of the most appropriate method depends largely on two factors: (a) the patient's surgical risk and (b) the extent and distribution of occlusive disease. Aortobifemoral bypass provides superior long-term results in terms of durability and sustained symptom relief. However, it is a major operative procedure that may not be well suited for patients with serious comorbid medical conditions. Thus, careful preoperative evaluation is important. For patients with relatively limited areas of disease, particularly for unilateral iliac disease, alternative "lesser" procedures such as percutaneous transluminal angioplasty (PTA) with or without intraluminal stents, femorofemoral bypass, or unilateral iliofemoral grafting may be more appropriate. For high-risk patients with bilateral iliac disease or patients with relative contraindications to direct aortic reconstruction such as heavy retroperitoneal scarring or contamination, the extra-anatomic axillobifemoral bypass may be a better alternative. However, the long-term patency rates of these grafts are inferior. Although all of these options may be appropriate in selected circumstances, aortobifemoral grafting provides clearly superior long-term results in terms of durability and sustained symptom relief.

Careful preoperative evaluation is important to identify and potentially correct any comorbid conditions that might increase the risk of revascularization. Preoperative evaluation of coronary artery disease is important for patients with evidence of ischemic heart disease by either history, symptoms, or electrocardiography. If the noninvasive screening studies such as exercise stress testing, adenosine thallium, dobutamine stress echocardiography, or similar studies suggest significant myocardial ischemia, preoperative coronary arteriography may be advisable.

Similarly, significant abnormalities of pulmonary, renal, or coagulation function should be routinely evaluated and optimized.

High-quality preoperative arteriography remains of paramount importance before aortoiliac revascularization. In addition to standard anteroposterior views, lateral and oblique images of the visceral, iliac, and profunda femoral vessels should be obtained. Complete, bilateral infrainguinal arteriograms are also generally advisable, both for operative planning and minimizing the chances of technical misadventure. In recent years, alternative imaging techniques such as contrast-enhanced computed tomographic angiography (CTA) and magnetic resonance angiography (MRA) with gadolinium administration have been increasingly employed for preoperative imaging evaluation. In addition, duplex ultrasound scanning may be employed to identify patients with likely aortoiliac occlusive disease. Most often these alternative imaging modalities are used for screening, and cannot match the visual clarity, detail, spacial resolution, and overall accuracy of standard catheter-based contrast arteriography.

Noninvasive vascular studies are generally performed in all patients. Segmental lower extremity pressure measurements and pulse volume recordings (plethysmography) confirm the diagnosis, quantify its severity, and establish a baseline for assessing the results of revascularization. Furthermore, exercise stress testing can serve to quantify the walking distances among claudicants.

SURGICAL TECHNIQUE

Aortobifemoral Bypass

Two to four units of packed red blood cells are typed and cross-matched. Preoperative donation of 2 units of autologous blood is encouraged and is generally possible in elective circumstances. Adequate preoperative hydration is ensured, including administration of intravenous fluids if clinically necessary. A broad-spectrum prophylactic antibiotic such as cefazolin (1 g) is given intravenously 1 to 2 hours before surgery and continued for 1 or 2 days postoperatively. In patients with infected lower extremity ischemic lesions or any other possible source of bacteremia, culture-specific oral antibiotics are often started several days before operation.

The patient is placed supine on the operating table with both arms extended at right angles on armboards to permit appropriate monitoring

during anesthesia and to establish vascular access. A radial artery cannula is inserted for continuous blood pressure monitoring and arterial blood gas determinations. A Swan-Ganz catheter is inserted in selected patients based on the preoperative assessment of cardiac and renal function. Most patients undergoing aortic surgery in contemporary practice are anesthetized with a combination of epidural analgesia and inhalation agents (combined general and epidural technique). Continuation of the epidural analgesia in the early postoperative period for pain control has had a significant impact on limiting systemic narcotic use, facilitating early extubation and reducing respiratory complications after aortic surgery. Warmed intravenous fluids and any one of the commercially available external wrapping devices (such as the Bair Hugger) can be very useful in maintaining body temperature and avoiding the potentially deleterious effects of hypothermia secondary to heat loss.

Incisions and Dissection

The infrarenal abdominal aorta may be exposed for the aortofemoral reconstruction using a variety of incisions. A long vertical midline incision is used most often (Fig. 204.1) and is generally preferred because it is fast, is easy to close, and affords maximal exposure and thereby technical flexibility in most patients. Alternatively, a retroperitoneal approach may be employed and may be advantageous in obese patients as well as those with hostile abdomens or previous aortic surgery. I generally prefer to first expose the femoral vessels before making the abdominal incision in order to minimize the length of time that the abdomen is open and thereby limit evaporative fluid and heat losses. As shown in Figure 204.1, the groin incisions are oriented slightly obliquely and placed so that the cephalad one third of the incision lies above the inguinal ligament. Retraction by an assistant during construction of the femoral anastomosis is generally unnecessary when the incisions are placed in this manner.

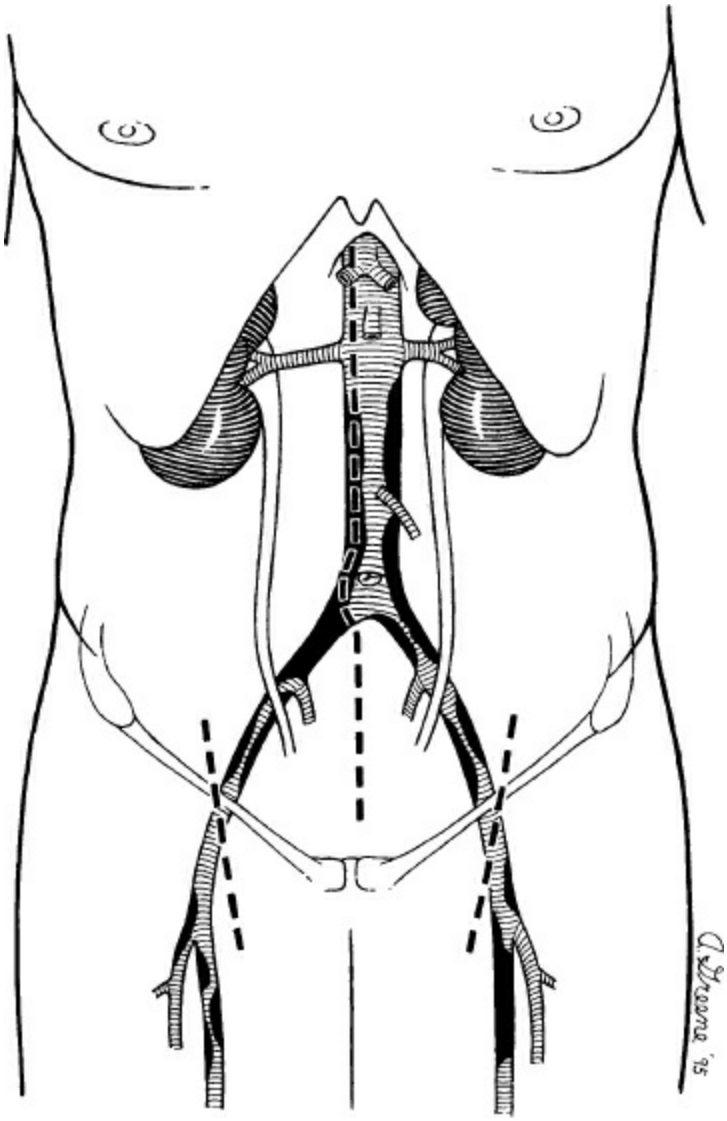

Figure 204.1. Standard incisions for aortobifemoral bypass.

Dissection is carried directly onto the anterior surface of the common femoral artery and then cephalad to the inguinal ligament. The lymph nodes and/or lymphatic tissue are best divided between clamps and then suture-ligated to minimize the possibility of a postoperative lymphatic leak with its associated risk of wound or graft infection. The caudal border of the inguinal ligament is partially divided directly over the femoral artery to ensure ample space for tunneling of the graft limb without compression. Dissection is then carried caudally to expose the common femoral artery bifurcation, and the proximal aspect of both the superficial and the profunda femoral arteries is encircled with vessel loops (Fig. 204.2). Similarly, any sizable side branches of the femoral arteries are preserved and controlled with such loops. If significant occlusive disease is found in the proximal profunda femoris artery on the preoperative arteriogram or by

intraoperative palpation, the vessel is exposed further caudally beyond the significant disease to allow concomitant profundaplasty at the time of distal anastomosis. This usually requires exposing an additional 2 to 3 cm of the vessel and often necessitates division of one or more branches of the profunda femoral vein that typically cross the anterior surface of the proximal deep femoral artery.

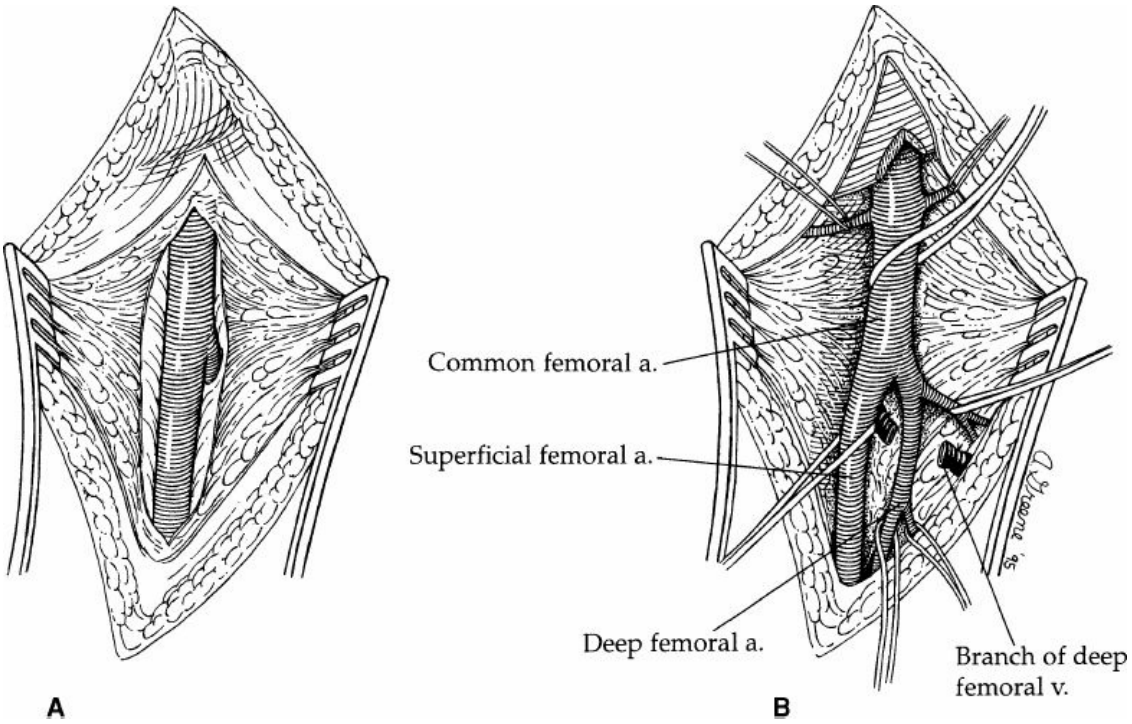

Figure 204.2. A. The common femoral artery is exposed from the inguinal ligament to the proximal portions of its superficial and profunda branches. **B.** More distal exposure of the profunda femoris usually requires division of one or more branches of the deep femoral vein that cross the artery anteriorly. The inguinal ligament has been partially divided to provide ample space for tunneling of the graft.

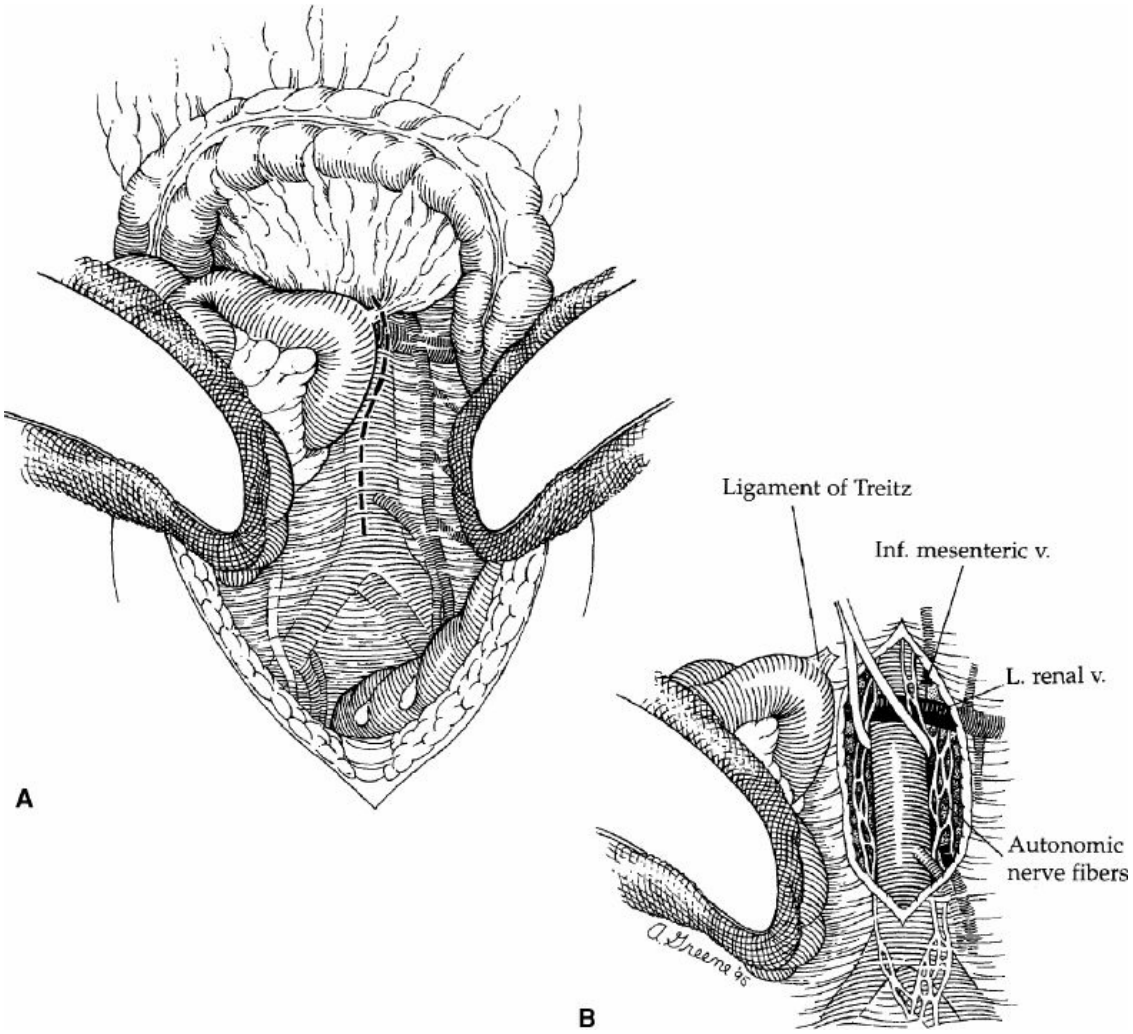

Figure 204.3. A. Following evisceration of large and small bowel, the retroperitoneum overlying the aorta is opened from the aortic bifurcation to above the crossing left renal vein, and the ligament of Treitz is divided to allow mobilization of the duodenum off the aorta. **B.** The inferior mesenteric vein will often require division. Automatic nerve plexuses are preserved as best as possible, and dissection in the region of the aortic bifurcation is avoided.

A midline abdominal incision is then created extending from the xiphoid to the pubis. After careful exploration of the intraabdominal organs, the transverse colon and greater omentum are elevated and retracted cephalad, and the entire small bowel eviscerated and displaced to the right (Fig. 204.3). The descending and sigmoid portions of the colon are retracted laterally and caudally. After these maneuvers, the posterior parietal peritoneum overlying the infrarenal aorta is visualized, and this is incised along the longitudinal axis of the aorta starting between the duodenum on the patient's right and the inferior mesenteric vein to the left.

Care is taken to avoid the plexuses of autonomic nerve fibers (Fig. 204.3B) that course primarily along the left anterolateral aspect of the infrarenal aorta and the proximal left common iliac artery. Careful dissection helps preserve these autonomic nerves and helps reduce the incidence of postoperative sexual dysfunction in male patients.

The retroperitoneal incision is extended cephalad and the ligament of Treitz is divided. This allows mobilization of the fourth portion of the duodenum off the aorta and facilitates visualization of the left renal vein as it crosses anterior to the aorta just below the renal artery origins. The left renal vein is an important landmark because the proximal graft anastomosis should be placed as close to it (and the renal arteries) as possible. This serves to minimize the potential for recurrent occlusive disease in the infrarenal aorta above the proximal anastomosis that could potentially compromise the late patency of the graft. The aortic dissection is extended distally just beyond the origin of the inferior mesenteric artery. This extent of aortic exposure is sufficient to allow construction of a proper proximal graft anastomosis and tunneling of each graft limb to the groin. Furthermore, it minimizes the dissection in the region of the aortic bifurcation itself, thereby reducing the possibility of autonomic nerve injury.

After completion of the aortic and femoral dissections, retroperitoneal tunnels are next made for the passage of each graft limb from the aorta to the groins. Such tunnels are best made by gentle blunt dissection using both index fingers in a simultaneous fashion with one extending from the groin cephalad and the other from the aortic bifurcation caudal (Fig. 204.4A). Dissection should be kept on a plane directly anterior to the common and external iliac vessels to guarantee that the graft is subsequently placed posterior to the ureter. This is important because passage of the graft anterior to the ureter may lead to compression and obstruction of the ureter with hydronephrosis. When starting the tunnel in the groin, care must be taken not to tear the circumflex iliac venous branches that cross the distal external iliac artery just above the inguinal ligament. After appropriate tunnels have been created to both groins, a long blunt-tipped clamp is placed through the tunnel and a Penrose drain drawn through the tunnel (Fig. 204.4B). Elevation of both ends of the drain facilitates later passage of the graft limbs.

Proximal Aortic Anastomosis

A variety of prosthetic grafts are available for aortobifemoral bypass, including conventional Dacron (knitted and woven), coated Dacron (collagen, albumin, or gelatin), and polytetrafluoroethylene (PTFE). Available data do not suggest that any graft material or fabrication has superior patency, and selection is based mostly on the surgeon's personal preference.

Use of a properly sized graft is important to minimize the possibility of sluggish flow and deposition of excessive laminar thrombus that is likely to occur in an oversized graft. For aortoiliac occlusive disease, a 16 × 8 mm bifurcated graft (body diameter, 16 mm; limb diameter, 8 mm) is used most commonly, but a 14 × 7 mm prosthesis may be more suitable for patients with a relatively small-caliber aortoiliac segment (predominantly women). For most patients, an end-to-end aortic anastomosis (Fig. 204.5) is preferred for several reasons. First, because all blood flows through the graft, there is less chance of "competitive" flow through the native aortoiliac vessels that may potentially increase the incidence of graft limb thrombosis. Second, an end-to-end anastomosis is theoretically a hemodynamically superior configuration. It is associated with less perianastomotic turbulence and therefore a smaller likelihood of developing recurrent atheroma or an anastomotic aneurysm. In addition, the end-to-end anastomosis is less likely to cause distal atheromatous embolization and is easier to cover with retroperitoneal tissue after implantation than the end-to-side anastomosis, which tends to protrude anteriorly off the aorta. This consideration may reduce the potential for late graft-enteric fistula formation. However, end-to-side anastomosis may be advantageous in certain anatomic patterns of disease to be described subsequently.

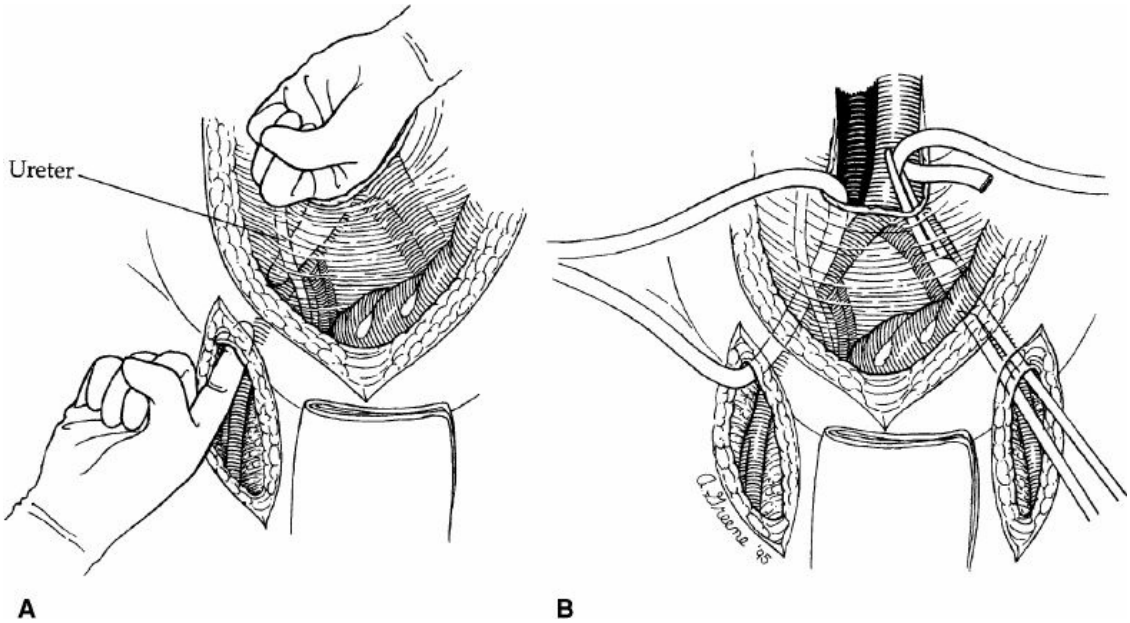

Figure 204.4. **A.** Retroperitoneal tunnels are constructed between the area of aortic exposure and femoral artery dissection in each groin. Tunneling is best performed by simultaneous blunt finger dissection from above and below, immediately on the anterior surface of the iliac arteries. This ensures passages of the graft limb posterior to the ureter that usually crosses the iliac vessels at their bifurcation. **B.** After tunneling is completed, a long clamp is passed through each tunnel and a rubber Penrose drain is pulled through the tract. Anterior traction on the drain facilitates proper passage of the graft through the tunnel at a later stage of the procedure.

After intravenous administration of 5,000 to 7,500 units of heparin, appropriate vascular clamps are applied to the aorta just caudal to the left renal vein and immediately caudal or cephalad to the inferior mesenteric artery (Fig. 204.5A). The aorta is then transected, and a 3- to 4-cm long segment between the clamps is resected. Any patent lumbar artery branches arising from this segment are clamped and ligated. Care should be taken to maintain a resection plane immediately on the posterior wall of the aorta to prevent injury and troublesome bleeding from the adjacent lumbar veins.

The transected distal aortic end is next oversewn in two layers with a 3-0 vascular suture (Fig. 204.5B). If this segment is heavily calcified or diseased, a limited endarterectomy of the calcific plaque and use of Teflon-pledgeted sutures may be necessary to achieve a secure and hemostatic closure. The body of the bifurcated prosthetic graft is shortened, leaving approximately 3 to 4 cm of the graft trunk to the graft

bifurcation. This allows the short graft body to be situated in the bed of the resected aortic segment, which facilitates closure of the retroperitoneum over the graft and separation of the anastomosis from the duodenum and other viscera. The short graft body also serves to advance the level of the graft bifurcation more cephalad and diminishes the takeoff angle of the graft limbs, thereby reducing the chance of kinking the graft at the origin of the limbs.

The divided proximal end of the aorta is inspected and thrombus or loose atheromatous debris removed. Standard graft anastomosis using a running 3-0 monofilament vascular suture is then performed (Fig. 204.5D). I usually start the anastomosis in the midline posteriorly using a double-armed suture. The anastomosis is performed in a running fashion extending both clockwise and counterclockwise approximately half the circumference of the aorta. A similar suture is then started on the midanterior aspect of the anastomosis and is similarly run in opposite directions. The anterior and posterior sutures are then tied to each other on the lateral aspects of the aorta to complete the anastomosis.

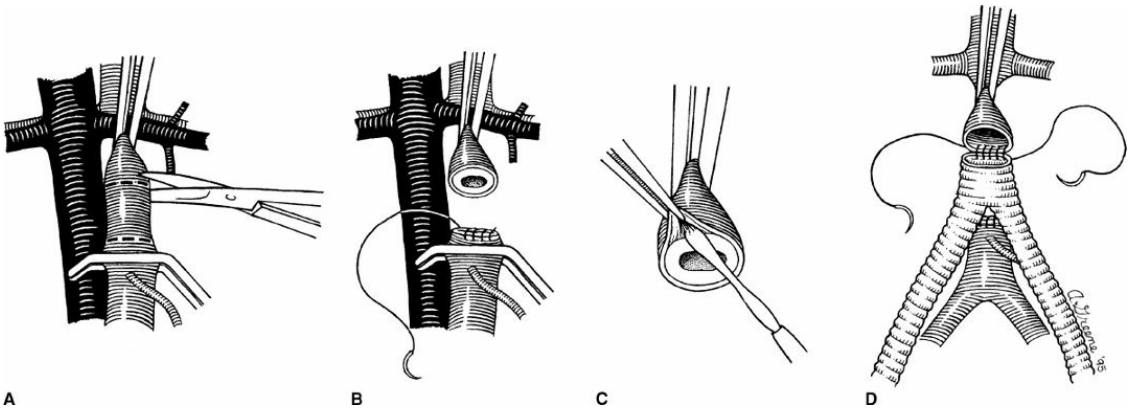

Figure 204.5. A. Following administration of systemic heparin, the aorta is clamped proximally and distally, and a segment of aorta ~3 to 4 cm long is resected. **B.** The distal aorta is oversewn with an over-and-over running suture. **C.** Thromboendarterectomy of the proximal aortic cuff below the cephalad clamp may be necessary if a thickened or calcified intima and media compromise its lumen. **D.** Proximal anastomosis is begun posteriorly with monofilament running vascular suture. The body or stem of the bifurcated graft is cut short, leaving a body that is only 3 to 4 cm in length so that it will occupy the area of the previously resected segment of native aorta.

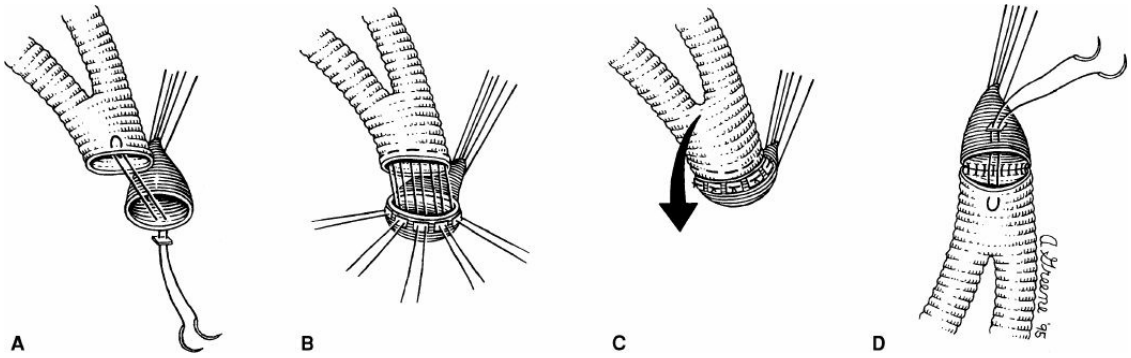

Figure 204.6. Technique of interrupted mattress suture anastomosis, often useful for a fragile diseased aorta or following cuff endarterectomy, is illustrated. **A.** The graft is oriented with its limbs directed superiorly and the anastomosis begun by a double-armed mattress suture in the midline, each needle passed from the outside of the posterior graft wall, then from the inside of the posterior wall of the aorta, and finally through a pledget of Teflon felt. **B.** Placement of five such mattress sutures around the posterior one-half circumference of the graft and aorta, tied down over the felt pledgets, completes the back wall of the anastomosis. Care is taken to place each mattress suture immediately adjacent to its neighbor, with proper spacing achieved by altering the width of travel between the two limbs of each individual mattress suture. **C.** After the back wall is completed, the graft is flipped down into a proper anatomic position, and (**D**) the anastomosis is completed by insertion of a similar anterior row of mattress sutures.

If the proximal transected infrarenal aorta is significantly diseased and its lumen compromised, I often perform a thromboendarterectomy of the aortic stump up to the level of the proximal clamp (Fig. 204.5C). The remaining adventitial layer is often quite thin, but usually holds sutures well and allows a technically perfect anastomosis. In this circumstance, I always prefer to use an interrupted mattress suture technique with each suture bolstered by a Teflon felt pledget (Fig. 204.6).

After the completion of the aortic anastomosis, the graft is clamped with an atraumatic vascular clamp (Fogarty soft-jawed clamp) and the proximal anastomosis tested by a slow release of the proximal aortic clamp. If inspection reveals any leaks or defects, they are repaired with interrupted mattress sutures with pledgets. After a hemostatic and secure anastomosis has been verified, the proximal aortic clamp is reapplied and the graft thoroughly suctioned to remove any clot or debris.

Attention is then directed to the femoral region. The Penrose drains,

previously placed in the graft tunnels, are elevated, and a long, blunt-tipped, slightly curved clamp such as a large DeBakey aortic clamp is passed from each groin incision to the region of the aortic dissection. The distal end of each femoral graft limb is then grasped with the clamp under direct vision, and each graft limb is pulled down through the tunnel (Fig. 204.7A). Care must be exercised to avoid twisting of the graft limbs. Fortunately, most of the currently utilized vascular grafts have stripes or marks that help maintain the correct orientation. Again, it is important to ensure the passage of each graft limb posterior to the ureter. This is usually best accomplished by properly constructing the initial graft tunnel immediately anterior to the iliac vessels and then elevating the Penrose drain “sling” that encompasses the ureter within the overlying retroperitoneal tissues during the actual pulling down of the graft limb. The ureter may be palpated at times as well. Gentle tension is applied to both graft limbs to eliminate any kinking or redundancy, but excessive tension must be avoided because this may contribute to late anastomotic aneurysm formation.

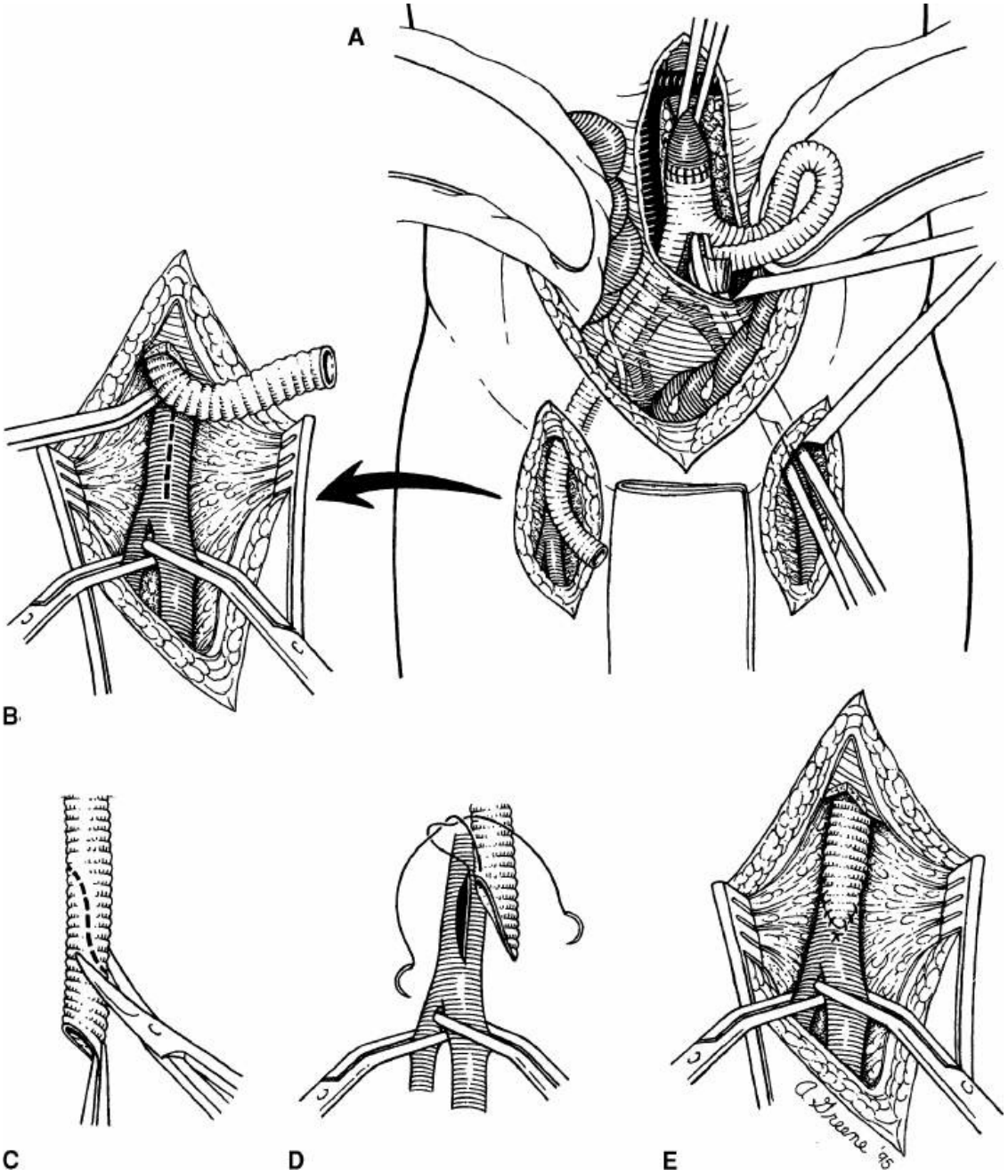

Figure 204.7. **A.** Passage of graft limbs through the retroperitoneal tunnels. Elevation of the Penrose drain sling facilitates graft tunneling and ensures positioning behind the ureter. **B.** Location of common femoral arteriotomy in the absence of any significant profunda origin disease. **C–E.** Cutting graft to appropriate length and construction of femoral anastomosis.

Femoral Anastomoses

Performance of a technically flawless femoral anastomosis is probably the most important technical aspect of the aortobifemoral bypass and the most

significant determinant of late graft patency. It is particularly critical to ensure unimpeded flow to the profunda femoris artery on each side. As previously emphasized, the majority of patients undergoing aortobifemoral bypass have diseased or occluded superficial femoral arteries at the time of surgery. In other patients, progressive distal occlusive disease may result in later development of superficial femoral artery obstruction. Prolonged graft limb patency is therefore heavily dependent on profunda outflow. Hence, it is imperative to detect and correct any disease at the origin of the profunda at the time of the femoral anastomosis.

The femoral anastomosis is begun by occluding the proximal common femoral artery at the level of the inguinal ligament and the proximal superficial femoral and profunda branches using appropriate atraumatic vascular clamps. The anterior surface of the mid common femoral artery is incised with a No. 11 scalpel blade and the femoral arteriotomy extended both proximally and distally with Potts scissors (Fig. 204.7B). The graft limb is gently stretched out with a slight tension and cut with a slightly curved bevel to a length appropriate to match the size of the arteriotomy. A standard vascular anastomosis is then performed with 5-0 monofilament vascular suture. I prefer to begin with a mattress suture placed at the “heel” of the graft. I usually tie this suture down and then continue the anastomosis in a running fashion down each side to its midpoint, but a “parachute technique” may be used if preferred. The direction of suture placement is always from outside to inside on the graft and inside to outside on the artery to minimize the chance that plaque or diseased layers of the vessel wall will be lifted or displaced and thus act as a potential obstructive flap. This is more apt to occur if the suture is passed from outside to inside on the vessel wall. At the midpoint of each side of the anastomosis, the running sutures are tagged with a rubber-shod hemostat to maintain some tension on the suture line, and a new suture is begun at the “toe” of the graft and distal apex of the arteriotomy. This is tied down and run on both sides to meet the previously tagged sutures at the midpoint (Fig. 204.7D).

If the superficial femoral artery is occluded or any significant occlusive disease is detected at the orifice of the profunda femoris, a simple anastomosis to the common femoral artery alone is not recommended. In this situation, the femoral arteriotomy is best carried into the proximal profunda femoris beyond its orificial stenosis (Fig. 204.8A) to construct a reliable outflow tract for the graft limb. In most circumstances, a “patch”

profundaplasty can be adequately performed using the long beveled toe of the graft (Fig. 204.8C). When the toe of the graft anastomosis is placed on the profunda, I recommend that three to five interrupted mattress sutures be used at the apex (Fig. 204.8D). These should be placed under direct vision and left untied until the final one is placed to optimize their accurate positioning and minimize any potential for narrowing this critical outflow vessel.

It is important to both flush the graft limbs and sequentially restore blood flow to the lower extremities to minimize the potential for distal thromboemboli and the so-called declamping hypotension, respectively. The surgeon should alert the anesthesiologist that blood flow will soon be reestablished in the lower extremities 5 to 10 minutes before the anticipated completion of the first femoral anastomosis. This enables the anesthesiologist sufficient time to optimize blood volume status and briefly administer vasoconstrictor medications if necessary to overcome the vasodilatory effects of the epidural anesthesia. Just before the completion of the femoral anastomosis, I place atraumatic vascular clamps (Fogarty soft-jawed clamp) on both proximal graft limbs and remove the aortic clamp to again ensure that the aortic anastomosis is hemostatic. The appropriate graft limb is then vigorously flushed through the nearly completed femoral anastomosis by briefly releasing the clamp on the graft limb (Fig. 204.9A). The clamp is reapplied, and the femoral artery clamps are released to back-bleed the native arterial system. The anastomosis is then rapidly completed and the graft limb slowly opened. The superficial femoral and profunda vessels are gently occluded so that all flow is initially retrograde up into the pelvic circulation, thereby further minimizing the chances of any distal embolization of clot or debris (Fig. 204.9B). Flow into the profunda and finally the superficial femoral artery is then reestablished by removing the distal arterial clamps (Fig. 204.9C). If any significant hypotension is observed, the graft limb is manually occluded and further fluid volume, sodium bicarbonate, and vasoconstrictors are administered as necessary. The limb is then slowly reopened as tolerated. Afterwards, the contralateral femoral anastomosis is completed in a similar fashion using the same sequence of flushing/declamping to complete graft implantation.

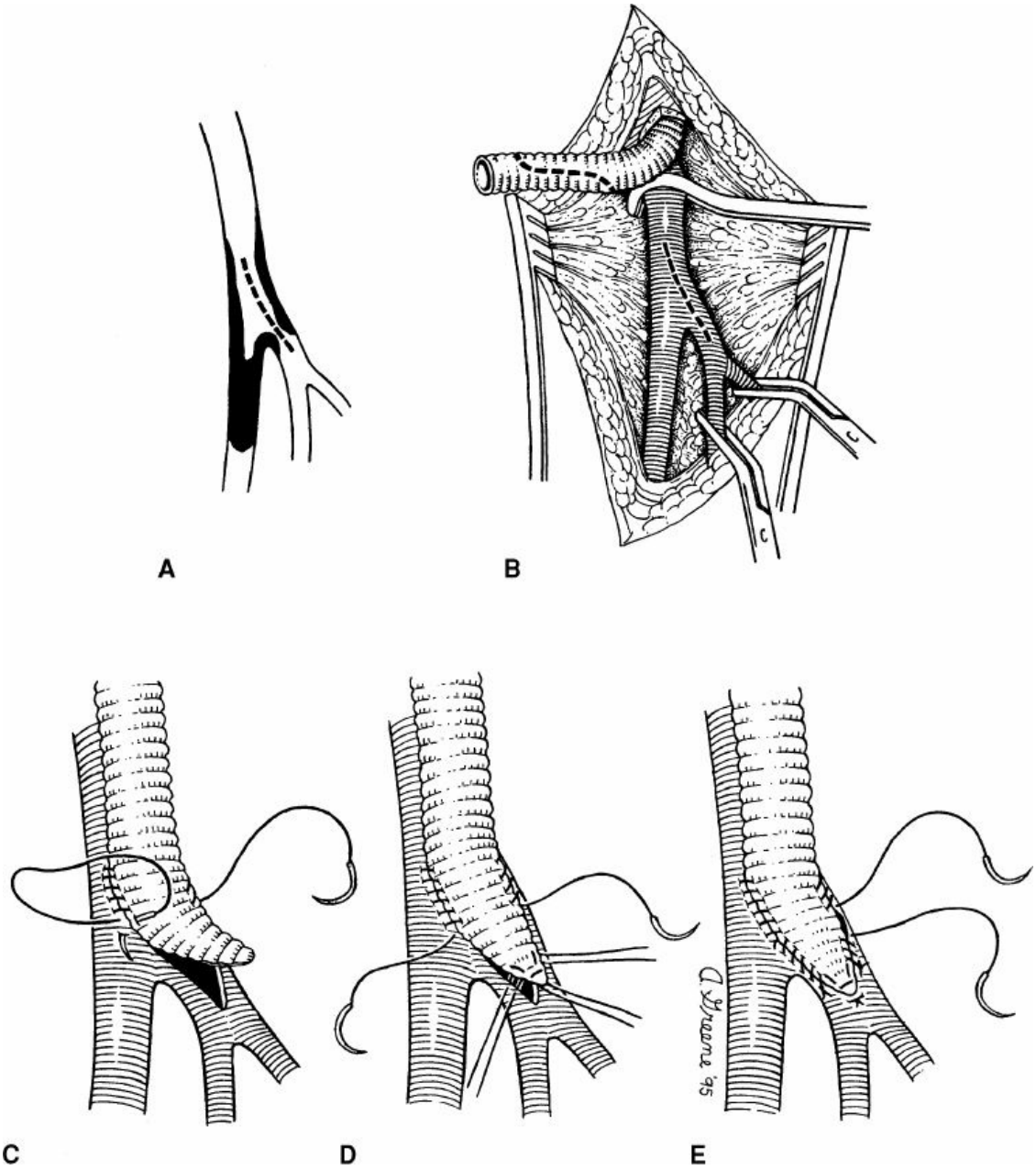

Figure 204.8. A. If significant profunda disease exists, especially with superficial femoral artery occlusion, the femoral arteriotomy is carried into the profunda beyond the orificial disease. **B.** The graft limb is cut to form a long beveled “hood” of approximate length. **C–E.** Construction of anastomosis. Interrupted mattress sutures are placed at the tip of the graft to ensure optimal visualization and suture placement and, thus, minimize the chance of constricting this critical aspect of the graft outflow tract.

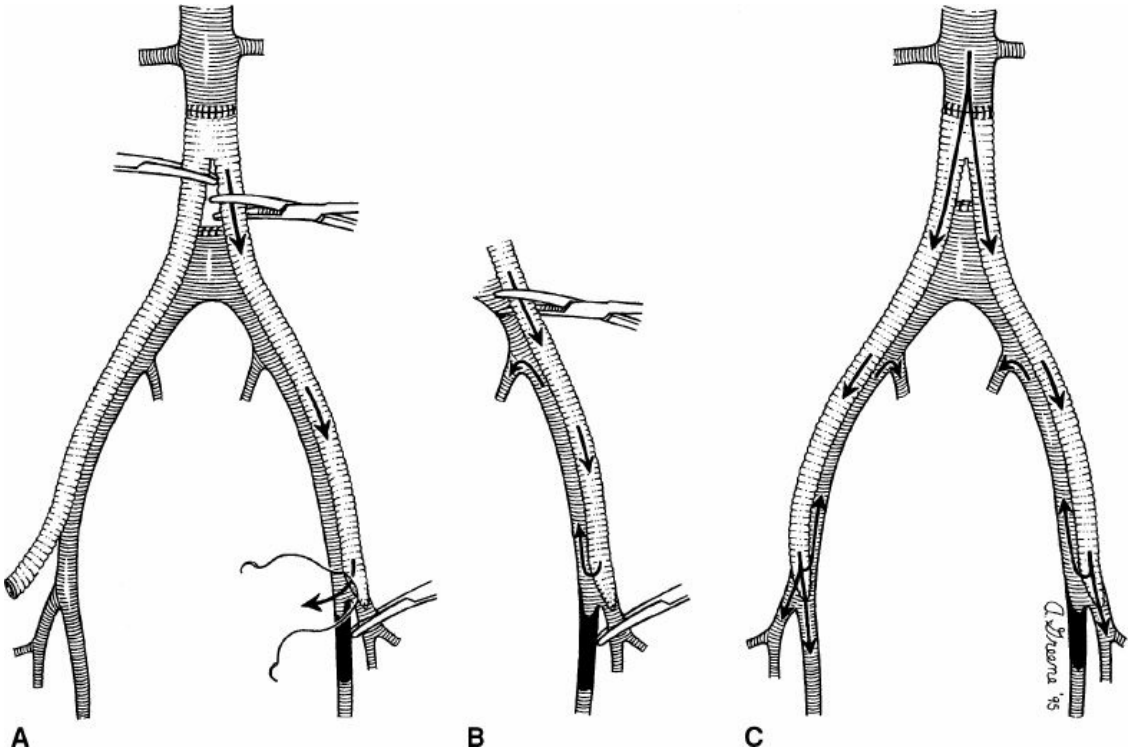

Figure 204.9. A–C. Sequence of graft limb flushing and restoration of blood flow to the extremity (see text).

End-to-Side Aortic Anastomosis

Although I prefer an end-to-end graft-to-aorta anastomosis in the great majority of patients, certain anatomic patterns of disease may make an end-to-side configuration potentially advantageous. As shown in Figure 204.10A, these anatomic patterns include patients with either a sizable accessory renal artery arising from the infrarenal aorta or a large, patent inferior mesenteric artery. Although these branch vessels may be preserved by reimplanting them into the body of an end-to-end graft, it is clearly easier to achieve this objective with the end-to-side aortic anastomosis that maintains the native antegrade aortic blood flow. More commonly, an end-to-side or “onlay” graft is used in patients in whom most of their occlusive disease is located in the external iliac arteries. In many of these patients, the aorta, common iliac, and internal iliac (hypogastric) arteries are relatively well preserved, with the latter providing the majority of collateral blood flow for the lower extremities. With such a pattern of disease, the retrograde blood flow in the external iliac arteries from the femoral artery anastomosis may not be sufficient to maintain pelvic perfusion if an end-to-end aortic anastomosis is constructed. The potential hemodynamic consequences include impotence in male patients, a higher

risk of postoperative colonic ischemia, and even rare instances of lower extremity neurologic dysfunction due to lumbosacral or cauda equina ischemia. An end-to-side graft configuration that maintains antegrade pelvic circulation via the hypogastric systems is clearly desirable in these circumstances (Fig. 204.10C).

The infrarenal aorta is exposed in an identical manner to that previously described. Although a partially occluding "side-biting clamp" may be used, I generally find it better to totally occlude the aortic segment with a standard horizontal aortic clamp and distal vertical clamp angled acutely posterior to the aorta to occlude the posterior lumbar arteries branches (Fig. 204.10B). The anastomosis is placed as cephalad as possible on the infrarenal aorta. I generally excise a bit of the aortic wall along the edges of a longitudinal arteriotomy in the excluded aortic segment to produce a slightly elliptical opening for the anastomosis. After the aorta is opened, any loose atheroma or thrombus is removed by a limited local endarterectomy. The body of the aortic graft is then tailored to the appropriate length for the arteriotomy with a bevel of ~60 degrees that extends close to the graft bifurcation. The anastomosis is constructed with two double-armed 3-0 monofilament vascular sutures with a suture starting at both the heel and the toe of the graft. These are extended in both directions (clockwise and counterclockwise), and the strands are tied to each other at the midpoint of the lateral aspect of the anastomosis. It is important to back-bleed the distal native aorta as much as possible before the completion of the anastomosis to evacuate any atheromatous debris that may have been dislodged by application of the distal clamp, since this debris may embolize when the flow is restored through the native aortoiliac vessels. Graft tunneling and femoral anastomoses are then completed as previously described.

Juxtarenal Aortic Occlusion

Juxtarenal aortic occlusion denotes a complete thrombosis of the aorta up to the level of the renal artery origins. In almost all circumstances, the causative obliterative atherosclerotic lesion itself is located more distally. Progression of disease leads to thrombosis of the aorta and retrograde propagation of clot to the level of the renal arteries unless the aortic outflow can be maintained by a patent inferior mesenteric artery or dominant lumbar arteries. Although the principles of aortobifemoral bypass are similar, several important modifications of the technique are

necessary. Specifically, the infrarenal aorta should not be clamped near the renal arteries until the occluding thrombotic material is removed for fear that the debris will be dislodged and "milked" superiorly by the clamp. This has the potential to occlude the renal arteries or cause distal embolization that may significantly compromise renal function. Although some surgeons advocate transecting the aorta several centimeters below the renal origins without applying an aortic clamp and extruding the thrombotic material using just arterial pressure, I have not found that this is satisfactory in terms of a thorough and complete evacuation of the clot. I prefer to briefly occlude the aorta above the renal arteries either at the supraceliac level via an approach through the lesser omentum or between the superior mesenteric and renal arteries as shown in Figure 204.11A. It is generally recommended that the renal arteries themselves also be temporarily occluded with Silastic vessel loops or gentle bulldog clamps to prevent embolization. After complete transection of the proximal infrarenal aorta, the thrombotic plug is teased out with an endarterectomy spatula (Fig. 204.11B). A deep endarterectomy plane is avoided to prevent creating flaps that might extend into the renal arteries and obstruct blood flow to the kidneys. After the thrombotic plug is removed, the lumen of the infrarenal aortic cuff is débrided with a gauze "peanut," the aorta is vigorously flushed, and the renal arteries are back-bleed. The aortic clamp is then reapplied at the standard infrarenal location, and flow is restored to the renal arteries. The graft is subsequently implanted using the standard technique described (Fig. 204.11C). Using this approach, the duration of renal ischemia is limited to ~15 minutes and the chances of inadequate clot removal and/or inadvertent renal embolization are minimized.

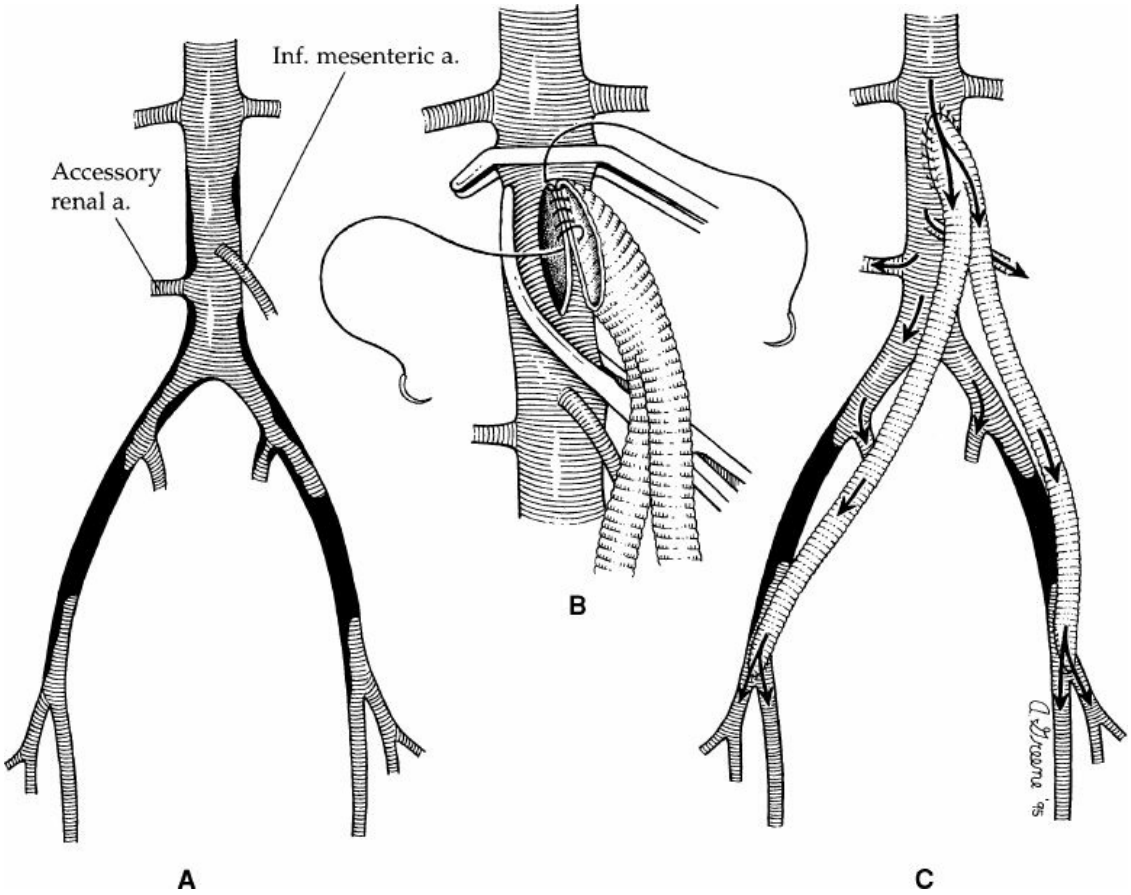

Figure 204.10. A. Pattern of aortoiliac occlusive disease favoring end-to-side proximal graft anastomosis. **B.** A longitudinal aortotomy is made in a segment of the proximal infrarenal aorta between two occlusive clamps, and a running suture is used for anastomosis of the beveled body of the bifurcation graft. **C.** Completed end-to-side bypass, with flow preserved into the pelvis via the native aortoiliac system, a patent inferior mesenteric artery, and an accessory renal artery branch arising from the aorta.

Aortoiliac Endarterectomy

Aortoiliac endarterectomy may be appropriate in 5% to 10% of patients with truly localized aortoiliac occlusive disease (type 1). Endarterectomy offers several theoretic advantages, including the fact that no prosthetic material is inserted, the infection rate is practically nonexistent, and the resulting inflow to the hypogastric arteries is likely better than after bypass procedures, thereby potentially improving erectile function in the male patient. Finally, because the procedure is totally autogenous, it may be utilized in unusual circumstances in which reoperation in a contaminated or infected field requires innovative reconstructive methods.

Despite its theoretic appeal, endarterectomy is definitely contraindicated in patients with aneurysmal disease, juxtarenal aortic occlusions, and extensive aortoiliac occlusive disease (types II and III). It is contraindicated in patients with aneurysmal disease because of the potential for continued aneurysmal degeneration in the endarterectomized segment. In patients with juxtarenal aortic occlusions, simple transection of the aorta below the renal arteries with thrombectomy of the aortic cuff followed by graft insertion as outlined above is technically easier and far more expeditious. Lastly, the success rate after extensive aortobifemoral endarterectomy is inferior to that after aortofemoral bypass and is associated with a higher incidence of early thrombosis and late failure due to recurrent stenosis. These difficulties are likely related to the fact that the external iliac artery is smaller in diameter, longer in length, more difficult to expose, and more difficult to endarterectomize than the common iliac arteries due to the adherent layers of the vessel wall. Indeed, extended aortoiliac endarterectomy has been essentially abandoned and replaced by aortofemoral bypass grafting.

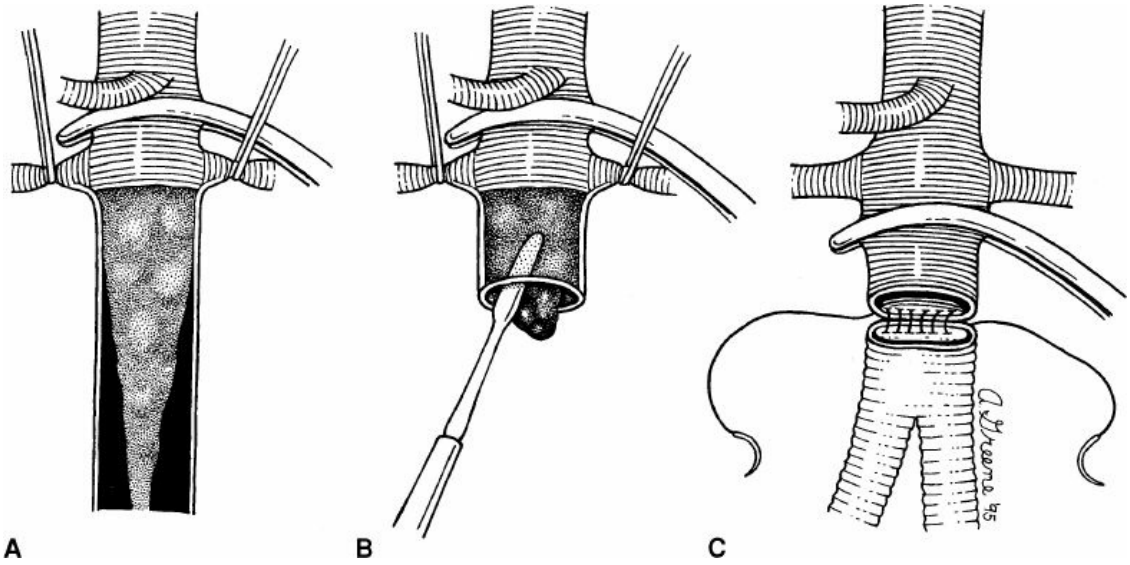

Figure 204.11. **A.** Total juxtarenal aortic occlusion is best managed by brief suprarenal clamping and protection of the kidneys by brief renal artery occlusion during removal of thrombus. **B.** With inflow occlusion, the aorta is divided several centimeters below the renal artery origin and the obstructing thrombus freed up with an endarterectomy spatula, but true endarterectomy is avoided (see text). **C.** Following removal of the juxtarenal thrombus, the aorta is clamped infrarenally, renal blood flow is restored, and standard aorta-graft anastomosis is performed.

Aortoiliac endarterectomy may be considered in carefully selected circumstances. The atherosclerotic disease process should terminate at the bifurcation of the common iliac arteries, thereby allowing the surgeon to achieve a satisfactory endpoint for the endarterectomy without extending >1 to 2 cm into the external iliac segment. Longitudinal arteriotomies are generally used with one extending caudal from the infrarenal aorta to the common iliac artery and the other confined to the contralateral common iliac artery (Fig. 204.12A). It is important to establish the endarterectomy plane at the level of the external elastic lamina and to secure a proper distal end point (Fig. 204.12B,C). The latter objective may require the use of interrupted tacking sutures. Primary closure of the arteriotomies is generally feasible (Fig. 204.12D), although a patch closure with either prosthetic materials or vein may occasionally be required. Aortoiliac endarterectomy can provide excellent and durable results when properly performed in the appropriate subset of patients. However, it must be acknowledged that patients with the localized aortoiliac occlusive disease amenable to endarterectomy are usually managed by means of angioplasty and/or stenting in current practice.

Iliofemoral Bypass

Patients with iliac occlusive disease may occasionally present with unilateral symptoms and a normal contralateral femoral pulse. Management of unilateral iliac occlusive disease remains controversial. The potential options include standard aortobifemoral bypass, unilateral aortofemoral bypass, iliofemoral bypass, extra-anatomic femoral-femoral bypass, and a variety of catheter-based or endovascular therapies. Admittedly, each option has vocal proponents and is associated with some real and/or theoretic benefits.

If unilateral disease is largely confined to the distal common and external iliac arteries, iliofemoral bypass offers a useful alternative. As shown in Figure 204.13, the common iliac artery is exposed using a retroperitoneal approach through a lower quadrant oblique abdominal incision while the femoral vessels are exposed using a separate standard vertical groin incision. An 8-mm prosthetic graft is generally used with both the proximal and distal anastomoses constructed in an end-to-side fashion. It is usually possible to obtain vascular control of the common iliac artery using a pair of straight vascular clamps placed on the proximal and distal aspects of the vessel. Patients with occlusive disease involving

the entire common iliac artery are likely better candidates for an aortounifemoral or aortobifemoral bypass procedure. The arteriotomy in the common iliac artery is extended along the longitudinal axis of the vessel between the occluding clamps, and the anastomosis is usually performed with a 4-0 monofilament vascular suture. The bypass graft is tunneled deep to the inguinal ligament along the anatomic course of the external iliac vessel. The graft is passed posterior to the ureter, but this is not usually a concern because the visceral structures and the ureter are usually reflected medially as part of the initial retroperitoneal dissection. The femoral artery anastomosis is performed as outlined above under the aortobifemoral bypass graft. Notably, the long-term patency rates for iliofemoral bypass grafts are quite good and the procedure can be performed with minimal morbidity.

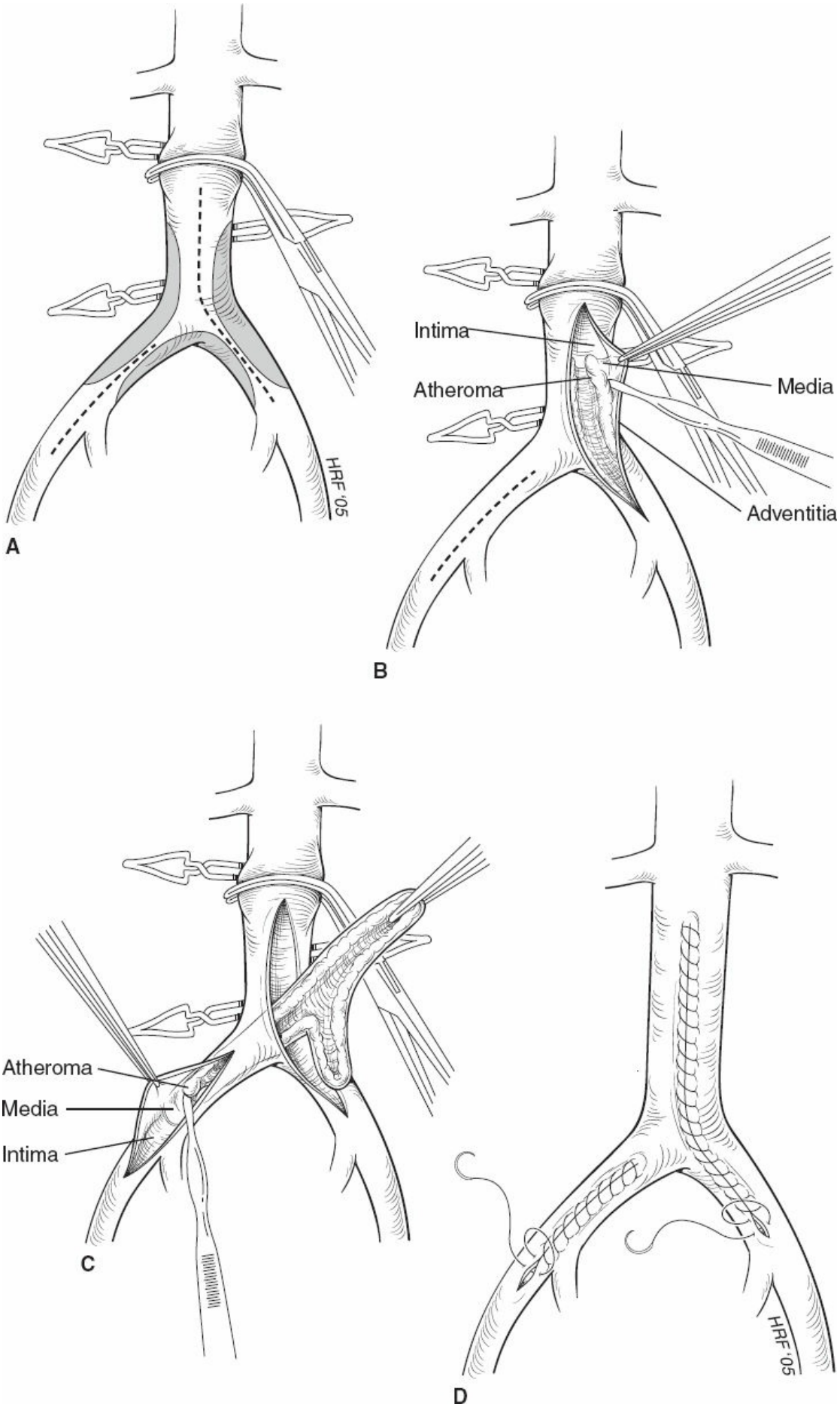
A
HRF '05
B
Intima
Atheroma
Media
Adventitia
C
Atheroma
Media
Intima
D
HRF '05

Figure 204.12. A. The infrarenal aorta and iliac vessels are exposed and controlled. The surgeon should ensure that occlusive disease stops at, or just beyond, the iliac bifurcation by the preoperative arteriogram or by intraoperative palpation. An arteriotomy is begun in one common iliac artery and extended into the abdominal aorta. On the contralateral side, the arteriotomy is confined to the mid- and distal common iliac artery. **B,C.** A proper endarterectomy plane is established deep to the diseased media, and plaque mobilized with an endarterectomy spatula. It is essential to achieve a secure end point distally in both iliac arteries. If disease does not “feather out” distally, the arteriotomies may be extended 1 to 2 cm into each external iliac and the intimal flap in the external iliac may be tacked down with several 5-0 and 6-0 sutures. **D.** Closure of the arteriotomies can usually be performed primarily, but a patch closure may be necessary for smaller vessels. (From Brewster DC. Direct open revascularization for aortoiliac occlusive disease. In: Zelenock GB, Huber TS, Messina LM, et al., eds. *Mastery of Vascular and Endovascular Surgery.* Philadelphia, PA: Lippincott Williams & Wilkins, 2005.)

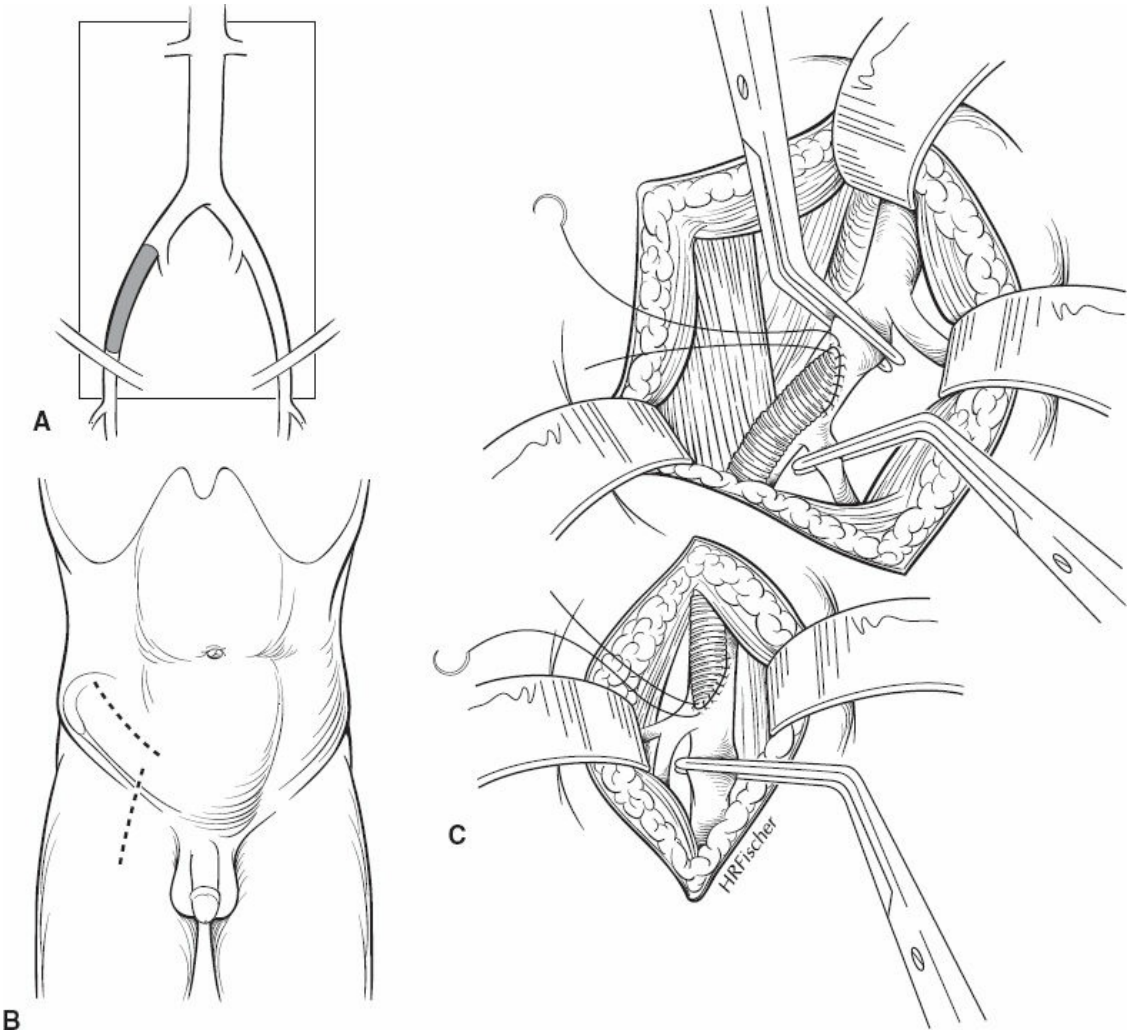

Figure 204.13. A. Disease must be limited to the distal common iliac and/or external iliac artery, thereby allowing a proximal anastomosis to a relatively disease-free segment of proximal common iliac artery. **B.** Separate lower quadrant abdominal wall and vertical groin incisions are preferred. **C.** The in-line graft is placed retroperitoneally and tunneled posterior to the ureter for an end-to-side anastomosis to the femoral artery using the standard technique. (From Brewster DC. Direct open revascularization for aortoiliac occlusive disease. In: Zelenock GB, Huber TS, Messina LM, et al., eds. *Mastery of Vascular and Endovascular Surgery.* Philadelphia, PA: Lippincott Williams & Wilkins, 2005.)

COMPLICATIONS

Aortobifemoral bypass and other direct revascularization procedures for aortoiliac occlusive disease are major operative procedures and are associated with multiple potential complications. Fortunately, the overall perioperative mortality rate is <5% and usually in the 1% to 2% range for

most large institutional series. The majority of the perioperative deaths are related to cardiac causes as would be predicted considering the patient population and the systemic nature of atherosclerosis. This observation underscores the importance of identifying and optimizing all significant coronary artery diseases during the preoperative assessment. The overall major complication rate should be <10% and includes the complications related to all major intraabdominal vascular procedures as well as those related more specifically to aortoiliac bypass. The former “generic” group of complications includes postoperative organ system failure (cardiac, pulmonary, renal, and pancreas), inadvertent intraoperative injury to the visceral structures (bowel, ureters, major veins, and spleen), abdominal wound breakdown, and intraabdominal bleed. Although these “generic” complications cannot become completely eliminated, they can be reduced by the guiding surgical principles of proper patient selection, thorough preoperative preparation, attention to detail intraoperatively, and a commitment to a technically perfect operation. The specific complications related to the aortoiliac bypass include colon/pelvic ischemia, atheroembolization, lower extremity ischemia, male sexual dysfunction, and groin wound complications.

Pelvic ischemia after aortoiliac bypass is fortunately very rare, although it can be both devastating and irreversible. It can manifest as colonic ischemia, infarction of the buttock musculature/surrounding skin, or cauda equina/lumbar plexopathy with neurologic deficit. The responsible mechanism is interruption of the pelvic blood flow. This has led to the generally accepted principle of maintaining flow in at least one internal iliac artery. The status of the pelvic circulation should be assessed during the operative planning as mentioned above, and consideration should be given to performing an end-to-side aortic anastomosis when indicated by the distribution of occlusive disease. Alternatively, one (or both) of the internal iliac arteries may be revascularized directly by using a limb of the bifurcated graft, then jumping off that limb down to the femoral artery in the groin with a second prosthetic graft.

Atheromatous debris may embolize at any time during the operative procedure, although the most vulnerable times occur when the vessels are manipulated such as during dissection or clamp application. The sequelae are dependent upon the size of the debris and the distribution of the involved vessels. Macroscopic particles may occlude the major, named vessels with the debris frequently lodging at the various arterial

bifurcations. Fortunately, the majority of these are amenable to removal with a thromboembolectomy catheter. In contrast, the microscopic particles lodge in the corresponding sized vessels and are not usually amenable to removal or treatment. They can result in a wide spectrum of injury ranging from the classic “blue toe” to extensive tissue loss of the buttock and lower extremity. The potential for embolization may be minimized using the strategies outlined above in the technique section, including rigorous flushing of the vessels before reperfusion with selective flushing into the pelvic and profunda femoris circulation before reestablishing flow to the superficial femoral artery.

Patients may develop ischemia of their lower extremities that may present either intraoperatively after the completion of the bypass or during the early postoperative period. The specific concerns vary slightly with the temporal presentation but include atheroemboli, in situ thrombosis, and technical problems. The remedial treatment is contingent upon the precipitating cause, although it is imperative that all potential technical defects such as a twist/kink in the graft limb or a narrowed anastomosis be excluded. The femoral anastomosis is usually interrogated first and thromboembolectomy catheters are passed both proximally (graft limb/aorta) and distally (superficial/profunda femoral). A thromboembolectomy of the popliteal and tibial vessels through a below-knee popliteal artery exploration may be necessary if the femoral thromboembolectomy is unsuccessful and no obvious causes for the problem identified. Infrainguinal revascularization is occasionally necessary in patients with persistent lower extremity ischemia, although the morbidity/mortality rates of combined inflow/outflow procedures are significant.

Male sexual dysfunction can occur after aortoiliac revascularization due to either inadequate pelvic perfusion or interruption of the autonomic nerves that course over the distal aorta and common iliac arteries. The reported incidence ranges from 5% to 15%. Notably, the injury to the autonomic nerve results in the disruption of the internal sphincter mechanism and retrograde ejaculation. The status of the pelvic circulation should be factored into the operative plan, and care should be exercised during the procedure to avoid injury to the responsible nerves. Furthermore, it is imperative that the potential for sexual dysfunction be discussed with patients preoperatively.

POSTOPERATIVE MANAGEMENT

The immediate postoperative care after aortofemoral bypass is comparable to that after other major intraabdominal vascular procedures. Patients are usually monitored in the intensive care unit on the night of their procedure, and then transferred to the general care floor. They are seen by the physical therapists when they reach the general care floor and are encouraged to start ambulating early. Their nasogastric tube is usually removed on the 2nd or 3rd postoperative day or when bowel function returns. Patients are usually discharged on their 6th or 7th postoperative day, but have to be sufficiently independent to care for themselves, eating adequately, and having normal bowel function. Patients are seen in the outpatient clinic biweekly until their wounds are healed and then at 6-month intervals indefinitely. Ankle brachial indices are obtained in the early postoperative period and at each 6-month follow-up visit.

The long-term outcome after direct aortoiliac revascularization is excellent. The reported patency rates after aortobifemoral bypass range from 80% to 90% at 5 years. The corresponding patency rates for aortoiliac endarterectomy are comparable, while those for unilateral iliofemoral bypass are nearly as good. Unfortunately, the long-term patient survival after aortoiliac bypass is only 75% and less than the corresponding age-matched controls. Majority of the late deaths are secondary to cardiovascular causes and further emphasize the importance of aggressive medical management of coronary artery disease and the associated risk factors for atherosclerosis. Approximately 5% of the patients may develop late anastomotic pseudoaneurysms, although the incidence is dependent upon the duration of follow-up and may exceed this value. These occur most commonly at the femoral anastomoses and can be related to technical errors, suture breakage, graft infection, and degeneration of the native artery, among other causes. The incidence of prosthetic graft infections after aortoiliac bypass is ~1% to 2%.

Suggested Readings

Brewster DC. Aortofemoral bypass for atherosclerotic aortoiliac occlusive disease. In: Stanley J, Veith FJ, Wakefield T, eds. *Current Therapy in Vascular and Endovascular Surgery*. 5th ed. Philadelphia, PA: Elsevier; 2014:418.

Brewster DC. Clinical and anatomic considerations for surgery in aortoiliac disease and results of surgical treatment. *Circulation* 1999;83(Suppl 1):42.

Brewster DC. Current controversies in the management of aortoiliac occlusive

disease. *J Vasc Surg* 1997;25:365.

Brewster DC. Direct reconstruction for aortoiliac occlusive disease. In: Rutherford RB, ed. *Vascular Surgery*. 6th ed. Philadelphia, PA: Elsevier Saunders; 2005:1106.

Brewster DC. Technical features to simplify or improve aortofemoral or aortoiliac reconstructions. In: Veith FJ, ed. *Current Critical Problems in Vascular Surgery*. Vol. 5. St. Louis, MO: Quality Medical Publishing; 1993:278.

Brewster DC, Cooke JC. Longevity of aortofemoral bypass grafts. In: Yao JS, Pearce WF, eds. *Long-Term Results in Vascular Surgery*. Norwalk, CT: Appleton & Lange; 1993:149.

Brewster DC, Darling RC. Optimal methods of aortoiliac reconstruction. *Surgery* 1978;84:739.

Chiu KW, Davies RS, Nightingale PG, et al. Review of direct anatomical open repair of atherosclerotic aortoiliac occlusive disease. *Eur J Vasc Endovasc Surg* 2010;39:460.

DeVries SO, Hunink MG. Results of aortic bifurcation grafts for aortoiliac occlusive disease: a meta-analysis. *J Vasc Surg* 1997;26:558.

Hertzer NR, Bena JF, Karafa MT. A personal experience with direct reconstruction and extra-an atomic bypass for aortoiliofemoral occlusive disease. *J Vasc Surg* 2007;45:527.

Reed AB, Conte MS, Donaldson MC, et al. The impact of patient age and aortic size on the results of aortofemoral bypass grafting. *J Vasc Surg* 2003;37:1219.

EDITOR'S COMMENT

The chapter by Dr. Brewster is written by a master surgeon who has a long published clinical experience with the aortofemoral bypass (AFB) technique for aortoiliac occlusive disease (AIOD). This is a procedure that is decreasing in number, but provides durable and safe revascularization (Bredahl K, Jensen LP, Schroeder TV, et al. Mortality and complications after aortic bifurcated bypass procedures for chronic aortoiliac occlusive disease. *J Vasc Surg* 2015;62:75–82). Certain factors may portend worse outcomes; namely, younger aged patients with small aortas and these factors should be kept in mind when choosing who to intervene on (Reed AB, Conte MS, Donaldson MC, et al. The impact of patient age and aortic size on the results of aortobifemoral bypass grafting. *J Vasc Surg* 2003;37:1219–25). I also am hesitant to perform these procedures on active smokers. There are numerous good technical points and pearls of wisdom throughout this chapter. There are several things that I do differently and will comment on.

First, I don't agree arteriography is required for most preoperative assessment of aortoiliac disease. Indeed, the high-quality thin-cut CT scans

denote accurately the anatomy from the aortic segment all the way to the superficial femoral arteries. Certainly, below the knee arteries are less well imaged, but saving a patient an invasive diagnostic procedure seems worthwhile for AIOD treatment planning.

Second, with regard to preoperative preparation, Swan-Gantz catheterization is rarely used or needed for these patients. If one is going to be clamping below the renals, a central line may occasionally be needed if the patient has poor intravenous (IV) access, but we try to get away from deep lines due to infection risk. Indeed, two large bore peripheral IVs should suffice. Furthermore, intraoperative transesophageal echocardiography is currently used by our anesthesiologists to guide intraoperative resuscitation on a real time basis.

In compliance with nationwide quality measures, prophylactic IV cefazolin is usually only continued for 24 hours rather than longer, as suggested in the chapter. If the patient is MRSA positive, we use vancomycin in addition to cefazolin (Alexander JW, Solomkin JS, Edwards MJ. Updated recommendations for control of surgical site infections. *Ann Surg* 2011;253:1082–93).

In terms of tunneling, this is critical technical aspect of the AFB as it is a blind procedure. Going fingertip to fingertip for safety as described makes a lot of sense. Rather than putting a tape or a Penrose drain, I use a curved sponge stick that then just sits in place while we are doing the proximal anastomosis. Perforating the colon with poor tunneling technique is a disaster, but it does occur.

Typically, if we do an end-to-end aortic bypass, we will use a continuous felt buttressing if the wall is particularly thin. This has saved a lot of issues with regard to problematic anastomotic bleeding. Whether the proximal anastomosis is done end to end or end to side, personally I don’t think it matters. I have found no data to support one over the other. Rather, it is whichever the surgeon is most comfortable with as well as what the anatomic issues are on the preoperative CT scan.

I do fully agree with Dr. Brewster that patients with a totally occluded aorta will ensure renal artery control and blowing out the thrombotic debris prior to any type of clamping. We may even occasionally place a suprarenal and then an infrarenal clamp, flush the material, and then clamp infrarenally as described in the chapter. Patients who have atherosclerotic debris embolization to the kidneys often go into complete renal failure. Even worse, if this material embolizes into the superior mesenteric artery, the patient often develops a diffuse gut ischemia and death.

In terms of other technical aspects, dividing the circumflex iliac vein electively rather than thinking you will be able to tunnel over these and not tear them always makes sense. It only takes one time where you have torn one of these veins high under the inguinal ligament (and after a liter of blood loss finally get control) to emphasize the benefit of this prophylactic measure.

I would note the postoperative management is most often complicated by

groin complications these days (Burke CR, Henke PK, Hernandez R, et al. A contemporary comparison of aortofemoral bypass and aortoiliac stenting in the treatment of aortoiliac occlusive disease. *Ann Vasc Surg* 2010;24:4–13). I speculate that multiple prior catheterizations and other endoluminal injury the lymphatic system for leaks in the groin. We not frequently see up to 10% to 15% of lymphatic leaks after groin incisions for aortofemoral or other femoral open access procedures: both our own patients and transfers from other institutions. Certainly closing the groin in multiple layers, absorbable skin sutures, and skin glue seems to cut down on this. Whether an external vacuum dressing type device will help decrease this even further is suggested by one study (Matatov T, Reddy KN, Doucet LD, et al. Experience with a new negative pressure incision management system in prevention of groin wound infection in vascular surgery patients. *J Vasc Surg* 2013;57:791–5) and bears more prospective evaluation.

Peter Henke

205 Aortoiliac Occlusive Disease: Extraanatomic Bypass

Enjae Jung, Gregory J. Landry, and Gregory L. Moneta

INTRODUCTION

Extraanatomic bypass typically refers to femorofemoral, axillofemoral, and axillobifemoral bypasses. The technique was developed in the 1950s and 1960s. Freeman and Leeds performed the first femorofemoral bypass in 1952 using an endarterectomized superficial femoral artery tunneled subcutaneously to the contralateral femoral artery, and both Blaisdell and Louw reported the first axillofemoral bypasses independently in 1963. Since then, the treatment of aortoiliac occlusive disease has dramatically evolved as endovascular techniques continue to improve and indications for their use continue to expand. Although extraanatomic bypass is largely regarded as a second-choice alternative to standard aortoiliac and aortofemoral reconstruction, it can be a life- and limb-saving procedure for a patient requiring aortofemoral reconstruction who is not a candidate for an open abdominal aortoiliac or aortofemoral grafting or a percutaneous revascularization. Extraanatomic bypass, however, remains a reliable and durable option for lower extremity revascularization that should be a part of the armamentarium of vascular surgeons.

INDICATIONS AND CONTRAINDICATIONS

Extraanatomic bypass has traditionally been reserved for the treatment of symptomatic aortoiliac occlusive disease in patients at high risk for direct aortoiliac replacement either from severe systemic illness increasing operative risk or in patients with local factors increasing the risk or difficulty of standard aortofemoral reconstruction. These factors include prior aortoiliac procedures, prior radiation, extensive intra-abdominal adhesions, severe aortic calcification, abdominal malignancy, intra-abdominal infection, aortic or aortic graft infection, colostomy or ileostomy, and enterocutaneous fistula. While infrequently used, endovascular repair of abdominal aortic aneurysms with an aortouniiliac

device has also resulted in an additional indication for femorofemoral bypasses. Femorofemoral or unilateral axillofemoral bypass is indicated for unilateral aortoiliac occlusive disease, with axillobifemoral bypass indicated for bilateral disease.

Extraanatomic bypass, similar to any surgical procedure, is contraindicated in patients with extreme risk for surgery or with a very short life expectancy. However, since femorofemoral bypasses can be performed with spinal or epidural anesthesia, and monitored local anesthesia can be used for both femorofemoral and axillofemoral bypasses, there are relatively fewer patients who are truly medically contraindicated for these procedures.

PREOPERATIVE PLANNING

Patients with aortoiliac occlusive disease of sufficient severity to warrant extraanatomic bypass grafting typically have absent or weak femoral pulses. Noninvasive vascular examination of the lower extremities is helpful in documenting the severity of ischemia and level of distal disease. Computed tomography angiography (CTA), magnetic resonance angiography (MRA), or digital subtraction angiography (DSA) is routinely performed for elective cases, but often is not essential in urgent or emergent cases. Unilateral iliac artery angioplasty and stenting can occasionally be performed to facilitate femorofemoral bypass.

The adequacy of axillary inflow can be determined noninvasively in most cases. Blood pressure in each arm is measured to select the optimal site for the proximal anastomosis. If pressures are equivalent, the right axillary artery is preferred for the proximal anastomosis, since the left subclavian artery has a higher reported incidence of developing atherosclerotic occlusive disease. A pressure difference >15 mm Hg between arms indicates significant occlusive disease and necessitates further workup, typically with upper extremity arteriography or CT angiography. Subclavian artery angioplasty with or without stenting can be performed when indicated to improve axillary artery inflow.

Prophylactic intravenous antibiotics, usually a first-generation cephalosporin, are administered within an hour prior to incision. Aspirin therapy (81 mg/day) is started preoperatively and continued indefinitely postoperatively. Ideally patients are also treated with a statin medication. Patients with an identified hypercoagulable state or a history of multiple graft failures should also be considered for long-term anticoagulation.

SURGICAL TECHNIQUE

Anesthesia

General anesthesia with endotracheal intubation is preferred. Femorofemoral bypasses can be performed with spinal or epidural anesthesia in higher risk cases. Monitored anesthetic care with local anesthesia can be used for axillofemoral and femorofemoral bypasses. Tunneling of the grafts will require supplemental sedation.

Patient Positioning and Draping

Patients are supine. For axillofemoral bypasses, some surgeons perform the operation with the donor side arm at the patient's side, but we prefer the arm abducted to 90 degrees. This position maximizes the distance between the axillary and femoral arteries, thereby minimizing tension on the axillary anastomosis postoperatively. It also allows visualization of the flank and lateral chest wall while passing the graft tunneling device to ensure that it passes over and not under the costal margin. Femoral regions are widely prepped and draped for femorofemoral bypasses, and the supra- and infraclavicular regions, axilla, chest, abdomen, and femoral regions for axillofemoral bypasses. Ideally, the lower extremities are prepped and draped into the operative field in case unanticipated adverse circumstances require additional infrainguinal revascularization. The operative sites are then covered with an iodine-impregnated incision drape. To minimize operative time, a multiple team approach is preferred if possible, with separate surgical teams operating simultaneously at each of the operative sites.

Femoral Artery Dissection

The femoral arteries are exposed through bilateral vertical groin incisions. Transverse or oblique groin incisions can be used, and should be considered in obese patients, but are less versatile if exposure must be extended distally. The choice of site for the distal anastomosis is based on patient circumstances and vessel patency, which is determined by preoperative imaging. Accordingly, the distal graft anastomoses may be to the common, profunda, or superficial femoral arteries. In most cases, the common femoral artery just proximal to the common femoral bifurcation is the preferred site for the distal anastomosis. Occasionally, endarterectomy of the outflow vessels is required. In special circumstances, distal anastomoses may be to more distal portions of the

profunda or superficial femoral arteries, and lateral approaches to these vessels may be used, especially in the presence of infection of previously placed femoral grafts or extensive scarring from multiple previous operations in the groin. In obese patients, more distal anastomotic sites are preferred to minimize perianastomotic graft kinking when the patient is in a sitting position.

Axillary Artery Dissection

We use the first part of the axillary artery for the proximal anastomosis. It only has a single collateral branch and is relatively fixed in position, so placing the axillary anastomosis as medially as possible avoids tension on the axillary anastomosis when the arm is abducted. In addition, the brachial plexus nerves interdigitate with the axillary artery and its branches. The first part of the artery lies anterior to the brachial plexus. The divisions and cords of the brachial plexus lie anterior to the third part of the artery. The second part of the axillary artery is enveloped by the brachial plexus cords passing from posterior to anterior. These anatomic relationships point out the advantages of using the first part of the axillary artery for the proximal anastomosis.

An infraclavicular incision is made approximately two fingerbreadths below the middle third of the clavicle, not directly parallel to the clavicle but along the anticipated course of the axillary artery. The fibers of the pectoralis major muscle are bluntly separated, revealing the clavipectoral fascia, which is incised. The pectoralis minor muscle is mobilized but not divided and serves as the lateral border of the dissection. If necessary, the pectoralis minor muscle may be divided to improve operative exposure but the graft should always be placed on the axillary artery medial to the pectoralis minor muscle. The axillary vein is mobilized and retracted caudally to reveal the axillary artery, a step that requires ligation and division of the cephalic vein and other small venous branches along the cephalad portion of the vein. The axillosubclavian arteries are considerably more fragile than the femoral arteries, and care must be taken not to injure them or the adjacent nerves and veins during dissection or during placement of retractors or vascular clamps. The thoracoacromial artery is left intact and used as the marker for the lateral corner of the anastomosis. Sufficient length of artery is dissected and mobilized medial to the thoracoacromial artery for the proximal anastomosis.

Femorofemoral Tunnel

A subcutaneous, suprapubic, inverted U tunnel is created bluntly between the two femoral incisions with fingers, curved aortic clamp, or tubular tunneler. The tunnel lies directly anterior to the external oblique and anterior rectus fascia. By placing the tunnel directly on top of the fascia and avoiding placement of the tunnel in the suprapubic fat, motion of the graft with positional changes and kinking in the groin area is minimized, which is particularly important in obese patients with a large suprapubic pannus. Dacron or polytetrafluoroethylene (PTFE) grafts have been used with equally good results. Cryopreserved femoral vein also is a suitable conduit and may have advantages when there is active infection in the groin. We prefer, however, in most cases, an externally supported PTFE graft (8 mm × 40 cm) for the cross-pubic graft.

Axillofemoral Tunnel

A subcutaneous tunnel is begun at the ipsilateral femoral incision. The standard tunnel passes medial to the anterior superior iliac spine and then along the lateral aspect of the abdomen in the midaxillary line. Grafts tunneled too anterior to the midaxillary line are prone to kinking due to the costal margin being more prominent anteriorly than in the midaxillary line. The tunnel continues posterior to the pectoralis major and minor muscle into the axilla (Fig. 205.1). The use of a long graft tunneling device allows the tunnel to be made without the need for counter incisions in all but taller patients. An externally supported PTFE graft (8 mm × 70 to 90 cm) is passed through the subcutaneous tunnel.

Graft Anastomoses

Femorofemoral Bypass

After completion of the tunnels, intravenous heparin is administered at a dose of 100 units/kg. The arteries are controlled proximally and distally with atraumatic vascular clamps or Silastic vessel loops. Bilateral end-to-side anastomoses are created to femoral arteriotomies with CV-6 PTFE sutures. The arteriotomies are typically 2.5 times the diameter of the graft in length. The anastomosis to the outflow artery depends on the patency of the outflow vessels. If the superficial and profunda femoral arteries are patent, the anastomosis can be placed on the common femoral artery. If the superficial femoral artery is occluded, as is often the case in patients with advanced atherosclerosis, the distal anastomosis can still be placed on the common femoral artery if the origin of the profunda femoral artery is

widely patent. The anastomosis can be extended across the profunda femoris origin or placed on the profunda itself if there is occlusive disease involving the origin of the profunda femoris artery.

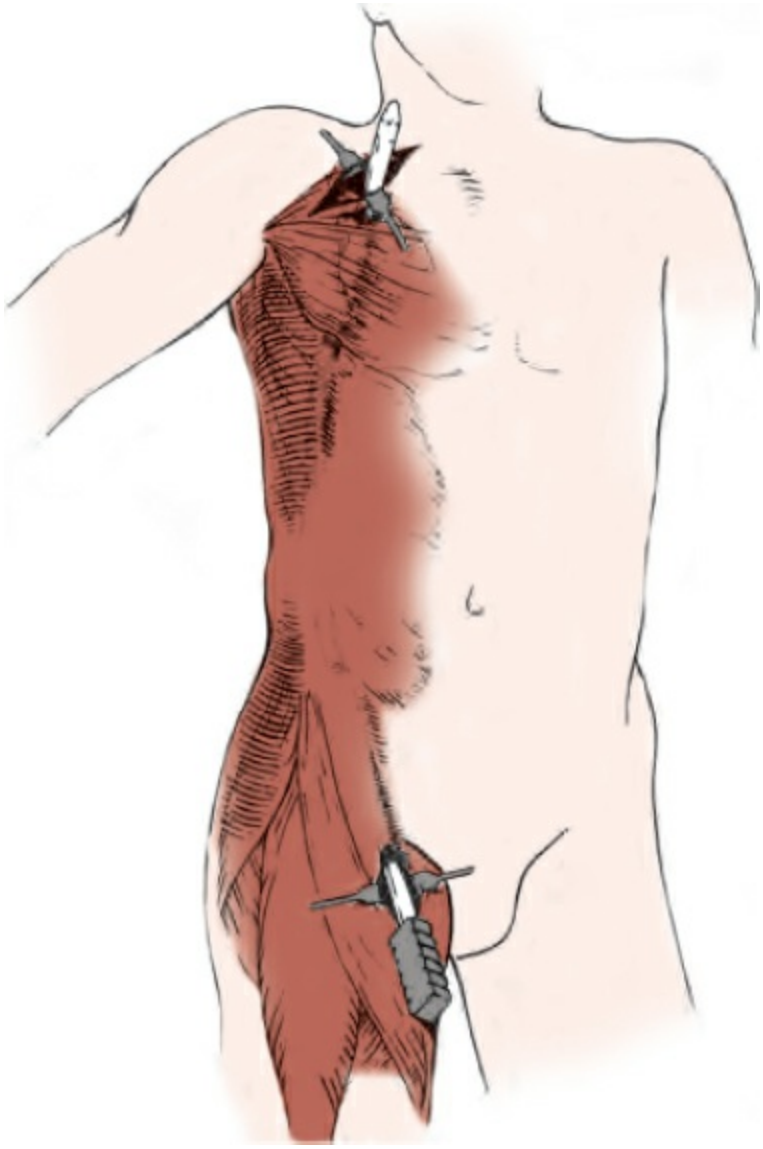

Figure 205.1. Route of subcutaneous axillofemoral tunnel made with a graft tunneler. The tunnel runs medial to the anterior superior iliac spine, along the midaxillary line, and posterior to the pectoralis minor muscle.

The anastomosis is at risk for kinking in both the coronal and sagittal planes, and careful attention is required during placement of the anastomosis to avoid this. Using a slight excess of graft material and making the tunnel as a continuous curve between the femoral incisions help reduce the tendency of the graft to kink at the heel of the anastomoses in the coronal plane. Kinking in the sagittal plane can be more pronounced

in an obese patient or patient with a more protuberant abdomen. Performing the anastomosis to a more distal part of the femoral arterial system or making a shorter arteriotomy and anastomosis can mitigate this. Extending the anastomosis at least partially onto the profunda may also be very helpful in reducing the tendency of the graft to kink in both the sagittal and coronal planes.

The graft is spatulated to create a “cobra-head” anastomosis. Sutures are placed in the heel and toe of the anastomosis and are run continuously out of each corner. Alternatively, a single suture can be placed in the heel and sewn circumferentially. The graft and vessel edges are everted, with suture bites approximately 1 mm in depth and travel between bites. The arteries are flushed and backbled prior to completion of the anastomosis.

Axillofemoral Bypass

The axillary anastomosis is also performed in an end-to-side fashion using a CV-5 PTFE suture. A longitudinal arteriotomy on the anterior-inferior surface of the first part of the axillary artery, medial to both the pectoralis minor muscle and the thoracoacromial artery, is made. The graft is routed parallel and adjacent to the axillary artery posterior to the pectoralis minor muscle for approximately 8 to 10 cm before beginning a gentle curve at the beginning of its inferior course (Fig. 205.2). This redundancy allows for arm extension, distributing any potential tension across the curve of the graft rather than at the proximal anastomosis. This is intended to prevent proximal anastomotic disruption. A finger is placed along the graft in the axilla to maintain the graft redundancy at this location, and the graft is then pulled tautly from the inguinal incision to remove any redundancy from the longitudinal portion of the tunnel. The graft is thereby mobile in its area of axillary redundancy but otherwise relatively immobile.

The distal end of the axillofemoral graft is then anastomosed in an end-to-side fashion to the cobra-head of the ipsilateral side of the femorofemoral graft (Fig. 205.3). This configuration maximizes the flow through the entire length of the axillofemoral graft. The final graft configuration is shown in Figure 205.4. When a femorofemoral graft is not simultaneously performed, the distal anastomosis is placed on the common, superficial, or profunda femoral artery depending on the quality of the arteries and their outflow. Hemostasis of needle-hole bleeding is obtained using topical spray thrombin and Gelfoam or other commercially available topical sealants. Heparin is reversed with protamine sulfate at a dose of 1 mg/100 units heparin given.

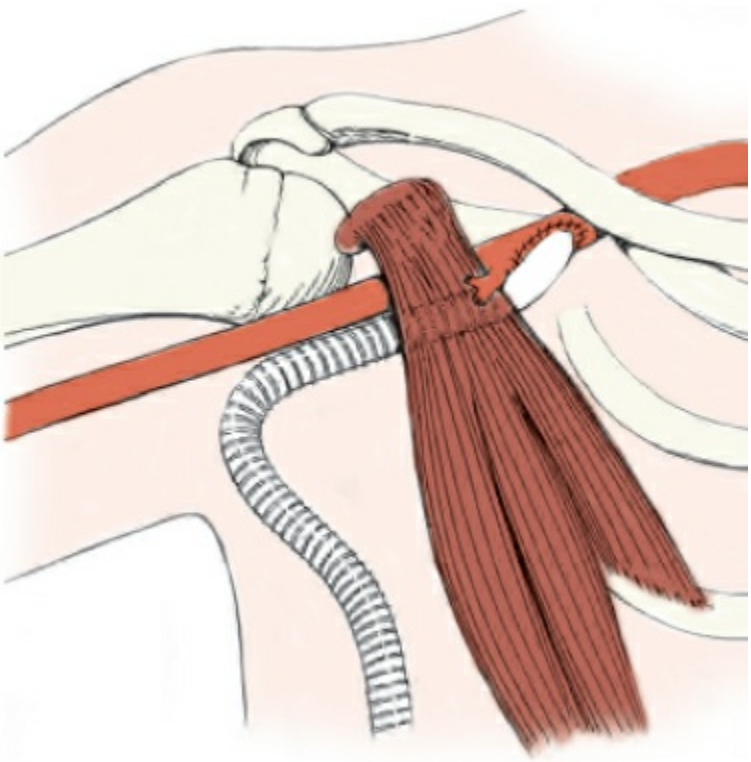

Figure 205.2. Axillary anastomosis showing end-to-side graft anastomosis. The anastomosis is to the first part of the axillary artery. The graft is routed parallel and adjacent to the axillary artery posterior to the pectoralis minor muscle for 8 to 10 cm before forming a gentle curve to its inferior course.

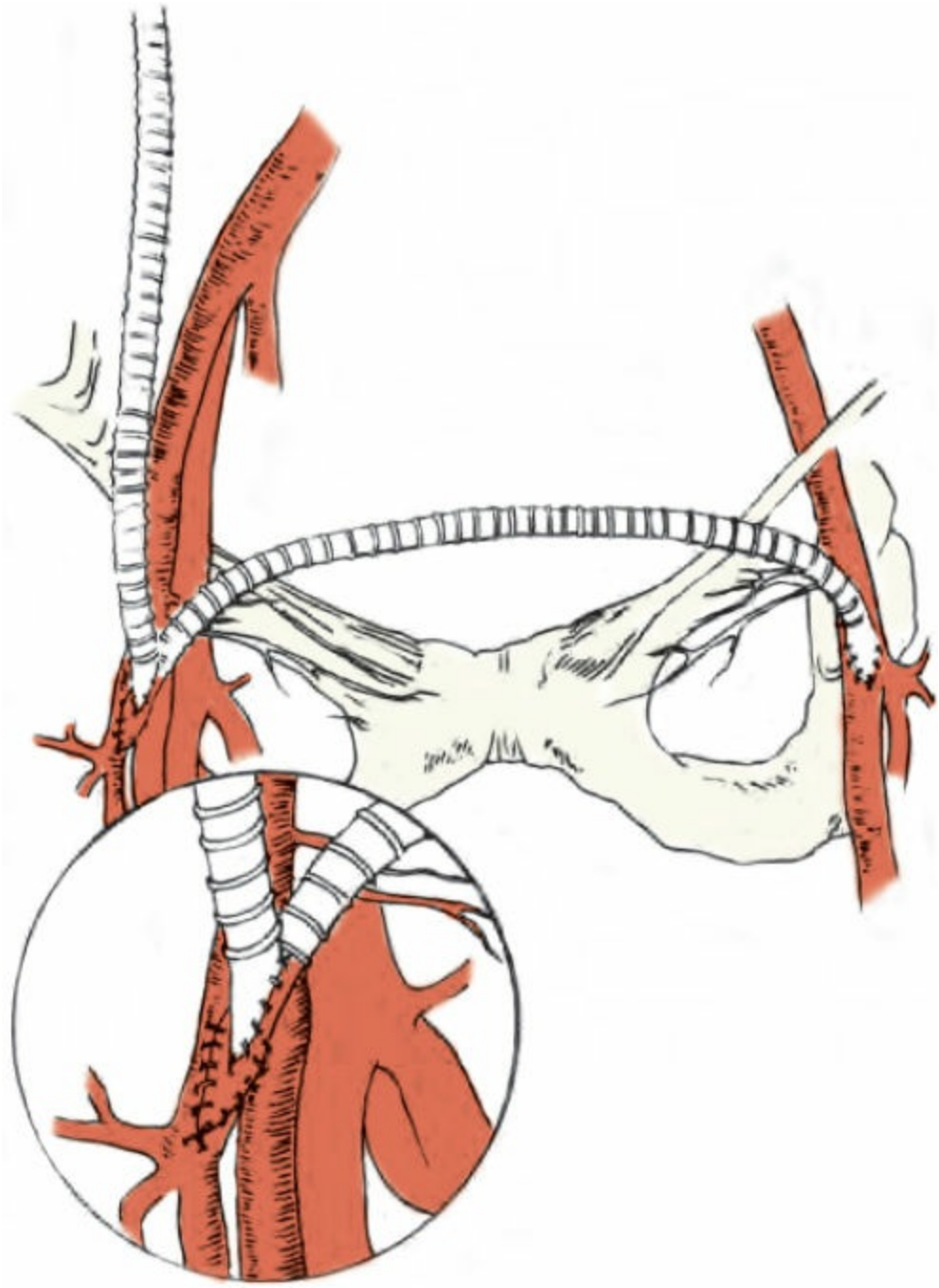

Figure 205.3. Distal axillofemoral anastomoses. The femoral–femoral graft is anastomosed in an end-to-side fashion to the femoral arteriotomies. The distal end of the axillofemoral graft is anastomosed in an end-to-side fashion to the femoral–femoral graft (*inset*).

Wound Closure

Following wound irrigation, all incisions are closed in three layers. In the femoral incision, running absorbable sutures are used to cover the grafts and the subcutaneous tissue. In very thin patients or where risk of wound

breakdown is increased, a rotational sartorius muscle flap can be placed over the graft in the groin. Running absorbable sutures are also used in the axillary incision to close the pectoral fascia and subcutaneous tissue. The skin is closed with a running absorbable subcuticular suture.

Special Situations

Aortobifemoral Graft Infection

Aortic graft infection can be treated with axillobifemoral grafting followed by complete excision of the infected graft. This sequence allows the performance of the sterile procedures prior to exposure of the infected field. In addition, it eliminates a prolonged period of leg ischemia prior to revascularization. The successful performance of axillofemoral grafting prior to excision of infected grafts requires special attention to the technique of patient preparation and draping, as well as modified graft tunneling and arterial exposure.

Most aortobifemoral graft infections are caused by Staphylococcal species, although other bacterial species can also be involved. Patients should be placed on the appropriate antibiotic coverage as soon as graft infection is noted, and this should be continued throughout the perioperative period. Prior to entering the operating room, any open wounds or sinus tracts are packed with iodine-soaked gauze and covered with an iodine-impregnated incision drape. The entire operative field is then sterilely prepared and covered with a complete layer of sterile occlusive plastic.

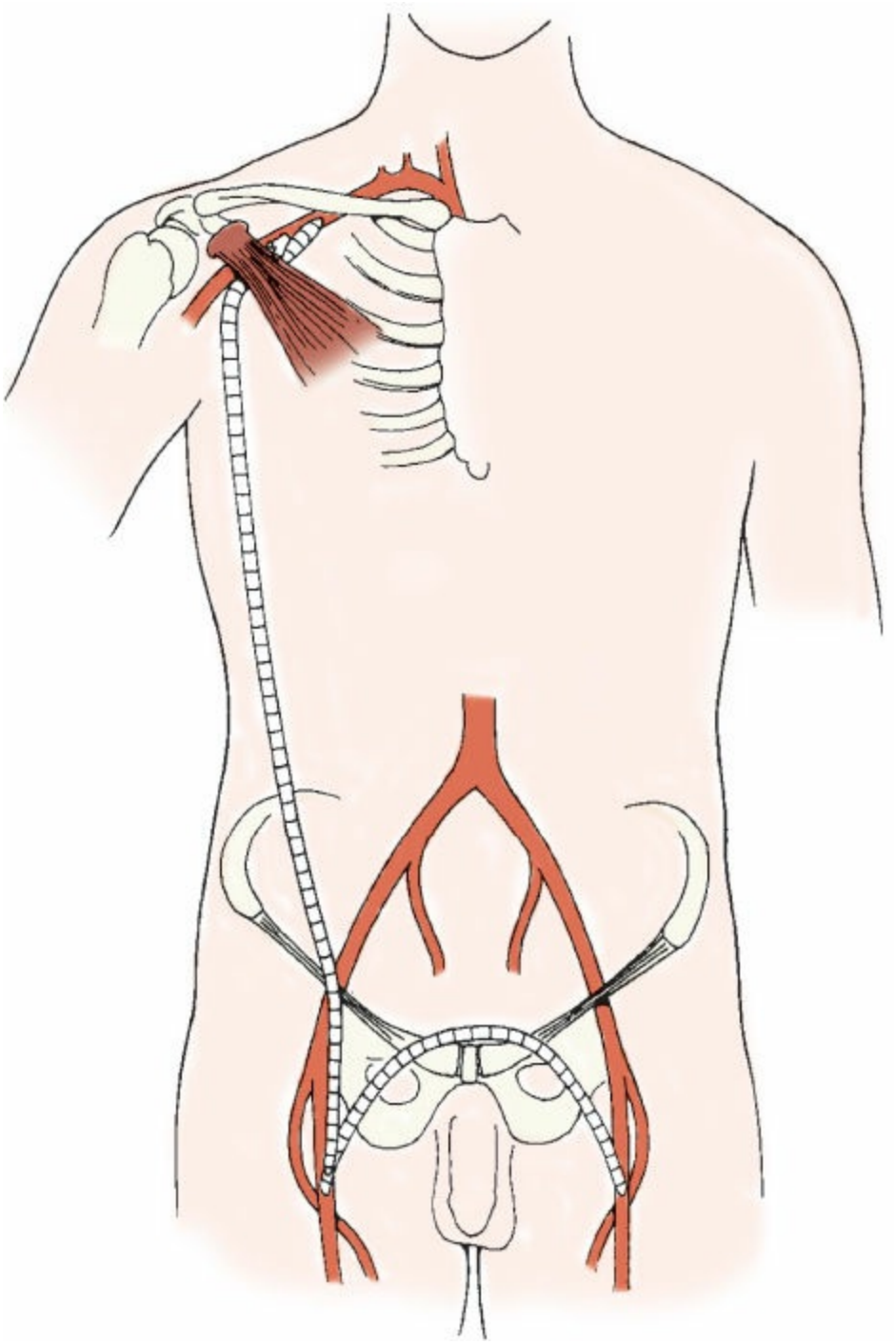

Figure 205.4. Final graft configuration of axillobifemoral bypass.

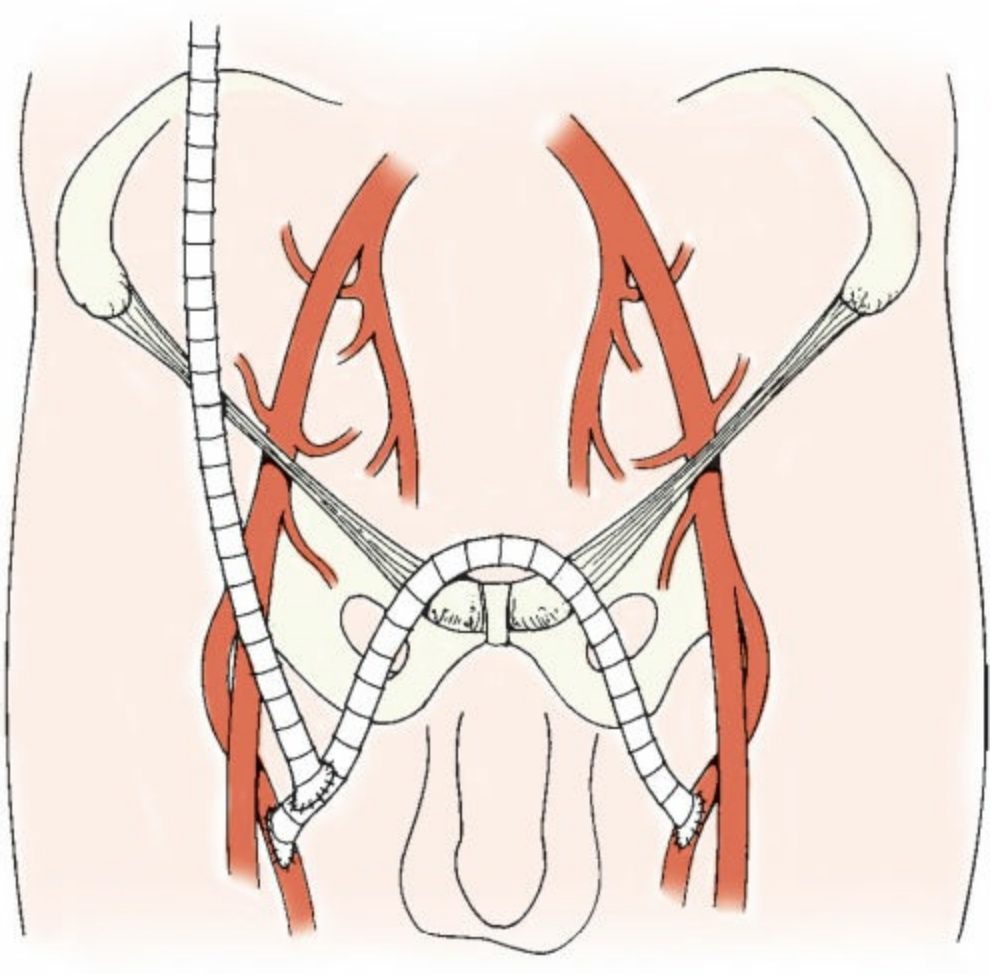

Figure 205.5. Axillofemoral graft configuration in the presence of groin infections. The axillofemoral graft is routed lateral to the anterior superior iliac spine. Femoral anastomoses are made to midsuperficial femoral arteries. The femoral–femoral graft is routed low over the midline to avoid infected fields.

Fresh incisions that are distal to and separate from the previous groin incisions are made to expose the midsuperficial femoral arteries, or if the superficial femoral arteries are occluded, the distal portion of the deep femoral arteries. A lateral approach to these vessels is frequently useful. Tunneling of the femorofemoral bypass is then performed subcutaneously under the medial thigh skin, very low over the midline, below the level of the pubic symphysis, just above the base of the penis or clitoris, in an effort to avoid the previous groin incisions. The axillofemoral graft is tunneled lateral and posterior to the anterior superior iliac spine, with the graft passing under the sartorius muscle arriving at its connection with the femorofemoral graft from the lateral side (Fig. 205.5). In a few cases, the authors have performed an axillary-to-contralateral femoral artery bypass

to avoid infected incisions in the ipsilateral groin or flank. The grafts were routed beneath the pectoralis major muscle and then subcutaneously across the chest and abdomen to the contralateral groin (Fig. 205.6). No adverse effects on patency have been noted with this graft configuration. In addition, when the extent of sepsis in the femoral areas precludes a femorofemoral synthetic graft, bilateral axillofemoral grafts may be placed or the cross-femoral component of the bypass constructed from femoral vein, or cryopreserved cadaveric femoral vein. A single femoral vein harvested from just above the knee to just below the profunda femoris vein usually provides adequate length for a femorofemoral bypass when anastomoses are to the common femoral arteries bilaterally.

Following completion of the axillobifemoral graft, the incisions are closed and covered with another layer of occlusive plastic drapes. Since the clean portion of the operation is now complete, it is not necessary to reprepare and drape the patient. Appropriate incisions are now made into the infected areas to allow graft removal. Obviously, use of multiple operating teams for such extensive procedures required for treatment of graft infections significantly shortens what is already a prolonged operation.

POSTOPERATIVE CARE

Patients with extensive comorbidities or infected aortic graft removal and reconstruction are transferred initially to a surgical intensive care unit. It is frequently difficult to evaluate the newly placed PTFE graft with ultrasound due to the presence of air within the graft interstices. Frequent physical examination and continuous wave Doppler examination of the dorsalis pedis and posterior tibial arteries assist in determining graft patency. Aspirin therapy is continued. Routine anticoagulation with heparin and warfarin is not advocated unless a known hypercoagulable state has been identified. Early ambulation is encouraged. Patients are cautioned to avoid placing the donor arm over the head for the first 6 weeks following surgery to avoid excess graft tension and potential axillary anastomotic disruption.

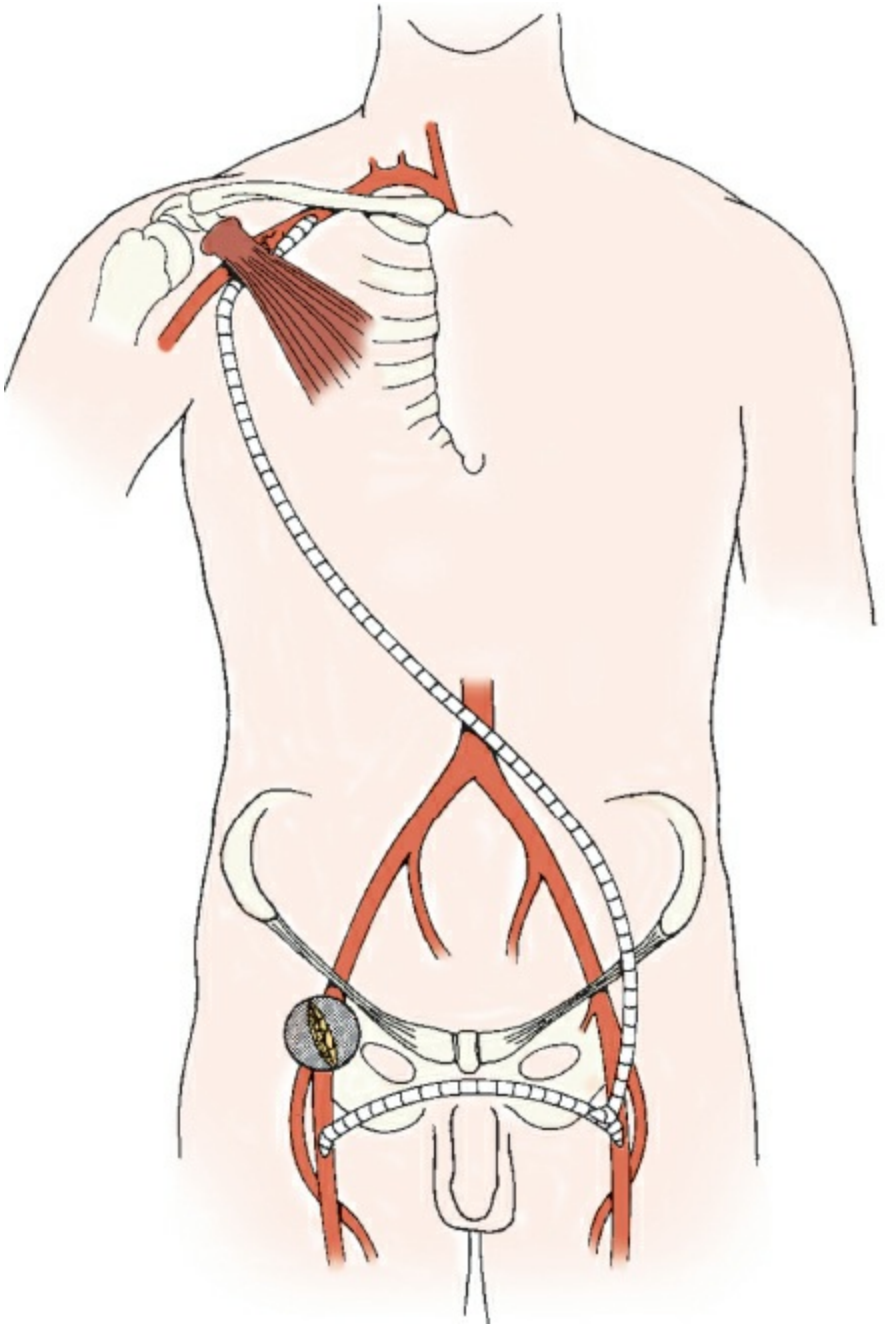

Figure 205.6. Axillary-to-contralateral femoral artery bypass used to avoid infected incision in ipsilateral groin (*shaded areas*).

Postoperative graft surveillance is performed by vascular laboratory duplex every 3 months for the first postoperative year, and then every 6 months. Flow velocities vary widely within axillofemoral grafts. In our experience, patency is associated with a midgraft peak systolic velocities >150 cm/s. A midgraft peak systolic velocity <80 cm/s is a risk factor for occlusion. Arteriography is performed when vascular laboratory testing suggests graft stenosis.

COMPLICATIONS

Graft Occlusion

Patency rates for axillofemoral and femorofemoral bypass are highly variable and are influenced by the operative indications, the graft configuration, and the status of the runoff vessels. Early studies reported disappointing 3-year primary patency rates <50%, but over the years, patency rates have improved considerably. With proper technique, 5-year primary patency of axillofemoral grafts approaches that of aortobifemoral reconstruction, ranging from 69% to 75%. Five-year patency of femorofemoral grafts ranges from 50% to 90%.

Proximal Graft Disruption

Disruption of the proximal anastomosis of the axillobifemoral grafts occurred in approximately 5% of patients in our early experience. They frequently occurred in early postoperative period (range 1 to 46 days; mean 21 days). Perioperative graft disruption was most often associated with forceful arm abduction or shoulder elevation, but also occurred in the absence of reported activity. The most frequent presenting symptoms were infraclavicular pain and swelling. Upper extremity ischemic symptoms were rare. Anastomotic disruption has been treated by emergent surgery, with the subclavian artery generally controlled through a supraclavicular incision prior to opening the infraclavicular incision. Operative findings have included sutures pulling through the graft or the vessel at the anastomosis, or graft disruption adjacent to but separate from the anastomosis (Fig. 205.7). In most cases, the grafts were trimmed back to undisrupted material and lengthened with an interposed segment of the same graft material with reanastomosis to the same site on the axillary artery.

Graft disruption is clearly related to excessive tension on the anastomosis from the marked changes in distance between axillary and femoral arteries with changing arm position. This tension can be minimized by incorporating considerable redundancy into the grafts as well as by positioning the anastomosis on the most proximal portion of the axillary artery. Since adopting the axillary anastomotic configuration described in this chapter, no additional anastomotic disruptions have occurred in our experience.

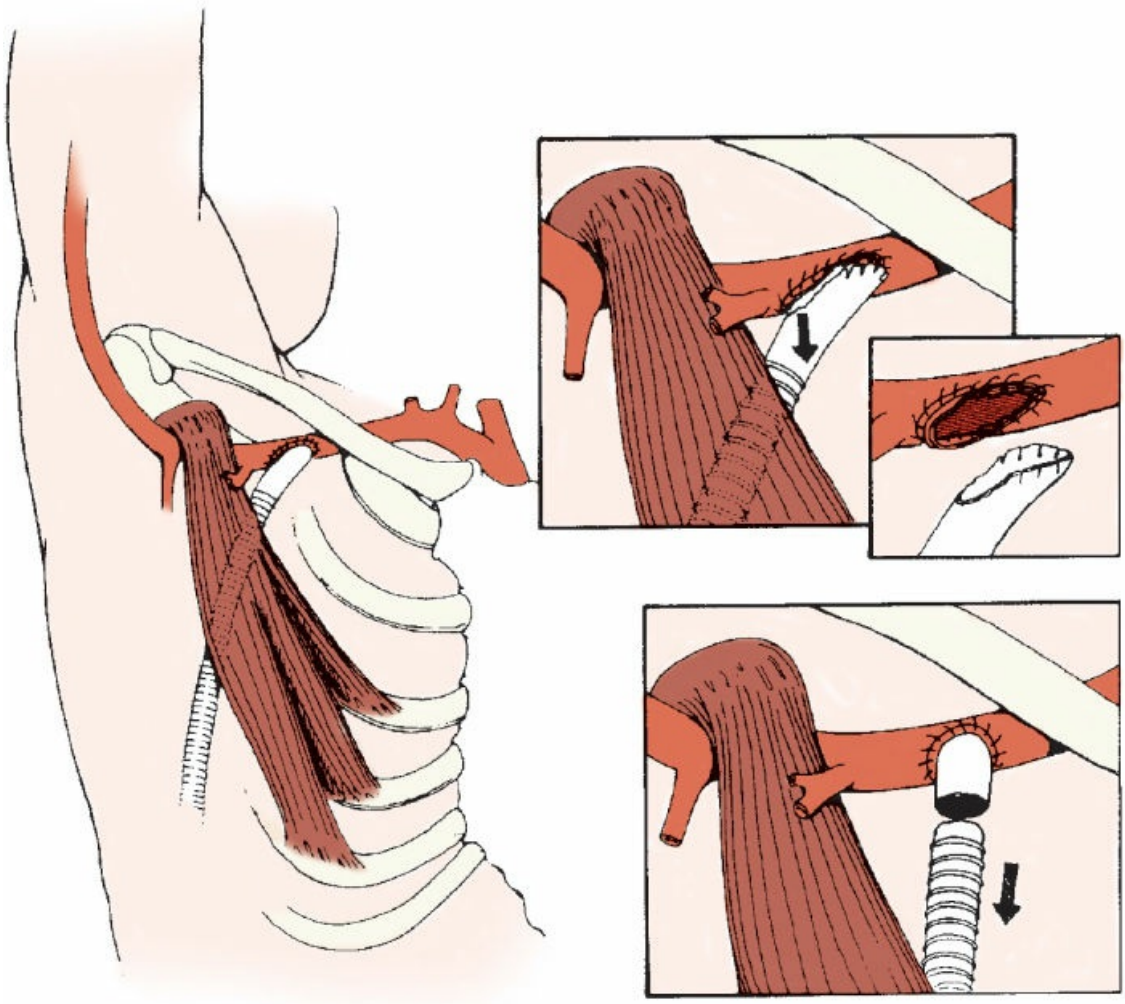

Figure 205.7. Proximal graft disruption. Causative factors include forceful arm abduction and lack of redundancy in the proximal portion of the graft. Operative findings include sutures pulling through the heel of the graft (*upper inset*) or graft disruption adjacent to but separate from the anastomosis (*lower inset*).

Thromboembolism

Thromboembolism to the donor upper extremity is relatively rare and does not occur in patients with a patent graft. In most cases of axillofemoral bypass graft occlusion, immediate graft revision has been performed following occlusion to restore lower extremity circulation. In rare cases, donor arm thromboembolism occurred simultaneously with graft occlusion, and in these cases, graft and arm embolectomy were performed. In a few cases, flow was not reestablished through occluded axillofemoral grafts, with lower extremity circulation provided by other means. Of these patients, up to 80% developed delayed thromboembolism to the upper extremity months to years (range 26 days to 7 years) following graft

occlusion. Upper extremity arteriograms in these patients revealed a blind stump in the occluded axillofemoral graft, which presumably serve as an embolic source. These patients were treated with graft disconnection, distal embolectomy, and patch repair of the axillary artery. Given the high risk of axillary graft stump syndrome, consideration should be given to disconnecting the graft from the axillary artery in appropriate risk patients with occluded bypass graft not requiring revascularization.

Infection

Extraanatomic graft infection occurs most frequently in the groins. CT is necessary to determine the extent of graft infection, since the entire graft is at risk for infection. The principles of graft replacement are the same as those described above for aortic graft infection. If the entire graft is involved, a new extraanatomic bypass is placed in noninfected tissue followed by removal of the involved graft. In cases of partial graft infection, it is usually sufficient to remove only the involved portion. Again, a new graft is placed in noninfected tissue prior to removing the infected graft segment.

Perigraft Seroma

Perigraft seroma is a rare complication following axillobifemoral bypass grafting. It consists of a sterile perigraft fluid collection surrounded by a fibrous pseudocapsule. The fluid appears to be a serum ultrafiltrate. The cause is unknown, although it has been suggested to be the result of a fibroblast growth inhibitor preventing graft incorporation by the surrounding tissues. Most cases will resolve with conservative therapy, although the length of time to resolution is variable. Aspiration is typically followed by fluid reaccumulaton. Repeat aspirations have not been shown to be more effective than conservative therapy and have been associated with a higher incidence of infection. Sclerotherpy is discouraged due to high incidences of infection and graft thrombosis. In symptomatic patients or for persistent seromas, the preferred treatment is complete graft and cyst excision with placement of a new graft in a different tissue plane. Using a graft of a different material has been shown to reduce the likelihood of perigraft seroma formation in the new graft.

OUTCOMES

Using the above technique, we have achieved 5-year life-table primary

patency, limb salvage, and survival rates of 71%, 92%, and 52%, respectively. The main cause of mortality is related to cardiac comorbidities, reflecting the overall poor health frequently noted in patients undergoing this procedure. Others have reported similar favorable results.

Patency rates for extraanatomic bypass are strongly influenced by the operative indications, the graft configuration, and the status of the runoff vessels. Axillobifemoral bypass performed for graft infection following aortic aneurysm repair with patent superficial femoral artery runoff has much higher reported 5-year patency rates than axillounifemoral bypass performed for atherosclerotic disease with an occluded superficial femoral artery. Similarly, patency rates for femorofemoral grafts placed during aortouniiliac endovascular abdominal aortic aneurysm repair exceed 90% at 4 years, greatly surpassing the patency rates noted in patients with occlusive disease.

Secondary patency rate is higher than primary patency rate, and effort should be made to restore the flow and revise the grafts when necessary. For graft failure due to thrombosis, graft replacement and/or anastomotic revision has superior patency rates to thrombectomy alone. In our series, patency rates of occluded grafts that were replaced or revised were 54% at 18 months versus 11% in those undergoing only thrombectomy.

CONCLUSION

Axillobifemoral bypass is an effective method for lower extremity revascularization for aortoilic occlusive disease or for patients with aortic sepsis. Historically, inferior patency rates compared with aortobifemoral bypass have resulted in the perception that it is a second-choice procedure. However, modern series report patency rates rivaling aortobifemoral bypass, suggesting that it may be appropriate to broaden the surgical indications in patients with aortoiliac occlusive disease not amenable to percutaneous endovascular therapy.

Suggested Readings

Hertzer NR, Bena JF, Karafa MT. A personal experience with direct reconstruction and extraanatomic bypass for aortoiliofemoral occlusive disease. *J Vasc Surg* 2007;45:527.

Lipsitz EC, Ohki T, Veith FJ, et al. Patency rates of femorofemoral bypass associated with endovascular aneurysm repair surpass those performed for

occlusive disease. *J Endovasc Ther* 2003;10:1061.

Martin D, Katz SG. Axillofemoral bypass for aortoiliac occlusive disease. *Am J Surg* 2000;180:100.

McLafferty RB, Taylor LM Jr, Moneta GM, et al. Upper extremity thromboembolism caused by occlusion of axillofemoral grafts. *Am J Surg* 1995;169:492.

Mii S, Mori A, Sakata H, et al. Fifteen-year experience in axillofemoral bypass with externally supported knitted Dacron prosthesis in Japanese hospitals. *J Am Coll Surg* 1998;186:581.

Musicant SE, Giswold ME, Olson CJ, et al. Postoperative duplex scan surveillance of axillofemoral bypass grafts. *J Vasc Surg* 2003;37:54.

Olson CJ, Edwards JM, Taylor LM Jr, et al. Repeat axillofemoral grafting as treatment for axillofemoral graft occlusion. *Arch Surg* 2002;137:1364.

Passman MA, Taylor LM Jr, Moneta GL, et al. Comparison of axillofemoral and aortofemoral bypass for aortoiliac occlusive disease. *J Vasc Surg* 1996;23:263.

Taylor LM Jr, Moneta GL, McConnell D, et al. Axillofemoral grafting with externally supported polytetrafluoroethylene. *Arch Surg* 1994;129:588.

Taylor LM Jr, Park TC, Edwards JM, et al. Acute disruption of polytetrafluoroethylene grafts adjacent to axillary anastomoses: a complication of axillofemoral grafting. *J Vasc Surg* 1994;20:520.

Thuijls G, van Laake LW, Lemson MS, et al. Usefulness and applicability of femorofemoral crossover bypass grafting. *Ann Vasc Surg* 2008;22:663.

Yeager RA, Taylor LM Jr, Moneta GL, et al. Improved results with conventional management of infrarenal aortic infection. *J Vasc Surg* 1999;30:76.



EDITOR'S COMMENT

The nicely written and detailed chapter by Dr. Jung et al. describes common extraanatomical bypass constructions for aortoiliac occlusive disease, namely the axillofemoral and cross-femoral artery bypasses. These techniques should be in every vascular surgeon's armamentarium as there are many times when the access to the abdominal or thoracic aorta is not able to be done safely. Similar indications include patients who are too ill to undergo abdominal surgery with an aortic cross-clamping. Often times, patients who undergo an axillofemoral graft are sicker than those undergoing aortofemoral bypass (AFB) (Passman MA, Taylor LM, Moneta GL, et al. Comparison of axillofemoral and aortofemoral bypass for aortoiliac occlusive disease. *J Vasc Surg* 1996;23:263–9; discussion 269–71). The preformed 8-mm axillofemoral grafts are convenient, and allow one less anastomosis to be created.

I agree with the authors that the current patency rate of axillobifemoral bypasses is likely better than historical series, but it certainly is dependent on the degree of the patient's outflow artery disease, particularly the deep femoral anatomy. For example, recent series suggest a good secondary patency of 70% to 86% (Passman MA, Taylor LM, Moneta GL, et al. Comparison of axillofemoral and aortofemoral bypass for aortoiliac occlusive disease. *J Vasc Surg* 1996;23:263–9; discussion 269–71; Liedenbaum MH, Verdam FJ, Spelt D, et al. The outcome of the axillofemoral bypass: a retrospective analysis of 45 patients. *World J Surg* 2009;33:2490–6). However, decreased patency is found in patients with aggressive early atherosclerosis and continued smoking. They often suffer repeated occlusive events, and have poor long-term success. Patients who require thrombectomy or thrombolysis of their extraanatomic bypass usually require warfarin and antiplatelet therapy, but there is no strong evidence for this; only clinical experience. Using anticoagulation for all axillobifemoral grafts is not supported by any evidence, and likely increases the risk of bleeding without benefit.

I would also state the cautious view that while the extraanatomic bypass techniques are useful, I think using these reconstructions when either endoluminal or aortofemoral bypass is possible is not wise. For example, endoluminal approaches are generally safe, technically successful, and are now most common for aortoiliac occlusive disease (Hong MS, Beck AW, Nelson PR. Emerging national trends in the management and outcomes of lower extremity peripheral arterial disease. *Ann Vasc Surg* 2011;25:44–54). Second, in-line blood flow with an AFB has the best durability. We often see patients referred after multiple extraanatomical bypass failures, when in-line flow is safe and possible. Thus, the extraanatomic bypass should be generally the third choice for aortoiliac reconstruction.

As most abdominal aortic aneurysms are treated with endovascular techniques, the use of the femoral to femoral bypass for aortounifemoral endovascular aneurysm repair with contralateral iliac occlusion is now much more common. This represents a different indication than occlusive disease, and often these patients do quite well, with excellent patency rates. One series reported an 11% rate of groin complications and 5-year patency of 83% (Hinchliffe RJ, Alric P, Wenham PW, et al. Durability of femorofemoral bypass grafting after aortouniiliac endovascular aneurysm repair. *J Vasc Surg* 2003;38:498–503). Monitoring with postoperative CT imaging that is done for endovascular aneurysm surveillance maybe of use in detecting inflow stenosis, which can cause bilateral lower limb ischemia. Similarly, duplex ultrasonography can detect stenosis directly if the waveform becomes monophasic. Nonetheless, due to the groin incision location, infection risks still remains, and more long term clinical series data is required.

One of the biggest issues that the authors very nicely detail is how to avoid axillo-graft disruption. As a surgeon who has had this happen, I entirely agree with the techniques they describe to diminish this risk. First, creating some

redundancy in the graft or having it go parallel to the artery for a distance makes sense and allows some flexibility. Second, keeping the arm abducted during the procedure to put maximum stretch on the axillary artery is also wise. Third, the patient should restrain from active and vigorous arm exercise for at least 6 weeks after the procedure. Fourth, unlike the authors, we usually divide the pectoralis minor, which also decreases the risk of disruption, as it can act as a fulcrum for graft stress.

In terms of emergency bail-outs for an acute axillo-graft disruption, a covered stent graft can be placed percutaneously via retrograde brachial approach to seal the axillary arteriotomy and this maybe lifesaving, if the bleeding is excessive. If able to potentially salvage the graft, then a temporary percutaneous balloon occlusion via the same route is reasonable to control of bleeding, and re-anastomosis of the graft. These hybrid techniques also allow vascular control without damaging the nerves and subclavian-axillary vein in the area. If a covered stent graft is used, this means a new graft will likely need to be constructed from the contralateral axillary artery. In terms of the distal graft arterial anastomosis, the bifurcation of the common femoral artery is, I believe, the best choice with the profunda patch angioplasty if the superficial femoral artery is occluded. This is a similar principle to AFB constructions.

It is not uncommon to develop a postoperative hematoma along the track of the graft, but usually this resolves without any sequelae. This is particularly common if the patient requires heparin anticoagulation postoperatively. If the graft is placed to treat a femoral graft groin graft infection, such as with an aortofemoral graft, the use of femoral vein can be used as a crossover graft as described by the authors, or using the basilic vein, which is often 3.5 to 6 mm in diameter and quite durable in this location.

Peter Henke

206 Endovascular Procedures for Aortoiliac Occlusive Disease

Vikram S. Kashyap and Karem C. Harth

ETIOLOGY AND PATHOPHYSIOLOGY

Aortoiliac occlusive disease (AIOD) is associated with a multitude of risk factors. Most commonly, patients with AIOD have a long-standing history of smoking, diabetes, hypertension, and hypercholesterolemia. Treatment of patients with peripheral arterial disease (PAD) requires attention to the ravages of atherosclerosis on a systemic level, as well as to the burden of disease in their limbs. Risk factor modification can diminish the long-term effects of atherosclerosis on the cardiovascular system in these patients and ameliorate systemic comorbidities at the time of operative or endovascular treatment. Controlling blood sugar, serum cholesterol, blood pressure, and importantly smoking can lead to substantial short- and long-term benefits. In consultation with the patient's medical physician, antihyperglycemic treatment, smoking cessation, lipid lowering therapy, and antihypertensive therapy are instituted for the appropriate risk factors. Antiplatelet therapy is generally in the form of low-dose aspirin. Less common therapies such as homocysteine-lowering therapy and antithrombotic therapy are considered. Patients with nondisabling claudication can be considered for supervised exercise programs, as well as cilostazol (Pletal, 100 mg BID) pharmacotherapy for at least 3 months. The importance of smoking cessation programs cannot be overemphasized. However, despite pharmacologic and counseling interventions, recidivism remains disappointingly high.

CLINICAL PRESENTATION

Extensive AIOD often results in debilitating symptoms. The majority of patients will present with claudication, while those with multilevel disease will have rest pain or tissue loss. Careful physical examination will be consistent with absent or faint femoral pulses. Calcification in the femoral region can also be appreciated in thin patients and in those with associated

femoral disease. Pedal pulses are usually absent, and ulceration or gangrene may result from concomitant infrainguinal occlusions.

INDICATIONS AND CONTRAINDICATIONS

Clinically, patients with AIOD considered for therapy will present with claudication or limb-threatening symptoms such as rest pain and ischemic ulceration. In the latter situation, improving inflow would aim to place the patient out of a limb-threatening state with the plan to reevaluate symptom improvement prior to any planned intervention on the distal disease.

Severe AIOD has been classically treated via open vascular reconstruction using aortobifemoral bypass (ABF). An endovascular-first approach has become a more increasingly favorable approach in the last two decades. The Trans-Atlantic Inter-Society Consensus (TASC) statement on treatment of PAD initially created in 2000 and updated in 2007 aimed to organize and review the available literature on patients with PAD. The framework allowed stratification of atherosclerotic lesions by length and morphology. According to the TASC definitions for iliac occlusive disease, short focal iliac *stenoses are* classified as TASC-A. *Iliac occlusions* can be stratified as B, C, and D lesions. TASC-B lesions include unilateral common iliac occlusions only. TASC-C iliac lesions include unilateral external iliac occlusions not extending into the common femoral artery, or bilateral common iliac occlusions. TASC-D lesions are bilateral external iliac occlusions or ipsilateral common and external iliac occlusions or diffuse disease of the aorta and both iliac arteries. Endovascular procedures are thought to be the treatment of choice for type A lesions (stenoses <3 cm only), and open surgical therapy is the procedure of choice for type D lesions. According to the TASC statement, more evidence is needed for type B and C lesions with a preference for endovascular methods for the former and surgical methods for the latter. This consensus statement reinforced the concept of treating short, focal stenoses via endovascular means and using surgical revascularization for long-segment occlusions based on the available data at that time. Treatment of aortoiliac *occlusions* remains a more challenging endovascular treatment modality than the treatment of iliac stenoses. As endovascular therapies have evolved, this has been mirrored by a decreasing number of patients undergoing ABF.

We believe that endovascular therapies can be used as first-line therapy for AIOD, irrespective of TASC classification. This is based on improved

catheter-directed techniques allowing recanalization and new angioplasty and stent designs. In addition, there is an increasing capability of vascular specialists in treating more complex disease with catheter-based methods. Lastly, we preferentially use endovascular procedures because operative options are not lost, even if the endovascular therapy is unsuccessful. In our elderly patients with severe comorbidities, in patients with life expectancy or a hostile abdomen, a minimally invasive option for revascularization leads to decreased morbidity and length of recovery.

There are situations where endovascular therapy may be precluded or should be carefully approached. These include the presence of abdominal aortic aneurysmal disease, occluded abdominal aorta, circumferential calcification making plaque fracture by angioplasty difficult without arterial rupture, or atrophic chronically occluded iliac vessels. If circumferential iliac calcification raises concern for iliac rupture, then the need for covered stent grafts should be anticipated if an endovascular approach is to be chosen. Disease extending into the aortic bifurcation may require contralateral iliac balloon angioplasty at the time of intervention to prevent plaque shift and subsequent contralateral iliac injury. Simultaneous femoral disease may not allow for a purely percutaneous approach, and a hybrid intervention would be more successful. In addition, acute iliac occlusive disease has the risk of embolizing thrombus, and these scenarios should be preceded by either thrombolytic therapy or open thrombectomy to protect outflow vessels.

PREOPERATIVE PLANNING

Paramount to the preoperative evaluation of patients with AIOD is careful evaluation of their cardiac and pulmonary status. A significant portion of patients with AIOD will have undiagnosed coronary disease. In the setting of no limb-threatening aortoiliac disease, symptomatic coronary disease will take precedence. Those with asymptomatic disease may still be considered for endovascular intervention. A case-by-case evaluation is needed as this particular group of patients may be asymptomatic secondary to a sedentary lifestyle and inability to ambulate. In these settings, preoperative cardiac stress testing should be considered.

Various imaging modalities will confirm a clinical diagnosis of AIOD but will also facilitate surgical management. Noninvasive vascular laboratory imaging with either segmental pressures/pulse volume recordings (PVRs) (Fig. 206.1) or duplex examination is helpful in

determining the level and degree of disease present. In the setting of AIOD, high-thigh segmental pressures and waveforms will be diminished. In unilateral disease, a horizontal gradient will be present. The presence of diabetes, renal disease, or a long history of smoking may lead to significant calcification in the iliac and femoral vessels causing noncompressibility and false elevation of the pressures. In these cases, PVR assessment and toe-brachial indices are more sensitive.

We choose additional imaging with workup with computed tomographic angiography (CTA). This allows cross-sectional imaging, as well as three-dimensional reconstruction to assist in the planning of treatment in patients with extensive AIOD (Fig. 206.2). CTA is very helpful in determining the extent of AIOD, the degree of calcification, presence of aortic occlusion, or the rare presence of an abdominal aortic aneurysm. Diagnostic angiography becomes less critical with good-quality CTA evaluation.

SURGICAL TECHNIQUE

Using endovascular techniques to treat chronic occlusive disease in the aortoiliac segment requires a creative approach tailored to the lesion anatomy in an individual patient. The specific steps are access, recanalization, angioplasty, and then usually stenting. In addition, one should fully evaluate the entire aortoiliac system, using oblique views and also evaluate the distal femoral-popliteal runoffs in a nonselective manner, as this will affect long-term outcomes. Each step requires specific skills and instrumentation. Experience with multiple means of access (i.e., femoral, brachial), a wide variety of guidewires and catheters, and an operative environment that allows surgical exposure of arteries are critical. We believe an endovascular suite (hybrid operating room) allows the high-fidelity fluoroscopic imaging combined with operating room facilities to allow the safe and efficient performance of these procedures. This allows for combined (hybrid) open and endovascular surgery in some challenging scenarios where arterial pathology prohibits a purely endovascular approach. Attention must be paid to operative sterility and radiation exposure. One critical clinical decision in planning for endovascular therapy for AIOD is whether a purely percutaneous procedure can be performed. If so, conscious sedation, rather than anesthesia, can be organized simplifying the logistics of the procedure. If femoral reconstruction is planned, regional or general anesthesia may be required.

In patients with occlusive disease of the aortoiliac segments that does not extend into the common femoral arteries, a purely percutaneous procedure can be planned. Conscious sedation using short-acting opiates and anxiolytics is given. Access is usually performed with ultrasound guidance since the femoral pulses are either barely or not palpable. This is done with an anterior wall puncture only. Retrograde access to the iliac artery with less atherosclerotic burden allows catheter placement (Fig. 206.3A) and aortography with special pelvic oblique views to assess hypogastric patency if present. Subsequent imaging of the contralateral limb can be done via nonselective aortography (Fig. 206.3B) or selective catheterization using an "up and over technique." Alternatively, brachial artery access can be the initial source of entry in cases with complete aortic occlusion, previous aortobifemoral graft, or heavily diseased femoral arteries. One must keep in mind that left brachial access does require a longer overall system, including long sheaths and catheters sometimes >100 cm. Additionally, if a brachial approach is planned and there is an absent or weak left radial pulse, evaluation for subclavian occlusion or stenosis should be considered as this would dictate feasibility.

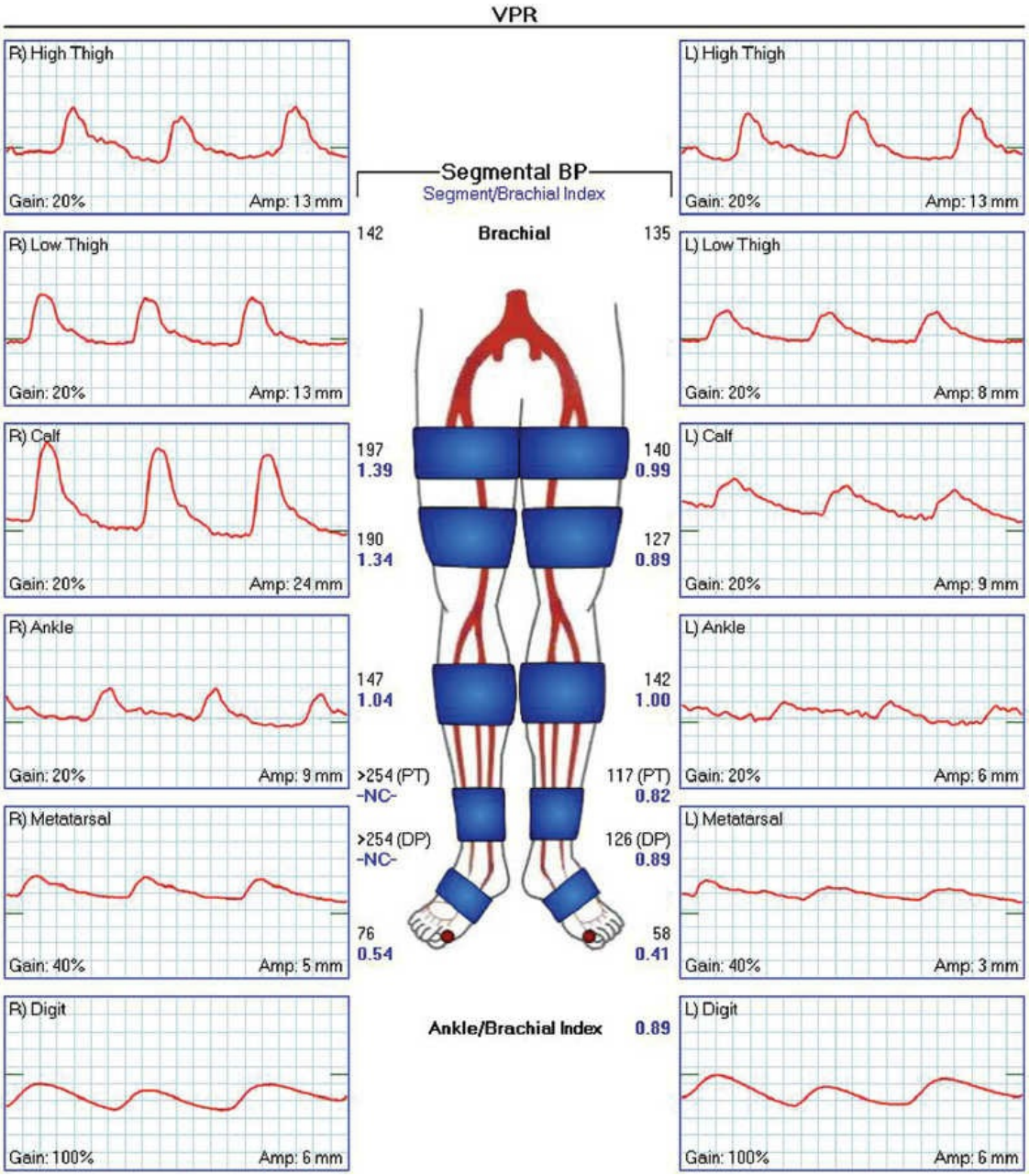

Figure 206.1. Segmental pressures and pulse volume recordings in a patient with left-sided inflow disease. Note the horizontal gradient at the high thigh level and the diminished waveforms secondary to left iliac occlusive disease.

For diagnostic angiography, percutaneous access, the placement of a 5-French (Fr) sheath, and eventual manual compression for hemostasis are common. However, if endovascular intervention is to be performed, larger sheaths (6 to 8 Fr) are often needed to accommodate delivery of the endoluminal devices and we often use a closure device at the completion of the procedure.

During diagnostic angiography, if a lesion is of questionable clinical

significance, one can measure intra-arterial pressures via different approaches and include provocative testing with papaverine (30 to 60 mg) or nitroglycerine (100 to 200 ug/mL) in order to unmask their hemodynamic impact. If the iliac artery ipsilateral to a femoral sheath is being evaluated, the sheath side arm can be connected to an arterial pressure monitor and compared to an arterial line in the upper extremity. Alternatively, an end hole catheter can be used to measure pressures proximal and distal to the lesion. Generally a gradient >10 mm Hg is considered significant. After diagnostic aortography and confirmation of preoperative AIOD burden, the contralateral femoral artery is accessed. A short, curved catheter (i.e., Kumpe, angled Glide) is brought to the level of the occlusion or high-grade stenosis for a retrograde angiogram (Fig. 206.3C). Following this, recanalization of an occluded segment is usually done using a standard Glide wire (Terumo, Inc.). This allows passage from the true lumen below to the aortic true lumen above.

Aortoiliac occlusions are more complex and challenging to treat via endovascular means than stenoses with chronic iliac occlusions representing 13% or more of the lesions in AIOD. Recanalization can be the most challenging portion of this endovascular procedure. The most common technique for recanalization of an occlusion is either intraplaque or subintimal passage of a hydrophilic wire and catheter via either antegrade or retrograde approaches. Reentry devices are not routinely used but are available. A slightly curved catheter with a hydrophilic coating helps direct a hydrophilic 0.035-in wire. In recanalization procedures, we have found that significant force has to be applied to the guidewire/catheter combination to cross a heavily calcified and diseased artery. This is best done via a femoral retrograde approach because of the “pushability” of the catheter system. Even with a retrograde approach, a subintimal passage may occur without successful reentry into true lumen. This then necessitates an antegrade approach using brachial access and placement of a long sheath in the aorta. The “pushability” from a left brachial artery approach is not as effective, as much of the force is dissipated via the multiple turns that the catheter has to traverse including the aortic arch. Thus, despite a long sheath, pushing on wire from the left brachial often does not translate to the effect desired in comparison to a straight retrograde trajectory.

Once a wire has successfully traversed the iliac occlusion, a snare capture device can be used to secure the brachial wire, withdraw it through

the femoral sheath, exchange catheters, and place a stiff wire from the femoral location. At this point, confirmation of true lumen location should be done by antegrade angiography. Larger sheaths can then be placed from the groin rather than the arm, where the brachial artery is subject to injury. After the target lesion is crossed, floppy hydrophilic wires are exchanged for stiffer braided wires to provide a stable system on which devices and balloons can be used.



Figure 206.2. Computed tomographic angiography scan of a patient with severe aortoiliac occlusive disease. Note the bilateral severe iliac occlusive disease and extensive calcification. This patient is traditionally treated with open reconstruction with aortobifemoral bypass. We performed a hybrid procedure with bilateral femoral endarterectomies, recanalization of the iliac arteries, and angioplasty with stenting (R/PTAS).

Following recanalization, angioplasty using a high-pressure balloon

allows a lumen to be created through the diseased section. A small 3- to 4-mm balloon is sufficient to achieving enough lumen through which to advance delivery devices or larger sheaths. This will also prevent aggressive angioplasty leading to iliac rupture. We have adopted a liberal posture to stenting these diseased vessels. Some may argue that percutaneous balloon angioplasty (PTA) may suffice, but in our experience significant recoil occurs in diseased, calcified iliac arteries. Either an uncovered balloon-expandable stent or nitinol, self-expanding stent is usually deployed. Balloon expandable stents, when being placed in high-grade stenoses or in the setting of recanalization, require delivery via long sheaths that go beyond the lesion in order to prevent stent dislodgement. Once the stent is in place, the sheath can be pulled back to expose the balloon mounted stent. Recently, covered stenting has been used for calcific hard plaque where recoil and rupture is a concern (Fig. 206.3D). Stent sizing can be judged by adjacent normal segments while road mapping or smart mask can guide accurate stent deployment. Aortic bifurcation disease may require implementation of “kissing stents” up front or additional intervention with either angioplasty +/− stenting on the contralateral iliac artery after completion angiography shows a concerning plaque shift. Remnant disease elsewhere should similary be evaluated and treated accordingly. Occasionally, intravascular ultrasound (IVUS) is utilized to ensure stent apposition.

In cases where the AIOD continues to the femoral region, femoral endarterectomy in combination with endovascular therapy is required. This is necessary in approximately one-quarter of our patients with AIOD. Thus, these patients need either general or regional anesthesia to adequately allow femoral dissection, endarterectomy, and patch closure. The steps in this procedure are as follows:

1. Femoral exposure
2. Sheath placement via the diseased femoral artery
3. Recanalization
4. Endarterectomy and patch closure (90%)
5. PTA/S via a large sheath through the incomplete suture line of the patch
6. Completion of the patch

Some technical issues are worthy of discussion. Recanalization of heavily calcified vessels can be challenging. Ensuring catheter delivery to the true lumen, both above and below the recanalized segment via targeted

angiography, is critical to successful therapy. In past years, thrombolysis was used in selected patients to decrease the chronic thrombus burden in the aortoiliac segments prior to recanalization, angioplasty, and stenting. This has largely been abandoned and reserved only for patients with acute limb ischemia and evidence of acute thrombosis. Systemic heparinization during the procedure is routine. External iliac disease is generally better approached via an antegrade brachial approach or from a contralateral femoral access point. Treatment of this lesion location may require angioplasty and stenting up to the inguinal ligament, which is not feasible from an ipsilateral access point. There are some specifics to keep in mind when choosing a stent. Self-expanding stents are mounted on a constraining sheath, thus being protected as they are introduced across a lesion. They generally require some (2 to 5 mm) oversizing to maintain radial force, come available in nitinol, are flexible and good for significant tortuosity, and come in smaller diameters. Balloon expandable stents come premounted on a balloon, do not come in a constraining sheath, can be expanded above their intended diameter with further balloon angioplasty, and are more rigid. Finally, covered stents are generally composed of polytetrafluoroethylene (PTFE) mounted on a stent and are theoretically intended to decrease tissue ingrowth and subsequent neointimal hyperplasia. Certainly, their role in a high rupture risk iliac lesion is important.

POSTOPERATIVE CARE

Antiplatelet therapy with Clopidogrel (Plavix) is usually instituted after endovascular therapy to prevent stent thrombosis at the loading dose of 300 mg once, followed by 75 mg/day for at least 3 months. Postoperative clinical and vascular laboratory evaluation for symptom improvement and physiologic response to treatment follows a standard paradigm for peripheral interventions. Noninvasive vascular studies can be performed at initial outpatient follow-up and then every 6 months for the first 2 years and then annually. In order to optimize primary patency rates, diagnostic angiography should be planned when arterial duplex velocities are >300 cm/s or patient symptoms recur. CTA may be useful in the postoperative period to confirm high velocities on duplex in the asymptomatic patient and avoid an invasive study.

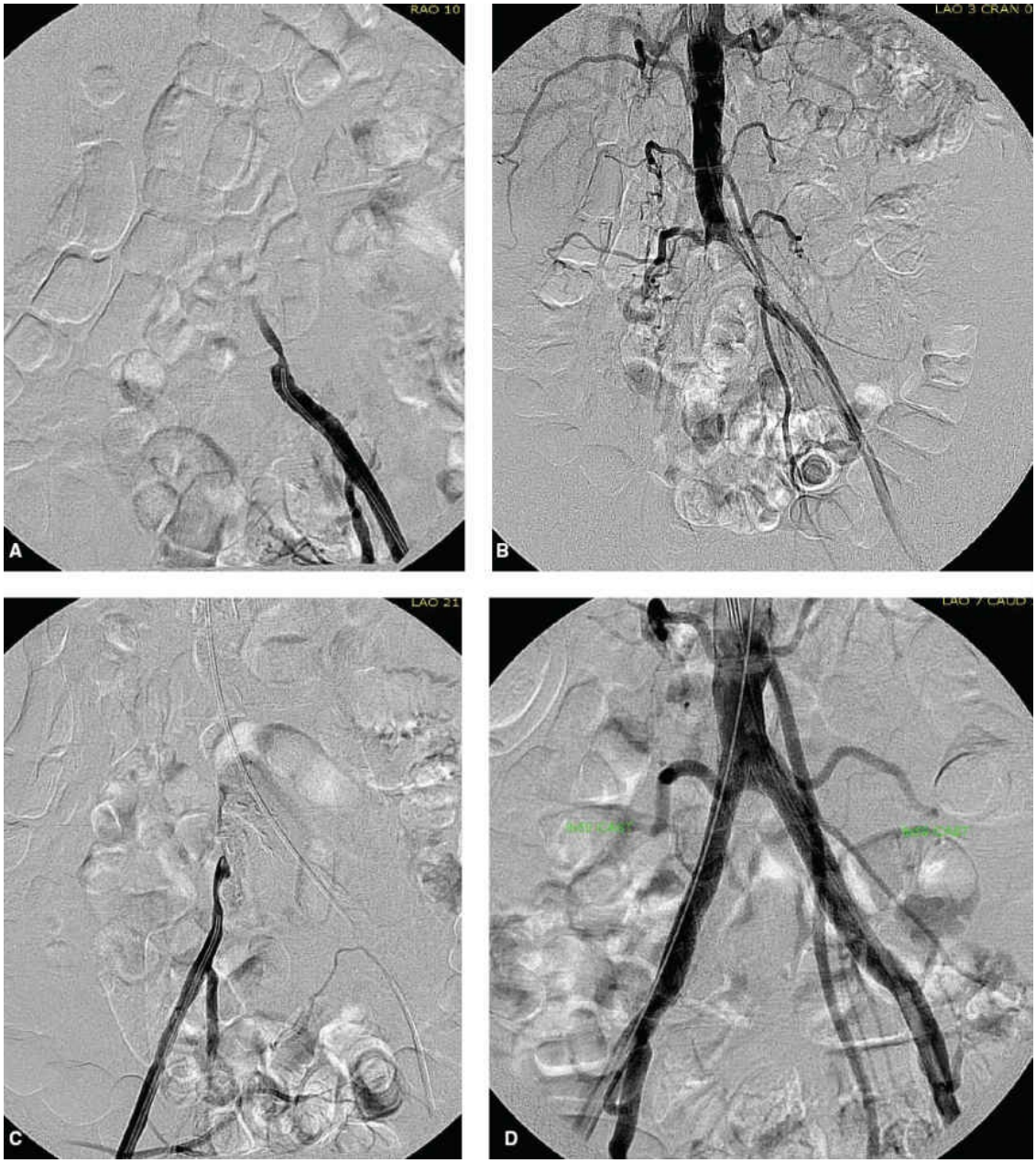

Figure 206.3. A. A young male with debilitating claudication and inability to work presents with extensive aortoiliac occlusive disease. After evaluation and risk factor optimization, endovascular therapy is performed. Femoral puncture is performed with ultrasound guidance, and retrograde access to the iliac artery with the less atherosclerotic burden allows catheter placement. **B.** Aortography allows imaging of the aorta and both ipsilateral and contralateral limbs. **C.** The contralateral femoral artery is accessed using ultrasound and a short, curved catheter is brought to the level of the occlusion for a retrograde angiography. **D.** Completion imaging after covered stenting (iCAST, Atrium Medical, Inc.) for calcific, hard plaque in the proximal common iliac arteries. Note the inferior mesenteric artery is preserved with prograde blood flow, as well as the

lumbar arteries and the hypogastric arteries (not shown on this image), lessening the chance of bowel or spinal cord ischemia.

COMPLICATIONS AND THEIR MANAGEMENT

The various specific steps in the endovascular treatment of AIOD should be carefully approached in order to prevent known potential complications. Percutaneous access and closure are associated with complications, including bleeding, infection, thrombosis or creation of a pseudoaneurysm, or arteriovenous fistula. The complication rate of major bleeding at the femoral artery is ~2%. The risk of access complication is slightly higher in the brachial location, especially in the setting of multiple catheter exchanges, larger sheaths, or in patients with small vessels, including many women. Open brachial exposure is an option here to minimize complications.

Iliac recanalization has been associated with distal embolization in the past, but we have not found embolization to be a significant concern as long as one does not angioplasty arteries with acute thrombosis. These patients with fresh thrombus need thrombolysis prior to intervention, or if embolization has occurred, require percutaneous/open thrombectomy for revascularization. Another risk in patients with severe, calcific disease relates to the ability to stretch the artery via angioplasty and stenting with the potential for rupture. CTA helps identify patients with “coral reef” atherosclerosis or circumferential calcification where controlled fracture of the plaque with angioplasty may lead to rupture of the artery (Fig. 206.4A–D).

Appropriate sizing of the balloon for PTA is critical, especially at the iliac bifurcation where the size of the native common iliac diminishes drastically to the smaller external iliac artery. This can be discerned via a combination of preoperative imaging, angiography, and adjunct use of IVUS. In the awake patient, excessive pain in conjunction with hemodynamic instability may be a sign of rupture. If this occurs, gentle balloon angioplasty in the area of rupture can be used to control the bleed while alternative access and/or a covered stent is prepared for deployment. Arterial dissection can occur anywhere along the working arterial path and should be carefully evaluated at various points when angiography is performed and certainly on completion angiography as it may require additional endovascular therapy. Untreated dissection either from PTA or wire/catheter trauma can result in early postoperative thrombosis.

Certainly, contrast-induced nephropathy can be a problem postoperatively. Periprocedural hydration, sodium bicarbonate protocols, using CO_2 angiography, and diluted contrast are some strategies to minimize this risk. Long-term, de novo stenosis or in stent stenosis can develop in up to 25% of patients at 2 years. Surveillance protocols and early intervention should be instituted.

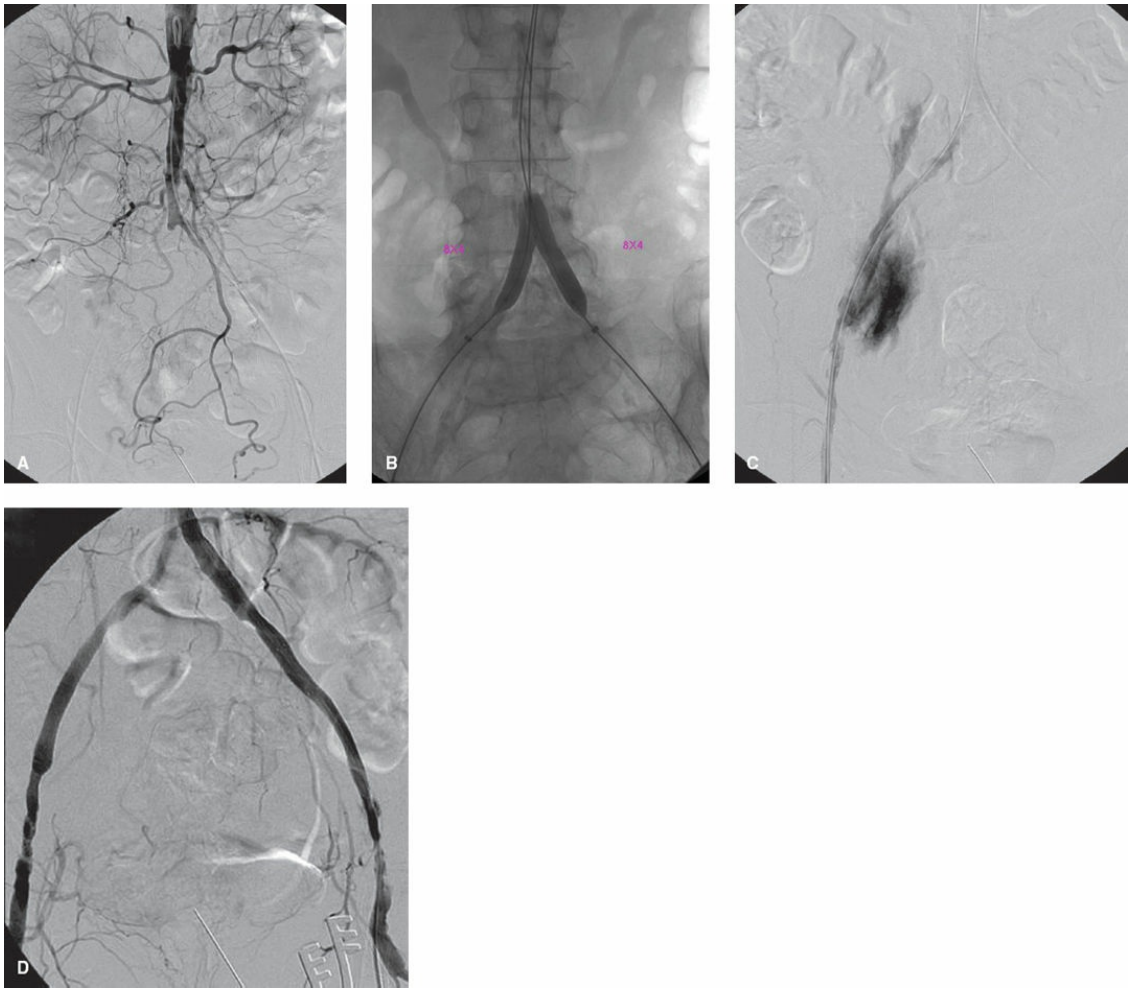

Figure 206.4. A. An elderly female with rest pain is identified as having extensive aortoiliac occlusive disease with femoral occlusive disease. Combined femoral endarterectomy and endovascular therapy is performed. After bilateral femoral exposure, femoral artery puncture and recanalization allow aortography, which reveals extensive bilateral iliac occlusive disease. **B.** After bilateral recanalization, percutaneous balloon angioplasty (PTA) is performed over stiff guidewires in a "kissing technique." PTA is continued through the iliac segments. **C.** The patient experienced sudden hypotension. Retrograde arteriography from the right-sided sheath documents free extravasation of blood from the proximal external iliac artery into the retroperitoneum. Rapid inflation of an angioplasty balloon across the iliac bifurcation halts the hemorrhage. **D.** Completion imaging after covered stenting (Viabahn, Gore, Inc.) allows sealing of the ruptured iliac artery and salvage of the situation. The patient did well, rest pain resolved, but she required a 5-day hospitalization to recover from an ileus.

OUTCOMES

In our experience, we have preferentially used primary stenting after recanalization of occluded iliac segments. A meta-analysis of trials after 1990 comparing PTA to PTA/S in iliac atherosclerotic disease has been performed. The majority of patients had iliac stenoses. However, for both stenoses and occlusions, stenting consistently gave better 4-year patency rates than PTA alone. The risk of long-term failure was reduced by 39% after stenting as opposed to PTA alone. The Dutch iliac stent trial compared a strategy of primary stenting to a strategy of PTA with provisional stenting for hemodynamic PTA failures. In this study of 279 claudicants, primary stenting did not result in improved initial success or 2-year clinical results. However, in the small group of iliac occlusions, 10 of 12 initially treated with PTA alone required eventual stent placement. The use of a stent increases the cost at the initial procedure, but may provide improved durability and thus reduce repeat interventions.

Since 1995, a review of the published data regarding endovascular treatment of complex aortoiliac occlusions reveals the primary patency ranges from 69% to 76% at 2 years with secondary patency rates of 85% to 95% at 2 years. Furthermore, overall complication rates were low in recent series (1.4% to 4.8%), likely due to improvements in technique and device technology.

Our current results in patients with severe AOID (TASC-B or higher) demonstrate an increasing ability by a multi-physician vascular surgery group to treat extensive iliac disease by endovascular means. Between 1998 and 2004, 86 patients (161 limbs) underwent open reconstruction, mostly with ABF. During the same interval, 83 patients (127 limbs) underwent endovascular therapy (recanalization and PTA/S). During this time interval, ~800 procedures for aortoiliac stenosis (TASC-A or B) were performed. All patients had severe symptomatic AIOD with claudication (53%), rest pain (28%), tissue loss (12%), or in rare cases, acute limb ischemia (7%). Patients undergoing ABF were younger (60 years) than patients undergoing endovascular therapy (65 years), and had higher rates of hyperlipidemia and smoking. All other clinical variables including cardiac status, diabetes, symptoms at presentation, TASC stratification, and presence of poor outflow were similar between the two groups. Patients underwent ABF with general anesthesia, often with concomitant treatment of femoral or infrainguinal disease with the majority undergoing common femoral endarterectomy and/or

profundaplasty. Patients underwent endovascular therapy with local anesthesia/sedation in 78% cases. Technical success was universal in both groups with marked improvement in ankle-brachial indices (0.48 to 0.84). Twenty-one percent of patients undergoing endovascular therapy underwent femoral endarterectomy/profundaplasty for concomitant infrainguinal disease. Postoperative complications occurred in both groups with slightly higher rates of respiratory failure and wound infection in the ABF group and slightly higher rates of limb ischemia/thrombosis and renal dysfunction in the endovascular group. None of these complications were statistically different.

Limb-based primary patency at 3 years was significantly higher for ABF than for the endovascular group (93% vs. 74%, $P = 0.002$). Most of the endovascular failures simply underwent repeat intervention with balloon angioplasty or additional stenting. For primary patency, univariate analyses indicated the presence of diabetes, and distal occlusive disease requiring a bypass significantly decreased primary patency of all patients treated for severe AIOD.

Secondary patency rates (97% vs. 95%), limb salvage (98% vs. 98%), and long-term survival (80% vs. 80%) were similar between the two groups. For overall survival, multivariable analyses indicated that worsening renal function adversely affected survival (HR 12). In addition, poor outflow as defined by superficial femoral artery occlusion was associated with diminished survival (HR 2).

In our experience, TASC classifications were the same in both open and endovascular groups indicating that the burden of occlusive disease was similar in both groups, and those easier, less extensive cases were not reserved for endovascular treatment.

In summary, the treatment of extensive aortoiliac artery occlusive disease can be accomplished via endovascular means with little morbidity and acceptable patency and limb salvage rates. The TASC stratification is an important tool in allowing us to assess the extent of lesion morphology, but extensive lesions do not preclude successful endovascular treatment. The fate of the limb is dictated by the infrainguinal disease that is often present in patients with complex iliac occlusions. Repair of the concomitant femoral occlusive disease is often needed regardless of open or endovascular treatment. Infrainguinal disease negatively impacts both durability of the procedure and survival of the patient. We believe that endovascular attempts should be exhausted prior to attempt at open

surgical repair of iliac occlusions since the perioperative morbidity and midterm durability rivals open reconstruction.

Treatment of AIOD remains gratifying for the patient and surgeon. Often, operative or endovascular treatment results in rapid symptom abatement, clearly discernible hemodynamic changes, and durable prevention of recurrent symptoms. We anticipate that with advances in our endovascular armamentarium, our ability to treat more complex and extensive AIOD will similarly improve.

Suggested Readings

Alvarez-Tostado JA, Moise MA, Bena JF, et al. The brachial artery: a critical access for endovascular procedures. *J Vasc Surg* 2009;49(2):378–85.

Bosch JL, Van Der GY, Hunink MG. Health-related quality of life after angioplasty and stent placement in patients with iliac artery occlusive disease: results of a randomized controlled clinical trial. The Dutch Iliac Stent Trial Study Group. *Circulation* 1999;99(24):3155–60.

de Vries SO, Hunink MG. Results of aortic bifurcation grafts for aortoiliac occlusive disease: a meta-analysis. *J Vasc Surg* 1997;26(4):558–69.

Kashyap VS, Pavkov ML, Bena JF, et al. The management of severe aortoiliac occlusive disease: endovascular therapy rivals open reconstruction. *J Vasc Surg* 2008;48(6):1451–7.

Leville CD, Kashyap VS, Clair DG, et al. Endovascular management of iliac artery occlusions: extending treatment to TransAtlantic Inter-Society Consensus class C and D patients. *J Vasc Surg* 2006;43(1):32–9.

Norgren L, Hiatt WR, Dormandy JA, et al. Inter-Society Consensus for the Management of Peripheral Arterial Disease (TASC II). *J Vasc Surg* 2007;45(Suppl S):S5–67.

Scheinert D, Schroder M, Ludwig J, et al. Stent-supported recanalization of chronic iliac artery occlusions. *Am J Med* 2001;110(9):708–15.

Upchurch GR, Dimick JB, Wainess RM, et al. Diffusion of new technology in health care: the case of aorto-iliac occlusive disease. *Surgery* 2004;136(4):812–8.

EDITOR'S COMMENT

The chapter by Kashyap and Harth details common endovascular approaches for the treatment of aortoiliac occlusive disease (AIOD), a very common revascularization method for peripheral arterial disease (Hong MS, Beck AW, Nelson PR. Emerging national trends in the management and outcomes of lower

extremity peripheral arterial disease. *Ann Vasc Surg* 2011;25:44–54). Indeed, first-line therapy for almost for all AIOD now is endoluminal, which if unsuccessful or fails long-term, can often be salvaged with an open aortofemoral bypass. Of course, experience and judgment are essential in choosing the best approach for these patients.

Several important points bear discussion from this chapter. First, I always tell the residents and students the most important pulse to check in vascular surgical patients is the femoral pulse exam. This defines inflow (e.g., AIOD) and outflow disease, and of course the inflow needs to be addressed first. Treating the AIOD usually suffices to relieve the patient's vascular symptoms, regardless of outflow status if a patent profunda artery is present. Interestingly, when the Transatlantic Inter-Society Consensus group devised its anatomical staging system for AIOD, it was felt that short and medium length arterial blockages were best treated endoluminally, and for long segment blockages that open surgery was recommended (Norgren L, Hiatt WR, Dormandy JA, et al. Inter-society consensus for the management of peripheral arterial disease (tasc ii). *J Vasc Surg* 2007;45(Suppl S):S5–67). As the authors' note, with new techniques of arterial recanalization, reentry devices, better imaging, and covered stents, most AIOD lesions now can be treated regardless of lesion characteristics.

Hybrid operative procedures are now much more commonly performed, as recently detailed (Chang RW, Goodney PP, Baek JH, et al. Long-term results of combined common femoral endarterectomy and iliac stenting/stent grafting for occlusive disease. *J Vasc Surg* 2008;48:362–7), with open surgical treatment of common femoral occlusive disease and retrograde iliac revascularization. Hybrid procedures take advantage of being able to clear the bulky obstructive lesions at the common femoral and profunda artery junction that is not possible with purely percutaneous techniques. A prosthetic or bovine pericardial patch for the angioplasty is often used, and through which the wire and sheath are placed. Whether you do the endoluminal procedure and then the endarterectomy, or the endarterectomy and then the endoluminal procedures depends on the degree of disease in the femoral vessel. I have found placing a wire through the common femoral artery into the iliac artery prior to the endarterectomy avoids the subintimal dissection with retrograde access after the endarterectomy that can be troublesome. I usually do the endoluminal procedures second, and get a final confirmatory angiogram particularly to assess end of external iliac plaque at endarterectomy site.

There are numerous techniques for recanalization, but usually a hydrophilic glide wire with a cobra catheter or glide catheter is most successful for reestablishing continuity to the aorta. Use of snare approach via access from the arm or the contralateral side is also useful in these sometimes challenging cases, the so called "body floss" technique. Patience and persistence are essential.

A definite consideration is whether open aortofemoral bypass is better for long segment AIOD versus endoluminal revascularization. This also certainly seems to be institution dependent, with more aggressive endoluminal centers

doing most everything endovascular, versus a more conservative approach using open surgery for extensive, diffuse AIOD or aortic occlusions. No randomized controlled trials are available comparing these modalities. Recent systemic review suggests safety and good durability with endovascular therapy for AIOD, with secondary patencies at 5 years of 80% (Jongkind V, Akkersdijk GJ, Yeung KK, et al. A systematic review of endovascular treatment of extensive aortoiliac occlusive disease. *J Vasc Surg* 2010;52:1376–83). We reviewed our own series of open surgery versus endoluminal therapy for AIOD and found very similar outcomes, with somewhat less durability of endoluminal procedures but greater morbidity form surgery (Burke CR, Henke PK, Hernandez R, et al. A contemporary comparison of aortofemoral bypass and aortoiliac stenting in the treatment of aortoiliac occlusive disease. *Ann Vasc Surg* 2010;24:4–13). Certainly, having both endovascular options and open surgical options is best to allow tapering of therapy to the individual patients.

Peter Henke

207 Reversed Vein Bypass Grafts to Popliteal, Tibial, and Peroneal Arteries

Joseph L. Mills and Layla C. Lucas

The use of venous autografts dates back to the beginning of the 20th century with Alexis Carrel and Charles Guthrie's description of the technique of vascular anastomosis in a canine model. In 1906, they published their experience of early bypass grafting using venous transplantation, work for which Carrel was subsequently awarded the Nobel Prize (Physiology and Medicine) in 1912. In 1948, Jean Kunlin's successful femoral-popliteal bypass using reversed saphenous vein graft in a 54-year-old man with tissue loss, who was a patient of Rene Leriche, generated enthusiasm for the arterial bypass era of vascular surgery, an era that lasted nearly half a century. The basic vein bypass techniques described by Kunlin remain in widespread use today.

Although endovascular interventions are increasingly utilized to treat peripheral artery disease (PAD), a significant number of patients continue to require open bypass either due to disease extent or after failure of endovascular therapy.

CLINICAL PRESENTATION

Patients with PAD may be asymptomatic. Those who are symptomatic generally present either with intermittent claudication (IC) or limb-threatening ischemia manifested by rest pain, ulceration, or gangrene. The diagnosis of PAD can usually be made based on a thorough history and physical examination. Claudicants most often complain of cramping or burning muscular calf, thigh or buttock pain that occurs with walking, resolves with rest, and is reproduced by the same walking distance and exertion level. Ischemic rest pain is an early manifestation of limb-threatening ischemia and typically occurs in the forefoot, with onset when the leg is flat or elevated and resolution when the limb is placed in a dependent position. The pain classically occurs when a patient goes to bed

at night and is relieved by sleeping upright or hanging the affected limb over the edge of the bed. Patients with limb threat may also develop non-healing ulcers that either arise spontaneously or in response to minor trauma. Gangrene is a late sign of severe limb ischemia. Nearly universal physical findings in such patients include absent pedal pulses, trophic changes, and dependent rubor with pallor on elevation. Gangrene and non-healing ulcers typically appear on the toes and forefoot or over bony prominences, especially in those with diabetes. Patients with diabetes less commonly complain of rest pain; neuropathy is a major contributory factor for most diabetic foot ulcers (DFU) that develop over bony prominences due to loss of protective sensation, deformity, and repetitive trauma. PAD is common in patients with DFU and may contribute to non-healing or delayed healing in as many as 50% of those so affected. The Society for Vascular Surgery WIfI classification for threatened limbs is useful to stage patients with non-healing, lower extremity ulcers to identify those most likely to require and benefit from revascularization.

DIAGNOSIS

Noninvasive vascular laboratory tests are generally indicated in symptomatic PAD patients, especially when intervention is planned, to confirm the diagnosis, document the degree of limb ischemia, determine the anatomic site(s) of involvement, and differentiate stenotic from totally occlusive lesions. The simplest baseline measurements are physiologic or hemodynamic tests. An ankle-brachial index (ABI) less than 0.9 is diagnostic for hemodynamically significant occlusive disease and has been found to be 95% sensitive in identifying angiographically confirmed PAD. Claudicants with single-level stenoses may only show a reduced ABI after exercise. A 20% or greater reduction in the ABI postexercise is abnormal. Arterial waveform patterns, toe waveforms and Doppler-derived pressures, and transcutaneous oxygen saturations are useful when the ABI cannot be measured due to medial calcinosis. Medial calcinosis is present when the ABI is >1.3 and is common in individuals with diabetes.

If intervention is planned, we generally next perform arterial duplex imaging. It is relatively inexpensive, does not require contrast or radiation exposure, is easily performed in the outpatient, office setting and readily identifies culprit lesions (sites of arterial occlusion or stenosis) which are characterized by color flow changes and elevated peak systolic velocities and velocity ratios. Duplex is extremely useful in predicting which patients

are good candidates for endovascular therapy and aids in planning the best approach. We reserve computed tomography (CT) or magnetic resonance (MR) angiographic imaging for those patients who have markedly diminished or bilaterally absent femoral pulses. These imaging techniques define the length and extent of aorto-iliac disease and the common femoral artery (CFA) disease burden, factors critical in selecting whether endovascular therapy or major open surgery such as aorto-bifemoral bypass is the better option. We perform percutaneous angiography for those patients in whom endovascular therapy is planned, usually at the same setting, or for patients with long-segment femoro-popliteal and/or tibial disease in whom bypass is planned in order to identify optimal inflow and outflow sites.

PREOPERATIVE ASSESSMENT

PAD is a systemic disease and a coronary artery disease (CAD) "equivalent." PAD is more of a marker for cardiovascular mortality, heart attack and stroke than it is a harbinger of limb loss. Mortality in patients with PAD averages 2% per year, and the incidence of nonfatal myocardial infarction, stroke, and vascular death is estimated at 5% to 7% per year for PAD patients. Therefore, medical therapy and risk factor modification are mandatory in all PAD patients, regardless of whether intervention is planned. Treating lesions by endovascular therapy or open bypass surgery without maximizing these noninvasive aspects of care is inadequate therapy.

The Society for Vascular Surgery (SVS) and American Heart Association (AHA) guidelines offer evidence-based recommendations for the medical management of important PAD risk factors. The major modifiable risk factors are smoking, hyperlipidemia, hypertension, and diabetes. Antiplatelet therapy should be routinely administered.

Smoking is an independent risk factor for PAD, increasing its prevalence and severity. Smokers are three to five times more likely to require amputation than nonsmokers. Physician advice, group counseling, nicotine replacement, and antidepressant drug therapy increase the success of tobacco abstinence.

Hyperlipidemia is an independent risk factor for PAD best controlled by statin administration and dietary modification. Target levels are a low-density lipoprotein (LDL) <70 mg/dL in patients with coronary disease/PAD and <100 mg/dL in those without. Statin administration has

pleiotropic effects, however, and seems to improve outcomes in patients with PAD regardless of LDL levels. Fibrates and/or niacin are useful in lowering triglycerides and in raising HDL, although raising HDL has yet to show clinical benefit.

Hypertension is another major PAD risk factor. Blood pressure control can reduce PAD-related complications by 22% to 26% and also significantly reduces both cardiovascular and cerebrovascular events. Current recommendations are a target blood pressure <140/90 mm Hg (<130/80 mm Hg in those with diabetes or renal insufficiency) in PAD patients. Comprehensive diabetes management is also an important component of PAD care. Large-scale studies have shown that diabetes management with a target hemoglobin A1c is <7.0% reduces diabetes-related myocardial infarcts and other diabetes-related endpoints.

Antiplatelet therapy is an essential tool to reduce subsequent cardiovascular and cerebrovascular events. Daily aspirin therapy confers a 25% reduction in cardiovascular events. Low-dose aspirin is as effective as full-dose aspirin with fewer adverse reactions. Other antiplatelet drugs are effective but may carry a higher risk of bleeding.

INDICATIONS FOR INFRAINGUINAL BYPASS

The presence of either limb-threatening ischemia or lifestyle-limiting IC is an indication for intervention. Once the diagnosis is established and the extent of disease determined, an assessment of the patient's ability to tolerate revascularization is necessary. A chest radiograph and electrocardiogram will give rough estimates of cardiopulmonary status. Further cardiac evaluation and/or optimization are recommended if the patient has unstable angina, significant arrhythmias, or symptoms of congestive heart failure.

Preoperative Planning

Selection of Inflow Artery

The inflow target for femoral-popliteal bypass is based on physical examination and noninvasive studies and confirmed by preoperative or immediate pre-bypass angiography. Hemodynamically significant aorto-iliac inflow lesions should be addressed before or in conjunction with the infrainguinal bypass procedure. Although the CFA frequently serves as the graft origin, distal origin sites, when appropriately selected, are equally effective, especially in redo operations and when vein conduit is limited. If

the CFA is significantly diseased, it is prudent to consider CFA endarterectomy to include the profunda femoris artery (PFA) origin if also involved. CFA exposure may be prohibitive in reoperative procedures or morbidly obese patients. The PFA or superficial femoral artery (SFA) can often serve as alternate inflow sources. Regardless of site of origin, adequate inflow is crucial to bypass success.

Selection of Outflow (Target) Artery

The distal target artery is ideally normal in caliber, free of stenosis and in general, should be in continuity with at least one of the arteries supplying the foot. The above-knee popliteal artery (AKP) has a higher incidence of atherosclerotic disease extending from the SFA. Therefore, the below-knee popliteal (BKP) artery is more commonly used for femoral-popliteal bypass. If the popliteal artery (PA) is highly diseased or occluded, the tibial artery with the best runoff to the foot should be selected as the target. With the increased prevalence of diabetes, it is increasingly important to consider the location of the foot ulcer. The angiosome model may be important to consider in patients with extensive pedal and arch occlusive disease in whom hindfoot and forefoot flow may be compartmentalized. A common example of this issue includes deep heel ulcers in patients with renal failure. Improper selection of the outflow target artery may precipitate graft failure and potentially jeopardize limb viability. Both preoperative duplex imaging and detailed angiography, including lateral magnified views of the foot, are essential to select the most appropriate target. Evidence to date suggests that when possible, angiosome-directed revascularization shortens wound-healing times.

Preoperative Assessment of Vein Quality

A complete history and physical examination will often reveal whether the great saphenous vein (GSV) has been previously used for coronary bypass, lower extremity revascularization, or stripped for varicosities. Preoperative venous duplex mapping should be routine because conduit quality is the key to both short- and long-term bypass patency. Vein mapping should evaluate the diameter, compressibility, wall thickness, and flow through the prospective conduit. The cephalic, basilic, and small saphenous veins should be evaluated if the GSV is absent or inadequate. Vein conduit diameter should be at least 3 mm to optimize patency. The location of the vein should be marked on the skin with an indelible marker to facilitate harvest and minimize creation of skin flaps during harvest.

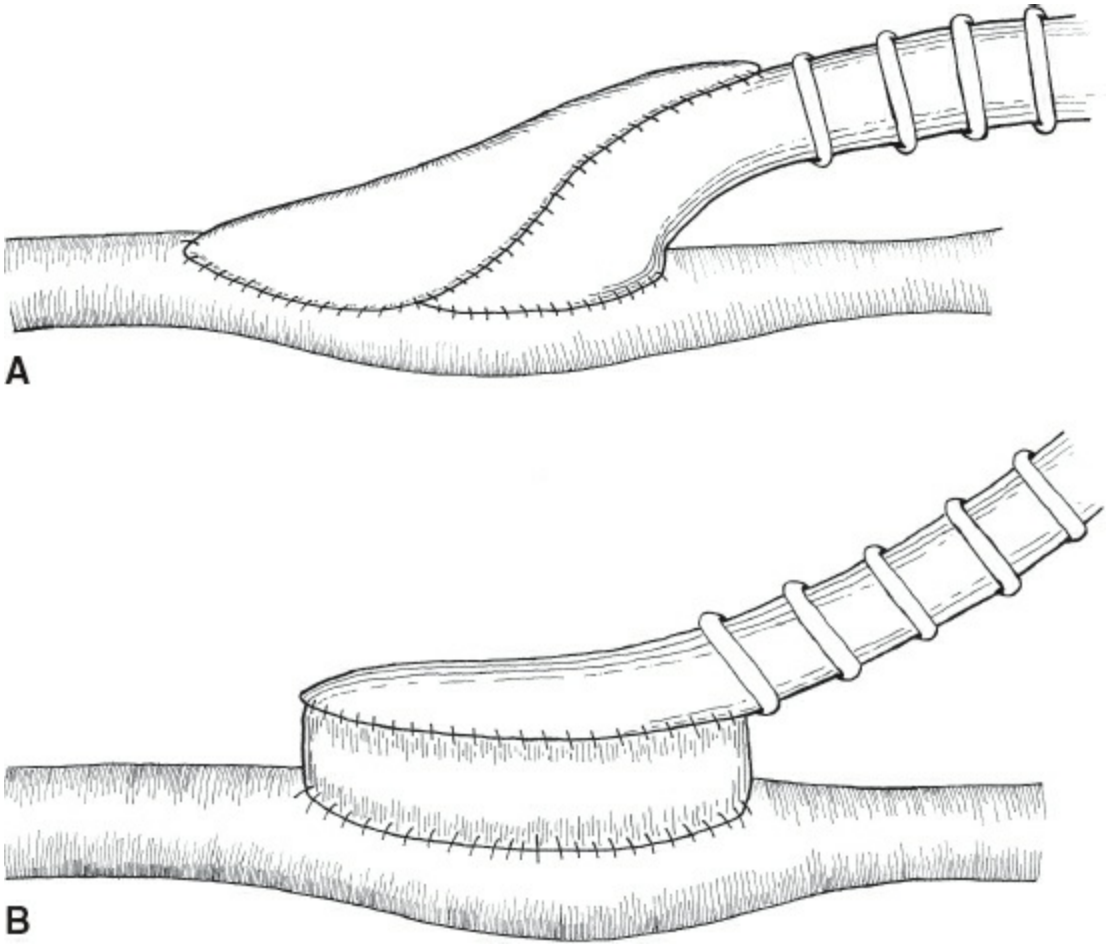

Figure 207.1. The Taylor patch (**A**) and Miller cuff (**B**) are useful adjuncts to aid in the anastomosis of PTFE grafts to smaller caliber tibial arteries and may improve short-term and intermediate graft patencies. (Reprinted from Rutherford RB. *Vascular Surgery*. 6th ed. Philadelphia, PA: Saunders; 2005. Copyright © 2005 Elsevier, with permission.)

Conduit Selection

Autogenous vein grafts provide the best patency rates in arterial bypass for all infrainguinal reconstructions, regardless of distal target level. The conduit of choice for a femoral-popliteal bypass is therefore ipsilateral GSV. Reversed and in situ configurations are equally effective, but reversed vein is applicable to more patients and generally simpler to employ. Although our own group and others prefer reversed vein, equivalent success has been reported with in situ vein conduits. If ipsilateral GSV is inadequate or unavailable, contralateral GSV is the next best option. Splicing the short saphenous veins (SSVs), and/or the cephalic and basilic veins from the arms often provides enough length for bypass in the absence of suitable leg vein.

Nonautogenous options exist for the uncommon patient who truly lacks suitable vein conduit. The most commonly used prosthetic conduit for femoral-popliteal bypass is PTFE (polytetrafluoroethylene). Recent clinical studies suggest that heparin-bonded PTFE may confer improved patency rates for femoropopliteal bypass comparing to ePTFE without heparin. In the case of femoral above-knee popliteal bypass, PTFE grafts have patency rates similar to RSVG for the first 2 years, but vein is superior thereafter and is thus preferable. Prosthetic bypasses to the BKP and tibial arteries have uniformly poor patency that can be modestly improved by the use of an adjunctive vein cuff (Miller or St. Mary's) or Taylor patch (Fig. 207.1). Cryopreserved vein grafts are expensive, have exceedingly poor patency rates and should be reserved as conduits of last resort for limb salvage indications; they may also have a niche in the management of patients with infected prosthetic grafts who require revascularization.

In Situ or RSVG

Nearly all randomized trials have shown equivalent patency and limb salvage rates for in situ and reversed vein. Small caliber veins perform poorly in either configuration. Reversed vein conduits are more user friendly and readily adaptable to a variety of clinical scenarios. Expected graft patency rates are shown in Table 207.1.

ANATOMY

Surgical Anatomy of the Femoral, Popliteal, and Tibial Arteries

The femoral triangle is an important anatomic space bordered by the inguinal ligament superiorly, the sartorius muscle laterally, and the adductor longus muscle medially. The floor of the femoral triangle consists of the iliacus, psoas major, pectineus, and adductor longus muscles. The vascular structures in the femoral triangle are contained within a fascial covering, the femoral sheath. The CFA is the continuation of the external iliac artery as it exits beneath the inguinal ligament. In the femoral triangle, it divides into two major branches (Fig. 207.2). The PFA is most commonly a posterolateral branch and not only provides blood to the thigh, but also serves as an important collateral in patients with SFA occlusive disease. The SFA is the continuation of the CFA and supplies blood to the lower leg. Exiting the femoral triangle, the SFA proceeds distally on its course into the adductor canal. The common femoral vein

(CFV) is located just medial to the CFA in the triangle and the GSV enters the CFV at the fossa ovalis. Other important structures in the femoral triangle include the femoral nerve, lying lateral to the artery and providing motor and sensory function to the lower extremity. The lymphatics are medial to the CFV.

TABLE 207.1 Expected Primary Patency Rates (%) of Infrainguinal Bypass Grafts

	1 Year	3 Year	5 Year
Above-Knee Popliteal			
Reversed vein	84	73	70–76
Arm vein	82	60	
PTFE	79	66	37–52
Below-Knee Popliteal			
Reversed vein	84	78	
In situ vein	80	73	
PTFE	65	29–44	
Infrapopliteal[a]			
Reversed vein	77	66	
In situ vein	82	74	
PTFE	46	<25	

[a]Limb salvage rates are 75–83% at 4 years (vein) and 48% (PTFE).

The popliteal fossa is another important anatomic location in lower extremity revascularization. It is a diamond-shaped space defined anteriorly by the femur, upper tibia, and popliteus muscle; posteriorly by the skin, subcutaneous tissue and fascia; laterally by biceps femoris and gastrocnemius muscles; and medially by semitendinosus and semimembranosus muscles. The SFA exits the adductor canal at the apex of the popliteal fossa where it becomes the PA. Paired popliteal veins are closely adjacent.

The below-knee PA in the distal popliteal fossa is variable in length before dividing into the anterior tibial (AT) artery and the tibioperoneal (TP) trunk. Most commonly, the AT is the first to originate and travels laterally to enter the anterior compartment of the lower leg and continues to the foot where it becomes the dorsalis pedis artery. The TP trunk subsequently branches into the posterior tibial (PT) artery and the peroneal artery, which enter the deep posterior compartment of the lower leg. They are exposed in their proximal and mid portions through medial calf

incisions, usually through the same incision used to harvest the GSV. After dividing the fascia to enter the superficial posterior compartment, the medial head of the gastrocnemius muscle is retracted posteriorly. The soleus is taken down off the tibia to gain entry into the deep posterior compartment, within which the posterior tibial artery is more superficially located while the peroneal artery is deeper, adjacent to the fibula.

The AT artery is exposed through a vertical incision in the anterior compartment 1 to 2 fingerbreadths lateral to the tibia. The proper plane is between the AT muscle and the extensor digitorum longus. The distal one third of the peroneal artery can be most expeditiously approached through a lateral leg incision directly over the fibula. Careful removal of a short segment of fibula uncovers this segment of the artery. Posterior approaches to the peroneal tibial arteries have also been described and are useful for performing popliteal-distal bypasses with SSV in patients lacking GSV (Fig. 207.3).

SURGICAL TECHNIQUE

Operative Technique for GSV, SSV, and Arm Vein Harvest

The GSV can be found in the femoral triangle through the same incision used to expose the CFA. Preoperative skin marking with duplex vein mapping is helpful, especially in obese patients. Skin incisions should be made directly over the vein to avoid undermined, subcutaneous flaps that are prone to necrose. The GSV should be clearly identified in the fossa ovalis as it enters the CFV and differentiated from its anterior branch. Gentle retraction provides exposure as the periadventitial tissue is sharply dissected from the vein. Small tributaries are ligated with silk suture. When tying close to the vein one should leave a short stump of the divided branch to avoid narrowing the conduit. Dissection is continued distally to obtain an adequate length of GSV. We prefer skip incisions, allowing bridges of skin to remain intact (Fig. 207.4). A small clamp is then placed flush with the CFV to maximize length of the conduit. The GSV is divided and the short proximal stump oversewn with running monofilament suture. The GSV should be treated gently to minimize trauma during the harvest.

The GSV is then prepared for use as a conduit by first placing it in a bath of heparinized saline and papaverine. The proximal end of the vein is clamped with a small bulldog clamp. Heparinized saline is flushed from the distal end. Small tears or missed branches are meticulously repaired with simple 7-0 polypropylene suture to avoid stenosis. The vein should be

blue in color, not thickened, soft and distend fully with gentle irrigation. Overdistension of the vein should be avoided. Irrigant should readily flow through the prepared conduit when the clamp is released. Focal areas of sclerosis may require resection. After preparation, the vein is stored on a back table in chilled, autologous heparinized blood until needed. Endoscopic GSV harvesting is an alternative less invasive method to obtaining the conduit. In our view, this technique has a steep learning curve, has minimal advantages in most circumstances, and may compromise conduit performance.

The SSV is most easily harvested with the patient prone. A longitudinal incision is created on the posterior aspect of the calf lateral to the tendo-Achilles. The subcutaneous tissue is carefully divided with scissors until the vein is identified. Small branches are carefully tied a short distance away from the vein. The sural nerve runs along the course of the SSV and should be protected during harvest.

If leg veins are unavailable, arm veins, as identified by preoperative duplex, should be used. Both the cephalic and basilic veins are useful conduits when of good caliber and unscarred or fibrotic from previous venipunctures. The cephalic and basilic veins originate at the wrist and extend to the shoulder. They may be joined at the elbow by the median antecubital vein. Multiple configurations of the arm and forearm components of both veins can be used to create a conduit for leg bypass. If two segments are connected by the median antecubital vein, the nonreversed segment will need valvulotomy. Segments of arm vein that are not in direct continuity will require splicing. When arm veins are needed, the use of two surgical teams expedites the procedure. While one team exposes the inflow and outflow arteries, the other may harvest and prepare the arm vein conduit.

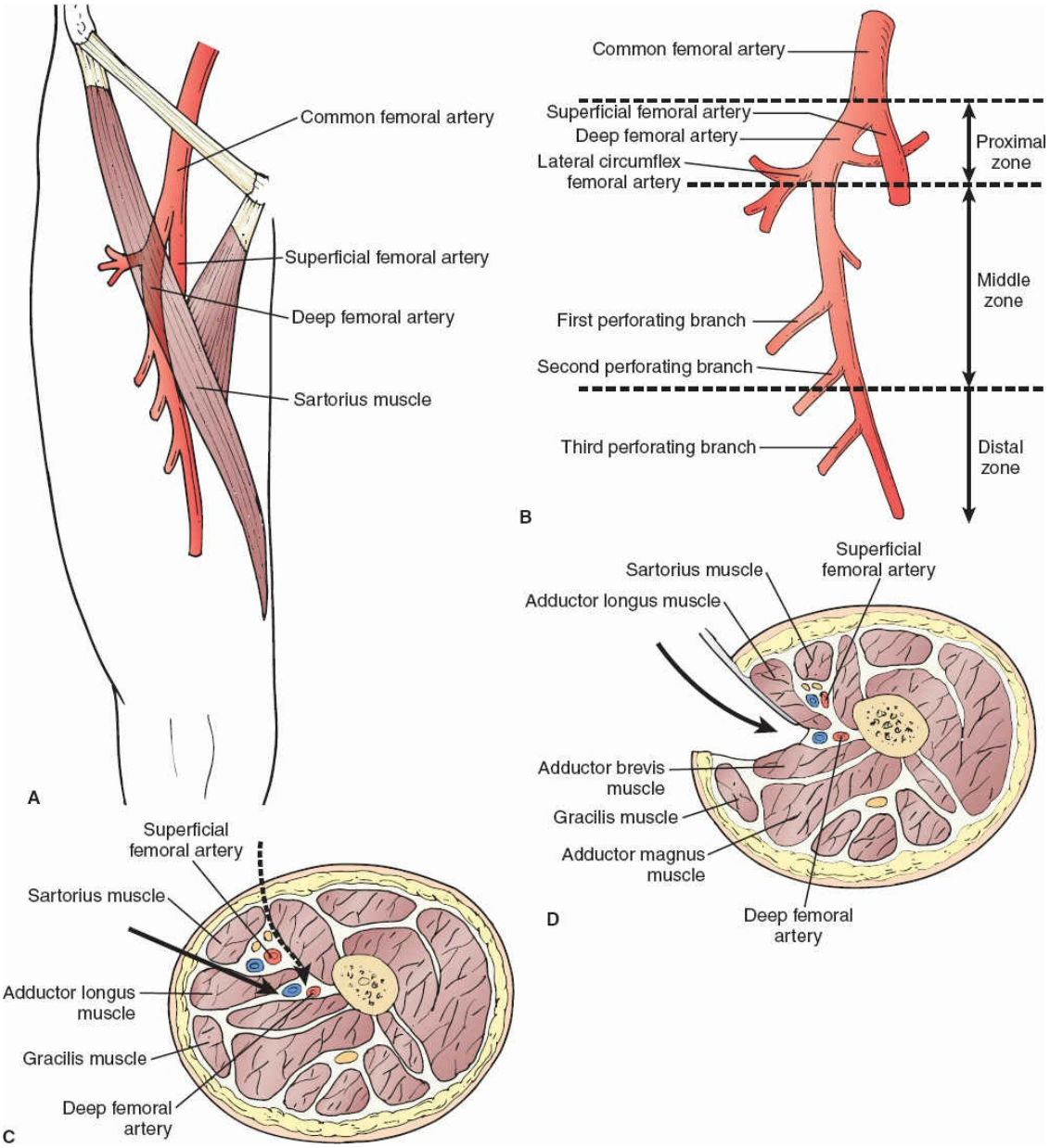

Figure 207.2. Alternate approaches to the distal deep femoral artery (DFA) are useful for reoperative femoral-distal bypass cases and when it is desirable to shorten the bypass due to limited length of vein conduit. **A.** Anatomy of the DFA showing surface landmarks used to identify the course of the DFA. **B.** The DFA can be divided into three zones. **C.** Transverse section of the thigh (viewed from above) shows the plane of dissection when the anterior-medial approach (*solid arrow*) is used. Alternatively, the DFA can be approached through an even more anterior route (*dashed arrow*) by an incision along the lateral border of the sartorius and by retracting this muscle and the superficial femoral neurovascular bundle medially to reach the distal DFA. **D.** Posterior approach to the distal DFA. Note the fascial plane and structures separating DFA from superficial

femoral vascular structures and isolating it from the subsartorial canal. (Reprinted from Rutherford RB. *Vascular Surgery*. 7th ed. Philadelphia, PA: Saunders; 2010. Copyright © 2010 Elsevier, with permission.)

Construction of a Spliced Vein Bypass

The surgeon may connect vein segments by performing a veno-venostomy to create a conduit of sufficient length for the intended bypass. Spliced vein conduits are particularly useful when using arm vein. The ends of each vein are spatulated to accommodate size mismatch and to create a wide oval anastomosis. Interrupted fine polypropylene sutures are recommended to avoid purse stringing and stenosis. Arm veins frequently harbor sclerotic segments or valve defects and should be assessed by careful inspection and either completion duplex imaging or angioscopy (if available).

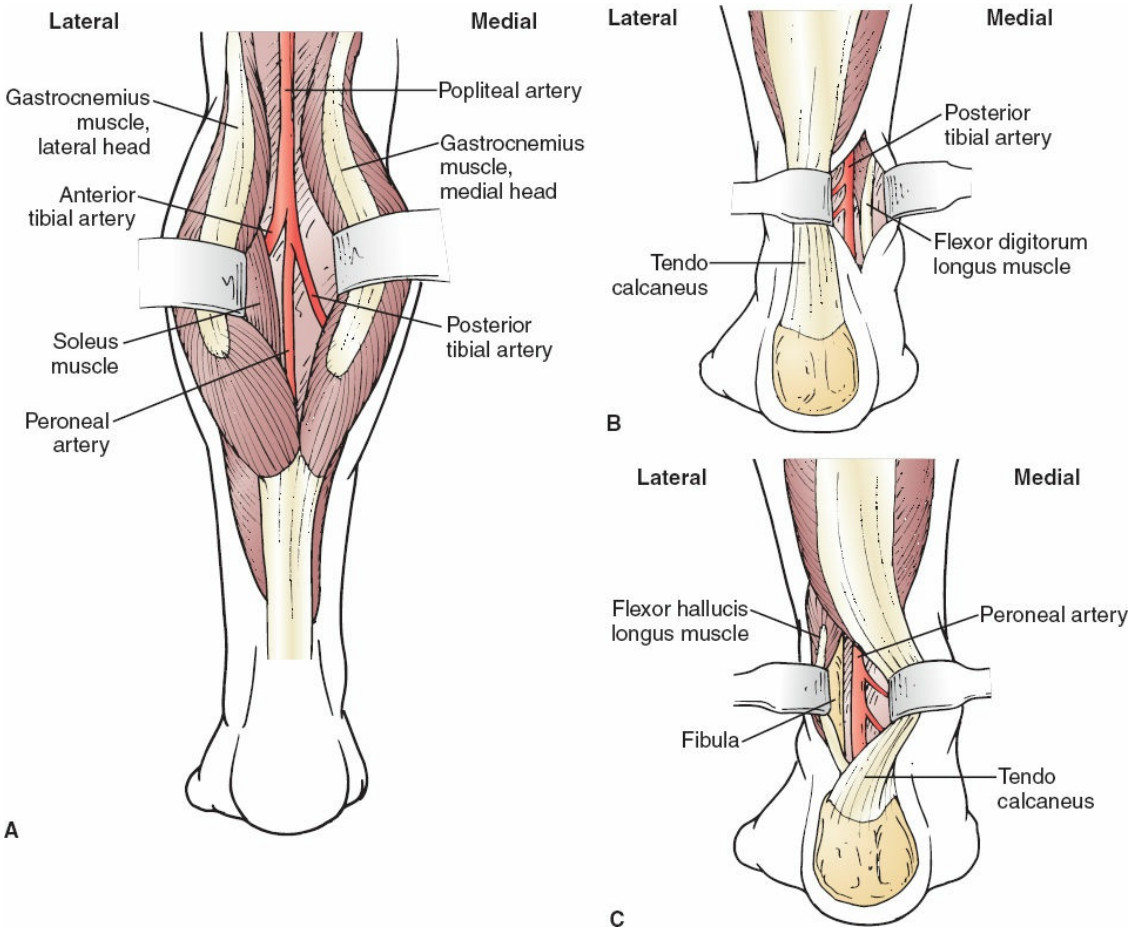

Figure 207.3. Posterior exposures of the infrageniculate arteries (**A, B, C**). **A.** Exposure of popliteal and proximal crural arteries via a posterior approach. Two heads of gastrocnemius muscle

are separated and soleus muscle is lysed from its tibial origin. **B.** Exposure of PT artery through posterior approach. Tendo calcaneus is retracted laterally. Flexor digitorum longus muscle is reflected medially in the lower portion of calf because artery lies posterior to lateral border of this muscle near level of malleoli. **C.** Exposure of peroneal artery through posterior approach. Tendo calcaneus is retracted medially and flexor hallucis longus muscle is reflected laterally to expose artery in groove next to fibula. (Reprinted from Rutherford RB. *Vascular Surgery*. 7th ed. Philadelphia, PA: Saunders; 2010. Copyright © 2010 Elsevier, with permission.)



Figure 207.4. A. Skip incisions for vein harvesting are used when possible. **B.** This technique avoids long incisions and extensive flaps that may necrose or compromise healing (incision well healed at 7 weeks).

Operative Technique for Femoral to Above-Knee Popliteal Bypass

The CFA is the inflow source used most frequently for AKP bypass. The

CFA pulse can be palpated midway between the pubic tubercle and anterior superior iliac spine below the inguinal ligament. A vertical incision is made directly over this pulsation. The soft tissue is dissected with electrocautery down to the femoral sheath. Self-retaining retractors provide adequate exposure. The CFA is sharply dissected and exposed proximally to the inguinal ligament. Distally, the dissection is carried out onto the proximal SFA. The PFA is identified and exposed. A blunt right-angle is employed to place medium silastic vessel loops around each vessel, facilitating subsequent clamp placement or providing vessel control if the artery is soft and nondiseased.

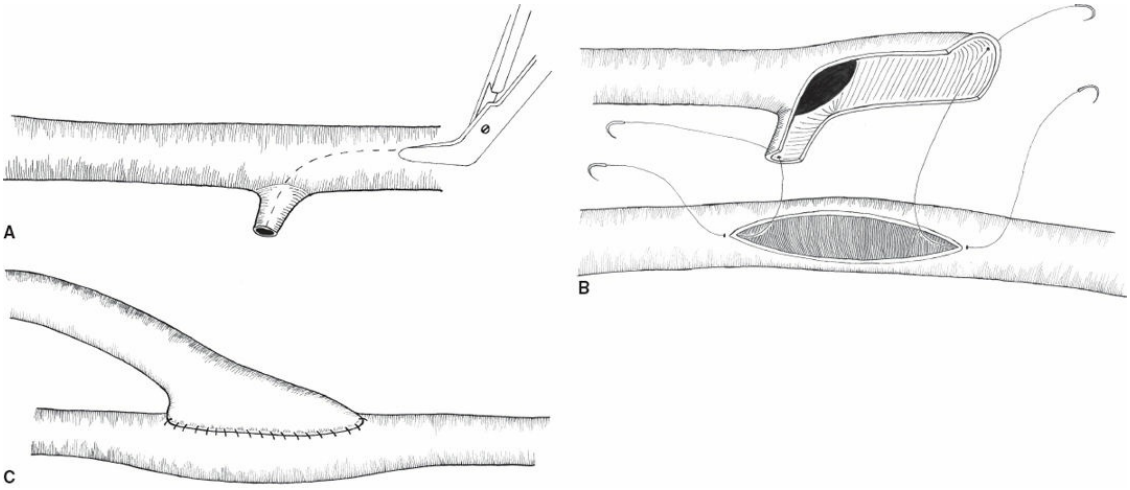

Figure 207.5. The venotomy through the reversed vein is extended out through a suitable side branch (**A**) and anastomosed to the inflow artery (**B** and **C**) to avoid anastomotic stenosis at the graft heel. This technique may be used both at the proximal anastomosis or the distal anastomosis and is useful when vein caliber is small or the arterial wall is thickened. (Reprinted from Rutherford RB. *Vascular Surgery*. 6th ed. Philadelphia, PA: Saunders; 2005. Copyright © 2005 Elsevier, with permission.)

The AKP is exposed from the medial thigh. A longitudinal incision is carried out anterior to the sartorius muscle above the knee. The soft tissue is divided with electrocautery and the sartorius muscle is retracted posterolaterally. The deep fascia overlying the adductor canal is then visualized and divided sharply to expose the popliteal fossa. The artery is dissected and mobilized to ensure adequate length for control and creation of an anastomosis. Palpation is used to identify a healthy segment of artery for the distal anastomosis. Proximal and distal vessel loops are placed.

Once proximal and distal arterial targets have been properly prepared, the conduit can be tunneled. A long hollow-bore, curved tunneling device with a removable blunt tip is passed from the groin incision to the popliteal fossa in the anatomic plane (or the subsartorial plane in reoperative cases). The prepared vein conduit is again checked for leaks. It is gently distended with heparinized blood and marked along its length in order to avoid twisting and to validate its correct orientation after tunneling. The proximal end of the vein conduit is attached to the obturator of the tunneler and pulled into position. The tunneler is then removed and proper orientation of the vein is reconfirmed. Systemic heparin is administered and allowed to circulate for 5 minutes prior to clamp placement.

The proximal anastomosis is performed first. If the distal vein was divided at a branch point, an incision is made through both branches to spatulate the end (Fig. 207.5). Otherwise, a longitudinal incision is made in the vein at least 1.5 times its diameter and tailored. The inflow vessels are clamped. An arteriotomy is created with an #11 blade scalpel on the anterior wall of the CFA and extended proximally and distally with Potts scissors to an appropriate length. Typically, running 5-0 or 6-0 polypropylene suture is used to create the anastomosis. The heel of the graft is secured first and the graft is sutured continuously to a point halfway toward the toe. A second suture is started at the toe and continued toward the heel suture. As the anastomosis progresses, attention is paid toward everting the suture line. After flushing, the clamps are then released and a surgical hemostatic agent applied. Single-repair sutures of 6-0 polypropylene are used if bleeding between running sutures is encountered. A soft bulldog clamp is placed on the proximal vein graft until the distal anastomosis is completed.

The distal anastomosis is performed in similar fashion. The AKP is most often controlled with vessel loops or clamps. A long arteriotomy is again performed 1.5 times the diameter of the graft. Fogarty catheters can be used for control in the presence of excessive calcification. Vein graft orientation is rechecked; release of the bulldog clamp should result in highly pulsatile flow. The vein is tailored appropriately. The heel is secured with a running 6-0 polypropylene suture and continued toward the toe. A second suture starting from the toe is sewn until it meets the first suture. Once the clamps or vessel loops are released, measures to ensure hemostasis are employed.

Operative Technique for Femoral to Below-Knee Popliteal Bypass

The BKP is exposed through a longitudinal incision 1 to 2 cm posterior to the medial edge of the tibia. The subcutaneous tissue is divided with electrocautery. The pes anserinus tendon is divided. The posterior fascia is identified and divided longitudinally as well. The medial head of the gastrocnemius muscle is bluntly mobilized and retracted posteriorly to expose the popliteal fossa. Gentle blunt dissection is performed until the neurovascular contents of the fossa are identified. Self-retaining retractors are placed. The fascial sheath around the vessels is entered with Metzenbaum or tenotomy scissors. The adherent popliteal vein(s) are carefully dissected from the artery and small venae comitantes are divided and ligated with 4-0 silk. Proximal and distal control is obtained with large vessel loops. The tunneler is advanced from the popliteal fossa between the heads of the gastrocnemius muscle to the groin incision. The gently distended conduit is passed through the tunneler, ensuring proper orientation. Anastomoses are created in the same fashion as for AKP bypass.

Operative Technique for Tibial Bypass

Inflow and outflow sites are exposed as described above. After a suitable conduit has been prepared, the reversed graft is tunneled in an anatomic plane using a large hollow bore tunneler. In reoperative settings or when arm or spliced vein from sites other than the ipsilateral extremity are used, we prefer to tunnel the graft in a deep subcutaneous plane. This technique is especially applicable when performing a redo bypass and in patients with threatened limbs and diabetes, in whom we often perform BKP to tibial or pedal bypass. In the latter case, thigh vein is harvested through skip incisions. Short incisions are used to expose the BKP and the tibial target artery. The graft is then reversed and tunneled in a deep subcutaneous plane beneath intact skin. This technique avoids wound complications and potential graft exposure associated with calf vein harvest (Fig. 207.4).

An additional concern is vessel wall calcification. The tibial arteries, particularly in patients with diabetes, are often heavily calcified. In such cases, the vessels should not be clamped and usually cannot be controlled with vessel loops alone. A tourniquet can be used for control. Alternatively, intraluminal control after arteriotomy can be obtained with

small 2 or 3 mm Fogarty catheters or intraluminal devices of an appropriate diameter such as a Flo-Rester (Synovis Surgical Innovations; St. Paul, Minnesota). The anastomoses should be created to the least calcified region possible. If calcification is excessive, a CC (calcified coronary) needle is extremely useful. Formal endarterectomy should be avoided; loose-calcified fragments that develop during anastomosis creation should simply be removed or flushed out. Running 6-0 or 7-0 Prolene suture is usually employed.

Intraoperative Bypass Graft Assessment

Intraoperative assessment should confirm graft patency, establish the integrity of the conduit, confirm adequacy of the outflow, and identify potential conduit, anastomotic, and technical defects that may predispose to thrombosis. A sterile Doppler probe is the easiest way to assess graft flow and flow in the foot. Intraoperative duplex imaging can also be used to detect technical or intrinsic conduit defects. Because of ease of use and the widespread availability of quality intraoperative imaging, we routinely perform completion arteriography by inserting a 21-gauge butterfly needle connected to a 3-way stopcock and extension tubing into the hood of the proximal anastomosis. DSA is performed to visualize from the proximal graft to the foot. The anastomoses, conduit and outflow should all be imaged and any major defects corrected.

Wound Closure

After confirming patency and achieving hemostasis, the wounds are closed in layers. The fascia and deep subcutaneous tissue are reapproximated with absorbable suture. In elective procedures, the skin can be closed in a subcuticular fashion. In patients with significant edema, the skin (particularly below the knee) should be closed with skin edge eversion using interrupted 3-0 or 4-0 nylon mattress sutures. A closed suction drain is occasionally placed in the groin if there is a concern for lymphatic leak, especially in reoperative procedures. Sterile dry gauze or skin glue is then used to cover the incisions.

Alternative Inflow Sources

The length of available vein may be insufficient to allow bypass origination from the CFA. In other instances, CFA exposure may be

prohibitive due to excessive scarring from previous revascularizations. The PFA may serve as a useful alternative inflow source (Fig. 207.2). The mid or distal PFA is exposed by a longitudinal incision on the upper thigh lateral to the sartorius muscle. The soft tissue is dissected until the sartorius can be retracted medially. The SFA is visualized and retracted medially as well. Dissection is carried out between the adductor longus and vastus medialis to expose the PFA. Ligation and division of crossing veins are often necessary to provide adequate exposure. Small PFA branches are controlled with silastic loops.

The SFA may also be used selectively as an alternate inflow source. If a vertical incision has been made in the groin, it can be extended distally. The sartorious is retracted laterally to further expose the SFA. The mid and distal SFA may be approached via a vertical medial thigh incision near the posterior border of the sartorious. The fascia is divided and the sartorious retracted anteriorly to expose the SFA in Hunter's canal.

Shortening the bypass is a useful technique to allow use of a single segment of optimal conduit. Adequate inflow and outflow should be assured by preoperative vascular lab studies and imaging and confirmed by intraoperative pulse palpation and completion angiography. If the proposed bypass cannot be shortened due to disease extent, additional good quality vein should be harvested and spliced to create a conduit of sufficient length.

Intraoperative Troubleshooting and Pitfalls

Distal bypass is one of the most taxing operations that vascular surgeons perform. Achieving optimal results requires proper planning, meticulous technique, and prudent judgment. A number of issues may arise during or early after leg bypass that must be carefully addressed to avoid graft failure and potential limb loss.

Inadequate Vein Conduit

The majority of vein conduit problems can be anticipated preoperatively if high-quality duplex vein mapping is performed. When vein problems are unexpectedly encountered, several options are available. If the vein abnormality is focal (sclerosis), the segment may be resected and a veno-venostomy performed. The ends should be spatulated to create a wide anastomosis. In the event that long segments of the vein are unusable, additional vein should be harvested from an alternate site—contralateral

GSV, SSV, or arm veins. Creating the proximal anastomosis to the PFA or SFA can allow utilization of shorter segments of vein.

Small-Caliber Vein

At times, there is a size mismatch between the small-caliber reversed vein and a larger, thick-walled artery at the proximal anastomosis. If possible, a large branch at the distal end of the GSV should be preserved during harvest. The venotomy can incorporate this branch to create a heel that sits up away from the artery (Fig. 207.5), avoiding suture line stenosis.

Unexpected Inflow Disease

Optimal diagnostic angiography (including oblique views of the iliac arteries with pull back pressures if uncertainty exists) will typically detect the presence of inflow disease. Atherosclerotic disease of the CFA and PFA can be addressed with an endarterectomy. This may entail partial division of the inguinal ligament to allow clamp placement on nondiseased external iliac artery. A long venotomy can be used for the anastomosis if the conduit is of adequate caliber. Otherwise, the arteriotomy may require a vein or Linton patch (Fig. 207.6) with subsequent anastomosis of the bypass conduit to the patch. Alternatively, a segment of occluded SFA can be endarterectomized and used to patch the arteriotomy.

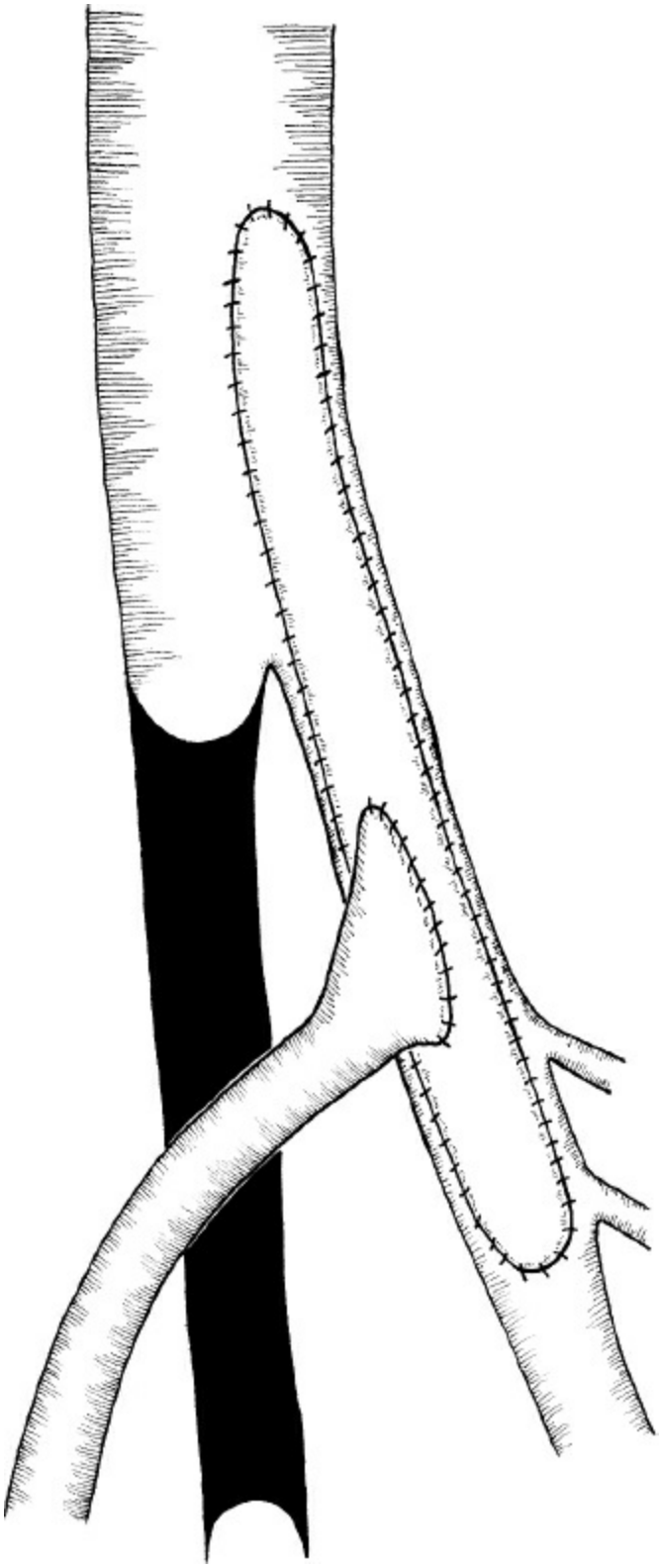

Figure 207.6. Use of Linton vein patch technique following endarterectomy of the distal common and proximal DFAs with anastomosis of the reversed vein graft to the patch. (Reprinted from Rutherford RB. *Vascular Surgery*. 6th ed. Philadelphia, PA: Saunders; 2005. Copyright © 2005 Elsevier, with permission.)

Unexpected Outflow Disease

The distal target for a femoral-popliteal bypass graft is generally an area free of disease with at least one continuous runoff artery to the foot. Unexpected, significant popliteal disease may require bypass extension to more distal tibial or pedal targets. Intraoperative angiography is employed to locate the most proximal segment of tibial or peroneal artery that is continuous with the foot. The bypass is performed to this site.

Sequential bypass is useful for situations in which an isolated patent popliteal segment exists between severely diseased SFA and distal popliteal-tibial arteries. A bypass graft from the thigh is connected to the proximal portion of the popliteal island. A separate bypass graft uses the distal popliteal segment as inflow and connects to a tibial or pedal vessel that is in continuity with the foot. The advantage of this technique is that it permits use of shorter vein segments and avoids the need to splice veins.

Tunneling Problems

An experienced member of the operative team should tunnel the conduit. Passing the conduit through a large bore tunneler protects it from tearing or shearing as it is pulled into place. The vein conduit should always be distended as it is passed in order to avoid twists or kinks. After tunneling, irrigation through the proximal end of the graft should produce vigorous flow. After completing the proximal anastomosis, the graft flow should be highly pulsatile. If these are not observed, the graft should be re-tunneled.

Anastomotic Stenosis

Prevention is the key to avoid anastomotic stenosis. Diligence in tailoring the graft during the anastomosis usually prevents this problem. When a size mismatch exists between the vein conduit and the artery, a suitable branch of the vein graft should be incorporated into the venotomy or a modified Linton patch utilized as already described. Completion angiography, intraoperative Doppler or duplex ultrasound will identify anastomotic stenoses that occur despite careful operative technique. If a stenosis occurs, the anastomosis is examined and any trapped adventitia is freed. If the narrowing persists, the anastomosis should either be redone or patched with vein.

Reoperative Bypass

Reoperative bypass can be difficult, even for the most experienced surgeon. Preoperative vein mapping and careful planning are critical.

Autogenous conduit should be used if at all possible. It is prudent to simplify dissection by avoiding previously operated fields through the use of alternative inflow and outflow sites; these approaches may require exposure of the distal PFA, SFA, and alternate tibial artery exposures.

COMPLICATIONS

Graft Thrombosis

Early vein graft thrombosis most often results from technical error, poor conduit, or poor outflow. In order to preserve the graft and distal perfusion, the patient requires timely return to the operating room. The presence of valves presents a challenge for graft thromboembolectomy. The incision for the popliteal exposure is reopened and the distal anastomosis is controlled. A dose of intravenous heparin is given. A longitudinal venotomy is made over the hood of the graft. Visible clot in the graft is teased out. An embolectomy catheter is then passed distally to treat the runoff vessels. An attempt is made to pass the embolectomy catheter proximally. If valves prevent catheter passage, the proximal anastomosis is re-exposed. After proximal control, an incision is made in the hood of the graft. The embolectomy catheter is passed proximally to distally and out the distal graftotomy. A separate embolectomy catheter is tied to the distal aspect of the first catheter, which is then retracted proximally. The tie is cut and the balloon on the catheter passed from below inflated and this catheter withdrawn in the direction of the valves and the thrombus retrieved through the distal graftotomy. The graft is then vigorously flushed with heparinized saline. Any evident anastomotic defect or intimal flap is corrected and patched if needed. Completion angiography is performed to assess the adequacy of thromboembolectomy and to ensure there are no residual conduit defects, tunneling problems or outflow issues. If there is concern for reperfusion syndrome, four-compartment fasciotomy should be considered.

Specific patient subgroups may be more prone to early graft thrombosis. A report based on the National Surgical Quality Improvement Program (NSQIP) evaluated 14,788 patients undergoing infrainguinal bypass. Patient factors associated with early graft thrombosis were age <60 years, African-American race, nondiabetics, and bypass to tibial vessels.

Late graft thrombosis occurs after 30 days and is usually not technical in nature. Vein grafts develop intimal hyperplasia, a process that is usually self-limited; 20% to 30% of vein bypass patients develop a graft-

threatening stenosis, usually solitary and focal, and most often within 2 years of graft implantation. Routine duplex surveillance identifies and monitors such lesions for progression, allowing timely intervention by percutaneous or open intervention to maintain graft patency and limb salvage.

Bleeding

Bleeding complications can be reduced by meticulous technique. When harvesting vein grafts, all small side-branches must be ligated. Larger branches, especially on delicate arm veins are suture ligated with fine Prolene. Hemostatic clips on the vein graft itself may become dislodged during tunneling and should be avoided. Careful inspection of the vein on the back table is time well spent. Bleeding of the vein graft in the tunnel can be repaired by direct cut down onto the area of concern. Focal bleeding from the anastomosis usually requires placing single-repair sutures. Severe bleeding from the anastomosis may be the result of improper technique, failure to include all layers of the arterial wall when suturing, poor vessel wall integrity, or excessive tension. The anastomosis may need to be redone if this occurs. Early postoperative bleeding is usually technical in nature or due to anticoagulation and antiplatelet therapy. Prompt return to the operating room with repair minimizes further complications.

Infection and Lymphatic Leak

Infection is a troublesome complication of leg bypass. In patients with pre-existing foot infection, appropriate systemic antibiotics should be administered and adequate drainage to control infection performed prior to bypass. In the absence of preoperative infection, a single perioperative dose of antibiotics to cover skin flora should be adequate. Surgical site infections are most often superficial and can be treated with drainage, simple dressing changes, and antibiotics. Deep wound infections may lead to graft exposure and even rupture. They require aggressive, early debridement, and muscle flap closure.

Lymphatic complications such as lymphocele or lymphatic leak may cause significant morbidity and increase late graft infection risk. These complications result from the disruption of the lymph channels, most commonly in the groin. Careful longitudinal dissection directly over the femoral artery with ligation of lymphatics during the initial operation helps

reduce lymphatic leaks. Reoperative procedures in the groin, however, are prone to the formation of lymphoceles and lymph leaks. Closed suction drains may be useful in selected redo operations. The wound should be re-explored and the offending lymphatics ligated for significant or persistent lymph leaks. Wound VAC (vacuum-assisted closure) therapy has been described both for prophylaxis and treatment of lymphatic leaks.

One of the best estimates of the real-world operative morbidity related to vein bypass operations comes from the PREVENT III trial, which enrolled over 1,400 patients from 83 different centers with limb-threatening ischemia. Thirty-day perioperative mortality was 2.7%. Early graft occlusion occurred in 5.2% of patients, while major wound complications (4.8%) and rates of hemorrhage (0.4%) were quite low.

POSTOPERATIVE MANAGEMENT

Postoperative leg bypass patients should be admitted to an appropriate surgical unit for cardiac monitoring and frequent neurovascular assessments. Any change in neurovascular status should provoke a complete evaluation for graft patency. In the event of early graft thrombosis, prompt return to the operating room is usually indicated. Although very uncommon in patients operated on for chronic limb ischemia, a developing compartment syndrome should not be overlooked.

Fluid and electrolytes should be monitored closely in the early postoperative period. PAD patients often suffer from concomitant cardiac disease. Antiplatelet therapy should be continued, as should antihypertensive medications and β-blockers. Any cardiac-related symptoms should be taken seriously and appropriately investigated. Unless the patient suffers from postoperative nausea and vomiting (we prefer regional techniques for most leg bypasses), diet can usually be resumed in the early postoperative period. Adequate pain control is important to allow early mobilization and to prevent complications related to immobility, such as deep venous thrombosis or generalized deconditioning. Physical therapy should be initiated early.

CONCLUSIONS

Resource utilization associated with leg bypass surgery is directly related to graft patency and the stage of limb-threatening ischemia (SVS WIfI) at presentation. Despite a widespread paradigm shift toward an endovascular first strategy, a balanced view would suggest that many patients with

severe PAD are best served with a bypass if their life expectancy is reasonable, operative risk is low or moderate, and good quality autologous vein is available. A comprehensive, longitudinal care approach includes performing every infrainguinal bypass with meticulous technique, using autogenous vein whenever possible, and following the patient closely with a serial, duplex surveillance program to optimize long-term graft patency. Long-term, ongoing medical treatment of PAD risk factors is also essential to prevent secondary cardiac and cerebrovascular events.

Suggested Readings

Carrel A, Guthrie CC. Uniterminal and biterminal transplantation of veins. *Am J Med Sci* 1906;132:415.

Conte MS, Bandyk DF, Clowes AW, et al. Results of PREVENT III: a multicenter, randomized trial of edifoligide for the prevention of vein graft failure in lower extremity bypass surgery. *J Vasc Surg* 2006:43(4):742–51.

Conte MS, Pomposelli FB, Clair D, Society for Vascular Surgery Lower Extremity Guidelines Writing Group. Society for vascular practice guidelines for atherosclerotic occlusive disease of the lower extremities part I: asymptomatic disease and claudication. *J Vasc Surg* 2015;61(3 Suppl):2S–41S.

Gerhard-Herman MD, Gornik HL, Barrett C, et al. 2016 AHA/ACC guideline on the management of patients with lower extremity peripheral artery disease: an executive summary. *Circulation* 2017;136(2):1–206.

Klinkert P, Schepers A, Burger DH, et al. Vein versus polytetrafluoroethylene in above-knee femoropopliteal bypass grafting: five-year results of a randomized controlled trial. *J Vasc Surg* 2003;37:149–55.

Kunlin J. Le traitement de l'ischemie arteritique par la greffe veineuse longue. *Rev Chir Paris* 1951;70:206–36.

Mills JL Sr. Chapter 109: Infrainguinal bypass. In: Rutherford RB, ed. *Rutherford Vascular Surgery.* 7th ed. Philadelphia, PA: Elsevier Saunders; 2010:1682–702.

Mills JL, Conte MS, Armstrong DG, et al. The society for vascular surgery lower extremity threatened limb classification system: risk stratification based on wound, ischemia and foot infection (WIfI). *J Vasc Surg* 2014;59:220–34.

Samson RH, Morales R, Showalter DP, et al. Heparin-bonded expanded polytetrafluoroethylene femoropopliteal bypass grafts outperform expanded polytetrafluoroethylene grafts without heparin in a long-term comparison. *J Vasc Surg* 2016;64(3):638–47.

Singh N, Sidawy AN, DeZee KJ, et al. Factors associated with early failure of infrainguinal lower extremity bypass. *J Vasc Surg* 2008;47(3):556–61.

Stonebridge PA, Prescott RJ, Ruckley CV. Randomized trial comparing infrainguinal polytetrafluoroethylene bypass grafting with and without vein interposition cuff at the distal anastomosis. The Joint Vascular Research Group. *J Vasc Surg* 1997;26(4):543–50.

Sumpio BE, Forsythe RO, Ziegler KR, et al. Clinical implications of the angiosome model in peripheral vascular disease. *J Vasc Surg* 2013;58(3):814–26.

Wang J, Shu C, Wu Z, et al. Percutaneous vascular Interventions versus bypass surgeries in patients with critical limb ischemia: a comprehensive meta-analysis. *Ann Surg* 2017. doi: 10.1097/SLA.0000000000002344

Watelet J, Soury P, Menard JF, et al. Femoropopliteal bypass: in situ or reversed vein grafts? Ten-year results of a randomized prospective study. *Ann Vasc Surg* 1999;18:149–57.

EDITOR'S COMMENT

Peripheral arterial disease (PAD) is the primary disease for which arterial revascularization is often performed. It is a marker of systemic atherosclerosis, as highlighted by the authors of this well-written chapter on reversed vein arterial bypass technique. However, the medical management is as important and relevant for all patients with PAD. This section is well detailed by the authors and I won't reiterate the details—suffice it to say, identification of vascular claudication is the first step, and then evidence-based therapies such as antiplatelet therapy, statins, and blood pressure control are paramount. I would add that all patients with PAD have their blood pressure goal be 120/80, as highlighted by the large SPRINT trial (Cushman WC, Whelton PK, Fine LJ, et al.; Group SSR. SPRINT Trial results: latest news in hypertension management. *Hypertension* 2016;67:263–5) and that Plavix did show a benefit in those patients with PAD, as compared with those that did not (CAPRIE Steering Committee. A randomised, blinded, trial of clopidogrel versus aspirin in patients at risk of ischaemic events (CAPRIE). CAPRIE Steering Committee. *Lancet* 1996;348:1329–39).

Mills and Lucas clearly describe the basics and the important caveats to make the reversed vein bypass successful—clearly from long experience. The details herein of performing the reversed vein technique will prevent common problems that may occur, and the technical points they make are almost exactly how I do my bypasses. I agree with the authors that the reversed technique is similar to the in situ technique with regard to patency and long-term success. Single-center series may suggest benefit of one technique over the other, but no large well-powered randomized controlled trials exist. Further, I believe that the surgeon should be comfortable with both techniques and use whichever one is most applicable to the clinical situation. For example, I mainly use the reversed vein technique, except for more distal bypasses such as posterior tibial and

peroneal. I like the reversed for above-the-knee and below-the-knee bypass targets, or when bypassing to the anterior tibial artery via a lateral pathway. The reversed technique tends to be a bit easier and has the advantage of anatomical tunneling, beneficial in patients with thin skin or at-risk patients for skin flap infection or breakdown that could lead to graft exposure with the in situ technique.

Recent data suggest that the conduit quality, greater than 3 mm and undamaged, is probably the most important factor influencing graft patency (Nguyen LL, Conte MS, Menard MT, et al. Infrainguinal vein bypass graft revision: factors affecting long-term outcome. *J Vasc Surg* 2004;40:916–23). I believe this plays a role in propensity to graft stenosis. The authors appropriately note that approximately 20% to 30% of patients with a reversed vein graft will develop significant neointimal hyperplasia with resultant stenosis —and can lead to graft thrombosis. One lesson learned by our group over the years is when you diagnose by duplex ultrasound surveillance a critical graft stenosis in clinic, don't let them leave. We admit these patients for heparinization and then next day endovascular cutting balloon angioplasty. This prevents the patient from returning with a thrombosed graft, even if only a few days. This also underlies the importance of post bypass duplex surveillance for any vein graft (Tinder CN, Bandyk DF. Detection of imminent vein graft occlusion: what is the optimal surveillance program? *Semin Vasc Surg* 2009;22:252–60).

Another aspect to highlight is in what circumstances to use anticoagulation after vein grafting. A cogent review (Hess CN, Norgren L, Ansel GM, et al. A Structured review of antithrombotic therapy in peripheral artery disease with a focus on revascularization: a TASC (InterSociety consensus for the management of peripheral artery disease) initiative. *Circulation* 2017;135:2534–55) suggests in high-risk grafts, such as a redo procedure or poor arterial outflow—that anticoagulation may be beneficial. We tend to follow this strategy, with low-dose heparin for the first 48 hours, then full IV heparin to bridge to Warfarin. It is not known whether the direct oral anticoagulants confer the same benefit, but is likely, and clinical experience will accrue.

Another technical aspect highlighted is careful and gentle dissection of the vein. I don't skeletonize the vein, but rather leave a good amount of periadventitial tissue as I think this leads to less local vein ischemia. There is no direct evidence for this, but I see no disadvantage. In addition to the heparinized blood for distending and testing the vein graft for leaks, we add papaverine to the blood solution to help break the vasospasm. Overdistension of the vein likely damages the endothelium, and may lead to neointimal hyperplasia.

Finally, for any type of revascularization in a patient with PAD, adhering to the proper indications cannot be overstated. Simply stated, severe claudication, rest pain, and tissue loss are the main ones. I recommend all surgeons who do vascular surgery to review the new consensus guidelines for treatment of PAD,

as the document is very clear and supported by multiple societies (Gerhard-Herman MD, Gornik HL, Barrett C, et al. 2016 AHA/ACC guideline on the management of patients with lower extremity peripheral artery disease: a report of the American college of cardiology/American heart association task force on clinical practice guidelines. *Circulation* 2017;135:e726–79). Even with an expertly performed reversed vein bypass, of which the durability can be greater than 10 to 15 years, some do fail and the patient may be worse (although less so than when a prosthetic bypass fails). Each later procedure or redo bypass has a greater chance of failure, and greater chance of leading to limb loss.

Peter Henke

208 Peripheral Arterial Disease: Prosthetic Bypass

Ahmed Kayssi, Ken Lee, and Richard F. Neville

INTRODUCTION

In the modern era of treating vascular disease, there has been a dramatic increase in the number of endovascular interventions and a corresponding reduction in the number of surgical bypasses performed for lower extremity peripheral arterial disease. The advent of endovascular therapy, however, has also resulted in an increase in the complexity of patients requiring bypasses for symptom relief, healing, and limb preservation, especially after failed endovascular intervention. For the foreseeable future, surgical bypass will continue to play an important role in the revascularization of patients with limb ischemia. A survey of vascular surgeons identified the following scenarios in which bypass continues to play a primary role in lower extremity revascularization: common femoral artery pathology, extensive tissue loss as an indication for revascularization, patients with a good life expectancy in whom durability is paramount, and long segment, infrageniculate occlusive disease especially in the setting of single tibial artery runoff.

Although surgical bypass with autogenous vein has an established clinical record, with excellent long-term patency rates, a certain proportion of patients needing bypass surgery lack suitable autogenous conduit. Reasons for the lack of vein include previous harvesting for lower extremity bypass, coronary bypass, small caliber or poor quality of the vein, varicose veins, or superficial thrombophlebitis. Several past series studying bypass with prosthetic conduit did not reflect a durable revascularization. In fact, primary amputation was considered as opposed to bypass with prosthetic conduit, especially if a tibial revascularization was required. But, more recent advances in technique and graft technology have led to improved results such that prosthetic conduit can now be considered a reasonable option for lower extremity bypass.

PREOPERATIVE PLANNING

Three factors must be considered when planning for a vascular bypass: the site from which the bypass will originate (the inflow), the site at which the bypass will restore flow (the outflow), and the choice of conduit for creating the bypass. Appropriate inflow and outflow sites are determined by the patient's clinical exam and preoperative imaging. The most commonly used inflow artery for a prosthetic infrainguinal bypass is the common femoral artery. However, the superficial femoral and popliteal arteries may be used in the absence of proximal occlusive disease as shorter bypasses have demonstrated excellent patency. However, one of the advantages of prosthetic conduit is length not functional as a factor to remain proximal to lesions affecting inflow. The most commonly performed lower extremity bypass with prosthetic conduit is the femoral-popliteal bypass. However, tibial bypass with prosthetic conduit has also been performed in numerous recent clinical series with encouraging results. Another consideration in the choice of target artery is the angiosome in which a non-healing wound or gangrene is located. Revascularization of the artery feeding the appropriate angiosome may lead to enhanced healing and limb preservation. Although this is merely one factor in the decision-making process, the use of prosthetic conduit, without length being a consideration, may allow revascularization of the appropriate angiosome and enhance tissue healing. Obviously, in planning a lower extremity bypass and prior to the use of a prosthetic conduit, careful examination should be made of all extremities for the presence of vein as an autogenous conduit supplemented with imaging in the noninvasive vascular lab.

GRAFT MATERIALS AND PROPERTIES

The ideal prosthetic graft would take advantage of many factors: impermeable to surrounding cells and fluids, resistant to thrombosis and infection, optimal compliance, biocompatibility, durability, availability in varying sizes, and cost-effectiveness. Electronegativity on the graft surface has been thought to be an advantage regarding inhibition of platelet aggregation with theoretic enhancement of this property by carbon coating of the luminal graft surface, although this has been difficult to prove in clinical application. Graft porosity has not been shown to significantly affect graft function, but may be implicated in tissue ingrowth. Several grafts have been developed with these properties in mind, but the most

commonly used prosthetic materials are Dacron and expanded polytetrafluoroethylene (ePTFE).

Dacron

The polyester fabric Dacron was developed by British chemists Whinfield and Dickinson in 1941, and is one of the oldest continuously used fabrics on the market. Dacron grafts can be knitted or woven. Knitted grafts have the advantage of better compliance, but have larger pores that tend to leak and require preclotting. As such, current versions of the knitted Dacron grafts are often coated with albumin to prevent leakage from those pores. Dacron is a resilient fabric estimated to last well over 30 years, but these grafts are at a higher risk of dilation compared with other graft materials. Dacron is currently used primarily as a large-diameter graft in the aortic position, but does maintain a role in lower extremity bypass surgery.

Expanded Polytetrafluoroethylene (ePTFE)

ePTFE is configured on a mandrel process with a nodal-fibril porous configuration with carefully constructed internodal distances to optimize function and healing properties. ePTFE grafts are available in several configurations: thin walled, ringed, and precuffed. The precuffed configuration was an attempt to optimize graft hemodynamics, but this has been difficult to confirm and may in fact be disadvantageous for optimal flow patterns. ePTFE grafts are produced by extruding a low porosity conduit in the form of a tube that is compliant, easy to suture, and should not be preclotted or soaked prior to implantation.

Several studies have been carried out to compare Dacron and ePTFE grafts for lower extremity bypasses. Rychlik and colleagues published a meta-analysis in 2014 that reviewed 91 publications and assessed 1,192 patients who underwent above-knee femoropopliteal bypass using Dacron versus ePTFE. The authors reported similar primary patency between the grafts up to 10 years, and no difference in the incidence of amputation, morbidity, or mortality between the patient populations. A Cochrane Review published in 2010 similarly reported that vein grafts were superior to prosthetic grafts, but that long-term outcomes when using Dacron and ePTFE for prosthetic bypass in the lower extremities were similar.

Polypropylene

Early experience with the use of this hydrocarbon material in the early 1990s was promising. A study of 4-mm lower extremity polypropylene grafts implanted in dogs by Greisler and colleagues from Illinois reported a 16-month patency of 81% compared with 69% and 20% for Dacron and ePTFE, respectively. Because of its susceptibility to oxidation, however, it is currently available only as part of multicomponent grafts that render the material inert.

Polyurethanes

Polyurethane grafts are produced by the reaction of isocyanates with an alcohol group. The advantage of this material is its high elasticity, but its poor biostability and loss of compliance after implantation have limited its widespread clinical application. This concern has been addressed by manufacturing a carbonate-reinforced polyurethane that is less susceptible to premature degradation.

Composite Grafts and Allografts

The successful implementation of prosthetic grafts has triggered the development of more novel materials such as composite grafts, which are biologic graft materials using human umbilical vein or ovine collagen. One such novel material is the Cytograft Tissue Engineering graft (Novato, California), which involves bilayer of living fibroblasts derived from cells extracted from patients rolled and matured over a steel mandrel. While this type of material has yet to be used in lower extremity bypasses, it has been used as a conduit in a hemodialysis access graft, which may hold an exciting future in the realm of prosthetic grafts.

Cryopreserved vein and human umbilical vein are alternative conduits that are biologic in their properties and therefore have an intrinsic appeal for distal reconstruction. First utilized in the 1960s, cryopreserved grafts are expensive when compared with other conduits, and have a greater incidence of aneurysmal degeneration and thrombosis from late rejection. The current data from multiple centers reported a 30% to 58% patency rate at 1 year using cryopreserved veins for infrapopliteal bypass, which are inferior to autologous conduits and inferior to heparin bonded ePTFE grafts. Some centers, however, have shown reasonable limb salvage rates, and therefore this material may have some value in bypasses that must traverse infected fields in the absence of any autogenous conduit options. The initial use of human umbilical vein grafts was also impeded by

aneurysmal degeneration of the graft material. This complication was addressed with modifications of the graft design; however, these grafts met with limited success when used for tibial bypass. In a large National Surgical Quality Improvement Program (NSQIP) database, human umbilical vein composite grafts had a significantly higher 30-day failure rate at 15.4% compared to 10.5% in PTFE grafts and 7.5% in great saphenous vein (GSV) conduits.

STRATEGIES FOR IMPROVING PROSTHETIC GRAFT FUNCTION

As previously mentioned, clinical outcomes with early prosthetic grafts were suboptimal especially for tibial artery bypass, with 1-year patency rates of 20% to 50% and 3-year patency rates of 12% to 40%. A comparison of venous and prosthetic conduits for infrapopliteal bypasses reinforced these findings, with 38% 2-year patency for ePTFE bypasses to tibial arteries. Beyond technical errors in the perioperative period, prosthetic graft failure occurs due to the development of myointimal hyperplasia (commonly between 6 and 24 months), or acceleration of atherosclerosis in the proximal or distal arterial bed (beyond 2 years). Efforts to improve outcomes for prosthetic grafts have focused on a reduction in graft thrombogenicity and myointimal hyperplasia formation. These efforts involve venous adjuncts at the distal anastomosis, heparin bonding to the graft surface, and addition of a distal arteriovenous fistula.

Vein Patches and Cuffs

Attempts to improve the performance of prosthetic grafts by altering the effect of anastomotic hyperplasia and graft thrombogenicity while improving hemodynamics and ease of suturing involved interposition of venous adjuncts at the distal anastomosis. The Miller cuff interposed autogenous vein at the distal anastomosis in a cuffed configuration (Fig. 208.1). Miller reported on 114 infrainguinal procedures using a vein cuff technique with a patency rate of 72% noted at 18 months. However, several disadvantages were recognized with this configuration, including significant turbulence at the anastomotic reservoir and difficulty in achieving an adequate angle between the graft and recipient artery. These factors may explain the immediate and early graft failures reported in Miller's initial series.

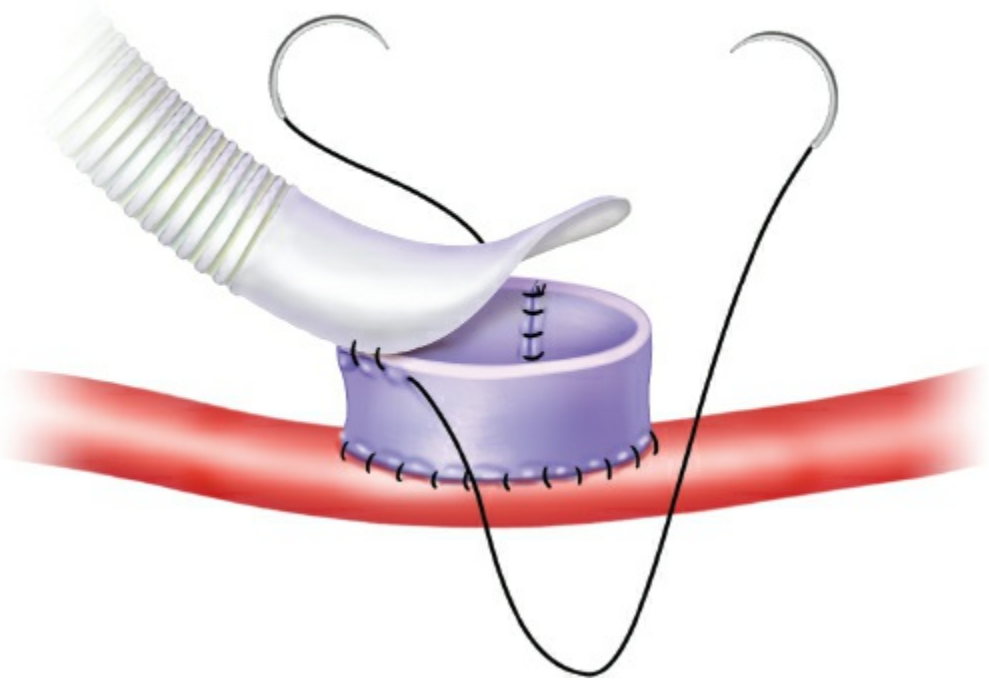

Figure 208.1. The Miller cuff technique. A venous cuff is interposed between a prosthetic graft and the target artery.

Taylor described a technique to address several of these concerns reporting on 256 grafts with 83 tibial bypasses, with 1-, 3-, and 5-year patency rates of 74%, 58%, and 54%, respectively (Fig. 208.2). However, there are also disadvantages to the Taylor patch technique. The tibial artery is directly exposed to PTFE graft material for the proximal portion of the anastomosis, thereby losing the advantage of venous endothelium for half the anastomosis. There can also be a point of anastomotic constriction where the three suture lines converge between the artery, ePTFE, and vein patch. Finally, a significant length of vein must be available to accomplish the anastomosis using the Taylor technique.

Several authors have reported their results with these techniques. Pappas obtained improved patency for prosthetic bypasses with the Miller cuff when as compared to historical controls with straight ePTFE. A prospective, randomized trial utilizing ePTFE grafts with and without a Miller vein cuff was reported by Stonebridge. This series did not demonstrate a statistically significant benefit for the vein cuff technique in tibial bypasses, although there was a trend toward improved patency at 24 months. Kreienberg compared grafts using ePTFE with a vein cuff versus composite saphenous vein grafts. Primary patency was similar at 2 years: 49% cuff versus 44% composite vein with secondary patency rates somewhat better for the composite vein group. The Albany group

compared all bypasses with spliced vein segments to ePTFE and a Miller vein cuff. The patency was better with the vein bypasses, although 25% of the spliced vein procedures required revision to obtain these results. In addition, spliced vein procedures involved increased operative time, hospital stay, intraoperative blood loss, and perioperative morbidity. Therefore, composite grafts of poor quality vein do not function any better than ePTFE with a vein cuff or patch and generate a higher rate of morbidity and use of hospital resources.

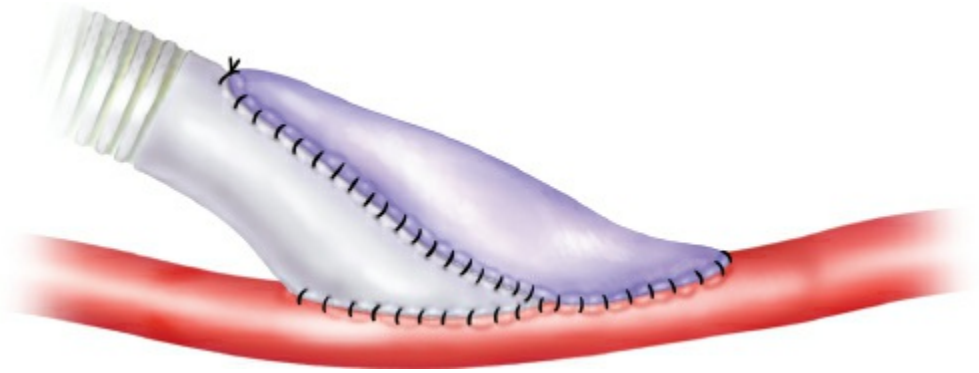

Figure 208.2. The Taylor patch technique. The graft is partially sutured onto the target artery, and a vein patch is used to suture the rest of the graft onto the artery and increase the anastomotic surface area.

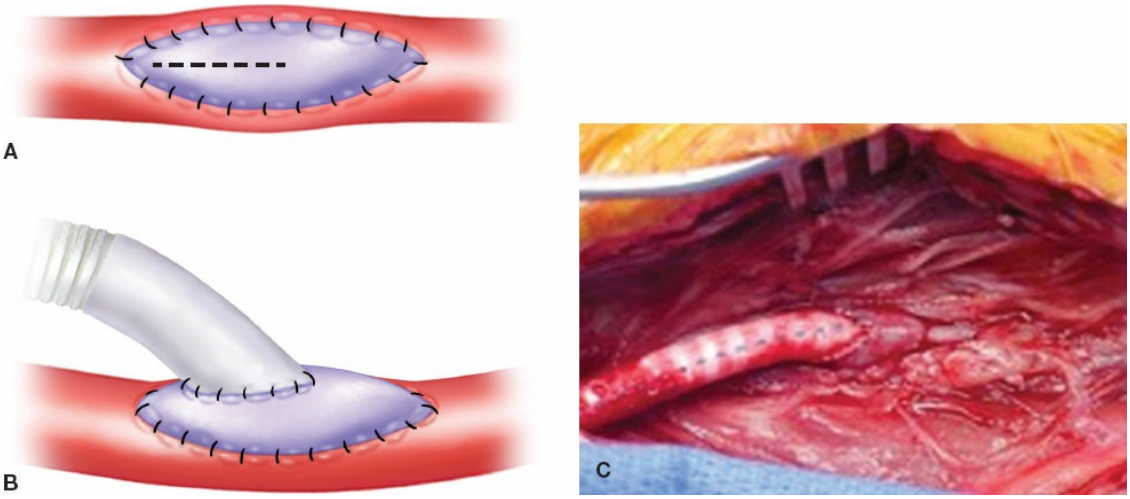

Figure 208.3. A. The Neville distal vein patch technique. A vein patch is created onto the target artery (**A**), and (**B, C**). A prosthetic graft is then sutured directly onto the vein patch.

The distal vein patch (DVP) technique was developed due to ease of technique and maintenance of the proposed advantages leading to improved outcomes for prosthetic grafts (Fig. 208.3A,B). The initial series

of tibial artery bypasses describing the DVP technique for patients with limb-threatening ischemia was reported in 1997. A subsequent initial clinical series using the DVP technique resulted in improved 4-year patency (62%) and limb salvage (79%) in a group of patients without adequate saphenous vein conduit options (Fig. 208.4). Since those initial reports, an expanded series with more robust follow-up has resulted in 51% patency at 4 years in a 290 patient cohort using the DVP technique for tibial bypass. This result is an improvement over reports of tibial bypass with straight prosthetic conduit and may be a better reflection of real-world clinical outcomes as compared to the initial publications.

Heparin-Bonded Grafts

The bonding of heparin to the inner surface of a prosthetic graft has been hypothesized to reduce graft thrombosis and hyperplasia. The ideal method of bonding uses end-point covalent bonding of heparin to the luminal surface of the graft to maintain the bioactivity of the heparin molecule. This process reduces platelet adherence, acute thrombus formation, and anastomotic myointimal hyperplasia in canine and primate models. The initial clinical experience with the heparin-bonded ePTFE graft was encouraging as Walluschek obtained 80% 1-year patency for below-knee bypasses. Peeters reported primary and secondary 1-year patency rates of 82% and 97%, respectively, with little difference between popliteal and tibial bypasses. Many other series followed with similar success. Devine reported a multicenter, randomized trial of heparin-bonded Dacron versus ePTFE for femoropopliteal bypass and reported significantly greater patency rates with the heparin-bonded grafts at 3 years, but the difference was no longer statistically significant at 5 years. This, however, was a small study of primarily above-knee bypasses, which limits its generalizability to the smaller vascular beds. Daenens and colleagues reported that bypasses with heparin-bonded grafts were statistically equivalent to saphenous vein for popliteal and tibial bypass. In order to confirm these findings, a comparison of tibial bypasses using heparin bonded ePTFE versus those with saphenous vein grafts was performed. This analysis showed that quality, single segment saphenous vein remained a superior conduit to heparin-bonded ePTFE. However, the use of a heparin-bonded conduit in combination with a venous adjunct at the distal anastomosis led to 1-year primary patency without a statistically significant difference when compared to the patency obtained with venous

conduit for tibial artery bypass (Fig. 208.5). Several additional series have been reported comparing standard PTFE to heparin-bonded ePTFE with apparent benefit in the femoral-femoral and femoral-popliteal configuration.

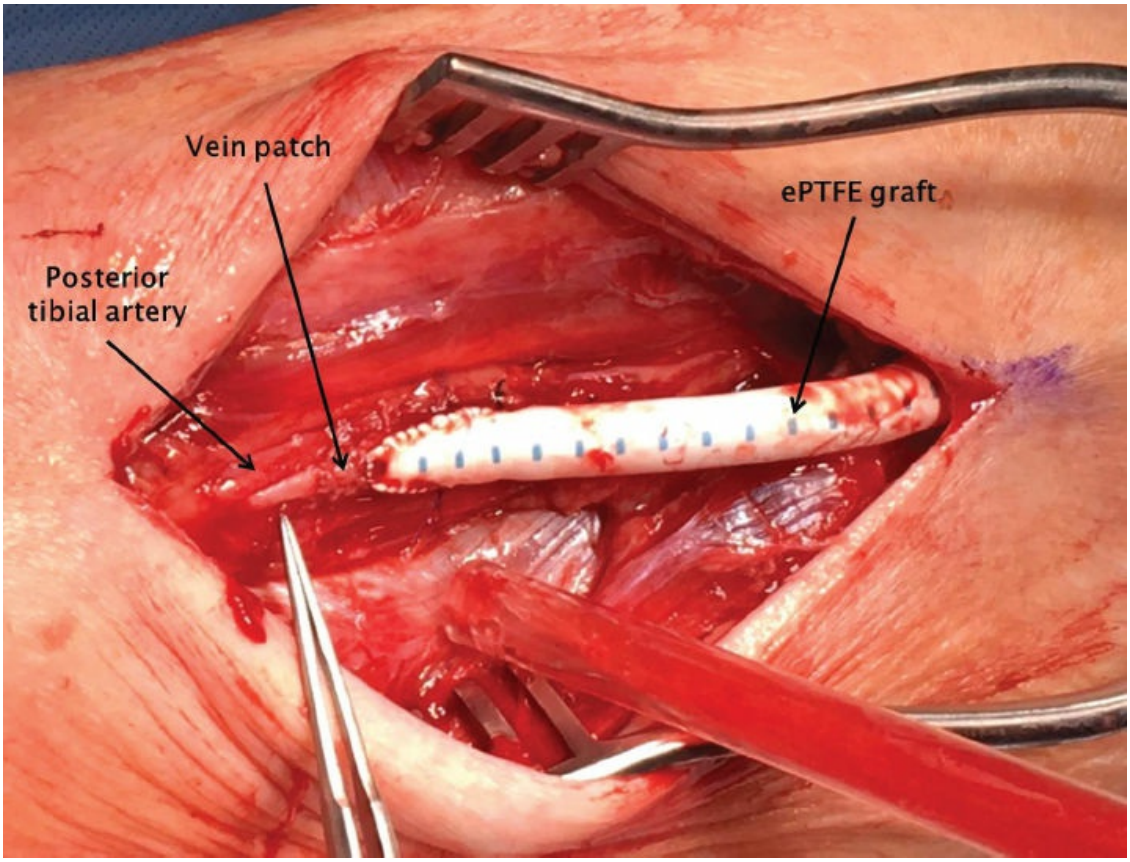

Figure 208.4. The Neville distal vein patch technique for creation of 6-mm ePTFE graft anastomosis onto the posterior tibial artery.

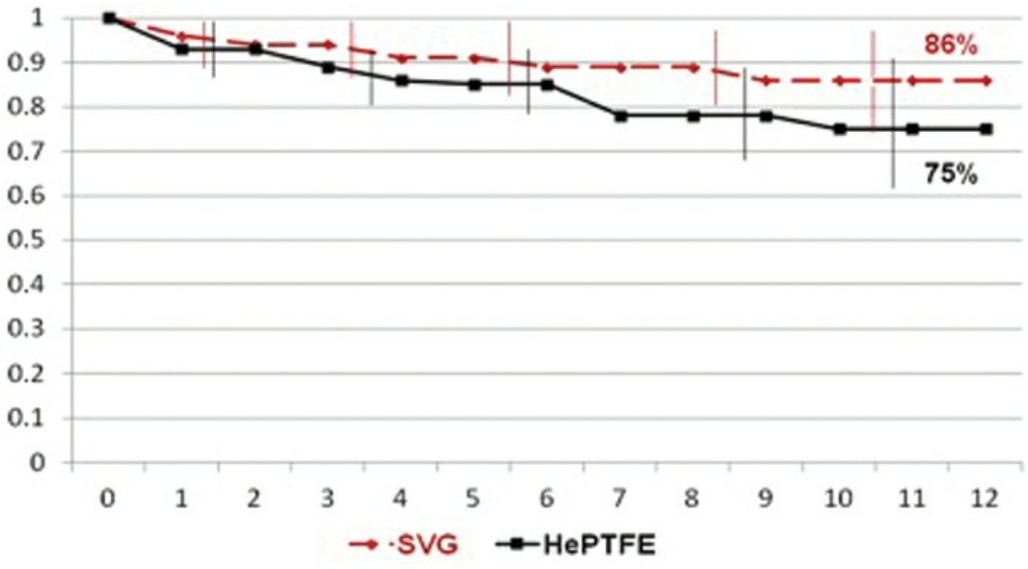

HePTFE	62	57	57	52	51	47	47
Vein	50	48	48	43	43	43	43

Figure 208.5. Kaplan–Meier survival curves with log-rank analysis show primary patency over 12 months by graft type. The error bars show the 95% confidence interval. Survival functions for patency between graft types did not differ significantly. SVG, saphenous vein graft; HePTFE, heparin-bonded ePTFE graft. (From Neville RF, Capone A, Amdur R, et al. A comparison of tibial artery bypass performed with heparin-bonded expanded polytetrafluoroethylene and great saphenous vein to treat critical limb ischemia. *J Vasc Surg* 2012;56(4):1008–14; with permission from Elsevier.)

A potential side effect of implanting heparin-bonded grafts is heparin-induced thrombocytopenia (HIT). This complication has been described in case reports of patients undergoing lower extremity bypass grafts for elective and urgent indications, necessitating graft explantation and replacement. However, it has been noted that patients' platelet counts were improving prior to graft explantation in cases where covalently bonded grafts were used, as compared with older grafts that used ionic interaction with the graft surface, leading subsequent release of the heparin into the bloodstream. Furthermore, a study of covalently bonded grafts found no increase in the systemic markers of hemostasis in vivo, and no antibodies against heparin were detected up to 6 weeks after implantation.

Distal Arteriovenous Fistula

When the target artery of a distal bypass is concomitant with arterial

outflow that is disadvantaged, the addition of an arteriovenous fistula at the distal anastomosis has been used to increase the chances of bypass success especially in regards to prosthetic conduit. A distal arteriovenous fistula has been used when the target artery for bypass is small, diseased, or discontinuous, leading to a runoff bed of presumed high resistance. In theory, the addition of the fistulous connection serves to decrease outflow resistance and maintain flow in the prosthetic conduit above the graft's critical thrombotic threshold for thrombosis. Intrinsic to the fistulous connection, some graft flow will be into the venous system and some mild edema is expected with a successful result. But, the fistula can help maintain graft patency in the face of disadvantaged arterial outflow. Dardik described a common ostium arteriovenous fistula in an attempt to decrease graft thrombosis by reduction of outflow resistance. Ascer described a technique involving construction of an arteriovenous fistula between the target tibial artery and corresponding tibial vein with a ePTFE bypass to the involved vein. Reported patency rates with this technique were 62% at 36 months, despite a fistula thrombosis rate of 37%. A prospective, randomized trial that compared distal bypasses using ePTFE with a Miller vein cuff with and without an arteriovenous fistula did not demonstrate a benefit to such an anastomotic fistula, but the authors did not stratify patients based on arterial runoff.

The incorporation of a common ostium arteriovenous fistula in combination with a DVP at the anastomosis of a prosthetic bypass has also been described (Fig. 208.6A,B). This modification has been performed only in those challenging patients with limb-threatening ischemia and no vein available for the bypass conduit and severely disadvantaged arterial runoff. The target tibial artery is opened longitudinally with a longitudinal venotomy in the corresponding tibial vein. A vein patch is then sutured to the common ostium created by this fistulous connection in a similar manner to the DVP technique. An anastomosis is then constructed between the ePTFE conduit and the vein patch as described in the DVP bypass configuration. Theoretically, the arteriovenous fistula decreases outflow resistance, reduces overload on a fixed arterial circuit, and increases flow velocity in the graft above the critical thrombotic threshold to improve graft outcomes. This technique has led to 62% primary patency and 57% limb salvage at 24 months in a patient group who would otherwise have been offered primary amputation.

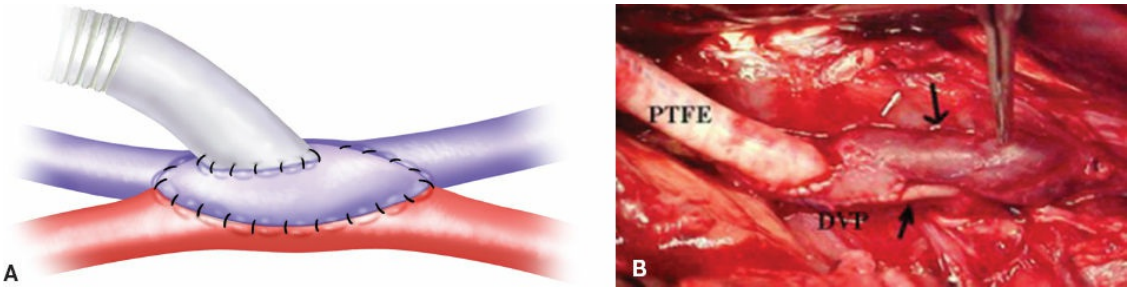

Figure 208.6. Distal vein patch bypass with arteriovenous fistula technique (**A** and **B**). (**B.** From Neville RF, Sidawy AN. Surgical bypass: when is it best and do angiosomes play a role? *Semin Vasc Surg* 2012;25(2):102–7; with permission from Elsevier.)

Adjunct Medical Therapies

The role of adjunct medical therapy in improving prosthetic graft patency has been debated, and there are no guidelines in regards to ideal medical therapy to improve the patency and function of prosthetic grafts. Common practice often involves antiplatelet therapy after bypass with consideration of anticoagulation in association with prosthetic grafts. However, a Dutch multicenter randomized trial comparing more than 2,000 patients who had undergone infrainguinal bypass using vein or prosthetic grafts and were randomly assigned to aspirin or warfarin postoperatively revealed no statistically significant advantage of one therapy over another. But when separated into prosthetic conduit and vein grafts, the prosthetic group had better results with aspirin, whereas the vein group had better results with warfarin. The Boston Veterans Affairs (VA) Hospital Prospective Study compared warfarin and aspirin dual therapy versus aspirin alone, and showed no difference in overall patency between the two groups. However, dual therapy showed moderate benefit for smaller diameter (6 mm) ePTFE grafts with a noted increase in hemorrhagic complications and overall mortality. A randomized study from the United Kingdom (CASPAR trial) examined the efficacy of dual antiplatelet therapy (clopidogrel and aspirin) versus aspirin alone in femoral-distal bypasses. Dual therapy did not reduce the occlusion rates in venous bypasses; however, in a subgroup of patients with prosthetic grafts, dual platelet therapy reduced graft occlusion with a 35% relative risk reduction and no side effects or hemorrhagic events. Bedenis and colleagues published a Cochrane Review on the role of antiplatelet medications in preventing postoperative thrombosis after lower extremity bypass, and similarly reported an improved graft patency with aspirin up to 12 months after

surgery in patients with prosthetic grafts. The role of direct thrombin inhibitors and Factor Xa inhibitors in association with peripheral bypass grafts has not been adequately explored. Some attempts have also been made to develop novel agents to prevent intimal hyperplasia to improve graft patency; however, no new agents have successfully achieved this goal. The DVP bypass experienced a higher failure rate in those patients who did not or could not take warfarin in combination with aspirin. Seemingly, aspirin should be included for the postoperative medical management of bypass patients with warfarin anticoagulation reserved for those patients with prosthetic tibial grafts or a history of hypercoagulable graft failure.

GRAFT COMPLICATIONS

Complications after placement of a prosthetic graft can include bleeding, infection, graft thrombosis, seroma formation, pseudoaneurysm, and steal phenomenon secondary to inadequate proximal blood flow. The two most problematic complications associated with prosthetic conduit will be discussed.

Graft Thrombosis

Prosthetic graft thrombosis occurs in the perioperative period due to technical issues, hypercoagulable conditions, and poor runoff as described above. Technical problems involve more than just technique and include judgment in planning the bypass such as choice of the proper target artery and avoidance of postoperative hematomas and incisional complications. Hypercoagulability should especially be considered in younger patients and prior failed bypasses. Beyond the perioperative period (predominantly 6 to 24 months), myointimal hyperplasia can lead to anastomotic stenosis and reduction in flow leading to eventual graft thrombosis. When myointimal hyperplasia results in the development of a hemodynamically significant stenosis prior to actual graft thrombosis, the bypass is referred to as a “failing graft” with diminished function. Flow in a “failing graft” is hemodynamically compromised, but may not result in clinical signs or symptoms of diminished flow. Therefore, many advocate a regular system of graft surveillance to detect the “failing graft” prior to occlusion. When graft failure does occur, the result is often a return of the patient’s original symptoms or a significant increase in symptom severity with possible limb-threatening ischemia. Revision of a failing graft is less demanding

and more often successful than attempted restoration of flow in an occluded graft or new bypass after graft occlusion.

Prosthetic grafts, as stated above, have a higher occlusion rate and lower patency compared with autogenous conduits, and graft occlusion can lead to significant morbidity if the recipient artery is involved in the thrombotic process. Thrombosis of bypasses performed for intermittent claudication can lead to limb-threatening ischemia and possible limb loss. The treatment of lower extremity prosthetic bypass graft occlusion is tailored to the patient and guided by the clinical presentation and patient's anatomy. A patient with an occluded graft but no concurrent signs of acute, critical limb ischemia may benefit from a trial of thrombolysis to both restore flow within the graft and unmask any underlying stenotic lesions that would be amenable to endovascular or open surgical treatment. Conversely, a patient with acute, critical ischemia or a chronically occluded graft may be better served by open thrombectomy or creation of a new bypass. Grafts performed with the DVP technique can undergo graft thrombectomy through a minimal incision over the distal anastomosis. The DVP configuration offsets the hyperplastic process from the target artery interface to the graft-vein patch interface leaving the target artery patent. The hood of the distal anastomosis can be incised, hyperplastic tissue excised, and a new patch placed across the stenotic lesion. This is done in conjunction with graft thrombectomy per the incision in the hood of the graft to reestablish graft inflow. The entire thrombectomy and revision can often be performed using local anesthesia with sedation.

Since its introduction in the 1970s as a technique to restore occluded arteries, thrombolysis is now also used for treating occluded prosthetic grafts. Thrombolysis can be administered systemically or as part of a catheter-directed or mechanical approach using specialized catheters. However, there are contraindications to this treatment approach, including recent surgery, hemorrhagic strokes, bleeding disorders, and a nonviable limb. Several retrospective studies have described a range of early technical success from 48% to 90% and a limb-salvage rate of 56% to 82% after thrombolysis. The STILE trial (Surgery or Thrombolysis for the Ischemic Lower-Extremity) and the TOPAS trial (Thrombolysis or Peripheral Arterial Surgery) assessed thrombolysis versus thrombectomy for limb ischemia, and reported that thrombolysis was superior to surgical thrombectomy in patients with less than 2 weeks of symptom duration, whereas surgical thrombectomy was superior to thrombolysis when

symptoms lasted for 2 weeks or longer. The treatment paradigm outlined by Greenberg and Ouriel for the management of bypass graft occlusion remains useful. Patients with more than 2 weeks of symptom duration should be treated with operative intervention and placement of a new bypass graft. Conversely, patients with acute (less than 2 weeks' duration) prosthetic graft occlusions and no evidence of critical limb ischemia should undergo a trial of thrombolysis, but consideration should be given to creating a new bypass graft if there is a suitable outflow target vessel and an adequate length of autogenous conduit is available. However, if the patient manifests sensory-motor dysfunction and impending tissue loss, surgical revision may be considered to establish perfusion in a more rapid manner.

Graft Infection

Prosthetic graft infection occurs in 1% to 6% of patients undergoing lower extremity prosthetic bypass. Graft infection is associated with considerable morbidity, including subsequent amputation and mortality rates as high as 20%. The most common causative organisms are *Staphylococcus* species: *Staphylococcus aureus* and *Staphylococcus epidermidis.* Graft infection can arise if microorganisms are seeded at the time of operation or post-operatively through wound complications, adjacent infections, or a bloodstream infection from a distant source. Predictors of prosthetic graft infection include repeat bypass, female gender, diabetes, and active infection at the time of bypass. There is no evidence that graft material, such as Dacron or ePTFE, is more predisposed to infections compared with other inert materials.

The diagnosis and management of graft infections are guided by the patient's clinical status and the type and extent of the infection. Patients typically present with fever and malaise, with or without an obvious wound infection and purulent discharge. Elderly, malnourished, and frail patients may not mount an adequate inflammatory response to indicate an active infection. Patients with suspected graft infections should have blood cultures and, if applicable, deep tissue cultures should be sent. Patients should then be started on broad-spectrum antibiotics that are reviewed and revised when culture results and antibiotic sensitivities become available. Imaging should be obtained early in the workup of patients with a suspected graft infection. Cross-sectional imaging such as computed tomography (CT) angiography and magnetic resonance imaging (MRI) has

the advantage of identifying any fluid collections in proximity to the graft or in the surrounding soft tissue. Other suggestive findings include perigraft air, fluid or soft-tissue attenuation, and pseudoaneurysm formation. Gallium scans and labeled white blood cell scans are used selectively.

There are several treatment strategies for prosthetic graft infections, depending on the patient's status and the type of infective organism. Graft preservation is sometimes possible in patients with limited infections and no signs of sepsis or extensive graft involvement. Grafts that are infected with *Pseudomonas* and methicillin-resistant *Staphylococcus aureus* (MRSA) are particularly virulent organisms, however, and require removal of the infected graft. In patients with graft thrombosis and clinical evidence of adequate collateralization, graft excision alone might be sufficient. In patients who require revascularization of the excised graft segment, an in situ graft might be considered or an extra-anatomic bypass might be created. Conduit options include autogenous and Rifampin-soaked prosthetic grafts. The graft excision and replacement may be done concurrently or in a staged manner, depending on the patient's clinical status.

If patients are known to be MRSA-positive, then a decolonization strategy in conjunction with an infectious diseases specialist should be pursued prior to the surgery whenever possible. Moreover, given the devastating complications associated with prosthetic graft infections, some have advocated for regular preoperative screening and, when detected, decolonization of MRSA. Lee and colleagues from Pennsylvania, for example, analyzed the economic impact of screening all vascular surgery patients prior to any vascular surgical procedure, and demonstrated that testing and decolonizing patients for MRSA may be cost-effective.

GRAFT SURVEILLANCE

As mentioned above, a graft surveillance program is very important especially for prosthetic grafts. Despite technological advances leading to improved performance of prosthetic conduits, graft failure continues to occur perioperatively and during follow-up. As such, it is important to detect the failing graft prior to thrombosis because the management and treatment of such grafts are often more complex than procedures required prior to graft occlusion. Early identification of these patients allows for a more tailored medical therapy that may improve outcome in the future, and

warfarin can be added in the medical management of patients with low-velocity grafts. Close surveillance also allows for early endovascular intervention, which may assist in maintaining patency. A failing graft can often be managed with endovascular techniques or more simplified surgical procedures such as local revision with patch angioplasty, resulting in enhanced secondary patency and enhanced limb preservation. Therefore, graft surveillance programs have been incorporated in most vascular surgical practices to detect the failing graft and intervene early enough to improve graft function and secondary patency of the vascular reconstruction.

Graft surveillance involves clinical evaluation for recurrent or new symptoms of limb ischemia, as well as an examination of pulses and an ankle brachial index. However, clinical assessment alone does not always identify significant stenoses that threaten graft function, especially in patients initially treated for critical limb ischemia. Therefore, vascular laboratory imaging has been added to surveillance protocols as a noninvasive assessment of graft function. While the overall benefit of graft surveillance has not been well-documented for prosthetic grafts, regular interval duplex ultrasound studies obtained at 3, 6, and 12 months postoperatively and then annually have been employed in many practices to identify threatened bypasses before they occlude.

Numerous authors have attempted to define the Doppler ultrasound criteria that should prompt further workup and potential repair of a stenotic graft. Bandyck and colleague have suggested that a peak systolic velocity exceeding 300 cm/s on Doppler ultrasound and a peak systolic velocity ratio across the stenosis exceeding 3.5 correlate with more than 70% stenosis in a graft. Another study led by Brumberg demonstrated that mid-graft peak velocity of 45 cm/s or less was predictive of graft failure. Sanchez and colleagues reported a series looking at surveillance to detect failing ePTFE grafts. These authors reported on a 12-year experience with over 90 ePTFE grafts and surmised that ultrasound surveillance was useful despite the observation that the progression of proximal and distal arterial disease was the primary cause of ePTFE graft failure in the series. These authors concluded that frequent graft surveillance may allow for the detection of hemodynamically threatening lesions prior to graft thrombosis and enhance long-term graft patency and function as the 5-year patency and limb preservation rate for treating “failing” ePTFE grafts was substantially improved over that for ePTFE grafts that have gone on to

occlude. A smaller study from Sweden randomized 156 patients between clinical surveillance and surveillance that included Duplex ultrasound evaluation. Although only 40 of the grafts in the trial were ePTFE grafts, the authors noted improved assisted primary and secondary patency in the group with regular Duplex ultrasound surveillance. More recently, a combined experience from Boston and the Netherlands found ultrasound surveillance to be effective in leading to a reduction in amputation and cost.

CONCLUSION

Surgical bypass continues to play a therapeutic role for those patients in need of lower extremity bypass. This patient cohort includes those with a good life expectancy, extensive long and long segment arterial occlusive disease, significant tissue loss requiring robust perfusion, and those with failed endovascular therapeutic attempts. Although saphenous vein remains the ideal conduit for lower extremity bypass, in today's practice, many patients needing surgical revascularization may not possess a quality venous conduit. Advances in technique and technology as described in this chapter have led to improved results with current prosthetic grafts. It is hoped that the reader will investigate more deeply the data summarized here. These results should stimulate consideration of prosthetic grafts with anastomotic configurations in place of poor quality vein, alternative venous conduits, or amputation due to the lack of a venous conduit.

Suggested Readings

Algra A, Tangelder MJ, Lawson JA, et al. Efficacy of oral anticoagulants compared with aspirin after infrainguinal bypass surgery (The Dutch Bypass Oral Anticoagulants or Aspirin Study): a randomised trial. *Lancet* 2000;355(9201):346–51.

Bedenis R, Lethaby A, Maxwell H, et al. Antiplatelet agents for preventing thrombosis after peripheral arterial bypass surgery. *Cochrane Database Syst Rev* 2015(2):CD000535.

Brumberg RS, Back MR, Armstrong PA, et al. The relative importance of graft surveillance and warfarin therapy in infrainguinal prosthetic bypass failure. *J Vasc Surg* 2007;46(6):1160–6.

Devine C, McCollum C. Heparin-bonded Dacron or polytetrafluorethylene for femoropopliteal bypass: five-year results of a prospective randomized multicenter clinical trial. *J Vasc Surg* 2004;40(5):924–31.

Farber A, Major K, Wagner WH, et al. Cryopreserved saphenous vein allografts in infrainguinal revascularization: analysis of 240 grafts. *J Vasc Surg* 2003;38(1):15–21.

Gessaroli M, Tarantini S, Leone M, et al. A comparison of femorocrural bypasses performed with modified heparin-bonded expanded polytetrafluorethylene grafts and those with great saphenous vein grafts to treat critical limb ischemia. *Ann Vasc Surg* 2015;29(6):1255–64.

Johnson WC, Williford WO. Benefits, morbidity, and mortality associated with long-term administration of oral anticoagulant therapy to patients with peripheral arterial bypass procedures: a prospective randomized study. *J Vasc Surg* 2002;35(3):413–21.

McPhee JT, Barshes NR, Ozaki CK, et al. Optimal conduit choice in the absence of single-segment great saphenous vein for below-knee popliteal bypass. *J Vasc Surg* 2012;55(4):1008–14.

Miller JH, Foreman RK, Ferguson L, et al. Interposition vein cuff for anastomosis of prosthesis to small artery. *The Australian and New Zealand J Surg* 1984;54(3):283–5.

Neville RF, Attinger CE, Bulan EJ, et al. Revascularization of a specific angiosome for limb salvage: does the target artery matter? *Ann Vasc Surg* 2009;23(3):367–73.

Neville RF, Capone A, Amdur R, et al. A comparison of tibial artery bypass performed with heparin-bonded expanded polytetrafluoroethylene and great saphenous vein to treat critical limb ischemia. *J Vasc Surg* 2012;56(4):1008–14.

Neville RF, Tempesta B, Sidway AN. Tibial bypass for limb salvage using polytetrafluoroethylene and a distal vein patch. *J Vasc Surg* 2001;33(2):266–71; discussion 71–2.

Rychlik IJ, Davey P, Murphy J, et al. A meta-analysis to compare Dacron versus polytetrafluroethylene grafts for above-knee femoropopliteal artery bypass. *J Vasc Surg* 2014;60(2):506–15.

Twine CP, McLain AD. Graft type for femoro-popliteal bypass surgery. *Cochrane Database Syst Rev* 2010(5):CD001487.

Visser K, Idu MM, Buth J, et al. Duplex scan surveillance during the first year after infrainguinal autologous vein bypass grafting surgery: costs and clinical outcomes compared with other surveillance programs. *J Vasc Surg* 2001;33(1):123–30.

EDITOR'S COMMENT

Although autologous vein, which is primarily greater saphenous vein, is best for

peripheral arterial bypass, many times the patient doesn't have adequate vein. Neville and colleagues describe prosthetic bypass techniques for patients who have one of the primary indications for vascular in peripheral artery disease, namely, severe life-limiting claudication, rest pain, or tissue loss. Critical limb ischemia patients are not controversial as often bypass procedures are indicated for limb salvage. However, most patients who have lifestyle-limiting claudication need to have exercise therapy and medical management prior to any invasive therapy (Gerhard-Herman MD, Gornik HL, Barrett C, et al. 2016 AHA/ACC Guideline on the Management of Patients With Lower Extremity Peripheral Artery Disease: Executive Summary: A Report of the American College of Cardiology/American Heart Association Task Force on Clinical Practice Guidelines. *J Am Coll Cardiol* 2017;69(11):1465–508.).

As compared to the above-the-knee arterial target, below-the-knee prosthetic bypasses are prone to high failure rates. A stipulation for the below-the-knee prosthetic bypass is if the patient has marginal vein or would need a composite of arm and leg vein that may also be inadequate. The venous conduit quality is critical for outcomes of the bypass (Schanzer A, Hevelone N, Owens CD, et al. Technical factors affecting autogenous vein graft failure: observations from a large multicenter trial. *J Vasc Surg* 2007;46:1180–90). As clearly described in this chapter, backed by the authors' publications, is the use of PTFE graft with a distal vein patch angioplasty in those without adequate autologous conduit for infrapopliteal bypasses. Personally, I have found this procedure to be a reasonably good option for patients who don't have adequate vein as conduit. Indeed, in my practice, I perform a prosthetic bypass with a distal vein patch angioplasty prior to using a marginal arm vein or composite vein. The more complex distal artery adjuncts don't have clear superiority in my opinion. The reported average patency rates are at least 60% at 5 years, similar to my anecdotal experience, and confirmed with the data presented in the chapter. Anticoagulation postprocedure I believe is the key, and is typically Warfarin, with an INR targeted to 2.5 to 3. Whether the direct oral anticoagulants are effective here is not yet known.

I have never personally used cryo-vein or umbilical vein due to the fact I think they have no real advantage over prosthetic bypasses with a distal adjunct, in terms of greater patency. However, they have all the disadvantages of prosthetic and pseudo-aneurysm formation. Of note, the use of dual antiplatelet therapy for above-the-knee popliteal prosthetic bypasses is well supported now (Belch JJ, Dormandy J, Biasi BM, et al. Results of the randomized, placebo-controlled clopidogrel and acetylsalicylic acid in bypass surgery for peripheral arterial disease [CASPAR] trial. *J Vasc Surg* 52:825–33, 833 e1–2), and the use of anticoagulation such as warfarin plus aspirin for below-the-knee popliteal bypasses seems to be the best strategy. This has been confirmed by several series, referenced in the chapter.

While patency is the major outcome consideration related to prosthetic bypasses, prosthetic graft infection is another major one. While the overall rates

as listed in the chapter are 6% or less from the literature, I would bet this is much higher due to under reporting and the fact that often the graft infection is treated at an institution that is different than the primary institution where the bypass was placed. These occurrences are disasters for patients, often leading to limb loss. Standard perioperative factors to reduce graft infection include appropriate preoperative antibiotics, redosing of antibiotics, use of chlorhexidine skin preparation, and limiting blood transfusions (Davis FM, Sutzko DC, Grey SF, et al. Predictors of surgical site infection after open lower extremity revascularization. *J Vasc Surg* 2017;65(6):1769–78 e3). A careful but speedy operation helps too.

Graft surveillance is generally performed for autologous vein grafts with good efficacy, allowing detection of neointimal hyperplasia within the graft. This is also a performance measure from a large multispecialty consensus document (American College of Cardiology F, American Heart Association Task Force on Performance M, American College of R, Society for Cardiac A, Interventions, Society for Interventional R, Society for Vascular M, Society for Vascular N, Society for Vascular S, Olin JW, Allie DE, Belkin M, et al. ACCF/AHA/ACR/SCAI/SIR/SVM/SVN/SVS 2010 performance measures for adults with peripheral artery disease. A report of the American College of Cardiology Foundation/American Heart Association Task Force on Performance Measures, the American College of Radiology, the Society for Cardiac Angiography and Interventions, the Society for Interventional Radiology, the Society for Vascular Medicine, the Society for Vascular Nursing, and the Society for Vascular Surgery (Writing Committee to Develop Clinical Performance Measures for Peripheral Artery Disease). Developed in collaboration with the American Association of Cardiovascular and Pulmonary Rehabilitation; the American Diabetes Association; the Society for Atherosclerosis Imaging and Prevention; the Society for Cardiovascular Magnetic Resonance; the Society of Cardiovascular Computed Tomography; and the PAD Coalition. Endorsed by the American Academy of Podiatric Practice Management. *J Vasc Surg* 2010;52:1616–52). I find surveillance useful for detecting low velocities in prosthetic grafts, mandating placement of these patients on full anticoagulation to protect against thrombosis (Brumberg RS, Back MR, Armstrong PA, et al. The relative importance of graft surveillance and warfarin therapy in infrainguinal prosthetic bypass failure. *J Vasc Surg* 2007;46:1160–6). However, I have not found it is useful for detecting proximal or distal anastomotic stenosis that needs to be treated. This may be a sampling error on my part, but is reflective of my partners' practice as well.

Peter Henke

I agree entirely with Dr. Henke in that the rate of the prosthetic graft infection is likely much higher than the listed 6% or less. When graft infection occurs, the patient is usually transferred to another institution rather than the primary institutions for various reasons. For one, infection is a disaster, for another

limb loss is a common outcome; for a third institution with experience one may get a better outcome.

J.E.F.

209 Dorsalis Pedis, Tarsal, and Plantar Artery Bypass

Bernadette Aulivola and Frank B. Pomposelli

INTRODUCTION

Arterial reconstruction to the arteries of the distal ankle and foot has become commonplace in those patients with occlusive disease of the infrapopliteal vessels, precluding bypass to a more proximal target vessel. This is especially the case in patients with diabetes mellitus presenting with ischemic foot lesions due to a characteristic pattern of occlusive disease, where the tibial and peroneal arteries are occluded but the foot vessels, especially the dorsalis pedis artery, remain patent (Fig. 209.1). Extending vein bypass grafts to the dorsalis pedis artery (DP bypass) when a more proximal suitable bypass target is not available has expanded our ability to salvage limbs in patients who would otherwise have required amputation. Our initial results with these patients were impressive enough that we standardized our technique and began performing DP bypass in preference to other more proximal target arteries. We also found that pedal bypass could be performed safely in patients presenting with foot infection and ischemia and worked well for healing heel ulcers. Others have documented better rates of wound healing and limb salvage in patients with critical limb ischemia with infrapopliteal occlusive disease after angiosome-targeted revascularization. In the era preceding the widespread application of endovascular therapy for limb ischemia, pedal bypass comprised 30% of all limb salvage bypasses done in our practice, which was composed of a large proportion of diabetic patients. Over a 13-year period prior to the routine use of endovascular intervention for tibial occlusive disease, 2.6% of over 4,700 lower extremity arterial bypass procedures performed by our group involved outflow to the tarsal and plantar arteries.

As is the case in other vascular domains, endovascular options for the treatment of tibial artery occlusive disease have been increasingly utilized over the past several years. Our own experience with infrapopliteal

angioplasty and selective stenting in 176 limbs over a 3-year period revealed that this treatment is a technically feasible and a reasonable option for revascularization of the ischemic foot in many patients. However, the technical success of endovascular intervention on tibial arteries decreases with progressive TransAtlantic Inter-Society Consensus (TASC) classification severity (Table 209.1). Technical success was 93% overall, but decreased from 100% in TASC A, B, and C lesions to 75% in TASC D lesions. Infrapopliteal angioplasty primary patency rates at 1 and 2 years were 53% and 51%, inferior to that noted in those undergoing surgical bypass, and presumably would decline further with a longer duration of follow-up. Our current practice is to consider endovascular intervention first for tibial artery occlusive disease that is limited to lower TASC classes or in patients without any suitable native conduit in the upper or lower extremities. Multiple comparisons of infrapopliteal angioplasty to surgical revascularization for limb salvage have been made in the literature. These studies may have limited applicability given that endovascular intervention is typically used as first-line therapy for patients with disease limited to stenoses or short occlusions, whereas surgical revascularization is more often used as first-line therapy for more extensive occlusive disease. In evaluating outcomes of surgical revascularization versus angioplasty for the treatment of critical limb ischemia in the presence of infrapopliteal disease, some data utilizing propensity score analysis to adjust for differences have documented better rates of wound healing and limb salvage with surgical revascularization over angioplasty. However, pedal bypass following failed endovascular intervention of the infrapopliteal arteries has been demonstrated to yield acceptable patency and limb salvage results with no change in outcomes in patients first undergoing endovascular intervention. Given that extensive tibial artery occlusive disease is the most common pattern of disease encountered in the diabetic population, the continued importance of extreme distal bypass to the foot arteries in limb salvage efforts for foot ischemia in these patients cannot be overemphasized. This chapter will outline our evaluation and approach to foot-level arterial bypass for limb salvage.

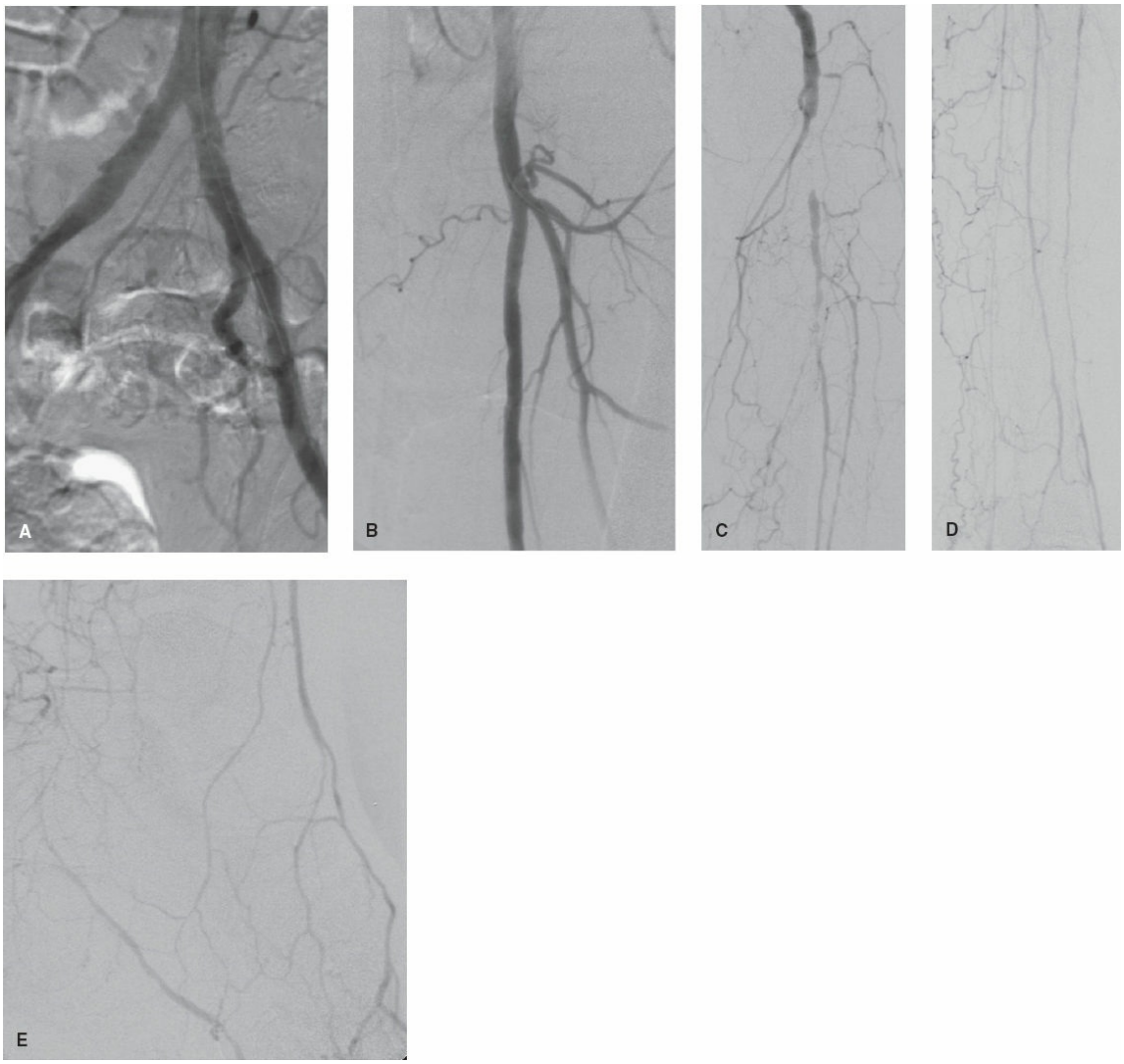

Figure 209.1. Intra-arterial digital subtraction arteriogram demonstrating the characteristic pattern of occlusive disease in diabetes. The aorta, iliac arteries (**A**), superficial femoral and profunda femoris arteries, (**B**) and popliteal arteries (**C**) are uninvolved. The tibial/peroneal arteries (**C, D**) are diffusely diseased and the dorsalis pedis artery (**E**) is patent. (Source: Fast Facts—Vascular Surgery Highlights 2002–2003. © 2003, Health Press Limited. www.fastfacts.com)

TABLE 209.1 TransAtlantic Inter-Society Consensus (TASC) Classification of Occlusive Disease in the Infrapopliteal Arteries

TASC A: Single stenosis <1 cm long
TASC B: Multiple focal stenoses <1 cm long or 1 or 2 stenoses <1 cm involving the trifurcation
TASC C: Stenoses 1–4 cm long, occlusion 1–2 cm long, or extensive stenosis involving the trifurcation
TASC D: Occlusion >2 cm long or diffusely diseased

Compiled from Management of peripheral arterial disease (PAD). TransAtlantic Inter-Society Consensus (TASC). *Eur J Vasc Surg* 2000 Jun 19.

CLINICAL PRESENTATION

Arterial insufficiency can present with a spectrum of clinical signs and symptoms. In some patients, arterial insufficiency may be completely asymptomatic, diagnosed on the basis of nonpalpable foot pulses or decreased ankle-brachial indices alone. As chronic arterial insufficiency progressively worsens, patients may present with symptoms of intermittent claudication, which manifests typically as cramping or tiredness in the calves with walking that is relieved by rest. More severe symptoms of arterial insufficiency are categorized as critical limb ischemia, which can present with ischemic rest pain or tissue loss. Tissue loss represents the most severe manifestation of critical limb ischemia and may present as non-healing ulceration or gangrene. This chapter focuses on surgical revascularization in patients presenting with critical limb ischemia. Often, in the diabetic population, critical limb ischemia is noted in patients with no discernable history of prior claudication symptoms. This illustrates that the development of severe critical limb ischemia does not always follow an orderly progression through each stage of ischemia severity.

INDICATIONS AND CONTRAINDICATIONS

Foot-level arterial bypass is reserved for patients with limb-threatening ischemic symptoms, including rest pain, non-healing ulcers, gangrene, or poor healing of toe amputations or other foot surgical sites. These surgical revascularization procedures are not appropriate for the treatment of intermittent claudication symptoms. In fact, claudication is rarely improved by pedal level bypass, since the arteries of the calf are occluded and rarely adequately perfused retrograde through the pedal circulation.

Good outcomes in efforts toward limb salvage often involve a multidisciplinary approach. Patients with extensive tissue loss in whom lower extremity revascularization is considered should be evaluated by a podiatrist preoperatively to confirm options for foot salvageability. If the

degree of ulceration or gangrene precludes salvage of the foot, revascularization may not be indicated, as the patient may be best served with primary major amputation. It is important to keep in mind that foot salvageability is dependent not only on adequate arterial perfusion, but also on adequate nutritional support and treatment of concomitant foot infection with antibiotics and possible incision and drainage. Foot salvage also, at times, requires toe, ray, or other minor foot amputations to achieve infection control and healing. The confirmation of an arterial bypass target vessel is a prerequisite to planning an inframalleolar bypass. This is generally achieved by performance of preoperative duplex and digital subtraction angiography (DSA) studies of the lower extremity arterial system. In very rare cases, when no suitable bypass target artery is identified, the patient may not be a suitable candidate for revascularization.

PREOPERATIVE PLANNING

Comprehensive, high-quality intra-arterial DSA is a key component in the planning process for DP or other inframalleolar artery bypass (Fig. 209.1). Appropriate evaluation of the lower extremity circulation includes imaging of the entire arterial tree from the renal arteries to the toes in all patients with critical limb ischemia. Proper imaging of the foot vessels requires magnified anteroposterior and lateral views in order to fully appreciate the quality of the DP, tarsal, and plantar arteries to assess their potential use as outflow target vessels. Magnetic resonance angiography (MRA) is used infrequently in our practice, and is generally reserved for those patients who are unable to undergo DSA, some due to severe contrast allergies. Some data suggest that occult foot vessels on DSA may be unmasked with MRA, resulting in successful bypass to these vessels. “Blind” operative exploration may also be performed in the case of nonvisible foot arteries on DSA in cases where patency is suspected on the basis of an audible Doppler signal, although this is rarely required due to the precise imaging capabilities of modern DSA. The less invasive nature of MRA makes it a more attractive imaging option in certain patients. In the past, MRA was considered a safer option than DSA for arterial imaging in the patient with chronic renal insufficiency given the risk of iodinated contrast-induced nephropathy with DSA. However, more recent data suggest that gadolinium-induced nephrogenic systemic fibrosis and acute renal insufficiency are more common than previously noted. Nearly all patients in our practice undergo intra-arterial DSA imaging prior to lower

extremity bypass surgery. Carbon dioxide (CO_2) gas DSA imaging can also significantly reduce the contrast load required to image the lower extremity arteries.

Given that many patients with tibial artery occlusive disease have diabetes and chronic renal insufficiency, care must be taken to perform arterial imaging in the safest way possible. This often entails taking precautionary measures prior to DSA imaging if using iodinated contrast agents. In patients with a creatinine level of ≥1.5 mg/dL or an estimated glomerular filtration rate (GFR) of <30 mL/min/1.73 m^2, corresponding to Stage 4 or 5 chronic kidney disease, use of sodium bicarbonate infusion has been demonstrated to have a more significant protective effect against contrast-induced nephropathy than sodium chloride infusion. The protocol for sodium bicarbonate infusion utilizes a 150 mEq/L sodium bicarbonate in D5W solution administered as a bolus of 3 mL/kg/h for 1 hour prior to the procedure and 1 mL/kg/h for 6 hours after the procedure.

The decision to perform inframalleolar bypass is made on the basis of several important anatomic and clinical factors. The goal of restoring a palpable foot pulse when possible in patients with diabetes and tissue loss is based upon our observation that this end point most reliably leads to healing and foot salvage in the setting of the compromised biology of the ischemic diabetic foot. If a more proximal outflow target artery cannot achieve that goal, preferential bypass to the DP artery should be considered. In situations of ischemic rest pain without tissue loss, the DP artery should be chosen as the outflow target vessel when it is the best-quality vessel for bypass or the only available outflow vessel as determined on DSA evaluation. In circumstances where a more proximal outflow vessel would restore a palpable foot pulse and tissue loss is the indication, DP bypass is not necessarily the procedure of choice. In cases of tissue loss or gangrene, however, DP bypass is often chosen in preference to a patent peroneal artery, given the technical ease of this bypass configuration. However, when the peroneal artery is evaluated to be a superior target vessel to the DP artery on DSA, or when the length of available autogenous vein conduit is inadequate for bypass to the DP artery, peroneal bypass may be considered. In cases of severe dorsal foot infection, or when the indication for arterial reconstruction is claudication alone, DP bypass is not preferentially performed. Bypass to the tarsal or plantar arteries is indicated less frequently and is generally preserved for cases in which the DP artery is not a viable option for bypass outflow.

Many limbs requiring DP, tarsal, or plantar artery bypass have undergone previous ipsilateral limb revascularization. In our own published collection of 98 tarsal or plantar bypasses over a 13-year period, ~18% had undergone previous bypass procedures and 5% had undergone previous DP bypass on the ipsilateral extremity. The most frequent indication for bypass in these patients was tissue loss present in 95%, with ischemic rest pain in an additional 3%, and failing bypass graft in 2%. All cases of tarsal or plantar artery bypass had no other reasonable bypass outflow target, including the DP artery.

In addition to DSA imaging of the affected extremity, preoperative planning includes routine duplex venous mapping for assessment of the most appropriate vein conduit for bypass graft use. In some cases, the availability of autogenous vein conduit may alter anatomic planning for inframalleolar-level bypasses. In our experience, patients presenting for inframalleolar arterial reconstruction have undergone ipsilateral lower extremity revascularization in ~18% of cases and coronary artery bypass grafting in just over 20% of cases. Given their prior history of other revascularization procedures, ipsilateral great saphenous vein, the conduit of choice, is not always available for use. Our preoperative venous mapping protocol includes evaluation of bilateral great and small saphenous veins and, when indicated, evaluation of bilateral upper extremity basilic and cephalic veins. When ipsilateral great saphenous vein is not available for use, contralateral great saphenous or arm vein may be used as bypass conduit. Venous mapping provides crucial information regarding possible vein conduit, including vein diameter and the presence of vein thrombosis or sclerosis. Vein diameter of >2 mm is desirable for adequate conduit. Especially in the upper extremity veins, which have typically undergone multiple punctures for blood draws or intravenous lines, preoperative venous mapping provides critical information regarding the condition of the vein. In patients with end-stage renal disease on hemodialysis, we do not generally consider arm vein as a conduit option. Venous mapping can also be used to plan composite vein conduit construction to yield adequate total length to bridge between the inflow and outflow target vessels.

SURGICAL TECHNIQUE

Dorsalis Pedis Artery Bypass

The overall strategy of DP bypass is designed to simplify the procedure

and minimize the use of prosthetic graft material. The key principles include the use of distal inflow artery sites and short, translocated, great saphenous vein grafts whenever possible. Short vein grafts with distal inflow have been demonstrated to result in acceptable limb salvage even in the face of poor arterial runoff and high outflow resistance. In rare cases of questionable adequacy or patency of an inframalleolar artery for bypass outflow, exploration of the target artery may be performed first such that extensive dissection is not carried out only to realize that the outflow vessel is inadequate.

Bypass procedures originating from the femoral level with an intact great saphenous vein are well suited for use of the in situ technique with angioscopy for valve lysis under direct visualization. Vein tributaries are ligated with silk suture. The length of saphenous vein needed is confirmed. The saphenofemoral junction is divided, and the stump on the femoral vein is oversewn with a silk suture ligature. The saphenous vein is divided distally at the appropriate location. The use of an angioscope with a pump irrigation system facilitates valve lysis and allows for thorough evaluation of the vein conduit for webs or stenoses. A 2-mm disposable angioscope is inserted into the proximal end of the vein graft, and a long flexible valvulotome is inserted from the distal end for valve lysis prior to performing the anastomoses (Fig. 209.2). Use of the pump irrigation system has been shown to decrease the amount of crystalloid infused while aiding in the clarity of the angioscopic examination. When transposed vein conduit is used, the vein may be harvested and angioscopy with valve lysis may be performed on a side table prior to performing the anastomoses. Composite grafts composed of multiple vein segments may also be used, but are only required on occasion. The use of angioscopy is especially important in evaluating the quality of arm and composite vein conduits. Vein conduit may be utilized in a reversed, nonreversed, or in situ fashion, although preference to in situ conduit exists for bypasses with inflow at the femoral level. For translocated vein conduit, the reversed vein technique is used if the distal vein is of greater caliber; otherwise, the vein is positioned in the nonreversed orientation after valve lysis. Evidence in the literature suggests that primary patency in ankle and foot level bypasses is superior with the use of nonreversed rather than reversed or composite vein conduit.

The importance of using the most distal appropriate inflow vessel is especially salient in cases of limited vein conduit. In these cases, every

effort should be made to originate the bypass at a distal inflow site. If the superficial femoral artery (SFA) has mild disease that is not felt to be hemodynamically significant, <50%, then the bypass may be originated from the popliteal artery. SFA stenoses of >50% diameter reduction are considered to be hemodynamically significant and should be treated. If adequate vein conduit allows, the inflow bypass anastomosis may be originated proximal to the stenosis. When significant yet focal SFA disease is present, an endovascular approach to treating areas of stenosis may be used in conjunction with a more distal inflow site. Angioplasty with or without stenting for treatment of areas of stenosis in the iliofemoral vessels may be performed either during the preoperative DSA or in the same setting as the bypass procedure. When performing SFA angioplasty in the same setting as a popliteal to DP bypass, the popliteal artery may be accessed during the surgical dissection, passing a sheath in the retrograde direction for SFA intervention prior to performing the proximal bypass anastomosis. Alternatively, when vein conduit is limited and more extensive SFA disease is present, then performing a simultaneous femoral to proximal popliteal bypass with a prosthetic graft and distal popliteal to DP bypass with vein may be considered, if anatomically feasible.

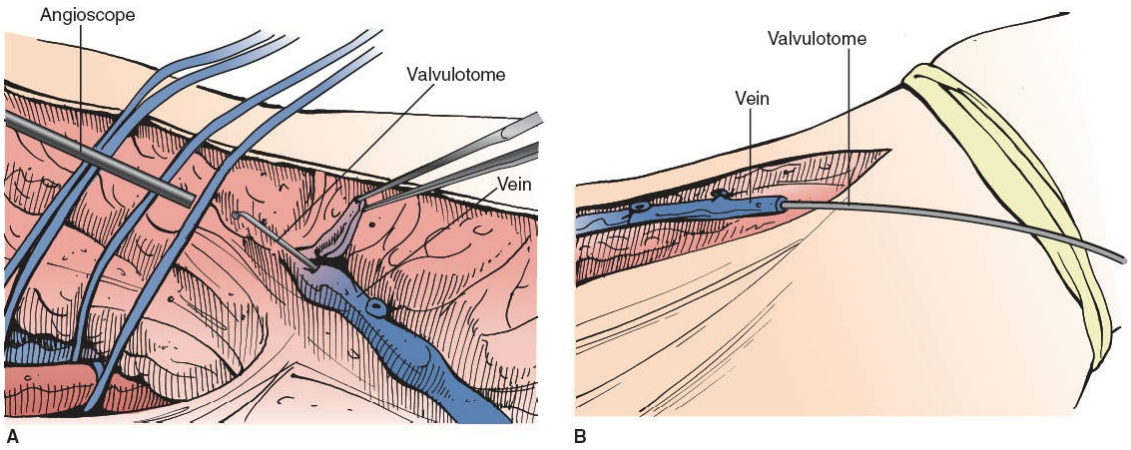

Figure 209.2. Insertion of the angioscope into the proximal great saphenous vein (**A**) and insertion of the valvulotome into the distal vein (**B**) for valve lysis under direct visualization.

The DP artery at a level just distal to the ends of the malleoli is usually located ~1 cm lateral to the extensor hallucis longus tendon (Fig. 209.3). Exposure of this artery is accomplished with a longitudinal incision directly over the Doppler signal of the artery on the dorsal foot. Occasionally, the artery may be located more laterally, underscoring the

importance of careful examination of the preoperative DSA and use of Doppler intraoperatively to precisely locate the artery prior to making the incision. The dissection is carried through the extensor retinaculum, under which the DP artery lies. The DP artery gives rise to the medial and lateral tarsal arteries proximally and bifurcates more distally, at the level of the proximal first metatarsal. At this level, the DP artery branches into the deep plantar artery and the first dorsal metatarsal artery. In most cases, the DP artery is amenable to bypass grafting between these two branch points. An internal luminal diameter of >1 mm is optimal. The heavily calcified dorsalis pedis artery may be controlled with an intraluminal coronary occluder rather than vascular clamps or vessel loops or by the use of a sterile tourniquet placed at the distal thigh. The use of tightened vessel loops or vascular clamps for control of the calcified foot vessel may cause crush injury, which may be detrimental to outflow from the bypass graft. The distal anastomosis is typically completed with a 6-0 or 7-0 monofilament polypropylene running suture. If the artery is calcified, a cardiovascular cutting needle may be used. Management of extensive circumferential calcification has been described with a fracture technique, but we find that this is generally not necessary with the use of small cutting needles, which pierce through the calcified vessel wall. Care should be taken to support the outer wall of the artery with forceps when the cutting needle is passed through the calcified wall to avoid tearing the artery.

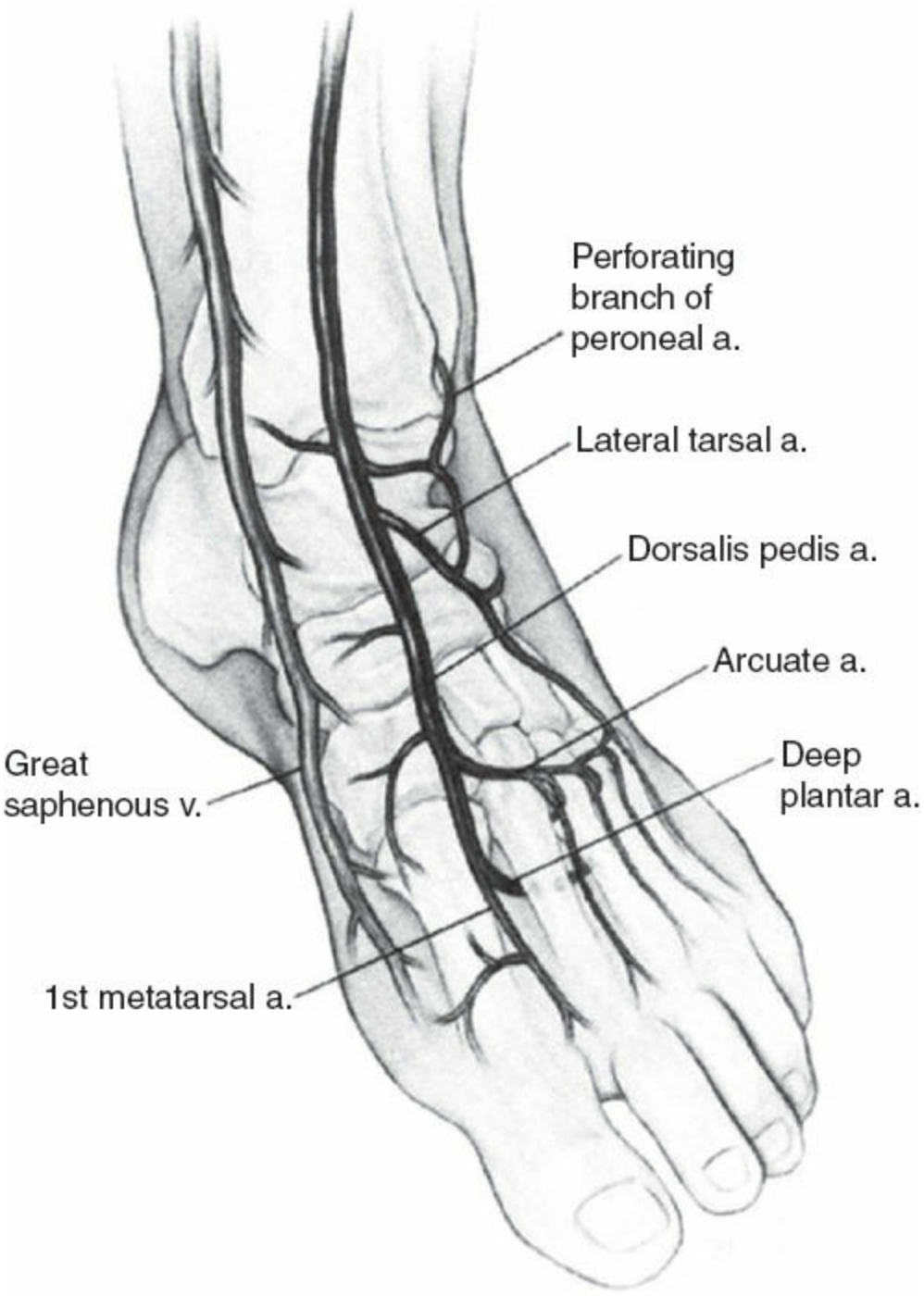

Figure 209.3. Anatomy of the dorsalis pedis artery and its branches. (Reprinted with permission from Pomposelli FB Jr, Jepsen SJ, Gibbons GW, et al. Efficacy of the dorsal pedal bypass for limb salvage in diabetic patients: short-term observations. *J Vasc Surg* 1990;11(6):745–752; with permission from Elsevier.)

When an in situ vein graft is used, it is tunneled at a gentle angle between the saphenous vein harvest incision and the parallel, more

laterally located, dorsal foot incision used to expose the DP artery, never directly under the resulting skin bridge (Fig. 209.4). Tunneling directly under the skin bridge may predispose this area to skin necrosis and subsequent wound complications over the distal anastomosis of the bypass graft. Foot wounds are usually closed primarily without the use of advancement or rotational flaps, but must be meticulous, avoiding undue tension. Closure of these incisions is best completed using a single layer of a 4-0 absorbable subcuticular or simple interrupted nylon suture. If the foot vessel exposure is performed early in the procedure, this wound may be difficult to close at the end of the case if foot edema develops during the interim. For this reason, foot artery exposure should be either performed last, or the incision may be temporarily held closed after arterial exposure with a single skin staple, such that the skin edges do not retract from each other, which may make closure without tension a challenge. Continuous wave Doppler interrogation of the bypass graft and outflow vessel is useful in evaluating the flow through the graft at the end of the case. Evidence has previously shown that most technical failures are associated with choice of poor conduit, which we believe is best avoided with the use of angioscopy in preparation of the vein. Completion arteriography is rarely necessary and should be reserved for cases where a particular concern exists regarding the bypass or Doppler signals at the end of the case.

Tarsal Artery Bypass

The medial and lateral tarsal branches of the DP artery usually originate at the level of the navicular bone. The lateral tarsal artery runs alongside the lateral branch of the deep peroneal nerve, underneath the extensor digitorum brevis muscle toward the fifth metatarsal bone. Exposure of the lateral tarsal branch is facilitated by Doppler localization and dissection of the DP artery first, as described above. The DP artery is followed distally to expose the lateral tarsal branch. The extensor hallucis brevis muscle may be partially transected to aid in exposure. The extensor digitorum longus tendon may either be retracted laterally or, if necessary, be transected to aid in exposure. The distal bypass anastomoses technique is the same as with DP bypass.

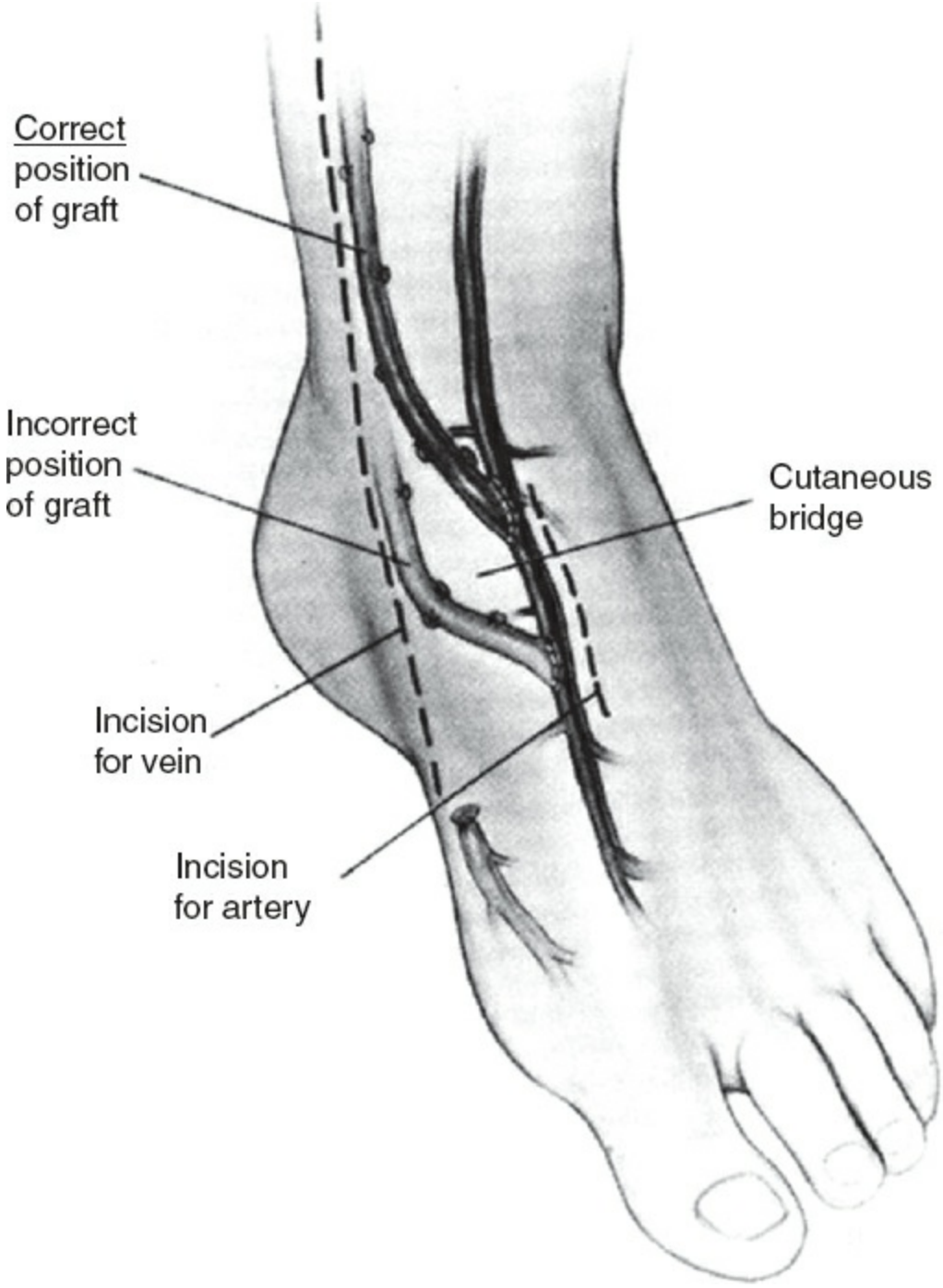

Figure 209.4. Correct and incorrect pathways for tunneling the saphenous vein for an in situ dorsalis pedis bypass. (Reprinted with permission from Pomposelli FB Jr, Jepsen SJ, Gibbons GW, et al. Efficacy of the dorsal pedal bypass for limb salvage in diabetic patients: short-term observations. *J Vasc Surg* 1990;11(6):745–752; with permission from Elsevier.)

Plantar Artery Bypass

Bypass to the plantar artery often poses the same technical challenge as DP

bypass, with small arterial lumen and significant wall calcification. The technical concerns associated with plantar bypass are quite similar to those important in bypass to the major infrapopliteal vessels and have been previously described. The plantar arteries arise from the posterior tibial artery, with the lateral plantar artery continuing on, alongside the lateral plantar nerve, to form the main plantar arch. The lateral plantar branch usually measures larger in diameter than the medial branch; therefore, this is often the best target of the plantar branches. In cases of lateral plantar branch occlusion, however, the medial branch may enlarge, offering an option for bypass outflow as well. Optimal operative positioning includes external rotation of the knee with the foot pronated and a rolled towel placed under the lateral malleolus. The operative approach includes an incision just posterior to the medial malleolus, first exposing the distal posterior tibial artery. This artery is followed distally, and the incision is extended onto the sole of the foot. The initial exposure of the retromalleolar posterior tibial artery facilitates localization of its distal branches, which tend to be small and located deep within the sole of the foot, making primary dissection of these branches more technically challenging. Once the dissection encompasses the bifurcation of the posterior tibial artery, the lateral and medial plantar branches can be distinguished from each other by their relative location, as the lateral branch is located inferiorly when the foot is in an externally rotated position on the operating table. Bypass anastomosis may be performed using whichever plantar artery provides the best outflow to the distal foot based upon preoperative DSA imaging. The distal bypass anastomosis may be located on the lateral or medial plantar artery entirely, or at the bifurcation of the plantar vessels, if this region is not significantly diseased.

POSTOPERATIVE CARE

The main components of the postoperative management of DP, tarsal, and plantar artery bypass are surgical wound care, physical rehabilitation, and bypass graft surveillance. In addition, any foot ulcerations or minor amputation sites must be cared for appropriately. Surgical wounds are kept clean and dry. Care is taken to protect the distal bypass surgical site from contamination with drainage from other foot wounds, especially if infection is present. An adherent occlusive dressing may be applied to the surgical site and left in place for several days if clean and dry. The

extremity is kept in a compression wrap from the foot proximally to at least the level of the proximal anastomotic site to prevent edema. Elevation of the foot on a pillow may also aid in edema prevention in the first few days after revascularization. Staples and sutures are removed after at least 2 weeks of healing, sometimes longer if indicated, especially when edema is present. Physical therapy is instituted within 2 to 4 days of revascularization, with care taken to avoid prolonged periods of the limb being in the dependent position to minimize edema.

Given the superficial location of the distal anastomosis in DP bypass, graft pulsations are quite easy to detect. Prior to discharge from the hospital, patients are instructed on monitoring the graft pulse by palpation over the dorsum of the foot. Graft surveillance duplex is performed at routine intervals, typically at 1, 3, 6, 12, 18, and 24 months, and annually thereafter. If on follow-up duplex, significant (>50% diameter) graft stenosis is suspected, more detailed imaging such as DSA should be performed. In the interest of prolonging the patency of the graft, confirmed stenosis should be intervened upon by balloon angioplasty or surgical revision promptly.

COMPLICATIONS AND THEIR MANAGEMENT

Many wound complications originate as a result of the significant leg edema that nearly always occurs postoperatively after bypass to inframalleolar vessels. A crucial component of the initial management of the limb is aimed at reduction of postoperative edema with the goal of avoiding wound complications. Patients should be restricted from weight bearing on the foot for 2 to 4 days or more, depending on the progress of surgical wound healing and location of other ulcers on the foot. Ambulation is resumed gradually and may require the use of partial weight bearing on crutches or a walker and the use of open-toe postoperative sandals until the foot is well healed. The leg should be elevated frequently and wrapped in an elastic bandage over the first few weeks to reduce edema. Despite taking these measures, some foot and leg wounds may have difficulties with healing. Minor skin dehiscence remote from the graft is common and usually responds well to conservative measures, such as local dressing care, debridement, elastic compression, and weight-bearing restriction. More serious wound issues including infection with graft exposure occasionally occur and may require more complex treatment, such as myocutaneous free tissue transfer, bypass graft revision with

rerouting, or skin grafting. Wound dehiscence, particularly when it occurs over the distal anastomotic site, can lead to anastomotic disruption and hemorrhage. Aggressive efforts should be made to address such wound issues before this happens. Graft thrombosis, bleeding, and infection are rare, but well-described complications of inframalleolar bypass and early recognition of such events are crucial to their treatment.

OUTCOMES

Dorsalis Pedis Artery Bypass

Our series of 1,032 DP bypasses comprises the largest collection of such patients reported to date. Perioperative mortality associated with DP bypass was 0.9%. Graft failure within 30 days was 4.2%. Clinically apparent cardiac morbidity occurred in only 3%. Limb-threatening postoperative wound infections occurred in 2% of extremities. Early reoperation for graft thrombosis, postoperative bleeding, or infection was required in 6.6%. Primary and secondary patency rates were 56.8% and 62.7% at 5 years and 37.7% and 41.7% at 10 years, respectively. Limb salvage was 78.2% at 5 years and 57.7% at 10 years (Figs. 209.5 and 209.6). Patient survival was 48.6% and 23.8% at 5 and 10 years, respectively, and did not differ significantly between male and female patients. Primary patency was 46.4% for female patients versus 61.6% for male patients at 5 years ($P < 0.009$). Other published reports have demonstrated similar findings of lower patency rates in females. Diabetic patients demonstrated superior secondary patency rates at 5 years. Saphenous vein grafts performed better than all other conduits, with a secondary patency rate of 67.6% versus 46.3% at 5 years ($P < 0.0001$) (Fig. 209.7).

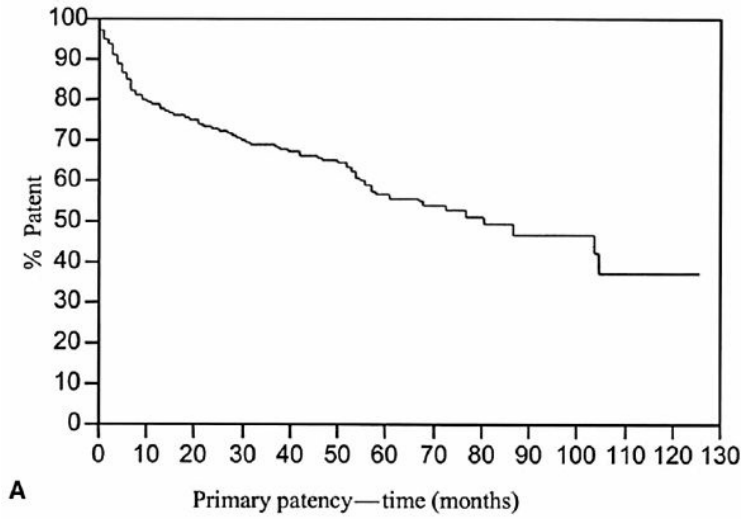

A

At risk 1032 535 395 285 203 142 83 52 31 16 11 7 3

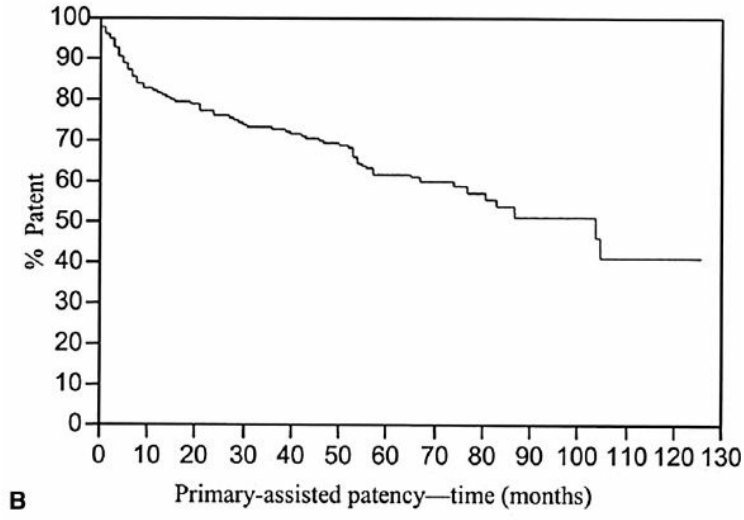

B

At risk: 1032 557 416 301 184 113 78 53 37 18 11 7 3

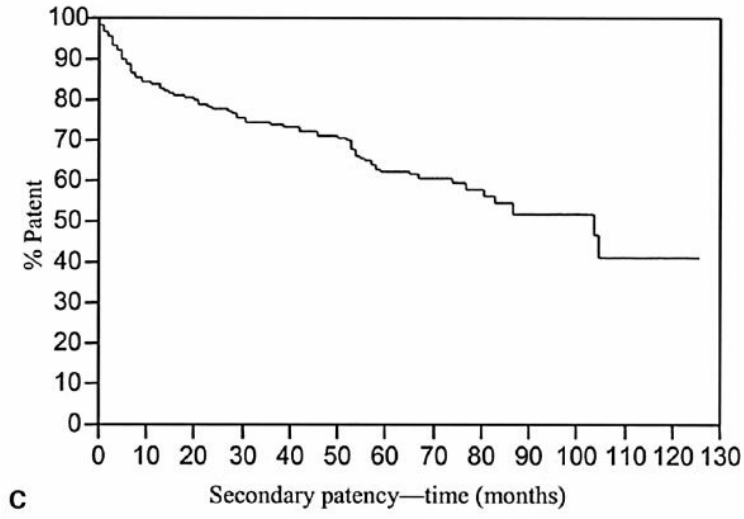

C

At risk 1032 566 422 306 222 158 94 62 37 18 11 7 3

Figure 209.5. Primary (**A**), primary assisted (**B**), and secondary (**C**) patency rates of dorsalis pedis bypass. (Reprinted with permission from Pomposelli FB, Kansal N, Hamdan AD, et al. A decade of experience with dorsalis pedis artery bypass: analysis of outcome in more than 1,000 cases. *J Vasc Surg* 2003;37(2):307–315; with permission from Elsevier.)

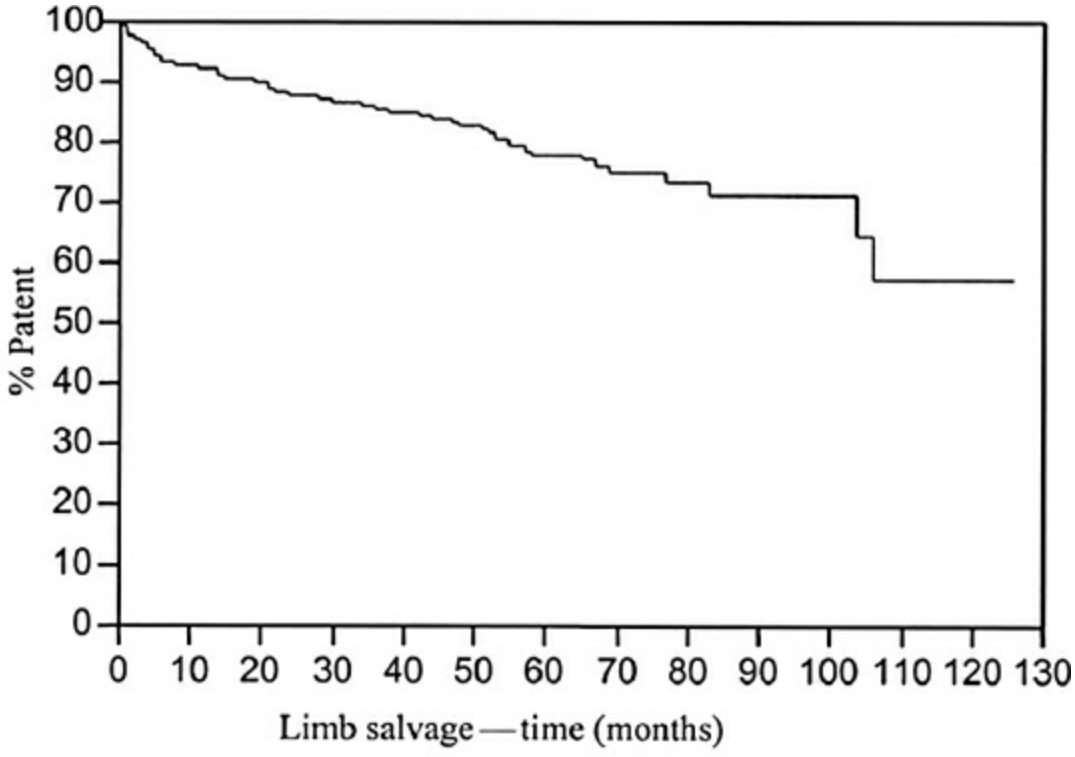

Figure 209.6. Limb salvage rates of dorsalis pedis bypass. (Reprinted with permission from Pomposelli FB, Kansal N, Hamdan AD, et al. A decade of experience with dorsalis pedis artery bypass: analysis of outcome in more than 1,000 cases. *J Vasc Surg* 2003;37(2):307–315; with permission from Elsevier.)

Smaller series have reported variable rates of graft patency for pedal bypass, with one early series of 73 cases documenting a primary patency of 59.2% at 2 years. Another series of 41 limbs in patients with end-stage renal disease undergoing DP bypass documented a primary assisted patency rate of 62% at both 1 and 2 years. This series reported a dismal limb salvage rate of 56% and 50% at 1 and 2 years, respectively, and pointed out that 44% of amputated limbs had functioning bypass grafts at the time of amputation. Notably, heel gangrene was a predictor of negative

outcome, including limb loss, a finding refuted by our series documenting the aid in healing of heel ulcers after DP bypass. Improved results have been noted in more recent series, such as one involving 49 DP bypasses with reported primary patency and limb salvage rates of 89% and 87% at 2 years, respectively. In a large series of patients in whom either peroneal or DP bypass options existed, outcomes for graft patency, limb salvage, and wound complications were similar. This series demonstrated a secondary patency of 67% for DP and 78% for peroneal bypasses at 5 years. Limb salvage was 86% for DP and 93% for peroneal bypass, failing to demonstrate statistical significance. In patients where a choice exists between these vessels, selection may depend on the length of available conduit or presence of adjacent soft tissue infection.

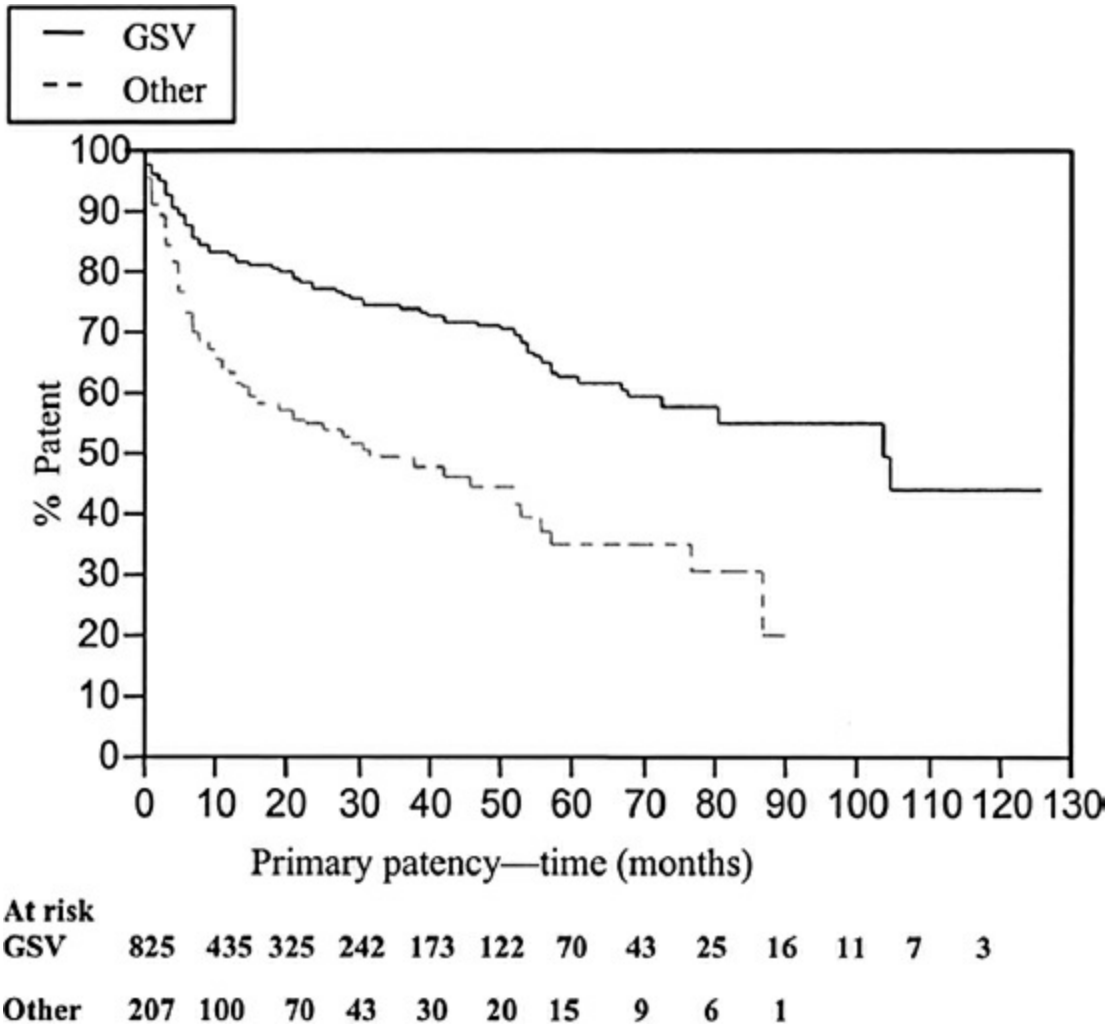

Figure 209.7. Primary patency rates for great saphenous vein versus all other conduit for dorsalis pedis bypass. (Reprinted with permission from Pomposelli FB, Kansal N, Hamdan AD, et al. A decade of experience with dorsalis pedis artery bypass: analysis

of outcome in more than 1,000 cases. *J Vasc Surg* 2003;37(2):307–315; with permission from Elsevier.)

Tarsal and Plantar Artery Bypass

In cases requiring bypass to the tarsal or plantar arteries due to unavailability of a DP or more proximal outflow target, patency rates comparable to those seen in DP bypass have been noted. Most reports document <5% of all infrainguinal arterial reconstructions involving outflow to the inframalleolar vessels. Our own published experience with 98 plantar and tarsal bypass procedures performed over a 13-year period revealed a perioperative mortality rate of 1%. Primary and secondary patency rates were 67% and 70% at 1 year and 41% and 50% at 5 years, respectively. Graft failure within 30 days postoperatively was 11%, as compared to only 4.2% in our DP bypass population. Limb salvage after bypass to the tarsal or plantar arteries approximated 75% at 1 year and 69% at 5 years. As has been demonstrated in our large series of DP bypass cases, the use of saphenous vein conduit was associated with a significantly higher 1-year patency rate of 83% versus 47% for all other conduit.

One series documented a primary patency rate of 72% at 2 years for 22 pedal branch bypasses in patients without a suitable DP bypass target. A similar report of 24 cases compared outcomes for pedal branch bypass to that for perimalleolar bypass within the same institution and found no significant difference in graft patency or limb salvage. In addition, above-knee versus below-knee inflow had no impact on outcome. One of the largest series of bypasses to the lateral plantar artery consists of 20 such bypass grafts. Follow-up yielded a primary patency rate of 73% at 2 years. The incidence of diabetes and the presence of gangrenous lesions with sepsis in this series were noted to be double that in the overall infrainguinal bypass population.

CONCLUSION

Bypass to the foot vessels for critical limb ischemia is a safe, effective, and durable procedure. In many patients, bypass to the DP, tarsal, or plantar arteries offers a reasonable alternative to major limb amputation. Graft patency and limb salvage rates are similar to those seen with more proximal infrainguinal arterial reconstructions. Optimal results are obtained with the use of autogenous saphenous vein, with excellent

durability and patency documented for >10 years in some patients. The typical distribution of atherosclerosis observed in the diabetic patient population mainly affects the tibial and peroneal arteries, often sparing the inframalleolar arteries. Therefore, bypass to the foot vessels is well suited to the treatment of foot ischemia in this patient population. For many patients, the DP artery may be the only outflow target artery available for bypass, and should always be included in the preoperative arteriogram. Tarsal and plantar artery bypass should be considered when the DP artery is occluded. While results are inferior to DP bypass, they are certainly reasonable and often preferable to performing a primary major amputation without an attempt at a limb-salvaging revascularization procedure.

In our practice, embracing the use of DP, tarsal, and plantar artery bypass appears to have had a significant impact on the decrease in the number of both major and minor amputations performed for treatment of ischemia over a 10-year follow-up period. The advantage of inframalleolar bypass seems intuitive in that restoration of arterial perfusion to the ischemic diabetic foot is direct, in close proximity to the ischemic lesion, and not dependent on terminal branches or collaterals. More importantly, when given equal consideration to popliteal or crural outflow targets, inframalleolar bypass adds another potential revascularization option, resulting in the ability to perform a limb-sparing arterial reconstruction in a group of patients previously offered primary amputation. Angioplasty of the more proximal arteries in conjunction with a shorter bypass may offer an alternative to primary amputation in patients with limited vein conduit. Inframalleolar bypass will continue to be a mainstay in our treatment of ischemic foot salvage in patients with diabetes mellitus. Bypass to the DP, tarsal, and plantar arteries should be in the armamentarium of all vascular surgeons caring for patients with diabetes mellitus and advanced limb ischemia.

Suggested Readings

Abu Dabrh AM, Steffen MW, Asi N, et al. Bypass versus endovascular interventions in severe or critical limb ischemia. *J Vasc Surg*. 2016;63:244.

Berceli SA, Hevelone ND, Lipstiz SR, et al. Surgical and endovascular revision of infrainguinal vein bypass grafts: analysis of midterm outcomes from the PREVENT III trial. *J Vasc Surg* 2007;46:1173.

Dorweiler B, Neufang A, Schmiedt W, et al. Pedal arterial bypass for limb salvage in patients with diabetes mellitus. *Eur J Vasc Endovasc Surg* 2002;24(4):309.

Gargiulo M, Giovanetti F, Bianchini Massoni C, et al. Bypass to the ankle and foot in the era of endovascular therapy of tibial disease. Results and factors influencing the outcome. *J Cardiovasc Surg* 2014;55(3):367–74.

Giles KA, Pomposelli FB, Hamdan AD, et al. Infrapopliteal angioplasty for critical limb ischemia: relation of TransAtlantic InterSociety Consensus class to outcome in 176 limbs. *J Vasc Surg* 2008;48(1):128–36.

Hughes K, Domenig CM, Hamdan AD, et al. Bypass to plantar and tarsal arteries: an acceptable approach to limb salvage. *J Vasc Surg* 2004;40(6):1149.

Kumada Y, Nogaki H, Ishii H, et al. Clinical outcome after infrapopliteal bypass surgery in chronic hemodialysis patients with critical limb ischemia. *J Vasc Surg*. 2015;61:400.

Laurila K, Luther M, Roth WD, et al. Adjuvant arteriovenous fistula as means of rescue for infrapopliteal venous bypass with poor runoff. *J Vasc Surg* 2006;44(5):985–91.

Leers SA, Reifsnyder T, Delmonte R, et al. Realistic expectations for pedal bypass grafts in patients with end-stage renal disease. *J Vasc Surg* 1998;28(6):976.

Pomposelli FB, Kansal N, Hamdan AD, et al. A decade of experience with dorsalis pedis artery bypass: analysis of outcome in more than 1000 cases. *J Vasc Surg* 2003;37(2):307.

Roddy SP, Darling RC III, Chang BB, et al. Outcomes with plantar bypass for limb-threatening ischemia. *Ann Vasc Surg* 2006;15(1):79–83.

Schneider PA, Caps MT, Ogawa DY, et al. Intraoperative superficial femoral artery balloon angioplasty and popliteal to distal bypass graft: an option for combined open and endovascular treatment of diabetic gangrene. *J Vasc Surg* 2001;33:955–62.

Spillerova K, Biancari F, Leppaniemi A, et al. Differnetial impact of bypass surgery and angioplasty on angiosome-targeted infrapopliteal revascularization. *Eur J Vasc Endovasc Surg* 2015;49:412–9.

EDITOR'S COMMENT

In their chapter on distal arterial infrapatellar bypass, Aulivola and Pomposelli detail almost a lost art, which is the peripheral arterial bypass with autologous vein. The number of open bypass procedures has declined over time by 42% as endoluminal procedures and technology have exploded (Goodney PP, Beck AW, Nagle J, et al. National trends in lower extremity bypass surgery, endovascular interventions, and major amputations. *J Vasc Surg* 2009;50:54–60). Moreover, the educational trainee exposure to lower extremity bypass has decreased by 66% between 1999 to 2012 (21 to 7 index procedures) (Krafcik

BM, Sachs TE, Farber A, et al. Assessment of open operative vascular surgical experience among general surgery residents. *J Vasc Surg* 2016;63:1110–15). These trends suggest that our vascular residents and fellows may not get enough experience with these often technically demanding procedures. Ultimately, peripheral bypass may be relegated to vascular surgeons who really specialize in this procedure.

It is still an open question of whether peripheral bypass first or endoluminal first for severe peripheral arterial disease is best. However, I argue that a bypass is more durable than a long segment recanalization of popliteal and tibial arteries, as compared to the more proximal artery (e.g., iliac and superficial femoral) endoluminal success. The best endovascular versus best surgical therapy in patients with critical limb ischemia (BEST-CLI) trial is currently ongoing to answer this question as it was fairly equivocal in the Bypass versus angioplasty in severe ischaemia of the leg (BASIL) trial, which was done more than 15 years ago (Adam DJ, Beard JD, Cleveland T, et al. BASIL: multicentre, randomised controlled trial. *Lancet* 2005;366:1925–34).

The ability to be creative when determining the best inflow and outflow targets as well as dealing with often very diseased vessels requires a lot of operative experience. Many important technical pearls are described within this chapter. This is an experienced group that has many thousands of bypasses under its belt, and it bears paying attention to many of the tips and techniques herein.

Additional technical issues that I think are important to highlight include the use of duplex ultrasonography to define the dorsalis pedis or posterior tibial arteries, the target size, and flow rates. Duplex often helps if the arteriogram does not delineate these targets sufficiently.

The most common indication for those requiring a pedal bypass is critical limb ischemia, encompassing rest pain and tissue loss, and often times, renal insufficiency is present. To avoid contrast-induced nephropathy, carbon dioxide arteriography is useful, and with proper technique of leg elevation and long duration filming allows visualization of smaller vessels not possible with contrast arteriography.

Choosing who to perform a peripheral bypass on is sometimes a challenge. The new WiFi Score (Mills JL Sr, Conte MS, Armstrong DG, et al.; Society for Vascular Surgery Lower Extremity Guidelines C. The society for vascular surgery lower extremity threatened limb classification system: risk stratification based on wound, ischemia, and foot infection (wifi). *J Vasc Surg* 2014;59:220–34 e221–2), promoted by the Society for Vascular Surgery, helps to stratify patients who are best served by improving their arterial flow as compared to those who may be best served with an amputation or other measures. In other words, it provides a multidimensional view of tissue loss rather than just the broad category of tissue loss that ranges from a small toe ulcer to extensive foot tissue involvement.

While having a vein bypass directly to the foot does provide palpable,

pulsatile blood flow, a series about a decade and a half ago showed that anastomosing to the peroneal artery as compared with the post tibial or dorsalis pedis was equivalent for limb salvage (Bergamini TM, George SM Jr, Massey HT, et al. Pedal or peroneal bypass: which is better when both are patent? *J Vasc Surg* 1994;20:347–55; discussion 355–6). This highlights the fact that the venous conduit quality is a very important determinant of bypass success and ultimately patency (Robinson WP 3rd, Owens CD, Nguyen LL, et al. Inferior outcomes of autogenous infrainguinal bypass in hispanics: an analysis of ethnicity, graft function, and limb salvage. *J Vasc Surg* 2009;49:1416–25). A vein graft of over 2.5 mm and preferably 3 mm yields much better results in those that are more marginal. Most bypass series show secondary patency of >70%.

Whereas I agree that a shorter bypass is generally better, such as a bypass from the above the knee popliteal to tibial artery, progression of superficial femoral artery disease does have to be monitored and occasionally treated. It is not an uncommon scenario that the bypass flow rates by duplex ultrasonography may diminish overtime, suggesting proximal disease. Then, either angioplasty and stenting or doing a sequential bypass from the femoral artery to the graft itself (hopefully with vein), can be done to salvage the graft. Long-term surveillance is the key.

Lastly, it is very important to maintain these patients in clinical follow-up. One of the joys of vascular surgery is seeing your patient back year after year with a patent graft and functional limb. It is always disheartening to get the call from the emergency room or have your patient come to clinic with an occluded bypass, and then unlikely able to be salvaged. Equally, should graft stenosis arise, prompt treatment almost always allows graft salvage.

Peter Henke

210 Peripheral Vascular Occlusive Disease: Endovascular

Richard Powell, Ryan Svoboda, and Jessica Wallert

PATIENT SELECTION

Patients with lifestyle-limiting claudication or critical limb ischemia in the form of rest pain or ischemic tissue loss are candidates for lower extremity angiogram and possible endovascular intervention. Patients with claudication can be given a trial of medical therapy with aspirin, statin, and cilostazol 100 mg bid, prior to considering intervention in those patients in whom the claudication is lifestyle limiting. Patients with present femoral pulses but absent popliteal pulses are likely to have hemodynamically significant lesions in the femoropopliteal segment, while those with present popliteal pulses and absent pedal pulses likely have tibial disease. In addition, tibial disease tends to occur more commonly in diabetic patients. Patients with ischemic rest pain or tissue loss typically have multilevel vascular disease.

PREOPERATIVE IMAGING

Preoperative imaging and noninvasive vascular laboratory studies are essential for procedure planning. All patients being considered for endovascular intervention should undergo noninvasive vascular laboratory studies, which should include, at a minimum, ankle-brachial index (ABI) measurement and segmental pressures. Diabetic patients should undergo toe pressure measurement, due to the possibility of falsely elevated ABIs secondary to tibial calcinosis. Patients with unilateral symptoms, fewer risk factors for atherosclerotic disease, and strong contralateral pedal pulses should undergo bilateral popliteal artery Duplex to rule out popliteal artery aneurysm. In patients with a decreased or absent femoral pulse and normal renal function, computerized tomography arteriography (CTA) or magnetic resonance arteriography (MRA) can be performed to rule out concurrent aortoiliac disease. In addition, CTA and MRA can be valuable to assess the degree of common femoral, superficial femoral artery (SFA),

and popliteal disease. We have not found these studies adequate to assess the severity of tibial disease.

Preoperative studies and intraprocedural angiogram are used to assess the location and length of stenosis or occlusion, as well as the degree of calcification. Lesions are categorized according to the Trans-Atlantic Inter-Society Consensus (TASC) II guidelines (Table 210.1). TASC A and B lesions are typically treated with endovascular therapy. TASC C and D lesions can be treated with endovascular therapy if the patient is not a suitable candidate for bypass or does not have a good conduit option.

PROCEDURAL DETAILS

Endovascular treatment of infrainguinal peripheral artery occlusive disease involves a customized approach for each individual that is determined by anatomic and lesion-specific characteristics of the disease being treated. However, the following basic algorithm applies in most circumstances.

Arterial Access and Diagnostic Imaging

The patient is consciously sedated using short-acting opiate and benzodiazepine medications. The site of arterial access is determined by preoperative imaging and pulse assessment. Typically, for more proximal lesions, contralateral femoral access is obtained overlying the femoral head. For more distal popliteal and tibial lesions, ipsilateral antegrade femoral access may be beneficial. After infiltration of local anesthetic, a 21-gauge 4-Fr micropuncture set is used under fluoroscopic and ultrasound guidance to gain access. After initial access is gained, the micropuncture catheter is exchanged for a 10-cm 5-Fr sheath over a 0.035-in J-wire. In patients for whom retrograde contralateral access has been obtained, an abdominal aortogram is performed through a flush catheter seated in the pararenal position (L1 to 2 disc space) in order to rule out disease in the infrarenal aorta and iliac vessels. The catheter is then lowered to just above the aortic bifurcation, and oblique pelvic arteriography is performed to assess the common and external iliac arteries (30 degrees contralateral). Our practice is to use a contrast medium that is cut by one half or one third. For aortic arteriography, we use a flow rate of 15 mL/s for a total volume of 30 mL. For a pelvic arteriogram, a flow rate of 10 mL/s and volume of 20 mL are used. Next, we typically use a curved catheter such as an Omni Flush in combination with a soft wire such as a 0.035-in J-wire or an angled gluide wire in order to cross “up and over” the aortic

bifurcation to the side of the affected extremity. The wire is advanced, the catheter is placed in the common femoral artery, and the entire extremity is imaged in a "bolus-chase" fashion using a flow rate of 5 mL/s for a total volume of 20 to 25 mL/s. Additional oblique views (30 degrees ipsilateral) can be useful for examining the common femoral artery bifurcation. If the patient has suboptimal renal function, selective single-station angiograms can be performed in lieu of a bolus-chase image, or CO_2 can be used instead of intravenous contrast. When imaging the tibial vessels, if significant vasospasm is suspected, a mixture of 500 mcg of verapamil, 50 mcg of nitroglycerin, and 500 units of heparin is administered through the sheath and the images repeated.

TABLE 210.1 Lesion Characteristics Used to Define the Trans-Atlantic Inter-Society Consensus (TASC) II Guidelines for Characterizing Infrainguinal Peripheral Vascular Disease

TASC Classification	Lesion Characteristics
Type A	Single stenosis ≤10 cm OR Single occlusion ≤5 cm
Type B	Multiple stenoses or occlusions, each ≤5 cm OR Single stenosis 10–15 cm or occlusion 5–15 cm (of the SFA or suprageniculate popliteal artery) OR Heavily calcified occlusion ≤5 cm OR Single infrageniculate stenosis or occlusion
Type C	Multiple stenosis or occlusions, >15 cm total OR Recurrent stenosis or occlusions that have undergone ≥2 prior endovascular interventions
Type D	Chronic total occlusion of the superficial femoral artery ≥20 cm, with extension into the popliteal artery OR Chronic total occlusion of the popliteal artery and proximal tibial vessels

Source: Norgren L, Hiatt WR, Dormandy JA, et al. Inter-Society Consensus for the Management of Peripheral Arterial Disease (TASC II). *J Vasc Surg* 2007;45(1):S5–67.

Crossing the Lesion

Following angiogram, the location and characteristics of the lesions are

considered and will dictate the approach to recanalization and treatment. If the lesions appear appropriate for endovascular treatment, a sheath is placed over the aortic bifurcation. If the planned treatment includes disease in the proximal SFA, the 10-cm 5-Fr sheath is exchanged for a 45-cm peripheral guiding sheath (Destination, Terumo) over a stiff 0.035-in wire (Stiff glide wire, Teruma or Amplatz Super Stiff, Boston Scientific) and the patient is heparinized (100 units/kg). If the lesion to be treated is in the distal SFA or popliteal region, a 65-cm peripheral guiding sheath is placed. Lastly, if only tibial disease is being treated, a 90-cm sheath (Flexor Shuttle Guiding Sheath, Cook Medical) is placed. The sheath diameter is largely dictated by the planned intervention. Many atherectomy devices require a 7-Fr sheath. Most Stents will go through a 6-Fr sheath. The treatment of tibial disease can frequently be performed with a 5-Fr sheath to accommodate 0.018- and 0.014-in balloons and coronary stents.

Superficial Femoral Artery Lesions

If the patient has an SFA lesion, it is recanalized and treated first. Attempts to cross an SFA stenosis are performed using any combination of 0.035-, 0.018-, or 0.014-in wires with a straight-tipped or angled-tipped catheter. See Table 210.2 for preferred wire and catheter selections. Total occlusions are treated with initial attempts at intraluminal recanalization. Weighted-tip wires (Victory, Boston Scientific) or devices such as the TruePath (Boston Scientific), a motorized diamond–coated tipped catheter on a 0.018-in platform, can assist in achieving intraluminal recanalization and are most helpful for entering a heavily calcified occlusion. If intraluminal recanalization is unsuccessful, subintimal recanalization can be performed and is often required for longer lesions. To attempt subintimal recanalization, a hydrophilic stiff wire is passed and forms a loop as it enters the subintimal plane. This requires the support of a catheter (Fig. 210.1). The wire will often reenter the lumen once the lesion is passed; however, if this does not occur, advancement of an angled catheter over the wire and guidewire manipulation usually results in successful reentry into the lumen. If attempts at reentry are unsuccessful, a reentry device (OffRoad, Boston Scientific; Outback LTD, Cordis; Pioneer, Volcano Corporation) can be used. Once recanalization has been achieved, a single-station angiogram performed through the catheter is vital to confirm of intraluminal position prior to additional intervention.

TABLE 210.2 Authors' Preferred Wires and Catheters for Infrainguinal Endovascular Interventions

Wires			Catheters	
0.035 in	0.018 in	0.014 in	Straight-Tip	Angled-Tip
Benston[a] Wholey[b] Hydrophilic Glidewire[c]	V18[d] Thruway[d] Victory[d]	V14[d] Thruway[d] Victory[d] Journey[d]	Quick-Cross[e] Rubicon[d]	Glidecath[c] Quick-Cross Select[e] Berenstein[f] Kumpe[a]

[a]Cook Medical.
[b]Covidien/Medtronic.
[c]Terumo Interventional Systems.
[d]Boston Scientific.
[e]Spectranetics.
[f]Angiodynamics.



Figure 210.1. A hydrophilic stiff wire is passed and forms a loop as it enters the subintimal plane.

For patients with SFA lesions that cannot be crossed via an antegrade approach, direct popliteal artery access can be obtained. The patient is placed in a prone position on the angiography table, and ultrasound guidance is used to access the popliteal artery directly with a 4-Fr micropuncture kit. The lesion is then crossed in a retrograde fashion, the wire is snared from the groin, and the lesion can then be treated antegrade.

Popliteal Artery Lesions

Popliteal artery lesions are crossed in a manner similar to that described for the SFA. It is important to note that chronic total occlusions of the below-knee popliteal artery with extension into all three proximal tibial vessels pose a significant challenge to safe reentry into the intraluminal space. In our practice, if a patient with such a lesion is a good surgical candidate and has adequate conduit for bypass, we will often opt for this method of treatment over endovascular attempts. If bypass is unfavorable or precluded due to patient-related factors, distal access of a patent pedal vessel and attempt at retrograde recanalization of the lesion may be performed.

Tibial Artery Lesions

Following treatment of any proximal lesions, attention is turned to recanalization of the tibial arteries. A 0.014- or 0.018-in wire is used in combination with a catheter to select the tibial artery of interest. For the anterior tibial artery, we prefer an angled catheter, whereas for the peroneal and posterior tibial arteries, a straight crossing catheter can usually be used (Table 210.2). After the target artery is selected, the lesion is crossed using the 0.014-in wire and crossing catheter in combination. If two of the tibial arteries have proximal lesions requiring endovascular treatment, a second “buddy wire” is used to select the second artery and recanalization is performed in a similar fashion.

Occasionally, if antegrade recanalization is unsuccessful, the occlusion can be crossed in a retrograde fashion via pedal access. This approach is typically reserved for patients with critical limb ischemia (Rutherford class IV–VI) who are not candidates for tibial bypass. In these cases, retrograde access of the dorsalis pedis or posterior tibial artery is performed under ultrasound guidance. A 22-gauge needle and a 0.014- or 0.018-in wire are placed. The inner cannula of a 4-Fr micropuncture sheath serves as the “sheath” (Fig. 210.2). If a crossing catheter is needed, a straight or curved crossing catheter (Table 210.2) is placed bareback through the skin and is used to cross the lesion. Although a 2- to 3.5-mm angioplasty balloon can be used to treat the lesion from a retrograde fashion, we prefer to recanalize the lesion from a retrograde fashion and use a snare to capture the retrograde wire and bring it through an antegrade catheter introduced through the common femoral artery, so that any treatment can then be performed through a stable platform.

Intervention

Once an arterial lesion is successfully crossed and angiography confirms intra-luminal access proximal and distal to the point of interest, attention is turned to intervention. Three general treatment strategies are employed:

Angioplasty

Angioplasty can be performed with one of three types of balloons: plain, cutting, or drug-coated. Plain old balloon angioplasty (POBA) has been shown to have inferior results to other forms of SFA treatment in all but short (TASC A) lesions not in the region of the adductor canal. We rarely use cutting balloons in everyday practice for treating infrainguinal disease. These are often reserved for treatment of anastomotic bypass lesions where neointimal hyperplasia has occurred. Drug-coated balloons have been shown to reduce rates of restenosis compared to POBA and in two early randomized placebo-controlled trials and approached patency rates similar to SFA stent placement at 1 year. There are currently two such devices approved by the FDA for use in the femoropopliteal system in the United States: Lutonix (Bard) and In.Pact Admiral (Medtronic) are both paclitaxel-coated balloons, which are available in a variety of treatment diameters and utilize a 0.035-in treatment platform. It is too early to recommend the utilization of drug-coated balloon angioplasty (DCB) as an adjunct to other treatments, such as atherectomy but early results are promising. For all angioplasty, a balloon diameter that is 5% to 10% larger than the target vessel is chosen (typically 5 to 7 mm for SFA lesions, 4 to 6 mm for popliteal, and 2 to 3 mm for tibial arteries). Balloon length is chosen to be slightly longer than the lesion length. All lesions are dilated under fluoroscopic guidance (Fig. 210.3).

Stenting

Stenting of the SFA or popliteal artery is recommended for most TASC A and B lesions, for vessel recoil, or for flow-limiting dissection that occurs following angioplasty or atherectomy. We consider three primary types of stents: balloon-expandable (bare or covered), self-expanding (bare or covered), and drug-eluting. Advantages to balloon-expandable include high radial force, minimal migration with placement, and the ability to overexpand the stent. These are all qualities that are more important when treating disease outside of the infrainguinal region. For this reason, we preferentially use self-expanding stents for treating femoropopliteal disease, which offer the advantages of increased flexibility and resistance to deformity. Specifically, for SFA lesions, self-expanding nitinol stents

can be deployed over a variety of wires. These cannot be overexpanded, thus upsizing 5% to 10% of the intended vessel diameter to ensure that apposition of the stent is recommended (Fig. 210.4). For long chronic total occlusions, a self-expanding covered stent, such as a Viabahn (Gore), due to its inherent flexibility can be used and may have improved patency compared to bare metal stents. We also often utilize drug-eluting stents (Zilver PTX, Cook Medical) for treating SFA disease. One additional advantage to the Zilver PTX is its low profile and ability for many sizes to be delivered through a 5-Fr platform. Following stent placement, angioplasty using a balloon of size equal to the stent or 1 to 2 mm smaller is performed.

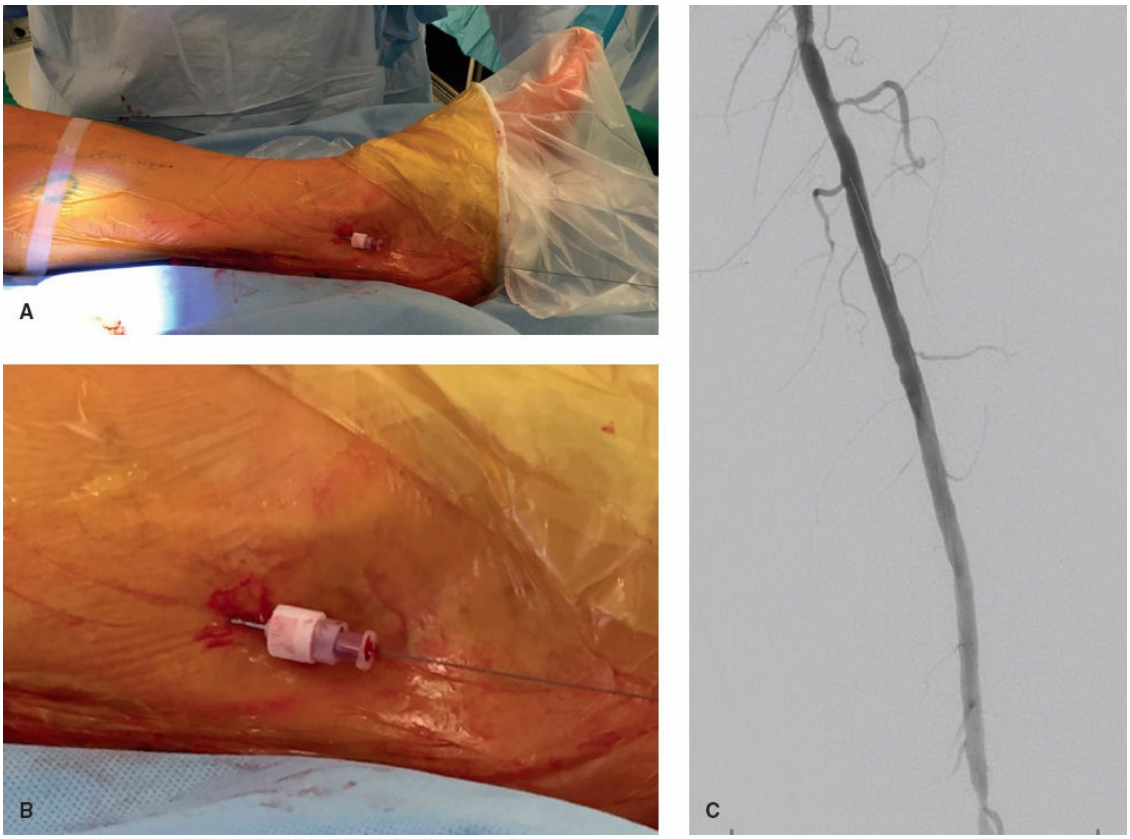

Figure 210.2. In some circumstances, when an occlusion is not successfully crossed in an antegrade fashion, retrograde pedal access is obtained, either via a percutaneous or direct cutdown approach (**A**). The lesion is then crossed retrograde (**B**), the wire snared from above, and the lesion can then be treated in an antegrade fashion (**C**).

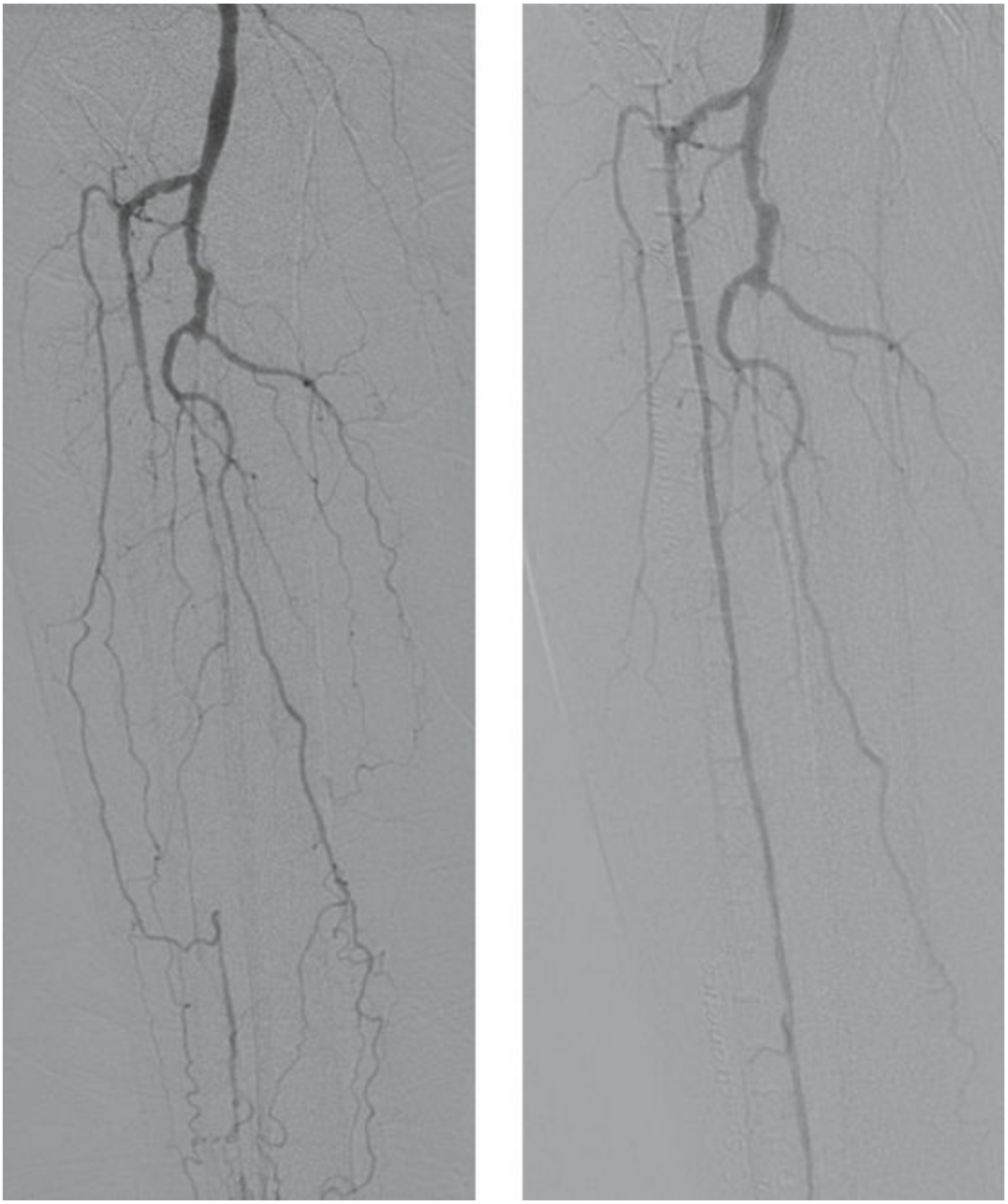

Figure 210.3. Example of a recannalized anterior tibial artery occlusion following treatment with balloon angioplasty.

Popliteal lesions distal to the femoral epicondyles are preferentially managed with balloon angioplasty alone if possible, as this is traditionally considered to be a “no-stent” zone due to the proximity to the knee joint and increased propensity for stent fracture. Atherectomy or drug-coated balloons, either alone or in combination, may obviate the need for a stent in this area.

Regarding tibial artery lesions, there is no high-level evidence showing superiority of primary stenting versus angioplasty alone. A recent meta-

analysis by Wu et al. (2014) showed that primary stenting was associated with a trend toward a higher primary patency rate and a lower secondary patency rate, but neither finding reached statistical significance. Thus, the authors concluded that there is insufficient evidence to judge superiority of one method versus the other. In our practice, we routinely treat tibial lesions with balloon angioplasty, reserving stenting for patients who experience restenosis following angioplasty.

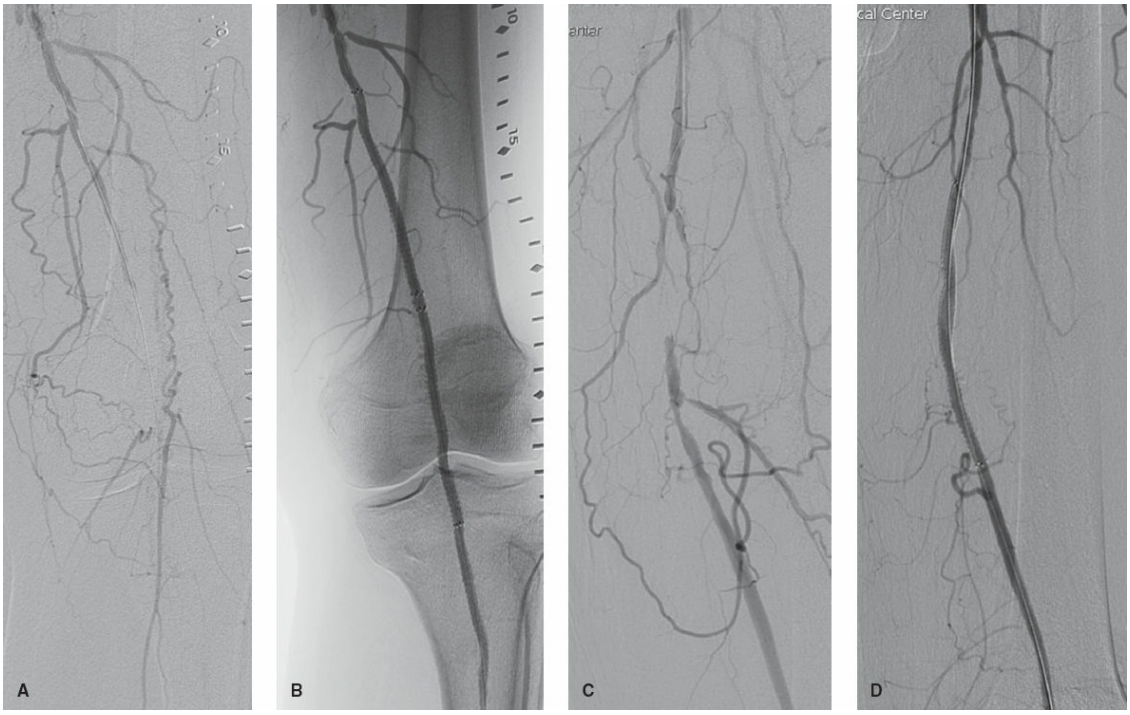

Figure 210.4. Example of a superficial femoral artery (**A, B**) and popliteal artery (**C, D**) occlusions successfully treated with bare metal stenting.

Atherectomy

Atherectomy devices can be classified in one of three ways (directional, rotational, laser) and are used to eliminate plaque. Directional devices (SilverHawk, Covidien) are best used to treat focal, calcified lesions. Rotational devices (JetStream, Boston Scientific; Diamondback 360, Cardiovascular Systems, Inc) use a high-speed burr mechanism to eliminate plaque. Laser recanalization (Turbo-Elite, Spectranetics) uses a specific wavelength of light to ablate plaque in both de novo and in-stent lesions. Our preferred practice is to use the Jetstream for de novo stenosis or occlusions. This is an over-the-wire, front-cutting rotational device with aspiration. It is approved for use in each the SFA, popliteal, and tibial vessels with a variety of catheter sizes available, and can treat multiple

morphologies from heavily calcified plaques to fresh thrombus (Fig. 210.5). It is unclear if the combination of atherectomy plus drug-eluting balloon will be superior to stent placement for calcified SFA lesions (Fig. 210.6). For in-stent restenosis, laser atherectomy can be used, and is also available in a wide range of sizes to treat both femoropopliteal and tibial vessels.

Posttreatment Assessment and Case Completion

Following treatment with any of the above listed interventions, completion arteriogram is mandatory to confirm proper treatment and absence of unintended consequences. Typically, this is performed via single-station angiography. If the result is suboptimal, adjunctive procedures can be considered. Once the operating surgeon is satisfied with the treatment result, the sheath is removed over a wire and the arteriotomy is closed with a closure device (Mynx, Cardinal Health; Perclose Proglide, Abbott) or manual compression. Protamine is administered if the bleeding risk is deemed to outweigh the risk of thrombosis of the endovascular repair.

OUTCOMES

Femoropopliteal Disease Outcomes

Outcomes following femoropopliteal interventions vary by type of intervention. In 2007, Rocha-Singh et al. published a report demonstrating an overall primary patency rate of 33% at 12 months following plain balloon angioplasty among patients with debilitating claudication. This effect varied by lesion length, with poorest results among those with long lesions (16% primary patency at 12 months for those with lesions 11.1 to 15 cm). Multiple trials show improved primary patency following stenting (Fig. 210.6). As with angioplasty, patency varied by lesion length, as well as by stent design; however, overall primary patency ranged from 70.8% to 86.3% at 12 months. Results from drug-eluting stents are proving even more favorable. A randomized trial comparing primary angioplasty to a paclitaxel-coated drug-eluting stent, Zilver PTX (Cook Medical) demonstrated superior rates of primary patency at 12 months for the drug-eluting stent (83% vs. 33%). This same trial noted increased primary patency for the drug-eluting stent over bare-metal stents for those patients who failed primary angioplasty alone and underwent provisional revascularization (90% vs. 73%). Data pertaining to drub-coated balloons

are limited. One trial, the LEVANT I, compared the Lutonix (Bard) paclitaxel-coated balloon to plain balloon angioplasty, and demonstrated improved rates of late lumen loss at 6 months following intervention (0.46 vs. 1.09). Similarly, data pertaining to atherectomy devices are also sparse, which is why our practice is typically to use these methods primarily as adjuncts to stenting in the femoropopliteal region.

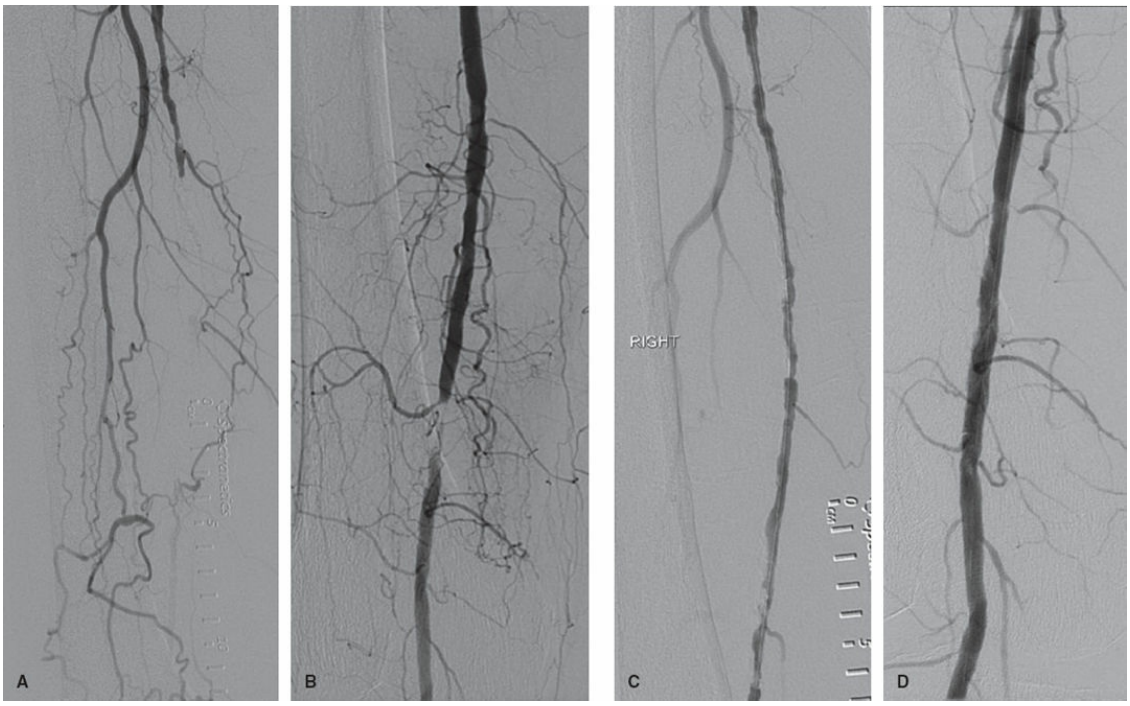

Figure 210.5. Examples of superficial femoral artery occlusions (**A** and **B**) that have been successfully crossed and treated with Jetstream Atherectomy System (Boston Scientific) (**C** and **D**).

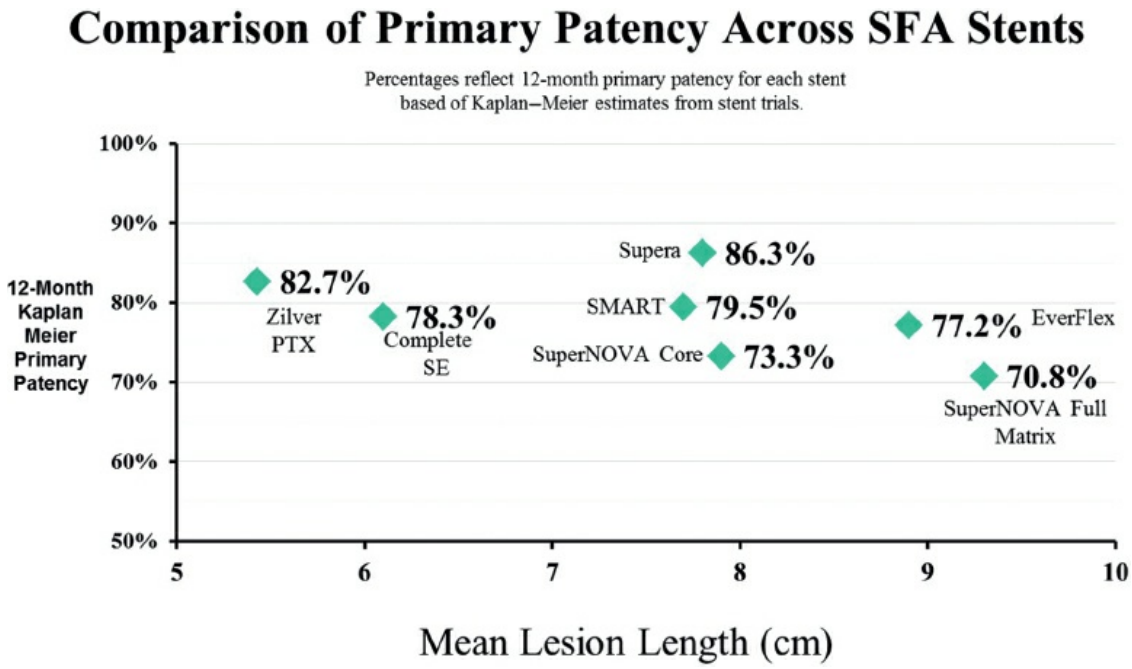

Figure 210.6. Comparison of primary patency across superficial femoral artery (SFA) stents.

Tibial Disease Outcomes

Outcomes following tibial angioplasty are generally poor, with technical success ranging from 89% to 95%, but 1-year primary in the realm on 53% to 68%. Despite this, reported limb salvage rates are higher, typically ranging from 84% to 86% at 1 year. Retrospective studies have shown similar results for bare metal stents placed in the tibial arteries. Limited data suggest that drug-eluting stents placed in the tibial system display superior patency rates—up to 81%—when compared to bare metal stents.

COMPLICATIONS

Complications following infrainguinal endovascular repair typically fall into one of four categories based on complication site: puncture site, treatment site, distal vessel, and systemic. Puncture site complications occur in approximately 4% of patients, with simple hematoma being the most common. Pseudoaneurysm, arteriovenous fistula, and retroperitoneal hematoma are less common complications of arterial puncture. In order to decrease the likelihood of these complications, accurate sheath placement in the common femoral artery is essential. In our practice, we routinely order a Duplex ultrasound to rule out pseudoaneurysm for patients with enlarging groin hematomas following endovascular procedures. If a pseudoaneurysm is present, we begin treatment with 30 minutes of

ultrasound-guided compression. If this fails, we typically treat large pseudoaneurysms with thrombin injection if the neck is long and narrow, or open surgical repair if the neck is short and wide. Retroperitoneal hematoma can be a lethal complication and should be suspected in any patient with back pain and hypotension following infrainguinal endovascular intervention.

Treatment site complications occur approximately 3.5% of the time and include dissection with or without acute thrombosis, and rupture. Completion angiography is essential to rule out a local complication. If dissection is noted following angioplasty, a stent is placed over the dissected area to “tack down” the dissection plane.

Complications in distal vessels occur approximately 2.7% of the time and include embolization and extension of arterial dissection. Use of distal embolic protection devices reduces risk of embolization and may be indicated when treating high-risk lesions or utilizing certain treatment modalities such as orbital atherectomy.

Finally, systemic complications are rare and most commonly occur in the form of contrast-induced nephropathy. In our practice, we routinely treat patients with chronic kidney disease and a baseline estimated GFR of less than 60 with a sodium bicarbonate infusion starting at 3 mg/kg/h for 1 hour prior to the procedure and continuing through the procedure followed by 4 hours after the procedure at 1 mg/kg/h. We no longer routinely treat with N-acetyl-cysteine due to the lack of evidence supporting this practice.

SUMMARY

Patients with lifestyle-limiting claudication or critical limb ischemia are candidates for lower extremity angiogram and intervention. Endovascular approaches to treating infrainguinal disease are variable and must be carefully individualized for each patient. However, in general, endovascular interventions can be divided into two primary aims: crossing a lesion and treating a lesion. Once a lesion is crossed, techniques for treatment vary and can include the use of atherectomy devices to debulk a lesion, plain balloon or drug-eluting balloon angioplasty, bare-metal stenting, drug-eluting stenting, and, in some circumstances, stentgrafting.



EDITOR’S COMMENT

This clearly written and comprehensive chapter by Powell highlights the now

standard, often initial revascularization procedure for claudication and critical limb ischemia; namely, endovascular revascularization. Over the last 15 years, with the advent of new techniques, devices, and technologies, the endovascular first approach is often the way it's done for everything from a short segment femoral artery stenosis to long segment femoral, popliteal, or tibial occlusions. The rapidly increasing use of endovascular techniques and decrease in open revascularization surgeries is significant. For example, endoluminal procedures have increased threefold and surgeries have decreased 42% (Goodney PP, Beck AW, Nagle J, et al. National trends in lower extremity bypass surgery, endovascular interventions, and major amputations. *J Vasc Surg* 2009;50:54–60). Indeed, the low-profile sheaths and closure devices allow almost any artery to be opened up with a good safety profile. However, several issues are relevant with these techniques.

One primary issue with endovascular revascularization is appropriateness, due to wide ranging specialists who perform catheter-based interventions, and a relatively limited evidence basis for procedural indications. Appropriateness issues are being raised in many areas of medicine, as evidenced by the "choose wisely" campaign (Rao VM, Levin DC. The overuse of diagnostic imaging and the Choosing Wisely initiative. *Ann Intern Med* 2012;157:574–6). There is a large grey zone of claudication severity, most of which is not truly lifestyle limiting, yet may be treated too aggressively with an endoluminal procedure. Unfortunately, failure of endovascular procedures may accelerate or worsen the natural history in a claudicant, rendering their limb at risk. Thus, I recommend the same conservative criteria for revascularization using an endolumenal approach as for an open procedure. Conversely, little concern or controversy exists regarding aggressive treatment for patients who have critical limb ischemia manifesting as rest pain or tissue loss.

The use of the Trans-Atlantic Inter-Society Consensus Document on Management of Peripheral Arterial Disease–II (TASC II) classification (Norgren L, Hiatt WR, Dormandy JA, et al. Inter-Society Consensus for the Management of Peripheral Arterial Disease (TASC II). *J Vasc Surg* 2007;45 Suppl S:S5–S67), while still commonly used, may be somewhat outdated and revisions are pending. However, it still provides a common language as an anatomic categorization system for most vascular interventialists. There is no discrete evidence for or against treating TASC A and B by endoluminal means, as compared with TASC C and D with a surgical bypass. Technically, TASC A or B lesions are generally easier to treat. The Bypass versus Angioplasty in Severe Ischemia of the Leg trial (Adam DJ, Beard JD, Cleveland T, et al. Bypass versus angioplasty in severe ischaemia of the leg (BASIL): multicentre, randomised controlled trial. *Lancet* 2005;366:1925–34) suggested equivalent early outcomes between endovascular and surgical revascularization, but surgical bypass may be better for those with a greater than 2-year life expectancy. A larger multicenter United States trial is undergoing recruitment, and will provide more definitive answers.

Advanced fixed imaging hybrid rooms are now standard at most major vascular practices, including inpatient and outpatient venues. Indeed, these new generation imaging machines enhance visualization as well decrease radiation exposure. Of note, the use of CO_2 angiography, as mentioned by authors, requires some technical changes for imaging acquisition, but is very useful in patients with renal insufficiency. It is possible to use only 10 to 15 cc of iodinated contrast, with much of the anatomical imaging obtainable using only CO_2 contrast. Details of CO_2 angiographic techniques are published (Caridi JM, Kyung J, Cho M, et al. Carbon dioxide digital subtraction angiography (CO_2 DSA): a comprehensive user guide for all operators. *Vasc Dis Manag* 2014;11:E221–56).

In terms of crossing femoral artery stenosis or occlusions, patience is critical as this often is quite a tedious process around a calcified, bulky lesion at the adductor canal. Performing retrograde arterial puncture, snaring the wire in proximal femoral artery may get around this problem. Indeed, this technique with the distal access and snaring, so the called “subintimal arterial flossing with antegrade–retrograde intervention” techniques, is commonly utilized now with good anecdotal success (Spinosa DJ, Harthun NL, Bissonette EA, et al. Subintimal arterial flossing with antegrade-retrograde intervention (SAFARI) for subintimal recanalization to treat chronic critical limb ischemia. *J Vasc Interv Radiol* 2005;16:37–44). One important technical aspect for success is a good inflow artery pressure and at least one good outflow artery, usually a tibial artery.

The use of drug-eluting balloons and drug-eluting stents has skyrocketed in treating peripheral artery disease. This is based in part on a modest number of patients in the trial of Paclitaxel-coated stents, as compared with angioplasty or bare metal stents, showing that drug-eluting stents have superior patency (Dake MD, Ansel GM, Jaff MR, et al. Sustained safety and effectiveness of paclitaxel-eluting stents for femoropopliteal lesions: 2-year follow-up from the Zilver PTX randomized and single-arm clinical studies. *J Am Coll Cardiol* 2013;61:2417–27). Despite reasonable efficacy with non–drug-eluting self-expanding nitinol stents, in our own practice most femoral artery stenting is performed with the drug-eluting type stents. Whether this is cost-effective is unclear. Certainly, if reduced need for vascular re-intervention is factored in to costs, then these stents may be cost-effective. However, this still needs to be proven with apples to an apples comparison in randomized controlled trials.

Another important issue, and a difficult one to answer, is whether the endovascular revascularization first approach “burns bridges” for later open surgical bypass options when the stents occlude. In other words, do the endoluminal technique and subsequent failure cause loss of outflow arteries that could accept a surgical bypass? At least one retrospective study suggests lower graft patency after failed endoluminal therapy (Gifford S, Stauffer K, De Martino R, et al. Impact of femoropopliteal endovascular interventions on subsequent open bypass. *J Vasc Surg* 2016 Sep;64(3):623–8). In my practice, I

have seen multiple patients who received a fully stented femoral artery, and an open above knee popliteal artery that upon return with stent occlusion, now presents with severe leg ischemia symptoms, and more limited outflow targets. This has a very negative impact on patients, as longer length and/or tibial bypasses have lower patency and conduit for these bypasses may be limited. Again, the critical issue is the initial revascularization appropriateness, and risk-benefit analysis for informed patient decision making.

Peter Henke

211 Minor Amputations

Peter Henke

INTRODUCTION

In the United States, hospital admissions for foot ulceration are very common. One of the most important and overlooked aspects of successful limb salvage in these patients is a properly timed and executed minor amputation, with preoperative assessments of blood flow and good postprocedure orthotics. Minor amputations are performed twice as frequently as major amputations. Avoidance of major amputation is critical for a myriad of reasons. Transtibial and transfemoral amputations result in inefficient ambulation. The increase in metabolic cost after these procedures is proportional to the number of functional joints that are lost.

DIABETES MELLITUS AND FOOT ULCERATION

Currently, there are over 25 million diabetics in the United States and the prevalence continues to rise. The CDC report shows that the percentage of US citizens with diabetes has increased from 4.9% in 1990 to 9.3% in 2014. Diabetes mellitus is the leading cause of lower-extremity amputation worldwide. Approximately 80% of all lower-extremity amputations are precipitated by foot ulceration. The overall prevalence of foot ulcers in diabetics in the United States is 12% with a 20-year cumulative incidence approaching 10% and a lifetime incidence up to 25%, most of whom will require hospitalization for this condition. Indeed, foot ulcerations are the most frequent cause of diabetes-related hospital admission. The length of stay is significantly longer than that of other diabetes-associated complications with a yearly cost in the tens of billions of dollars. After amputation, diabetics heal at a rate similar to that of nondiabetics, but their overall survival is significantly worse.

The continued development of our understanding of the pathophysiology of foot ulceration in diabetics has led to numerous advances in limb salvage. In the past, microvascular arterial obliteration or “small vessel disease” was thought to result in poor skin perfusion and

necrosis. We now understand ulceration to be a result of a complex interplay between various sequelae of diabetes mellitus, often with large artery atherosclerosis.

Nerve damage in diabetics can result in a sensory dysfunction. The loss of protective sensation in the foot leads to injury from abnormal repetitive stress, poorly applied footwear, and even undetected hazards such as a foreign object in a shoe. Diabetics with reduced sensation are more likely to injure their feet and are less likely to notice injuries, resulting in delayed treatment. Peripheral neuropathy can also lead to changes in foot structure. Denervation of the intrinsic arch muscles can cause the toes to be pulled back by the now-unopposed long tendons, leading to hammertoe formation. Plantar and intrinsic muscle atrophies result in prominent metatarsal heads and less foot surface area overall to bear weight, a common source of pressure ulceration. Repetitive injury to a malformed insensitive foot leads to ligament laxity and further abnormal pressure points such as those seen in Charcot deformity. Autonomic neuropathy produces dry skin and decreased sweating. Callus formation is thus initiated, triggering abnormal pressure points and ulcer formation. All these factors increase the chance for ulceration and infection.

Clinical Presentation and Diagnosis

If the patient is a known diabetic, glycosylated hemoglobin should be sent. If the patient states they are not diabetic, our preference is to perform a screening fasting glucose level according to the American Diabetes Association guidelines (Table 211.1). In our experience, nearly half of the patients who present with a foot ulcer and are not a known diabetic will test positive for occult diabetes or prediabetes. The patient must be asked whether they suffer from complications of diabetes including neuropathy, retinopathy, and nephropathy. The existence of end-stage renal disease (ESRD) will negatively affect the patient's ability to heal as well as dramatically reduce his or her overall life expectancy.

TABLE 211.1 The American Diabetes Association Guidelines for Fasting Blood Glucose Screening

Fasting Plasma Glucose (mg/dL)	Result
<100	Normal fasting glucose
100–125	Prediabetes
>126 on two measurements	Diabetes mellitus
≥200	Diabetes mellitus

The majority of patients who require lower-extremity amputation will present initially with a foot ulcer. A thorough history and physical examination is the cornerstone for developing an effective treatment plan and limiting the extent of amputation required. Pertinent questions include a history of previous ulceration and length of healing involved. For example, how long has the current ulcer been present? Does it appear to be healing with healthy granulation tissue? Signs of systemic infection including fever, chills, and difficulty with glucose control should be solicited. If the patient has been recently hospitalized or immobilized, a pressure etiology must be suspected, especially for ulcers in the posterior heel location. The patient's functional status and capacity for independence will also help determine the ideal amputation level.

Physical examination of the involved extremity is essential. Pulses should be palpated manually, and with handheld Doppler as necessary, in the femoral, popliteal, posterior tibial, and dorsalis pedis artery locations. In the foot itself, look for any structural deformity, which is simply defined as a contracture that cannot be manually reduced. Investigation of the circulatory status of the patient begins with the history and physical examination and proceeds to the noninvasive laboratory. Ankle brachial indices are obtained first, with normal findings usually defined as >0.95. Unfortunately, the calcified arterial media in many diabetics lead to falsely elevated readings; therefore, we augment our investigation with pulse volume recordings and toe pressures when possible. Transcutaneous oximetry ($TcPO_2$) has been advocated by many practitioners as both a screening test for peripheral vascular disease as well as a marker for determining healing potential. It is important to note that oximetry measures oxygen partial pressure in the adjacent skin and not in the wound itself. Also, after revascularization the maximum measured increase in

$TcPO_2$ may be delayed by as much as 72 hours.

Limited joint mobility is a marker for diabetes and a risk factor for ulcer formation. Fissures and calluses may mask underlying wounds. All toenails should be inspected for both fungal infection and as a possible source of pressure ulceration. The performance of a 10 g Semmes-Weinstein monofilament test on three ipsilateral foot sites (heel, first and fifth metatarsal areas) by an experienced physician is a well-validated and sensitive test for peripheral neuropathy.

The location and characteristics of a wound ulcer must be carefully examined and recorded. Constant low pressure such as that caused by ill-fitting footwear usually leads to medial ulceration. Plantar ulcers suggest repetitive stress to abnormal pressure points such as the metatarsal heads or the midfoot in the case of Charcot deformity. Circumferential involvement of the distal toes is suggestive of ischemic gangrene rather than trophic ulceration. Wound depth and size should be vigilantly measured, the latter preferably using wound tracing or digital planimetric assessment since manual measurements are notoriously inconsistent. Signs of infection such as drainage and erythema should be sought. Osteomyelitis can be assumed if bone is contacted during exploration of the ulcer with a sterile probe. The use of a documented ulcer classification system has many benefits including standardized communication among involved physicians, monitoring of wound healing, and as a tool to validate investigational treatment methods. Though the most popular system is the Wagner Ulcer Classification System (Table 211.2), the author prefers the newly validated Society for Vascular Surgery Wound, Ischemia and Foot Infection (WIfI) system (Table 211.3). The WIfI score is also very useful for limb salvage prognosis.

TABLE 211.2 The Wagner Ulcer Classification System

Grade	Ulcer
1	Superficial diabetic ulcer
2	Ulcer involves ligament, tendon, joint capsule, or fascia
3	Grade 2 ulcer with abscess or osteomyelitis
4	Partial forefoot gangrene
5	Extensive foot gangrene

TABLE 211.3 WIfI System Study Data Categories

Wound Characteristics
Wound Size
1 <1 cm
2 1–3 cm
3 >3 cm
Wound Depth
1 Ulcer not extending to SQ
2 Ulcer extending to SQ tissue
3 Ulcer extending to bone or joint space
Wound Type
1 Ulcer
2 Gangrene
Location
1 Forefoot
2 Midfoot
3 Heel

Infection Categories

1 None
2 Erythema
3 Purulence
4 Systemic evidence of infection

Ischemia Categories

1 TP >60 mm Hg/ABI >0.9/Palpable pulse/AP >80 mm Hg
2 TP 30–60 mm Hg/ABI 0.5–0.9/AP 50–79 mm Hg
3 TP <30 mm Hg/ABI <0.5/AP <50 mm Hg

Data from Mills JL, Conte MS, Armstrong DG. et al. The society for vascular surgery lower extremity threatened limb classification system: Risk stratification based on wound, ischemia, and foot infection (WIfI). *J Vasc Surg* 2014;59(1):220–34.e2.

Though a simple probe examination will uncover many cases of osteomyelitis, in nearly one third of patients it will be nondiagnostic. Therefore, if bone is not readily encountered during the sterile probe examination, the next step is to obtain plain x-ray imaging of the foot. Classic findings of osteomyelitis on plain film are demineralization, periosteal reaction, and bony destruction, whereas lesser signs include effacement of fat planes and soft tissue edema. It is important to note that these findings may be delayed or absent in early cases. In addition, osteomyelitis is rare without a point of entry; if bone degradation is present with intact skin, osteoarthropathy should be suspected. Clinically, osteoarthropathy occurs in a midfoot location and is polyarticular in nature, whereas osteomyelitis is found most frequently as a focal cortical lesion in the toes or metatarsal heads. If x-ray imaging is negative, MRI may be helpful and has high sensitivity and a high negative predictive value. However, the presence of neuroarthropathy or chronic bone changes due to trauma, surgery, or arthritis will adversely affect the sensitivity and specificity of MRI. Other diagnostic modalities include tagged white blood cell scanning and CT imaging, but the authors would recommend open or image-guided bone biopsy as the next diagnostic step if the presence of

osteomyelitis remains in doubt.

TREATMENT

The Team Approach

The core team consists of a vascular surgeon and a podiatrist trained in the management of complex foot wounds, although often general surgeons, plastic surgeons, and orthopedic surgeons contribute. Rehabilitation specialists and prosthetists are invaluable postoperatively. Screening and referral to a multispecialty foot care clinic has shown to be the most effective method for preventing amputation in high-risk individuals.

Avoiding Amputation

With a properly executed treatment plan, most noninfected, nonischemic wounds will heal without amputation. The first step is to perform a sharp debridement of the wound until all margins are healthy, bleeding tissue. After all nonviable tissue is removed, a culture can be taken from the deepest portion. The most common organisms cultured are Gram-positive cocci, but diabetic wounds are known to be polymicrobial with aerobes and anaerobes present. Antibiotics should be administered as appropriate. Failure to clear minor infections within a month or so should alert the physician to underlying osteomyelitis and/or vascular insufficiency. Prolonged IV antibiotics almost never lead to cure.

After debridement the wound should be offloaded with total contact casting or a nonremovable fiberglass cast. These have been demonstrated to be more effective than traditional dressing changes in decreasing infection and promoting ulcer healing. Good evidence is lacking for the use of felted foam or pressure-relief half-shoe.

There is a myriad of adjunctive wound healing techniques that have marginal evidence. Human skin equivalent stimulates tissue growth via cytokine stimulation and dermal matrix components. Its benefit in ulcer healing, limb salvage, and preventing osteomyelitis has been demonstrated over saline and gauze in high-quality randomized controlled trials. Cost and availability limit its use.

TABLE 211.4 Independent Predictors of Limb Loss as Determined by Logistic Regression Analysis

Risk Factor	Wald Test	OR	95% CI
ESRD	$P < 0.01$	1.72	1.12–2.83
TMA[a]	$P < 0.01$	1.62	1.15–1.93
Subsequent bypass[b]	$P < 0.005$	2.11	1.39–4.21

OR, odds ratio; CI, confidence interval; ESRD, end-stage renal disease; TMA, transmetatarsal amputation.
[a]A transmetatarsal as the initial amputation level.
[b]A revascularization performed after the minor amputation, ≤30 days.

Systemic hyperbaric oxygen increases oxygen partial pressure in tissues and is reimbursed by the Center for Medicare and Medicaid Services for a variety of conditions. Studies regarding its use for ulcer healing, however, have been poorly designed and there remains no high-quality evidence for its use in this condition. We currently advocate hyperbaric therapy only in the case of the severely infected diabetic ulcer, and even then only as an adjunct to proper surgical treatment.

Evidence is lacking regarding topical growth factors whether they are platelet-derived, protein-based, or epidermal. Similarly, the use of retinoids and human cultured dermis has not been adequately investigated. We currently encourage practitioners to avoid the use of any of these adjuvants except as part of a randomized, controlled trial.

Timing of Revascularization in Setting of Minor Amputation

The performance of a delayed bypass after amputation was found to independently predict limb loss (Table 211.4). In addition, the patients who converted to a major amputation within 30 days of the original minor amputation had a significantly reduced life expectancy (Fig. 211.1). Though survival and limb salvage are obviously complex outcomes with many confounding variables, these results do stress the importance of accurately predicting healing ability after minor amputation, as failure of minor amputation often leased to major amputation. Any deferment of a necessary bypass is predictive of treatment failure and limb loss. Our protocol for dealing with forefoot ischemia in patients with peripheral vascular disease is as follows:

1. Prompt and complete surgical drainage of any underlying infection. Debridement of uninfected necrotic tissue is not performed initially in ischemic wounds.
2. Institution of broad-spectrum antibiotics pending culture results.
3. If a clearly palpable dorsalis pedis or posterior tibial artery pulse is not

present, angiography is performed.

4. Intra-arterial digital subtraction angiography is then obtained with anterior–posterior and lateral views of the involved foot.
5. Revascularization is then performed either through endovascular means or a bypass to the most proximal vessel that will yield a palpable pulse in the foot.
6. Final debridement, amputation, and wound closure can then be accomplished under conditions of optimal perfusion. This is often done concurrently with the bypass.

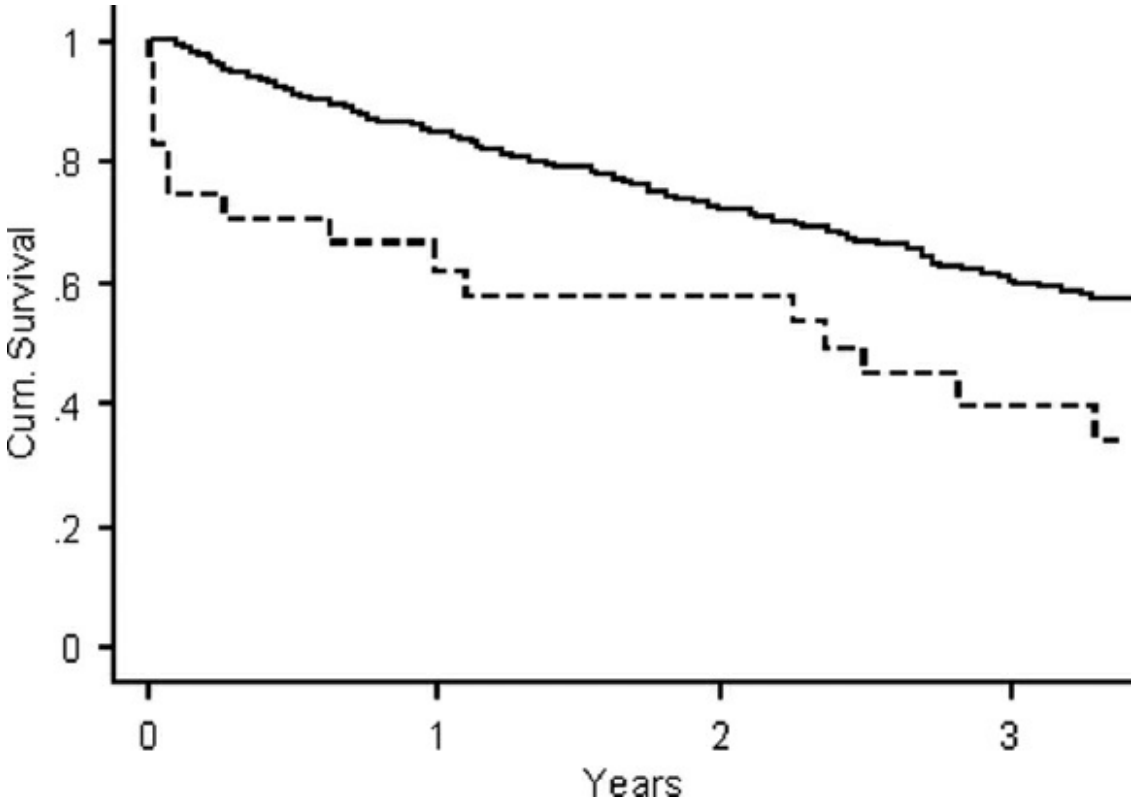

Figure 211.1. Kaplan–Meier analysis demonstrating survival for all individuals in the series. Patients have been divided into two groups representing those who required a major ipsilateral amputation ≤30 days of their initial minor amputation and those who did not. Standard error is <10% in the displayed series. *Solid line*, no early major amputation; *dashed line*, early major amputation ($P < 0.01$).

INDICATIONS

The goals of minor amputation surgery are to:

1. Remove anatomic pressure points and prevent recurrent ulceration.
2. Remove osteomyelitic bone and drain infection.

3. Preserve and restore the foot to optimum ambulatory function.
4. Control and relieve pain.

A simple toe amputation is indicated in the case of irreversible tissue loss or osteomyelitis of one toe distal to the proximal interphalangeal joint. The more extensive ray amputation is performed when gangrene or osteomyelitis extends to the web space, metatarsophalangeal joint, or metatarsal head. Other indications for ray amputation include the need to decompress one deep fascial compartment or extension of skin necrosis past margins acceptable for a simple amputation.

The basic indication for transmetatarsal foot amputation is irreversible tissue loss or infection extending beyond the boundaries of a single-ray amputation but still allowing for the creation of a viable plantar flap. Many patients undergoing TMA have had previous ipsilateral foot procedures such as ray amputation and incision and drainage. Common scenarios include failure of previous toe amputation, the need for multiple-ray amputations, forefoot infection involving multiple deep fascial compartments, forefoot deformity causing severe disability, and intractable pain. As a TMA spares the tibialis anterior, peroneus longus, and peroneus brevis tendon insertions, it is a much more functional amputation than the Lisfranc, Chopart, or Syme. These latter three, in the authors' opinion, provide little to no advantage over a below-knee amputation.

Relative contraindications to a minor forefoot amputation include extensive tissue loss especially on the plantar aspect of the foot, untreatable foot ischemia, knee contractures, and immobility without chance for rehabilitation. These conditions usually necessitate a major amputation. Patients with forefoot sepsis do not have the option to wait for revascularization. They should undergo debridement urgently, as this is a true surgical emergency. This presentation usually includes drainage, cellulitis, hyperglycemia, fever, and leukocytosis and occasionally organ failure. Findings of forefoot sepsis may be more subtle, particularly in the diabetic where we have found that the development of unilateral dorsal forefoot edema in the absence of trauma is pathognomonic for ascending infection and immediate debridement should be considered even in the absence of other objective findings. Stab incisions should be avoided. They do not allow for the proper wide debridement that is necessary in these potentially lethal infections. Delaying debridement can lead to a nonsalvageable foot.

SURGICAL TECHNIQUE

In general, most solitary minor foot amputations can be performed under local or regional block with monitored intravenous sedation. If infection or cellulitis is present, local anesthesia may be ineffective and a block should be performed above the level of infection. Many patients will already have a profound neuropathy. If a concomitant arterial bypass is planned, general anesthesia is preferred.

Transphalangeal Toe Amputation

The foot is prepped and draped to the knee using sterile technique. The incision is made at the level of the midproximal phalanx down to the level of the bone. The incision should be circumferential rather than fish-mouth when possible to avoid compromising blood supply to the flap. In case of the first toe, the approach may be altered to include a plantar flap if possible (Fig. 211.2). The periosteum is stripped with an elevator. The bone is then transected with an oscillating saw at the proximal phalangeal level, ~1 cm proximal to the level of the skin incision. In first toe amputations, the metatarsophalangeal joint should be spared as possible to improve gait stability. The tendons are pulled down, sharply divided, and allowed to retract. After hemostasis is obtained and the wound is irrigated, the skin is closed without tension in an anterior–posterior orientation. Interrupted monofilament sutures are preferred. Dry gauze dressing is applied and full weight bearing is avoided until wound healing has occurred.

Transmetatarsal (Ray) Toe Amputation

The foot and leg are prepped to the thigh and draped using a sterile technique. A racquet-type longitudinal incision is made on the dorsum of the foot parallel to the metatarsal bone extending on each side of the toe as a semielliptical incision converging on the plantar surface of the foot. This so-called racquet incision with wedge resection of the involved toe and metatarsal bone is demonstrated in Figure 211.3. A circular-type incision should be avoided if primary closure is to be attempted, as there will be less tension in the closure of an elliptical incision, and therefore greater chance of wound healing. A ratio of incision length to width of at least 3:1 will aid primary closure. If ulceration is present on the plantar surface at the level of the metatarsal head, this may be included in the excision as

well. Preoperative assurance of adequate circulation is critical to the healing of this amputation type, and is often the longest duration to heal.

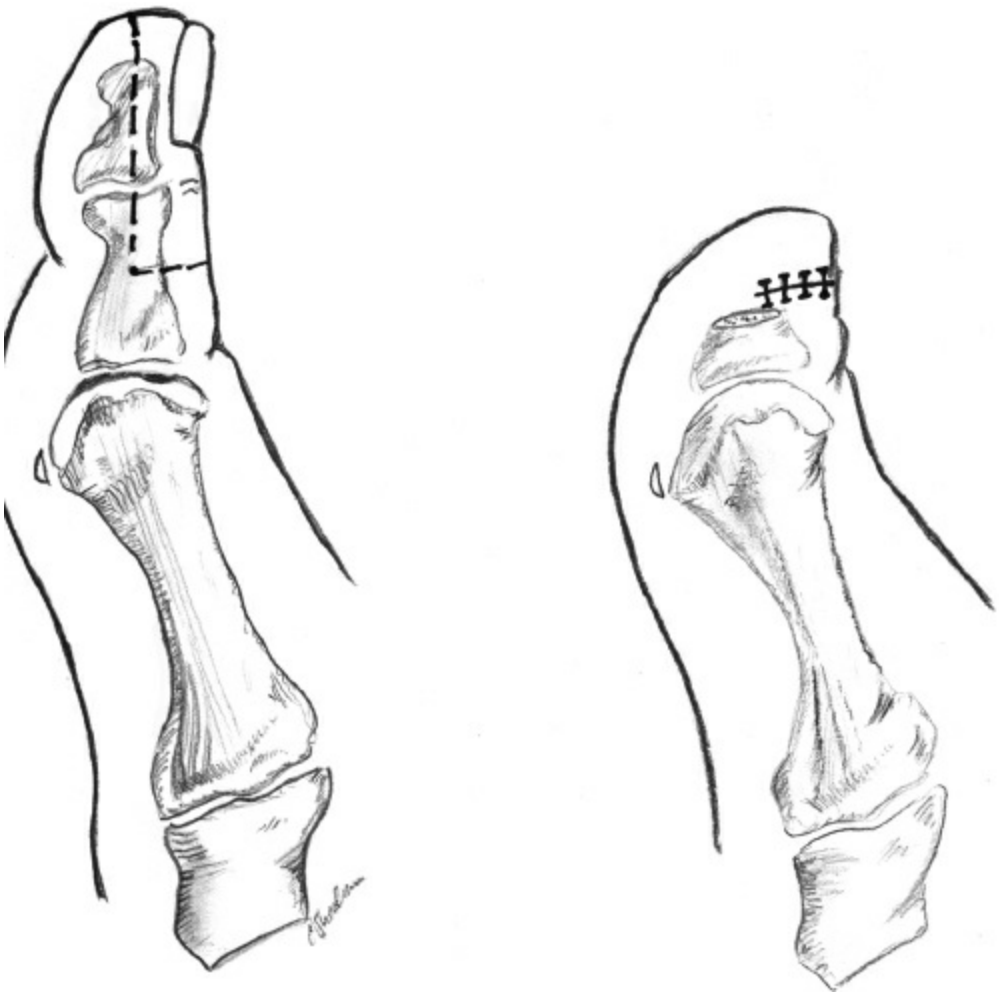

Figure 211.2. Digital amputation of the first toe demonstrating an alternative skin incision yielding a plantar flap.

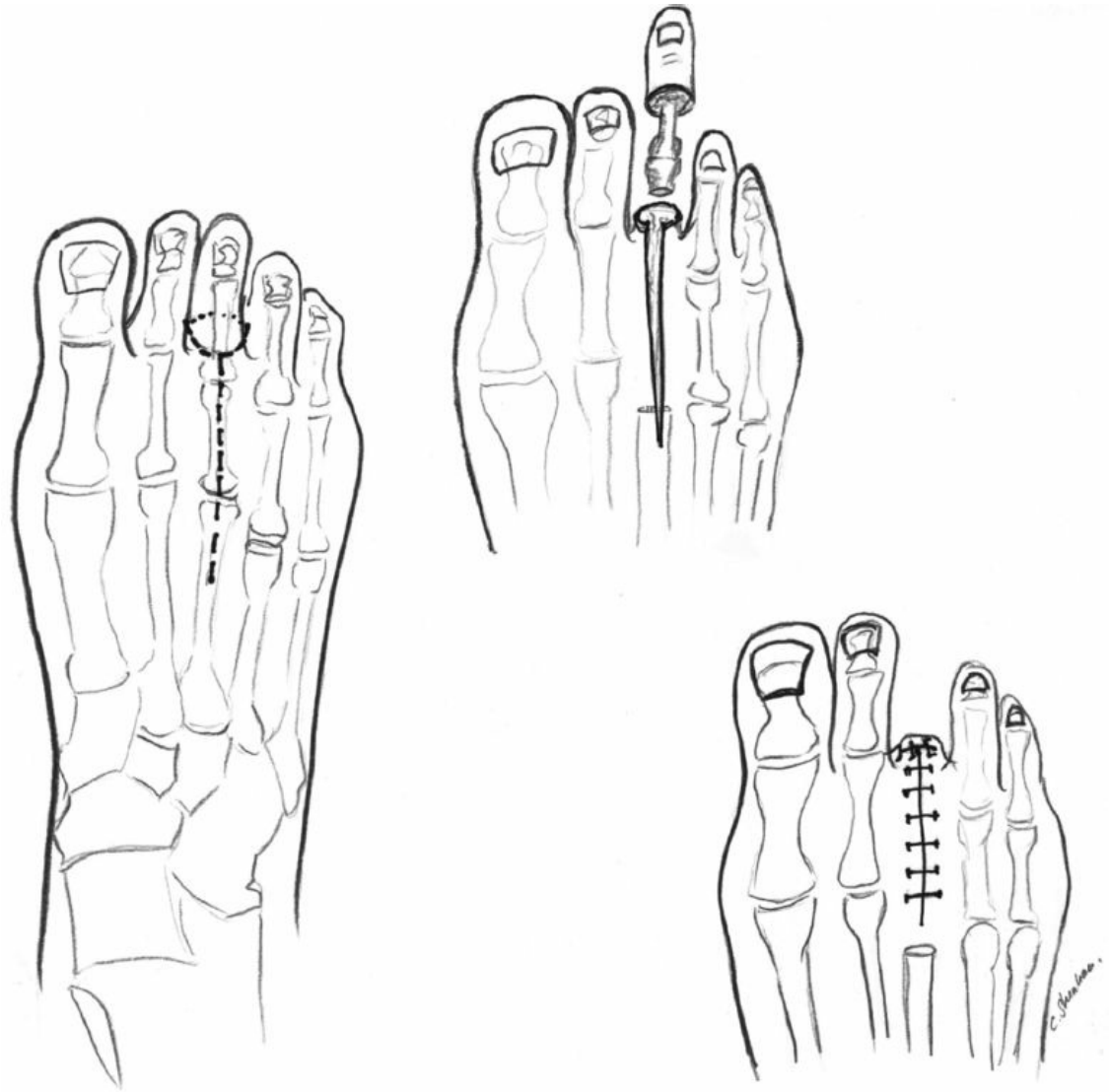

Figure 211.3. Ray amputation of the third toe with a “racquet” incision.

The initial incision is carried down to bone and the toe is disarticulated at the metatarsophalangeal joint. The periosteum is elevated circumferentially down the shaft of the metatarsal bone as far proximally as necessary. This is determined based on preoperative imaging of bony involvement of infection as well as intraoperative inspection of the quality of the viable tissue and extent of infection. It is only rarely necessary to extend this to the level of the metatarsal–cuneiform joint. In the case of the second, third, or fourth toe, removal of the entire metatarsal disrupts the Lisfranc joint, leading to foot instability. The bone is then transected at the proximal diaphysis or the diaphyseal–metatarsal junction. This is best accomplished using an oscillating saw rather than rongeur as splintering is sure to occur with the latter. The bone is passed off, and if wound healing

parameters are found to be adequate, primary closure may be performed after irrigation. Interrupted monofilament sutures are placed in the skin. There is no role subcuticular sutures in these wounds. Dry gauze dressing is applied taking care to avoid contact of tape with the skin. Full weight bearing should be avoided until wound healing has occurred, generally about a month.

If the amputation is being performed for control of forefoot sepsis, the wound is left open. Special considerations should be made in this setting when making the initial incision to protect the future plantar flap for TMA closure. If ischemic eschar is present that is not part of the immediate infectious process, it should not be debrided at the initial drainage procedure as this can ultimately hurt the chances of creating a functional foot. After removing the head of the metatarsal, the foot is then assessed for ascending infection. In compressing the foot if pus is noted along the extensor or flexor tendons, these compartments are opened for more aggressive drainage. After draining all purulence and debridement of all involved tissue, aggressive irrigation is undertaken. We use a power irrigation and suction system with 3 L of antibiotic mixture. The wound is then left open to either heal by secondary intention or delayed primary closure. Postoperative care of the open wound should include moist saline gauze dressings changed twice daily. Cultures are obtained during the debridement and appropriate antibiotics are administered until all objective parameters of infection have resolved. If osteomyelitis was present, intravenous antibiotics are continued for a total of 6 weeks after debridement.

In the case of a first-ray amputation, the incision is made as two curvilinear lines on both the dorsum and plantar surfaces of the foot, extending down to the level of the bone, exposing the metatarsal head. The flexor hallucis tendon will be visible and is usually sacrificed to prevent recurrence of infection. The sesamoids should now be apparent and are resected as well. When transecting the first metatarsal head, as much of the metatarsal should be left behind as possible to maintain function without leaving infected bone. The shaft is cut obliquely to prevent prominence of the bone afterward which could lead to pressure ulceration. The skin is closed with interrupted, nonabsorbable, monofilament sutures. Deep sutures are avoided due to the risk of retained infection. Often, first-ray amputations do not allow for primary closure given the extensive tissue loss. Again, these may be left to heal by secondary intention or delayed

primary closure with skin grafting in some cases.

For a fifth-ray amputation, an incision is made directly over the metatarsal shaft and extended down to encircle the fifth toe. Again, as in the first-ray amputation, the cut in the metatarsal shaft is made obliquely to avoid protrusion of bone.

Transmetatarsal Foot Amputation

The entire leg and foot are prepped and draped using sterile technique. If the blood supply to the foot is normal, exsanguination and a tourniquet may be desired. First, a transverse incision is made on the dorsum of the foot at the midmetatarsal level. A right-angle turn is performed at the medial aspect and the incision is extended around the foot to the plantar surface at the level of the metatarsophalangeal joints (Fig. 211.4). The incision is sharply carried through the tendons and neurovascular structures to the bone. Large vessels, such as the dorsalis pedis artery, should be ligated. The extensor tendons are pulled out, sharply divided, and allowed to retract. Examine the tendon sheaths for pockets of infection. The plantar fascia and fat pad are included in the flap. As Dr. Sanders demonstrated in 1997, the plantar incision line can be modified to include excision of an ulcer (Fig. 211.5). The periosteum of the metatarsal shafts is elevated circumferentially to the level of the intended transection. Retract the skin flaps carefully and transect the bones with an oscillating or Gigli saw at the midmetatarsal level, ~2 cm proximal to the skin incision, thereby preserving the insertions of the peroneus longus, peroneus brevis, and tibialis anterior tendons. Manual bone cutters are to be avoided as they cause bone splintering and may also lead to unwanted bone regrowth which can precipitate late ulceration. The first and fifth metatarsal bones are transected in an oblique fashion to avoid bone protrusion, the first in a medial and plantar direction, the fifth laterally and plantar. Any sesamoids should be resected. The second through fourth metatarsals should be divided in a parabolic manner with a longer cut on the dorsal aspect, beveling in the plantar direction. Care must be taken to divide all of the metatarsals at the same length. The divided bones are reflected upward proximally to distally and the amputation is completed at the level of the plantar flap. All neurovascular structures are ligated. Carefully remove all nonviable tissue. Resect the flexor tendons in a similar manner to the extensors, again inspecting the sheaths for residual infection. The key to success in this procedure is a thick, well-vascularized plantar flap that can

be closed without tension. Release the tourniquet if one was placed. Irrigate copiously with normal saline solution. Allow at least 2 to 3 minutes after tourniquet release to assure hemostasis. A drain can be placed if prolonged bleeding is encountered, but this is not our usual practice. The skin is closed with interrupted vertical mattress monofilament sutures. Just enough tension is applied to barely approximate the skin edges as postoperative edema will occur. Skin is at a premium here and great care should be used in its handling. Potentially ischemic wounds are closed once infection is controlled as the limited circulation will not lend itself to effective granulation of the wound. The foot is dressed with a soft, circumferential dressing from the stump to the midshin. If the incision was not left open, we splint the foot in neutral position to prevent equinus contracture.

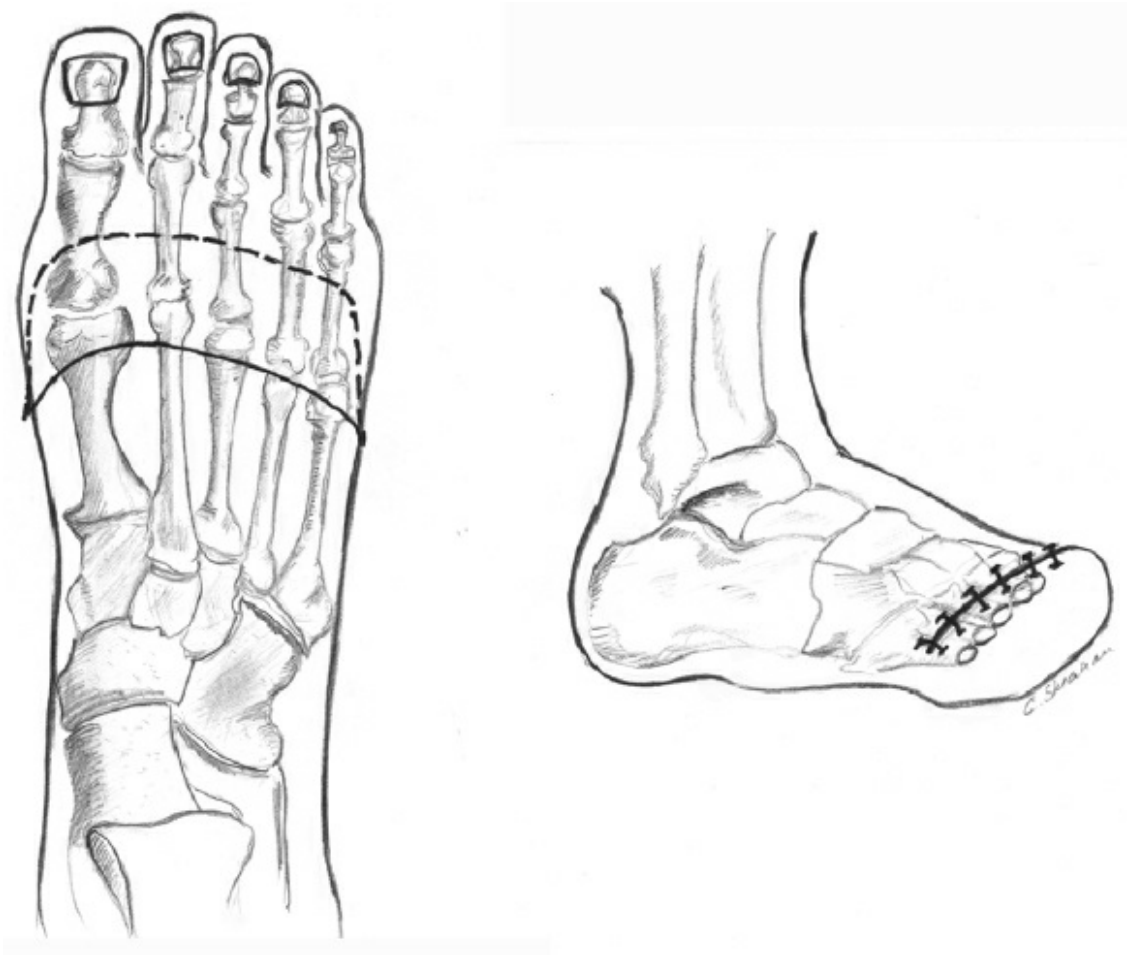

Figure 211.4. TMA with long plantar flap.

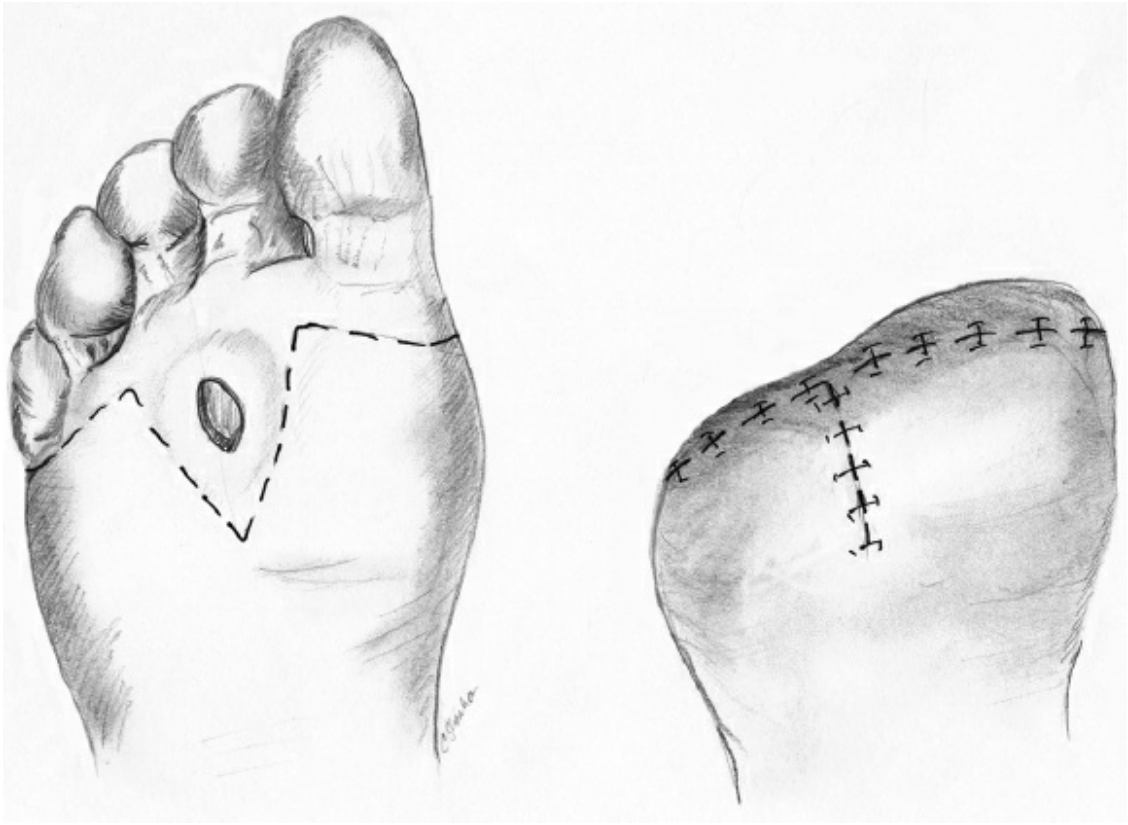

Figure 211.5. An alternative incision for TMA allowing for the excision of a plantar ulcer.

Postoperative Management

In the case of a simple toe or ray amputation, an early evaluation by a prosthetist for shoe fitting is vital. Cane-assisted ambulation can begin early, usually within 24 hours. If the wound was left open, dressing changes should be provided twice a day with normal saline and sterile gauze. If packing was required, this should be reduced on a daily basis to allow for wound contraction. Full weight bearing should be delayed until complete wound healing. Culture-directed antibiotics are administered as indicated and the sutures are left for at least 14 days, but there is no evidence for duration of antibiotics once the osteomyelitic bone is removed.

After a transmetatarsal foot amputation, the patient remains strictly non–weight bearing until the incision is completely healed. If a drain was placed, it should be removed within 24 to 48 hours. The foot and ankle are elevated as often as possible, especially in the early postoperative period. Sutures are left in place for 2 to 4 weeks. If the incision was not left open, we prefer to splint the foot in neutral position until ambulation. In preparation for ambulation, a prosthetist should evaluate for appropriate

footwear. Some patients will require a functional brace or molded footwear, but most will need only a shoe with insert. After ambulation, the patient should be monitored for transfer ulcers.

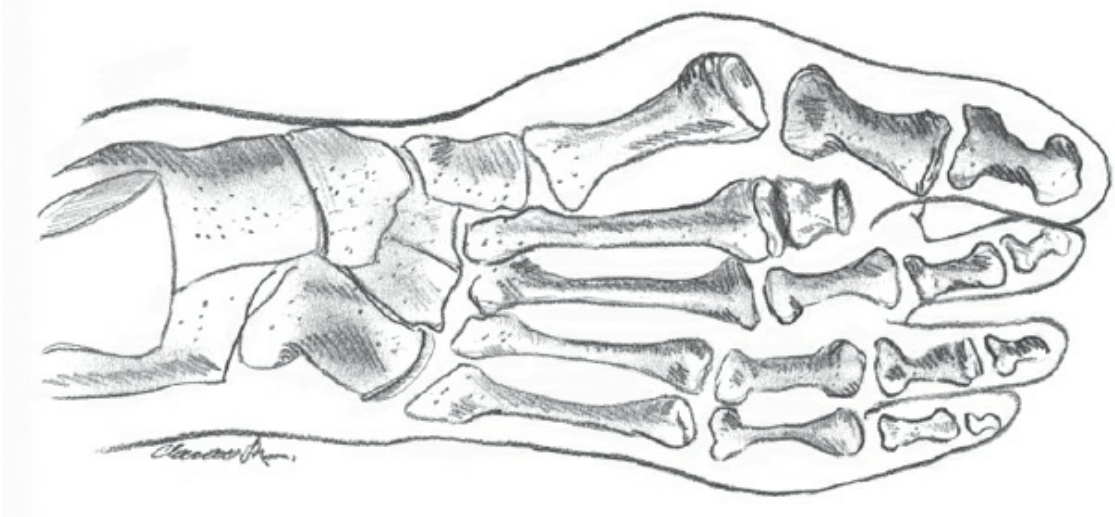

Figure 211.6. Hallux valgus deformity of the first toe after second toe amputation.

COMPLICATIONS

Failure to heal suggests vascular insufficiency, persistent infection, or malnutrition. Premature weight bearing is another culprit. Most simple toe amputations are tolerated well with few gait disturbances. Resection of a lesser toe rarely results in long-term disability with the exception of the second toe which may precipitate a hallux valgus deformity (Fig. 211.6). A spacer can prevent this medial deviation of the first toe.

The first toe is important for propulsion and even a simple amputation can cause problems in this regard. In addition, abnormal pressure may be placed on the plantar aspect of the second or even first metatarsal head after first toe amputation. These issues can be prevented or corrected with orthotics. A ray amputation of the first toe is even more likely to cause a transfer lesion to the second metatarsal head or occasionally the tip of the second toe. This can be severe enough to require conversion to TMA. Other mechanical complications of first-ray amputation include increased pronation during ambulation and midtarsal Charcot deformity.

Ray amputations of the other toes are usually well tolerated. The fewest complications occur when the third metatarsal is amputated. Again, occult sources of deep space infection should always be suspected when poor wound healing is displayed.

Soft tissue contracture after transmetatarsal foot amputation often leads to an abnormal plantar flexion or equinus deformity. Achilles tendon lengthening procedures are a reasonable option to correct this condition. Improper bone resection can cause pressure points in the stump leading to skin breakdown and ulceration. Treatment is usually reoperation with resection of the involved metatarsal. Intractable pain will require conversion to a major amputation. Because of the prolonged non–weight-bearing status after a TMA, these patients are at increased risk for deep venous thrombosis and pulmonary embolus.

Outcomes

There are surprisingly few studies in the literature addressing long-term outcomes after lower-extremity minor amputation. In our mainly diabetic series of 670 patients, limb salvage was 89.8% at 1 year and 82.3% at 5 years. Limb loss was associated with ESRD and the need for an initial amputation at the transmetatarsal level. As mentioned earlier, the need to perform a bypass subsequent to the amputation was an independent predictor of limb loss. Overall patient survival was 83.9% at 1 year and 43.5% at 5 years. Renal insufficiency and conversion to major amputation (Fig. 211.1) were associated with adverse long-term survival.

ACKNOWLEDGMENT

We acknowledge Drs. Malichai and Claudie Sheahan for all their work on the 6th Edition Chapter.

Suggested Readings

Berceli S, Brown JE, Irwin P, et al. Clinical outcomes after closed, staged, and open forefoot amputations. *J Vasc Surg* 2006;44:347–51.

Brem H, Sheehan P, Boulton AJ, et al. Protocol for treatment of diabetic foot ulcers. *Am J Surg* 2004;187:1S–10S.

Clayton W, Elasy T. A review of the pathophysiology, classification, and treatment of foot ulcers in diabetic patients. *Clin Diabetes* 2009;27:52–8.

Henke PK, Blackburn SA, Wainess RW, et al. Osteomyelitis of the foot and toe in adults is a surgical disease: conservative management worsens lower extremity salvage. *Ann Surg* 2005;24:885–92.

Hingorani A, LaMuraglia GM, Henke P, et al. The management of diabetic foot: a clinical practice guideline by the society for vascular surgery in collaboration with

the American podiatric medical association and the society for vascular medicine. *J Vasc Surg* 2016;63:3S–21S.

LoGerfo FW, Coffman JD. Current concepts. Vascular and microvascular disease of the foot in diabetes. Implications for foot care. *N Engl J Med* 1984;311:1615–9.

Mills JL Sr, Conte MS, Armstrong DG, et al. The society for vascular surgery lower extremity threatened limb classification system: risk stratification based on wound, ischemia, and foot infection (WIfI). *J Vasc Surg* 2014;59:220–34.

Pomposelli FB, Kansal N, Hamdan AD, et al. A decade of experience with dorsalis pedis artery bypass: analysis of outcome in more than 1000 cases. *J Vasc Surg* 2003;37:307–15.

Rogers L, Andros G, Caporusso J, et al. Toe and flow: essential components and structure of the amputation prevention team. *J Am Podiatr Med Assoc* 2010;100:342–8.

Sheahan M, Hamdan A, Veraldi J, et al. Lower extremity minor amputations: The roles of diabetes mellitus and timing of revascularization. *J Vasc Surg* 2005;42:476–80.

EDITOR'S COMMENT

In this chapter by Dr. Henke entitled "minor amputations," I have to beg the question, is any amputation really minor? Both the physical and mental ramifications of even a minor amputation are often real, impacting ambulation and overall body image. The idea of better foot care following an amputation speaks to the question: What is the likelihood that a patient who necessitated an amputation to begin with can now control their blood glucose, stop smoking, and get some better foot care?

There is little doubt that multidisciplinary care is critical in providing, especially diabetics, better care. In a recent review, Salvo and coauthors state that "it makes inherent sense that a multidisciplinary team approach to these patients is necessary." (Salvo NL, Walsh MD, Brewster LP. Promoting limb salvage through multi-disciplinary care of the diabetic patient. *Curr Treat Options Cardiovasc Med* 2017;19(7):55). In this review, they suggest that the fields of podiatric surgery/medicine, vascular and plastic surgery, all be used in combination to introduce a multidisciplinary limb salvage center that can result in saving lives and limbs of patients, especially those with diabetes.

In an interesting article published by the Vascular-Independent Research and Education-European Organization 9, the authors clearly state that our renewed goal should be to eliminate amputations (Kolossváry E, Farkas K, Colgan MP, et al. "No more amputations": a complex scientific problem and a challenge for effective preventive strategy implementation on vascular field. *Int Angiol* 2017;36(2):107–15). This means shifting the focus from the performance of

minor amputations to a more intense program of diabetes and risk factor modification. They state that “as a consequence of critical limb ischemia, often associated with diabetes, it is highly critical to health care service aiming at prevention of limb loss. Understanding of the nature and complexity of amputation scenarios is paramount for the effective preventive strategy planning and implementation. Lower limb vascular amputations represent a lifetime risk; therefore, not only the effective revascularization is to be achieved, but the importance of the early recognition of peripheral arterial disease, no delay in referral to special vascular care, effective vascular risk prevention, and collaboration in multidisciplinary teams should be also emphasized.” I think this statement very eloquently suggests that we should manage these patients’ risk factors better.

The question is always what patient starts with a minor amputation and then progress to a major amputation. In an article from the Orthopedic Surgery literature, the authors examined risk factors for major lower extremity amputation (LEA) after minor foot amputation in diabetic patients. A total of 163 diabetic patients had undergone an initial minor foot amputation and then had undergone at least one subsequent major or minor LEA. Among the many risk factors examined, there were no statistical differences found between the two groups in terms of hemoglobin A1c, smoking status, chronic kidney disease, end-stage renal disease requiring dialysis, kidney or kidney–pancreas transplantation, or vascular intervention (peripheral arterial bypass). Interestingly, there was a significant difference in the minor group (22.2%) versus the major group (71.2%) in terms of severe peripheral arterial disease (PAD, $p < 0.001$). The take-home message demonstrates the importance of assessing peripheral vascular disease in all diabetic patients with minor LEA. The authors conclude by suggesting that “early referral to a vascular surgeon might delay (or prevent) major LEA.” (Nerone VS, Springer KD, Woodruff DM, et al. Reamputation after minor foot amputation in diabetic patients: risk factors leading to limb loss. *J Foot Ankle Surg* 2013;52(2):184–7.)

Finally, based on the above and a lifetime of practicing vascular surgery, I just have to make a plea for vascular surgeons to continue to stay at the forefront of vascular care in patients with diabetes and peripheral arterial disease. Especially following endovascular therapy, there are a myriad of patients who get an intervention from a nonvascular surgeon and then sent to a vascular surgeon for a minor amputation. Really, no other specialties other than vascular surgeons have the full tool kit to manage these complex patients from risk factor modification to amputation (Robinson WP, Loretz L, Hanesian C, et al. Society for Vascular Surgery Wound, Ischemia, foot Infection (WIfI) score correlates with the intensity of multimodal limb treatment and patient-centered outcomes in patients with threatened limbs managed in a limb preservation center. *J Vasc Surg* 2017; pii: S0741–5214(17)30375–0 [Epub ahead of print]).

Please stay involved and lead the way in preventing amputations, even “minor amputations.”

Gilbert R. Upchurch, Jr

212 Major Lower Extremity Amputation

Mark R. Nehler

INTRODUCTION

The exponential increase in various endovascular techniques for limb salvage in critical limb ischemia (CLI) has changed the patient population undergoing amputation. Historically, many patients needing amputation had undergone multiple failed open procedures with substantial morbidity. Prior incisions made subsequent amputation more difficult and retarded primary flap healing. However, despite these advances in revascularization, large registries including the Department of Veterans Affairs National Surgical Quality Improvement Program (NSQIP) and the National Hospital Discharge Survey (NHDS) show minimal reduction in major lower extremity amputations in the United States. The aging of the US population, uneven access to care, continued increase in patients with end-stage renal disease, and the relatively short patency of many endovascular interventions are major reasons for this. Therefore, major lower extremity amputation will continue to be a common operative procedure for the general and vascular surgeon.

INDICATIONS

The three most common indications for major lower extremity amputation are chronic CLI, major infection due to diabetic malperforans ulcers with normal arterial circulation, and acute limb ischemia. The first two have significant clinical overlap, with many diabetic patients having poor or marginal circulation suffering neuropathy and malperforans ulcers as an initiating event leading to eventual limb loss. Failure to recognize the arterial ischemia leads to a significant amount of unnecessary limb loss due to delay in referral for potential revascularization often following failed forefoot directed amputations. This ultimately leads to limbs not considered salvageable due to extensive pedal necrosis or who fail to salvage despite successful revascularization due to the same. Recent trends

in a primary endovascular approach to revascularization have helped this issue twofold: (1) Patients with comorbidities who would not be considered for bypass are undergoing endovascular revascularization, and (2) there is a larger group of clinicians from different specialties with endovascular skills who are providing care for the population.

Acute Limb Ischemia

Most occlusions in acute limb ischemia involve the popliteal or more proximal arteries, and therefore significant muscle beds are usually threatened. The majority of acutely threatened limbs have some attempt at salvage, so the majority of amputations in acute limb ischemia occur in patients suffering from the morbidity of a revascularization procedure and often significant reperfusion injury with rhabdomyolysis and renal damage. Because of the proximal nature of the ischemia, most major amputations are at the knee level or above. Currently in the United States, many patients with acute limb ischemia also undergo primary endovascular therapy; however, prior incisions can complicate amputation flaps. Acute limb ischemia patients are often receiving anticoagulants for therapy of the underlying thrombotic or embolic event, further increasing the risk of hematoma and wound complications. Finally, increasing numbers of acute limb ischemia involve iatrogenic vascular injury or delay in diagnosis/referral, increasing the psychological complexity of the care and having medical legal implications. The need to perform a major amputation in that setting is especially problematic.

Chronic Critical Limb Ischemia

The majority of major lower extremity amputations are due CLI. Accurate guidelines on potential salvage of limbs based on revascularization potential and extent of necrosis are lacking in CLI, contrary to the care of aneurysm and carotid disease where practice patterns have been established with level 1 evidence. This leads to significant differences in limb salvage based on geography, access to revascularization and vascular imaging, and clinician experience in the use of open or endovascular techniques. There is a more granular scoring system for CLI—the Wound Ischemia foot Infection (WIfI) system proposed by the Society of Vascular Surgery that may help to stratify patients more accurately in the future. Unlike cardiac disease, there is no established route of access for suspected CLI to revascularization in modern health care systems, leading to

potential delays in referral and diagnosis, wide differences in practice patterns, and ultimately greater costs. Therefore, eventual amputees with CLI fall into two categories: (1) patients who are not offered revascularization either due to the extent of pedal necrosis on vascular presentation, failure to recognize CLI and futile forefoot amputations, and/or comorbidities (medical and/or functional) that would preclude same, or very rarely, anatomy not amenable to revascularization; and (2) patients who fail revascularization (either ongoing occlusion or ongoing pedal necrosis despite improved circulation). Most centers with aggressive limb salvage practice perform far fewer primary amputations than revascularizations, so that many patients with CLI who require amputation have had prior endo- or open revascularizations that have failed. Although several studies have demonstrated no effect of a failed infrainguinal revascularization on amputation level, below-knee amputations (BKA) after failed infrainguinal bypasses have greater wound complications and prolonged healing times. With the increase in endovascular techniques for CLI, these wound issues from prior bypass have been reduced.

Malperforans Ulcer/Normal Circulation

Patients with diabetes with normal circulation who develop overwhelming foot infections are another major amputee group. Typical patterns include first or fifth metatarsal osteomyelitis from a chronic malperforans ulcer in that location. Patients with Charcot foot can have chronic ulceration at the midplantar area due to chronic midfoot fracture, leading to osteophytes and pressure points. Many of these diabetic amputees have had prior digit or ray amputations that may have healed, only to have another malperforans ulcer occur in the adjacent digit as the initial amputation destabilizes the distribution of pressure on the remaining metatarsal heads. The cause of eventual limb loss in these patients is multifactorial. Poor compliance (often demonstrated in significantly elevated glycosylated hemoglobin values), obesity (increasing the pressure on the neuropathic foot when ambulatory), and inadequate footwear are major contributors. A less recognized but equally important cause is patient education. Many poorly educated diabetic patients assume that seeking health care for foot lesions will lead to a major amputation, and therefore delay care until a major amputation is inevitable, which continues to perpetuate this widespread fear. Another issue is access to care as many of these patients are in lower socioeconomic settings.

PREOPERATIVE PLANNING

General

Fewer vascular surgery procedures have the psychological and functional impact of a major lower extremity amputation. Amputation-free survival is considered the primary end point for any clinical trial for patients with CLI. However, in clinical practice, a number of variables can markedly change this end point that has no relationship to efficacy of therapy. Understandably, patients often adamantly refuse amputation. CLI (the most common indication for amputation worldwide) rarely results in overwhelming infection and imminent patient death if left untreated. Therefore, patient pain tolerance is often the deciding variable. Many patients turn to unproven therapies in desperation. The widespread use/advertising of wound centers gives patients hope that all wounds can ultimately be healed, but the reality is some wounds need to be removed. All of these issues increase amputation-free survival. Therefore, for many patients, the first step in preoperative preparation is the acceptance of the procedure—which frequently takes days to weeks and sometimes multiple visits to answer questions and work through the various stages of grief and loss—for the patient and family members. Often consultation with rehabilitation medicine, physical therapy, prosthetics, and even other amputees is very helpful in preparing the patient and family for the realities of life as an amputee.

Standard evaluation with a thorough history and physical examination should be performed in all patients. Active congestive heart failure, unstable angina, or concurrent myocardial infarction must be addressed. In the absence of active cardiac symptoms, evidence of congestive heart failure on history or physical examination, or acute changes on electrocardiogram, thorough cardiac evaluation is not routinely performed. It is important to recognize that most patients presenting for amputation have had limited activity and may not manifest covert cardiac disease due to the lack of physiologic stress, so even minor symptoms should be very concerning.

Beta-blockade prior to vascular surgery has become very controversial. Although a reduction in nonfatal myocardial infarction has been shown, increased risk of mortality and stroke is also felt to be a consequence. Therefore, the use of beta-blockade prior to amputation is not advocated. Management of associated hypertension, diabetes, and renal failure should be optimized. An aggressive approach to normalize glucose levels is

essential to ensure proper wound healing. The timing of hemodialysis in relation to operation is important in managing fluids and electrolytes in the perioperative period. Perioperative nutrition is critical, as many patients are depressed, manifested by severe emaciation. Depressed patients who are not eating or participating in their postoperative rehabilitation programs are at risk for a host of complications, including further nutritional depletion, incisional wound complications, decubitus ulcers, contractures, and deep venous thrombosis (DVT).

Finally, because of relative inactivity and frequent hypercoagulable states in the amputation population, venous thromboembolism is a major source of postoperative morbidity/mortality. Recent data would indicate the incidence is 15%. In addition to the risk of fatal pulmonary embolism, postoperative DVT may cause severe stump swelling and impaired primary healing of the amputation. Routine DVT prophylaxis and/or careful perioperative screening for DVT with duplex scanning in amputation patients appears prudent.

Determination of Amputation Level

The goals of major lower extremity amputation are several: to eliminate the nonviable tissue, to provide a stump that has the best chance to heal, and to provide a stump with the best chance of long-term function—ambulation with a prosthesis. However, which of these factors is the priority often depends on the age, baseline function, and comorbidities of the patient. On balance, it is important to avoid additional operative procedures in this compromised group of patients. In all reported series, healing of an above-knee amputation (AKA) is more rapid and involves less incisional complications than healing a BKA. However, any chance at rehabilitation and prosthetic use in older vascular patients requires the knee joint. Importantly, physicians and patients wish to preserve as much limb length as possible. More recently, the through-knee amputation has been advocated. With the use of a computerized C-leg prosthesis, patients have a much better return to ambulation than with an above knee ambulation due to the longer lever arm for mechanical advantage and balance. In addition, a through knee amputation has minimal muscle transaction and is considered to be faster and with less blood loss.

Worldwide, the ratio of AKAs to BKAs performed is 1. Many AKAs are performed in patients with limited rehabilitation potential and significant comorbidities, as the primary healing is better and there is a

risk of knee contracture in BKAs done in patients who are unable to participate in postoperative physical therapy. Despite this, most patients are considered for BKA due to a variety of reasons, and the surgeon needs to determine if a BKA will heal primarily. The arteriographic status of the ipsilateral profunda femoris artery has been a key component for success. A number of studies in the literature describe various circulatory measures to determine amputation level healing. As a general point, many of these techniques are not practical in clinical practice. A palpable pulse at a level immediately proximal to a proposed amputation has been associated with a 100% rate of healing. Most surgeons agree that a BKA without a femoral pulse is unlikely to do well. However, a palpable femoral pulse does not guarantee success. The clinical judgment of the operating surgeon (skin temperature, hair growth, tissue bleeding, viable muscle, and wounds without tension) has been demonstrated to be reasonably accurate (75% to 85%) in several large clinical series (combined, around 1,000 patients). Finally, despite the plethora of research regarding the technical aspects of salvaging the knee joint, the sobering fact is that many vascular patients will take minimal advantage of this in rehabilitation.

Thermography, skin perfusion via radioisotope injection, and segmental pulse volume recordings (PVRs)/limb pressures have been used to try to improve on the success of clinical judgment in predicting BKA healing. Each has limitations ranging from clinically impractical (thermography and skin perfusion) to not accurate due to calcified vessels (PVRs and pressures) in many amputees. Arguably the most reproducible noninvasive test used to determine BKA healing is transcutaneous measurement of the partial pressure of oxygen ($TcPO_2$). Measurements are obtained in the supine position by placing an oximetry probe on the skin in question and heating the area to 44°C. The generation of heat results in local skin hyperemia, a decrease in flow resistance, and subsequent arterialization of capillary blood. The probe then records skin oxygen tension reflecting the true arterial oxygen pressure in the area in millimeters of mercury. Absolute measurements, measurements compared to a control location such as the chest, and measurements compared to transcutaneous carbon dioxide values have been reported. Various studies have shown that $TcPO_2$ measurements of ≥30 mm Hg have an accuracy of 87% to 100% in predicting BKA healing. In addition, this technique can be used in patients with arterial calcification. However, supplemental oxygen can falsely elevate $TcPO_2$, and edema can falsely reduce $TcPO_2$.

SURGICAL TECHNIQUE

Basic Principles

The authors follow several general principles in amputation surgery. When at all possible, Esmarche bandages and tourniquets are used to minimize blood loss despite liberal use of the knife for dissection—supported by a single small comparative trial in the United Kingdom. The exceptions are diabetic patients with significant calcification where all is accomplished in reducing venous outflow and actually increasing venous bleeding. All major vessels are suture ligated. We do not use bone wax for control of any bone marrow bleeding, for concern of leaving a foreign body and potential infection. We transect both the tibia and the fibula with a saw, to avoid any spiral fracture of the fibula. Major nerves are transected short under tension, with minimal use of chromic ligatures to avoid excessive neuroma formation later and accepting some bleeding as a consequence. Care is taken to débride as much soleus from the BKA muscle flap to avoid a bulbous stump, as this is a difficult prosthetic fit. Some have recommended myodesis, with muscle flaps sutured to the bone, but currently that has not been our practice. Skin is closed with nylon suture in a vertical mattress with long ends, as we often leave the sutures in for several weeks (due to edema and concern for wound separation in patients who are often malnourished) and it helps with later removal in the clinic. We plan plaster casting of BKAs, usually within a few days. We have not done this with AKAs. We have also used subcutaneous and sub-fascial fenestrated catheters to deliver local analgesia via a computerized pump for 48 hours postoperatively with success.

Guillotine Amputation

If there is any question regarding uncontrolled pedal sepsis, a two-staged amputation should be considered. We have found that many diabetic patients in our practice present acutely with unsalvageable pedal sepsis and the majority of our BKAs end up being done in a two-stage manner. These are compromised patients with significant perioperative morbidity/mortality—much of which can be septic. Guillotine amputations offer the ability to remove the septic focus relatively quickly and also provide direct examination of the calf muscle compartments for septic extension. If discovered, a longitudinal incision either medially or laterally in the leg (similar to a fasciotomy) drains the affected compartment and

allows for debridement of nonviable muscle. The patient can be returned to the operating room for the BKA once the edema, fever, and leukocytosis have resolved (usually 3 to 5 days).

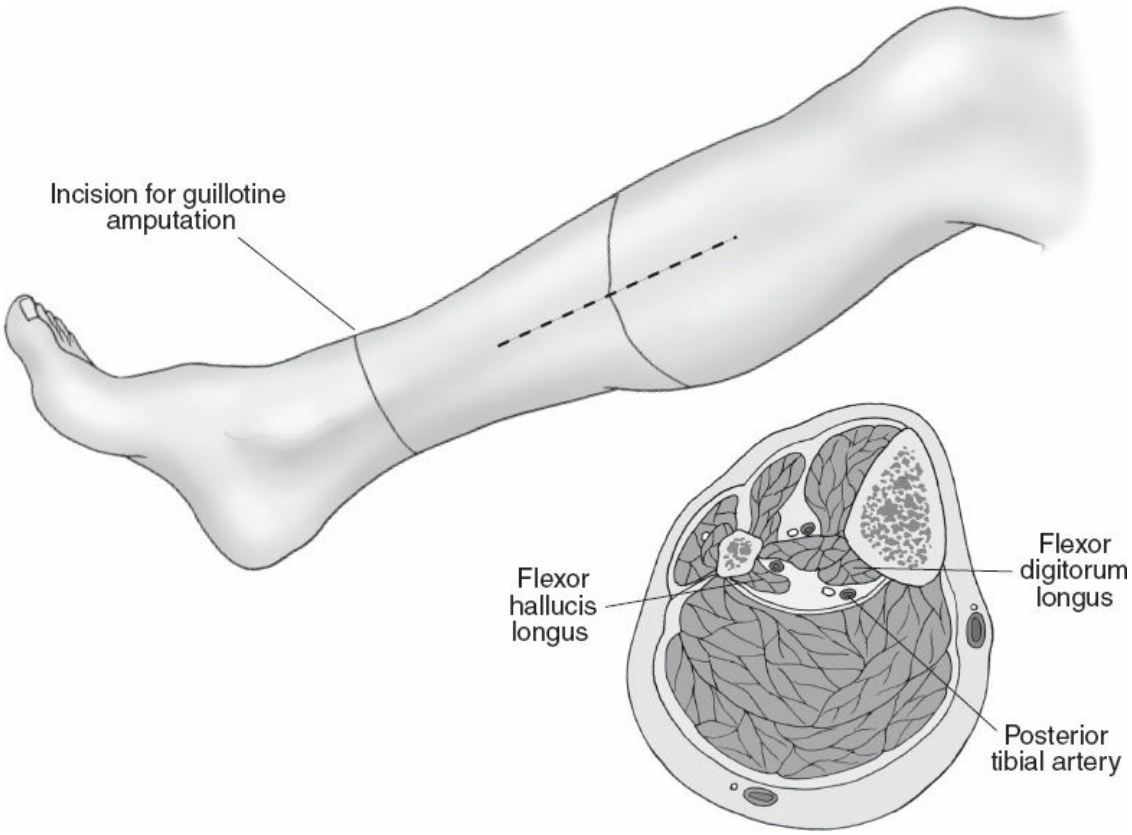

Figure 212.1. Skin incision for guillotine amputation.

The guillotine amputation is relatively straightforward. The limb is prepped to the knee level in case an incision in the calf is needed to drain purulence/necrosis proximally (most commonly the anterior compartment). The authors do not find tourniquets for guillotine necessary, as the assistant can provide some level of arterial control with a firm grip at the distal calf. In addition, Esmarch exsanguination in a septic foot would be contraindicated. The knife is used to make a circular incision just above the malleolus down to the tibia and fibula (Fig. 212.1). Electrocautery is often not useful due to significant edema. Either a power saw or a Gigli saw is used to transect the distal tibia and fibula. The three major vascular bundles are oversewn with silk (Fig. 212.2). Of the three, the peroneal artery is the most difficult to control as it is between the fibula and tibia, making exposure a problem. All of the arteries retract after transection adding to exposure issues. The calf is compressed to check for purulence in the compartments. Finally, the authors place a large piece of

thrombin-soaked Gelfoam over the stump to assist in hemostasis postoperatively. A bulky dressing is applied over this and then an ace wrap over this. It is our practice to not examine the stump for a day or two if there was no sign of proximal infection, as the patient's clinical course is often adequate to gauge therapy, and early dressing changes in a patient with relatively normal circulation at the ankle (as is often the case) risk hemorrhage.

Below-Knee Amputation

Long Posterior Myocutaneous Flap (Burgess)

The Burgess technique is the most frequently used technique in BKA. It takes advantage of the well-vascularized myocutaneous flap consisting of the gastrocnemius muscle, partial soleus muscle, and posterior skin. The disadvantage is that the tibia is directly over the incisional closure, and any trauma to that area can cause dehiscence and exposure of bone. In addition, it requires reasonable distal skin posteriorly, which can be an issue if the patient has chronic venous skin changes.

The patient is positioned supine with some padding at the level of the thigh to assist in elevation of the extremity. The leg is prepped to the groin level. We often use a tourniquet with Esmarch exsanguination of the leg (see comments above). The anterior skin incision should be located 12 cm (roughly one handbreadth) below the tibial tuberosity. The skin incision should then be continued transversely for a distance approximately one third of the calf circumference to minimize the formation of redundant tissue at the stump edges ("dog ears"), which make prosthetic fit more difficult. The incision is then extended along the vertical axis of the extremity for a length ~1.5 times of the length of the transverse incision. The posterior flap is then completed with a transverse incision at this level (Fig. 212.3). The skin incision is then extended sharply through the fascia throughout, with division of the greater saphenous vein.

Initial attention is to the anterior compartment. The anterior compartment muscles (tibialis anterior, extensor hallucis longus, extensor digitorum longus, and fibularis longus) are divided at the same level as the anterior incision. Central in the anterior compartment is the anterior tibial artery and vein and the deep peroneal nerve. The vessels are suture ligated, and the nerve is transected under tension, as outlined above (Fig. 212.4). The tibia is then cleared of lateral and posterior attachments with the periosteal elevator and the interosseous membrane is incised sharply. The

tibia is divided at or just proximal to the skin incision with an anterior bevel. The lateral compartment muscles (fibularis longus and brevis) are divided to expose the fibula. A periosteal elevator is then used to carefully clear the fibula 1 to 2 cm proximal to the level of the tibial transection where it is transected (Fig. 212.5).

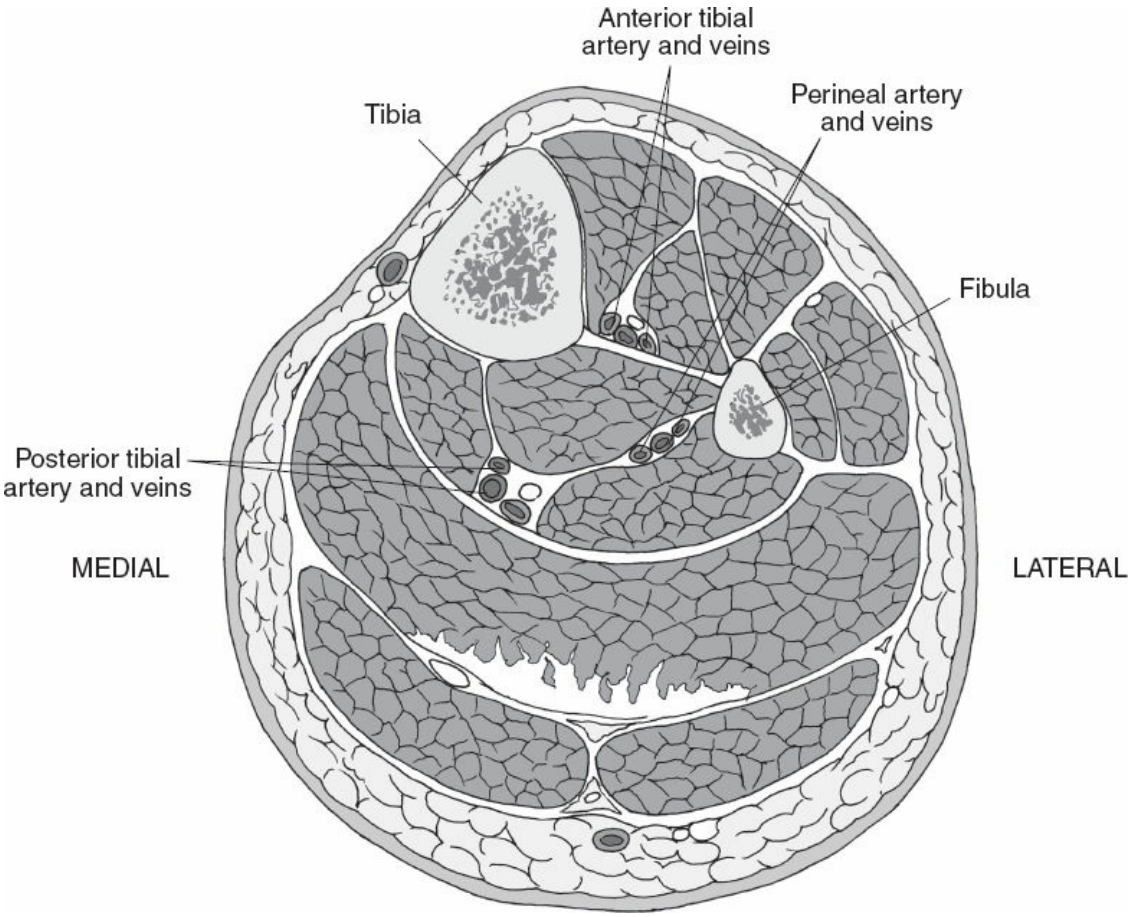

Figure 212.2. Locations of the anterior tibial, posterior tibial, and peroneal vasculature.

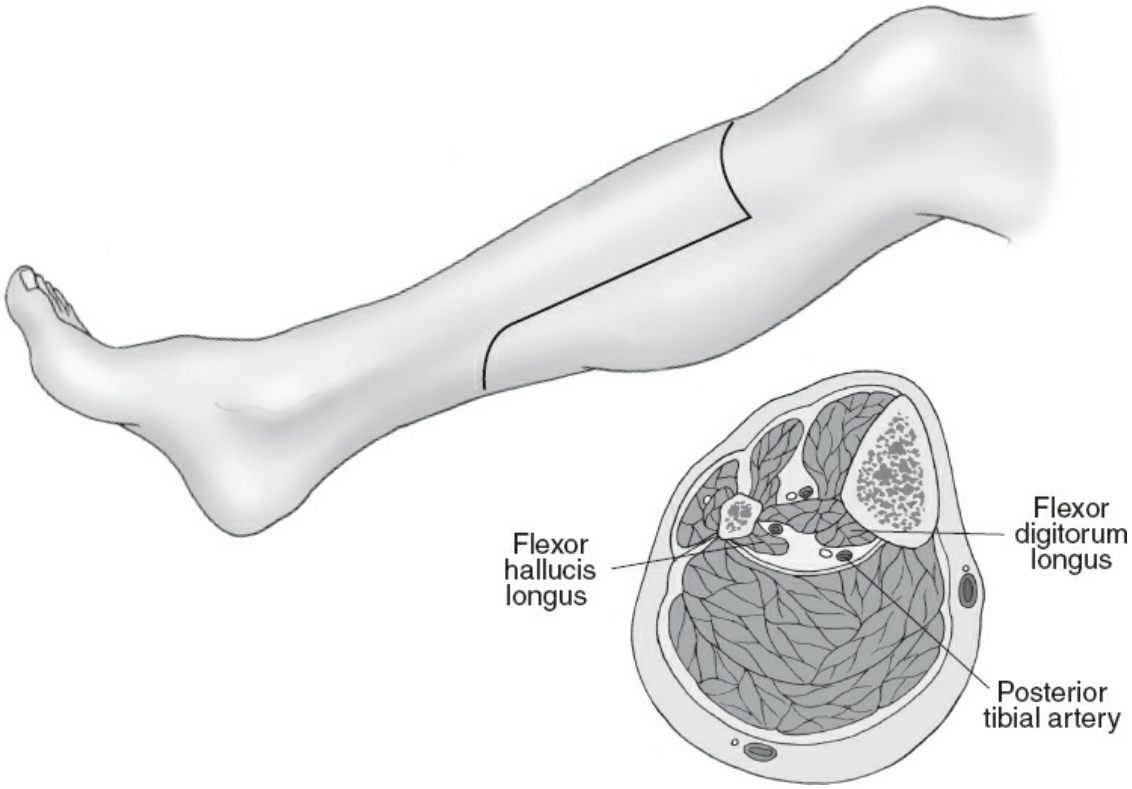

Figure 212.3. Skin incision for Burgess below-knee amputation.

The posterior compartment muscles (soleus and gastrocnemius) are then divided obliquely to create a posterior muscle flap. In general, enough soleus needs to be removed to allow for flap closure without excessive bulk and tension (Fig. 212.6A) but not so much that the end of the soft tissue is not flush with the transected tibia when closed. The posterior tibial and peroneal vessels are suture ligated, as are the extensive venous plexus in the remaining soleus. Prior to the closure of the flaps, bone edges are contoured smoothly. The fascial edges are closed with interrupted absorbable sutures, followed by interrupted vertical mattress nylons for skin closure (Fig. 212.6B).

Skew Flap Transtibial Amputation

A modification of the long posterior myocutaneous flap technique is the skew flap technique. The advantage of this technique is placement of the skin incision lateral to the tibial stump to avoid wound complications caused by tension and to facilitate closure of the incision without redundant tissue or a dog-ear deformity (and therefore improved prosthetic fit). Creation of the skin flaps again involves marking the anterior incision one handbreadth below the tibia. A point in this incision 2 cm lateral to midline over the anterior muscle compartment is then identified as the

anterior junction of the proposed flaps. A string or tape is used to measure the calf circumference at this level. Half of this tape length can then be used to determine the length of the base of the flaps and also to determine the posterior junction of the flaps. Once this is completed, one fourth of the tape length or string should be used to mark the midpoint of each flap. From this point, the most distal extent of the flaps should be marked in a circular fashion at a distance consistent with one fourth of the tape length (Fig. 212.7). Once the flaps are marked, the skin incision may be extended to the level of the fascia. Deep to the fascia, the amputation is performed with the same technique as the long posterior flap. With the skew technique, the posterior muscle compartment is divided 5 cm distally to the previously created posterior skin flap. After appropriate narrowing of the gastrocnemius muscle, it is brought forward and used to cover the anterior tibial periosteum (Fig. 212.8). The skin is then approximated as previously described. Ultimately, this technique results in the creation of two distinct flap coverages for the stump—a deep myofascial flap covering the tibia and anteromedial and posterolateral fasciocutaneous flaps covering the deeper flap (Fig. 212.9).

Above-Knee Amputation

Through Knee or Knee Disarticulation

This technique is advocated for several reasons: (a) Minimal muscle is transected and therefore postoperative bleeding and operative time are minimized; (b) it preserves more limb length than a transfemoral amputation for transfers; (c) although historically it has been a difficult prosthetic fit, excision of the femoral condyles/patella and use of the C-limb prosthesis have improved fitting dramatically; and (d) it avoids any flexion contractures. However, synovial fluid can accumulate, and the flaps can break down due to tension from the underlying femoral condyles.

Equal anterior and posterior fasciocutaneous flaps extending approximately two thirds of the diameter of the leg in length are created (Fig. 212.10). The incision is then extended through the collateral, medial, lateral, and cruciate ligaments, and the hamstring tendons are transected. The tibial nerve, the peroneal nerve, and the popliteal artery and vein should then be identified. The nerves should be transected proximally under tension to avoid neuroma formation, and the vessels should be suture ligated. The patellar tendon can then be separated from the tibia and sutured to the cruciate ligaments and hamstring tendons over the femoral

condyles (Fig. 212.11). The fascial layers are closed with absorbable sutures and the skin with interrupted nylon sutures as described above.

Transfemoral Amputation

The decision to perform a transfemoral amputation (AKA) is influenced by the determination that a patient will be unable to heal a BKA or is unlikely to mobilize after an amputation, or in the patient who has a significant knee contracture. Several vascular centers are now advocating a through-knee amputation over an AKA in most patients to preserve limb length; however, widespread adoption of this practice has yet to occur. Important technical considerations include preserving as much femoral shaft length as possible to improve prosthetic fitting and lever function of the shaft. Creation of equal anterior and posterior flaps involves marking the point of femoral shaft transection ~12 cm from the knee joint. The circumference of the extremity should be estimated at this point, and the intersection of the anterior and posterior flaps should be one half of this. In addition, the distal aspect of the flaps should then extend to a distance two fingerbreadths proximal to the patella (Fig. 212.12). After determining the extent of the flaps, the skin and subcutaneous tissue may then be sharply divided at this level. The quadriceps and the hamstrings (semitendinosus, biceps femoris, and semimembranosus) should then be divided sharply two fingerbreadths distally to the point of femoral shaft division and the vastus lateralis and adductor muscles may be divided at the level of femoral shaft division (Fig. 212.13). Next, the bone is transected with a power saw or Gigli saw, and the edges are contoured with a rasp. As the femoral artery and vein are identified, these should be suture ligated and the sciatic nerve should be divided sharply under tension. After hemostasis is achieved, the fascial edges of the muscles should then be closed over the remaining femoral shaft with interrupted absorbable sutures, and the skin edges should be opposed with interrupted nylon sutures.

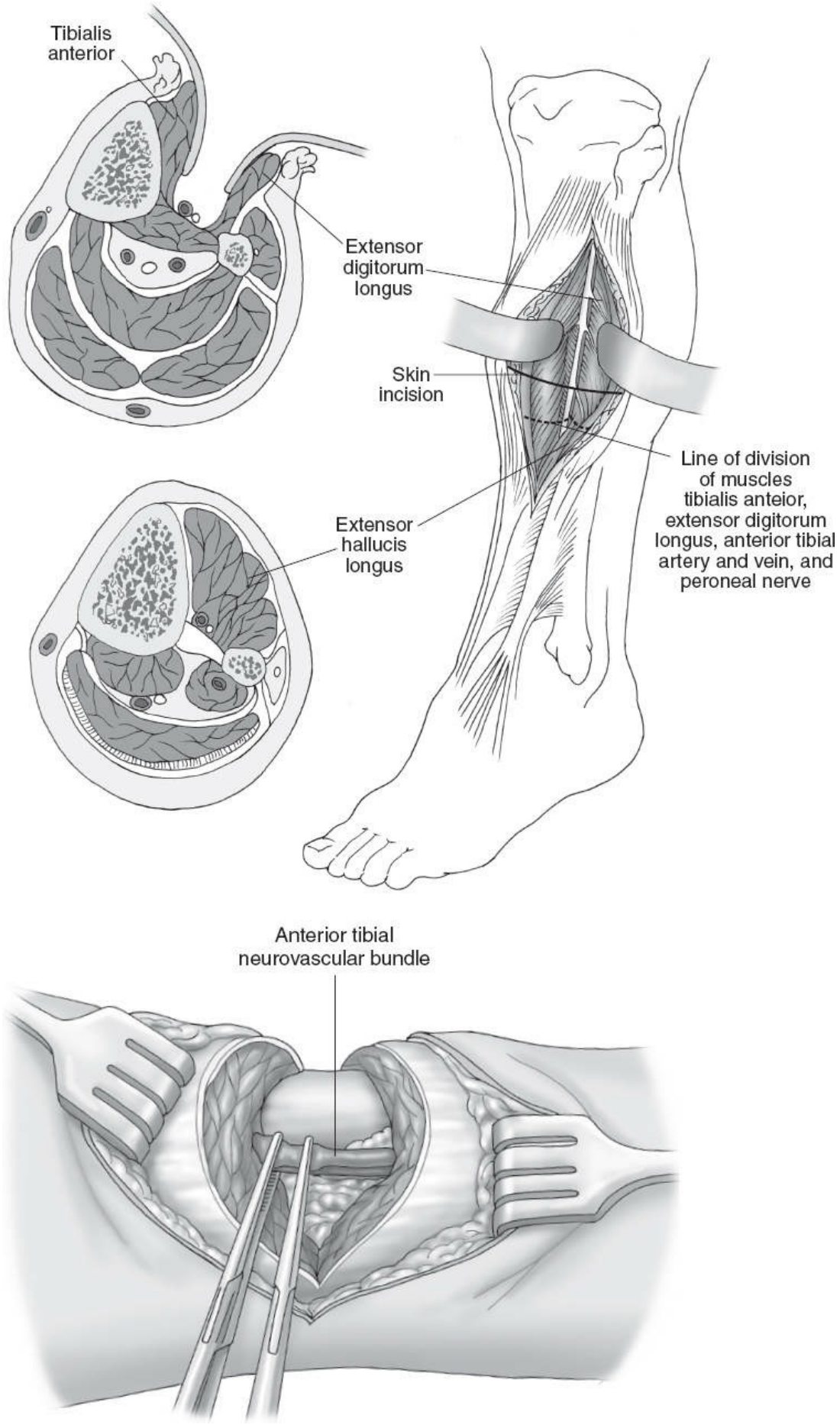
Tibialis anterior
Extensor digitorum longus
Skin incision
Line of division of muscles tibialis anteior, extensor digitorum longus, anterior tibial artery and vein, and peroneal nerve
Extensor hallucis longus
Anterior tibial neurovascular bundle

Figure 212.4. Division of the anterior compartment in the Burgess below-knee amputation.

POSTOPERATIVE MANAGEMENT/COMPLICATIONS

Based on results, major lower extremity amputations are arguably one of the most difficult procedures the modern vascular surgeon will perform. Perioperative mortality rates of 5% to 7% for BKA and 10% to 15% for AKA are typical. Compare this with the 3% perioperative mortality rate published in the recent Veterans Affairs multicenter open versus endovascular repair aneurysm trial. The potential lethal nature of amputations is not due to the complexity of the procedure, but rather to the patient population requiring it. Available data would indicate significant medical comorbidities, poor nutrition, anemia, and generally a severely deconditioned state secondary to the immobility enforced secondary to the nature of the presenting foot lesions and/or prior forefoot procedures. Many patients are in the last months of their lives, and could be described as dying from the periphery inward. An episode of aspiration pneumonitis, subendocardial infarct, or exacerbation of congestive failure can easily prove to be fatal. Compounding the problem, amputations are rarely considered by anesthesia and/or surgeons as a case of the same magnitude as a major vascular reconstruction or cardiac case.

In addition to the typical cardiovascular morbidities, patients undergoing major amputation are immobile in both the preoperative and perioperative periods. Not surprisingly, the incidence of DVT is high in this population, mandating some level of prophylaxis. As many of these patients have underlying hypercoagulable states or undergo amputation for acute arterial thrombosis, anticoagulation is frequent, which often leads to bleeding complications. Finally, many diabetic patients require amputation for severe forefoot sepsis. These patients can suffer septic complications from delay in definitive removal of the septic focus and/or bacteremia at the time of the procedure.

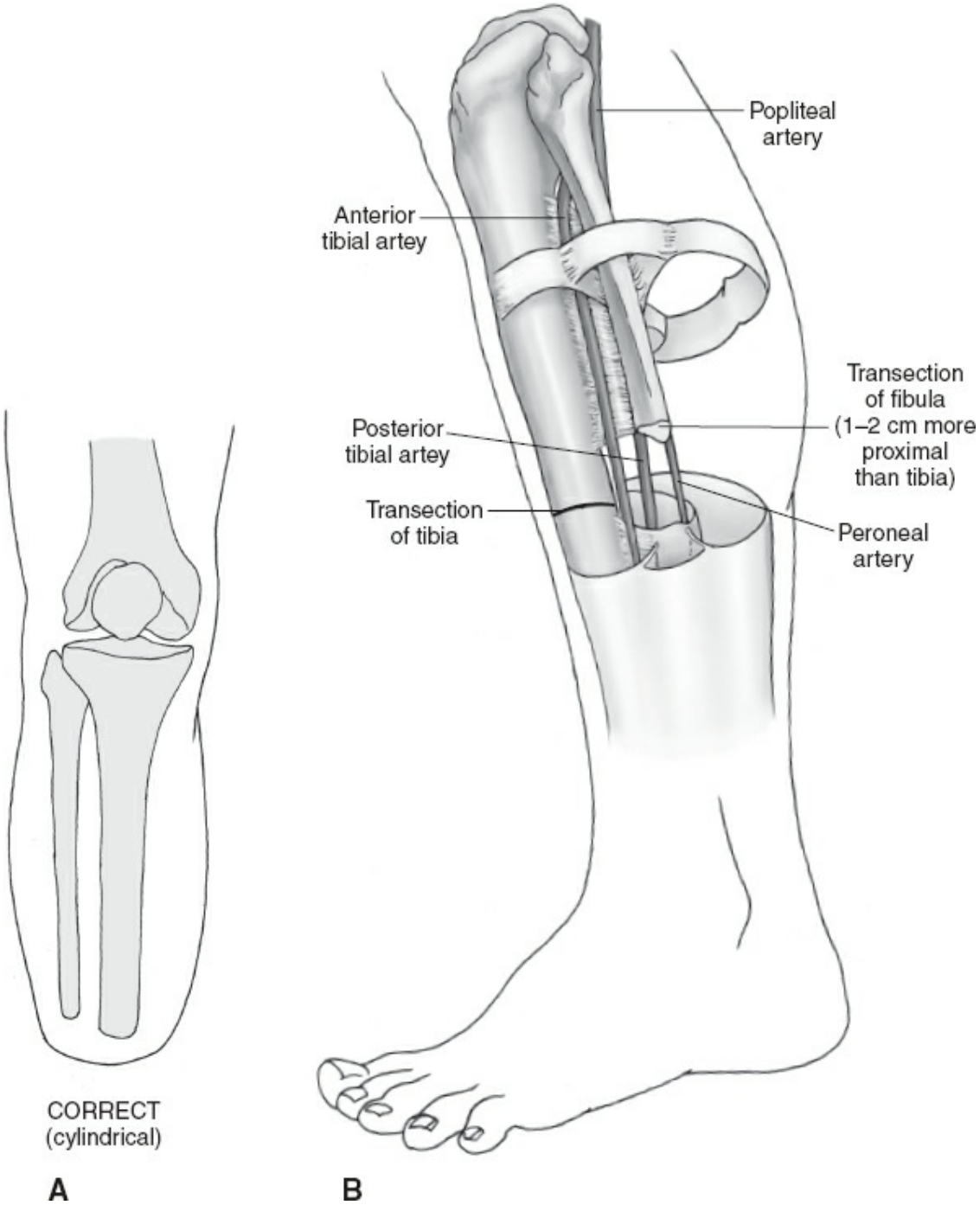

Figure 212.5. Relationship between tibial and fibula transection in the Burgess below-knee amputation.

Healing rates of BKA vary, but failure in 10% to 20% is widely reported. These patients often have one or more operations attempting to salvage the knee joint, followed by an eventual AKA. Amputation healing times are often measured in months rather than weeks. Part of the difficulty in wound healing is related to falls and stump trauma. However, even without postoperative trauma, CLI patients heal incisions below the

knee poorly. Casting the BKA stump appears useful to reduce trauma and edema, but the single small trial using these devices did not demonstrate efficacy compared to standard protective bandages.

From the patient perspective, one of the most important morbidities of amputation is postoperative pain. Chronic postoperative amputation pain can be divided into two groups—residual limb (stump pain) and phantom limb pain. The prevalence is in the range of 50% to 80% of amputees. Both central and peripheral pain mechanisms appear to be involved, including ectopic activity originating from afferent fibers in a neuroma and cortical reorganization/spinal cord sensitization. For most patients, the pain is episodic in nature and not particularly troublesome. In approximately one in four of patients, however, the symptoms are very disabling. In addition, some data suggest that the duration and intensity of preamputation limb pain play a role in early post amputation residual limb and phantom limb pain.

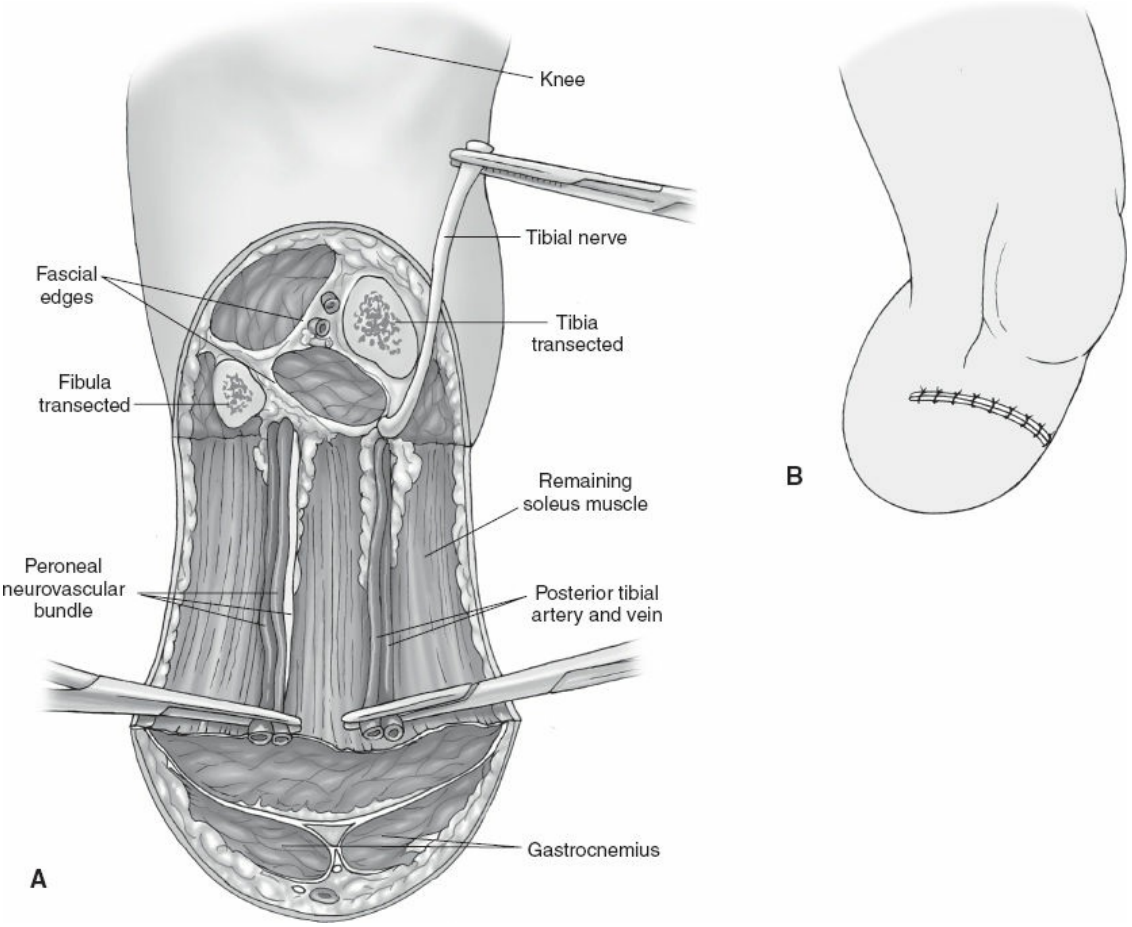

Figure 212.6. **A.** Posterior flap with remaining soleus and gastrocnemius in Burgess below-knee amputation. Transected tibial vessels (*open arrow*) and tibia nerve (*closed arrow*). **B.**

Finished BKA stump in Burgess below-knee amputation.

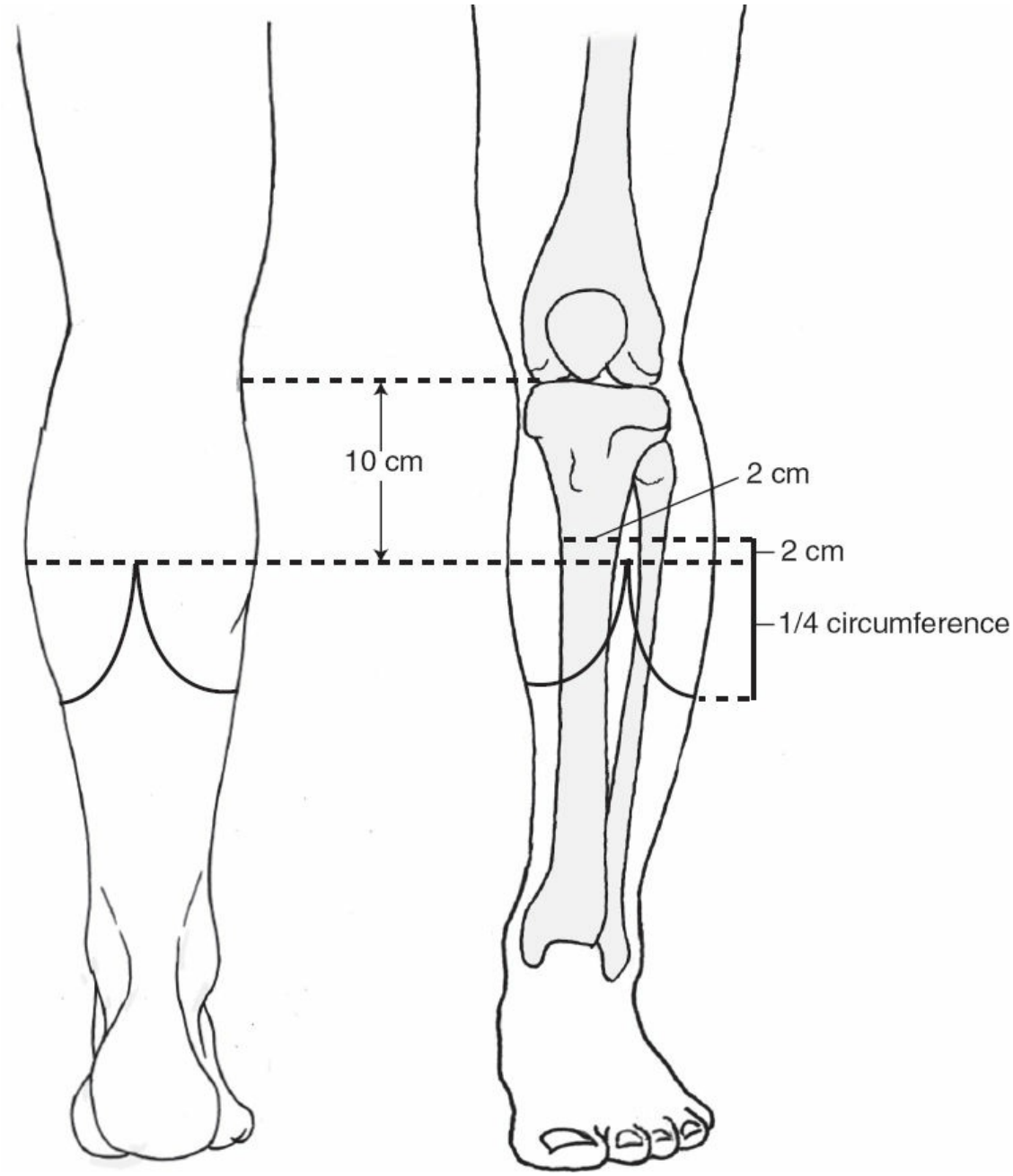

Figure 212.7. Initial measurements for skin flap incisions in skew flap below-knee amputation.

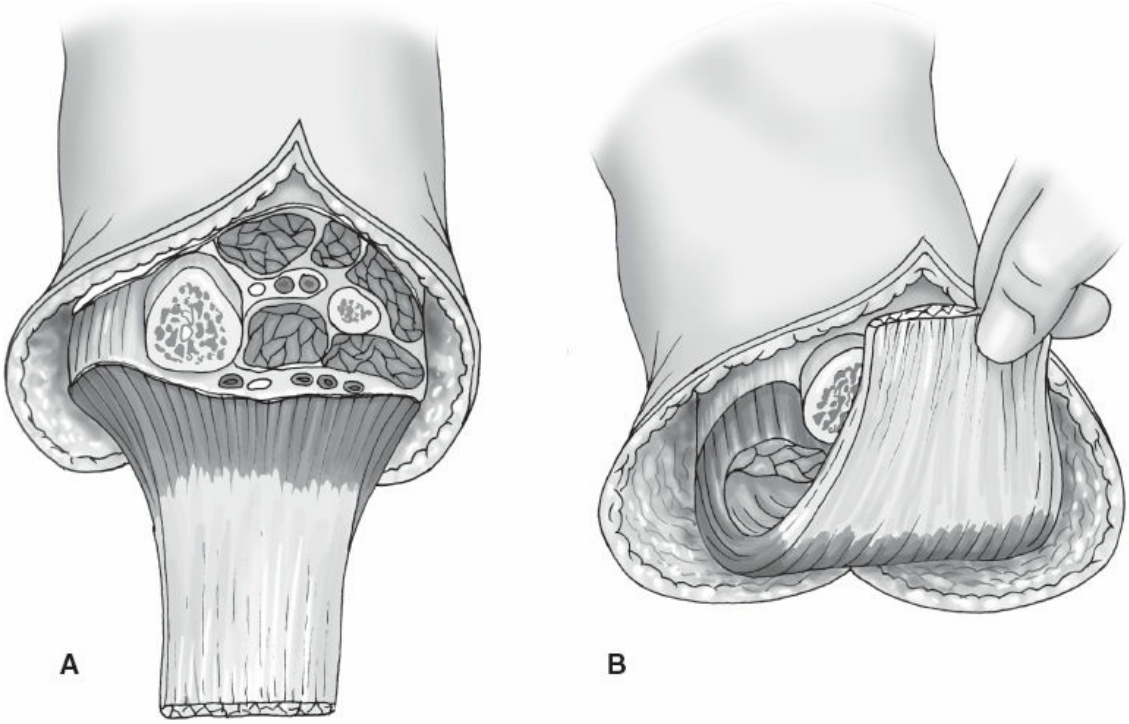

Figure 212.8. Gastrocnemius muscle covering tibia in skew flap below-knee amputation.

FUNCTIONAL OUTCOMES

A substantial amount of research has focused on preoperative evaluations to determine if a BKA will heal, with preservation of the knee joint and improved function and potential mobility. This is extremely relevant in the younger amputee population. However, the sobering fact is that many elderly patients will not be able to complete an arduous rehabilitation program to ambulate to any extent with a prosthesis. Much of this is related to the comorbidities in the population as previously stated with regard to perioperative mortality. However, in the United States, the passage of the Americans with Disability Act in 1990 has improved wheelchair access by mandating it for public buildings. Frequently, elderly amputees choose to focus effort toward modifying the home to allow at least some mobility in a wheelchair. A review at our institution demonstrated that less than half of amputees were ambulatory postoperatively, but relatively few required transition to a care facility—a more recent study from Sweden demonstrated similar findings in a BKA population as did studies from the United Kingdom and Singapore. A patient with a healed amputation (AKA or BKA) who can independently transfer and take a few limited steps but remains in the community is the end result for many elderly amputees. The prevalence of vascular

amputees who ambulate postoperatively declines over time due to a variety of issues, such as mortality, contralateral limb loss, and clinical events. Finally, the occasional patient will fall and suffer a major fracture during prosthetic use.

Conversely, if patients are to have any realistic hope of extensive prosthetic ambulation postoperatively, the knee joint must be spared. Many of the AKAs performed are done so based on the lack of rehabilitation potential rather than inability to eventually heal a BKA—with some recent movement toward more through-knee amputations. One obvious question is the potential benefit of the knee joint in the nonambulatory patient. Although statements regarding improved transfer potential and balance are frequently made, the available data to support this are lacking. Thigh muscle atrophy has been noted to correlate with the length of the AKA stump. Balance is clearly an issue with prosthetic use, and has been widely studied. However, similar data regarding balance and wheelchair use are lacking. Finally, small series of the bilateral amputee (both above and below knee) have been reported. Ambulation is unusual, but pressure ulcers as seen in neurologically impaired patients do not appear to be a long-term issue.

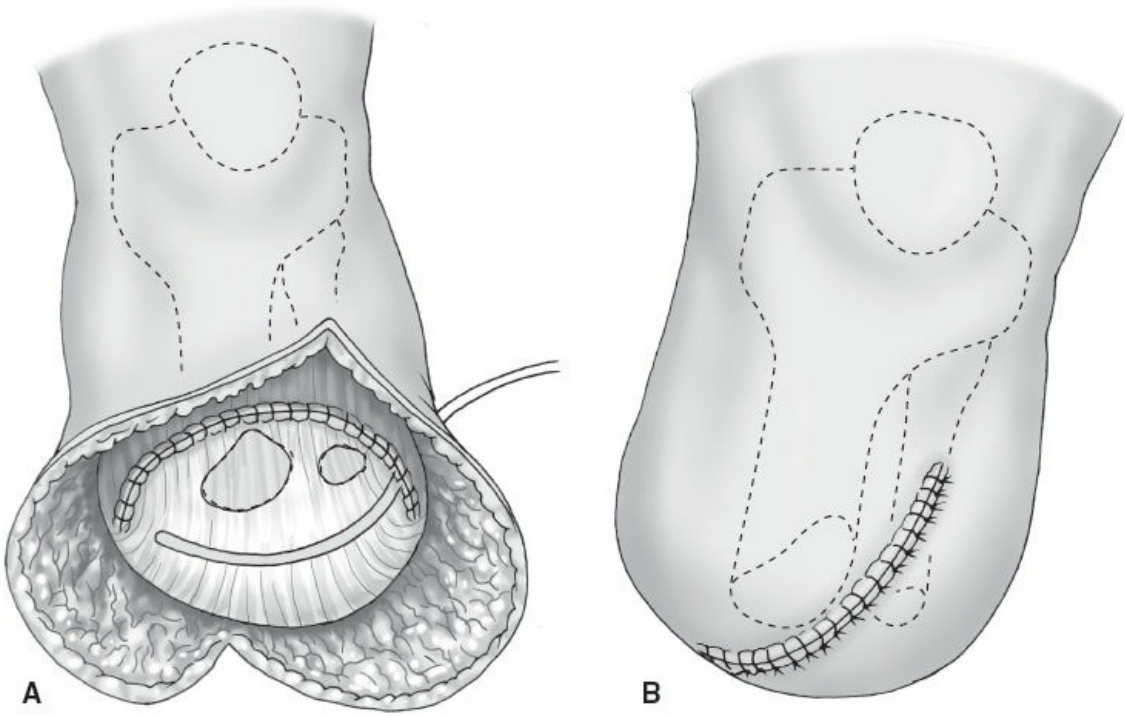

Figure 212.9. Finished below-knee amputation stump in skew flap amputation.

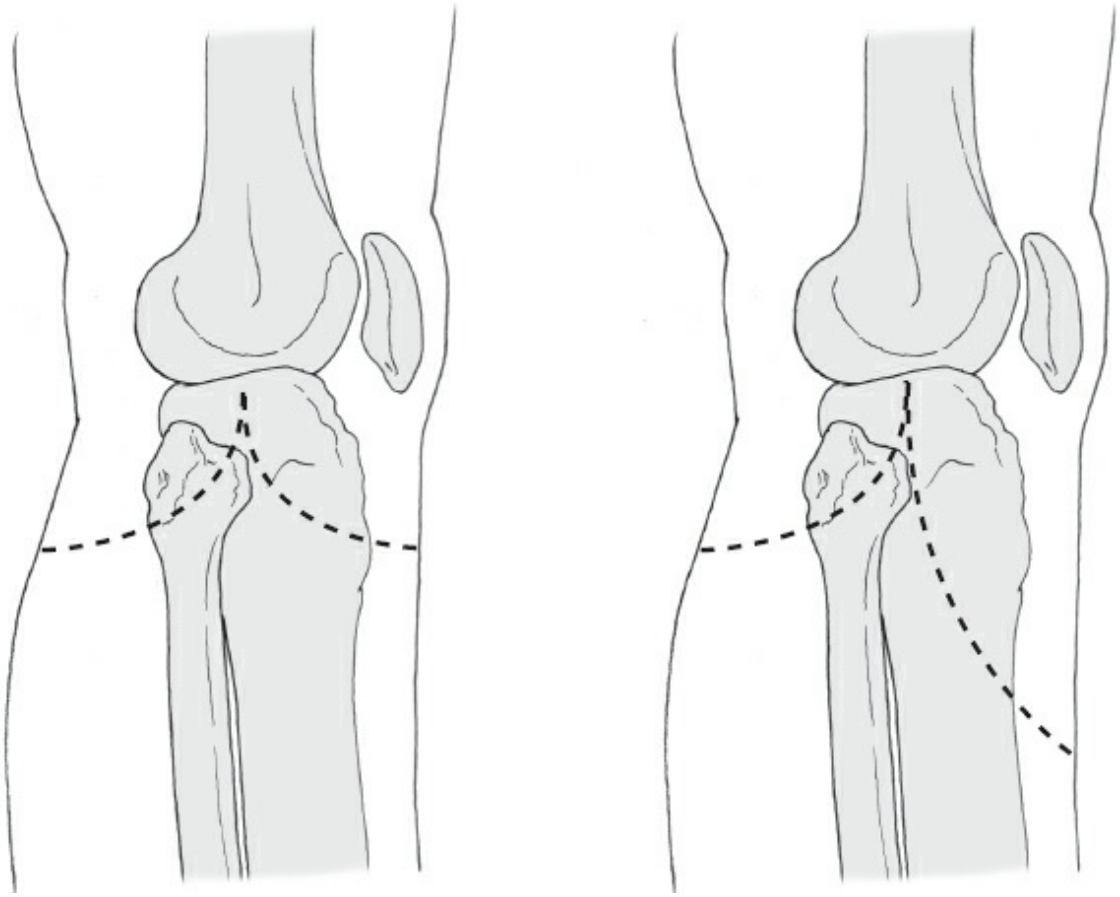

Figure 212.10. Skin incisions for through-the-knee amputation.

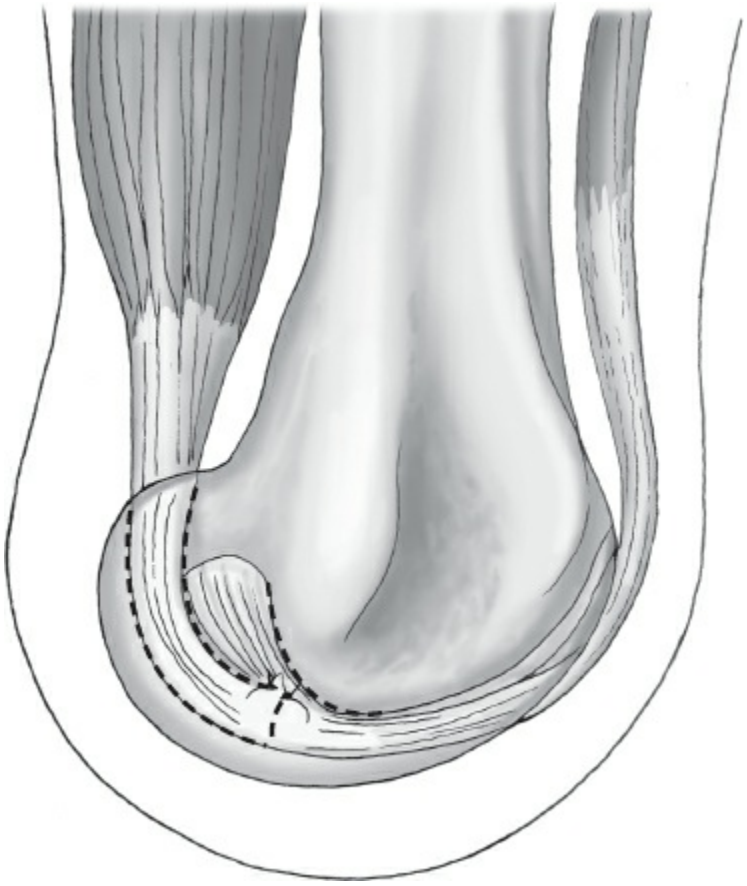

Figure 212.11. Tendon reapproximation in through-the-knee amputation.

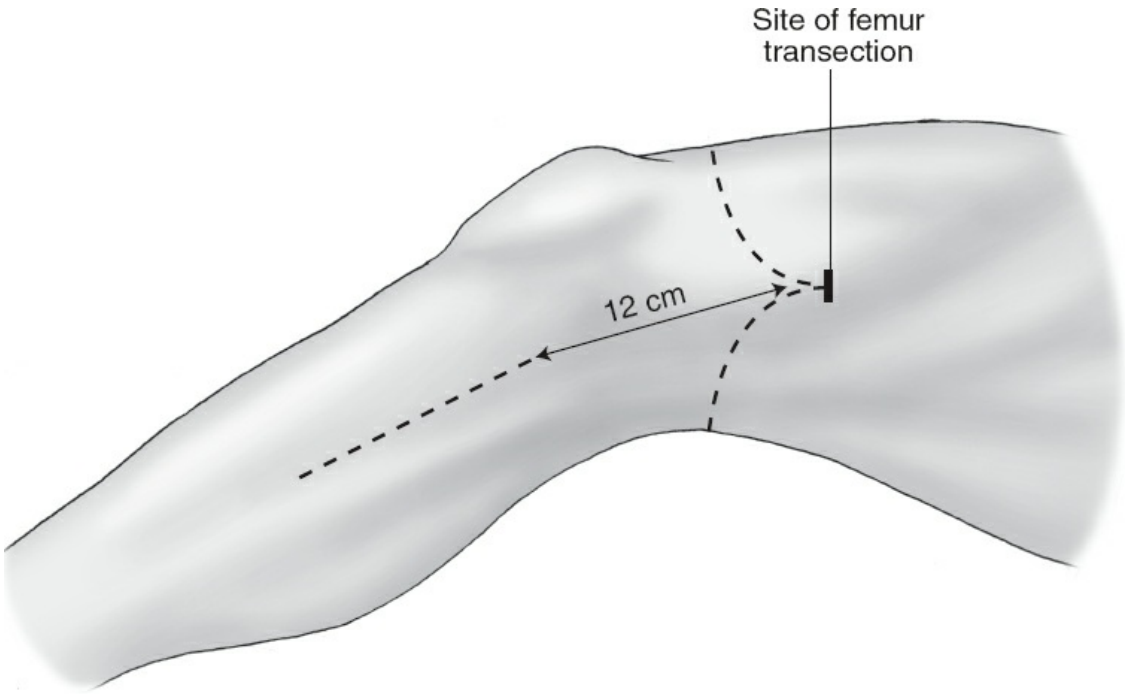

Figure 212.12. Skin flaps and site of femur transection in above-knee amputation.

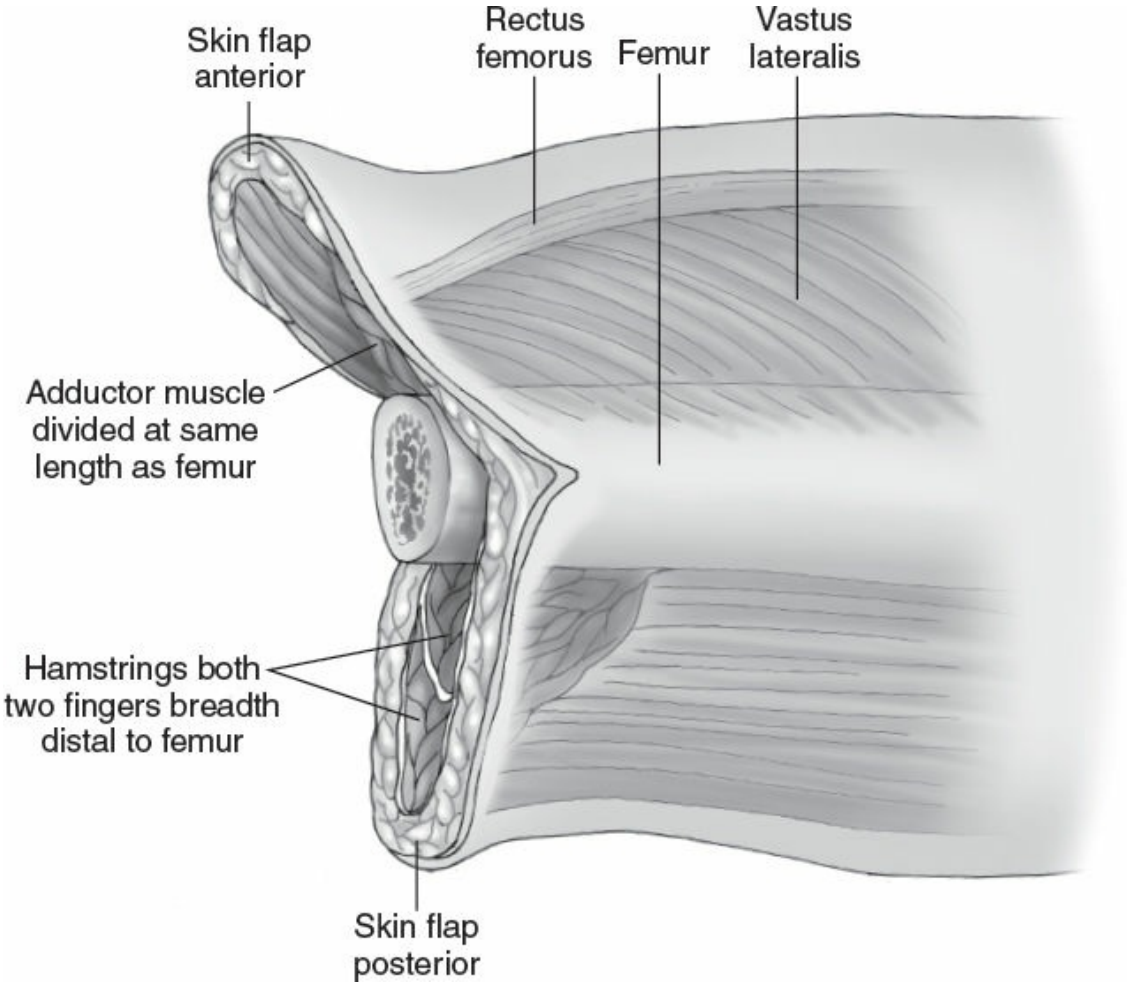

Figure 212.13. Muscle division in relationship to femur division in above-knee amputation.

NATURAL HISTORY

Patient survival in the NSQIP amputation series for BKA and AKA was 57% and 39% at 3 years, respectively, again emphasizing the palliative nature of these procedures in most patients. This significant long-term mortality has been confirmed in studies outside the United States as well. In addition to mortality, significant ongoing morbidity occurs in both the remaining stump (BKA) and contralateral limb following major lower extremity amputation. At 2 years, 15% of patients with an initially successful BKA will convert to an AKA, and another 15% will suffer a major contralateral amputation.

Suggested Readings

Bacharach JM, Rooke TW, Osmundson PJ, et al. Predictive value of transcutaneous oxygen pressure and amputation success by use of supine and

elevation measurements. *J Vasc Surg* 1992;15:558.

Dillingham TR, Pezzin LE, MacKenzie EJ. Limb amputation and limb deficiency: epidemiology and recent trends in the United States. *South Med J* 2002;95:875.

Feinglass J, Pearce WH, Martin GJ, et al. Postoperative and late survival outcomes after major amputation: findings from the Department of Veterans Affairs National Surgical Quality Improvement Program. *Surgery* 2001;130:21.

Mills JL, Conte MS, Armstrong DD, et al. The Society for Vascular Surgery threatened limb classification system: risk stratification based on wound, ischemia, and foot infection (WIfI). *J Vasc Surg* 2014;59:220–34.

Nehler MR, Coll JR, Hiatt WR, et al. Functional outcome in a contemporary series of major lower extremity amputations. *J Vasc Surg* 2003;38:7.

Yeager RA, Moneta GL, Edwards JM, et al. Deep vein thrombosis associated with lower extremity amputation. *J Vasc Surg* 1995;22:612.

EDITOR'S COMMENT

Dr. Mark Nehler's comprehensive and thoughtful chapter highlights a very common surgical operation, the lower extremity amputation. Few textbooks pay attention to the fine operative points of amputations, and this chapter accomplishes that.

Amputations are often the end stage of peripheral vascular occlusive disease (PVOD) and/or severe foot infection, and performed frequently by orthopedics, plastic, vascular, and general surgeons. Amputations are generally low morbidity and mortality operations, but medium and long-term mortality is high given the patients' underlying comorbidities, as pointed out by the authors. For example, long-term mortality after amputation is worsened with older age, high American Society of Anesthesia score, and chronic kidney disease; all of which are not modifiable (Scott SW, Bowrey S, Clarke D, et al. Factors influencing short- and long-term mortality after lower limb amputation. *Anaesthesia* 2014;69:249–58).

It is not uncommon that patients have had numerous prior endoluminal and sometimes open operations for management of severe PVOD, although the intensity of therapies is dependent on region, socioeconomic, and racial status (Goodney PP, Holman K, Henke PK, et al. Regional intensity of vascular care and lower extremity amputation rates. *J Vasc Surg* 2013;57:1471–9, 1480 e1471–3; discussion 1479–80). How aggressive to be in the setting of PVOD is not well defined by evidence. However, one of the primary considerations is the patients' functional status, and while many technical arterial interventions are possible, the quality of life, frailty, and mobility of the patient are important when considering an amputation as compared to very aggressive limb salvage procedures. Sometimes, the safest and most beneficial procedure is an

amputation.

In terms of preoperative preparation, most of these patients should proceed with surgery and an extensive cardiovascular assessment usually is not required. Indeed, these patients can undergo regional or epidural anesthesia, with less pulmonary risk. I would partially agree with the authors that specifically prescribing beta-blockade prior to amputation is not needed. However, if the patient is on beta-blocker therapy, they should remain on this to avoid tachycardia and rebound hypertension. It also is important to make sure these patients are on statin and antiplatelet therapy for general cardiovascular health if they have significant underlying PVOD.

Determining the level of amputation is critical, and the most distal level that heals allows the most function. Whereas in the past, popliteal pressures or doppler wave forms were used to determine an above the knee versus below the knee amputation site, now transcutaneous partial oxygen level ($TcPO_2$) offers a more sensitive way to determine healing for below the knee amputations (Poredos P, Rakovec S, Guzic-Salobir B. Determination of amputation level in ischaemic limbs using $tcPO_2$ measurement. *Vasa* 2005;34:108–12). Data suggest the $TcPO_2$ levels >40 mm Hg at the ankle are associated with the best chance of healing a below the knee amputation.

Several important technical aspects are well highlighted by the authors, including constructing a good posterior muscle flap. It is critical to create a full but not too bulky posterior muscle bundle as stuffing in too much muscle will lead to ischemia and flap loss. Ligation of the vascular bundles is straightforward, and allowing the nerve to retract to decrease neuroma formation is key. I usually inject the nerve at the time with Marcaine for additional analgesia. For closure, I use staples rather than sutures to close the skin as these are easier to remove at 4- to 6-week timepoint than sutures. I must admit I have no experience with through-the-knee amputation, although Dr. Nehler suggests that with new prosthesis these may be a reasonable or better alternative than a transfemoral amputation. Further study will determine whether this is a useful level of amputation, but mixed evidence of low quality is available (Murakami T, Murray K. Outcomes of knee disarticulation and the influence of surgical techniques in dysvascular patients: a systematic review. *Prosthet Orthot Int* 2016;40(4):423–35).

I disagree that patients with a transfemoral amputation are rarely ambulatory. I have had numerous patients, albeit slightly on the more robust and younger side, fitted with a prosthesis and attain mobility if their other leg is functional. However, if any chance of a below the knee site, it should be pursued. It is common that frail and debilitated patients with a transfemoral amputation will often be bedbound; hence, preoperative discussion of quality of life issues is critical.

Lastly, one of the tougher clinical scenarios is a patient with significant aorto-iliac occlusive disease and who requires an amputation. For example, will a patient who needs a proximal amputation but has an occluded iliofemoral

system heal his or her stump? Proceeding with an endoluminal or an open endarterectomy and angioplasty or bypass to allow a high amputation to heal is controversial. Outside of clinical judgment, little data are present to guide the surgeon. I usually find if their thigh is warm, it will heal at the proximal site even if there is no palpable femoral pulse, although sometimes very slowly, and require debridement, dressing changes, etc. Conversely, if improving aortoiliac blood flow via endoluminal or open surgery will improve the potential healing of a below the knee as compared to a proximal level, I think this is reasonable.

Peter Henke

213 The Prevention and Treatment of Problems With the Diabetic Foot

Norman J. Galbraith, T. Jeffrey Wieman, and Hiram C. Polk, Jr.

INTRODUCTION

Diabetes mellitus remains a growing problem in the Western world, as do the various manifestations of this disease; we focus here upon the diabetic foot. In 2012, 29.1 million Americans were diagnosed with diabetes, with 1.25 million of these diagnosed with type I diabetes and it remains one of the top ten killers in the United States. More concerning is the massive prevalence of prediabetes, counted at 86 million Americans in 2012 with a growing number of undiagnosed cases, to which the ongoing obesity epidemic is almost certainly the key contributor to the growing number of prediabetic and type II diabetic patients. The total cost of diagnosed diabetes in the United States has been estimated at $245 billion per year. Direct medical costs, as well as loss of productivity, can result from many of the common manifestations such as myocardial infarction and stroke from large vessel disease, as well as renal impairment, retinopathy, and of course peripheral neuropathy associated with microvascular disease. Both type I and type II diabetics can suffer from all microvascular complications; thus it is common for diabetic foot patients to have decreased visual acuity, which will impair their ability to see early warning signs in their legs and feet of impending problems.

Furthermore, neuropathy can not only interfere with the autonomic control of the blood supply to the skin, but will decrease light touch and pain sensation as well as proprioception, abetted by diabetic myopathy which accounts for 25% of weakness when compared to nondiabetics. This multiplies the additional risk in allowing a small ulcer to progress to limb-threatening disease. The surgeon must notice these subtleties during the consultation in order to improve early recognition. Educating and instigating the crucial role of the spouse/caregiver helps in close monitoring of the feet. Specific examination of the feet with shoes and socks off in every consultation lessens the likelihood that missed injuries

or ulcers will occur and is probably far more important than the focus on hemoglobin A1c. Notably, numerous papers studying the diabetic gait with remote sensors shows that patients tend to strike the same location of the plantar surface with every step, a de facto decubitus-type injury.

The surgeon can play important roles in the multidisciplinary approach to the diabetic foot. This includes assessment and improvement of the vascular supply to the periphery, procedures to off-load bony prominences at risk, and of course multiple levels of amputation in the elective and emergency setting if prevention fails. However, approximately 1 in 10 diabetics will have a diabetic foot ulcer (DFU) at some point in their life. Diabetes continues to be the most common cause of nontraumatic limb amputation and diabetic foot ulceration precedes more than 80% of amputations. In fact, half of patients who develop a DFU will be dead in 5 years. Therefore, we unapologetically focus on the role of *prevention* in the diabetic foot, in order to try and limit the downward spiral that can arise from first consultation to amputation.

PATHOPHYSIOLOGY

The foot is a complex structure of 26 bones, 33 joints and various larger muscles controlling movements such as dorsi- and plantar-flexion, and small internal muscles controlling finer movements of the foot and toes. The principle role of the foot is balance, weight bearing, weight distribution, and bipedal locomotion. In order to carry out these roles, we all rely heavily on the afferent nerves from the periphery to detect fine touch, pain, changes in temperature, and of course proprioception. Loss of sweating and skin lubrication in autonomic neuropathy are major causes of pathologic callus formation. The autonomic dysfunction also produces subnormal capillary shunting and fragility of vessels at the dermal–subdermal interface, making these vessels more susceptible to disruption which is the original cause of bleeding and ulcer formation beneath callus. DFUs are classified into three types:

Neuropathic: Pink with granulation tissue, classically on plantar surfaces at sites of high plantar pressures
Ischemic: Often distal including between digits, can be dorsal, edges are pale without granulation tissue
Mixed: (50%) are both ischemic-neuropathic

Peripheral neuropathy results from persistently high blood glucose

levels through various poorly understood molecular mechanisms. Hyperglycemia causes increased intracellular glucose levels within peripheral nerves, saturating the normal glucose metabolism pathways. This results in the activation of the polyol pathway, with glucose being converted to sorbitol and fructose. Resulting impairment of sodium–potassium–ATPase pumps leads to structural breakdown and impaired axonal transport. Glucose further interferes with proteins, nucleotides, and lipids resulting in the accumulation of advanced glycation end (AGE) products, which further impair nerve metabolism and function. Oxidative stress further contributes to neuropathy due to increased mitochondrial production of free radicals due to the saturation of neurons by elevated glucose. Peripheral nerves can be damaged due to glycosylation of the vasa nervosum, causing capillary basement membrane thickening and endothelial hyperplasia. Resulting chronic hypoxia to nerves lead to decreased function, beginning with the smallest, unmyelinated fibers such as light touch and temperature which are most readily affected. Finally, nerve entrapment occurs beneath tendon retinacula which exacerbate edema of the nerves, especially the posterior tibial nerve and diminishes its function; under certain circumstances surgical release re-establishes neural function. These nerve changes are intimately linked to microvascular changes in the local small vessels supplying the skin. The process of diabetic neuropathy affects sensory, motor, and autonomic tracts of the nervous system. The decreased function of the afferent **sensory fibers** promotes the glove and stocking distribution of numbness, loss of sensation, and sometimes paraesthesia and pain.

Diabetic ulceration is far from a spontaneous event, and patients influenced by such changes often do not notice even the most minor injury or cut to their feet. Furthermore, bony prominences that bear weight would normally be off-loaded to prevent repeated friction, but without normal proprioceptive function thick callus will develop, with eventually ulceration (Fig. 213.1). Hyperglycosylation of callus makes it stiff and increases plantar pressures at “at-risk” sites.



Figure 213.1. These images show classic neuropathic ulcers (*arrows*) in a diabetic. Areas of high plantar pressure such as the heels and the metatarsal heads on the plantar surface are at special risk. (With permission from Smeltzer SC, Bare BG. *Textbook of Medical-Surgical Nursing,* 9th ed. Lippincott Williams & Wilkins, 2000.)

Autonomic nerves provide control of the blood supply to the skin of the peripheries, a further target of neuropathy. This can result in abnormal distribution of blood to the skin which leads to dry, cracked skin with fissuring, especially at the heel.

Motor neuropathy leads to intrinsic foot muscle wasting, and to claw foot and hammer toe deformities. This change in plantar architecture results in increased plantar pressures, known to be a major risk factor in the development of ulceration. Indeed, peak plantar pressures are higher at sites of established ulcers and at risk sites, which is predictable and not surprising. Diabetic patients, particularly those with neuropathy, experience various **gait abnormalities**. Gait analysis reveals increased step width and less step variability, poor balance, and walking is slower in general. Decreased shock absorption during heel strike results in increased anterior displacement of weight bearing. Subsequently, higher plantar

pressures are seen in the forefoot compared with nondiabetics, maximally at the great toe and 5th metatarsal. This is confounded by direct muscle dysfunction from hyperglycemia, and higher body weight by the average diabetic patient. Therefore, a patients gait must also be examined during a consultation to detect abnormal weight loading. If there are areas of concern, such as ulceration, callus, or evidence of abnormal weight loading then the patient should be prescribed orthotic shoes that will protect and off-load weight from areas of concern, but only after calluses have been completely sanded. Frequently, there is a new ulcer beneath it which must be diagnosed and removed. In fact, as a rule of thumb, all diabetics must wear comfortable, well-cushioned sports shoes, preferably fitted by an orthotist that can decrease the pressure on bony prominences in the foot. The periodicity of reassessment of shoes is uncertain but needs to be discussed by the surgeon with the patient. A weekly examination of both feet of the patient by their caregiver must be instigated, allowing a second pair of eyes to detect early signs of diabetic foot disease. Beware of the elderly couple that both have poor eyesight! Good education of the patient and caregivers should inform that any areas of concern should expedite an appointment with a physician and prevent the downward spiral into an ulcer.

Peripheral vascular disease can occur in the diabetic patient, with hyperglycemic tissue damage and ischemia often coexisting. Peripheral arterial disease in the lower limbs can be present in at least one fourth of all diabetic foot patients, and carries an additional poor prognosis. It is often inadequately addressed in this setting. Specifically, large-vessel disease must be assessed at least by Doppler examination as a vital part of a first visit. In diabetics, the femoro-popliteal and tibial vessels are more commonly affected, compared to aortoiliofemoral vessels in nondiabetics. The clinical aspects of addressing large vessel ischemia will be dealt with later, but young surgeons must remember to consider the potential contribution, and therefore therapeutic avenue, of peripheral artery disease in the diabetic neuropathic foot.

Doppler ultrasound of the dorsalis pedis and anterior tibial artery pulses in both feet, and the calculation of an ankle–brachial pressure index (ABPI) aids the clinical assessment. Do not forget that diabetic vessels are prone to calcification, thus can potentially give misleading readings. If concerned, CT angiography to give an accurate assessment of the arterial

tree can rule out significant stenosis, should renal function tolerate intravenous contrast.

THE SKILLED PROFESSIONAL TEAM IN DIABETIC FOOT CARE

The diabetic foot is a perfect example of a condition that can greatly benefit from a multidisciplinary team approach. The team begins with the patient themselves and their spouse/caregiver—who must be present at first consultation. Prompt and reinforced education of the early warning signs of diabetic foot disease and emphasis of the importance and risks therein is crucial. The delayed presentation of an infected, advanced, and progressing lesion is a prelude to amputation and death.

The internal medicine physician or family physician should lead the care in parallel with surgeon, and is often the source for referral, but are also important in instigating treatment and monitoring diabetic control. Should a patient present with new diabetic foot disease or have elevated HbA1c either in clinic or in hospital, they should continue to see their primary physician to ensure an optimum oral hypoglycemic and/or insulin regime.

The general or vascular surgeon has to determine whether there are elements of large vessel peripheral vascular disease, which could potentially be amenable to reconstruction and enhance healing. Furthermore, they will often be consulted in the emergency setting in the context of invasive infection. The role here is looking at three levels of assessment: the wound, the foot, and the patient as a whole. The surgeon must aim to drain infection and prevent the progression to sepsis, while preserving as much function as possible. Later, optimizing proper footwear designed for the patient in terms of prevention is essential whether by an orthotist, a podiatrist, or a skilled shoemaker. Secondly, should an ulcer arise, they need to ensure optimum off-loading either with specialist shoes or, infrequently, a temporary cast. The surgeon also plays an important role in maintenance of good foot hygiene including sanding down callus, debridement, trimming of toenails, and education. Added skin care with lanolin coconut oil should be done daily. Photographs with smart phones should be taken at each visit. All patients should have a digital plantar pressure measurement taken initially and once a year for comparison of changes. It is highly predictive and should always precede metatarsal head resection (MHR). It will demonstrate other high pressure points and

minimize the risk of a transfer ulcer.

The surgeon can play a vital role in surgical off-loading (through a variety of procedures depending on the location of the lesion), as well as fore- and mid-foot amputation, selected arthrodesis, and in Charcot arthropathy. Other important roles can be played by the family physician in coordinating care, visiting nurses for patients who cannot adequately care for themselves, and diabetic nurse specialists who can closely monitor all aspects of diabetic care. Dieticians, biomechanics/orthotist services, and tissue viability nurses can play an important role but this is often best orchestrated by an informed surgeon.

With any multidisciplinary team, important *leadership*, accountability, and good communication can eliminate preventable amputations. In areas where most patients do not have access to a specialized diabetic foot multidisciplinary team, a patient's prognosis can depend on the surgeon's knowledge, expertise, and commitment to long-term care. Fascinatingly in the United States, in Medicare patients these sessions are well paid but require specific coding, perhaps on a special diabetic foot page in the chart. An example of appropriate documentation would be:

"Sanded two plantar calluses plus evolving cutaneous horn; trimmed all ten toes, especially watch left great toe for ingrowing nail next visit; return 2 months or sooner PRN" becomes a very important communication to other members of the team and, with associated codes, as basis for payments.

PREVENTION OF OCCULT INJURY TO THE DIABETIC FOOT

Undoubtedly, the most important take home message of this chapter is preventing the development of the first DFU. The first opportunity in educating the patient about the risks of the diabetic foot should happen at first diagnosis of diabetes mellitus (Table 213.1). This can be an overwhelming time for a patient with information overload, but both verbal and written information such as a booklet about the warning signs, potential risks, and consequences of the diabetic foot should be delivered in an easy to understand format, combined with early follow-up to see how such instructions have been assimilated.

At every visit thereafter, whether it is with the family physician or surgeon, the consultation must include:

Socks-off examination of both feet
Skin assessment and lubrication
Check for bony prominences and callus with sanding down as appropriate
Re-emphasis of the importance of foot hygiene, nail care, and a weekly examination by a spouse/caregiver
Consideration of diabetic control—such as plasma glucose and HbA1c with referral to the diabetologist as need if this is consistently elevated
Orthotic evaluation
A follow-up plan

- We recommend at least 3 weekly visits initially, then 3 monthly, and then 6 monthly intervals if no complications supervene

Patients should be given specific phone numbers they can call, such as a diabetic nurse who can examine the foot and will expedite care as required, should they have any concerns.

Any wound, callus, skin breakdown, or ulceration should be taken seriously and patients referred to a surgeon ideally with an interest in diabetic foot disease. Clinics such as these can offer an intense program up to 10 weeks that can avoid an amputation (Fig. 213.2).

Numerous nonsurgical options for off-loading bony prominences at risk can range from comfortable, well-cushioned orthotic shoes with personalized in-soles, to a specialist for removable boots and/or nonweight bearing fitted plaster cast. There cannot be enough emphasis placed on the role of proper footwear. Like any intervention in medicine, there must be a follow-up within 4 weeks after new footwear has been initiated to check that the condition of the foot has improved. Bed rest and/or constant foot elevation may be required at home but is seldom actually done; orthotic intervention is more desirable.

TABLE 213.1 Clinical Assessment of the Diabetic Foot

Proper assessment of all diabetic ulcers include:

- Ulcer location, depth, and width
- History of neuropathic foot ulcer or the presence of synchronous ulceration
- Overt ulcer infection (been shown to be present in half of all ulcers). Associated calluses completely removed
- Exudate/purulence/new malodor
- Tissue loss especially necrosis/gangrene distally
- Systemic signs of infection such as chills, fever, nausea/vomiting, and malaise
- Sensation in all plantar areas of the foot should be assessed using a monofilament perpendicular to the skin—note areas of callus might give false positives
- Vascular assessment
  - Absence of both pulses by an experienced clinician is suggestive of vascular disease but must be accompanied by Doppler examination
- Digital plantar pressure measurements
- Transcutaneous oxygen measurements, where available, suggest a loss of perfusion in an affected limb
- Skin assessment and plans for ongoing lubrication
- Warmth can give false reassurance of good perfusion due to arteriovenous shunting in the skin, assuming it is nontender and does not represent invasive infection. However, a difference in temperature between feet is a crude but useful sign of large vessel disease.
- Consider acute Charcot degeneration, easily confused with infection

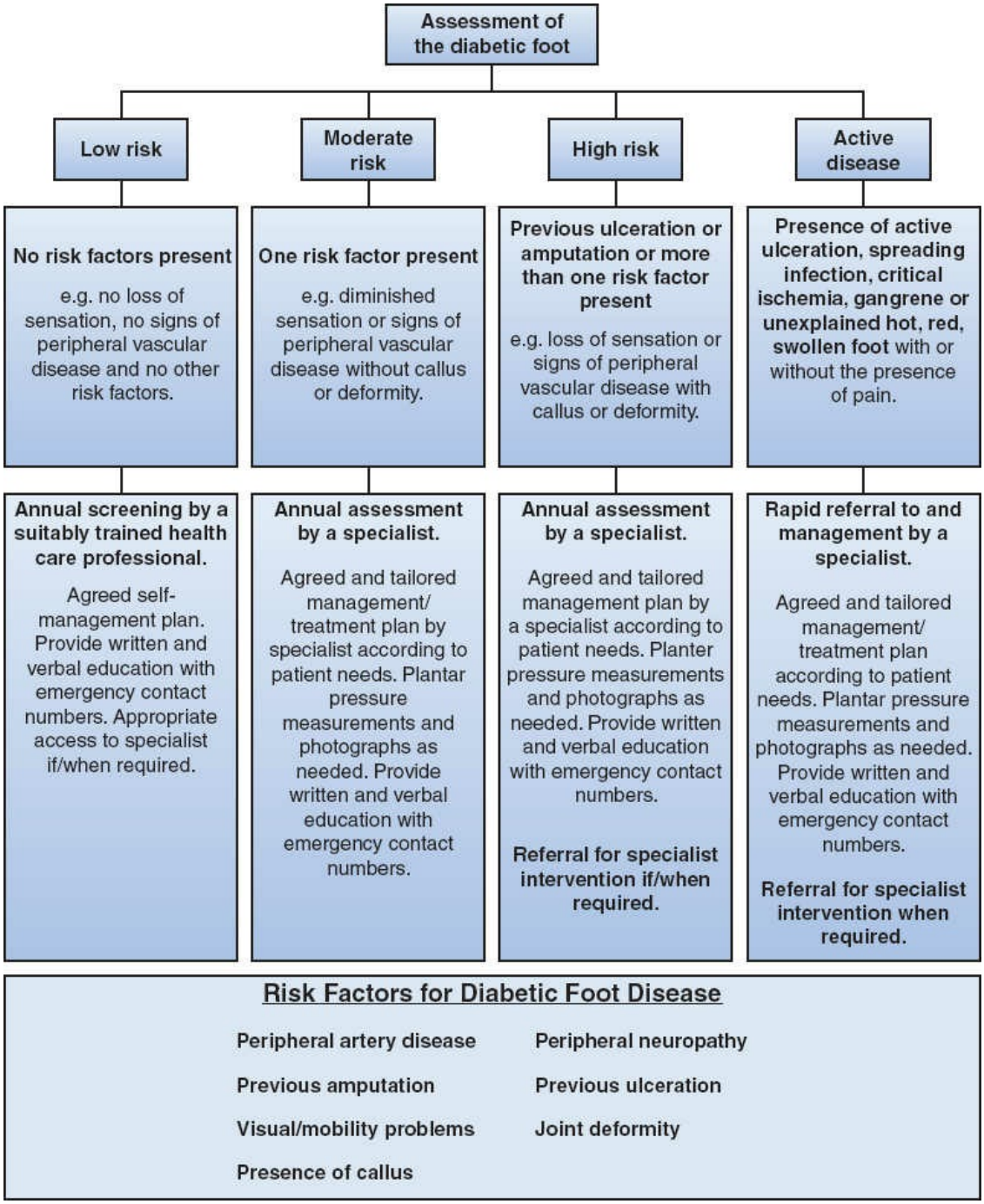

Figure 213.2. Risk stratification and triage of the diabetic foot. Risk factors are also noted.

In the presence of any DFU, the surgeon must ensure ongoing proper assessment of vascular status of the affected and contralateral limb. This can be a reversible factor in the pathogenesis of ulceration, through an endovascular (such as percutaneous transluminal angioplasty) or open (bypass) arterial reconstruction depending on the lesion(s) and the patient. Indications for percutaneous transcutaneous or open angioplasty for

diabetic peripheral artery disease are usually disabling claudication and critical limb ischemia (<30 mm Hg). The former can be very useful when open bypass surgery is contraindicated, and in lesions with a stenosis less than 4 cm long, and occlusions shorter than 10 cm. Even in the absence of the above signs, if there is proven peripheral arterial disease and a nonhealing ulcer despite best medical management, revascularization should be considered.

While many patients may have lost sensation and are pain-free, this is not always the case. For ischemic rest pain, lumbar sympathectomy may still have a minimal and transient role in symptom management. In the context of neuropathic pain, tricyclic drugs such as paroxetine, as well as gabapentin, may be emerging as effective analgesics. At present, they seem modest in effect with substantial side effects. Biofeedback schemes may be helpful.

Ideally, all DFUs, and especially infected diabetic feet, should have photographic documentation (**smartphones**) at the time of examination. This allows for serial comparisons and is particularly helpful when team members alternate care.

Topical Therapies

Emollients should be prescribed and used frequently in patients with dried, cracked skin to lessen other injuries. The choice of dressings can be overwhelming but should be kept simple. If there is active infection, topical antimicrobial dressings such as mafenide or silver sulfadiazine, iodine, honey, or polyhexamethylene biguanide (PHMB) can increase local antimicrobial action. Removal of the biofilm with proper wound bed preparation, consideration for moisture balance, and a suitable secondary dressing such as crepe bandaging should be individualized to the lesion and the patient. The key is to see the patient again promptly. Topical antimicrobials such as silver impregnated dressings can have a role to play, particularly in patients without heavy commensal load or poor vascular supply; only mafenide (Sulfamylon) has the capacity to be absorbed transcutaneously.

In general, in situ dressings designed for 5 days or longer should not be used for the diabetic foot (inviting neglect) due to the risk of rapid progression of infection that necessitates more frequent exposure and examination.

TREATMENTS FOR DIABETIC FOOT ULCERS

Surgical Offloading for Diabetic Foot Ulcers

MHR in the context of an ulcer has been shown to decrease the plantar pressures at the affected site, and often leads to the resolution of the ulcer. Where possible, incisions should be longitudinal over the affected metatarsal and must be on the dorsal surface of the foot through healthy, soft tissues free of inflammation (see Fig. 213.3). Creating new wounds on the poor healing plantar surface, near the affected ulcer itself is asking for trouble. Some concerns exist that by off-loading one ulcerated area of the foot, can lead to weight being transferred to another bony prominence and lead to a so called “transfer ulcer.”

In patients treated without MHR the rate of ulcer recurrence is 60% within 6 months and transfer ulcer rate is 60% to 70% in 5 years. With MHR the transfer ulcer rate is 10% at 5 years and recurrence rate after MHR at the same site is about 5% over 5 years. It is important to have digital plantar pressure measurements done after MHR to predict and prevent future ulceration.

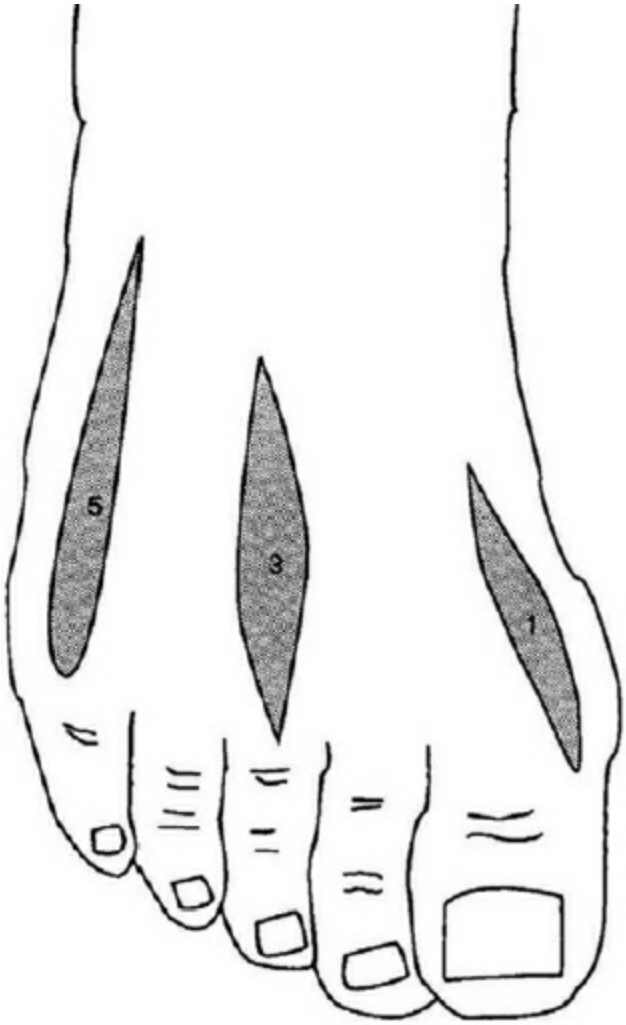

Figure 213.3. Dorsal incisions are preferable for operations on the diabetic foot. Incisions *1, 3,* and *5* would be appropriate for a metatarsal head resection for the corresponding metatarsal from right to left. Some have been concerned that it alters gait, it does—by improving it! These people do not have normal gaits to begin with, so the typical argument does not hold water as it would in nonneuropathic patients. Healing is prompt and complete if the procedure is done properly. Healing time is proportionate to the initial ulcer size. Weight bearing is permissible as soon as the drain is removed. Metatarsal head resection is simpler, faster, and less morbid than traditional transmetatarsal amputation. (With permission from Wieman TJ. Principles of management: the diabetic foot. *Am J Surg* 2005;190:295–9; permission conveyed through Copyright Clearance Center, Inc.)

Treatment of the Diabetic Patient With Lower-Extremity Infection

Although mild infection in a superficial ulcer can be referred to a specialist

within 1 working day, many are more urgent. The presence of infection of the diabetic foot should be considered a medical emergency and patients should be admitted to the hospital. The presentation of this is often delayed, with the classic signs of pain, redness, and fever potentially missed or blunted due to autonomic and sensory neuropathy, poor eyesight, and immune suppression (such as after organ transplantation), respectively (Table 213.2).

When infection is suspected, important aspects of the initial assessment should include: complete debridement of the wound/ulcer, microbiologic culture of the deepest part of the ulcer, blood tests including leukocyte count with a differential count, random plasma glucose, HbA1c, and possible use of inflammatory markers such as C-reactive protein.

Depending on depth of the ulcer, consider **radiographic assessment** for osteomyelitis. The presence of this can be confirmed by plain radiographs of the foot; however, this is not very sensitive and sometimes MRI or even a nuclear imaging white cell scan may be required to rule out osteomyelitis. However, the gold standard for diagnosing osteomyelitis is bone biopsy.
Urgent surgical review to determine the presence of abscess, deep seated infection including fascial compartments, and to determine the presence of wet gangrene, warranting hospitalization.
Subsequent assessment of the biomechanics of the foot and **off-loading treatments** as appropriate, is warranted when acute infection is controlled and amputation anticipated
Early and frequent **reassessment**—to rule out ascending and progressive limb- and life-threatening infection
Tissue viability assessment for consideration of exotic treatments such as negative pressure dressings, larval therapy, or hyperbaric oxygen therapy

The key steps of **therapy** in the presence of infection should include:

Cleaning and complete debridement of the wound
Appropriate wet dressings with coarse mesh gauze, either saline or consider topical antimicrobials such as silver impregnated dressings if there is a significant biofilm of contaminating bacteria
Elevation
Adequate and prompt surgical drainage of abscess/purulence; emergency operation on some occasions is required on the day of admission
Off-loading with custom orthotics or new fitted shoes as recovery

evolves

Close monitoring and follow-up is essential which includes examination of the wound (including photographic documentation) and a footwear specialist assessment to assess the response to altered bone structure or shoes.

In elderly and disabled patients, the role of home health monitoring to deliver regular wound inspection and dressing changes should flag any concerns in a timely fashion. Use of internet communication sent to the lead physician by patients or nurses can be very helpful, as is direct phone calls to the surgeon when invasive infection is thought to be present or to be recurrent and/or worsening.

Early follow up with the surgeon is also important to determine whether surgical intervention was adequate, or if further debridement or amputation is required (Table 213.3).

Debridement

Sharp debridement by an experienced practitioner will aid healing, and can be done in the clinic or by the bedside. However, formal sharp debridement should be cautioned if there is known, treatable peripheral vascular disease. Larval (maggot) therapy is an underrated form of debridement, and is relatively easy to use. Note that they cannot remove callus, so it should not be the sole method of debridement. Debridement should precede a vascular procedure by 24 hours if a prosthetic graft is possible.

CLINICAL SITUATIONS

Tissue Loss

Dry gangrene usually does not require surgical intervention, and can be monitored allowing for autoamputation. However, wet gangrene necessitates urgent surgical intervention and usually warrants leaving the amputation site open, with topical antimicrobials treatment applied.

Microbiology

Most diabetic foot infections are polymicrobial, with aerobic gram positive staphylococci being the most common causative organisms. Oral antistaphylococcal agents have been described as taking special advantage but can be very expensive. Gram negative bacilli and obligate anaerobes are frequent copathogens and seldom warrant systemic antibiotics.

Antimicrobial therapy should depend on local guidelines based on resistance, but should consider co-pathogens as noted above. Superficial swabs can often grow misleading skin commensals or contamination. Note that while infection is common, swab testing of clinically uninfected ulcers should be avoided as this leads to confusing results and inappropriate antibiotic therapy. When infection is present, **always ascertain recent bacteriology culture and sensitivity results** from that patient to guide antibiotic choice. Failure to optimize antibiotics is a missed opportunity to help your patient, but at the same time increase resistant bacterial forms.

It is common for many diabetic foot patients to have had multiple recent courses of antibiotics. Therefore, the possibility of methicillin-resistant *Staphylococcus aureus* (MRSA) may warrant adjunctive agents such as vancomycin to address this. To the same end, many older diabetics might be at risk of *Clostridium difficile*, so this should be taken into account if a prolonged, broad spectrum agent has been or is being used. Diarrhea in patients with prolonged antibiotics is a worrisome sign.

TABLE 213.2 Clinical Classification of Infection, With Definitions

	IWGDF/IDSA Classification
Uninfected: No systemic or local symptoms or signs of infection	1 (Uninfected)
Infected At least 2 of the following items are present: ■ Local swelling or induration ■ Erythema >0.5 cm[a] around the wound ■ Local tenderness or pain ■ Local warmth ■ Purulent discharge Other causes of an inflammatory response of the skin should be excluded (e.g., trauma, gout, acute Charcot neuro-osteoarthropathy, fracture, thrombosis, venous stasis).	
Infection involving only the skin or subcutaneous tissue (without involvement of deeper tissues and without systemic manifestations as described below). Any erythema present extends <2 cm[a] around the wound No systemic signs or symptoms of infection (see below).	2 (Mild infection)

Infection involving structures deeper than skin and subcutaneous tissues (e.g., bone, joint, tendon, muscle) or erythema extending >2 cm[a] from the wound margin. No systemic signs or symptoms of infection (see below).	3 (Moderate infection)
Any foot infection with the systemic inflammatory response syndrome (SIRS), as manifested by ≥2 of the following: ■ Temperature >38°C or <36°C ■ Heart rate >90 beats/minute ■ Respiratory rate >20 breaths/minute or $PaCO_2$ <4.3 kPa (32 mm Hg) ■ White blood cell count >12,000 or <4,000/mm^3, or >10% immature (band) forms	4 (Severe infection)

[a]In any direction, from the rim of the wound; the presence of clinically significant foot ischemia makes both diagnosis and treatment of infection considerably more difficult.
From Lipsky B, Berendt A, Cornia PB. 2012 Infectious Diseases Society of America clinical practice guideline for the diagnosis and treatment of diabetic foot infections. IDSA guidelines. *Clin Infect Dis* 2012;54(12):e132–73; by permission of Oxford University Press.

Osteomyelitis

If osteomyelitis is suspected, cultures of actually involved bone are the gold standard for diagnosis and microbial culture and sensitivity testing. It is imperative to excise the infected bone with a margin of healthy cortex. This can easily be done because healthy cortex is hard and infected bone is demineralized and therefore soft, and easily felt.

NOTE: An infection going down to the bone is not automatically osteomyelitis; that occurs when the bony tissue is invaded or necrotic and requires resection of the involved bone.

If one can probe from an ulcer down to the level of the bone, the patient is at increased risk of future amputation. Other risk factors include the combination of infection and ischemia, and osteomyelitis (especially at the heel) carries an increased risk of major amputation.

TABLE 213.3 Indications for Surgical Over Medical Management of the Infected Diabetic Foot

Presence of ulcer
Crepitus
Bone involvement (confirmed osteomyelitis by plain radiograph/MRI)
Joint involvement (including septic arthritis)
Necrotizing fasciitis
Abscess
Substantial skin/muscle necrosis
Gangrene

In some settings of documented osteomyelitis, particularly if there is adequate blood supply to allow for good intravenous antibiotic penetrance in a compliant patient with reasonable glucose control, they may be eligible for conservative therapy with 6 weeks of intravenous antibiotics guided by cultures and sensitivities from bone biopsy with close monitoring. Medical treatment is protracted, complex, hard to administer, expensive, and prone to failure. Surgical resection is definitive, without complications of long-term antibiotic therapy and is simple and inexpensive compared to medical treatment. If there is clinical and biochemical resolution, and in the absence of systemic signs of infection, it is reasonable to step down to oral antibiotics if the cultures suggest sensitivity to an appropriate agent.

However, in the patient with poor compliance, progressive infection and poor vascular supply (or a failure of the above treatment), then surgical debridement is usually indicated. The approach will depend on the location and extent of infection. This may require only a single incision and drainage, but if infection is deep seated along fascial planes, filleting of the affected area is appropriate followed by specific systemic and topical antibiotics. Ray amputations often heal reasonably well, with the space filled with granulation tissue thus ultimately limiting functional loss. In the context of osteomyelitis, the metatarsal bone and the metatarsophalangeal joint can be excised, similar to a Keller procedure common for hallux valgus. MHR as described is much preferable. In these cases, it is important to dissect close to the bone itself to minimize disruption to the neurovascular bundles.

Surgical principles must be obeyed including removal of any foreign bodies, debridement of all devitalized tissues, and deep tissue culture for

bacterial identification and sensitivities. After thorough irrigation, the wound may be left open with negative pressure (V.A.C.) dressings, or closed with interrupted sutures over a corrugated drain. Prior to discharge, the patient must have competed at least 5 days of antibiotic therapy, been reviewed by physiotherapy, have clean wounds and a clear plan for dressing changes and early follow-up including limits for ambulation.

NOTE: Signs of ascending infection include spreading intense erythema, increasing induration, rigors, lymphangitis, regional palpable lymphadenitis, or hypotension.

Indications for a more **conservative** surgical approach with aggressive debridement or minor amputation, over primary amputation include:

A good blood supply to the foot
Small vessel disease and gangrenous toes
Successful arterial bypass
Neuropathic foot with little arterial disease
Osteomyelitis with little arterial disease

Debridement should go back to healthy bleeding tissue. However, the presence of wet gangrene, life-threatening sepsis, extensive muscle necrosis, and, when revascularization is technically impossible or the patient is bedridden, primary proximal amputation is preferred.

Amputation

In general, amputation can potentially result in a loss of function, loss of independence, and significant psychosocial comorbidity. However, there are circumstances when this option is in the ultimate best interests of the patient. These include:

Intractable ischemic rest pain which cannot be managed by analgesia or revascularization
Life-threatening limb infection that cannot be managed by lesser measures
Nonhealing ulcer that is accompanied by a higher burden of disease than would result from amputation, that is, a well-performed below-the-knee amputation may be better than a **nonfunctional limb**. Prostheses are always a partial answer but in fact, are seldom really used in the older aged diabetic.

Early definitive management of the problem in the absence of gangrene or vascular disease almost completely eliminates the need for amputation

when combined with regular preventive care for the remainder of the patient's life.

One should aim to eliminate infection, while preserving as much normal anatomy and function as possible. From distal to proximal, amputation can occur at the level of metatarsophalangeal, transmetatarsal (Lisfranc), mid foot, and through the ankle joint itself (Syme procedure). Where possible, a pan-MHR can avoid the biomechanical pitfalls of the transmetatarsal amputation. However, below-the-knee amputation is most amenable to a good fitting prosthesis allowing a return of function. This is especially the case compared to an above-the-knee amputation, which sacrifices the important role of the knee joint itself. For below-the-knee amputation, the authors generally prefer leaving a longer posterior skin flap (Burgess method), thus avoiding a suture line over the stump (Fig. 213.4).

Patients who have undergone amputation should remain under regular review, not just for monitoring of the stump, but half of these patients will develop an ulcer in the contralateral limb within 18 months if not under proper and active surveillance.

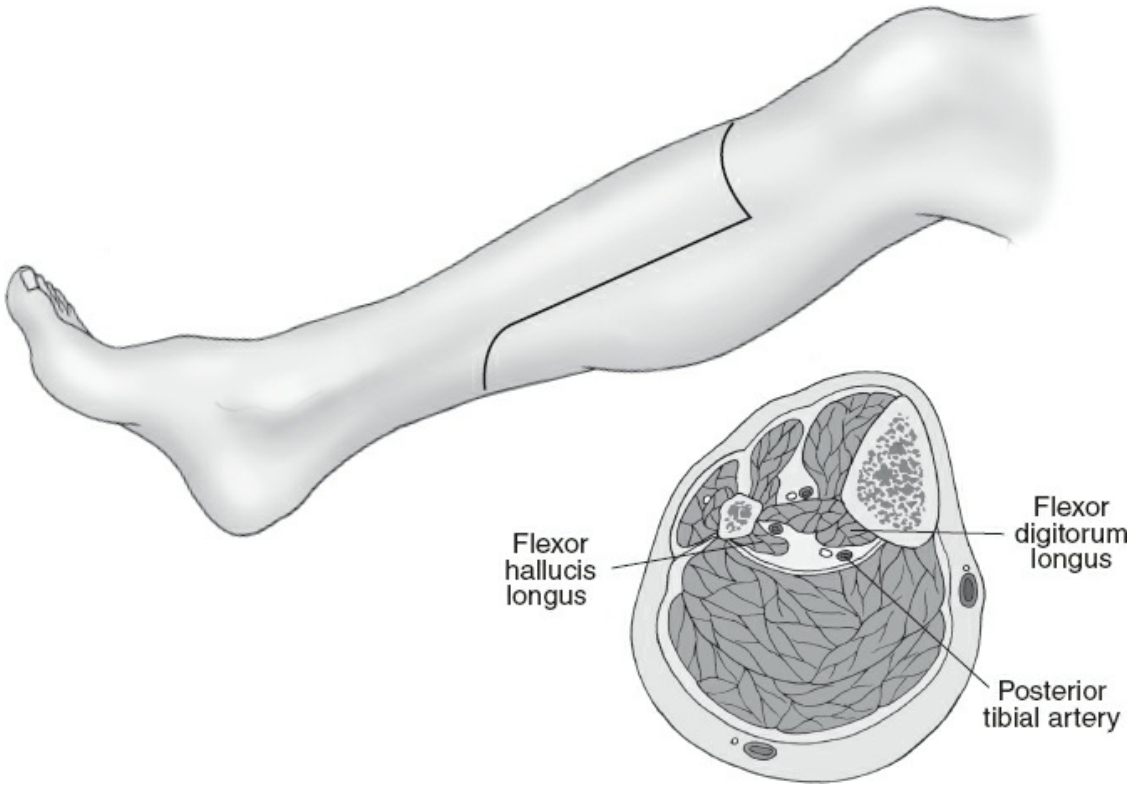

Figure 213.4. Below-the-knee (transtibial) amputation offers better function with prosthesis compared to above-the-knee amputation. The longer posterior flap can be wrapped anteriorly,

which prevents the suture line lying over the weight bearing area. (From Fischer JE, Bland KI, eds. *Mastery of Surgery.* 6th ed. Philadelphia, PA: Wolters Kluwer Health/Lippincott Williams & Wilkins; 2012. Fig. 3, Chapter 232.)

Charcot Arthropathy

Charcot joint occurs in only 0.2% of diabetics, but is very important to recognize. Joint destruction occurs due to a mixture of peripheral and/or autonomic neuropathy, osteopenia, or often repetitive trauma. The acute phase is characterized by a red, hot, swollen joint which is often painless. Sometimes this can be difficult to distinguish from osteomyelitis, and MRI can be misleading. Once recognized, initial treatment is by immobilization by nonweight bearing casting. A well-trained orthotist can construct a brace and orthotic, combined with autoinflammatory regime. **Remember: all red, hot ankle joints in a diabetic should be treated as Charcot joint until proven otherwise.**

HOLISTIC CARE OF THE DIABETIC PATIENT

Although the key responsibility of the surgeon is ensuring adequate blood supply and eliminating infection, consultation allows opportunistic assessment of all aspects of care of the diabetic. Ensure that their glycemic control is adequate and that they manage their own regimen effectively and self-monitor their glucose levels. The fact that they may be considered for surgical intervention itself is a sign of poor disease control and a failure of preventive measures. They remain at elevated risk of cardiovascular events such as stroke and ischemic heart disease. Should your patient be on special medications to those ends?

One must remember that the extremely high 5-year mortality in patients with diabetic foot disease is partly due to high rates of myocardial infarction and stroke in this population. At every opportunity smoking cessation should be encouraged, and treatments such as nicotine replacement therapy considered.

Federal pay-schemes are available for the management of the diabetic foot. Medicare pays for 6 monthly medical assessments if a formal diagnosis of diabetic sensory neuropathy is made. In addition, routine foot-care, including sanding and debridement of corns and calluses, and trimming of nails are also covered.

SUMMARY

The diabetic foot continues to carry significant morbidity for our patients, creating a huge socio-economic burden. Yet the spiral toward amputation is all too common, and frustratingly, often preventable. Patient education and empowerment in the prevention of DFUs should begin at the time of their first diagnosis of diabetes mellitus. Every consultation is an opportunity to re-educate both the patient and their caregiver about the importance of proper footwear, good foot hygiene, and close, regular self-examination for ulcers and wounds. The role of the attending surgeon is crucial and the secret to the management of diabetic foot problems is their prevention. Due to neuropathy and poor eye-sight, many patients will present relatively late with ulceration. Sanding or debridement of callus and enrollment of the patient in a skilled professional team that includes an interested and informed surgeon, are keystones in preventing progression. The surgeon must determine if there is an ischemic component to the pathology, and consider correction when at all possible. In the event of infection, one must ensure adequate drainage of abscess when required, and debridement of necrotic or diseased tissue. Should the patient require it, such as limb- or life-threatening infection, amputation should be done in a timely fashion aiming to preserve function as much as possible, while ensuring adequate source control of the infective source. Prevention, good communication with the patient and other doctors and health specialists, with close follow-up should minimize the not inevitable outcome of amputation.

Suggested Readings

Bakker K, Apelqvist J, Lipsky BA, et al. The 2015 IWGDF guidance documents on prevention and management of foot problems in diabetes: development of an evidence-based global consensus. Diabetes/metabolism research and reviews 2015.

Giurini JM. Surgical approaches to the diabetic foot. In: Fischer JE, Bland KI, eds. *Mastery of Surgery*. 6th ed. Philadelphia, PA: Wolters Kluwer Health/Lippincott Williams & Wilkins; 2012.

Lipsky B, Berendt A, Cornia PB. Infectious Diseases Society of America clinical practice guideline for the diagnosis and treatment of diabetic foot infections. IDSA guidelines. *Clin Infect Dis* 2012;54(12):132–73.

National Institute for Health and Care Excellence (NICE): Clinical Guidelines. Diabetic Foot Problems: Prevention and Management. London, UK: National Institute for Health and Care Excellence (UK). 2015. (NICE clinical guideline

NG19). Available from URL: http://www.nice.org.uk/guidance/ng19

Patel VG, Wieman TJ. The effect of metatarsal head resection for diabetic foot ulcers on dynamic plantar pressure distribution. *Am J Surg* 1994;167:297–301.

Scottish Intercollegiate Guidelines Network (SIGN). Management of Diabetes. Edinburgh, UK. Updated May 2014. Guideline 116. Available from URL: http://www.sign.ac.uk/guidelines/fulltext/116/

Wieman TJ. Principles of management: the diabetic foot. *Am J Surg* 2005;190(2):295–9.

EDITOR'S COMMENT

The chapter by Galbraith et al. focuses on an extremely common and troubling problem in general and vascular surgery, namely, prevention and treatment of the diabetic foot. Notably, diabetes mellitus has increased to epidemic levels, particularly type II diabetes (Mathers CD, Loncar D. Projections of global mortality and burden of disease from 2002 to 2030. *PLoS Med* 2006;3(11):e442). Foot and leg complications are a major source of morbidity and mortality for these patients. Certainly, prevention of initial foot injury is the key and the authors emphasize that fact throughout the chapter. A multidisciplinary approach seems best, and includes physical therapy, orthotics, podiatry, and vascular or general surgery. It requires the engagement and an informed patient as well. These efforts can decrease foot calluses and ulcers that directly lead to infection and subsequent amputations. The pathophysiology underlying the numerous clinical issues is cogently discussed, as are the pathobiologic processes underlying diabetic foot ulcers (DFUs).

Recently published SVS guidelines on diabetic foot care emphasize similar strategies as discussed in this chapter with regard to prevention (Hingorani A, LaMuraglia GM, Henke P, et al. The management of diabetic foot: A clinical practice guideline by the society for vascular surgery in collaboration with the American podiatric medical association and the society for vascular medicine. *J Vasc Surg* 2016;63:3S–21S). For example, annual foot inspections, physical examination with neuropathy testing, custom footwear in high-risk patients, and adequate glycemic control are evidence-based preventative measures. These measures are also likely cost effective.

The authors provide detailed recommendations to prevent injury to the diabetic foot, emphasizing good history and physical examination points. One thing that is missing is the use of the Semmes Weinstein multifilament test, which allows accurate delineation of peripheral neuropathy, and can direct these patients to prophylactic orthotic foot ware (Feng Y, Schlosser FJ, Sumpio BE. The Semmes Weinstein monofilament examination as a screening tool for diabetic peripheral neuropathy. *J Vasc Surg* 2009;50:675–82, 682 e1). The other noted absence is the use of nerve release to treat lower-extremity neuropathy.

Evidence supports the benefit of this approach for prevention of DFU and amputation (Dellon AL, Muse VL, Nickerson DS, et al. Prevention of ulceration, amputation, and reduction of hospitalization: outcomes of a prospective multicenter trial of tibial neurolysis in patients with diabetic neuropathy. *J Reconstr Microsurg* 2012;28:241–6).

Adequate arterial blood flow to promote DFU healing is critical for amputation prevention. Many times, patients with DFU have been treated for months with no improvement and no assessment of blood flow has been made. It is noted by the authors that measuring the ankle brachial index may aide assessment of perfusion and healing potential. However, as they rightly note, tibial arteries are prone to calcification and falsely elevated readings. We tend to use the toe–brachial index or better yet, transcutaneous partial pressure oxygen measure, particularly if an amputation is planned. The use of peripheral bypass and/or endovascular therapies to improve blood flow is also central in the treatment of patients who have DFU, gangrene, and so forth, and who have insufficient blood flow. Standard dogma is that pulsatile blood flow to the foot is requisite for successfully healing any type of significant tissue loss. While the techniques of revascularization may be debated and dependent on multiple factors such as anatomic location of the lesions, their extent, and patient comorbidities (Mills JL, Sr. Open bypass and endoluminal therapy: complementary techniques for revascularization in diabetic patients with critical limb ischaemia. *Diabetes Metab Res Rev* 2008;24 Suppl 1:S34–9), it is reasonable to be aggressive with these patients to prevent limb loss once an open wound is present. Patients with DFU are often younger than the more elderly arterial disease patients, and limb loss may impact the ability to keep a job.

There is evidence that tight glycemic control can decrease foot and leg problems in diabetics. In particular, a meta-analysis showed that tight as compared with standard glycemic control is associated with a decrease in major limb amputation (Hasan R, Firwana B, Elraiyah T, et al. A systematic review and meta-analysis of glycemic control for the prevention of diabetic foot syndrome. *J Vasc Surg* 2016;63:22S–28S.e1–2). For example, intensive glycemic control (HbA1c <7.5%) as compared with less intensive control is associated with a 35% reduction in amputation. This strategy should be standard.

Patients with a diabetic foot infection need to be treated as an emergency. This is well highlighted by the authors, as these patients can often have an invasive infection that if it is delayed in terms of operative drainage, may progress to a nonsalvageable foot. The so-called “septic foot” can sometimes be subtle and requires a high index of suspicion so that rapid care can be given to prevent loss of limb and potentially life. It is important to pay attention to planter tenderness in particular, as that suggests advanced infection.

It is often not clear how best to treat osteomyelitis related to a DFU. The authors note that when osteomyelitis of the foot bones is suspected, the use of

plain films may not be very sensitive. I certainly agree with this. The diagnostic test that I would add is using the Westergren sedimentation rate, which is sensitive but not specific to increase or decrease the pretest probability. The MRI is certainly the best test to diagnose osteomyelitis (Dinh T, Snyder G, Veves A. Current techniques to detect foot infection in the diabetic patient. *Int J Low Extrem Wounds* 2010;9(1):24–30) and I feel is better than radio-labeled leukocyte imaging. Use of broad spectrum antibiotics is standard and obtaining a bone culture to narrow the antibiotics is much favored as compared to using a wound swab; a practice to be discouraged. The latter practice actually may misguide antibiotic therapy, as well as waste money.

Few areas in surgery are less glamorous but as common and important as diabetic foot care. Much research is needed to produce evidence to guide prevention and treatment. Prevention of wounds are critical, and the surgeon is at the center of prevention to proper treatment for limb salvage.

Peter Henke

D ACUTE LOWER EXTREMITY ISCHEMIA

214 Embolectomy

Peter Henke

EPIDEMIOLOGY AND BRIEF PATHOPHYSIOLOGY

Acute limb ischemia (ALI), for which embolectomy remains a standard therapy, is one of the most common vascular emergencies that surgeons encounter. The incidence remains significant, but the estimated incidence has decreased from 42.4 to 23.3 per 100,000 persons between 1988 and 2007. Prompt recognition and diagnosis followed by rapid restoration of blood flow to the ischemic extremity will decrease limb loss and subsequent reperfusion-related local and remote organ injury. This disease most often occurs in aged or critically ill patients, who often have significant comorbidities, which can lead to their demise even after successful revascularization of a limb.

A useful limb ischemia categorization system is the Society for Vascular Surgery/International Society for Cardiovascular Surgery (SVS/ISCVS) joint consensus document (Table 214.1). Class I is a viable limb that is not immediately threatened, no sensory or muscle weakness is present, and arterial Doppler and venous Doppler signals are audible. Category II is a threatened limb, with IIa being marginally threatened if promptly treated, with minimal to no sensory loss, inaudible arterial Doppler signals, but audible venous Doppler signals present. Category IIb is an immediately threatened limb, which requires rapid revascularization, and is associated with sensory loss and associated mild muscle weakness with inaudible arterial and venous signals. Category III is irreversible limb ischemia, with major tissue loss or permanent nerve damage, a profoundly anesthetic and paralyzed limb, with rigor and inaudible signals. The patient whose disease falls into this category almost always requires amputation.

The pathophysiology of ALI is due to an abrupt and complete blockage

of the main arterial supply to the extremity. Unlike chronic limb ischemia, collaterals are not well developed. The distal tissue bed in the limb becomes ischemic with energy metabolism shifting from an aerobic to an anaerobic process. Progressive ischemia leads to cell dysfunction and death. Nerve cells, followed by muscle cells, are most susceptible. A patient without underlying vascular disease and an acute arterial blockage has approximately 5 to 7 hours for revascularization before irreversible functional tissue damage occurs. Upon reperfusion, release of cellular products may cause systemic organ injury, such as renal and pulmonary failure. Both these factors need to be kept in mind when treating these patients.

ANATOMY, DIAGNOSIS, AND INDICATIONS

The etiology of ALI is often an embolic process, usually a thromboembolism, and commonly from a cardiac source. This is typically observed after a patient develops atrial fibrillation with a left atrial thrombus or after a myocardial infarction with a left ventricular thrombus. Common locations of embolic lodgment are at arterial bifurcations where the artery size changes, such as the aortic bifurcation, femoral bifurcation, or popliteal artery, and less frequently at other locations (Fig. 214.1).

The diagnosis is made with a combination of history and physical examination findings. The classical findings are the six P's; pain, pulselessness, poikilothermia, pallor, parathesis, and paralysis. The clues important for determining the etiology of ALI are readily obtainable by the history and physical features (Table 214.2). Often, the location of the embolism can be determined by physical examination. For example, in a patient with new onset atrial fibrillation and right leg ALI, a nonpalpable right femoral pulse and normal left lower extremity pulse examination suggests thromboembolism, for which embolectomy would be appropriate. Conversely, an aged patient with longstanding peripheral arterial disease and claudication, who presents with a cool right lower extremity and a weakly palpable femoral pulse and only dopplerable signals in the contralateral nonaffected side, probably does not have an embolic etiology causing their limb ischemia. This patient would be best addressed with an arteriogram or computed tomography angiogram (CT angiogram) and possible endoluminal intervention.

TABLE 214.1 SVS Grade Acute Limb Ischemia

Category	Description	Neuromuscular Findings	Doppler	Intervention
I	Viable	No sensory or muscle weakness	Audible arterial and venous	Elective
IIa	Threatened (marginally)	Minimal	Often inaudible arterial, audible venous	Urgent
IIb	Threatened (immediately)	Mild to moderate, associated with pain	Usually inaudible arterial, audible venous	Emergent
III	Irreversible	Profound deficit	No signals	Emergent

Adapted from Rutherford R, Baker JD, Ernst C, et al. Recommended standards for reports dealing with lower extremity ischemia: revised version. *J Vasc Surg* 1997;26:517–38.

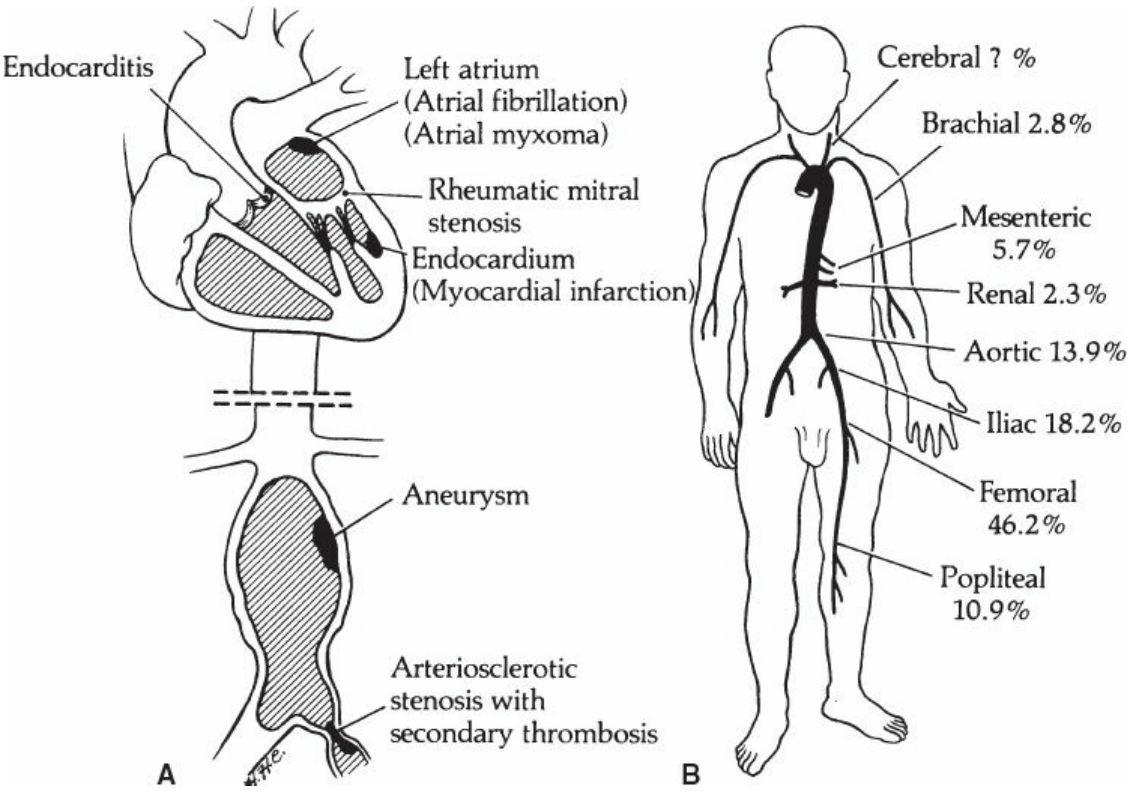

Figure 214.1. The source (**A**) and distribution (**B**) of clinically significant arterial emboli.

Other etiologies of ALI include in situ arterial thrombosis, peripheral bypass thrombosis, peripheral arterial aneurysms, trauma (popliteal artery disruption or penetrating injury), or acute aortic dissection with occlusion of the aorta or iliac arteries. These need to be considered in the differential, but will not be discussed in this chapter as they are not primarily treated with embolectomy.

Men and women are equally affected by ALI. Modern series amputation rate is 13%, mortality is approximately 7% to 10%, and the average hospital length of stay estimated for these patients is approximately 10 days. Generally, ALI does not occur in young people outside of trauma, but it may occur in young patients due to unusual

circumstances, such as paradoxical emboli, hypercoagulable disorders, popliteal artery entrapment syndrome, or in those with severe early onset cardiac disease.

TABLE 214.2 History and Physical Features of Acute Limb Ischemia

	Embolism	Others
History	Rapid onset Prior cardiac event No prior PVOD history	Vague onset or trauma No recent cardiac event History of PVOD
Physical examination	Cold, mottled, paralyzed Normal contralateral limb Clear demarcation	Cool, bluish, paresthesias Abnormal contralateral pulse examination No distinct demarcation
Etiology	Cardiac thrombus Arch plaque	Plaque rupture Hypercoagulable state Cardiac failure
Prior vascular surgery	Usually no	Often yes
Typical location	Arterial bifurcations	Long segment occlusions, diffuse
Most common ischemic class	IIb	IIa

PVOD, peripheral vascular occlusive disease.

Excellent judgment is needed for late SVS grade III limb ischemia. While perhaps obvious, it is important not to attempt embolectomy in those with nonrecoverable ischemia, as the tissue is not viable. Sometimes, the limb examination is marginal, and revascularization with reassessment of tissue viability is reasonable with close observation and a low threshold to amputate if warranted by clinical status. Frank discussion with the patient and their family is important, as there is high potential for limb loss, and setting expectations is critical.

Two primary factors underlie the morbidity and mortality that result from ALI: the patients' underlying comorbid illness and delay in recognition and revascularization of the limb(s). It is uncommon that embolectomy itself will directly cause death. In a mixed etiology of ALI, factors associated with amputation-free survival (AFS) have been evaluated. Decreased AFS is associated with non-Caucasian race, older age, a history of neurologic disease, malignancy, congestive heart failure, and low body weight. Not surprisingly, skin mottling and rest pain are

associated with increased risk of amputation. Another study suggested that ALI-related mortality was increased with delay in treatment of ischemia, significant underlying atherosclerosis, and poor arterial back bleeding at operation.

Selection of appropriate therapy is also an important factor to decrease amputation occurrence and mortality. While strong evidence suggests equivalence of endovascular or surgical therapies, as measured by mortality and amputation, the etiology of the ALI needs to be factored into this equation. Two landmark articles were published in the 1990s, which suggested that thrombolytic therapy had equivalent outcomes to surgical therapy in patients with ALI. These were the Surgery or Thrombolysis in Lower Extremity Ischemia (STILE) and Thrombolysis or Peripheral Artery Surgery (TOPAS) trials, which randomized patients to arteriography and thrombolytic therapy with urokinase, versus arteriography and embolectomy or urgent bypass. While these data are compelling, a majority of patients in both of these trials had class I and IIa ischemia, with <25% having class IIb or III limb ischemia, for which embolectomy is most commonly performed. A large national database study suggested that in those patients with an embolic etiology (generally stage IIb ischemia), amputation is significantly less likely with embolectomy, but not thrombolytic therapy. Importantly, patients who failed thrombolytic therapy had a significantly greater risk of amputation and death. The bottom line is that providers must choose the appropriate therapy very carefully for patients with ALI.

PERI- AND POSTOPERATIVE MEDICAL THERAPY FOR ACUTE LIMB ISCHEMIA

Patient management includes intravenous fluid resuscitation, without potassium, immediate anticoagulation (if no contraindications), and all patients should receive per oral or per rectum aspirin (Fig. 214.2). Standard chemistry and hematology laboratory screening should be done, including a type and screen. Consideration of intravenous mannitol to induce a diuresis, as well as yielding some oxygen radical protection, should be given. It is also reasonable to alkalinize the urine if myoglobinuria is present. Similarly, while no level I evidence exists, use of extracorporeal renal support with CVVHD in patients who have significant tissue ischemia and acute renal insufficiency makes sense to decrease potentially fatal reperfusion hyperkalemia that may result. This

therapy can be ongoing with the patient in the operating room.

It cannot be emphasized strongly enough that all patients with ALI receive rapid, full anticoagulation (except if actively bleeding). This is typically with heparin, with an intravenous bolus of 100 to 150 U/kg, and then titrated to maintain an activated partial thromboplastin time (aPTT) of two to two-and-a-half times baseline. If the patient has a known history of heparin-induced thrombocytopenia or an anti-thrombin deficiency, alternative agents, such as direct thrombin inhibitors (lepirudin or argatroban), can be used and aPTT can be used to guide dosage.

Laboratory markers may help predict major amputation risk in those with ALI. For example, creatinine phosphokinase (CPK) elevation and neutrophilia upon presentation confer a tenfold increased risk of amputation, as compared to those without CPK elevation. It is not clear if CPK elevation after revascularization carries the same prognosis, but is unlikely, as washout of the ischemic tissue bed normally occurs.

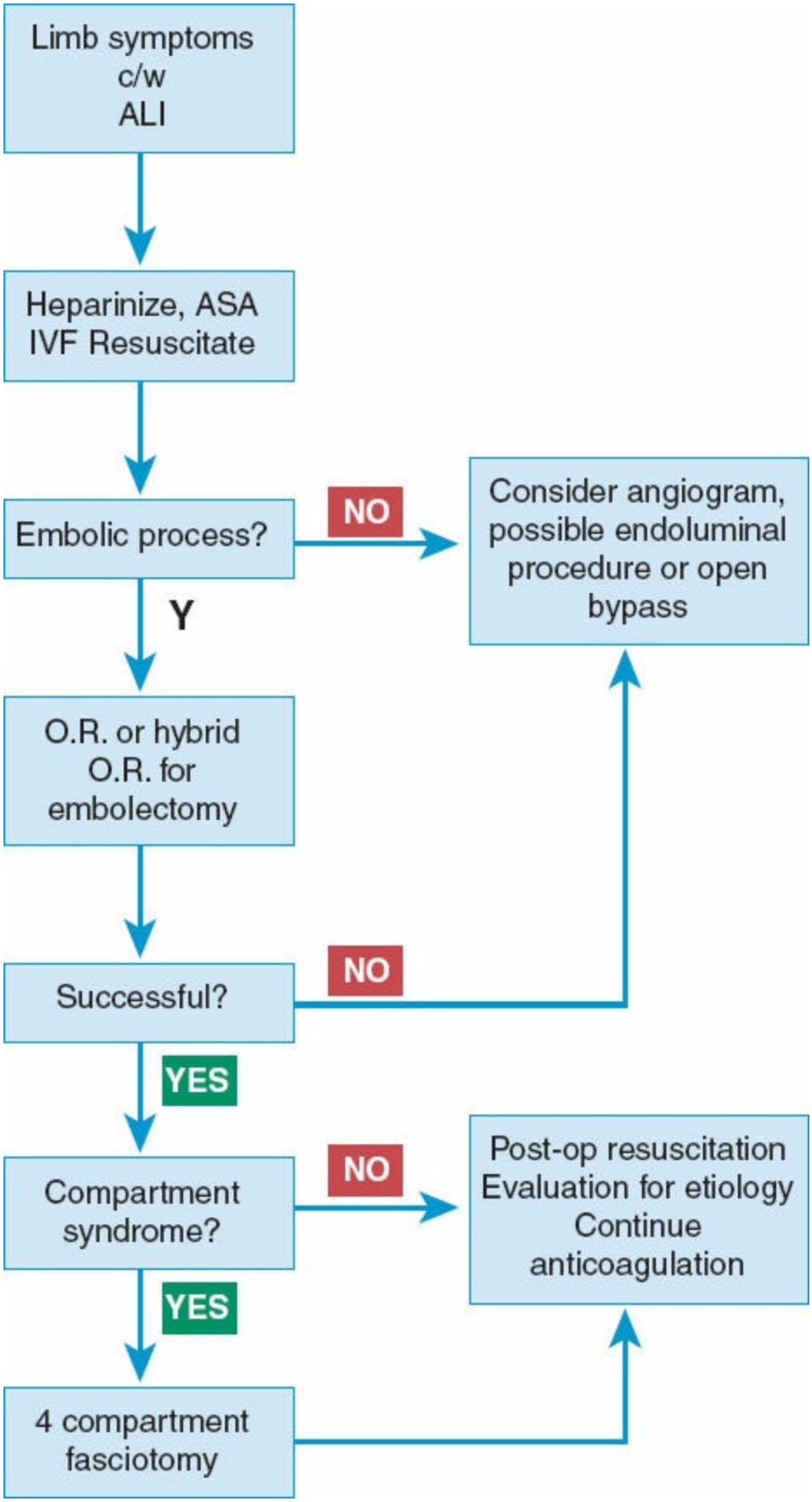

Figure 214.2. Algorithm of treatment for acute limb ischemia (ALI) and catheter embolectomy. ASA, aspirin; OR, operating room.

OPERATIVE SETTING, TECHNIQUES, AND EXPOSURE

Most modern hybrid operating suites have endovascular capabilities with either fixed equipment or a high-quality C-arm and a full array of catheters, wires, and balloons. Rigid distinction between endoluminal and surgical revascularization for ALI is outdated, but is presented below for purposes of clarity and for those surgeons without these resources.

Embolectomy Catheter Basics

The standard embolectomy catheter is a hollow, pliable catheter body with a soft, distensible balloon placed at its tip. It is available in graduated sizes from No. 2 to 7 Fr. A syringe fitting at the proximal end allows controlled inflation and deflation of the balloon. The smaller catheters are constructed with a flexible spring tip to decrease the chance of intimal damage or arterial perforation. Each catheter size has an optimal level of balloon distention, and that recommended volume should not be exceeded.

Saline solution is the routine used for balloon inflation; however, air is more appropriately used with the No. 2 and 3 French catheters. Because air is considerably more compressible than saline solution, the balloon exerts less force on, and is less likely to cause damage to, the smaller vessels.

The general aspects of embolectomy catheter use are as follows: The instrument is threaded into the artery and passed either through the thrombus or between the thrombus and the vessel wall. Although the pliability of the catheter tip is designed to facilitate safe proximal or distal passage, forceful probing at sites of nonembolic obstruction can lead to vessel wall dissection or perforation. When the appropriately sized catheter has been gently advanced as far as possible, the balloon is progressively inflated while the catheter is being slowly withdrawn all in a single continuous motion. Inflating the balloon while static can damage or rupture the artery (Fig. 214.3). The surgeon who withdraws the catheter should also control balloon size because the “feel” is an important factor in ensuring complete clot retrieval and preventing vessel damage. When pull-back catheter resistance appears excessive, it is imperative to allow sufficient balloon deflation to permit smooth passage across segments of atherosclerotic luminal narrowing. As catheter withdrawal continues, reinflation of the balloon should occur to maintain gentle wall contact (Fig. 214.4). Embolic material and associated thrombus do not offer significant resistance to catheter advancement. Usually two to three passes with no further clot suggest complete clearance.

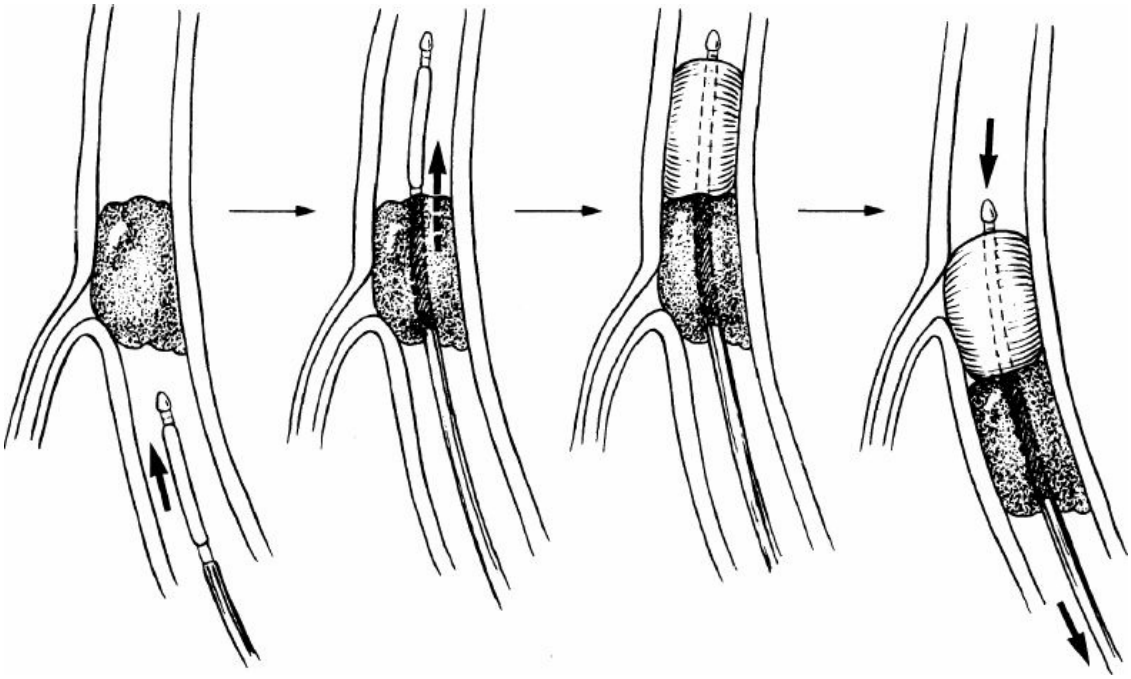

Figure 214.3. The technique of balloon catheter embolectomy with catheter insertion in the distal vessel.

Passage of the catheter may be hindered by angulation at bifurcations or by vessel tortuosity. Maneuvers often helpful in these circumstances include preforming the tip of the catheter at an angle, followed by the rotation of the catheter at the site of obstruction, the simultaneous introduction of more than one catheter, or the progressive flexion of a nearby joint to alter the advancement angle of the catheter tip. An additional technique particularly useful in passing an eccentric plaque involves gentle balloon inflation at the site of the difficult catheter passage, followed by gentle advancement of the catheter during deflation. This maneuver brings the catheter tip away from the wall and toward the residual lumen.

Removal of Mature Adherent Thrombotic Material

The standard fluid or air-filled Fogarty balloon catheter is usually sufficient for removing soft, fresh thrombus, but it is limited in its ability to remove more adherent material, such as older clot of thrombotic origin. Two devices can be used for tenacious clot: the adherent clot catheter (ACC) and the graft thrombectomy catheter (GTC).

The ACC consists of a No. 4 or 6 French flexible catheter body with an adjustable-pitch, corkscrew-shaped distal tip. The corkscrew balloon consists of a latex balloon membrane covering an outer cable that is

loosely spiraled around an inner wire, running the length of the catheter to a control handle at the proximal end. The control handle allows the surgeon to adjust the pitch and diameter of the corkscrew from straight to fully spiraled.

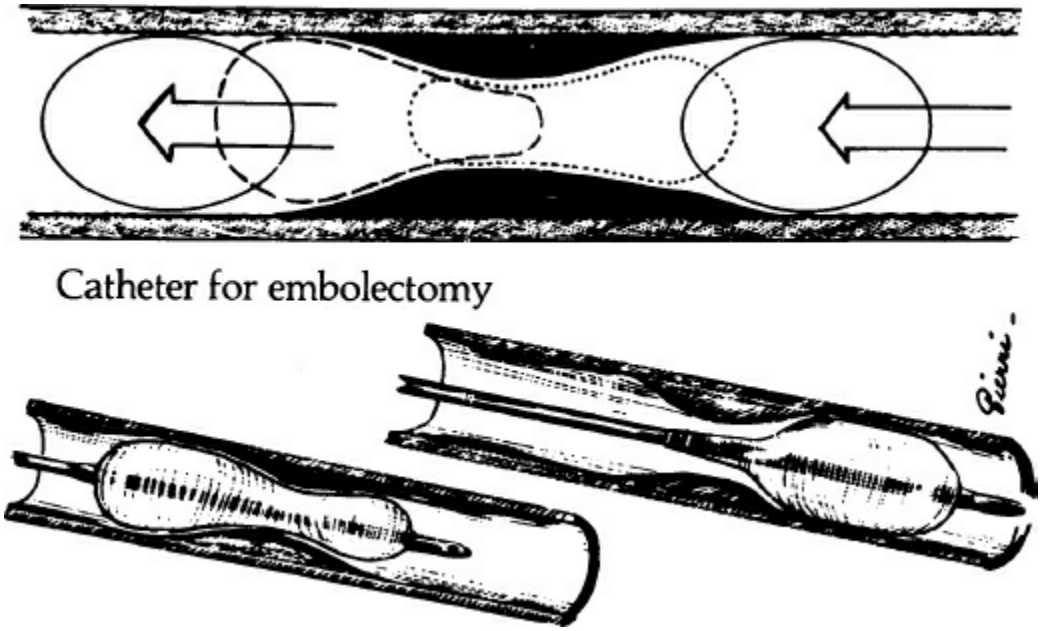

Figure 214.4. Fluid displacement in the specially designed balloon maintains wall contact while minimizing the potential for vessel wall injury.

The ACC is used like the conventional balloon embolectomy catheter. After initial exploration with the standard balloon catheter, the ACC tip is collapsed to its low-profile position and passed into the vessel and beyond the thrombus. The knob on the control handle is then retracted until the spiral is enlarged to the desired diameter, thereby engaging the thrombotic material within the interstices of the spiral. Subsequently, the catheter is drawn slowly back along the vessel and the material is removed through the arteriotomy. The diameter of the spiral can be adjusted according to "feel" in response to resistance within the vessel. The catheter system is appropriate for vessels whose diameters range from 4 to 10 mm, but care is essential for minimizing vessel damage.

The GTC is similar to the ACC, but only for use in synthetic grafts. It consists of a No. 5 or 6 French flexible catheter body; a noninflating, adjustable-diameter, spiral-wire retrieval region with a flexible tip; and a control handle. Unlike the ACC, however, the double-helix-wire region of the GTC is shorter and sturdier, and its wires are not covered by latex. The

exposed spiral wires collapse to ~4 mm and can expand to >16 mm.

Surgical Technique: Extraction of Aortic and Iliac Emboli

The patient is widely prepped and draped as the need for an operative inflow bypass (e.g., femoral to femoral or axillofemoral bypass) may need to be done if embolectomy to restore inflow is unsuccessful and endovascular options are not readily available.

The presence of back bleeding is no assurance that distal patency has been established, because collateral circulation may result in vigorous back bleeding, even in the presence of distal arterial thrombus. If the status of the distal arterial tree is uncertain, intraoperative angiography should be performed. Similarly, if the patient has obstructed outflow or signals are not present at the ankle after retrieval of thrombus, an angiogram should be performed to document any residual thrombi or native arterial lesions that may cause recurrent limb ischemia.

In the surgical management of an aortic embolus, bilateral vertical groin incisions are made and the common, superficial, and deep femoral (profunda femoris) arteries are isolated and looped with silastic (polymeric silicone) tapes. Use of intraoperative handheld duplex or Doppler can speed directed dissection for the femoral artery when a pulse is not present.

After positioning of the clamp high on the common femoral artery, the arteriotomy should be made in the common femoral artery, just proximal to its bifurcation, to allow direct visualization of the superficial and deep femoral orifices. The vessel should be carefully palpated and the location of plaque should be noted. Although it is standard to perform a transverse arteriotomy to avoid narrowing the artery during closure, the presence and location of plaque may dictate tangential or longitudinal incision. At the time of closure, if luminal narrowing results from a primary repair, one should plan to perform a vein or bovine pericardium patch angioplasty. Often, thrombus can be directly removed with forceps at arterial entry to aid proper catheter placement in the lumen.

The distal embolectomy of the superficial femoral artery is usually done first (Fig. 214.5). Depending on the size of the vessel, a No. 3 or 4 French catheter is gently introduced into the superficial femoral artery as far as possible distally and inflated until the arterial wall presents mild resistance. The catheter is then extracted, with the balloon in the inflated position. The material is extracted and should be sent to pathology. The

deep femoral artery is explored in a similar manner, but the No. 3 French catheter in this vessel rarely passes beyond a distance of 25 cm. Care must be taken so that the catheter is introduced into the deep femoral artery and not into one of the large circumflex branches, which has an early origin from this vessel.

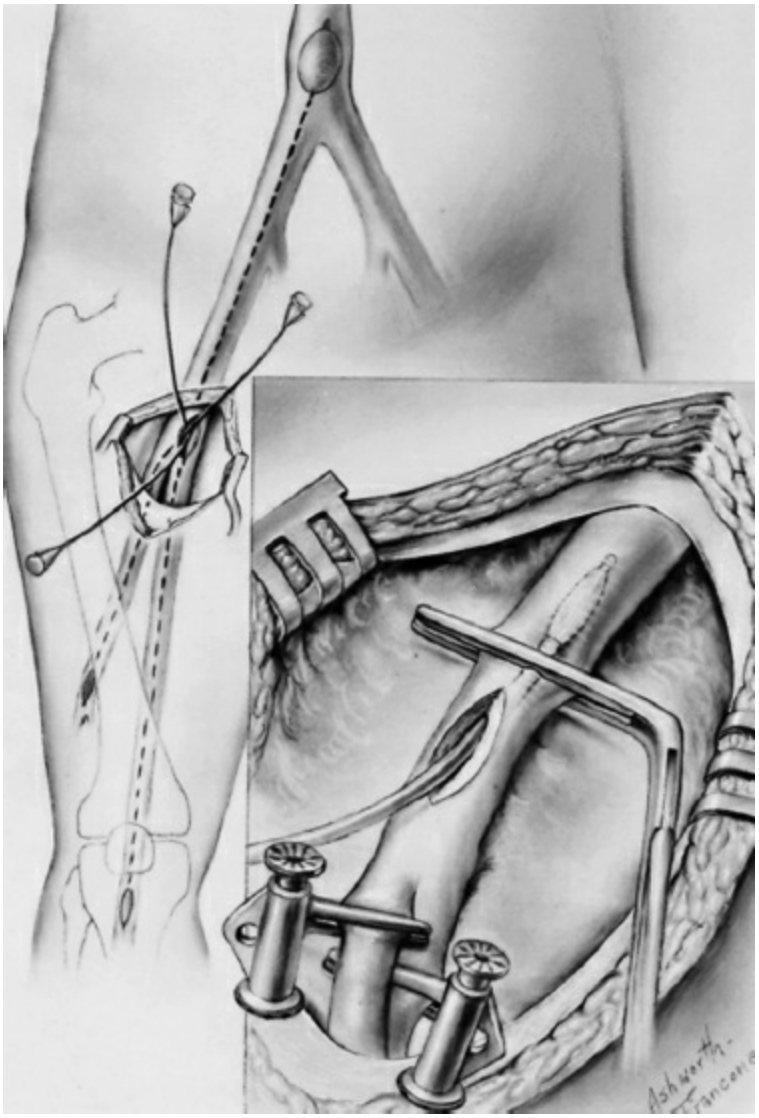

Figure 214.5. Technique of catheter arterial embolectomy of the iliofemoral system.

After successful exploration of the distal arteries as suggested by back bleeding and no further clot, 25 to 50 mL of heparinized solution (5,000 units of heparin in 250 mL of injectable saline solution) is injected into the distal artery. Occasionally, direct injection of 10 mg tissue plasminogen activator with controlled inflow is helpful for small artery distal branch thrombi. Similarly, injection of nitroglycerine (100 to 200 mcg) or

papaverine (10/mg) may help with arterial spasm. A No. 5 to 6 French embolectomy catheter is placed in the common femoral artery and threaded into the aorta. The balloon is inflated with the appropriate amount of fluid and extracted in the inflated position. During the process of extraction, the balloon can be deflated to accommodate a narrowed vessel. The procedure should be repeated if forceful, pulsatile flow is not obtained on the first passage. Significant bleeding, even somewhat pulsatile, may occur from the proximal common femoral artery in the presence of partial continued obstruction, and repeated passes should be made until one is confident that all obstructing thrombi have been removed. After adequate extraction of the clot from one side, a similar procedure is performed on the opposite limb. Both arteriotomies are closed with polypropylene suture after ensuring bilateral simultaneous pulsatile flow. The groins are closed in layers and the skin with subcuticular suture.

In the removal of an isolated iliac or proximal femoral artery embolus, the incision is made only on the affected side in the same manner as described above. Both limbs are prepared for surgical incision because of the small, but real possibility of dislodging a high iliac embolus, with subsequent occlusion of the previously unaffected contralateral vessel.

Extraction of Femoral and Popliteal Emboli

When thrombus remains in the distal popliteal and/or tibial vessels and efforts to remove it from the common femoral artery (CFA) approach prove unsuccessful, a direct approach to the below the knee popliteal artery is required. This is done through a second incision made medially just below the knee. The distal popliteal artery is exposed, and the proximal portions of the anterior and posterior tibial arteries as well as the peroneal artery are looped with Silastic tapes (Fig. 214.6). Note that division of a large crossing tibial vein may be necessary. Through a transverse incision in the distal popliteal artery, No. 2 or 3 French embolectomy catheters should be directly introduced into the anterior, peroneal, and posterior tibial arteries, respectively. If these vessels were previously patent and uninvolved in an arteriosclerotic process, the No. 2 French catheter should be passed beyond the ankle joint. The course of the catheter can be felt by placing the fingers over the distribution of the anterior and posterior tibial arteries. If the catheter is hindered at the ankle joint, it can frequently be passed farther by plantar flexion of the foot.

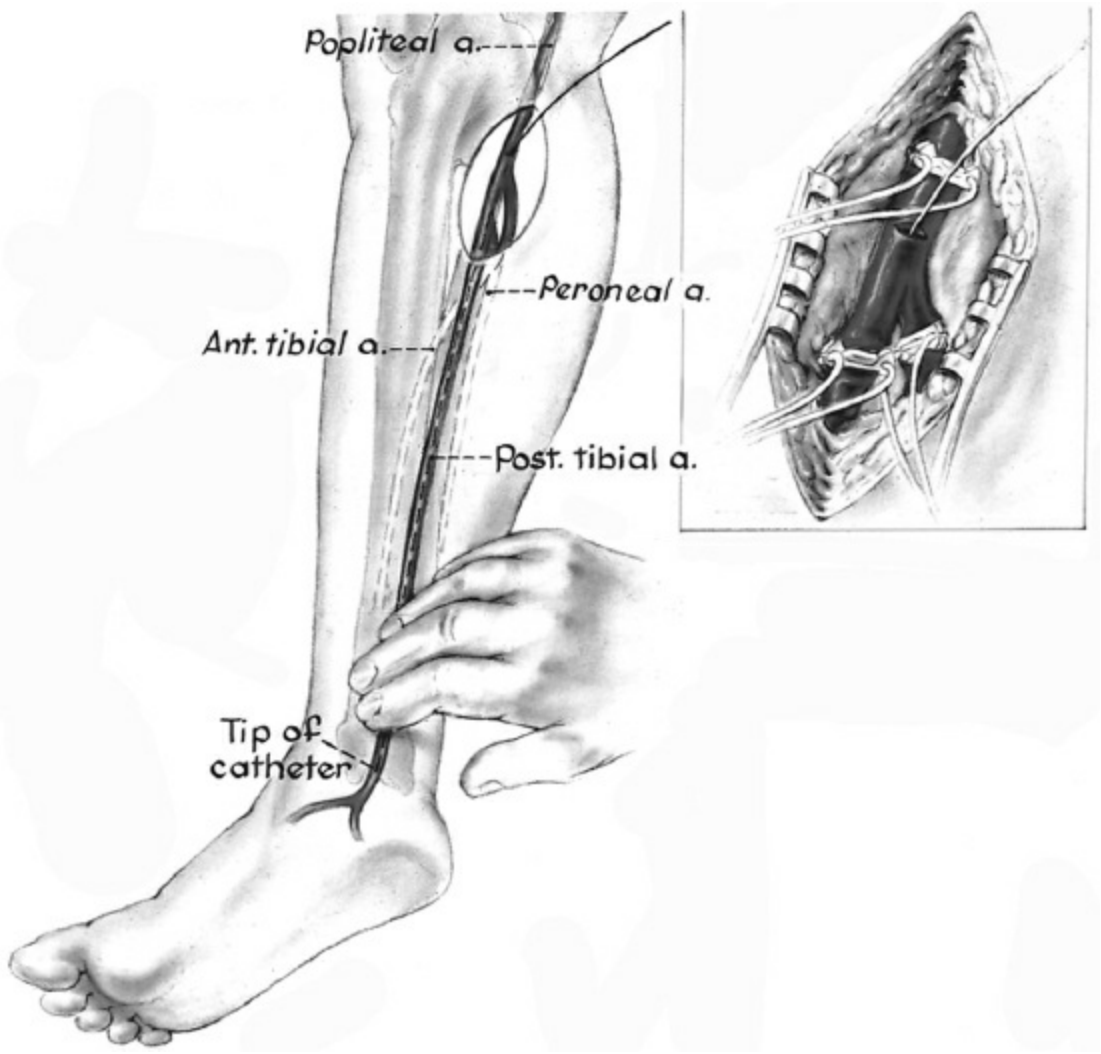

Figure 214.6. Technique of popliteotibial exploration and embolectomy.

Inability to pass a No. 2 French catheter beyond the ankle joint in the presence of angiographic evidence of obstruction beyond this point necessitates direct exposure of the anterior and posterior tibial arteries at the ankle. By direct manipulation of the vessel, combined with gentle simultaneous probing of the catheter from the proximal end, the catheter often passes beyond the point of obstruction without the necessity of an arteriotomy. If an arteriotomy at the ankle level in either of these vessels is required, a transverse arteriotomy—only large enough to allow the introduction of the No. 2 French catheter—is made. The catheter is threaded distally, inflated, and withdrawn in the inflated condition. This maneuver frequently brings the thrombotic material above the small arteriotomy. Additional attempts to extract this thrombotic material should be made by introducing a No. 2 or 3 French catheter into either the anterior

or posterior vessels at the level of the popliteal arteriotomy. This maneuver avoids the necessity of enlarging the arteriotomy at the ankle joint and decreases the possibility of reocclusion. After removal of the thrombotic material, copious irrigation of the distal arterial system should be carried out with a heparinized solution. Once successful, arteriotomies are closed with interrupted monofilament polypropylene suture.

Extraction of Upper Limb Emboli

The technique for embolectomy of the upper limb arteries is identical to that described for the lower limb. Proximal subclavian artery emboli can be routinely removed under local anesthesia by retrograde extraction from a brachial arteriotomy. The standard approach is operative exposure at the distal brachial artery in the proximal forearm, with a transverse or S-shaped incision. Here, the brachial, radial, and ulnar arteries can be encircled and accessed with the balloon catheters. Care must be maintained that if the embolus resides in proximity to the origin of the cranial vessels, fragmentation of the embolus may occur during manipulation, resulting in stroke.

Endovascular Therapy

Arteriography and thrombolysis should be considered in patients in whom the etiology of ALI is unclear or the history and physical examination strongly suggest a diagnosis of arterial or graft thrombosis in situ (Table 214.3). Endovascular therapy is also appropriate in most instances of nonembolic ALI (stage IIa), as mean thrombus lysis times may be 12 to 24 hours.

The technique itself is consistent with standard catheter etiquette and principles. Usually, the unaffected contralateral femoral artery is cannulated and an aortic outflow arteriogram performed to define the exact location and extent of blockage. A guide wire, such as one with a Teflon coating, is passed through the segmental thrombus. A multisidehole catheter follows and the entire thrombus is laced with the lytic agent. Heparin is given at a low dose (e.g., ~300 U/h) through the side port of the sheath to prevent catheter-associated thrombus development. The infusion (usually 1 mg/h of tPA) is maintained for at least 12 hours and reimaging is done to determine success of thrombus dissolution. Thrombolytic success can be followed by clinical examination as evidenced by improvement in limb temperature, capillary refill, pulses,

and patient symptoms. It is quite common for the patient to have significantly more pain with early lysis that over several hours improves that the distal thrombus shower resolves.

TABLE 214.3 Take Home Points

Caveats:

1. Pull the embolectomy catheter as you inflate the balloon, and make it one continuous motion; do not force the catheter
2. Always systemically and fully anti-coagulate (unless active bleeding)
3. If you think about the need for a fasciotomy, then you should do it
4. For massive lower extremity ischemia and acute renal failure, consider active ongoing CVVHD while in the OR during the embolectomy and reperfusion
5. Arteries that reclot intraoperatively or immediately postembolectomy have an uncontrolled and untreated embolic source; consider angiography and intervention
6. Do not perform embolectomy on patients with advanced grade III ischemia; save life over limb and amputate
7. If you have access to a hybrid OR, consider using this for all cases

While an over-the-wire embolectomy balloon catheter is available and useful in situations where occlusive disease is present, newer endovascular mechanical thrombolytic techniques and devices, including catheter suction thrombectomy, thrombus fragmentation/aspiration (rheolytic), and ultrasound energized wires are becoming more commonly used. Promising early results have been published with techniques done in native arteries, the pulmonary artery circulation, and arteriovenous prosthetic access

grafts. Many of these catheter devices also allow concurrent pulse spray of the lytic agent. Larger clinical experience will better define their role in patients with ALI, but this technology has the potential to minimize the two main drawbacks of endovascular ALI therapy: long duration of thrombolytic infusion needed to reestablish arterial perfusion and hemorrhagic complications.

POSTOPERATIVE MANAGEMENT AND COMPLICATIONS

Patients who are critically ill may undergo a thromboembolectomy under local anesthesia if necessary. Typical complications from a surgical thromboembolectomy include infectious, hemorrhagic, and cardiac events. The severity of postoperative complications is often determined by the patient's premorbid state. Groin incision complications are most frequent.

In almost all instances, anticoagulation with intravenous heparin should be continued through the procedure and until the patient is fully anticoagulated with a vitamin K antagonist (VKA), started ~24 hours after the procedure. Hematomas are not uncommon, and a drain for 24 to 48 hours may be useful. The VKA is continued for at least 6 months. If the patient has a major bleed not related to the surgical site, anticoagulation must be stopped and only restarted once the bleeding source is identified and treated. Needless to say, this is a hazardous state for the patient as early recurrent thrombosis increases if anticoagulation is not provided for.

Early ambulation is encouraged, and ACE wraps may be helpful for edema. During the early postoperative period, an echo and CT angiography (CTA) of the chest, abdomen, and pelvis should be done to find the source of the embolus. If this occurs in a younger patient without a source, a thrombophilia workup should commence, including a deep venous thrombosis (DVT) scan to search for a paradoxical embolism.

Repeated procedures after embolectomy are not uncommon. These include need for repeat thrombectomy, exploration for bleeding, fasciotomy, or other procedures. Recurrent loss of pulses often signals a proximal lesion exists that can be treated with an endoluminal procedure if not diagnosed ahead of embolectomy. Hybrid operating suites are valuable for these situations, particularly with upper extremity emboli. If a vascular reconstruction is warranted, it should be performed early. A high incidence of limb loss and mortality accompanies subsequent episodes of rethrombosis, as does a sicker patient.

As a cause of ALI, an occluded aortofemoral limb is not an uncommon problem. In this situation, the ACC is useful for thromboembolus extraction. However, an arteriogram with proximal stent or a covered stent graft limb relining is often necessary if the proximal limbs are kinked or if a stenosis is found proximally. These patients too should be anticoagulated.

Whether long-term anticoagulation is required after acute thromboembolic limb ischemia is not clear if the underlying cause has been corrected. Our practice has been to continue the VKA for at least 6 months if bleeding risk is not excessive. Certainly, there are risks with prolonged anticoagulation, and these must be balanced against recurrent embolism. Non-vitamin K oral antagonists may be safer and easier to administer than coumadin, and thus should be considered once trials show safety and efficacy, although no data yet exist.

Lower extremity four-compartment fasciotomies are routinely performed to prevent a postreperfusion compartment syndrome, in the setting of class IIb and III ischemia with surgical thromboembolectomy. Fasciotomy may need to be done after successful thrombolysis as well (see Chapter 215 for fasciotomy description). Thus, frequent neurovascular extremity examinations are essential during ongoing lytic therapy.

Suggested Readings

Currie IS, Wakelin SJ, Lee AJ, et al. Plasma creatine kinase indicates major amputation or limb preservation in acute lower limb ischemia. *J Vasc Surg* 2007;45(4):733–9.

Earnshaw JJ, Whitman B, Foy C. National Audit of Thrombolysis for Acute Leg Ischemia (NATALI): clinical factors associated with early outcome. *J Vasc Surg* 2004;39(5):1018–25.

Eliason JL, Wainess RM, Proctor MP, et al. A national and single institutional experience in the contemporary treatment of acute lower extremity ischemia. *Ann Surg* 2003;238:382–90.

Hynes BG, Margey RJ, Ruggiero N, 2nd, et al. Endovascular management of acute limb ischemia. *Ann Vasc Surg* 2012;26:110–24.

Kashyap VS, Gilani R, Bena JF, et al. Endovascular therapy for acute limb ischemia. *J Vasc Surg* 2011;53:340–6.

Klonaris C, Georgopoulos S, Katsargyris A, et al. Changing patterns in the etiology of acute lower limb ischemia. *Int Angiol* 2007;26(1):49–52.

Korabathina R, Weintraub AR, Price LL, et al. Twenty-year analysis of trends in

the incidence and in-hospital mortality for lower-extremity arterial thromboembolism. *Circulation* 2013;128:115–21.

Ouriel K, Veith FJ, Sasahara AA. A comparison of recombinant urokinase with vascular surgery as initial treatment for acute arterial occlusion of the legs. Thrombolysis or Peripheral Arterial Surgery (TOPAS) Investigators. *N Engl J Med* 1998;338(16):1105–11.

Rutherford RB, Baker JD, Ernst C, et al. Recommended standards for reports dealing with lower extremity ischemia: revised version. *J Vasc Surg* 1997;26(3):517–38.

STILE investigators. Results of a prospective randomized trial evaluating surgery versus thrombolysis for ischemia of the lower extremity. The STILE trial. *Ann Surg* 1994;220(3):251–66; discussion 266–8.

Vorwerk D. Mechanical thrombectomy is an alternative way to go: the European experience commentary on: quality improvement guidelines for percutaneous management of acute limb ischemia. *Cardiovasc Intervent Radiol* 2006;29(1):7–10.

EDITOR'S COMMENT

In this chapter, Peter Henke does a nice job of describing the standard surgical technique of open embolectomy. This advance made possible by the creation of the Fogarty balloon (Green RM, DeWeese JA, Rob CG. Arterial embolectomy before and after the Fogarty catheter. *Surgery* 1975;77:24–33) has clearly saved thousands of limbs and is a significant advance on the use of systemic heparin alone. Having practiced with Dr. Henke for a decade, I know he is dogmatic about the use of high doses of heparin being given to the patient even in transport prior to going to the operating room (OR) or endosuite. This is meant to ameliorate further clot propagation, but also usually has some vasodilatory properties that make the patient feel better.

While the performance of this operation is well described in this chapter, it is amazingly clear to me that these patients are anything but straightforward. The patients almost always present with multiple comorbidities that just make taking them to the OR for a "quick little embolectomy" anything but quick and little. Multiple questions arise on these patients including—where was the source of the embolus, is this an embolus or thrombosis in situ, and should we try a course of thrombolytics first?

Little is written on the above questions, but there are some useful data worth reviewing. A paper from 2008 tried to determine the clinical and echocardiographic measures governing thromboembolism destination in patients with nonvalvular atrial fibrillation (McBane RD, Hodge DO, Wysokinski WE. Clinical and echocardiographic measures governing thrombolembolism destination in atrial fibrillation. *Thromb Haemost*

2008;99:951–5). Embolism occurred to the periphery 85% of the time, as opposed to the cerebral vasculature. In addition, lower extremity involvement was twice as common as the upper extremity. Severe left ventricular dysfunction, spontaneous echo contrast, and left atrial thrombus were two- to threefold more common in peripheral embolism patients, while mean CHADS-2 scores were low and comparable for both groups. This of course does not answer the question as to whether patients with peripheral emboli should get an echo or not before they go to the OR. I think it is always prudent to get one, but I note that some thin slice CT scanners can also determine if thrombus is present in the atrium or ventricle, and in these circumstances an echo may not be needed.

Part of the workup for patients with evidence of peripheral emboli, in addition to an echocardiogram and electrocardiogram, is a CTA of the chest, abdomen, and pelvis. Therefore, we are also often asked to look at CT scans with aortic pathology that looks like a source of peripheral emboli. These lesions are almost always in the descending thoracic aorta and very scary looking (I know that is not really scientific, but how else do you best describe a pedunculated mass floating in the descending thoracic aorta). A recent paper from the group at Pittsburgh I believe is the largest series to look at these lesions (Jeyabalan G, Wallace JR, Chaer RA, et al. Endovascular strategies for treatment of embolizing thoracoabdominal aortic lesions. *J Vasc Surg* 2014;59:1256–64). In their series of 25 embolizing aortic lesions, 16 (64%) presented with peripheral embolic events and 6 with renal emboli. While only 8 patients were tested, 4 of them had a hypercoagulable state. Twenty-four percent of patients had aneurysm disease present. Importantly, the majority of the patients (19) had chronic kidney disease. The 1-year mortality of this group was 25%!

Dr. Henke in his chapter originally suggested that *most* of these cases should be done in a hybrid OR. I have to say that I edited that to read **all** cases should be done in a hybrid OR. There are multiple modalities that can be used during these cases, and therefore being in a hybrid OR allows you do an over-the-wire embolectomy, suction embolectomy, as well as completion angiogram. While the dogma used to be that one needed a palpable pulse to leave the OR following an embolectomy, it is very reassuring to leave the OR with angiographic evidence of flow to the foot *and* a palpable pulse in the foot.

Finally, after reviewing this chapter my thoughts were how long do we leave patients on anticoagulation following a peripheral arterial embolus. There is a lot written about this related to deep venous thrombosis (DVT) and pulmonary embolus, as well as in peripheral arterial disease (Kearon C, Akl EA, Comerota AJ, et al.; American College of Chest Physicians. Antithrombotic therapy for VTE disease: Antithrombotic Therapy and Prevention of Thrombosis, 9th ed: American College of Chest Physicians Evidence-Based Clinical Practice Guidelines. *Chest* 2012;141(2 Suppl):e419S–94S; Alonso-Coello P, Bellmunt S, McGorrian C, et al.; American College of Chest Physicians. Antithrombotic

therapy in peripheral artery disease: Antithrombotic Therapy and Prevention of Thrombosis, 9th ed: American College of Chest Physicians Evidence-Based Clinical Practice Guidelines. *Chest* 2012;141(2 Suppl):e669S–90S) but little about peripheral arterial emboli. I think my answer rests on the DVT literature, but also has to do with the root cause of the peripheral emboli and whether it has been adequately managed (i.e., atrial fibrillation now in sinus rhythm for some time, etc.). I suspect a minimum of 6 months of anticoagulation is reasonable, but I really only base that on our current management of DVT.

Gilbert R. Upchurch

215 Fasciotomy

Jonathan L. Eliason

ETIOLOGY AND PATHOPHYSIOLOGY

A discussion of the surgical procedure known as fasciotomy cannot occur without understanding the underlying pathophysiologic changes that necessitate its use. Compartment syndrome (CS) is the condition that results in the need for fasciotomy, and although CS can occur in the abdomen, upper extremity, or lower extremity, the scope of this chapter will be restricted to the lower extremity. The principles discussed here apply to other anatomical compartments within the body, however. Osseofascial boundaries within the leg that surround muscles, nerves, and blood vessels are nonelastic and form compartments. When the pressure within a given compartment impairs perfusion across tissue capillary beds, CS will ensue. Although the etiologies of CS are varied (trauma, ischemia-reperfusion injury with muscle swelling, etc.), the common pathway for injury is anoxia on a cellular level. If left untreated, a stepwise progression of nerve dysfunction, rhabdomyolysis, and blood vessel compression will occur, ultimately resulting in ischemic necrosis of the tissues within that compartment. The ensuing chapter will include discussion of fasciotomies performed for the prevention and/or treatment of CS in the gluteal region, thigh, and leg.

A thorough understanding of the compartments of the lower extremity is necessary to recognize CS and inform appropriate diagnostic and therapeutic treatments, including the gluteal, thigh, and leg regions. The gluteal region is commonly thought of as a single compartment. However, the fascial boundaries really form three distinct compartments, each surrounding a primary muscle group. The largest compartment surrounds the gluteus maximus. The next compartment surrounds both the gluteus medius and minimus muscles. Finally, a third smaller compartment includes only the tensor fascia lata (Fig. 215.1). The sciatic nerve is the most notable neurovascular structure affected by gluteal CS, and it lies under the gluteus maximus muscle, exiting from the inferior border of the piriformis muscle. The inferior gluteal artery and nerve, which supply the

gluteus maximus muscle, and superior gluteal artery and nerve, which through a complex branching pattern supply the remaining compartments, are also noteworthy (Fig. 215.2).

Three functional and osseofascial boundaries are present in the thigh as well. The anterior compartment contains the quadriceps, sartorius, iliopsoas, and pectineus muscles. This compartment also contains the femoral artery and vein, as well as the femoral, and lateral femoral cutaneous nerves. The posterior compartment contains the biceps femoris, semimembranosus, and semitendinosus muscles, as well as the posterior portion of the adductor magnus muscle. The sciatic nerve lies within this compartment. The medial compartment includes the gracilis, adductor longus, adductor brevis, most of the adductor magnus, and the obturator externus muscles. The obturator artery and vein and obturator nerve lie within this compartment (Fig. 215.3).

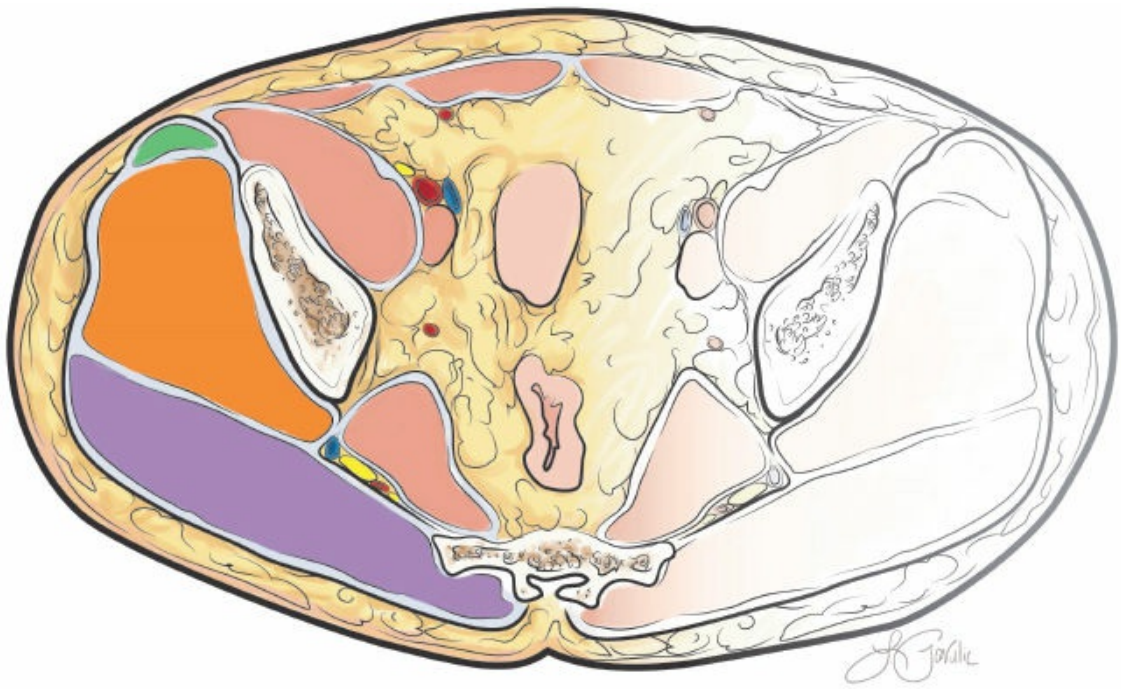

Figure 215.1. Axial view of the pelvis denoting the gluteus maximus compartment in purple, gluteus medius/minimus compartment in orange, and tensor fascia lata compartment in green.

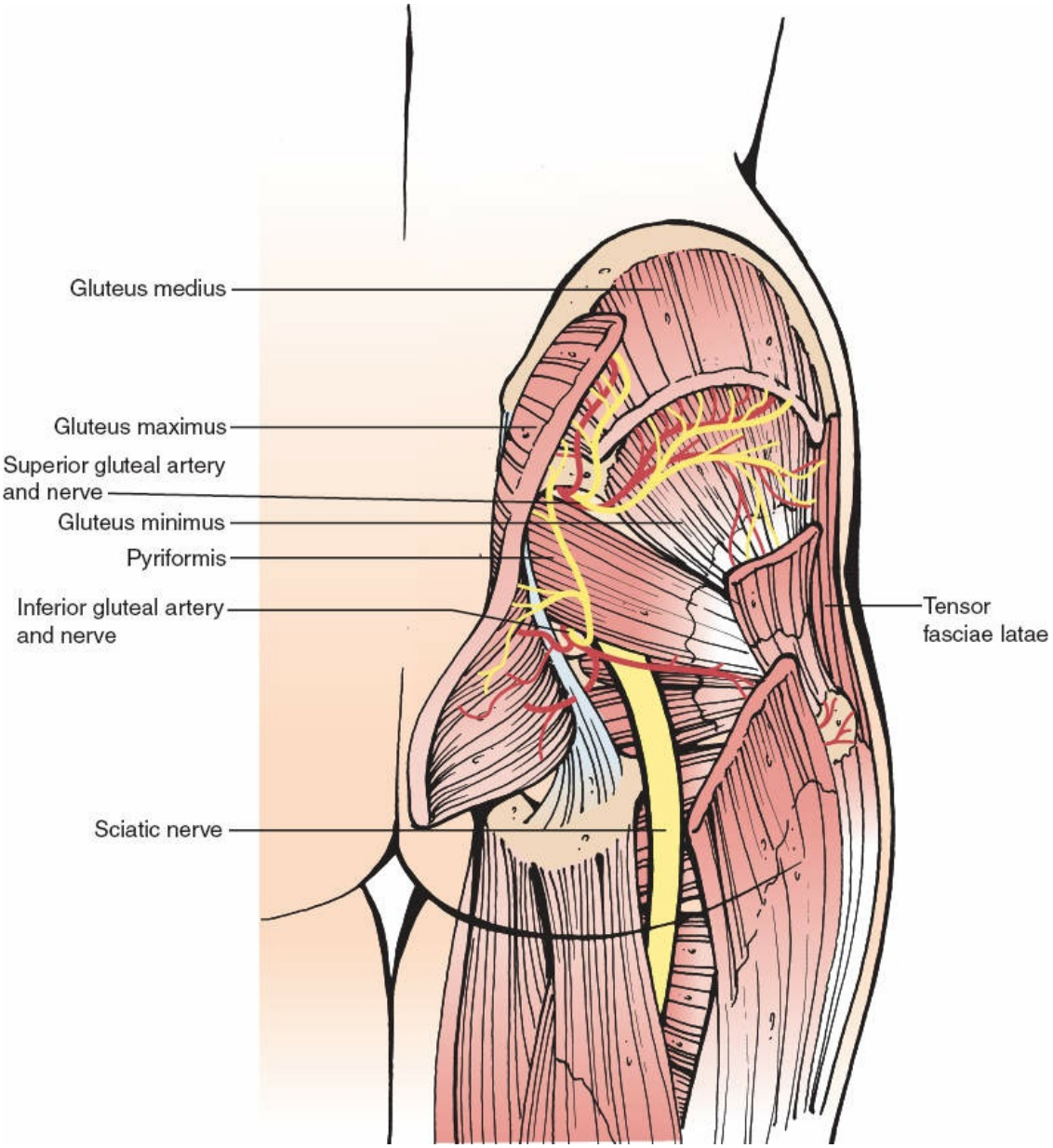

Figure 215.2. Illustration demonstrating major neurovascular structures within the gluteal compartments.

Finally, the leg consists of four distinct compartments described as anterior, lateral, superficial posterior, and deep posterior. The anterior compartment is bordered by the lateral aspect of the tibia, the interosseous membrane, and the intermuscular septum between the anterior and lateral compartments, which is partially contiguous with the fibula. The muscles that produce dorsiflexion of the foot and toes are contained within this compartment. Neurovascular structures in the anterior compartment include the anterior tibial artery and veins, and the deep peroneal nerve. The lateral compartment boundaries include the anterior intermuscular septum, the fibula medially, and the posterior intermuscular septum. The

muscles controlling eversion of the foot are contained within this compartment. The superficial branch of the peroneal nerve courses through the lateral compartment until it exits the fascia typically 10 to 12 cm superior to the lateral malleolus (Fig. 215.4). This nerve is particularly susceptible to harm during fasciotomy, and results in altered sensation over the dorsum of the foot if injured. The superficial posterior compartment contains the gastrocnemius muscle and soleus muscle, and is surrounded by the deep fascia of the leg, with the exception of anteriorly, where this fascial plain joins the posterior intermuscular septum. The deep posterior compartment is the most difficult anatomic compartment in the leg to surgically expose. It is bounded by the tibia, interosseous membrane, and fibula along its anteromedial and anterolateral extent. A small component is bounded medially by the deep fascia of the leg, with the remainder posteriorly being surrounded by the posterior intermuscular septum. The long flexors of the toes are included in this compartment, as well as the posterior tibial and peroneal vessels. The tibial nerve also lies within this compartment (Fig. 215.5).

CLINICAL PRESENTATION

Gluteal Compartment Syndrome

Within the lower extremity, the gluteal region is the least frequently reported location for CS. The most common cause for CS in this location is a patient with prolonged pressure over the gluteal region, such as an unconscious or severely traumatized patient, or a patient with prolonged positioning for a surgical procedure. Musculoskeletal trauma is the next most common cause of this rare syndrome, with motor vehicle collisions and explosive/concussive mechanisms being included in this category. Vascular specific causes may also occur, such as an Ehlers-Danlos patient with spontaneous bleeding from a gluteal artery aneurysm, or gluteal CS following open abdominal aortic aneurysm repair.

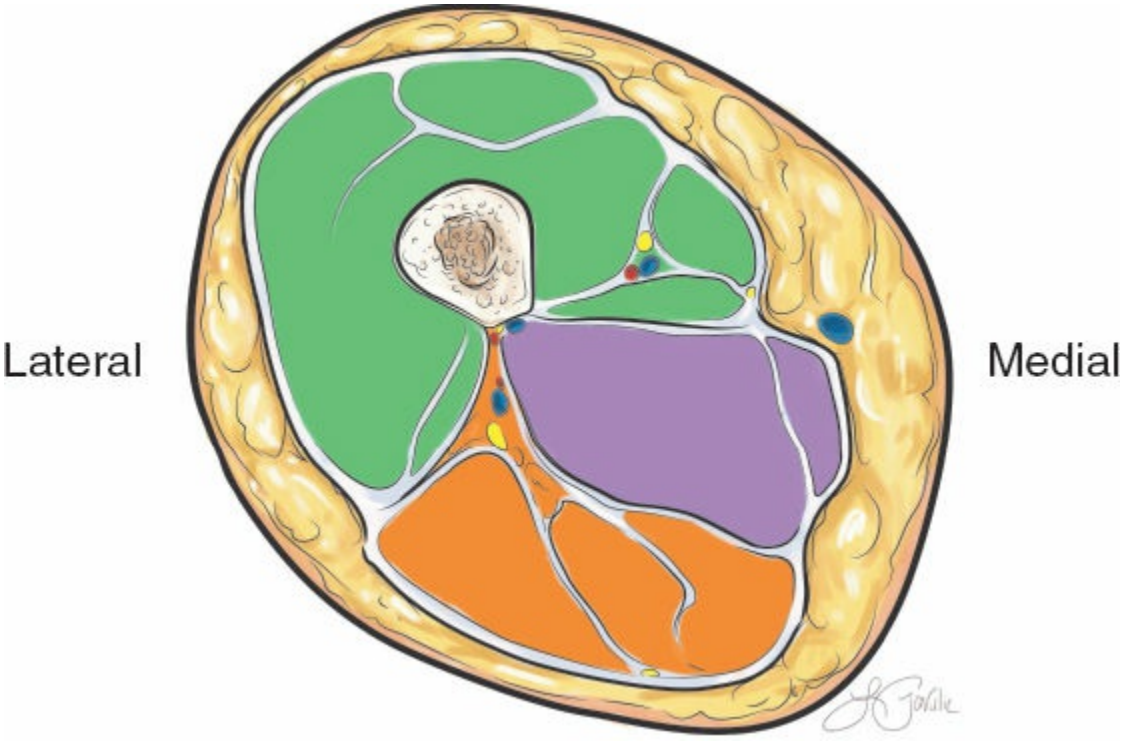

Figure 215.3. Axial view of the thigh denoting the medial compartment in purple, posterior compartment in orange, and anterior compartment in green.

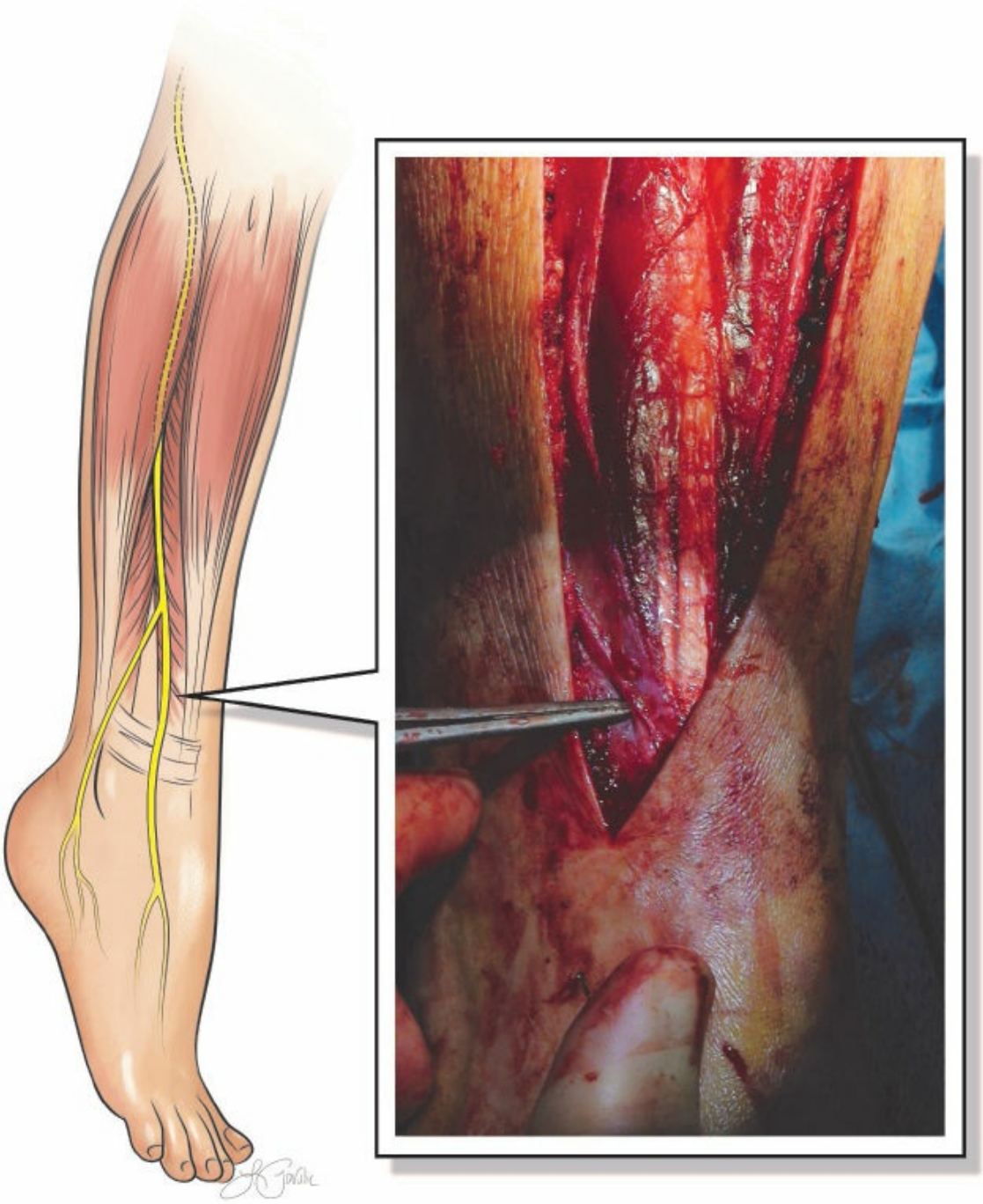

Figure 215.4. Lateral exposure from a two-incision leg fasciotomy demonstrating the superficial peroneal nerve branch coursing toward the foot after exiting the fascia of the lateral compartment.

The majority of patients presenting with this syndrome are unable to give a history, so physical examination findings become extremely important. Almost uniformly, patients with gluteal CS have a massively swollen and extremely firm buttock as part of their presentation (Fig. 215.6). If the patient is able to give a history, symptoms may include

hypesthesia or increasing pain in the region of the injury, or a nerve deficit in the leg correlating to the sciatic nerve distribution. Finally, because of the large mass of muscle in the gluteal compartments, if elevated compartment pressures and/or the injury itself results in significant muscle injury, laboratory findings typically include marked elevation of creatine phosphokinase (CPK) enzyme levels and myoglobinuria from rhabdomyolysis, with the subsequent potential for renal failure.

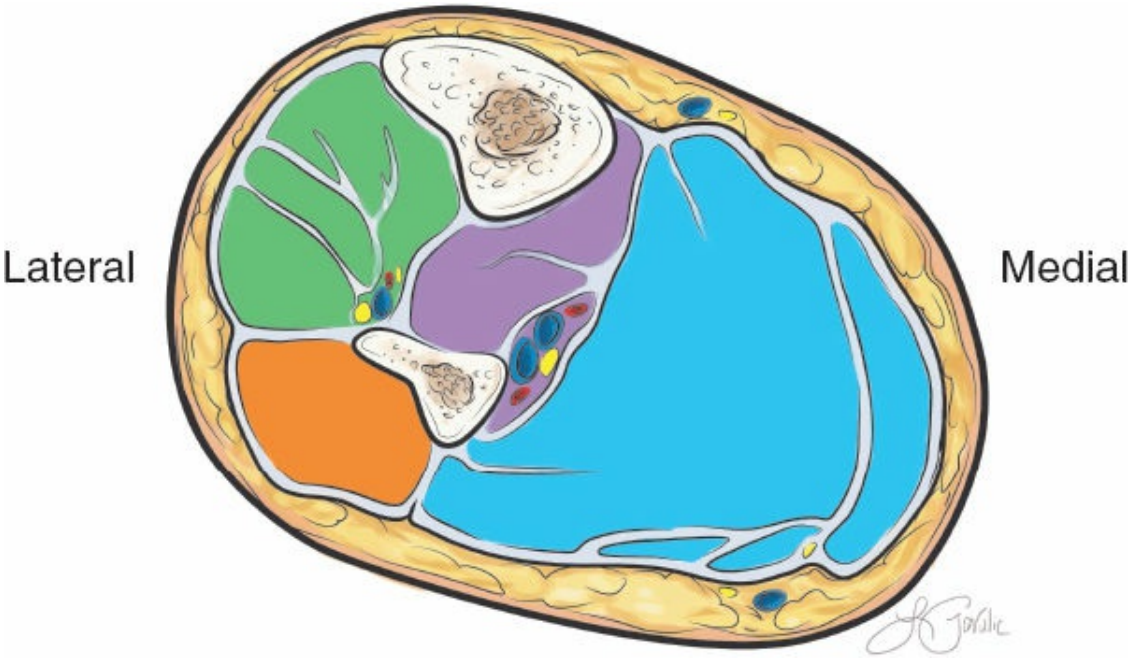

Figure 215.5. Axial view of the right calf denoting the anterior compartment in green, lateral compartment in orange, deep posterior compartment in purple, and superficial posterior compartment in blue.

Thigh Compartment Syndrome

Acute CS of the thigh is also rare. Blunt trauma is the most common cause, with nearly half of the patients with thigh CS having an associated femur fracture. Penetrating trauma, vascular injury, prolonged intraoperative positioning, or external compression from a comatose patient may also cause this syndrome. All patients present with a tensely swollen thigh. Noncomatose patients complain of intolerable pain, with focal paresthesias or paresis also being common. A pulseless extremity may also be a component of the patient presentation for thigh CS in the acute setting, occurring in 1 out of 5 patients. As one would expect, a pulseless extremity occurs more commonly when CS includes a femur fracture.

High CPK levels are less common in thigh CS than gluteal CS, but can certainly be a component of the presentation.

Leg Compartment Syndrome

The leg is the most common site for CS of the lower extremity. Blunt and penetrating trauma are common causes, again being frequently associated with tibia fractures, but ischemia reperfusion also contributes significantly to the prevalence of this disease process. National data suggest that >4% of patients presenting to US hospitals with diagnosis codes consistent with acute limb ischemia undergo a fasciotomy. A high index of suspicion is critical in making the clinical diagnosis of CS. In the obtunded patient, firmness of the compartment is the earliest sign of his syndrome, with loss of pulses being rare and a late finding. In the awake patient, excessive pain, palpable tightness, and severe pain with passive stretch of the muscles are common early findings, with paresthesias, progressive paralysis, and changes in pulse exam being late findings. Understanding which muscles and nerves travel within each of the four different compartments can aid in making the clinical diagnosis of which compartments are affected. Although rhabdomyolysis can occur with this syndrome, it is quite rare. History has shown that revascularization of a densely ischemic leg, especially in the setting of neurologic changes, will likely result in significant reperfusion injury, muscle edema, and CS. In such a patient, prophylactic fasciotomy is often performed in order to prevent this syndrome.



Figure 215.6. Blunt trauma causing gluteal compartment syndrome. Ecchymosis is clearly visible in the region of tense swelling and hematoma.

INDICATIONS AND CONTRAINDICATIONS

Fasciotomy is performed in a prophylactic fashion for those patients at high risk for developing elevated intracompartmental pressures and CS. The most common scenario for prophylactic fasciotomy is the patient with prolonged limb ischemia who has undergone revascularization and will subsequently experience increased muscle swelling from reperfusion injury. Wisdom is found in the surgical dictum stating, “if one thinks about doing a fasciotomy for limb ischemia, one should do one.” The indication for performing a therapeutic fasciotomy is the recognition of the early signs and symptoms of CS. A delay in diagnosis may have devastating consequences. Increased compartment pressure measurements may provide additional objective information and aid in the decision-making process. There are no absolute contraindications to performing a fasciotomy if deemed necessary. However, severe coagulopathy should be corrected prior to fasciotomy if possible.

Although the diagnosis of CS, whether in the gluteal, thigh, or leg compartments, is based upon clinical presentation, there are many clinical scenarios in which the diagnosis is not absolute or is quite difficult to make. In the preoperative period, a patient may be unable to give an accurate history or a reliable response to physical examination due to neurologic impairment, heavy sedation, or other reasons. Even if the patient is awake and alert, there are many other potential confounding reasons for severe pain and a swollen compartment such as long bone fracture, vascular injury with intracompartmental bleeding, or severe contusion. Determining when such an injury has crossed the threshold where elevated compartment pressures are additive to the underlying injury can be extremely challenging. Early CS is not detectable with laboratory evaluation. Elevated CPK and myoglobinuria are found later in the presentation and are unhelpful for making an early diagnosis, although they may be useful in determining the severity of injury or for continuous monitoring during injury recovery, if they are found to be elevated.

When clinical cues are insufficient to make a diagnosis of a CS, direct measurement of the compartment pressures may be necessary. This can be performed using a variety of instruments; however, a handheld monitor

using built-in microchip technology and a side-ported, noncoring needle for pressure measurements have become standard (Fig. 215.7). It is important to remember that safe needle insertion is critical in sampling compartment pressures. A thorough understanding of the anatomy in the compartment being tested is vital. Inadvertent puncture of vascular structures may result in increased bleeding and further tissue injury. Measurement of compartment pressures in patients with coagulopathy or who are receiving systemic anticoagulation should be performed with great caution.

Pressure measurements within the gluteal compartments are performed infrequently, but careful cadaveric studies have demonstrated the locations for proper placement of needles in order to avoid the neurovascular bundles. For the gluteus maximus compartment, the posterior superior iliac spine is the primary landmark, with the needle inserted perpendicular to the surface of the iliac wing 2 cm inferior and lateral to the posterior superior iliac spine. This is in the proximal and inner quadrant of the buttock. For the gluteus medius and minimus compartment, the needle should be placed 2 cm inferior to the iliac crest within the middle third of the iliac wing. Finally, for the tensor fascia lata compartment, the greater trochanter is the bony landmark, and the needle should be inserted 3 cm distal and 2 cm anterior to the tip of the trochanter (Fig. 215.8). Pressures ≥30 mm Hg in the appropriate clinical scenario are considered an indication for fasciotomy, while normal pressures in the gluteal compartment are ~13 to 14 mm Hg.

The upper limit of normal for compartment pressures in the thigh is debatable, but is typically considered to be 30 to 45 mm Hg, although some authors recommend a much higher threshold due to risk of infection. Sampling of compartment pressures should be performed in the mid-thigh. Needle insertion should only be deep enough to access the compartments, without injuring vascular structures. The anterior compartment should be accessed slightly lateral to the midline anteriorly, while the posterior compartment should be accessed slightly medial to the midline posteriorly. The medial compartment is sampled infrequently, but access to this compartment requires a true medial insertion of the needle with the patient in anatomic position (Fig. 215.9).



Figure 215.7. Stryker handheld compartment pressure monitor uses a noncoring needle with a side port for more accurate compartment pressure measurements.

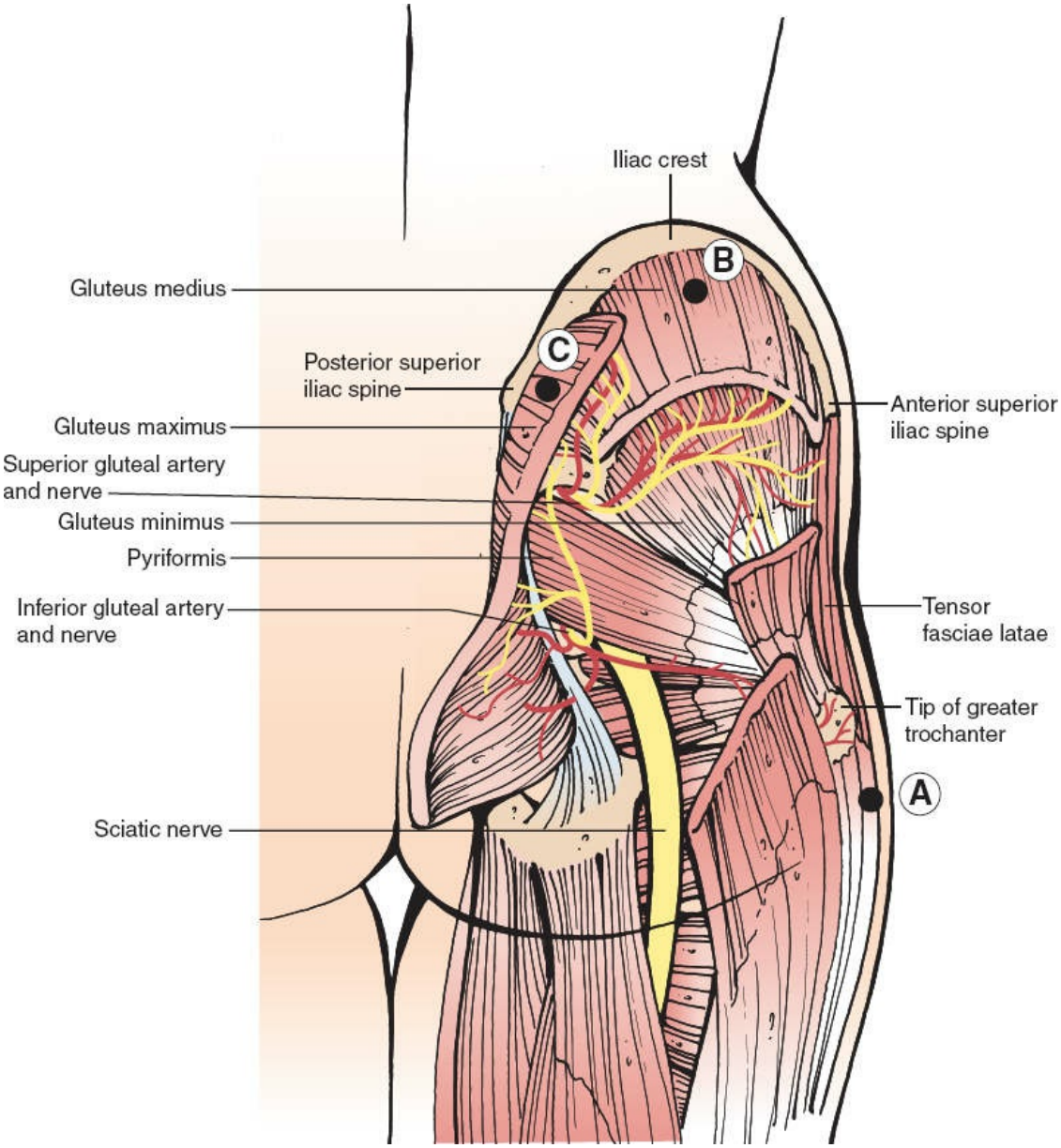

Figure 215.8. Illustration demonstrating the safe regions for obtaining gluteal compartment pressures. (Adapted from Figure 2.)

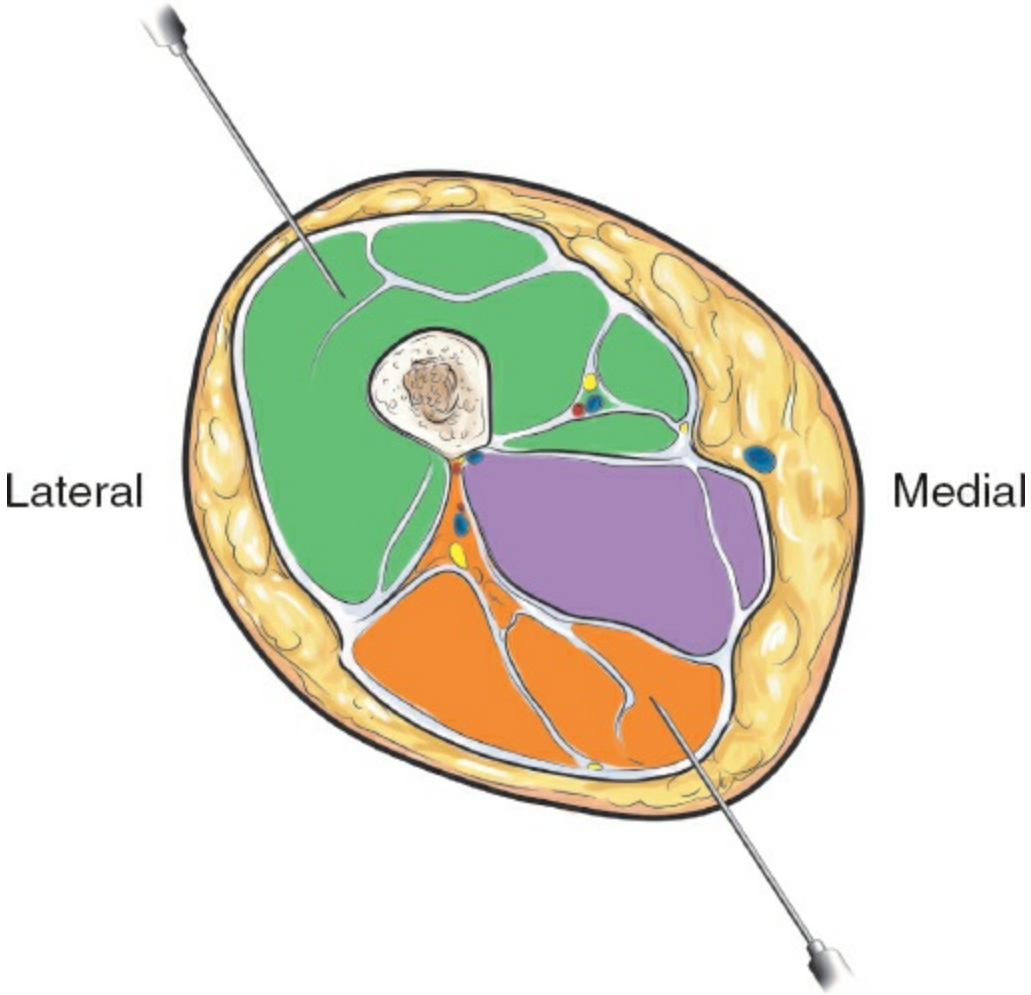

Figure 215.9. Illustration demonstrating the typical compartment pressure measurement locations in the thigh.

Compartment pressure measurements for the leg are commonly performed compared to the thigh and gluteal regions. Compartment pressures >30 mm of mercury are generally considered to be elevated and consistent with CS. However, it is important to remember that clinical evidence of muscle and nerve ischemia is a more reliable indicator of CS than an absolute number. Nevertheless, if there is a clinical indication to obtain compartment pressure measurements, the anterior compartment should be sampled in the mid-calf ~1 to 2 fingerbreadth lateral to the tibia, while the lateral compartment is sampled just lateral to the fibula. The deep posterior compartment is accessed in the mid-calf just posterior to the tibia, with the knowledge that the posterior tibial artery and vein will lie just posterior to this access site. The superficial posterior compartment may be accessed safely from the true posterior position of the mid-calf (Fig. 215.10).

PREOPERATIVE PLANNING

Fasciotomy should be performed without delay once the indication for intervention is recognized. It may be necessary to type and cross-match blood products for reversal of coagulopathy at the time of surgery in order to limit excessive blood loss. An operative suite is preferential for maintaining sterile technique for this procedure, although fasciotomies can be performed at the bedside. The choice of anesthesia includes local, regional, or general. Regional or general anesthesia is preferred unless a single compartment release in the leg is being performed, in which case local anesthesia may be adequate.

SURGICAL TECHNIQUE

The appropriate treatment for all CS is implied in the name "fasciotomy." The Latin root word "*fascia*" literally means band, while the root word "*-tomy*" is Greek for cut. The objective for CS treatment is to normalize compartment pressures and restore tissue perfusion. This requires access via the skin and subcutaneous tissues through a surgical incision, with a wide release of the fascial boundary encircling the affected compartment.

Gluteal Compartment Release

The gluteal compartments are released through a surgical exposure similar to a posterior approach to the hip, utilizing the greater trochanter as a landmark. A curvilinear incision is made in a gentle curve over the buttock, following the arc of the iliac crest (Fig. 215.11). The fascia overlying the gluteus maximus muscle is divided, and the fibers of this muscle split to expose the gluteus medius and minimus muscles. The inferior aspect of the incision may need to be carried onto the proximal thigh near the gluteal fold to access the tensor fascia lata compartment.

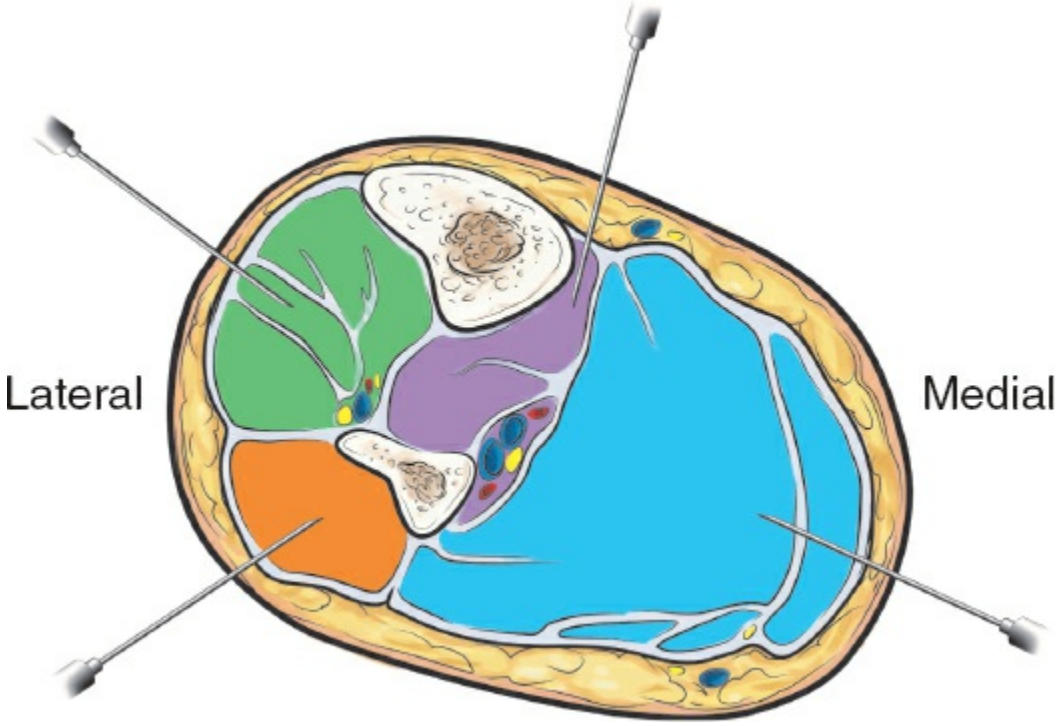

Figure 215.10. Illustration demonstrating the typical compartment pressure measurement locations in the leg.

Thigh Compartment Release

Decompression of the anterior and posterior thigh compartments is performed through a posterolateral approach (Fig. 215.12). The anterior compartment is decompressed first, with a longitudinal incision in the muscular fascia exposing the vastus lateralis. Once anterior decompression is accomplished, the vastus lateralis is retracted medially. The lateral intermuscular septum is then identified, and incised through the anterior compartment, thus decompressing the posterior compartment.



Figure 215.11. Illustration with *dashed line* demonstrating the typical skin incision location for gluteal compartment release. The skin incision may need to be extended across the greater trochanter to allow access to tensor fascia lata compartment.

Leg Compartment Release

A two-incision technique is most commonly employed to release the compartments of the leg (Fig. 215.13A,B). A generous medial calf skin incision is made ~1 fingerbreadth posterior to the medial portion of the tibia. The greater saphenous vein and saphenous nerve often run in this position, parallel to the incision, and injury to this vessel and nerve should be avoided if possible to maximize venous drainage of the lower extremity and limit postoperative neuralgia. The superficial posterior compartment is

released by longitudinally incising the fascia overlying the gastrocnemius muscle. In the mid-calf, the fibers of the soleus muscle running transversely will be exposed. Soleal attachments to the tibia are divided with electrocautery exposing the fascia of the deep posterior compartment. This fascia is incised longitudinally for release of this compartment.

For the lateral and anterior compartment release, a single longitudinal skin incision is made ~2 to 3 fingerbreadths lateral to the tibia. Once the skin and subcutaneous tissues are divided, the fascia is exposed, and separate longitudinal fascial incisions are created on either side of the intermuscular septum that runs between the anterior and lateral compartments. Care should be taken to avoid injury to the superficial branch of the peroneal nerve in the lateral compartment as it exits the fascia ~10 to 12 cm superior to the lateral malleolus.



Figure 215.12. Illustration with dashed line demonstrating the typical skin incision location for a posterolateral, single-incision, two compartment release of the thigh.

POSTOPERATIVE CARE

The performance of appropriate fasciotomies relies on wide surgical exposure of skin, subcutaneous fat, and fascia. These large wounds can be difficult to manage, and the surgeon is often considering how these wounds will be closed by the time the fasciotomy is completed. Immediate closure of the skin is not recommended, as ongoing swelling of the underlying tissues may result in continued elevation of compartment pressures. However, several methods have been employed to facilitate early closure of the skin and subcutaneous tissues. These have included: (1) immediate placement of monofilament nonabsorbable sutures that can be tightened to reapproximate the tissues in a delayed primary fashion, (2) utilization of skin staples along the edges of the wound and lacing vessel loops or tapes back and forth between them for delayed reapproximation (“shoe-lace” or “Roman Sandal” technique), and (3) more recently, utilization of closed suction vacuum-assisted dressings, among others. Each of these therapies is designed to obviate the need for split-thickness skin grafting. If early wound reapproximation is not possible without creating undue tension on soft tissues, however, a split-thickness skin graft is indicated.

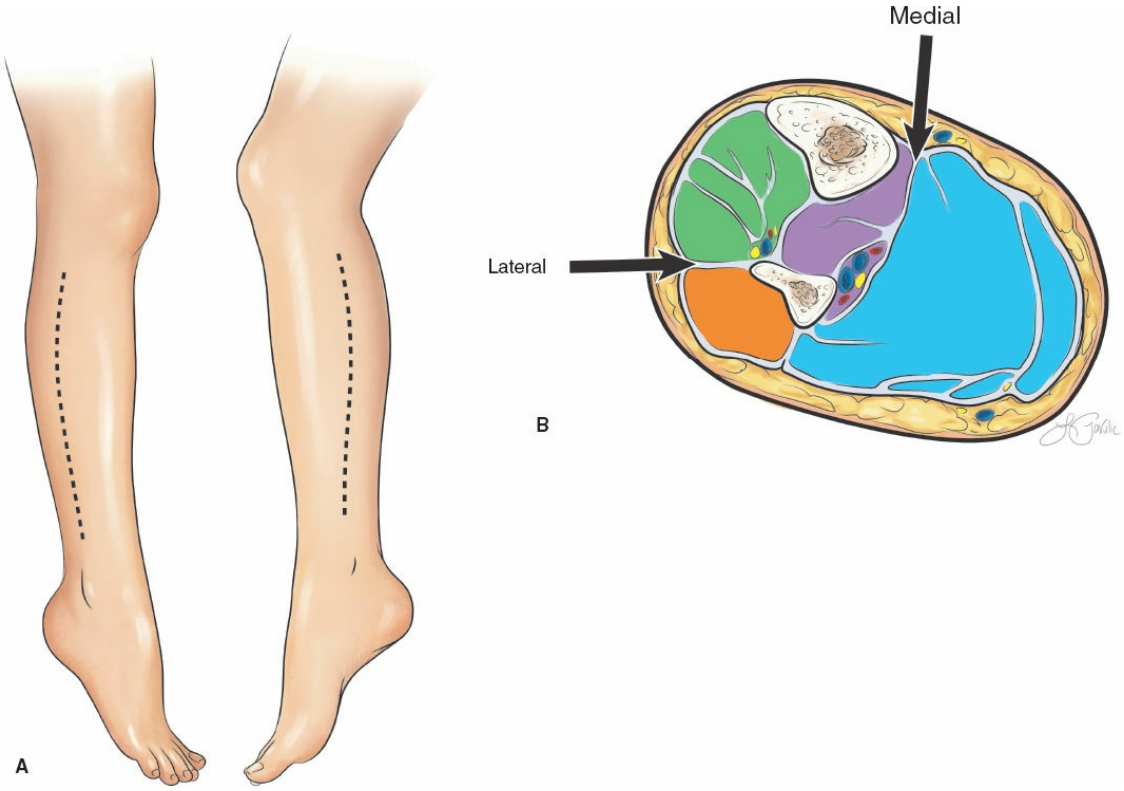

Figure 215.13. A. Illustration with *dashed lines* demonstrating generous longitudinal skin incisions on the medial and lateral calf approximately one and three fingerbreadths from the tibia, respectively. **B.** Illustration of an axial view of the leg with *arrows* demonstrating the locations of skin incisions for medial and lateral calf compartment release.

COMPLICATIONS AND THEIR MANAGEMENT

Complications are common following fasciotomy. A careful review of patients undergoing leg fasciotomy via two incisions in the setting of trauma reflected an overall fasciotomy-related complication rate of 31%. Skin, soft tissue, or deep infections occur with variable rates, but are higher with delay in fasciotomy of the leg, and have been reported to be as high as 67% for fasciotomy of the thigh. Antibiotics are not indicated unless a documented infection is present. Any necrotic muscle or tissue should be debrided at the time of initial fasciotomy in order to minimize infectious complications. Reexploration of fasciotomy wounds in which necrotic tissue was identified may be necessary at 48- to 72-hour intervals, with serial debridement as needed. Obviously, wounds in which significant necrosis or documented infection have occurred should be left open despite the potential negative cosmetic and functional results.

The most significant complication related to fasciotomies results from a

delay in their implementation. Postponed treatment of CS, or inadequate decompression at the time of fasciotomy, will both result in poor outcomes. A high index of suspicion, serial physical examinations, and timely assessment of compartment pressures when appropriate are keys to preventing such complications.

OUTCOMES

Outcomes following fasciotomy for CS may be classified by cosmetic, functional, and limb-salvage, but overall data are limited. Cosmetic disfigurement following fasciotomy, although important to patients, is a natural consequence of this procedure. Delayed primary closure often results in retracted and thickened scars, while skin grafts have obvious cosmetic effects. Avoiding infection, appropriate debridement of necrotic muscle (best achieved through prompt recognition and treatment of CS aligned with serial operative debridement when necessary), and split-thickness skin grafting by experienced practitioners may limit cosmetic disfigurement. Functional outcomes and limb-salvage rates may be measured objectively, but heterogeneity in etiology makes measuring these outcomes challenging.

While functional outcomes for gluteal CS outcomes are very difficult to assess because of low incidence and sporadic reports in the literature, one review of 18 patients with acute CS of the thigh demonstrated long-term functional deficits in 8 patients. Prolonged interval to decompression, among other factors, was associated with poorer functional outcomes. Perhaps the most robust data regarding frequency of fasciotomy with severe injury have resulted from recent military conflict. Analysis of wartime injured from 2001 to 2010 identified 25,731 casualties in the registry with wounds in any body region, of which 17,166 had limb trauma. Nineteen percent of the limb-trauma group underwent fasciotomy. Unfortunately, functional outcomes were not able to be assessed in this report. The incidence of fasciotomy was higher in those undergoing amputation than those with nonamputation injury, as expected. Another historical report assessing outcomes for leg and forearm fasciotomy identified that fasciotomy performed <12 hours after the onset of symptoms resulted in normal function in 68%, while delayed treatment had only 8% normal function. Regardless of the site of fasciotomy, the most important determinate of functional outcome is the minimizing delay in treating CS.

Suggested Readings

Blaisdell FW. The pathophysiology of skeletal muscle ischemia and the reperfusion syndrome: a review. *Cardiovasc Surg* 2002;10(6):620–30.

David V, Thambiah J, Kagda FH, et al. Bilateral gluteal compartment syndrome. A case report. *J Bone Joint Surg Am* 2005;87(11):2541–5.

Jensen SL, Sandermann J. Compartment syndrome and fasciotomy in vascular surgery. A review of 57 cases. *Eur J Vasc Endovasc Surg* 1997;13(1):48–53.

Kragh JF Jr, Dubick MA, Aden JK 3rd, et al. U.S. military experience from 2001 to 2010 with extremity fasciotomy in war surgery. *Mil Med* 2016;181:463–8.

Mithofer K, Lhowe DW, Vrahas MS, et al. Clinical spectrum of acute compartment syndrome of the thigh and its relation to associated injuries. *Clin Orthop Relat Res* 2004;(425):223–9.

Mubarak SJ, Owen CA, Hargens AR, et al. Acute compartment syndromes: diagnosis and treatment with the aid of the wick catheter. *J Bone Joint Surg Am* 1978;60(8):1091–5.

Olson SA, Glasgow RR. Acute compartment syndrome in lower extremity musculoskeletal trauma. *J Am Acad Orthop Surg* 2005;13(7):436–44.

Sheridan GW, Matsen FA 3rd. Fasciotomy in the treatment of the acute compartment syndrome. *J Bone Joint Surg Am* 1976;58:112–5.

Velmahos GC, Theodorou D, Demetriades D, et al. Complications and nonclosure rates of fasciotomy for trauma and related risk factors. *World J Surg* 1997; 21(3):247–52; discussion 253.

Whitesides TE, Haney TC, Morimoto K, et al. Tissue pressure measurements as a determinant for the need of fasciotomy. *Clin Orthop Relat Res* 1975(113):43–51.

Williams AB, Luchette FA, Papaconstantinou HT, et al. The effect of early versus late fasciotomy in the management of extremity trauma. *Surgery* 1997;122(4):861–6.

Zweifach SS, Hargens AR, Evans KL, et al. Skeletal muscle necrosis in pressurized compartments associated with hemorrhagic hypotension. *J Trauma* 1980; 20(11):941–7.

EDITOR'S COMMENT

The chapter by Dr. Eliason describing many key points of fasciotomy represents a straightforward treatise on an important adjunctive procedure for many of our ill and injured patients who develop compartment syndrome. This chapter includes several anatomical locations beyond that typically performed in the lower leg. I fully agree with the author that "if fasciotomy is thought about, it

should be done," and is akin to "thinking that a patient should be intubated, they probably should be." The morbidity with this adjunctive procedure is low, and missing the diagnosis, even if it is recognized rapidly, results in a repeat operation, time, and hassle for both the patient and the surgeon. Typically, the technical performance of fasciotomy is fairly straightforward, but recognition of when it is required is key as overall amputation rates are ~13% (Lollo L, Grabinsky A. Clinical and functional outcomes of acute lower extremity compartment syndrome at a Major Trauma Hospital. *Int J Crit Illn Inj Sci* 2016;6:133–42).

The primary reason fasciotomy is done is to relieve tissue compartmental pressure, which negatively impacts the neuromuscular function of a limb. Missing the primary diagnosis of a compartment syndrome is not only devastating to the patient long term, but is also a major medical legal liability. Leg pain and neurologic changes are sensitive and specific in the right clinical scenario. The anterior compartment in the lower leg, housing the deep peroneal nerve, is most sensitive to elevated compartment pressure and often the first symptomatically involved compartment. Nerve tissue is most sensitive to ischemia, so by the time arterial flow is impaired, the nerve damage may be permanent. Even with rapid treatment, the neuropathy that results from compartment syndrome, unless it's done prophylactically, often takes month to improve.

The occurrence of a gluteal compartment syndrome is rare but important to consider in the right settings. Examining the buttocks in a patient who has had massive reperfusion injury as well as patients who have had atheroembolism to the internal iliac artery system is important, and may direct one to this diagnosis. The description as put forth is straightforward, and as with most fasciotomies, the morbidity is low.

The most common type of fasciotomy is the four-compartment release of the lower leg. One thing to keep in mind is that the skin and fascial incision needs to be generous enough that you fully release the compartments to allow the muscle release. From my own experience (inadvertently), performing a limited fasciotomy has resulted in the need to take the patient back for further release of the compartments. This may be more common in those younger patients with marked and massive reperfusion, and they often have persistently elevated CPK and myoglobinuria. In the lower extremity four-compartment fasciotomy in a large leg or with extensive trauma, it is important to make sure that you open the anterior compartment and not mistake for the lateral. That is, if you place the incision too far laterally over the fibula, you may incise the lateral compartment twice and miss the anterior compartment. This results in a dead anterior muscle compartment and a need for an above the knee amputation. Need for fasciotomy revision is also associated with a significant increase in muscle necrosis and mortality (Ritenour AE, Dorlac WC, Fang R, et al. Complications after fasciotomy revision and delayed compartment release in combat patients. *J Trauma* 2008;64:S153–61, discussion S161–2).

A common complication that often accompanies fasciotomies is significant bleeding. Patients who had an acute embolic process or thrombotic process usually need to be kept on anticoagulation periprocedurally. However, the open wound beds, skin, and venous tributaries often bleed quite extensively. Wrapping and elevating the patient's limb and at times reversing the systemic anticoagulation are necessary. However, this needs to be balanced against recurrent thrombosis. Furthermore, patients who are on dual antiplatelet therapy, particularly with the newer agents, may also have a greater risk of bleeding. Again, ongoing antiplatelet therapy needs to be balanced for cardiac protection against persistent bleeding. Making sure adequate cautery of the skin bleeders, oversewing of small veins, and the like are done and can help decrease this problem.

Peter Henke

E MESENTERIC AND RENAL ARTERY DISEASE

216 Renal Artery Occlusive Disease: Open and Endovascular Management

Laura A. Peterson and Matthew Edwards

ETIOLOGY AND PATHOPHYSIOLOGY

Etiology

The etiology of occlusive renovascular disease in adults can be divided into essentially two main categories: atherosclerosis and fibromuscular dysplasia (FMD), with the vast majority of cases secondary to atherosclerosis. Population-based studies and other reports from the medical literature would suggest that >90% of treated renovascular occlusive lesions arise from atherosclerosis and the majority of the remaining treated lesions are fibrodysplastic (most commonly medial fibroplasia) in nature. Other conditions do cause renal artery occlusive disease, including arteritis (most commonly Takayasu's) and complications of arterial dissections, but these conditions are rarely recognized and treated outside of specialized referral centers.

Children can also be affected by renal artery occlusive disease. In fact, renovascular disease is one of the most common causes of secondary hypertension in young patients. In children, the most common culprit pathologies are congenital lesions, hypoplastic lesions, and variants of fibrodysplasia.

Pathophysiology: Renovascular Hypertension

Atherosclerotic disease of the renal artery primarily affects the renal ostia, usually as an extension of aortic atheroma. Atherosclerotic disease may

also involve any level of the renal vasculature including the small intraparenchymal vessels, but such distal extension of disease is quite uncommon. Histologic evaluation of renal artery plaques has demonstrated features consistent with atherosclerotic plaques in other vascular beds, with typical cholesterol rich lipid containing plaque and disruption of normal intimal and medial histologic architecture and frequent central plaque degeneration and (very frequently) lesion calcification. Contributing factors to the development of renal artery atherosclerosis are essentially the same conditions associated with atherosclerosis elsewhere in the body.

One consideration that is unique to the renal and visceral artery ostial lesions is the continuous nature of the ostial plaque with a sheet of aortic plaque. This characteristic makes these lesions more resistant to balloon dilation than isolated vascular lesions. As a result, balloon angioplasty for the treatment of atherosclerotic lesions of the renal vasculature has largely been abandoned as a stand-alone therapy in favor of balloon-expandable stents when an endovascular repair is indicated.

FMD is the second most common cause of renal artery stenosis (RAS). FMD is actually a group of nonatherosclerotic and noninflammatory conditions, which result from abnormal cell growth, and frequently fibrosis, within the histologic architecture of the arterial wall, especially the media. Multiple variants of FMD occur, but the medial fibroplasia variant is the most common cause of occlusive lesions in adults, with younger females being disproportionately affected. Medial fibroplasia is most commonly identified secondary to a pathognomonic “string of beads” appearance on arteriography resulting from alternating areas of stenosis and poststenotic dilation. The majority of cases demonstrate involvement of both renal arteries. In cases isolated to one kidney, the right renal artery is affected more frequently than the left. The underlying cause of FMD is unknown.

In patients with significant decreases in renal perfusion secondary to occlusive lesions, there are neuroendocrine effects that result in a multitude of downstream issues increasing the patient’s risk of adverse cardiac, neurologic, and renal events, most notably severe, secondary hypertension. The hormonal regulation underlying renovascular hypertension is complex and involves activation of the neuroendocrine–renin–angiotensin–aldosterone system. The stenotic renal artery creates a situation of relative hypoperfusion in the affected kidney. Not all stenotic

lesions are capable of producing impaired blood flow of sufficient magnitude to create a pressure gradient prompting hormonal response. In investigational work, the degree of arterial occlusion requires between a 60% and 80% decrease in cross-sectional area. However, once renal hypoperfusion does occur, a predictable and reproducible physiologic response occurs. First, the juxtaglomerular cells of the renal parenchyma release renin, which enzymatically converts angiotensinogen into angiotensin I. Angiotensin I is converted into angiotensin II by angiotensin converting enzyme (ACE). Angiotensin II is the primary hormonal driver of renin induced hypertension, through effects that are mediated by the activation of downstream receptors: angiotensin type I receptor (ATR1) and angiotensin type 2 receptor (ATR2).

Clinical pathophysiology differs according to whether a single kidney or both kidneys (or a solitary kidney) are affected. In unilateral lesions, compensatory natriuresis and excretion of other metabolites can occur through the unaffected kidney reducing the degree of volume expansion experienced by the patient. Unilateral renovascular hypertension is often treated quite effectively using ACE inhibitors or angiotensin receptor antagonists for this reason, and affected patients are less likely to experience volume-dependent cardiac disturbance issues and measurable decline in excretory renal function. When both kidneys (or a solitary kidney) are affected, the resulting hypertension requires diuretic management of the volume expansion for hypertension control and the decreased excretory function operates across the entire functional nephron mass, increasing the likelihood of clinically apparent renal dysfunction (ischemic nephropathy).

It is important to note that these initial mechanisms of hypertension in renovascular disease are mediated mainly by the effects of angiotensin II. However, over time remodeling both the heart and peripheral vessels occurs, which can lead to hypertension that is more difficult to treat and that may not respond favorably or completely to renal artery revascularization. This cardiovascular remodeling that occurs in renovascular hypertension is distinct from that seen in essential hypertension. In essential hypertension, there is no significant change in the arterial wall mass. In patients who exhibit chronic hyperreninemia, such as in renovascular hypertension, there is a hypertrophic remodeling of the arterial wall with notable expansion of the medial layer.

Pathophysiology: Ischemic Nephropathy

Although the underlying mechanisms leading to renovascular hypertension are well understood, the basis for renal insufficiency secondary to RAS remains poorly defined. The decreased blood flow leads to impaired glomerular filtration, but the role of frank ischemia is less well established. Acute renal artery occlusion leads to dramatic ischemia within minutes and necrosis within hours, but the gradual chronic decrease in blood flow impairs renal function in a more insidious way. In this pathway, as in renovascular hypertension, it is apparent that angiotensin II plays a key role. Angiotensin II increases efferent arteriole pressure and thus glomerular capillary pressure to maintain filtration in the setting of reduced renal blood flow secondary to more proximal renal vasculature obstruction. Through the perirenal effects mediated by ATR1, there is increased transforming growth factor β (TGFβ), PDGF, and nuclear factor-κB. These local regulators create a profibrotic state and lead to both glomerulosclerosis and tubulointerstitial injury. There is also evidence to support that the atheromatous plaque involved in some renal artery stenotic lesions can contribute to ischemic nephropathy by releasing atheroembolic debris leading to microvascular occlusion and associated renal parenchymal loss.

CLINICAL PRESENTATION

Epidemiology

In adults, the most common cause of RAS is atherosclerosis. The presence of atherosclerotic lesions in another vascular bed increases the chance that a patient will have concomitant RAS. The baseline prevalence of RAS depends on the population screened. A community screening program of 834 adults over the age of 65 demonstrated that 6.8% of the population had >60% RAS by renal duplex ultrasonography (DUS). In that study, RAS was almost twice as common in men compared with women (9.1% vs. 5.5%), but there was no difference noted between Caucasian and African-American individuals. Other studies have identified risk factors for RAS including age, systolic hypertension, and reduced high-density lipoprotein cholesterol level. Autopsy data from the 1960s looking at the prevalence of RAS in the general population in comparison to the hypertensive population demonstrated that 27% of patients over the age of 50 had RAS (defined as >50%) and this increased to 53% in those who had a medical

history of diastolic hypertension. A further study, reviewing 154 consecutive autopsies found that the prevalence of RAS in those younger than 55 years of age was only 6% but the prevalence dramatically increased in those over the age of 75 to 40%.

History and Physical Examination

The majority of patients with RAS are asymptomatic. Patients with symptomatic disease will in general present with severe hypertension with or without impaired renal function. In young patients, particularly children, a new diagnosis of hypertension should prompt further evaluation for a secondary cause.

Physical examination findings and laboratory abnormalities are nonspecific. The physician must take care to consider which patients are at greatest risk of having underlying renovascular disease prior to subjecting the patient to further testing. Patients with advanced age, uncontrolled hypertension, or a history of atherosclerotic disease in other vascular beds are at higher risk. Almost all patients, in our experience, with ischemic nephropathy have synchronous severe hypertension. This represents the fact that hypoperfusion severe enough to impair excretory function will also be severe enough to activate the renin-based neurohumoral cascade discussed previously. Therefore, renal insufficiency without hypertension should prompt further evaluation for other intrinsic renal disease. It is important to state, though, that blood pressure may be well controlled on medications and it is important to factor in the degree of antihypertensive treatment into one’s consideration of the severity of the underlying hypertension.

Physical examination may prove a useful if nonspecific evaluation in patients with renovascular disease. The patient may have severe hypertension, abdominal bruits, or nonspecific signs of cardiovascular disease, including diminished or absent peripheral pulses. A diminished lower extremity pulse exam may be present in children presenting with congenital abnormalities, aortic coarctation, or in adults with Takayasu arteritis.

Patients may present with acute worsening of their renal function after initiation of treatment with either an ACEI or ARB. This occurs most frequently in the setting of bilateral RAS due to the functional dependence on the increased efferent arteriolar tone maintained by angiotensin II to maintain glomerular filtration. Once pharmacologic blockage of this

compensatory mechanism occurs, there is an acute decompensation. If this effect is recognized early, and the medication discontinued, then return to baseline renal function usually occurs. Confirmation of RAS by renal artery duplex may be indicated and a different medical regimen prescribed.

A patient who presents with hypertensive urgency or emergency must be carefully evaluated. These hypertensive crises are most common when the patient has long-standing hypertension that has led to compensatory end-organ remodeling. Of particular concern is the patient who presents in congestive heart failure with pulmonary edema. Patients who present with such “flash” pulmonary edema as result of congestive heart failure and hypertension are more likely to have bilateral RAS with expanded intravascular volume, increased left ventricular mass, and diastolic dysfunction. Patients may also present with neurologic symptoms ranging from headache to stroke. The underlying physiology of this presentation is a severe increase in hydrostatic pressure, which drives fluid into the interstitial space causing generalized edema of both the organs and extremities. Hypertensive crisis can also cause transient damage to the kidney. Individuals may have proteinuria and elevated creatinine. As blood pressure is controlled and symptoms managed, there is a trend toward normalization to baseline of both proteinuria and renal insufficiency. Although prompt evaluation of RAS may be desired by the clinician, it is critical to allow sufficient time for renal function to recover prior to initiation of contrast studies or associated interventions that may involve renal ischemia, if possible.

Initial Laboratory Findings

Basic laboratory evaluation is nonspecific in the evaluation of renovascular disease. There may be elevations in blood urea nitrogen or, more commonly, serum creatinine. It is important to note that estimations of GFR are merely measures of total renal excretory function and are not representative directly of the changes in each kidney. These values can be influenced by a multitude of factors, including age, body mass, and protein intake. Historically, there was a call for “split” renal function studies to evaluate the importance of each kidney in the progression of the patient’s renovascular disease. This used a complex system of separate ureteral catheters to collect individual urine specimens and measure values from each kidney. Although very useful in predicting response to therapy, these studies have been abandoned in favor of less invasive radionuclide testing

to estimate fractional blood flow and filtration to each kidney.

If the patient has been suffering from the disease process for a protracted period of time, there may be nonspecific electrocardiogram changes demonstrating a strain pattern with increased voltages suggestive of ventricular wall thickening. An echocardiogram may demonstrate ventricular hypertrophy with poor diastolic relaxation. These findings are particularly common in children, and are reversible in young patients with timely revascularization. If a patient has hypokalemia, a plasma aldosterone level may prove useful in differentiating a diagnosis of primary hyperaldosteronism from RAS. Furthermore, urine metanephrines or serum catecholamines can identify other biochemically active adrenal tumors that can cause secondary hypertension.

Natural History

Once the clinician has identified a patient with RAS, it is important to further understand the natural history of the lesions involved as well as the role of expectant management. In patients with asymptomatic RAS or well-controlled hypertension, there is no roll for invasive treatment. Even in patients who have more severe hypertension and renal insufficiency, an understanding of anatomic lesion progression is necessary in order to best assess which patients require invasive therapy. Historical studies performed in the late 1960s through early 1980s demonstrated dramatic progression of renovascular disease in 11% to 35% of patients as measured by invasive arteriography. In these studies, there was up to a 10% progression to complete arterial occlusion. Although these results would seem to warrant aggressive intervention, it is important to note that the selected population studied had disease with preexisting severe stenosis warranting serial invasive imaging. More recent studies used duplex ultrasonography to evaluate a high-risk patient population and demonstrated an extremely low rate of lesion progression, with a rate of progression to occlusion of <0.5% per year. The reasons for the difference are incompletely understood, but likely stem from better medical management, among other factors. Patient factors that were associated with progression of disease in that cohort were age, uncontrolled hypertension, and continued smoking.

PREOPERATIVE PLANNING

Diagnostic Evaluation: Functional Studies

In the past, measurements of renal vein renin levels were used in order to plan surgical revascularization for hypertension. These measurements were obtained by sampling the renal vein, vena cava, and each individual main renal artery. This allowed the clinician to estimate the contribution of each kidney to the total circulating levels of renin with a ratio of 1.5 compared to the contralateral kidney being accepted as proof of renin hyperproduction from a hypoperfused kidney with RAS. These tests are of little or no value in patients with bilateral RAS. In patients with unilateral lesions, the prognostic value of lateralizing renin values is controversial with proponents and detractors. These studies are also notoriously difficult to perform in terms of medical management, need for prolonged patient recumbence, and patient discomfort/tolerance. For these reasons, renal vein renin analysis is an infrequently used test in contemporary practice. Other functional tests, including captopril renography, have also fallen out of favor.

Diagnostic Evaluation: Noninvasive Imaging

Duplex Ultrasonography

Duplex ultrasonography is an inexpensive test with excellent diagnostic accuracy when performed by experienced operators. Duplex also has the additional benefit of requiring no contrast agents or ionizing radiation exposure. Because of these factors, it is often used to initially diagnose RAS and monitor renovascular occlusive disease at sequential time points to evaluate for progression of disease. The reliability of renal duplex ultrasound, however, is heavily dependent on the expertise of the technician obtaining the images. Furthermore, study times can be considerable requiring appropriate resources. Patient barriers also exist as bowel gas can obscure adequate imaging so the patient must be fasting for a minimum of 8 hours prior to the examination to maximize the likelihood of obtaining the best images and Doppler samples possible. Obese patients also provide a significant challenge. At our institution, these factors can lead to an incomplete examination in up to 4% of the population.

Despite the fact that duplex ultrasonography has more technical considerations than other forms of noninvasive diagnostic testing, its accuracy can exceed 90% when compared to catheter-based arteriography. Several criteria have been used in the literature to predict a critical stenosis. In our laboratory, we employ peak systolic velocity (PSV) of 180 cm/s as a validated indicator of 60% or greater RAS. Other institutions

employ PSV, but also place emphasis on the renal to aortic ratio (RAR) of PSV in order to identify hemodynamically significant RAS. A RAR >3.5 is another indicator of >60% RAS.

Magnetic Resonance Angiography

Magnetic Resonance Angiography (MRA) is also frequently used in the evaluation of occlusive lesions of the renal arteries. Multiple studies have specifically examined its use in evaluation of the renal arteries. A meta-analysis published in 2001 demonstrated that the sensitivity and specificity of contrast enhanced MRA ranged from 88% to 100% as compared to angiography in evaluation of the renal arteries. Multiple studies, however, have demonstrated that there is frequently overestimation of the degree of RAS by contrast enhanced MRA, up to 30% in some series. Nonetheless, there are advantages of MRA over other imaging modalities. It does not require radiation or iodinated contrast agents as with computer tomographic angiography nor does it require the operator skill of duplex ultrasonography. There are drawbacks as well including long scan times, enclosed scanners, and the concern for nephrogenic systemic fibrosis if gadolinium is used in patients with excretory renal dysfunction. Any metal structure, including previously placed vascular stents, can also cause image distortion.

Computer Tomographic Angiography

Computed Tomographic Angiograph (CTA) is another frequently utilized test for defining renal artery occlusive disease. CTA can provide precise three-dimensional visualization and evaluation. Furthermore, there are fewer technical demands in terms of image acquisition and processing compared to the other imaging modalities when evaluating the renal arteries. CTA does however expose the patient to ionizing radiation and iodinated contrast agents with their attendant risks. CTA is less accurate at identifying stenosis of accessory and polar vessels as compared to conventional catheter-based angiography, may provide incomplete definition of changes consistent with FMD, and may provide incomplete luminal characteristic information in the presence of frequent dense perirenal vascular calcification.

Diagnostic Evaluation: Invasive Imaging

Digital Subtraction Angiography

Digital subtraction angiography (DSA) is the historic gold standard by which all other diagnostic imaging modalities in renovascular disease are measured; however, we view angiography as a therapeutic modality, and not a diagnostic modality per se, in contemporary practice. It is highly accurate in delineating renal anatomy and providing clear understanding of the diseased segment and provides an opportunity to treat many variants of renovascular pathology at the time of its performance. There are of course liabilities with DSA: it is invasive, costly, associated with potential access site complications, and requires exposure to radiation and potentially nephrotoxic contrast agents.

ENDOVASCULAR REPAIR

Indications and Contraindications

Indications for endovascular (and open) treatment of RAS have come under scrutiny in the previous decade. With the results of the CORAL, ASTRAL, and STAR, more stringent criteria have been considered for patient selection as none of these trials demonstrated any evidence for significant renal, cardiovascular, or survival benefit with endovascular renal revascularization. However, as with all clinical trials, these investigations had limitations, most notably a relatively limited study sample of patients who would be considered severely affected by RAS with renal insufficiency, bilateral disease, and/or truly difficult to control or uncontrollable hypertension. Given these points, contemporary use of renal revascularization is controversial, but there is expert consensus that the following patient groups represent the populations requiring further study and groups with the highest potential to achieve a beneficial clinical response.

Patients with truly uncontrollable or poorly controlled hypertension on multiple medications, especially if their course is complicated by symptoms or cardiac disturbance (i.e., flash pulmonary edema, symptomatic hypertension, etc.)
Patients with an observed rapid decline in renal function, especially in the setting of RAS involving the entire renal mass (i.e., bilateral disease or unilateral disease to a solitary kidney)

For patients selected for renal revascularization, endovascular methods represent the contemporary standard of care. In general, revascularization with balloon mounted stents rather than stand-alone angioplasty or

angioplasty with selective secondary stenting is recommended for initial treatment. However, there are anatomic characteristics that are relative contraindications for endovascular repair. These include a short main renal artery, multiple small renal arteries, concomitant need for aortic replacement secondary to aneurysmal or occlusive disease, presence of a coral reef atheromas, disease in close proximity to branch points, and congenital or hypoplastic lesions in children.

Preoperative Management

In addition to the preoperative measures described for open repair, preparation for endovascular intervention includes saline hydration. Those patients at risk for contrast nephropathy (i.e., diabetes mellitus, excretory renal insufficiency) receive iso-osmolar iodinated contrast agents. In these cases, carbon dioxide may be employed as a contrast agent to reduce the volume of iodinated materials.

Arteriography

Detailed arteriographic images of the renal arteries and perirenal aorta are essential to endovascular renal revascularization. Common femoral artery access is the most versatile access with the least risk. The femoral artery contralateral to the renal artery considered for endoluminal therapy is preferentially selected. If femoral artery access is not available, left brachial artery access is chosen. In this latter instance, an open approach to the brachial artery can be made through a small incision at the antecubital fossa or it may be percutaneously accessed if the vessel is large. Arteriography is obtained through a multisided hole flush catheter positioned at the L1 to L2 interspace. Initial anteroposterior views are supplemented with oblique views as necessary to visualize the renal artery ostia. A 15-degree left anterior lateral oblique view is often helpful in visualizing ostia orthogonally

Percutaneous Transluminal Angioplasty and Endoluminal Stenting (PTAS)

A variety of guidewires, catheters, sheaths, balloons, and stents exist that are used for renal artery endovascular intervention. Familiarity with individual institution stock supply is necessary for the surgeon. Most devices in current practice will pass through a 6-Fr sheath or guide

catheter. Guide sheaths and guide catheters are used to provide mechanical support for stable guide wire placement into the renal artery and for easy passage of therapeutic devices. They are configured to facilitate access to the renal artery orifices. After arteriography has delineated the renal artery lesion, an appropriately configured 6-Fr guide catheter is positioned at or just within the renal artery orifice (Fig. 216.1). The patient is systemically heparinized prior to cannulation of the renal artery lesion. It is our preference to select the renal artery with a 0.014-inch guide wire. In the presence of renal insufficiency, an embolic protective device may be considered, but data supporting this are lacking.

With the guide wire secured distal to the lesion, a pressure measurement may be obtained. After a significant gradient is defined, a coaxial or rapid exchange balloon mounted stent is chosen. Preferred balloon size is chosen based on quantitative angiographic images. If predilatation is necessary prior to endoluminal stent placement, a low profile 3-mm angioplasty balloon is chosen. Stent size for definitive treatment should be of the same or only slightly larger diameter than the adjacent normal artery for primary treatment. For treatment of ostial atherosclerosis, the stent is positioned with 1- to 2-mm extension into the aorta. Once in position, the balloon is inflated slowly to full profile at the rated nominal pressure before deflation. Once fully deflated, the balloon is removed, selective angiography is repeated, and the pressure measurements are repeated. A residual gradient of >10 mm Hg is considered significant. This is usually treated by additional balloon angioplasty.

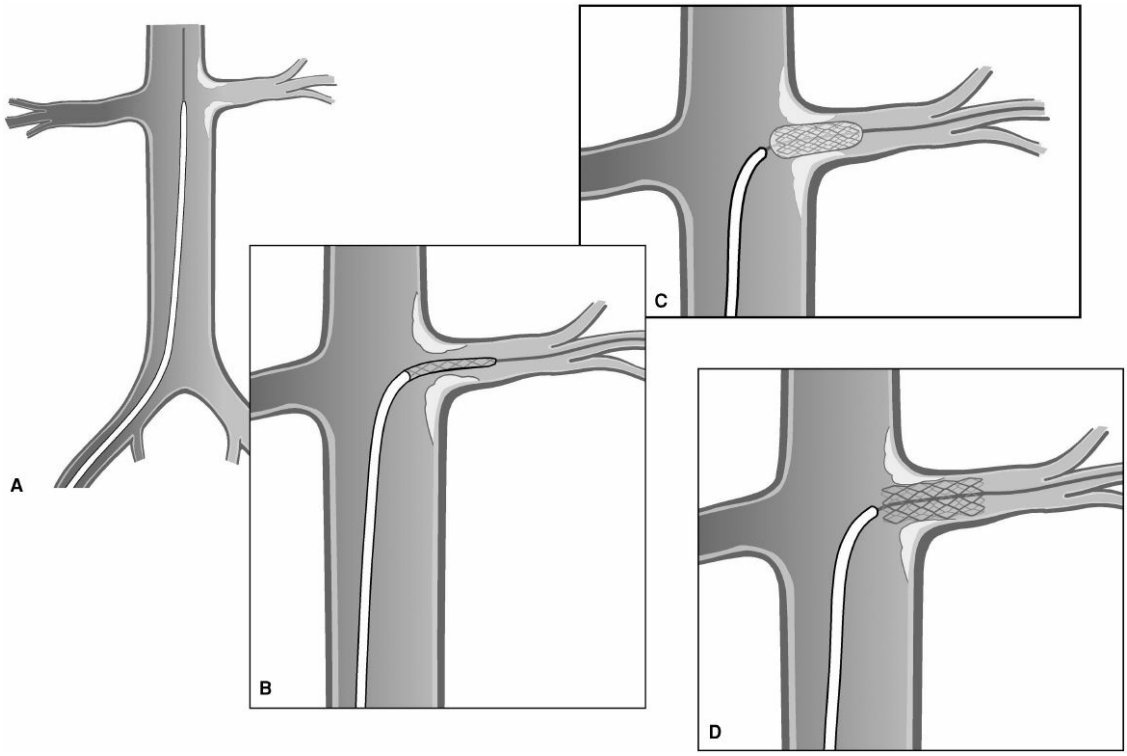

Figure 216.1. Left renal artery angioplasty and endovascular stenting of an ostial atherosclerotic stenosis. **A.** Femoral access contralateral to the renal artery for intervention with guidewire and No. 6-Fr guiding sheath. **B.** Selective placement of a soft tip guidewire to the level of the second-order renal artery branches. **C, D.** Balloon dilatation and deployment of endoluminal stent with complete stent overlap of the aortic atheroma.

OPEN REPAIR

Indications and Contraindications

With the advent of endovascular therapy in RAS, there has been reconsideration for the role of open surgical repair. General indications for open repair should be the same as those for endovascular intervention. Because of the less invasive nature of endovascular treatment of RAS, open surgical repair is now reserved for patients who have more complex anatomic lesions described previously, for failed endovascular treatments, and for aneurysmal disease.

Preoperative Management

There are key periprocedural steps that are common to every open renovascular surgical operation. Patients who require multiple medications for hypertension may experience reduced medication requirements while

hospitalized and at bed rest. Both converting enzyme inhibitors and angiotensin receptor antagonists are discontinued. Perioperative and postoperative medical therapy for blood pressure control includes vasodilators (e.g., amlodipine, nicardipine) and selective β-adrenergic blocking agents (e.g., atenolol, metoprolol). Patients with significant heart disease in combination with sever renal insufficiency may require preoperative placement of invasive monitoring to optimize cardiac index and intravascular volume prior to operation.

Certain steps are common to almost every open renal artery procedure. Intravenous mannitol is administered during periods of aortic and perirenal dissection, as well as before and after periods of renal ischemia. Small repeated intravenous doses are administered up to a total dose of 1 g/kg body weight. Prior to aortic or renal artery cross clamp, 100 units of heparin per kilogram of body weight are administered intravenously and systemic anticoagulation is verified by activated clotting time. During periods of aortic or renal cross-clamp, measurement of activated clotting time is repeated every 45 minutes and additional intravenous heparin is administered as necessary. Protamine is not routinely administered at the conclusion of the procedure unless required for hemostasis.

Renal Artery Exposure

Open repair of RAS is most commonly approached through an abdominal midline incision. Extension of the proximal incision 1 to 2 cm lateral to the xiphoid is critical in obtaining exposure of the proximal abdominal aorta and the renal branches. Mechanical retraction is put in place, and the abdominal exposure and dissection is continued. The posterior peritoneum overlying the aorta is incised longitudinally. Care is taken to mobilize the ligament of Trietz identifying collateral veins that may run in course with the inferior mesenteric vein at this level (Fig. 216.2). The duodenum is retracted gently to the right to allow for exposure of the renal vein (Fig. 216.3A). The renal vein must be mobilized from the inferior vena cava to the renal hilum (Fig. 216.3B). The inferior border of the pancreas is mobilized with this maneuver in the avascular plane. The left gonadal, adrenal, and lumbar branches of the left renal vein may be ligated to allow for retraction of the renal vein to provide better exposure. Often a lumbar branch of the left renal vein enters posteriorly. This can be readily avulsed unless special care is taken when mobilizing the left renal vein. The proximal portion of the right renal artery may be exposed through the base of the mesentery by ligating lumbar branches of the vena cava and

retracting the left renal vein cephalad and the vena cava to the right (Fig. 216.3C). The exposure of the distal aspect of the right renal vein requires mobilization of both the duodenum and right colon medially with the right renal vein being retracted cephalad (Figs. 216.4 and 216.5). Accessory renal arteries occur in 15% to 20% of patients and provide an additional technical challenge. All arteries that course anterior to the vena cava should be considered accessory or polar arteries and should be carefully preserved if of significant size.

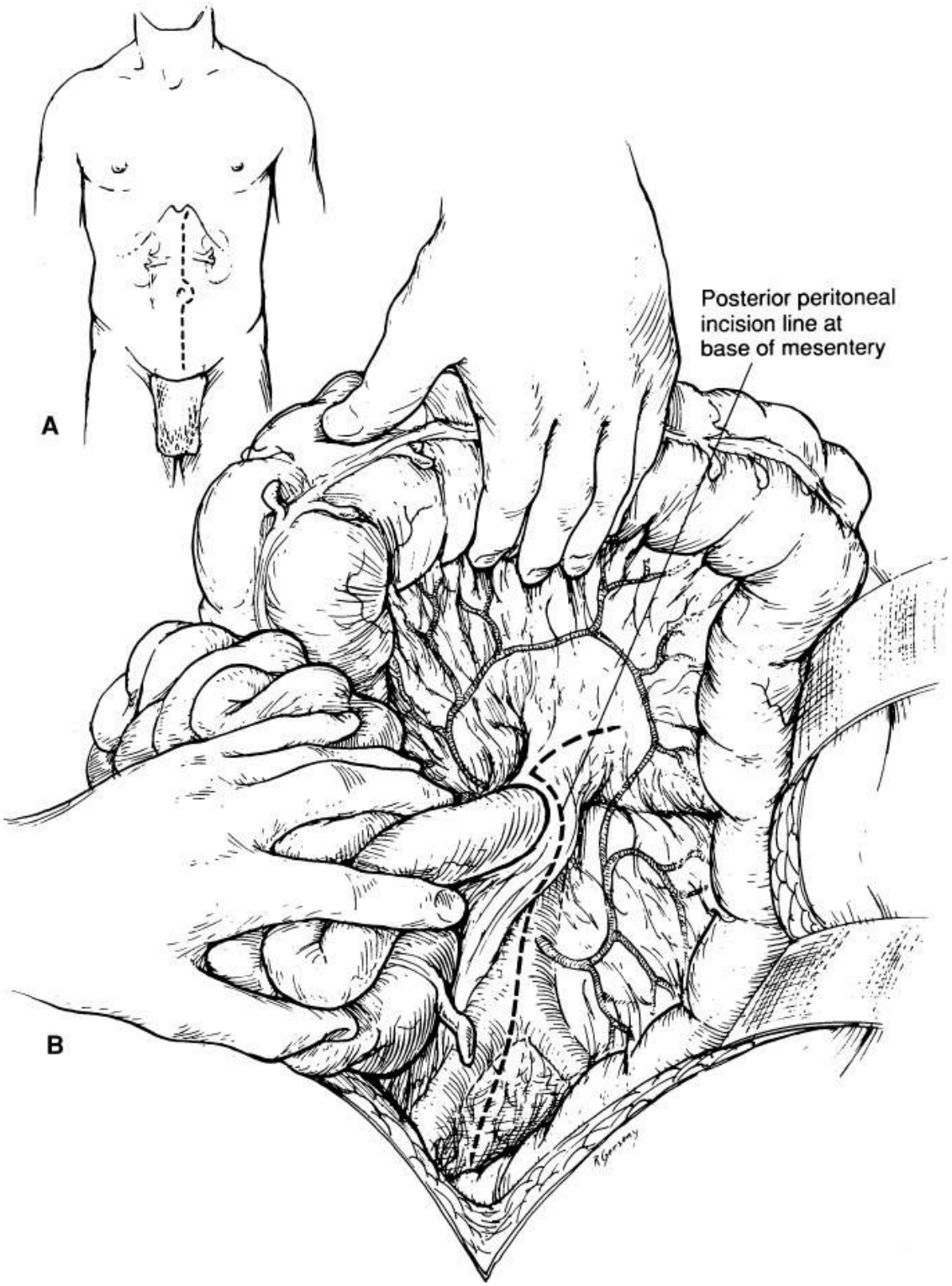

Figure 216.2. A, B. Exposure of the aorta and left renal hilum through the base of the mesentery. Extension of the posterior peritoneal incision to the left, along the inferior border of the pancreas, provides entry to an avascular plane behind the pancreas. This allows excellent exposure of the entire left renal hilum as well as the proximal right renal artery. (Reprinted from Benjamin ME, Dean RH. Techniques in renal artery

reconstruction: part I. *Ann Vasc Surg* 1996;10(3):306–14, with permission from Elsevier.)

In cases where the supraceliac aorta is used as an inflow, combined visceral-renal artery revascularization, or ex vivo branch renal artery repair is required, a generous transverse incision is planned from the contralateral semilunar line, bisecting the ipsilateral costal margin and extending to the pelvic crest. In these cases, the ipsilateral flank is elevated with either a rolled sheet or similar padding. A left visceral mobilization allows the surgeon access to the renal arteries, celiac axis, superior mesenteric artery, and supraceliac aorta. If needed, the diaphragmatic crus may be divided allowing further dissection and access to the extrapleural aorta up to the T10 level of the descending thoracic aorta.

If bilateral renal artery revascularization is required, the exposure technique can be modified. The base of the small bowel mesentery may be mobilized to allow for evisceration of the small bowel, right and transverse colon. In this exposure, the ligament of Treitz is divided and the posterior peritoneal incision proceeds along the base of the mesentery to the cecum then up the lateral gutter to the foramen of Winslow. The inferior border of the pancreas is fully mobilized, which exposes the aorta above the superior mesenteric artery. This latter exposure can be complicated postoperatively by chylous ascites, which can prove quite problematic.

Open Renal Arterial Reconstructions

There is no single operative method of renal artery reconstruction that provides optimal surgical reconstruction for all renal artery lesions. Patient anatomy, disease morphology, and surgeon preference must each be weighed when considering operative technique. There are three basic methods of repair: renal bypass, renal artery thromboendarterectomy, and renal artery reimplantation. Of these methods, renal bypass is the most common and versatile. Saphenous vein is the preferred conduit for an isolated renal artery bypass in an adult. Hypogastric artery is selected for renal reconstruction in the child and adolescent. In the absence of satisfactory autogenous material and a renal artery of <4 mm in diameter, a 6-mm thin walled polytetrafluoroethylene graft provides patency equivalent to autogenous reconstruction.

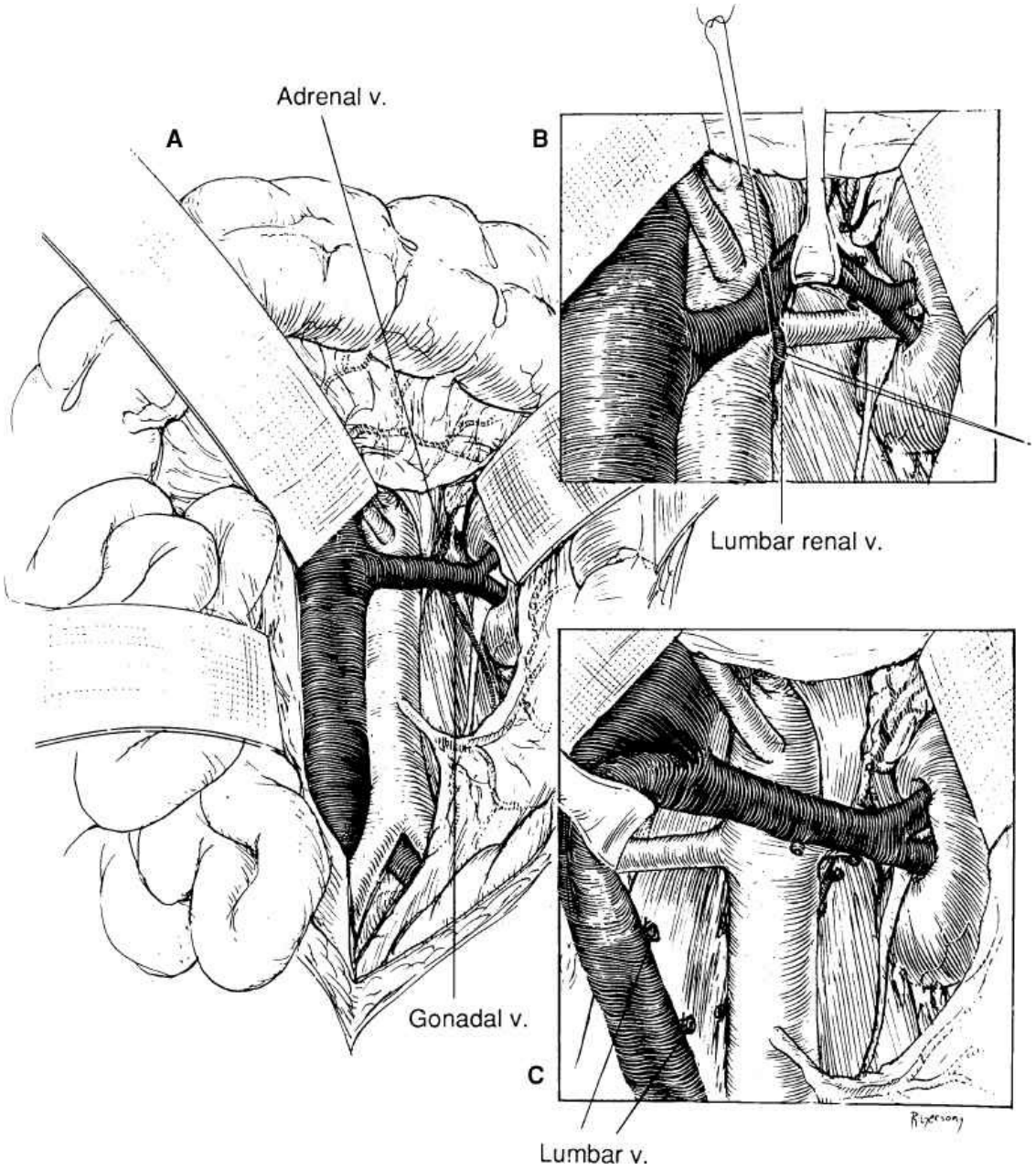

Figure 216.3. **A.** Exposure of the proximal right renal artery through the base of the mesentery. **B.** Mobilization of the left renal vein by ligation and division of the adrenal, gonadal, and lumbar–renal veins allows exposure of the entire left renal artery to the hilum. **C.** Two pairs of lumbar vessels have been ligated and divided to allow retraction of the vena cava to the right, revealing adequate exposure of the proximal renal artery disease. (Reprinted from Benjamin ME, Dean RH. Techniques in renal artery reconstruction: part I. *Ann Vasc Surg* 1996;10(3):306–14, with permission from Elsevier.)

Aortorenal Bypass

Regardless of the conduit chosen, proximal aortorenal anastomosis is

performed first to minimize warm ischemic time. A segment of infrarenal aorta proximal to the inferior mesenteric artery is controlled and an aortotomy created along the anterolateral aspect of the aorta. It is important to excise an ellipse of aorta with the length of the aortotomy at least three times the diameter of the renal artery conduit. Several applications of a 4.8-mm aortic punch can be used to create this ellipse. The proximal anastomosis is performed with a continuous 6-0 polypropylene suture (Fig. 216.6).

In the past, the distal graft to renal artery anastomoses were frequently created in an end-to-side fashion; however, distal end-to-end anastomosis is preferred. In this case, both conduit and renal artery are spatulated widely (two to three times the diameter of the renal artery) and the anastomosis accomplished with a continuous 7-0 polypropylene suture. Prior to the completion of the anastomosis, the graft is flushed of air and debris and blood flow reestablished to the kidney. In most instances, the warm renal ischemia time can be limited to 20 minutes or less.

Thromboendarterectomy

Transaortic thromboendarterectomy is particularly useful in patients with multiple renal arteries that demonstrate orificial atherosclerotic stenosis. Prior to undertaking thromboendarterectomy, the extent of atherosclerotic disease should be clearly defined. All visible and palpable renal artery atheroma should end within 1 to 1.5 cm of the aortic origin. Thromboendarterectomy requires more extensive aortic exposure than aortorenal bypass (Fig. 216.7A). The aorta proximal to the superior mesenteric artery should be exposed for control at this level (Fig. 216.7B). As discussed previously, exposure is facilitated by partial division of the diaphragmatic crura. The superior mesenteric artery origin is exposed and controlled with an elastic vessel loop. After preliminary control of each renal artery and the proximal and distal aorta, the aorta is opened longitudinally to the base of the superior mesenteric artery. First a sleeve endarterectomy of the aorta is performed. The correct endarterectomy plane is best defined at the site of the most advanced atherosclerotic disease. The aortic atheroma is divided sharply at the proximal and distal end points flush with the residual adventitia. Distal tacking sutures may be applied if necessary. Following sleeve endarterectomy of the aorta, an eversion endarterectomy of each renal artery is performed. The renal artery is everted into the aorta to allow the distal end point of the endarterectomy to be visualized. The aortic arteriotomy is then closed primarily with a

continuous 5-0 polypropylene suture.

As with thromboendarterectomy at all anatomic sites, this procedure is contraindicated by the presence of degenerative aneurysmal changes of the aortic wall and aortic atheroma complicated by transmural calcification. This later condition is defined by gentle palpation of the aorta. Transmural calcification may feel like fine grade sandpaper on palpation. When thromboendartectomy is performed in this setting, multiple, difficult to control, defects may be created within the adventitia, which are apparent only after blood flow is restored.

Renal Artery Reimplantation

If after extensive mobilization of the renal artery there is sufficient redundancy in the vessel, an aortic reimplantation may be considered. As with aortorenal bypass, the procedure requires that an ellipse of the aorta be taken and that the renal artery be spatulated two to three times its normal diameter and then reimplanted into the aorta at the anatomic level (Fig. 216.8). This technique is particularly appealing in children and adolescents as it obviates concerns regarding renal artery conduit in these age groups.

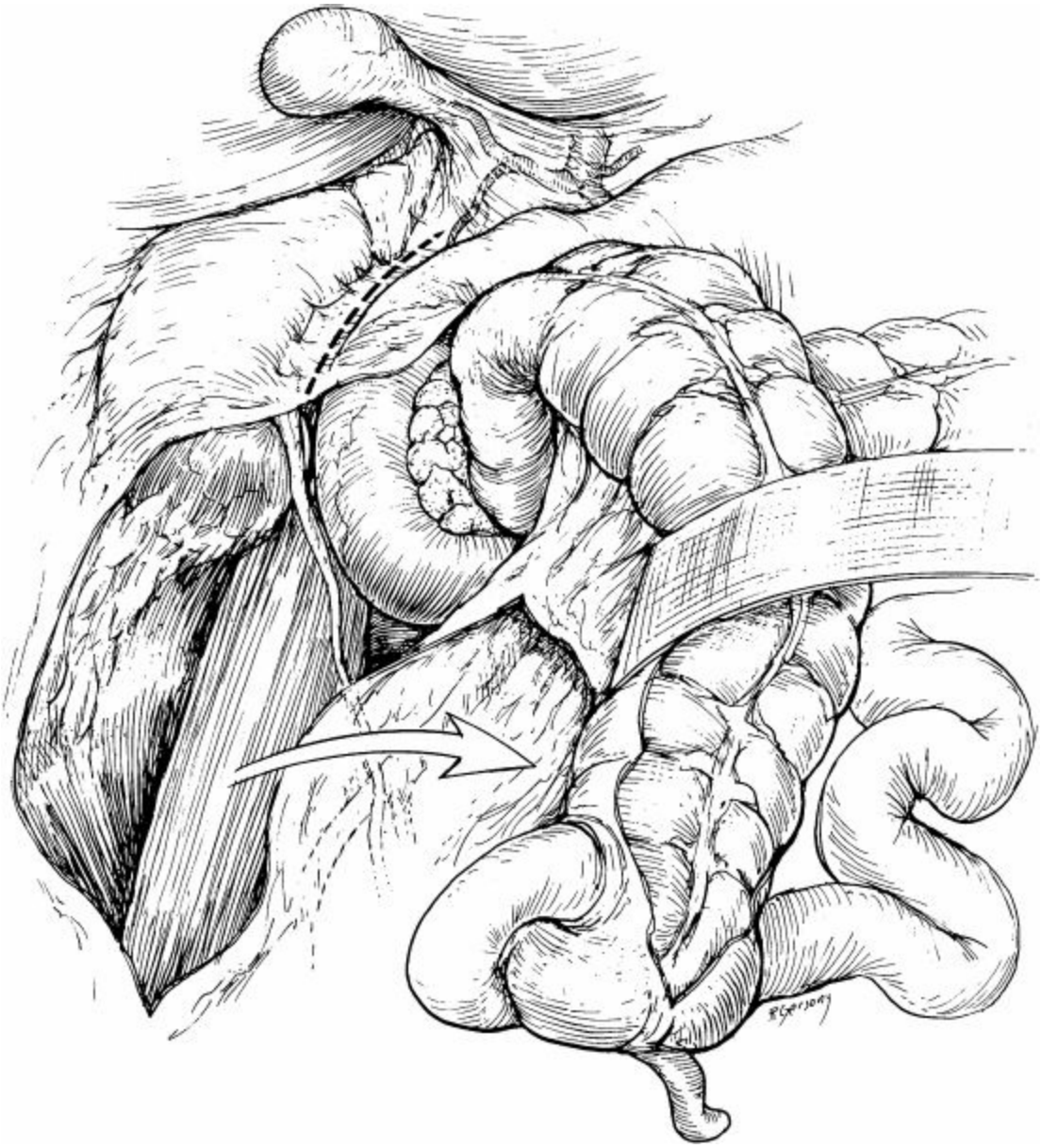

Figure 216.4. With the right colon mobilized medially, a Kocher maneuver exposes the right renal hilum. (Reprinted from Benjamin ME, Dean RH. Techniques in renal artery reconstruction: part I. *Ann Vasc Surg* 1996;10(3):306–14, with permission from Elsevier.)

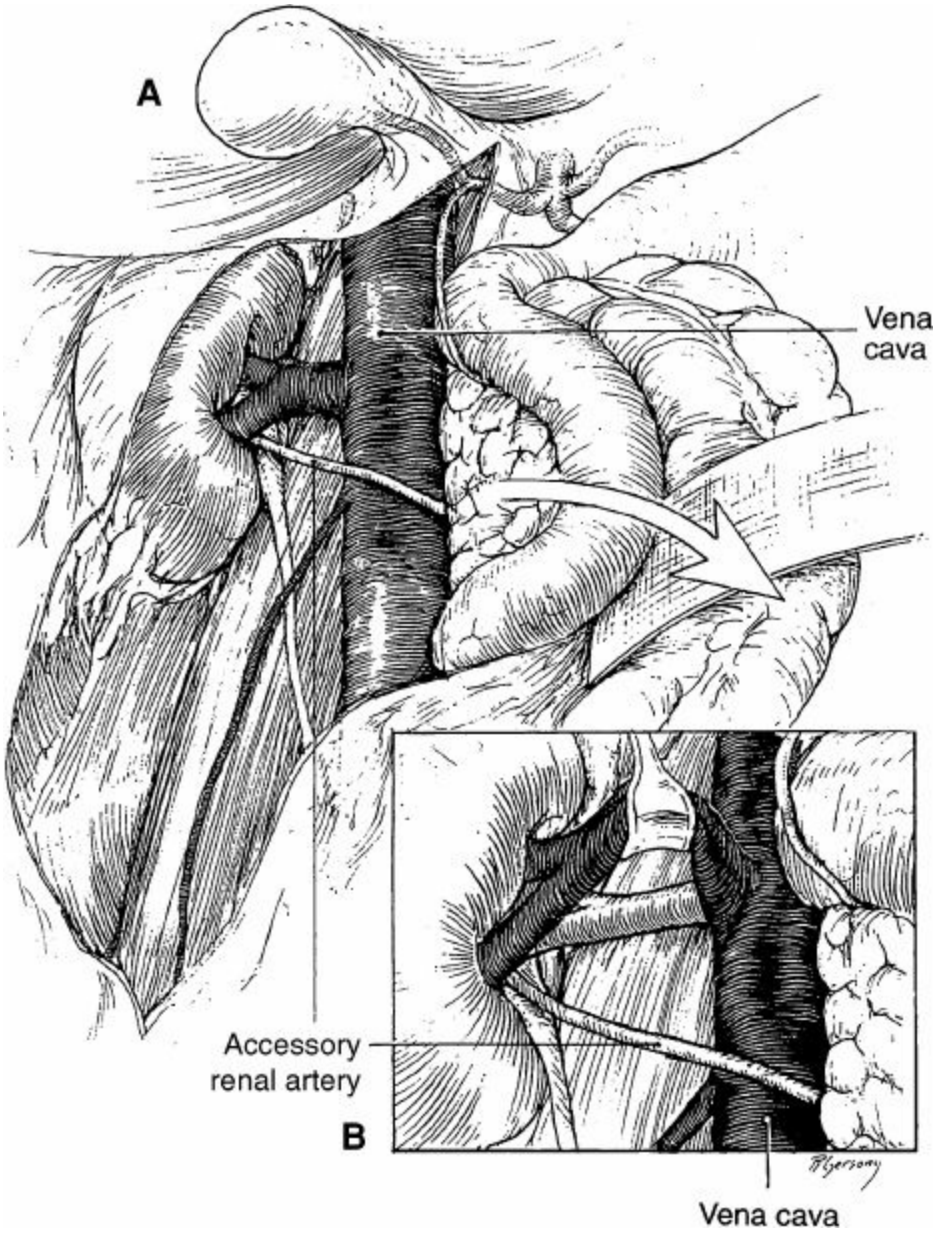

Figure 216.5. **A.** Not uncommonly, an accessory right renal artery arises from the anterior aorta and crosses anterior to the vena cava. **B.** The right renal vein is typically mobilized superiorly for exposure of the distal right renal artery. (Reprinted from Benjamin ME, Dean RH. Techniques in renal artery reconstruction: part I. *Ann Vasc Surg* 1996;10(3):306–14, with permission from Elsevier.)

Splanchnorenal Bypasses

Splanchnorenal bypasses have been used as an alternative method for renal revascularization. It is essential that the celiac axis and its branches be free of hemodynamically significant disease prior to reconstruction. In addition, significant compression during respiratory motion by the arcuate

ligament must be excluded. The exposure for a hepatorenal bypass is obtained through a right subcostal incision (Fig. 216.9). The common hepatic artery is exposed after incising the lesser omentum. A Kocher maneuver is performed to identify the inferior vena cava, the right renal vein, and the right renal artery (Fig. 216.10). A greater saphenous vein segment is ideally used to construct the bypass. The proximal anastomosis is made to the common hepatic artery in an end-to-side fashion with a continuous 6-0 polypropylene suture. The vein craft courses through the foramen of Winslow anterior to the vena cava. The distal renal artery anastomosis is constructed in an end-to-end fashion as described previously.

The splenorenal bypass is usually undertaken through a left subcostal incision. The splenic flexure of the colon is mobilized and the lateral attachments of the descending colon are transected and the dissection plane is carried just anteriorly to Gerota fascia to identify the left renal vein. This anatomic landmark serves as reference to identify the left renal artery. The inferior and lateral border of the pancreas is mobilized in order to expose the splenic artery (Fig. 216.11). In the majority of cases, the proximal most splenic artery is preferable as a point of inflow. Ideally, a greater saphenous vein segment is used to create a proximal end-to-side anastomosis to the splenic artery with a continuous 6-0 polypropylene suture. The distal anastomosis is made in an end-to-end fashion after spatulation of both the renal artery and the vein graft. Alternatively, the splenic artery may be divided in its proximal portion and sewn in an end-to-end fashion to the renal artery avoiding the need for a conduit. Rarely, the left renal artery is redundant and can be reimplanted into the splenic artery.

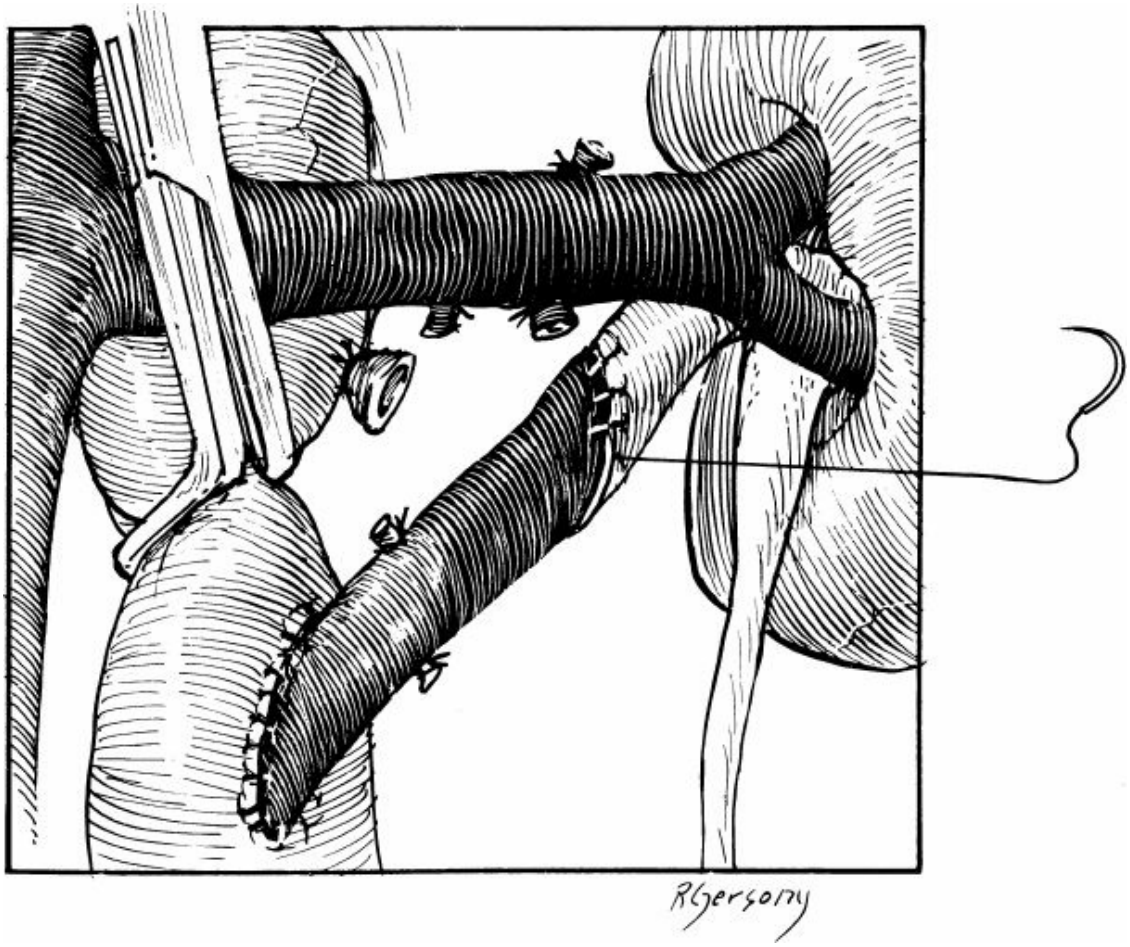

Figure 216.6. Technique for end-to-end aortorenal bypass grafting. The length of arteriotomy is at least three times the diameter of the artery to prevent recurrent anastomotic stenosis. For the anastomosis, 6-0 or 7-0 monofilament polypropylene sutures are used in continuous fashion, under loupe magnification. If the apex sutures are placed too deeply or with excess advancement, stenosis can be created, posing a risk of late graft thrombosis. (Reprinted from Benjamin ME, Dean RH. Techniques in renal artery reconstruction: part I. *Ann Vasc Surg* 1996;10(3):306–14, with permission from Elsevier.)

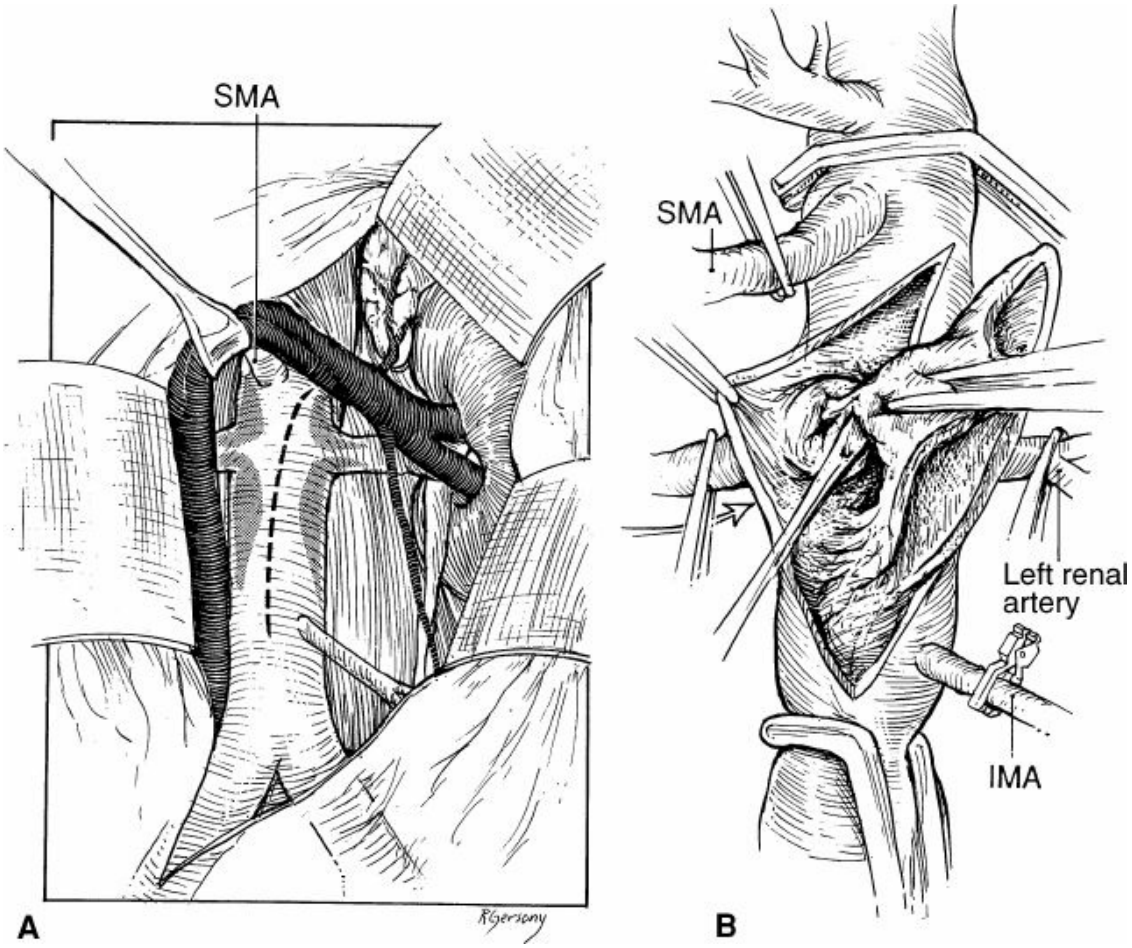

Figure 216.7. Exposure for a longitudinal transaortic endarterectomy is through the standard transperitoneal approach. The duodenum is mobilized from the aorta laterally in standard fashion or, for more complete exposure, the ascending colon and small bowel are mobilized. **A.** *Dotted line* shows the location of the aortotomy. SMA, superior mesenteric artery. **B.** The plaque is transected proximally and distally, and with eversion of the renal arteries, the atherosclerotic plaque is removed from each renal ostium. The aortotomy is typically closed with a running 4-0 or 5-0 polypropylene suture. IMA, inferior mesenteric artery. (Reprinted from Benjamin ME, Dean RH. Techniques in renal artery reconstruction: part I. *Ann Vasc Surg* 1996;10(3):306–14, with permission from Elsevier.)

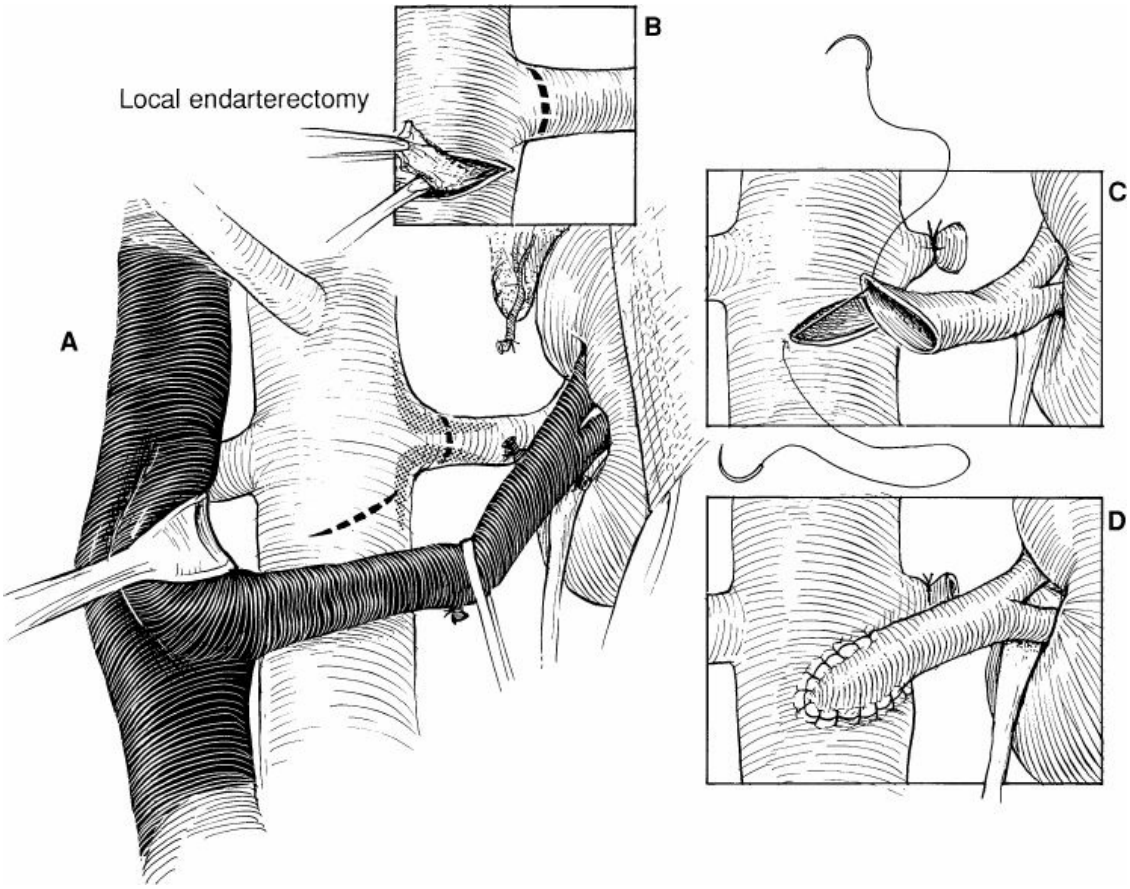

Figure 216.8. When the renal artery is redundant and the disease orificial, the vessel usually can be reimplanted at a lower level (**A**). Local endarterectomy (**B**) allows for placement of the monofilament suture in the aortic wall (**C**). The native renal artery is then ligated, proximally spatulated, and reimplanted (**D**). (Reprinted from Benjamin ME, Dean RH. Techniques in renal artery reconstruction: part I. *Ann Vasc Surg* 1996;10(3):306–14, with permission from Elsevier.)

Ex Vivo Reconstruction

Ex vivo reconstruction should be considered when satisfactory exposure of the distal renal artery and its branches is inadequate or if warm ischemia is projected to be >40 minutes due to the technical complexities of repair. When undertaking this approach, measures to provide protection to the kidney should be employed. Cold perfusion preservation of the kidney, including topical ice slush, can be used to safely extend the ischemic period. This technique is increasingly being used in management of failed endovascular stent placement in which endoluminal stents have been placed into the distal most renal artery and its branches. An ex vivo reconstruction is also employed in management of renal artery aneurysms involving the renal artery branches.

When a branch renal artery reconstruction is planned, the kidney is exposed through an ipsilateral flank incision (Fig. 216.12). The ureter is mobilized to the pelvic brim, but care is taken not to skeletonize it by preserving the periureteric retroperitoneal tissue. At this location, the ureter is looped with an elastic sling. This controls renal perfusion from periureteric collateral present when significant occlusive disease involves the main renal artery. The kidney is mobilized from Gerota space after the fascia is opened anteriorly in cruciate fashion. The kidney is then completely mobilized within the avascular plane of Gerota space. The key to this portion of the procedure is early mobilization of the superior pole of the kidney, which facilitates the remainder of the dissection. The renal artery and renal vein are mobilized in their entirety, and systemic anticoagulation with intravenous heparin is achieved.

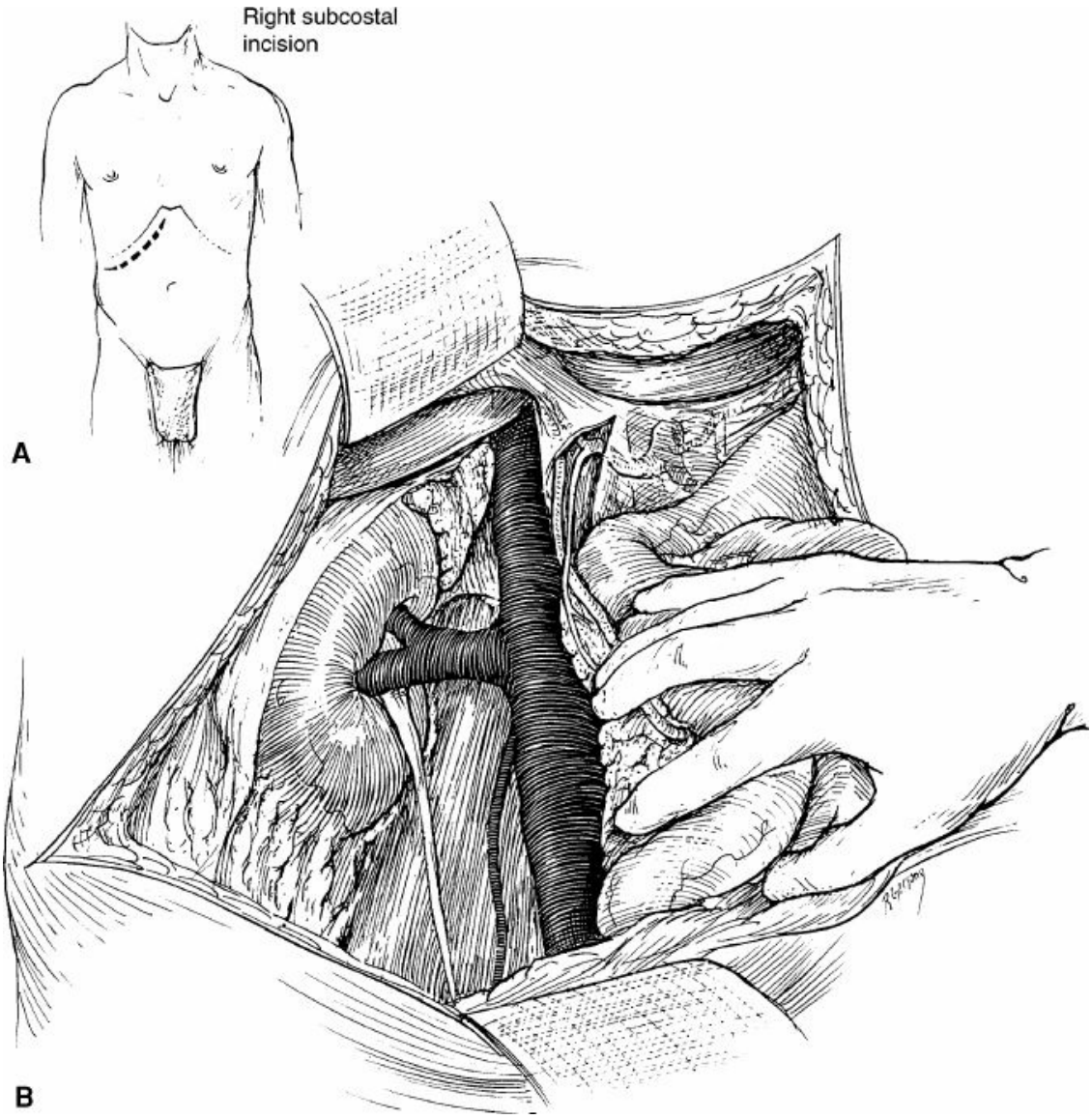

Figure 216.9. A, B. In preparation for extra-anatomic reconstruction of the right renal artery, the common hepatic artery and the proximal gastroduodenal artery are exposed in the hepatoduodenal ligament. Exposure would typically be through a right subcostal skin incision. (Reprinted from Benjamin ME, Dean RH. Techniques in renal artery reconstruction: part I. *Ann Vasc Surg* 1996;10(3):306–14, with permission from Elsevier.)

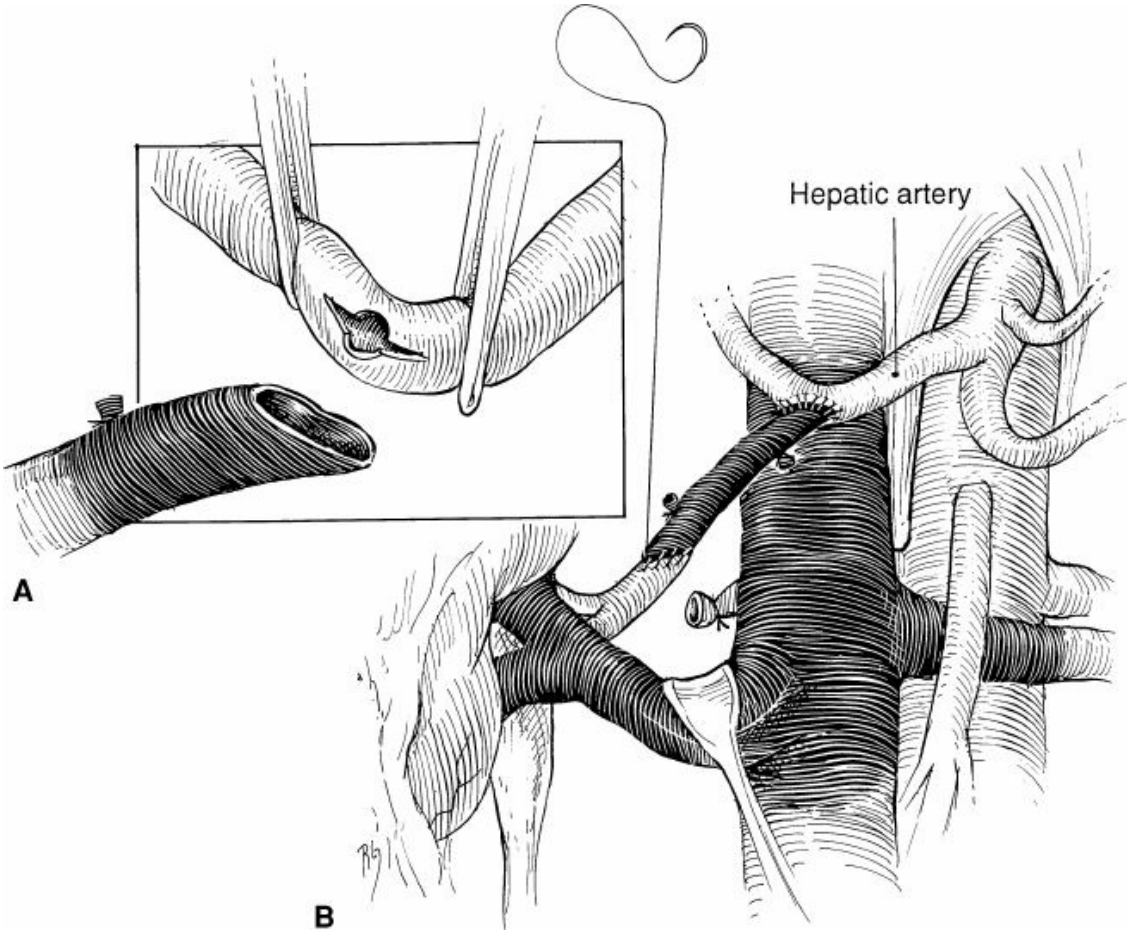

Figure 216.10. The reconstruction is completed using a saphenous vein interposition graft between the side of the hepatic artery (**A**) and the distal end of the transected right renal artery (**B**). (Reprinted from Benjamin ME, Dean RH. Techniques in renal artery reconstruction: part I. *Ann Vasc Surg* 1996;10(3):306–14, with permission from Elsevier.)

When arterial exposure is satisfactory, the renal vein may be left intact but controlled with an atraumatic clamp. A small venotomy is made and the kidney is perfused using a chilled (5°C) solution with an intracellular composition. This should be held at a height of approximately 1 to 2m above the operating table. If arterial exposure is insufficient with the vein

intact, a partial occluding clamp is placed at the caval origin and the vein is divided with a caval cuff. In either instance, the kidney is perfused with 300 to 500 mL of chilled perfusate and placed on a plastic sheet covered with ice slush. Only the vascular hilum is exposed while the remainder of the kidney remains surrounded by ice slush to serve as a supplement to cold perfusion. The aortorenal anastomosis is performed at an infrarenal level as previously described. When the vein is divided, the kidney is returned to the renal fossa after arterial reconstruction. The venous anastomosis is created at its original site. Autotransplantation is not usually necessary. A semicontinous 6-0 polypropylene suture is used to avoid constriction of the venous anastomosis.

Intraoperative Assessment

The short course and high blood flow rates of direct aortorenal reconstructions favor their patency. A flawless technique plays a dominant role in determining postoperative patency of repair. Regardless of the method of reconstruction, each renal artery repair is assessed with intraoperative duplex sonography. The operative site is filled with warm saline. A 18 MHz compact linear array probe with Doppler color flow imaging designed for intraoperative assessment is placed within a sterile sheath with the latex tip containing the sterile gel. A B-scan image is obtained at all sites of aortic control and vascular reconstruction. These sites are imaged in both longitudinal and transverse projection. Doppler samples are obtained proximal and distal to B scan lesions in longitudinal projection to determine their hemodynamic significance. Focal increases in renal artery PSV of >1.8 m/sec associated with distal turbulent wave form are considered major defects, and these are revised immediately. In more than 1,300 renal artery reconstructions, major B scan defects requiring immediate revision have been observed in 10% to 12% of cases. A disproportionate number of these defects occur after transaortic renal endarterectomy

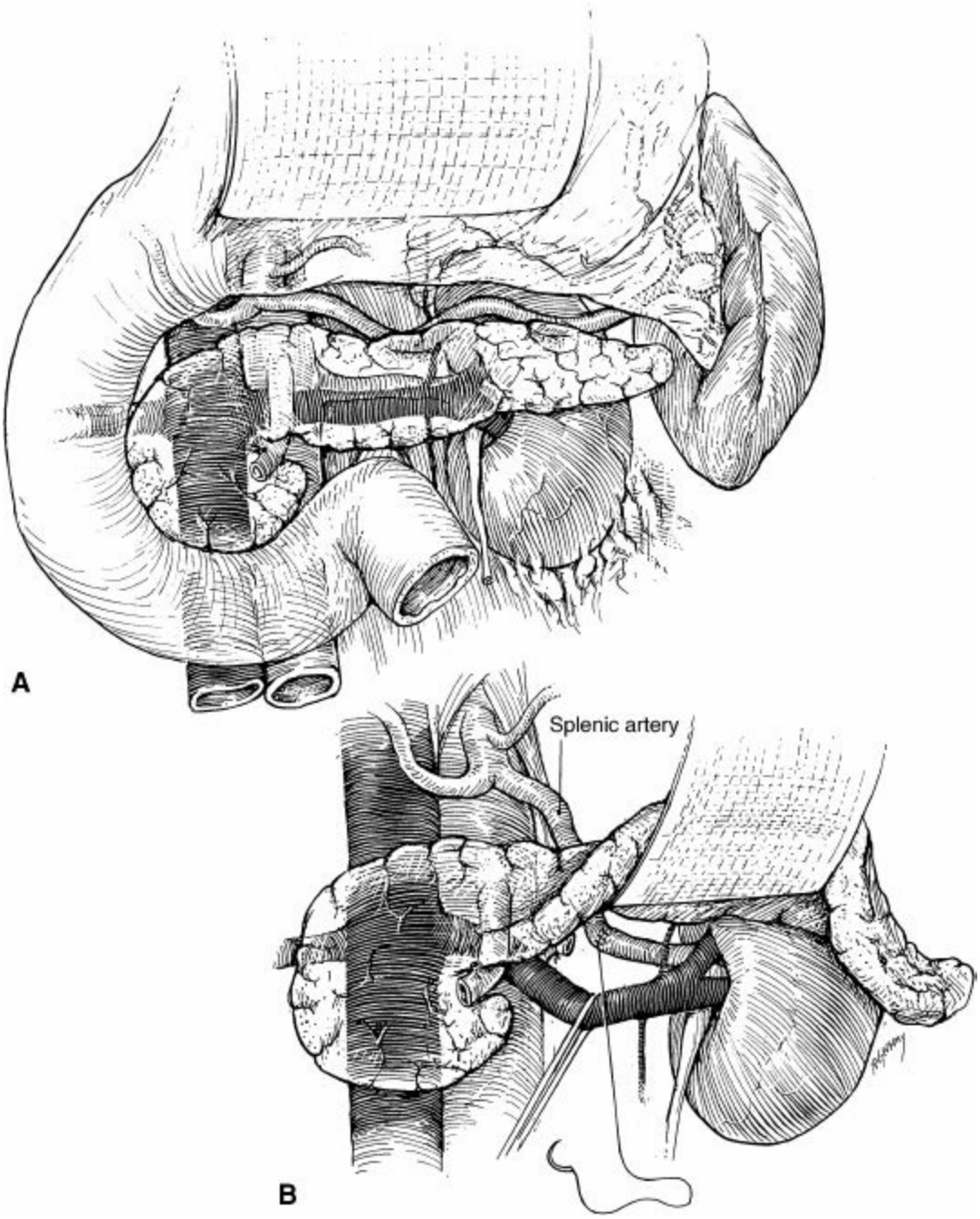

Figure 216.11. A. Exposure of the left renal hilum in preparation for splenorenal bypass. The pancreas has been mobilized along its inferior margin and retracted superiorly. **B.** The transected splenic artery is anastomosed end-to-end to the transected left renal artery. A splenectomy is not routinely performed. (Reprinted from Benjamin ME, Dean RH. Techniques in renal artery reconstruction: part I. *Ann Vasc Surg* 1996;10(3):306–14, with permission from Elsevier.)

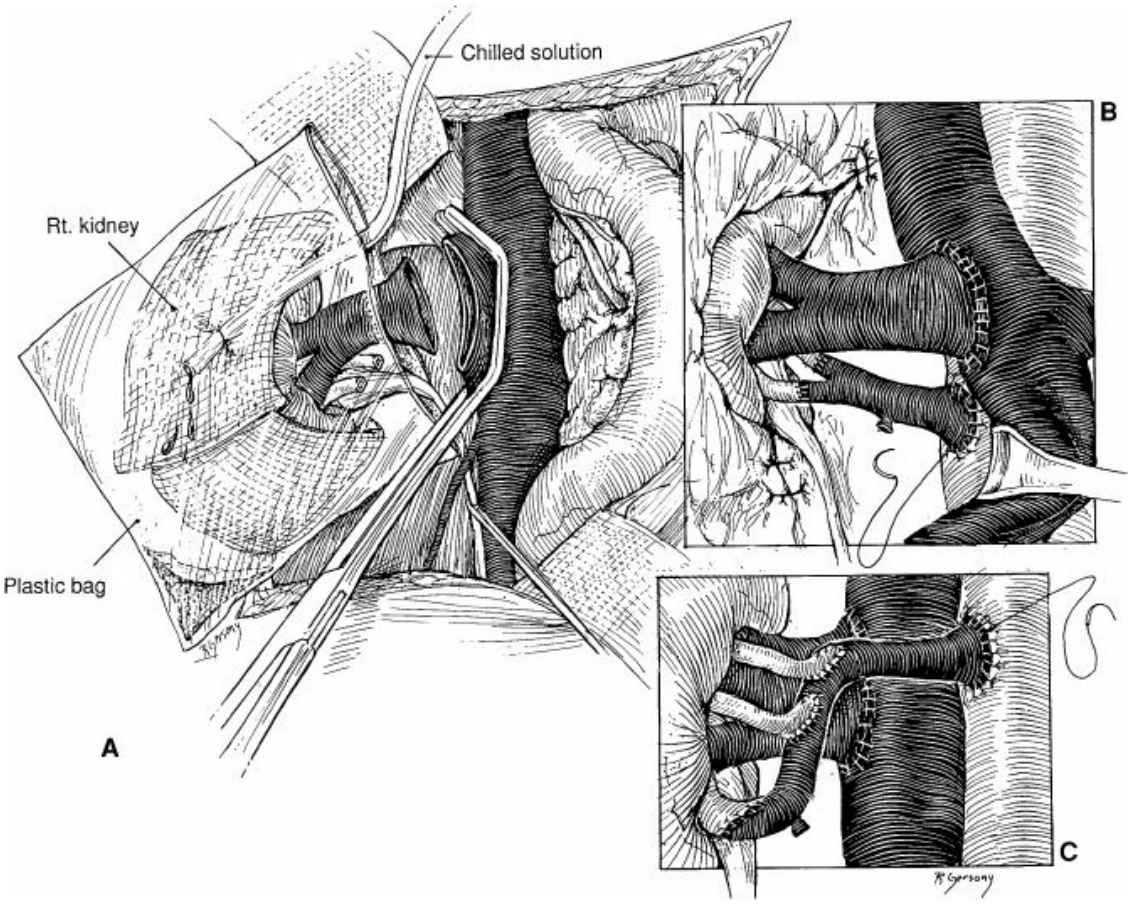

Figure 216.12. A. An ellipse of the vena cava containing the renal vein origin is excised by placement of a large partially occluding clamp. After ex vivo branch repair, the renal vein can then be reattached without risk of anastomotic stricture. **B.** The kidney is repositioned in its native bed after ex vivo repair. Gerota fascia is reattached to provide stability to the replaced kidney. **C.** Arterial reconstruction can be accomplished via end-to-end anastomoses (as in **B**) or occasionally with a combination of end-to-end and end-to-side anastomoses. (Reprinted from Benjamin ME, Dean RH. Techniques in renal artery reconstruction: part I. *Ann Vasc Surg* 1996;10(3):306–14, with permission from Elsevier.)

RESULTS OF RENAL ARTERY INTERVENTION AND OUTCOMES

Open renal artery reconstruction has proven anatomic durability in the treatment of renovascular hypertension and renovascular renal insufficiency (i.e., ischemic nephropathy). However, the morbidity and mortality associated with open reconstruction have favored the application of percutaneous transluminal angioplasty and endoluminal stent placement

(PTAS). Although the hypertension and renal function benefit of PTAS is less well documented than open surgical repair, the procedure offers the benefit of decreased morbidity and mortality, reduced hospitalization, and brief recovery time. These benefits are countered by increased rates of restenosis and a lack of level 1 evidence demonstrating any improved event-free survival after PTAS. Indeed recent randomized trials have demonstrated no benefit in reduction of hypertension or renal insufficiency with PTAS.

Morbidity and mortality associated with open surgical reconstruction for atherosclerotic renovascular disease vary with the patient's age, associated renal insufficiency, left ventricular cardiac performance, and magnitude of the operation. Large contemporary series have demonstrated perioperative mortality <1% for unilateral renal artery reconstruction in good risk patients compared with more than 7% perioperative mortality in patients of advanced age, requiring complex reconstruction for excretory renal insufficiency. These same series suggest that when open operations are undertaken in patients with severe hypertension, a blood pressure benefit (hypertension cured or improved) is observed in 85% of patients. In patients with severe hypertension associated with excretory renal insufficiency, 60% have demonstrated >20% improvement in glomerular infiltration rate after open operation. When direct aortorenal methods of reconstruction are used in combination with intraoperative duplex sonography, 97% of repairs should demonstrate primary patency at 10 years. Recurrent stenosis or occlusion after open repair has demonstrated significant and independent associations with eventual dialysis dependence.

TABLE 216.1 Results After Primary Renal Artery Stent Placement for Atherosclerotic Renal Artery Stenosis

References	Patients (n)	Technical Success (%)	Patients With Renal Dysfunction (n)	Renal Function Response (%)			Hypertension Response (%)			Restenosis (%)	Major Complications (%)
				Improved	Unchanged	Worsened	Cured	Improved	Failed		
Rees CR (1991)	28	96	14	36	36	29	11	5	36	39	18
Kuhn FP (1991)	8	92	NR	NR	NR	NR	22	34	44	17	13
Joffre F (1992)	11	91	4	50	50	0	27	64	9	18	13
Hennequin LM (1994)	15	100	6	20	40	40	7	93	0	27	19
MacLeod M (1995)	28	100	16	25	75		0	40	60	17	19
van de Ven PJG (1995)	24	100	NR	33	58	8	0	73	27	13	13
Dorros G (1995)	76	100	29	28	28	45	6	46	48	25	11
Henry M (1996)	55	100	10	20	80		18	57	24	9	3
Iannone LA (1996)	63	99	29	36	46	18	4	35	61	14	32
Harden PN (1997)	32	100	32	35	35	29	NR	NR	NR	13	19
Blum U (1997)	68	100	20	0	100	0	16	62	22	17	0
Boisclair C (1997)	33	100	17	41	35	24	6	61	33	0	21
Rundback JH (1998)	45	94	45	18	53	30	NR	NR	NR	26	9
Fiala LA (1998)	21	95	9	0	100	0	53		47	65	19
Dorros G (1998)	163	99	63	No change in mean SCr			1	42	57	NR	14
Tuttle KR (1998)	120	98	74	16	75	9	2	46	52	14	4
Gross CM (1998)	30	100	12	55	27	18	0	69	31	13	NR
Henry M (1999)	200	99	48	29	67	2	19	61	20	11	2

Rodriguez-Lopez JA (1999)	108	98	32	No change in mean SCr			13	55	32	26	12
van de Ven PJ (1999)	40	88	29	17	55	28	15	43	42	14	30
Baumgartner I (2000)	64	95	NR	33	42	25	43		57	28	9
Giroux (2000)	30	95	21	76		24	53		47	NR	NR
Lederman (2001)	300	100	111	8	78	14	70		30	21	2
Bush (2001)	73	89	50	23	51	26	NR	NR	NR	NR	9
Zeller (2004)	456	98	239	34	39	27	46		54	NR	NR
Nolan (2005)	82	95	38	23	53	24		81	19	95	6
Galaria (2005)	147	98	21	97		3	84	16	21	5	
Holden (2006)	63	NR	63	25	36	3	0	55	45	8	NR
Ovrehus (2007)	122	NR	NR	13	59	28	13	72	15	7	3
Kahyap (2007)	125	95	125	42	25	33	NR	NR	NR	8	2
Arthurs (2007)	18	100	9	No change in mean SCr			0	6	94	17	0
Corriere (2008)	99	95	74	28	65	7	1	21	78	NR	5
Davies (2009)	315	95	44	10	82	10	7	44	49	15	0
Balzer (2009)	22	90	NR	No change in mean SCr			9	61	26	35	13
ASTRAL (2009)	403	95	302	No difference compared to medical therapy			No difference compared to medical therapy			NR	7
Totals	3,487	97	1,586	23	48	16	15	52	39	22	11

NR, not reported; SCr, serum creatinine.

Table 216.1 summarizes the technical success, renal function and blood pressure response, restenosis rate, and rate of major complications from 25 reports after PTAS for atherosclerotic renovascular disease. Overall, 98% of procedures were technically successful. Blood pressure benefit was observed in 61% and renal function was improved in 22% of patients with ischemic nephropathy. Among those studies with objective measures of patency, recurrent stenosis was noted in 19% with major periprocedural complications in 9%. It is important to recall that PTAS has not been shown to reduce the occurrence of subsequent adverse cardiovascular events, renal events, or mortality in large clinical trials. This creates the present controversy currently surrounding this topic and provides grounds for further avenues of study.

Suggested Readings

ASTRAL Investigators; Wheatley K, Ives N, Gray R, et al. Revascularization versus medical therapy for renal-artery stenosis. *N Engl J Med* 2009;361(20):1953–62.

Cherr GS, Hansen KJ, Craven TE, et al. Surgical management of atherosclerotic renovascular disease. *J Vasc Surg* 2002;35(2):236–45.

Cooper CJ, Murphy TP, Cutlip DE, et al. Stenting and medical therapy for atherosclerotic renal artery stenosis. *N Engl J Med* 2014;370(1):13–22.

Edwards MS, Corriere MA. Contemporary management of atherosclerotic renovascular disease. *J Vasc Surg* 2009;50(5):1197–210.

Hansen KJ, Cherr GS, Craven TE, et al. Management of ischemic nephropathy: dialysis-free survival after surgical repair. *J Vasc Surg* 2000;32(3):472–81.

Marone LK, Clouse WD, Dorer DJ, et al. Preservation of renal function with surgical revascularization in patients with atherosclerotic renovascular disease. *J*

Vasc Surg 2004;39(2):322–9.

EDITOR'S COMMENT

In the peak of open vascular surgery, renal artery reconstructions were one of the most common operations performed. Multiple sophisticated diagnostic studies were developed and used, including invasive procedures such as renal vein renin sampling, to confirm that renal artery stenosis (RAS) was leading to renovascular hypertension. Creative surgeons, like the groups from Wake Forest University headed by Dr. Dean and the group from the University of Michigan headed by Dr. Stanley, were able to offer patients bypasses, reimplantations, and thromboendarterectomies to often cure renovascular hypertension secondary to RAS. Fortunately, two major developments occurred over the last 20 years to make renal artery stenting/surgery for RAS leading to renovascular hypertension almost a thing of the past.

First, renal artery stenting exploded in the treatment of renal artery stenosis, not necessarily in the treatment of renovascular hypertension. We documented back in 2004 using a large nationally representative database from 1998 to 2001, that combined aortic and renal, as well as isolated renal revascularizations, decreased by 73% and 56%, respectively (Knipp BS, Dimick JB, Eliason JL, et al. Diffusion of new technology for the treatment of renovascular hypertension in the United States: surgical revascularization versus catheter-based therapy, 1988–2001. *J Vasc Surg* 2004;40(4):717–23). During this same time period, the number of catheter-based procedures exploded by 173%. "Drive by" renal artery stenting for renal artery stenosis was rampant for even moderate <60% renal artery stenosis. Renal artery stenting became so widespread with such large expenditures in the setting of no real increase in the diagnosis of renovascular hypertension that multiple randomized controlled trials were performed to sort out whether renal artery stenting really impacted the natural history of the disease.

While none of the renal artery stenting trials were really ever compared with surgery, they have for the most part showed noninferiority of medical therapy alone compared with renal artery stenting and medical therapy. The best of the trials in my opinion was the so-called CORAL trial (Cooper CJ, Murphy TP, Cutlip DE, et al.; CORAL Investigators. Stenting and medical therapy for atherosclerotic renal-artery stenosis. *N Engl J Med* 2014;370(1):13–22). The authors randomized 947 patients who had atherosclerotic RAS (defined by multiple and various methods, and not always severe RAS), systolic hypertension, and were taking two more blood pressure medications. Over a median follow-up of 43 months, the rate of the primary composite end point did not differ between the stented group (and best medical therapy) and best medical therapy group. During follow-up, there was a consistent difference in systolic blood pressure favoring the stent group. However, in long-term follow-

up, renal artery stenting did not confer benefit in relation to clinical events when added to best medical therapy. Which brings me around to my second point relevant to renal artery stenosis from atherosclerosis and associated with renovascular hypertension; namely, that the pharmacologic therapies improved significantly over time with entire new classes of medications, including direct renin inhibitors, now available.

As with everything, let's not throw out the baby with the bath water (i.e., there are still some surgical indications for isolated renal artery surgery or endovascular approaches). Clearly, patients with fibromuscular dysplasia (FMD) benefit from percutaneous angioplasty. In addition, pediatric patients with renal artery stenosis are much better treated with surgery (Stanley JC, Criado E, Upchurch GR Jr, et al.; Michigan Pediatric Renovascular Group, Kershaw DB, Williams DM, Berguer R, et al. Pediatric renovascular hypertension: 132 primary and 30 secondary operations in 97 children. *J Vasc Surg* 2006;44(6):1219–28; discussion 1228–9) rather than an endovascular approach. In fact, multiple people have tried treating pediatric renovascular hypertension with stenting with pretty woeful results (Eliason JL, Coleman DM, Criado E, et al. Remedial operations for failed endovascular therapy of 32 renal artery stenoses in 24 children. *Pediatr Nephrol* 2016;31(5):809–17) even though stenting may be indicated when the child is extremely young (and small) or to aid in getting a child through a hypertensive emergency.

Finally, most of the renal artery surgery we do now in my practice is associated with thoracoabdominal aortic aneurysm (TAAA) repair. While the situations are not exactly parallel, talking about renal artery surgery associated with TAAA is sort of like talking about results from combined CABG and carotid endarterectomy versus carotid endarterectomy alone. The operations are really not the same as doing a bypass for renal artery stenosis secondary to atherosclerosis with the renal artery bypass always playing second fiddle to repairing the TAAA. On the other hand, at least the trainees get to expose and sew to the renal artery.

Gilbert R. Upchurch

217 Acute Mesenteric Artery Ischemia: Open and Endovascular

James T. McPhee, Edward Kelly, and C. Keith Ozaki

ETIOLOGY AND PATHOPHYSIOLOGY

Management of the patient facing life-threatening acute mesenteric ischemia maximally challenges the intellectual, technical, clinical, and team leadership skills of the surgeon. Several pathologic mechanisms can result in acute mesenteric ischemic syndromes, including embolism to the superior mesenteric artery (SMA), mesenteric arterial thrombosis (e.g., acute thrombosis of a chronic SMA atherosclerotic lesion), arterial dissections, low-flow nonocclusive mesenteric ischemia (usually with splanchnic vasoconstriction), and mesenteric venous thrombosis. The heart stands as the most common source for emboli, and cardiac pathologies that predispose to thrombus formation include atrial fibrillation (especially in patients with anatomic abnormalities, such as atrial dilation who are not anticoagulated or are underanticoagulated), recent myocardial infarction with mural thrombus formation, and ventricular aneurysm. SMA thromboembolism and acute-on-chronic thrombosis together account for the majority (~75%) of acute mesenteric ischemia cases.

The SMA serves as the primary supplier of blood to the bowel. Anatomically the SMA arises from the anterior aorta typically 1 to 2 cm below the celiac artery, and 1 to 2 cm cephalad to the takeoff of the renal arteries. It usually originates at the level of the first lumbar vertebral body and passes inferiorly and to the right, posterior to the pancreas, and anterior to the fourth portion of the duodenum. This blood vessel, which in the adult is about the size of the fifth finger in diameter, supplies the distal duodenum, the small intestine, and the ascending and transverse colon. Early branches off of the SMA are the pancreaticoduodenal artery (which can serve as a major collateral network between the SMA and celiac axis in occlusive ostial lesions that develop slowly) and the middle colic artery. Since the blood vessel changes caliber with the takeoff of these early

branches, most clinically apparent emboli lodge near the origin of the middle colic, leading to ischemia from the proximal jejunum to the splenic flexure (Fig. 217.1). In 10% to 20% of the population, the right hepatic artery has a replaced origin from the SMA. The SMA terminates as the ileocolic artery. While acute occlusion of the celiac or the inferior mesenteric arteries is usually well tolerated, acute SMA occlusion produces widespread infarction throughout the small bowel and colon.

With abrupt cessation of SMA inflow, small intestinal ischemia rapidly initiates within the usually well-vascularized bowel mucosa, where epithelial and endothelial cell damage lowers mucosal barrier function, leading to bacterial invasion, susceptibility to degrading enzymes, microcirculatory stasis, edema, and intravascular thrombosis. Bacterial toxins and host-derived damage-associated molecular pattern (DAMP) molecules, such as cytokines and particles from cellular death, are released into the portal venous circulation and beyond, and drive systemic effects such as increased capillary permeability with edema formation and shock. Even after restoration of organ perfusion, the endothelial cell dysfunction often persists. The resultant ischemia–reperfusion syndrome drives distant multiple organ insufficiency or failure.

CLINICAL PRESENTATION

The key factor limiting clinical progress in lowering the high morbidity and mortality in acute mesenteric ischemia remains prompt diagnosis; thus, symptoms and signs require careful scrutiny. A key to diagnosis is a high index of clinical suspicion in high-risk patients, especially those with advanced age, cardiac dysrhythmias, recent myocardial infarction, valvular heart disease, congestive heart failure, systemic atherosclerosis, and hypercoagulable states, such as malignancy. Patients with acute mesenteric arterial occlusion typically note abrupt onset of severe, constant epigastric or midabdominal pain, followed soon after by defecation (sometimes diarrhea and/or rarely blood per rectum) and vomiting. The surgeon should also inquire about evidence of chronic symptoms such as postprandial cramping pain with “food fear,” change in bowel habits, and weight loss, since the distinction between acute versus acute-on-chronic disease may impact technical approaches to bowel revascularization. Finally, in the case of SMA embolization, approximately 25% of patients reveal a history of prior embolic events (cerebral, extremity, visceral, etc.).



Figure 217.1. CTA reconstruction showing lateral view of the abdomen. *Red arrow* points to filling defect in the distal superior mesenteric artery (SMA), corresponding to an embolus.

Physical findings in acute mesenteric thromboembolism can be subtle and nonspecific. The abdomen may be distended with diminished intestinal peristaltic sounds. Classically, abdominal tenderness is less than expected from the patient's complaints of severe pain. Document a thorough pulse examination to aid in subsequent bypass graft inflow artery selection or vessel cannulation. Bloody fluid may be retrieved from a nasogastric tube and on rectal examination. Later in the clinical course, as the bowel progresses to infarction, the patient will appear toxic, with shock and peritonitis.

Laboratory tests also yield little sensitivity and specificity. Notable findings may include a leukocytosis with a predominance of immature

white blood cells and a metabolic acidosis. D-dimer has been noted to have a high sensitivity for SMA occlusion, but the specificity of this test is low.

Plain roentgenograms are usually normal but occasionally demonstrate thickened intestinal walls, and in late stages gas in the intestinal wall, or in the portal vein or peritoneum. While emerging as a useful modality in chronic mesenteric occlusive disease, duplex is of limited benefit in the acute setting due to dilated, air-filled loops of bowel. In cases of diagnostic uncertainty and a clinically stable patient, thin-cut computed tomography (CT) scan with intravenous contrast screens for other pathologies. Relevant acute findings on CT scan include whether the contrast-filled SMA can be identified out to its peripheral branches, and bowel abnormalities such as segmental bowel wall thickening. The diagnosis of mesenteric venous obstruction (which is managed primarily with anticoagulation and nutritional support unless it has progressed to significant bowel complications) is made via CT scan—a “halo” or “target” sign can be identified in the superior mesenteric vein. Finally, magnetic resonance angiography can provide anatomic proximal mesenteric vasculature anatomy, although availability and timing limit this modality’s utility in most circumstances.

Visceral biplanar digital subtraction arteriography best defines mesenteric anatomic occlusive lesions. However, angiography is not mandatory, and can result in revascularization delays that adversely affect outcome. In addition to anterior-posterior views, a lateral view starting at the first lumbar artery can demonstrate the characteristic appearance of an embolus with a meniscus sign. Nonocclusive mesenteric ischemia (resulting from a depressed cardiac output and oxygen delivery) findings on angiogram include narrowing at the origin of branches of the SMA, spasm of arcade vessels, and impaired filling of intramural vessels. This syndrome is managed nonoperatively by intra-arterial instillation of dilating compounds (papaverine bolus dose of 60 mg directly into the SMA, followed by a constant infusion of 30 to 60 mg/h until the next angiogram) and correction of the underlying cause of impaired delivery.

INDICATIONS AND CONTRAINDICATIONS

In patients where there has been a clear intra-abdominal catastrophe (which is often the case with acute mesenteric ischemic), extensive laboratory and radiographic testing unnecessarily delays bowel

revascularization, leading to increased bowel loss and higher rates of patient mortality. Resuscitation must proceed expeditiously as the patient is prepared for emergency laparotomy. Surgeons may reasonably immediately move to operative exploration in patients presenting with classical history and physical findings with minimal laboratory testing and no preoperative imaging. That said, in most facilities with high acuity capabilities, a CT angiogram can be obtained within minutes and can greatly impact the approach to revascularization. Terse preoperative frank yet sensitive discussions with the patient and family can reinforce the life-threatening nature of acute mesenteric ischemia, and this may also serve as a time to introduce the concept of “inoperable” circumstances, such as massive bowel infarction. Determination of ischemic versus infarcted bowel remains difficult with currently available clinical and imaging tools, so exploration is most often necessary for assessment. With less dramatic clinical presentations, symptomatic acute mesenteric embolus or thrombosis diagnosed by way of the algorithms outlined above also usually warrants emergency exploration and bowel revascularization.

PREOPERATIVE PLANNING

The surgeon’s focus on timely clinical diagnosis, immediate laparotomy, and urgent bowel reperfusion via surgical interventions builds from the report of Klass from almost 60 years ago. Patients suffering acute SMA obstruction require multiple parallel interventions in preparation for the operating room. Yet none of these should stand as a rate-limiting step toward skin incision, since these patients can deteriorate rapidly and every minute of delay jeopardizes outcome. Upon diagnosis of acute mesenteric ischemia, the patient is systemically heparinized to minimize clot propagation. Activated clotting times (ACT) throughout the operative period ensures adequate systemic anticoagulation. Empiric broad spectrum antibiotics are commonly employed since many of these patients have early sepsis, and they additionally serve as some surgical wound prophylaxis (third-generation cephalosporin, such as ceftriaxone and metronidazole and in the penicillin-allergic patient a fluoroquinolone and metronidazole). Patients who are health care experienced (recent hospital/nursing home stay, regular visits to hemodialysis centers, etc.) should have their coverage tailored based on local antibiograms. As many of these patients are hypovolemic and have electrolyte abnormalities, fluid volume resuscitation is almost always indicated. Fluid infusion should be

targeted to clinical endpoints such as urinary output, skin turgor, and capillary refill; electrolyte abnormalities (especially hypokalemia, hypomagnesemia, and hypophosphatemia) should be corrected as resuscitation proceeds. There is ongoing debate over the optimal type of fluid to use for resuscitation. While the evidence does not support one type of fluid over another, it is best to keep in mind that no matter what type of fluid is used, the clinical response to resuscitation should be closely monitored to prevent both underresuscitation (which can lead to organ failure) and overresuscitation (which can stress the heart and lungs and precipitate myocardial ischemia). All available personnel should work in parallel to place hemodynamic monitors such as arterial lines, secure venous access, a Foley catheter, and a nasogastric tube. Simultaneously, the status of lower extremity pulses is again documented since this patient subset often holds risk factors for lower extremity occlusive disease and may have embolized to the lower extremity arteries.

When endovascular approaches may be a component of the care plan, then an appropriate operating room table and equipment are secured. In a warmed operating room, the patient is prepped from the nipples to the toes bilaterally since veins may be required for patch or conduit (a large greater saphenous vein or the femoral vein functions well for bypass conduit in the setting of peritoneal contamination from gastrointestinal contents). Once the airway is secured, intraoperative transesophageal echocardiogram can assess volume status and ventricular function, and delineate cardiac anatomic abnormalities that may predispose to clot formation and embolization.

SURGICAL TECHNIQUE—OPEN

Typically the incision is made from the xiphoid bone to the pubis in the midline. Gangrenous or perforated bowel is immediately resected or oversewn to reduce soilage. It must be emphasized that intestinal resection alone is not acceptable therapy when ischemic or infarcted bowel is found at laparotomy, and a systematic interrogation into the potential cause of the bowel loss must be conducted. The pattern of ischemia is important to establishing diagnosis. Vascular compromise of the entire jejunum, ileum, and portions of colon stands as the hallmark of SMA occlusion at the origin. With an embolus to the SMA, there is often sparing of the first portion of jejunum due to some perfusion from the celiac branches via the pancreaticoduodenal artery. Patchy, segmental small bowel

ischemia/infarction is consistent with showers of emboli or the vasospasm associated with nonocclusive mesenteric ischemia.

If gut vascular compromise is suspected, steps are initiated to assess the cause of impaired blood supply. Tilt of the operating room table to the right helps keep the small bowel out of the surgical field, and self-retaining retractor systems such as the Bookwalter or Omni-Tract facilitate exposure. To evaluate the SMA, the omentum and transverse colon are lifted cephalad. All small bowel is then retracted to the right, and the sigmoid colon is packed to the left (Fig. 217.2). The ligament of Treitz and the superior attachments of the duodenum are then sharply divided, with the goal of mobilizing the last portion of the duodenum to the right. Then, with four fingers behind the small bowel mesentery and with the thumb anteriorly, the SMA should be palpable at the base of the transverse colon mesentery. This maneuver has been described as “shaking hands with the root of the mesentery.” If a pulse is palpable, then continuous-wave handheld Doppler is used to ensure that there is diastolic flow and not just a water hammer pulse proximal to an occlusion.

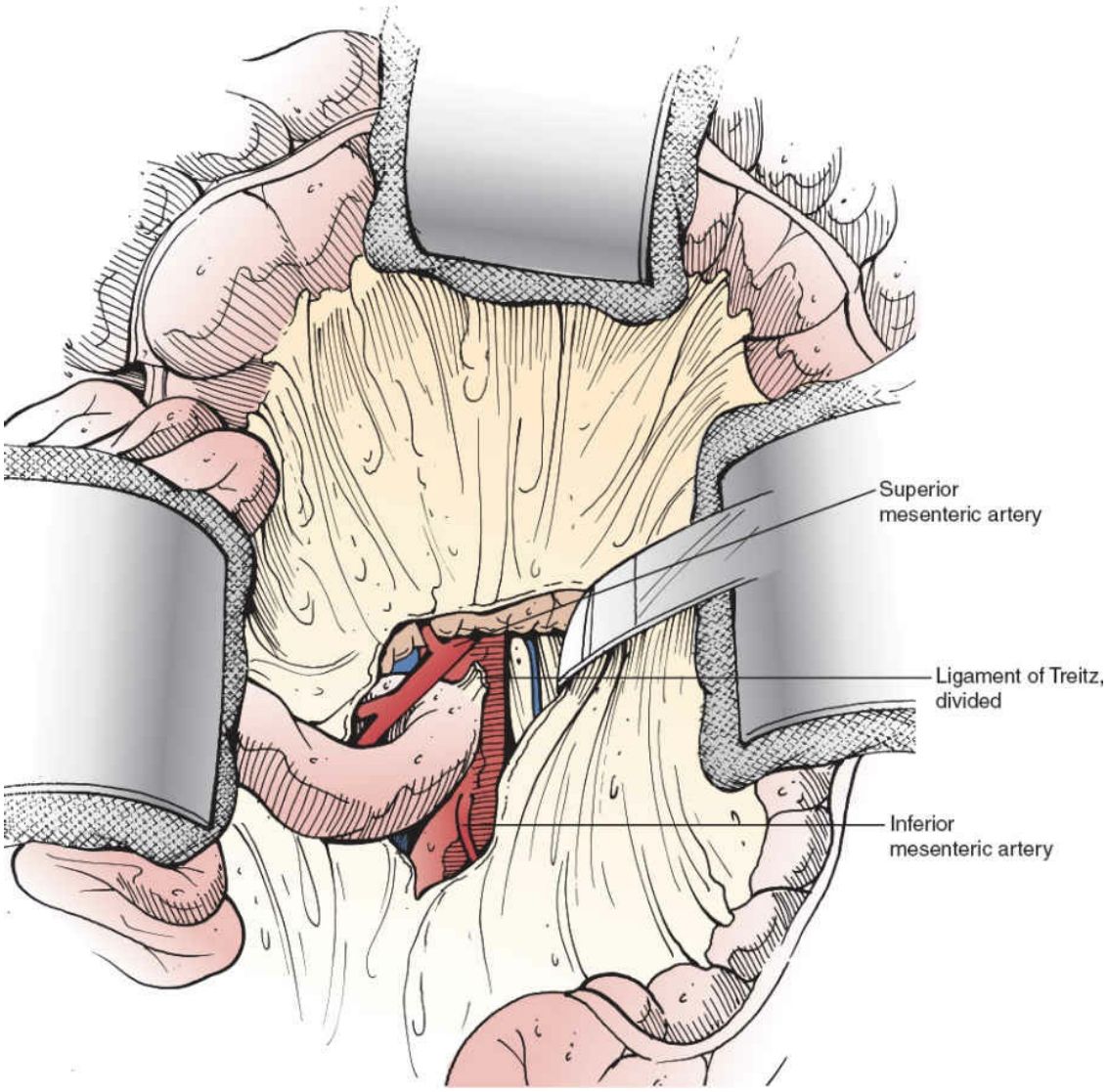

Figure 217.2. Exposure of the superior mesenteric artery (SMA) for embolectomy. The omentum and transverse colon are lifted cephalad. All small bowel is retracted to the right, and the sigmoid colon packed to the left. The ligament of Treitz and the superior attachments of the duodenum are sharply divided, with the goal of mobilizing the last portion of the duodenum to the right. Then, with four fingers behind the small bowel mesentery and with the thumb anteriorly, the SMA should be palpable near the base of the transverse colon mesentery.

If normal blood supply via the SMA cannot be confirmed via these algorithms, then the artery should be surgically exposed. Continuing the maneuvers above at the level of the transverse mesocolon base, the soft tissues overlying the artery are carefully dissected, including ligation of overlying small blood vessels, neural tissue, and lymphatics; and avoiding damage to the superior mesenteric vein, which usually lies to the right of

the SMA (Fig. 217.3). The SMA has a larger caliber proximal to the middle colic origin, making for technically easier arteriotomy. An approximately 3- to 4-cm length of artery is exposed and elastic vessel loops placed for proximal and distal control. If large in caliber and if an embolus is suspected, transverse arteriotomy offers the potential for simple closure. Conversely, if bypass for occlusive disease may be necessary (based on palpation of substantial atherosclerosis in the proximal SMA), the arteriotomy is best made longitudinally in the event that this site is needed as the distal anastomosis location for a bypass graft.

Open mechanical thrombectomy is completed using appropriately sized Fogarty balloon catheters passed proximally and distally. To minimize trauma, the devices are passed into the large portion of the SMA and pulled back gently until one pass retrieves no further clot material. Extreme care must be taken to avoid blood vessel disruption in the peripheral SMA branches, which are soft and small. The radial balloon force on the blood vessel wall can only be inferred by resistance (tactile feedback as the balloon is moved along the intima). Thus, the balloon should never be inflated while the catheter is stationary, but rather as it is withdrawn.

Assuming a normal-caliber vessel, a transverse arteriotomy is closed via a simple interrupted closure using double-armed monofilament sutures so that the intima is retacked up from within. Longitudinal arteriotomy usually requires a patch closure to prevent stenosis with the closure.

If adequate inflow is not attained with thromboembolectomy, then bypass grafting is appropriate (Fig. 217.4). In a recent report from Schermerhorn et al. on surgical revascularizations from 2000 to 2006 for acute mesenteric ischemia, embolectomy was utilized in 49% of cases and bypass in 44%. In the emergency setting externally supported prosthetic bypass conduits are reasonable, assuming there is no enterotomy or enterectomy. Woven fabrics such as Dacron have the largely theoretical added benefit of absorbing a concentrated rifampin solution in the case of very minor contamination. The common iliac arteries, infrarenal aorta, or supraceliac aorta (which tends to be spared from extensive atherosclerosis, though rarely appropriate for the acute setting) may serve as inflow sites for such a bypass. If frank bowel infarction has occurred, then autogenous conduit lessens the chance of infectious complications. Femoral vein serves as a durable bypass material; however is timely to expose and remove, and the conduit lies best with less opportunity for kinking if the

proximal anastomosis is completed at the supraceliac aorta, allowing for antegrade blood flow to the SMA. Because of more difficult exposure and longer dissection time in the often obese body habitus acute mesenteric ischemia patient, the supraceliac aorta should rarely be utilized for inflow in the emergency situation and the common iliac is preferred (retrograde). While revascularization of both the celiac and SMA stands as a standard in operations for chronic mesenteric ischemia, it is reasonable to limit the procedure to the SMA alone in the acute setting to minimize operative duration and trauma.

SURGICAL TECHNIQUE—ENDOVASCULAR

Endovascular approaches including angioplasty (with and without stenting) and thrombolysis (chemical and mechanical) are being used with increasing frequency for revascularization of acute mesenteric ischemia, though open explorations and repairs still predominate. It is emphasized that while less invasive endovascular approaches have substantially positively impacted patient care in many areas of vascular surgery, the role of such strategies in acute SMA embolism and thrombosis has not been well defined. While the results of reports to date summarily compare favorably with open surgical approaches, the small number of patients, enormous bias due to patient selection, and potential for reporting only cases with favorable outcomes limit the applicability of this literature to an evidence-based practice. Since thrombolysis often takes significant amounts of time to achieve end organ perfusion, the bowel may progress to infarction during treatment. Choice between an open versus endovascular first strategy requires thoughtful patient selection. The tenets of management of acute mesenteric ischemia remain revascularization and assessment of bowel in a timely fashion; therefore if any aspect of the endovascular technique will cause significant delay, then standard surgical approaches are preferred.

Technical experience with endovascular approaches to chronic mesenteric ischemia in conjunction with techniques from acute arterial occlusions in other vascular beds has allowed for the adoption of these techniques in the approach to acute mesenteric ischemia. A recent administrative-based national cohort study demonstrated a significant increase in the use of endovascular approaches for acute mesenteric ischemia, the rate of which increased from 11% in 2005 to 30% in 2009. Likewise, a recent institutional review from the Cleveland Clinic found

that an endovascular approach was technically successful 87% of the time when attempted. Compared with their open cohort, endovascular patients had significantly lower rates of mortality, abdominal exploration, and mean length of bowel resected.

Endovascular Access

Appropriate assessment of vascular access is prudent as many patients will have had prior procedures and may have occlusive disease in other beds. Bilateral upper and lower extremity pulse exams will help to inform the best site of vascular access for the intervention. In general, the approach to the mesenteric vasculature is with upper extremity access, as this allows for more favorable cannulation of the celiac as well as the SMA based on the natural contour of these vessels. However, femoral access is an acceptable choice for mesenteric interventions as well. As in other upper extremity cases, an appropriate pulse exam as well as bilateral blood pressure measurements should be performed to assess for subclinical supra-aortic arch branch vessel occlusive disease. Typically left-sided upper extremity access is preferred to minimize wire and catheter manipulation in the arch with its attendant risk of cerebrovascular embolization seen with traversing the cerebrovascular vessels with a right-sided approach.

Left brachial arterial access is achieved either percutaneously or via cutdown depending on patient factors, surgeon preference, and logistic considerations such as availability of a hybrid OR suite. Known risks of percutaneous brachial access include vessel thrombosis, brachial sheath hematoma, and pseudoaneurysm formation. Complication rates range from 3% to 15% depending on sheath size and indication for the procedure and typically require surgical correction when they occur. In the case of acute mesenteric ischemia, most of these patients will be systemically heparinized at the outset and throughout the duration of the procedure, which may have implications for percutaneous brachial access as well as planned sheath removal at the conclusion of the case. While the use of closure devices in the brachial artery has been described, more typically manual compression is employed.

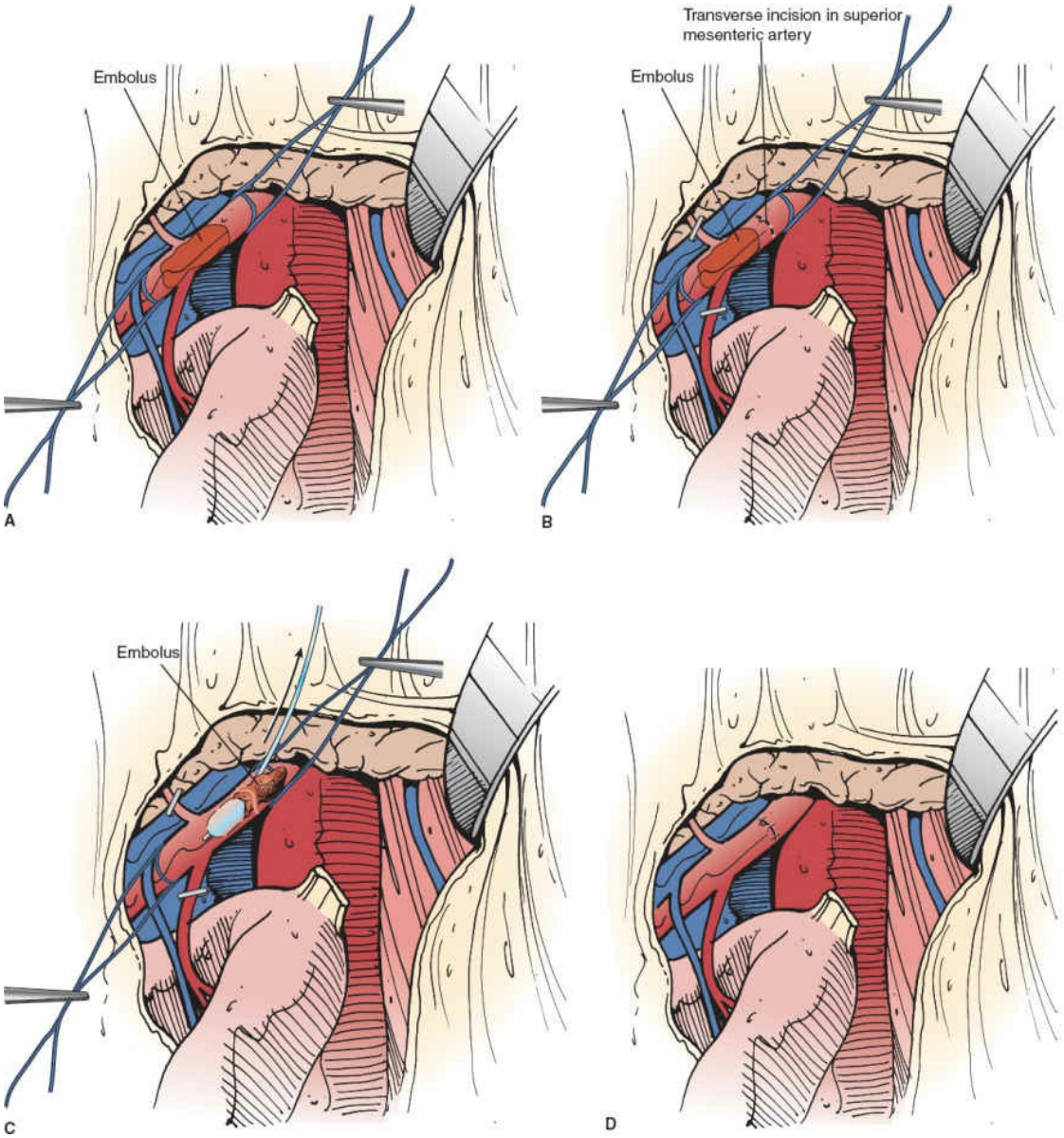

Figure 217.3. Technique of superior mesenteric artery (SMA) embolectomy using Fogarty balloon catheter. If normal blood supply via the SMA cannot be confirmed by palpation and Doppler examination, then the artery is surgically exposed, including ligation of overlying small blood vessels and lymphatics (**A**). If large in caliber and an embolus is suspected, transverse arteriotomy offers the potential for simple closure (**B**). Conversely, if small (will need patch angioplasty closure) or if bypass for occlusive disease is potentially necessary, then the arteriotomy is best made longitudinally in the event that this site is needed as the distal anastomosis site for a bypass graft. Mechanical thrombectomy is completed using Fogarty balloon catheters (**C**). The transverse arteriotomy is closed via simple interrupted closure using double-armed monofilament sutures so that the intima is retacked up from within (**D**).

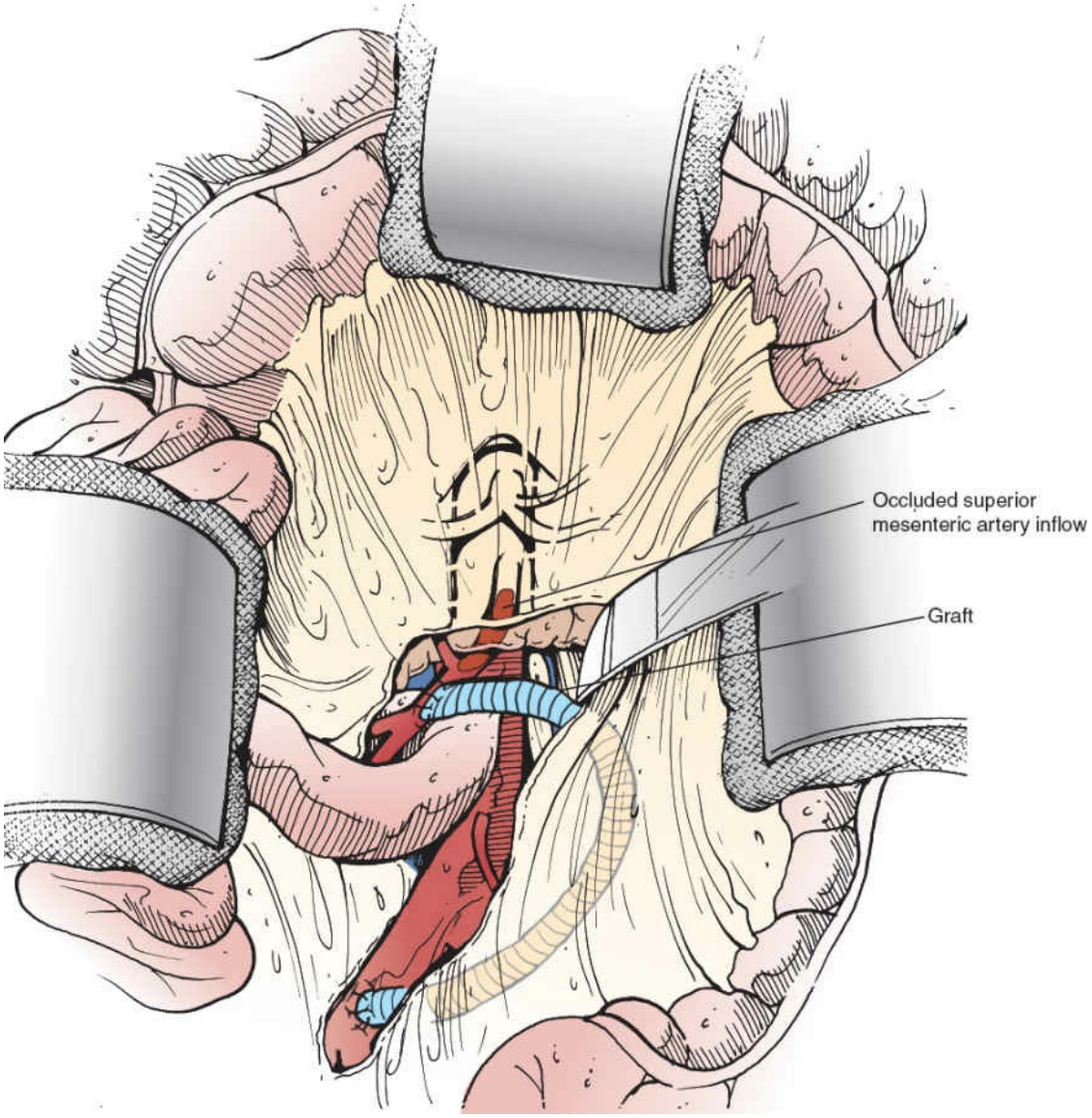

Figure 217.4. Bypass grafting for acute mesenteric ischemia, ileomesenteric as representative image.

Increasing experience with radial artery access has allowed for broadening of its use to include the mesenteric vasculature. Radial access will allow for up to 6-Fr sheath access and may be prone to fewer thrombotic and hemorrhagic complications when compared to femoral and brachial access. Prior to proceeding with radial access, a bedside or formal duplex arterial Allen's test can be performed to ensure the presence of a complete palmar arch and adequate collateral ulnar flow. Typically a bedside duplex is performed with the probe over the palmar arch; reversal of flow with manual radial artery compression is typically adequate confirmation that the patient can tolerate radial occlusion if that were to occur. Further consideration for the radial approach is that currently

hydrophilic sheaths are limited to 25-cm lengths; therefore, familiarity and comfort with guiding catheters through the 6-Fr hydrophilic sheath will be necessary. Using a standard long 6-Fr sheath without hydrophilic coating is not recommended, as it may lead to vessel thrombosis, dissection and/or rupture upon removal. The 0.014 wire platforms may be necessary through the guiding catheter, and 0.014 platform 6- and 7-mm balloon expandable stents are available. Closure of radial access can be safely performed with "patent hemostasis" with the use of the TR Band. A cuffed compression device is placed over the access point and inflated to allow for radial artery hemostasis with preserved downstream perfusion. Typically it can slowly be removed over 1 to 2 hours depending on extent of anticoagulation and reversal thereof. A pulse oximeter is placed on the ipsilateral thumb to ensure adequate perfusion to the hand during compression.

Femoral access is obtained in a standard fashion as for aortography. Ultrasound-guided access allows safe entry into a calcium-free segment of the vessel, and decreases the rate of access complications. Most predilate the tract (also under ultrasound guidance) to facilitate the use of a closure device. After aortagram is performed in the lateral projection, a long 6-Fr (90-cm) sheath can be advanced to the visceral segment of the aorta. The SMA can be cannulated with a selective catheter and the intervention follows.

Endovascular Diagnostic and Revascularization Techniques

For the upper extremity, the left arm is circumferentially prepped from axilla to the hand with an alcohol-based preparation solution. A micropuncture system with ultrasound guidance is employed to gain initial access just above the antecubital fossa where the brachial artery is superficial and can be easily compressed against the medial epicondyle of the humerus at the conclusion of the case. If radial access is selected, ultrasound-guided access is obtained 2 to 3 cm proximal to the wrist where the vessel has a straighter course. This also allows for adequate space to place the TR band upon completion. A short 4-Fr or 5-Fr diagnostic sheath can be placed. Therapeutic heparinization is maintained throughout the case. If time allows, a diagnostic sheath injection can be performed to assess the runoff distal to the elbow as a baseline assessment. If the vessel is small and/or the sheath is potentially occlusive, we will commonly give intra-arterial nitroglycerin (100 to 200 mcg) and/or verapamil (2.5 to 5 mg) through the sheath if the patient's hemodynamics allows to minimize the

extent of vasospasm around the sheath.

When a therapeutic ACT has been confirmed (>250 seconds), a 0.035 glidewire can be navigated proximally toward the arch with a 4-Fr or 5-Fr angled support catheter. We typically favor using exchange length wires (260 cm) and longer catheters (100 cm) to limit the number of exchanges. In left anterior oblique projection, a hydrophilic wire and angled support catheter or other selective catheter are used to direct the wire toward the descending thoracic aorta. On occasion with a type II or III arch, if the origin of the left subclavian is unfavorably low on the arch, then a reverse-angle catheter may be necessary to direct the wire into the descending thoracic aorta. With wire access in the distal abdominal aorta, a flush diagnostic catheter can be advanced to the visceral segment of the aorta for an aortogram (usually a lateral projection angiogram at this point for diagnostic angiography).

Based on diagnostic angiography, if the decision is made to proceed with endovascular treatment, long sheath access at the level of the visceral segment will be necessary. An exchange-length (260 cm) stiff wire is advanced through the diagnostic catheter to the abdominal aorta. A long (90 cm) 6-Fr hyperflexible sheath can be advanced to the visceral segment over the stiff wire. If there was difficulty negotiating the arch, one often advances the sheath under direct fluoroscopic visualization from the arm to the abdominal aorta.

The patient’s clinical condition dictates to what extent endovascular approaches will be utilized. In the acute setting, revascularization of the SMA will be the priority. The clinical presentation and CT angiogram should give some additional information as to the etiology of the acute mesenteric condition, which in turn informs the planned intervention. If an adequate CT angiogram was performed preoperatively, in the interest of minimizing the contrast load a diagnostic aortagram can be skipped in favor of direct vessel cannulation based on bony landmarks.

Acute Embolus

In the case of acute arterial embolus to the SMA, the characteristic finding of an abrupt cutoff will be seen on lateral projection angiogram, and on the preoperative CT angiogram the SMA itself may be a normal vessel with absence of calcific disease. Classically embolization occurs not at the origin of the SMA but rather beyond the first jejunal branches and/or takeoff of the middle colic at the site of vessel caliber decrease. Options

for embolectomy include direct thrombolytic agent injection (e.g., tissue plasminogen activator [TPA]), suction thrombectomy, pharmacomechanical thrombectomy, and TPA infusion. Typically a combination of these techniques is employed. With the patient fully heparinized, a combination of hydrophilic wire and low-profile crossing catheter can be used to select the SMA and traverse the embolus. A stiffer wire with atraumatic tip is then placed in the more distal SMA. Either a 6-Fr sheath or a 6-Fr guiding catheter is advanced across the thrombosed segment. Pre-instillation of TPA into the clot serves to soften the clot in order to facilitate embolectomy. The wire is removed and the guiding catheter, sheath, or aspiration catheter is pulled back using a large (60 mL) syringe on the end of the catheter or side-port of the sheath. Multiple passes can be performed by repeating the above steps.

In the case of incomplete embolic/thrombotic removal, reports of using pharmacomechanical thrombectomy with either the Angiojet (Medrad, Minneapolis, MN) or EKOS (EKOS, Bothell, WA) catheter have also been reported. More typically (as in peripheral arterial thrombosis when residual clot lines the vessel or if there is side branch/terminal branch occlusion), a multiple side hole TPA infusion catheter can be left in the SMA across the residual thrombus, and TPA is infused in a controlled fashion at typically 1 mg/h. Intra-arterial heparin is also infused through the sideport of the access sheath.

The patient is taken to the surgical ICU for close serial monitoring of clinical status, abdominal examination, access site bleeding, coagulation labs, strict blood pressure control, and neurovascular examination. Proponents of endovascular approaches utilize selective rather than routine laparotomy/laparoscopy based on the patient’s clinical status. Patients undergoing catheter-directed thrombolysis are taken for repeat angiogram within 12 hours or sooner if clinical status were to change. If clot resolution is seen, the patient may be systemically anticoagulated and abdominal exploration is dictated by clinical status. If incomplete clot resolution is seen, either ongoing lytic infusion, mechanical catheter thrombectomy, or open surgical thrombectomy/bypass can then be considered depending on the clinical situation and extent of patient’s symptoms. Frequently additional periods of lysis will be needed to adequately clear the clot burden. Adjunctive angioplasty and stenting can be used as needed if underlying SMA stenosis is seen upon clearance of the clot burden.

Primary angioplasty and stenting in the setting of acute SMA embolus is unlikely to be a successful stand-alone treatment, and has the potential to lead to downstream embolization that will necessitate further intervention.

Acute Thrombosis in the Setting of Chronic Occlusive Disease

Managing the patient with in-situ thrombosis of the mesenteric vasculature is akin to managing chronic mesenteric ischemia. The technical aspects are similar to chronic disease interventions, and are predicated on the ability to successfully cross the lesion. Most patients can be adequately treated with primary angioplasty and stenting. A recent institutional retrospective study from Finland noted that of 50 patients with acute mesenteric ischemia, 32 were thrombotic, and of those, 29 (91%) were treated with primary angioplasty and stenting, while the minority (9%) required mechanical thrombectomy. A similar approach is taken as described above. Long-sheath access to the visceral segment of the aorta will be necessary. A hydrophilic wire (0.014/0.035) with appropriate low-profile support catheter is used to traverse the occlusion. Predilatation with a semi-compliant balloon allows for sheath insertion into the mesenteric branch. A balloon expandable stent or stent graft can then be placed and unsheathed in its desired location. As in chronic disease interventions, it is customary to have a small portion of the stent protrude into the aorta to decrease the spillover effect of aortic calcification into the vessel origin.

Retrograde Open Mesenteric Stenting

In the event that antegrade recanalization of an acutely thrombosed SMA is not technically possible or if the patient has already been taken to the operating room for rapid operative exploration, retrograde approaches to the SMA are feasible. Operative exposure of the SMA at the base of the transverse mesocolon is performed as described above. The Dartmouth group advocates performing a longitudinal arteriotomy of the SMA with patch angioplasty (vein or bioprosthetic) and intervening through the patched segment. This allows for focal SMA thrombectomy if needed but also allows for preserved angiographic visualization of the SMA downstream from the intervention without losing intraluminal access. Other authors advocate for direct puncture/wire insertion of the SMA. A 6-Fr sheath is inserted and a hydrophilic glidewire is advanced to the aorta (Fig. 217.5). Full-lateral angiography is performed. It is recommended that

alternative arterial access (brachial or femoral) be established to allow for a landmark/endpoint for the intervention by way of a catheter placed in the aorta at the visceral segment. Again, predilation of the diseased/occluded segment is performed, and a balloon expandable stent/stents are deployed with minimal overhang (2 to 3 mm) into the aortic lumen. Completion angiogram can be performed to assess the SMA run-off at that point. The arteriotomy is closed with interrupted 6-0 Prolene suture.

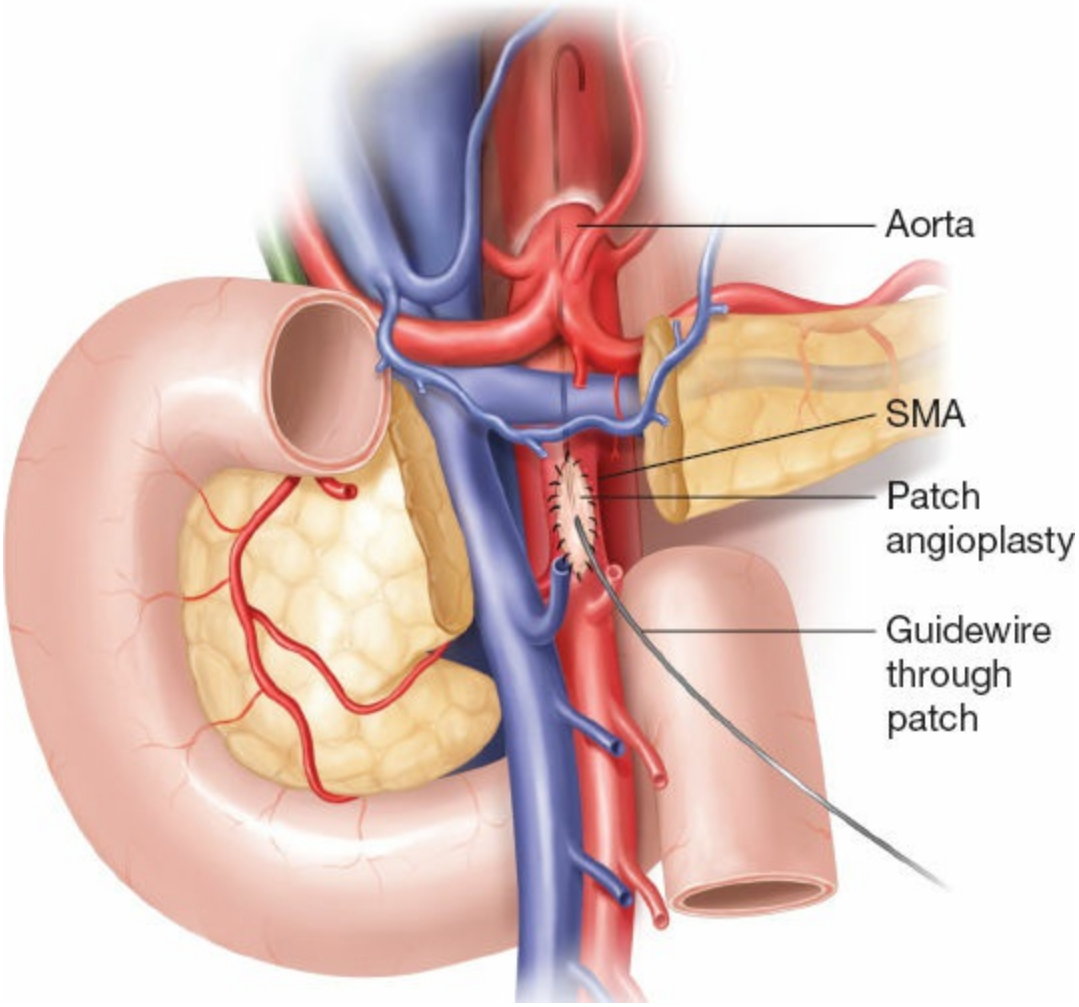

Figure 217.5. Retrograde endovascular (via open SMA exposure) treatment of proximal SMA occlusive disease. Longitudinal arteriotomy of the SMA with patch is performed. A 6-Fr sheath is inserted, and a hydrophilic glidewire is advanced to the aorta. Full-lateral angiography is performed. It is recommended that alternative arterial access (brachial or femoral) be established to allow for a landmark/endpoint for the intervention by way of a catheter placed in the aorta at the visceral segment. Predilation of the diseased/occluded segment is performed, and a balloon expandable stent/stents are deployed

with minimal overhang (2 to 3 mm) into the aortic lumen in the setting of orificial SMA occlusive disease. Intervening through the patch allows for continual flow to the SMA branches and angiographic assessment of run-off patency.

POSTOPERATIVE CARE

Immediately after open setting revascularization, 15 to 30 minutes should pass prior to determination of bowel viability. Clearly dead bowel is resected. Return of color and peristalsis and lack of venous thrombosis indicate viable bowel. However, this clinical judgment can be quite difficult, and adjuncts in addition to close bowel inspection include listening for Doppler signals at the antimesenteric border and bowel fluorescence under Wood's (ultraviolet) lamp examination after intravenous fluorescein infusion. Occasionally, SMA injection of vasodilators (papaverine 30 to 60 mg) and glucagon (0.25 to 0.5 mg) may be of benefit.

Despite these maneuvers, delineation of salvageable versus unsalvageable bowel often remains obscure. In this setting, bowel ends can be stapled off or brought up as ostomies, and the abdomen closed in a temporary fashion of the surgeon's choice (e.g., vacuum-assisted closure dressing, Bogota bag, skin level closure). A second-look operation is planned and carried out in 24 to 48 hours. During this time frame, the patient's oxygen delivery and metabolic status are optimized. A second-look strategy commits the operative team to another procedure in 24 to 48 hours (even if the patient's clinical status improves dramatically); however, in 50% of second-look procedures, additional necrotic bowel will be present, requiring re-resection. Thus, the threshold for second look should be fairly low. Conversely, if the patient's status deteriorates during this early operative period, further interrogation (such as angiogram to ensure optimal intestinal revascularization) and reexploration (for signs of progression to transmural bowel infarction with subsequent complications) may be warranted sooner. Since these patients are often quite ill and the bowel viability may be in question, construction of a primary anastomosis may lead to subsequent anastomotic dehiscence and enteric contents spillage in a critically ill patient. Exteriorizing questionable bowel as stomas enables direct observation postoperatively for viability. One important caveat to this rule is that very proximal jejunostomies (within 20 cm to the ligament of Treitz) can lead to severe losses of fluid,

electrolytes, and other nutrients. Multiple trips (e.g., third looks) to the operating room are not infrequently required to care for the bowel complications of SMA occlusion and revascularization.

Results of published reports vary depending on patient characteristics such as age, comorbidity, and cause for ischemia, but as a rule at least 50 cm of bowel is required to maintain enteral nutrition long term. The ileocecal valve is important to preserve if possible, as shorter segments of bowel have been shown to support enteral nutrition if the ileocecal valve is functional. In cases where the remaining bowel is short and the ileocecal valve is dusky or otherwise questionable, it may be more acceptable to risk a fistula with an anastomosis than to resect the cecum and risk permanent intestinal insufficiency. In patients without advanced comorbidities, long-term survival can be achieved through parenteral support, intestinal adaptation, and, potentially, small intestinal transplantation. The surgeon is occasionally faced with catastrophic complete small bowel infarction, which would leave inadequate intestinal length to nutritionally support life in this often elderly patient population. In this inoperable setting, the abdomen is closed and patient care, in partnership with the available family, transitions to focus on comfort measures only.

COMPLICATIONS AND THEIR MANAGEMENT

The reperfusion syndrome after visceral revascularzation for acute ischemia is largely managed by usual supportive critical care measures. These will be tailored to the individual patient's comorbidities and risks, but the systemic inflammatory syndrome observed in a large majority of these patients requires judicious fluid resuscitation with attention to electrolyte balance, particularly with respect to hyperkalemia. Acute kidney injury is frequently encountered and may be severe enough to require renal replacement therapy. Myocardial function is often impaired due to the combined influences of hypovolemia, acidosis, and mediators with negative inotropic or vasodilatory effects, and invasive monitoring is frequently employed when heart failure develops. Cardiac dysrhythmia may be the underlying cause for embolism and may require advanced management strategies including cardioversion. In cases where cardioversion is indicated, it is crucial to verify that thrombus is not present in the cardiac chambers, usually with transesophageal echocardiography, prior to conversion in order to prevent recurrent embolism.

Patients who have suffered SMA occlusion from an embolus are at high risk for recurrent thromboemboli. Therefore, they should be anticoagulated with heparin, followed by warfarin. Fortunately, these patients are usually well nourished at the onset, so in the early postoperative period nutritional support may usually be safely deferred. Once the acute phase resolves, enteral nutrition should be used as tolerated, as enteral delivery of nutritional factors improves mucosal recovery and promotes intestinal adaptation to intestinal insufficiency. If the patient does not tolerate full enteral feeding, parenteral support should be initiated to prevent malnutrition, which retards intestinal adaptation.

OUTCOMES

Acute mesenteric ischemia remains a highly lethal clinical event, with mortality averaging around 70% from several series. Markers for delayed diagnosis and advanced bowel infarction (such as preoperative presence of peritonitis and need for bowel resection) stand as independent predictors of perioperative mortality or survival dependent on total parental nutrition.

While uncommon, the incidence of this problem may be increasing in the aging population and with the rising incidence of the metabolic syndrome, defined as the accumulation of atherogenic risk factors (e.g., obesity, dyslipidemia, hypertension, glucose intolerance), resulting in pro-atherogenic, prothrombotic, and proinflammatory states. It is also possible that the contribution of the metabolic syndrome to the incidence of acute mesenteric ischemia may be offset by increasing use of anticoagulation for other diagnoses, such as dysrhythmias. A recent population-based series cites an incidence rate as high as 5.3 cases per 100,000 inhabitants per year.

Suggested Readings

Acosta S, Bjorck M. Acute thrombo-embolic occlusion of the superior mesenteric artery: a prospective study in a well-defined population. *Eur J Vasc Endovasc Surg* 2003;26(2):179.

Barakate MS, Cappe I, Curtin A, et al. Management of acute superior mesenteric artery occlusion. *Aust N Z J Surg* 2002;72(1):25.

Bingol H, Zeybek N, Cingoz F, et al. Surgical therapy for acute superior mesenteric artery embolism. *Am J Surg* 2004;188(1):68.

Bjorck M, Acosta S, Lindberg F, et al. Revascularization of the superior mesenteric artery after acute thromboembolic occlusion. *Br J Surg* 2002;89(7):923.

Edwards MS, Cherr GS, Craven TE, et al. Acute occlusive mesenteric ischemia: surgical management and outcomes. *Ann Vasc Surg* 2003;17(1):72.

Hladik P, Raupach J, Lojik M, et al. Treatment of acute mesenteric thrombosis/ischemia by transcatheter thromboaspiration. *Surgery* 2005;137(1):122.

Park WM, Gloviczki P, Cherry KJ Jr, et al. Contemporary management of acute mesenteric ischemia: factors associated with survival. *J Vasc Surg* 2002;35(3):445.

Schermerhorn ML, Giles KA, Hamdan AD, et al. Mesenteric revascularization: management and outcomes in the United States, 1988–2006. *J Vasc Surg* 2009;50(2):341.

Schoots IG, Levi MM, Reekers JA, et al. Thrombolytic therapy for acute superior mesenteric artery occlusion. *J Vasc Interv Radiol* 2005;16(3):317.

Wyers MC. Retrograde mesenteric stenting during laparotomy for acute occlusive mesenteric ischemia. *JVS* 2007;45:269–75.

EDITOR'S COMMENT

I was walking down the hall last week, and a high-ranking administrator who is a supporter of vascular surgery remarked, "We sure have a lot of dead bowel (mesenteric ischemia) at our institution." While for a second I of course felt personally attacked for operations gone bad, I quickly realized that his observation was indeed true and for the most part he was not talking about failed surgical or endovascular interventions. I also harkened back to my old institution and remembered our quality officer showing us that we had more deaths from mesenteric ischemia on our service than we did from ruptured aortic aneurysms. Acute mesenteric ischemia kills patients.

In this chapter by McPhee and colleagues, the authors nicely describe the pathophysiology of acute mesenteric ischemia and the subsequent reperfusion injury that occurs following treatment of acute mesenteric ischemia. I have been overwhelmed recently with the injury the liver sustains even after retrograde or antegrade revascularization procedures to the isolated SMA. I know treatment of this disease is not completely like chronic mesenteric ischemia (Hollier LH, Bernatz PE, Pairolero PC, et al. Surgical management of chronic intestinal ischemia: a reappraisal. *Surgery* 1981;90(6):940–6) especially in the setting of embolic disease, but maybe with acute on chronic mesenteric disease, we should be revascularizing both the SMA and the celiac more aggressively.

The authors are correct to point out that any comparison of endovascular and open revascularization is fraught with biases. Maybe the patients committed to an endovascular approach have less suspicious dead bowel or are "less sick" and therefore have more time before frank dead bowel occurs. However, a recent paper using the NSQIP database suggests that patients who undergo an endovascular approach have a lower mortality rate (2.5 times lower than open)

and a decreased need for laparotomy compared with open surgery. In addition, postoperative complications were much lower in the endovascular group (Branco BC, Montero-Baker MF, Aziz H, et al. Endovascular therapy for acute mesenteric ischemia: an NSQIP analysis. *Am Surg* 2015;81(11):1170–6). This suggests to me that perhaps all patients with a suspicion for dead bowel should be placed in a hybrid operating room where endovascular therapy is an option. Others have advocated for an endovascular first approach for all acute mesenteric ischemia (Naylor AR, Forbes TL. Trans-Atlantic debate: Is an "endovascular first" strategy the optimal approach for treating acute mesenteric ischemia? *Eur J Vasc Endovasc Surg* 2015;50(3):279–80). I am not sure that is correct either especially in the setting that typically ends in a "peak" and closes the abdomen without bowel resection scenario when the entire small bowel is dead. It seems like spending hours revascularizing frankly dead bowel is to no one's benefit.

The truth is the management of acute mesenteric ischemia takes great communication between the "bowel resection" team and the "blood flow revascularization" team. Optimal management of these patients also requires a high index of suspicion by our emergency room colleagues on the front line seeing these patients. Embolic disease to the SMA is the great masquerader and often the surgeon will get called in after the diagnosis of acute mesenteric ischemia is no longer in question when pneumatosis in the small bowel or portal vein gas is seen on CT. While both of these signs on imaging can be omnious, it is important to realize that there are some patients without an abdominal catastrophe with benign causes of pneumatosis intestinalis and portal vein gas, and therefore it is important to have an algorithm in working these patients up (Wayne E, Ough M, Wu A, et al. Management algorithm for pneumatosis intestinalis and portal venous gas: treatment and outcome of 88 consecutive cases. *J Gastrointest Surg* 2010;14(3):437–48).

Finally, while this chapter primarily focuses on embolic and acute on chronic mesenteric ischemia, we are seeing an increasing number of patients with both acute type A and B dissections with acute mesenteric ischemia. Some believe that mesenteric ischemia can be managed percutaneously prior to type A repair, (Deeb GM, Patel HJ, Williams DM. Treatment for malperfusion syndrome in acute type A and B aortic dissection: a long-term analysis. *J Thorac Cardiovasc Surg* 2010;140(6 Suppl):S98–S100) while others just proceed to type A repair. This is an ongoing argument among cardiac surgeons. Since I primarily see type B dissections (Lombardi JV, Cambria RP, Nienaber CA, et al. STABLE investigators. Prospective multicenter clinical trial (STABLE) on the endovascular treatment of complicated type B aortic dissection using a composite device design. *J Vasc Surg* 2012;55(3):629–40), I am hoping that new endovascular stent graft systems will also serve to decrease the mortality associated with acute mesenteric ischemia in these ill patients who do not tolerate mesenteric ischemia very well and who also have very few good revascularization options available as the inflow for most bypasses is dissected.

Gilbert R Upchurch Jr.

218 Techniques of Open and Endovascular Revascularization to Treat Chronic Mesenteric Ischemia

Thomas C. Bower and Gustavo S. Oderich

BACKGROUND

The first clinical and anatomical descriptions of intestinal ischemia were recognized in the late 1800s. In 1938, Dunphy described a correlation between recurrent abdominal pain, fatal intestinal infarction, and mesenteric artery occlusive disease. *Intestinal angina* was coined to describe the classic symptom of chronic abdominal pain after meals, the cardinal symptom of *chronic mesenteric ischemia* (CMI).

Shaw and Maynard introduced mesenteric endarterectomy as surgical treatment in 1958. Since then, revascularization has evolved to antegrade or retrograde bypass, and now endovascular therapy. The latter came into vogue in 1980, and over the last decade, the use of endovascular techniques to treat patients with CMI has surged. Mesenteric artery stenting is now first-line treatment at most centers. Open surgery generally is relegated to patients who have complex lesions unsuitable to stenting, those who fail endovascular therapy, and the small subset of patients with inflammatory disorders. This chapter will briefly review the pathophysiology, etiology, clinical presentation, and indications for treatment and outcomes in CMI, but the primary focus is on open surgical and endovascular techniques.

PATHOPHYSIOLOGY, ETIOLOGY, AND NATURAL HISTORY

The mesenteric circulation accounts for approximately 20% of the cardiac output, but blood flow increases to 1 to 2 L/min over 3 to 6 hours after a meal. Patients with mesenteric ischemia are unable to meet the postprandial blood flow and oxygen demands for intestinal secretion and

absorption. In general, at least two of the three arteries need to be occluded or severely stenotic to have symptoms because of the rich collateral network between the celiac artery (CA), superior mesenteric (SMA), inferior mesenteric (IMA), and internal iliac arteries (Fig. 218.1).

Atherosclerotic disease is the cause of CMI in 90% of patients, and is usually isolated to the first 2 to 3 cm of the CA and SMA. Associated aortic, iliac, and renal artery disease is common. Nonatherosclerotic mesenteric lesions include vasculitis (Giant cell arteritis, Takayasu disease, and polyarteritis nodosa), systemic lupus, Buerger disease, spontaneous dissection, fibromuscular dysplasia, neurofibromatosis, radiation arteritis, drug-induced arteriopathy from cocaine or ergot use, and mesenteric venous thrombosis. Patients with abdominal aortic coarctation or mid-aortic syndrome may have concomitant mesenteric stenoses, with or without symptoms. As a broad group, these patients are younger than those with atherosclerosis.

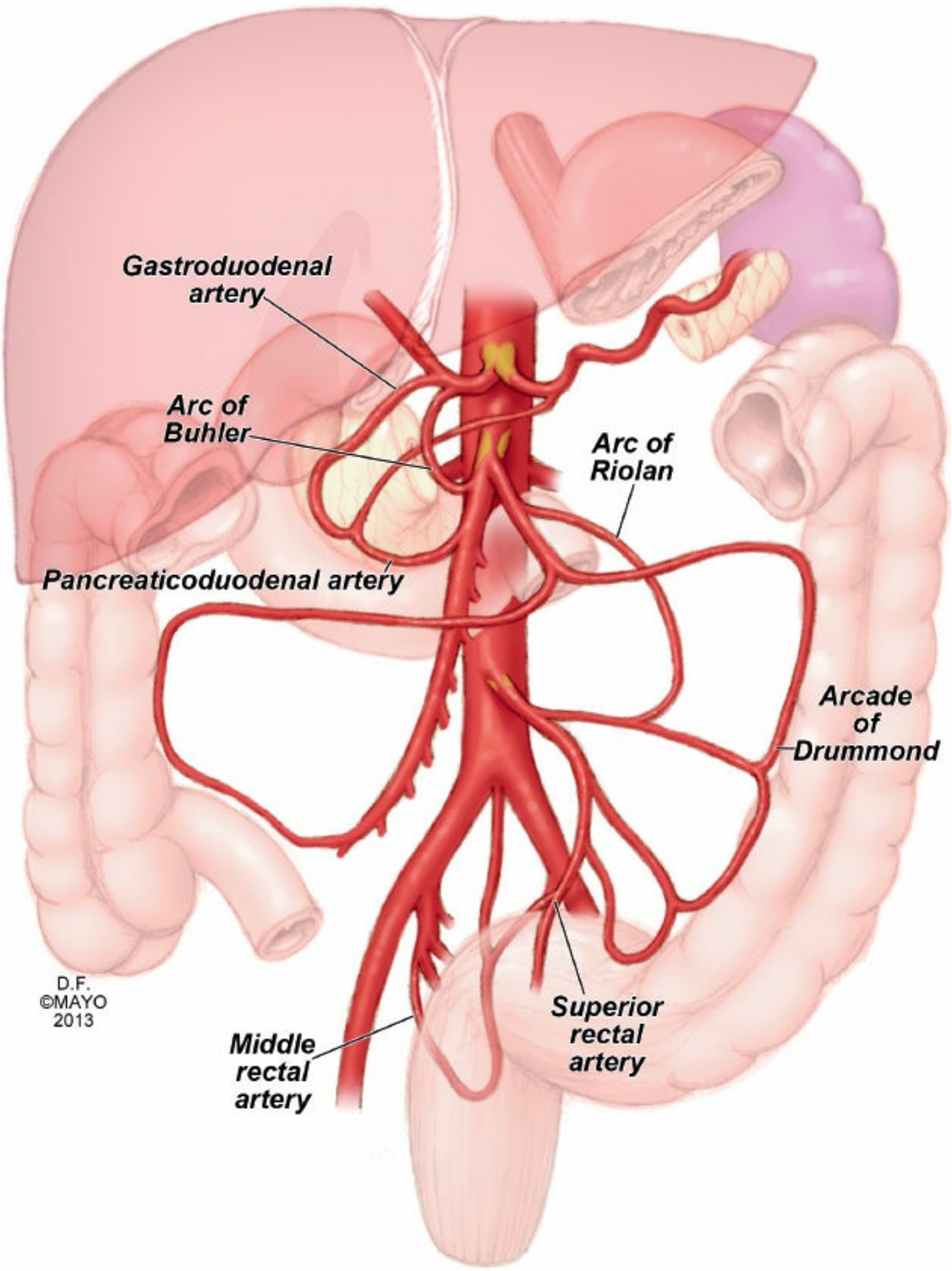

Figure 218.1. Schematic representation of the collateral circulation between the celiac axis, superior mesenteric, inferior mesenteric, and internal iliac arteries. (Image © Mayo 2013.)

The natural history of mesenteric artery disease is not fully understood. Asymptomatic patients have a low risk of bowel infarction if there is non-SMA single vessel involvement. However, 15% to 50% of patients with

bowel gangrene due to in situ arterial thrombosis have no antecedent warning signs. Such patients either have an SMA thrombosis with poorly developed collaterals or have severe three vessel disease.

CLINICAL PRESENTATION

The classic patient with CMI from atherosclerosis is a female smoker between 50 and 70 years of age who has postprandial mid abdominal pain, weight loss, and “food fear.” Pain is present in over 90% of patients, is crampy or dull, begins within a few minutes to 30 minutes after meals, and may persist for several hours. As compensatory collateral blood flow worsens, pain progresses to be near constant and unrelenting. A rare patient has little if any pain because of adaptive strategies to tolerate it. Patients alter eating habits to avoid foods that precipitate symptoms. Unintentional weight loss occurs in more than three fourths of patients, and leads to malnutrition and cachexia in the late stage of disease. Duration of symptoms prior to revascularization averages 15 months. Not every patient has “classic” symptoms. At times, abdominal pain is vague, nausea and vomiting is present, or there is a change in bowel habits. Tobacco use, hypertension, and hyperlipidemia are noted in over 60% to 70%. Physical examination is nonspecific. Most individuals are thin, have a scaphoid abdomen, and at advanced stages have muscle wasting. Laboratory tests are nonspecific, even in acute situations. A low serum albumin, pre-albumin, or transferrin is a marker of malnutrition, while an increase in inflammatory markers, such as sedimentation rate and C-reactive protein suggests systemic inflammation. Diffuse stomach or duodenal ulcers, liver function abnormalities, or patchy areas of ischemia in the colon occur, and should raise suspicion of CMI.

DIAGNOSTIC IMAGING

The diagnosis of CMI is suggested by clinical history and confirmed by imaging studies after other causes of chronic abdominal pain and weight loss such as inflammatory, infectious, and malignant diseases have been excluded. Upper and lower gastrointestinal endoscopy, duplex ultrasonography (DUS), computed tomography (CT), and magnetic resonance imaging (MRI) of the abdomen are common investigative studies. A negative DUS essentially excludes mesenteric artery disease. CT or MR imaging of the abdomen excludes causes of abdominal pain and provides anatomical detail to plan revascularization. Multidetector CT is

considered the best study to evaluate lesion characteristics (calcification, thrombus, diameters, and lengths) and anatomy. The bane of CT angiography is dense arterial calcification. Gadolinium-enhanced MRA has improved with shorter acquisition times. Catheter-based arteriography is rarely used for diagnosis because of improvements in CTA and MRA, except for patients with suboptimal imaging due to dense calcification or metallic artifact from prior stents.

TREATMENT STRATEGIES

There is no role for long-term parenteral nutrition in patients with symptomatic mesenteric artery disease. Delay in treatment leads to clinical deterioration, bowel infarction, and risk of sepsis from catheter-related complications. Revascularization is necessary in all patients with CMI, either by endovascular or open techniques, unless the patient refuses treatment.

Goals of treatment are to alleviate symptoms, improve nutrition to allow weight gain, and prevent bowel infarction. Prophylactic intervention in asymptomatic patients remains controversial. Mesenteric reconstruction sometimes is needed during open aortic reconstruction to prevent perioperative bowel ischemia, and is rarely considered in asymptomatic patients with severe three-vessel disease who live in remote areas. These latter patients are counseled about warning symptoms and monitored closely.

Endovascular therapy has changed treatment approach and patient selection at most centers, and its use increased 10-fold in the United States in the last decade, largely due to improved outcomes. Angioplasty and stenting is now utilized in over 70% to 80% of patients treated for CMI, and is first-line therapy for patients with suitable lesions, regardless of clinical risk.

The SMA is the primary target for revascularization, whether treatment is rendered by endovascular or open techniques. We found no clinical benefit to stent both the SMA and celiac artery, though prefer two vessel bypasses for open repair in most patients. The SMA anatomy is critical if endovascular treatment is to be successful and durable. The ideal lesion for SMA angioplasty and stenting is a short, focal stenosis or occlusion with minimal calcification or thrombus. Stenting of CA lesions carries high rates of restenosis because of external compression by the median arcuate ligament. Severe eccentric SMA calcification, flush occlusion at the aorta,

long lesions (>2 to 3 cm), small target vessel, and tandem lesions increase the difficulty and success of endovascular therapy. Although such anatomy does not preclude stenting, the results of treatment are poorer compared to "ideal lesions," and complications such as distal embolization, dissection, and restenosis are higher.

Preoperative Evaluation

In addition to visceral, aortic, and iliac artery anatomy, preoperative evaluation focuses on surgical risk and assessment of nutritional status. Cardiac, pulmonary, and renal functional assessments are important, and noninvasive cardiac stress and pulmonary function tests are the cornerstones of medical evaluation. Optimal medical therapy is needed before and after operation, and includes smoking cessation, aspirin, a beta-blocker, and statins if tolerated. Patients with severe cachexia, dehydration, and stable symptoms may benefit from intravenous (IV) hydration and a brief period of parenteral nutrition before operation.

OPEN SURGICAL REVASCULARIZATION

Our preference for low-risk patients who either fail stenting or are not considered candidates for it is open revascularization. Mesenteric bypass also becomes necessary for symptomatic patients with chronic stent occlusion not suitable to recanalization, and is the preferred option to treat patients with nonatherosclerotic lesions. Key issues include choice of inflow, status of the target arteries, and graft configuration.

Mesenteric bypass may be antegrade or retrograde to the SMA only, or to both the SMA and celiac. Rarely, are all three visceral vessels reconstructed. Antegrade bypass implies graft origin from the supraceliac aorta. Retrograde bypass originates from the infrarenal aorta, common or external iliac arteries, and is used as a straight graft or placed in a C-shape. Choice of reconstruction is based on patient risk and anatomy. Outcomes are equally good, regardless of graft origin, the number of arteries reconstructed, or graft configuration. Prosthetic is the preferred conduit except in contaminated fields or in a patient with a small target artery. Saphenous vein, femoral vein, cryopreserved artery, or endarterectomy is an alternative to prosthetic in such cases.

In our practice, most patients undergo antegrade bypass from the supraceliac aorta. High-risk patients or those with calcification of the supraceliac aorta are better treated with a retrograde bypass from the

common iliac artery, more often the right one because the graft lays better in the retroperitoneum. If the common iliac arteries are heavily calcified, the external iliac artery can be used for inflow. A rare high-risk patient with iliac disease, who is not a candidate for mesenteric stenting, can be managed with iliac artery stents followed by a retrograde single limb SMA bypass from the external iliac.

Technique and Exposure

Exposure is everything in open vascular surgery, and choice of incision is paramount to success. The supraceliac aorta is approached through an upper midline or bilateral subcostal incision, depending on body habitus. Either incision allows for transperitoneal exposure of the aorta and visceral arteries. For a midline approach, a 2-cm incision along the side of the xiphoid process releases six muscular and aponeurotic attachments and allows for upward and lateral retraction of the body wall (Fig. 218.2). If medial visceral rotation is planned, a small bump placed under the left side of the patient with the knees secured allows rotation of the operating table to facilitate exposure. Once the incision is made, the patient is placed slightly head up, which allows the small bowel to fall caudally. Isolation of the supraceliac aorta begins by take down of the left triangular ligament of the liver. The lesser sac is opened, the crura of the diaphragm is divided or resected, and the aorta is isolated (Fig. 218.3). Care must be taken to protect the esophagus, and having a nasogastric (NG) tube in place is helpful. As much as 5 to 6 cm of the lower descending thoracic or supraceliac aorta can be dissected free, though it is easy to enter the left pleural space in thin patients.

Exposure of the CA is done before the SMA if an antegrade two-vessel bypass is planned. Laparotomy pads or a folded moist towel is laid over the pancreas and bowel, which allows them to be retracted caudally. The artery can be identified at its origin and circumferentially dissected free toward its bifurcation. At times, there are one or more small arterial branches near the celiac origin, which cause troublesome bleeding if not identified and ligated. Peri-arterial ganglionic and fibrous tissue requires resection to free up the celiac trunk. Often, the left gastric artery is ligated and divided, which helps when creating a retro-pancreatic tunnel for the SMA graft limb. Alternatively, if there is scarring around the CA or it is occluded, the common hepatic artery is dissected free and used as the target. One or more small veins alongside the artery may need ligation.

The SMA is isolated above the pancreas if disease is confined to the first centimeter or two of the artery, or at the base of the transverse mesocolon, which is the more common exposure (Fig. 218.3). For the latter, the transverse colon is lifted upward and the small intestine is retracted toward the right side except for the duodenal sweep. The ligament of Treitz is taken down so that the SMA can be palpated in the mesentery. Lymphatic and fibro fatty tissues are ligated and divided along the left side of the duodenal mesentery, which allows the SMA limb to lay better. Care should be taken when isolating the jejunal branches along the side and posterior wall of the SMA, as they tear easily. If a replaced right hepatic artery is present, it needs to be preserved. Extensive calcification and long segment stenosis may be present in heavy smokers, patients with prior radiation or in reoperative cases. In these cases, the surgeon must dissect free the SMA and its branches further distally into the mesentery to find a suitable site for an anastomosis. This maneuver requires ligation and division of crossing mesenteric vein branches. A retropancreatic tunnel is created by blunt and sharp dissection from the supraceliac aorta to the exposed SMA, and is made anterior to the left renal vein and along the left anterolateral aorta. The tunnel must be free of fibrous bands and large enough to avoid compression of the graft. Plasma tubing is passed through the tunnel to simplify passage of the SMA limb.

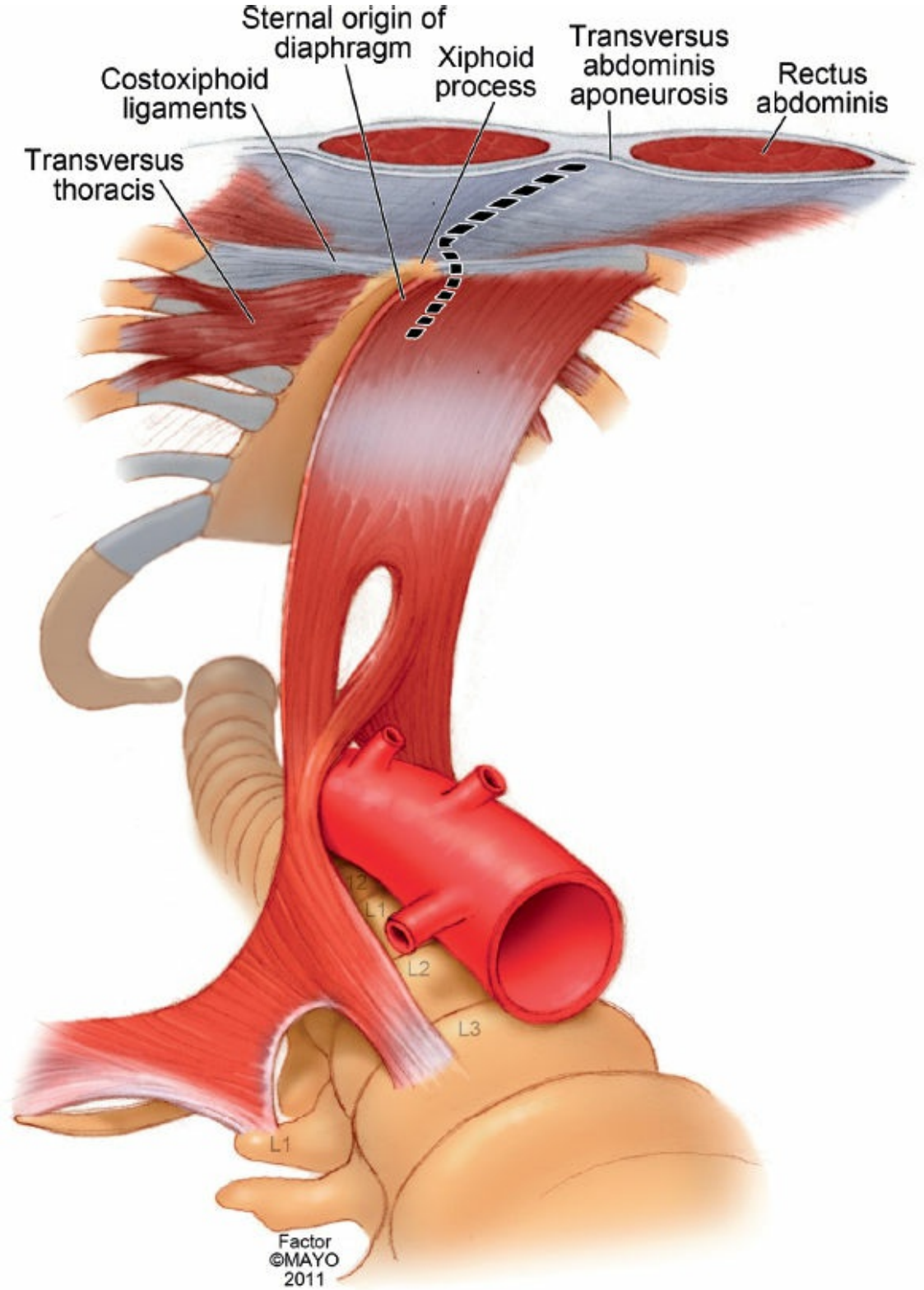

Figure 218.2. Upward and lateral retraction of the body wall aids in exposure of the upper abdominal aorta and visceral arteries. This is enhanced with a midline incision by incising alongside the xiphoid process, which releases six muscular and aponeurotic attachments. (Image © Mayo 2011.)

For supraceliac aorta-based bypass, patients are given between 50 and 100 units per kg of IV heparin and 12.5 g of mannitol before placement of the aortic cross clamp. A partial occlusion clamp allows for distal perfusion during the aortic anastomosis, and the authors have found the all-purpose aortic clamp to work well if the aorta is 18 mm or larger in diameter and not calcified. Deep patients or those with a thick aortic wall are better served with a double clamp technique to allow better visualization for suturing the graft (Fig. 218.4). It is preferable to fully cross-clamp the aorta than to struggle using a partial occlusion clamp and risk an imperfect anastomosis, which has to be redone. A straight aortic clamp is used on the proximal supraceliac aorta. A hypogastric clamp is placed on the distal supraceliac aorta or across it from behind the celiac artery so that it occludes the aorta and the lumbar arteries. Close communication with the anesthesiology team lessens the adverse effects of increased cardiac afterload during aortic clamping, and declamping hypotension when blood flow is restored to the kidneys and lower extremities. A straight or slightly oblique aortotomy is made on the anterior or left anterolateral wall. A stay stitch can be placed, or a small ellipse of wall excised to facilitate the proximal graft anastomosis. Two vessel reconstructions are done with a 12 × 7 mm or 14 × 7 mm knitted polyester graft. Smaller diameter limbs seem more prone to failure from pseudo intima in our experience. The bifurcated graft body is fashioned with the limbs side by side or on top of one another, based on patient anatomy. If a single antegrade bypass is done, the body of the bifurcated graft is cut near the origin of the limb to create a flange. This allows the graft to “sit up from the aorta,” which avoids flattening of graft at the heel that may result in stenosis or graft failure. The latter is why we abandoned the use of saphenous vein in this position unless it is in a pantaloon configuration. Once the aortic graft anastomosis is completed, it is tested by infusing saline into the limbs with clamps still in place. This maneuver allows repair sutures to be placed without having to reclamp the aorta, thereby lowering the risk of clamp injury. If hemostatic, blood flow is slowly restored through the native aorta after back-bleeding and fore-bleeding through the limbs has been done. The body of the graft is clamped at its origin, and blood is suctioned from the limbs so they are clean. A coarctation clamp is placed at the origin of the celiac limb. If ischemia time exceeds 20 minutes during complete aortic crossclamp, additional mannitol and Lasix are given to stimulate urine output.

The distal anastomosis to the celiac artery can be done end-to-end or end-to-side. An end-to-end celiac anastomosis is challenging in two ways. First, the graft can be cut too long if retraction is not temporarily released to gauge the length. This mistake causes a kink or buckle when bowel retraction is relaxed. Second, the artery may be fragile, so if the graft is too taught, the artery will tear. Both necessitate revision. For these reasons, the authors favor an end-to-side celiac anastomosis as it simplifies assessing graft length because the CA is in fixed position. The artery is ligated immediately proximal to the heel to create a functional end-to-end anastomosis (Fig. 218.5). If the celiac is occluded or severely calcified, the bypass target is the common hepatic artery. The graft is sewn to the hepatic end-to-side. Back-bleeding is allowed prior to completion of the anastomosis. Fore-bleeding is done through the SMA graft limb by temporary release of the clamp on the graft body. This limb is irrigated and suctioned to be sure it is clean. The coarctation clamp at the origin of the celiac limb is transferred to the origin of the SMA limb. Clamps on the graft body and CA are released to allow blood flow into the celiac branches.

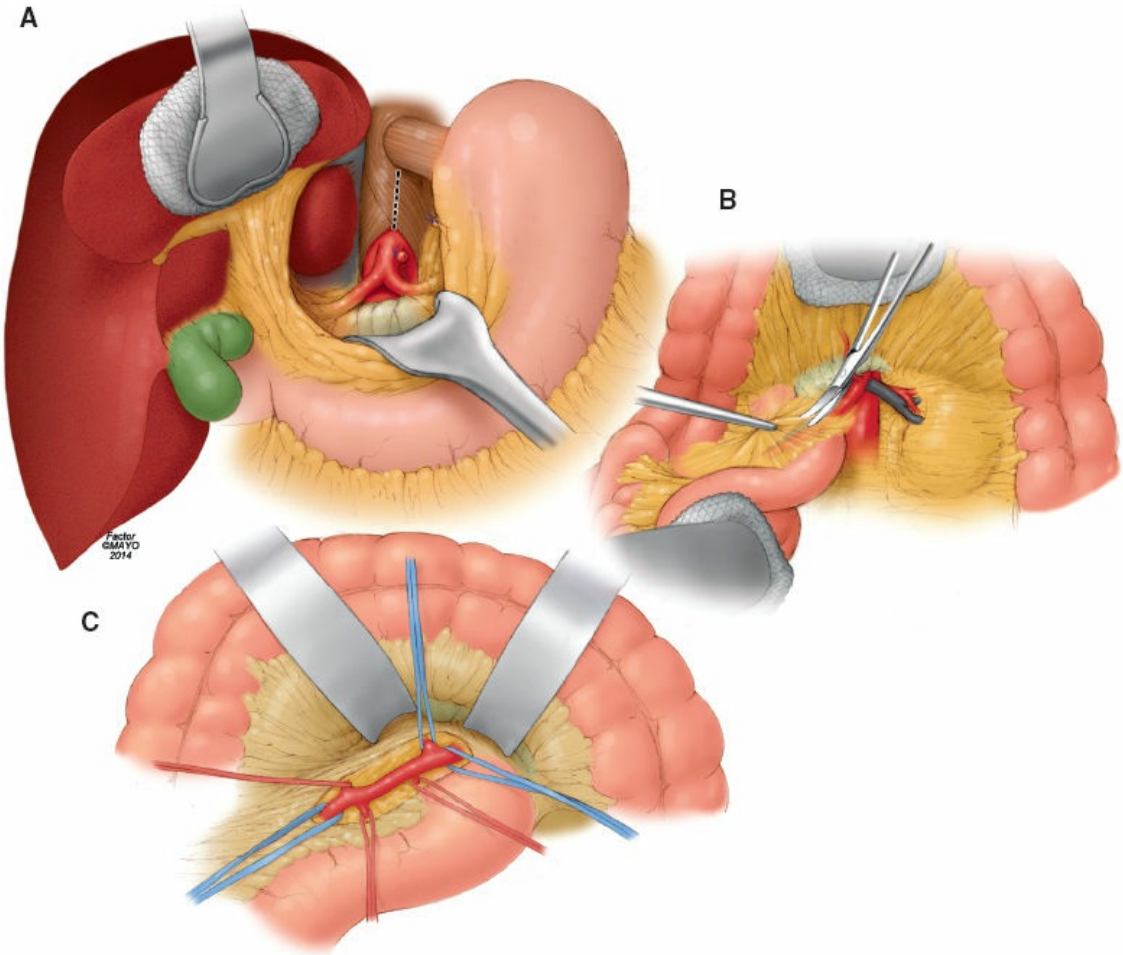

Figure 218.3. Transperitoneal exposure of the supraceliac aorta and celiac artery involves takedown of the left triangular ligament of the liver, opening of the lesser sac, and division of the crura of the diaphragm (**A**). The supraceliac aorta can be isolated first, followed by identification of the celiac trunk, or the common hepatic artery can be identified to guide dissection proximally to the celiac. For antegrade bypass, the left gastric artery often is divided to make it easier to create a retropancreatic tunnel for the SMA graft limb. The SMA usually is isolated at the base of the transverse colon (**B**), and side branches are controlled with silastic loops (**C**). (Image © Mayo 2014.)

A ringed forceps is placed on the caudal end of the plasma tubing that had been passed through the retropancreatic tunnel (Fig. 218.5). The transverse colon is lifted upward, the tubing is pulled cranially, and the clamp guided through the tunnel. The SMA graft limb is grasped, brought through the tunnel, straightened, and secured with a clamp at the base of the transverse mesocolon in an infracolic position. This maneuver fixes graft length and keeps blood or debris from getting into the limb during the

distal anastomosis. This tunnel is remarkably short in length. The retractors on the liver and intestine are released, and exposure reset for the SMA anastomosis. The SMA is opened vertically on its left lateral or anterolateral side in preparation for an end-to-side anastomosis. If there is SMA plaque that requires focal endarterectomy, the arteriotomy is closed with a patch. This facilitates the graft anastomosis and lessens the risk of anastomotic stenosis, particularly in women whose SMA diameter is small. The graft is cut to length after retraction on the small bowel is relaxed. Backbleeding is allowed, the anastomosis completed, and clamps are released to allow blood flow into the SMA.

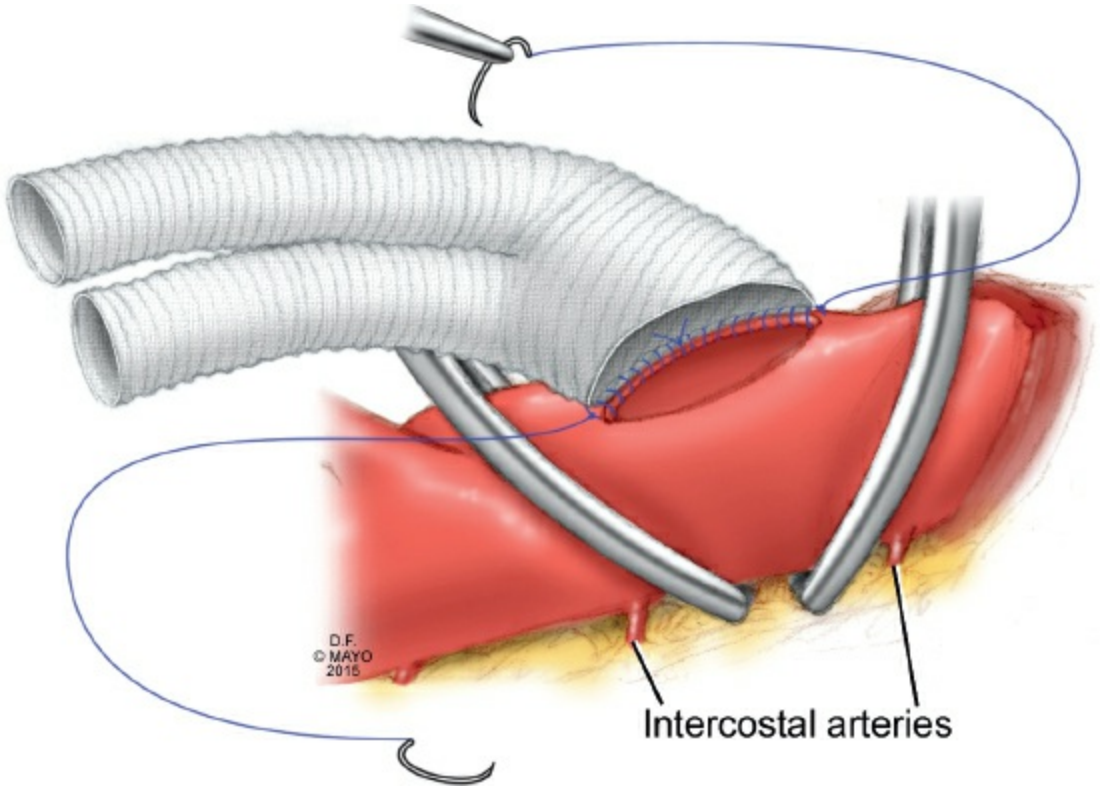

Figure 218.4. The supraceliac aortic-graft anastomosis can be done using a side-biting clamp or a two-clamp technique as shown here. For a two-vessel bypass, the graft limbs can be placed side-by-side, or on top of one another, depending on patient anatomy. (Image © Mayo 2015.)

Retrograde bypass from an iliac artery is done with prosthetic to the SMA alone, or to the SMA and common hepatic (Fig. 218.6). If both arteries are reconstructed, which rarely is needed, a side-to-side anastomosis is done to the SMA. The bypass then is gently curved behind the pancreas or on top of it, and sewn end-to-side to the common hepatic.

Patient anatomy determines the graft course so that it does not kink. Conduit size is chosen by the size of the target artery, with 7-mm or 8-mm prosthetic preferred over vein in most cases. The graft seems to lie better if inflow can be obtained from the right common iliac artery, whether the graft is done in a straight or C-shape configuration (Fig. 218.6). The latter allows antegrade blood flow vis-à-vis the SMA. If the common iliacs are circumferentially calcified but not stenotic, the external iliac artery is used for inflow. For a straight iliac to SMA bypass, the iliac artery anastomosis is done first. If a C-shape is chosen, either the iliac or SMA anastomosis can be done first based on surgeon preference. In this situation, we prefer to do the SMA anastomosis first, clamp the graft flush at its anastomosis and fill it with saline, let the bowel relax, and then lay the graft in a C-shape so that there is no redundancy when sewn to the iliac.

Inflow from the infrarenal aorta is used less often than the iliac artery because it is difficult to gauge graft length when the small bowel returns to its normal position. The graft has a tendency to buckle or kink. The use of a short stove-pipe bypass graft between the aorta and SMA obviates this risk and works well in select high-risk patients who may not tolerate a supraceliac clamp, or those who have calcification of the supraceliac aorta and/or iliac arteries (Fig. 218.7). The graft is first sewn to the posterior or left posterolateral side of the SMA. Retraction on the mesentery and bowel is relaxed, and the aorta is marked where the graft wants to sit. The infrarenal aorta is fully or partially cross-clamped, and the anterior wall is opened vertically. If the anterior wall is thick, a coronary punch or a small curved scissors is used to create an elliptical opening. The graft is cut short and beveled according to whether it will sit in a slight retrograde or antegrade position. The right lateral wall of the aorta and graft are sewn with running polypropylene suture using a parachute technique. The suture begins at the center and extends to the cranial and caudal end. The bowel is relaxed and the suture tightened. A double armed corner suture is placed at each end, tied and secured to the running suture. The left side of the anastomosis is completed by running each new suture toward the center, or by using interrupted sutures.

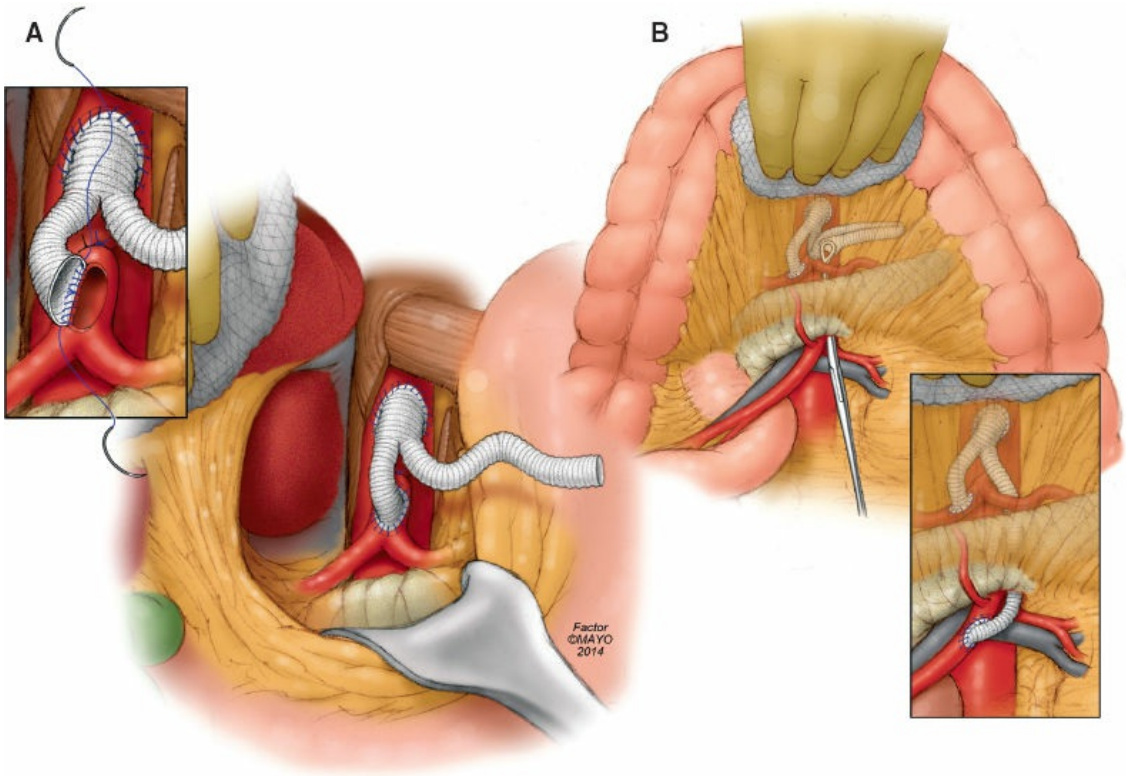

Figure 218.5. Anastomosis to the celiac can be done end-to-end, or configured as a functional end-to-end anastomosis, as illustrated in **A.** The latter simplifies cutting the graft to length and creating an anastomosis without tension. The graft limb is sewn end-to-side to the celiac, and the celiac trunk is ligated immediately proximal to the anastomosis. The SMA graft limb is passed through a retropancreatic tunnel; tension on the limb is fixed with a clamp at the base of the transverse colon, and the graft cut to length and sewn end-to-side to the artery as shown in **B.** (Image © Mayo 2014.)

Transaortic visceral endarterectomy is infrequently used, but works well for patients with atherosclerotic disease confined to the origin or first 2 cm of the SMA and CA. This technique is also useful for select patients with acute mesenteric ischemia and feculent spillage, which obviates the need for prosthetic, or for the rare patient who has concomitant symptomatic renal artery disease amenable to endarterectomy. The aorta and visceral arteries are isolated via left medial visceral rotation with the kidney kept down (Fig. 218.8). The spleen and pancreas are carefully mobilized, padded, and gently retracted. The crura is divided and the aorta is dissected free from its supraceliac to the juxtarenal segment. The adrenal vein is ligated and divided so that the renal vein can be retracted caudally. The renal artery origins are identified to ascertain distal aortic clamp

position, which often is the upper infrarenal aorta. Several centimeters of the celiac and SMA are circumferentially dissected free from their origins to allow for an eversion endarterectomy. Similar mobilization of the renal arteries is done if they require endarterectomy. Left phrenic and other small side branches may require ligation and division. The reconstruction begins by occlusion of the CA, SMA, and sometimes the renal arteries with vessel loops or atraumatic clamps, followed by application of distal and proximal aortic clamps. Lumbar arteries are controlled with small vessel loops or bull dog clamps. A curvilinear or trapdoor aortotomy is made from above the celiac to below the SMA. An endarterectomy plane is developed, and the aortic plaque is circumferentially freed from around the orifices of the SMA and celiac. The plaque is trimmed across the proximal and distal aorta, which facilitates eversion endarterectomy of the visceral arteries. At times, it is easier to evert the plaque from each artery by creating separate buttons, rather than trying to remove the endarterectomy specimen as one piece. The distal aortic endpoint is secured as necessary, and the aortotomy closed with running polypropylene suture. Back-bleeding and fore-bleeding are allowed prior to removal of the aortic and visceral clamps. If concomitant renal endarterectomy is needed, the aortotomy is carried distally on the anterior wall beyond the renal artery origins. An eversion technique is used to remove the occlusive plaque from them. Diuresis is induced with Lasix and mannitol after the cross clamp. Completion endarterectomy is needed in some patients if there is residual plaque or loose intima, which occurs more often in the SMA than the CA. The affected artery is gently clamped at its origin. A transverse or longitudinal arteriotomy is made in the artery, the plaque or intima is removed, and the endpoint secured. If the artery is opened transversely, it is closed primarily with interrupted sutures. If a longitudinal arteriotomy is made, a patch closure is done (Fig. 218.8).

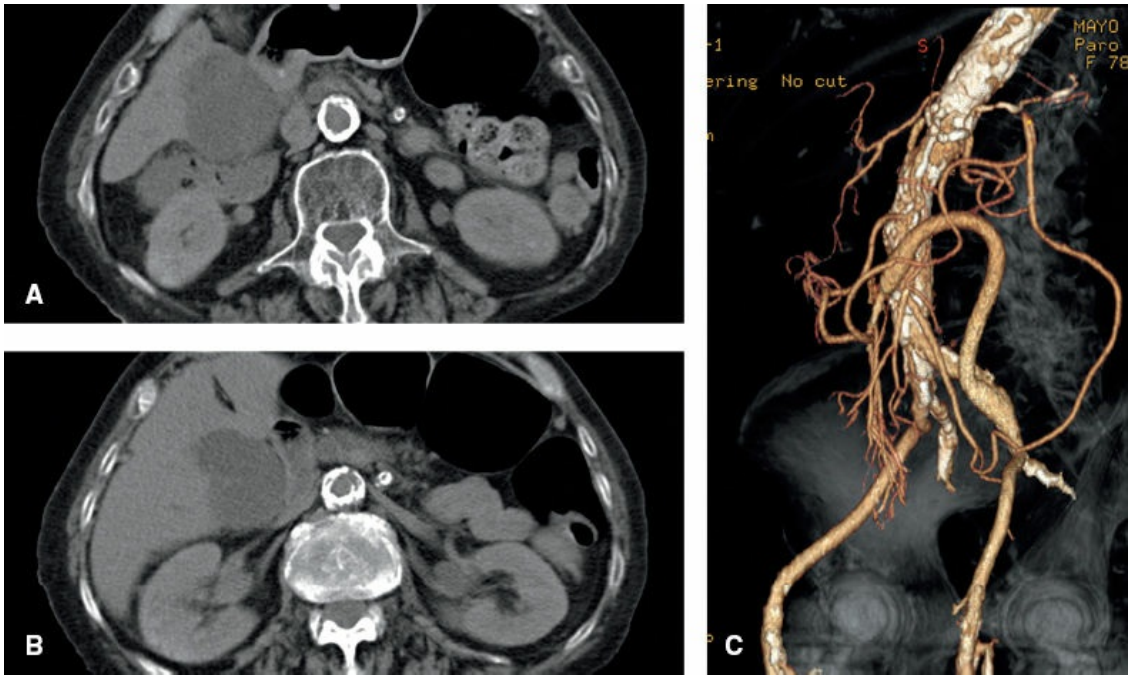

Figure 218.6. Retrograde bypass from the iliac artery can be done as a straight graft to the SMA, or more commonly in a C-shape. A retrograde configuration is used for high-risk patients, or those with severe calcification of the aorta as shown in both CT scan images (**A, B**). In this example, the left iliac artery was used for inflow, and the postoperative CTA shows a widely patent graft (**C**).



Figure 218.7. The challenge with a retrograde graft originating from the infrarenal aorta is kinking or buckling of the graft when the viscera are laid back in place. While rarely used, a short stove pipe graft (~2 cm) between the aorta and SMA obviates this problem. The SMA graft anastomosis is done first to the posterior or left posterolateral wall of the artery. The position of the aortic anastomosis is marked by relaxing retraction on the bowel. A button is cut from the anterior aortic wall, and the right lateral aortic suture line (back wall) is done with a parachute technique. The suture line is pulled tight as the bowel is relaxed. The left lateral suture line (front wall) is completed as a running or interrupted suture line. (Image © Mayo 2002.)

Redo open reconstruction for symptomatic patients with a failed bypass graft poses several challenges. Bowel adhesions and periarterial scar tissue make reoperation technically more difficult, as patients with a chronic graft occlusion can rarely be rescued by endovascular techniques. The burden of atherosclerotic disease may be greater in the SMA, so dissection must be carried further distally along the artery, which risks injury to arterial collaterals. Moreover, long length of disease may necessitate endarterectomy and patch angioplasty to facilitate the distal graft

anastomosis, which technically complicates the reconstruction. If a supraceliac aorta based bypass was done, a bypass from the iliac artery should be considered. If that is not possible because the infrarenal aorta and iliac arteries are too calcified to clamp or are diffusely stenotic, a bypass from the lower thoracic aorta may be needed if the supraceliac aorta cannot be easily isolated.

Completion intraoperative DUS is routinely used to assess technical outcome after mesenteric reconstruction. Bowel retraction is relaxed before the imaging is done to alleviate stretch on the CA and SMA, which otherwise may cause false elevation in blood flow velocities. Identification and immediate correction of technical defects in the operating room lowers early graft failure or arterial thrombosis.

Postoperative care

Postoperative fluid shifts are common during the first 48 postoperative hours because of the loss of mesenteric arteriolar autoregulation. This phenomenon is especially true for patients with subacute on CMI, who not only need fluid support, but may also need IV pressors to maintain adequate perfusion pressure because of a systemic inflammatory response. Adequate volume resuscitation is imperative before pressors are used, to avoid irreversible splanchnic vasoconstriction and bowel infarction that may occur if the central or pulmonary venous pressure is low. Close monitoring of the intravascular volume, cardiac function, and acid-base status is best done in an intensive care unit. Perioperative graft occlusion is rare if the intraoperative DUS shows a widely patent reconstruction. Nonetheless, an increase in fluid requirements, reduction in urine output, thrombocytopenia and/or leukocytosis, and subtle but steady narrowing of the A-aO_2 gradient or pulse pressure are harbingers of bowel ischemia. Metabolic acidosis is a late finding. These signs should prompt CT angiography, as ultrasound imaging of the bypass graft may be hampered by bowel gas. If the graft proves widely patent, abdominal exploration may still be needed if the clinical course worsens. An occluded graft warrants abdominal exploration and thrombectomy. If no technical cause of graft occlusion is found, a hypercoagulable state may be the culprit.

Perioperative complications range between 20% and 40% in most reports, and were listed as 36% in a Mayo Clinic study. The most common problems are pulmonary (15%) because these patients often are smokers with chronic obstructive pulmonary disease (COPD) and susceptible to

lung infection or pulmonary edema; gastrointestinal (14%), including prolonged ileus; and cardiac (10%) or renal (4%). Incisional problems occur in 4% to 8% of patients. Ascites is rare, but may develop in patients with subacute on chronic ischemia because the bowel weeps fluid for several days after surgery, IV requirements are high during this time, and the patients may be hypoproteinemic. Abdominal compartment syndrome is uncommon.

Intravenous nutrition supplemented with vitamins and trace elements is administered to malnourished patients until bowel function returns and caloric goals are met. Some patients benefit from oral nutritional supplements or six small daily meals to reach caloric goal. Diarrhea occurs in some patients and may last days to weeks until intestinal autoregulation improves. This problem can prove difficult to treat, even with antimotility and stool thickening agents. Monitoring of outpatient weight and volume status and involvement of a nutrition team are needed in these cases. Hospital length of stay ranges between 7 and 14 days after open revascularization. DUS surveillance is done at 6-month intervals for the first 2 years, then annually thereafter if the arteries and graft remain widely patent.

ENDOVASCULAR REVASCULARIZATION

The primary goal of percutaneous treatment is to restore antegrade flow into at least one of the three mesenteric arteries, preferentially the SMA. Early reports described successful results with balloon angioplasty alone, but elastic recoil and restenosis have limited its utility when used for ostial lesions. Most experts agree that primary stenting using a balloon-expandable stent offers the best chance for technical success and long-term patency. There is no proven benefit that routine two-vessel stenting provides more durable symptom relief or patency, and a second intervention adds cost and potential risk of complications.

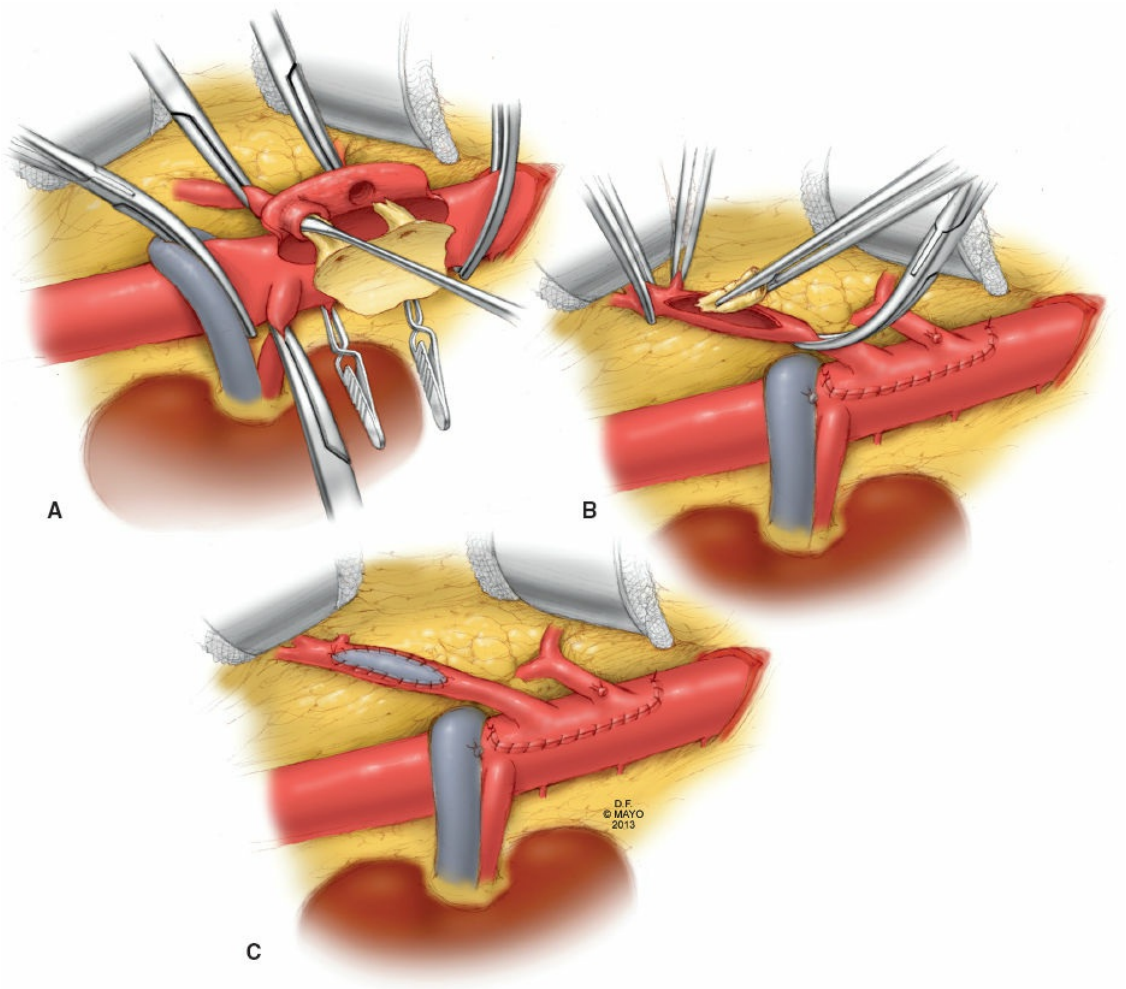

Figure 218.8. Transaortic visceral artery endarterectomy is applicable to patients with chronic, or acute on chronic, mesenteric ischemia who have short segment celiac and SMA occlusions or stenoses. Isolation of the supraceliac and juxtarenal aorta, and the celiac and SMA is done with a left medial visceral rotation, leaving the left kidney down. The visceral and/or renal arteries are clamped before the aortic clamps are placed. An eversion endarterectomy is done through a trapdoor or curvilinear incision as shown (**A**). Here, the entire specimen is shown being removed in one piece. Creation of separate buttons of plaque around the origin of each artery facilitates the eversion endarterectomy in some patients. Sometimes a completion endarterectomy and patch are needed for the SMA (**B, C**). (Image © Mayo 2013.)

Diagnostic Angiography

A diagnostic study includes a biplane abdominal aortography with anterior-posterior and lateral projections. A lateral view is imperative to provide visualization of the origins of the CA and SMA. A right anterior

oblique view demonstrates the origin of the IMA. For better visualization of ostial lesions and quantification of the degree of stenosis, selective catheterization of the visceral arteries is necessary. In patients who had prior CTA or MRA, abdominal aortography may be avoided, unless it is needed to identify the origin of a vessel prior to selective catheterization.

Access is established using ultrasound guidance and 0.035-in guidewire system. A 5-Fr sheath is positioned in the external iliac artery and 5-Fr diagnostic flush catheter is advanced to T12 level over a 0.035-in guidewire. Modest IV heparinization (40 units/kg) is recommended prior to selective catheterization of the mesenteric arteries. Low-osmolar contrast (e.g., Visipaque) minimizes abdominal discomfort during selective injections. Choice of catheter shape is dependent upon access site, angle of origin, and individual preference. MPA catheter is ideal for selective catheterization via brachial approach, whereas a secondary curve catheter (e.g., SOS or Simmons) or a catheter with more acute curve (e.g., Cobra 2) can be used for interventions done via femoral approach. Selective angiography is necessary to confirm the severity of disease and to identify tandem lesions and collateral patterns. In patients with questionable lesions, pressure gradients can be measured using pressure wire, “pull-back” or simultaneous pressure measurement technique.

Technique

A brachial artery approach is preferred for patients with a very angulated origin of the aorta and in those with occlusions or longer lesions (Fig. 218.9). It offers excellent support with small profile systems and allows precise stent deployment in patients with acute SMA angles. Although the risk of puncture-related complications is higher using percutaneous technique, the risk of complications is low using a small 1- to 2-cm incision under local anesthesia to expose and repair of the brachial artery.

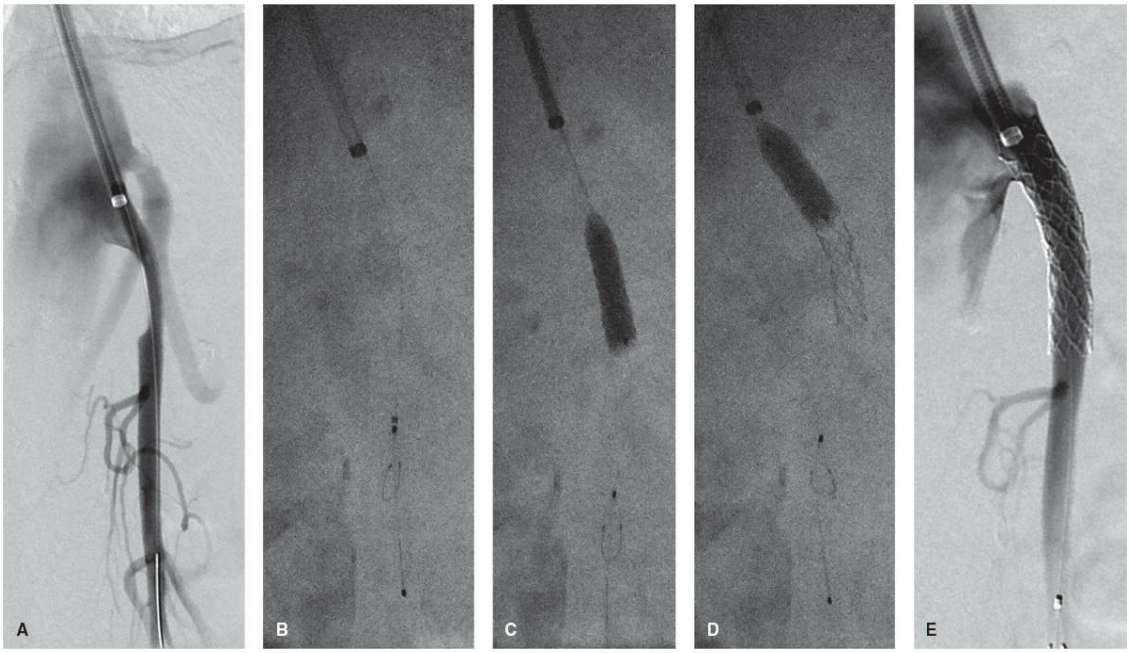

Figure 218.9. Selective angiography of the superior mesenteric artery (SMA) using brachial approach demonstrates high-grade stenosis (**A**). The lesion was crossed using a filter wire (**B**) and stented with balloon-expandable stents (**C, D**). Completion angiography shows widely patent SMA.

Arterial access is established with a 0.018-in micro-puncture set using ultrasound guidance, after which the system is exchanged to 0.035 in. Full systemic heparinization (80 mg/kg) is administered prior to catheter manipulations to achieve an activated clotting time of >250 seconds. A 6- or 7-Fr 90-cm hydrophilic sheath is positioned in the descending thoracic aorta above the CA origin. A 5-Fr MPA catheter is ideal for selective catheterization of the mesenteric arteries using the brachial approach, whereas an SOS or VS1 catheter can be used from the femoral approach. The initial selective angiography should demonstrate the origin of the vessel from the aortic wall, the severity of the stenosis, and should document the distal branches for comparison with postintervention views. The target lesion is initially crossed using a 0.035-in soft angled glide-wire, which is exchanged for the interventional wire after confirmation of true lumen access. Most patients are treated using 0.014- or 0.018-in guide-wire system, which should be visualized and positioned within the main trunk of the SMA, rather than within small jejunal branches, which are prone to perforate or dissect. Embolic protection devices can be useful in patients with occlusions, severe calcification, or acute thrombus, such as in patients with acute or subacute symptoms. Our preference is to use a

320-cm working length 0.014-in filter wire (Spider RX, Medtronic, Plymouth, MN) coupled with a 0.018-in “buddy wire”; the 0.035-in stent is introduced via both wires for better support and to facilitate subsequent retrieval of the embolic protection device. Predilatation is recommended for tight stenosis, occlusions, severe calcification, and to size stents. A balloon-expandable stent with diameters ranging from 5 to 8 mm is used in >95% of cases, allowing precise deployment and greater radial force. Our preference has been to use a covered stent in most patients with proximal lesions that do not extend beyond branches. The stent is positioned under protection of the sheath, covering slightly more than the entire length of the lesion. Positioning the stent in the aortic lumen is critical to avoid missing the proximal portion of the lesion. It is important to position the stent 1 to 2 mm into the aortic lumen. Ideally, the stent should be flared gently into the aorta, which prevents missing the ostia and facilitates recatheterization if needed. Occasionally, a self-expandable stent is needed to treat a nonostial lesion or segments with excessive tortuosity, extending beyond the angulated portion of the SMA.

The technique is slightly modified in patients with occlusions (Fig. 218.10). In these difficult cases, it is of paramount importance to use the brachial approach and a stiff support system, which is accomplished by combining a 7-Fr sheath, 7-Fr MPA guide-catheter, and 5-Fr MPA catheter (Fig. 218.10). Ideally, the tip of the MPA catheter is used to engage the stump of the occluded SMA, and sufficient support is provided by the combination of the sheath and guide-catheter. The lesion is crossed using a straight tip, hydrophilic, soft 0.035-in glide-wire, but also using 0.018-in or 0.014-in guide-wires if needed. It is ideal to avoid the subintimal plane, which is best achieved by using straight tip guide-wires. A Quick-cross (Spectranetics, Colorado Springs, CO) or an alternative support catheter, or even a small coronary balloon may be needed to cross a tight lesion. Once the lesion is crossed, access into the true lumen should be confirmed. Our preference has been to use embolic protection device (e.g., Spider RX, Covidien, Plymouth, MN) with two-wire technique routinely in cases of total occlusion.

Following deployment and flaring of the stent, the embolic protection device is retrieved with careful attention to avoid entrapment into the stent. The basket is examined for debris. A formal completion angiography should be obtained, including a focal magnified view of the stent with the sheath into the aorta to demonstrate the vessel origin and a panoramic view

of the entire SMA and its branches to rule out embolization or perforation. The stiff guide-wire should be retracted and nitroglycerin may be administered via the sheath to minimize spasm or kinks caused by the guide-wire tip. It is particularly important to note the presence of distal embolization, dissection, thrombus, or branch perforation. These complications occur in 5% to 10% of patients and remain a major source of morbidity and mortality if not immediately recognized.

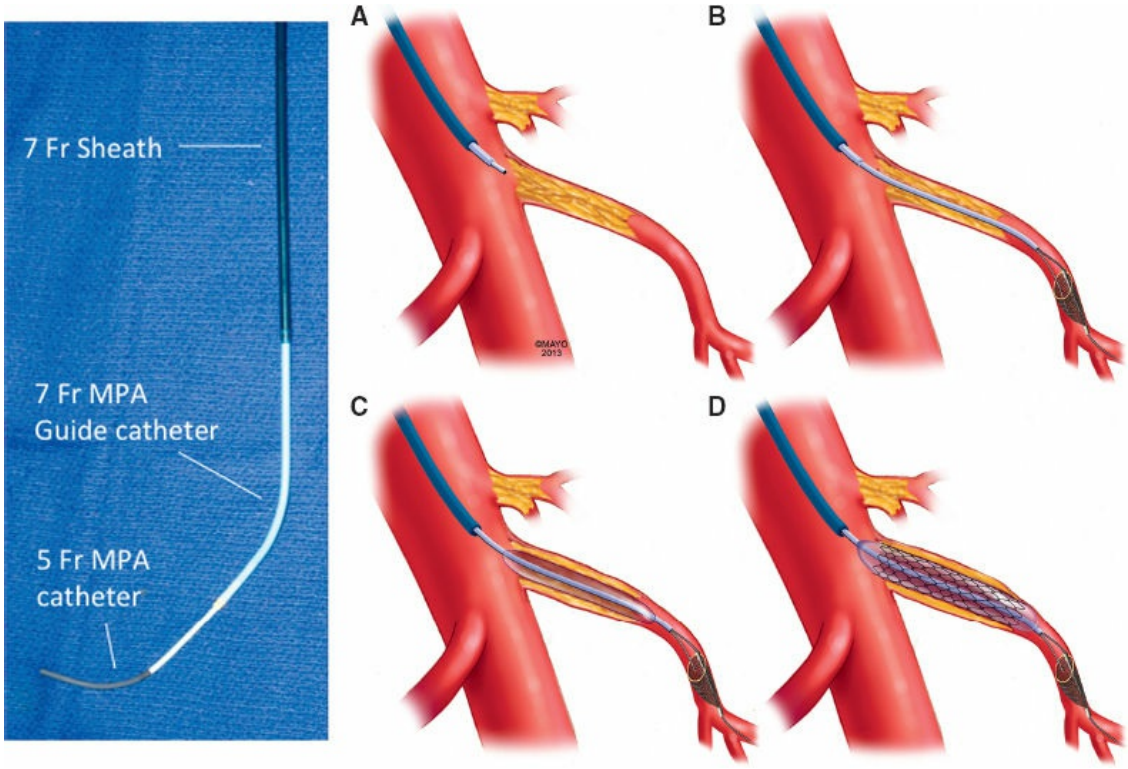

Figure 218.10. Technique of recanalization using co-axial system with 7-Fr sheath, 7-Fr guide catheter, and 5-Fr MPA catheter. The occluded superior mesenteric artery (SMA) stump is engaged with the co-axial system (**A**). The lesion is crossed using a glidewire and catheter (**B**), followed by predilatation (**C**) and stent placement (**D**). (Image © Mayo 2013.)

A number of adjunctive techniques can be used to optimize results of mesenteric stents in patients with complex lesions, but the authors acknowledge that these techniques are anecdotal or supported by a limited number of case reports. The presence of acute and subacute symptom presentation suggests fresh thrombus or complicated plaque. In these cases, local administration of t-PA into the diseased segment 20 to 30 minutes prior to stent placement may improve technical success. For eccentric, calcified lesions, percutaneous atherectomy has been carefully

used in very select cases. It is critical to have an appreciation of the limitations of this technique when applied as off-label use in the mesenteric arteries.

Hybrid Revascularization

The term retrograde open mesenteric stenting (ROMS) has been coined to describe a hybrid approach using a midline laparotomy to expose the SMA and endovascular technique to place a retrograde SMA stent. This was first reported by Milner and colleagues from the University of Pennsylvania and Dartmouth Group. ROMS avoids the need for extensive dissection, vein harvesting, and use of a prosthetic graft. Its utility is for patients with extensive aortoiliac disease and no good source of inflow, or in those with acute mesenteric ischemia, bowel gangrene, and contamination (Fig. 218.11).

The SMA is dissected below the pancreas as previously described. Several jejunal branches are controlled with silastic vessel loops and occluded prior to manipulation to avoid distal embolization. Retrograde SMA access is established using a micro-puncture set with 0.018-in guide-wire. This is exchanged for a 0.035-in guide-wire system and a 6- to 7-Fr sheath is advance to the SMA. Retrograde angiography is obtained and the SMA occlusion or stenosis is crossed, predilated and stented with a balloon-expandable stent. Prior to restoring antegrade flow to the SMA, the sheath is flushed to prevent distal embolization. The puncture site may be closed with interrupted sutures or opened longitudinally and closed over a patch if severely diseased.

Postprocedure Management

The postprocedure care after mesenteric interventions is comparable to that of other peripheral endovascular procedures. All patients are admitted for observation overnight. Worsening abdominal pain after the procedure is unusual and warrants evaluation to rule out thrombosis, embolization, or a mesenteric hematoma from jejunal branch perforation. Patients are allowed to resume a regular diet within 6 to 8 hours. Antiplatelet therapy is typically started prior to the intervention with acetylsalicylic acid, and continued indefinitely thereafter. Clopidogrel is started the day of the intervention with a loading dose of 300 mg, and continued for 6 to 8 weeks as a dual antiplatelet agent, after which patients are kept on acetylsalicylic acid alone. The author’s preference is to obtain a duplex ultrasound scan

prior to discharge or within the first few days after the procedure to serve as a baseline for future comparison. The presence of elevated velocity on duplex ultrasound may be due to inadequate stenting with missed lesion proximal or distal to the stent. Follow-up includes clinical examination and duplex ultrasound every 6 months during the first year and annually thereafter.

RESULTS

Outcome measures for open and endovascular treatment include mortality and morbidity, symptom relief, freedom from restenosis, and symptom recurrence and reintervention. Anatomy, patient age, comorbidities and frailty, surgeon experience, and intraoperative and perioperative management are all influential to outcome. Interpretation of outcomes between centers is hampered by a mix of patients with acute and chronic presentations, those with median arcuate ligament syndrome, and inconsistent reporting of disease severity, clinical and imaging follow-up for patency, and the aforementioned outcome measures. Standards in reporting and risk stratification are needed to compare effectiveness of treatment. Similar to outcome for other open vascular operations, the lowest mortality rates for mesenteric bypass are reported by high-volume surgeons at high-volume centers. Mortality rates of 10% or more reported at some hospitals are excessive in our opinion. Isolated bypass performed by experienced surgeons can be done safely, even for redo reconstructions.

A Mayo Clinic report assessed risk-stratified outcomes in 229 CMI patients treated by open bypass or endovascular procedures, using the Society for Vascular Surgery comorbidity scoring system. The data from this paper can be used to gauge treatment. Patients were categorized into high- or low-risk open and endovascular groups. Overall mortality was similar between the open (2.7%) and endovascular (2.4%) groups. However, low-risk patients treated with open bypass had a perioperative mortality rate of only 1% compared with 6.7% for high-risk patients. Operative mortality varied based on the number of high-risk criteria present. Patients with no high-risk factors had a 30-day mortality rate of 0.7%. This sharply contrasted to mortality rates of 3.1% if one high-risk criterion was present, to more than 25% if four criteria were present. Moreover, concomitant aortic reconstruction carried an 8.9% mortality rate. Therefore, mesenteric revascularization should be the sole goal of therapy, and the type of revascularization tailored to what patient risk and

anatomy allow. Aortic replacement should only be done if inflow cannot be otherwise obtained, or if the patient has a large aneurysm. Old sick or malnourished patients are at high risk for perioperative problems, and are better served by the least stressful procedure possible. Mortality and morbidity of open revascularization are higher compared to endovascular approach in review of large datasets.

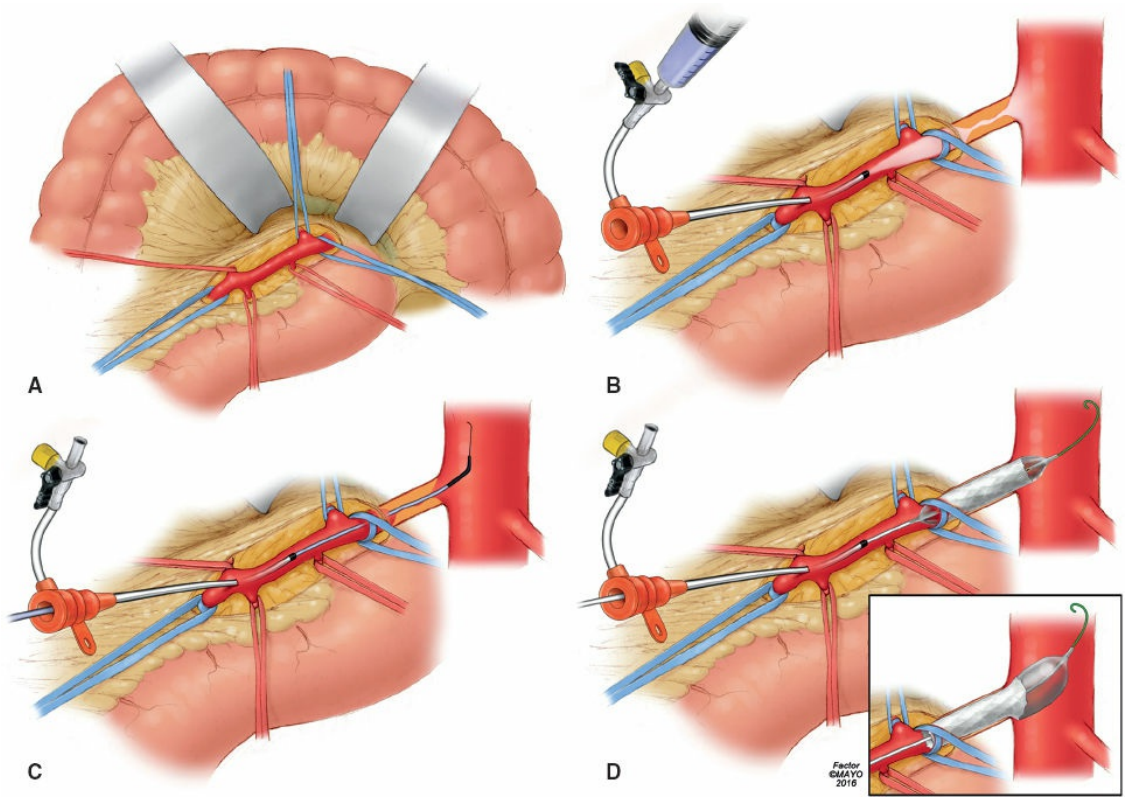

Figure 218.11. Technique of retrograde open mesenteric stenting (ROMS) requires exposure of the SMA via laparotomy (**A**). The SMA is accessed in a retrograde fashion with a 7-Fr sheath (**B**). Retrograde angiography demonstrates near occlusion of the SMA, which is crossed using glidewire and catheter (**C**). The stenotic SMA is stented using a balloon expandable covered stent (**D**). (Image © Mayo 2016.)

Both methods of revascularization are highly effective, with symptom improvement averaging 88% with endovascular and 93% with open revascularization. Most single center series show mesenteric bypass to carry a higher patency rate, lower risk of restenosis, better freedom from recurrent symptoms, and fewer reinterventions than patients treated with angioplasty and stenting. Primary patency 5 years after open bypass averages almost 90% in a review of the pooled literature (range 57% to

92%), and reintervention is needed in less than 10% of cases. One theoretic advantage of two-vessel bypass is that occlusion of one graft limb does not always necessitate reintervention or cause recurrent symptoms.

Endovascular treatment is offered over open revascularization at most centers, because of its low mortality, morbidity, and short hospital stay. Recurrent stenosis may occur at the edges of the stent in 50% or more of the patients, with in-stent stenosis in the remainder. Patency can be maintained with another endovascular intervention, such as cutting or cryo-balloon angioplasty, redo stenting with bare metal or drug-eluting stents, atherectomy or covered stents. To date, while none has been proven better than standard angioplasty, our preference is to treat restenosis with a balloon expandable covered stent. Some data suggest that primary use of a covered stent may be better than placing a bare metal stent. This paradigm shift in treatment has relegated open bypass to patients with more challenging anatomy and for endovascular failures. Even in these circumstances, nearly three fourths of bypass grafts remain patent at 5 years.

PATIENT SURVIVAL

Many factors affect long-term survival after mesenteric revascularization, including advanced age, impaired cardiac, pulmonary or renal function, and type of therapy. The use of propensity matched scores among a cohort of 343 patients treated for CMI by endovascular techniques and open bypass at Mayo Clinic sheds some light on survival trends. The 5-year survival rates were nearly identical in patients treated by open (57%) or endovascular techniques (60%), yet patient comorbidity and risk score impacted survival. For example, 5-year patient survival was approximately 71% for low-risk patients, 49% for intermediate-risk ones, and 38% for high-risk patients. Open bypass and endovascular treatment provided excellent 5-year freedom from mesenteric-related death, over 90% in each group. Age over 80 years, home oxygen therapy, advanced chronic kidney disease, and diabetes increased all-cause mortality, whereas the latter two problems influenced mesenteric-related death. The most common cause of late death is cardiac events, which suggests the need for long-term monitoring of cardiovascular risk factors in these patients.

NONATHEROMATOUS PROBLEMS

Mesenteric vasculitis is the second most common cause of CMI after atherosclerosis, but the literature is sparse. Medical treatment with steroids or other immunosuppressants is initiated first. Stenting does not work well, and operation should be avoided in the active phase of disease unless absolutely necessary to treat an acute event because of the high risk of graft occlusion. For symptomatic patients with mesenteric stenoses whose arteritis is quiescent or chronically controlled by steroids, bypass is effective. Arterial outflow and inflow must be done to and from healthy vessels to achieve the best durability. Long-term survival is similar to the general population. Reconstructions are safe, and provide similar graft patency (83% vs. 84%) and freedom from recurrent symptoms (83% vs. 75%) as patients treated for atherosclerotic disease. The reader is referred to other literature for the management of mesenteric ischemia caused by aortic or isolated visceral dissection, coarctation, neurofibromatosis, and radiation injury.

SUMMARY

Intervention for patients with CMI is done with endovascular techniques as first-line therapy at most centers. Even patients with difficult lesions are considered for angioplasty and stenting, accepting a higher rate of technical failure and reintervention in those with long occlusions or severe calcification. Primary stenting using a balloon-expandable covered stent seems to afford the best technical result and long-term patency rate. Open mesenteric revascularization is done for low-risk patients with flush SMA occlusion, long segment calcified stenoses not amenable to stenting, women with small vessels, and for nonatheromatous diseases. Our preference is to use the supraceliac aorta for inflow, and to reconstruct both the CA and SMA when possible. However, SMA bypass alone works well, whether done antegrade or retrograde. Mesenteric bypass can be performed safely by experienced surgeons, even for reoperation. Surgical treatment should focus on mesenteric artery revascularization as the primary goal, and concomitant aortic replacement should be avoided.

Suggested Readings

Foley MI, Moneta GL, Abou-Zamzam AM Jr, et al. Revascularization of the superior mesenteric artery alone for treatment of intestinal ischemia. *J Vasc Surg* 2000;32(1):37–47.

Moneta GL, Lee RW, Yeager RA, et al. Mesenteric duplex scanning: a blinded

prospective study. *J Vasc Surg* 1993;17(1):79–84.

Oderich GS, Bower TC, Sullivan TM, et al. Open versus endovascular revascularization for chronic mesenteric ischemia: risk-stratified outcomes. *J Vasc Surg* 2009; 49(6):1472–9e3.

Oderich GS, Erdoes L, LeSar C, et al. Comparison of covered stents versus bare metal stents for treatment of chronic atherosclerotic mesenteric arterial disease. *J Vasc Surg* 2012;55(6):23S.

Sarac TP, Altinel O, Kashyap V, et al. Endovascular treatment of stenotic and occluded visceral arteries for chronic mesenteric ischemia. *J Vasc Surg* 2008;47(3):485–91.

Schermerhorn ML, Giles KA, Hamdan AD, et al. Mesenteric revascularization: management and outcomes in the United States, 1988–2006. *J Vasc Surg* 2009; 50(2):341–8e1.

Thomas JH, Blake K, Pierce GE, et al. The clinical course of asymptomatic mesenteric arterial stenosis. *J Vasc Surg* 1998;27(5):840–4.

EDITOR'S COMMENT

This chapter by Bower and Oderich serves as the master's guide on how to define and manage chronic mesenteric ischemia and really helps to remind me why this book is important for our readers. Dr. Tom Bower is a master open surgeon who has spent his entire career at the Mayo Clinic really performing open surgery on all comers, but really mainly on people who could not have an endovascular approach who has already had an open/endovascular approach that failed. Dr. Gustavo Oderich is an expert endovascular specialist, who has developed novel endovascular techniques to make stenting of previously nonstentable lesions (i.e., occlusions) safely treatable via endovascular techniques.

The description of open surgery using the supraceliac aorta or an iliac artery is spot on. I, likely because I used to do a lot of abdominal aortic debranchings, am more comfortable with the iliac as the inflow source (Kabbani LS, Criado E, Upchurch GR Jr, et al. Hybrid repair of aortic aneurysms involving the visceral and renal vessels. *Ann Vasc Surg* 2010;24(2):219–24). It seems like many of the patients I have taken care of always have diseased supraceliac aortas, making the idea of clamping in this region less than attractive. My old partner Ramon Berguer used to love doing supraceliac aortic bypasses. However, he used a single graft off the aorta that he then sewed on another graft in a y-configuration, rather than a bifurcated aortic graft. His results paralleled those of the Mayo Clinic presented in this chapter.

I should comment on the idea of getting chronic mesenteric arteries that are occluded open. Dr. Oderich describes using a filter wire and a buddy 0.035 wire

to both protect the distal SMA and also deliver the balloon expandable covered stent. This makes sense but seems pretty cumbersome and makes one wonder why a company doesn't make a 0.035 filter wire that can be used in such a situation.

There are data in open mesenteric revascularization surgery to support an approach that supports revascularizing as many mesenteric vessels as one can (Hollier LH, Bernatz PE, Pairolero PC, et al. Surgical management of chronic intestinal ischemia: a reappraisal. *Surgery* 1981;90(6):940–6). I believe this suggestion has stood the test of time and remains true. However, it is interesting to note that most endovascular enthusiasts don't support this approach when it comes to endovascular revascularization in patients with CMI. Almost universally people only stent the SMA and I don't really understand it other than the fact that I recognize that celiac stents can be crunched and I personally don't think they work that well (Ahanchi SS, Stout CL, Dahl TJ, et al. Comparative analysis of celiac versus mesenteric artery outcomes after angioplasty and stenting. *J Vasc Surg* 2013;57(4):1062–6). Some have even suggested that celiac stenting be abandoned, especially in the setting of suspected median arcuate ligament compression of the celiac (Delis KT, Gloviczki P, Altuwaijri M, et al. Median arcuate ligament syndrome: open celiac artery reconstruction and ligament division after endovascular failure. *J Vasc Surg* 2007;46(4):799–802). It also sort of suggests that important collaterals are lost when open surgery is performed. I have gone to using a retrocolic, retrogastic tunnel, not a retropancreatic tunnel for bypasses as I worry about the creating the retropancreatic tunnel (and have seen some serious misfortune while creating that tunnel!) In contrast, others have stented the inferior mesenteric artery in the setting of an occluded celiac and SMA stent and the patients benefited (Wohlauer M, Kobeiter H, Desgranges P, et al. Inferior mesenteric artery stenting as a novel treatment for chronic mesenteric ischemia in patients with an occluded superior mesenteric artery and celiac trunk. *Eur J Vasc Endovasc Surg* 2014;27(3):e21–e23). Really hard to make sense of what the right thing to do in a one-size-fits-all type of algorithm. It is best to recognize that one needs to approach every patient individually and trying to figure out a revascularization strategy that works best for their patient.

Finally, it is sort of interesting to me that when patients have SMA stents go down, especially in the chronic setting, they seem to tolerate it and don't have complete collapse from an entirely ischemic small bowel. Of course this is completely anecdotal, but I have seen a number of these occluded stents rescued with posis and restenting. Having said that, I would still treat this like a surgical emergency and be quick to get the patient to the hybrid endosuite. Dr. Oderich is probably right in this in this setting similar to the native occluded SMA, the use of a filter wire is likely indicated.

Gilbert R. Upchurch

F VASCULAR INFECTION

219 Mycotic Aneurysms

Cheong J. Lee

Originally introduced by Osler in 1885 to describe peripheral arterial aneurysms initiated by septic embolization from bacterial endocarditis, the term “mycotic aneurysm” is now generally applied to aneurysmal degeneration of an artery from infection. Although the term “mycotic” implies fungal etiology, the majority of these aneurysms are caused by bacteria. Mycotic aneurysms can be found in any peripheral vascular bed, and within this spectrum, aortic infections or aortitis represents one of the most challenging entities to manage surgically.

Aortitis as a clinical entity is generally viewed as the early stage of a mycotic aortic aneurysm. The dilemma of aortitis lies in how to differentiate between infectious versus noninfectious causes, since infectious aortitis without intervention often leads to aortic rupture and death. Aortitis account for approximately 1% to 2% of all cases of abdominal aortic aneurysms. Aseptic or inflammatory aortitis is more commonly encountered; however, the majority of surgically relevant aortitis and mycotic aortic aneurysms result from arterial wall degradation by pathogenic organisms. Infective aortitis is associated with substantial morbidity and mortality. As such, high index of suspicion is required for confirming the diagnosis, which is often based on morphologic changes of the aortic wall that range from thickening, endarteritis, emphysema, ectasia, ulcerations, to ultimately aneurysms. Once aortitis has been confirmed radiographically, its nature should be considered infectious until proven otherwise.

ETIOLOGY AND PATHOPHYSIOLOGY

Mechanisms by which mycotic aneurysms form are by direct pathogenic inoculation of the arterial wall, bacteremia, local contamination by

infection, and septic embolism. Underlying risk factors of patients that increase vulnerability to arteritis and subsequent mycotic aneurysm development include patients with direct arterial injury, those with history of an antecedent infection, patients with impaired immunity, and preexisting disease of the arterial intima, such as atherosclerosis and aneurysms.

The most common pathways behind the development of mycotic aneurysms are via direct bacterial inoculation and bacteremia from an antecedent infection. Seeding of the arterial wall can occur at the time of vascular injury by mode of self-inflicted processes (intravenous drug use), iatrogenic (contaminated instrumentation), or due to penetrating trauma leading to the development of mycotic pseudoaneurysms in which there is complete degradation of arterial wall integrity. Contaminated needle sharing is probably the most common mode of peripheral mycotic aneurysm development. With regard to iatrogenic causes, recently there have been increasing reports of mycotic aneurysms developing in patients who have had intravesicular Bacillus Calmette-Guérin (BCG) instillation for treatment of bladder cancer. BCG is a strain of *Mycobacterium bovis* that elicits a local granulomatous inflammation to temper progression of bladder tumor cells. It is thought that septic dissemination of BCG via the vasa vasorum leads to mycotic arteritis and aneurysms. BCG-associated mycotic aneurysms can develop in any vascular bed in this inherently immunocompromised patient population. Although cases seem exceptional and rare, the author of this chapter has treated two patients with tubercular mycotic aneurysms that formed in the carotid, femoral, popliteal, aortoiliac, and coronary arterial beds following long-term BCG use.

Extension of a focus of infection is another means for direct arterial contamination. Infected aortoiliac aneurysms have been reported as a result of local sepsis caused by gastrointestinal perforations and colorectal infections. Pancreatitis and vertebral osteomyelitis have been reported to cause mycotic visceral artery and aortic aneurysms. Infected orthopedic hardware and other prosthetic implants adjacent to a vascular bed can also conceive arterial infections.

Septic embolism from endocarditis (from which the term “mycotic aneurysm” originates) can evolve into arteritis and on to infected aneurysms. In the pre-antibiotic era, the majority of infected aneurysms were due to endocarditis. Typically, emboli lodge at arterial bifurcations and as such mycotic aneurysms from septic emboli most commonly

develop in the peripheral arterial bed. Intracranial arteries, followed by visceral arteries, and upper or lower extremity arteries are the most commonly involved sites.

Although normally resistant to infection, a diseased intima, such as in atherosclerotic plaques or preexisting aneurysms, allows pathogens into deeper layers of the arterial wall. Aorta is the most commonly involved arterial bed by bacteremic seeding and inoculation given that it is burdened with the greatest amount of atherosclerosis. Preexisting aortic aneurysms are also at risk for infection. When cultured, a significant number of aortic aneurysms are found to have bacterial colonization in the aortic tissue, although the majority of patients go on to have no known negative sequelae.

The microbiology of mycotic aneurysms continues to change over time. In most cases, blood and tissue cultures are positive in over 50% of patients with the diagnosis; however, no pathogen is isolated in up to 25% of cases. The organisms classically known to have the greatest affinity for the vascular wall are *Staphylococcus* and *Salmonella*. In the western hemisphere, *Staphylococcus aureus* and *Streptococcal* species are typically the most common pathogens reported in infected arterial beds. Salmonella is the most common organism seen in the eastern hemisphere. Gram-negative organisms overall are associated with higher incidence of aneurysm rupture and associated mortality. More rare are anaerobic and fungal pathogens, along with mycobacterial causes as mentioned previously.

CLINICAL PRESENTATION

The presentation of patients with mycotic aneurysms varies depending on the arterial bed involved. For more peripheral or superficial arterial segments, the classic presentation of a mycotic aneurysm is a painful, pulsatile, enlarging mass in the setting of systemic responses, such as fever and malaise. Nonaortic peripheral aneurysms that deviate from their natural history and present with rupture should raise suspicion for underlying infection. In general, aseptic peripheral aneurysms (e.g., popliteal and brachial) more commonly present with distal embolization and not rupture. Unless the process is an acute pseudoaneurysm from recent trauma, it is atypical for true peripheral aneurysms to be tender and symptomatic, or present with rupture (Fig. 219.1). Infected aneurysms may be masked by overlying inflammation and presence of a soft tissue

infection adjacent to a major blood vessel should raise suspicion for a mycotic process. The process can be easily misdiagnosed as cellulitis, abscess, or thrombophlebitis.

Deeper seeded arterial infections may present with more nonspecific systemic symptoms. Mycotic aneurysms involving the aorta or iliac arteries may be accompanied by abdominal or back pain but vague systemic symptoms such as fever, chills, and night sweats are more common. As such, the diagnosis may not be apparent until the aneurysm has ruptured. Mycotic aortic aneurysms can occur throughout the aorta. The most common location is thought to be the infrarenal aortic segment, which is seen in up to 50% of the cases. The descending thoracic aorta is the next most common (~25%), followed by paravisceral (16%), and ascending (10%) segments. A recent report from Northwestern Memorial Hospital (Chicago, IL), however, suggests that the paravisceral aorta maybe involved more frequently. Of 13 patients treated over a 10-year span with primary infectious aortitis, 8 (61%) involved the paravisceral aortic segment.

Profound mass effect or erosion of a mycotic aneurysm can result in enterobiliary and at times pulmonic erosion and fistulae. Gastrointestinal bleeing or hemoptysis as a result of arterial erosion can have catastrophic outcomes and expedient management is required. Similarly, arteriovenous communications have been reported following rupture of an infected aneurysm to an adjacent major venous bed. Such events can lead to high-output cardiac failure. At times, mass effect of aneurysms can result in neurologic sequelae. Mycotic aneurysms of the carotid artery can present with hoarseness due to vagus nerve compression, aortoiliac processes can result in femorosciatic radiculopathy, and intracranial mycotic aneurysms can present as acute stroke.

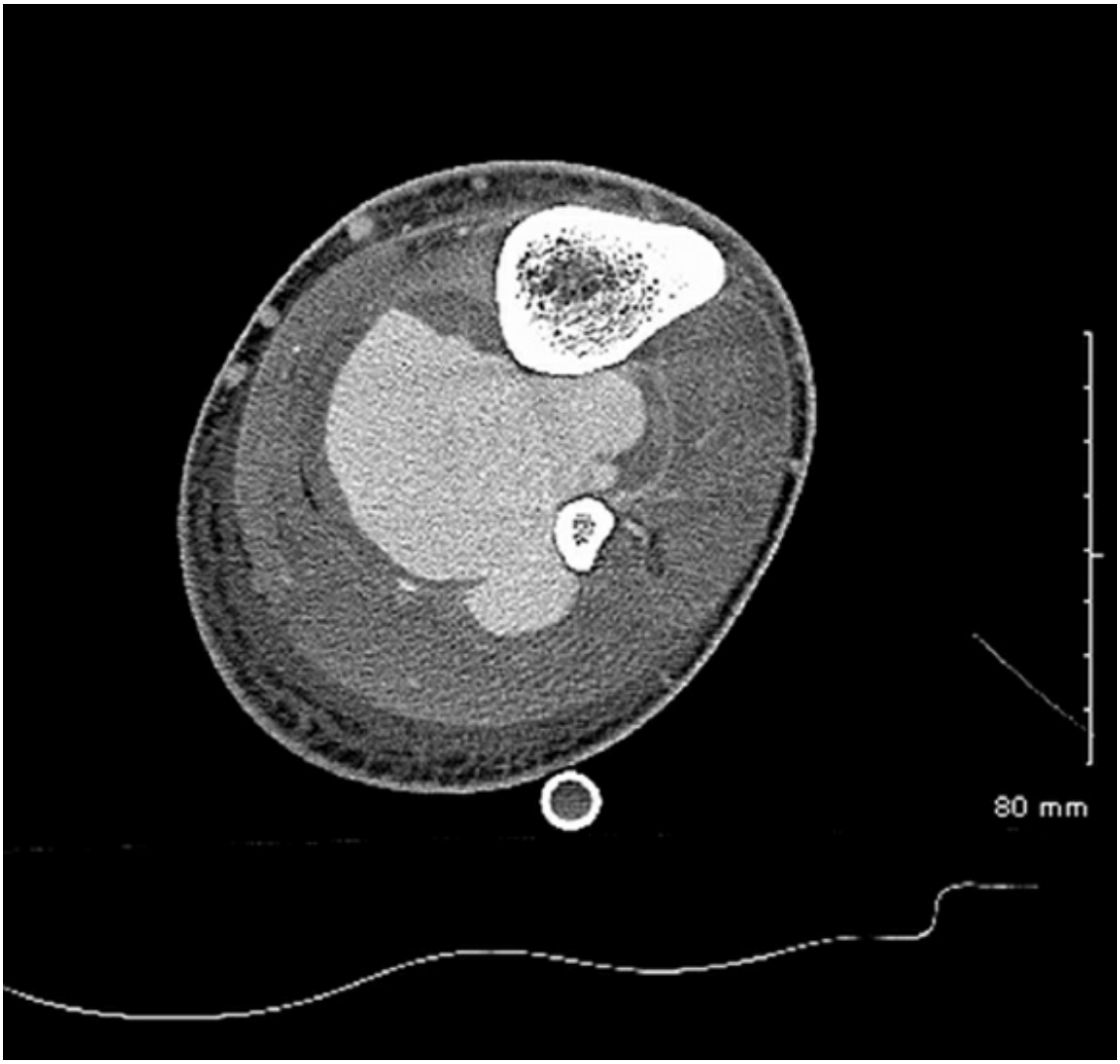

Figure 219.1. CT scan of a ruptured mycotic popliteal artery aneurysm that developed in an IV drug user with bacterial endocarditis. Infectious etiology should be considered when nonaortic peripheral aneurysms deviate from their natural history, which is generally distal embolization and occlusion.

DIAGNOSIS

Imaging plays a critical role in the diagnosis of mycotic aneurysms. In cases of aortitis, it is difficult to distinguish mycotic aortic aneurysms from inflammatory aortic aneurysms as clinical presentation is similar. Both processes can present with a spectrum of symptoms suggestive of systemic inflammatory response syndrome (SIRS), such as fever, weight loss, nonspecific abdominal pain, and elevated serum inflammatory markers including leukocytosis, C-reactive protein, and sedimentation rate. Both entities involve the arterial wall, but inflammatory aortitis is primarily characterized by adventitial thickening and fibrosis. Indistinct

retroperitoneal tissue planes between structures, such as the duodenum, ureter, and vena cava, can be seen on imaging. Wall thickening does occur with infective aortitis, but notable morphologic deterioration can ensue ranging from thickening, edema, endarteritis, emphysema, ectasia, ulcerations, to ultimately aneurysmal development and frank rupture (Fig. 219.2).

Contrast-enhanced computed tomography (CT) scan is probably the most useful modality in differentiating the types of aortitis and other peripheral mycotic aneurysms. Magnetic resonance imaging (MRI) can be helpful in cases where intravenous contrast is contraindicated. Saccular or multilobular type aneurysm or eccentric irregularity of an arterial wall with ulcerations is suspicious for a mycotic aneurysm (Fig. 219.3). Presence of perivascular fluid or edema, intramural air or extraluminal air surrounding the vessel and stranding are additional features to help confirm the diagnosis. Interval imaging to mark evolution and rapid enlargement of a possible infected aneurysm is beneficial in cases where the diagnosis is uncertain. Other modalities including ultrasound and conventional angiography are not as beneficial as arterial wall characterization is not as easily made. Nuclear imaging including indium-111 tagged white blood cell scan can be beneficial in confirming the diagnosis if conventional axial imaging demonstrates uncertainty but suspicion for an infectious process remains high.

MANAGEMENT

Once the diagnosis is suspected, regardless of the underlying etiology, expedient treatment of the infected artery is required as rapid degeneration of the arterial wall will occur leading inevitably to rupture, even in cases without aneurysms. If diagnosed correctly, noninfectious, immune-mediated aortitis will respond to immunosuppressive therapy, whereas infectious aortitis requires appropriate antimicrobial therapy in conjunction with surgical debridement and revascularization. Antimicrobial therapy alone in the setting of infectious aortitis demonstrates mortality rates that approach 100%. Similarly, medical therapy alone for infectious peripheral aneurysms will result in eventual catastrophic bleeding and end organ loss.

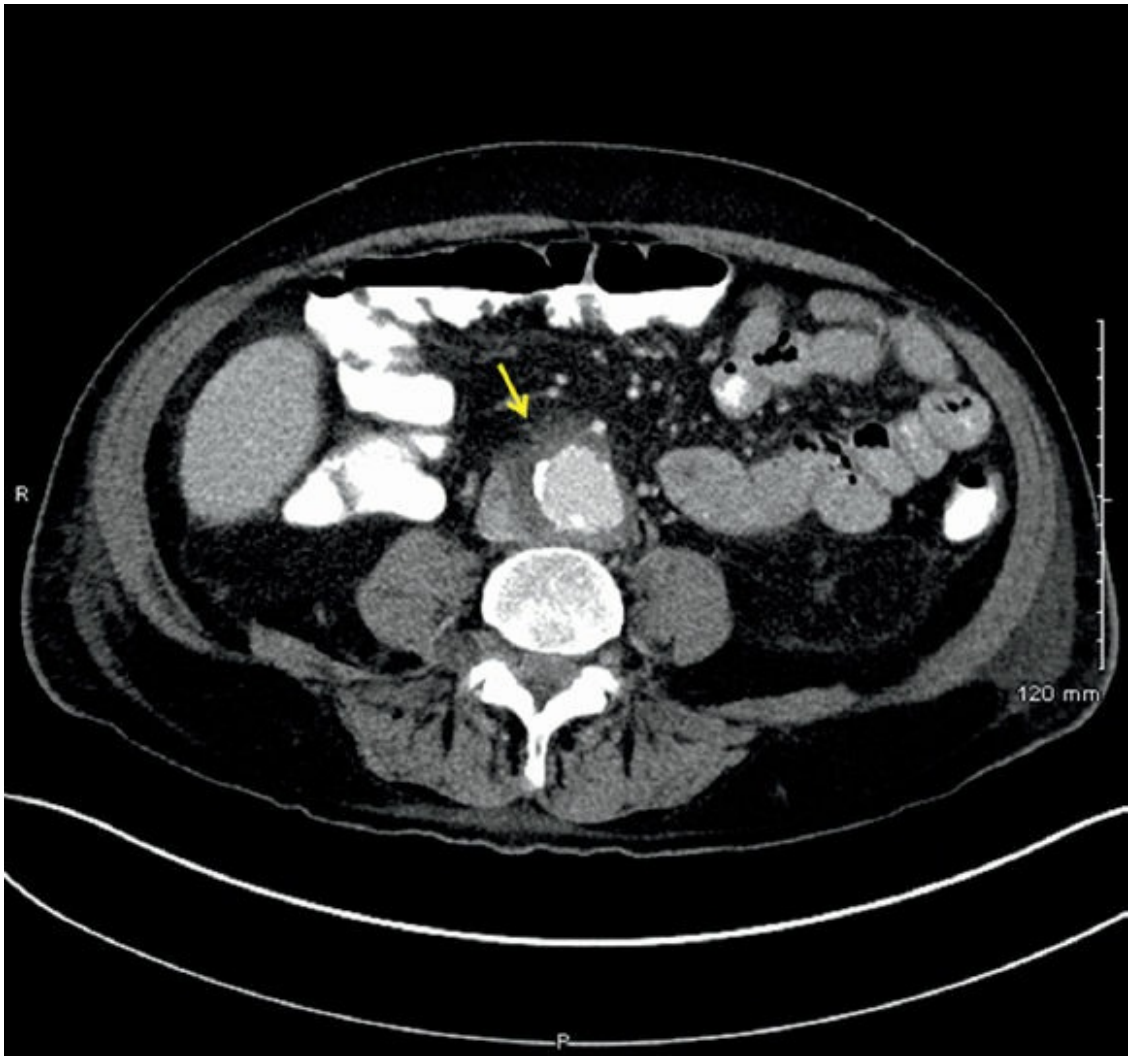

Figure 219.2. Contrast-enhanced computed tomography (CT) scan of the abdominal aorta demonstrating irregular wall thickening (*arrow*) and ectasia suggestive of aortitis.

The initial antimicrobial therapy should be broad spectrum, but dependent on the most likely infecting organism based on clinical circumstance. A combination of Vancomycin to treat an array of gram-positive organisms with a good broad enteric gram-negative agent such as piperacillin-tazobactam or third- and fourth-generation cephalosporins (e.g., cefipime, ceftriaxone) is recommended. Following culture results and susceptibility findings, the antibiotics should be appropriately tailored.

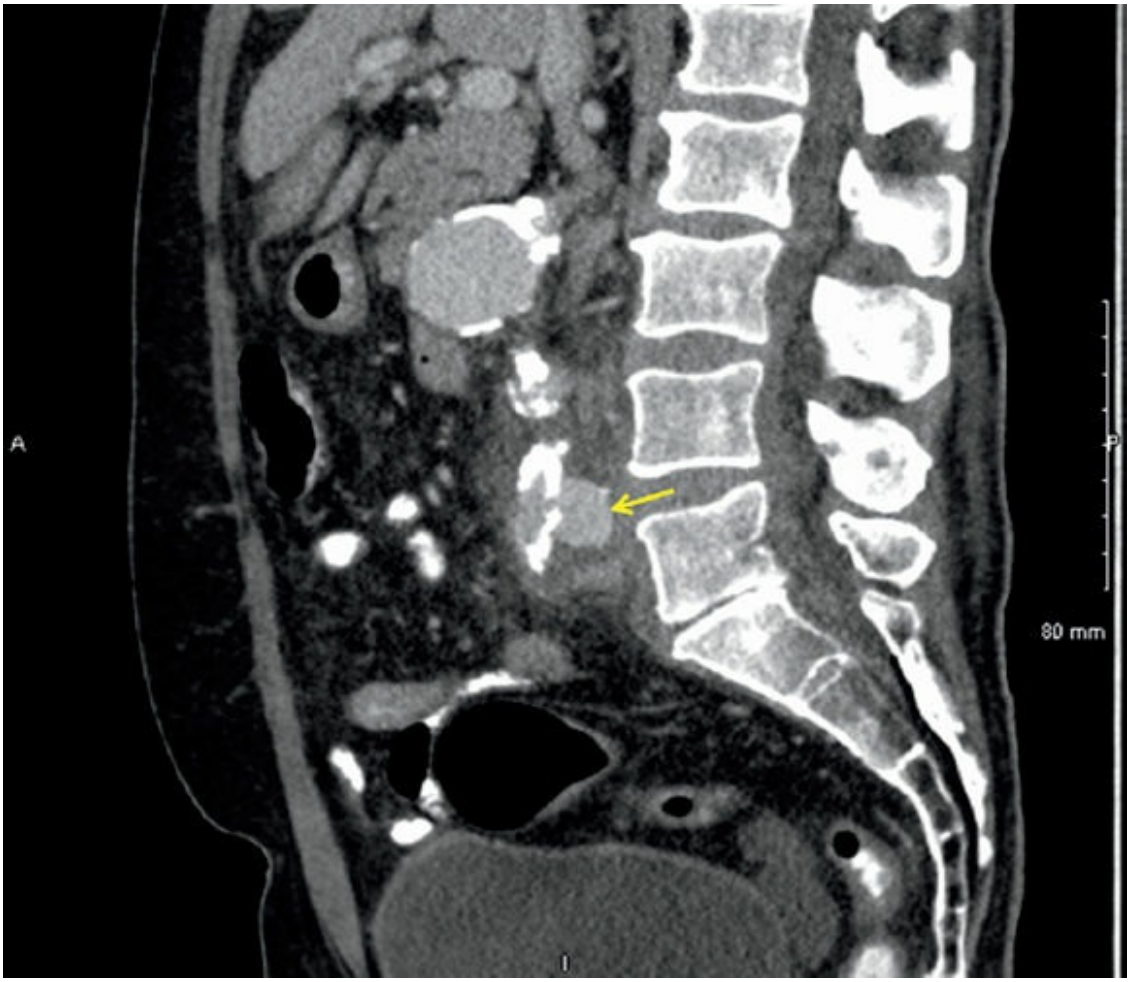

Figure 219.3. CT scan of a mycotic, saccular common iliac artery aneurysm demonstrating an atherosclerotic nidus (*arrow*), arterial wall enhancement and thickening, and retroperitoneal soft tissue stranding.

There are no data on the optimal duration of antibiotic therapy, but it is recommended that the patient should receive, at a minimum, a 6- to 8-week course. The duration of antimicrobial therapy should be guided by patient factors, including the location of the infection, specific bacteria (resistant or biofilm producing organisms), type of vascular reconstruction performed (autogenous versus prosthetic), and levels of observed systemic inflammatory markers (e.g., erythrocyte sedimentation rate, C-reactive protein). Chronic suppressive therapy may be warranted in cases where persistent positive cultures are seen or in cases where prosthetic graft material is used in situ for revascularization or aneurysm exclusion.

NONAORTIC ANEURYSMS

Surgical management of mycotic aneurysms in the periphery follows the

general principles of source control—wide debridement and drainage of infected or inflammatory tissue, and vascular control. Revascularization to address the end organ ischemia following radical debridement should be attempted in most situations; however, in some cases definitive ligation of the artery followed by amputation of the ischemic organ or limb may be the best option. Depending on the end organ, the timing of revascularization could be staged and may be warranted to prevent recurrent infection in the new reconstruction. In general, the artery involved should be debrided back to healthy tissue. Whether ligation or anastomosis is to be performed, permanent suture should be used.

When possible, vascular reconstructions in situ should be performed with autologous tissue. In most peripheral arteries, the saphenous vein is a good conduit to use for replacing the involved arterial segment. Upper arm veins are options, but may demonstrate inferior patency. In cases where larger caliber conduits are required, creation of panel grafts using saphenous vein or procurement of the deep femoral and jugular veins has been described. If no autologous conduits are available, the options available are use of either antibiotic-impregnated prosthetic grafts and cadaveric grafts. One word of caution about using cadaveric vein grafts in infected beds, the author has experienced several anastomotic blowouts of cadaveric saphenous vein in grossly infected beds, particularly with gram-negative infection. If gram-negative infection is suspected, antibiotic-impregnated prosthetic conduits may be more preferable over cadaveric vein grafts. When possible, all suture lines should be covered with vascularized tissue (i.e., adjacent muscle, omentum) following completion of the vascular reconstruction. For further local eradication of infective biofilms, the use of antibiotic-loaded methyl methacrylate cement, which elutes strong local concentration of antibiotics, has shown some benefit (Fig. 219.4).

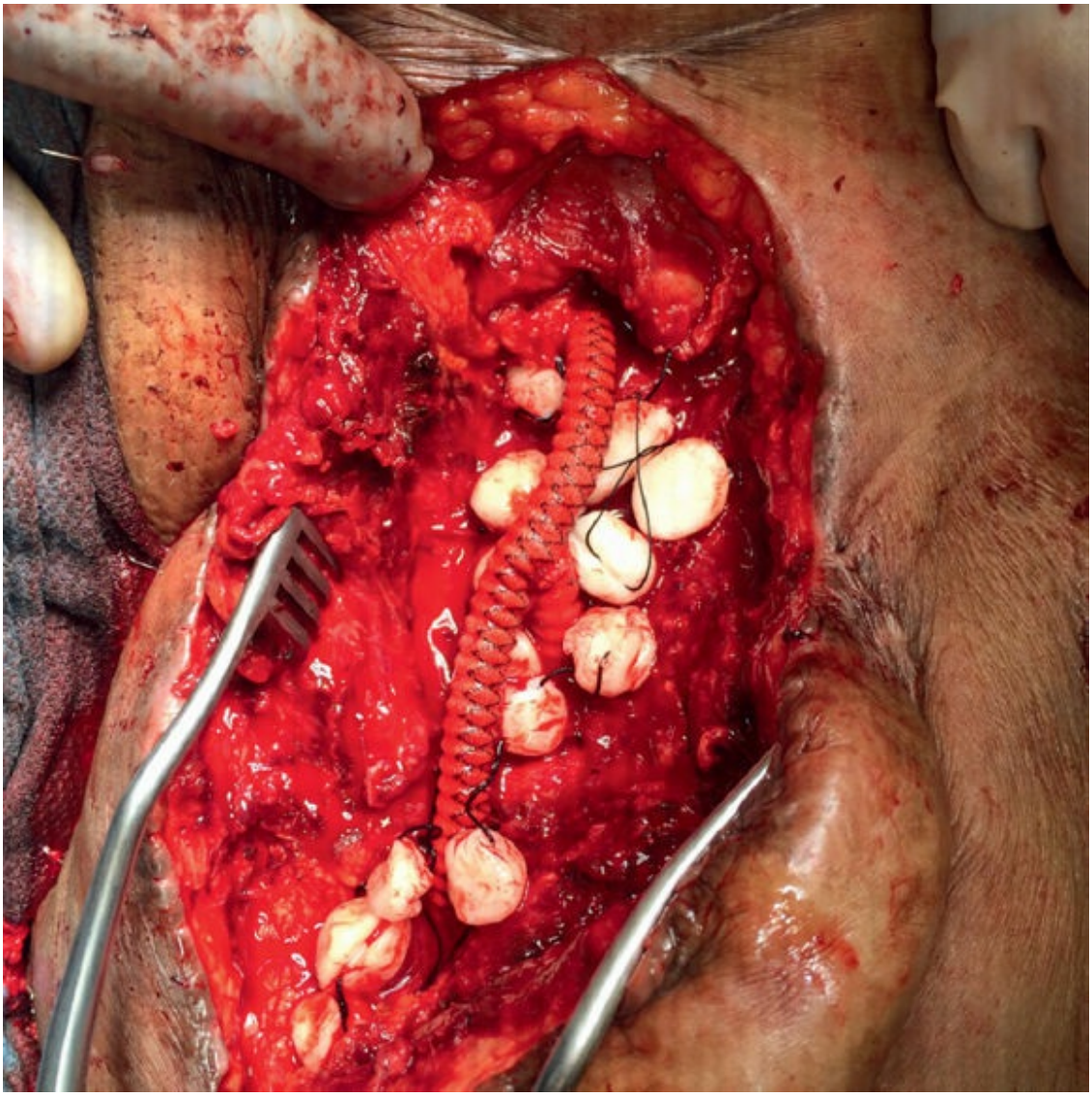

Figure 219.4. Intraoperative photo demonstrating in situ reconstruction of the femoral artery bifurcation with Rifampin-soaked Dacron grafts and placement of Tobramycin-impregnated methyl methacrylate cement beads following wide local debridement of an infected common femoral artery.

MANAGEMENT OF AORTITIS AND MYCOTIC AORTIC ANEURYSMS

"There is no disease more conducive to humility than aneurysm of the aorta."

– William Osler

Aortic infections present a particularly challenging surgical problem as management paradigms shift depending on the aortic segment involved. Generous exposure should be obtained, and aortic clamping should occur

well away from the infected segments. Following radical debridement of infected tissue, approaches in aortic replacement include in situ reconstruction with antibiotic-impregnated grafts (rifampin-soaked dacron), cryopreserved aortic homograft, autologous deep femoral vein-constructed neo-aortoiliac system (NAIS) championed by Clagett and colleagues, or extra-anatomic bypass. The purported advantage of aortic homograft over prosthetic grafts is its relative resistance to reinfection. The NAIS procedure offers a durable option for aortic replacement with lowest rates of reinfection and excellent long-term patency; however, the procedure should be reserved for stable patient. The procedures can be long and become a burden on patients who present with relative instability. The disadvantage of immediate in situ reconstruction is the potential for recurrent infection and subsequent breakdown of the anastomoses leading to hemorrhage. Suprarenal aortic involvement, however, precludes extra-anatomic bypass.

The decision to perform in situ repair or extra-anatomic bypass also depends upon the severity of the patient's underlying peripheral occlusive disease, patient's hemodynamic stability, and virulence of the infection involved. Severe atherosclerotic occlusive disease of the aortoiliac segments requiring long segment reconstruction may be better served with extra-anatomic bypass. Aortofemoral reconstructions are not recommended as it would require creation of anatomic tunnels that originate from a contaminated field. If the patient is hemodynamically unstable due to shock, the operation may be expedited with an in situ repair rather than prolong ischemia time with performing a separate exposure. Highly virulent organisms such as *Pseudomonas* and aerobes result in greater potential for reinfection and anastomotic complications, thus obviate in situ repairs. The character and degree of aortic degradation should be assessed at the time of aortic debridement. High degree of wall and tissue friability and loss of integrity and gross area of involvement should be informative of organism's virility,

Suprarenal and paravisceral involvement requires in situ reconstructions through either thoracoabdominal or transperitoneal approaches. If the aortitis is seen involving the base of the celiac artery, the author recommends a retroperitoneal or thoracoabdominal exposure. The visceral arteries can be reimplanted either individually to the graft or as an island pedicle. It cannot be stressed enough that all anastomosis should be created onto healthy aortic segments. There are key technical considerations when

cryopreserved aortic homografts are used for aortic replacement. The most important maneuver is to avoid direct clamping of the graft. The graft should also be sewn in with the posterior of the graft facing anteriorly (the sutured lumbar arteries should be facing up). Allografts are essentially decelluarized scaffolding that do not have robust structural integrity; direct clamping can result in aneurysmal degeneration and blowout at these sites. The aortic branches, namely the posterior lumbar arteries, are suture ligated and these areas are susceptible to degradation following preservation processes. Procurement and preparation of the aorta are also never perfect. When the graft is sewn in with the posterior side facing up, the potential imperfections are readily accessible for repair.

Extra-anatomic bypass with inflow from the axillary arteries for distal perfusion (Fig. 219.5) has advantages over in situ reconstruction in the setting of severe septic shock, large infected retroperitoneal hematoma, significant aortoiliac atherosclerosis and calcification, and adjacent infections such as vertebral osteomyelitis or enteric compromise. A staged approach of extra-anatomic bypass first with subsequent wide debridement and aneurysm excision is preferred. Physiologically, the patient endures less lower extremity ischemia time if extra-anatomic bypass is performed first. It is also preferable to create sterile incisions first for the bypass rather than follow exploration of a contaminated field. Typically, a right axillobifemoral bypass is performed. The right axillary artery is preferable for inflow if brachial pressures are equivocal between the two arms in the event some need arises for a left thoracotomy for aortic control. After completing the bypass and the incisions are closed and sterilely covered, a laparotomy is performed with the goals of radical debridement of infected aortic tissue and closure of the aortic stump proximally and distally at healthy segments. It is highly recommended to mobilize a well-vascularized pedicle of omentum to reinforce the aortic suture line and the aortic bed. Drains are then placed in the retroperitoneum.

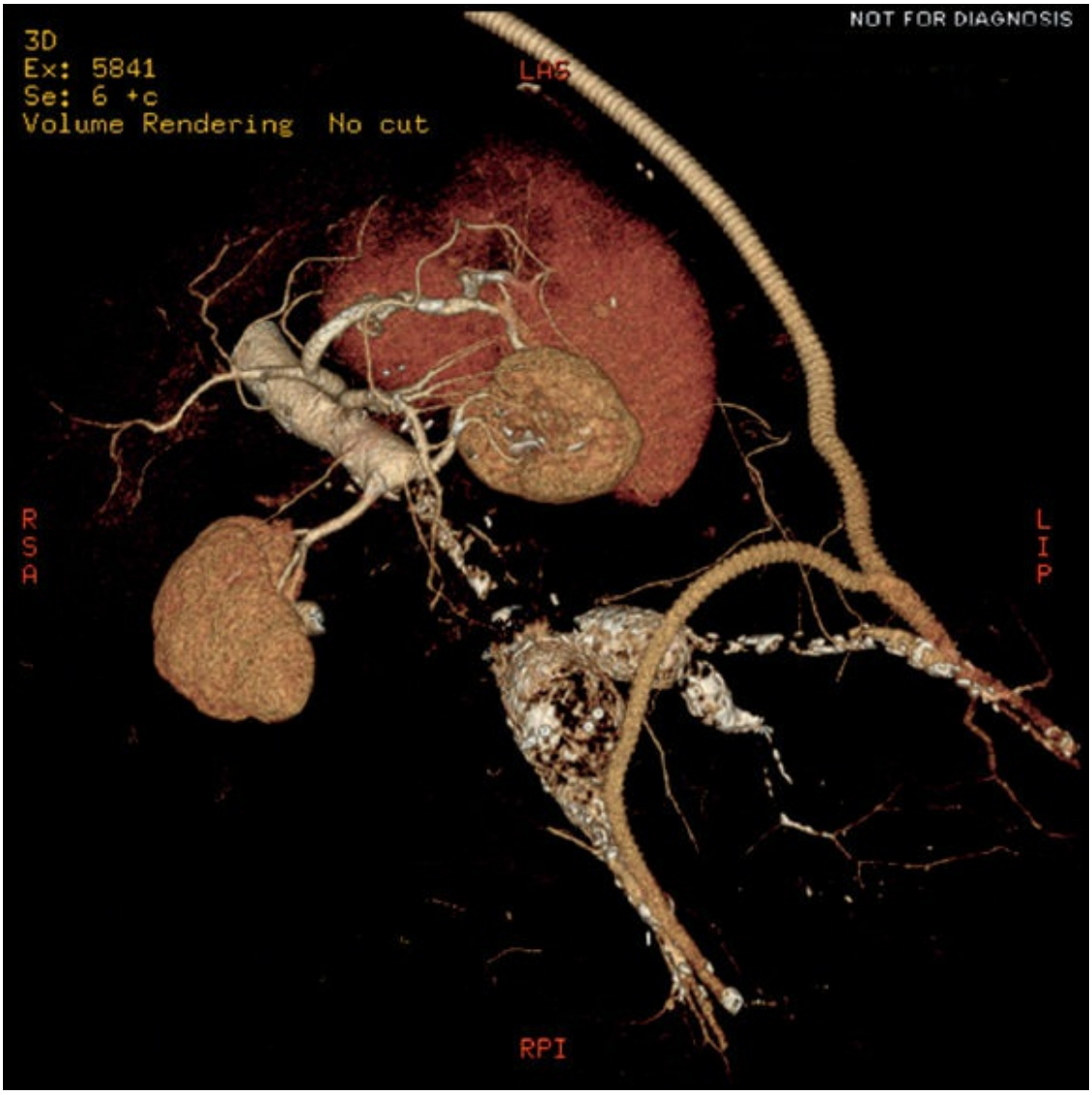

Figure 219.5. Volume-rendered CT scan of a patient status post ligation and wide excision of an infected infrarenal abdominal aorta and extra-anatomic bypass (left axillary artery to bilateral common femoral artery bypass).

ROLE OF ENDOVASCULAR TECHNIQUES

Employing an endovascular graft in an infected environment is controversial but may provide an option for patients who are unfit for conventional surgery. Covered stent grafts have been utilized for rapid control of ruptured aneurysms in many arterial beds, including the carotid and popliteal territories with good short-term results. Late reinfection is common, and can be associated with end organ or limb loss. With infected aneurysms of the aorta, endovascular repair is gaining more popularity. The primary purpose of endovascular aortic repair (EVAR) in infected aneurysms is to exclude the aneurysm in the setting of rupture or rapid

aneurysm instability in whom morbidity and mortality of open surgery would be prohibitive. Anatomic location of the aneurysm, as discussed previously, can make conventional surgical repair demanding. For infected thoracic aortic aneurysms for instance, endovascular repair provides a significantly less invasive means for aortic control.

Debridement of the infected tissues, however, is not accomplished with EVAR and reinfection and late failure rates are expected even with antibiotics. As such, EVAR for mycotic aortic aneurysms may be considered as the definitive therapy, in essence for palliation or as a bridge to definitive therapy. EVAR allows time for the patient to stabilize so that debridement and reconstruction can be performed under more elective circumstances.

Long-term, and in many incidences, life-long antibiotics accompany the use of EVAR in the treatment of mycotic aneurysms. Some argue to institute broad spectrum antibiotics to a point of negative blood cultures prior to EVAR with hopes of minimizing complications related to late infection. Limited or percutaneous drainage of infected fluid associated with the arteritis in combination with antibiotics may further assist long-term stability with EVAR in infected aneurysms. Coating the stent graft directly with antibiotics prior to its deployment in the aneurysm has been done, but no data exist on the efficacy of this technique.

Imaging follow-up is essential when EVAR is employed for treatment of mycotic aneurysms. CT is the best imaging modality to use compared to ultrasound or MRI. Manifestations of EVAR complications include new fluid or stranding at areas of repair, proximal or distal seal zone degeneration with subsequent endoleak, new endoleak, device movement and migration due to progressive wall degeneration, and graft occlusion. There is no set interval for imaging from the time of EVAR; however, surveillance should be performed more frequently in comparison to conventional EVAR.

OUTCOMES

Nonaortic Aneurysms

The major morbidity of nonaortic, peripheral mycotic aneurysms is high rates of end organ loss. In the distal extremity, infected femoral and popliteal aneurysms are associated with amputation rates as high as 30% despite repair and revascularization owing to distal embolization at time of presentation. Upper extremities often tolerate interruption of arteries

without significant ischemic consequence, owing to robust collateral networks around the shoulder and elbow, and have lower rates of limb loss. Infected aneurysms of visceral arteries have significant morbidity and mortality. Ruptured visceral arteries carry mortality rates as high as 20%. Intestinal ischemia resulting from ligation and aneurysm excision carry high morbidity and mortality as high as 40%. Interruption of the carotid or vertebral arteries without revascularization carries a risk of stroke as high as 30%.

Aortitis and Mycotic Aortic Aneurysms

Generally, short-term mortality of conventional open repair for mycotic aortic aneurysms ranges from 20% to 40%. The overall long-term survival following repair approaches 30% to 60% at 5 years. Early surgical management of aortitis before its evolution into an aneurysm may be associated with improved outcomes as overall morbidity and mortality are compounded by both progression of the aortic infection and the technical difficulty of the surgical procedure. In most large series, the location of the mycotic aneurysm is a determinant of mortality. Paravisceral or thoracoabdominal involvement can be common and is associated with operative mortality as high as 50%. Surprisingly, rupture status was not a significant determinant of overall mortality in most recent large studies. Overall surgical morbidity and mortality do not differ between extra-anatomic and in situ repair techniques. Reinfection, however, is more common with in situ reconstructions, while graft-limb occlusion is more common with extra-anatomic bypass.

Reinfection rates after in situ repair of mycotic aneurysms are between 2% and 10%. Late reinfections are associated with high mortality nearing 100%, related to uncontrollable sepsis or rupture. The NAIS procedure has the lowest reported reinfection rate of about 2% with long-term (5-year) patency of the graft approaching 90%; however, it is associated with long operative times. Aortic reconstruction using cryopreserved aortic homografts has reinfection rates of 7% with graft-related complications approaching 19%, including allograft limb occlusions. Antibiotic-impregnated grafts for aortic replacement have reinfections rates of 4% to 10%. Gram-negative organisms are associated with higher rates of graft infection, which is the culprit behind 60% of reoperations that are performed for graft reinfection.

EVAR outcomes generally show more favorable short-term mortality in

comparison to open surgery with a 30-day mortality of 10%. Long-term survival at 5 years approaches 55%, which is comparable to the outcomes reported following conventional open surgery. As expected, however, the reinfection rates are as high as 20% following endovascular repair. Late reinfection develops when antibiotic therapy is discontinued, and many authors recommend long-term and possibly life-long therapy as a prerequisite for EVAR in the treatment of mycotic aneurysms. Majority of the patients following reinfection of their EVAR graft die (70%). In addition to reinfection, the rates of secondary operations are also high following EVAR due to graft-related issues. In the largest current report, conversion to open repair from EVAR occurred in 5% of patients in the perioperative period and cumulative incidence of intervention for EVAR graft complications occurred in 17% of patients.

Suggested Readings

Brown SL, Busuttil RW, Baker JD, et al. Bacteriologic and surgical determinants of survival in patients with mycotic aneurysms. *J Vasc Surg* 1984;1:541.

Harding GE, Lawlor DK. Ruptured mycotic abdominal aortic aneurysm secondary to Mycobacterium bovis after intravesical treatment with bacillus Calmette-Guérin. *J Vasc Surg* 2007;46:131.

Lee CJ, Kibbe MR, Eskandari MK, et al. Surgical management of aortitis with early aneurysmal dilation. *Ann Vasc Surg* 2014;28(3):568–74.

Leon LR Jr, Mills JL Sr. Diagnosis and management of aortic mycotic aneurysms. *Vasc Endovascular Surg* 2010;44:5.

Moneta GL, Taylor LM Jr, Yeager RA, et al. Surgical treatment of infected aortic aneurysm. *Am J Surg* 1998;175:396.

Oderich GS, Panneton JM, Bower TC, et al. Infected aortic aneurysms: aggressive presentation, complicated early outcome, but durable results. *J Vasc Surg* 2001;34:900.

Osler W. The Gulstonian lectures on malignant endocarditis. *Br Med J* 1885;1:467.

Sorelius K, Mani K, Martin B, et al. Endovascular treatment of mycotic aortic aneurysms: a European multicenter study. *Circulation* 2014;130(24):2136–42.

Yegane RA, Salehi NA, Ghaseminegad A, et al. Surgical approach to vascular complications of intravenous drug abuse. *Eur J Vasc Endovasc Surg* 2006;32:397.

Yu SY, Hsieh HC, Ko PJ, et al. Surgical outcome for mycotic aortic and iliac aneurysm. *World J Surg* 2011; 35(7):1671–8.

EDITOR'S COMMENT

Mycotic aneurysms remain one of the most dreaded and perhaps least well-understood of all the diseases surgeons take care of. In the present chapter by Lee, he has elaborated on the etiology, diagnosis, and treatment strategies for both aortic and nonaortic mycotic aneurysms. Clearly, a strategy of obliteration in the case of complicated mycotic femoral artery aneurysms from intravenous drug injection has more or less stood the test time in terms of the saving the patient's life, but not always the limb (Feldman AJ, Berguer R. Management of an infected aneurysm of the groin secondary to drug abuse. *Surg Gynecol Obstet* 1983;157(6):519–22). This scenario at least historically has some point of reference in the literature.

When patients present with a clear-cut scenario as described above, the diagnosis of a mycotic aneurysm is never really in doubt. Unfortunately, it seems like the patient with a mycotic aneurysm, especially aortic aneurysm, often presents a diagnostic conundrum. Patients will present with low-grade fevers, vague abdominal or back pain, with an overall chronic course of overall health decline. The patient may have seen multiple other specialists prior to seeing a surgeon for this problem. While the diagnosis is more easily confirmed following the attaining of positive blood cultures, often we fail to have positive cultures prior to operating on patients (Lee CJ, Kibbe MR, Eskandari MK, et al. Surgical management of aortitis with early aneurysmal dilation. *Ann Vasc Surg* 2014;28(3):568–74). I am not sure there is good science to support this practice, but I always like to treat patients with intravenous antibiotics for at least 48 hours prior to operating on them. If the aneurysm is not ruptured, some also advocate placement of a percutaneous drain to both attempt to have culture-directed data for antibiotics and also perhaps decrease the pain associated with "pus under pressure."

In general, imaging is the key to confirming the diagnosis (Deipolyi AR, Rho J, Khademhosseini A, et al. Diagnosis and management of mycotic aneurysms. *Clin Imaging* 2016;40(2):256–62). A fine-cut computed tomography angiography almost always suggests either an atypical or saccular aneurysm and may document a surrounding phlegmon around the aneurysm. Others have recommended MRI/A as a better in terms of cross-sectional imaging. Finally, the use of nuclear medicine scans, in particular CT-PET scans with fludeoxyglucose (18F) or labeled white blood cell scans, as a method to confirm an atypical aneurysm is mycotic (Sörelius K, Mani K, Björck M, et al. European MAA collaborators. Endovascular treatment of mycotic aortic aneurysms: a European multicenter study. *Circulation* 2014;130(24):2136–42). These scans can be useful if they are positive, but a negative scan by no means rules out a mycotic aneurysm.

In terms of treatments, Dr. Lee has done a nice job of describing the multiple options for managing a mycotic aneurysm. For the readers of this chapter, I

would like to clearly delineate the difference between a mycotic native aneurysm and a graft infection (chapter to follow). The reason this is important to clearly define is because of what some might say that what I am about to espouse is heresy. Over time and having seen a number of these patients, especially with complex aortic aneurysms, I believe consideration for a primary endovascular management of these true mycotic aneurysms may be called for (Murakami M, Morikage N, Samura M, et al. Fluorine-18-fluorodeoxyglucose positron emission tomography-computed tomography for diagnosis of infected aortic aneurysms. *Ann Vasc Surg* 2014;28(3):575–8). The reason I believe this strategy may be best is that when an aneurysm is mycotic, the intima and most importantly the adventia of the vessel wall are still intact, just infected. This is very different from a graft infection. I think this type of approach is most justified in the thoracic aorta, and there are data to suggest that this approach is justified.

The issue of whether an endovascular approach is just a temporizing maneuver is also controversial. I do note that if lung, bowel, ureter, etc. are still attached to the mycotic aneurysm, this connection or fistulae need to be taken down, preferably after placement of an endovascular prosthesis (Setacci C, de Donato G, Setacci F. Endografts for the treatment of aortic infection. *Semin Vasc Surg* 2011;24(4):242–9). Failure to remove the offending source of the infection, almost always dooms an open or endovascular approach to reinfection and likely patient's demise. Likewise, lifelong antibiotics are required in all of these patients. While there are no level 1 data to support or refute this approach (and likely never will be), we have a series of mycotic thoracic aortic aneurysms that we are writing up for publication in which the patients, after a period of relatively good health and an endograft in place, stopped their suppressive oral antibiotics. Two of the patients reinfected their stent grafts and expired. I therefore strongly suggest continued lifelong oral antibiotics.

Finally, a word on mycotic aneurysms that occur secondary to infected embolic material from a remote cardiac source, often a valve or valve prosthesis (Rega FR, Nevelsteen A, Peetermans WE, et al. Simultaneous valve replacement and venous patch repair of superior mesenteric artery aneurysm due to infective endocarditis: a case report. *Heart Surg Forum* 2006;9(5):E741–3). As with all patients with mycotic aneurysms, these patients are often difficult to manage. Which pathology gets treated first is always a debate with your cardiac colleagues, and as a rule unless end organ damage or limb loss is pending, we typically like to have the cardiac source adequately treated first prior to operating on a patients with a septic embolic and a potential mycotic aneurysm. Historically, superior mesenteric artery aneurysms were always secondary to septic emboli from a cardiac source (Sharma G, Semel ME, McGillicuddy EA, et al. Ruptured and unruptured mycotic superior mesenteric artery aneurysms. *Ann Vasc Surg* 2014;28(8):1931.e5–8). That fact may be worth remembering for in service or qualifying exams!

Gilbert R. Upchurch Jr.

220 Surgical Management of Aortic Graft Infections

Manuel Garcia-Toca and Guillermo A. Escobar

INTRODUCTION

The management of aortic graft infections remains one of the greatest challenges to the vascular surgeon, with amputation and mortality rates exceeding 11% and 40%, respectively. The incidence varies from 0.2% to 3%, depending on whether the prosthesis is entirely intrathoracic (1% to 2%), aortoiliac (<1%), extends to the femoral arteries (1% to 3%), or is an endovascular stentgraft (<1%). Keys to a successful management of these infections include accurate and timely diagnosis of the infection, the extent of the graft infection, administration of appropriate antibiotic therapy, and a well-planned and executed surgical intervention.

ETIOLOGY AND PATHOPHYSIOLOGY

Infections of aortic prosthesis occur by perioperative contamination at the time of implantation, translocation and seeding from bacteremia, mechanical erosion of the graft into the bowel or genitourinary tract, and/or direct contact of the graft with a contiguous infectious process (like a spine infection or retroperitoneal abscess). Underlying immunosuppression can further increase the risk for infection.

Bacteriology

Cultures may be negative in as many as half of cases, and virtually any microorganism can infect a graft. In addition, the offending organism or organisms will vary, depending on the mechanism of infection, such as bacteremia or enteric erosion. This explains the wide variability in the infectious agents reported in series that combine all organisms they cultured in primary and secondary graft infections.

Staphylococcus aureus is historically the most prevalent pathogen of primary graft infections, and accounts for about 20% to 30% of graft infections. However, individual case series also have reported

Streptococcus viridans accounting for approximately 40% of cases, while other series find graft infections from *S. epidermidis* or gram-negative bacteria, which are becoming more prevalent.

Graft-enteric erosions and graft-enteric fistulae are typically polymicrobial and often include fungi like *Candida* sp. Among gram-negative organisms recovered from infected grafts, the most common are *Escherichia coli, Klebsiella, Proteus, Enterobacter, Pseudomonas, Bacteroides,* and non-hemolytic streptococci. Infections associated with negative culture results can be due to systemic antibiotics started empirically prior to a culturing, low virulence organisms with low rates of bacteremia, or on occasion not using the correct cultures in cases of fungus or even rare organisms, such as mycobacteria.

The outcomes after surgery can be dramatically affected depending on what organisms are detected in the blood or intraoperative cultures. The odds ratio for perioperative mortality after an aortic graft infection treated with a femoral vein reconstruction is highest with positive cultures for Candida (any *Candida* OR 3.4 and *C. glabrata* OR 7.6), *Klebsiella pneumonia* (OR 3.5), and *Bacteroides fragilis* (OR 4.1). Conversely, the results of cultures might impact what type of conduit should be used or avoided in the reconstruction. For example, *Enterococcus faecium* is very frequently resistant to rifampin, so rifampin-treated Dacron grafts should not be used for these infections; while this technique may be ideal for a *Mycobacterium* or susceptible *Staphylococcus* infection.

Primary fungal (e.g., *Candida*, and *Aspergillus* species) or *Mycobacterium* graft infections are rare. Most cases are associated with severe immunosuppression, have an established fungal infection elsewhere (usually other prosthetics), or the patients were exposed to the organism iatrogenically (e.g., after *Mycobacterium bovis* treatments for transitional bladder cancer). These organisms should be sought out using their atypical culture media, especially when there is clear evidence of a graft infection, but traditional (bacteriologic) cultures appear negative. Even if these organisms are only diagnosed after repair, it will assist long-term antibiotic management and identify resistant strains (especially in multidrug-resistant organisms like *Pseudomonas* and *Mycobacterium*).

CLINICAL PRESENTATION AND DIAGNOSIS

The clinical manifestations of an aortic graft infection depend on the interval between graft implantation and the onset of the infection, the

nature of the organism, and the anatomic location of the prosthesis. Early graft infections (less than 4 months after implantation) are more likely to involve the graft diffusely and usually have systemic manifestations and more intra-abdominal manifestations. Some early infections may manifest only with pseudoaneurysm and disruption of the anastomosis leading to tragic outcomes.

In general, aortic graft infections tend to manifest remotely from implantation and have a broader spectrum of nonspecific symptoms. These can be subtle with malaise, fever of unknown origin, discomfort and/or weight loss alone. In contrast, there are patients who present with a high fever, leukocytosis, and severe shock from systemic sepsis or from uncontrolled bleeding either into the bowel (aortoenteric fistulae) or into free ruptures (anastomotic pseudoaneurysms). Low-virulence organisms can also create indolent fluid collections, where the abscesses can grow to compress neighboring structures (i.e., ureters, vena cava, and femoral nerve) and can even necessitate out of the skin. The latter present as subacute wound infections or draining sinus tracts (usually in the groin incisions).

The most common site for the graft to erode into the bowel is into the small intestine, especially near the level of the fourth portion of the duodenum, usually overlying the proximal aortic anastomosis. This notwithstanding, any portion of a prosthetic graft that comes in direct contact with the small or large bowel will eventually erode into it. These erosions are not the same as graft-enteric (or “aortoenteric”) fistulae, which is when the graft disrupts and bleeds into the intestinal lumen. They will typically present with a bout of severe hematemesis and/or hematochezia. Any indication of this “sentinel bleed” in the setting of previous aortic surgery should mandate aggressive investigation and early intervention to treat the fistula as the subsequent hemorrhage may be fatal. Graft-ureteral fistulae are also well described, typically after injuries to the ureter lead to disruption and pseudoaneurysms at the anastomosis of the graft to the iliac arteries.

Isolated pseudoaneurysms occur spontaneously, or when infections disrupt the graft-arterial anastomosis. The aortic anastomosis can sometimes be disrupted in absence of enteric leaks, but pseudoaneurysms are far more common at the level of the femoral anastomosis. Infection and disruption of aortic patch angioplasties used for aortoiliac endarterectomies can also lead to large pseudoaneurysms on the anterior

wall of the aorta and iliac arteries. These pseudoaneurysms can be contained in the retroperitoneum or within scar tissue in the groin, presenting with nonspecific pain and compression symptoms.

Graft infections can also manifest as acute graft occlusions, particularly in aortofemoral bypass limbs. Thus, a suspicious review of the incisions and all imaging studies looking for any signs of infection are important to avoid discovering a graft infection in the operating room.

The diagnosis of aortic graft infection is the first of many challenges, and commonly requires multiple diagnostic modalities:

Computed Tomography (CT) Imaging

The current gold standard for the initial diagnosis is CT angiography because it can assess of the extent of graft infection and native vascular involvement, establish patency, and help determine the ideal locations needed for vascular control during the reconstruction. CT also provides information to help determine if percutaneous aspiration of a fluid collection for microbial analysis or if a conservative approach is contemplated. CT scanning can identify aortic graft infections with a sensitivity of up to 94% and a specificity of 85%. Characteristic CT findings suggesting the presence of late aortic prosthetic graft infection include periprosthetic gas or fluid (Fig. 220.1), soft tissue thickening, hydronephrosis from compression, vertebral body degeneration/infection, bowel wall thickening in proximity to the graft (suggesting aortoenteric erosions), and locating pseudoaneurysms. Although the presence of fluid or loculated air around the graft is common in the early postoperative period after graft implantation, gas seen around the graft more than 2 months after initial aortic surgery is strongly suggestive of graft infection. Any patient with signs and symptoms of infection with suspicious CT findings should be treated as a graft infection until proven otherwise.

Nuclear Tagged White Blood Cell Imaging

These techniques allow infections to be detected using labeled white cell scans (usually using ^{111}Indium). When used alone, studies report variable sensitivities and specificities ranging from 75% to even 100%. Generally, it should be considered a useful adjunct to clinical suspicion and other imaging techniques, but not as a stand-alone method for diagnosis or exclusion.

Fluorodeoxyglucose-Positron Emission Tomography (FDG-PET)

This has a high sensitivity derived from the increase FDG uptake observed in inflammatory cells, but has low specificity. As it is the most expensive imaging technique, its use should potentially be considered when a more sensitive analysis of the extent of involvement of the infection, or when infection is suspected, but the above-mentioned techniques are not demonstrative of infection.

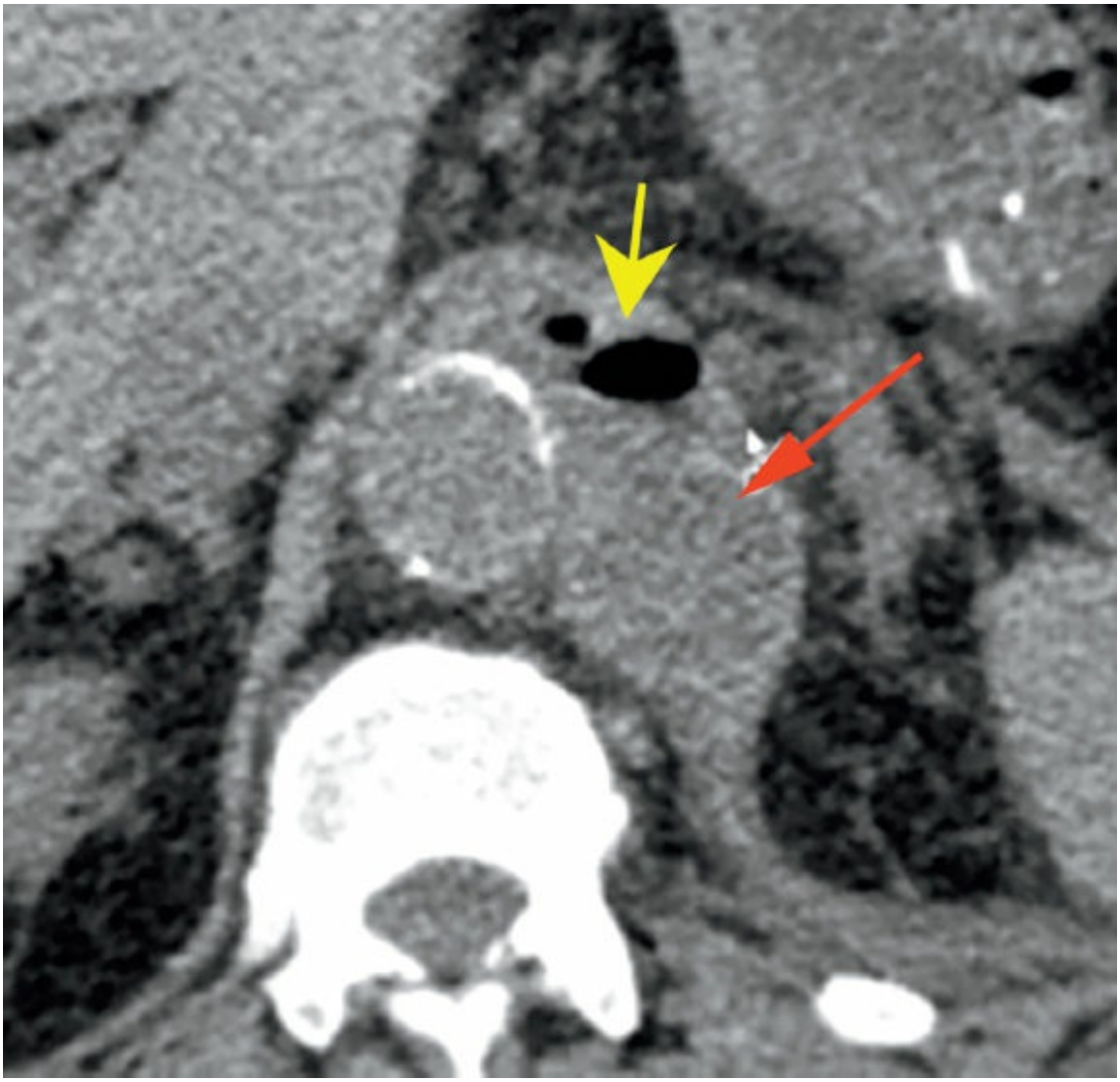

Figure 220.1. Noncontrast CT demonstrating an abscess in the psoas muscle on the left of the aorta (*long red arrow*) and gas seen around aortic graft (*short yellow arrow*).

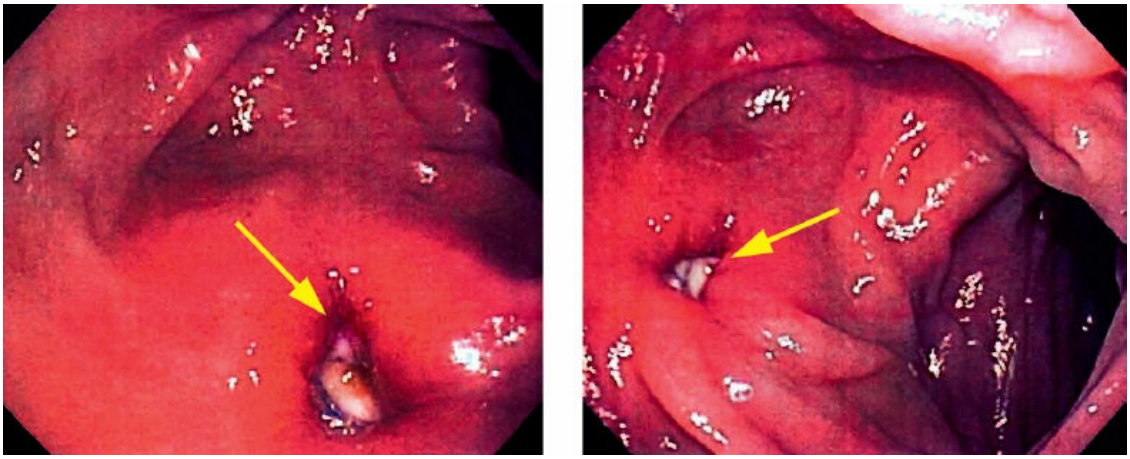

Figure 220.2. Endoscopic view of an aortoenteric fistula. This patient presented with hemorrhagic shock from and was treated with an axillary–femoral bypass and removal of all infected graft material. *Arrows* identify the ulcer in the fourth portion of the duodenum with the white graft material seen at the base.

Gastrointestinal Endoscopy

This modality is often how the graft erosion is first discovered when an endoscopist is asked to evaluate someone with cryptogenic upper gastrointestinal bleeding (Fig. 220.2). The authors only use it secondarily when there is a low suspicion of a graft-enteric erosion by CT scan, but surgical planning is needed to determine the need for a complex intestinal reconstruction in addition to a vascular reconstruction. Endoscopy can miss graft-enteric erosions if they are distal to the fourth portion of the duodenum, where push-endoscopy may be needed. Careful communication with the endoscopist prior to the procedure is paramount. The goal of the test should be clear to both parties and avoid performing biopsies near the ulcer for any reason.

PREOPERATIVE PLANNING

Regardless of the technique used to eradicate the graft infection, success is measured by patient survival, freedom from recurrent infection, patency of the revascularization, and avoidance of major morbidity including amputation. We highly recommend treatment with targeted or broad-spectrum antimicrobials for several days prior to reconstruction whenever possible. This may mitigate the systemic infection, improve the patient's anorexia from illness, and minimize re-infection rates after reconstruction (especially when prosthetics are used in the reconstruction).

Extent of Graft Infection

Determination of the extent of graft infection is important to successful treatment planning. In order to be fully prepared in the operating room, one should always assume that the entire graft in infected, and then work backwards. One should always plan for more extensive graft involvement than what was expected from the imaging tests, and be prepared to obtain a more proximal site for vascular control. If the aortic neck looks tenuous and inflamed near the renal or mesenteric arteries, plan for a prolonged supra-renal clamp, and the possibility of even needing preemptive bypasses to the renal or mesenteric arteries to maintain perfusion after graft removal (especially when explanting aortic endografts with supra-renal fixation barbs). If the entire graft is involved, it will require removal in its entirety when possible. However, if only one portion/limb of an aortobifemoral graft is involved, it may be possible to remove only the infected portion and salvage the remaining, uninfected graft. Complete graft excision is usually required in early infections, because the graft is not incorporated into the tissue. However, late infections with limb involvement limited to the groin can often be treated with unilateral graft excision.

Nutritional and Constitutional Assessment

Patients with aortic graft infection are often elderly and debilitated, especially if the diagnosis was delayed and the process is chronic. Adequate nutritional support is critical to meet the metabolic demands of sepsis and a prolonged operative and postoperative course. If the infection is stable and indolent, it may be wise to postpone the surgery for weeks or months to augment the patient's nutrition and activity in the interim. An elderly, deconditioned, and malnourished patient will be unlikely to survive surgery, regardless of the surgeons' technique or skill.

In the presence of aortoenteric fistula, enteral nutrition may need to be delayed for a lengthy period of time. Transition to enteral nutrition may be facilitated by the use of feeding gastrostomy or jejunostomy after surgical intervention. Parenteral nutrition may be needed, although it should be avoided when possible to minimize the risk of infection.

Preoperative Cardiovascular Risk Assessment

As previously mentioned, the morbidity and mortality of these cases are

some of the highest in the surgical literature. Therefore, patient selection and preparation are critical. In cases of emergent need for intervention (hemorrhagic or septic shock), then the decision to proceed depends on the surgeon's best assessment of survival. Placement of temporary, rifampin-soaked endografts may assist in some cases until optimal conditions are achieved. Otherwise, careful risk-assessment and cardiovascular optimization should be sought prior to revascularization when possible in order to adequately select (or exclude) patients for surgery. Conservative modalities for patients deemed too high risk for any reason include antibiotics alone, percutaneous drainage, and antibiotic lavage or use of "destination" rifampin-soaked endografts to treat pseudoaneurysms.

Assessment of Lower Extremity Perfusion

Preoperative assessment of lower extremity perfusion is necessary to plan treatment and may be based on physical examination and lower extremity noninvasive studies. If the infected prosthesis is occluded and the lower extremities are viable, excision of the infected graft material alone should be adequate, and vascular procedures to improve lifestyle can be done at a later time. However, if lower extremity perfusion depends on the involved graft, extra-anatomic bypass or in situ reconstruction will be required to avoid amputation once the infected graft is removed. Meticulous evaluation of CT or conventional arteriography can identify patent vessels available for revascularization of the lower extremities. Low arterial-brachial indices or toe pressures may also predict the need for fasciotomy after reconstruction in cases where prolonged perioperative ischemia will be present.

Vein Mapping

Venous duplex ultrasonography is essential in planning reconstruction when the saphenous or femoral veins are considered as conduit. Examination of the lower extremity venous system establishes the diameter and available length of the deep veins. In addition, duplex ultrasonography can evaluate acute or chronic thrombosis, recanalization changes, and congenital venous abnormalities that may dissuade from using these veins. Femoral or saphenous veins that are less than 5 mm in diameter may not be useful for aortic conduits unless two veins are sewn together (which will ultimately limit potential length of the final venous conduit), and other conduits or approaches may be needed. Conversely,

even saphenous veins may be used as conduits in some women if the native vessels are small and the saphenous veins are large (4 to 5 mm) at the thigh (Fig. 220.3).



Figure 220.3. Saphenous vein used as conduit for aortic reconstruction.

SURGICAL TECHNIQUE

Selection of the surgical approach is based on two major principles. The

first focuses on eradication of the infection and its sequelae by removal of the affected graft and debridement of all infected tissue with minimal morbidity. The second principle focuses on maintaining or restoring perfusion to the lower extremities.

Considerations influencing the choice and timing of reconstruction in aortic prosthetic graft infections include the stability of the patient, extent of the graft infection, the offending organism, the potential consequence to the visceral organs or limbs from ischemia, and the patient's comorbidities. Always consider a staged approach for extra-anatomic and venous reconstructions to lessen the burden on the patient and the surgical team. Appropriate antibiotic therapy for the primary infection and to prevent secondary infection in the new reconstruction is fundamental; preoperative aspiration/sampling may be useful when fluid can be obtained safely.

Exposure of the Aorta and Graft Excision

Complete removal of an infected aortofemoral graft begins with the femoral exposures to minimize the time the abdomen is open. Aortic exposure can then be done through the previous incision, but sometimes using an alternative approach (retroperitoneal or celiotomy) than the one used for the initial implantation may facilitate access to the aorta and iliac arteries. Preoperative placement of ureteral stents may be helpful to avoid/treat any injury, especially when hydronephrosis or extensive left sided-retroperitoneal inflammation is present.

Access to the aorta can be done via celiotomy or retroperitoneal approach. Celiotomy allows for good exposure of the bowel and most of the aorta from the superior mesenteric artery to the external iliac arteries, but is limited in visibility of the aorta near the celiac artery. Any intra-abdominal adhesions may slow down access to the infected graft. A retroperitoneal avoids adhesions and allows for greater access to the supraceliac and thoracic aorta, as well as all the proximal portions of the visceral arteries. This approach may be preferred if the inflammation/infection seems to extend to the visceral segments of the aorta. However, retroperitoneal exposure has limited visibility and access to the more distal portions of the right iliac artery, renal artery, and tunneled grafts. In addition, access to the bowel to perform a complex repair of a graft-enteric erosion in retroperitoneal exposures can be more challenging.

Early control of the supraceliac aorta should always be considered for infections involving the aortic neck, and done prior to exposing an infected aortic anastomosis, especially if there is significant periaortic inflammation or pseudoaneurysm. Sudden graft disruption during vascular dissection can be a disastrous and potentially unsurmountable complication without adequate vascular control. Although intraluminal balloon occlusion of the aorta and iliac arteries may be possible, there is greater potential for large-volume blood loss and inability to maintain a dry surgical field during reconstruction. Thus, direct dissection and clamping of uninvolved iliac and mesenteric vessels distal to the infected segments may be safer. Only expose the portion of the infected vessel needed for vascular control. Trying to completely encircle scarred and inflamed arteries may lead to their injury and/or large-volume hemorrhage from puncturing adhered veins.

The perirenal aorta should be exposed from proximal to distal, starting above the area of concern to identify the best place for a proximal clamp, and then move caudal toward the infected aorta. The iliacs should also be identified far from the area of concern and then work caudally. If the left renal vein is patent, its location can be difficult to locate within the inflamed periaortic lymphatic tissue. This can lead to bleeding that is difficult to control. Using a vascular-load automatic stapler to sequentially ligate and expose the anterior aorta may decrease bleeding and expedite access to the suprarenal aorta. Care must be taken to ensure the location of the mesenteric and renal vessels as this is done to avoid injury to them with the stapler.

After gross removal of the infected graft, the vessel is debrided back to normal-appearing aortic wall. All graft material should be removed, taking care to remove the entire suture line that can be hard to see in the thickened aortic wall. Identification of the suture material while cutting out the anastomosis is important to ensure all prosthetic is removed. After debridement, the residual vascular bed is often topically “sterilized” with local lavage using antibiotic solutions or treating the area with high-energy surface cautery. While not evidence-based, it seems irresistible to most surgeons to try and treat spilled purulent material. Pledgets using prosthetic material should be avoided as they are nidus for recurrent infection. In critical cases, reinforcements for sutures can be made from fascia lata as a form of autologous pledget (obtained from an incision on the lateral thigh), or cut pieces of rifampin-soaked Dacron.



Figure 220.4. Endograft transected with high energy electrocautery.

Removing infected aortic endografts can pose significant difficulties when they have supra-renal fixation, and should be done only by very experienced aortic surgeons. These barbs are specifically designed to stay attached to the aortic wall under caudal traction, and they usually affix to the aorta at (or above) the superior mesenteric artery origin. Supraceliac clamping is critical in these cases, as is control and clamping of all renal and mesenteric branches to minimize the inevitable acute blood loss that follows. Placing clips on all visible lumbar arteries before entering the aortic sac is advised to avoid subsequent bleeding. In order to cross-clamp an aortic endograft, we use two soft-jaw Fogarty clamps because traditional aortic clamps may not be hemostatic. Access to powerful scissors and wire cutters is imperative to be able to cut and remove the graft. However, cutting across the endograft can be very difficult, time-consuming, and accompanied by voluminous, life-threatening bleeding. One author routinely transects the main body of the graft using high-

energy electrocautery that effectively melts the fabric off the metallic stent skeleton. This allows for easier transection and allows it to be clamped and removed. This technique is especially useful when there are multiple endograft cuffs, making cutting through them nearly impossible (Fig. 220.4). Any attempts to simply oversew an infected aortic endograft and leave it in place will lead to uncontrolled infection, and potential pseudoaneurysm that will ascend the periaortic region.

CHOICE OF RECONSTRUCTION

Extra-Anatomic Axillary–Femoral Revascularization

The primary benefit of an extra-anatomical revascularization is that it poses the lowest morbidity from the reconstruction itself, and subsequent graft excision can be performed at a later stage (or done simultaneously, ideally with a two-team approach). It also allows for minimal ischemic time to the limbs as they are perfused at all times by the bypass, unlike when techniques are used to reconstruct the aorta. The axillary–femoral bypasses can also be done entirely under local anesthesia and sedation if needed. The extra-anatomic configurations for the bypasses can be created using a single, "Y" shaped axillary–bifemoral graft, a single axillary–femoral bypass, followed by a femoral–femoral bypass, or two separate axillary–femoral bypasses.

While often considered otherwise, the complete procedure is certainly not "low risk." The reality is that independent of the extra-anatomic bypass, the aortic graft excision remains a formidable procedure and mortality remains significant. In clinically stable patients, staged management with an initial axillary–femoral bypass, followed 1 to 2 days later by the excision of the aortic graft, has a significantly lower perioperative mortality than doing everything in a single surgery. Simultaneous ex situ bypass with graft excision (ideally using two surgical teams) may be necessary in more unstable patients with systemic sepsis, intra-abdominal hemorrhage, or aortoenteric fistula.

The procedure consists of first exposing all vessels, followed by the tunneling of the graft material before any anastomosis is done. This will ensure adequate angles are chosen for the anastomosis of the grafts and avoid kinking. It is not uncommon for the end-to-side anastomosis of the graft to the axillary artery to be at nearly a 90-degree angle off the anterior wall. This is especially true in larger or obese patients where the distance from the subcutaneous tunnel to the axillary artery is far.

Axillary–bifemoral bypasses typically originate from the first (proximal/medial) portion of the right axillary artery. The axillary artery is more mobile distally and moves in conjugation with the elevation of the arm, leading to less injury and kinking. Ideally, the right side is preferred as it is statistically less likely to have atherosclerotic disease of the subclavian artery, and allows for future access to the left chest for retroperitoneal or thoracic approaches to the aorta. Bilateral blood pressures are obtained; and if there is more than 10 mm Hg difference, then the better side is chosen.

A transverse incision is made about one fingerbreadth below the clavicle, and taken down through the fascia of the pectoralis major. Difficulties finding the artery in obese patients can be aided by a Doppler during the exposure, and by identification of the thoracoacromial or superior thoracic arteries and following them posteriorly. We prefer the proximal inflow graft to be reinforced polytetrafluoroethylene (PTFE), at least 7 mm in diameter (preferably 8 mm). Rifampin-soaked Dacron grafts are sometimes used when the distal anastomosis must land in nonsterile femoral arteries. To obtain good visibility into the lumen of the fragile axillary artery, we use an arterial punch to widen the orifice. Small distal vessels can be accommodating larger grafts by making a wide mouth arterial anastomosis, or joining a smaller graft to it at the groin. This is preferable to using a small, long, high-resistance graft for the inflow feeding both legs.

If the infected graft involves the common femoral artery, then the new anastomosis should be beyond the inguinal region (onto profunda femoris branch artery, superficial femoral artery, or even popliteal). This is done through a lateral incision, distal to the original femoral anastomosis, and the axillofemoral graft is routed lateral to the anterior superior iliac spine. In cases of minimal groin sepsis, a prosthetic femoral–femoral graft may be routed in a subcutaneous tunnel medial to the original femoral incisions, avoiding the areas of infection. In selected cases with extensive femoral abscess/infection or extreme obesity, bilateral axillofemoral prosthetic grafts can be utilized. In addition to a typical axillary–bifemoral bypass, an axillary–unifemoral bypass with prosthetic can be used, followed by a femoral–femoral bypass with saphenous or femoral vein, especially in cases with unilateral femoral graft infections (Fig. 220.5).

Proximal vascular control in the groin is obtained well away from the femoral anastomosis, and may need a suprainguinal retroperitoneal

exposure for large pseudoaneurysms near the inguinal ligament. Once the femoral vessel and infected graft are exposed, it is debrided and either closed (primary lateral closure or autogenous vein patch closure), or it is used for the anastomosis if an autologous vein is the conduit. We routinely use muscle flaps to cover the repair, and the skin may be left open (with or without a negative-pressure dressing) in cases of severe infection. The authors prefer a sartorius muscle flap or rotating the gracilus muscle if the groin is too scarred. This is particularly important in cases where autologous tissue is not used as part of the femoral artery repair.

If a two-stage approach is used, function and adequacy of the extra-anatomic arterial reconstruction should be assessed prior to the second stage. A pulse examination, ankle-brachial pressure indexes, and/or duplex scanning are critical. The patient should return to the operating room within 4 days for the resection of the aortofemoral prosthetic, debridement of the infected retroperitoneal tissues, and oversewing of the infrarenal aortic stump. It is important to minimize this time period to avoid a new infection, but also to avoid thrombosis of the extra-anatomic bypass due to poor, “competitive flow” to the legs from both conduits (infected aortic graft and extra-anatomic grafts). Once the aortic graft has been removed, it is imperative to again ensure patency of the axillary–femoral limbs prior to leaving the operating room.

Adequate closure of the aortic stump after graft excision is essential, but can pose quite a challenge because of the inflamed aortic tissue and fragile aortic wall. Various techniques have been proposed to ensure stump integrity. These include a double layer of Prolene sutures using a reinforcement using various “pledgets” made from vein, fascia (from spine or lateral thigh), rifampin-soaked Dacron or felt, double-plane sutures, and vascular stapler devices. A similar, two-layer closure technique should be used for the distal aortic or iliac arteries should be performed to maintain retrograde flow from extra-anatomic bypasses at the femoral level into at least one pelvic artery system (external iliac and hypogastric) to avoid distal colonic, pelvic, and lower spinal cord ischemia. Careful vigilance for signs of aortic stump disruption should be maintained.

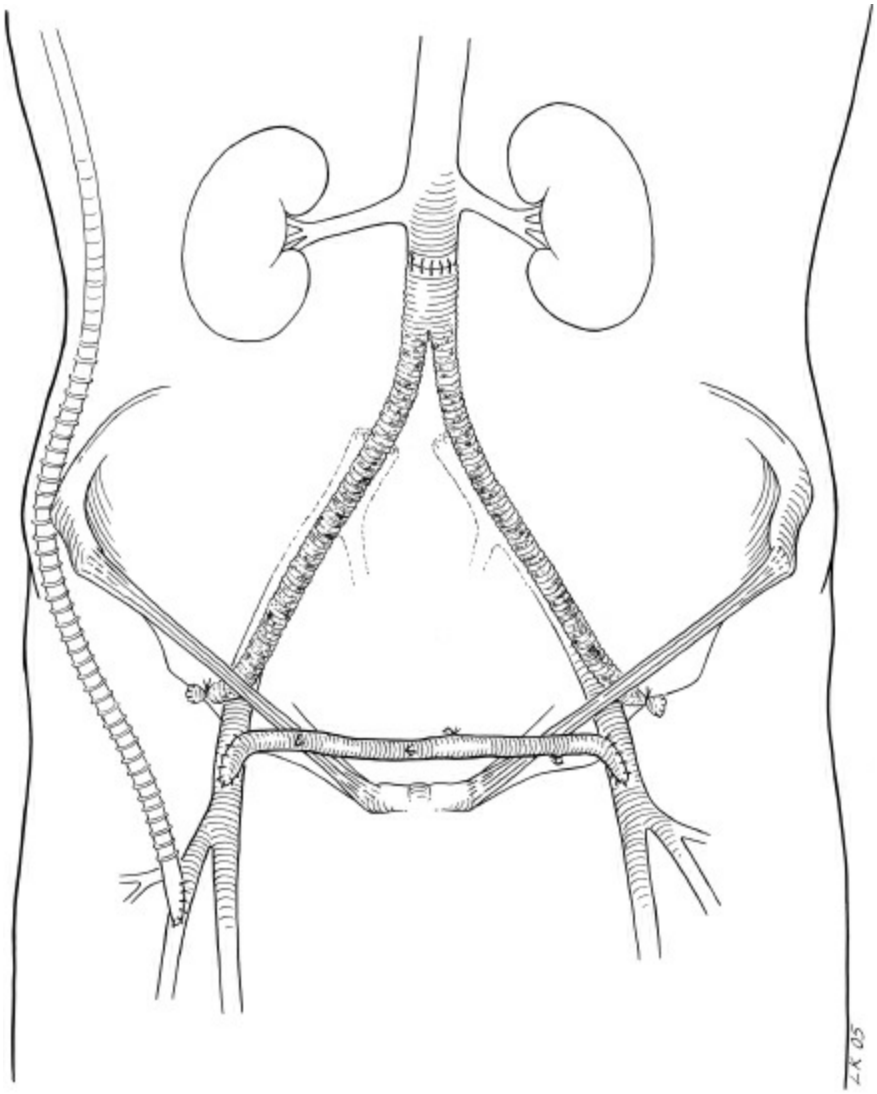

Figure 220.5. Right axillofemoral prosthetic bypass and femoral–femoral bypass using autogenous femoral vein. Axillofemoral prosthetic bypass routed lateral to the anterior superior iliac spine with distal anastomosis at the midprofunda femoral artery.

IN SITU VEIN RECONSTRUCTION

Neoaortic Iliac System With Femoral Vein (NAIS)

This technique was championed by Dr. Patrick Clagett, demonstrating outstanding durability with low amputation rates. Its primary benefit is that these patients do not require treatment with lifelong anticoagulants or antibiotic therapy when successful. The disadvantage of the NAIS reconstruction is that the procedure is time-consuming (mean operating time >8 hours), technically demanding (especially when there is significant size-mismatch or length discrepancies of the conduits), and can lead to significant morbidity to the legs from the venous harvesting (10% to 20%

need fasciotomies and many have significant swelling long-term). The NAIS procedure is sequenced into major steps designed to minimize lower extremity ischemia time and time that the abdomen is left open. The sequence is as follows: (1) dissection of the femoropopliteal veins (FPVs), which are left in situ until needed (and you may stop here, when staging the procedure); (2) isolation and control of the femoral vessels; (3) entry into the abdomen and dissection and control of the aorta above the anastomotic site (may involve suprarenal dissection); (4) removal and preparation of measured lengths of FPVs that will be required for the reconstruction; (5) application of aortic and femoral cross-clamps with removal of the infected prosthesis; and (6) reconstruction with FPV grafts.

Exposure begins via an incision that follows the anterolateral border of the Sartorius. The common femoral vein is identified and followed until the division of the deep femoral vein and FPV is identified; the latter will be the conduit and the deep femoral vein must be left intact. The profunda femoris vein is easily recognized as a large posteriorly penetrating vein in the proximal thigh with multiple, large branches. The femoral vein is then dissected parallel to the superficial femoral artery, through the adductor hiatus to the proximal portion of the popliteal vein. The segment in the adductor canal has multiple large branches, which must be carefully ligated. The dissection can easily be taken down to the level of the knee joint. The veins are left in situ and measured to determine length of the conduit needed from the aortic anastomosis to the distal anastomotic site. Measure the vein while in situ as it will dramatically shorten when cut, and return to its original length or longer when pressurized with aortic pressure.

The FPV has many large and small side branches. Careful, meticulous suture ligation of these branches with prolene is critical. Failure to ligate a branch adequately will result in exsanguinating hemorrhage if a tie pops off when exposed to aortic pressure, or when tunneled. Although the FPV is larger and sturdier than the typical great saphenous vein, it is thin walled in some areas where valves and branches are present. If a branch is avulsed during dissection, suture repair with 6-0 or 7-0 polypropylene is necessary. Unlike saphenous veins, these branches are ligated close to their bases because this is where the vein wall tends to be thin; the larger caliber of the FPV allows this to maintain a large caliber lumen.

The femoral vein is divided and suture-ligated flush with the profunda femoris vein. The grafts are then distended in a heparin-blood solution and

leaks are repaired with sutures. Next, the valves in the vein grafts are lysed. This is a critical step because the grafts are usually placed in a nonreversed fashion to optimize size matching with the aorta for the proximal anastomosis. You must evert the vein grafts and excise all valves with scissors under direct vision, and valve lysis with valvulotomes will be invariably incomplete, may tear the vein, and the remnants of the valves may become sites of graft stenosis and failure.

Multiple configurations have been successfully employed to reconstruct the aortoiliac/femoral vasculature (Fig. 220.6). The proximal anastomosis is performed with a continuous 4-0 prolene suture. The diameter of the FPV graft is typically about 1.5 cm or greater, and the mismatch in diameter between the graft and the aorta is dealt with by taking slightly more advancement on the aortic wall than on the graft wall. If the caliber discrepancy between the two structures is excessively large, another technique must be employed, such as plication of the aorta, joining the venous grafts in a pantaloon configuration, or placement of a triangular patch at the proximal aspect of the graft (Fig. 220.7). After the proximal anastomosis is complete, the venous graft is distended under aortic pressure, and the side branches are carefully examined to confirm that all ligatures are securely placed. Any questionable areas are repaired. Measurement usually demonstrates an even longer graft than when in situ. Anastomotic leaks are repaired with the aorta clamped again to ensure that the venous graft is not torn by the needle during repair. Extending the graft into the groins should be done by an end-to-end anastomosis of the entire contralateral vein and allowing it to fully distend as one long tube. The vein is tunneled and anastomosed into the femoral artery with the infection first. The remnant femoral vein is then anastomosed end to side as distal as possible on the aortofemoral conduit to shorten the distance for the next tunnel to the femoral artery. If concern arises as to the length of the last segment, then a rifampin-soaked Dacron graft can be anastomosed end to end to the FPV and pulled in the tunnel toward the femoral artery. Once the rifampin-treated graft is brought to the groin and allowed to pressurize, there usually is minimal prosthetic needed to be left in the groin. By using prosthetic only in the groin, if it gets infected later, it can be more easily managed than if prosthetic is left in the abdomen.

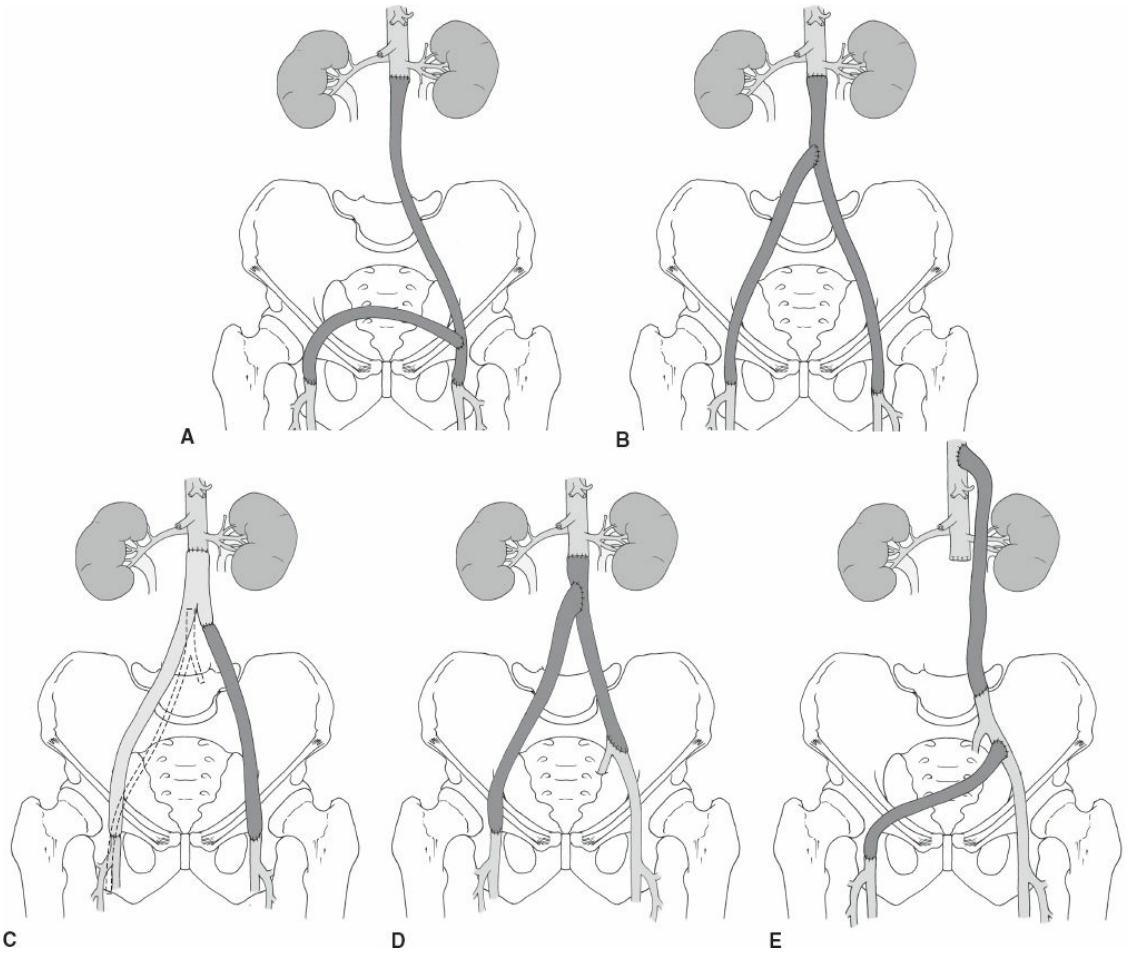

Figure 220.6. **A.** An aortofemoral bypass is fashioned on the left side with the femoropopliteal vein (FPV) graft. Another FPV graft is used to cross over to the right femoral region. **B.** Instead of a crossover femoral bypass, the right limb is connected to the left aortofemoral bypass using an end-to-side anastomosis. In both A and B, a shorter length of FPV graft is required for the right side of the reconstruction. **C.** In this example, infection was limited to the femoral region and the distal limb was replaced with an FPV graft. Care must be taken to prevent cross-contamination and the FPV graft routed lateral to the infected area or via a transobturator route. **D.** In this circumstance, a left common aortoiliac bypass is fashioned from one third to one half of an FPV graft and the right limb is fashioned from the remainder of the graft. This technique allows harvest of only a single FPV graft. **E.** In some circumstances, it is easier to approach the paraceliac aorta via a retroperitoneal approach and use this area for proximal anastomosis as shown in this figure. Although the distal anastomosis is to the common iliac artery in this case, additional length of FPV graft can be harvested to reach the femoral vessels if necessary

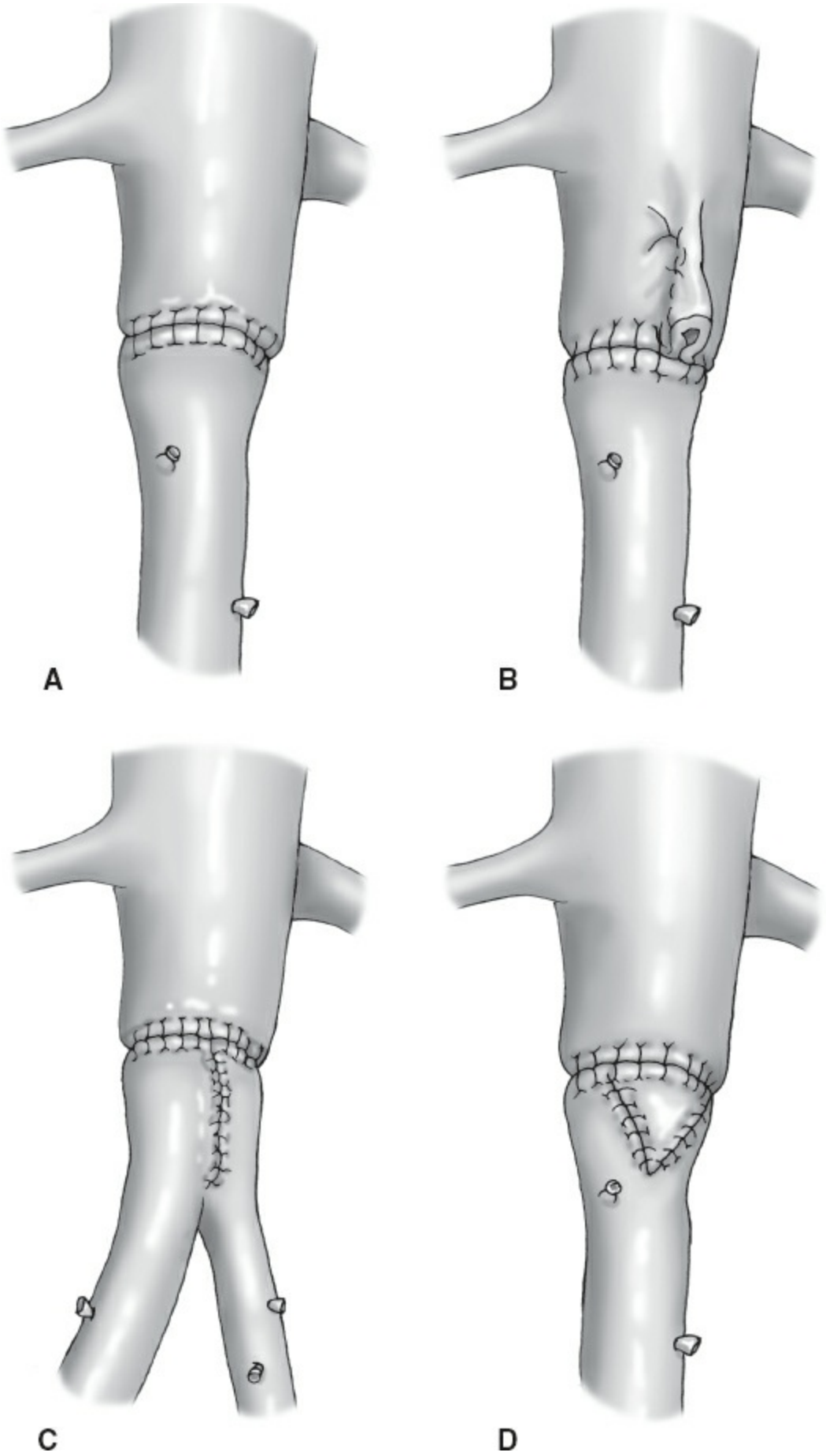
A
B
C
D

Figure 220.7. A. When the aorta is of normal size, the proximal end of the femoropopliteal vein (FPV) graft is anastomosed end to end. **B.** Simple plication of a portion of the aorta can be performed to allow comfortable end-to-end anastomosis when the aorta is either larger than normal or the FPV graft is comparatively small. **C.** In this example, two FPV grafts are joined together (pantaloon technique) and sewn end to end to the aorta. This effectively doubles the circumference of the vein graft and is used to accommodate very large aortas. **D.** In this case, a wedge-shaped portion of vein is incorporated into the proximal end to increase the circumference of the FPV graft.

RECONSTRUCTION USING NONAUTOLOGOUS MATERIALS

Cryopreserved Allografts

The versatility of cryopreserved allografts rapidly extended the indication for its use in the treatment of graft infection involving patients who need major concomitant surgery due to infective destruction or associated comorbidities.

These grafts allow safe in situ replacement of infected vascular or prosthetic segments, limit extended debridement at the site of infection, and obviate the need for complex extra-anatomic reconstructions with their distinct disadvantages (e.g., aortic stump blowout syndrome, suture line rupture, anastomotic aneurysms, and reinfection of the extra-anatomic grafts leading to multiple reoperations, distal amputations, and prolonged, even lifelong antibiotic treatment). A distinct advantage of allografts is the possibility to partially replace a graft when the vascular prosthetic infection is limited (involving only a small portion of the graft or the anastomosis itself, e.g., a false aneurysm of the proximal anastomosis or, in the case of groin infection, in a patient with aortobifemoral bifurcation prosthesis). Preparation of cryopreserved allografts is critical, as thawing and washing before implantation require a defined protocol. Sound surgical technique is critical—critical selection of allografts, eliminating those that are particularly friable, proper timing of allograft thawing, appropriate length and anastomosis without the slightest tension, proper ligature of allograft side branches using a through-and-through polypropylene suture (Fig. 220.8), avoidance of any exudate collection around the allograft by means of aggressive wound drainage, circumferential anastomotic reinforcement with allograft strips,

gentamycin-impregnated fibrin glue covering all anastomosis, and prolongation of antifungal treatment to 3 months postoperatively. A major drawback of allografts is the timely acquisition of an adequate allograft covering the individual patient's need. This is particularly true for those hospitals without an in-hospital allograft bank. They are stored in a –70°C freezer (or flown in just for the case), and the dimensions of the available grafts are limited and variable as they are obtained sporadically from cadavers. Furthermore, allografts may be more expensive than conventional prosthetic grafts. Allograft-related technical problems include intraoperative rupture caused by allograft friability, late allograft rupture from ligated allograft side branches, anastomotic stricture after partial graft replacement, anastomotic failure caused by inappropriate mechanical stress, allograft failure caused by inappropriate wound drainage, and recurrence of infection after inappropriate duration of antifungal treatment.

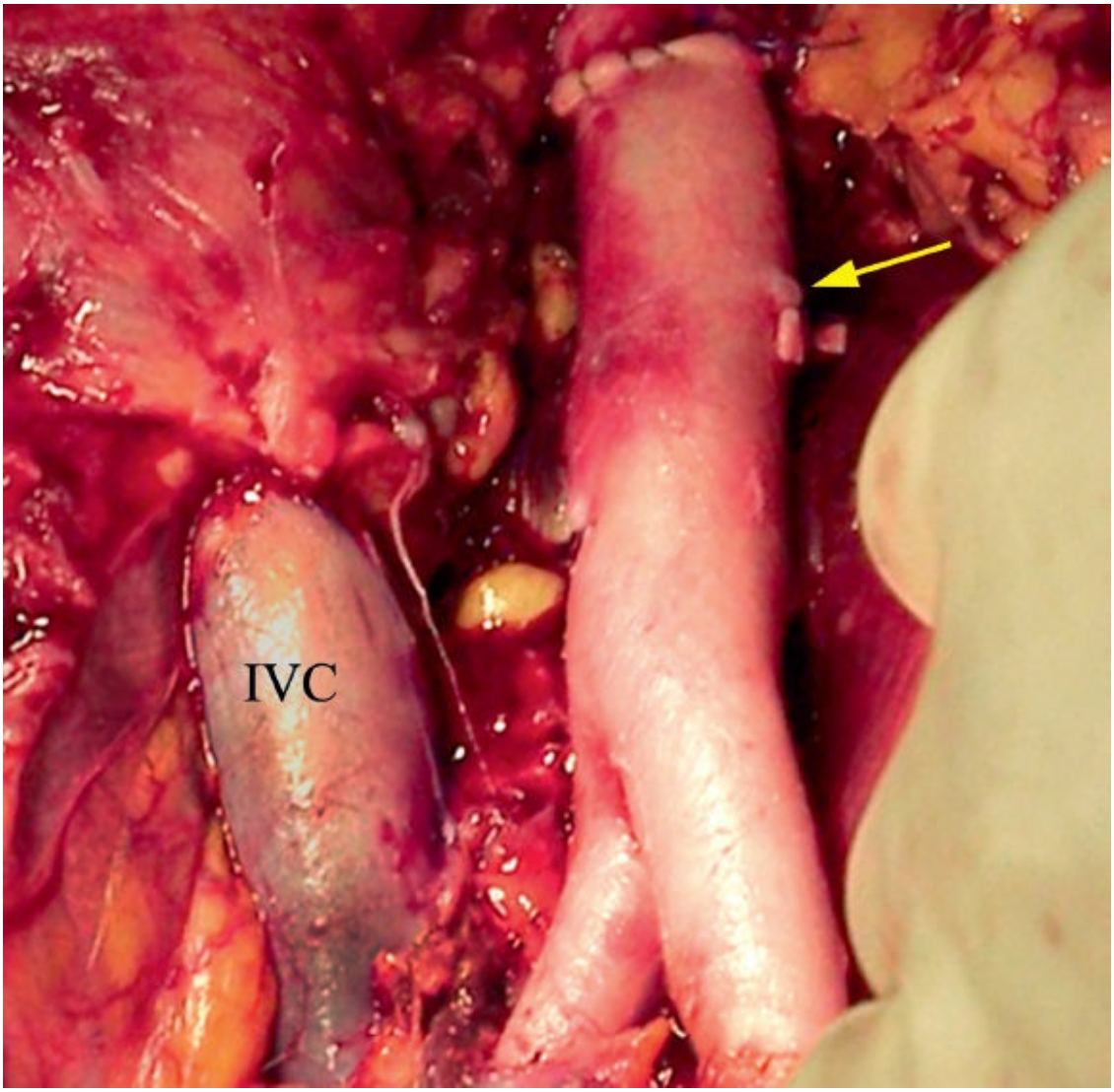

Figure 220.8. Aortic homograft used to replace an infected aortic graft. *Arrow* identifies ligated lumbar artery on the homograft. Inferior vena cava (IVC).

Antibiotic Impregnated Dacron Graft

Graft excision and in situ replacement using rifampin-treated Dacron grafts has been well documented since the late 1980s. It was most studied in-vivo for infections involving *Staphylococcus aureus* and *S. epidermidis* with a reported graft reinfection rate of 5% to 20% and limited morbidity.

Recurrent infections are usually due to from inadequate removal of all prosthetic at the first operation, or due to rifampin-resistant organisms (most notably *Enterococcus* sp.). Dacron grafts are soaked in Rifampin (60 mg/mL) for approximately 15 minutes prior to implantation. They have been found to retain their antibacterial effects for at least 2 to 3 days after implantation without additional antibiotics, depending on the organism.

Other antibiotics found to resist graft colonization *in vitro* include Daptomycin and nebacetin, as well as silver-woven grafts; but none of these have the extensive in-vivo experience that is reported with Rifampin. The authors also recommend the use of a pedicled omental flap to wrap the entirety of the rifampin graft after it is implanted. This is facilitated by allowing the graft to be a little more lax than usual when completing all the anastomosis. This leaves some room posterior to the graft to allow you to completely wrap the omentum behind and in front of the graft. This isolates the graft from the infected bed, potentially allows antibiotics to be circulating locally, and isolates it from the bowel. The largest series reported from the Mayo Clinic found a 5-year patient survival, primary graft patency, and limb salvage rates ranges are 60%, 92%, and 100%, respectively. Perioperative survival is overall 90%, but worse in unstable patients (～40%).

We recommend at least 6 weeks of intravenous antibiotics after implantation of all nonautologous grafts, followed by lifelong oral antibiotic suppressive therapy.

OUTCOMES

The optimal treatment for an infected aorta has historically been extra-anatomical bypass and removal of the infected graft. This is now being challenged. In a meta-analysis of treatments for infected aortic grafts, extra-anatomical bypass was compared to in situ rifampin-soaked Dacron, cryopreserved allografts, or autogenous veins using studies dating back to 1985.

Mean event rates for all outcomes combined (i.e., amputations, conduit failures, reinfections, <30-day mortalities, and >30-day mortalities) were calculated for each treatment modality. The results were 0.16 for extra-anatomic bypass, 0.07 for rifampin-bonded prostheses, 0.09 for cryopreserved allografts, and 0.10 for autogenous vein. A lower value meant fewer overall events. Despite the inherent weakness of a meta-analysis, in situ aortic reconstruction with rifampin-bonded prosthesis had the best outcomes. The authors questioned whether extra-anatomic bypass should remain the gold standard for treatment of aortic graft infection. The Society for Vascular Surgery Low Frequency Diseases Consortium studied outcomes of the use of cryopreserved grafts and found that in 220 patients the outcomes were comparable to femoral vein and only 10 (5%) patients required allograft explant.

Rifampin-treated Dacron with omental wrapping has a reinfection rate of about 12% and was not associated with procedure-related death. Comparing the procedure-related death rate for patients treated with this technique was slightly lower, but not significantly different than those treated with axillobifemoral bypass (9% vs. 23%; $P = 0.11$). However, there was a significant improvement in the primary patency 5 years (89% in Rifampin-treated grafts vs. 48% in the extra-anatomic group; $P = 0.01$), and a higher rate of major complications or procedure-related death in the axillobifemoral group (30% vs. 60%, respectively, $P < 0.04$).

Thus, in order to offer patients with this complex problem the optimal outcome possible, we stress that the approach be individually tailored to each case. They should be ideally managed by surgeons who are facile with each of the above-mentioned approaches, taking into consideration the risks and benefits of each technique.

Suggested Readings

Ali AT, Modrall JG, Hocking JA, et al. Long-term results of the treatment of aortic graft infection by in situ replacement with femoral popliteal vein grafts. *J Vasc Surg* 2009;50:30–9.

Clagett GP, Valentine RJ, Hagino, RT. Autogenous aortoiliac/femoral reconstruction from superficial femoral-popliteal veins: feasibility and durability. *J Vasc Surg* 1997;25:255.

Escobar GA, Eliason JL, Hurie J, et al. Rifampin soaking dacron-based endografts for implantation in infected aortic aneurysms—new application of a time-tested principle. *Ann Vasc Surg* 2014;28(3):744–8.

Harlander-Locke MP, Harmon LK, Lawrence PF, et al. The use of cryopreserved aortoiliac allograft for aortic reconstruction in the United States. *J Vasc Surg* 2014;59:669–74.

Laser A, Baker N, Rectenwald J, et al. Graft infection after endovascular abdominal aortic aneurysm repair. *J Vasc Surg* 2011;54:58–63.

O'Connor S, Andrew P, Batt M, et al. A systematic review and meta-analysis of treatments for aortic graft infection. *J Vasc Surg* 2006;44:38–45.

Oderich GS, Bower TC, Hofer J, et al. In situ rifampin-soaked grafts with omental coverage and antibiotic suppression are durable with low reinfection rates in patients with aortic graft enteric erosion or fistula. *J Vasc Surg* 2011;53:99–106.

Reilly LM, Stoney RJ, Goldstone J, et al. Improved management of aortic graft infection: the influence of operation sequence and staging. *J Vasc Surg* 1987;5:421.

Seeger JM, Pretus HA, Welborn MB, et al. Long-term outcome after treatment of aortic graft infection with staged extra-anatomic bypass grafting and aortic graft removal. *J Vasc Surg* 2000;32:451.

EDITOR'S COMMENT

While mycotic aneurysms are difficult to deal with, graft infections in my mind remain the most confusing and life-threatening conditions we treat as surgeons. Plagued with the concept as suggested in this chapter by Garcia-Toca and Escobar that there is not a "one size fits all" when it comes to graft infections, the challenges of taking care of patients with this condition are multiple.

Importantly, one needs to first admit or decide that a graft infection is present. While the graft infection that shows up with air around it usually is clear, as most graft infections are *Staph* species, graft infections can also be indolent and smolder for years. It is clear that a good history is important as one needs to know what previous surgery has been done and what graft material has been used. I so remember a graft infection I was managing when all of the operative notes from a complicated aortic and groin graft infection were not received. I so remember discovering that a jump graft had been performed under the inguinal ligament to the very distal external iliac artery and then to the femoral, rather than just straight to the groin. The patient did fine, but the amount of bleeding that occurred during that operation was more than it should have been.

Imaging is once again key in the setting of graft infections, especially aortic graft infections (Bruggink JL, Slart RH, Pol JA, et al. Current role of imaging in diagnosing aortic graft infections. *Semin Vasc Surg* 2011;24(4):182–90). Remember that sometimes infected grafts present with occlusion. In addition, noticing on an angiogram that one can still see the waves or ripples in a Dacron graft is a subtle sign that a graft is not well incorporated and thus may be infected. Cross-sectional imaging with computed tomography angiography (CTA) or magnetic resonance angiography (MRA) remains the mainstay of diagnosis with nuclear imaging only required if the diagnosis is not clear cut (Keidar Z, Nitecki S. FDG-PET in prosthetic graft infections. *Semin Nucl Med* 2013;43(5):396–402).

As described in the present chapter, there are literally a myriad of ways to treat a graft infection. The general tenet has changed somewhat in that cryopreserved and antibiotic-soaked grafts are now commonly used; however, historically the treatment was to remove in total the offending infected graft and replace it through a noninfected field. This would typically involve performing the clean portion of the operation first (axillary to bifemoral bypass, obturator bypass, etc.) first, closing, and then performing the removal of the infected graft (Berger P, Moll FL. Aortic graft infections: is there still a role for axillobifemoral reconstruction? *Semin Vasc Surg* 2011;24(4):205–10). If this

can be done, I can't help but believe this type of approach is still the best for gram-negative and fungal infections or those associated with lung, bowel, or urine fistulae. My guess is that recurrent infection will always be less when this approach is used.

The use of autogenous vein, namely the femoral vein (used to be called the superficial femoral vein), for graft infections sort of changed the way we think about and manage graft infections (Chung J, Clagett GP. Neoaortoiliac System [NAIS] procedure for the treatment of the infected aortic graft. *Semin Vasc Surg* 2011;24(4):220–6). I personally like a direct approach to this problem and think the extra-anatomic bypasses we perform for graft infections are really not that durable and don't show great long-term patency. I just don't see how bilateral axillary to distal superficial or proximal above knee popliteal arteries are ever a solution for anything. While I have performed multiple neo-aortic replacements, these long procedures are brutal on patients who typically are already chronically ill. The literature now supports the use of two teams (one harvest, one performing graft explanation and repair) for these long surgeries, or to break the surgery up into two settings (one where the veins are exposed), followed a day later by vein excision and infected graft replacement (Budtz-Lilly J, Eldrup N, Vammen S, et al. Femoral vein repair of arterial infections: technical tips to reduce procedure time. *Vasc Endovascular Surg* 2014;48(5–6):367–71).

I also have on multiple occasion used Rifampin-soaked grafts with antibiotics beads, as well as the creation of an omental or muscle flap (Davila VJ, Stone W, Duncan AA, et al. A multicenter experience with the surgical treatment of infected abdominal aortic endografts. *J Vasc Surg* 2015;62(4):877–83). One can use this sort of approach when the bacteria involved in the aortic graft infection are a gram-positive species. However, the key is removing the previous graft, debriding the infected area, and finally and importantly making sure some real and substantial autogenous tissue coverage is placed around the rifampin-soaked graft. Others have used cryografts in a similar fashion and they seem to work just about as well (Noel AA, Gloviczki P, Cherry KJ Jr, et al.; United States Cryopreserved Aortic Allograft Registry. Abdominal aortic reconstruction in infected fields: early results of the United States cryopreserved aortic allograft registry. *J Vasc Surg* 2002;35(5):847–52).

Finally, I need to provide just a thought on the "conservative management" of these patients with graft infections, namely those that have an indolent where the patient is not septic from their graft infection, and the patient is not fit for repair. Others much more commonly use this approach, even though I am sure that my infectious disease colleagues would never go along with this approach. One of my senior partners Dr. Ken Cherry once suggested to me that an alive patient with or without a drain on chronic lifetime suppressive antibiotics is better than a dead patient who underwent a heroic attempt at an operation that ultimately failed.

Gilbert R. Upchurch

G VENOUS DISORDERS

221 Contemporary Operative Venous Thrombectomy

Anthony J. Comerota and Faisal Aziz

INTRODUCTION

The controversial history of operative venous thrombectomy necessitates a background discussion before embarking upon a description of the technique. Patients with multilevel deep venous thrombosis (DVT) are at increased risk for severe postthrombotic syndrome, and those with iliofemoral DVT represent the highest risk subset. Therefore, it is appropriate to approach patients with iliofemoral DVT with an initial treatment strategy to eliminate their thrombus. Occasionally, catheter-based techniques will not be an appropriate option. Therefore, the option remaining to restore venous patency is operative venous thrombectomy.

Postthrombotic syndrome results from valve reflux or luminal obstruction. It is increasingly severe with combined reflux and obstruction, and most severe in patients with postthrombotic iliofemoral venous obstruction. Intuitively, if unobstructed venous drainage from the leg into the vena cava can be restored, patients should enjoy a significantly better quality of life as a result of fewer postthrombotic sequelae. This has been shown with catheter-directed thrombolysis, as well as a randomized trial of operative venous thrombectomy versus anticoagulation. Adopting a strategy of thrombus removal is an important first step in the management of these patients (Fig. 221.1).

Venous thrombectomy was largely abandoned in the United States because of two early reports. Interestingly, the procedures were performed approximately 50 years ago at a time when true “vascular” techniques did not exist. Vascular imaging was in its infancy, and anticoagulation was inconsistent. Unfortunately, some guidelines on the management of venous thromboembolism (VTE) continue to focus on the outdated retrospective

reports and overlook more recent studies showing improved outcomes using contemporary vascular techniques. Until 2008, guideline authors overlooked a multicenter *randomized* trial evaluating contemporary venous thrombectomy versus standard anticoagulation. A Scandinavian randomized trial demonstrated significant benefit to those undergoing operative venous thrombectomy, with fewer postthrombotic sequelae, increased iliac vein patency, lower venous pressures, and improved valvular function, compared to those treated with anticoagulation alone.

The technique of contemporary venous thrombectomy reviewed here is designed to maximize the chance of a favorable outcome (Table 221.1) and is significantly different compared to the technique used in earlier reports (Table 221.2).

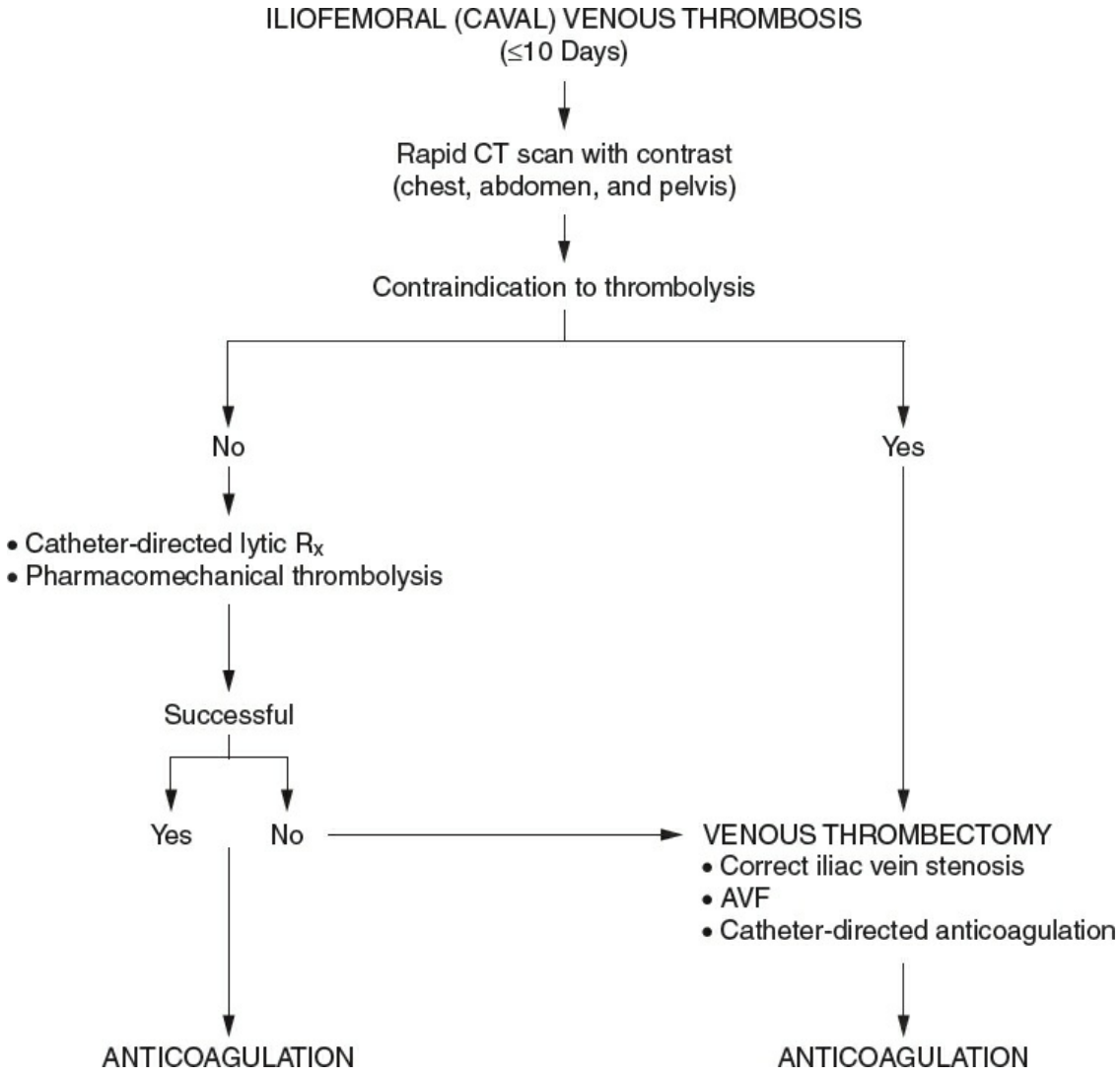

Figure 221.1. Algorithm for the recommended treatment for iliofemoral venous thrombosis. CT, computed tomography; AVF, arteriovenous fistula.

TABLE 221.1 Technique of Contemporary Venous Thrombectomy

1. **Define full extent of thrombus**
   a. Venous duplex examination
   b. Rapid CT scan of head, chest, abdomen, and pelvis
   c. Contralateral iliocavagram
2. **Prevent pulmonary embolism (numerous techniques)**
   a. Initiate nticoagulation
   b. Vena caval filter (if nonocclusive clot in vena cava), or
   c. Balloon occlusion of vena cava cephalad to nonocclusive caval thrombus during iliocaval thrombectomy
   d. Positive end-expiratory pressure during thrombectomy of iliocaval segment
3. **Perform a complete thrombectomy**
   a. Iliofemoral (vena cava) thrombectomy
   b. Infrainguinal venous thrombectomy (if required) using compression. If compression techniques fail direct balloon catheter thrombectomy from distal to proximal is recommended.
4. **Prevent recurrent thrombosis**
   a. Correct iliav veni stenosis if present
   b. Construct arteriovenous fistula (saphenofemoral)
   c. Maintain continuous therapeutic anticoagulation
   d. Catheter-directed postoperative anticoagulation (if infrainguinal venous thrombectomy was performed) via catheter in posterior tibial vein
   e. Extended oral anticoagulation

TECHNIQUE OF OPERATIVE VENOUS THROMBECTOMY

The principles of successful venous thrombectomy are briefly summarized in Table 221.1. The important conceptual elements of the procedure are numbered sequentially, with methods to achieve these goals listed beneath each numbered item.

PREOPERATIVE PATIENT EVALUATION AND PLANNING

Of all the patients presenting with lower extremity DVT, those with iliofemoral DVT represent the patient population with the highest thrombus burden. Often, there is a reason for this degree of extensive thrombosis, which may include an underlying thrombophilia or malignancy.

It is crucial to determine the proximal and distal extent of thrombus. The infrainguinal veins are well examined by venous duplex. We prefer a contralateral iliocavagram to evaluate the vena cava and iliac veins. Magnetic resonance venography or spiral computerized tomography (CT)

with contrast may obviate the cavagram.

A rapid CT scan with intravenous contrast of the head, chest, abdomen, and pelvis is performed. Asymptomatic pulmonary emboli (PE) are found in approximately 50% of cases. Extending imaging from the head and chest to the abdomen and pelvis is an effective way to rapidly screen for other pathology. In addition to identifying the proximal extent of thrombus and PE, CT scans have revealed new findings of renal cell carcinoma, adrenal tumors, hepatic metastases, retroperitoneal lymphoma, iliac vein aneurysms, and congenital absence of the vena cava. Each of these findings can have important implications for immediate and long-term patient care.

TABLE 221.2 Venousthrombectomy: Comparison of Old and Contemporary Techniques

Technique	Old	Contemporary
Pretreatment phlebography/computed tomography scan	Occasionally	Always
Venous thrombectomy catheter	No	Yes
Operative fluoroscopy/phlebography	No	Yes
Correct iliac vein stenosis (stent)	No	Yes
Arteriovenous fistula	No	Yes
Infrainguinal thrombectomy	No	Yes
Full postoperative anticoagulation	Occasionally	Yes
Catheter-directed anticoagulation	No	Yes
Intermittent pneumatic compression postoperatively	No	Yes

Adapted from Comerota AJ, Gale SS. Surgical venous thrombectomy for iliofemoral deep vein thrombosis. In: Greenhalgh RM, ed. *Towards Vascular and Endovascular Consensus.* London: BIBA Publishing; 2005.

While a hereditary thrombophilia evaluation was performed early in our experience, it has been recognized that it is no longer necessary as the patient's existing thrombosis is a higher risk for recurrence than any detected hereditary thrombophilia. Furthermore, a negative panel may mistakenly mislead the physician into thinking the patient is at a low risk for rethrombosis. In general, the risk of rethrombosis associated with extensive DVT is greater than the risk associated with a hereditary thrombophilic condition. We recommend that first-degree female relatives of child-bearing potential be studied for Factor V Leiden, prothrombic gene mutation and antithrombic deficiency, as a positive test may affect

treatment during subsequent pregnancy. Antiphospholipid antibodies are obtained in all patients.

Therapeutic anticoagulation with unfractionated heparin (UFH) or low–molecular-weight heparin (LMWH) is initiated and the patient fully anticoagulated. UFH is used during the procedure and early postoperative period. Intravenous UFH offers temporal control of the degree of anticoagulation, and of course is the agent used for postoperative catheter-directed anticoagulation.

Vena caval filtration is generally not required; however, an exception may be the patient with nonocclusive thrombus in the vena cava or those with symptomatic PE. Also, patients can be protected from intraoperative PE by balloon occlusion of the proximal vena cava during the operative procedure (Fig. 221.2). The vena caval balloon can be positioned from the contralateral femoral vein using fluoroscopic guidance during preoperative iliocavagraphy. Once the balloon is properly positioned, it remains deflated until the time of thrombus extraction. During thrombectomy, the caval balloon is inflated and the thrombectomy performed under fluoroscopic guidance, inflating all balloons with contrast mixed with saline. If fixed imaging is not available, the operating room is prepared for fluoroscopy with any necessary modifications in operating room table positioning. An autotransfusion device is also available during the procedure.

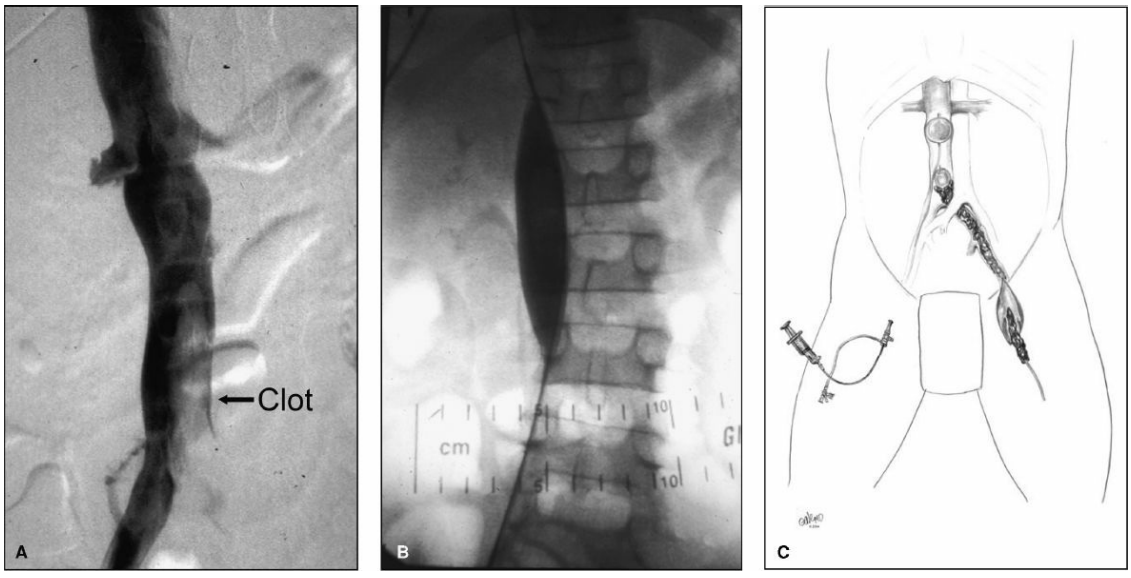

Figure 221.2. A. Preoperative iliocavagram shows nonocclusive thrombus extending from the left iliofemoral venous system into the vena cava. Insert to left of vena cava shows caval thrombus was removed in its entirety. **B.** A balloon catheter was placed

from the contralateral femoral vein and inserted under fluoroscopy; positioned above the caval thrombus. The caval balloon is inflated at the time of thrombectomy. **C.** Schematic of iliocaval thrombectomy performed with the double balloon catheter technique, protecting the patient from pulmonary embolism.

SURGICAL TECHNIQUE

Following the induction of general anesthesia, the entire involved leg, lower abdomen, and opposite leg to the knee are prepped into the field. If there is any doubt that successful iliac vein patency can be restored, both legs are prepped into the operative field, in the event that an autogenous cross-pubic venous bypass is required. A longitudinal inguinal incision is made in the groin, exposing the common femoral vein to the inguinal ligament, the saphenofemoral junction, the origin of the profunda femoris vein and the proximal femoral vein (Fig. 221.3A). A longitudinal venotomy is performed near the saphenofemoral junction. The exact location of the venotomy will depend upon the extent and location of the thrombosis. Since the femoral vein is distended, a longitudinal venotomy is preferred and can be closed primarily without compromising vein lumen.

In patients with infrainguinal thrombosis, an infrainguinal venous thrombectomy is performed first. Initially the leg is elevated and wrapped tightly with an elastic bandage. The leg is squeezed and the foot dorsiflexed, and the leg is milked in an effort to remove clot from below. If these maneuvers are successful, the femoral vein below the venotomy is clamped. The distal posterior tibial vein is exposed to perform an infrainguinal venous thrombectomy (Fig. 221.3B). A No. 3 balloon catheter is passed proximally from below to exit the common femoral venotomy (Fig. 221.4A). The silastic sheath of a large intravenous catheter (12 to 14 gauge) is cut from its hub and slid halfway onto the balloon catheter that was passed from below. Another No. 4 balloon catheter is placed into the proximal end of the silastic sheath. A single operator applies pressure to the syringes attached to the two catheters, which firmly secures the balloons inside of the sheath, providing protective passage distally through the clotted venous system and valves (Fig. 221.4B). The catheters exit the posterior tibial venotomy (Fig. 221.4C). A standard balloon catheter thrombectomy can then be performed in the direction of the venous valves (Fig. 221.4D,E). Repeated balloon thrombectomy (with

a larger catheter if necessary) can be performed until no further thrombus is extracted. The infrainguinal venous system is then vigorously flushed with a heparin-saline solution to hydraulically force residual thrombus from the deep venous system (Fig. 221.5). This is accomplished by placing a No. 14 to 16 red rubber catheter into the proximal posterior tibial vein and flushing with a bulb syringe. It is often surprising to see the amount of additional thrombus flushed. After flushing, a vascular clamp is applied below the femoral venotomy and the infrainguinal venous system is then filled with a large volume of dilute plasminogen activator solution. Commonly, 3 to 4 mg of rt-PA is diluted in 200 mL of saline and injected into the infrainguinal venous system. If the infrainguinal thrombectomy is not successful due to chronic disease in the femoral vein, or if there is multichannel recanalization of the femoral vein, it is ligated and divided just below its junction with the profunda. Patency of the profunda femoris vein must be ensured prior to ligation of the femoral vein. This maneuver prevents the inevitable venous reflux through the diseased femoral vein. Venous drainage through an unobstructed profunda system, which may have competent valves, offers a better chance at reducing postthrombotic sequelae.

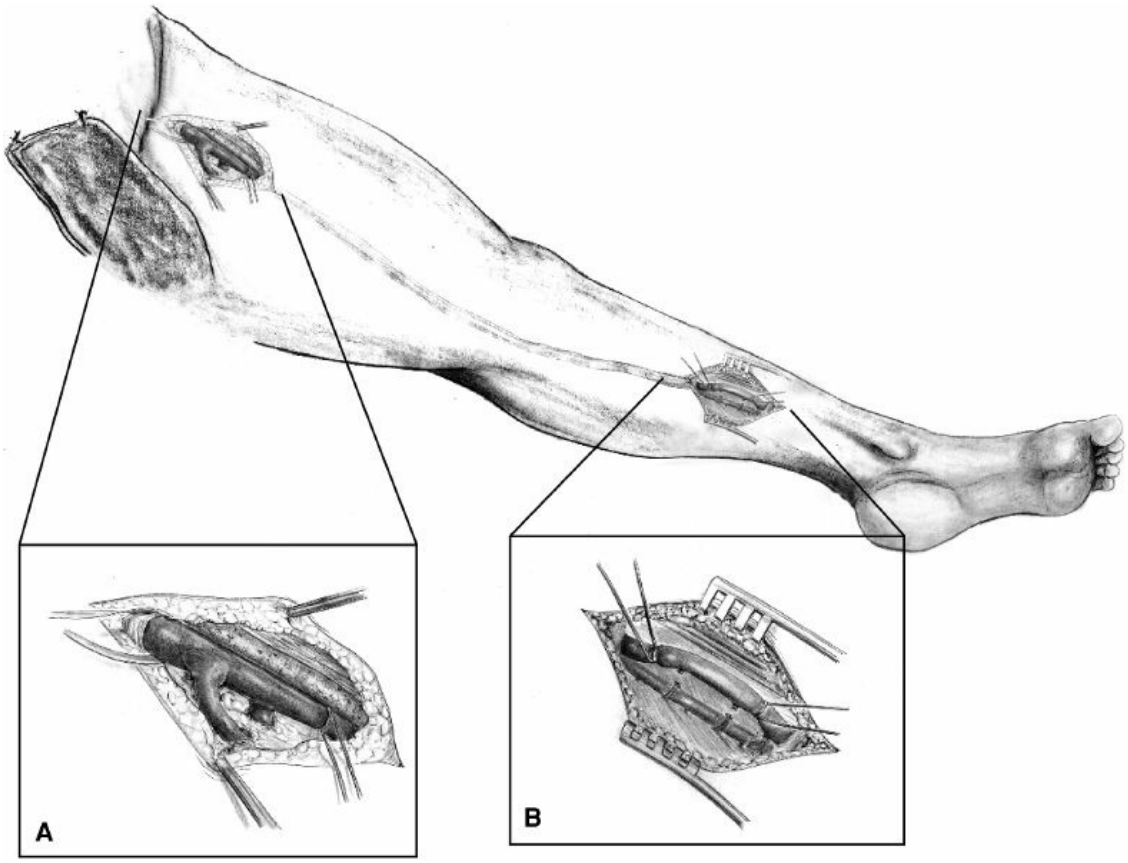

Figure 221.3. **A.** Exposure of the common femoral, femoral, and profunda femoris veins. **B.** Exposure of the posterior tibial vein.

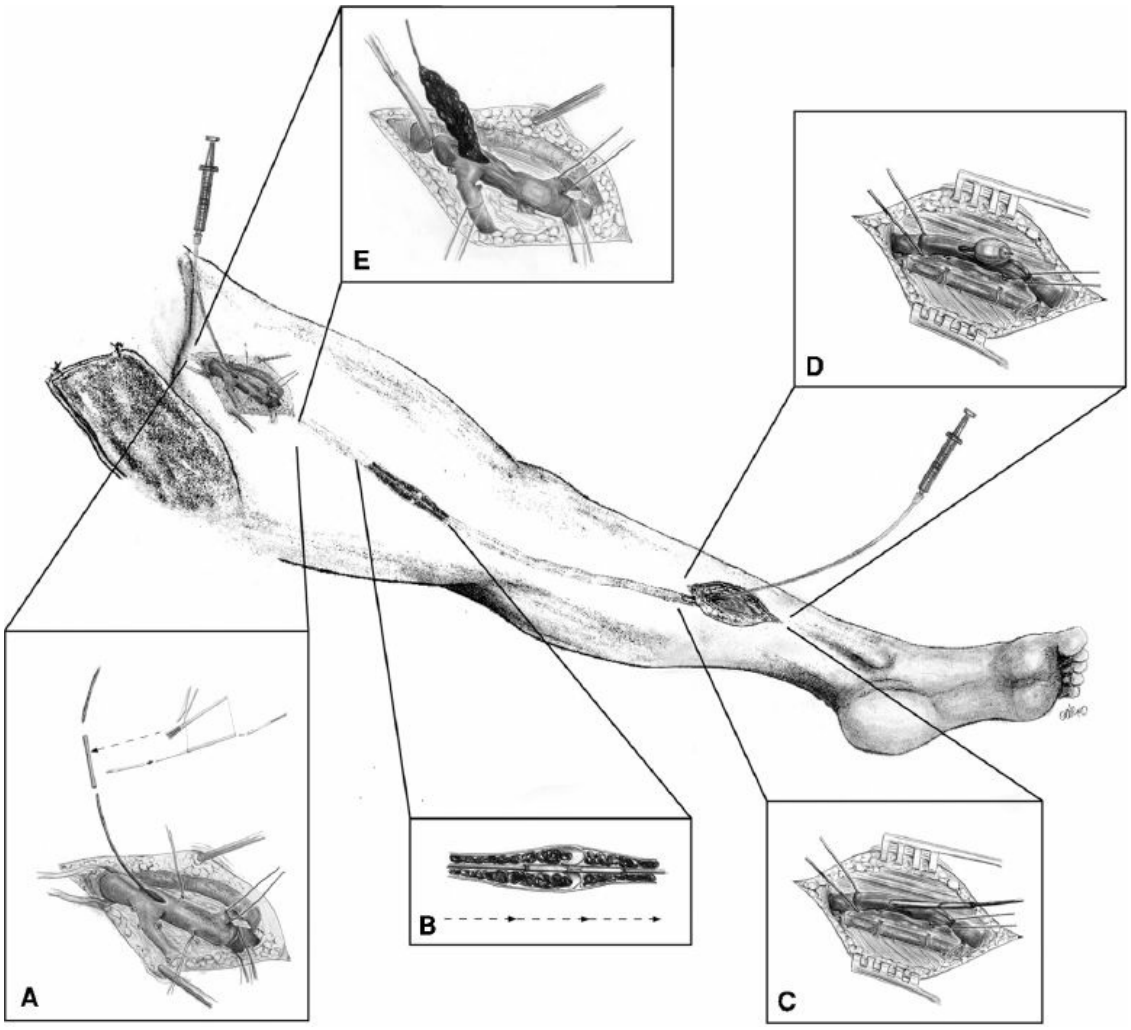

Figure 221.4. Technique of infrainguinal balloon catheter venous thrombectomy begins with passage of a No. 3 balloon catheter from the posterior tibial vein proximally (**A**), exiting the femoral venotomy. A silastic IV sheath is placed halfway onto the No. 3 catheter, and a second No. 4 balloon catheter inserted into the cephalad end of the sheath. **B.** The balloons are pressurized to fix the catheter tips inside of the sheath, with the pressure applied by a single individual guiding them distally through the clotted veins and venous valves no resistance to catheter passage should be encountered. **C.** Catheters and sheath exit the posterior tibial venotomy. **D.** The No. 4 thrombectomy catheter balloon is gently inflated as the catheter is pulled proximally (**E**) to exit the femoral venotomy, extracting thrombus. This is repeated several times until not thrombus is retrieved.

The iliofemoral and caval thrombectomy is performed using a No. 8 or 10 *venous* thrombectomy catheter. The catheter is passed partway into the iliac vein several times to remove the majority of the iliac vein thrombus before advancing into the vena cava. The proximal thrombectomy is performed under fluoroscopy using a contrast-saline solution to expand the balloon. This is especially important if a vena caval filter is present, if there is clot in the vena cava, or if the surgeon experiences resistance to catheter passage. The anesthesiologist applies positive end-expiratory pressure during the iliocaval thrombectomy to further reduce the risk of intraoperative PE.

Following completion of the iliofemoral and vena caval thrombectomy, the iliofemoral system and vena cava are examined with a biplane intraoperative venogram to ensure unobstructed venous drainage into and through the vena cava. If there is any question about an iliac stenosis, intravascular ultrasound is used to examine the iliac veins. An underlying iliac vein stenosis is corrected with balloon angioplasty and, if necessary, a stent to maintain the desired luminal diameter (Fig. 221.6). If a stent is placed into the common iliac vein, it should be no smaller than 14 mm in diameter, with most being larger.

The importance of correcting an underlying venous stenosis at the time of venous thrombectomy cannot be overstated (Fig. 221.6). Long-term patency with this approach has been reported to be 84% to 86%. If early rethrombosis is avoided, this has proven to be a durable and worthwhile procedure.

The venotomy is closed with a running fine monofilament suture. The proximal saphenous vein is exposed and may require thrombectomy in anticipation of constructing an arteriovenous fistula (AVF). The AVF is constructed by anastomosing the end of the transected proximal saphenous vein (or a large proximal side branch of the saphenous vein) to the side of the proximal superficial femoral artery. The anastomosis should be no greater than 3.5 to 4.0 mm in diameter. A small piece of bovine pericardium or PTFE is placed around the saphenous AVF, and a large permanent monofilament suture is looped around the PTFE graft and clipped, leaving approximately 2 to 3 cm in the subcutaneous tissue (Fig. 221.7A). This maneuver is performed in the event that operative closure of the AVF becomes necessary. Although others have used the AVF as temporary and report closure by percutaneous or open occlusion, we view the AVF as permanent, since it is small and cannot enlarge there has been

no hemodynamic consequence. Most patients tolerate the AVF well, and the flow through this small channel often diminishes with time due to neointimal fibroplasia. Since approximately 15% of patients with early closure of AVFs have early recurrent thrombosis, and since our patients have tolerated the AVF without difficulty, we believe that routine, elective closure of this small AVF is not warranted. However, if the AVF is large (≥6 mm), it will produce arterial and venous dilation. In this instance, the AVF should be closed.

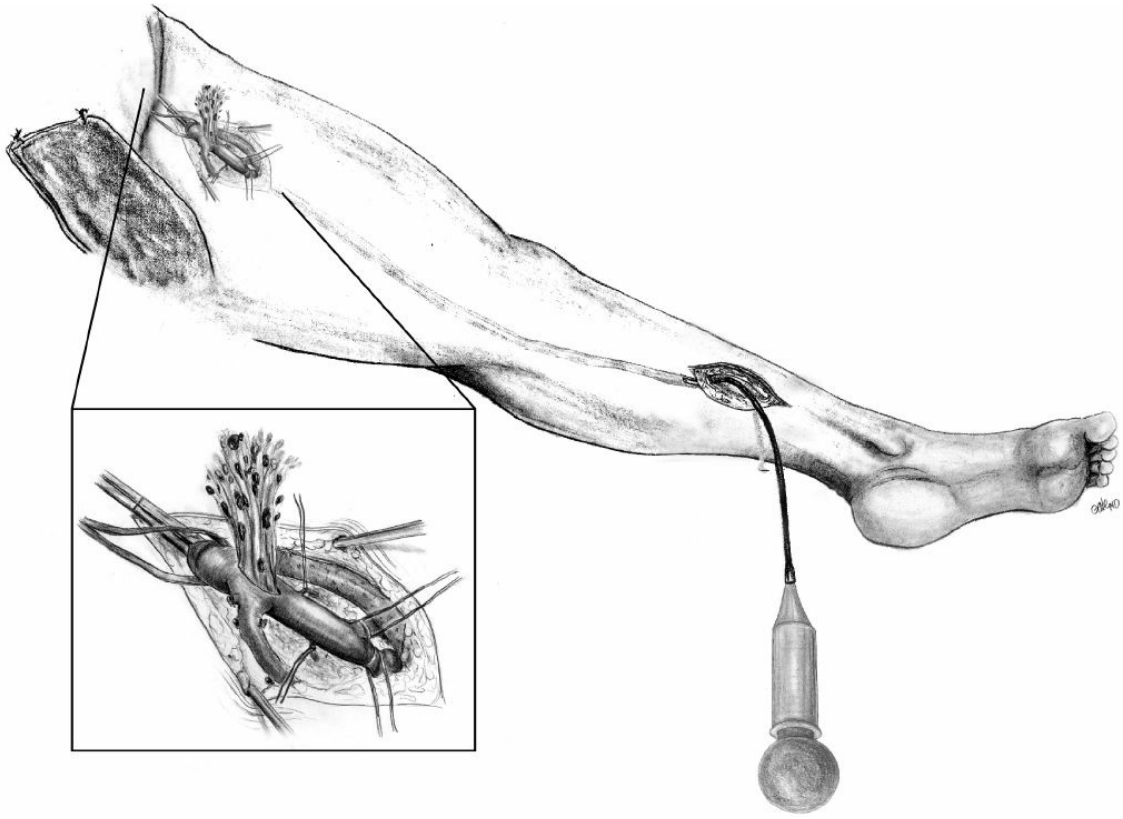

Figure 221.5. A red rubber catheter (largest diameter possible) is placed into the posterior tibial vein and vigorously injected with a heparin-saline solution using a bulb syringe to flush residual thrombus. After flushing, the femoral vein is clamped and the leg veins injected with 150 to 200 mL of a dilute 2- to 3-mg rt-PA solution.

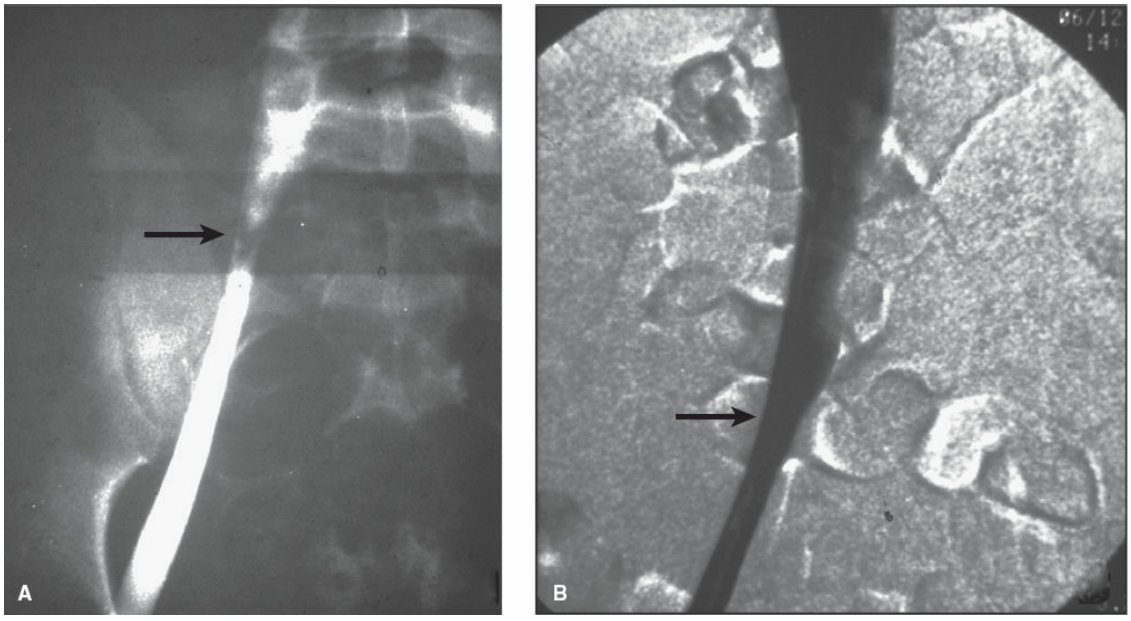

Figure 221.6. **A.** After iliac vein thrombectomy, a completion phlebogram of the right common iliac vein shows a residual stenosis (*arrow*). **B.** Following iliac vein venoplasty, the stenosis is corrected (*arrow*), restoring unobstructed venous drainage into the vena cava. Most patients will require stenting to correct their stenosis.

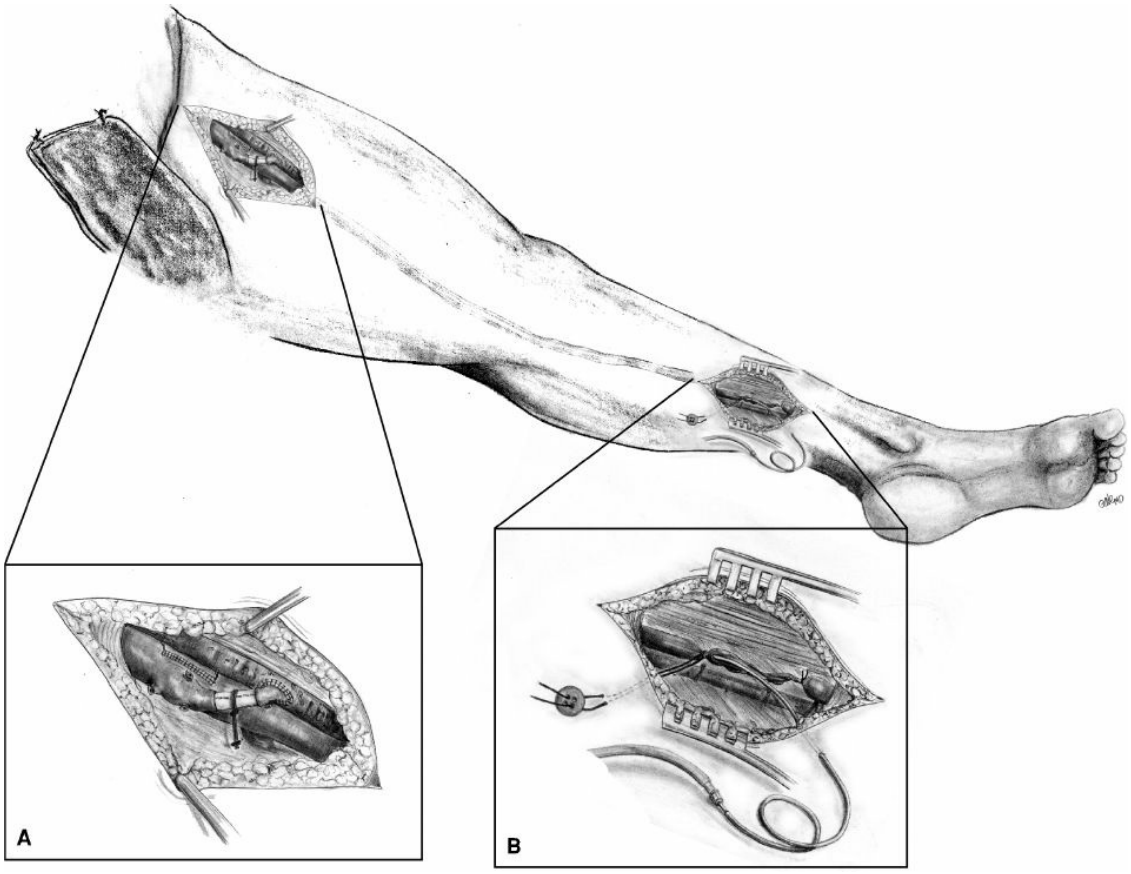

Figure 221.7. **A.** The venotomy is closed with fine monofilament

suture, and a 3.5- to 4.0-mm arteriovenous fistula (AVF) is constructed sewing the transected end of the saphenous vein to the side of the superficial femoral artery. A piece of bovine pericardial patch is placed around the saphenous AVF, looped with No. 0 monofilament suture, and the ends clipped, leaving approximately 2 to 2.5 cm in the subcutaneous tissue. This eliminates the risk of the AVF enlarging and serves to guide surgical closure of the AVF, should it become necessary. **B.** The distal posterior tibial vein is ligated. An infusion catheter (pediatric nasogastric tube) is brought into the wound through a separate stab wound in the skin and inserted and fixed in the proximal posterior tibial vein. The proximal posterior tibial vein and catheter are looped with No. 0 monofilament suture and fixed to the skin through a sterile button, which is used to snugly occlude the posterior tibial vein at the time of catheter removal.

Common femoral vein pressures are measured before and after the AVF is opened (Fig. 221.8), the pressure should not change. If the femoral vein pressure increases when the AVF is opened, the iliac veins should be reevaluated for residual stenosis or obstruction and the proximal lesion corrected. If the pressure remains elevated in the absence of proximal disease, the AVF should be constricted to decrease flow and normalize pressure.

If there appears to be notable serous fluid in the wound, a careful search for transected lymphatics is performed and they are ligated. A closed suction drain is placed in the wound to evacuate blood and serous fluid that may accumulate postoperatively in an effort to reduce hematoma or seroma formation. The drain exits through a separate puncture site adjacent to the incision, and the wound is closed with multilayered running absorbable sutures to obliterate dead space and achieve hemostatic and lymphostatic wound closure.

Before closing the distal incision, the distal posterior tibial vein is ligated. A small infusion catheter is brought into the wound via a separate stab incision in the skin and inserted into the proximal posterior tibial vein. We frequently use a pediatric feeding tube (Fig. 221.7B). This catheter is used for postoperative therapeutic anticoagulation, with continuous infusion of UFH directly into the previously thrombosed venous system, which is continued for 4 to 5 days until the patient is therapeutic on warfarin. Prior to catheter removal, a phlebogram is performed. Postoperative heparin infusion through this catheter ensures

supratherapeutic heparin concentration into the affected venous segment. Heparin binds to endothelium, smooth muscle cells, and subendothelial collagen. We believe this to be a valuable addition to this procedure. A 2-0 monofilament suture is looped around the posterior tibial vein (and catheter) with both ends exiting the skin adjacent to the wound. Both ends of the suture are passed through adjacent holes of a sterile button, which is secured to the skin snugly when the catheter is removed. This maneuver obliterates the proximal posterior tibial vein and eliminates any risk of bleeding following catheter removal.

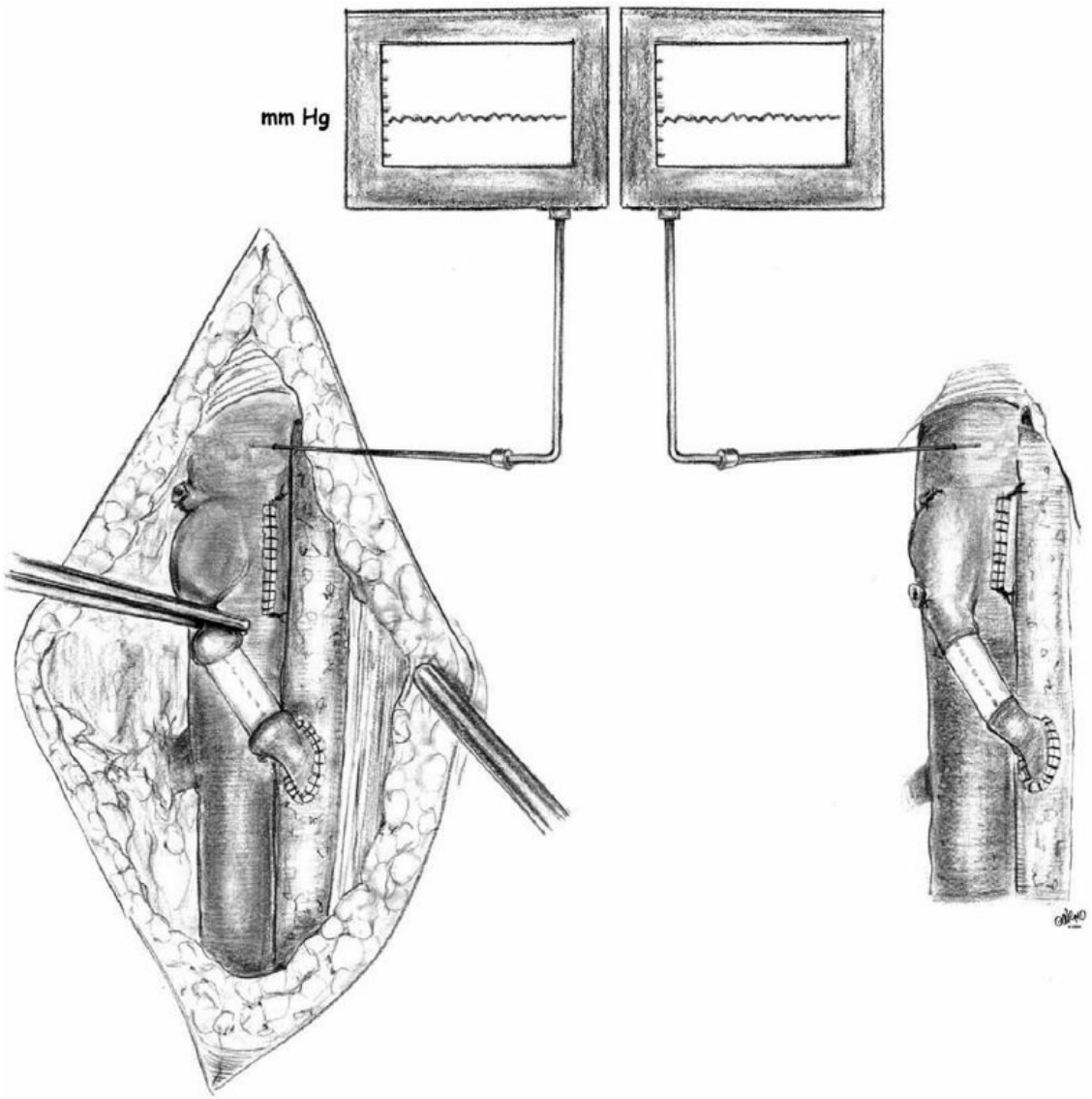

Figure 221.8. The common femoral vein pressure is measured before and after the arteriovenous fistula is opened; the pressure should not change.



Figure 221.9. An ascending phlebogram evaluates venous patency prior to catheter removal, after the patient is therapeutic on warfarin.

POSTOPERATIVE MANAGEMENT

After wound closure, antibiotic ointment and sterile gauze are applied to the wounds. The patient's leg is wrapped from the base of the toes to the inguinal area with cotton gauze and elastic bandages. Full anticoagulation is continued postoperatively with UFH infused through the catheter secured in the posterior tibial vein (as mentioned previously). The patient is encouraged to ambulate beginning the first postoperative day. Oral anticoagulation is begun immediately postoperatively when the patient resumes oral intake. The heparin infusion is continued for a minimum of 4 to 5 days and the international normalized ratio reaches 2.0 to 3.0, if the patient is treated with a VKA. Intermittent pneumatic compression garments are used on both legs during the postoperative period when the patient is not ambulating. While the direct oral IIa and Xa inhibitors are as effective as heparin/warfarin treatment for the majority of patients with acute DVT, we prefer to manage these patients with heparin and warfarin,

at least for the first 6 to 12 months.

Prior to removing the posterior tibial vein catheter, an ascending venogram is obtained to evaluate venous patency (Fig. 221.9). The femoropopliteal veins are well visualized; however, the iliofemoral venous system may not be adequately imaged due to washout and dilution of contrast by the AVF. If imaging of the iliofemoral venous system is required, alternative techniques such as direct femoral vein puncture, contrast injection into the artery, or a CT scan with IV contrast may be used. Any significant stenosis or occlusion in the iliofemoral segment should be promptly treated to provide unobstructed venous drainage into the vena cava.

Oral anticoagulation is recommended for an extended period of time. Patients are anticoagulated for a minimum of 1 year, with most treated longer. Elastic compression stockings with a 30- to 40-mm ankle gradient are used in all patients and have been found to further reduce postthrombotic sequelae. However, if patents have no swelling without the use of elastic compression stockings, they generally will receive no benefit from their use.

SUMMARY

The technique of contemporary operative venous thrombectomy has been refined and the early and long-term results have been considerably improved compared to initial reports. Operative morbidity is low, with fewer, if any, reports documenting an operative mortality. Fatal PE has not occurred in the contemporary experience, and in fact no patient in the author's experience has suffered from a symptomatic pulmonary embolism in association with operative venous thrombectomy, even when thrombus extended into the vena cava.

TABLE 221.3 Venous Thrombectomy With Arteriovenous Fistula: Long-Term Iliac Vein Patency

Author/Year	No.	Follow-up (mo)	Patent Iliac Vein (%)
Plate et al., 1984	31	6	76
Piquet et al., 1985	57	39	80
Einarsson et al., 1986	58	10	61
Vollmar, 1986	93	53	82
Juhan et al., 1999	150	102	84
Torngren et al., 1988	54	19	54
Rasmussen et al., 1990	24	20	88
Eklof et al., 1996	77	48	75
Neglen et al., 1991	34	24	88
Meissner et al., 1996	27	12	89
Pillny et al., 2003	97	70	90
Hartung et al., 2008	29	63	86
Holper et al., 2009	25	68	84
TOTAL	**756**	**55 mo (mean)**	**80% (mean)**

Adapted from Comerota AJ, Gale SS. Surgical venous thrombectomy for iliofemoral deep vein thrombosis. In: Greenhalgh RM, ed. *Towards Vascular and Endovascular Consensus.* London: BIBA Publishing; 2005.

Operative venous thrombectomy follows basic vascular surgical principles. By achieving complete or near-complete thrombus extraction from the deep venous system and preventing rethrombosis, significant morbidity from postthrombotic sequelae can be avoided. Basic strategies to minimize rethrombosis include:

(a) Ensuring that thrombus removal is optima

(b) Dilating and stenting any residual iliac vein stenosis

(c) Increasing the velocity of blood flow in the iliofemoral venous system with a small AVF

(d) Postoperative catheter-directed anticoagulation in the thrombectomized infrainguinal venous system (if an infrainguinal venous thrombectomy is required)

(e) Therapeutic and prolonged anticoagu-lation

TABLE 221.4 Venous Thrombectomy With Arteriovenous Fistula: Long-Term Valve Competence of Femoropopliteal Venous Segment

Author/Year	No.	Follow-up (mo)	Femoral-Popliteal Valve Competence
Plate et al., 1984	31	6	52
Einarsson et al., 1986	53	10	42
Ganger et al., 1989	17	91	82
Neglen et al., 1991	37	24	56
Kniemeyer et al., 1992	37	55	80
Juhan et al., 1999	150	60	80
Meissner et al., 1996	27	60	30
TOTAL	**352**	**45 mo (mean)**	**63% (mean)**

Cumulative results in reports published within the past 25 years demonstrate that in patients followed for a mean of 41 months, 76% of the iliac veins remained patent and 63% of the femoropopliteal segments maintained competent valves (Tables 221.3 and 221.4). These good results can be improved by incorporating more of the details described herein. In the author's 43-patient experience, 3 patients suffered recurrent iliac vein thrombosis—the first due to chronic disease, the second due to an uncorrected iliac vein stenosis (early in the experience), and the third rethrombosed the vena cava because anticoagulation could not be given secondary to an intracranial malignancy.

In summary, active individuals with iliofemoral DVT have better long-term outcomes if treated with strategy of thrombus removal. If the patient has a contraindication to or failed catheter-based techniques, operative venous thrombectomy should be recommended. Since the benefit to patients is well-established, surgeons who manage patients with venous disease should include contemporary venous thrombectomy as part of their therapeutic armamentarium.

Suggested Readings

Principal References

Comerota AJ, Gale SS. Technique of contemporary iliofemoral and infrainguinal venous thrombectomy. *J Vasc Surg* 2006;43:185–91.

Eklof B, Rutherford RB. Surgical thrombectomy for acute deep vein thrombosis. In: Rutherford RB, ed. *Vascular Surgery*. 6th ed. Philadelphia, PA: Elsevier Saunders; 2005:2188.

Hartung O, Benmiloud F, Barthelemy P, et al. Late results of surgical venous thrombectomy with iliocaval stenting. *J Vasc Surg* 2008;47:381–7.

Plate G, Akesson H, Einarsson E, et al. Long-term results of venous thrombectomy

combined with a temporary arterio-venous fistula. *Eur J Vasc Surg* 1990;4:483.

Plate G, Einarsson E, Ohlin P, et al. Thrombectomy with temporary arteriovenous fistula: the treatment of choice in acute iliofemoral venous thrombosis. *J Vasc Surg* 1984;1:867.

Additional References

Akesson H, Brudin L, Dahlstrom JA, et al. Venous function assessed during a 5 year period after acute ilio-femoral venous thrombosis treated with anticoagulation. *Eur J Vasc Surg* 1990;4:43.

Comerota AJ, Aldridge SC, Cohen G, et al. A strategy of aggressive regional therapy for acute iliofemoral venous thrombosis with contemporary venous thrombectomy or catheter-directed thrombolysis. *J Vasc Surg* 1994;20:244.

Comerota AJ, Throm RC, Mathias SD, et al. Catheter-directed thrombolysis for iliofemoral deep venous thrombosis improves health-related quality of life. *J Vasc Surg* 2000;32:130.

Eklof B. Arteriovenous fistulas as an adjunct to venous surgery. *Semin Vasc Surg* 2000;13:20.

Elsharawy M, Elzayat E. Early results of thrombolysis vs anticoagulation in iliofemoral venous thrombosis. A randomised clinical trial. *Eur J Vasc Endovasc Surg* 2002;24:209.

Juhan C, Alimi Y, Di MP, et al. Surgical venous thrombectomy. *Cardiovasc Surg* 1999;7:586–90.

Kearon C, Kahn SR, Agnelli G, et al. Antithrombotic therapy for venous thromboembolic disease: American College of Chest Physicians Evidence-Based Clinical Practice Guidelines (8th edition). *Chest* 2008;133(6 Suppl):454S–545S.

Lansing AM, Davis WM. Five-year follow-up study of iliofemoral venous thrombectomy. *Ann Surg* 1968;168:620.

Pillny M, Sandmann W, Luther B, et al. Deep venous thrombosis during pregnancy and after delivery: indications for and results of thrombectomy. *J Vasc Surg* 2003;37:528.

Plate G, Eklof B, Norgren L, et al. Venous thrombectomy for iliofemoral vein thrombosis—10-year results of a prospective randomised study. *Eur J Vasc Endovasc Surg* 1997;14:367.

EDITOR'S COMMENT

The nicely detailed chapter by Aziz and Comerota highlights a rarely performed, but occasionally necessary procedure for potential limb salvage in the setting of extensive deep venous thrombosis (DVT). Most commonly, an

open venous thrombectomy is utilized when the patient has either failed or cannot undergo catheter-based pharmacomechanical thrombolysis for opening up the deep venous system in patients with either phlegmasia or a very large thrombus burden for which decreasing the risk of postthrombotic syndrome is the indication. Interestingly, a prospective randomized trial data support this procedure as compared with medical therapy with the endpoint of significantly reduced postthrombotic syndrome, but it is still rarely done (Plate G. Venous thrombectomy for iliofemoral vein thrombosis—10-year results of a prospective randomized study. *European J Vasc Endovasc Surg* 1997;14:367–734). The technique described is logical and clearly derived from operative experience.

General venous exposure and vascular control are well described, but whether an arteriovenous fistula should be constructed postthrombectomy is more controversial. The idea behind an arteriovenous fistula is to create a venturi flow effect and prevent blood stasis in the iliac vein segments. At our institution, we typically perform a prophylactic arteriovenous fistula more often than not. However, if the deep femoral vein is widely patent and provides a good venous inflow, we may not create an arteriovenous fistula. The use of a small prosthetic graft for an arteriovenous fistula is reasonable as is the ability to close this with a small percutaneous incision or using endovascular techniques as described by the authors. The idea to use a pedal vein catheter to allow direct heparinization infusion is a neat idea, and whether it's an improvement over systemic heparinization is not clear, but is unlikely to hurt.

Although heparin followed by warfarin anticoagulation is standard, the non-vitamin K oral antagonists are a reasonable alternative and will become more commonplace as reversal agents become available (Weitz JI, Bates SM. New anticoagulants. *J Thromb Haemost* 2005;3:1843–53.) Several are FDA-approved for treating DVT. The major bleeding complications are lower with most of these agents. If the patient has evidence of heparin-induced thrombocytopenia, these new agents offer a safe and effective alternative for long-term anticoagulation. In patients with extensive iliofemoral DVT, we typically recommend lifelong anticoagulation as the benefits generally outweigh the risk, unless they have a high bleeding risk.

One of the more difficult patient groups to treat are those who have a significant cancer burden and/or cannot be directly anticoagulated postprocedure and require open venous thrombectomy. These patients may have small amounts of heparin used locally, and generally will not increase bleeding risk. Even if the patient cannot be anticoagulated postprocedurally, it is not unreasonable to clear out the thrombus via thrombectomy, as the recurrent thrombus is often less firmly formed, and is easier with compression to allow salvage of the limb, despite rethrombosis. Frank discussion on endpoints with the patient and family is important with these difficult situations.

Peter Henke

222 Acute Deep Venous Thrombosis: Endovascular

Moon O. Kwoun

INTRODUCTION

Approximately 600,000 cases of acute deep vein thrombosis (DVT) are diagnosed in the United States annually. Pulmonary embolization, its most serious acute complication, has a 3-month all-cause mortality of 15% to 30%, making it the third most common cardiovascular-related mortality after myocardial infarction and cerebral vascular accident.

One of the most serious, long-term sequelae of DVT is postthrombotic syndrome (PTS), affecting between 25% and 46% of individuals with DVT over a 5-year period. The symptoms are often characterized by chronic pain and swelling of the affected limb, and sometimes progressing to chronic ulcerations. The estimated annual direct care cost in the United States for patients with DVT is over $200 million. PTS impairs quality of life (QOL), as the Venous Thrombosis Outcomes cohort study clearly demonstrates, showing that the presence and severity of PTS to be the leading predictor of health-related QOL, 2 years after a DVT. The indirect cost of PTS is 2 million workdays lost annually, mainly due to chronic pain from venous claudication, as well as chronic venous ulcers and their sequelae.

Treatment to prevent pulmonary embolization, thrombus progression, and recurrence obviously remains important in the overall care of those patients who sustain venous thromboembolism (VTE). More specifically, several studies have clearly delineated the significance of proximal versus distal limb DVT, in terms of the increased risk for pulmonary embolization, decreased restoration of flow, and the higher incidence of PTS in the patients with iliofemoral thrombosis, ranging from 50% to 82%. Thus, the importance of aggressive treatment for proximal iliofemoral thrombosis will be highlighted in this chapter.

The most recent guidelines for treatment of VTE established by the American College of Chest Physicians (ACCP), in 2012, softened their

stance on treatment of DVTs in the iliofemoral veins, in contrast to previous guidelines established by the same group in 2008. Their guidelines now favor anticoagulation alone versus catheter-directed thrombolysis (CDT) or pharmacomechanical thrombolysis (PMT). Nonetheless, the Society of Interventional Radiology (SIR) and the Society for Vascular Surgery (SVS) both suggest CDT or PMT as a viable option in select patients, pointing to the growing number of studies supporting a more rapid and efficacious method of reducing thrombus burden. More recent randomized studies, evaluating the efficacy and safety of CDT and PMT, are currently underway to assess their role in patients with proximal symptomatic iliofemoral DVTs.

ETIOLOGY AND PATHOPHYSIOLOGY

Etiology

There are numerous risk factors for the development of VTE (Table 222.1), all of which stem from Virchow Triad: hypercoagulability, stasis, and endothelial injury. A single abnormality may be sufficient to induce a thrombotic event, but in the majority of cases, there is more than one defect of the triad identified. The most common site of DVT is in the legs, followed by DVTs in the pelvic veins, the vena cava, the right side of the heart, and then the arms.

TABLE 222.1 Risk Factor for Venous Thromboembolism



Plasma coagulation factors are usually in a nonactivated state. Intrinsic regulatory systems maintain a coagulation balance and prevent excessive activation. Significant abnormalities in clotting levels, mutations in intrinsic protein structure, or circulating antibodies can result in hypercoagulability, of which there are inherited or acquired forms of thrombophilia. Of the inherited type, factor V Leiden mutation is the most common. Others include factor II G20210A mutation, elevated factor VIII, protein C and S deficiencies, and hyperhomocysteinemia. Acquired hypercoagulability usually occurs with known or occult malignancies and may be a factor after recent trauma.

Stasis is a predominant factor in the development of thrombosis. The initial site for thrombus formation is the vein valve sinuses, usually due to turbulence and eddy of flow. Any condition that hampers flow, either through increased venous resistance, reduced cardiac output, diminished muscular contraction, or commonly due to immobilization, may diminish flow in the veins, allowing for thrombus formation.

Endothelial injury is probably the least important of the factors for development of thrombus. This is usually caused from direct trauma sustained to the vessel wall that leads to adherence of platelets to the vessel wall leading to a coagulation cascade. Immune complex deposition

from autoimmune disease or bacterial septicemia may also lead to an acute vasculitis, generating a venous thrombosis. Chronic vessel injury from previous DVT holds the greatest risk factor for DVT recurrence with a likelihood approaching 30% at 8 years.

Pathophysiology

The pathogenesis of PTS is complex and incompletely understood. Studies have demonstrated that an initial inflammatory response to thrombosis strongly influences thrombus resolution, organization, and subsequent wall injury. Factors that play a role include inflammatory and growth factor mediators, chemokines, extracellular matrix-derived factors, blood-borne elements, and endothelial factors. Ultimately, the result of this process is thickening of the vessel wall and reduction in compliance. Macroscopically, there is incomplete clearance of thrombus, as the inflammatory response directly damages the venous valves and alters the wall, leading to venous reflux. Existing clot burden can cause increased venous hypertension from vessel occlusion, causing further damage to venous valves distally by disrupting the calf muscle pump function. Studies have consistently found that patients with chronic venous obstruction have the most severe PTS, with occlusion of the iliofemoral segment causing the most profound morbidity. A paracrine-like scarring process in the adjacent wall and subsequent fibrosis lead to valve failure, which in turn will allow for venous hypertension. The inflammatory process also incites a localized action of leukocytes that express multiple matrix metalloproteinases (MMPs), which play a role in collagen degradation. The mechanism causing nonhealing skin ulcers is likely due to increased ambulatory venous hypertension caused by superficial and deep venous incompetence, and subsequent alteration of the skin microcirculation. Capillaries become dilated and tortuous as they respond to the increased hydrostatic pressures. They begin leaking plasma, proteins, and erythrocytes. Chronic leakage of fibrinogen leads to formation of extravascular cross-linked fibrin around capillaries, fibrin cuffs. This pericapillary protein acts as a barrier to decrease oxygen diffusion contributing to tissue hypoxia despite adequate arterial supply.

CLINICAL PRESENTATION

Clinical features of DVT can be divided into local, distant, and systemic. The classic local symptoms of the leg are swelling of the leg or along a

vein in the leg, pain with associated increased warmth, and red or blue skin discoloration on the affected leg. The more proximal and severe the thrombosis, the more pronounced the symptom and signs. Distant clinical signs are pulmonary embolism (PE) and very rarely paradoxical embolization through a congenital atrioseptal defect (ASD) or pulmonary arteriovenous malformation (AVM). The most common systemic effect is fever. Unfortunately, the diagnostic accuracy of clinical signs of DVT is <40%.

The manifestations of PTS can vary from minimal to extreme, ranging from venous varicosities, leg pain, swelling, lifestyle-limiting venous claudication, skin hyperpigmentation, to, in some cases, venous stasis ulcers.

STANDARD OF CARE FOR DEEP VENOUS THROMBOSIS

Anticoagulation and Elastic Compressive Stocking Therapy

There have been great advancement in and usage of anticoagulants in recent years. Low–molecular-weight heparins, factor Xa inhibitors, as well as the availability of direct thrombin inhibitors, are used to arrest the progression of thrombus, reduce the rate of recurrence, and aid in managing patients with a history of heparin-induced thrombocytopenia. However, anticoagulation alone has proven ineffective for clot removal in the majority of cases, with complete resolution in <10% of patients. Placebo-controlled, multicenter randomized trials, such as the SOX Trial, have failed to show the efficacy of anticoagulation in conjunction with elastic stocking therapy (even when used for 2 years) to decrease the incidence of PTS in patients with proximal DVT.

Open Vein Concept

The strategy of early thrombus removal, to reduce the incidence of PTS long term, comes from natural history studies of acute DVT, venous thrombectomy data, and studies of systemic thrombolysis and CDT.

Pooled analyses indicate that only 4% of patients treated with anticoagulation alone had significant or complete lysis, with an additional 14% having partial lysis. Most patients (82%) had either no objective phlebographic clearing or actually had extension of their thrombus. Recanalization rates in iliofemoral thromboses are much lower than

extremities with distal clot.

In a randomized, controlled study, Prandoni found that patients who had residual thrombus developed more frequent PTS at the initial 6-month follow-up. A separate, published randomized trial found that surgical venous thrombectomy with anticoagulation resulted in better venous patency and reduced PTS than when patients were treated with anticoagulation alone. In the Cochrane group analysis of 12 randomized trials, evaluating systemic thrombolysis versus anticoagulation, PTS was significantly lower in the lysis group (with a relative risk of 0.66).

Open Surgical Thrombectomy

Venous thrombectomy is effective in relieving iliofemoral obstruction and may preserve distal valvular function. In a randomized trial of patients with acute iliofemoral DVT, as well as pooled analysis, patients treated with contemporary surgical thrombectomy along with anticoagulation therapy experienced better long-term limb outcomes than patients treated with anticoagulation therapy alone. The techniques and adjuvant treatments are largely guided by case series and expert opinion rather than comparative trials. Although thrombectomy does appear to be associated with improved long-term outcomes, open thrombectomy has fallen out of favor due to excessive bleeding, morbidity, and its invasiveness, especially as the rationale for the use of modern endovascular thrombus removal therapies for DVT is now being widely accepted and trialed.

INDICATIONS AND CONTRAINDICATIONS TO THROMBOLYSIS

Because the effectiveness of endovascular therapy depends on multiple factors, including predisposing risks, symptom duration, extent of thrombus, technical approaches, and interventional success, accurate identification and timing are critical to maximize treatment benefits, while minimizing the risks to the patient.

Systemic Thrombolysis Therapy

The basic mechanism of thrombolysis is the activation of fibrin-bound plasminogen to the active enzyme plasmin, which dissolves clot. During thrombolysis, circulating Glu-plasminogen binds to fibrin and is converted to Lys-plasminogen, which has more binding sites for plasminogen

activators and is more efficiently activated to plasmin than Glu-plasminogen.

The use of systemically administered (i.e., via a peripheral intravenous line distant from the affected limb) thrombolytic agents to treat acute proximal DVT has been systematically assessed in randomized clinical trials. In patients treated with systemic thrombolysis, 45% had significant or complete clot resolution, 18% had partial clearing, and 37% failed to improve or worsened. Whereas, anticoagulation alone showed <5% complete lysis and 15% to 20% partial lysis.

By directing the lytic agent directly into the thrombus, catheter-directed lysis should improve lytic efficacy. Intrathrombus delivery naturally protects plasminogen activators from neutralization by circulating plasminogen activator inhibitor (PAI-1) and also protects the resultant active enzyme plasmin from instantaneous neutralization by circulating antiplasmins. Several studies report an initial success rate of >80%. Those with successful lytic outcome reported a significantly better health utilities index, increased physical functioning, less stigmata of chronic venous disease, less health distress, and fewer overall postthrombotic symptoms.

Who Should Be Treated?

There is a great heterogeneity in the clinical and biologic phenotypes with the patient population with DVT. Given the clinical importance of PTS to the long-term health of the patient and the invasiveness, risks, and costs of thrombolytic therapy, it is important for clinical decision making to be guided by rigorously performed randomized trials. While these studies are ongoing, we must be thoughtful to use these procedures in those patients who are most likely to benefit and least likely to be harmed.

1. Assessment of risk of bleeding

   Patients must undergo careful evaluation for factors that may increase the risk of bleeding, including recent major surgery, trauma, pregnancy, cardiopulmonary resuscitation, or other invasive procedures. Patients with lesions that may have potential for bleeding in critical areas such as the CNS will likely need to be excluded.
2. Clinical severity of the DVT

   Urgent endovascular thrombolysis is indicated to prevent life-, limb-, or organ-threatening complications of acute DVT, such as phlegmasia cerulea dolens or extensive inferior vena cava (IVC) thrombus (especially with suprarenal extension that may lead to fatal

PE or renal failure). These techniques may be the only viable option and may be necessary even when moderate risk factors for bleeding exist.

3. Anatomic extension of DVT

   Patients with iliofemoral DVT, defined as involving the iliac vein or common femoral vein, are at significantly increased risk for both PTS and recurrent VTE. Patients should be given a thorough and balanced discussion of the risks and possible benefits of nonurgent first-line endovascular thrombolytic therapy for the purpose of PTS prevention.

4. Assessment of life expectancy, functional status, and comorbidities

   Patients who are chronically unable to walk or have a very short life expectancy are less likely to benefit meaningfully for aggressive therapy to prevent PTS.

5. Patient preference

   For therapy whose benefits have not been conclusively established, it is important for the patient to receive a balanced discussion regarding the rationale, intended benefits and inconveniences, and treatment alternatives.

Successful thrombolysis of acute DVT is most likely to be achieved in patients with recently formed thrombus, of <10 to 14 days. Patients with symptoms of 14 to 28 days usually also experience significant thrombolysis, but such patients often require adjunctive iliac vein stent placement for maximum benefit of treatment.

Patients with short life expectancy, those who do not ambulate, and those with factors predisposing them to bleeding complications are poor candidates as are those fitting three subsets: (1) patients with chronic DVT (>28 days) limited to the femoropopliteal segment, since thrombolytic therapy tends to be ineffective for them; (2) patients with isolated calf vein DVT, as they tend to be less symptomatic and develop PTS less frequently; and (3) patients with asymptomatic DVT, who rarely develop PTS.

PREOPERATIVE PLANNING

Early Identification

Early identification and confirmation of VTE are vital for life- or limb-saving therapy. Past studies have demonstrated that >50% of patients with symptomatic DVT will have a PE (symptomatic or asymptomatic), and

approximately 70% of those patients with symptomatic PE will also have DVT (symptomatic or asymptomatic). The risk of early death from VTE due to either the initial acute episode or recurrent VTE is much greater after presenting with PE than with DVT, thus the treatment plan must be set in motion more rapidly and aggressively. Recurrent episodes of DVT are three times as likely to present as a PE after an initial PE than after an initial DVT.

Diagnostic Techniques for Full Assessment of Length and Location of Thrombosis

Venous Duplex

A comprehensive study utilizing real-time B-mode ultrasonography as well as color Doppler imaging, venous compression under direct visualization, assessment of venous respirophasic flow, and response to Valsalva maneuvers is widely accepted as the first-line investigation for DVT. The weighted mean sensitivity and specificity of venous ultrasonography (including all types) for the diagnosis of symptomatic proximal DVT are 97% and 94%, respectively. A negative single, complete duplex color ultrasound of the entire lower extremity to assess for suspected DVT has a negative predictive value of 99.5% (Fig. 222.1).

Specific findings include the following:

Incompressibility: A thrombosed vein does not compress.
Loss of augmentation: Loss of appropriate increased flow when the lower extremity is compressed implies an obstruction (clot) between the transducer and the compressed area.
Visualization: DVT may be directly visualized as moderately echoic to hyperechoic masses separate from anechoic fluid.
Doppler flow: Doppler color-flow imaging can depict absent or abnormal flow in an area where isoechoic clot might not be visible.
Below-the-knee thrombus: A clot below the popliteal vein level remains an elusive area in duplex scanning. It is challenging to detect, and detection is operator-dependent.

Visualization of iliac or proximal thrombus is often difficult. In the presence of thigh swelling or an abnormal common femoral vein, the central iliocaval veins may warrant evaluation by other diagnostic modalities. Interposed bowel gas may also compromise duplex ultrasonography, for which CT venogram (CTV) or MRI venous phase (MRV) has been useful adjunct.

Multidetector CTV or MRV

Either diagnostic studies are feasible second-line options or additional information is required. Studies of multidetector CTV showed that venous-phase scanning after arterial-phase scanning is feasible and possibly cost-effective. By adding the indirect CTV to standard computed tomography (CT) pulmonary arteriography for suspected PE allows for an increase of 15% to 38% in the diagnosis of VTE. CTV reliably depicts the extent of the thrombus and underlying anatomic abnormalities, and may help in defining the chronicity of the lesion. Increased attenuation of the thrombus (>60 HU) and an increased diameter of the vessel (>150% the diameter of the contralateral normal vein) are correlated with higher acuity, and may, therefore, be predictors of successful CDT (Fig. 222.2). However, CTV deals with irradiation and contrast, with its potential allergies and nephropathy. Studies in which indirect CTV was compared with venography showed 95.9% sensitivity and 95.2% specificity. The clear advantage is visualization of the entire venous system with one diagnostic study. The radiation dose, cost, and scanning time may make it prohibitive to use CT to evaluate extremity DVT alone.

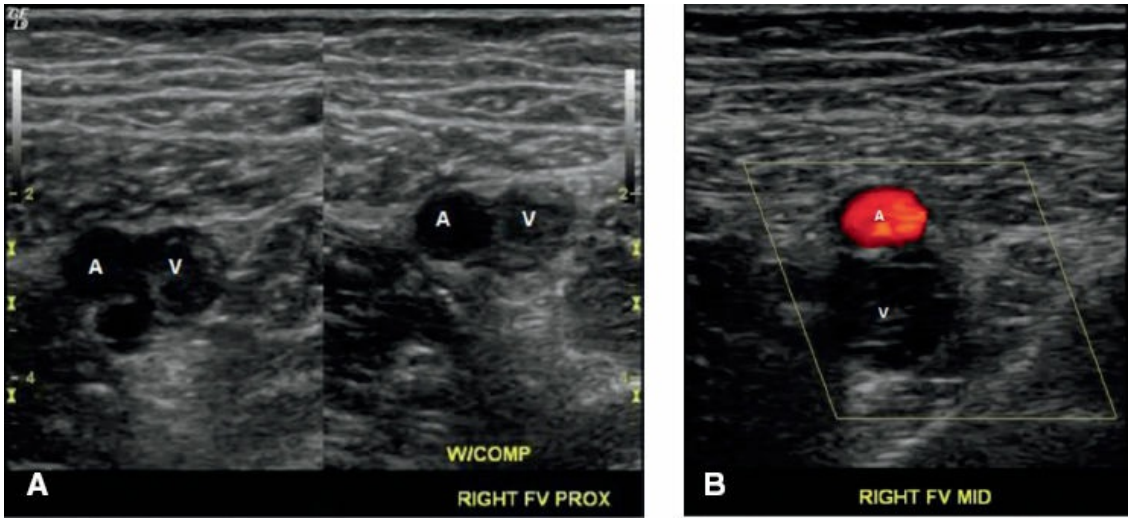

Figure 222.1. A, B. Ultrasound Duplex demonstrating occlusive thrombus of right femoral vein (FV) in 38-year-old female with acute onset of leg pain and swelling. **A.** Transverse aspect of thrombosed vein without and with compression (noncompressible). **B.** Transverse view of femoral artery and vein with color flow Doppler. No flow noted in femoral vein.

MRV (Fig. 222.3) is effective and accurate, with a sensitivity and specificity for iliac and femoral DVT 95.7% and 92.9%, respectively,

compared with venography and a 92% sensitivity in detecting isolated calf-vein thrombus. In addition, pelvic veins that are nearly impossible to visualize on ultrasound and difficult to view by other means are consistently imaged well with either CTV or MRV. However, MR tends to be subject to more artifacts that simulate vascular disease.



Figure 222.2. CT venous phase of patients with extensive IVC and iliofemoral thrombus, with associated pulmonary embolus.

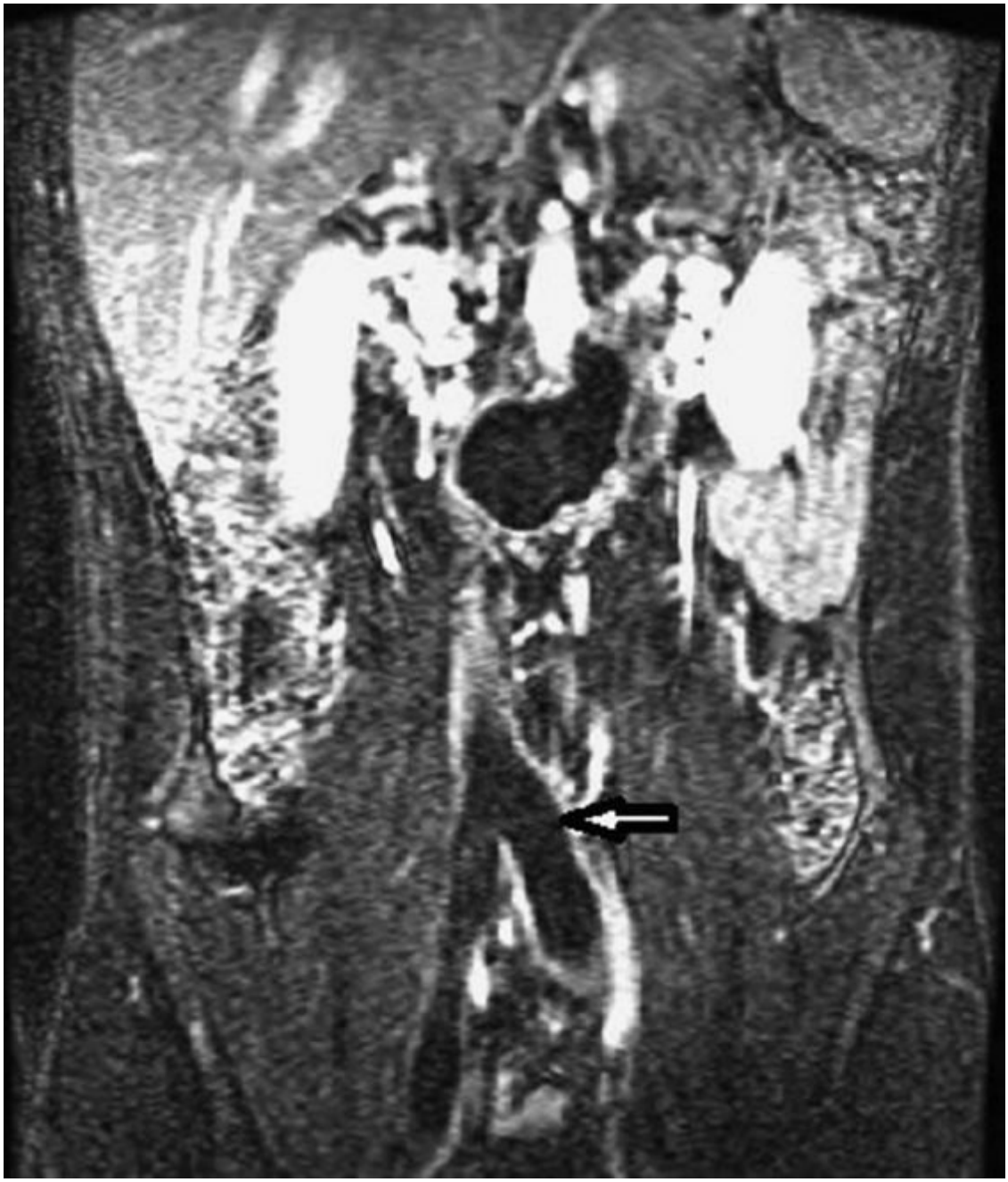

Figure 222.3. MRV illustrating extensive clot burden in the iliac veins and IVC.

Although MRV is highly sensitive and relatively specific, the cost of the examination, the technical complexity, and the lack of general availability limit the use of MRV as a screening tool. Specific indications for MRV are primarily as an alternative to CT (particularly in patients with an allergy to contrast material, in those with renal failure, and those in whom an evaluation of the iliocaval veins is required for questionable sonographic findings) or for an evaluation of the extent of a thrombus in preparation of an intervention.

Limitations include those patients with ferromagnetic implants or in those who depend on metallic devices that cannot be placed in the imaging unit. Relative contraindications include claustrophobia, extreme patient girth, certain metallic implants, or an inability to remain immobile that can produce nondiagnostic studies.

Venography

Before the 1990s, venography was considered the gold standard for evaluation of venous thrombus. With the advancement and evolution of newer and better technology, as well as issues of patient discomfort from needle puncture, the potential for infiltration of contrast agent at the injection site or allergy to the product, plus the cost in time and necessary infrastructure, its use is now relegated to specific indications. Venography remains the examination of choice when absolute determination of the presence and extent of thrombus is needed or in conjunction with a therapeutic treatment option (Fig. 222.4).

Technical limitations include poor intravenous access in the foot, poor contrast opacification of the deep veins (contrast material shunted to superficial veins, injection too slow, poor tourniquet compression), motion artifact, and excessive muscular contractions or spasms. Also, the internal iliac vein in the pelvis is not imaged, and a clot in this area cannot be excluded.

SURGICAL TECHNIQUE

Inferior Vena Cava Filter Placement

The goal of IVC filter placement is to prevent pulmonary emboli or recurrence of emboli. Indications and candidacy for IVC filter placement are beyond the scope of this chapter.

CDT has not demonstrated an added risk of PE to warrant routine filter placement. However, for patients with contraindications to pharmacologic lysis in whom a percutaneous mechanical thrombectomy device is to be used, a filter may be a useful adjunct.



Figure 222.4. Venogram of the iliofemoral demonstrating significant DVT in the left lower extremity.

SITE-SPECIFIC TREATMENT OF DEEP VENOUS THROMBOSIS

Catheter-Directed Thrombolysis (CDT)

A fibrinolytic agent, such as tissue plasminogen activator (tPA) or its derivative, is infused continuously and directly at low dose (0.5 to 1 mg/h), with an adjuvant infusion of intravenous heparin at subtherapeutic levels. The technical aspects, as with any interventional procedures, involve remote location access either from a patent ipsilateral popliteal vein with the patient in a prone position or from the contralateral limb. Maneuvering and positioning of a thrombolytic catheter into the proximal segment of the

clot burden is required to allow for maximal infusion of the lytic drug for several hours, with postprocedure evaluation and care, usually in the intensive care unit. We typically utilize a Uni*fuse infusion catheter (Angiodynamics) (Fig. 222.5) in a majority of our directed lysis cases, primarily due to its ease of use, uniformity of lytic distribution, and compatibility with a 0.035 system. Repeat venography is performed every 12 to 24 hours to assess for complete lysis.

The theoretical advantage of using image-guided, catheter-directed, intrathrombus drug delivery is recognized as potential avenue to safely and efficiently lysis of thrombus with (1) an ability to achieve a high intrathrombus drug concentration and to avoid bypass of the drug around the occluded venous segments; (2) the ability to reduce thrombolytic agent dose, treatment time, hospital resource utilization, and bleeding complications by achieving more efficient thrombolysis; and (3) an ability to prevent recurrent DVT episodes by concomitantly using adjunctive catheter-based techniques, such as stents, to treat anatomic venous abnormalities. The significant disadvantage is the need for a prolonged ICU stay during infusion, often ranging from 36 to 72 hours. This infusion technique may become costly if the infusion time extends into days. Bleeding complications continue to be a major concern; therefore, strict protocols and laboratory evaluations must be maintained and monitored to minimize these risks.



Figure 222.5. Uni*fuse thrombolysis catheter with occluding ball wire in place.

Mechanical Thrombectomy (MT)

The Trerotola Arrow is a catheter-based rotational fragmentation cage that is pulled through the vein as it macerates and strips the thrombus from the vein walls. The technical success has been reported to approach 99%, but also has an increased chance for pulmonary embolization without an adjunct IVC filter in place. Vessel wall damage has also been identified

with this and similar devices, such as the Amplatz thrombectomy device, that may attribute to potential complications in the future.

This technique has largely grown out of favor due to the significant number of complications, including an increased risk of embolization, and largely replaced by a pharmacomechanical technique.

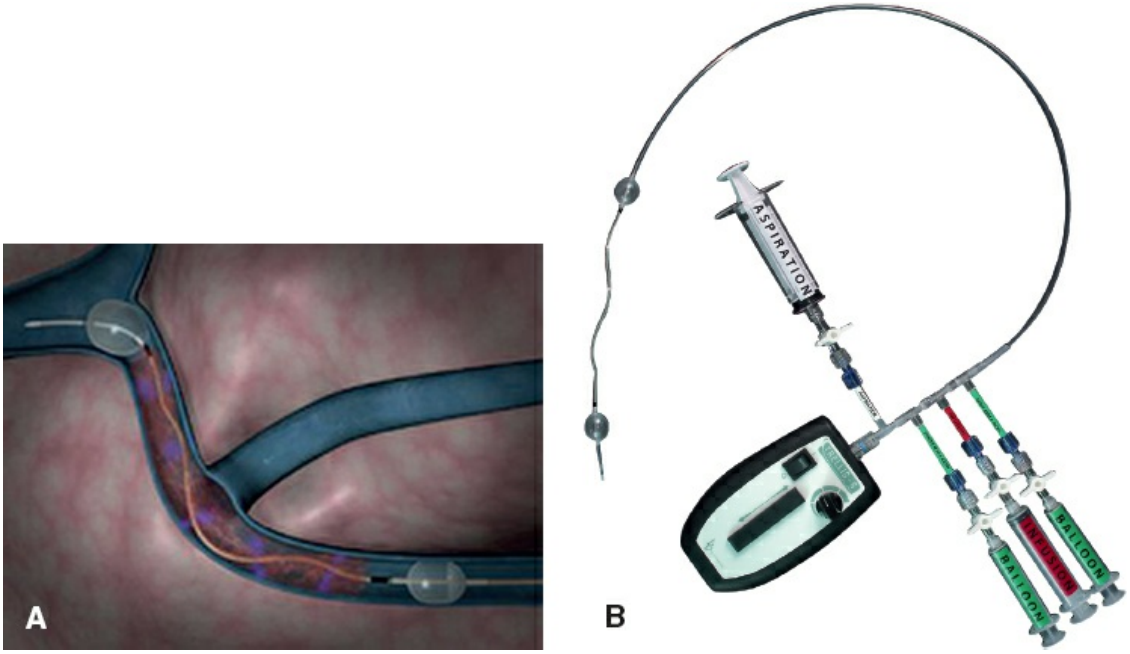

Figure 222.6. A, B. Trellis-8 peripheral infusion system for single use treatment of DVT. (Courtesy of Covidien.)

Pharmacomechanical Thrombolysis (PMT)

As the most effective modality for endovascular thrombus removal, it utilizes the combination of intrathrombus drug delivery with the use of percutaneous mechanical thrombectomy. Various devices have been manufactured and marketed, with new products currently undergoing clinical trials.

Isolated Segmental Pharmacomechanical Thrombolysis

The Trellis device (TPM) is a single-use catheter that features a multilumen catheter with two occluding balloons and a dispersion wire attached to the drive unit (Fig. 222.6). The device disintegrates the thrombus with a sinusoidal Nitinol wire rotating at high speed (1,500 revs/min) between the two occlusion balloons, 15 to 30 cm apart, in a zone where the tPA is injected (Trellis system: Bacchus Vascular). The Trellis system is activated for periods of 10 to 15 minutes, interspersed with infusions of 5 to 10 mg of tPA (1 mg/min and up to 10 mg) followed by

manual thromboaspiration. An auto-expanding stent may be inserted if any underlying anomaly is discovered. An optional IVC filter is not always inserted unless there is a PE or extensive clot in the vena cava. The initial reports through the Galway Trellis Experience, reported by O'Sullivan 2007, demonstrated in 36 patients presenting with acute DVT, reporting 100% technical success with 96% clearance of at least 50% of the clot burden, effectiveness achieved in <2 hours, and primary permeability after 2 days of 85%. No bleeding was observed with his experience (Fig. 222.7).

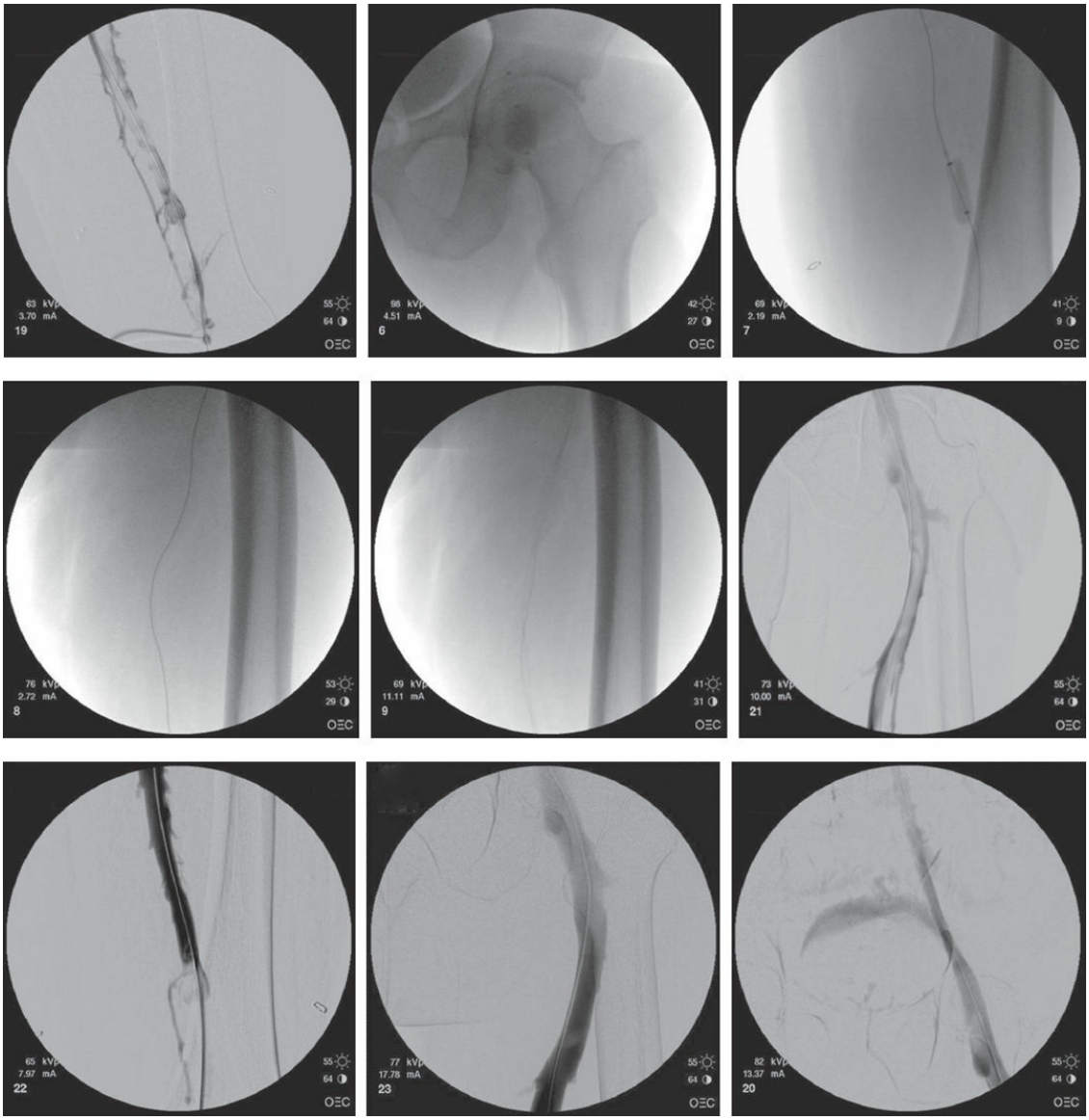

Figure 222.7. Case of a symptomatic DVT in left lower extremity. Top row, from left to right: venogram showing a thrombosed segment of the venous system; inflated proximal occluding balloon; inflated distal occluding balloon. Middle row, from left to right: Trellis dispersion wire within the balloon catheter; sine wave of the Trellis wire; SFV during clot dispersion and aspiration of the remnant material through the Trellis catheter. Bottom row, from left to right: SFV after mechanical thrombectomy; CFV after mechanical thrombectomy.

"Rheolytic" instruments can also be used (Angiojet; Possis; Hydroliser; Cordis, Oasis Thrombectomy System Boston Scientific) (Fig. 222.8). With the "powerpulse" technique, the thrombus is initially sprayed with fibrinolytic agent, then after an appropriate time for the tPA to interact with the thrombus, very high velocity jets (400 km/h) of saline are applied,

thereby creating a depression by way of a Venturi effect, so that the fragmented thrombotic material can be aspirated. The device does not come in contact with the vessel wall, but there is theoretical risk of hemolysis. The results of 160 patients from the PEARL register showed that lysis was achieved in 93% of segments treated, achieved in almost 100% of cases in under 48 hours, and in two thirds of cases, in under 6 hours. Major bleeds are estimated to occur in 2% to 4% of patients receiving pharmacomechanical catheter-directed thrombolysis (PCDT) (Fig. 222.9).

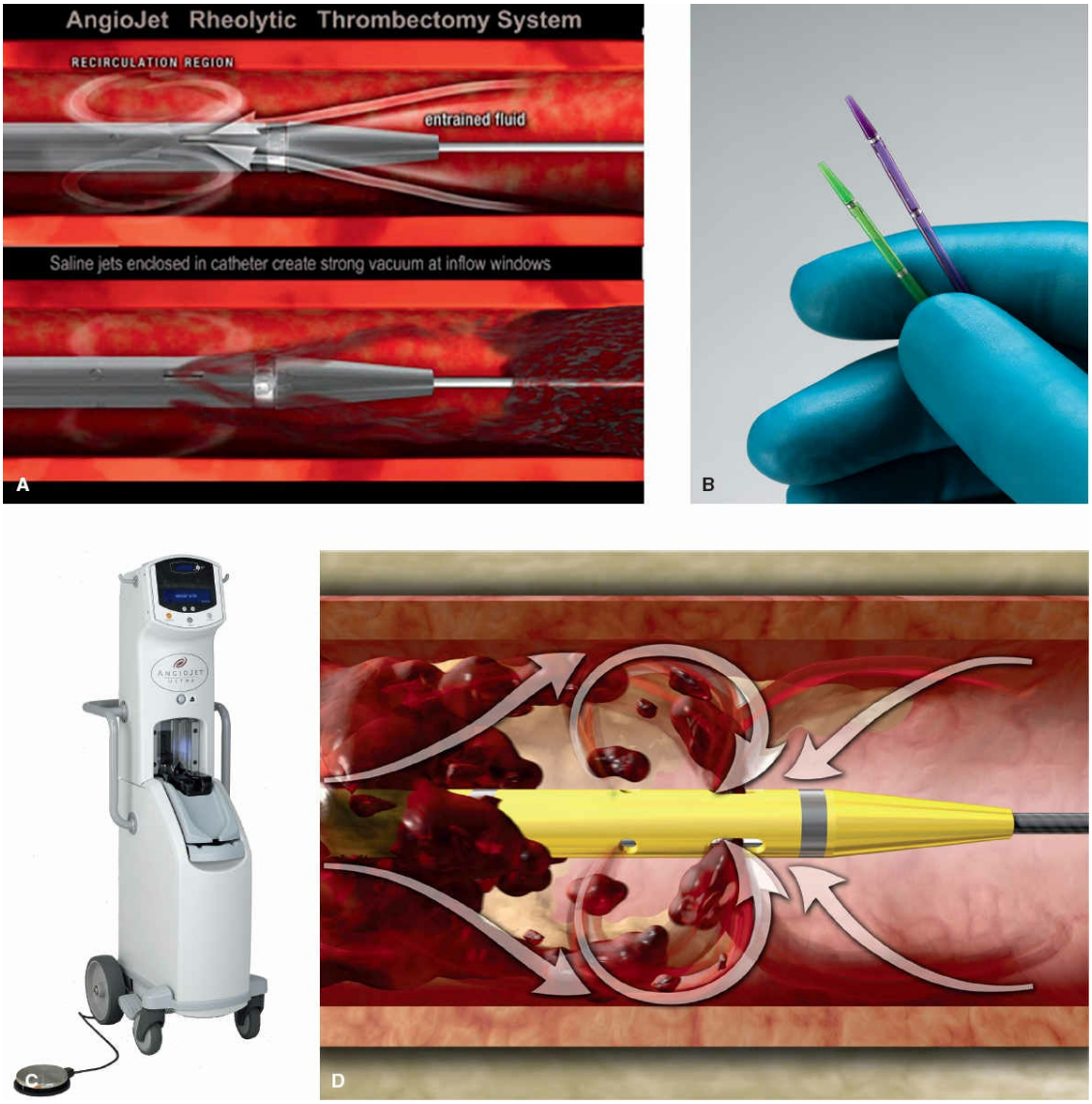

Figure 222.8. **A.** Angiojet rheolytic thrombectomy system. **B.** Various tips utilized for the pulse power spray technique. **C.** Drive unit with single use pump set. **D.** Active jet of saline and aspiration to retrieve thrombus. (Courtesy of Boston Scientific.)

Another technique, described as a "rapid lysis technique," utilizes the rotation of an angled 8-Fr hockey stick angled catheter with the Angiojet protruding from its end, and with the outflow set open. By spiralling the catheter and Angiojet in tandem as there is gentle retraction from central to peripheral, there is a larger area of potential clot clearance. Because the vacuum phenomenon is active, the possibility of embolization is minimized.

Finally, the concept based on boosting the effectiveness of the thrombolytic drug with ultrasound (Ekos Endowave; Ekos Corporation, Omniwave; OmniSonics Corp) (Fig. 222.10) comes in the form of a triple

lumen catheter with multiple ultrasonic transducers that emit high-frequency, low-energy ultrasound that destroys the strands of fibrin of the thrombus, thereby helping to expose the plasminogen receptors to the locally injected fibrinolytic drug. There is no mechanical effect, and the infusion time will be longer. The fibrinolytic drug used is rtPA at a dose of 2 mg/h for 5 hours, then 1 mg/h up to a maximum of 20 mg. Its major drawbacks include longer initial procedure time and expense primarily due to device cost.

Adjunctive Use of Venous Stents

There is an intermediate recommendation to use self-expanding metallic stents for the treatment of chronic iliocaval compression or obstructive lesions discovered during removal, and is considered a grade 1C recommendation, where the benefit to risk ratio is clear, but the quality of evidence is low.



Figure 222.9. Angiojet treatment.

POSTOPERATIVE CARE

Complications and Their Management

Major bleeding is the most frequent major complication of endovascular DVT thrombus removal. The bleeding risk is almost always dependent on duration and concentration of the treatment and medications, respectively. In patients undergoing CDT, major bleeding risk, in a prospective registry, was observed in 11.4% of patients, a very low 0.4% suffering intracranial bleeding. More recent series and multicenter RCT utilizing low-dose rtPA have demonstrated a much lower rate of bleeding at 3%. Venous access with ultrasound guidance and use of micropuncture systems (Fig. 222.11) should help contribute to minimizing local trauma during the access procedure. Although there is no conclusive evidence to support the

relationship between fibrinogen levels and bleeding, the majority opinion is that serial monitoring of fibrinogen levels during venous CDT may help prevent complications. Levels at or below 150 mg/dL demonstrated a significantly higher rate of major bleeding, leading to extended or unexpected hospitalization, surgery, or blood transfusions.

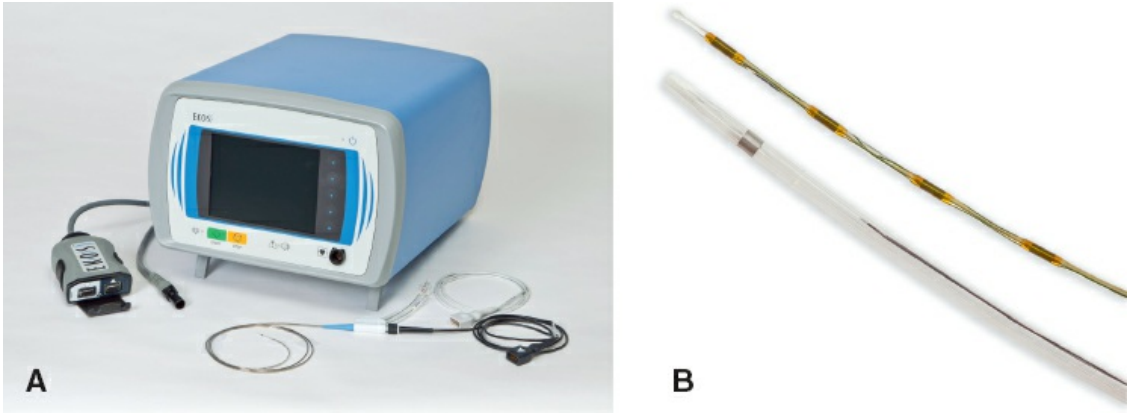

Figure 222.10. **A** and **B.** Endowave peripheral vascular system. **A.** Control unit. **B.** Ultrasound core. (Courtesy of EKOS Corp.)

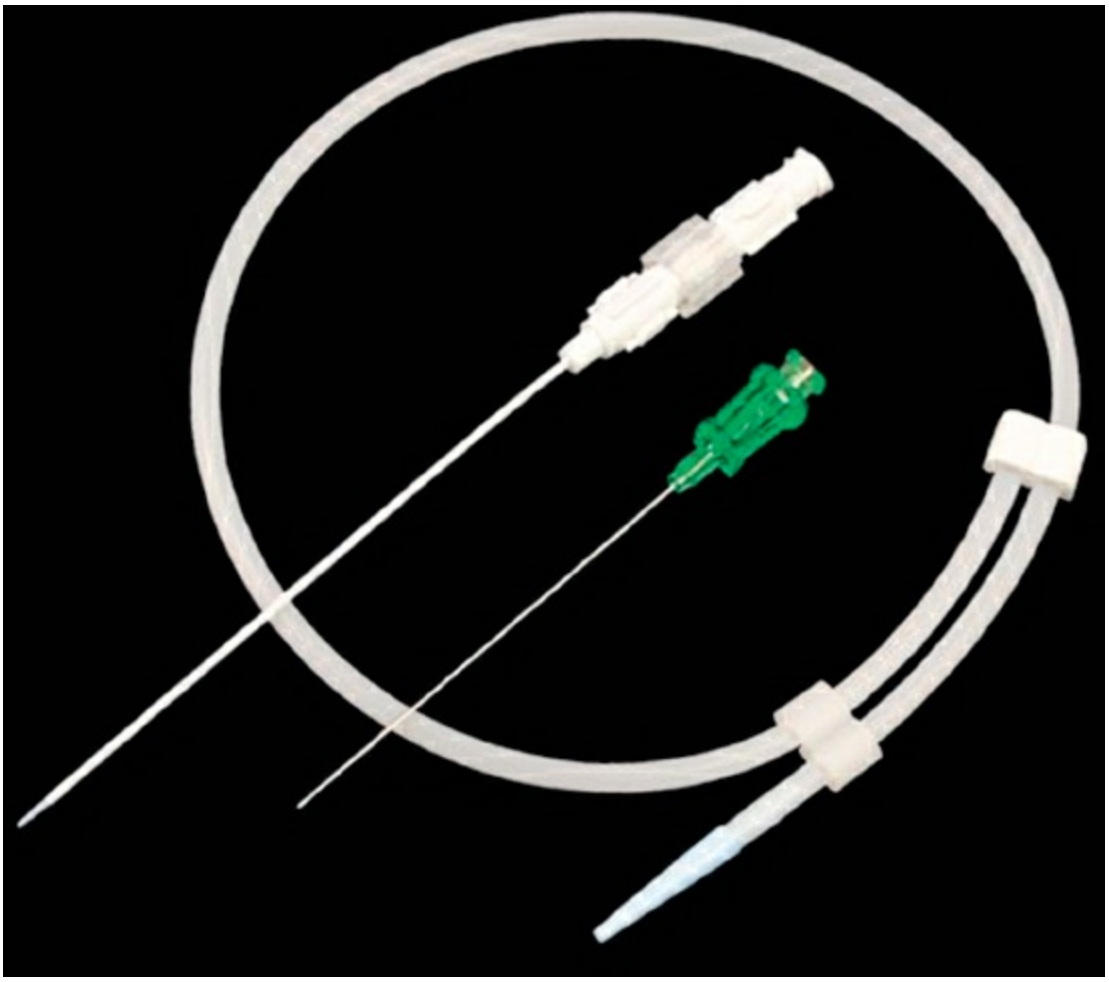

Figure 222.11. Capella Micropuncture system with 4.0 French sheath and 0.018 guidewire. (Courtesy of BardPV.)

Complete Lysis Versus Partial Clearance

Success rates with catheter-directed PMT vary depending on the age of the thrombus and the proximity to the IVC. Success with this technique in acute iliofemoral venous thrombosis has been reported to be 80% to 85%, with 1-year patency at 60% to 65%. Major bleeding complication rates vary from 3% to 11%; most bleeding occurs at the puncture site.

Large observational studies have underscored the importance of recurrent DVT being associated with severe PTS. It has also been shown that patients with residual venous thrombus and increasing thrombus activity have a significant rate of recurrence. Aziz et al. reported that recurrent DVT following CDT correlated with the amount of residual thrombus at the end of their initial lysis. Failures were predicted with <50% lysis or malignant disease.

The SIR has graded procedural success in relation to luminal patency:

Grade 1 SIR thrombolysis – <50% thrombus removal
Grade 2 SIR thrombolysis – 50% to 95% thrombus removal
Grade 3 SIR thrombolysis – >95%

The Thrombus Obliteration by Rapid Percutaneous Endovenous Intervention in Deep Venous Occlusion (TORPEDO) study, a randomized trial, compared anticoagulation alone versus pharmacomechanical treatment: a combination of mechanical thrombectomy, angioplasty, stenting, and rtPA. While it did not use validated measurements to define the extent of patient suffering, it revealed a significant reduction in the incidence of cases of weak or moderate PTS after 6 months, when compared to the traditional treatment (3.4% vs. 27.2%). Even more compelling was that the recurrent DVT developed in 2.3% of the endovascular patients versus 14.8% of the control patients (P = 0.003), without an increase in the risk of hemorrhage, which was estimated to be 2%.

TABLE 222.2 Villalta Scale

Symptoms/Clinical Signs	None	Mild	Moderate	Severe
Symptoms				
Pain	0 points	1 point	2 points	3 points
Cramps	0 points	1 point	2 points	3 points
Heaviness	0 points	1 point	2 points	3 points
Paresthesia	0 points	1 point	2 points	3 points
Pruritus	0 points	1 point	2 points	3 points
Clinical signs				
Pretibial edema	0 points	1 point	2 points	3 points
Skin induration	0 points	1 point	2 points	3 points
Hyperpigmentation	0 points	1 point	2 points	3 points
Redness	0 points	1 point	2 points	3 points
Venous ectasia	0 points	1 point	2 points	3 points
Pain on calf compression	0 points	1 point	2 points	3 points
Venous ulcer	Absent			Present

PTS, postthrombotic syndrome.

OUTCOMES

Kahn analysis showed that the strongest predictor of PTS within 2 years' follow-up is the severity of residual venous symptoms and signs 1 month after the diagnosis of the DVT. About 3% of patients develop severe postthrombotic symptoms, including venous stasis ulcers. Quite interestingly, in their findings, factor V Leiden and prothrombin mutations seemed to protect against the PTS.

Ultimately, we must gauge the success of our treatments by looking at the long-term sequelae of PTS, which can be validated by the Villalta PTS scale (Table 222.2), and endorsed by the International Society of Thrombosis and Hemostasis or the VSCS scale. The Villalta Scale incorporates patient self-assessment of five common symptoms of PTS along with a blinded clinician's assessment of six common PTS signs on physical examination. Secondary outcomes may be assessed, and include venous disease-specific and generic QOL, using the Venous Insufficiency Epidemiological and Economic Study-QOL and SF-36 measures.

Upcoming Trials

The National Heart, Lung, and Blood Institute is sponsoring an "Acute Venous Thrombosis: Thrombus Removal with Adjunctive Catheter-Directed Thrombolysis (ATTRACT) Trial," with a 2016 target completion date. It is a randomized, double-blind, multicenter study with two parallel arms. Carried out in 60 centers throughout North America on 692 patients

with symptomatic DVT, patients will receive either pharmacomechanical treatment combined with standard traditional treatment or the standard traditional treatment. The endovascular arm use either rtPA alone at a dose of 0.01 mg/kg per hour for a maximum of 24 hours with a maximum of 3 mg, or rtPA delivered in one-spot via Trellis system or AngioJet, with up to a maximum of 25 mg administered. The study is to ascertain whether using pharmacomechanical techniques might reduce the occurrence of PTS by a third after 2 years of follow-up. PTS is assessed every 6 months against the Villalta scale, quantifying quality of life, symptom relief cost, and safety.

SUMMARY

Thrombus recurrence and postthrombotic syndrome are critical factors to consider when treating an acute proximal DVT. Despite the guidelines presented by the ACCP in 2012, where CDT and PMT are more secondary treatment options, the benefit of early clot removal via endovascular means, when done safely and efficiently, has become apparent. The ATTRACT study should provide the necessary information to qualify the safety and efficacy of PMT. By utilizing these newer techniques, the systemic circulation of the lytic agent can be greatly diminished, thus lowering the bleeding complications of nondirected therapy and allow for a speedier, and more effective, recovery. This evolution in our approach to treat extensive DVT, from catheter-directed lysis to a pharmacomechanical one, will allow for early restoration of patency in these veins, thus reducing the incidence of PTS, and recurrence, and improving overall QOL.

Suggested Readings

Avgerinos ED, Hager ES, Naddaf A. Outcomes and predictor of thrombolysis for iliofemoral deep venous thrombosis. *J Vasc Surg* 2015;3:25–41.

Comerota AJ. Thrombolysis for deep venous thrombosis. *J Vasc Surg* 2012;55:607–11.

Comerota AJ, Gravett MH. Iliofemoral venous thrombosis. *J Vasc Surg* 2007;46:1065–76.

Hager E, Yuo T, Avgerinos E, et al. Anatomic and functional outcomes of pharmacomechanical and catheter-directed thrombolysis of iliofemoral deep venous thrombosis. *J Vasc Surg* 2014;2:246–52.

Hallett JW Jr, Mills JL, Earnshaw JJ, et al. *Comprehensive Vascular and Endovascular Surgery*. London: Mosby; 2004.

Kahn SR, Shrier I, Julian JA, et al. Determinants and time course of the postthrombotic syndrome after acute deep venous thrombosis. *Ann Intern Med* 2008;149(10):698–707.

Kearon C, Aki EA, Comerota AJ, et al. Antithrombotic therapy for VTE disease. *Chest* 2012;141(2 Suppl):e419s–94s.

Meissner MH, Gloviczki P, Comerota AJ, et al. Early thrombus removal strategies for acute deep venous thrombosis: clinical practice guidelines of the society of vascular surgery and the American venous forum. *J Vasc Surg* 2012;55:1449–62.

Phillips LJ 2nd, Sarkar R. Molecular characterization of post-thrombotic syndrome. *J Vasc Surg* 2007;45(Suppl):A116–22.

Popuri RK, Vedantham S. The role of thrombolysis in the clinical management of deep vein thrombosis. *Arterio Thromb Vascular Biology* 2011;31:479–84.

Soosainathan A, Moore HM, Gohel MS, et al. Scoring systems for the post-thrombotic syndrome. *J Vasc Surg* 2013;57(1):254–61.

Vedantham S. Interventional approaches to deep vein thrombosis. *Am J Hematol* 2012;87:S113–8.

Vedantham S, Sista AK, Klein SJ, et al. Quality improvement guidelines for the treatment of lower-extremity deep vein thrombosis with use of endovascular thrombus removal. *J Vasc Interv Radiol* 2014;25:1317–25.



EDITOR'S COMMENT

The endovascular management for acute deep vein thrombosis (DVT), sometimes called pharmacomechanical thrombolysis (PMT), is now much more commonplace, although it is still controversial based on the current 2012 *Chest* guidelines. The basics of DVT treatment are well stated in this chapter. As detailed by Dr. Kwoun, anticoagulation, ambulation, compression, and assessment for risk factors for recurrence are the cornerstones of DVT therapy. Herein, the authors nicely detail aspects of DVT pathophysiology with regard to the inflammatory vicious cycle. It is well known that inflammation can both promulgate DVT, and that DVT itself is an inflammatory nidus. Indeed, the DVT sets up an inflammatory response for which the vein wall is injured and the thrombus must resolve via thrombolysis, fibrosis, and neovascularization (Wakefield TW, Myers DD, Henke PK. Mechanisms of venous thrombosis and resolution. *Arterioscler Thromb Vasc Biol* 2008;28:387–91). It is the extent to which the body naturally dissolves (lyses) the clot that directly portends whether a venous obstruction remains, and if so, increases the risk of postthrombotic syndrome. Endovascular methods to remove the DVT may thus

decrease this sequlae.

Hypercoagulable states are often evaluated for, but the diagnostic yield is low. Regardless, most patients with an extensive DVT or one of idiopathic nature support lifelong anticoagulation. The patient's duration of therapy can be modified by two things: first, if persistent "clot" is present on duplex ultrasonography of the veins affected, and second, persistent elevation of d-Dimer. For example, if d-Dimer is elevated 1 month after ceasing 3 months of anticoagulation, then they should be restarted and continue on anticoagulation indefinitely (Palareti G, Cosmi B, Legnani C, et al. D-dimer testing to determine the duration of anticoagulation therapy. *N Engl J Med* 2006;355:1780–9). If the d-Dimer value is in the normal range, the patient can usually safely stop anticoagulation. It is important to remember in patients who cannot undergo PMT that extended use of low–molecular-weight heparin (LMWH) with compression significantly decreases risk of PTS, as compared with standard oral anticoagulation (Hull RD, Pineo GF, Brant R, et al. Home therapy of venous thrombosis with long-term LMWH versus usual care: patient satisfaction and post-thrombotic syndrome. *Am J Med* 2009;122:762–9 e763). It is likely that LMWH confers a distinct advantage over coumadin with anti-inflammatory and pro-thrombus resolution activities. It may also be that LMWH enhances endothelial recovery after thrombus juxtaposition with the vein wall (Moaveni DK, Lynch EM, Luke C, et al. Vein wall re-endothelialization after deep vein thrombosis is improved with low-molecular-weight heparin. *J Vasc Surg* 2008;47:616–24).

The use of the techniques described in this chapter is fairly well established and for which numerous devices are detailed. Clinically, whether aggressive endovascular removal of the DVT decreases incident postthrombotic syndrome is beginning to be answered from trials. For example, the CaVenT trial suggested a modest benefit of aggressive endoluminal techniques to clear iliofemoral thrombosis over standard medical therapy (Enden T, Haig Y, Klow NE, et al. Long-term outcome after additional catheter-directed thrombolysis versus standard treatment for acute iliofemoral deep vein thrombosis (the cavent study): a randomised controlled trial. *Lancet.* 2012;379:31–8). However, the larger ATTRACT trial will answer this question and hopefully suggest patients who are best treated with PMT as compared with those who are best treated with medical therapy.

One particularly vexing problem is DVT age determination and its relation to the effectiveness of PMT. The older the DVT, the less successful the clearance. For example, a patient presents with an apparent acute DVT by history, but is actually older and more fibrotic, and not able to be cleared with PMT. In other words, the thrombus age is imprecisely known and methods to define this are not widely available in humans. The use of MR scanning may be beneficial as suggested by experimental data (Saha P, Andia ME, Modarai B, et al. Magnetic resonance t1 relaxation time of venous thrombus is determined by iron processing and predicts susceptibility to lysis. *Circulation* 2013;128:729–36)

and enhanced ultrasound diagnostic techniques or PET scanning may also be helpful. Further research will define this critical parameter to direct patients to the best therapeutic option.

Peter Henke

223 Chronic Deep Vein Thrombosis/Postthrombotic Syndrome: Open and Endovascular Treatment

Peter Gloviczki and Arjun Jayaraj

INTRODUCTION

Reconstruction of the obstructed iliofemoral vein or the inferior vena cava (IVC) may be required in patients with chronic venous insufficiency (CVI), who present with primary nonthrombotic iliac vein obstruction (NIVO) or with secondary, postthrombotic obstruction. Venous reconstruction may also be beneficial in those patients who undergo excision of primary or metastatic malignant tumors invading large veins like the IVC or the iliac veins and in those with acute traumatic or iatrogenic venous injury.

Chronic NIVO-like May–Thurner syndrome (MTS) is responsible for the symptoms in up to one third of the patients with CVI. Endovascular treatment for iliocaval obstruction has progressed rapidly, and today venous stenting is the primary choice for treatment of benign iliac, iliofemoral or iliocaval venous occlusions in patients who fail conservative compression therapy. Venous stenting is used for patients with malignancy only in those cases when excision of the tumor is not possible and the goal of therapy is palliation. Hybrid procedures are performed occasionally when femoral vein exposure and endophlebectomy are added to improve inflow for venous stenting. In the last two decades, results of open surgical reconstructions have improved, and symptomatic patients who are not candidates for or who failed endovascular reconstructions can be treated with venous bypasses to relieve venous outflow obstruction. A thorough preoperative evaluation to identify significant venous outflow obstruction and establish adequate inflow and outflow to the bypass in these patients is essential.

Etiology

Chronic deep venous obstruction is usually the result of a previous acute deep venous thrombosis (DVT) leading to postthrombotic syndrome (PTS). PTS develops in 20% to 50% of patients who develop DVT. MTS where compression of the left common iliac vein (CIV) by the overriding right common iliac artery occurs has been recognized now as the most frequent cause of left iliofemoral venous thrombosis. May and Thurner observed secondary changes, such as an intraluminal web or “spur,” in the proximal left CIV in 20% of 430 autopsies. While MTS is the most frequent form of NIVO, obstruction can also occur in the right CIV or in one of the external iliac veins (EIVs), although these conditions are less frequent. Acute symptoms generally are more common (73%) than a chronic presentation with MTS. Compression of the left iliac vein without coexistent DVT is an important etiology of symptomatic chronic venous outflow obstruction. In a series of 982 patients who underwent venous stenting, 53% of the femoro-ilio-caval lesions were of primary and not postthrombotic etiology.

Iliofemoral or IVC obstruction can also be caused by retroperitoneal fibrosis; iatrogenic, blunt, or penetrating trauma; congenital venous anomalies; or benign or malignant tumors (Fig. 223.1). The most frequent primary malignant tumor originating from large veins is primary venous leiomyosarcoma; secondary tumors invading the vena cava include adenocarcinoma or liposarcoma. Renal carcinoma may extend into the IVC, and the tumor thrombus in some patients may reach all the way up into the right atrium. Rarely, congenital suprarenal IVC occlusion can occur due to webs or caval coarctation that may also present with associated hepatic vein occlusion (Budd–Chiari syndrome).

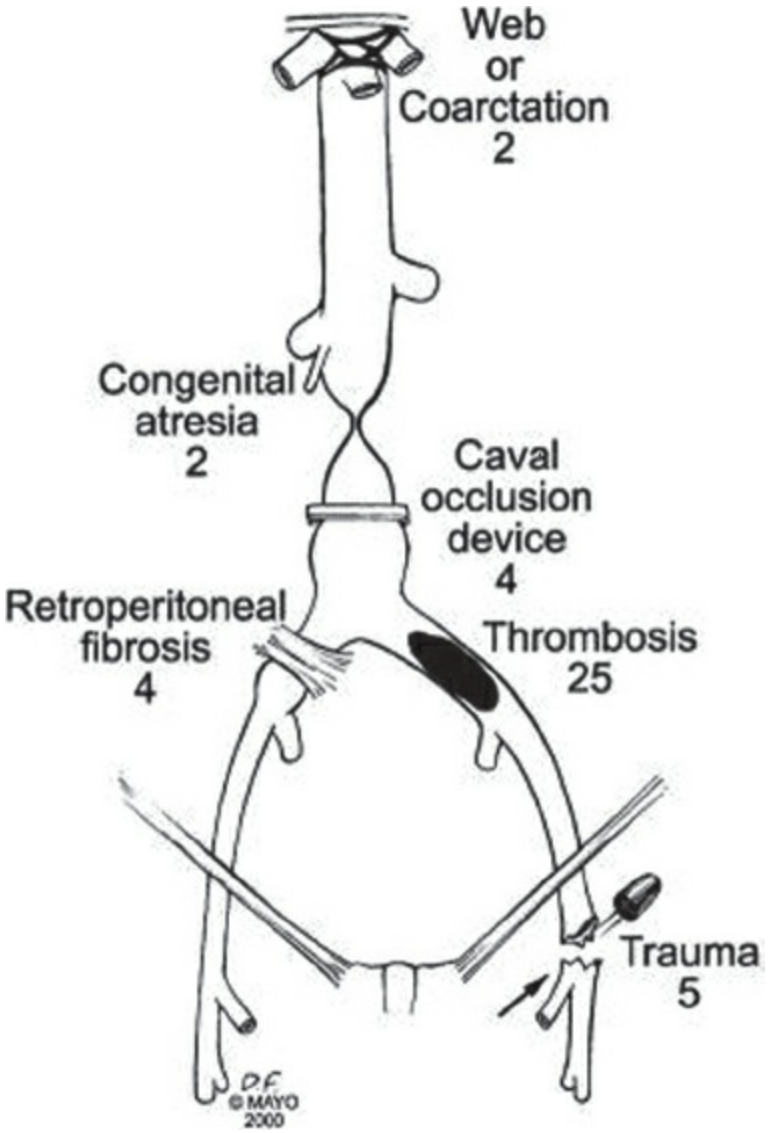

Figure 223.1. Cause of venous occlusion in 42 patients who underwent open surgical reconstruction for nonmalignant venous occlusive disease. (Reprinted with permission from the Mayo Foundation.)

Pathophysiology

During the acute phase of DVT, the thrombus in the vein activates the inflammatory cascade, which in turn promotes partial lysis of the thrombus and leads to recanalization. However, these processes are also responsible for damage to the vein wall and to the venous valves, leading to chronic obstruction and valvular incompetence. If collateral venous circulation in iliofemoral venous occlusion is inadequate, ambulatory venous hypertension develops due to a functional venous outflow obstruction. In PTS, deep reflux and obstruction of multiple venous segments often coexist.

Diagnosis

Patients with chronic iliofemoral vein or iliocaval obstruction present with signs and symptoms of CVI. These include pelvic, thigh, or hip pain that frequently develops after exercise (venous claudication), swelling, varicosity, pigmentation, skin, and subcutaneous inflammatory changes (eczema, induration, lipodermatosclerosis, dermatitis, and venous ulcerations) of the affected limb. In the Mayo Clinic experience with 64 open venous reconstructions, performed in 60 patients with benign disease, mean duration of symptoms was 6 years; 94% of patients presented with swelling, 90% with venous claudication, and 84% with both. Leg ulcers were present in 12 patients (19%) and 12% had healed ulcerations.

Preoperative evaluation of CVI must focus on two major issues: confirming the cause of chronic iliofemoral venous occlusion and establishing the presence and significance of poor venous outflow due to venous obstruction. In addition, careful attention must be paid to inflow and outflow that would determine outcome of any intervention, open or endovascular. The physician must exclude any abdominal or pelvic malignancy and consider MTS or other NIVOs as the cause of benign left iliac vein thrombosis.

Venous duplex scanning should be performed in all patients with symptoms of CVI to help define the location, cause, and severity of the underlying problem. Duplex scanning will diagnose both valvular incompetence and venous obstruction. Typical appearance of a postthrombotic vein at duplex scanning is that of a thickened, hardly compressible vessel with damaged, incompetent valves and variable degrees of venous flow due to partial recanalization. Obesity and bowel gas may prevent good visualization of the common hepatic veins and the IVC with ultrasound.

Air or strain gauge plethysmography is designed to evaluate the global leg hemodynamics by measuring reflux, obstruction, and calf pump function. Decreased vein wall compliance in patients with PTS may interfere with proper evaluation of calf muscle pump function. Unfortunately, the site and the level of reflux cannot be localized with plethysmography, and this test is absent today from many vascular laboratories. Plethysmography, however, is suitable to confirm functional venous outflow obstruction.

Magnetic resonance (MR) imaging, MR venography, and computed tomographic (CT) venography will identify any obstructing mass or tumor,

and provide sufficient information in most patients about venous anatomy, collateral circulation, occlusion, or stenosis. Contrast venography is useful in some patients before open surgical deep venous reconstructions, and it is routinely done in those who have endovascular intervention. Ascending venography provides a “road map” of the deep veins of the limb; it defines the sites of obstruction, images the collateral venous circulation, and the patterns of preferential flow. This is typically done by cannulation of the dorsal vein of the foot to assess the veins of the leg and through separate access of the common femoral vein (CFV) to assess the iliocaval system. Descending venography under fluoroscopy permits evaluation of sites of reflux in the saphenous and deep system. Contrast venography is combined with direct venous pressure measurement to document a pressure difference between the femoral vein and the vena cava. A resting pressure differential of 5 mm Hg or greater is considered evidence for significant obstruction. A lower pressure at rest but an increase to 10 mm Hg after exercise is also a sign of functional obstruction. Exercise consists of 10 dorsiflexions of the ankle or 20 isometric contractions of the calf muscle. Ambulatory venous pressure measurement by venous cannulation in the foot will help quantify venous hypertension and guide follow-up post intervention. Intravascular ultrasound (IVUS) is used frequently today to assess the degree of iliac vein stenosis before stenting, but in patients with complete venous occlusions IVUS has a limited role.

TREATMENT

Conservative Management

Symptoms of chronic deep venous obstruction should be first treated with frequent leg elevation, graduated compression stockings (30 to 40 mm Hg), and local wound care of venous ulcerations, if there are any. Compression garments result in variable degrees of success and mandate strict patients’ compliance, which in a hot climate can be both distressing and difficult. The benefits of graduated compression stockings reside in their theoretic effects on venous hemodynamics, skin circulation, and calf muscle pump function. Patients with persistent disabling symptoms, such as venous claudication, severe swelling, and nonhealing or recurrent ulcers not responding to conservative treatment, should be considered for endovascular or open surgical reconstruction.

Endovascular Treatment

Iliac or iliocaval stenting has become the primary treatment for chronic nonmalignant venous occlusions. The approach is most frequently through ultrasound-guided percutaneous access of the common femoral or mid-thigh femoral vein. A retrograde access through the right internal jugular vein is also used if the obstruction cannot be crossed from the femoral access. Access is obtained with an 18-gauge needle (some use a 21-gauge micropuncture set first) and a floppy tip or J tip 0.35-in guidewire. A 6-Fr short sheath (11 cm) is placed first and a venogram is performed to delineate anatomy if not done previously and provided the patient does not have significant renal dysfunction. The sheath is then upsized to a 9- to 11-Fr short sheath for the remainder of the procedure, depending on the size of the stent used. An IVUS exam is then carried out to assess diameters and luminal surface areas in the CFV, EIV, and CIV. Using planimetry, the normal luminal cut off areas are 125 mm^2, 150 mm^2, and 200 mm^2 respectively for the CFV, EIV, and CIV respectively. Predilation of any areas of narrowing is performed by using a 14- to 18-mm angioplasty balloon, and stent sizes of 14 mm for the external iliac vein and 16 to 18 mm for the CIVs are selected. Our preference is for the self-expanding Wall stents (Boston Scientific, Marlborough, MA) (Fig. 223.2A–D). Raju et al. uses extra support of the iliac confluence by Gianturco stents (Cook Medical, Bloomington, IN). The advantage of the Gianturco stent in addition to radial strength is the wide distance between the stent struts, preventing development of a continuous pseudointima, that favors thrombosis of the contralateral CIV, if the stent extends too much into the IVC. Any residual narrowing on IVUS interrogation is overcome by post dilation using an 18-mm or 20-mm angioplasty balloon, but excessive overdilatation and stents beyond 18 mm of diameter should be done selectively.

Kurlinksky et al. reported the Mayo Clinic experience with stenting 91 postthrombotic iliac or iliofemoral veins. Primary, primary-assisted, and secondary patencies at 3 years were 71%, 90%, and 95%, respectively. In the largest study from a single institution, 6-year follow-up data of 982 stents placed by Neglen et al. for chronic nonmalignant obstructive lesions of the femoro-ilio-caval vein demonstrated a primary, primary-assisted, and secondary patency rates of 79%, 100%, and 100% in nonthrombotic disease and 57%, 80%, and 86% in postthrombotic disease, respectively. Venous stenting was performed with no mortality and low morbidity. Risk factors for restenosis/stent occlusion after venous stenting were the

presence and severity of thrombotic disease; thrombophilia by itself was not a risk factor.

Hybrid Treatment

Patients with CFV, iliac, or iliocaval obstruction are candidates. Venous stents are combined with femoral vein endophlebectomy and patch angioplasty to improve inflow to the stents. The stent may be placed only proximal to the patch, or it can also be placed into the venous patch. In our practice, we perform these procedures rarely, as the last resort. The groups of Comerota and Wittens reported improved patency when a femoral arteriovenous fistula was used for this procedure.

Open Surgical Treatment

Patients who are not candidates or who failed endovascular reconstructions can be treated with venous bypasses to relieve symptomatic venous outflow obstruction. Venous reconstruction is also performed in those patients who undergo excision of malignant tumors invading the vena cava or iliac veins.

Crossover Saphenous Vein Transposition (Palma Procedure)

Patients with symptomatic unilateral iliac vein obstruction are candidates for saphenous vein transposition (Palma procedure) (Fig. 223.3). With this technique, the contralateral saphenous vein is used for a crossover bypass to decompress venous congestion in the affected limb. The CFV on the affected side is exposed first through a 6- to 8-cm long longitudinal groin incision. The collateral veins should be preserved if possible. The great saphenous vein of the contralateral leg is dissected through a 3- to 5-cm incision made in the groin crease, starting just medial to the femoral artery pulse. Tributaries of the saphenous vein are ligated and divided and the saphenous vein is mobilized in a length of about 10 to 12 cm. A short second upper-thigh incision is made to dissect a 20- to 25-cm long portion of the saphenous vein. Distally the vein is ligated, and proximal to the ligature it is divided and pulled up to the groin incision. Alternatively, endoscopic harvesting of the saphenous vein can also be performed, but the vein proximally should not be divided. It is essential to free up the saphenofemoral junction completely and dissect at least the anterior wall of the CFV around the saphenous vein so that there is no kink or buckle when the saphenous vein is pulled into the suprapubic tunnel. In some

patients with a low saphenofemoral junction, a kink is unavoidable. Excision of the saphenous vein with a 2-mm cuff from the CFV and reanastomosis to the femoral vein with running 6-0 polypropylene suture, after turning the junction upward 180 degrees, is the way to solve this problem. Before tunneling, a small Satinsky clamp is placed on the CFV to allow distention of the saphenous vein and the saphenofemoral junction under gentle pressure using heparinized papaverine-saline solution. The vein is then tunneled subcutaneously in the suprapubic space over to the contralateral side using an aortic clamp to ensure a large tunnel without any constriction of the graft whatsoever. Saphenous vein graft in morbidly obese patients is not recommended because of the high chance of external compression of the vein. The CFV is cross-clamped with small vascular clamps or bulldogs and the vein is opened longitudinally in a length of about 2 cm. The anastomosis between the saphenous vein and the femoral vein is performed with running 6-0 polypropylene suture. A vein at least 5 mm in diameter is required to achieve a satisfactory result and provide high venous flow to treat the basic problem in these patients, which is poor venous emptying. For a smaller vein, a temporary arteriovenous fistula (AVF) can be added between the superficial femoral artery and the saphenous or CFV using a 4- to 5-mm polytetrafluoroethylene (PTFE) graft or a large tributary of the saphenous vein. This fistula must be taken down at 3 months to enjoy the full benefit of the saphenous bypass. Endovascular occlusion of the fistula with coils or a plug should be considered. The Palma procedure, however, should not be performed with veins 4 mm or smaller.

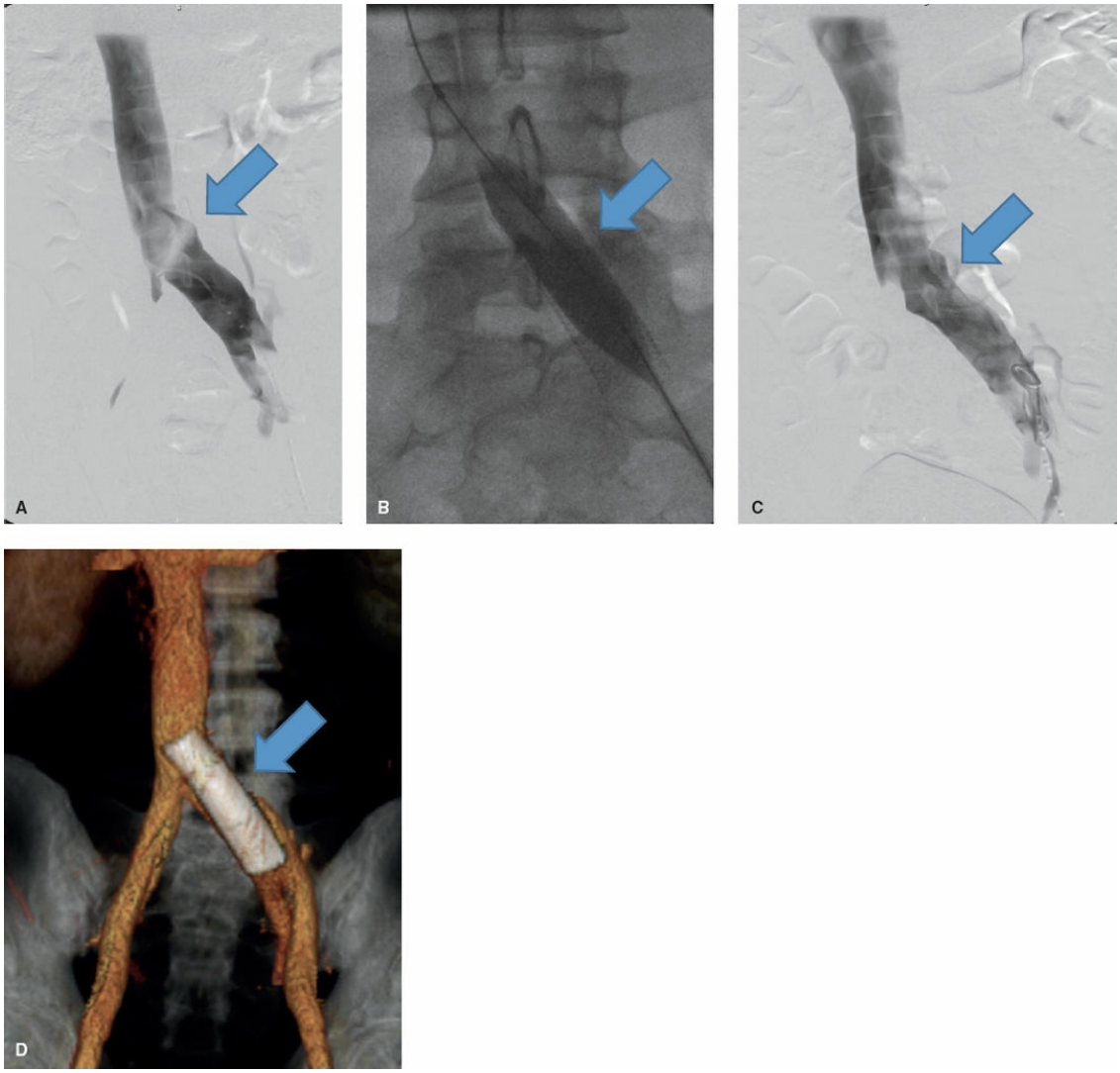

Figure 223.2. **A.** Venogram before stenting the narrowed left iliac vein (*arrow*) in May–Thurner syndrome. **B.** Balloon angioplasty of the stented (self expanding stent) left iliac vein. **C.** Poststent venogram shows excellent flow in the widely patent stent. **D.** Postoperative computed tomographic venogram confirms successful stenting. (Reprinted with permission from the Mayo Foundation.)

Although fewer large series have been reported, overall patency of Palma grafts in nine series including 412 operations ranged between 70% and 83% at 3 to 5 years. Results were better in patients who had no or minimal infrainguinal venous disease and in those with MTS without previous deep vein thrombosis. We observed a 70% primary and a 78% secondary patency rate at 5 years in 25 Palma vein grafts. Endoscopic vein harvest was associated with decreased primary but not secondary patency rates.

Crossover Femoral Venous Prosthetic Bypass

When the saphenous vein is small or not available, a crossover femoral venous prosthetic bypass with an 8- or 10-mm externally supported expanded PTFE (ePTFE) graft is a good alternative (Fig. 223.4). Similar to the autologous femoral suprapubic bypass, the femoral veins are exposed bilaterally, the ePTFE graft is positioned in the subcutaneous suprapubic tunnel, and an end-to-side anastomosis is performed to the CFVs at each side. A distal AVF on the affected side is routinely added to the procedure using a 4- to 5-mm PTFE graft for the fistula between the PTFE graft and the superficial femoral artery. Satturai recommended cutting out a small window rather than just making a longitudinal cut in cross-femoral graft at the hood of the femoral anastomosis to optimize inflow and decrease intimal hyperplasia of the AVF.

Variable patency rates of ePTFE grafts in this location have been reported and range between 0% and 100%, with data from one large series quoting a 100% (19 of 19) patency rate at long-term follow-up. Gruss and Hiemer observed 77% patency at 5 years in 27 PTFE Palma grafts. In the authors' experience, long-term patency is about 50% and preference still should be given to saphenous crossover grafts.

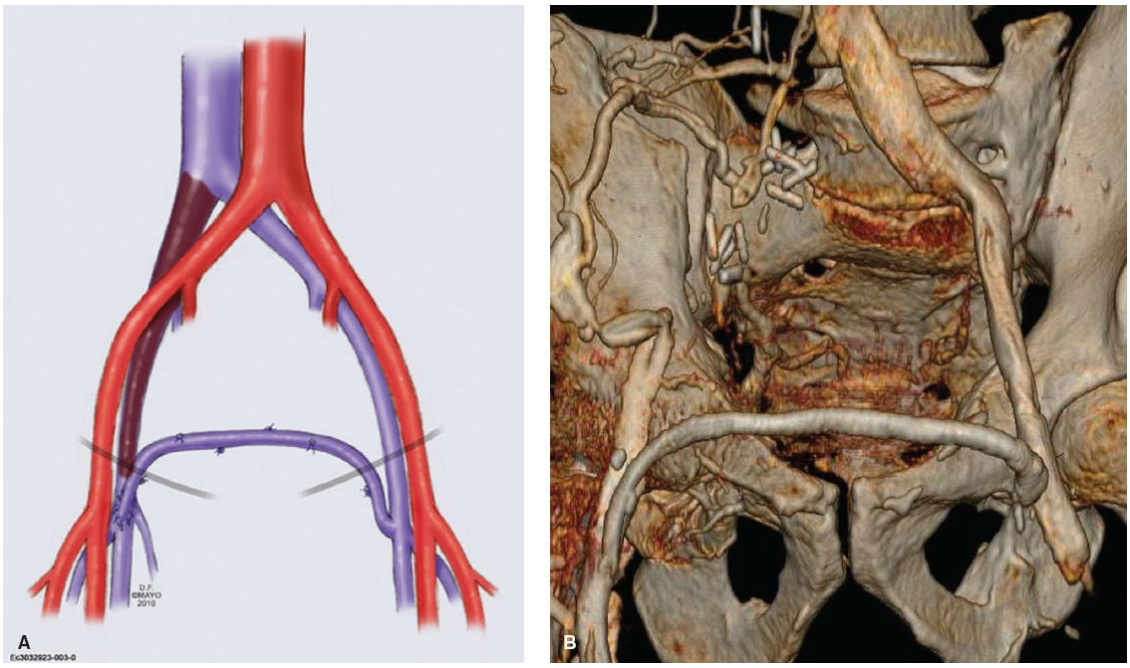

Figure 223.3. A. Suprapubic saphenous vein transposition (Palma procedure) for chronic thrombosis of the right common and external iliac vein and portion of the right common femoral vein. Bilateral groin incisions were performed to expose the right femoral vein and the left saphenofemoral junction. The left

saphenous vein was harvested open through two short incisions in the thigh. The saphenous vein was anastomosed to the right femoral vein using 6-0 running polypropylene suture. (Reprinted with permission from the Mayo Foundation.) **B.** CT venography confirmed patency at 2 months after surgery.

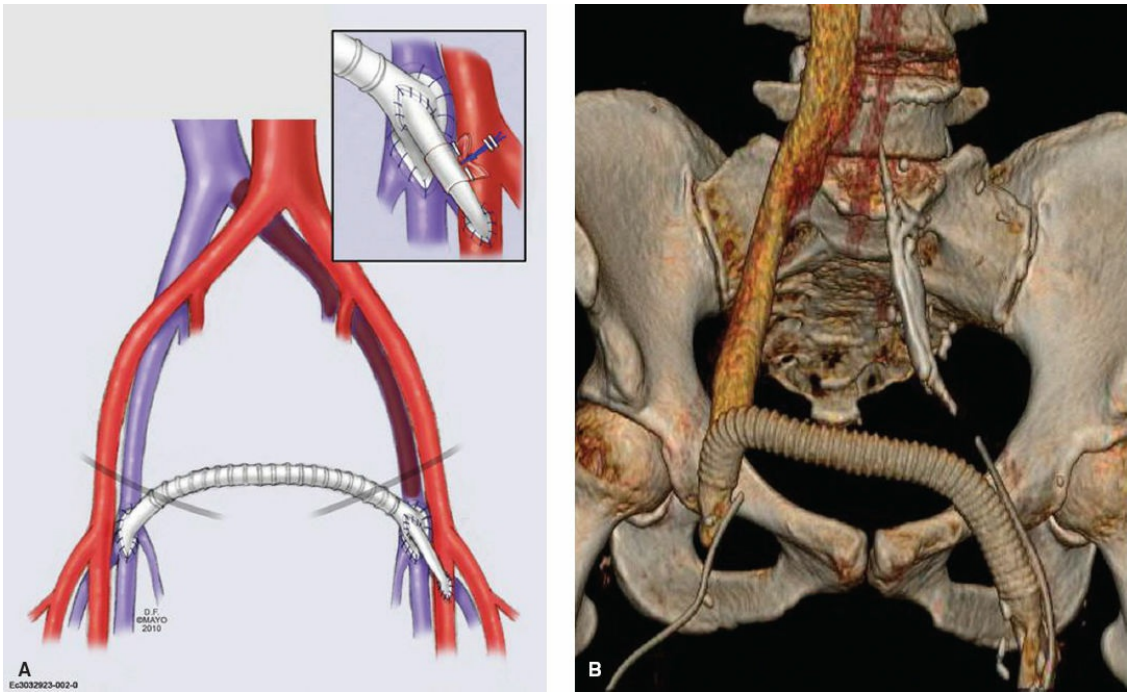

Figure 223.4. A. Polytetrafluoroethylene femorofemoral bypass with a left femoral arteriovenous fistula. A silastic sheath was placed around the fistula to avoid tissue ingrowth and easy ligation of the fistula, if needed. (Reprinted with permission from the Mayo Foundation.) **B.** Computed tomographic venogram at 1 year shows patent bypass and patent fistula.

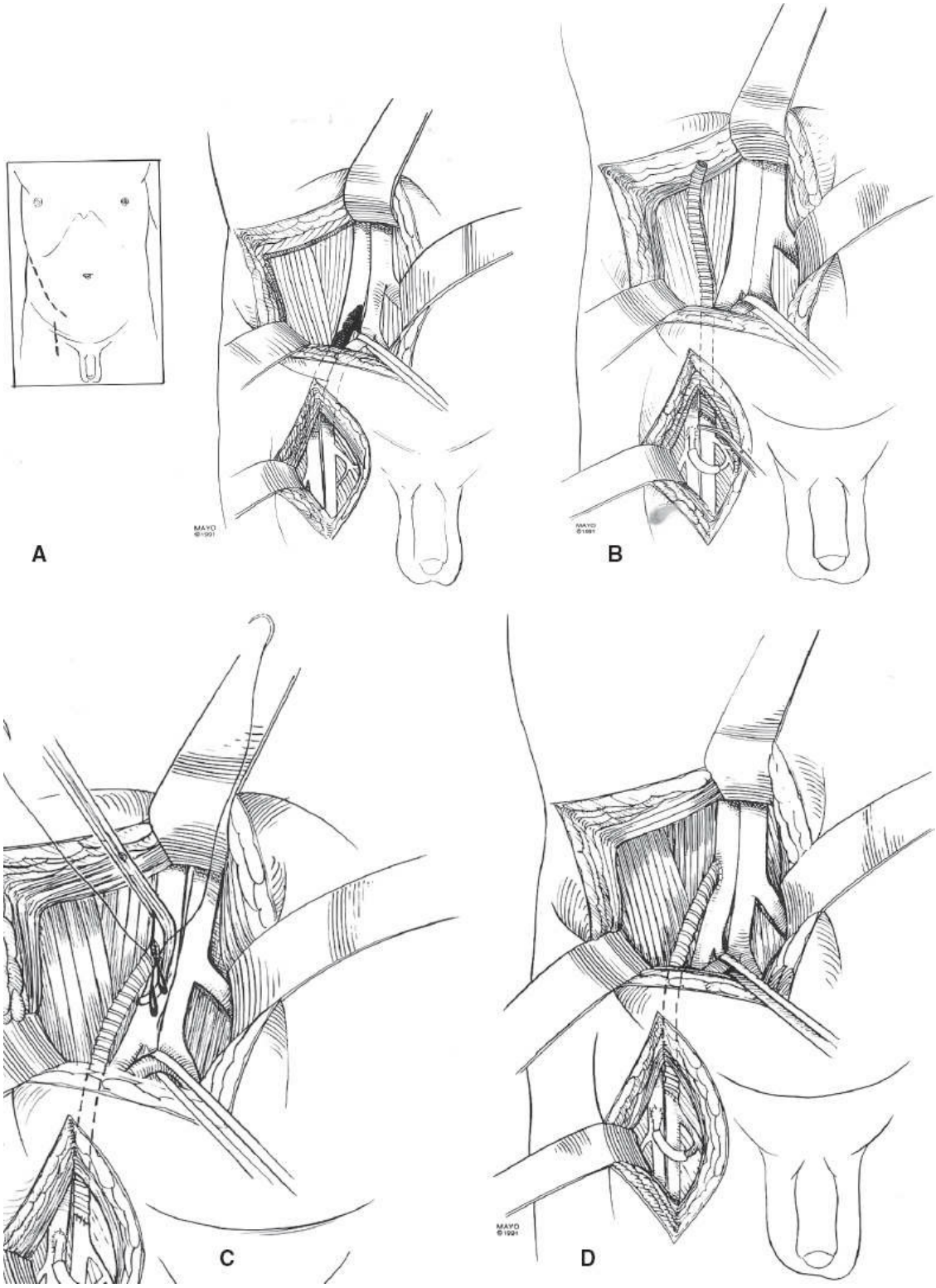

Figure 223.5. A. Location of the incisions of a right femorocaval bypass. The common femoral and the proximal saphenous veins are exposed through a 6- to 8-cm vertical incision at the groin. The distal inferior vena cava (IVC) is exposed retroperitoneally through a right oblique anterolateral flank incision, transecting the abdominal muscles and the transversalis fascia. The ureter is retracted medially. **B.** The femoral arteriovenous fistula is

performed first in this case with a large tributary of the saphenous vein and the femoral artery. A silastic sheath is wrapped around the vein for easy late identification. The distal anastomosis is performed then in an end-to-end fashion between the common femoral vein and the 10-mm externally supported polytetrafluoroethylene graft. **C.** The anastomosis between the graft and the IVC is performed in an end-to-end fashion using 5-0 polypropylene suture. Air is carefully flushed from the graft before removing the clamp from the IVC. **D.** Completed femorocaval bypass with a saphenofemoral arteriovenous fistula. (Reprinted with permission from the Mayo Foundation.)

Iliocaval and Femorocaval Bypass

Low-risk patients with bilateral iliac obstructions or with iliocaval obstruction that cannot be treated with stents or who have failed stents should be considered for an in-line femorocaval (Fig. 223.5A–D) or iliocaval (Fig. 223.6) bypass. For in-line reconstruction of iliocaval or caval occlusions, an ePTFE graft with external support is the preferred conduit (Fig. 223.7). Short, large-diameter (12-mm) grafts are used most frequently; a diameter of 12 to 14 mm is used for iliocaval bypasses and at least 10 mm for femorocaval bypass. The upper portion of the infrarenal IVC at and immediately distal to the renal veins is best approached transperitoneally through a midline incision, reflecting the ascending colon medially and mobilizing the duodenum using the Kocher maneuver. The low IVC just above the iliac bifurcation is well approachable through a right flank incision retroperitoneally (Fig. 223.5A). If the occlusion is limited to the right CIV, the same incision is used to expose the external iliac vein for the distal anastomosis. The graft is tunneled under the ureter.

If a femorocaval graft is placed, a separate 8-cm long vertical groin incision is made on the affected side and the graft is tunneled under the inguinal ligament (Fig. 223.5A). To all grafts originating from the femoral vein and to most long iliocaval grafts, an AVF is added at the groin (Fig. 223.5B). To start local heparin therapy (500 units/hr), a 20-gauge catheter is introduced through a tributary of the saphenous vein (Fig. 223.6) and advanced to the distal anastomosis. This catheter can be used for completion venography 24 to 48 hours after reconstruction and removed the 3rd postoperative day, when full anticoagulation is started. Early clinical improvement can be expected in the majority of patients, but presence of coexisting femoropopliteal reflux can still be the cause of

significant disability.

The use of autologous vein for femoroiliac or femorocaval reconstruction is also an option. Because of a relatively small size, saphenous vein in this location can only rarely be used. If short segment of the common femoral or iliac vein has to be reconstructed, a better size match is a spiral saphenous vein graft, prepared using the contralateral saphenous vein (Fig. 223.8). The excised vein is opened longitudinally, the valves are excised, and the graft is wrapped around a 28- or 32-mm argyle chest tube. The edges are approximated with running 6-0 polypropylene sutures or with stainless steel nonpenetrating vascular clips. The internal or external jugular veins are other conduits that can be considered for venous reconstruction. The femoral vein is also an alternative for reconstruction of abdominal veins, although morbidity of removing this vein in many of these patients with underlying thrombophilia or PTS is high and other options are recommended. Cryopreserved saphenous or femoral vein has also been reported for venous reconstruction, but long-term patency of these grafts for venous replacement in our experience has been poor.

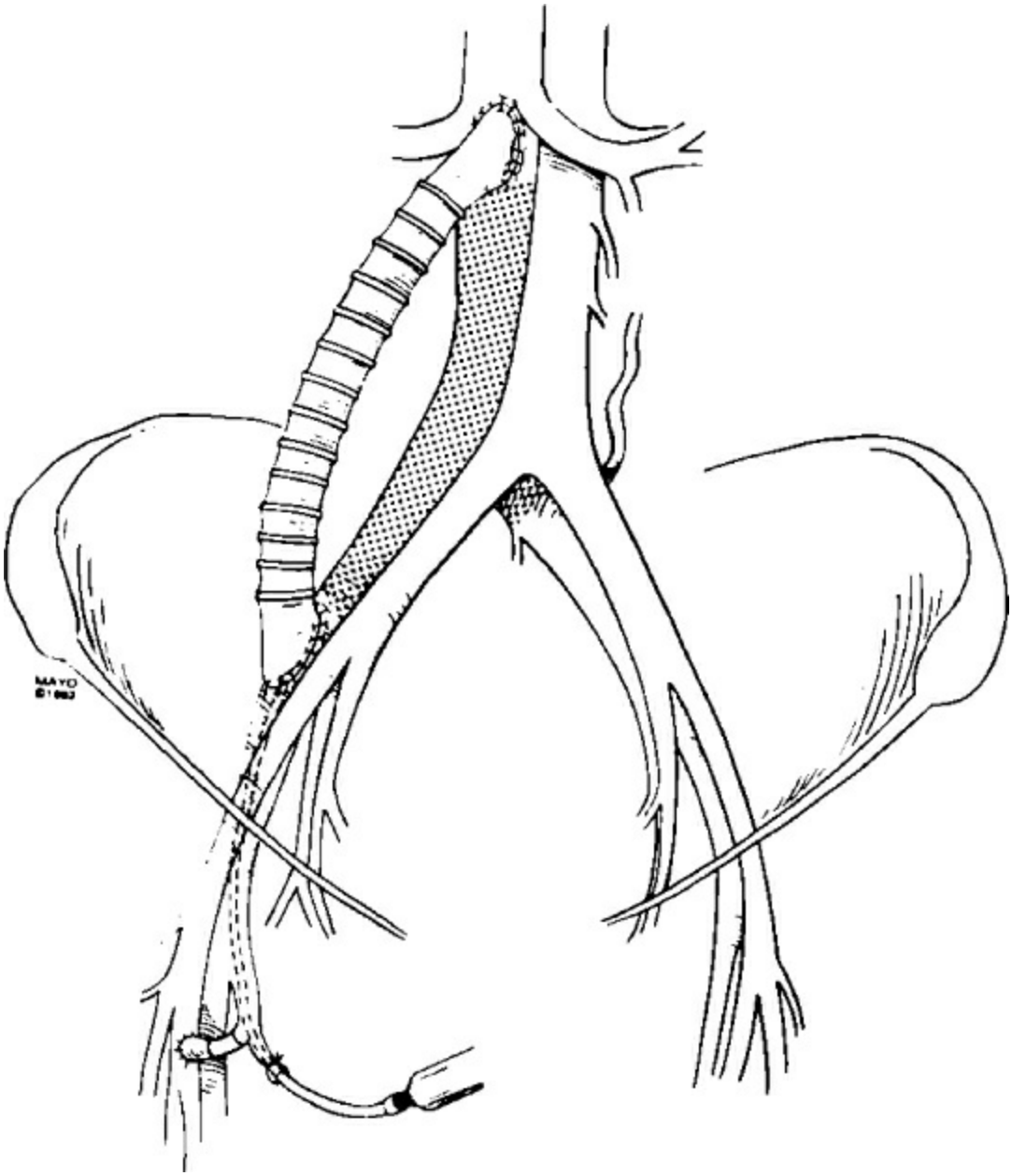

Figure 223.6. Iliocaval polytetrafluoroethylene bypass between the right external iliac vein and the infrarenal inferior vena cava. Note the saphenofemoral arteriovenous fistula and placement of a 20-gauge pediatric central line into the saphenous vein and advanced up to the graft to perfuse heparin to prevent early thrombus formation on the graft surface. (Reprinted with permission from the Mayo Foundation.)

Experience with femorocaval or iliocaval PTFE bypass grafts for benign disease has been limited; reported primary and secondary patency rates at 2 years were 37% and 54%, respectively. In one series, published by Satturai, long-term patency of 77% (10 of 13) was reported. We observed an 86% 5-year patency in short femoroiliac or iliocaval grafts

and a 57% patency of long femorocaval bypasses.

Cavoatrial Bypass

Patients with symptomatic short membranous occlusion of the IVC or longer congenital or acquired narrowing (caval coarctation) without or with hepatic venous outflow obstruction (Budd–Chiari syndrome) can be treated by cavoatrial bypass when attempts at percutaneous angioplasty or stenting have failed, or if transcardiac membranotomy is not feasible.

The suprahepatic IVC or right atrium is approached through an anterolateral right thoracotomy (Fig. 223.9A–D). The pericardium is opened anterior to the phrenic nerve. If the membranous occlusion is short and is located to this area, a short PTFE interposition graft can be performed from this exposure. If the occlusion extends distal to the hepatic veins, the abdomen is entered through the same thoracotomy, transecting the diaphragm circumferentially and mobilizing the liver forward and medially. Division of the triangular and the right coronary ligament will help mobilization of the liver. The adrenal gland and the kidney are left in their bed and dissection is moved more medially. Excellent exposure of the suprarenal IVC can be achieved through this approach. If the distal anastomosis has to be made more distally, a separate right subcostal or midline incision can be performed as previously described.

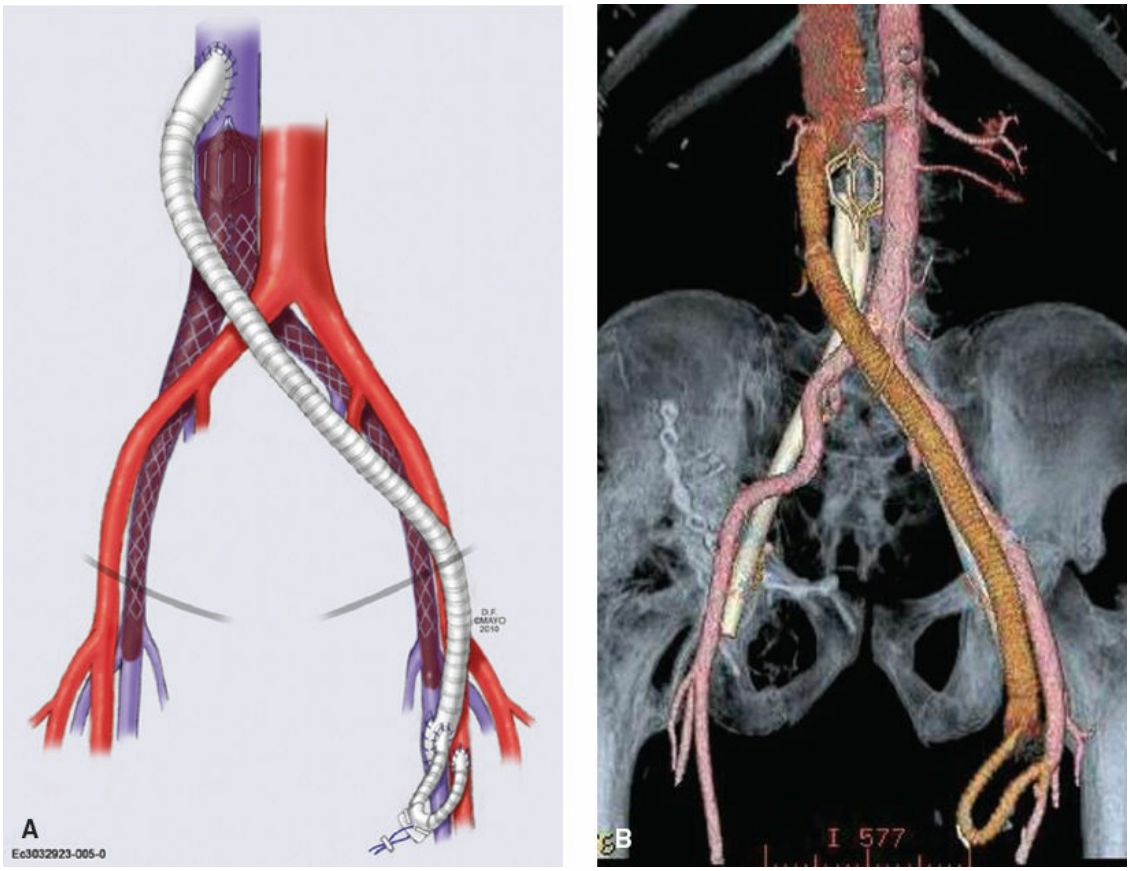

Figure 223.7. **A.** Femorocaval polytetrafluoroethylene (PTFE) bypass in a 42-year-old male who had inferior vena cava (IVC) and bilateral iliac vein stent thrombosis after placement of an IVC filter. The left femoral–suprarenal IVC bypass was performed with a 12-mm PTFE graft and a left femoral loop arteriovenous fistula. **B.** Computed tomographic venogram at 7 months shows patent graft and a patent fistula. The patient had excellent clinical improvement after surgery. (Reprinted with permission from the Mayo Foundation.)



Figure 223.8. Technique to prepare a spiral saphenous vein graft. The vein is cut open longitudinally, valves are excised, and the vein is wrapped around a 28- or 32-gauge argyle chest tube. The edges are approximated with running 6-0 polypropylene sutures, making interrupted stitches after each circle to minimize purse stringing. Alternatively, nonpenetrating vascular clips can be used for this purpose. (Reprinted with permission from the Mayo Foundation.)

For a cavoatrial bypass, an end-to-side anastomosis to the IVC is performed and the graft is routed under the liver parallel to the IVC. The graft is then anastomosed end to side to the suprarenal IVC or the lower portion of the right atrium. Partially occluding clamps are used to perform the anastomoses, and cardiopulmonary bypass is not needed. Traumatic or iatrogenic occlusions can also be managed by this technique. The use of a 16- to 20-mm externally supported PTFE graft is recommended.

The reported clinical success rate with cavoatrial grafts is about 77%, with a perioperative mortality of 3% and 2-, 5-, and 10-year patency rates of 86%, 78%, and 57%, respectively. Kieffer's group reported on long-

term patency in five of six grafts placed for membranous occlusion of the vena cava. Victor and co-workers reported patent grafts at 21 months to 6 years after the operation in five patients. Three cavoatrial grafts placed for nonmalignant disease were reported by our group: the patient with an ePTFE graft was asymptomatic at 10 years, the long Dacron graft failed at 3 years, and the spiral vein graft occluded within 1 year.

Inferior Vena Cava Reconstruction Following Excision of Malignant Tumors

Primary venous leiomyosarcoma or secondary tumors invading the vena cava, such as hepatic tumors, retroperitoneal sarcomas, or adrenal tumors, are the most frequent indications. Most renal carcinomas that extend into the vena cava do not invade the wall of the vessel and the tumor thrombus can frequently be removed from the IVC without the need for venous reconstruction. Attention must be paid to avoid tumor embolization into the pulmonary arteries. Patients with extension of the tumor thrombus into the right atrium need cardiopulmonary bypass to permit safe removal of the tumor.

The incision for resection of primary IVC tumors is transperitoneal, usually midline or right subcostal. Hepatic tumor resection may require a right thoracolaparotomy (Fig. 223.10A–D). The IVC is exposed by mobilizing the ascending colon and performing the Kocher maneuver to mobilize the second portion of the duodenum medially, as described before. PTFE grafts (14 to 20 mm) with external support provide excellent patency of the reconstructed suprarenal or infrarenal IVC, since inflow is usually excellent and there is no associated iliac vein thrombosis. Short, 8- or 10-mm wide, externally supported PTFE grafts can also be used to reconstruct the renal veins if nephrectomy for treatment of the tumor does not have to be performed. For partial invasion of the IVC, wide excision of the wall and direct suture or a PTFE or bovine pericardial patch are options for reconstruction.

A venovenous bypass between the IVC or iliac vein and the axillary or internal jugular vein using a mechanical (Biomedicus) pump is only rarely needed in patients with poor cardiac function who cannot maintain a systolic blood pressure above 100 mm Hg when both the IVC and the hepatic veins are occluded for an anastomosis. When resection of the retrohepatic suprarenal vena cava has to be performed, the proximal anastomosis is performed first to allow early restoration of hepatic venous outflow (Fig. 223.10C,D). A femoral AVF is usually not required because

of the excellent venous inflow.

Perioperative complications are frequent (43%), and operative mortality because of the associated liver resection can be high (7%). Graft patency is excellent, 93% at 3 years. Survival in many patients, however, is limited due to recurrent local tumor or distant metastases. Nevertheless, aggressive surgical management may offer the only chance for cure or palliation of symptoms for patients with primary or secondary IVC tumors. Caval reconstruction may result in significant improvement of the quality of life in these patients, even if their survival is short due to the underlying malignant disease.

Special Considerations

Endophlebectomy

Postthrombotic femoral veins frequently have multiple lumens due to partial recanalization of the thrombus. Excision of the organized and fibrotic thrombus will enlarge the lumen, although the exposed collagen in the media of the vein wall is more thrombogenic than the intact venous wall. Still, careful endophlebectomy will improve inflow to a great extent; attention, however, must be paid to avoid injury to the thin residual venous wall. This procedure has also been performed combined with deep venous valve transplantation in patients with PTS. In patients who have localized high-grade stenosis of the CFV, this operation alone is sufficient to improve venous outflow. The defect is closed with a patch using a segment of the saphenous vein or bovine pericardium. The endophlebectomized segment can also be used to improve inflow for iliocaval stenting (see hybrid procedures) or for a cross-femoral or femorocaval bypass. In a series of 10 patients who underwent endophlebectomy alone, early results showed 77% patency of the operated segments at 8 months.

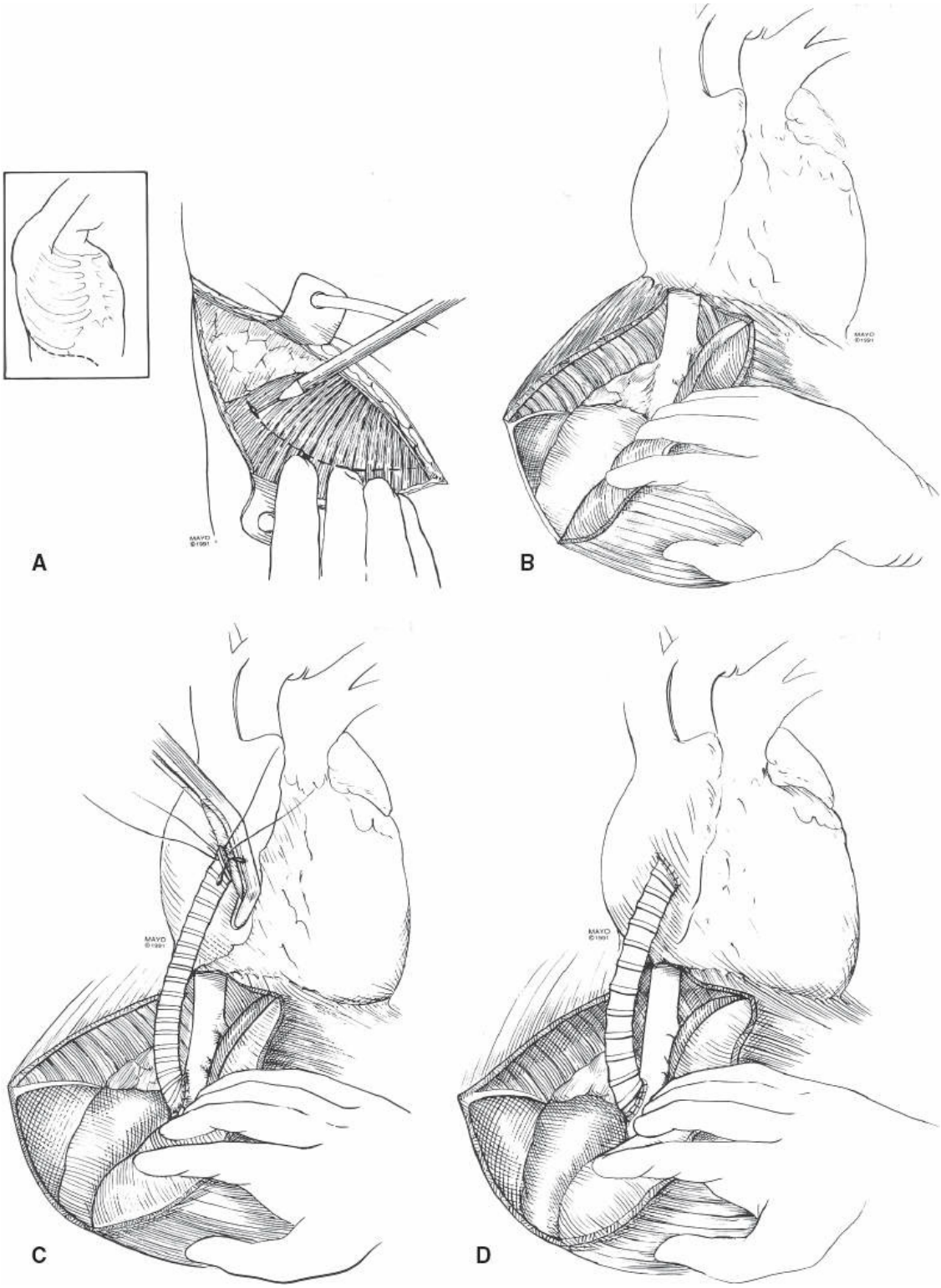

Figure 223.9. A. For a cavoatrial bypass, the thorax is entered through the eighth intercostal space performing an anterolateral thoracotomy. The costal arch is sharply divided through the eight and ninth ribs, but the abdomen is not entered. The inferior pulmonary ligament is divided and the diaphragm is circumferentially incised and the abdomen is entered. (Reprinted with permission from the Mayo Foundation.) **B.** The triangular

and right coronary ligament is divided and the right lobe of the liver is mobilized medially and anteriorly. (Reprinted with permission from the Mayo Foundation.) **C.** The suprarenal inferior vena cava is dissected and partially cross-clamped. A 14- or 16-mm externally supported polytetrafluoroethylene graft is anastomosed first to the cava, then to the right atrium. Air is carefully flushed before opening up flow in the graft. **D.** Completed cavoatrial PTFE bypass. (Reprinted with permission from the Mayo Foundation.)

Adjunctive Procedures

With the exception of caval reconstructions or short iliocaval grafts, prosthetic bypasses used for venous outflow obstruction of the legs need an adjunctive temporary AVF to maintain patency. The best technique is a 4- to 5-mm PTFE graft that is about 2-cm long and is placed between the superficial femoral artery and the lower portion of the PTFE venous graft. The authors use a tapered 4- × 7-mm PTFE graft to obtain a segment suitable for AVF. Short straight graft or a small loop fistula can be created. Both anastomoses are performed with 6-0 polypropylene sutures. A small silastic sheet is wrapped around the bypass to avoid healing and permit easy identification later when the fistula is closed. A 2-0 polypropylene suture is then tied to this silastic sheath and positioned under the skin incision for easy identification. A longer PTFE straight or loop graft used for the fistula can also be closed later percutaneously, using an Amplatz plug. Patients who have saphenous Palma grafts undergo takedown of the fistula at 3 months, with endovascular or open procedure. Patients who have PTFE grafts will keep the AVF longer, if possible. The AVF increases flow through the graft, decreases platelet and fibrin deposition, and contributes to improved patency. It also provides time for pannus formation over the anastomoses during the initial period when the graft surface is most thrombogenic. Potential side effects are a high cardiac output, functional outflow obstruction resulting in high distal venous pressures, and accelerated intimal hyperplasia.

Prevention of Complications

In general, large vein reconstructions for benign disease are performed in good surgical candidates only, with a low risk of systemic complications. Of the local, nonvascular complications, wound infection, hematoma, and lymphatic leaks (fistula, lymphocele) are the most frequent, and atraumatic

surgical technique, antibiotic prophylaxis, and standard surgical principles are helpful in prevention.

Intraoperative air embolism, especially during caval reconstruction, is a potentially fatal complication and may be prevented by meticulous flushing of the grafts before reestablishment of the circulation and passive Valsalva maneuver (30 mm Hg) as well as Trendelenburg position before release of the proximal clamp.

DVT and pulmonary embolism are serious systemic vascular complications. During 64 procedures that we performed for nonmalignant disease, there were no mortality and pulmonary embolism. Although early thrombosis rate was high (20%), and reinterventions were needed, 96% of the patients left the hospital with a patent graft after open surgical bypass. In a recent review of 65 patients who underwent IVC reconstruction, mostly for renal cell cancer and retroperitoneal sarcoma, Hicks et al. reported a perioperative VTE rate of 22% (n = 14), including pulmonary embolism in 12%. Perioperative anticoagulation with heparin and warfarin, the use of elastic stockings, intermittent pneumatic compression pumps, and early ambulation help prevent thromboembolic complications. Local vascular complications are rare; they are specific to venous reconstructions and include graft stenosis or thrombosis, perioperative bleeding, graft infection, and injury to the surrounding vascular and nonvascular structures.

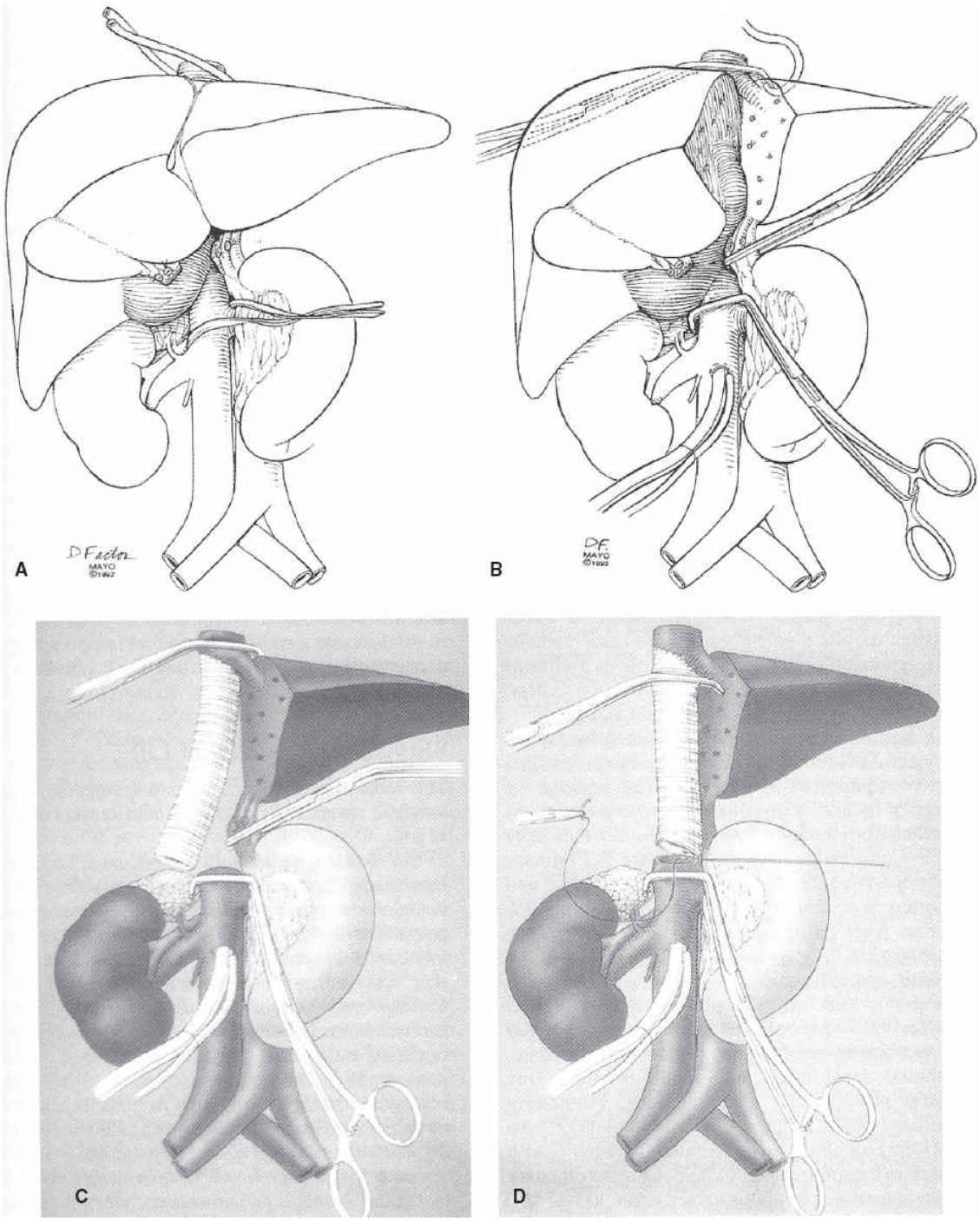

Figure 223.10. Technique for polytetrafluoroethylene graft replacement of the suprarenal inferior vena cava following right hepatic lobectomy for a malignant tumor with caval invasion. **A.** Isolation of the suprahepatic and suprarenal segments of the vena cava and division of the right hepatic artery and portal vein branches. **B.** Hepatic vascular exclusion used to complete resection of the liver, tumor, and retrohepatic vena cava. If necessary, venovenous bypass via an infrarenal cannula is used. **C.** The upper caval anastomosis is performed first to minimize hepatic ischemia. **D.** The suprahepatic caval clamp is transferred

across the graft after acid metabolites have been flushed from the liver. The lower caval anastomosis is completed. (From Bower TC, Nagorney DM, Toomey BJ, et al. Vena cava replacement for malignant disease: is there a role? *Ann Vasc Surg* 1993;7(1):51–62. Copyright © 1993 Annals of Vascular Surgery, Inc., with permission.)

Anticoagulation

Grafts placed in the venous system have a higher rate of thrombosis than arterial grafts due to relatively slower venous velocities. Infrainguinal venous obstruction and valvular incompetence further decrease inflow to the graft, and it is a major contributing factor to failure. Thrombophilia is prevalent among patients undergoing venous reconstructions, and many patients have absent circulating anticoagulants such as protein factor C, protein factor S, and Antithrombin, or have factor V Leiden mutation. The thrombogenic surface of any prosthetic graft also increases the risk of graft failure. For these reasons, perioperative anticoagulation is indicated in patients undergoing reconstructive venous surgery for deep venous obstruction.

The patient is fully heparinized during reconstruction and protamine is avoided at the completion of the procedure. Heparin at a dose of 500 units/hr is started in the operating room through a 20-gauge pediatric central line that is placed through the saphenous vein of the affected limb and advanced to the distal anastomosis of the prosthetic graft. Complete postoperative systemic heparinization is achieved by 48 hours, and full-dose low–molecular-weight heparin is continued subcutaneously for another 3 to 5 days, given simultaneously with warfarin. The incidence of postoperative bleeding has been between 5% and 10%, mainly as a result of anticoagulation. Warfarin is continued indefinitely in most patients with prosthetic grafts and in all with a known underlying coagulation abnormality.

Following iliocaval stenting for postthrombotic disease or in those with thrombophilia, we recommend anticoagulation for at least 3 months. In nonthrombotic patients, antiplatelet treatment with clopidogrel (75 mg daily) or a combination of aspirin (81 mg) and Cilastazol (50 mg twice daily) is used. There is some evidence that the latter retards instent restenosis/neointimal hyperplasia. In the presence of significant instent restenosis, but lack of symptom recurrence we use low-dose Coumadin (1 mg)/Apixaban (2.5 mg) on a daily basis. Recurrence of symptoms is an

indication to repeat IVUS and perform balloon angioplasty. Raju et al. reported on benefit from dilation using a balloon with a larger diameter than that of the stent.

Follow-Up and Reinterventions

Duplex scan on the first postoperative day or contrast CT/MR venography is performed to confirm graft patency. Stenosis or thrombosis is corrected immediately after recognition. If thrombosis occurred in a graft without fistula, thrombectomy is done with addition of a fistula. Graft stenosis discovered during surveillance in the late postoperative period is treated first with angioplasty or venous stenting. Late graft thrombosis is treated with thrombolysis, angioplasty, and stenting. Surgical revision is usually limited to patch angioplasty of the stenotic portion of the graft, although occasionally aneurysmal dilation of the saphenous crossover graft may also need surgical correction. For stent, postoperative duplex is performed on day 1 with repeat duplex exam being performed 2 and 6 weeks post procedure to ensure adequacy of symptom relief and stent patency. Annual follow-up is required subsequently.

Suggested Readings

Bower TC, Nagorney DM, Cherry KJ Jr, et al. Replacement of the inferior vena cava for malignancy: an update. *J Vasc Surg* 2000;31:270.

Garg N, Gloviczki P, Karimi KM, et al. Open surgical and hybrid reconstructions for non-malignant obstruction of the iliofemoral veins and the inferior vena cava: factors affecting long term outcome. *J Vasc Surg* 2011;53:383–93.

Gloviczki P, Oderich GS. Open surgical reconstructions for non-malignant occlusion of the inferior vena cava and iliofemoral veins. In: Gloviczki P, ed. *Handbook of Venous Disorders: Guidelines of the American Venous Forum.* 3rd ed. London: Hodder Arnold; 2009:514–22.

Neglen P, Hollis KC, Olivier J, et al. Stenting of the venous outflow in chronic venous disease: long-term stent-related outcome, clinical, and hemodynamic results. *J Vasc Surg* 2007;46:979.

Xu PQ, Ma XX, Ye XX, et al. Surgical treatment of 1360 cases of Budd-Chiari syndrome: 20-year experience. *Hepatobiliary Pancreat Dis Int* 2004;3:391.

EDITOR'S COMMENT

The chapter by Gloviczki and Jayaraj describes, based on extensive institutional experience, endoluminal and open treatment of chronic venous occlusive

disease (CVD). The workup and planning as written in the chapter are well supported. We typically will use CT scanning and then contrast venography for patients in whom a stent and/or possibly bypass procedure is planned. We have less expertise with regard to MRI. To my knowledge, each has some advantages and disadvantages, but no head-to-head comparisons for which imaging modality is better. Probably the most accurate is intravascular ultrasound, which can determine apposition of the stented vein wall with sizing and post ballooning of the vein. Moreover, intravascular ultrasound is most accurate for determining stenosis severity. For example, single plane venography had only 45% sensitivity and a 49% negative predictive value as compared with intravascular ultrasound (Neglen P, Raju S. Intravascular ultrasound scan evaluation of the obstructed vein. *J Vasc Surg* 2002;35:694–700).

The patients for whom these types of procedures are most applicable are those with severe venous insufficiency, such as CEAP class 5 and 6. In particular, the patient with recalcitrant ulcerations or venous claudication and severe disability should be considered for invasive therapy. Much experience of CVD treatment comes from Dr. Raju's group in Mississippi. Durability of the iliac venous stenting seems good, as about 13% may need re-intervention, with good secondary success (Raju S, Tackett P Jr., Neglen P. Reinterventions for nonocclusive iliofemoral venous stent malfunctions. *J Vasc Surg* 2009;49:511–8). Specifically, certain aspects such as stenting into the IVC, use of oversized self-expanding stents, as well as stenting into common femoral vein seem to be efficacious and supported by their data. Similarly, the published Mayo data support similar endovascular approaches as described in this chapter.

As noted by the authors, hybrid procedures with endoluminal treatment are more common today, particularly an endophlebectomy of the common femoral segment followed by a retrograde iliac venous stenting procedure. Indeed, significant symptomatic and durable improvement in symptoms is likely utilizing the hybrid approach (Vogel D, Comerota AJ, Al-Jabouri M, et al. Common femoral endovenectomy with iliocaval endoluminal recanalization improves symptoms and quality of life in patients with postthrombotic iliofemoral obstruction. *J Vasc Surg* 2012;55:129–35). This allows the establishment of venous inflow and outflow into the iliac and the vena cava with angioplasty and stenting, providing revascularization to the anatomical segments most causative of severe CVD.

In our own series, we found iliac vein stenting patency was diminished in males and younger aged patients, but not in those with hypercoagulability (Knipp BS, Ferguson E, Williams DM, et al. Factors associated with outcome after interventional treatment of symptomatic iliac vein compression syndrome. *J Vasc Surg* 2007;46:743–9). Moreover, non-occlusive May–Thurner disease usually has excellent long-term stent patency, whereas those patients with diffuse iliac occlusive disease after a DVT are significantly less successful long term.

Open venous bypass procedures are rare. For example, the Palma procedure

using a saphenous vein crossover is likely to be rarely performed by most surgeons, but the critical technical points are clearly described herein. Several technical aspects that are well established to prevent kinking are well described. Use of an arteriovenous fistula may be beneficial in those patients in whom poor venous inflow is noted. These arteriovenous fistulas can be occluded 6 to 12 months afterwards or remain open indefinitely. Rarely does this lead to leg swelling or congestive heart failure.

We find that most of these patients with postthrombotic syndrome do need to be anticoagulated for life. We continue anticoagulation perioperatively, whereas those patients without postthrombotic syndrome aspirin and plavix will usually suffice. Whether the new, more potent, antiplatelet therapies will better requires further study. Interestingly, Vorapaxar, a direct protease activated receptor-1 inhibitor, may be useful in this regard as it seems to be associated with less native arterial thrombosis (Bonaca MP, Gutierrez JA, Creager MA, et al. Acute limb ischemia and outcomes with vorapaxar in patients with peripheral artery disease: results from the trial to assess the effects of vorapaxar in preventing heart attack and stroke in patients with atherosclerosis-thrombolysis in myocardial infarction 50 (tra2 degrees p-timi 50). *Circulation* 2016;133:997–1005) and this may translate well into preventing recurrent venous thrombosis in the stented segments. Certainly, these questions are ripe for a controlled trial to answer.

Peter Henke

224 Vena Cava Filter Placement

Mark Levin and John E. Rectenwald

INTRODUCTION

Deep venous thrombosis (DVT) and pulmonary embolism (PE) together comprise venous thromboembolic disease (VTE), and occur with an annual incidence of 1 per 1,000 adults. Each year in the United States, an estimated 350,000 to 600,000 individuals develop VTE and 100,000 to 180,000 people die of PE. With an aging population, an increased disease burden is expected as VTE rates are nearly 13-fold higher in octogenarians. Moreover, elderly individuals are more susceptible to adverse outcomes associated with VTE, highlighting the importance of both management and prevention. Although anticoagulation with Lovenox, Coumadin, or more recent novel oral agents remains the mainstay of therapy, situations arise when these medications are contraindicated or inadequate. In these instances, vena cava filters are used to prevent PE.

INDICATIONS FOR FILTER PLACEMENT

The impetus for placing an inferior vena cava (IVC) filter is to prevent a potentially fatal pulmonary embolus, and indications fall into three general categories: absolute, relative, and extended. Absolute indications for filter placement are as follows:

1. The presence of a VTE when anticoagulation is contraindicated
2. Failure of anticoagulation in the setting of VTE
3. Emergency treatment following massive PE
4. Chronic, recurrent PE when anticoagulation has failed or is contraindicated

Table 224.1 highlights all of the indications for filter placement. Although seemingly straightforward, the decision to place a vena cava filter should not be made lightly as its use has recently fallen under intense scrutiny by the U.S. Food and Drug Administration (FDA) and in medicolegal circles given the propensity for filters to fracture, migrate,

perforate the IVC, or embolize to the heart or lungs. At the same time, the occurrence of perioperative VTE is a measure of quality, and well-intended attempts at risk mitigation may influence the decision to place a filter using more lenient or extended criteria. Nevertheless, in 2013 the FDA issued a position statement advocating that the prophylactic use of IVC filters in patients without PE is off-label. Despite this recommendation, off-label or prophylactic use has become more prevalent as clinicians recognize that certain subsets of patients, including those with multisystem trauma, bariatric patients, immobile patients, and cancer patients all have increased risk for VTE. While patients with absolute and relative indications for filter placement have existing thromboembolic disease and either a contraindication to anticoagulation, complications relating to anticoagulation, or overt failure of anticoagulation, placing filters utilizing extended criteria should be tailored to each patient after thorough discussion of the risks and benefits of the procedure, and with the understanding that off-label use may pose a liability risk to the physician. In addition, every attempt should be made to remove these filters when the risk of VTE has decreased or the patient can be safely anticoagulated.

TABLE 224.1 Indications for Vena Cava Filter Placement

I. Absolute indications
   VTE with
      Contraindication to anticoagulation
      Recurrent thromboembolic disease despite adequate anticoagulation therapy
      Significant bleeding complications of anticoagulation therapy
II. Relative indications
   VTE with
      Large, free-floating iliocaval thrombus (>6 cm in length)
      Pre- or postpulmonary thromboembolectomy
      Thromboembolic disease with limited cardiopulmonary reserve
      Poor compliance with medications
      Thrombolysis of iliocaval thrombus
      Patients with ataxia or significant fall risk
III. Extended indications (No requirement for VTE)
   High-risk trauma patients
      Head or spine injury
      Spine, pelvis, or long bone fracture
   Bariatric surgery
   Preoperative patients with multiple risk factors for VTE
   High-risk immobilized patients

The only absolute contraindications to filter placement are complete thrombosis of the IVC and lack of caval access due to extensive thrombosis. Caution is advised in the setting of coagulopathy and in children and pregnant patients.

TYPES OF AVAILABLE VENA CAVA FILTERS

The stainless steel Greenfield filter, introduced in 1972 and deployed using an open venotomy and 24-French sheath, was the original endoluminal caval interruption device. It consisted of a cone of six steel wires ending in tethering hooks. Two thirds of the filter cone could be filled with thrombus while leaving 50% of the caval diameter patent to allow for the native fibrinolytic system to lyse the clot. Percutaneous introduction techniques evolved 12 years later, followed by multiple iterations of other lower profile devices, and ultimately retrievable filters (Table 224.2).

An ideal filter would be securely fixed within the vena cava, biocompatible, nonthrombogenic, low profile, easy to deploy and retrieve, and have a low complication rate. While newer devices have some of these characteristics, the perfect filter does not exist. Retrievable devices, by definition, must be less secure than permanent filters. Access-related complications persist, despite lower profile deployment systems. Caval thrombosis, recurrent PE, and fracture are still major concerns to be dealt with. Table 224.3 depicts features of an ideal IVC filter.

TABLE 224.2 Characteristics of Available Vena Cava Filters

Filter	Introducer Size (FR)	Maximal Caval Diameter (mm)	Magnetic Resonance Compatibility	Other
Greenfield	14	28	Safe	Greatest clinical experience
Bird's nest	12	40	Not recommended	IVCs >30 mm
Simon nitinol	7	28	Safe	
Vena Tech LP	7	28	Safe	
TrapEase/ OptEase	6	30	Safe	OptEase is retrievable within 23 days
Gunther-Tulip/ Celect	8.5 Femoral 7 Jugular	30	Safe	Nonspecific retrievable window
Denali	8.4	28	Safe	Nonspecific retrievable window
Option	6.5	30	Safe	Nonspecific retrievable window

IVC, inferior vena cava.

TABLE 224.3 Characteristics of an Ideal Vena Cava Filter

Nonthrombogenic, biocompatible
High filtering efficiency with no flow impedance
Secure fixation within vena cava
Ease of insertion
Low profile
Simple deployment
Able to reposition
Magnetic resonance imaging compatibility
Low incidence of complications (migration, fracture, occlusion, perforation, insertion-site thrombosis)
Retrievable, with no time limit
Low cost

PREPROCEDURE EVALUATION

Once indications are confirmed and the decision made to place a filter, preparation includes a thorough physical exam, review of basic laboratory data, and evaluation of pertinent imaging. With fewer exceptions, IVC filters should be placed with the intent for removal; however, all currently available temporary filters carry approval for permanent use. Access for an infrarenal filter is most easily obtained via the right common femoral vein, as this provides the most direct route for device deployment and comfort for the operator. If right common femoral venous access is precluded, the right internal jugular vein is a reasonable second choice. The left common femoral vein, although feasible, is less desirable as the left common iliac vein drains into the IVC via an acute angle that may direct the filter delivery system into the right lateral wall of the IVC, causing the filter to tilt. Lab data including creatinine and a coagulation profile should be obtained. Anticoagulation should be held for 2 to 4 hours prior to the procedure. Imaging, including venous duplex studies, computed tomography (CT) venogram, or magnetic resonance venography (MRV) should be reviewed with specific attention focused on determining patency of the iliofemoral veins and vena cava. If CT or magnetic resonance imaging is available in the preoperative period, these studies may help

delineate anatomic features of the IVC that may alter the surgical plan by identifying the location of the renal veins, caval diameter, the presence of a circumaortic or retroaortic left renal vein, or duplicated IVC.

ANATOMIC VARIATIONS OF THE IVC AFFECTING FILTER PLACEMENT

The IVC develops between the 6th and 8th week of gestation from growth and regression of three paired cardinal veins. Anatomic variants arise due to abnormalities in the process and become relevant in patients requiring a filter as their presence may necessitate alteration of the surgical plan in up to 3% to 15% of cases.

Duplication of the IVC

With an incidence of 0.2% to 3%, duplication of the IVC occurs when the right and left supracardinal veins persist, leading to a double IVC to the level of the left renal vein. The left IVC drains into the left renal vein, which subsequently drains into the right IVC. Filter placement in one side, while leaving the other uninterrupted, is inadequate prophylaxis for PE. To rule out this anomaly, during venography through a flush catheter, one should visualize contrast refluxing into the contralateral common iliac vein. In the absence of this finding, duplicated IVC should be suspected and confirmed by accessing the contralateral side and performing venography to identify contrast filling the left renal vein. Additional clues hinting at the presence of a duplicated IVC would be a diminutive right IVC, or a high volume of nonopacified blood filling the right IVC above the level of the left renal vein.

Circumaortic and Retroaortic Left Renal Vein

Circumaortic renal veins occur in 1.6% to 14.0% of the population and carry significance for filter placement as the hilar junction of these veins with the IVC may be quite large, allowing for an alternative pathway for thrombi to escape the filter. To mitigate this risk, filters should be placed inferior to the entire circumaortic venous complex, where the overall diameter of the IVC is smaller, or in the suprarenal IVC. The presence of a retroaortic left renal vein should be noted, but does not carry an increased risk of embolism.

Left IVC

Persistence of the left supracardinal vein and regression of the right supracardinal vein results in a left-sided IVC in 0.2% to 0.5% of the population. In this situation, the infrarenal IVC lies on left, and the suprarenal IVC lies on the right. Generally, the left IVC crosses anterior to the aorta to join the right at the level of the renal veins; however, retroaortic left IVC has also been described. With left IVC, venous anatomy may be reversed whereby the left gonadal and adrenal veins drain directly into the IVC and the right gonadal and adrenal veins drain into the right renal vein. In addition, patients with a left IVC frequently have multiple renal veins. In this situation, a suprarenal filter may be necessary.

Megacava

Megacava, defined as an IVC diameter of >28 mm, is an important entity to identify prior to placing a filter. Currently, all commercially available devices can be used with caval diameters up to 28 mm; however, only a few (Gunteher-Tulip/Celect, the TrapEase/OptEase, and the Option filter) can be used for diameters up to 30 mm, and only one device (the Bird's Nest filter) is approved for megacava up to 40 mm. Alternatively, two IVC filters can be placed in both iliac veins or a single suprarenal IVC filter can be positioned in the suprarenal cava if it is of appropriate diameter. Filters are secured in place either with lateral force exerted by the legs, active fixation via tethering hooks, or a combination of both. As caval diameters increase, the legs of an undersized filter may not exert enough force on the wall to maintain position or sink the hooks, thereby resulting in migration. Obtaining accurate measurements, either with contrast venography or intravascular ultrasound (IVUS), is critical when choosing a device of appropriate size.

FLUOROSCOPICALLY GUIDED INFERIOR VENA CAVA FILTER PLACEMENT

The common femoral vein is identified using ultrasound. Obtaining access over the femoral head is critical to facilitate gentle manual compression at the conclusion of the case. Overaggressive compression of the femoral vein has been cited as one possible cause for perioperative venous thrombosis. Appropriate position is confirmed by placing a clamp at the intended access site and shooting a spot view under fluoroscopy. The groin

is then anesthetized and a 2- to 3-mm skin incision is made with an 11-blade scalpel. The common femoral vein is percutaneously cannulated with a double-wall needle, and a soft wire (Glidewire, Bentson, or J-wire) is advanced into the IVC under continuous fluoroscopic guidance. A 10-cm No. 5-French sheath is then advanced over the wire, into the common femoral vein, using Seldinger technique. A flush catheter is then advanced over the wire and an iliocavagram obtained (Fig. 224.1). At this point, the surgeon should take note of several key factors:

1. The presence of iliac and vena cava thrombus should be ruled out. Distal IVC thrombus generally necessitates jugular access.
2. Anomalous venous anatomy should be noted, and the surgical plan altered as necessary.
3. The location of the renal veins (particularly the lowest renal vein) should be documented.
4. The diameter of the infrarenal IVC should be determined. If megacava with diameters between 30 and 40 mm is identified, either a bird's nest, bilateral iliac vein filters, or a suprarenal IVC filter may be required.
5. The distance between the lowest renal vein and the confluence of iliac veins should be documented.

Occasionally, venacavagram may fail to clearly identify the renal veins. In this instance, the renal veins should be selectively catheterized (with a LIMA, RDC, Bernstein, or C2 Cobra catheter) and injected to eliminate any ambiguity in their location (Fig. 224.2). Most available filters are 60 mm in length or shorter, except the bird's nest filter, which is 80 mm long.



Figure 224.1. Iliovenacavagram showing the absence of thrombus in the vena cava and visualized iliac veins, the diameter of the infrarenal vena cava, the level of the lowest renal vein, and normal caval anatomy.

Once the anatomy is confirmed and measurements are taken, the device is opened and prepared on the back table. The 5-French sheath is exchanged for the long delivery sheath that accompanies each filter. In general, IVC filters have similar deployment systems; however, each device has its own idiosyncrasies that the surgeon must take into account. Deployment typically involves advancing the delivery sheath, under

fluoroscopic guidance, to a point just below the lowest renal vein. Deploying the device as close to the renal veins as possible is important to avoid creating a low-flow zone above the filter and below the vein that could create a nidus for thrombosis outside the filter. The dilator and wire are then removed while precisely maintaining sheath position in the IVC. The filter is then inserted in the back of the delivery sheath and advanced to the end under fluoroscopic surveillance. To deploy the filter, the delivery system is immobilized with one hand, while the other pulls the sheath back. Most filters deploy fully with this technique, but some have additional steps to facilitate more precise delivery and to avoid tilting and uncontrolled forward advancement of the filter (the so-called “watermelon seed” effect). Once deployed, completion venography is performed to document the final position and ensure patency of the IVC and renal veins. The device is removed from the common femoral vein and manual compression is held to achieve hemostasis. A completion spot film is then obtained to document the final position of the IVC filter (Fig. 224.3) for future reference if needed.

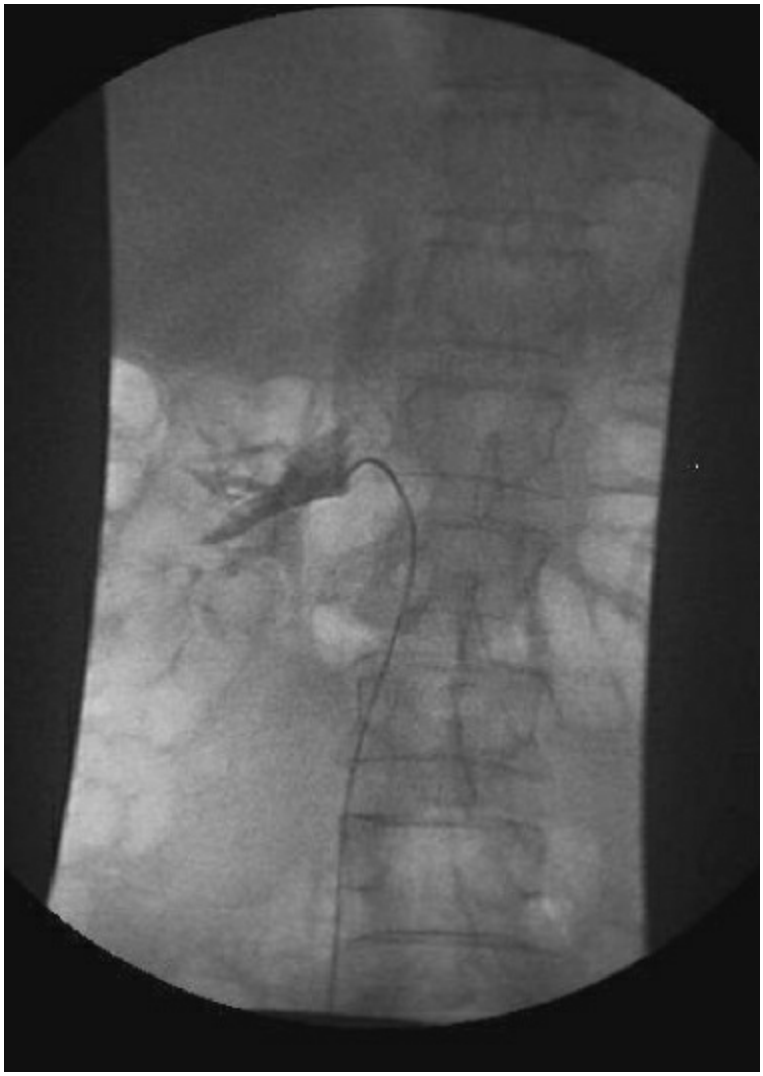

Figure 224.2. Selective cannulation of the right renal vein with a C2 Cobra catheter to confirm its location.



Figure 224.3. Completion spot film documenting adequate placement of the filter and filter position in relation to bony landmarks.

ULTRASOUND-GUIDED INFERIOR VENA CAVA FILTER PLACEMENT

Some patients may be poor candidates for fluoroscopically guided IVC filter placement due to clinical instability and inability to transfer to an operating room, or have prohibitively elevated creatinine levels precluding the use of contrast media. Under such circumstances, placing an IVC filter is still possible with the aid of a portable IVUS system brought to the bedside. IVUS allows for precise device deployment without the use of contrast, and data suggest that IVUS measurements are more accurate than those obtained with traditional contrast venography, which tends to overestimate IVC diameter. Despite these advantages, there are several caveats to this technique. The learning curve is steep and rates of filter malposition range from 2% to 8%, attributable primarily to inexperience

leading to misidentification of normal anatomy, and failure to appreciate abnormal anatomy. Familiarity with basic wires and IVUS interpretation is a prerequisite to any attempt at IVUS-guided IVC filter placement.

The first IVUS-guided filter was placed in 1999, but the technique was initially met with some resistance as bilateral access was required to maintain real-time ultrasound imaging during deployment. The IVUS catheter was advanced into the IVC via one common femoral vein, and the delivery device was placed via the contralateral side. With both the IVUS catheter and delivery system in the IVC, deployment is directly observable. An alternative technique, utilizing a single-puncture, involved mapping the IVC with IVUS, measuring the distance from the puncture site to the renal vein, removing the IVUS catheter, and then advancing and deploying the filter blindly.

With this technique, common femoral access is obtained and the delivery sheath for the filter is advanced a few centimeters into the vein over a wire. A No. 8-French sheath and an IVUS catheter are then inserted and advanced with the wire to the level of the heart, verified by visualizing cardiac motion. The IVUS catheter is then withdrawn to map the anatomy of the entire IVC. Renal vein identification is aided by noting the location of the right renal artery posterior to the vena cava just below the level of the renal veins. Once the IVUS catheter is in position below the renal vein, the No. 8-French sheath is advanced until its tip just overshadows the IVUS probe. The wire and IVUS catheter are then removed, maintaining sheath position. The filter is then loaded with its obturator through the No. 8-French sheath and advanced until the shaft reaches the level of sheath diaphragm. The filter is now at the end of the sheath, ready for deployment. The obturator is then removed using a “pin-and-pull” technique to deploy the filter. Position can be confirmed either with an abdominal plain film, or by reinserting the IVUS catheter over a wire and evaluating the IVC directly.

Single puncture methods involving the use of transabdominal ultrasound for real-time guidance during deployment have been described in the literature and appear to be a promising technique.

SUPRARENAL AND SUPERIOR VENA CAVA FILTER PLACEMENT

Placing a filter in an infrarenal location is preferable whenever possible, but situations do arise that require placement in the suprarenal vena cava.

Heavy thrombus burden in the IVC, thrombus extending to the renal veins, renal or gonadal vein thrombosis, pregnancy, and a duplicated IVC may all necessitate a suprarenal filter. The suprarenal IVC tends to have a larger diameter than the infrarenal IVC; thus, filters may be more prone to migration in this segment. In 2008, Kalva et al. published their 20-year experience with 70 with suprarenal filters and found no occurrences of caval thrombosis, 3 patients had CT evidence of thrombus in the filter, there was one incidence of filter fracture, and asymptomatic filter penetration of the IVC wall occurred in 2 patients. Postfilter PE was suspected in 10 patients (11.5%), 8 of whom underwent CT, but only 1 of those patients had radiographic evidence of a new PE. They concluded that the safety and efficacy of suprarenal IVC filters are comparable to that of filters placed below the renal veins.

If a superior vena cava filter is to be placed for the prevention of PE from upper extremity DVT, placement proceeds following the steps described for the IVC filter. The ideal location is immediately proximal to the innominate vein. It is important to remember that, in this case, the orientation of the filter must be reversed in comparison to a standard IVC filter. Therefore, a femoral IVC filter kit must be used from a jugular approach or, more commonly a jugular kit from the femoral approach. Care must be taken to avoid extension of the IVC filter into the right atrium.

THE PREPIC TRIALS

To date, there has only been one long-term randomized study evaluating the roll of IVC filters in the prevention of PE. The PREPIC (Prevention du Risque d'Embolie Pulmonaire par Interruption Cave) study, whose initial 2-year results were published in 1998, and whose 8-year long-term follow-up results were published in 2005, randomized 400 patients with proximal DVT to treatment with anticoagulation alone (with low–molecular-weight heparin for 8 to 12 days, followed by a vitamin K antagonist for a minimum of 3 months) versus anticoagulation and a permanent vena cava filter. At 12 days, 2 PEs occurred in the filter group (1.1%) versus 9 PEs in the nonfilter group (4.8%) ($P = 0.03$). At 2 years, there were 6 PEs (3.4%) in the filter cohort and 12 PEs (6.3%) ($P = 0.16$) in the nonfilter group. Recurrent DVT occurred in 37 (20.8%) patients in the filter group and 21 (11.6%) patients in the nonfilter group ($P = 0.02$). The 2-year results suggest that IVC filters provide significant short-term protection from PE

compared with anticoagulation alone, but this benefit wanes over time and that filters are associated with an increased risk of recurrent DVT.

Eight-year results of the PREPIC trial demonstrated 9 PEs in the filter group (6.2%) versus 24 PEs in the nonfilter group (15.1%) ($P = 0.08$). The filter group had 57 patients with DVT (35.7%) versus 41 (27.5%) in the nonfilter group ($P = 0.042$). Postthrombotic syndrome (PTS) occurred at similar rates in both groups, and was found in 109 (70.3%) patients in the filter group and 107 (69.7%) in the nonfilter group. This rate is substantially higher than other rates reported in the literature; however, it should be noted that 24% of patients in the PREPIC trial had PTS at the time of inclusion in the study. Mortality rates between the groups did not differ as there were 98 (48.1%) deaths in the filter group and 103 (51.0%) deaths in the nonfilter group. Of note, the predominant cause of death was cancer (in 49 patients), followed by cardiovascular-related mortality (32 patients), cardiac disease (22 patients), and bleeding (17 patients).

PREPIC results suggest that at 8 years, vena cava filters reduce the risk of PE but increase the incidence of DVT. IVC filters have no effect on the incidence of PTS or on survival.

The results of the PREPIC 2 trial were recently published. This extension of the PREPIC trial looked at the effect of routine placement of IVC filters on rates of recurrent PE in high-risk patients compared to anticoagulation alone. This multicenter, controlled trial randomized 399 patients to IVC filter ($n = 200$) and anticoagulation or anticoagulation alone ($n = 199$) at 17 centers in France from 2006 to 2012. Follow-up was at 3 and 6 months and the primary outcome was recurrent symptomatic PE at 3 months. The study reported rates of symptomatic or fatal recurrent PE were 3% in the IVC filter group versus 1.5% in the group with anticoagulation alone (RR 1.4, $p = 0.29$). Recurrent PE at 6 months was similar (3.5% filter group vs. 2% anticoagulation alone, RR 1.75, $p = 0.54$). There was no difference in all-cause mortality or major bleeding events between both groups at any time point. The PREPIC 2 study suggests that in patients with PE, at high risk of recurrence, the routine placement of IVC filters does not reduce the risk of recurrent PE when compared to anticoagulation alone.

Despite their longstanding and widespread use, long-term data on the safety and efficacy of vena cava filters are lacking. The PRESERVE trial (Predicting the Safety and Effectiveness of Inferior Vena Cava Filters), a joint venture between the Society for Vascular Surgery, the Society of

Interventional Radiology, and the FDA, began enrolling patients in 2015 in the first large-scale multispecialty prospective study designed to evaluate the use of IVC filters and follow-up. The trial aims to evaluate 2,100 patients at 60 centers in the United States, with 300 patients enrolled from each of the major filter manufacturers. Results will likely be available in the years to come and may answer many of the questions about IVC filter use and performance in the real-world environment.

RETRIEVABLE FILTERS

The intent of a retrievable filter is risk mitigation for patients with a transiently increased risk of PE. However, when retrievable filters are placed prophylactically in a patient without a DVT or PE, it is considered off-label use of the device. The FDA estimates that nearly 50% of filters are placed using extended criteria. Retrievable filters are placed in a manner identical to permanent filters, but have design features allowing for recapture and removal during a second procedure from a jugular approach. Ironically, key features of the filter that allow for recapture may also lower the safety profile of these devices, promoting fracture or migration. Ease of retrieval requires less secure fixation, more shallow or flexible anchoring hooks, and reduced endothelialization of the anchoring portion of the filter. Nevertheless, all currently available retrievable filters carry dual FDA approval for either temporary placement or permanent use. Although the option of retrieval is appealing at face value, in real-world clinical practice, there are no defined follow-up criteria and only a paucity of these devices is ever removed.

TABLE 224.4 Factors to Consider Before Discontinuing a Retrievable Filter

1. No indication for a permanent filter
2. Expected period of increased VTE risk has passed and the patient will not return to a high-risk state
3. Risk of PE is low
4. Life expectancy is long enough for the patient to derive benefit from removal
5. Filter retrieval is safe and technically feasible

The development of retrievable filters was spurred by several factors. Data obtained from the PREPIC trial suggested that IVC filters, left in place long-term, increase the risk of recurrent DVT. Second, physicians across multiple specialties are implanting ever-increasing numbers of filters using off-label extended criteria as certain subsets of patients were perceived to have an increased risk of thromboembolism in temporal relation to their condition or procedure and a relative contraindication to standard primary VTE chemoprophylaxis. Multisystem trauma patients, orthopedic patients, bariatric patients, and pregnant patients all represent higher-risk cohorts for whom these filters are used in an off-label prophylactic fashion.

Currently available retrievable filters are shown in Figure 224.4. All of these filters have a window of time during which they can safely be removed and retrieval times may vary between filter designs. There are no strict criteria to guide the decision-making process for removal, but several factors should be considered, as seen in Table 224.4. Well-controlled clinical trials evaluating the impact of retrieval versus permanence are lacking; however, mathematical modeling suggests an optimal time frame for removal lies between 29 and 54 days after the VTE risk subsides.

Several iterations of retrievable filters have come and gone from the market, but the majority share similar design features, including a hook at the top allowing for capture with a gooseneck snare and recovery through a sheath. Figure 224.5 demonstrates the recapture and filter retrieval process.

COMPLICATIONS

Although a myriad of filter-related complications have been described,

major adverse events fortunately are rare. During the procedure or immediately thereafter, filter malposition, migration, access site hematoma, and femoral vein thrombosis are most frequent. New femoral vein thrombosis on the side ipsilateral to the procedure and after insertion is common, occurring in up to 20% to 40% of patients by 1 to 2 weeks in some series. In general however, less than half of these new DVTs are symptomatic. Disappointingly, new lower profile devices have not been shown to lower this rate. Recurrent PE, perhaps the most important measure of a filter's efficacy, occurs in an estimated 2% to 5% of patients. However, these data may underreport the true incidence as the number of asymptomatic recurrences is difficult to quantify.

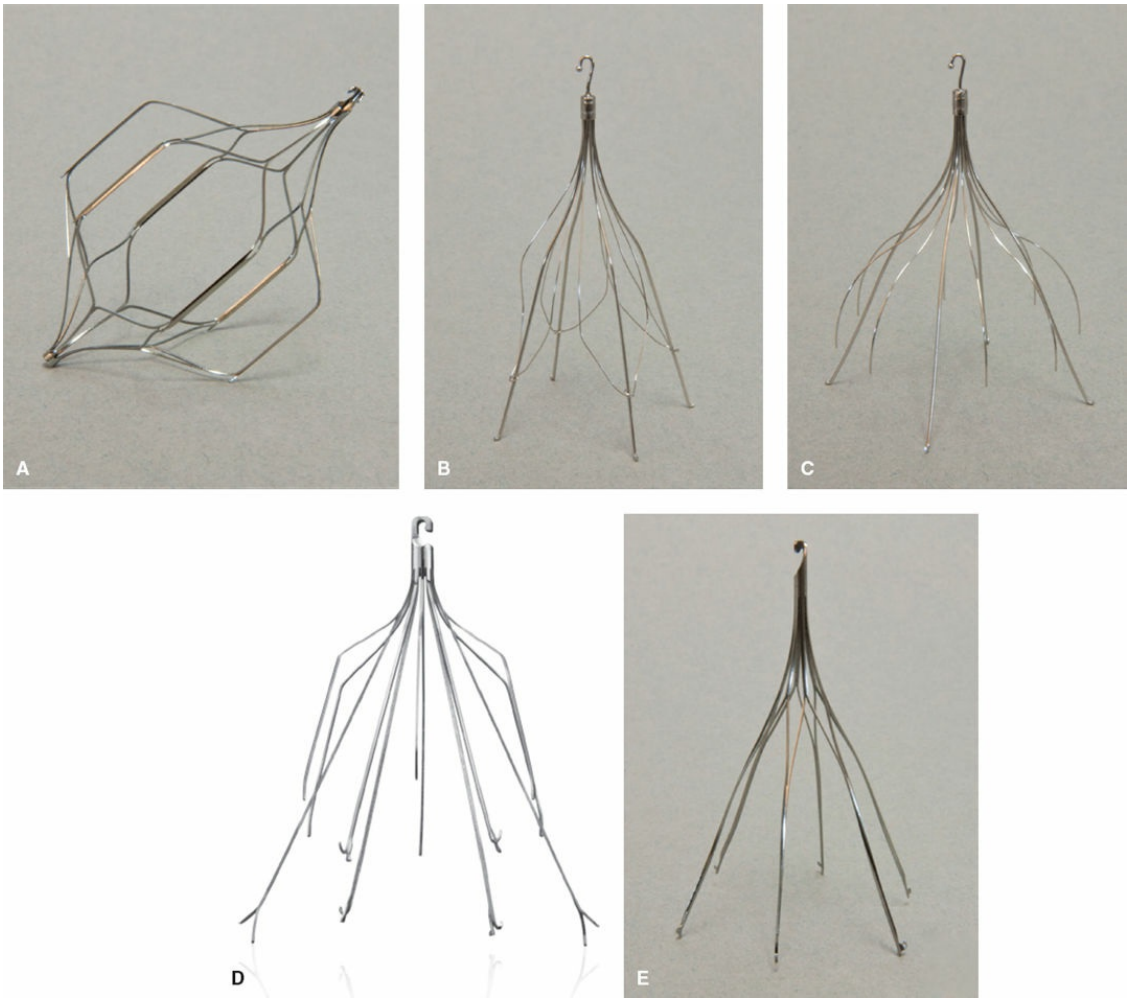

Figure 224.4. Examples of currently available retrievable IVC filters. (**A**) Optease, (**B**) Günther Tulip, (**C**) Celect, (**D**) Denali, and (**E**) Option filters.

Asymptomatic perforation of the IVC with a chronically indwelling filter is one of the most common findings observed in patients who undergo abdominal imaging for other indications. Durack and colleagues reported a retrospective series of 50 patients with either the Gunther Tulip or Celect filters who had abdominal CT scans obtained between 1 and 880 days after insertion. Forty-three (86%) of these filters had at least one component perforating the vena cava. By 71 days, all filters imaged demonstrated some degree of caval perforation. Isolated reports of filters perforating the vena cava and injuring surrounding organs, including the aorta, duodenum, or small bowel have been reported, but the true incidence of these rare events is unknown.

Filter fracture and embolization are common events, the incidence of which increases with longer dwell time; but whose clinical significance remains unclear. Data suggest that between 6% and 25% of filters left in

place longer than 2 years will fracture. But the clinical consequences when a portion of a filter dislodges are highly variable, ranging from asymptomatic to immediately life-threatening. The majority of embolized fragments lodge harmlessly in distal pulmonary arteries. However, a minority of events have led to lethal cardiac arrhythmias and cardiac tamponade (Fig. 224.6).

The importance of removal of retrievable IVC filter has recently been underscored by two safety alert communications from the FDA. Currently, very few retrievable IVC filters are actually removed with published retrieval rates ranging from as low as 13% to 18%. In 2009, in a review of the FDA's Manufacturer and User Facility Device Experience (MAUDE) data base, the FDA noted 951 IVC filter complications over a 5-year period documented in the database and that a significant majority of these were occurring with retrievable IVC filters. This resulted in an FDA alert communication in August of 2010 recommending "that implanting physicians and clinicians responsible for the ongoing care of patients with retrievable IVC filters consider removing the filter as soon as protection from PE is no longer needed." This communication was followed by a second update on the original safety alert in May of 2014 "encouraging all physicians involved in the treatment and follow up of patients receiving IVC filter to consider the risk and benefits of filter removal for each patient. A patient should be referred for IVC filter removal when the risk/benefit profile favors removal and the procedure is feasible given the patient' health status." According to a decision analysis published by representatives of the FDA, patients without PE should have their filters removed between 29 and 54 days after the time their filters were placed as the transient risk of PE has passed and the benefit/risk profile favors filter removal.

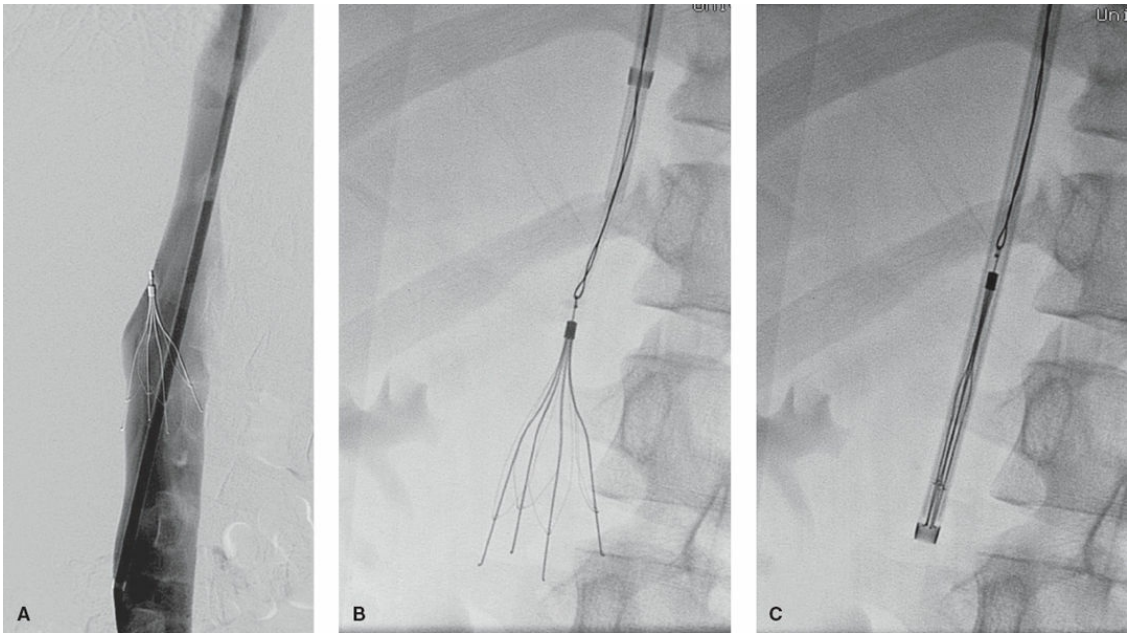

Figure 224.5. Retrieval process for the Günther Tulip filter. **A.** Preretrieval venogram confirming patency of the vena cava and lack of thrombus in the filter. **B.** Retrieval hook at apex of the filter is snared. **C.** The retrieval sheath is advanced over the filter until free from the cava and the filter removed.



Figure 224.6. Coronal CT image depicting an embolization of a fractured Recovery Nitinol IVC filter strut into and through the left ventricle of the heart with resultant subdiaphragmatic hematoma.

Suggested Readings

Ashley DW, Gamblin TC, Burch ST, et al. Accurate deployment of vena cava filters: comparison of intravascular ultrasound and contrast venography. *J Trauma* 2001;50(6):975–81.

Blebea J, Wilson R, Waybill P, et al. Deep venous thrombosis after percutaneous insertion of vena caval filters. *J Vasc Surg* 1999;30:821–9.

Cushman M. Epidemiology and risk factors for venous thrombosis. *Semin Hematol* 2007;44(2):62–9.

Decousus H, Leizorovics A, Parent F, et al. A clinical trial of vena caval filters in the prevention of pulmonary embolism in patients with proximal deep-vein thrombosis. *N Engl J Med* 1998;338(7):409–16.

Eldefrawy A, Arianayagam M, Kanagarajah P, et al. Anomalies of the inferior vena cava and renal veins and implications for renal surgery. *Cent European J Urol* 2011;64(1):4–8.

Friedland M, Kazmers A, Kline R, et al. Vena cava duplex imaging before caval interruption. *J Vasc Surg* 1996;24:608–13.

Hislop S, Fanciullo D, Doyle A, et al. Correlation of intravascular ultrasound and computed tomography scan measurements for placement of intravascular ultrasound-guided inferior vena cava filters. *J Vasc Surg* 2014;59(4):1066–72.

Jacobs DL, Motaganahalli RL, Peterson BG. Bedside vena cava filter placement with intravascular ultrasound: a simple, accurate, single venous access method. *J Vasc Surg* 2007;46(6):1284–6.

Kalva SP, Chlapoutaki C, Wicky S, et al. Suprarenal inferior vena cava filters: a 20-year single-center experience. *J Vasc Interv Radiol* 2008;19:1041–7.

Kaufman JA, Kinney TB, Streiff MB, et al. Guidelines for the use of retrievable and convertible vena cava filters: report from the society of interventional radiology multidisciplinary consensus conference. *J Vasc Interv Radiol* 2006;17:449–59.

Kinney TB. Update on inferior vena cava filters. *J Vasc Interv Radiol* 2003;14:425–40.

Kuo WT, Tong RT, Hwang GL, et al. High-risk retrieval of adherent and chronically implanted IVC filters: techniques for removal and management of thrombotic complications. *J Vasc Interv Radiol* 2009;20:1548–56.

Mismetti P, Laporte S, Pellerin O, et al.; PREPIC2 Study Group. Effect of a retrievable inferior vena cava filter plus anticoagulation alone on risk of recurrent pulmonary embolism: a randomised clinic trial. *JAMA* 2015;313(16):1627–35.

Morales JP, Li X, Irony TZ, et al. Decision analysis of retrievable inferior vena cava filters in patients without pulmonary embolism. *J Vasc Surg* 2013;1:376–84.

Rectentwald JE. Vena cava filters: uses and abuses. *Semin Vasc Surg* 2005;18:168–75.

The PREPIC Study Goup. Eight-year follow-up of patients with permanent vena cava filters in the prevention of pulmonary embolism: the PREPIC (Prevention du risque d'embolie pulmonaire par interruption cave) randomized study. *Circulation* 2005;112:416–22.

Turba U. Before you place that filter: A guide to IVC filter placement and troubleshooting procedural challenges. *Endovascular Today* 2010;2:59–66.

Vijay K, Hughes JA, Burdette AS, et al. Fractured bard recovery, G2, and G2 express inferior vena cava filters: incidence, clinical consequences, and outcomes of removal attempts. *J Vasc Interv Radiol* 2012;23:188–94.

EDITOR'S COMMENT

The cogently written chapter by Levin and Rectenwald highlights inferior vena cava (IVC) filter placement, a straightforward and common procedure to prevent pulmonary embolism in those who cannot have anticoagulation, or have had complications related to anticoagulation. IVC filter placement is ubiquitous because it is technically straightforward, effective, and is associated with a low number of complications. However, recently filter design changes have rendered them less safe with regard to potential stent fracture and embolization, as well as trans-caval perforation.

First, the proper indication for an IVC filter cannot be overemphasized, as the authors state. It serves to reiterate here the absolute indications for an IVC filter. These are when anticoagulation is contraindicated in the presence of a venous thromboembolism (VTE), the failure of anticoagulation in the presence of a VTE, an emergency treatment following massive PE, or chronic recurrent PE when anticoagulation has failed. These indications are well established and also included in the 2016 *Chest American College of Chest Physicians Venous Thromboembolism* guidelines (Kearon C, Akl EA, Ornelas J, et al. Antithrombotic therapy for VTE disease: CHEST guideline and expert panel report. *Chest* 2016;149:315–52). Unfortunately, over the recent years, prophylactic IVC filter indications have liberalized and now account for the majority of filters placed (Stein PD, Matta F, Hull RD. Increasing use of vena cava filters for prevention of pulmonary embolism. *Am J Med* 2011;124:655–61). Although filters are quite safe, they are still associated with complications, and are costly. For example, patients who undergo bariatric surgical procedures have been found to have no benefit from prophylactically placed IVC filters (Birkmeyer NJ, Share D, Baser O; Michigan Bariatric Surgery C. Preoperative placement of inferior vena cava filters and outcomes after gastric bypass surgery. *Ann Surg* 2010;252:313–8) despite the fact that obesity remains a major risk factor for venous thromboembolism (Heit JA, Ashrani AA, Crusan DJ, et al. Reasons for the persistent incidence of venous thromboembolism. *Thromb Haemost* 2017;117(2):390–400).

Another common IVC filter prophylactic indication is for the poly-trauma patient. However, the risk of death in trauma patients is not reduced with a prophylactic IVC filter. Specifically, data from a large statewide trauma registry showed that those patients who underwent a prophylactic IVC filter placement as compared with those who did not had no change in overall mortality, despite risk stratification (Hemmila MR, Osborne NH, Henke PK, et al. Prophylactic inferior vena cava filter placement does not result in a survival benefit for trauma patients. *Ann Surg* 2015;262:577–85).

Multiple types of filters now exist, and I would say that based on both basic research and clinical experience, the conical design makes most sense. This allows an embolus to be trapped in the center, and provides for perithrombus

flow to be maintained. Filter designs that are not of that geometry tend not to be as effective, particularly with regard to filter thrombosis. This was highlighted in a comparative trial of the Trapeze filter design (nonconical) versus the Greenfield filter (Usoh F, Hingorani A, Ascher E, et al. Prospective randomized study comparing the clinical outcomes between inferior vena cava Greenfield and TrapEase filters. *J Vasc Surg* 2010;52:S394–9).

There are numerous routes by which to place a filter, although fluoroscopic guidance is most common and is generally quite safe. Transabdominal and intravascular ultrasound-related filter placement takes additional skills and experience, although it is used at some institutions quite frequently. For critically ill patients, this option may be particularly useful.

It should be noted that suprarenal and superior vena cava IVC filter placements are quite different. Suprarenal placements rely on the same principals, and are as efficacious and safe as infrarenal IVC filter. They are of particular use in those patients who may become pregnant or have a duplicated IVC system. It is unclear if a superior vena cava filters are indicated; based on the high mortality, many of these patients have due to their underlying diseases (Ascher E, Hingorani A, Tsemekhin B, et al. Lessons learned from a 6-year clinical experience with superior vena cava Greenfield filters. *J Vasc Surg* 2000;32:881–7). Moreover, it is difficult to discern if upper extremity DVT really accounts for large pulmonary emboli that would lead to right heart strain and potentially death. Thus, we rarely recommend them.

The lack of actual filter retrieval in the optional retrieval IVC filters is quite striking. This has been documented in several studies and the FDA is aware. Maintaining a patient registry and patient call backs for retrieval of their IVC filter is laudable and hopefully will increase the retrieval rates as the authors' highlight. This will also be better defined with the ongoing PRESERVE trial.

The complications that occur with filters are rare but once in a while do require a late IVC filter removal. There are now numerous endovascular techniques, including using a bronchial forceps, large sheaths, multiple snare wires, and laser cutting of stents for late removable of a retrievable IVC filter. Open surgical removal can be morbid and associated with significant blood loss, although with some patients who have perforation of either their aorta or the duodenum, this can be effective therapy relieving chronic abdominal pain.

Peter Henke

225 Venous Insufficiency

Megan Tracci

Superficial venous insufficiency is perhaps the most prevalent of vascular disorders. The range of reported prevalence is attributable to the use of a variety of clinical and functional definitions, ranging from the presence of any visible manifestation of venous disease (from spider veins to severe trophic changes) to the demonstration of significant reflux on duplex ultrasound. Nevertheless, in a large population study, 28% of patients (30%) of women were found to have either deep or superficial reflux exceeding 0.5 second on duplex ultrasound and far more to manifest visible changes typically associated with venous insufficiency. More than 5% demonstrated trophic skin changes, consistent with prior findings that approximately 0.5% of the population suffers from active ulcers and 0.6% to 1.5% have healed ulcers. Venous insufficiency is two to three times more common in women than men and also seems to occur more frequently in non-Hispanic whites than in other ethnic populations. The incidence of symptomatic venous insufficiency also rises with age, pregnancy and parity, obesity, heredity, venous thromboembolic disease, and the presence of certain genetic disorders.

ETIOLOGY AND PATHOPHYSIOLOGY

Familiarity with the venous anatomy of the lower extremity is essential to understanding the pathophysiology of venous insufficiency (Fig. 225.1). The superficial veins of the leg travel above the muscular fascia. The great saphenous vein (GSV) and small saphenous vein (SSV) are the primary axial superficial veins and may give rise to anterior and posterior accessory veins that cross the thigh in an oblique fashion, to a posterior accessory vein termed the “posterior arch vein” arising from the GSV in the leg, and to a vein providing communication between GSV and SSV systems. The GSV joins the femoral vein at the groin, in a region termed the saphenofemoral junction (SFJ). The SSV most commonly joins the popliteal vein behind the knee, though its anatomy is more variable and this junction may occur as high as the midthigh femoral vein. As with the

saphenofemoral junction, the initial portion is termed the saphenopopliteal junction (SPJ), referring to the segment from the orifice of the vein to the penultimate valve. The deep system comprises the common femoral, profunda or deep femoral, and femoral (previously termed “superficial femoral”) veins, the popliteal vein, and the paired tibial veins. While the deep and superficial system are assessed separately, they communicate via numerous perforating veins and form an interconnected physiologic system. The veins of the lower extremity are endowed with delicate, bicuspid endothelial valves designed to promote unidirectional, central flow and to resist gravity in preventing reflux of blood. Valve dysfunction may be either primary or secondary to damage associated with thromboembolic disease, injury, or distension associated with conditions such as central obstructive disease or pregnancy, which combines hormonal, volume, and obstructive components. The venous hypertension associated with valve dysfunction contributes to the development of visible and/or symptomatic venous disease. Outflow obstruction within the venous system may also contribute to the progression of disease in a number of ways. Thromboembolic disease may either directly damage involved valves or lead to chronic obstruction, particularly in the deep venous system. Obstruction may also result from direct venous trauma or from external compression, such as compression of the left iliac vein by the iliac artery in May–Thurner syndrome.

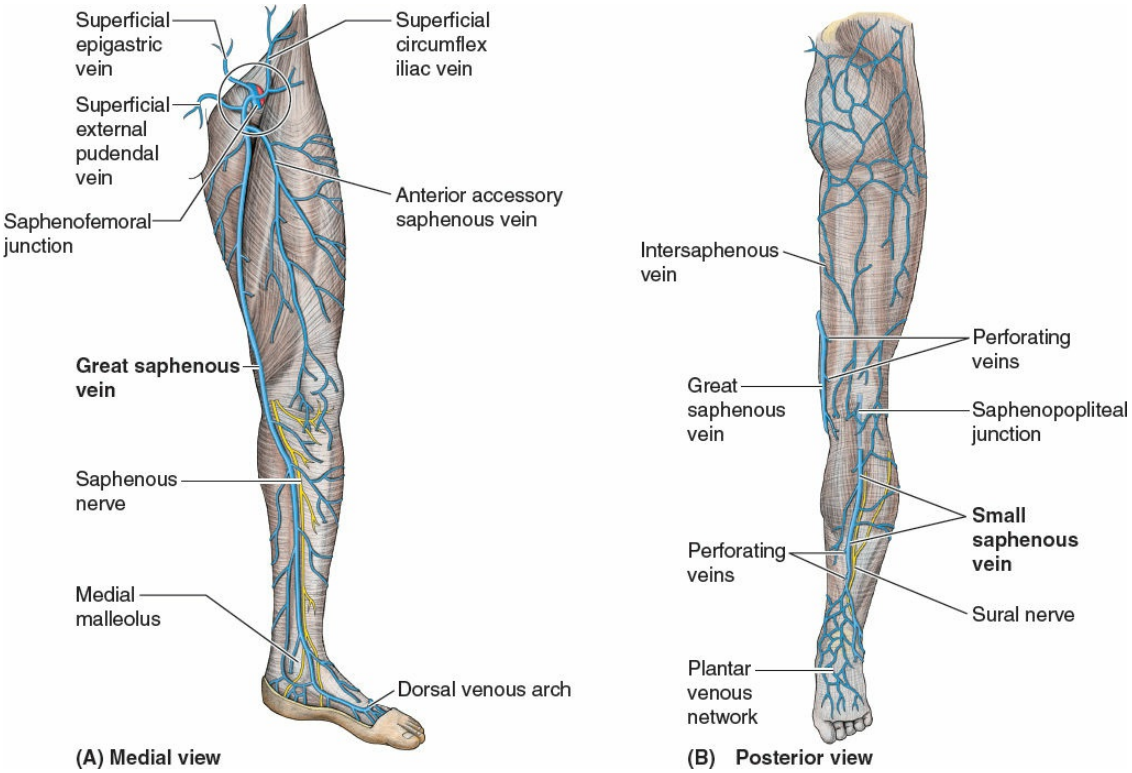

Figure 225.1. Superficial venous anatomy of the lower extremity is highly variable. **A.** Medial view; **B.** Posterior view. Generally, one should be aware of the great saphenous, accessory saphenous, small saphenous, and intersaphenous veins, and their zones of influence in the leg. (Modified from Moore KL, Dalley AF II. *Clinical Oriented Anatomy,* 4th ed. Baltimore, MD: Lippincott Williams & Wilkins; 1999.)

CLINICAL PRESENTATION

The clinical presentation of mild to moderate venous insufficiency is widely variable, ranging from asymptomatic visible manifestations such as telangiectasia (spider veins) or varicosities to disease that causes symptoms ranging from aching, edema of the foot and ankle, itching, dermatitis, or heaviness, to trophic changes such as ulceration. These symptoms typically progress over the course of the day or with prolonged standing and may be relieved by leg elevation. The severity of symptoms varies widely and often correlates poorly with the visible appearance of varicosities or with physiologic findings. In more advanced disease, venous hypertension contributes to microangiopathy, with elongation and dilatation of small vessels, endothelial damage, pericapillary edema, hemosiderin deposition, and fibrin cuff formation, culminating in lipodermatosclerosis, with its characteristic fibrotic changes to the dermis

and subcutaneous tissue. These trophic skin changes herald the formation of venous ulcers, typically in a perimalleolar position.

An important tool in the assessment and documentation of venous disease is the CEAP classification, which characterizes venous disorders based on clinical, etiologic, anatomic, and pathophysiologic characteristics (Table 225.1).

In addition to ulcers, venous disease may give rise to other troublesome complications. Varicosities may be prone to thrombus formation giving rise to superficial thrombophlebitis, which manifests as a tender, warm, inflamed region associated with the affected vein segment, which may itself form a palpable cord. Thrombosis within large, axial veins may predispose patients to deep vein thrombosis and further thromboembolic complications through propagation of clot centrally. Varicosities may also rupture and bleed either spontaneously or as a result of local trauma, resulting in significant blood loss.

TABLE 225.1 CEAP Classification of Venous Disease[a]

Class	Description
0	No visible or palpable signs of venous disease
1	Telangiectasias or reticular veins
2	Varicose veins
3	Edema
4	Skin changes such as pigmentation, eczema, lipodermatosclerosis
5	Skin changes with healed ulceration
6	Skin changes with active ulceration

[a]CEAP, clinical etiologic, anatomic, and pathologic signs.

TREATMENT OF SUPERFICIAL VENOUS INSUFFICIENCY

Conservative and Medical Therapy

Graduated compression garments are available in a variety of configurations, from knee- and thigh-high stockings through full compression hose, as well as a range of degrees of compression. Patients with symptomatic superficial venous insufficiency may benefit from moderate compression (20 to 30 mm Hg) for symptom management, though compression has not been demonstrated to affect the progression of disease, including the development of future varices. Compliance with compression therapy is often a challenge, as patients may find the garments themselves uncomfortable or may have physical difficulty donning stockings, even with the use of commercially available donning aids. Compression therapy is considered the mainstay of treatment for patients with venous ulcers, with multilayer dressings preferred for ulcer healing and stockings utilized for maintenance therapy and the prevention of new ulcers. A number of vasoactive medications, many of which are commercially available in the United States as nutritional supplements rather than FDA-approved drugs, have also shown utility in the relief of symptoms (diosmin, hesperidin, horse chestnut seed extract, rutosides, sulodexide, and micronized purified flavonoid fraction) or the healing of venous ulcers (pentoxifylline, micronized purified flavonoid fraction).

Endovascular Therapy

Indications and Contraindications

Endovenous thermal ablation using either radiofrequency or laser energy may be used for closure of axial superficial veins (GSV or SSV) and is indicated when axial reflux is present either for the treatment of symptomatic varicose veins, including to aid the healing or prevent recurrence of a venous ulcer. There are few true contraindications to these procedures. Historically, the presence of a patent deep vein system was viewed as a prerequisite for saphenous vein removal or closure. However, it has become apparent that the multitude of collateral pathways in the venous system preserve adequate venous outflow after ablation of a refluxing superficial axial vein. Similarly, the presence of thrombus in a saphenous vein, typically as a sequella of prior phlebitis, does not preclude treatment. Multiple authors report successful treatment of large diameter saphenous veins (>1 to 1.5 cm), though it is noted that treating surgeons often utilize more energy/cm in the closure of these vessels. Tortuous veins or those with stenotic segments may often be traversed with the

assistance of a hydrophilic guidewire, or the operator may elect more than one access point in order to treat the entire segment. Ultimately, contraindications comprise patient factors such as pregnancy and uncorrectable coagulopathy.

Preoperative Planning

Preoperative planning should include a focused history, including personal or family history of thrombophilia or disorders of hemostasis, the use of relevant drugs such as anticoagulants, and drug allergies or intolerances that might interfere with anesthesia or analgesia. If intravenous sedation is planned, factors such as obesity and the presence of sleep apnea are relevant. A thorough duplex ultrasound should be performed to delineate anatomy, including vein diameters and branching patterns and to evaluate for the presence, severity, and location of occlusive disease or reflux. Attention should be paid to the anatomy of junctional areas such as the saphenofemoral and saphenopopliteal junctions and to the anatomy of the veins to be treated, including tortuosity or segmental disease that may interfere with passage of guidewire or catheter (see Fig. 225.1).

Surgical Technique (Including Diagrams)

This procedure may, at the surgeon's discretion, be performed under general anesthesia, monitored IV sedation, or with oral medications only. For ablation of the GSV, the patient is placed either supine or in a slight reverse Trendelenburg position. The leg is sterilely prepped from ankle to groin and draped. Ultrasound is used to localize the desired point of access, which is typically at the level of the knee or proximal calf, but may be selected further distally based on anatomic considerations. The skin and subcutaneous tissue overlying the access point are infiltrated with 1% lidocaine and the vein accessed under ultrasound guidance using a 21-gauge micropuncture needle. The 0.018″ micropuncture guidewire is carefully advanced and a small skin nick created with a No. 11 blade. The needle is removed and replaced with a 4-Fr microsheath. The inner dilator and microwire are removed and a 0.35″ guidewire, typically either a J- or Bentson configuration, is advanced across the SFJ. The 4-Fr microsheath is then exchanged for a 5-Fr long sheath (typically available in 45, 60, and 90 cm configurations), which is also advanced across the SFJ. The wire and inner dilator are then removed and the laser fiber or RF probe advanced through the sheath. Ultrasound is used to guide careful tip placement, typically 1 to 2 cm distal to the SFJ.

Both laser and RF techniques require perivenous infiltration using a dilute lidocaine solution (445 mL of 0.9N saline, 50 mL of 1% lidocaine, and 5 mL of 8.5% sodium bicarbonate). The infiltration is performed under ultrasound visualization, with a goal of achieving circumferential infiltration within the saphenous compartment along the entire treated length of the vein. This infiltration should ideally provide 1 cm of buffer around the vein and, in particular, between treated vein and skin. Special attention should also be paid to careful infiltration of any below-knee segment treated, due to the proximity of the saphenous nerve. The tumescent solution creates a heat sink, buffering the nerve, skin, and surrounding tissues from thermal injury, as well as compressing the vein around the catheter, reducing vein volume and aiding in effective thermal ablation. For large-diameter veins, this compressive effect may be aided by placing the patient in the Trendelenburg position or by aspirating on the side port of the sheath.

If laser is used, the operator, patient, and other staff present must don protective glasses rated to the appropriate wavelength. The proper location of the fiber tip should be confirmed once again by ultrasound prior to initiating therapy. The vein is then ablated by activation of the energy source during catheter pullback. The laser systems utilize continuous pullback of 2 to 3 mm/s, with a goal of delivering 30 to 50 J/cm energy. Most operators have slightly modified this technique to deliver higher energy (up to 80 J/cm) for the first 10 cm below the SFJ by slowing the pullback rate to 1 to 2 mm/s. The literature describing successful closure of large diameter veins does also note a slightly higher average energy delivery by operators in these cases.

The RF system utilizes sequential treatment of overlapping 7 cm segments of vein for 20-second cycles. As with laser, more energy is delivered to the first segment below the SFJ, in this case by applying two cycles of heating before pulling the catheter back to the next station.

At the conclusion of the procedure, the catheter and sheath are removed and gentle pressure applied to the access site. Completion imaging at the SFJ should confirm cessation of flow in the saphenous vein beyond the first 1 to 2 cm and, more importantly, note the absence of thrombus extending into the deep (common femoral or popliteal) vein.

Minor variations apply when treating the SSV or accessory/branch veins. When treating the SSV, careful attention must be paid to appropriate catheter tip placement, as there is significant anatomic variability in the

junction of the SSV and the deep system. Furthermore, the potential proximity of the tibial and common peroneal nerves (in the proximal/saphenopopliteal region) and the sural nerve (in the distal lower leg) should prompt thorough infiltration of these areas with tumescent solution and careful catheter placement with avoidance of the saphenopopliteal junction and the more distal lower leg. The origin of the anterior accessory saphenous vein in the thigh may also be variable, with this vein emptying either into the proximal portion of the GSV or directly into the femoral vein. Ablation typically begins just distal of the junction of the GSV in the former case or 1 to 2 cm distal to the junction with the deep vein in the latter.

Of note, cyanoacrylate adhesive and combined mechanical–chemical endovenous ablation techniques which do not require the use of tumescent have been reported within the past 5 years, though these have not yet been widely adopted in the United States.

Postoperative Care

Waist high (GSV) or thigh high (SSV) graduated compression stockings providing 30 to 40 mm Hg compression are then placed. Surgeon practice is highly variable with regard to need for or duration of compression therapy. However, the majority of operators continue to recommend compression with a range of 2 to 14 days reported. Durations of therapy from 7 to 14 days have been associated with some reduction in pain and analgesic use. There is no strong data suggesting a benefit with regard to therapeutic effectiveness or the incidence of VTE. Although some argue that the very low rate of PE (thought to be <0.01%) following endothermal ablation obviates the need for routine postprocedure screening of asymptomatic patients, duplex ultrasound screening for DVT remains common practice at intervals of 48 hours to 2 weeks postprocedure.

COMPLICATIONS AND THEIR MANAGEMENT

The most commonly observed form of thrombus has been termed endothermal heat-induced thrombosis (EHIT), and classified as EHIT 1 to 6 based on the degree of extension into the femoral vein. In general, levels 1 to 4 are managed with observation with serial duplex ultrasonography or without the addition of antiplatelet therapy. Levels 5 and 6 are frequently treated with observation and a short course (1 to 6 weeks) of anticoagulation.

Open Surgical Therapy

Surgical Saphenectomy

Indications and Contraindications

The indications for surgical treatment of the saphenous vein by high ligation, division, and invagination saphenectomy ("stripping") parallel those for the endovenous thermal ablation procedures that have largely supplanted this technique. Ligation alone at the SFJ is ineffective and associated with a high rate of persistent or recurrent symptoms. The procedure may be carried out under general anesthesia or under local tumescent anesthesia with or without moderate IV sedation. Once again, contraindications relate to patient characteristics that may preclude safe anesthesia, analgesia, or surgical intervention. Preoperative evaluation should encompass the same factors as for endovenous intervention as well as further investigation warranted based on the choice of anesthesia techniques. While endovenous therapy may be undertaken without interrupting antiplatelet or anticoagulant regimens, the potential for significant bruising and discomfort dictate a period of abstinence prior to open venous surgery. Careful duplex ultrasonography is important prior to saphenectomy and can alert the surgeon to the presence of accessory veins or atypical anatomy, as well as to diseased or tortuous segments of the saphenous veins that may not be amenable to passage of the stripper.

Surgical Technique (Including Diagrams)

The patient is laid supine. A prophylactic single dose of subcutaneous heparin or low molecular weight heparin is administered. A 2- to 3-cm incision is made in the groin crease overlying the SFJ. In an obese patient, the use of ultrasound to localize the SFJ can minimize both the size of the incision and the extent of dissection with attendant risk of lymph leak. In addition, careful sonography can identify accessory veins, typically arising within several centimeters of the SFJ that should, if incompetent, be addressed at the time of operation to prevent recurrent symptoms. Dissection is limited to that required to provide sufficient visualization of femoral vein at the junction, permitting ligation of the saphenous vein with nonabsorbable suture and division at this level. Care should be taken to avoid injury to the femoral vein, but also to achieve a relatively flush ligation to avoid leaving an extensive blind stump of saphenous vein. A flexible stripper is then passed down the saphenous vein through a small venotomy. The stripper should be palpable, and is often visible, at the level

of the knee. A small counterincision is performed to permit circumferential dissection of a short segment of the saphenous vein at this level. The vein is ligated distally and divided. The proximal end of the saphenous vein is affixed to the stripper either using a 0 silk or by utilizing the removable tip provided with the stripper. It is then invaginated on itself and removed in a proximal to distal direction and removed via the distal incision. Surgical saphenectomy should typically be limited to the thigh segment, with the distal incision at or just below the knee, in order to minimize trauma to the saphenous nerve, which is closely associated with the vein below the knee.

Several approaches to hemostasis are frequently utilized. Use of a tourniquet may require general anesthesia and is of greatest utility when additional phlebectomy, particularly of sizeable veins, is anticipated. In this case, an appropriately sized tourniquet should be placed over soft webbed dressing on the high thigh and the leg elevated, exsanguinated from foot to groin with an Esmarch bandage, and the tourniquet inflated prior to additional phlebectomy. This technique is not effective in patients whose femoral arteries are noncompressible. The use of tumescent anesthesia with a dilute lidocaine solution to infiltrate along the course of the saphenous vein may permit the performance of this operation without general anesthesia and is also helpful in reducing the degree of bruising, swelling, and discomfort associated with accumulation of blood in the saphenous tunnel. In any case, immediate compression of the saphenous tunnel aids with this. The incisions are closed in layers, reinforced with surgical strips or a dermal adhesive, and sterilely dressed before placement of gauze fluffs dressings over the course of the saphenous vein and the application of a compressive elastic dressing.

The Small Saphenous Vein

As noted in the discussion of endovenous ablation, the anatomy of the saphenopopliteal junction may be variable and the SSV, itself, in proximity to motor as well as sensory nerves.

Postoperative Care

The compressive dressing is left in place for 48 hours, then removed. This dressing may be left in place for up to 4 days when more extensive phlebectomy has been performed. Patients are instructed that they may benefit from wearing either an elastic compressive dressing or compression stockings for comfort for the first postoperative week. Once

the dressing is removed, bathing is permitted and activity advanced as tolerated. A postoperative visit is scheduled at 4 weeks.

Ambulatory Phlebectomy

Phlebectomy yields gratifying results in the management of isolated, pressurized varicosities and those that persist following successful treatment of axial reflux. It can be performed awake with local tumescent anesthesia alone, with mild to moderate sedation as an adjunct, or under general anesthesia, based on the extent of disease and patient and surgeon preference. The selection of ambulatory phlebectomy may incorporate a number of factors, including the characteristics of the targeted veins, with large and pressurized veins often proving somewhat resistant to percutaneous sclerotherapy, patient preference, surgeon experience, and the potential to stage later percutaneous therapy.

Surgical Technique

The veins to be treated are marked with the patient well hydrated and standing. The patient is then positioned for optimal access to the target veins and the skin sterilely prepped and draped. If local tumescent anesthesia is used, the area to be treated is infiltrated and treatment proceeds to contiguous areas to minimize patient discomfort. If the veins to be treated are large and extensive and general anesthesia is used, utilization of a tourniquet and exsanguination of the leg using an Esmarch bandage can afford hemostasis and minimize postprocedure pain and bruising. A 1- to 3-mm skin incision is made over the target vein, typically in a longitudinal orientation, except in flexural areas, where the incision should be oriented with the lines of skin tension (Langer lines). For very small, dermal veins, this incision may be made using an 18-gauge needle or the tip of a No. 11 blade. Small veins may be elevated using a fine vein hook, which minimizes stretching of the incision. These are available in a variety of configurations. Larger veins may be grasped and elevated more effectively using a fine, curved hemostat. The vein is then grasped between two hemostats, divided, and the hemostats are gently rotated in order to extract the greatest length possible, often several centimeters, in each direction. Occasionally, larger tethering branches will become visible. These can be grasped, divided from the main trunk, and avulsed in a similar fashion. Typically, the compression afforded by tumescent infiltration along with a minute or two of gentle manual pressure are

adequate for hemostasis. In this fashion, the marked veins may be removed using as few incisions as possible. Vein ligation is rarely indicated, except in the relatively infrequent circumstance of varices arising directly from intact axial veins or the use of ultrasound localization to focally ligate a perforating vein associated with a cluster of varices. At the conclusion of the procedure, the incisions are cleaned and either sterile surgical strips or a dermal adhesive applied. As with saphenectomy, a layered gauze and compressive dressing is then applied and left in place for 48 hours.

Complications and Their Management

The most common complaints following surgical phlebectomy are pain and bruising. Patients not infrequently benefit from several days of prescription pain medication following saphenectomy or particularly extensive phlebectomy. Subsequently, and for typical microphlebectomy, NSAIDs or acetaminophen provide sufficient analgesia. Bruising is more common with extensive phlebectomy, impaired platelet function, or anticoagulation and may take several weeks to resolve completely. Compliance with compression following the procedure can help to minimize the duration and severity. Wound complications such as significant bleeding, hematoma, or infection occur infrequently.

Deep vein thrombosis following saphenectomy is likely both underreported and infrequently clinically symptomatic. Surveillance duplex following saphenectomy or phlebectomy is not standard in most practices. However, new onset symptoms consistent with DVT should be promptly evaluated.

Nerve injury presenting with numbness, paresthesia, or pain may also occur. These typically improve over time, though complete resolution may not be achieved. Persistent pain may necessitate targeted therapy. The saphenous nerve distribution results in symptoms along the medial calf, malleolus, and a portion of the medial foot. The nerve is more closely associated with the saphenous vein distal to the tibial tuberosity, supporting the modern practice of limiting stripping to the segment cephalad to this region. Due to the variable anatomic relationship of the SSV with the nerves of the popliteal fossa, dissection in this area may affect the sural, peroneal, or tibial nerves.

Neovascularization and recurrent varicose veins may also result in late recurrence of symptoms. In some instances, extensive dissection, particularly at the SFJ, is thought to contribute to neovascularization. In the popliteal fossa and distribution of the SSV, it is most likely that

recurrent symptoms are attributable to the multiple collateral pathways from the popliteal vein to the proximal SSV via perforating veins or large medial gastrocnemius veins. On occasion, communication may also be found with the greater saphenous vein.

Percutaneous Therapy (Sclerotherapy)

Indications and Contraindications

Percutaneous sclerotherapy using, most commonly, polidocanol (Asclera, BioForm Medical Inc) or Sotradecol can be quite effective in the treatment of varicose and reticular veins (1 to 3 mm) and telangiectasias. Both agents are detergents that act on the intima to promote vein closure. Polidocanol is available in 0.5% and 1% formulations in 2 mL ampules and is FDA approved for the treatment of reticular veins and telangiectasias. Sodium tetradecyl sulfate/STS (Sotradecol, Bioniche Pharma Group) is manufactured in 3% and 1% concentrations and is approved for the treatment of small, uncomplicated varicose veins.

Both agents have favorable safety profiles, with polidocanol exhibiting a slightly lower incidence of allergic reaction, of extravasation necrosis, and of posttreatment hyperpigmentation. Thrombotic complications may be seen and these sclerosants should not be used in the setting of acute venous thrombosis. Osmotic agents such as hypertonic saline and irritants such as glycerine or alcohol have less favorable safety and side-effect profiles and are infrequently used in modern venous practice.

Preoperative Planning

Understanding of vessel size and underlying patterns of venous hypertension are critical to achieving optimal results. Appropriate duplex ultrasound imaging should be obtained when axial reflux is suspected and patients should be appropriately advised that untreated reflux of saphenous or perforating veins will render visible varicosities, reticular veins, or telangiectasias more resistant to sclerotherapy and that, similarly, deep reflux will tend to contribute to persistent or recurrent veins. The agent and concentration should be selected based on vein size. Telangiectasias of 1 mm or less in diameter can be treated effectively with liquid 0.5% polidocanol or 0.2% to 0.3% Sotradecol. Typical blue–purple reticular veins of 2 to 3 mm in diameter are effectively treated with 0.5% to 1% polidocanol or concentrations up to 0.5% Sotradecol. At this size, many clinicians find that utilizing these solutions off-label as a room air or

carbon dioxide microfoam is quite effective. Veins larger than 3 mm may be treated with concentrations up to 1% polidocanol or 3% Sotradecol, typically in microfoam form.

Higher concentrations and more aggressive therapy are associated with an increased incidence of posttreatment hyperpigmentation. The maximum recommended volume per treatment session of either agent is 10 mL.

Surgical Technique (Including Diagrams)

Treatment of telangiectasias is best accomplished using a very dilute solution injected at a low angle to the skin using a 1- to 3-cc syringe and either a 27- or 30-gauge short needle. Visualization may be aided by the use of dedicated lighting and surgical loupes for magnification. Each injection is performed slowly with minimal pressure to prevent or quickly detect any extravasation and typically totals only 0.2 to 0.3 cc in volume. The course of the sclerosant is apparent due to visible, transient blanching of the treated portion of the vein. Reticular veins may be treated in a similar fashion with slightly higher sclerosant concentrations and volumes.

Veins larger than the 2 to 3 mm blue reticular form are often addressed using a microfoam technique. If foam is used, it is created using the Tessari method of agitation of a 1:4 to 1:5 mixture of sclerosant and either air or carbon dioxide using two syringes and either a Luer connecter or three-way stopcock. The fine foam created by vigorous to-and-fro agitation between syringes is typically stable for several minutes.

The treatment of larger, deeper varicosities or saphenous veins is best accomplished using ultrasound guidance by an experienced operator using a probe with sterile cover to ensure intravenous instillation, observe the course of the sclerosant, and guide the termination of injection once the microfoam is observed approaching or entering the deep system. The point of communication can be compressed manually or with the probe to prolong contact with the target segment and minimize exposure of the deep system. When treating axial veins, this is accompanied by elevation of the limb to decrease drainage centrally into the deep system, using a maximum of 15 to 20 mL of foam. Successful therapy of relatively large axial (great, small, or accessory saphenous) veins by this technique has been reported. This can be a helpful adjunctive technique when very tortuous segments not amenable to catheter passage are encountered when using laser or radiofrequency techniques for saphenous vein closure.

Postoperative Care

The injection sites are covered with folded 2 × 2 gauze and a compressive wrap or stocking to provide moderate compression. The patient is briefly observed to detect any allergic or anaphylactic reaction. Compression is recommended following sclerotherapy to reduce the risk of deep vein thrombosis and to optimize cosmetic results. The duration and method are widely variable among providers, but are typically 2 to 3 days for telangiectasias and small reticular veins and up to 7 days for extensive reticular veins or larger varicosities using 20–30 mm Hg stockings or an elastic wrap.

Complications and Their Management

It is typical for patients to notice some increase in discoloration in the first few days postprocedure. When this is associated tenderness, local firmness, and dark pigmentation in the region of a small thrombosed vein, recovery may be enhanced by local microthrombectomy, typically using an 18-gauge needle and gentle pressure to express retained clot. Phlebitis may otherwise be relieved by traditional methods of warm compresses, gentle compression, and the use of NSAIDs. Where it is associated with partial vein thrombosis, additional treatment to induce complete vein closure is helpful. Some degree of brown hyperpigmentation may affect up to 20% to 30% of patients treated with Sotradecol and a somewhat smaller proportion of those treated with polidocanol. This is associated with the use of higher concentration solutions and more extensive treatment. This hyperpigmentation will tend to fade on its own over the course of several months, though some patients will elect cutaneous laser treatment to accelerate this process. Neovascularization or telangiectatic matting describes the development of new, fine networks of red capillaries that can appear like a bruise in the area of treatment. Again, this tends to resolve over a matter of months postprocedure, but further sclerotherapy should be carefully considered in a patient prone to this complication. Nd:YAG laser or Intense Pulsed Light (IPL) treatment can be effective in treating persistent matting and may be an alternative for the management of remaining telangiectasias in a patient prone to matting postinjection.

Significant complications may also be associated with inadvertent extravascular or intra-arterial injection of sclerosant, which may, in the former case lead to focal skin necrosis and in the latter to more extensive and severe tissue loss. Small volume extravasation is generally well tolerated with the detergent agents.

It must be noted that while commonly practiced, the creation and

injection of microfoam is an off-label use of the detergent agents and that stroke in the setting of foam injection in a patient with patent foramen ovale and associated shunting has been reported. Less marked symptoms such as headache and transient visual symptoms have also been described. The use of carbon dioxide as a mixing agent may reduce the risk of these complications.

TREATMENT FOR DEEP VENOUS INSUFFICIENCY

While the majority of the treatment of venous insufficiency focuses on management of the superficial veins, there are several surgical methods that continue to find application in the repair or replacement of dysfunctional valves of the deep venous system.

Indications and Contraindications

Valve reconstruction by replacement or repair is indicated when severe symptoms (CEAP 4b to 6) are unrelieved by compression and treatment of superficial insufficiency or where deep insufficiency occurs in isolation. Results are compromised by the presence of extensive postphlebitic changes with scarring or occlusion in the distal vein segment.

Preoperative Planning

A thorough evaluation by duplex ultrasonography should demonstrate the location and function of the lower extremity valves, the anatomy of the incompetent segments and relationship varicosities, skin changes, or ulcers present on examination. The presence of any concomitant occlusive disease must also be documented. Reconstruction is focused on the most proximal dysfunctional segment. The structure and function of these valves must be carefully assessed. Primary valve dysfunction is less likely to be associated with thickened, damaged leaflets than postphlebitic dysfunction. A handful of surgeons have developed successful techniques of open/internal or “closed”/external repair of valves with preserved leaflet structure to bring the leaflets back into appropriate apposition and restore function. These valves may also be replaced through valve transplantation, most commonly using a segment of axillary vein that has been similarly assessed ultrasonographically and found to have healthy, functioning valves. Finally, in vein relocation/transposition, a functioning valve is present within a collateral system, such as a competent SFJ and proximal

greater saphenous vein in the presence of severe femoral vein reflux, and the incompetent vein can be transposed below the competent valves of the collateral system.

Surgical Technique (With Figures)

Open Valve Repair

The femoral vein is exposed and duplex ultrasound used to locate the most proximal incompetent valve. The vein is controlled proximally and distally with atraumatic clamps and a “T”-shaped venotomy performed at the level of the valve to permit exposure of the cusps without excessive distortion of the valve’s structure. Interrupted 7-0 or 8-0 Prolene sutures are placed from the corners of the valve cusps to improve apposition. Great care must be taken in handling the cusps both during repair and in assessment of apposition to avoid injury to these delicate structures. The venotomy is then closed in a running fashion after purging of air and the function of the repaired valve is assessed using duplex ultrasound and provocative maneuvers.

Closed Valve Repair

A similar repair may, in skilled hands, be effected by location of the valve using ultrasound and placement of commissural sutures transmurally through the external vein wall. These sutures are then retracted and their effect assessed using duplex ultrasound and provocative compression of the distal vein to induce reflux. If the suture improves apposition and function, it is carefully tied externally. The ability to assess valve function and cusp orientation in situ avoids the need, in open repair, of visually assessing the valve in its exposed state and delaying full function assessment until closure of the venotomy. The use of angioscopy, though not widely available, has been described as a helpful adjunct to aid in the placement and assessment of these external sutures, particularly early in the surgeon’s experience with this technique.

Both valve repair techniques may be accompanied by placement of a reinforcing external cuff to prevent subsequent dilation and recurrent failure of cusp apposition.

Valve Transplantation

The arm is abducted and an incision made along the course of the axillobrachial vein in the superior axilla. At this level, collateral pathways

provide adequate venous drainage to avoid significant postharvest swelling of the upper extremity. The donor segment of the axillary vein is resected after careful ultrasound confirmation of valve location and ligation and division of tributaries. The donor segment is inserted as an interposition graft in the proximal femoral vein. Valve function is assessed by duplex ultrasound and additional suture modification of the valve or external cuff reinforcement performed at the surgeon's discretion.

Valve Transposition

An incompetent tributary may be transposed below a competent valve within a collateral vessel in either and end-to-side or, less frequently, end-to-end configuration. Care must be taken to avoid kinking that would compromise either patency or valve function. The end-to-side configuration permits outflow from both veins, greater latitude with regard to the "lie" of the veins, and addresses size mismatches between transposed and outflow veins.

Complications and Management

The postoperative course of valve reconstruction is marked by a close balancing of the prothrombotic milieu of the vein and the potential for bleeding complications associated with the necessary perioperative course of anticoagulation, which is typically initiated immediately and extended from 8 to 12 weeks postprocedure.

OUTCOMES

In recent years, the latest generation endovenous ablation techniques using either laser or radiofrequency technology have yielded results equivalent to gold-standard high ligation and saphenectomy with a favorable complication profile. Deep venous reconstruction, in the hands of the relatively few, experienced operators reporting in the literature can also benefit the selected group of patients suffering severe complications of deep venous insufficiency using valvuloplasty, autogenous vein valve transplantation, and transposition techniques. Reconstruction using artificial, tissue-engineered, or cryopreserved vein valves has not, to date, yielded comparable results. Assessment of outcomes will increasingly incorporate quality of life and other patient-reported outcomes in addition to traditional clinical endpoints.

Suggested Readings

Cavezzi A, Tessari L. Foam sclerotherapy techniques: different gases and methods of preparation, catheter vs. direct injection. *Phlebology* 2009;24:247–51.

Criqui MH, Jamosmos M, Fronek A, et al. Chronic venous disease in an ethnically diverse population. The San Diego Population Study. *Am J Epidemiol* 2003;158(5):448–56.

Dalsing MC. Chronic venous insufficiency: deep vein valve reconstruction. In: Cronenwett JJ, Johnston KW, eds. *Rutherford's Vascular Surgery*. 7th ed. Philadelphia, PA: Saunders/Elsevier; 2010:903–17.

Gloviczki P, Comerota AJ, Dalsing MC, et al. The care of patients with varicose veins and associated chronic venous disease: clinical practice guidelines of the society for vascular surgery. *J Vasc Surg* 2011;53(5 Suppl):2S–48S.

Kerver AL, van der Ham AC, Theeuwes HP, et al. The surgical anatomy of the small saphenous vein and adjacent nerves in relation to endovenous thermal ablation. *J Vasc Surg* 2012;56(1):181–8.

Kistner RL, Eklof B, Masuda EM. Deep venous valve reconstruction. *Cardiovascular surgery* 1995;3(2):129–40.

Maleti O, Perrin M. Reconstructive surgery for deep vein reflux in the lower limbs: techniques, results, and indications. *Eur J Vasc Endovasc Surg* 2011;41(6):837–48.

Raju S, Hardy JD. Technical options in venous valve reconstruction. *Am J Surg* 1997;173(4):301–7.

Schweighofer G, Muhlberger D, Brenner E. The anatomy of the small saphenous vein: fascial and neural relations, saphenofemoral junction, and valves. *J Vasc Surg* 2010;51(4):982–9.

EDITOR'S COMMENT

Superficial venous insufficiency is, as Dr. Tracci states, the most prevalent vascular disorder in humans. This primarily encompasses varicose veins and related superficial venous reflux. The venous reflux is a major contributor to hydrostatic hypertension, of which the limb complications are swelling, pain, pruritus, and occasionally ulcers. While rarely limb- or life-threatening, it is a source of significant disability, particularly in the severe stages (Gloviczki P. The changing face of care for venous disease. *J Vasc Surg* 2011;53:1S). This nicely organized chapter highlights the primary etiologies, pathophysiology, and treatments for this disease.

Several important points bear discussion. First, there has been a rapid explosion of new techniques and devices to treat superficial venous insufficiency. In fact, the number of procedures that are related to superficial

venous disease treatment has exploded by approximately 4,000%, as cited by Dr. Lawrence in his Society for Vascular Surgery Presidential talk (Lawrence PF. “Better” (sometimes) in vascular disease management. *J Vasc Surg* 2016;63:260–9). This reflects not only improved physician recognition, but new devices, industry involvement, and more physicians treating these patients. Selection and appropriate indications for treating patients with superficial venous disease is paramount, and nicely highlighted by the author.

Second, it is important to use a consistent venous insufficiency classification system as highlighted. The clinical etiologic anatomic pathophysiology (CEAP) classification system is very useful, and widely accepted. The most common class of disease for patients with superficial venous insufficiency is usually C2 to C3. This is primarily leg heaviness, fullness, and occasional pain with the varicosities. The higher the category, such as C4B, C5, and C6, the more disabling it is due to chronic wounds, rash, swelling, and inability to ambulate as one desires.

Third, a major controversy is the recommendation or stipulation from health payers that compression therapy should be instituted for at least 3 to 6 months prior to any invasive therapy. However, the REACTIV trial has shown that this is of no benefit and proceeding with an invasive procedure for properly selected patients who are symptomatic and otherwise is warranted (Michaels JA, Brazier JE, Campbell WB, et al. Randomized clinical trial comparing surgery with conservative treatment for uncomplicated varicose veins. *Br J Surg* 2006;93:175–81). There are many options to treat superficial venous insufficiency, including foam sclerotherapy (now FDA approved, called Verathina), as well as surgical striping (much out of favor), and endoluminal venous ablation whether by radio frequency or laser catheters, glue, or other nonheat-related devices (Gloviczki P. The changing face of care for venous disease. *J Vasc Surg* 2011;53:1S). These procedures are often done in the office, and in part related to reimbursement from professional and facility fees, is the reason these procedural numbers have increased. Despite this, the outpatient setting seems most appropriate and is likely less costly than performing these procedures in the hospital setting. Interestingly, a randomized controlled trial showed most major techniques were nearly equivalent in outcomes, including quality-of-life measures (Brittenden J, Cotton SC, Elders A, et al. A randomized trial comparing treatments for varicose veins. *N Engl J Med* 2014;371:1218–27).

Fourth, endovascular heat-induced deep vein thrombosis, unique to these new endoluminal techniques are caused by endothermal heat-induced vein injury, occurring at the saphenous femoral junction after ablation. E-Hits are the primary complication outside of nerve and wound complications, and sometimes mandate limited treatment anticoagulation if protruding into the common femoral vein. A classification system of types is well described but whether routine postprocedure duplex should be performed is questionable (Suarez L, Tangney E, O’Donnell TF, et al. Cost analysis and implications of

routine deep venous thrombosis duplex ultrasound scanning after endovenous ablation. *J Vasc Surg Venous Lymphat Disord* 2017;5:126–33). Very rarely are these to a true DVT as the pathophysiology is different. Nonetheless, we recommend all patients should be stratified preoperatively by the Caprini venous thromboembolism risk scoring system to determine the risk for DVT. Some patients may benefit from unfractionated heparin periprocedurally.

Lastly, the procedural sequence of whether stab phlebectomy should be performed at the same time as endovenous ablation, or should be done in a staged setting is up in the air. However, most surgeons opt to do these procedures at the same time as many patients return with continued symptoms. Further research is needed in all aspects of superficial venous disease treatments.

Peter Henke

H DIALYSIS ACCESS

226 Autogenous Arteriovenous Hemodialysis Access

Robert J. Feezor and Thomas S. Huber

INTRODUCTION

End-stage renal disease (ESRD), and the maintenance of hemodialysis access, is a tremendous public health problem that has reached near epidemic proportions in the United States. In 2013, there were 661,648 prevalent (prevalence—patient count at a single point in time) and 117,162 incident (incidence—new patients over a time interval) ESRD patients. Although the number of incident cases has remained relatively stable since 2010, the number of prevalent cases has increased approximately 20,000 per year. It has been estimated that the prevalent and incident patient counts will be 784,613 and 150,772 respectively by 2020. The majority of patients with ESRD are on hemodialysis (hemodialysis, 64%; transplant, 29%; peritoneal dialysis, 7%). There was a record 18,000 kidney transplants performed in 2006, largely due to an increase in the number of deceased donors, but the annual volume has been somewhat stable since then with 17,600 kidney transplants being performed in 2013. Unfortunately, the number of patients on the transplant list has continued to increase and has outstripped the number of available organs. For candidates listed or relisted for renal transplantation in 2009, the median waiting time was 3.9 years. The Medicare costs associated with ESRD are staggering. Although ESRD patients account for <1% of the general Medicare population, dialysis-related expenditures accounted for 7% ($30.9 billion) of the general Medicare costs in 2013. The Medicare expenditure per ESRD patient per year is greatest for patients on hemodialysis (hemodialysis, $84,550; peritoneal, $69,919; transplant, $29,920). Not surprisingly, maintaining hemodialysis access is a significant burden for most health care providers. This is compounded by

the limited functional patency rates for the various access options and, almost paradoxically, the improved patient survival.

The National Kidney Foundation Dialysis Outcome Quality Initiative (KDOQI) has emphasized the importance of autogenous access, commonly referred to as an arteriovenous fistula or simply a fistula. Their "preferred" access choices include the radiocephalic, brachiocephalic, and brachiobasilic autogenous access, although they concede that prosthetic or biologic accesses are acceptable. It is interesting to note that there has been an evolution in the guidelines with a change in the emphasis from an "autogenous" to a "functional" access (i.e., both autogenous and prosthetic access acceptable). Not surprisingly, they recommend that long-term dialysis catheters should be avoided. The guidelines have a set an autogenous access target rate of >65% with a catheter rate of <10%. The Center for Medicare and Medicaid Services' (CMS) National Vascular Access Improvement Initiative or "Fistula First Breakthrough Initiative" was implemented to attain the initial KDOQI targets or specifically to "increase the proportion of hemodialysis patients who use arteriovenous fistulas as the primary mode of vascular access." This multidisciplinary approach was defined by 11 original concepts designed to impact practice patterns (Table 226.1). Notably, a significant proportion of the "Fistula First" effort was targeted at access surgeons. The "Fistula First" effort was largely successful as reflected by the prevalence of autogenous access across the country relative to the 2003 baseline year (Fig. 226.1). Despite these national initiatives, the prevalence of autogenous accesses in the United States remains well below the 80% rate reported from Europe (France, Germany, Italy, United Kingdom, Spain).

The KDOQI recommendations for autogenous accesses are based partly upon the presumption that the patency rates for autogenous access are superior to their prosthetic counterparts. However, the data in the KDOQI cited to justify the superiority of autogenous accesses were limited by Evidence-Based Medicine Standards and included retrospective case series and expert opinion. Murad et al. performed a systematic review and meta-analysis to compare autogenous and prosthetic hemodialysis access as part of the Society for Vascular Surgery Clinical Practice Guidelines and concluded that the autogenous accesses had better patency rates at both 12 and 36 months. However, they stated that these conclusions were based upon "low-quality evidence from inconsistent studies with limited protection against bias." Our group published a formal systematic review

of the literature comparing the patency rates of upper extremity polytetrafluoroethylene (PTFE) and autogenous accesses in adults. Studies were considered acceptable for inclusion if patency was reported using either the life table or Kaplan-Meier methods and included the number of patients at risk. Unfortunately, there were only 34 studies at that time that satisfied the inclusion criteria with the majority composed of cases series or nonrandomized controlled studies with the data collected in a retrospective fashion. The primary annual patency rates for the autogenous and PTFE accesses were approximately 60% and 40% respectively, while the corresponding secondary patency rates were 80% and 60% (Fig. 226.2). Al-Jaishi et al. reported comparable results in a more recent systematic review of autogenous access with primary and secondary patency rates at 1 year of 60% and 71%, respectively. Notably, these secondary patency rates are significantly lower than the outcome targets defined by KDOQI (autogenous access—thrombosis rate 0.25 episodes/patient year at risk, patency rate >3 years; prosthetic access—thrombosis rate 0.5 episodes/patient year at risk, patency rate >2 years).

TABLE 226.1 Fistula First Breakthrough Initiative Practice Recommendations

1. Routine quality review for vascular access
2. Timely referral to a nephrologist
3. Early referral to a surgeon for "AVF" (AVF—autogenous arteriovenous hemodialysis access) evaluation and timely placement
4. Surgeon selection based on best outcomes, willingness, and ability to provide access services
5. Full range of appropriate surgical approaches for AVF evaluation and placement
6. Secondary AVF placement in patients with AV grafts (AV grafts—prosthetic arteriovenous hemodialysis access)
7. AVF placement in patients with catheters when indicated
8. Cannulation training for AVFs
9. Monitoring and maintenance to ensure adequate access function
10. Education for care givers and patients
11. Outcome feedback to guide practice

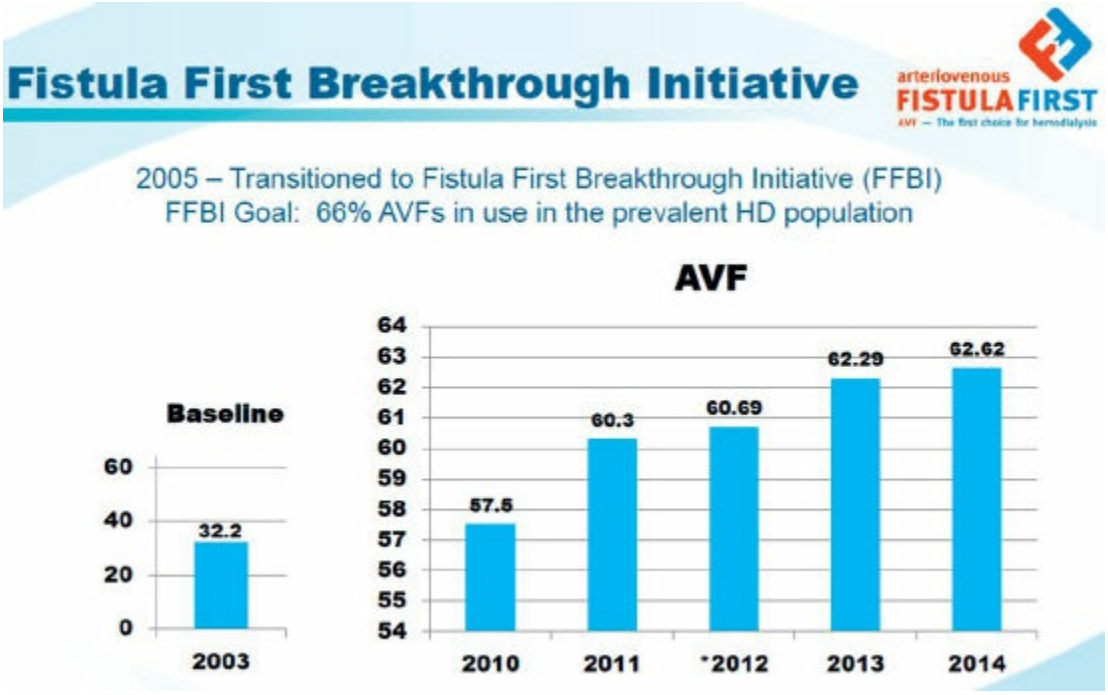

Figure 226.1. The percentage (%) of AVFs (arteriovenous fistulas) or autogenous hemodialysis accesses is shown across the United States from 2010 to 2014 relative to the baseline year in 2003. Note the dramatic improvement in the overall autogenous utilization rate that approaches the KDOQI (65%) and Fistula First (66%) goals. (With permission from the End Stage Renal Disease National Coordinating Center (ESRD NCC).)

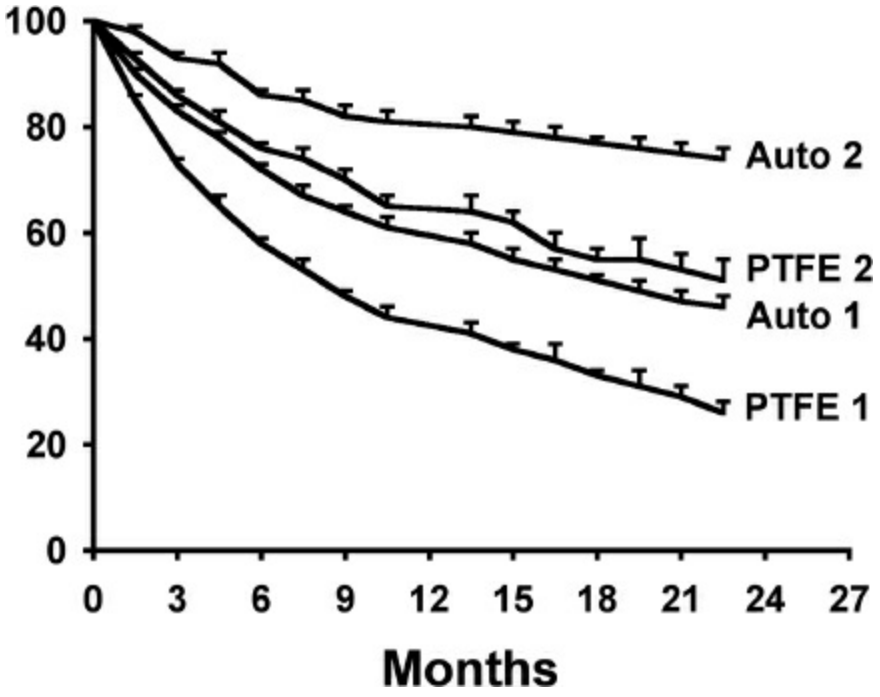

Figure 226.2. The patency rates (percent patent) for the

autogenous (**Auto**) and PTFE (**PTFE**) upper extremity hemodialysis accesses are plotted against time (months) with the positive standard error bars. Both the primary (**Auto 1, PTFE 1**) and secondary (**Auto 2, PTFE 2**) patency rates for the two access types are shown. The patency rates for the autogenous accesses were better than their corresponding PTFE counterparts with the one exception of the initial (1.5 mos) time point for the primary patency comparison. (From Huber TS, et al. Patency of autogenous and PTFE upper extremity arteriovenous hemodialysis accesses: a systematic review. *J Vasc Surg* 2003;38:1005–11.)

The KDOQI also justified the use of autogenous accesses based upon their lower complication rates. Notably, Murad et al. reported that autogenous accesses were associated with a lower infectious risk in their systematic review, although there was no difference in the other complication rates. We were unable to determine accurate complication rates in our systematic review of the literature either because the complications were not described in the individual studies, the descriptions were not standardized, or the means of reporting were not amenable to meta-analysis. However, the results from the individual studies suggest that the perioperative mortality rate was essentially 0 (median—0, range 0% to 1%), while the incidence of hand ischemia (median—2%, range 0% to 14%), access infection (median—7%, range 0% to 30%), and aneurysm/pseudoaneurysm formation (median—4%, range 0% to 6%) was low for both autogenous and PTFE accesses. Not surprisingly, the overwhelming majority of the access infections were seen in the PTFE accesses. Ravani et al. performed a more recent systematic review of the literature to look at the association between complications and access type. Not surprisingly, they concluded that tunneled dialysis catheters were associated with the highest risk of death, infections, and cardiovascular events, while autogenous accesses were associated with the lowest risk.

The annual mortality rate associated with dialysis catheters and prosthetic accesses has been consistently shown to exceed those for autogenous accesses. Notably, Dhingra et al. reported from the United States Renal Data System that the relative mortality risk (reference group autogenous accesses) was 1.41 and 1.54 for diabetic patients dialyzed with prosthetic accesses and catheters respectively while the corresponding values were 1.08 and 1.70 respectively among nondiabetics. Indeed, the annual unadjusted mortality rate for all hemodialysis patients across the

United States was a staggering 21.7% in the Dialysis Outcomes and Practice Patterns Study (DOPPS) and was significantly greater than those reported from Europe (15.6%) and Japan (6.6%). Although the mean patient age and the burden of comorbidities were greater in the United States, the adjusted relative risk of mortality was 1.33 greater in the United States relative to Europe and 3.78 relative to Japan. It is likely that the discrepancy in the prevalence of the autogenous accesses between the three continents contributed.

There are a few distinct disadvantages to autogenous accesses. The obligatory period to allow the autogenous access to mature usually exceeds the corresponding “maturation” time for prosthetic access. Notably, prosthetic accesses have traditionally not been cannulated for 3 to 6 weeks after creation to allow incorporation of the graft into the surrounding tissue. However, there are several newer prosthetic grafts that allow immediate cannulation. Rayner et al. reported from the DOPPS that the median duration from autogenous access creation to cannulation in the United States was 98 days. This obligatory period usually requires the use of dialysis catheters as a “bridge” and subjects the patients to all the potential catheter-related complications. Admittedly, the use of dialysis catheters in this setting may be reduced by early patient referral to an access surgeon prior to the initiation of dialysis although this has not been particularly successful across the country. Furthermore, a significant proportion of the autogenous accesses fail to mature sufficient for cannulation. Dember et al. reported from the Dialysis Access Consortium, a multicenter randomized trial evaluating the role of clopidogrel on access maturation, that the failure to mature rate for autogenous accesses was >60%. Lok et al. developed a scoring system to predict maturation and found that age, race, peripheral arterial occlusive disease, and coronary artery occlusive disease were all associated with failure. Using their system, the predicted “failure to mature” rate for an autogenous access in a 70-year-old African American with both coronary artery and peripheral vascular disease was approximately 70%. Lastly, approximately 25% of the initial autogenous accesses need some type of remedial imaging or procedure to facilitate maturation, potentially further prolonging the obligatory catheter time for patients already on dialysis.

Despite these limitations, it is generally well accepted that a “mature” autogenous access is the optimal choice for permanent hemodialysis access as recommended by the national initiatives. We have attempted to

optimize the use of autogenous access in our own practice, but would concede that an autogenous access is not possible and/or appropriate for all clinical settings and believe that the ultimate goal should be a “functional” permanent access as emphasized by the evolution in the national guidelines. We currently construct prosthetic accesses for patients without autogenous options on the preoperative imaging, those with limited life expectancy, and those with marginal autogenous access options in which previous autogenous access attempts have not matured sufficiently for cannulation. These indications are consistent with the thoughtful review about the role of prosthetic access in the Fistula First era.

DETERMINATION OF AUTOGENOUS ACCESS CONFIGURATION

General Principles (Fig. 226.3)

The overwhelming majority of patients presenting for permanent access are candidates for an autogenous access. Our approach, designed to optimize the use of autogenous upper extremity accesses, is predicated upon the standard principles of vascular surgery, including adequate arterial inflow, adequate venous outflow, and a suitable conduit. Furthermore, it is based upon the use of dialysis catheters as a “bridge” or temporary access until the permanent access is suitable for cannulation and an aggressive approach to “failing” or “nonmatured” accesses. Despite our use of the catheters as a “bridge,” we have made every attempt to limit the use of these catheters, in accordance with the national guidelines, because of their limited patency, infectious complications, and potential to cause central vein stenoses and/or occlusions.

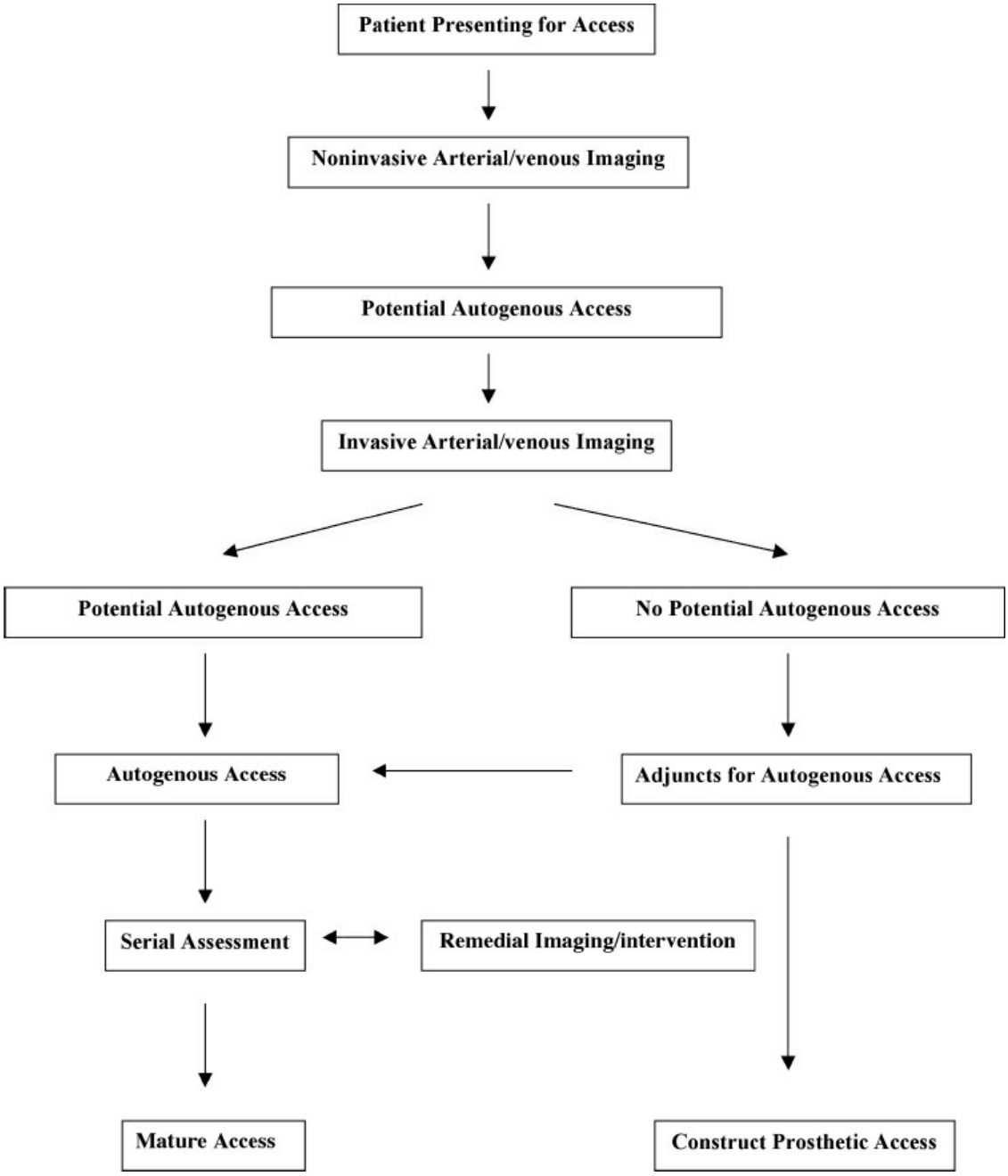

Figure 226.3. The algorithm for patients presenting for permanent hemodialysis access is shown. The individual steps are outlined within the text. Patients who fall into the group **No Potential Autogenous Access** due to peripheral veins that are insufficient diameter (<3 mm) are either reimaged in the operating room after induction of anesthesia and the resultant vasodilation or the veins are dissected and explored directly. **Adjuncts for Autogenous Access** include endovascular treatment of arterial inflow/venous outflow lesions and composite access configuration with saphenous vein. (Reprinted from Huber TS, Ozaki CK, Flynn TC, et al. Prospective validation of an algorithm to maximize arteriovenous fistulae for chronic

hemodialysis access, *J Vasc Surg* 2002;36(3):452–9. Copyright © 2002 The Society for Vascular Surgery and The American Association for Vascular Surgery, with permission.)

History/Physical Examination

The initial evaluation of patents presenting for permanent hemodialysis access includes a focused history and physical examination. Special attention should be directed at documenting the access history, including procedures, revisions, and associated complications. This should include any history of central vein cannulation, arm edema, and hand ischemia. Physical examination should include a detailed pulse examination with an Allen test to determine the forearm vessel responsible for the dominant arterial supply to the hand and examination of the neck and chest to look for venous collaterals.

Noninvasive Imaging

Noninvasive testing in the diagnostic vascular laboratory is the cornerstone of our algorithm. The examinations involve interrogation of both the arterial and venous circulation. The arterial studies include blood pressure measurements of the brachial, radial, ulnar, and digital arteries along with the corresponding Doppler waveforms of all but the digital vessels (Fig. 226.4). Additionally, the Allen test is repeated and the diameters of both the radial (wrist) and brachial (antecubital fossa) arteries are measured. Venous imaging includes the interrogation of the cephalic and basilic veins from the wrist to the axilla to assess their patency, quality (e.g., evidence of prior thrombosis), and size (i.e., diameter), similar to the preoperative vein survey obtained prior to infrainguinal arterial revascularization (Fig. 226.5). Additionally, the upper extremity and central veins are examined for the presence of deep venous thrombosis, although the interrogation of the veins within the thoracic cavity is somewhat limited due to the bony structures.

Potential Autogenous Access Configuration

A preliminary operative plan is then generated based upon the results of the history/physical and noninvasive imaging. Our objective has been to select the combination of artery and vein that would most likely result in a successful autogenous access. We have not felt constrained by the usual conventions of using the nondominant more than dominant extremity and

the forearm more than arm, although we have followed these standard approaches when the choices are equivocal. The criteria for an adequate artery and vein include no hemodynamically significant arterial inflow stenoses, no venous outflow stenoses, and a peripheral vein segment of suitable length and diameter (Table 226.2). Our preferences in descending order include the radiocephalic, radiobasilic, brachiocephalic, and brachiobasilic autogenous accesses prior to use of prosthetic material (Table 226.3). Notably, these preferences are consistent with the current KDOQI guidelines. We have had particularly good results with the autogenous brachiobasilic configuration. Indeed, the basilic vein is an excellent conduit for an autogenous access since it is usually relatively thick-walled, large in diameter, and well preserved in terms of cannulation for venipunctures and intravenous catheters due to its relatively deep course.

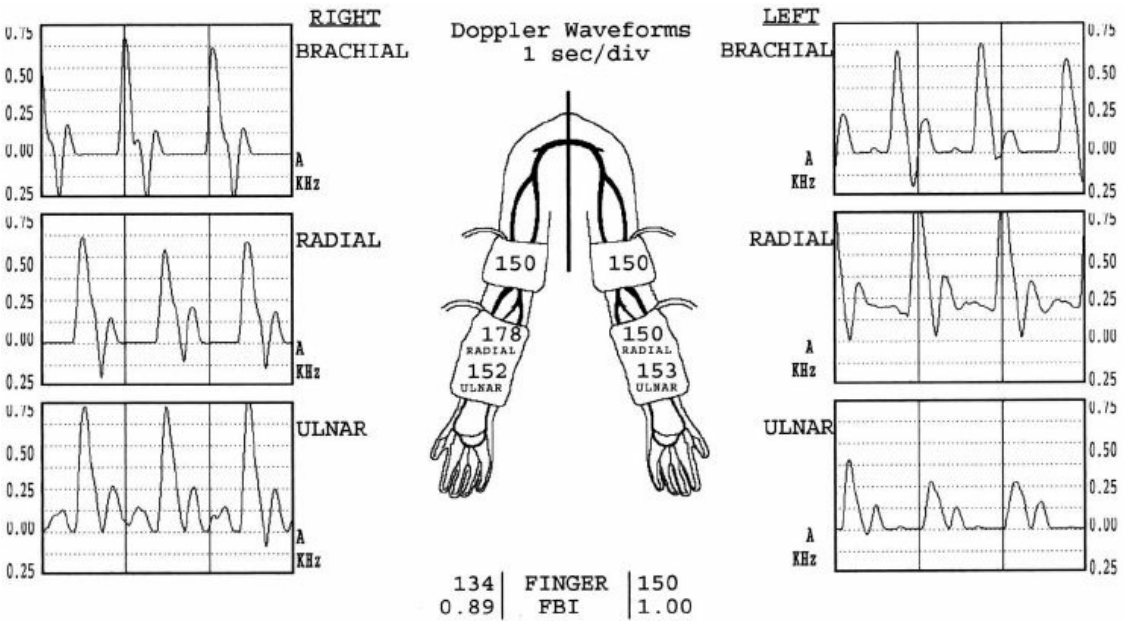

Figure 226.4. Part of the preoperative noninvasive arterial imaging studies is shown. The brachial, radial, and ulnar arterial pressures (mm Hg) are shown on the diagram of the upper extremities, while the finger pressures are shown in the center of the figure at the bottom. The corresponding Doppler waveforms (sec/div) are shown for the brachial, radial, and ulnar arteries. The FBI denotes the finger/brachial index and is the ratio of the finger pressure to the ipsilateral brachial artery pressure. Note the symmetric brachial artery pressures and the corresponding normal appearing triphasic velocity waveforms. (From Huber TS, Seeger JM. Approach to patients with “complex” hemodialysis access problems. *Semin Dial* 2003;16(1):22–9. Copyright © 2003

by John Wiley & Sons, Inc. Reprinted by permission of John Wiley & Sons, Inc.)

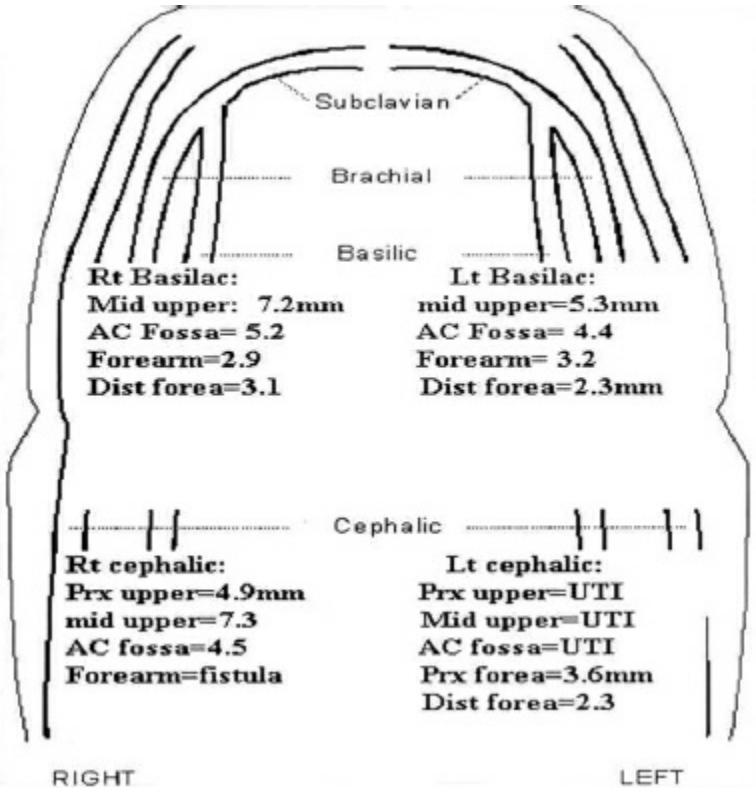

Figure 226.5. Part of the preoperative noninvasive venous imaging studies is shown. The diameters (mm) of both the basilic and cephalic veins are shown on the diagram of the upper extremities. The diameters are reported for the corresponding anatomic segment (prx upper—proximal upper arm, mid upper—mid upper arm, ac fossa—antecubital fossa, dista forea—distal forearm). Note that the basilic vein segments in both upper arms and the cephalic vein in the right upper arm are suitable for arteriovenous fistula using the diameter criteria (≥3 mm). The cephalic vein in the left upper arm was unable to be imaged (UTI). Additionally, the patient has a patent fistula in the right forearm that was not imaged. (From Huber TS, Seeger, JM. Approach to patients with complex hemodialysis access problems. *Semin Dial* 2003;16:22–9; with permission of John Wiley and Sons.)

TABLE 226.2 Criteria to Determine Suitability of Artery and Vein for Autogenous Access

Vein
Diameter >3 mm without evidence of significant stenosis
Suitable segment from wrist to antecubital fossa (forearm access) or antecubital fossa to axilla (upper arm access)
Absence of significant central vein stenosis in the ipsilateral extremity
Artery
Diameter 2 mm
Absence of hemodynamically significant inflow stenosis[a]
Nondominant radial artery for wrist access

[a]≥15 mm Hg pressure gradient between the brachial arteries for proposed arm accesses or between the ipsilateral brachial and radial arteries for proposed forearm accesses.
From Huber TS, Ozaki CK, Flynn TC, et al. Prospective validation of an algorithm to maximize arteriovenous fistulae for chronic hemodialysis access. *J Vasc Surg* 2002;36:452–9.

TABLE 226.3 Hierarchy for Permanent Hemodialysis Accesses Configurations

Autogenous radiocephalic
Autogenous radiobasilic
Autogenous brachiocephalic
Autogenous brachiobasilic
Forearm prosthetic brachiocephalic/ brachiobasilic/brachiobrachial (deep brachial vein)
Arm prosthetic brachiocephalic/ brachiobasilic/brachioaxillary (axillary fossa)

From Huber TS, Seeger JM. Approach to patients with complex permanent hemodialysis access problems. In: Zelenock GB, Huber TS, Lumsden A, et al., eds. *Mastery of Vascular and Endovascular Surgery*. Philadelphia, PA: Lippincott Williams & Wilkins; 2006.

Additional Imaging

Contrast arteriography and venography can be used to confirm the preliminary access choice. Although we have previously used these modalities more routinely, we now reserve them for select indications. The potential indications for arteriography (i.e., catheter-based or computed tomography [CT] arteriography) include the presence of peripheral arterial occlusive disease, diabetes mellitus, complex access procedures, multiple failed access procedures, abnormal noninvasive studies, and prior episodes of access-related hand ischemia. The potential indications for venography (i.e., catheter-based or CT venography) include arm edema, multiple venous collaterals, pacemakers, multiple central venous catheters, multiple prior access procedures, and complex reconstructions. A catheter-based venogram can be performed simply by cannulating a superficial vein in the forearm with a 20-gauge intravenous catheter and injecting a bolus of 20 mL of contrast followed by an equal volume of saline. Hemodynamically significant stenoses are suggested by the presence of collaterals. Although the catheter-based venogram has not been particularly helpful as a means to interrogate the more superficial basilic and cephalic veins, we have found it to be more reliable than CT venography in determining central vein stenoses or occlusions. An ipsilateral catheter-based arteriogram can be performed, as necessary, if no central vein problems are identified. The

arteriogram is typically performed using a retrograde femoral approach with complete visualization of the arterial tree from the aortic arch to the digits. This requires a flush catheter arteriogram of the thoracic aortic arch followed by selective cannulation of the extremity and contrast arteriography with the arm abducted at 90 degrees relative to the torso. If a significant central vein problem is identified, a venogram on the contralateral extremity is performed before proceeding with the arteriogram. Endovascular treatment, either angioplasty alone or in combination with an intraluminal stent, may be performed at the same time of the invasive imaging studies or at the time of the access procedure itself. However, the decision to proceed with intervention is contingent upon the clinical scenario and the other potential access options identified by the noninvasive testing. Iodinated contrast is nephrotoxic and relatively contraindicated in patients with chronic kidney disease (i.e., those patients not on dialysis). The contrast-associated nephrotoxicity may be reduced with a combination of hydration, acetylcysteine, and sodium bicarbonate. Unfortunately, the alternative contrast agent gadolinium is absolutely contraindicated for patients with chronic kidney disease and ESRD because of the risk of nephrogenic systemic fibrosis. Similarly, the use of carbon dioxide in the upper extremity is also contraindicated because of the potential to enter the cerebral circulation. In the event that the invasive imaging does not support the initial access configuration, a second choice is made based upon the same principles (i.e., artery/vein requirements, imaging studies, hierarchy of procedures, conventions).

Urgent Need for Dialysis

Catheters are used for patients needing urgent dialysis. Indeed, these “temporary” catheters afford the luxury of time to allow the autogenous accesses to mature. The complications associated with these catheters are well known, and every attempt is made to minimize their use. Ideally, patients should have their access procedures well in advance of their anticipated dialysis start date. However, <20% of patients in the United States actually start dialysis with a permanent access (i.e., autogenous or prosthetic access).

Validation of the Algorithm

During the prospective validation of our algorithm, we were able to construct a successful autogenous upper extremity access in 70% of the

patients referred for permanent access. Notably, 83% of the 139 consecutive patients were candidates for an autogenous upper extremity access using the criteria defined above with a mean of 2.7 ± 2.1 possible configurations per patient. Among the subset of patients who had previously undergone a permanent hemodialysis procedure, 75% were candidates for an upper extremity autogenous access with a mean of 2.1 ± 2.0 possible configurations. The invasive imaging demonstrated some type of abnormal finding in approximately 40% of the cases, and these findings impacted the operative plan generated by the noninvasive studies alone almost 20% of the time. The accesses were suitable for cannulation in a mean of 3 months, although almost 25% of the patients required some type of remedial procedure to facilitation maturation. Although it has been a few years since our original publication, our approach has remained essentially the same with the noted exception that the invasive imaging is used selectively.

PREOPERATIVE EVALUATION

Patients with ESRD usually have multiple comorbidities and represent a significant operative risk. Although the access procedures are relatively minor compared to most general and vascular operations and not associated with significant bleeding or fluid shifts, our perioperative mortality over the past few years (encompassing >2,000 procedures) has been approximately 3% and the annual mortality rate for all ESRD patients in the United States is approximately 22% as noted above. In light of these concerns, the preoperative evaluation should be essentially the same as that for any major vascular surgical procedure. It is important to coordinate the hemodialysis schedule with the operative procedure. We prefer to operate on nondialysis days for both medical and logistical reasons. Patients are usually tired and volume contracted immediately after dialysis. Furthermore, dialyzing patients immediately postoperatively may increase the incidence of wound hematomas. The superficial arm veins selected for the planned access may be marked on the skin in the noninvasive vascular laboratory during the preoperative evaluation in an effort to minimize the tissue trauma associated with the exploration of the vein. Alternatively, the vein can be marked by the surgeon immediately before the start of the case using ultrasound as detailed below.

OPERATIVE TECHNIQUE

General

Regional anesthesia is used preferentially for the forearm, brachiocephalic, and first-stage brachiobasilic autogenous accesses, while general anesthesia is used for the transposed brachiobasilic autogenous accesses (both the single- and second-stage procedures). Patients with peripheral veins that are deemed too small (<3 mm) for autogenous accesses by the preoperative noninvasive imaging are reimaged preoperatively in the vascular laboratory or intraoperatively after induction of anesthesia using ultrasound. We have been impressed with the variability in the vein diameter measurements during serial imaging performed on different days and have attributed it to the volume changes associated with hemodialysis. The general and regional anesthetic agents seem to act as vasodilators, occasionally leading to the identification of a suitable peripheral vein that was deemed too small based upon the initial noninvasive imaging. Alternatively, the veins can be dissected and examined directly. The upper extremity from the wrist to the axilla is included in the operative field and positioned on a hand table attached to the standard operating room table.

Autogenous Radiocephalic Access (Fig. 226.6A,B)

The autogenous radiocephalic access is constructed using a 3-cm longitudinal incision in the distal forearm midway between the radial artery and the cephalic vein. Alternatively, the artery and vein can be exposed using an incision in the anatomic snuffbox, although the caliber of the vessels is somewhat smaller in this location. A small skin flap is elevated and the cephalic vein dissected free from the surrounding tissue. Two small spring retractors can be oriented diagonally across the wound to facilitate exposure. The vein should be dissected beyond the distal extent of the incision to assure a sufficient length (~3 cm) to transpose onto the artery. A second small skin flap is created to expose the course of the radial artery. The investing soft tissue is excised and a 2-cm segment of the artery is exposed. The desired segment of the artery usually has a few small branches that need to be ligated or occluded with surgical clips. The transected vein is distended with saline using a small olive tipped cannula and its terminal aspect spatulated. We routinely administer 5,000 units of heparin intravenously prior to occluding the radial artery, although we do not monitor the activated clotting time. The artery is occluded with two small microvascular clamps (e.g., Cooley microvascular clamps), and a 0.75-cm arteriotomy is created using a No. 11 scalpel blade and fine

arteriotomy scissors (e.g., Pott scissors). The anastomosis is performed in an end-side fashion using a running 6-0 monofilament vascular suture. Other anastomotic configurations have been reported (i.e., side–side, end artery–end vein, end artery–side vein), although it is the general impression that the end of vein–side of artery is associated with the greatest long-term patency and the lowest incidence of venous hypertension in the hand. The arteriovenous fistula and the arterial perfusion of the hand should be interrogated with continuous wave Doppler. Although a thrill may not be detected in the cephalic vein immediately upon completing the anastomosis (presumably due to arterial spasm), a continuous signal throughout systole and diastole should be detected. A pulsatile or arterial signal in the cephalic vein suggests an outflow obstruction and mandates further investigation with a fistulagram or revision of the anastomosis. Occasionally, it may be necessary to mobilize the cephalic vein more proximal on the forearm to facilitate the proper orientation of the vein/artery. It is rarely necessary to reverse the anticoagulation with protamine. The wounds are closed using an interrupted 3-0 braided, absorbable suture placed into the deep dermis, and the skin is closed using a running 4-0 monofilament, absorbable suture in a subcuticular fashion.

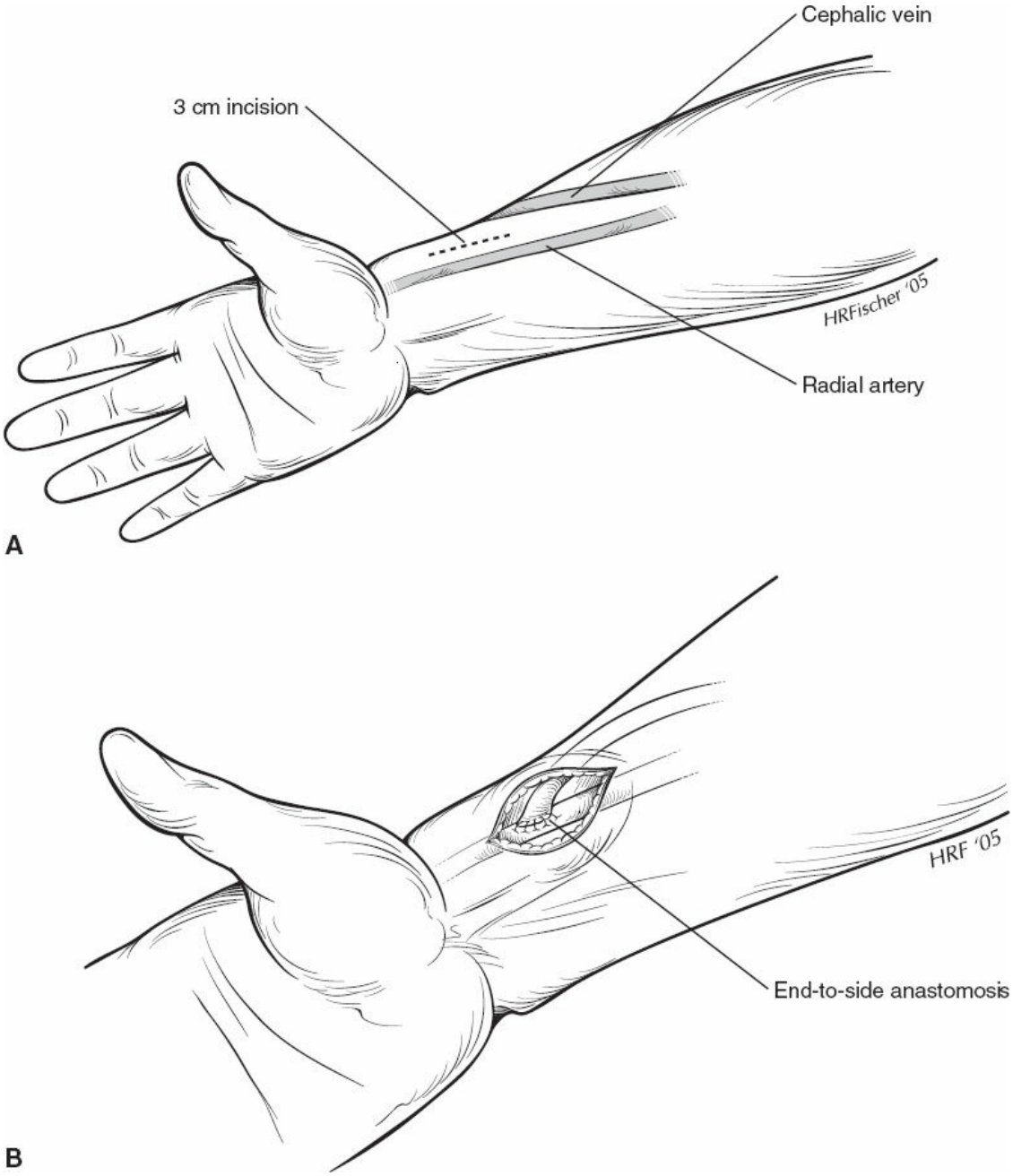

Figure 226.6. Radiocephalic autogenous access. **A.** Approximately a 3-cm longitudinal incision is made between the cephalic vein and the radial artery proximal to the skin crease at the wrist. **B.** The cephalic vein is transected and anastomosed in an end of vein—side of artery fashion. (From Englesbe MJ, Campbell DA. Upper extremity arteriovenous hemodialysis access. In: Zelenock GB, Huber TS, Lumsden A, et al., eds. *Mastery of Vascular and Endovascular Surgery*. Philadelphia, PA: Lippincott Williams & Wilkins; 2006.)

Autogenous Radiobasilic Access (Fig. 226.7A,B)

Although rarely feasible, the transposed autogenous radiobasilic access is

an excellent option. The radial artery is exposed using a 3-cm incision directly over the vessel immediately proximal to the wrist. The basilic vein is exposed using an incision extending from the antecubital fossa to the wrist and the branches are ligated. The vein is transected at the wrist and the residual stump suture ligated. The vein is distended with saline using the olive-tipped cannula and any defects are repaired. The vein is tunneled across the volar aspect of the forearm to the radial artery incision using a vascular clamp (e.g., Debakey aortic, Kelly) or a hollow graft-tunneling device. The vein should be tunneled immediately deep to the dermis, particularly in patients with considerable subcutaneous fat. The proper orientation of the vein can be maintained by marking one side and passing it through the tunnel while distended. The remaining portions of the procedure, with the exception of the basilic vein closure, are identical to that outlined above for the radiocephalic access. The basilic vein harvest incision can be closed with a running 3-0 braided, absorbable suture in the subcutaneous layer and 4-0 monofilament, absorbable suture for the skin.

Autogenous Brachiocephalic Access (Fig. 226.8A–C)

The incision for the autogenous brachiocephalic access is dictated by the patient's body habitus and the specific location of the cephalic/median antecubital vein and the brachial artery. Three incisions are acceptable: a transverse incision across the antecubital fossa, a sigmoid incision coursing medially in the upper arm across the antecubital fossa and along the cephalic vein in the forearm, and separate incisions over the brachial artery and cephalic vein in the upper arm. The sigmoid incision will be used to illustrate the technique, although more recently we have favored the transverse incision. The brachial artery is palpated in the distal upper arm and its course is marked on the skin. The sigmoid incision is started at this point and extended across the antecubital crease and onto the forearm incorporating the previously marked cephalic vein. It can be helpful to place marks transversely across the course of the planned incision to facilitate the appropriate alignment of the skin at the closure. Care should be exercised during the skin incision since the cephalic and median antecubital veins are very superficial and can be inadvertently injured. Exposure can be facilitated with two large spring retractors—one directed along the longitudinal axis of the arm and the other transversely across the antecubital crease. The cephalic vein is dissected free for approximately 4 cm by creating superior and inferior skin flaps. The cephalic, and its

continuation as the median antecubital vein, bifurcates or trifurcates in the antecubital fossa. It can be helpful to preserve the proximal aspects of these branches to help create a generous hood for the anastomosis. These large, deep branches should be suture-ligated since they tend to retract into to muscle and soft tissue. The brachial artery is exposed by incising the overlying bicipital aponeurosis and approximately 2 to 3 cm of the artery is dissected free. A pair of deep brachial veins flanks the artery, and they communicate via crossing branches that overlie the artery. These delicate branches must be dissected to allow exposure of the artery. The vein is distended with saline using an olive tipped catheter, spatulated, and all defects are repaired. Patients are administered 5,000 units of heparin intravenously and the brachial artery is occluded proximally and distally with the appropriate-sized vascular clamps (e.g., Cooley microvascular or Gregory bulldogs). A 0.75- to 1-cm incision is created in the artery using a No. 11 blade scalpel blade and arteriotomy scissors. The anastomosis is performed using a 6-0 monofilament vascular suture and standard surgical technique. Upon completion, the fistula and the arterial signals at the wrist are interrogated with the continuous wave Doppler. Unlike the radial artery-based autogenous accesses, a thrill should be detected in the proximal aspect of the fistula. The absence of a thrill or a pulsatile Doppler signal merits further investigation. This may be as simple as dissecting the vein more proximal on the arm to assure that it takes a gentle, unobstructed course. A diminished or monophasic Doppler signal at the wrist suggests that the hand may be ischemic. It is impossible to determine at this point whether this is due to reversible vasospasm or frank hand ischemia. All patients with suspected hand ischemia merit very close observation throughout the immediate postoperative period with aggressive remedial treatment as necessary. As detailed below, access-related hand ischemia is one of the most worrisome complications and we usually challenge our trainees at this point in the procedure to devise a strategy to address the potential future phone call from the recovery room nurse stating that the patient’s hand is severely ischemic. The wound edges are reapproximated with an interrupted 3-0 braided, absorbable suture and the skin is closed with a subcuticular stitch (e.g., 4-0 monofilament, absorbable) to complete the procedure. Unfortunately, there is not a lot of soft tissue to cover the anastomosis, and, thus, a wound breakdown potentially places the anastomosis at risk.

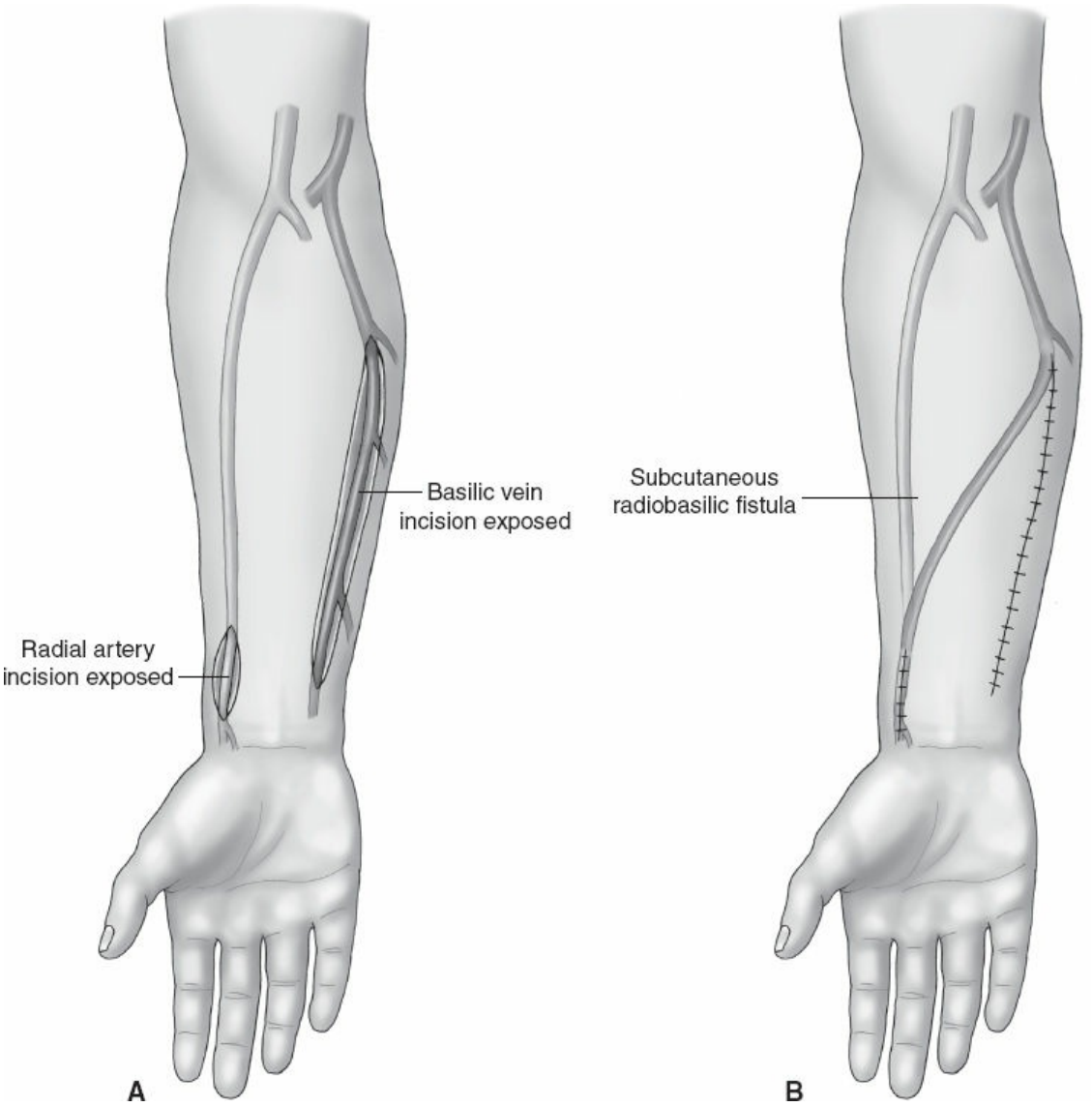

Figure 226.7. Radiobasilic autogenous access. **A.** Approximately a 3-cm longitudinal incision is made overlying the radial artery immediately proximal to the wrist. The basilic vein is exposed using an incision extending from the antecubital fossa to the wrist. The vein is tunneled across the volar aspect of the forearm using a clamp or a tunneling device. **B.** The completed access is shown. Note the course of the access across the forearm.

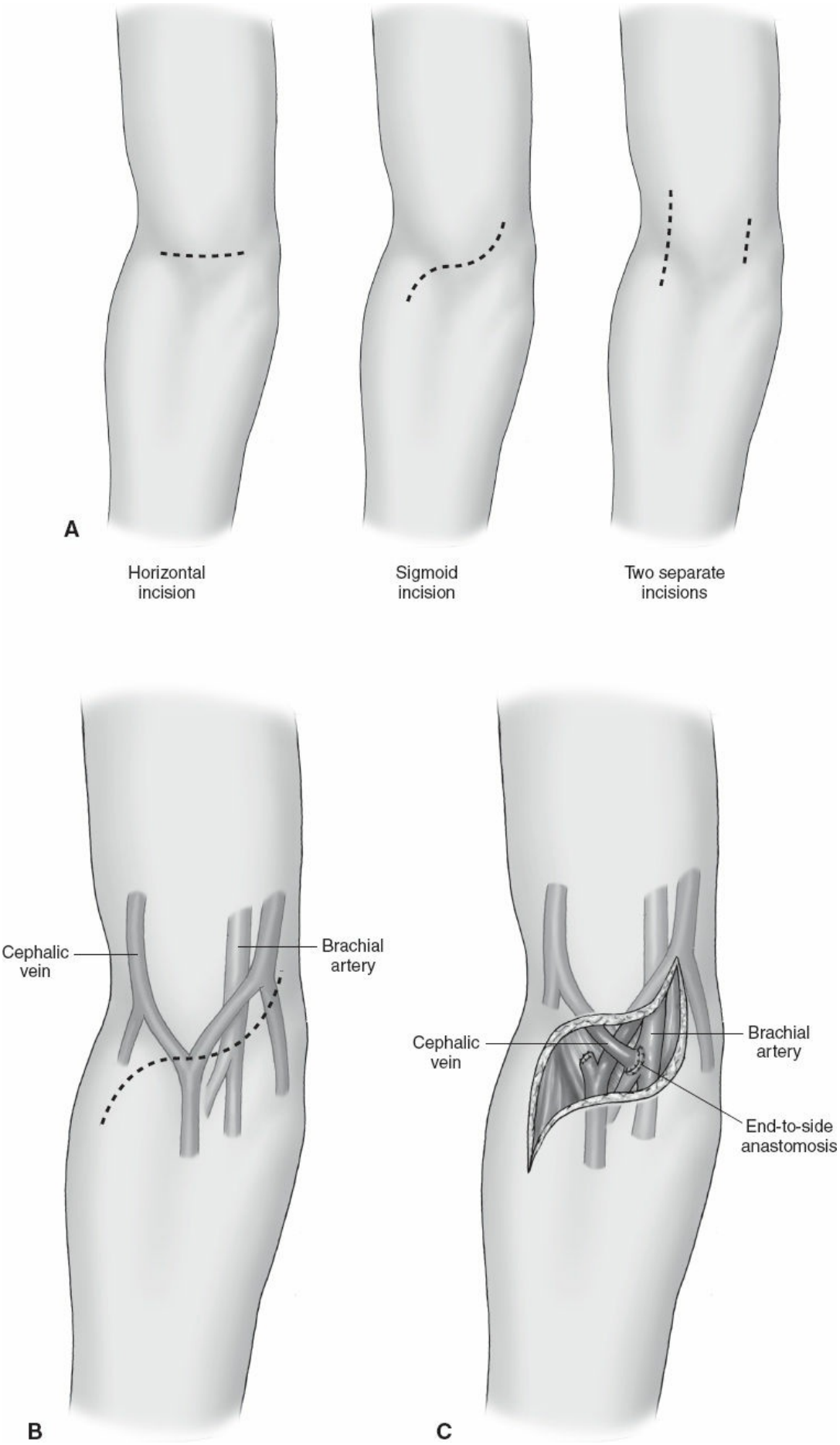
A
Horizontal incision
Sigmoid incision
Two separate incisions
Cephalic vein
Brachial artery
B
Cephalic vein
Brachial artery
End-to-side anastomosis
C

Figure 226.8. Brachiocephalic autogenous access. **A.** The possible incisions for the autogenous brachiocephalic access are shown. The simple horizontal or transverse incision is our current preferred approach, but the choice is usually dictated by the patient's body habitus. **B.** A sigmoid incision is started over the brachial artery in the proximal arm and extended across the antecubital crease and along the forearm incorporating the previously marked cephalic vein. Approximately 4 to 6 cm of the cephalic vein is dissected free to facilitate rotating it medially onto to the artery to construct the anastomosis. **C.** The cephalic vein is transected and anastomosed in an end of vein—side of artery fashion. (Figures **B** and **C** from Englesbe MJ, Campbell DA. Upper extremity arteriovenous hemodialysis access. In: Zelenock GB, Huber TS, Lumsden A, et al., eds. *Mastery of Vascular and Endovascular Surgery*. Philadelphia, PA: Lippincott Williams & Wilkins; 2006.)

The proximal radial artery can be used as an alternative arterial inflow source for upper arm cephalic- or basilic-based autogenous access procedures. The potential advantages of using the proximal radial artery include a lower access flow rate that may result in less venous hypertension and potentially a lower incidence of access-related hand ischemia. The proximal radial artery can be exposed by dissecting further distal on the brachial artery than outlined above, and this is facilitated by the sigmoid incision demonstrated in the figures. The median antecubital vein and its deep branches should be preserved and can be used for the anastomosis.

Autogenous Brachiobasilic Access—Single-Stage Procedure (Fig. 226.9A,B)

An incision is made in the distal upper arm along the course of the previously marked basilic vein. Alternatively, surgeon-directed ultrasound immediately prior to the procedure can be used to guide the location of the incision as noted above. We prefer to make a limited incision initially and identify the vein prior to making the full incision in an attempt to minimize the extent of the skin flaps. The basilic vein courses deep to the subcutaneous tissue and can actually be quite deep relative to the skin in obese patients. It courses adjacent to the medial antecubital cutaneous nerve in the distal upper arm, and this nerve can serve as a landmark. The skin incision and the dissection should extend proximally to the axilla and

distally to at least the antecubital crease. Notably, the forearm basilic vein is joined by the median antecubital vein at the level of the antecubital crease. We usually extend the incision across the antecubital crease or onto the proximal forearm and dissect the largest branch of the vein (i.e., median antecubital or forearm basilic vein). Indeed, the “longer the vein the better” since a longer segment facilitates a more lateral subcutaneous course for the transposition. The basilic vein should be dissected throughout its course and the branches ligated. It is imperative to mobilize the basilic vein in the proximal arm at the level of the axilla to prevent any undo tension on the vein at the swing segment for the transposition. Indeed, it has been our anecdotal impression that the tension on this segment resulting from inadequate mobilization leads to focal intimal hyperplasia, a common mechanism of failure for brachiobasilic accesses. We frequently suture-ligate the larger, broad-based branches with a 5-0 monofilament vascular suture. After the proximal end of the vein is transected (antecubital end), it is distended and all defects are repaired. The distended vein is then gently draped over the upper arm in an arc and the future course of the transposed vein is marked on the skin. The brachial artery is dissected free in the distal upper arm at the site of the planned anastomosis. The brachial artery courses in the groove formed between the triceps and biceps muscles beneath the deep fascia. The brachial artery lies deep to the median nerve, adjacent to the paired brachial veins and on top of the ulnar nerve. Approximately a 3-cm segment of artery is dissected free to facilitate the anastomosis. A tunnel is then created along the course marked on the skin using a semicircular, hollow tunneling device, and we prefer to pass the tunnel from the antecubital crease to the axilla. The tunneler is passed deep to the subcutaneous tissue near the antecubital fossa and the axilla, but immediately below the dermis throughout the region that will actually be used for cannulation. A sharp-tipped or pointed-tipped tunneler is particularly helpful because it facilitates passing the device in the correct plane. This helps assure that the access can be easily identified by the technologists, and this concern is particularly relevant for obese patients. Patients are heparinized with 5,000 units after the tunnel is created and the anastomosis is performed as outlined above for the brachiocephalic access. A thrill should be detected in the proximal aspect of the access. A closed suction drain (e.g., No. 10 Jackson-Pratt) is placed in the bed of the basilic vein harvest and brought out through a separate stab wound on the distal upper arm. The wound is closed in two

layers with a running 2-0 braided, absorbable suture and the skin is reapproximated with a subcuticular suture. It is important to examine the access (i.e., the thrill) during the closure to assure that it has not been inadvertently narrowed or kinked.

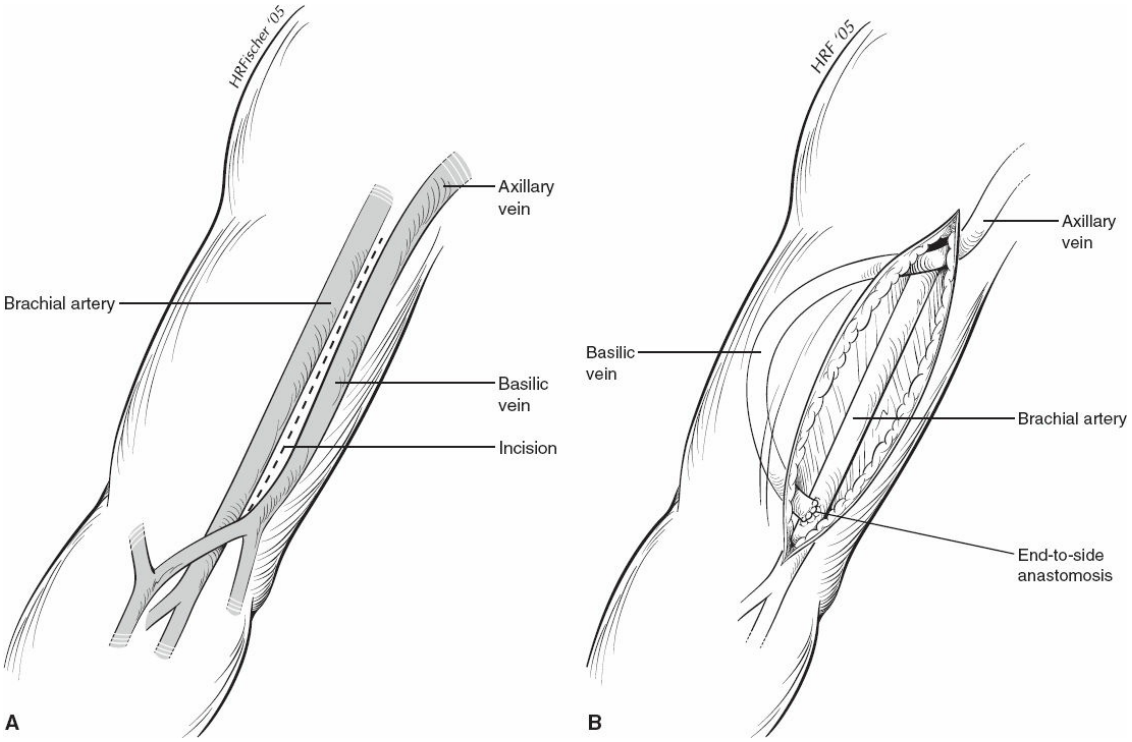

Figure 226.9. Brachiobasilic autogenous access. **A.** An incision is made extending from the antecubital fossa to the axilla. The basilic vein is dissected completely free and the multiple branches are ligated. **B.** The vein is tunneled laterally over the biceps muscle in the subcutaneous plane using the semicircular vascular tunneler and anastomosed to the brachial artery proximal to the antecubital fossa in an end of vein—side of artery configuration. (From Englesbe MJ, Campbell DA. Upper extremity arteriovenous hemodialysis access. In: Zelenock GB, Huber TS, Lumsden A, et al., eds. *Mastery of Vascular and Endovascular Surgery*. Philadelphia, PA: Lippincott Williams & Wilkins; 2006.)

Autogenous Brachiobasilic Access—Two-Stage Procedure

The brachiobasilic autogenous access can be created as a two-stage procedure. Indeed, it has been our preference over the past several years to use the two-stage approach. The theoretical benefit to this approach is that the vein may dilate or mature better in situ (vs. the transposed location) and that it doesn't subject the patient to a more involved operation (and

potential for wound complications) unless the vein has matured and is, thus, likely to be successfully used for cannulation. Unfortunately, the literature supporting the two-stage procedure is somewhat equivocal with Cooper et al. reporting from their meta-analysis that there was no difference in failure and primary patency rates despite the two-stage procedure being used in patients with smaller basilic veins.

The principles for the two-stage procedure are similar to those outlined above for the single-stage procedure with a few notable differences. The first-stage procedure is typically done as an outpatient procedure under regional anesthesia and a drain is not required. A limited, 4-cm incision is made over the basilic vein in the distal upper arm, although the incision can be extended across the antecubital crease if the vein is suitable. Patients are seen in clinic on a monthly basis until the vein is deemed suitable in size for the second-stage procedure, and we use a diameter measurement of 6 mm, based on ultrasound, as our criteria. The mobilization of the basilic vein that comprises the fistula is similar to the single-stage procedure, although there is additional scar tissue near the anastomosis and an element of venous hypertension. We traditionally dissect the basilic vein all the way up to the anastomosis to optimize the available length of vein. There are several reported techniques to handle the vein in terms of creating a usable segment for cannulation. Specifically, the vein can be simply elevated with the anastomosis left intact and the subcutaneous tissue reapproximated below the vein, thus, “elevating” the vein to the level of the skin. This technique has some appeal because it avoids having to revise the anastomosis, but requires transecting the antecubital cutaneous nerve. Furthermore, the fistula sits immediately below the incision and is at risk if the wound were to break down while the ultimate course of the fistula and the usable segment of the fistula sits very medial on the upper arm and is somewhat awkward to cannulate when the patient is in the dialysis chair. Alternatively, a subcutaneous pocket can be created by undermining the skin, and the mobilized segment of the vein can be “tucked” into the pocket to avoid having the vein course immediately below the harvest incision. Lastly, the anastomosis can be completely dissembled and vein tunneled as outlined above for the single-stage procedure. This requires re-siting the anastomosis more proximal on the brachial artery. The original fistula anastomosis on the brachial artery can be repaired with a vein patch or the proximal part of the fistula can be transected and simply oversewn. This

approach overcomes the limitations of simply elevating the vein and facilitates tunneling the vein in a more lateral course away from the harvest incision. It has been our anecdotal impression that the basilic veins tend to elongate in addition to just dilate after the first-stage procedure, thus facilitating a more lateral tunnel. This final technique has been our preferred approach, and we have found that re-siting the anastomosis is not particularly difficult nor does it add too much to the duration and complexity of the procedure.

POSTOPERATIVE MANAGEMENT

Patients undergoing a forearm, brachiocephalic, or first-stage brachiobasilic autogenous access are usually discharged home from the recovery room, while those undergoing a brachiobasilic autogenous access are admitted overnight. It is imperative to confirm that the hand is not ischemic before patients are discharged. The adequacy of the hand perfusion can usually be determined by the absence of any subjective complaints and a focused motor and sensory examination. Admittedly, this can be confounded by any regional anesthesia, although the underlying neurologic deficits are usually different. Notably, we specifically use short-acting regional anesthetic agents to allow accurate assessment of the hand in the early postoperative period. We routinely check a set of serum electrolytes to confirm that the patients do not need to dialyze. As noted above, we try to schedule the access procedures on days between dialysis sessions. Patients admitted to the hospital are placed on telemetry with a pulse oximeter. Although these precautions may seem unnecessary, we have had a few patients die in the immediate postoperative period without an identifiable cause. The closed suction drain is removed on the first postoperative day, provided that the drainage is minimal, and patients are discharged home after their regular dialysis session. All patients discharged from the recovery room (i.e., outpatient procedure) are contacted the day after their procedure to make sure that they are doing well and, specifically, that their hand is not ischemic.

Patients are seen in the outpatient clinic within 2 weeks after their operative procedure and at monthly intervals thereafter until their accesses are usable for dialysis. During the prospective validation of our algorithm, it took a mean of 3 months until the autogenous accesses were suitable for cannulation, although it has been our anecdotal impression that the time course is now closer to 4 months. The access must be sufficiently dilated

before the technologists can consistently cannulate the lumen and must be “arterialized” to sustain the repeated trauma of cannulation. We have used the KDOQI “rule of 6s” to determine whether the access is suitable for cannulation: 6 mm in diameter, 6 mm depth below the skin, 600 mL/min. Unfortunately, there are no means to assess the integrity of the access wall. During the follow-up period, we obtain ultrasounds of any accesses that do not appear to be maturing or dilating. We have found the ultrasound-based diameter measurements of the accesses to be particularly helpful, although the absolute velocity measurements have not been particularly informative, unlike the scenario of lower extremity bypass graft surveillance. The accesses that fail to dilate and those without a thrill are imaged with either a catheter-based fistulagram or an arteriogram in an attempt to identify the specific problem and facilitate maturation. The choice of procedures is contingent upon the clinical suspicion with the latter reserved for those patients in which an arterial inflow problem is suspected since the full extent of the access (including the arterial anastomosis and central venous runoff) can usually be imaged with a fistulagram. Additional open, surgical, or endovascular procedures are performed as necessary. Balloon angioplasty is our preferred initial approach, and it has proven quite effective for focal lesions. Furthermore, failure of the endovascular approach does not usually preclude a remedial open procedure. When the accesses are ultimately deemed suitable for cannulation, the patients are provided with a diagram of the specific configuration and instructions for cannulation while an identical facsimile is sent to their dialysis unit. Notably, we have become very conservative about releasing the autogenous accesses for cannulation based upon a few bad experiences in which accesses were damaged from premature cannulation. We have established a relationship with the patients and nephrologists such that the accesses are not cannulated until released from our clinic. It is important to remember that the ultimate goal is long-term access patency and a few additional weeks delay on the front end is likely irrelevant.

COMPLICATIONS

Many of the postoperative complications after autogenous hemodialysis access procedures are generic to all vascular surgical procedures and include both local (i.e., thrombosis, infection, and wound complications) and systemic problems (i.e., myocardial ischemia, dysrhythmias, cerebrovascular accidents). As noted above, many of these adverse

outcomes have been used to justify the choice of autogenous accesses. The KDOQI Clinical Outcome Goals include a thrombosis rate of 0.25 episodes/patient year and life expectancy of >3 years for autogenous accesses and a thrombosis rate of 0.5 episodes/patient year and a life expectancy of >2 years for prosthetic accesses. In our own meta-analysis, the primary and secondary annual patency rates for the autogenous accesses were 80% and 60% respectively as noted above (see Fig. 226.2). Furthermore, KDOQI stated that the infectious complication rates should not exceed 1% and 10% over the functional life of an autogenous and prosthetic access respectively. In the prospective validation of our algorithm, the perioperative complication rate was approximately 20% with half of these due to wound problems. Fortunately, the majority of the wound complications after autogenous access are self-limited and do not translate into access loss.

Postoperative hand ischemia is specific to hemodialysis access procedures and represents one of the most worrisome complications. This access-related hand ischemia or “steal” results from the diversion of blood from one anatomic bed to another. Despite the colorful label, there is nothing “illegal” about the condition since the blood flow simply follows pressure gradients. An arteriovenous fistula is a low resistance circuit that causes a decrease in both blood flow and perfusion in the arteries distal to the anastomosis. Hand ischemia occurs when the compensatory changes (i.e., vasodilation, increased cardiac output, collateral flow through the profunda brachial) are inadequate to maintain tissue perfusion. Predictably, the decrease in perfusion (and potential symptoms) is further exacerbated by the presence of arterial occlusive disease in the inflow (i.e., axillary, subclavian) and the forearm arteries distal to the anastomosis. Some type of “steal” phenomenon is common after all access procedures, although symptomatic “steal” or hand ischemia is relatively rare with an incidence of 2% and 10% after radial and brachial artery based procedures respectively. Unfortunately, there are no preoperative tests to predict which patients will absolutely develop hand ischemia (and therefore the access procedure should be avoided). However, several clinical predictors have been identified, including female gender, advanced age (i.e., ≥60 years), diabetes, peripheral arterial occlusive disease, large conduits (e.g., femoral vein), brachial artery based procedures, autogenous accesses, and a previous episode of access-related hand ischemia. Indeed, it has been our anecdotal impression that patients with a previous episode of hand

ischemia have almost a 100% incidence of developing the same during subsequent procedures regardless of the upper extremity (i.e., ipsilateral or contralateral).

The diagnosis of hand ischemia is predominantly a clinical one. Indeed, all hand complaints after a prosthetic or autogenous hemodialysis access should be attributed to hand ischemia until proven otherwise. Importantly, patients can have access-related hand ischemia despite having a weakly palpable pulse. Both noninvasive (i.e., upper extremity arterial pressures and waveforms) and invasive (i.e., catheter-based arteriography) imaging can be used to confirm the diagnosis and are helpful in equivocal cases, but the clinical symptoms should take precedence over the imaging findings. Diminished wrist and digital pressures and the inability to visualize the forearm vessels are suggestive of the diagnosis on the noninvasive and invasive imaging respectively. Hand ischemia may develop either early (i.e., immediate postoperative) or late (i.e., weeks/months postoperative) relative to the index access procedure. Patients who present with delayed hand ischemia usually complain of their initial symptoms during dialysis due to the concomitant decrease in blood pressure.

The treatment goals for patients with hand ischemia are to relieve the symptoms and preserve the access, although the primary objective is to maintain normal hand function. A variety of treatment options have been proposed, including access ligation, proximal revascularization, proximalization of the arterial inflow (PAI) narrowing of the anastomosis or access outflow (i.e., “banding”), revision using distal inflow (RUDI), and distal revascularization/interval ligation (DRIL). The most appropriate treatment is usually dictated by the clinical scenario with the treatment considerations, including the severity of the symptoms, the long-term potential of the access, the available autogenous conduit, and the other potential access options. Importantly, the various remedial procedures should be viewed as complementary since they all serve a potential role in the treatment algorithm. Access ligation is the simplest and most definitive treatment to relieve the symptoms, although, needless to say, the access is sacrificed. The DRIL procedure (Fig. 226.10) is very effective in terms of achieving both objectives (i.e., relief of symptoms, access preservation), although it is a moderate undertaking, requires a segment of autogenous vein (usually saphenous), and creates a scenario in which the perfusion of the hand is dependent upon the integrity of the bypass. In our own

experience, the DRIL procedure salvaged the access and reversed the presenting symptoms in the overwhelming majority of the cases. Patients with a presumed inflow stenosis as the source of their hand ischemia should undergo an arteriogram and remedial therapy as indicated. However, this scenario is somewhat unusual in our practice given the noninvasive arterial imaging described in the algorithm and our liberal use of preoperative arteriography. Limiting the flow through the access (i.e., “banding”) such that it is adequate to sustain dialysis yet sufficient to maintain hand function may be difficult, although there has been a resurgence in the technique. This technique usually requires some type of objective measurement intraoperatively to confirm that the distal perfusion has been augmented. The proximalization of the arterial inflow likely represents a variant of the flow limiting procedures, although it can be helpful in patients who don’t have a suitable segment of autogenous conduit for a DRIL procedure. Furthermore, the technique essentially converts an autogenous access to a composite access since the described technique uses a prosthetic graft as the conduit, although it is possible to use an autogenous conduit. The revision using distal inflow may be helpful for “high flow” autogenous access and essentially converts a brachial artery-based access to a radial artery-based one.

In our practice, the usual clinical decision is whether to simply ligate the access or perform a DRIL procedure. We have elected to perform DRIL procedures on good-risk patients with an autogenous access that is likely to mature sufficiently for cannulation. Indeed, it has been our anecdotal impression that the larger diameter veins (i.e., those more desirable in terms of their potential to develop into a mature autogenous access) are more likely to cause hand ischemia. Furthermore, we usually make the decision about the most appropriate remedial treatment (i.e., ligation vs. DRIL) at the time of the original access procedure.

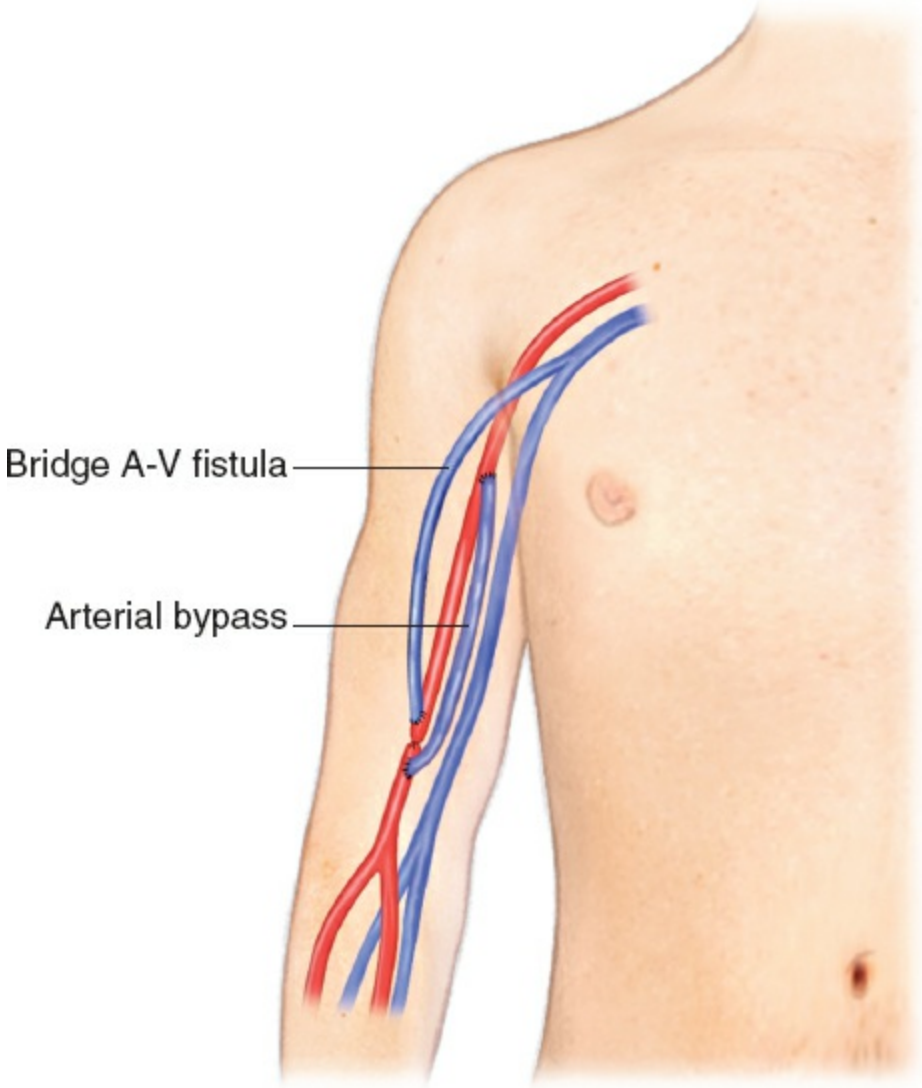

Figure 226.10. The configuration of the DRIL (distal revascularization and interval ligation) procedure is illustrated. A brachial artery–brachial artery bypass is performed using saphenous vein with the proximal anastomosis sited 7 to 10 cm above the arteriovenous fistula anastomosis. The brachial artery immediately distal to the arteriovenous fistula anastomosis is ligated.

EVALUATION OF PATIENTS WITH COMPLEX ACCESS PROBLEMS

General

The majority of patients labeled with “complex” or “tertiary” access problems are candidates for upper extremity autogenous accesses using the outlined algorithm. However, there are subsets of patients who pose additional challenges within this framework. Analysis of the reasons that

they are not candidates for the algorithm suggests potential solutions and treatment options, albeit not always autogenous accesses.

Inadequate Ipsilateral Arm Vein

Autogenous vein is the optimal conduit, but prosthetic accesses are acceptable when autogenous accesses are not feasible. Thus, inadequate ipsilateral arm vein should rarely comprise a legitimate contraindication to constructing an access provided there is a suitable arterial inflow and venous outflow. Indeed, it is possible to construct numerous brachial artery-based prosthetic accesses with the venous anastomosis sited anywhere along the axillary, subclavian, or internal jugular veins. The options for constructing autogenous accesses with upper extremity veins that are of adequate diameter (≥3 mm) but *inadequate length* include composite saphenous—arm vein configurations. When the ipsilateral veins are of *inadequate diameter*, the autogenous options include a translocated transposed femoral/popliteal vein. Indeed, we have had particularly good success with the translocated femoral/popliteal vein used in the brachioaxillary configuration, although the magnitude of the procedure is significant and the configuration associated with a moderate amount of hand ischemia given the large conduit. A variety of alternative or more heroic (e.g., brachial artery–brachial vein) autogenous accesses have been reported, although their success rates and longer-term durability remain undefined.

Inadequate Arterial Inflow

Inadequate arterial inflow can complicate the choice of an access configuration in a patient with a reasonable peripheral vein and patent central runoff. This scenario is relatively common and frequently due to the presence of an orificial subclavian artery stenosis or occlusion. A variety of endovascular and surgical options are available with the choice contingent upon the location and extent of the lesion. Balloon angioplasty in combination with an endoluminal stent is an ideal solution for most orificial subclavian lesions and can be performed simultaneous with the access procedure working retrograde through the brachial artery, oftentimes through the site chosen for the anastomosis.

Central Vein Stenosis/Occlusion

The presence of a significant central vein stenosis or occlusion is a *relative* contraindication to an ipsilateral permanent hemodialysis access due to the potential to develop significant venous hypertension and arm edema with the *absolute* contraindications being patients with superior vena cava syndrome or prolonged arm edema. Central vein stenoses and occlusions have become the most common complex or tertiary access-related complication, likely the sequelae of prior central venous catheters (including tunneled dialysis catheters), prior permanent accesses, and deep venous thromboses. Occasionally, a patient's only upper extremity access options are ipsilateral to a significant central vein lesion. The potential options in this setting include abandoning the upper extremities in favor of a lower extremity site, correcting the ipsilateral central vein lesion prior to placing the permanent access, or placing the permanent access and correcting the vein lesion if the patient develops significant, sustained arm edema. Our preferred approach is the latter, and we have been anecdotally impressed that not all of the patients with a central vein lesion develop significant edema after the procedure. The likely explanation for this finding is that a significant collateral network develops that reduces the venous hypertension, thereby preventing the edema. The invasive treatment options (i.e., endovascular or surgical) are the same whether they are performed before or after the access and they are not particularly complicated by the procedure itself. Indeed, the high flow in the access may improve the initial patency after central vein angioplasty or stenting so that there may be a theoretical advantage to performing these interventions postoperatively. Unfortunately, the long-term durability of central vein angioplasty is only fair with primary patency rates ranging from 20% to 30% at 12 months. However, the majority of the lesions are amenable to remedial angioplasty procedures either alone or in combination with an intraluminal stent. Notably, the recurrent central vein stenoses after endovascular (or open surgical) revascularization may not necessary result in recurrent arm edema if additional collateral pathways develop. The reported, open surgical options include jugular vein turn down, axillary/subclavian–jugular vein bypass, axillary/subclavian–contralateral axillary/subclavian vein bypass, axillary–common femoral vein bypass, and central vein–atrial bypass. The choice of procedures, obviously, is dictated by the patent central veins, and we have found CT venography particularly helpful to delineate their status.

The HeRO Graft (Merit Medical, South Jordan, UT) is a novel hybrid

catheter-graft combination that may play a role in patients with refractory central vein stenoses or occlusions. It is composed of a 6-mm PTFE graft that is coupled to a 6.3-mm outflow catheter and functions essentially as a prosthetic access hooked to a dialysis catheter. Notably, the graft and catheter components are all implanted beneath the skin, and thus it has the appearance of a prosthetic access. The initial results are somewhat encouraging, although the patency and infectious complication rates remain concerning. Implantation requires crossing the central vein stenosis or occlusion with the relatively large catheter component (OD 6.3 mm, 19 Fr) and can be challenging. We have used the HeRO graft both as the initial access for patients with known central vein occlusions and as remedial treatment for patients with a functional access and refractory arm edema secondary to a central vein lesion.

Multiple Prosthetic Access Failure

There is a subset of patients in which prosthetic accesses do not appear to work. In the typical scenario, patients are referred for access after multiple previous prosthetic accesses (and revisions) have failed to function for any appreciable length of time. Although it is conceivable that this subset of patients is hypercoagulable, formal hypercoagulable evaluations and medical therapies (i.e., anticoagulants, antiplatelet agents) have not been particularly beneficial. The optimal treatment in this setting is to construct an autogenous access. For those patients with limited autogenous conduit, there are several alternatives as noted above.

Obesity

Similar to most surgical problems, obesity complicates the challenges of constructing permanent hemodialysis access due to the depth of the “superficial” veins below the surface of the skin and the increased incidence of wound complications. Notably, obese patients have been shown to have comparable number of autogenous access configurations, similar revision/failure rates, but a lower maturation rate among those considered morbidly obese (i.e., highest quartile). The deep course of the “superficial” veins can be overcome by transposing or elevating the veins such that they course immediately beneath the skin or by excising the adipose tissue (i.e., “lipectomy”). We have had good results with the elevation procedure and prefer to do this as part of a two-stage procedure (first stage—access construction, second stage—elevation) since it has

been our anecdotal impression that the veins mature better in situ. An incision is made over the course of the dilated vein that comprises the fistula and the vein is dissected free. The subcutaneous tissue is then reapproximated underneath the vein with interrupted absorbable sutures, thereby elevating it to the level of the skin. This requires a little trial and error to assure that the vein is elevated sufficient to facilitate easy cannulation, yet there is an adequate amount of soft tissue overlying the vein and the skin is not closer under undue tension. The healed incision helps identify the ultimate course of the fistula for the technologist and the scar if fairly insensate, and thus, cannulation is well tolerated by the patients. Bourquelot et al. have reported a novel “lipectomy” technique that involves making a series of parallel transverse incisions over the access and then excising the excess adipose tissue below the skin, thereby “elevating” the vein. Alternatively, implantable guides (VWing, Vital Access, Salt Lake City, UT) have been described that direct the needle through the subcutaneous tissue into the vein that comprises the access.

Thin Skin

Patients with thin skin such as the elderly and those on chronic steroids present a problem because any breakdown of the skin over the access can lead to an access infection or bleeding. This is particularly a concerning in the immediate postoperative period for the incision adjacent to the anastomosis. We have approached patients with thin skin using our same algorithm, but have attempted to tunnel the prosthetic grafts or autogenous vein as deep beneath the skin and subcutaneous tissue as possible. We have been anecdotally impressed that the repeated trauma from accessing the conduit can lead to fibrosis over the conduit that can be protective.

Human Immunodeficiency Virus

The life expectancy for patients infected with human immunodeficiency virus (HIV) is quite good given the recent advances in medical therapy and, thus, it is essentially a chronic illness with a reasonable life expectancy. Indeed, the decision to offer patients hemodialysis or permanent hemodialysis access is no longer relevant given these advances. The patency rates for prosthetic accesses may be reduced among patients with HIV while the associated infectious complications may be increased. Because of these concerns, autogenous access is likely the most ideal choice for patients with HIV and every option in the algorithm outlined

above should be exhausted prior to considering a prosthetic access.

Elderly Patients

The elderly represent one of the most rapidly expanding cohort of patients on dialysis. Although there is no specific age cutoff to define the elderly population, the generic concerns are consistent across patients of advanced age. These concerns advanced comorbidities, decreased functional status, generalized frailty, limited life expectancy, and increased morbidity/mortality associated with interventions. There is no consensus across the literature for elderly patients, although concerns have been expressed that the autogenous maturation rate is lower and that a large percentage of patients with chronic kidney disease who undergo placement of an autogenous access never use it for dialysis. Our approach for elderly patients is essentially the same as outlined above, and we have attempted to construct autogenous access in the majority of patients. However, our threshold for constructing a prosthetic access is somewhat lower and we frequently delay intervention until the patients are closer to dialysis with the overarching goal of achieving a functional access, not necessary an autogenous access.

Prior Hand Ischemia

A history of access-related hand ischemia is problematic and predictive of future ischemic events regardless of the extremity (i.e., contralateral or ipsilateral). A catheter-based or CT arteriogram is mandatory during the preoperative evaluation in this setting, independent of the noninvasive studies. An arterial inflow lesion may not become hemodynamically significant until an arteriovenous fistula is constructed and it has been estimated that up to one third of all access-related ischemic events are due to inflow stenoses or occlusions. All arterial inflow lesions should be corrected prior to constructing a new access and a remedial plan should be generated *preoperatively* to address any *postoperative* hand ischemia. We have had very good results with the DRIL procedure as noted above and have performed a few preemptive DRIL procedures (planned simultaneous access, DRIL). We routinely survey the saphenous vein during the preoperative evaluation in these patients. Alternatively, the arterial anastomosis for the access can be sited more proximal (e.g., proximal brachial artery) or distal (e.g., proximal radial artery) on the arterial tree relative to the brachial artery at the antecubital fossa. This has been shown

to have a favorable hemodynamic benefit in terms of the distal perfusion or magnitude of the “steal” phenomenon. Indeed, these approaches are the basis of the “proximalization of the arterial inflow” and “revision using distal inflow” that comprise two of the remedial treatments for access-related hand ischemia. The typical example is a prosthetic brachioaxillary access in which the arterial anastomosis is performed on the proximal brachial artery rather than the segment near the antecubital fossa.

Upper Extremity Access Precluded

Permanent lower extremity hemodialysis accesses are only indicated for patients who are truly precluded from any upper extremity procedures (i.e., superior vena cava syndrome, refractory arm edema, uncorrectable access-related hand ischemia). The complication rates (particularly the infectious complications) associated with lower extremity accesses are significant and rival those for catheters. We routinely obtain preoperative ankle/brachial indices and lower extremity vein survey (i.e., duplex ultrasound) of the saphenous and femoral system in addition to the CT venogram noted above in patients with complex access issues who are being considered for lower extremity access. Both the autogenous and prosthetic options in the lower extremity are somewhat limited. Several studies have reported reasonable results using the femoral vein as an autogenous access, but we have had a hard time reproducing these experiences (largely due to the development of significant wound complications) despite multiple attempts and various modifications of the technique (e.g., skip incisions, composite configurations with prosthetic or cadaveric grafts). Alcoer et al. have reported a technique that involves a limited incision in the mid third of the thigh, mobilization of the femoral vein from the adductor canal to the confluence of the profunda vein, and then elevation of the vein to the level of the skin incision. We have had some success with this approach, but its use is limited to thin patients because of the limited length of the femoral vein and the need to elevate it to the level of the skin. Our preferred lower extremity prosthetic access is the thigh loop based off the common femoral artery and vein. It is certainly possible to use the proximal superficial femoral artery for the inflow and the saphenous vein for the venous outflow, although we have favored the common femoral artery and vein because of their larger size. Flarup and Hadimeri have reported using the superficial femoral artery and vein in the distal thigh, although it is not clear whether the wound complications are

lower and the configuration may be precluded in patients with lower extremity occlusive disease.

STRATEGIES TO MAINTAIN ACCESS

It is important to emphasize that maintaining adequate access is a lifelong process that requires a lifelong plan. Strategies should be designed to preserve all possible access options, select the access most likely to have the best long-term patency, and sustain each individual access as long as is possible. Specifically, the cephalic and basilic veins should be preserved. They should not be used for blood draws, intravenous catheters, peripherally inserted central catheters (i.e., PICC lines) or conduits for lower extremity arterial bypass if at all possible. For the inpatients, we traditionally post a sign over the head of their bed, although it is likely more effective to counsel the patients about the importance of preserving these potential conduits and allow them to serve as their own advocate. The subclavian vein should not be used for dialysis access catheters, and, ideally, not for any other type of central vein catheter. Notably, subclavian vein dialysis catheters are associated with approximately a 30% incidence of subclavian vein stenosis or occlusion that precludes permanent hemodialysis access on the ipsilateral extremity. Every effort should be made to construct autogenous accesses as emphasized by KDOQI due to their better long-term patency rates. An aggressive surveillance protocol should be devised to identify “failing” accesses and appropriate remedial procedures performed. Admittedly, the ideal surveillance technique remains to be identified, and it is likely that a variety of different ones are suitable. Lastly, attempts should be made to salvage all thrombosed accesses. The treatment algorithms have been worked out reasonably well for thrombosed prosthetic accesses, although the guidelines are less clear for thrombosed autogenous accesses. It has been our anecdotal impression that the same treatment options (i.e., chemical lyses, mechanical thrombectomy) are appropriate for thrombosed autogenous accesses, although the success rates may not be as good as those for prosthetic accesses.

ALTERNATIVE STRATEGIES FOR RENAL REPLACEMENT THERAPY

Despite our aggressive algorithm, there is a very small subset of patients

who are not candidates for permanent hemodialysis access due to anatomic restrictions, limited life expectancy, or prohibitive comorbidities. Fortunately, we have been able to obtain some type of access or use other strategies for renal replacement therapy in these difficult patients. However, most nephrologists have had patients in their practices who have succumbed due to the inability to obtain long-term dialysis access. We have used tunneled "temporary" catheters as the permanent hemodialysis access in this group of patients. Fortunately, the interventional radiologists at our institution have shared our dedication to these patients. Admittedly, these tunneled catheters are associated with significant complication rates and need to be changed frequently. Furthermore, we have aggressively explored the alternative options for renal replacement therapy, including peritoneal dialysis and transplantation.

Suggested Readings

Al-Jaishi AA, Oliver MJ, Thomas SM, et al. Patency rates of the arteriovenous fistula for hemodialysis: a systematic review and meta-analysis. *Am J Kidney Dis* 2014;63(3):464–78.

Bakken AM, Protack CD, Saad WE, et al. Long-term outcomes of primary angioplasty and primary stenting of central venous stenosis in hemodialysis patients. *J Vasc Surg* 2007;45(4):776–83.

Bourquelot P, Rawa M, Van LO, et al. Long-term results of femoral vein transposition for autogenous arteriovenous hemodialysis access. *J Vasc Surg* 2012;56(2):440–5.

Cooper J, Power AH, DeRose G, et al. Similar failure and patency rates when comparing one- and two-stage basilic vein transposition. *J Vasc Surg* 2015;61(3):809–16.

Cull JD, Cull DL, Taylor SM, et al. Prosthetic thigh arteriovenous access: outcome using the SVS/AAVS reporting standards. *J Vasc Surg* 2004;39:381–6.

Flarup S, Hadimeri H. Arteriovenous PTFE dialysis access in the lower extremity: a new approach. *Ann Vasc Surg* 2003;17(5):581–4.

Huber TS, Carter JW, Carter RL, et al. Patency of autogenous and PTFE upper extremity arteriovenous hemodialysis accesses: a systematic review. *J Vasc Surg* 2003;38:1005–11.

Huber TS, Hirneise CM, Lee WA, et al. Outcome after autogenous brachial-axillary translocated superficial femoropopliteal vein hemodialysis access. *J Vasc Surg* 2004;40(2):311–8.

Huber TS, Ozaki CK, Flynn TC, et al. Prospective validation of an algorithm to

maximize native arteriovenous fistulae for chronic hemodialysis access. *J Vasc Surg* 2002;36(3):452–9.

Malas MB, Canner JK, Hicks CW, et al. Trends in incident hemodialysis access and mortality. *JAMA Surg* 2015;150(5):441–8.

Murad MH, Elamin MB, Sidawy AN, et al. Autogenous versus prosthetic vascular access for hemodialysis: a systematic review and meta-analysis. *J Vasc Surg* 2008;48(5 Suppl):34S–47S.

National Kidney Foundation. K/DOQI Clinical Practice Guidelines for Vascular Access, 2006 updates. *Am J Kidney Dis* 2001;37:S137–81.

Ravani P, Palmer SC, Oliver MJ, et al. Associations between hemodialysis access type and clinical outcomes: a systematic review. *J Am Soc Nephrol* 2013;24(3):465–73.

Scali ST, Chang CK, Raghinaru D, et al. Prediction of graft patency and mortality after distal revascularization and interval ligation for hemodialysis access-related hand ischemia. *J Vasc Surg* 2013;57(2):451–8.

Vassalotti JA, Falk A, Cohl ED, et al. Obese and non-obese hemodialysis patients have a similar prevalence of functioning arteriovenous fistula using pre-operative vein mapping. *Clin Nephrol* 2002;58(3):211–4.

EDITOR'S COMMENT

The need for hemodialysis access creation has markedly increased over the last 20 years and will likely to continue to do so as patients generally live longer due to improvement in cardiovascular health. Indeed, elderly patients were once defined as over 65, but now make up the bulk of all hemodialysis access procedures. Several important points are brought up in this very comprehensive and detailed chapter by a group with much experience and outstanding published outcomes.

One of the primary benefits of timely autologous access creation is to avoid a tunneled catheter. Tunneled catheters are associated with numerous problems, but most concerning is bloodstream infection (Napalkov P, Felici DM, Chu LK, et al. Incidence of catheter-related complications in patients with central venous or hemodialysis catheters: a health care claims database analysis. *BMC Cardiovasc Disord* 2013;13:86). Indeed, septicemia related to catheter use contributes to endocarditis and potential significant mortality. Hemodialysis access created with autogenous tissue is ideal because it avoids the risk of infection associated with a prosthetic, and, if the fistula matures, has an excellent long-term patency rate of ~60% to 70% (Al-Jaishi AA, Oliver MJ, Thomas SM, et al. Patency rates of the arteriovenous fistula for hemodialysis: a systematic review and meta-analysis. *Am J Kidney Dis* 2014;63:464–78). However, the "Achilles heel" of autogenous access is fistula maturation. While

the technical aspects of fistula creation are straightforward, and actual fistula thromboses are low, incomplete fistula maturation is a problem that effects up to 30% or 40% of all hemodialysis access cases (Patel ST, Hughes J, Mills JL, Sr. Failure of arteriovenous fistula maturation: an unintended consequence of exceeding dialysis outcome quality Initiative guidelines for hemodialysis access. *J Vasc Surg* 2003;38:439–45; discussion 445). Research to define and improve this is ongoing, including a large prospective multicenter trial sponsored by the NIH to look at access fistula maturation factors. However, in my experience, the conduit size and quality are most important for early success. This of course assumes an adequate inflow arterial source, readily confirmed in the vascular lab and by checking bilateral blood pressures.

Another major issue is predicting when a patient should have an autogenous access created, in relation to when they will start hemodialysis (Shechter SM, Skandari MR, Zalunardo N. Timing of arteriovenous fistula creation in patients with CKD: a decision analysis. *Am J Kidney Dis* 2014;63:95–103). This has still not been devised with good prognostic certainty; however, patients with lower glomerular filtration rate, diabetes, and significant proteinuria all have a more accelerated rate of requiring hemodialysis for renal replacement. A concern is that creating a fistula too early means the patient may undergo an unneeded surgery, but more so that when the fistula is needed, it may now have a diminished lifespan because it has been in place for months to years. Placing a fistula after the patient is on hemodialysis is fraught with an increased failure rate and the need for a temporary tunneled catheter, with all its attendant problems.

Salvage of autogenous arteriovenous access is now more commonly successful, and effectively done using covered endoluminal stents for areas of long segment stenosis, stricture, and sometimes pseudoaneurysms. Indeed, prosthetic-covered stents are well utilized in this regard and seem to have less risk of neointimal hyperplasia than a primary prosthetic arteriovenous fistula graft configuration. However, infection risk does remain, occasionally necessitating stent removal with loss of access.

Whether post procedure duplex ultrasound can help define those fistulas at increased risk of failure has recently been shown in a retrospective study (Itoga NK, Ullery BW, Tran K, et al. Use of a proactive duplex ultrasound protocol for hemodialysis access. *J Vasc Surg* 2016;64:1042–9.e1). One of my partners uses this strategy to detect potentially failing grafts and uses the balloon-assisted maturation technique that has been popularized over the last several years (Roy-Chaudhury P, Lee T, Woodle B, et al. Balloon-assisted maturation (BAM) of the arteriovenous fistula: the good, the bad, and the ugly. *Semin Nephrol* 2012;32:558–63). Whether this leads to actual increase fistula utilization or increased fistula life has yet to be proven.

The operative techniques are well described in this chapter, including the diagrams and technical points. I would only differ in that I see no benefit to a staged brachial-basilic access as compared to a single stage. A two-stage

approach subjects the patient to two operations, and often the need to move the fistula up to a more proximal arterial site, as noted by the authors. Given the average size of the basilic vein, maturation is not an issue. However, many disagree with the single-stage procedure, but I have not found a detriment to a single-stage procedure to change my practice.

Complications of arterial steal are real, and are well highlighted in this chapter. Steal needs to be recognized in a rapid manner to prevent critical hand debility issues, such as ischemic changes, neuropathic pain, and inability to use the hand. This can be a devastating complication if unrecognized. The authors lay out useful risk predictors of ischemia related to autogenous arteriovenous fistulas.

Lastly, this topic highlights that novel conduit options for hemodialysis access are needed. A holy grail is to have a prosthetic graft that would be resistant to infection and resistant to neointimal hyperplasia. However, this is unlikely to be seen within the next decade. However, there are biologic grafts that are now being tested for use in the hemodialysis access arena and hold promise that there would be a true biologic construct that rivals or betters human vein.

Peter Henke

227 Hemodialysis Access-Prosthetic Arteriovenous Access

Robyn A. Macsata and Anton N. Sidawy

In 2012, data from the United States Renal Data System (USRDS) showed that 114,813 new patients began therapy for end-stage renal disease (ESRD), whereas the prevalent dialysis population reached 636,905. Of note, after a continuous rise in ESRD patients between 1980 and 2010, for the first time a plateau or even slight decline was seen between 2010 and 2012. Despite this, total Medicare costs for ESRD patients increased by 3.2%, to $28.6 billion, accounting for 5.6% of the total Medicare budget. Not surprising to vascular access surgeons, most of these costs come between the transitions from chronic kidney disease (CKD) to ESRD and are related to dialysis access. With these ongoing numbers and ever increasing cost of care of renal patients, placement of successful permanent arteriovenous (AV) access is essential.

Because of known higher long-term patency rates and lower complication rates of autogenous AV access in comparison with prosthetics, we attempt to place autogenous AV access in all our patients with ESRD. In order to achieve success, we stress early referral of these patients from our nephrologists, a thorough preoperative evaluation including noninvasive vascular laboratory testing, particularly superficial venous mapping, and contrast studies if necessary, and routine postoperative follow-up with secondary procedures if indicated. Unfortunately, even with these efforts, it is sometimes impossible to construct an autogenous AV access, requiring placement of a prosthetic AV access. To achieve success in this population, thorough pre- and postoperative evaluations as well as meticulous surgical technique are even more imperative.

INDICATIONS

The National Kidney Foundation-Disease Outcomes Quality Initiative (NKF-KDOQI) guidelines recommend that patients be referred to a

vascular access surgeon for permanent AV access when their creatinine clearance is less than 25 mL/min. Once preoperative evaluation is complete, if we feel the patient will require a prosthetic AV access, we delay construction of the access until 3 to 6 weeks prior to the initiation of dialysis; this is due to the fact that prosthetic access patency is limited by time of access placement, and not by access use.

PREOPERATIVE PLANNING

History and Physical Examination

A thorough patient history is taken documenting patient's dominant extremity, recent history of peripheral intravenous lines, site of indwelling or previous central venous lines including pacemakers and defibrillators, all previous access procedures, any history of trauma or previous nonaccess surgery to the extremity, and all co-morbid conditions. On physical examination, the brachial, radial, and ulnar arteries are evaluated for compressibility and equality; an Allen test is performed to evaluate for palmar arch patency. With a venous tourniquet in place, the cephalic and basilic veins are evaluated for diameter, distensibility, and continuity; the arm is examined for any signs of central venous stenosis including prominent venous collaterals, edema, or a differential in extremity diameter.

Arterial Assessment

If any abnormality is noted on clinical arterial examination, the patient is further evaluated with segmental pressures and duplex ultrasound. Any abnormalities noted on noninvasive testing, including pressure gradients between the bilateral upper extremities, arterial diameters less than 2.0 mm, and nonpatent palmar arches, are further evaluated with an arteriogram. Any inflow stenosis is treated first with endovascular techniques such as angioplasty and/or stenting, and if not amenable or unsuccessful, open surgical techniques such as patch angioplasty or bypass.

Venous Assessment

If superficial veins cannot be visualized or any abnormality is noted on the superficial venous examination, the patient is further evaluated with superficial venous duplex; using duplex the superficial veins are examined

for diameter, distensibility, and continuity. We only use superficial veins for autogenous access that are greater than 2.5 mm in diameter.

If any central venous stenosis is suspected by history or any abnormality is noted on physical examination, the patient is further evaluated with deep venous duplex; if the deep venous duplex is non-diagnostic or any central venous stenosis is noted, the patient is further evaluated with a venogram. Any central venous stenosis is treated first with endovascular techniques such as angioplasty and/or stenting, and if not amenable or unsuccessful, open surgical techniques such as internal jugular to axillary venous bypass or subclavian vein turndown.

In patients nearing dialysis, the risk of contrast arteriogram or venogram is weighed against the need for an access to mature before beginning dialysis; in this population, we use renal protective agents prearteriogram, including intravenous fluids, *N*-acetylcysteine, and sodium bicarbonate.

ACCESS LOCATION SELECTION

Table 227.1 lists the various types of autogenous and prosthetic AV access available in the upper and lower extremities and body wall; when planning AV access, a few general principles apply.

1. Given their superior patency rates and lower complication rates, autogenous AV accesses are always attempted before a prosthetic AV access.
2. Due to easier accessibility and lower infection rates, upper-extremity access sites are used first, with the nondominant arm given preference over the dominant arm.
3. To preserve proximal sites for future accesses, AV accesses are placed as far distally in the extremity as possible.
4. Autogenous AV access configurations, in order of preference, are direct AV anastomosis, venous transpositions, and venous translocations.

For purposes of this chapter, we will focus on prosthetic AV access.

TABLE 227.1 Arteriovenous Access Configuration

Upper Extremity

Forearm

1. Autogenous
   a. Autogenous posterior radial branch–cephalic wrist direct access (snuffbox fistula)
   b. Autogenous radial–cephalic wrist direct access (Brescia–Cimino–Appel fistula)
   c. Autogenous radial–cephalic forearm transposition
   d. Autogenous brachial (or proximal radial)–cephalic forearm looped transposition
   e. Autogenous radial–basilic forearm transposition
   f. Autogenous ulnar–basilic forearm transposition
   g. Autogenous brachial (or proximal radial)–basilic forearm looped transposition
   h. Autogenous radial–antecubital forearm indirect greater saphenous vein translocation
   i. Autogenous brachial (or proximal radial)–antecubital forearm indirect looped greater saphenous vein translocation
   j. Autogenous radial–antecubital forearm indirect femoral vein translocation
   k. Autogenous brachial (or proximal radial)–antecubital forearm indirect looped femoral vein translocation
2. Prosthetic
   a. Prosthetic radial–antecubital (or brachial) forearm straight access
   b. Prosthetic brachial (or proximal radial)–antecubital (or brachial) forearm looped access

Upperarm

1. Autogenous
   a. Autogenous brachial (or proximal radial)–cephalic upper arm direct access
   b. Autogenous brachial (or proximal radial)–cephalic upper arm transposition
   c. Autogenous brachial (or proximal radial)–basilic upper arm transposition
   d. Autogenous brachial (or proximal radial)–brachial (vein) upper arm transposition
   e. Autogenous brachial (or proximal radial)–axillary (or brachial) upper arm indirect greater saphenous vein translocation
   f. Autogenous brachial (or proximal radial)–axillary (or brachial) upper arm indirect femoral vein translocation
2. Prosthetic
   a. Prosthetic brachial (or proximal radial)–axillary (or brachial) upper arm straight access

Lower Extremity

1. Autogenous
   a. Autogenous femoral–greater saphenous lower-extremity (straight or looped) transposition
   b. Autogenous tibial (anterior or posterior)–greater saphenous lower-extremity direct access
   c. Autogenous femoral–femoral (vein) lower-extremity (straight or looped) transposition
2. Prosthetic
   a. Prosthetic superficial femoral–femoral (vein) lower-extremity straight access
   b. Prosthetic superficial femoral (or common or profunda femoral)–femoral (vein) lower-extremity looped access

Body Wall

1. Prosthetic
   a. Prosthetic axillary–axillary (vein) chest (straight or looped) access
   b. Prosthetic axillary–internal jugular chest looped access
   c. Prosthetic axillary–femoral (vein) body wall access

Adapted from Sidawy AN, Gray R, Besarab A, et al. Recommended standards for reports dealing with arteriovenous hemodialysis accesses. *J Vasc Surg* 2002;35(3):603–10; with permission from Elsevier.

Forearm

In the upper extremity, the cephalic and basilic veins are both options for autogenous AV access; however, when unavailable, we perform a prosthetic upper-extremity access, beginning in the forearm. Sources of arterial inflow include the distal or proximal radial and brachial arteries; we use the most distal artery in the arm felt to be adequate by preoperative evaluation for inflow to preserve more proximal arteries for future accesses. Sources of venous outflow include the antecubital vein or the brachial vein; we prefer to use the superficial system if felt to be adequate on exploration to help with venous dilation of the upper arm superficial veins for future accesses. Therefore, when the distal radial artery is adequate, we perform a prosthetic radial–antecubital (or brachial vein) forearm straight access (Fig. 227.1). If the distal radial artery is inadequate but the brachial or proximal radial artery is adequate, we perform a prosthetic brachial (or proximal radial)–antecubital (or brachial vein) forearm looped access (Fig. 227.2).

One of the interesting debates in this area is whether, after exhausting the forearm autogenous options, the surgeon should recommend a forearm prosthetic access before proceeding to an upper arm autogenous access. We handle this decision by having a discussion with the patient about this alternative option and its advantages and disadvantages, and allow the patient to make an informed decision. If a prosthetic forearm access is chosen, we explain to the patient that this access is used as a "bridge" to an autogenous upper arm access; we minimize attempts to salvage this access to avoid damaging the venous outflow so it can still be used for an autogenous upper arm access.

Upper Arm

When use of the forearm has been exhausted, efforts are directed to the upper arm. Like the forearm, the cephalic and basilic veins are both options for autogenous access; however, when unavailable, we perform a prosthetic upper arm access. Sources of arterial inflow include the proximal radial and brachial arteries; we use the most distal artery in the arm felt to be adequate by preoperative evaluation for inflow to preserve more proximal arteries for future access. Sources of venous outflow include the proximal brachial and axillary vein. Therefore, in patients with no adequate vein, a prosthetic brachial (or proximal radial)–axillary (or brachial vein) upper arm straight access (Fig. 227.3) is performed.

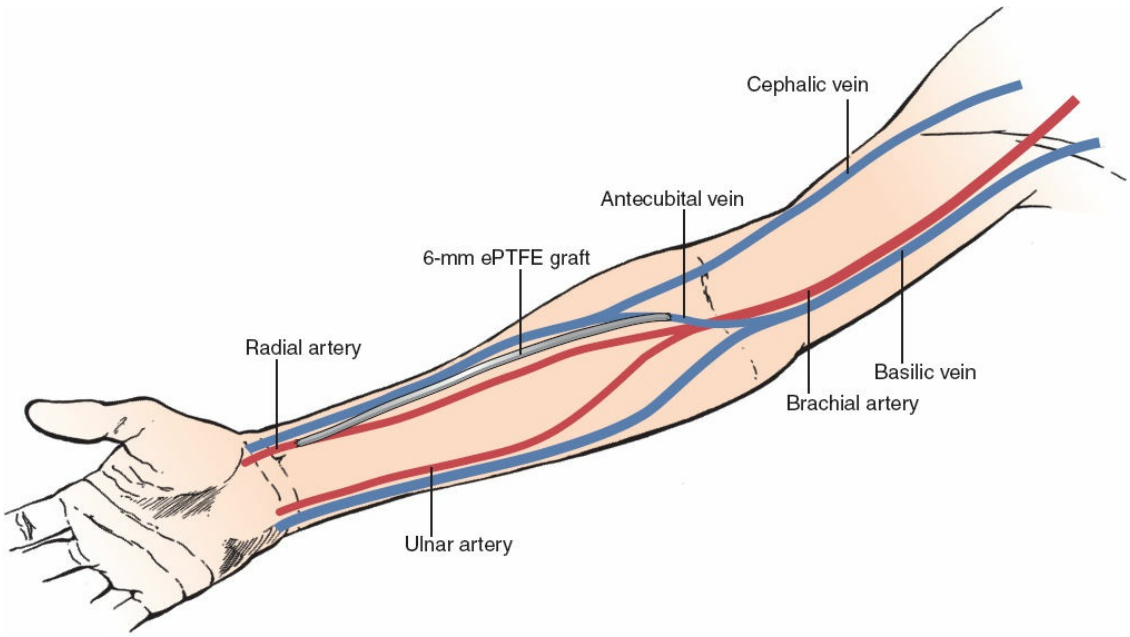

Figure 227.1. Prosthetic radial–antecubital forearm straight access. ePTFE, expanded polytetrafluoroethylene.

Lower Extremity

When use of the bilateral upper extremities has been exhausted, efforts are directed to the lower extremity; this access is less desirable due to the higher incidence of occlusive disease, arterial steal, and infections. As with upper-extremity access, autogenous access is preferred; the greater saphenous and superficial femoral veins are both options for autogenous AV access. When these veins are not available, we perform a prosthetic lower-extremity access. Sources of arterial inflow include the common, proximal and distal superficial, and profunda femoral arteries; we use the most distal artery in the leg felt to be adequate by preoperative evaluation for inflow to preserve more proximal arteries for future access. Sources of venous outflow include the common, superficial, and profunda femoral vein. Therefore, in patients with an adequate distal superficial femoral artery, we perform a prosthetic superficial femoral–femoral (vein) lower-extremity straight graft (Fig. 227.4). In patients with an inadequate distal superficial femoral artery but adequate proximal artery, we perform a prosthetic superficial femoral (or common or profunda femoral)–femoral (vein) lower-extremity loop graft (Fig. 227.5).

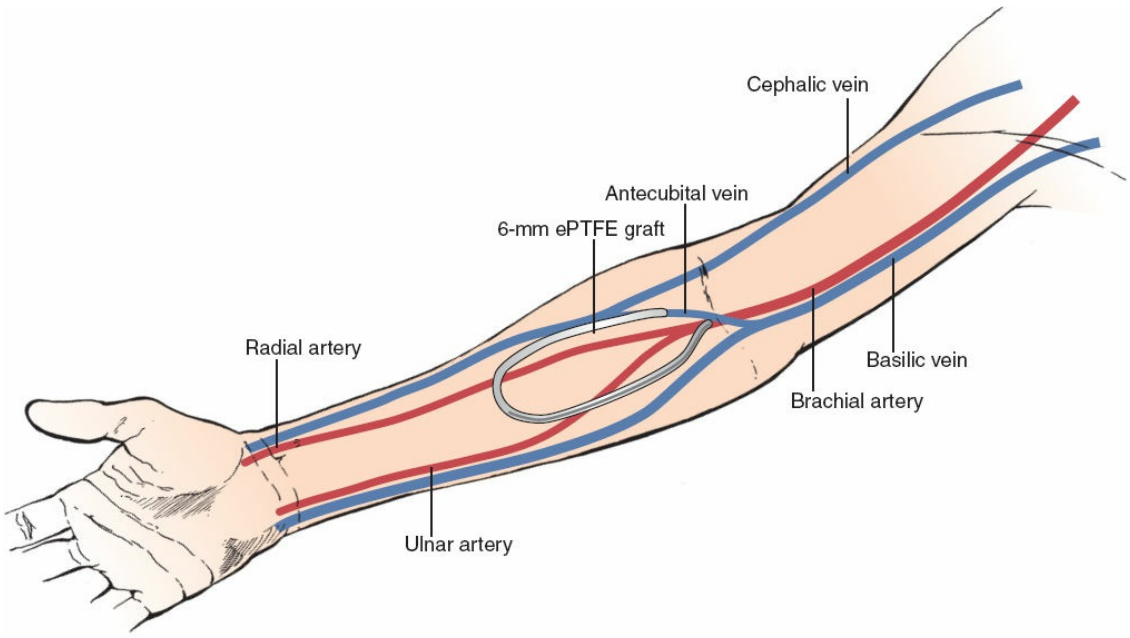

Figure 227.2. Prosthetic brachial–antecubital forearm looped access. ePTFE, expanded polytetrafluoroethylene.

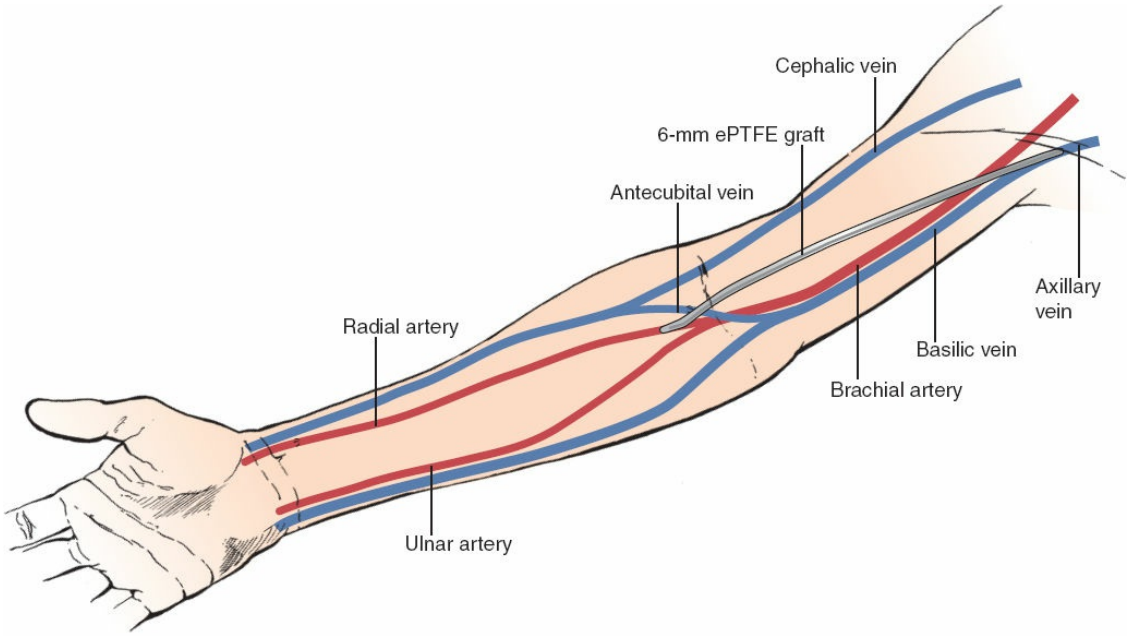

Figure 227.3. Prosthetic proximal radial–axillary upper arm straight access. ePTFE, expanded polytetrafluoroethylene.

Body Wall

After both upper and lower extremities have been exhausted, body wall access is used as a last alternative access site; these accesses almost always require a prosthetic graft. The main source of arterial inflow is the axillary artery. Sources of venous outflow include the axillary, internal jugular, and femoral veins. Appropriate options include a prosthetic axillary–axillary (vein) chest (straight or looped) access, a prosthetic axillary–internal jugular chest looped access, and a prosthetic axillary–femoral (vein) body wall access.

Choice of Graft Material

A standard 6-mm expanded polytetrafluoroethylene (ePTFE) is our choice for graft material for prosthetic AV accesses. Variations of the standard ePTFE graft include thin-walled, extended stretch, external rings, various tapered configurations, and heparin coating, which are all meant to ease handling, provide external support, and improve patency rates. To date, there is only minimal evidence that any of these variations improve long-term results, and therefore, use of any of these variations remains a matter of surgeon preference.

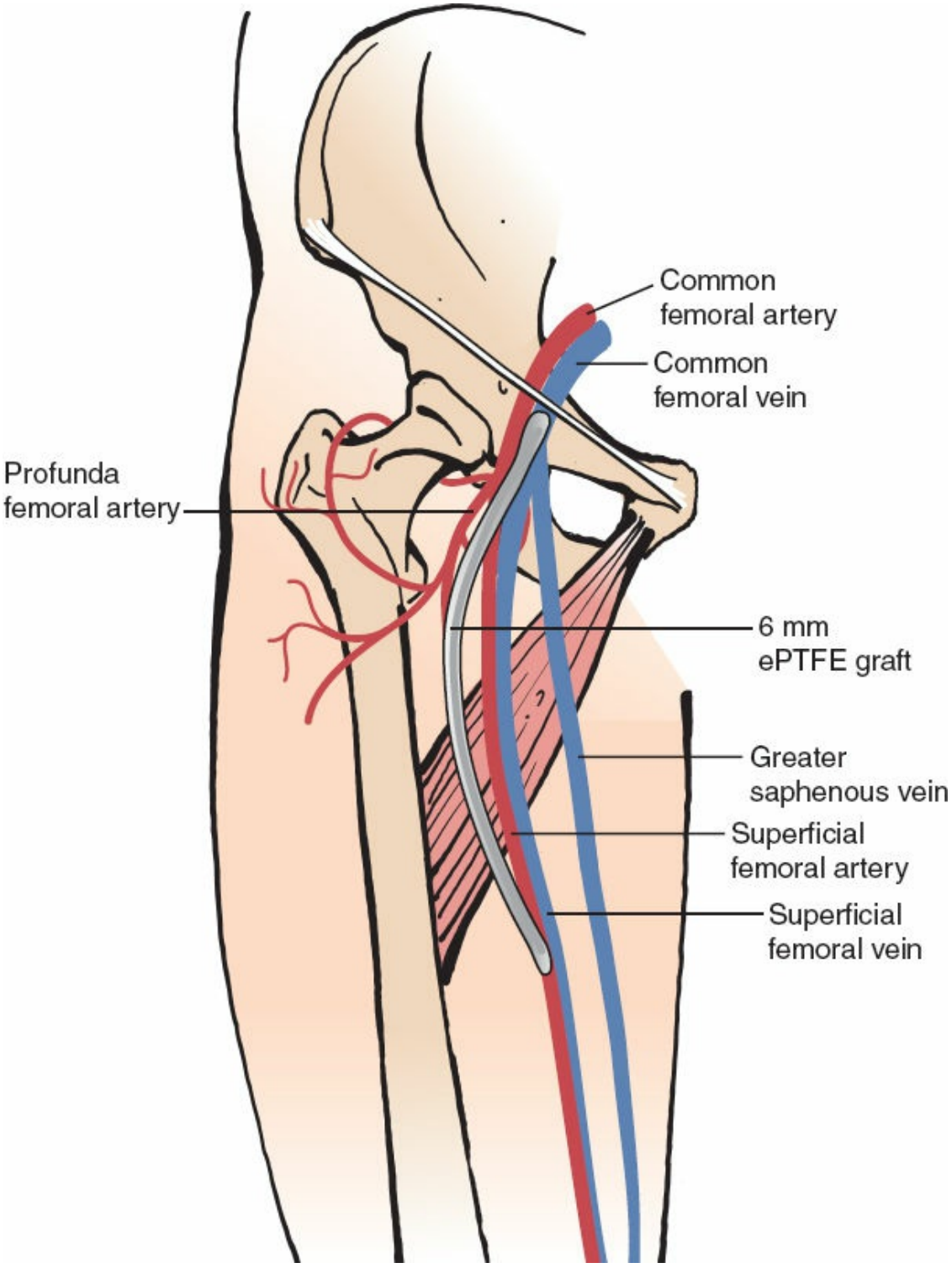

Figure 227.4. Prosthetic superficial femoral–femoral (vein) lower-extremity straight access. ePTFE, expanded polytetrafluoroethylene.

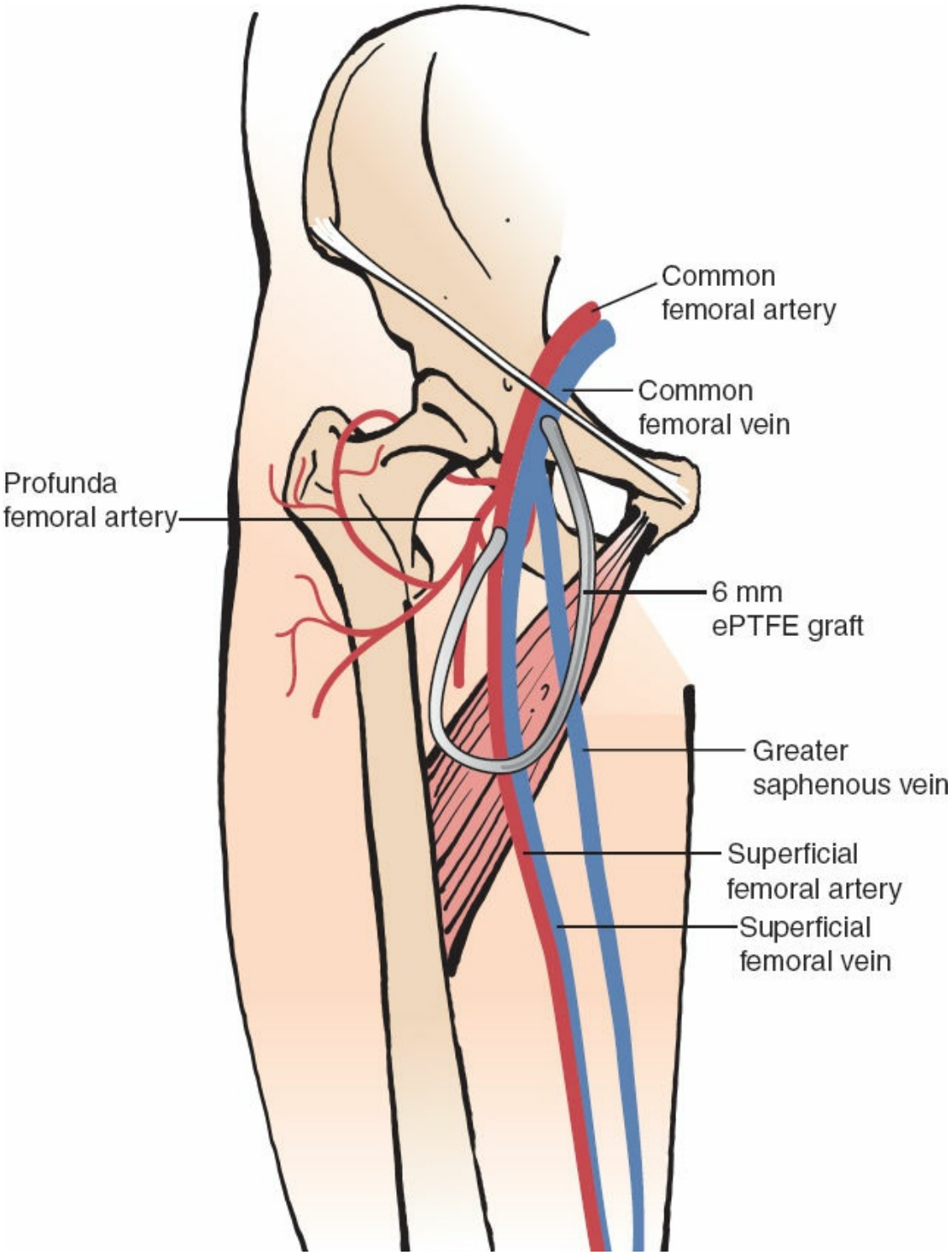

Figure 227.5. Prosthetic superficial femoral–femoral (vein) lower-extremity looped access. ePTFE, expanded polytetrafluoroethylene.

There has also been development of early cannulation prosthetic grafts (Acuseal, W. L. Gore, Flagstaff, AZ, Flixene Maquet-Atrium Medical Rastatt Germany, and Vectra Bard Covington GA), generally constructed

in three layers, with an elastomeric membrane sandwiched in between two layers of ePTFE material. This configuration hinders suture line and dialysis cannulation needle bleeding allowing for early cannulation, reported as soon as 24 hours from implantation. Thus, offering the potential for either avoidance of or early removal of short- and long-term dialysis catheters. Similar to other variations of prosthetic accesses, there is minimal evidence that this variation improves long-term results; therefore, use or this variation remains a matter of surgeon preference.

Hemodialysis Reliable Outflow Graft

The Hemodialysis Reliable Outflow (HeRO) graft (Hemosphere/CryoLife Inc, Eden Prairie, MN) is an innovative approach to obtain permanent AV access in patients with central venous occlusions not amenable to open or endovascular means of recanalization. The HeRO graft has two components: the venous outflow component, which is inserted into the central venous system proximal to any occlusion, similar to a temporary dialysis access line, and the arterial graft component, which is made of 6 mm ePTFE and is tunneled under the skin and sewn into the arterial inflow similar to permanent AV access (Fig. 227.6). Due to its relatively low patency and high complication rates, we generally reserve HeRO grafts for a last resort measure on ESRD patients with central venous occlusions and temporary lines as their only alternative option for dialysis access.

SURGICAL TECHNIQUE

As described above, prosthetic AV access may be performed with multiple different options for arterial inflow, conduit, and venous outflow. Despite these different options, surgical technique is similar. Steps common to all prosthetic AV accesses include the following:

1. Due to the risk of cardiopulmonary complications associated with general anesthesia, we prefer to perform AV accesses with local nerve block.
2. Because most early access failures are due to inadequate venous outflow, the venous outflow is dissected first, to ensure that it is adequate before proceeding further; it is controlled with vessel loops.
3. The arterial inflow is dissected and controlled with vessel loops.
4. A standard 6-mm ePTFE prosthetic graft is used for conduit.
5. The subcutaneous tunnel is made with a Kelly–Wick tunneler; the tunnel is made as superficial as possible to allow easy detection by

dialysis personnel and as long as possible for a large service area to prevent repetitive trauma to the same area of the graft and subsequent pseudoaneurysm (PSA) formation. Of note, early cannulation grafts generally require tunnelers specialized to the manufacturer.

6. If the venous outflow and arterial inflow are located away from each other, a straight prosthetic AV access configuration is performed. If the venous outflow and arterial inflow are located close to each other, a loop prosthetic AV access configuration is performed; this requires a counter-incision at the apex of the loop.
7. The length of the arteriotomy is not limited; the diameter of the graft will limit the incidence of arterial steal.
8. The artery is flushed proximally and distally with heparinized saline to avoid thrombosis during the anastomosis.
9. The arterial anastomosis is performed using a 6-0 or 7-0 monofilament nonabsorbable suture in a continuous manner.
10. As with arteriotomy, the length of the venotomy does not need to be limited.
11. The vein is flushed proximally and distally with heparinized saline to avoid thrombosis during the anastomosis.
12. The venous anastomosis is performed using a 6-0 or 7-0 monofilament non-absorbable suture in a continuous manner.
13. After completing both anastomoses, a thrill should be felt in the prosthetic graft and venous outflow tract.
14. The incision is closed in layers, to provide surface coverage for the graft; careful attention to sterile technique is paramount to avoid graft infections.

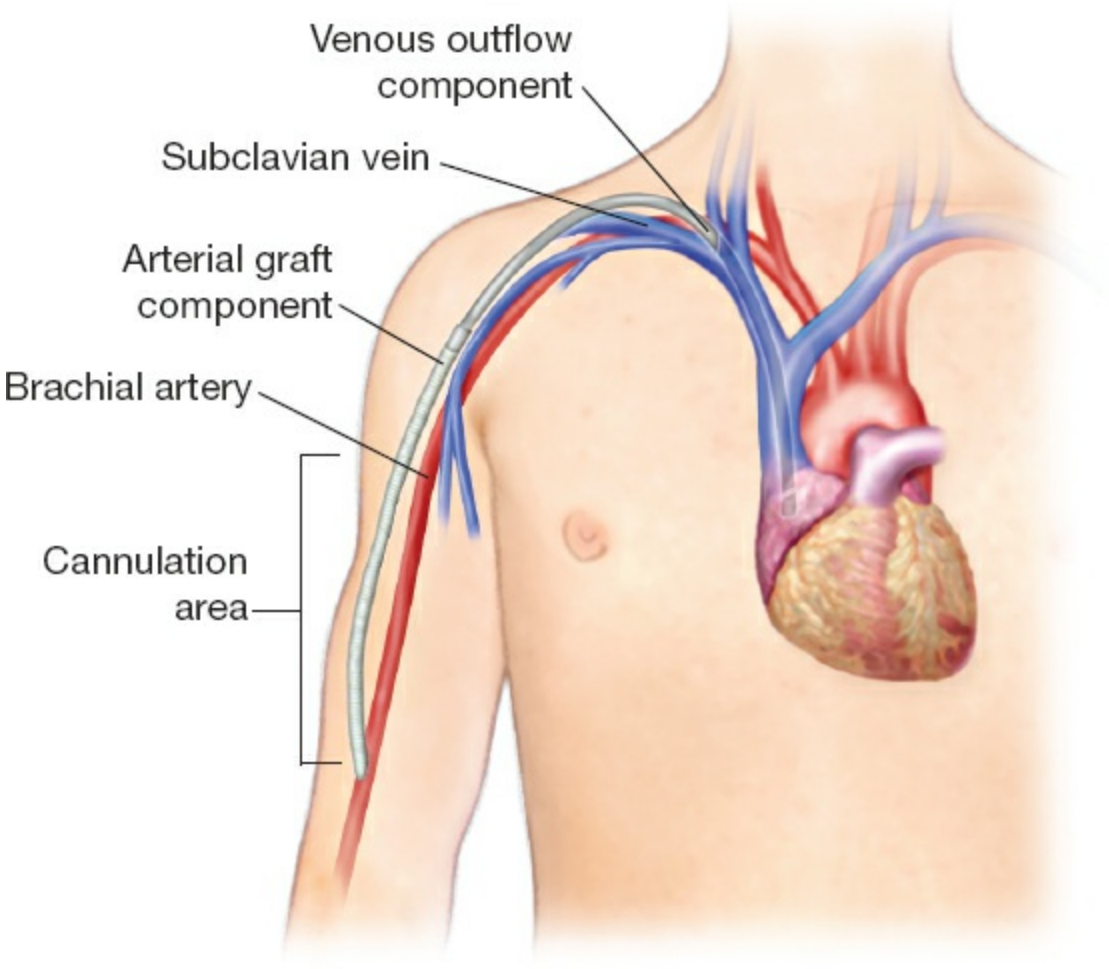

Figure 227.6. HeRO catheter insertion.

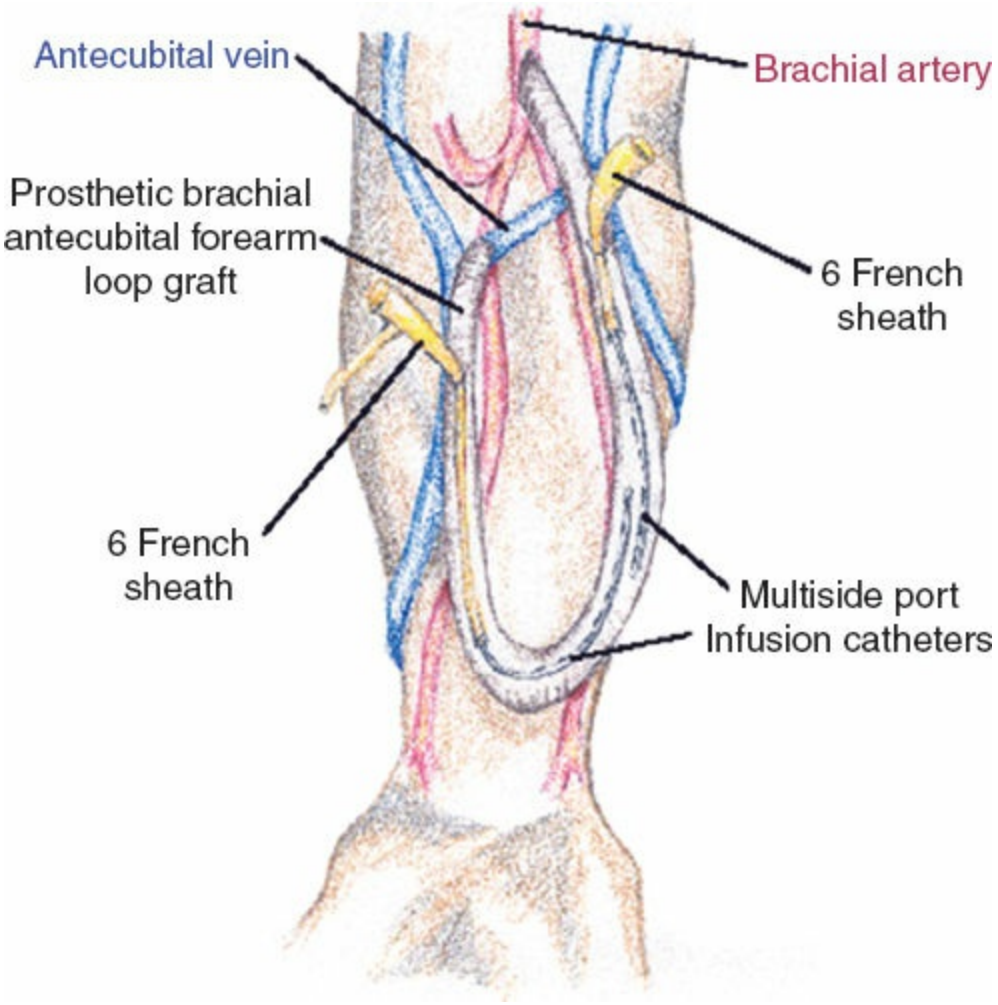

Figure 227.7. Prosthetic brachial-antecubital forearm looped access thrombolysis using cross-catheter technique.

POSTOPERATIVE CARE

We follow up our patients postoperatively until their access is mature and ready for cannulation; for standard prosthetic AV access this may be as soon as 2 weeks and for early cannulation prosthetic AV access immediate. After initial maturation, the AV access is monitored by nephrology while on dialysis. Our preferred method of monitoring is monthly determination of access flow by ultrasound dilution, conductance dilution, thermal dilution, or Doppler technique. Other options include measurement of static venous pressures, measurement of prepump arterial dialysis pressure, measurement of access recirculation using urea concentrations or dilution techniques, evaluation of physical findings such as arm edema, altered characteristics of access thrill, or notation of prolonged bleeding after needle removal. We have found routine duplex surveillance not to be beneficial for long-term patency rates, and therefore,

do not use this method.

COMPLICATIONS AND THEIR MANAGEMENT

For the purposes of this chapter, we will highlight the management of complications more commonly associated with prosthetic accesses.

Late AV Access Thrombosis

Late AV access thrombosis occurs due to intimal hyperplasia; this is most commonly seen at the graft–venous anastomosis but may also occur in the central veins related to catheter use. Treatment options for declotting a prosthetic AV access are either percutaneous techniques including thrombolysis and mechanical thrombectomy or open surgical thrombectomy. Once the prosthetic access is successfully declotted, to avoid repeated thrombosis, it is imperative that the source of thrombosis be identified and appropriately treated.

For endovascular treatment, we prefer thrombolysis using a cross-catheter technique. We perform this by placing two 6-Fr sheaths into the prosthetic access, one placed at the arterial end aimed to the venous end and the other placed at the venous end aimed to the arterial end. Each sheath is accessed with a 0.035-in hydrophilic wire; multi side port infusion catheters are fed over the wires, and left in the thrombosed portion of the AV access (Fig. 227.7). About 5 mg of tPA with 70 IU/kg of heparin is administered via the infusion catheters using a pulse-spray technique balloon; angioplasty (4- to 6-mm balloon) is used to macerate any residual thrombi. After successful declotting, we perform a fistulogram/venogram and balloon angioplasty (6- to 10-mm balloon) for any underlying stenosis identified.

For open surgical treatment, we expose the graft–venous anastomosis and perform a thrombectomy using Fogarty balloons through this anastomosis. After successful declotting, we perform a patch angioplasty to treat any intimal hyperplasia. As with the endovascular technique, we perform a completion fistulogram/venogram and balloon angioplasty (6- to 10-mm balloon) of any other underlying stenosis identified.

TABLE 227.2 Autogenous AV Access Patency Rates

Access Location	Primary Patency (%)	Primary Patency (%)	Secondary Patency (%)	Secondary Patency (%)
	1-year	**2-year**	**1-year**	**2-year**
Upper extremity	43–85	40–69	46–90	62–75
Lower extremity	73	68	86	87–94

Infection

Prosthetic graft infections usually are due to Gram-positive organisms, most commonly *Staphylococcus aureus*, however, up to 25% of infections may involve Gram-negative organisms or be polymicrobial. Infections are seen at a rate to 4% to 20% per year in prosthetic AV access while only at a rate of 0.56% to 5% in autogenous.

Treatment varies based on presentation; if a patient has only a mild cellulitis, we use a trial of broad spectrum antibiotics with close observation. If a patient fails antibiotics or presents with a more severe cellulitis, an abscess, exposed prosthetic material, or sepsis, we remove the infected portion of the graft, leaving all wounds open, and place the patient on broad spectrum antibiotics. If on exploration, either anastomosis is involved, we remove the entire graft to prevent anastomotic disruption.

Pseudoaneurysm

PSAs are due to continuous accessing of the graft in the same location by dialysis personnel; since this requires an arterial and venous puncture with each session, they usually occur in pairs and are located along the length of the access. If they are located at either the arterial or venous anastomosis, they are due to graft infection and are treated as such.

We monitor most puncture site PSAs, instructing dialysis personnel to use alternative sections of the access for cannulation. We repair PSAs that are greater than 3.0 cm, ulcerated, or are noted to be significantly expanding while being monitored. Our preferred method of repair is replacement of the involved section with a new graft; an alternative approach is endovascular treatment with covered stent grafts. With either procedure, postoperative dialysis is continued by accessing the uninvolved portion of the access.

TABLE 227.3 Prosthetic AV Access Patency Rates

Access Location	Primary Patency (%)	Primary Patency (%)	Secondary Patency (%)	Secondary Patency (%)
	1-year	**2-year**	**1-year**	**2-year**
Upper extremity	40–54	18–30	59–65	40–60
Lower extremity	54	18–47	64	18

Seroma

The exact etiology of seromas are unknown, but they are presumed to occur from transudation of serous fluid from the porous graft. They are most commonly seen within 1 month of graft placement and surrounding the arterial anastomosis.

Seromas rarely resolve without intervention and commonly reoccur if treated with aspiration or incision and drainage alone. We find graft replacement, using a different type of graft material routed in a new tunnel, to have the highest likelihood of success.

Steal

Arterial steal occurs secondary to low access tract resistance, creating reversal of blood flow in the arterial outflow tract toward the access and away from the hand. Occurrence rates depend on the site of arterial inflow, with clinically symptomatic steal being seen in 0.25% to 1.8% of wrist accesses and 4% to 9% of upper arm access, regardless of the access being autogenous or prosthetic.

Outflow Venous Obstruction

Venous hypertension occurs secondary to venous outflow stenosis; the outflow obstruction is commonly located in the subclavian vein as a result of intimal hyperplasia associated with venous catheters but may be seen anywhere in the outflow tract. Similar to arterial steal, its occurrence is similar in both autogenous and prosthetic AV access.

OUTCOMES OF AVG

In the upper extremity, prosthetic AV access has consistently been shown to have poorer primary and secondary patency rates when compared to autogenous AV access. Prosthetic AV access 1- and 2-year primary patency rates of 40% to 54% and 18% to 30%, respectively, are clearly inferior to autogenous access 1- and 2-year primary patency rates of 43%

to 85% and 40% to 69%, respectively. Similarly, prosthetic access 1- and 2-year secondary patency rates of 59% to 65% and 40% to 60%, respectively, are also inferior to autogenous AV access 1- and 2-year secondary patency rates of 46% to 90% and 62% to 75%, respectively. Furthermore, to achieve these secondary patency rates, prosthetic AV access requires more interventions (Tables 227.2 and 227.3).

Similar to the upper extremity, lower-extremity prosthetic AV access has consistently been shown to have poorer primary and secondary patency rates then autogenous AV access. Prosthetic AV access 1- and 2-year primary patency rates of 54% and 18% to 47%, respectively, are clearly inferior to autogenous access 1- and 2-year primary patency rates of 73% and 86%, respectively. Similarly, prosthetic access 1- and 2-year secondary patency rates of 64% and 18%, respectively, are also inferior to autogenous AV access 1- and 2-year secondary patency rates of 86% and 87% to 94%. And again, to achieve these secondary patency rates, prosthetic AV access requires more interventions (Tables 227.2 and 227.3).

Suggested Readings

Al Shakarchi J, Houston JG, Jones RG, et al. A Review on the Hemodialysis Reliable Outflow (HeRO) graft for haemodialysis vascular access. *Eur J Vasc Endovasc Surg* 2015;50(1):108–13.

Glickman MH, Burgess J, Cull D, et al. Prospective multicenter study with a 1-year analysis of a new vascular graft used for early cannulation in patients undergoing hemodialysis. *J Vasc Surg* 2015;62(2):434–41.

Huber TS, Carter JW, Carter RL, et al. Patency of autogenous and polytetrafluoroethylene upper extremity arteriovenous hemodialysis accesses: a systematic review. *J Vas Surg* 2003;38(5):1005–11.

Kapadia MR, Popowich DA, Kibbe MR. Modified prosthetic vascular conduits. *Circulation* 2008;117:1873–82.

Padberg FT, Calligaro KD, Sidawy AN. Complications of arteriovenous hemodialysis access: recognition and management. *J Vasc Surg* 2008;48(S):55S–80S.

Sidawy AN, Gray R, Besarab A, et al. Recommended standards for reports dealing with arteriovenous hemodialysis accesses. *J Vasc Surg* 2002;35:603–10.

Sidawy AN, Spergel LM, Besarab A, et al. The Society for Vascular Surgery: clinical practice guidelines for the surgical placement and maintenance of arteriovenous hemodialysis access. *J Vasc Surg* 2008;48(S):2S–25S.

Silva MB, Hobson RW, Pappas PJ, et al. A strategy for increasing use of autogenous hemodialysis access procedures: impact of preoperative noninvasive evaluation. *J Vasc Surg* 1998;27(2):302–8.

The National Kidney Foundation Kidney Disease Outcomes Quality Initiative (NKF KDOQI) [Internet]. The National Kidney Foundation. 2014 [cited 2015 Aug 25]. Available from: https://www.kidney.org/professionals/guidelines

United States Renal Data System. 2014 USRDS annual data report: *Epidemiology of kidney disease in the United States. National Institutes of Health, National Institute of Diabetes and Digestive and Kidney Diseases,* Bethesda, MD: 2014.

EDITOR'S COMMENT

As noted by the authors, the US Renal Data System suggests a projected dramatic increase in end-stage renal failure patients who will need HD access. This is, in part, because of patients living longer due to good cardiovascular care and other medical innovations. Thus, many patients who would have died of other causes ultimately succumb to renal failure and require renal replacement therapy, and are not able to get a transplant. Herein, the arterial venous graft (AVF) access technique is nicely described.

The AVG access is not the primary HD choice given the durability of native autologous AV access. However, while the NKF-KDOQI guidelines have made a significant impact for increasing autologous access creation, maturation and ultimate usability remain a problem. Further, many patients may not have adequate venous conduit to use for an AVF. The least acceptable HD route is the tunneled central venous catheter that is associated with higher morbidity/mortality primarily related to infectious and thrombotic complications (Astor BC, Eustace JA, Powe NR, et al. Type of vascular access and survival among incident hemodialysis patients: The choices for healthy outcomes in caring for ESRD (choice) study. *J Am Soc Nephrol* 2005;16:1449–55). As noted, many patients ultimately have long periods of time with invasive catheters, prior to AVF maturation or other issues.

There is recently a move toward proceeding with a prosthetic AVG if the vein is marginal as these can be accessed sooner and salvage techniques of AVG are reasonable, often comparable AVF in secondary patency (Disbrow DE, Cull DL, Carsten CG, 3rd, et al. Comparison of AV fistulas and AV grafts in patients with favorable vascular anatomy and equivalent access to health care: Is a reappraisal of the fistula first initiative indicated? *J Am Coll Surg* 2013;216:679–85; discussion 685–6). As noted by the authors, using the forearm and moving up the arm is generally accepted and I agree with that. Loop forearm AVGs at the antecubital site allows good venous outflow through the cephalic and basilic systems as well as the brachial venous system. Whether proceeding with a forearm prosthetic access before an upper arm autologous

access is debatable (Leake AE, Yuo TH, Wu T, et al. AV grafts are associated with earlier catheter removal and fewer catheter days in the united states renal data system population. *J Vasc Surg* 2015;62:123–7), and generally the decision should be based, I believe, on whether the patient is already on HD. If they are not and they are approaching dialysis, an autologous attempt is reasonable as they often have the luxury of time. However, if the patient has imminent need for dialysis, then utilizing an AVF is reasonable, particularly since it can be accessed within a month's time, or less.

Several unusual configurations such as body wall or more exotic inflow and outflow artery vein constructs are noted. Lower-extremity AVF are used rarely as they are at higher risk of infection, and may lead to leg steal that is more common than the upper extremity.

As noted also by the authors, the HeRO graft has been fraught with several reports of significant complications related to this technique and I agree with reserving this for rare occasions. The complications of AVG are nicely delineated in this chapter and include late thrombosis usually due to venous outflow and neointimal hyperplasia. Certainly this is an area where drug-luting balloons, stents, and other technologies may improve the patency. Infection remains a concern, although it is surprising given how often these grafts are accessed percutaneously; they really rarely develop, and salvage techniques are possible.

Peter Henke

I THORACIC

228 Thoracic Outlet Syndrome

Robert Thompson

Thoracic outlet syndrome (TOS) is a group of conditions caused by compression of the neurovascular structures that serve the upper extremity. The thoracic outlet is located within the lower part of the neck, behind the clavicle and above the first rib, and extending into the axilla, and it is often described by several closely related anatomic spaces, including the scalene triangle, the costoclavicular space, and the subcoracoid space (Fig. 228.1). Knowledge of these spaces and the structures that define them is critical toward understanding the clinical manifestations and optimal management of TOS.

ANATOMY

Musculoskeletal Structures and Spaces of the Thoracic Outlet

The scalene fat pad lies deep to the platysma layer in the supraclavicular space of the lower neck where it helps to protect the deeper muscular and neurovascular structures of the thoracic outlet. It attaches adjacent to the internal jugular vein and the undersurface of the clavicle, and contains lymph nodes and lymphatic channels as well as small arteries and veins. The lateral part of the omohyoid muscle also passes through the scalene fat pad as it traverses the lower part of the neck. The anterior scalene muscle (ASM) lies directly behind the scalene fat pad, arising from the transverse processes of the cervical vertebrae and running vertically to attach to the top of the first rib. The middle scalene muscle (MSM) also arises from the cervical spine, runs vertically posterior to the ASM, and attaches to the top of the posterolateral first rib. The narrow vertical space formed between the ASM and MSM, with the first rib at the base, is called the scalene triangle. The major nerves and blood vessels serving the upper extremity lie within or adjacent to the scalene triangle as they pass through the upper

part of the thoracic outlet. The area immediately between the first rib and the clavicle is the costoclavicular space. It is traversed by the subclavius muscle, which runs along the underside of the clavicle to attach to the first rib medial to the ASM. The subclavius muscle forms a band of dense connective tissue immediately lateral to and underneath the sternoclavicular joint, called the costoclavicular ligament. The subcoracoid space lies beyond the first rib and underneath the clavicle and is defined by the pectoralis minor muscle. This muscle lies deep to the pectoralis major muscle in the anterior upper chest, arising from the second, third, and fourth ribs. It runs upward to attach to a protrusion from the scapula known as the coracoid process, to which the short head of the biceps muscle tendon is also attached.

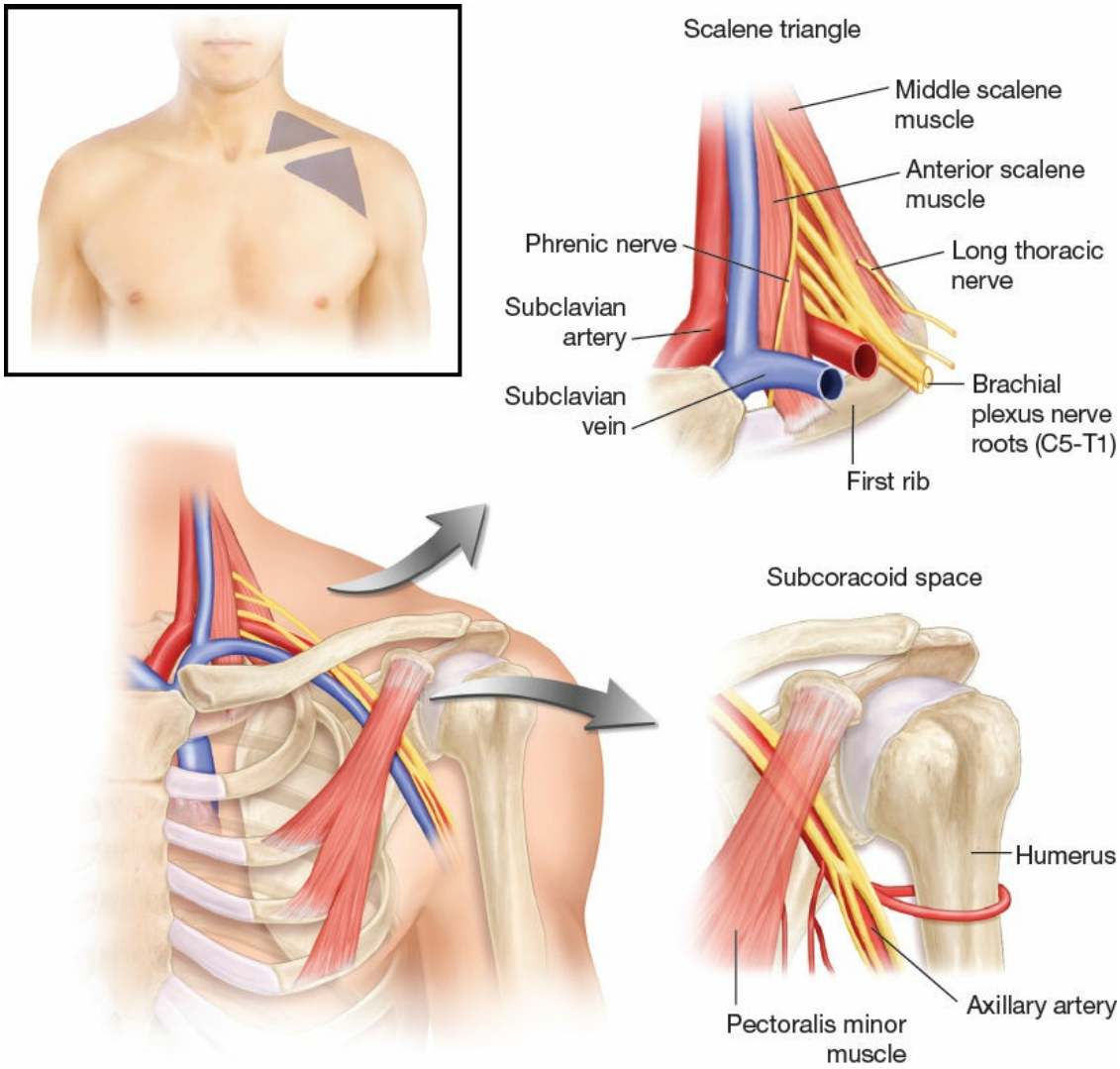

Figure 228.1. Overview of the anatomy of the thoracic outlet, focusing on the scalene triangle and the subcoracoid space. (From Thompson RW, Vemuri C. Neurogenic thoracic outlet

syndrome exposure and decompression: supraclavicular. In: Mulholland MW, Hawn MT, Hughes SJ, et al., eds. *Operative Techniques in Surgery*. Philadelphia, PA: Wolters Kluwer Health; 2015:1848–61.)

Nerves of the Thoracic Outlet

The motor and sensory nerves serving the upper extremity arise from cervical nerve roots C5 through T1. After leaving the spine and passing into the scalene triangle, these nerve roots bundle together and interconnect to form the initial trunks of the brachial plexus. The three trunks of the brachial plexus include the upper trunk (formed by fusion of the C5 and C6 nerve roots), the middle trunk (composed of the C7 nerve root), and the lower trunk (formed by fusion of the C8 and T1 nerve roots). The brachial plexus nerves pass through the scalene triangle and over the lateral first rib, before passing underneath the clavicle and pectoralis minor muscle to the axilla. Further merging and branching result in formation of the divisions, cords, and terminal nerves of the brachial plexus, as well as the peripheral nerves of the upper extremity.

The phrenic nerve forms from C3, C4, and C5 at the lateral border of the ASM, then descends on the muscle surface in a lateral to medial direction. It passes behind the subclavian vein into the superior mediastinum, then on to innervate the ipsilateral hemidiaphragm. The long thoracic nerve arises from C5, C6, and C7 within the body of the MSM, where its three components merge to form a single nerve. It passes through the MSM and over the posterolateral first rib, then descends to supply the serratus anterior muscle underneath the scapula. The cervical sympathetic chain passes vertically between the neck and the upper chest, lying along the posterior inner curve of the ribs. The sympathetic supply to the upper extremity arises from ganglia at T1 to T3, with several ganglia fused at the level of the first rib to form the large stellate ganglion that also supplies part of the face and eye.

Blood Vessels of the Thoracic Outlet

The subclavian artery arises from the innominate artery on the right and from the aorta on the left, in the upper chest and base of the neck. It passes up and over the first rib behind the ASM and immediately in front of the brachial plexus nerve roots, and is therefore within the scalene triangle. The vertebral artery and the internal thoracic artery arise from the

subclavian artery proximal to the scalene triangle, and several smaller branches arise behind the ASM, including the transverse cervical and inferior thyroid arteries (often from a common origin). Beyond the first rib and clavicle, the subclavian artery becomes the axillary artery where it passes underneath the pectoralis minor muscle. The distal axillary artery has a number of branches that serve the shoulder girdle, including the subscapular artery and the (anterior and posterior) circumflex humeral arteries. After passing in front of the shoulder, the axillary artery becomes the brachial artery.

Blood returning from the arm passes through a number of superficial and deep veins, which combine underneath the pectoralis minor muscle to form the axillary vein. The axillary vein passes underneath the clavicle and is joined by the cephalic vein to become the subclavian vein. The subclavian vein crosses over the first rib in front of the ASM (and is therefore not within the scalene triangle). It then passes through the space between the anterior first rib, clavicle, subclavius muscle, and costoclavicular ligament. After passing over the first rib, the subclavian vein joins the internal jugular vein as it descends from the neck, forming the innominate (or brachiocephalic) vein behind the sternoclavicular joint. The innominate vein passes further underneath the sternum to join with its counterpart from the other side, forming the superior vena cava.

Anatomic Variations and Acquired Changes in the Thoracic Outlet

Many natural variations in anatomy are found in the thoracic outlet. The most obvious is a congenital cervical rib, which occurs in approximately 0.5% of the population. Cervical ribs arise from the C7 transverse process and lie within the plane of the MSM. Osseous cervical ribs are readily detected by plain radiographs, but those composed of cartilage may not be easily identified. Complete cervical ribs attach directly to the first rib and act to displace the structures of the scalene triangle anteriorly. Partial cervical ribs can also occur, with a short segment of bony cervical rib and a ligamentous extension that attaches to the first rib; a wide C7 transverse process can also be associated with a ligamentous band in the same manner. Other rare bony anomalies include a partial (hypoplastic) first rib, an unusually high-lying first rib, or a fusion between the first and second ribs. Any of these anomalies may predispose to the development of neurovascular compression.

Soft tissue variations in the thoracic outlet are often too small to be detected by standard imaging (plain x-rays, computed tomography [CT] or magnetic resonance imaging [MRI] scanning), but are frequently seen at the time of surgery. For example, a scalene minimus muscle is a frequent variant in which muscle arising from the plane of the MSM passes between the nerve roots of the brachial plexus, then joins with the ASM to attach to the first rib. A number of different ligamentous or fibrofascial bands may also be present in the thoracic outlet, which frequently pass in front of or between the brachial plexus nerve roots. One of the best described is a fibrous band that runs from the back of the first rib to the front, crossing over (and compressing) the lower nerve roots. Langer's axillary arch is another anomalous fibrous band, which extends from the latissimus dorsi muscle to the coracoid process. When present, any of these soft tissue structural variations can contribute to nerve or blood vessel compression.

Acquired changes in the anatomy of the thoracic outlet often contribute, either directly or indirectly, to compression of the neurovascular structures. The most obvious examples are fractures of the first rib or clavicle. Fractures of the first rib are usually the result of considerable trauma associated with other severe injuries, but evidence of previous first rib fracture is occasionally observed during surgery for TOS, where callous at the fracture site may act to compress the adjacent neurovascular structures. Calcification, osteophytic degeneration, and occult nondisplaced fractures of the anterior first rib are also a frequent observation in patients with venous TOS. Fractures of the clavicle are relatively common and occur with a lesser degree of trauma than overt first rib fractures. Most clavicular fractures heal without consequence, but a large callous from a healed (or unhealed) fracture can protrude posteriorly to compress the underlying neurovascular structures. Anatomic changes can also occur within the soft tissues of the thoracic outlet, particularly when the scalene muscles are subjected to previous stretch injury, chronic strain, and repetitive overuse. In these situations, the scalene muscles undergo an inflammatory healing response that leads to fibrosis and other microscopic changes, making the muscles firm, prone to persistent spasm, and less resilient to positional changes. Localized healing responses can also lead to scarring and fibrosis directly around the brachial plexus nerve roots, which can subsequently contribute to nerve compression, irritation, and production of symptoms.

CLINICAL PRESENTATION

The clinical presentation of patients with TOS depends on the specific structures compressed, giving rise to three distinct conditions: (1) Neurogenic TOS, caused by compression of the brachial plexus nerves; (2) Venous TOS, caused by compression of the axillary and/or subclavian veins; and (3) Arterial TOS, caused by compression of the axillary and/or subclavian arteries. All three types of TOS are considered rare conditions, but clinical recognition and differentiation of these conditions are crucial in planning further steps in diagnosis and treatment.

Neurogenic TOS

Neurogenic TOS (85% to 95% of all patients with TOS) is characterized by compression of the brachial plexus nerve roots within the scalene triangle and/or subpectoralis space. This may be due to a combination of two factors: (a) predisposing variations in anatomy, such as anomalous scalene musculature, aberrant fibrofascial bands, or cervical ribs, and (b) neck or upper extremity injury that has resulted in scalene or pectoralis minor muscle spasm, fibrosis, and other pathologic changes. The symptoms of brachial plexus nerve root compression consist of pain, numbness, and tingling (paresthesias) in the neck, shoulder, arm, and hand. These symptoms can be somewhat variable throughout the day, and they may differ day-to-day, depending on levels of activity. The symptoms are also typically dynamic, with marked positional exacerbation during arm abduction, elevation, and other maneuvers. There are usually localizing tenderness and reproduction of symptoms on palpation over the scalene triangle and/or subpectoralis space. Patients with neurogenic TOS often have gradual development of symptoms, but can have acute exacerbations or a steady progression with increasing disability. The diagnosis of neurogenic TOS is difficult and often elusive, and may involve extensive testing, multiple specialist evaluations, and prolonged attempts at various forms of management.

Venous TOS

Venous TOS (10% to 15% of all patients with TOS) is characterized by subclavian vein compression between the clavicle, subclavius muscle, and first rib. Most patients present with abrupt spontaneous swelling of the entire arm, often with cyanotic discoloration, heaviness, and pain, which

form the characteristic features of axillary–subclavian vein "effort thrombosis." Effort thrombosis (also known as the "Paget–Schroetter" syndrome) is distinct from more common forms of deep venous thrombosis (DVT), in that it occurs in young, active, and otherwise healthy individuals, with no associated central venous catheters or underlying blood clotting disorder. The pathogenesis of effort thrombosis involves repetitive extrinsic compression of the subclavian vein during activities involving arm elevation or exertion, leading in time to chronic venous injury and progressive fibrous stenosis of the vein. This involves scar tissue formation and contraction around the outside of the vein, as well as fibrosis and wall thickening within the wall of the vein itself. The initial phase of venous TOS is usually asymptomatic due to simultaneous expansion of collateral veins passing around the narrowed subclavian vein, but stagnant blood within the narrowed subclavian vein eventually leads to thrombotic occlusion. Growth and extension of this clot into the axillary vein can then result in further obstruction of critical collateral veins, resulting in the acute clinical presentation. Pulmonary embolism from clot within the proximal subclavian vein may also occur, particularly with motion of the arm, but this is infrequent compared to DVT in the lower extremities.

Arterial TOS

Arterial TOS (2% to 5% of all patients with TOS) is caused by subclavian artery compression within the scalene triangle, leading to the development of subclavian artery occlusions or poststenotic subclavian artery aneurysms. These lesions almost always occur in association with a congenital cervical rib or other bony anomaly. Ulcerative subclavian artery lesions and aneurysms are often accompanied by mural thrombus formation, and frequently complicated by distal thromboembolism with hand and/or digital ischemia. Patients with acute thromboembolism present with a sudden onset of hand pain and weakness, numbness and tingling, and cold and pale fingers. Those with more longstanding ischemia may present with chronic arm fatigue or claudication, nonhealing wounds, or ulcerations in the fingers. Subclavian artery occlusions or aneurysms may also be asymptomatic. Occlusions may be identified by a significant blood pressure differential between arms, and aneurysms occasionally present as a nontender pulsatile mass in the anterolateral neck. A second form of arterial TOS is observed almost solely in overhead

throwing athletes, associated with occlusive or aneurysmal lesions of the distal axillary artery. These lesions are caused by repetitive trauma from hyperextension during the throwing motion, in which the axillary artery can be compressed by forward motion (subluxation) of the head of the humerus. The complications of these lesions are similar to those of arterial TOS caused by subclavian artery lesions at the level of the first rib.

DIAGNOSIS

Neurogenic TOS

The diagnosis of neurogenic TOS is based on clinical evaluation according to the criteria listed in Table 228.1, supplemented by relevant testing procedures to exclude alternative conditions. The extent of brachial plexus compression attributable to either the scalene triangle or the subcoracoid space is characterized by physical examination. A chest x-ray can help determine the presence or absence of a cervical rib, but other imaging studies of the brachial plexus are usually not helpful. Although conventional electromyography and nerve conduction studies (EMG/NCS) are often performed to exclude peripheral nerve compression disorders or cervical radiculopathy, these tests are usually negative or nonspecific in neurogenic TOS. Patients with a suspected diagnosis of neurogenic TOS may undergo an image-guided anterior scalene and/or pectoralis minor muscle block with a short-acting local anesthetic, both to support the clinical diagnosis and to help predict the reversibility of symptoms with treatment.

TABLE 228.1 Clinical Diagnostic Criteria for Neurogenic TOS

Upper extremity symptoms that extend beyond the distribution of a single cervical nerve root or peripheral nerve have been present for at least 12 weeks, have not been satisfactorily explained by another condition, and meet at least one criterion in at least four of the following five categories:

Principal Symptoms
1A: Pain in the neck, upper back, shoulder, arm and/or hand
1B: Numbness, paresthesias, and/or weakness in the arm, hand, or digits

Symptom Characteristics
2A: Pain/paresthesias/weakness exacerbated by elevated arm positions
2B: Pain/paresthesias/weakness exacerbated by prolonged or repetitive arm/hand use, including prolonged work on a keyboard or other repetitive strain tasks
2C: Pain/paresthesias radiate down the arm from the supraclavicular or infraclavicular spaces

Clinical History
3A: Symptoms began after occupational, recreational, or accidental injury of the head, neck, or upper extremity, including repetitive upper extremity strain or overuse
3B: Previous ipsilateral clavicle or first rib fracture, or known cervical rib
3C: Previous cervical spine or ipsilateral peripheral nerve surgery without sustained improvement in symptoms
3D: Previous conservative or surgical treatment for ipsilateral TOS

Physical Examination
4A: Local tenderness on palpation over the scalene triangle and/or subcoracoid space
4B: Arm/hand/digit paresthesias on palpation over the scalene triangle and/or subcoracoid space
4C: Objectively weak handgrip, intrinsic muscles, or digit 5, or thenar/hypothenar atrophy

Provocative Maneuvers
5A: Positive upper limb tension test (ULTT)
5B: Positive 3-min elevated arm stress test (EAST)

Exclusion of other conditions typically includes nonspecific or negative findings on physical examination (Spurling's test, axial compression test, Tinel's sign over the carpal tunnel or cubital tunnel, and Phalen's test), imaging studies (MRI of cervical spine and shoulder), and conventional electrophysiologic tests (upper extremity electromyography and nerve conduction studies). Adapted from preliminary consensus diagnostic criteria developed by the Consortium for Research and Education on Thoracic Outlet Syndrome (CORE-TOS).

Venous TOS

The diagnosis of venous TOS is based on the stereotypical clinical presentation of axillary–subclavian vein effort thrombosis. Upper extremity venous Duplex studies may confirm the presence of upper extremity DVT, but Duplex imaging of the subclavian vein is inaccurate and therefore cannot be used to exclude the diagnosis. More definitive information on the location and extent of axillary–subclavian vein thrombosis is obtained by contrast-enhanced imaging studies, such as

computed tomographic angiography, magnetic resonance angiography, or direct catheter-based venography. When there is incomplete subclavian vein obstruction, these studies can also be performed with the arms at rest and in elevation. The advantage of using catheter-based upper extremity venography as the initial diagnostic step is that this can be followed immediately by thrombolytic therapy, with completion venograms typically revealing a focal area of residual subclavian vein stenosis or occlusion at the level of the first rib. Although blood coagulation testing is often performed in patients with upper extremity DVT, these tests are usually negative and add little to the initial diagnosis or management.

Arterial TOS

The diagnosis of arterial TOS is suspected by clinical findings and potentially confirmed by noninvasive vascular laboratory studies, such as Duplex imaging and segmental arterial waveform analysis. Plain radiographs are also used to determine if a cervical rib or first rib anomaly is present. Positional angiography (with either contrast-enhanced MRI, CT, or catheter-based arteriography) is often performed to determine the presence or absence of a subclavian artery aneurysm. Similar imaging studies are performed in patients who have presented with upper extremity arterial thromboembolism to detect a proximal source of embolism in the subclavian or axillary artery.

INITIAL TREATMENT

Neurogenic TOS

Neurogenic TOS is initially treated with physical therapy to relieve scalene/pectoralis muscle spasm, improve postural disturbances, enhance functional limb mobility, strengthen associated shoulder girdle musculature, and diminish repetitive strain exposure in the workplace. It is important that the patient be referred to a therapist with experience, expertise, and interest in TOS, since the management of this condition is different than that of other disorders affecting the neck, shoulder, spine, and upper extremity. Incorrect approaches to physical therapy can result in worsening of symptoms and premature failure of conservative management. After an initial 4- to 6-week course of physical therapy, significant improvement is observed in most patients with mild symptoms of neurogenic TOS or those in whom therapy has been started early after

the onset of symptoms. Therapy is then continued with the expectation that continued benefits will preclude the need to consider surgical treatment. Because neurogenic TOS is considered a chronic condition subject to occasional “flare-ups” of more acute symptoms (often related to overuse activities or new injury), it remains important for the patient to continue regular physical therapy exercises and occasional therapist visits as needed during long-term follow-up.

Venous TOS

Current approaches to venous TOS emphasize early diagnosis by contrast venography and prompt use of catheter-based thrombolytic therapy to reduce the amount of thrombus within the axillary and subclavian veins. This is facilitated by use of pharmacomechanical approaches, where thrombolysis can usually be accomplished in a single setting rather than by infusion over several days. In some cases, balloon angioplasty may be used following thrombolysis, in attempting to reduce the degree of stenosis in the subclavian vein. However, because the residual subclavian vein obstruction is usually caused by external compression between the clavicle and first rib as well as scar tissue within the wall of the vein, balloon angioplasty is often unsuccessful or results in only short-lived improvement. It has also become clear over the past decade that placement of stents within the subclavian vein frequently leads to poor outcomes and should be avoided. Conservative treatment of subclavian vein effort thrombosis consists of chronic anticoagulation, long-term restrictions in arm activity, and intermittent arm elevation and use of compression sleeves to reduce edema, with the hope that increased collateral development will eventually compensate for axillary–subclavian vein occlusion. Even with satisfactory anticoagulation, this approach is associated with recurrent thrombosis or chronic venous congestion in 50% to 70% of patients, and aggravation of symptoms during active use of the arm may require considerable limitations for young active patients. The proper duration of anticoagulation for subclavian vein effort thrombosis is also not known, and because this condition is caused by repetitive mechanical compression of the vein rather than a disorder of blood clotting, lifelong anticoagulation may be required in the absence of surgical treatment. For these reasons, most experts recommend early surgical treatment for almost all patients with venous TOS, to avoid long-term disability from venous obstruction and the need for long-term

anticoagulation, and to permit a prompt return to normal arm activities.

Arterial TOS

In arterial TOS, the necessity of immediate anticoagulation and urgent surgical treatment is undisputed in patients with acute upper extremity ischemia due to thromboembolism. Initial treatment may involve brachial artery exposure and thromboembolectomy to improve the distal circulation in the hand, with or without intra-arterial infusion of thrombolytic and vasodilator agents. In this setting, treatment of the distal circulation should be immediately followed by thorough arteriographic assessment of the axillary and subclavian arteries as proximal sources of thromboembolism. In patients with stable distal circulation found to have arterial TOS during more elective evaluation, direct surgical treatment is recommended. In all patients, therapeutic anticoagulation and anti-platelet therapy are continued from the time of diagnosis until definitive surgical treatment.

INDICATIONS FOR SURGERY AND PREOPERATIVE PLANNING

Neurogenic TOS

Surgical treatment is recommended for patients with neurogenic TOS when the diagnosis is sound, the patient has substantial disability (symptoms interfere with daily activities and/or work), and there has been an insufficient response to a course of physical therapy directed by a therapist with specific expertise with this condition. Surgical treatment is also recommended in selected patients with persistent or recurrent symptoms of neurogenic TOS following a previous operation, when there has been no response to appropriate conservative measures. In each of these situations, we find that supraclavicular decompression—based on complete scalenectomy, first rib resection, and brachial plexus neurolysis—provides the most definitive approach for surgical treatment. Supraclavicular decompression also appears to have a lower rate of recurrence than other approaches used for neurogenic TOS. For patients with symptoms of neurogenic TOS referable to the subcoracoid space, surgical decompression includes pectoralis minor tenotomy as an addition to supraclavicular thoracic outlet decompression, or as an isolated procedure when this site is the dominant location of nerve compression symptoms. In the presence of distinct localizing findings, pectoralis minor

tenotomy may also be performed in patients with persistent or recurrent neurogenic TOS who have previously undergone thoracic outlet decompression by other approaches.

Venous TOS

For patients with venous TOS who have presented with effort thrombosis, anticoagulation is maintained after thrombolytic therapy and surgical treatment is recommended within several weeks, even for those with lengthy venous occlusions. Surgical treatment is also recommended in patients with previous axillary–subclavian vein thrombosis who remain symptomatic despite anticoagulation and restricted activity, as well as for asymptomatic individuals in whom long-term anticoagulation and restrictions on upper extremity activity are undesirable. With the addition of an infraclavicular incision to ensure complete medial first rib resection and to facilitate direct subclavian vein reconstruction, the supraclavicular (paraclavicular) approach is ideal for all of these circumstances.

Arterial TOS

Surgical treatment based on supraclavicular decompression is recommended for all patients with arterial TOS and subclavian artery occlusive lesions or aneurysms. This should include direct arterial reconstruction for subclavian aneurysms that have already produced distal emboli, those associated with imaging evidence of intimal ulceration or mural thrombus, or those larger than twice the diameter of the normal proximal subclavian artery.

SURGICAL TECHNIQUE

Under general anesthesia, the patient is positioned supine with the head of the bed elevated 30 degrees. The neck is turned to the opposite side and an inflatable pillow is placed between the shoulders to help extend the neck. The neck, upper chest, and affected upper extremity are prepped into the field, with the arm wrapped in stockinette and held comfortably across the abdomen (Fig. 228.2). A transverse neck incision is made parallel to and just above the clavicle, beginning at the lateral border of the sternocleidomastoid muscle and extending to the anterior border of the trapezius muscle. The incision is carried through the platysma layer, and the edge of the sternocleidomastoid muscle is not divided but simply

retracted medially. The scalene fat pad is mobilized beginning at the lateral edge of the internal jugular vein, and a short segment of the omohyoid muscle is resected. The scalene fat pad is completely mobilized from its inferior and superior attachments, with ligation of small blood vessels and lymphatic tissues. On the left side, the thoracic duct is usually identified entering the venous system near the inferomedial aspect of the scalene fat pad, where it may be ligated and divided.

The tissue plane underneath the scalene fat pad is gently dissected with a fingertip, exposing the underlying ASM and phrenic nerve. The phrenic nerve is identified by its location and course, and by gentle manipulation resulting in contraction of the diaphragm (a diaphragmatic startle, or "dartle" response). Lateral mobilization of the scalene fat pad further reveals the brachial plexus along the lateral edge of the ASM, followed by the MSM attaching to the upper surface of the first rib behind the brachial plexus. The long thoracic nerve is identified where it emerges from the MSM to pass across the lateral first rib. Direct visualization of these structures within the operative field represents the first "critical view" to be obtained during supraclavicular decompression (Table 228.2). The scalene fat pad is subsequently held in position with several retraction sutures, and the exposure is maintained with a Henley self-retaining retractor, using the third arm to hold the edge of the sternocleidomastoid muscle (Fig. 228.3).



Figure 228.2. Patient position and planned incision(s) for supraclavicular thoracic outlet decompression (left side). The supraclavicular skin incision is made just above and parallel to

the clavicle, extending from the lateral border of the sternocleidomastoid muscle to the anterior border of the trapezius muscle. For pectoralis minor tenotomy, a vertical deltopectoral groove incision is used. (From Thompson RW, Vemuri C. Neurogenic thoracic outlet syndrome exposure and decompression: supraclavicular. In: Mulholland MW, Hawn MT, Hughes SJ, et al., eds. *Operative Techniques in Surgery*. Philadelphia, PA: Wolters Kluwer Health; 2015:1848–61.)

The brachial plexus and subclavian artery are separated from the lower lateral edge of the ASM, gently passing a fingertip behind the muscle just above the first rib. With the neurovascular structures displaced posteriorly, blunt finger dissection is continued behind the ASM toward its medial edge, where the proximal subclavian artery and the phrenic nerve are well visualized and protected. Once the insertion of the ASM onto the first rib has been isolated under direct vision, it is sharply divided using a curved scissors (Fig. 228.4).

The end of the divided ASM is elevated, and any additional slips of muscle, fascia, or tendon are divided, including direct attachments of the muscle to the subclavian artery and the thickened extrapleural fascia. The ASM is passed underneath the phrenic nerve to its medial side and lifted further, with division of its posterior attachments and protection of the upper brachial plexus nerve roots, until it is held on a pedicle from its origin on the transverse process of the cervical spine. The ASM is then sharply divided from its origin, and the entire muscle is removed and weighed (Fig. 228.4).

During resection of the ASM, any scalene minimus muscle anomalies are identified and resected, as represented by fibers that pass between the brachial plexus nerve roots and insert on the extrapleural fascia or first rib (along with or independent of the ASM). Anomalous fibrofascial bands may also be observed after ASM resection, typically passing in front of the lower brachial plexus nerve roots. These structures are also resected as they are encountered to ensure thorough decompression and full mobility of the nerve roots.

TABLE 228.2 Six “Critical Views” During Supraclavicular Thoracic Outlet Decompression

1. View of the operative field after lateral reflection of the scalene fat pad, with visualization of the internal jugular vein, anterior scalene muscle, phrenic nerve, brachial plexus, subclavian artery, middle scalene muscle, and long thoracic nerve.
2. View of the lower part of the anterior scalene muscle where it attaches to the first rib, with space sufficient to allow a finger to pass behind the anterior scalene muscle and in front of the brachial plexus and subclavian artery, prior to division of the anterior scalene muscle from the top of the first rib.
3. View of the upper part of the anterior scalene muscle at the level of the transverse process of the cervical spine, in relation to the C5 and C6 nerve roots, prior to division of the origin of the anterior scalene muscle.
4. View of the insertion of the middle scalene muscle on the first rib, with each of the five nerve roots of the brachial plexus and the subclavian artery retracted medially and the long thoracic nerve retracted posteriorly, prior to division of the middle scalene muscle from the top of the lateral first rib.
5. View of the posterior neck of the first rib, with the T1 nerve root passing from underneath the rib to join the C8 nerve root to form the inferior trunk of the brachial plexus, prior to division of the posterior first rib.
6. View of the anterior portion of the first rib underneath the clavicle, with placement of the rib shears medial to the scalene tubercle, prior to division of the anterior first rib.

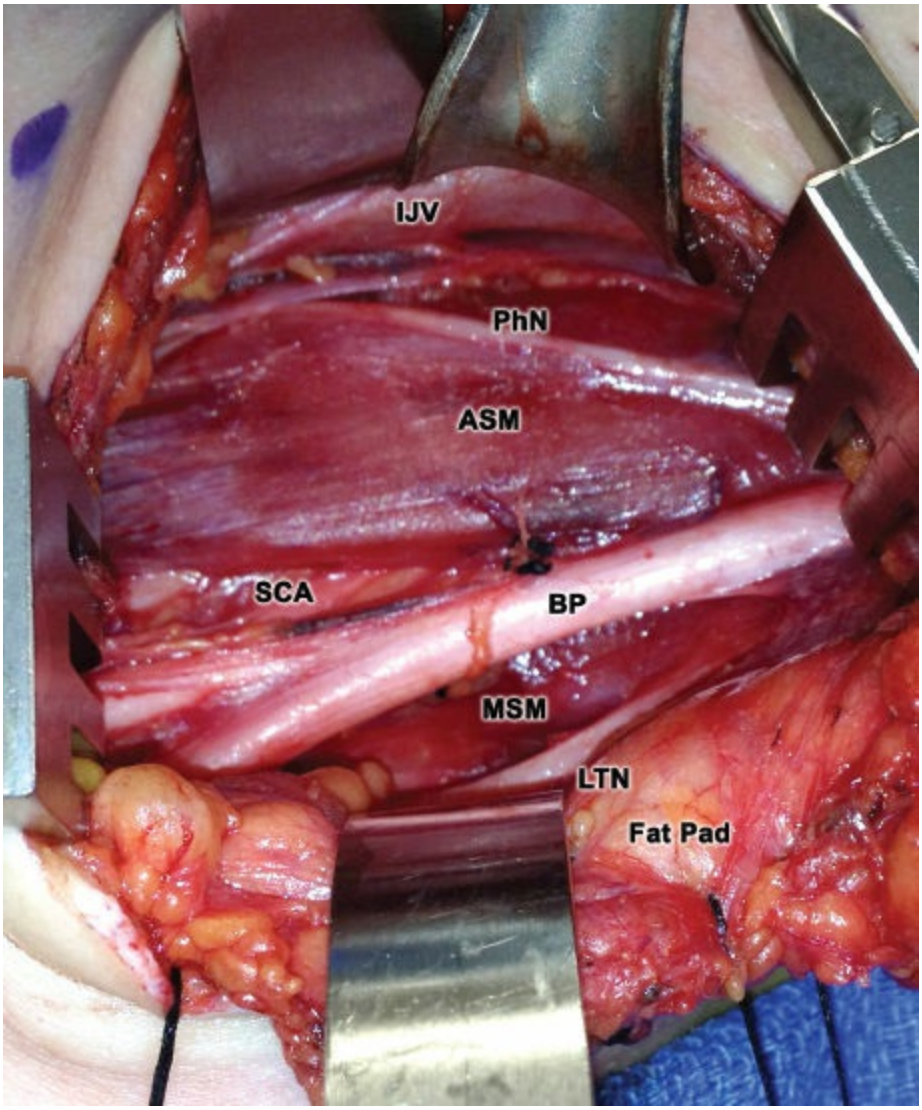

Figure 228.3. Supraclavicular exposure (left side). Following mobilization and lateral reflection of the scalene fat pad, direct visualization is obtained of the internal jugular vein (IJV), anterior scalene muscle (ASM), phrenic nerve (PhN), brachial plexus (BP), subclavian artery (SCA), middle scalene muscle (MSM), and long thoracic nerve (LTN). (From Thompson RW, Vemuri C. Neurogenic thoracic outlet syndrome exposure and decompression: supraclavicular. In: Mulholland MW, Hawn MT, Hughes SJ, et al., eds. *Operative Techniques in Surgery*. Philadelphia, PA: Wolters Kluwer Health; 2015:1848–61.)

The brachial plexus nerve roots are separated from the front edge of the MSM until a small malleable retractor can be placed behind the brachial plexus, and each nerve root from C5 to T1 is sequentially identified. With medial retraction of the brachial plexus and posterolateral retraction of the long thoracic nerve, the attachment of the MSM to the first rib is then

exposed and divided from the rib using the electrocautery (Fig. 228.5). The MSM is further detached along the top of the first rib using a periosteal elevator, extending to a point parallel with the T1 nerve root. The plane separating the MSM and posterior scalene muscles is defined by the long thoracic nerve, and muscle tissue anterior to the nerve is divided to complete the resection of the MSM.

Following complete anterior and middle scalenectomy, intercostal muscle attachments to the lateral first rib are divided using the electrocautery under direct vision. Blunt finger dissection between the brachial plexus and the inner side of the first rib then allows the extrapleural tissues to be swept away from the undersurface of the bone. The posterior neck of the first rib is exposed where the T1 nerve root emerges from underneath the rib to join the C8 nerve root above the rib to form the lower trunk of the brachial plexus. Any remaining intercostal muscle is detached from underneath the rib and the first intercostal nerve is displaced. A modified Giertz-Stille rib shears is inserted around the neck of the first rib with protection of the C8 and T1 nerve roots under direct vision, and after verifying mobility of the nerve roots the bone is divided (Fig. 228.6). A Kerrison bone rongeur is used to remove additional bone as needed, to ensure that the posterior stump of the first rib will not impinge upon the lower nerve roots, and the end of the bone is sealed with bone wax.

Remaining intercostal muscle and fascial attachments to the anterior first rib are divided to the level of the scalene tubercle. The clavicle is elevated with a small Richardson retractor, and the proximal portion of the rib is displaced inferiorly with fingertip pressure, to open the anterior costoclavicular space. The rib shears are placed around the anterior first rib immediately medial to the scalene tubercle under direct vision, and the proximal first rib is then divided (Fig. 228.7). The specimen is extracted from the operative field. The remaining anterior end of the first rib is remodeled to a smooth surface with a Kerrison rongeur.

Cervical ribs arise within the plane of the MSM behind the brachial plexus and subclavian artery, and are therefore encountered, when present, during the course of scalene muscle resection. The anterior end of a cervical rib may be unattached, with a ligamentous extension to the first rib, or it may be attached to the first rib, often forming a true joint. Cervical ribs are carefully exposed along their course while carefully protecting the brachial plexus nerves, and in most cases the posterior

portion is divided before and in the same manner as used for first rib resection. The anterior portion of the cervical rib is then divided, and the bone is removed. When the cervical rib forms a true joint with the first rib, the anterior portion may be left attached while the first rib resection is completed, with the two removed together as a single specimen (Fig. 228.8).

Following scalenectomy and removal of the first rib, attention is returned to the brachial plexus and each of the contributing nerve roots is meticulously dissected free of any perineural fibrous scar tissue. This aspect of the operation ("external neurolysis") is not complete until each nerve root from C5 to T1 is completely dissected throughout its course in the operative field to ensure full mobility (Fig. 228.9).

Reoperations for Neurogenic TOS

Reoperations for neurogenic TOS are optimally performed using the supraclavicular approach, because this provides the most thorough exposure of the anatomy with the greatest margin of safety. Following lateral reflection of the scalene fat pad, the brachial plexus nerve roots are carefully exposed and mobilized. Any structures that were retained at the initial operation are then resected, including the scalene muscles, anomalous fibrofascial bands, and/or the first rib. Fibrous scar tissue is removed by performing a complete brachial plexus neurolysis, with each nerve root fully mobilized. Great care must be taken during this dissection to avoid nerve and blood vessel injury, given the dense fibrous scar tissue usually present within operative field.

Pectoralis Minor Tenotomy

To perform pectoralis minor tenotomy, a short vertical infraclavicular incision is made in the deltopectoral groove, beginning just below the coracoid process. The deltoid and pectoralis major muscles are separated with the plane of dissection kept medial to the cephalic vein. The lateral edge of the pectoralis major muscle is retracted medially and lifted, and the underlying fascia is exposed. The pectoralis minor muscle is identified and encircled near its insertion on the coracoid process, taking care to protect the underlying neurovascular bundle and to avoid the tendon of the short head of the biceps muscle. The pectoralis minor tendon is then divided with electrocautery under direct vision, within 2 cm of the coracoid process, and the medial edge of the divided muscle is oversewn

with sutures to ensure hemostasis. The remaining clavipectoral fascia is opened to the level of the clavicle, but no further dissection of the brachial plexus or axillary vessels is performed once the pectoralis minor muscle has been divided.

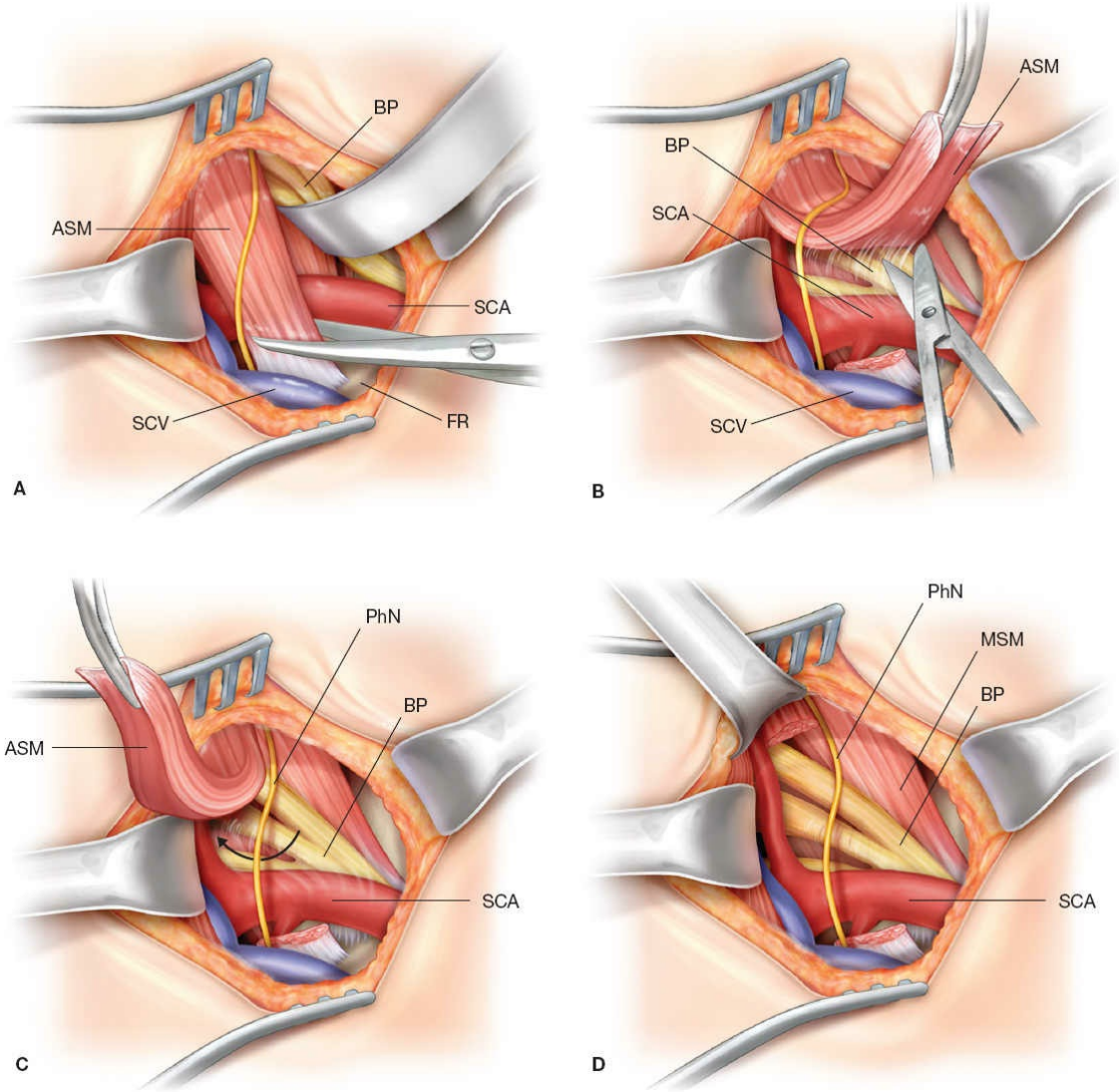

Figure 228.4. Anterior scalene muscle (left side). **A.** The anterior scalene muscle (ASM) insertion is isolated by displacing the underlying subclavian artery (SCA) and brachial plexus (BP), using blunt fingertip dissection behind the muscle, and the muscle is sharply divided from the top of the first rib (FR) behind the subclavian vein (SCV). **B.** The end of the divided anterior scalene muscle is lifted and sharply dissected free of structures lying behind the muscle, including the subclavian artery. **C.** As it is mobilized, the anterior scalene muscle is passed underneath and to the medial side of the phrenic nerve (PhN). **D.** The dissection is carried up to the level of the C6 transverse process where the anterior scalene muscle can be safely divided from its origin and removed. (From Thompson RW, Vemuri C. Neurogenic thoracic outlet syndrome exposure and decompression: supraclavicular. In: Mulholland MW, Hawn MT, Hughes SJ, et al., eds. *Operative Techniques in Surgery*. Philadelphia, PA: Wolters Kluwer Health; 2015:1848–61.)

Upon completion of thoracic outlet decompression, the apex of the pleural membrane is opened and a closed-suction drain is placed into the supraclavicular field, where it is positioned behind the brachial plexus with its tip lying in the upper posterior pleural space. Two multi-hole catheters are placed within the wound, adjacent to the brachial plexus and within the bed of the resected first rib, for postoperative infusion of local anesthetic. A bioresorbable (polylactide) film is wrapped around the brachial plexus to limit development of postoperative perineural fibrosis, and the scalene fat pad is reattached to lie over the brachial plexus. The edges of the platysma muscle are reapproximated, and the procedure is completed with a subcuticular skin closure.

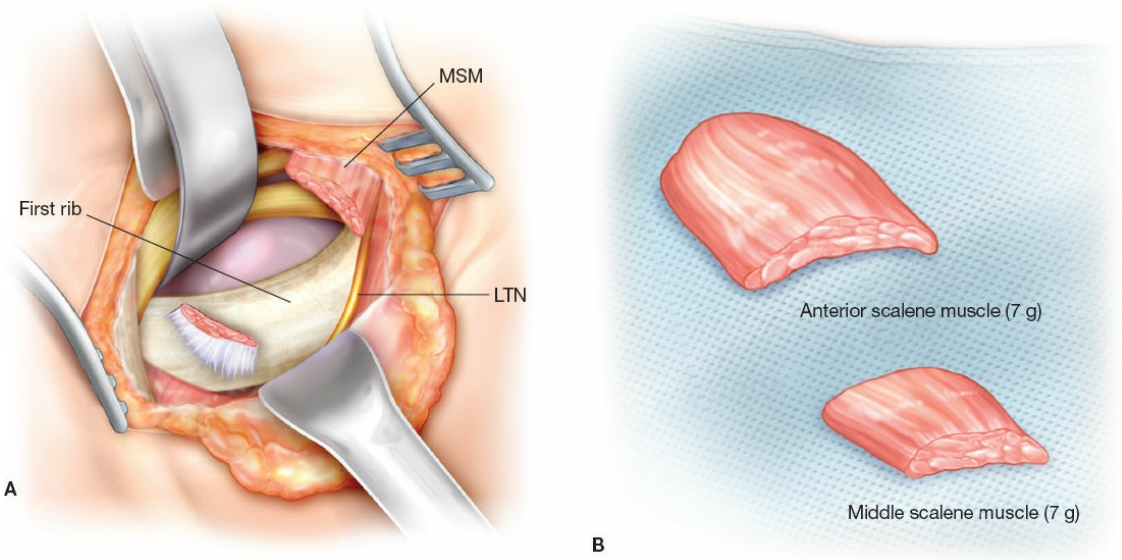

Figure 228.5. Middle scalene muscle (left side). **A.** After detaching the middle scalene muscle (MSM) from the top of the posterolateral first rib using the electrocautery, the muscle tissue lying anterior to the long thoracic nerve (LTN) is excised. **B.** Typical operative specimens of the anterior and middle scalene muscles. (From Thompson RW, Vemuri C. Neurogenic thoracic outlet syndrome exposure and decompression: supraclavicular. In: Mulholland MW, Hawn MT, Hughes SJ, et al., eds. *Operative Techniques in Surgery*. Philadelphia, PA: Wolters Kluwer Health; 2015:1848–61.)

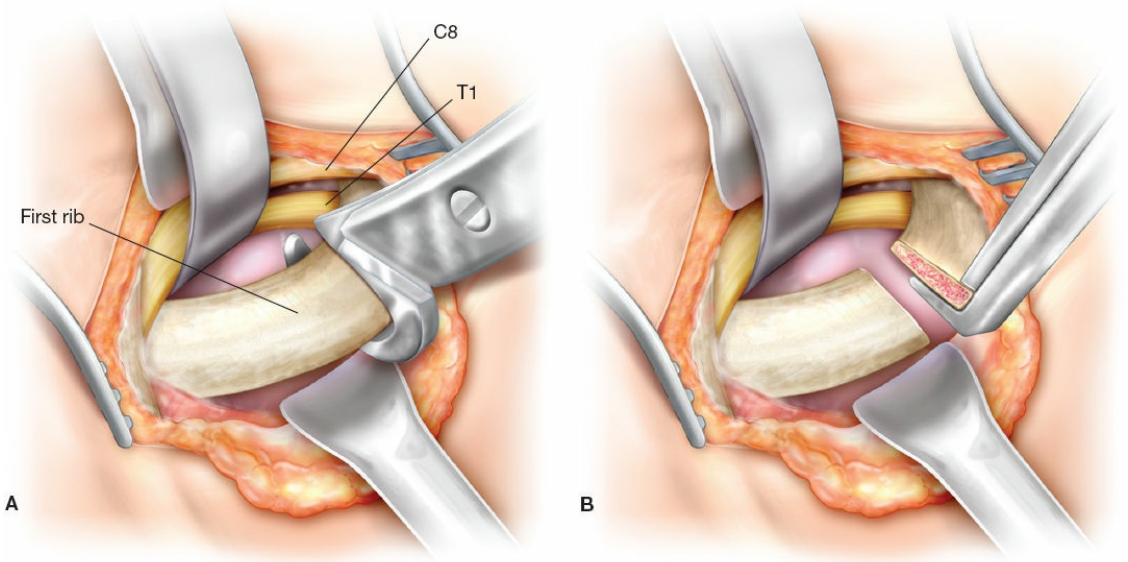

Figure 228.6. First rib resection, posterior (left side). **A.** The posterior portion of the first rib is exposed following removal of the middle scalene muscle, with visualization of the C8 and T1 brachial plexus nerve roots immediately above and below the posterior first rib, respectively. A modified Giertz-Stille rib shears is placed around the posterior portion of the first rib in preparation for division of the bone. **B.** Following application of the rib shears, the remaining posterior first rib is further remodeled with a Kerrison rongeur to obtain a smooth edge immediately medial to the T1 nerve root. (From Thompson RW, Vemuri C. Neurogenic thoracic outlet syndrome exposure and decompression: supraclavicular. In: Mulholland MW, Hawn MT, Hughes SJ, et al., eds. *Operative Techniques in Surgery*. Philadelphia, PA: Wolters Kluwer Health; 2015:1848–61.)

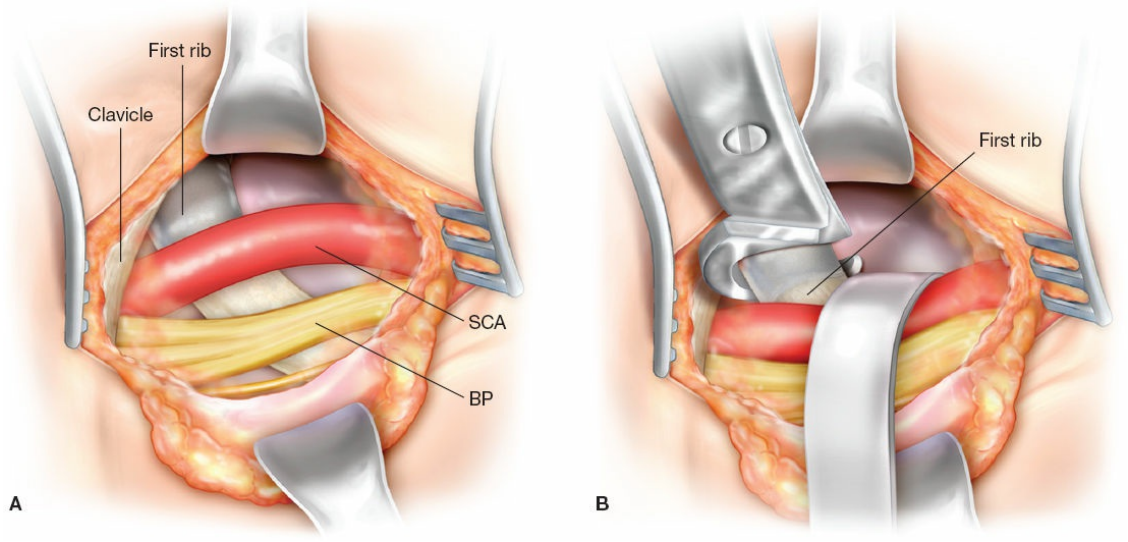

Figure 228.7. First rib resection, anterior (left side). **A.** The

anterior portion of the first rib is exposed underneath the clavicle and subclavian vein, anterior to the subclavian artery (SCA) and brachial plexus (BP), where it will be divided immediately medial to the scalene tubercle. **B.** A Giertz-Stille rib shears is placed around the anterior portion of the first rib for division of the bone. The remaining anterior first rib will be remodeled with a rongeur as needed to obtain a smooth edge. (From Thompson RW, Vemuri C. Neurogenic thoracic outlet syndrome exposure and decompression: supraclavicular. In: Mulholland MW, Hawn MT, Hughes SJ, et al., eds. *Operative Techniques in Surgery*. Philadelphia, PA: Wolters Kluwer Health; 2015:1848–61.)

Management of Venous TOS

Operative management for venous TOS begins with supraclavicular decompression as described above, with the exceptions that the anterior first rib is not yet divided and brachial plexus neurolysis is not performed. To accomplish complete resection of the anteromedial portion of the first rib as needed for venous decompression, a second transverse skin incision is made several centimeters below the medial clavicle. The upper and middle portions of the pectoralis major muscle are spread and the cartilaginous portion of the first rib is identified. This may be facilitated by applying downward fingertip pressure to the divided posterior segment of the first rib from the supraclavicular incision, thereby displacing the attachments between the medial first rib and clavicle. The superior edge of the first rib is then dissected from soft tissue attachments through the infraclavicular incision, and the subclavius muscle tendon, the costoclavicular ligament, and the muscles of the first intercostal space are all divided under direct vision. The anterior first rib is divided adjacent to the sternum with a duckbill rongeur, and the entire first rib is then withdrawn from the operative field as a single specimen.

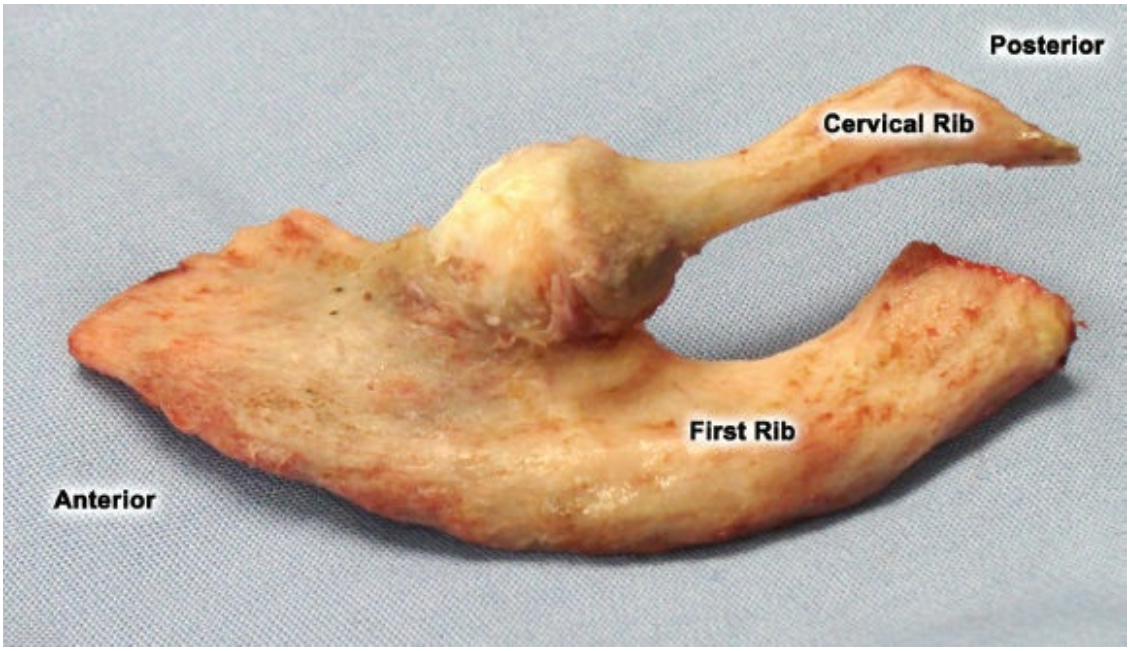

Figure 228.8. Operative specimen following combined resection of the cervical rib and first rib (left side). (From Thompson RW, Vemuri C. Neurogenic thoracic outlet syndrome exposure and decompression: supraclavicular. In: Mulholland MW, Hawn MT, Hughes SJ, et al., eds. *Operative Techniques in Surgery*. Philadelphia, PA: Wolters Kluwer Health; 2015:1848–61.)

The axillary vein is first identified underneath the clavicle through the lateral portion of the infraclavicular incision, where it is carefully separated from the subclavius muscle. Collateral vein branches that enter the subclavian vein are ligated and divided, and the subclavius muscle is completely resected. Further exposure of the subclavian vein is accomplished through the supraclavicular incision, moving medially toward the junction of the subclavian and internal jugular veins to form the innominate vein. The internal jugular vein is circumferentially exposed for several centimeters above its junction with the subclavian vein, and the innominate vein is exposed for several centimeters into the upper mediastinum. There are usually one or two significant venous collaterals to the subclavian vein underneath the medial clavicle, which are ligated and divided to permit the subclavian vein to fall away from the clavicle. The course of the phrenic nerve is noted, and it is protected where it passes underneath the subclavian vein.

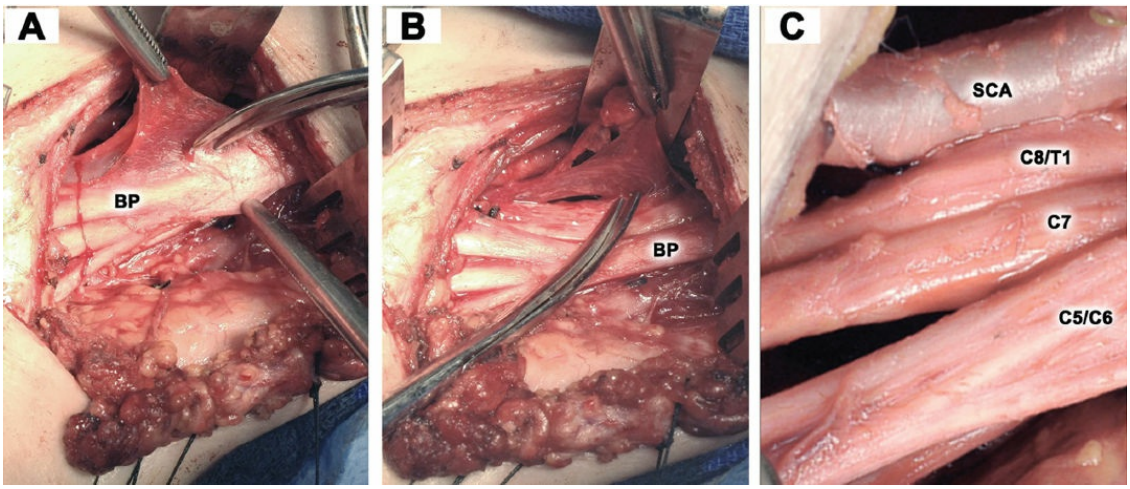

Figure 228.9. Brachial plexus neurolysis. **A–C:** Fibrous scar tissue is sharply removed from each of the brachial plexus (BP) nerve roots by external neurolysis. (From Thompson RW, Vemuri C. Neurogenic thoracic outlet syndrome exposure and decompression: supraclavicular. In: Mulholland MW, Hawn MT, Hughes SJ, et al., eds. *Operative Techniques in Surgery*. Philadelphia, PA: Wolters Kluwer Health; 2015:1848–61.)

Pathologic changes in the medial subclavian vein are assessed both visually and by digital palpation, and any residual scar tissue surrounding the vein is completely excised ("circumferential external venolysis"). In many patients with venous TOS, this allows re-expansion of the previously constricted segment of the vein, and if the underlying vein is soft to palpation and easily compressible, it is likely that no further venous reconstruction will be necessary. Additional venous reconstruction is performed when external venolysis has not eliminated subclavian vein obstruction or when there is residual venous stenosis demonstrated by intraoperative venography. This is accomplished after infusion of low molecular weight Dextran and administration of intravenous heparin, beginning with clamp control of the axillary or distal subclavian vein, the lower portion of the internal jugular vein, and the upper portion of the innominate vein. The anterior aspect of the subclavian vein is opened along its axis and the lumen is thoroughly inspected. If the luminal surface is smooth and free of thrombus, reconstruction is performed with a vein patch angioplasty using a segment of autologous greater saphenous vein, bovine pericardium, or a cryopreserved femoral vein allograft. It is important to construct the patch angioplasty along the entire length of the affected vessel, both proximal and distal to the stenotic segment, including extension into the innominate vein.

When there is dense fibrosis within the wall of the subclavian vein, or ulceration and mural thrombus upon inspection of the luminal surface, the affected segment of the subclavian vein is excised and replaced by an interposition bypass graft. The interposition graft is constructed using a widely beveled end-to-end anastomosis to the unaffected axillary–subclavian vein, and the proximal anastomosis is extended into the anteromedial aspect of the innominate vein. Because the saphenous vein is too small for replacement of the subclavian vein, use of a cryopreserved femoral vein allograft is usually preferred for subclavian vein reconstruction.

At the completion of the procedure, an intraoperative venogram is performed to confirm a satisfactory subclavian vein reconstruction. In patients for whom a long axillary–innominate vein bypass has been performed for chronic axillary–subclavian vein occlusion, construction of a temporary radiocephalic arteriovenous (AV) fistula between the end of the distal cephalic vein and the side of the radial artery at the wrist may also be considered, as a simple and useful adjunct to increase upper extremity venous blood flow. In this event, the AV fistula is maintained until 12 weeks after surgical treatment, at which time it is ligated under local anesthesia and a final follow-up venogram is performed.

Management of Arterial TOS

Following supraclavicular decompression as described above, including removal of the cervical and first ribs, the subclavian artery is mobilized in preparation for interposition graft repair. Satisfactory distal control of the nonaneurysmal subclavian artery can usually be achieved through the supraclavicular incision alone, once the artery has been fully mobilized. When the lesion is more extensive, exposure of the axillary artery for distal vascular control can be accomplished by adding a transverse infraclavicular incision, with division of the pectoralis minor muscle if needed. The proximal subclavian artery is clamped immediately distal to the vertebral artery and the distal subclavian artery is clamped immediately beyond the aneurysm. The aneurysmal segment of subclavian artery is excised and replaced with an interposition bypass graft using slightly beveled end-to-end anastomoses. The distal anastomosis is usually performed first, and the artery is allowed to relax into its normal position. The graft is then measured and cut to an appropriate length for a tension-free proximal anastomosis. Reversed saphenous vein grafts are suitable for

this reconstruction but are often too small in caliber for subclavian artery replacement, in which case reconstruction can be performed with a cryopreserved femoral/popliteal artery allograft, Dacron or PTFE prosthetic grafts, or autologous deep vein (e.g., superficial femoral) or artery (e.g., iliac) grafts. Following reconstruction, a completion arteriogram is performed to evaluate the subclavian artery bypass graft in different positions of the arm, as well as to reassess the distal circulation.

POSTOPERATIVE MANAGEMENT

An upright chest x-ray is performed in the recovery room and daily for 3 days after surgery. Any small air or pleural fluid collections are observed with the expectation of spontaneous resolution. Postoperative analgesia is provided by patient-controlled intravenous opiates until adequate pain control can be achieved by oral medications, and continuous-infusion local anesthesia is discontinued on postoperative day 3. Oral narcotics, a muscle relaxant, and a nonsteroidal anti-inflammatory agent are routinely prescribed upon hospital discharge and for at least several weeks following surgery. Postoperative hospital stay is typically 3 to 4 days and the closed-suction drain is removed when output is less than 50 mL/day, usually 5 to 7 days after surgery. Physical therapy to maintain range-of-motion is resumed the day after surgery and continued upon hospital discharge, with patients advised to avoid excessive reaching overhead or heavy lifting with the affected upper extremity, and with caution against activities that can result in muscle strain, spasm, and significant pain in the sternocleidomastoid, trapezius, and other neck muscles. A gradual return to use of the upper extremity is encouraged, with the majority of patients permitted cautious light-duty work by 4 to 6 weeks. Patients are seen in follow-up every 3 months in the first year to assess long-term results, and physical therapy is continued for as long as necessary to achieve an optimal level of function. For patients who have undergone treatment for venous TOS, anticoagulation and antiplatelet therapy are both continued for 12 weeks after operation, at which time all medications are discontinued and unrestricted activity is allowed. Patients treated for arterial TOS are maintained on daily aspirin but no anticoagulation, and normal activity with the upper extremity is allowed early after recovery from the surgical procedure.

COMPLICATIONS

Symptoms of numbness and tingling in the hand or fingers are common early after any form of thoracic outlet decompression, arising as a result of previous neurologic damage, intraoperative mobilization of the brachial plexus, and postoperative inflammation and perineural wound healing. The use of continuous local anesthetic infusions for postoperative pain control may also result in sensory neurologic symptoms. More pronounced neurologic dysfunctions including motor deficiencies are rarely observed, particularly arm weakness and loss of handgrip strength, but may represent temporary brachial plexus neuropraxia or pain-limited restrictions in mobility. Spontaneous resolution of such symptoms usually occurs within several days to weeks, but may persist for several months. It is notable that patients with longstanding neurogenic TOS can often display residual symptoms that may not be completely eliminated by thoracic outlet decompression. While these symptoms may be tolerable and are expected to gradually improve, the surgeon must provide continuing support and reassurance during the prolonged period of recovery and rehabilitation.

Mild-to-moderate pleural fluid collections are often observed on the side of surgery following supraclavicular decompression, consisting of serosanguinous fluid that can be expected to spontaneously reabsorb within several days to weeks. Although well-tolerated by most patients, some may experience shortness of breath with exertion until the fluid has resolved. In such individuals, chest radiographs are useful to distinguish the presence of a pleural effusion from the effects of diaphragmatic elevation due to phrenic nerve dysfunction.

Postoperative bleeding is rare but can result in wound hematomas, or when substantial, may lead to hemothorax. Early anticoagulation following operations for venous TOS can elevate the risk of bleeding complications. While often self-limited, reexploration of the supraclavicular wound allows the operative site to be directly inspected and any specific site of bleeding to be controlled. Evacuation of hemothorax can usually be achieved through this approach as well, avoiding the need for chest tube placement.

If there is persistent or increasing drain output of lymphatic fluid greater than 250 mL/day, particularly when chylous in appearance and on the left side, a clear liquid diet is maintained along with administration of octreotide to reduce the volume of lymph flow, and removal of the closed-suction drain is deferred until the leak has subsided. Early supraclavicular reexploration is recommended for persistent high-volume lymph leaks

(more than 500 mL/day for more than 5 days) or those resulting in chylothorax.

Elevation of the ipsilateral diaphragm on postoperative chest x-rays indicates the presence of phrenic nerve dysfunction, which may be associated with shortness of breath on exertion or supine positioning, as well as lower lateral chest discomfort. Most individuals with a unilateral phrenic nerve palsy can compensate satisfactorily with the contralateral diaphragm and intercostal muscles and many become asymptomatic within a short period of time, but patients with severe underlying pulmonary disease may be at risk for significant disability. Postoperative phrenic nerve dysfunction is usually temporary, due to intraoperative mobilization of the nerve or postoperative infusion of local anesthetic, but on occasion phrenic neuropraxia can persist for several weeks; in rare situations, phrenic neuropraxia may be prolonged up to 9 to 10 months before signs of reinnervation appear. The vast majority of such patients should be managed expectantly.

Postoperative dysfunction of the long thoracic nerve is occasionally observed following thoracic outlet decompression, resulting in a winged scapula defect due to weakness of the serratus anterior muscle. Scapular dysfunction due to this defect is readily detectable by physical examination, and it may interfere with shoulder girdle mechanics and physical therapy, thereby prolonging full recovery from operation. While there is no specific treatment, long thoracic neurpraxia is usually self-limited and recovery can be expected within several months.

Suggested Readings

Ambrad-Chalela E, Thomas GI, Johansen KH. Recurrent neurogenic thoracic outlet syndrome. *Am J Surg* 2004;187:505–10.

Caputo FJ, Wittenberg AM, Vemuri C, et al. Supraclavicular decompression for neurogenic thoracic outlet syndrome in adolescent and adult populations. *J Vasc Surg* 2013;57:149–57.

Duwayri YM, Emery VB, Driskill MR, et al. Positional compression of the axillary artery causing upper extremity thrombosis and embolism in the elite overhead throwing athlete. *J Vasc Surg* 2011;53:1329–40.

Hempel GK, Shutze WP, Anderson JF, et al. 770 consecutive supraclavicular first rib resections for thoracic outlet syndrome. *Ann Vasc Surg* 1996;10:456–63.

Illig KA, Thompson RW, Freischlag JA, et al., eds. *Thoracic Outlet Syndrome.* London: Springer-Verlag; 2013.

Sanders RJ, Hammond SL. Management of cervical ribs and anomalous first ribs causing neurogenic thoracic outlet syndrome. *J Vasc Surg* 2002;36:51–6.

Sanders RJ, Hammond SL, Rao NM. Diagnosis of thoracic outlet syndrome. *J Vasc Surg* 2007;46:601–4.

Sheng GG, Duwayri YM, Emery VB, et al. Costochondral calcification, osteophytic degeneration, and occult first rib fractures in patients with venous thoracic outlet syndrome. *J Vasc Surg* 2012;55:1363–9.

Thompson RW. Comprehensive management of subclavian vein effort thrombosis. *Semin Interv Radiol* 2012;29:44–51.

Vemuri C, Wittenberg AM, Caputo FJ, et al. Early effectiveness of isolated pectoralis minor tenotomy in selected patients with neurogenic thoracic outlet syndrome. *J Vasc Surg* 2013;57:1345–52.

EDITOR'S COMMENT

The beautifully detailed chapter on thoracic outlet syndrome (TOS) is written by one of the masters of these procedures in the world. Dr. Thompson has accrued a very large patient experience and that knowledge is clear with the well-described specifics of this procedure to make it effective and safe. The detailed anatomy of the thoracic outlet is well described, particularly the key landmarks that are important to stay out of trouble with. The pictures and procedural details are clear and relevant throughout the whole chapter. Nonetheless, patients who undergo TOS decompression should see someone who specializes in this technique, as the volume outcome relationship and more so experience is key for good outcomes.

Thoracic outlet syndrome is primarily three syndromes, the least controversial of which to treat surgically are the venous and arterial TOS. These are rare, but for affected patients, the thoracic decompression with often vascular reconstruction is definitely beneficial. The neurogenic type is typically the most common, causing hand- and arm-related pain, but is a little more nebulous with regard to outcomes. However, quality of life and patient-reported outcomes are now more commonly being used as important factors, as noted in the recent report standards document by the Society of Vascular Surgery (Illig KA, Donahue D, Duncan A, et al. Reporting standards of the Society for Vascular Surgery for thoracic outlet syndrome. *J Vasc Surg* 2016;64:e23–e35).

The initial treatment of neurogenic TOS patients should be physical therapy, occupational therapy, and sometimes psychiatry and counseling, particularly if longstanding chronic pain issues are present. Postural strengthening and core muscle conditioning are also important for neurogenic TOS treatment. Neurogenic TOS may sometimes be associated with work injuries, and thus excellent clinical documentation is critical.

Venous TOS manifested by effort thrombosis is typically treated by

thrombolysis acutely, to open the axillary and subclavian vein systems (Vemuri C, Salehi P, Benarroch-Gampel J, et al. Diagnosis and treatment of effort-induced thrombosis of the axillary subclavian vein due to venous thoracic outlet syndrome. *J Vasc Surg Venous Lymph Disord* 2016;4:485–500). Similar to the author's recommendation, at our institution we typically wait 2 to 4 weeks after thrombosis and full anticoagulation and then bring the patient back for decompression to allow some of the perivascular inflammation to resolve. Not all groups agree with this approach (Guzzo JL, Chang K, Demos J, et al. Preoperative thrombolysis and venoplasty affords no benefit in patency following first rib resection and scalenectomy for subacute and chronic subclavian vein thrombosis. *J Vasc Surg* 2010;52:658–62; discussion 662). We also believe the supraclavicular approach is most straightforward. A major caveat is that subclavian venous stenting should not be done after thrombolysis and balloon angioplasty, due to stent crushing. This can make a salvageable vein stenosis very difficult to successfully treat as the authors' note.

The pectoralis minor syndrome is often not considered as a diagnosis, and with release provides good relief for these patients in whom it is diagnosed. Here, clinical history and carefully physical examination are critical, with pain and tenderness over anterior chest wall and axilla, rather than the supraclavicular space (Sanders RJ, Rao NM. The forgotten pectoralis minor syndrome: 100 operations for pectoralis minor syndrome alone or accompanied by neurogenic thoracic outlet syndrome. *Ann Vasc Surg* 2010;24:701–8). Pectoral minor tenotomy is very successful for these patents.

Complications of TOS decompression are few but do need to be watched for, including hemo-pneumothorax, brachial plexus nerve injury, and wound infection. However, there is no prosthetic placed in this area and so the infection risk is fairly low and not catastrophic.

TOS decompression is safe and effective, but experience and focus of the surgeon are essential to excellent outcomes as highlighted in this chapter.

Peter Henke

229 Thoracic Aortic Transection

Himanshu J. Patel and Bo Yang

ANATOMY, NATURAL HISTORY, AND CLINICAL PRESENTATION

Blunt thoracic aortic injury (BTAI) is the second leading cause of death from vehicular trauma. The classic autopsy study by Parmley et al. as well as more contemporary studies has suggested that the mortality of BTAI exceeds 85% at the time of injury, while mortality risk beyond 4 hours following presentation remains low at 6%. More recently, selective delayed operative management advocated by our group as well as others suggests that with aggressive antihypertensive therapy, survival rates following admission are higher than those seen in autopsy reports.

Although the location of injury can occur at any site in the aorta, the most frequent location identified in operative series is the segment just distal to the ligamentum arteriosum. Although the pathogenesis remains debated, potential etiologies for disruption include both differential deceleration forces on the aorta relative to surrounding tissues and thoracic compression forces impacting the aorta directly.

BTAI can have a spectrum of injury ranging from complete disruption with a true double barrel aorta, to a partial wall disruption with pseudoaneurysm formation, and finally to an isolated intimal injury without associated mural hematoma. In our estimation, the best grading of injury has been reported by Azzizadeh et al. from Houston describing grade 1 (intimal injury), grade 2 (intramural hematoma), grade 3 (pseudoaneurysm formation), and grade 4 (frank rupture).

This spectrum of disease likely results in disparate trajectories in the natural history. Isolated intimal injury is likely a benign process, and will often heal spontaneously without intervention. Partial wall disruption will often result in pseudoaneurysm formation medially into the mediastinum with associated mediastinal hematoma, and on exploration resembles an entry tear of an acute type B dissection. Those presenting with lateral wall (i.e., projecting into lung parenchyma) involvement are considered by us

to be somewhat more unstable, and are less frequent perhaps because these patients have succumbed to free rupture. Finally, complete disruption is considered by us to be the least stable pathology and at the highest risk for rupture. In general, partial tears and complete disruption transections are often transverse in orientation, and the natural longitudinal tension in the aorta separates the disruption by several centimeters.

Clinical Presentation and Diagnosis

BTAI should be suspected on initial primary survey, based upon both the mechanism of injury and physical signs or imaging findings. High-impact mechanism including vehicular accidents with significant deceleration forces, falls, or blast injuries should prompt evaluation for BTAI. Physical signs such as first or second rib or thoracic spine fractures, shock, dyspnea, or hemothorax are also suggestive.

Imaging studies are of vital importance in confirming the diagnosis of BTAI. Aortography, widely considered the gold standard in evaluation for BTAI, has a near 100% sensitivity and specificity in experienced hands, but is time-consuming and often negative. An often underutilized tool in diagnosis is the transesophageal echocardiogram (TEE). The main advantage of this test is its portability, and its use can be important in those patients presenting requiring immediate surgery for concomitant injuries. At the time of operative repair of concomitant injuries, TEE can be performed safely during the operative procedure to obtain the diagnosis. The previously routine use of aortography in diagnosis of BTAI has now been supplanted by the widespread use of computed tomography (CT), which in the modern era is obtained rapidly and can also be used in aiding diagnosis of concomitant injuries. Suggestive findings on CT scanning include mural and mediastinal hematoma, intimal flaps, or pseudoaneurysm formation. This test is important for multiple reasons, particularly in the endovascular era where endograft sizing is dependent on good thin cut (1.25 to 3 mm) imaging with three-dimensional (3D) reconstruction.

INDICATIONS AND TIMING OF INTERVENTION

In BTAI, the indication for operation is aortic repair for improvement in life expectancy. As was discussed earlier, we believe that not all aortic injuries require operation. While the partial and complete disruptions have a risk for rupture without repair, intimal injuries or mural hematomas

(Azzizadeh grades 1 or 2) likely do not portend the same risk. We and others have noted that a large percentage of patients will spontaneously heal these lesions with aggressive medical therapy. In our experience, these do not subsequently develop pseudoaneurysms without surgery and likely have a relatively low risk for rupture.

Following presentation, patients are immediately treated with parenteral antihypertensive therapy. At our institution, we will aggressively reduce blood pressure for at least a week (goal systolic BP 100 to 120 mm Hg), with beta blockers used as a first-line agent. If repair is delayed by more than 1 week for reasons of comorbidities or associated injuries, we then liberalize control to let systolic pressures rise to no more than 150 mm Hg, and institute oral pharmacotherapy. If operative repair is delayed, we will obtain repeat imaging at 48 hours to be certain that there is no significant change in the injury, such as rapid growth of pseudoaneurysm or increased mediastinal hematoma. It is not unusual for patients to develop pleural effusions that can increase in size over the first 24 to 48 hours with volume resuscitation, and this in and of itself does not represent an indication for more urgent repair.

Repair of the aortic injury is performed as soon as appropriate. However, life-threatening abdominal or neurologic injuries will preclude early repair. In our experience, the most frequent reason for operative delay involves the presence of closed head injury precluding use of heparin for either open or endovascular repair. Another frequent reason is the presence of significant pulmonary contusion, precluding use of single lung ventilation for open descending thoracic aortic repair (DTAR). In the current era, if thoracic endovascular aortic repair (TEVAR) is not felt appropriate, we will delay the open procedure until the time when the patient's pulmonary status allows proceeding with surgery. Finally, in the event that deep hypothermic circulatory arrest is deemed a necessary adjunct (<5%), we will often wait until the patients have been extubated, and have undergone some degree of rehabilitation, as this operative approach requires a significantly increased physiologic reserve.

The determination of the type of repair (i.e., DTAR vs. TEVAR) is based upon several premises. Unlike some institutions that espouse one or another approach exclusively, we take a more conservative strategy understanding that we have an extensive positive experience with both open and endovascular approaches to the descending aorta. There are no long-term data (>15 years) reported with TEVAR for BTAI, and this is an

important consideration in this younger population. Another important consideration is that frequently, follow-up is incomplete making serial imaging that is needed after TEVAR impossible in all patients. A growing concern is also that the serial imaging needed after TEVAR is associated with a large accumulated contrast and radiation exposure over the patient's lifespan, particularly in the younger population. The configuration of the arch is more hazardous in the younger patient population, particularly with the currently available stent graft technology. This is shown in Figure 229.1. Finally, there is a demonstrated natural growth rate of the aorta from the second to eighth decade that can be as much as 1 cm normally. The stability of the stent grafts is uncertain over this time frame.

Certain patient populations such as older patients may benefit from an endovascular approach, both because of the impact of open repair on early recovery, morbidity, and mortality, and because the aortic arch anatomy may be more conducive for TEVAR. We will preferentially use TEVAR in patients over 60 years of age, and in those who have significant or incompletely evaluated comorbid conditions, such as coronary artery disease without known extent, congestive heart failure, chronic renal failure, or emphysema. If TEVAR is not felt suitable, we will then delay the open repair if possible until these conditions have been more adequately evaluated. While we often will consider the gold standard as the open procedure, improvements in device design have led us to use an endovascular paradigm even in younger patients. The potential of branched arch endograft technology may shift the preference further toward TEVAR.

CONVENTIONAL OPEN REPAIR

Preoperative Planning

We rely on CT scan imaging with an aortic protocol as the preoperative test of choice. In performing this test, the contrast bolus is timed to reside within the aortic lumen and thin 1.25- to 2.5-mm cuts are obtained to provide fine details regarding the pathology. Images are obtained starting at the base of the brain and extending to the femoral heads. In this way, we obtain critical information regarding the patency of the Circle of Willis, the extent of mediastinal hematoma, and evaluation of the pelvic vasculature. The performance of 3D reconstructions of the aorta is imperative to better aid in planning for both open and endovascular options.

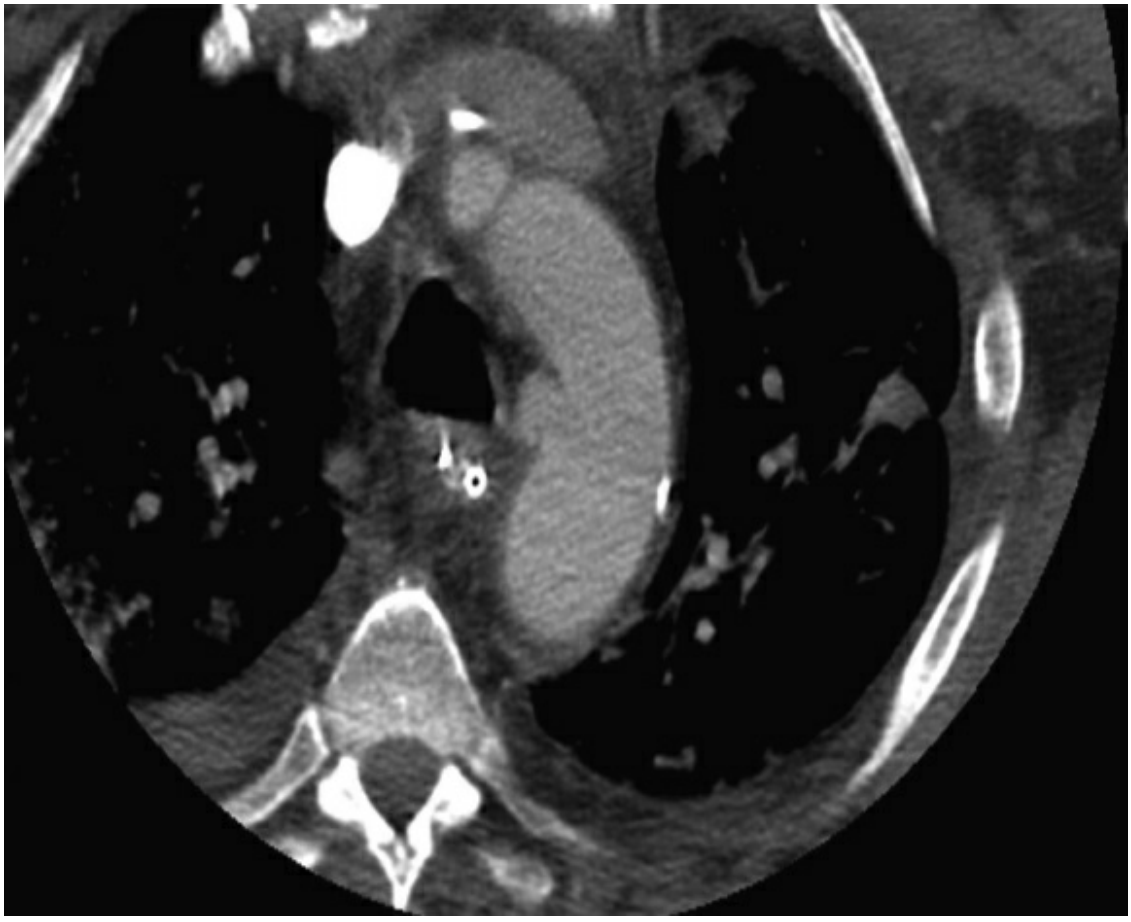

Figure 229.1. This cross-sectional CT scan displays a pseudoaneurysm secondary to blunt traumatic aortic injury. The scan was obtained after a delay period of 7 days, and the periaortic hematoma frequently present on the early scan has now resolved leaving only the grade 3 injury.

Operative Technique

All open repairs (DTAR) are conducted with the use of extracorporeal circulation. The technique of “clamp and sew” is to be avoided as the risks of paraplegia are markedly increased. If a sufficient neck exists for placement of the cross-clamp, left heart bypass with a Carmeda coated system is utilized. The Carmeda coating allows us to reduce the heparin dosing to keep the activated clotting times at about 200 to 250 seconds. Although others have reported safety in using this system without anticoagulation, we have found that even with a lower heparin dosing regimen, clot often forms on the graft itself in the absence of continued flow, and may present a risk for thromboembolism following the release of the distal clamp. Although the procedure can be done without use of an oxygenator, in the acute setting, an oxygenator is preferred as the patient

may have significant right-sided pulmonary contusion impairing gas exchange on one lung ventilation.

The aortic neck in BTAI often exists in the mid-arch aorta, and the placement of the proximal cross-clamp is usually just distal to the left carotid artery. A good rule of thumb is that the inadequacy of a 2 cm neck distal to the left carotid artery prior to the origin of the tear often precludes the use of left heart bypass, cross-clamp application, and still sufficient aorta to which to suture a graft. The use of deep hypothermic circulatory arrest with construction of an open proximal anastomosis is then mandatory. We have found this adjunct needed in less than 5% of our series.

The operative procedure starts with the use of general anesthetic with a double lumen tube to isolate the left lung. A lumbar drain for spinal cord protection is typically not employed for the standard distal arch and proximal descending aortic replacement. A left posterolateral thoracotomy with entrance into the fourth intercostal space is made. We will often preserve the serratus anterior muscle and will try to avoid extending the thoracotomy posteriorly. In this manner, the thoracotomy wound will then not be in a posterior location prone to breakdown with an ill intubated patient. The mediastinal hematoma in the acute injury is usually immediately visible in the posterior mediastinum as a bluish discoloration of the pleura. Particular attention is paid to the preoperative CT scan, as dissection in the area where the rupture is located is avoided until both proximal and distal control are obtained. We initially attempt to obtain distal aortic control first by mobilizing the aortic segment at about the T6 level. If the injury is acute, we mobilize the proximal aorta only after the patient is cannulated for left heart bypass. If the injury is subacute or chronic, dissection is then continued proximally to mobilize the mid-arch aorta prior to cannulation. The phrenic nerve is preserved and serves as a good marker for location of the left carotid artery. Dissection of the mid-arch starts by opening the pleura posteriorly to the phrenic nerve and identifying the aorta. The dissection is best continued superiorly identifying the distal arch vessels. Often in the acute setting, the hematoma often partially dissects the planes, thereby facilitating aortic mobilization. A finger is then used to separate the trachea and left mainstem bronchus medially from the aorta laterally until the inferior edge of the aorta is reached. Then, starting often close to the proximal arch lesser curvature where the pericardial reflection sits, the lesser curve dissection is

continued to the ligamentum arteriosum. Great care should be taken in this region given the proximity of the contained rupture. The left recurrent laryngeal nerve is not usually identified until the aorta is ready to be clamped proximally and the patient is placed on left heart bypass.

Cannulation for left heart bypass is performed with division of the inferior pulmonary ligament and exposure of the left inferior pulmonary vein or by placement in the superior pulmonary vein. A right angle tip cannula is placed through this vessel into the left atrium for venous drainage. Arterial return is accomplished via either the distal aorta (if no hematoma is present) or the left femoral artery (if significant aortic mural hematoma exists down into the infradiaphragmatic aorta). We usually do not cool much more than 33°C to 34°C to avoid the risk of ventricular fibrillation.

Further mobilization of the aorta is then often performed after placing the patient on left heart bypass. Cross-clamps are then applied to isolate the aortic segment ready for resection, and the limited injured segment of aorta is mobilized off the esophagus after incision into the aorta. Any back bleeding intercostal vessels in the region where resection is to occur are ligated. If any intercostal arteries can be preserved but are located within the isolated aortic segment, small occlusion clamps are placed externally, or small Fogarty balloon catheters are placed into their lumina to prevent blood loss from back bleeding. We would previously resect the pseudoaneurysm completely and then interpose a Dacron graft. Now, we will often start with a linear aortotomy along normal aorta to inspect the defect. If there is a partially disrupted wall confined to one side of the aorta, we would consider patching this defect with a Dacron patch sewn on with a 4-0 polypropylene suture. This can even be done endoluminally, running the patch along the rim of the defect, and keeping the pseudoaneurysm intact externally to keep it separate from adjacent viscera such as lung or esophagus. Occasionally, if the defect is not large, the adjacent aorta can be mobilized and the tear primarily repaired with a running 4-0 polypropylene suture to avoid leaving prosthetic material. It is imperative to leave this anastomosis without tension with adequate aortic mobilization.

If there is a spiral tear, we will resect the aorta and construct the proximal anastomosis of aorta to the Dacron graft with a running 4-0 polypropylene suture with or without Teflon felt reinforcement (Fig. 229.2B). The cross-clamp is then moved onto the graft and the proximal

suture line checked for hemostasis. The graft is sized to an appropriate length, and then cut to reach the distal aorta. This anastomosis is then similarly constructed and the clamps removed after de-airing maneuvers are performed (Fig. 229.2C). We then reverse the heparin with protamine and decannulate the patient. Finally, the graft is then separated from the adjacent lung with pleura if available, or with bovine pericardium or separate Dacron graft strips wrapped around the anastomoses.

Postoperative Management and Potential Complications

Routine postoperative care involves management of concomitant injuries and hemodynamic support. In particular, the spinal cord is protected with a regimen of permissive hypertension with maintenance of systolic blood pressures at 120 to 140 mm Hg. As stated previously, routine use of cerebrospinal fluid drains is not necessary as few intercostal vessels are sacrificed in the typical repair and distal aortic perfusion is maintained with left heart bypass. The expected risk for paraplegia after open repair for BTAI should be less than 5%.

We usually remove chest tubes after confirming the absence of a chyle leak by enteral feeding of 80 cc of heavy cream. If a chyle leak is suspected, conservative measures including a no fat diet are employed. Protracted observation of a chyle leak is discouraged, as severe malnutrition can ensue particularly in the multisystem trauma patient. Rather, in that event, a postpyloric enteral feeding tube is inserted and cream instilled continuously 6 hours before and (most importantly) into the operating room to help identify the source of chyle leak on re-exploration via a left thoracotomy. The leaking duct is then ligated with clips or multiple silk ligatures.

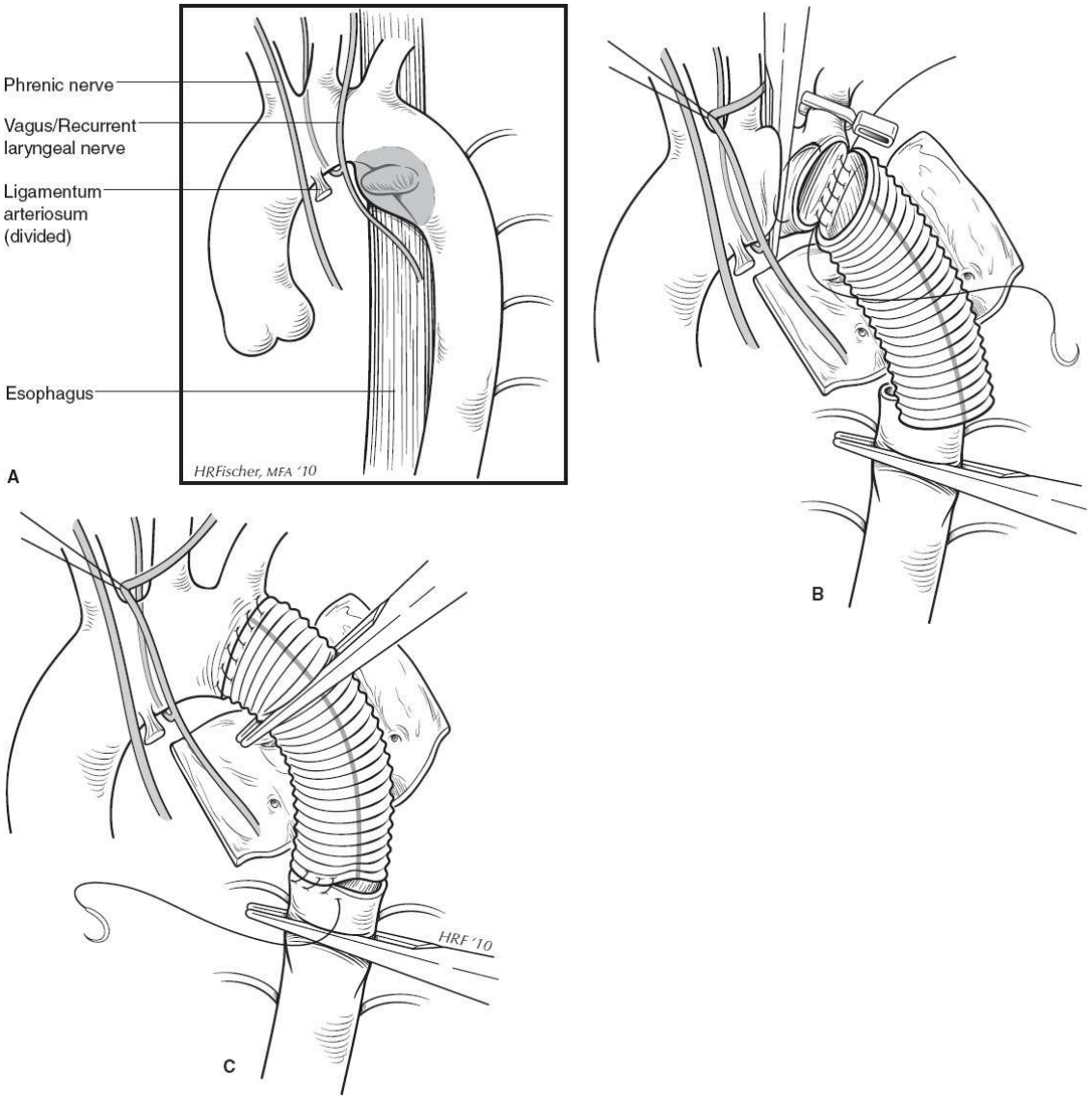

Figure 229.2. *Open repair of the traumatic aortic transaction.* This depicts the usual location of the thoracic aortic transaction. The important anatomical landmarks include the left phrenic, vagus, and recurrent laryngeal nerves as well as the esophagus (**A**). Proper mobilization of the aortic arch and proximal descending aorta is required for complete repair. Note that the ligamentum arteriosum has been divided to allow for proper placement of the proximal cross-clamp that is normally applied proximal to the left subclavian artery. In addition, the left vagus and recurrent laryngeal nerves are mobilized anteriorly to allow for arch exposure. On the medial aspect of the proximal cross-clamp, the trachea is usually palpated (not shown in figure). The extent of injury is usually very localized, and few if any intercostal arteries require sacrifice (**B**). After construction of the proximal anastomosis, the proximal cross-clamp is moved onto the aortic graft to restore antegrade perfusion of the left subclavian artery (**C**). The distal anatomosis is then constructed with 3-0

polyprolene suture.

THORACIC AORTIC ENDOVASCULAR REPAIR (TEVAR)

The recent advent of endoluminal techniques for aortic disease has been applied to the multisystem trauma patient with great success (Figure 229.3). Numerous studies have focused on early outcomes. However, late outcomes (>15 years) remain yet to be defined. Despite the lack of long-term data, this approach has rapidly been applied in the setting of BTAI as a potential means of decreasing early morbidity and mortality. The recent American Association for Surgery of Trauma (AAST) trial suggested that this treatment modality has become much more prevalent than open repair in multiple trauma institutions.

Preoperative Planning

Again, the preoperative imaging modality of choice is the CT scan with 3D reconstruction. Similar to other pathology, the successful use of TEVAR in this setting is critically dependent on preoperative anatomy. The CT scan obtained in this setting is obtained again extending from the base of the brain to the pelvis, with the contrast bolus timed to reside within the aorta itself. In this way, key information regarding the pathology, the circle of Willis, and access vessels is defined. Given the need to access peripheral vessels with large bore sheaths, we will also obtain preoperative ankle-brachial indices to determine a baseline measurement.

With the current second-generation thoracic endografts, certain contraindications to standard TEVAR exist. These include: (1) inadequate (<2 cm) proximal neck defined as the distance from the left carotid artery to the tear, (2) inadequate access vessels to deliver the device, (3) aortic diameters outside of the range of currently available devices, and (4) a “gothic” rather than an “elliptical” aortic arch configuration (Figure 229.4). However, it must be recognized that these represent relative contraindications, as “advanced” TEVAR techniques such as arch debranching for inadequate proximal neck, use of abdominal endograft components in small native aortic diameters, or device delivery via the ascending aorta can be applied to overcome these limitations.

The choice of endograft is then made based upon the 3D reconstructive anatomy. It is important to consider the volume status of the patient at the time of the CT scan, and remember that a properly resuscitated patient

may have an aortic diameter that is up to 10% larger than a patient who acutely arrives in the hospital in the setting of hemorrhagic shock. When aortic repair is delayed, we will consider repeating the CT scan after the patient is volume resuscitated in the event that TEVAR is considered the appropriate therapy. Generally, diameter specification is made first, and this chosen diameter stent graft is oversized by approximately 10%. Next, the treatment length is determined by a centerline of flow assessment of length (i.e., center portion of the 3D reconstructed aorta). We use the shortest possible graft that will allow coverage of the entire length of the pseudoaneurysm, along with the 2 cm length needed for the proximal and distal landing zones.

Need for Adjunctive Left Carotid to Left Subclavian Artery Bypass

Given the location of the typical BTAI injury, the left subclavian artery (LSA) often requires at least partial coverage. Absolute indications for LSA revascularization with either a bypass or a transposition include presence of a pedicled left internal mammary artery to left anterior descending coronary artery bypass graft or a dominant left vertebral artery. We will often include a direct origin of the left vertebral artery from the aortic arch as an important indication for LSA revascularization. There are emerging data suggesting a decrease in the risk of stroke and paraplegia with left subclavian arterial revascularization. On the basis of these data as well as our personal experience, we will routinely perform LSA revascularization prior to complete coverage unless a contraindication exists such as a neck fracture or hemodynamic instability. As branched endograft technology evolves, the need to perform adjunctive maneuvers may diminish.

Finally, a discussion of complex TEVAR with so-called “chimney” or “snorkel” stent grafts for branch vessel is warranted. With this approach, a bare stent or endograft is placed into the branch vessel, and spanned across the landing zone into the more proximal uncovered aorta as a parallel conduit. Branch vessel flow is preserved despite branch vessel origin coverage, and the landing zone is extended without open adjunctive extra-anatomic revascularization. We will reserve this option for emergent procedures where more conventional methods will not be possible, or for other reasons such as inability to turn the neck for performance of the LSA bypass in the setting of an absolute indication for its revascularization.

Operative Technique

The open access vessel (usually femoral artery) is exposed and made ready for isolation. The femoral artery is exposed via a transverse infrainguinal incision. If the caliber of the iliac artery is smaller than what is required, an iliac artery is exposed via a lower quadrant incision and mobilization and exposure of the vessel staying in the preperitoneal and retroperitoneal planes. A Dacron graft is then anatomosed to the common iliac artery in an end-to-side fashion and the open distal end of the graft brought out through the abdominal wound to serve as the conduit for device delivery. Percutaneous access is obtained in the contralateral femoral artery with a 5-Fr sheath. Via the percutaneous access, a marker pigtail catheter is situated into the arch aorta.

The endograft is then advanced over a super-stiff wire via the open arterial access site and placed into the ascending aorta. We will routinely heparinize the patient unless a contraindication exists. Generally, if a contraindication exists (e.g., traumatic brain injury), we delay the operative procedure to a time when heparin administration is considered relatively safe. Although there have been reports of safely performing this procedure without heparin, we find the delivery sheaths for the devices generally occlusive up to the level of the iliac arteries. In this situation, there exists a catastrophic potential for not only iliac artery thrombosis, but also thrombus formation on wires, catheters, and sheaths placed in the ascending and arch aorta.

An arch aortogram is then performed, delineating the pathology and critical branch vessels. In general, the projection of the image intensifier should be in a location whereby all of this information is obtained with one injection. If significant renal failure exists preoperatively, we have performed this procedure with the use of intravascular ultrasound to mark the branch vessels and minimize contrast exposure. Assuming the ileofemoral system has an adequate caliber to accommodate the devices, the stent grafts are advanced into the intended landing zone and then deployed. Gentle balloon dilation of the proximal and distal landing zones can be performed, but is not mandatory. Completion thoracic aortography is performed to determine the presence of endoleaks (usually type I as these repairs usually only need one stent graft component). If they exist, consideration is then given to determine whether a more proximal extension is feasible, or whether these can be left alone. Since there is typically no outflow in the pseudoaneurysm sac, we have found that even

if an endoleak persists despite re-ballooning the aorta, by the time of the first CT scan at 1 month postoperatively, the pseudoaneurysm has collapsed and no endoleak exists.

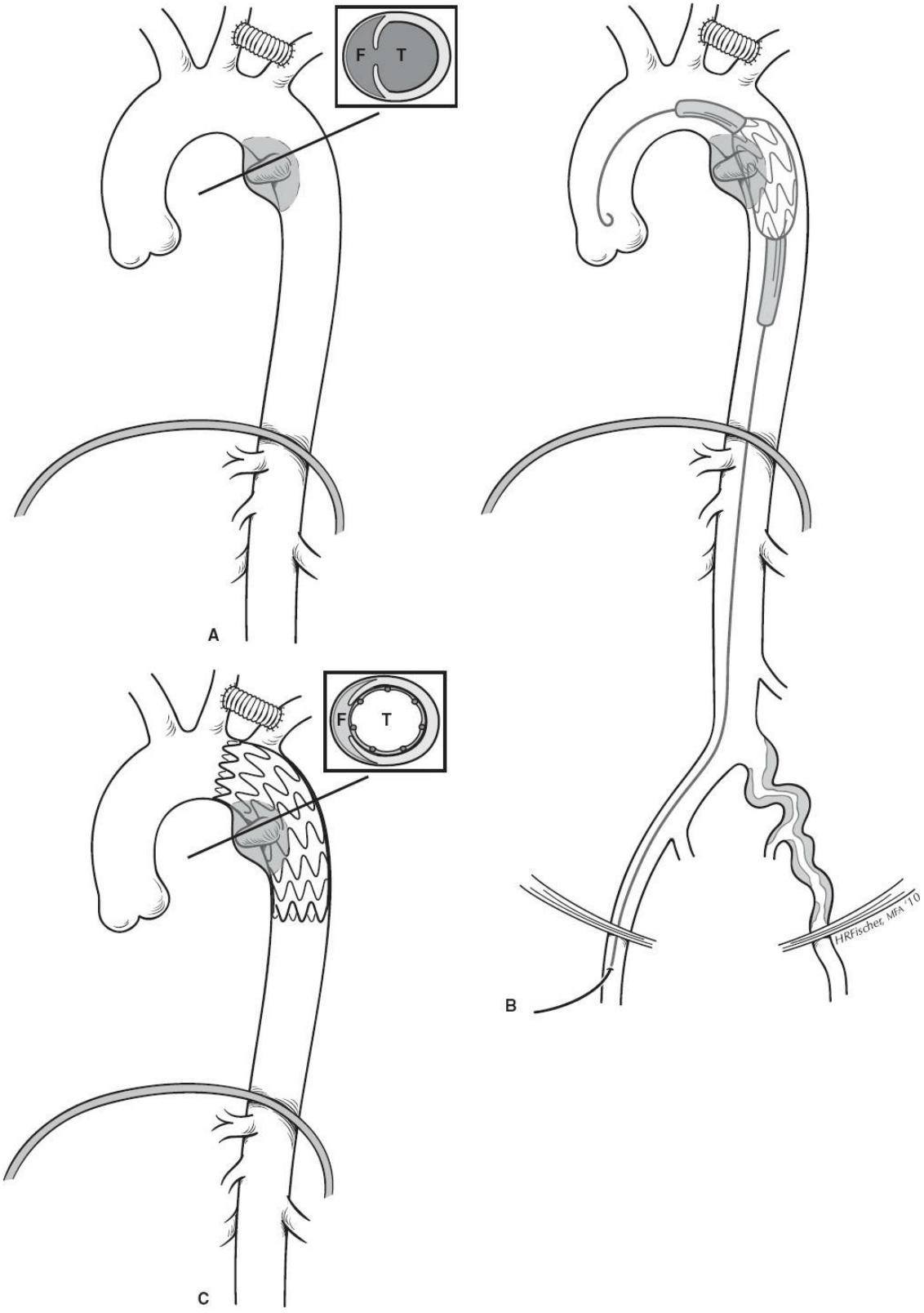

Figure 229.3. *Thoracic endovascular repair of the traumatic aortic injury.* This again depicts the injury in a left anterior oblique projection (**A**), but in preparation for TEVAR, a left carotid to left subclavian artery bypass has been constructed. The stiff wire has been advanced into the ascending aorta (**B**) via the better right femoral access vessel. The endograft is brought toward the base

of the left carotid artery and then subsequently deployed to cover the origin of the left subclavian artery (**C**). In general, we do not preemptively place occlusion devices into the orifice of the subclavian vessel unless the pseudoaneurysm abuts its origin along the greater curvature. Endoleaks that are identified early are rarely seen late, as there is usually no outflow thus promoting sac thrombosis and regression.

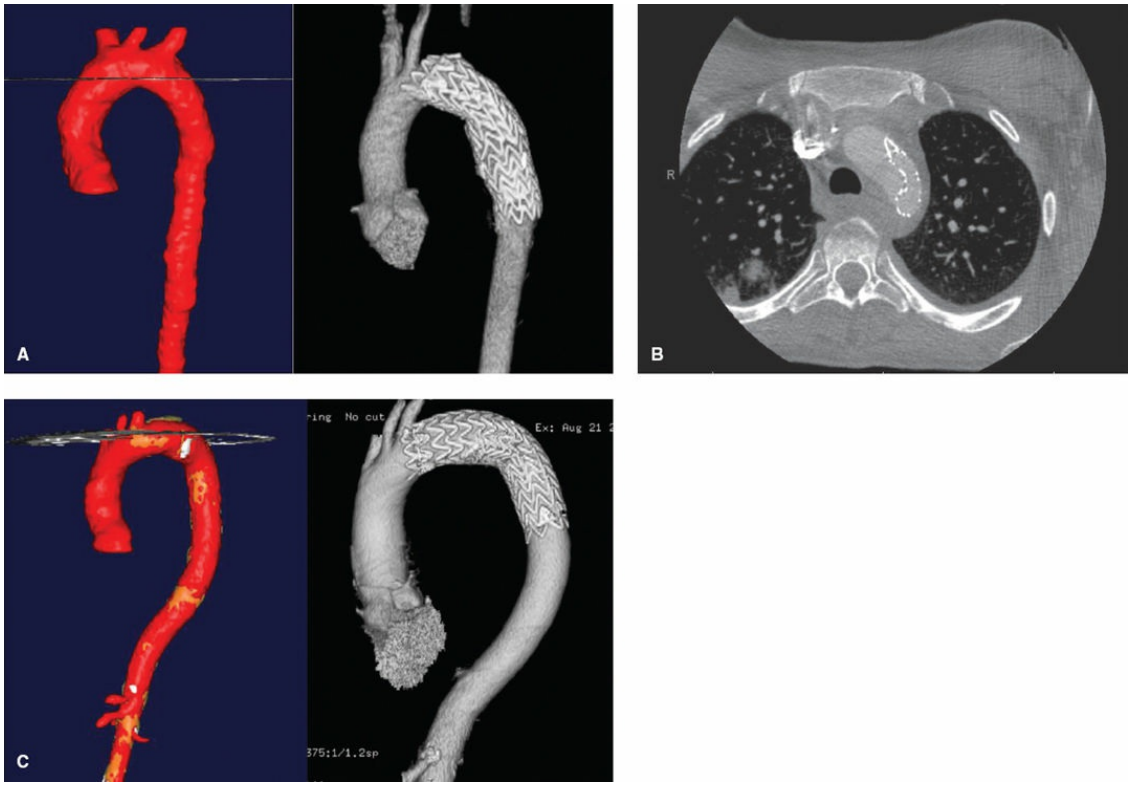

Figure 229.4. (**A**) This 3D reconstruction reveals the typical "gothic arch" in a 23-year-old male with a blunt injury (not shown in this projection). Deployment of the stent graft results in a "bird beak" configuration with incomplete apposition of the stent graft to the lesser curvature. In this setting, there is a possibility of resulting collapse of the endograft (shown in **B**). Maneuvers to diminish this risk include placement of a second endograft or a balloon expandable stent to increase radial force. In contrast in (**C**), this 71-year-old male has a relatively flat arch more amenable to coaxial stent graft alignment and good lesser curvature apposition.

Finally, the discussion of whether to occlude the subclavian artery prior to stent graft deployment often arises. In our experience, it is unusual for the LSA to cause a retrograde type II endoleak as the pseudoaneurysm is typically located along the lesser curvature. In the event that this occurs,

coil embolization from a percutaneous brachial approach is simple and associated with minimal morbidity. Indications for preemptive LSA plug occlusion however include a marginal proximal neck (<2 cm), or the presence of a tear abutting the origin of the subclavian artery.

Following completion of the stent graft deployment, we withdraw the device sheaths from the open arterial access initially maintaining wire access to be certain that iliac rupture has not occurred. The femoral or iliac artery is carefully repaired with interrupted 5-0 polypropylene sutures, taking care to tack down the inevitable flap created by sheath advancement. Protamine is then administered and the percutaneous access then removed with manual hemostasis.

Postoperative Management

The standard postoperative management following TEVAR is similar to that described above for open repair. Vascular system checks are imperative as is the need to evaluate all percutaneous puncture sites for hematoma or pseudoaneurysm formation. We will obtain ankle-brachial indices the next day to be certain that there is no change from preoperative status.

Complications

The complications from open surgery (stroke, paraplegia, renal failure) can still occur following TEVAR. To minimize contrast-induced renal failure, we hydrate the patient both prior to and following the TEVAR procedure. Several complications unique to TEVAR exist. The first is an access related one, namely, iliac artery rupture, which usually occurs at the iliac artery bifurcation following device sheath removal. In our experience, this is a common cause of death after TEVAR for any indication. The best treatment is prevention, and liberal use of iliac conduits when necessary. In the event of rupture, we now repair the artery with an iliac stent graft inserted over the wire used for thoracic device delivery. The importance of maintaining wire access cannot be underemphasized, and we have a “rupture kit” available when access vessels are marginal to start with. The first sign of iliac rupture is not hypotension, but loss of pulse distal to the ruptured artery. In rapid sequence, a 20-Fr sheath is advanced into the iliac artery, followed by an occluding balloon (size selected prior to start of TEVAR procedure) placed just distal to the aortic bifurcation. An angiogram is performed through the sheath, distal to the occluding balloon

confirming the diagnosis and site of rupture. After the patient is volume rescusitated, we then rapidly deflate and withdraw the balloon and advance and deploy the iliac stent graft (also selected prior to start of TEVAR procedure). Return of hemodynamic stability and distal pulses confirms exclusion of rupture, but angiographic control is performed.

The second unique complication is that of endograft collapse following TEVAR. This can result in repressurization of the pseudoaneurysm, or even a coarctation-like presentation if it is occlusive. Prevention is paramount, and the risk is decreased if oversizing or treatment in a "gothic" arch configuration is not performed. In addition, at the conclusion of each TEVAR procedure, we will examine the leading edge of the endograft under magnification views with fluoroscopy to ensure that the lesser curvature segment is not mobile. Also, the postprocedure angiogram provides an idea of potential instability if there is a significant "bird-beaking" effect where the leading edge is separated from the lesser arch curvature by >0.75 cm. If any of these indicators exist, consideration is then given for either placement of a balloon expandable bare metal stent into this segment or a second endograft placed within the first. Both maneuvers will increase the radial force of the graft and minimize risk of collapse. The incidence of this unique occurrence has diminished as second-generation devices have become available, and as its awareness particularly for this pathology has increased.

CONCLUSIONS

The last decade has seen dramatic shifts in the management of blunt thoracic aortic injury. Advances in imaging have reduced the need for invasive angiography for therapy, and have identified the injury in a more rapid and consistent manner. The importance of medical therapy in the early postinjury period has been recognized. Not only has the paradigm shifted from immediate repair for all patients to a selective management toward early intervention, but the type of therapy in the "real world" appears to have shifted favoring an endovascular approach. The surgeon(s) evaluating this lethal injury should be well versed in all of these issues, whether they perform the procedure or not, in order to provide the best care of the complex injured patient.

Suggested Readings

Akins CW, Buckley MJ, Daggett W, et al. Acute traumatic disruption of the

thoracic aorta: a ten year experience. *Ann Thorac Surg* 1981;31:305–9.

Azzizadeh A, Keyhani K, Miller CC 3rd, et al. Blunt traumatic aortic injury: initial experience with endovascular repair. *J Vasc Surg* 2009;49:1403–8.

Demetriades D, Velmahos GC, Scalea TM, et al. Blunt traumatic thoracic aortic injuries: early or delayed repair—results of an American Association for the Surgery of Trauma Prospective Study. *J Trauma* 2009;66:967–73.

Demetriades D, Velmahos GC, Scalea TM, et al. Operative repair or endovascular stent graft in blunt traumatic thoracic aortic injuries: results of an American Association for the Surgery of Trauma Prospective Study. *J Trauma* 2008;64:561–71.

Fabian TC, Davis KA, Gavant ML, et al. Prospective study of blunt aortic injury and helical CT is diagnostic and antihypertensive therapy reduces rupture. *Am Surg* 1998;227:666–77.

Kato N, Dake MD, Miller DC, et al. Traumatic thoracic aortic aneurysm: treatment with endovascular stent-grafts. *Radiology* 1997;205:657–62.

Parmley LF, Mattingly TW, Manion WC, et al. Nonpenetrating traumatic injury of the aorta. *Circulation* 1958;17:1086–101.

Patel HJ, Hemmila MR, Williams DM, et al. Late outcomes following open and endovascular repair of blunt thoracic aortic injury. *J Vasc Surg* 2011;53(3):615–20.

EDITOR'S COMMENT

Complete aortic transections are almost universally lethal at the scene. While I am not sure of any literature that suggests more people in motor vehicle or motorcycle accidents are surviving with aortic injuries with all the new safety prevention strategies (airbags, etc.), I do know that the diagnosis, as well as the management, of this disease process has changed radically for the better. When I think back to all of the mainly unneeded aortograms we used to perform on trauma patients and then the "clamp and sew" repairs of these injuries when found, I really suspect that few areas of care have been improved more than how we take care of patients with traumatic aortic injuries. Unfortunately, both reporting standards and follow-up of these often young patients are woeful, making comparison of open versus endovascular repair (TEVAR) of the thoracic aorta difficult (Karmy-Jones R, Ferrigno L, Teso D, et al. Endovascular repair compared with operative repair of traumatic rupture of the thoracic aorta: a nonsystematic review and a plea for trauma-specific reporting guidelines. *J Trauma* 2011;71(4):1059–72). I think a good general consensus however is that TEVAR is associated with a lower mortality and paralysis rates, but that comes at the expense of more strokes in the TEVAR group.

First, cross-sectional imaging with high-resolution CTA followed by 3D

immediate reconstructions has given us pause for treating all aortic injuries, short of a complete aortic transection. As Patel and coauthors point out, we now recognize that there are degrees of aortic injury that range from a small intimal tear to an intramural hematoma to a full-blown transection. My guess is that we have become more conservative over time especially with the small intimal tears and localized injuries (Mosquera VX, Marini M, Lopez-Perez JM, et al. Role of conservative management in traumatic aortic injury: comparison of long-term results of conservative, surgical, and endovascular treatment. *J Thorac Cardiovasc Surg* 2011;142(3):614–21). Many of these patients can safely undergo repeat imaging with almost all of them healing their aortic tear. In addition to the grading system around these injuries, I think we have become more comfortable with delaying repair when no blood is present in the mediastinum or chest. I am not advocating a policy of delaying for extended periods of time, even though I am not sure we know a lot about the perfect timing of repair in these patients. I am suggesting that taking these multitrauma's down in the middle of the night with less than the "A team" can probably be delayed long enough to get the appropriate staff and environment, specifically an hybrid operating room with experienced interventional radiology technician's and nursing personnel.

Second, while Dr. Patel has well described open surgery for patients with aortic transections, except for in the rare event where the aortic injury is an isolated injury, almost all of these patients are now treated with endovascular stenting as they typically are multitraumas (i.e., more than one system injured) (Mwipatayi BP, Boyle A, Collin M, et al. Trend of management of traumatic thoracic aortic injuries in a single center. *Vascular* 2014;22(2):134–41). In fact, there are now three endograft companies that manufacture grafts that have traumatic aortic injury as an FDA-approved indication. Most of the endograft companies now have developed thoracic endografts that are smaller profile in terms of the delivery sheath size. These smaller diameter sheaths make for fewer iliac artery injuries when delivering the endograft to the thoracic aorta (that when they occur, you quickly realize upon sheath removal when the blood pressure goes to 0!). They also have recognized the need for smaller diameter aortic endografts to treat smaller aortas in these often young, multitrauma patients. Gone are the days when short aortic cuffs were "shingled" into the thoracic aorta in order to treat aortic transections (Thompson JK, Reed AB, Giglia JS. Novel endovascular treatment of blunt thoracic aortic trauma with a self-expanding stent lined with aortic extender cuffs. *Ann Vasc Surg* 2006;20(2):271–3). This is definitely a good thing.

Finally, I would comment on two other issues that Patel has addressed in this chapter, but I need to add my two cents worth on. I almost always use heparin prior to delivering the thoracic endograft. Recognizing that the incidence of thromboembolic disease to the lower extremities is low, I still believe most patients can tolerate some heparin, say 3,000 to 5,000 units intravenously. I am not talking about giving cardiopulmonary bypass doses, but enough heparin to

potentially prevent what I think is the most devastating complication of stent grafting in the aortic arch (i.e., stroke) (McBride CL, Dubose JJ, Miller CC 3rd, et al. Intentional left subclavian artery coverage during thoracic endovascular aortic repair for traumatic aortic injury. *J Vasc Surg* 2015;61(1):73–9). I think that is especially important in patients you are planning to cover the left subclavian artery, as this is associated with more manipulation of the endograft in the aortic arch. I agree that most patients tolerate left subclavian artery coverage fine, especially in the emergent setting. However, I always get a CTA of the head and neck to make sure of the patients intracerebral anatomy, including the course and dominance of the vertebral arteries (McBride CL, Dubose JJ, Miller CC 3rd, et al. Intentional left subclavian artery coverage during thoracic endovascular aortic repair for traumatic aortic injury. *J Vasc Surg* 2015;61(1):73–9). Obviously, I would not cover the left subclavian artery in a patient who has a LIMA (left internal mammary artery) graft to a coronary artery and would do a left carotid to left subclavian artery bypass for these patients, until branched aortic arch endografts become available (which is not that long from now!).

Gilbert R Upchurch Jr.

Suggested Reading

Cho JW, Kwon OC, Lee S, et al. Traumatic aortic injury: single-center comparison of open versus endovascular repair. *Korean J Thorac Cardiovasc Surg* 2012;45(6):390–5.

230 Vascular Injuries to the Neck, Including the Subclavian Vessels

Nam T. Tran

BACKGROUND

The neck is unique in that it contains vital organs from the respiratory, digestive, vascular, neurologic, and endocrine systems. In the severely injured trauma patient, all of these structures must be assessed and treated accordingly. While vascular injuries to the neck only account for 5% of all civilian vascular injuries, rapid management is critical once the airway has been secured to ensure patient survival and optimal outcome. Both penetrating and blunt mechanisms can cause injury to vascular structures in this region. Unlike other anatomic areas of the body, penetrating wounds comprise the majority of vascular injury in the neck in urban trauma centers. While less common, blunt mechanisms can also result in significant injury to vascular structures as well.

HISTORICAL PERSPECTIVE

In 1552, the French surgeon Ambroise Pare ligated both carotid arteries and a jugular vein of a soldier injured in a duel. The soldier survived the operation, but unfortunately was left with hemiplegia and aphasia. Two centuries later, a young naval surgeon, Fleming, ligated the common carotid artery on a suicidal sailor with a successful outcome. The mortality associated with cervical vascular injuries in World War I was approximately 16% to 30% for both nonoperative management and ligation of actively hemorrhaging vessels. In World War II, a more aggressive policy toward routine exploration resulted in a significant reduction in mortality with cervical vascular trauma. The first attempt at surgical repair of a cervical vascular structure, an injured carotid artery,

was performed during the Korean War. Repairs at that time consisted of direct suture, primary anastomosis, and interposition vein graft. Modern-day management has included the addition of endovascular approaches with coil embolization of bleeding vessels and the placement of both covered and bare metal stents.

GENERAL APPROACH—ANATOMIC ZONES

Classically, the management of cervical trauma is dictated by anatomic zones originally described by Monson at the Cook County Hospital in 1969 and still remain in use today (Fig. 230.1). Zone I is defined by the thoracic inlet inferiorly and the cricoid cartilage superiorly. In this area, structures at risk include the subclavian vessels, brachiocephalic vessels, aortic arch, and origins of the carotid artery. Zone II is the midportion of the neck and is demarcated by the cricoid cartilage inferiorly and the angle of the mandible superiorly. This zone contains the carotid arteries, vertebral arteries, and the jugular veins. Lastly, zone III is the highest in the neck and is bound by the angle of the mandible inferiorly and the base of the skull superiorly. In this region, the carotid arteries and jugular veins are at greatest risk. Typically, injuries to structures in zone III are the most difficult to access surgically.

ETIOLOGY/EPIDEMIOLOGY

Overall, gunshot wounds account for the majority of cervical penetrating trauma. Stab wounds often cause injury to the left neck due to the majority of the population being right handed. The common carotid artery is the vessel most often injured followed by the internal carotid and subsequently the external carotid artery. Mortality from penetrating missile wounds ranges anywhere between 2% and 10% and is dependent upon other associated injuries, time between injury and presentation, and the patient’s overall neurologic status. In particular, those with profound neurologic deficits carry the worst prognosis.

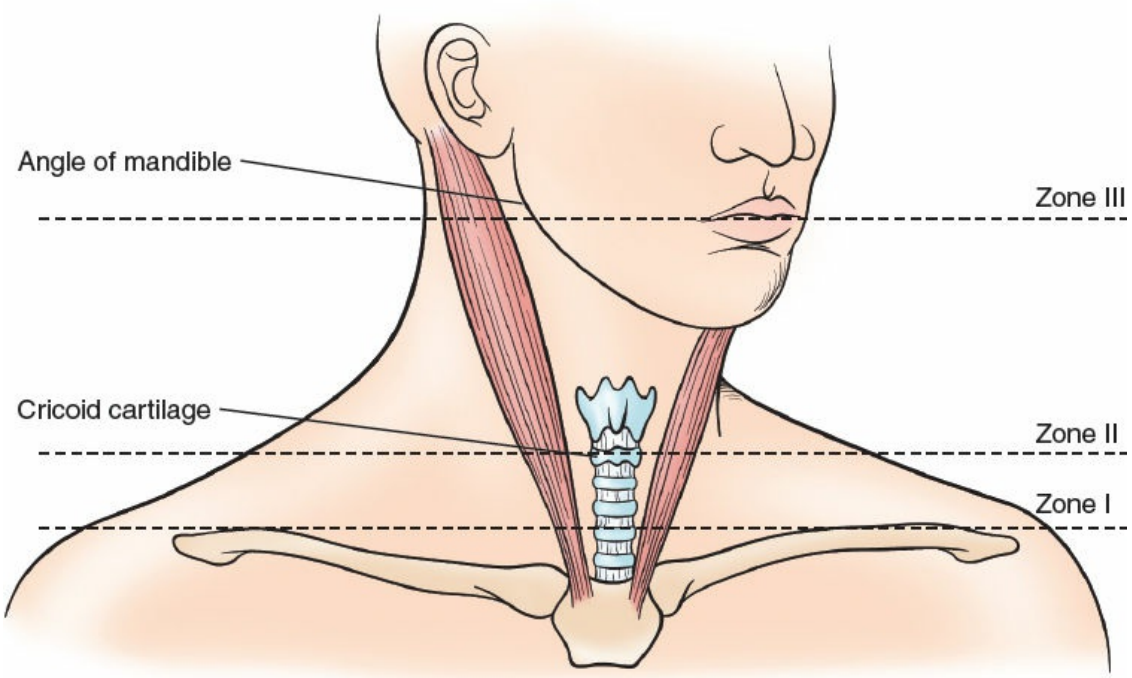

Figure 230.1. Zones of the neck. (Adopted from *Anatomic Exposures in Vascular Surgery*, 2nd ed. Valentine, Wind, LLW Publishing, 2003.)

Penetrating neck injury can be due to direct effect of the projectile resulting in partial or complete vessel transection. Localized effect, such as blast injury, can result in the formation of an intimal flap, dissection, pseudoaneurysm, or arteriovenous (AV) fistula. In 25% to 40% of cases, penetrating trauma results in vessel thrombosis. Of the vascular structures in the neck, the internal jugular vein (95%) and carotid artery (7%) are most often injured.

While penetrating neck trauma is often discussed and written about, the majority of injuries to the neck are caused by blunt force trauma. This can be the result of motor vehicle collision or due to sports-related injury (i.e., clothesline tackle), chiropractic manipulation, blow from the fists or feet, and strangulation.

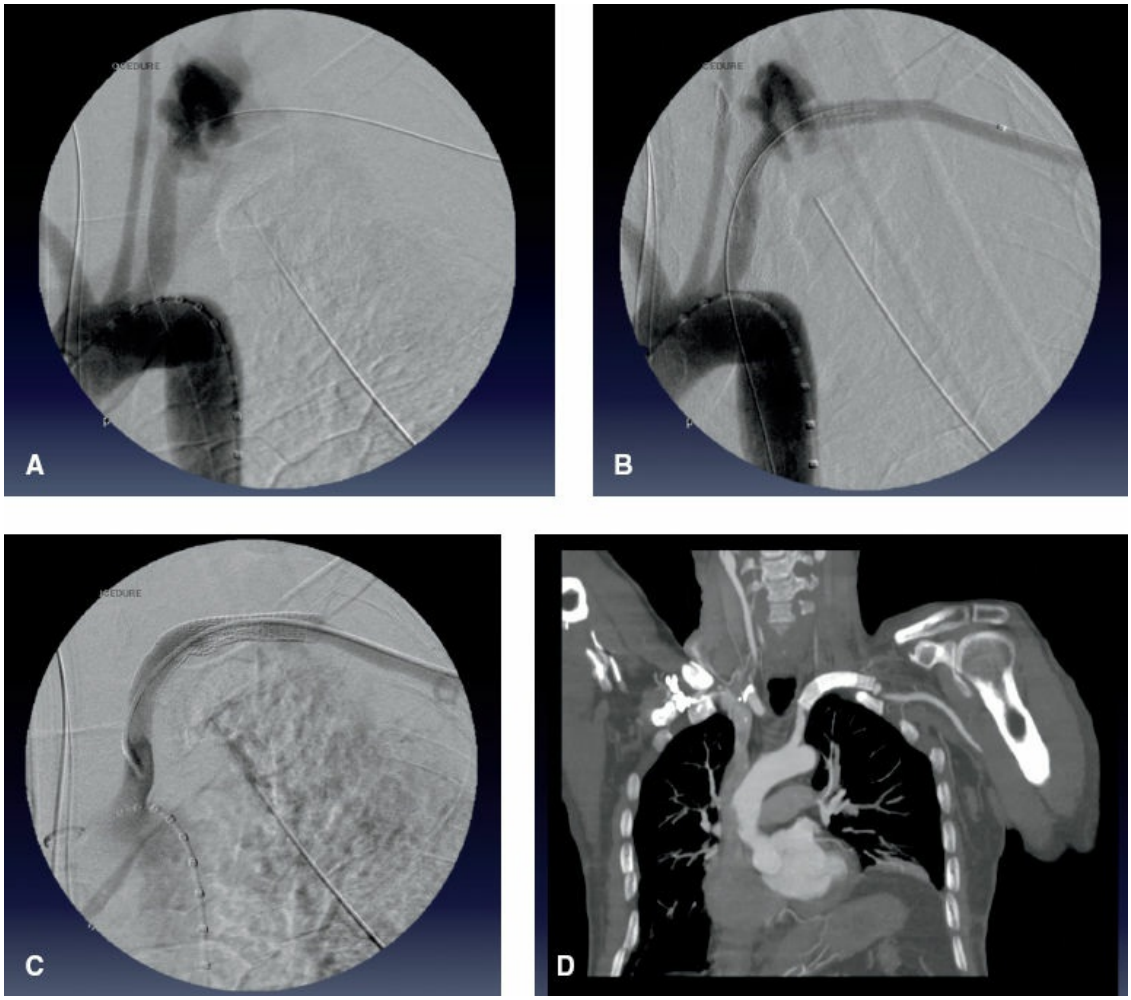

Figure 230.2. (**A**) Initial diagnostic arteriogram showed extravasation from the left subclavian artery secondary to GSW, (**B**) initial placement of a covered stent across the injury, (**C**) completion angiogram demonstrated patency of the subclavian and exclusion of the injury, (**D**) follow-up CT scan at 1 month.

MANAGEMENT—OPERATING ROOM SETUP/HYBRID SETUP

In the past, cervical vascular injury was treated via open surgical approach once the injury was identified. Often, this involved diagnostic imaging in a separate hospital location such as that of a computed tomographic (CT) scanner or the angiographic suite. This paradigm is suboptimal and often prolonged the time to surgical intervention especially in critically ill patients.

With the adoption of endovascular techniques, modern vascular surgeons are able to provide a full range of services to the patient with cervical vascular trauma from diagnosis to surgical intervention.

Furthermore, the adoption of endovascular techniques has allowed most cervical vascular injuries to be treated in a "minimally invasive" manner, thus avoiding the morbidity of a full open exposure and repair (Fig. 230.2).

The modern operating room (OR) needs to be able to function as both an open operating theater and an angiographic suite. This OR needs to be able to allow one to perform a full range of open vascular reconstructions from simple vascular repair to complex aortic reconstruction with the use of cardiopulmonary bypass. At the same time, the use of ceiling-mounted imaging equipment or portable C-arm fluoroscopy enables the surgeon to acquire high-resolution diagnostic imaging of the vascular system and perform life-saving therapeutic interventions.

In the case of cervical trauma, the "hybrid OR" will need to be set up to allow for efficient interactions of all team members involved. Specifically, the anesthesiologist will need to have full access to the patient's airway, as well as one or both upper extremities for invasive hemodynamic monitoring and fluid resuscitation. The OR staff will need adequate space for open surgical trays and endovascular equipment. Finally, the imaging technologist should be able to maneuver the ceiling-mounted or portable imaging equipment with ease and with full access to all the required regions for endovascular intervention.

MANAGEMENT—ZONE I PENETRATING INJURY

Patients presenting with hard signs of arterial injury at the base of the neck should be considered for immediate surgical exploration (Table 230.1). In stable patients, diagnostic studies are usually indicated first to fully define the location and extent of associated vascular injuries. Ultrasound has a limited role in the evaluation of vascular structures in this location due to depth of the vascular structures and the overlying rib cage. Arteriography has been considered to be the gold standard for the diagnosis of vascular injuries in this region. Recently, dynamic contrast-enhanced CT angiography (CTA) has been used with anatomic resolution and accuracy equivalent to that of traditional arteriography. CTA is rapid and allows for identification of associated injuries to the surrounding aerodigestive structures.

TABLE 230.1 Clinical Indications Suggestive of Blunt Cerebrovascular Injury

Arterial hemorrhage from the neck, mouth, nose, or ear Cervical hematoma Cervical bruit in a patient <50 years of age Focal or lateralizing neurologic deficit (i.e., hemiparesis, TIA, Horner syndrome) Presence of major thoracic trauma

Data from Franz et al. A systematic review and meta-analysis of diagnostic screening criteria for blunt cerebrovascular injuries. *J Am Coll Surg*. 2012;214(3):313–27; Buriew et al. Blunt cerebrovascular injuries: redefining screening criteria in the era of non-invasive diagnosis. *J Trauma Acute Care Surg*. 2012;72(2):330–5; and Berne et al. A multivariate logistic regression analysis of risk factors for blunt cerebrovascular injury. *J Vasc Surg*. 2010;51(1):57–64.

Open Surgical Approach

Penetrating injury to zone I can result in massive blood loss from injury to the subclavian vessels, brachiocephalic vessels, or proximal portion of the carotids. Rapid control has traditionally been performed via a sternotomy with or without cervical extension.

Vascular injury in zone I usually involves the named arterial vessel's origin, as well as surrounding neurovascular structures. The first structure seen upon entering the mediastinum is the brachiocephalic vein. With superior and inferior retraction, one can visualize the aortic arch. From this exposure, the origins of the innominate artery, the left common carotid artery, and the left subclavian artery can be controlled, usually with vessel loops. Care is taken to identify and protect the left recurrent laryngeal and vagus nerve prior to application of vascular clamps. Partial side-biting clamps can allow for control of the great vessel origin without the need for complete aortic occlusion.

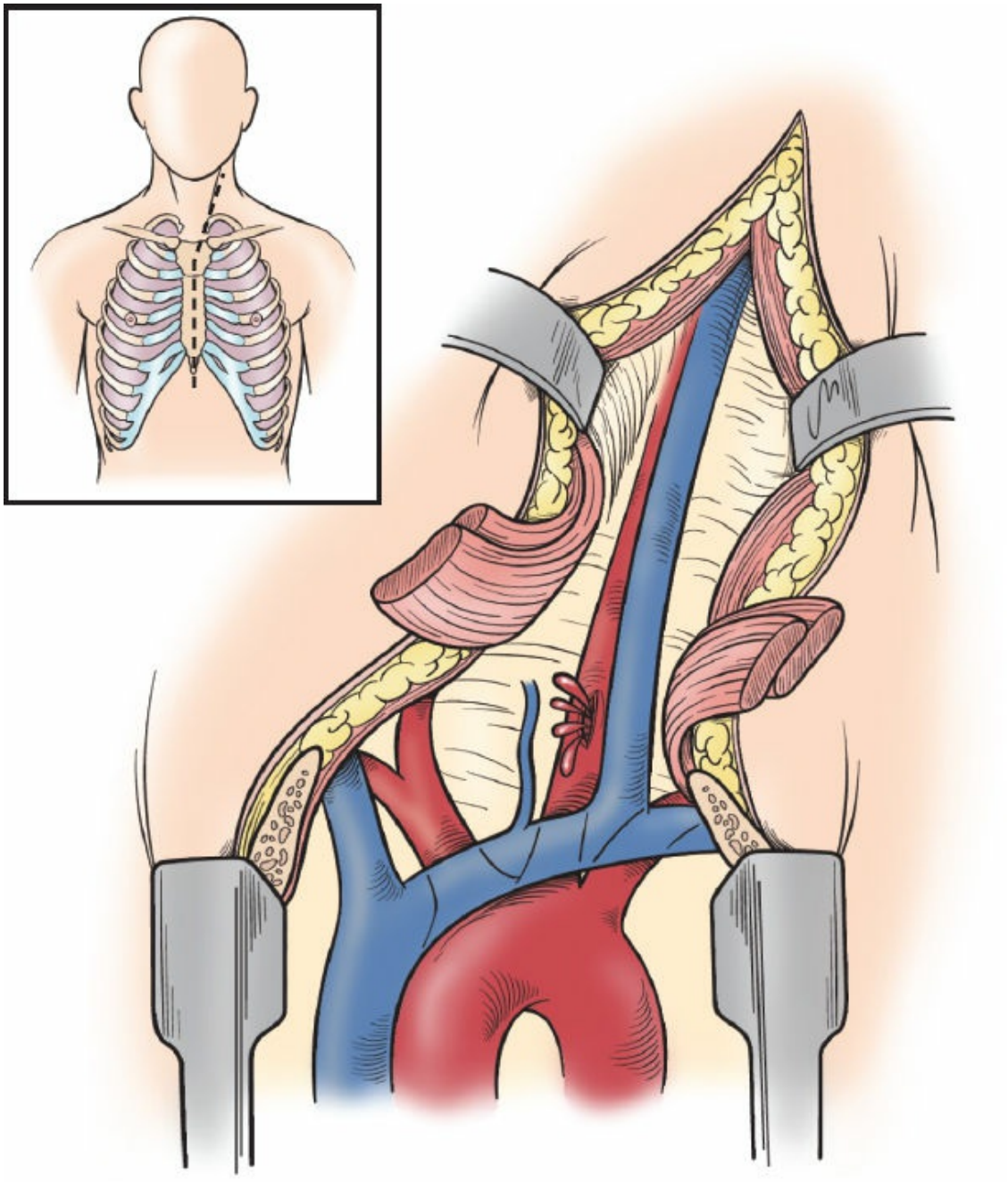

Figure 230.3. Sternotomy with neck extension for control of carotid injury.

Once vascular control has been obtained, primary repair of the injured vessel can be performed. Often, this will require segmental resection to remove the devitalized vessel wall followed by an interposition bypass. Because of the large caliber and flow associated with the vessels in this location, prosthetic conduits are appropriate. Alternatively, panel or spiral grafts can be constructed by using a long segment of saphenous vein incised longitudinally and wrapped around a chest tube of correlating size

and sutured together.

While the origin of the left common carotid artery can be seen through a midline sternotomy, distal control of this artery can be accomplished through oblique extension of the vertical sternotomy incision based on the anterior border of the sternocleidomastoid muscle (SCM) as one traverses toward the cervical region (Fig. 230.3). The carotid sheath is located just underneath the anterior border of the SCM. Once the sheath of connective tissues is divided, one can assess the injury and determine the best plan for operative repair.

The origin of the innominate artery is also often injured in zone I. Usually, surgical repair involves ligation of the origin with a bypass graft based off the ascending aorta. This can be done with partial side-biting clamps and does not require full cardiopulmonary bypass (Fig. 230.4).

In a strictly open approach, the patient should be positioned as shown in Figure 230.5, with both arms tucked. The bilateral neck, entire chest, abdomen, bilateral groin, and upper thighs should be prepped into the field. This allows for extension of the sternotomy to the neck, laparotomy, proximal saphenous vein harvest, as well as femoral cannulation for fluid resuscitation or cardiopulmonary bypass if needed.

A difficult and vexing problem is that of the proximal left subclavian artery. Because of its anterior to posterior course in zone I, the best surgical exposure of this vessel involves both a sternotomy for proximal control and a high anterolateral thoracotomy to gain access to the more distal portion. In this situation, the combination of both endovascular and open surgical techniques can be employed to obtain vascular control and perform the necessary open surgical repair. The patient should be taken directly to the hybrid OR where a diagnostic arteriogram can be performed to define the exact nature of the injury. Subsequent to that, the vascular surgeon can deploy a compliant occlusion balloon for temporizing vascular control via a retrograde femoral approach. With hemorrhage control achieved with the occlusion balloon, a sternotomy is completed and the left subclavian artery exposed, the balloon replaced with a vascular clamp, and the injury repaired or ligated.

In this scenario, the arrangement shown in Figure 230.6 allows the surgical team to perform the initial diagnostic imaging as well as place an occlusion balloon from the femoral artery to obtain vascular control. Once this has been completed, the imaging equipment can be pulled back and the case converted to a routine open procedure.

In zone I, endovascular treatment of penetrating subclavian and axillary arterial injury is extremely attractive as surgical exposure often requires multiple incisions as described above. Vascular control of the injured subclavian artery may be carried out using compliant occlusion balloons inserted from the femoral or retrograde brachial approach. Once balloon vascular control is successful, one can contemplate using a covered stent graft for repair (Fig. 230.2). The stent can easily be delivered via a retrograde brachial approach. In case of vessel transection, a wire may not be able to traverse the hematoma between each end of the vessel. However, the passage of the wire can be overcome by employing wires from both the groin and arm with snaring of the two wires to create a brachio-femoral “through and through” technique.

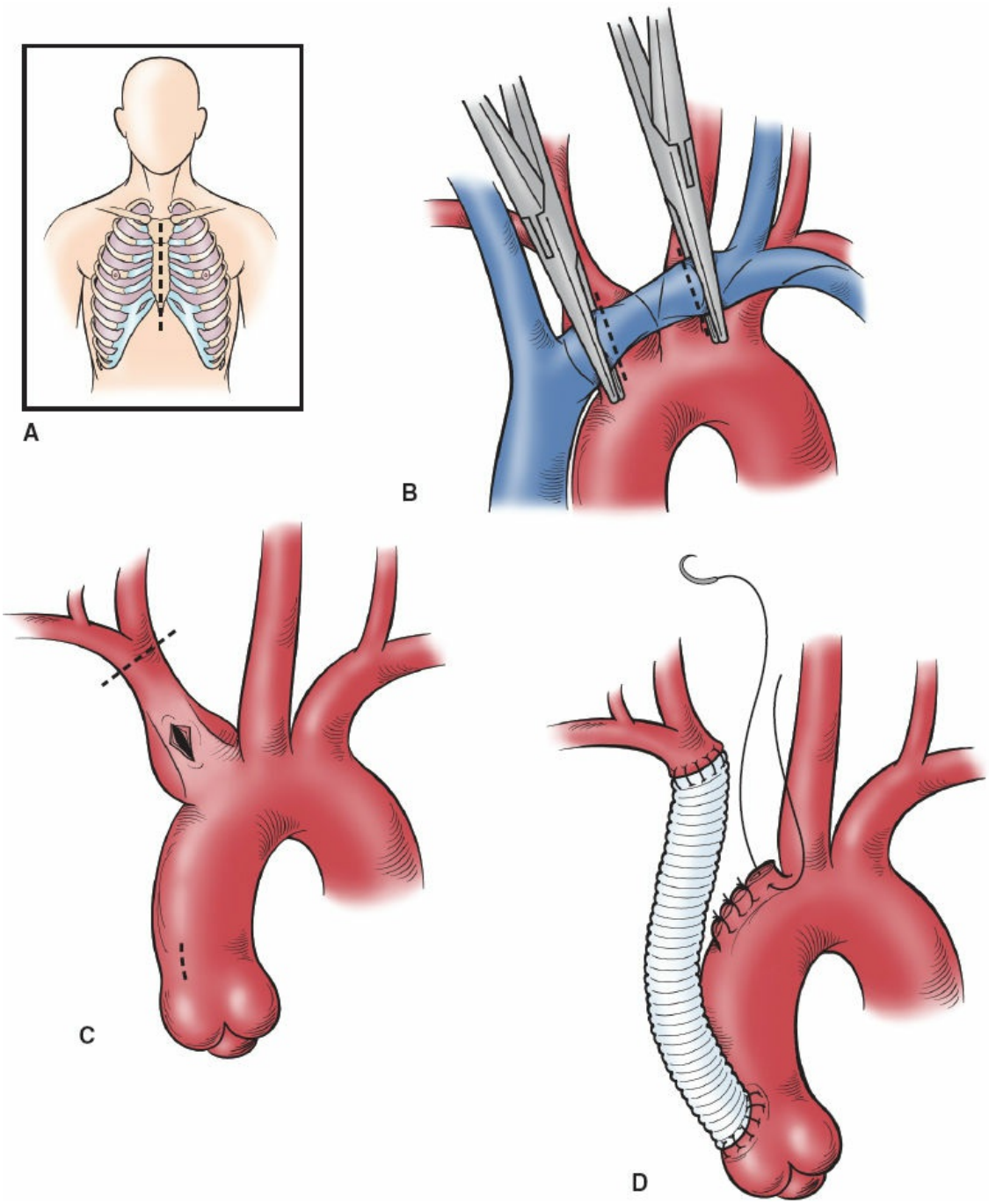

Figure 230.4. Innominate artery repair via sternotomy with interposition graft from the ascending aorta.

In this scenario, the room arrangement adds an arm table to allow for access to the brachial artery (Fig. 230.7). Typically, the brachial artery is surgically exposed. This allows for use of larger vascular sheaths, typically 9 to 11 Fr, to deliver a covered stent in a retrograde manner.

Venous injury in zone I to both the brachiocephalic and internal jugular can be ligated without major consequences.

MANAGEMENT—ZONE II PENETRATING INJURY

Vascular structures in zone II are easily accessible through standard open surgical exposures. In addition, zone II injuries comprise the majority of penetrating trauma to the neck. Those patients with hard signs require immediate exploration. The dilemma is what to do with those patients who are stable or semistable without hard signs of vascular injury. The pendulum has swung from nonoperative management alone, nonoperative management with careful imaging, selective exploration based on physical examination with or without imaging to routine exploration.

In the past, mandatory exploration for all wounds penetrating the platysma was the accepted practice regardless of the presence or absence of hard signs of vascular injury. This approach resulted in a rate of missed injury of only 1% to 2%. However, complications associated with negative exploration can be severe due to inadvertent cranial nerve injury, bleeding, and delay in the treatment of associated injuries. With the widespread use of arteriography, patients without hard signs were being managed by imaging alone with exploration reserved for those with positive findings on angiography.

In the 1990s, Demetriades championed careful physical examination and color flow Doppler imaging in stable patients. Others have advocated physical examination alone with serial observation and no imaging tests. This approach resulted in a missed rate of 0.6% and is no different than other management algorithms.

If one decides on surgical exploration, the patient is prepared similarly as in an elective carotid endarterectomy with the patient supine and the neck hyperextended in a semi-Fowler position. The groin can be prepped in case the greater saphenous vein (GSV) is needed for patch repair or bypass. The carotid artery is best exposed through an oblique cervical incision based on the anterior border of the SCM. The anatomical landmark that guides the surgeon toward the carotid bifurcation is the crossing facial vein. This can be routinely ligated to allow full access to the carotid bifurcation. Often, the external carotid artery will have several branches that will need individual control with vessel loops.

Limited injury can be primarily repaired with interrupted lateral sutures. In most cases, a patch or interposition graft will be required after one has debrided all devitalized tissue. Unlike zone I injury, the GSV is the conduit of choice rather than prosthetic materials. Care is taken to identify intimal flaps, which should be tacked down by incorporation it into the vascular

repair. Useful adjunctive techniques include transposition of the external carotid artery to replace the injured internal carotid artery (ICA) (Fig. 230.8). The injured external carotid artery is usually ligated.

Controversy abounds regarding whether or not one should ligate or repair carotid injury. Careful preoperative neurologic evaluation is critical if the situation permits. If the patient is neurologically intact, then repair or interposition bypass should be carried out. If one needs to clamp the carotid, consideration should be made for carotid shunting. In the Vietnam War, carotid artery repair was carried out safely without use of vascular shunts for up to 60 minutes. Unfortunately, a similar experience with civilian trauma has not been reported. As such, placement of an arterial shunt should be left to individual surgeon preference with critical stump pressure of <50 mm Hg as the cutoff for shunt placement.

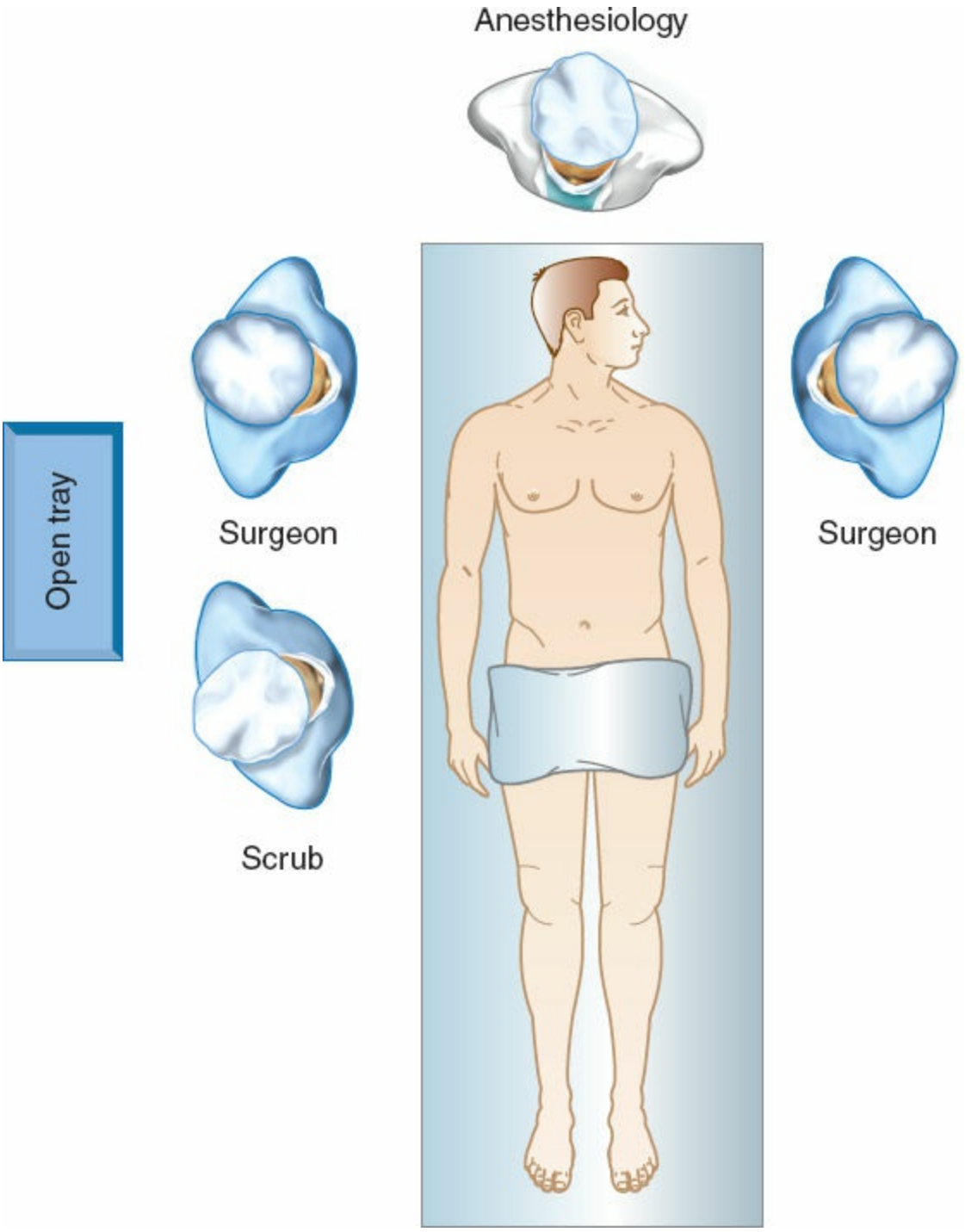

Figure 230.5. Standard room arrangement and patient positioning for an open approach.

MANAGEMENT—ZONE III PENETRATING INJURY

In this region, the distal ICA traverses behind the mandible. As such, surgical exposure is difficult and bleeding can be massive. The unstable, actively hemorrhaging patient should be taken directly to the OR where attempts at direct repair of the ICA can be carried out. In order to gain

adequate visualization of the distal ICA, the oblique cervical incision is extended superiorly toward the posterior aspect of the ear. The posterior belly of the digastric muscle is divided. The vagus, hypoglossal, and glossopharyngeal nerves are carefully identified as they often are closely associated in this region. Useful techniques to improve surgical exposure include anterior mandibular subluxation, osteotomy of the mandibular ramus, and use of a 3-Fr Fogarty balloon catheter for distal control. While often discussed, mandibular manipulation only allows a few more centimeters of distal exposure. Based on the surgeon's experience and comfort with skull-based exposure, the use of a craniofacial specialist can be extremely useful. There have been case reports of cervical ICA to petrous ICA vein bypass in patients with inadequate cross-over cerebral circulation.

If possible, simple direct repair is carried out. Interposition bypass is difficult if not impossible due to lack of adequate visualization of the distal vessel as it enters the base of the skull. In this situation, carotid ligation should be considered even though it is associated with significant stroke risk.

The use of endovascular techniques to access the ICA for balloon tamponade of life-threatening hemorrhage can be much quicker than that of an attempt at surgical exposure. Furthermore, placement of a covered stent can provide for definitive treatment without the morbidity associated with a difficult skull-based exposure.

Thankfully, zone III penetrating vascular injury is uncommon likely due to the protective nature of the overlying mandible. With either direct surgical exposure or an endovascular approach, the threshold for ligation/embolization should be low due to difficulty with surgical access in this region and the lethal consequences of massive hemorrhage.

In the stable patient, zone III penetrating injuries are managed expectantly with imaging such as contrast-enhanced dynamic CTA or arteriography. One often discovers pseudoaneurysm or an AV fistulae formation in these patients. Endovascular treatments of these lesions with self-expanding covered stents carry low morbidity and mortality risk. Other injuries such as intimal flaps can be managed with antiplatelet agents. Over time, most of these lesions heal, but careful imaging follow-up will be required.

MANAGEMENT—BLUNT VASCULAR INJURY

Blunt injuries to the cervical vessels are usually due to motor vehicle crashes (MVC). Other more unusual etiologies include sports-related injuries (the clothes line tackle), strangulation, and aggressive cervical manipulation, such as that of chiropractic treatment.

Unlike penetrating trauma where patients usually present in extremis with active hemorrhage, patients with blunt injury are often stable and asymptomatic. The involved vessel typically sustained an intimal tear that can lead to dissection, distal embolization, pseudoaneurysm formation, thrombosis, or even active extravasation from complete vessel transection.

Because of the benign nature of the initial presentation, the diagnosis of blunt cervical vascular injury can be difficult to uncover as up to 80% of patients are asymptomatic. There is typically a latent period, usually >12 hours, between the time of injury and when the appearance of clinical manifestations is usually seen. Thus, screening for blunt injuries during this time window allows for effective therapy to be initiated and can reduce the rate of permanent neurologic deficits from 21% down to as low as 0.5%.

Imaging modalities, such as CTA, MR angiography, and duplex ultrasonography can all be used in the screening of the trauma patients with suspicion for blunt cerebrovascular injury. Of these, fine-cut CTA (≥16 slices) is the most reliable modality with arteriography reserved for those cases where the CTA is normal but a strong clinical suspicion for injury still exists. By using screening guidelines, especially for those patients who are asymptomatic, blunt cerebrovascular injury can be detected in up to 34% of screened patients (Table 230.2).

The majority of blunt vascular injury occurs at the base of the skull in zone III due to the force exerted on the ICA as it enters the skull base. Typically, the pattern of injury includes intimal flap formation, nonocclusive and occlusive dissection, and vessel thrombosis (Table 230.3). Embolization can occur and can lead to severe neurologic morbidity. The mainstay of treatment of these lesions usually involves anticoagulation. In Fabian's experience, heparin is the single variable independently associated with improved neurologic outcomes. Transcranial Dopplers (TCDs) have been valuable in the detection of cerebral emboli and follow-up of anticoagulation therapy. However, some of these patients are not candidates for anticoagulant therapy due to concomitant injuries. In these instances, there may be a role for endovascular stents to "tack down" the intimal flap and prevent further

embolization.

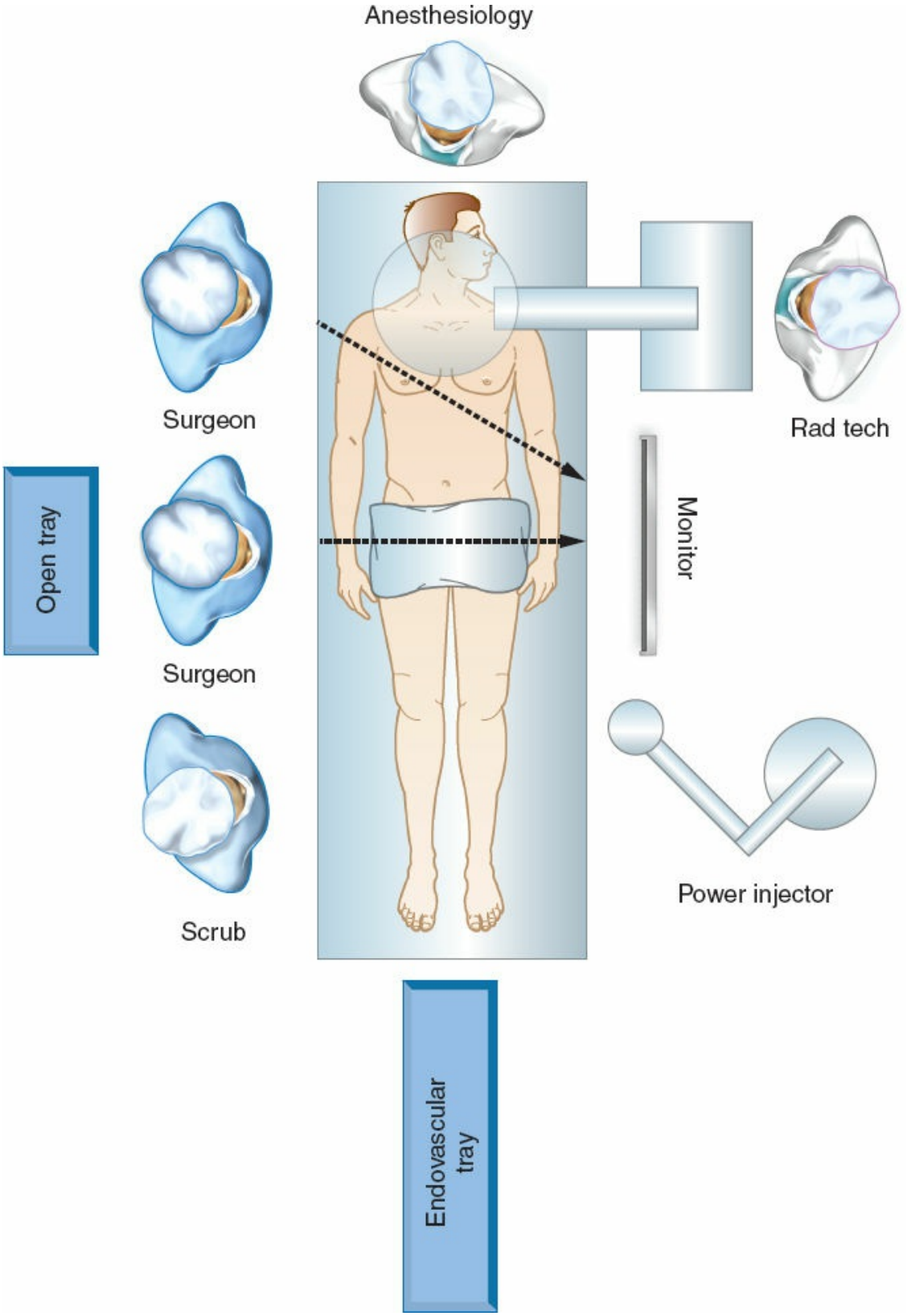

Figure 230.6. Remotely placed occlusion balloon from a femoral approach.

In follow-up studies, most injuries are noted to heal on their own. Of

those requiring intervention, the location of the injured internal carotid in zone III makes open surgical approach a challenge even for the experienced surgeon. Maneuvers described under the previous penetrating carotid injury section can be used. Often, this will lead to limited exposure. As such, endovascular treatment is extremely attractive in this region. Intimal dissection flaps can be tacked down with self-expanding stents delivered percutaneously from the groin. In cases where a pseudoaneurysm develops, multiple authors have reported successful exclusion with bare metal stents. Usually, coverage of the origin of the pseudoaneurysm is sufficient to cause its thrombosis. If not, coil embolization of the pseudoaneurysm can be performed through the interstices of the stents.

VERTEBRAL ARTERY TRAUMA

The incidence of vertebral artery trauma is extremely small, making up only 5% of cervical vascular trauma, with over 95% due to penetrating missile wounds. Blunt trauma is usually the result of a MVC. Injury can occur at any level with zone I being the most common followed by zone III.

TABLE 230.2 Risk Factor for Blunt Cerebrovascular Injury (BCVI)

Displaced mid-face fracture (LeFort II or III) Mandible fracture Basilar skull fracture Occipital condyle fracture Severe traumatic brain injury (TBI) with GCS <6 Cervical spine fracture, subluxation or ligamentous injury at any level Near hanging with anoxic brain injury Clothesline type injury or seat belt abrasion with significant swelling, pain, or altered MS Scalp degloving Major thoracic vascular injury Blunt cardiac injury Upper rib fractures
(Data from Biffl WL, et al. Western Trauma Association critical decisions in trauma: screening for and treatment of blunt cerebrovascular injuries. *J Trauma* 2009;67(6):1150; Bromberg WJ, et al. Blunt cerebrovascular injury practice management guidelines: the Eastern Association for the Surgery of Trauma. *J Trauma* 2010;68(2):571; and Mundinger GS, et al. Blunt-mechanism facial fracture patterns associated with internal carotid artery injuries: recommendations for additional screening criteria based on analysis of 4,398 patients. *J Oral Maxillofac Surg* 2013;71(12):2092–100.).

TABLE 230.3 Grading Scale for Blunt Cerebrovascular Injury

Grade I	Irregularity of the vessel wall or a dissection/ intramural hematoma with <25% luminal stenosis
Grade II	Intraluminal thrombus or raised intimal flap is visualized, or dissection/ intramural hematoma with 25% or more luminal narrowing
Grade III	Pseudoaneurysm or hemodynamically insignificant arteriovenous fistula
Grade IV	Complete occlusion
Grade V	Transection with active extravasation

Adapted from Biffl WL, Moore EE, Offner, et al. Blunt carotid arterial injuries: implications of a new grading scale. *J Trauma* 1999;47(5):845.

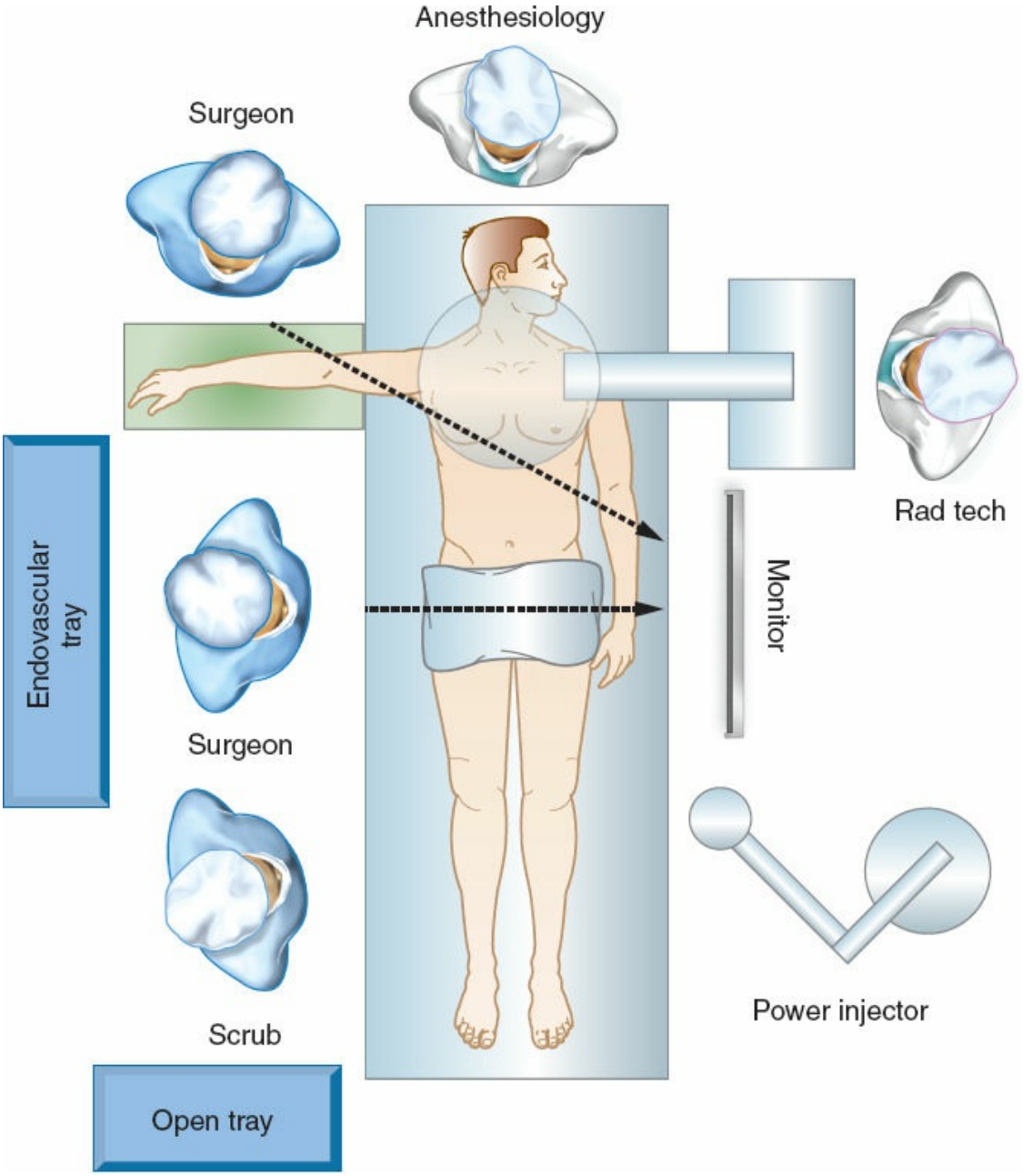

Figure 230.7. Combined endovascular and open approach for repair of subclavian/axillary artery injury.

Anatomically, the vertebral artery is the first branch vessel originating from the subclavian artery. It enters the transverse foramen of the cervical vertebral body at C6 and exits at C2. The two vertebral arteries join together to form the basilar artery at the base of the skull. Generally, one of the vertebral arteries can be ligated without significant consequences. However, in about 15% of cases, the contralateral vertebral artery is small and hypoplastic. In these cases, every attempt should be made to preserve flow in order to avoid a posterior circulation stroke.

Seventy-five percent of patients with vertebral artery injury will not exhibit any overt clinical sign. This is due to the redundancy of the paired vertebral arteries in that flow is needed only through one to maintain flow to the basilar and the posterior cerebral circulation. As such, a high index of suspicion for diagnosis is warranted. Certainly, clinical evidence of vertebral artery injury can manifest as high cervical quadriplegia, Horner syndrome, ataxia, cranial deficit, and respiratory failure to name a few. Proximity to the path of the penetrating missile indicates the need for further workup. Similarly, associated injuries to the cervical spine in the region should raise the index of suspicion for blunt vertebral artery trauma. While four-vessel arteriography was used exclusively in the past, most modern trauma centers now use CTA to work up vertebral artery injury with high degree of specificity and sensitivity. Because of the overlying bony structures, ultrasonography has limited utility in this region.

Once the injury has been identified, the method of treatment is dependent on several factors, such as the nature of the injury (active extravasation, intimal flap, dissection, or thrombosis). As mentioned previously, the clinical status of the patient and the quality of the contralateral vertebral artery are important discriminators.

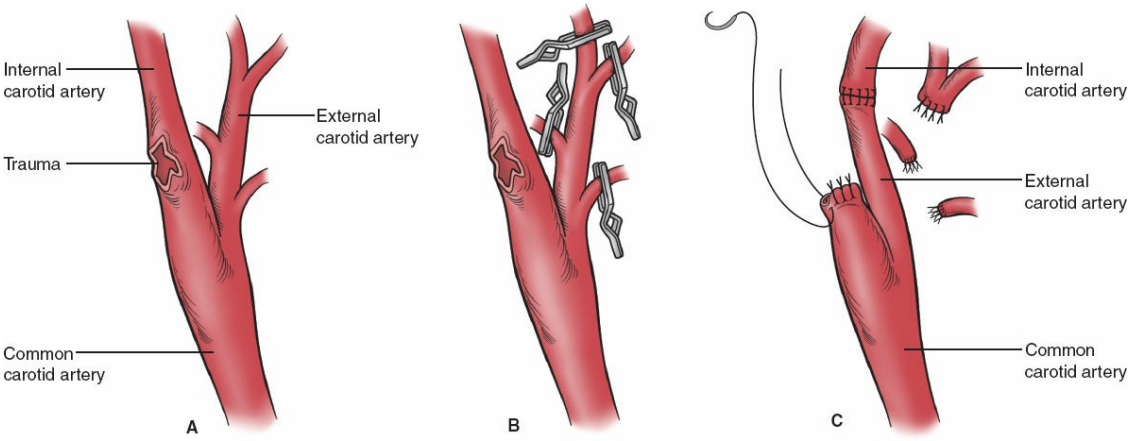

Figure 230.8. Transposition of the external carotid in order to replace the injured proximal segment. The distal ends of the external carotid can usually be ligated.

Active bleeding from the vertebral artery in zone I can be treated with surgical ligation or endovascular embolization. Surgical exposure of the vertebral artery in zone I can be done through the same oblique cervical incision for exposure of the carotid artery. In this situation, the carotid sheath is retracted medially and the anterior scalene is retracted laterally to

exposure the vertebral artery. It can then simply be ligated or an interposition vein bypass performed if patency is required. For endovascular embolization, both proximal and distal ends of the artery should be treated to prevent hemorrhage from backbleeding distally.

Injury to zone II or III can be a challenge due to the difficulty associated with exposure of the vertebral artery in this location. Even in the hands of the most experienced surgeon, the procedure is extremely difficult due to the urgent nature of the case.

If required, the vertebral artery can be approached via an oblique incision, which is carried posteriorly to the ear. Typically, the carotid sheath is retracted medially and the SCM laterally (Henry procedure), or both are retracted medially (modified Henry procedure). In these approaches, the surgeon will see the longus colli muscle as a guide. Dissection deep to this muscle will expose the prevertebral muscles and sympathetic chain. Often, brisk bleeding will be encountered at this point. The most expedient method of hemorrhage control is by placing vascular clips directly on the vertebral artery. Care must be taken to not traverse posteriorly as the neural cervical roots are directly behind the vascular structures.

In zone II and III vertebral artery trauma, application of endovascular technology has been extremely helpful due to difficulty with surgical exposure. Percutaneous vertebral artery embolization (both proximal and distal) can halt nearly all hemorrhage. Others have described endovascular techniques used to treat posttraumatic AV fistula in this region with great success.

Overall, the mortality associated with vertebral artery trauma ranges from 10% to 25%. While actual mortality can be attributed to the injured vertebral artery in <5% of patients, the overall cause of mortality in these cases is due to associated injuries of which the most common is neurologic.

SUMMARY

While rare, the presence of cervical vascular trauma can result in early death from exsanguinating hemorrhage. Late morbidity is usually the result of associated injury to surrounding structures or cerebral infarct. Expedient workup and rapid control of vascular structures is critical. In the stable patient, a detailed assessment and protocol-driven workup can successfully identify and manage most injuries. The role of endovascular

techniques has been expanded in recent years in the treatment of these injuries. Specifically, the application of remote balloon occlusion for proximal control of hemorrhage and subsequent repair with covered stents can result in improved outcomes especially in surgically difficult access areas, such as zone I and III. The surgeon managing these trauma patients should be adept at employing both open and endovascular techniques in the management of cervical vascular injuries. Similarly, the modern OR should be of a hybrid design to allow the full range of therapy from simple diagnostic arteriography to full cardiopulmonary bypass.

Suggested Readings

Beitsch P, Weigelt JA, Flynn E, et al. Physical examination and arteriography in patients with penetrating zone II neck wounds. *Arch Surg* 1994;129(6):577–81.

Berrouschot J, Bormann A, Routsi D, et al. Sports-related carotid artery dissection. *Fortschr Neurol Psychiatr* 2009;77(9):528–31.

Biffl WL, Moore EE, Offner PJ, et al. Blunt carotid arterial injuries: implications of a new grading scale. *J Trauma* 1999;47(5):845–53.

Demetriades D, Theodorou D, Cornwell E 3rd, et al. Penetrating injuries of the neck in patients in stable condition. Physical examination, angiography, or color flow Doppler imaging. *Arch Surg* 1995;130(9):971–5.

Demetriades D, Theodorou D, Cornwell E, et al. Transcervical gunshot injuries: mandatory operation is not necessary. *J Trauma* 1996;40(5):758–60.

Demetriades D, Theodorou D, Cornwell E, et al. Evaluation of penetrating injuries of the neck: prospective study of 223 patients. *World J Surg* 1997;21(1):41–7; discussion 47–8.

Eastman AL, Muraliraj V, Sperry JL, et al. CTA-based screening reduces time to diagnosis and stroke rate in blunt cervical vascular injury. *J Trauma* 2009;67(3):551–6; discussion 555–6.

Fabian TC, Patton JH Jr, Croce MA, et al. Blunt carotid injury. Importance of early diagnosis and anticoagulant therapy. *Ann Surg* 1996;223(5):513–22; discussion 522–5.

Hatzitheofilou C, Demetriades D, Melissas J, et al. Surgical approaches to vertebral artery injuries. *Br J Surg* 1988;75(3):234–7.

Hughes CW. Acute vascular trauma in Korean War casualties; an analysis of 180 cases. *Surg Gynecol Obstet* 1954;99(1):91–100.

McNeil JD, Chiou AC, Gunlock MG, et al. Successful endovascular therapy of a penetrating zone III internal carotid injury. *J Vasc Surg* 2002;36(1):187–90.

Munera F, Danton G, Rivas LA, et al. Multidetector row computed tomography in the management of penetrating neck injuries. *Semin Ultrasound CT MR* 2009;30(3):195–204.

Rostomily RC, Newell DW, Grady MS, et al. Gunshot wounds of the internal carotid artery at the skull base: management with vein bypass grafts and a review of the literature. *J Trauma* 1997;42(1):123–32.

Sekharan J, Dennis JW, Veldenz HC, et al. Continued experience with physical examination alone for evaluation and management of penetrating zone 2 neck injuries: results of 145 cases. *J Vasc Surg* 2000;32(3):483–9.

White PW, et al. Sixty-four slice multidetector computed tomographic angiography in the evaluation of vascular trauma. *J Trauma* 2010;68(1):96–102.

EDITOR'S COMMENT

The management of vascular injuries to the neck represents a nice combination of anatomic lessons learned from the past combined with the use of modern endovascular techniques to provide the patient with the best outcome. I was struck by the complexity of injuries affecting so many systems while reviewing this excellent chapter written by Dr. Tran. In addition to most of the vascular injuries now being managed by endovascular means, it is becoming apparent that imaging has gotten so much better such that many patients even with penetrating neck injuries (PNI) can be managed with selective nonoperative management (SNOM). In a large review from a South African trauma service, 510 trauma patients with 452 stab wounds (SW) and 58 gunshot wounds (GSW) were reviewed (Madsen AS, Laing GL, Bruce JL, et al. An audit of penetrating neck injuries in a South African trauma service. *Injury* 2016;47(1):64–9). Injuries occurred to the airway (6%), pharyngo-esophageal area (8%), and vasculature (17%). Of the total, 76% underwent CTA. Of the 70 patients with a suspected vascular injury, catheter-directed therapy confirmed injury in only half the patients. A total of 401 (79%) patients were managed conservatively for PNI, while 109 (21%) were managed with either surgery or endovascular means. Importantly, only 5 patients (1.2%) failed SNOM and required further surgery with no deaths attributed to failure of SNOM. The authors concluded (as do I), that SNOM of PNI is safe and appropriate management strategy even in penetrating neck trauma. Furthermore, the authors suggested that CTA had a pretty significant false positive rate and suggested that clinical assessment remains one of the cornerstones of management of these complex, often multitrauma patients.

Little has really changed in that we still use the same anatomic levels described in 1969 to assess which anatomic structures are most likely to be injured. In contrast, what has evolved is the operative/interventional algorithm that is used in these patients. For example, it appears that the patient with a

knife injury in zone II may safely not undergo emergency surgical exploration of the carotid sheath if an ultrasound or CTA is not suggestive of an injury to the carotid artery or internal jugular vein. I would add that CTA is often used as well to exclude injury to these vessels. A recent study over a 4-year period suggested that even in the presence of clinical hard signs in zone II, CTA in addition to the Western Trauma association (WTA) algorithm significantly decreased the rate of negative neck exploration without a significant increase in the rate of missed injuries (Schroll R, Fontenot T, Lipcsey M, et al. Role of computed tomography angiography in the management of Zone II penetrating neck trauma in patients with clinical hard signs. *J Trauma Acute Care Surg* 2015;79[6]:943–50). In this study of 183 zone II neck traumas, the use of CTA prevented 17 unnecessary neck explorations. The authors called for a prospective study of CTA in addition to the WTA algorithm in zone II PNI.

I would add that one of the things I think that has changed in the management of neck trauma is the management of carotid and vertebral dissections (not of course based on any good literature). When I typed in vertebral artery dissection and trauma into Pubmed.gov, I retrieved 1,668 pieces of literature. Almost all of them are single case reports of a dissection associated with some sort of manipulation. The issues for me are do these need to be anticoagulated or is aspirin adequate, and then do we really need to aggressively treat vertebral artery dissections or pseudoaneurysms. My treatment algorithm has moved toward only anti-platelet therapy and to just follow up these other injuries unless clinically indicated. The same is also true of carotid dissections I think, but they seem to be more symptomatic more often. A large experience by Dr. Greer and coauthors examined vertebral artery injuries (VAI) in a single military institution (Greer LT, Kuehn RB, Gillespie DL, et al. Contemporary management of combat-related vertebral artery injuries. *J Trauma Acute Care Surg* 2013;74(3):818–24). The authors concluded that VAI are infrequent in modern combat and only occur in 3% of casualties. Most of these injuries are discovered incidentally during the secondary evaluation at higher echelons of care. These injuries should be suspected in patients with cervical spine fractures. Like most neck trauma, they recommended treatment with endovascular coils or covered stents if needed.

Gilbert Upchurch

231 Injury to the Abdomen: Open and Endovascular

Dennis Y. Kim and Matthew C. Koopmann

INTRODUCTION

Abdominal vascular injuries are potentially devastating injuries associated with significant morbidity and mortality. The vast majority of these injuries occur following a penetrating mechanism of injury, particularly gunshot wounds (GSWs), and are more commonly encountered in urban civilian versus military settings. Abdominal vascular injuries may occur in up to 10% of patients with abdominal stab wounds and 25% of patients with GSWs. Major abdominal vascular injuries rarely occur in isolation as one third of patients will also have a hollow or solid visceral organ injury. Although the incidence of concomitant vascular injuries varies, combined arterial and venous injuries are the most common.

Because of the overall rarity of abdominal vascular injuries, experience in managing these challenging and life-threatening injuries may be limited. In addition, patients with these injuries often present “in extremis” with minimal physiologic reserve. Surgical access, as well as exposure of the involved retroperitoneal vasculature, may also prove difficult. Therefore, it is incumbent upon surgeons to have an organized and systematic approach to the identification and management of these injuries. Application of damage control surgery techniques, in conjunction with modern hemostatic resuscitation principles, is critical to successful patient outcomes.

ANATOMY AND PATHOPHYSIOLOGY

Abdominal vascular injuries occur as a result of injury to named retroperitoneal, visceral, or mesenteric vessels. The finding of a retroperitoneal hematoma or free hemorrhage originating from the retroperitoneum is consistent with a major abdominal vascular injury. Anatomically, the retroperitoneum is divided into three zones (Fig. 231.1). These zones, in combination with the mechanism of injury, dictate the

surgical approach at the time of laparotomy and should alert surgeons to the potentially injured vessels (Table 231.1).

Zone I extends from the aortic hiatus to the sacral promontory in the midline anterior to the spinal column. Zone I is further divided by the transverse mesocolon into *supramesocolic* and *inframesocolic* regions. The finding of hemorrhage or hematoma in Zone I supramesocolic is consistent with injury to the suprarenal abdominal aorta, celiac and proximal superior mesenteric arteries (SMA), and proximal renal arteries. Venous structures include the suprarenal inferior vena cava (IVC) and proximal superior mesenteric vein (SMV). Major vessels found in the inframesocolic region of Zone I include the infarenal abdominal aorta, distal SMA, and inferior mesenteric artery, as well as infrarenal IVC and distal SMV.

Zone II encompasses the upper lateral retroperitoneum along the pericolic gutters on both the right and left sides. Hematoma or hemorrhage in Zone II is indicative of injury to the distal renal arteries, renal veins, or kidneys.

Zone III begins at the sacral promontory and consists of the pelvic retroperitoneum. Injury to the iliac arteries, veins, or both, should be suspected in patients with hematoma or hemorrhage in this area.

Mechanism

Penetrating injuries due to stab wounds or GSWs account for the vast majority of abdominal vascular injuries. Lateral defects occur more commonly than complete transection of vessels. Both partial and complete transections may present as expanding or pulsatile hematomas or free hemorrhage. Blast effect is common following GSWs and may result in intimal dissection or flaps with secondary thrombosis. Pseudoaneurysms and arteriovenous fistulas may also occur following penetrating mechanisms of injury.

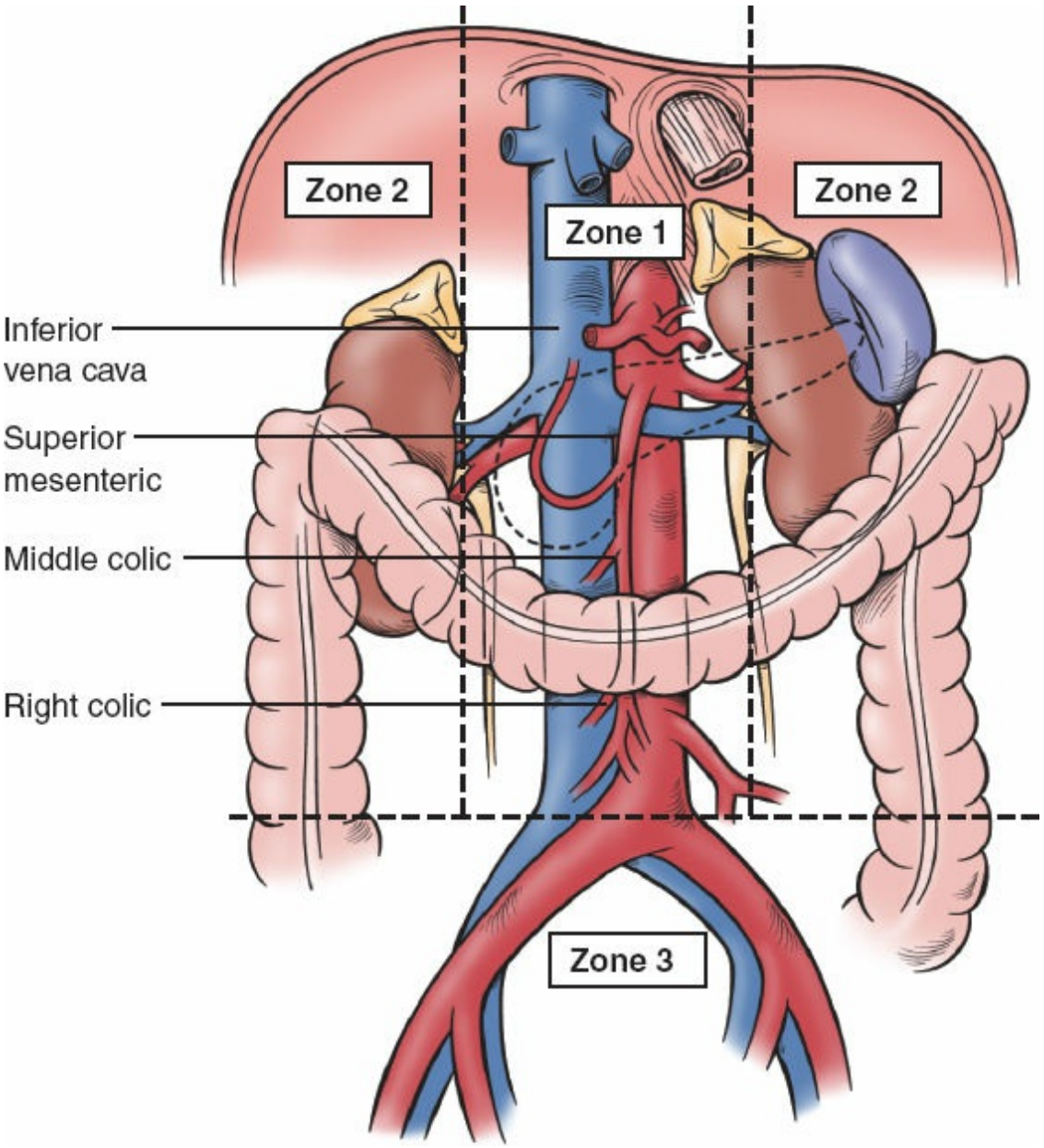

Figure 231.1. Zones of the retroperitoneum.

Blunt mechanisms result in vascular injuries as a result of rapid deceleration, crushing injuries, or direct blows. Deceleration may result in shearing or avulsion of blood vessels with resultant thrombosis or hemorrhage. Avulsion of small branches of major vessels such as the intestinal branches at mesenteric fixation sites may result in thrombosis or pseudoaneurysms. Venous injuries usually occur at the confluence of smaller venous tributaries. Crushing injuries as may occur due to a seatbelt may cause intimal tears or flaps with or without thrombosis. Partial or complete transections may also occur following crushing injuries or direct blows.

CLINICAL PRESENTATION AND DIAGNOSIS

The clinical presentation of patients with abdominal vascular injuries varies based on the nature of injuries sustained. Tachycardia, hypotension, and a narrowed pulse pressure are commonly encountered in patients with abdominal vascular injuries. Responsiveness of these physiologic variables to resuscitative efforts may indicate ongoing bleeding versus the establishment of tamponade or cessation of bleeding. Findings of abdominal distension, tenderness, or generalized peritonitis are dependent on the volume of blood loss and presence of associated injuries. Unilateral absence of a femoral pulse should raise suspicions for an ipsilateral common or external iliac artery injury, particularly among patients with penetrating transpelvic trajectories. Unlike patients presenting with vessel disruption, those with acute traumatic thrombosis may present hemodynamically stable but with abdominal pain and subtle or occult signs of end-organ dysfunction, for example, hematuria in the setting of a blunt renovascular injury.

TABLE 231.1 Operative Management Strategies by Mechanism and Zone of Injury

	Zone I	Zone II	Zone III
Blunt	Explore	Selective	Do not explore
Penetrating	Explore	Explore	Explore

In addition to the history and findings on physical examination, several other diagnostic and adjunctive tests may provide further information regarding the presence and location of an abdominal vascular injury, as well as guide resuscitative and operative planning efforts. Focused assessment with sonography for trauma (FAST) is an accurate and readily available modality for detecting intra-abdominal free fluid as well as associated cardiothoracic injuries, particularly following blunt trauma. Plain film radiographs, with or without radiopaque markers, may be helpful in delineating the trajectory of injury in patients sustaining GSWs.

For patients who present hemodynamically stable without an immediate indication for exploratory laparotomy, contrast-enhanced computed tomography (CT) should be undertaken. Depending upon the findings from physical examination and the initial arterial phase CT, further imaging phases may provide useful information regarding suspected

injuries. Venous and delayed image acquisition may be invaluable in confirming the presence of a blush or other injuries, for example, urinary extravasation in patients with renal injuries.

Although rarely used, diagnostic peritoneal aspiration (DPA) may still play a role in hemodynamically unstable patients presenting with a blunt pelvic fracture and a negative or equivocal FAST examination. Aspiration of gross blood or enteric contents is an indication to proceed with emergent laparotomy.

Finally, laboratory testing rarely provides useful information in the acute management of patients with abdominal vascular injuries. Point of care testing, if available, is performed routinely. A complete blood count (CBC), type and cross, basic metabolic panel, and arterial or venous blood gas may be sent. Serial rapid thromboelastography may provide valuable information regarding dynamic changes in coagulation parameters.

PREOPERATIVE PLANNING

The initial assessment and management of patients with suspected abdominal vascular injuries should be carried out in accordance with the principles of Advanced Trauma Life Support. Establishment of a definitive airway and peripheral intravenous (IV) lines are critical in hemodynamically unstable patients. IVs should be preferentially placed in the upper extremities in patients in whom the potential for major abdominal venous injuries exists. Following penetrating truncal trauma, resuscitative efforts with crystalloids and blood products should be withheld until patients arrive in the operating room (OR) provided that they are conscious and have a palpable pulse. Although permissive or hypotensive resuscitation is a reasonable strategy for victims of penetrating trauma, this concept should not be extended to patients following blunt polytrauma, as the potential for traumatic brain injury remains high. Foley and nasogastric catheter insertion allows for monitoring of urine output and decompression of the stomach.

There should be a low threshold for initiating the institutional massive transfusion protocol, and consideration may be given to the administration of tranexamic acid. Hemostatic or balanced resuscitation in a 1:1:1 ratio of platelets-to-plasma-to-packed red blood cells should be targeted. In addition, the administration of crystalloids should be minimized, and attempts to maintain normothermia should be initiated.

For patients in extremis or who arrive pulseless, resuscitative

thoracotomy should be performed. In addition to cross-clamping the descending thoracic aorta in order to maintain cardiocerebral perfusion, other measures include confirming endotracheal tube placement, direct control of bleeding, relieving cardiac tamponade, open cardiac massage and internal defibrillation, as well as identification and control of bronchovenous embolism. The right hemithorax may also be interrogated for traumatic pathology by passing one's hand across the anterior mediastinum and opening the right pleural space. The finding of a massive right hemothorax may require extension of the anterolateral thoracotomy to a bilateral or clamshell thoracotomy.

INDICATIONS AND INITIAL SURGICAL MANAGEMENT

The two absolute indications for operative intervention or exploratory laparotomy following either blunt or penetrating abdominal trauma are hemodynamic instability and peritonitis. Shock in the setting of trauma is always attributable to bleeding until proven otherwise. Extra-abdominal sources of hemorrhage include the chest, pelvis, extremities, and external blood loss. In addition, causes of obstructive shock including tension pneumothorax and cardiac tamponade should be considered. Clinical examination in conjunction with diagnostic adjuncts such as chest and pelvic radiographs are invaluable in identifying sources of blood loss and shock.

Patients should be placed supine on the OR table and prepped from the chin to knees. This will allow for access to the left chest should a resuscitative thoracotomy be required as well as to the groins to allow for harvesting of saphenous vein, if necessary. If not already intubated, induction should occur while the patient is being prepped as the sympatholysis that accompanies induction may result in significant hypotension. Appropriate perioperative antibiotics should be administered and attention should be directed toward minimizing heat loss through the application of external warming devices and raising of ambient room temperature. Other considerations include, but are not limited to, presence of senior assistants, adequate lighting, appropriate equipment including a vascular tray and sutures, autotransfusion devices, and hemostatic adjuncts.

Access begins through a standard midline incision extending from the xiphoid process to the pubis. The two key objectives upon entry into the peritoneal cavity are temporary hemorrhage control and minimization of

contamination. Following evacuation of clots and pooled blood, the abdominal cavity is surveyed to identify ongoing sources of bleeding. Active hemorrhage is controlled by packing of solid organs and standard vascular techniques with an emphasis on exposure, digital compression, and obtaining proximal and distal vascular control. The use of sponge sticks and kitners is very helpful for obtaining vascular control of venous injuries, particularly of the IVC, renal, and iliac veins. Following temporary vascular control, enteric injuries should be controlled using a combination of temporary clamps, oversewing, or stapling. Once major hemorrhage has been temporarily controlled, attention should be directed toward identifying the source or anatomic location of bleeding according to retroperitoneal zone.

The options and principles for managing abdominal vascular injuries are similar to those for extremity vascular injuries and include damage control techniques such as ligation or temporary intravascular shunting, as well as more definitive repair techniques. These range from simple lateral repair to patch angioplasty and end-to-end or end-to-side anastomosis, with or without the use of an autologous or prosthetic conduit. For the majority of patients with abdominal vascular injuries, simple damage control techniques are favored over definitive repairs so that patients may be brought expeditiously to the intensive care unit (ICU) where ongoing resuscitative efforts may continue with a focus on reversing acidosis, hypothermia, and coagulopathy. In instances where definitive or complex vascular repairs are able to be safely undertaken, meticulous attention should be directed toward gentle handling of vessels, debridement of vessel walls, instillation of heparinized saline, and passing of Fogarty catheters to remove clot and ensure adequate proximal inflow and distal outflow. In the absence of significant concomitant injuries, systemic heparinization should also be employed.

SURGICAL TECHNIQUE—OPEN

Zone I

Following initial access and exposure, the next steps are dictated by operative findings, specifically, the presence of a contained hematoma or active hemorrhage. A contained Zone I supramesocolic hematoma is generally approached via a left-sided medial visceral rotation. This involves incising the lateral retroperitoneal attachments along the avascular line of Toldt starting at the distal left colon and proceeding

cephalad around the spleen toward the gastroesophageal junction. This maneuver will allow for the left colon, distal pancreas, spleen, and stomach to be rotated toward the midline (Fig. 231.2). Occasionally, the left kidney may also be mobilized from the retroperitoneum. Left-sided medial visceral rotation provides complete exposure of the abdominal aorta and its major visceral branches (celiac, SMA, left renal vascular pedicle, IMA) from the aortic hiatus to the bifurcation of the common iliac arteries (Fig. 231.3).

In the case of a contained Zone I inframesocolic hematoma, it may not be necessary to perform a left-sided medial visceral rotation. Rather, with the small bowel reflected to the patient's right and the transverse colon/mesocolon placed on tension cephalad, the ligament of Treitz may be incised and the duodenojejunal junction mobilized along the aorta until the left renal vein is encountered, thereby allowing for exposure of the infrarenal abdominal aorta.

Exposure of the IVC is accomplished by performing a right-sided medial visceral rotation as is done when mobilizing the right colon during the performance of an open right colectomy. A Kocher maneuver is then performed to reflect the C-loop of the duodenum and head of the pancreas medially (Fig. 231.4). Additional exposure of the confluence of the common iliac veins can be achieved by performing a Cattell–Braasch maneuver, whereby the base of the small bowel mesentery is incised starting at the ileocecal junction toward the ligament of Treitz. With the small bowel completely eviscerated, a panoramic view of the major retroperitoneal vasculature is obtained.

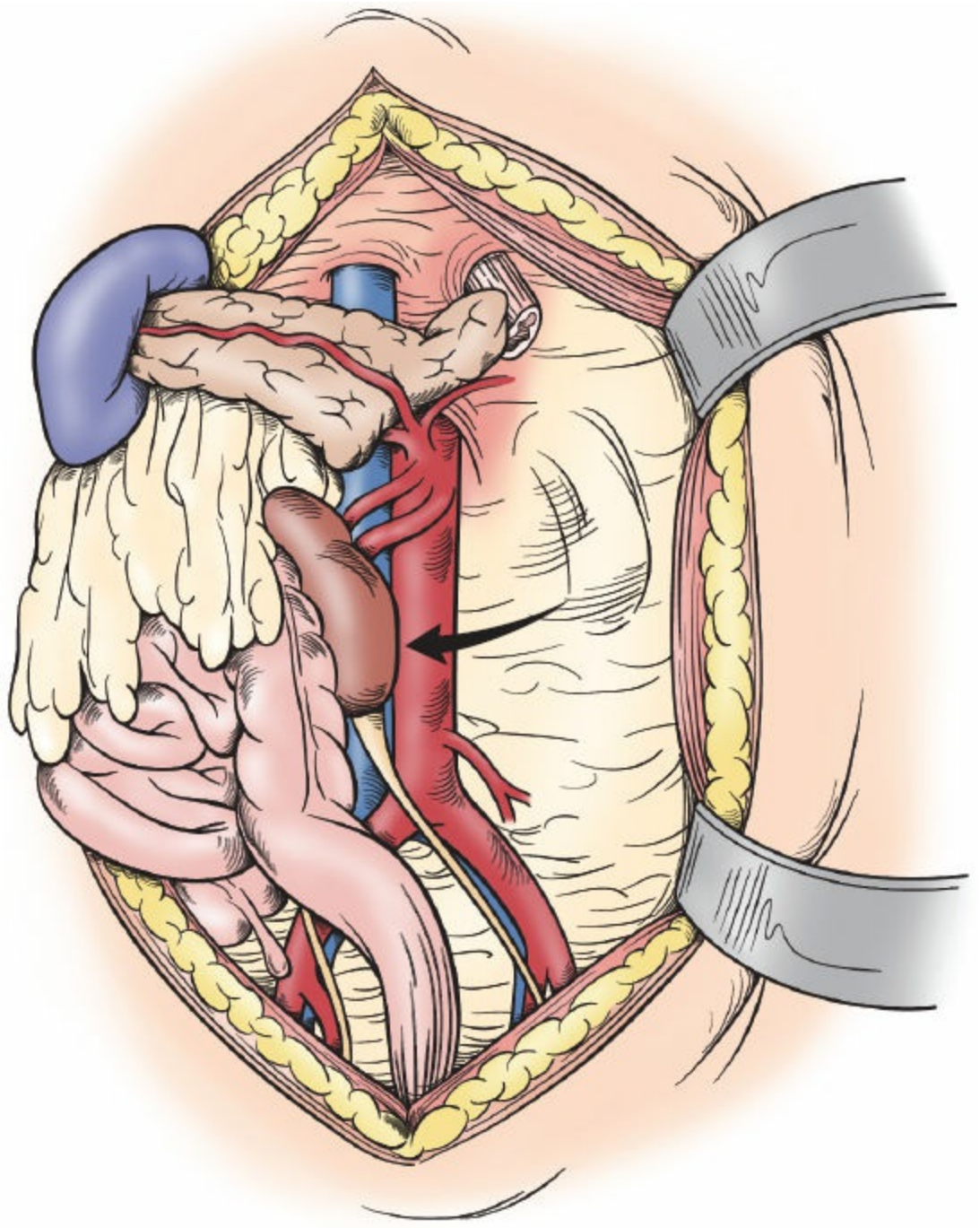

Figure 231.2. Left-sided medical visceral rotation.

If free hemorrhage is encountered, proximal aortic control should be obtained immediately. Supraceliac aortic control may be rapidly achieved using an aortic compressor device or application of digital pressure. Although a rapid means of preventing further blood loss, a major disadvantage of this technique is the need for an assistant's hand and difficulty exposing and working around the device. The authors' preferred approach is to obtain proximal aortic control via supraceliac cross-

clamping of the descending thoracic aorta. To this end, the lesser omentum or gastrohepatic ligament is sharply incised or opened bluntly and lateral traction is placed on the stomach and esophagus. The crura muscle fibers enveloping the aorta may be dissected bluntly using finger dissection on either side of the aorta or sharply by incising the left crura with scissors or electrocautery, typically at the 2 o'clock position, followed by placement of a gently curved aortic vascular clamp.

Injuries of the celiac trunk are managed with simple ligation. Occasionally lateral repair of the common hepatic artery may be undertaken; however, this is not usually possible with the smaller caliber left gastric and splenic arteries. Injuries to the SMA are classified according to the Fullen classification that divides the SMA anatomically into four zones and grades of injury (Table 231.2). For proximal SMA injuries (Zones I and II), lateral repair should be undertaken whenever possible. Insertion of a temporary vascular shunt allows for expeditious management of bleeding while maintaining midgut viability. When the injury is retropancreatic, division of the pancreas may facilitate exposure. The formation of a vascular anastomosis should be tempered against the potential for disastrous anastamotic breakdown in the face of pancreatic injury and leak. For distal SMA injuries, particularly Zones III, lateral or primary repair should be undertaken. Zone IV or segmental injuries can be managed with simple ligation and, if necessary, segmental bowel resection.

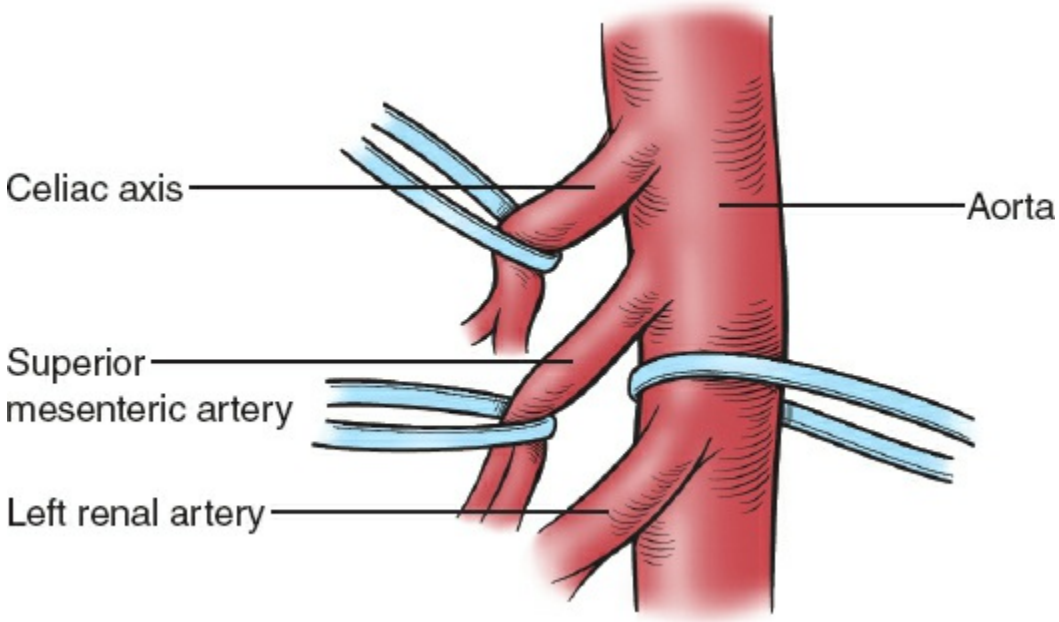

Figure 231.3. Abdominal visceral vessels.

Injuries of the abdominal aorta and IVC are classified anatomically in relation to the renal arteries and liver. Small tears or injuries to the either the supra- or infrarenal aorta can be repaired using 4-0 polypropylene suture. Patch aortoplasty may be performed for larger injuries in order to avoid iatrogenic stenosis. The choice of material will be contingent upon the presence or absence of enteric contamination. In the case of an isolated aortic injury, synthetic graft such as polytetrafluoroethylene (PTFE) or Dacron may be used with minimal risk for infection. In the presence of contamination, native saphenous vein or bovine pericardium should be considered. An end-to-end anastamosis is used for short segmental defects provided a tensionless repair can be performed. Should a prosthetic graft be necessary, a 14–18-mm Dacron or PTFE graft is usually sufficient in the nondiseased adult aorta. Care should be taken to cover the suture lines with pedicled omentum. In the presence of concomitant bowel injury and an extensive infrarenal aortic injury not amenable to repair without a conduit, consideration should be given to ligation of the infrarenal aorta and extra-anatomic bypass via an axillobifemoral bypass.

Management of IVC injuries is dictated by the location and extent of injury, as well as the overall status of the patient. Proximal and distal control can be achieved using digital compression or sponge sticks. Simple lacerations as may occur following a stab wound are usually amenable to lateral venorrhaphy. For larger lacerations, once hemorrhage is controlled and the injury identified, the edges of the laceration may be picked up with atraumatic tissue forceps and a side-biting Satinsky clamp placed to achieve partial occlusion of the IVC, followed by oversewing of the IVC with 4-0 or 5-0 polypropylene suture. Another effective method of preparing the wound for lateral venorrhaphy is to achieve tamponade with a tightly rolled pack followed by serial application of Allis or Babcock clamps as the pack is slowly rolled distally.

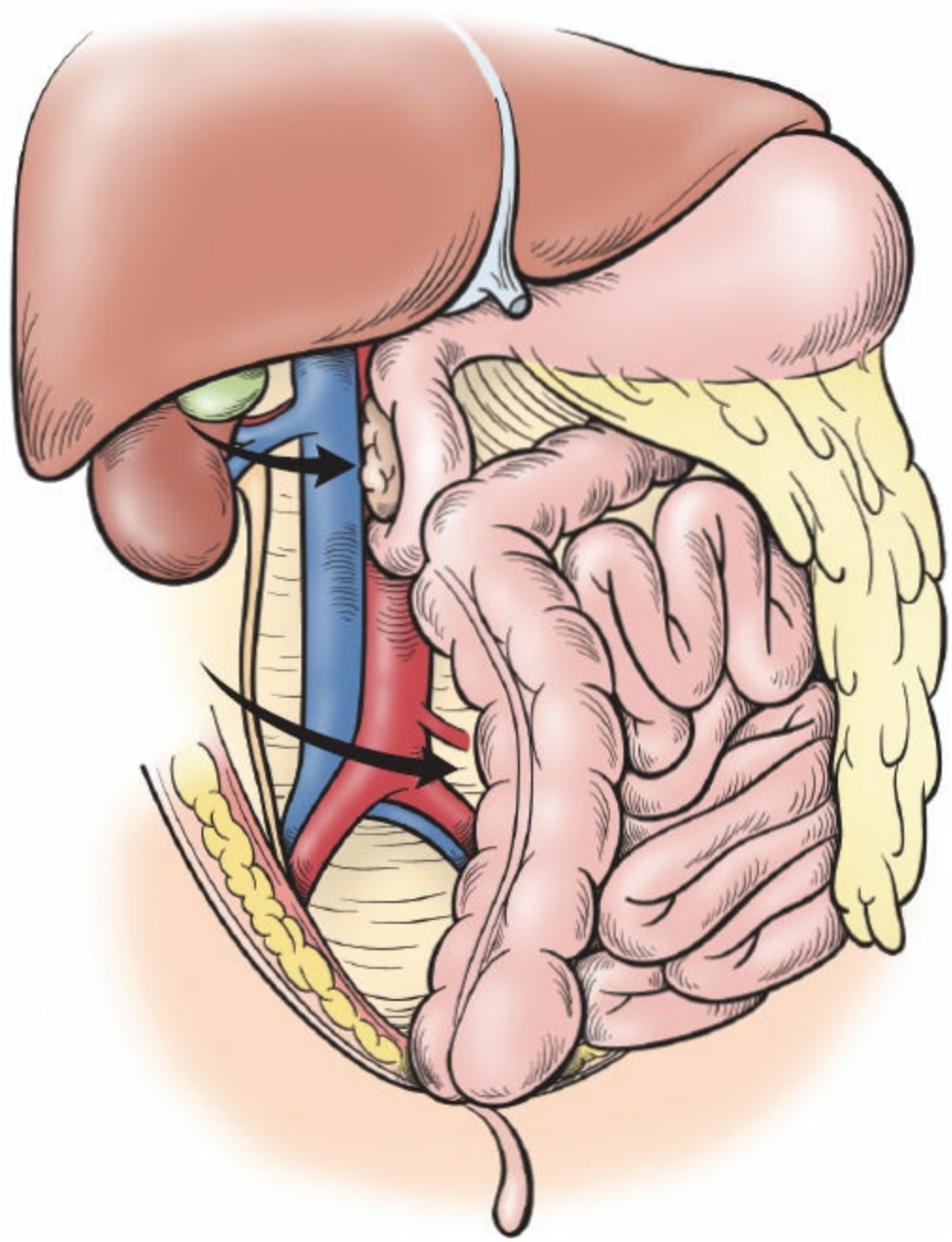

Figure 231.4. Right-sided medical visceral rotation.

It is important to rule out a through-and-through injury to the posterior wall of the IVC. This can usually be performed by rolling or rotating the IVC after freeing it bluntly from its loose surrounding retroperitoneal attachments, being careful not to inadvertently avulse any lumbar veins. Alternatively, the posterior wall may be interrogated by extending the anterior perforation and visualizing the posterior wall from within the lumen of the IVC. This is rarely necessary. For extensive infrarenal IVC injuries accompanied by hemodynamic instability and shock, ligation should be performed without hesitation. Infrahepatic suprarenal injuries

should be repaired whenever possible. In general, ligation of the suprarenal IVC is associated with poor survival. Following ligation of the IVC, massive lower extremity edema should be anticipated. Elevation of the lower extremities in conjunction with early application of circumferential lower extremity elastic bandages or wraps will help to minimize edema.

TABLE 231.2 Fullen Classification for SMA Injuries

Zone	Segment of Superior Mesenteric Artery	Grade	Ischemic Category	Bowel Segments Affected
I	Trunk proximal to inferior pancreaticoduodenal	I	Maximal	Jejunum, ileum, right colon
II	Trunk between inferior pancreaticoduodenal and middle colic	II	Moderate	Major segment, small bowel, right colon
III	Trunk distal to middle colic	III	Minimal	Minor segment or segments, small bowel or right colon
IV	Segmental branches-jejunal, ileal, or colic	IV	None	No ischemic bowel

For patients with evidence of a subhepatic retroperitoneal hematoma immediately below the liver or a retrohepatic hematoma, a retrohepatic IVC injury should be suspected. In such cases, the optimal management strategy is to leave the hematoma alone and to not make any efforts to mobilize that attachment of the liver. Provided that the suspensory ligaments of the liver, posterocentral liver, and diaphragm remain intact, retrohepatic IVC injuries should tamponade. In cases where spontaneous tamponade is not achieved, hemorrhage control may be attempted via direct compression. Other measures to control hemorrhage include total hepatic vascular isolation, insertion of an atriocaval shunt, and institution of venovenous bypass followed by direct suture repair of the IVC. For patients with massive hemorrhage due to a retrohepatic IVC injury, early consideration and application of these more aggressive strategies is paramount to good outcomes.

Zone II

Injuries to the lateral retroperitoneum in Zone II may involve the renal vascular pedicle, renal parenchyma, or both. In stable patients with a blunt mechanism of injury, Zone II hematomas are generally not opened unless

they are pulsatile or expanding. Following a penetrating mechanism, exploration is recommended. An exception to this may be the occasional patient who is hemodynamically stable and who has undergone preoperative imaging, which demonstrates an absence of a high-grade renal injury or active hemorrhage.

In patients who are stable without extensive hemorrhage, control of the ipsilateral renal vessels may be obtained in the midline at the base of the mesocolon. The technique of midline looping is a reasonable option in patients with Zone II hematomas (Fig. 231.5). The alternative and simpler option, particularly among patients who are actively bleeding or hemodynamically unstable, is to simply incise the retroperitoneum and Gerota fascia lateral to the kidney and elevate it to the midline followed by application of a vascular clamp.

Renal artery injuries represent a technical challenge due to their small caliber and location deep in the retroperitoneum. For partial injuries, lateral repair may be undertaken. If lateral repair is not feasible, palpation and confirmation of the presence of a contralateral kidney should be undertaken, followed by nephrectomy. For patients with a solitary kidney, renal salvage via aortorenal interposition grafting with saphenous vein or prosthetic graft may be performed. Less commonly, renovascular reconstruction may be performed by translocating splenic or hepatic arteries to the left or right kidney respectively. Definitive reconstruction is suitable for patients who are hemodynamically stable or in those patients found to have a solitary kidney. Those patients in shock with active hemorrhage due to a kidney or renal vascular pedicle injury, following confirmation of a contralateral kidney, should undergo a nephrectomy. For patients with renal vein injuries, attempts at lateral repair should be undertaken. Left-sided renal vein injuries near the confluence with the IVC may be ligated and observed. Collateral outflow via the left gonadal vein and adrenal veins should preserve renal function.

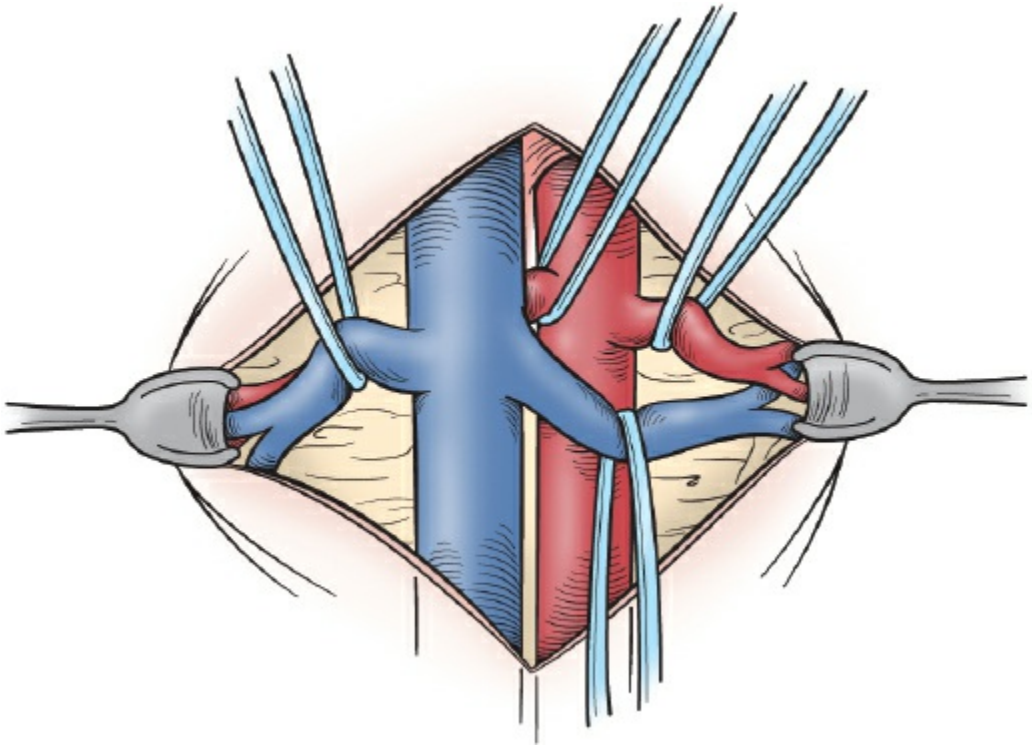

Figure 231.5. Midline looping.

Blunt renovascular injuries continue to be difficult injuries. The majority of these injuries are confirmed by CT scan and occur as a result of an intimal tear and subsequent thrombosis of the distal renal artery, 2 to 4 cm from the aorta. Overall outcomes following attempts at revascularization remain poor. In general, outcomes are dictated by severity of injury and time to revascularization or warm ischemic time. The operative approach involves resection of the involved segment and interposition grafting with saphenous vein or PTFE. Endovascular stenting may play a role in patients with evidence of active extravasation or in those patients with evidence of an intimal tear and downstream emboli. Patients should be followed closely for the delayed development of hypertension or end-stage renal disease.

Zone III

The presence of a Zone III hematoma or active hemorrhage following a penetrating mechanism of injury mandates exploration as the potential for an iliac vessel injury remains high. Exposure of the iliac vessels involves medial mobilization of the cecum on the right or the sigmoid colon on the left by dividing the avascular line of Toldt. For injuries near the aortic bifurcation, confluence of the common iliac veins, or suspected bilateral

injuries, a Cattell–Braasch maneuver should be performed with further caudad dissection of the pelvic peritoneum as necessary. Identification of the ureter as it passes over the ipsilateral common iliac artery proximal to the bifurcation of the external and internal iliac arteries is critical to avoid iatrogenic ureteric injury.

Initial temporary bleeding control should be obtained by direct compression followed by proximal and distal control. In cases where the source of bleeding is apparent, this may be achieved through the application of digital pressure or compression with sponge sticks. More often, the exact site of injury is not readily apparent and attempts at hemorrhage control prove difficult. In these cases, pelvic vascular isolation should be considered, which entails proximal aortic and IVC control combined with distal control at the level of the external iliac vessels bilaterally (Fig. 231.6). Distal control may be obtained intra-abdominally by inserting Deaver retractors and compressing the external iliac vessels against the pubic bones. Alternatively, a separate longitudinal groin incision or oblique incision in continuity with the inferior midline incision, followed by division of the inguinal ligament, may provide access to the distal external iliac artery and proximal common femoral artery. Once proximal and distal control have been obtained, the technique of sequentially “walking the clamps” toward the site of injury should allow for more precise identification of the vascular structure(s) involved.

Common and external iliac artery injuries are usually amenable to lateral repair. For more extensive injuries, an end-to-end anastomosis may be performed with either autogenous or prosthetic graft (size 6 or 8 PTFE). For patients who are in shock, insertion of a temporary intravascular shunt should be performed. Care must be taken to ensure that the shunt is adequately secured. Ligation of the common iliac or external iliac artery is poorly tolerated and associated with a high risk of lower extremity limb loss. Should ligation be performed, consideration for an extra-anatomic (femoral–femoral bypass) should be done, with or without lower extremity fasciotomies. Injuries of the internal iliac artery injuries are generally managed with ligation.

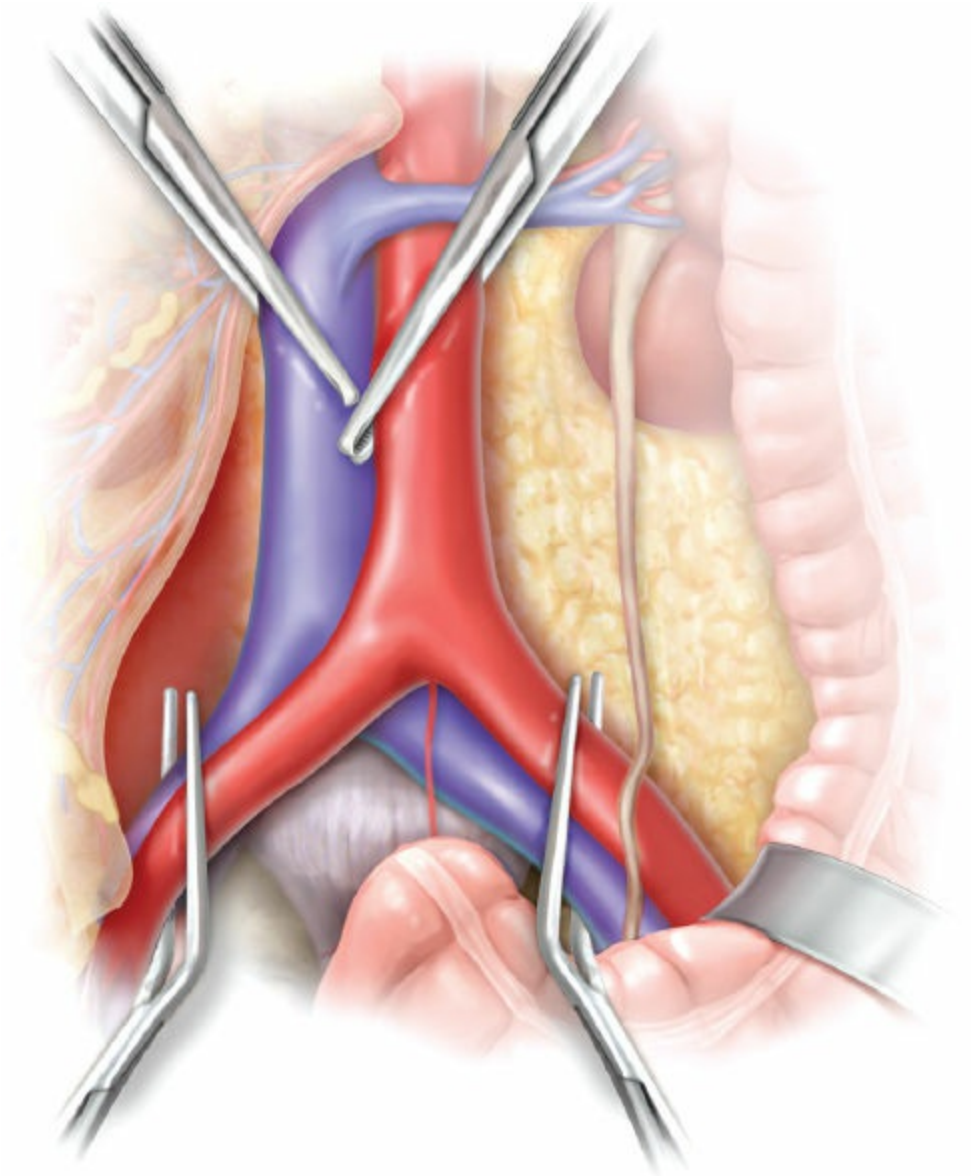

Figure 231.6. Pelvic vascular isolation.

Iliac venous injuries are usually much more difficult to manage owing to their challenging anatomic location in relation to the iliac arteries, which makes exposure technically demanding. This is especially true for the confluence of the common iliac veins located deep to the right common iliac artery. Although transecting the overlying iliac artery is an option for gaining access to an injured iliac vein, this is seldom necessary. Whenever possible, lateral venorrhaphy should be attempted for small venous injuries. Shunting is a viable option, as is ligation. Ligation of the common or external iliac vein is generally well tolerated. Postoperative edema and lower extremity compartment syndrome requiring fasciotomy should be anticipated. Insertion of intravascular balloon catheters is another helpful

adjunct in gaining distal control of external iliac vein injuries.

In patients with extensive iliac vessel injuries associated with concomitant bowel injuries, options for repair include ligation, with or without extra-anatomic bypass, shunting, or insertion of an interposition graft. Provided that there is minimal contamination, insertion of a prosthetic graft is a reasonable and much quicker alternative to using an autologous graft. Prior to grafting, all enteric contents should be removed and the peritoneal cavity thoroughly lavaged. Following repair, the peritoneum should be closed over the graft and antibiotics continued into the postoperative period.

Patients with a Zone III hematoma following a blunt mechanism and a known pelvic fracture should not undergo exploration or unroofing of the pelvic hematoma. Exceptions to this rule include patients who are found to have a pulsatile or expanding hematoma accompanied by hemodynamic instability or an absent femoral pulse. The operative principles for exposure and hemorrhage control are similar for patients with penetrating injuries. Bilateral ligation of the internal iliac arteries is a reasonable option in patients with unstable pelvic fractures and ongoing hemodynamic compromise. The risk for gluteal necrosis is low, particularly among patients without significant associated gluteal soft tissue injuries.

INJURIES IN THE PORTA HEPATIS

Portal vein injuries are among the most lethal of abdominal vascular injuries, and the majority of patients with these injuries succumb to intraoperative exsanguination. Formed by the confluence of the superior mesenteric and splenic veins, the low-pressure portal vein accounts for 80% of the hepatic blood flow. These injuries may present as a hematoma or hemorrhage originating from the hepatoduodenal ligament, upper central retroperitoneum, or root of the mesentery. In general, portal vein injuries rarely occur in isolation and associated IVC, hepatic artery, and pancreaticoduodenal injuries are commonplace.

Anatomically, wounds of the portal vein are classified into *suprapancreatic* and *retropancreatic* locations. For patients found to have a stable hematoma, initial exposure and hemorrhage control should be obtained via right medial visceral rotation and a Kocher maneuver followed by application of a Pringle maneuver and compression of the duodenum and head of the pancreas between lap pads. Precise

identification and characterization of the location and presence of associated injuries will dictate the operative approach. For patients with uncontrolled hemorrhage, direct compression of bleeding in combination with supraceliac crossclamping of the aorta should be performed. Distal aortic control in the infrarenal location may help to further minimize blood loss by decreasing splanchnic circulation and reducing portal venous flow. Backbleeding may be controlled by clamping the portal triad immediately adjacent to the liver or through the insertion of intravascular balloon catheters into the left and right portal veins. Options for repair of suprapancreatic portal vein injuries include lateral venorrhaphy, patch angioplasty, and insertion of an interposition graft. Generally, complex reconstructions are discouraged unless a concomitant irreparable injury of the common hepatic artery is present. Options for repair of retropancreatic portal vein injuries are limited. If lateral repair is not possible, early and immediate consideration should be given to ligation of the portal vein, provided that the proper hepatic artery remains intact. Transection of the pancreas rarely offers additional meaningful exposure. Postoperatively, patents undergoing portal vein or SMV ligation will undergo massive bowel edema due to splanchnic hypervolemia, which is accompanied by a systemic hypovolemia. Aggressive fluid administration and planned second look laparotomy are mandatory in this patient subset.

SURGICAL TECHNIQUE—ENDOVASCULAR

Endovascular management of abdominal trauma in the current era consists of three general modalities: balloon occlusion, angioembolization, and stent-grafting. These techniques can be used percutaneously in the emergency department or endovascular suite. Alternatively, they can be combined with open surgery using a mobile C-arm in a traditional OR or using fixed imaging systems in a “hybrid” OR. The choice of treatment setting depends on the stability of the patient, the types of procedures required, and institutional capabilities and practice patterns.

Endovascular surgery treats the same traumatic pathology as open surgery (hemorrhage, vessel dissection or occlusion, pseudoaneurysm, arteriovenous fistula), only using minimally invasive equipment and techniques. Vessel access, wires, catheters, and sheaths provide the “exposure” for the intervention. Wires can also be viewed as a vascular clamp: once you have a wire across a vascular lesion, you have “control” of the vessel and can treat it. Coils, occluders, and embolic materials (glue,

gelfoam, etc.) are used to embolize, or “ligate,” traumatized vessels. Stents and covered stent-grafts are the endovascular equivalent of primary vessel repair or bypass.

The basic treatment platform is essentially the same for most endovascular interventions. Vessel access is usually via the common femoral artery for arterial interventions and the common femoral or internal jugular vein for venous interventions. Alternative arterial access can be obtained using the axillary or brachial artery, usually from the left arm, although this requires a longer length of wires and catheters to reach vascular structures in the abdomen, retroperitoneum, or pelvis. Access is obtained via an angioaccess needle, using anatomic or fluoroscopic landmarks or ultrasound guidance. Micropuncture kits are available that allow precise ultrasound-guided access with minimal trauma to the vessel. Once the vessel is successfully punctured, a short wire is advanced and then a short sheath with dilator is advanced over the wire. The sheath is flushed with heparinized saline, and then a floppy wire is advanced into the aorta. At this point, a diagnostic catheter with multiple side-holes, such as a pigtail or Omni flush catheter, can be advanced over the wire, and a diagnostic aortoiliac angiogram can be performed using a power injector to delineate the anatomy and the pathology in the area of interest. Once the area of interest is identified, a stiff wire can be placed and a longer sheath advanced close to the area of intervention to provide additional support. The sheath should be of sufficient French size to allow passage of the devices that are anticipated to be used for treatment. Sheaths are sized by their inner diameter, while catheters are sized by their outer diameters (e.g., a 6-Fr sheath will accept a 6-Fr catheter or device). Wires should be at least twice the length of any catheter or sheath that is advanced over it to avoid losing wire access. Once the sheath is in place, a selective catheter coupled with a floppy wire can be used to select the vessels of interest and treatment can begin.

Balloon Occlusion

Noncompressible torso hemorrhage is a leading cause of early mortality in trauma patients, and early aortic occlusion is often necessary before definitive control of the bleeding organ or vessel can be performed. Traditionally this has been managed with thoracotomy or laparotomy with cross-clamping of the descending thoracic or supraceliac aorta. Resuscitative endovascular balloon-occlusion of the aorta (REBOA) can

be used in the emergency department, the angio suite, or the OR to rapidly occlude the aorta proximal to the source of hemorrhage and increase central aortic pressure while definitive hemorrhage control is achieved.

Femoral artery access is obtained and a 5- to 6-Fr short (8 cm) sheath is placed. A stiff wire is advanced into the distal aortic arch under fluoroscopic guidance. The short sheath is exchanged for a longer sheath (45 to 60 cm) large enough to accommodate the aortic occlusion balloon (at least 12 Fr). The sheath is positioned in Zone I (between the origin of the L subclavian artery and the celiac artery) (Fig. 231.7). The dilator of the sheath is removed over the wire, and the balloon is advanced over the wire until it is out of the sheath. A 30-mL syringe filled with a 50–50 mixture of contrast and saline is attached to the balloon stopcock. The balloon is inflated until it forms a cylinder that mimics the contour of the aorta. The stopcock on the balloon is turned off to keep the balloon inflated, and the sheath is either sewn to the skin or held in place by hand to prevent distal migration by aortic pressure. Balloon deflation occurs when hemorrhage control is achieved and, like removing an aortic clamp, should be communicated to the anesthesia team in preparation of the resultant hypotension related to reduced afterload and reperfusion of ischemic organs. The balloon and the wire can be removed from the sheath and the sheath flushed with heparinized saline. The sheath should be removed via a groin cutdown after proximal and distal control of the femoral artery has been achieved and the arteriotomy is closed primarily with permanent monofilament suture. Newer balloon catheters are available that can be placed into the aorta transfemorally without wire or fluoroscopic guidance. These low-profile (7 Fr) catheters are placed using external anatomic landmarks and can be accurately and safely placed in settings without radiographic capabilities. The low-profile catheter allows a smaller sheath and a totally percutaneous approach.

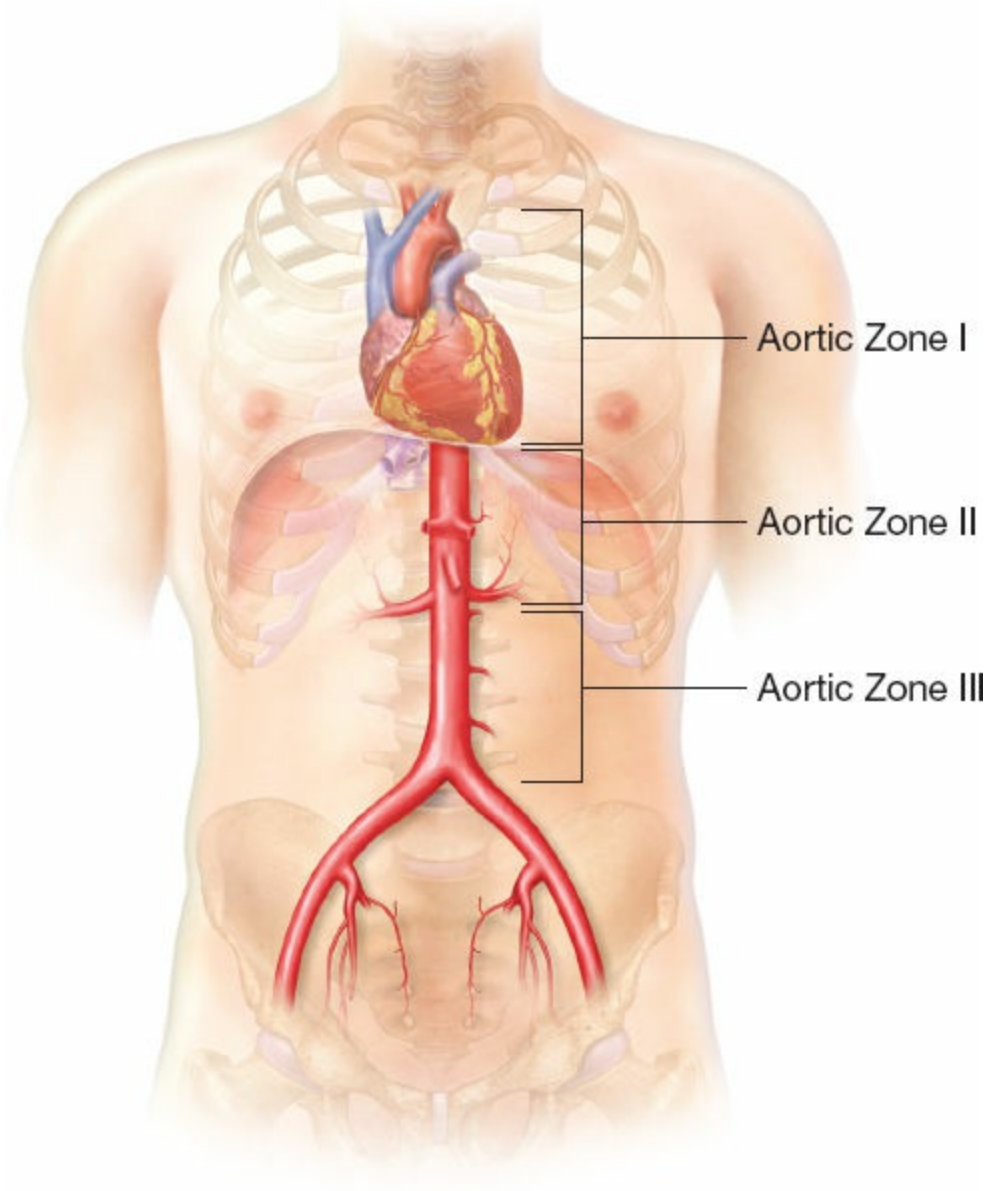

Figure 231.7. Aortic zones related to REBOA.

Angioembolization

Embolization can be performed to treat bleeding abdominal or retroperitoneal vessels or blunt solid organ injury in the absence of peritonitis. Usually, a CT with contrast will show a contrast blush, pseudoaneurysm, or arteriovenous fistula and will guide the angiographic procedure. Femoral access is obtained and selective catheterization of the main aortic branch vessel is performed using a 5-Fr selective catheter. Digital subtraction angiography is performed in multiple projections to identify the vascular lesion. The selective catheter can be used to embolize proximal vessels; but for distal lesions, a coaxial platform using microcatheters telescoped within the selective catheter can allow access to

small branch vessels to deliver embolic agents to a focal area of injury.

Splenic embolization can be performed with either proximal or distal embolization depending on the location and severity of the injury. Multiple injured sites or severe (grade IV or V) injury can be treated with proximal splenic artery embolization with large coils (1 to 2 mm larger than the vessel) or vascular occluders (oversized 40% greater than the vessel) ensuring that the proximal splenic branches supplying the pancreas are spared to avoid postprocedure pancreatitis. Distal embolization is performed using microcatheters to perform superselective catheterization of the branch artery. Small coils, cyanoacrylate, or gelfoam can be used as embolic agents. Coils are a good choice for a single focus of extravasation, while gelfoam and cyanoacrylate are good choices for multifocal extravasation as they can reach multiple areas of distal extravasation from one catheter position. Liver and renal embolization usually requires superselective distal embolization due to the decreased tolerance of the parenchyma to proximal embolization.

Embolization is the treatment of choice for trauma of the pelvis resulting in hemorrhage. Access is usually via the common femoral artery; but if injuries or pelvic devices preclude femoral access, the approach can be made from the arm. If the patient is hemodynamically unstable, an occlusion balloon can be delivered via contralateral access as described above to occlude the aorta until the hemorrhage is definitively treated. While pelvic bleeding usually arises from the internal iliac artery, an initial aortogram should be performed to ensure that alternative bleeding sites are not present, such as the lumbar arteries or the external iliac artery. A pelvic angiogram should then be performed using a contralateral anterior oblique view to image the internal iliac artery. The internal iliac artery is selected with a catheter, and a selective internal iliac angiogram is performed with ipsilateral anterior oblique views to allow visualization of the superior gluteal and the internal pudendal arteries. If the patient is hemodynamically unstable or multiple areas of injury are identified, proximal embolization of the internal iliac artery or its anterior or posterior divisions can be performed with coils or vessel occluders. However, in cases of discrete bleeding, superselective catheterization and embolization are performed using coils or gelfoam, either alone or in combination. Gelfoam is a temporary embolic agent, allowing vessel recanalization over a period of weeks and reperfusion of the embolized area after the injury has healed.

Complications of angioembolization include tissue infarction from vessel occlusion, migration of embolic agents into nontarget vessels, and rebleeding due to unsuccessful embolization or missed injuries. Delayed hemorrhage can occur due to recanalization of occluded vessels or resolution of arterial vasospasm after resuscitation. It is often a good idea to leave the access sheath in place after the initial embolization procedure if there is any concern for incomplete embolization or if the patient needs further resuscitation. This allows repeated attempts at embolization without needing to regain arterial access.

Stent-Grafting

Stents are used to open stenotic or occluded vessels or to cover holes in vessels leading to hemorrhage, pseudoaneurysm, or arteriovenous fistula. Stent types are defined by whether they are self-expanding or balloon-expandable and whether they are bare-metal or covered (stent-grafts). Self-expanding stents are deployed by retracting the sheath they are housed in. They are usually oversized by 10% to 20% greater than the diameter of the vessel. Self-expanding stents can be used in any location, but are particularly well suited to superficial locations and in mobile arteries near joints since they elastically recover when externally compressed. Balloon-expandable stents are mounted on an angioplasty balloon and are deployed by inflating the balloon to expand the stent. They are usually sized to the actual diameter of the vessel. Balloon-expandable stents can collapse with external pressure, so are not well suited for superficial locations or in mobile arteries such as those that cross joints. Stent-grafts can be delivered over a wire and deployed to treat arterial injuries in the aorta and iliac vessels as well as branch vessels such as the renal arteries. Complications include vessel rupture from aggressive balloon angioplasty, acute thrombosis, and stent migration due to inaccurate sizing or deployment. Long-term complications include stent fracture, migration, in-stent stenosis, thrombosis, and infection.

POSTOPERATIVE CARE

Following damage control surgery in patients with abdominal vascular injuries, patients should be brought expeditiously to the ICU where further resuscitation and invasive monitoring efforts are continued. On occasion, it may be helpful to obtain a torso CT scan en route to the ICU to identify potential sources of ongoing bleeding, missed injuries, or previously

undefined wound trajectories. The majority of patients will undergo temporary abdominal closure, with or without the use of drains, and close attention to both the quality and quantity of abdominal outputs is critical in determining the need for a return trip to the OR. Serial monitoring of abdominal compartment pressures, in conjunction with other physiologic variables, should allow for the early identification of intra-abdominal hypertension and the abdominal compartment syndrome. Reversal of the acute coagulopathy of trauma, hypothermia, and metabolic acidosis is essential for optimal outcomes and patient survival. Serial neurovascular checks and balanced resuscitation, with or without the use of invasive hemodynamic monitoring such as pulmonary artery catheters, are key components in the postoperative management of patients with abdominal vascular injuries. Timing of reoperation and attempts at definitive repair and closure should be dictated by patient physiology.

COMPLICATIONS AND THEIR MANAGEMENT

Abdominal vascular injuries are associated with numerous complications that may be directly related to the injuries inflicted or the interventions undertaken to control hemorrhage and restore physiologic stability. Because of the severity of blood loss and shock that accompany vascular injuries, multiorgan system involvement is the rule rather than the exception. In the immediate postoperative period, ongoing or recurrent hemorrhage usually signifies uncontrolled bleeding requiring reoperation in conjunction with optimization of coagulation parameters. Missed injuries, dislodgement of intravascular shunts, and dehiscence or anastamotic breakdown are but a few of the potential causes of early postoperative bleeding. Thrombosis or distal embolism may also occur in an early or delayed fashion. Therefore, careful monitoring of abdominal outputs, serial abdominal and neurovascular examinations, and trending of endpoints of resuscitation are mandatory. The decision to administer anticoagulation should be made on an individual basis. The development of abdominal compartment syndrome usually mandates decompression either at the bedside or in the OR. Venous vascular injuries treated with ligation are invariably associated with venous hypertension, edema, and fluid sequestration. In the extremities, this may mandate lower extremity fasciotomies. An uncommon but feared delayed complication of vascular repairs is the development of a vascular enteric fistula. The decision to proceed with an open or endovascular operative approach is based on

patient stability, anatomy, and institutional capabilities. Arteriovenous fistulas and pseudoaneurysms can usually be managed using endovascular stents. The risk for surgical site infection is related to a variety of factors, including administration of appropriate perioperative antibiotics, patient comorbidities, and associated injuries. Source control and administration of appropriate broad spectrum antibiotics form the cornerstone of sepsis management.

Suggested Readings

Asensio JA, Chahwan S, Hanpeter D, et al. Operative management of 302 abdominal vascular injuries. *Am J Surg* 2000;180:528–34.

Asensio JA, Forno W, Roldán G, et al. Visceral vascular injuries. *Surg Clin North Am* 2002;82:1–20.

Bickell WH, Wall MJ, Pepe PE, et al. Immediate versus delayed fluid resuscitation for hypotensive patients with penetrating torso injuries. *N Engl J Med* 1994;331:1105–9.

Buckman RF, Pathak AS, Badellino MM, et al. Injuries of the inferior vena cava. *Surg Clin North Am* 2001;81:1431–47.

Dente CJ, Feliciano DV. Abdominal vascular injury. In: Feliciano DV, Mattox KL, Moore EE, eds. *Trauma.* 6th ed. New York: McGraw-Hill Medical; 2008:737–56.

Feliciano DV, Bitondo CG, Mattox KL, et al. Civilian trauma in the 1980s. A 1-year experience with 456 vascular and cardiac injuries. *Ann Surg* 1984;199:717–24.

Feliciano DV. Injury to the abdominal aorta and visceral arteries. In: Rich NM, Mattox KL, Hirschberg A, eds. *Vascular Trauma.* 2nd ed. Philadelphia, PA: Elsevier Saunders; 2004:299–313.

Holcomb JB, Tilley BC, Baraniuk S, et al. Transfusion of plasma, platelets, and red blood cells in a 1:1:1 vs. a 1:1:2 ratio and mortality in patients with severe trauma: the PROPPR randomized clinical trial. *JAMA* 2015;313:471–82.

Rotondo MF, Schwab CW, McGonigal MD, et al. “Damage control”: an approach for improved survival in exsanguinating penetrating abdominal injury. *J Trauma* 1993;35:375–82.

EDITOR’S COMMENT

I will use this chapter by Kim and Koopmann on injury to vessels in the abdomen every time in the next 5 years or so that I need a refresher on how to manage this problem, which fortunately is not that frequently as I practice in a

small college town. The classic description of the zones of the abdomen associated with trauma and how they are managed are textbook perfect. However, realistically it seems to me that the management of trauma has evolved somewhat away from management by zones to an algorithm that begins with a computed tomographic angiography (CTA) from the head to the toes, and then is quickly followed by endovascular management of trauma to almost all vascular beds. Originally this approach was felt to be most suitable for patients with hemodynamic stability, but now it appears that even unstable patients with retroperitoneal trauma can undergo an expeditious endovascular approach (Boufi M, Bordon S, Dona B, et al. Unstable patients with retroperitoneal vascular trauma: an endovascular approach. *Ann Vasc Surg* 2011;25(3):352–8). The use of endovascular approaches to repair vascular injuries following trauma has become so common that courses have been developed to teach this approach (Villamaria CY, Eliason JL, Napolitano LM, et al. Endovascular Skills for Trauma and Resuscitative Surgery [ESTARS] course: curriculum development, content validation, and program assessment. *J Trauma Acute Care Surg* 2014;76(4):929–35; discussion 935–6).

While an endovascular solution may not always be the primary means by which vascular injuries are repaired, endovascular approaches can often be used as an adjunct allowing for concurrent repair performed in a safer fashion (Beyer C, Zakaluzny S, Humphries M, et al. Multidisciplinary management of blunt renal artery injury with endovascular therapy in the setting of polytrauma: a case report and review of the literature. *Ann Vasc Surg* 2017;38:318.e11–318.e16). In a recent study by Abe et al. examining a nationwide trauma registry in Japan, patients with critical trauma were compared who had their aorta cross-clamped with those who underwent resuscitative endovascular occlusion of the aorta (REBOA). When a total of 903 patients were compared, only 67% of patients who underwent REBOA died (odd ratio 0.26), while 90% of those who had their aorta cross-clamped died, suggesting that REBOA was protective. While the authors admit there was clearly a risk of selection bias, they concluded by suggesting that REBOA might be a favorable alternative method to resuscitative cross-clamping of the aorta for severe trauma. Thus, even when used in a hybrid manner, endovascular approaches in trauma offer selective advantages. This is true not only for aortic injury but also really for almost all vascular beds, including the renals (Abe T, Uchida M, Nagata I, et al. Resuscitative endovascular balloon occlusion of the aorta versus aortic cross clamping among patients with critical trauma: a nationwide cohort study in Japan. *Crit Care* 2016;20(1):400). A recent review senior authored by Dr Rasmussen is highly recommended (Brenner M, Hoehn M, Rasmussen TE. Endovascular therapy in trauma. *Eur J Trauma Emerg Surg* 2014;40(6):671–8).

Clearly, the military has been a leader in the management of vascular trauma, but also in its evolution to include more endovascular approaches, as well as the expanding use of shunts. The newly created American Association for the Surgery of Trauma PROspective Observational Vascular Injury Treatment

(PROOVIT) registry focusing on modern vascular injury diagnosis, management, and outcomes will clearly serve as a repository that can be used to help us better understand how we manage vascular trauma (DuBose JJ, Savage SA, Fabian TC, et al.; AAST PROOVIT Study Group. The American Association for the Surgery of Trauma PROspective Observational Vascular Injury Treatment [PROOVIT] registry: multicenter data on modern vascular injury diagnosis, management, and outcomes. *J Trauma Acute Care Surg* 2015;78(2):215–22; discussion 222–3). Whereas in many civilian trauma series patient follow-up is limited after discharge as many trauma patients are young and follow-up is lacking, this registry will hopefully help us to define a new treatment paradigm based on long-term outcomes about how best to manage patients with intra-abdominal vascular trauma.

Gilbert Upchurch Jr.

232 Injury to the Extremities: Open and Endovascular Management

W. Darrin Clouse

CLINICAL PRESENTATION, DIAGNOSIS, AND ASSESSMENT

Extremity vascular injury typically presents with hemorrhage, ischemia, or soft signs thereof. The principles of initial limb evaluation and examination have remained constant. Hard signs of vascular injury include absent pulses, active bleeding, clinically evident ischemia, expanding hematomas, and palpable thrills or audible bruits. These are clear indications for immediate assessment and intervention. When more subtle or "soft" signs of vascular injury are present, a more deliberate thought process in assessment can occur. These soft signs may include asymmetric/diminished pulse examination, a history of hemorrhage, stable hematoma, neurologic deficits, or wound proximity and character whereby vascular injury may have occurred.

Continuous wave Doppler utilization with ankle-brachial indices (ABI), or arm contralateral brachial index in upper extremity injuries, can be invaluable. Reduction of bony injury with restoration of length should be done prior to pulse examination and ABI. An ABI of <0.9 is highly suggestive of injury and is a quick and simple tool. Studies have indicated sensitivities of 80% to 97% for arterial injury, but specificities in the 40% to 100% range due to a noteworthy false positive rate. However, negative predictive values are well over 80%. Thus, if no hard signs are present but either soft signs are present or injury is suspected, a critical pulse examination and ABI performance are indicated. In those with a normal examination and ABI, observation is appropriate, while reduction in ABI below 0.9 indicates the need for further localization, definition, and imaging. Some minor injuries may not be recognized by ABI, yet these are generally rare. Minor injuries infrequently evolve and rarely declare themselves by clinical deterioration. Only 1% to 2% of those with minimal or soft signs and normal examination come to operation for an

unrecognized injury. Indeed, in those with wounds in proximity to major axial arteries but no pulse or perfusion abnormalities and no signs of vessel injury, the occurrence of occult abnormal findings on imaging is 10% to 12% with only 1.4% ultimately proceeding to need for intervention. In assessing 300 patients with penetrating extremity injury, proximity wound, and otherwise normal physical examination and ABI, Conrad and colleagues found no missed injuries in 51% of the cohort with follow-up available between 1 and 48 months. Thus, there is plain support for no further assessment in patients with normal examination and ABI.

Computed tomographic angiography (CTA) has largely replaced catheter-based angiography in the diagnosis and definition of arterial and venous injury in the extremity. Sensitivities and specificities of over 90% have been reported (Fig. 232.1). It is quickly performed in minutes after presentation with most patients requiring CT for other indications in today's trauma environment. CTA provides information on soft tissue and bony injuries as well. It can be particularly helpful when several levels of injury are suspected viz blunt injury or multiple penetrating injuries. It is relatively inexpensive compared to angiography, and its performance over the last two decades in this fashion has created familiarity with its use. Limitations include dependence on proper bolus timing, poor luminal definition in those with atherosclerosis and significant arterial calcification, and artifact with foreign bodies and metal fragments including bullets or projectiles. Indeed, a remaining indication for initial diagnostic catheter-based arteriography in extremity injury is the limb with multiple retained metallic fragments over a large region such as shot-gun blasts with requirement for anatomic imaging. Arteriography has principally been relegated to performance as part of endovascular therapy.

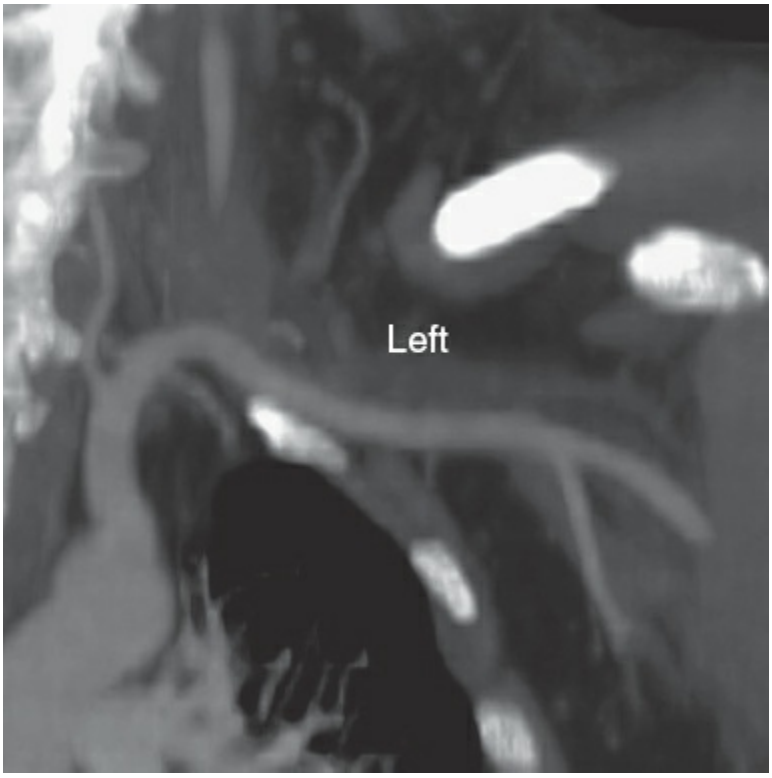

Figure 232.1. Computed tomographic angiography (CTA) reconstruction showing normal left subclavian artery with injury at the distal axillary, proximal brachial artery and absence of arterial flow.

Duplex ultrasound (DUS) has been shown to be a reasonable first-line diagnostic modality. However, it has a broader range of sensitivity and specificity than CTA. It is user-dependent and does not afford the degree of definition of inflow, outflow, and extent of injury that CTA provides. It is also limited anatomically and can only be realistically considered in evaluation beyond the junctional zones of the thoracic inlet and lower pelvis. Yet, it does have some decidedly useful applications in extremity injury. Minimal vascular injuries such as intimal flaps, pseudoaneurysms, arteriovenous fistulas, and nonspecific narrowings ("spasm") can be further physiologically defined and serially imaged with Duplex. In this regard, DUS has an additional adjunctive surveillance role. It is the initial modality of choice in iatrogenic injury. Another arena where DUS may be helpful diagnostically is knee dislocation and assessment of the popliteal artery. These injuries carry a 10% to 40% risk of popliteal artery injury. Pulse examination and ABI performance are, of course, first-line assessment, and Duplex is easy and quick to assess this focal area after reduction. Yet, as noted above, the anatomic benefits of CTA are apparent

if repair is needed. Duplex's role in most centers is relegated to confirmation of normalcy, recognition, and surveillance of minor injury, or when hardware makes CT impractical or uninterpretable.

TABLE 232.1 Mangled Extremity Severity Score (MESS)

Variable	Injury Assessment	Points
Skeletal	Low Energy (stab; simple fracture; "civilian" GSW)	1
	Medium Energy (open or multiple Fxs, dislocation)	2
	High Energy (close-range shotgun or "military" GSW; crush injury)	3
	Very High Energy (above + gross contamination; soft tissue avulsion)	4
Limb Ischemia	Pulse Reduced or Absent but Perfusion Intact	1[a]
	Pulseless; Paresthesias; Diminished Capillary Refill	2[a]
	Cool; Paralyzed; Insensate; Numb	3[a]
Shock	SBP always >90 mm Hg	0
	Transient Hypotension	1
	Persistent Hypotension	2
Age (yrs)	<30	0
	30–50	1
	>50	2

Adapted from Johansen K, Daines M, Howey T, et al. Objective criteria accurately predict amputation following lower extremity trauma. *J Trauma* 1990;30(5):568–73. Wolters Kluwer Health, Inc.
[a]Score doubled for ischemia time >6 hours.

A mangled extremity is defined as a complex injury involving soft tissue, bone, nerve, and vasculature. Determining which patients and mangled extremities will benefit from aggressive attempts at limb salvage, or which would be better served with primary amputation in the early stages of management can be challenging. Exhaustive efforts at limb salvage in severely injured patients may result in misdirection of care, whereas premature extremity amputation may preclude optimal functional outcome.

Scoring systems have been developed to take into consideration concomitant injuries, as well as the degree and nature of the bony, soft tissue, nerve, and vessel features of extremity injury. These systems are designed to assist the surgeon in decision making during the early phases of mangled limb management and also provide a mechanism to do comparative retrospective study of extremity injury. Application of

different scoring systems such as the Mangled Extremity Severity Score (MESS), Mangled Extremity Syndrome Index (MESI), Predictive Salvage Index (PSI), and Limb Salvage Index (LSI) has been evaluated regarding their ability to predict limb salvage and long-term functional outcome.

The most robust validation studies of mangled extremity scores focused on the lower extremity, and caution was proposed in applying MESS to upper extremity injury by the original authors Johansen et al. (Table 232.1). Recommendations against its relevance for upper extremities are found. Yet, the simplicity of determining the 4 clinical variables in MESS has resulted in its application in upper extremities. Slauterbeck et al. reported on 43 mangled upper extremities, and found all 9 arms with a MESS of ≥7 were primarily amputated, whereas a score of <7, found in 34 upper extremities, resulted in salvage. Durham et al. also retrospectively evaluated the application of limb salvage scores independently for both upper and lower mangled extremities and concluded MESS and MESI both decently predicted limb salvage. Interestingly, these authors concluded that these scores did not accurately predict functional outcome, iterating limb viability and function are related but not identical.

In Iraq, using a combination of 17 upper and 43 lower extremity injuries, Rush and colleagues suggested a MESS of 7 or greater predicted limb loss. In our propensity-adjusted, multivariate analysis of 64 shunted versus 61 matched, un-shunted arterial extremity injuries with nearly 2-year mean follow-up Gifford confirmed the seeming fidelity of MESS. This case control study included 35 upper extremities along with 90 lower extremity injuries. Proportional hazards modeling showed significant prediction of amputation using MESS (MESS 5–7 [RR 3.5; 95% CI 0.97–12.4; $p = 0.06$] and MESS 8–12 [RR16.4; 95% CI 3.79–70.98; $p < 0.001$]) (Table 232.2).

The general sentiment regarding mangled extremity scores suggests they serve as an objective reminder of subjective clinical experience. They provide cues to the nuances leading to either limb salvage or limb loss in significantly injured extremities, and provide a broad framework of important considerations. Yet, their clear and unquestioned use as an indicator of whether an extremity should be primarily amputated in the acute setting, or aggressive salvage pursued, remains to be proven. The expertise and opinion of the evaluating surgeon remain most essential in determining management approach.

Use of tourniquets in modern day civilian trauma has not been

systematically endorsed, but the effectiveness of tourniquets has been recently demonstrated in the combat environment. This has led to some provocative dialogue in the trauma community. Early application of tourniquets in Operation Iraqi Freedom (OIF)/Operation Enduring Freedom (OEF) has proven effective and life saving in patients with extremity injuries. In 2009, Kragh and colleagues reported on application of an extremity tourniquet in casualties in Iraq. Among 2,838 civilian and military casualties with major limb trauma, survival among 232 (8%) casualties with emergency tourniquet use was investigated. Casualties were evaluated for shock and prehospital versus emergency department (ED) tourniquet placement. There were 31 deaths (13%). Tourniquet use when shock was absent was strongly associated with survival (90% vs. 10%; $P < 0.001$). Prehospital tourniquets were applied in 194 casualties of which 22 died (11% mortality), whereas 38 patients had ED application of which 9 died (24% mortality; $P = 0.05$). The authors concluded that tourniquet use overall and particularly prehospital use was strongly associated with survival in major limb injury. A small percentage (1.7%) experienced nerve palsy at the level of application, but no amputations resulted from tourniquet use.

TABLE 232.2 Multivariate Proportional Hazards Regression Modeling for Factors Independently Affecting Time-to-Amputation in 125 Extremity Arterial Injuries (64 Shunted; 61 Unshunted)

Proportional Hazards Model			
Effect	Relative Risk	95% CI	*P* Value
TVS Group[a]	0.47	(0.18,1.19)	0.11
MESS Score (5–7)[b]	3.46	(0.97,12.36)	0.06
MESS Score (8–12)[b]	16.37	(3.79,70.79)	<0.001
Venous repair[c]	0.2	(0.04,0.99)	0.05
Associated bone injury	5.01	(1.45,17.28)	0.01

Propensity score adjustment was used to account for the differences noted in the comparison of the TVS and control group concerning Injury Severity Score and Level 2 care.
[a]Compared with no shunting control group.
[b]Compared with MESS of 1–4.
[c]Compared with venous ligation where venous injury was present.
CI, confidence interval; MESS, mangled extremity severity score; TVS, temporary vascular shunting.
Reprinted from Gifford SM, Aidinian G, Clouse WD, et al. Effect of temporary shunting on extremity vascular injury: an outcome analysis from the Global War on Terror vascular injury initiative. *J Vasc Surg* 2009;50(3):549–55, with permission from Elsevier.

In another evaluation over a 4-year period by Israeli Defense Forces, 110 tourniquets were applied to all extremity injuries. The 35 applied to the upper extremities were effective in controlling hemorrhage in 94% of the injuries as compared to 74% of tourniquets applied to the lower extremity injuries. Neurologic complications developed in 7 limbs (6%). Recent data from Davidson and the group at Oregon Health and Science University indicate that with tourniquet occlusion of the common femoral artery (CFA) in human subjects, there remained 25% to 35% residual arterial perfusion via collaterals as measured by contrast-enhanced ultrasound perfusion imaging. This information is obviously encouraging and supportive as renewed civilian interest in tourniquet applications is appearing. It seems likely that tourniquet use will be further studied and incorporated into civilian care systems in some way. Current experience supports their use for initial control of extremity vascular injury to proceed in assessment and management.

ETIOLOGY AND PATHOPHYSIOLOGY

Vascular injury of the extremities occurs in a spectrum depending upon mechanism, anatomic location, temporal circumstances, and concomitant injuries. Vessel laceration, complete and partial transection, contusion with or without secondary wall or intimal defect, secondary thrombosis or aneurysm, pseudoaneurysm, arteriovenous fistula, tapered lesions, and external compression in the perivascular space may all be at play. These may be the result of low- or high-powered blunt or penetrating mechanisms, including blast or combined, multimodal trauma. Direct damage to the blood vessel may occur, or it may be secondary to cavitation effects. Life-threatening hemorrhage may occur. Tissue ischemia, particularly if prolonged, may lead to ischemic neuropathy/plexopathy, compartment syndromes, soft tissue and muscular necrosis, and contractures. Venous congestion can contribute to relative tissue ischemia and inflammation. Associated direct injuries to the nerves, bones, and soft tissues also contribute to pain and dysfunction.

EPIDEMIOLOGY, AMPUTATION, AND MORTALITY

Civilian

Within civilian series, the overall rate of vascular injury remains low representing a mere 1% to 4% of injured patients. The extremities have

long been known as the location most often affected by vascular injury accounting for 40% to 80% of arterial injuries identified depending upon the circumstances of the reported series. Extremity injury appears to occur relatively equally in the upper and lower extremities with perhaps a slight increase in upper extremity injury recently. Mortality from extremity vascular injury, even in isolated cases, can approach 5% to 10% depending upon the vessels injured. Kauvar and colleagues queried the National Trauma Data Bank (NTDB) from January 2002 to December 2005 and identified 651 isolated lower extremity vascular injuries and found a mortality of 2.8% with amputation occurring in 6.5%. The more proximal the arterial injury, the higher the mortality as CFA injuries led to an 8% mortality. Mortality was significantly higher with injury to common femoral and superficial femoral arteries compared to popliteal and distal vessels (4.8% vs. 1.4%; $p = 0.02$) (Fig. 232.2A). Nearly 80% of deaths were from penetrating injury. On the other hand, amputation occurred more commonly with injury to the popliteal and tibial arteries compared to the femoral arteries (8.3% vs. 4.1%; $p = 0.03$). Amputation occurred twice as often when the mechanism of injury was blunt (9.1% vs. 5.1%; $p = 0.05$) (Fig. 232.2B).

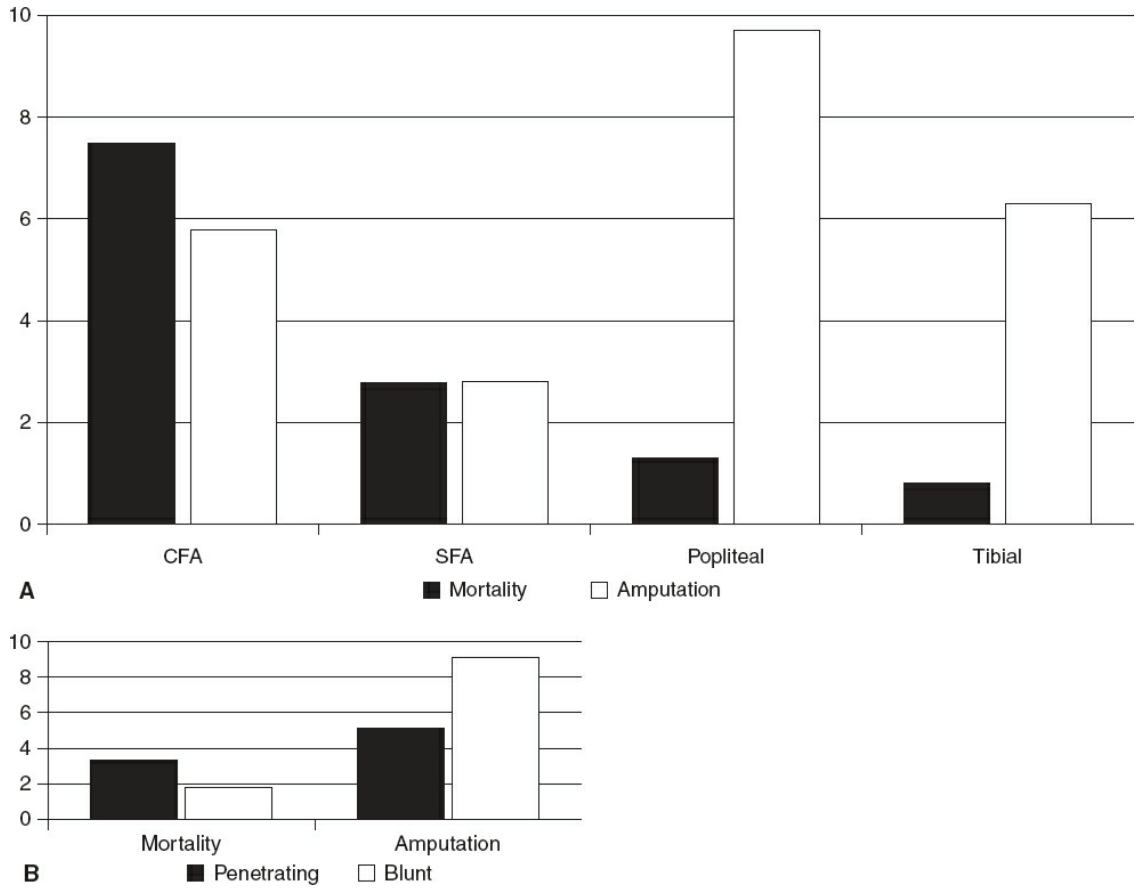

Figure 232.2. **A.** Mortality rates and amputation rates by anatomic injury level in isolated lower extremity arterial injuries. **B.** In these patients, mortality and amputation rates by general mechanism of injury. (Reprinted from Kauvar DS, Sarfati MR, Kraiss LW. National trauma databank analysis of mortality and limb loss in isolated lower extremity vascular trauma. *J Vasc Surg* 2011;53(6):1598–603. Copyright © 2011 Society for Vascular Surgery, with permission.)

Perkins and colleagues provided a recent meta-analysis of almost 3,200 lower extremity vascular injuries, which reported factors associated with secondary amputation after arterial repair. Significant prognostic factors heightening amputation risk were soft tissue injury (26% vs. 8%; OR 5.8), compartment syndrome (28% vs. 6%; OR 5.1), multiple arterial injuries (18% vs. 9%; OR 4.9), and ischemia over 6 hours (24% vs. 5%; OR 4.4). Mechanism of injury was also significant as blast and blunt injuries led to amputation more than penetrating injury (19% vs. 15% vs. 5%, respectively). Age over 55 was also an important characteristic as was the central proximity of injury. Secondary amputation occurred in 18% of iliac, 14% of popliteal, and 10% of tibial injuries while femoral artery injuries led to amputation in only 4%. Most of these factors are indeed what is appreciated experientially across trauma centers.

Injuries to upper extremity arteries in the civilian setting less commonly lead to death or amputation. The more proximal the injury, the higher the risk of amputation or death. Tan and colleagues queried the NTDB investigating over 8,000 civilian extremity arterial injuries to compare lower extremity and upper extremity outcomes. They describe lower extremity injury more commonly resulting from blunt mechanisms, and upper extremity injury more likely penetrating in nature. Lower extremity injury was independently associated with increased mortality (OR 2.2; $p < 0.0001$) and risk for amputation (OR 4.3; $p < 0.0001$). This relationship was maintained when stratified by type of mechanism. Blunt mechanism portended higher mortality and amputation (Fig. 232.3). Overall, mortality was 2.2% in upper extremity injuries versus 7.7% in those of the lower extremity ($p < 0$ .0001). Amputation occurred in 7.8% of lower extremity injuries compared to only 1.3% of upper extremity arterial injuries ($p < 0.0001$).

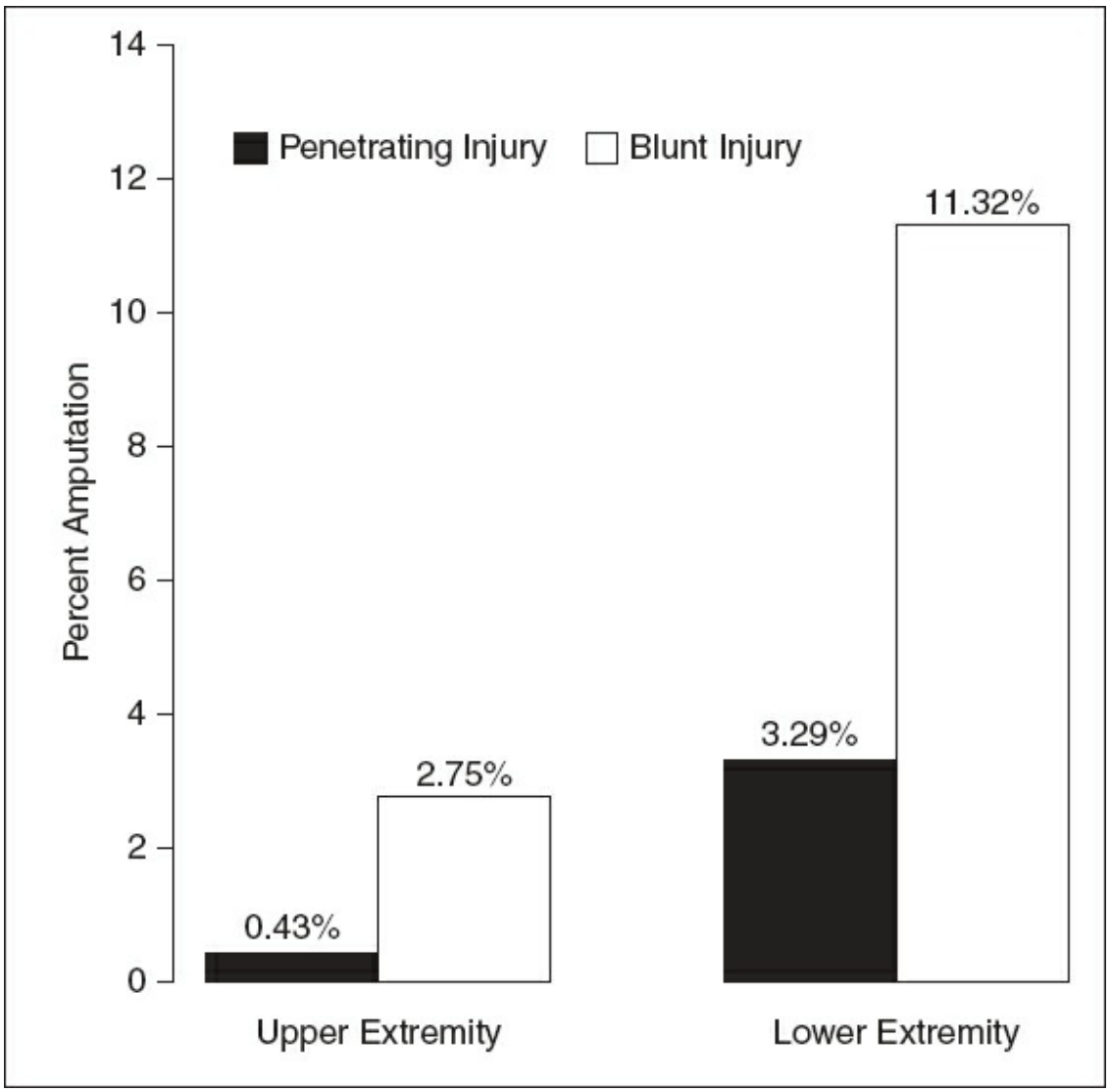

Figure 232.3. Comparative amputation rates by upper and lower extremity arterial injury stratified by mechanism of injury. (From Tan TW, Joglar FL, Hamburg NM, et al. Limb outcome and mortality in lower and upper extremity arterial injury: a comparison using the National Trauma Data Bank. *Vasc Endovasc Surg* 2011;45:592–7. Copyright © 2011 SAGE Publications Ltd, All rights reserved.)

Military

Rates of vascular injury during military operations have been a point of interest throughout documented history. Modern assessment began when DeBakey and Simeone reported an identified arterial injury rate of 0.96% in World War II. Accounts from the Korean War cited rates of 1% to 3%. Recent data show the rate of vascular injury during war appears to have increased from 2% to 3% of battle-related injuries during the Vietnam War

to 4% to 12% during the wars in Iraq and Afghanistan. Over 2004 to 2006 in Balad, Iraq, using a cohort of 6,800 casualties with nearly 350 vascular injuries, we documented an incidence of vascular injury (4.8%), the accompanying operative mortality (4.3%), and early amputation rate (6.6%). Extremity injuries accounted for 75% of vascular reconstructions performed. This was significantly expanded by White et al. who, using the tools of the Joint Theater Trauma System and the Joint Theater Trauma Registry (JTTS/JTTR), were able to more precisely describe this apparent augmentation in vascular injury rates. Between January 2002 and September 2009, over 13,000 battle-related injuries occurred in U.S. troops. Of these, 12% had identified vascular injuries documented and 9% underwent operative intervention for these injuries. Seventy-nine percent of vascular injuries occurred in the extremities with distal arterial injury in the forearm vessels or tibial vessels accounting for 40% of all identified injuries. Only 12% of injuries were in the torso, and 8% cervical (Fig. 232.4). Mortality in OIF/OEF extremity wartime injuries has been determined to be 2% to 4%. This clear temporal uptick in vascular injury identification is most likely due to modern casualty care strategy and tactics with better battlefield evacuation, forward surgical assets, and newer diagnostic modalities.

REPAIR INDICATIONS AND NONOPERATIVE MANAGEMENT

Identification of extremity arterial injury associated with hemorrhage or ischemia is an indication for repair. The goal of course is to prevent exsanguination, restore appropriate axial arterial perfusion, and perhaps maintain venous continuity. When identified extremity arterial injuries are minimal and there is no active hemorrhage or critical diminution in distal perfusion, observation may be considered. These lesions are clinically silent. They include intimal flaps and defects, tapered narrowings, small pseudoaneurysms, and arteriovenous fistulae as noted previously. This discussion has become even more relevant due to the continual, significant improvements in arterial imaging techniques leading to more sensitive recognition of these injuries. Yet, only 1% to 2% of minimal injuries will re-present requiring repair, and in available series no interventions have been required after 3 months in identified and observed minimal extremity injuries. A mature, but small body of descriptive literature, including animal intimal injury models, has indicated that the most benign of these

lesions are small intimal flaps, and nonspecific taperings (i.e., spasm in otherwise normal vessels) that heal at rates well over 90%. It has been suggested that intimal flaps producing over 75% luminal stenosis are more problematic and repair considered. Small pseudoaneurysms (<5 mm) also spontaneously heal but may require intervention in up to 30% to 40%. Arteriovenous fistulas, which are least common, may also spontaneously close when small (<5 mm). Initial nonoperative surveillance is appropriate. Larger ones are probably best served with repair. When surveillance of these lesions shows progression or enlargement, repair is indicated. Aspirin in minimal lesions appears beneficial and improves patency. How endovascular intervention may impact these minimal injuries is unclear, and must be considered on a case-by-case basis. When repair is pursued, endovascular methods logically may simplify this technically. Given the historical rates of resolution and the complication profile of endovascular therapies, this decision is likely to remain left to clinical intuition.

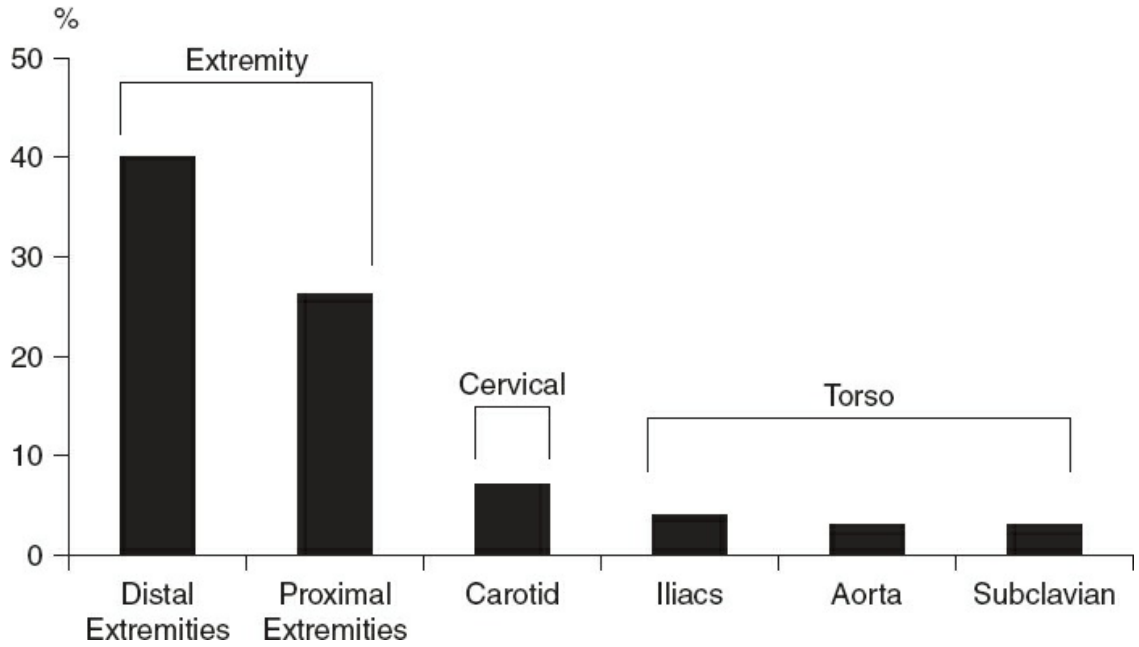

Figure 232.4. Distribution of identified vascular injury in U.S. forces during Operation Iraqi Freedom and Operation Enduring Freedom noting the high prominence of extremity injury. (From White JM, Stannard A, Burkhardt GE, et al. The epidemiology of vascular injury in the wars in Iraq and Afghanistan. *Ann Surg* 2011;253(6):1184–9.)

Because of vessel size and reactivity, nonoperative management may be considered in young children if the limb appears viable or distal flow can

be documented. In newborns and infants, nonoperative management is preferred and use of a systemic antithrombotic therapy, topical vasodilators, warming mechanisms, and plastic covers on the limb to augment vasodilation and flow logical options. In the severely injured patient with poor prognosis or a prohibitive risk, a nonoperative approach to nonhemorrhaging lesions can be considered.

PREOPERATIVE PLANNING

Depending upon injury location, active hemorrhage may require digital control from an assistant, or placement of an available windlass tourniquet or pneumatic tourniquet to prevent exsanguination. The patient should be placed on a fluoroscopically compatible table to allow for endovascular control and angiography. Today, utilizing hybrid, fixed imaging operating rooms permits the full management spectrum of open surgical and endovascular therapeutic options and comprehensive flexibility. Prepping and draping should be circumferential with extension extended contiguously onto the torso to allow for any conceivable control option. Other extremities in which autogenous conduit may be harvested should be prepared. Not uncommonly, to avoid thermal loss as possible, prepping widely with sterile sheets placed over areas until or if they are required is prudent.

SURGICAL TECHNIQUE (INCLUDING DIAGRAMS)

General Operative Topics

There are several general operative considerations that should be reviewed in the care of the patient with an extremity vascular injury. These include the proper role for shunting techniques, vein repair, conduit selection, wound management, as well as the impact of fasciotomy.

Temporary Vascular Shunting (TVS)

Temporary intravascular shunts can allow for rapid restoration of distal limb perfusion when immediate vascular reconstruction is not possible (Fig. 232.5). This may be due to delays involving orthopedic fixation, major wound debridement and definition, vein harvest, lack of clinical expertise at the initial treating facility, or addressing more life-threatening injuries. Arterial injury identification, thrombectomy, regional heparin, and selective intra-arterial vasodilators with temporary shunt placement

provide reperfusion and time. This has become known as vascular damage control. Use of intravascular shunting has been specifically applied as a method to stabilize and temporize peripheral vascular injuries, avoid vascular reconstructions in austere environments with limited resources and time, and allow for restitution and preservation of extremity perfusion during transport to definitive care. Furthermore, shunting has been used during mass casualty events and during damage control in those with significantly adverse physiology or concomitant injuries. Patency reports for temporary shunts have refuted the obligatory need for systemic anticoagulation for maintenance in the first 24 to 48 hours after placement.

We chronicled descriptive data from the Balad Vascular Registry demonstrating that shunts placed for proximal vascular injuries (at or proximal to the knee or elbow) had a significantly greater patency (86%, n = 22) than shunts placed in distal vascular injuries (distal to the knee or elbow) (12%, n = 8). However, no difference in early limb viability was identified between the groups (95% and 88%, respectively; p = NS). Thus failure of the distal shunts did not result in decreased limb viability. Our experience with shunt use in 126 femoropopliteal arterial injuries specifically described that 43% were shunted. Of these, 93% were patent on arrival to us with only two (4.7%) shunts dislodged during evacuation. Stability in mobility was confirmed.

In 2009, Gifford presented longer-term outcome analysis in a case-controlled, propensity matching fashion with a time-to-event analysis portraying TVS's impact on freedom from amputation using data collected from the Joint Theater Trauma Registry (JTTR), including the Balad Vascular Registry (BVR), and the Walter Reed Vascular Registry (WRVR). Cases and controls consisting of 64 and 61 extremity arterial injuries, respectively, had a mean follow-up of 22 months. While the shunted group showed significant higher mean injury severity scores when compared with the control group (18 vs. 15, p = 0.05), after propensity score adjustment, use of TVS suggested a reduced risk of amputation, but was not statistically significant (RR = 0.47; 95% CI [0.18–1.19]; p = 0.11) (Table 232.2). Similar freedom from amputation was identified in both shunted and nonshunted extremities after definitive reconstruction (78% vs. 77% at 3 years; p = 0.5), but relative, graduated improvement in limb salvage with shunting as the severity of extremity injury increased was noted (Fig. 232.6A,B).

Civilian series report similar results and considerations regarding use of

shunts and corroborate potential benefits. Animal study evidence, both physiologic and histologic, in support of venous shunting in combined arterial/venous extremity injuries is scant but available. The generally beneficial effects in these experiments speak to the potential of venous repair. The theoretic benefits of venous shunting, as well as those of arterial therapeutic, or pharmacologic, shunting remain to be further studied and defined. As this information develops, the posture of shunting in civilian settings should be clarified.

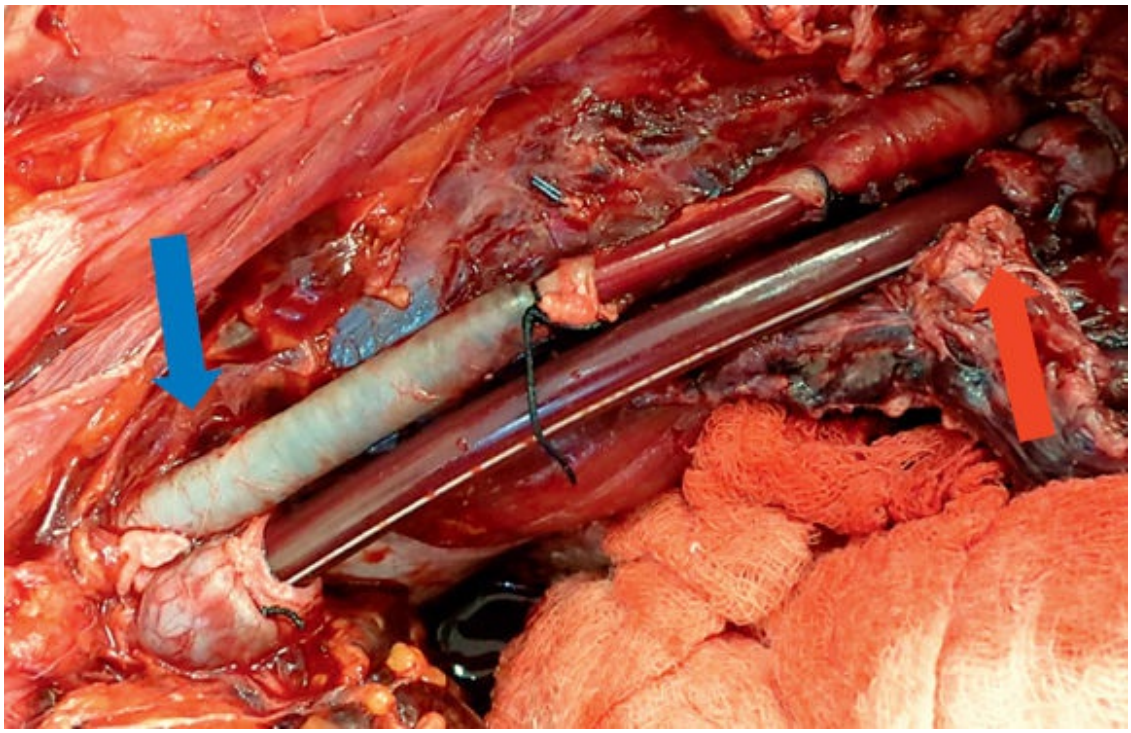

Figure 232.5. Arterial and venous shunting of proximal superficial femoral artery and femoral vein in major multimechanistic injury to the right upper thigh. Note the difference in color and apparent viability of the blood vessels (*red arrow*) versus the lack of perfusion and viability distally (*blue arrow*).

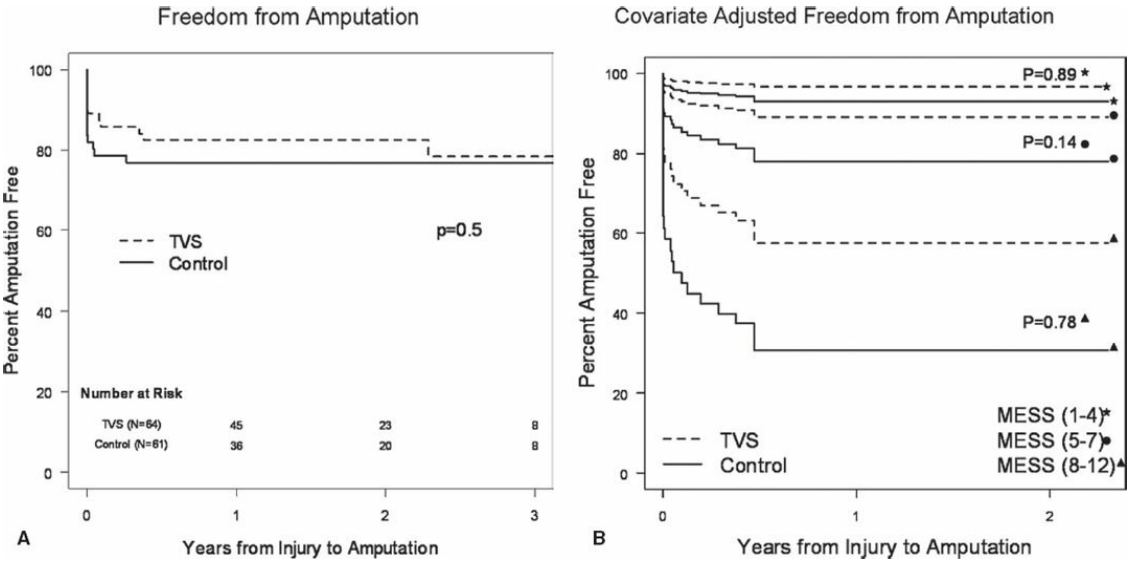

Figure 232.6. **A.** Freedom from amputation in shunted versus matched unshunted extremity arterial injury cohorts showing no difference in long-term outcome but no detriment to shunting. **B.** Graduated, relative benefit of shunting as the severity of extremity injury worsens. (Reprinted from Gifford SM, Aidinian G, Clouse WD, et al. Effect of temporary shunting on extremity vascular injury: an outcome analysis from the Global War on Terror vascular injury initiative. *J Vasc Surg* 2009;50(3):549–56. Copyright © 2009 Elsevier, with permission.)

Potential drawbacks of TVS such as unrecognized iatrogenic vessel injury, or necessity for more extensive repair owing to securing mechanisms seem negligible overall. Even when faced with primary vascular injury at the time of definitive management, the author finds initial shunt use can be quite effective in providing time for operative planning and optimization in the operating room. This simple strategy may create an environment for a more precise and durable final revascularization with improved neuromuscular outcome.

Traditional surgical teaching, based upon simple muscle histology evidence, promulgated 6 hours as the ischemic threshold beyond which functional recovery was likely not possible. However, a new porcine model has provided more scientifically rigorous assessment. Our initial model reported by Gifford describing the biochemical effects of various temporal profiles of ischemia confirmed TVS reversed ischemia. Utilizing this model and allowing for survival, Burkhardt studied neuromuscular recovery by electromyography and modified Tarlov functional scores. Just under 5 hours of ischemia was identified as the breakpoint after which neuromuscular recovery was worse than initial ligation at 14 days after

injury. This was then taken one step further and Hancock reported this threshold was reduced to 3 hours of ischemia with 35% hemorrhage and class III shock. Exactly how this animal model reflects the physiology of human traumatic ischemia is not certain, but it seems clear 6 hours of ischemia is indeed an extreme regarding the functional recovery potential of the limb, and in most injuries, it is likely less. The clinical physiology and shock status of the patient is, as one would anticipate, important, and may reduce this threshold.

Conduit Selection

Primary repair and interposition grafting are the technical open methods used in most arterial repairs for extremity injury. The decision for and knowledge of proper conduit use are therefore essential. Autogenous venous conduit should generally be procured from an uninjured extremity so as not to further disrupt venous return. This is usually the great saphenous vein (GSV). However, for shorter interposition grafts, a single segment of arm vein is acceptable. Also, should the injury in the extremity not lead to substantial soft tissue injury and no associated axial venous injury is present, a short segment of ipsilateral great saphenous vein, or superficial arm vein in upper extremities, can be considered. When multiple extremities are involved, autogenous vein harvest from the extremity with the least amount of injury is proper. Occasionally, femoral vein, jugular vein, or hypogastric artery may be rational. We have also used both autogenous venous and arterial conduit from other primarily amputated limbs.

The use of prosthetic grafts for reconstruction of military extremity vascular trauma has been consistently discouraged. In a report from the Vietnam Vascular Registry, only four (0.4%) patients with arterial injuries were managed using prosthetic graft interposition grafts. The importance of autogenous conduit for contaminated war wounds has also been encouraged and emphasized in OIF/OEF. Among 301 arterial injuries in OIF, only 8 (2.7%) were repaired using a prosthetic graft and 3 of these were in the abdomen or chest.

Vertrees and colleagues underscored the need for surgical judgment in knowing when a prosthetic graft may be useful. As of 2010, the Walter Reed Vascular Registry only had 17 (4.6%) casualties who had undergone emergent vascular reconstruction using polytetrafluoroethylene (PTFE) grafts. Despite a prosthetic graft being emergently placed into large

contaminated soft tissue wounds, 79% of these prosthetic grafts were patent in the short term. This strategy allowed for patient stabilization, transport to stateside facility, and elective rather than emergent revascularization with remaining autologous (arm or leg) vein. There were no prosthetic graft disruptions or amputations performed because of prosthetic graft failure. The authors concluded for complex repairs, when autologous conduit is limited, a temporary prosthetic graft followed by staged, definitive autogenous reconstruction may be a reasonable option. Recently, Watson and colleagues performed a small, retrospective cohort matched study assessing PTFE (n = 25) versus autogenous vein (n = 24) in arterial injury in the JTTR. Mean follow-up was over 5 years. While PTFE in the carotid-subclavian domain performed equal to vein, PTFE in the extremity performed poorly. The 8-year freedom from complication was significantly worse for prosthetic (77% vs. 31%; p = 0.044). These PTFE failures were evenly distributed among thrombosis, infection, and restenosis and were distributed throughout the follow-up timeframe. Autogenous failure did not occur after the first few months.

Civilian literature has also espoused the use of PTFE prosthetic as a reasonable alternative conduit. This is most logical and successful in proximal, larger vessels for appropriate size match in low impact injuries with little soft tissue injury. Patency in PTFE grafts for extremity vascular injury, generally however, has not been encouraging. In a recent meta-analysis of almost 1,200 lower extremity injuries repaired by interposition grafts, the use of PTFE was associated with a nearly twofold higher risk of secondary amputation (OR 1.88; CI 0.55–5.83, p = 0.88). This likely reflects two features of extremity injury grafting. The available data indicate autogenous conduit is preferred, particularly in high-impact, high-velocity injuries leading to major soft tissue destruction. Yet, even in this considerable number of patients, statistical superiority was not realized indicating that when clinical reasoning dictates, PTFE can logically be used.

Arterial Repair

Wide exposure of the injured artery with local control is accompanied by assessment of surrounding soft tissue. Once local control is achieved, release of more global control, if utilized, should be a priority to diminish ischemia. Debridement of devitalized tissue with an eye toward reconstruction coverage is necessary. Revascularization is usually able to

be accomplished in an anatomic way, but in extensive injury with severe tissue destruction and debridement, creative graft tunneling in septal planes may be needed and is essential. Prior to repair, vessel debridement should also be performed. While it is easy to say this should be done to "healthy" vessel, this is sometimes difficult and subjective. In the author's experience, the color of the vessel is key (Figs. 232.5 and 232.7). Arterial appearance should be bright with red vasa vasorum indicating their patency. When the artery is opened, the intima should not only be intact, but moist and tan, not hemorrhagic, contused, or gray. More debridement is usually safer than too little within reason. The author tends to debride to areas for anastomosis while leaving the back wall intact when the artery is not fully transected in order to maintain length and tension. Identified major nerve injuries can either be repaired early or in a delayed fashion depending upon wound and mechanism, but discussion regarding this disposition is essential during operative management.

Systemic use of heparin should be considered when other injuries do not afford undue risk. In isolated injuries, standard doses can normally be given. Graduated use based upon other injuries is reasonable, and in those with systemic use contraindicated, regional heparin saline is particularly important. The general approach to arterial injury repair should include gentle Fogarty balloon thromboembolectomy proximally and distally starting for just a few centimeters looking for strong, thrombus-free inflow and patent outflow. Too vigorous of embolectomy can cause irritation and spasm. Further thrombectomy is only occasionally necessary. Regional heparin should be instilled after judgment of distal and proximal patency. Vasodilators such as nitroglycerine should be considered both topically and instilled into the inflow and outflow. In low-velocity, penetrating trauma, with laceration, primary repair or patch angioplasty is occasionally feasible. With blunt injury, gunshot wounds, or extensive blast injury, interposition or bypass grafting is the correct construct. The size, quality, and reactivity of arteries in children require a specific comment. These features make them quite difficult to adequately repair. Should repair be necessary, liberal use of topical and infused vasodilators can be helpful. Interrupted anastomoses are important to allow for radial growth of the vessels. In children, the great saphenous vein can be a reasonable conduit, but femoral vein, internal jugular vein, and hypogastric artery are important considerations.

Vein Repair

The optimal management of extremity venous injury remains a controversial topic. Ligation of the named veins of the extremity can be performed in austere conditions, when another life-threatening injury takes precedence, or when the patient's physiology will not allow extended operation with relatively low acute morbidity. It has been previously recommended that venous injuries ideally should be repaired when the patient's condition permits. Extremity venous repair gained prominence during the Vietnam War with Rich reporting 377 venous injuries, in which 124 (32.9%) were repaired. Lateral suture was the most common repair performed (n = 106) followed by end-to-end anastomosis (n = 10), vein interposition graft (n = 5), and vein patch graft (n = 3). It was noted in this report, and further emphasized later from the Vietnam Vascular Registry, that concern for thromboembolic complications did not materialize as was historically expected with venous repair. Rich went on to also suggest that extremity venous repair may be important to limb salvage, and although many repairs fail, a major proportion of these may recanalize without higher risk. How recanalization relates to meaningful venous return and later insufficiency has not been defined. It was further work by Rich and Hobson that identified the negative impact of proximal femoral venous ligation on arterial flow in a canine model and formed the foundation of the current venous shunting and repair mindset. This also established the premise that vein repair might facilitate arterial flow and serve as an important component in arterial reconstruction durability.

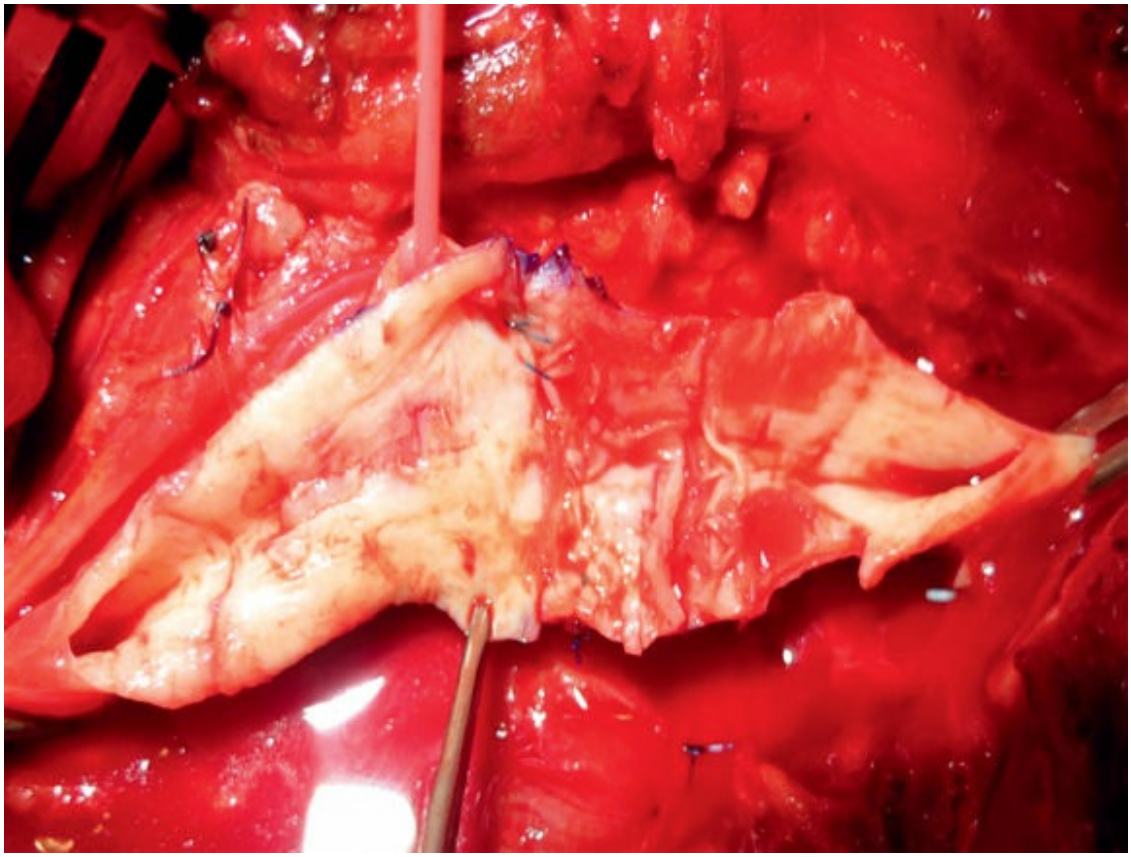

Figure 232.7. Inspection of injured superficial femoral artery shows disrupted vessel wall and the artery opened to healthy, normal appearing intima.

In another large, more recent military series, Quan et al. retrospectively reviewed 82 patients with 103 venous injuries. While a majority of patients (63%) were treated with ligation, no significant difference in postoperative thromboembolic complications was seen between the group that had ligation and the group that underwent venous repair. In 2009, our reported cohort matched shunting evaluation identified venous repair as independently protective against amputation (RR = 0.2; 95% CI [0.04–0.99], $P = 0.05$) during evaluation of 125 combat extremity vascular injuries (Table 232.2). Most recently, a comprehensive meta-analysis of the world's literature on lower extremity vascular injury was conducted by Perkins and colleagues. They were able to identify 904 venous injuries associated with arterial injury along with described limb outcomes. Astoundingly, venous repair provided a six times lower risk of secondary amputation compared to ligation (OR 0.17 [95% CI: 0.06–0.39]; $p < 0.01$). It seems to be becoming clearer the advantages of venous repair do extend to limb salvage particularly in combined arterial and venous injuries.

Civilian series evaluating extremity venous repair are small,

descriptive, and without consensus. These have indicated a significant early repair thrombosis rate, but have confirmed recanalization with generally low morbidity rates in civilian environments. There has been no identifiable difference in outcomes with repair versus ligation or formal associations with amputation based upon management. Smith and coworkers reported that in 20 major extremity venous injury repairs, patency at 72 hours was 55% but increased to 85% at 6 weeks with little morbidity. Meyer et al. reported 34 patients with venous injury (26 lower extremity, 8 upper extremity), and showed 61% early patency for all venous repairs with a 40% early patency for interposition vein grafts. Nypaver and colleagues reviewed longer-term follow-up (mean 49 months; range 6 to 108 months) for 32 patients who had venous reconstruction, and found long-term patency to be 90% as determined by duplex ultrasound. Yet, in 74 patients with extremity venous injury, Yelon and Scalea concluded that ligation was a safe and reasonable option as no differences in outcomes were identified between the 44 ligated and the 30 repaired. Finally, Timberlake and Kerstein reported on 322 patients with venous injury—83 injuries were isolated venous injuries, while 239 were combined arterial and venous. With mean follow-up of 34 months, only 4 patients (1.2%) had long-term edema. All four had arterial and venous injury at the popliteal level. This seems to speak to the wide variability in civilian extremity trauma severity and mechanism. Arguments against venous repair surround time required, difficulty in repair, the patient's associated injuries and general condition, and unidentified long-term benefit.

TABLE 232.3 Triage Categories of Extremity Venous Injury Management

Triage Category	Injury Characteristic	Recommendation on Vein Repair
1.	Isolated extremity injury	Vein repair
2.	Vascular injury with other Non–life-threatening injuries	Vein repair
3.	Multiple vascular injuries	Vein repair if simple. Based on location and patient condition. Consider shunting/ delayed decision in OR
4.	Vascular injury with other life-threatening injuries	Diminished role. No vein Consider shunting/delayed repair
5.	Vascular injury and instability	No vein repair. Ligation Consider delayed repair if reasonable

From Williams TK, Clouse WD. Current concepts in repair of extremity venous injury. *J Vasc Surg: Venous Lym Dis* 2016;4:238–47.

These thoughts have collectively led to the author's relatively aggressive stance to repair veins particularly in the proximal limb and in confluence veins where larger veins represent watershed areas of venous drainage such as in the axillosubclavian venous segment, common femoral vein, or a single popliteal vein. Contemplative of Rich's Vietnam work, our initial OIF reports characterized a 60% to 70% repair rate for identified extremity venous injury. Furthermore, we have suggested five triage categories for extremity venous injury along with management considerations (Table 232.3). Duplicate venous systems can be present, and should be identified. For instance, a duplicate popliteal venous system can be present in up to 30% to 40% of individuals.

Extremity vein repair should also be heavily considered in instances where there is multimechanistic injury resulting in a soft tissue defect likely to compromise venous collateral network return. Rich, in his experimental work, suggested each limb has many collateral venous channel networks, and these are important in limb drainage when the main axial channel is disrupted. With extensive soft tissue injury, these are also compromised, and repair's significance is likely more robust. In these instances it is the author's observation that maintenance or reestablishment of the main axial venous outflow is important in quality limb salvage. The caveat, of course, is that the patient should be in a physiologic state in which repair can be tolerated and no other life-threatening injuries should take precedence. Ligation is logical and appropriate in this situation. As noted, the role of venous shunting is undefined but intriguing. The general goals of venous repair are acute decompression of the congested, injured

limb decreasing venous blood loss, to permit venous collateral development or maturation, enhance arterial repair durability, and to reduce edema and long-term postphlebitic changes.

Debridement for venous repair is quite challenging as these veins usually have some element of thrombosis, but similar principles should apply with normal appearing intima and external features after preparation. Vein repair, when performed, is initiated by ESMARCH exsanguination of the elevated distal limb with the distal aspect of the vein widely free and open without occluding control in order to clear distal thrombus as possible. Gentle thromboembolecotmy with Fogarty balloons smaller than the veins can be helpful in catching strands of thrombus. Regional heparin should be instilled. Depending upon mechanism and destruction, primary repair, patch angioplasty, interposition grafting or panel grafting can be performed (Fig. 232.8A,B). It is difficult to gauge what the allowable size mismatch is for venous repair. The author's tact in repair has been to accept up to a 50% decrease in diameter using interposition grafts, as long as the distended autogenous graft diameter is 5 mm or more. Anything less requires panel grafting. Spiral grafting is described but requires more time and is technically demanding to fashion appropriately and secure. A panel graft allows for placement in situ with appropriate tension to assist construction when each panel is first secured to the proximal and distal ends of the vein. Panel grafting much more than 10 cm of venous defect is simply too time demanding in these acute situations to be normally justifiable. The author has tended to repair venous injury prior to arterial repair when (1) TVS normalizes distal flow with either palpable pedal pulses or brisk continuous wave Doppler signals, (2) the extremity injury is isolated or there are only minor concomitant injuries, (3) autogenous conduit is adequate and generous, and (4) there is substantial soft tissue injury. As noted, this latter scenario often leads to rapid tissue edema and venous oozing with significant ongoing blood loss. Restoration of venous outflow prior to definitive arterial reconstruction can impressively reduce bleeding and the appearance of venous congestion.

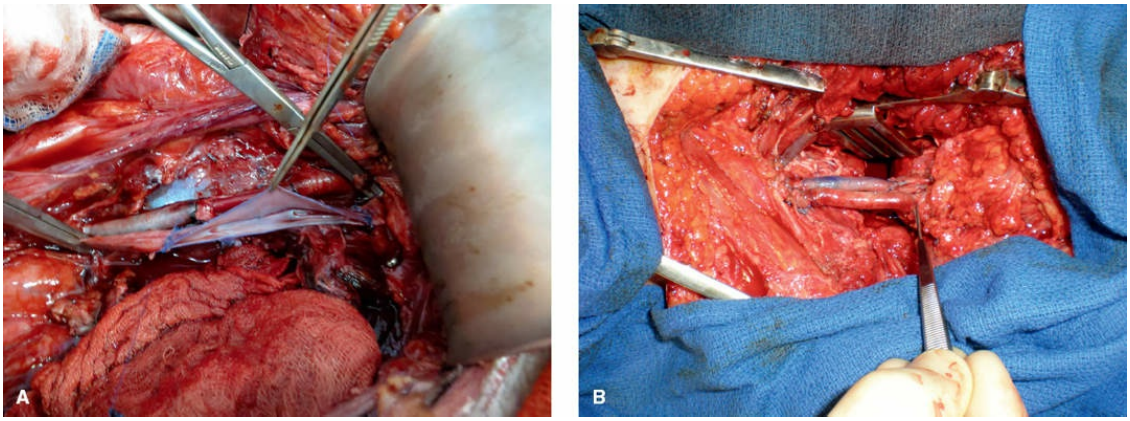

Figure 232.8. Constructs of extremity vein repair. **A.** Creation of a panel vein graft with two panels of great saphenous vein to repair the proximal femoral vein. **B.** Interposition vein grafts of the popliteal artery and vein above-knee.

Fasciotomy

The traditional indications for fasciotomy in extremity injury include ischemia over 4 hours, significant blast, soft tissue or crush injury, patient evacuation scenarios, and inability of the patient to subjectively participate in examination (i.e., head injury). In reality, fasciotomies are best done whenever they are considered and remain an integral component of the surgical treatment of extremity vascular injury. The argument for selective fasciotomies stems from small series touting long-term pain and reduction in calf-pump efficiency. However, the flaw in this logic is noted by recent assessments of delayed fasciotomy and missed release. Ritenour and colleagues reported on 336 U.S. combat wounded undergoing fasciotomy for major limb trauma. They found those with fasciotomies needing revision had significantly more muscle excision and higher overall mortality (20% vs. 6%; $p < 0.01$). Furthermore, they noted statistically significant increases in muscle excision, amputation (31% vs. 15%; $p < 0.01$), and mortality (19% vs. 5%; $p < 0.01$) if fasciotomies were performed after evacuation, or delayed, than if done in theater. This theme was reiterated by Farber et al. who recently reviewed outcomes of civilian patients with fasciotomies and lower extremity arterial injury repair in the NTDB. Compared to those who had fasciotomies accomplished beyond 8 hours of repair, those within 8 hours of repair had a significantly lower amputation rate (8.5% vs. 24.6%; $p < 0.001$), infection rate (6.6% vs. 14.5%; $p = 0.028$), and shorter hospital stay (18.5 ± 20.7 days vs. 24.2 ±1 4.7 days, $p = .007$). On multivariate analysis, early fasciotomy was protective against amputation (OR 0.26, 95% CI 0.14–0.50; $p < 0.0001$)

and led to a 23% shorter stay ($p = 0.01$).

Two-incision lower extremity compartment release is recommended. Via the medial incision, the posterior superficial compartment is opened with initial fascial incision. The posterior deep compartment is entered by release of the fibrous attachment of the soleus on the tibia for its length. The lateral incision is performed 2 to 3 fingerbreadths lateral to the tibial edge. The anterior compartment is opened by fascial incision in this plane. The lateral compartment is either entered via separation of the intercompartmental septum as viewed in the anterior compartment, or it may be entered separately by posterior retraction of the skin and subcutaneous tissue of the incision to expose the lateral compartment external fascia. The skin incisions should be generous and fascia of these compartments separated from just below the knee to the ankle.

Upper extremity fasciotomy can be more complex. Performance of upper extremity fasciotomy should begin medially in the arm, and become sinusoidal from medial to lateral at the antecubital fossa incorporating the bicipital aponeurosis. Extension must be sufficiently lateral to open the fascia over the extensor wad. Rarely, a second dorsal fasciotomy incision over the dorsal wad extensor muscles is necessary. Gentle incision back to the volar fascia will help to also release this aspect (Fig. 232.9). Depending upon the severity of soft tissue damage and mechanism, this may need to be lengthened into a concomitant carpal tunnel release.

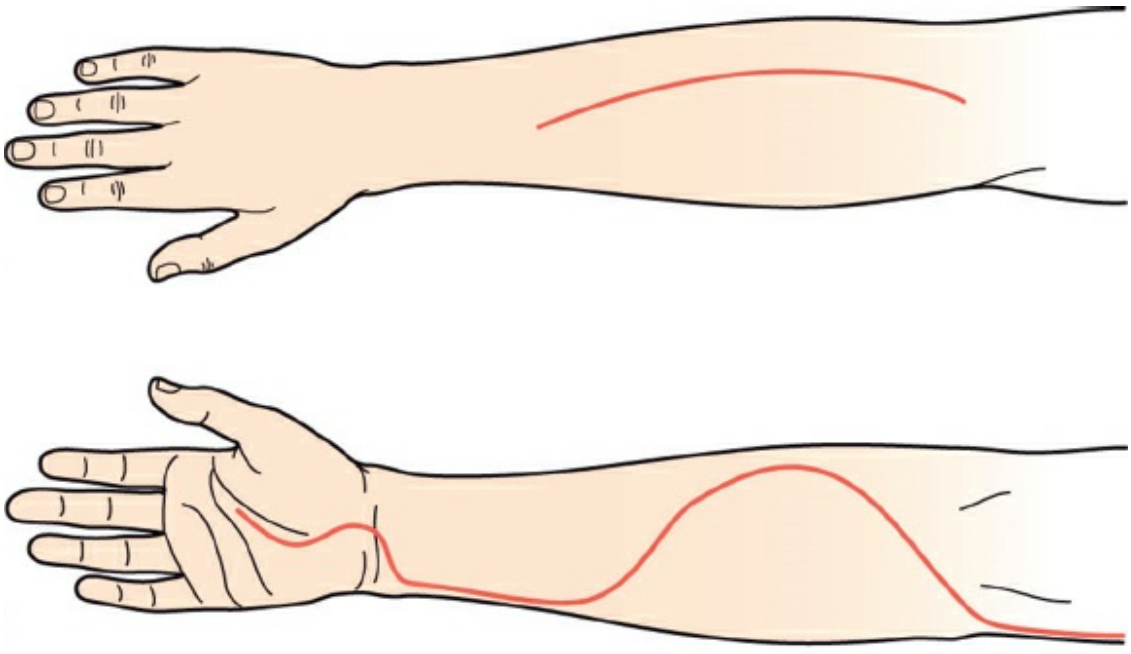

Figure 232.9. Incision lines for performance of upper extremity fasciotomy with mid-medial arm proceeding to S-shaped

antecubial fossa incision opening bicipital aponeurosis then laterally the extensor muscle wad back medially to the forearm muscles and finally through a carpal tunnel release if necessary. A separate dorsal incision to further release the extensor muscles can be created if required.

Wound Management

Contemporary wound care strategies and definitive reconstructive surgery for casualties with vascular injury have also influenced limb salvage rates. Large cavitary wounds require continual assessment and periodic debridement of devitalized tissue to ensure grafts remain covered with healthy muscle tissue. The use of closed negative pressure wound therapy has advanced the practice of closing deep soft tissue wounds to achieve sufficient muscle coverage. The impact of this technology is now used every day in every trauma environment and cannot be underemphasized. Some benefits of negative pressure therapy include wound splinting, perfusion enhancement, stimulation of cell division, wicking of edema and lymph, decreasing bacteriophilic exudate, and downregulation of adverse molecular regulators. Peck described our experience with 134 extremity vascular injuries with extensive soft tissue wounds undergoing repair, serial debridement, negative pressure therapy, and delayed closure. Of these, 57% were able to be managed with early delayed primary closure, confirming the effective use of negative pressure with vascular reconstruction. For wounds that cannot be closed easily, repeated debridements, wound washouts, and changes of negative pressure dressing can properly prepare the site for a split thickness skin graft. Early complications did occur, some requiring alternative revascularization routing. Wound infection occurred in 3.7%, anastomotic disruption in 3%, graft thrombosis in 4.5%, with amputation and mortality rates of 3% and 1.5%, respectively. Thus, a closure strategy must evolve as promptly as feasible and prudent use of extra-anatomic graft routing in large defects must be contemplated and prepared for. Definitive reconstructive surgery has also expanded horizons and demonstrated the effectiveness of both local rotational and microvascular free tissue transfers to salvage extremity wounds in those with vascular injury. This should also be considered in the closure strategy, and expertise sought early in the patient’s management should this be potentially relevant.

UPPER EXTREMITY

Subclavian Artery Injuries

Subclavian artery injuries are rare. They account for <8% of upper extremity arterial injury and 2% of all arterial injury. The right subclavian artery origin can be exposed via a median sternotomy. Further mid-portion exposure may require a clavicular extension with or without clavicular resection. The origin of the left subclavian artery is in a more posterior location on the aortic arch and is exposed through a left anterolateral thoracotomy. The left subclavian artery can be controlled through a median sternotomy with a supraclavicular or cervical extension, but is more classically described with origin control in an anterolateral thoracotomy and separate supraclavicular exposure as the former exposure is deep and can be challenging. A scapular/shoulder roll can be quite helpful. When exposure is difficult, particularly in large, muscular individuals, the clavicle can be resected in a subperiosteal fashion to aid exposure. When the goal is to expose the mid-portion of the subclavian artery in stable patients, a combined supraclavicular/infraclavicular two-incision technique has also been described, but in the authors' experience a single incision approach with subperiosteal clavicular resection used liberally with or without contemporaneous reconstruction of the clavicle seems most expeditious and flexible. The distal subclavian artery and proximal axillary artery are potentially treatable from a two-incision approach, but injury management may require a lateral clavicular resection, again with or without bony replacement. In our experience, longer-term issues with clavicle resection have been minimal. Others, however, do not share this view, and concerns over shoulder stability and use do exist.

Dissection in the area of the subclavian artery and vein should be performed with care given the abundance of adjacent nerve structures at risk for inadvertent injury. Aside from the brachial plexus and vagus nerve, the phrenic nerve sits on the anterior scalene muscle and should be identified and avoided. The anterior scalene muscle can be divided sharply once phrenic nerve identification occurs. Care must be taken to avoid the thoracic duct on the left and right lymph duct as they enter the jugulosubclavian venous confluence. The abundance of collaterals around the shoulder and neck may allow for ligation of the subclavian artery in emergency situations with the upper extremity remaining viable. Temporary shunting, however, may be considered, and in the author's

opinion provides a better expeditious alternative to ligation with delayed reconstruction possible. Tension-free repair of the subclavian artery cannot be overemphasized as the vessel is relatively thin, and delicate. Because of this, primary repair and patch angioplasty are challenging. If these are entertained, use of pledgets can be helpful. Prosthetic material can be used as an interposition graft for these larger, more proximal great vessel and upper extremity reconstructions. Autologous conduit such as saphenous vein, paneled saphenous vein, internal jugular vein, or even femoral vein can be entertained depending upon size, length, injury, and patient considerations. In more extensive injuries, ligation and revascularization using bypass with inflow based more proximally from the ascending aorta, innominate artery, or common carotid may also be an option.

Axillary Artery Injuries

Axillary artery injury occurs slightly more frequently than subclavian injury but is still rare compared to more distal vessels. It represents 2% to 8% of upper extremity and 2% to 3% of arterial injury. Sterile preparation of the ipsilateral neck, chest, supraclavicular fossa, and the circumferential arm is essential in order to fully prepare for optimal exposure and ease repair.

An infraclavicular incision made 2 fingerbreadths below and parallel to the clavicle will allow for access to the proximal axillary artery. Again, a scapular/shoulder roll can be useful. The clavipectoral fascia is next divided through the superior aspect of this incision opening a space, which allows visualization of the proximal most axillary artery. Identification and division of the pectoralis minor muscle through this exposure are frequently necessary to show the entire axillary artery. Exposure of the subclavian artery as discussed may also be required for more proximal axillary artery injuries. Precise clamping is essential given the proximity to the axillary vein and brachial plexus cords. Most axillary artery injuries require interposition grafting. Wide mobilization with side branch division for primary repair disrupts collateral flow and the author avoids it. Conduit concerns are similar to subclavian injury.

Brachial Artery Injuries

The brachial artery is frequently injured and represents 14% to 30% of arterial injuries and up to 60% of those in the upper extremity. Proximal control can often be obtained by manual compression of the brachial artery

against the humerus should ongoing hemorrhage be present. However, brachial artery contraction and local thrombosis after development of hematoma are not uncommon. A wide prep and drape including the ipsilateral neck and chest should be performed in case more proximal exposure is required. Access to the hand and wrist for palpation and Doppler interrogation of radial and ulnar arteries is also an important consideration in draping.

A longitudinal incision is made in the palpable groove on the medial side of the upper arm between the biceps and the triceps. This incision can be extended proximally and distally as needed. With retraction of the pectoralis muscles, exposure as high as the distal axillary artery is possible. The median nerve and ulnar nerve are in close proximity to the artery, and dissection should be performed with this in mind avoiding excessive retraction. The basilic vein should be preserved if possible, and ligation of side branches can aid with mobilization to allow for easier retraction. Distally, the bicipital aponeurosis must be divided to expose the brachial artery. The median nerve will be located deep and lateral to the artery proximal in the arm with the ulnar nerve medial. The median nerve crosses the brachial artery distally in the arm and will lie medial and deep to the artery in the antecubital fossa.

Brachial artery injuries resulting from low-velocity mechanisms may be repaired primarily if there is not a segment of devitalized artery. Injuries resulting from higher velocity mechanisms with or without soft tissue involvement, as well as blunt injuries, require a more extensive reconstruction. With any anastomosis on the brachial artery, spatulation is necessary to avoid narrowing. In some instances, an interrupted suture technique should be used given the relative small size of the artery and its tendency to spasm. Injuries to the brachial artery that occur distal to the profunda brachii origin may or may not present with critical ischemia depending upon the type of injury and the amount of associated damage to the collateral circulation from soft tissue wound or fracture.

Radial and Ulnar Artery Injuries

Forearm vascular injuries account for the majority of upper extremity arterial injury. Typically, control of forearm hemorrhage can be obtained with direct pressure or tourniquet. The proximal portion of the arm, hand, and fingers should be prepped and draped in a circumferential manner in order to allow for adequate proximal and distal control and adequate operative exposure and assessment of the radial and ulnar arteries. An S-

shaped incision over the antecubital fossa will allow for proximal exposure of both the radial and ulnar arteries. Identifying the brachial artery as described above and then tracing it distally may aid in identifying the ulnar and radial arteries. The radial artery follows the medial border of the brachioradialis muscle, and the medial groove of this muscle can be used as a landmark to make an incision in the mid forearm. In the distal wrist, the radial artery can be exposed by a longitudinal incision slightly lateral to the artery. The ulnar artery dives deep to the pronator teres slightly beyond the bifurcation and remains deep to the flexor muscles of the proximal forearm before emerging to a more superficial position in the midpoint of the arm that makes proximal exposure more difficult. A longitudinal incision is made on the medial side of the arm about 4 fingerbreadths distal to the medial epicondyle, and the artery can be identified between the flexor carpi ulnaris and flexor digitorum superficialis. In the wrist, the ulnar artery can be exposed through a longitudinal incision on the radial side of the flexor carpi ulnaris muscle in order to avoid the ulnar nerve, which runs medial to the ulnar artery.

Typically, the management of forearm artery injury is dependent upon whether or not there is a satisfactory continuous wave Doppler signal at the wrist and/or in the palmar arch of the hand. Should a reasonable signal be present with the injured vessel occluded, ligation is a viable alternative. With simple lacerations, primary repair using fine, permanent sutures is also reasonable. Vasodilators may be needed. Spatulation is required because of the small size of the vessel. Interrupted technique is useful. In significant forearm injuries with critical ischemia, vein graft interposition or bypass based from the more proximal brachial artery may be necessary. For reconstructions at the wrist, it may be helpful to have a hand surgeon present. Conduits for wrist/hand level reconstruction can include forearm or foot vein as well as various other autogenous arterial conduits.

LOWER EXTREMITY

Femoral Artery Injuries

The femoral arteries are the most commonly injured lower extremity arteries accounting for 25% to 50%. The superficial femoral artery (SFA) is injured most frequently. Control for common CFA injuries can be accomplished in several ways. First, if the patient is not doing well with ongoing hemorrhage or growing hematoma, it may be most expeditious to perform a lower laparotomy and control the distal external iliac artery in

the abdomen. Alternatively, if time allows but the groin morphology is obscure, retroperitoneal exposure of the distal external iliac artery for control is reasonable. This can be accomplished either by extending the traditional longitudinal incision over the groin obliquely onto the abdomen and entering the retroperitoneum with fascial incision parallel to the external oblique fibers (Fig. 232.10), or via a separate oblique lower abdominal incision. If the patient is stable and the situation permits, consideration for standard, longitudinal femoral exposure with control at the inguinal ligament can be appropriate if the mechanism is stab or puncture and the groin is stable. If there is any concern for any reason, more extensive exposure and control are encouraged rather than needing to seek further proximal control after hemorrhage control is less stable. Use of self-retaining retractor systems can be essential. The author prefers the pediatric OMNI system, but others can suffice. Selective iliac endovascular balloon control from the contralateral femoral artery or the arm can also be performed. Nonselective resuscitative endovascular balloon aortic control (REBOA) can be considered in unstable patients, but should be replaced by open control or selective iliac balloon control as soon as possible. Endovascular control is particularly useful when the clinical situation requires manual hemorrhage control in the groin. When the injury is proximal, division of the inguinal ligament has been espoused. This can be frequently avoided with endovascular control, or peritoneal or retroperitoneal exposures. These allow for broader control away from the femoral artery that makes repair easier with the extent of hematoma and edema in the groin.

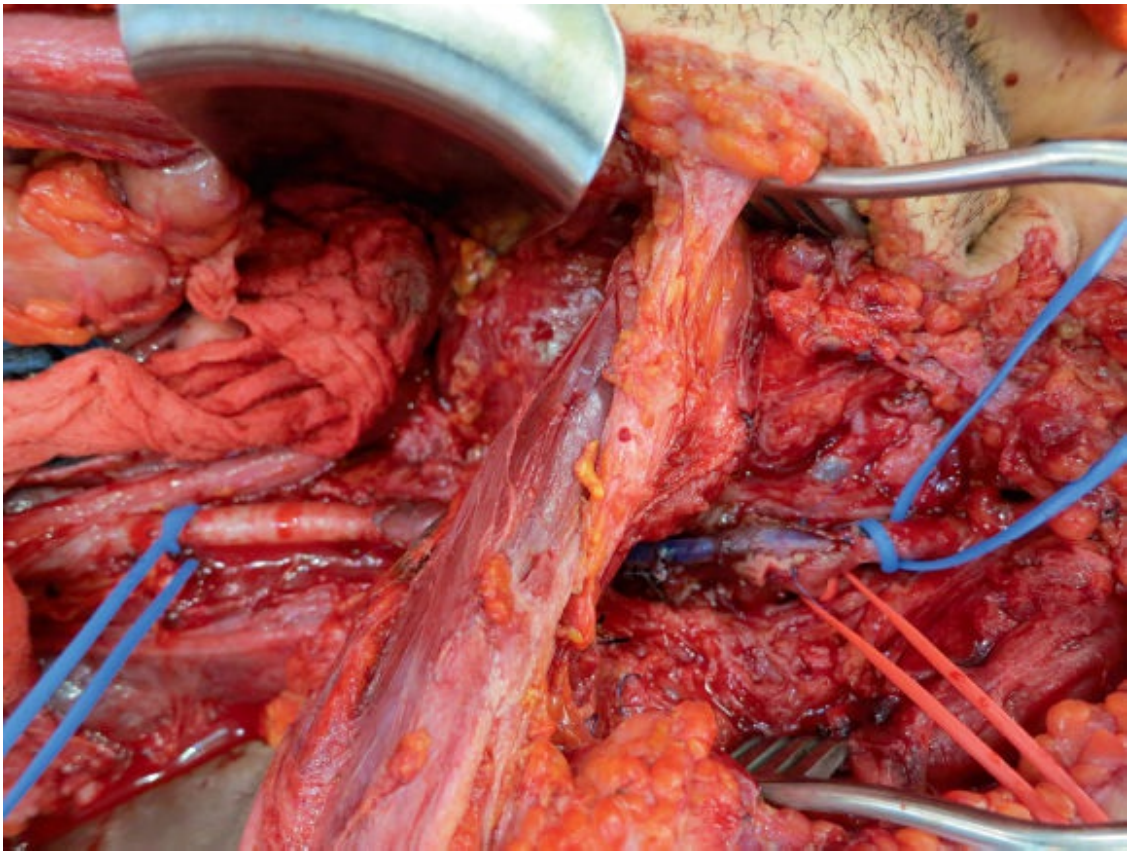

Figure 232.10. Vein graft repair of a common femoral artery injury preserving the bifurcation by beveling of the graft. The distal external iliac artery and common femoral artery are exposed through a single incision with both groin and retroperitoneal exposure. The retroperitoneum has been entered via an oblique fascial incision above the groin.

Repair of CFA injuries requires judgment. Arterial debridement and primary repair, autogenous or prosthetic patch angioplasty can be performed. These should not narrow the artery's original diameter. In more extensive injuries, interposition grafts are necessary. Autogenous saphenous vein interposition, prosthetic grafts, femoral vein, internal jugular vein, arm veins, or panel vein grafts can be considered. Proximal basilic vein is often a good option. It can be formidable to determine if simple vein interposition is adequate in the CFA. As the vein will enlarge over time, it has been the author's practice to accept vein sizes of at least two thirds the normal CFA size that is mostly in the 5 to 8 mm range. Salvage of the femoral bifurcation allowing flow into not only the SFA but also the profunda femoris artery (PFA), the major collateral supply to the limb, is important and repair should be purposeful in this regard. This can be accomplished with beveling of the femoral bifurcation, reimplantation

of the PFA origin onto the graft or the SFA, or separate bypass graft to the PFA. In damage control scenarios, separate parallel TVS or an inverted and cut hemodialysis catheter from the external iliac artery (EIA) to the SFA and PFA have been used with a well-planned full revascularization after resuscitation. Isolated SFA injury is largely repairable with GSV or prosthetic. PFA injuries can be ligated if necessary.

Popliteal Artery Injuries

The popliteal artery is injured frequently and accounts for some 12% to 25% of lower extremity arterial injuries. Combined popliteal venous injury is not uncommon and occurs in 30% to 60% of injuries. The tibial nerve is involved in 10% to 30% irrespective of the clinical mechanism. This milieu establishes popliteal artery injury as the arterial level carrying the highest risk of amputation in the extremities. Surgical approach to the popliteal vessels is usually medially that can utilize both traditional above and below knee incisions. This provides the freedom to exposure further proximally or distally as needed. Proximal control may be at the common femoral, or SFA level should above-knee popliteal artery control be impractical. The posterior approach should be reserved for only patients in whom the injury is isolated, are physiologically normal, and injury contained within a very focal area of the artery with little soft tissue injury. The prone position limits the overall systemic care of the trauma patient. The posterior approach may be more applicable in focal injury evolution late after injury event in a more elective situation. Occasionally, mostly in later, chronic scenarios or in cases of major tissue destruction or infection the lateral approach to the popliteal artery can be useful. Above knee, the incision is made at the posterior aspect of the iliotibial band with dissection between the vastus lateralis muscle anteriorly and the biceps femoris posteriorly. Below the knee, resection of the proximal fibula is required with protection of the common peroneal nerve. With the fibular periosteum retracted anteriorly, the vessels are found anterior to the gastrocsoleus complex. The lateral soleal arch must be divided.

With the medial approach, most injuries can be defined, and exposed. Yet, some 5 cm of retrogeniculate artery is inaccessible and when injured, must simply be ligated above and below with bypass performed. Late problems, such as bleeding or false aneurysm formation, in this segment due to residual branch flow are not reported but are ostensibly possible. With soft tissue injury, edema, and hematoma, exposure becomes more difficult and increases the length of this poorly exposable area. In many

multisystem injuries, proper exposure and repair require external fixation devices to either be loosened and then repositioned after vascular repair, or simply accomplished after vascular repair. It can be difficult to appropriately estimate graft length in these circumstances. A helpful method to address this is to expose and control the injury, shunt, and then allow proper reduction and placement of the external fixator pins. If necessary, measure the projected length of graft needed when reduced. Then, loosen the fixator, repair the vessel, and re-reduce appropriately and secure. This requires multidisciplinary team coordination. Leg exsanguination with tourniquet control can be considered in limbs with minimal deformity, and no major bony or soft tissue injury, but in the author's experience has not been utilized.

Tibial Artery Injuries

Tibial artery injuries represent 25% to 40% of lower extremity arterial injuries. The surgical approach to the tibial arteries is standard. The mid-distal anterior tibial artery (ATA) is approached through an incision 2 to 3 fingerbreadths lateral to the anterior tibial edge. It is identified on the interosseous membrane in the raphe lateral to the anterior tibialis muscle and medial to the extensor digitorum longus and extensor hallucis longus muscles. The posterior tibial artery (PTA) is approached medially via an incision 1 to 2 fingerbreadths posterior to the medial border of the tibia. Proximally, it runs underneath the soleal arch and this should be divided after identification of the below-knee popliteal artery taking care to stay superficial to the arteries (Fig. 232.11). The origin of the ATA is just distal to the soleal arch attachment. The tibioperoneal trunk and its bifurcation can be identified with distal dissection from the arch providing exposure of the proximal PTA. Distal to this, the PTA is found between the soleus and the flexor digitorum longus muscle and posterior to the flexor tendon just at and above the medial malleolus. The peroneal artery is more challenging and is usually approached medially with further dissection anterior to the posterior tibial vessels and nerve in the raphe behind the tibialis posterior. The lateral approach to the peroneal with excision of the fibula is rarely used in traumatic injury. These incisions, in standard positions, allow for simultaneous four-compartment fasciotomy.



Figure 232.11. Vein graft from the above-knee popliteal artery to the proximal posterior tibial artery. The soleal arch has been taken off the tibial edge to expose the proximal infrageniculate arterial system.

Similar to the forearm arterial injuries, the redundant perfusion to the foot allows for simple ligation of identified injuries should reasonable perfusion be appreciated. Continuous wave Doppler examination or on-table Duplex can be invaluable in determining tibial vessel patency and perfusion with ligation. The experiential dictum that one tibial vessel in continuity with the foot is acceptable should be followed. Patients with tibial level injury frequently have other injuries or reasons to be in shock making clinical assessment difficult. Furthermore, tibial reconstruction for traumatic injury is quite challenging and time-consuming, thus making selection of those who need revascularization thought-provoking and vital. Tibial reconstruction should only be pursued in true critical ischemia without viable distal perfusion, in those who do not have significant other life-threatening injuries and have a reasonable salvage potential with little soft tissue loss or foot deformities. We have recently shown statistically that this selective posture toward tibial injury repair results in similar amputation-free survival in those receiving tibial bypass versus those not,

and is a reasonable stance. When otherwise normal, these muscular arteries can easily develop spasm and resuscitation after addressing other life-threatening injuries with vigilant reassessment is prudent without hard indication of disruption. Anecdotally, the author has operated on infrageniculate injuries and been nearly unable to identify the tibial arteries due to this process. Yet, 12 to 24 hours later a palpable pulse is present with a warm foot in a vessel not intervened upon. Because of spasm, and the points above, it is wise to perform end-to-side anastomoses proximally to maintain axial flow to any vessels remaining inline distal.

ENDOVASCULAR TREATMENT

Application of endovascular techniques in the diagnosis and treatment of vascular trauma has become common. Yet, addressing arterial injury with endovascular methods remains relatively rare today as it is utilized in <8% of injuries. For obvious reasons, aortic and torso injuries have been the focus while the majority of reports delineating extremity use involve the junctional zones. Catheter-based techniques offer advantages in both acute vessel injuries and less urgent traumatic sequelae such as arteriovenous fistula and pseudoaneurysm particularly in junctional zones as they avoid operative dissection. Furthermore, use of covered stents is becoming recognized as a feasible alternative in definitive management in both penetrating and blunt trauma. These should be sized in a similar way to that of age-related vascular disease; however, the generally healthy arteries in trauma are smaller than atherosclerotic vessels and more like 20% to 30% oversizing may be needed for self-expanding devices. Even in the presence of hard signs of vascular injury (pulsatile bleeding, absent distal pulses, expanding hematoma, bruit or thrill) and hemodynamic instability, patients now may be considered for emergent endovascular balloon control and repair by either open or endovascular methodologies in the operating room with open conversion possible. Endovascular management requires endovascular expertise is available and the operating room is capable of timely endovascular proficiency. Today, as fixed hybrid operating room technology with state-of-the-art imaging becomes more commonplace, this is more and more realistic. In stable patients, today’s use of noninvasive anatomic imaging, usually CTA, allows for injury definition and endovascular treatment planning.

Upper Extremity

Control and definitive endovascular management of axillo-subclavian artery injuries is arguably the arena in which there is the most experience currently. These may require femoral access, retrograde ipsilateral brachial access, or both. Passing the wire under fluoroscopic guidance across vessel disruption from either the retrograde femoral or brachial approach may be challenging. Because of the shorter distance from the access site to the injury, many prefer the retrograde brachial approach. Directional catheters, balloon centering guidance, as well as combined femoral and brachial access with snare capture of the wire through the injury are techniques used to achieve wire access across the upper extremity vessel injury. Endovascular control and repair allow the surgical team to address other life-threating injuries avoiding the time and morbidity of median sternotomy, thoracotomy, or junctional zone open exposure.

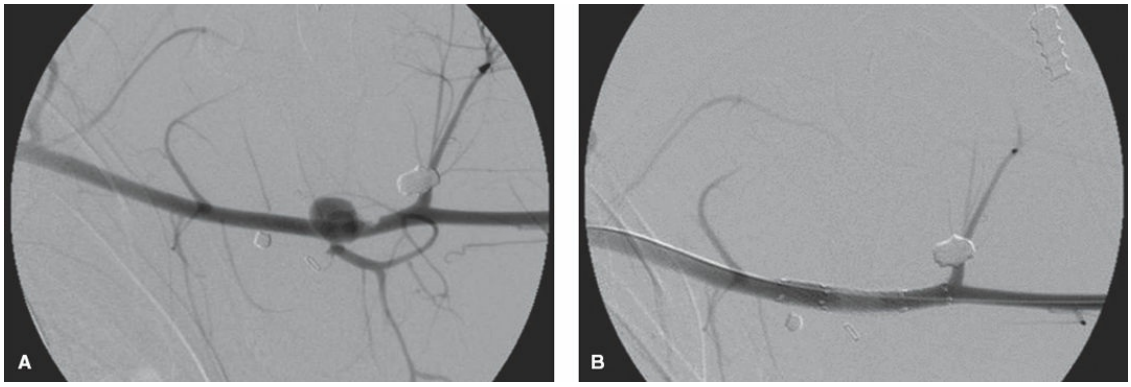

Figure 232.12. A. Retrograde left brachial artery access with arteriography showing a proximal brachial artery penetrating injury. **B.** Covered stent repair of the injury using two short segment self-expanding covered stents to exclude the injury and maintain axial brachial artery perfusion.

Either self-expanding or balloon expandable covered stents have been effective in managing select innominate and axillosubclavian injuries. In contrast, bare metal stents have been more commonly reported with treatment of small dissections or intimal flaps. One multicenter trial evaluating use of the self-expanding Wallgraft Endoprothesis (Boston Scientific; Natick, MA) for the treatment of 62 iliac, femoral, or subclavian arterial injuries showed the endoprosthesis achieved exclusion of the injury in 93.5% of cases and 90% of the subclavian artery injuries. Freedom from bypass was achieved in 100% of the subclavian injuries. Overall early mortality was 6.5%, but no procedure-related mortalities were reported and the most common post procedure complication involved

stenosis or occlusion. While the data support use of endovascular management of arterial injury, most procedures in this series were performed for iatrogenic injury (78%) and comparison of this study population with major accidental traumatic vascular injuries should be done with caution. Du Toit and colleagues reported 57 patients with penetrating subclavian artery injury who underwent stent graft repair during a 10-year period. One patient in this series died due to other injuries, and 3 (5%) developed early, non–limb-threatening stent graft occlusion. Complete follow-up data were available for 16 patients at a mean of 61 months (range 8 to 104 months), which showed that 5 patients had claudication and >50% in-stent stenosis on arteriogram. These patients were successfully re-treated with balloon angioplasty. Three additional asymptomatic patients in the follow-up cohort had stent occlusion, but did not require reintervention. There are also multiple case reports exhibiting use of endografts in the setting of upper extremity arterial trauma. Hershberger et al. reviewed 195 studies published between 1995 and 2007 and suggested the overall treatment success rate for supradiaphragmatic extremity arterial injury was 96%. When all reports reviewing endovascular treatment of innominate (n = 7), subclavian (n = 91), and axillary (n = 12) artery injuries were assessed, technical success rates were 85.7%, 96.7%, and 100%; periprocedural morbidity was 0%, 12.1%, and 8.3%; and mortality 0%, 3%, and 0%, respectively for each segment. The infrequent complications that were reported following endovascular repair of upper extremity vascular injury include access site pseudoaneurysm, arm claudication due to restenosis or thrombosis, and stent fracture.

While short-term durability has been suggested to be equivalent to operative repair, long-term durability of endovascular stents in upper extremity traumatic injuries has not been completely defined. Current results are encouraging. Specifically, patency rates appear to be acceptable with fewer reports describing the need to revascularize following upper extremity stent graft occlusion. Although the possibility of infection remains a legitimate concern, there is no suggestion that use of today's covered stents in trauma patients poses an undue risk. In our review of available literature on axillosubclavian arterial injury handled with endovascular repair, of 160 cases, no infections were noted, 3% underwent open conversion, and 8.5% required reintervention. Thus, use of endovascular stenting does not preclude either future open repair or catheter-based reintervention. Longer follow-up periods and larger

experiences are needed before definitive durability of these interventions can be appreciated. Reports describing endovascular intervention for successful management of brachial artery injury and transection are appearing (Fig. 232.12A,B). Whether this technique becomes widely applicable remains to be seen.

Lower Extremity

Description of lower extremity arterial endovascular repair is much less mature than that of the proximal upper extremity. As early as 1994, lower extremity trauma has been approached with endovascular methods when Marin and the Montefiore group in New York described three patients with homemade stent grafts in the SFA location for pseudoaneurysms and arteriovenous fistulas. However, since then most communications are case reports with many describing embolization of branch vessel bleeding and fewer axial endografts. As noted above, White and coworkers described use of axial stent grafts at the femoral and iliac levels. Early injury exclusion failures were most common in the femoral artery, and early mortality was not endograft related. Exclusion success at 1 year was 91.3% for iliac arteries but only 62.3% at the femoral level. No femoral failure required reintervention. Recent assessment of lower extremity arterial injury at a level I trauma center from 2005 to 2010 indicated endovascular methods for repair of infrainguinal arterial injury occurred in four femoral level injuries representing only 7.5% of injuries. An initial report from the multicenter Prospective Observational Vascular Injury Treatment Registry (PROOVIT) describing over 500 arterial injuries at 13 trauma centers over 1 year indicated only 3 endovascular interventions in the lower extremity. Practice Guidelines on lower extremity arterial injury from the Eastern Association for the Surgery of Trauma were provided in 2012, and they decried the lack of series and data describing stent grafting for axial vessel injury. They recommended case-by-case selection. The general technical approach to arterial injury in the lower extremity is similar to that of the upper extremity. The caveat being combined antegrade and retrograde access for transection traversal is more difficult, or may be simply contraindicated. Infrageniculate injuries can be approached via a contralateral, retrograde “up and over” method, or percutaneous or open antegrade access. Proximal extremity injuries may be approached from brachial access. More information is unmistakably needed in order to better define the rolls and outcomes of endovascular

repair of axial lower extremity arterial injury. At this point, feasibility and safety are discernable.

POSTOPERATIVE CARE AND COMPLICATIONS

Postrepair antiplatelet therapy should be utilized in arterial repair unless contraindicated due to other injuries. The use of inferior vena cava (IVC) filters in venous repair or ligation is debated with no clear consensus, but consideration is justifiably important when other injuries preclude antithrombotic use. To this end, the proper antithrombotic regimen indicated with extremity venous repair or ligation is also debated. It would make sense that in isolated extremity injury, anticoagulants should be considered with venous ligation or repair. When concomitant injuries preclude this, the maximal antiplatelet regimen reasonable should be instituted as soon as feasible. When combined arterial and venous injuries occur, low-intensity antiplatelet therapy, such as aspirin, with anticoagulants should be contemplated. These obviously must be tempered with the degrees of soft tissue injury, neuroaxial injury, or cavitary injury. However, as noted above Quan and colleagues have recently reconfirmed that the incidence of clinically important pulmonary embolism after either venous repair or ligation in combat injuries with selective use of antithrombotic regimens is <5%. Elevation and compression postoperatively are essential. Standard postoperative surgical care surrounds graft monitoring surveillance with physical examination and duplex ultrasound. Wound care for operative wounds, traumatic wounds, and fasciotomies is paramount. As noted, this may include serial washout, debridement, and negative pressure therapy. Aggressive physical therapy is important. Wound infection occurs in 3% to 5%, anastomotic disruption in 3% to 5%, early graft thrombosis in up to 5%, with in-hospital amputation and mortality rates of 3% to 5% and 1% to 2%, respectively. Anastomotic disruption may occur due to poor coverage, infection or prolonged negative pressure therapy and desiccation. Reoperation for re-grafting, rerouting or coverage improvement thus occurs in this minority of patients. Compartment syndrome may occur depending upon vascular and orthopedic concerns and injury mechanisms. It may be present in over 50% of extremity injuries associated with ischemia and fracture. Venous injury can play a role. Thus, as noted, fasciotomy is a key component of the care of the patient with extremity vascular injury. Neuromuscular recovery dictates long-term limb salvage that is estimated at roughly 80%

at 3 years.

Suggested Readings

Clouse WD, Rasmussen TE, Peck MA, et al. In-theater management of vascular injury: 2 years of the balad vascular registry. *J Am Coll Surg* 2007;2014:625–32.

Farber A, Tan TW, Hamburg NM, et al. Early fasciotomy in patients with extremity vascular injury is associated with decreased risk of adverse limb outcomes: a review of the national trauma data bank. *Injury* 2012;43:1486–91.

Gifford SM, Aidinian G, Clouse WD, et al. Effect of temporary shunting on extremity vascular injury: an outcome analysis from the global war on terror vascular injury initiative. *J Vasc Surg* 2009;50:549–55.

Hancock HM, Stannard A, Burkhardt GE, et al. Hemorrhagic shock worsens neuromuscular recovery in a porcine model of hind limb vascular injury and ischemia-reperfusion. *J Vasc Surg* 2011;53:1052–62.

Kauvar DS, Sarfati MR, Kraiss LW. National trauma databank analysis of mortality and limb loss in isolated lower extremity vascular trauma. *J Vasc Surg* 2011;53:1598–603.

Perkins ZB, Yet B, Glasgow S, et al. Meta-analysis of prognostic factors for amputation following surgical repair of lower extremity vascular trauma. *Br J Surg* 2015;102:436–50.

Rasmussen TE, Clouse WD, Jenkins DH, et al. The use of temporary vascular shunts as a damage control adjunct in the management of wartime vascular injury. *J Trauma* 2006;61:8–15.

Ritenour A, Dorlac W, Fang R, et al. Complications after fasciotomy revision and delayed compartment release in combat patients. *J Trauma* 2008;64(suppl 2):S153–S162.

Tan TW, Joglar FL, Hamburg NM, et al. Limb outcome and mortality in lower and upper extremity arterial injury: a comparison using the national trauma data bank. *Vasc Endovasc Surg* 2011;45:592–7.

Watson JDB, Houston R IV, Morrison JJ, et al. A retrospective cohort comparison of expanded polytetrafluoroethylene to autologous vein for vascular reconstruction in modern combat casulaty care. *Ann Vasc Surg* 2015;29:822–9.

Williams TK, Clouse WD. Current concepts in repair of extremity venous injury. *J Vasc Surg: Venous and Lym Dis* 2016;4:238–47.

Woodward EB, Clouse WD, Eliason JL, et al. Penetrating femoropopliteal injury during modern warfare: experience of the balad vascular registry. *J Vasc Surg* 2008;47:1259–65.

EDITOR'S COMMENT

Dr. Clouse in this chapter draws extensively on his long and decorated experience in the Air Force, especially during the Iraqi conflict. After reading this chapter on injury to the lower extremities, I believe it represents what this book is intended to provide for its readers, namely, detailed coverage of a topic written by a master clinician in the field. Two things are true of the management of extremity trauma for sure. There is little doubt that endovascular therapy has positively impacted outcomes from lower and upper extremity trauma (Scott AR, Gilani R, Tapia NM, et al. Endovascular management of traumatic peripheral arterial injuries. *J Surg Res* 2015;199(2):557–63). Second, the concept of damage control continues to work, even though at times it is hard to leave the operating room, while the salient outcome rendered in the operating room is not perfect, but acceptable (DuBose JJ, Savage SA, Fabian TC, et al.; AAST PROOVIT Study Group. The American Association for the Surgery of Trauma PROspective Observational Vascular Injury Treatment (PROOVIT) registry: multicenter data on modern vascular injury diagnosis, management, and outcomes. *J Trauma Acute Care Surg* 2015;78(2):215–22; discussion 222–3).

I learned a number of things from reading this chapter. One is that those of us managing civilian trauma would do well to use more shunts in injured extremities with arterial and venous injuries (Hornez E, Boddaert G, Ngabou UD, et al. Temporary vascular shunt for damage control of extremity vascular injury: a toolbox for trauma surgeons. *J Vasc Surg* 2015;152(6):363–8). The age-old dilemma when managing extremity trauma has to do with who goes first: orthopedics with the external fixators or surgery with restoration of blood flow. I know that the ABC's should necessitate that circulation is before orthopedics, but who hasn't done a bypass without the bone extracted only to find the vascular reconstruction has failed because of tension, compression, etc. The data are pretty strong suggesting that shunts save limbs, remarkably even when they thrombose (Hornez E, Boddaert G, Ngabou UD, et al. Temporary vascular shunt for damage control of extremity vascular injury: a toolbox for trauma surgeons. *J Vasc Surg* 2015;152(6):363–8). We need to use more shunts in civilian lower extremity trauma.

In addition, the use of wound management systems has also improved the outcomes of extremity trauma (Fang R, Dorlac WC, Flaherty SF, et al. Feasibility of negative pressure wound therapy during intercontinental aeromedical evacuation of combat casualties. *J Trauma* 2010;69(Suppl 1):S140–5; Kanakaris NK, Thanasas C, Keramaris N. The efficacy of negative pressure wound therapy in the management of lower extremity trauma: review of clinical evidence. *Injury* 2007;38(Suppl 5):S9–18). Often despite performing an eloquent bypass, the wound that is contaminated to begin with is closed. As the wound progresses and becomes frankly infected, bypasses either blow out or

thrombose. The idea that one can perhaps just cover the bypass with nearby viable muscle and come back and wash out the wound using a wound management system has also likely helped to save some limbs.

On that same note, I often find in civilian trauma we are slow to make large incisions for fasciotomies. I have found on more than one occasion an inadequate fasciotomy in a trauma patient. Let me encourage readers of this commentary to make larger incisions and to use wound closure devices/systems to help accelerate healing placed on about day 2 or 3. It would be hard for me to provide objective data on this, but anecdotally it seems like I see fewer foot drops with more complete fasciotomies.

Finally, I am not sure about the use of IVC filters in young trauma patients (Quirke TE, Ritota PC, Swan KG. Inferior vena caval filter use in U.S. trauma centers: a practitioner survey. *J Trauma* 1997;43(2):333–7). I am sure there are data supporting their use, but the placement of IVC filters to prevent pulmonary embolus has been so overperformed largely based on soft indications. Clearly the immobilized, multitrauma patient with long bone fractures who may not be able to be placed on prophylactic heparin may benefit from an IVC filter. However, we now on a routine basis see patients with complications from IVC filters with hooks in the duodenum, aorta, iliacs, etc. Maybe I should make a plea that these filters, if placed temporarily, be removed as soon as these patients who have experienced extremity trauma are up and ambulatory and/or can be placed on prophylactic anticoagulation.

Gilbert Upchurch Jr.

INDEX

Note: Page numbers followed by *f* indicate figures: those followed by *t* indicate tables.

A

- A cells, glucagon secretion, 1472
- A mode, US, 178, 193
- AAST. *See* American Association for the Surgery of Trauma (AAST)
- Abbe flaps, 328, 329*f*
- "A-B-C-D-E" mnemonic, 411–412, 415, 418
- ABCDEF bundle compliance, 140
- Abdomen
  - closure of, 2453
  - dissection
    - anatomic relationships, 919*f*
    - in APR, 1855–1857
    - minimally invasive, 1846–1847
    - open, 1845–1846
  - exploration of, 2159*f*
  - lateral view of, 2444*f*
  - lower, anatomic landmarks, 2213*f*
  - magnetic resonance angiography, 766*f*
  - pain, 850, 2020
  - reconstruction, 237–240
  - traumatic injuries, 193
  - ultrasound evaluation of, 193
  - vagal structures of, 1073*f*
  - viscera, distribution of pain, 780
  - visceral anatomy, 2157*f*
  - visceral vessels, 2580*f*
- Abdominal aorta

- anatomic relationships, 2004*f*, 2005*f*
- anatomy, 856*f*
- branches, 834
- imaging of, 2467*f*
- upper, exposure of, 2456*f*

- Abdominal aortic aneurysms (AAAs), 2299–2305, 2311–2315, 2465. *See also* Aneurysms
  - FDA-approved devices, 2299–2301, 2299t, 2300*f*
  - imaging, 2299
  - rupture repair, 2317–2318
    - clinical presentation, 2304, 2304*f*
    - complications, 2315–2317, 2316*f*
    - endovascular repair, 2305–2309, 2307–2308*f*
    - endovascular rupture, 2309–2310
    - historical perspectives, 2303
    - management and triage, 2304–2305
    - pathophysiology, 2303–2304
    - rupture after EVAR, 2311–2315, 2311*f*, 2314*f*
    - secondary intervention, 2310–2311
  - surgical techniques
    - endoluminal repair, 2301–2302, 2302*f*
- Abdominal compartment syndrome (ACS)
  - IAH and, 153–156
  - management of, 155–156
  - presentation, 155, 155*t*
- Abdominal esophagus, 828–830
  - length of, 905*f*, 916
  - overview of, 828–829
  - perforation of, 1023*f*, 1024, 1030, 1031
- Abdominal pain syndrome, 1488
- Abdominal rectopexy, 1959
- Abdominal sphincter, 905*f*
- Abdominal splanchna, 1053
- Abdominal vascular injuries

- diagnosis, 2578
- mechanism of, 2577–2578
- overview of, 2577
- presentation, 2578
- treatment
  - algorithm, 2586
  - angioembolization, 2584–2585
  - balloon occlusion, 2584
  - complications and their management, 2585
  - indications and initial surgical management, 2579
  - midline looping, 2582*f*
  - operative management strategies, 2578*t*
  - postoperative care, 2585
  - preoperative planning, 2578–2579
  - stent-grafting, 2583
  - surgical techniques, 2579–25836

Abdominal wall

- anterior, section through, 2190*f*
- anterolateral, layers of, 2182–2283, 2182*f*
- closure after cesarean, 2125–2126
- closure of, 153
- defects, closure, 238*f*
- dilations of, 880*f*
- incisions, 152
  - closure of, 152, 153, 154*f*, 155*f*, 156*f*, 168
  - flexibility of, 152
  - midline, 168
  - morbidity from, 152
  - paramedian, 168
  - selection of, 153
  - transverse, 168
  - types of, 152–153, 152*f*
  - vertical midline, 152, 154*f*
- midline defects, 162*f*

- newborn infant, 2184*f*
- posterior lumbar region, 2194*f*
- posterolateral lumbar region, 2194

Abdominal wall hernias
- incisions
  - abdominal, 153
  - choice of, 167–168
  - extraperitoneal, 152–153
  - oblique, 152
  - retroperitoneal, 152–153
  - thoracic, 153
  - thoracoabdominal, 153
  - transverse, 152
  - vertical, 152
- posterolateral, 2202*t*
- repair
  - indications, 163–164
  - laparoscopic ventral, 163–164
  - outcomes, 166
  - robotic-assisted, 266–267
- supravesical, 2206*f*

Abdominal wall reconstruction (AWR)
- algorithm for, 157*f*
- midline defects and, 157*f*
- options for, 166–167
- patient selection, 157
- use of mesh in, 156

Abdominal wall tract dilations, 880*f*

Abdominolithotomy position, 1874*f*

Abdominoperineal excision (APE). *See also* Abdominoperineal resection (APR)
- description of, 1814
- disadvantages, 1814–1815
- historical perspective, 1797

- ideal specimens, 1811
- outcomes, 1822, 1823

Abdominoperitoneal resection (APR). *See also* Abdominoperineal excision (APE)
- complications, 1850–1852, 1860
- contraindications, 1842–1843, 1853–1854
- conventional *vs.* extralevator, 1853*f*, 1857–1858
- dissection planes, 1857*f*
- historical perspective, 1841–1842
- indications, 1842–1843, 1853–1854
- intersphincteric dissection, 1858*f*
- outcomes, 1851–1852
  - volume-outcomes relationships, 1860
- pain management, 1844
- patient positioning, 1843–1844, 1847–1849
  - lithotomy position, 1849–1850
  - Trendelenburg position, 1856
- perineal defects, coverage of, 1865*t*
- postoperative care, 1850, 1859–1860
- preoperative planning, 1843–1844, 1854–1855
  - extent of resection, 1843
  - minimally-invasive *vs.* open, 1843
  - ostomy marking, 1843
  - perineal dissection, 1843–1844
- for rectal cancer, 1841–1852, 1852–1861
- risks, 1853
- robotic-assisted, 1847*f*
- surgical technique, 1844–1850
  - abdominal dissection, 1855–1857
  - anatomic considerations, 1844–1845
  - closure, 1859*f*
  - extralevator dissection, 1859*f*
  - intersphincteric dissection, 1857*f*
  - ischioanal dissection, 1858*f*, 1859*f*

- open abdominal dissection, 1845–1846
- positioning, 1855
- trends, 1860

Abductor digit minimu, 249*f*

Abductor pollicis brevis, 249*f*

ABLATE trial, 658, 660

Ablation modalities
- categories of
  - chemical, 194
  - energy-based, 194
- classes of
  - nonenergy, 196
- coagulative necrosis and, 195
- energy based, 196–200
- in HCC, 201–202
- heat-sink effect, 195
- image-guidance issues, 205
- immunologic benefit of, 196
- intraoperative pericavitary, 205
- problems with
  - imaging technology and, 205
- in prostate cancer, 202–203
- tumor, 194–206
- tumorigenesis and, 205

Ablation therapy
- breast cancer, 204
- breast tumors
  - indications and contraindications, 655, 655t
  - preablation planning, 655–656
  - techniques
    - comparison of, 655t
    - cryoablation, 658–660, 660*f*
    - laser ablation, 660–661
    - microwave ablation, 661–663, 662–663*f*

- radiofrequency ablation, 656–658, 656*f*–659*f*, 658*t*
- ultrasound ablation, 663–665, 664*f*–665*f*
- with chemotherapy, 195
- renal cell carcinoma, 203–204

Able, Ron, 48

ABO incompatibility, 109*t*

Abscesses

- abdominal, CD and, 1662
- anorectal, 1915–1917
  - conservative therapy, 1916
  - diagnosis, 1916
  - supralevator, 1917
  - surgical technique, 1916–1917
- anterior supralevator, 1916
- collar button, 255
- colonic, 1710
- in Crohn disease, 1715
- deep space infections, 255
- diverticular disease and, 1756–1757
- diverticulitis, 1756–1757, 1757*f*
- drainage, 1540, 1715, 1715*f*, 1916–1917, 1917*f*
- intersphincteric, 1916–1917
- intra-abdominal
  - NEC and, 1981
  - postsurgical, 1724
  - small bowel obstruction, 1634
- ischiorectal, 1916, 1917*f*
- liver, 1278, 1286, 1288, 1291*t*
- midpalmar space, 255
- pancreas, 1540
- pelvic, 1902
- perianal, 1715*f*, 1916, 1917*f*
- periappendiceal, 1689–1690
- piloidal, 1929–1931

- postsurgical, 1724
- proas muscle, 2472*f*
- subcutaneous, 251
- suprasphincteric, 1915*f*

- Abscopal effects, antitumor responses and, 196
- Absorbable polyglactin (Vicryl-Ethicon) sutures, 1013*f*
- Abstinence, in opioid epidemic, e7–e8
- Acalculous cholecystitis, 1273
- Accessory membrane-spanning protein (ACP), 4*f*
- Accessory nerve anatomy, 776*f*
- Accessory pancreas, 1473
- Accessory pancreatic ducts, 1478
- Accessory parotid ducts, 316
- Accordion-type plication, 853*f*
- ACE inhibitors, 29*t*
- Acellular dermal matrix (ADM) meshes, 158
- Acellular dermis, 225–226
- Acetylcholine receptors (AChRs), 560
- Acetylcholine (ACh) release of, 560
- Achalasia
  - anatomy of, 968–969
  - characteristics of, 890
  - diagnosis, 969–971
  - esophageal cancer and, 984
  - indications for surgery, 971–973
  - inflammatory responses and, 969
  - management of, 961
  - minimally invasive treatment of, 968–983
  - myenteric plexus involvement in, 897
  - peroral endoscopic myotomy for, 962–968
  - physiology of, 968–969
  - POEM and, 210
  - POEM contraindication, 962
  - postoperative care, 979–980

- preoperative preparation, 973–974
- subtypes of, 971*f*
- treatment of, 962, 971–973
  - esophagomyotomy, 950, 961, 1000, 1031
  - laparoscopy, 901
- vigorous, 970

Achlorhydria, 1092

Acidosis
- d-lactic, 1982
- metabolic, 1177
- ventilator weaning failures and, 100

Acinetobacter spp.
- *A. baumanii*, 112*t*
- VAP and, 92

Acoustic cavitation, 199–200

Acquired cystic disease, RCC and, 2019

Acquired diaphragmatic eventration, 848

Acquired eventration, 826

Acquired immunity, function of, 142

Acquired immunodeficiency syndrome (AIDS), 1913

Acquired von Willebrand disease, 2079

Acromion, anatomy of, 775*f*

ACS. *See* Abdominal compartment syndrome (ACS)

ACTH stimulation testing, 30

Actinic cheilitis, 328

Actinomycosis, 1630*t*

Activated protein C, 104

Activin receptor-like kinase (ALK-1), 381

Activities of daily living
- after inguinal hernia repair, e78
- and breast pain (mastalgia), 609–610

Acute cholecystitis, 1354

Acute abdomen, splenectomy in, 1996*f*

Acute appendicitis, 1688–1693. *See also* Appendicitis

- antibiotic therapy
  - appendectomy *versus*, 1690*t*
  - surgery *versus*, 1697–1698
- in children, 1694, 1694*t*
- complications, 1696
- CT scan, 1689*f*
- etiology, 1688
- imaging, 1689
- laboratory values, 1689
- nonoperative management, 1689
- operative approaches
  - complications, 1693
  - incisions, 1691, 1691*f*
  - open appendectomy, 1690–1692, 1691*f*
- outcomes, 1693, 1696
- pathophysiology, 1688
- postoperative care, 1692–1693
- preoperative preparation, 1690
- presentation, 1688–1689

- Acute bacterial skin and skin structure infections (ABSSSIs), 128–129
- Acute calculous cholecystitis, 1272–1273
- Acute cholecystitis
  - diagnosis of, 1285, 1354
  - HIDA scan in, 1354
- Acute colonic volvulus, 1699
- Acute coronary syndrome (ACS), 23
- Acute deep venous thrombosis (DVT). *See also* Deep vein thrombosis (DVT)
  - endovascular treatment
    - clinical presentation, 2490
    - etiology and pathophysiology, 2489–2490
    - overview of, 2489
    - treatment, 2490–2498, 2499
- Acute edematous interstitial pancreatitis, 1528*f*

- Acute embolus
  - surgery for, 2450
- Acute hemolytic reactions
  - transfusion-related, 109*t*
- Acute limb ischemia (ALI)
  - embolectomy, 2416–2423
  - fasciotomy, 2423–2430
- Acute lung injury (ALI)
  - PEEP and, 86
- Acute mesenteric artery ischemia
  - clinical presentation, 2444–2445
  - deaths from, 2452
  - etiology and pathophysiology, 2444
  - management of, 2453
  - surgery
    - bypass grafting, 2449*f*
    - complications and their management, 2452, 2453
    - endovascular, 2447–2451, 2448*f*, 2449*f*, 2451*f*, 2452–2453
    - indications and contraindications, 2445
    - open, 2446–2447, 2451*f*, 2452
    - outcomes, 2452
    - postoperative care, 2451–2452
    - preoperative planning, 2445–2446
    - transaortic visceral endarterectomy, 2458
- Acute necrotizing pancreatitis, 1523–1535
- Acute pancreatitis. *See also* Chronic pancreatitis; Pancreatitis
  - causes of, 1525*t*
  - complications
    - management of, 1536–1551
  - management of, 1366
  - progression to necrosis, 1550
  - proplylactic antibiotics in, 1550
  - pseudocyst formation, 1542
  - Ranson criteria, 1527*t*

- recurrent, 1492
- Acute peritonitis. *See also* Peritonitis
  - diagnosis, 1526–1527
  - signs, 1526
  - symptoms, 1526
- Acute phase proteins (APPs), 2, 19
- Acute quadriplegic myopathy, 36–37
- Acute respiratory distress syndrome (ARDS)
  - definition of, 94–95, 95*t*
  - early *vs.* late, 96–97
  - following trauma, 95*f*, 96
  - incidence of, 95
  - inflammatory responses and, 2
  - inhaled NO for, 80–81
  - interventions, 97*t*
  - pathophysiology of, 95–99
  - physiology of, 87
  - presentation, 95
  - primary *vs.* secondary, 95–96
  - treatment of, 95–99
- Acute thrombosis, 2450–2451
- Acute traumatic coagulopathy (ATC), 103–104
- Acute Venous Thrombosis: Thrombus Removal with Adjunctive Catheter-Directed Thrombolysis (ATTRACT) Trial, 1249, 2498
- Acyl-CoA production, 60
- Adalimumab, 1718, 1734
- Adam's apple, 303
- Adaptive immunity
  - cellular immunity, 5
  - cytokines and, 5–6
  - role in inflammation, 3
- Addiction hotlines, e7
- Adductor magnus muscle, 1965
- Adductor pollicis, 249*f*

- Adenoid cystic carcinomas, 310–311
- Adenomas
  - cortisol-producing, 583
  - detection rates, 212
  - growth rates, 513
  - parathyroid, 532
  - size of, 513
  - subclinical, 583
  - toxic, 520
- Adenomatous polyposis coli *(APC)* gene, 1742
- Adenomatous polyposis coli *(APC)* mutations, 516
- Adenosine triphosphate (ATP), 13, 49–50
- Adenosis, sclerosing, 605
- ADH. *See* Hyperplasia, atypical ductal
- Adhesion molecules, induction of, 6
- Adhesions
  - gallbladder, 1345
  - gastrocolic omentum, 1345
  - gastroduodenal, 1057*f*
  - intra-abdominal, 1660
  - lysis of, 1633–1634
  - small bowel obstruction and, 1630, 1630*t*, 1633–1634, 1636
  - transverse colon, 1345
- Adhesives. *See also Specific* compounds
  - endoscopic injection
    - for gastric varices, 1627
  - procedures, 1627
- Adipocytes, lipolysis of, 2
- Adipokines, release of, 2
- Adipose capsule, 2002
- Adipose tissues, 13
- Adjacent fasciocutaneous flaps, 216
- Adjustable gastric banding
  - laparoscopic

- complications, 1242
- conversion to RYGB, 1248
- conversion to sleeve gastrectomy, 1248
- revision for weight regain, 1247–1248
- weight loss and, 1179
- robotic-assisted, 266

Adnexa, 1249–2151, 2138

Adrenal glands
- anatomic relationships, 510*f*, 570*f*, 579*f*
- anatomy, 508
  - blood supply, 570
  - lymphatic drainage, 570
  - venous drainage, 570
- attachments, 2028*f*
- cortex, stimulation of, 9
- embryology of, 508
- etiology of, 570
- incidentalomas, 572, 573, 582
- medulla, 12
- metastatic disease to, 573
- pathophysiology, 570
- surgical approaches, 508–512
  - anterior (transabdominal), 508–509
  - laparoscopic (transperitoneal), 509–510
- surgical specimen removal, 577*f*
- tumors, 513
  - anatomic relationships, 510*f*, 511*f*
  - benign, 583
  - clinical presentation, 570–573
  - diagnosis, 571*t*
  - needle biopsies, 582
  - preoperative preparation, 571*t*

Adrenal insufficiency, 10

Adrenal myelolipomas, 573

- Adrenalectomy, 569–583
  - aldosteromas, 583
  - complication rates, 515, 581–582
  - contraindications for, 574
  - for Cushing syndrome, 572
  - endoscopic, 579
  - indications for, 571*t*, 574
  - laparoscopic
    - for adrenocortical carcinomas, 513–514
    - hand-assisted, 577–579
    - patient positioning, 574–575, 575*f*, 576*f*, 577
    - setup, 574–575
    - steps in, 578*f*
  - left, 511–512
  - open
    - anterior approach, 579–581
    - exposure, 580*f*
    - incision, 580*f*, 581*f*
    - posterior approach, 581, 581*f*
    - thoracoabdominal approach, 581
  - open *vs.* laparoscopic, 513–514, 574–575
  - partial, 514
  - patient positioning, 579*f*
  - postoperative care, 581–582
  - preoperative planning, 573–574
  - right, 510–511
  - robotic-assisted, 269–270
  - surgical technique, 574–581, 574*t*
- Adrenergic stress, adverse effects of, 12
- Adrenocortical carcinomas (ACCs)
  - incidence, 573
  - laparoscopic adrenalectomy for, 513–514
  - preoperative considerations, 573
- Adrenocorticotropic hormone (ACTH), 572

- Adson clamps, 357, 362
- Adson-Beckman retractors, 1966
- Adult respiratory distress syndrome (ARDS), 65
- Advanced Trauma Life Support (ATLS), 433
- Advancement flaps, 216
- Aechoic, ultrasonographic definition, 179
- Aerodigestive injuries, repair of, 471
- *Aeromonas* spp., 253
- Afferent limb syndrome, 1150–1154
  - diagnosis, 1154
  - etiopathogenesis, 1153–1154
  - symptomatology, 1150–1153
  - treatment, 1154
- Afferent loop syndrome
  - Billroth II gastrojejunostomy and, 1146–1147
  - Billroth II reconstruction and, 1146–1147
  - diagnosis of, 1154
  - etiopathogenesis, 1153–1154
  - overview of, 1150
  - symptomatology, 1150–1151
  - treatment, 1154
- Afirma gene expression classifier (GEC), 518
- After Mapping of the Axilla Radiotherapy Or Surgery (AMAROS) trial, 672, 673t, 756
- Aganglionic bowel
  - in Hirschsprung disease, 1971, 1972*f*
  - removal of, 1972
- Agastria, embryology of, 1057*f*
- Age/aging. *See also* Children; Elderly patients; Infants; Pediatric patients
  - surgical pulmonary risk, 89
- Aggregometry, platelet function and, 105
- AH. *See* Hyperplasia, atypical
- Air emboli, penetrating injuries and, 789
- Air leaks, lung injuries, 791

- Airway management, ventilation and, 101
- Airway obstruction, tracheotomy and, 489
- Airways
  - emergent, 494, 495*f*, 497
  - major disruption, 788
  - narrowing, 489
  - stenosis, 489
- Alagile syndrome, 1429
- Alanine, function of, 18
- Alarmins, 4–5, 133
- Albumin
  - fluid resuscitation and, 135–136
  - function of, 56
  - half-life of, 56
  - levels on admission, 67
  - measurement of, 44
  - nutritional status and, 44, 56
- Albumisol for fistulas, 1653
- Alcock canal, 1686
- Alcohol, metabolism of, 983
- Alcohol abuse
  - chronic pancreatitis and, 1493, 1503, 1510*f*
  - duodenal ulcer disease and, 1104–1105
  - esophageal varices and, 1587
  - liver abscesses and, 1286
  - pancreatic cysts and, 1549
  - presurgical cessation of, 985
  - squamous cell carcinoma and, 345
  - trauma risk and, 1341–1342
- Alcoholic cirrhosis, ulcers in, 1105
- Alcoholism, e21, e28
- Aldehyde dehydrogenase 2 (ALDH2) deficiency, 983
- Aldosteromas, 571–572, 583
- Aldosterone, 2, 513

- Alemutuzumab, 149
- ALH. *See* Hyperplasia, atypical lobular
- ALI. *See* Acute limb ischemia
- Alimentary tract. *See also* Gastrointestinal tract; *Specific* sections
  - bacteria in, 65
  - obstruction, TPN in, 46
- Alkaline phosphatase levels, 521
- Alkalosis
  - hypokalemic, 1173
  - in infants, 1166
- Allen, Robert, Sr., 763
- Allen test, 69, 404
- Alliance A011202 trial, 760
- Allis clamps, 226, 523*f*, 861, 862*f*, 2171*f*
  - esophageal suture line, grasping with, 1011*f*
- Allison repair, 829
- AlloDerm, 861, 864
- Alloengraftment
  - immune tolerance and, 1452–1453
- Allograft survival, immunosuppression and, 145–146
- ALND. *See* Axillary lymph node dissection
- Alopecia, hemangiomas and, 374
- Alpha 1-antitripsyn, 56
- Alpha fetoprotein (AFP), 1249
- Alpha-2 agonists, 29*t*
- Altemeier procedure, 1894, 1906, 1909*f*, 1910*f*
- Altemir, Hernandez, 400
- *Alternaria* spp., 984
- Altmeier procedure, 1904
- Aluminum levels, 554, 1961
- Alveolar pressures, 74
- Alveoli, oxygen tension, 86
- Alvimopan (Entereg), 32, 1635, 1781
- Alzheimer disease, 1083

- Amaurosis fugax, 2247
- Amblyopia, hemangiomas and, 374
- Ambulation
  - muscle weakness and, 36, 40*t*
- Ambulatory phlebectomy, 2521–2522
- Amebic cycle, 1292
- A-melanocyte stimulating hormone (α-MSH)
  - response to surgical trauma, 8
- Amelanotic melanoma, 412
- American Association for the Surgery of Trauma (AAST), 857*f*
- American Cancer Society, 613
- American College of Surgeons Oncology Group (ACOSOG)
  - Z0011 trial, 759, 761–762
  - Z1071 trial, 759–760
  - Z6041 trial, 1938, 1945
  - Z6051 trial, 1820, 1840
- American Gastroenterologic Association (AGA), 1582*t*
- American Joint Committee on Cancer (AJCC), 2021*t*
- American Society for Enhanced Recovery (ASER), 33
- American Society for Radiation Oncology/SSO Margin Consensus for Invasive Breast Cancer trial, 756
- American Society of Clinical Oncology (ASCO), 762
- American Society of Radiation Oncology (ASTRO), 649
- Americans with Disability Act, 2405
- Amine precursor uptake and decarboxylation (APUD), 1695
- Amino acids, metabolism of, 55
- Aminocaproic acid, 108
- Amoxicillin, 1115, 1344
- Ampicillin/sublactam resistance, 121
- Ampulla of Vater. *See also* Major duodenal papilla
  - anatomy, 1353
  - cannulation of, 214
  - description, 1491
  - destruction of, 1577*f*

- formation of, 1573
- identification of, 209, 1390*f*, 1393
- impacted stones in, 1364–1365
- incision into, 1390*f*

Amputations
- acute limb ischemia, 2417
- diabetic foot, 2414, 2414*f*
- of diabetic foot, 2397–2398
  - clinical presentation and diagnosis, 2391–2393, 2392t
  - complications, 2397
  - indications, 2394
  - outcomes, 2397
  - postoperative management, 2396–2397
  - surgical technique, 2394–2396, 2394*f*, 2395*f*, 2396*f*
  - treatment, 2393–2394, 2393*f*
  - ulceration, 2391
- digits, 261
  - critical time periods, 253
  - etiology, 253
- hands
  - critical time periods, 253
  - injuries, 261
- lower extremity, 2407–2408
  - functional outcomes, 2405–2407
  - indications, 2398–2399
  - natural history, 2407
  - postoperative management, 2403–2405
  - preoperative planning, 2399–2940
  - surgical technique
    - above knee amputation, 2402–2403, 2406–2407*f*
    - below-knee amputation, 2401–2402, 2402*f*
    - guillotine amputation, 2400–2401, 2401*f*
    - skew flap transtibial amputation, 2402, 2405*f*
- part preservation, 261

- penile, 2104–2105
- postoperative care, 253
- replantation, 253, 261
- revascularization, 253
- traumatic, 261
- urgent attention to, 251

Amrinone, 79
Amussat, Jean, 1841
A-amylase
- function of, 59

Amylin, lactate production and, 51*f*
Anal adenocarcinoma, 1717
Anal canal
- access device, 1944*f*
- mucosal defect closure, 1926*f*
- normal closure, 1949
- rerouting of, 1955*f*
- sepsis, 1950

Anal cancers, 430
Anal columns of Morgagni, 1824
Anal condylomata, 1928
Anal encirclement, 1906
Anal fissures, 1715. *See also* Fissure in ano
Anal fistulae
- in Crohn disease, 1715–1717
- retrograde probing, 1918*f*
- sphincter repair after, 1953*f*
- transsphincteric, 1716

Anal manometry, 1950–1951
Anal melanoma, 425
Anal plugs, 1921
Anal sphincters
- function of, 1840
- incompetent, IPAA and, 1734

- muscles of, 1684*f*
- obstetric injury, 1953*f*
- perineal dissection, 1848*f*
- reconstruction of, 241–242, 242*f*
- repairs, 1953–1954, 1954*f*
- spasm of, 1913

Anal stenosis, 1715
Anal strictures, 1715, 1719
Anal triangle, 2197
Anal tuberculosis, 1913
Anal ultrasonography, 1951, 1952*f*
Anaphylaxis, transfusion-related, 109*t*
Anastomoses
- aortofemoral bypass
  - end-to-side, 2338, 2339*f*
  - femoral, 2336*f*–2338*f*, 2337–2338
  - proximal aortic, 2334–2337, 2335*f*–2336*f*
- in central splenorenal shunt, e33, e33*f*
- for duodenal ulcer vagotomy, antrectomy, and gastroduodenostomy, 17–18*f*, e9, e16–17
- in EA/TEF repair, 1040–1041, 1041*f*
- end-to-end hand sewn, 1664
- grafts for extraanatomic bypass, 2345–2346, 2345*f*–2346*f*
- infrahepatic vena cava, 1440
- infrarenal and pararenal aortic aneurysms, 2294
- inner layer of, 1666*f*
- in intestinal bypass, e38–e39, e39*f*
- portal vein, 1440
- proximal and distal, 2278–2288
- stenosis, 2365
- suprahepatic vena cava, 1440–1441

Anastomosis-in-continuity, 1783*f*
Anastomotic leaks (ALs)
- after rectal surgery, 1836–1837

- after transanal pull-through, 1974
- ileostomy, 1648
- postoperative, 997
- postsurgical, 2163

- Ancef dosage, BMI and, 2120
- And renal artery occlusion disease, 2443
- Anderson-Hynes dismembered pyeloplasty, e52–e55*f*
- Androgens
  - aromatization to estrogens, 11
  - production, surgical trauma and, 11
- Androstenedione production, 11
- Anemia, chronic
  - hemorrhoids and, 1922
- Anemia, paraneoplastic syndrome and, 2020
- Anergy, T cells and, 143
- Anesthesia
  - blood pressure monitoring and, 68
  - classes of, 90
  - facial injuries and, 436–438
  - lip subunits, 327
  - postoperative pulmonary complications and, 89
  - regional blocks, 544–545
  - topical, 207
- Aneurysmal bone cysts, retrorectal, 1883
- Aneurysms
  - abdominal aortic, 2299–2305, 2311–2315, 2465
  - femoral artery, 2319–2325
  - infrarenal and pararenal aortic, 2298
    - clinical presentation, 2291
    - complications, 2297
    - etiology and pathophysiology, 2290–2291
    - indications and contraindications, 2291, 2291t
    - outcomes, 2297
    - postoperative care, 2297

- preoperative planning, 2291–2292, 2291*f*, 2292t
- surgical technique, 2292*f*–2296*f*, 2295–2297
- popliteal artery (*See* Popliteal artery aneurysm)
- splenic artery, 2328–2331
- thoracoabdominal aortic, 2279–2290
  - anatomy, 2279–2280, 2280*f*
  - cardiac and pulmonary risk, 2282–2283
  - classification, 2279–2280
  - clinical presentation, 2280
  - complications, 2288–2289, 2289*t*
  - diagnostic imaging, 2281, 2281*f*–2282*f*
  - etiology, 2279
  - patient selection, 2281–2282
  - postoperative care, 2288
  - preoperative evaluation, 2281–2282
  - surgical techniques
    - clamp-and-sew *vs.* atrial-femoral bypass, 2285
    - clamping and proximal anastomosis, 2285–2286
    - distal anastomosis, 2287–2288
    - intercostal vessel reconstruction, 2287
    - left pleural space dissection, 2284–2285
    - operative exposure, 2283–2284, 2284*f*
    - options, 2283
    - renal and spinal cord protection, 2283
    - renal/visceral artery reconstruction, 2286–2287, 2286–2287*f*
- Angina, unstable, 24
- Angina pectoris after intestinal bypass, e42
- Angioembolization
  - in abdominal injury repair, 2584–2585
  - complications of, 1341–1342
- Angiography
  - for aortofemoral bypass, 2332
  - esophagogastric varices on, 1601
- Angiojet rheolytic thrombectomy system, 2496*f*, 2497*f*

- Angioplasty, percutaneous transluminal (PTA), 2332, 2435, 2436*f*
- Angiotensin
  - in renovascular hypertension, 2431–2432
- Angiotensin receptor blockers (ARBs)
  - postoperative resumption of, 34
- Angiotensin-converting enzyme (ACE) inhibitors
  - postoperative, 34
- Angle of His, 1060
  - dissection at, 1199–1200, 1200*f*
  - recreation of, 939
- Angle of Ludwig
  - anatomy, 772–773
- Animal bite infections
  - hand/wrist, 255–257
- Ankle reconstruction. *See* Dorsalis pedis, tarsal, and plantar artery bypass
- Ankle-brachial pressure index (ABI)
  - endovascular procedure, 2384
  - reversed vein bypass grafts, 2358
- Annular pancreas
  - anatomy, 1471
  - asymptomatic, 1491
  - description of, 1473*f*, 1491
  - development of, 1491
  - embryology of, 1473, 1474*f*
- Annular ring
  - division of, 1473
- Anococcygeal ligament
  - division of, 1849*f*
  - exposure of, 1849*f*
- Anoderm
  - tissue beneath, 1926*f*
- Anomalous pancreaticobiliary duct junction (APBDJ), 1422
- “Anomaly” (defined), 1368

- Anorectal abscesses, 1915–1917
  - conservative therapy, 1916
  - diagnosis, 1916
  - supralevator, 1917
  - surgical technique, 1916–1917
- Anorectal advancement flaps
  - fistulectomy and, 1920
  - for perineal fistulae, 1933–1934, 1934*f*
  - technique, 1921*f*
- Anorectal disorders, 1913–1937
- Anorectal fistulae
  - causes, 1918
  - classification of, 1918
  - congenital, 1918
  - diagnosis, 1918
  - presentation, 1917
  - treatment, 1918–1921
- Anorectal manometry
  - postsurgical use of, 1974
- Anorectal sepsis
  - causes, 1915–1916
  - classification of, 1915*f*
  - presentation, 1915
  - sites of, 1915–1916
  - spread of, 1916
- Anorectal spaces
  - clinical significance, 1685
- Anorectal warts
  - causes, 1928
  - diagnosis, 1928
  - presentation, 1928
  - surgical treatment, 1928, 1929*f*
  - treatment, 1928
- Anorectum

- anatomy, 1824–1826, 1824*f*
- blood supply, 1685
- distal to cancer, 1809–1810
- functional assessment, 1743
- innervation, 1685–1686, 1949
- lymphatic drainage, 1685

Anorexia of illness, 62

Ansa cervicalis
- anatomy, 284, 468*f*
- innervation by, 504

Antecolic gastrojejunostomy
- hernias after, 2208

Antegrade colonic enema
- appendicostomy for, 1959*f*

Antegrade continence enema (ACE) procedures, 1677
- use after surgery for Hirschsprung disease, 1976

Antenna coupling
- electrosurgical injuries, 276–277
  - clinical examples, 277
  - preventative strategies, 277

Anterior inferior pancreaticoduodenal artery (AIPD)
- anatomic relationships, 1482

Anterior intercostal arteries
- anatomic relationships, 777

Anterior interosseous nerve
- function of, 247

Anterior jugular veins
- anatomy of, 305–306, 501

Anterior levatorplasty, 1953*f*
- for fecal incontinence, 1952–1953
- for outlet obstruction, 1963

Anterior mediastinal nodes
- anatomic relationships, 786

Anterior mediastinoscopy

- lung cancer staging, 802–803
- Anterior mediastinum
  - robotic-assisted surgery, 268
- Anterior nerve of Latarjet, 1064
- Anterior pancreaticoduodenal arcade, 1474
- Anterior rectus sheath
  - closure of, 153
  - incision in, 2220*f*
  - splitting of, 768
- Anterior resection syndrome
  - anorectal incisions and, 1927
- Anterior sacral meningoceles, 1882
- Anterior scalene compression syndrome
  - anatomy of, 308
- Anterior scalene muscle (ASM)
  - anatomy of, 2549
  - surgical technique, 2555*f*
- Anterior superior iliac spine
  - anatomy, 775*f*
- Anterior superior pancreaticoduodenal artery (ASPD), 1482, 1486, 1516
- Anterior supralevator abscesses
  - gender and, 1916
- Anterior triangle
  - suprahyoid portion of
    - anatomy of, 319
- Anterior vagal trunk, 1073–1074, 1073*f*
  - anterior gastric division, 1074, 1074*f*
  - celiac branches, 1074
  - hepatic division, 1074
- Anterograde sphincterotomy
  - endoscopic biliary
    - for impacted stones, 1364–1365, 1365*f*
- Anthropometric assessment, 55
- Antiarrhythmics, 2249

- Antibiotic impregnated dacron graft, 2479
- Antibiotics
  - presurgical, 985, 1662
  - prophylatic
    - nonparenteral, 116*t*
    - parenteral, 115*t*
    - for wound infections, 33
  - resistance to, 121
  - selection of, 130
  - in SSI prevention, 130
  - stewardship, 130
  - therapy, biomarkers, 130–131
- Antibiotic-soaked grafts, 2480
- Antibody-mediated rejection (ABMR), 145
- Anticholinergics, 34
- Anticoagulants
  - bleeding associated with, 107
  - deep venous thrombosis treatment with, 2490, 2499, 2509
  - postthrombotic syndrome treatment with, 2510
  - presurgical management of, 522
  - reversal of, 110
  - surgical risks and, 28
  - VTE prophylaxis, 1996*f*
- Anticoagulation
  - acute limb ischemia, 2418, 2421–2423
  - for carotid bifurcation disease, 2249
  - for extraanatomic bypass, 2349
  - for plug-and-patch groin repair, 2233
  - reversed vein bypass graft, 2367
  - therapeutic
    - surgical risk and, 28
- Anti-CTLA-4, 427
  - for melanoma, 422
- Antidepressants

- pain management and
  - in chronic pancreatitis, 1581
- slow transit constipation and, 1961

Antidiuretic hormone (ADH)
- stress response and, 2, 10

Antiepileptic agents, 30*t*

Antifungal therapy, 124

Antigen presenting cells (APCs), 142

Antigens
- recognition of, 142
- spread of, 1454*f*

Antihistamines
- slow transit constipation and, 1961

Anti-inflammatory drugs
- complications of, 1148

Antilymphocyte globulin
- immunosuppression by, 148

Antimicrobial agents
- prophylactic
  - clinical practice guidelines, 114*t*
- wound infections and, 32

Antimicrobial stewardship
- elements of, 114–115
- in SSI prevention, 130
- surgical site infections and, 113–115

Antioxidants in enteral formulations, 64

Anti-Parkinson agents, 30*t*

Antiplatelet therapy
- for carotid bifurcation disease, 2249, 2250
- coagulopathies and, 105
- endovascular therapy for aortoiliac occlusive disease, 2353
- indications, 110
- and leg amputation, 2407
- presurgical management of, 522

- prosthetic grafts, 2372
- and reversed vein bypass grafts, 2358
- surgical management and, 28

Antireflux mechanisms, 901

Antireflux surgery, 1158–1159
- abdominal, 949
- after crural repair, 870
- basic tenets of, 948
- complications of, 865, 880–881, 958–959, 1158–1159
- contraindications, 874, 948
- increase in, 945
- indications, 874, 883, 906–907, 947–948
- laparoscopic (*See* Laparoscopic antireflux surgery)
- Nissen-Rossetti antireflux fundoplication, 928–935
- outcomes, 881–883, 881*t*, 884
  - laparoscopic surgery, 957–958, 957*t*
- postoperative care, 879–881
- preoperative planning, 874–876
- principles of, 904–906
- reoperative surgery, 916, 959–960
- techniques, 876–879, 881*t*, 907–915, 948–950, 948*t*
- thoracic, 906–915, 949

Antirheumatic agents
- perioperative management, 29*t*

Antiseptic prophylaxis, SSIs, 116*t*

Antithrombotic medications, 985

Antitumor responses, ablation therapy and, 196

Antrectomy. *See also* Duodenal ulcer
- gastric resections accompanied by, 1149*f*
- loop gastrojejunostomy with, 1149*f*
- in peptic ulcer disease, 1147
- truncal vagotomy with, 1151*f*
- for ulcer disease, 1165
- vagotomy following, 1147

- Anus
  - anatomy of, 1684–1685
  - coronal section, 1683*f*
  - ectopic, rerouting of, 1955
  - innervation of, 1686*f*
  - mesh, 1907*f*
- Anxiolytics, perioperative, 30*t*
- Aorta
  - anatomic relationships, 1186*f*
  - diaphragm and, 833*f*
  - diaphragmatic opening of, 830–831, 830*f*
  - exposure of, 2474
  - great vessels, injuries, 795–796
  - opening, 830–831
  - reconstruction, 2470, 2474*f*
  - transection (*See* Thoracic aortic transection)
  - traumatic rupture, 796–797
- Aortic aneurysms, mycotic, 2470. *See also* Abdominal aortic aneurysms (AAAs)
- Aortic arches
  - anatomic relationships, 784
  - anatomy, 298*f*
  - in brachiocephalic reconstruction, 2259, 2262
  - branched endografts for, 2568
  - in carotid bifurcation disease, 2246
  - risk to, 2569
  - stent grafting in, 2568
- Aortic coarctation, 777*f*
- Aortic cross-clamping, 2586
- Aortic emboli, 2419–2420, 2420*f*
- Aortic graft infections
  - aortic homograft to replace, 2479*f*
  - clinical presentation and diagnosis, 2471–2473
  - etiology and pathophysiology, 2471

- imaging, 2472–2473, 2472*f*, 2480
- overview of, 2471
- surgery
  - imaging, 2473*f*
  - outcomes, 2479
  - preoperative planning, 2473–2474
  - reconstruction, 2475–2479
  - technique, 2474–2475

- Aortic hiatus, 820*f*, 856*f*
- Aortic homografts
  - aortic graft, infected replacement with, 2479*f*
  - benefits of, 2468
  - cryopreserved, 393
- Aortic infections, 2468
- Aortic injuries, 2567. *See also* Blunt thoracic aortic injury (BTAI)
- Aortic nodes, 802*f*
- Aortic occlusion balloon, 2307–2308*f*
- Aortic valves, robotic-assisted reconstruction, 269
- Aortitis
  - clinical presentation of, 2467*f*
  - management, 2468–2469
  - as mycotic aortic aneurysm stage, 2465
- Aortoenteric fistulae, 1106, 2473*f*
- Aortofemoral bypass
  - with femoropopliteal vein (FPV) graft, 2477*f*
  - indications, 2332
  - postoperative management, 2342
  - preoperative assessment, 2332–2333|
  - surgical technique
    - anesthesia, 2333|
    - aortoiliac endarterectomy, 2339–2340, 2340*f*
    - complications, 2341–2342
    - end-to-side anastomosis, 2338, 2339*f*|
    - iliofemoral bypass, 2340–2341, 2341*f*

- incisions and dissection, 2333–2334, 2333*f*
- juxtarenal aortic occlusion, 2338–2339, 2339*f*
- proximal aortic anastomosis, 2334–2337, 2335*f*–2336*f*

- Aortoiliac bypass, 2477*f*
- Aortoiliac occlusive disease
  - aortofemoral bypass, 2332
  - endovascular procedures, 2357
    - clinical presentation, 2350
    - complications, 2354–2355, 2355*f*
    - endoliminal therapy *vs.*, 2357
    - etiology and pathophysiology, 2350
    - indications and contraindications, 2350–2351
    - postoperative care, 2353
    - preoperative planning, 2351, 2352*f*–2353*f*
    - surgical technique, 2351–2353, 2354*f*
  - extraanatomic bypass, 2349–2350
    - complications, 2348–2349, 2348*f*
    - indications and contraindications, 2343–2344
    - infection, 2346–2347, 2347*f*, 2348
    - postoperative care, 2347–2348
    - preoperative planning, 2344
    - surgical technique
      - anesthesia, 2344
      - axillary artery dissection, 2344–2345
      - axillofemoral tunnel, 2345
      - femoral artery dissection, 2344
      - femorofemoral tunnel, 2345
      - graft anastomosis, 2345–2346, 2345–2346*f*
      - patient positioning and draping, 2344
      - wound closure, 2346
    - survival rates, 2349
- Aortoiliac segments, 2468
- Aortomesenteric angle, normal, 1186*f*
- *APC* mutations, 516

- Aperistalsis of achalasia, 982
- Apheresis platelets, 107–108
- Aphthous ulcers, 1661
- Aplasia, pancreatic, 1472
- Aponeuroses, e63, e73
- Aponeurotic arch, 2212*f*
- Apoptosis
  - CD95 moderation of, 143
  - cell death by, 196
  - immunosuppression and, 196
  - triggers, 14
- Apparent short esophagus, 823–824
- Appendectomy
  - antibiotic therapy vs, 1690*t*
  - complications, 1693
  - frequency of, 1688
  - incidental, 1693
  - incisions, 1691, 1691*f*, 1698
  - laparoscopic, 1692, 1692*f*, 1698
  - NOTES, 210
  - postoperative care, 1692–1693
- Appendiceal abscesses, 1690, 1690*f*
- Appendiceal adenomas
  - diagnosis, 1696
  - etiology, 1696
  - management, 1696–1697
  - pathophysiology, 1696
  - presentation, 1696
- Appendiceal cancer, 1877–1882
- Appendiceal diverticulitis, 1693–1694
- Appendiceal phlegmon, 1689–1690
- Appendiceal tumors
  - adenocarcinomas
    - complications, 1697

- diagnosis, 1697
- etiology, 1697
- management, 1697
- outcomes, 1697
- pathophysiology, 1697
- presentation, 1697

- adenomas, 1696–1697
- carcinoid, 1695
- cytoreductive surgery, 1698
- epithelial, 1695*t*
- hyperthermic intraperitoneal chemotherapy for, 1698
- incidence, 1695
- management of, 1698
- metastatic, 1695*t*
- mucinous neoplasms, 1696–1697, 1698
- neuroendocrine, 1695
- nonepithelial, 1695*t*

- Appendicitis. *See also* Acute appendicitis
  - acute, 1688–1693, 1689*f*
  - chronic, 1694
  - in elderly patients, 1694
  - enterocutaneous fistulas and, 1650
  - in pediatric patients, 1694, 1694*t*
  - in pregnancy, 1693, 1693*f*
  - stump, 1693
- Appendicostomy, 1959*f*
- Appendicular artery, 1679
- Appendix
  - anatomic relationships, 1688, 1688*f*
  - anatomy of, 1676–1677
  - blood supply, 1688
  - gangrenous, 1691–1692
  - tumors of, 1695*f*
- Appendo-cecectomy, 1692*f*

- Appetite, cortical centers for, 1182
- APPs. *See* Acute phase proteins (APPs)
- Arantius ligament, 1322
- Arch of Riolan, 1680, 1791
- Arcuate ligaments, 827. *See also* Median arcuate ligament
- Arcuate line, 2185
- Arcus tendineus fascia, 2175*f*
- Areola reconstruction, 233
- Areolar dissection, 1802*f*
- Areolar space, 1845, 1846*f*
- Arginine in EN formulas, 64
- Arginine vasopressin (AVP) release, 9
- Argon gas, intravascular embolism, 275
- *ARIDIA* mutations, 1246, 1247
- ARM. *See* Axillary reverse mapping
- Arms, veins. *See also* Upper extremities
  - ipsilateral, inadequate, 2536
  - for reversed vein bypass grafts, 2360–2361, 2362*f*
- Aromatic amino acids (AAA), 64
- Arozullah Respiratory Failure Index, 26*t*
- Arsenic trioxide, 195
- Arterial arcades, omentum and, 1682
- Arterial imaging studies, preoperative, 2528*f*
- Arterial inflow, inadequate, 2536
- Arterial partial pressure of CO_2, 86
- Arterial pressure waveforms, 69*f*
- Arterial reconstructions, ultrasound-guided, 193
- Arterial repair in extremity trauma, 2593
- Arterial thoracic outlet syndrome (TOS)
  - clinical presentation, 2550
  - diagnosis, 2551
  - indications for surgery and preoperative planning, 2552–2553
  - initial treatment, 2552
  - operative management of, 2558–2559, 2560

- Arterial thrombosis, catheter-induced, 69
- Arteries, reconstruction, e40
- Arteriography, 2435
- Arteriovenous fistulae (AVFs). *See also* Prosthetic arteriovenous hemodialysis access
  - after endovascular therapy, 2354, 2389
  - benefits of, 2510, 2525
  - common femoral vein pressure before and after, 2487*f*
  - complications of, 2535
  - construction of, 2486*f*, 2489
  - maturation, 2539
  - overview of, 2547
  - statistics, 2526*f*
  - venous thrombectomy with, 2488*t*
- Arteriovenous graft (AVG). *See* Prosthetic arteriovenous hemodialysis access
- Arteriovenous hemodialysis access. *See* Autogenous arteriovenous hemodialysis access; Prosthetic arteriovenous hemodialysis access
- Arteriovenous malformations (AVMs), 374*t*
  - diagnosis, 381
  - embolization, 381–382
  - presentation, 381
  - Schobinger staging, 381*t*
  - treatment, 381–382
- Artery suitability for autogenous hemodialysis access, 2528*t*
- Arthritis
  - psoriatic, surgical risks and, 27
- Arthritis, septic, 257–258, 258*f*
- Artificial bowel sphincters, implantable, 1957, 1958*f*
- Aryepiglottic fold, 304*f*
- Arytenoids, 303
- Ascending aorta, interposition graft from, 2572*f*. *See also* Aorta
- Ascending colon. *See also* Colon
  - attachments, 1671*f*
  - catheter lavage, 1722*f*

- mobilization of, 1671*f*
- Ascites
  - colostomy creation and, 1767–1768
  - and distal splenorenal shunts, e21, e27–e28
- *Aspergillus* spp., 984
- Aspiration, in facial trauma, 434
- Aspirin
  - bleeding and, 2233
  - for carotid bifurcation disease, 2250
  - colorectal cancer risk and, 1752
  - drug induced coagulopathy and, 104
  - perioperative, 24, 29*t*
  - preoperative, 522, 985
  - revascularization and, 253
- Asplenic state, risks of, 1988–1989
- Associating liver partition and portal vein ligation for staged hepatectomy (ALPPS), 1460–1470
  - complications, 1466–1468
  - contraindications, 1461
  - decision-making algorithm, 1467*f*
  - indications, 1461
  - mini, 1465*f*
  - outcomes, 1468–1469, 1468*t*
  - postoperative care, 1466
  - preoperative planning, 1461–1462
  - surgical technique, 1462–1466, 1462*f*–1465*f*
  - variations, 1464–1466
- Asthma, surgical pulmonary risk, 89
- Asthmatics, prophylactic glucocorticoids, 24
- ASTRO. *See* American Society of Radiation Oncology
- ATC. *See* Acute traumatic coagulopathy (ATC)
- Atelectasis
  - after LRPLND, 2066
  - physiology of, 87

- postoperative, 996
- postoperative complications, 85
- on radiographs, 858

Atherectomy, 2388, 2389f

Atherosclerotic disease
- aortofemoral bypass for, 2332
- and brachiocephalic reconstruction, 2258
- as chronic mesenteric ischemia (CMI) cause, 2453
- and intestinal bypass, e37

Athletic pubalgia, 244–245

Atlanta definitions, 1528, 1528*t*

Atlantoaxial joints, 285

Atlanto-occipital joints, 285

Atrial fibrillation
- after esophagectomy, 925
- anticoagulation in, 28
- postoperative management, 996
- as thrombus formation risk factor, 2444

Atrial septal defects, robotic-assisted repair, 269

Atrial-femoral bypass, 2285–2286

Atrogen-1, 38

Atrogenes, 38

Atropine for achalasia, 972

Auditory tube, 300

Auditory tubes. *See* Eustachian tubes

Auricle, 318

Auricles, innervation of, 317

Australasian Laparoscopic Cancer of the Rectum Trial (ALaCaRT), 1820

Autogenous arteriovenous hemodialysis access
- complex access problems
  - arterial inflow, inadequate, 2536
  - central vein stenosis/occlusion, 2536–2537
  - elderly patients, 2537

  - general, 2536
  - hand ischemia, prior, 2537–2538
  - human immunodeficiency virus, 2537
  - ipsilateral arm vein, inadequate, 2536
  - multiple prosthetic access failure, 2537
  - obesity, 2537
  - thin skin, 2537
  - upper extremity access precluded, 2538
- complications, 2535–2536, 2539
- configuration determination
  - algorithm validation, 2529
  - artery and vein suitability criteria, 2528*t*
  - general principles, 2527
  - history/physical examination, 2528
  - imaging, noninvasive, 2528, 2528*f*, 2529
  - permanent access configuration hierarchy, 2529*t*
  - potential configuration, 2528–2529
  - temporary measures, 2529
- creation, timing of, 2539
- maintenance strategies, 2538
- mortality rate associated with, 2526
- operative technique
  - brachiobasilic autogenous access, 2532–2534, 2533*f*, 2539
  - brachiocephalic autogenous access, 2531–2532, 2532*f*
  - general, 2530
  - radiobasilic autogenous access, 2531, 2531*f*
  - radiocephalic autogenous access, 2530–2531, 2530*f*
- overview of, 2525–2527
- patency rates, 2526*f*, 2546*t*
- percentage of, 2526*f*
- postoperative management, 2534–2535
- preoperative evaluation, 2529–2530
- salvage of, 2539, 2547
- types of, 2540–2544, 2541*t*

- Autogenous vein for graft infections, 2480
- Autoimmune pancreatitis, 1403
- Automated Endoscopic System for Optimal Positioning (AESOP), 262
- Autonomic nerves, function of, 2409
- Autonomic neuropathy, 1961
- Autophagy, 62
- Avulsion injuries, zones of injury, 253
- Axial flaps, 216, 220*f*
- Axilla
  - anatomy of, 594–597, 595*f*, 596*f*
  - in breast-conserving surgery
    - dissection technique, 638–641, 638*f*–640*f*
    - internal mammary node biopsy, 638
    - reverse mapping, 638, 670
    - sentinel lymph node biopsy, 635–638, 638*f*
  - in Halsted mastectomy, 708
  - lymphatic system, 598–599, 599*f*–601*f*
- Axillary artery
  - anatomy of, 2549
  - cannulation, 69
  - injury, repair of, 2575*f*, 2597
- Axillary lymph node dissection (ALND), 667, 669–670, 671, 682
- Axillary lymph node staging, 758–760
- Axillary Lymphatic Mapping Against Nodal Axillary Clearance (ALMANAC), 759
- Axillary reverse mapping (ARM)
  - and embryology of breast, 603
  - of lymphedema, 643, 676–678, 677*f*, 677t
- Axillary Reverse Mapping study, 762
- Axillary veins, 2549
- Axillofemoral bypass. *See* Aortoiliac occlusive disease
- Axillofemoral prosthetic bypass, 2476*f*
- Azathioprine (Imuran), 146, 1716
- Azygos veins

- anatomic relationships, 776, 777, 785
- diaphragmatic drainage into, 835
- diaphragmatic opening for, 831
- main connections, 779*f*

B

- B cell receptors (BCRs), 142
- B cells
  - function of, 144–145
  - immune responses and, 142
  - insulin secretion, 1472
  - maturation of, 144–145
- B mode, US, 178, 193
- Babcock clamps
  - diaphragm repair using, 861
  - end, 1643
  - placement, 1639–1640
  - rectal prolapse delivery, 1908*f*
  - stoma construction, 1765–1766
  - stomach, grasping with, 1010*f*, 1011*f*
  - use of, 936*f*, 939, 940*f*
- Babcock forceps, 931, 931*f*
- Babinski reflexes, 477
- Bacterial endocarditis, 2466*f*
- *Bacteroides* spp.
  - anorectal sepsis and, 1915
  - *B. fragilis*
    - antimicrobial resistance in, 121
    - aortic graft infection death associated with, 2471
    - in appendicitis, 1692
    - in liver abscesses, 1287
    - metronidazole susceptibility, 123
  - gut microbiome and, 65
- Baden vaginal defect, 2169
- β-Adrenergic receptor agonists

- cardiovascular support, 78–80
- Baker end-to-end anastomosis, 1835, 1835*f*
- Bakri Balloon placement, 2124
- BALANCE duodenal stimulation device, 1183
- Ballistic injuries. *See also* Gunshot wounds
  - facial trauma, 439, 444
- Balloon angioplasty
  - in endovascular therapy for aortoiliac occlusive disease, 2355
  - of peripheral vascular occlusive diseases, 2386, 2390
- Balloon catheters for embolectomy, 2419, 2419*f*, 2422
- Balloon occlusion
  - for abdominal aortic aneurysm repair, 2307–2308*f*
  - in abdominal injury repair, 2584
  - in cervical injury repair, 2571, 2574*f*, 2576
- Balloon tamponade
  - for bleeding control, 466*f*, 1617
  - four lumen balloon tube, 1619*f*
  - for variceal bleeding, 1618, 1619–1620
- Balloon-assisted maturation technique, 2539
- Bannayan-Riley-Ruvalcaba syndrome, 383
- Banner flaps, 219–221, 220*f*
- Barbiturates for critical care patients, 138
- *BARD1* mutation, 1249
- Bariatric surgery, 1153*f*. *See also Specific* procedures
  - complications of, 1150, 1162–1164
  - conversions and, 1242–1246
  - effects on neural pathways, 1182
  - increase in, 1165
  - malnourishment after, 1234
  - metabolic problems, 1162–1164
  - for metabolic syndrome, e36
  - in morbid obesity, 1233
  - outcomes, 1203, 1218
  - patient evaluation, 1217

- patient selection, 1210–1211
- prophylactic antimicrobial agents, 114*t*
- psychiatric considerations, 1256*t*
- review of, 1150
- revision, 1241–1250
  - postoperative care, 1242
  - preoperative evaluation, 1241–1242
  - for weight recidivism, 1246–1249
- robotic-assisted, 265–266
- safety of, 1257
- types of, 1153*f*, 1165, 1218
- vena cava filter placement following, 2517

Barium, slow transit constipation and, 1961

Barium enemas, 1711

Barium radiographs, abnormal, 206

Barium swallow esophagram (UGI)
- achalasia workup, 962

Barium swallows
- in achalasia diagnosis, 970
- after fundoplication, 914
- timed, 970
- in Zenker diverticulum, 1145*f*

Barium-meal radiography, 929

Barrett esophagus
- ablation endoscopy in, 206
- clinical and surgical points of interest, 892
- conditions associated with, 838
- congenital short esophagus *versus*, 823–824
- diagnosis of, 946, 947
- esophageal cancer and, 984, 998
- laparoscopic esophagectomy for, 917–918
- radiofrequency ablation for, 210
- reflux and, 962
- short esophagus compared to, 823

- short esophagus *versus*, 839
- Barrett metaplasia, 895
- Barretts adenocarcinomas, 985
- Basal cell carcinomas
  - ear, 217
  - excision of, 217
  - flap coverage, 217
  - nose, 217
  - upper lip, 325
- Basal cistern, narrowing, 484
- Basal metabolic rate, 2
- Bascombe operation, 1929, 1930*f*
- Basic Life Support (BLS), 433
- BASIL. *See* Bypass *vs.* Angioplasty in Severe Ischemia of Leg
- Basiliximab, 148
- Bassini, Edoardo, 2215
- Bassini method
  - hernia repair, 2211, 2215, 2215*f*
    - technique, 2215–2219, 2215*f*–2219*f*
  - in plug-and-patch groin repair, 2230
- Bathing, preoperative, 117*t*
- Battle's sign, 477
- Beck triad, 789, 793
- Beckwith-Wiedemann syndrome (BWS)
  - characteristics of, 2078
  - congenital diaphragmatic hernia, association with, 841
  - description of, 1472
- Bed rest, muscle wasting and, 36
- Bedside ultrasound, 1284
- BEFANV mnemonic, 253
- Beger procedure
  - characteristics, 1498*t*
  - clinical trials, 1500*f*
  - outcomes, 1522–1523

- PD *versus*, 1496
- surgical outcomes, 1512–1513
- therapeutic targets, 1513*t*

- Behavioral modification, preoperative, 27–28
- Belatacept, 148
- Belchew, Mitiku, 1198
- Belsey 240-degree partial fundoplication, 909*f*, 910*f*, 912*f*–913*f*
- Belsey Mark IV partial fundoplication
  - benefits of, 916
  - historic developments, 904
  - technique, 907–911, 949
- Benign mixed tumors, salivary gland, 311
- Benson spreaders, 1167, 1167*f*
- Benzimidazole carbamates, 1303
- Benzodiazepines, 138
- Bernard, Claude, 1471
- Bernard Webster operation, 330, 330*f*
- Bernatz system, 559
- Berne procedures, 1496
- Berry ligament, 502, 524*f*
- Beta agonists, inhaled, 34
- Beta cells, incretin action on, 1217
- Beta-blockers, 29*t*, 1622, 2399–2400, 2407
- Beta-catenin, 1278
- Beta-defensins, 4–5
- Betadine®, 2233
- Bethesda criteria, 517–520, 530, 530*t*
- Bethesda Thyroid Atlas Project, 530
- Bezoars
  - after ileostomy, 1649*t*
  - ileostomy patients, 1647
  - small bowel obstruction and, 1630*t*
- *BHD1* mutation, 2020
- β-Hydroxy-β-methylbutyrate, 41

- Bianchi procedure, 1983, 1983*f*
- Bifidobacterium strains, 64–65
- Bilateral thoracoscopic splanchiectomy (BTS), 1581–1585, 1584*f*
- Bile, composition of, 1651*t*
- Bile acids, metabolic surgery and, 1182
- Bile duct cancer, 1410, 1411
- Bile duct injuries
  - Bismuth classification, 1367
  - Hannover classification, 1367
  - laparoscopic cholecystectomy in, 1271
  - liver abscesses and, 1286
  - MacMahon classification, 1367
  - mechanisms of, 1363*t*
  - Stewart-Way classification, 1361, 1362*f*
  - Strasberg classification, 1367
- Bile duct reconstruction
  - after elective resection, 1380
  - approach to, 1373
  - biliary anatomy and anomalies of importance in, 1368, 1370–1373, 1381
  - indications for, 1368
  - outcomes, 1382
  - overview and history of, 1368
  - preoperative planning and preparation, 1374–1375
  - stents and stenting, 1382
  - surgical techniques
    - anastomoses, multiple, 1379
    - cholecystojejunostomy, 1381
    - choledochoduodenostomy, 1381, 1382
    - end-to-end reconstruction, 1379, 1382
    - end-to-side anastomosis, 1378, 1380–1381
    - hepatic duct exposure and preparation, 1377, 1377*f*
    - hepaticojejunostomy and variations, 1378–1379, 1379*f*, 1382
    - hepatocoduodenostomy, 1380*f*

- incision and access, 1376–1377, 1377*f*
- minimally invasive biliary reconstruction, 1381
- overview and general principles, 1376
- Roux-en-Y hepaticojejunostomy (HJ), 1377–1378, 1382
- side-to-side anastomosis, 1378–1379
- vertically disposed ducts, 1379*f*
- very small ducts, 1380–1381

- Bile ducts
  - anatomy of, 1267–1268, 1415
  - blood supply to, 1371–1372, 1372*f*
  - cholangiocarcinoma, involvement in, 1411
  - dominant (*See* Dominant bile duct)
  - in duodenal ulcer vagotomy, antrectomy, and gastroduodenostomy, e9–e10, e14
  - extrahepatic, 184–185, 190*f*
  - injury to, 1373–1375, 1373*f*, 1374*f*, 1375*f*, 1376*f* (*See also* Iatrogenic bile duct injuries)
  - intraduodenal, 1353
  - intrahepatic, 1268
  - laparoscopic scanning, 189, 189*f*
  - lesions, 1411
  - modification of, 1415*f*
  - perforations into, 1387*f*
  - reconstruction, 1509*f*
  - resectable cancer, 187*f*
  - resection, 1401
  - strictures, 1397*t*, 1403
  - surgical anatomy of, 1259–1271
  - variations, 1271
- Bile fistulae, cause of, 1381
- Bile leaks
  - after hepaticojejunoscopy, 1420
  - after LC, 1363*f*
  - after primary sclerosing cholangitis surgery, 1401

- cause and prevention of, 1381–1382, 1401
- hepatic trauma and, 1340

Bile reflux esophagitis, 1161–1162, 1165

Bile reflux gastritis, 1147, 1165

Bile salts, 1647, 1675

Biliary anastomosis, 1420, 1441

Biliary anatomy
- hepatic plate system, 1369*f*
- variations and anomalies, 1368, 1370–1373, 1381

Biliary atresia
- classification of, 1428
- diagnostic evaluation, 1428–1429, 1429*t*
- etiology, 1427–1428
- operative procedure, 1429
- portoenterostomy for, 1427–1434
- prognostic factors, 1432*t*

Biliary bypass
- stents and stenting, 1420
- survival, 1420

Biliary colic, 1343, 1353

Biliary cystadenocarcinomas (BCACs), 1277

Biliary cystadenomas (BCAs), 1276

Biliary dilatation, 1492

Biliary disease
- diagnostic considerations, 1271–1286
- presentation, 1272
- survival, 1393

Biliary drainage
- gallbladder use for, 1412–1413
- preoperative, 1406

Biliary duct-to-duct anastomoses, 1444*f*

Biliary dyskinesis
- description of, 1285
- diagnosis, 1285

- presentation, 1353–1354
- prevalence of, 1393

Biliary endoscopic anterograde sphincterotomy, 1364–1365

Biliary enteric anastomosis
- complications, 1420
- in pediatric patients, 1420
- surveillance following, 1420
- technique, 1416*f*, 1418, 1418*f*

Biliary hypoplasia, 1429

Biliary malignancy, 1397

Biliary obstruction
- benign and malignant, 1405
- causes of, 1286–1287
- diagnosis, 1274–1275
- effects of, 1406
- by malignant periampullary lesions, 1412
- without gallstones, 1275

Biliary peritonitis, 1381

Biliary reflux, 1146–1147

Biliary sepsis, gall stones and, 1343

Biliary sludge, 1524

Biliary sphincter dysfunction, 1393

Biliary stent placement, 1492

Biliary stones
- clearance of, 1403
- laparoscopic ultrasound, 188
- ultrasonographic detection, 193

Biliary surgery, open, 1389*t*

Biliary system
- anatomical features of, 1405*f*
- anatomy of, 1415
- Blumgart surgery, 1417*f*
- choledochal cysts and, 1421–1427
- decompression of, 1412

- imaging studies of, 1372–1373
- malignancies, 1410
- normal anatomy of, 1421*f*
- strictures, 1397*f*, 1415–1416

Biliary tree
- carcinoma, 1420
- evaluation of, 1411
- US scanning of, 185, 186*t*

Biliary ultrasonography, 1359

Biliary-enteric bypass, 1412, 1420

Biliodigestive bypass procedures, 1307

Biliopancreatic diversion with duodenal switch (BPD-DS), 1179, 1181*f*, 1218, 1225–1233, 1226*f*
- contraindications, 1226
- history of, 1225
- indications, 1226
- laparoscopic
  - complications, 1230
  - follow-up, 1229–1230
  - outcomes, 1230–1231
  - postoperative care, 1229–1230
  - technique, 1226–1228
  - trocar arrangement, 1227*f*
  - weight loss after, 1232
- morbidity after, 1230*t*
- preoperative planning, 1226
- sleeve gastrectomy conversion to, 1248
- sympathetic nervous response, 1182

Bilirubin levels, 1420, 1985

Billroth, Theodor, 386*f*, 1084, 1140, 1141

Billroth I gastrectomy, 1089–1090

Billroth I gastroduodenostomy
- arguments in favor of, 1084–1085
- Billroth II *versus*, 1084–1095

- complications, 1146
- Finney modification of, 1085*f*
- Harkins modification of, 1085*f*
- history of, 1140, 1141
- Kocher modification of, 1085*f*
- Kutscha-Lissberg modification of, 1085*f*
- Nyhus modification of, 1085*f*
- outcomes, 1147–1148
- pros and cons, 1134, 1141–1142
- and Roux-en-Y compared, 1147–1148
- Shoemaker modification of, 1084, 1085*f*
- stapled anastomoses, 1088–1089
- surgical technique, 1086–1090, 1086*f*–1089*f*
- von Haberer modification of, 1085*f*
- Winkelbauer modification of, 1085*f*

Billroth I reconstruction
- bile-reflux gastritis after, 1147
- quality of life after, 1147
- Roux-en-Y-gastrojejunostomy *versus*, 1142–1143

Billroth II gastrectromy
- surgical technique, 1090–1091, 1090*f*

Billroth II gastroduodenostomy
- arguments in favor of, 1085
- Billroth I *versus*, 1084–1095

Billroth II loop gastrojejunostomy, 1136*f*
- blood loss during, 1141
- complications, 1146
- history of, 1141–1142
- operating room time, 1141
- outcomes, 1141, 1147–1148
- reconstructive use of, 1134–1138
- and Roux-en-Y compared, 1165
- technique, 1134–1135, 1136*f*

Billroth II reconstruction

- afferent loop syndrome, 1146–1147
- bile-reflux gastritis after, 1147
- biliary reflux and, 1146–1147

Bilobar biliary strictures, 1397*f*

Bioelectric impedance (BIA), 55

Biofeedback
- for fecal incontinence, 1951–1952
- for outlet obstruction, 1963

Bioimpedance spectroscopy, 674–676

Biologic meshes
- in breast reconstruction, 225–226
- diaphragm repair using, 861, 864

Bioprosthetics, 843

Bipolar energy circuits, 275, 275*f*

BI-RADS. *See* Breast Imaging Reporting and Data System

Birthmarks, skin cancer and, 411

Birt-Hogg-Dube syndrome, 2019–2020

Bisacodyl suppositories, 1952

Bismuth, slow transit constipation and, 1961

Bismuth cholangiocarcinoma (CCA) classification system, 1399*f*, 1406, 1406*f*

Bismuth classification, 1367

Bismuth subsalicylate, 1115

"Björk flap," 491, 491*f*

Bladder
- anatomic relationships, 2005*f*, 2008*f*, 2009–2010, 2010*f*
- anatomic supports, 2169–2170
- anatomy of, 2034–2035
- blood supply to, 2034–2035
- dysfunction, 1838–1839
- fascias, 2009–2010
- filling
  - nervous control of, 1825
- innervation, 2035

- internal view, 2009*f*
- intraoperative injury, 2133
- lateral vascular pedicle, 2041
- lymphatics, 2010, 2035
- operative injury to, 2225–2226
- orthotopic reconstruction, 2034
- ruptures, 2101–2102, 2107
- separation from the cervix, 2129–2130
- staging, 2036*t*
- superolateral view, 2009*f*
- supravesical hernias, 2206*f*
- traumatic injuries, 2099–2102, 2102*f*
- trigone, 2009*f*
- vascular supply, 2010

Bladder cancer
- AJCC staging, 2035*t*
- carcinoma in situ (CIS), 2035
- cystectomy for
  - abdominal exploration, 2038, 2039*f*
  - incisions, 2038
  - indications, 2036–2037
  - patient positioning, 2038, 2039*f*
  - radiation therapy *versus*, 2036
- diagnosis, 2035–2036
- invasive, 2034
- locally advanced, 2038
- LPLND in, 2055
- outcomes, 2050–2052, 2051*t*
- positive lymph nodes, 2051*t*
- presentation, 2035
- radical cystectomy, 2034–2054
- recurrence, 2034, 2050–2052
- treatment, 2036–2037
- urethral recurrence, 2037–2038

- urinary diversion in, 2037–2038
- Bladder neck dissection, 2069–2070
- Bladder pillars, stitches, 2176*f*
- Blair incision, modified, 311
- Blalock, Alfred, 556
- Bleeding, massive, prevention
  - THE, 1008, 1014–1015, 1016, 1018, 1020
- Bleeding esophageal varices (BEVs), 1599, 1605
- Bleeding risk, evaluation of, 105
- Bleomycin, sclerotherapy, 372, 379
- Blepharoplasty, 443
- Blindness
  - in carotid bifurcation disease, 2247
  - diabetic retinopathy and, 1177
- Bloating, antireflux surgery complication, 959
- Blood cell chimerism, 1452
- Blood components, hemorrhagic risk and, 103–110
- Blood gas analyses, 70
- Blood glucose levels, control, 119*t*
- Blood loss
  - into chest, 1016*f*
  - wound infections and, 32
- Blood pressure
  - monitoring of patients
    - cuff size and, 68
    - invasive measures, 68–70
    - noninvasive measures, 68
    - pitfalls of invasive monitoring, 70
  - perioperative lability, 24
- Blood supply
  - of breast and axilla, 596–597, 596*f*, 597*f*
  - carotid body tumors, 2267, 2271–2273
  - in oncoplasty, 713
- Blood transfusions, 223

- Blood urea nitrogen (BUN), 22
- Blood-brain barrier (BBB), 7
- Bloodstream infections, 72, 2539
- “Blow-out” fractures, orbital, 442
- Blue dye
  - in axillary reverse mapping, 676–677
  - in sentinel lymph node biopsy, 668–669, 668*f*, 671
- Blue rubber bleb nevus syndrome (BRBNS)
  - description of, 380
- Blue toe syndrome
  - aortofemoral bypass, 2332, 2342
  - popliteal artery aneurysm, 2325
  - pseudoaneurysm of femoral artery, 2323*f*
- Blunt cerebrovascular injury (BCVI)
  - clinical indications suggestive of, 2570*t*
  - grading scale for, 2574*t*
  - risk factors for, 2574*t*
- Blunt thoracic aortic injury (BTAI)
  - advances in, 2567
  - clinical presentation and diagnosis, 2561
  - endovascular repair (*See* Thoracic aortic endovascular repair (TEVAR))
  - imaging, 2566*f*
  - indications and timing of intervention, 2561
  - open repair
    - endovascular repair (TEVAR) compared to, 2567
    - operative technique, 2562–2563
    - postoperative management and potential complications, 2563–2564
    - preoperative planning, 2561–2562
  - overview of, 2560–2561
  - pseudoaneurysm secondary to, 2562*f*
- Blunt vascular injury (neck), 2573–2574
- B-Lynch technique, 2125*f*
- BMT (bismuth/metronidazole/tetracycline) regimen, 1115

- Bocca, Ettore, 350
- Bochdalek hernias
  - appearance of, 825*f*
  - characteristics of, 822*t*
  - definition and overview of, 840
  - Morgagni hernia compared to, 839
  - potential, 824*f*
  - prevalence of, 820
- Body composition. *See also* Body mass index (BMI)
  - assessments, 55
  - fat-free mass estimates, 55
- Body fluids, composition of, 1651*t*
- Body mass index (BMI)
  - determination of, 55
  - obesity grades and, 1233
  - outcomes and, 55
  - preoperative assessment of, 26
  - unintentional weight loss and, 56
- Body wall
  - arteriovenous hemodialysis access in, 2543, 2547
  - embryogenesis, 820
  - mesoderm, 840
  - muscles of, 820
- Body weight. *See also* Obesity; Weight loss
  - assessment of, 55
  - reduction of, 1233
- Bone, exposure of, 216
- Bone marrow transplantation, 1452
- Bone mineral density (BMD)
  - evaluation of, 534
  - parathyroidectomy and, 513
  - secondary HPT and, 551
- Bony thorax, anatomy, 773
- Bookwalter retractors, 1790, 1967

- Botulinum toxin (BOTOX), 1165
  - efficacy for achalasia, 982
  - for fissure in ano, 1914
  - injections
    - for achalasia, 972
    - into pyloric muscle, 1158
    - pyloric relaxation and, 1165
- Bougie
  - esophageal perforation repair, use in, 1031
  - paraesophageal hernia repair, use in, 870*f*, 872
  - size, recommended, 876*t*
- Bovie, William, 274
- Bowel
  - dead, 2452–2453
  - function after LAR, 1837–1838
  - functional disorders, 1949–1964
  - gaining length, 1687
  - infarction, 1817*f*, 2454
  - injury after LRPLND, 2066
  - ischemia, preventing, 2455
  - lengthening procedures, 1982
  - mobilization, 2039
  - preparation
    - benefits of, 1750
    - mechanical, 33, 54, 117*t*, 1781, 1878
    - polyethylene glycol-based, 1781
    - preoperative, 1919
    - rectal prolapse surgery, 1894
  - resection
    - abdomen closure without, 2453
    - in ovarian cancer surgery, 2160–2161
  - rest, in NEC, 1977
- Bowel anastomosis, 1901*f*
- Bowel obstruction

- adhesive, 1253
- after bariatric surgery, 1230
- after RYGB, 1253–1255
- malignant, 1250
- post hysterectomy, 2144
- postsurgical, 2163
- presentation after RYGB, 1253–1255

Brachial artery injuries
- penetrating, 2600*f*
- repair of, 2597
- stents and stenting, 2600*f*

Brachial plexus
- anatomy of, 71*f*, 288*f*, 307, 358*f*, 2549
- block, 289
- formation of, 286
- nerve injury, 2560
- neurolysis, 2558*f*

Brachial-antecubital forearm, prosthetic, 2542*f*, 2545*f*

Brachiobasilic autogenous access
- in autogenous arteriovenous hemodialysis, 2533*f*
  - single-stage procedure, 2532–2533, 2539
  - two-stage procedure, 2534, 2539

Brachiocephalic artery, 784

Brachiocephalic autogenous access, 2531–2532, 2532*f*

Brachiocephalic nodes, 786

Brachiocephalic reconstruction, 2265–2266
- clinical presentation, 2259
- diagnosis, 2259
- etiology and pathophysiology, 2258–2259
- outcomes, 2265
- patient selection, 2259
- postoperative care, 2265
- surgical techniques
  - aneurysm, innominate or subclavian, 2262, 2263*f*

- aortic arch reconstruction, 2262
- carotid subclavian bypass, 2262–2264, 2263*f*
- endovascular reconstruction, 2264
- innominate artery, 2260–2262, 2261*f*, 2262*f*, 2265, 2265*f*
- left subclavian intervention, 2264–2265, 2264*f*
- open reconstruction, 2259–2260, 2260*f*, 2261*f*
- subclavian, 2262, 2264

Brachiocephalic trunk, 287, 298*f*, 469

Brachiocephalic veins
- anatomic relationships, 778*f*, 783, 785
- anatomy, 288*f*, 2549
- metastatic spread via, 778

Brachiocephalic vessels, 2569

Brachytherapy, 336, 647–648*f*, 647–649

Bradykinin, 133

BRAF inhibitors, 427

BRAF mutations, 422–423
- ovarian cancer and, 1246
- in papillary thyroid carcinoma, 530
- thyroid cancer and, 516

Brain herniation
- description of, 483*f*
- mass effect and, 482–484
- symptomatology, 483–484
- transtentorial, 484*f*

Brainstem, functional impairment, 483–484

Branched-chain amino acids (BCAA), 64

Branchial arches, development of, 368

Branchial cleft anomalies
- clinical presentation, 368
- cysts, 368–369, 369*f*
- etiology of, 368
- fistulae, 370*f*
- pathophysiology of, 368

- surgical resection
  - contraindications, 368–369
  - indications, 368–369
  - outcomes, 369–370
  - postoperative care, 369–370
  - preoperative planning, 369
  - technique, 369
- Braun anastomosis, 1091, 1147–1148
- Braun enteroenterostomy, 1123
  - evaluation of, 1165
  - Roux gastrojejunostomy and, 1124
  - side-to-side, 1124
  - technique, 1545
- *BRCA1* mutations, 1247
- *BRCA2* mutations, 1247
- Breast
  - ablation of tumors (*See* Ablation therapy)
  - benign disease
    - classification of, 604t
    - core biopsy, 603–604
    - histopathology of, 604
    - hyperplasia, atypical, 606
    - imaging -pathology concordance, 604
    - lobular carcinoma in situ, 606–607
    - nonproliferative disease, 604–605
    - phyllodes tumors, 607
    - proliferative disease, 605–606
    - risk reduction strategies, 607
  - embryology and anatomy, 603
    - axilla, 594–597, 595*f*, 596*f*
    - blood supply, 596*f*, 597, 597*f*
    - functional anatomy, 594, 595*f*
    - hormonal effects, 594
    - lymphatic drainage, 598–601, 599*f*–602*f*

- mammary milk line, 594*f*
- microscopic anatomy, 601–602
- nerve anatomy, 597–598, 598*f*
- pain (mastalgia)
- clinical presentation, 607–608, 608t
- etiology and pathology, 607
- evaluation, 608
- management, 608
- projection of, 222*f*
- ptosis of, 222, 222*f*

- Breast cancer
- ablative therapy, 204
- advanced/recurrent, 742–754
- axillary lymph node staging, 758–760
- BCT, ultrasound-guided, 193–194
- clinical trials, 755–762, 761–762
- extirpation of, 221
- invasive, surgical therapy for, 755–756
- metastatic disease, 754, 778
- noninvasive, 756–757
- patient positioning, 742–744
- patterns of spread, 2067
- radiation therapy, 234–235
- reconstruction, 748*f*, 763–771
- recurrence
- chest wall, 754
- management of, 233–234
- nodal ER positivity and, 762
- types of, 754
- surgical management, 742
- surgical technique, 742–744, 743*f*, 744*f*

- Breast Imaging Reporting and Data System (BI-RADS), 604, 613–614. 614t
- Breast milk, growth factors in, 1981–1982

- Breast reconstruction, 221–234
  - after mastectomy, 740–741
    - contralateral prophylactic, 732
    - delayed reconstruction, 738–739
    - early flaps, 726, 727*f*
    - historical developments, 724
    - history of, 721
    - ideal total, 721–722, 722*f*
    - immediate reconstruction, 739–740
    - implants and expanders, 732–733
    - modified radical, and extensive skin excision, 723, 723*f*
    - myocutaneous flaps
      - latissimus dorsi, 733, 733*f*
      - transverse rectus abdominus (TRAM), 733–736, 735–736*f*
    - nipple reconstruction, 738
    - nipple sparing, 722
    - oncoplastic reconstruction, 737
    - opposite breast mammoplasty, 737–738
    - partial, 722–723
    - primary closure, 724–725, 725*f*
    - radiation, 724
    - radical, 723–724, 724*f*
    - reconstruction with fat graft, 737
    - silicone implants, 726, 728*f*
    - skin grafting, 725, 726*f*
    - tissue expansion, 726–728, 728*f*
    - tissue transfer, 731, 732*f*
  - autologus, indications, 764
  - closing axillary defects, 222
  - expanders, 224–225, 224*f*
    - advantages, 225
    - disadvantages, 225
    - procedures, 225
  - fish-tail flaps, 234*f*

- immediate *vs.* delayed, 223–224
- implants, 224–225, 225*f*
- ipsilateral flaps, 230*f*
- molding of, 229*f*
- objectives of, 221–223
- options for, 224–234
- preoperative planning, 764–765
- principles of, 221
- projection of, 222
- skate flap, 233*f*
- superficial inferior epigastric, 232
- sutures, 228*f*

Breast-conserving therapy (BCT), 642–643
- axillary surgery
  - axillary reverse mapping, 638
  - dissection technique, 638–640*f*, 638–641
  - follow-up, 642
  - internal mammary node biopsy, 638
  - sentinel lymph node biopsy, 635–638, 636–638*f*
- carcinoma in situ
  - atypical lobular hyperplasia (ALH), 635
  - clinical presentation, 633
  - diagnosis and histology, 633
  - epidemiology, 633
  - LCIS, 635
  - low-grade DCIS, 634
  - treatment, 633–634
- clinical and pathological factors, 625
- impalpable lesions, 628–630, 629–630*f*
- indications and contraindications, 624–625, 624t
- lymphedema incidence, 673
- mastectomy and, clinical trials, 755
- oncoplasty
  - anatomy, 713, 713*f*

- complications, 718
- etiology and pathophysiology, 712–713
- indications/contraindications, 713–714
- postoperative care, 718
- preoperative planning, 714
- surgical techniques
  - batwing lumpectomy, 715, 717*f*
  - central lumpectomy, 715, 717*f*
  - donut mastopexy lumpectomy, 716–718, 718*f*
  - lateral segmentectomy, 714–715, 716*f*
  - parallelogram lumpectomy, 714, 715–716*f*
  - reduction mastopexy lumpectomy, 715–716, 718*f*
- postoperative complications, 630–631, 631t, 641–642
- preoperative planning, 625
- recurrence after surgery
  - patient-related factors, 632
  - treatment-related factors, 632–633
  - tumor-related factors, 632
- reexcision, 631–632
- *vs.* mastectomy, 624
- wide local excision
  - cancer excision, 626–627, 626*f*–627*f*
  - central tumors, 627–628, 628*f*
  - marker placement, 627

- Breathing, abnormal patterns of, 484
- Breslow thickness, 419
- Bricker ileal conduit, 2034, 2108–2110
- Bricker uterointestinal anastomosis, 2108–2109, 2109*f*
- *BRIP1* mutation, 1249
- Broad ligament, 2006*f*
- Bronchi
  - closure of, 807*f*
  - embryology of, 782*f*
  - fistulas, urgent surgery for, 789

- right mainstem, 815*f*
- Bronchioalveolar carcinoma (BAC), 800
- Bronchitis, postoperative complications, 85
- Bronchoalveolar lavage (BAL), 92
- Bronchodilators, 29*t*, 89
- Bronchomediastinal trunks, 786
- Bronchopleural fistulae, 234
- Bronchopulmonary dysplasia, 845
- Bronchorrhea, 28
- Bronchoscopes, small-gauge, 805–806
- Bronchoscopic specimen brush (PSB), 92
- Bronchoscopy
  - history of, 386–387
  - lung cancer staging, 801–802
  - rigid, 447
- Bronchospasm, 85, 89
- Bronchus, right mainstream, 1017*f*
- Brooke ileostomy, 1639, 1641
  - creation of, 1723
  - end, 1724*f*
  - total protocolectomy for, 1726
- Brooke technique, 1713–1714, 1767*f*
- BTS. *See* Bilateral thoracoscopic splanchiectomy (BTS)
- Buccal mucosa
  - anatomy, 335*f*
  - carcinoma of, 340–342, 341*f*, 343*f*
- Buccinator muscle, 326
- Buccopharyngeal fascia, 300
- Buchwald, Henry, 1176
- Buck fascia, Fournier gangrene, 128
- Budd-Chiari syndrome (BCS)
  - caudate lobe drainage in, 1270
  - caval-atrial shunts and SSPCS, 1603*f*
  - hepatic venous outflow obstruction in, 1284

- occluded hepatic veins and, 1590
- overview, 1601–1603

Buess, Gerhard Friederik, 1940
Bulbourethral gland, 2007*f*
Bupivacaine, 437, 1925
Buprenophine, e7
Burch, John Christopher, 2167
Burnet, F. Macfarlane, 141
Burns
- genital, 2105
- gut barrier failure in, 20
- metabolic demand after, 54
- muscle wasting in, 35

N-butyl-2-cyanoacrylate, 1627
Byler syndrome, 1429
Bypass. *See Specific* bypass procedure
Bypass grafts, 2449*f*, 2459
Bypass *vs.* Angioplasty in Severe Ischemia of Leg (BASIL), 2383, 2390

C

- C HOBBS, 1527
- CA19-9 (carbohydrate antigen 19-9), 1249, 1405, 1552
  - in HCC, 1282
- CA125 (carbohydrate antigen 125), 1249
- Cadaver donor hepatectomy, 1436–1438
- Caffeine, breast pain and, 608
- Cahexia, paraneoplastic syndrome and, 2020
- Cajal cells, 1142
- Calcification
  - breast, 614–615, 615*f*
  - pheochromocytoma and, 582
  - splenic artery aneurysms, 2330*f*
- Calcimimetics in HPT, 551, 555
- Calcineurin, 143
- Calcineurin inhibitors, 146–147
- Calciphylaxis
  - description of, 555
  - in HPT, mortality rates, 552
  - secondary HPT and, 551
- Calcitonin, 520, 521
- Calcitonin production of, 500
- Calcitriol
  - after parathyroidectomy, 554
  - dosage post thyroidectomy, 527
  - postoperative, 527
  - renal synthesis of, 532
- Calcium
  - deficiencies, 1241
  - extra osseous deposits, 551
  - homeostasis, 550
  - inonized, 79–80
  - levels, regulation of, 532

- supplementation
  - after parathyroidectomy, 554
  - after thyroidectomy, 512
  - dosage post thyroidectomy, 527
  - in HPT, 551
  - postoperative after thyroidectomy, 527
  - preoperative in Graves' disease, 521
  - slow transit constipation and, 1961
- Calcium carbonate
  - dosage post thyroidectomy, 527
- Calcium channel blockers, 29*t*, 972
- Calcium gluconate, 528
- Calcium-sensing receptor *(CaSR)* gene, 534
- Calne, Roy, 141
- Caloric deficits, outcomes and, 54. *See also* Malnourishment
- Caloric density, enteral formulations and, 63
- Caloric intake, impaired, 1000
- Caloric requirements, 45
- Calorie to nitrogen ratios, 45
- Calories, in severe illness, 59
- Calot's triangle
  - anatomy, 1266, 1342
  - cleaning out, 1271
- Calpain, 37, 38
- Camper fascia, 2182, 2182*f*
- *Campylobacter jejuni*, 1719
- Cancer and Leukemia Group B (CALGB) 9343 trial, 756
- Cancers. *See also Specific* cancers
  - catabolism and, 37*f*
  - metabolic derangements, 50*t*
  - muscle wasting in, 35, 36*f*
  - nutritional support in, 49–51, 52
  - proteolysis in, 51–52
- *Candida* spp.

- aortic graft infection death associated with, 2471
- *C. albicans*
  - surgical site infections, 112*t*, 124
- *C. glabrata*
  - liver abscesses, 1289
  - surgical site infections, 124
- liver abscesses, 1289
- surgical site infections, 112*t*
- therapy for, 122

- Candidiasis, stoma-related, 1778–1779
- Canthal tendon, release of, 436
- Cantile line, 1260, 1264
- Cantrell's pentalogy, 772, 826
- Canvaxin vaccine, 427
- Capacitative coupling, electrosurgical injuries, 279, 279*f*
- Capecitabine, 1867
- Capella Micropuncture system, 2497*f*
- Capillary leaks, peripheral edema and, 55
- Capillary malformation-arteriovenous malformation (CM-AVM), 381, 382
- Capillary malformations (CM), 374*t*, 378
- Caprini venous thromboembolism risk scoring system, 2524
- Capsule endoscopy, 1673
- Caput Medusae, 1590
- Carbamazepine, 138
- Carbapenem-resistant *Enterobacteriaceae* (CREs), 110
- Carbohydrates
  - absorption of, 59
  - energy per gram, 59
  - metabolism of, 15–17
  - preoperative loading with, 66
  - utilization of, 59
- Carcinoembronic antigen (CEA)
  - baseline, preoperative, 1827*f*

- in HCC, 1282
- in pancreatic cancer, 1552
- preoperative testing, 520, 1854
- rectal neoplasm workup, 1938
- screening for ovarian cancer, 1249
- surveillance using, 1869

Cardia
- carcinoma of, 1000
- circular muscle fibers at, 901*f*

Cardiac contusions, 788

Cardiac devices, implanted, 278*f*

Cardiac dysrhythmias, 76

Cardiac ectopia, 772

Cardiac failure, TPN and, 48

Cardiac index (CI), 69

Cardiac injuries
- blunt, 793–794
- penetrating
  - diagnosis, 793
  - operative approaches, 793
  - presentation, 793
  - treatment, 793
- urgent operative care for, 788

Cardiac output (CO)
- description of, 75
- measurement pitfalls, 75
- stress response and, 2
- thermodilution method, 75

Cardiac resynchronization, robotic-assisted, 269

Cardiac revascularization, robotic-assisted, 269

Cardiac surgery
- da Vinci Robotic system in, 264
- prophylactic antimicrobial agents, 114*t*
- robotic-assisted, 269

- sternal wound reconstruction, 236–237
- valve repair, robotic-assisted, 269

Cardinal ligaments, division of, 2140*f*
Cardioesophageal arteries, 1064
Cardiogenic shock, 77*t*
Cardiomyopathy, HPT and, 551
Cardiophrenic space, 833
Cardiopulmonary bypass, 448
Cardiothoracic surgery, complications after, 86*t*
Cardiovascular disease
- obesity and, 28
- perioperative management, 25*f*
- postoperative telemetry, 34
- rheumatologic, 27
- surgical risk and, 23, 27

Cardiovascular monitoring, 68–85
Cardiovascular mortality, HPT and, 554
Cardiovascular risks
- for aortic graft infection patients, 2473
- assessment of, 83
- predictors, 83
- procedural, 83

Cardiovascular support, 77–78
Cardiovascular system, assessments, 23–24
Carinal resection, 455*f*
Carney triad, 1193
Carotid arteries
- anatomy, 293*f*
- angiography, 289
- dissections, 2577
- identification of, 358
- injuries
  - risk and prevalence, 2569–2570
  - surgical management of, 473

- surgical repair, 2569, 2571*f*
- interruption of, 2469
- left carotid bypass (*See* Left carotid to left subclavian artery bypass)
- origins of, 2569
- repair, 470, 470*t*

Carotid artery disease (CAD), 2248–2249

Carotid bifurcation disease, 2258

- anatomy
  - aortic arch, 2246
  - circle of Willis, 2247
  - internal carotid artery, 2247, 2247t
  - vertebral artery, 2247
- clinical presentation
  - hypoperfusion syndrome, 2248
  - lacunar infarct, 2248
  - TIA/stroke, 2247–2248
- complications
  - bleeding, 2256
  - cardiac, 2256
  - cerebral hyperperfusion syndrome, 2256
  - cranial nerve injury, 2255–2256
  - hemodynamic, 2256
  - infection, 2256
  - perioperative stroke, 2255
  - recurrent stenosis, 2256
- etiology and pathophysiology, 2246
- imaging, 2249–2250, 2250*f*
- management, 2247, 2250
  - indications, 2248, 2248t
    - CEA *vs.* CAS, 2249
    - crescendo TIA, 2248
    - internal carotid artery occlusion, 2248–2249
    - symptomatic carotid artery disease, 2248, 2248t
    - timing of surgery, 2248

- outcomes
  - ACAS, ACST, REACH Registry, 2256–2257
  - CREST, 2257
  - NASCET and ECST, 2257
- postoperative care, 2255
- preoperative planning, 2249–2250
- risk factors, 2246
- surgical techniques
  - carotid artery stenting, 2254–2255, 2255*f*
  - carotid endarterectomy, 2250–2253, 2250–2254, 2252–2253*f*

- Carotid body tumors, 2278
  - clinical presentation, 2267–2268
  - complications, 2277
  - natural history and indications, 2268
  - pathology, 2267
  - postoperative management, 2277
  - preoperative planning, 2268–2271, 2269*f*–2271*f*
  - radiation therapy, 2277
  - surgical techniques
    - cerebral monitoring and protection, 2272–2273
    - exposure, 2273–2274, 2273*f*–2274*f*
    - preoperative embolization, 2272
    - resection of tumor, 2274–2276, 2275*f*–2276*f*
    - wound closure, 2276–2277
- Carotid endarterectomy (CEA)
  - antiplatelet agents and, 110
  - in carotid bifurcation disease, 2247–22498
- Carotid Revascularization Endarterectomy *vs.* Stenting Trial (CREST)
  - carotid bifurcation disease, 2249, 2257, 2258
- Carotid sheath, 286, 307–308
- Carotid triangle
  - anatomy, 291*f*
  - deep dissection of, 463*f*
  - deep structures, 291*f*

- muscular boundaries, 291*f*
- Carpal bones
  - anatomy of, 247, 250*f*
  - dislocations, 251
- Carpometacarpal joint, thumb, 250*f*
- Carpus, anatomy, 247
- Carrel, Alexis, 141
- Carrel patch, vascular, 1339, 1339*f*
- CARS. *See* Compensatory anti-inflammatory response syndrome (CARS)
- Carter-Thompson needle suture passer, 1324
- Caspases, muscle wasting and, 38
- Cassava ingestion, 1493
- Cast syndrome, 1186, 1192
- Catabolism
  - catecholamines and, 12
  - muscle wasting and, 37*f*
  - protein breakdown and, 18
  - stress response and, 2, 18
- Catecholamines
  - after injury, 16
  - stress response and, 2
- Cathelicidin, inflammation and, 4–5
- Catheter-based pharmacomechanical thrombolysis. *See* Pharmacomechanical thrombolysis (PMT)
- Catheter-directed thrombolysis (CDT), 2493
- Catheter-related blood stream infections (CLABSIs), 44–45, 46
- Catheters
  - antimicrobial-impregnated, 72
  - arterial
    - complications of, 69
    - insertion of, 69
  - bloodstream infections related to, 72
  - in continent ileostomy, e46–e47

- for embolectomy, 2418–2419, 2419*f*
- in endovascular treatment, 2385
- indwelling intra-arterial
  - BP measurement, 69
- infections related to, 72
- knotting of, 76
- pulmonary artery, 73–77
- risk of blood-stream infections, 44–45

- Catheters for dialysis. *See* Dialysis catheters
- Cattell-Braasch maneuver, 1563
- Caudal block, 1973
- Caudal pancreatic artery, 1483–1484
- Caudate lobe
  - anatomy of, 1407*f*
  - bile ducts draining, 1371
  - hanging maneuver, 1271
- Cauliflower ear, 439
- Caustic injury, esophageal, 1022
- Cauterization of carotid body tumors, 2278
- Caval foramen, 820*f*, 856*f*
- Caval hiatus, 828
- Caval veins, 779*f*
- Caval-atrial shunts, 1603*f*
- Cavitation effects, 275
- Cavitron Ultrasonic Surgical Aspirator (CUSA), 1318
- Cavoatrial bypass, 2505–2506, 2507*f*
- CD3, function of, 143
- CD19, costimulation signals, 144
- CD21, costimulation signals, 144
- CD25, function of, 143
- CD25 antagonists, 148
- CD28, 144
- CD52, 149
- CD80, 144

- CD86, 144
- CD95 (Fas), apoptosis and, 143
- CD152 (CTLA-4)
  - antibodies to, 422
  - belatacept and, 148
  - inhibition of, 149
  - upregulation of, 144
- CD178 (FasL), 144
- *CDC73* mutations, 542
- CDH. *See* Congenital diaphragmatic hernia (CDH)
- C/EBP transcription factors, 38
- Cecal intubation rates, 212
- Cecal volvulus, 1699
- Cecostomy, 1768*f*, 1772
- Cecum
  - anatomy of, 1676–1677
  - identification of, 212*f*
  - peritoneal attachments, 1677*f*
  - scope insertion, 212
- Cefazolin dosage
  - preoperative, 2233
  - at surgery, 1894
- Ceftazidime/avibactam, 125
- Ceftolozane/tazobactamis, 125
- Ceftriaxone excretion of, 1353
- Cefuroxime for biliary organisms, 1344
- Celestin tubes, 1703
- Celiac artery
  - anastomosis to, 2456, 2458*f*
  - anatomic relationships, 1482*f*
  - arteriogram, 2329
  - atherosclerotic disease of, 2453, 2458
  - exposure of, 2455, 2457*f*
  - mesenteric bypass, 2455

- reconstruction of, 2464
- revascularization of, 2452
- stents and stenting, 2455, 2464

- Celiac artery compression syndrome (CACS), 831–832
- Celiac axis
  - circulation, 2454*f*
  - compression of, 839
  - exposure of, 2158*f*
  - stenosis, 1566
- Celiac ganglia
  - anatomy of, 838
  - innervation by, 1580
  - location of, 831
  - overview of, 838
- Celiac plexus block (CPB), EUS-guided, 1581
- Celiac plexus neurolysis (CPN), 1511
  - in chronic pancreatitis, 1581
  - intraoperative, 1583*f*
  - open, 1582–1584
  - ultrasound-guided, 1582
- Celiac trunk, anatomic relationships, 1481*f*, 2005*f*
- Cellular immunity, 5, 142
- Cellular-mediated immune dysfunction, 8
- Cellulitis
  - postsurgical, 2163
  - stoma-related, 1778–1779
  - vaginal cuff, 2133
- Cellulose, oxidized regenerated, 1346
- Centers for Disease Control and Prevention (CDC)
  - on HAI prevention, 114
  - Healthcare Infection Control Practices Advisory Committee (HICPAC), 7.3, 7.5
  - on SSI prevention, 115*t*–116*t*
- Centers for Medicare & Medicaid Services (CMS), 114

- Central arterial pressures, 69
- Central line-associated bloodstream infections (CLABSIs), 72, 84
- Central nerve dysfunction, 850
- Central nervous system (CNS)
  - response to trauma, 7
  - role in surgical trauma response, 8–11
  - role of TNF in, 6
  - symptomatic diseases, 486
- Central splenorenal shunts (CSRS). *See also* Shunts, central splenorenal
  - incision, e30, e30*f*
  - indications, e30, e30t
  - surgical technique, e30–e34, e30*f*–34*f*
- Central tendon (of diaphragm)
  - anatomy of, 829*f*
  - characteristics of, 827–828
  - function of, 840
- Central vein stenosis/occlusion, 2536–2537
- Central venous catheters (CVCs), 70–72
  - care for, 35
  - complications of, 72
  - morbidity/mortality associated with, 2547
  - placement of, 46
  - subclavian vein cannulation, 70–71
  - wave forms, 70*t*
- Central venous pressures (CVPs), 70
- Central venous stenosis, 84
- Cephalosporins, 2055
- Cerebral edema, 1434
- Cerebral gigantism, 2078
- Cerebral hyperperfusion syndrome, 2256
- Cerebral ischemia, IAH and, 155*t*
- Cerebral mass lesions, 193
- Cerebral perfusion pressures (CPPs), 476*t*
- Cerebrospinal fluid (CSF)

- leaks, sources of, 479
- otorrhea, 436, 477
- rhinorrhea, 436, 477

Cerebrovascular disease. *See Specific* conditions

Cerebrovascular injuries. *See* Blunt cerebrovascular injury

Certulizumab, presurgical, 1734

Cervical block anesthesia
- conversion to general, 545*t*
- parathyroid exploration under, 546
- in parathyroidectomy, 544*f*

Cervical cancer
- extrafascial hysterectomy in, 2136
- human papillomavirus and, 334
- incidence of, 2145
- staging of, 2145

Cervical esophageal cancer, 985

Cervical esophagectomy, 985

Cervical esophagogastric anastomosis (CEGA)
- complications, potential from, 1019
- overview of, 1010–1012
- rediscovery of, 1000

Cervical esophagus
- cross-section of, 898*f*
- endoscopic measurements of, 1021*f*
- mobilization of, 1007*f*
- perforation of, 1022, 1024, 1030

Cervical fascia, 286

Cervical injury management
- endovascular approach, 2576
- open approach, 2573*f*, 2574*f*, 2576
- operating room setup and preliminary preparation, 2570, 2573*f*, 2576
- operative/interventional algorithm, 2576–2577
- selective nonoperative management (SNOM), 2576
- zone 1, 2570–2572

- zone 2, 2572–2573
- zone 3, 2573

- Cervical lymph nodes
  - anatomy of, 346–347
  - leveling, 345*f*
  - metastatic disease
    - patterns of, 348–349
    - risk factors for, 347–348, 348*f*
  - removal of, 349
- Cervical lymphadenectomy, three-field, 990
- Cervical mediastinoscopy
  - contraindications, 803
  - lung cancer staging, 801, 802
- Cervical myotomes, migration of, 820*f*
- Cervical pleura, 773
- Cervical plexus
  - anatomy of, 296, 359*f*
  - formation of, 285, 896
  - neck, 286*f*
  - spinal accessory nerve and, 507*f*
- Cervical plexus nerve block, 297
- Cervical ribs
  - anatomy, 289
  - congenital, 2549
  - and first rib resection, combined resection of, 2557*f*
- Cervical spine, traumatic injuries, 443
- Cervical sympathetic chain, 285, 307, 2549
- Cervical ultrasonography, 534, 535*f*
- Cervical vascular injuries
  - blunt force trauma, 2570
  - diagnosis and imaging, 2576, 2577
  - etiology/epidemiology, 2569–2570
  - historical perspective, 2569
  - overview of, 2569, 2576

- penetrating missile wounds, 2570
- penetrating wounds, 2575, 2576
- surgical repair, 2569
- vertebral artery trauma, 2574–2576

- Cervical-rib compression syndrome, 308
- Cervicoaxillary sheath, 289, 295
- Cervicothoracic ganglion, 285
- Cervix, retraction of, 2160*f*
- Cesarean delivery
  - complications
    - infections, 2126–2127
    - pain, 2126
  - definition of, 2119
  - history of, 2119
  - indications, 2119
  - maternal mortality, 2119
  - outcomes, 2119–2120
  - postoperative management, 2126–2127
  - preoperative planning
    - anesthesia, 2120
    - patient preparation, 2120
  - prophylactic antimicrobial agents, 114*t*
  - rates of, 2119
  - recovery from, 2126
  - risks, 2119
  - sterilization at time of, 2123
  - surgical technique, 2120–2121, 2120*f*
  - uterine incisions, 2122*f*
- Cetavon, 1306
- *CFTR* gene, 1493, 1525
- Chagas disease, 897, 969
- Chao, James, 251
- Charcot arthropathy, 2391, 2392, 2414
- CHARGE syndrome (Coloboma, Heart anomalies, Atresia of the

choanae, Retardation, Genital hypoplasia, and Ear deformities), 1033–1034
- CHARISMA. *See* Clopidogrel for High Atherothrombotic Risk and Ischemic Stabilization, Management, and Avoidance
- Chemical ablation, tumor, 196
- Chemodectoma, carotid body tumors, 2267
- Chemokines, 5, 6
- Chemoradiation therapy (CRT)
  - preoperative, 1839
  - salvage esophagectomy after, 998
- Chemoreceptors, carotid body tumors, 2267
- Chemotactic chemokines. *See* Chemokines
- Chemotherapy
  - ablation therapy with, 195
  - intravesical, 2036
  - liposomal, 195–196
  - neoadjuvant
    - in bladder cancer, 2036–2037
    - in rectal cancer, 1823
    - timing in CRC, 1812–1813
  - in recurrent rectal cancer, 1867
  - surgical risk and, 27
- Chemotherapy-associated steatosis (CASH), 1326
- Chest
  - drains, 750
  - embryology of, 772
  - increase in volume, 826
  - muscles of, 772
  - pain, nutcracker esophagus and, 981
  - physiotherapy, presurgical, 985
  - radiography in PUD, 1114
  - traumatic injuries
    - air leaks in, 789
    - initial evaluation, 788

- Chest tubes, blood loss assessment with, 1016*f*
- Chest wall
  - anatomy
    - arteries, 776–777
    - neurovascular bundles, 745, 745*f*
    - topographic, 743*f*
    - veins, 777–778
  - applied anatomy of, 772–787
  - back, superficial muscles, 776*f*
  - breast cancer recurrence, 754, 754*f*
  - congenital anomalies, 772, 773*f*
  - embryogenesis, 772, 772*f*
  - imaging
    - MRI, 742
    - PET, 742
  - injuries to
    - flail chest, 791
    - rib fractures, 790
    - sternal fractures, 790–791
  - lymphatics
    - deep, 778–779
    - superficial, 778
  - muscles, extrinsic, 773–775
  - nerves, 779–780
  - reconstruction, 234–236
    - in breast cancer, 742–754
    - closure, 753*f*
    - complications, 750–753
    - outcomes, 752–753
    - postoperative management, 750
    - preoperative considerations, 743*t*
    - skeletal stabilization, 234, 235–236
    - wound complications, 751
  - resection

- beyond 4 ribs, 742
- in breast cancer, 742–754
- completed, 746*f*
- technique, 744–748
- surface anatomy, 772–773

Chest X-rays (CXRs)
- preoperative, 23, 23*t*
- pulmonary risk and, 24

Chevrel onlay prosthesis, 162, 162*f*

Child-Pugh classification, 25, 1616, 1616*t*

Children. *See also* Infants; Pediatric patients
- in Crohn disease, 1662
- growth retardation, 1662
- Hirschsprung disease, 1972
- natal injuries, 2106
- obesity in, 1176
- passive smoking, 102
- rectal prolapse in, 1905
- renal artery occlusive disease, 2433, 2443
- renal tumors, 2086 (*See also* Wilms tumor)
- shock in, 2106
- urinary reflux in, 2045–2046

Child-Turcotte classification, 25

Child-Turcotte-Pugh (CPT) class A, 1316

ChloraPrep, wound preparation, 438

Chlorhexidine (CHG), 2120

Chlorhexidine-alcohol use, 33

Cholangiocarcinoma (CCA). *See also* Hilar cholangiocarcinoma (CCA)
- chronic liver disease and, 1316
- classification and staging, 1399*f*, 1406, 1406*f*
- diagnosis, 1403, 1411
- hilar, management of, 1283
- imaging studies, 1374*f*
- liver transplant for, 1401, 1410

- percutaneous transhepatic cholangiogram, 1374*f*
- perihilar, 1281
- prevalence of, 1410
- primary sclerosing cholangitis, association with, 1395, 1402
- PSC as risk factors for, 1283
- recurrence, 1410
- risk factors for, 1403, 1404
- surgery
  - contraindications, 1406
  - indications, 1406
  - postoperative care, 1411
  - resection, 1399, 1410
  - transplantation, 1411–1412
- treatment, 1411
- ultrasonographic image, 187*f*

Cholangiograms
- intraoperative, 1320*f*, 1346, 1347*f*, 1353–1367, 1359*f*
  - fluoroscopic, 1268, 1269*f*
- left hepatectomy, 1267

Cholangiopancreatography, 1302

Cholangitis, 1274–1275
- biliary choledochoduodenostomy followed by, 1420
- biliary enteric anastomosis followed by, 1420
- presentation, 1354

Cholecystectomy
- bile leak after, 1381–1382
- early *versus* late, 1366
- for gallstone disease, 1343
- hemorrhage, 1346
- hemostatic agents, 1346
- history of, 1393, 1394
- incidence of, 1393–1394
- incisions, 1345
- indications for, 1343

- injuries occurring during, 1373–1374
- in intestinal bypass, e40
- laparoscopic, 271, 1342, 1353–1367
  - anesthesia, 1355
  - in bile duct injuries, 1271
  - bile leaks after, 1363*f*
  - biliary scanning, 190*f*
  - complications, 1360, 1360*t*
  - contraindications, 1354
  - conversion to open, 1351, 1360
  - hemorrhage, 1360–1361
  - hernias after, 1365
  - mobility gained, 1346
  - operative equipment, 1354–1355
  - outpatient, 1351
  - pneumoperitoneum, 1355–1356
  - porta hepatis exposure, 1356
  - post-cholecystectomy syndrome, 1365
  - postoperative care, 1360
  - preoperative planning, 1354–1355
  - room setup for, 1355*f*
  - surgical technique, 1355–1356
  - technique, 1351
  - timing of, 1366
  - trocar placement, 1356
- laparoscopic and open compared, 1382
- laparoscopy, ultrasound-guided, 193
- mini version, 1345
- NOTES, 210
- open, conversion to, 1360
- open pancreatic necrosectomy and, 1534
- in pancreatitis, 1523–1524
- patient selection, 1285
- postoperative management, 1350–1351

- primary open, 1344*t*
- for primary sclerosing cholangitis, 1400
- surgical, 1347–1348

Cholecystitis
- acalculous, 1273
- acute, treatment of, 1273
- acute calculous, 1272–1273
- acute perforated, 1352
- emphysematous, 1272–1273
- gangrenous, 1273, 1347
- octreotide and, 1654

Cholecystojejunostomy. *See also* Laparoscopic cholecystojejunostomy
- in bile duct reconstruction, 1376, 1381
- gastrojejunostomy combined with, 1412
- overview of, 1412–1414
- side-to-side, 1413*f*

Cholecystostomy
- drainage tube during, 1344*f*
- indications, 1344
- open, indications, 1344–1345
- tube placement, 1351–1352

Choledochal cysts (CCs)
- classification, 1421, 1422*f*
- diagnosis of, 1422–1423
- dissection of, 1424*f*
- etiology, 1421
- infected, 1274
- malignancy of, 1422
- operative specimen, 1425*f*
- operative treatment of, 1421–1427
- pathophysiology, 1421
- presentation, 1421–1422
- resection, 1423*f*
- transection of, 1425*f*

- treatment, 1423–1425
  - outcomes, 1425–1426
- type I, 1422*f*
- type II, 1424
- type III, 1424
- type IV, 1424
- typeIV, 1424–1425

- Choledocho-choledochostomy, 1441
- Choledochoduodenostomy
  - in bile duct reconstruction, 1376, 1381, 1382
  - biliary enteric bypass combined with, 1420
  - Carrel patch for, 1339, 1339*f*
  - complications
    - cancer, 1420
    - cholangitis, 1420
  - end-to-side, 1419*f*
  - indications, 1349–1350
  - lateral (*See* Lateral choledochoduodenostomy)
  - in pediatric patients, 1420
  - side-to-side, 1350*f*
  - surgical technique, 1388*f*, 1390*f*
- Choledochojejunostomy, 1441
  - alternatives to, 1420
  - biliary enteric bypass combined with, 1420
  - end-to-side, 1417*f*
  - gastrojejunostomy combined with, 1412
  - side-to-side, 1413*f*, 1418–1419, 1419*f*
- Choledochojejunostomy/hepaticojejunostomy
  - indications, 1414–1415
  - laparoscopic, 1419
  - postoperative care, 1419
  - preoperative evaluation and planning, 1415
  - surgical technique, 1415–1419
- Choledocholithiasis

- biliary obstruction and, 1286
- decision making, 1362
- diagnosis, 1274–1275
- diagnosis and treatment, 1393
- with obstruction, 1274–1275
- treatment, 1274–1275

Choledochotomy
- closure of, 1348–1349
- history of, 1362
- retaining sutures, 1349*f*
- T-tube secured, 1349*f*

Cholelithiasis. *See also* Gallstones
- diagnosis of, 1343
- in pregnancy, 1284
- symptomatic, 1272, 1353

Cholescintigraphy, radionucleotide, 1272

Cholestasis, 19

Cholesterol, e36–e43

Cholestyramine (Questran), 1646, 1647

Cholinergic pathway, activation of, 8

Chondrocalcinosis, 257, 259*f*

Chondrocutaneous advancement flaps, 219*f*

Chorda tympani, 321, 322

Chordomas, retrorectal, 1882

Choroid plexus, 7

Chromaffin cells, 508, 572–573

Chromosomal (trisomy 18) abnormalities, 848

Chronic appendicitis, 1694

Chronic deep venous thrombosis (DVT)
- diagnosis, 2500–2501
- etiology and pathophysiology, 2500
- overview of, 2499
- treatment
  - adjunctive procedures, 2507

- anticoagulation, 2509
- complications, preventing, 2507–2509
- conservative management, 2501
- endovascular treatment, 2501
- follow-up and reinterventions, 2509
- hybrid treatment, 2501, 2509
- open surgical treatment, 2501–2506, 2504*f*, 2505*f*, 2506*f*, 2507*f*, 2508*f*
- special considerations, 2506–2509

Chronic illnesses
- monitoring of, 34–35
- postoperative management of, 34–35
- preoperative assessments, 23–27
  - cardiovascular testing, 23–24
  - liver function, 25–26
  - pulmonary function testing, 24
  - renal function testing, 24–25

Chronic kidney disease (CKD)
- end-stage renal disease (ESRD), transition to, 2540
- liver abscesses and, 1286
- preoperative evaluation in, 2021
- radical nephrectomy and, 2022
- secondary HPT and, 551*t*

Chronic mesenteric artery occlusion
- opening, 2464

Chronic mesenteric ischemia (CMI)
- causes of, 2464
- clinical presentation, 2454
- diagnostic imaging, 2454
- overview of, 2453
- pathophysiology, etiology, and natural history, 2453–2454
- treatment strategies
  - endovascular revascularization, 2459, 2460–2463
  - endovascular techniques, 2453, 2464

- open surgical revascularization, 2453, 2455–2459, 2462–2463, 2464
- outcomes, 2462–2463
- overview of, 2454–2455
- preoperative evaluation, 2455
- survival, 2463–2464

- Chronic neurogenic bladder, after RT, 2136
- Chronic obstructive pulmonary disease (COPD)
  - postoperative ventilatory support, 99–100
  - preoperative testing, 24
  - surgical pulmonary risk, 88, 89
  - and thoracoabdominal aortic aneurysm, 2280, 2282
- Chronic occlusive disease, 2450–2451
- Chronic pancreatitis (CP). *See also* Acute pancreatitis; Pancreatitis
  - alcohol abuse and, 1510*f*
  - complications, 1505, 1536–1551
  - CT imaging, 1494*f*
  - diagnosis, 1492, 1493–1495
  - endoscopic interventions, 1501–1502
    - denervation procedures, 1501
  - etiology, 1493
  - evaluation, 1493–1495
  - operative interventions, 1505–1514
  - pain management, 1503–1504, 1581–1582, 1582*t*
  - pancreas excision, 1501*f*
  - pathogenesis, 1493
  - PPPD, 1512–1513
  - strictures, 1509*f*
  - surgical therapy for, 1492–1505
    - patient selection, 1495
    - preparation for, 1495
    - procedure selection, 1495–1503
    - types of, 1496*f*
  - worldwide incidence, 1503
- Chronic venous insufficiency (CVI), 2499

- Chronic venous occlusive disease (CVD), 2509
- Chyle fistulae, 529
- Chyle leaks, 529
- Chylomicrons, 60
- Chylous ascites, 2066, 2085
- Cigarette smoking
  - and aortoiliac occlusive disease, 2350
  - reversed vein bypass grafts, 2358
  - and thoracoabdominal aortic aneurysm, 2280, 2282
- Cimetroopium bromide, 972
- Cinacalcet, in HPT, 551
- Ciprofloxacin, 1715
- Circle of Willis, 2247
- Circumaortic renal veins, 2512
- Circumferential limb measurement, 674
- Circumferential resection margins (CRM)
  - evaluation of, 1832
  - full-thickness dissection, 1942*f*
  - MRI prediction of, 1817, 1817*f*
  - rectal neoplasm workup, 1938
  - recurrences and, 1822–1823, 1837
  - shifting paradigms, 1854
- Circumflex scapular (CS) vessels, 771
- Circumventricular organs (CVOs), 7
- Cirrhosis
  - alcoholic, 1599
  - BEVs in, 1605
  - liver transplantation for, 1597–1598
  - presurgical assessments, 25
  - thrombocytopenia and, 1603
  - traumatic hepatic injuries and, 1341–1342
- Cisatracurium, 96
- Cisplatin
  - in bladder cancer, 2036–2037

- for esophageal cancer, 984
- neoadjuvant chemotherapy, 2036–2037
- before resection, 984

- Cisterna chylii, 780*f*
- *Cladosporium* spp., 984
- Clamp-and-sew, 2285
- Clarithromycin, 1115
- Claudication
  - aortoiliac occlusive disease and, 2350
  - brachiocephalic reconstruction. and, 2259
  - endovascular treatment, 2384
  - reversed vein bypass graft, 2367
- Clavicle, sternal development, 773*f*
- Clavien-Dindo classification, 1520–1521
- Clear cell carcinomas, 1247, 2087
- Cleft lip, 369
- Cleft palate, 369
- Cleido-cliedo ligament, 564
- Clindamycin
  - dosage, preoperative, 2233
  - MRSA susceptibility, 253
  - presurgical in LPLND, 2055
- Clinical trials. *See Specific* conditions; *Specific* procedures
- Clitoris, swelling of, 1825
- Clopidogrel (Plavix)
  - coagulopathies and, 105
  - drug induced coagulopathy and, 104
  - preoperative discontinuation of, 110
  - presurgical management of, 985
  - surgical management and, 28
- Clopidogrel for High Atherothrombotic Risk and Ischemic Stabilization, Management, and Avoidance (CHARISMA), 2250
- Cloquet node, 430–431, 431*f*
- Clorpactin, 1609

- Closed valve repair, in venous insufficiency, 2523
- *Clostridium* colitis
  - acute toxic, 1751
  - antibiotic therapy, 1724
  - refractory, 1720–1721
  - severe complicated, 1720
  - trends, 1751
- *Clostridium* spp.
  - *C. difficile*
    - hospital-acquired infections, 1724
    - prevalence of, 1719
    - pseudomenbranous colitis and, 1719
  - endotoxins, 238
  - gut microbiome and, 65
- Clotting disorders, pulmonary complications and, 90
- Clotting factors, storage issues, 107
- Clouqet node, 1967
- CLOVES syndrome, 382
- Clubbing in liver disease, 1620
- Coagulation cascade, activation of, 2
- Coagulation factors, 1346
- Coagulation studies
  - perioperative, 27
  - preoperative, 22, 23, 23*t*
- Coagulative necrosis, 195
- Coagulopathies
  - drug induced, 104
  - in the injured, 136*f*
  - postsurgical, 2163
  - surgical risk and, 27
- Coagulopathy of liver disease, 104
- Cobb Dissector, 1879*f*
- Cobimetinib, 427
- Coccyx, excision, 1810

- Codeine, ostomy output and, 1774
- Coffee
  - dyspepsia and, 1105
  - gallstone risk and, 1353
- Cohen, Jacob Solis, 385, 386*f*
- Colchicine, 1928
- Colectomy
  - ALPPS and, 1462*f*
  - for *C. difficile* colitis, 1751
  - complications
    - leaks, 1793
    - pulmonary emboli, 1794–1795
    - retrograde ejaculation, 1795
    - urinary retention, 1795
  - laparoscopic
    - for diverticulitis, 1758–1759
    - hand-assisted approach, 1749–1750
    - outcomes, 1780–1781
    - utilization of, 266
  - left-sided
    - laparoscopic, 1791–1793
    - patient positioning, 1791
    - port placement, 1793*f*
    - robotic-assisted, 1792–1794
    - trocar placement, 1791
  - open
    - left-sided, 1790–1791
    - medial-to-lateral approach, 1749
  - open sigmoid, 1758
  - postoperative care, 1794
  - prophylactic in HNPCC, 1743
  - robotic-assisted, 266, 267*f*, 1787
  - segmental, 1705
  - subtotal, 1741–1752

- end ileostomy and, 1734*f*
- ileorectal anastomosis, 1960*f*
- for toxic megacolon, 1723
- total
  - ileorectal anastomosis and, 1741–1752
  - laparotomy, 1741
  - for toxic megacolon, 1723
- total abdominal, 1711–1712, 1741–1752

Colic flexures, 1678*f*, 2003*f*

Colitis. *See also Clostridium* colitis
- pseudomenbranous, 1719
- severe/fulminant, 1733–1734
- surgery for, 1724

Collagen vascular disease, 2279

Collagenase, 238

Collagens
- breast reconstruction, 225–226
- in hernia repair, 2242
- platelet aggregation and, 133

Collar button abscesses, 255

Collen’s sign, 1526

Colles’ fascia, Fournier gangrene, 128

Collis gastroplasty
- alternatives to, 916, 959
- hiatal hernia repair using, 932
- indications for, 948
- overview of, 911–913, 911*f*
- for presbyesophagus, 868
- thoracotomy with, 958

Colloid solutions, 135–136

Coloanal anastomosis, 1961*f*
- handsewn, 1835, 1836*f*
- using stapling devices, 1910–1911, 1910*f*, 1911*f*

Colocutaneous fistulae, 1756

- Coloduodenal fistulae, 1664
- Cologastric fistulae, 1710
- Colon. *See also* Ascending colon; Descending colon; Transverse colon
  - adenocarcinoma, 1283–1284
  - attachment, 1676*f*
  - blood supply, 1679–1681
  - catheter lavage, 1722*f*
  - colectomy, 1789–1794
  - decompression
    - intraoperative, 1706*f*
    - self-expanding metallic stents, 1703–1705, 1704*f*
    - for sigmoid volvulus, 1701–1703
  - innervation of, 1681, 1686*f*
  - ischemia, 2315–2316
  - lymphoid drainage, 1681
  - mesentery
    - division of, 1749*f*
    - ligation of, 1749–1750
  - mobilization of, 1713, 1723, 1782*f*, 1828–1829
    - laparoscopic, 1761*f*
    - lateral-to-medial approach, 1747–1749, 1828
    - medial-to-lateral approach, 1828, 1829*f*, 1830*f*
  - motility, 1743
  - needle decompression, 1722*f*
  - normal function, 1732–1733
  - normal physiology, 1732–1733
  - obstructions
    - colostomy creation and, 1768
    - stenting of, 213–214
  - peritoneal attachments, 1765*f*
  - pool suction decompression, 1722*f*
  - preparation for colostomy, 1764–1765
  - pseudo-obstruction, 206
  - retroperitoneal attachments, 1747*f*

- stents, deployed, 1705*f*
- vascular supply, 1680*f*, 2156*f*
- washout after anesthesia, 1973

Colon cancer
- histology, 1818*f*
- preoperative planning, 1789
- presentation, 1789
- risk factors, 1395
- surgery and chemotherapy for, 1877–1882

Colon conduits
- transverse, 2111*f*
- urinary diversions, 2110–2111

Colon pouch, 1810, 1810*f*

Colonic conduits
- preparation of, 994–995, 995*f*
- transverse, 1959*f*
- vascular supply, 994

Colonic inertia, 1743

Colonic interposition, esophagectomy with, 1152*f*

Colonic lavage
- diverting loop ileostomy and, 1723
- ontable, 1705
- in toxic megacolon, 1724

Colonoscopies
- colonic Crohn disease, 1711
- indications for, 206
- lesion sampling, 213*f*
- preoperative planning, 1816
- in primary sclerosing cholangitis, 1395, 1402
- scope insertion, 211*f*
- screening use of, 206
- technique of, 211–212
- therapy during, 212–214

Colonscopes

- positioning of, 211, 212*f*
- withdrawal, 212

Colony stimulating factors, 27

Coloplasty, 1810, 1835*f*

Color, perfusion assessed by, 250

Colorectal anastomoses
- complications, 1836
- hydro-pneumonic testing, 1836
- retroileal, 1867

Colorectal cancer (CRC)
- anterior resection, 1794
- aspirin prophylaxis, 1752
- clinical presentation, 1781
- in colonic Crohn disease, 1709–1711
- embryologic basis of, 1799
- family histories of, 206
- hepatic metastases and, 1316
- incidence, 1860
- large bowel obstruction and, 1699
- liver abscesses and, 1286
- lymph nodes, 1801
- mortality rates, 1824
- peritoneal metastases, 1877
- recurrence rates, 1868
  - radical resections in, 1868
- right colectomy for
  - contraindications, 1781
  - indications, 1781
  - preoperative planning, 1781
- total protocolectomy for, 1719

COlorectal Cancer Laparoscopic or Open Resection (COLOR) Trial, 1819–1820

Colorectal surgery
- complications, 1750

- mechanical bowel prep, 117*t*
- postoperative care, 1669–1670, 1750
- robotic-assisted, 266

Colostomy
- closure, 1763–1772, 1768–1770
- colon preparation, 1764–1765
- complications, 1770–1771
- construction, 1763–1772
- creation of, 1771, 1773
  - Brooke technique, 1767*f*
  - indications, 1763
- end
  - closure, 1769*f*
  - resection with, 1705–1706
- exposure, 1763–1764
  - laparoscopic, 1763–1764
- extraperitoneal tunneling, 1768*f*
- irrigation kit, 1776*f*
- laparoscopic, 1763–1764
- loop, 1767*f*
  - closure, 1768–1769, 1769*f*
  - for large bowel obstruction, 1706
- open, 1767*f*
  - planning for, 1764
- output, 1771
- permanent, 1809–1810
- permanent end, 1766–1767
- placement of, 1763
- postoperative care, 1770
- preoperative planning, 1763
- self-dilatation, 1771
- site of, 1763*f*
- stoma site preparation, 1765–1766
- transverse loop, 1771

- Colotomy, supporting column, 1665*f*
- Colovaginal fistulae, 1756
- Colovesical fistulae, 1756
- Colporrhaphy, 2166–2181
  - anterior
    - planning for, 2170
    - technique, 2170–2173
  - posterior
    - goals of, 2177–2178
    - technique, 2178–2180
  - postoperative management, 2173–2175, 2180*f*
  - sutures, far-near, near-far, 2173*f*, 2174*f*
- Columnar cell change, 605
- Columnella, 325*f*
- Columns of Morgagni, 1824
- Combined sliding and paraesophageal hernia, 828, 831*f*
- Common bile duct (CBD)
  - anatomic relationships, 1342, 1476*f*, 1482*f*
  - anatomy of, 1330
  - blood supply, 1420
  - clearance of, 1348
  - closure of, 1365
  - dilated, 1387
    - medium stones and, 1363–1364
  - exploration of, 1348–1349, 1354, 1388*f*
    - fluoroscopic, 1364*f*
  - exposure of, 1388
  - Fogarty catheter passage through, 1390*f*
  - formation of, 1268, 1343
  - incision into, 1390*f*
  - injuries to, 1362*f*
    - classification of, 1361
    - incidence, 1361
    - management, 1361–1362

    - prevention, 1361
    - repair of, 1339
  - laparoscopic exploration, 1362
  - ligation of, 1420
  - locating, 1415*f*
  - narrowing of, 1359
  - resection, 1410
  - retained stones, 1362–1364
  - small stones and, 1362–1363
  - stenosis, 1515
  - stones, LC management of, 1364*f*
  - strictures, 1554
  - transcystic *vs.* transductal approach, 1362
  - ultrasound evaluation, 187*f*, 193, 1347*f*
  - variations, 1480*f*
- Common bile duct exploration (CBDE), 1352, 1353–1367
- Common carotid artery
  - anatomy of, 71*f*, 288*f*, 291, 298*f*, 321*f*, 359*f*, 363*f*
  - branches, 292*f*
  - division of, 308
  - exposure of, 506*f*, 526
- Common facial vein, 305, 318, 320
- Common femoral artery, 2588
- Common femoral vein, 2483*f*, 2487*f*, 2509
- Common hepatic artery
  - aberrant, 1484*f*
  - anatomic relationships, 1437*f*, 1482*f*, 1484
  - anatomy, 1266
  - anomalous, 1484
  - configuration, 1331*f*
  - retrograde bypass to, 2457
- Common hepatic duct, 1268, 1342
- Common iliac artery (CIA), 1825*f*, 2008*f*
- Common iliac vein (IMV), 1825*f*

- Community-associated infections, 121, 122–123
- Comparison of Open *versus* Laparoscopic Surgery for Mid and Low Rectal Cancer After Neoadjuvant Chemotherapy (COREAN) trial, 1820
- Compartment syndrome
  - conditions leading to, 258
  - description of, 258
  - hand injuries, 258–259
  - urgent attention to, 251
  - wrist, 258–259
- Compensatory anti-inflammatory response syndrome (CARS), 132
- Complement system, 3–4
- Complete blood counts (CBCs)
  - preoperative testing, 22, 23*t*
  - results in PUD, 1114
- Complete mesocolic excision (CME), 1786–1787, 1788
- Composite grafts and allografts, 2368–2369
- Composix mesh, 861
- Compression bandages, 675, 678–679
- Compression stockings, 32
  - deep venous thrombosis treatment with, 2490
  - venous insufficiency
    - postoperative care with, 2520
    - presurgical treatment with, 2524
- Compressor urethrae, 2009*f*
- Computed tomographic angiography (CTA)
  - for aortofemoral bypass, 2332
  - aortoiliac occlusive disease, 2351, 2353*f*
  - axillary injury shown in, 2587*f*
  - for brachiocephalic reconstruction, 2259
  - carotid bifurcation disease, 2249, 2250*f*
  - carotid body tumors, 2269–2270*f*, 2269–2271
  - cervical injury diagnosis with, 2571–2573, 2575–2577
  - endovascular procedure, 2384
  - extra-anatomic bypass, 2344

- extremity injury diagnosis with, 2587
- for femoral artery aneurysm, 2319
- of renal artery occlusive disease, 2434
- for reversed vein bypass grafts, 2358
- thoracoabdominal aortic aneurysm, 2281, 2281*f*

- Computed tomographic enterography (CTE), 1673
- Computed tomography (CT)
  - aortic graft infection diagnosis through, 2472, 2472*f*
  - body composition assessment, 55
  - colonic Crohn disease, 1711
  - contrast-enhanced, 2091–2092
  - in Crohn disease, 1663
  - helical, of portal veins, 1604
  - in liver hydatidosis, 1302
  - in nephrolithiasis, 2012
  - overuse of, 582
  - pancreas-protocol, 1553–1554
  - in PUD, 1114
  - in RCC, 2020
  - rectal neoplasm workup, 1938
  - renal, in nephrolithiasis, 2011
  - in renal trauma, 2091–2092
  - studies in ovarian cancer, 1249
  - surveillance, 1869
- Computed tomography enterography (CTE), 1663, 1711
- Computed tomography venography, 2492–2493
- Computer Motion, Inc., 262
- Computer tomography-based three-dimensional conformal radiation, 645, 649
- Concussion, at-home observation, 488
- Conduit selection, 2592–2593
- Condylomata, 1928
- Congenital central hypoventilation syndrome, 1971
- Congenital diaphragmatic anomalies

- types of, 820–821, 823–826

- Congenital diaphragmatic hernia (CDH), 820–823
  - classification of, 844*f*
  - diagnosis in utero, 839
  - diagnosis of, 841
  - disorders associated with, 841, 848
  - hernia recurrence, 843–844, 845
  - interventions, 841–845, 843*f*
  - left
    - on postresuscitative radiograph, 842*f*
    - surgical correction of, 845*f*
  - murine nitrofen model, 821, 823
  - overview of, 820–821, 823, 840, 846
  - pathophysiology, 842–843
  - prognosis, 841, 845
  - right, overview of, 845–846
  - in utero treatment of, 839
- Congenital duodenal obstruction, 1166–1175
- Congenital eventration, 825–826
- Congenital hamartomas, 1275
- Congenital heart disease, NEC and, 1976
- Congenital hemangiomas, 373
- Congenital high airway obstruction syndrome (CHAOS), 823
- Congenital paraesophageal hernia, 823
- Congenital pyloric stenosis, 1166–1175
  - embryology of, 1057*f*
  - genetic predisposition to, 1166
  - pathophysiology of, 1166
- Congenital short esophagus. *See* Short esophagus
- Congenital-Bochdalek hernias, 2203*t*
- Congestive heart failure (CHF), 103
- Conscious sedation in facial trauma, 437–438
- Constipation
  - chronic, colonic inertia and, 1743

- Hirschsprung disease and, 1972
- slow-transit, 1961–1962
  - causes, 1961
  - diagnosis, 1961–1962
  - treatment, 1962
- Constitutional assessments, 2473
- Consultations, preoperative, 30–31
- Continence. *See also* Incontinence
  - definition of, 2052
  - fecal (*See also* Incontinence, fecal)
    - after Hirschsprung disease surgery, 1976
    - maintenance of, 1824
  - urinary, 2069
- Continent cutaneous diversions, 2037*t*
- Continent neobladder, 2037
- Continuous positive airway pressure (CPAP), 97*t*
- Contralateral prophylactic mastectomy (CPM), 223
- Contrast esophagograms, 999
- Contrast media, contraindications, 543
- Conus elasticus, 303, 304*f*
- Conventional *versus* Laparoscopic-Assisted Surgery in Colorectal Cancer (CLASSIC) trial, 1819, 1821
- Cooper, Astley, 556
- Cooper's ligaments, 2186
  - anatomic relationships, 2211–2212, 2211*f*, 2212, 2219*f*
  - of breast, 594, 595*f*, 601
  - exposure of, 164
  - hernia repair, 2210, 2217–2218
  - in inguinal hernia repair, 2230, e81
  - in Kugel method for groin hernia, e91
- Coracobrachalis muscle, 775*f*
- Coracoid process, 2549
- Cordectomy. open, 392
- Core needle biopsies

- and ablation therapy, 655
- benign breast disease, 603–604

Corlette cholangiocarcinoma (CCA) classification system, 1406*f*

Coronary air emboli, initial evaluation, 788

Coronary artery bypass graft (CABG)
- robotic-assisted, 269

Coronary artery disease (CAD)
- after abdominal aortic aneurysm repair, 2316
- after intestinal bypass, e42–e43

Coronary artery revascularization prophylaxis (CARP), 23

Coronary ligaments, 833

Coronary sinus, connections, 779*f*

Coronary subclavian steal, 2259

Corticosteroids
- antenatal administration of, 839
- in CDH, 839
- immunosuppression and, 146
- for infantile hemangiomas, 376
- intralesional, 376
- intraoperative
  - nausea and vomiting prophylaxis, 522
  - postoperative pain reduction and, 522
- preoperative, 89
- response to surgical trauma, 8
- topical, 375

Corticotropin release, 9

Corticotropin-releasing hormone (CRH), 6

Cortisol, 2, 9

Cortisol-releasing hormone (CRH), 9

Costal groove, rib, 775*f*

Costal portion of diaphragmatic musculature, 826

Costimulation blockade, 148–149

Costocervical trunk, 288*f*

Costoclavicular compression syndrome, 308

- Costoclavicular ligament, 2549
- Costoclavicular space, 289, 2549
- Costodiaphragmatic recess
  - anatomic relationships, 2002
  - anatomy, 774*f*
  - description of, 773
  - location of, 833
- Costomediastinal recess, 774*f*
- Costomediastinal sinuses, 773
- Coumadin®, 2233. *See also* Anticoagulants
- Coupling, ultrasound definition of, 180
- Courvoisier, Ludwig, 1362
- Cowden syndrome, 383, 516
- CPB. *See* Celiac plexus block (CPB)
- CPN. *See* Celiac plexus neurolysis (CPN)
- Cranial nerves. *See also Specific* nerves
  - injuries, 2277
- Craniectomy, surgical goals, 478–479
- Craniotomy, surgical goals, 478–479
- C-reactive protein (CRP)
  - in Crohn disease, 1661
  - inflammation and, 1351
  - in monitoring antibiotic therapy, 130–131
  - regulation of, 6
  - synthesis of, 56
- C-reactive protein:prealbumin ratios, 56
- Creatinine-height index (CHI), 55
- Creatinine elevation, 2144
- Creatinine phosphokinase, 2418
- Cremaster muscle, 2234
  - incision of, 2216
  - in inguinal hernia repair, e72–e74, e73*f*
  - in inguinal herniorrhaphy, e61, e63, e63*f*
  - in plug-and-patch groin repair, 2233–2234

- Cremer cystotome, 1537
- CREST. *See* Carotid Revascularization Endarterectomy *vs.* Stenting Trial
- Cribiform fascia, e61, e64, e65f
- Crichoid cartilage, 284
- Cricohyoidopexy, 392
- Cricoid bone, 307
- Cricoid cartilage
  - anatomy of, 71*f*, 303, 304*f*
  - incision superior to, 1003*f*
  - risk to, 2569
- Cricopharyngeal muscle, 298*f*, 1149
- Cricopharyngeal myotomy, 1146–1147, 1146*f*, 1149
- Cricopharyngeus muscle, 301, 889
- Cricothyroid, innervation of, 291
- Cricothyroid ligament, 304*f*
- Cricothyroidotomy
  - description, 289
  - emergent, 434
  - in facial trauma, 434
- Cricothyrotomy, 489, 494
- Criminal nerve of Grassi, 1099*f*, 1111, 1113
- Critical illness myopathy (CIM), 36
- Critical illness polyneuropathy (CIP), 36
- Critical illnesses. *See also Specific* conditions
  - gut barrier failure in, 20
  - hyperglycemia in, 16
  - lipid metabolism in, 17–18
  - liver dysfunction in, 19
  - metabolic demand after, 54
- Critical limb ischemia. *See also* Acute limb ischemia
  - revascularization, 2375–2377, 2383
- Crohn colitis
  - associated conditions, 1709

- ileorectal anastomosis and, 1742
- laparoscopic total proctocolectomy, 1713–1714
- total colectomy, 1742

- Crohn disease (CD)
  - adenocarcinoma risk and, 1662
  - anal adenocarcinoma in, 1717
  - anal canal strictures, 1719
  - capsule endoscopy in, 1673
  - clinical presentation, 1661
  - colonic
    - abscesses, 1710
    - fistulae, 1710
    - indications for surgery, 1710
    - outcomes, 1714
    - preoperative planning, 1711
    - presentation, 1710
    - surgical technique, 1711–1714
    - surgical treatment, 1709–1719
    - total proctocolectomy for, 1714*f*
    - toxic megacolon, 1710
  - complications, septic, 1714
  - and continent ileostomy, e45, e47–e48
  - description, 1709
  - diagnosis, 1673
  - enterocutaneous fistulas and, 1650–1651
  - etiology, 1661
  - fibrostenotic scars, 1661
  - fibrotic ilial stricture, 1634*f*
  - fissure in ano and, 1913
  - ileal pouch surgery for, 1712
  - imaging, 1663
  - incidence of, 1661
  - infliximab for, 1654
  - laboratory findings, 1661

- large bowel obstruction in, 1709
- outcomes, 1671–1672
- pathophysiology, 1661
- perianal
  - anal stenosis, 1715
  - anal strictures, 1715
  - approaches to, 1730
  - causes, 1935
  - diagnosis, 1935
  - drainage of pus, 1935–1936
  - fistulizing, 1716*f*
  - incidence, 1709
  - multiple setons, 1717*f*
  - onset, 1709
  - preoperative planning, 1717
  - presentation, 1714–1717, 1935
  - surgical treatment, 1709–1719, 1717–1718
  - treatment, 1935–1936
- phenotypes, 1673
- postoperative therapy, 1672*f*
- primary sclerosing cholangitis, association with, 1395
- recurrence, 1672*t*, 1674, 1711
- retrovaginal fistulas, 1717
- small bowel
  - endoscopic recurrence scores, 1667*f*
  - outcomes, 1671–1672
  - surgical treatment of, 1661–1674
- small bowel obstruction, 1630, 1630*t*, 1634
- stricturing, 1661
- surgical treatment
  - complications, 1670–1671
  - minimally invasive techniques, 1668–1669
  - preoperative planning, 1662–1663
- “top-down” treatment algorithm, 1673

- total colectomy in, 1741
- TPN in, 46
- transmural, 1718
- treatment, historical perspective, 1718
- ventilatory risk and, 102

- Cross-catheter technique, 2545*f*
- Crossover femoral venous prosthetic bypass, 2502, 2504
- Crossover saphenous vein transposition, 2501–2502, 2509–2510
- “Crows foot” of Prayne, 1064
- Crow’s Foot of the vagus, 1099–1100
- Cruciform transverse ligament, 828
- Crura
  - anatomy, 827
  - as aortic opening margins, 831
  - arrangement of, 900, 900*f*
  - closure, figure-of-eight sutures, 939*f*
  - description of, 827*f*
  - diaphragmatic, 828*f*
  - dissection, 868, 953*f*
  - esophagus, securing to, 878*f*
  - muscular arms of, 828
  - origins and insertions at, 827
  - repair of, 869–870, 872, 882*f*, 915, 916, 954–955, 956*f*, 961
    - posterior, 869*f*, 878*f*
  - types of, 828*f*
- Crush injuries, zone of injury, 253
- Cruveilhier-Baumgarten syndrome, 1590, 1620
- Cryoablation
  - advantages of, 200
  - breast cancer, 204
  - of breast tumors, 658–660, 660*f*
  - HCC, 201
  - methodology, 200, 201*f*
  - in prostate cancer, 203

- in RCC, 204
- Cryoprecipitate, 108
- Cryopreservation, prosthetic grafts, 2369
- Cryopreserved allografts, 2478–2479, 2480
- Cryotherapy for RCC, 2022
- Cryptorchidism, incidence of, 2072
- *Cryptosporidium* spp., 1719
- Crystalloids, 135–136
- CSRS. *See* Central splenorenal shunts
- CTA. *See* Computed tomographic angiography
- CTLA-4. *See* CD152
- *CTNNB1* mutations, 1247
- Cuffitis, 1739
- Cuffs, vein, 2369–2370, 2369*f*
- Culp-Deweerd pelvic flap pyeloplasty, e56, e56*f*
- Cupid's bow, 325*f*, 326
- Cushing, Harvey, 274
- Cushing syndrome
  - causes of, 572
  - diabetes and, 16
  - diagnosis, 572
  - preoperative management of, 573–574
  - subclinical, 513, 572
- Cutaneous lymphocyte antigen (CLA), 5
- Cutaneous purpura, 1620
- Cutaneous uterostomy, 2108
- Cuthbertson, David, 2
- Cyanoacrylate, facial trauma and, 438
- Cyanotic heart disease, 1034
- Cyclooxygenases, 6
- Cyclosporine (CsA), 147, 1716
- Cylothorax after esophagectomy, 925
- Cystadenocarcinomas, 1276
- Cystadenomas, 1277

- Cyst-duodenostomy, 1544–1545
- Cystectomy
  - complications, 2048–2050
  - LPLND and, 2055
  - minimally invasive approaches, 2038
  - outcomes, 2052*f*
  - preoperative planning, 2038
  - presurgical radiation therapy, 2038
  - radical
    - for bladder cancer, 2034–2054
    - extended lymphadenectomy and, 2038–2045
    - female dissection, 2044–2045, 2044*f*–2046*f*
    - male dissection, 2041–2044, 2042*f*–2044*f*
    - outcomes, 2052
    - postoperative management, 2048*f*
    - supravesical diversion after, 2107
  - robotic-assisted, 270–271
  - urinary diversion and, 2116–2117
- Cyst-gastrostomy, 1529
  - anterior transgastric, 1547
  - dilatation of, 1539*f*–1540*f*
  - intragastric, 1546–1547
  - for pancreatic pseudocysts, 1543, 1544, 1546–1547
- Cystic artery
  - anatomy, 1266
  - control of, 1357
  - dissection of, 1345*f*
  - division, 1361*f*
  - identification of, 1267
- Cystic duct
  - anatomic relationships, 1342
  - cannulation of, 1463*f*
  - control of, 1357
  - Fogarty catheter passage through, 1390*f*

- gallstone blockage of, 1343
- orifice, ligation, 1347
- percutaneous access, 1359
- variations of, 1370
- visualization, 1356*f*
- wide-mouthed, 1359, 1360*f*

- Cystic fibrosis, toxic megacolon and, 1719
- Cystic fibrosis transmembrane conductance regulator *(CFTR)*, 1493
- Cystic hepatobiliary neoplastic lesions, 1277
- Cystic hygroma, 372*f*
- Cystic liver lesions, 1276
- Cystic plate
  - anatomic relationships, 1264, 1265
  - gallbladder on, 1268, 1342–1343
  - surface anatomy, 1264*f*
- Cystic retrorectal lesions, 1882
- Cystitis after radiation therapy, 2136
- Cyst-jejunostomy, 1544, 1545, 1547
- Cystobiliary communication (CBC), 1298, 1306–1307, 1307*t*
- Cystoceles, 1906
  - lateral repair, 2167
  - paravaginal defects and, 2167–2168
  - presentation, 2166
  - surgical repair, 2170–2173
  - symptoms, 2169
- Cystohepaticoducts, 1381
- Cystostomy, 1547*f*
- Cysts
  - aneurysmal bone, 1883
  - aspiration of, 191
  - branchial cleft, 368–369, 369*f*
  - of breast, 618–619, 619*f*
  - choledochal, 1421–1427
  - dermoid, 1884

- echonococcal, 1303
- enteric, 1882
- hydatid, 1298–1313
- lung, 2020
- neuroenteric, 1884
- pancreatic, 1549
- renal, 2020
- simple hepatic, 1276–1277
- tailgut, 1882, 1884, 1885*f*, 1886*f*, 1887*f*, 1888*f*, 1889
- thyroglossal duct, 366*f*, 367*f*, 500*f*

- Cytogastrostomy, 1548*t*
- Cytograft Tissue Engineering graft, 2368
- Cytokine storms, 133
- Cytokines
  - adaptive immunity and, 5–6
  - inflammation and, 6–7
  - levels after trauma, 16–17
  - postelective surgery, 6–7
  - release of, 2
  - response to surgical trauma, 8
- Cytomegalovirus (CMV)
  - congenital infection with, 848
  - pulmonary, 1454*f*
  - toxic megacolon and, 1719
  - transmission risk, 106*t*
- Cytoreduction surgery
  - goals of, 1878
  - plus HIPEC, 1881
  - surgical technique, 1878–1879
- Cytoskeleton, gluconeogenesis and, 51*f*
- Cytotec, 2124
- Cytotoxic T lymphocyte-associated antigen 4 (CTLA4). *See* CD152
- Cytotoxic T lymphocytes (CTLs), 142, 1456

D

- D cells, 1472
- D2 lymphadenectomy
  - description of, 1140
  - laparoscopic gastrectomy with, 1148
  - minimally invasive esophagectomy and, 927
  - operative procedure sequence for, 1131
  - technique, 1133–1134, 1134*f*
- Da Vinci Robotic Surgical System
  - da Vinci Xi, 263–264, 263*f*
  - development of, 262
  - FDA approval, 263
  - high-definition (HD) vision, 263
  - introduction of, 263
  - Mona, 264
  - in pharyngeal cancer, 409
  - representative uses of, 263–264
  - right hemicolectomy, 1784–1786, 1784*f*
  - system overhauls, 263
  - thyroidectomy
    - outcomes, 515
  - total proctocolectomy, 1738
  - transoral oropharyngeal cancer, 402–403
- Dabigatran (Pradaza), 28, 29*t*
- Daclizumab, 148
- Dacron prosthetic graft, 2368
- Dafrafenib, 427
- Damage control laparotomy, 1576*f*
- Damage control resuscitation, 1575
- Damage-associated molecular pattern (DAMP) molecules, 4–5, 2444
- Danazol, 608
- Danger-associated molecular patterns (DAMPS), 133
- Dartos' fascia, 128
- Dart-throwers motion, 247
- Davis intubated ureterotomy, e56–e57, e57*f*

- DCIS. *See* Ductal carcinoma in situ
- D-dimer testing, 103
- De Filippi classification, 560, 561*t*
- Dead bowel, 2452–2453
- Deaver retractors, 406, 929
- Debris, atheromatous, 2341
- Deceleration injuries, 2106
- Deep cervical lymph nodes, 71*f*
- Deep inferior epigastric perforator flap (DIEP)
  - anatomy of, 765–766
  - breast cancer reconstruction, 763–771, 763*f*, 765, 765*f*
  - complications, 770, 771
  - contraindications
    - radiation therapy, 771
  - harvesting, 766, 768*f*
  - indications, 770
  - isolation of, 766–768
  - postoperative management, 769–770
  - preoperative imaging, 766
  - surgical technique, 766–769
- Deep inguinal ring, 2007*f*, 2188–2189, 2189*f*
- Deep perineal pouch, 2010, 2010*f*
- Deep space infections
  - hand and wrist, 255
  - hypothenar space, 255
  - Parona's space, 255
  - urgent attention to, 251
- Deep vein thrombosis (DVT). *See also* Acute deep venous thrombosis (DVT); Chronic deep venous thrombosis
  - imaging, 2495*f*, 2509
  - incidence, RYGB and, 1252
  - pathophysiology, 2499
  - prevalence of, 2510
  - prevention of, 32

- prophylaxis, 2048
  - presurgical, 1662
- regional anesthesia and, 90
- risks associated with, 2481, 2482, 2524
- standard of care for, 2490–2491
- symptoms and clinical signs, 2498
- treatment
  - complete lysis *versus* partial clearance, 2497
  - complications and their management, 2496–2497
  - considerations and goals, 2498
  - drug therapy, 2490, 2499, 2509
  - limb salvage, potential in, 2489
  - outcomes, 2498, 2499
  - peripheral infusion system for, 2494*f*
  - postoperative care, 2496–2497
  - preoperative planning, 2491–2493
  - site-specific, 2493–2496
  - surgical technique, 2493, 2499

- Deep venous insufficiency treatment
  - complications and management, 2524
  - indications and contraindications, 2523
  - outcomes, 2524
  - overview of, 2523
  - preoperative planning, 2523
  - surgical technique, 2523–2524
- Defecating proctography, 1893, 1894*f*
- Defecation, straining at, 1893
- Defecography, diagnostic, 1906
- Defense Advanced Research Projects Agency (DARPA), 262
- Degenerative aneurysms, 2281–2282
- Dehydration
  - after ileostomy, 1648, 1649*t*
  - in ileostomy patients, 1774
  - laboratory results and, 67

- management of, 1649*t*
- post-ileostomy, 1647
- risk in SBS, 1982
- in stoma patients, 1772

- Delayed hemolytic reaction, transfusion-related, 109*t*
- Delirium
  - characteristics of, 138
  - hyperactive, 138
  - hypoactive, 138
  - intensive care unit, 140
  - management of, 138
- Delorme operation
  - choice of, 1894
  - options of, 1906
  - patient positioning, 1912
  - selection of, 1904, 1911
  - technique, 1907–1909, 1907*f*
- Delphian nodes, 502
- Deltoid muscles, 775*f*
- Deltoideus, 776*f*
- DeMeester scores, 942
- Dendritic cells
  - function of, 142
  - role in inflammation, 3
- Denonvilliers fascia
  - anatomic relationships, 1844, 2011
  - anatomy, 1815*f*, 1825
  - formation of, 2043*f*
- Denonvilliers septum, 1800
- Denovillier’s fascia, 1683*f*, 1807*f*
  - anatomic relationships, 1686
  - cutting through, 1807*f*
- Denovillier’s septum, 1807
- Dens epistrophe, 284

- Denys-Drash syndrome, 2078
- Depressor anguii oris muscle, 326*f*, 327
- Depressor labii inferioris muscle, 326, 326*f*
- Depth, ultrasonographic definition, 179
- Dermabond, 438
- Dermatomes, for skin grafts, 724–725, 726*f*
- Dermatomyotomes, 772
- Dermoid cysts, 1884
- Descendends hypoglossi, 359*f*
- Descending colon. *See also* Colon
  - anatomic relationships, 1678–1679
  - anvil secured in, 1791*f*
  - left hemicolectomy for, 1795
  - mesentery, division of, 1748*f*
- Descending thoracic aortic replacement (DTAR), 2561, 2562–2563
- Deschamps ligature, 2175*f*
- Desmoids, small bowel obstruction and, 1630*t*, 1631*f*, 1634
- Desmopressin (DDAVP), 27, 108
- Desquamation in SBS, 1982
- Detrusor muscle, 2009
- Dexamethasone tests, 572
- Dexmedetomidine, 138
- Diabetes mellitus (DM). *See also* Foot, diabetic; Glycemic control
  - and aortoiliac occlusive disease, 2350
  - bariatric surgery and, 1224
    - benefits of, 1218
  - comorbidities, 1177–1178
  - Cushing syndrome and, 16
  - diagnosis of, 1177
  - etiology of, 1176–1177
  - foot
    - amputation, 2414
    - care, 2409–2410, 2415
    - infections, 2412–2414

    - osteomyelitis and, 2413–2414
    - problems, 2408–2415
    - risk stratification, 2411*t*
  - holistic care in, 2414
  - incidence, 2408
  - liver abscesses and, 1286
  - lower extremity infections in, 2412
  - metabolic surgery
    - contraindications, 1178
    - indications, 1178
  - in metabolic syndrome, e36
  - microvascular complications, 2408
  - pathophysiology of, 1176–1177
  - remission after metabolic surgery, 1182–1183
  - response to gastric bypass, 1216
  - reversed vein bypass grafts, 2358
  - surgical operations for, 1178–1181
    - complications, 1179–1180
    - postoperative care, 1179
  - surgical risk and, 26
  - type I
    - characteristics, 1176
    - clinical presentation, 1177
    - etiology, 1176
  - type II
    - characteristics, 1176–1177
    - clinical presentation, 1177
    - complications of, 2415
    - EndoBarrier treatment in, 1233–1240
    - etiology, 1176–1177
  - WHO statistics, 1218
- Diabetic foot ulcers (DFUs)
  - assessment of, 2410*t*
  - classification of, 2409

- healing of, 2415
- imaging, 2412
- locations, 2409*f*
- prevention of, 2408
- prognosis, 2408
- surgical review, 2412
- treatment of
  - debridement, 2412
  - dressings, 2411
  - surgical offloading, 2411, 2412

- Diabetic patients, hemodialysis access for, 2526, 2539
- Diabetic retinopathy, 1177
- Diacyl glycerol (DAG) release, 143
- Dialysis
  - PTH levels and, 554
  - thoracoabdominal aortic aneurysm repair, 2288
- Dialysis catheters
  - avoiding long-term, 2525, 2539
  - mortality rate associated with, 2526, 2547
  - as renal replacement therapy alternative, 2538
  - temporary use of, 2529
- Diaphragm
  - anatomic relationships, 833–834, 833*f*, 2005*f*
  - anatomy of, 826–828, 829*f*, 833*f*, 835*f*, 839–840, 856, 856*f*
  - anomalies, 820 (*See also* Congenital diaphragmatic anomalies)
    - overview of, 820
  - anterior projection of, 826*f*
  - arterial supply, 833*f*
  - arterial supply of, 833*f*
  - bare area of, 834*f*
  - blood supply, 856
  - central portion of, removal of ellipse of, 852*f*
  - central tendon, 827–828
  - defects, 820–826

- descent of, 820, 821*f*
- development of, 783*f*
- disruption of, urgent operative care for, 788
- embryogenesis of, 820, 820*f*, 839, 840–841
  - anomalies, 820
  - body wall muscles, 820
  - pleuroperitoneal membranes, 820
  - transverse septum, 820
- esophageal hiatus, 1061*f*
- eventration of, 825–826, 825*f*
- function, assessing, 849
- gastric fundus tacking to, 961
- hernias, 2200
- herniation of, 860
- incisions, 749*f*
- inferior (abdominal) surface of
  - lymphatic drainage of, 836
  - peritoneal attachments on, 833–834
- lacerated, stitches, 862*f*
- lymphatic drainage of, 836, 836*f*, 837*f*
- mediastinal and pleural relations with, 832–833
- musculature, 826–828
  - attachment, 827*f*
  - origins and insertions of, 826
  - sternal portion, 826
- nerve supply to, 836–838, 837*f*
- openings of, 828–832, 830*f*
- origin of, 820*f*
- pediatric, 826–828
- peritoneal attachments, 833–834
- peritoneal reflections, 834*f*
- pinchcock action of, 1060
- reattachment, 862*f*
- repair, meshes in, 864

- schematic, 829*f*
- surgical anatomy of, 820–840
- traumatic injury to, 856–864
  - blunt, 857
  - chronic, 864
  - complications, 863*f*
  - diagnosis, 857–859, 864
  - diagnostic laparoscopy, 858–859
  - etiology of, 856–857
  - imaging, 858, 858*t*
  - incidence, 864
  - laparoscopy, 859–860
  - laparotomy, 860–863
  - pathophysiology of, 856–857
  - penetrating, 856–857, 864
  - postoperative care, 863*f*
  - preoperative planning, 859
  - presentation, 857
  - surgical management, 858–859
  - surgical technique, 859–863
  - sutures in repair of, 860*f*
  - treatment, 859
- vascularization of, 834–836, 835*f*
- venous drainage, 835*f*
- ventilatory support and, 36
- viscerosomatic regulation, 836, 838

Diaphragm peritonectomy, 2157–2158

Diaphragmatic eventration
- anatomy of, 848
- characteristics of, 822*t*
- clinical presentation and diagnosis of, 848–849
- left diaphragm, 825*f*
- overview of, 848
- recurrence of, 854

- surgery and treatment, 849–854
- types of, 825–826

Diaphragmatic flap, 1028*f*

Diaphragmatic hernias
- characteristics of, 822*t*
- chronic, 857
- diaphragmatic eventration differentiation from, 849
- small bowel obstruction and, 1630*t*
- surgical anatomy, 2202*t*

Diaphragmatic hiatus
- finger insertion through, 1017*f*
- repair of, 867
- structures at, 832*f*

Diaphragmatic lymph nodes, 600–601

Diaphragmatic musculature
- origins and insertions of, 826–828, 827*f*

Diaphragmatic paralysis, 848

Diaphragmatic pleura, 833

Diaphragmatic plication (for eventration)
- completed, 852*f*
- with interrupted sutures, 850–851
- laparoscopic, 853–854
- minimally invasive, 851–852
- suture placement before, 851*f*
- techniques, 852*f*, 853*f*

Diaphragmatic resection, 850, 853*f*

Diaphragmatic rupture, traumatic, 858

Diaphragmatic stimulation, 850

Diathermy coagulation, 1348*f*

Diatrizoate meglumine (Gastrografin), 473, 1359, 1631*f*

Diazepam, 138, e2

Diclofenac, preoperative, 1781

Dicyclomine for achalasia, 972

Diet. *See also* Malnourishment; Nutritional assessment

- diverticular disease and, 1753
- for fecal incontinence, 1951
- fiber-rich, 1753
- stoma odor and, 1776*t*
- stoma output and, 1776*t*

- Dieulafoy ulcers, 1106
- Differential jugular venous sampling, 535
- Diffuse esophageal spasm (DES), 968, 981
- Diffusing capacity, 87*t*
- Diffusing capacity for CO (D_{LCO}), 804–805
- Digastric muscle
  - anatomy of, 309, 319*f*, 322*f*, 323*f*, 359*f*, 361*f*
  - attachment of, 319
  - exposure of, 313
  - parotid space and, 319
  - triangles of the neck and, 290
- Digestive endoscopy, 206–207
- Digital rectal examination, 1816, 1913
- Digital subtraction angiography (DSA), 2249, 2250*f*, 2344
- Digital tomosynthesis, 616–617
- Digitoclasy, 1318
- Digits
  - amputations
    - critical time periods, 253
    - etiology, 253
    - traumatic, 261
  - ischemia, 253
  - perfusion of, 250
  - replantation, 254*f*–255*f*
- Dihydropyridine, 29*t*
- Dilantin dosing table, 479*t*
- Diltiazem
  - creams, 1926
  - for fissure in ano, 1913

- Diphenoxylate, 1774
- Diplopia
  - globe injuries and, 442
  - myasthenia gravis and, 560
- Dipyridamole, 29*t*
- Direct application, electrosurgical injuries and, 278
- Direct coupling
  - electrosurgical injuries and, 278–279, 279*f*, 281*f*
  - to staple lines, 278*f*, 279*f*
- Direct endoscopic necrosectomy (DEN), 1532–1533, 1542
- Direct thrombin inhibitors, 104–105, 110
- Displacement cystocele, 2167, 2167*f*, 2174*f*
- Disposal of opioids, e6
- Disseminated intravascular coagulopathy (DIC), 103, 380
- Distal common bile duct, 1383, 1383*f*
- Distal esophagus
  - blood supply to, 835*f*
  - diagrams of, 900*f*
  - in esophageal hiatus, 829
  - mobilization of, 954
  - obstruction of, 867
  - perforation of, 1023
    - buttressing of, 1027*f*
  - restoration of, 890
- Distal fistula (TEF). *See* Tracheoesophageal fistulae (TEF)
- Distal gastrectomy (DG)
  - GI tract reconstruction after, 1147–1148
  - indications for, 1142–1143
  - postoperative care, 1146
  - postoperative complications, 1146–1147
  - preoperative planning, 1143
  - reconstruction after, 1142
  - with Roux-en-Y reconstruction, 1145*f*
  - surgical technique, 1143–1146

- vagotomy combined with, 1148
- Distal interphalangeal (DIP) joints, 250, 250*f*
- Distal pancreatectomy, 1498–1499
- Distal phalanx, 250*f*
- Distal radioulnar joints (DRUJ), 247, 250*f*
- Distal revascularization/internal ligation. *See* DRIL (distal revascularization/internal ligation)
- Distal splenorenal shunts
  - ascites, e27–e28
  - durability, e28
  - encephalopathy, e28
  - indications, e21
  - modification of DSRS
    - clamping of splenic artery, e25
    - renosplenic end-to-side shunt, e25–e26, e28*f*
    - splenocaval shunt, e26, e28*f*
  - occlusion of, e27
  - postoperative management, e26
  - preoperative planning, e21
  - rebleeding, e26–e27
  - surgical technique, e21–e25, e22–e27*f*
  - survival, e28
  - survival rates, e28
  - *vs.* CSRS, e28–e29, e29*f*
- Distention cystocele, 2167, 2167*f*, 2171*f*
- Diuretics
  - perioperative management, 29*t*
  - in postoperative care, 1138, 1141
- Diverticula
  - description of, 1752–1753
- Diverticular disease
  - abscesses, 1756–1757
  - fistulas, 1756
  - strictures, 1756

- twin studies, 1753

Diverticulectomy
- endoscopic, 1150
- stapled, 1146*f*
- ZD repair, 1146*f*

Diverticulitis
- abscesses, 1756–1757, 1757*f*
- appendiceal, 1693–1694
- complicated
  - management of, 1756–1758
  - risk of, 1755
- CT findings, 1754*f*, 1754*t*
- diagnosis of, 1762
- dietary management of, 1754
- differential diagnoses, 1753*t*
- enterocutaneous fistulas and, 1650
- etiology, 1752–1753
- gender and, 1756
- incidence in the U.S., 1752
- laparoscopic lavage for, 1760
- management of, 1754–1756
- pathology, 1752–1753
- perforated
  - classification of, 1757*t*
  - laparoscopic lavage, 1762
- presentation of, 1753–1754
- recurrent, 1755
  - after resection, 1761
- risk of perforation, 1755
- small bowel obstruction and, 1630
- surgery for, 1752–1762
  - elective resection, 1758–1759
  - indications, 1754–1756
  - laparoscopic colectomy, 1758–1759

- open sigmoid colectomy, 1758
- postoperative care, 1760
- reoperative, 1760
- triggers, 1753
- young patients with, 1756

Diverticulopexy, 1145, 1146*f*, 1149
Diverticulosis, diverticulitis and, 1752–1753
Divided loop ileostomy, 1642–1643, 1644*f*
Dixon, Claude, 1839
D-lactic acidosis, 1982
Dobutamine, 78
Docosahexaenoic acid (DHA), 64
Dominant bile duct stricture, 1403
Donor-specific antibodies (DSA), 145
Dopamine, 78
Doppler ultrasound. *See also* Ultrasonography
- and ablation therapy, 656, 657*f*
- cardiac evaluation using, 193
- for carotid endarterectomy, 2253
- description of, 178
- perfusion assessment by, 250

Dor anterior fundoplication, 973
Dor fundoplication
- outcomes, 968
- overview of, 950, 950*f*
- technique, 1152*f*

Dorsal pancreatic artery, 1481–1482, 1481*f*, 1483*f*
Dorsal rami
- cutaneous branches, 776*f*
- innervation by, 779

Dorsalis pedis, tarsal, and plantar artery bypass, 2383–2384
- clinical presentation, 2376–2377
- complications, 2380–2381
- indications and contraindications, 2377

- outcomes
  - dorsalis pedis artery bypass, 2381–2382, 2381–2382*f*
  - tarsal and plantar artery bypass, 2382
- postoperative management, 2380
- preoperative planning, 2376*f*, 2377–2378
- surgical techniques
  - dorsalis pedis artery bypass, 2378–2379, 2378*f*
  - plantar artery bypass, 2380
  - tarsal artery bypass, 2379–2380

- Dorsoscapular nerve, 295
- "Double bubble" sign, 1169–1170, 1170*f*, 1473
- Doublet View, gallbladder, 1367
- Douglas pouch, 1911
- Doxycycline
  - MRSA susceptibility, 253
  - sclerotherapy, 372, 379
- Dragstedt, Lester Reynolds, 1095, 1113, 1148
- Drains, e9
  - management, 1030
  - pelvic, 1835–1836, 1847–1849
  - SSI prophylaxis and, 120*t*
- Drapes, use of, 119*t*
- Dressings, advanced, 120*t*
- DRIL (distal revascularization/internal ligation), 2535–2536, 2536*f*
- Drug abuse, liver abscesses and, 1287
- Drug monitoring programs, e6
- Drug-eluting stents, 24
- Dry gangrene, in diabetic feet, 2412
- Dual Anti-Platelet Therapy (DAPT) Score, 28
- Duct of Luschka
  - anatomy of, 1342
  - division of, 1268
  - leaks, 1381–1382
- Duct of Santorini, 209, 1478, 1480–1481

- Duct of Stensen, 439, 439*f*
- Duct of Wirsung, 1573
- Ductal carcinoma in situ (DCIS)
  - ablation therapy, 657
  - breast-conserving surgery, 633
  - clinical presentation, 633
  - definition of, 756
  - diagnosis and histology, 633
  - endocrine therapy, 634
  - epidemiology, 633
  - incidence, 756
  - low-grade, 634
  - mastectomy, 634
  - radiotherapy, 634
- Ductography, breast, 616, 617*f*
- Ductus deferens, 2007*f*, 2009
- Dudrick, Stanley, 42
- Duhamel procedure, 1972
- Dumping syndrome
  - after partial gastrectomy, 1092
  - diagnosis, 1156
  - diagnosis of, 1156
  - as distal gastrectomy complication, 1146
  - etiopathogenesis, 1156
  - overview of, 1156
  - postoperative, 1146
  - predisposition for, 1146
  - Roux-en-Y gastrojejunostomy in, 1101–1102
  - symptomatology, 1156, 1165
  - symptoms, resolution of, 1165
  - treatment, 1156–1157
- Dunbar syndrome, 831–832. *See also* Celiac artery compression syndrome (CACS)
- Dunphy sign, 1689

- Duodenal atresia, 1175
- Duodenal brake, 1084–1085
- Duodenal bulb, inspection of, 210*f*
- Duodenal fistulae, 1659
- Duodenal mucosa, arrangement, 1480*f*
- Duodenal obstruction, congenital, 1166–1175
  - associated conditions, 1169
  - clinical presentation, 1169–1170
  - diagnosis of, 1169
  - intrinsic *versus* extrinsic, 1169
  - laparoscopic surgery for, 1171
  - open surgery for, 1170–1171
  - pathophysiology, 1169
  - postoperative care, 1171–1172
  - preoperative management, 1170
- Duodenal stump leaks, 1139
- Duodenal switch
  - biliopancreatic diversion with, 1218, 1225–1233
  - overview of, 1153*f*
  - single-anastomosis, 1229*f*, 1231
- Duodenal transection, 1133, 1133*f*, 1228*f*
- Duodenal tumors, 1106
- Duodenal ulcer disease, 1104–1126, 1148
  - bleeding ulcers, 1105
    - ligation of, 1096*f*
  - diagnosis, 1106
  - emergencies related to, 1103
  - endoscopic therapy, 1106
  - etiology of, 1104–1105
  - interventions for, 1148
  - operative management, 1115–1116
    - abdominal wall closure, 1117
    - incisions, 1116–1117
    - indications, 1115

- outcomes, 1117
- patient positioning, 1116
- postoperative care, 1117
- preoperative preparation, 1116
- prognosis, 1117
- pathogenesis of, 1104–1105
- perforated ulcers, 1113
- laparoscopic management, 1117–1119
- management algorithm, 1115*f*
- plugging, 1118*f*
- procedures, 1116*f*
- radiologic therapy, 1106
- recurrent bleeding, 1113
- selective vagotomy, antrectomy, and gastroduodenostomy
- drainage, e9
- history, e9
- ligatures, e10
- open anastomosis, e9
- resection, e9
- surgical techniques, e10–e17, e11*f*–e14*f*, e16*f*–17*f*, e17*f*–e18*f*
- sutures, e9
- ulcer removal, e10
- vital structure protection, e9–e10
- surgical technique, 1107–1108
- surgical treatment, 1106–1107
- choice of incision, 1107, 1108*f*
- choice of operation, 1107

Duodenal-jejunal bypass liners, 1233–1234, 1234*f*
- adverse events, 1239
- efficacy, 1237–1239, 1238*f*
- cardiac risk factors, 1239
- glycemic control, 1238–1239, 1239*f*
- weight loss, 1237–1238
- explantation

- complications, 1239*t*
- equipment needed, 1236*t*
- technique, 1237
- follow-up, 1238*f*
- implantation
  - complications, 1237
  - contraindications, 1235*t*
  - equipment needed, 1236*t*
  - technique, 1236–1237
- indications for, 1234
- patient selection, 1234–1235
- positioning, 1234*f*
- postimplantation management, 1237
- preimplantation preparation, 1236, 1236*f*
- retrieval systems for, 1235*f*

Duodenal-jejunal junction, 1729*f*
Duodenal-preserving pancreatic head resection, 1522–1523
Duodenectomy, longitudinal, 1389–1390
Duodenoduodenostomy
- for annular pancreas, 1473
- congenital duodenal obstruction and, 1170
- Kimura Diamond-shaped, 1170–1171, 1171*f*
- retrocolic, 1172*f*

Duodenoileostomy, 1228, 1228*f*
Duodenojejunal bypass sleeves, 1184
Duodenojejunostomy
- for annular pancreas, 1473
- for duodenal compression, 1190–1191
- Roux-en-Y, 1191*f*
- side-to-side, 1191*f*

Duodenoscope, side-viewing, 1365*f*
Duodenoscopy, injuries, 1387*f*
Duodenostomy, catheter, 1121*f*
Duodenotomy

- Heinike-Mikulicz pyloroplasty, 1107–1108
- longitudinal, 1349
- surgical technique, 1111–1112

- Duodenum
  - anatomic relationships, 1053, 1186*f*
  - anatomy of, 1056–1057
  - arteries of, 1068*f*
  - blood supply of, 1067–1068, 1068*f*
  - closure of, 1392*f*, 1393
  - congenital anomalies of
    - atresia, 1056
    - diverticula, 1056
    - malrotation, 1055–1056, 1056*f*
    - nonrotation, 1055–1056, 1056*f*
    - nutcracker syndrome, 1056
    - preduodenal portal vein, 1056
    - SMA syndrome, 1056
    - stenosis, 1056
  - Crohn disease involvement, 1663–1664
  - descending
    - anatomic relationships, 2003*f*
    - scoping of, 210*f*
  - embryology of, 1051–1055, 1051*f*, 1055*f*
  - exposure of, 1559, 1744*f*
  - fixation of, 1473*f*
  - GIST, excision, 1198
  - innervation of, 1072–1076
  - Kocherization of, 1348*f*
  - lymphatics of, 1071–1072
  - parts of, 1056
  - peritoneal attachments, 1475*f*
  - peritoneal reflections, 1062–1063
  - strictures, 1492–1493, 1664
  - suspensory ligament division, 1190*f*

- vascular compression of, 1185–1192
  - clinical presentation, 1186–1187
  - decision-making algorithm, 1189*f*
  - diagnosis, 1187–1188
  - duodenojejunostomy, 1190–1191
  - historical names for, 1185*t*
  - laparoscopic approaches, 1191–1192
  - management, 1188
  - surgical technique, 1188–1192
- vascular supply, 1063

Duodenum-preserving pancreatic head resection (DPPHR)
- characteristics, 1498*t*
- clinical trials, 1500*f*
- endocrine function after, 1521*t*
- indications, 1515–1516, 1516*t*, 1517*f*
- operative specimen, 1519*f*
- outcomes, 1497*t*
- selection of, 1496
- steps, 1498*f*
- subtotal, 1518*f*, 1519–1520
  - outcomes, 1521*t*
  - postoperative results, 1520–1522, 1520*t*
- total, 1518–1519
  - postoperative results, 1520–1522
  - reconstruction after, 1520*f*
- uncinatectomy, 1517*f*

DuoDerm, 1653

Duplex subtraction angiography, 2377

Duplex ultrasonography
- description of, 178
- for femoral artery aneurysm, 2319
- of portal veins, 1604

Duplex venous mapping, 2378

Dupuytren contractures, 1620

- Dynamic CT angiography, 1543
- Dysejaculation, e68–e69
- Dyspepsia, 1105
- Dysphagia
  - after surgery for achalasia, 979–980
  - as fundoplication complication, 872, 880, 884, 914–915, 916
    - in antireflux surgery, 958
    - Nissen fundoplication, 950
  - nutcracker esophagus and, 981
  - post fundoplication, 933
- Dysphonia, myasthenia gravis and, 560
- Dysplatic nevus syndrome, 411
- Dyspnea, 848

E

- Ear interpolation flaps, 219*f*
- Ears
  - abnormalities
    - branchial cleft anomalies and, 369
  - defects
    - helical rim, 219*f*
    - segmental helical rim, 217
    - soft tissue flaps, 217
  - hematomas, 439, 440*f*
  - injuries to, 440
  - lacerations, repair of, 441*f*
- Eastern Cooperative Oncology Group (ECOG)
  - E5194 trial, 757
  - performance status, 2022
- E-cadherin *(CGH1)* gene, 1127
- Ecchymosis, periorbital, 435–436
- Echinococcal cysts, 1303
- Echinococcosis, 1294–1295
- *Echinococcus* spp.
  - cestodes, 1294
  - cysts, 1295
    - approaches, 1294–1314
    - incidence, 1277–1278
  - *E. granulosus*, 1295
  - *E. multilocularis*, 1295
  - *E. oligarthus*, 1295
  - *E. vogeli*, 1295
  - epidemiology, 1295
  - management of, 1295
  - metacestodes, 1294
- Echocardiography
  - for acute limb ischemia, 2422

- of aortofemoral bypass, 2343
- Echogenicity, ultrasonographic definition, 179, 179*f*
- Ectopia cordis, 772
- Edema. *See also* Lymphedema
  - leg, 430
  - postoperative, 2380–2381
- EDT. *See* Emergency department thoracotomy (EDT)
- Efferent limb syndrome, 1154
- "Eggplant penis," 2104
- Ehlers-Danlos syndrome, 848
- Eicosapentaenoic acid (EPA), 64
- Eisenhower, Dwight, 1673
- Ejaculation, nervous control of, 1825
- Ejaculatory ducts, 2007*f*
- ELAPE specimens, 1812*f*
- Elastic stocking therapy. *See* Compression stockings
- Elderly patients
  - appendicitis in, 1694
  - autogenous arteriovenous hemodialysis access for, 2537, 2539
  - bladder cancer in, 2036
  - dietary habits, 67
  - fecal impaction, 1962
  - muscle wasting in, 35–36
  - nutritional status, 67
  - rectal prolapse in, 1905
  - right hemicolectomy, 1788
- Electrical burns, skull, 216
- Electrocardiography (EKG, ECG)
  - monitoring of patients, 68
  - preoperative, 23, 23*t*
- Electrocautery, 2475*f*
- Electroencephalography (EEG), 2272–2273
- Electrolytes
  - composition of body fluids, 1651*t*

- preoperative testing, 22, 23*t*
- serum, monitoring of, 1655

Electromagnetic interference, 279*t*

Electromyography, 1951, 1962

Electroporation, irreversible, 200, 1316

Electrosurgical injuries, 273

- antenna coupling, 276–277
- capacitative coupling, 279, 279*f*
- direct application and, 278
- direct coupling and, 278–279, 279*f*
- insulation failure and, 277, 277*f*
- reproducible patterns, 276–279
- residual heat and, 277–278, 277*f*
- risk of, 281*t*

Electrosurgical unit (ESU), 274

Elion, Gertrude, 141

Embolectomy, 2422–2423

- anatomy, 2416, 2417*f*
- complications, 2421–2422
- diagnosis, 2416–2417, 2417t
- epidemiology, 2416, 2416t
- indications, 2417–2418
- operative techniques
  - aortic and iliac emboli extraction, 2419–2420, 2420*f*
  - catheters, 2418–2419, 2419*f*
  - endovascular therapy, 2421, 2421t
  - femoral and popliteal emboli extraction, 2420–2421, 2420*f*
  - thrombosis removal, 2419
  - upper limb emboli extraction, 2421
- peri- and postoperative medical therapy, 2418, 2418*f*
- postoperative management, 2421–2422

Embolic material, infected, 2470–2471

Embolization

- carotid body tumors, 2272, 2278

- in endovascular therapy for aortoiliac occlusive disease, 2355
- peripheral, 2332, 2342

Embolus. *See* Acute embolus

Embryology
- 5-week embryos, 772*f*
- abdominal organs, 821*f*
- of breast (*See* Breast, embryology and anatomy)
- foregut of, 886*f*

Emergency department thoracotomy (EDT), 788, 798

Emergency portacaval shunts (EPCS)
- myths, 1603*f*
- studies of, 1597–1599
- survival, 1600*f*, 1601*f*

Emesis, infants, 1173, 1174–1175

Emotional stress, 1104–1105

Empyema
- management strategies, 101
- posttraumatic, 797

Encephalopathy
- in central splenorenal shunt, e33*f*, e34
- and distal splenorenal shunts, e28
- hepatic, 1434
- portal-systemic, 1598, 1599, 1599*f*

End Brooke ileostomy, 1724*f*

End colostomy
- closure, 1769*f*
- resection with, 1705–1706

End ileostomy, toxic megacolon and, 1723*f*

End loop ileostomy, 1643*f*

Endarterectomy
- aortoiliac, 2339–2340, 2340*f*
- carotid, 2246–2258

Endo Stitch devices, 172, 176, 1944

Endoabdominal esophagus, 834, 1060*f*

- EndoBarrier
  - adverse events, 1239
  - appeal of, 1240
  - availability, 1233–1234
  - complications, 1240
  - contraindications, 1235*t*
  - deployment of, 1234*f*
  - efficacy, 1237–1239, 1238*f*, 1240
    - cardiac risk factors, 1239
    - glycemic control, 1238–1239, 1239*f*
    - weight loss, 1237–1238
  - endoscope hood for, 1234–1235
  - explantation
    - complications, 1239*t*
    - equipment needed, 1236*t*
    - technique, 1237
  - fluorscopic exposure time, 1240
  - follow-up, 1238*f*
  - implantation
    - complications, 1237
    - equipment needed, 1236*t*
    - technique, 1236–1237
  - mechanism of action, 1240
  - for morbid obesity and diabetes, 1233–1240
  - patient selection, 1234–1235
  - positioning, 1234*f*
  - postimplantation management, 1237
  - proximal end of, 1234*f*
  - retrieval of, 1234*f*
- Endobiliary stents, safety of, 1572
- Endobronchial ultrasound (EBUS)
  - lung cancer staging, 801, 804, 804*f*, 818
- Endocarditis, infective, 1287
- Endocrine factors

- for atypical ductal hyperplasia (ADH), 634
- carotid body tumors, 2268
- for ductal carcinoma in situ, 634
- surgical trauma response and, 8–11

- Endocrine surgery
  - da Vinci Robotic system in, 264
  - high-volume, complication rates and, 515
  - minimally-invasive, 515
  - robotic-assisted, 269
  - training in, 514–515
  - trends in, 514–515
- Endocrinopathies, surgical risk and, 26
- ENDOFLATOR 40 SCB, 1942
- Endo-GIA universal staple cartridge, 1012*f*
- Endo-GIA universal staplers, 919
- Endografts, electrocautery, 2475*f*
- ENDOLOOP Ligature, 1359
- Endometrial hyperplasia, 2128–2129
- Endometrioid carcinomas, 1248
- Endometriosis
  - atypical, 1247
  - clear cell carcinomas and, 1247
  - endometrioid carcinomas and, 1248
  - hysterectomies for, 2128–2129
- Endomucosal resection, 895
- Endophlebectomy, 1250, 2507
- Endorectal ultrasound (ERUS)
  - clinical workup, 1938
  - preoperative planning, 1816
  - in rectal cancer, 1854
  - sensitivity of, 1842
- Endorphins, surgical trauma and, 9
- Endoscopes
  - balloon-assisted, 207

- introduction of, 207–209, 207*f*
- types of, 207
- withdrawal of, 207–208

Endoscopic anterograde sphincterotomy, 1364–1365, 1365*f*

Endoscopic clip applier, 1038*f*

Endoscopic mucosal resection (MSR), 209

Endoscopic myotomy, peroral, 962–968

Endoscopic nasoenteric tubes, 62*t*

Endoscopic papillotomy, 1383, 1393

Endoscopic retrograde cholangiopancreaticography (ERCP)
- in acute peritonitis, 1524
- availability of, 1393
- benefits of, 1393, 1411
- biliary tree, evaluating with, 1411
- complications of, 1386–1387
- diagnostic, of choledochal cysts, 1422–1423
- as diagnostic tool, 1392
- in gallstone pancreatitis, 1354
- in liver hydatidosis, 1302
- Oddi sphincter manometry compared to, 1384
- outcomes, 1393
- overview of, 1373
- for pancreatic cancer, 1402
- for pancreatic pseudocysts, 1536, 1538*f*
- pros and cons, 1394
- for stones, 1274

Endoscopic sclerotherapy (EST)
- emergency portacaval shunts and, 1597–1599
- survival, 1598*f*

Endoscopic sphincterectomy
- indications, 1393
- outcomes, 1394
- overview of, 1383
- for sphincter of Oddi dysfunction, 1386

- technique, 1385*f*
- Endoscopic sphincterotomy (ES)
  - in gallstone pancreatitis, 1354
- Endoscopic submucosal dissection (ESD), 209–210
- Endoscopic ultrasound (EUS)
  - diagnostic, in gastric cancer, 1127
  - lung cancer staging, 801, 804, 804*f*, 818
  - pancreatic pseudocyst drainage, 1537
  - transmural pseudocyst drainage, 1538, 1539*f*–1540*f*
- Endoscopic ultrasound (EUS) gastroscope, 1541*f*
- Endoscopic ultrasound-guided celiac plexus block (EUS-CPB), 1581
- Endoscopic variceal banding, single band, 1625
- Endoscopy. *See Specific* procedures
- Endostaplers, in diaphragmatic resection, 853*f*
- Endostomal therapists, 1645–1646
- Endothelial cells
  - chemokine receptors in, 6
  - hepatic, Kupffer cells and, 19
  - procoagulated activity of, 6
  - sinusoidal, 18–19
- Endothermal heat-induced thrombosis (EHIT), 2520
- Endothoracic fascia, 829
- Endotoxin, toxic megacolon and, 1733–1734
- Endotracheal aspirate (EA), 92
- Endotracheal tubes (ETTs)
  - foreshortened, 497
  - reintubation, 493
  - removal of, 491
- Endotrachial intubation, after ventilator weaning failure, 101
- Endotrachial tubes (ETTs), 544, 549
- Endovascular access, assessment of, 2447, 2449–2450
- Endovascular aortic repair (EVAR), 2469, 2470
- Endovascular heat-induced deep vein thrombosis (EHIT), 2524
- Endovascular procedures. *See also* Peripheral vascular occlusive disease

- abdominal aortic aneurysms, 2302–2303
  - FDA-approved devices, 2299–2301, 2299t, 2300*f*
  - imaging, 2299
  - operating room setup, 2306
  - postoperative care, 2300–2301
  - surgical technique, 2299–2300
    - endoluminal repair, 2301–2302, 2302*f*
- acute limb ischemia, 2421
- aneurysm repair (EVAR), 2290
- for aortoiliac occlusive disease, 2350–2357
  - clinical presentation, 2350
  - complications, 2354–2355, 2355*f*
  - etiology and pathophysiology, 2350
  - indications and contraindications, 2350–2351
  - outcomes, 2356
  - postoperative care, 2353
  - preoperative planning, 2351, 2353*f*
  - surgical technique, 2351–2353, 2354*f*
- for brachiocephalic reconstruction, 2264, 2265, 2266
- fenestrated aneurysm repair (FEVAR), 2290, 2298
- thoracoabdominal aortic aneurysm repair, 2289–2290

Endovascular stents, renal trauma and, 2106

Endowave products, 2495, 2496*f*

EndoWrist®, development of, 262

End-stage liver disease (ESLD), 1448–1450
- assessments, 25
- preoperative risk assessment and, 26*f*

End-stage renal disease (ESRD)
- care outcomes, 2547
- comorbidities, 2529
- hemodialysis access needed in, 2547
- perioperative care in, 24–25
- renal cell carcinoma and, 2019
- statistics, 2525, 2540

- End-to-end anastomosis (EEAs)
  - anvil insertion, 173*f*
  - anvil stapler mating, 174*f*
  - anvil transoral placement, 174*f*
  - in bile duct reconstruction, 1376
  - EEA stapler, 923*f*
    - alignment, 923*f*
    - gastric reconstruction using, 1139*f*
    - insertion, 923*f*
    - Roux limb, 1243*f*
  - gastroduodenostomy, 1084
  - pouch preparation, 173*f*
- End-to-end bile duct reconstruction, 1379, 1382
- End-to-end biliary anastomosis
  - in liver transplantation, 1420
- End-to-end biliary-enteric anastomosis, 1416*f*
- End-to-side anastomosis, 1378
- End-to-side choledochoduodenostomy, 1419*f*
- End-to-side choledochojejunostomy, 1417*f*
- End-to-side gastroduodenostomy, 1084, 1088, 1090*f*
- End-to-side hepaticojejunostomy (HJ), 1378*f*, 1416*f*
- Enemas, in outlet obstruction, 1963
- Energy requirements, 45
- Energy substrates, delivery of, 54
- Enhanced Recovery After Surgery (ERAS) protocols, 53
  - advantages of, 1727
  - after APR, 1859–1860
  - after cystectomy, 2048*f*
  - benefits of, 1670
  - in colorectal surgery, 1714, 1861
  - development of, 1669–1670
  - ileostomy care, 1645–1646
  - lengths of stay and, 818
  - postoperative care, 1729–1730

- safety of, 1788
- for thoracic surgery, 818

Enoxaparin, 104

Entamoeba histolytica
- amebic cycle, 1292*f*
- complications, 1292–1293
- diagnosis, 1292
- liver abscesses, 1278
- toxic megacolon and, 1719
- treatment, 1292–1293

Enteral nutrition (EN), 60–63
- access, 61, 62*t*
  - complications, 65
  - naso/oroenteric, 61
  - percutaneous, 61
- administrative methods, 61
- benefits of, 60, 61*f*
  - nonnutritional, 60, 61
  - patient outcomes, 60
- bolus feeding, 62–63
- complications of, 65–66
- continuous feeding, 62–63
- contraindications, 60–61
- disease-specific formulations
  - antioxidant additives, 64
  - hepatic formulations, 64
  - immunonutrition, 64
  - in malabsorptive conditions, 63
  - prebiotics in, 64–65
  - probiotics in, 64–65
  - in pulmonary conditions, 63
  - renal formulas, 63–64
- dosing, 62
- feeding access, 1030

- formulations, 59, 63–65
- history of, 54
- hyperosmolality and, 1655
- indications, 27
- intermittent feeding, 62–63
- level of infusion, 62
- monitoring tolerance, 63
- parenteral nutrition *vs.*, 60
- in perioperative settings, 66
- permissive underfeeding strategies, 62
- PN and, 65
- postoperative, 34–35
- support, 54–67
- support in fistulas, 1654
- timing of initiation, 61–62, 66
- total parenteral nutrition and, 47
- vitamin requirements, 49*t*

- Enteric cysts, types of, 1882
- Enteric nervous system, adaptability of, 1165
- *Enterobacter* spp. in SSIs, 112*t*
- Enteroceles, 1905, 1906
- *Enterococcus* spp.
  - antibiotics for, 124
  - in appendicitis, 1692
  - *E. facium*
    - vancomycin-resistant, 121
  - *E. faecalis*
    - surgical site infections, 112*t*
  - rifampin, resistance to, 2471
  - surgical site infections, 112*t*
- Enterocolitis
  - after anorectal pull-through, 1974
  - infants with, 1972
- Enterocutaneous fistulae (ECFs)

- causes of, 1650
- classification of, 1655–1656
- closure, 1655, 1656*t*
- description, 1650
- drainage of
  - control of, 1653–1654
  - sepsis and, 1653
  - skin care, 1653–1654
- elective operations for, 1656–1659, 1657*f*–1658*f*
- management of, 1660
  - phases in, 1652*t*, 1653–1659
  - sump system for, 1653*f*
- nutritional status in, 1651–1652
- nutritional support in, 1651
- output, reduction of, 1654
- postoperative, 1651, 1660
- prevention of, 1650, 1660
- sepsis and, 1652
- spontaneous, 1650–1651
- TPN in, 46

Enterocytes, carbohydrate absorption, 59

Enteroenterostomy
- Braun type, 1165
- creation of, 1229*f*
- Roux limb and, 1214*f*

Enterogastric reflux, 1092

Enterography in Crohn disease, 1663

Enterosigmoid fistulae, 1710*f*

Enterostomal therapy (ET) nurses, 1638–1639

Enterotomy
- antimesenteric longitudinal, 1665*f*
- closure, 174
- in jejunum, 1413*f*
- juxtaposed, 1666*f*

- linear stapled anastomosis and, 174
- measurement of, 1666*f*
- rates in LVHR, 164
- supporting column
  - distances between, 1665*f*

- EOD. *See* Extent of disease
- Eosinophil-derived neurotoxins (EDN), 4–5
- Eosinophilia, postsplenectomy, 1988
- Epididymis, anatomic relationships, 2007*f*
- Epididymitis
  - management of, 2237
  - post hernia repair, 2237
- Epidural anesthesia, postoperative complications, 90
- Epidural hematomas, 479–480, 480*f*
- Epigastric hernias
  - description of, 2183
  - Proline patches, 2237
  - repair of, 158–159
  - surgical anatomy of, 2201*t*
- Epigastric vessels, superior, 831
- Epiglottic cancer, infrahyoid, 395*f*
- Epiglottis, anatomy of, 303, 304*f*
- Epinephrine
  - cardiovascular support, 78
  - glucagon release and, 16
  - insulin resistance and, 16
  - lactate production and, 51*f*
  - metabolic impacts of, 12
  - sclerotherapy needle injection, 207
  - stress response and, 12
- Epiploic foramen of Winslow hernias, 2203*t*
- Epirubicin, 2036
- Epithelial atypia, flat (FEA), 606
- Epoprostenol, inhaled, 81

- Epstein-Barr virus (EBV)
  - gastric cancer and, 1127
  - as gastric cancer risk factor, 1127
  - nasopharyngeal cancer and, 398, 409
- *ERBB2* mutations, 1246
- Erectile dysfunction, prostate cancer therapy and, 203
- Erector spinae, fascia and, 286
- Erigent nerves, rectal innervation and, 1825
- Erigent pillars, 1806, 1806*f*, 1807–1808
- Ertapenem dosage, 1939
- Erythrocyte sedimentation rates (ESRs), 1661
- Erythromycin, MRSA susceptibility, 253
- *Escherichia coli*
  - ampicillin/sublactam resistance, 121
  - anorectal sepsis and, 1915
  - in appendicitis, 1692
  - ESBL-producing, 121
  - fluoroquinolone-resistant, 114
  - in liver abscesses, 1287
  - quinolone-resistant, 121
  - resistant, VAP and, 92
  - surgical site infections, 112*t*
- Esmolol, 796
- Esophageal adenocarcinomas, 946–947
- Esophageal anastomosis, 1011*f*, 1038*f*
  - completion of, 1039*f*
  - hand-sewn, 994
- Esophageal atresia (EA)
  - anatomic relationships, 784
  - anomalies seen in, 1033*f*
  - clinical presentation of, 1033–1034
  - duodenal atresia and, 1175
  - etiology of, 1032–1033
  - imaging studies of, 1033*f*

- overview of, 1032
- tracheoesophageal fistula without, 1034*f*, 1042

Esophageal atresia (EA) repair
- complications and their management
  - anastomotic leak, 1040–1041
  - anastomotic stricture, 1041
  - gastroesophageal reflux and esophageal dysmotility, 1042
  - recurrent TEF, 1041–1042, 1042*f*
  - tracheomalacia, 1042
- outcomes, 1043
- postoperative care, 1040
- preoperative planning, 1034–1035
- surgical technique
  - open approach, 1039–1040
  - operating personal location, 1036, 1036*f*
  - patient positioning, 1035, 1036, 1036*f*
  - thoracoscopic approach, 1035–1038

Esophageal calibration
- bougie size recommended for, 876*t*

Esophageal cancers
- clinical presentation, 984
- epidemiology of, 998
- esophagectomy for, 926
- etiology of, 983–984
- intended lymphadenectomy in, 986–987
- lymph node involvement, 895–896, 896*f*
- margin lengths, 999
- metastatic spread of, 986–987, 992*f*
- neoadjuvant treatments, 984
  - chemoradiotherapy, 984, 998
  - chemotherapy, 984
- pathophysiology of, 983–984
- preoperative planning
  - assessments, 985

    - disease staging, 984
    - patient preparation, 984–985
    - patient selection, 984–985
  - surgery
    - approach choices, 985–987
    - planning for radiotherapy after, 987
    - thoracoscopic esophagectomy, 901
    - transhiatal esophagagectomy, 1000
  - thoracic lymphadenectomy in, 999
- Esophageal fistulae, revision for, 1245–1246
- Esophageal hiatus
  - anatomy, 828, 831*f*, 856*f*
  - blood supply to, 835*f*
  - diagrams of, 820*f*
  - distal esophagus in, 829
  - exposure of, 938*f*
  - formation of, 827
  - overview and types of, 828
  - repair of, 832, 930–931, 930*f*
  - in sagittal section, 831*f*
  - surgery, risks during, 833
  - sutures, 940*f*
  - vagal structures through, 1073, 1073*f*
- Esophageal injuries
  - diagnosis, 795
  - operative approach, 795
  - presentation, 795
  - treatment, 795
- Esophageal length, assessment of, 868
- Esophageal lengthening, 868, 869*f*
- Esophageal mamometry, 970
  - achalasia workup, 962
  - before antireflux surgery, 947
  - antireflux surgery outcome measuring through, 916

- development of, 904
- intraoperative, 270, 973
- overview of, 904*f*
- in reflux, 928–929

Esophageal mesentery, 840

Esophageal motility
- classification of, 867
- dysmotility in EA/TEF repair, 1042

Esophageal mucostomy, closure of, 981*f*

Esophageal muscle, types of, 890–891, 892*f*

Esophageal myotomy
- mucosal perforation, visualizing with, 126*f*
- transabdominal *versus* transthoracic, 983

Esophageal perforation
- clinical presentation, 1022–1023
- diagnosis of, 1023
- endoscopic intervention
  - clips, 1025, 1025*f*
  - defect closure, 1025
  - enteral access, 1025–1026
  - management and overview of, 1024–1025, 1031
  - stents and stenting, 1025, 1031
  - therapy, 1030–1031
  - vacuum-assisted devices and therapy, 1026, 1031
- etiology of, 1020–1022
- managing, 1032
- overview of, 1020
- pathophysiology, 1022
- preventing, 1031
- repair
  - complications, 1030
  - drainage alone, 1029
  - enteral feeding access, 1030
  - exclusion and diversion, 1029, 1029*f*

- intraoperative, 1031–1032
- outcomes, 1030–1031
- postoperative care, 1030, 1031
- postoperative repair, 1031–1032
- preoperative planning, 1023–1024
- primary closure, exceptions to, 1028–1029
- primary closure and reinforcement, 1026–1028
- primary repair, 1027*f*
- resection, 1029–1030
- techniques and approach, 1024
- T-tube drainage, 1029
- T-tube management, 1029*f*

- Esophageal pouch, proximal, 1041*f*
- Esophageal pressure topography (EPT), 937–938
- Esophageal sphincters
  - anatomy of, 889–890
  - lower (*See also* Lower esophageal sphincter (LES))
    - anatomy of, 889–890
    - discovery of, 904
    - fibers of, 890*f*
    - length of, 906*f*
    - manometric tracing of, 904*f*
    - physiology of, 838
    - shortening of, 916
    - surgical treatment, 890
  - physiology of, 839
  - pressure, reflux and, 828–829
  - upper
    - anatomy of, 889, 889*f*
    - surgical treatment, 889, 890
- Esophageal surgery
  - consequences of, 1148
  - robotic-assisted, 267–268
- Esophageal suture line

- stapled, grasping of, 1011*f*
- tracheal fistula closure, 1039*f*

- Esophageal varices
  - endoscopic ligation, 1626*f*
  - intravariceal injections, 1623*f*
  - ligation, 1621, 1627
  - management of, 1616–1629
  - portal hypertension and, 1587
  - upper GI bleeding and, 1106
- Esophagectomy. *See also* Thoracoscopic esophagectomy; Transhiatal esophagectomy
  - adverse effects, 917
  - after CRT, morbidity related to, 998
  - anastomotic strictures, 927
  - approaches, 925–926
  - complications of, 1150
  - for esophageal cancer, 926
  - intrathoracic anastomosis, 267
  - Ivor-Lewis, 267, 927
  - laparoscopic, 917–927
    - complications, 924–925, 925*t*
    - indications, 917–918
    - port placement, 918*f*
    - reconstruction, 924*f*
    - results, 923–924
    - surgical technique, 918–920
  - minimally invasive, 917, 926
  - mortality rates, 917
  - open, mobiditity, 924
  - outcomes, 984–985
  - pain management, 996
  - perioperative care, 996
  - repair in, 916
  - robotic-assisted, 267, 927

- with thoracotomy, 1019
- three-field, 267
- total, gastric pull-up and, 407
- transhiatal
  - popularity of, 787
  - total, 267
- transthoracic *vs.* transhiatal, 925*t*

- Esophagitis. *See also* Bile reflux esophagitis
  - development of, 903
  - factors preventing, 829
  - reflux and, 962
  - as Toupet fundoplication complication, 961
  - upper GI bleeding and, 1106
- Esophagocardiomyotomy
  - for achalasia, 972
  - efficacy for achalasia, 981–982
  - laparoscopic, 974–976
- Esophagogastrectomy
  - cervical anatomy, 991*f*
  - complications of, 996–998, 1158, 1165
  - conduit preparation, 993–996
  - for esophageal carcinoma, 983–999
  - indications, 1158
  - perioperative management, 997*f*
  - phases of, 987–993
    - abdominal phase, 987–988
    - cervical lymphadenectomy, 990
    - cervical phase, 990–993
    - lymph node dissection, 990
    - right transthoracic phase, 988–990, 989*f*
  - procedures, 1150
  - procedures, other accompanying, 1152*f*
  - resections, 1152*f*
  - routes of reconstruction, 993–994

- total, with gastric pull-ups, 1152*f*
- without pyloroplasty, 1165

Esophagogastric disconnection, 874

Esophagogastric junction. *See also* Gastroesophageal junction (GEJ)
- incision along, 1099*f*
- procedures at, 1150, 1152*f*
- "z" line, 208*f*

Esophagogastric resections, 1152*f*

Esophagogastric surgery, functional disorders after, 1155–1162

Esophagogastroduodenoscopy (EGD)
- in achalasia diagnosis, 970
- achalasia workup, 962
- indications for, 206
- information from, 1241
- technique of, 207–209

Esophagogastropexy, 950, 950*t*, 951*f*

Esophagogastroscopy, 1600

Esophagojejunostomy, history of, 1140

Esophagomyotomy. *See also* Heller esophagomyotomy
- for achalasia, 950, 1000
- robotic-assisted laparoscopic, 976–977
- thoracoscopic, 977–978
- videoscopic, 972

Esophagus
- abdominal, 828–830
  - anatomic relationships, 1058–1060
  - peritoneal reflections and, 1060*f*
  - surgical considerations, 1063
- adenocarcinoma of
  - chemoradiotherapy for, 984
  - increasing incidence of, 946–947
  - risk factors, 984, 998
  - surgical risk factors, 984–985
- aligning, 1012*f*

- anatomic relationships, 784, 785
- anatomical dissections, 786*f*
- anatomical relationships, 900–902
- anatomy of
  - anatomical relations, 897–902, 898*f*, 899*f*
  - anteroposterior view, 887*f*
  - arterial supply, 892–893, 892*f*
  - cross-sections, 898*f*, 899*f*
  - divisions, 888*f*
  - endoscopic view, 890*f*
  - gross, 887–888
  - lateral view, 888*f*
  - lymph system, 894–896, 894*f*, 895*f*
  - mucosa and submucosa, 894*f*
  - nerve supply, 896–897, 897*f*
  - tissue architecture, 890–892, 891*f*
  - venous drainage, 893–894, 893*f*
- anvil placement, 922*f*
- arterial supply, 893
- arteries of, 1064*f*
- baseline pressure, 904*f*
- blood supply, variations in, 835*f*
- carcinoma of, 983–999
- cervical incision behind, 1006*f*
- circumferential dissection, 918
- clamp stabilization, 1136*f*
- congenital short, 823–824
- Crohn disease involvement, 1663–1664
- diaphragm and, 833*f*
- diaphragmatic opening of, 830*f*
- disruption of, urgent operative care for, 788
- dissection, risks of, 877*f*
- division of, 1008*f*, 1136*f*
- drain placed around, 955*f*

- embryology of, 781, 886–887, 886*f*, 1053
- GIST and, 1196, 1198
- gross anatomy, 888
- indentations of, 886*f*
- injuries (*See also* Esophageal perforation)
  - preventing, 953, 1031
  - repair of, 471–472, 472*t*
- lengthening of, 916
- longitudinal muscle fibers, 976*f*
- lower, tumors of, 896*f*
- lower esophageal sphincter, 889–890
- lymphatic drainage, 895–896
- middle, tumors of, 896*f*
- mobilization of, 867, 868, 907, 908*f*, 916, 930
  - elevation, 1005*f*
  - obstacles to, 1000
  - retraction, 1007*f*
  - right side, 953
  - risks of, 877*f*
- motility disorders, 892
- neurodegenerative processes, 982
- nodal stations, 986*f*–987*f*
- obstruction, treatment of, 1000
- overview of, 886
- perforation of, accidental, 933
- pH assessment, 947
- plexus, 897
- resection
  - approach to, 1000
  - contraindications for, 984
  - indications for, 984
  - pathophysiology relevant to, 1000
  - for perforation, 1029–1030
  - reconstructive technique, 987

- retraction of, 907–908, 908*f*
- short, 839
- squamous cell carcinoma of, 984
  - chemoradiotherapy for, 984
  - lymphadenectomy in, 986–987, 986*f*–987*f*
  - surgical approaches, 985
  - surgical risk factors, 984–985
- staple cartridge insertion into, 1012*f*
- sutures, 878*f*, 1013*f*
- tissue architecture, 891–892
- transected, 459*f*
- transection, 1134
- transhiatal approach, 985–986
- upper, tumors of, 895, 896*f*
- upper esophageal sphincter, 889
- venous drainage, 893–894

- EsophyX device, 965, 965*f*
- Essential hypertension
  - preoperative, 24
- Estlander pedicle flap, 330, 331*f*
- Estrogen receptors, 762
- Estrogen replacement therapy, 2177
- Estrogens, 609
- Ethanol
  - ablation, in thyroid cancer, 520
  - effects on tissues, 196
  - injection of, 196
  - sclerotherapy
    - for lymphatic malformations, 372, 379
    - for vascular malformations, 380
- Ethanolamine oleate, 1923
- European Association of Endoscopic Surgeons (EAES), 272
- European Organization for Research and Treatment of Cancer (EORTC)
  - 1081 trial, 756

- 10853 trial, 756
- 10981 trial, 756

- Eustachian tubes (ET). *See also* Auditory tube
  - anatomy, 300
  - opening of, 398
- Eutectic mixture of local anesthetics (EMLA), 437
- Euthyroid sick syndrome, 10
- EVAR. *See* Endovascular aortic repair (EVAR)
- EVD placement, 480*f*
- Eventration, diaphragmatic. *See* Diaphragmatic eventration
- Ewing sarcoma, neoadjuvant therapy, 1892
- Excision techniques
  - wide local
    - in breast-conserving surgery, 626–627, 626*f*–627*f*
    - of central tumors, 627–628, 628*f*
- Exercise
  - complication rates and, 28
  - and lymphedema, 678, 679
- EXIT-to-ECMO, 842
- Exocrine insufficiency, symptoms of, 1492
- Exophthalmos, 516
- Expanded polytetrafluoroethylene (ePTFE)
  - for arteriovenous hemodialysis access
    - forearm, 2542*f*
    - lower extremity, 2543*f*, 2544*f*
    - overview of, 2543–2544
    - upper arm, 2543*f*
- Expanders, mastectomy, 732–733
- Explosions, operating room, 276
- Extended spectrum β-lactamases (ESBLs), 110, 114, 117*t*
- Extensor digitorum communis tendon, 250
- Extent of disease (EOD) in oncoplasty, 714
- External abdominal oblique muscle
  - anatomy, 774, 775*f*

- insertion of, 2211*f*
- origin of, 2211

External acoustic meatus, 317

External anal sphincter (EAS), 1684–1685, 1825*f*

External beam radiotherapy (XRT), 387, 520, 1938

External carotid artery
- anatomy of, 71*f*, 288*f*, 292, 292*f*, 321*f*, 323*f*
- anteromedial branches
  - anatomy, 298
- branches, 292*f*
- injury
  - repair, 2575*f*
  - risk and prevalence, 2569–2570
- parotid space and, 317, 319

External iliac artery
- anatomic relationships, 2005*f*, 2007*f*, 2008*f*
- skeletonizing of, 2041*f*
- tumor invasion, 1869

External iliac vein
- anatomic relationships, 2005*f*
- skeletonizing of, 2041*f*
- tumor invasion, 1869

External inguinal ring, 2191*f*
- secondary, 2191, 2191*f*

External intercostal muscles
- embryology of, 772

External jugular veins (EJVs)
- anatomy of, 71*f*, 289, 296, 305
- formation of, 318
- parotid space and, 319

External laryngeal nerve, 298*f*

External oblique aponeurosis (EOA)
- exposure of, 2233
- fibers of, 2212*f*

- incision, 2215*f*
- separation of, 163*f*

External oblique muscles
- anatomic relationships, 2182
- embryology of, 772
- freeing of, 230*f*

External supravesical hernias, 2192–2193

External urethral sphincter, 2009*f*

Extra domain A (EDA) fibronectin, 196

Extra-anatomic axillary-femoral revascularization, 2475–2476

Extra-anatomic bypass
- for graft infections, 2480
- imaging, 2469*f*
- mycotic aortic aneurysm management with, 2468–2469

Extracorporeal knots
- with Endo Stitch, 172
- paraesophageal hernias and, 176
- technique, 171

Extracorporeal membranous oxygen (ECMO), 448, 842

Extrahepatic artery, variants, 1266

Extrahepatic biliary ducts, embryology, 1471

Extrahepatic biliary strictures
- dominant, 1403
- endoscopic treatment, 1400*f*
- percutaneous treatment, 1400*f*
- resection, 1400*f*

Extrahepatic biliary strictures associated fibrosis, 1403

Extrahepatic biliary tree
- injuries, repair of, 1339
- overview of, 1400*f*
- reconstruction, 1400*f*
- surgical resection
  - benefits, 1402, 1403
  - need for, 1404

- outcome and complications, 1402*f*
- technique, 1399–1400, 1400*f*

- Extrahepatic cholangiocarcinomas, 1286
- Extrahepatic portal block, 1605
- Extrahepatic portal hypertension (EHPH), 1600–1601
- Extralevator abdominoperineal excision (ELAPE), 1853
- Extraperitoneal space, 2183
- Extremities. *See also* Lower extremities; Upper extremities
  - injury to, 2586–2588, 2587*f*, 2588*t*
    - civilian, 2588–2589
    - etiology and pathophysiology, 2588
    - military, 2589
    - mortality and amputation rates, 2589*f*
  - injury treatment
    - arterial repair, 2593
    - complications, 2601
    - conduit selection, 2592–2593
    - endovascular, 2599–2601
    - fasciotomy, 2595–2596, 2596*f*, 2602
    - general operative topics, 2591
    - outcomes, 2602
    - postoperative care, 2601
    - preoperative planning, 2591
    - repair, 2588–2591
    - shunts and shunting, 2591–2592, 2601–2602
    - survival, 2588
    - triage categories, 2594*f*
    - vein repair, 2593–2595, 2594*f*, 2595*f*
    - wound management, 2596, 2602
- Eyelids, lacerations, 439–440, 440*f*
- Eyes
  - brainstem impairment and, 484
  - pupillary changes, 484
  - soft tissue injuries to, 439–440

F

- Facial artery
  - anatomic aids, 321
  - anatomy, 321*f*
  - division of, 360
  - lip and, 327
- Facial defects, soft tissue flaps, 217, 219–221
- Facial expressions, facial nerve and, 318
- Facial nerve (CN VII)
  - anatomic relationships, 309*f*
  - anatomy of, 308–309, 312*f*, 318, 439, 439*f*
  - branches of, 312
    - buccal, 316, 318
    - cervical, 317, 318, 321
    - mandibular, 318, 321
    - marginal, 318, 360*f*
    - temporofacial, 318
    - zygtomatic, 318
  - cervical branch of, 320
  - evaluation of, 309
  - exit from the skull, 318
  - exposure of, 360
  - identification of, 309, 312
  - main trunk of, 319
  - traumatic injuries, 439
- Facial process, anatomy of, 316
- Facial skeleton, palpation of, 435*f*
- Facial transplantation, 441
- Facial trauma
  - ballistic injuries, 439
  - cleansing of, 435
  - evaluation of, 433–446
    - initial, 434–436
    - radiologic, 436

    - secondary survey, 434
  - facial nerve injuries, 439
  - fractures
    - management of, 440–444
    - midface, 435*f*
    - panfacial, 444, 444*f*
  - postoperative management, 444–445
  - prophylactic antibiotics in, 436
  - repair of, 433–446
  - scarring, 444–445
  - soft tissue injuries, 436–439
  - wound closure, 438
  - wound preparation, 438–439
- Facial trauma, nerve blocks
  - sites for, 436–437, 437*f*
- Facial vein
  - anatomy, 321*f*
  - ligation of, 360, 360*f*
- Factor IX, dosage, 107
- Factor VII, activated, 27
- Factor Xa inhibitors
  - coagulopathies and, 105
  - drug induced coagulopathy and, 104
  - indications, 110
- Factor XII activation, 133
- Fagel, Jean, 1839
- Falciform ligament
  - anatomic relationships, 833, 1259, 1328
  - embryology of, 1052–1053
  - overview of, 833
- False vocal cords, 303
- Familial adenomatous polyposis (FAP)
  - *APC* mutation and, 516
  - colonscopy in, 206

- description of, 1726–1727
- ileal pouch-anal anastomosis for, 1732
- IPAA for, 1733
- mesenteric desmoid and, 1631*f*
- prophylactic surgery, 1751
- rectal cancer in, 1751
- surgery, timing of, 1735
- surgical options, 1727
- total colectomy and, 1741
- Whipple procedure and, 1734

Familial hypercalcemic hypocalciuria (FHH), 534
Familial hypertriglyceridemia, 1177
Familial leiomatosis, genetics of, 2020
Fansler proctoscope, 1924–1925
Farnesid X receptor (FXR), 1182
Fas. *See* CD95 (Fas)
Fascia lata grafts, 236
Fascia of Toldt, 1676*f*
Fascia of Treitz, 1472
Fascia propria of rectum, 1683*f*
Fascial dehiscence, postsurgical, 1724
Fasciocutaneous V-Y flaps, 1859
Fasciotomy, 2430

- clinical presentation
  - gluteal compartment syndrome, 2425, 2426*f*
  - leg compartment syndrome, 2426
  - thigh compartment syndrome, 2425–2426
- complications, 2429
- contraindications, 2426–2428
- etiology and pathyphysiology, 2423–2425, 2423*f*–2425*f*
- in extremity trauma treatment, 2595–2596, 2602
  - incision lines, 2596*f*
- indications, 2426–2428, 2426*f*–2428*f*
- outcomes, 2429–2430

- postoperative care, 2429
- preoperative planning, 2428
- surgical technique, 2428–2429, 2428*f*–2429*f*

- FasL. *See* CD178 (FasL)
- FAST. *See* Focused assessment with sonography in trauma
- Fasting, energy sources, 13
- Fasting glucose in diabetes, 1177
- Fat
  - grafts and, 737
  - necrosis
    - of breast, 615, 616*f*
    - in breast oncoplasty, 718
    - breast reconstruction and, 223
    - pancreatic duct, 1575
- Fat/glucose switch, 52
- Fats, synthesis of, 15. *See also* Lipids
- FDA. *See* Food and Drug Administration
- FEA. *See* Epithelial atypia, flat
- Febrile nonhemolytic reaction
  - transfusion-related, 109*t*
- Fecal antigen tests, 1114
- Fecal calprotectin, 1661
- Fecal diversions for rectovaginal fistula, 1933
- Fecal in continence severity index (FISI), 1947
- Fecal incontinence
  - permanent end ileostomy for, 1639
  - in rectal prolapse, 1893
  - sacral nerve stimulation for, 1954–1955
- Fecal incontinence quality of life (FIQL) assessment, 1947
- Fecal microbiota transplants (FMT), 1721, 1724
- Fecaloma in caverous rectum, 1960
- Feeding jejunostomy, 920–921
- Feeding tubes
  - “eel” skin, 54

- insertion, 1038*f*
- Felons, management of, 251
- Femoral arteriovenous fistulae
  - left, 2503*f*
  - right, 2504*f*
- Femoral artery
  - bifurcation, reconstruction of, 2468*f*
  - cannulation, 69
  - debridement of infected, 2468*f*
  - endovascular therapy, 2385–2386, 2385t, 2386*f*
  - injury
    - imaging, 2593*f*
    - repair of, 2597–2598, 2598*f*
  - occlusion balloon from, 2571, 2574*f*
  - shunting of, 2591*f*
  - surgical removal of embolus, 2420–2421
  - transverse view of, 2492*f*
- Femoral artery aneurysms, 2331
  - degenerative
    - anatomy, 2319
    - clinical manifestations, 2319
    - diagnosis, 2319
    - incidence and risk factors, 2319–2320
    - surgical treatment, 2319–2320
  - mycotic, 2324–2325
  - normal anatomy and size, 2319
  - pseudoaneurysms
    - anastomotic, 2322–2324, 2323*f*
    - clinical manifestations, 2321
    - diagnosis, 2321
    - incidence and risk factors, 2320–2321
    - post-instrumentation, 2320–2321
    - surgical treatment, 2322
    - ultrasound-guided compression, 2321–2322

- ultrasound-guided thrombin injection, 2322
- Femoral cutaneous nerves, 2194
- Femoral hernias, e84, e84*f*, e86, *e86f*
  - description of, 2193, 2193*f*
  - incidence of, 2211
  - Kugel method for groin hernia, e92
  - repairs, 2211–2228
    - preoperative planning, 2227
  - surgical anatomy of, 2201*t*
- Femoral lymphadenectomy, 1965
- Femoral nerve, branches, 1966
- Femoral triangle, incisions, 431*f*
- Femoral vein
  - after thrombectomy, 2495*f*
  - autogenous
    - axillofemoral prosthetic bypass with, 2476*f*
    - femoral-femoral bypass with, 2476*f*
    - for graft infections, 2480
  - cannulation of, 71–*73*
  - exposure of, 2483*f*
  - prosthetic bypass (*See* Crossover femoral venous prosthetic bypass)
  - shunts and shunting, 2591*f*
  - thrombosis of, 2492*f*, 2515
  - transverse view of, 2492*f*
- Femoral vein-constructed neo-aortoiliac system (NAIS), 2468
- Femoral-femoral bypass, 2476*f*
- Femoral-femoral lower extremity, prosthetic, 2543*f*, 2544*f*
- Femoral-popliteal disease
  - above-knee bypass, 2362–2363, 2363*f*
  - endovascular therapy, 2388–2389, 2389*f*
  - prosthetic conduit bypass, 2368
- Femorocaval bypass
  - chronic DVT treatment with, 2504–2505
  - right, incisions of, 2504*f*

- Femorocaval polytetrafluoroethylene (PTFE) bypass, 2505*f*
- Femorocaval reconstruction, 2504
- Femorofemoral bypass. *See* Aortoiliac occlusive disease
- Femoroiliac reconstruction, 2504
- Femoropopliteal vein (FPV) graft, 2477*f*, 2478*f*
- Femoropopliteal venous segment, 2488*t*
- Fenestrated endovascular aneurysm repair (FEVAR), 2290. *See also* Aneurysms
- Fertility preserving surgery in ovarian cancers, 1250, 2166
- Fetal anomalies, comparisons, 1033
- Fetal hydrocephalus, caesarian delivery in, 2119
- Fetal interventions
  - for congenital diaphragmatic hernia, 841–842
  - risks of, 841
- Fetal lamb models, 821, 823
- Fetal magnetic resonance imaging (MRI), 841
- Fetal surgery, for CDH, 820, 823, 843–845
- Fetal thoracic conditions, 1033
- Fetal tracheal occlusion, 839, 841–842
- Fetendo balloon occlusion, 823
  - trials, 823
- Fetor hepaticus, 1620
- FEVAR. *See* Fenestrated endovascular aneurysm repair
- Fevers
  - hypermetabolic response to, 57
  - prostaglandins and, 7
- Fiber, dietary, 1753
- Fibrin glues, 1929–1930, 1936
- Fibrinogen (factor I)
  - human, in hemorrhage, 1346
  - release of, 196
  - synthesis of, 56
- Fibrinogen degradation products (FDPs), 103
- Fibrinolysis, DIC and, 103

- Fibroadenomas
  - ablation therapy, 654, 659–660
  - histopathology and management, 604–605
- Fibroadipose vascular anomaly (FAVA), 380
- Fibroblasts, chemokine receptors in, 6
- Fibrofascial bands, anatomy of, 2549
- Fibrofolliculomas, 2020
- Fibronectin, extra domain A (EDA) of, 196
- Fibrosis, imaging studies of, 1396*f*
- Fidler, Isaiah, 2067
- Fight-bite infections, hand/wrist, 255–257
- Fine needle aspiration (FNAs) biopsies
  - parathyroid glands, 534
  - salivary gland, 310
  - thyroid, 529–530
    - Bethesda criteria, 517–520
    - methodology, 517
  - ultrasound-guided
    - PHTH and, 546
- Fingers
  - extension of, 250, 251*f*
  - flexion, 250
  - innervation, 247
- Fingertip injuries, 261
- Finney pyloroplasty, 1099*f*, 1100*f*, 1109
- Finney stricturoplasty, 1666–1668, 1667*f*
- Fires
  - electrosurgical injuries, 276
    - clinical examples, 276
    - preventative strategies, 276
  - operating room risk, 33
- First rib resection
  - anterior, 2557*f*
  - and cervical rib, combined resection of, 2557*f*

- posterior, 2556*f*

Fish oil in EN formulas, 64, 1985

Fish-tail flaps, 234*f*

Fissure in ano

- causes, 1913
- diagnosis, 1913
- presentation, 1913
- secondary, 1913
- surgical principles, 1914
- treatment, 1913–1914

Fistula First Breakthrough Initiative, 2525, 2525*t*, 2526*f*

Fistulae

- anal, types of, 1716*f*
- appliances, cut-to-fit, 1660
- arteriovenous, 2371, 2371f
- diverticular, 1756
- duodenal, 1659
- formation of, 1652
- forniceal, causes, 1932
- gastrointestinal-cutaneous, 1650–1660
- management of, 1653*f*
- output, reduction of, 1654
- perineal
  - causes, 1932
  - treatment of, 1933–1934
- postobstetric, 1935
- postoperative, 1650, 1660
- prevention of, 1660
- recurrent, management of, 1042*f*
- repair of rectal prolapse and, 1902
- septal
  - causes, 1932
  - surgical treatment, 1933
- spontaneous, 1650

- Fistulectomy, 1920
- Fistulograms, 1652, 1655
- Fistulotomy
  - for anal fistulas, 1918–1919
  - complete, 1920–1921
  - for perianal Crohn disease, 1717–1718
  - principle of, 1919
  - seton, 1919–1920, 1920*f*
  - surgical, 1715
- Fixed hiatal hernia, 822*t*, 823
- Flail chest
  - clinical presentation, 791
  - diagnosis, 791
  - mortality and morbidity, 798
  - presentation, 798
  - thoracic trauma and, 788
  - treatment, 791
- Flank hernias, 164, 166
  - fascial defects in, 164
  - operating room setup, 167*f*
  - patient positioning, 164, 167*f*
- Flank pain, ultrasounds in, 2020
- Flap techniques, soft tissue reconstruction, 215–246
- Flapping tremor in liver disease, 1620
- Flaps
  - anatomy of, 216
  - definition of, 216
  - delayed procedures, 216
  - in mastectomy
    - latissimus dorsi myocutaneous, 733, 733*f*
    - myocutaneous, autogenous (TRAM), 729–731, 730–731*f*
    - Tansini method, 726, 726*f*
  - vascular anatomy of, 216
- Flatulence, post fundoplication, 933

- Flatus incontinence, 1926–1927
- Flexible endoscopy, GI, 206–215
- Flexor digiti minimi, 249*f*
- Flexor digitorum profundus (FDP) insertion, 248
- Flexor digitorum superficialis (FDS) insertion, 248
- Flexor pollicis brevis, 249*f*
- Flexor sheath infections, 255
- Flexor tenosynovitis (FTS)
  - management of, 255
  - right ring finger, 256*f*
  - urgent attention to, 251
- Floppy Nissen
  - completed, 871*f*
  - fundoplication, other compared to, 949*f*
  - for gastroesophageal reflux disease, 874
  - procedure/technique, 870, 949
- Florida pouch, 2112
- FloTRac Sensors, 69
- Flow cytometry, platelet function and, 105
- Flow reversal in carotid endarterectomy, 2254
- Fluconazole dosage, 962
- Fluid resuscitation, 33–34, 135–136, 1977
- Fluorescent angiography, stomach, 268*f*
- Fluorodeoxyglucose-positron emission tomography (FDG-PET), 2472
- 5-Fluoruracil
  - for anal condylomata, 1928
  - for esophageal cancer, 984
  - in recurrent rectal cancer, 1867
  - before resection, 984
- FNABs. *See* Fine-needle aspiration (FNABs) biopsies
- Focal nodular hyperplasia (FNH), 1278, 1279*f*
- Focus, ultrasonographic definition, 179
- Focused assessment with sonography in trauma (FAST), 858, 2304
- Fogarty catheters, 1390*f*, 2448*f*

- Foker technique, 1042*f*
- Folate in Crohn disease, 1661
- Foley catheter, 1768
- Foley-YV-plasty, e52, e55*f*, e56
- FOLFIRNOX regimen, 1572
- FOLFOXRI regimen, 1326
- Folkman, Judah, 1799
- Follicle-stimulating hormone (FSH), 11
- Follicular thyroid cancer, 518
- Follicular variant of papillary thyroid cancer (FVPTC), 518
- Folliculitis, stoma-related, 1778–1779, 1779*f*
- Food and Drug Administration (FDA)
  - breast pain medication, 608
  - da Vinci approval by, 263
- Foot
  - diabetic, 2408–2415 (*See also* Amputations)
    - assessment of, 2410*t*
    - incisions, 2412*f*
    - occult injuries, 2410–2411
    - pathophysiology of, 2408–2409
    - self-examination, 2410
  - melanoma, 419, 423–424, 424*f*
  - ulcers
    - in diabetes, 2392
    - reversed vein bypass grafts, 2358
- Footwear, diabetic, 2409–2410
- Foramen of Bochdalek. *See also* Bochdalek hernias
  - herniation, 824*f*, 825*f*
  - posterolateral, 820
- Foramen of Morgagni
  - hernia through (*See* Morgagni hernia)
  - herniation, 824*f*, 825
  - substernal, 820
- Foramen of Winslow

- anatomic relationships, 1589, 1609, 2157*f*
- hernias through, 2200, 2203*t*, 2205*f*

Forced expiratory volume (FEV), 848–849

Forced expiratory volume in 1 sec. (FEV_1), 804–805

Forced vital capacity (FVC), 848–849

Forearm. *See also* Upper extremities
- anatomy, 247–249
- arteriovenous hemodialysis access in, 2541, 2542*f*, 2545*f*
- bones of, 249*f*
- compartment syndrome, 258–259

Foregut
- development of, 1472*f*
- embryonic, 781, 1815

Forehed flap, 221*f*

Foreign bodies
- esophageal injuries, 1022
- impaction
  - upper endoscopy in, 206
- small bowel obstruction, 1630*t*

Forkhead Box O 1 (FOXO1), 38, 41

Forkhead Box O 3a (FOXO3a), 38

Formen of Winslow, 1330

Forniceal fistulae, causes, 1932

Fossa of Luschka, 1677

4DCT scans, parathyroid, 543

Fournier gangrene, 128

Fowler-Stephens procedure, 2076

Fowler-Weir extension, 1691

Fraenkel, Bernhard, 386, 386*f*

Frederickson classification, 1177

Free fatty acids (fFAs)
- blood plasma levels, 18
- energy sources, 13
- excess of, 18

- oxidation, 20
- release of, 9
- in serious illnesses, 18
- stress responses and, 2

"Free flaps," 216
Free muscle flaps, 216
Free radicals, detoxification of, 20
Free tissue transfers, 216
Freeze buttons, ultrasonographic, 179
Frenulum, 335*f*
Frequency, ultrasonographic definition, 179
Fresh frozen plasma (FFP), 106–107
Freund, Herbert, 48
Frey, Charles, 1522
Frey procedure
- characteristics, 1498*t*
- in chronic pancreatitis, 1496, 1497
- clinical trials, 1500*f*
- steps, 1498*f*, 1499*f*
- surgical outcomes, 1512–1513
- therapeutic targets, 1513*t*

Frey syndrome, 312
Frontal bone fractures, 443
Frontal sinus, frontal bone fractures and, 443
Frostbite, risk of, 261
Fructose absorption, 59
Fryns syndrome, 841
Fulguration, 274
Fully covered self-expanding metallic stents (FCSEMS), 1537
Fulminant colitis, 1733–1734
Fulminant hepatic failure, 25
Fumarate hydratase gene, 2020
Functional Assessment of Cancer Therapy-Gastric (FACT-Ga), 1147
Functional gallbladder disorder (FGBD), 1393, 1394

- Functional gastric stasis, 1122–1123
- Functional status, complication rates and, 28
- Functional tests
  - assessments using, 55
  - preoperative status, 23
- Fundamental Use of Surgical Energy (FUSE) curricula, 273
- Fundamentals of Endoscopic Surgery (FES), 169, 173
- Fundoplication. *See also* Nissen fundoplication
  - achalasia diagnosis and, 970
  - anterior partial, 977*f*
  - basic tenets of, 948
  - complications and risks, 1031
  - construction of, 908
  - conversion to gastric bypass, 1250
  - failures of, 933, 958, 958*f*, 1000, 1020
    - obesity and, 1250
  - for GERD, 962
  - historic developments, 904
  - indications for, 874
  - in infants, 877*f*
  - instruments, orientation of, 875*f*
  - in laparoscopic antireflux surgery (*See* Laparoscopic fundoplication)
  - outcomes, 916
  - partial, 949–950, 950*t* (*See also* Toupet fundoplication)
    - in antireflux surgery, 874 (anterior), 956–957, 958, 961
    - for GERD prevention, 983
  - partial posterior, 978*f*
  - redo, 882*f*
  - resistance, overcoming, 907*f*
  - robotic-assisted, 271
  - sphincter pressure, surgery impact on, 906*f*
  - suture line for, 879*f*
  - sutures, placement of, 871*f*
  - technique, 931

    - checking, 932*f*
    - suture placement, 931*f*
  - transabdominal, 933
  - wrap migration
    - fundoplication, repeat due to, 881*f*
    - preventing, 877*f*
- Fungal graft infections, 2471
- Fungemia, 46
- Funnel chest, 772
- *Fusarium* spp.
  - esophageal cancer and, 984
  - *F. nucleatum*, 1288
- Future liver remnant (FLR), 1316, 1317*f*

G

- Ga, 1214*f*
- GA LAW, 1527
- Gabapentin, 138, 1781
- Gabapentoids, 1581
- Gadolinium, 2299
- Gadolinium chloride, 19
- Gadoxetic acid transporters, 1281
- Gain, ultrasonographic definition, 179
- Gait abnormalities in diabetes, 2409
- Galactose absorption, 59
- Gallbladder
  - adenomyomatosis, 1273
  - adhesions, 1345
  - anatomic relationships, 1342–1343
  - anatomy of, 1267–1268
  - atretic, 1429*f*
  - bed exposure, 1358*f*
  - biliary drainage via, 1412–1413
  - contraction, stimulation of, 1285
  - disease presentation, 1354

- dissection, stone spillage during, 1361
- Doublet View, 1367
- embryology, 1471
- excision of, 1347–1348
- exposure of, 1345*f*
- fossa
  - biliary ductules in/bile ducts running along, 1381
  - hemostasis, 1357
  - retraction of, 1357
  - visualization of, 1382
- gangrene, 1343
- hydrops of, 1359
- infected, 1343
- infundibulum
  - clipping, 1357*f*
  - elevation of, 1356*f*
  - retraction, 1358*f*
- laparoscopic scanning, 189, 189*f*
- localization of, 1344
- mucosa, diathermy coagulation, 1348*f*
- pathologies, 1272
- pedunculation of, 1356–1357, 1357*f*
- perforated, 1352
- peritoneal attachments, 1346*f*
- polyps, 1273–1274, 1274*f*
- porcelain, 1273
- primary sclerosing cholangitis, 1395
- removal of, 1357–1358, 1358*f*
- resection of, 1357
- stasis, 1284, 1353
- ultrasound evaluation, 179*f*, 184–185, 187*f*

- Gallbladder cancer, 1420
- Gallbladder ejection fraction (GBEF) estimates, 1353
- Gallbladder muscularis, 1342–1343

- Gallstone pancreatitis
  - presentation, 1354
  - recurrent, 1366
- Gallstones. *See also* Cholelithiasis
  - after ileostomy, 1649*t*
  - biliary obstruction and, 1274–1275
  - diagnosis of, 1343
  - etiology of, 1353
  - Hartmann pouch creation by, 1268
  - identification of, 1284–1285
  - ileostomy and, 1647
  - impacted, 1364–1365
  - medium-sized
    - dilated CBD and, 1363–1364
  - octreotide and, 1654
  - pathophysiology of, 1353
  - presentation, 1343
  - risk factors, 1353
  - small, 1362–1363
  - spillage, 1361
  - surgical management, 1343–1350
  - treatment of, 1343
  - types of, 1353
  - ultrasonogram, 1347*f*
- Gambee sutures, 153, 1103
- Gamolenic acid, 609
- Ganglioneuromas
  - imaging, 1885, 1886*f*
  - presacral, 1883–1884
  - retrorectal, 1884*f*
- Gangrene
  - critical limb ischemia, 2377
  - dry in diabetic feet, 2412
  - Fournier, 128, 2105

- gallbladder, 1343
- Garfield, James, 54
- Gas-bloat syndrome, 950, e41
- Gastrectomy. *See also* Distal gastrectomy
  - consequences of, 1148
  - with D2 lymphadenectomy, 1148
  - distal
    - Billroth I or Billroth II, 1084–1095
    - indications for, 1142–1143
    - laparoscopically-assisted, 1094
    - pylorus-preserving variant, 1142
    - with Roux-en-Y reconstruction, 1145*f*
  - extent of, 1142–1143
  - gastric remnant necrosis, 1066
  - history of, 1140
  - LDG *versus* DG, 1142–1143
  - lymph node removal in, 1140
  - open *versus* laparoscopic, 1141
  - partial, indications, 1085–1086
  - resections, 1149*f*
  - with Roux-en-Y gastrojejunostomy, 1149*f*
  - subtotal, 1091*f*
    - for gastric cancer, 1130–1131, 1134
    - indications, 1142
    - surgical technique, 1091–1092
  - subtotal or total, 1130–1131
  - total
    - for gastric cancer, 1130–1131, 1134
    - reconstruction after, 1135–1136
  - vagotomy not needed after, 1147
- Gastric acid suppression, 1720
- Gastric banding
  - adjustable, 266, 1153*f*, 1179, 1203, 1242, 1247–1248
  - illustration, 1180*f*

- outcomes, 1203
- Gastric bubble, fetal anomalies and, 1033
- Gastric bypass surgery. *See also* Roux-en-Y gastric bypass
  - complications, 1250–1258
  - multisystem effects, 1210
  - staplers in, 174–175
- Gastric cancer, 1127–1141
  - adjacent organ resection, 1130
  - classification of, 1127
  - clinical trials, 1128–1129, 1140
  - decision algorithm, 1127*f*
  - diagnosis, staging and treatment algorithm, 1127*f*
  - evidence-based approach to, 1140
  - gastric resection
    - extent of, 1128, 1130*f*
  - lymph node dissection
    - extent of, 1128–1130, 1130*f*
    - lymph node stations, 1129*f*
  - lymphadenectomy, 1133–1134, 1134*f*
  - overview of, 1127
  - partial gastrectomy for, 1086
  - postoperative care, 1138–1139
    - chemoradiotherapy, 1139–1140
    - enteral feeding, 1138–1139
    - pain management, 1138–1139
  - preoperative planning, 1127–1128, 1143
  - reconstruction, 1139*f*
  - regionalization of care, 1140
  - resection, pyloric function after, 1142
  - staging, 1127–1128
  - surgery, 1128, 1130–1134, 1143–1146
    - complications, 1139
    - considerations, 1128
    - D2 lymphadenectomy, 1131, 1133–1134, 1134*f*, 1148

- duodenal transection, 1133, 1133*f*
- esophageal transection, 1134
- exploration, 1130–1131
- gastrectomy, 1130–1131
- gastric or esophageal transection, 1134
- gastric transection, 1134
- greater curvature mobilization, 1131, 1132*f*
- infrapyloric mobilization, 1131–1132, 1132*f*
- intrapyloric mobilization, 1131–1132, 1132*f*
- luminal resection, extent of, 1128
- lymph node dissection, extent of, 1128–1130
- minimally invasive, 1140
- operative procedures sequence, 1131, 1131*f*
- outcomes, 1139–1140
- postoperative care, 1138–1139, 1141
- preoperative planning, 1127–1128
- reconstruction, 1134–1138, 1136*f*–1137*f*, 1138*f*, 1139*f*, 1140, 1141
- regionalization of, 1141
- sequence of procedures, 1131, 1131*f*
- suprapyloric mobilization, 1132–1133, 1133*f*

- Gastric conduits
  - closure of, 923*f*
  - creation of, 919, 920*f*
  - specimen attachment to, 920*f*
- Gastric distension
  - preventing, 914
  - sphincter, impact on, 916
- Gastric drainage procedures
  - choice of, 1123
  - indications for, 1122–1123
- Gastric emptying, delayed, 1159
  - causes of, 1165
  - early postoperative, 1159
  - reducing, 1165

- treatment, 1158
- Gastric fistulae, revision for, 1245–1246
- Gastric flaps, 1028*f*
- Gastric fluids, composition of, 1651*t*
- Gastric fundoplication, robotic, 264–265
- Gastric fundus
  - after staple line creation, 869*f*
  - diaphragm, tacking to, 961
  - drawing through hiatus, 908*f*
  - mobilization, 868, 954
  - pulling in antireflux surgery, 955
  - retraction, use for, 956*f*
  - retroesophageal window, passage through, 870*f*
  - rotational tension and torsion, checking for, 954
  - stapling of, 911–912*f*
- Gastric hematoma, 915
- Gastric lipase, 60
- Gastric lumen, 1078, 1078*f*
- Gastric mobilization, laparoscopic sites or, 993*f*
- Gastric necrosis, 865
- Gastric neurostimulators, 1183
- Gastric obstruction, 867
- Gastric outlet obstruction, 1120–1121, 1122
- Gastric pouches, 1214*f*, 1247*f*
- Gastric pressure, baseline, 904*f*
- Gastric pull-up, 1152*f*
- Gastric resection
  - complications, 1149–1150
  - extent of, determining, 1128–1130, 1130*f*
  - as gastric cancer risk factor, 1127
  - general review of, 1149–1150
  - subtotal, 1086
  - types of, 1149*f*
- Gastric residual volumes (GRVs), 63

- Gastric sleeves, 1153*f*
- Gastric staple line, 1011*f*
- Gastric strangulation, 865
- Gastric stump cancer, 1092
- Gastric transection, technique, 1134
- Gastric tubes, attachment of, 920*f*
- Gastric ulcers, 1085. *See also* Ulcers
- Gastric varices (GVs)
  - endoscopic treatment of, 1627
  - outcomes, 1627
  - upper GI bleeding and, 1106
- Gastric volvulus
  - classification and types of, 866
  - definition and overview of, 865
  - as hiatal hernia complication, 865
  - laparotomy for, 850
  - in paraesophageal hernia, 868
  - paraesophageal hernia accompanied by, 867
  - postoperative, 867
- Gastric walls
  - anatomy of, 1057
  - arterial circulation of, 1066
- Gastrin levels, serum, 1114
- Gastrinoma triangle, 1474*f*
- Gastrinomas, topography of, 1473–1474
- Gastritis
  - bile reflux-related, 1147
  - chronic, 1092
  - remnant, 1165
- Gastrocolic fistulae, 1081
- Gastrocolic ligament, 1489, 1745*f*
- Gastro-colic omentum
  - adhesions, 1345
  - division of, 918–919

- in duodenal ulcer vagotomy, antrectomy, and gastroduodenostomy, e12–e15, e14*f*
- Gastroduodenal adhesions, embryology of, 1057*f*
- Gastroduodenal anastomosis, 1140
- Gastroduodenal artery
  - anatomic relationships, 1068, 1481*f*, 1482*f*
  - identification of, 1507
  - three-suture ligation, 1108*f*
  - variants, 1266
- Gastroduodenal junction
  - anatomic relationships, 1061–1062
  - histology of, 1061*f*
  - muscle fibers, 1062*f*
- Gastroduodenal surgery, anatomic considerations, 1051–1077
- Gastroduodenal ulceration, 1148
- Gastroduodenostomy
  - duodenal ulcer (*See* Duodenal ulcer)
  - end-to-end, 1149*f*
  - end-to-end, antrectomy with, 1149*f*
  - incision, 1085*f*
  - postoperative care, 1092
  - postoperative disease, 1092–1093
  - results, 1092
  - truncal vagotomy with, 1151*f*
- Gastroduodenostomy (Billroth I). *See* Billroth I gastroduodenostomy
- Gastroduodenum, surgicoanatomic units of, 1057–1058
- Gastroenterostomy, history of, 1141
- Gastroepiploic arcade, 918–919, 925
- Gastroepiploic arteries, 235*f*, 1066–1067
- Gastroesophageal flap valve, 936*f*
- Gastroesophageal junction (GEJ)
  - adenocarcinomas of
    - postoperative chemoradiotherapy in, 984
  - anatomic relationships, 1058–1061, 1060*f*

- anatomy of, 889
- approach to, 833
- cancer, surgical approaches, 986
- carcinoma of, 1000
- circular muscle fibers at, 901*f*
- coronal junction through, 1061*f*
- diagrams of, 900*f*
- endoscopic view of, 890*f*
- lifting of, 930*f*
- location, 824 (relative to hiatus), 828, 868
- malignancy of, 1165
- mobilization of, 834, 838
- nonresective procedures at, 1150
- peritoneal reflections, 834*f*
- placement of, 904
- posterior fixation of, 832
- procedures at, 1152*f*
- rubber drain encircling, retraction of, 1006*f*
- stricture cephalad to, 823
- structures at, 832*f*

- Gastroesophageal reflux (GER)
  - anatomic barriers to, 935, 936*f*
  - cervical esophagogastric anastomosis (CEGA) followed by, 1000
  - in EA/TEF repair, 1042
  - overview of, 873, 883, 945
  - resolution after gastric bypass, 1216
- Gastroesophageal reflux disease (GERD)
  - after partial gastrectomy, 1092
  - anatomy, 945, 946*f*
  - cervical esophagogastric anastomosis (CEGA) followed by, 1000
  - clinical presentation, 873–874, 945
  - congenital diaphragmatic hernia followed by, 845
  - demographics, 945
  - diagnosis and testing for, 946–947, 946*t*

- endoluminal approaches, 962–968
  - contraindications, 965
  - indications, 965
  - preoperative planning, 965
- endoscopic treatment of, 214
- esophageal cancer and, 984, 998
- etiology and pathophysiology, 873
- factors contributing to, 839
- historic developments, 903–904
- incidence, 962
- lifestyle modifications for, 947*t*
- modified Hill repair for, 935–944
- Nissen-Rossetti antireflux fundoplication, 928–935
- overview of, 873, 883
- paraesophageal hernia accompanied by, 867
- pathologic after surgery for achalasia, 979–980
- pathophysiology, 945–946
- short esophagus *versus*, 839
- sleeve gastrectomy and, 1224
- surgery (*See* Antireflux surgery)
- symptoms, 872, 945*t*
- treatment, non-surgical, 947

Gastroesophageal valves, grades of, 937*f*

Gastro-esophageal varices (GOVs), 1627

Gastrogastric fistulae, 1244, 1253

Gastrografin. *See* Diatrizoate meglumine (Gastrografin)

Gastrohepatic ligament, division of, 953*f*

Gastrointestianl-cutaneous fistulae
- drainage, 1653–1654
- etiology, 1650
- mortality in, 1659*t*
- prevention of, 1650

Gastrointestinal bleeding
- lower, 1743

- upper, 1046
- Gastrointestinal cancers, 1197
- Gastrointestinal endoscopy, 206–215, 2473
- Gastrointestinal perforation, upper, 1031
- Gastrointestinal stromal tumors (GIST), 1193–1198
  - anal, 1843
  - distal gastrectomy for, 1142
  - etiology, 1193
  - laparoscopic approach, 1198
  - metastasis of, 1194*f*
  - outcomes, 1197
  - preoperative planning, 1193
    - metastatic disease, 1194–1195
    - neoadjuvant therapy, 1194
    - observation, 1193–1194
    - recurrent disease, 1194–1195
  - presentation, 1193
  - surgical technique
    - duodenal GIST, 1195–1196, 1196*f*
    - gastric GIST, 1195, 1195*f*
    - minimally invasive vs open, 1195
    - postoperative care, 1196–1197
- Gastrointestinal tract. *See also Specific* organs
  - closure of defects, 1025, 1025*f*
  - embryology of, 1815
  - microbiome, 1182
  - neural mechanisms, 1181–1182
  - obstruction, TPN in, 46
  - reconstruction, 1147–1148
  - surgery, prophylactic antimicrobial agents, 114*t*
- Gastrojejunal anastomosis
  - leaks, 1146
  - manual, 1145*f*
  - techniques, 1144–1145

- two-layer, hand-sewn, technique for, 1137*f*
- two-layer manual, 1145*f*

Gastrojejunal stenosis, anastomotic, 1253

Gastrojejunostomy. *See also* Laparoscopic gastrojejunostomy
- antecolic, hernias after, 2208
- anterior, 1122
- bypass, other combined with, 1412
- circular-stapled, 1213
- complications, 1124, 1257
- drainage, 1189*f*
- end-to-side, 1567–1568
- gastric outlet obstruction and, 1120–1121
- hand-sewn, 1214
- history of, 1141
- laparoscopic gastrectomy with, 1165
- leak from, 1146
- linear stapled, 1213–1215
- loop (*See also* Billroth II loop gastrojejunostomy)
  - antrectomy with, 1149*f*
  - technique, 1134–1135, 1136*f*
- postoperative management, 1124
- pyloric exclusion with, 1578*f*
- pyloroplasty or, 1123
- retrocolic, hernias after, 2208
- revision, 1242–1244, 1243*f*
  - completion of, 1244*f*
  - for weight gain, 1246–1247
- stenosis, 1217, 1257
- technique, 1413*f*

Gastronomy/jejunostomy, 62*t*

Gastro-omental arteries, 1065

Gastroparesis
- after antireflux surgery, 1158
- bloating due to, 959

- causes of, 1165
- diagnosis of, 1157
- as distal gastrectomy complication, 1146
- etiopathogenesis, 1157
- forms of, 1158
- overview of, 1157
- symptomatology, 1157
- treatment, 1157–1159, 1165

- Gastropexy, 870, 872
- Gastrophrenic ligament, 834
- Gastroschisis
  - anatomy of, 2186*f*
  - diaphragmatic anomalies associated with, 826
  - surgical anatomy of, 2201*t*
- Gastroscopes
  - EUS, 1541*f*
  - placement, 1627
- Gastrostomy, 877–879, 879*f*
  - performing, 1011*f*
  - sutures placed at, 1013*f*
- Gastrostomy balloons, 880*f*
- Gastrostomy catheters, 1080*f*
- Gastrostomy tubes, 1123
  - contrast media, 1081*f*
  - for enteral feeding, 1083
  - migration of, 1081
  - positioning, 1080*f*, 1081*f*
- “Gate flaps”
  - lip reconstruction, 331, 332*f*
- Geenen-Hogan sphincter of Oddi classification system, 1385–1386, 1388–1389
- Gelpi retractors, 1735
- GelPOINT Path, 1943–1945
- Gelport devices, 1727

- Gemcitabine, 1411, 1572, 2036
- Gender
  - diverticulitis and, 1756
  - Hirschsprung disease and, 1971
  - rectal prolapse in, 1905
- General anesthesia, conversion to, 545*t*
- Generalized convulsive status epilepticus (GCSE), 485, 486, 487
- Geniohyoid muscles, 286, 319*f*, 322, 323
- Genital hiatus, widened, 2180*f*
- Genital prolapse, 2166, 2168–2169
- Genitofemoral nerve, 2194
- Genitourinary dysfunction, 1838–1839, 1850
- Genitourinary tract trauma, 2088–2107
  - external genital, 2104–2105, 2107
  - genital burn injuries, 2105
  - genital skin loss, 2105
  - overview, 2088
  - radiographic staging, 2090–2092
  - renal, 2088–2092, 2089*f*
  - shock, hypoperfusion and, 2106
  - traumatic renal injuries
    - parenchymal injury, 2094
    - surgical exploration, 2092–2094
    - vascular injuries, 2094
- "Gentilation," 840, 842, 846
- *Geotrichum* spp., 984
- Germ cell tumors
  - nonseminomatous, 2060–2061, 2068
  - seminomatous, 2060
  - testicular, 2060
  - thymic, 558
- Gerota fascia, 1677, 2002, 2029*f*
- Gharbi, Hassen, 1300
- Ghrelin, 1181, 1182*f*, 1240

- Ghrelin agonists, 1165
- GIA stapler
  - duodenal transection with, 1133, 1133*f*
  - Roux-en-Y conduit, dividing with, 1415
  - stomach division with, 1136*f*
- Giant duodenal ulcers (GDUs), 1119–1120, 1120*f*
- Gila monster venom, 1525
- Gillies fan flaps, 330, 331*f*
- Gingiva, 335*f*
- Gingivobuccal sulcus incisions, 442, 443
- Giordano Giovanetti diet, 48
- GIST. *See* Gastrointestinal stromal tumors (GIST)
- Glands of Montgomery, 602
- Glasgow Coma Scores (GCS), 434, 434*t*, 477, 477*t*
- Glisson capsule, 1259
- Glisson sheath, 1264, 1265
- Glissonian approach, 1319*f*, 1322, 1322*f*
- Global functionality, outcomes and, 55
- Globe
  - evaluation of, 435
  - injuries, 479
- Glomerular filtration rates, 2, 554
- Glomus tumors. *See* Carotid body tumors
- Glossectomy, pull-through approach, 341*f*
- Glossoepiglottic folds, 300
- Glossopharyngeal nerve (CN IX), 293, 320, 468, 468*f*
- Glottic cancer
  - management, 387
  - presentation, 387
  - recurrent, 393*f*
  - surgery, 388–389
  - treatment
    - endoscopic angiolytic laser, 389–391
    - history of, 385–387

    - surgery *vs.* radiation, 387–388
  - vascular pattern, 390*f*
- Glottic stenosis, 497–498
- Glucagon
  - levels after trauma, 16
  - secretion of, 1472
  - stress response and, 2
- Glucagon-like peptide 1 (GLP-1), 1181, 1182*f*, 1525
- Glucagonomas, 1474, 1961
- Glucocorticoids
  - muscle proteolysis and, 13*f*
  - perioperative management, 29*t*
- Glucocorticosteroids
  - hemodynamics and, 9
  - insulin resistance and, 16–17
  - response to surgical trauma, 9
  - surgical trauma and, 9–10
- Gluconeogenesis
  - catecholamines and, 16
  - liver, 1587
  - starvation and, 56–57
  - stimulation of, 9
  - stress responses and, 2
- Glucose
  - absorption, 59
  - blood plasma levels, 18
  - energy and, 13
  - glycolysis and, 50
  - liver production of, 15
  - metabolism of, 15
  - preoperative testing, 23*t*
  - utilization, 15
- Glucose control, in ICUs, 17. *See also* Glycemic control
- Glucose levels, preoperative testing, 22

- "Glue Grant cohort," 133–135
- Glue injections, 1627
- Glutamine
  - in EN formulas, 64
  - function of, 18
  - TPN solutions and, 48–49
- Glutathione, 20
- Gluteal compartment syndrome
  - clinical presentation, 2425, 2426*f*
  - fasciotomy, 2428, 2428*f*
- Gluteal free flaps, 233
- Gluteus maximus
  - anal sphincter reconstruction using, 241–242, 242*f*
  - exposure of, 241
  - transposition, 1955, 1955*f*
  - vascular supply to, 241*f*
- Gluteus maximus myocutaneous flaps, 240–241, 240*f*–243*f*
- Glycemic control. *See also* Glucose control, in ICUs
  - importance of, 2410
  - management, 26
  - SSI prophylaxis, 116*t*
  - tight, 34, 2415
- Glycerin suppositories, 1952
- Glyceryl trinitrate cream, 1913
- Glycogen, 13, 15, 52*f*
- Glycolysis, aerobic, 1587–1588
- *GNAQ* mutations, 378
- Goblet cell carcinoids, 1698
- Goiter
  - ectopic, mediastinal, 781
  - multinodular, 520
  - recurrent, 520
- "Golden hour" concept, 798
- Goldman Cardiac Risk factors, 83

- Golligher, John, 1797–1798
- Gonadal veins, dissection of, 2065*f*
- Gonadal vessels, 2005*f*
- Gonadotropin-releasing hormone (GnRH), 8, 11
- *Gonoccocus* infections, 257–258
- Goodsall rule, 1919, 1919*f*
- Goodwin technique, 2112
- GoreTex mesh, 236, 861
- Gortex mesh, 1894
- Gout, postoperative flares of, 35
- Gowns, 119*t*
- G-protein-coupled receptors, 3
- Gracilioplasty, 1719
- Gracilis free flaps, 233
- Gracilis muscle
  - musculocutaneous flaps, 243
  - transposition, 1955–1956
- Gracilis muscle flaps, 1859
- Gracilis neosphincter, 1956–1957
- Graciloplasty
  - bilateral, 1956, 1956*f*
  - stimulated, 1957*f*
  - unilateral, 1956, 1956*f*
- Graduated compression stockings, 2520
- Graft excision
  - benefits of, 2480
  - technique, 2474–2475
- Graft infection. *See also* Aortic graft infections; Fungal graft infections
  - diagnosis and imaging of, 2480
  - extent of, assessing, 2473
  - mycotic native aneurysm compared to, 2470
  - surgery for
    - evolving, 2480
    - imaging, 2473*f*

- Graft injuries, rejection and, 146
- Grafts
  - for abdominal aortic aneurysms, 2299–2300, 2300*f*
  - aortic injury as indication for, 2567
  - for arteriovenous hemodialysis access, 2543–2544
    - hemodialysis reliable outflow (HeRO) graft, 2544, 2544*f*, 2547
  - occlusion in extraanatomic bypass, 2348
  - reversed vein bypass, 2367
    - alternative inflow, 2361*f*, 2364
    - anatomy of femoral, popliteal, and tibial arteries, 2359–2360, 2361*f*–2362*f*
    - clinical presentation, 2357–2358
    - complications, 2364–2365, 2365–2366, 2365*f*, 2366, 2366*f*
    - diagnosis, 2358
    - indications, 2358
    - postoperative management, 2366
    - preoperative planning, 2358–2359, 2359*f*, 2360t
    - surgical technique, 2361–2363, 2363*f*, 2364–2365
    - wound closure, 2364
  - for thoracoabdominal aortic aneurysm, 2283, 2285–2286
- Graft-*versus*-host disease (GVHD), 1452–1453
- Graham Omental Patch, 1115
- Granny knots, 170
- Granulation tissue, 216
- Graves' disease
  - cervical lymphadenopathy in, 547
  - risk factors for, 516
  - thalmopathy and, 516
  - treatment of, 520
- Gray-Turner signs, 1526
- Great auricular nerve, 296, 319, 525
- Great pancreatic artery, 1483
- Great saphenous vein (GSV), 2360–2361, 2362*f*
- Great vessels of the aorta

- injuries
  - clinical presentation, 795
  - diagnosis, 795
  - operative approach, 795
  - treatment, 795–796
- Greater curvature mobilization (stomach), 1131, 1132*f*
- Greater omentum
  - anatomic relationships, 919*f*
  - arterial supply, 1066–1067, 1067*f*
  - development of, 1054*f*
  - innervation of, 1076
  - intra-abdominal vasculature, 748*f*
  - lymphatic drainage of, 1071, 1071*f*
- Greater splanchnic nerve, 786*f*, 1581, 1581*f*
- Green, Horace, 385, 385*f*
- Greenfield filter, 2511, 2517
- Groin
  - dissection, 430–433
    - complications, 1969–1970
    - incisions, 430*f*, 433
    - morbidity rates, 432
    - radical, 1964–1971, 1968*f*
    - superficial lymph nodes, 432*f*
    - treatment protocols, 432–433
  - repair
    - classification of, e83, e83*t*
    - Kugel method, e89–e92, e89*f*, e91*f*, e92*f*, e93
    - plug-and-patch procedure, 2229–2239, 2230*f*, 2232*f*, 2233*t*, 2234*f*, 2235*f*–2236*f*, 2237*t*, 2238*f*
  - triple triangles of, 2231*f*
- Groin hernias, 2187*f*
  - anatomic relationships, 2192*f*, 2230–2231
  - description of, 2186–2194
  - direct, surgical anatomy of, 2201*t*

- external supravesical
  - surgical anatomy of, 2201*t*
- indirect, surgical anatomy of, 2201*t*
- Kugel repair, 2210
- lifetime risk of, 2211
- open prosthetic repair, 2220–2222
- preoperative planning, 2214
- presentation, 2213
- Stoppa repair, 2222
- techniques, 2215–2219

- Groves, Ernest W. Hey, 2166
- Growth factors for diabetic foot, 2393
- Growth failure, fundoplication for, 874
- Growth hormone (GH)
  - in critical illness, 11
  - inflammatory responses and, 3
  - for muscle wasting, 41
  - resistance to, 11
  - stress response and, 2
- Growth retardation, pediatric, 1662
- GRVs. *See* Gastric residual volumes (GRVs)
- Guaiac positive stool, 1699–1700
- Gubernaculum, 2072, 2074*f*
- Gunshot wounds (GSW), 481–482. *See also* Ballistic injuries
  - abdominal vascular injuries due to, 2577–2578
  - cervical trauma due to, 2569
  - facial, 444
  - head, 483*f*
  - penile, 2105
  - subclavian artery extravasion secondary to, 2570
- Günther Tulip filter, 2516*f*
- Gussenbauer, Carl, 1839
- Gustatory sweating, 312
- Gut, embryology of, 1051*f*

- Gut barriers
  - bacterial translocation and, 20
  - failure of, 20
  - nutrition and, 20
  - stress responses, 20
- Gut ischemia, stress and, 60
- Gut-directed therapy, 131
- Gynecologic surgery, robotic-assisted, 264, 271
- Gynecomastia, 611, 612*f*, 1620

H

- *Haemophilus influenzae*, 92
- Hagar dilator, 1973, 1973*f*
- Hair removal, preoperative, 118*t*
- Hair tourniquets, 255*f*
- “Half-sponge on a stick,” insertion of, 1006*f*
- “Halo” sign, CSF leaks and, 436
- Haloperidol, 138
- Halothane, 195
- Halsted theory, 2067
- Halstedian operation, 2136
- Hamartomas, retrorectal cystic, 1882
- Hand dynamometry, 55
- Handoffs, clinical pathways and, 34
- Hands
  - amputations, critical time periods, 253
  - anatomy, 247–249
  - animal bite infections, 255–257
  - assessment of, 252*f*
  - C curvatures, 249–250, 251*f*
  - closed fractures, 251–252
  - compartment syndrome, 258–259
  - deep space infections, 255
  - dislocations, 251
  - dorsal innervation, 247
  - emergency surgery, 247–261, 260–261
  - examination of, 249–250, 261, 261*t*
  - fight-bite infections, 255–257
  - high-pressure injections, 258
  - injuries, assessment of, 261*t*
  - ischemia
    - history of, 2537–2538
    - prevention, 2539

- treatment for, 2535–2536
- melanoma, 423–424, 424*f*
- metacarpal bones, 250*f*
- open fractures, 251
- perfusion of, 250
- preparation, surgical, 118*t*
- traumatic injuries
  - preoperative planning, 251–253
- vascular compromise, 253

Hanging maneuver, 1321

Hannover classification, 1367

Hard palate
- anatomy, 335*f*
- carcinoma of, 342–343, 343*f*

Harmonic scalpels, 1112–1113

Harrington retractors, 938, 938*f*

Harris-Benedict equations, 45, 1655

Harrison Narcotics Act of 1914, e1

Hartmann pouches
- clamping, 1345
- creation by gallstones, 1268
- creation of, 1723
- gallstones impacted in, 1352
- selection of, 1721

Hartmann procedure, 1700
- mucus evacuation, 1772
- port placement, 1770*f*
- preoperative marking, 1705–1706
- with resection, 1701
- reversal, 1770*f*

Hartmann resection
- for diverticulitis, 1755
- emergency for diverticulitis, 1759–1760
- persistent abdominal symptoms, 1760–1761

- reversal, 1760
- Hartmann stump, 1723, 1734*f*
- Hartrampf, Carl, 763
- Hashimoto thyroiditis, 547
- Hassan technique, 1828, 2030
- Hassan trocar, 1100–1101, 1643
- Hasselbach triangle, e82, e82*f*, e83, e86
- Hasson cannulas, 1692
- Hasson technique, 1354, 1355–1356
- Hautmann neobladder, 2116, 2116*f*
- Hayes Martin maneuver, 312
- HDAC3 deacetylase, 40
- HDAC6 deacetylase, 40
- HDGC. *See* Hereditary diffuse gastric cancer (HDGC)
- Head and neck surgery
  - prophylactic antimicrobial agents, 114*t*
- Head injuries
  - emergencies, 474
  - facial trauma and, 434
  - imaging, 480*t*
  - muscle wasting in, 35
  - radiologic facts, 480*t*
- Heald, Bill, 1841
- Heald, Richard, 1814
- Heald retractor, 1804, 1856
- Health care-associated infections (HAIs)
  - intra-abdominal, 123–124
    - antimicrobials in, 123*t*
  - microbiology in patients with, 121–122
  - MRSA and, 113
  - national action plan, 114
- Heaney maneuver, 1337, 1337*f*
- Heart
  - cardiac resynchronization

- robotic-assisted, 269
- as emboli source, 2444
- in embryo, 821*f*
- function of, 826

Heart valves, prosthetic, 28

Heat shock proteins (HSPs)
- chaperoning by, 19
- function of, 19–20
- immune stimulation by, 196
- inflammation and, 4–5
- liver dysfunction and, 19–20
- surgical trauma and, 19–20
- synthesis of, 19–20

Heat sink effects, 197

Hedgehog/Notch complex, 1971

Heights, assessment of, 55

Heineke-Mikulicz pyloroplasty, 1107–1109, 1109*f*, 1121*f*
- esophagectomy and, 988
- technique, 1098–1099, 1099*f*

Heineke-Mikulicz stricturoplasty
- in Crohn disease, 1663–1664
- follow-up, 1663–1664
- technique, 1666, 1667*f*

Heister valves, 1358, 1362

Helicobacter pylori
- after partial gastrectomy, 1092–1093
- as gastric cancer risk factor, 1127
- gastric ulcers and, 1127
- giant duodenal ulcers and, 1119–1120
- peptic ulcer disease and, 1148
- protective action of
  - against reflux, 984
- screening for, 1578
- serum antibody tests, 1114

- testing for, 1114
- transmission of, 1104
- treatment of, 1096, 1102, 1104, 1115
- ulcers and, 1103

- Heliox, administration of, 447
- Heller esophagomyotomy
  - for achalasia, 950, 961
  - complications, 1031
- Heller myotomy, 983
  - Dor anterior fundoplication plus, 973
  - POEM contraindication, 962
  - robotic-assisted, 265
- HELLP syndrome, 106–107
- Hemabate, 2124
- Hemangioblastomas, 2019
- Hemangiomas, 376–377, 1276*f*
- Hemantiomas, 1275–1276
- Hematogenous venous dissemination, 1286
- Hematolymphopoietic cells, engraftment, 1452
- Hematomas
  - after endovascular therapy, 2389
  - ear, 439, 440*f*
  - epidural, 480*f*
  - evacuation of, 528
  - external plexus, 1921
  - failed grafts and, 215
  - and impalpable cancers, 630, 631
  - in inguinal herniorrhaphy, e68
  - intraparenchymal, 481
  - liver, 1333*t*
  - nasal septal area, 439
  - retrobulbar, 442
  - subdural, 480–481, 481*f*
- Hematotympanon, 477

- Hematuria, 2032, 2090
- Hemiangiomas, giant, 1275
- Hemiazygos veins, 776, 779*f*, 785, 786*f*, 835
- Hemicolectomy
  - extended right, 1782*f*
  - left
    - open and minimally invasive, 1789–1796
    - patient positioning, 1790*f*
  - preoperative planning, 1789–1790
  - right, 1780–1789
    - complications, 1787
    - in Crohn disease, 1711
    - laparoscopic, 1783–1784
      - port placement, 1783*f*
    - lymphadenectomy, 1786–1787
    - open, 1781–1783, 1782*f*
    - open vs minimally invasive, 1780–1789
    - outcomes, 1787
    - postoperative care, 1786
    - robotic, 1784–1786, 1784*f*, 1785*f*, 1786*f*
- Hemicraniectomy
  - decompressive, 485, 485*f*
  - SDH evacuation and, 482*f*
  - technical considerations, 485
- Hemidiaphragm
  - elevation of, 849, 850
  - exposure, 861*f*
  - inspection of, 860*f*
  - on radiographs, 858
  - right, 848
- Hemihepatectomy, 1446*f*
- Hemipancreatectomy, distal, 1576*f*
- Hemiparesis, 484
- Hemithorax, 850

- Hemobilia, cholangitis and, 1274
- Hemodialysis access. *See also* Autogenous arteriovenous hemodialysis access; Prosthetic arteriovenous hemodialysis access
  - algorithm for patients presenting for, 2527*f*
  - increasing need for, 2539, 2547
  - novel conduit options for, 2539
  - outcomes, 2526
  - overview of, 2525–2527
- Hemodialysis reliable outflow (HeRO) catheter insertion, 2544*f*, 2547
- Hemodialysis reliable outflow (HeRO) graft, 2544
- Hemodyalysis, emergent, 84
- Hemodynamic status, monitoring of, 1617–1618
- Hemodynamics
  - after carotid endarterectomy, 2256
  - of distal splenorenal shunts (*See* Shunts, distal splenorenal)
- Hemoglobin (Hb), preoperative, 22
- Hemoglobin A1c (HgbA1c), 1177
- Hemoperitoneum, splenectomy in, 1996*f*
- Hemophilias, 27, 81, 104
- Hemopneumothorax, 2560
- Hemorrhage
  - control after cesarean delivery, 2122–2125
  - in facial trauma, 434
  - gastrointestinal
    - peptic ulcers and, 1105
    - PUD and, 1096
    - resuscitation in, 1105–1106
  - in hepatic injuries, 1340
  - hypovolemia and, 788
  - hypoxia and, 14
  - intestinal in CD, 1662
  - life-threatening in facial trauma, 434
  - postpartum, 2125*f*
  - postsurgical, risk factors, 1724

- risks, blood components and, 103–110
- subarachnoid, 481
- therapeutic anticoagulation and, 28
- urgent operative care for, 788

Hemorrhagic shock, 136

Hemorrhoidectomy
- cautery, 1923–1924
- closed, 1924–1926, 1926*f*
- complications, 1926–1928
- convential, 1926–1928
- laser, 1923–1924
- open, 1924, 1925*f*
- pain related to, 1924
- patient positioning, 1924
- patient selection, 1922

Hemorrhoids
- causes, 1922
- complications, 1921–1922
- diagnosis, 1922
- excision of, 1925*f*
- injection sclerotherapy, 1923, 1924*f*
- outpatient therapy, 1922–1923
- photocoagulation, 1923
- presentation, 1921
- primary, 1922
- prolapsing, 1906
- rubber-band ligation, 1923, 1923*f*
- secondary, 1922
- strangulated, 1921–1922
- suture ligation, 1924
- thrombosed, 1921
- treatment, 1922–1926

Hemostasis
- surgical, 110

- vasopressin and, 81
- Hemostatic agents, 1346
- Hemothorax
  - drainage, 101
  - retained, 797, 798
    - management strategies, 101
    - postoperative management, 797
    - treatment, 797
  - thoracic trauma and, 788
- Heparin. *See also* Low-molecular weight heparin (LMWH)
  - for acute limb ischemia, 2418, 2422
  - contraindications for, 2602
  - thoracic endograft delivery preceded by, 2567–2568
- Heparin sulfate proteoglycan release, 196
- Heparin-bonded grafts, prosthetic, 2370–2371, 2371*f*
- Heparin-induced thrombocytopenia (HIT), 105, 2489
- Heparins, perioperative, 29*t*
- Hepatectomy
  - abdominal situs after, 1439*f*
  - cadaver donor, 1436–1438
  - caudate resection during, 1407*f*
  - exposure and portal dissection, 1407–1408
  - living donor, 1268–1269, 1442–1443, 1443*f*
  - optimizing hepatic duct margin, parenchymal transection, and reconstruction, 1408–1409
  - outcomes, 1410–1411
  - rationale and planning, 1407
  - recipient, 1438–1439, 1438*f*
  - ultrasound-guided, 192
- Hepatic arteries. *See also* Common hepatic artery
  - anastomosis, 1440–1441
  - anatomic relationships, 1266
  - anomalies, 1331*f*
  - cholangiocarcinoma, involvement in, 1411

- dissection of, 2455
- embryology of, 1052, 1266
- injuries, liver abscesses and, 1286
- liver perfusion, 1587
- location of, 1415*f*
- resections of, 1404
- supply of, 1329–1330
- thrombosis, 1288*f*
- variations, 1271, 1484*f*

Hepatic bed drainage, 1359

Hepatic ducts. *See also* Left hepatic ducts; Right hepatic ducts
- adenocarcinomas in, 1410
- anatomic variants in, 1382
- dissection of, 1408
- formation of, 1330

Hepatic encephalopathy, 1434

Hepatic failure, TPN and, 47–48

Hepatic flexure mobilization, 1671*f*

Hepatic hilar area, 1368

Hepatic hilum, 1264–1265, 1408*f*

Hepatic incidentalomas, 1286

Hepatic lobectomy
- left, 1337*f*
- right, 1337*f*

Hepatic plate system, 1369*f*

Hepatic portal vein, 1485*f*

Hepatic resection
- anesthetic consideration, 1317*f*
- cholecystectomy in, 1343
- complications, 1325
- contraindications, 1314–1316
- drainage, 1324
- incisions, 1317*f*
- indications, 1314–1316, 1337–1338

- laparoscopic, 1323, 1325
- portal vein and, 1604
- postoperative care, 1324
- preoperative planning, 1316–1317
- scalpel handle, 1336*f*
- surgical technique
  - exposure, 1317–1318
  - incisions, 1317–1318, 1317*f*
  - patient positioning, 1317–1318
- survival rates, 1326
- tumors requiring, 1315*t*
- venovenous bypass, 1338*f*

- Hepatic steatosis, 1327
- Hepatic trauma
  - angioembolization, 1341–1342
  - blunt, 1331–1332
  - complications, 1339–1340
  - diagnosis, 1332–1333
  - evaluation algorithm, 1328*f*
  - initial operative approach, 1333–1334
  - jaundice after, 1340
  - liver packing, 1338, 1338*f*
  - major, 1327–1342
  - management of, 1340–1341
  - nonoperative management, 1333
  - operative management, 1335*t*
    - damage control procedures, 1342
    - incisions, 1334*f*
  - pathophysiology, 1331–1332
  - penetrating injury, 1341
  - postoperative management, 1339–1340
  - shear injuries, 1332
  - surgical technique, 1334–1339, 1341
  - transfusions in, 1342

- triage in, 1340
- Hepatic veins
  - anatomic relationships, 2005*f*
  - anatomy of, 1262–1264, 1262*f*
  - identification of, 182, 183*f*
  - occlusion of, 1602
- Hepaticojejunostomy (HJ). *See also* Choledochojejunostomy/hepaticojejunostomy; Roux-en-Y hepaticojejunostomy (HJ)
  - in bile duct reconstruction, 1376
  - biliary enteric bypass combined with, 1420
  - complications, 1382
  - drainage, 1410
  - gastrojejunostomy combined with, 1412
  - illustration of, 1568*f*
  - with or without stenting, 1420
  - outcomes, 1420
  - Roux-en-Y, 1350*f*
  - techniques
    - end-to-side, 1378*f*, 1416*f*
    - running suture technique, 1379*f*
    - stents and stenting, 1420
    - Strasberg variation, 1378*f*
    - variations, other, 1379
- Hepatitis
  - HBV
    - alcoholism and, 1587
    - transfusion-related, 109*t*
  - HCV, 1458
  - HCV, alcoholism and, 1587
  - presurgical assessments, 25
- Hepatobiliary disease, 1284, 1286
- Hepatobiliary scintigraphy, 1467*f*
- Hepatocellular adenomas (HAs), 1278–1279

- Hepatocellular carcinoma (HCC)
  - ablation therapy, 201
  - biliary obstruction and, 1275
  - chronic liver disease and, 1316, 1326
  - focal, 197*f*
  - hepatitis B and, 1279
  - incidence, 1279
  - microwave ablation, 203*f*
  - Milan criteria, 1281
  - nonenergy based ablation, 196
  - prevalence of, 1410
  - primary sclerosing cholangitis, association with, 1395
  - radiofrequency ablation, 202*f*, 203*f*
  - screening guidelines, 1280*f*
  - treatment algorithm, 1280*f*, 1282*f*
- Hepatocholedochojejunostomy, 1418*f*
- Hepatocystic triangle, 1266, 1342. *See also* Calot's triangle
- Hepatocyte nuclear factor-1alpha (HNF-1α), 1278–1279
- Hepatocytes, response to stress, 18–19
- Hepatoduodenal ligament, 1259
- Hepatopancreatic ampulla
  - anatomy, 1480–1481
  - blood supply of, 1480*f*
  - classification of, 1480
  - embryology of, 1480
- Hepp-Couinaud technique, 1377*f*
- Herbal supplements, perioperative, 29*t*–30*t*
- Hereditary breast and ovarian cancer syndrome (HBOC), 1249
- Hereditary diffuse gastric cancer (HDGC), 1127
- Hereditary hemorrhagic telangiectasia (HHT), 381, 1284
- Hereditary nonpolyposis colorectal cancer (HNPCC)
  - as gastric cancer cause, 1127
  - mutations in, 1127
  - surgical options, 1751–1752

- total colectomy with ileorectal anastomosis, 1742
- Hereditary papillary RCC, 2020
- Hereditary pheochromocytoma, 514
- Hernia belts, 1776*f*
- Hernia sac
  - reduction, 867, 868, 869
- Hernial rings, surgical anatomy of, 2182–2210, 2201*t*–2204*t*
- Hernias. *See also* Congenital diaphragmatic hernia; Ventral abdominal hernias
  - abdominal wall reconstruction for, 839–840
  - acquired, SBO and, 1630*t*
  - Bassini operation, 2230
  - congenital, 839
  - congenital, SBO and, 1630*t*
  - congenital-Bochdalek, 2203*t*
  - demographics, 2210
  - description of, 2194
  - diaphragmatic, 2202*t*
  - direct, 2234
  - epigastric, 2183, 2183*f*, 2201*t*
  - epiploic foramen of Winslow, 2203*t*
  - external supravesical, 2192–2193
  - femoral
    - description of, 2193, 2193*f*
    - incidence of, 2211
    - preoperative planning, 2227
    - repairs, 2211–2228
    - surgical anatomy of, 2201*t*
  - foramen of Winslow, 2200
  - groin, 2187*f*
    - anatomic relationships, 2192*f*
    - description of, 2186–2194
    - Kugel repair, 2210
    - lifetime risk of, 2211

    - open prosthetic repair, 2220–2222
    - preoperative planning, 2214
    - presentation, 2213
    - Stoppa repair, 2222
    - surgical anatomy of, 2201*t*
    - techniques, 2215–2219
- hiatal esophageal, 2202*t*
- history of repairs for, 2210
- incidence of, 2210
- indirect, 2234
- infracolic, 2203*t*
- inguinal (*See also* Inguinal hernias)
    - direct, 2192
    - incidence of, 2211
    - indirect, 2191–2192, 2192*f*
    - preoperative planning, 2227
    - repairs, 2211–2228
- internal supravesical, 2204*t*, 2206–2207
- Kugel technique (*See* Groin hernias)
- laparoscopic ventral repair, 163–164
- Lichtenstein tension-free repair, 2210, 2230
- management of, 1649*t*
- McVay repair, 2230
- mesh placement, 158, 160*f*
- mesh selection, 158
- omphalocele
    - surgical anatomy of, 2201*t*
- pantaloon, 2234
- paraduodenal, 2200, 2203*t*, 2204
- parastomal, 1647
- patient demographics, 2233*t*
- pericardial ring, 2203*t*
- plug-and-patch repairs, 2229–2239
    - history of, 2229–2230, 2230*f*

- umbrella plugs, 2230*f*
- post LC, 1365
- posterolateral abdominal wall, 2202*t*
- postoperative, 1630*t*
- postsurgical, 2204*t*
- quality of life and, 2238
- recurrence risk, 157, 2236, 2238
- repair
  - anesthesia, 2228
  - complications, 2225, 2237*t*
  - outcomes, 2236–2238
  - post-op pain, 2232
  - postoperative care, 2225
  - preoperative planning, 2232–2233
  - principles of, 2231–2232
  - Prolene system, 2232*f*
  - Proloop plugs, 2237*f*
  - prophylactic antimicrobial agents, 114*t*
  - quality of life issues, 2232
  - Shouldice technique, 2218–2219
  - suture repair, 2230
  - tension-free mesh type, 2230
- retroanastomic, 2207
- Shouldice repair, 2210, 2230
- sliding, e83–e84
- spigelian, 2187*f*
  - description, 2185–2186
  - repair of, 2210
  - surgical anatomy of, 2201*t*
- Stoppa repairs, 2230
- superior ileocecal
  - surgical anatomy, 2203*t*
- into superior ileocecal fossa, 2206*f*
- surgical anatomy, 2203*t*

- through the pericecal fossae, 2205
- transmesenteric, 2200, 2203*t*
- transomental, 2200, 2203*t*
- trocar placement, 166*f*, 2237
- umbilical, 2183–2184, 2201*t*, 2210

Herniated stomach, reduction of, 867

Herniated viscera, 840–841

Herniorraphies, laparoscopic, 2223

Heroin, e1

Herpes simplex virus (HSV)
- active infection, 2119
- hand infections, 255

Hesselbach triangle, 2192, 2193*f*, 2212, 2213*f*

Heterotaxy syndrome, 1175

Heterotopic neobladder, 2107

H-graft portacaval shunts (HGPCS)
- clinical trials, 1614
- completed, 1613*f*
- failure, 1615
- hepatic blood flow and, 1608*t*
- indications, 1608–1609
- surgical technique, 1609–1613
- survival data, 1608*f*

Hiatal esophageal hernias, 2202*t*

Hiatal hernia
- anatomy, 824*f*
- characteristics of, 822*t*
- classification and types of, 824*f*, 865–866, 865*f*
- defined, 828
- embryology of, 823
- endoscopic view of, 890*f*
- esophageal hiatus repair in cases of, 832
- esophageal sphincter and, 839
- gastroesophageal reflux disease in patients with, 839, 961

- historic developments, 903–904
- incidence in elderly, 901
- large, surgical technique, 932
- overview of, 823, 865
- paraesophageal, 828
- repair, 829, 904
- sliding, 828

Hiatus of Schwalbe, 2199, 2199*f*

Hibiclens solution, 438

Hidradenitis suppurativa, 1931–1932

High malignant biliary tract obstruction
- adjuvant and neoadjuvant therapy, 1411
- clinical presentation, 1404–1405
- etiology and pathophysiology, 1404
- imaging studies, 1411
- issues surrounding, 1412
- source of, 1410
- surgery, 1411
- therapies, potential future, 1412

High mobility group box 1 (HMGB1), 4–5, 196

High-intensity focused ultrasound (HIFU)
- breast cancer, 204
- HCC, 201
- hyperthermic responses to, 197
- immune-stimulation and, 196
- methodology, 199, 199*f*
- prostate cancer, 203

High-pressure injections
- hand injuries, 258, 259*f*
- urgent attention to, 251

High-resolution manometry (HRM)
- achalasia diagnosis and, 970–971, 970*f*, 971*f*
- evolution of, 961

Hilar adenopathy, 801

- Hilar cholangiocarcinoma (CCA)
  - appearance of, 1373*f*
  - biopsy of, 1411
  - classification and staging, 1406, 1406*f*, 1407, 1411
  - clinical presentation, 1404
  - diagnosis, 1405, 1411
  - highly malignant obstruction from, 1411
  - imaging studies, 1411
  - management, 1405*f*
  - molecular biology of, 1410
  - overview of, 1404, 1410
  - recurrence, 1410
  - surgery
    - adjuvant therapies following, 1409–1410
    - complications and their management, 1409
    - indications and contraindications, 1406
    - liver transplantation, 1409, 1411
    - outcomes, 1410
    - palliative procedures, 1409
    - postoperative care, 1409, 1411
    - preoperative planning
      - biliary drainage, 1406
      - portal embolization (PVE), 1406–1407
    - resection, 1412
    - techniques, 1407–1410
  - survival, 1410, 1411–1412
  - therapeutic approaches, 1411
    - adjuvant and neoadjuvant therapies, 1412
  - tumors, 1410
- Hilar lymph nodes, 810–811, 817
- Hilar plate, 1264, 1264*f*
- Hilar plexus, 1268
- Hilar release technique, 452*f*
- Hill, Lucius, 935

- Hill esophagogastropexy, 950, 951*f*
- Hill repair
  - discussion, 942–943
  - laparoscopic
    - surgical technique, 941–942, 942*f*, 943*f*
  - modified
    - for GERD, 935–944
    - indications, 937–938
  - open
    - results, 940–941, 941*f*
    - surgical technique, 938–940
    - sutures, 941*f*
- Hindgut, embryology, 1815
- Hippocrates, 654
- Hirner, Andreas, 1614
- Hirschsprung disease, 875–876
  - anal sphincter reconstruction in, 241–242
  - anatomical considerations, 1972–1973
  - diagnosis in adults, 1975
  - etiology of, 1971
  - gender differences, 1971
  - pathophysiology of, 1971
  - preoperative planning, 1972
  - presentation, 1971
  - quality of life, 1976
  - surgical management, 1971–1972
  - transanal pull-through for, 1971–1976
    - complications, 1974
    - outcomes, 1974–1975
    - postoperative care, 1974
    - technique, 1973–1974
- Histamines, vasodilation and, 133
- Histoacryl, 438
- Histone acetyl transferase (HAT), 40, 42

- Histotripsy, 199–200
- Hitchings, George, 141
- HIV patients, surgical risks for, 27
- Hjortsjo's crook, 1370*f*
- Hoarseness
  - after thyroidectomy, 528–529
  - postoperative, 996–997
  - recurrent laryngeal nerve, 984
- Hochenegg, J., 1839
- Homeostasis, caloric revision and, 62
- Hormonal changes, skin cancer and, 411
- Hormone replacement therapy, 522
- Hormone-sensitive lipase (HSL), 17
- Horner syndrome, 784
- Horse antithymocyte globulin (ATGAM), 148
- Hospital-acquired pneumonia, 2163
- Hourglass stomach, embryology of, 1057*f*
- H-pouches, reservoir formation, 1732*f*
- HPT. *See* Hyperparathyroidism
- H-type fistulae, 1042–1043, 1043*f*
- Human immunodeficiency virus (HIV)
  - autogenous arteriovenous hemodialysis access problem due to, 2537
  - infections, 1456
  - liver transplantation in, 1449
- Human mobility box group-1 (HMBG-1), 133
- Human papillomavirus (HPV)
  - anorectal warts and, 1928
  - esophageal cancer and, 984
  - head and neck SCC and, 409
  - HPV-6, SCC and, 428
  - HPV-11, SCC and, 428
  - HPV-16, 345, 427–428
  - laryngeal cancer and, 397
  - oral cavity cancer and, 334, 345

- oropharyngeal cancer positive for, 355
- vaccine, 2145

Humerus, anatomy of, 247, 249*f*
Humoral immunity, 142
Hunger, cortical centers for, 1182
Hunter, John, 54
Hürthle cell neoplasms, 503, 518
Hyaluronan, 196
Hyaluronate film, 1736
Hyaluronidase, 238
Hydatid cysts

- bile duct communication, 1298, 1299*f*, 1305–1306
- clinical presentation, 1298–1300
- cystectomy
  - closed, 1310
  - complications, 1312–1313
  - engaging the diaphragm, 1311
  - laparoscopic approach, 1311–1312
  - near-total, 1310
  - open, 1310
  - results, 1312–1313
  - subadvential, 1310–1311
- cystic cavity
  - capitonnage, 1308
  - introflexion, 1308
  - marsupialization, 1308
  - myoplasty, 1308–1309
  - omentoplasty, 1308, 1309*f*
  - residual, 1307–1309, 1308*f*, 1309*f*
  - Roux-en-Y cystojejunostomy, 1308
  - tube drainage, 1308
- daughter cysts, 1313*f*
- decompression, 1305
- diagnosis, immunologic, 1302–1303

- incidence, 1277–1278
- liver, 1295–1296
  - daughter cyst formation, 1296–1297
  - histology, 1297*f*
  - multiple, 1297*f*
  - parasitology, 1295–1296
  - paricysts, 1296*f*
  - pathology, 1296–1298
- open surgery, 1304
  - contraindications, 1304
  - indications, 1304
  - preoperative planning, 1305
- percutaneous drainage, 1303–1304
- rupture, 1298
  - communicant, 1299–1300
  - free, 1298–1299
  - intraperitoneal, 1298–1299
  - intrathoracic, 1299
  - obscure, 1298
- sterilization, 1305–1306
- terminology, 1295
- types of, 1301*f*
- WHO-IWGE classification, 1301*f*

- Hydatid fluid, allergic reactions to, 1296–1297
- Hydatidosis, 1300–1303
- Hydroceles in inguinal herniorrhaphy, e68
- Hydrocortisone therapy
  - in resuscitated patients, 10
  - for severe/fulminant colitis, 1721
- Hydrogen peroxide
  - irrigation, 1541
  - protoscolicidal effects, 1306
- Hydronephrosis, 2012
- Hydrophilic biliary guide wires, 1704

- Hydrostatic balloons, 209
- Hydroureteronephrosis, 2136
- Hydroxy iminodiacetic acid scanning, 1343
- 3-Hydroxy-3-methylglutaryl coenzyme A reductase inhibitors (statins), e37
- Hydroxyethyl starch (HES), 136
- Hyoepiglottic ligament, 303
- Hyoglossus muscles, 320, 321, 322
- Hyoid bone
  - anatomy of, 71*f*, 284, 303, 308, 319*f*, 468*f*
  - elevation of, 319
  - formation of, 368
  - submental triangle and, 322, 322*f*
- Hyoscyamine, 1976
- Hyperalcemia, 1961
- Hyperaldosteronism, 571–572
- Hyperalimentation, 42
- Hyperbaric oxygen therapy, 253
- Hyperbilirubinemia, 1166
- Hypercalcemia
  - acute peritonitis and, 1525
  - causes of, 533*t*
  - pancreatitis and, 1493
  - paraneoplastic syndrome and, 2020
- Hypercapnia, permissive, 840, 846
- Hypercatabolic syndrome, 12–13
- Hyperchloremia, 1173
- Hypercholesterolemia, 2350. *See also* Intestinal bypass, for hypercholesterolemia
- Hypercoagulability
  - liver and, 18–19
  - warfarin management and, 28
- Hypercortisolism after trauma, 16
- Hyperdynamic states, starvation *versus*, 56–58

- Hyperechoic, ultrasonographic definition, 179, 179*f*
- Hyperemia, tumor necrosis and, 195
- Hyperglycemia. *See also* Diabetes mellitus (DM); Glycemic control
  - catecholamine-related, 12
  - cortisol and, 16
  - in critical illness, 16
  - diabetes and, 1177
  - iatrogenic causes of, 16
  - insulin for, 17
  - intensive care unit management of, 17
  - sympathetic tone and, 16
- Hyperglycosylation, 2409
- Hyperinsulinism, 1146
- Hyperkalemia, 553–554
- Hyperlipidemia
  - in carotid bifurcation disease, 2247
  - classification of, 1177
  - diagnosis, 1177–1178
  - etiology, 1177
  - familial, 1177
  - in metabolic syndrome, e36
  - pathophysiology, 1177
  - presentation, 1177
  - and reversed vein bypass grafts, 2358
- Hypermetabolism, post trauma, 16
- Hyperostotic bone changes, 551
- Hyperparathyroidism (HPT). *See also* Primary hyperparathyroidism (PHTH)
  - kidney failure and, 554
  - secondary, 550–555
    - clinical manifestations, 551
    - differential diagnoses, 551*t*
    - in kidney disease, 554
    - medical management, 551

    - surgical management, 551–552
  - supernumerary parathyroid glands and, 505
  - tertiary
    - description of, 551
    - kidney transplants in, 554–555
    - medical management, 551
    - renal transplantation for, 552
- Hyperparathyroidism-jaw tumor syndrome (HPT-JT), 532–533
- Hyperperistalsis, 1636
- Hyperphosphatemia, 550
- Hyperphosphaturia, 532
- Hyperplasia
  - atypical, 606
  - atypical ductal, 606, 634–635
  - atypical lobular, 606
  - columnar cell, 606
  - mild ductal, 605
  - moderate/florid ductal, 605
  - pancreatic, 1472
- Hypersplenism, e34
- Hypertension. *See also* Essential hypertension
  - and aortoiliac occlusive disease, 2350
  - in metabolic syndrome, e36
  - poorly controlled, 24
  - renal cell carcinoma and, 2019
  - renovascular, 2431–2432
  - and reversed vein bypass grafts, 2358
  - secondary HPT and, 551
- Hyperthermia, 195, 1881
- Hyperthermic ablation, 196–197
- Hyperthermic intraperitoneal chemotherapy (HIPEC)
  - administration of, 1879–1880
  - for appendiceal tumors, 1698
  - cytoreductive surgery with, 1878

- for metastatic disease, 1877
- postoperative care, 1880
- results, 1880

Hyperthermic technologies
- cytotoxic temperatures, 197
- tumor ablation and, 197

Hyperthyroidism
- management of, 520
- in pregnancy, 520
- presurgical management of, 521
- symptoms of, 516
- TRAb and, 516

Hypertriglyceridemia
- diagnosis, 1177–1178
- etiology, 1177
- familial, diagnosis, 1177
- pancreatitis and, 1493
- pathophysiology, 1177
- serious illness and, 18

Hypertrophia, pancreatic, 1472

Hypertrophic pyloric stenosis (HPS). *See* Congenital pyloric stenosis

Hypervolemia, 70

Hypglossal nerve, 320

Hypoalbuminemia, wound healing and, 1651

Hypocalcemia
- after parathyroidectomy, 554
- monitoring for, 527–528
- postoperative, 521
- symptoms of, 528

Hypodermic needles, e1

Hypoechoic, ultrasonographic definition, 179, 179*f*

Hypofibrinogenemia, 103

Hypofusion syndrome, 2248

Hypogammaglobulinemia, 558

- Hypogastric artery, 2126*f*
  - ligation, 2124–2125
- Hypogastric lymph nodes, 431
- Hypogastric nerves, 1686*f*, 1826*f*, 1845
  - anatomy, 1825
  - preservation of, 1967
- Hypoglossus muscle, 319*f*, 320, 468*f*
- Hypoglossus nerve (CN XII)
  - anatomic aids, 321
  - anatomy of, 292, 309, 320, 320*f*, 359*f*
  - evaluation of, 309
  - exposure of, 313
  - identification of, 360
  - protection of, 406
  - tongue innervation by, 322
- Hypoglycemia
  - deleterious effects of, 34
  - dumping syndrome and, 1146
  - reactive, 1159–1160
  - tight glycemic control and, 34
- Hypoglycemia, reactive. *See* Reactive hypoglycemia
- Hypoglycemics, oral, 29*t*, 34
- Hypogonadotropism, 11
- Hypokalemia, 1000, 1961
- Hypomere, embryology of, 772
- Hypometabolic phase, 2
- Hypoparathyroidism
  - permanent, 553
  - postoperative, 521
  - thyroidectomy and, 528
- Hypoperfusion, blood lactate levels and, 50
- Hypopharyngeal cancer
  - open procedrues
    - partial laryngopharyngectomy, 405–406

- partial pharyngectomy, 405
- total laryngectomy, 406
- total laryngopharyngectomy, 406
- squamous cell carcinoma
  - etiology, 404
  - pathophysiology, 404
- squamous cell carcinoma
  - etiology, 404
  - preoperative planning, 404–405
  - presentation, 404
  - treatment, 405
- transoral procedures, 405
  - laser microsurgery, 405

- Hypopharyngeal tumors, 271
- Hypopharynx
  - anatomy, 398*f*, 404
  - cancer of, 352
  - positive lymph nodes, 349*t*, 350*t*
  - reconstruction, 407, 407*f*
    - complications, 407
    - management of the neck, 407, 408*f*
    - postoperative care, 407
    - rehabilitation, 407–408
  - surgical pathology, 404
- Hypophosphatemia, risks of, 67
- Hypopituitarism, 1961
- Hypoplasia, pancreatic, 1472
- Hyposomatotropism, 11
- Hypotension
  - blood lactate levels and, 50
  - refractory, 10
- Hypothalamus, PGE2 production, 7
- Hypothalamus-pituitary-adrenal (HPA) axis, 7, 7*f*, 8
- Hypothenar muscle groups, 247, 249*f*

- Hypothenar muscle wasting, 67
- Hypothenar space, 255
- Hypothyroidism
  - hyperlipidemia and, 1177
  - management, 26
  - slow transit constipation and, 1961
  - symptoms of, 516
- Hypovolemia, 70, 788
- Hypovolemic shock, 77*t*
- Hypoxemia, inhaled NO for, 80–81
- Hypoxia, 14, 50
- Hysterectomy
  - abdominal, 2128–2135
    - complications, 2133–2134, 2133*f*
    - indications, 2128–2129
    - postoperative care, 2132–2133
    - technique, 2129–2132, 2129*f*–2132*f*
  - alternatives of, 2124
  - extended radical, 2143
  - extrafascial, 2136, 2141
  - in intestinal bypass, e40
  - modified radical, 2141–2142
  - power morcellators in
    - FDA warnings, 2135
  - radical, 2136–2146
    - anesthesia, 2136
    - classification of, 2141–2143
    - clinical trials, 2145–2146
    - complications, 2136
    - cystoscopy and, 2136
    - intraoperative complications, 2144
    - laparoscopic, 2136
    - nerve-sparing, 2142–2143
    - overview, 2136–2137

- patient positioning, 2136
- port placement, 2143*f*
- postoperative complications, 2144
- postoperative management, 2143–2144
- proctosigmoidoscopy, 2136
- robotic-assisted, 2143
- steps, 2136
- technique, 2137–2139, 2138*f*–2143*f*
- robotic-assisted, 271
  - benefits of, 2135
- simple *versus* radical, 2136
- subtotal, 2132*f*
- surgical routes for, 2128
- total, 2132*f*
- types of, 2135
- vaginal, benefits of, 2128, 2135

I

- IABP. *See* Intra-aortic balloon pumps (IABPs)
- IAH. *See* Intra-abdominal hypertension (IAH)
- Iatrogenic bile duct injuries
  - classification of, 1374, 1375*f*
  - management algorithms, 1375*f*–1376*f*
  - MRI showing, 1373*f*
  - overview of, 1373–1375
  - percutaneous transhepatic cholangiogram showing, 1374*f*
  - repair of
    - immediate, 1378*f*
    - immediate *versus* delayed, 1374, 1382
- Iatrogenic perforation, esophageal, 1021–1022, 1030, 1031
- Iatrogenic urinary incontinence, 2169
- ICP bolt placement, 480*f*
- ICUAW. *See* Intensive care unit-acquired weakness
- Idarucizumab, 110
- Ideal body weights, 59, 97. *See also* Body weight; Obesity; Weight loss

- Idiopathic cortical adrenal hyperplasia, 571–572
- IgG4 disease, 1403, 1404
- IκB kinase (IKKβ), 4*f*
- Ileal conduits
  - contraindications, 2108–2110
  - technique, 2108–2110
  - urinary diversion, 2037*t*
- Ileal neobladder
  - continence with, 2052*t*
  - minimally invasive approaches, 2038
  - outcomes, 2052
- Ileal pouch surgery, 2113–2114
  - for Crohn disease, 1712
  - hand-sewn anastomosis, 1737*f*
- Ileal pouch-anal anastomosis (IPAA)
  - for benign disease, 1736–1738
  - complications, 1739–1740
  - contraindications, 1712, 1733–1734
  - female infertility and, 1740
  - indications, 1732, 1733–1734
  - postoperative care, 1739
  - preoperative planning, 1734–1735
  - surgical technique, 1735–1736
- Ileal pouches, reservoir formation, 1732, 1732*f*
- Ileoanal pouches, 1732–1741
- Ileocecal valve, 1677, 1687
- Ileocolic artery, 1679, 1736*f*
- Ileocolic resection
  - laparoscopic-assisted, 1669, 1670*f*
    - operating room setup, 1670*f*
    - port sites, 1670*f*
- Ileocolic vein, 1589*f*
- Ileocolic vessels, dissection of, 1670*f*
- Ileoduodenal fistulae, 1664

- Ileoproctostomy, 1741
- Ileorectal anastomosis (IRA)
  - side-to-side, 1746*f*
  - subtotal colectomy, 1960*f*
  - total abdominal colectomy and, 1711–1712
  - total colectomy and, 1741–1752
- Ileosigmoid fistulae, 1668
- Ileostomy
  - closure of, 1638–1649
  - complications, 1646–1648, 1730
    - bezoar formation, 1647–1648
    - bezoars, 1649*t*
    - bleeding, 1647, 1649*t*
    - dehydration, 1647, 1648, 1649*t*
    - gallstones, 1649*t*
    - management of, 1649*t*
    - parastomal hernias, 1647, 1649*t*
    - pouching, 1646–1647, 1649*t*
    - prolapse, 1647, 1649*t*
    - readmissions, 1647
    - renal failure, 1647
    - skin irritation, 1646–1647
    - small bowel obstruction, 1647–1648, 1649*t*
    - stoma necrosis, 1647, 1649*t*
    - stone formation, 1647
    - urinary stones, 1649*t*
  - continent
    - historical background, e45
    - indications and contraindications, e45
    - postoperative care, e46–e47, e46*f*
    - pouchitis syndrome, e48–e49
    - quality of life, e49–e50, e49t
    - revisional surgery
      - anatomosis conversion to Kock pouch, e48, e49*f*

    - pouch malfunction, e48, e49*f*
  - surgical technique, e45–e47, e46–e47*f*
- creation of, 1638–1649
  - indications, 1638*t*
  - postoperative care, 1645–1646
  - site selection, 1773
- diverting loop, 1723
- divided loop, 1642–1643, 1644*f*
- end
  - creation of, 1640*f*
  - reversal of, 1645
- end loop, 1641–1642, 1643*f*
- failure, 1771
- food blockage, 1774
- incisions, 1640*f*
- laparoscopic, 1643–1644
- loop
  - creation of, 1642*f*
  - indications, 1641
  - in large bowel obstruction, 1706–1707
  - reversal of, 1645*f*, 1646*f*
  - stoma construction, 1641
- patient selection, 1649
- permanent, 1712
- permanent end, 1638*t*
- postsurgical care, 1648
- preoperative planning, 1638–1639, 1639*f*
- readmissions after, 1648
- reversal, 1648
- revision, 1714
- surgical technique, 1639–1641
- temporary end, 1638*t*, 1732
- temporary loop, 1638*t*
- trephine, 1644

- wound complications, 1648
- Ileostomy-colostomy in toxic megacolon, 1722
- Ileum
  - anatomic relationships, 1675
  - blood supply of, 1676*f*
  - distal, buttressing, 2113*f*
  - division, 1745*f*
  - GIST, 1196
- Ileus
  - adynamic, 1676
  - alvimopam, 1635
  - persistent, 2066
  - postoperative
    - dysphoria and, 67
  - postoperative prevention, 32, 1635
  - postsurgical, 2163
- Iliac arteries
  - aneurysm of, 2467*f*
  - internal, 2454*f*
  - retrograde bypass from, 2457, 2458*f*
- Iliac emboli, 2419–2420, 2420*f*
- Iliac lymph nodes, 431
- Iliac occlusive disease, 2509
- Iliac vein thrombectomy, 2485*f*
- Iliac veins
  - clot burden in, 2493*f*
  - imaging, 2512*f*
  - patency of, 2488*t*
- Iliac venous stenting, 2509
- Iliocavagram, preoperative, 2483*f*
- Iliocaval bypass, 2504–2505
- Iliocaval obstruction, 2499
- Iliocaval polytetrafluoroethylene bypass, 2505*f*
- Iliofemoral bypass, 2340–2341, 2341*f*

- Iliofemoral thrombus, 2492*f*
- Iliofemoral vein reconstruction, 2499
- Iliofemoral venous system, left, 2483*f*
- Iliofemoral (caval) venous thrombosis (DVT)
  - risks associated with, 2481
  - thrombosis burden in, 2482
  - treatment, 2489, 2499
  - treatment algorithm, 2481*f*
- Iliohypogastric nerve, 2002, 2193–2194
- Ilioinguinal nerves
  - anatomic relationships, 2002, 2193
  - preservation of, 1967
- Iliopubic tract repair. *See* Inguinal hernias
- Imaging technology. *See also* Computed tomography (CT); Magnetic resonance imaging (MRI); Positron emission tomography (PET); Radiography
  - lack of sensitivity, 205
- Imbrication
  - in diaphragmatic surgery, 850–851, 851*f*
- Iminodiacetic acid, 99mTc-hepatic (HIDA), 1353, 1354
- Immune competence testing, 55
- Immune nonreactivity, 1453*t*
- Immune paralysis, 8
- Immune recognition, rejection and, 141–145
- Immune responses, nutrition and, 55
- Immune system, 9, 1988–1989
- Immune thrombocytopenia purpura (ITP), 1991
- Immune tolerance, alloengraftment and, 1452–1453
- Immunity, tolerance and, 1454–1455
- Immunocompromise, surgical risk and, 27
- Immunodeficiency syndromes. *See also* Human immunodeficiency virus (HIV)
  - thymus and, 558
- Immunoglobulins (Igs)
  - IgA, function of, 144

- IgG, function of, 144
- IgM, function of, 144
- isotype switching, 144–145
- isotypes of, 144
- response to surgical trauma, 8

- Immunonutrition, 64, 66
- Immunosuppression
  - chronic, costs of, 1457–1458
  - degrees of, 146
  - induction, 1447
  - maintenance, 146, 1447
  - melanoma risk and, 411
  - organ transplantation and, 141–150, 145–149
  - tolerance-friendly, 1456*f*
  - tumor surveillance and, 1458–1459
- Immunosuppressive agents
  - off-label indications, 146
  - preoperative discontinuation, 118*t*
  - sites of action, 147*f*
  - surgical risk and, 27
  - TCRs and, 143
- Impedance testing in GERD, 938
- Implants, mastectomy, 726, 728*f*, 732–733
- In situ vein reconstruction, 2476–2478
- Incentive spirometry, presurgical, 985
- Incisional hernias
  - description of, 2194
  - incidence of, 168
  - preoperative preparation for, 159
  - Proline patches, 2237
  - repair of, 159
- Incisional wound irrigation, 119*t*
- Incisions. *See Specific* procedures
- Incontinence. *See also* Continence

- after radiation therapy, 2136
- fecal
  - causes, 1949–1950
  - conservative therapy, 1951–1957
  - diagnosis, 1950–1951
  - functional bowel disorders, 1949–1957
  - posterior tibial nerve stimulation, 1955
  - presentation, 1949
- lifestyle and, 1963
- urinary, cystocele and, 2169

Incretins, 1217

Index fingers, assessment, 250, 252*f*

Indiana Pouches, 1677, 2112, 2112*f*

Indirect calorimetry (IC), 59

Indirect inguinal hernias, 2192*f*

Indocyanine green
- organ perfusion staining, 268, 268*f*
- Spy Elite, 229
- “SPY” system, 233

Infantile hemangiomas (IH)
- diagnosis, 375
- frontal, 377*f*
- head, 374
- hepatic, 374–375
- incidence, 373
- multiple, 374
- neck, 374
- presentation, 374–375
- scalp, 377*f*
- structural abnormalities and, 375
- treatment, 375–376

Infants
- biliary atresia in, 1427
- cholestatic, 1428*t*

- delivery of, 2121–2122
- emesis in
  - bilious, 1166
  - causes of, 1166
  - hypochloremia and, 1173
  - malrotation and, 1175
  - nonbilious, 1174–1175
- with enterocolitis
  - fluid resuscitation, 1972
- inguinal hernia, e71, e84
- with intestinal obstruction, 1972
- intracranial pressures, 475*f*
- malrotation in
  - diagnosis of, 1166
- vascular anomalies, 373–384
- volvulus, diagnosis of, 1166
- weaning from TPN, 1985

Infected embolic material, 2470–2471

Infected pancreatic necrosis (IPN), 1523
- antibiotics, 1535
- drainage, 1531–1532
- minimally invasive surgery, 1533, 1534*f*
- open necrosectomy in, 1533–1535
- standard treatment, 1551
- step-up approach, 1531–1532
- timing of interventions, 1551

Infections
- after carotid endarterectomy, 2256
- bloodstream, 2539
- central venous catheter related, 72
- clinical classification, 2413*f*
- diabetic foot, 2412–2414, 2415
  - microbiology, 2412–2413
  - surgical management, 2413*t*

- in endovascular therapy for aortoiliac occlusive disease, 2354
- failed grafts and, 215
- fasciotomy, 2429
- inflammatory responses to, 2–21
- joint, 253–258
- metabolic responses to, 2–21
- noncytopathic microorganisms, 1456
- postoperative prevention, 32–33
- postsplenectomy, 1988–1989
- and prosthetic grafts, 2372, 2373
- pseudoaneurysm of femoral artery, 2323–2324
- tendon sheath, 253–258
- tolerance and, 1453–1454

Infectious aortitis, 2465

Inferior alveolar nerve, 320*f*, 322, 327

Inferior epigastric artery, 228, 2007*f*

Inferior epigastric vessels, 232*f*

Inferior hypogastric plexus, 1686*f*

- anatomic relationships, 1815
- anatomy of, 1825
- erection and, 2069

Inferior ileocecal hernias, 2203*t*

Inferior labial arteries, 327

Inferior mediastinal nodes, 802*f*

Inferior mesenteric artery (IMA)

- anatomic relationships, 1679, 2005*f*
- circulation, 2454*f*
- colon blood supply by, 1680*f*
- division of, 1828–1829
- exposure of, 1855, 1855*f*
- ligation of, 1748, 1765*f*, 1789, 1792*f*, 1856
- vascular division sites, 1830*f*

Inferior mesenteric vascular pedicle, 1791*f*

- Inferior mesenteric vein (IMV)

- anatomic relationships, 1589, 1589*f*
- division of, 1828–1829
- drainage, 1475
- high ligation of, 1803–1804
- ligation, 1790
- protection of, 2011

- Inferior pancreaticoduodenal arteries (AIPDs), 1483
- Inferior phrenic artery, 1064*f*
- Inferior rectal arteries, 1685
- Inferior rectal nerve, 1686*f*
- Inferior thyroid artery
  - anatomy of, 284, 287–288, 288*f*, 298, 298*f*, 308
  - dissection of, 507
  - function of, 502
  - origin of, 501
  - protection of, 507
- Inferior thyroid vein, 71*f*
- Inferior triangle of Petit, 2194
- Inferior vena cava (IVC)
  - anastomosis with graft, 1612*f*
  - anatomic relationships, 832, 2004*f*, 2005*f*
    - adrenal gland and, 510*f*
  - anatomical variations, 2511
  - anatomy of, 1262, 1262*f*
  - clamping, 1596*f*
  - clot burden in, 2493*f*
  - diaphragm openings for, 830*f*
  - diaphragmatic drainage into, 835
  - diaphragmatic opening of, 830*f*, 833*f*
  - duplication of, 2511–2512
  - electrocautery, 1592*f*
  - exposure, 1609
  - filters
    - embolization of, 2516*f*

- indications for, 2510–2511
- placement of, 2493, 2512–2513, 2517
- precautions concerning, 2602
- retrievable, 2515–2516, 2515*f*
- venous repair with, 2601
- hiatus of, 828
- isolation of, 1594*f*
- liver surface and, 1259
- main connections, 779*f*
- as mediastinum structure, 834*f*
- mobilization, 1594*f*, 1596*f*
- opening of, 1611*f*
- pressures, 1594, 1610
- reconstruction of, 2499
  - malignant tumor excision followed by, 2506
- suturing, 1596*f*
- tumor thrombi, 2021
- veins running into, 835–836
- window in, 1612*f*

Inferior vena cava (IVC),
- left, 2512

Inferior vesicle arteries, 2010, 2034–2035

Inflammation
- DVT relationship to, 2499
- genomic storm in trauma, 132*f*
- signal transduction pathways, 4*f*
- small bowel obstruction and, 1630*t*, 1635*f*

Inflammatory aortitis, 2465

Inflammatory bowel disease (IBD)
- EN formulations, 63
- IPAA for, 1733
- liver abscesses and, 1287
- passive smoking in childhood and, 102
- primary sclerosing cholangitis, association with, 1394, 1395, 1403

- proctectomy for, 1713*f*
- severe/fulminant colitis secondary to, 1721
- surgery
  - decision rules for, 1726
  - elective *versus* urgent, 1734–1735
- total colectomy
  - complications in, 1750
  - ileorectal anastomosis and, 1741–1742
- toxic megacolon and, 1719
- TPN in, 46
- trends in, 1726
- VTE risk and, 1671

- Inflammatory diseases, colonic obstruction and, 1700
- Inflammatory responses
  - to infections, 2–21
  - to injury, 3
  - innate immune system and, 3–5, 133
  - liver and, 18–19
  - metabolic demand of, 54
  - to trauma, 2–21
- Infliximab, 46, 1654, 1718, 1721, 1734
- Informed consent
  - in bariatric surgery, 1210–1211
  - for carotid artery stenting, 2254
  - for carotid endarterectomy, 2250–2251
  - hernia-specific, 2233
  - for plug-and-patch groin repair, 2233
  - replantation and, 253
- Infracolic hernias, 2203*t*
- Infrahepatic vena cava, 1439*f*, 1440, 1441*f*
- Infrainguinal balloon catheters, 2484*f*
- Inframammary folds, 221–222
- Infraorbital nerve, 327
- Infrapiriformic ring, 2195

- Infrarenal abdominal aorta, 2469*f*
- Infrarenal aorta, 2459*f*
- Infraumbilical incisions, 1692
- Infundibulopelvic ligaments, 2129, 2130*f*
- Inguinal area, 2190*f*
- Inguinal canal
  - anatomic relationships, 2007*f*, 2186–2192, 2188*f*
    - boundaries, 2186–2188
    - deep inguinal ring, 2188–2189
  - medial elements, 2219*f*
  - posterior wall
    - division of, 2217
- Inguinal hernias
  - direct, 2192
  - esophagectomy compared to, 1019–1020
  - iliopubic tract repair
    - anterior (inguinal canal) approach
      - complete hernia, e77–e78, e77*f*
      - convalescence, e78
      - direct hernia, e75–e76, e76*f*
      - indications, e71
      - indirect hernia, e73–e74*f*, e73–e75
      - preparation, incision, and exposure, e71–e73, e71–e73*f*
      - relaxing incision, e76
      - wound closure, e78
  - incidence of, 2211
  - indirect, 2191–2192, 2192*f*
  - posterior (preperitoneal) approach
    - anatomy, e81
    - classification of groin hernia, e83, e83*t*
    - contraindications, e84
    - femoral hernia, e86, e86*f*
    - Hesselbach triangle, e82, e82*f*
    - iliopubic tract, e81, e82*f*

- laminar structure, e81
- prosthetic materials, e87, e87*f*
- sling of internal inguinal ring, e82
- surgical technique, e84–e85*f*, e84–e86
- transversalis crura, e82
- transversalis fascia, e81

- repairs, 2211–2228
  - contraindications, 2213–2214
  - indications, 2213–2214
  - open, 2228
  - preoperative planning, 2227
  - robotic-assisted, 266
- Shouldice method of herniorrhaphy
  - anatomy, e60
  - anesthesia, e60, e60*t*
  - complications
    - dysejaculation, e68–e69
    - hematoma, e68
    - hydrocele, e68
    - infection, e68
    - mortality, e68t, e69
    - recurrence, e67–e68, e68t
    - testicular atrophy, e68
  - historical background, e59–e60
  - postoperative period, e67
  - reconstruction, e64–e67, e65–e67*f*
  - results and follow-up, e67–e68t
  - sedation, e60
  - surgical technique, e61–e65, e62*f*
  - weight control, e61–e65

- Inguinal lymph node dissection, 430
- Inguinal orchiopexy, 2073–2075
- Inguinal region, nerves of, 2193–2194
- Inguinodynia, hernia-related, 2238

- Inguinofemoral lymphadenectomy, 1968*f*
- Inguinofemoral node dissection, 1965–1967
- Inguinofeoral lymphadenectomy, 1966*t*
- Inhaled pulmonary vasodilators, 80–81
- Inhibin screening in adnexal masses, 1249
- Inhibitor of κB (IκB), 4*f*
- Injection sclerotherapy, 1620–1621
- Innate immune system
  - activation of, 2, 142
  - functions of, 142
  - inflammatory responses and, 3–5, 133
- Innate immunity, 142
- Innominate artery
  - in brachiocephalic reconstruction, 2260–2261
    - aneurysm, 2262, 2263*f*
    - bypass, 2262, 2262*f*
    - endarterectomy, 2261–2262, 2261*f*
    - intervention, 2265, 2265*f*
  - repair, 2572*f*
  - tracheal erosion, 493*f*
- Innominate vein, 469, 2549
- Inosine monophosphate dehydrogenase, 146
- Inositol triphosphate (IP3) release, 143
- Insulation failures, 277, 277*f*
- Insulin
  - inflammatory responses and, 3
  - levels after trauma, 16
  - perioperative management, 29*t*
  - secretion of, 1472
  - stress response and, 2
- Insulin resistance. *See also* Diabetes mellitus (DM); Hyperglycemia
  - glucocorticosteroids and, 16–17
  - postinjury, 16
  - secondary HPT and, 551

- unmasking of
  - postoperative, 34
- Insulin-glucagon rations, 56
- Insulin-like growth factor I (IGF-I), 3, 41
- Insulinomas, 1474
- Intensity modulated radiation therapy (IMRT), 645, 651
- Intensive care unit-acquired weakness (ICUAW), 35, 36*f*
- Intensive care units (ICUs)
  - acute quadriplegic myopathy and, 36–37
  - agitation in, 140
  - ambulation in, 40
  - blood pressure monitoring, 68–69
  - conditions associated with, 35
  - delirium, 140
  - glucose control in, 17
  - muscle atrophy in, 35
  - pain in, 140
  - surgical (SICU), 131
  - ventilator-associated pneumonia in, 91
- Intercompartmental pressure (ICP), 259, 260*f*
- Intercostal arteries, 776, 787, 834
- Intercostal flaps, 1028*f*, 1029*f*
- Intercostal lymph nodes, 600, 602*f*, 778
- Intercostal muscles, 776*f*
- Intercostal nerves
  - anatomic relationships, 778*f*
  - distribution of, 780
  - morphology of, 779
  - nerve blocks, 779
  - typical, 781*f*
- Intercostal veins, 785
- Intercourse after inguinal hernia repair, e78
- Interdental spaces, 551
- Interferon λ (IFN-λ), 5, 6, 11

- Interferons
  - alpha-2b, 415
  - pegylated, 415
- Interleukin-1 (IL-1)
  - carbohydrate metabolism and, 17
  - inflammation and, 6
  - Kupffer cell secretion of, 19
  - muscle proteolysis and, 13*f*
  - phagocytosis and, 133
  - signal transduction pathways, 4*f*
- Interleukin-1 receptor-activated kinase (IRAK), 4*f*
- Interleukin-1b (IL-1b), 6
- Interleukin-2 (IL-2), 11, 143
- Interleukin-6 (IL-6)
  - inflammation and, 6
  - Kupffer cell secretion of, 19
  - phagocytosis and, 133
- Interleukin-8 (IL-8), 6
- Interleukin-10 (IL-10), 8
- Interleukin-12 (IL-12), 6
- Interleukins, inflammation and, 6
- Interlobar lymph nodes, 810–811
- Interlobar pulmonary artery, 809
- Intermittent pneumatic compression devices, 32
- Internal abdominal oblique muscle, 775*f*
- Internal anal sphincter (IAS), 1683*f*, 1684, 1824*f*, 1949
- Internal anal sphincterectomy, 1914
- Internal carotid artery
  - anatomy of, 71*f*, 288*f*, 468*f*
  - injury, 2569–2570
  - parotid space and, 317, 319
- Internal iliac artery, 2126*f*
  - anatomic relationships, 2005*f*, 2008*f*
  - bladder supply from, 2034–2035

- branches, 1965
- Internal iliac trunk, 2034–2035
- Internal inguinal ring, 2190*f*
- Internal intercostal muscles, 772, 778*f*
- Internal jugular vein (IJV)
  - anatomy of, 71*f*, 292, 293*f*, 321*f*, 323*f*, 359*f*, 363*f*
  - cannulation, 71
  - catheterization, 289
  - common facial vein and, 320
  - dissection of, 359*f*
  - *en bloc* dissection of, 507*f*
  - exposure of, 506*f*, 526
  - identification of, 358, 359*f*
  - main connections, 779*f*
  - neck dissection and, 506*f*
  - repair of, 470
  - sampling, 540
- Internal mammary artery (IMA), 745, 767*f*
- Internal mammary vein (IMV), 767*f*
- Internal oblique muscles, 774
  - anatomic relationships, 2004*f*, 2182
  - exposure, 245*f*
  - flaps for athletic pubalgia, 244–245
  - plication of, 231*f*
- Internal pudendal artery, 1685, 2034–2035, 2068
- Internal supravesical hernias, 2204*t*
  - invaginating type, 2207, 2207*f*
  - pathways, 2208*f*, 2209*f*
  - surgical anatomy, 2206–2207, 2206*f*, 2207*f*
- Internal thoracic arteries, 776–777
  - branches, 563*f*
- Internal thoracic nodes, 778
- Internal thoracic veins, 778
- International Breast Cancer Study Group (IBCSG) 23-01, 759

- Interosseous nerves, 247
- Interrupted sutures, imbrication with, 850–851, 851*f*
- Intersigmoid recess, 1682*f*, 1683*f*
- Intersphincteric abscesses, 1916–1917
- Intersphincteric dissection, 1858*f*
- Intersphincteric protectomy, 1726–1727
- Interstitial cells of Cajal (ICC), 969, 1197
- Interstitial edema, 3
- Interstitial laser therapy (ILT), 198, 204
- Interstitial ultrasound ablation, 199
- Interuteric crest (fold), 2009, 2009*f*
- Intestinal angina, 2453
- Intestinal atresias
  - diaphragmatic anomalies associated with, 826
  - pediatric, 1985
- Intestinal bypass
  - for hypercholesterolemia
    - athrosclerosis, e37
    - history of procedure, e36–e37, e36*f*
    - metabolic surgery, e36
    - mortality and morbidity, e38-e40
      - angina pectoris, e42
      - cardiac procedures, e42
      - xanthomata, e42
    - partial ileal bypass, e40–e41, e41*f*
    - surgical technique
      - arterial operations, e40
      - cholecystectomy, e40
      - laparoscopy and stapling, e39, e40*f*
      - micro-orifice, e40
      - open, e37–e39, e38–e40*f*
      - pelvic gynecologic, e40
- Intestinal duplication, 1630*t*
- Intestinal ischemia, 2469

- Intestinal microbiome, 64–65
- Intestinal obstruction
  - abdominal compartment syndrome and, 153
  - after transanal pull-through
    - management algorithm, 1975*f*
    - management of, 1974
  - in Crohn disease, 1662
- Intestinal perforation
  - laparotomy for, 1980
  - surgical interventions in
    - NEC, 1977
  - very low birth-weight infants, 1985
- Intestinal rehabilitation, pediatric, 1985
- Intestinal resection, massive, 1981
- Intestinal stenoses, 826
- Intestinal transplantation
  - in children, 1985
  - midgut volvulus and, 1175
  - in SBS, 1983
- Intestines. *See also* Gut barriers
  - abdominal cavity, return to, 820
  - herniation of, 825*f*
  - mesentery, 781
  - obstruction in infants, 1972
  - stress responses, 20
- Intra-abdominal abscesses
  - NEC and, 1981
  - postsurgical, 1724
  - small bowel obstruction, 1634
- Intra-abdominal hemorrhage, 153
- Intra-abdominal hypertension (IAH), 153–156, 155*t*
- Intra-abdominal infections
  - antimicrobials for, 122*t*
  - clinical outcomes, 126

- health care-associated, 123–124, 123*t*
- prognosis, 126
- source control, 126, 130

Intra-abdominal sepsis
- complicated, 120–121
- pharmacodynamics of, 124–125
- pharmacokinetics of, 124–125

Intra-aortic balloon pumps (IABPs), 82–83
- counterpulsation
  - cardiovascular support, 82–83
- indications, 82–83

Intracellular adhesion molecules (ICAM), 6

Intracorporeal knots
- with Endo Stitch, 172
- laparoscopic suturing, 176
- technique, 171–172
- tying of, 170

Intracorporeal neobladder, robotic-assisted, 2118

Intracranial pressure (ICP), 155, 155*t*, 475*f*
- in head injuries, 475
- management of, 477
- monitoring in TBIs, 488

Intraductal papillary mucinosis neoplasia (IPMN), 1515

Intraductal papillary neoplasm of the bile duct (IPNB), 1277

Intrahepatic bile duct strictures, 1402*f*

Intrahepatic biliary tree, 1405, 1405*f*

Intraluminal impedance monitoring, 947

Intramural myenteric plexus, 982

Intraocular pressure, increased, 442

Intraoperative intraoperative ultrasound (IOUS)
- growth of, 194
- indications, 176–177, 177*t*
- open, 181–187
- probes, 178, 178*f*

- scanning techniques, 180–181
- in transgastric necrostomy, 1529
- utility of, 193

- Intraoperative neural monitoring (IONM), 512, 552
- Intraoperative parathyroid hormone (IOPTH) monitoring, 513
  - impacts of, 531, 549–550
  - interpretation of results, 546*f*, 553–554
  - in secondary HPT, 553–554
  - surgical technique, 545–546
- Intraoperative pericavitary ablation, 205
- Intraoperative radiotherapy (IORT)
  - electron IORT, 650
  - partial breast, 649–651, 650*f*
  - in recurrent rectal cancer, 1862, 1864, 1877
  - whole breast, 646
- Intraparenchymal hematomas, 481
- Intraperitoneal catheters, 2162
- Intraperitoneal onlay mesh (IPOM) procedure, 2223
- Intrapyloric mobilization, 1131–1132, 1132*f*
- Intrathoracic anastomosis, 1019
- Intrathoracic esophageal cancer, 985–986
- Intrathoracic esophagogastrectostomy, 1152*f*
- Intrathoracic esophagus carcinoma, 1000
- Intrathoracic stomach, 916
- Intravascular depletion, postsurgical, 2163
- Intravascular ultrasound, 2509
- Intravenous fluid, volume management, 33
- Intravesical immunotherapy, 2036
- Intubation, asthma patients, 89
- Intussusception, 1699–1700, 1893
- Invagination technique, 853*f*
- Iodine, radioactive, 520
- Iodoquinolol, 1293
- Iodothyronine diodinase, type 3, 375

- Ionotropic agents, 77–80
- IORT. *See* Intraoperative radiotherapy
- Ipilimumab (Yervoy), 418, 422, 425–426
- IRE. *See* Irreversible electrocorporation (IRE)
- Irinotecan, 1316
- Iron compounds, 1961
- Iron deficiency, preoperative workup, 1241
- Iron deficiency anemia
  - in Crohn disease, 1661
  - diagnosis, 1163, 1164
  - etiopathogenesis, 1163
  - paraesophageal hernia accompanied by, 867
  - symptomatology, 1163
  - treatment of, 1163, 1164
- Irreversible electrocorporation (IRE), 200
- Irvin, George, 513, 538
- Irving, Miles, 50
- Ischemia
  - after aortoiliac bypass, 2341
  - aortofemoral bypass for, 2332
  - critical limb
    - endovascular treatment, 2384
    - revascularization, 2375, 2376, 2383
  - limb
    - and amputation, 2399
    - embolectomy (*See* Embolectomy)
    - reversed vein bypass grafts, 2357–2358
- Ischemia-reperfusion syndrome, 2444
- Ischemic bowel, 1634–1635
- Ischemic conditioning, stomach, 999
- Ischemic foot ulcers, 2409
- Ischemic stroke, 482–483, 484–485
- Ischioanal fossae, 2199*f*
- Ischiorectal abscesses, 1916, 1917*f*

- Ischiorectal fossa, 1798*f*, 1852*f*
- Ischiorectal spaces, 1685
- Islet cell harvesting, 1502*f*
- Isolated limb perfusion (ILP), 426*f*
- Isolated segmental pharmacomechanical thrombolysis (PMT), 2494–2496
- Isolated ventral pancreas. *See* Pancreas divisum
- Isoperastatic stricturoplasty, 1667–1668, 1668*f*
- Isoproterenol, 79
- Italian Gastric Cancer Study Group, 1140
- Ivalon Sponge, 1894
- Ivor Lewis esophagectomy, 1019

J

- Jaboulay pyloroplasty, 1109
- Jackknife position, 1848*f*, 1849–1850, 1924
- Jackson-Pratt drains, 922
- Jammerecke, 1088, 1089*f*
- Janus kinase-signal transducer and activator of transcription (Jak-Stat), 11
- Jaundice. *See also* Malignant obstructive jaundice
  - drainage for patients with, 1415
  - hepatic trauma and, 1340
  - in liver disease, 1620
- Javid shunt, 2273
- Jaw fibromas, 534
- Jejunal conduits, 995–996, 996*f*
- Jejunoileal bypass (JIB), 1225*f*
  - electrolyte imbalances, 1179
  - history of, 1225
  - malabsorption after, 1179
  - results of, 1249
  - weight loss results, 1179
- Jejunojejunal anastomosis, 1141
- Jejunojejunostomy

- Braun, 1165
- distal gastrectomy with, 1141, 1144, 1146
- in gastric cancer surgery, 1135
- mesenteric defect at, 1253*f*, 1255
- revision, for weight gain, 1247
- Roux limb and, 1212–1213
- stenosis at, 1253

- Jejunostomy
  - creation of, 1772
  - feeding, 920–921
  - hand-sewn anastomosis, 1137*f*
  - percutaneous, 921
- Jejunostomy tubes, 921*f*, 1123
- Jejunum
  - anatomy, 1675*f*
  - blood supply of, 1675, 1676*f*
  - enterotomy created in, 1413*f*
  - GIST, 1196
  - transection, 1562*f*
- Joel-Cohen technique, 2121
- Joints, septic, 257–258
- Joule effect, 198
- J-pouches
  - blood supply, 1736
  - construction of, 1834*f*
  - ileoanal reconstruction, 1741
  - reservoir formation, 1732, 1732*f*, 1740
  - trends, 1732
- Jugular compartments, 504*t*
- Jugular node dissection, 363–364
- Jugular trunk, 778*f*
- Jugular veins, injury, 2569, 2570
- Jugulocarotid node, 306
- Jugulodigastric nodes, 400

- Jugulo-omohyoid node, 306
- Juguloparotid node, 306
- Juxtarenal aneurysms
  - endovascular repair, 2290, 2295–2296, 2295*f*–2296*f*, 2301–2302, 2301*f*–2302*f*
- Juxtarenal aortic occlusion, 2338–2339, 2339*f*

K

- Kalloo, Anthony, 1943
- Kanaval signs, 255, 257*f*
- Kaposi sarcoma, 1719
- Kaposiform hemangioendothelioma (KHE)
  - diagnosis, 378
  - incidence, 373
  - presentation, 377–378
  - treatment, 378
- Karapandzic operation, 331, 332*f*
- Karl Storz-Endoskope, 1942
- Karydakis procedure, 1931, 1931*f*
- Kasabach-Merritt syndrome, 1276
- Kasai procedure, 1427, 1431–1432, 1432*f*
- KcKeown approach, 917
- KDOQI (National Kidney Foundation Dialysis Outcome Quality Initiative), 2525, 2526, 2536
- Kefzol dosing table, 479*t*
- Kehlet, Henri, 1669
- Kelly clamps, 467, 1358*f*
- Kelly forceps, 2223*f*
- Kelly-type urethral plication stitch, 2172*f*
- Keratinocytes, 6
- Kernohan notch, 484
- Ketamine for critical care patients, 138
- Ketogenesis, 56, 60
- Ketone bodies, 2, 13
- Ketorolac (Toradol), 35

- Keynes, Geoffrey, 556
- Kidney disease
  - biochemical abnormalities in, 554
  - EN formulations, 63–64
- Kidney failure. *See also* Renal failure
  - platelet dysfunction in, 554
  - toxic megacolon and, 1719
- Kidney injury, acute (AKI), risk factors for, 1141
- Kidney transplantation. *See also* Renal transplantation
  - parathyroid follow-up after, 555
- Kidney transplants
  - as renal replacement therapy alternative, 2538
  - statistics, 2525
- Kidneys. *See also* Renal function
  - anatomic relationships, 2002, 2003*f*, 2028*f*
  - anatomy of, 2002–2004
  - blunt trauma staging algorithm, 2090*t*
  - blunt trauma treatment algorithm, 2092*f*
  - calcium resorption by, 532
  - clear cell carcinomas, 2087
  - CT scans, 2020
  - cysts, 2020
  - dysfunction, after abdominal aortic aneurysm repair, 2316–2317
  - exposure of, 2029*f*
  - internal structure of, 2004*f*
  - lifting of, 2028*f*
  - lymphatics, 2003–2004
  - masses, 2020
  - parenchyma, 2002
  - penetrating trauma treatment algorithm, 2093*f*
  - renal calculi, 193
  - renal cell carcinoma, 203–204
  - rhabdoid tumors of, 2087
  - stones, after intestinal bypass, e41

- structure, 2002
- superior attachments, 2026
- and thoracoabdominal aortic aneurysm repair, 2283, 2288
- traumatic injuries, 2088–2092
  - angioembolism, 2097
  - classification of, 2091, 2091*f*
  - complications, 2097, 2098, 2098*f*
  - endovascular stents for, 2097
  - exploration, 2094–2096
  - interventional radiology, 2097–2098
  - mechanisms of, 2089–2090
  - nonoperative management, 2106
  - parenchymal injury, 2094
  - postoperative care, 2097
  - proximal vascular control, 2094–2095, 2095*f*
  - reconstruction, 2095–2096, 2097
  - severity scale for, 2090*t*
  - staging of, 2088–2090
  - surgical exploration, 2092–2094
  - vascular, 2094
- vascular supply, 2003–2004
- venous drainage, 2003–2004

Killian, Gustav, 386–387, 386*f*

Killian triangle, 889, 889*f*, 1145

Kirstein, Alfred, 386, 386*f*

Kit (CD117) expression, 1197

KIT mutations, 1193–1194

Kittner disector, 1345

Klebsiella spp.
- in appendicitis, 1692
- ESBL-producing, 121
- *K. oxytoca*
  - surgical site infections, 112*t*
- *K. pneumoniae*

- aortic graft infection death associated with, 2471
- drug resistance and, 122
- in liver abscesses, 1288–1289
- surgical site infections, 112*t*
- VAP and, 92

Klinkosch, Josef, 2185
Klippel-Trénaunay syndrome (KTS), 382
Knobology, ultrasonography, 178–179
Knot pushers, types of, 170
Kocher clamps, 1657*f*, 2045*f*, 2129*f*
Kocher incisions, 349
- abbreviated, 545*f*
- closure of, 153
- parathyroidectomy, 552
- technique, 155*f*

Kocher maneuver
- colon mobilization, 1423*f*
- disadvantages, 1614
- pancreatic head visualization, 1575
- in pancreatic resection, 1559, 1560*f*
- in Puestow procedure, 1510
- in vagotomy, 1103

Kocher/Holm position, 1807
Kock pouch. *See* Ileostomy, continent
Kono-S-anastomosis, 1664
Kraissl lines, 625–626, 626*f*
KRAS mutations, 1246, 1247
Kraske, Paul, 1839, 1937, 1938
Kreb cycle, 50
KRIT1 mutation, 380
Kugel method of hernia repair. *See* Groin hernias
Kugel technique, 2210
Kupffer cells
- APP regulation of, 19

- blockage of, 19
- function of, 19
- liver response to stress, 18–19
- sepsis and, 19

Kusmak band, 1198
Kyphoscoliosis, 1192

L

Labial artery, 327*f*
Labial hypertrophy, 378
Labiomental crease, 325*f*, 326
Laboratory tests. *See also Specific* procedures
- perioperative, 22
- preoperative, 23*t*

LAC (lansoprazole/amoxicillin/clarithromycin) regimen, 1115
Lacrimal apparatus, 439–440
Lactate
- blood levels, 50, 76
- production of, 50–51, 51*f*

Lactobacillus strains, 64–65
Lacunar infarct, 2248
Lacunar (Gimbernat) ligament, e81
Ladd bands, formation of, 1172
Ladd procedure
- in heterotaxy syndrome, 1175
- for malrotation, 1173–1174, 1173*f*, 1174*f*
  - laparoscopic, 1174

Lahey dissector, 1345
Laimer area, 298*f*
Laimer triangle, 889, 889*f*
Lamina propria, 2036
Laminar flow ventilation, 120*t*
Langenbuch, Carl, 1353
Langer line incisions, 1691*f*
Langer's axillary arch, 2549

- Lanz line incisions, 1691*f*
- Lanzoprazole, 1115
- Lap Band, 1198
  - access port, 1202*f*
  - anterior fixation, 1201
  - calibrating, 1201
  - closing, 1201
  - mesh fixation, 1202*f*
  - perioperative management, 1199
  - placement, 1203
  - placer, 1200–1201, 1201*f*
  - positioning, 1201
  - size selection, 1201
- Laparoscopic adjustable gastric band, 1153*f*
- Laparoscopic antireflux surgery
  - abdominal access and port placement, 952–953, 952*f*
  - basic tenets of, 948
  - complications, 960
  - contraindications for, 948*t*
  - dissection technique, 960
  - indications for, 947*t*
  - initial dissection, 953–955, 953*f*
  - magnetic sphincter augmentation, 960
  - outcomes, 957–958, 957*t*, 960, 961
  - overview of, 945, 960–161
  - patient positioning and equipment, 951–952
  - port removal and closure, 956
  - postoperative management, 956
  - preoperative planning, 950–951
  - reoperative, 959–960, 959*t*
  - as standard, 901
  - technical principles, 950
  - techniques, 961
- Laparoscopic cholecystectomy, 1373–1374, 1382

- Laparoscopic cholecystojejunostomy, 1414*f*
- Laparoscopic choledochojejunostomy/hepaticojejunostomy, 1419
- Laparoscopic common bile duct exploration, 1393
- Laparoscopic distal gastrectomy (LDG), 1142, 1147–1148
- Laparoscopic esophageal surgery, 901–902
- Laparoscopic esophagocardiomyotomy, 974–976
- Laparoscopic esophagomyotomy, 976–977
- Laparoscopic fundoplication
  - in antireflux surgery, 876–877, 881–882, 884, 955–957, 958
  - increase in, 1000
- Laparoscopic gastrectomy, 1141, 1148, 1165
- Laparoscopic gastric banding (LAGB)
  - components, 1199
  - introduction of, 1198
  - operative position, 1199
  - perioperative care, 1199
  - perioperative management, 1199
  - placement, 1198–1203
  - port placement, 1199, 1199*f*
  - preoperative assessments, 1199
  - safety of, 1198–1199
  - surgical technique, 1199–1202, 1200*f*–1202*f*
- Laparoscopic gastric bypass
  - beneficial effects of, 1216
  - cholecystectomy and, 1215
  - complications, 1215–1216
  - final steps, 1215
  - history, 1210
  - overview, 1210
  - patient selection, 1210–1211
  - postoperative management, 1215–1216
  - weight loss after, 1216
- Laparoscopic gastric sleeves (LSG), 1218–1224. *See also* Sleeve gastrectomy

- complications, 1221–1223
  - bleeding, 1221
  - staple line leaks, 1221–1222, 1224
  - stenosis, 1222–1223
- contraindications, 1218–1219
- history of, 1218
- indications, 1218–1219
- outcomes, 1223
- overview, 1218
- postoperative care, 1221
- preoperative planning, 1219
- surgical technique, 1219–1221
  - trocar placement, 1219*f*

- Laparoscopic gastrojejunostomy, 1414*f*
- Laparoscopic Heller myotomy (LHM)
  - for achalesia, 972–973
  - failed, 979
  - outcomes, 968
  - POEM *versus*, 983
  - postoperative care, 979–980
- Laparoscopic inguinal hernia repair (LIHR), 2222, 2223*f*
- Laparoscopic myotomy, 975*f*
- Laparoscopic Nissen fundoplication (LNF), 942–943
- Laparoscopic orchidopexy, 2075–2076
- Laparoscopic paraesophageal repair, 867–868, 872
- Laparoscopic partial nephrectomy, 2022
- Laparoscopic pelvic lymph node dissection (LPLND)
  - anatomic landmarks for, 2057*f*
  - completed, 2059, 2059*f*
  - complications, 2059
  - incision, 2057*f*
  - operating room setup, 2055–2056, 2056*f*
  - outcomes, 2055
  - patient positioning, 2055–2056, 2055*f*

- port placement, 2056, 2057*f*
- postoperative management, 2059
- preoperative planning, 2055–2056
- surgical technique, 2056, 2057*f*–2059*f*

Laparoscopic plication, 853–854

Laparoscopic radical nephrectomy (LRN), 2021, 2030–3031

Laparoscopic retroperitoneal lymphadenectomy (LRPLND)
- complications, 2066–2067
- port placement, 2066*f*
- postoperative management, 2066
- robotic-assisted, 2065–2067
- specimen collection, 2066*f*
- in testicular cancer, 2060–2065

Laparoscopic surgery
- insulation failure in, 277*f*
- skill set for, 262

Laparoscopic ultrasound (LUS)
- benefits of, 177
- extrahepatic bile ducts, 190*f*
- gallbladder, 189
- HCC on, 202*f*
- indications, 177, 177*t*
- liver, 188–189
- methods, 188–189
- pancreas, 189
- probes, 178
- scanning techniques, 180–181, 180*f*
- trocar placement, 188–189

Laparoscopic ventral hernia repair (LVHR)
- description of, 163
- enterotomy rates, 164
- equipment, 164
- indications, 163–164
- materials, 164

- operating room technique, 164
- outcomes, 166
- postoperative care, 164

Laparoscopic-assisted distal gastrectomy (LADG), 1148

Laparoscopy
- in chest wall reconstruction, 235–236
- diagnostic, 858–859
- in intestinal bypass, e39
- minimally-invasive surgery, 175
- Morgagni hernia, examining with, 846
- for paraesophageal hernia, 867
- postoperative pulmonary complications and, 90
- stapling in, 173
- suturing, simulation and training, 173
- suturing courses, 175

Laparotomy
- in diaphragmatic trauma, 860–863
- emergent in liver trauma, 1340–1341
- incisional hernias, 168
- midline, wound dehiscence and, 169
- minimally-invasive, 273
- for paraesophageal hernia, 867
- remote, 1632
- small bowel obstruction after, 1631–1632
- superior mesenteric artery exposure through, 2463*f*
- wound healing, 153

Laplace Law, 890, 1676

Lapra-TY device, 1944, 2030

Large bowel
- obstruction, 1677
  - causes of, 1699*t*
  - chronic, 1700
  - clinical guidelines, 1709
  - colorectal cancer and, 1699

- in Crohn disease, 1709
- etiology, 1699
- intraoperative colonic lavage, 1709
- loop colostomy for, 1706
- loop ileostomy, 1706–1707
- malignant, 1701, 1704*f*, 1708
- operative interventions, 1700–1701
- pathophysiology, 1699
- presentation, 1699–1700
- SEMS for, 1707–1708
- stents used in, 1705
- stricture visualization, 1703*f*
- subacute, 1700
- surgical technique, 1701–1707

- perforation, 1662
- pseudobstruction, 1700

- Large intestine, anatomy, 1675*f*
- Laryngeal cancer
  - early stage, 396
  - epidemiology of, 385, 397
  - incidence, 396
  - staging, 387, 388*t*, 397
  - surgical treatment of, 384–397
  - treatment
    - open surgery, 392
- Laryngeal nerve. *See also* Recurrent laryngeal nerve
  - external branch, 528–529
  - injury to, 305, 528–529
  - origin and branching of, 896–897
- Laryngeal stroboscope, 386
- Laryngectomy
  - extended open partial, 393–394
  - for laryngeal cancer, 385–386
  - robotic-assisted surgery, 271

- Laryngofissure, transcervical, 392
- Laryngopharyngeal reflux (LPR), 489
- Laryngopharyngectomy
  - partial, 405–406
  - total, 406–407, 406*f*
- Laryngopharyngoesophatectomy, 406–407, 407*f*
- Laryngopharynx, 300, 303
- Laryngoscopy, 2250
- Laryngotracheal resection, 454–456, 456–457
- Laryngotracheal trauma, 457–459
- Larynx
  - anatomy, 284
    - blood supply, 305
    - cartilages of, 302*f*
    - innervation of, 302, 305
    - interior, 304*f*, 305*f*
    - intrinsic muscles, 304–305
    - joints, 304–305
    - laryngeal cartilages, 303
    - ligaments, 303–304
    - membranes, 303–304
    - skeletal, 303
  - bypass, 489
  - injuries, repair of, 472
  - interior membranes, 304*f*
  - positive lymph nodes, 349*t*, 350*t*
  - retraction of, 1004*f*
  - strap muscles, 294
  - subblottic, 456*f*
- Laser ablation
  - of breast tumors, 660–661
  - hyperthermic responses and, 197
  - methodology, 198
- Laser therapy

- for infantile hemangiomas, 376
- pulse-dye, 378

Lasers, surgical energy, 276
Latarjet, Andre, 1095
Lateral arcuate ligaments, 827
Lateral choledochoduodenostomy
- indications, 1387, 1393
- outcome, 1387–1388
- overview of, 1383, 1387
- reduced need for, 1394
- surgical technique, 1388

Lateral circumflex femoral artery, 239
Lateral cutaneous arteries, 776
Lateral cutaneous nerves
- anatomy, 776*f*

Lateral decubitus position, 1992*f*
Lateral femoral cutaneous nerve injury, 1965
Lateral ligament, 1805, 1805*f*–1806*f*
Lateral pancreaticojejunostomy (LPJ)
- advantages, 1499–1500
- pancreatic drainage, 1499–1501
- results, 1501*t*

Lateral pharyngeal space, 308
Latissimus dorsi flap, pedicled, 747*f*
Latissimus dorsi muscle
- anatomy, 775*f*, 776*f*
- division of, 1040*f*
- landmarks, 226*f*
- muscle flaps using, 216
- myocutaneous flap, 221, 225, 226–227

Latissimus dorsi myocutaneous flap, 733, 733*f*
LC. *See* Cholecystectomy, laparoscopic
LCIS. *See* Lobular carcinoma in situ
LCTs. *See* Long chain triacylglycerols (LCTs)

- Le Fort-type fractures
  - evidence of, 435
  - hemorrhage and, 434
  - management of, 440–444, 442*f*
  - patterns in, 443
- Lean body mass
  - albumin levels and, 44
  - early mobilization and, 35
  - estimates of, 55
  - health of, 44
  - loss of, 27, 35
  - preservation of, 55
- Least splanchnic nerve, 1581
- Lebske knife, 790
- Lecithinase, 238
- Leech therapy, 253
- Left brachiocephalic vein, 71*f*, 783, 786*f*
- Left carotid to left subclavian artery bypass, 2564, 2568
- Left colic flexure, 2002
- Left coronary vein, 1069
- Left epiploic artery, 1067*f*
- Left gastric artery, 919*f*, 1064*f*
  - anatomic relationships, 1064–1065
  - divisions of, 1064
  - identification of, 1135*f*
  - origins of, 1064
  - route of, 1064
- Left gastric vein
  - anatomic relationships, 1069, 1589*f*
  - variations, 1069*f*
- Left gastro-epiploic artery
  - branches of, 1065*f*
  - course of, 1065*f*
  - origin of, 1065*f*

- Left gastro-epiploic nodes, 1070–1071
- Left gastro-omental artery, 1065
- Left hemiliver, 1370
- Left hepatectomy
  - extended, 1321–1323, 1322*f*
  - laparoscopic, 1324
    - port placement, 1325*f*
- Left hepatic artery, aberrant, 1484*f*
- Left hepatic ducts
  - anatomical variations of, 1268, 1371
  - on cholangiogram, 1269*f*
  - formation of, 1371*f*
  - presurgical exposure and preparation, 1377, 1377*f*
- Left hepatic veins
  - anatomy of, 1262, 1262*f*
  - isolation of, 1264*f*
  - middle hepatic veins and, 1270
- Left hypogastric nerve, 1825
- Left inferior phrenic artery, 835
- Left internal mammary artery (LIMA), harvesting of, 269
- Left lateral segmentectomy, 1336*f*
- Left lobectomy, resection for, 1336
- Left phrenic nerve, 836, 863
- Left phrenic vein, 1262*f*
- Left portal vein
  - absent, 1265
  - anatomic relationships, 1330
  - caudate lobe supply, 1270*f*
  - identification of, 185*f*
- Left renal artery, 2008*f*
- Left suprarenal gland, 2005*f*
- Left vagus nerve, 71*f*, 784
- Leg, edema, 430. *See also* Lower extremities
- Leg compartment syndrome. *See also* Fasciotomy

- clinical presentation, 2426
- fasciotomy, 2428–2429, 2429*f*

Leiomatosis, familial, 2020

Leiomyosarcomas
- pelvic, 1886*f*, 1887*f*
- rectal, 1885

Léman Index, 1718

Lembert interrupted sutures, 1667*f*

Lentigo maligna, 423, 423*f*

Lepidic predominant adenocarcinoma, 800

Lesfranc, Jacques, 1937

Lesser omentum
- division, 919*f*
- opening of, 929*f*
- surgical considerations, 1063

Lesser sac, entrance to, 1062–1063, 1063*f*

Lesser splanchnic nerve, 1581

Lesshaft space, 2194

Leukocytes, activated, 133

Leukocytosis, 1287

Leukocytosis, postsplenectomy, 1988

Leukoplakia, tongue, 336*f*

Leukotriene inhibitors, 29*t*, 34

Levator anguii oris muscle, 326*f*

Levator ani, 1684, 1685
- anatomy, 1824*f*, 1853*f*
- division of, 1841*f*

Levator glandulae thyroidea, 297

Levator labii superioris, 326, 326*f*

Levator muscles
- division of, 1850*f*, 1851*f*
- exposure of, 1849*f*

Levator scapular muscle, 294, 295, 358*f*, 776*f*

Levatorplasty, 1960*f*

- Levatorplasty, posterior, 1910*f*
- Levosimendan, 79–80
- Levothyroxine dosage, 528
- Lewis-Tanner esophagectomy, 986, 990
- Leydig cells, 2072
- Libermann-Meffert, Dorothea, 1067
- LIC. *See* Localized intravascular coagulopathy (LIC)
- Lichtenstein, Irving, 2220
- Lichtenstein tension-free repair (TFR), 2210, 2211, 2230
  - groin hernias, 2220–2222, 2222*f*
  - outcomes, 2239
- Lidocaine
  - facial anesthesia, 437
  - regional block anesthesia using, 544
- Lienorenal ligament, embryology, 1052
- Ligament of Berry, 298, 524, 524*f*
- Ligament of Henle, 2186
- Ligament of Treitz
  - anatomic relationships, 921, 1186*f*
  - attachments to, 1188*f*
  - division of, 1189–1192
- Ligament of Treves, 1688
- Ligaments of breast, 594, 595*f*, 601–602
- Ligamentum arteriosum, 2560
- Ligamentum teres, 1328
- Ligamentum venosum
  - anatomic relationships, 1259, 1260, 1260*f*, 1589
  - division of, 1322
- LigaSure
  - hemorrhoid ligation, 1924
  - in truncal vagotomy, 1112–1113
  - vessel division using, 524*f*
- Ligation of intersphincteric fistula tract (LIFT), 1716
- LIMA (left internal mammary artery) graft, 2568

- Limb Salvage Index (LSI), 2587
- Limbs. *See also* Lower extremities; Upper extremities
  - amputation
    - prediction of, 2588
    - rates, 2589*f*, 2590*f*
    - timing of, 2592*f*
  - ischemia
    - and amputation, 2399
    - embolectomy (*See* Embolectomy)
  - upper
    - surgical removal of embolus, 2421
- LINAC. *See* Linear accelerator
- Line of Douglas, 2185
- Linea alba, 158, 775*f*, 2183, 2183*f*
- Linear accelerator (LINAC), 645, 650
- Lines of Langer, 289
- Lingual artery, 320, 322–323, 323*f*
- Lingual nerve
  - anatomic aids, 321
  - anatomy, 320, 320*f*, 321
  - exposure of, 360, 362*f*
- Lingual tonsil, 300
- Lingual vein, 323*f*
- Lip cancer, pathogenesis of, 325
- “Lip shave” procedure, 328
- Lipid emulsions, 1985
- Lipidol, glue dilution with, 1627
- Lipids. *See also* Fats
  - absorption of, 60, 1587
  - energy per gram, 60
  - function of, 60
  - metabolism of
    - surgical trauma and, 17–18
  - storage of, 60

- utilization of, 60
- Lipolysis, starvation and, 56
- Lipopolysaccharide (LPS), 3
- Lipoproteins, 2247
- Liposomes, 195–196
- Liposuction, 764
- Lipoxygenase, 6
- Lips
  - anatomy of, 325–327, 327*f*
  - anesthesia of, 327
  - lower
    - innervation of, 327
    - muscles of, 326*f*
  - lymphatic drainage, 325
  - reconstruction, 325–333
    - excisions, 329*f*–332*f*
    - free tissue transfer in, 332–333
    - lower lip, 329, 330–333
    - peri-alar crescentic excision, 328, 328*f*, 329
    - principles of, 328
    - upper lip, 328–333
  - surface landmarks of, 325*f*
  - upper
    - innervation of, 327
    - muscles of, 326*f*
  - vascular supply, 327*f*
- Lithium, 532–533, 542
- Lithotomy position, 1833*f*, 1849–1850, 1912
- Liver. *See also* Hepatic trauma; Left hemiliver; Liver transplantation; Right hemiliver
  - abscesses
    - amebic, 1290–1292, 1294
    - clinical trials, 1291*t*
    - diagnosis, 1278

  - microbiology, 1288–1289
  - MRI, 1289*f*
  - pathogenesis, 1292
  - pyogenic, 1287, 1294
  - spontaneous rupture, 1291*f*
  - subhepatic, 1293, 1293*f*
  - subphrenic, 1293
  - treatment, 1293
  - ultrasound, 1288, 1287*f*
- anatomic relationships, 1270, 1322*f*, 1328–1332, 2002
- anatomic resection, 1261, 1311
- arterial anatomy, 1437*f*
- attachments, 1346*f*
- bear claw-type injuries, 1332
- biliary drainage, 1330–1331
- blunt trauma to, 1340
- cancer of, 1410–1412 (*See also* Cholangiocarcinoma)
- caudate lobe
  - removal, 1319–1320
  - scanning of, 185*f*
- circumferential packs of, 1338, 1338*f*
- cirrhosis, e30*t*
- congenital diaphragmatic dysplasia, involvement in, 846
- cystic masses, 1277*f*
- development of, 820
- in distal splenorenal shunts (*See* Shunts, distal splenorenal)
- echinococcal cysts, 1294–1314
- embryology of, 1052*f*
- focal HCC, 197*f*
- fracture
  - approach to, 1335*f*
  - hemostasis and, 1334*f*
- functional status, 1616, 1617*t*, 1620–1621
- glucose metabolism, 1182

- glutathione depletion and, 20
- heat shock proteins and, 19–20
- herniation, 826, 841
- hilar dissection, 1265
- hydatid cysts, 1295–1296
- hydatidosis, 1298*t*, 1300–1303
- hypercoagulability and, 19
- immunologic function and, 18–19
- injuries
  - acute, 1434
  - chronic, 1434
  - grading of, 1333*t*
- innervation, 1073–1074
- IOUS scanning method, 181–184, 182*t*
- laparoscopic ultrasound, 188–189
- lesions
  - cystic, 1276
  - summary of, 1275*t*
- major trauma, 1327–1342
- malignant tumors, 1279–1283
- masses, diagnosis of, 1275–1278
- metastatic disease, 1283–1284
  - synchronous, 1326
- mobilization of, 1408, 2156–2157
- neurovascular supply, 1052
- nonanatomic resection, 1311
- parenchyma
  - scanning of, 182, 186*f*
  - transection, 1408–1409
- penetrating injury, 1341
- perfusion of, 1587
- preoperative assessments, 25–26
- resection, 1261
- retraction, 1212*f*

- rupture of, 1328*t*
- segmental anatomy of, 182, 1260–1261, 1260*f*, 1261*f*, 1315*f*, 1329–1330, 1329*f*, 1330*f*
- simple hepatic cysts, 1276–1277
- stress responses, 18–20
- surface anatomy of, 1259–1260, 1328–1332, 1329*f*
- surgery
  - Blumgart, 1417*f*
  - resection sites, 1377*f*
- surgical anatomy of, 1259–1271
- total volume of, 1261
- TPN and, 47
- tumor ablation in, 200–202
- tumors
  - hepatic resection for, 1314–1327
  - IOUS of, 186*f*
- ultrasonographic scanning, 186*f*
- ultrasound probe placement, 182
- venous drainage, 1330
- wedge resection, 2157

- Liver cancer, 1460. *See also* Hepatocellular adenomas (HAs); Hepatocellular carcinoma (HCC)
- Liver disease
  - bilirubin levels and, 1985
  - coagulopathy of, 104
  - diagnostic considerations, 1271–1286
  - EN formulations, 64
  - presentation, 1272
  - signs of, 1620
- Liver failure
  - criteria for liver transplantation, 1436*t*
  - etiologies, 1435*t*
  - posthepatectomy, 1460
  - presentation of, 1434–1435

- Liver function
  - abnormal, 2020
  - laboratory tests, 1620
  - paraneoplastic syndrome and, 2020
- Liver function tests (LFTs)
  - in chronic pancreatitis, 1494
  - in gallbladder disease, 1343
  - laboratory tests, 1655
  - preoperative testing, 22, 23*t*
- Liver Imaging Reporting and Data System (LI-RADS)
  - risk stratification and, 1281, 1281*t*, 1286
- Liver plate system. *See* Hepatic hilar area; Hepatic plate system
- Liver transplantation, 1434–1450
  - after major trauma, 1339
  - alloengraftment, 1452–1453
  - biliary complication in, 1268
  - biliary (re)construction in, 1420
  - branch patch technique, 1442*f*
  - cadaver donor hepatectomy, 1436–1438, 1449–1450
  - choledochoduodenostomy combined with, 1420
  - for cirrhosis, 1597
  - contraindications, 1435*t*
  - criteria, 1436*t*
  - distal splenorenal shunts and, e21
  - donor liver preparation, 1438
  - graft survival, 1447*f*
  - in HCC, 1281
  - for hilar cholangiocarcinoma, 1409, 1410, 1411–1412
  - historic milestones, 1451*t*
  - implantation of cadaver allograft, 1440–1441
  - indications, 1435*t*
  - legacy of, 1450–1460
  - liver abscesses and, 1286
  - living donor, 1442–1444, 1446*f*

    - implantation, 1443–1444
  - organ availability, 1449, 1607
  - outcomes, 1449
  - piggyback technique, 1441–1442, 1445*f*
  - for portal hypertension, 1607, 1623
  - posttransplant outcomes, 1447–1448
  - preoperative planning, 1435–1436
  - for primary sclerosing cholangitis, 1401–1402, 1403–1404
  - prophylactic antimicrobial agents, 114*t*
  - research opportunities, 1450–1451
  - small for size syndrome, 1442
  - split liver, 1444–1447
- Liver volumetry, 1462
- Lloyd-Davies, O. V., 1841
- Lloyd-Davies position, 1843, 1855, 1888*f*
- Lobectomy
  - left lower, 810, 811*f*, 813–814
  - left upper, 807*f*, 809–810, 810*f*, 813
  - in lung injuries, 792
  - in NSCLC, 816–817
  - open, 807–811
  - right lower, 809, 812–813
  - right middle, 809, 812
  - right upper, 807–809, 807*f*, 808*f*, 811*f*, 812
  - robotic-assisted, 818
  - temporal, 482*f*
  - thoracoscopic, 816–817
  - thyroid gland, 522–525, 525*f*
  - VATS, 811–814, 812–814
- Lobular carcinoma in situ (LCIS)
  - breast-conserving surgery, 635
  - pleomorphic, 635
  - in proliferative breast disease, 606–607
- Localized intravascular coagulopathy (LIC), 380

- Lomotil, postoperative, 1646
- LoneStar retractors, 1735, 1848, 1858*f*
- Long chain triacylglycerols (LCTs), 60
- Long thoracic nerve, 308, 2549
- Longitudinal intestinal lengthening and tailoring (LILT)
  - complications, 1983
  - postoperative management, 1983
  - in SBS, 1982, 1983*f*
  - technique, 1982–1983
- Longitudinal pancreaticojejunostomy. *See also* Puestow procedure
  - anastomosis, 1512*f*
  - procedure, 1509–1512
  - Roux-en-Y limb, 1511*f*
  - selection of, 1545
  - steps, 1514
- Longus capitis muscle, 285
- Longus coli muscle, 285, 285*f*, 287
- Loop colostomy
  - advantages, 1763
  - incisions, 1766
  - indications, 1641
  - for large bowel obstruction, 1706
- Loop gastrojejunostomy
  - technique, 1123–1124
- Loop ileostomy
  - creation of, 1642*f*
  - diverting, 1723
  - divided, 1642–1643, 1644*f*
  - in large bowel obstruction, 1706–1707
  - reversal of, 1645*f*, 1646*f*
- Loop ligatures, ready-to-use, 169–170, 170*f*
- Loperamide (Imodium), 1646, 1774, 1976
- Low anterior resection syndrome (LARS), 1837–1838, 1838*f*
- Low-dose unfractionated heparin (LDUH), 91

- Lower esophageal sphincter (LES)
  - characteristics of, 968
  - dilation of, 982–983
  - failure of relaxation, 982
  - hypertensive, 981
  - motility disorders, 968–969
  - nonrelaxation of, 962
  - relaxation of, 968
- Lower extremities
  - access, hemodialysis, 2546
  - amputations, 2398–2408, 2414*f*
  - arteriovenous hemodialysis access in, 2542–2543, 2543*f*, 2544*f*, 2547
  - edema after radiation therapy, 2136
  - infections in diabetes, 2412
  - injury to
    - amputation, 2590*f*
    - endovascular treatment, 2600–2601
    - femoral artery injuries, 2597–2598, 2598*f*
    - mortality and amputation rates, 2589*f*
    - overview of, 2601
    - popliteal artery injuries, 2598
    - shunts and shunting, 2602
    - tibial artery injuries, 2598–2599, 2599*f*
  - perfusion assessment, 2473
  - venous anatomy of, 2518*f*
- Lower extremity deep venous thrombosis (DVT), 2482, 2493*f*
- Lower intercostal arteries, 834–835
- Lower jugular compartment, 504*t*
- Lower urinary tract, orthotopic reconstruction, 2045–2046
- Low-molecular weight heparin (LMWH)
  - coagulopathies and, 104
  - deep venous thrombosis treatment with, 2499
  - revascularization and, 253
  - VTE prevention and, 91

- LPLND. *See* Laparoscopic pelvic lymph node dissection (LPLND)
- LRPLND. *See* Laparoscopic retroperitoneal lymphadenectomy (LRPLND)
- LSG. *See* Laparoscopic gastric sleeves (LSG)
- Lumbar sympathectomy, 2411
- Lumbar triangle, 776*f*
- Lumbocostal trigone, 820
- Lumpectomy. *See also* Oncoplasty for breast conservation
  - ablation therapy and, 654
  - defects left by, 234
  - lymphedema incidence, 673
  - radiation therapy after, 223*f*
  - trials, 756
- Lunate bone, 247, 250*f*
- Lung buds, 781, 782*f*
- Lung cancer
  - carcinoma in situ, 800
  - chemotherapy for, 817
  - epidemiology, 799–800
  - histologic groups, 799–800
  - imaging, 801
  - international staging systems, 800*t*
  - metastatic, 801
  - molecular analysis of, 818
  - mortality rates, 799
  - pneumonectomy, 799
  - resection, pericardiectomy following, 828
  - staging, 800*t*, 801*t*, 817
    - invasive, 801–804
    - noninvasive, 801, 817
  - types of, 817
- Lung cysts, 2020
- Lung function tests. *See* Pulmonary function tests
- Lung membrane, 820

- Lung-expansion maneuvers, 90
- Lungs
  - accelerated growth, 823
  - anatomic relationships, 773
  - apex of, 287
  - blunt dissection, 803*f*
  - development, 839–840
  - expansion maneuvers, 90
  - hilum of, 814*f*
  - hypoplasia, 820–821
  - injuries, 791–793
    - contusions, 792–793
    - resections, 792
    - transfusion-associated, 108–109
  - lacerations, 791–792
    - operative approaches, 791
    - operative indications, 791
    - treatment, 791–792
  - lymph nodes, 802*f*
  - nodes of the roots of, 786
  - pleuroperitoneal canal, persistence in, 820
  - pulmonary resection, 268–269
  - root of the neck and, 287*f*
  - scanning, 88
  - selective ventilation of, 799
  - sublobar resection, 799
  - ventilation of single, 1017*f*
  - ventilation-perfusion, 86–87
  - volumes
    - in CDH, 841
    - pulmonary function testing, 87*t*
    - pulmonary mechanics and, 87
    - standard measurements, 87*f*
  - zones, 86–87

- Lung-to-head ratios (LHRs)
  - in congenital diaphragmatic hernia, 841, 842, 845
  - in diaphragmatic eventration, 849
- Lupus erythematosus, 558
- Luteinizing hormone (LH), 11
- Lymph node dissection
  - laparoscopic
    - patient positioning, 2054–2068
    - pelvic and retroperitoneal, 2054–2068
- Lymph node mapping, 521
- Lymph nodes
  - cholangiocarcinoma, involvement in, 1411
  - dissection
    - extent of, 1128–1130
    - hepatic hilum after, 1408*f*
  - regional
    - metastases, 1411
  - resection
    - robotic-assisted, 271
  - resection, extent of, 1130*f*
  - stations, 1129*f*
  - suprapancreatic, 1486–1487
- Lymphadenectomy
  - benefits, 1140
  - classification of, 1140
  - D1, description of, 1140
  - D2
    - benefits of, 1140
    - description of, 1140
    - gastrectomy with, 1148
    - for gastric cancer, 1093
    - in gastric cancer, 1130–1131, 1133–1134, 1134*f*
    - laparoscopic gastrectomy with, 1148
    - operative procedure sequence for, 1131

- stomach resection with, 1086
- technique, 1133–1134, 1134*f*
- D3, description of, 1140
- distal retroperitoneal, 2040–2041
- extended, 1140, 2038–2045
- extent of, 1140
- femoral, 1965
- inguinofemoral, 1966*t*, 1968–1969, 1968*f*
- mediastinal, 2162
- minimally invasive, 1970–1971
- in oral cavity cancer, 336–337
- outcomes, 1140–1141
- in ovarian cancer surgery, 2161–2162
- pelvic, 1965, 2040–2041
  - robotic-assisted, 1969–1970
- in positive SLNB, 430, 432
- pulmonary resection and, 810–811
- radical hysterectomy with, 2136
- radical in APR, 1855*f*
- in rectal cancer, 1839
- requirements for adequate, 1135*f*
- retroperitoneal, 2060*f*, 2061, 2061*f*
- in skin cancers, 417
- videoscopic inguinal, 431, 433

Lymphangiectasia, 378

Lymphangiogenesis, tumor, 1964

Lymphatic leaks, 2366

Lymphatic malformations (LM), 374*t*
- clinical presentation, 378
- treatment, 379

Lymphatic system
- of breast, 598–601, 599f–601*f*
- formation of, 370
- malformations

- clinical presentation, 370
- etiology of, 370
- outcomes, 371–372
- pathophysiology, 370
- postoperative care, 371
- preoperative planning, 371
- mapping, 420*f*, 421*f*, 429

Lymphedema, 682–683, 711
- anatomy, 672
- diagnosis, 674–675
- etiology and pathophysiology, 672
- incidence, 672–673, 673t
- lymphadenectomy and, 432
- post hysterectomy, 2144
- prevention of
  - clinical trials, 676
  - prediction, 676
- risk factors, 673–674
- staging and early detection, 675–676, 675*t*, 676*f*
- surgery, 676–678, 677*f*–678*f*, 677*t*, 679–680
- treatment
  - complex decongestive therapy, 678–679
  - exercise, 679
  - reconstructive surgery, 679–680

Lymphocele, 2066

Lymphocysts, 2144

Lymphocyte-depleting agents, 148

Lymphomas, anterior mediastinum, 781

Lymphoscintigraphy, 414*f*, 423

Lymphovenous anastomosis
- for lymphedema, 680

Lynch, Robert Clyde, 386*f*

Lynch mutations, 1249

Lysosomes, 37

M

- M mode, US, 178
- MacMahon classification, 1367
- Macroglossia, 378
- Macronutrients
  - absorption of, 59–60
  - delivery of, 54
  - depletion of, 55
  - metabolic complications and, 55
  - utilization of, 59–60
- Macrophages
  - activated, 5
  - innate immunity and, 142
  - muscle proteolysis and, 13*f*
  - role in inflammation, 3
- Macrosomia, caesarian delivery, 2119
- Magnetic resonance angiography (MRA)
  - aortofemoral bypass, 2332
  - brachiocephalic reconstruction, 2259
  - carotid bifurcation disease, 2249, 2250*f*
  - carotid body tumors, 2270–2271, 2271*f*
  - critical limb ischemia, 2377
  - endovascular procedure, 2384
  - extraanatomic bypass, 2344
  - femoral artery aneurysm, 2319
  - renal artery occlusive disease, 2434
  - reversed vein bypass grafts, 2358
- Magnetic resonance cholangiopancreatography (MRCP), 1494, 1604–1605
- Magnetic resonance enterography (MRE), 1663, 1673
- Magnetic resonance enterography (MTE), 1711
- Magnetic resonance imaging (MRI)
  - of breast, 618, 618*f*
  - and breast-conserving surgery, 624

- diagnostic, 2020
- in liver hydatidosis, 1302
- ovarian, 1249
- of portal veins, 1604–1605
- rectal, 1854, 1862, 1862*f*, 1938
- surveillance, 1869

- Magnetic resonance venography, 2492–2493, 2493*f*
- Main pancreatic duct (MPD), 1492
- Mainz II pouches, 2112
- Mainz neobladder, 2116
- Mainz pouches, 2114*f*
- Major duodenal papilla, 1478–1480. *See also* Ampulla of Vater
- Major histocompatibility complex (MHC) molecules, 142, 143
- Makuuchi's ligament, 1262, 1318*f*
- Malar muscle wasting, 67
- Malar processes, expansion of, 551
- Maldigestion
  - diagnosis, 1164
  - etiopathogenesis, 1164
  - overview of, 1164
  - as postgastrectomy complication, 1163
  - symptomatology, 1164
  - treatment, 1164
- Male breast cancer (gynecomastia), 611, 612*f*
- Malecot catheter, 1768
- Malignant media infarction, 484–485
- Malignant melanoma (MM), 418–429
  - adjuvant therapy, 422
  - amelanotic, 412
  - anal, 425, 1843
  - biopsy confirmation, 412, 412*f*, 418
  - clinical presentation, 411–412, 411*f*
  - cutaneous, 353
    - diagnosis, 417

- *de novo*, 411
- desmoplastic, 422–423
  - recurrence, 423
- diagnosis, 418
- epidemiology, 418
- excision of
  - flap coverage, 217
- familial, 418
- gender and, 410
- genetics, 418
- groin dissection in, 430
- hand and foot, 423–424
- head and neck, 423, 423*f*
- intralesional therapies, 425–426, 427*f*
- in-transit disease, 425–427, 426*f*
- life time risk of, 417
- local staging, 412–413
- lymph node considerations, 413–415
- lymphatic mapping, 429
- metastatic, 427
- mitotic rate
  - prognosis and, 413
- neck, 354–355
- necrotic metastatic, 1966*f*
- neoadjuvant therapy, 425
- pathogenesis, 410–411
- pediatric, 424–425
- in pregnancy, 422
- punch biopsies, 419*f*
- recurrence, 415–416
- regional chemotherapy, 425
- risk factors, 410–411
- second primaries, 414
- sentinal lymph node biopsy, 430

- in situ, 419
- skin cancer and, 410–418
- stage, 418–422, 419*f*
- stage III, adjuvant therapy, 422
- subungual, 412
- surgical margins, 420*t*
- surgical resection, 415
- survival rates, 417
- systemic, treatment of, 418
- treatment, 413, 413*t*, 418–422
- trials, 420*t*
- of unknown primary, 422

- Malignant mixed tumors, salivary gland, 311
- Malignant obstructive jaundice, 1412
- Mallory Weiss tears, 1106
- Malnourishment
  - after bariatric surgery, 1230–1231, 1234
  - preoperative workup, 1241
  - protein-calorie, 1241
- Malnutrition
  - and amputation of diabetic foot, 2397
  - definition of, 55
  - enterocutaneous fistulas and, 1651
  - surgical risk and, 26–27
- Maloney dilator, 869, 872
- Malperforans ulcer, 2399
- Malrotation
  - bilious emesis and, 1175
  - clinical presentation, 1172–1173
  - congenital heart defects and, 1175
  - diagnostic evaluation, 1172–1173
  - duodenal obstruction and, 1169
  - esophogeal, 823
  - in infants, 1166

- Ladd procedure, 1173–1174, 1173*t*, 1174*f*
- laparoscopic approaches, 1175
- postoperative considerations, 1174*f*
- small bowel obstruction and, 1630*t*

- Mammaplasty, 737–738
- Mammography, 611–615, 613t, 614–615*f*, 614t
- Management of Athero Thrombosis with Clopidogrel in High-risk patients (MATCH), 2250
- Mandible
  - anatomy of, 71*f*, 319*f*
  - depression of, 322
  - fractures of, 441
    - incidence of, 443
    - management of, 443, 443*f*
  - osteoradionecrosis, 336
- Mandibular alveolar ridges, 326
- Mandibulectomy, 338*f*
- Mandibulo-maxillary fixation (MMF), 443
- Mandl, Felix, 533*t*
- Mangled extremity (defined), 2587
- Mangled extremity severity score (MESS), 2587–2588, 2587*f*
- Mangled Extremity Syndrome Index (MESI), 2587, 2588
- Manitol dosing table, 479*t*
- Manometry, preoperative, 937
- Manson, Paul, 443
- Manual lymphatic drainage, 678
- Manubrium, embryology of, 772
- Manufacturer and User Facility Device Experience (MAUDE)
  - surgical stapler reports, 175
- Marfan syndrome, 823, 2279, 2280
- Marginal artery of Drummond, 1680
- Marginal ulcers, 1253
- Marjolin ulcers, 428
- Marketing, opioid prescriptions, e2–e3

- Marlex meshes, 236, 1894
- Marshall-Marchetti-Krantz operation, 2167
- Martin forceps, 357
- Martin's Arm, 1940
- Maruyama computer program, 1130
- Maryland grasper, 1363
- Masaoka classification, 559, 564
- Mass effect, herniation and, 482–484
- Masseter muscle, 308
- Massive transfusion policies, 110
- Mastectomy
  - adjuvant chemotherapy after, 223
  - bilateral
    - immediate DIEP, 769*f*
    - indications, 222–223
    - preoperative image, 765*f*
    - reconstruction, 765*f*
  - breast reconstruction (*See* Breast reconstruction)
  - for ductal carcinoma in situ, 634
  - Halsted radical, 755
  - inframammary fold, 221–222
  - lymphedema incidence, 673
  - NSABP B-04 trial, 755
  - NSABP B-06 trial, 755–756
  - radiation effects, 724
  - radiation necrosis after, 218*f*
  - radical (RM) and modified radical
    - advanced (stage 111a, 111b), locoregional, 687–688
    - classification, 685–686t
    - early invasive (stage 1, 11a, 11b), 687
    - Halsted procedure, 704–710, 705*f*–709*f*, 710*f*, 724*f*
    - history of surgery, 684, 685–686t
    - indications, 686, 687t
    - reconstruction, 698–700, 701*f*–702*f*

- recurrence, locoregional, 688
- risk factors, 686–687
- in situ breast cancer (stage 0), 687
- stages of, 686t
- surgical technique, 688–697, 689*f*–695*f*, 697*f*–700*f*
- scars, 227*f*
- skin-sparing, 225, 229, 766*f*
- *vs.* breast-conserving surgery, 624–625

Mastoid process, 319*f*
Mastopexy lumpectomy
- in oncoplasty of breast
  - donut, 716–718, 718*f*
  - reduction, 715–716, 718*f*

Matrix metalloproteinases (MMP), 2291, 2304
MatrixRIB plates, 236
Maxilla, fractures of, 441, 442, 442*f*
Maxillary alveolar ridges, 326, 435
Maxillary artery, 317
Maxillary vein, 318
Maximal respiratory pressures, 87*t*
Mayo scissors, 1633, 1633*f*
Mayo-McCall culdoplasty, 2168
May-Thurner syndrome (MTS), 2499, 2500*f*, 2509
McBurney incisions
- abdominal wall, 152, 152*f*
- for appendicitis, 1691, 1691*f*
- closure of, 153
- selection of, 153

McBurney point, 1689
McGregor flaps, 331, 331*f*
McKeown approach, 985–986
McKeown resection, 1019
McVay repair, hernias, 2230
Mean arterial pressures, 69

- Mebendazole, 1303
- Mechanical thrombectomy (MT), 2494
- Mechanical ventilation
  - after esophageal perforation surgery, 1030
  - in diaphragmatic eventration, 850, 851
  - physical examination and radiological findings not evident during, 849
- Mechanistic target of Rapamycin (mTOR), 148
- Meckel diverticulum, 1473
- Medawar, Peter, 141
- Median arcuate ligament
  - anatomy, 831–832
  - aorta passing posteriorly to, 899
  - as aortic opening border, 831
  - celiac axis compression, association with, 839
  - esophageal hiatus margin formed by, 828
  - lack of, 832
  - overview of, 831–832
- Median arcuate ligament syndrome, 839
- Median nerve, 247, 248*f*
- Median sacral artery, 1826*f*, 2005*f*, 2006*f*
- Median sternotomy
  - advantages of, 789–790
  - with optional extension, 790*f*
  - in penetrating injuries, 789, 793
- Median umbilical ligament, 2009, 2009*f*
- Mediastinal bleeding
  - tamponading, 1015*f*, 1016*f*
  - as transhiatal esophagectomy complication, 1014–1015, 1018
- Mediastinal compression, 840
- Mediastinal dissection, 1004–1010
- Mediastinal esophagus, 824
- Mediastinal lymph nodes, 810–811, 817
- Mediastinal masses, 268
- Mediastinitis, 236

- Mediastinoscopes, 803*f*
- Mediastinoscopy
  - anterior, 802–803
  - cervical, 802
  - endoscopic approaches *versus*, 818
  - lung cancer staging, 802–803
- Mediastinotomy, anterior, 804*f*
- Mediastinum
  - anatomical dissections, 786*f*
  - anatomical relationships, 832–833, 834*f*
  - anatomy
    - divisions of, 784*f*
    - lymph nodes, 786–787
  - applied anatomy of, 772–787
  - compartments of, 781–787
    - anterior, 781, 783
    - borders, 781
    - contents, 781–786
    - inferior, 784
    - middle, 783
    - posterior, 784–786
    - superior, 783–784, 785*f*
  - defects, omentum flaps, 236–237
  - diaphragmatic and pleural relations with, 832–833
  - dissection of, 953–954, 989*f*
  - embryogenesis, 780–781
  - esophagus freed into, 1024
  - infections, mortality rates in, 787
  - left, 832*f*
  - posterior
    - inspection of, 1008
    - stomach, positioning within, 1000
    - views of, 892*f*, 893*f*, 897*f*
  - right, 834*f*

- stabilizing, 850
- structures left of, 832*f*
- superior, dissection from, 1005*f*
- surgical anatomy, 464*f*
- transverse section, 783*f*

- Medical expulsive therapy (MET), 2012
- Medical histories, preoperative, 22
- Medications
  - perioperative management, 29*t*–30*t*
  - surgical risk and, 28–30
- Medigus Ultrasonic Surgical Endostapler, 966–967, 967*f*
  - complications, 967
  - outcomes, 967
  - postoperative care, 967
  - technique, 966–967
- Medium chain triglycerides (MCTs), 60, 63
- Medullary thyroid carcinoma (MTC), hereditary, 530
- Megabowel
  - causes, 1960
  - diagnosis, 1960
  - presentation, 1960
  - treatment, 1960
    - conservative, 1960
    - surgical, 1960–1961
  - varieties of, 1960
- Megacava, 2512
- Megarectum, pan-colonic inertia and, 1733*f*
- Melanocyte-stimulating hormone (MSH)
  - melanoma and, 411
- Melanoma. *See* Malignant melanoma
- Melena, 1699–1700
- Memorial Sloan-Kettering Cancer Center leveling system, 346–347
- MEN type 2, 514
- *MEN1* mutation, 542

- Meningoceles, anterior sacral, 1882
- Menorrhagia, 11
- Mentatis muscle, 326*f*
- 6-Mercaptopurine, 1716
- Merkel cell carcinoma, 430
- Mesenteric arterial thrombosis, 2444
- Mesenteric artery disease, 2454
- Mesenteric artery revascularization, 2464
- Mesenteric artery stenting, 2453
- Mesenteric bypass, 2455, 2464
- Mesenteric circulation, 2453, 2454*f*
- Mesenteric ischemia, 2460*f*. *See also* Acute mesenteric artery ischemia; Chronic mesenteric ischemia
- Mesenteric lesions, nonatherosclerotic, 2453–2454
- Mesenteric reconstruction, 2455
- Mesenteric revascularization surgery, 2464
- Mesenteric windows of Deaver, 2047
- Mesentericoaxial volvulus, 866*f*
- Mesenteries, hernias through, 2200
- Mesentery
  - blood flow, 1764
  - diagrammatic representation, 781*f*
  - embryology, 787
- Mesh prosthetics, implantation of, 1964
- Meshes
  - absorbable, 1994
  - biologic, 157, 225–226
  - choice of materials for, 158
  - diaphragm repaired using, 862*f*
  - GoreTex, 236
  - hernia repair with, 843, 2229
    - cruroplasty, 869–870, 869*f*
  - location of placement, 158, 161*f*
  - Marlex, 236

- peritoneal cavity, 165*f*
- placement of, 168
- in plug-and-patch groin repair, 2230–2237, 2235*f*–2238*f*
- proline, 235–236
- skeletal reconstruction and, 236
- tension of, 1908*f*
- titanium, 236
- types of, 158

Mesoappendix, 1691, 1691*f*

Mesocolic resection, 1681

Mesocolic vessels, 1910*f*

Mesocolon
- in toxic megacolon, 1723
- transverse, 1255*f*, 1474

Mesoenteroaxial gastric volvulus, 867

Mesoesophagus, embryology of, 1053

Mesorectal excision, partial, 1808–1809

Mesorectal fascia, 1825*f*

Mesorectal resection, 1681

Mesorectum
- anatomic relationships, 1683–1684, 1815, 1844
- anterior cancer, 1801*f*
- audit of, 1800–1801
- cross-section of, 1684*f*
- dissection, 1808
- embryology of, 1815
- surgical anatomy, 1799–1800
- tapering of, 1808*f*
- washout, 1809*f*

Metabolic acidosis, 1177

Metabolic diseases, surgery for, 1178–1181

Metabolic needs, calculation of, 1655

Metabolic surgery
- clinical trials, 1183*t*

- complications, 1179–1180
- contraindications, 1178
- effects on hormones, 1182*f*
- efficacy of, 1184
- indications, 1178
- intestinal bypass for hypercholesterolemia, e36–e43
- laparoscopic, 1184
- outcomes, 1181–1183
- postoperative care, 1179–1180
- preoperative planning, 1178

- Metabolic syndrome, 1210
- Metacarpal bones, 250*f*
- Metacarpophalanges (MP), 247, 250*f*
- Metanephrines, 520
- Metaraminol, 81–82
- Metastatic disease. *See Specific* cancers
- Metformin, 34
- Methacholine, 969
- Methadone, e7
- Methergine, 2124
- Methicillin-resistant *Staphylococus aureus* (MRSA)
  - colonization by, 113
  - hand infections, 253
  - postoperative infections, 124
  - surgical site infections, 112*t*
  - VAP and, 92
- Methicillin-sensitive *Staphylococcus aureus* (MSSA), 92, 112*t*
- Methimazole, 520
- Methotrexate
  - discontinuation, 1662
  - postoperative resumption of, 35
- Methyl methacrylate “sandwich,” 746*f*, 748
- Methylprednisolone, 1721
- Methylxanthines, 608

- Metoclopramide, 1165
- Metronidazole, 1278
  - after colonic lavage, 1723
  - for anal fistulas, 1715
  - for *C. difficile* colitis, 1724
  - for *H. pylori* infections, 1115
  - postoperative, 1723
- Metzenbaum scissors, 1657, 1657*f*
- Miami pouches, 2112
- Michelassi stricturoplasty, 1667–1668
- "Mickey Mouse" silhouette, 189
- Microhematuria, 2091
- Micronutrients
  - deficiencies in SBS, 1982
  - delivery of, 54
  - depletion of, 55
- Microorganism-associated molecular patterns (MAMPs), 3
- Micro-orifice in intestinal bypass, e40
- Microsatillite instability (MSI), 1743
- Microsurgery for lymphedema, 683
- Microvasculature, hyperthermia and, 195
- Microwave ablation (MWA)
  - breast cancer, 204
  - of breast tumors, 661–663
    - focused microwave thermotherapy, 661–663, 662–663*f*
    - percutaneous coagulation, 663
  - HCC, 201, 203*f*
  - hyperthermic responses and, 196–197
  - methodology, 198–199
  - surgical energy, 276
- Micturition, nervous control of, 1825
- Mid-arm circumference (MAC), 55
- Midazolam, 138, 1623
- Middle cerebral artery infarction, 484–485, 484*f*

- Middle cervical ganglion block, 289
- Middle colic artery
  - anatomic relationships, 1063*f*, 1476*f*, 1679
  - anomalous, 1484, 1484*f*
  - as superior mesenteric artery branch, 2444
- Middle colic vein, 1589*f*
- Middle constrictor muscle, 320
- Middle hepatic artery, 1266, 1266*f*
- Middle hepatic veins, 1262, 1262*f*, 1264*f*, 1270
- Middle jugular compartment, 504*t*
- Middle phalanx, 250*f*
- Middle rectal artery, 1685, 1845
- Middle scalene muscle (MSM), 285, 2549, 2556*f*
- Middle suprarenal artery, 2005*f*
- Middle thyroid vein
  - anatomy of, 71*f*, 359*f*
  - exposure, 537
  - identification of, 522
- Mid-esophageal perforation, 1022–1023
- Midface fractures, 435*f*
- Midgut, embryonic, 1055*f*, 1815
- Midgut volvulus, 1172–1173, 1175
- Midpalmar space abscesses, 255
- MIE. *See* Minimally invasive esophagectomy (MIE)
- Milan I study, 755
- Miles, W. Ernest, 1797, 1798, 1814, 1839, 1841, 1852
- Miles resection, drawbacks, 1822
- Milk line, mammary, 594*f*
- Milrinone, 79
- Milroy disease. *See* Lymphedema
- Milwaukee classification system for sphincter of Oddi dysfunction (SOD), 1386*t*
- Minerals, dietary, 60
- Minimally invasive biliary reconstruction, 1381

- Minimally invasive esophagectomy (MIE)
  - benefits of, 986
  - efficacy of, 999
  - frequency, 1019
  - postoperative morbidity, 999
  - quality of life after, 999
  - thoracoscopy in, 991–993
- Minimally invasive partial nephrectomy (MIPN), 2022
- Minimally-invasive partial nephrectomy, 2030
- Minimally-invasive surgery (MIS)
  - benefits of, 262
  - suturing in, 175
    - courses, 175–176
  - thoracic, 268–269
- Minor duct sphincteroplasty, 1394
- Minor duodenal papilla, 1481
- Minor papillary sphincteroplasty, 1393
- Minor papillary stenosis, 1392–1393
- Mirizzi syndrome, 1274, 1352
- Mirizzi-type phenomenon, 1272
- Misgav-Ladach modification, 2121
- Mitochondria
  - changes in, 37
  - dysfunction, 14–15, 14*f*
  - in injury, 14*f*
  - metabolism, 13–15
  - MODS and, 140
  - muscle wasting and, 37
  - oxidative phosphorylation in, 14*f*
  - permeability transition pores, 14
  - sestamibi scans and, 543
- Mitogen-activated protein kinases (MAPKs), 6, 11
- Mitomycin C, 1880, 2036
- Mitral valves, robotic-assisted repair, 269

- Mitrofanoff catherizable channel, 2113, 2115*f*
- *MLH1* mutation, 1249, 1743
- MLS1 protein, 1247
- Model for end-stage liver disease (MELD) scores, 1434, 1435, 1616
- Modified radical neck dissection (MRND), 350
- Modiolus, 326*f*
- Molecular imaging of breast, 617–618
- Mondor disease, 607
- Monitored anesthesia care (MAC), 544
- Monoamine oxidase inhibitors (MAOIs), 30*t*
- Monoclonal antibodies (MAb), 144, 149
- Monopolar energy tissue effect, 274*f*
- Monopolar radiofrequency energy, 274–275
- Monro-Kellie doctrine, 475–476, 475*f*
- Monti catherizable channel, 2113
- Monti technique, 2114, 2115*f*
- Montreal classification system, 1034, 1034*f*
- Moore, Francis, 2
- Morgagni hernia
  - Bochdalek hernia compared to, 839
  - characteristics of, 822*t*
  - definition and overview of, 840, 846
  - mediastinal, 781
  - potential, 824*f*
  - prevalence of, 820
- Morphine, synthesis, e1
- Morson’s waist, 1822
- Morton, William, 1937
- Motor neuropathy in diabetes, 2409
- Motor vehicle accidents (MVAs)
  - compressive forces, 1332
  - hospital admissions, 487
  - liver trauma and, 1332*f*
  - restraints, 1332*f*

- steering wheels, 1332
- T-bone accidents, 1332, 1332*f*
- traumatic brain injuries, 476, 487

Mouret, Philippe, 1353

Mouth, floor of
- anatomy, 322–323
  - deep structures, 323*f*
- cancers of, 334
  - early-stage carcinoma, 337*f*
  - surgical management, 337–339
- contents of, 323
- lymphatic drainage, 323
- musculoskeletal background, 319*f*
- transmandibular access to, 338*f*

MRA. *See* Magnetic resonance angiography

MSH2 mutation, 1249, 1743

MSH2 protein, 1247

MSH6 mutation, 1249, 1743

MSH6 protein, 1247

MSKCC cholangiocarcinoma (CCA) classification system, 1406, 1407

MTOR inhibitors, 148

Mucinous ascites, 1696

Mucinous cystic neoplasia (MCN), 1515

Mucocutaneous junction, lip, 325

Mucoepidermoid carcinoma, 311

Mucosal heterotopia, embryology of, 1057*f*

Mucosal sleeve resection, 1906, 1907–1909

Mucostomy, esophageal, 981*f*

Mucous fistulae, creation of, 1723

Müller-Hermelink (M-H) classification, 559*t*

Multidetector CT (MDCT), 1553

Multidetector CTV or MTV, 2492–2493

Multidrug resistance in bacteria, 121

Multidrug-resistant (MDR) organisms, 92

- Multidrug-resistant protein 2 (MRP2), 19
- Multigland hyperplasia, 537
- Multiglandular disease (MGD), 534, 542, 543
- Multinodular goiter, 520
- Multiple endocrine neoplasia (MEN)
  - Hirschsprung disease and, 1971
  - *RET* proto-oncogene and, 516
  - supernumery parathyroid glands and, 505
  - type 1, 532
  - type 2, 516, 1971
- Multiple organ failure (MOF)
  - after abdominal aortic aneurysm repair, 2317
  - epidemiology of, 131
  - shock-induced, 132
- Multiple-organ dysfunction syndrome (MODS), 131–141
  - damage control surgery, 137, 140
  - definition of, 140
  - description of, 5
  - disability after critical care, 139
  - etiology, 131–135
  - gut barrier failure in, 20
  - innate host responses and, 134*f*
  - management strategies, 135–136
  - outcomes, 139
  - pathogenic mechanisms of, 135*f*
  - pathophysiology of, 131–135
  - surgical technique, 137
    - postoperative care, 137–139
  - surgical trauma and, 8
  - systemic inflammation and, 6
- Multitraumas, 2567
- Mu-opioid receptor agonists (PAM-OR), 32
- Mupirocin ointment, 117*t*
- MuRF1, muscle wasting and, 38

- Murine nitrofen model, 821, 823
- Muromonab-CD3 (OKT3), 148
- Murphy sign, 1272
- Murray, Joseph E., 141
- Murtha, John, 273
- Muscle
  - anterior body, 775*f*
  - antibacterial effect of, 216
  - of breast and axilla, 594–596, 595*f*
  - catabolism of, 2, 18
  - proteolysis in sepsis, 13*f*
  - relaxants, 1961
  - replenishment of, 67
  - strength assessment, 55
  - strength assessment of, 55
  - stress response and, 2
- Muscle flap repair, 843–844. *See also Specific* flaps
- Muscle wasting, 67
  - biologic treatment, 41–42
  - in cancer patients, 36*f*
  - catabolism and, 37*f*
  - diagnosis of, 37
  - factors in, 49*f*
  - hormonal treatment of, 41
  - mechanisms of, 37
  - nuclear cofactors and, 38
  - prevention of, 40, 40*t*
  - proteolytic mechanisms of, 37–38
  - in surgical disease, 35
    - consequences of, 35–36
  - transcription factors in, 38
  - treatment of, 40, 40*t*
    - clinical trials, 43*t*
- Muscle-specific ubiquitin ligases atrogin-1 (MAFbx), 38

- Musculocutaneous blood vessels, 216
- Musculocutaneous flaps, 238–240, 242–243
- Musculophrenic arteries, 777, 778*f*, 834
- Musculophrenic veins, 778*f*
- MUTYH-associated polyposis (MAP), 1742
- Myasthenia gravis (MG)
  - classification, 561*t*
  - description of, 559–560
  - ocular, 560, 561
  - pathophysiology, 560
  - presentation, 560
  - thymectomy in, 555
  - thyrotoxicosis
    - recurrent, 556
- Myasthenia Gravis Foundation of America, 560, 561*t*
- *Mycobacerium fortuitum*, 2236
- *Mycobacterium* graft infections, 2471
- Mycophenolate mofetil (Cellcept, MMF), 146
- Mycotic aneurysms
  - aortic, 2468–2469
  - challenges presented by, 2480
  - clinical presentation, 2466
  - definition and overview of, 2465
  - diagnosis, 2466, 2470
  - etiology and pathophysiology, 2465–2466
  - femoral, 2324–2325
  - imaging, 2470
  - management
    - aortitis and aortic aneurysms, 2468–2469
    - endovascular techniques, 2469, 2470
    - nonaortic aneurysms, 2467–2468
    - outcomes, 2469–2470
    - overview of, 2466–2467
    - in situ repair, 2469–2470

- native, 2470
- Myelolipomas, adrenal, 573
- Myenteric plexus, 897
- Mylohyoid line, 301
- Mylohyoid muscle
  - anatomy of, 71*f*, 309, 320, 361*f*, 363*f*, 468*f*
- Mylohyoid nerve, 320*f*
- Myocardial contusions, 794
  - diagnosis, 794
  - presentation, 794
  - treatment, 794
- Myocardial infarction (MI)
  - with mural thrombus formation, 2444
  - stress tests after
    - preoperative, 24
  - ST-segment monitoring, 68
  - traumatic injuries and
    - initial evaluation, 788
- Myoclonus, repetitive generalized, 487
- Myocutaneous flap, latissimus dorsi, 226–227
- Myofibrills, 37, 39*f*
- Myomata, hysterectomies for, 2128–2129
- Myopectineal orifice (MPO), 2231*f*
  - in plug-and-patch groin repair, 2229–2239, 2231*f*
  - posterior view, 2234*f*
  - protection of, 2229
- Myopectineal orifice of Fruchard, 2212*f*, 2214*f*
- Myostatin
  - catabolism and, 52*f*
  - expression of
    - muscle wasting and, 37
  - inhibition of, 42
  - muscle wasting and, 42
- Myotomes, differentiation of, 772

- Myotomy
  - completed, 977*f*
  - esophageal, 983
  - laparoscopic
    - patient positioning, 975*f*
    - port placement, 975*f*
  - thoracic
    - port placement, 979*f*
  - transabdominal *versus* transthoracic, 983
  - for Zenker diverticulum, 1149
- Myxedema, pretibial, 516

N

- NACT. *See* Chemotherapy, neoadjuvant
- Nail bed injuries, 251
- Naltrexone, e7
- Narrow band imaging (NBI), 207
- Nasal bridge flattening, 551
- Nasal screening, 129
- Nasal septum, 439
  - hematomas, 439
- Nasalis musculocutaneous flaps, 220*f*
- Nasogastric decompression, 1115, 1632, 1636
- Nasogastric tubes
  - after fundoplication, 914
  - after transhiatal esophagectomy, 1013*f*
  - Gastrografin via, 1631
  - inability to pass, 867
  - placement, 922, 1636
- Nasogastric/orogastric tubes, 61, 62*t*
- Nasojejunal decompression, 1137
- Nasojejunal feeding tubes, 62*t*
- Nasolabial flaps, 219
- Nasolacrimal ducts, 441*f*
- Nasolacrimal system, traumatic injury to, 441*f*

- Nasomaxillary angles, 551
- Nasopharyngeal carcinomas (NPC)
  - clinical presentation, 398–399
  - epidemiology of, 409
  - etiology, 398
  - incidence of, 409
  - preoperative planning, 399
  - surgical technique, 399
    - complications, 400
    - endoscopic, 399
    - lateral approach, 400
    - maxillary swing approach, 400
    - transcervical approach, 399–400
    - transpalatal approach, 399
- Nasopharynx
  - anatomy, 299, 398
  - mucosa, 398
- Nasopharynx cancer
  - nodal staging for, 347*t*
  - squamous cell, 348*f*
- Nathanson flexible triangular retractor, 1107
- Nathanson liver retractor, 1199
- National Accreditation Program for Rectal Cancer (NAPRC), 1821–1822
- National Aeronautic and Space Administration (NASA), 262
- National Cancer Centers Network (NCCN), 762
- National Cancer Database, 644–645, 648
- National Comprehensive Cancer Network (NCCN), 603–604, 606
- National Healthcare Safety Network (NHSN), 111*t*, 113*t*
- National Nosocomial Infections of Surveillance System (NNIS), 112*t*
- National Surgical Adjuvant Breast and Bowel Project (NSABP), 623, 672, 755–759, 762
- National Surgical Quality Improvement Program (NSQIP)
  - graft thrombosis, 2365

- preoperative assessments, 88
- prosthetic grafts, 2369

Natural killer (NK) cells, 3, 142

Natural Orifice Transluminal Endoscopic Surgery (NOTES), 1943
- for esophageal perforation repair, 1031
- safety of, 215
- transgastric, 210

Nausea, postsurgical, 871

Nausea and vomiting, prophylaxis, 522

Navicular bone. *See* Scaphoid bone

NEC. *See* Neonatal necrotizing enterocolitis (NEC)

Neck
- anatomic zones, 1269, 1269*f*
- anatomy, 71*f*
  - compartments, 503–504, 504*f*, 504*t*, 519*f*, 525–527, 526*f*
  - fascia, 286, 307
  - ligamentous background, 285
  - lymph nodes, 347*t*
  - lymphatic pathways, 306–307, 306*f*
  - muscular background, 285
  - nerve background, 285–286
  - nodal levels, 519*f*
  - penetrating injuries, 462–463
  - superficial venous system, 305–306
  - superior mediastinum and, 464*f*
  - zones, 463*f*
- central compartment
  - lymph node dissection, 530
  - nodes, clinically negative, 354
  - total thyroidectomy, 527*f*
- cervical ultrasonography, 534
- clinically positive nodes, 354
- congenital lesions, 366–373
- cross-section of, 898*f*

- dissection, 345–365
  - anesthesia, 355–356
  - anterolateral, 363–364
  - central compartment, 525, 530–531
  - classification of, 349–355, 350*t*, 352*f*
  - compartments, 503–504
  - comprehensive, 350
  - incisions, 356, 356*f*
  - indications for, 349–355
  - lateral compartment, 525–527, 528
  - modified radical, 351*f*, 404, 503–504, 505*f*, 527*f*
  - nomenclature, 353, 353*t*
  - planned, 354
  - post chemoradiation, 353–354
  - posterolateral, 352–53, 352*f*, 364
  - procedure, 356–361, 357*f*–364*f*
  - salvage, 354
  - selective, 350–351, 361–364, 404
  - suction drains, 364
  - supramohyoid (SOHND), 351, 361–363
  - technique, 355–364
- FNA biopsy, 517*f*
- injuries (*See* Cervical injury management; Cervical vascular injuries)
- lateral compartment
  - boundaries of, 525
  - lymph nodes of, 526*f*
  - total thyroidectomy, 527*f*
- lateral compartment nodes, 354
- lymph nodes, landmarks, 347*t*
- melanoma, 354–355
- palpation of, 309
- penetrating injuries, 462–474
  - airway management, 466
  - circulatory support, 466

- clinical presentation, 463–466
- diagnosis, 463–466
- exposure of, 465*f*
- hard signs, 464*t*
- imaging, 473
- management algorithm, 465*f*
- mortality rates, 473
- preoperative planning, 466–467
- presentation, 473
- primary survey, 466
- soft signs, 466*t*
- surgical technique, 467–470
- treatment, 470–472

- root of the, 287–290
- squamous cell carcinoma, 347
- structure of, 284–286
  - aortic arch, 288*f*
  - cervical plexus, 286*f*
  - ganglia, 286*f*
  - muscular triangle, 293–294, 294*f*
  - posterior triangle, 294–297, 294*f*, 295*f*, 296*f*
  - skeletal background, 284
  - subclavian vein origin, 288*f*
- structure or, 285*f*
- surface anatomy, 284
- surgical access, emergency airways, 494
- thyroid cancer, metastatic, 354
- triangles of, 290–297
  - anterior triangle, 290
  - boundaries, 290*f*
  - carotid triangle, 290–293, 291*f*
  - posterior triangle, 290
- vascular repair
  - complications, 473

- postoperative management, 472–473
- visceral compartment, 297–305, 471*f*

- Neck mass. *See* Carotid body tumors
- Necrosectomy
  - for acute necrotizing pancreatitis, 1523–1535
  - direct endoscopic, 1540–1541
  - endoscopic transluminal drainage, 1532–1533
  - endoscopic *versus* minimally invasive, 1541
  - hydrogen peroxide irrigation during, 1541
  - laparoscopic, 1533
  - minimally-invasive, 1533
  - open, 1523, 1533–1535
    - advantages, 1533–1534
    - disadvantages, 1535
    - drains after, 1535
  - timing of, 1551
  - transgastric endoscopic, 1533
- Necrosis
  - cell death by, 196
  - in inguinal hernia repair, e84
- Necrostomy, pancreatic, 1532*f*
- Necrotizing fascititis, 237–238
- Necrotizing pancreatitis, 1528*f*
- Needle drivers, laparoscopic, 170
- Needle exchange programs, e7
- Needles for fasciotomy, 2426–2427, 2426f
- Negative pressure wound therapy
  - use of, 119*t*
  - in wound dehiscence, 1866, 1866*f*
- Neoadjuvant Chemotherapy (NACT). *See also* Chemotherapy, neoadjuvant
  - in breast-conserving surgery, 630, 631*f*
  - and sentinel lymph node biopsy, 667
- Neo-aortoiliac system (NAIS)

- with femoral vein, 2476–2478
- pros and cons of, 2468
- reinfection rate, 2469–2470

Neonatal necrotizing enterocolitis (NEC)
- Bell stages of, 1977*t*
- comorbidities, 1976–1977
- diagnosis, 1977
- extensive, 1980*f*
- management algorithm, 1979*f*
- mortality rates, 1981
- overview, 1976–1977
- patchy/diffuse, 1980*f*
- pathophysiology of, 1977*f*
- presentation, 1977
- radiographs, 1978*f*
- risk factors for, 1976
- stricture following, 1981*f*
- surgical management
  - indications, 1977
  - preoperative planning, 1977–1979
- treatment, 1977

Neostigmine, 1700

Neovagina, defects, 243*f*

Nephrectomy
- anterior transabdominal approach, 2025
- complications
  - intraoperative, 2031–2032
  - postoperative, 2032
- flank thoracoabdominal approach, 2023–2025
- incisions, 2023–2025, 2023*f*, 2024*f*, 2026*f*–2027*f*
- laparoscopic in Wilms tumor, 2083
- long-term follow-up, 2031
- minimally-invasive partial, 2030
- partial

- laparoscopic, 2022
- open, 2022, 2027–2030
- for RCC, 2022
- robotic-assisted, 270
- technique, 2097*f*
- in Wilms tumor, 2083–2084
- postoperative management, 2031
- primary radical, 2079
- radical
  - infrahepatic IVC involvement, 2027
  - laparoscopic, 2030–3031
  - for renal cell carcinoma, 2019–2033
- radical, open, 2025–2026
- robotic-assisted, 270

- Nephrogenic rests (NRs), 2078
- Nephrolithiasis
  - antibiotic prophylaxis, 2012
  - emergency room visits, 2011
  - Houndsfield density, 2013–2014
  - management of, 2012
  - preoperative evaluation, 2011–2012
  - surgical management of, 2011–2018
- Nephron-sparing surgery, 2019
- Nephrostomy, percutaneous, 2107
- Nephrostomy tubes, 2012
- Nerve hooks, 1111*f*
- Nerve of Latarjet, 1112–1113
- Nerve-sparing radical hysterectomy (NSRH), 2142–2143, 2145
- Nervi erigentes, 1686, 1686*f*, 1815, 1825
- Neuraxial blockade, 90
- Neurocristopathies, 1971
- Neurodevelopment, impaired, 1978, 1981
- Neuroendocrine adenomas, pancreas, 1514–1523
- Neuroendocrine tumors

- appendiceal, 1695
  - etiology, 1695
  - imaging, 1695
  - laboratory diagnosis, 1695
  - management, 1695–1696
  - operations, 1696
  - pathophysiology, 1695
  - postoperative care, 1696
  - preoperative preparation, 1696
  - presentation, 1695
- gastrointestinal, 1283–1284
- pancreatic, 189*f*, 1473–1474
- size of, 1523
- transanal excision, 1938

- Neuroenteric cysts, 1884
- Neurogenic shock, 77*t*
- Neurogenic thoracic outlet syndrome (TOS)
  - clinical presentation, 2550
  - diagnosis, 2550–2551, 2551*t*
  - indications for surgery and preoperative planning, 2552
  - initial treatment, 2551, 2560
  - reoperations for, 2554
  - surgical outcomes, 2560
- Neurogenic tumors, retrorectal, 1884
- Neuro-immune axis
  - afferent/sensory input to brain, 7–8
    - efferent regulation, 7
    - humoral route, 7
    - immunosuppression, 7–8
    - neural route, 7
- Neurological deficits, cervical injuries, 2570
- Neurolylsis, chemical, 1583
- Neuromuscular function, 2430
- Neuropathic foot ulcers, diabetic, 2409

- Neuropathic pain
  - carbamazepine, 138
  - in diabetes, 2408
  - gabapentin for, 138
- Neuropathies, diabetic, 1177
- Neurovascular bundle (NVB), 2070
- Neutropenia, postoperative, 27
- Neutrophil-endothelial adherence, 133
- Neutrophils
  - adherence to endothelial cells, 133
  - infiltration, 5*f*
  - innate immunity and, 142
  - priming of, 5
  - recruitment of, 5*f*
  - role in inflammation, 3
- Newborn infants, abdominal wall, 2184*f*. *See also* Infants
- Nicotinamide adenine dinucleotide diaphorase (NADPH), 657
- Nifedipine for achalasia, 972
- Nil per os (NPO), 26
- Nipples
  - reconstruction, 233, 738
  - in total mastectomy, 603, 722
- Nissen, Rudolf, 962
- Nissen fundoplication
  - alternatives to, 916
  - completed, 871*f*, 915*f*
  - complications of, 950, 958
  - construction of, 913*f*, 914*f*
  - for gastroesophageal reflux disease, 874, 876–877, 884, 961
  - historic developments, 904
  - laparoscopic, 904, 945, 948, 960–961
  - overview of, 870
  - partial fundoplication compared to, 948
  - placement of, 869*f*

- robotic-assisted, 264
- technique, 949, 1152*f*
- transthoracic, 907, 913–915
- variations of, 949*f*
- without Bougie, 872

Nissen-Rossetti antireflux fundoplication
- additional procedures, 933
- complications, 933
- description of, 936–937
- failure of, 933
- open procedure, 928–935
  - indications, 928
  - preoperative investigations, 928–929
  - preoperative planning, 928
- outcomes, 933–934
- postoperative care, 931–932
- postprocedure side effects, 933
- recurrent GERD after, 937
- reoperative surgery, 933
- surgical technique
  - fundoplication, 931, 932*f*
  - hiatal dissection, 929–930
  - hiatal repair, 930–931
  - instrumentation, 929
  - patient positioning, 929, 929*f*

Nitric oxide, inhaled, 80–81

Nitric oxide donors, 1913

Nitric oxide synthase, 1166

Nitrofen, 821, 823

Nitrogen, urinary output, 18

Nitrogen balance, 55

Nitroglycerine, 80

Nitroprusside, 80, 796

NKF-KDOQI (National Kidney Foundation Disease Outcomes Quality

Initiative)
- arteriovenous access guidelines, 2540, 2547
- Nocturnal enuresis, 81
- *NOD2CARD15* mutations, 1671–1672
- Nonaortic aneurysms, 2467–2468, 2469
- Nonaortic mycotic aneurysms, 2470
- Nonatheromatous problems, 2464
- Nonautologous materials, 2478–2479
- Noncontinent diversions, 2108–2111
- Nonconvulsive status epilepticus (NCSE), 486–487
- Noncytopathic microorganisms, 1456
- Non-germ cell tumors, testicular, 2060
- Noniatrogenic perforation, esophageal, 1020–1021, 1022
- Noninsulinoma pancreatogenous hyperglycemia syndrome (NIPHS), 1159–1160
- Noninsulinoma pancreatogenous hypoglycemia syndrome (NIPHS). *See* Reactive hypoglacemia
- Noninvoluting congenital hemangiomas (NICH)
  - incidence, 373
  - presentation, 376
  - treatment, 376–377
- Nonocclusive mesenteric ischemia (NOMI), 65
- Nonselective beta-blockers (NSBBs), 1622
- Non-small cell lung cancer (NSCLC)
  - 5-year survival, 800
  - genomic alterations in, 818
  - stage I
    - segmentectomy in, 799
    - treatment, 805
  - stage II
    - treatment, 805
  - stage IIIA
    - treatment, 805
  - stage IIIB

- treatment, 805
- stage IV
- treatment, 805
- staging, 800–804
- treatment of, lobectomy as, 816, 817
- Nonsteroidal anti-inflammatory drugs (NSAIDs)
- complications of, 1148
- ulcer perforation and, 1104
- Nonthrombotic iliac vein obstruction (NIVO), 2499
- Norepinephrine (NE), 11–12, 78–79
- Norman, James, 513
- Normothermia
- maintenance of, 33
- perioperative, 118*t*
- SSI prophylaxis guidelines, 116*t*
- Normovolemia, perioperative, 119*t*
- Norton, Arthur, 1839
- Nose
- defects, soft tissue flaps, 217, 219–221
- forehead flaps, 221
- fractures, 441
- frequency of, 441–442
- incisions, 221*f*
- injuries to, 440
- laceration repair, 441*f*
- NPO after midnight orders, 66
- NRS-2002, 56, 66
- *NTRK1* mutations, 516
- Nuchal ligament, 285
- Nuclear factor κB (NF-κB)
- activation of, 143
- inflammation and, 6
- inhibition of, 146
- in muscle wasting, 38

- upregulation of, 3
- Nuclear factor κB essential modulator (NEMO), 4*f*
- Nuclear factor κB-inducing receptor (NIK), 4*f*
- Nuclear factor of activated T cells (NF-AT), 143
- Nuclear tagged white blood cell imaging, 2472
- Nutcracker esophagus, 968, 981
- Nutcracker syndrome, 1056, 1058*f*
- Nutrition. *See also* Malnutrition
  - algorithm for support of, 57*f*–58*f*
  - gut barrier and, 20
  - laboratory values
    - preoperative testing, 23*t*
  - muscle weakness and, 40–41
  - perioperative, 66
  - in stoma patients, 1772
  - tools for assessment of, 56
- Nutritional assessments, 55, 56
  - albumin levels and, 44
  - anthropometric assessment, 55
  - for aortic graft infection patients, 2473
  - body composition in, 55
  - caloric requirements, 45
  - calorie to nitrogen ratios, 45
  - need for support, 42–52
  - total energy requirements, 45
- Nutritional status
  - assessment of, 55, 67
  - preoperative, 1662–1663
- Nutritional support
  - after esophageal perforation surgery, 1030
  - algorithm for, 57*f*–58*f*
  - nutritional assessment and, 42–52
  - perioperative, 118*t*
  - postoperative, 34–35

- Nuts, gallstone risk and, 1353
- Nystatin, 962

O

- OAC (omeprazole/amoxicillin/clathromycin) regimen, 1115
- Oatmeal enemas, 1751–1752
- Obesity
  - cardiovascular disease and, 28
  - colostomy creation and, 1767, 1771
  - consequences of, 1240
  - and continent ileostomy, e45
  - costs of, 1232
  - definition of, 26
  - demographics, 1240
  - epidemic of, 1232
  - esophageal cancer and, 984, 998
  - fundoplication failure and, 1250
  - grades of, 1233
  - health hazards accompanying, 961
  - hemodialysis access problem due to, 2537
  - hiatal hernia in, 823
  - and inguinal hernia repair, e84
  - and inguinal herniorrhaphy, e59, e60
  - lymphedema incidence, 673, 682
  - management of, 1233
  - in metabolic syndrome, e36
  - morbid
    - demographics of, 1232
    - EndoBarrier treatment in, 1233–1240
  - postgastrectomy syndromes associated with, 1165
  - protein requirements in, 59
  - and radical mastectomy, 711
  - renal cell carcinoma and, 2019
  - short necks in, 491
  - stoma retraction in, 1778*f*

  - surgical risk and, 26
  - tracheotomy in, 491
  - as venous thromboembolsim risk factor, 2517
  - WHO statistics, 1176, 1203, 1218
- Obicularis oris muscle, 326*f*
- Oblique abdominus externus, 776*f*
- Obliterative peritonitis, postoperative, 1632
- Observed-to-expected lung volume (O/E FLV), 840, 841
- Obstructive jaundice, 1412, 1420
- Obstructive pulmonary disease, 1719
- Obstructive sleep apnea, 89
- Obturator canal, 2195, 2198*f*
- Obturator foramen, 2195
- Obturator framen, 2010*f*
- Obturator hernia ring, 2195–2197, 2202*t*
- Obturator internus muscle, 2009–2010
- Obturator membrane, 2195, 2198*f*
- Obturator nerve, 243, 1967, 2042*f*
- Obturator node removal, 2142*f*
- Obturator region, 2195
- Obturator sign, 1689
- Occipital artery, 295
- Occlusion, e27
- OCOG. *See* Ontario Clinical Oncology Group
- Octreotide, 1618, 1654
- 2-Octyl-cyanoacrylate, 1627
- Oddi sphincter. *See* Sphincter of Oddi
- Odontoid process, 284
- Oertel’s laryngeal stroboscope, 386
- Ogilvie syndrome, 1676, 1700
- OK-432, 379
- OKT3, 148
- Oligosaccharides, 59
- Olsen cholangiogram clamp, 1358

- Omega 3-fatty acids, 64
- Omega 6-fatty acids, 64
- Omega-e fatty acid-coated mesh, 2232
- Omegaven, 1985
- Omenta, embryology of, 1051–1055, 1051*f*
- Omental arcade, 235*f*
- Omental bursa
  - development of, 1472
  - embryology of, 1052, 1052*f*
- Omental flaps, 748–749
- Omental pedicles, 1687
- Omentoplasty, 1309*f*
- Omentum
  - anatomy of, 1682
  - blood supply, 1118*f*, 1682
  - fixation, 1119*f*
  - incision, 1682*f*
  - intra-abdominal vasculature, 748*f*
  - laparoscopic detachment, 1747*f*
  - lengthening of, 1682*f*
  - mediastinal reconstruction, 236–237
  - mobilization of, 749*f*
  - pathologic fixation of, 1063*f*
  - tongue of, 1118*f*
- Omeprazole, 1115
- Omni bariatric retractors, 1609, 1967
- Omohyoid muscle
  - anatomy of, 71*f*, 293–294, 308, 322*f*, 468*f*, 2549
  - dissection of, 526
  - division of, 406
  - exposure of, 503
  - identification of, 1004*f*
  - isolation of, 505*f*
  - resection of, 505*f*

- triangles of the neck and, 290
- Omphalocele, 826, 2186*f*
- Omphalocele hernias, 2201*t*
- Omphaloenteric veins, 1053
- Oncocytomas, 2020
- Oncoplasty for breast conservation, 643, 719–720, 737
  - complications, 718
  - etiology and pathophysiology, 712–713
  - indications/contraindications, 713–714
  - postoperative care, 718
  - preoperative planning, 714
  - re-excision, 719
  - surgical techniques
    - batwing lumpectomy, 715, 717*f*
    - central lumpectomy, 715, 717*f*
    - donut mastopexy lumpectomy, 716–718, 718*f*
    - lateral segmentectomy, 714–715, 716*f*
    - paralellogram lumpectomy, 714, 715–716*f*
    - reduction mastopexy lumpectomy, 715–716, 718*f*
- Ontable colonic lavage, 1705–1706, 1706*f*, 1709
- Ontario Clinical Oncology Group (OCOG), 646
- Oophorectomy, 210, 2151
- Open biliary surgery, contraindications, 1389*t*
- Open cholecystectomy, 1382
- Open esophageal surgery, 902
- Open fractures, hand, 251
- Open fundoplication, 879, 881. *See also* Fundoplication
- Open gastrectomy, 1141, 1148. *See also* Gastrectomy
- Open partial nephrectomy (OPN), 2022, 2027–2030
- Open valve repair, 2523
- Open vein concept, 2490
- Open Versus Endovascular Repair (OVER), 2300, 2302
- Operating rooms
  - fires, 276

- causes of, 276
- prevention of, 276
- risk of, 33
- types of energy in, 274–276

Operative venous thrombectomy
- drug therapy, 2489
- outcomes, 2487–2488
- overview of, 2481
- postoperative management, 2487
- preoperative patient evaluation and planning, 2482
- technique, 2482–2486, 2483*f*–2486*f*

Opioid epidemic, e5–e6
- addiction treatment
  - buprenorphine, e7
  - methadone, e7
  - naltrexone, e7
- early publications, e2
- geographic distribution, e3–e5, e4*t*
- history of, e1, e1*t*
- needle exchange programs, e7
- overprescriptions by surgeons, e5
- pharmaceutical advertising, e1–e2, e8
- prescriptions for opiates, e2–e3, e3*t*
- prevention of
  - deterrents, e6
  - drug monitoring, e6
  - opioid disposal, e6
  - overdose prevention, e6
  - patient education, e5, e6*t*
  - research, e6
- supervised injection facilities, e7

Opioid receptors, 9

Opioids
- disposal of, e6

- perioperative management, 30*t*
- Opium, tincture of, 1774
- Opponens digiti minimi, 249*f*
- Opponens pollicis, 249*f*
- Optical coherence tomography (OCT), 207
- Oral cancers, pathogenesis of, 325
- Oral cavity
  - anatomy, 334
  - cancers of
    - carcinoma in situ, 335–336
    - clinical presentation, 334
    - diagnostic workup, 334–335
    - etiology, 334
    - human papillomavirus (HPV) and, 345
    - incidence, 334
    - lymph node detection, 345
    - microinvasive carcinoma, 335–336
    - mortality, 334
    - postoperative care, 343–344
    - sentinel lymph node biopsy, 336–337
    - staging, 334–335
    - surgery for, 334–345
      - complications of, 344
    - T1, 336–337
    - T2, 336–337
    - T3, 337
    - T4, 337
    - treatment, 335–337
    - tumor thickness, 345
  - hemorrhage, 434
  - positive lymph nodes, 349*t*, 350*t*
  - squamous cell carcinoma
    - metastatic sites, 309
  - subsites, 335*f*

- Oral contraceptives, 29*t*
- Oral glucose tolerance testing, 1177
- Oral intubation
  - in facial trauma, 434
  - postintubation injuries, 447
- Orbicularis oris muscle, 326
- Orbitozygomaticomazilary (OZMC) fractures, 441, 442
- Orbits
  - fractures, 442
  - soft tissue injuries to, 439–440
- Orchialgia after hernia repair, 2242
- Orchiopexy
  - complications, 2076
  - contraindications, 2073
  - indications, 2073
  - inguinal
    - technique, 2073–2075, 2073*f*–2075*f*
  - laparoscopic, 2075–2076
  - outcomes, 2076
  - scrotal, 2075
- Organ failure, peripheral edema and, 55
- Organ injury scale-diaphragm (AAST), 857*f*
- Organ insufficiency, causes of, 2444
- Organ Procurement and Transplantation Network (OPTN), 1281*t*
- Organ transplantation
  - bone marrow transplantation and, 1453*t*
  - chronology of, 1452–1453
  - engraftment, 1456–1457, 1459*f*
  - graft survival, 1457*f*
  - history of, 141
  - immunosuppression in, 141–150, 1447
  - liver donors, 1438
  - posttransplant years, 1457*f*, 1458*f*
  - rejection responses, 145, 1454–1455

- time after, 1452*f*
- Organoaxial volvulus, 866*f*
- Organs, resection of, 1130. *See also Specific* procedures
- Oropharyngeal cancer
  - clinical presentation, 400–401
  - etiology, 400, 409
  - HPV-positive, 334
    - management of the neck in, 355
    - neck metastases, 355*f*
    - survival in nodal disease, 356*f*
  - pathophysiology, 400
  - preoperative planning, 401
  - surgical treatment
    - hemostasis, 402
    - transoral robotic, 402–403, 403*f*
  - treatment, 401
- Oropharyngeal squamous cell carcinoma (OPSCC), 400
- Oropharyngeal wall, examination of, 309
- Oropharynx
  - anatomy, 299, 398*f*, 400
  - metastatic disease, 403
  - positive lymph nodes, 349*t*, 350*t*
  - reconstruction, 404
    - complications, 404
    - postoperative care, 404
  - surgical pathology, 400
  - transoral laser microsurgery, 401*f*
- Oropharynx cancer, staging, 347*t*
- Orotracheal intubation, 489–490
- Orr incision for mastectomy, 692–693*f*, 705
- Orthopaedic surgery, prophylactic antimicrobials, 114*t*
- Orthotopic liver transplantation (OLTxp), 1427
- Orthotopic neobladders
  - complications, 2048–2050, 2051*t*

- outcomes, 2052
- robotic intracorporeal, ileal, 2118
- urinary diversion, 2037*t*, 2114–2116
- use of, 2112

Orthotopic urinary diversions
- for bladder cancer, 2034–2054
- contraindictions, 2037*t*

Oseophagoectomy. *See* Esophagectomy

Osmolality, enteral formulations, 63

Osteitis fibrosa cystica, 533*t*

Osteitis pubis, 2227

Osteoblastomas, retrorectal, 1883

Osteodystrophy, renal, 551

Osteoid osteomas, retrorectal, 1883

Osteomy, gas production, 1774

Osteomyelitis
- chronic
  - wound coverage and, 216
- diabetic foot and, 2392, 2413–2415

Osteopenia
- prevention of, 35
- in SBS, 1982

Osteoporosis, parathyroidectomy and, 513

Osteoradionecrosis, mandibular, 336

Ostomy
- appliances, 1773–1774
- blood in, 1647
- diet in, 1774–1776
- lifestyle and, 1774–1776
- marking, 1843
- medications and, 1774–1776
- siting of, 1773, 1774*f*
- skin barriers, 1773, 1774
- supplies, 1775*f*–1776*f*

- OSTRiTCH Consortium (Optimizing the Surgical Treatment of Rectal Cancer), 1821
- Otolaryngology, robotic-assisted, 264, 271
- Otorhinolaryngologists, 307
- Otorrhea
  - in facial trauma, 436
  - in TBI, 477
- Outflow venous obstruction, 2546
- Outlet obstruction
  - causes, 1962–1963
  - diagnosis, 1963
  - presentation, 1962
- Ovarian cancers
  - advanced disease
    - debulking surgery, 2152–2153
    - management of, 2151–2153
  - biomarkers for, 2166
  - carcinosarcomas, 1246, 1247
  - clear cell carcinomas, 1246, 2154–2155
  - complications, 2162–2163
  - early stage, 1250
  - endometrioid carcinoma, 1246, 2154–2155
  - epithelial tumors, 1246–2147
  - fertility preserving surgery, 1250, 2166
  - high-risk women, 1249
  - hypercoagulation in, 2154–2155
  - intraoperative care, 2155
    - bowel resection, 2160–2161
    - closure, 2162
    - determining resectabliity, 2155
    - diaphragm peritonectomy, 2157
    - distal pancreatectomy, 2157
    - intraperitoneal catheters, 2162
    - liver mobilization, 2156–2157

    - liver wedge resection, 2157
    - lymphadenectomy, 2161–2162
    - omentectomy, 2155–2156
    - splenectomy, 2157
    - upper right quadrant metastases, 2156
  - maximum cytoreductive surgery
    - survival and, 2154*f*
  - metastatic patterns, 1247–2163, 1248*f*
  - mortality rates from, 2165
  - mucinous, 1247
  - mucinous carcinomas, 1246
  - para-aortic nodes, 2155*f*
  - preoperative preparation, 2153–2162
  - prognosis, 2165–2166
  - recurrent disease, 1250, 2153
  - residual disease, 2152*f*
  - screening, 1249
  - secondary cytoreduction surgery, 2153*t*, 2154*f*
  - serous carcinomas, 1246, 1247
  - staging, 1247–2148, 2148*t*
  - surgical management of, 1246–2166
  - type I, 1247
  - type II, 1247
- Ovarian tumors, borderline, 1250–2151
- Ovarian vessels, 2006*f*
- Ovaries, androgen production of, 11
- Oven effect, tumor ablation and, 197
- OVER. *See* Open *versus* endovascular repair
- Overflow incontinence, 2169
- Overgrowth syndromes, 382
- Overwhelming postsplenectomy infections (OPSIs), 1988–1989
- Ovesco OTSC clips, 1025, 1025*f*
- Oxalate malabsorption, 2117
- Oxaliplatin, 1316, 1880

- Oxidative phosphorylation, 14*f*
- Oxidative stress, neuropathies and, 2409
- Oximetry, pulmonary function testing, 87*t*
- Oxycontin, e2–e3
- Oxygen
  - hyperbaric, for diabetic foot, 2393
  - metabolism, indices of, 75–76
  - perioperative supplementation, 33
- Oxygen consumption (VO_2)
  - stress response and, 2
  - total body oxygen delivery and, 76
- Oxygen saturation, 76
- Oxygenation
  - delivery of, 54
  - perioperative, 118*t*
- Oxytetracycline, e1–e2
- Oxytocin after uterine closure, 2122

P

- P2Y12 activity, 105
- *p14*^{ARF} gene, 334
- *p16* gene, 334
- *p53* gene, 334
- *P53* gene, 1247
- *p53* mutations, 334
- p300, 38, 40, 42
- Pacemaker/defibrillatory, 278*f*
- Packed red blood cells (pRBCs), 105–106
- Paget, Stephen, 2067
- Pain. *See also Specific* conditions
  - in abdominal aortic rupture, 2304
  - abdominal viscera, 780
  - in breast (*See* Breast, pain)
  - intractable, 1580
  - Kugel method for groin hernia, e92, e93
  - management
    - after gastric cancer surgery, 1138
    - in flail chest, 791
    - postoperative, 54
    - in rib fractures, 790
  - and mastectomy, 712
  - opioid prescriptions, e2
  - in plug-and-patch groin repair, 2236–2239
  - postoperative, leg amputation, 2404
  - and thoracoabdominal aortic aneurysm, 2280
- Pain, agitation, and delirium (PAD) guidelines, 137
- PAL. *See* Physical Activities and Lymphedema
- Palatine fossa, 300
- Palatoglossal arch, 300
- Palatoglossus muscle, 322
- Palatopharyngeus muscle, 301, 302

- *PALB2* mutation, 1249
- Palma procedure, 2501–2502, 2503*f*, 2509–2510
- Palmar erythema in liver disease, 1620
- Pancreas
  - abscesses, drainage of, 1540
  - accessory, 1473
  - anatomic relationships, 1471*f*, 1472*f*, 1476*f*, 1573
    - head, 1474–1475
  - anatomy, 1573
    - anomalies, 1471
    - pain and, 1580–1581
  - arterial supply of, 1481–1485, 1481*f*, 1482*f*
  - body
    - exposure of, 1489–1490
    - veins of, 1485–1486
  - congenital anomalies
    - agenesia, 1472
    - aplasia, 1472
    - hypooplasia, 1472
  - cystic neoplasms, 1514–1523, 1998*f*
  - diabetes, 1492
  - distal
    - blood supply to, 1483*f*
    - mobilization of, 1569*f*, 1570*f*
  - ectopic, 1473
  - embryology of, 1052*f*, 1055*f*, 1471–1472, 1473*f*, 1491
  - excision, 1501*f*
  - exploration of, 1488–1490, 1489*f*
  - exposure of, 1490
  - fixation of, 1473*f*
  - head
    - adenocarcinoma, 1554, 1554*f*
    - anatomy of, 1474–1475, 1475*f*, 1573
    - chronic pancreatitis and, 1522

  - duodenum-preserving excavations, 1496–1498
  - exploration of cancer at, 1557–1558
  - exposure of, 1516–1517
  - hematoma of, 1575*f*
  - lesions, 1999–2000, 1999f*f*
  - maceration of, 1577*f*
  - resectable adenocarcinoma, 1555*f*
  - resection, 1516*t*, 1517–1518
  - retroperitoneal attachments, 1508*f*
  - separation from the SMV, 1562*f*
  - stellate fracture of, 1999*f*
  - total resection, 1514–1523, 1519
  - uncinate process, 1472
  - veins of, 1484–1485
- heterotopic, 1473
- inferior border of, 1998*f*
- inflammatory tumors, 1514–1523
- intraoperative complications, 1514
- IOUS, 188*f*
- laceration, 1577*f*
- laparoscopic ultrasound, 189
- lymphatic drainage, 1486–1487, 1486*f*, 1487
- major arterial supply of, 1481*f*
- neck
  - anatomy, 1475–1477, 1475*f*, 1573
  - sagittal section, 1476*f*
  - veins of, 1485–1486
- neoplastic cysts, 1542–1543
- nerve supply, 1487–1488, 1488*f*
- neuroendocrine tumors of, 189*f*, 1473–1474
- organ injury scale, 1574*t*
- parenchyma, transection, 1576*f*
- parts of, 1474–1478, 1475*f*
- peritoneal attachments, 1475*f*

- peritoneal relationships of, 1474
- resection, 2001
  - drainage after, 1572
  - steps, 1558*f*–1565*f*
  - technique, 1558–1566
- splanchnic denervation, 1580–1586
- splenic portas and, 1477*f*
- surgical anatomy of, 1471–1491
- surgicoanatomical segments, 1477–1478, 1477*f*, 1478*f*
- tail
  - anatomy, 1477*f*
  - veins of, 1485–1486
- ultrasound evaluation, 185–187, 188*t*, 189
- uncinate process, 1508*f*, 1557*f*
  - anatomy, 1475, 1475*f*, 1477*f*, 1573
  - resectable adenocarcinoma, 1555*f*
  - separation from the SMV, 1562*f*
- vascular system, 1481–1486
- venous drainage, 1484–1486, 1485*f*

Pancreas divisum
- anatomy, 1471
- description of, 1472–1473
- overview of, 1392–1393
- treatment, 1392–1393
  - endotherapy, 1394

Pancreatectomy
- complications, 1570–1571
- distal, 1498–1499, 1570
  - in ovarian cancer, 2157
  - with splenectomy, 1577*f*
  - splenic salvage and, 1996–1999, 1996*f*–1999*f*
- perioperative management, 1570–1571
- robotic-assisted, 270

Pancreatic amylase, 1574

- Pancreatic arcades, 1481
- Pancreatic ascites, 1536
- Pancreatic cancer
  - acute peritonitis and, 1524–1525
  - anatomic relationships, 1552
  - borderline resectable disease, 1556*t*
  - diagnostic evaluation
    - pretreatment, 1552–1557
  - extrahepatic biliary obstruction in, 1554
  - intractable pain in, 1580
  - IRE studies in, 200
  - laparoscopy, 1556–1557
  - management algorithm, 1555*f*
  - metastatic disease, 1572
  - multimodality therapy, 1552
  - pain management in, 1488, 1582
  - pancreaticoduodenectomy in, 1552–1573
  - public health threat of, 1552
  - resectable adenocarcinoma, 1553*f*, 1554*f*, 1557
  - resectable patients, 1554–1555
  - subperitoneal spread, 1489
  - survival rates, 1412
  - systemic nature of, 1572
  - total pancreatectomy in, 1552–1573
  - unresectable
    - pain management in, 1582
    - treatment outcomes, 1420
- Pancreatic cysts, 1549
- Pancreatic duct of Wirsung, 1478
- Pancreatic ductal hypertension, 1580
- Pancreatic ducts
  - anatomy o, 1478
  - anatomy of, 1383, 1383*f*
  - capacity of, 1478

- cyst communication with, 1550
- diameter of, 1479*f*
- in duodenal ulcer vagotomy, antrectomy, and gastroduodenostomy, e9–e10, e15
- embryology, 1471
- fat necrosis, 1575
- length of, 1478
- localization of, 1391*f*
- reconstruction, 1509*f*
- stenosis of, 1472–1473
- stents and stenting, 1392–1393, 1537
- variations, 1478, 1479*f*
- width of, 1478

- Pancreatic fluid
  - collections
    - acute, 1543
    - definition of, 1540
  - electrolyte composition of, 1651*t*
  - leakage
    - in pancreatic trauma, 1575
- Pancreatic fluids
  - leak from FNA, 1420
  - postsurgical leaks, 2163
- Pancreatic necrosis
  - infected, 1531, 1531*f*
  - laparoscopic debridement, 1548
  - pseudocyst development and, 1536
  - sterile necrosis, 1529–1531
  - transgastric drainage, 1530*f*
- Pancreatic necrostomy, 1532*f*
- Pancreatic neuritis, 1580
- Pancreatic neuroendocrine tumors (PNETs), 1515, 1521*t*
- Pancreatic panniculitis, 1526, 1527*f*
- Pancreatic parenchymal resection, 1543

- Pancreatic pseudocysts, 1493
  - acute pancreatic fluid collection *vs.*, 1543
  - bulging into mesocolon, 1545
  - complications from, 1536
  - drainage, 1500*f*
    - endoscopic, 1537–1538, 1538*f*, 1542, 1550
    - laparoscopic, 1545, 1547–1548, 1548*t*
    - percutaneous, 1536, 1541–1542
    - percutaneous catheter, 1549–1550
    - sump drains, 1548
    - timing of, 1543
    - transmural, 1538
    - transpapillary, 1550
  - elective *vs.* urgent surgery, 1543–1544
  - interventions
    - indications, 1546*t*
  - intragastric cyst-gastrostomy, 1546–1547, 1546*f*
  - lesser sac approach, 1547, 1547*f*
  - localization of, 1545–1546
  - recurrent, 1542
    - drainage methods and, 1550
    - open surgery for, 1542–1543
  - surgical management of, 1543
  - traumatic, 1575*f*
  - treatment of, 1536–1537
  - ultrasound images, 1541*f*
  - video-assisted retroperitoneal debridement, 1541–1542
- Pancreatic trauma
  - associated injuries, 1573
  - clinical presentation, 1573–1574
  - diagnosis, 1574, 1574*t*
  - etiology, 1573
  - nonoperative management, 1574
  - operative management, 1573–1580

- operative options, 1576*f*
- organ injury scale, 1574*t*
- pathophysiology, 1573
- postoperative management, 1578
- preoperative preparation, 1575
- surgical technique, 1575–1578

Pancreatic tumors, 1515
Pancreaticobiliary disease, 1524
Pancreaticoduodenal arcade, 1482*f*
Pancreaticoduodenal arteries, 1481*f*, 1482*f*, 2444
Pancreaticoduodenal veins, 1589
Pancreaticoduodenectomy (PD)

- choice of, 1496
- complications, 1165
- delayed emptying after, 1165
- description, 1557–1558
- frozen-section analysis at, 1557
- history of, 1552
- indications, 1343
- IOUS in, 177
- outcomes, 1420
- in pancreatic cancer, 1552–1573
- perioperative mortality, 1512
- procedure, 1603–1604
- pylorus-preserving, 1506–1509
- robotic-assisted, 270
- safety of, 1552
- specimen removal, 1563*f*
- vascular resection, 1563–1566

Pancreaticojejunostomy

- end-to-side, 1508
- illustration of, 1567*f*
- pseudocyst drainage, 1500*f*
- pylorus preservation, 1568–1569, 1569*f*

- reconstruction after, 1567–1568, 1568*f*
- steps, 1510*f*
- suture placement, 1511*f*

- Pancreaticosplenic nodes, 1070–1071
- Pancreatitis. *See also* Acute pancreatitis; Chronic pancreatitis
  - abdominal compartment syndrome and, 153
  - acute edematous interstitial, 1528*f*
  - acute necrotizing, 1523–1535
  - alcohol-induced, 1542
  - autoimmune, 1493
  - causes of, 1392
  - chronic
    - operative interventions, 1505–1514
    - quality-of-life assessments, 1493
    - surgical therapy for, 1492–1505
  - chronic calcific, 1493
  - chronic pancreatitis and, 1493
  - drug-induced, 1525
  - enterocutaneous fistulas and, 1650
  - gallstones and, 1343
  - idiopathic, 1493
  - necrotizing, 153
  - pancreas diversum and, 1472–1473
  - pathogenesis, 1491
  - postoperative, 1146
  - postsurgical, 1146, 2163
  - recurrent pseudocysts, 1542
  - severe acute, 1523
  - topical, 1493
- Pancreatobiliary diversion, 1153*f*
- Pancreatobiliary diversion/duodenal switch, 1153*f*
- Pancreatoduodenal vascular arcades, 1474
- Pancreatoduodenectomy specimens, 1557*f*
- Pancreatojejunostomy, Roux-en-Y, 1578*f*

- Panfacial fractures, 444, 444*f*
- Pantaloon hernias, 2234–2235
- Papillary cystadenoma lymphomatosum, 310
- Papillary thyroid carcinomas (PTCs)
  - considerations, 512
  - detection of, 512
  - nodes suspicious for, 518
  - thyroglossal duct cysts and, 500
- Papillary thyroid microcarcinomas (PTMCs), 512
- Papillomas
  - in proliferative breast disease, 605–606
- Papillomatosis, 397
- Paracervical ligaments, 2132*f*
- Parachlorometazylenol (PCMX), 2120
- Paracolic gutter
  - left, anatomy, 1675*f*
  - right, anatomy, 1675*f*
- Paraduodenal hernias
  - description of, 2200, 2204
  - surgical anatomy, 2203*t*, 2204–2205, 2205*f*, 2206*f*
- Paraesophageal hernias
  - anatomy of, 824*f*, 865–866
  - appearance of, 865*f*, 866*f*
  - characteristics of, 822*t*, 824*f*, 831*f*
  - clinical presentation and diagnosis of, 867
  - overview of, 828, 865
  - robotic repair of, 264–265
  - surgery and treatment
    - complications, 871
      - abdominal esophagus injury, 1031
    - open repair, 867–871, 872
  - suturing of, 176
- Paraesophageal hiatal hernia, 828
- Paraesthesias, hypocalcemia and, 528

- Paraganglioma, cervical. *See* Carotid body tumors
- Paraneoplastic syndromes, 2020
- Paranephric fat, 2002
- Parapharyngeal masses, 309*f*
- Paraplegia, 2289–2290
- Pararectal spaces, 2137*f*
- Pararenal fat, 2002
- Parasternal (Morgagni) defects, 825
- Parasternal lymph nodes, 600, 778*f*, 786
- Parastomal hernias
  - incidence, 1780
  - management of, 1647, 1649*t*
  - mesh use, 1771–1772, 1780
  - painful, 1780
  - rates of, 1766–1767
  - repair of, 1647
  - risk of, 1777
- Parathyroid adenomas
  - CT scan, 535*f*
  - end-arterial blood supply, 545*f*
  - identification, 545*f*
  - PHPT and, 532
  - sestamibi scans of, 549
  - ultrasound results in, 543
  - vascularity of, 543
- Parathyroid carcinoma, 533
- Parathyroid cells
  - calcium sensing receptors, 550
  - mitochondria in, 543
  - vitamin D receptors, 551
- Parathyroid glands
  - abnormal, 537
  - anatomy, 284, 298*f*, 299, 500–501, 531–533
    - aids, 299

    - vascular supply, 299
  - autotransplantation, 525, 553
  - blood supply to, 502, 503*f*, 507
  - cryopreservation of tissue, 553
  - dissection of, 505–508
  - distribution of, 532*f*
  - ectopic, 532*f*, 538*f*
  - embryology of, 500, 504–505, 508*f*, 532, 556*f*
  - hyperphosphatemia and, 550
  - hyperplasia, 532, 550–551
  - imaging of, 549
  - inferior, location of, 524
  - locations of, 537
  - mediastinal, 781
  - migratory distribution, 532
  - pathophysiology, 531–533
  - secondary survey, 538*f*
  - sestamibi scan, 508
  - supernumery, 505, 531–532
    - renal HPT and, 552
  - surgery, 307
  - surgical anatomy, 505–508
  - tissue, 540
- Parathyroid hormone (PTH)
  - calcium regulation and, 532, 550
  - intraoperative, 539*f*
  - intraoperative monitoring, 545–546
  - IV sampling, 544*f*
  - postoperative monitoring of, 512, 527
- Parathyroid hormone-related peptide (PTH-RP), 534
- Parathyroid tumors, kidney damage and, 554
- Parathyroidectomy
  - complications, 547–548
  - indications for, 534, 536*t*

- minimal-access, 508, 512–513
- minimally invasive, 542–550
  - background, 542
  - benefits of, 550
  - definitions of, 549
  - in hyperparathroidism, 549
  - indications, 543
  - preoperative planning, 543–544
- outcomes, 541, 547–548
- for PHTH, 531
- postoperative care, 540–541, 547
- preoperative imaging, 552
- preoperative management, 553–554
- preoperative planning, 534–536
- reoperative, 540
- robotic-assisted, 269
- for secondary HPT, 551–552
- in secondary HPT, 554
- surgical approaches, 552–553
- surgical technique, 536–540
  - incisions, 536–537
  - intraoperative hormone monitoring, 538–540
  - intraoperative PTH monitoring, 545–546
  - outcomes and, 545
  - regional block anesthesia, 544–545
- video-assisted, 550

Paratracheal nodes
- anatomic relationships, 786

Paraumbilical veins, 1590

Paravaginal defects
- vaginal view, 2175*f*

Paravaginal space
- vaginal view of, 2174*f*

Paravesical spaces, 2137*f*

- Parenteral hydration, 1772
- Parenteral nutrition (PN)
  - caloric requirements, 45
  - enteral nutrition and, 65
  - in fistulas, 1654
  - indications, 27
  - postoperative, 34–35
  - in small bowel obstruction, 1632
- Parietal pelvic fascia (PPF), 1825*f*, 1826*f*
- Parietal peritoneum, 834*f*
- Parietex mesh, 1894, 1895, 1896*f*–1987*f*
- Parkes Weber Syndrome, 382–383
- Parkinson disease, 1961
- Parks, Alan, 1732, 1839, 1939, 1942
- Parks' retractor, 1939
- Parks' transanal excision, 1939–1940, 1940*f*, 1947
- Paromomycin, 1293
- Parona's space, 255
- Paronychias, 251
- Parotid bed
  - anatomy of, 316*f*
  - superficial view of, 317*f*
  - vascular background, 317*f*
- Parotid gland
  - adenoid cystic carcinomas, 310–311
  - anatomic relationships, 309*f*
  - anatomy of, 308–309, 316–319, 361*f*, 439, 439*f*
    - arterial plane, 317, 317*f*
    - fascial relations, 316
    - nerve plane, 318, 318*f*
    - neurovascular relations, 316–318
    - venous plane, 318
  - innervation of, 318
  - isthmus, 316

- lobes of, 316, 318
- lymphatic drainage of, 318
- mucoepidermoid carcinoma of, 311
- sialendoscopy, 324

- Parotid space, anatomy of, 316
- Parotid veins, 318
- Parotidectomy, 311–312
- Paroxysmal nocturnal hemoglobinuria, 1601
- Pars umbilicus, 1589
- Partial fundoplication. *See* Fundoplication, partial
- Partial prothrombin times (PTTs), 103, 104
- PASH. *See* Pseudoangiomatous stromal hyperplasia
- Patches, vein, 2369–2370, 2369*f*
- Patent processus vaginalis, 2074
- Pathogen-associated molecular patterns (PAMPs), 3, 133, 142
- Pavlov, Ivan, 1095
- *PAX8-PPAR* mutations, 516
- PD. *See* Pancreaticoduodenectomy (PD)
- Pectinate line, 1824*f*
- Pectoralis advancement musculocutaneous flaps, 236
- Pectoralis major muscles, 236, 286, 775*f*
- Pectoralis minor muscle
  - anatomy of, 775*f*, 2549
  - division of, 469
- Pectoralis minor syndrome, 308, 2549
- Pectoralis minor tenotomy, 2554–2555, 2560
- Pectoralis muscles, 237*f*, 767, 773–774
- Pectorals minor muscles, 775*f*
- Pectus carinatum, 772
- Pectus excavatum, 772
- Pediatric appendicitis score (PAS), 1694*t*
- Pediatric gastroesophageal reflux disease (GERD), 883, 884
- Pediatric patients
  - appendicitis in, 1694, 1694*t*

- biliary atresia in, 1427
- blunt renal trauma in, 2090*t*
- diaphragm, 826–828
- Hirschsprung disease, 241–242
- intracranial pressures, 475*f*
- melanoma in, 424–425
- neonatal necrotizing enterocolitis, 1976–1981
- penetrating neck injuries, 473
- short bowel syndrome in, 1981–1984
- splenic injuries in, 2000
- tracheal stenosis, 459
- vascular anomalies, 373–384, 375*f*

- Pediatric surgery
  - robotic-assisted, 271
  - surgical energy, 280
- Pediatric transplants, 1420
- Pelvic abscesses
  - postsurgical, risk factors, 1724
  - Well's repair complication, 1902
- Pelvic cavity, sagittal view, 2159*f*
- Pelvic diaphragm, 2177
- Pelvic exteneration with sacrectomy
  - compartments for, 1870*f*
  - contraindications, 1869
  - indications, 1869
  - patient selection, 1877
  - rehabilitation after, 1877
  - technique, 1869–1875
    - patient positioning, 1869, 1874*f*
- Pelvic floor
  - anatomy of, 2195
  - musculature, 2069
- Pelvic gynecologic operations, e40
- Pelvic inlet, 2008*f*

- Pelvic innervation, 1684*f*
- Pelvic lymph node dissection (pLND), 2069, 2070
- Pelvic lymphadenectomy, 1965
  - laparoscopic, 2054–2055
  - radical hysterectomy and, 2140–2141
  - robotic-assisted, 1969–1970
- Pelvic musculature, 1684*f*
- Pelvic organs, prolapse, 1906
- Pelvic peritonectomy, 1879
- Pelvic splanchnic nerves (SPNs), 1825*f*, 1826*f*
- Pelvic vascular isolation, 2582*f*
- Pelvis
  - anatomic relationships, 1857*f*
  - anterior wall, 2195
  - autonomic nervous system, 1845
  - bimanual examination, 1802–1803
  - dissection
    - lateral, 1805
    - in ovarian cancer surgery, 2159*f*
    - plane of, 2160*f*
    - total mesorectal excision and, 1804
  - examination of, 2177
  - fascial layers of, 1799*f*
  - female, 1825*f*
    - anterior view, 2159*f*, 2161*f*
    - diagram from below, 2196*f*
  - lateral walls, 2195
  - male, 1825*f*
    - anatomic relationships, 1826*f*, 1857*f*, 2007*f*
    - diagram from below, 2196*f*
    - medial wall, 2198*f*
    - transverse section of, 1816*f*
  - MRI in rectal cancer, 1816
  - overhead view, 2040*f*

- planes of, 1799–1800
- posterior wall, 2195
- right lateral external view, 2197*f*
- walls, 2195

Pemberton's sign, 516
Penicillium spp., 984
Penile cancer, 430
Penile squamous cell carcinoma, 2055
Penis
- amputation, 2104–2105
- lymphedema, 683
- penetrating injury, 2105
- reimplantation, 2105
- traumatic injuries, 2104–2105

Penn pouch, 2112
Penrose drains, 834, 955*f*
Pentagastrin, 969
Peptic ulcer disease (PUD)
- antrectomy for, 1147
- bleeding, 1125–1126
- causes of, 1148
- complications of, 1105–1106
- diagnosis, 1113–1114
  - imaging studies, 1114
  - laboratory studies, 1114
  - presentation, 1113–1114
- duodenal perforation in, 1104
- elective surgery for, 1126
- emergency surgery for, 1125
- enterocutaneous fistulas and, 1650
- *H. pylori* infection and, 1104
- medical management, 1096
- perforation, 1126
- risk stratification, 1114

- surgical management, 1096
- treatment, 1114–1115

- Peptide YY (PYY)
  - after metabolic surgery, 1181
  - in bowel motility, 1985
  - metabolic surgery and, 1182*f*
- *Peptostreptococcus* spp., 1288
- Percent predicted lung volume (PPLV), 841
- Percutaneous acetic acid injection (PAI), 196
- Percutaneous coronary interventions (PCIs), 23
- Percutaneous dilatational tracheotomy (PDT)
  - airway access and, 489
  - anatomy, 495*f*
  - bedside, 489
  - description of, 498
  - instrumentation, 495*f*
  - kit-based techniques, 494–495
  - suspension laryngoscopy-assisted, 496–497, 496*f*
- Percutaneous drainage of hydatid cysts (PAIR), 1303
- Percutaneous endoscopic gastrostomy (PEG), 62*t*, 65, 1077–1084
  - contraindications, 1077–1078
  - indications, 1077–1078
  - with jejunal extension, 1082
  - technique, 1078–1080
    - complications, 1080–1081
    - fluoroscopic observations, 1082*f*
    - laparoscopic, 1082
    - safe tract method, 1078, 1079*f*, 1082, 1082*f*
    - transabdominal approach, 1082
- Percutaneous endoscopic jejunoscotomy, 62*t*, 65
- Percutaneous ethanol injection (PEI)
  - chemical ablation using, 196
  - disadvantages of, 196
  - HCC, 201–202

- Percutaneous nephrolithotomy (PCNL)
  - complications, 2017
  - for nephrolithiasis, 2011
  - patient positioning, 2016
  - postoperative drainage, 2017
  - postoperative infection rates, 2012
  - technique, 2016–2017
  - ultrasound-guided, 2017
- Percutaneous therapy (sclerotherapy), 2522–2523
- Percutaneous transhepatic cholangiography (PTC)
  - cholangiocarcinoma revealed in, 1374*f*
  - iatrogenic bile duct injury revealed in, 1374*f*
  - overview of, 1373
  - for pancreatic cancer, 1412
- Percutaneous transluminal angioplasty, 2332
- PerFix Plug, 2239
- Perforasome, 765
- Perforation severity score (PSS), 1031
- Perforator flaps (DIEP), 223, 232, 232*f*
- Perfusion
  - organ-specific, 68*t*
  - systemic, 68*t*
- Periampullary carcinoma
  - biliary obstruction and, 1286
  - postoperative morbidity, 1522*t*
  - surgery, 1412
- Periampullary malignant tumors, 1514–1523
- Perianal abscesses
  - drainage, 1715*f*, 1916, 1917*f*
  - imaging, 1888*f*
- Perianal area
  - melanoma, 419
  - sepsis, spread of, 1916*f*
- Perianal spaces, 1685

- Periappendiceal abscesses, 1689–1690
- Periappendicitis, 1694–1695
- Peribronchial lymph nodes, 808
- Pericardial cavity, embryology of, 781
- Pericardial fat pad, 815*f*
- Pericardial patches, fenestrated, 817*f*
- Pericardial ring hernias, 2203*t*
- Pericardial tamponade, 788, 793
- Pericardiectomy, 828
- Pericardioperitoneal canals, 782*f*
- Pericardiophrenic arteries, 834
- Pericardium
  - anatomical dissections, 786*f*
  - diaphragm area in contact with, 833*f*
  - in embryo, 821*f*
  - embryology of, 781
  - transverse septum covered by, 820
- Pericecal fossae, hernias through, 2205
- Perihilar cholangiocarcinoma. *See* Hilar cholangiocarcinoma
- Perinatal asphyxia, 1976
- Perineal body (PB), 1826*f*, 2176, 2179*f*
- Perineal dissection, 1848*f*
  - patient position, 1833*f*
  - prone *versus* lithotomy, 1843–1844
  - reconstruction options, 1844
- Perineal fistulae, 1932, 1933–1934
- Perineal hernia ring, 2197–2199, 2199*f*, 2202*t*
- Perineal membrane, 2010*f*
- Perineal nerve, 1686
- Perineal plication stitches, 2180*f*
- Perineal rectosigmoidectomy, 1894, 1906, 1909*f*
- Perineal trauma, 1950
- Perineal wounds, 240–245, 1858–1859
- Perineorrhaphy, 2177

- postoperative management, 2180*f*
- technique, 2178–2180

Perinephric fat, 2004*f*, 2028*f*

Perinephritic hematomas, 2014

Perineum
- definition of, 2197
- female, 2199*f*
- incisions, 2178*f*
- male, 2198*f*
- preparation for surgery, 1848
- reconstruction, 2179*f*

Perioperative management, 22–54. *See also Specific* procedures
- evaluations, 22
- risk reduction, 31
- screening tests, 22–23

Perioperative periods, 22

Perioperative Quality Initiative (POQI-I), 33

Periorbital edema, 516

Periorbital hemangiomas, 374, 376

Periorbital region, 435

Periorbital trauma, 439–440

Peripancreatic fluid collections (PFCs)
- access to, 1536
- Atlanta definitions, 1528, 1528*t*
- definition of, 1536
- drainage, 1542

Peripelvic fat, 2028*f*

Peripheral arterial disease (PAD)
- diabetic, 2411
- prosthetic bypass, 2374–2375
  - complications, 2372–2373
  - graft function improvement, 2369–2372, 2369*f*, 2371*f*
  - graft materials, 2368–2369
  - graft surveillance, 2373–2375

    - preoperative planning, 2368
  - reversed vein bypass grafts. (*See* Grafts, reversed vein bypass)
- Peripheral autoregulatory functions, 838
- Peripheral edema, 55, 1620
- Peripheral infusion system, 2494*f*
- Peripheral neuropathy, diabetic, 2409
- Peripheral vascular disease, 2409
- Peripheral vascular occlusive disease
  - endovascular procedures, 2389–2391
    - femoral artery superficial lesions, 2385–2386, 2385t, 2386*f*
    - outcomes, 2388–2389, 2389*f*
    - patient selection, 2384
    - popliteal artery lesions, 2386
    - postoperative assessment, 2388
    - preoperative imaging, 2384–2385, 2385t
    - surgical technique, 2386–2388, 2387*f*, 2388*f*
    - tibial artery lesions, 2386
- Peripherally inserted central catheter (PICC) lines
  - placement of, 46
- Perirectal spaces, 1824–1825
- Perirectal tissue planes, 1824–1825
- Peristomal candida, 1778*f*
- Peristomal leakage, 1646–1647
- Peristomal skin care, 1774
- Peritoneal cavity
  - embryologic development, 1053*f*
  - entrance, 1506
  - hernias, 2200
- Peritoneal dialysis
  - dialysate fluid, 1660
  - as renal replacement therapy alternative, 2538
  - statistics, 2525
- Peritoneal drainage
  - drain placement, 1979*f*

- neonates for NEC, 1978
- Peritoneal drains
  - placement, 1979–1980, 1979*f*
  - postoperative management, 1980–1981
- Peritoneal envelope, 2160*f*
- Peritoneal lavage
  - diagnostic, 858, 1327
- Peritoneal reflections, 1063
- Peritoneal sac
  - anatomy of, 2231*f*
- Peritoneal windowing, 1736*f*
- Peritonectomy, pelvic, 1879
- Peritoneopericardial hernia, 826
  - characteristics of, 822*t*
  - definition and overview of, 826
- Peritoneoscopy, NOTES, 210
- Peritoneum
  - finger beneath, 1744*f*
  - incision of, 844*f*, 1895*f*
  - in inguinal herniorrhaphy, e61
  - periampullary complex into, 1387*f*
  - stripping, 1356
- Peritonitis. *See also* Acute peritonitis
  - abdominal compartment syndrome and, 153
  - enterocutaneous fistulas and, 1652
  - postsurgical, 2163
- Peri-Vaterian duodenal diverticulum, 1393
- Perlman syndrome, 2078
- Permeability transition pores, 14
- Pernicious anemia, 1127
- Peroneal artery. *See* Grafts, reversed vein bypass
- Peroneal artery bypass. *See* Grafts, reversed vein bypass
- Peroral endoscopic myotomy (POEM)
  - achalasia and, 210, 961, 1031

- anesthesia, 210–211
- complications, 964
- contraindications, 962
- description of, 973
- evolution of, 968
- GIST management, 1198
- indications, 962
- LHM *versus*, 983
- outcomes, 214, 964
- postoperative care, 964, 980
- preoperative planning, 962
- steps in, 974*f*, 978–979
- technique, 962–964, 963*f*–964*f*

Peroral endoscopic staplers, 1538*f*

Petechiae in liver disease, 1620

Petersen, Walther, 1154

Petersen hernias, 1153–1154
- diagnosis of, 1155
- etiopathogenesis, 1155
- overview of, 1154–1155
- symptomatology, 1155
- treatment, 1155

Peterson space, 1253, 1257

Petit triangle, hernia through, 2195*f*

Pezzer catheters, 1715, 1715*f*

Pfannensteil incision, 2129

Phagocytes, 3

Phagocytosis, 133

Pharmaceutical advertising
- of opioids, e1–e2, e8

Pharmacomechanical thrombolysis (PMT)
- deep venous thrombosis treatment with
  - alternatives to, 2489
  - overview of, 2494–2496, 2499

- safety and efficacy of, 2498
- Pharyngeal artery, 291
- Pharyngeal cancer, 398–410, 399*f*
- Pharyngeal nervous plexus, 302
- Pharyngeal raphe, pharynx and, 301
- Pharyngeal recess, 300
- Pharyngeal tumors, robotic-assisted surgery, 271
- Pharyngeal veins, 359*f*
- Pharyngeal wall
  - anatomy, 400
  - reconstruction, 404
- Pharyngectomy
  - limited partial, 402*f*
  - partial, 405, 406
- Pharyngo-laryngo-esophagectomy (LPE), 985
- Pharyngolaryngoscopy, 401
- Pharyngotomy
  - surgical technique
    - lateral, 403
    - mandibular swing, 403–404
    - transhyoid, 403
- Pharynx
  - anatomy of, 299–303
    - constrictor muscles of, 301*f*
    - innervation of, 302, 303
    - interior view, 300*f*
    - ligamentous background, 301
    - muscular background, 301–302
    - posteiror view, 300*f*
    - posterior view of, 302*f*
    - skeletal framework, 301*f*
    - wall of, 302–303
  - subdivisions, 398*f*
  - topical anesthesia, 207

- Phenoxybenzamine, 2174
- Phenylephrine, 81
- Pheochrome cells, 508
- Pheochromocytomas
  - assessment for, 513
  - description of, 572–573
  - hereditary
    - partial adrenalectomy in, 514
  - intralesional calcifications, 582
  - laboratory tests, 520
  - preoperative planning, 573–574
  - recurrent, 514
  - screening for, 572–573
  - slow transit constipation and, 1961
  - surgery
    - arrhythmias, 582
    - intraoperative hypertensive crisis, 582
  - von Hipple-Lindau disease and, 2019
- Philtrel columns, 325*f*, 326
- Phlebothromboses, 380
- Phosphate levels on admission, 67
- Phosphodiesterase inhibitors, 79
- Phosphoinositide 3 kinase (PI3K), 11
- Photoangiolysis, 389
- Photocoagulation, hemorrhoids, 1923, 1924*f*
- Photodynamic therapy, 754
- Photophobia, globe injuries and, 442
- *Phox2B* mutations, 1971
- Phrenic arteries
  - inferior, 833*f*, 834, 835
  - superior, 834
- Phrenic ganglia
  - diaphragmatic representation of, 838*f*
  - extraphrenic innervation and, 836, 838*f*

- function of, 836
- histologic examination of, 838

Phrenic nerve injuries, 863

Phrenic nerves
- anatomy of, 287, 288*f*, 358*f*, 359*f*, 363*f*, 503, 2549
- branches, 837*f*
- branches of, 837*f*–838*f*, 851, 851*f*
- descent of, 850*f*
- diaphragm and, 836
- diaphragmatic openings for, 831
- dysfunction of, 848
- exposure of, 506*f*, 809, 1871*f*
- identification of, 357, 358*f*, 362
- injury to, 826, 848, 849, 850
- innervation by, 286
- location of, 836
- muscle innervation by, 820
- origin of, 821*f*
- protection of, 563

Phrenic veins, inferior, 835

Phrenicoesophageal ligament, 829–830, 901, 915–916

Phrenicoesophageal membrane, 829–830

Phrenicomediastinal recess, 833

Phrenoesophageal ligament, 929*f*, 1060
- formation of, 900*f*

PHTH. *See* Primary hyperparathyroidism (PHTH)

Phyllanthus niruri (chanca piedra), 2014

Phyllodes tumors, 607

Physical Activities and Lymphedema (PAL), 676

Physical stress, 1104–1105

Physical therapy
- complex decongestive lymphedema, 683
- for fecal incontinence, 1951–1952
- postoperative, 35

- Physiologic examinations, 946*t*, 947
- Picibanil (OK-432), 372
- Pico-Salex, 1894
- Picture archiving and communication system (PACS), 614
- Pierre-Robin disorder, 841
- Piezoelectric effect, 177–178
- Pigeon breast, 772
- *PIK3CA* mutations, 380, 1246
- Pilonidal sinus
  - causes, 1929
  - curettage, 1930*f*
  - diagnosis, 1929
  - excision, 1930–1931
  - laying open, 1930, 1930*f*
  - presentation, 1929
  - treatment, 1929–1931
- Piperacillin/tazobactam, 1894
- Pisiform bone, 247, 250*f*
- Placenta, delivery of, 2121–2122
- Plantar artery bypass. *See* Dorsalis pedis, tarsal, and plantar artery bypass
- Plasma
  - liquid, 107
  - lyophilized, 107
- Plasma energy, 275–276, 275*f*
- Plasma renin activity (PRA), 513
- Platelet activating factors, 6
- Platelet-derived growth factor receptor-α (PDGFA), 1193
- Platelets
  - counts, 103, 107–108
  - function of, 105
  - preoperative transfusions of, 27
  - preparation of, 107–108
  - transfusion of, 107–108

- Platysma muscles, 286, 312*f*, 501
- Plavix®, preoperative pause in, 2233
- Pleomorphic adenomas, 310
- Plethysmography, 68
- Pleurae, 774*f*, 820, 832–833
  - anatomic relationships, 773
  - mediastinal
    - division of, 922
- Pleural cavity, 833
- Pleural effusions
  - as diaphragmatic surgery complication, 854
  - postsurgical, 2163
  - on radiographs, 858
- Pleural flaps, parietal, 1027*f*
- Pleuropericardial folds, 781, 782*f*
- Pleuroperitoneal folds, 781, 840
- Pleuroperitoneal membranes, 820
- Plexus, interconnection of, 897
- Plummer disease, 520
- *PMS2* mutation, 1249
- PMS2 protein, 1247
- PNALD. *See* Prenteral nutrition-associated liver disease (PNALD)
- Pneumatoenteric recess, 1052
- Pneumatosis intestinalis, 1977
- Pneumonectomy
  - carinal resection after, 455*f*
  - indications, 814
  - left, 816, 816*f*
  - for lung cancer, 799
  - preparation, 814
  - right, 814–816
  - stumps, 807
- Pneumonia
  - after LRPLND, 2066

- physiology of, 87
- postoperative, 996
- postoperative complications, 85
- recurrent, 1043
- ventilator-associated
  - diagnosis of, 91–95
  - management of, 91–95

Pneumonitis, aspiration-related, 795
Pneumoperitoneum, 918, 1355–1356
Pneumothorax
- Birt-Hogg-Dube syndrome and, 2020
- as diaphragmatic surgery complication, 854
- evacuation of, 750
- postsurgical, 2163
- residual, 863*f*
- thoracic trauma and, 788

Podophyllum resin, 1928
POEM. *See* Peroral endoscopic myotomy (POEM)
Politano-Leadbetter ureteral implant, 2100*f*
Polycystic liver disease (PCLD), 1276, 1277
Polycythemia, 1601, 2020
Polydioxanone sutures (PDS), 153
Polyester meshes, 158
Polygalactic acid mesh, 156
Polyglycylic acid sutures, 168
Polyhydramnios
- causes of, 841
- in diaphragmatic eventration, 849
- fetal anomalies accompanied by, 1033

Polymyositis, thymomas and, 558
Polyneuropathy, critical illness and, 100
Polypectomy
- colonoscopic, 213, 214
- endoscopy, 281*f*

- pedunculated polyps, 213*f*
- snares, 1079

Polypropylene mesh (PPM)
- choice of, 158

Polypropylene meshes (PPM)
- chest wall resection, 746*f*
- for Kugel hernia repair, e89–e90, e89*f*, e93
- for plug-and-patch groin repair, 2232–2239, 2232*f*, 2235–2238*f*, 2243
- for prosthetic graft, 2368

Polyps
- hyperplastic, 213
- pedunculated, 213*f*
  - snaring, 213*f*

Polytetrafluoroethylene (PTFE). *See also* Expanded polytetrafluoroethylene (ePTFE)
- expanded, for prosthetic graft, 2368
- hernia repair with, 843
- for reversed vein bypass grafts, 2359

Polytetrafluoroethylene femorofemoral bypass, 2503*f*

Polytetrafluoroethylene graft replacement, 2508*f*

Polytetrafluoroethylene (ePTFE) meshes, 158

Polyurethane, 2368

Popliteal artery
- aneurysms
  - clinical manifestation, 2324*f*, 2325
  - diagnosis, 2325–2326
  - incidence and risk factors, 2325
  - mycotic, 2466*f*
  - normal anatomy and size, 2325
- injuries, repair of, 2598
- lesions, endovascular procedures, 2386
- reversed vein bypass grafts (*See* Grafts, reversed vein bypass)
- surgical removal of embolus, 2420–2421, 2420*f*
- vein graft from above-knee, 2599*f*

- Porcelain gallbladder, 1273
- Porphyria, 1961
- Porta hepatis
  - access to, 1335*f*
  - anatomic relationships, 1589
  - anatomical structures at, 1259, 1369*f*
  - dissection, 1561*f*
  - exposure, 1356, 1356*f*
  - injuries in, 1339, 2583
- Portacaval shunts
  - anatomy of, 1588–1607
  - elective, 1599–1600
  - emergency, 1597–1599
  - end-to-side, 1270, 1588
  - side-to-side, 1588–1607, 1590, 1593*f*
    - operative field, 1593*f*
    - patient positioning, 1593*f*
- Portal dissection, 1407
- Portal fibrous mass, 1430, 1430*f*, 1431*f*
- Portal hypertension, 1587–1588
  - causes of, 1616, 1616*t*
  - decompression, 1606
  - definition of, 1616
  - diagnosis, 1605
  - extrahepatic, 1602
  - gastro-omental veins during, 1068–1069
  - laparoscopic splenectomy with, 1993
  - liver transplantation in, 1607
  - natural history, 1616
  - portal-systemic venous shunts, 1592*f*
  - portosystemic collaterals, 1591*f*
  - treatment, 1587–1588, 1605
  - treatment principles, 1616–1617
- Portal system

- anatomy of, 1588–1607
- overview, 1589*f*

Portal triad, occlusion of, 1318

Portal vein
- anastomosis, 1440
- anatomic relationships, 1265, 1265*f*, 1330, 1589, 1589*f*
  - hepatic resection and, 1604
  - imaging, 1604–1605
- bifurcation, scanning of, 183*f*, 184*f*
- cholangiocarcinoma, involvement in, 1411
- clamping, 1596*f*
- coverage of, 1263
- dissection, 1507, 1559
- embryology of, 1052, 1056, 1056*f*
- formation of, 1486, 1680
- identification of, 184*f*
  - IOUS method, 182
- invasion of, 1604
- isolation of, 1595*f*
- mobilization, 1595*f*, 1596*f*
- preduodenal, 1056, 1056*f*
- pressures, 1594, 1610
- supply by, 1330
- suturing, 1596*f*
- thrombosis, 1602*f*
- tributaries of, 1485*f*
- variations, 1271

Portal vein embolization (PVE), 1317, 1327

Portal venous system, extrahepatic, 1590*f*

Portal-systemic encephalopathy (PSE), 1598, 1599

Portal-systemic shunts, 1602*f*

Portal-systemic venous shunts, 1592*f*

Portoenterostomy, 1427–1434
- laparoscopic, 1431

- postoperative care, 1431
- reoperation, 1431
- steps in, 1429–1430

- Portography, 1604
- Portosystemic shunts, 1590–1597, 1622
- Positive end-expiratory pressure (PEEP)
  - in ARDS, 97–99, 97*t*
  - ventilation-perfusion and, 86
- Positron emission tomography (PET)
  - lung cancer imaging, 801, 817
  - surveillance, 1869
- Post-cholecystectomy syndrome, 1365
- Postembolizaiton syndrome (PES), 2330
- Posterior auricular artery, 317, 319
- Posterior auricular muscles, 318
- Posterior cecal artery, 1679
- Posterior facial vein, 360*f*
- Posterior gastric artery, 1066
- Posterior inferior pancreaticoduodenal artery (PIPD), 1483
- Posterior intercostal arteries, 776
- Posterior intercostal nodes, 786
- Posterior intercostal veins, 288*f*, 777
- Posterior interosseous nerves, 247
- Posterior oropharyngeal wall (PPW), 402
- Posterior superior pancreaticoduodenal artery (PSPD), 1482, 1486
- Posterior tibial nerve stimulation, 1955
- Posterior triangle, 504*t*
- Posterior vagal trunk
  - anatomy of, 1075, 1075*f*
  - celiac division, 1075, 1075*f*
  - posterior gastric division, 1075, 1075*f*
- Posterolateral (Bochdalek) defects, 824–825
- Postgastrectomy syndromes, 1148–1165
  - functional disorders, 1155–1162

- mechanical disorders, 1150–1151, 1153–1155
- metabolic disorders, 1162–1164
- overview of, 1148, 1165
- surgeries relevant to, 1149–1164

- Posthepatectomy liver failure (PHLF), 1460
- Posthepatic membrane, 820
- Postherniorrhaphy inguinodynia
  - anatomy, 2240–2241, 2240*f*, 2242*f*
  - causes of pain, 2241
  - surgical techniques
    - orchialgia, 2242
    - preperitoneal repairs, 2242
    - triple neurectomy, 2242
- Postoperative pulmonary complications (PPCs), 85
  - high-risk patients, 89*t*
  - intraoperative ventilatory support and, 99
  - patients at risk of, 89
  - preoperative preparation for, 89*t*
  - prevention of, 89–90
  - risk factors, 85–86
- Postradiation wound reconstruction, 237
- Postthrombotic iliofermoral venous obstruction, 2481
- Postthrombotic syndrome (PTS)
  - anticoagulants to treat, 2510
  - deep venous thrombosis (DVT) associated with, 2497
  - as deep venous thrombosis complication, 2489
  - incidence of, reducing, 2490, 2497, 2498
  - overview of, 2481
  - pathogenesis of, 2490
  - predictors of, 2498
  - risk of
    - increasing, 2499
    - reducing, 2489, 2499
  - sequelae of, 2498, 2498*t*

- symptoms and clinical signs, 2498, 2498*t*
- Posttransplant lymphoproliferative disease (PTLD), 149
- Posturing, brainstem impairment and, 484
- Postvagotomy diarrhea, 1146
  - diagnosis, 1160
  - etiopathogenesis, 1160
  - overview of, 1160
  - symptomatology, 1160
  - treatment, 1146, 1160
- Postvagotomy syndromes, 1148
- Potassium citrate, 2014
- Pott's tie, 2252
- Pouch of Douglas
  - anatomic relationships, 2034
  - disease in
    - rectovaginal fistulas and, 1933
  - enterocele and, 1905
  - opening, 1910*f*
- Pouching in ileostomy, 1649*t*
- Pouchitis, 1739, e48–e49
- Pouch-vaginal fistula, 1739*f*
- Poupart ligament, 2186, 2211
- Power morcellators, 2135
- *PP2R1A* mutations, 1247
- PPARγ coactivator-1 (PGC-1), 40
- PPomas, 1473–1474
- *PRADI* mutation and, 542
- Prasad end-loop stoma, 1707*f*
- Prazosin, 2174
- Pre-albumin, 56
- Prebiotics in enteral formulations, 64–65
- Precursor T cells, 142–143
- Prediabetes, diagnosis of, 1177
- Predictive Salvage Index (PSI), 2587

- Prednisolone, 376
- Prednisone, 30
- Pregablin, 1581
- Pregnancy
  - appendicitis in, 1693, 1693*f*
  - and continent ileostomy, e47
  - hepatobiliary disease in, 1284
  - hyperthyroidism in, 520
  - melanoma in, 422
  - MRI imaging during, 543
  - preoperative testing, 22, 23, 23*t*
  - skin cancer and, 411
  - surgical energy, 280
- Premature neonates
  - NEC in, 1978
  - respiratory status, 1978
- Prenatal care, 841–842
- Prenatal ultrasonography, 841
- Prenteral nutrition-associated liver disease (PNALD), 1982, 1983
- Preoperative assessments, 30–31
- Preperitoneal space, 2214*f*
- Preperitoneum, e91–e92, e92*f*
- Prepyloric ulcers, 1085–1086
- Prepyloric vein of Mayo, 1058*f*
- Presacral fascia, 1683*f*
- Presacral space, 1889*f*
- Presacral spaces, 1815*f*
- Presbyesophagus, 868, 872
- Prescriptions
  - for opiates, e2–e3, e3*t*
    - physician role, e5, e8
- Pressure measurements
  - for fasciotomy, 2426–2427, 2426*f*, 2428*f*
  - and leg amputation, 2400

- Pressure sores
  - cleaning of, 216
  - coverage of, 216
  - prevention of, 35
- Presternum, sternal development, 773*f*
- Pretibial myxedema, 516
- Pretracheal lymph nodes, 502
- “Prevailing pattern” (defined), 1368
- Prevertebral space, 1024*f*
- Primary biliary cirrhosis, 1403
- Primary esophageal motility disorder (PEMD), 980–981
- Primary hyperparathyroidism (PHTH). *See also* Hyperparathyroidism (HPT)
  - challenges
    - coexistent thyroid disease, 547
    - equivocal imaging, 546
    - previously operated patients, 547
    - static PTH post-excision, 546–547
  - diagnosis of, 531, 533–534, 533*t*, 535
  - incidence of, 531, 542
  - normocalcemic, 533*t*, 534
  - presentation, 533–534
  - recurrent, 547
  - signs and symptoms of, 533*t*
  - treatment of, 531–542
- Primary sclerosing cholangitis (PSC)
  - associated conditions, 1395, 1395*t*
  - biliary malignancy in, 1397
  - cholangiocarcinoma in, 1283, 1411
  - clinical presentation, 1395*f*, 1396, 1396*f*, 1398*f*
  - diagnosis, 1274, 1403
  - differential diagnosis, 1396, 1403*t*
  - epidemiology, 1394–1395
  - etiology

- bacterial, 1395–1396
- etiopathogenesis, 1402
- genetic, 1395
- immune, 1395
- pathophysiology, 1396
- small duct PSC, 1396
- management
  - current conditions, 1403
  - endoscopic therapy, 1399, 1401
  - liver transplant, 1401–1402
  - medical therapy, 1397–1398
  - outcomes, 1400*f*, 1401–1402, 1403–1404
  - percutaneous therapy, 1399
  - postoperative care and complications, 1401
  - surgical resection
    - of bile duct, 1401
    - overview of, 1399
    - technique, 1399–1401
- overview of, 1394, 1402
- ulcerative colitis and, 1734

Primary thyroid lymphomas, 519–520
Primary voice restoration, 406
Pringle maneuver, 1335, 1336*f*
Probe standoff scanning, 180*f*, 181*f*, 185
Probes. *See also* Transducers (probes)
- shapes of, 178

Probiotics in enteral formulations, 64–65
Procalcitonin (PCL), 130–131
Processus vaginalis, 2074, 2074*f*
Proctectomy for IBD, 1713*f*
Proctitis, rectal urgency and, 1949
Proctocolectomy
- with end ileostomy, 1723–1724
- laparoscopic total, 1713–1714

- for perineal Crohn disease, 1936
- single-stage, 1714
- total
  - in CD with CRC, 1719
  - with permanent ileostomy, 1712
  - permanent ostomy after, 1639
  - robotic-assisted, 1738*f*
- Proctopexy
  - sigmoid, 1898*f*–1901*f*
  - suture placement, 1901, 1901*f*
- Proctoscopy, 1918
- Proctosigmoidoscopy
  - diagnostic, 1916
  - in hemorrhoids, 1922
  - radical hysterectomy and, 2136
  - in sepsis, 1916
- Profunda femoris vein, 2483*f*
- Progesterone, 609
- Program on Surgical Control of Hyperlipidemias (POSCH). *See* Intestinal bypass, for hypercholesterolemia
- Programmed cell death. *See* Apoptosis
- Prolactin
  - secretion of, 11
  - surgical trauma and, 11
  - synthesis of, 11
- Proliferating cell nuclear antigen (PCNA), 657
- Proline hernia system®
  - deployment, 2235, 2235*f*
  - insertion, 2235
  - onlay patch, 2235–2236, 2235*f*, 2236*f*
  - outcomes, 2239
  - size of devices, 2233*t*
  - triple fold overlay, 2235*f*
  - for umbilical hernias, 2237

- Proline mesh
  - fixation, Lap Band, 1202*f*
  - in rectal prolapse, 1894, 1903
  - in skeletal stabilization, 235–236
- ProLoop mesh, 2237–2239, 2238*f*
- Proloop® plugs, 2237, 2237*f*, 2238*f*
- Propofol, 138
- Propranolol, 376, 1622
- Prostaglandin e2, 6, 7
- Prostate arteries, 2068
- Prostate cancer
  - IRE studies in, 200
  - LPLND in, 2055
  - palliative therapy, 203
  - salvage therapy, 203
  - treatment options, 202–203
  - tumor ablation, 202–203
- Prostate gland
  - anatomic relationships, 1683, 2010*f*
  - anatomical relationships, 1826*f*
  - blood supply to, 2035
  - defattening of, 2069
  - dissection behind, 1847*f*
  - metastatic disease of, 1827*f*
- Prostatectomy
  - LPLND and, 2055
  - radical
    - contraindications, 2069
    - indications, 2069
    - outcomes, 2068
    - preoperative planning, 2069
    - technique, 2069–2070
  - robotic-assisted, 270, 272
    - radical, 2068–2072

- Prosthetic arteriovenous hemodialysis access
  - access location selection
    - body wall, 2543
    - forearm, 2541, 2542*f*, 2545*f*
    - lower extremity, 2542–2543, 2544*f*
    - overview of, 2540
    - upper arm, 2541–2542
  - complications and their management
    - infection, 2546
    - late AV access thrombosis, 2545
    - outflow venous obstruction, 2546
    - overview of, 2547
    - pseudoaneurysm, 2546
    - seroma, 2546
    - steal, 2546
  - graft material selection, 2543–2544
  - guidelines and recommendations, 2525
  - indications, 2540
  - mortality rate associated with, 2526
  - multiple failures, 2537
  - outcomes, 2546
  - overview of, 2540, 2541*t*
  - patency rates, 2546, 2546*t*
  - postoperative care, 2545
  - preoperative planning, 2540
  - surgical technique, 2544–2545
- Prosthetic bypass, 2367–2375
- Prosthetic grafts
  - homograft compared to, 2468
  - infections, 2546, 2547
- Prosthetic interposition shunts, 1607–1615
- Prosthetic materials, e87, 2359
- Protamine sulfate, 104
- Protectomy

- in Crohn disease, 1712–1713
- endo-anal, 1730
- hand-assisted laparoscopic, 1829
- laparoscopic, 1828*f*
- robotic-assisted, 1828*f*, 1891*f*
- set-up for, 1891*f*
- trocar placement, 1828*f*

- Protein
  - body content of, 13
  - energy per gram, 59–60
  - percent of body weight, 59
  - requirements in severe illness, 59
- Protein coagulation, radiofrequency energy, 274, 274*f*
- Protein kinase C (PKC), 143
- Protein malnutrition, 1230–1231, 1234
- Protein-calorie malnourishment, 1241
- Proteins
  - absorption of, 60
  - catabolism of, 55
  - functions of, 18
  - homeostasis, 35–42
  - metabolism of, 18–20
  - turnover of, 18
- Proteolysis
  - in cancer, 51–52
  - pathways of, 37–38
  - in sepsis, 51–52
  - urinary urea nitrogen and, 56
- Prothrombin complex concentrates (PCCs), 107
- Prothrombin times (PTs), 103, 104
- Proton pump inhibitors (PPI)
  - for duodenogastric ulcer disease, 1148
  - gastric output and, 1654
  - for GERD, 962

- ulcer rates and, 1253
- Proton-pump inhibitors, 916, 961
- Protoscolescidal agents, 1306
- Proximal interphalangeal (PIP) joints, 247, 250*f*
- Proximal phalanx, 250*f*
- Proximal radioulnar joints (PRUJ), 247
- *PRSSI* gene, 1493, 1525
- Pseudoaneurysms
  - after endovascular therapy, 2389–2390
  - blunt thoracic aortic injury (BTAI) accompanied by, 2562*f*
  - in endovascular therapy for aortoiliac occlusive disease, 2354
  - femoral artery
    - anastomotic, 2322–2323, 2323*f*
    - post-instrumentation, 2320–2321, 2322*f*
  - as prosthetic arteriovenous hemodialysis complication, 2546
  - and prosthetic grafts, 2372
  - treating, 2577
- Pseudoangiomatous stromal hyperplasia (PASH), 605
- Pseudocyst-enterostomy, operative, 1366
- Pseudocysts
  - pancreatic, 1493, 1494
  - pancreatic fluid, 1366, 1489
  - serum enzyme levels, 1494
- Pseudogout, radiograph, 259*f*
- Pseudomenbranous colitis, 1719
- *Pseudomonas* spp.
  - in appendicitis, 1692
  - *P. aeruginosa*
    - antibiotic therapy and, 121
    - multidrug resistant, 125
    - surgical site infections, 112*t*
    - VAP and, 92
- Pseudomyxoma peritonei, 1696
- Pseudoptosis, breast, 222

- Pseudoverrucous lesions, 1778, 1778*f*
- "Psoas hitch," 2098, 2100*f*
- Psoas major muscle, 2003*f*, 2004*f*, 2005*f*
- Psoas muscle abscesses, 2472*f*
- Psoriasis, peristomal, 1779, 1779*f*
- Psoriatic arthritis, 27
- Psychostimulants, perioperative, 30*t*
- Psyllium (Metamucil), 1646, 1774
- PTEN hamartoma-tumor syndrome, 383
- *PTEN* mutations, 383
  - Cowden syndrome and, 516
  - in endometrioid carcinomas, 1247
  - ovarian cancer and, 1246
- Pterygoid hamulus, 301
- Pterygoid plate, 301
- Pterygoid venous plexus, 318
- Pterygomandibular raphe, 301, 326
- PTFE. *See* Polytetrafluoroethylene
- Ptosis
  - breast, 222
  - myasthenia gravis and, 560
- Pubalgia, athletic, 244–245
- Pubic symphysis, 164, 2010
- Pubic tubercle, 2010*f*
- Puboprostatic ligaments, 2010*f*, 2169
- Pubourethral ligament, 2169, 2175*f*
- Pubourethral plication, 2174*f*
- Pubovesical ligaments, 2010*f*
- Pudendal canal, 1686
- Pudendal electrodes, 1951*f*
- Pudendal motor nerve, 1905
- Pudendal nerves, 1686
  - anatomy of, 1845
  - damage to, 1950

- neuropathy of, 1893, 1905
- terminal motor latency, 1951

- Pudendal vessels, 1685
- Puestow procedure, 1493, 1496, 1509–1512. *See also* Longitudinal pancreaticojejunostomy
  - clinical trials, 1500*f*
  - pancreatic drainage, 1499–1501
  - therapeutic targets, 1513*t*
- Pulmonary artery
  - anatomic relationships, 784
  - catheters, 73–77
    - complications, 76–77
    - features of, 73
    - hemodynamic variables, 75*t*
    - insertion of, 73–76
  - division of, 815*f*
  - endoleader around, 815*f*
  - in pulmonary resection, 806–807
- Pulmonary artery diastolic pressures (PADP), 74
- Pulmonary artery wedge pressures (PAWP), 73
  - hemodynamic variables, 74–76
  - interpretation of, 74, 74*f*
- Pulmonary contusions
  - diagnosis, 792
  - presentation, 792
  - treatment, 792–793
- Pulmonary emboli (PE)
  - after bariatric surgery, 1230
  - after colectomy, 1795
  - iliofemoral thrombus with associated, 2492
  - in operative venous thrombectomy, 2488
  - postoperative complications, 85
  - prevalence of, 2510
  - prevention, 90–91

- recurrent, 2511, 2515, 2517
- risk factors, 90–91

Pulmonary EN formulations, 63

Pulmonary function
- evaluation of, 804–805
- postoperative assessment, 87–88
- preoperative testing, 23, 23*t*, 24

Pulmonary function tests, 87*t*, 845, 848–849

Pulmonary hypertension
- animal studies, 823
- in CDH, 820
- definition of, 89
- in diaphragmatic hernia, 820
- inhaled NO for, 80–81
- preoperative risk factors, 89
- surgical pulmonary risk, 89

Pulmonary hypoplasia
- animal studies, 823
- in CDH, 820
- in congenital diaphragmatic hernia, 840, 845
- in diaphragmatic eventration, 849, 851
- in diaphragmatic hernia, 820–821
- impact of, 841

Pulmonary resection, 799–818
- anesthetic considerations, 805–806
- closure of the bronchus, 807*f*
- epidemiology, 799–800
- history, 799
- mediastinal lymph nodes, 810–811
- outcomes, 817
- pain control, 805–806
- preoperative evaluation, 804–805
- principles of, 806–807
- robotic-assisted surgery, 268–269

- Pulmonary risks, preoperative, 88
- Pulmonary sepsis, 1000
- Pulmonary system
  - anatomy of, 86–87
  - physiology of, 86–87
  - postoperative complications, 86*t*, 88*t*
  - risks
    - preoperative assessment of, 88*t*
    - ventilatory support and, 85–103
- Pulmonary vein
  - ablation, 269
  - fistulas, 789
  - isolation, 269
- Pulse volume recording, 2351, 2352*f*, 2357
- Pupillary changes, 484
- Pure red cell aplasia, 558
- Purine analogs, 146
- PV-10, 427
- Pyeloplasty, 270–271
- Pyloric relaxation, 1165
- Pyloric relaxation, blunted, 1165
- Pyloric stenosis, 1166–1167
  - congenital, 1166–1175
  - diagnosis of, 1166–1167
  - incidence of, 1174–1175
  - short esophagus associated with, 823
  - surgical correction
    - complications, 1168
    - laparoscopic, 1168, 1168*f*
    - open, 1167–1168
    - postoperative care, 1168–1169
- Pyloric vein, 1589–1590
- Pyloroduodenal junction, 1061
- Pyloromyotomy, 1123

- alternatives to, 1165
- closure of, 1108–1109
- complications after, 1175
- for congenital pyloric stenosis, 1166
- esophagectomy and, 988
- esophagogastrectomy and, 1158
- open *versus* laparoscopic, 1175
- technique, 1167*f*

‣ Pyloroplasty
- alternatives to, 1165
- choice of, 1123
- gastric emptying, delayed treated with, 959
- gastric outlet obstruction and, 1120–1121
- gastrojejunostomy or, 1123
- laparoscopic, 921*f*
- laparoscopic esophagectomy and, 920
- truncal vagotomy with, 1151*f*
- vagotomies and, 1098

‣ Pylorus
- congenital pyloric stenosis and, 1175
- hypertrophied, 1175
- identification of, 1219
- preservation, 1568*f*, 1569*f*

‣ Pylorus-preserving variant (PPPD) gastrectomy, 1142

‣ Pylorus-preserving pancreaticoduodenectomy (PPPD), 1506–1509, 1507*f*, 1512–1513, 1513*t*

‣ Pyocystitis, 2108

‣ Pyoderma gangrenosum, 1779

‣ Pyogenic granuloma (PG)
- incidence, 373
- management, 378
- presentation, 378

‣ Pyogenic liver abscesses
- CT, 1287

- epidemiology, 1286
- operative approach, 1290
  - complications, 1290
  - incisions, 1290*f*
- pathophysiology, 1286–1287
- source control, 1289–1290
- treatment, 1288–1289, 1293

- Pyramidal signs, 484
- Pyruvate, metabolism of, 15

Q

- Quadrangular membrane, 303, 304*f*
- Quadrantectomy, 625
- Quadratus lumborum muscle, 856*f*, 2002, 2003*f*, 2004*f*
- Quadriplegia, 36–37
- Quality of life
  - and continent ileostomy, e49–e50
  - gastrectomy reconstruction method outcomes compared, 1147–1148
  - with lymphedema, 683
  - and plug-and-patch groin repair, 2232
- Questonnaires, preoperative, 22*t*
- *Quick*DASH (Disability ARM and Shoulder) study, 762
- Quinolones, 121

R

- Rabbit antithymocyte globulin (RATG), 148
- Raccoon eyes, 477
- RACE acronym, 276
- Race/ethnicity
  - biliary atresia and, 1427
  - congenital pyloric stenosis and, 1166
  - Crohn disease, 1661
  - esophageal cancer and, 983
  - malignant melanoma and, 417
  - melanoma and, 429

- *RAD51C* mutation, 1249
- *RAD51D* mutation, 1249
- Radial artery cannulation, 69
- Radial artery injuries, 2597
- Radial free forearm flap (RFFF), 404
- Radial nerve, 247
- Radial-antecubital forearm, prosthetic, 2542*f*
- Radial-axillary upper arm, 2543*f*
- Radiation enteritis, 1635*f*
- Radiation exposure, goiters and, 516
- Radiation necrosis, 218*f*
- Radiation therapy
  - after surgery, 987
  - for carotid body tumors, 2277
  - for ductal carcinoma in situ, 634
  - injuries, 721
  - and mastectomy, 724
  - postlumpectomy, 223*f*
  - postradiation defects, 239*f*
  - postradiation ulcerations, 234–235
  - postradiation wound reconstruction, 237
  - presurgical, 2038
  - small bowel obstruction after, 1634
  - whole and partial breast, 651–653
    - commonly used terms, 645t
    - overview and historical perspective, 644–645
    - partial breast, 646–647, 647–649, 647*f*–648*f*, 649–651, 650*f*
    - whole breast, 645–646, 645f
  - xerostomia and, 336
- Radiation therapy Oncology Group (RTOG) 1304, 758
- Radical hysterectomy, 2136–2146
- Radioactive iodine ablation (RIA), 528
- Radiobasilic autogenous access, 2531, 2531*f*
- Radiocephalic autogenous access, 2530–2531, 2530*f*

- Radiofrequency ablation (RFA)
  - breast cancer, 204
  - of breast tumors, 656–658, 656–659*f*, 658t
  - equipment, 198*f*
  - HCC, 201–202, 202*f*
  - immune-stimulation and, 196
  - liver tumors, 1318
  - radiation therapy and, 195
  - in RCC, 204, 2022
  - surgical energy, 276
  - systemic therapies and, 195
  - TACE combined with, 195
  - in thyroid cancer, 520
  - tumor necrosis and, 197–198
  - ultrasound guided, 191*f*
- Radiofrequency energy, transmission of, 278
- Radiofrequency energy circuit, monopolar, 274*f*
- Radiography. *See also Specific* conditions
  - chest X-rays (CXRs)
    - preoperative, 23, 23*t*
    - pulmonary risk and, 24
  - KUB in nephrolithiasis, 2011
  - in liver hydatidosis, 1300
- Radiologic gastronomy, 62*t*
- Radioulnar angulation, 248
- Radioulnar deviation, 247
- Radius, 247
- Raloxifene, 634
- Ramstedt procedure, 1166
- Ranula, salivary gland, 311
- “Rapid lysis technique,” 2495
- Rapidly involuting congenital hemangiomas (RICH), 373–374
- RapidPort device, 1202
- RARP. *See* Robot-assisted radical prostatectomy (RARP)

- *RAS* mutations, 516
- *RASA1* mutation, 382
- Ravitch, Mark, 173
- RCC. *See* Renal cell carcinoma (RCC)
- Reactive airway disease, 845
- Reactive antibody assays (PRAs), 145
- Reactive hypoglycemia
  - diagnosis of, 1159–1160
  - etiopathogenesis, 1159
  - symptomatology, 1159
  - treatment, 1160
- Reactive oxygen species (rOS), 14, 14*f*
- Recanalization, coaxial system use in, 2462*f*
- Receptor-interacting protein (RIP), 4*f*
- Recombinant factor VIIa, 108
- Recovery Nitinol IVC filter strut, fractured, 2516*f*
- Rectal adenocarcinoma
  - clinical presentation, 1852–1853
  - imaging, 1854
  - preoperative planning, 1854–1855
  - treatment planning, 1854
  - workup, 1854
- Rectal advancement flap, 1718
- Rectal cancers
  - abdominoperineal resection for, 1841–1852, 1852–1861
  - advanced, 1854*f*
  - clinical presentation, 1826
  - clinical trials, 1819–1821, 1839
  - CRM, recurrence rates and, 1837
  - etiology, 1861–1862
  - field of spread, 1798*f*
  - functional outcomes, 1837–1838
  - history of treatments for, 1814–1822
  - imaging, 1815–1817

- local excision, 1938
- magnetic resonance imaging, 1801*f*
- mesorectal excision for, 1796
- metastatic spread, 1814*f*, 1826, 1827*f*
- MRI, 1842*f*
- pathophysiology, 1861–1862
- perineal excision, 1839
- preoperative planning, 1735, 1815–1817
- recurrence, 1861–1862, 1862*f*
  - after TME, 1837
  - clinical presentation, 1862–1863
  - complications, 1865–1866
  - etiology, 1868
  - incidence, 1868
  - postoperative care, 1865
  - preoperative assessments, 1868–1869
  - preoperative considerations, 1863
  - presentation, 1868
  - prognosis, 1875, 1875*t*
  - sacral resection for, 1868–1882
  - sacrectomy for, 1870–1876
  - surgical technique, 1864–1865, 1864*t*
- reoperative pelvic surgery, 1861–1867
- resection for
  - contraindications, 1826–1827
  - indications, 1826–1827
  - preoperative planning, 1827–1828
- specimens, 1842*f*
- sphincter-sparing procedures, 1839
- spread of, 1815
- standard oncologic resection, 1938
- surgery for
  - complications, 1836–1837
  - postoperative care, 1836

- surgical classification of, 1833*f*
- transanal excision, 1938
- transsacral approach, 1839

Rectal disease, urgency and, 1949

Rectal emptying, assessment of, 1951

Rectal flatulence, 916

Rectal leiomyosarcomas, 1885

Rectal neoplasms
- local excision
  - clinical outcomes, 1947
  - complications, 1945–1946
  - decision-making in, 1939
  - functional outcomes, 1947
  - palliative, 1939
  - preoperative planning, 1939
  - surgical technique, 1939–1945
  - suture repair, 1946*f*
- margins of excision, 1944*f*, 1945*f*
- Parks' transanal excision, 1939–1940, 1940*f*
- specimens for pathology, 1941*f*
- transanal endoscopic microsurgery, 1940–1941, 1942–1943
- transanal excision of, 1937–1948, 1938
- transanal minimally invasive surgery, 1943–1945

Rectal pouches, 2112

Rectal procidentia. *See also* Rectal prolapse
- bowel preparation, 1894
- clinical manifestations, 1893
- diagnosis, 1893
- duration of, 1904
- etiology of, 1893, 1904
- hidden, 1893
- occult, 1903
- open abdominal approach, 1893–1904
- operative treatment, 1902–1903

- overt, 1893*f*
- pathological anatomy, 1893
- preoperative evaluation, 1894
- surgical treatment
  - indications for, 1893–1894
  - postoperative care, 1897
  - technique, 1894–1897, 1895*f*–1897*f*
- Well's repair for, 1894

Rectal prolapse, 1957–1960. *See also* Rectal procidentia
- anal encirclement, 1907–1911
- causes, 1957–1959
- clinical presentation, 1905–1906
- complete, 1905*f*
- definitions, 1905
- delivery, 1908*f*
- epidemiology, 1905
- mucosal, 1906*f*
- postoperative care, 1912
- preoperative planning, 1907
- presentation, 1957
- recurrence, 1912
- repair, 1904
- surgical treatment, 1906–1907

Rectal reservoir compromise, 1949

Rectal wall defects, 1941*f*

Rectal washout, self-administered, 1952

Rectoceles
- anatomic considerations, 2176–2177
- anterior levatorplasty and, 1952–1953
- outlet obstruction and, 1963
- on perineal relaxation, 2176
- physical examination, 2177
- repair, 2177–2178
- symptoms, 2176

- Rectopexy
  - mortality rates, 1902
  - for rectal prolapse, 1959, 1959*f*
  - suture, recurrence rates, 1902
- Rectosacral fascia, 1683*f*, 1684, 1805
- Rectosacral ligament, 1805
- Rectosigmoid colon, 2133, 2161*f*
- Rectosigmoidectomy, 1960*f*
- Rectourethralis, 1852*f*
- Rectouterine pouch, 1683, 1683*f*
- Rectovaginal fistulae
  - causes of, 1932
  - classification of, 1932*f*
  - coloanal reconstruction, 1933*f*
  - diagnosis, 1932–1933
  - laying open, 1935*f*
  - preliminary fecal diversion, 1933
  - presentation, 1932–1935
  - reconstruction, 1935*f*
  - seton fistulotomy for, 1934–1935
  - transsphincter repair, 1934*f*
  - transvaginal repair, 1934*f*
  - treatment, 1933
- Rectovaginal septum, 2177
- Rectovaginal space
  - anatomy of, 2170
  - entering, 1899*f*, 2178*f*
- Rectovesicular pouch, 1683*f*
  - anatomic relationships, 2009
  - anatomy, 1683
- Rectrocele, perineal defects and, 2178*f*
- Rectum
  - anastomotic techniques, 1834
  - anatomic relationships, 1824, 2005*f*, 2010

- anatomy of, 1683–1684, 1683*f*
- autonomic nervous system and, 1825
- blood supply to, 1845
- circumferential adenomas, 1942
- coronal section, 1683*f*
- dissection planes, 1832*f*
- division of, 1746*f*
- empty, 1952
- GIST, 1196
  - excision, 1198
- interruption, incontinence after, 1949–1950
- left hemicolectomy for, 1795
- lymphatic drainage, 1825–1826
- mobilization of, 1712–1713, 1728, 1824–1825, 1895–1896, 1895*f*, 1897–1898
- parasympathetic innervation of, 1825
- reconstructive techniques, 1834
- resection, postoperative care, 1836
- resection distal to tumor, 1831–1834
- submucosal venous plexus, 1590
- transection planes, 1832*f*
- upper, dissection of, 1856*f*
- vascular supply, 1825–1826
- washout after anesthesia, 1973

- Rectus abdominis muscle
  - anatomic relationships, 765, 778*f*
  - anatomy, 775*f*
  - division of, 229
  - embryology of, 772
  - ileostomy through, 1638
  - musculocutaneous flap, 242–243
  - origin of, 245*f*
- Rectus diastasis, 159
- Rectus femoris fasciocutaneous flaps, 238–240, 239*f*

- Rectus femoris muscle, 239
- Recurrent laryngeal nerve (RLN)
  - after thyroidectomy, 528–529
  - anatomical dissections, 786*f*
  - anatomy of, 71*f*, 287, 298*f*, 308, 471
  - cervical anatomy, 991*f*
  - division of, 305
  - esophageal cancer involvement, 984
  - exposure of, 501
  - identification of, 523
  - injuries, postoperative, 996
  - intraoperative monitoring of, 512
  - nonrecurrent, exposure of, 502*f*
  - parathyroidectomy, 537–538
  - protection during surgery, 897, 901
  - protection of, 545*f*
- Recurrent respiratory papillomatosis (RRP), 385, 397
- "Red-breast syndrome," 225–226
- Reducible short esophagus, 823–824
- Refeeding syndrome
  - EN and, 65
  - prevention of, 65
  - signs of, 65
- Reflux. *See also* Gastroesophageal reflux (GER)
  - preventing, 829, 890
  - symptoms of, 928
- Regulatory T cells (T_{ref} cells), 144
- Rehabilitation, leg amputation, 2405
- Rejection, 145
  - acute, 145
  - chronic, 145
  - classification of, 145
  - hyperacute, 145
  - immune recognition and, 141–145

- Renal artery
  - anatomy, 2004*f*
  - aneurysms, 2331
  - clamping of, 2022
- Renal artery occlusive disease, 2341–2443
  - arteriography, 2435
  - diagnosis
    - functional studies, 2434
    - invasive imaging, 2434
    - noninvasive imaging, 2434
  - endoluminal stenting, 2435, 2436*f*, 2441
  - epidemiology, 2432–2433
  - etiology, 2431
  - history and physical examination, 2433
  - indications and contraindications, 2434–2435, 2436
  - laboratory tests, 2433
  - morbidity and mortality, 2441
  - pathophysiology
    - ischemic nephropathy, 2432
    - renovascular hypertension, 2431–2432, 2432*f*
  - percutaneous transluminal angioplasty, 2435, 2436*f*, 2441
  - procedure assessment, 2441–2443, 2443t
  - surgical techniques
    - aortorenal bypass, 2438, 2438*f*
    - ex-vivo reconstruction, 2440
    - open renal artery reconstruction, 2437–2438
    - reimplantation of renal artery, 2439, 2439*f*
    - renal artery exposure, 2436–2437, 2437–2438*f*
    - splanchnorenal bypass, 2439–2440, 2440*f*
    - thromboendarterectomy, 2438–2439, 2439*f*
- Renal blood flow, 2
- Renal calculi, 193
- Renal capsule, 2002
- Renal cell carcinoma (RCC)

- ablation therapy, 203–204
- active surveillance, 2022–2023
- AJCC staging for, 2021*t*
- chromobphobe, 2019
- clear cell, 2019
- diagnosis, 2020
- etiology of, 2019–2020
- genetics of, 2019–2020
- metastatic sites, 2020
- nephron-sparing approaches, 195
- papillary, 2019
  - hereditary, 2020
  - incidence, 2019
- partial nephrectomy, 2022
- pathology of, 2019
- pediatric, 2087
- preoperative evaluation, 2021
- presentation, 2020
- radical nephrectomy for, 2019–2033
- staging, 2020–2021
- treatment options, 203–204
  - radical nephrectomy, 2021–2023

Renal columns, 2002, 2004*f*

Renal cortex, 2004*f*

Renal disease, occult

- screening for, 22

Renal failure. *See also* Kidney failure

- post-ileostomy, 1647
- TPN and, 48

Renal fascias, 2002, 2004*f*

Renal function. *See also* Kidneys

- calcium metabolism and, 550
- phosphate excretion and, 550
- preoperative testing, 22, 24–25

- Renal insufficiency
  - inflammatory responses and, 2
  - preoperative assessment, 24–25
- Renal ischemia, 2022
- Renal medulla, 2004*f*
- Renal organ injury scale, 2088–2089
- Renal papilla, 2002, 2004*f*
- Renal pelvis, 2004, 2004*f*
- Renal replacement therapy, 2538
- Renal sinuses
  - anatomy, 2002, 2004*f*
- Renal solute load, 63
- Renal stones, guidelines, 2013
- Renal subcapsular hematomas, 2014
- Renal transplantation. *See also* Kidney transplantation
  - parathyroid tissue autotransplantation, 553
  - parathyroidectomy after, 552
- Renal trauma, 2088–2092
- Renal ultrasonography
  - detection of masses, 2020
  - in nephrolithiasis, 2011–2012
- Renal vein, right
  - cannulation of, 2512*f*
- Renal veins
  - anatomic relationships, 2005*f*
  - left
    - anatomic relationships, 2002
    - circumaortic and retroaortic, 2512
    - stents and stenting, 2500*f*
  - main connections, 779*f*
  - tumor thrombi, 2021
- Renin, secretion of, 571
- Renin-angiotensin-aldosterone system, 12
- Renorrhaphy, 2096, 2096*f*

- Renovascular injuries, 2096–2097, 2106
- Replantation, digits, 254*f*–255*f*
- Reproductive endocrinologists (REIs), 1250
- Residual heat, 277–278, 277*f*
- Respiratory distress
  - in diaphragmatic eventration, 850
  - neonatal, 1976
- Respiratory failure
  - after abdominal aortic aneurysm repair, 2316
  - after extubation, 36
  - TPN and, 48
- Rest pain, 2350, 2357
- Resting energy expenditures (REEs), 56–57, 59
- Resuscitation
  - blood lactate levels and, 50
  - endpoints of, 137
  - goal-directed, 84
  - initial, in CDH, 842–843
  - intraoperative, 33
  - peripheral edema and, 55
  - volume, considerations, 77–78
- Resuscitative endovascular balloon-occlusion of the aorta (REBOA), 2584, 2584*f*, 2586
- *RET* mutations, 516, 530, 542
- *RET* proto-oncogene, 520, 1971
- Retained antrum syndrome, 1150
- Retention sutures, controversies, 168–169
- Rethrombosis
  - in deep vein thrombosis (DVT), 2482
  - in operative venous thrombectomy, 2488
- Reticuloendothelial system, 8
- Retinal angiomas, 2019
- Retinal-binding protein, 1651–1652, 1655
- *RET/PTC* rearrangements, 530

- Retroanastomic hernias, 2207, 2209*f*
- Retroaortic renal veins, 2512
- Retrobulbar hematomas, 442
- Retrocaval ligament, 1318*f*
- Retrocolic gastrojejunostomy, 2208
- Retroesophageal space, 954
- Retrograde ejaculation, 1795
- Retrograde open mesenteric stenting (ROMS), 2451, 2463*f*
- Retrograde urethrography (RUG), 2103*f*, 2107
- Retromandibular vein, 317, 318, 321*f*
- Retromesocolic dissection, 1847
- Retromolar trigone, 335*f*, 340–342, 341–342, 342*f*
- Retroperitonal incisions, 152–153
- Retroperitoneal lymphadenectomy (RPLND), 2060–2063
  - contraindications, 2060
  - indications, 2060
  - left-sided tumor, 2064–2065
  - patient positioning, 2062, 2062*f*
  - port placement, 2062–2063, 2062*f*
  - preoperative planning, 2060–2063
  - right-sided tumor, 2063–2064, 2063*f*–2064*f*
  - room setup, 2062*f*
- Retroperitoneum, 2578*f*
- Retropharyngeal space, 289
- Retrorectal cystic hamartomas, 1882
- Retrorectal spaces
  - anatomy of, 1815*f*
  - entering, 1898, 1899*f*
  - neurogenic tumors, 1882–1883, 1884
- Retrorectal tumors
  - classification of, 1883*f*
  - complications, 1889–1890
  - congenital, 1882
  - etiology of, 1882

- management of, 1882–1892
- neurogenic, 1882–1883
- outcomes, 1890–1891
- pathophysiology of, 1882
- postoperative care, 1889
- preoperative planning, 1884–1886, 1892
- presentation, 1883–1884
- rectal mobilization
  - port sites for, 1890*f*
  - robotic set-up for, 1891*f*
- recurrence rates, 1892
- resection
  - contraindications, 1884
  - indications, 1884
- surgical technique, 1886–1889

- Retrosacral ligament, 1805*f*
- Retrovaginal fistulae, 1717, 1719
- Retrovesical fascia, 2009
- Retzius veins, 1590
- Revascularization
  - in carotid bifurcation disease, 2247–2248, 2248t
  - critical limb ischemia, 2375, 2376
  - reversed vein bypass graft, 2367
- Reversed vein bypass grafts. *See* Grafts, reversed vein bypass
- Revised Cardiac Risk Index (RCRI), 23, 24*f*
- Reynolds scissors, 357, 362
- RFA. *See* Radiofrequency ablation
- Rhabdoid tumors, 2087
- “Rheolytic” instruments, 2494, 2496*f*
- Rheumatologic diseases, 27, 35
- Rhinorrhea
  - CSF, 436
  - in TBI, 477
- Rhomboid flaps, 216

- Rhomboid muscles, 295
- Rhomboideus major, 776*f*
- Rhomboideus minor, 776*f*
- Rib cage, 826*f*
- Ribavirin, 1448
- Ribs
  - anatomy, 773, 774*f*, 775*f*
  - deformities of, 772
  - embryology of, 772
  - fractures
    - diagnosis, 790
    - operative repair, 790
    - presentation, 790
    - thoracic trauma and, 788
    - treatment, 790
- Richard Wolf Company, 1940
- Richardson retractors, 362
- Ricordi chamber, 1503*f*
- Rifampin, 253, 2471
- Rifampin-soaked grafts, 2480
- Right adrenal vein, 575–576
- Right brachiocephalic vein, 783
- Right colic artery, 1679
- Right colic vein, 1589*f*
- Right common iliac artery, 2005*f*
- Right epiploic artery, 1067*f*
- Right gastric artery, 1064
- Right gastric vein, 1069
- Right gastro-epiploic artery, 1067, 1067*f*
- Right gastro-omental artery, 1065
- Right gastro-omental vein, 1068, 1069–1070, 1070*f*
- Right hemiliver, 1370
- Right hepatectomy, 1262*f*
  - anterior approach, 1320–1321, 1320*f*

- extended, 1321
- laparoscopic, 1323–1324
  - port placement, 1324*f*
- living donor, 1263*f*
- with resection, 1320*f*
- surgical technique, 1318–1320, 1319*f*

- Right hepatic artery, 1343, 1484, 1484*f*
- Right hepatic ducts
  - absent, 1267–1268
  - anatomic variants of, 1382
  - formation of, 1370*f*
  - injury to, 1373*f*
  - presurgical exposure and preparation, 1377
  - stricture, 1398*f*
- Right hepatic vein, 1262, 1263*f*
- Right hypogastric nerve, 1825
- Right inferior hepatic vein (RIHV), 1263*f*
- Right lymphatic duct, 287
- Right paracolic gutter, 1675*f*
- Right phrenic nerve, 836, 863
- Right phrenic vein, 1262*f*
- Right posterior sectional bile duct (RPSBD), 1268*f*, 1269*f*, 1370*f*
- Right posterior sectional duct (RPSD), 1267*f*
- Right renal artery, 2008*f*
- Right subclavian artery, 288*f*, 298*f*, 786*f*
- Right suprarenal gland, 2005*f*
- Right vagus nerve, 784, 786*f*
- Right ventricular ejection fractions (RVEF), 74–75
  - CO_2 measurement and, 73–76
- Right ventricular end-diastolic volumes (RVEDV), 74–75
- Right ventricular failure, 80–81
- Rigiflex balloon system, 971–973
- Ring finger, flexor tenosynovitis, 256*f*
- Ripstein repair

- mortality rates, 1902
- in rectal prolapse, 1894
- recurrence rates after, 1902

Risk-reducing salpingo-oophorectomy (RRSO), 1249

Rituximab, 149

Rives-Stoppa repair, 159–160, 161*f*

Robinson catheters, 1764–1765, 1766

Robot-assisted radical prostatectomy (RARP), 2068–2072
- anatomical considerations, 2068–2069
- outcomes, 2070
- port placement, 2069
- preoperative planning, 2069

Robotic Endolaryngeal Flexible Scope (Robo-ELF), 271

Robotic gastrectomy, 1142, 1148

Robotic surgery, 262–273
- equipment
  - console, 264
  - control tower, 264
  - detachable instruments, 264
  - surgical arm cart, 264
- evolution of, 262–264
- exploration of, 1142
- marketing efforts, 272
- platforms, 262–264
- setup fundamentals, 264
- summary, 264
- training regimens, 263
- transoral, 402–403, 403*f*

Robotic-assisted laparoscopic esophagomyotomy, 976–977

Robotic-assisted thoracoscopic surgery (RATS), 566–567

Rochard retractor, 929

Rockey-David incisions
- abdominal wall, 152, 152*f*
- for appendectomy, 1691, 1691*f*

- closure of, 153
- selection of, 153

Roentgen, Wilhelm, 556
Rokitansky, Carl Von, 1185
Root-of-the-neck, 287–290
- compression syndromes, 308

Roprocaine (Nescaine®), 2233
Rosemont classification, 1495
Rossetti-Hell modification of Nissen fundoplication, 949*f*
Rotational thromboelastometry (ROTEM), 105, 106*t*
Rotter's lymph nodes, 598, 599*f*, 600*f*
Round ligament, 1259, 1260*f*
Roux, César, 1141
Roux gastrojejunostomy, 1124
Roux limbs
- delivery of, 1400
- division of, 1243*f*
- EEA stapler insertion, 1243*f*
- jejunojejunostomy and, 1212–1213
- preparation of, 1401, 1404

Roux stasis syndrome, 1142
- causes of, 1147
- description of, 1146
- diagnosis, 1161
- as distal gastrectomy complication, 1146, 1147
- overview of, 1160–1161
- pathogenesis, 1161
- symptomatology, 1161
- treatment, 1161

Roux-en-Y anastomosis, 1430, 1431*f*
Roux-en-Y choledochojejunostomy, 1420
Roux-en-Y cystojejunostomy, 1308
Roux-en-Y duodenojejunostomy, 1191*f*
- A, 1663

- Roux-en-Y enteroenterostomy, 1416*f*
- Roux-en-Y gastrectomy, 1093–1095
- Roux-en-Y gastric bypass (RYGB)
  - alternatives to, 1165
  - antireflux surgery complications, treating with, 959
  - completed, 1139*f*
  - complications, 1217
    - anastomotic leaks, 1251
    - avoidance in, 1146–1147
    - bleeding, 1251–1252
    - cardiopulmonary, 1252
    - dumping syndrome, 1165
    - early bowel obstruction, 1252
    - esophageal perforation, 1031
    - intraluminal hemorrhage, 1251–1252
    - marginal ulcers, 1252–1253
    - micronutrient deficiencies and anemia, 1162–1163
    - thromboembolic, 1252
  - complications of, 1242–1244
    - avoidance in, 1146–1147
    - dumping syndrome, 1165
    - esophageal perforation, 1031
    - micronutrient deficiencies and anemia, 1162–1163
  - conversion to, 1245*f*
  - conversion to LAGB, 1248
  - equipment, 1139*f*
  - for esophagectomy, 1020
  - gastrectomy with, 1149*f*
  - glycemic control and, 1217
  - history and evolution of, 1141
  - illustration, 1180*f*
  - indications, 1250
  - laboratory tests after, 1256*t*
  - laparoscopic, 1217

- limb length, 1147
- mechanism of action, 1211
- nutritional deficiencies, 1255
- for obesity, 1179
- outcomes, 1141, 1142, 1147–1148, 1203, 1217
- patient evaluation, 1217
- postsurgical care, 1217
- reconstruction, 1145*f*
- as reoperative surgery, 1020
- revision for weight regain, 1246–1247
- robotic-assisted, 265
- sympathetic nervous response, 1182
- technique, 1134, 1135, 1137–1138, 1138*f*, 1153*f*, 1212*f*–1214*f*
  - access, 1211
  - exposure, 1211
  - gastric pouch, 1211–1212
  - port placement, 1211*f*
- uncut, 1147–1148
- vertical banded gastroplasty revision to, 1206*f*
- weight recidivism, 1255–1256

Roux-en-Y gastroduodenostomy, 1085–1086

Roux-en-Y gastrojejunostomy, 1101–1102, 1659
- afferent loop syndrome after, 1146–1147
- biliary reflux after, 1146–1147
- Billroth I reconstruction *versus*, 1142–1143
- blood loss during, 1141
- completed, 1139*f*
- gastrojejunostomy with, 1165
- history of, 1141–1142
- loop gastrojejunostomy or, 1123
- operating room time, 1141
- postoperative care, 1146
- procedure, 1153*f*
- quality of life after, 1147

- reconstructive use of, 1134–1138
  - distal gastrectomy with, 1145*f*
- retrocolic
  - reconstruction using, 1138*f*
- total gastrectomy with, 1149*f*

- Roux-en-Y hepaticojejunostomy (HJ)
  - anastomosis of, 1416*f*
  - in bile duct reconstruction, 1376, 1377–1379, 1382
  - conduit, creating, 1415
  - extrahepatic biliary tree resection with, 1399–1400, 1400*f*, 1401
  - reconstruction using, 1425*f*
- Roux-en-Y jejunostomy, 1420
- Roux-en-Y pancreatojejunostomy, 1578*f*
- Rovsing sign, 1689
- “Rubens” flap, 233
- Rugal folds, 208, 209*f*
- Rutherford-Morison extension, 1691
- RYGB. *See* Roux-en-Y gastric bypass (RYGB)

S

- Sacral chordomas, 1883, 1885, 1886*f*
- Sacral edema, 1620
- Sacral nerve stimulation, 1904, 1954–1955, 1954*f*, 1964
- Sacrectomy, 1870*f*–1874*f*
  - abdominolithotomy position, 1874*f*
  - abdominopelvic phase, 1870–1873
    - complications, 1874*t*
  - classification of, 1870
  - complications, 1873–1875
  - incisions, 1872*f*
  - postoperative care, 1873
  - preparation for, 1871
- Sacrococcygeal junction (SCJ), 1825*f*
- Sacrococcygeal teratomas, 1883
- Sacromeres, disruption of, 37
- Sacropelvic externation, 1868
- Sacrum, 1825*f*
- SAFARI. *See* Subintimal Arterial Flossing with Antegrade-Retrograde Intervention
- Safe Surgery Saves Lives Study Group, 31
- SAGES Safe Chylecystectomy Program, 1361, 1367
- Saline-hydrogen peroxide, 438
- Salivary ducts, 323
- Salivary fistulae, 1000
- Salivary glands
  - adenocarcinoma, 344*f*
  - cancer of
    - management of the neck in, 355
  - floor of mouth, 323
  - FNABs, 309–310
  - imaging, 310
  - patient evaluation, 309–310
  - tumors of

- incidence of, 310
- surgery for, 310–311

Salmonella typhi, 1719
Salpingo-oophorectomy
- risk-reducing, 1247, 1249
- robotic-assisted, 271

Salpingopharyngeal fold, 300
Salpingopharyngeus muscle, 300
Sampson artery, 2129
Sanka, Madhu, 968
Saphenectomy, 2520–2521
Saphenous femoral junction, 2524
Saphenous vein
- anatomic relationships, 1965, 2182
- as aortic reconstruction conduit, 2474*f*
- crossover transposition (*See* Crossover saphenous vein transposition)
- division, 1969*f*
- thigh, 1965*f*

Sarcocolpopexy, robotic-assisted, 271
Sarcoidosis, lymphadenopathy in, 547
Sarfeh, Jim, 1607
Sarney-Stratakis syndrome, 1193
Sartorius muscle, 1965
Satiety, cortical centers for, 1182
Satinsky clamps, 1136*f*, 1445*f*, 1594, 1611*f*, 1612*f*
Sauerbruch, Ernst Ferdinand, 556
Savlex, 1306
SBS. *See* Short bowel syndrome (SBS)
Scalene fat pad, 2548–2549
Scalene minimus muscle, 2549
Scalene muscles
- anatomy, 285*f*, 358*f*
- exposure of, 506*f*
- neck, 285*f*

- release of, 469
- Scalene nodes, 307
- Scalene triangle, 2549
- Scalp
  - infantile hemangioma, 377*f*
  - innervation of, 317
  - lacerations, 434
  - melanoma, 423*f*
- Scaphoid bone
  - anatomy, 247, 250*f*
  - fractures, 247
- Scapula, elevation of, 284
- Scarpa fascia, 2182, 2182*f*
- Scarring
  - facial trauma and, 444–445
  - mastectomy, 227*f*
  - in proliferative breast disease, 605
  - radial, 605
  - retention sutures and, 153
  - Vitamin A and, 445
  - vitamin C and, 445
- SCFAs. *See* Short chain fatty acids (SCFAs)
- Schistosomiasis, 1605
- Schnidt clamps, 2109*f*
- Schoemaker suture line, e16, e17*f*
- Schuchardt operation, 330, 330*f*
- Sciatic hernia rings, 2195, 2202*t*
- Sciatic nerve, protection of, 241
- Scleroderma, 27
- Sclerosing cholangitis, 1403, 1404. *See also* Primary sclerosing cholangitis
- Sclerosing lesions, 605
- Sclerotherapy
  - in distal splenorenal shunts, e21

- emergency, 1624*f*
  - complications, 1624–1625
  - intravariceal, 1624
  - paravariceal, 1624
- for hemorrhoids, 1922–1923
- injection, 1620–1621, 1621*f*
  - technical variants, 1623–1624
- for lymphatic malformations, 372, 379
- superficial venous insufficiency treatment with, 2522–2523

Sclerotherapy needles, 207
Sclerotomes, differentiation of, 772
Scopinaro, Nicola, 1225
Scrotal orchipexy, 2075
Scrotum, in inguinal hernia repair, e77
SCS. *See* Subclinical Cushing syndrome (SCS)
Second hit phenomenon, 8
Secondary diaphragmatic eventration, 848
Secretory acini, 1471–1472
Sedation. *See Specific* procedures
Sedatives, selection of, 138
Segmental bile ducts, 1267–1268
Segmentectomy, lateral, 714–715, 716*f*
Segmentectomy, ultrasound-guided, 192
Segura basket, 1363
Seizures, 485–486
Seldinger technique, 70, 1083
Selective estrogen receptor modulators, 29*t*
Selective estrogen receptor modulators (SARMs), 41
Selective histamine receptor agonists, 1165
Selective serotonin reuptake inhibitors (SSRIs), 30*t*
Selective venous sampling (SVS), 544
Selenium
- in EN formulas, 64
- glutathione peroxidase and, 20

- supplementation, 20
- Self-antigens, presentation of, 196
- Self-care checklists, 1648
- Self-catheterization, 2053
- Self-expanding metallic stents (SEMS)
  - colon decompression with, 1703–1705
  - colonic perforation by, 1704–1705, 1707
  - migration of, 1707
- Semilateral decubitus position, 1992*f*
- Seminal vesicles
  - anatomic relationships, 1826*f*, 2007*f*, 2009
  - dissection behind, 1846*f*
  - dissection of, 2070
  - protection of, 2011
- Semon's law, 305
- Sensorcaine (Marcaine®), 2233
- Sensorineural hearing loss, 845
- Sentinel lymph node biopsies (SLNBs), 336–337, 671
  - ALND and, 762
  - in cutaneous melanoma, 417
  - indications and contraindications, 667–668
  - intraoperative, 421*f*
  - lymphedema, 672, 673t, 677*f*
  - in malignant melanoma, 413–415, 414*t*
  - neck dissection and, 353
  - positive, lymphadenectomy in, 432
  - surgical technique, 668–669, 668*f*–669*f*
  - in urologic cancers, 2067–2068
- Sentinel lymph nodes
  - of axilla, 600
  - in breast oncoplasty, 717
- Sentinel NeoAdjuvant (SENTINA) trial, 760
- Sentinel Node Versus Axillary Clearance Trial (SNAC), 758–759
- Seprafilm, 1736

- Sepsis
  - anorectal, 1915*f*
  - catabolism and, 37*f*
  - catheter-associated, 1982, 1983
  - classification of, 1915*f*
  - early LC and, 1366
  - hepatocytes and, 19
  - inflammatory responses and, 2
  - intra-abdominal, 46
  - Kupffer cell function in, 19
  - liver response to, 18
  - metabolic derangements, 50*t*
  - muscle proteolysis in, 13*f*
  - nutritional support in, 49–51, 52
  - pelvic, 1918
  - perianal, spread of, 1916*f*
  - postoperative, 997, 2163
  - proteolysis in, 51–52
- Septal fistulae, 1932, 1933
- Septectomy
  - overview of, 1389, 1389*f*
  - surgical technique, 1391*f*
- Septic arthritis
  - urgent attention to, 251
  - wrist, 257–258, 258*f*
- Septic shock
  - hemodynamic profile, 77*t*
  - IABP use in, 82
  - metabolic demands in, 76
  - respiratory muscle weakness in, 36
  - TNF and, 6
- Septicemia, 2539
- Septocutaneous blood vessels, 216
- Septocutaneous flaps, 217*f*

- Septoplasty, 1389
- Septum transversum
  - diaphragm origin, role in, 840
  - embryogenesis, 820
  - formation of, 821*f*
- Serial transverse enteroplasty (STEP)
  - postoperative management, 1983
  - procedure, 1984*f*
  - in SBS, 1982
  - technique, 1982–1983
- Serine protease inhibitor, Kazal type 1, 1493
- Seromas
  - extraanatomic bypass, 2346–2349
  - failed grafts and, 215
  - formation of, 168
  - in inguinal herniorrhaphy, e68
  - Kugel method for groin hernia, e93
  - as prosthetic arteriovenous hemodialysis complication, 2546
  - and prosthetic grafts, 2372
  - with reversed vein bypass graft, 2366
- Seromuscular colonic flaps, 1687
- Serous pseudopapillary neoplasms, 1515–1516
- Serous tubal intraepithelial carcinoma (STIC), 1247
- Serratus anterior muscle, 775*f*, 1040*f*
- Serratus anterior nerve, 774
- Sertoli cells, 2072
- Serum creatinine, 55
- Serum gastrin levels, 1114
- Serum lipase, 1354
- Serum proteins, nutritional status and, 55–56
- Sestamibi scans
  - limitations of, 543
  - parathyroid, 508, 509*f*, 534, 543, 549
- Seton fistulotomy, 1919–1920, 1920*f*, 1934–1935, 1936

- Setons, fistula drainage and, 1716
- Severe acute pancreatitis (SAP)
  - interventions, 1529
  - open necrosectomy in, 1533–1535
  - preoperative, 117*t*
  - presentation, 1523
- Severe illnesses
  - caloric requirements, 58–59
  - energy requirements, 58–59
  - metabolic alterations, 56
  - protein requirements, 58–59
- Sexual abuse, outlet obstruction and, 1963
- Sexual dysfunction
  - after aortofemoral bypass, 2342
  - after APR, 1850
  - after hernia repair, 2242
  - post hysterectomy, 2144
- Sexual function, rectal cancer surgery and, 1838–1839
- Shear, failed grafts and, 215
- *Shigella* spp., 1719
- Shock
  - hemodynamic profiles, 77, 77*t*
  - hemorrhagic
    - threat of, 110
  - hypoperfusion and, 2106
  - pediatric patients, 2106
- Shockwave lithotripsy (SWL)
  - background, 2013
  - complications, 2014–2015
  - contraindications, 2014
  - for nephrolithiasis, 2011
  - for parotid gland stones, 324
  - patient factors, 2013–2014
  - recommendations, 2013

- renoprotective protocols, 2014
- shock wave rate, 2014
- stone-free rates after, 2014
- voltage escalation, 2014

- Short bowel syndrome (SBS)
  - complications of, 1982
  - conventional therapy, 1636, 1637
  - definition of, 1636
  - low-birth-weight preterm infants, 1985
  - pediatric
    - overview, 1981
    - treatment, 1981–1982
  - in pediatric patients, 1420
  - risk factors, 1675
  - TPN in, 46
- Short chain fatty acids (SCFAs), 59
- Short esophagus
  - characteristics of, 822*t*, 831*f*
  - definition and overview of, 823–824
  - description of, 839
  - embryology of, 823–824
  - gastroplasty, lengthening for, 901
  - as hiatal hernia type, 828
  - as preoperative concern, 868, 872
  - sphincteric incompetence resulting from, 829
  - theories, 839
- Short gastric arteries, 1065–1066
- Short gastric veins, 1070, 1070*f*
- Short gastric vessels, 919*f*, 976*f*, 1477
- Short right adrenal vein, 2011
- Short saphenous vein (SSV), 2360–2361, 2362*f*
- Shoulder, bursitis, 609
- Shouldice, Earle, 2218
- Shouldice method, 2221*f*

- hernia repair, 2210, 2218–2219
- in plug-and-patch repair, 2230

Shunting
- extremity injury treatment with, 2591–2592, 2591*f*, 2592*f*

Shunts
- central splenorenal (CSRS)
  - incision, e30, e30*f*
  - indications, e30, e30t
  - surgical technique, e30–34*f*, e30–e34
- distal splenorenal
  - ascites, e27–e28
  - durability, e28
  - encephalopathy, e28
  - indications, e21
  - modification of DSRS
    - clamping of splenic artery, e25
    - renosplenic end-to-side shunt, e25–e26, e28*f*
    - splenocaval shunt, e26, e28*f*
  - occlusion of, e27
  - postoperative management, e26
  - preoperative planning, e21
  - rebleeding, e26–e27
  - surgical technique, e21–e25, e22–e27*f*
  - survival, e28
  - *vs.* CSRS, e28–e29, e29*f*
- renosplenic end-to-side, e25–e26, e28*f*

Sialadenitis
- causes of, 309–310, 324
- chronic, 323–324
- diagnosis of, 324
- management of, 311
- patient evaluation in, 309
- submandibular, 324

Sialendoscopy, interventional, 324

- Sialograms, indications for, 310
- Sialolithiasis, sialadinitis and, 311
- Sibson fascia, 287
  - anatomy of, 308
- Side-to-side anastomoses, 1378
- Side-to-side cholecystojejunostomy, 1413*f*
- Side-to-side choledochojejunostomy, 1413*f*, 1418–1419, 1419*f*
- Side-to-side portacaval shunts (SSPCS)
  - caval-atrial shunts and, 1603*f*
  - completed, 1597*f*
  - indications, 1590
  - operative field, 1593*f*
  - patient positioning, 1593*f*
  - postoperative management, 1605
  - in schistosomiasis, 1605
  - vein preparation, 1596*f*
- Sigmoid colon
  - anatomy, 1679
  - diverticula in, 1753
  - division of, 1748*f*, 1804
  - fistula, 1710*f*
  - left hemicolectomy for, 1795
  - mobilization of, 1745*f*, 1845*f*, 1897–1898, 1898*f*
  - redundant, 1898–1901
  - resection of, 1900*f*
    - complications, 1901–1902
    - postoperative management, 1901
  - robotic-assisted resection, 1759
- Sigmoid mesentery, 1749–1750, 1804, 1804*f*
- Sigmoid mesocolon, 1745*f*
- Sigmoid proctopexy, 1898*f*–1901*f*
- Sigmoid vein, 1589*f*
- Sigmoid volvulus, 1701–1703
- Sigmoidectomy, 1959*f*

- Sigmoidoscope
  - flexible, 1701*f*, 1702*f*, 1894
  - rigid, 1701*f*, 1702*f*
  - volvulus detorsion with, 1702*f*
- Sigmoidoscopy
  - for fissure in ano, 1913
  - preoperative planning, 1816
- SILASTIC stents, 1985
- Sildenafil, 972
- Silicone implants, 726, 728*f*
- Silver nitrate, protoscolicidal effects, 1306
- Simple hepatic cysts, 1276–1277
- Simple partial status epilepticus, 486
- Simpson-Golabi-Behmel syndrome, 2078
- Singapore flaps, 243–244, 244*f*
- Single anastomosis duodenoileal bypass with sleeve gastrectomy (SADI-S), 1231, 1232
- Single Incision Laparoscopic Surgery (SILS), 277
- Single photon emission computed tomography (SPECT), 543
- Single-Incision Laparoscopic Surgery PORT (SILS PORT), 1943–1945
- Single-layer anastomosis, 1041*f*
- SIRS
  - liver response to, 18
  - systemic inflammation and, 6
- SIRT1 deacetylase, 40
- Sistrunk procedure, 367
- Situation-Background-Assessment-Recommendation model, 34
- Skate flaps, 233*f*
- Skeletal muscle, body totals, 18
- Skin
  - excision in radical mastectomy, 723, 723*f*, 724
  - grafts in mastectomy, 725, 726*f*
- Skin and soft tissue infections (SSTIs), 126–129
  - classification of, 126–127, 127*f*

- complicated (cSSTIs), 126*t*, 127–129
  - antimicrobial therapy for, 126–128, 126*t*
  - microbiology of, 127
  - surgical interventions, 128
  - treatment of, 130
- MRSA in, 113

Skin barriers, 1775*f*–1776*f*

Skin cancer. *See also Specific* skin cancers
- malignant melanoma and, 410–418
- pigmented lesions, 419*f*
- unknown primary, 416

Skin fold thickness, assessment of, 55

Skin grafts
- description of, 215–216
- “taking” of, 215–216

Skin irritations, 1649*t*

Skin sealants, antimicrobial, 118*t*

Sklar Gelpi Retractor, 1848

Skull, exposed, 216

Skull base, 468–469

Skull fractures
- characteristics of, 481
- depressed, 482*f*
- indications for surgery, 481

Sleep apnea, postoperative care, 1229

Sleep deprivation, pain and, 138

Sleeve gastrectomy (SG). *See also* Laparoscopic gastric sleeves (LSG)
- advantages of, 1223
- complications of, 1224, 1244–1246
  - sleeve stenosis, 1245
- conversion to RYGB, 1248–1249
- final anatomy of, 1219*f*
- gastric sleeve, 1153*f*
- illustration, 1180*f*, 1227*f*

- impact on GERD, 1224
- as most commonly performed bariatric surgery, 1165
- neural pathways and, 1182
- outcomes, 1203, 1223–1224
- patient selection, 1223
- prevalence of, 1223
- revision for, 1244
- revision for weight regain, 1248–1249
- robotic-assisted, 265–266
- staged, weight loss and, 1179
- twisted sleeves, 1224

Sliding gluteus maximus myocutaneous flaps, 240*f*, 242*f*

Sliding hiatal hernia, 828
- as antireflux surgery complication, 958
- appearance of, 865*f*
- characteristics of, 822*t*, 824*f*, 828, 831*f*
- stomach location in, 833

Sling of internal inguinal ring
- in inguinal hernia repair, e82

SLNB. *See* Sentinel lymph node biopsy

SMAD2, 38

SMAD3, 38

Small bowel
- adherent, 1634
- anatomy, 1675–1676
- attachment, 1676*f*
- Crohn disease, 1664
  - outcomes, 1671–1672
  - surgical treatment of, 1661–1674
- division of, 1213*f*
- fistula, 1710*f*
- fluids, composition of, 1651*t*
- GIST prognosis, 1196
- hypoperfusion, 1635*f*

- intraoperative injury, 1750
- laparoscopic resection, 1636–1637
- length of, 1655
- perforation, 1662
- radiography, 1663
- surgery, antimicrobial prophylaxis, 114*t*
- technique, 1664–1668
- transection, 1665*f*

Small bowel obstruction (SBO), 1630–1637
- abdominal film, 1632*f*
- adhesions, 1636
- after hysterectomy, 2134
- after ileostomy, 1649*t*
- after laparotomy, 1631–1632
- after RYGB, 1252, 1257
- after Wilms tumor surgery, 2084
- anastomotic leaks, 1648
- causes of, 1630*t*
- conservative therapy, 1631
- contrast media, 1637
- CT scans, 1632*f*, 1637
- early postoperative (ESBO), 1637
- etiology, 1630
- ileostomy patients, 1647
- management algorithm, 1633*f*
- pathophysiology, 1630
- postoperative care, 1635
- preoperative planning, 1633
- repair of rectal prolapse and, 1902
- surgical management
  - contraindications, 1631–1633
  - indications, 1631–1633
- surgical technique
  - complications, 1635–1636

    - desmoids, 1634
    - laparoscopy, 1634
    - lysis of adhesions, 1633–1634
  - volvulus and, 1631*f*
  - without antecedent surgery, 1632–1633
- Small cell lung cancer (SCLC), 799, 800
- Small duct primary sclerosing cholangitis (PSC), 1396
- Small intestine, strangulation of, 1636
- Small molecule drugs, in gastroparesis, 1165
- Small saphenous vein, 1221
- Smoking
  - duodenal ulcer disease and, 1104–1105
  - as gastric cancer risk factor, 1127
  - lip cancer and, 325
  - passive, in childhood, 102
  - renal cell carcinoma and, 2019
  - surgical complications linked to, 1020
  - surgical pulmonary risk, 89
  - ventilatory risk and, 102
  - Warthin tumors and, 310
- Smoking cessation
  - preoperative, 27–28, 89, 985, 1020, 2227
  - before RYGB, 1252
  - wound healing and, 159
- Smooth muscle of esophagus, 892*f*
- Snuff, oropharyngeal cancer and, 409
- Soave procedure, 1972
- Society for Vascular Surgery/International Society for Cardiovascular Surgery (SVS/ISCVS), 2416
- Society of Surgical Oncology (SSO)/ASTRO Margin Consensus for Invasive Breast Cancer trial, 756
- Sofosbuvir, 1448
- Soft palate reconstruction, 404
- Soft tissue

- injuries, 436–439
- reconstruction, 215–246
- wound coverage, 216–217

Soft tissue flaps
- techniques
  - ear defects, 217
  - facial defects, 217, 219–221
  - nose defects, 217, 219–221

Soft tissue infections (STIs)
- necrotizing, 128
  - diagnosis of, 128
  - microbiology of, 128
  - presentation of, 128

Solid pseudopapillary neoplasia (SPN), 1515

Somatostatin, 1472, 1618, 1654

Somatostatinomas, 1473–1474

Sorafenib, 195

Sotos syndrome, 2078

SOUND (Sentinel Node *vs.* Observation after Axillary Ultra-Sound) study, 762

Sound waves, piezoelectric effect and, 177–178

SOX-10 mutations, 1971

Space of Bogros, 2229, 2231

Space of Couinaud, 1320–1321

Space of Retzius
- anatomy, 2173*f*
- description of, 2034
- opening of, 2069

Spaces of the urogenital triangle, 2197

Specialized pro-resolving molecules (SPMs), 64

Spermatic cord
- anatomic relationships, 2007*f*
- dissection of, 2063*f*
- in inguinal hernia repair, e72–e73, e73*f*, e81

- isolation of, 2216–2217
- in plug-and-patch groin repair, 2233–2236

Sphincter of Boyden, 1481. *See also* Sphincter of Oddi

Sphincter of Oddi. *See also* Sphincter of Boyden
- anatomy, 1353, 1481
- dilation of, 1363
- disorders and dysfunctions, 1383, 1384, 1384*f*
- manometry, 1384, 1384*f*, 1385–1386
- musculature and biliary cannulation, 1385*f*
- physiology of, 1383–1384
- surgeries, 1389–1392, 1389*f*

Sphincter of Oddi dysfunction (SOD)
- classifications, 1385–1386, 1386*t*, 1388–1389, 1394
- and endoscopic sphincterectomy, 1384–1386
- treatments for, 1388–1389

Sphincter pressure, postoperative, 906*f*

Sphincter tone, 905, 905*f*

Sphincter urethrovaginalis, 2009*f*

Sphincterectomy. *See also* Endoscopic sphincterectomy
- definition and overview of, 1389, 1389*f*
- internal anal
  - for fissure in ano, 1914
- lateral choledochoduodenostomy compared to, 1387
- lateral subcutaneous, 1914, 1914*f*
- open internal, 1914–1915, 1915*f*
- surgical technique, 1388*f*
- sutures for, 1391*f*

Sphincteroplasty
- definition and overview of, 1389, 1389*f*
- fashioning, 1349*f*
- outcomes, 1394
- reduced need for, 1394

Sphincterotomy, 1349*f*
- endoscopic, 1480–1481

- endoscopic biliary anterograde, 1364–1365, 1365*f*
- intraoperative, 1362
- pancreatic, 1537
- studies, 1394
- transduodenal, 1349–1350

- Sphygmomanometer, 68
- Spider angiomata, 1620
- Spieghel, Adrianan van der, 2185
- Spigelian hernias, 2187*f*
  - description, 2185–2186
  - Proline patches, 2237
  - repair of, 2210
  - surgical anatomy of, 2201*t*
- Spigelian lobe, 1269
- Spinal accessory nerve (CN XI)
  - anatomy, 292, 296, 468, 468*f*
  - anatomy of, 291
  - dissection of, 507*f*
  - identification of, 357*f*, 362, 525, 526
  - injuries
    - after thyroidectomy, 529
  - location of, 504
  - protection of, 526
  - radical neck dissection and, 503
- Spinal cord, 2283
- Spinal cord injury, 2280, 2288–2289, 2289t
- Spinal sympathetic stimulation, 90
- *SPINK1* gene, 1493, 1525
- Spiral saphenous vein graft, 2506*f*
- Spiral valves of Heister, 1271
- Spirometry, pulmonary function testing, 87*t*
- Spironolactone, 572
- Spitz classification system, 1034, 1034*f*
- Spitz nevus, 424–425

- Spitzoid tumors, atypical, 424–425
- Splanchiectomy, 1581
- Splanchnic artery, 1587
- Splanchnic denervation, 1580–1586
- Splanchnic nerves
  - cautery, 1584, 1585*f*
  - types of, 1581
- Splanchnic pelvic nerves, 1845
- Splanchnic perfusion, 65
- Splanchnic thoracic nerves, 780
- Spleen
  - anatomic relationships, 2002
  - anatomy of, 1989, 1989*f*
  - in central splenorenal shunt (*See* Central splenorenal shunts)
  - detachment of, 1990
  - embryology of, 1052*f*
  - exposure of, 1990, 1990*f*
  - functions of, 1989
  - hemorrhagic shock and, 110
  - injuries
    - classification of, 1995*t*
    - grades of, 1988*f*
    - nonoperative preservation, 1995–1996
    - type II, 1997*f*
    - type III, 1996*f*
    - type V, 1995*f*
  - lacerations, 1993*f*, 1994
  - lymphatics, 1487
  - mobilization of, 1569*f*, 1570*f*
  - preservation, 2000
  - removal of, 1066
  - retraction of, 511*f*
  - salvage of, 1993, 1993*f*, 1996–1999, 1996*f*–1999*f*
  - traumatic injuries, 110

- Splenectomy
  - distal pancreatectomy with, 1577*f*
  - incisions, 1989
  - laparoscopic, 1988–2001, 1991–1993, 2001
    - patient positioning, 1991, 1992*f*
    - port placement, 1992*f*
    - with portal hypertension, 1993
  - Nissen-Rosetti fundoplication and, 933
  - open, 1989–1990
  - in ovarian cancer, 2157
  - partial, 1994
  - postoperative bleeding, 1991
  - with splenic replantation, 1994–1995
- Splenic artery
  - anatomic relationships, 1437*f*, 1482*f*
  - arteriogram, 2329*f*
  - branches of, 1483
  - catheterization of, 2329*f*
  - distal pancreas, 1483*f*
  - identification of, 2001
  - ligation of, 1065
- Splenic artery aneurysms (SAAs), 2328–2331
  - calcified, 2330*f*
  - CT angiogram, 2328*f*
  - etiology of, 2328
  - indications for intervention, 2328
  - pathophysiology of, 2328
  - preoperative planning, 2328–2329
  - presentation, 2328
  - surgical management
    - complications, 2330
    - embolization, 2329, 2330*f*
    - endovascular, 2329–2330
    - follow-up, 2331

- open, 2329, 2329*f*
- open *vs.* endovascular, 2331
- outcomes, 2330–2331
- patient selection, 2331

- Splenic blush, 1995
- Splenic flexure
  - ligaments of, 1679*f*
  - mobilization of, 1748*f*, 1762
  - taking down, 1746*f*
- Splenic portas, 1477*f*
- Splenic veins
  - anatomic relationships, 1589*f*
  - drainage, 1475
  - identification of, 2001
  - ligation of, 1065
  - occlusion of, 1069*f*
  - origin of, 1477
  - superior mesenteric vein and, 1475
  - thrombosis, 1492
- Splenius capitus muscle, 294, 358*f*
- Splenocaval shunts, e26, e28*f*
- Splenomegaly, 1989
- Splenorenal ligament, 1052, 1053, 1477
- Splenorenal shunts. *See* Central splenorenal shunts (CSRS); Distal splenorenal shunts
- Splenorrhaphy, 1993–1994, 2000
- Split-rib grafts, 236
- Spontaneous perforation, esophageal, 1020, 1030, 1031
- Squamous cell carcinoma (SCC)
  - anal, 1842–1843
  - definition of, 427
  - diagnosis, 428
  - ear, 217
  - esophageal, 984

- etiology, 427–428
- excision of, 217
- head and neck, 345
  - distribution of patients with, 345*f*
  - HPV and, 409
  - survival rates, 345*f*
- hypopharyngeal, 404–408
- incidence, 427–428
- lower lip, 325
- mucosal, 353
- neck, staging system, 347
- oral cavity, 309, 334
- oropharyngeal, 400
- presentation, 428
- prevention, 427–428
- rectal, local excision of, 1938
- salivary gland, 311
- skin, management of, 416
- staging system, 347*t*
- treatment, 428

SRY gene, 2072

St. Mark’s retractor, 1804, 1856

St. Martin, Jacques Lis-Franc de, 1839

Stab wounds. *See also* Traumatic injuries, penetrating
- abdominal vascular injuries due to, 2577–2578
- cervical trauma due to, 2569
- median sternotomy in, 789

Stamm gastrostomy, 1654

Standardization of Breast Radiotherapy (START), 646

Stanford Research Institute (RSI), 262

Staphylococci, coagulase-negative, 112*t*

Staphylococcus aureus
- colonization by, 113, 114
- as graft infection pathogen, 2471

- nasal carriage of, 115*t*, 117*t*
- penetrating trauma and, 257–258
- surgical site infections, 112*t*
- susceptibility patterns for, 121

Stapled hemorrhoidectomy (PPH), 1927–1928, 1927*f*, 1928*f*

Staplers
- circular
  - end-to-end, 1835*f*
- linear, 173*f*
  - benefits of, 174

Staples
- in intestinal bypass, e39
- length of, 174

Stapling
- complications of, 175
- laparoscopic, 169–176, 173

START. *See* Standardization of Breast Radiotherapy

Starvation
- hyperdynamic states *versus*, 56–58
- impact on the heart, 48

Static compliance, 87

Statins, 29*t*, e37

Status epilepticus (SE)
- background, 485–486
- causes for, 486*f*
- epidemiology, 486
- etiology, 486

"Stauffer syndrome," 2020

Stay sutures, 1012*f*

Steal phenomenon
- complications of, 2539
- hand ischemia due to, 2535
- leg, 2547
- as prosthetic arteriovenous hemodialysis complication, 2546

- and prosthetic grafts, 2372
- reducing, 2538

Steatohepatitis, 20

Steatorrhea, 1492

Steering wheels, 1332

Stellate ganglion, 285

Stem cells, 1175

Stenosis
- anastomosis, 2365
- recurrent, 2256
- renovascular, 2431
- severity, determining, 2509

Stenson duct, 308, 309

Stent grafting
- in abdominal injury repair, 2583, 2585
- in cervical injury repair, 2571–2572

Stents
- for abdominal aortic aneurysm repair, 2307, 2308*f*
- for abdominal aortic aneurysms, 2299
- for anastomotic leaks, 1795
- AXIOS LAMS, 1537–1538, 1540*f*
- AXIOS TM lumen opposing, 1537
- carotid, 2246–2258
- endovascular therapy for aortoiliac occlusive disease, 2353, 2355, 2356
- migration of, 1707
- pancreatic duct, 1537–1538
- for peripheral vascular occlusive diseases, 2386–2388, 2388f
- for renal artery occlusive disease, 2443
- self-expanding, 1703–1705
- through-the-scope, 1703–1705

“Step Port” dilating system, 1547

Step sheath, 875*f*

Stereotactic ablative radiotherapy (SABR), 805

- Sterilization at time of cesarean delivery, 2123
- Steri-strips
  - facial trauma and, 439
  - in gastrostomy, 880*f*
- Sternal bands, 773*f*
- Sternal bar, 773*f*
- Sternocleidomastoid flap, 1028*f*
- Sternocleidomastoid (SCM) muscle
  - anatomy of, 71*f*, 284, 290, 293–294, 322*f*, 775*f*
    - innervation, 284
  - dissection of, 359*f*
  - fascia and, 286
  - neck exploration, 464*f*
  - parotid gland and, 308
  - retraction of, 1004*f*
  - sacrifice of, 503
  - separation, 463
- Sternohyoid muscle
  - dissection of, 501
- Sternohyoid muscles, 293–294, 322*f*, 359*f*, 468*f*
- Sternomastoid muscle, 358*f*
- Sternothyroid muscles, 71*f*, 322*f*, 501
- Sternotomy
  - in brachiocephalic reconstruction, 2259–2260, 2260*f*
  - carotid injury control through, 2571*f*
  - innominate artery repair via, 2572*f*
  - median
    - extension of, 469
  - mediastinitis after, 236
- Sternum
  - anatomic relationships, 778*f*, 856*f*
  - anatomy, 772–773
  - development of, 773*f*
  - embryology of, 772

- fractures
  - clinical presentation, 790
  - diagnosis, 790
  - treatment, 790–791
- ossification of, 773*f*
- wound reconstruction, 236–237
  - flap options, 236–237
  - infections and, 236

Steroid injections, 1936
Steroids, immunosuppression and, 146
Stewart incision for mastectomy, 690–691*f*, 705
Stewart-Way classification, 1361, 1362*f*, 1363*t*
STILE. *See* Surgery or Thrombolysis in Lower Extremity Ischemia
Stillborn infants, hiatal hernia in, 823
Stoma

- anatomy of, 1772–1777
- care of, 1772–1780
- closure, 1644–1645, 1770*f*
- color changes, 1647
- complications, 1724, 1777–1778, 1850–1851
- construction of, 1765–1766, 1957
- continent, 1677
- cyanosis, 1777
- defect closure, 243*f*
- dermatitis, 1778
- double-barrel, 1772
- education, preoperative, 1639
- end-loop, 1772–1777
- incision around, 1769*f*
- marking sites for, 1709
- mucocutaneous separation, 1777, 1777*f*
- mucosal transplantation, 1779, 1779*f*
- necrosis, 1647, 1649*t*, 1777–1778
- output, effects of food on, 1776*t*

- parastomal hernias, 1647
- patient education, 1779
- perioperative care, 1777
- peristomal complications, 1778
- physiology, 1772–1777
- Prasad end-loop, 1707*f*
- prolapses, 1647, 1777, 1777*f*
- protectomy, 1713
- pseudoverrucous lesions, 1778*f*
- psoriasis, 1779
- retraction, 1778
- site preparation, 1765–1766
- site selection, 1648–1649
- stenosis, 1778, 1778*f*
- ulceration, 1778
  - after RYGB, 1252
  - diagnosis of, 1155
  - etiopathogenesis, 1155
  - symptomatology, 1155
  - treatment, 1155
- varices, 1779

Stoma belts, 1776*f*

Stomach

- aligning, 1012*f*
- anatomic relationships, 2003*f*
- anatomy of, 1056–1057, 1058*f*
- antrum, 1061
- antrum resection, 1561*f*
- antrum-body junction, 1059*f*
- arteries of, 1064*f*
- bougie passage into, 870*f*
- cardia, 209*f*, 1060
- congenital anomalies of, 1057*f*, 1057*t*
- construction of, 1639–1641

- Crohn disease involvement, 1663–1664
- distension (*See* Gastric distension)
- division of, 1136*f*
  - linear stapler in, 1212*f*, 1213*f*
  - ultrasonic dissector, 1220*f*
  - in VBG, 1207*f*
- embryology of, 1051–1055, 1051*f*, 1052*f*, 1053*f*
- en-bloc resections, 1072*f*
- fixation of, 867, 870
- fundus (*See also* Gastric fundus)
  - inspection of, 209*f*
- gastric units, 1057, 1059*f*
  - blood supply, 1072
  - lymphatic drainage, 1072
- inflation of, 208
- innervation of, 1072–1076, 1072*f*, 1075–1076, 1075*f*
- ischemic conditioning of, 999
- in lateral decubitus position, 208*f*
- lymphatics, 1070–1071, 1071*f*, 1071*t*
- mesenteries, 1062*f*
- mobilization of, 916, 954*f*, 988*f*, 1000
  - anterior chest, placement on, 1009*f*
  - clamp for grasping, 1010*f*
  - laparoscopic sites or, 993*f*
- musculature, 1059*f*, 1061–1062, 1062*f*
- peritoneal reflections, 834*f*, 1062–1063
- posterior aspect of, 1143*f*
- pylorus, 1061
  - innervation, 1073–1074, 1074*f*
- reduction of, 867, 868*f*
- referred pain from, 1076
- resection, indications, 1142–1143
- in sliding hiatal hernia, 833
- staple cartridge insertion into, 1012*f*

- stapling, 1220–1921, 1220*f*, 1221*f*
- thorax, ascent into, 823
- transection, 1144*f*, 1560
- upper, division of, 1009*f*
- vagal nerve supply, 1097*f*, 1102*f*
- vascular supply, 1063–1067, 1068–1070, 1069*f*
- vessels, division of, 954*f*

- Stomach intestinal pylorus-sparing (SIPS) procedure, 1231
- STOP-BANG screening tool, 26
- Stoppa, René, 2222
- Stoppa repair, 2222, 2230
- Strap muscles, 294
  - anatomy of, 308
  - dissection of, 501
  - division of, 406, 523*f*
  - separation of, 502*f*
  - transection of, 308
- Strasberg classification, 1367
- Strattice, diaphragm repair using, 861
- Strauss maneuver, e14–e15
- *Streptococcus* spp.
  - in appendicitis, 1692
  - as graft infection pathogen, 2471
  - in liver abscesses, 1287
  - VAP and, 92
- Stress
  - duodenal ulcer disease and, 1104–1105
  - metabolism and, 56–57
  - nutritional response to, 54
  - testosterone levels and, 11
- Stress responses
  - catabolism and, 18
  - cortisol secretion and, 9
  - hypercoagulability, 19

- liver, 18–20
- liver dysfunction, 20
- sympathetic, 11–12
- to systemic insult, 2

- Stress-related mucosal injury (SRMI), 91–92
- Stretta device, 966*f*
  - technique, 965–966, 967*f*
    - complications, 966
    - outcomes, 966
    - postoperative care, 966
- Striated muscle, esophageal, 892*f*
- Stricturoplasties
  - in Crohn disease, 1665–1666
  - sites of, 1673
  - techniques, 1666–1668, 1670*f*–1671*f*
- Stroboscopes, laryngeal, 386
- Stroke volumes, variation, 69
- Strokes
  - after carotid endarterectomy, 2255
  - risk factors for, 2469
  - TEVAR followed by, 2567, 2568
- Stromal ulcers, 1155
  - diagnosis, 1155
  - etiopathogenesis, 1155
  - treatment, 1155
- Studer neobladder, 2046–2047, 2115–2116, 2116*f*
- Studer pouch, 2045–2046, 2046*f*
- Stump appendicitis, 1693
- Stump syndrome, ICA, 2248
- Styloglossus muscle, 319*f*, 322
- Stylohyoid ligament
  - anatomy, 303, 320
  - pharynx and, 301
- Stylohyoid muscle

- anatomy of, 71*f*
- innervation of, 319
- parotid space and, 319

- Stylomandibular ligament, 316
- Stylomandibular membrane, 309*f*
- Stylopharyngeus muscle, 293, 301, 302
- Subarachnoid hemorrhages, 481
- Subclavian artery
  - anatomical relationships, 776
  - anatomy of, 284, 285, 307, 469, 2549
  - bleeding control, 466*f*, 467*f*
  - in brachiocephalic reconstruction, 2260–2261
    - aneurysm, 2262, 2263*f*
    - bypass, 2262–2264, 2263*f*
    - left, intervention, 2264–2265, 2265*f*
    - transposition, 2264
  - exposure of, 469, 789
  - injuries, repair of, 2596
  - left
    - aortic arch endograft manipulation, 2568
    - carotid to left subclavian artery bypass, 2564
    - extravasion from, 2570*f*
  - repair of, 470
- Subclavian lymphatic trunk, 778*f*
- Subclavian vein
  - anatomy of, 71*f*, 286, 2549
  - cannulation, 70–71
  - catheterization, 84
  - venous access, 84
- Subclavian vessels, risks to, 2569
- Subclavian/axillary artery injury, 2575*f*
- Subclavius muscle, 775*f*, 2549
- Subclinical Cushing syndrome (SCS), 572
- Subcoracoid space, 2549

- Subcostal arteries, 2182
- Subcostal incisions, 152, 152*f*
- Subcostal nerves, 2002
- Subcostal veins, 779*f*
- Subdural hematomas, 480–481, 481*f*
- Subglottic hemangiomas, 374
- Subglottic stenosis, 491, 497–498
- Subintimal Arterial Flossing with Antegrade-Retrograde Intervention (SAFARI), 2390
- Sublingual gland, 309
- Sublingual space, boundaries of, 309
- Submandibular duct, 320, 320*f*. *See also* Wharton duct
- Submandibular ganglion, 321
- Submandibular glands
  - anatomy, 320, 320*f*, 321*f*, 361*f*
  - excision of, 324
  - lymphatic drainage, 321
  - release of, 313
  - resection, 313*f*
  - separation of, 363*f*
- Submandibular lymph nodes, 325
- Submandibular triangle
  - anatomic aids, 321
  - anatomy of, 313*f*, 319–321, 322*f*
  - contents of, 320, 321*f*
  - deep structures, 323*f*
  - dissection
    - complications of, 314
    - endoscopic approaches, 314
    - incision, 312*f*
    - lateral transcervical approach, 312–314
    - revision surgeries, 314
    - transcervical approaches, 314
    - transoral approach, 314

- floor of the mouth and, 320*f*
- location, 504*t*
- muscular boundaries, 319–320, 319*f*
  - fascial coverings, 320
  - muscular floor, 319–320
- neurovascular structures, 320–321

- Submaxillary gland resection, 313*f*
- Submental triangle, 310*f*, 322, 322*f*
- Submental vein, 321*f*
- Submucosal endoscopic tumor resection (SET)
  - for GISTs, 1198
- Submucosal spaces, significance, 1685
- Submucosal tunnel, anal, 1907*f*
- Submucous abscesses, anal, 1917
- Subscapularis muscle, 775*f*
- Subspinous ring, 2195
- Subungual hematomas, 248–249
- Subungual melanoma, 412
- Sucralfate, 1253, 1654
- Sugarbaker technique, 1647, 1766–1767. *See also* Hyperthermic intraperitoneal chemotherapy (HIPEC)
- Sump syndrome, 1387–1388, 1388*f*
- Sun exposure, skin cancer and, 410–411, 417
- Super saturated sodium iodine (SSKI), 521
- Superficial circumflex artery, 2182
- Superficial epigastric artery, 2182
- Superficial Inferior Epigastric Perforators (SIEPs), 771
- Superficial inguinal lymph nodes, 430
- Superficial inguinal ring, 2007*f*, 2189–2191
- Superficial lamina propria (SLP), 387, 388–389
- Superficial postanal space, 1683*f*
- Superficial radial nerve, 248*f*
- Superficial temporal artery, 317
- Superficial temporal veins, 317

- Superficial thoracoepigastric veins, 777
- Superficial venous insufficiency, 2524
- Superficial venous insufficiency treatment
  - advances, 2524
  - ambulatory phlebectomy
    - complications and their management, 2521–2522
    - overview of, 2521
    - surgical technique, 2521
  - conservative and medical therapy, 2519
  - endovascular therapy
    - complications and their management, 2520, 2524
    - indications and contraindications, 2519
    - postoperative care, 2520
    - preoperative planning, 2519–2520, 2524
    - surgical technique, 2520
  - open surgical therapy
    - indications and contraindications, 2520–2521
    - postoperative care, 2521
    - surgical technique, 2521
  - outcomes, 2524
  - percutaneous therapy (sclerotherapy)
    - complications and their management, 2522–2523
    - indications and contraindications, 2522
    - postoperative care, 2522
    - preoperative planning, 2522
    - surgical technique, 2522
- Superior constrictor muscles, 320
- Superior epigastric artery, 777
- Superior gluteal artery, 1965
- Superior hypogastric plexus, 1686*f*, 1815, 1825
- Superior ileocecal fossa, hernias into, 2206*f*
- Superior ileocecal hernias, 2203*t*
- Superior ileocecal recess, 1677
- Superior inferior epigastric artery (SIEA), 763

- Superior intercostal veins, 779*f*, 785, 786*f*
- Superior labial arteries, 327
- Superior laryngeal artery, 302
- Superior laryngeal nerve, 468*f*
- Superior lumbar triangle, 2194
- Superior mediastinal nodes, 802*f*
- Superior mesenteric artery (SMA)
  - anastomosis, 2457
  - anatomic relationships, 1186*f*, 1476*f*, 1482*f*, 2005*f*
  - angiography of, 2461*f*
  - atherosclerotic disease of, 2453, 2458
  - bypass, 2464
  - circulation, 2454*f*
  - classification for, 2481*t*
  - colon blood supply by, 1680*f*
  - compression of the duodenum and, 1185
  - distal, defect in, 2444*f*
  - division of, 1736*f*
  - embolectomy, 2446*f*, 2448*f*
  - embolism to, 2444
  - embryology of, 1053
  - exposure of, 2446*f*, 2451*f*, 2463*f*
  - function of, 2444
  - mesenteric bypass, 2455
  - proximal, occlusive disease, 2451*f*
  - recanalization of, 2462*f*
  - reconstruction of, 2464
  - revascularization, 2452, 2455
  - stenosis of, 2461*f*
  - stents and stenting, 2455, 2464
  - tumor adhesion to, 1572
- Superior mesenteric artery (SMA) syndrome, 1056, 1058*f*, 1192
- Superior mesenteric veins (SMVs)
  - anatomic relationships, 1589, 1589*f*

- dissection of, 1507
- infrapancreatic, 1557
- mobilization of, 1562, 1564*f*
- resection, 1566*f*
  - safety of, 1572
- splenic veins and, 1475
- tumor adhesion to, 1572
- tumor invasion of, 1558*f*
- at unicate process level, 1564*f*

- Superior nuchal line, 284, 294
- Superior pancreaticoduodenal arteries, 1068, 1482*f*
- Superior pancreaticoduodenal artery, 1475
- Superior phrenic lymph nodes, 778*f*
- Superior pulmonary vein, 812*f*
- Superior rectal artery
  - anatomy, 1680
  - anorectal supply, 1685
  - exposure, 1846*f*
  - field of, 1685
  - ligation of, 1856
- Superior rectal veins
  - anorectal supply, 1685
  - course of, 1845
  - exposure, 1846*f*
- Superior thyroid artery, 298, 298*f*, 299, 359*f*
- Superior thyroid vein, 71*f*, 359*f*
- Superior vena cava
  - anatomical dissections, 786*f*
  - anatomy, 71*t*
  - embryology of, 781
  - filter placement, 2513, 2517
  - formation of, 783
- Supervised injection facilities (SIF), e7
- Suppositories, for outlet obstruction, 1963

- Supra-aortic trunks (SAT). *See* Brachiocephalic reconstruction
- Supraceliac aorta, 2457*f*
- Supraceliac aorta-based bypass, 2456, 2464
- Supraceliac aortic-graft anastomosis, 2457*f*
- Supraclavicular nerves, 297
- Supraclavicular nodes, 802*f*
- Supraclavicular thoracic outlet decompression
  - benefits of, 2560
  - critical views during, 2552*t*
  - preliminary preparation, 2553*f*
  - supraclavicular exposure, 2554*f*
- Supracricoid laryngectomy, 392
- Supraglottic carcinoma, 394–395
  - management, 394
  - presentation, 394
  - resection, 394–395
- Supraglottic laryngectomy, 394, 395*f*
- Supraglottic larynx, tumors of, 348
- Suprahepatic vena cava, 1439*f*, 1440–1441
- Supralevator accesses, 1917, 1917*f*
- Supralevator spaces, 1685
- Supramohyoid neck dissection (SOHND), 361–363
- Suprapiroformic ring, 2195
- Suprapubic hernias, trocar placement, 164
- Suprapublic saphenous vein transposition, 2503*f*
- Suprapyloric mobilization, 1132–1133, 1133*f*
- Suprarenal gland, 2002, 2003*f*
- Suprarenal inferior vena cava, 2508*f*
- Suprarenal vena cava, filters, 2513, 2517
- Suprascapular artery, 288*f*
- Suprascapular nerve, 295
- Suprasphincteric abscesses, 1915*f*
- Supraspinous ligaments, 284
- Suprasternal cartilage, 773*f*

- Supratonsillar fossa, 368
- Supreme intercostal artery, 288*f*
- SurgAssist stapler, 1538, 1540*f*
- Surgeons
  - console for robotic surgery, 264
  - impact on cancer survival, 2152*t*
  - responsibilities, 22
  - role in opioid epidemic, e5–e6
- Surgery
  - cardiovascular risk, 83
  - clinical pathways, 34
  - early mobilization after, 35
  - handoffs, 34
  - metabolic demand after, 54
  - postoperative risk minimization, 34
- Surgery or Thrombolysis in Lower Extremity Ischemia (STILE), 2417
- Surgical Care Improvement Project, 32
- Surgical energy, 273–282
  - devices, 279*t*, 280–281, 281*t*
  - electromagnetic interference, 279*t*
  - pediatric surgery, 280
  - pregnancy, 280
- Surgical gloves, 120*t*
- Surgical instruments, changing of, 120*t*
- Surgical Safety Checklist (WHO), 31–32, 31*f*, 53
- Surgical saphenectomy
  - superficial venous insufficiency treatment with
    - indications and contraindications, 2520–2521
    - postoperative care, 2521
    - surgical technique, 2521
- Surgical site infections (SSIs)
  - antimicrobial management, 121
  - antimicrobial stewardship, 113–115
  - antiseptic prophylaxis, 116*t*

- care bundles and, 140
- classification of, 111, 111*f*
  - deep incisional, 111*f*, 111*t*
  - organ/space, 111*f*, 111*t*
  - pathogens and, 112*t*
  - procedures and, 112*t*
  - superficial, 111*f*, 111*t*
- clinical outcomes, 126
- definition of, 111
- diagnostic workup, 121
- guidelines on prevention of, 115*t*–116*t*
- microbiology of, 112–113
- National Healthcare Safety Network criteria, 111*t*
- nonoperative procedures, 125–126
- pathogenesis of, 112–113
- polymicrobial, 125
- preoperative prophylaxis, 113
- prevention of, 110–113, 117*t*–120*t*, 129–130
- prognosis, 126
- prophylaxis, 110–131
- prophylaxis, antibiotic, 113
- risk factors, 112*t*
- smoking and, 159
- source control, 126
- surgical interventions, 125–126
- treatment of, 110–131, 115, 120

Surgical site preparation, 118*t*

Surgisis, fistula, plugging with, 1042*f*

Surgisis Gold, 882*f*

Surviving Sepsis Campaign, 132, 133–135

Suture Assist device, 172

Suture rectopexy, 1902

Sutures. *See also Specific* procedures
- absorbable, continuous, 153, 168

- antimicrobial-coated, 120*t*
- barbed, 172
- clamping of, 165*f*
- degradation of, 168
- polyglycylic cid, 168
- retention, 153
- tensile strength of, 168
- transfascial, 164
- unidirectional, 172

- Suturing
  - instrumentation, 170–171
  - laparoscopic, 169–176
    - simulation and training, 173
  - mechanical devices, 172
- SVS/ISCVS. *See* Society for Vascular Surgery/International Society for Cardiovascular Surgery
- Swallowing, impaired, 1000
- Sweat, composition of, 1651*t*
- Swenson operation, 1972
- Sympathetic chain, 308
- Sympathetic nerve supply, 897
- Sympathetic trunk, 1686*f*
- Systemic inflammatory response syndrome (SIRS)
  - CARS and, 132
  - innate host responses and, 134*f*
  - multiple organ failure and, 131
  - postoperative, 2012
  - surgical trauma and, 8
- Systemic lupus erythematosis (SLE), 27
- Systemic vascular resistance (SVR), 74

T

- T cell receptors (TCRs), 142, 144
- T cell-mediated rejection (TCMR), 145
- T cells

- activation of, 147*f*
- CD4, 142, 143
- CD8, 142, 143
- function of, 143–144
- immune responses and, 142
- maturation of, 142–143, 557
- thymus-centered, 558

- T helper cells (T_H), 142, 144
  - depletion of, 560
  - prolactin and, 11
  - subsets, 5
  - types of, 144
- Tabes dorsalis, 1961
- TACE. *See* Transarterial chemoembolization (TACE)
- Tachycardia, stress response and, 2
- Tachypnea, stress response and, 2
- Tacrolimus (Prograf), 147–148, 1654
- Taenia, 1675*f*
- Tailgut cysts, 1882
  - complications, 1889
  - imaging, 1884, 1885*f*, 1886*f*, 1887*f*, 1888*f*
- TAILORx study, 762
- Tamoxifen, 608, 634, 756
- Tamsulosin, 2014
- TandemHeart, 82–83
- Tanning beds, 410, 417
- Tansureteroureterostomy, 2101*f*
- Tarsal artery bypass. *See* Dorsalis pedis, tarsal, and plantar artery bypass
- TASC. *See* Trans-Atlantic Inter-Society Consensus
- Taste, glossophryngeal nerve and, 322
- TBIs. *See* Traumatic brain injuries (TBIs)
- TDLU. *See* Terminal duct lobular units
- Technetium
  - in sentinel lymph node biopsy, 668–669, 668*f*

- TEE. *See* Transesophageal echocardiography (TEE)
- Teflon mesh in rectal prolapse, 1894
- TEG analysis, ROTEM and, 105, 106*f*
- Telementoring, 262
- Telemetry, 34
- Telepresence, development of, 262
- Telesurgery, development of, 262
- Temperatures
  - intraoperative, 32, 33
  - perfusion assessed by, 250
- Temporary vascular shunting (TVS), 2591–2592
- Temporofacial nerve, 309
- Tendon sheath infections, 253–258
- Tenesmus, severe, 1705
- Tenia coli, 1688
- Tension pneumothorax, 788
- Tensor fascia flaps, 240*f*
- Teratocarcinomas, retrorectal, 1882
- Teratomas, retrorectal, 1882
- Terbutaline, 972
- Terlipressin (glypressin), 1618
- Terminal duct lobular units (TDLU), 604
- Terminal ileitis, 1711
- Terminal ileum, 1713
- Terramycin, e1–e2
- Testes
  - atrophy, in inguinal herniorrhaphy, e68
  - atrophy in liver disease, 1620
  - descent, phases of, 2072–2073
  - in inguinal hernia repair, e77
  - nonpalpable, 2075
  - phases in descent of, 2072*t*
  - traumatic injuries, 2104
  - undescended, 2072–2077

- presentation of, 2072–2073
- surgical contraindications, 2073
- surgical indications, 2073

- Testicular arteries, 2008*f*
- Testicular cancer
  - classification of, 2060
  - LRPLND in, 2060–2065
  - patterns of spread, 2060
- Testosterone, 11
- Tetanus prophylaxis, 437*t*
- Tetracycline, 253, 1115
- Tetralogy of Fallot, 1034
- Tetrodotoxin (TTX), 969
- Tetromas, embryology of, 1057*f*
- Thalmopathy, 516
- Thenar muscle groups, 247, 249*f*
- Theophylline, 29*t*, 972
- Thermal injuries, 278
- Thermal sinks, 276
- Thermotherapy, 198, 661–663, 662–663*f*
- Thienopyridines, 29*t*
- Thiersch procedure, 1906, 1907
- Thigh compartment syndrome
  - clinical presentation, 2425–2426
  - fasciotomy, 2428, 2428*f*
- Thin skin, 2537
- Thionamides, 520
- Thiopeta, 1928
- Third spacing, postsurgical, 2163
- Thompson retractor system, 1967
- Thoracentesis, needle insertion, 787
- Thoracic aorta, 786*f*, 2470
- Thoracic aortic endovascular repair (TEVAR)
  - adjunctive left carotid to left subclavian artery bypass, 2564

- alternatives to, 2561
- benefits, 2567
- complications, 2566–2567
- endograph use in, 2567
- open repair compared to, 2567
- operative technique, 2564–2566, 2565*f*, 2566*f*
- overview, 2564
- postoperative management, 2566
- preoperative planning, 2564

- Thoracic aortic transection
  - indications and intervention timing, 2561, 2567
  - mortality, 2567
  - open repair, 2561–2564, 2563*f*
  - open *versus* endovascular, 2567
- Thoracic cavity, 1037*f*
- Thoracic ducts
  - anatomic relationships, 778*f*, 780*f*, 785, 786
  - anatomical relationships, 776
  - anatomy of, 71*f*, 308
  - lymphatics, 307
- Thoracic endografts, 2567
- Thoracic esophagus
  - perforation of, 1024, 1030
  - trapping of, 1008*f*
  - upper, measurements of, 1021*f*
- Thoracic inlet, creation of, 287
- Thoracic myotomy, 979*f*
- Thoracic outlet
  - anatomy of
    - blood vessels, 2549
    - musculoskeletal structures and spaces, 2548–2549
    - nerves, 2549
    - overview, 2548*f*, 2560
    - variations and acquired changes, 2549–2550

- injury exposure at, 469–470

Thoracic outlet compression syndrome, 289

Thoracic outlet decompression. *See also* Supraclavicular thoracic outlet decompression
- complications following, 2559, 2560
- guidelines, 2560

Thoracic outlet syndrome (TOS)
- clinical presentation, 2550
- diagnosis
  - arterial TOS, 2551
  - neurogenic TOS, 2550–2551
  - venous TOS, 2551
- indications for surgery and preoperative planning
  - arterial TOS, 2552–2553
  - neurogenic TOS, 2552
  - venous TOS, 2552
- initial treatment
  - arterial TOS, 2552
  - neurogenic TOS, 2551
  - venous TOS, 2551–2552
- overview of, 2548, 2560
- surgical technique
  - arterial TOS management, 2558–2559
  - brachial plexus neurolysis, 2558*f*
  - complications, 2559
  - diagrams, 2555*f*, 2556*f*–2557*f*, 2558*f*
  - neurogenic TOS reoperations, 2554
  - overview, 2553–2554
  - pectoralis minor tenotomy, 2554–2555, 2557
  - postoperative management, 2559
  - supraclavicular thoracic outlet decompression, 2552*t*, 2553*f*, 2554*f*
  - thoracic outlet decompression, 2559, 2560
  - venous TOS management, 2557–2558

Thoracic region

- 5-week embryo, transverse section, 772*f*
- bony thorax, 773
- embryology of, 781
- lymphatic relations, 780*f*

Thoracic splanchnic nerves, 1075

Thoracic surgery
- prophylactic antimicrobial agents, 114*t*
- robotic-assisted, 267–269

Thoracic trauma, 788–799
- deaths related to, 788
- definitive diagnosis, 788
- initial evaluation in, 788
- lung injuries, 791–793
- operative interventions, 788–789
- secondary evaluation, 788
- surgical approaches, 789*t*

Thoracic wall
- anatomic relationships, 777
- anterior, 778*f*
- arteries of, 777*f*
- venous drainage, 777

Thoracoabdominal incisions, 2024, 2024*f*
- abdominal wall, 152, 152*f*

Thoracoabdominal nerves, 779–780

Thoracoepigastric flaps, 751*f*, 752*f*

Thoracoscopic esophagectomy, 901

Thoracoscopic esophagomyotomy, 977–978

Thoracoscopic pictation, 851–853, 852*f*, 854

Thoracoscopic repair, 844–845

Thoracoscopy
- in diaphragmatic trauma, 859
- laparoscopic, 920
- lung cancer staging using, 803–804
- in MIE, 991–993, 992*f*

- patient positioning, 921
- port placement, 920, 992*f*

Thoracostomy tubes, 851

Thoracotomy
- in antireflux surgery, 916, 958, 959–960
- in brachiocephalic reconstruction, 2260
- for diaphragmatic eventration, 850
- emergency department
  - incisions, 789–790
  - indications, 788, 798
  - surgical technique, 788
- esophagectomy with, 1019
- left posterolateral, 791*f*
- for paraesophageal hernia, 867
- pneumothorax and, 750
- posterolateral, 789, 806
  - incisions, 806*f*
- right, 790
- right posterolateral, 850, 850*f*
- transhiatal esophagectomy without (*See* Transhiatal esophagectomy)
- urgent, 789

Thorax
- bony, 774*f*
- lymphatic vessels of, 602, 602*f*
- vagal structures of, 1073*f*

Thorocoabconinal nerves, 2182

Three-dimensional (3D) visualization, 262

Thrombin, human, 1346

Thrombocytopenia
- cirrhosis and, 1603
- disseminated intravascular coagulation and, 103
- and prosthetic grafts, 2371

Thromboelastograms (TEG)
- coagulopathy of liver disease and, 104

- examples, 106*f*
- transfusion protocol and, 1575

Thromboembolectomy, 2421, 2422

Thromboemboli. *See also* Deep vein thrombosis (DVT); Pulmonary emboli (PE)
- in carotid bifurcation disease, 2247
- extraanatomic bypass, 2348
- PA catheter insertion and, 76
- prophylaxis, 32*f*, 1781
- risk, 32*f*

Thrombolysis
- complete *versus* partial clearance, 2497
- indications and contraindications, 2491
- thoracic outlet syndrome treatment with, 2552, 2560

Thrombolysis or Peripheral Artery Surgery (TOPAS), 2417

Thrombomodulin protein C, 104

Thrombophlebitis, 607

Thromboprophylaxis, 32

Thrombosis
- after endovascular therapy, 2390
- assessment of, 2491–2493
- in endovascular therapy for aortoiliac occlusive disease, 2354
- as late arteriovenous access complication, 2545, 2547
- microvascular, 196
- in reversed vein bypass graft, 2365
- treatment for, 2481

Thrombosis Obliteration by Rapid Percutaneous Endovenous Intervention in Deep Venous Occlusion (TORPEDO), 2497

Thrombus
- assessment of, 2482
- recurrence of, 2498

Through-the-scope stents (TTSs), 1703–1705

Thumb
- assessment, 250

- carpometacarpal joint, 250*f*
- function of, 247
- opposition confirmed, 252*f*
- salvage of, 247

Thymectomy, 555–569
- contraindications, 560–561
- indications, 560–561
- outcomes, 568
- postoperative care, 567–568
- preoperative planning, 561–562
- robotic-assisted, 268, 566–567
- surgical technique, 562–564
  - incisions, 563–564, 563*f*
- transcervical, 556
  - contraindications, 564
  - surgical technique, 564–565
- transsternal, 556, 562–563
- video-assisted thoracic, 565–566

Thymic carcinoids, 558, 559*t*

Thymic disease, presentation, 560

Thymic tissue
- ectopic mediastinal, 783
- extraglandular, 558*f*

Thymomas
- approaches to, 558
- classification of, 558–559, 559*t*
- incidence of, 558
- malignant transformation, 559
- mediastinal, 781
- origins of, 558–559
- presentation of, 558
- staging of, 559*t*

Thymus gland
- anatomy, 289, 557, 557*f*, 784*f*

- arterial supply, 557
- blood supply, 563
- cervical poles of, 565*f*
- clinical importance of, 555–556
- embryology of, 556, 556*f*
- en block resection, 564
- mediastinum and, 781
- mobilization of, 567*f*
- physiology, 557–558
- surgery of
  - history, 555–556
- vascular supply, 783

Thyroarytenoid muscle, 305, 387

Thyrocervical trunk
- anatomy of, 287, 288*f*, 296

Thyroepiglottic muscle, 305

Thyroglobulin, 521

Thyroglossal duct cysts, 366*f*, 367*f*, 500*f*
- development, 500
- etiology, 366
- pathophysiology, 366
- presentation, 366
- recurrence risk, 368
- recurrent, 500
- surgical resection
  - contraindications, 366
  - indications, 366
  - outcomes, 368
  - postoperative care, 367–368
  - preoperative planning, 366–367
  - technique, 367, 367*f*

Thyroglossal duct embryology, 500

Thyrohyoid membrane, 303, 468*f*

Thyrohyoid muscles, 286, 322*f*

- Thyroid cancer
  - anaplastic, 519
  - clinical presentation, 516
  - CT scans in, 521
  - detection of, 512
  - familial medullary, 516
  - FNA, malignant, 518–520
  - genetic analysis, 516
  - Hürthle cell, 503
  - incidence of, 516, 529
  - isthmus, 490
  - lobectomy, 518
  - lymph node staging, 347*t*
  - malignant potential of, 529
  - management of, 516–531
  - medullary, 503
  - metastatic, 354
  - metastatic spread, 502
  - papillary, 503
  - patient history in, 516
  - physical examination in, 516
  - risk factors for, 516
  - surgical treatment of
    - contraindications, 520
    - indications, 520
    - informed consent, 521–522
    - preoperative planning, 520–522
  - symptoms of, 516
- Thyroid cartilage, 71*f*, 284, 303, 304*f*
- Thyroid gland
  - anatomy of, 71*f*, 297–299, 500–501, 501*f*
    - lymphatic drainage, 299
    - posterior view of, 298*f*
    - right lateral view, 299*f*

- vascular, 501
- vascular supply, 298*f*
- anterior/medial retraction of, 524*f*
- benign nodules, 516
- cytopathology, 530, 530*t*
- dissection, 501–504
- embryology, 500
- FNA biopsy, 517, 517*f*
- indications for surgery, 517
- isthmus, 297, 525*f*
- lobectomy, 522–525, 527–528
- medial retraction of, 523*f*
- nodules, 518, 529
- remedial surgery, 520
- right lobe, 502*f*
- ultrasound, 517, 521

Thyroid goiters, 516

Thyroid lobe, 501–504, 503*f*

Thyroid notch incisions, 494

Thyroid stimulating hormone (TSA), 517, 520

Thyroidea ima artery, 501, 501*f*

Thyroidectomy
- complications
  - hematomas, 528
  - hoarseness, 528–529
  - hypoparathyroidism, 528
  - nerve injuries, 528–529
- incision site, 522*f*
- outpatient, 512, 515
- postoperative complications, 515
- robotic-assisted, 269, 515
- surgical technique, 522–525
- total
  - for Graves' disease, 520

- for Plummer disease, 520
- postoperative care, 527–528
- resected specimen, 527*f*
- in thyroid cancer, 519
- tracheal resection after, 457*f*

- Thyroid-releasing hormone (TRH), 10
- Thyroid-stimulating hormone receptor antibodies (TRAb), 516
- Thyrothymic ligament, 505
- Thyrotropin-releasing hormone (TRH), 8
- Thyroxine (T4), 29*t*
- Thyroxine-binding prealbumin, 1651–1652, 1655
- TIA. *See* Transient ischemic attack
- Tibia, traumatically exposed, 216
- Tibial artery
  - injuries, repair of, 2598–2599, 2599*f*
  - lesions, endovascular procedures, 2386, 2389
  - reversed vein bypass grafts (*See* Grafts, reversed vein bypass)
- Tibial vein, posterior
  - catheter placement into, 2485*f*
  - exposure of, 2483*f*
  - ligation of, 2486*f*
- Tidal volumes (V_T), 87
- TIF. *See* Transoral incisionless fundoplication (TIF)
- Time gain compensation (TGC), 179
- Timolol, 375
- Tinea epiploica, 1878
- TIPS. *See* Transjugular intrahepatic portosystemic shunt
- “Tisseal” glue, 1930
- Tissue damage, innate immunity system and, 131
- Tissue desiccation, 274, 274*f*
- Tissue dissection, ultrasound-guided, 192
- Tissue expansion, 726–728, 728*f*
- Tissue factor (TF), 133
- Tissue glue, 2232

- Tissue hypoperfusion, shock and, 136
- Tissue transfers, 731, 732*f*
- Titanium meshes, 236
- Titanium STRATOS bars, 236
- TK Ti-Knot device, 172
- TNM Classification of Malignant Tumors, 800, 800*t*, 801*t*
- Tobacco, chewing, 409–410
- Todd's fascia, 1052
- Tolerance
  - immunity and, 1454–1455
  - infection perspective, 1453–1454
  - organ-induced, 1455*f*
  - spontaneous, 1455*f*
- Toll-like receptors (TLRs)
  - expression of, 3
  - function of, 142
  - genetic polymorphisms, 3
  - immune stimulation and, 196
  - innate immunity and, 3
- Tongue
  - anatomy, 319*f*, 322–323, 323*f*, 335*f*
    - extrinsic muscles, 322
    - innervation of, 322
    - intrinsic muscles, 322
    - movement of, 322
    - vascular supply, 322–323
  - base of
    - reconstruction, 404
    - tumors of, 402
  - carcinoma of, 339–340
    - resection, 339*f*, 340*f*
  - "commando" procedure, 339
  - leukoplakia, 336*f*
  - "tongue-jaw-neck" procedures, 339

- Tonsillar fossa, 300
- Tonsillar tumors, 402, 402*f*
- Tonsils, reconstruction, 404
- TOPAS. *See* Thrombolysis or Peripheral Artery Surgery
- Toradol (ketorolac), 2126
- Torso injuries, Abbreviated Injury Scale, 797
- Total abdominal colectomy, 1711–1712
- Total abdominal proctocolectomy, 1726–1727
- Total abdominal vagotomy, 1109–1111, 1110*f*
- Total body oxygen delivery (DO_2), 76
- Total colectomy
  - ileorectal anastomosis and, 1741–1743
  - laparoscopic, 1746–1747
    - port placement, 1747*f*
  - surgical technique
    - complications in, 1750
    - open resection, 1743–1746
    - outcomes, 1750–1751
    - patient positioning, 1747
  - for toxic megacolon, 1723
- Total laryngectomy, 394
- Total mesorectal excision (TME)
  - advances in, 1814–1823
  - anterior dissection, 1819*f*
  - approach from below, 1811–1812
  - autonomic nerve preservation and, 1829–1830
  - basic principles, 1797
  - Basingstoke experience in, 1813
  - building blocks, 1810
  - cancer recurrence rates and, 1815
  - correct excision dissection, 1831*f*
  - functional outcomes, 1823
  - historical perspectives, 1796–1813
  - incorrect excision dissection, 1831*f*

- laparoscopic, 1820*f*, 1823
- laparoscopic anterior, 1803
- minimally-invasive approaches
  - outcomes, 1819–1821
- multidisciplinary team, 1801
  - sequences, 1802–1803
- open
  - incisions, 1803
  - manual palpation, 1803
  - packing, 1803
- outcomes, 1837–1839
- patient positioning, 1807, 1810–1811, 1811*f*
- perineal defects, 1865*t*
- plane for, 1831*f*
- posterior dissection, 1819*f*
- postoperative care, 1836
- proctetomy with, 1828
- protection of seminal vesicles, 2011
- relationships in, 1684
- robotic-assisted, 1820
- specimens, 1800*f*
  - assessment of, 1821–1822, 1821*t*
  - bilobed, 1832*f*
  - grading guidelines, 1834
  - standardized templates, 1822*f*
- steps in, 1817–1819
- surgical principles, 1861
- transanal (TaTME), 1830–1831

Total pancreatectomy, 1552–1573, 1569–1570

Total pancreatectomy with islet cell autotransplantation (TPIAT)

- endoscopic, 1501–1503
- islet cell harvesting, 1502*f*
- selection of, 1495–1496

Total parenteral nutrition (TPN)

- complications of, 49–52
- enteral nutrition and, 47
- GCF mortality rates and, 1659, 1659*t*
- general indications for, 45–46
- history of, 42–44
- immunologically active solutions, 49
- management during operations, 47
- patient selection for, 45
- in severe acute pancreatitis, 1529
- solutions for, 47
- weaning from
  - infants, 1985

- Total proctocolectomy (TPC)
  - in CD with CRC, 1719
  - follow-up, 1731
  - indications, 1726–1727, 1731
  - with permanent ileostomy, 1712
  - preoperative planning, 1727
  - robotic-assisted
    - instrumentation, 1739*f*
    - port placement, 1738*f*
  - specimen, 1714*f*
  - surgical technique
    - conventional laparotomy, 1729
    - ilecolic pedicle identification, 1728*f*
    - minimally invasive approach, 1727–1729
    - postoperative complications, 1730
    - surgical team position, 1728*f*
- Totally extraperitoneal (TEP) herniorrhaphy, 2223, 2224–2225, 2238–2239
- Toupet fundoplication
  - benefits of, 872
  - completed, 870*f*
  - complications following, 961

- outcomes, 916
- overview of, 870, 950, 951*f*
- technique, 1152*f*

- Tourniquet use, 2588
- Toxic megacolon
  - in colonic Crohn disease, 1710
  - early recognition of
    - outcomes and, 1724
  - emergency surgery for
    - contraindications, 1720–1721
    - indications, 1720–1721
  - endoscopy, 1720
  - etiology, 1719
  - imaging, 1721
  - incidence, 1719
  - initial management, 1720
  - IPAA for, 1733–1734
  - needle decompression, 1721
  - operative options, 1721*t*
  - pathophysiology of, 1719
  - positional therapy, 1720
  - presentation, 1720
  - surgery for, 1719–1725
    - complications, 1724
    - outcomes, 1724
    - postoperative care, 1724
    - preoperative planning, 1721
  - surgical technique
    - exploration, 1721–1722
    - planning, 1721–1722
- Toxic multinodular goiter, 520
- *Toxoplasma* spp., 848
- *TP53* mutations, 1247
- TPIAT. *See* Total pancreatectomy with islet cell autotransplantation

(TPIAT)
- T-pouches
  - antireflux mechanism, 2048*f*, 2049*f*
  - development of, 2046
  - modification, 2047–2048
- TRAb. *See* Thyroid-stimulating hormone receptor antibodies
- Trace elements, daily requirements, 49*f*
- Trachea
  - anatomical dissections, 786*f*
  - anatomy of, 71*f*, 284
  - embryology of, 782*f*
  - erosion, 493*f*
  - fistula (*See* Tracheoesophageal fistulae (TEF))
  - injuries, repair of, 472, 472*t*
  - occlusion of, 823
  - reconstruction, 447–462
  - reoperative surgery, 459
  - resection, 447–462
  - retraction of, 1004*f*
  - subtotal resection, 459
  - tracheosophageal fistula, 458*f*
  - transected, 459*f*
- Tracheal agenesis, 826
- Tracheal bifurcation, 894*f*, 898
- Tracheal occlusion
  - in utero (*See* Fetal tracheal occlusion)
- Tracheal resection
  - anesthesia, 447–448
  - complications, 459–461
  - etiology, 447
  - extensive, 454*f*
  - indications, 447
  - lower trachea, 451*f*
  - postoperative management, 459–461

- preoperative planning, 447
- surgical technique
  - Abruzzini incision, 452
  - anterior approach, 448–450
  - carinal resection, 452–454, 453*f*, 454*f*
  - principles, 448
  - traction sutures, 450
  - transthoracic approach, 450–452, 451*f*
- symptoms, 447
- upper trachea, 449*f*

- Tracheal rings, 284
- Tracheal stenosis, pediatric, 459
- Tracheal tears, 1015–1017, 1017*f*, 1020
- Trachelectomy, radical, 2145
- Tracheobronchial diverticulum, 886*f*
- Tracheobronchial injuries
  - diagnosis, 794
  - operative approach, 794
  - postoperative management, 794–795
  - preoperative planning, 794
  - presentation, 794
  - treatment, 794
- Tracheocutaneous fistulae (TCF), 493–494
- Tracheoesophageal fistulae (TEF), 457, 458*f*
  - appearance of, 1037*f*
  - clinical presentation of, 1033
  - esophageal atresia (EA) with, 1033*f*
  - esophageal atresia (EA) without, 1034*f*, 1042
  - etiology of, 1032–1033
  - H-type fistula, 1042–1043, 1043*f*
  - imaging studies of, 1033*f*
  - locating, 1035*f*
  - overview of, 1032
  - prevalence in VACTERL association, 1034

- repair
  - anastomosis, single-layer in, 1041*f*
  - closure, 1039*f*, 1040*f*
  - complications and their management, 1040–1042
  - mobilization of, 1040*f*
  - outcomes, 1043
  - postoperative care, 1040
  - preoperative planning, 1034–1035
  - recurrent, management of, 1041–1042, 1042*f*
  - surgical technique, 1035–1040, 1038*f*
- Tracheoesophageal groove, 287, 501, 507
- Tracheoesophageal lymph nodes, 502
- Tracheomalacia, 492, 1042
- Tracheoplasty, slide, 460*f*
- Tracheosophageal puncture (TEP), 406
- Tracheostomy
  - after ventilator weaning failure, 101
  - emergent
    - in facial trauma, 434
  - indications, 501
  - “mature stoma,” 491
  - matured, 489
  - open surgical, 498
    - techniques, 490–491
  - surgically matured stoma, 492*f*
  - timing of, 497–498
- Tracheostomy tube removal, 489
- Tracheotomy, 489–498
  - complications of, 491–494
    - erosions, 493
    - infections, 493–494
    - tracheocutaneous fistulas, 493
  - emergent bedside, 494–497
  - for nonhilar injuries, 792*f*

- open surgical, 489–497, 490*f*
- operating room, 494
- percutaneous dilatational, 494–497
- "slash," 489
- stoma, 492*f*

- Trachetomy, 792
- Traction sutures, pledgeted, 1042*f*
- TRAM flaps, 698, 702–703*f*. *See* Transverse rectus abdominis muscle (TRAM) flaps; Transverse rectus abdominis myocutaneous flap
- Trametinib, 427
- Tranexamic acid, 108
- Transabdominal intrathoracic vagotomy, 1109–1111
- Transabdominal preperitoneal (TAPP) herniorrhaphy, 2223–2224, 2224*f*, 2225*f*, 2226*f*, 2238–2239
- Transampullary septectomy, 1389*f*
- Transanal endoscopic microsurgery (TEM)
  - ERUS in planning for, 1816
  - history of, 1937, 1938*t*
  - outcomes, 1947
  - rectal neoplasms, 1940–1943
    - equipment, 1940–1942
    - technique, 1940–1942
- Transanal endoscopic operation (TEO)
  - history of, 1937, 1938*t*
  - outcomes, 1947
- Transanal excision, 1937–1938
- Transanal minimally invasive surgery (TAMIS)
  - E-NOTES, 1943
  - history of, 1937, 1938*t*
  - outcomes, 1947
  - planning for, 1816
  - rectal neoplasms, 1943–1945
    - operating room setup, 1943
    - surgical technique, 1943–1945

- total mesorectal excision, 1830–1831
- Transanal pull-through
  - complications, 1974
  - for Hirschsprung disease, 1973–1974
  - outcomes, 1974–1975
  - postoperative care, 1974
  - technique, 1973–1974
- Transanal total mesorectal excision (TaTME), 1821–1822, 1832*f*, 1837
- Transaortic visceral endarterectomy, 2458, 2460*f*
- Transarterial chemoembolization (TACE), 195, 1281
- Transarterial radioembolization (TARE), 1281
- Trans-Atlantic Inter-Society Consensus (TASC), 2351, 2375, 2376t, 2390
- Transcervical diverticulectomy, 1146, 1147
- Transcervical laryngofissure, 392
- Transcutaneous abdominal ultrasound, 1620
- Transducers (probes)
  - movement/manipulation of, 180–181, 181*f*, 182*f*
  - placement of, 180
  - ultrasonographic, 177–178
- Transduodenal sphincteroplasty
  - indications, 1393
  - outcomes, 1420
  - overview of, 1383, 1388–1389
  - postoperative management, 1392
  - surgical technique, 1389–1392, 1392*f*
- Transesophageal echocardiography (TEE), 77
- Transferrin, 1651–1652, 1655
- Transforming growth factor-β (TGF-β), 8
- Transfusion-associated acute lung injury (TRALI), 108–109, 109*f*, 109*t*
- Transfusion-associated circulatory overload (TACO), 108, 109*t*
- Transfusion-related immunomodulation (TRIM), 108
- Transfusions
  - complications related to, 108–109, 109*t*

- lesions from war theaters, 110
- massive, in liver injury, 1342
- preoperative platelets, 27

Transgastric endoluminal cytogastrostomy, 1548*t*

Transgastric necrosectomy, 1529

Transhiatal esophagectomy

- complications and their management, 1013–1017
- contraindications, 1000
- indications, 1000, 1001*t*
- outcomes, 1017–1019
  - survival and mortality, 1019
- overview of, 1000
- pathophysiology relevant to, 1000
- patient selection and preoperative preparation, 1001
- popularity of, 787
- postoperative care, 1012–1013
- reoperative surgery, 1020
- surgical technique
  - abdominal phase, 1001–1003, 1002*f*
  - cervical esophagogastric anastomosis, 1010–1012
  - cervical phase, 1003–1004
  - mediastinal (transhiatal) dissection, 1004–1010
  - overview of, 1001
- transthoracic esophagectomy compared to, 1019

Transhiatal total esophagectomy, 267

Transhyoid pharyngotomy, 403

Transient ischemic attack (TIA), 2246–2248

Transjugular intrahepatic portosystemic shunt (TIPS), 1587, e30

- adequacy of, 1607
- decision-making, 1607
- disadvantages, 1622–1623
- hepatic blood flow and, 1608*t*
- indictions, 1619, 1620
- survival data, 1608*f*

- for variceal bleeding, 1622–1623, 1622*f*
- Transmesenteric hernias, 2200, 2203*t*
- Transmural pressures, 74
- Transomental hernias, 2200
  - surgical anatomy, 2203*t*
- Transoral duct slitting, 324
- Transoral incisionless fundoplication (TIF)
  - EsophyX device, 965
    - complications, 965
    - images, 966*f*
    - outcomes, 965
    - postoperative care, 965
    - technique, 965
- Transoral laser microsurgery (TLM), 401–402, 409
- Transrectal ultrasound (TRUS), 203
- Transsphincteric fistulae, 1920*f*
- Transsphincteric mucosal advancement, 1934
- Transthoracic esophagectomy
  - esophageal resection and construction with, 1000
  - robotic-assisted, 999
- Transthoracic truncal vagotomy, 1121
- Transurethral resection of the bladder tumor (TURBT), 2035–2036
- Transvaginal advancement flap, 1934, 1934*f*
- Transvaginal ultrasonography (TVUS), 1249
- Transversalis crura, e82
- Transversalis fascia
  - anatomic relationships, 2183
  - in inguinal hernia repair, e73, e77, e81
  - opening of, 2217*f*
  - as phrenicoesophageal ligament component, 829
- Transverse abdominal pain (TAP) block, 54
- Transverse abdominis muscles
  - embryology of, 772
  - origin of, 1677

- release, 839–840
- Transverse cervical artery, 288*f*, 359*f*, 526
- Transverse cervical nerve, 296–297
- Transverse colon. *See also* Colon
  - adhesions, 1345
  - anatomic relationships, 1678
  - blood supply, 1681*f*
  - preparation, 994–995
- Transverse facial artery, 316
- Transverse mesocolon, 1474
- Transverse pancreatic artery, 1482*f*, 1483*f*
- Transverse rectus abdominis muscle (TRAM) flaps, 750*f*
  - bipedicle, 230–231
  - breast reconstruction, 227–228
  - in breast reconstruction, 221
  - conventional flap, 735–736, 735*f*
  - delayed unipedicle, 228–230
  - fat necrosis and, 223
  - free flap, 231–232, 231*f*, 736, 736*f*–737*f*
  - history of, 770
  - indications, 233
  - popularization of, 763
  - postradiation wound coverage, 217
  - unipedicle, 228–230
  - VRAMs and, 242–243, 242*f*
- Transverse septum, 820, 821*f*
- Transverse throacis muscle, 778*f*
- Transverses abdominis muscle, 163*f*
- Transversus abdominis muscle
  - anatomic relationships, 2002, 2003*f*, 2004*f*, 2182
  - origin of, 2212
- Transversus abdominis plane (TAP) blocks, 1827, 1844
- Trapeze filter design, 2517
- Trapezius muscle

- anatomy of, 71*f*, 284, 290, 775*f*, 776*f*
  - innervation, 284
- vascular supply, 238*f*

- Trapezius myocutaneous flaps, 237
- Trauma surgery, team management in, 433
- Traumatic aortic injury. *See* Aortic injuries; Blunt thoracic aortic injury (BTAI)
- Traumatic brain injuries (TBIs)
  - basics of, 475
  - basilar injuries, 477
  - blunt *versus* penetrating, 474–476
  - conservative measures, 478*t*
  - diagnostic studies, 478
  - epidemiology of, 474–476
  - examination, 476
  - first responders, 487
  - Glasgow Coma Scores and, 477, 477*t*
  - gun shot wounds (GSW), 483*f*, 483*t*
  - hematomas, 480–482
  - hospital admissions, 487
  - imaging, 488
    - interpretation checklist, 480*t*
  - initial data evaluation, 476–477
  - initial treatment, 477–478
  - injury patterns, 477*t*
  - primary injuries, 476, 476*t*, 488
  - secondary injuries, 476, 476*t*, 488
  - surface injuries, 477
  - surgical interventions, 478–482
  - vault injuries, 477
- Traumatic diaphragmatic injury (TDI). *See also* Diaphragm, traumatic injury to
  - incidence, 863
- Traumatic hernias, diaphragmatic, 822*t*

- Traumatic injuries. *See also* Hepatic trauma; Traumatic brain injuries (TBIs)
  - blunt
    - classification of, 2091
    - renal injury staging, 2089*f*
  - catabolism and, 37*f*
  - genomic storm in, 132*f*
  - gut barrier failure in, 20
  - hand, preoperative planning, 251–253
  - immunosuppression following, 7–8
  - inflammatory responses to, 2–21
  - liver injury and, 1340
  - mechanisms of injury, 2089–2090
  - metabolic demand after, 54
  - metabolic responses to, 2–21
  - multiple organ failure and, 131
  - multisystem support for, 488
  - muscle wasting in, 35
  - neck
    - penetrating injuries, 462–463
  - pediatric, classification of, 2091
  - penetrating
    - air emboli in, 789
    - air leaks in, 789
    - classification of, 2091
    - EDT in, 788
  - primary survey, 476
  - splenic, 1988–2001
  - thoracic, 788–799
  - thoracic viscera, 789*t*
- Traumatic perforation, esophageal, 1020–2021
- Trazepius muscle, 358*f*
- “Tree climbing” muscle, 226
- Trellis catheter, 2495*f*

- Trellis device (TPM), 2494
- Trellis-8 peripheral infusion system, 2494*f*
- Trephine ileostomy, 1644
- Triamcinolone, 376
- Triangle (of Truesdale), 832–833
- Triangle of ausculation, 776*f*
- "Triangle of doom," 2213
- Triangle of Truesdale, 832–833
- Triangular ligaments
  - attachments, 1259
  - formation of, 1328
  - function of, 2169
  - overview of, 833
- Tricuspid valve, robotic-assisted repair, 269
- Trigeminal nerve, parotid space and, 317
- Triglyceride breath test, 1164
- Triglycerides, intestinal bypass and, e40–e41
- Trigone, bladder, 2009, 2009*f*
- TRIM32 ligase, 38
- Trimethoprin/sulfamethoxazole, 253
- Triple lumen catheter, 2495–2496
- Triquetrium, 247, 250*f*
- Trisomy, CDH and, 841
- Trisomy 18, 2078
- Trisomy 21, 1971
- Trochanteric free flaps, 233
- Trophozoites, 1292, 1292*f*
- Truncal vagotomy, 1109–1111, 1151*f*
- *Trypanosoma cruzi* infection, 897
- Trypsinogen
  - inactivation, 1526*f*
  - pancreatitis and, 1493
- Tubal ligation in intestinal bypass, e40
- Tube feeding, osmolality of, 1655

- Tube gastrostomy, 206
- Tubercle of Zuckerkandl, 523
- Tuberculosis, 1630
- Tuberous sclerosis, 2020
- Tumor lymphangiogenesis, 1964
- Tumor necrosis factor (TNF)
  - carbohydrate metabolism and, 17
  - inflammation and, 6
  - muscle proteolysis and, 13*f*
  - phagocytosis and, 133
- Tumor necrosis factor (TNF) receptors, 4*f*, 143
- Tumor necrosis factor-α (TNF-α) antibodies, 1661, 1672, 1674
- Tumor suppressor genes
  - *p14*^{ARF}, 334
  - *p16*, 334
  - *p53*, 334
- Tumor thrombi, 2021
- Tumorigenesis, ablation therapy-related, 205
- Tumors. *See also Specific* tumors
  - ablation of, 194–206
    - benefits of, 195–196
    - in clinical practice, 200–204
    - combination therapy, 195–196
    - surgery combined with, 195–196
    - technologies used for, 196–200
  - carotid body (*See* Carotid body tumors)
  - ischemia, 196
  - metastatic spread
    - ablation therapy and, 205
  - necrosis, 1276
  - phyllodes, 607
  - resection, ablation following, 205
- Tunica vaginalis, 2007*f*
- Tunneled catheters

- avoiding long-term, 2539
- complications from, 2547
- as renal replacement therapy alternative, 2538

- Tunnels, extraanatomic bypass, 2345
- Turgor, perfusion assessed by, 250
- Turnbull “blow-hole” procedure, 1722, 1722*f*, 1724
- Turnbull loop stoma, 2110, 2110*f*
- T-Vek, 427
- 26S proteasome, 38
- Twin studies, diverticular disease, 1753
- Tympanic membrane, 317
- Tyrosine kinase inhibitors, 520

U

- Ubiquitin activating enzyme (E1), 38
- "Ugly duckling sign," 412
- UK-TREC, 1938–1939
- Ulcer surgery, 1148
- Ulcerations, postradiation, 234–235
- Ulcerative colitis
  - colonscopy in, 206
  - compromised rectal reservoir, 1949
  - enterocutaneous fistulas and, 1650
  - ileal pouch-anal anastomosis for, 1732
  - pouchitis in, 1739
  - primary sclerosing cholangitis, association with, 1395, 1403
- Ulcers. *See also* Diabetic foot ulcers (DFUs); Peptic ulcer disease (PUD)
  - after gastric bypass, 1217
  - and aortoiliac occlusive disease, 2350
  - critical limb ischemia, 2377
  - gastrectomy for, 1165
  - limb, and amputation, 2399
- Ulna, 247, 249*f*
- Ulnar artery, 69
- Ulnar artery injuries, 2597
- Ulnar nerve, 247, 248*f*
- Ultrapro® hernia system, 2237
- Ultrasonic energy, 275
- Ultrasonography. *See also* Doppler ultrasound; Duplex ultrasonography; Endoscopic ultrasound (EUS); Intravascular ultrasound
  - ablation of breast tumors, 660, 663–665, 664*f*–665*f*
  - in acute appendicitis, 1689
  - bedside, 1284
  - biliary, 1359
  - of breast, 615–616, 617*f*
  - and breast-conserving surgery, 625, 643
  - deep venous thrombosis (DVT) treatment using, 2495–2496, 2496*f*

- duplex
  - for carotid bifurcation disease, 2249, 2250*f*
  - of portal veins, 1604
- in gallbladder disease, 1343
- intraoperative
  - in cholecystectomy, 1346–1347
  - in liver hydatidosis, 1301–1302
  - of portal veins, 1604
- in liver hydatidosis, 1300–1301
- parathyroid, 543
- prenatal, 1169
- procedure planning using, 191–192
- procedures guided by, 190–193
- renal, 2011
- of renal artery occlusive disease, 2433
- surgeons use of, 176–194
- surgical training in, 192
- terminology, 179
- thyroid gland, 521
- transducers (probes), 177–178

Ultrasound ablation therapy, 199
Ultrasound-guided FNA, 546
Ultraviolet radiation (UV), 429
Umbilical artery, 2184*f*
Umbilical fascia, 2184*f*
Umbilical fissure, 1322*f*
Umbilical hernias
- description of, 2183–2184
- differential diagnoses, 158
- infantile, 2184–2185
- Proline hernia repair for, 2237
- repair of, 158–159, 2210
- sagittal section, 2185*f*
- surgical anatomy of, 2201*t*

- Umbilical plate, 1264, 1264*f*
- Umbilical region, 2184*f*
- Umbilical ring, 2185*f*
- Umbilical vein, 2184*f*
- Umbilicus
  - hernia repair, 2210
  - normal, sagittal section, 2184*f*
- Uncinate process, 1475, 1475*f*, 1508*f*
- Uncinatectomy, 1517*f*
- Unfractionated heparins, 104
- Unifuse thrombolysis catheter, 2494*f*
- United States Gastric Cancer Collaborative, 1140–1141
- Universal Protocol for Preventing Wrong Site, Wrong Procedure, Wrong Person surgery (JACHO), 31
- Upper arm, hemodialysis access, 2541–2542, 2543*f*
- Upper extremities. *See also* Arms; Forearm
  - injury to
    - amputation, 2590*f*
    - axillary artery injuries, 2597
    - brachial artery injuries, 2597
    - endovascular treatment, 2599–2600
    - fasciotomy, 2596*f*
    - radial and ulnar artery injuries, 2597
    - subclavian artery injuries, 2596
- Upper extremity access, hemodialysis, 2538, 2546
- Upper extremity polytetrafluoroethylene (PTFE) hemodialysis access, 2526, 2526*f*
- Upper gastrointestinal (UGI) series
  - in PUD, 1114, 1126
  - pyloric stenosis diagnosed by, 1167
- Upper jugular compartment, 504*t*
- Upper thigh, right, 2591*f*
- Urachus, 2184*f*
- Urata formula, 1261

- Urea breath tests, 1114
- Urea excretion of, 55
- Uremia, slow transit constipation and, 1961
- Ureteral injuries
  - timing of repair, 2106
- Ureteral obstruction
  - post hysterectomy, 2144
- Ureteral stents
  - cystoscopic placement, 2012
  - postoperative, 2016
  - symptoms related to, 2016
- Ureteral stones
  - management of, 2012–2013
- Ureteral tunnel
  - dissection, 2138*f*, 2139*f*
- Ureteropelvic junction
  - anatomic relationships, 2008*f*
  - constrictions at, 2004
- Ureteropelvic junction procedures
  - Anderson-Hynes dismembered pyeloplasty, e52–e55*f*
  - Culp-Deweerd pelvic flap pyeloplasty, e56, e56*f*
  - Davis intubated ureterotomy, e56–e57, e57*f*
  - Foley-YV-plasty, e52, e55–e56*f*, e56
- Ureteropelvic obstruction
  - robotic-assisted repair, 270–271
- Ureteroscopy
  - flexible, 2015–2016
  - for nephrolithiasis, 2011
  - semi-rigid, 2015–2016
  - technique, 2015–2016
- Ureterotomy, Davis intubated, e56–e57, e57*f*
- Ureters
  - abdominal course of, 1681*f*
  - anatomic relationships, 2002, 2005*f*, 2008*f*

- anatomy of, 1681–1682, 2004*f*
- exposure of, 1744*f*
- female pathway, 2006–2007
- identification of, 1791*f*, 1845
- intraoperative injury, 1750
- lymphatics, 2008–2009
- male pathway, 2007–2008
- metastatic disease, 1863*f*
- obstruction of, 2004
- pathway, 2005–2006
- reimplantation, 2100*f*
- spatulated, 2109*f*
- traumatic injuries
  - decision algorithm, 2099*f*
  - reconstruction, 2098–2099
  - staging, 2098
- vascular supply, 2008–2009

Urethra
- anatomic relationships, 1811
- anatomic supports, 2169–2170
- dissection
  - in radical cystectomy, 2039–2040
- injuries, identification of, 2107
- transection of, 2070
- traumatic injuries, 2102–2104
  - decision algorithm, 2103*f*
- tunneling, 2172*f*

Urethral cancer, 2055

Urethral spasm, 2174

Urethrocele, 2174*f*

Urethro-vesicle anastomosis, 2070

Uric acid
- crystal formation, 1647
- immune stimulation and, 196

- Urinalysis, preoperative testing, 22, 23*t*
- Urinary catheters, 32
- Urinary conduits, maturation of, 2110*f*
- Urinary diversions, 1677
  - choice of, 2037–2038
  - colon conduits, 2110–2111
  - complications, 2117, 2118
  - continent, 2111–2116
    - rectal diversions, 2111–2112
  - Hautmann neobladder, 2116, 2116*f*
  - heterotopic continent, 2112–2114
  - long-term follow-up, 2118
  - noncontinent
    - technique, 2108–2111
  - orthotopic neobladders, 2114–2116
  - postoperative management, 2116–2117
  - procedure options, 2118
  - quality of life issues, 2118
  - robotic-assisted, 2118
  - Studer neobladder, 2115–2116, 2116*f*
  - supravesical, 2107–2118
    - indications, 2107
    - preoperative planning, 2107–2108
  - types of, 2037, 2037*t*
- Urinary reflux, prevention of, 2045–2046
- Urinary retention, 1795, 2053
- Urinary stones, 1647, 1649*t*
- Urinary stress incontinence, 2169
- Urinary system obstruction, 2012
- Urinary tract fistulae, 2144
- Urinary urea nitrogen, 55, 56
- Urine
  - composition of, 1651*t*
  - lasix and, 1651*t*

- nitrogen loss, 13, 18
- reabsorption, 2117

Urinomas, drains for, 2032
Urogenital diaphragm, 2173*f*
Urogenital triangle, 2197
Urologic cancers, SLNB in, 2067–2068
Urologic surgery
- da Vinci Robotic system in, 264
- prophylactic antimicrobial agents, 114*t*
- robotic-assisted, 270–271

Uropathies, obstructive, 826
Urostomy
- creation of, 1773
- for urinary diversion, 2034

Urothelial carcinoma, 2034
Ursodeoxycholic acid (UDCA), 1403, 1985
Urticarial reactions, 109*t*
Usher, Francis, 2220
Ustekinumab, 1718
Uterine artery
- anatomy, 2006*f*
- ligation of, 2124*f*, 2142*f*

Uterine prolapse, 2128–2129
Uterine scar dehiscence, 2119
Uterocolonic anastomosis, 2112*f*
Uterointestinal anastomosis, 2108–2110
Uteronecocystostomy, 2100*f*
Uterosacral ligaments, 2139*f*
Uteroscopic lithotripsy, 2016
Uteroscopy
- complications of, 2016
- postoperative infection rates, 2012
- success rates for, 2013

Uterosigmoidostomy, 2111–2112

- Uterovarian ligaments, 2130*f*
- Uterus
  - anatomic relationships, 2121*f*
  - closure after cesarean delivery, 2122–2125
  - incisions, 2121, 2122*f*, 2123*f*
  - myomatous, 2133
- Utsonimia, Joshi, 1732
- Uvula vesicae, 2009

V

- VACTERL association (vertebral, anal, cardiac, trachea-esophageal, renal/kidney, and limb defects), 1033, 1034
- Vacuum-assisted therapy, 1030, 1031
- Vacuum-assisted wound closure (VAWC) dressing, 156, 1026*f*
- Vagal nerves
  - identification of, 953*f*
  - injury to
    - effects of, 897, 959
    - preventing, 953
- Vagal trunks, 1096–1097
- Vagina
  - anatomic relationships, 2010, 2169*f*
  - anatomic supports, 2169–2170
  - closure
    - after radical cystectomy, 2045*f*
  - fistulization, 1945–1946
  - pouch-vaginal vistula, 1739*f*
  - reconstruction, 243, 243*f*, 244*f*
  - separation, 2171*f*
- Vaginal artery, 2010
- Vaginal birth after cesarean delivery (VBAC), 2119–2120
- Vaginal cuff
  - cellulitis, 2133
  - closure of, 2140*f*
- Vaginal delivery, outlet obstruction and, 1962–1963

- Vaginal packing, benefits of, 1847
- Vaginal prolapse, 1906
- Vaginal segment defects, 2166
- Vaginal wall
  - descent of, 2167–2168
  - dissection, 2174*f*
  - incisions, 2171*f*, 2178*f*
  - posterior, 1812, 2179*f*
  - reconstructed, 2176*f*
  - rectum and, 1683
  - thickness, 2176*f*
- Vaginography, 1933
- Vagotomies
  - antropyloric coordination and, 1157
  - blunted pyloric relaxation and, 1165
  - complications of, 1101–1102, 1146, 1150, 1157, 1165
  - diarrhea after, 1146
  - as duodenal ulcer disease intervention, 1148
  - esophagogastrectomy accompanied by, 1158
  - gastric drainage procedures, 1122
  - highly-selective, 1099–1100, 1100*f*, 1112–1113, 1112*f*
    - closure, 1101*f*
    - postoperative care, 1101
  - indications, 1147
  - laparoscopic
    - port placement, 1101*f*
    - technique, 1100–1101
  - open selective, 1098
  - open truncal, 1097–1098
  - operative room arrangement, 1097*f*
  - overview of, 1147
  - pyloroplasty, 1098
  - selective, 1098, 1098*f*, 1147
  - selective and nonselective, 1095–1103

- surgical technique, 1097–1101
- therapeutic, 1150, 1151*f*
- total abdominal, 1109–1111, 1110*f*
- transabdominal intrathoracic, 1109
- transthoracic truncal, 1121
- truncal, 1102, 1109–1111, 1111*f*–1112*f*
- truncal with loop gastrojejunostomy, 1151*f*
- truncal with pyloroplasty, 1151*f*
- types of, 1095, 1151*f*

- Vagus nerve (CN X)
  - anatomic relationships, 784, 785
  - anatomy of, 287, 292, 298*f*, 308, 359*f*, 363*f*, 471
  - anterior trunk of, 1111*f*
  - branches, 305
  - exposure of, 526
  - identification of, 358
  - innervation by
    - stomach, 1072–1075
  - protection of, 930
- Valium, e2
- Vallecula epiglottica, 303
- Valsalva maneuver, 2168
- Valve repair, robotic-assisted, 269
- Valve transplantation, 2523
- Valve transposition, 2523–2524
- Valves of Houston, 1844
- Vancomycin
  - after colonic lavage, 1723
  - for *C. difficile* colitis, 1724
  - *Enterococcus* resistant to, 121
  - for MRSA infections, 92
  - postoperative, 1723
  - for severe *Clostridium* colitis, 1720
- VAP. *See* Ventilator-associated pneumonia (VAP)

- Varco, Richard, 1176, 1179
- VARD. *See* Video-assisted retroperitoneal debridement (VARD)
- Varenicline (Chantix®), 102
- Variceal banding
  - endoscopic
    - multiband, 1625–1627, 1625*f*
    - single band, 1625, 1625*f*
- Variceal bleeding
  - acute, management of, 1617–1618
  - devascularization, 1622
  - emergency management options, 1620
  - endoscopic management, 1618
    - failed, 1619
  - long-term management, 1620–1621, 1621–1622, 1621*t*, 1622
  - management of, 1618*f*
  - portal hypertension and, 1616
  - recurrent, 1616
- Vas deferens, 2058*f*
- Vascular anomalies, 375*f*
  - classification of, 373, 374*t*
  - diagnosis of, 373
  - terminology
    - incorrect, 374*t*
  - tumors, 374–378
- Vascular compromise, ischemia and, 253
- Vascular endothelial growth factor (VEGF) inhibitors, 195
- Vascular endothelial growth factors (VEGFs), 1964
- Vascular injuries, military, 2590*f*
- Vascular injuries, urgent operative care for, 788
- Vascular malformations (VMs), 378–383
- Vasoactive intestinal polypeptide (VIP), 969
- Vasoconstriction, stress response and, 2
- Vasodilators, 77–78, 80
- Vasopressin, 81. *See also* Antidiuretic hormone (ADH)

- Vasopressors, 77–78, 81
- Vater, Abraham, 1478
- VCare uterine manipulator, 2143
- Vector manometry, 1950*f*
- Vedolizumab, 1718, 1733
- Vegetarians,
  - diverticular disease in, 1753
- Vein grafts
  - from above-knee popliteal artery, 2599*f*
  - femoral artery injury repair using, 2598*f*
  - use of, 253
- Vein mapping, 2473–2474
- Vein of Kocher, 306
- Vein repair, 2593–2595
- Vein suitability for autogenous hemodialysis access
  - criteria to determine, 2528*t*
- Vemurafenab (Zelboraf), 418, 427, 429
- Vena cava
  - anastomosis, 1445*f*
  - imaging, 2512*f*
  - thrombus extending into, 2483*f*
- Vena cava filter placement
  - anatomical variations affecting, 2511–2512
  - complications, 2514–2516, 2516*f*, 2517
  - discontinuing/removal, 2514, 2514*t*, 2515–2516, 2516*f*, 2517
  - film documenting, 2513*f*
  - filter types and selection criteria, 2511, 2511*t*, 2515*f*, 2517
  - fluoroscopically guided, 2512–2513, 2517
  - indications for, 2510–2511, 2510*t*, 2517
  - outcomes, 2517
  - overview of, 2510
  - PREPIC trails, 2513–2514
  - preprocedure evaluation, 2511
  - retrievable filters, 2514, 2514*t*, 2515–2516, 2515*f*

- suprarenal and superior, 2513
- surgical technique, 2493
- ultrasound-guided, 2513

- Venography, 2493
- Venoplasty, 2485*f*
- Venotomy closure, 2486*f*
- Venous assessment, 2540
- Venous disease, 2519*t*
- Venous duplex, 2491–2493, 2492*f*
- Venous imaging studies, preoperative noninvasive, 2528*f*
- Venous insufficiency, 2509. *See also* Deep venous insufficiency; Superficial venous insufficiency
  - CEAP classification of, 2524
  - clinical presentation, 2519
  - etiology and pathophysiology, 2518–2519
  - overview of, 2518
- Venous malformations, 379–380
- Venous occlusion, 2500*f*
- Venous occlusive disease, 2500*f*
- Venous patency, evaluation of, 2481
- Venous reconstruction, 1566*f*
- Venous reflux, 2524
- Venous stents and stenting
  - DVT treatment using, 2496
  - for malignancy, 2499
- Venous thoracic outlet syndrome (TOS)
  - clinical presentation, 2550
  - diagnosis, 2551
  - indications for surgery and preoperative planning, 2552
  - initial treatment, 2551–2552, 2560
  - operative management of, 2557–2558, 2560
- Venous thrombectomy
  - with arteriovenous fistula, 2488*t*
  - historic developments, 2481, 2482*t*

- open
  - indications, 2489
  - pros and cons, 2490–2491
- technique, 2482*t*, 2484*f*

- Venous thromboemboli (VTE)
  - central venous catheters and, 72
  - diagnosis, 2492*f*
  - identification and confirmation of, 2491
  - inflammatory bowel disease and, 1714
  - management, 2481
  - overview of, 2510
  - postsurgical
    - management of, 2163
  - prevention, 32*f*, 90–91
  - prophylaxis, 1788
  - recurrent, preventing, 2510
  - risk, 32*f*
  - risk factors, 90–91, 91*t*, 2497*t*, 2517
  - vena cava filter placement to treat, 2517
- Venovenus bypass, 1440*f*
- Ventilation
  - intraoperative, 33, 99
  - mechanical
    - liberation from, 100–101
    - rules, 138–139
  - modes of
    - ARDS and, 98–99
  - postoperative, 99–100
  - weaning failures, 100–101
    - causes of, 100
  - weaning readiness, 100
- Ventilator-associated events (VAE), 92, 93*f*
- Ventilator-associated pneumonia (VAP)
  - antibiotic regimens for, 94*t*

- CDC monitoring of, 92
- definition of, 92
- diagnosis of, 91–95
- management of, 91–95

- Ventilator-induced lung injury, 98*f*
- Ventilators
  - ETT conversion to tracheostomy, 497–498
  - in multitrauma injuries, 488
  - pulmonary risk and, 85–103
  - respiratory failure after extubation, 36
  - weaning from, 63
- Ventral abdominal hernias, 152–169
  - approaches, 157–158
  - component release and, 156–157
  - component separation, 162–163, 169
  - contraindications, 169
  - indications, 169
  - open repair, 156–157
  - skin coverage, 157–158
  - soft-tissue coverage, 157–158
- Ventral abdominal herniorrhaphy, 1650
- Ventral hernia repair (VHR)
  - classification of, 157
  - patient selection, 157
  - postoperative morbidity, 157
  - reinforcement, 158
  - types of
    - intraperitoneal, 160–162
    - Rives-Stoppa, 159–162
- Ventricular aneurysm, 2444
- Ventriculoseptal defects (VSDs), 1034
- Veress needle, 875*f*, 1100–1101
- Veress techniques, 2030
- VerifyNow, 105

- Vermiform appendix, 1675*f*, 1676–1677
- Vermillion
  - anatomy, 325*f*
  - lip, 325
  - resection of, 328
  - tattooing, 328
- Vermillion border
  - anesthesia, 438*f*
  - lacerations, 438*f*
  - lip, 325
- Verrucous venous malformations (VVM), 380
- Vertebral arteries
  - anatomy, 284, 288*f*
  - in carotid bifurcation disease, 2247
  - interruption of, 2469, 2577
  - repair of, 470, 471*f*
  - risk to, 2569
- Vertebral artery trauma (neck), 2574–2576, 2577
- Vertebrocostal trigone
  - defects beginning at, 824–825
  - description, 825
  - diagrams, 820*f*
- Vertebroplural fascia, 287
- Vertical banded gastroplasty (VBG), 1204–1209
  - band-related complications, 1179
  - conversion of, 1204–1209
  - dilated gastric pouch, 1204*f*
  - failure of, 1204
    - erosion, 1205
    - pouch enlargement, 1205
    - staple-line dehiscence, 1204–1205
  - for obesity, 1179
  - reversal, 1249
  - revision of, 1204–1209, 1206*f*

- complications, 1208
- contraindications, 1205
- indications, 1205
- laparoscopic, 1207
- open Faberge' technique, 1206
- outcomes, 1208
- postoperative care, 1208
- preoperative planning, 1205
- to Roux-en-Y gastric bypass, 1206–1207, 1206*f*
- surgical techniques, 1205
- staple-line dehiscence
  - repair of, 1205–1206

- Vertical incisions, abdominal wall, 152, 152*f*
- Vertical partial laryngectomy
  - endoscopic, 392
  - transcervical, 392
  - types of, 392*f*
- Vertical ramus osteotomy, 469
- Vertical rectus abdominus muscle (VRAM) flaps
  - in APR closure, 1859
  - TRAMs and, 242–243, 242*f*, 243*f*
- Very-low-density lipoproteins (VLDLs), 60
- Vescouterine peritoneum, 2131*f*
- Vesical venous plexus, 2010
- Vestibular fold, 304
- Vestibular ligaments, 303, 304*f*
- Video endoscopic inguinal lymphadenectomy (VEIL), 1971
- Video-assisted retroperitoneal debridement (VARD), 1541–1542
- Video-assisted thoracic surgery (VATS), 562
  - for hemothoraces, 797, 798
  - lobectomy, 811–814
- Video-assisted thoracic thymectomy (VATET), 565–566
- Video-assisted thoracoscopic surgery (VATS), 844–845, 851
  - for hemothorax, 101

- pulmonary resection, 268–269
- robotic-assisted, 269

Videoproctography, 1951
Vigorous achalasia, 970
Villalta PTS scale, 2498, 2498*t*
Visceral arteries
- exposure of, 2456*f*
- ruptured, 2469

Visceral compartment, alimentary layer of, 471*f*
Visceral hernia repair, 839–840
Visceral ligaments, 830
Visceral rotation
- left-sided medical, 2580*f*
- right-sided medical, 2581*f*

Viscerosomatic communication (regulation), 836, 838
Vitamin A
- supplementation, 1982
- topical, scarring and, 445

Vitamin B_{12}
- absorption of, 1675
- in Crohn disease, 1661
- deficiencies, 1241, 2050
- supplementation
  - in SBS, 1982

Vitamin B_{12} anemia
- diagnosis, 1164
- etiopathogenesis, 1163–1164
- overview of, 1163
- symptomatology, 1163
- treatment, 1164

Vitamin C
- in EN formulas, 64
- gallstone risk and, 1353
- topical, scarring and, 445

- Vitamin D
  - calcium regulation and, 532, 550
  - deficiency
    - hyperparathyroidism and, 535–536
    - preoperative workup, 1241
    - PTH production and, 533*t*
    - secondary HPT and, 551*t*
  - preoperative levels, 521
  - supplementation, 1982
    - after parathyroidectomy, 554
    - after thyroidectomy, 512
    - in HPT, 551
    - in hypocalcemia, 528
- Vitamin E supplementation, 1982
- Vitamin K antagonists, 107, 2421
- Vitamin K supplementation, 1982
- Vitamins
  - deficiencies, 1163, 1982
  - fat soluble, 60
  - function of, 60
- Vitelline veins, embryology of, 1053
- Vocal cord paralysis, 521, 528–529, 897
- Vocal folds
  - cancer of
    - angiogenic microcirculation, 390*f*
    - endoscopic angiolytic laser treatment, 391–392
    - histology, 390*f*
    - microlaryngoscopic exam, 391*f*
  - coronal section, 389*f*
- Vocal ligaments
  - anatomy of, 303, 304*f*
  - preservation of, 387
  - superior view of, 304*f*
- Volume pressure curves, 475*f*

- Volume resuscitation, 77–78
- Volvulus
  - acute colonic, 1699
  - colonscopy in, 206
  - derotation of, 1170
  - detorsion, 1702*f*
  - duodenal obstruction and, 1169
  - in infants, 1166
  - midgut, 1172–1173
  - predisposition for, 1676
  - sigmoid, 1701–1703
  - small bowel obstruction and, 1630, 1631*f*
- Von Hipple-Lindau disease (VHL)
  - clear cell RCC and, 2019
  - manifestations of, 2019
  - pheochromocytoma in, 514
- Von Recklinghausen disease, 1961
- Von Willebrand disease (vWD)
  - acquired
    - Wilms tumor and, 2079
  - hemorrhagic risk and, 104
  - surgical risk and, 27
  - vasopressin and, 81
- Von Willebrand factor, 81
- Vulvar carcinoma, 430
- V-Y advancement flaps, 216, 219

W

- Wagner Ulcer Classification System, 2392, 2392*t*
- WAGR syndrome, 2078
- Waldeyer fascia, 1684, 1800, 1825, 1844
- Waldeyer's ring, 400
- Wallace uterointestinal anastomosis, 2109*f*
- Walled-off pancreatic necrosis (WOPN), 1524, 1524*f*
  - definition of, 1540

- development of, 1550
- endoscopic drainage, 1540
- endoscopic transgastric damage, 1529
- inflammatory markers, 1550
- management of, 1532
- morbidity and mortality, 1550–1551
- necrotic fluid collections and, 1536
- prophylactic antibiotics, 1550
- transpapillary drainage, 1529

Wangensteen, Owen, 1140

Warfarin
- drug induced coagulopathy and, 104
- management of, 28
- mechanism of action, 104
- perioperative management, 29*t*
- withdrawal before surgery, 28

Wartenberg's sign, 250

Warthin tumors, 310

Wasting syndrome, 11

Water displacement, 674

Waterston classification system, 1034, 1034*f*

Watson fundoplication, 950

WBXRT. *See* Whole breast radiation therapy

Weck clips, 2030

Wedge fundectomy, 869*f*

Weerda scope laryngoscope, 1146, 1147, 1147*f*

Weight loss, e59, e60. *See also* Body weight
- after bariatric surgery, 1230–1231
- after laparoscopic gastric bypass, 1216
- in cancer patients, 35–36, 36*f*
- paraneoplastic syndrome and, 2020
- preoperative, 27–28, 2228
- unintentional, 56

Weight recidivism, 1255–1256

- Weinberg pyloroplasty, 1103*f*
- Weitlaner retractors, 1966
- Weitlaner self-retaining retractors, 467
- Welch, Calude, 1659
- Well's repair, 1894, 1902
- Werdnig-Hoffmann disease
  - congenital diaphragmatic hernia accompanied by, 848
- WEXNER Operating Instruments, 1942
- Wharton duct, 310. *See also* Submandibular duct
- Whipple procedure
  - antrectomy in, 1507–1508
  - choice of, 1545
  - in chronic pancreatitis, 1495
  - dissection, 1490–1491
  - distal gastrectomy in, 1142
  - outcomes, 1420
  - in pancreatic trauma, 1577*f*
  - prophylactic antimicrobial agents, 114*t*
- White, George R., 2167
- White line of Toldt, 1676*f*, 1678, 1792*f*, 1856
- "White roll" anatomy, 325–327, 325*f*
- Whitehead deformity, 1927
- Whole breast radiation therapy (WBXRT), 642
- WIFI. *See* Wound, ischemia, and foot Infection
- Wilkie syndrome. *See* Duodenum, vascular compression of
- Wilms tumor
  - abdominal incision, 2081*f*
  - biology of, 2087
  - clinical presentation, 2079
  - clinical trials, 2086
  - complications, 2084–2085
  - early detection of, 2078
  - etiology, 2078–2079
  - extra renal, 2078

- genes associated with, 2078*t*
- grading system, 2079*t*
- histologic subtypes, 2079
- intravascular venous thrombosis, 2087
- intravenous thrombus, 2083*f*
- metatastic sites, 2084
- outcomes, 2085
- pathophysiology, 2078–2079
- postoperative chemotherapy, 2085
- postoperative management, 2084
- preoperative planning, 2079
- recurrence, 2084, 2086
- staging, 2087
- surgical management of, 2078–2087
- syndromes associated with, 2078*t*
- treatment, 2079–2081
  - clinical trials, 2080–2081
  - recommended protocols, 2080*t*, 2082*f*

- Windsock deformity, 1169
- Wires in endovascular procedures, 2385–2386, 2386*f*
- Witzel jejunostomy, 1578
- Witzel tunnel, 1657
- Wolff, Martin, 1614
- Wolffian ridge layer, 1799–1800
- WOPN. *See* Walled-off pancreatic necrosis (WOPN)
- World Health Organization (WHO)
  - on adult obesity, 1176
  - on childhood obesity, 1176
  - diabetes statistics, 1218
  - on obesity in children, 1176
  - on SSI prevention, 113, 115*t*–116*t*, 117*t*–120*t*
  - statistics on obesity, 1176, 1203, 1218
  - Surgical Safety Checklist, 31*f*, 53
  - thymic carcinoma classification, 559, 559*t*

- thymoma classification, 559, 559*t*
- Wound, Ischemia, and Foot Infection (WIFI), 2392, 2392t
- Wound, Ostomy, and Continence Nurse (WOCN), 1773
- Wound classes
  - clean, 113*t*
  - clean-contaminated, 113*t*
  - contaminated, 113*t*
  - dirty, 113*t*
  - infected, 113*t*
  - NHIS, 113*t*
  - NNIS, 112*t*
- Wound closure
  - for duodenal ulcer vagotomy, antrectomy, and gastroduodenostomy, e17, e18
  - in Halsted mastectomy, 709–710, 710*f*
  - in inguinal hernia repair, e78, e86
  - for reversed vein bypass grafts, 2364
- Wound dehiscence
  - abdominal operations and, 168–169
  - after perineal surgery, 1865–1866
  - management of, 1866*f*
- Wound healing
  - in breast oncoplasty, 718
  - in Crohn patients, 1714
  - in fasciotomy, 2429
  - hypoalbuminemia and, 1651
  - improvement of, 1731
  - leg amputation, 2404
  - mTOR inhibition and, 148
  - smoking and, 159
- Wound infections
  - after APR, 1850
  - after perineal surgery, 1865
  - postoperative prevention, 32–33

- postsurgical, 2163
  - risk factors, 1724
- as thoracic outlet decompression complication, 2560

Wound protector devices, 119*t*

Wounds
- chronic, 216
- granulation and, 216
- management, in trauma, 2596, 2602
- open, 251
- postradiation, 217
- soft tissue, 216–217
- types of, 216

W-pouches, 1732, 1732*f*, 1740

Wrists
- anatomy, 247–249
- animal bite infections, 255–257
- carpal bones, 247, 250*f*
- compartment syndrome, 258–259
- deep space infections, 255
- extension, 247
- fight-bite infections, 255–257
- flexion, 247
- high-pressure injections, 258
- innervation, 247
- sensation, 247
- septic arthritis, 257–258, 258*f*

WT1 gene, 2078

WT2 deletions, 2078

WT2 gene, 2078

WTX tumor suppressor gene, 2078

X

Xanthomata, e42

Xerostomia, 336

Xiphisternal junction, 773

- Xiphoid hernias, 164
- Xiphoid process, 775*f*
- Xylocaine spray, 1623

Y

- Yankauer suction, 1610, 1610*f*, 2109*f*
- Yellowfin stirrups, 1727
- *Yersinia enterocolitica*, 1719

Z

- "Z" line, 208*f*
- Z-bands, sarcomere, 38
- Z-disks, disintegration of, 37
- Zenker area, 298*f*, 301–302
- Zenker diverticulum
  - clinical presentation, 1145, 1145*f*
  - complications, 1148
  - ethology of, 1145
  - evaluation of, 1145–1146
  - management of, 1149
  - pathophysiology of, 1145
  - postoperative management, 1147–1148
  - preoperative planning, 1145–1146
  - repair of, 1146*f*
  - results, 1148–1149, 1148*f*
  - symptoms, 1145*f*
  - transoral stapling, 1147*f*
- Zeus Robotic Surgical System, 262
- Zinc in TPN solutions, 47
- Zollinger-Ellison syndrome, 1103
- Zona fasciculata, 9
- Zuckerkandl organ, 508
- Zygoma, parotid gland and, 308
- Zygomaticus major, 326

目录

Title Page 4
Copyright 6
Dedication 8
Commentary Editors 9
Contributors 16
Preface 82
Contents 85
VOLUME I 103
SECTION I PERIOPERATIVE CARE OF THE SURGICAL PATIENT 103
CHAPTER 1: Metabolic and Inflammatory Responses to Trauma and Infection 104
CHAPTER 2: Perioperative Management: Practical Principles, Molecular Basis of Risk, and Future Directions 162
CHAPTER 3: Enteral Nutrition Support 254
CHAPTER 4: Cardiovascular Monitoring and Support 290
CHAPTER 5: Pulmonary Risk and Ventilatory Support 342
CHAPTER 6: Hemorrhagic Risk and Blood Components 393
CHAPTER 7: Perioperative Antimicrobial Prophylaxis and Treatment of Surgical Infection 414
CHAPTER 8: Multiple Organ Dysfunction Syndrome: Prevention and Clinical Management 462
CHAPTER 9: Immunosuppression in Organ Transplantation 490
CHAPTER 10: Surgeons and the Opioid Epidemic 515
SECTION II BASIC SURGICAL SKILLS: NEW AND EMERGING TECHNOLOGY 537
CHAPTER 11: Ventral Abdominal Hernia: Open and Minimally Invasive and Component Separation Release 538
CHAPTER 12: Laparoscopic Suturing and Stapling 583
CHAPTER 13: Ultrasonography by Surgeons 603
CHAPTER 14: Tumor Ablation: Technologies and Clinical Applications 652

CHAPTER 15: Upper and Lower Gastrointestinal Endoscopy 685
CHAPTER 16: Soft Tissue Reconstruction With Flap Techniques 712
CHAPTER 17: Hand Surgery: Traumatic and Infectious Emergencies 795
CHAPTER 18: Robotic Surgery 832
CHAPTER 19: Surgical Energy 867
SECTION III THE HEAD AND NECK 895
CHAPTER 20: Anatomy of the Head and Neck 896
CHAPTER 21: Surgery of the Major Salivary Glands 968
CHAPTER 22: Anatomy of the Parotid Gland, Submandibular Triangle, and Floor of the Mouth 991
CHAPTER 23: Lip Reconstruction 1017
CHAPTER 24: Surgery for Cancer of the Oral Cavity 1040
CHAPTER 25: Neck Dissection 1071
CHAPTER 26: Congenital Lesions: Thyroglossal Duct Cysts, Branchial Cleft Anomalies, and Cystic Hygromas 1119
CHAPTER 27: Vascular Anomalies of Infancy and Childhood 1142
CHAPTER 28: Surgical Treatment of Laryngeal Cancer: A Legacy of Minimally Invasive Innovation and the Preservation of Airway, Swallowing, and Vocal Function 1173
CHAPTER 29: Surgical Treatment of Pharyngeal Cancer 1212
CHAPTER 30: Malignant Melanoma and Skin Cancer 1247
CHAPTER 31: Melanoma 1270
CHAPTER 32: Inguinal Lymph Node Dissection: Indications and Surgical Technique 1302
CHAPTER 33: Evaluation and Repair of Common Facial Injuries 1312
CHAPTER 34: Resection and Reconstruction of the Trachea 1352
CHAPTER 35: Penetrating Neck Injuries 1390
CHAPTER 36: Neurosurgical and Neurologic Emergencies for Surgeons 1420
CHAPTER 37: Tracheotomy 1461

SECTION IV ENDOCRINE SURGERY 1486
CHAPTER 38: Surgical Anatomy of the Thyroid, Parathyroid, and Adrenal Glands 1487
CHAPTER 39: Biopsy, Lobectomy, Total Thyroidectomy, and Lymph Node Dissection for Thyroid Cancer 1534
CHAPTER 40: Comprehensive Parathyroidectomy for the Treatment of PHPT, Including Intraoperative Parathyroid Hormone Assay–Guided Parathyroidectomy 1577
CHAPTER 41: Minimally Invasive Parathyroidectomy 1610
CHAPTER 42: Secondary and Tertiary Hyperparathyroidism 1633
CHAPTER 43: Transsternal, Transcervical, and Minimally Invasive Thymectomy for Benign and Malignant Disease 1648
CHAPTER 44: Adrenalectomy—Minimally Invasive and Open 1688
CHAPTER 45: Pancreatic Neuroendocrine Tumors 1725
SECTION V THE BREAST, CHEST, AND MEDIASTINUM 1753
CHAPTER 46: Embryology and Anatomy of the Breast 1754
CHAPTER 47: Benign Disease and Breast Pain 1780
CHAPTER 48: Diagnostic Approach to Breast Abnormalities 1801
CHAPTER 49: Breast-Conserving Surgery 1843
CHAPTER 50: Radiation Treatment, Whole and Partial Breast and Intraoperative Irradiation 1905
CHAPTER 51: Ablative Techniques for Benign and Malignant Breast Tumors 1933
CHAPTER 52: Sentinel Lymph Node Biopsy in Breast Cancer 1969
CHAPTER 53: Lymphedema—Pathophysiology, Prevention, and Treatment 1986
CHAPTER 54: Modified Radical Mastectomy and Radical Mastectomy 2022
CHAPTER 55: Oncoplastic Techniques for Breast Conservation Surgery 2086
CHAPTER 56: Breast Reconstruction Following Mastectomy 2109

CHAPTER 57: Chest Wall Resection and Reconstruction for Advanced/Recurrent Carcinoma of the Breast 2160
CHAPTER 58: Clinical Trials and Follow-Up for Breast Cancer 2192
CHAPTER 59: The Deep Inferior Epigastric Perforator Flap for Breast Reconstruction 2216
CHAPTER 60: Applied Anatomy of the Chest Wall and Mediastinum 2239
CHAPTER 61: Thoracic Trauma 2278
CHAPTER 62: Pulmonary Resection 2310
SECTION VI THE DIAPHRAGM 2365
CHAPTER 63: Surgical Anatomy of the Diaphragm 2366
CHAPTER 64: Congenital Diaphragmatic Hernia 2420
CHAPTER 65: Eventration of the Diaphragm 2442
CHAPTER 66: Traumatic Injury to the Diaphragm 2467
CHAPTER 67: Paraesophageal Hernia—Open Repair 2492
CHAPTER 68: Gastroesophageal Reflux Disease in Infants and Children 2518
SECTION VII THE GASTROINTESTINAL TRACT 2549
Part A: The Esophagus 2550
CHAPTER 69: The Anatomy of the Esophagus 2550
CHAPTER 70: Transthoracic Antireflux Procedures 2597
CHAPTER 71: Laparoscopic Esophagectomy 2636
CHAPTER 72: Nissen–Rossetti Antireflux Fundoplication (Open Procedure) 2667
CHAPTER 73: Modified Hill Repair for Gastroesophageal Reflux 2689
CHAPTER 74: Laparoscopic Antireflux Surgery 2714
CHAPTER 75: Peroral Endoscopic Myotomy for Achalasia and Endoluminal Approaches for GERD 2763
CHAPTER 76: Minimally Invasive Treatment of Achalasia and Other Esophageal Dysmotility 2784
CHAPTER 77: Esophagogastrectomy for Carcinoma of the Esophagus 2827
CHAPTER 78: Transhiatal Esophagectomy Without Thoracotomy 2875

CHAPTER 79: Esophageal Perforation 2936
CHAPTER 80: Repair of Esophageal Atresia and Tracheoesophageal Fistula 2972
CHAPTER 81: Pathology and Treatment of Zenker Diverticulum 3007
Part B: The Stomach and Duodenum 3023
CHAPTER 82: Anatomic Considerations in Gastroduodenal Surgery 3023
CHAPTER 83: Percutaneous Endoscopic Gastrostomy 3097
CHAPTER 84: Distal Gastrectomy With Billroth I or Billroth II Reconstruction 3117
CHAPTER 85: Selective Vagotomy, Antrectomy, and Gastroduodenostomy for the Treatment of Duodenal Ulcer 3151
CHAPTER 86: Selective and Nonselective Vagotomies 3185
CHAPTER 87: Duodenal Ulcer Disease: Pathogenesis and Management of Complications 3208
CHAPTER 88: Gastric Cancer 3276
CHAPTER 89: Distal Gastrectomy With Roux-en-Y Reconstruction and Laparoscopic Gastrectomy 3313
CHAPTER 90: Postgastrectomy Syndromes in the Current Era 3332
CHAPTER 91: Congenital Pyloric Stenosis and Duodenal Obstruction 3379
CHAPTER 92: Diabetes and Other Metabolic Diseases 3408
CHAPTER 93: Vascular Compression of the Duodenum 3433
Part C: Bariatric and Metabolic Diseases 3454
CHAPTER 94: Gastrointestinal Stromal Tumors 3454
CHAPTER 95: The Laparoscopic Gastric Band Technique of Placement 3468
CHAPTER 96: Revision and Conversion of Vertical Banded Gastroplasty 3484
CHAPTER 97: Laparoscopic Gastric Bypass 3501
CHAPTER 98: Laparoscopic Gastric Sleeve 3525
CHAPTER 99: Laparoscopic Biliopancreatic Diversion With Duodenal Switch 3547

CHAPTER 100: EndoBarrier for the Treatment of Morbid Obesity and Type II Diabetes 3572
CHAPTER 101: Revisional Bariatric Surgery 3594
CHAPTER 102: Management of Complications of Gastric Bypass and Repair 3624
VOLUME II 3647
Part D: The Liver and Biliary Tract 3647
CHAPTER 103: Surgical Anatomy of the Liver and Bile Ducts 3647
CHAPTER 104: Diagnostic Considerations in Biliary and Liver Disease 3681
CHAPTER 105: Approaches to Drainage of Hepatic, Perihepatic, and Subhepatic Abscesses 3719
CHAPTER 106: Echinococcal Cyst—Open and Laparoscopic Approach 3740
CHAPTER 107: Hepatic Resection for Primary and Metastatic Tumors 3796
CHAPTER 108: Treatment of Major Hepatic Trauma 3834
CHAPTER 109: Cholecystostomy, Cholecystectomy, and Intraoperative Evaluation of the Biliary Tree 3878
CHAPTER 110: Laparoscopic Cholecystectomy, Intraoperative Cholangiography, and Common Bile Duct Exploration 3907
CHAPTER 111: Reconstruction of the Bile Duct: Anatomic Principles and Surgical Techniques 3951
CHAPTER 112: Current Application of Endoscopic Sphincterotomy, Lateral Choledochoduodenostomy, and Transduodenal Sphincteroplasty 3990
CHAPTER 113: Primary Sclerosing Cholangitis 4022
CHAPTER 114: High Malignant Biliary Tract Obstruction 4049
CHAPTER 115: Cholecystojejunostomy and Choledocho/Hepaticojejunostomy 4072
CHAPTER 116: Operative Treatment for Choledochal Cysts 4095
CHAPTER 117: Biliary Atresia—Portoenterostomy 4116
CHAPTER 118: Liver Transplantation 4138

CHAPTER 119: Special Comment: The Unfinished Legacy of Liver Transplantation 4184
CHAPTER 120: The Associating Liver Partition and Portal Vein Ligation for Staged Hepatectomy (ALPPS) Approach 4211
Part E: The Pancreas 4237
CHAPTER 121: Surgical Anatomy of the Pancreas 4237
CHAPTER 122: Selection of Surgical Therapy for Chronic Pancreatitis 4299
CHAPTER 123: Operative Interventions for Chronic Pancreatitis 4332
CHAPTER 124: Parenchyma-Sparing, Limited Partial and Total Pancreatic Head Resection for Inflammatory Tumor, Cystic Neoplasia, Neuroendocrine Adenoma, and Low-Risk Periampullary Malignant Tumor 4359
CHAPTER 125: Necrosectomy for Acute Necrotizing Pancreatitis 4383
CHAPTER 126: Management of Complications of Acute and Chronic Pancreatitis: Endoscopic, Laparoscopic, and Open Approaches to Pancreatic Pseudocysts and Pancreatic Necrosis 4414
CHAPTER 127: Pancreaticoduodenectomy and Total Pancreatectomy for Cancer 4459
CHAPTER 128: Operative Management of Pancreatic Trauma 4516
CHAPTER 129: Splanchnic Denervation of the Pancreas for Intractable Pain 4537
Part F: Introduction to Portal Hypertension 4556
CHAPTER 130: Anatomy of the Portal System and Experience With Portacaval Shunt 4561
CHAPTER 131: Small-Diameter Prosthetic Interposition Shunt 4608
CHAPTER 132: Distal Splenorenal Shunts: Hemodynamics of Total Versus Selective Shunting 4632
CHAPTER 133: Central Splenorenal Shunts 4660
CHAPTER 134: Endoscopic Therapy in the Management of Esophageal Varices 4675
Part G: Surgery of the Small Intestine 4715

CHAPTER 135: Small Bowel Obstruction 4715
CHAPTER 136: Metabolic Surgery and Intestinal Bypass for Hypercholesterolemia 4738
CHAPTER 137: The Continent Ileostomy 4764
CHAPTER 138: Technique of Ileostomy Construction and Closure 4785
CHAPTER 139: Gastrointestinal-Cutaneous Fistulas 4814
CHAPTER 140: Surgical Treatment of Small Bowel Crohn Disease 4845
Part H: Surgery of the Colon 4885
CHAPTER 141: Clinical Anatomy for Procedures Involving the Small Bowel, Colon, Rectum, and Anus 4885
CHAPTER 142: The Appendix 4916
CHAPTER 143: Large Bowel Obstruction 4949
CHAPTER 144: Surgical Treatment of Colonic and Perianal Crohn Disease 4977
CHAPTER 145: Surgery for Toxic Megacolon 5006
CHAPTER 146: Total Proctocolectomy and Inter-Sphincteric Proctectomy for Benign Disease 5026
CHAPTER 147: Ileoanal Pouch Procedure for Ulcerative Colitis and Familial Adenomatous Polyposis 5042
CHAPTER 148: Total Colectomy and Ileorectal Anastomosis 5067
CHAPTER 149: Surgery for Diverticulitis 5107
CHAPTER 150: Technique of Colostomy Construction and Closure 5138
CHAPTER 151: Care of Stomas 5164
CHAPTER 152: Open and Minimally Invasive Right Hemicolectomy for Cancer 5187
CHAPTER 153: Open and Minimally Invasive Left Hemicolectomy for Neoplasms of the Descending Colon, Sigmoid, and Upper Rectum 5211
CHAPTER 154: Historical Perspectives on Total Mesorectal Excision 5234
CHAPTER 154A: Advances in Total Mesorectal Excision 5284
CHAPTER 155: Open and Minimally Invasive Sphincter-

Preserving Radical Resection for Malignant Disease of the Middle and Lower Thirds of the Rectum 5311
CHAPTER 156: Abdominoperineal Resection for Rectal Cancer 5354
CHAPTER 157: Abdominoperineal Resection for Rectal Cancer 5387
CHAPTER 158: The Approach to Reoperative Pelvic Surgery in Rectal Cancer 5412
CHAPTER 159: Sacral Resection for Recurrent Rectal Cancers 5429
CHAPTER 160: Cytoreductive Surgery and Hyperthermic Intraperitoneal Chemotherapy for Cancers of the Appendix and Colon 5457
CHAPTER 161: Management of Retrorectal Tumors 5471
CHAPTER 162: Rectal Prolapse: The Open Abdominal Approach 5504
CHAPTER 163: Rectal Prolapse 5535
CHAPTER 164: Anorectal Disorders 5562
CHAPTER 165: Transanal Excision of Rectal Neoplasms 5637
CHAPTER 166: Functional Bowel Disorders 5669
CHAPTER 167: Groin Dissection 5714
CHAPTER 168: Transanal Pull-Through for Hirschsprung Disease 5735
CHAPTER 169: Neonatal Enterocolitis and Short Bowel Syndrome 5749
SECTION VIII NONGASTROINTESTINAL TRANSABDOMINAL SURGERY 5771
Part A: The Spleen 5772
CHAPTER 170: Laparoscopic Splenectomy 5772
Part B: The Urinary Tract and Bladder 5811
CHAPTER 171: Anatomy of the Kidneys, Ureter, and Bladder 5811
CHAPTER 172: Surgical Management of Nephrolithiasis 5833
CHAPTER 173: Operations on the Ureteropelvic Junction 5855
CHAPTER 174: Radical Nephrectomy for Renal Cell 5872

Cancer 5872

CHAPTER 175: Radical Cystectomy and Orthotopic Urinary Diversion for Bladder Cancer 5912

CHAPTER 176: Laparoscopic Pelvic and Retroperitoneal Lymph Node Dissection 5975

CHAPTER 177: Robot-Assisted Radical Prostatectomy 6020

CHAPTER 178: The Undescended Testis 6032

CHAPTER 179: Surgical Management of Wilms Tumor 6049

CHAPTER 180: Genitourinary Tract Trauma 6077

CHAPTER 181: Supravesical Urinary Diversion 6121

Part C: Gynecologic Surgery 6156

CHAPTER 182: Cesarean Delivery 6156

CHAPTER 183: Abdominal Hysterectomy 6183

CHAPTER 184: Radical Hysterectomy 6204

CHAPTER 185: Surgical Management of Ovarian Carcinoma 6237

CHAPTER 186: Anterior and Posterior Colporrhaphy 6294

Part D: Surgery of the Hernia 6348

CHAPTER 187: Surgical Anatomy of the Hernial Rings 6348

CHAPTER 188: Overview of Inguinal and Femoral Hernia Repairs 6417

CHAPTER 189: The Shouldice Method of Inguinal Herniorrhaphy 6463

CHAPTER 190: Iliopubic Tract Repair of Inguinal Hernia: The Anterior (Inguinal Canal) Approach 6498

CHAPTER 191: Iliopubic Tract Repair of Inguinal and Femoral Hernia: The Posterior (Preperitoneal) Approach 6526

CHAPTER 192: Kugel Technique of Groin Hernia Repair 6550

CHAPTER 193: Generations of the Plug-and-Patch Repair: Its Development and Lessons From History 6569

CHAPTER 194: Postherniorrhaphy Inguinodynia: Causes, Prevention, and Surgical Treatment: Triple Neurectomy 6603

SECTION IX VASCULAR SURGERY 6619

CHAPTER 195: Carotid Bifurcation Disease: Carotid Endarterectomy and Stenting 6620
CHAPTER 196: Brachiocephalic Reconstruction: Open and Endovascular 6659
CHAPTER 197: Carotid Body Tumors 6678
Part B: Aneurysmal Disease 6711
CHAPTER 198: Open Thoracoabdominal Aortic Aneurysm Repair 6711
CHAPTER 199: Open Infrarenal and Pararenal Aortic Aneurysm Repair 6739
CHAPTER 200: Endovascular Repair of Abdominal Aortic Aneurysms 6763
CHAPTER 201: Ruptured Abdominal Aortic Aneurysms 6778
CHAPTER 202: Femoral and Popliteal Artery Aneurysms 6819
CHAPTER 203: Treatment of Splenic Artery Aneurysms: Open and Endovascular 6846
Part C: Chronic Lower Extremity Occlusive Disease 6859
CHAPTER 204: Aortofemoral Bypass 6859
CHAPTER 205: Aortoiliac Occlusive Disease: Extraanatomic Bypass 6892
CHAPTER 206: Endovascular Procedures for Aortoiliac Occlusive Disease 6913
CHAPTER 207: Reversed Vein Bypass Grafts to Popliteal, Tibial, and Peroneal Arteries 6932
CHAPTER 208: Peripheral Arterial Disease: Prosthetic Bypass 6960
CHAPTER 209: Dorsalis Pedis, Tarsal, and Plantar Artery Bypass 6982
CHAPTER 210: Peripheral Vascular Occlusive Disease: Endovascular 7006
CHAPTER 211: Minor Amputations 7024
CHAPTER 212: Major Lower Extremity Amputation 7046
CHAPTER 213: The Prevention and Treatment of Problems With the Diabetic Foot 7072
Part D: Acute Lower Extremity Ischemia 7097

Part D: Acute Lower Extremity Ischemia 7097
CHAPTER 214: Embolectomy 7097
CHAPTER 215: Fasciotomy 7118
Part E: Mesenteric and Renal Artery Disease 7141
CHAPTER 216: Renal Artery Occlusive Disease: Open and Endovascular Management 7141
CHAPTER 217: Acute Mesenteric Artery Ischemia: Open and Endovascular 7176
CHAPTER 218: Techniques of Open and Endovascular Revascularization to Treat Chronic Mesenteric Ischemia 7200
Part F: Vascular Infection 7232
CHAPTER 219: Mycotic Aneurysms 7232
CHAPTER 220: Surgical Management of Aortic Graft Infections 7251
Part G: Venous Disorders 7279
CHAPTER 221: Contemporary Operative Venous Thrombectomy 7279
CHAPTER 222: Acute Deep Venous Thrombosis: Endovascular 7298
CHAPTER 223: Chronic Deep Vein Thrombosis/Postthrombotic Syndrome: Open and Endovascular Treatment 7328
CHAPTER 224: Vena Cava Filter Placement 7356
CHAPTER 225: Venous Insufficiency 7381
Part H: Dialysis Access 7402
CHAPTER 226: Autogenous Arteriovenous Hemodialysis Access 7402
CHAPTER 227: Hemodialysis Access-Prosthetic Arteriovenous Access 7446
Part I: Thoracic 7465
CHAPTER 228: Thoracic Outlet Syndrome 7465
CHAPTER 229: Thoracic Aortic Transection 7497
Part J: Trauma 7517
CHAPTER 230: Vascular Injuries to the Neck, Including the Subclavian Vessels 7517
CHAPTER 231: Injury to the Abdomen: Open and

CHAPTER 232: Injury to the Extremities: Open and Endovascular Management 7571

Index 7615